Includes fully searchable text and image bank online

Thyroid Cytopathology

An Atlas and Text

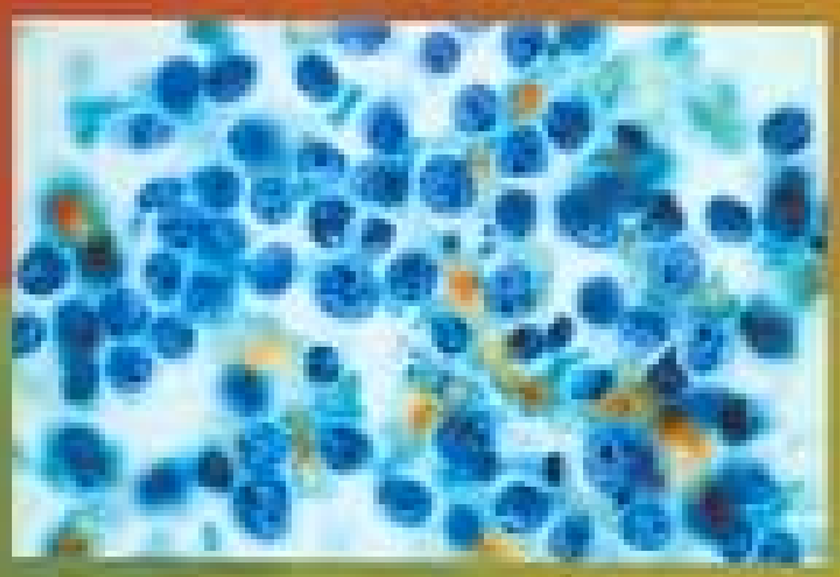
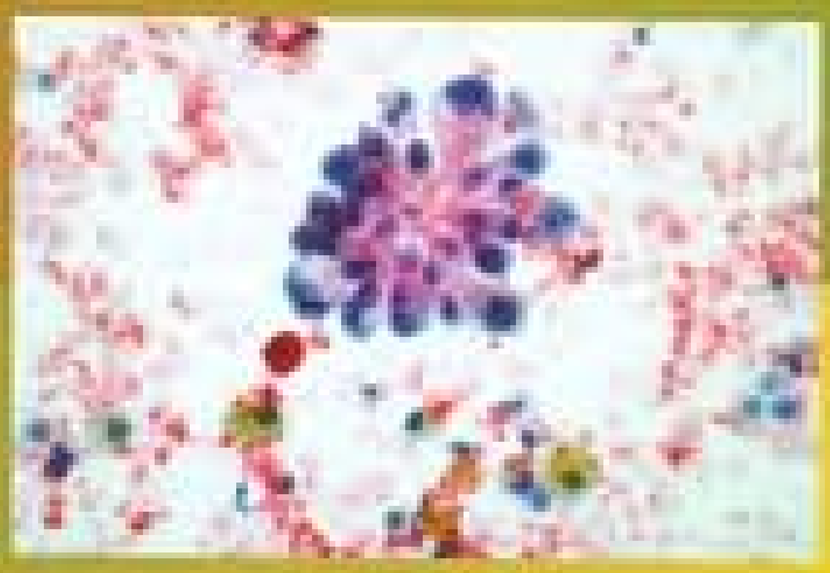

Sudha R. Kini

Wolters Kluwer Health | Lippincott Williams & Wilkins

SOLUTION

Editors: Kini, Sudha R.
Title: *Thyroid Cytopathology: A Text and Atlas, 1st Edition*

Copyright Â©2008 Lippincott Williams & Wilkins

Editor

Sudha R. Kini
Henry Ford Hospital

Department of Pathology

Division of Cytopathology

Detroit, Michigan

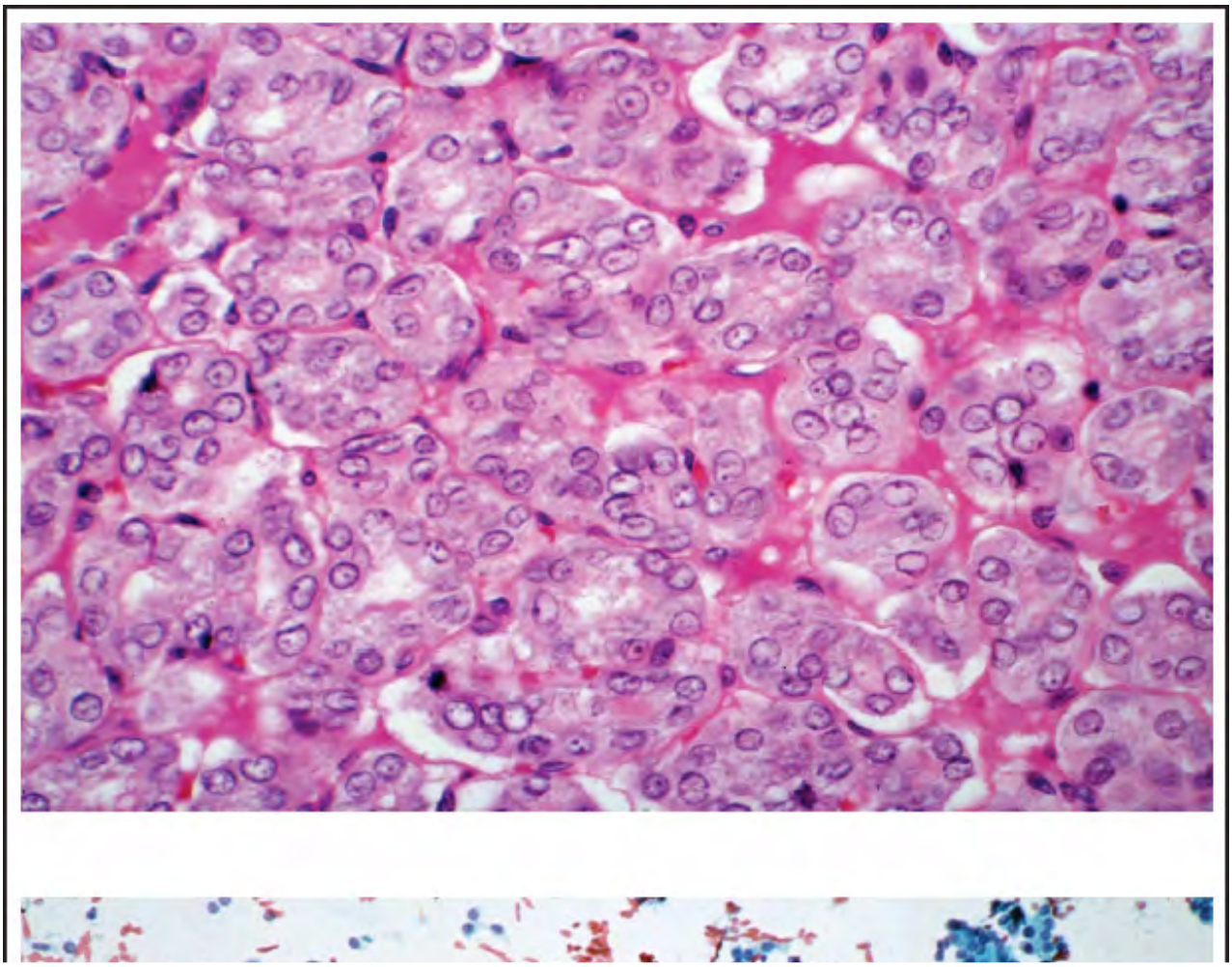

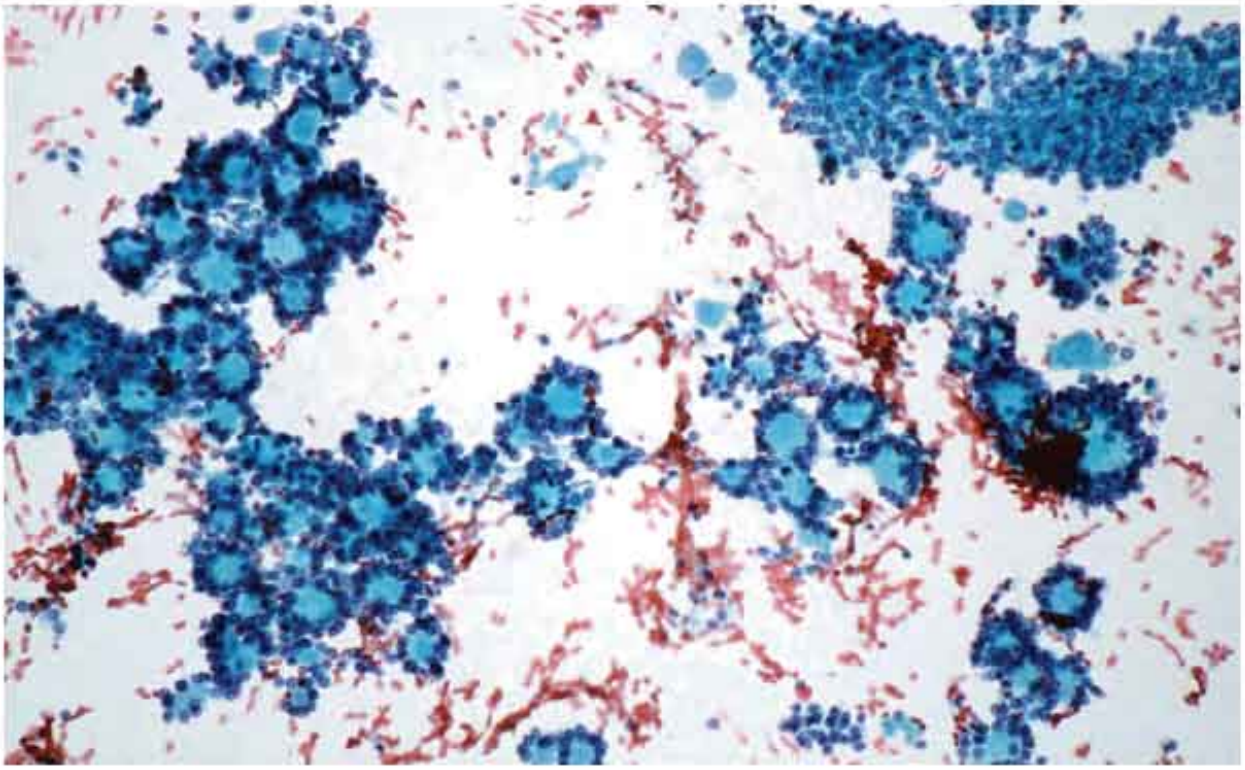

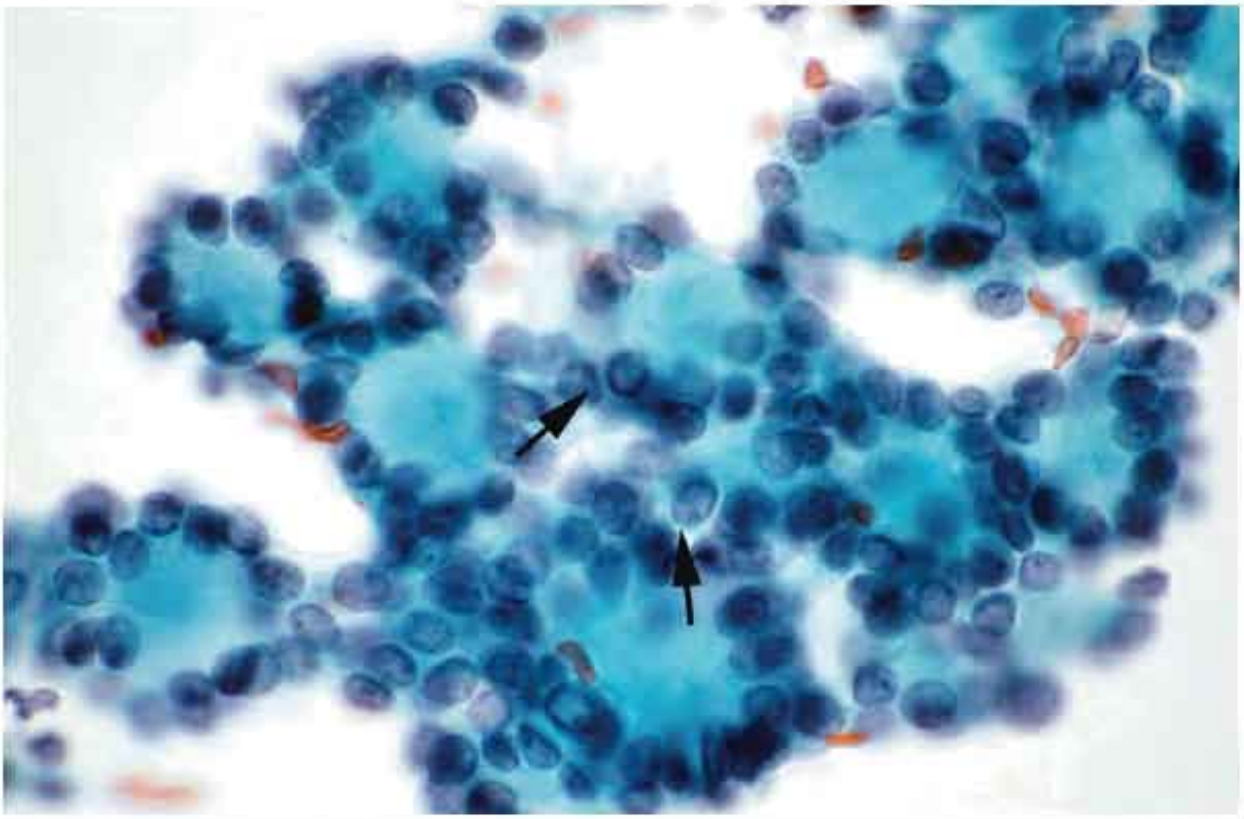

Contributors

J. MARTIN MILLER, MDKINI
Emeritus Consultant
Division of Endocrinology
Department of Internal Medicine
Henry Ford Hospital;+

Endocrinologist
Associated Endocrinologists
Southfield, Michigan;

Emeritus Clinical Associate Professor
University of Michigan
Ann Arbor, Michigan

MAX WISGERHOF, MD
Division of Endocrinology and Metabolism
Department of Internal Medicine
Henry Ford Hospital
Detroit, Michigan

VINOD NARRA, MD
Department of General Surgery
Henry Ford Hospital;

Clinical Assistant Professor
Wayne State University
Detroit, Michigan

OSAMA ALASSI, MD

Senior Staff Pathologist
Department of Pathologist
Henry Ford Hospital
Detroit, Michigan

MELINA CANKOVIC, PHD
Division Head, Molecular Pathology
Department of Pathology
Henry Ford Hospital
Detroit, Michigan

CLAIRE W. MICHAEL, MD
Associate Professor of Pathology
Director, Cytopathology
University of Michigan
Ann Arbor, Michigan

Editors: Kini, Sudha R.
Title: *Thyroid Cytopathology: A Text and Atlas, 1st Edition*

Copyright Â©2008 Lippincott Williams & Wilkins

Acknowledgments

Permission to reproduce the following is gratefully acknowledged:

From Miller JM, Kini SR, Hamburger JI. *Needle Biopsy of the Thyroid*. New York: Praeger Publishers; 1983 for Figures 2.2, 2.3, 2.4 and 2.5.

From Kini SR, Miller JM, Hamburger JI, et al. Cytopathology of follicular lesions of the thyroid gland. *Diagn Cytopathol*. 1985;1:123â€“132, published by Igaku-Shoin, New York for Figures 5.21 and 5.25.

From Cervino JM, Paseyro P, Grosso O, et al. La exploration citologic de la glandula tirodes y sus correlaciones anatomoclinicas. *An Facultad Med*. 1962;47:128â€“143 for Figure 7.48.

From Crissman JD, Druzdowicz S, Johnson C, et al. Fine needle aspiration diagnosis of hyperplastic and neoplastic follicular nodules of the thyroid. A morphometric study. *Anal Quant Cytol Histol*. 1991;13:321â€“328 for Tables 7.15 to 7.18.

From Kini SR. *Color Atlas of Differential Diagnosis in Exfoliative and Aspiration Cytopathology*. Philadelphia: Lippincott Williams & Wilkins;1999 for Figure 5.18.

The permission to photograph cases or reproduce the images is gratefully acknowledged from:

Mariza de Peralta-Venturina, MD, William Beaumont Hospital, Royal Oak, Michigan for Figures 6.22, 6.30A and 6.30B, 6.40, 6.45, 7.20A to 7.20E, 7.42A to 7.42D, 7.54A to 7.54D, 8.21A and 8.21B, 9.14G, 9.17E, 9.19D, 9.36B, 17.11A to 17.11C, 18.12, and 19.52.

Mithra Baliga, MD, University of Mississippi, Jackson, for Figures 7.13A and 7.13B, 7.56A to 7.56C, 8.14A to 8.14D, 8.20A to 8.20F, 10.19A to 10.19B, 11.27A to

11.27E, 12.49A and 12.49B, 16.14A and 16.14B.

David B. Kaminsky, MD, Palm Springs Pathology Associates, Palm Springs, California for Figures 19.9 and 19.19.

Sedigheh-Keyhani, MD, FIAC, Professor of Clinical Pathology, Ohio State University Hospital, Columbus, for Figures 13.3 and 13.18.

John F. Goellner, MD, formerly of Department of Pathology, Mayo Clinic Rochester, Minnesota for Figures 12.54 and 19.20.

W. K. Ng, MBBS, Department of Pathology, University of Hong Kong, Queen Mary Hospital, Hong Kong for Figure 19.46.

Rene? Gerhard, MD, Department of Pathology, Hospital das Clinicas, University of Sao Paulo, Brazil for Figure 19.47.

Edward Bernecki, MD, William Beaumont Hospital, Royal Oak, Michigan for Figures 19.48A to 19.48C.

Claire Michael, MD, University of Michigan Hospital, Ann Arbor, for Figures 19.48D to 19.48F.

Chris Jenson, MD, University of Iowa Hospitals, Iowa City, for Figure 19.49.

Ricardo Gonzalez-Campora, MD, FIAC, Department of Pathology, Faculty of Medicine, University of Seville, for Figure 19.51.

A. Vodovnik, Calderdale Royal Hospital, HX3 OPW Halifax, England for Figures 12.69 and 19.63.

Fadi Abdul-Karim, MD, Institute of Pathology, University Hospitals of Cleveland, for Figure 19.54.

Ms. I. Kikuchi, CT (IAC), Department of Pathology, Central Clinical Laboratory, Iwate Medical University, Morioka, Japan for Figure 19.56.

A. Watts, MD, Cedar Sinai Hospital, Los Angeles, California for Figure 13.2.

Yun Gong, MD, University of Texas M.D. Anderson Cancer Center, Houston, for Figure 16.19.

Ami J. Walloch, MD and Rashead Hammadeh, MD, Christ Hospital, Oaklawn, Illinois

for Figure 15.21.

DV. Trivedi, MD, Methodist Hospital, Peoria, Illinois for Figure 13.51.

Michael Glant, MD, Director, Diagnostic Cytology Clinic, Indianapolis, for Figures 21.4A to 21.4D.

Sajal Choudhary, MD, formerly of Mt. Carmel Mercy Hospital, Detroit, Michigan for Figure 16.16.

Editors: Kini, Sudha R.
Title: *Thyroid Cytopathology: A Text and Atlas, 1st Edition*

Copyright Â©2008 Lippincott Williams & Wilkins

Dedication

To all the patients, for their thyroid biopsies and thyroidectomies, that provided the invaluable learning opportunities and experience.

To all of my clinical colleagues in Endocrinology & EndocrineSurgery for their confidence in my cytologic interpretations.

To my daughters, Sarita and Sunita, whose support I can always count on.

To my granddaughter Maya, for bringing immense joy in my life.

And

To the loving memory of my late husband, Ratnakar. I cannot ever forget hisencouragement and the moral support that I enjoyed throughoutour married life. The fond memories have and always will guide me in spirit.

Editors: Kini, Sudha R.
Title: *Thyroid Cytopathology: A Text and Atlas, 1st Edition*

Copyright Â©2008 Lippincott Williams & Wilkins

Preface

This *Atlas and Text on Cytopathology of the Thyroid Gland* is essentially the third edition of "Thyroid" Guides to Clinical Aspiration Cytology. It comes 12 years after the second edition, in a new format and all in color.

The atlas has retained the organization of the second edition and also most of the text, modified whenever necessary with additional information. Several hundred images have been added to illustrate the wide spectrum of cytologic features for each disease entity. I have attempted to include the usual and unusual patterns of disease entities in each chapter, as well as their diagnostic pitfalls. A few images have been repeated just to emphasize the characteristics. Familiarity with the histopathologic features of various thyroid lesions is extremely important. I have therefore included more images in this atlas than in the second edition. The urge to illustrate more examples was irresistible and I thank the publishers for allowing me to do so.

The contributions made by the late Dr. Martin Miller (Chapters 1, 2, and 23) in the two editions of the "Thyroid" Guides to Clinical Aspiration Cytology are retained in this atlas for several reasons. First of all, the credit for success of fine-needle aspiration biopsy of thyroid in the United States goes to a large extent to the efforts of Dr. Miller.1 He strongly believed that too many thyroid glands with benign disease were being removed, and was willing to explore ways to differentiate benign from malignant nodules. Dr. Miller's expertise in thyroidology, his deep concern for patients, and his enthusiasm and persistence in carrying through the biopsy project since it was launched are all testimony to the success of fine-needle biopsy. I am indeed privileged to have had a long association with him. Dr. Miller's observations and approach are still applicable, and in my opinion worth retaining.

Writing this atlas was not as easy a task as I had thought it would be. The target audience now is more sophisticated (and opinionated), experienced, and knowledgeable in thyroid cytopathology. This is in sharp contrast to the time, some three decades ago, when most cytopathologists were inexperienced in thyroid cytology, especially the author, who had to struggle her way through. As aspiration biopsy of thyroid nodules has become a standard of practice, the literature has been inundated with case reports, review articles, differential diagnosis and ancillary diagnostic tests, chapters and textbooks. I have made every attempt to review most of the publications and incorporate the important information.

The diagnostic criteria for various thyroid lesions described in previous editions have not changed but are expanded in this atlas. The criteria are still valid, applicable, and reproducible (if tried on Papanicolaou-stained preparations). The old statistical data is also retained, as it has been a very important part of my learning experience. The importance of cytohistocorrelations of misinterpreted cases cannot be overemphasized.

One of the main reasons for the wide variations in interpretations in thyroid cytology is the inconsistency and lack of standardization in cytopreparations. Fixation of the cellular material, cytopreparatory techniques, and type of staining vary considerably from laboratory to laboratory. Cytopathologic criteria based on one type of preparation may not be applicable to the specimen processed by other techniques and stains. The cytologic criteria described and illustrated in this atlas are entirely based on spray-fixed material stained by the Papanicolaou method. I firmly believe that the interpretation of a cytologic specimen not only requires appreciation of the pattern but most importantly, the nuclear details such as presented in the Papanicolaou-stained preparations. I am also not convinced that liquid-based cytology is a good alternative. This may be due to my lack of experience with the preparations for non-gynecologic cytology, specifically for thyroid aspirates. But I make no apologies. Something that has worked wonderfully for the last 30 years need not be changed unless there are striking advantages in terms of diagnostic yield, accuracy, and cost containment. I see none with liquid-based cytologic preparations. However, I have included images of the Romanowsky-stained preparations and have added a section on liquid-based cytology for the benefit of a wider audience.

I still believe that follicular and HÃ¼rthle cell neoplasms can be cytologically differentiated from non-neoplastic lesions in a high proportion of cases, especially with the Papanicolaou-stained preparations. Diagnostic accuracy of follicular and HÃ¼rthle cell lesions cannot be judged fairly against the gold standard of surgical pathology when there is no consistency in surgical pathology diagnoses of these neoplasms. It is always taken for granted that the histologic diagnosis is accurate when cytologic and histologic diagnoses in any given case are discordant. The fact that histologic diagnoses could be in error is usually not taken into consideration when the accuracy of cytologic diagnosis is measured. I have personally reviewed several discordant cases where the diagnoses rendered by pathologists were inaccurate (in my opinion). I have illustrated some examples in Chapter 9.

The diagnostic problems in follicular/HÃ¼rthle cell lesions of the thyroid gland have served as an impetus for developing special markers either at the tissue level or at the molecular level. This field has exploded with newer diagnostic techniques in the hope of finding a magic tumor marker that would solve all the controversies and differentiate the various follicular/HÃ¼rthle cell lesions. Chapter 22 barely touches this subject.

I am extremely grateful to so many individuals for their participation. I sincerely appreciate the contributions by my professional colleagues, Max Wisgerhof, MD, Vinod Narra, MD, Osama Alassi, MD, and Melina Cancovic. PhD. I am

very thankful to Clair Michael, MD, for contributing the section on liquid-based cytology for thyroid aspirates.

The images are an essential part of any atlas and its success depends on the quality of the images. I cannot thank enough our past supervisor of the Cytopathology Laboratory, Mrs. M. Jane Purslow, CT (ASCP, MIAC), for taking thousands of images of a wide variety of thyroid lesions during her years at Henry Ford Hospital, Detroit. The quality of those images has always been superb. I am indebted to my past fellows: Osama Alassi, MD, Songling Liang, MD, and Dongping Shi, MD, who were always willing to photograph any new cases that I needed for this atlas. I had requested several of professional colleagues from the United States and abroad for the examples of interesting and rare lesions. I sincerely appreciate their generosity and prompt response. In particular, I would like to thank Mariza dePeralta, MD and

Mithra Baliga, MD for several cases, especially of Romanowsky-stained preparations.

I am very grateful to Mrs. Linda Brandt for her secretarial assistance. Ms. Laure Porzondek's help in retrieving the voluminous literature necessary to compile this text is gratefully acknowledged. I would like to express my appreciation to Mrs. Toni Klimowicz, our Cytopathology Laboratory supervisor, for providing the archival data and to Ms. Dawn M. Webb for her input in cytopreparatory techniques.

Finally, I must acknowledge the efforts of the members of the Department of Media Resources at Henry Ford Hospital, Detroit. Scanning hundreds of slides, merging the files with digital images, color balancing, and keeping all in order (1,800 of them, to be exact) has been a laborious process. I am grateful to Ms. Patricia Muldoon, Ms. Reva Sayegh, Mr. John Grybas, Mr. Jeff Boni, and Mr. Ray Manning for their diligence and prompt work.

Sudha R. Kini, MD

REFERENCE

1.Gharib H. Changing trends in thyroid practice: understanding nodular thyroid disease. *Endocr Pract*. 2004;10:31â€“39.

Editors: Kini, Sudha R.
Title: *Thyroid Cytopathology: A Text and Atlas, 1st Edition*

Copyright Â©2008 Lippincott Williams & Wilkins

Note to Readers

STAINS

Most of the thyroid aspirates are wet-fixed, using spray fixatives and stained by the Papanicolaou method. Any other stain used is so specified.

MAGNIFICATIONS

Unless otherwise specified, the photomicrographs are taken at 40 Ã— (or high power). All other magnifications are noted in the legends (low power at 4 Ã— and medium power at 10 Ã—).

All electron micrographs are taken on uranyl acetate and lead citrate preparations.

Editors: Kini, Sudha R.
Title: *Thyroid Cytopathology: A Text and Atlas, 1st Edition*

Copyright Â©2008 Lippincott Williams & Wilkins

1

Introduction

J. Martin MillerKINI

Max Wisgerhof

*The approach to thyroid nodularity, as recounted in late Dr. Miller's introduction to the second edition of Thyroid: Guides to Clinical Aspiration Biopsy, has not been eclipsed. Instead, the attempt at a cytologic diagnosis of thyroid nodularity by fine-needle aspiration has become the standard of care. The clinical purpose of Thyroid Cytopathology: A Text and Atlas remains the same as that stated by the late Dr. Miller in Thyroid: Guides to Clinical Aspiration Biopsy.*Deceased.*

â€"Max Wisgerhof

Shortly after World War II, articles appeared in the medical literature stating that the incidence of thyroid cancer in surgically removed thyroid nodules was 20% to 30%. These articles also suggested that these findings were representative of the entire nodular goiter population.1, 2 Opponents of this point of view cited the low incidence of thyroid cancer as a cause of death in autopsy material,3 and a controversy was born regarding the true risk of a thyroid nodule. By the 1950s, it was generally agreed that the morbidity and mortality of thyroid cancer did not justify removal of all thyroid nodules4; today the controversy focuses on the means of selection of patient nodules for surgical biopsyâ€"that is, the method of determining the risk of a given thyroid nodule.

During the 1960s and 1970s, it became evident to physicians in the United States that radionuclide or ultrasound images of the thyroid were successful in eliminating

consideration of thyroid surgery for no more than 10% to 20% of thyroid nodules. However, as early as 1950 in the Scandinavian countries, attention was focused on the use of a fine needle to aspirate a cytologic sample from thyroid nodules5 and thus determine the probable pathologic diagnosis. For 25 years, such reports evoked little interest in North America. The reasons for this are speculative and include dissatisfaction with the variably reported sensitivity of the European studies, failure of authors to provide direction for use of biopsy data in avoiding thyroid surgery, and the "certain knowledge" that cytology would not provide a diagnosis of a lesion, often requiring many histologic sections for identification. Overreaction to one reported case of subcutaneous tumor implant by needle biopsy6 was also a factor, as was the use of Giemsa stain by the Europeans, a cytologic stain not popular among American cytopathologists accustomed to Papanicolaou staining techniques.

By the late 1970s, the Canadians had reported experience with fine-needle biopsy,7 and groups in Cleveland and Boston had evaluated large-needle biopsy.6, 8 The first American study combining both was reported in 1979 by our group.9 Since that time, numerous reports have appeared in the English-language literature on the diagnosis of thyroid nodules by needle biopsy, mostly by the cytologic specimens obtained by fine-needle aspiration. In spite of limited but definite advantages to the combined use of large- and fine-needle biopsy in a biopsy program,10 the universal application, simplicity, safety, ease of performance, and patient acceptance of fine-needle biopsy account for its exclusive use in most reported studies.11

Our experience with over 4,500 satisfactory biopsies spans the 10 years from 1975 to 1985 and has provided us with over 1,100 correlations with surgical specimens. Our purpose has been twofold: (i) to provide diagnostic information for the management of our patients and those of our referring doctors, and (ii) to record our experience in obtaining and diagnosing thyroid needle biopsy specimens in such a way that others might profit from our trials and errors. This book is our third attempt to make available to our colleagues our total needle biopsy experience. Unlike the first two attempts,12, 13 we have limited this work to fine-needle biopsy. Its purpose is to assist the cytopathologist in the proper interpretation of cytologic samples from the thyroid gland. Therefore, most of the text is concerned with our experience in obtaining these samples by the fine needle and interpreting

them. If cytologic diagnosis was an exact science, and if there was a predictable correlation between a particular diagnosis and tumor behavior, this information would suffice. Such is not the case, and certain ancillary information is of value to the interpreter of thyroid cytopathology. This includes the gross and histologic anatomy of the lesion subjected to biopsy, the life history of benign and malignant

thyroid nodules, and the management of thyroid nodules with and without biopsy.

IMPORTANCE OF NEEDLE BIOPSY

The morbidity and mortality of thyroid cancer do not qualify it as an important public health problem. The number of noninvasive diagnostic tests and surgical lobectomies done to establish or exclude its presence, however, makes it a disease of economic importance. Living in a society concerned with containment of medical costs, we should carefully select the most cost-effective diagnostic tests. The experience of our group is that needle biopsy is far more accurate for the selection of patients with nodules for diagnostic lobectomy and is much cheaper than any combination of noninvasive tests. Its use has halved the number of operations prescribed and has doubled the number of cancers identified per 100 surgical removals.14 Cutting surgical and hospital bills for nodule management in half is a worthwhile achievement. Our figures also suggest that we are now identifying cancers that were initially diagnosed as benign nodules, or we are making the diagnosis of cancer at an earlier stage. Determining whether this too is advantageous, and will favorably influence the morbidity and mortality of thyroid cancer, will require many years of study.

In summary, most physicians agree that neither removing all thyroid nodules nor removing no thyroid nodules is a sensible management approach. Therefore, they employ some process of selection in prescribing surgical lobectomy. The most cost-effective method of selection is needle biopsy.

REFERENCES

1.Cerise EJ, Randall S, Ochsner A. Carcinoma of the thyroid and nontoxic nodular goiter. *Surgery*. 1952;31:552.

2.Cole WH, Majarakis JO, Slaughter OP. Incidence of carcinoma of the thyroid in nodular goiter. *J Clin Endocrinol*. 1949;9:1007.

3.Rogers WF, Asper SP, Williams RH. Clinical significance of malignant neoplasms of the thyroid gland. *N Engl J Med*. 1947;237:569.

4.Miller JM. Carcinoma and thyroid nodules. Problem in endemic goiter. *N Engl J Med*. 1955;252:247â€“251.

5.SÃ¶derstrÃ¶m N. Puncture of goiters for aspiration biopsy. A preliminary report. *Acta Med Scand*. 1952;144:235â€“244.

6.Crile G Jr, Hawk WA Jr. Aspiration biopsy of thyroid nodules. *Surg Gynecol Obstet*. 1973;136:241â€“245.

7.Crockford PM, Bain GO. Fine-needle aspiration biopsy of the thyroid. *Can Med Assoc J*. 1974;110:1029â€“1032.

8.Wang C, Vickery AL Jr, Maloof F. Needle biopsy of the thyroid. *Surg Gynecol Obstet*. 1976;143:365â€“368.

9.Miller JM, Hamburger JI, Kini SR. Diagnosis of thyroid nodules by fine needle aspiration and needle biopsy. *JAMA*. 1979;241: 481â€“486.

10.Miller JM, Hamburger JI, Kini SR. Fine needle aspiration cytology, cutting biopsy or both in the evaluation of thyroid nodules? In: Thompson NW, Vinik AI, eds. *Endocrine Surgery Update*. New York: Grune & Stratton; 1983:23.

11.Ashcraft MW, Van Herle AJ. Management of thyroid nodules II. Scanning techniques, thyroid suppression therapy and fine needle aspiration. *Head Neck Surg*. 1981;3:297.

12.Hamburger JI, Miller JM, Kini SR. Clinical-pathological evaluation of thyroid nodules. In: *Handbook & Atlas, Part I*. Southfield, MI: private publication; 1979;15.

13.Miller JM, Kini SR, Hamburger JI. *Needle Biopsy of Thyroid*. New York: Praeger; 1983.

14.Miller JM, Hamburger JI, Kini SR. The impact of needle biopsy on the preoperative diagnosis of thyroid nodules. *Henry Ford Hosp Med J*. 1980;28:145.

Editors: Kini, Sudha R.
Title: *Thyroid Cytopathology: A Text and Atlas, 1st Edition*

Copyright Â©2008 Lippincott Williams & Wilkins

2

Techniques of Fine-Needle Aspiration Biopsy

J. Martin MillerKINI

Max Wisgerhof

*It is axiomatic that a pathologist must have an adequate biopsy specimen to make a satisfactory interpretation. Obtaining an adequate cellular sample requires enough capillary blood or tissue fluid to serve as a vehicle, but not so much as to cause a problem by dilution. The sample must then be fixed and stained in such a way as to permit the most accurate interpretation possible. Obtaining an adequate cytologic sample from the thyroid is a simple procedure. However, the number of failures by physicians with little experience suggests that matters of technique, although simple, are indeed essential.*Deceased.*

Before beginning the discussion of technique, we acknowledge the prerequisite of experience in palpating thyroid nodules for the biopsy physician. Little experience is needed to palpate a nodule of 4 to 5 cm in its greatest dimension, but the 1-cm nodule on the posterior aspect of a lobe requires skillful palpation. Nodules felt by single-digit palpation with the patient erect can always be felt with the patient in the recumbent biopsy position. Most nodules felt by bidigital examination with the patient seated can at least be localized with the patient supine.

PREPARATION

Mental

Proper mental preparation is the first step in the performance of a thyroid biopsy. Most of the pain experienced by patients is minor discomfort magnified by anxiety.

The patient should be reassured as to the simplicity, painlessness, and brevity of the procedure. The prick of the anesthetic needle and the sting of the local anesthetic should be described immediately before they are felt by the patient. The patient should be asked to not swallow while the needle is in the nodule, and should be assured that this represents a small fraction of the total time involved in doing a biopsyâ€”that is, swallowing is minimally restricted. (Pain and even serious vascular injury may result if the patient swallows when the needle has passed through the nodule.) We find that anxiety is lessened by maintaining pleasant conversation with the patient during the procedure.

Physical

With a few exceptions (we have performed biopsies on a few patients while they were sitting), the patient assumes a supine position, with the head and neck extended over a pillow. The degree of extension should not produce skin tension that interferes with nodule palpation or partially obstructs vertebral artery blood flow in the elderly. The site of the needle puncture is cleaned by firm application of an alcohol swab. We attribute the total absence of infection in over 7,000 biopsy attempts to the adequacy of normal body defense mechanisms rather than to the excellence of our sterile technique.

ANESTHETIC: TO USE OR NOT TO USE?

If the operator can be certain that only one needle will be necessary, a local anesthetic is superfluous. This assumes no bloody aspirates, no degenerated nodules, no cystic lesions, and no grossly unsatisfactory specimens. It also assumes adequate sampling by multiple passes of the same needle, as recommended by some Swedish physicians.1, 2 We make none of these assumptions, so to limit patient discomfort to one needle, we

use lidocaine. There are two possible disadvantages to the use of an anesthetic. First, the patient may be allergic to lidocaine and may not be aware of it. We have had several patients with known allergies to lidocaine for whom we have used either mepivacaine (Carbocaine) or nothing, but we have not encountered a patient with a lidocaine allergy of which he or she was unaware. Second, the anesthetic may obscure the nodule. In such a situation, a little local massage will disperse the fluid.

Many physicians consider local anesthetic to be superfluous even when three or four needles are used. We agree that most patients can tolerate this discomfort, but why should they?

We use 1 to 2 mL of 1% lidocaine for the skin and subcutaneous tissues. Care is exercised not to infiltrate the nodule, which might cause a "lidocaine aspirate."

SYRINGE

A 10-mL syringe provides ample negative pressure for obtaining cytologic specimens.

NEEDLES

The larger the needle, the larger the tissue sample, and the greater the possibility of an unwanted volume of blood. We have found the 25-gauge, 1.5-inch needle to be suitable for the majority of nodules. With less vascular nodules, a 22- or even a 20-gauge needle gives better results. When we use a mechanical suction device, we prefer the greater rigidity of a 22-gauge needle.

NEEDLE PLACEMENT

The right-handed physician fixes right-sided nodules between the second and third digits of the left hand and inserts the needle with the right hand while standing behind the patient. For left-sided nodules, it is more comfortable to perform nodule immobilization while standing on the right side of the patient. For nodules 1.5 cm or smaller, simply inserting the needle into the nodule is a reasonable goal. With larger nodules, peripheral subcapsular parts of the nodule should be sampled rather than the center. The periphery is more apt to be predictive of histologic behavior. The center often is undergoing degenerative change.

SUCTION: HOW AND HOW MUCH

Suction is applied once, repetitively, or during maneuvers designed to further disrupt the follicular epithelium. The total procedure should be sufficient to make aspirate appear in the hub of the needle, but not in the barrel of the syringe. Aspirate within the syringe must be removed by a washing procedure followed by a concentrating one, both of which tend to distort cytologic features and add to the complexity and cost of the problem.

Many pioneers in needle biopsy consider a mechanical device for producing suction absolutely essential for this procedure (Fig. 2.1). Producing suction with this device and maintaining it requires only one hand, and allows the operator to continuously fix nodules with the left hand while suction is maintained with the right (Fig. 2.2). It also allows the maximum possible suction from a 10-mL syringe.

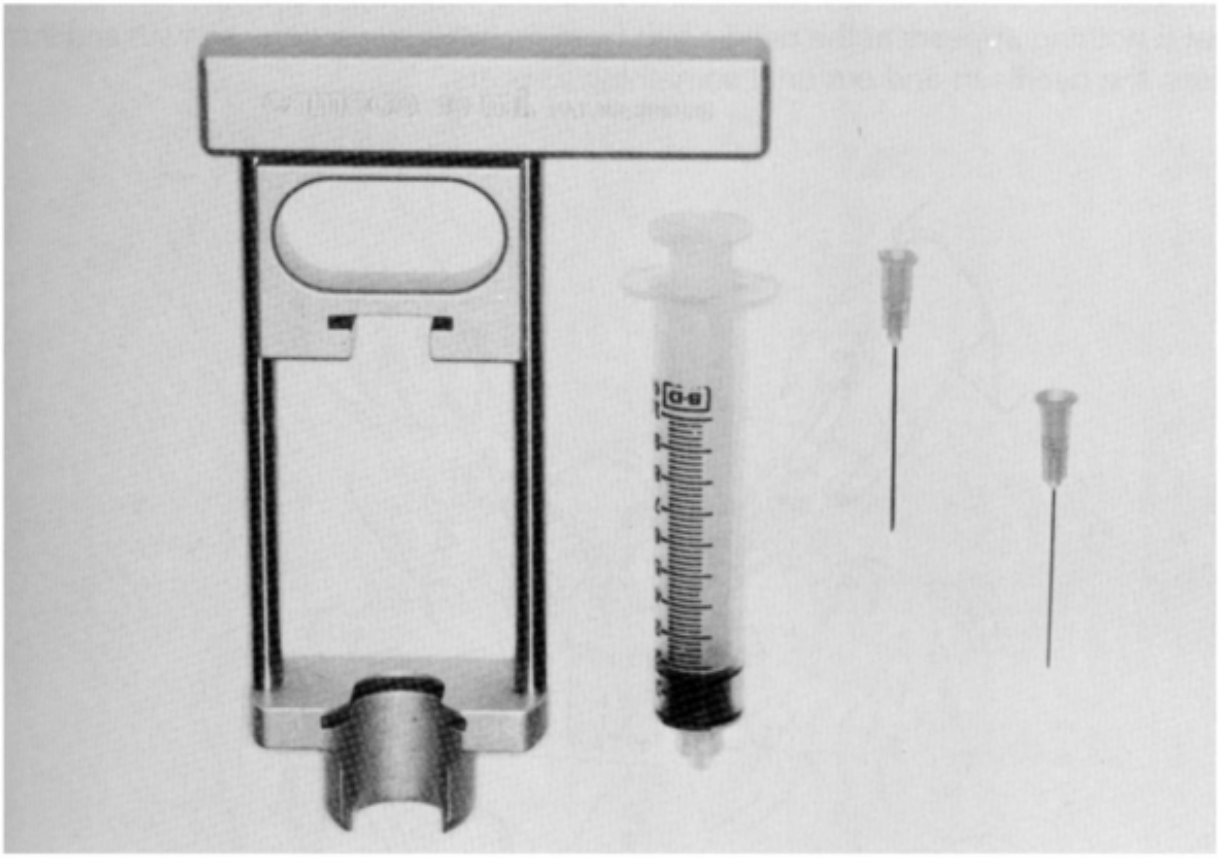

Figure 2.1. Mechanical syringe holder; 10-mL plastic BD syringe; 22-gauge, 1.5-inch needle; and 25-gauge, 1.5-inch needle.

Figure 2.2. Aspiration using the mechanical device to produce suction. Tissue disrupted by vertical movement.

We performed our first 3,000 satisfactory biopsies without recourse to, or even knowledge of the existence of, this mechanical device. We find it simple to maintain suction with one hand, with no mechanical assistance, once suction has been achieved and the needle is in the nodule (Fig. 2.3). This requires reestablishing fixation, which seems to be a disadvantage only in very small nodules. Among the disadvantages of the mechanical suction device are its one-time expense of approximately $150, the more

remote "touch" occasioned by the hand being a greater distance from the needle, and the fact that the needle cannot be twirled while suction is being applied (see "Tissue Disruption," below).

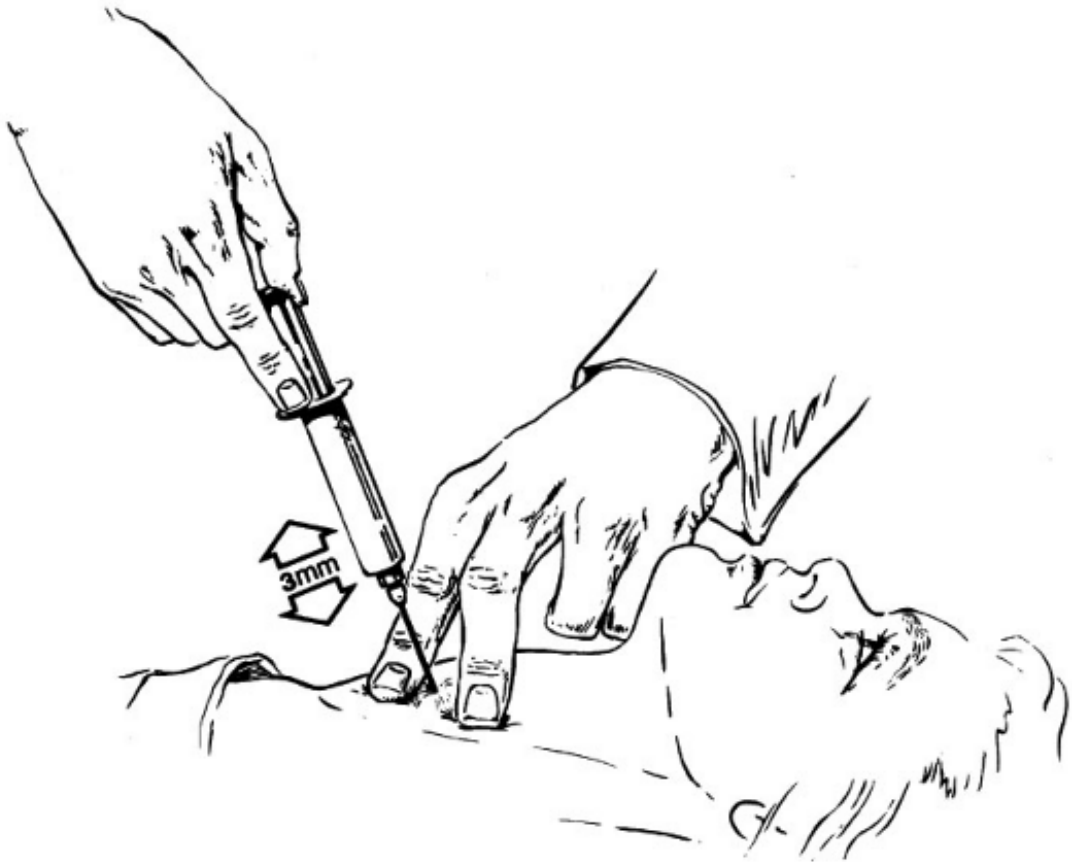

Figure 2.3. Same maneuver shown in Figure 2.2, but without a mechanical holder.

TISSUE DISRUPTION

Simple application of suction by pulling the plunger of the syringe back to 6 or 7 mL is often unsatisfactory. Results may be improved if a pumping action is used, and improved even more if the barrel of the syringe is rotated rapidly while the plunger is

held stationary as suction is maintained (Fig. 2.4). Moving the needle in and out (but with the tip in the nodule) has much the same effect (Fig. 2.2 and Fig. 2.3). The nodule must be fixed during this maneuver to prevent a small nodule from moving with the needle, thus eliminating the motion of the needle within the nodule.

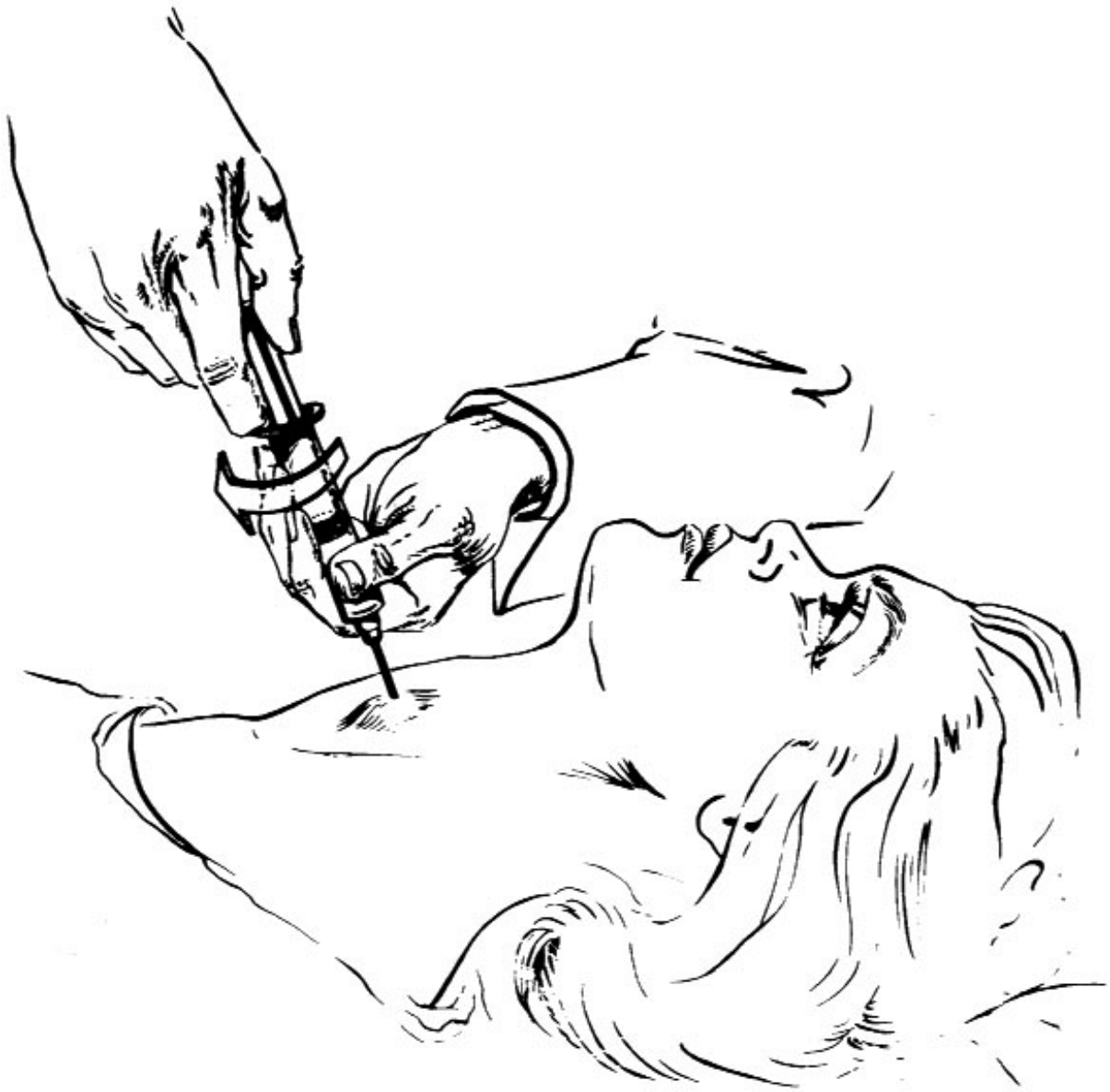

Figure 2.4. Rotation technique for fine-needle biopsy. Note that the index finger of the right hand maintains suction while the left hand rotates the barrel of the syringe.

The cutting action of any needle motion is improved by speed. It is our practice that if nothing appears in the needle hub from maintained suction, we twirl and then move the needle in and out until something appears.

ADDITIONAL TECHNIQUES

Two additional techniques, one major and one minor, can be added to those of the late Dr. Miller as described above.

The minor additional technique is that of performing the thyroid aspiration by inserting the needlesâ€”25, 22, or 20 gaugeâ€”for the six to eight smears, without a syringe attached to the needle. The tissue disruption is as with the syringe attached, although the hub of the needle, rather than the syringe, is held by the fingers to produce the vertical and rotational movements of the needle in the thyroid. The needle shaft and the needle hub fill by capillary action. The needle is withdrawn as the hub is nearly filled with the aspirate, which is then expelled through the needle and smeared as described below. This additional technique can lessen the amount of obscuring blood, aspirated by suction, and the aspirate is expelled from the hub more readily than when suction makes it adhere to the inner surface of the hub.

The major additional technique is the use of real-time thyroid ultrasound to identify the thyroid nodule to be aspirated, particularly the incidentally detected, nonpalpable nodule, and to guide the placement of the aspirating needle tip into the part of the tissue or nodule most likely to yield a cytologic diagnosis. (It might well be that many nodules thought not to be palpable targets for aspiration and identifiable only by ultrasound could have been palpated and aspirated by those with considerable experience in palpation of the thyroid. Also, it could be contended that palpable nodules are those that have important potential for morbidity and will more likely yield sufficient aspirate for cytologic diagnosis.) The technique of real-time ultrasound guidance of thyroid aspiration has two major differences from aspiration by palpation.

- The hand that fixed the nodule or tissue now holds and positions the ultrasound probe against the skin over the nodule or tissue. A small amount of sterile gel is applied to the probe and the skin to transmit the sound waves (care must be taken not to include gel in the aspirate). The other

hand guides the insertion of the needle alongside the probe, so that the course of the needle tip is within the sound wave.

- The person performing the aspiration looks at the real-time ultrasound image displayed on the screen to guide the course of the needle tip immediately after inserting the needle through the skin over the thyroid tissue or nodule. The vertical and rotational movements of the needle tip are as in palpation aspiration, and often can be visualized by the ultrasound image. The aspirate sample is visualized in the hub, whether or not a syringe is attached to the needle, as in palpation aspiration.

Proficiency and skill in ultrasound-guided thyroid aspiration is soon achieved if aspirations are performed with frequency, as in palpation aspiration. A discussion of thyroid ultrasound as a technique to distinguish benign from malignant thyroid lesions is beyond the scope and purpose of this book. It is generally concluded that the ultrasound characteristics of thyroid nodularity, including Doppler imaging, are not reliable to diagnose benign or malignant thyroid disease.

SMEARS

After suction, the needle is removed and the plunger is withdrawn a couple of milliliters. The needle is reaffixed, and the specimen is expressed onto the slide. This procedure is the same with or without the use of a mechanical suction device. At this point, an estimate is made as to whether the volume of the aspirate is suitable for smearing on the slide. If it is not excessive, it may be either smeared with the edge of another slide, as is usual with a blood smear (Fig. 2.5, method 1) or if particulate matter or colloid is visibly present, the material may be compressed between two slides and smeared (Fig. 2.5, method 2). If the volume of the specimen seems too great for the slide, tilt it and remove the blood that flows to the low side by using an absorbent tissue (Fig. 2.6). Smearing is then done as described above. Another recommended technique for concentrating cellular material is shown in Figure 2.5, method 3. The slide with the specimen may be tilted, frosted end down, to enlist the aid of gravity while the edge of the smearing slide is drawn up. After the blood has been separated, the smearing slide is flattened, and the smear is completed.

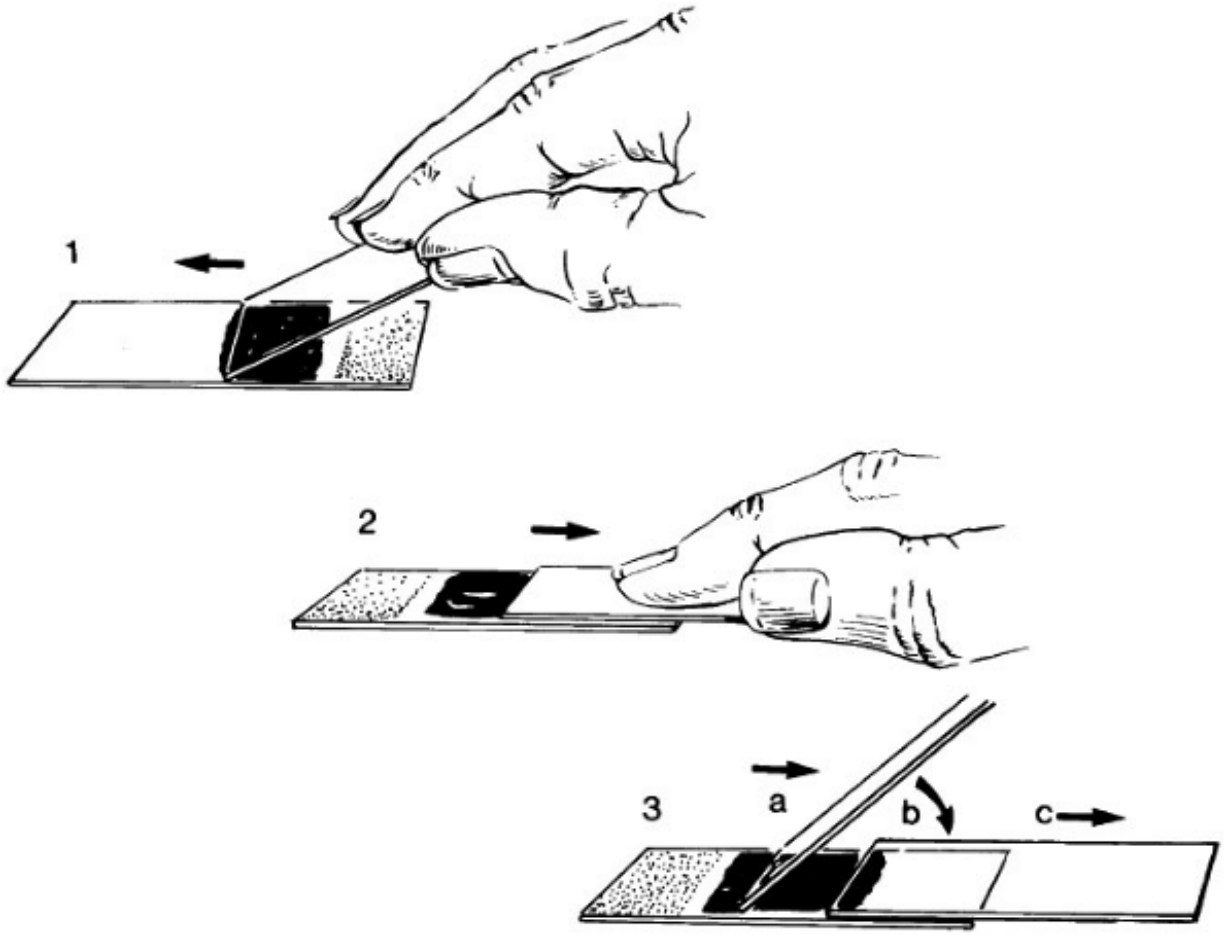

Figure 2.5. Three methods of smearing the fine-needle aspirate. See text for details.

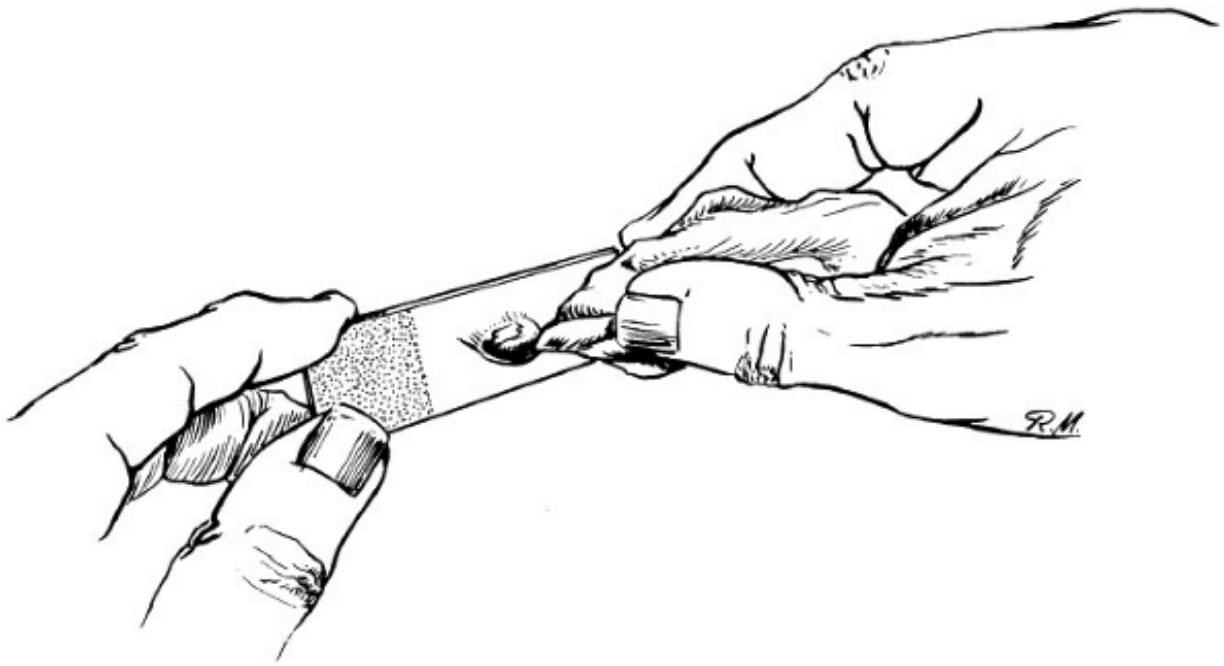

Figure 2.6. To remove excess blood or fluid, the slide is tilted and a tongue of absorbing tissue is touched to the dependent portion of the drop.

There have been elegant treatises on the exact hand and slide maneuvers necessary to produce the best smears.3 It is sometimes difficult to determine whether the experiences recounted are of those who perform biopsies only of the thyroid or those who perform biopsies of many types of more cellular tumors. As 70% of thyroid specimens will be from benign disease and will have minimal cell density, the procedures suggested for transferring material to two or more slides are probably unnecessary. Be that as it may, the simple instructions given here have served us very well with fairly extensive experience.

Number of Smears

If a smear looks unsatisfactory, it usually is. If it looks satisfactory, it may be so. We take six smears to ensure three good ones and adequate sampling.

FIXATION

Fixation must be matched to the staining technique employed. We use a modified Papanicolaou staining technique and therefore fix immediately with alcohol as part of a spray. If Mayâ€“GrÃ¼nwaldâ€“Giemsa stain is used, the smear is air dried and no prompt fixation is necessary.

POSTBIOPSY CARE

If there has been no intranodular bleeding, we apply an elastic bandage and keep the patient under surveillance for about 15 minutes. If there has been some bleeding into the nodule, we ask the patient to maintain pressure for about 30 minutes. In either instance, removal of the bandage after 1 hour is authorized.

REFERENCES

1.Willems JS, LÃ¶whagen T. Fine needle aspiration cytology in thyroid disease. In: Williams, ed. *Clinics in Endocrinology and Metabolism*. Vol 10. Philadelphia: Saunders; 1981:247â€“266.

2.LÃ¶whagen T, Willems JS, Lundell G, et al. Aspiration biopsy cytology in diagnosis of cancer. *World J Surg*. 1981;5:61â€“73.

3.Abele JS, Miller TR, King EB, et al. Smearing techniques for the concentration of particles from fine needle aspiration biopsy. *Diagn Cytopathol*. 1985;1:59â€“65.

Editors: Kini, Sudha R.
Title: *Thyroid Cytopathology: A Text and Atlas, 1st Edition*

Copyright Â©2008 Lippincott Williams & Wilkins

3

Cytopreparatory Techniques

The importance of optimal cytopreparatory technique and staining cannot be overemphasiz Inferior cytologic preparation will not allow adequate cytopathologic evaluation. Several methods exist for specimen collection, fixation, processing, and staining. The cytomorpholo varies according to the mode of fixation, type of fixative, and choice of staining technique. Because of familiarity, convenience, or personal preference, every cytopathology laborator its own guidelines for specimen collection, cytopreparation, and staining. Cytologic criteria applicable to one preparation may not always apply to other types of preparation. The diagnostic criteria for various thyroid lesions described in this chapter are based on cellular details seen in the preparations from the cytopathology laboratory at Henry Ford Hospital in Detroit, Michigan.1 The cytologic criteria used in differentiating certain thyroid neoplasms a very subtle and are dependent on the cellular details that are best demonstrated in smears with spray fixative and stained by the Papanicolaou method. The architecture of the tissue fragments, relationship of one cell to the other, cytoplasmic quality, cell borders, nuclear chromatin, and nucleoli can all be appreciated very well in spray-fixed smears. The pros anc cons of different methods of collection, fixation, and staining will be discussed.

SPECIMEN COLLECTION

Specimens obtained by an aspiration biopsy procedure can be submitted in the following wa

- Specimen (aspirate) expelled on the slides and smears prepared at the site (direct smears).
- Specimen collected in a preservative (e.g., Saccomanno fixative).2

- Rinsing of the needle in balanced salt solution after the direct smears have been ma
- Specimen collected in special collection medium for liquid-based cytology.
- Cyst fluid with or without fixative.

METHODS FOR SMEAR PREPARATION

There are several methods of preparing smears, whether directly from the aspirates or from centrifuged sediments (cell spreads) of specimens (e.g., specimens collected in liquid mediu such as needle rinsing or in Saccomanno fixative). The method or methods employed in any laboratory reflect the preference, choice of fixative and stain, convenience, comfort level, the results. Whichever method is chosen, the goal should be sameâ€"to obtain a monolayer well-fixed, well-stained, and well-visualized cells. Every laboratory should set its own stand This chapter describes only a few methods, as it is beyond the scope of this text to describe every available method.

Prior to cytopreparation, there are certain prerequisites that must be followed rigidly. Ever specimen container, every test tube in which any given specimen is processed, and every gl slide used to prepare the smear must be labeled properly with the patient's name, unique identifying number, and laboratory accession number. Cytopreparation must be performed u the biologic hood and by following universal precautions. If the smears are prepared in the clinic, the clinicians must be properly instructed as to the preferred way of making smears, fixation, and most importantly, to identify the slides appropriately by labeling with patient's name and unique identifying number.

The frequently used smear techniques for thyroid aspirates include:

- Peripheral blood smear technique (see Fig. 2.5 , method 1).
- Pull-apart method (see Fig. 2.5 , method 2).

We prefer and recommend using plain glass slides with frosted ends. In our experience, cellu distortion is seen on smears prepared using fully frosted slides.

Peripheral Blood Smear Technique

The peripheral blood smear technique is routinely used for making peripheral blood or bone

marrow smears. However, it has provided excellent results with thyroid aspirates. It is recommended that the specimen be fresh and in its normal state when the smears are made possible, the smears should be made before any balanced salt solution or preservative is add to the specimen. For reasons not very clear, cells from specimens to which a balanced salt solution has been added tend to explode during air-drying. The smears are made in such a w as to create a feathered edge where the nucleated cells migrate and produce the best exam of the monolayer.

Procedure

- Label the slide.
- Place a small drop of specimen on the glass slide a little distance away from the fros end.
- Place another glass slide on the specimen drop at a 45-degree angle. Let the specim spread along the edge.
- Smear the specimen on the labeled slide with a fast, single motion in the direction a from the frosted edge.
- Spray-fix for Papanicolaou stain or let air-dry for Romanowsky stain.

NOTE: Technique in creating a feathered edge is very important and requires practice.

Pull-Apart Method

The pull-apart method is used for preparing direct smears of a fine-needle aspirate or cell spreads of fine-needle aspirates collected in a liquid medium, centrifuged with visible sedin It results in a monolayer, provided that not too much of the specimen is placed on the slide

Procedure

- Place a drop of aspirate or the sediment on a labeled glass slide.
- Place another labeled glass slide face down on top.

- Allow the sediment to spread naturally.
- Pull the slides apart, either vertically or horizontally.
- Fix both the slides immediately. The canister of the spray fixative should be aimed a least 12 inches away from the slide surface so as not to dislodge the cells.
- Allow the slides to dry completely.

Pucker or bubble artifacts may occur when droplets of spray fixative impact the slide surfac pushing aside any cellular material. The "hills and valleys" thus created may leave thick area alternating with clear thin ones, the former being quite tedious to screen. Tilting the slide l and forth, spreading the material evenly, can prevent this problem.

The techniques for making smears vary in every laboratory. These are described in detail in literature.3 , 4 , 5

FIXATION AND FIXATIVES

The term "fixation" refers to a procedure whereby the cells to be examined are treated so a prevent autolysis (self-digestion) or degeneration by bacteria and fungi. Fixation is a means which the cells are permanently preserved and remain in the state they were at the time of fixation. The process results in cells that are stabilized, maintaining their shape and structu The fixation process prevents the loss of cell contents, makes available the reactive sites fo linking with coloring agents (staining), and renders the cell membrane permeable by the dy Smears may be air-dried if Romanowsky stains are used. This is the method of choice for hematologic malignancies and is popular among some pathologists for rapid assessment of specimen adequacy during fine-needle aspiration biopsy procedures.

Wet fixation is necessary for Papanicolaou stains or hematoxylin-eosin stains. The methods c wet fixation include:

- Spray fixative.
- 95% ethyl alcoholâ€"universally accepted as the best fixative for Papanicolaou stain.
- Isopropyl alcohol.
- Buffered formalin for hematoxylin-eosin stain.

- Specimen collected in Saccomanno fixative.

Spray Fixative

The author's lab highly recommends spray fixative for thyroid aspirates. Several spray fixati are commercially available. The smears must be immediately flooded with the spray fixative The spray can should be held at least 12 inches from the slide. The slightest delay in fixing result in air-drying of the cells, which will stain poorly with the Papanicolaou method. Once sprayed, the fixative on the slide must be completely dried (do not enclose the wet slides ir cardboard folder, as cellular material will adhere to the cardboard folder and be lost foreve is subsequently removed by soaking the slides in 95% ethyl alcohol before staining. There ar several advantages to spray fixatives. They are inexpensive, less messy than other fixatives, easy to store. Cellular details are well preserved and are easy to interpret, and the red bloc cells in the background are not hemolyzed. The intact red blood cells serve as a guide in juc the follicular nuclear size. The cytoplasm and the cell borders are preserved and nuclear chromatin and nucleoli are beautifully displayed. *There are no disadvantages to using spr fixatives.*

95% Ethyl Alcohol

The universally accepted, ideal fixative for Papanicolaou stain is 95% ethyl alcohol. Also, 80 isopropyl alcohol is sometimes used as a fixative. These fixatives have the following disadvantages:

- The water content of 95% ethyl alcohol or the isopropyl alcohol causes lysis of the re blood cellsâ€”that is, it is cytolyticâ€”and it also destroys the cytoplasm of epithelia cells. The relationship of one cell to the other is often lost. Aspiration biopsy specim are often bloody. The precipitate after hemolysis of red blood cells interferes with t staining quality, producing eosinophilia.
- The nuclei are also affected to some extent; they shrink, the chromatin stains darkl compact, and the nucleoli are not often visualized.
- The thyroid aspirates generally do not adhere to the slides. There seems to be a "fal of cellular material when smears are dropped in the fixative. Precoating the slides w egg albumin to prevent falloff will impart diffuse eosinophilia to the slide and the ce

- A ribbing effect is seen if the smears are not dropped swiftly into the alcohol contai
- Alcohol is flammable.

Saccomanno Fixative

Saccomanno fixative (2% Carbowax or polyethylene glycol, in 50% ethyl alcohol) has been recommended by some2 as an ideal method of collecting aspirates. The specimen can be collected at any site away from the cytopathology laboratory. There is no fear of cell deterioration or air-drying, and there is no need for others to make thin cell spreads. A cell block can also be prepared if necessary. Saccomanno fixative has following disadvantages:

- A longer period of time is needed for cytopreparation.
- Lysis of red cells will precipitate in the background and cause nuclear shrinkage.

Rinsing of the needle in balanced salt solution is used as an adjunct after the smears are ma
Table 3.1 lists the advantages and disadvantages of fixation by air-drying and wet fixation.

Dependence on smearing
technique
Strong
Moderate
Moderate
Dependence on fixation
None
Strong; immediate wet fixation
is critical
Strong; immediate wet fixation
is critical
Cell loss during fixation
None
None with spray fixative; cell
loss may be considerable with

95% ethyl alcohol

If smears are air-dried first and then hydrated, cell loss may be minimal; loss varies with liquid fixative

Need for fixative to be removed

Not applicable

Yes if spray-fixed or if smears are prepared from prefixed specimen

No

Length of time required for staining

Up to 2 minutes

Longer time required for the routine staining technique; up to 2 minutes with rapid staining technique

Up to 2 minutes

Coverslipping

Not required

Required

Required

Architecture of the tissue fragments

Visualized if the smear is thin; poor details with thick tissue fragments

Well-visualized

Well-visualized

Cell and nuclear size

Flattened, appear larger

Comparable to that seen in

tissues; smaller than seen in air-dried smears

Comparable to that seen in tissues; smaller than seen in air-dried smears

Nuclear morphology

Not crisp, chromatin structure not comparable to Papanicolaou-stained cells; micronucleoli difficult to appreciate

Crisp; excellent nuclear details as to chromatin structure, nuclear membrane, and nucleoli

Crisp; excellent nuclear details as to chromatin structure, nuclear membrane, and nucleoli

Cytoplasmic details

Variable; squamous differentiation and keratinization cannot be appreciated; oncocytic cells resemble histiocytes and sometimes difficult to identify

Cytoplasm clearly visualized, squamous differentiation and keratinization well demonstrated; oncocytic cells readily identified

Cytoplasm clearly visualized, squamous differentiation and keratinization well demonstrated; oncocytic cells readily identified

Psammoma bodies
Not well-visualized
Well-visualized; presents variable morphology with multiple colors
Well-visualized; basophilic concentric lamellated structure
Colloid
Stains lavender to magenta (metachromatic stain)
Cyanophilic to eosinophilic; orange when mixed with blood
Eosinophilic
Use in hematologic malignancies and lymphoproliferative disorders
Ideal stain
Not as specific as Romanowsky stain
Usefulness in differentiating follicular or HÃ¼rthle cell lesions
Limited
Very useful
Very useful
Application for immunostains
Useful for certain lymphoid markers
Stained smears can be selected for cellularity and processed for immunostains
Not known

[a] Wet fixation can be achieved with 95% ethyl alcohol, spray fixative, specimen collected in Saccomanno fixative.
[b] Wet fixation for hematoxylin-eosin can be achieved with absolute or 95% ethyl alcohol, or smears can be air-dried and then rehydrated for Papanicolaou stain.

Fixation by Air-Drying Romanowsky-Type Stain	Wet Fixation[a] Papanicolaou Stain	Wet Fixation[b] Hematoxylin-Eosin Stair

TABLE 3.1 Comparison of Air-Dried Smears with Romanowsky-Type Stain, Wet-Fixed Smears with Papanicolaou Stain and Hematoxylin-Eosin Stain

Air-Dried Rehydration

Air-dried rehydration is a very useful method for utilizing air-dried smears for Papanicolaou staining following rehydration.6

Procedure

- Immerse the air-dried smears in balanced salt solution or preservative for 30 second
- Place in a jar of 95% ethyl alcohol for 30 seconds.
- Stain by the Papanicolaou method.

LIQUID-BASED CYTOPREPARATION

Liquid-based cytopreparation is a newer cytopreparatory technique being utilized in several laboratories. The author's laboratory has not adopted the liquid-based cytology for thyroid aspirates. It is described in detail in Chapter 22 .

Procedure for Cyst Fluids

The gross quality of the cyst fluid determines the method for cytopreparation.

- If the specimen is clear, centrifuge it at 2,500 rpm for 10 minutes. If the sediment is visible, make a wet-film preparation (see below). If the specimen is poorly cellular, cytospin preparation is preferred.
- If the specimen or sediment is grossly bloody, the saponin technique may be used to hemolyze red cells.

Toluidine Blue Wet-Film Preparation

The wet-film preparation of sediment from the centrifuged specimen allows rapid assessmen its cellularity, as well as its cell type, that is, benign or malignant.7 This examination guides cytotechnologists to follow a suitable method for processing the specimens and helps preven cross-contamination. The method consists of the following steps:

- Place a drop of centrifuged sediment on the slide.
- Place one drop of toluidine blue solution on the slide and mix.
- Coverslip and examine.

SAPONIN TECHNIQUE FOR REMOVING BLOOD FROM THE SPECIMEN

Saponin is an enzyme that lyses red blood cells. A saponin solution is extremely useful in processing grossly bloody specimens.1 , 8 , 9 Caution must be exercised to avoid using exces saponin, which may destroy the cellular component of the specimen. When saponin techniq controlled, it selectively lyses red blood cells. The technique used consists of the following steps:

- Resuspend the sediment in 30 mL of balanced salt solution.
- Add 5 drops of saponin solution and agitate gently for 1 minute.
- Add 15 drops of calcium gluconate solution to stop the action of saponin enzyme anc well.
- Centrifuge for 10 minutes at 2,500 rpm.

- If no sediment is visible, prepare by the membrane-filter technique.
- If the sediment is visible and clear of blood, prepare direct smears, spray fix, and st
  If the sediment is still very bloody, repeat the above procedure.

Saponin technique should not be used more than twice, as it may lyse the cells of diagnostic importance. Any leftover sediment is further processed for a cell block (see below).

CYTOCENTRIFUGATION AND CYTOSPIN PREPARATION

Cytospin preparation is the method of choice for harvesting poorly cellular samples. Cytocentrifugation allows the concentration of cells on a glass slide by way of collecting the over a filter placed on the "well" etched on a special glass slide manufactured for the proce It produces a monolayer of cells within a clearly defined area. The specimen should be non mucoid or else it will clog the filter. The addition of Saccomanno fixative to the specimen w Papanicolaou stain is used will prevent air-drying. The procedure recommended by the manufacturer should be closely followed

CELL BLOCK TECHNIQUE

Cell block refers to the examination of sediment, blood clots, or grossly visible flecks of tiss from cytologic specimens that are processed by paraffin embedding and staining by hemato and eosin. Small tissue flecks must be wrapped in tissue paper and then placed in the casset Sediments can be embedded in either Histogel or agar.

Histogel Prepared Cell Blocks

Histogel is solid at room temperature. It must be liquefied before use by heating to 60Â°C Â 5Â°C by placing Histogel in a water bath to about 60Â°C.

Procedure

This method is suitable for sediments or smaller tissue fragments.

- Place 2 to 3 drops of Histogel onto the bottom part of a labeled Petri dish.
- Place sediment or tissue particles inside the Histogel button. Alternately, place 2 to drops of Histogel over the specimen.

- Cover the Petri dish and refrigerate for 10 minutes for hardening.
- Once the button hardens, trim off the excess Histogel.
- Place the button in a cell block bag, to be transferred to a cassette.
- Keep the cassette in formalin until ready for tissue processing.

Agar Method for Cell Block

The agar method for a cell block consists of the following steps:

- Agitate the tube containing the sediment remaining after smears have been prepare
- Add 4 mL of 6% melted agar to the sediment and mix well.
- Centrifuge for 10 minutes at 2,500 rpm to make a cell button.

- Refrigerate the tube until the agar is completely solidified (approximately 30 minute
- Gently pry the agar clot from the tube. Slice the visible material into thin sections a process for paraffin embedding.

The author's laboratory does not routinely prepare cell blocks from thyroid aspirates. In our experience, the cell block does not provide any additional information. However, they are prepared from cyst aspirates if the sediment is visible and adequate for embedding. Several laboratories do routinely prepare the cell blocks.

STAINING

Of the various stains in use, Papanicolaou is the most popular stain utilized in the practice c cytopathology. Romanowsky-type stains are ideal for hematologic disorders. It is also popula used in rapid assessment of adequacy of fine-needle aspiration biopsies.10 Hematoxylin and eosin stains are utilized for cell blocks, but can also be used for the smears. In addition to t three routine stains, a host of special stains is available for specific purposes. Most are performed in histology laboratories. Hence, only the Papanicolaou, hematoxylin-eosin, and Romanowsky-type staining procedures will be described here.

Papanicolaou Stain

Papanicolaou stain is a polychrome stain containing multiple dyes to differentially stain the various components of the cells. The smear must be wet fixed swiftly and rapidly. The sligh air-drying will result in poor staining, rendering the smears unsatisfactory for cytologic evaluation. The main components of Papanicolaou stain include a basic dyeâ€"hematoxylin, which stains the nucleus; and three acid dyesâ€"light green, eosin, and orange G, which sta the cytoplasm. With the Papanicolaou stain, the nucleus stains deep blue, nuclear details ar sharp, the nucleolus stains red, and the cytoplasm stains eosinophilic, cyanophilic, or orang Keratin stains deep orange.

Romanowsky-Type Stain

Romanowsky-type stain is a combination of an acid dye and a basic dye in the same solution The colored cation and anion may combine, forming a colored salt referred to as a neutral s The latter can react with certain cell components. In addition, the acid component and the basic component of the neutral salt can react with other cell elements. Thus all threeâ€"th neutral salt, cation, and anionâ€"can color different components of the cell. Because of thi threefold action, a neutral stain can produce a very useful differentiation of cell componen one staining solution. The two components of the stain include methylene blue (basic dye) a eosin Y (acid dye). The combination of these two dyes result in staining the nucleus purple, the nucleolus and cytoplasm blue. Any stain that contains a combination of these two dyes i called Romanowsky-type stain, and the results are referred to as Romanowsky effect. There several modifications of Romanowsky stain. Romanowsky-type stains are also useful for evaluating the background substances that stain metachromaticallyâ€"mucin, colloid, and chondroid tissue basement membrane-like material, all of which stain bright magenta pink.

Romanowsky-type stain is used for rapid assessment of adequacy of the fine-needle aspirate is a preferred stain for hematologic malignancies. Some examples of Romanowsky stains inc May-Grunwald-Geimsa, Leishman, Diff-Quik, Heme-3, and Wright.

Hematoxylin and Eosin Stain

Hematoxylin and eosin is traditionally used for staining tissues processed by formalin fixatio and paraffin embedding, sections cut at 5 Âµm. Rapid hematoxylin and eosin stain used for frozen sections is also applicable to cytologic specimens for on-site adequacy assessment. Hematoxylin and eosin stain is used routinely in some laboratories.11 This stain provides

excellent nuclear details (please refer to Figs. 8.14 , 8.20 , 11.27 , and 11.31B).

STAINING PROCEDURES

Papanicolaou Staining Procedure (As Used in the Henry Fo Hospital Cytopathology Laboratory)

1. 95% ethyl alcohol (to soak off the Carbowax from the spray fixative)

15 minutes

2. Deionized water

10 dips

3. Gill II hematoxylin

45 seconds

4. Deionized water

3 changes/10 dips each

5. Scott's water

1 minute

6. Deionized water

3 changes/10 dips each

7. 95% ethyl alcohol

10 dips

8. OG-6

3 minutes

9. 95% ethyl alcohol

10 dips

10. 95% ethyl alcohol

10 dips

11. EA-65

3 minutes

12. 95% ethyl alcohol

10 dips

13. 95% ethyl alcohol

10 dips

14. Absolute alcohol

10 dips
15. Absolute alcohol
10 dips
16. Absolute alcohol
10 dips
17. Xylene
1 minute

Reagent	Time or Dips

It is absolutely essential to stain one or two test smears and check the staining quality befor staining the entire batch of prepared smears from specimens received in the laboratory. Th timing of each step must be recorded in a daily log as a quality control measure. This proces must be followed every single day.

Staining Procedure for Rapid Papanicolaou Stain (As Used the Henry Ford Hospital Cytopathology Laboratory)

Rapid Papanicolaou stain is used for on-site assessment of the aspirates.

1. Rinse in deionized water

10 dips

2. Gill's hematoxylin

10 seconds

3. Rinse in deionized water

10 dips

4. Scott's tap water

10 seconds

5. Rinse in deionized water

10 dips

6. 95% ethanol

10 dips

7. Cytostain

15 seconds

8. 95% ethanol

10 dips

9. 100% ethanol

10 dips

10. 100% ethanol

10 dips

11. Dip in xylene until slide is clear

12. Coverslip

Hematoxylin and Eosin Stain, Method 1, for FNA Smears (A Used in the Henry Ford Hospital Histopathology Laborator

This stain is used for frozen sections. It is also suited for FNA smears or scrape preparations rapid assessment.

- Fix the smear by swiftly immersing in absolute alcohol and remove it.
- Hematoxylin 1 minute.
- Rinse in water thoroughly.
- Blue in lithium carbonate 5 times.
- Rinse and wash thoroughly.
- Stain with eosin for 20 seconds, agitating.
- Dehydrate in absolute alcohol for 30 seconds.
- Dehydrate in absolute alcohol for 30 seconds.
- Dehydrate in absolute alcohol for 1 minute.
- Clear with xylene for 30 seconds.
- Clear with xylene for 30 seconds.
- Clear with xylene for 1 minute.

- Coverslip.

Hematoxylin and Eosin Stain, Method 2, for FNA Smears

The prepared smears of the aspirate are air-dried. Rehydrate the smears first in normal salii for 1 minute.

1
Fixative (Pen-Fix)
1 minute
2
Tap water
Rinse
3
Tap water
Rinse
4
Hematoxylin III
30 seconds
5
Tap water
Rinse
6
Tap water
Rinse
7
Clarifier
5 seconds
8
Tap water
Rinse
9
Bluing reagent
10 seconds
10

Tap water
Rinse
11
Tap water
Rinse
12
Eosin Y
15 seconds
13
Absolute ethyl alcohol
10 dips
14
Absolute ethyl alcohol
10 dips
15
Absolute ethyl alcohol
10 dips
16
Xylene
10 dips
17
Xylene
10 dips
18
Xylene
10 dips
Coverslip
*Courtesy of Mithra Baliga, MD, University of Mississippi, Jackson.

Step	Solution	Time/Dips*

Diff-Quik Stain

Reagents

Diff-Quik (American Scientific Products) staining kit includes:

- Fixative: trimethane dye and methyl alcohol.
- Solution I: xanthene dye.
- Solution II: buffered solution of thiazine dyes.
- Distilled water.

Procedure

- Dip air-dried smears in fixative 5 times, 1 second each time; allow excess to drain.
- Dip smears 5 times in solution I, 1 second each time; allow excess to drain.
- Dip smears 5 times in solution II, 1 second each time; allow excess to drain.
- Rinse the smears in distilled water.
- Check the quality of the stain before coverslipping. If necessary, restain in Solutions and II for one or two seconds.
- Allow the slides to dry.
- Coverslip.

Heme-3 Stain

Reagents

- Heme-3 fixative
- Heme-3 solution I
- Heme-3 solution II
- Distilled water

Procedure

- Dip air-dried smears in fixative 5 times, 1 second each time; allow excess to drain.
- Dip smears 5 times in solution I, 1 second each time; allow excess to drain.
- Dip smears 5 times in solution II, 1 second each time; allow excess to drain.
- Rinse the smears in distilled water.
- Check the quality of the stain before coverslipping. If necessary, restain in solutions and II for 1 or 2 seconds.
- Allow the slides to dry.
- Coverslip.

SUBMITTING THE SLIDES FOR IMMUNOSTAINS

Immunostains can be performed on smears prepared from cytologic samples. The smears ma submitted as unstained and wet-fixed, Papanicolaou stained, or destained already stained b Papanicolaou method. Study has shown that destaining is not necessary and may even lower sensitivity of the immunostaining procedure.12 , 13 A Papanicolaou-stained smear can be directly processed without destaining, and with good results. The advantage of using a prestained slide is that the slide may be selected based on cellular material or number of diagnostic cells. Although an unstained wet-fixed smear is considered slightly better than th stained one, it is not known whether the given slide will have the cells in question.

A smear tested nonreactive to a particular antibody may be reprocessed to check another antibody, especially when the cellular material is of limited amount. While choosing a smea immunostains, it is prudent to avoid one with excess blood, as it will result in background staining, leading to nondiagnostic results. For surface immunoglobulins, air-dried smears are preferred.

The laboratory must keep positive and negative controls by preparing wet-fixed scrape smea known lesions. The controls normally used are tissues that are fixed in formalin and may not ideally suited as controls for cytologic samples.

Cell blocks are preferred for immunostains, because multiple sections can be made availabl
a large battery of stains.

APPENDIX*

FIXATIVES

Fix-Rite 2 (Spray Fixative)

Richard Allan Scientific
Kalamazoo, MI
(800) 522-7270
www.rallansci.com
Reorder # 76150
12 per case/4 oz (120 mL) each

Surgipath Cytology Fixative Nonaerosol

Surgipath Medical Industries, Inc.
5205 Route 12
P.O. Box 528
Richmond, IL 60071
800-225-3025
www.surgipath.com
Item # 01800
12 per case/4oz (188 mL) each

Saccomanno Fixative

Saccomanno fluid
Fisher Scientific
Kalamazoo, MI
1-800-522-7270

Cat # 751-054
1 gallon

Pen-Fix (for Hematoxylin and Eosin Stain)

Richard Allan Scientific
Kalamazoo, MI
1-800-522-7270
www.rallansci.com
Cat # 6101
1 gallon

SUBMITTING THE SPECIMEN FOR ELECTRON MICROSCOPY

Ultrastructural evaluation of the cytologic specimen is occasionally necessary. The sampling such as small flecks of tissue or sediment, can be collected in glutaraldehyde prior to proces

SUBMITTING THE SPECIMEN FOR FLOW CYTOMETRY

The specimen should be fresh and unfixed. An ideal transport medium is a balanced salt solution.

HENRY FORD HOSPITAL CYTOPATHOLOGY NONALCOHOLIC PRESERVATIVE

This is a liquid medium for transporting the specimen and is meant for short-term preservat The solution contains several nutrients and broad-spectrum antibiotics. It is recommended t the preservative be frozen in aliquots and thawed as needed.

Stock Solution

Balanced salt solution
400 mL
Fetal bovine serum
200 mL
Heparin
4,000 international units

Broad-spectrum antibiotics
(e.g., penicillin)
20,000 units

Method

Using aseptic techniques, reconstitute the antibiotics by injecting enough sterile water into vial of antibiotic. Shake vigorously until the powder is dissolved. Mix all the ingredients in a 1,000-mL sterile container. Divide in equal quantities in 50-mL tubes and freeze. Label all tl tubes with preparation and expiration dates (6 months).

Preparation of Working Preservative Solution from Stock Solution

Inject 100 mL of thawed stock solution into a 1-L bag of balanced salt solution. Label the ba with preparation and expiration dates (1 week). Keep the solution refrigerated.

REAGENTS FOR SAPONIN TECHNIQUE

Saponin Solution

Deionized water
100 mL
Saponin
1.0 g
P-hydroxybenzoic acid
sodium salt
0.2 g

Mix thoroughly. Filter twice through 5.0-millipore filter.

Saponin

- Acros
- 500 American Road
- Morris Plains
- New Jersey 07950
- USA
- 1-800-ACROS-01
- Cat # 41923-1000 100 g

P-Hydroxybenzoic Acid Sodium Salt

- Pfaltz and Bauer, Inc.
- 172 East Aurora Street
- Waterbury, CT 06708
- Cat # 09910

CAUTION: Fungi grow rapidly in Saponin solution. The solution must be filtered every morni

Calcium Gluconate

Deionized water
100 mL
Calcium gluconate powder
3.0 g
P-hydroxybenzoic acid sodium salt
0.2 g

Mix thoroughly. Filter twice through 5.0-millipore filter.

Calcium Gluconate Anhydrous Powder

- Mallinckrodt Baker, Inc.
- Phillipsburg, NJ 08865
- 1-908-859-2151
- www.jtbaker.com
- Cat # 1272-01 500 g

REAGENTS FOR WET-FILM TECHNIQUE

Toluidine Blue Supravital Stain

Toluidine blue
0.5 g
95% ethyl alcohol
20.0 mL
Deionized water
80.0 mL

Dissolve toluidine blue in ethyl alcohol. Add water and store in a dark bottle. Refrigerate wł not being used.

Toluidine Blue O

- Fisher Scientific
- Fairlawn, NJ 07410
- 1-201-796-7100
- Cat # 52040

PREPARATION OF SCOTT'S TAP WATER

Scott's tap water is used as a bluing agent for Gill's hematoxylin during the Papanicolaou sta

process.

Procedure

- Carefully weigh out the required amount of magnesium sulphate and sodium bicarbo and add them to the container.
- Add the appropriate quantity of deionized water and shake vigorously.
- Label the container with date and contents.

Reagents

Hydrous magnesium sulphate
20 g
Sodium bicarbonate
2 g
Deionized water
1,000 mL

OR

Anhydrous magnesium sulphate
10 g
Sodium bicarbonate
2 g
Deionized water
1,000 mL

Sodium Bicarbonate

- Fischer Scientific

- Fairlawn, NJ 07410
- 1-201-796-7100
- Cat # S233-500 500 g

Magnesium Sulfate Heptahydrate

- Fischer Scientific
- Fairlawn, NJ 07410
- 1-201-796-7000
- www. fischersci.com
- Cat # M63-500 500 g

STAINS

Papanicolaou Stain

Gill 2 Hematoxylin

- Richard Allan Scientific
- Kalamazoo, MI
- 1-800-522-7270
- www.rallansci.com
- Reorder # 72511
- 1 gallon/3.8 L

Pap Stain EA 65

- Richard Allan Scientific

- Kalamazoo, MI
- 1-800-522-7270
- www.rallansci.com
- Reorder # 75611
- 1 gallon/3.8 L

Pap Stain OG-6

- Richard Allan Scientific
- Kalamazoo, MI
- 1-800-522-7270
- www.rallansci.com
- Reorder # 75211
- 1 gallon/3.8 L

Cyto- Stain

- Richard Allan Scientific
- Kalamazoo, MI
- 1-800-522-7270
- www.rallansci.com
- Reorder # 7501R
- 1 gallon/3.8 L

Diff-Quik Stain

- Dade Behring Inc.
- 1717 Deerfield Road
- Deerfield, IL
- 1-847-267-5300
- www.dadebehring.com

Protocol Heme-3 Stain Set

- Fisher Diagnostics
- Fisher Scientific
- 8365 Valley Pike
- Middle Town, VA 22645-0307
- 1-800-524-0294

Hematoxylin Eosin Stain (Used for Frozen Sections at Henr Ford Hospital)

Harris' Hematoxylin

Anatech; cat # 842

Stock 1% Alcoholic Eosin

- Eosin-Y, water soluble (C.I. 4538) dissolved in 20 mL distilled water
- Add 80 mL 95% ethyl alcohol

Working Eosin Solution

Stock 1% alcoholic eosin
100 mL

80% ethenol
300 mL
Glacial acetic acid
2 mL

1% Acid Alcohol

Absolute ethyl alcohol
2,079 mL
Distilled water
891 mL
Concentrated hydrochloric acid
30 mL

Saturated Lithium Carbonate

Lithium carbonate
1 g
Distilled water
100 mL

Hematoxylin Eosin Stain 2 (Used for Air-Dried FNA Smears)

Gill III Hematoxylin

- Richard-Allen Scientific
- 4481 Campus Drive
- Kalamazoo, MI 49008
- 1-800-522-7270

- Cat # 72604 (one gallon)

Eosin-Y

- Richard-Allen Scientific
- Cat # 7111 (one pint)

Bluing Agent

- Richard-Allen Scientific
- Cat # 7301 (one gallon)

Clarifier 2

- Richard-Allen Scientific
- Cat # 7402 (one gallon)

Histogel

- Richard-Allen Scientific
- 4481 Campus Drive
- Kalamazoo, MI 49008
- 1-800-522-7270
- www.rallansci.com
- Reorder # HG-4000-012
- Cat # 904012
- 12 vials/10 mL each

HistoPrep Xylene

- Fischer Scientific
- Pittsburgh, PA 15275
- 1-201-796-7100
- Cat # HC700
- 1 gallon

Agar

- Nutrient Agar (Difco)
- Fisher Scientific
- 4500 Turnberry Drive, Ste A
- Hanover Parks, IL 60133
- 1-800-640-0640
- www.fishersci.com
- Cat No DF0001-17-0-(500 MG)

*The reagents listed in this appendix are those currently being used in the Cytopathology Laboratory at the Henry Ford Hospital, Detroit. This is not an endorsement for any particula product.

REFERENCES

1.Henry Ford Hospital. *Cytopathology Laboratory Manual* . Detroit: Henry Ford Hospital; 2006.

2.Jennings AS, Atkinson BF. Thyroid needle aspiration: collection and handling the specim

N Eng J Med . 1983;308:1602â€“1603.

3.Geisinger KR, Stanley MV, Raab SS, et al. Fine-needle aspiration: equipment, basic and clinical techniques, and results reporting. In: *Modern Cytopathology* . Philadelphia: Churchill-Livingstone; 2004;9â€“34.

4.Powers CN. Frable WJ. *Fine needle aspiration biopsy of the head and neck* . Boston: Butterworth-Heinemann; 1996.

5.Able JS, Miller TR, Lowhagen T. Smearing techniques for the concentration of particles from fine needle aspiration biopsy. *Diagn Cytopathol* . 1985:1:59â€“65.

6.Yang GC, Alvarez H. Ultrafast Papanicolaou stain: an alternative preparation for fine-needle aspiration cytology. *Acta Cytol* . 1995;39:55â€“60.

7.Naylor B, Toivonem T. The use of toluidine blue-stained wet films in diagnostic cytology *Cytopathol Ann* . 1993;279â€“287.

8.Gill G. Personal communication.

9.Coughlin D, Lukeman JM. The use of saponin for hemolysis in effusion cytology. *Acta Cyt* . 1982;26:739.

10.Boon ME, Drijver JS. *RoutineCytologic Staining Techniques: Theoretical Background Practice* . London: MacMillan Education; 1986.

11.Baliga M. Personal communication.

12.Abendroth CS, Dabbs DJ. Immunocytochemical staining of unstained versus previously stained cytologic preparations. *Acta Cytol* . 1995;39:379â€“386.

13.Dabbs DJ, Wang X. Immunocytochemistry on cytologic specimens of limited quantity. *Diagn Cytopathol* . 1998;18:166â€“169.

Editors: Kini, Sudha R.
Title: *Thyroid Cytopathology: A Text and Atlas, 1st Edition*

Copyright Â©2008 Lippincott Williams & Wilkins

4

Specimen Adequacy and Assessment, Reporting System

The ultimate result of an aspiration biopsy procedure should be smear(s) prepared and stain such a way as to enable a cytopathologist to give an accurate and meaningful cytopathologi evaluation, one that is in the best interest of the patient. The specimen must be adequate i terms of cellularity and the smear must be satisfactory in terms of qualityâ€"that is, thickne fixation, and staining. The final product should be an ideal smear that fulfills the criteria lis in Table 4.1 and illustrated in Figure 4.1 . This chapter will deal with specimen adequacy an our reporting system/scheme, including unsatisfactory and inadequate diagnoses.

Adequately cellularity and a thin, monolayered smear.
Adequately wet-fixed (for Papanicolaou staining).
Well-visualized, well-stained cellular material.
Must provide assessment of architectural patterns of tissue fragments.
Must provide details of nuclear morphology.
Demonstrates cytoplasmic characteristics.
Psammoma bodies are well-visualized when present.
Stains colloid.

TABLE 4.1 CHARACTERISTICS OF AN IDEAL SMEAR OF THYROID ASPIRATE

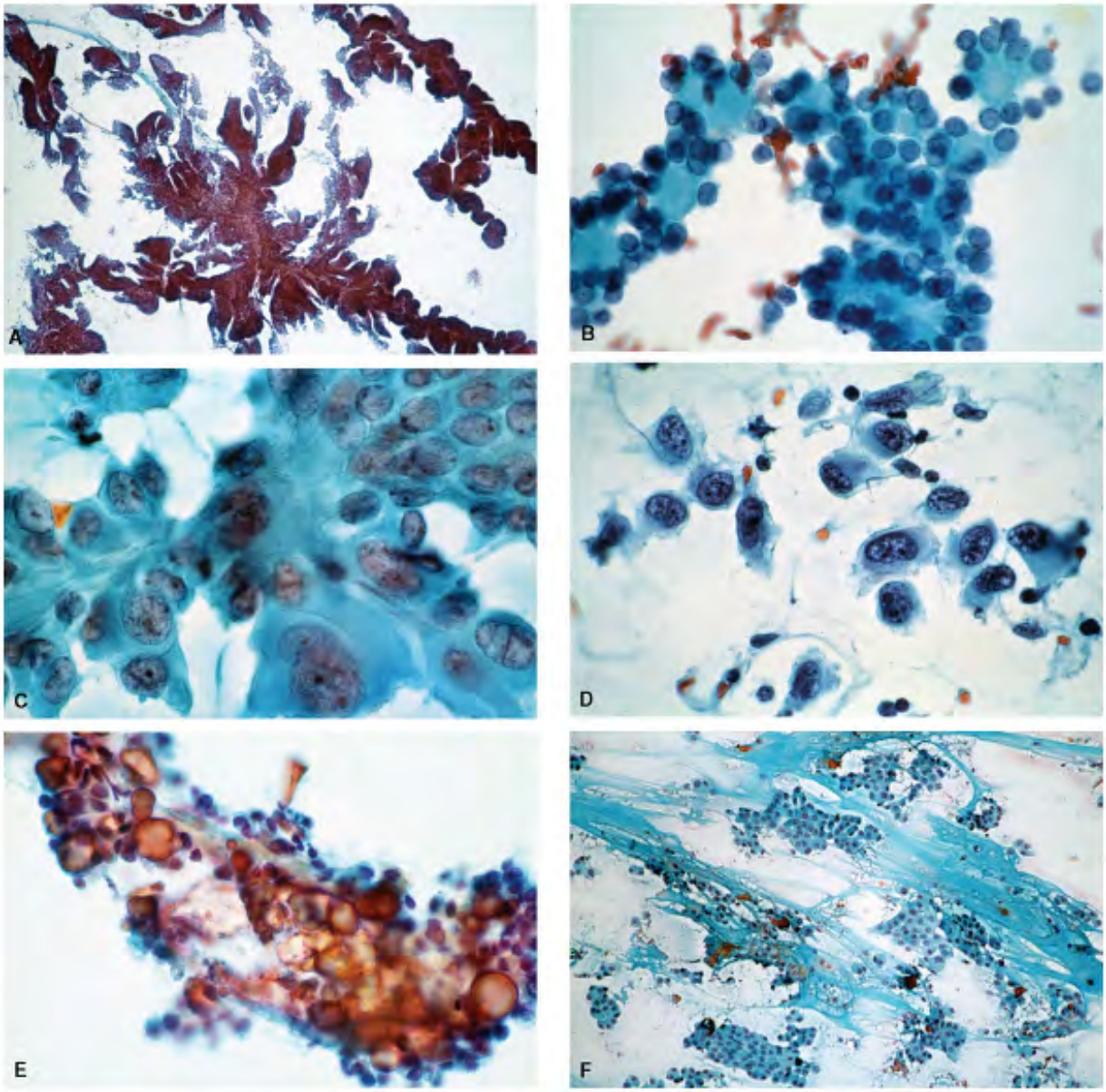

Figure 4.1. An Ideal smear. A. Low-power view of an aspirate of papillary thyroid carcinoma showing adequate cellularity. The architectural patterns of the tissue fragments are well visualized. B. This tissue fragment presents a follicular growth pattern. The follicular cells a well fixed and stained well. C. The nuclei demonstrate excellent morphology. The powdery chromatin, nucleoli, grooves, and inclusions are well visualized. D. These anaplastic carcino cells present clearly malignant nuclei. Diagnosis can be made based on small number of cell Psammoma bodies are well stained and readily identified. F. The colloid is stained in the background.

ADEQUACY

It is very difficult to define an adequate cytologic specimen of a thyroid aspirate. The assessment greatly depends on several factors, such as quality of the specimen (fixation anc cytopreparation), quantity or the number of diagnostic cells, the interpreter's skills, and the comfort level. This comfort level is built on experience, not only with cytologic interpretati but years of follow-up of cytologic specimens and their correlations with the histologic diagı whenever available. Misinterpreted cytologic diagnoses are often an educational experience when correlated with histologic findings. The reverse is also true.

Additional factors that impact both adequacy assessment and interpretation include the clir data, ultrasound findings, size of the nodule, and risk factors (if any).

An adequate specimen is one in which the cytologic material is sufficient to render a diagno benign or otherwise. A rare group of benign follicular cells should not be considered indicati a benign disease.

Our criteria of 8 to 10 tissue fragments of follicular cells (Fig. 4.2) on each of at least two smears were subjectively derived from our experience with over 3,000 specimens.1 They ha been remarkably helpful in rendering a benign or non-neoplastic diagnosis. These criteria ar still applicable and are used in the author's laboratory. The requirement of 8 to 10 tissue fragments may seem rigid and will raise the percentage of unsatisfactory results. For examp because of this requirement, the rate of unsatisfactory results in our series was reported to 20%.1 But such rigid criteria will minimize the risk of false-negative diagnoses. Most of our f negative diagnoses were encountered during the first few years of biopsy experience and or retrospective review; the majority were based on inadequate specimens.2 Poor cellular yiel can be due to several factors (Table 4.2).

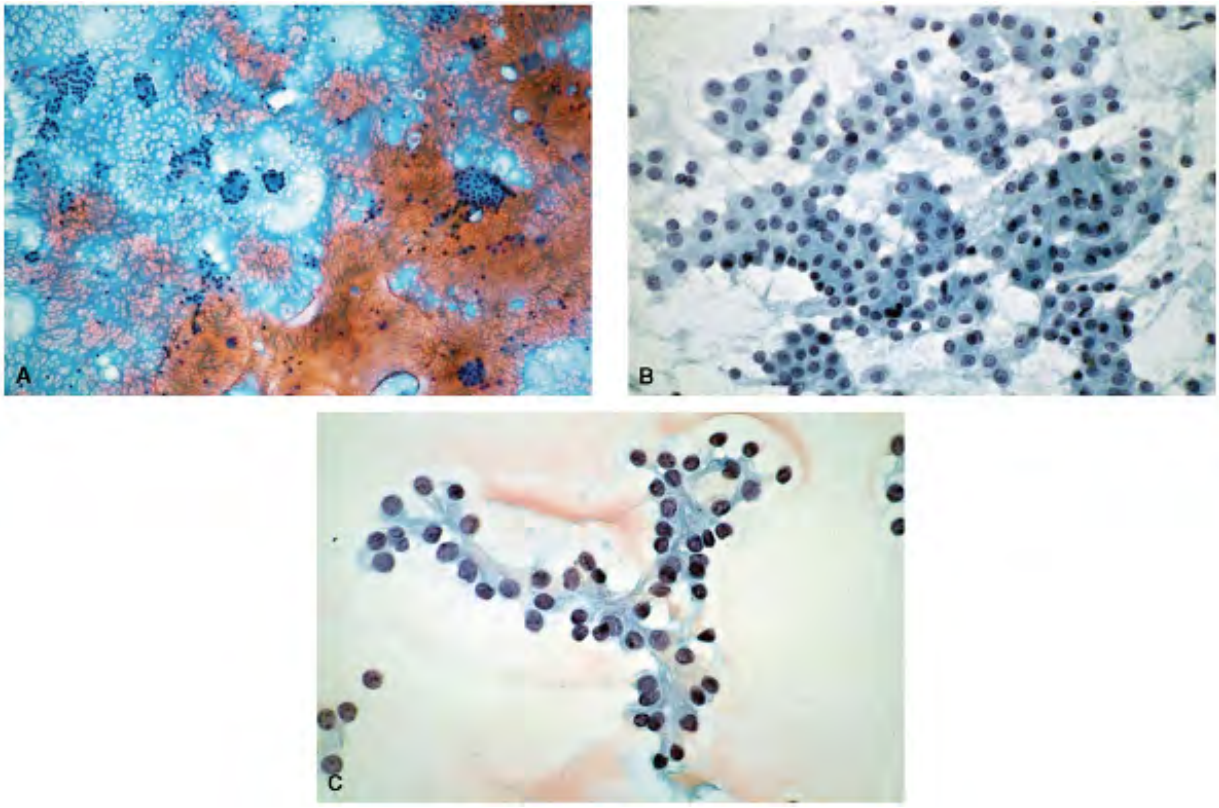

Figure 4.2. A. An adequately cellular aspirate of thyroid with at least 7 to 8 tissue fragment follicular epithelium in the background of colloid. B. This aspirate demonstrates several wel preserved follicular cells in tissue fragments, with 8 to 10 cells in each fragment. C. Well-preserved follicular cells forming regular follicles. Note thin colloid in the background.

1. Sclerotic lesions
    - Scarring in nodular goiter
    - Fibrous variants of Hashimoto's thyroiditis
    - Riedel's thyroiditis
    - Neoplasms with marked desmoplasia
2. Thick, fibrous, calcified capsule of the nodule in question
3. Large lesions with cystic degeneration
4. Long-standing cysts
5. Necrotic lesions
    - Abscess
    - Infarct

Necrosis of the tumor

6. Very vascular neoplasms
7. Sampling error: biopsy needle in tissue surrounding the nodule
8. Faulty biopsy technique: too much or too little suction

TABLE 4.2 PROBABLE REASONS FOR INADEQUATE SPECIME

How strictly can these guidelines be followed? With a large nodule, 8 to 10 tissue fragments not be adequate. Does one need the same amount of cellularity to diagnose an anaplastic carcinoma? Perhaps not. A few groups of clearly malignant cells, as depicted in Figure 4.1D only one smear are sufficient and diagnostic for rendering an interpretation of anaplastic carcinoma. This has to be done in context with the patient's clinical data and clinical diagnc What if only one smear is very cellular and the rest are acellular? Does one need two smears a diagnosis of papillary carcinoma? A single smear of an overwhelmingly cellular aspirate, as shown in Figure 4.1A , is diagnostic when all the criteria are visualized. However, with marginally cellular aspirate, the presence of minimal criteria on at least one smear is critica (see Chapter 9).

The adequacy criteria recommended by others vary.3 , 4 , 5 , 6 Goellner and associates3 an Caruso and Mazzaferri4 require 5 or 6 groups of well-preserved follicular cells, each group consisting of at least 10 to 15 cells. They have not specified the number of slides, and it is n clear whether 6 tissue fragments or groups is a cumulative number from all of the smears. Hamburger and Hussain5 recommended at least 6 aspirates of a nodule in question, with at two containing 6 clusters of benign cells (number of cells per group not specified). Nguyen a colleagues6 require 10 clusters of follicular cells with at least 20 cells in each cluster. Again number of smears is not specified.

Besides adequate cellularity, preservation of epithelial cells is also very critical in Papanico stained material. An adequately cellular aspirate must also be satisfactory for cytopatholog evaluation. Too much blood, cellular and

necrotic debris, thick smears, poor fixation, and suboptimal stain can all influence the final product. An adequate cellular specimen can be unsatisfactory for cytopathologic evaluation to any of these causes. Guidelines for ensuring a satisfactory and adequate sample are prese

in Table 4.3 .

1. Multiple punctures of the nodule in question, so that several areas are sampled (easily done if the aspiration biopsy is performed under local anesthesia).
2. At least six properly prepared thin cell spreads.
3. Immediate wet fixation for Papanicolaou staining technique.
4. A minimum of 8 to 10 tissue fragments of well-preserved follicular epithelial cells on at least 2 slides.

TABLE 4.3 RECOMMENDED GUIDELINES FOR ENSURING ADEQUATE AND SATISFACTORY SPECIMENS

REPORTING SCHEME FOR THYROID ASPIRATES

A reporting system or scheme in cytopathology practice is a means of communicating the re of cytologic evaluation and diagnostic interpretation to the clinician. The scheme should be simple, succinct, and easily understood. The

patient management depends greatly on how the results are communicated. Ambiguous terminology must be avoided at all costs.

In general, the reporting schemes in cytopathology vary, depending on the type of specimer well as the organ or site. The schemes for exfoliative cytopathology are generally simple, consisting of four basic categories: unsatisfactory, negative, atypical/suspicious, and positiv This simple scheme is broadened in aspiration cytology, because of the wide range of diagnc possibilities, which are often site specific.

In aspiration cytology of thyroid aspirates, the reporting of the cytologic evaluation and interpretation (diagnosis) has caused considerable confusion over the years. Several formats have been suggested or recommended in the literature and are currently in use.7 The professional societies have published broad guidelines.8 Most published schemes7 , 9 are individualized and customized to suit the respective institutions and are strongly dependent (i) the

cytopathologists' interpretations based on specimen adequacy, cytopreparations, and experience; (ii) institutional experience with the aspirates and the diagnostic accuracy; and the management strategy of the endocrinologists and the surgical management. These sche although practical for the particular institutions, may not be applicable in different settings

No matter how the scheme and the algorithms are designed and recommended, the importa factor is the cytopathologic interpretation. For example, an aspirate interpreted as nondiagnostic by one pathologist may be interpreted as negative, indeterminate, or suspicic by another. The case illustrated in Figure 4.3 is such an example, where three cytopatholog interpreted the aspirate differently. The suspicious diagnosis resulted in surgery, which was confirmed as papillary carcinoma.

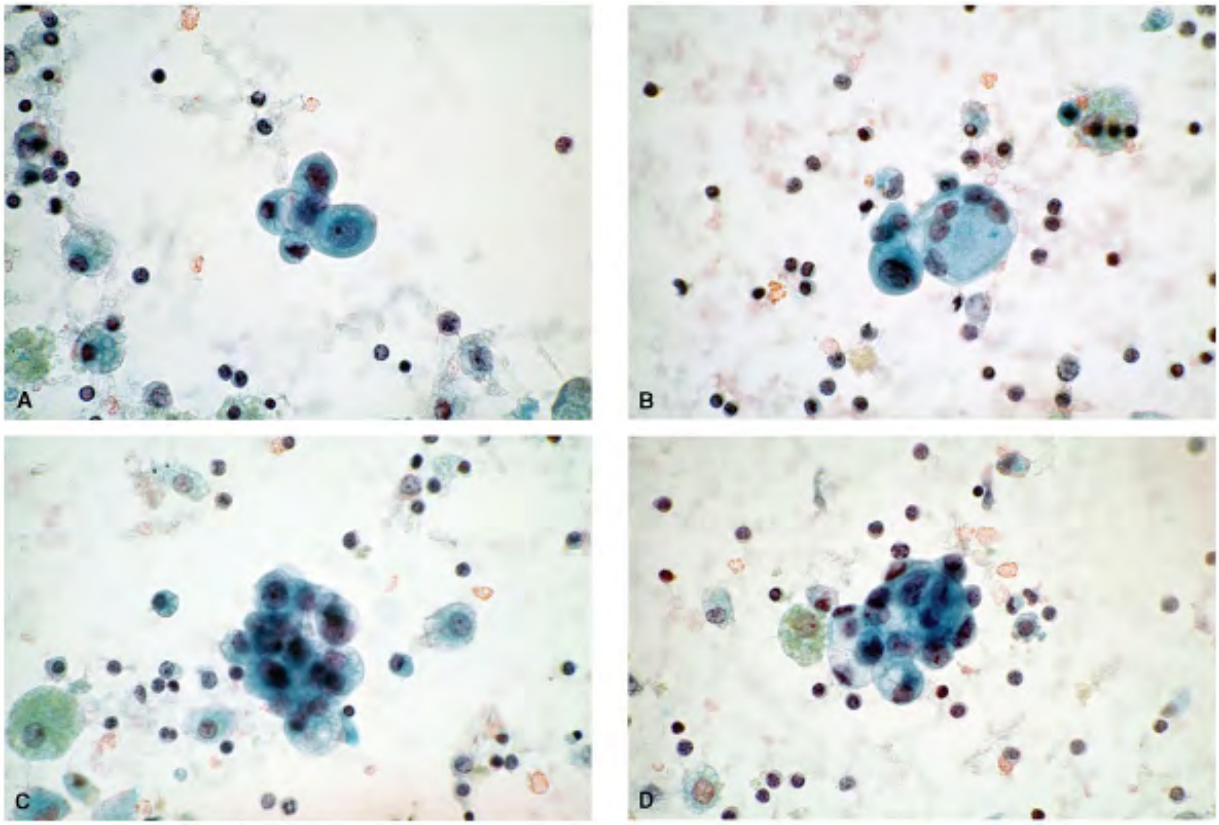

Figure 4.3. These four images represent the only cells present in a cytospin preparation of clear cyst fluid from the thyroid. The diagnostic impression by three cytopathologists were inadequate/non-diagnostic, negative for malignant cells, and suspicious for papillary carcin Surgery confirmed the diagnosis of papillary carcinoma.

The customized reporting schemes may have three tiers, four tiers, or more.7 Stratification very essential in thyroid aspiration cytology because of the extremely wide range of possibil and multiple options open to the clinicians. It is critical that whichever scheme is chosen or followed, there should be a clear communication between the cytopathologists, endocrinologists, and surgeons.

The reporting scheme used in author's laboratory is listed in Table 4.4 . It varies from severa others in that (i) the acellular or unsatisfactory and inadequate categories are separate inst of having one category, "nondiagnostic," that includes both; (ii) the follicular/HÃ¼rthle cell neoplasms are reported as "abnormal"; and (iii) the suspicious diagnosis is a separate catego at variance with the practice of other institutions of combining follicular/HÃ¼rthle cell neoplasms and suspicious diagnosis as "indeterminate."

Unsatisfactory [a]

Inadequate [a]

Negative
(Benign)

Abnormal [b]

Suspicious [b]

Positive

- Acellular smears; no follicular cells; bloody; smears too thick.
- Adequate cellularity but poor cell preservation due to air-drying in Papanicolaou-stained preparations.
- Scant cellularity with or without mild nuclear atypia.
- Abundant colloid with no or few follicular cells.

- Cyst fluids with only histiocytes and no or few follicular cells.
- Nodular goiter: benign follicular cells, with or without colloid and histiocytes.
- Thyroiditis; chronic lymphocytic or Hashimoto's type.
- Subacute or granulomatous thyroiditis.
- Cellular features of follicular adenoma.
- Cellular features of HÃ¼rthle cell neoplasms.
- Cellular material inadequate but suggestive of malignancy.
- Diagnostic criteria insufficient for a definite diagnosis of malignancy.
- Malignant cells present. (Malignancy to be typed.)

[a] Non-diagnostic. In some reporting schemes, this category includes acellular and inadequat diagnoses.
[b] Indeterminate. In some reporting schemes, this category includes follicular neoplasms, HÃ¼rthle cell
neoplasms, and suspicious diagnoses.
From Henry Ford Hospital, Detroit.

Category	Observations

TABLE 4.4 REPORTING SCHEME FOR THYROID ASPIRATES

The management strategies based on above described reporting scheme are described in Chapter 23 .

Explanation of the Diagnostic Terms Used in the Reportinc Scheme and Their Significance

Unsatisfactory

The specimen is unsatisfactory for cytologic evaluation due to lack of follicular cells. Presen only stromal cells and/or only lymphocytes is of no significance. The cytologic smears must properly prepared and wet-fixed promptly for Papanicolaou staining. The slightest delay in will result in poor cellular details, rendering the specimen unsatisfactory for cytologic evaluation, regardless of the cellularity. Abundant venous blood and thick smears obscure tl

cellular details and will also render the specimen unsatisfactory for evaluation.

Inadequate

The aspirate is considered inadequate for cytologic evaluation when the number of follicula cells is small (see "Adequacy" earlier in this chapter). The inadequate category also includes abundant colloid with no follicular cells and with or without histiocytes or with few benign follicular cells; (ii) cyst fluid aspirates with few or no follicular cells; and (iii) rare groups of follicular cells with minimal nuclear atypia, not sufficient for any specific diagnosis, may be included in this group, and may indicate degenerative/reactive changes.

Although cystic change and degeneration are frequent in nodular goiters, they are also seen substantial number of papillary carcinomas. The presence of histiocytes alone cannot be tak as a feature in favor of benign disease. The aspirate may be reported simply as cyst content without using the prefix "benign."

In some reporting schemes,3 , 4 the unsatisfactory and inadequate diagnoses are grouped together in a nondiagnostic category, with an explanation that the term "nondiagnostic" doe mean negative but warrants a repeat biopsy.9

The unsatisfactory and inadequate categories (nondiagnostic) together comprise roughly 10% 21% of the fine-needle biopsy procedures.2 , 4 , 9 , 10 Results as low as 2%11 and as high as 31%12 are also reported in the literature. These numbers are dependant on adequacy criteri which vary considerably from institution to institution. The incidence of diagnostic results following rebiopsy is reported to be 62%.13 Roughly 30% to 38% remain nondiagnostic due to factors inherent to the lesions (e.g., fibrosis, increased vascularity, cystic change). The malignancy yield in the nondiagnostic group is variably reported to be 2%,14 5%,15 and 9%16 Chow and co-workers13 reported 7% overall malignancy in the nondiagnostic group, but the percentage increased to 37% when only surgical cases were considered.

Negative

The specimen is representative of benign non-neoplastic diseases, either nodular goiter or a type of thyroiditis. This is the most common diagnosis encountered, comprising 60% to 70% c diagnoses. Negative diagnosis means no malignancy in the aspirated samples and the patien are managed conservatively.

Isolated groups of mildly atypical follicular cells in the background of nodular goiter may be

described in the microscopic description and their presence alluded to by using a phrase "se comments" in the diagnosis. This type of diagnosis is usually followed by clinical observation and/or repeat biopsy. The diagnostic term "abnormal/atypical" or "indeterminate" for these atypical cells will confuse the clinicians and often leads to unnecessary surgery. The same h true for Hashimoto's thyroiditis, where epithelial atypia is of common occurrence. If the aty marked and a neoplasm is strongly considered, the suspicious category is recommended.

The incidence of malignancy in the benign group is very low, although a true incidence can never be determined, because the majority of patients with benign diagnoses are managed conservatively.

Abnormal

The abnormal category is used when the cytologic features indicate a benign neoplasm such follicular adenoma or a HÃ¼rthle cell neoplasm.

An abnormal/atypical diagnosis corresponds to the indeterminate category of some reportin schemes,9 and is followed by surgical excision. Usually, the decision for surgical excision an extent of surgery rests with the clinician, taking into account any risk factors and the patie

If the specimen is inadequate but presents some features suggestive of a benign neoplasm, features may be included in

the inadequate category with specific comments in the microscopic description. Repeat bio are usually indicated.

Suspicious for Malignancy

This category includes three cytologic patterns: (i) adequate cellularity and cytologic featu suggesting malignancy but lacking all the criteria for a definite diagnosis (e.g., cellular folli adenomas with a differential diagnosis of follicular carcinoma or a follicular variant of papil carcinoma); (ii) adequate cellularity, with most but not all the features of papillary carcino and (iii) inadequate cellularity but cellular features strongly favoring malignancy.

Many laboratories lump indeterminate and suspicious results into one category as indeterminate/suspicious. The malignancy yield is apt to be different when each category is considered separately. This group represents 11% to 21% of cytology results,4 , 9 , 17 , 18 ar surgical excision is recommended for all. Most are found to be benign. The surgical follow-u

this group reports 20% to 40% malignant neoplasms, 30% to 40% follicular/HÃ¼rthle cell adenomas, and 20% to 30% non-neoplastic diseases.4

Positive (Diagnostic of Malignancy)

Several malignant neoplasms of the thyroid offer accurate cytologic diagnosis with a high de of sensitivity and specificity, allowing proper management strategy. The malignant tumors t can be diagnosed from cytologic samples include papillary carcinoma, HÃ¼rthle cell carcinc poorly differentiated follicular carcinoma, insular carcinoma, medullary carcinoma, anaplas carcinoma, large cell malignant lymphoma, and metastatic carcinoma. The malignant diagn in a compilation of 10 series ranged from 1% to 18%, with an average of 4%.4

False-negative diagnoses imply malignant diagnoses in surgical specimens from patients wit benign diagnosis. The incidence is variable, ranging from less than 1% to 6%.4 The reasons include unsatisfactory/inadequate samples or sampling errors and interpretation.

False-positive diagnoses imply no malignancy detected in surgically removed thyroids that h positive fine-needle biopsy diagnosis. The reported incidence ranges from 0% to 7.7%.4 The errors are always interpretative, due to overlapping features, degenerative changes, an inadequate specimen, or simply inexperience. Papillary carcinoma is the most common fals positive diagnosis.

The diagnostic accuracy is usually determined by sensitivity and specificity. The reported sensitivity for thyroid fine-needle aspirates is 83%, with a range of 65% to 98%; the specificit 92%, with a range of 72% to 100%.9

Table 4.5 lists several examples from the diagnostic categories of unsatisfactory and inadeq (nondiagnostic).

Acellular, bloody;
no thyroid follicular cells;
Unsatisfactory for cytologic
evaluation
Faulty technique; vascular or cystic lesion;
desmoplasia (see Table 4.2); repeat the FNA.
Acellular, bloody;
no thyroid follicular cells;

spindle cells of stromal origin
(Fig. 4.4)

Unsatisfactory for cytologic evaluation

Stromal cells or tissue fragments may originate from granulation tissue or fibrosis in nodular goiters or Hashimoto's thyroiditis; rarely they may represent an anaplastic carcinoma or a papillary carcinoma with desmoplasia; review the smear(s) carefully; single spindle cells with bizarre, pleomorphic nuclei may represent an anaplastic carcinoma with marked desmoplasia; repeat the FNA; clinical correlation required.

Acellular, bloody; *no thyroid follicular cells;* only histiocytes with or without hemosiderin (Fig. 4.5)

Unsatisfactory for cytologic evaluation (nondiagnostic)

Probably represents cystic change in nodular goiter; rarely, a cystic papillary carcinoma may present a similar pattern; reaspirate if a residual is palpable or if the cyst recurs; clinical correlation required.

Acellular, bloody; *no thyroid follicular cells;* only lymphocytes (Fig. 4.6)

Unsatisfactory for cytologic evaluation

Confirm that the needle was in thyroid and not in the adjacent lymph node; may represent late stages of Hashimoto's thyroiditis; repeat the FNA; clinical correlation required.

Acellular; abundant colloid; *no thyroid follicular cells*

(Fig. 4.7)

Unsatisfactory for cytologic evaluation (nondiagnostic)

Probably represents a colloid nodule (hyperinvolution in nodular goiter or a macrofollicular adenoma); clinical correlation required; repeat FNA may be indicated.

Poor cellular preservation due to improper fixation (air-drying) (Fig. 4.8) for Papanicolaou-stained preparations, thick smears, excessive blood

Unsatisfactory for cytologic evaluation (*regardless of cellularity)*

Repeat the FNA.

Histiocytes with or without hemosiderin; few follicular cells with or without degenerative changes (Fig. 4.9)

Inadequate for cytologic evaluation due to scant cellularity; (nondiagnostic)

Probably represents nodular goiter; clinical correlation required; repeat FNA may be indicated based on clinical and radiologic findings.

Histiocytes with or without hemosiderin; few follicular cells with atypia; some but not all the cytologic features of papillary carcinoma (Figs. 4.10 and 4.11)

Suspicious for papillary carcinoma

May represent either a nodular goiter with degeneration or a cystic papillary carcinoma; repeat

FNA or recommend surgery.

Abundant colloid, few benign follicular cells; histiocytes Â± (Fig. 4.12)

Negative for malignant cells; colloid nodule, (hyperinvoluted nodular goiter) or a macrofollicular adenoma

If the lesion is large, (>2 cm in diameter), adequate sampling may be a problem; lesions yielding abundant colloid and few benign-appearing cells are rarely if ever malignant; differential diagnosis includes a macrofollicular variant of papillary carcinoma; look for syncytial architecture of the tissue fragments and nuclear features of papillary carcinoma; repeat FNA only if cytologic atypia is present.

Few (fewer than 6 to 8) well-preserved tissue fragments of follicular cells, honeycomb arrangement, and regular follicles; small nuclei <9 Âµm in diameter with compact chromatin; absent or scant colloid (Fig. 4.13)

Inadequate for cytologic evaluation due to scant cellularity; (nondiagnostic)

Probably represents nodular goiter; nodule size must be taken into consideration; repeat FNA based on clinical judgment; sometimes clinically followed.

Rare group or tissue fragment of follicular cells, syncytial arrangement, nuclei with granular/powdery chromatin, nucleoli (Fig. 4.14).

Suspicious for a neoplasm

Repeat FNA or recommend excision.

Few groups or tissue fragments of atypical cells; poor preservation; some features suggestive of papillary carcinoma (Fig. 4.15)

Suspicious for papillary carcinoma

Recommend surgery.

Cellular Features	Interpretation/Diagnosis	Explanation/Recommendat

TABLE 4.5 CRITERIA FOR ADEQUACY AND GUIDELINES FOI REPORTING UNSATISFACTORY/INADEQUATE (NONDIAGNOSTIC) SPECIMENS

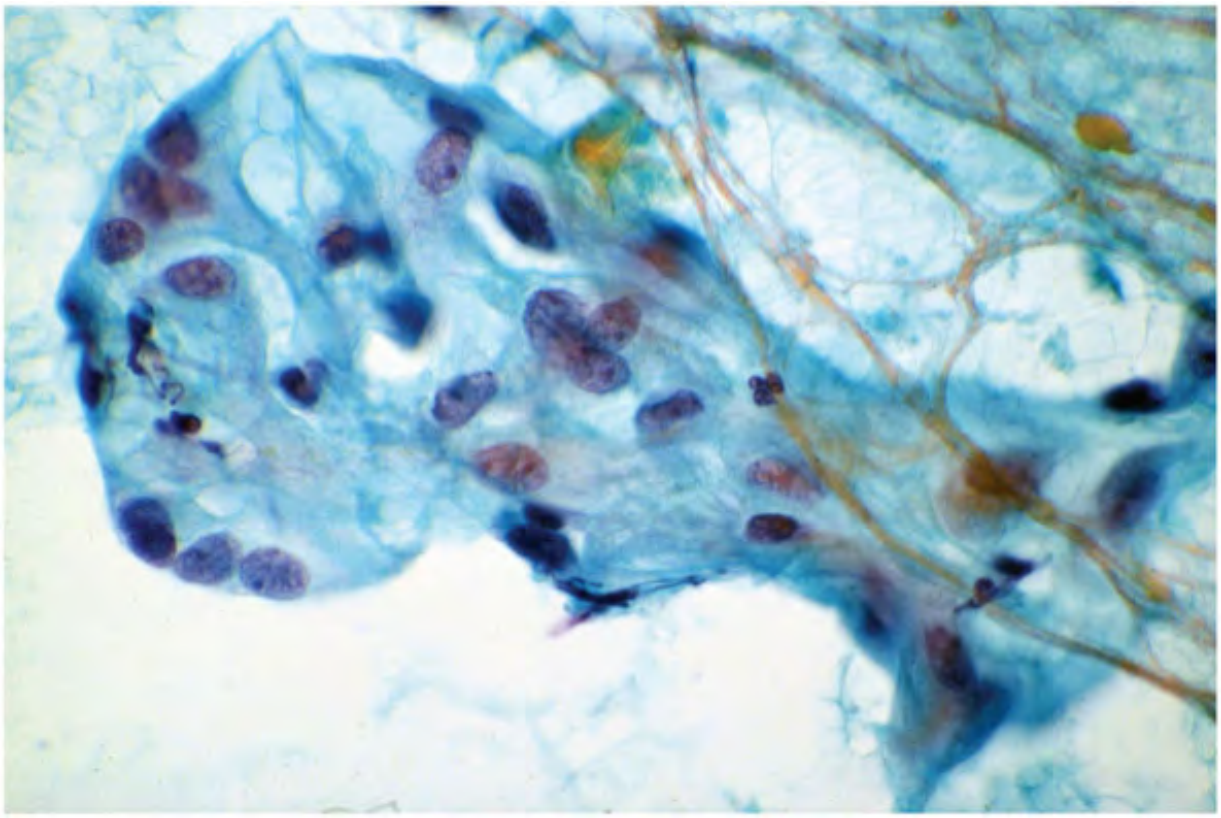

Figure 4.4. The presence of only benign stromal cells in the absence of follicular cells is inconsequential. The aspirate is unsatisfactory for evaluation.

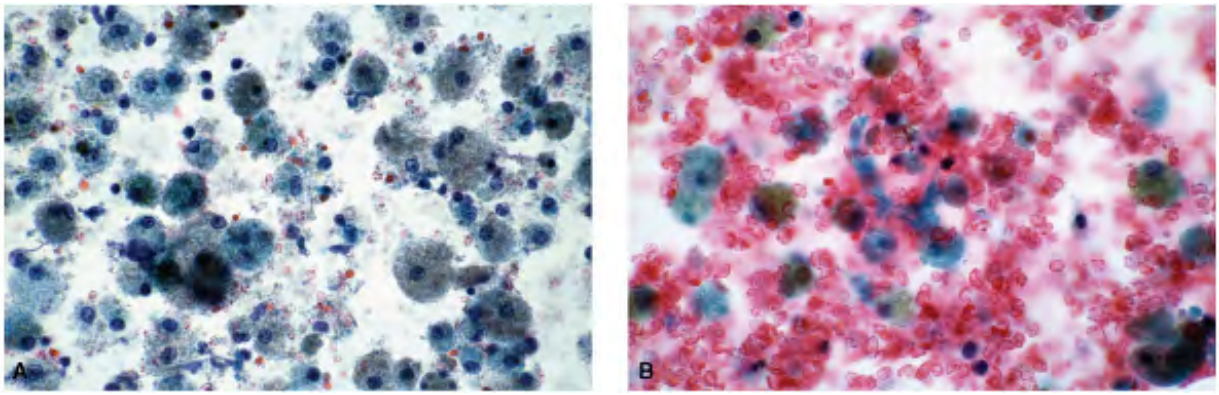

Figure 4.5. A. An aspirate of a thyroid cyst containing only histiocytes. Follicular cells are n present. This aspirate is inadequate for cytologic evaluation. B. This cyst aspirate containec histiocytes in a hemorrhagic background. Because it recurred, a thyroidectomy was perform which revealed a cystic papillary carcinoma. Presence of histiocytes even in large numbers i diagnostic of a cyst. A cystic papillary carcinoma must always be considered in the different

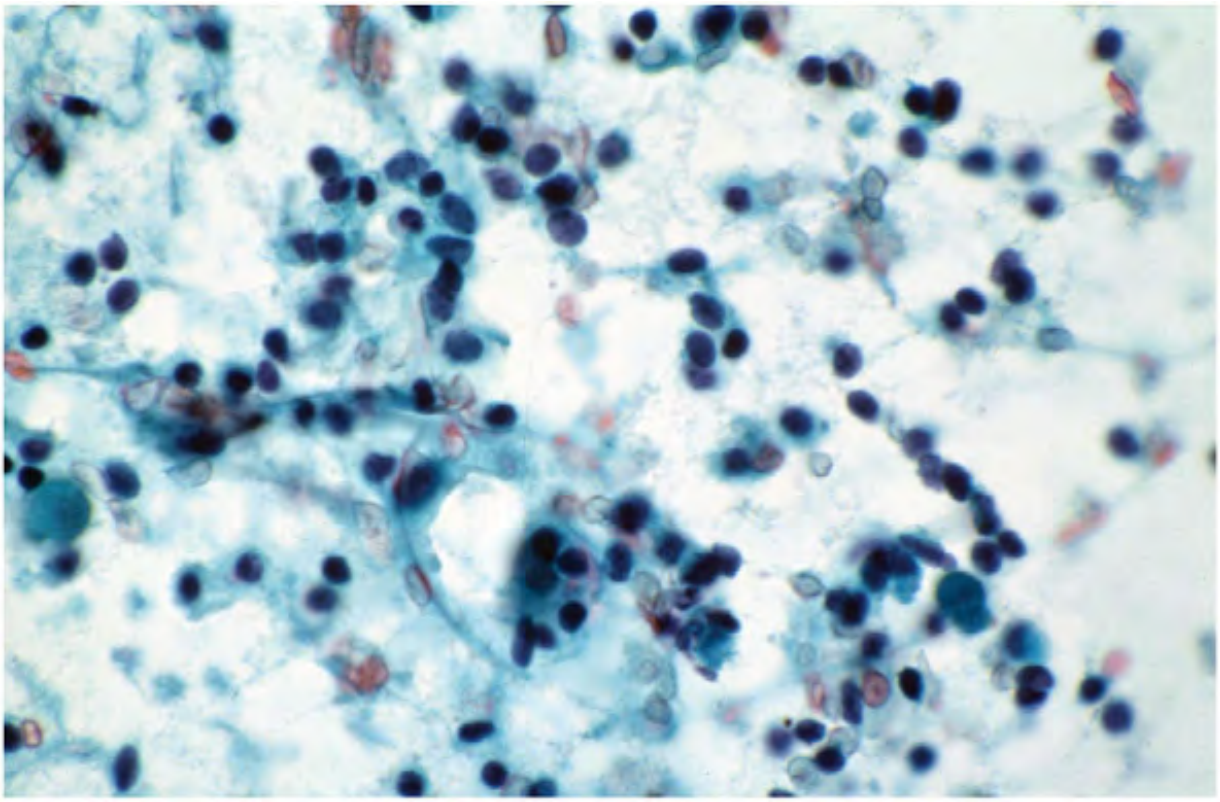

Figure 4.6. Only lymphocytes are present in FNA of a documented case of Hashimoto's

thyroiditis. The aspirate is unsatisfactory for cytologic evaluation due to lack of follicular ce

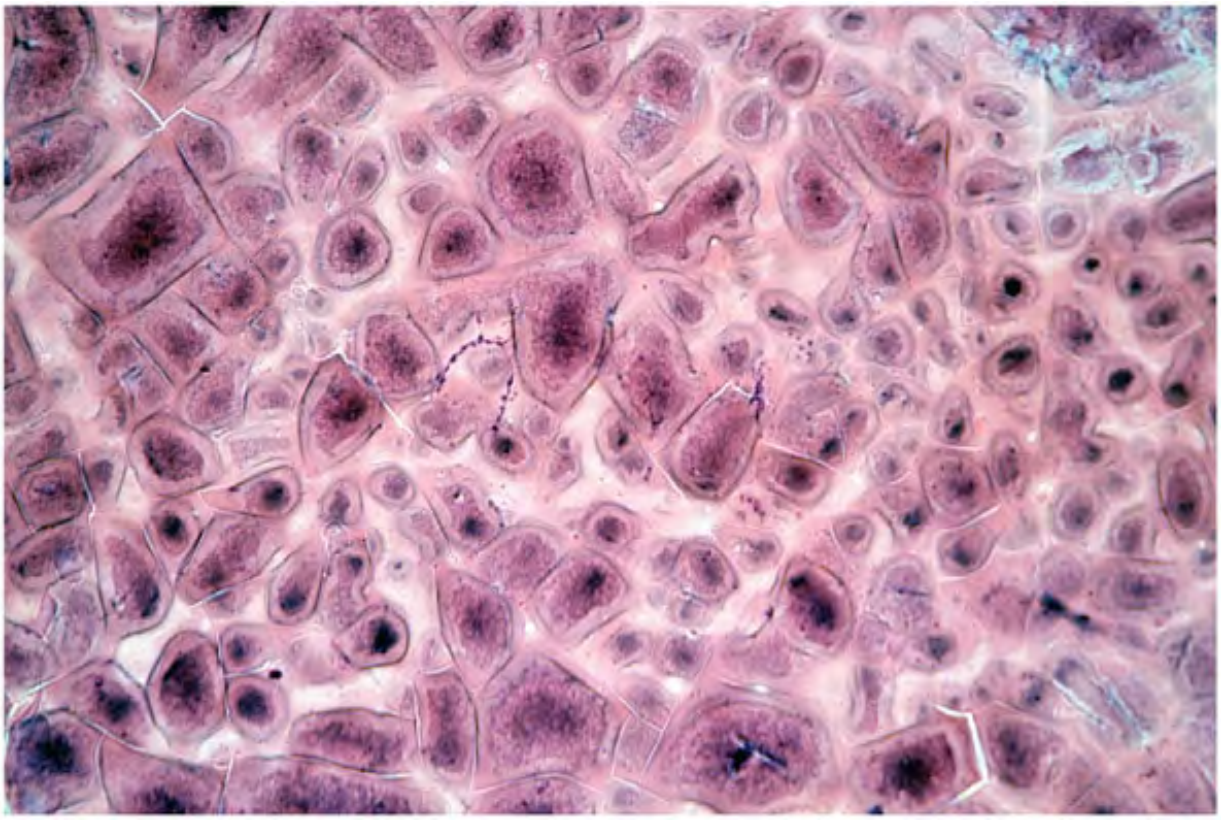

Figure 4.7. Abundant colloid. No follicular cells. Although this may represent a nodular goit the aspirate is inadequate due to lack of follicular cells. A clinical correlation is required.

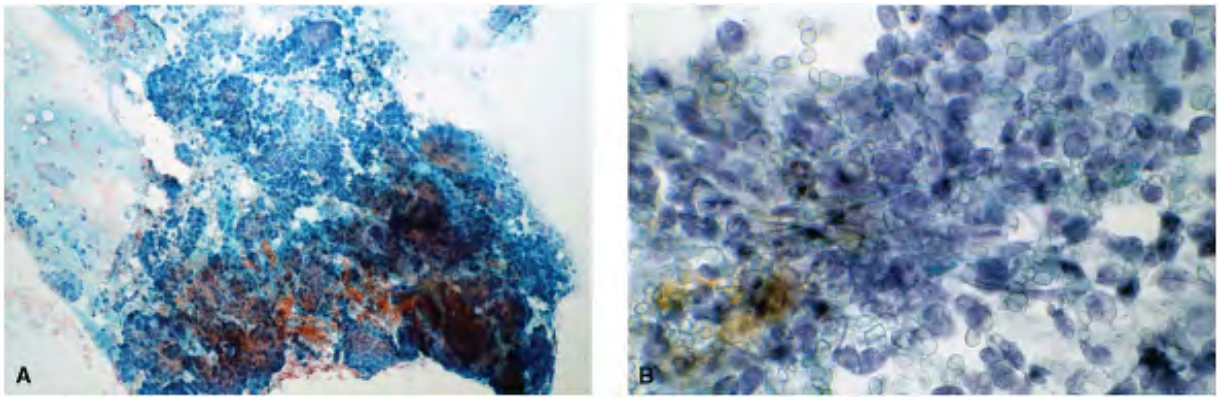

Figure 4.8. Poor cytopreparation will result in an unsatisfactory smear. A. This aspirate fro papillary carcinoma is very cellular but air-dried, resulting in poor cellular details. The aspi

is unsatisfactory in spite of the cellularity. B. This aspirate from Hashimoto's thyroiditis is ai dried, resulting in pale nuclei, and misinterpreted as suspicious for papillary carcinoma. Thi preparation should be addressed as unsatisfactory. Errors are apt to happen when a diagnosi rendered on a suboptimal preparation.

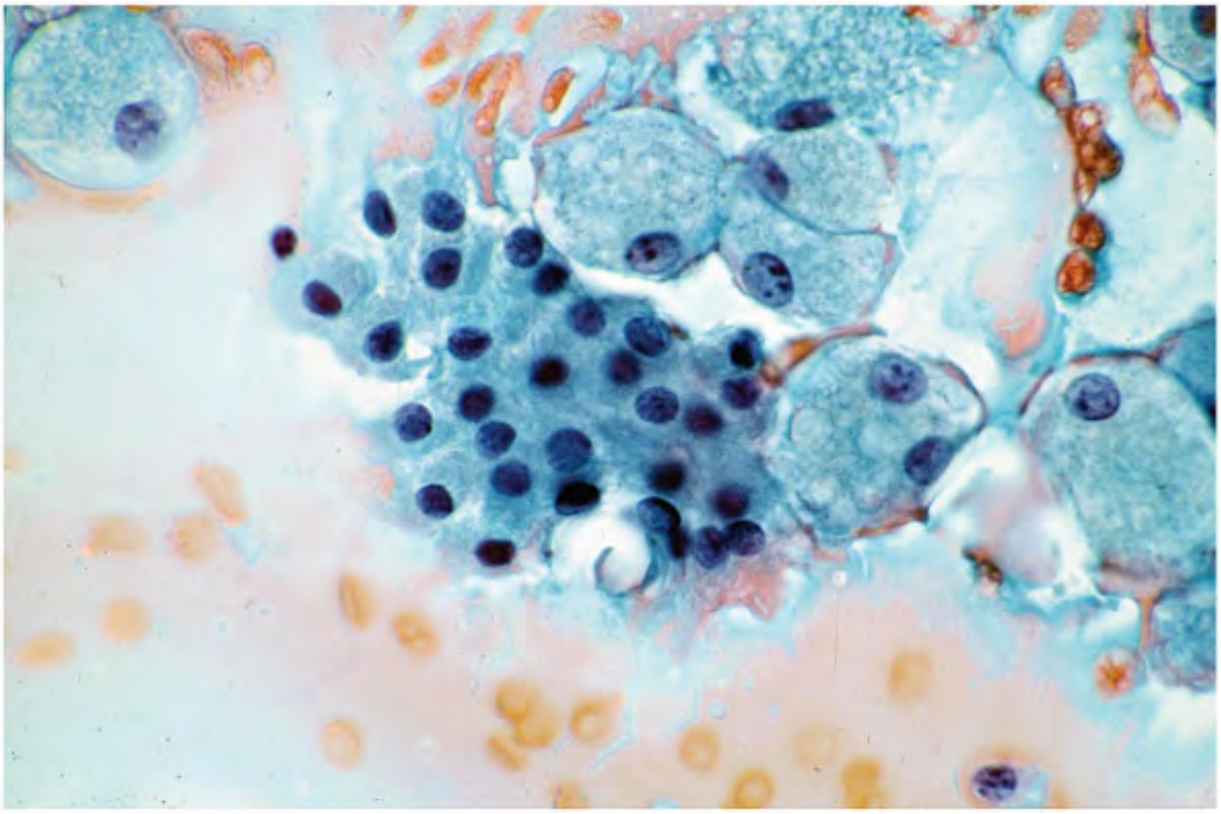

Figure 4.9. A cyst aspirate containing histiocytes and few benign follicular cells. This aspira inadequate for cytologic diagnosis.

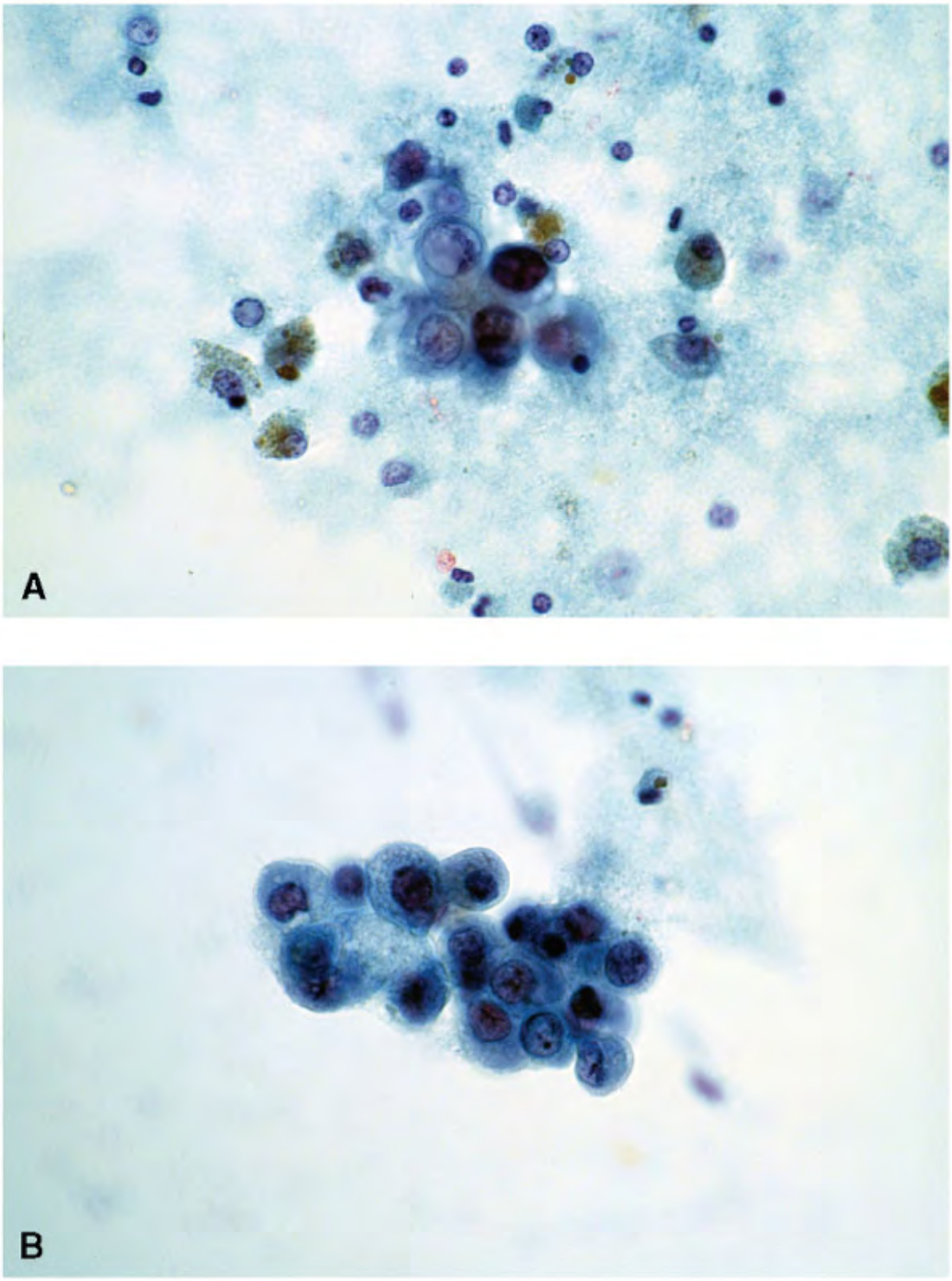

Figure 4.10. Cyst fluid. A. This image shows few follicular cells with poorly preserved nucle

with high N/C ratios. There are histiocytes in the background. B. The syncytial tissue fragme of follicular cells demonstrates high N/C ratios and well-defined cell borders with variable f cytoplasm. Micronucleoli are occasionally seen. The N/C ratios are high. The variable cytopl is bubbly and foamy. The cell borders are well defined. The aspirate shows some but not all features of papillary carcinoma.

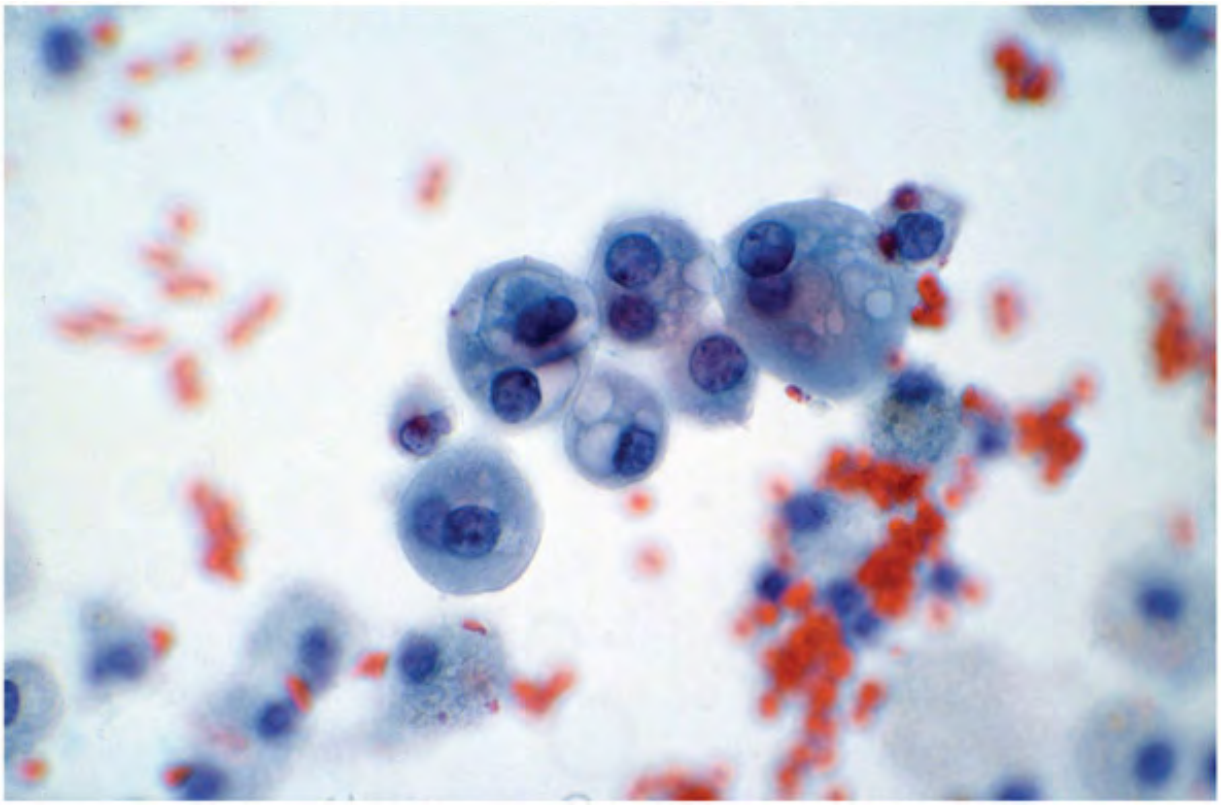

Figure 4.11. This poorly cellular aspirate shows very few discrete follicular cells, pleomorph size, and resembles histiocytes. The cell borders are well defined and the cytoplasm is varia dense to vacuolated. The nuclei are enlarged with irregular chromatin along the nuclear membrane. Micronucleoli are occasionally present. Experience is required to appreciate the subtle atypical features that are suspicious for papillary carcinoma.

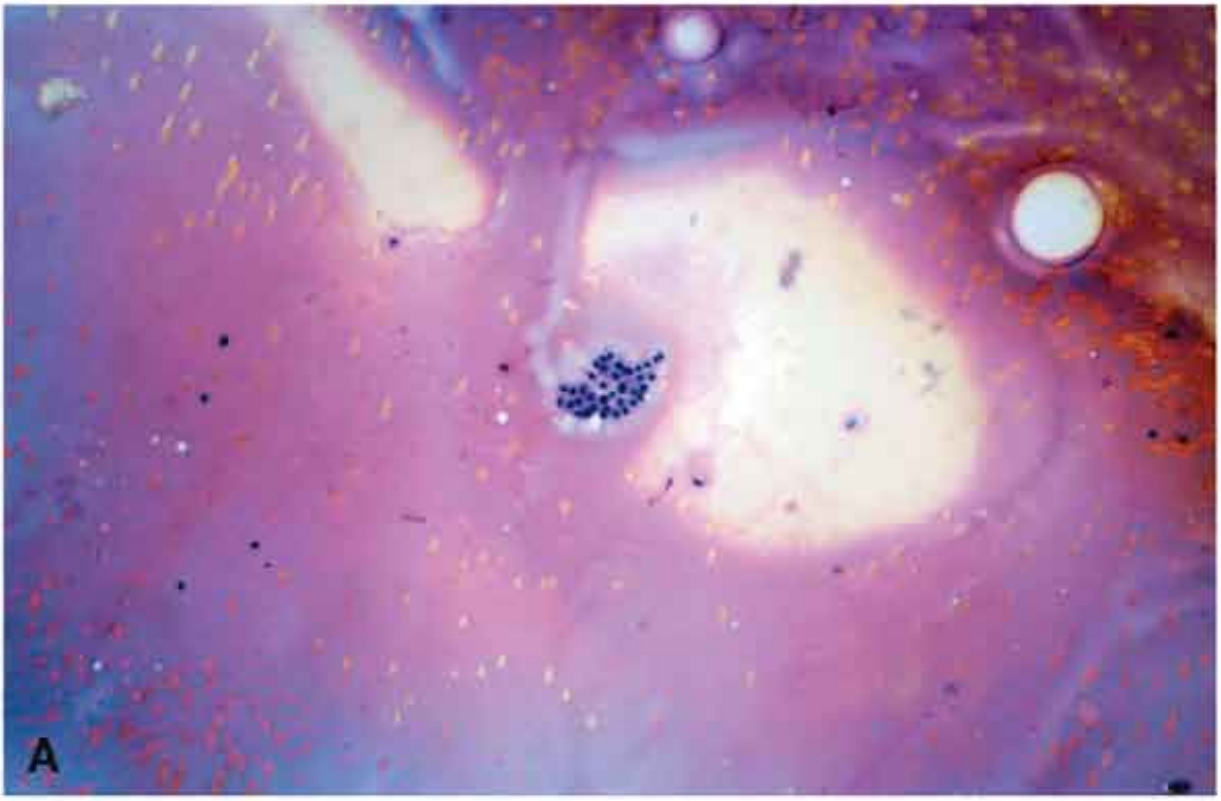
A

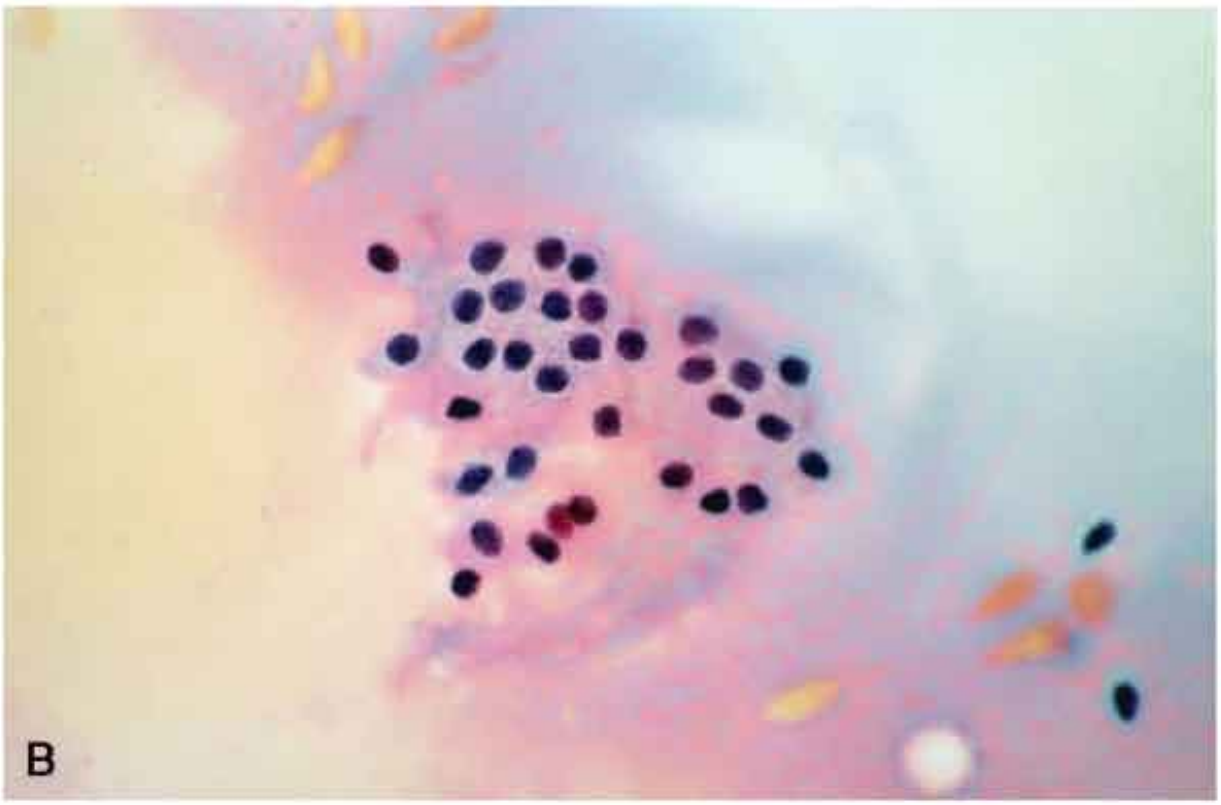
B

Figure 4.12. A. Abundant colloid and rare group of benign follicular cells (low power). B. Hi magnification showing small follicular cells with pyknotic nuclei. Although in terms of quant this aspirate is inadequate, it probably represents a nodular goiter.

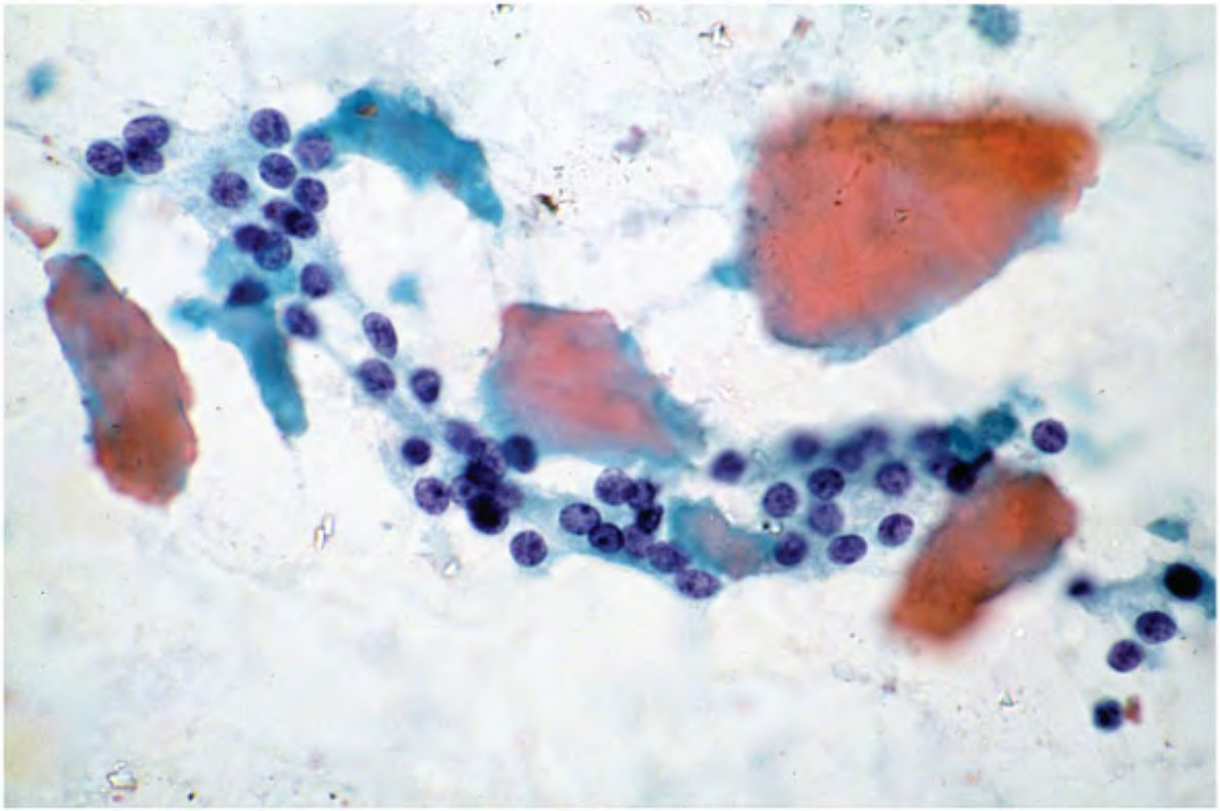

Figure 4.13. Scant cellularity, minimal colloid, small numbers of well-preserved follicular c This aspirate is inadequate for cytologic evaluation but may represent nodular goiter. Clinic correlation required.

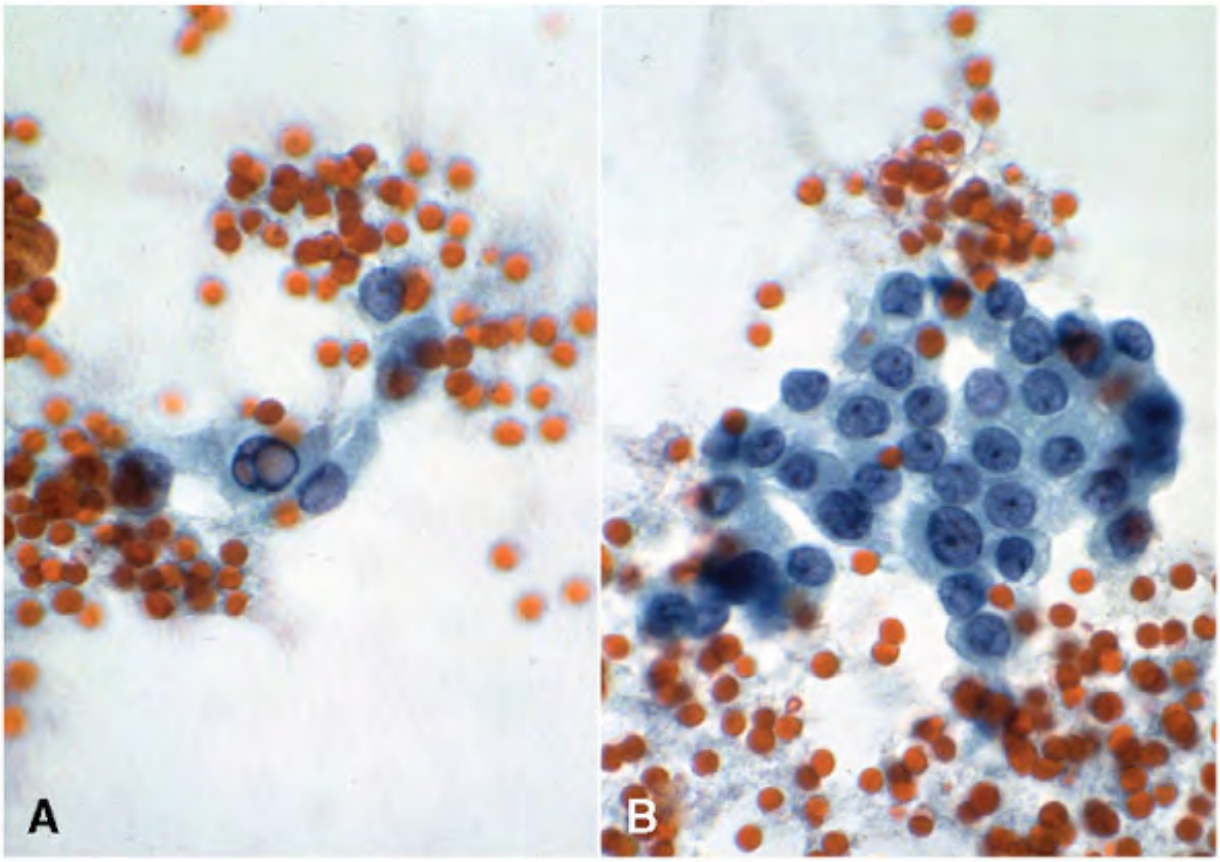

Figure 4.14. The aspirate is poorly cellular. The tissue fragments are syncytial with only a n
increase in the nuclear size. Note intranuclear inclusions. This aspirate should be interprete
suspicious.

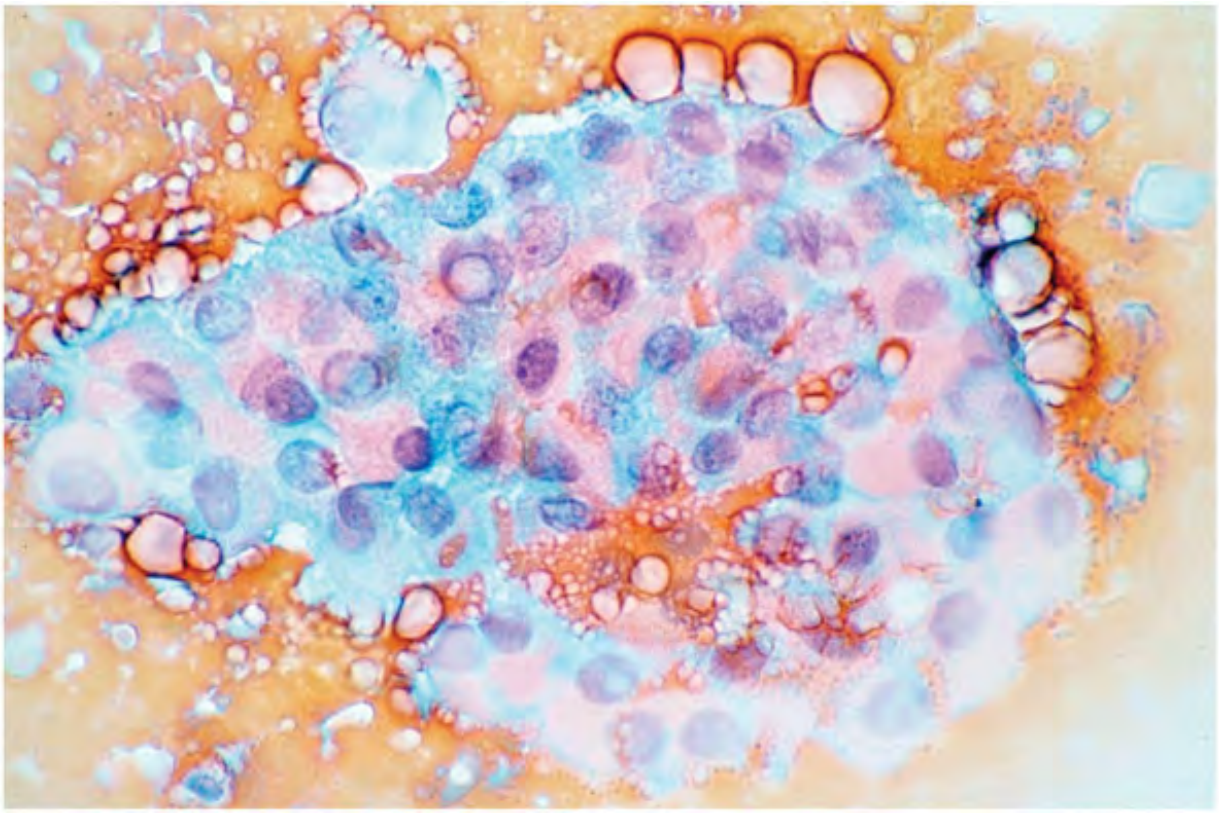

Figure 4.15. The cells are air-dried with suboptimal nuclear morphology. The syncytial architecture of the tissue fragment and a sharp intranuclear inclusion are disturbing feature suggesting a diagnosis of papillary carcinoma. A suspicious diagnosis is justified in this case.

REFERENCES

1.Kini SR, Miller JM, Hamburger JI, et al. Cytopathology of follicular lesions of the thyroid gland. *Diagn Cytopathol* . 1985; 1:123â€“132.

2.Miller JM, Kini SR, Hamburger JI. *Needle Biopsy of the Thyroid.* New York: Praeger; 198

3.Goellner JR, Gharib H, Grant CS, et al. Fine needle aspiration cytology of the thyroid, 1 to 1986. *Acta Cytol* . 1987;31: 587â€“590.

4.Caruso D, Mazzaferri EL. Fine needle aspiration biopsy in the management of thyroid nodules. *Endocrinologist* . 1991;1: 194â€“202.

5.Hamburger JI, Hussain M. Semiquantitative criteria for fine-needle biopsy diagnosis: reduced false-negative diagnosis. *Diagn Cytopathol* . 1988;4:14â€“17.

6.Nguyen GK, Ginsberg J, Crockford PM. Fine-needle aspiration biopsy cytology of the thyroid. Its value and limitations in the diagnosis and management of solitary thyroid nodules. *Pathol Ann* . 1991;26â€“63.

7.Wang HH. Reporting thyroid fine-needle aspiration: literature review and a proposal. *Di Cytopathol* . 2006;34:67â€“76.

8.Papanicolaou Society of Cytopathology Task Force on Standards of Practice. Guidelines the Papanicolaou Society of Cytopathology for the examination of fine-needle aspiration specimen from thyroid nodules. *Diagn Cytopathol* . 1996; 15:84â€“89.

9.Gharib H, Goellner JR. Fine-needle aspiration biopsy of the thyroid: an appraisal. *Ann In Med* . 1993;118:282â€“289.

10.Hamburger JI. Extensive personal experience. Diagnosis of thyroid nodules by fine nee biopsy: use and abuse. *J Clin Endocrinol Metab* . 1994;79:335â€“339.

11.Pepper GM, Zwickler D, Rosen Y. Fine needle aspiration biopsy of the thyroid nodule. Results of a start-up project in a general teaching hospital setting. *Arch Intern Med* 1989;149:594â€“601.

12.Burch HB, Burman KD, Reed L, et al. Fine needle aspiration of thyroid nodules. Determinants of insufficiency rate and malignancy yield at thyroidectomy. *Acta Cytol* . 1996;40: 1176â€“1183.

13.Chow LS, Gharib H, Goellner JR, et al. Nondiagnostic thyroid fine-needle aspiration cytology: management dilemmas. *Thyroid* . 2001:11:1147â€“1151.

14. MacDonald L, Yazdi HM. Nondiagnostic fine needle aspiration biopsy of the thyroid glar a diagnostic dilemma. *Acta Cytol* . 1996:40:423â€“428.

15. Schmidt T, Riggs MW, Speights VO Jr. Significance of nondiagnostic fine needle aspirati biopsy of the thyroid. *South Med J* . 1997;90:1183â€“1186.

16. McHenry CR, Walfish PG, Rosen IB. Non-diagnostic fine needle aspiration biopsy. A dilemma in management of nodular thyroid diseases. *Am Surgeon* . 1993;59:415â€“419.

17. Gharib H, Goellner JR, Johnson DA. Fine-needle aspiration cytology of the thyroid. A 1: year experience with 11,000 biopsies. *Clin Lab Med* . 1993;13:699â€“709.

18. Gharib H. Changing trends in thyroid practice: understanding nodular thyroid disease. *Endocr Pract* . 2004;10:31â€“39.

APPENDIX TO CHAPTER 4

Classification of Thyroid Tumors

The two classifications for thyroid neoplasms are the traditional classification recommendec the World Health Organization1 and another classification modified by Rosai and associates. The author has followed the modified classification in this Atlas.

WHO HISTOLOGICAL CLASSIFICATION OF THYROID AND PARATHYROID TUMORS1

Thyroid Carcinomas

- Papillary carcinoma
- Follicular carcinoma

- Poorly differentiated carcinoma
- Undifferentiated (anaplastic) carcinoma
- Squamous cell carcinoma
- Mucoepidermoid carcinoma
- Sclerosing mucoepidermoid carcinoma with eosinophilia
- Mucinous carcinoma
- Medullary carcinoma
- Mixed medullary and follicular carcinoma
- Spindle cell tumor with thymus-like differentiation
- Carcinoma showing thymus-like differentiation

Thyroid Adenomas and Related Tumors

- Follicular adenoma
- Hyalinizing trabecular adenoma

Other Thyroid Tumors

- Teratoma
- Primary lymphoma and plasmacytoma
- Ectopic thymoma
- Angiosarcoma
- Smooth-muscle tumors
- Peripheral nerve-sheath tumors
- Paraganglioma
- Solitary fibrous tumor

- Follicular dendritic cell tumor
- Langerhans cell histiocytosis
- Secondary tumors

Parathyroid Tumors

- Parathyroid carcinoma
- Parathyroid adenoma
- Secondary tumors

MODIFIED HISTOLOGICAL CLASSIFICATION OF THYROID TUMORS2

Primary Tumors

Tumors of Follicular Cells

- Benign Follicular Adenoma
- Conventional
- Variants

Malignant: Carcinoma

- Differentiated
    - Follicular carcinoma
    - Papillary carcinoma
        - Conventional
        - Variants

- Poorly Differentiated
    - Insular
    - Others

Undifferentiated (Anaplastic)

- Tumors of C-Cells and Related Endocrine Cells
    - Medullary carcinoma
    - Others
- Tumors of Follicular and C-Cells
- Sarcomas
- Malignant Lymphoma (and Related Hematopoietic Neoplasms)
- Miscellaneous Neoplasms

Secondary Tumors

Cytologic features resulting in special tumor types and subtypes that cross lines in the above classification for the tumors of follicular cells and, to a lesser extent of Câ€“cells, include t following.

- Tumors with Oncocytic (HÃ¼rthle cell) Features
    - Oncocytic adenoma (HÃ¼rthle cell adenoma)
    - Onvocytic carcinoma (HÃ¼rthle cell carcinoma)
    - Papillary oncocytic (HÃ¼rthle cell) tumors
- Tumors with Clear Cell Features

- Tumors with Squamous Features
- Tumors with Mucinous Features

REFERENCES

1.DeLellis RA, Lloyd RV, Heitz PU, et al, eds. *Pathology and Genetics of Tumors of Endocr Organs. World Health Organization Classification of Tumors* . Lyon: IARC Press; 2004.

2.Rosai J, Carcangiu ML, DeLellis RA. Tumors of the thyroid gland. In: Rosai J, Sobin LH, e *Atlas of Tumor Pathology* . Washington, DC: Armed Forces Institute of Pathology; 1993: 19â€“20.

Editors: Kini, Sudha R.
Title: *Thyroid Cytopathology: A Text and Atlas, 1st Edition*

Copyright Â©2008 Lippincott Williams & Wilkins

5

Concepts Basic to Thyroid Cytopathology and Guidelines for Evaluating Thyroid Fine-Needle Aspirates

Aspiration biopsy is essentially a form of microbiopsy. The aspirated material consists of minute tissue fragments (multicellular formations; Fig. 5.1), isolated cells (Fig. 5.2), and cells in groups or aggregates. The tissue fragments usually retain the architectural patterns of the lesion aspirated, even when smeared on the slide, and are very similar to those seen in paraffin-embedded hematoxylin-and eosin-stained sections. The only difference is that the thickness of the cellular material smeared on the slide is not uniform or even, unlike a section cut by a microtome. What makes the aspiration biopsy specimen so interesting is that both the nuclear morphology and cytoplasmic differentiation can be appreciated in great detail, especially in Papanicolaou-stained preparations. Thus, fine-needle aspiration biopsy is a blend of histopathology and cytopathology, and interpretation of the architectural configuration of the tissue fragments (pattern diagnosis), as much as cytomorphology of the component cells and isolated cells (exfoliative cytopathology) is an integral part of the evaluation. Mere pattern diagnosis or only cytomorphologic evaluation is inadequate. A sound knowledge of surgical pathology and expertise in cytopathology are essential.

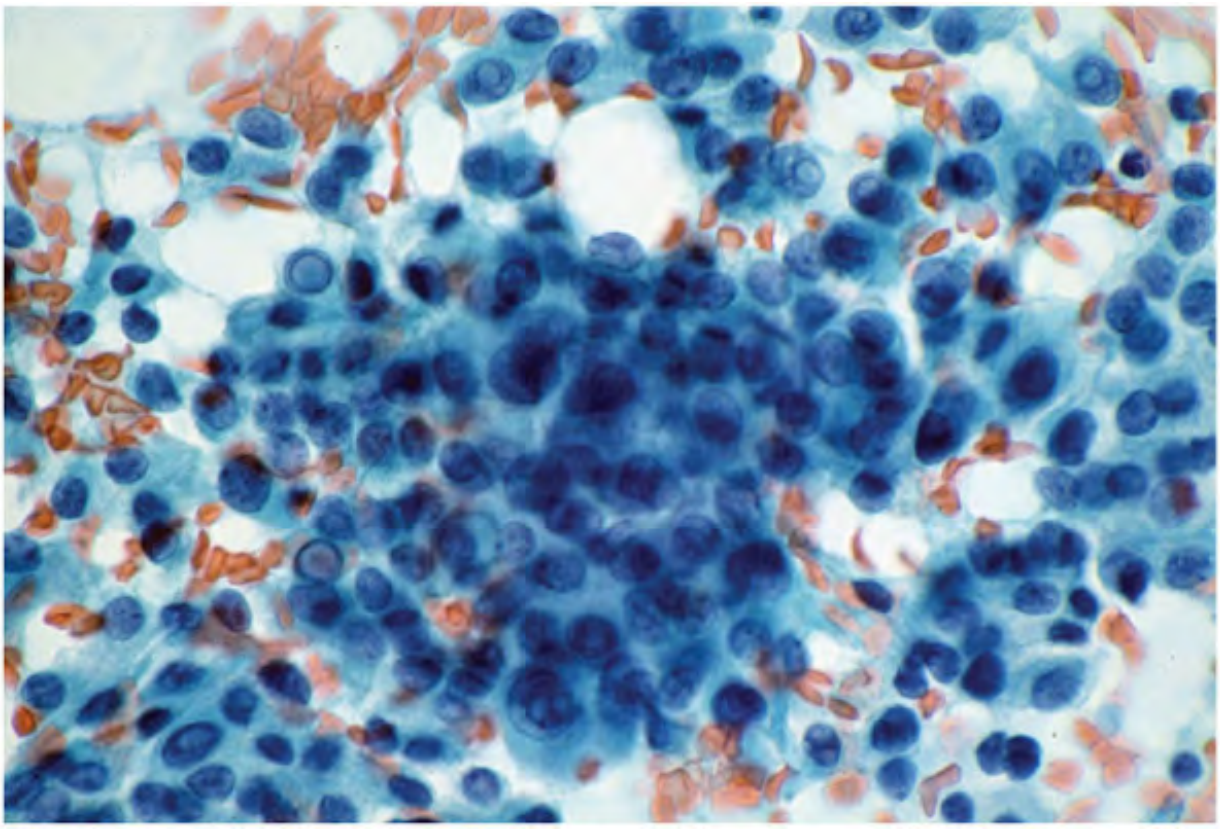

Figure 5.1. A multicellular formation (tissue fragment) in contrast to single cells.

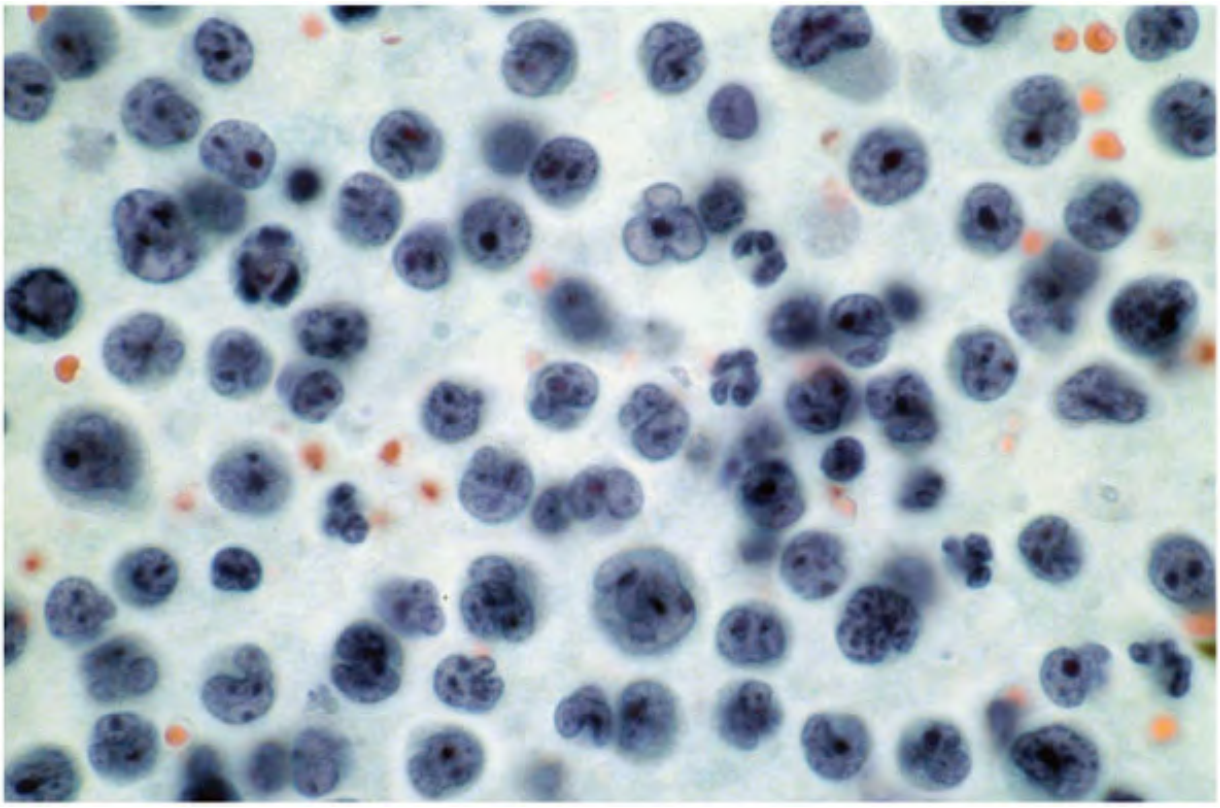

Figure 5.2. Single dispersed cells.

The tissue fragments present a wide range of architectural patterns. Similarly, the individual cells demonstrate a broad array of features based on their size, shape, and type.

How does one evaluate the architectural pattern of the tissue fragments in cytologic preparations, and why is a given tissue fragment papillary or follicular? To appreciate these patterns, certain expressions frequently used in cytopathology are described in following sections.

TISSUE FRAGMENT

A tissue fragment (Fig. 5.1) is a multicellular tissue formation, in contrast to single cells (Fig. 5.2).1

SHEET

A sheet (Fig. 5.3) is a monolayered tissue fragment in which the component cells are regularly arranged in relation to one another and possess distinct cell boundaries.2 The nuclear polarity is maintained, resulting in a honeycomb pattern. Sheets are two-dimensional and display all the component cells in one plane of focus. Any structure that is single layered will present as a sheet when viewed en face in both cytologic and histologic preparations. The common examples are thyroid follicles, endocervical glands, mammary or pancreatic ducts, or a mesothelium.

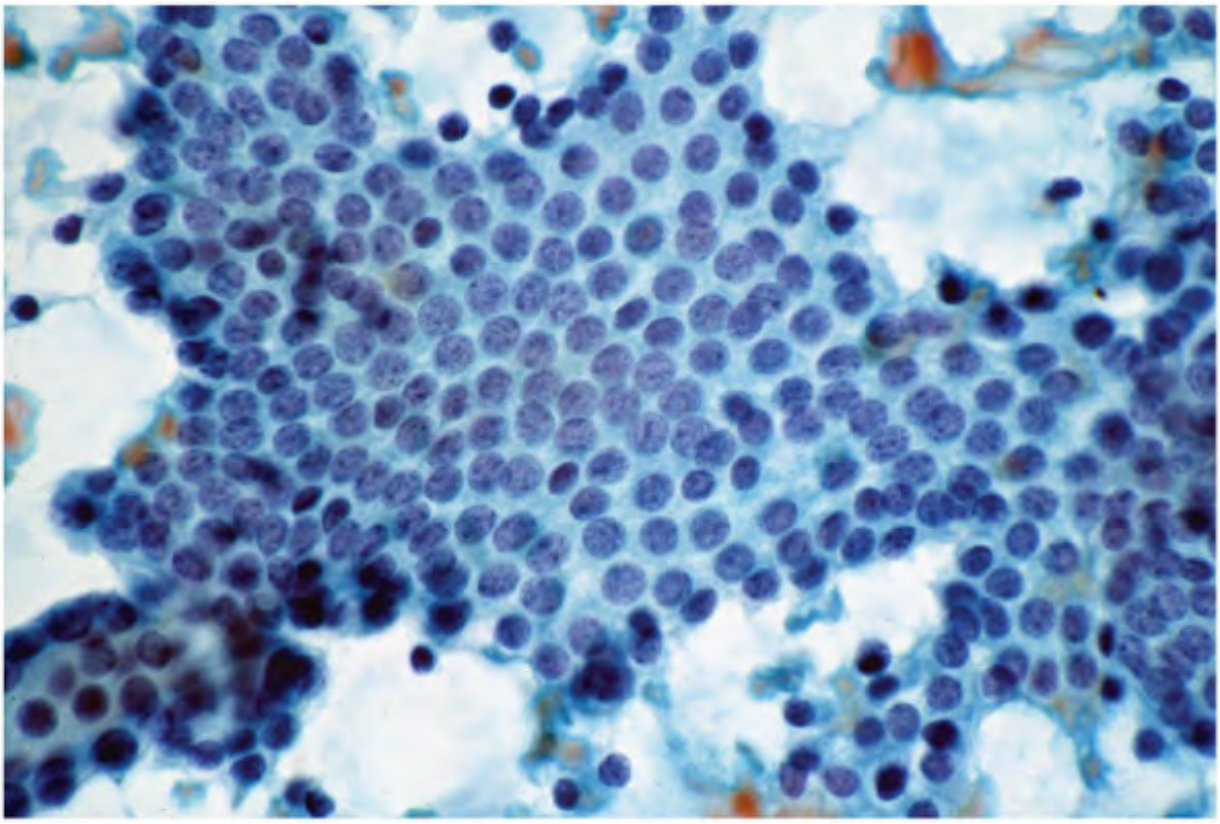

Figure 5.3. Sheet (honeycomb). Two-dimensional tissue fragment. The component cells are visualized in one plane of focus. The cell borders are well-defined, nuclei regularly placed in relation to one another, and nuclear polarity is maintained. This pattern is seen when a structure composed of a single cell layer is seen en face, as with a thyroid follicle, endocervical gland, mesothelium, mammary duct, or pancreatic duct.

SYNCYTIUM OR SYNCYTIAL TISSUE FRAGMENT

A syncytium or syncytial tissue fragment (Fig. 5.4) is a tissue fragment consisting of cells that are irregularly arranged with respect to one another and have indistinct cell borders2 and nuclear polarity. Because of the nuclear crowding and the lack of well-defined cell borders, the nuclei often appear to be in several planes of focus. Syncytial architecture differentiates a neoplasm from a benign structure that presents as a sheet. Depending on the growth pattern of the neoplasm, the tissue fragments may demonstrate various configurations or patterns that allow recognition and typing of the neoplasm. A given neoplasm may show more than one growth pattern, and consequently the aspirate may demonstrate tissue fragments with different configurations, as in a case of papillary carcinoma. Figures 5.3, 5.4, 5.5, 5.6, 5.7, 5.8, 5.9, 5.10, 5.11, 5.12, 5.13, 5.14 and 5.15 illustrate commonly encountered patterns of tissue fragments in thyroid aspirates.

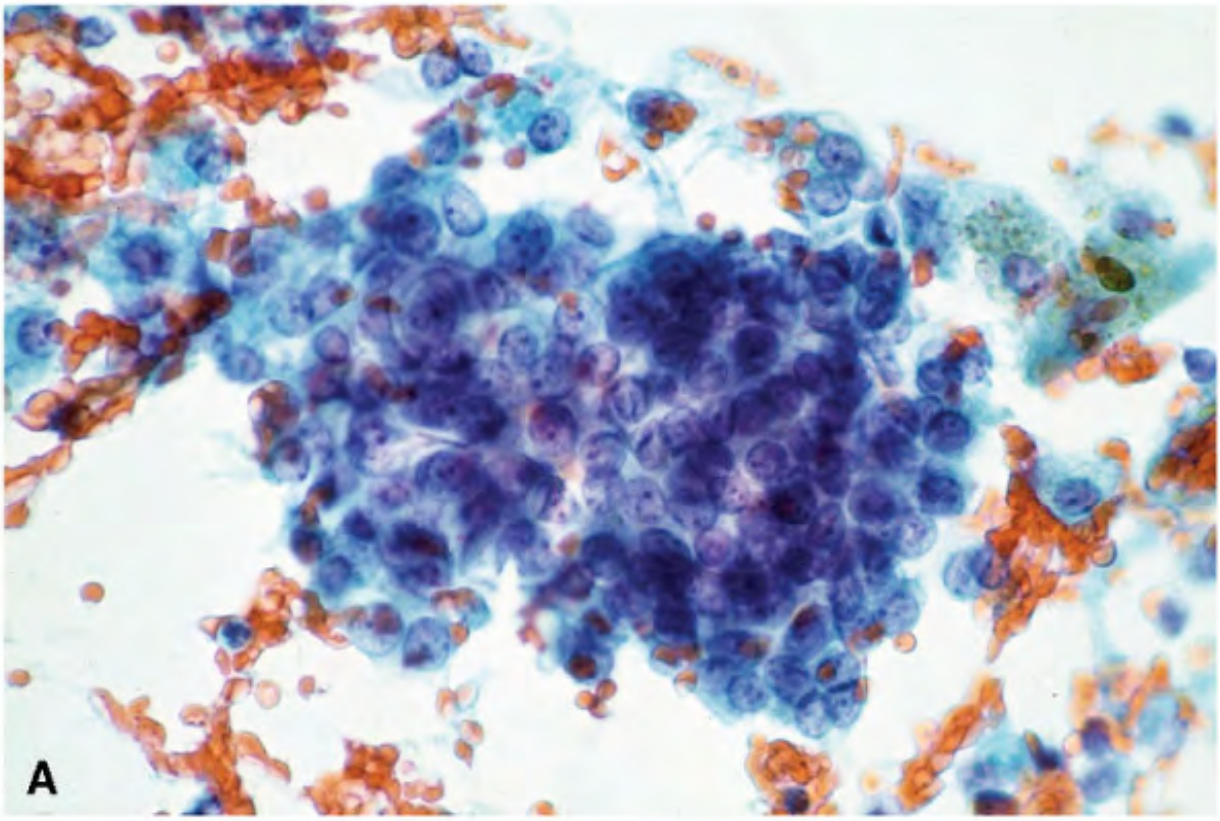

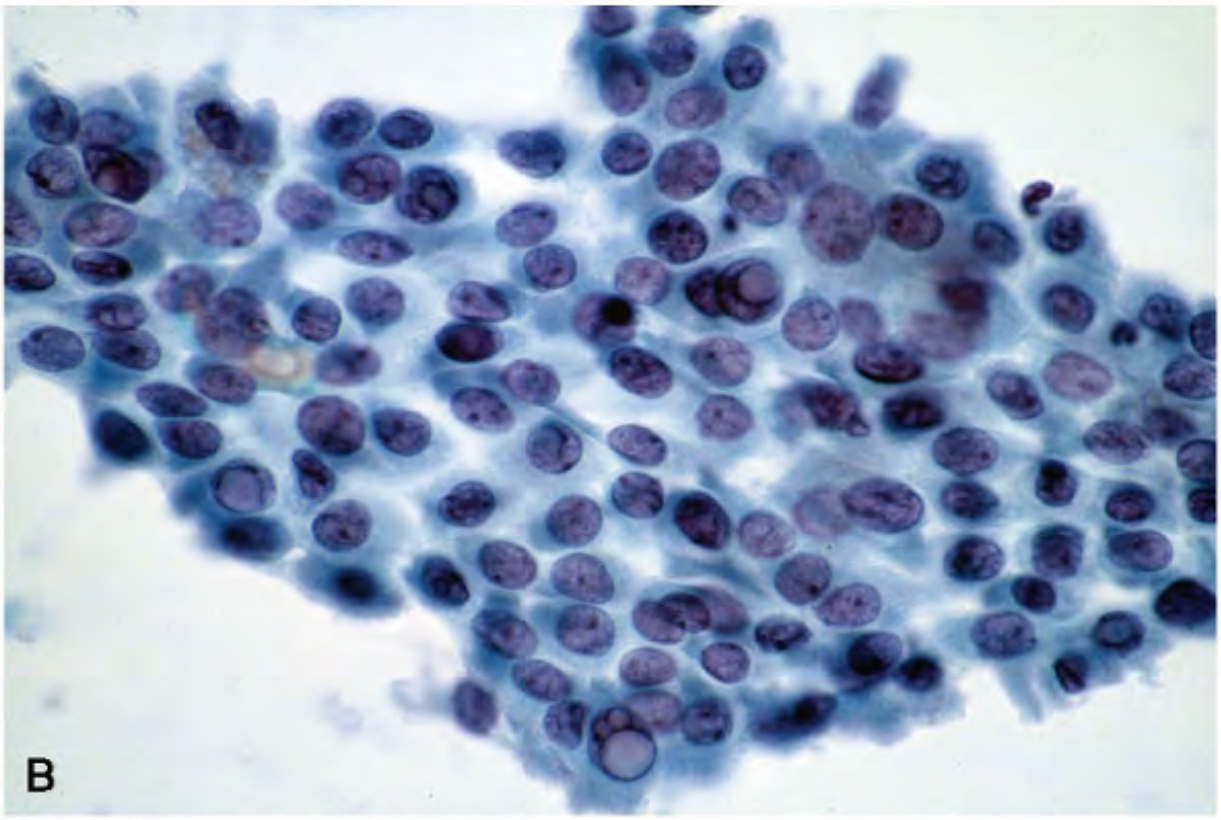

Figure 5.4. Syncytium. A syncytium can be two- or three-dimensional, with the component cells often visualized in multiple planes of focus and with poorly defined cell borders, crowded and overlapping nuclei, and altered polarity. Syncytial architecture is indicative of a neoplasm (an exception being pseudostratified epithelium).

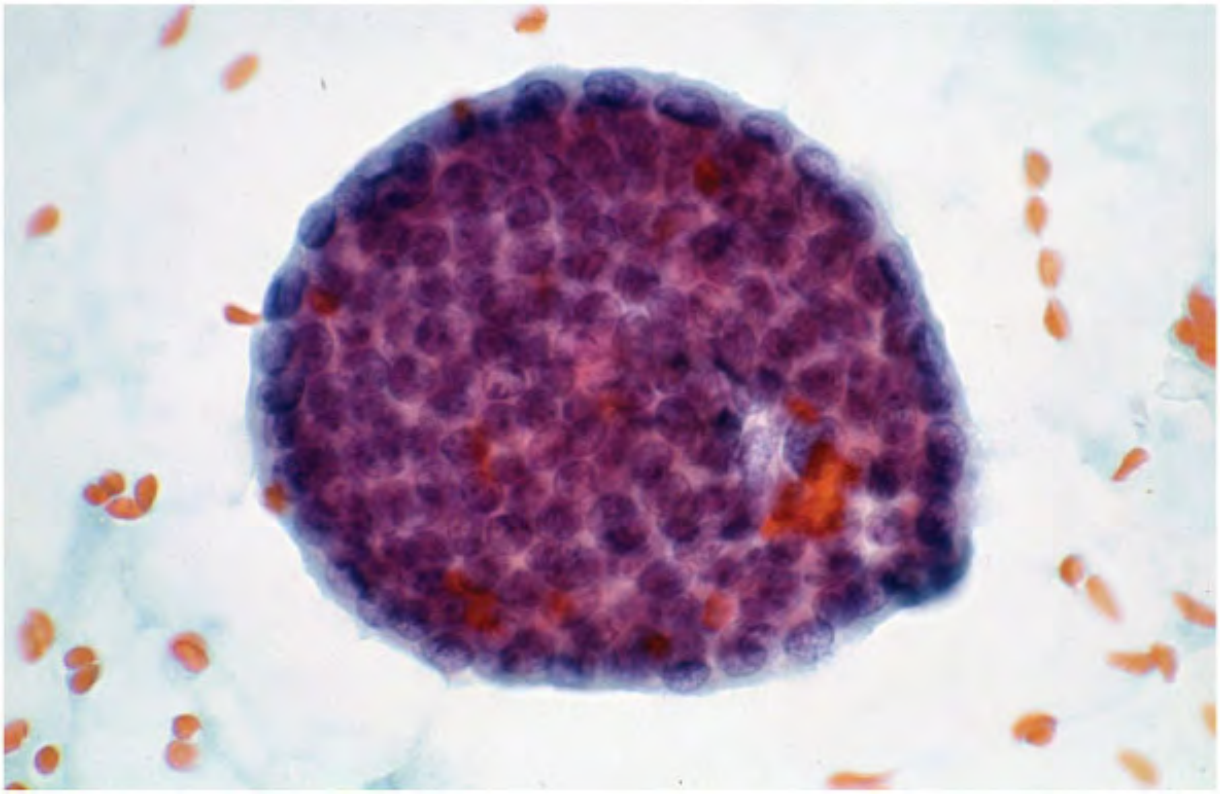

Figure 5.5. Cluster. A tissue fragment exhibiting a syncytial architecture with marked crowding and overlapping of nuclei, visualized in multiple planes of focus, appearing three-dimensional.

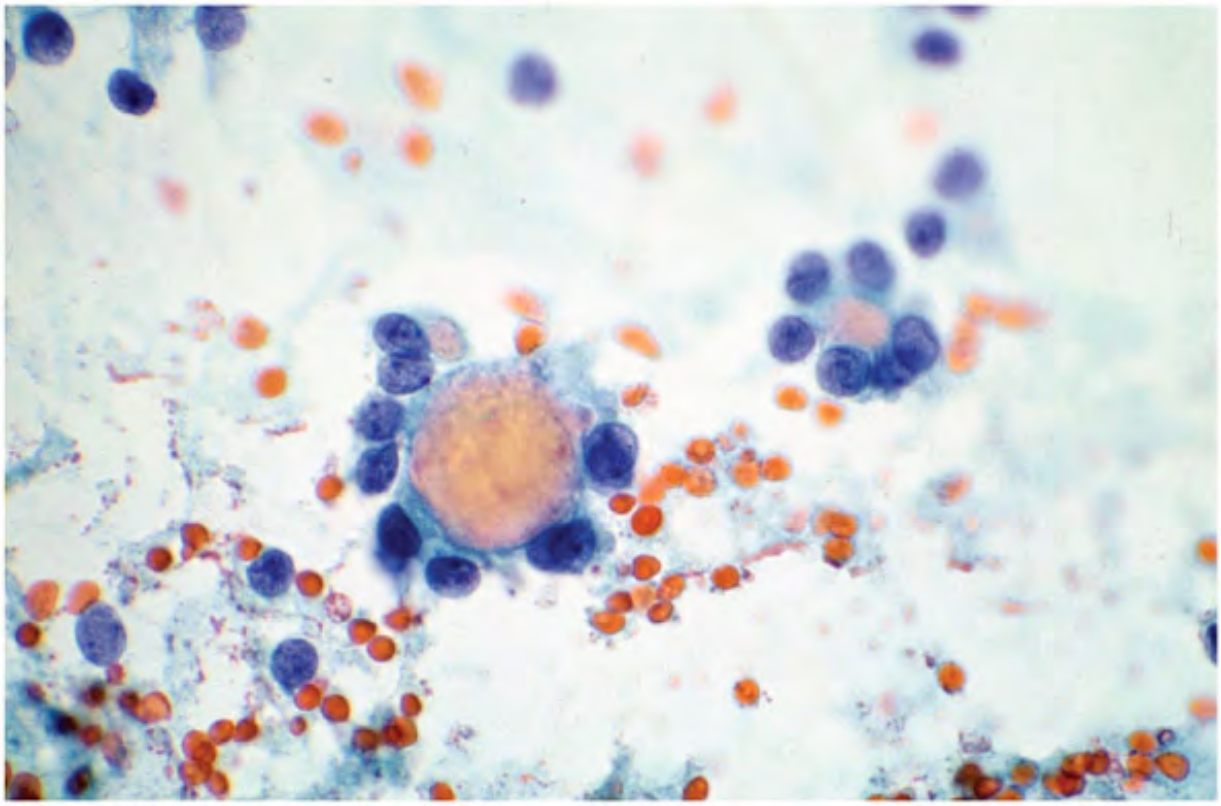

Figure 5.6. A follicle. The cells are arranged around a central lumen. A follicle can vary in size and be seen in cross-section or in its entirety. The term "macrofollicular" is used when a large monolayered tissue fragment is present. A large follicle or macrofollicle cannot be seen in its entirety in cytologic specimens, unlike in a tissue section, and is best appreciated when seen en face.

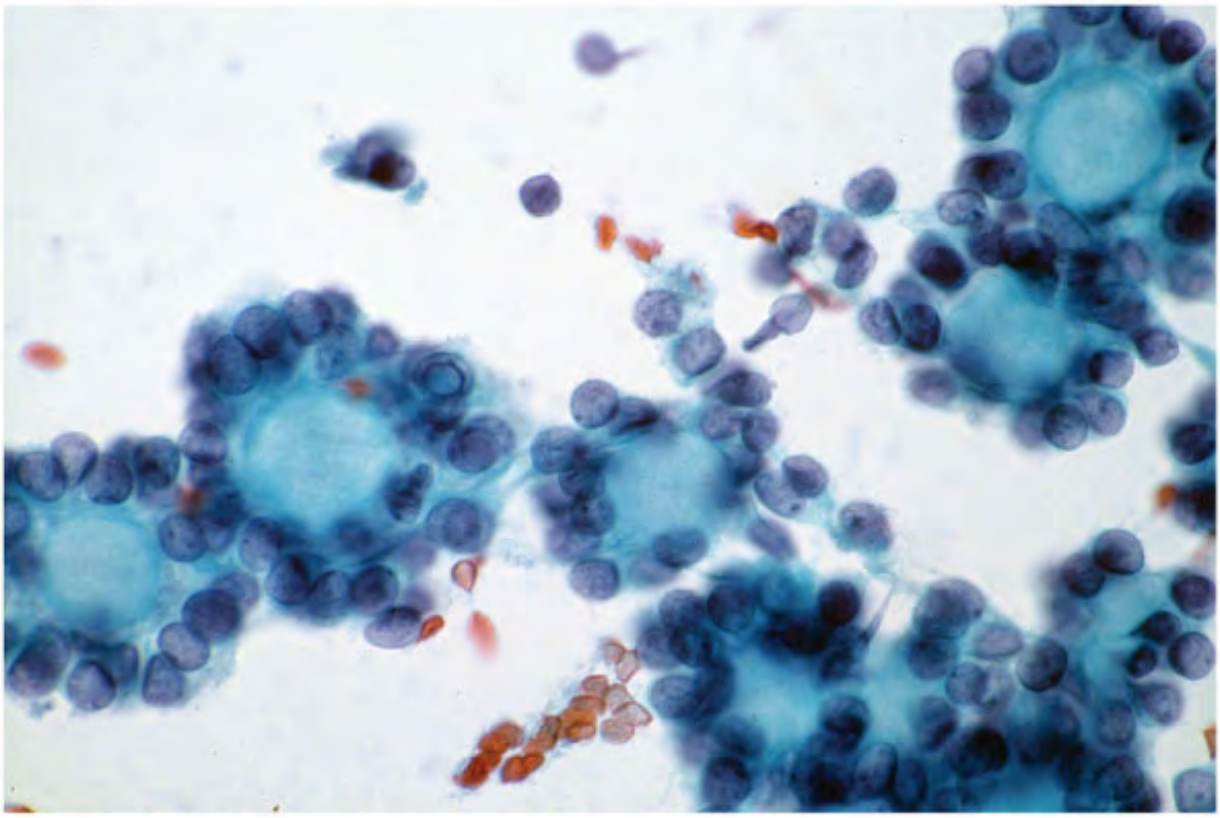

Figure 5.7. Syncytial tissue fragment with follicular pattern.

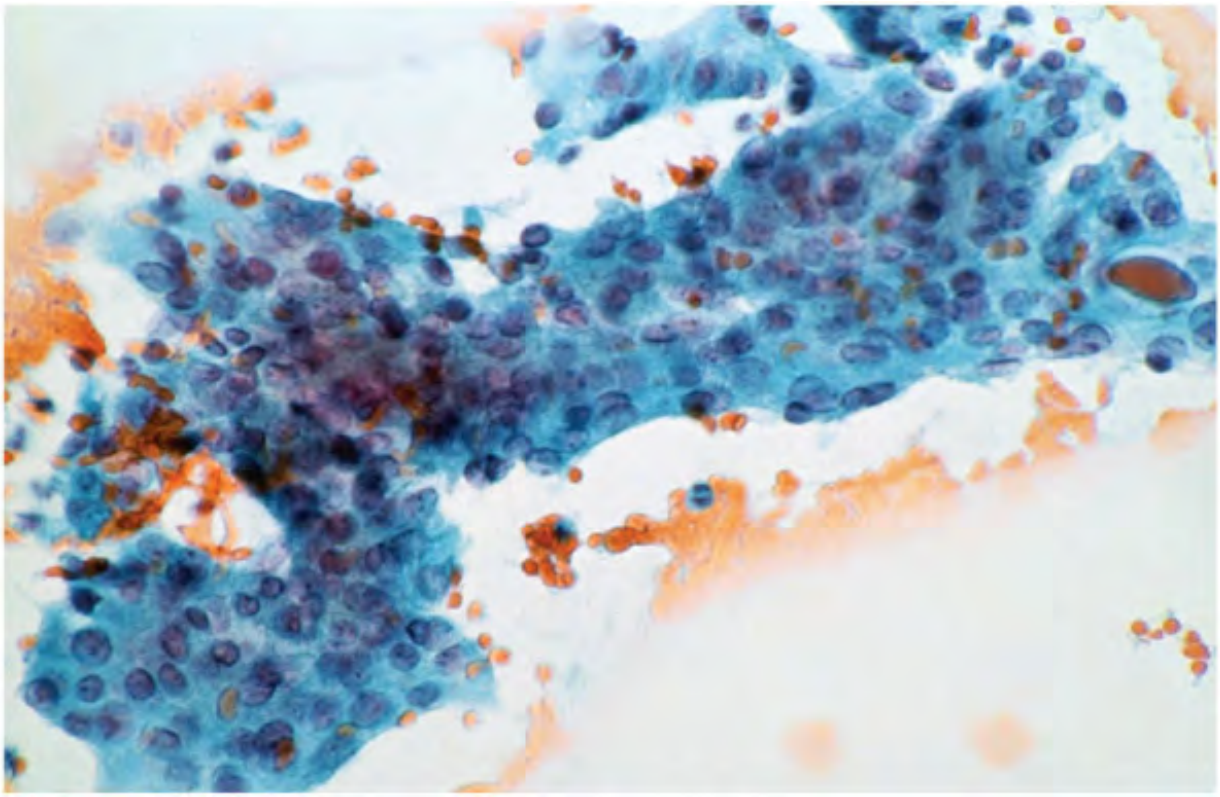

Figure 5.8. Trabecular pattern. Straight or curved chords, two or more cells thick.

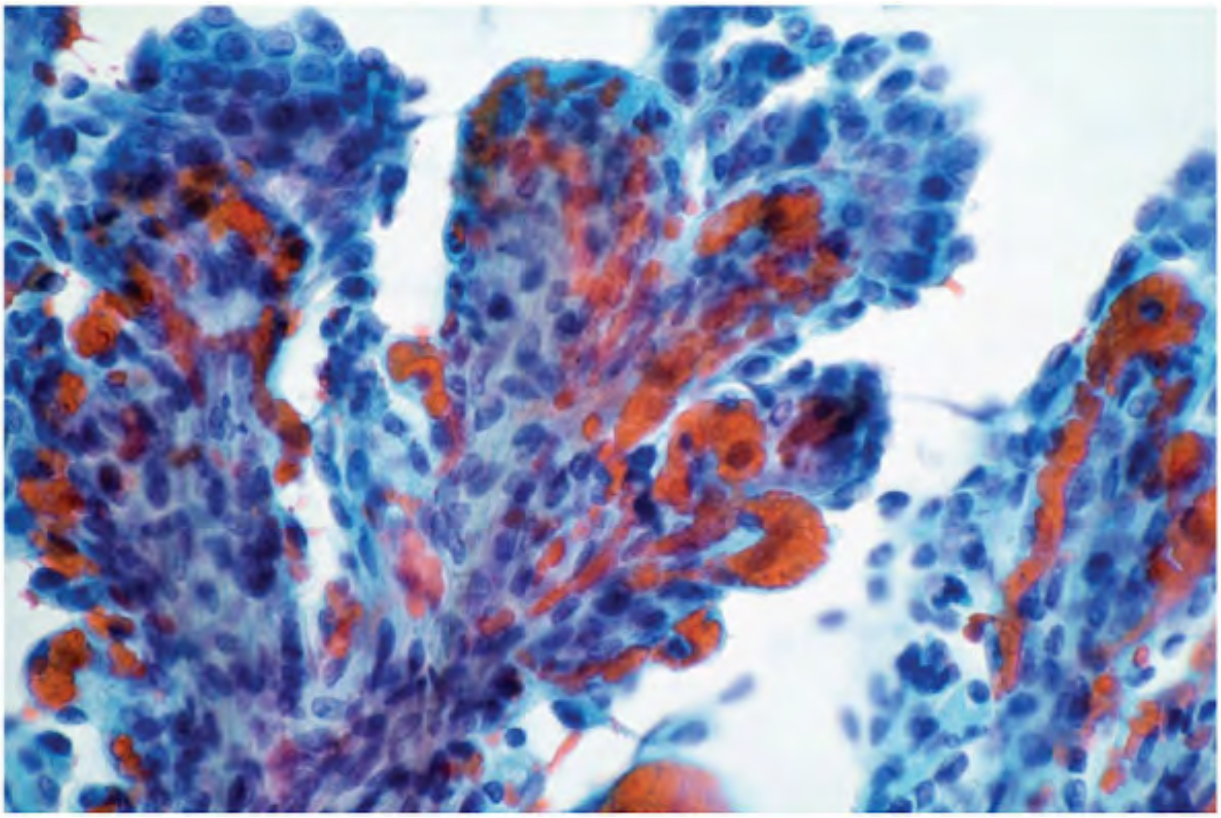

Figure 5.9. Papillary. Finger-like slender tissue fragments with or without branching; central core of fibrovascular stromal tissue; epithelial cells line the cores.

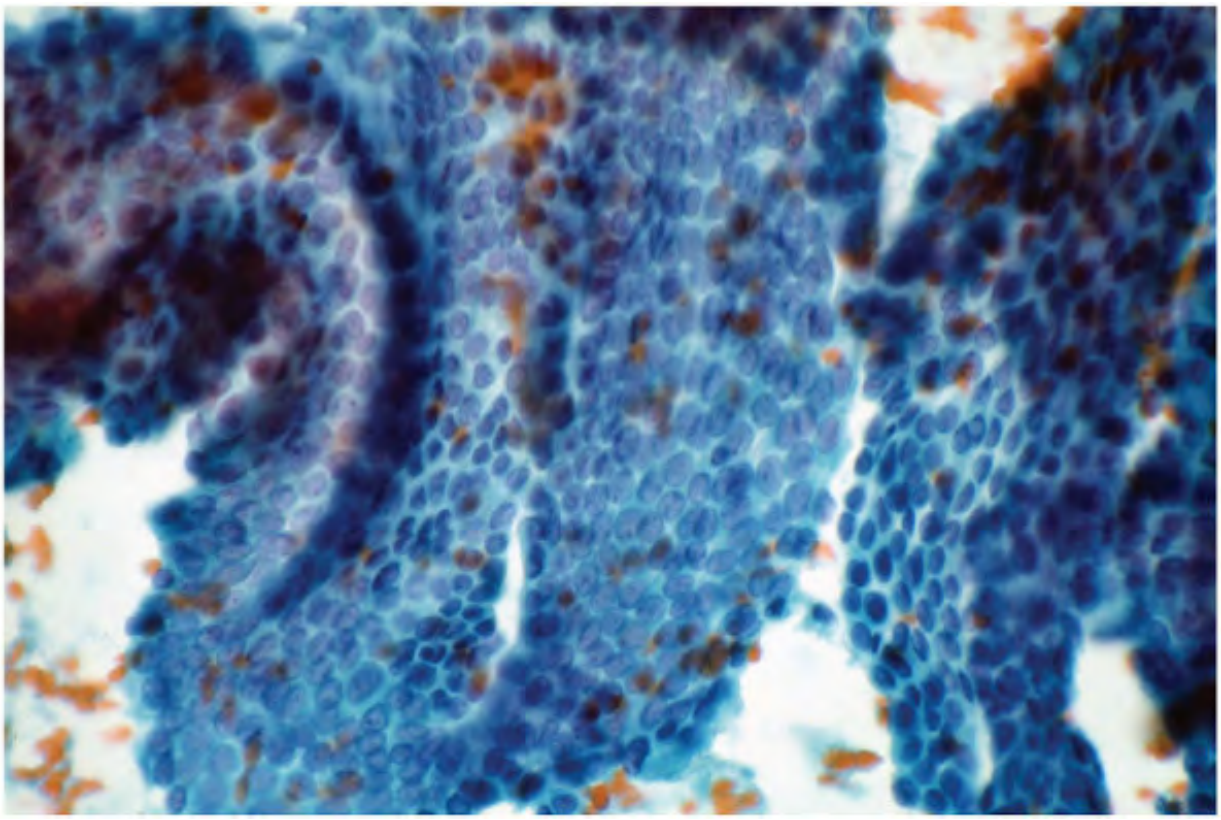

Figure 5.10. Papillary-like. Finger-like slender tissue fragments of epithelial cells with or without branching, lacking central core of fibrovascular stromal tissue.

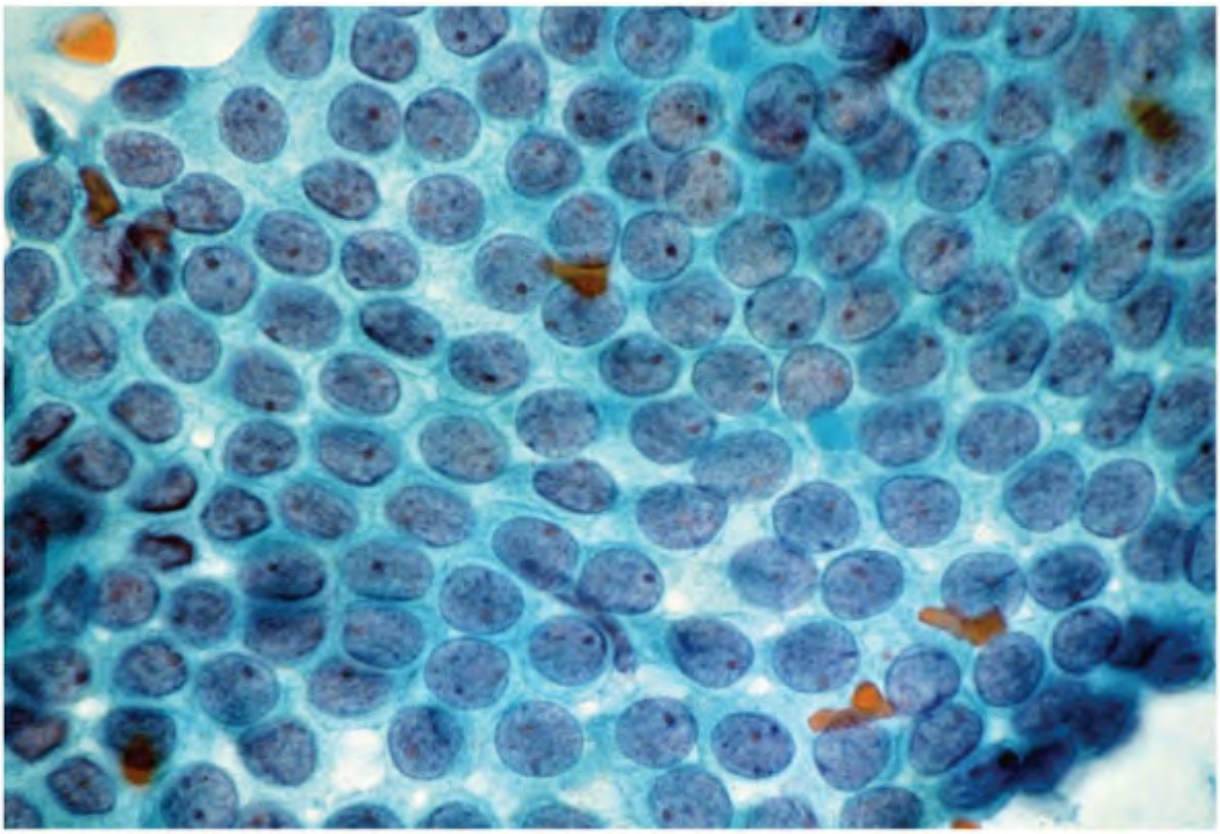

Figure 5.11. A syncytial tissue fragment that is monolayered, lacking a honeycomb pattern. Note the absence of well-defined cell borders. There is minimal crowding and altered nuclear polarity.

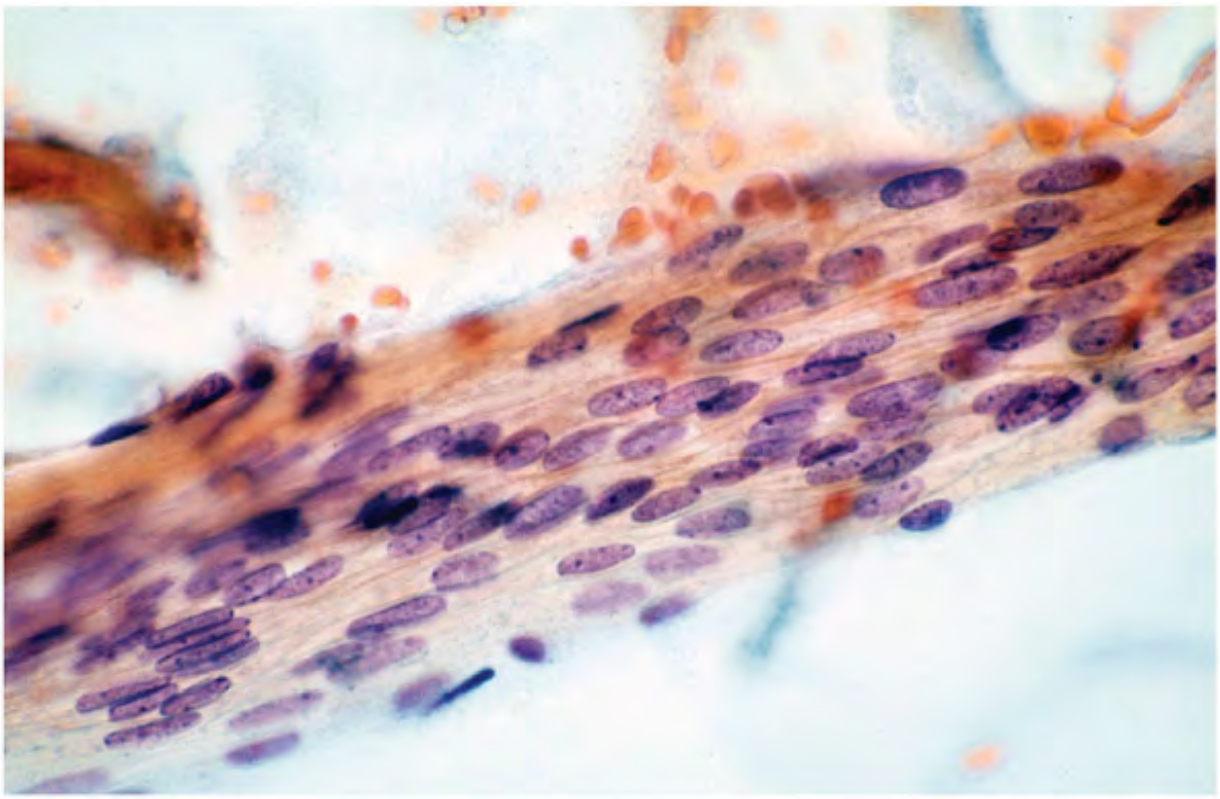

Figure 5.12. Fascicle. A bundle. The spindle cells are arranged in a fascicle.

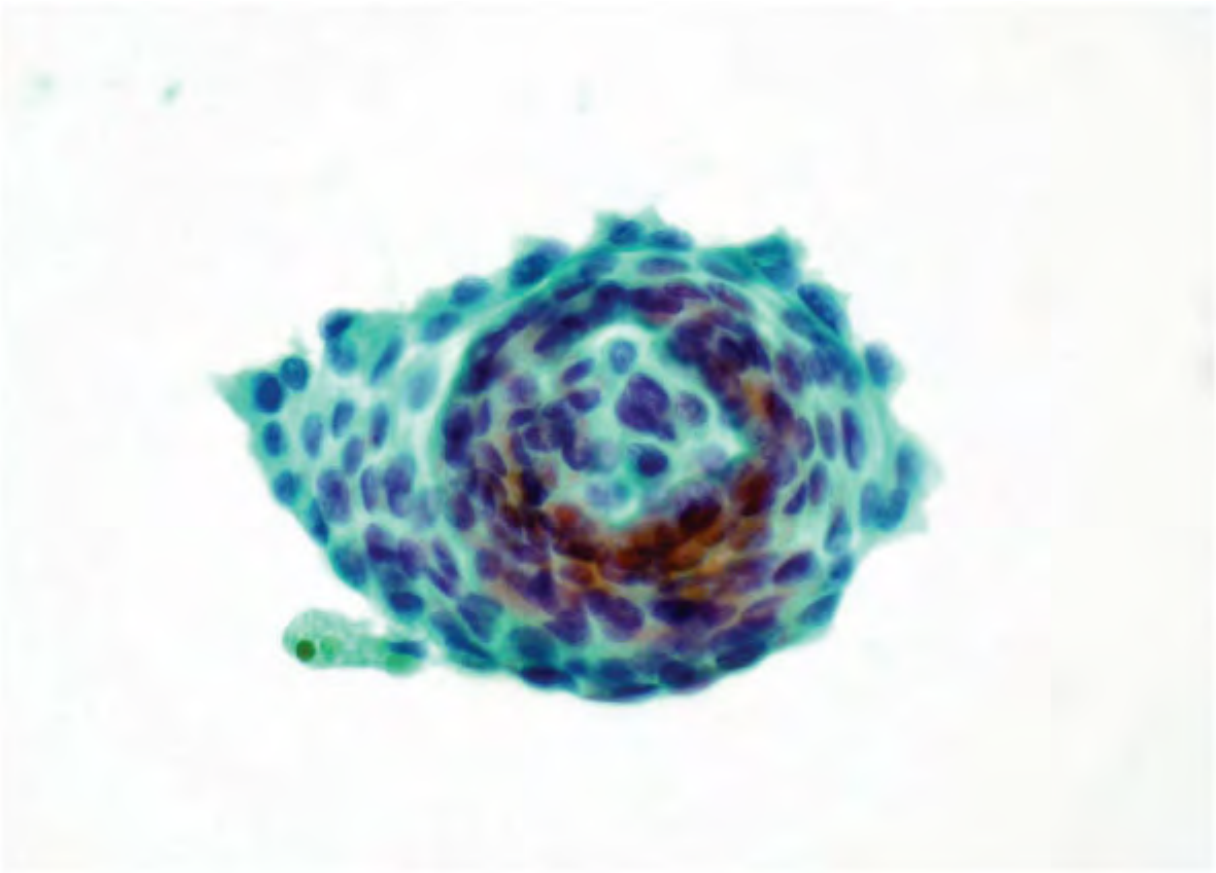

Figure 5.13. Onion-skin. A syncytial tissue fragment with cells/nuclei arranged in concentric fashion.

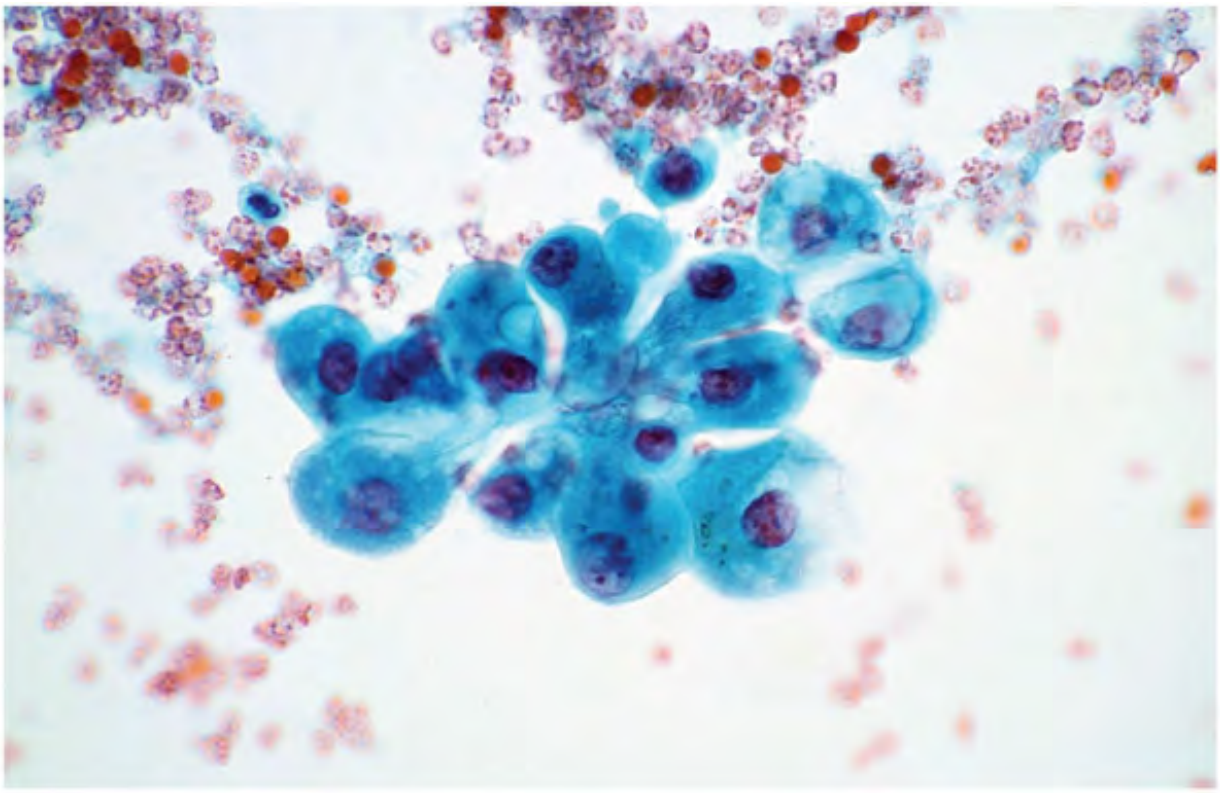

Figure 5.14. Cartwheel. A tissue fragment with cells radiating from the center.

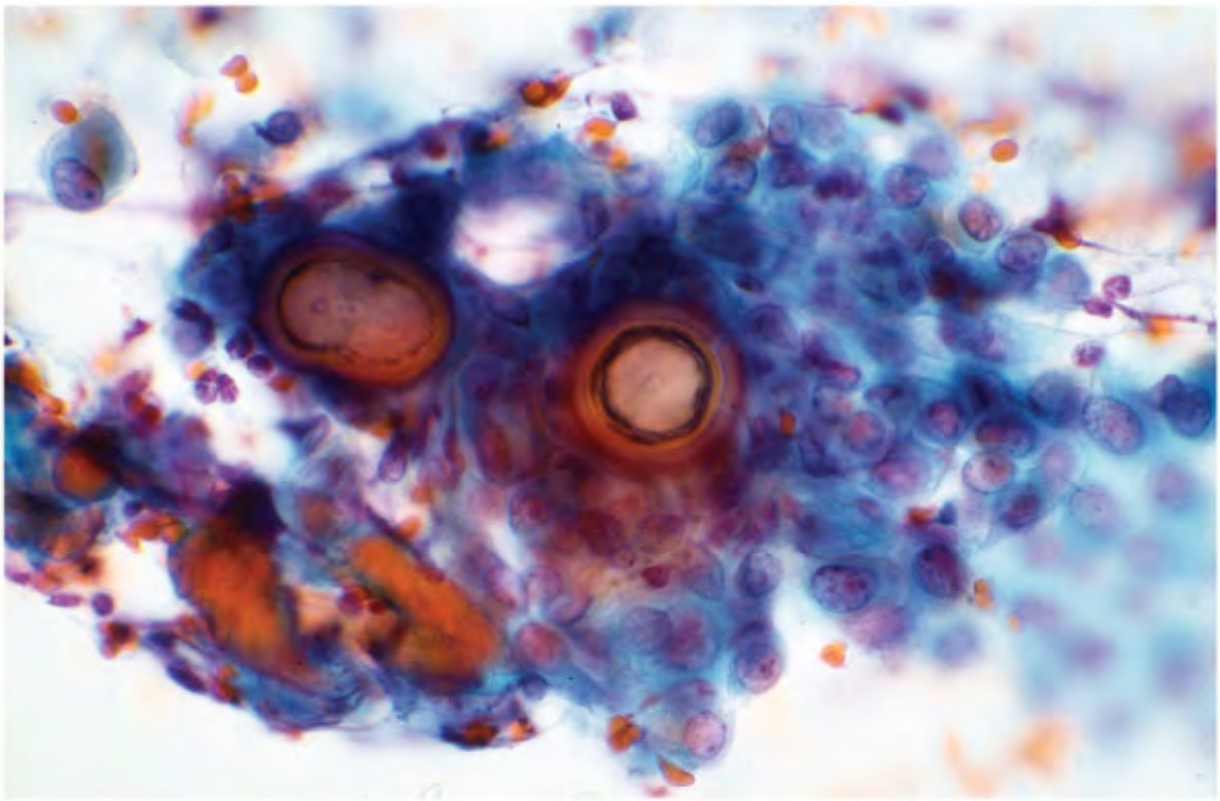

Figure 5.15. A tissue fragment incorporating psammoma bodies. A psammoma body is a calcific concretion with concentric lamellations, which always stains basophilic in tissue sections with hematoxylene and eosin but takes multiple stains with the Papanicolaou method. In cytologic specimens, a psammoma body can have various appearances: concentric lamellations, refractile, starburst.

Besides the architecture of the tissue fragments, the nuclear characteristics are very important, and include the nuclear size, shape, nuclear membrane, chromatin pattern, parachromatin clearing, presence or absence of nucleoli, grooves or inclusions, and mitoses (Figs. 5.16 and 5.17). The size of the

P.30
P.31
P.32

cell or the nucleus is usually compared against a known structure, such as a red blood cell, an entire neutrophil, a histiocytic nucleus, or a resting lymphocyte. In thyroid

aspirates, the follicular cell nucleus is compared against the red blood cell, which is roughly 7 Âµm in its longest dimension. Figure 5.18 describes the size range of the cell when compared to a resting lymphocyte. For detailed description of various morphologic characteristics of the cell, nuclei, stroma, and background features, the reader is referred to the literature.3

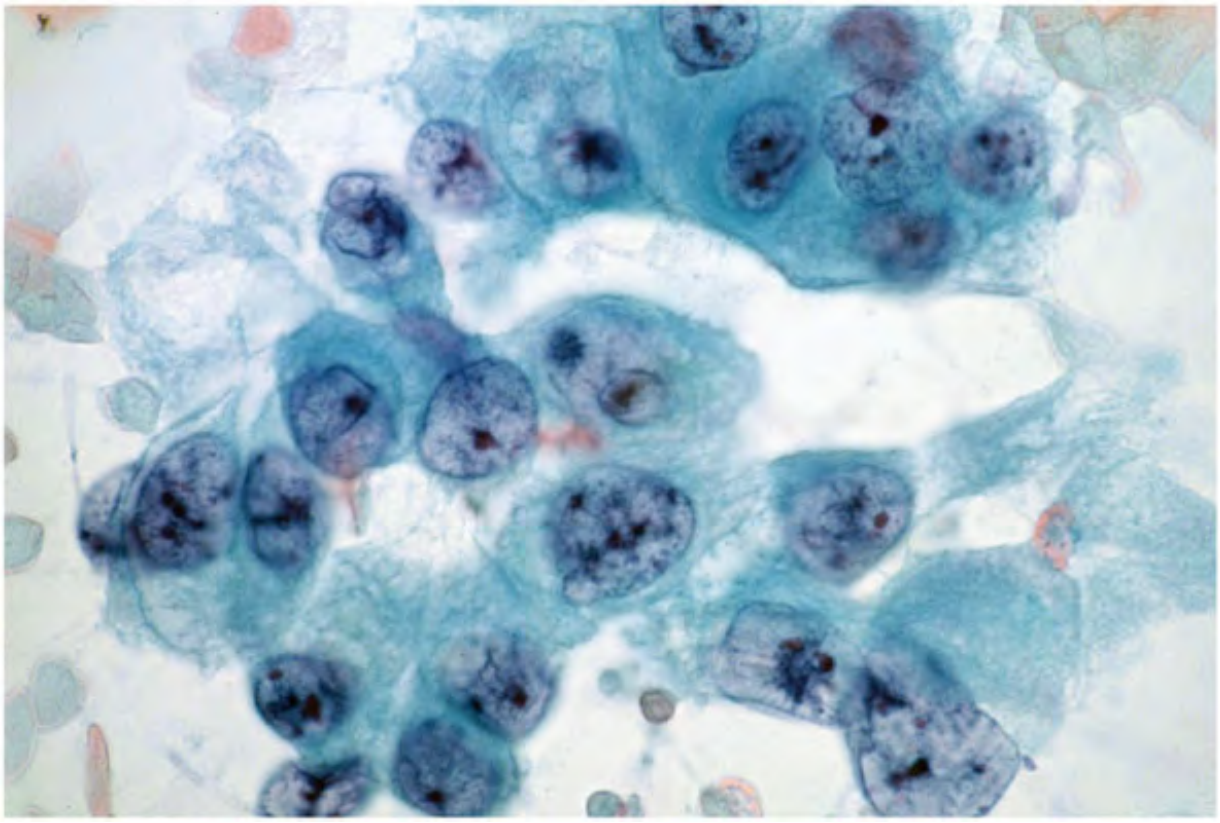

Figure 5.16. Nuclei exhibiting malignant characteristics. Note the pleomorphic size, nuclear membrane irregularities, irregular chromocenters separated by excessively cleared parachromatin, and multiple and variable micro/macronucleoli.

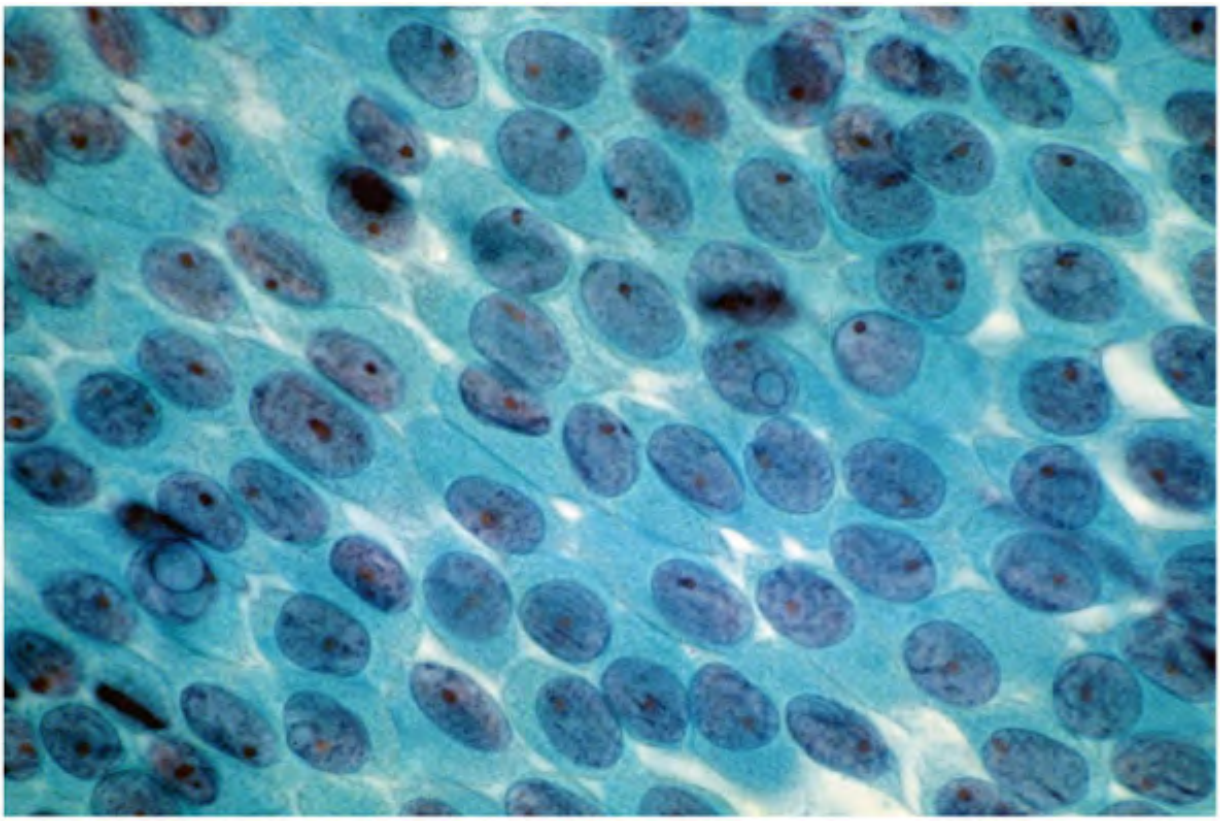

Figure 5.17. Nuclear morphology: round, oval, and oblong nuclei demonstrating powdery chromatin, nucleoli, grooves, and intranuclear inclusions.

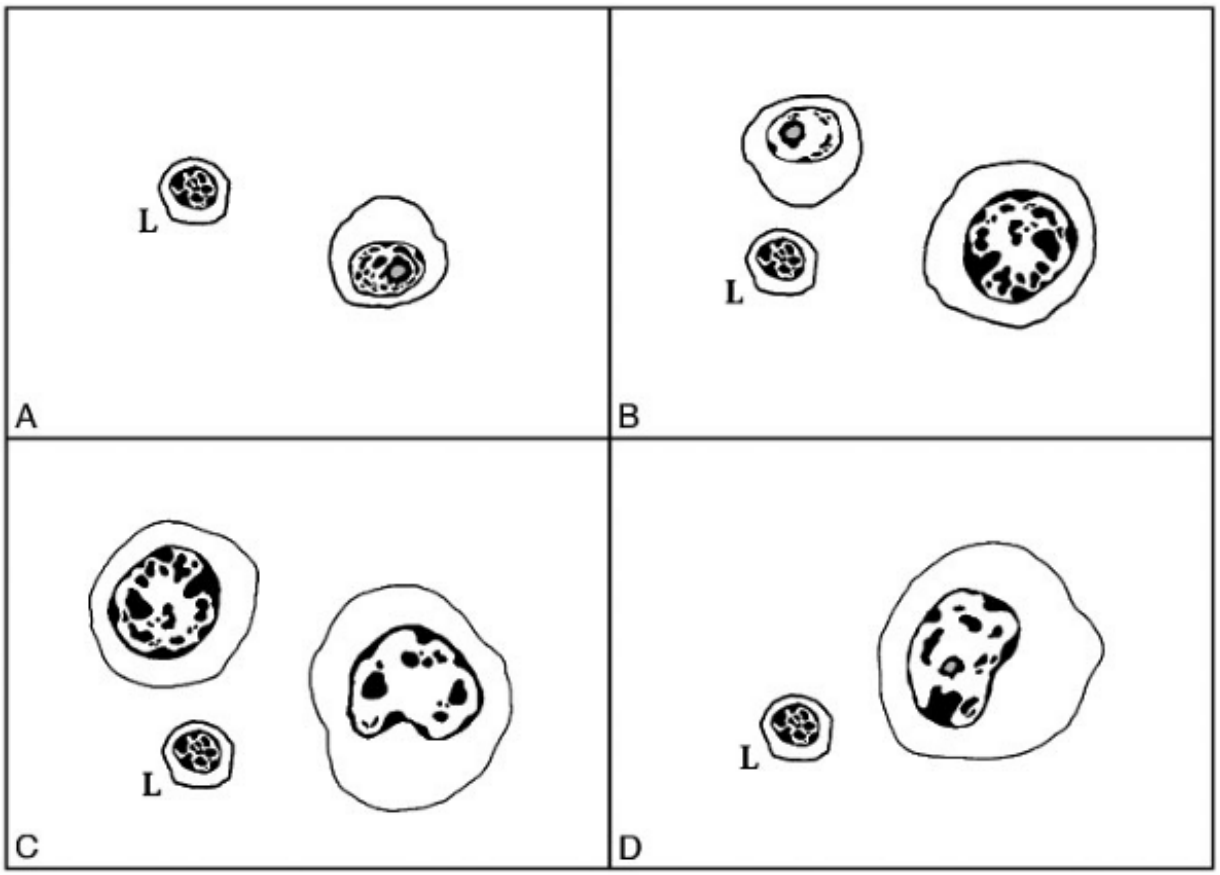

Figure 5.18. Cell size. A. Small: 1 to 3 times the size of a resting lymphocyte. B. Medium: 3 to 5 times the size of resting lymphocyte. C. Large: 6 to 10 times the size of resting lymphocyte. D. Giant: 10 times or larger than the resting lymphocyte.

Most thyroid cancers are differentiated carcinomas. Unlike the diagnosis of anaplastic carcinoma, which can easily be made from bizarre pleomorphic cells presenting glaringly malignant criteria (Fig. 5.16), differentiated cancers are identified from (i) the architectural patterns of the tissue fragments (e.g., papillary or follicular) and (ii) the cytomorphology of the component cells. The nuclear changes are generally very subtle.

The various structural aberrations presented in aspirated specimens of thyroid lesions can be best appreciated when the anatomy and histology of the thyroid, as well as the

basic concept of the thyroid follicle, are understood.

The normal thyroid gland is located in front of the neck, straddling the trachea. It consists of two lobes joined by an isthmus (Fig. 5.19), and weighs approximately 15 g. Each lobe consists of multiple lobules, and each lobule is composed of several follicles (Fig. 5.20) supported by a delicate but very vascular connective tissue stroma. A follicle represents a unit of thyroid parenchyma. It is a three-dimensional closed sac (Fig. 5.21A) filled with colloid and lined by a single layer of

cuboidal epithelium resting on a basement membrane. The nuclei of these cells are centrally located and round to oval, with finely granular chromatin. The cell borders are well defined, and the cytoplasm is moderate. A follicle seen in cross-section appears as a ringlet of cuboidal cells, with regularly spaced nuclei and an appreciable amount of cytoplasm, around a central lumen (Fig. 5.21B). Viewed en face, it appears as a monolayered sheet of cells with well-defined cell borders and centrally spaced nuclei, giving a honeycomb pattern (Fig. 5.21C). This two-dimensional architecture results from the follicles being lined by a single layer of cells. Thus, depending on how the thyroid follicles are sectioned or smeared, they may appear as regular follicles or honeycomb sheets. Such a pattern is seen in non-neoplastic thyroid lesionsâ€”such as, nodular goiterâ€”both cytologically and histologically (Figs. 5.22 and 5.23). A normal or benign thyroid follicle if aspirated in its entirety will show a honeycomb architecture in different planes (Fig. 5.24). A large, distended follicle is not seen in its entirety in smears, as it gets ruptured. Instead it presents as a large monolayered sheet, referred to as macrofollicle. The regular arrangement of cells of a normal follicle is usually not seen in neoplastic lesions, whether benign or malignant. A neoplastic follicle is irregular (Fig. 5.25A), and whether seen in a cross-section (Fig. 5.25B) or en face (Fig. 5.25C), it appears as a syncytial-type tissue fragment with poorly defined cell borders and crowded, overlapping nuclei. These structural aberrations are easily appreciated in aspirates of follicular neoplasms, both cytologically and histologically (Figs. 5.26, 5.27 and 5.28). The exceptions are adenomas with well-formed follicles that recapitulate the structure of normal thyroid.

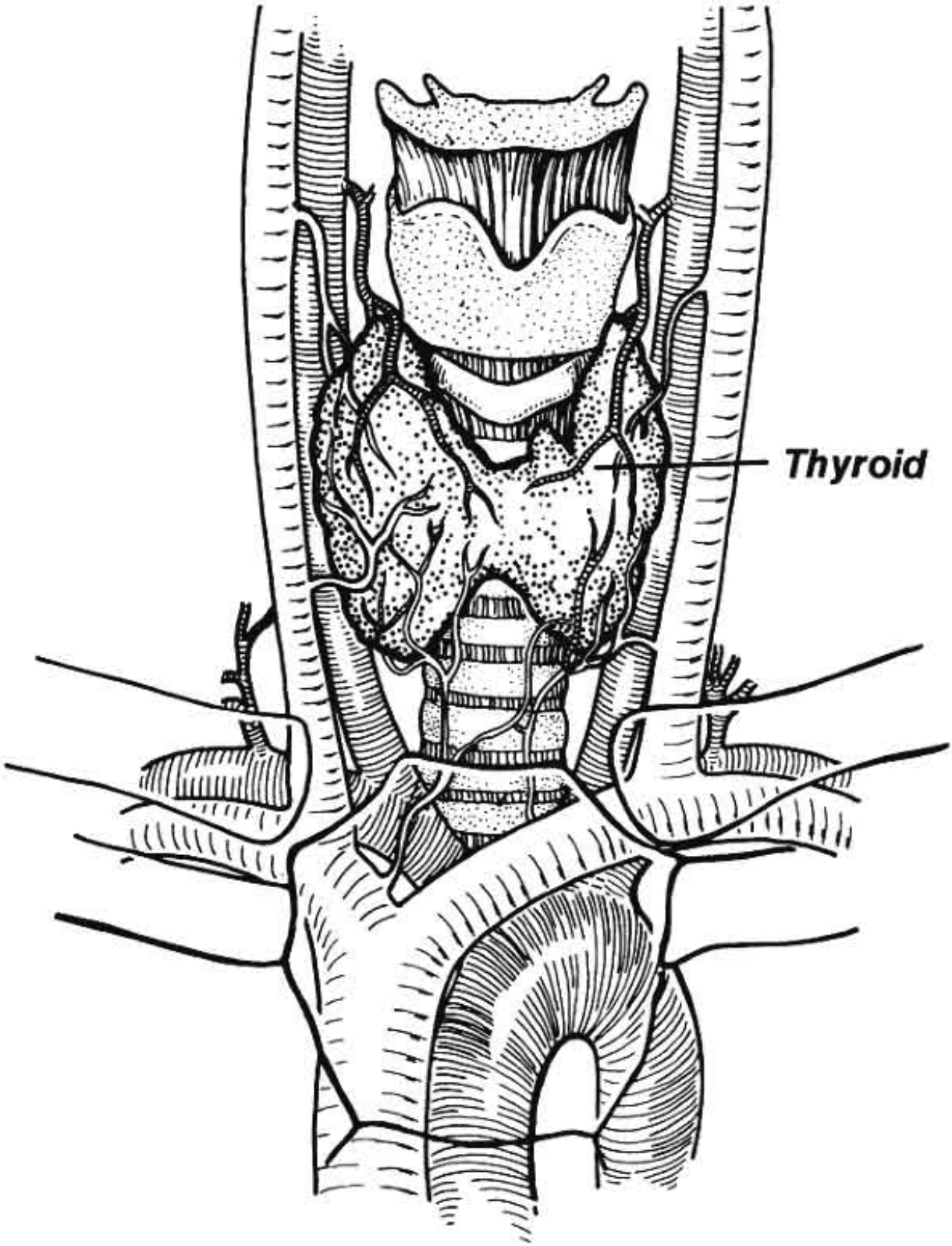
Thyroid

Figure 5.19. Anatomy of the thyroid.

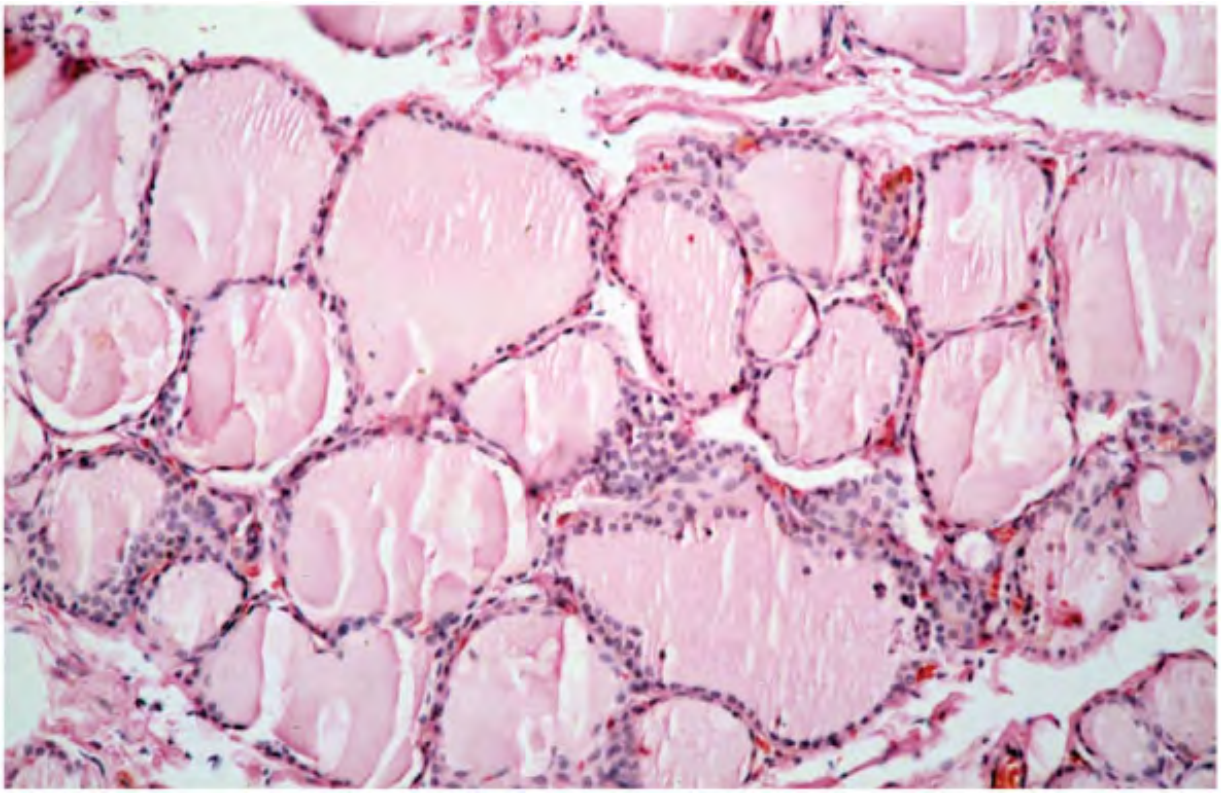

Figure 5.20. Histologic section of a normal thyroid showing follicles containing colloid. The lining epithelium is low cuboidal.

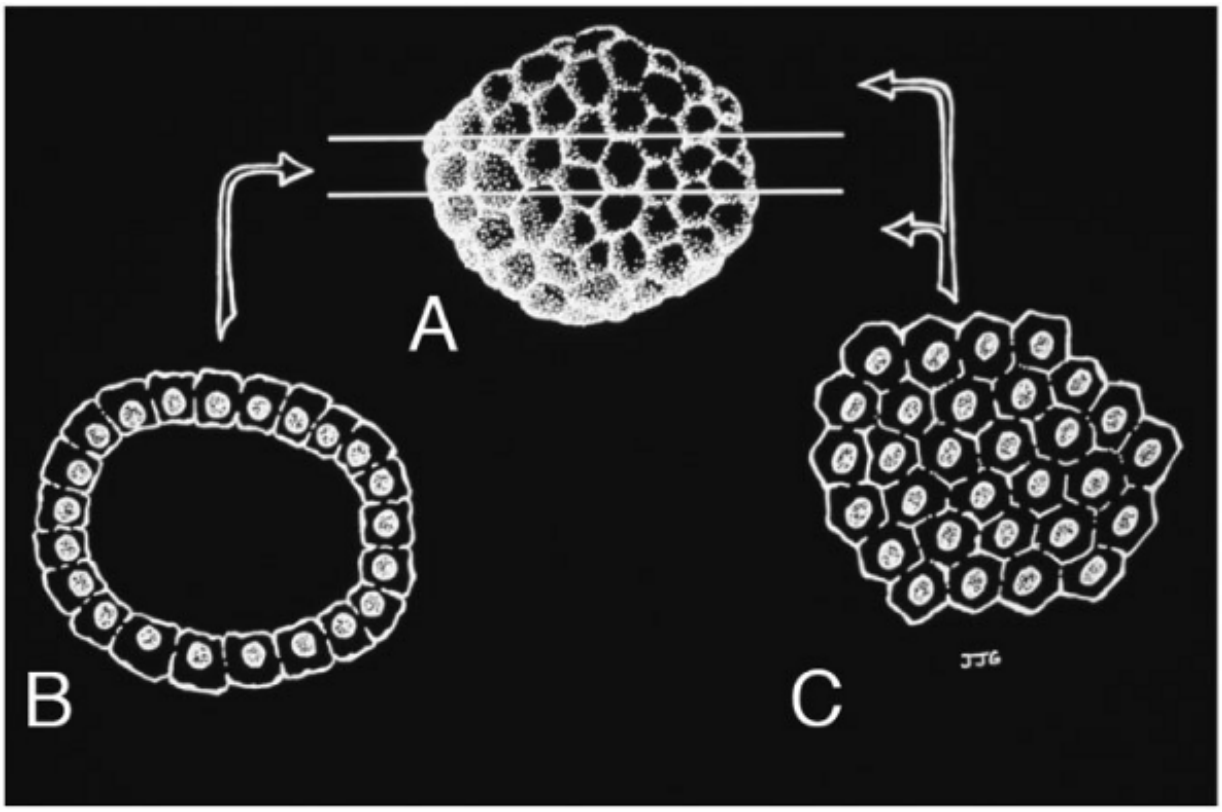

Figure 5.21. A. Concept of normal thyroid follicle. B. Cross-section of the follicle. C. Follicle seen en face presenting a honeycomb pattern.

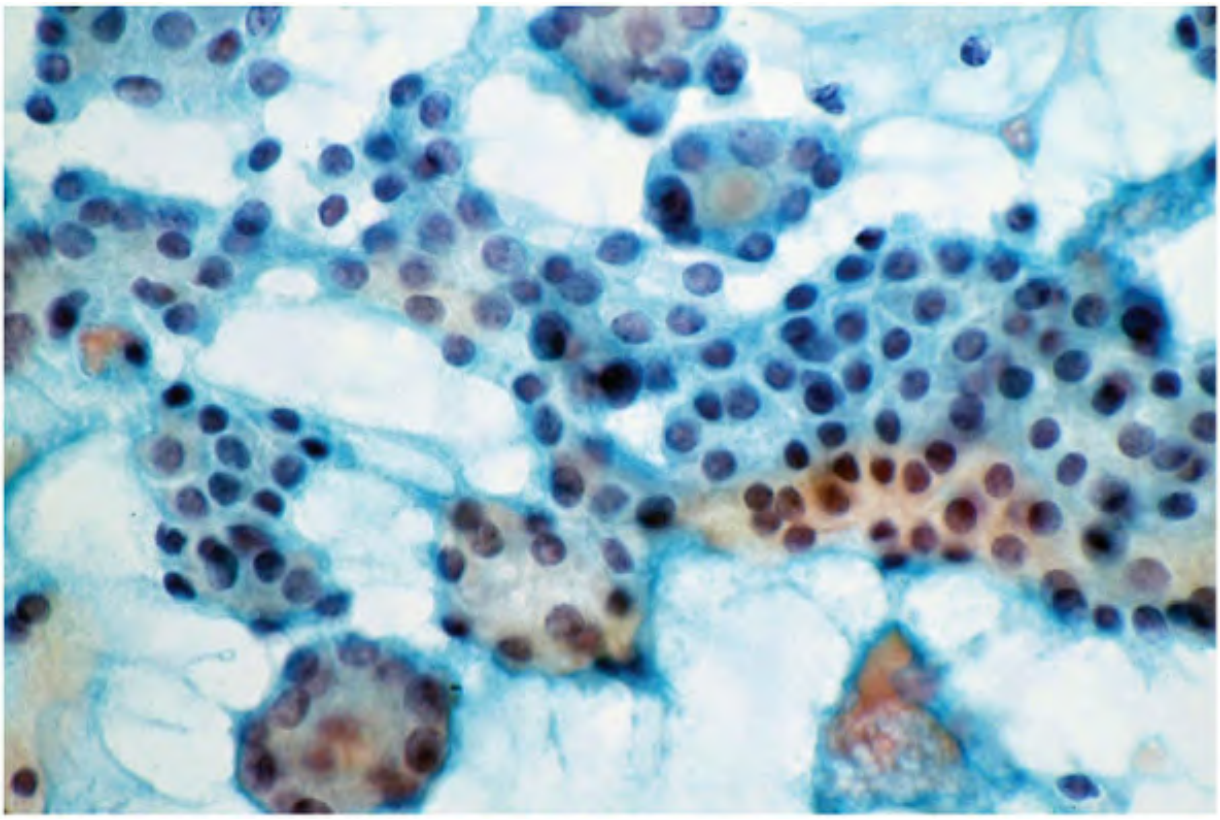

Figure 5.22. Aspiration biopsy specimen of nodular goiter with regular follicles and monolayered sheets of cells with a honeycomb pattern, similar to that seen in Figure 5.23.

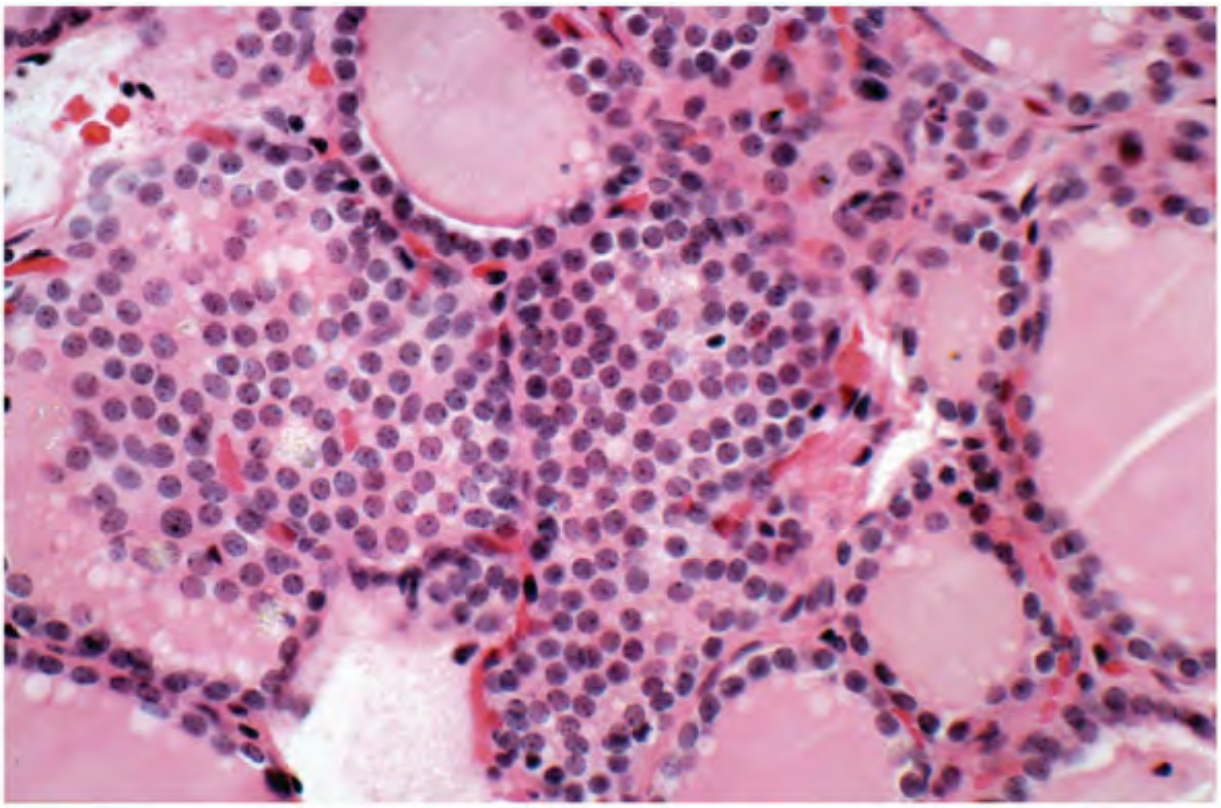

Figure 5.23. Histologic section of nodular goiter with regular follicles and a monolayered sheet with a honeycomb pattern. Note the similarity to Figure 5.22.

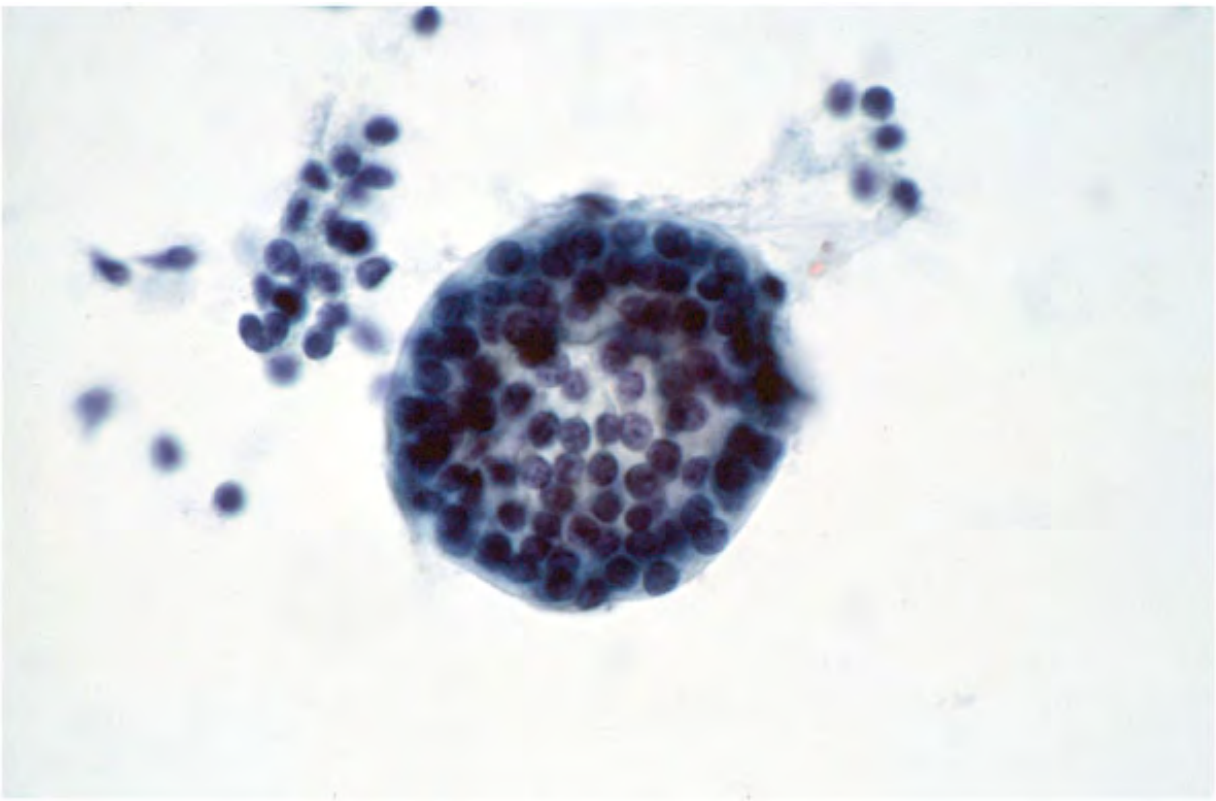

Figure 5.24. A benign follicle aspirated in its entirety showing a honeycomb arrangement of cells.

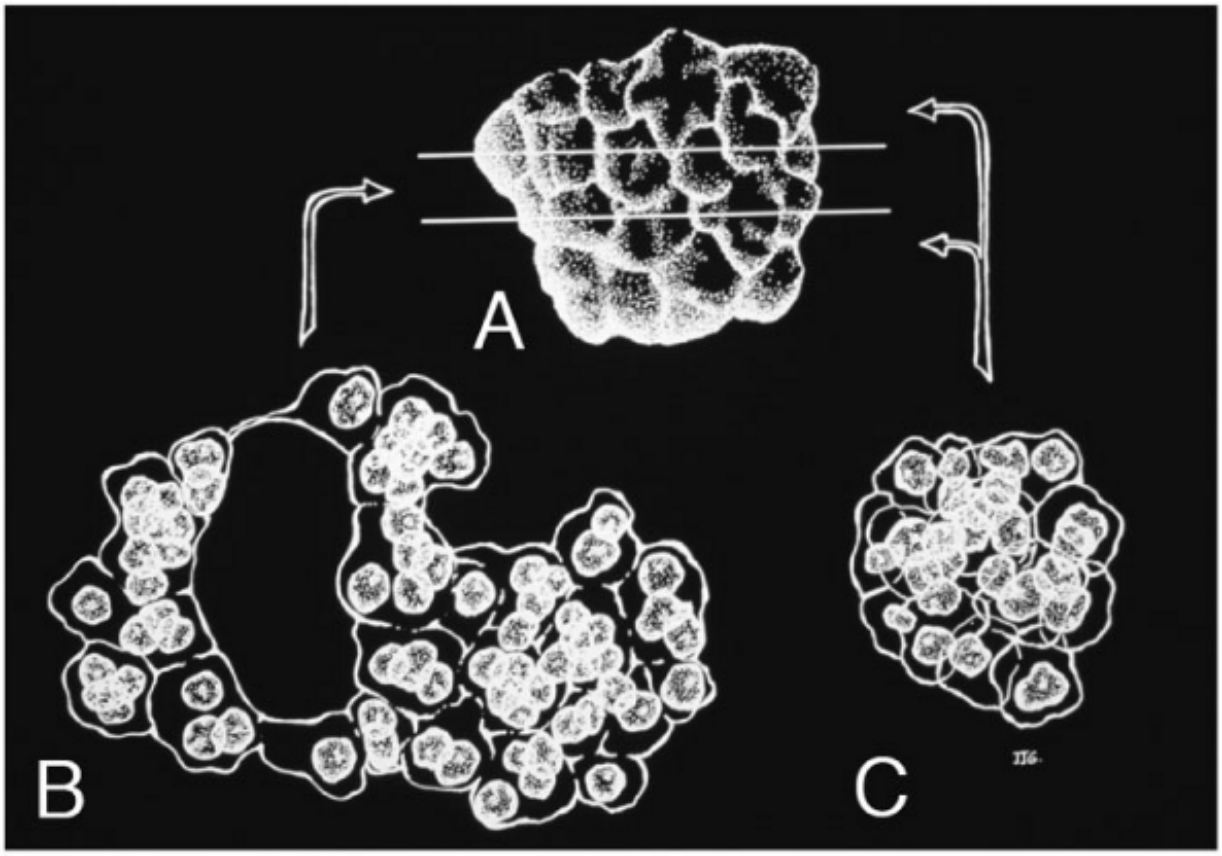

Figure 5.25. A. Concept of a neoplastic thyroid follicle. B. Cross-section of the neoplastic follicle. A lumen may or may not be present. C. Neoplastic follicle seen en face, showing syncytial-type tissue fragments with crowded, overlapped nuclei.

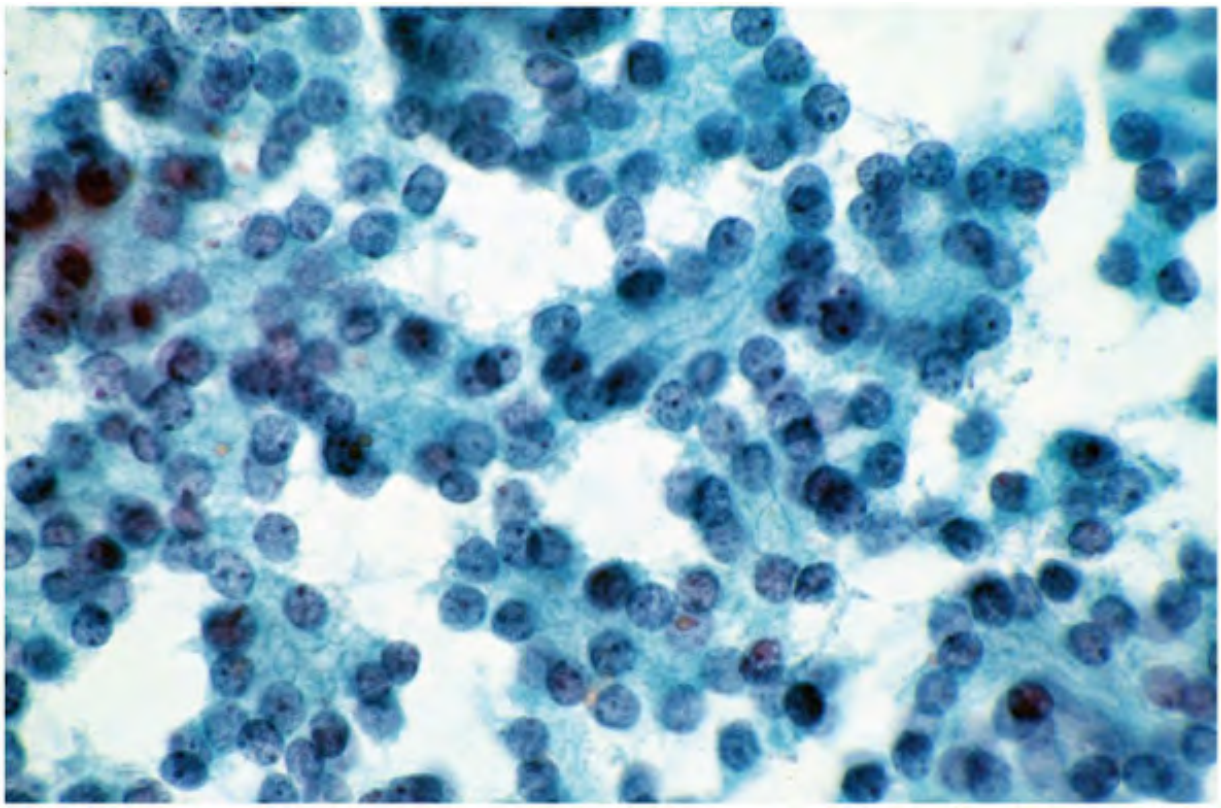

Figure 5.26. A syncytial-type tissue fragment, with and without a follicular pattern from a cellular follicular adenoma. Compare the disturbed architecture to the uniform pattern of nodular goiter in Figure 5.22.

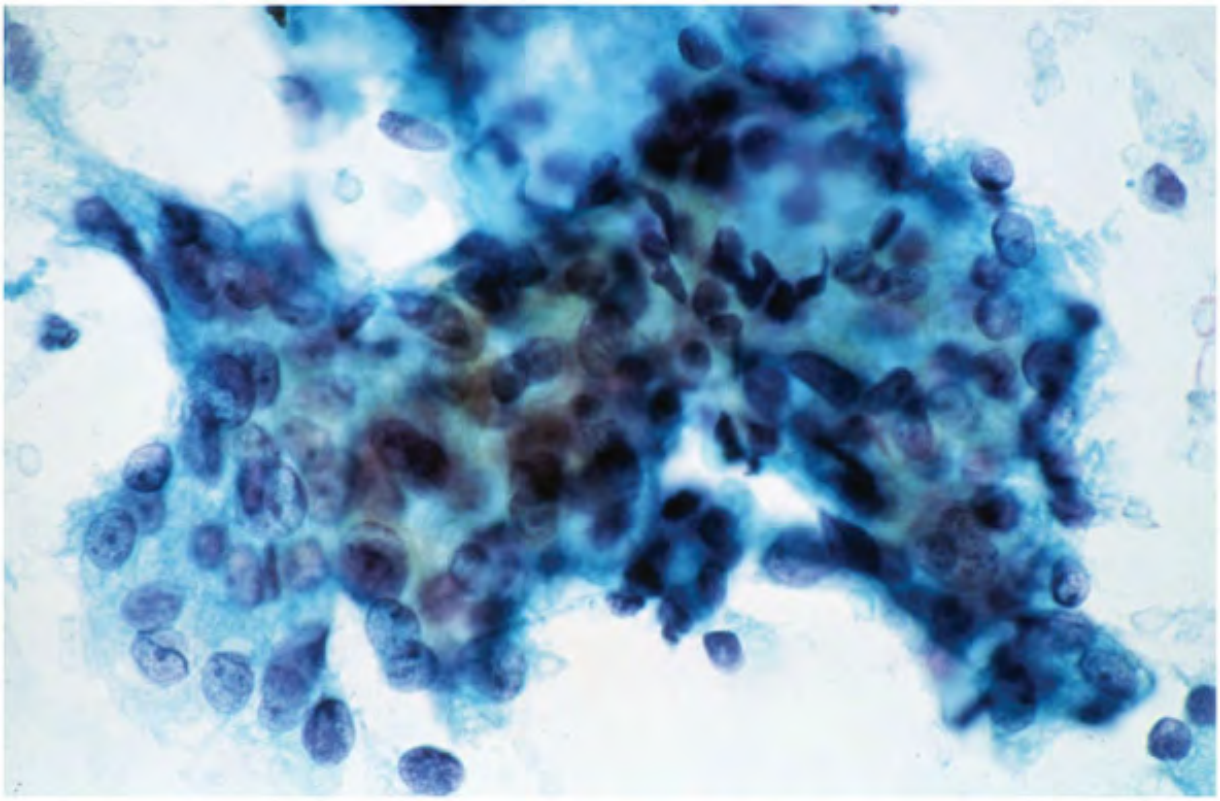

Figure 5.27. Syncytial-type tissue fragment of follicular carcinoma. Note the lack of a two-dimensional configuration that is, a monolayered sheet and uniform spacing of nuclei.

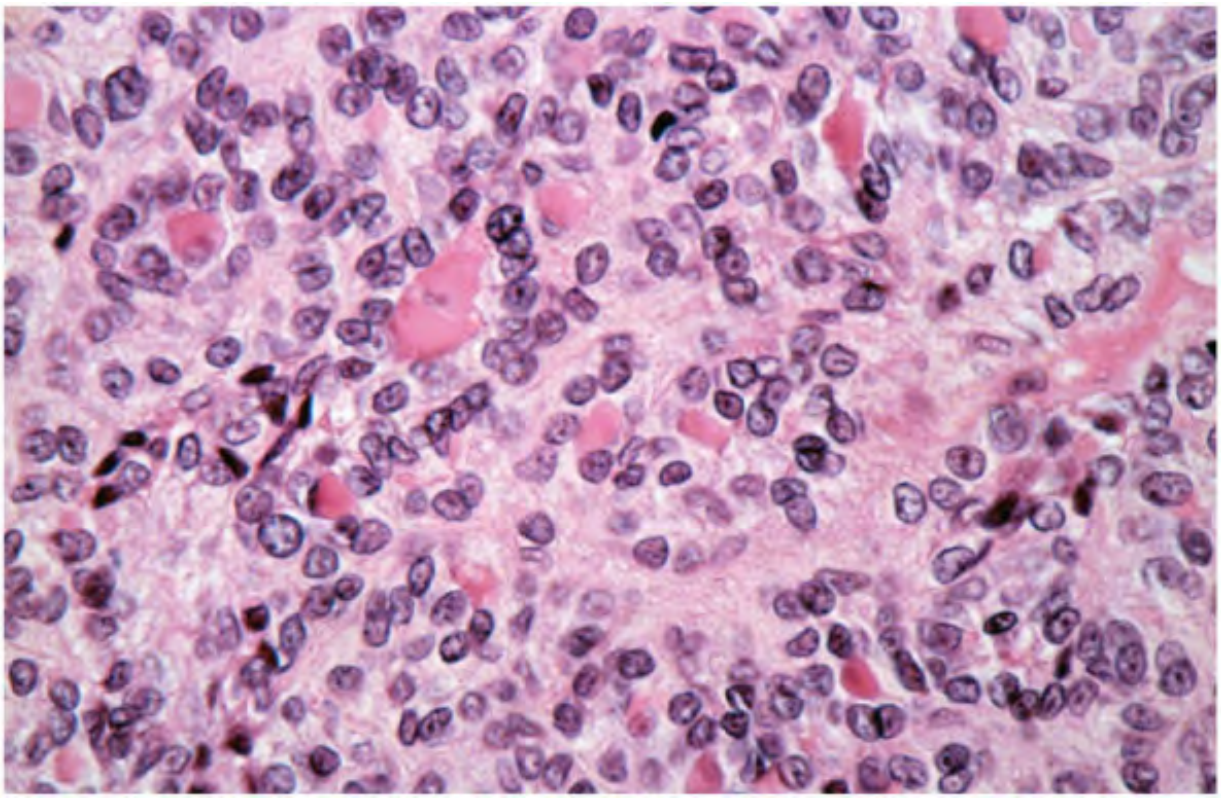

Figure 5.28. Histologic section of a follicular carcinoma. Note the solid and a follicular growth pattern of the neoplasm, with poorly developed follicles.

With this understanding of follicular structure, we can now focus on the papillary architecture of the tissue fragments, both in papillary hyperplasia and in papillary carcinoma of the thyroid. Papillary hyperplasia of the thyroid follicles involves an infolding of the lining epithelium composed of tall columnar cells with basally located, uniform nuclei (Fig. 5.29). There is usually no central core of fibrovascular tissue.4 In contrast, papillary carcinoma has a central core of fibrovascular tissue usually covered by one, and sometimes more than one, layer of cells with crowded nuclei at all levels. The lining cells in papillary hyperplasia show basally located small nuclei containing compact chromatin (Figs. 5.29 and 5.30A) and lack typical nuclear features of conventional papillary carcinoma (Fig. 5.30B).

Figure 5.29. Histologic section showing papillary hyperplasia. The infolding of the lining epithelium has edematous stroma and mimics the fibrovascular cores of true papillary fronds. The lining epithelium is cuboidal with basally located uniform nuclei, containing compact chromatin.

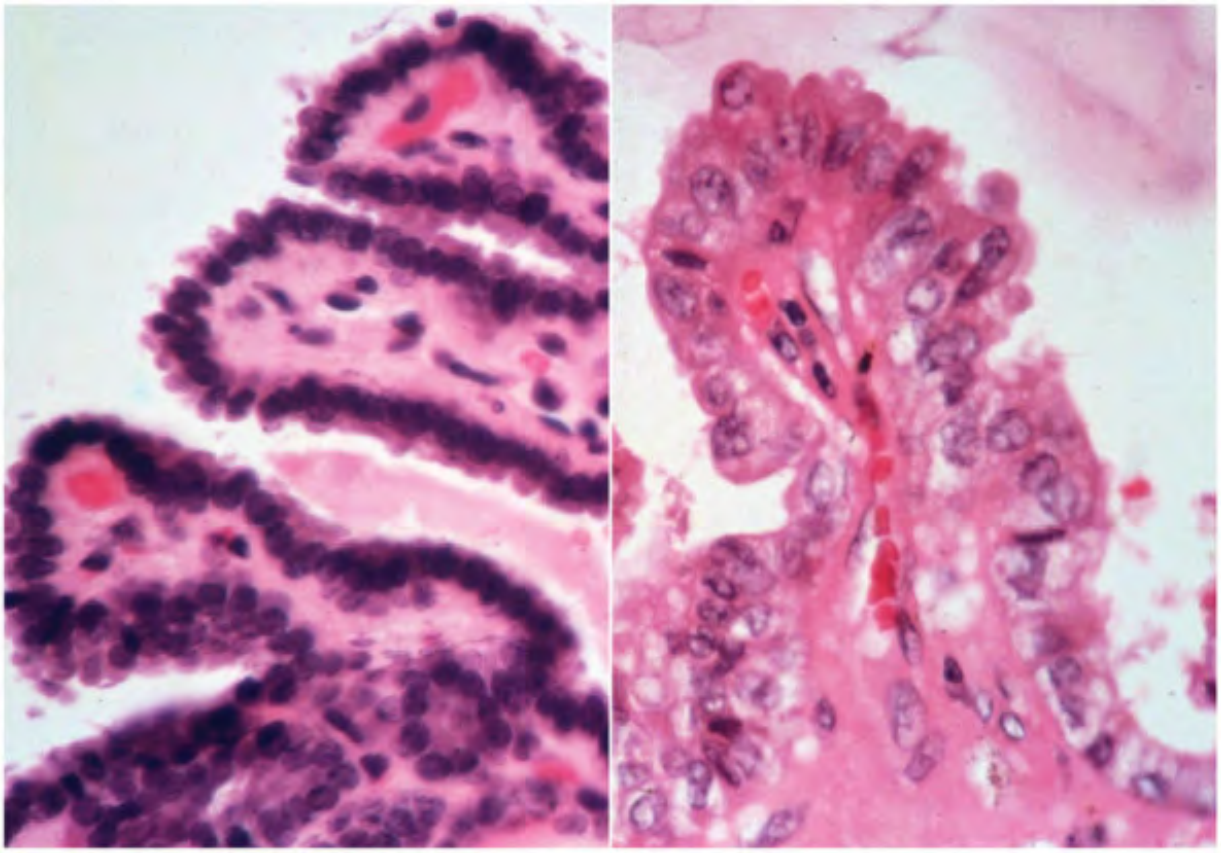

Figure 5.30. Composite of histologic sections showing (A) papillary hyperplasia and (B) papillary carcinoma. Note the basally located, small, uniform nuclei with compact chromatin in hyperplasia in contrast to the typical nuclear features of conventional papillary carcinoma.

GENERAL GUIDELINES FOR EVALUATION OF A SMEAR OF A THYROID ASPIRATE

A prepared and stained smear of a thyroid aspirate is usually evaluated in three steps. The initial step consists of scanning the smear using a 4Ã— objective (low power). This allows assessment of the following:

- Quality of the cytopreparation (e.g., fixation, staining, evenness of the cellular

material).

- Cellularity (adequacy).
- Concentration of the cellular material in any particular area/s of the slide/smear.
- Presentation such as dispersed pattern or an admixture of cells and tissue fragments.
- Architectural pattern(s) of the tissue fragments.
- Background features, including absence or presence of colloid and its amount, blood, diathesis, calcific debris, inflammatory infiltrate, and granuloma.

The next step involves examination using a 10Ã— objective (medium power) to focus on the architectural pattern of the tissue fragmentsâ€"sheet versus syncytium, regular or irregular follicular patterns, and cytomorphology. Most often, a diagnosis can be made after this second step.

The last step involves examination under a 40Ã— objective (high power) for assessment of the nuclear features of the follicular cells as compared to intact red blood cells in terms of size, shape, chromatin pattern, presence or absence of nucleoli, grooves, and nuclear inclusions. The intact red blood cells are the best indicators of the size. This helpful feature is lost if the smear is wet-fixed in ethyl alcohol or other liquid medium, which results in lysis of red blood cells. The nuclear size is an important parameter in interpretation of thyroid aspirates. Assess the cell borders and the amount and quality of the cytoplasm.

Once the smear is evaluated and the diagnostic interpretation is made, the findings are reported as per the reporting scheme presented in Table 4.4.

REFERENCES

1.Frost JK. *Concepts Basic to General Cytopathology.* Baltimore: Johns Hopkins; 1972.

2.Patten SF Jr. Diagnostic cytology of the uterine cervix. In: Weid GC, ed.

Monographs in Clinical Cytology, vol. 3. New York: S. Karger; 1969:5.

3.Kini SR. *Atlas and Text of Differential Diagnosis in Exfoilative and Aspiration Cytopathology*. Philadelphia: Lippincott Williams & Wilkins; 1999.

4.Vickery AL Jr. Thyroid papillary carcinoma: pathological and philosophical controversies. *Am J Surg Pathol*. 1983;7:797â€“807.

Editors: Kini, Sudha R.
Title: *Thyroid Cytopathology: A Text and Atlas, 1st Edition*

Copyright Â©2008 Lippincott Williams & Wilkins

6

Nodular Goiter

Nodular goiterâ€”also referred to as "adenomatous" goiter, colloid goiter, nontoxic nodular goiter, and multinodular goiterâ€” is an enlargement of the thyroid caused by intermittent or persistent hyperplasia in response to thyroid-stimulating hormone (TSH) or thyroid-growth immunoglobulin. The compensatory rise in serum may be caused by hypothyroxinemia related to iodine deficiency, environmental goitrogens, or unknown factors. Nodular goiter is the most common benign condition mistaken for a thyroid tumor.1

Initially, as the thyroid gland undergoes cycles of hyperplasia and involution/hyperinvolution, the gland is diffusely enlarged and all of the lobules are involved. As the cycles continue, they eventually lead to nodule formations. Because the lobules do not respond in a uniform manner, the nodules vary in size. Some nodules are appreciated only microscopically, while others are large enough to cause clinical enlargement and may even cause pressure symptoms. One or more nodules may become dominant. These nodules often undergo degeneration, resulting in hemorrhage, necrosis, and granulation tissue leading to fibrosis and calcification. Cyst formation is very frequent.

The nodules are usually cold on radionuclide imaging and cannot be differentiated from a neoplasm.

RADIOLOGIC FINDINGS

The ultrasound findings of nodular goiter are variable.2, 3 Small, less than 1 cm solitary or multiple fluid-filled nodules are often caused by thyroid nodular

hyperplasia. The cystic spaces represent either colloid-filled cysts or fluid from degeneration and necrosis. A comet tail artifact may be visualized in colloid cysts, a finding reported to have a sensitivity and specificity of 100% in predicting the benign nature.4 Multiple cystic spaces separated by septations in a honeycomb pattern strongly indicate benign non-neoplastic nodules.

GROSS AND HISTOLOGIC FEATURES

The thyroid with nodular goiter is variably enlarged. It may be massive, bulky with asymmetric lobes and multiple nodules (Fig. 6.1). Nodules vary greatly in size, and some may be fluid-filled cysts. The cut surface demonstrates a variegated pattern. The nodules may be uniform, solid and fleshy, hemorrhagic, or cystic. Fibrotic areas and calcification are often noted (Fig. 6.2). These changes are more frequent with the larger nodules.

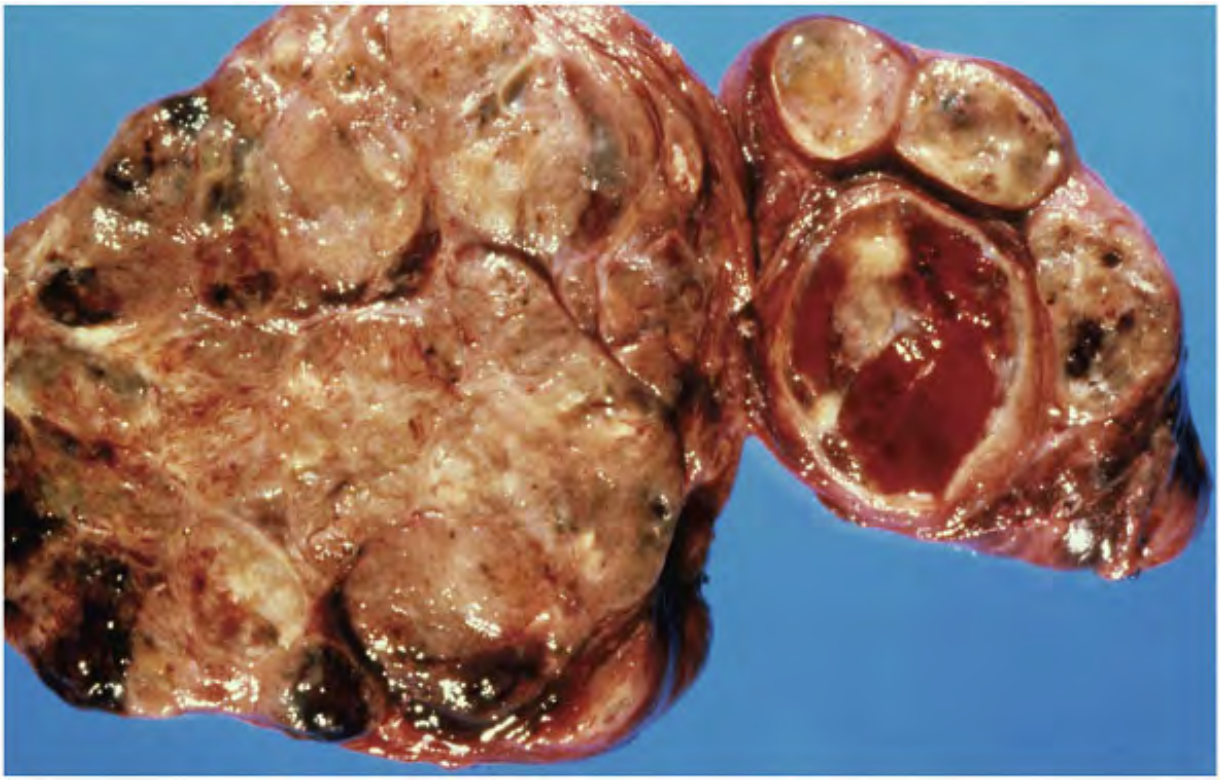

Figure 6.1. Multinodular goiter. Both lobes of the thyroid show asymmetric enlargement due to multiple nodules, some with cystic changes and hemorrhage.

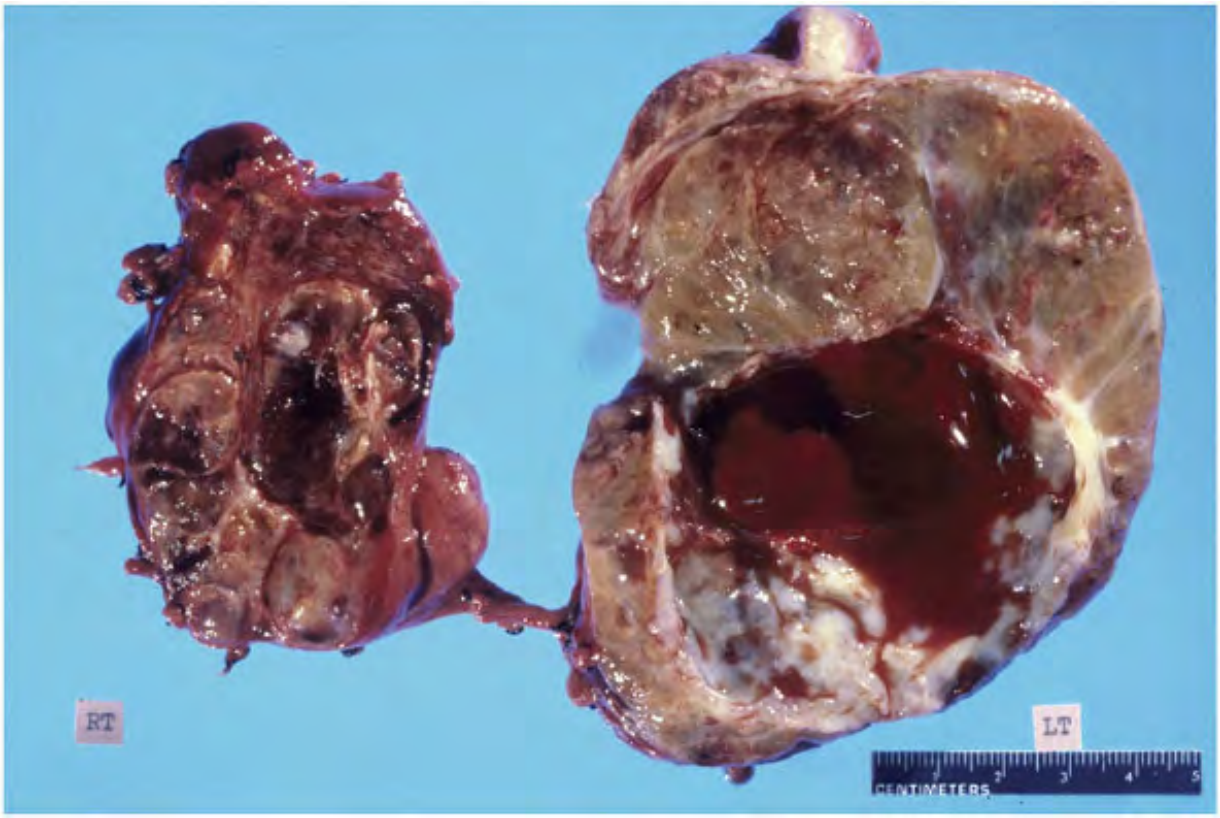

Figure 6.2. Another example of multinodular goiter with asymmetric enlargement of the lobes due to multiple nodules. The largest nodule, involving the left lobe, is completely cystic.

The microscopic pathology varies widely (Figs. 6.3, 6.4, 6.5, 6.6, 6.7, 6.8, 6.9, 6.10, 6.11, 6.12, 6.13, 6.14, 6.15 and 6.16), dominated by non-encapsulated, small to large distinct nodules (Fig. 6.3) exhibiting changes ranging from hyperplasia, to involution, to hyperinvolution. The hyperplastic nodules consist of closely packed small to medium-sized follicles without colloid and are lined by tall columnar epithelium,

sometimes with papillary changes (Figs. 6.4 and 6.5). The follicular cell nuclei have a vesicular chromatin pattern and sometimes appear ground-glassâ€“like, similar to those seen in papillary carcinoma (Fig. 6.6). Involution is characterized by variably distended follicles with accumulation of colloid and low cuboidal epithelium (Fig. 6.7). With hyperinvolution, the follicles are overdistended with colloid, resulting in flattening of the lining epithelium containing pyknotic nuclei (Fig. 6.8). HÃ¼rthle cell metaplasia of follicular cells is very common in nodular goiter. It can be focal or generalized and may form large nodules (Figs. 6.9 and 6.10).

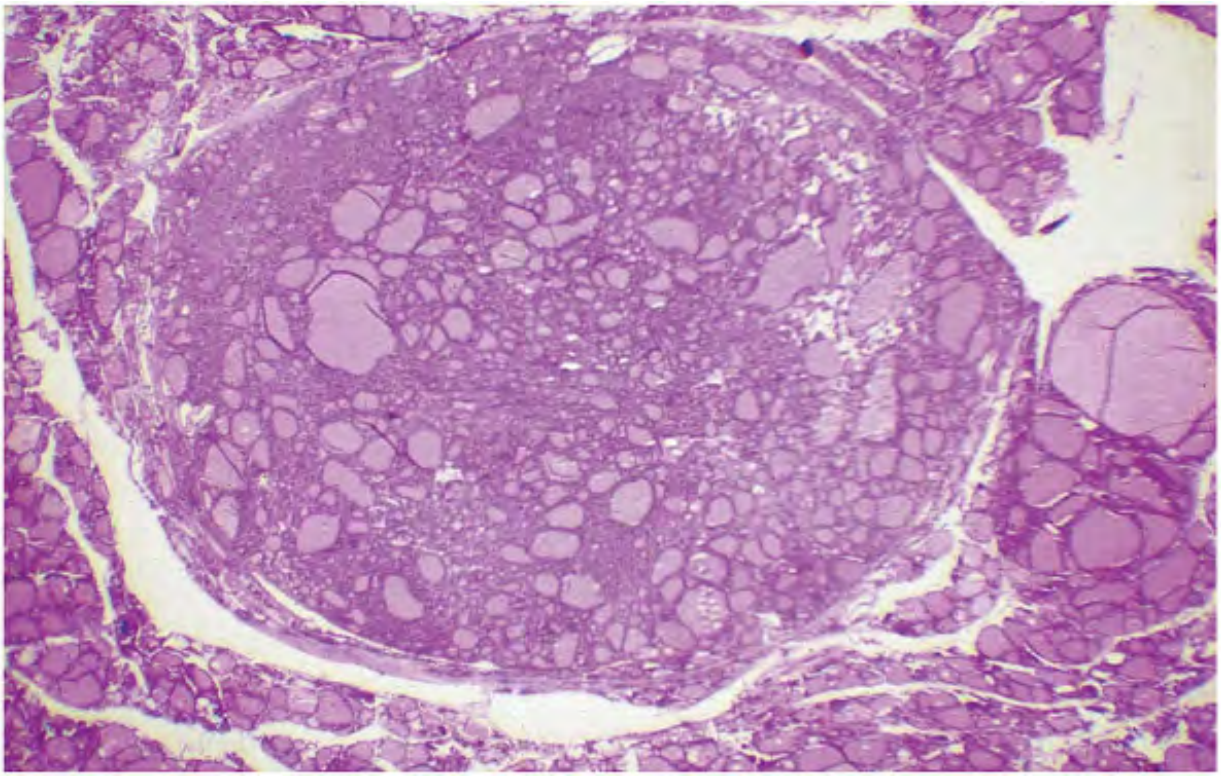

Figure 6.3. Histologic section of nodular goiter showing a distinct non-encapsulated nodule.

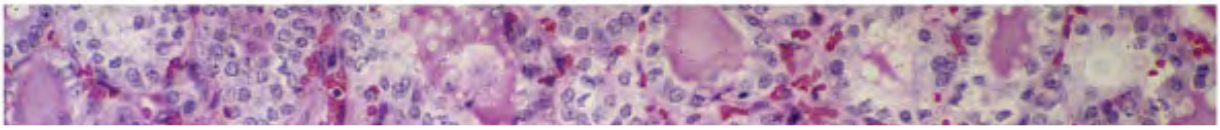

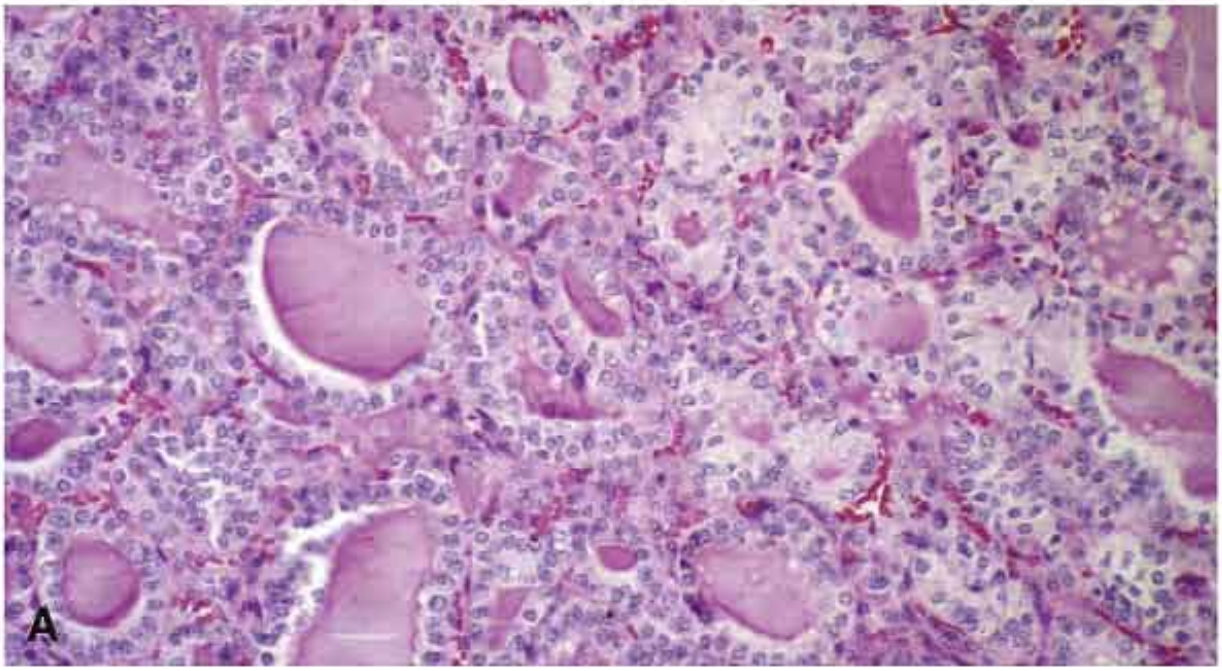
A

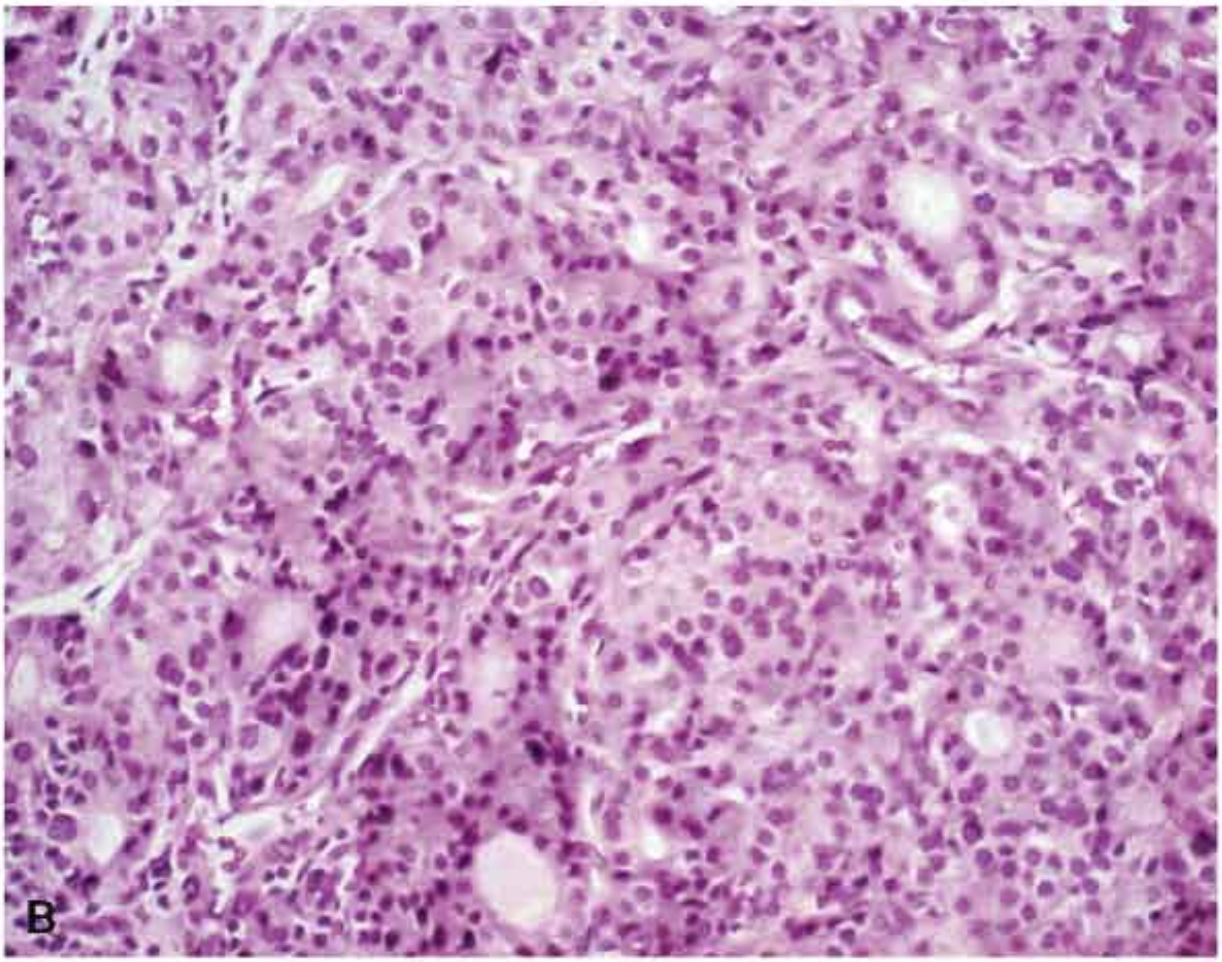
B

Figure 6.4. Histologic sections demonstrating hyperplastic phase of nodular goiter. The follicles are crowded and lined by cuboidal epithelium. Very few follicles contain colloid. Aspirates from such areas may be misinterpreted as follicular neoplasms.

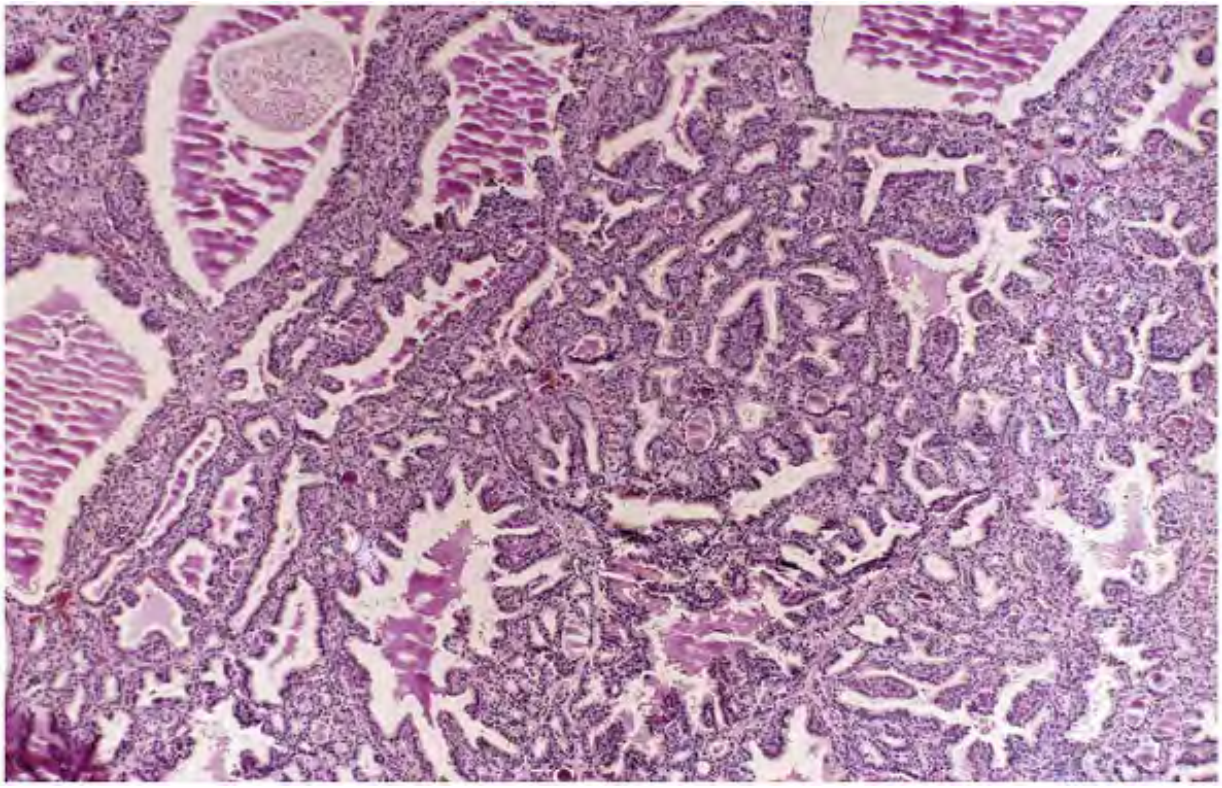

Figure 6.5. Hyperplastic nodular goiter showing papillary hyperplasia. Aspirates from such nodules may be misinterpreted as papillary carcinoma.

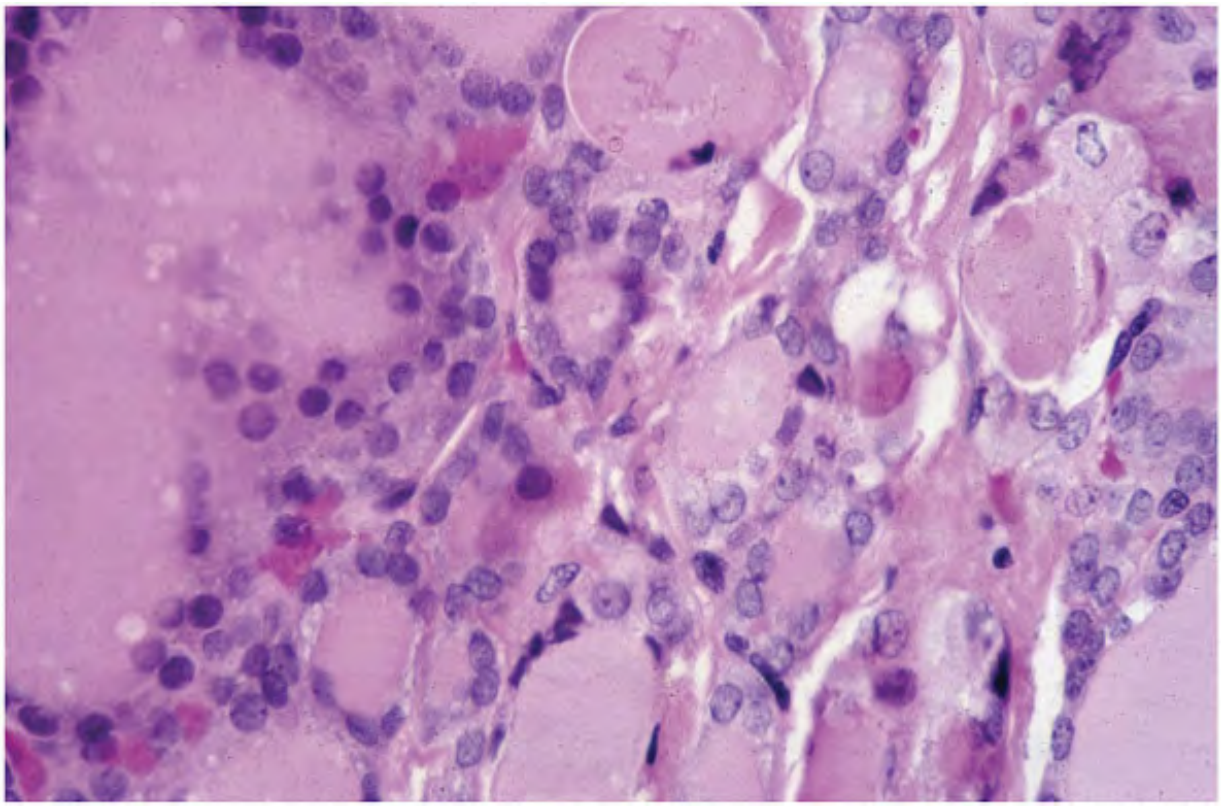

Figure 6.6. Nodular goiter. Pale nuclei with vesicular chromatin pattern bearing some resemblance to the nuclei of papillary carcinoma.

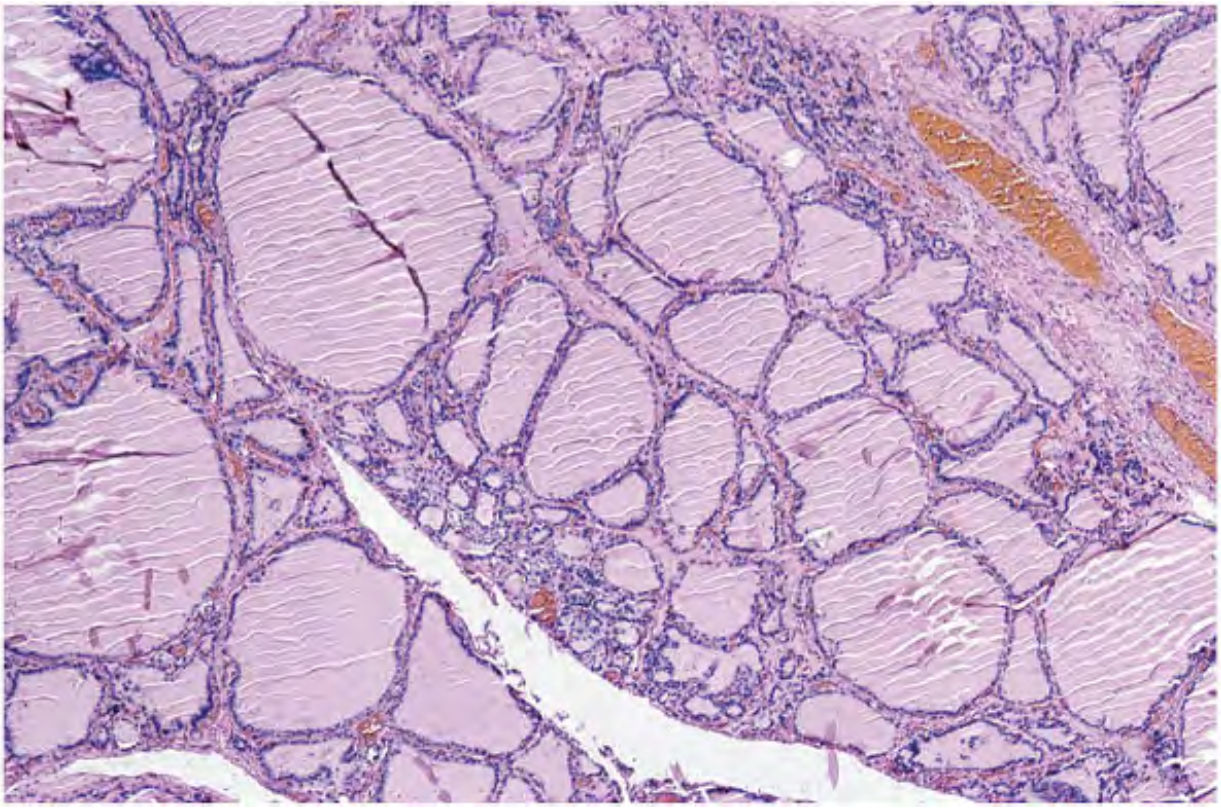

Figure 6.7. Involution. Some follicles are distended with colloid. The lining epithelium is low cuboidal.

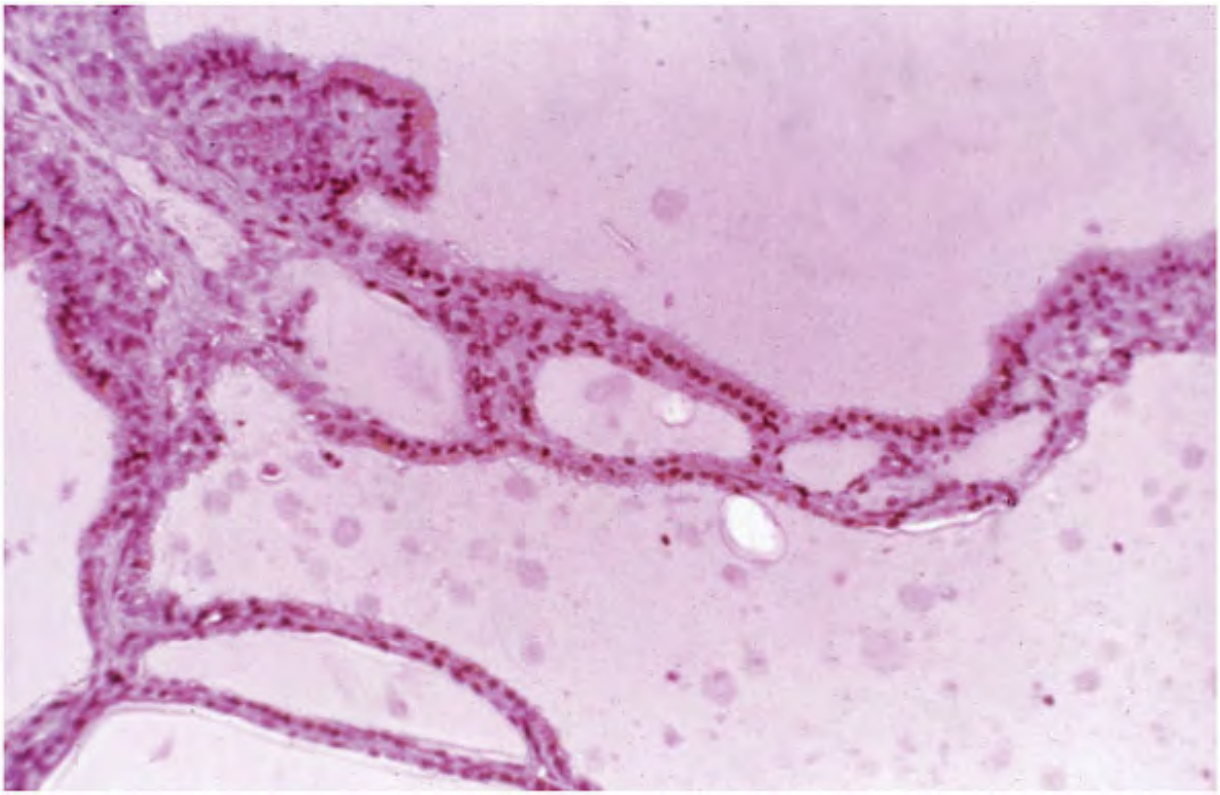

Figure 6.8. Hyperinvolution. The thyroid follicles are over-distended with colloid and lined by flattened epithelium.

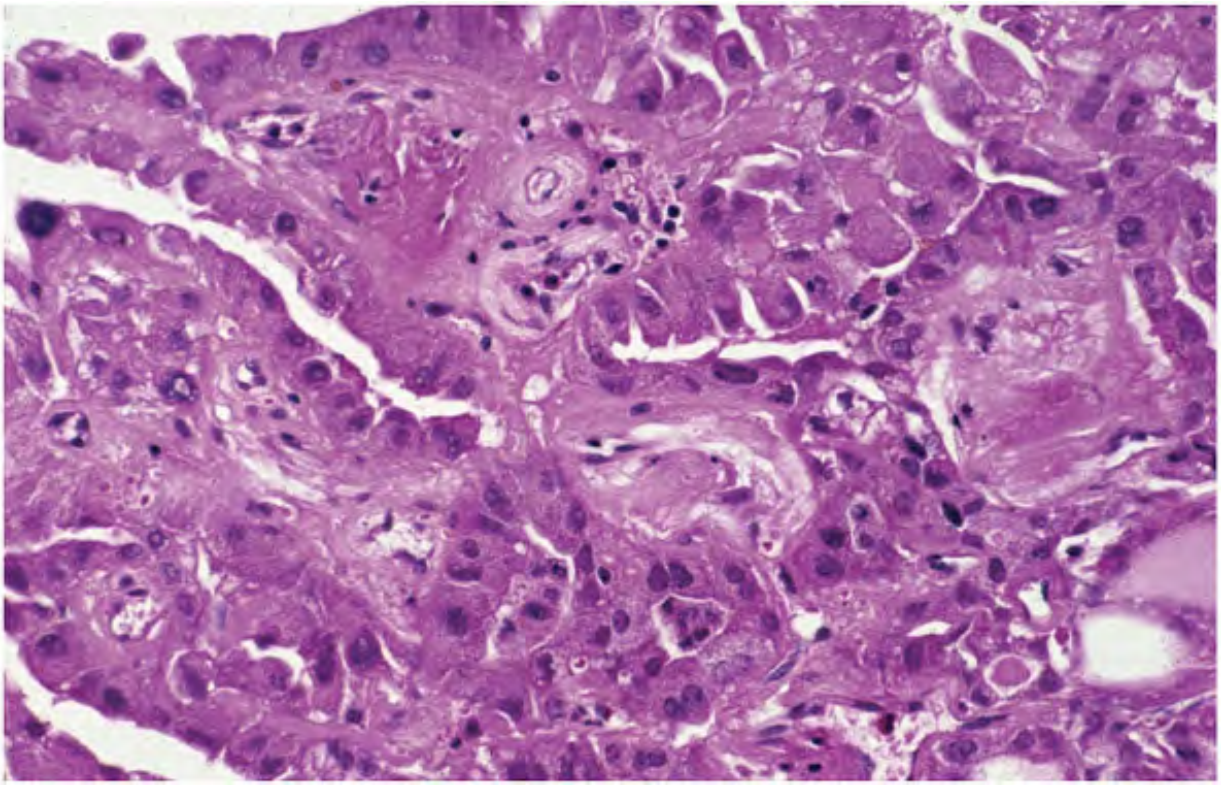

Figure 6.9. Nodular goiter with HÃ¼rthle cell metaplasia. The follicles are lined by large cells with abundant granular, eosinophilic cytoplasm. Note considerable stromal fibrosis.

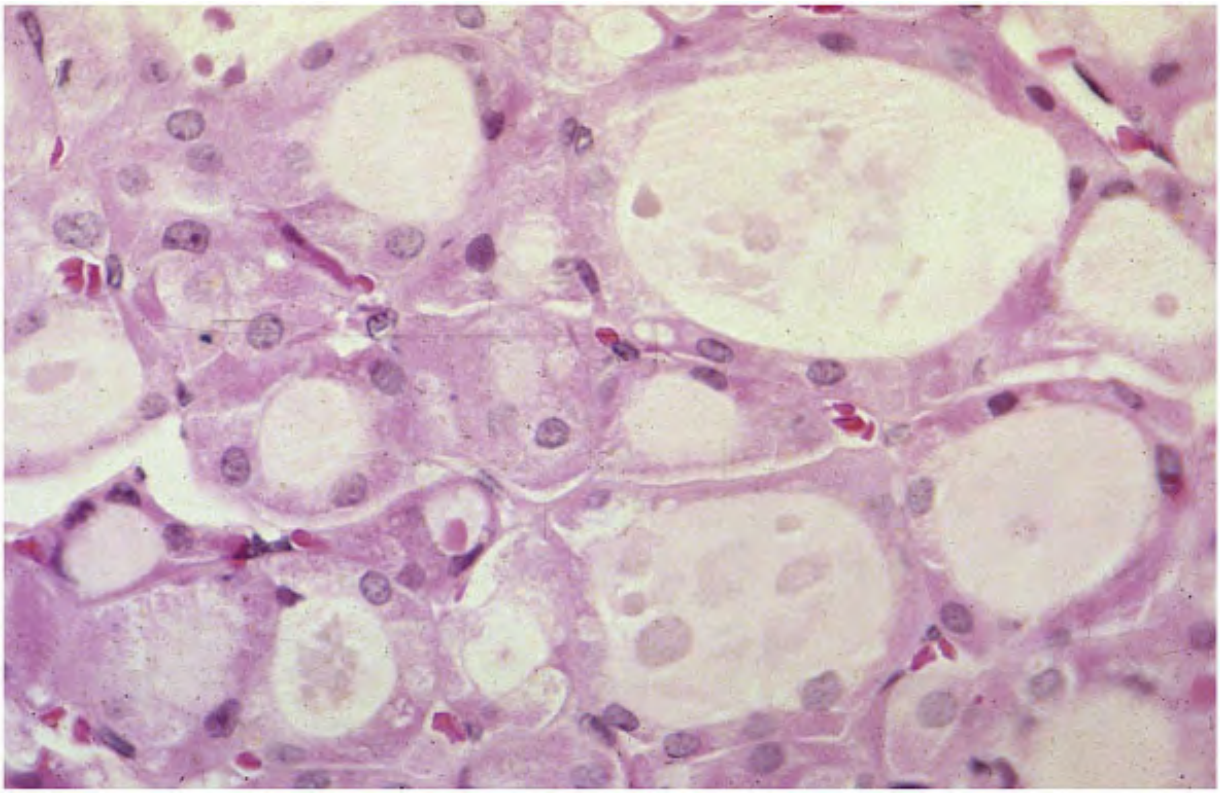

Figure 6.10. HÃ¼rthle cell metaplasia. The follicles are lined by large cells with abundant granular, eosinophilic cytoplasm.

Retrogressive changes in nodular goiter occur frequently and are characterized by recent and/or old hemorrhage, degeneration of the follicular cells, cyst formation, and accumulation of histiocytes with or without hemosiderin (Fig. 6.11). Nuclear atypia may be pronounced (Fig. 6.12). Squamous metaplasia is occasionally present. With cystic changes, the follicles get dilated; the follicular lining epithelium forms papillary-like projections that are directed towards the center within the cystic cavity (Fig. 6.13). With recent hemorrhage, granulation tissue may be present (Fig. 6.14). Fibrosis eventually develops. It can be focal or extensive with broad bands of collagenized tissue. Calcification may also be present. Occasionally, psammoma bodies are identified in nodular goiters.

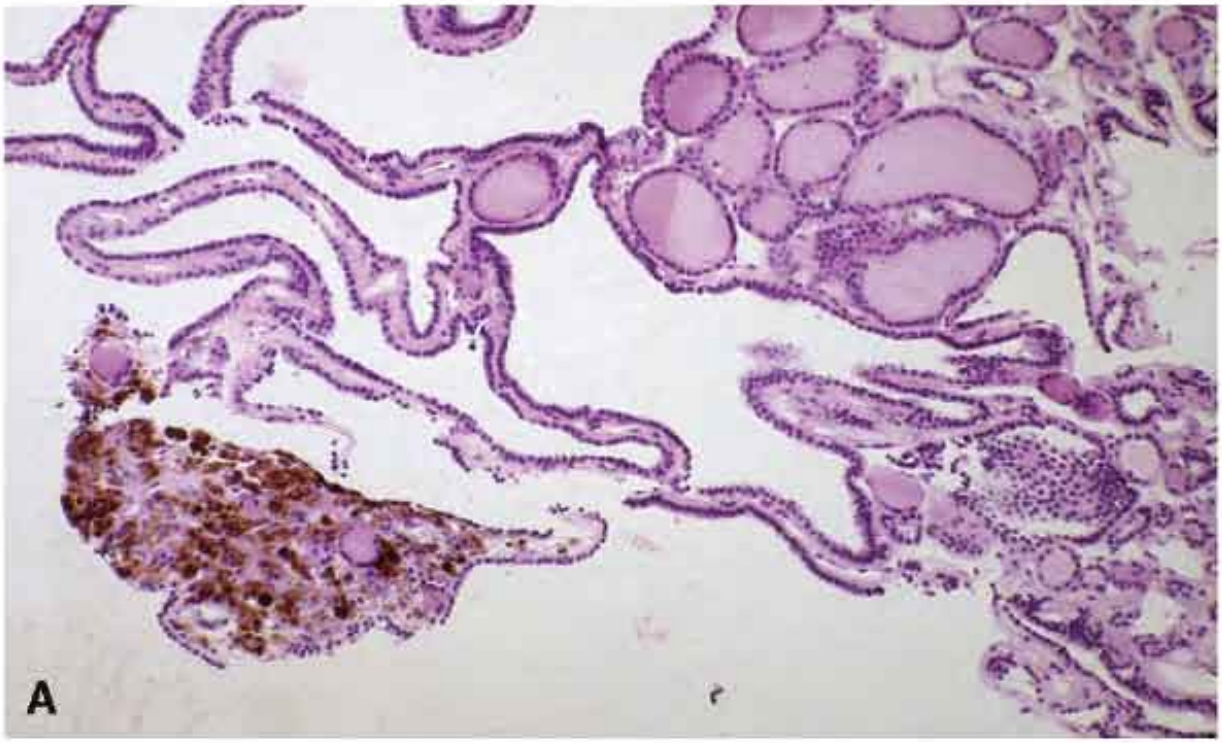
A

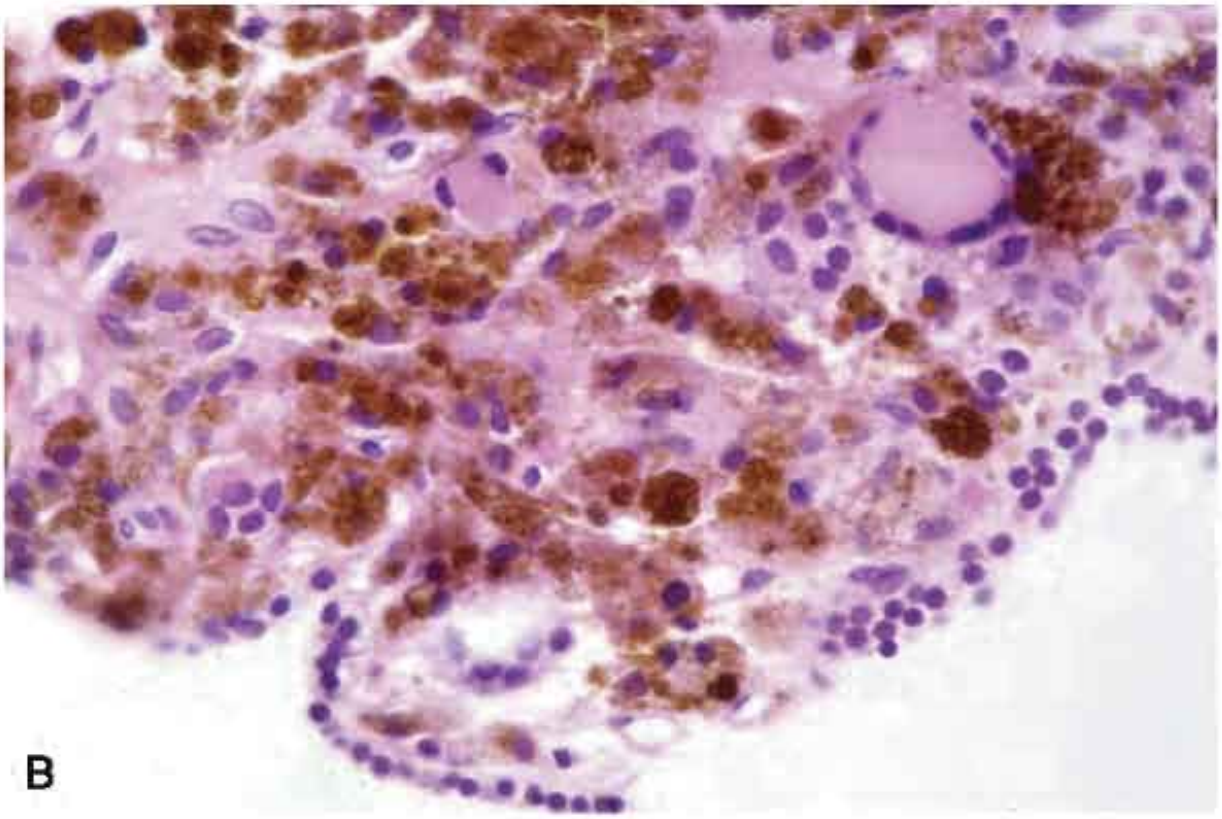
B

Figure 6.11. A. Nodular goiter. Histologic section showing degeneration with dilated follicles, cyst formation, and an area of old hemorrhage. B. Higher magnification showing follicular cells and histiocytes containing hemosiderin.

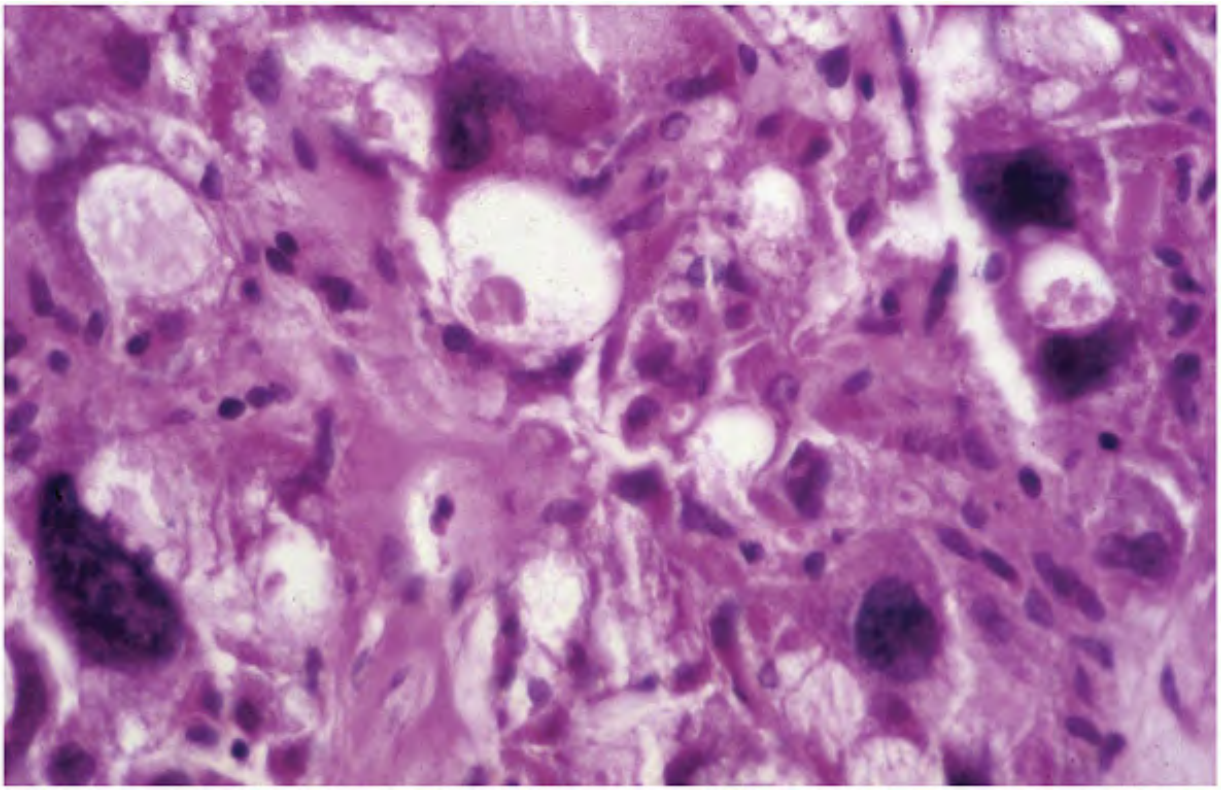

Figure 6.12. Histologic section of nodular goiter showing extreme nuclear pleomorphism with pyknosis.

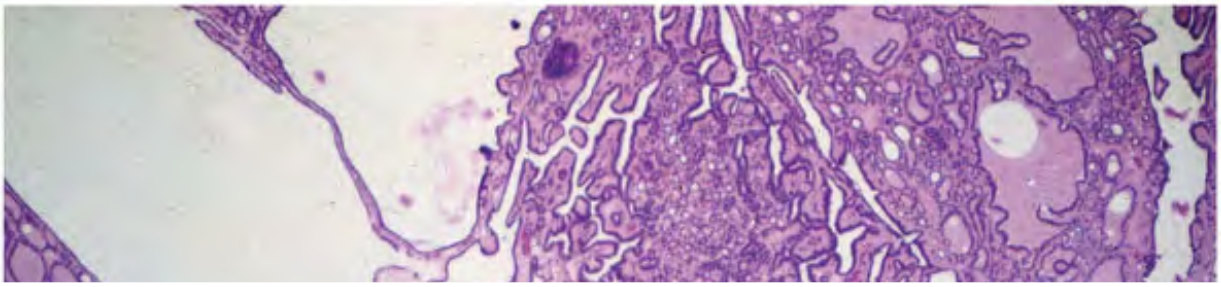

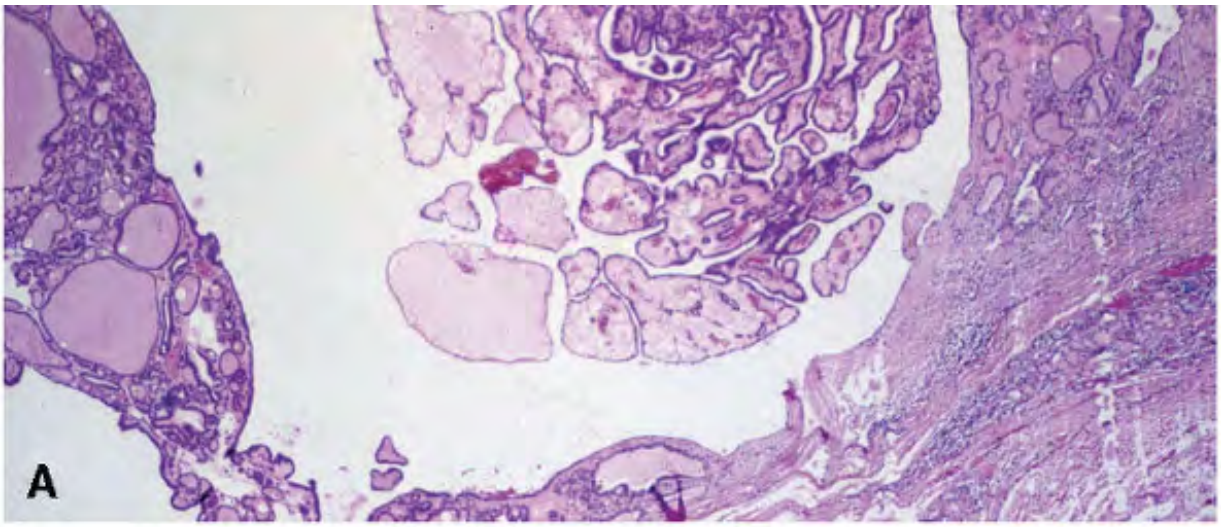

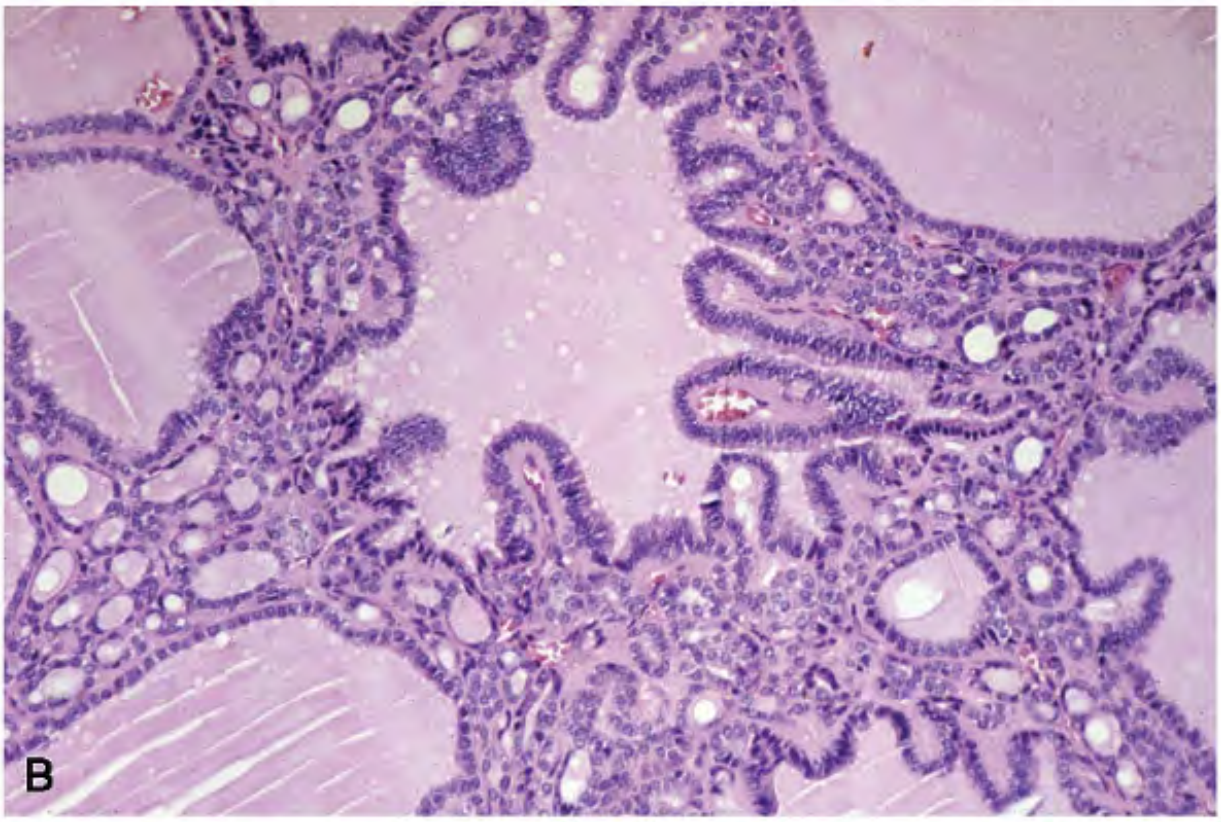

Figure 6.13. A. Nodular goiter with cystic change exhibiting a pseudopapillary change. Note the central cystic cavity with papillary- like projections of the lining epithelium, directed towards the center of the cavity. B. Another field showing multiple follicles with papillary projections of the epithelium.

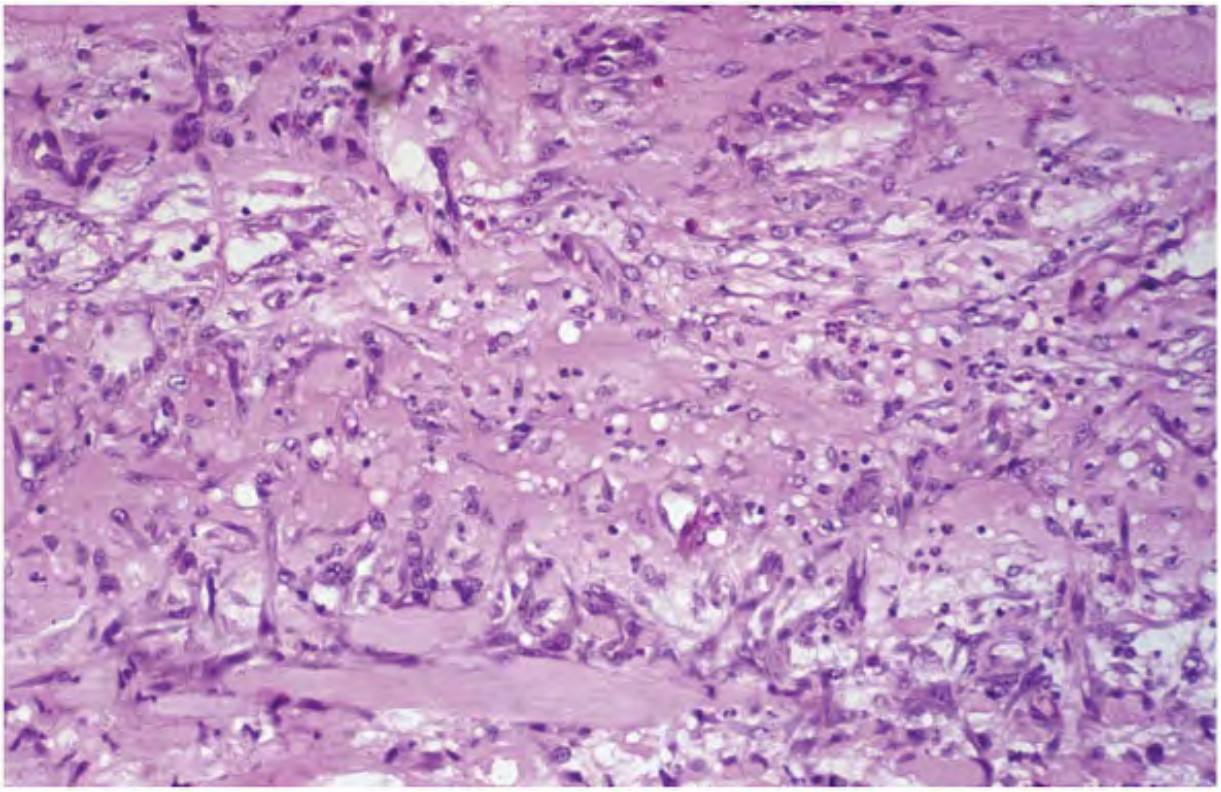

Figure 6.14. Histologic section of nodular goiter showing granulation tissue with proliferating fibroblasts and capillaries with plump endothelial lining cells. An aspirate from such an area will yield spindle-shaped stromal cells with atypical nuclei, causing diagnostic difficulties.

CYTOPATHOLOGIC FEATURES

The cytopathologic features of nodular goiter span a very wide spectrum (Figs. 6.15, 6.16, 6.17, 6.18, 6.19, 6.20, 6.21, 6.22, 6.23, 6.24, 6.25, 6.26, 6.27, 6.28, 6.29, 6.30, 6.31, 6.32, 6.33, 6.34, 6.35, 6.36, 6.37, 6.38, 6.39, 6.40, 6.41, 6.42, 6.43, 6.44, 6.45, 6.46, 6.47, 6.48, 6.49, 6.50, 6.51, 6.52, 6.53, 6.54, 6.55, 6.56 to 6.62, Table 6.1), reflecting the various stages of the disease process: hyperplasia, involution/hyperinvolution, and several of the secondary changes such as

HÃ¼rthle cell metaplasia and recent or old hemorrhage and its sequelaeâ€”degeneration, necrosis, granulation tissue, fibrosis, and calcification. Fine-needle aspirates generally show an admixture of colloid and benign follicular cells in varying proportions (Fig. 6.15). The colloid is abundant in hyperinvoluted goiters (Fig. 6.16) while scant or absent from the hyperplastic areas (Fig. 6.17). These two patterns represent two ends of the spectrum of cytopathologic features of nodular goiter, with most cases exhibiting a pattern somewhere in between, with or without secondary changes.

TABLE 6.1 CYTOPATHOLOGIC FEATURES OF NODULAR GOITER

Presentation	Admixture of colloid and follicular epithelial cells in varying proportions; cells isolated, in loosely cohesive groups and in tissue fragments
Architectural Patterns of the Tissue Fragments	Regular follicles with evenly spaced nuclei, monolayered sheets with honeycomb arrangement; papillary-like pattern in hyperplastic goiters with component cells in a honeycomb arrangement
Follicular Cells	Small, cuboidal to round with well to poorly defined cell borders; degenerating or reactive/regenerating follicular cells with enlargement and spindle shapes
Nucleus	Round to oval, 7â€“9 Âµm in diameter; smooth nuclear membrane; uniformly distributed finely granular to compact chromatin; pyknotic nuclei in

	hyperinvoluted goiters; nucleoli inconsistent but may be present in hyperplastic goiters
Cytoplasm	Scant to moderate, pale
HÃ¼rthle Cell Metaplasia	Frequent, isolated and sheets of HÃ¼rthle cells with well-defined cell borders, size variable, larger than the normal follicular cells; moderate to abundant granular cytoplasm; transition forms from normal follicular cells to HÃ¼rthle cells within a tissue fragment; nucleus similar to or larger than the normal follicular cells; lack prominent macronucleoli
Colloid	Pale, thin film to thick, inspissated blobs with or without cracks (fissures); cyanophilic to eosinophilic in Papanicolaou-stained preparations, lavender to purple with Romanowsky stain
Psammoma Bodies	Rarely present; naked or incorporated in a tissue fragment of benign follicular cells
Secondary Changes	Histiocytes with or without hemosiderin; multinucleated foreign body-type giant cells; stromal cells, mostly in tissue fragments but isolated spindle cells may be present; calcific debris; frequent squamous metaplasia

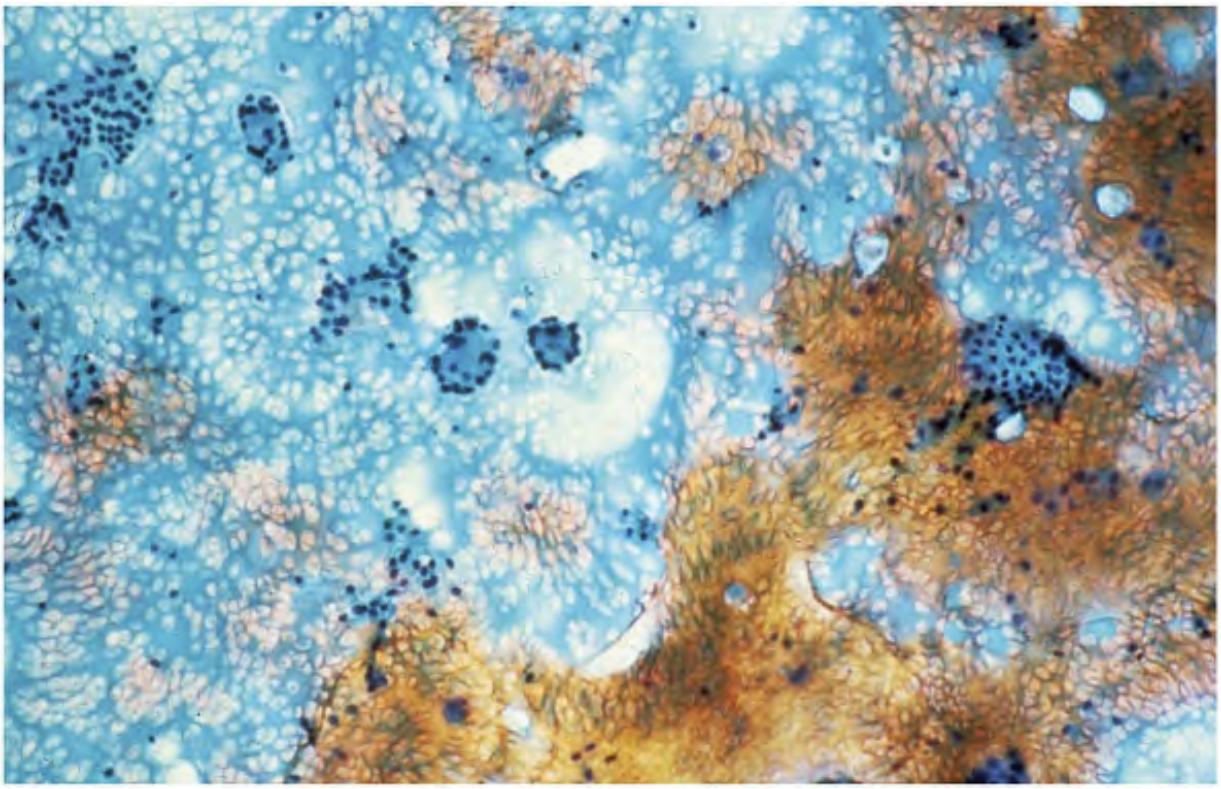

Figure 6.15. FNA of a nodular goiter with an admixture of follicular cells and colloid.

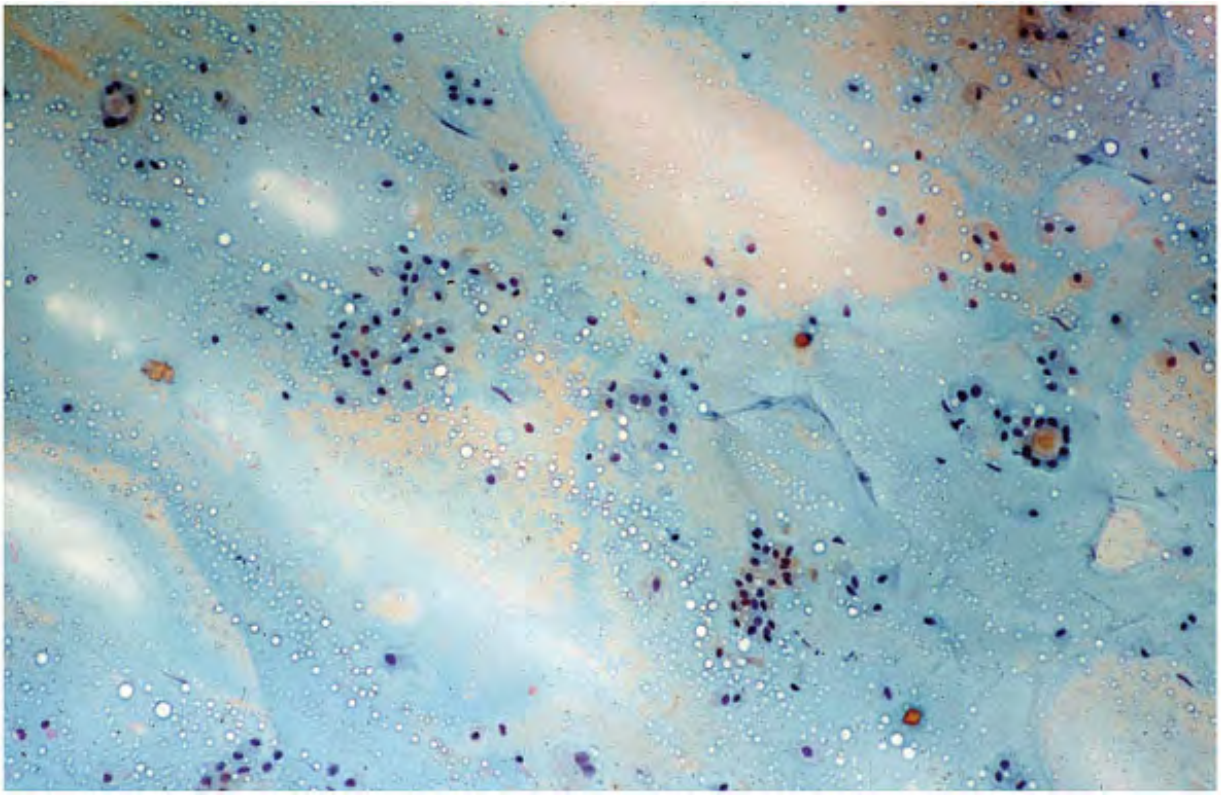

Figure 6.16. FNA of a nodular goiter with abundant colloid and sparse follicular cells, a pattern characteristic of involution or hyperinvolution.

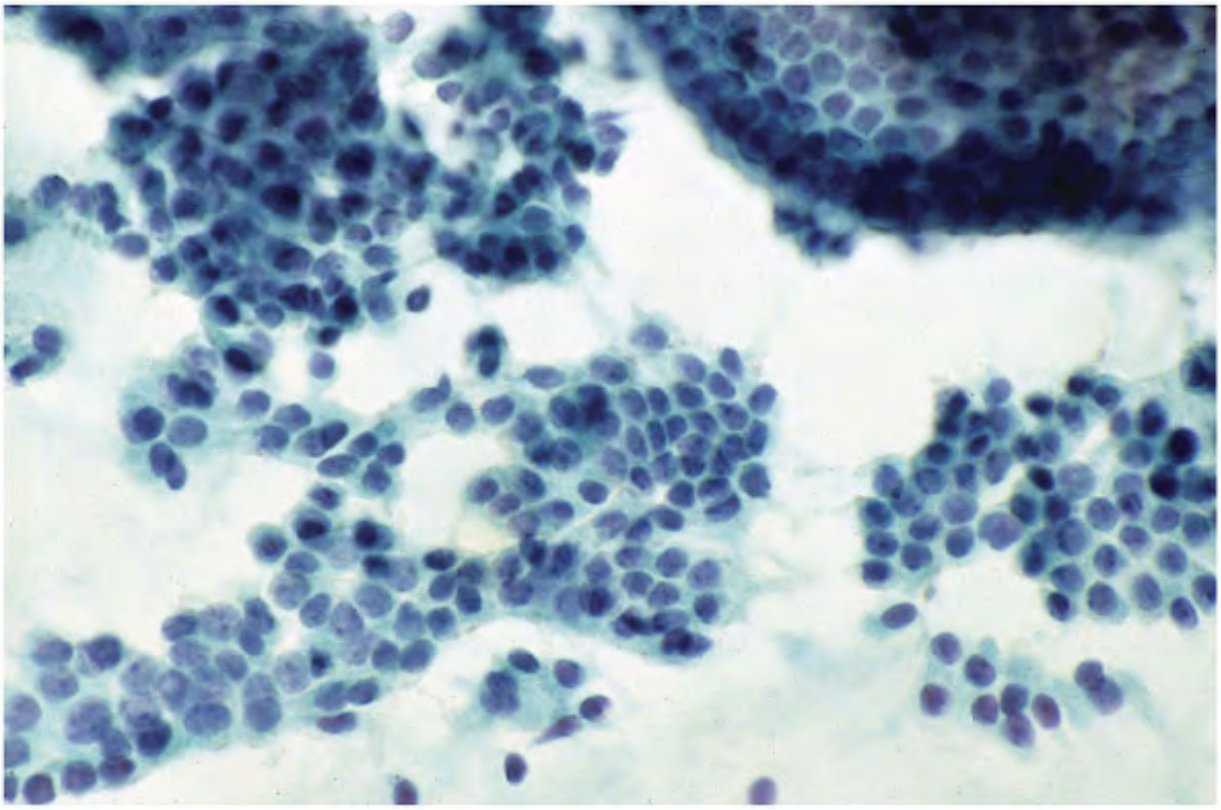

Figure 6.17. FNA of a nodular goiter. Note the hypercellularity of the aspirate and absence of colloid in the background.

The appearance of the colloid in Papanicolaou-stained preparations varies (Figs. 6.18, 6.19, 6.20 and 6.21). In its pure form, the colloid appears as a thin film of homogeneous material staining pink or greenish-blue. It stains orange when mixed with blood. After the colloid has been smeared on the glass slide, it retracts from the slide. The inspissated colloid stains dense, appearing as droplets suggestive of follicular luminal casts. Colloid also shows a tendency to crack in a linear fashion (Fig. 6.18), occasionally simulating a psammoma body. Large lakes of colloid with multiple fissures tend to give a mosaic pattern.5 Colloid stains light purple to blue-violet in air-dried Romanowsky-stained preparations (Fig. 6.22). The presence of colloid in fine-needle aspirates of thyroid nodules is taken

by some as presumptive evidence that the thyroid nodule is benign and not a true neoplasm.6, 7

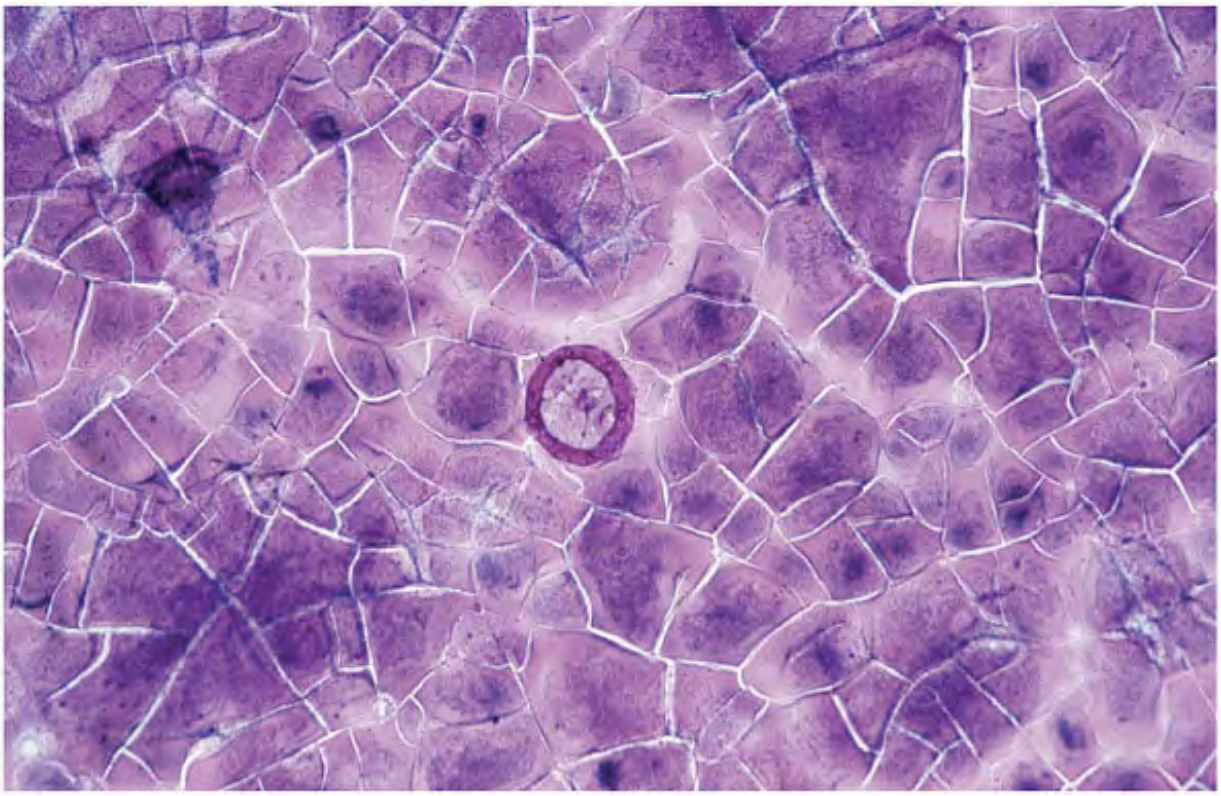

Figure 6.18. FNA of a nodular goiter. Note abundant colloid with linear cracks forming a mosaic pattern.

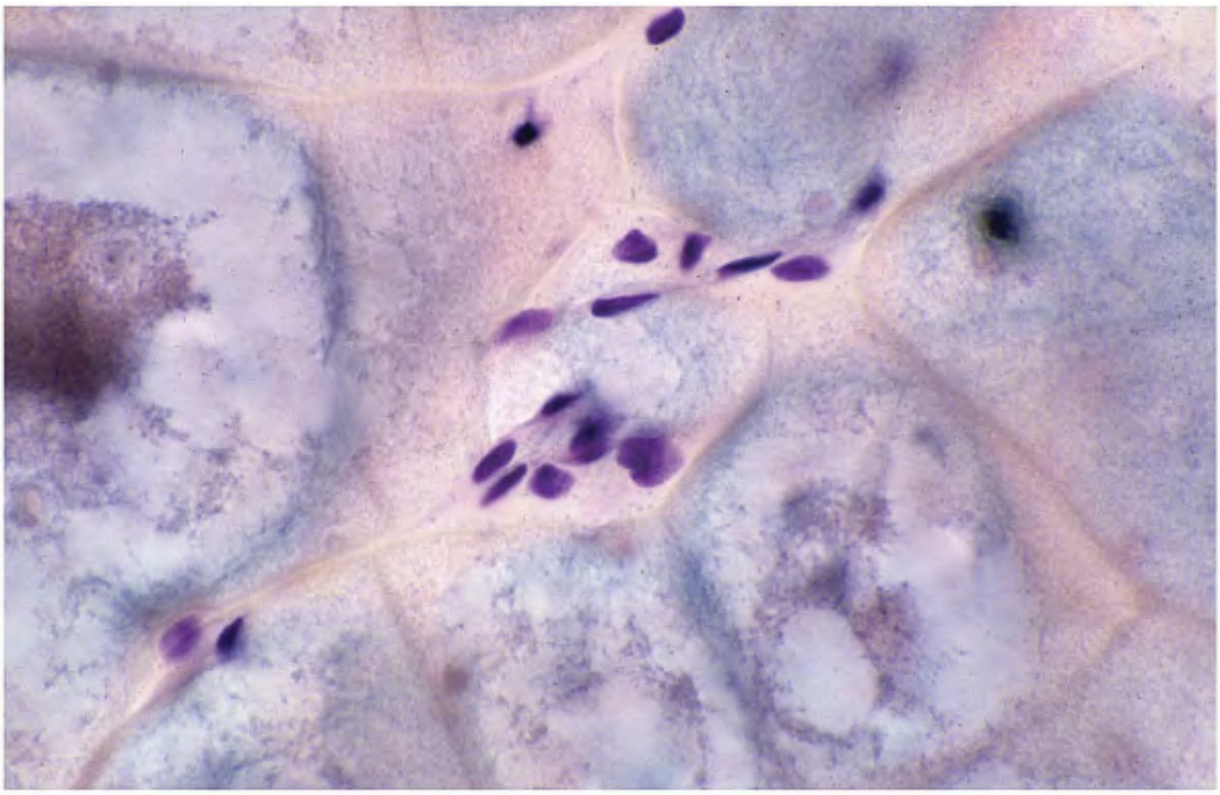

Figure 6.19. FNA, nodular goiter. A few small groups of follicular cells with pyknotic nuclei, floating in pools of colloid.

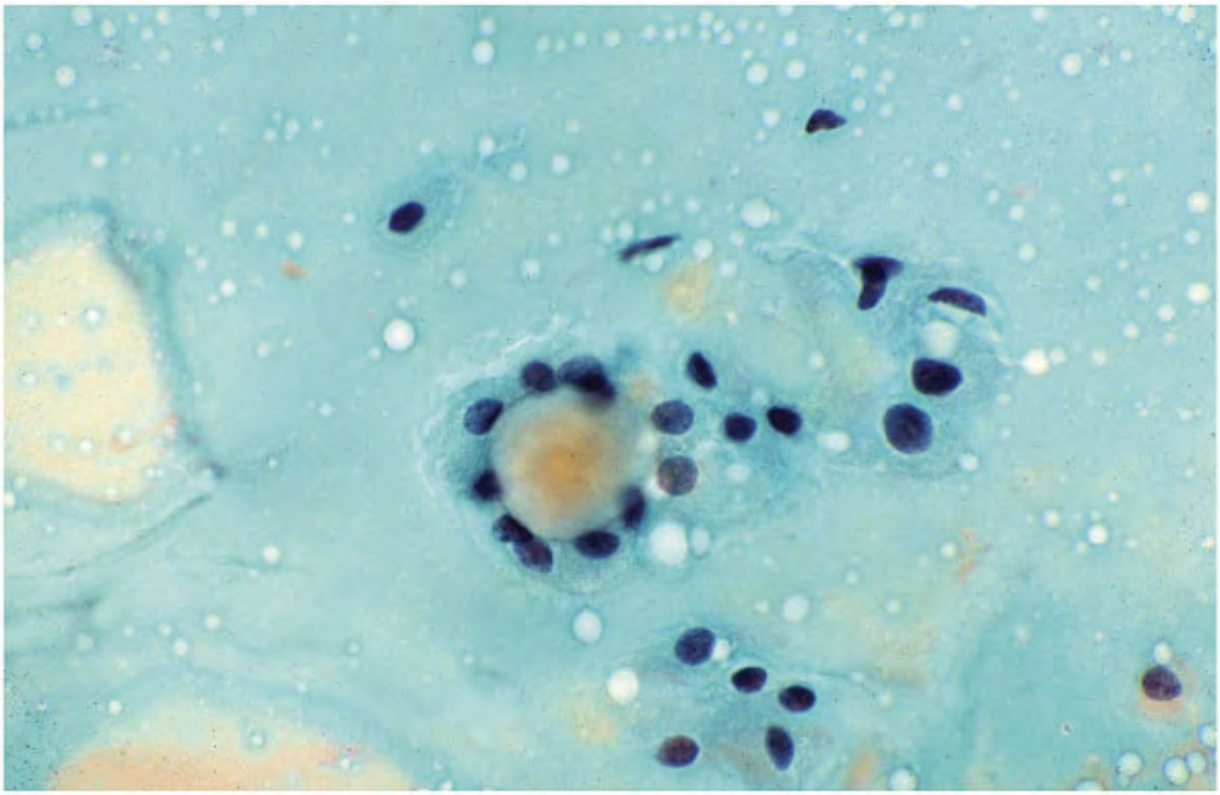

Figure 6.20. FNA nodular goiter. The abundant colloid is stained cyanophilic showing a single follicle bordered by regularly spaced follicular cells with small uniform nuclei. Note the chromatin is compact.

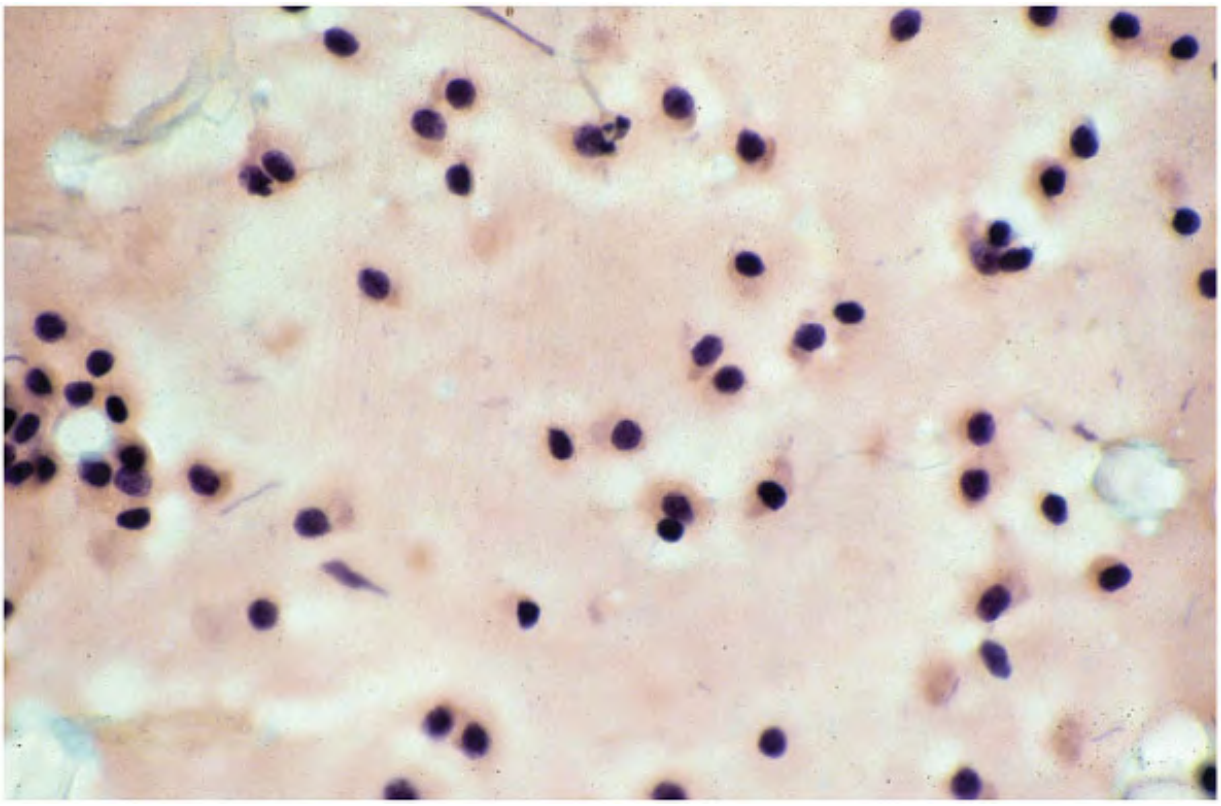

Figure 6.21. FNA, nodular goiter. The colloid is stained eosinophilic. The follicular cell nuclei appear naked and resemble lymphocytes.

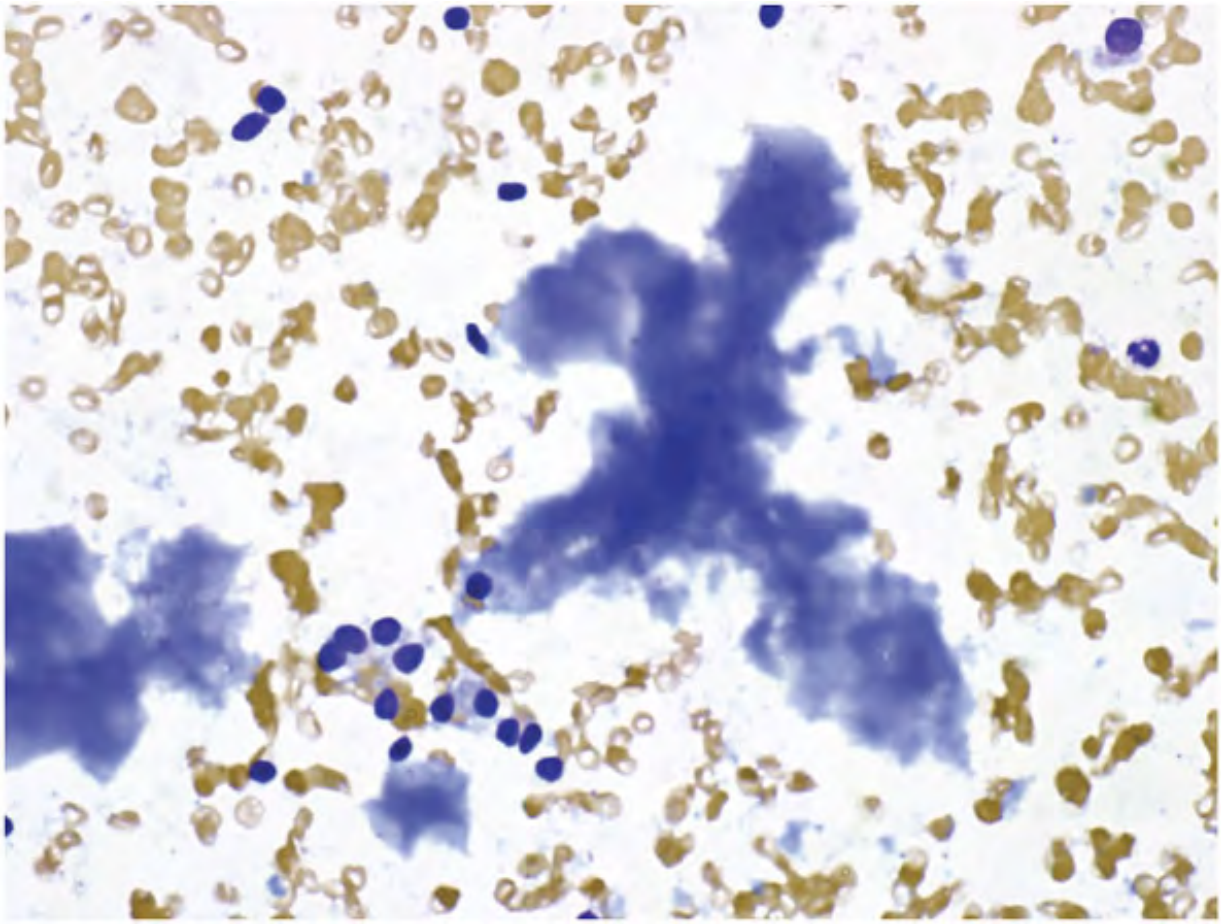

Figure 6.22. FNA nodular goiter. The colloid stains purple to violet in preparations stained by the Romanowsky method. (Courtesy of Dr. Mariza de Peralta-Venturina, William Beaumont Hospital, Royal Oak, Michigan.)

The benign follicular cells in aspirates from nodular goiters are seen isolated, in aggregates, or in tissue fragments, with and without a follicular pattern (Figs. 6.23, 6.24, 6.25, 6.26, 6.27, 6.28, 6.29, 6.30, 6.31, 6.32, 6.33 and 6.34). The follicles are generally small, showing a central lumen bordered by cuboidal cells with regularly spaced, small, uniform nuclei (Fig. 6.23). Colloid may be present within their lumina. Occasionally, a follicle is seen in its entirety (Fig. 6.24) in a three-dimensional form. The entire follicles exhibit a honeycomb arrangement in different planes of focus. The tissue fragments without a follicular pattern appear as monolayered sheets, with a resemblance to a honeycomb (see Chapter 4). The component cells have well-defined

cytoplasmic borders and contain regularly spaced, uniform nuclei that maintain their polarity (Figs. 6.25, 6.26, 6.27, 6.28, 6.29 and 6.30). There is small amount of

P.42

P.43

clear to pale cytoplasm. The follicular cell nuclei are round, with diameters ranging from 7 to 9 Âµm.8 The nuclear chromatin is finely granular and uniformly distributed or compact. Nucleoli are generally not seen, but may be present in hyperplastic follicular cells or with reparative/regenerative changes. Small, pyknotic, dense-staining nuclei are characteristic of hyperinvoluted goiters, where the follicular cells are seen singly or in small groups, floating in large lakes of colloid (Figs. 6.19, 6.20 and 6.21). Their scanty, pale cytoplasm fades away against the background of the colloid, and their pyknotic nuclei appear bare and are difficult to differentiate from lymphocytes. The aspirates of hyperplastic goiters show abundant cellular material (Figs. 6.31, 6.32, 6.33 and 6.34) consisting of tissue fragments of benign follicular cells with and without a follicular pattern. The cellularity can be overwhelming (Fig. 6.32). The colloid is usually scant or absent, and the aspirates are often interpreted as follicular neoplasms. The papillary hyperplasia yields papillary-like tissue fragments of follicular epithelium with a branching pattern and smooth external contours (Figs. 6.32, 6.33 and 6.34). However, their component cells show well-defined borders in a honeycomb pattern, a feature that

P.44

P.45

greatly helps distinguish hyperplasia from papillary carcinoma. They also lack the nuclear features of papillary carcinoma.

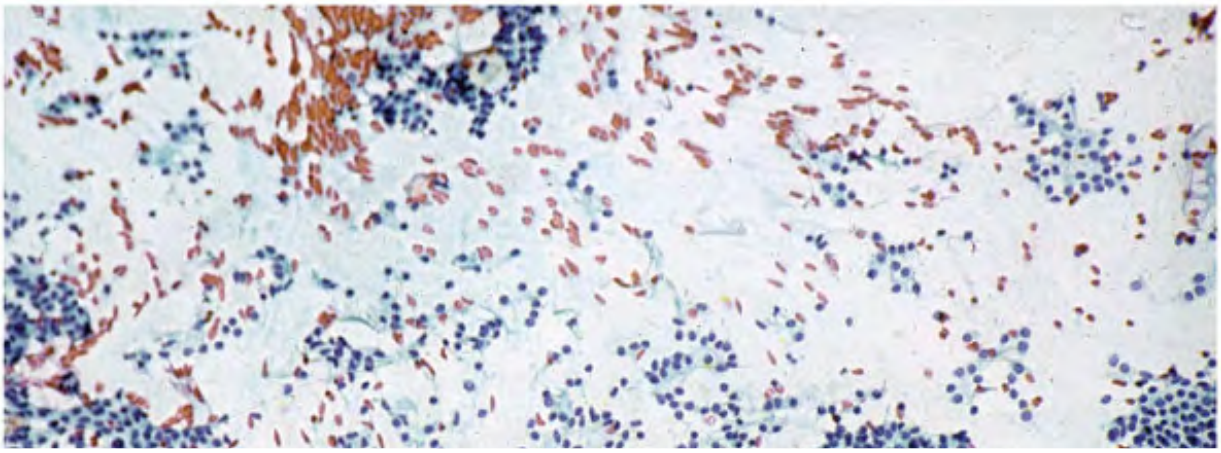

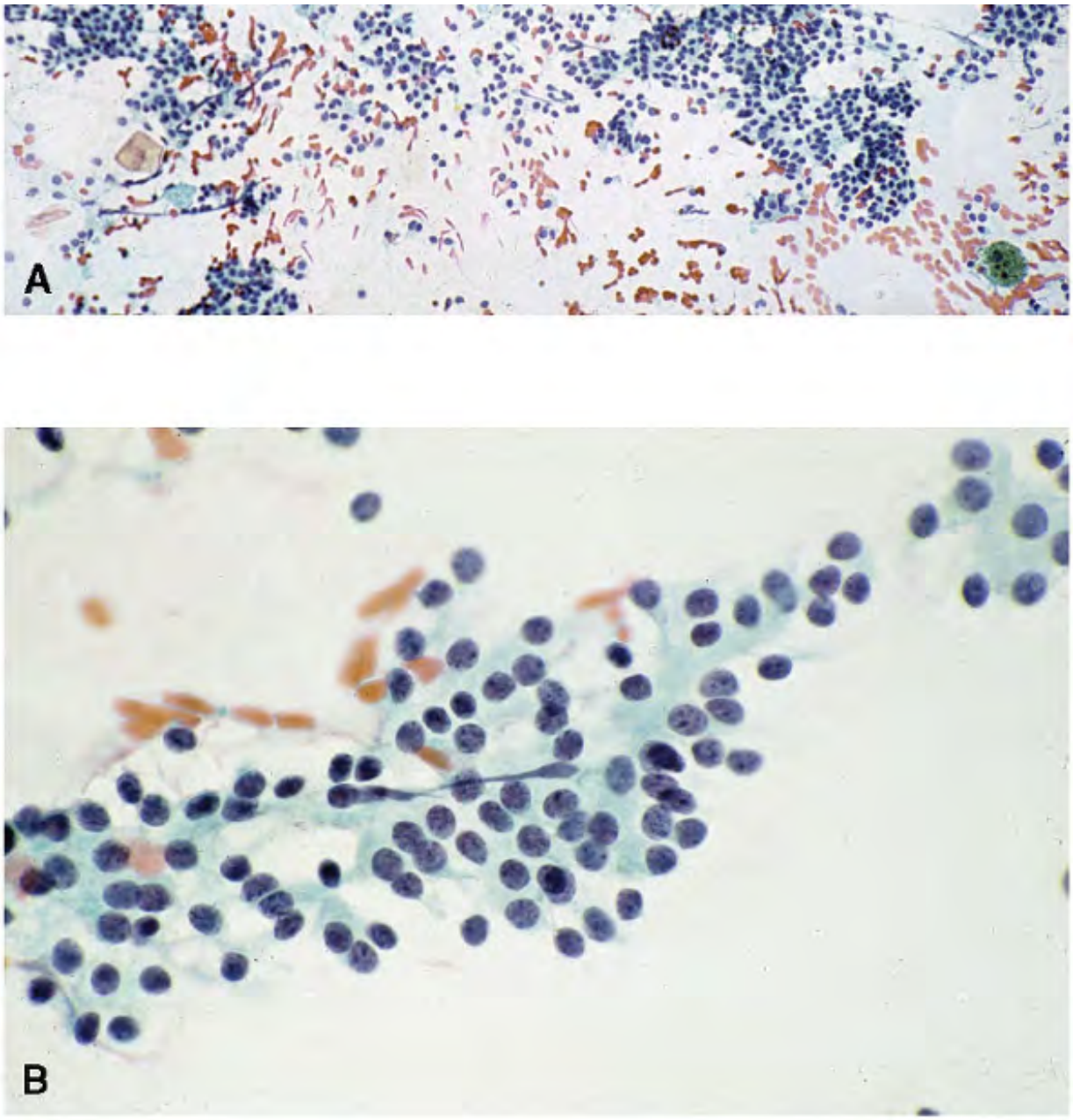

Figure 6.23. Nodular goiter. A. Cellular aspirate with minimal colloid in the background. The follicular cells are isolated or form small, regular follicles. The nuclei are small; low power. B. Higher magnification showing the follicular cells with uniform, small nuclei containing compact chromatin. Compare the nuclear size with the red blood cells in the background.

Figure 6.24. Nodular goiter. Two follicles seen in their entirety and presenting a three-dimensional pattern. Note uniform, small nuclei with compact chromatin and well-defined cell borders. The honeycomb pattern is seen indifferent planes of focus.

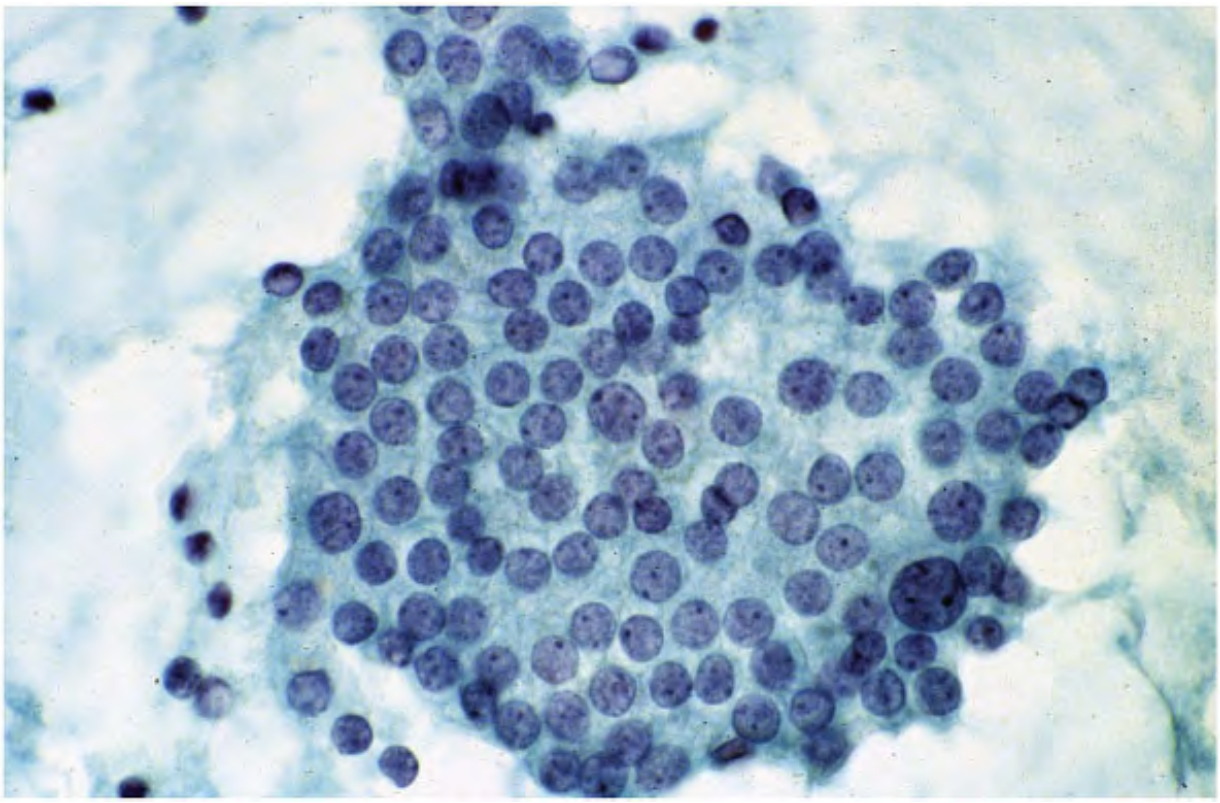

Figure 6.25. FNA of nodular goiter. A monolayered sheet of follicular epithelium with well-defined cell borders and centrally located, uniform, small nuclei. The honeycomb pattern is well demonstrated.

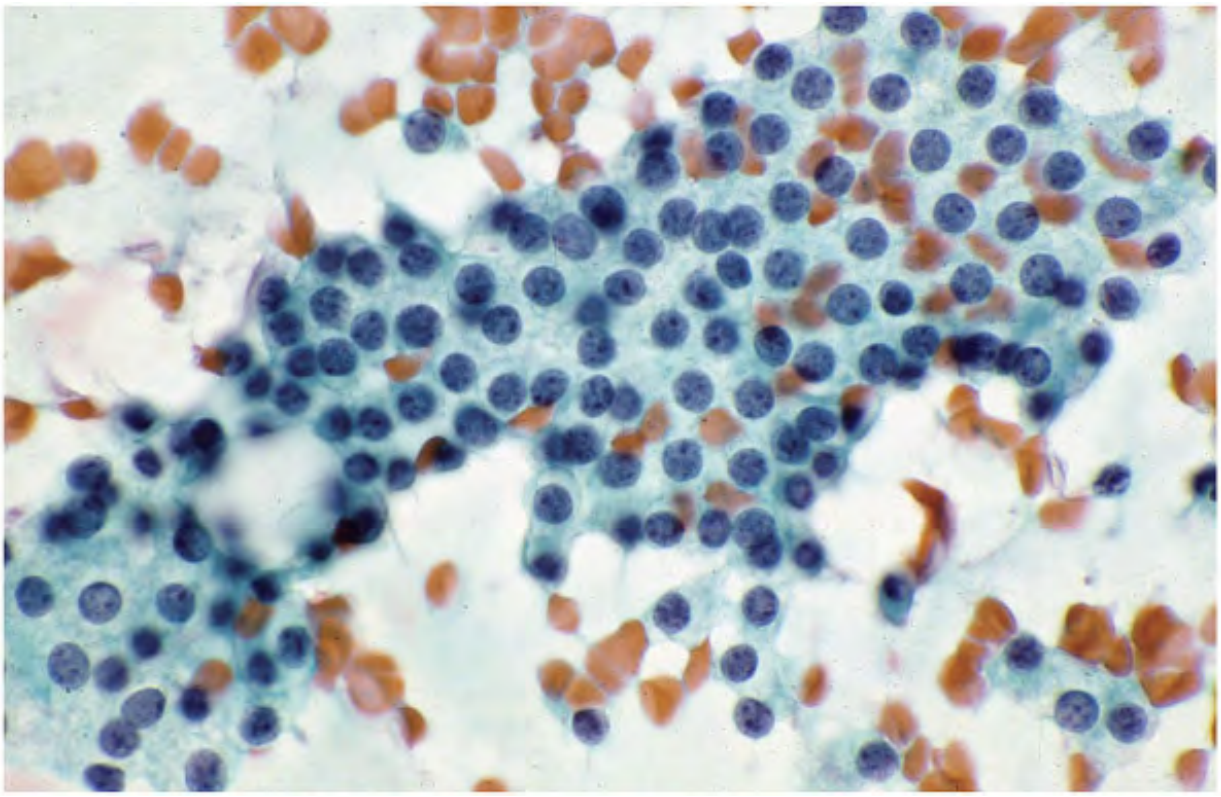

Figure 6.26. FNA, nodular goiter. A different case to illustrate the characteristic monolayered sheet of follicular epithelium with well-defined cell borders and centrally located, uniform small nuclei. The honeycomb pattern is well demonstrated. Compare the nuclear size to the red cells in the background.

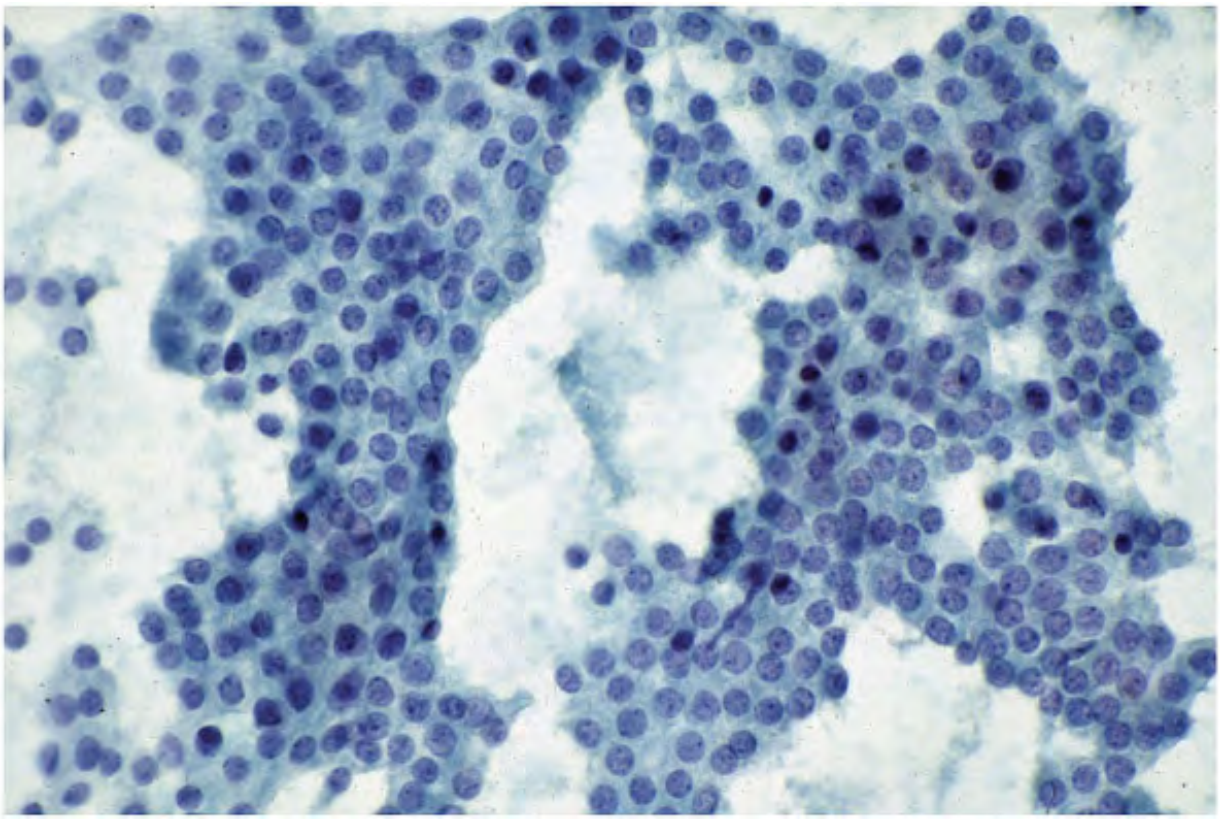

Figure 6.27. FNA, nodular goiter. Abundant cellular material and lack of colloid in the background may suggest the diagnosis of follicular neoplasm. However, the monolayered tissue fragments with a honeycomb pattern, and small, uniform nuclei suggest the diagnosis of nodular goiter.

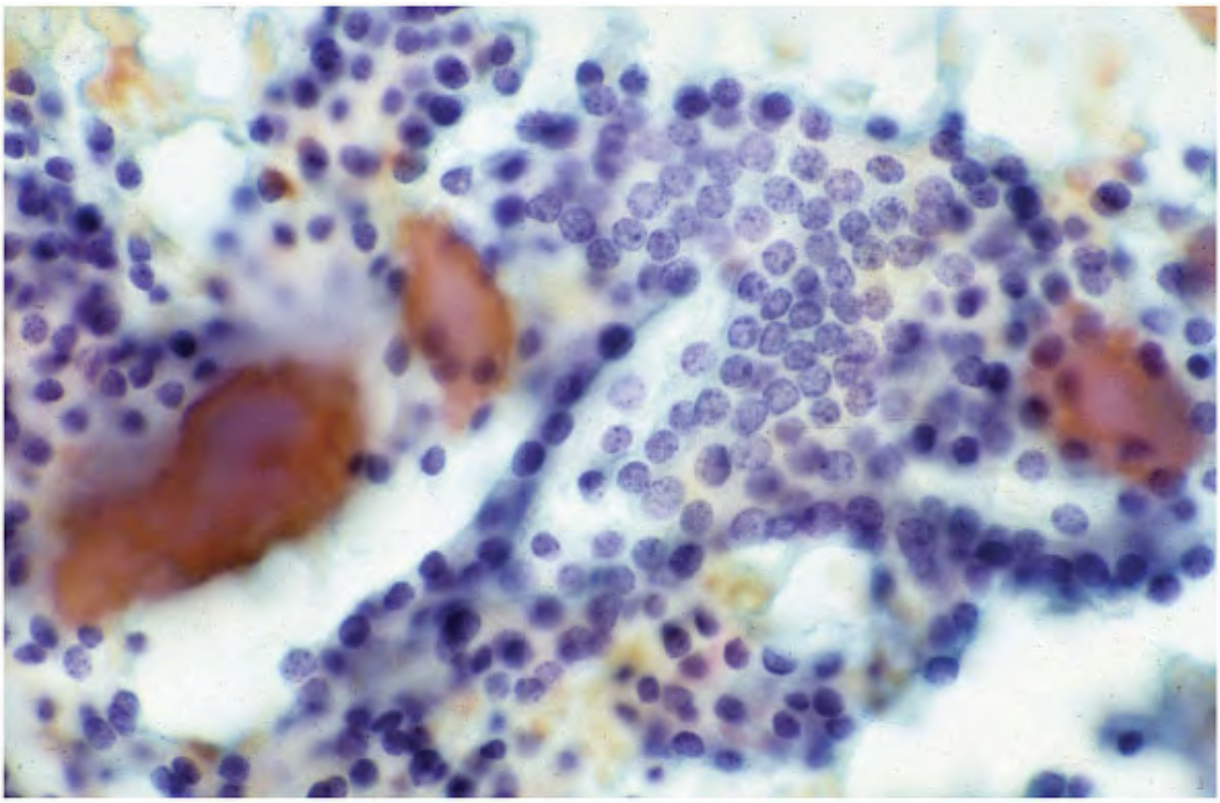

Figure 6.28. FNA, nodular goiter. Another example of a cellular aspirate containing monolayered tissue fragments of follicular epithelium with a honeycomb pattern, and small, uniform nuclei that suggest the diagnosis of nodular goiter. Note dense-staining colloid.

A

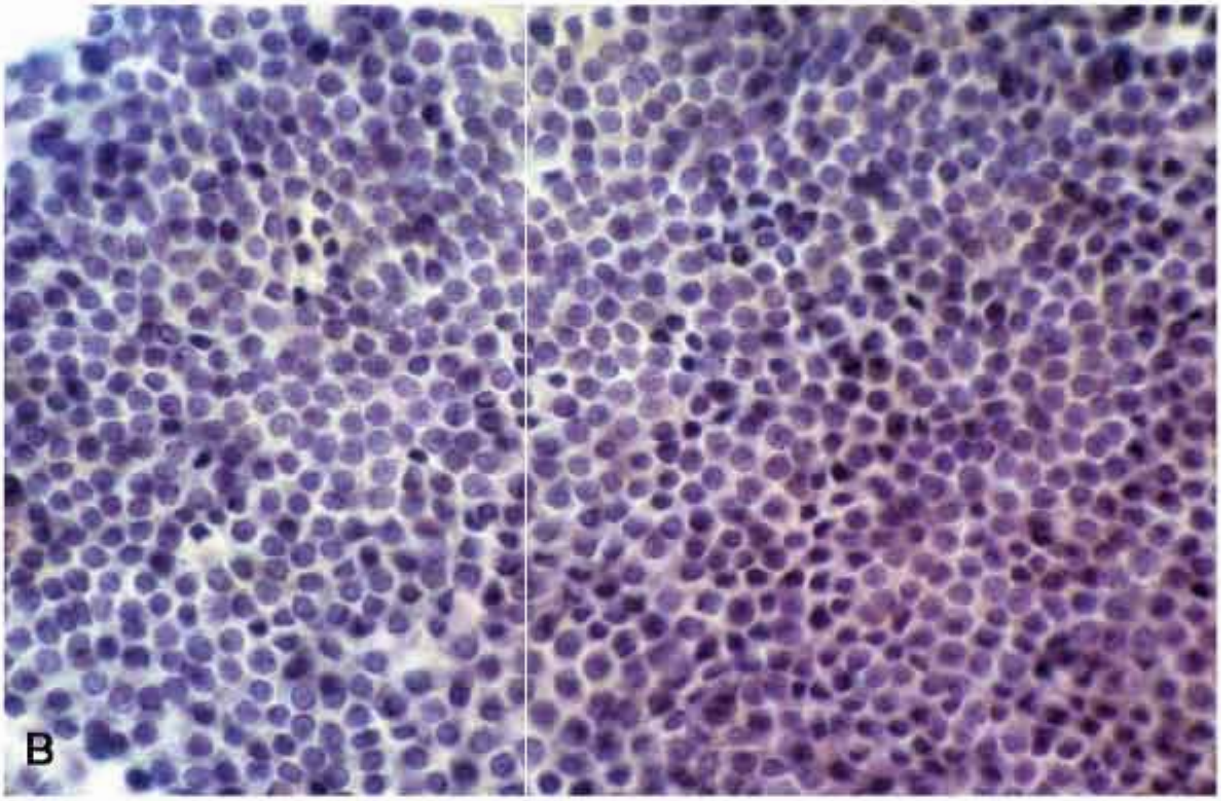
B

Figure 6.29. Nodular goiter. A. Large, monolayered tissue fragment of follicular epithelium. The honeycomb pattern is evident even at low magnification. B. Higher magnification showing small, uniform nuclei with compact chromatin.

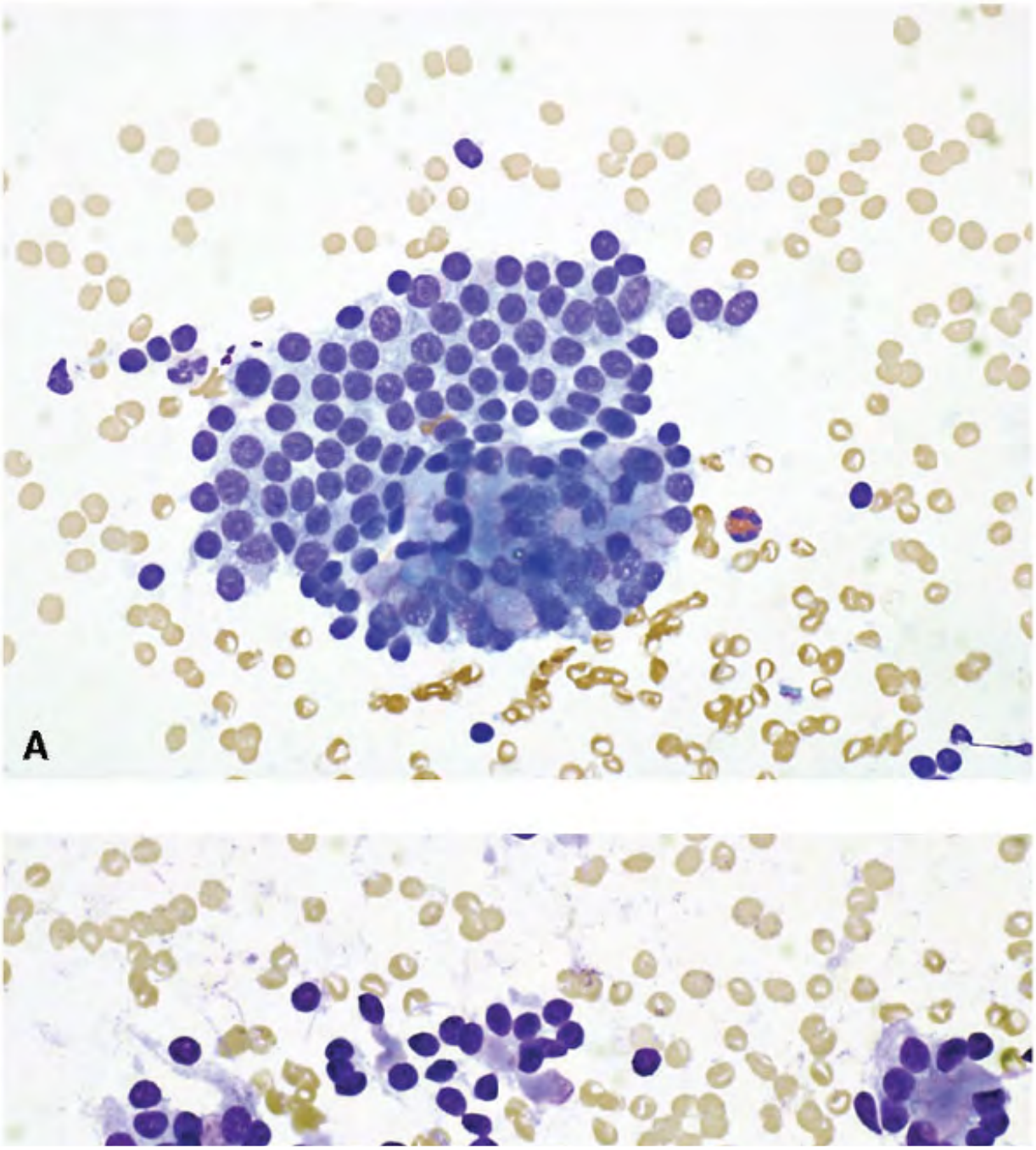

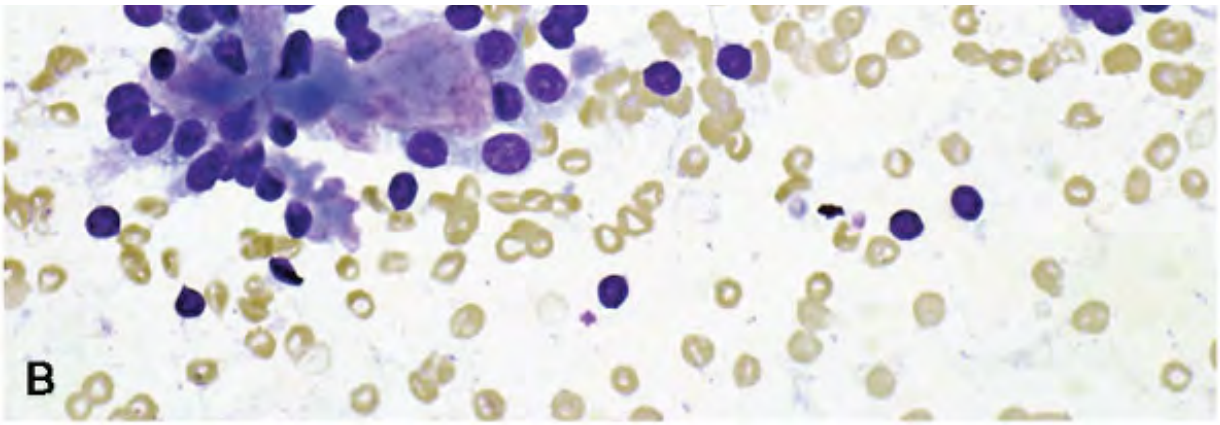

Figure 6.30. FNA, nodular goiter. A. Monolayered tissue fragment of follicular cells with honeycomb arrangement. The nuclei are uniform and regularly spaced. Also note a follicular pattern with colloid within the lumens. B. A different field from the same case. Note a regular follicle bordered by uniform small nuclei. Diff-Quik stain. (Courtesy of Dr. Mariza de Peralta-Venturina, William Beaumont Hospital, Royal Oak, Michigan.)

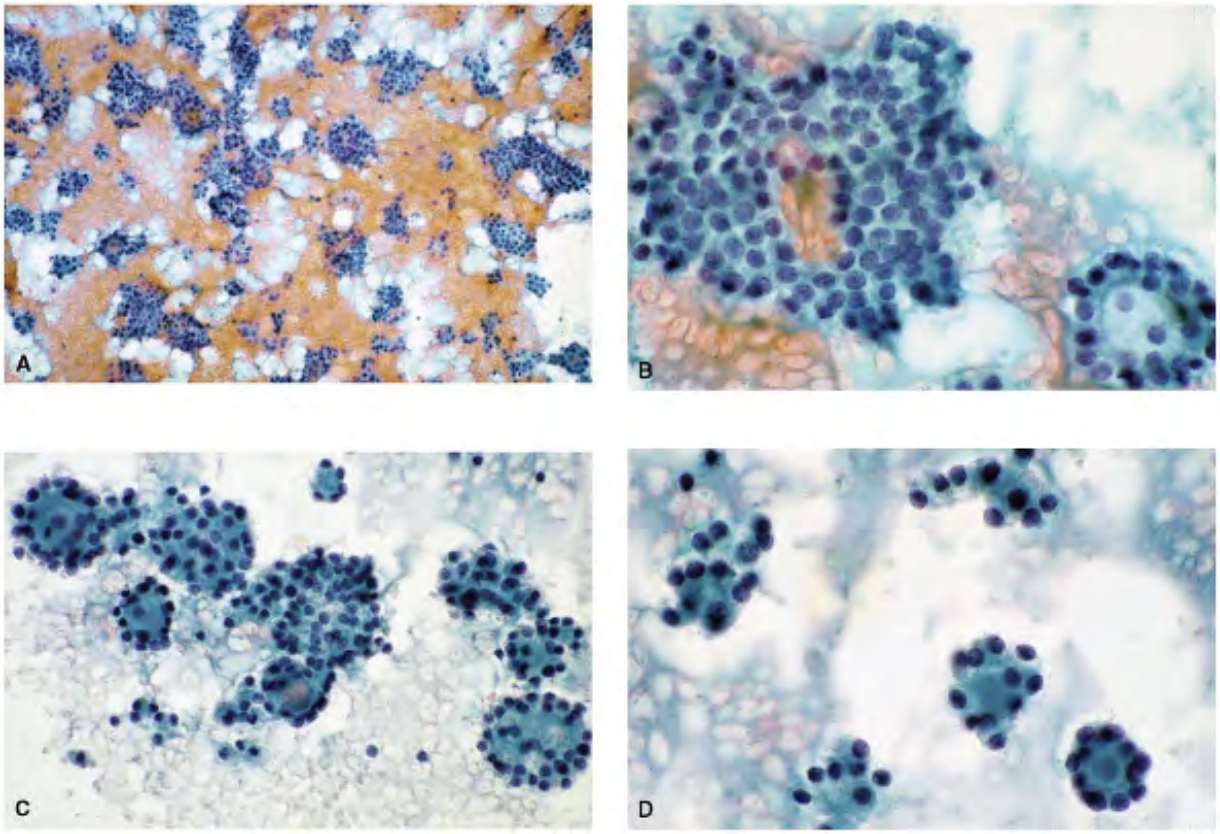

Figure 6.31. FNA, nodular goiter. A. This hypercellular aspirate consisting of several tissue fragments of follicular cells in the background of abundant colloid may prompt a diagnosis of follicular neoplasm, low power. B. Higher magnification showing the tissue fragments with a honeycomb architecture with regularly spaced uniform nuclei. The chromatin is granular to compact. C. This field shows several follicles, seen en face presenting a honeycomb pattern with small uniform nuclei containing compact chromatin. D. Another field showing microfollicles consisting of small nuclei with compact chromatin.

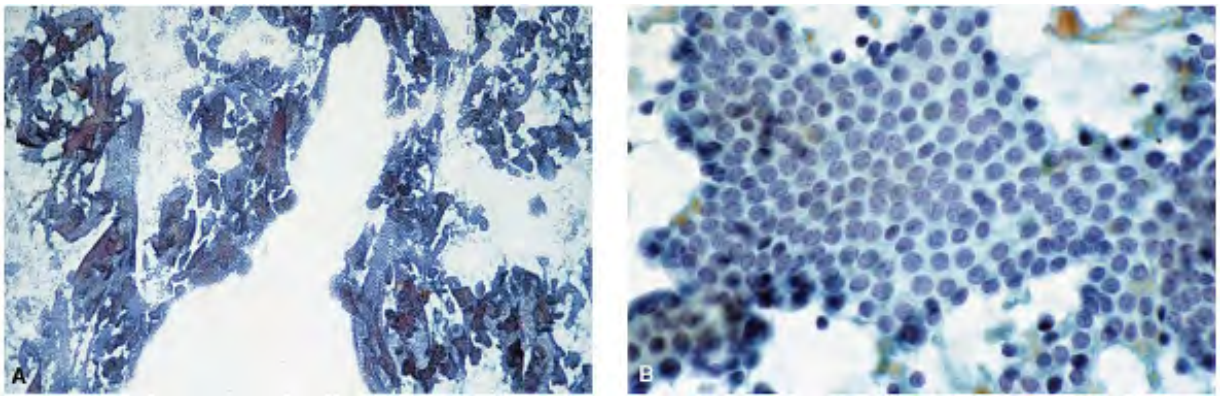

Figure 6.32. Hyperplastic goiter. A. This overwhelmingly cellular aspirate consists of a large number of papillary-like and monolayered tissue fragments. Under low magnification, this may be mistaken for a papillary carcinoma. B. Higher magnification showing uniform, small nuclei and a honeycomb pattern, ruling out neoplasia.

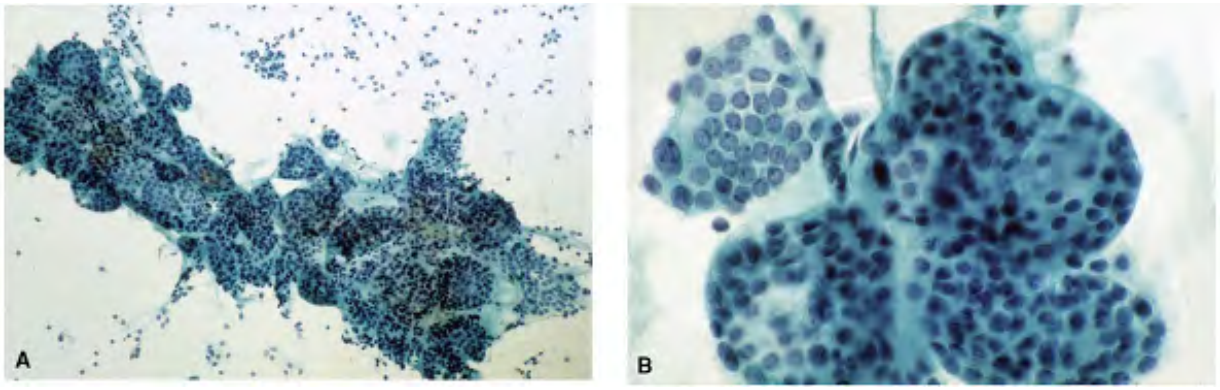

Figure 6.33. Hyperplastic goiter. A. Low power depicting a large tissue fragment of follicular epithelium. B. Higher magnification shows several follicles with a honeycomb arrangement and uniform small nuclei with compact chromatin.

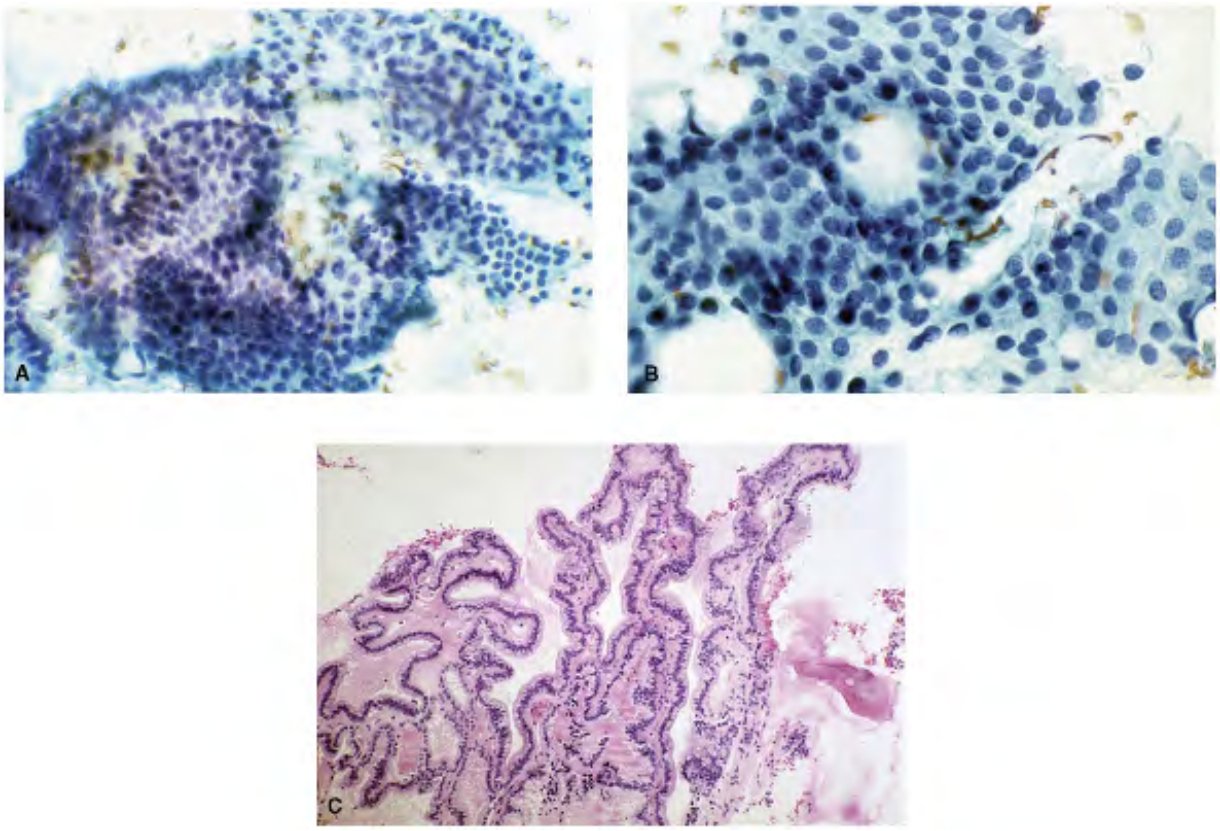

Figure 6.34. Hyperplastic goiter. A, B. Cellular aspirate with large tissue fragments of follicular cells with papillary-like architecture. The nuclei appear crowded and are slightly enlarged. A papillary carcinoma was suspected. C. A core needle biopsy showing hyperplastic goiter with papillary change.

HÃ¼rthle cell metaplasia of follicular cells is a common occurrence in nodular goiters. The metaplastic HÃ¼rthle cells are usually present in tissue fragments and less often as discrete cells or in groups (Figs. 6.35, 6.36, 6.37, 6.38, 6.39 and 6.40). They vary in size, ranging from medium-sized to large; are cuboidal, oval to polygonal; and contain abundant granular or sometimes dense cytoplasm and slightly eccentric nuclei. Their cell borders are usually well defined. The nuclei of the metaplastic HÃ¼rthle cells tend to be pleomorphic in size with frequent giant forms. Their chromatin pattern is variable from granular to pyknotic, structureless, and deep staining. The presence of nucleoli is not common. Transition forms from regular follicular cells to

HÃ¼rthle cells are often noted, serving as a feature in favor of metaplasia rather than a neoplasm (Figs. 6.35, 6.36, 6.37, 6.38 and 6.39). A cellular aspirate from a nodular goiter with a predominance of metaplastic HÃ¼rthle cells represents a potential diagnostic pitfall and may be misinterpreted as a HÃ¼rthle cell neoplasm. The differentiating features are discussed in Chapter 8.

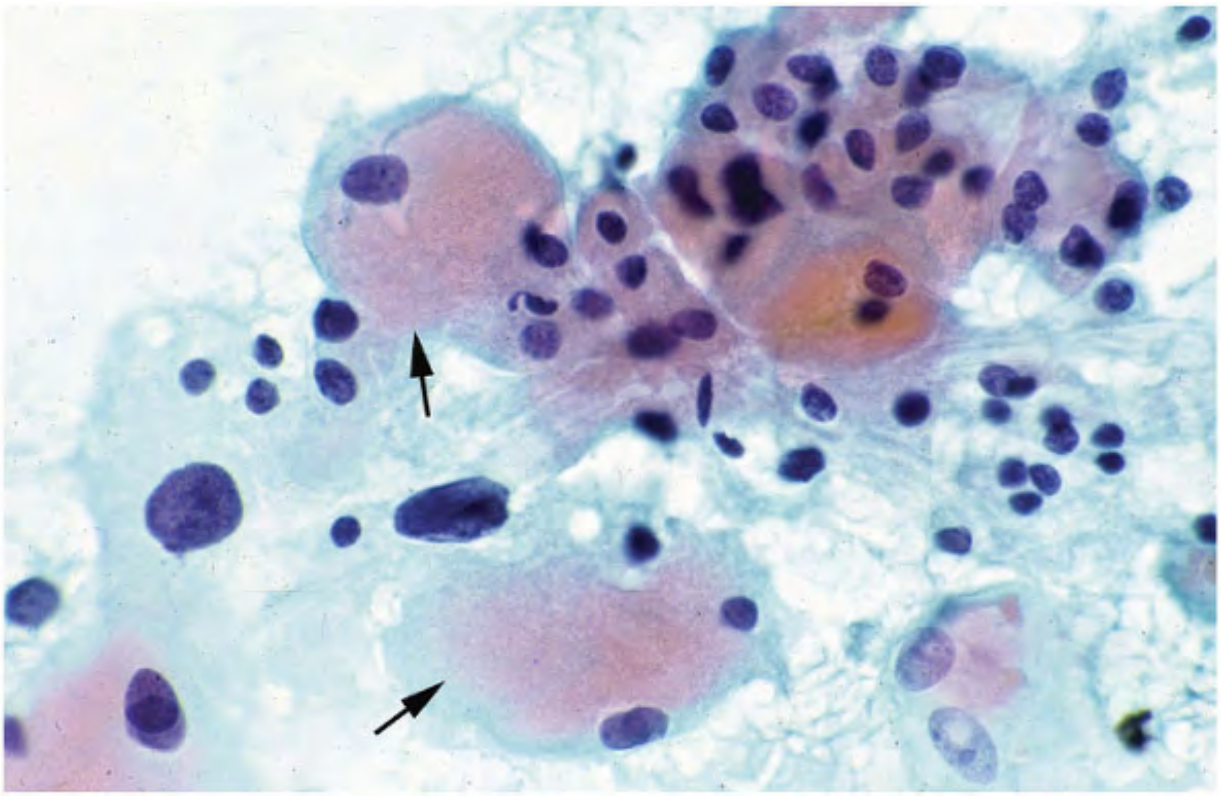

Figure 6.35. HÃ¼rthle cell metaplasia. Benign follicular cells mixed with metaplastic HÃ¼rthle cells (*arrow*) containing abundant granular cytoplasm and pyknotic, variably sized nuclei.

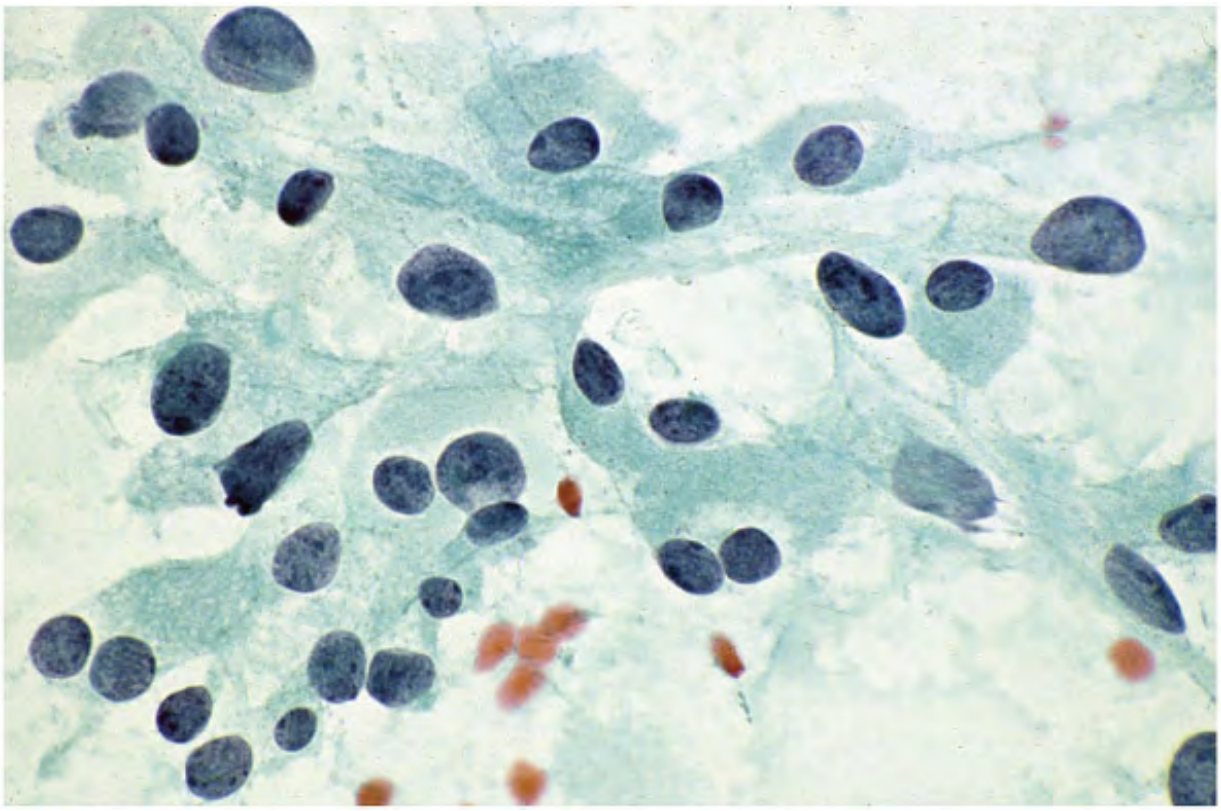

Figure 6.36. HÃ¼rthle cell metaplasia, nodular goiter. The HÃ¼rthle cells are large and pleomorphic with abundant cytoplasm. Their nuclei are likewise pleomorphic with pyknotic nuclei.

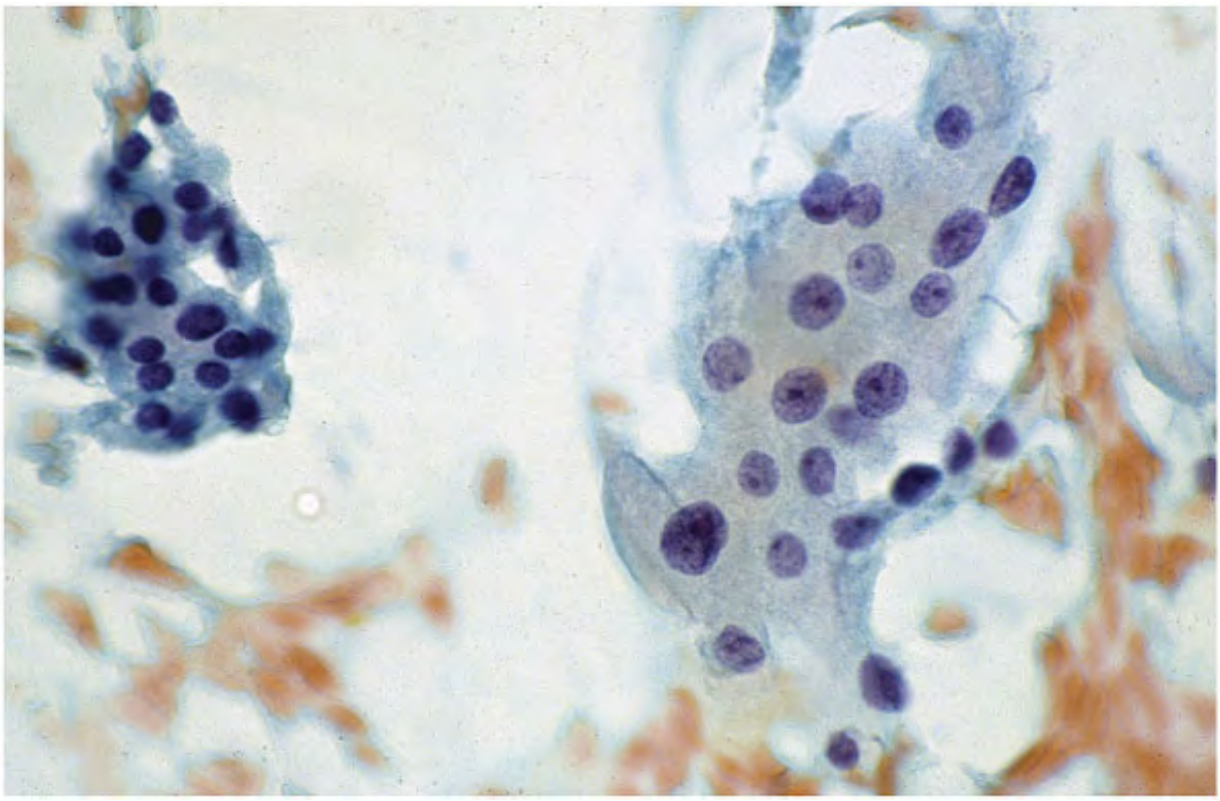

Figure 6.37. This aspirate demonstrates two tissue fragments, one of benign follicular cells and the other consisting of larger cells, pleomorphic in size, with abundant granular cytoplasm, representing HÃ¼rthle cell metaplasia. Their nuclei are slightly pleomorphic and occasionally pyknotic.

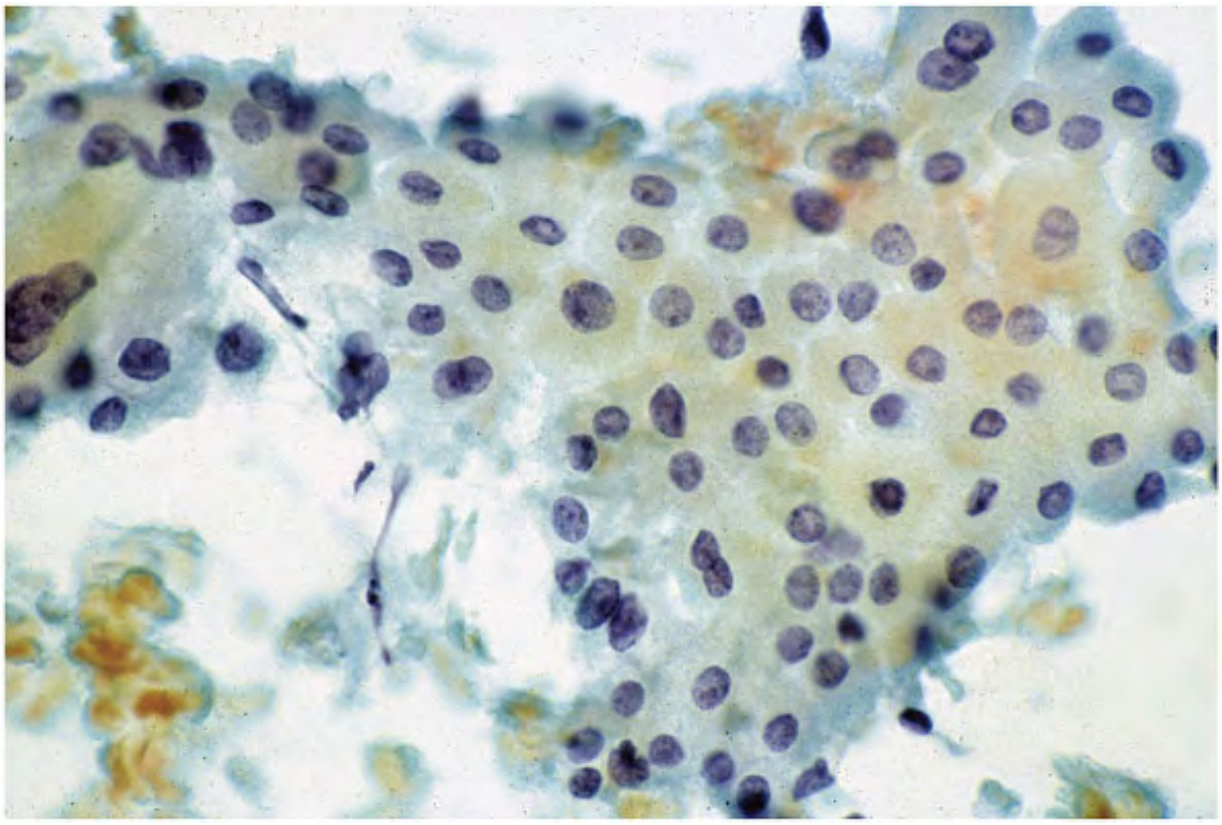

Figure 6.38. This large tissue fragment of follicular cells consists of benign follicular cells with transition forms to metaplastic HÃ¼rthle cells.

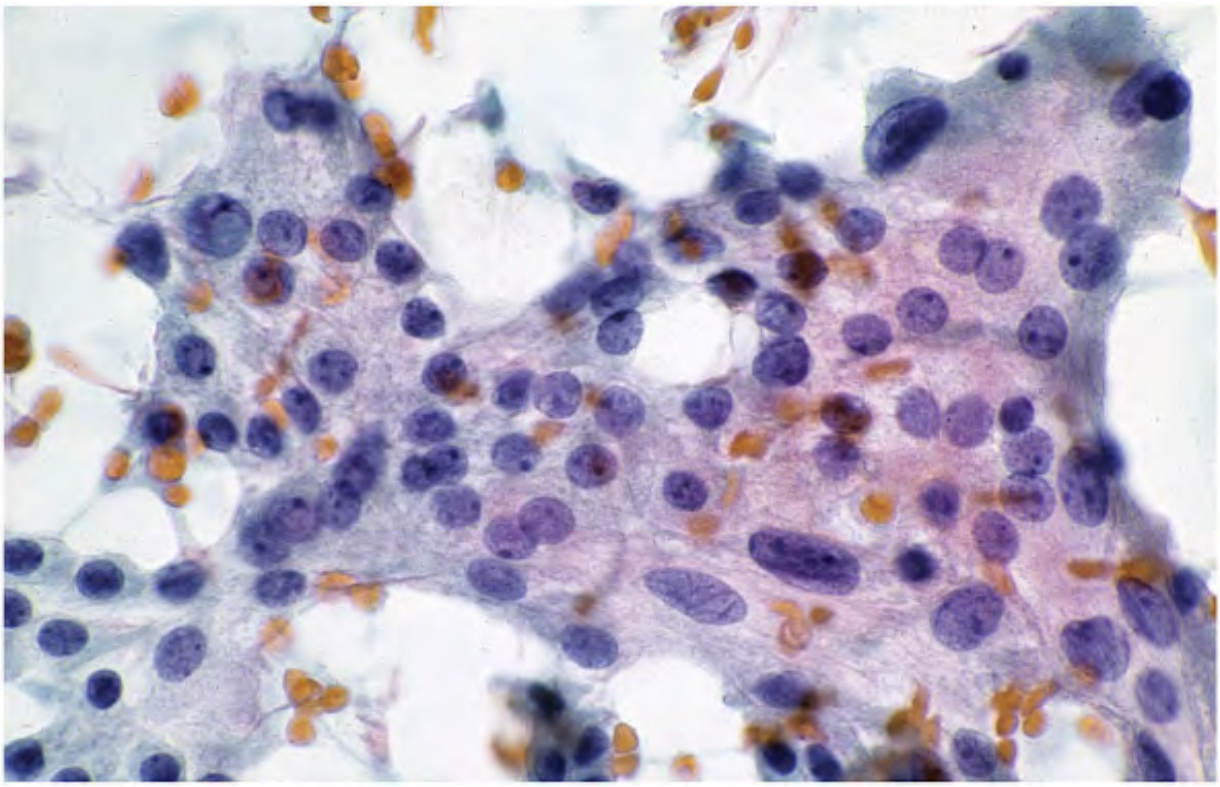

Figure 6.39. This large tissue fragment of follicular cells consists of benign follicular cells with transition forms to metaplastic HÃ¼rthle cells. Note abundant eosinophilic granular cytoplasm.

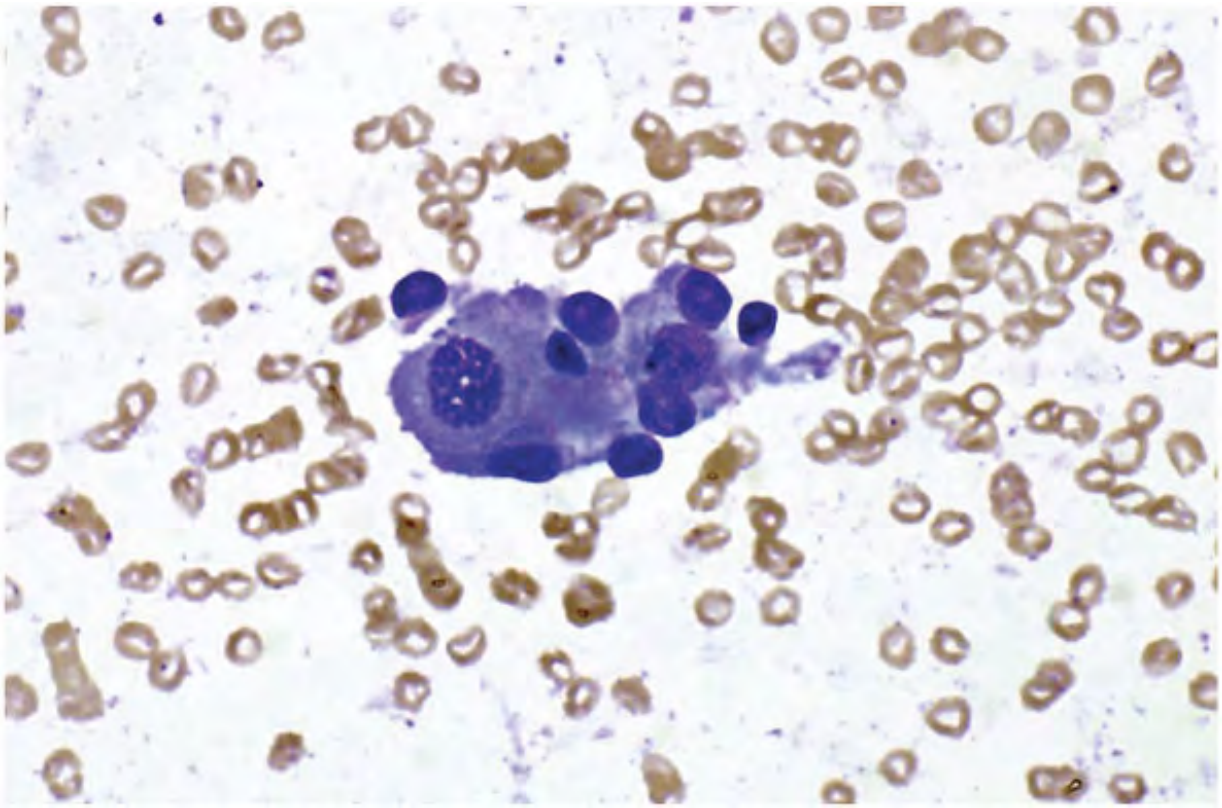

Figure 6.40. A group of HÃ¼rthle cells from a case of nodular goiter. Diff-Quik stain. (Courtesy of Dr. Mariza de Peralta-Venturina, William Beaumont Hospital, Royal Oak, Michigan.)

Hemorrhage and degeneration in a nodular goiter are common events initiating the regressive changes in the follicular cells. These events eventually lead to cyst formations, fibrosis, and calcifications. The aspiration biopsy may yield variable amounts of clear to bloody fluid of varying consistency. The cytologic specimens demonstrate degenerating follicular cells, which appear enlarged, with abundant granular, foamy, or vacuolated cytoplasm, and sometimes with phagocytized hemosiderin pigment (Fig. 6.41).9 Their nuclei remain normal-sized to slightly enlarged, and may contain prominent nucleoli. These cells with prominent nucleoli often cause concern8, 9, 10 and may be misinterpreted as neoplastic (Figs. 6.42, 6.43, 6.44 and 6.45). The degenerating follicular cells, because of expanded granular cytoplasm containing hemosiderin, strongly resemble macrophages. The only

differentiating feature is that the follicular cells occur in tissue fragments, unlike macrophages, which occur singly. The aspirates of nodular goiter that has undergone degenerative changes may contain isolated groups or tissue fragments of cells with varying degrees of nuclear atypia and represent diagnostic pitfalls (Figs. 6.46, 6.47, 6.48 and 6.49). Misinterpretation may lead to unnecessary surgery. The follicular cells with regressive changes may assume spindle shape or undergo squamous metaplasia (Figs. 6.48 and 6.49).

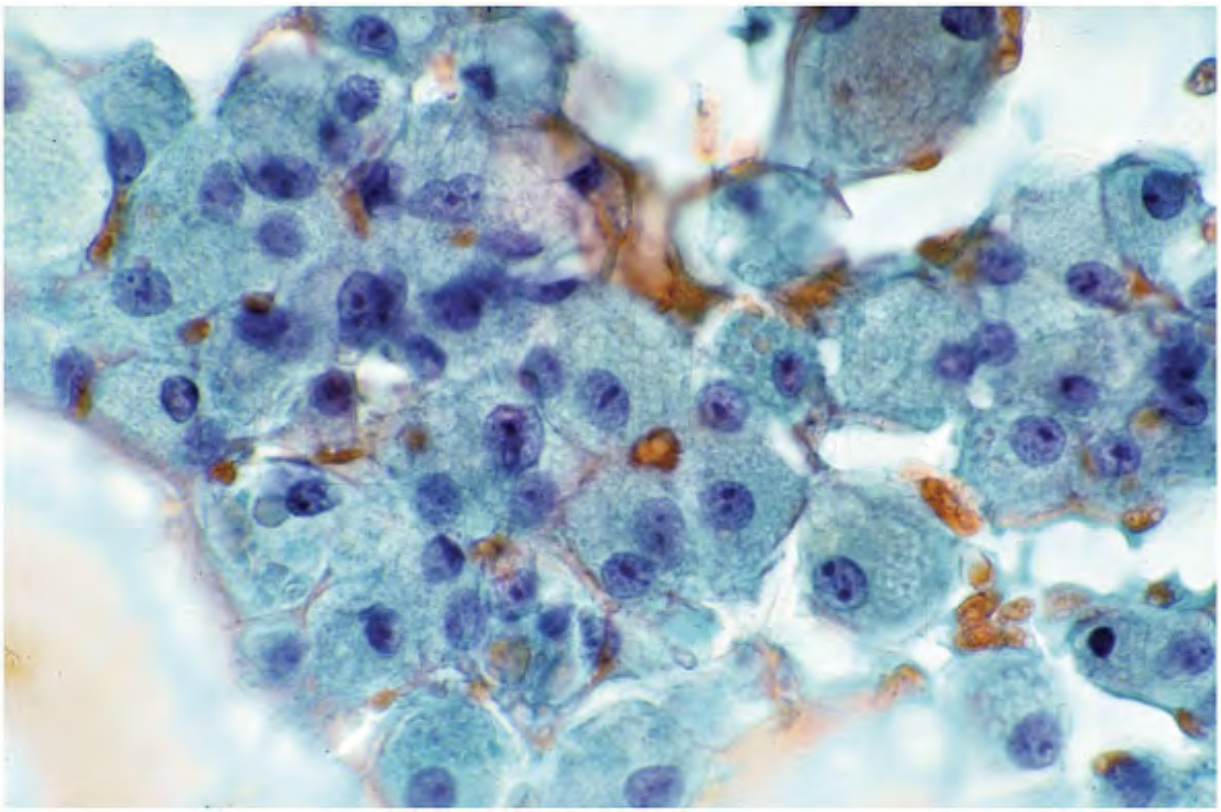

Figure 6.41. Degenerating follicular cells from nodular goiter. Note that the cells are in a monolayered tissue fragment, large with abundant granular cytoplasm and strongly resemble macrophages. Some even contain hemosiderin pigment.

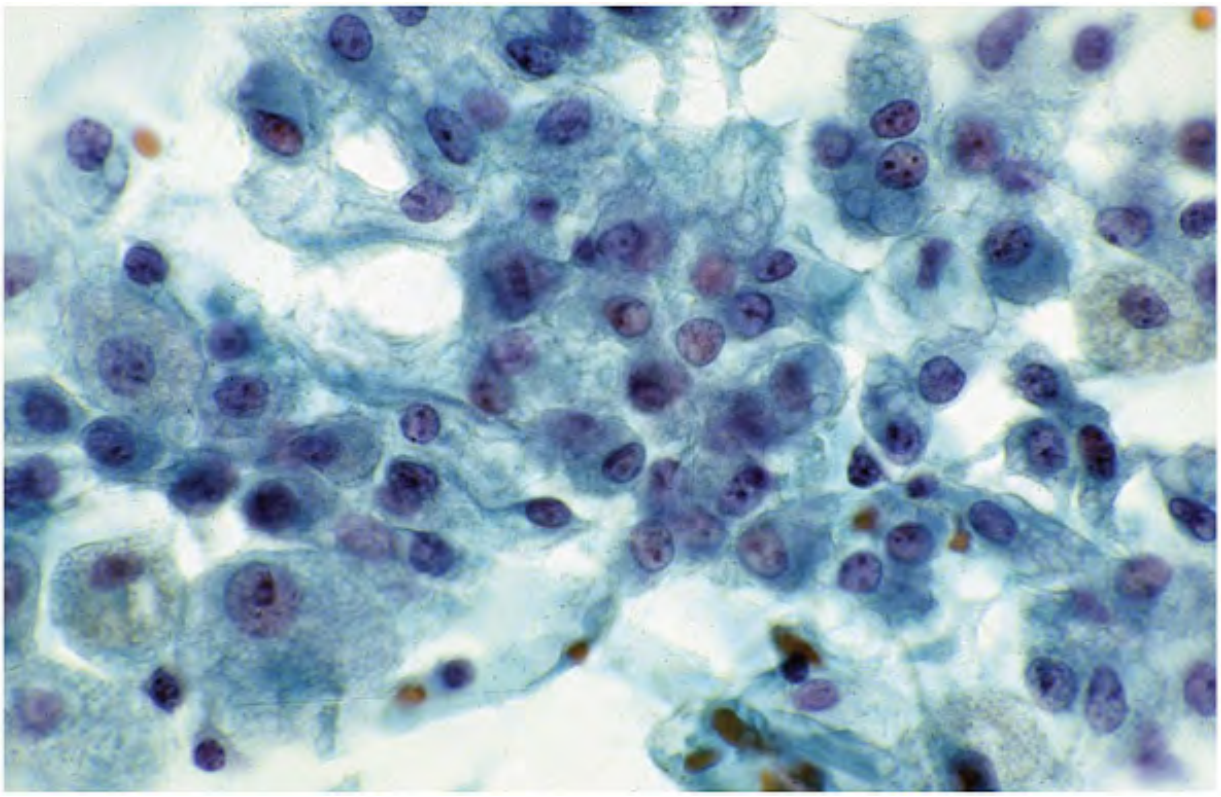

Figure 6.42. Degenerating follicular cells from nodular goiter. Note that the follicular cells are large, loosely cohesive, and in monolayered tissue fragments. Their cytoplasm is moderate to abundant, and foamy to granular. The nuclei are moderately enlarged with nucleoli; the N/C ratios are low.

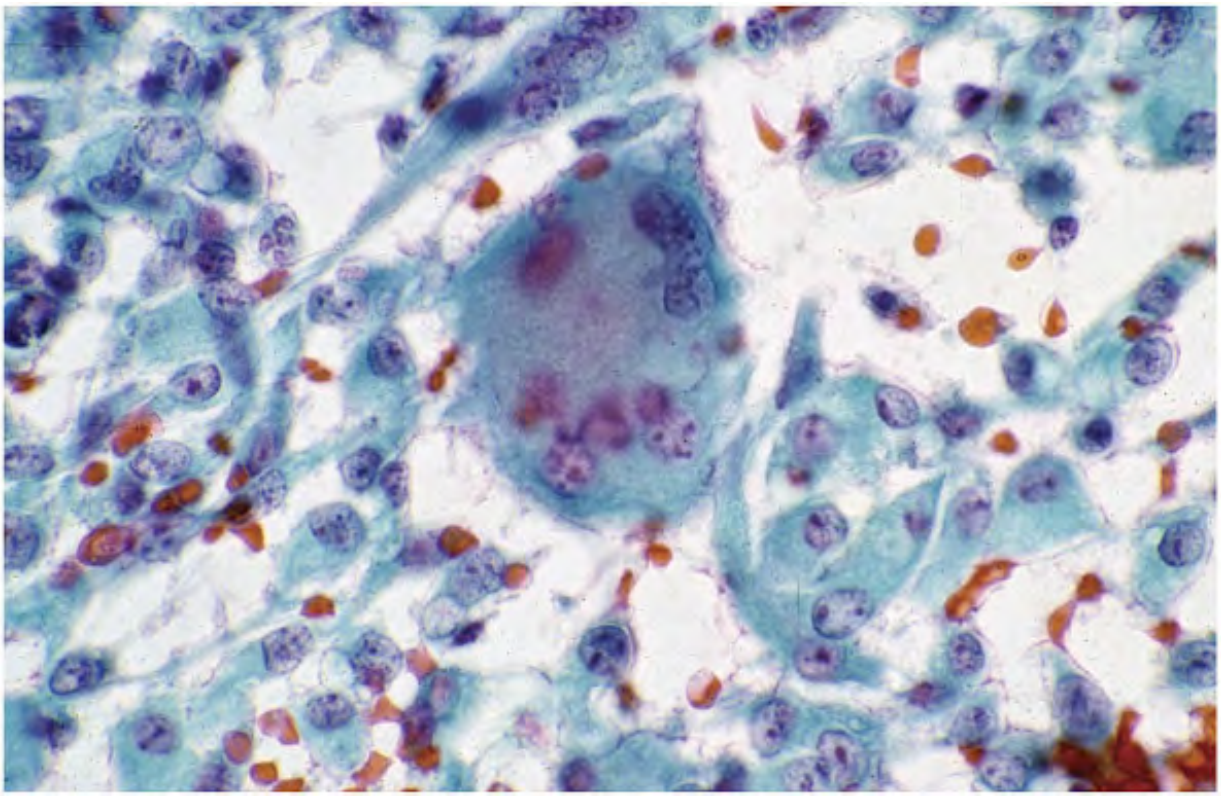

Figure 6.43. Degenerating follicular cells from nodular goiter. The follicular cells are mostly discrete, enlarged with abundant granular cytoplasm. The nuclei contain prominent nucleoli. Note a multinucleated giant cell.

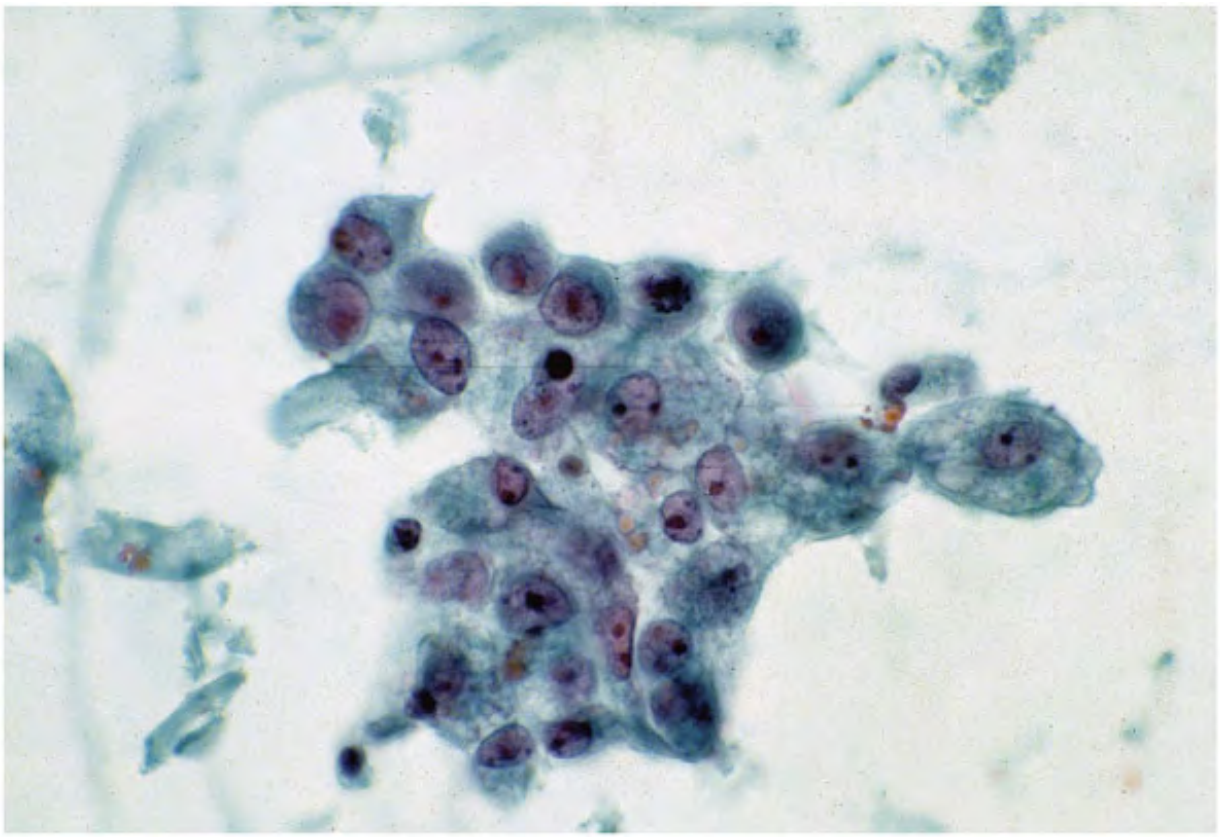

Figure 6.44. These follicular cells from nodular goiter contain enlarged nuclei with prominent nucleoli and probably represent a reactive/regenerative response. Such cells are usually few in number in the background features of nodular goiter.

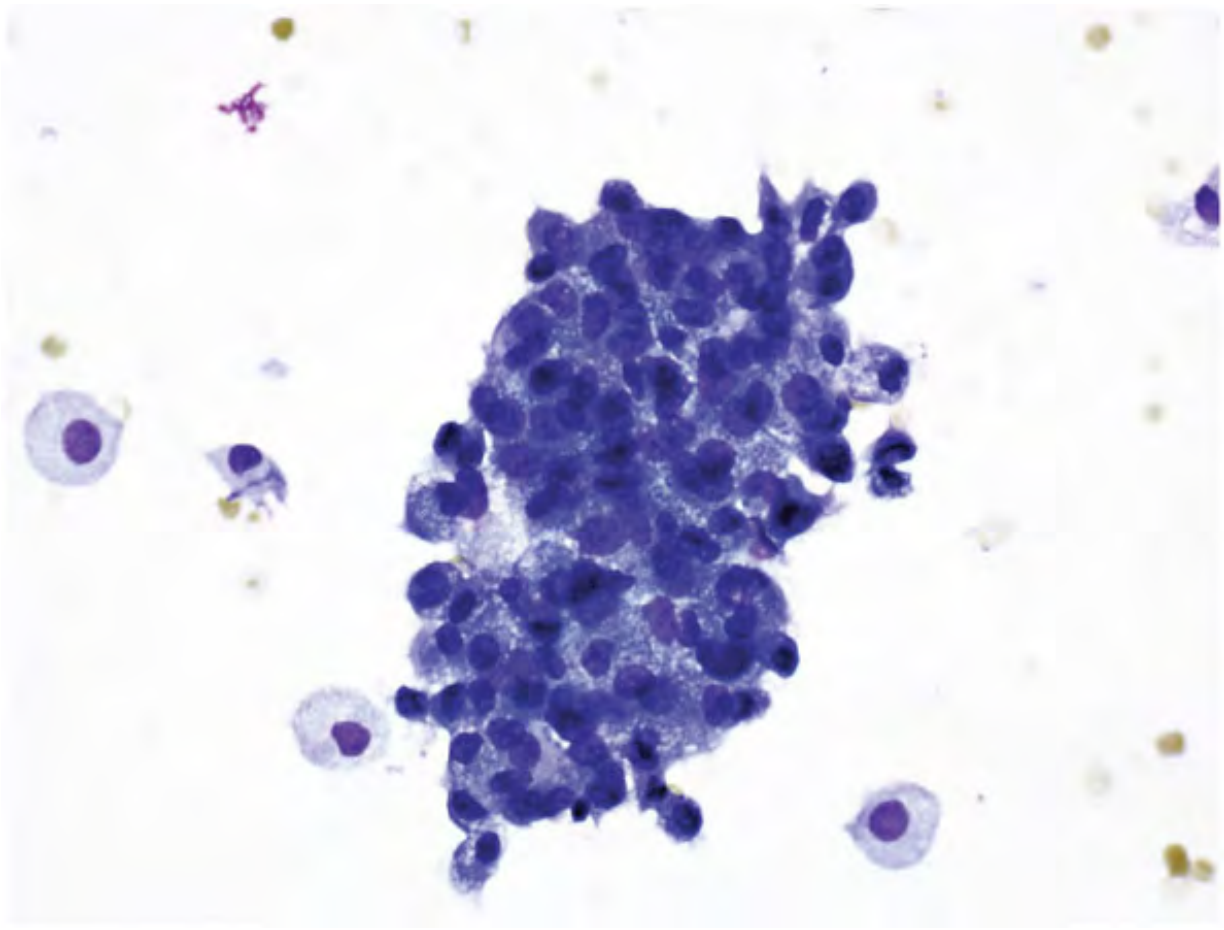

Figure 6.45. Degenerating follicular cells from nodular goiter. Note that the cells are in a monolayered tissue fragment, large, with abundant granular, vacuolated cytoplasm, and that they strongly resemble macrophages. Diff-Quik stain. (Courtesy of Dr. Mariza de Peralta-Venturina, William Beaumont Hospital, Royal Oak, Michigan.)

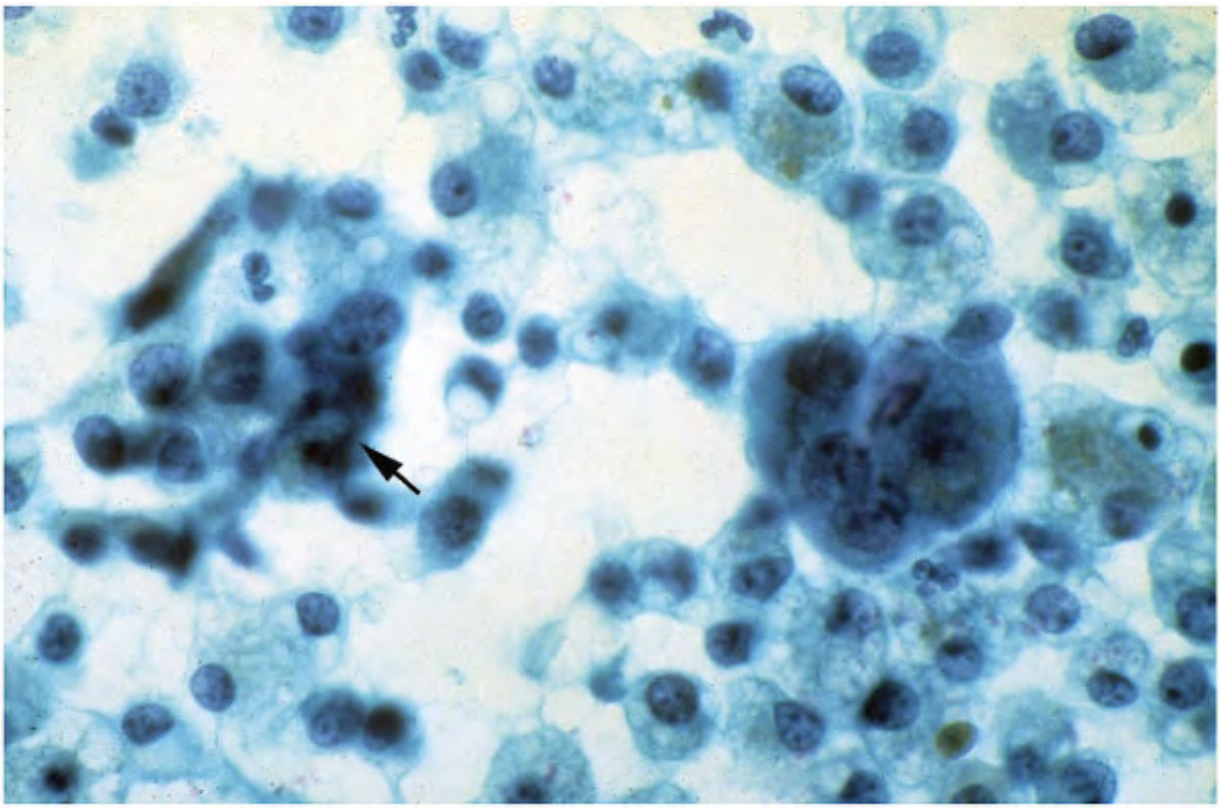

Figure 6.46. A large population of discrete follicular cells with foamy, vacuolated cytoplasm. The nuclei have a uniform chromatin pattern and contain nucleoli. These cells may represent either degenerating follicular cells or histiocytes. Note the tissue fragment of follicular epithelium with pyknotic nuclei.

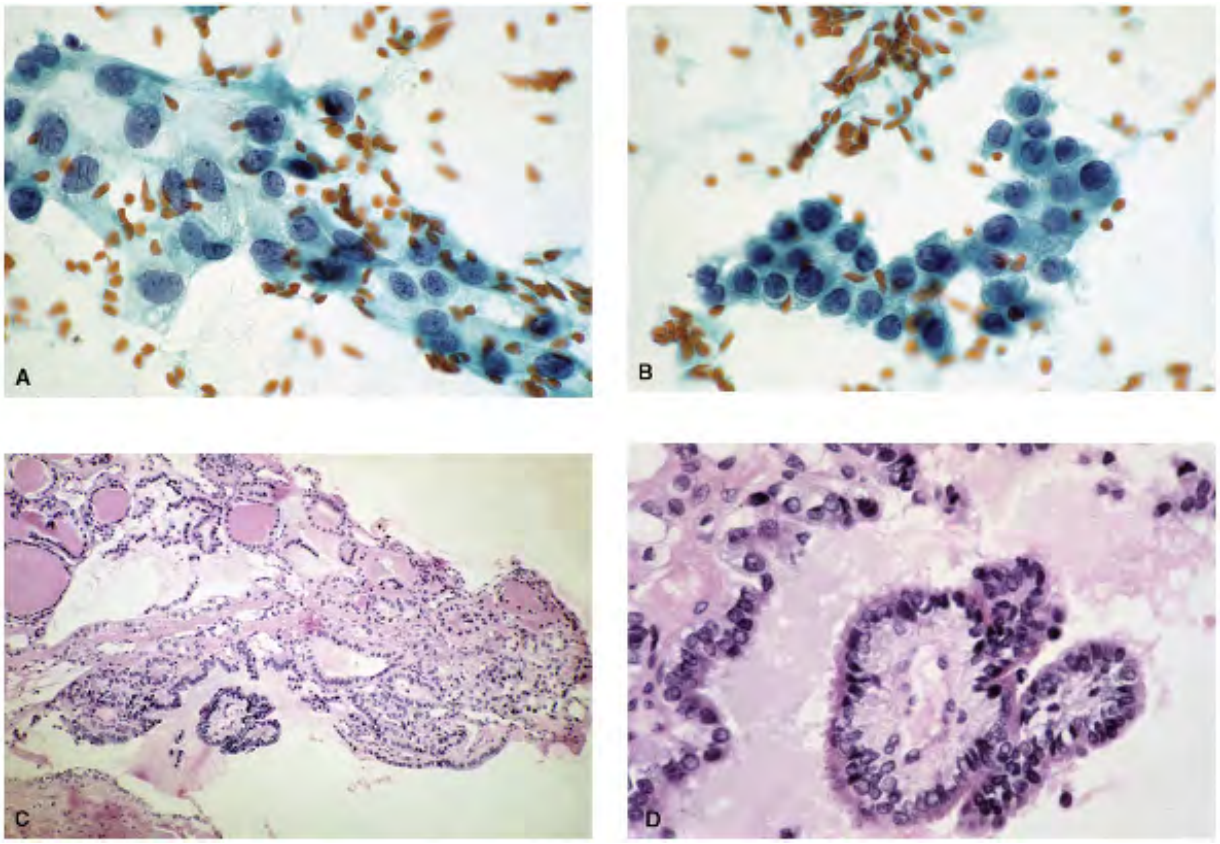

Figure 6.47. A, B. FNA of a thyroid nodule showing tissue fragments of follicular cells with enlarged, pleomorphic nuclei, containing coarsely granular chromatin. Although the background features were suggestive of nodular goiter, a suspicious diagnosis was rendered. C. A core needle biopsy revealed a cystic nodular goiter with papillary change (low power). D. Higher magnification highlighting the atypia of the lining follicular cells.

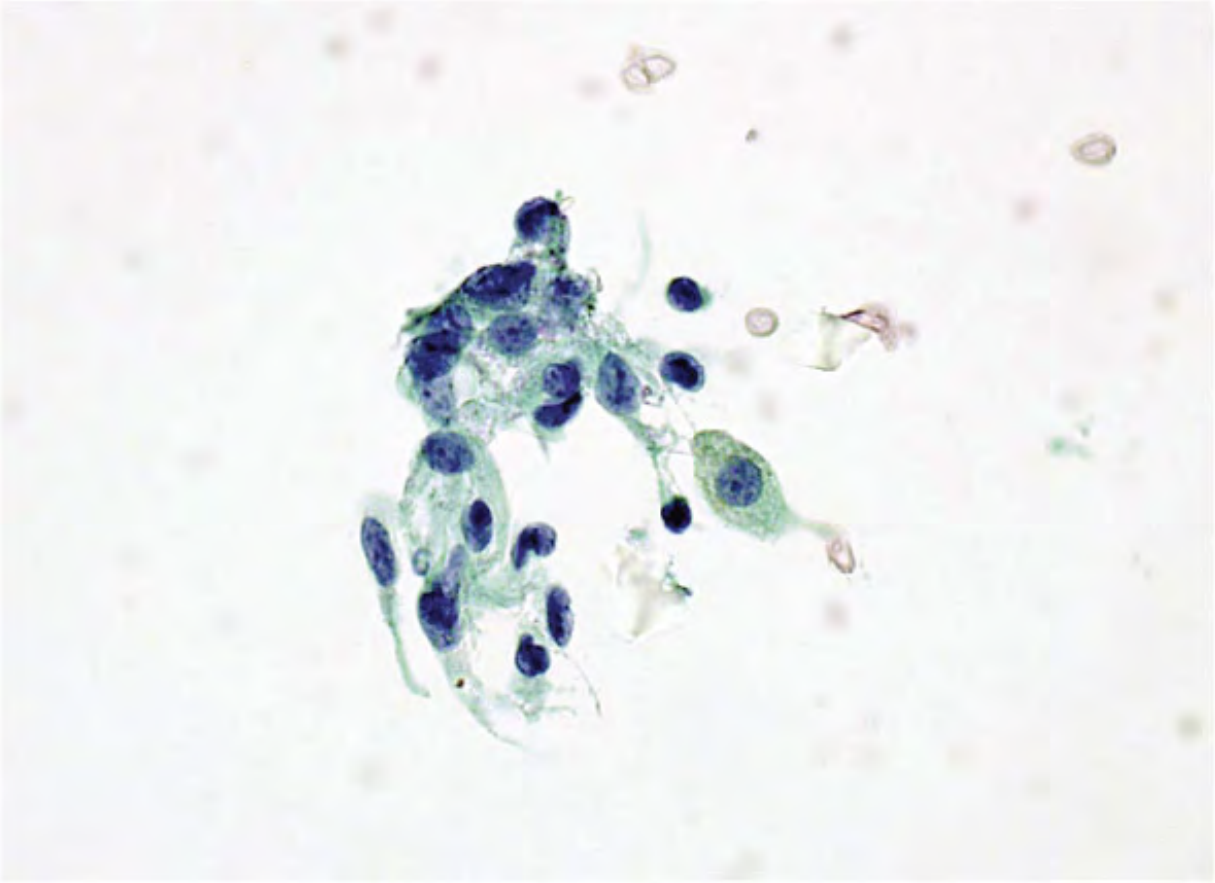

Figure 6.48. Aggregate of round to spindle-shaped cells from an aspirate of a nodular goiter. The nuclei are enlarged with coarsely granular chromatin. The rounded cells with appreciable cytoplasm suggest the origin of these cells to be follicular cells. These cells, when occurring in the background of nodular goiter, have no significance.

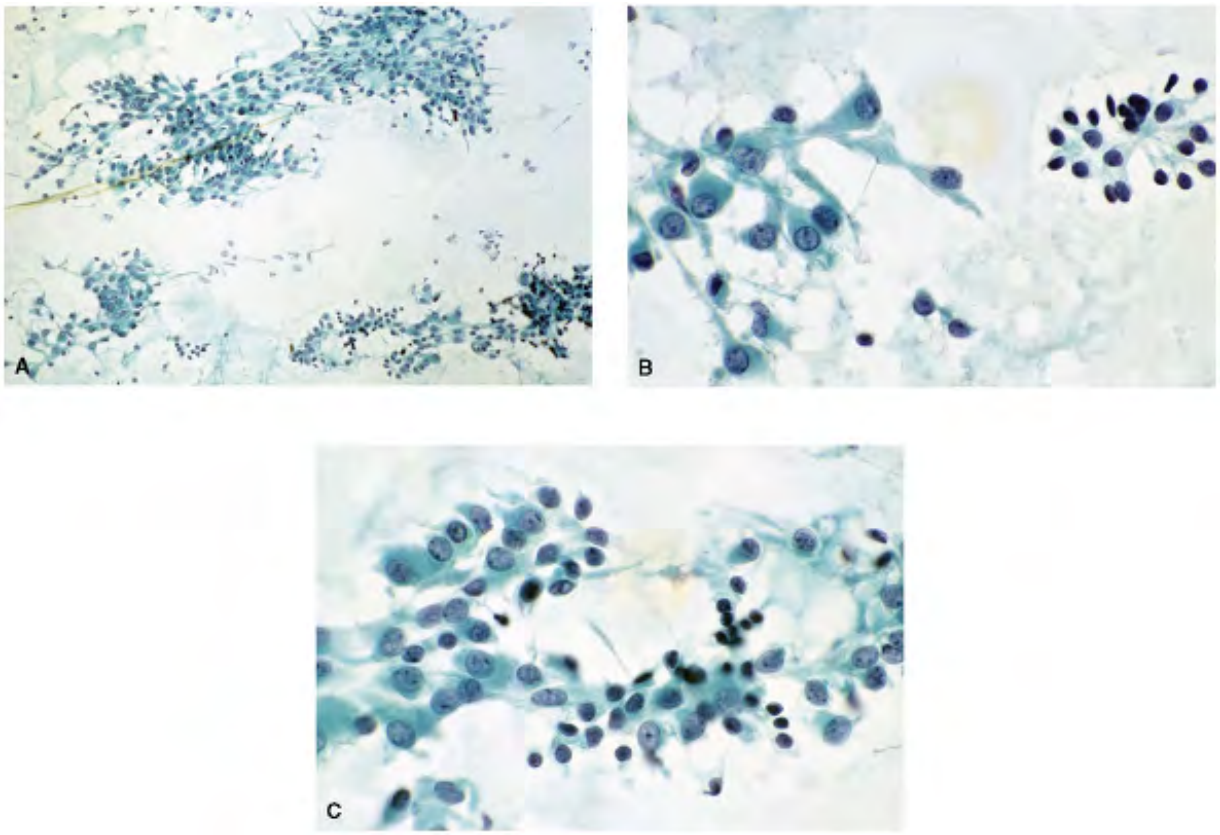

Figure 6.49. A. FNA of a nodular goiter showing fragments of spindle cells, low power. B. Higher magnification showing varying sized follicular cells from normal to enlarged ones with appreciable cytoplasm and slightly enlarged nuclei. Some follicular cells appear spindle shaped. C. Different field showing enlarged follicular cells with spindle shape and cytoplasmic processes. Note benign follicular cells in the background. These were the only abnormal-appearing cells in the background features of nodular goiter and are considered as a reactive/reparative process.

With cystic change, the fine-needle biopsy will often yield fluid contents of variable consistency. Their cytologic preparations show large numbers of histiocytes or macrophages. Histiocytic aggregates occasionally may be mistaken for cells

of papillary carcinoma.11 The cytoplasm of the macrophages contains large, coarse, greenish-brown granules of hemosiderin pigment, indicating old hemorrhage in the nodule (Figs. 6.50, 6.51 and 6.52). The cyst contents when examined fresh often show cholesterol and oxalate crystals. Accompanying the histiocytes, are multinucleated histiocytic foreign body-type giant cells (Fig. 6.53). The presence of such cells has no practical significance. The same holds true for calcific debris (Fig. 6.54).

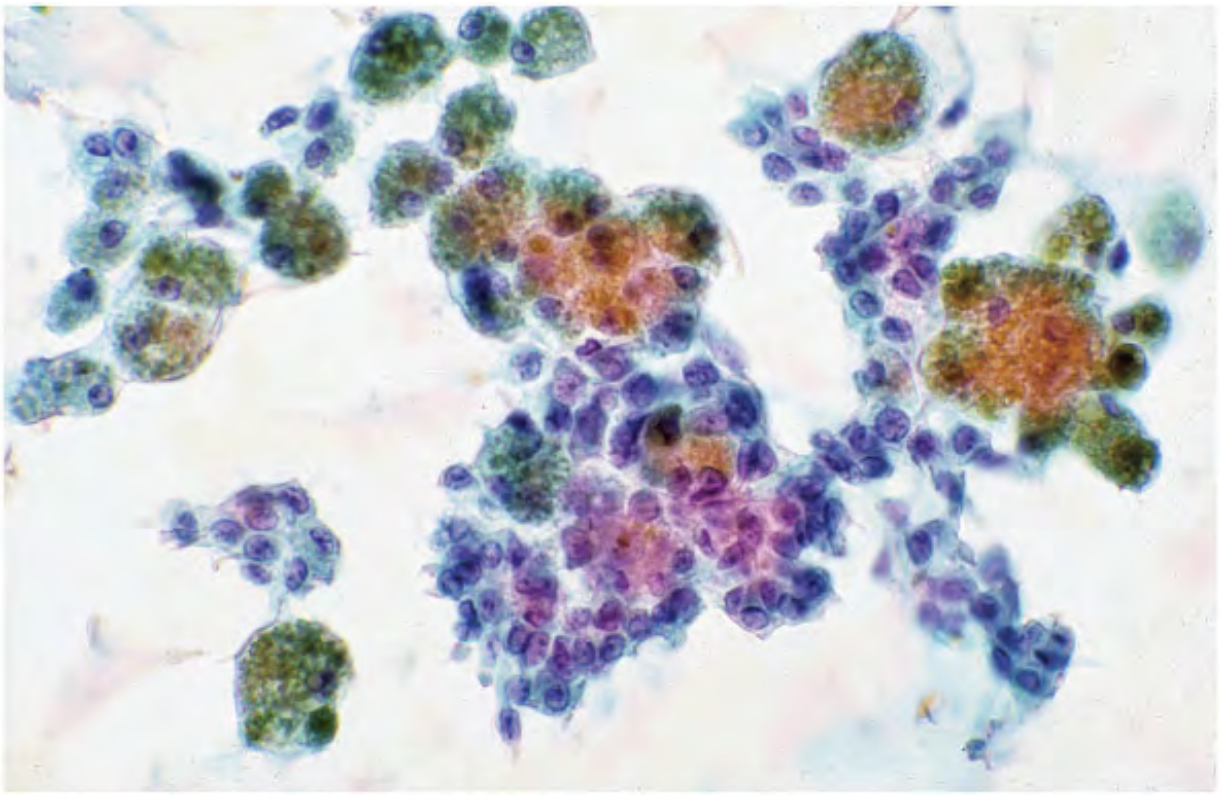

Figure 6.50. FNA of a nodular goiter. The presence of macrophages with and without hemosiderin is a frequent finding and indicates old hemorrhage. Note benign follicular cells in the background.

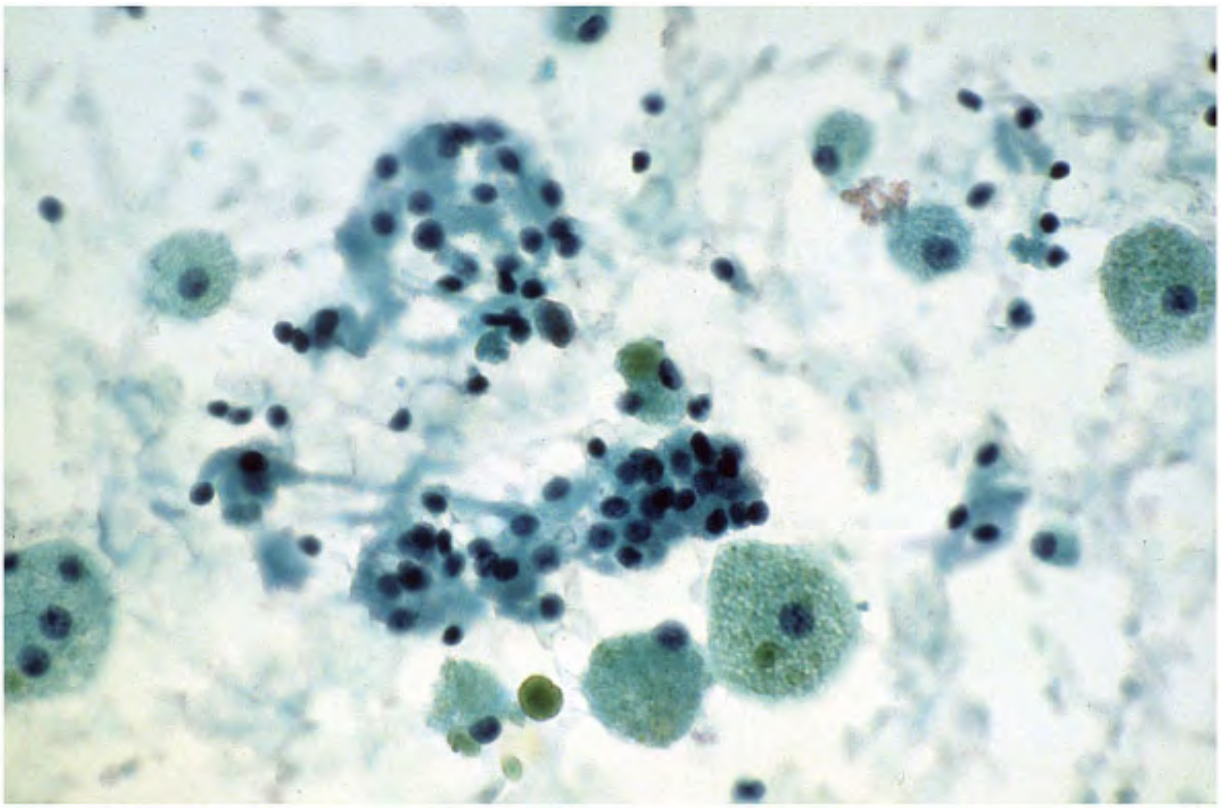

Figure 6.51. FNA of a nodular goiter. The benign follicular cells and macrophages containing hemosiderin pigment.

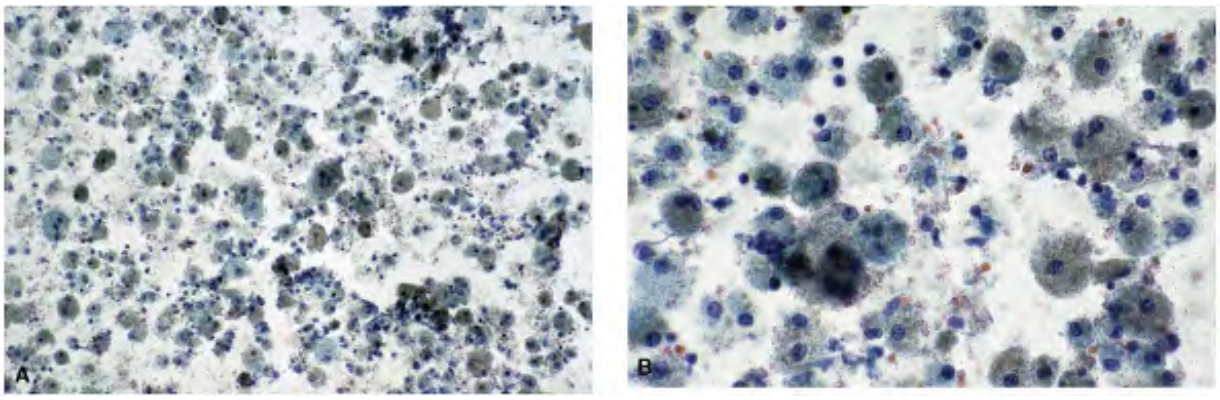

Figure 6.52. FNA of a nodular goiter. A. This aspirate consisting of predominantly histiocytes with and without hemosiderin probably represents a cystic nodular goiter (low power). B. Higher magnification shows the histiocytes to be discrete. No follicular cells are present. Lack of follicular cells will warrant an unsatisfactory diagnosis.

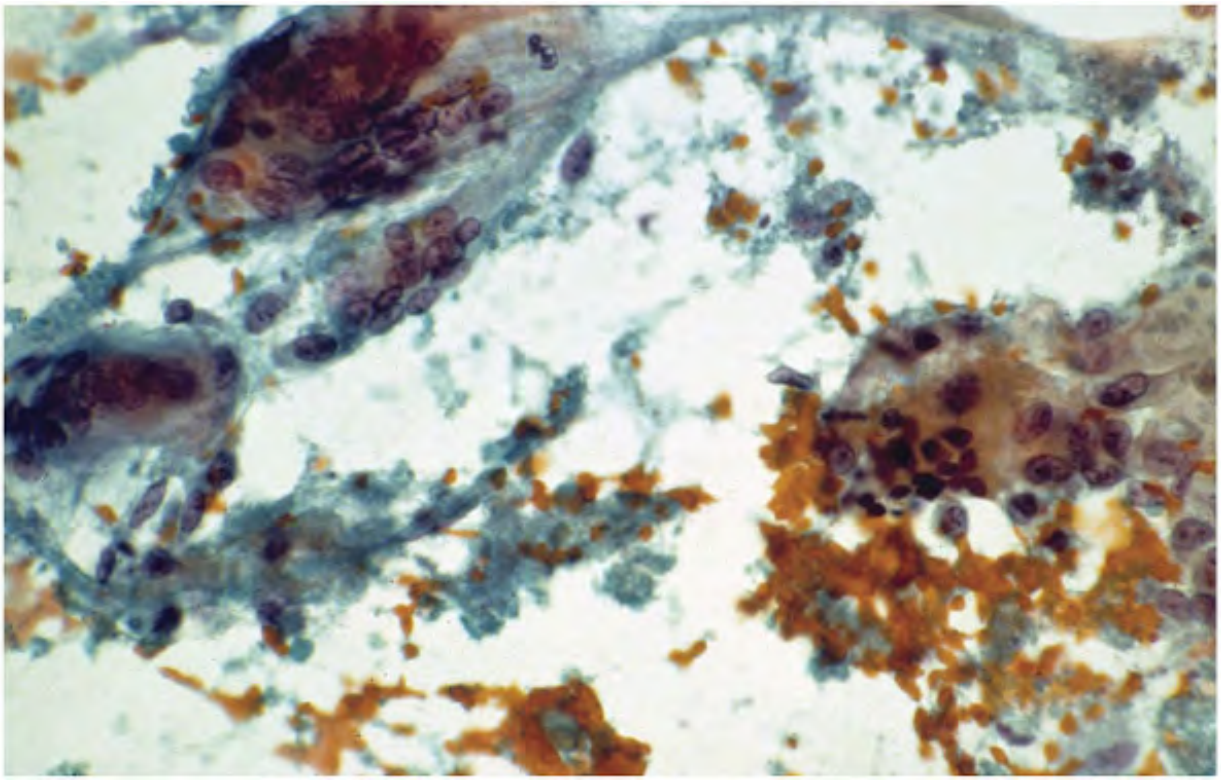

Figure 6.53. FNA nodular goiter. Multinucleated foreign body-type giant cells, a very common finding in the presence of degeneration and cystic change.

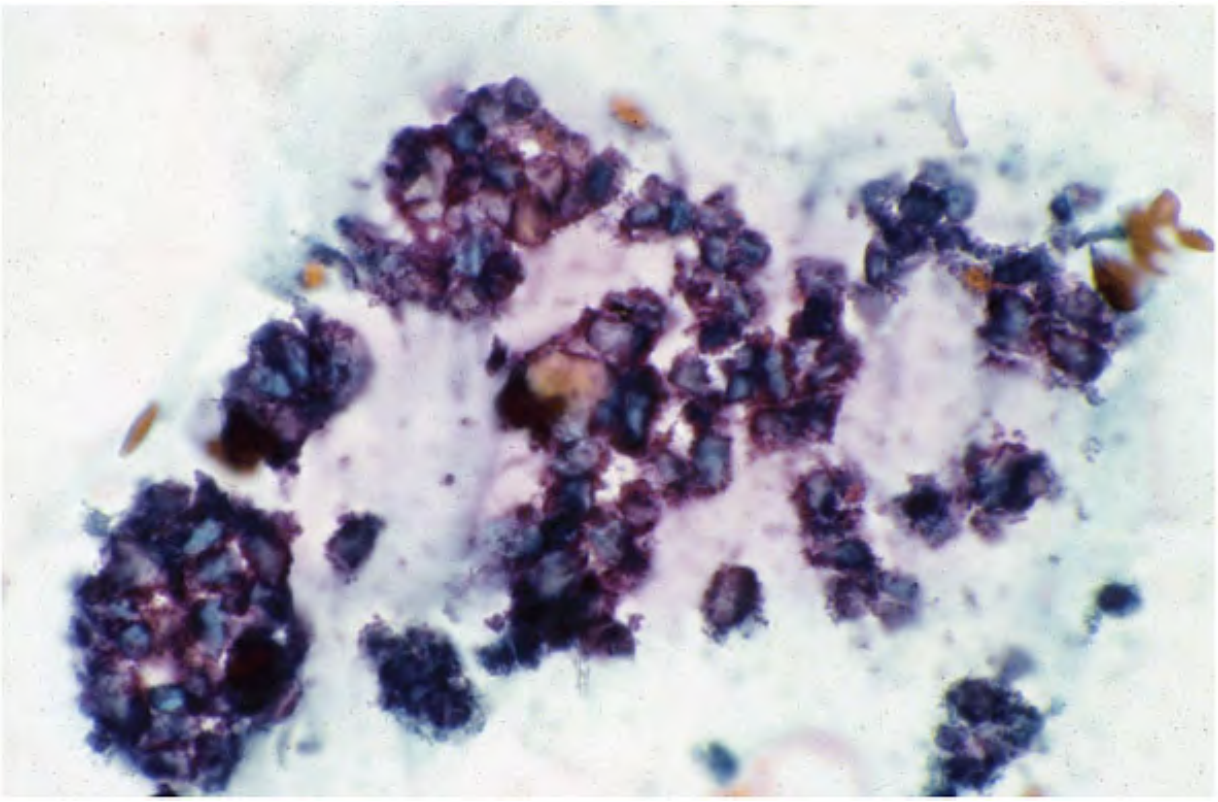

Figure 6.54. FNA nodular goiter. Calcific debris.

Because of the old hemorrhage, granulation tissue, and fibrosis, the aspirates of nodular goiter may also show stromal cells, either isolated or in tissue fragments. Isolated stromal cells have large, elongated to spindle-shaped nuclei with nucleoli (Figs. 6.55). Their uniform size and bland chromatin suggest their benign nature.

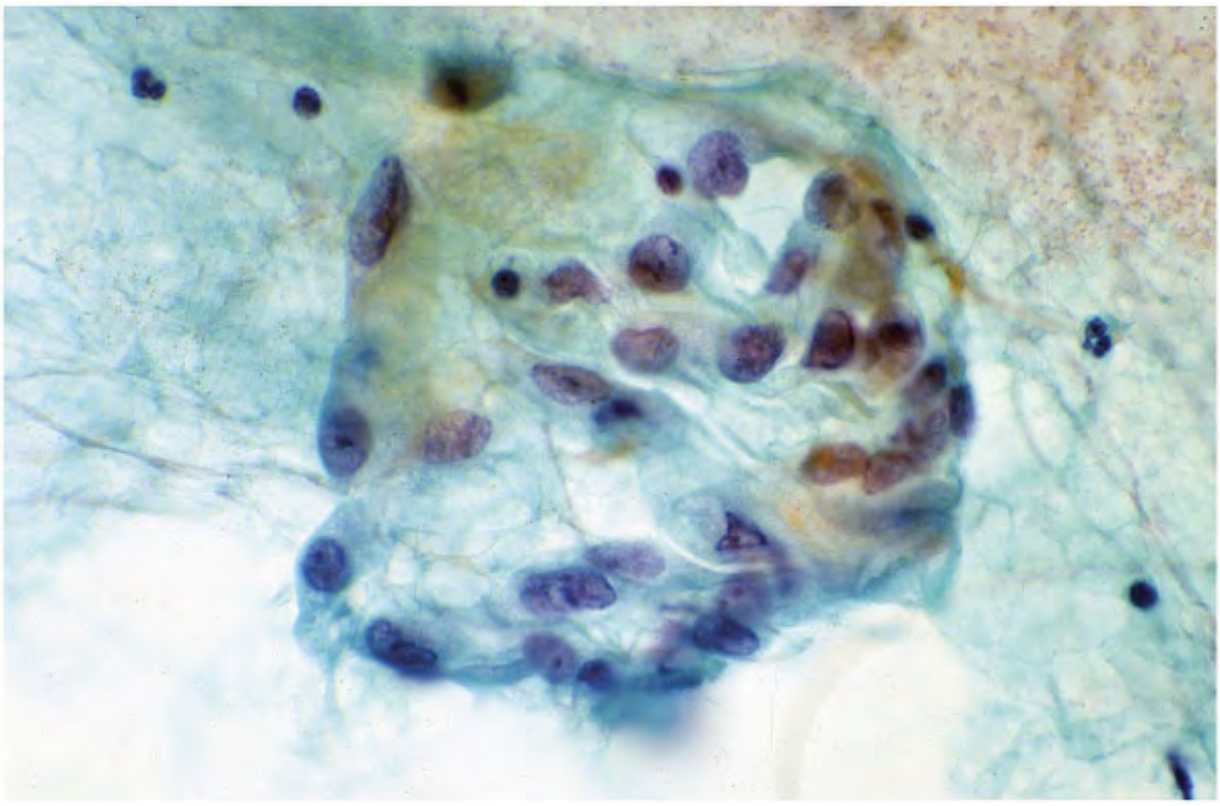

Figure 6.55. FNA of a nodular goiter. A group of large spindle cells of stromal origin. These are usually an isolated finding and are of no significance. Note low N/C ratios and bland nuclear chromatin.

Rarely, aspirates of nodular goiter may show psammoma bodies,12 which may be either naked or incorporated in tissue fragments of benign follicular cells (Fig. 6.56). Their presence is a potential diagnostic pitfall. The differentiation between psammoma bodies seen in nodular goiter and those seen in papillary carcinomas is described in Table 9.24.

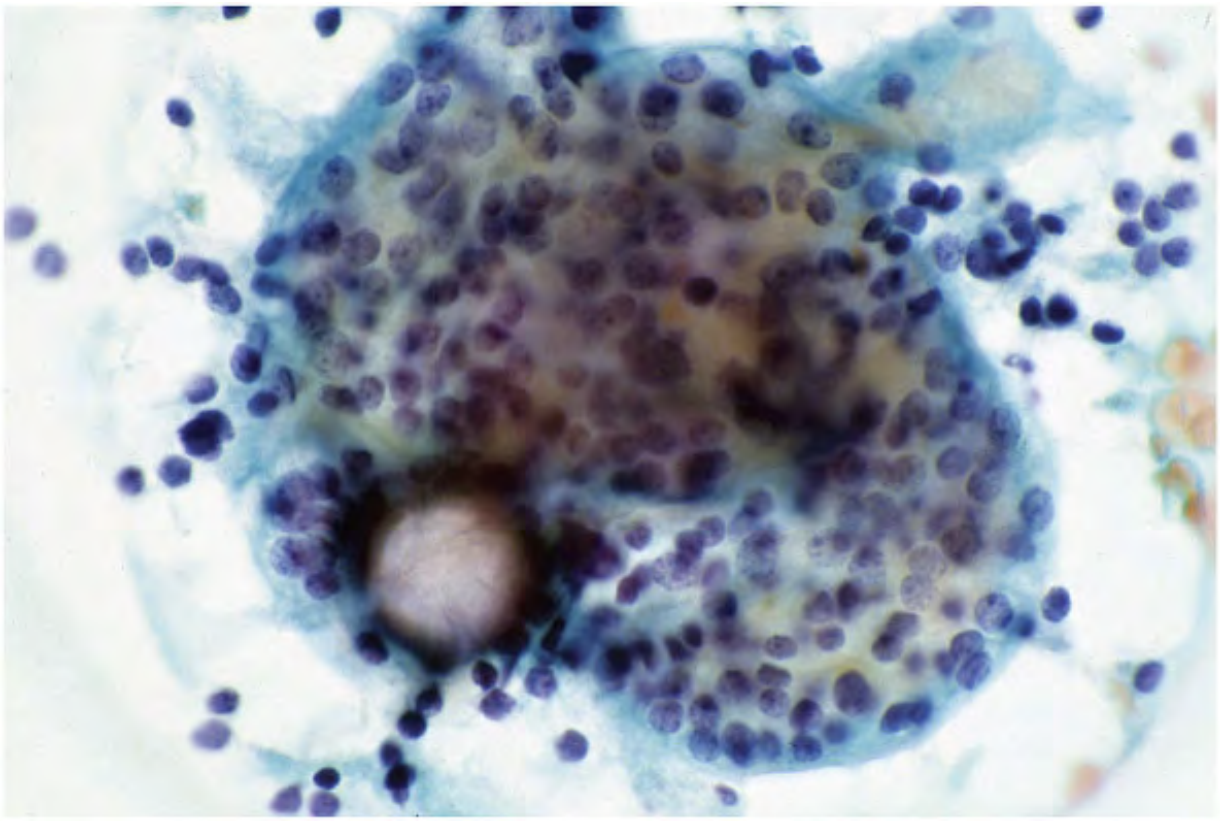

Figure 6.56. FNA nodular goiter. This psammoma body is incorporated in a tissue fragment of benign follicular cells arranged in a honeycomb pattern, containing small uniform nuclei with compact chromatin.

DIAGNOSTIC ACCURACY AND POTENTIAL DIAGNOSTIC ERRORS

The usual cytologic pattern of nodular goiter (Table 6.1) thus consists of benign follicular cells and colloid in variable proportions. HÃ¼rthle cell metaplasia and histiocytes with and/or without hemosiderin, multinucleated giant cells, and calcific debris suggest secondary changes. All of these features may not be present in aspirates of every nodular goiter,13 and it is not necessary to fulfill all the criteria listed in Table 6.1 to make a cytologic diagnosis of nodular goiter. The presence of colloid

and/or histiocytes should not be a requirement for the diagnosis of nodular goiter. Colloid reflects the functional activity of the follicular cells and does not indicate whether the follicular cells are neoplastic or nonneoplastic. Likewise, histiocytes represent a degenerative phenomenon. At the same time, hypercellularity is not a feature that is diagnostic of neoplasia. The aspirates of hyperplastic goiters can yield markedly cellular specimens. One needs to focus on the architecture of the tissue fragments and nuclear morphologyâ€"size, shape, chromatin pattern, and the presence or absence of nucleoli.

Variations in the usual pattern of nodular goiter, as described above, create settings for potential errors that may lead to false-positive results.13, 14, 15, 16, 17, 18, 19, 20 Some of the listed criteria of nodular goiter, if present in excess and to the exclusion of other features, may lead to interpretive traps, and a nodular goiter may be mistaken for a neoplasm.13, 14, 15, 16, 17, 18, 19, 20, 21 Such cases with unusual presentations of nodular goiter are infrequent, but they constitute important diagnostic pitfalls and may lead to unnecessary surgery. In fact, cellular features from nodular goiters can be misinterpreted as almost every type of thyroid neoplasm including metastatic tumors, as listed in Table 6.2. The differentiation of nodular goiter with atypical cytologic features from various neoplastic entities is best understood when one is familiar with the cytopathologic features of thyroid neoplasms. For this reason, and also not to repeat the contents, this is discussed in great detail in subsequent chapters.

TABLE 6.2 DIFFERENTIAL DIAGNOSES OF NODULAR GOITER

Cytopathologic Pattern	Diagnostic Entity Mistaken for	Clues for Differentiation
Hypercellular aspirate with a large number of tissue fragments of follicular cells with	Follicular neoplasm (adenoma/carcinoma)	Honeycomb arrangement, regular follicles, small

or without a follicular pattern; background clean with scant or absent colloid		evenly spaced nuclei, finely granular, uniformly dispersed chromatin; nucleoli inconsistent; folded large tissue fragments may mimic syncytial pattern
Hypercellular aspirate with several tissue fragments, either monolayered and/or papillary-like	Papillary carcinoma	Lack of syncytial arrangement and absence of or minimal criteria[a]
Follicular cell nuclei with one or more but not all of the following features: enlarged, pale chromatin, micronucleoli, nuclear grooves, intranuclear inclusions	Papillary carcinoma	Lack of syncytial arrangement and absence of minimal criteria[a]
Occasional psammoma body, single or multiple; either naked or	Papillary carcinoma	Lack of minimal criteria[a] in cells forming tissue

incorporated in tissue fragments of follicular cells; inspissated, dense-staining colloid with cracks or fissures simulating a psammoma body		fragments incorporating the psammoma body; naked psammoma bodies are not diagnostic
A large HÃ¼rthle cell population	HÃ¼rthle cell neoplasm	HÃ¼rthle cells in sheets with transition forms; pyknotic nuclei with pleomorphism; lack prominent cherry-red macronucleoli and monomorphic patterns of HÃ¼rthle cell neoplasm; feature of nodular goiter in the background
Spindle-shaped cells either stromal or epithelial origin	Anaplastic carcinoma	Lack of extreme nuclear pleomorphism and malignant criteria; clinical correlation is very helpful

Spindle-shaped cells either stromal or epithelial origin	Medullary carcinoma	Immunostain for calcitonin is negative; spindle cells in medullary carcinoma have eccentric nucleoli with coarser chromatin; nucleoli inconsistent
Degenerating follicular cells containing pleomorphic nuclei with micro/macronucleoli, cytoplasmic vacuoles; in the background features of nodular goiter; histiocytic aggregates	Metastatic carcinoma	Lack of obvious malignant criteria; features of nodular goiter in the background; no history of primary cancer
Aggregates of histiocytes with foamy cytoplasm or degenerating follicular cells with bubbly, finely vacuolated cytoplasm	Papillary carcinoma	Lack of dense cytoplasm with well-defined cell borders; minimal criteria absent[a]

[a]Minimal criteria for cytologic diagnosis of papillary thyroid carcinoma:

syncytial arrangement with enlarged nuclei, dusty; powdery chromatin; multiple micro/macronucleoli; nuclear grooves; pseudoinclusions (see Table 9.19).

The problem of atypical cells in nodular goiter is discussed in the present chapter and in Chapters 9, 17, and 18. There are several reasons for this. The atypia are discussed in a different context in each of these chapters. This has also provided an opportunity for the author to present many examples of this difficult but very common problem in thyroid cytopathology.

The important facts to remember are that the presence of colloid is not an absolute requirement for the diagnosis of nodular goiter, and the absence of colloid is not an absolute criterion for a neoplasm.

REFERENCES

1.Meissner WA, Warren S. Tumors of the thyroid gland. Fascicle four, second series. *Atlas of Tumor Pathology*. Washington, DC: Armed Forces Institute of Pathology; 1969.

2.Reading CC, Charboneau JW, Hay ID, et al. Sonography of thyroid nodules: A "classic pattern" diagnostic approach. *Ultrasound Q*. 2005;2:1â€“19.

3.Khati N, Adamson T, Johnson KS, et al. Ultrasound of the thyroid and parathyroid glands. *Ultrasound Q*. 2003;19:162â€“176.

4.Ahuja A, Chick W, King W, et al. Clinical significance of the comet tail artifact in thyroid ultrasound. *J Clin Ultrasound*. 1996;24: 124â€“129.

5.LÃ¶whagen T, Linsk JA. Aspiration biopsy cytology of the thyroid gland. *Clinical Aspiration Cytology.* In: Linsk JA, Sixteen F, eds. Philadelphia: Lippincott; 1983:67â€“69.

6.Frable WJ. *Thin Needle Aspiration Biopsy*. Philadelphia: Saunders; 1983;152â€“182.

7.Friedman M, Shimaoka KC, Getaz P. Needle aspiration of 310 thyroid lesions. *Acta Cytol*. 1979;23:196â€“203.

8.Cervino JM, Pasegro P, Grosso OT, et al. La exploration citologic de la glandula tiroides y sus correlaciones anatomoclinices. *Ann Facultad Med*. 1962;47:1728â€“1743.

9.Droese M. *Cytologic Aspiration Biopsy of the Thyroid Gland*. Stuttgart: F.R. Schattauer-Verlag; 1980;55â€“57.

10.Faqin WC, Cibas ES, Renshaw AA. Atypical cells in fine-needle aspiration biopsy specimens of benign thyroid cysts. *Cancer (Cancer Cytopathol)*. 2005;105:71â€“79.

11.Nassar A, Gupta PK, LiVolsi VA, et al. Histiocytic aggregates in benign nodular goiters mimicking cytologic features of papillary thyroid carcinoma (PTC). *Diagn Cytopathol*. 2003;29:243â€“245.

12.Riazmontazer N, Bedayat G. Psammoma bodies in fine needle aspirates from thyroids containing nontoxic hyperplastic goiters. *Acta Cytol*. 1991;35:563â€“566.

13.Harach HR, Zusman SB, Day S. Nodular goiter: A histocytological study with some emphasis on pitfalls of fine-needle aspiration cytology. *Diagn Cytopathol*. 1993;8:409â€“419.

14.Bakhos R, Selvaggi SM, De-Jong S, et al. Fine-needle aspiration of the thyroid: Rate and causes of cytohistopathologic discordance. *Diagn Cytopathol*. 2000;23:233â€“237.

15.Sidawy MK, Del Vecchio DM, Knoll SM. Fine-needle aspiration of thyroid

nodules. Correlation between cytology and histology and evaluation of discrepant cases. *Cancer (Cancer Cytopathol)*. 1997;81;253â€“259.

16.Busseniers AE, Oertel YC. "Cellular adenomatoid nodules" of the thyroid: Review of 219 fine-needle aspirates. *Diagn Cytopathol*. 1993;9:581â€“589.

17.Caraway NP, Sneige N, Samaan NA. Diagnostic pitfalls in thyroid fine-needle aspiration. A review of 394 cases. *Diagn Cytopathol*. 1993;9:345â€“350.

18.Fiorella RM, Isky W, Miller L, et al. Multinodular goiter of the thyroid mimicking malignancy. Diagnostic pitfalls in fine-needle aspiration biopsy. *Diagn Cytopathol*. 1993;9:351â€“354.

19.Anderson RJ, Pragasam PJ, Nazar T. Atypical, retrogressive and metaplastic changes in nodular goiters. Potential pitfalls in aspiration cytology of the thyroid. *Acta Cytol*. 1990;34:715â€“716.

20.Hall TL, Layfield LJ, Philippe A, et al. Sources of diagnostic error in fine needle aspiration of the thyroid. *Cancer*. 1989;63:718â€“725.

21.Hsu C, Boey J. Diagnostic pitfalls in the fine needle aspirates of thyroid nodules: A study of 555 cases in Chinese patients. *Acta Cytol*. 1987;31:69.

Editors: Kini, Sudha R.
Title: *Thyroid Cytopathology: A Text and Atlas, 1st Edition*

Copyright Â©2008 Lippincott Williams & Wilkins

7

Follicular Adenoma and Follicular Carcinoma

This chapter on the cytopathology of follicular adenoma and follicular carcinoma begins wit brief commentary, unlike the other chapters (except Chapter 8 on HÃ¼rthle cell lesions). Tl commentary is deemed necessary by the author because, in general, the role of cytopatholc the diagnosis of follicular adenomas and follicular carcinomas is considered unclear and questionable. The reasons for this are many. First of all, the histologic diagnosis of follicula carcinomas is based strictly on demonstrating the invasive characteristics, which cannot be assessed from cytologic samples. Hence the cytologic differentiation of follicular adenoma a carcinoma is considered not possible, and the notion that the differentiation can be done cytologically is totally unacceptable to surgical and many cytopathologists. The problem, however, is compounded because of the continuing debate and controversies among surgica pathologists on what constitutes the true invasion. The interpretation and the final histolog diagnosis become subjective, leading to a marked interobserver variability and making the cytohistologic correlation difficult. Also, many hyperplastic goiters are interpreted histologi as follicular adenomas, because the criteria for differentiating them from follicular neoplas are not consistent. To avoid disparities, the Scandinavian cytopathologists1 , 2 recommende that all thyroid aspirates containing abundant follicular cells be grouped into one category c "follicular neoplasms," indicating that the cytologic differentiation between benign and malignant follicular neoplasms is not possible. This approach suited most of the pathologists/cytopathologists as well as the clinicians, including endocrinologists and surgec (with the exception of few), here in the United States. Pathologists in general do not like tc overdiagnose malignancy for the fear of over-treatment. At the same time, there is a fear o missing a cancer. Consequently, the diagnostic category of "indeterminate/ suspicious," lum together of the aspirates that contained an abundance of follicular or HÃ¼rthle cells, becar

popular one, with recommendation for surgical excision.3 , 4 Interestingly enough, there ha been only a few studies reported in the literature on any attempt at the cytologic differentiation of follicular adenomas and follicular carcinomas.5 , 6 , 7 , 8 , 9 Most of the relevant literature emphasizes only an apparent limitation of cytology in discriminating folli adenomas from carcinomas. It is not clear how this conclusion was reached without docume studies on cytologic analysis and cytohistologic correlations. The only study9 that attemptec cytologically differentiate adenomas from carcinomas, and which concluded that the separa of follicular neoplasms into adenoma and carcinoma was not possible, involved only a few c to make a judgment.

The author is at variance with the general sentiment that follicular lesions cannot be separa cytologically. Unlike many pathologists/cytopathologists, the author has attempted to differentiate hyperplastic goiters, follicular adenomas, and follicular carcinomas, initially a request of endocrinologists who were concerned with unnecessary surgeries for benign disea With adequate specimen and proper cytopreparation, the majority of the hyperplastic goite can be differentiated from follicular adenomas. Likewise, most follicular adenomas can be identified from cytologic samples. Poorly differentiated follicular carcinomas are readily recognized. This leaves a small proportion of cellular follicular adenomas and well-different follicular carcinomas that are difficult to differentiate cytologically. These are interpreted either cellular adenomas or suspicious for follicular carcinomas. The criteria for differentiat various follicular neoplasms were described in earlier publications,6 are time-tested, and ar still applicable. By attempting to cytologically differentiate hyperplastic goiters, follicular adenomas and carcinomas, we are providing probabilities of malignancy that have greatly influenced patient management. This chapter will describe the cytopathologic features of follicular adenomas and carcinomas, their diagnostic accuracy, and differential diagnostic features.

FOLLICULAR ADENOMA

Follicular adenomas are encapsulated, follicular, cell-derived benign neoplasms of the thyrc demonstrating a follicular growth pattern.10 , 11 , 12 , 13 They occur more commonly in wc over a wide age range but are frequent in the 5th to 6th decades. After nodular goiter, folli adenomas are the most common cause of nonfunctioning thyroid nodules. The true incidenc follicular adenomas may not be known for two reasons: (i) many hyperplastic nodules may b interpreted as adenomas10 and (ii) oncocytic or HÃ¼rthle cell tumors are often considered

morphologic variants of follicular neoplasms.10 Adenomas are common in iodine-deficient areas.13 Clinically they present as a painless neck mass of varying duration. Smaller lesions often detected as incidental findings. Adenomas are most often solitary, but multiple adenc in the same lobe or both lobes are not uncommon. Frequently of great size, they may under degenerative changes, hemorrhage, necrosis, and infarction. Acute hemorrhage is usually associated with painful, rapid enlargement. In larger adenomas, the central areas tend to b edematous and with scarring.

Radiologic Findings

Thyroid imaging with radionuclide shows a hypofunctioning area or a "cold nodule." On ultrasound, follicular adenomas appear as solitary hypoechoec areas.

Gross and Microscopic Features

Grossly, follicular adenomas are sharply circumscribed, discrete, solitary, expansile lesions (7.1 and 7.2). Follicular adenomas vary greatly in size. Areas of degeneration and hemorrha are often present especially in larger lesions. Cystic change is reported in roughly 30% of follicular adenomas.14 Solid neoplasms show a fleshy, bulging cut surface, while the colloid- adenomas show minute cysts filled with glistening amber-colored colloid.

Figure 7.1. Gross photograph of a follicular adenoma involving the left thyroid lobe.

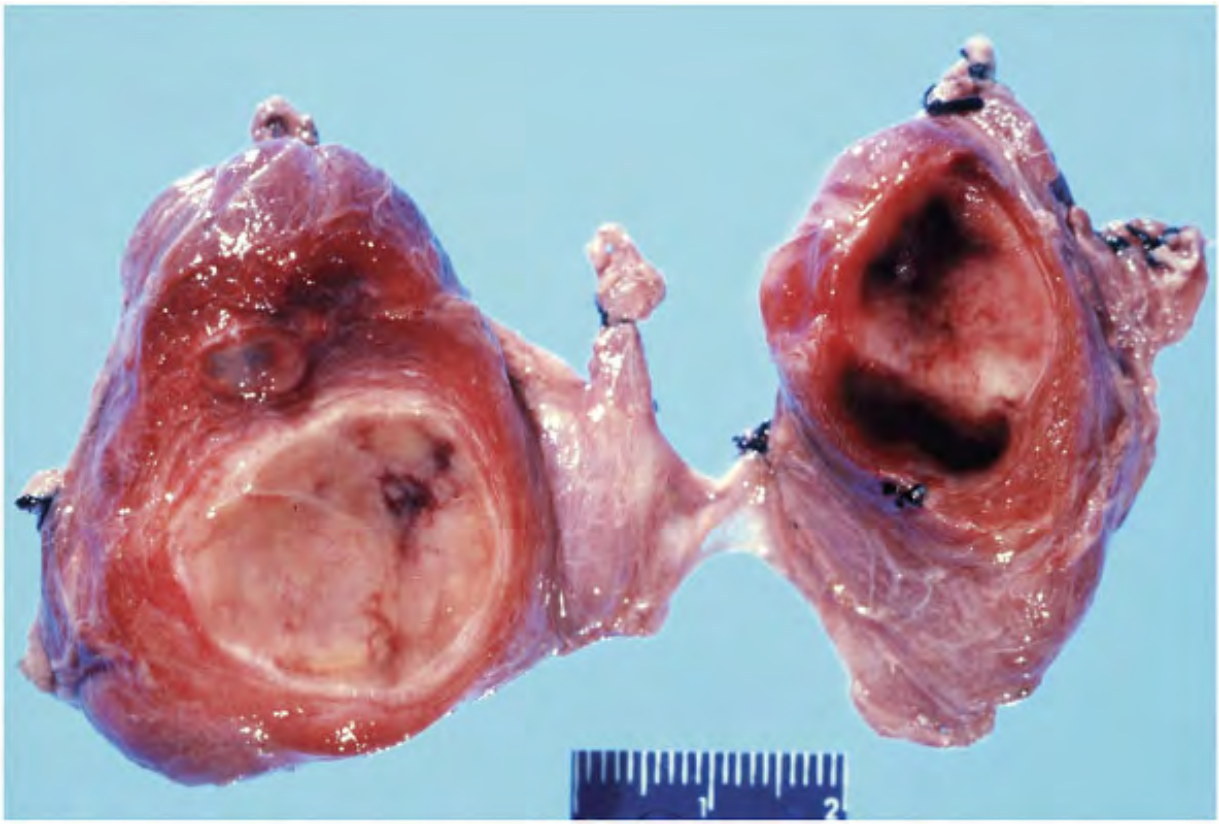

Figure 7.2. Gross photograph of a thyroid with follicular adenomas involving both lobes. No hemorrhage within the left lobe adenoma.

Microscopically, follicular adenoma is encapsulated (Fig. 7.3 A and B), a feature that differentiates it from a nonneoplastic nodule of an adenomatous or nodular goiter (Fig. 7.3 The thyroid parenchyma adjacent to the capsule is compressed and presents a different morphology than the adenoma itself. The capsule is of varying thickness. Follicular adenoma present an array of morphologic patterns based on their architecture (growth pattern), cell morphology or types, and functional differentiation (amount of colloid), the common denominator being total encapsulation and benign behavior.10 , 11 , 12 Recognition of any morphologic variant carries no clinical significance. However, in cytopathology practice, it i extremely useful in cytohistologic correlations, as well as in understanding the overlapping cytopathologic patterns. The questions of why some nodular goiters cannot be differentiate from follicular adenomas, and why some follicular adenomas have cytopathologic as well as histopathologic patterns similar to those of follicular carcinomas, can only be appreciated if is familiar with the spectrum of morphologic patterns described below.

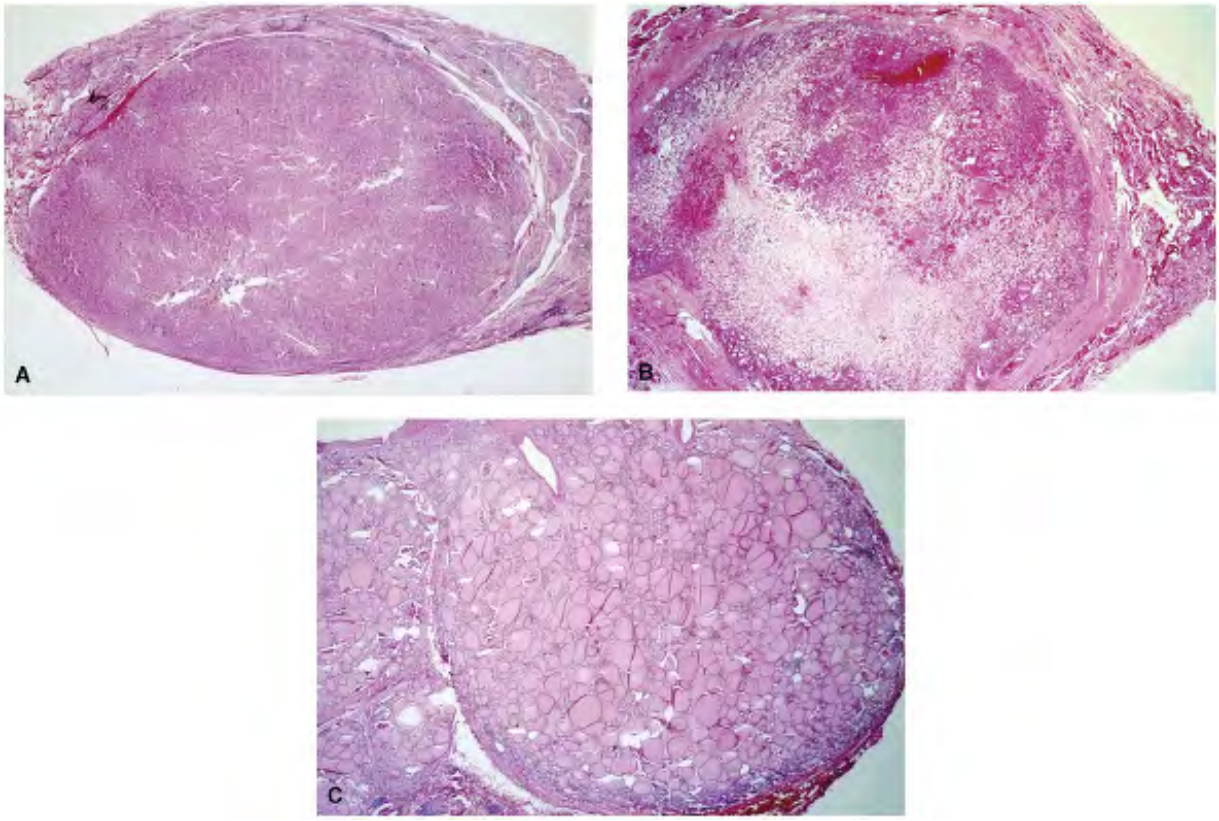

Figure 7.3. A. Low power showing complete encapsulation. B. The follicular adenoma is encapsulated and shows large clear areas representing degeneration, low power. Aspirates f such areas may result in poor cellularity. C. A non-encapsulated nodule of nodular goiter, lo power.

Follicular adenomas are classified into conventional types and several morphologic variants, former being more common (Table 7.1).

Conventional

- Macrofollicular (colloid)
- Normofollicular (simple)
- Microfollicular (fetal)
- Trabecular (embryonal)

Oncocytic (HÃ¼rthle cell) adenoma[a]
Hyalinizing trabecular
Adenoma with clear cell change
Adenoma with papillary hyperplasia
Atypical adenoma
Miscellaneous
[a] Oncocytic or HÃ¼rthle cell adenomas are described separately in Chapter 8.

TABLE 7.1 MORPHOLOGIC VARIANTS OF FOLLICULAR ADENOMAS

The conventional type of follicular adenomas present four basic histomorphologic patterns: colloid or macrofollicular, simple or normofollicular, fetal or microfollicular, and embryonal trabecular (Fig. 7.4).11 In a given adenoma, the pattern remains generally uniform, althou combination of one or two patterns may be encountered, particularly when the lesion is larg This factor must be taken into account when performing aspiration biopsy of a large nodule that several areas can be sampled.

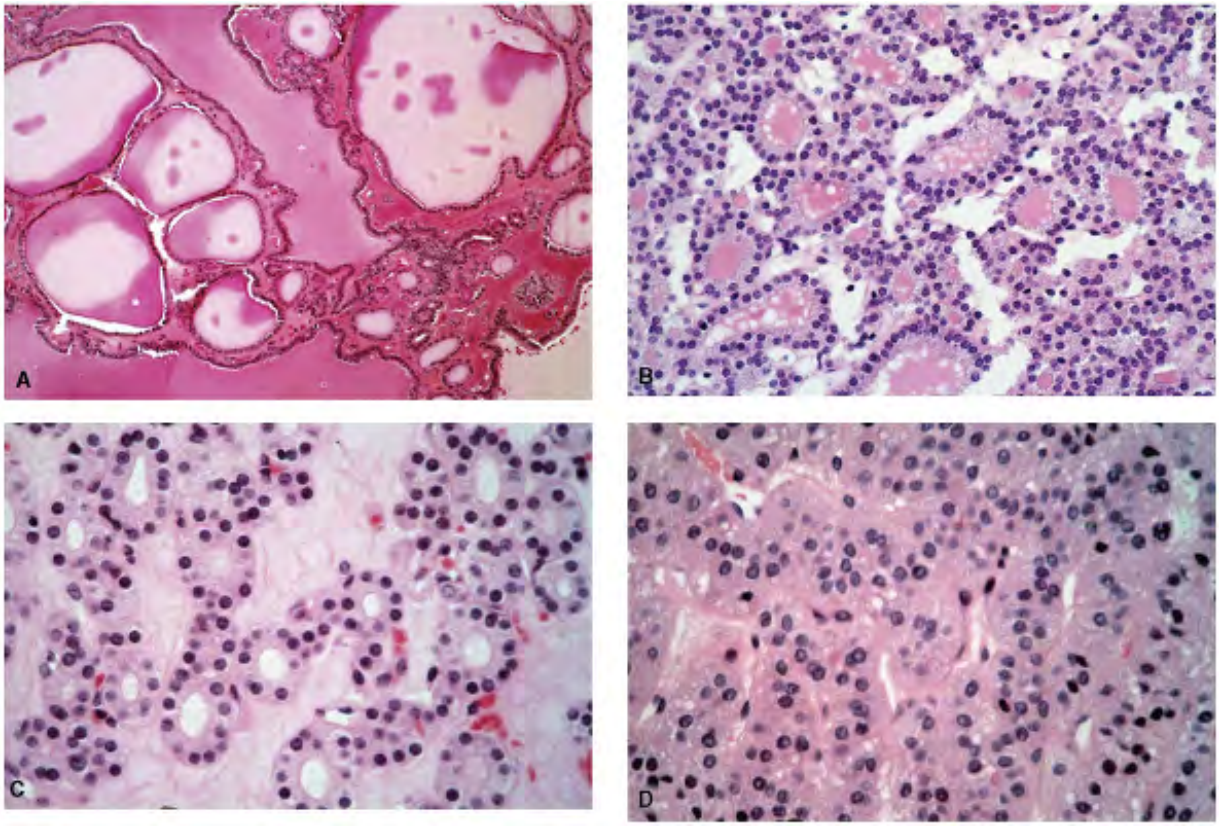

Figure 7.4. Morphologic patterns of conventional follicular adenomas. A. Macrofollicular adenoma consisting of varying-sized but large follicles distended with colloid. B. Simple or normofollicular adenoma with normal-sized follicles. C. Microfollicular adenoma with small microfollicles. D. Trabecular adenoma consisting of trabeculae formed by follicular cells.

Colloid Adenoma

Colloid adenoma (also referred to as colloid nodule by some) represents the most differenti follicular adenoma (macrofollicular adenoma), with overdistended varying-sized but large follicles containing abundant colloid (Fig. 7.5 A). The lining epithelium is flattened with pyk nuclei. This adenoma virtually replicates the pattern of hyperinvoluted goiter, except for th encapsulation.

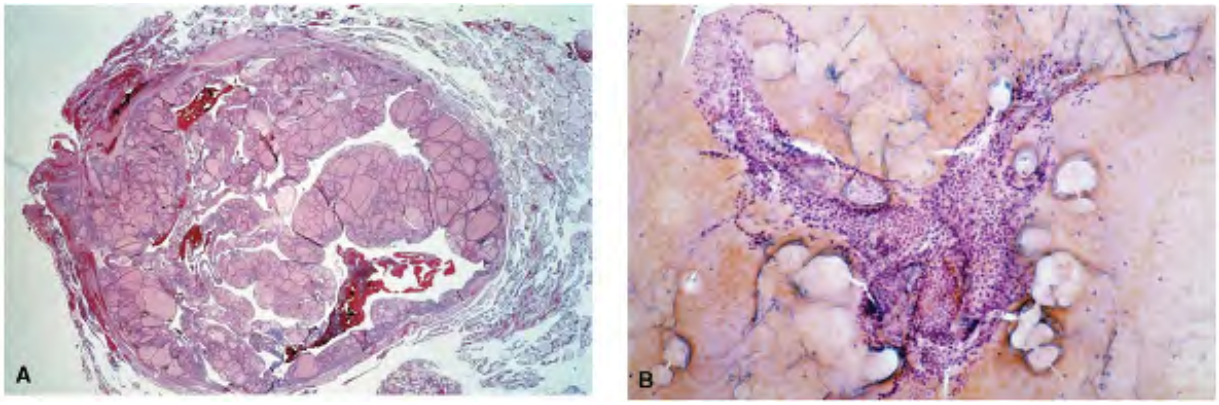

Figure 7.5. Characteristics of macrofollicular adenoma. A. Histologic section, low power, tc demonstrate an encapsulated lesion. The large colloid-filled follicles are evident even at th magnification. B. FNA consisting of abundant colloid and a large tissue fragment of benign follicular cells forming a honeycomb sheet with uniform nuclei.

Cytopathologic Features

Aspirates of colloid or macrofollicular adenoma exhibit abundant colloid and have a sparse cellular component, with tissue fragments of follicular epithelium forming small follicles or honeycomb pattern. Nuclei are small; the chromatin is compact and deep-staining (Table 7. Fig. 7.5 B). The presence of abundant colloid and absent or sparse cellular component may render the aspirate inadequate or nondiagnostic.

Histology
Encapsulated; colloid filled varying-
  sized but large follicles, distended
  with colloid; lining follicular epithelium
  flattened with pyknotic nuclei
Cytopathology
Abundant colloid; may be inspissated
  with fissures and cracks; sparse
  epithelial cells with pyknotic nuclei
Differential
  Diagnosis
Nodular goiter; macrofollicular variant

of papillary carcinoma

[a] Note that cytologically, macrofollicular adenomas cannot be differentiated from nodular goiter. The diagnosis of an adenoma is histologically based on total encapsulation.

TABLE 7.2 MACROFOLLICULAR OR COLLOID TYPE FOLLICULAR ADENOMA[a]

The cytologic pattern of colloid adenomas, indistinguishable from that of hyperinvoluted go rarely if ever represents a malignant process.15 The only malignant neoplasm that strongly resembles a colloid adenoma or a hyperinvoluted goiter, both macroscopically and microscopically, is the macrofollicular variant of papillary carcinoma. The distinguishing fea is the typical nuclear morphology of papillary carcinoma.

Simple Adenoma

Simple adenoma (normofollicular) consists of well-developed follicles of approximately norn size (Fig. 7.6). The lining epithelium is low cuboidal, with either normal-sized or slightly enlarged nuclei. The amount of colloid within the follicles varies. Cellular areas consisting o well-developed follicles may be present, along with more well-developed follicles, especiall very large adenomas.

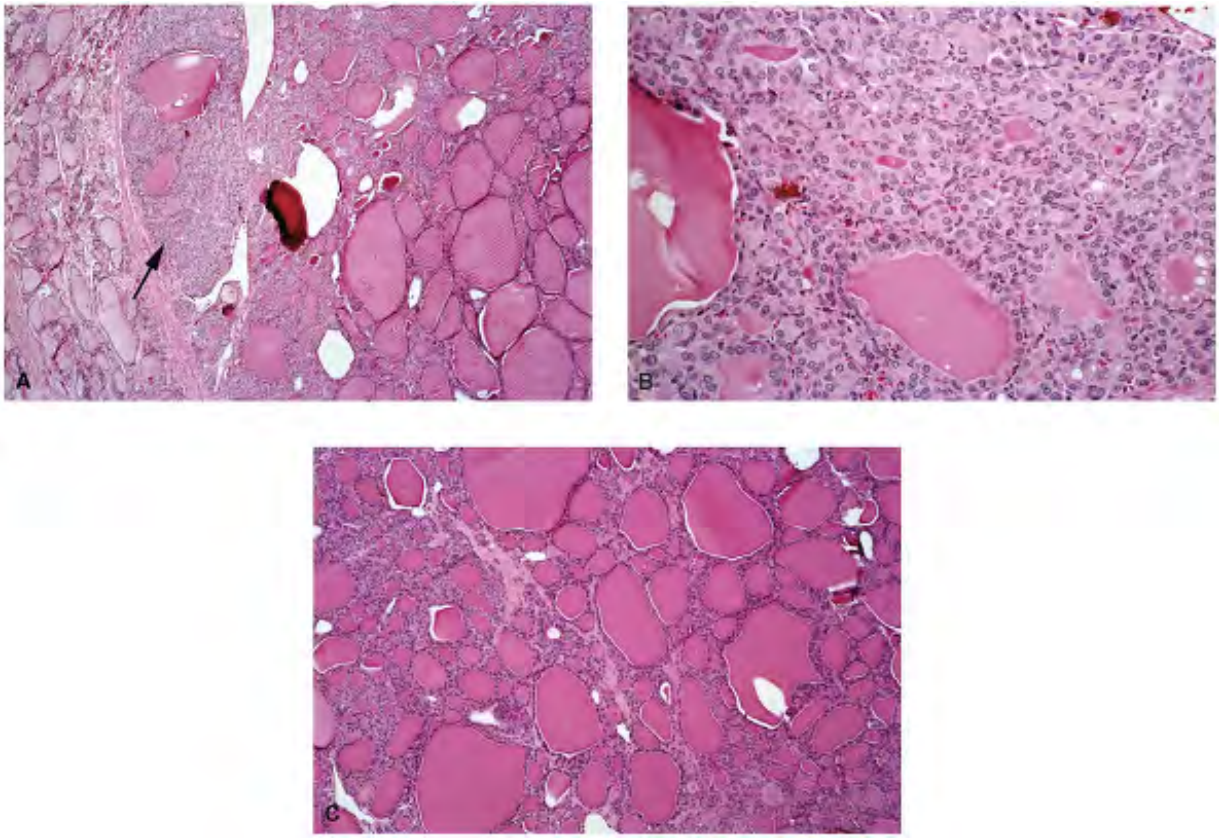

Figure 7.6. Multiple morphologic patterns in a large follicular adenoma. A. This field depict both a macrofollicular pattern and a solid pattern (arrow). B. Higher magnification demonstrating a solid pattern. C. Macrofollicular areas mixed with normal-sized follicles. Th cytologic presentation of an adenoma like this will vary, depending on the area sampled.

Cytopathologic Features

The cytopathologic pattern of simple adenoma depends on the histologic differentiation of t areas sampled (Table 7.3).

When the adenoma resembles a normal gland, the aspirates present cytologic features of a nodular goiterâ€"an admixture of colloid and benign follicular epithelium with honeycomb sheets and regular folliclesâ€"and are often interpreted as such. The differentiation betwee the nodular goiter and a simple follicular adenoma is often impossible, the final diagnosis depending on the demonstration of encapsulation.

Histology

Encapsulated; resembles normal thyroid parenchyma, consisting of normal sized follicles containing colloid;
lining epithelium low cuboidal with basally located uniform round nuclei
Cytopathology
A mixed pattern

1. Varying proportion of colloid and benign follicular cells forming regular follicles or honeycomb sheets; uniform
   or minimally enlarged, round nuclei with granular chromatin; nucleoli absent, representing normofollicular pattern
2. Syncytial tissue fragments with or without a follicular pattern; uniform or minimally enlarged, round nuclei with
   granular chromatin; nucleoli absent, representing cellular areas.

[a] The aspirate may be interpreted as a nodular goiter.

TABLE 7.3 NORMOFOLLICULAR OR SIMPLE-TYPE FOLLICUL ADENOMA[a]

A varied morphologic pattern consisting of micro/macrofollicular areas will yield a combinat of cytologic patterns; sampling of cellular areas exhibits syncytial tissue fragments

with and without a follicular pattern similar to that seen in cellular follicular adenomas (microfollicular/trabecular). The cytologic diagnosis depends on the area sampled. A combination of cytologic features of nodular goiter and cellular follicular adenoma strongly supports the diagnosis of a follicular adenoma with mixed morphology. Such a varied patter frequently seen in a large adenoma demonstrating more than one pattern (Figs. 7.7 and 7.8

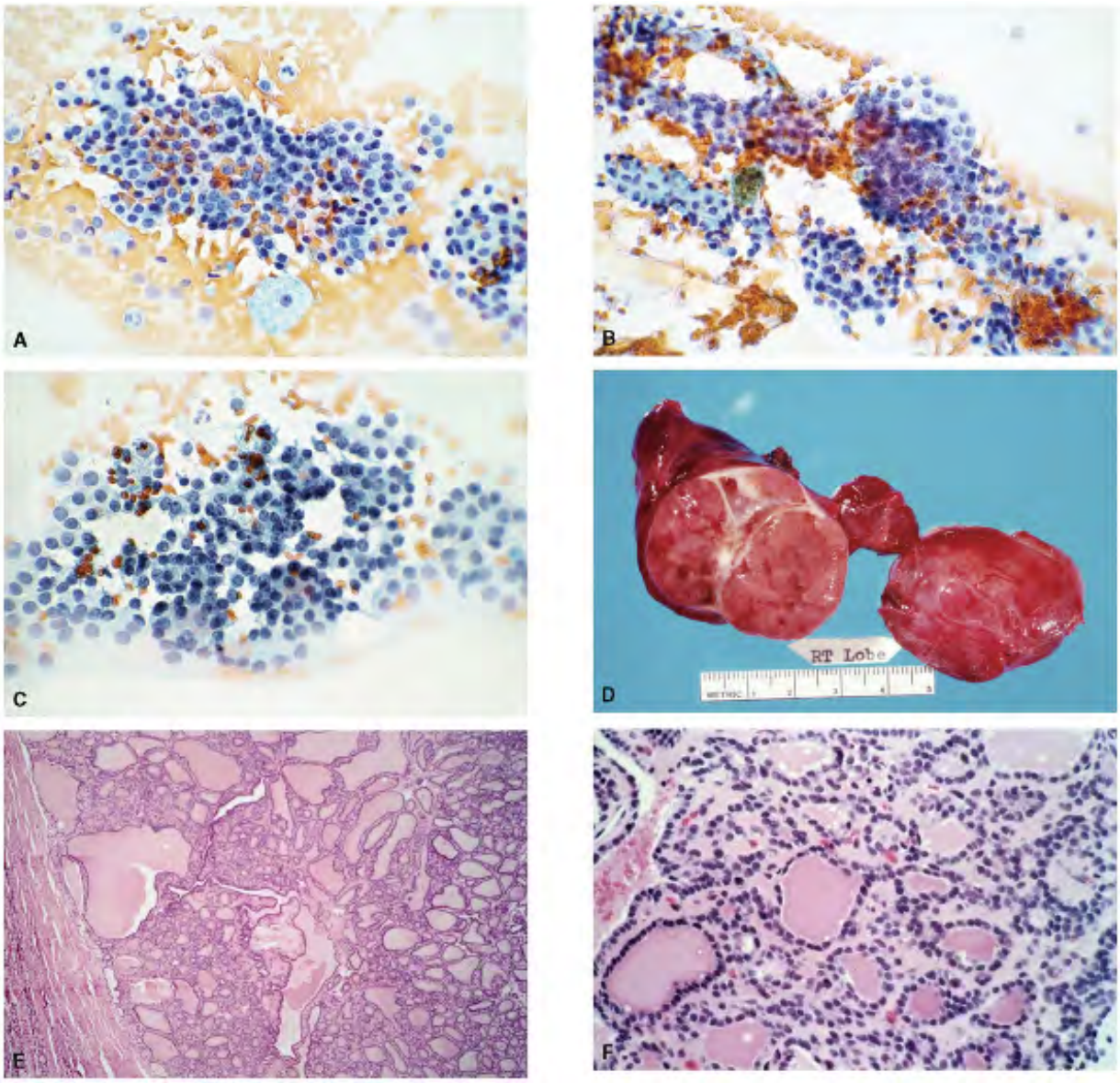

Figure 7.7. Simple follicular adenoma. A, B. FNA showing tissue fragments of follicular cells a honeycomb pattern and uniform small nuclei. This cytologic presentation is similar to that seen with nodular goiter and may be interpreted as such. C. The tissue fragments of follicul cells are syncytial type with a follicular pattern exhibiting crowding and overlapping of minimally enlarged nuclei. The cytologic presentation is consistent with a cellular follicular adenoma. D. Thyroidectomy showed a large, discrete encapsulated follicular adenoma with multiple morphologic patterns. E. Low power showing capsule and varying sized follices. F. follicles are normal sized, lined by uniform nuclei.

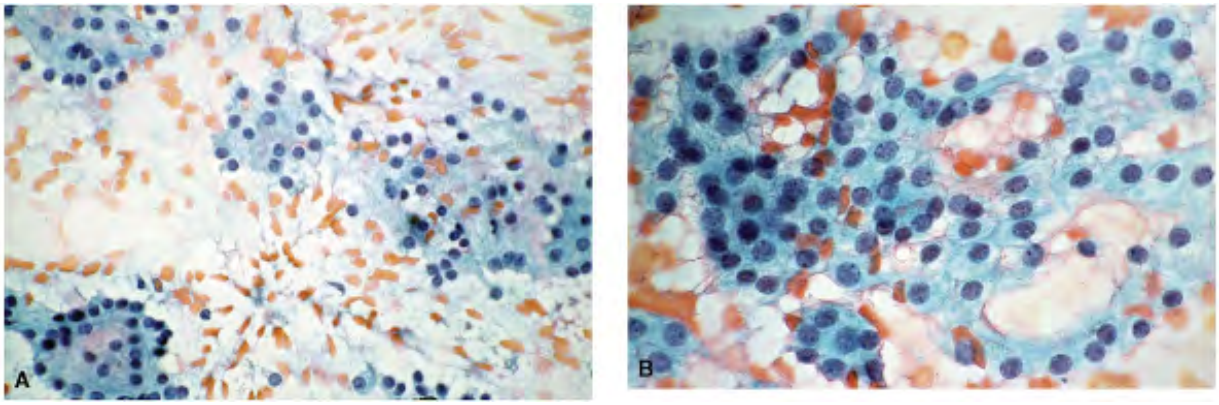

Figure 7.8. FNA of a simple follicular adenoma. A. Note marginal cellularity with few large follicles. B. The component cells have uniform nuclei with compact chromatin. The pattern consistent with nodular goiter. Thyroidectomy revealed a solitary encapsulated follicular adenoma.

Microfollicular/Trabecular Adenoma (Cellular Follicular Adenoma)

Microfollicular adenoma (or fetal adenoma), as the name implies, is composed of poorly developed or maldeveloped follicles with little or no colloid, denoting poor architectural as as functional differentiation (Fig. 7.4 C). The lining epithelium is cuboidal, with nuclei that be variably increased in size (Fig. 7.9 C).

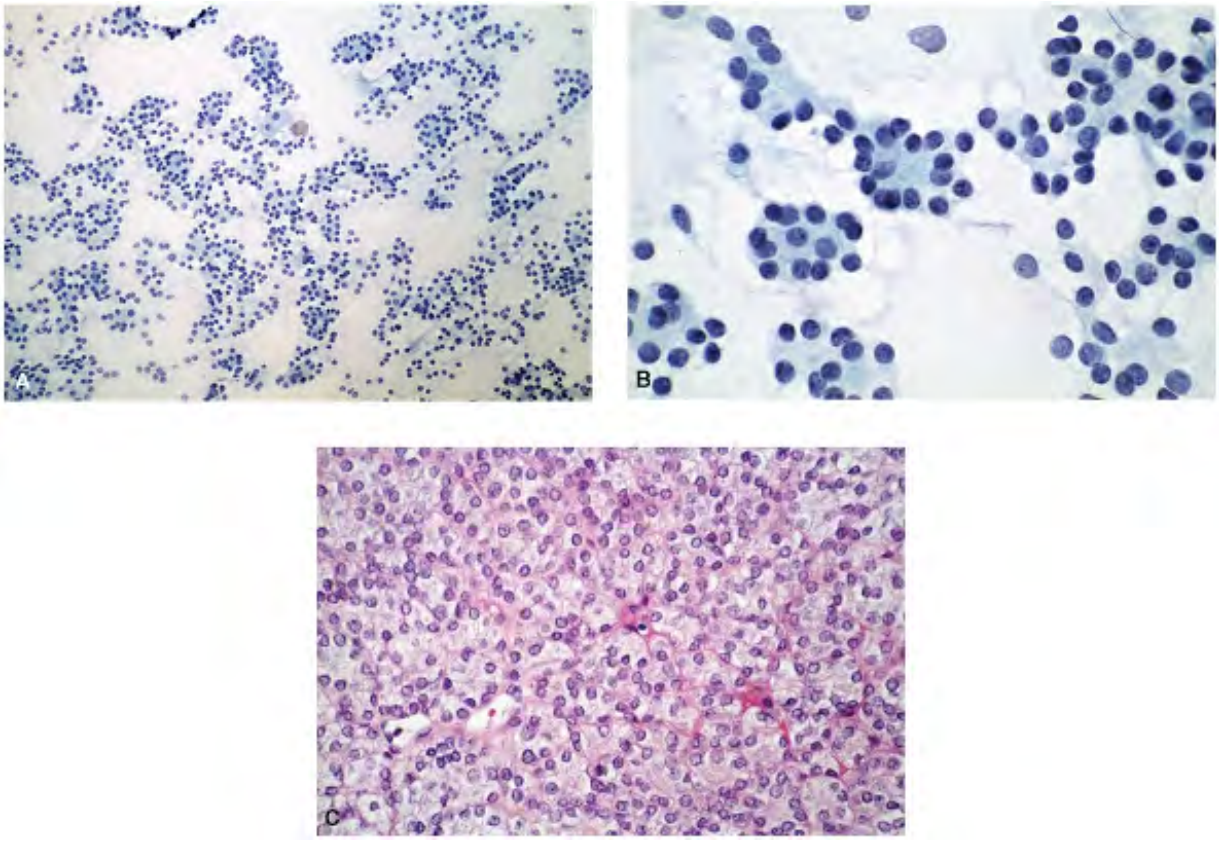

Figure 7.9. FNA of a cellular follicular adenoma. A. Cellular aspirate showing several tissue fragments of follicular cells with follicular pattern, low power. B. Higher magnification to sł the syncytial architecture with a follicular pattern, crowded, overlapped, mildly but uniforr enlarged nuclei. The background is clean with no colloid. Thyroidectomy revealed a microfollicular adenoma. C. Histologic section of the microfollicular adenoma.

Trabecular adenoma (or embryonal adenoma) displays a trabecular growth pattern with anastomosing ribbons or trabeculae of follicular epithelium (Fig. 7.4 D). There is neither a follicular growth pattern nor the presence of colloid, indicating a lack of both architectural functional differentiation at the light-microscopic level in routinely stained material.

Because microfollicular and trabecular adenomas are cellular neoplasms, they will hencefor be referred to as "cellular follicular adenomas."

P.58
P.59

Cytopathologic Features

Unlike macrofollicular and simple adenomas, aspirates of cellular follicular adenomas (Figs. 7.10 , 7.11 , 7.12 , 7.13 , 7.14 and 7.15) show a distinctly different cytopathologic pattern (Table 7.4). The aspirate is usually very cellular and consists of syncytial-type tissue fragme of follicular epithelium, with or without a follicular pattern. A follicular pattern is more commonly seen in a microfollicular adenoma, whereas in the trabecular

P.60
P.61
P.62
P.63

type, syncytial-type tissue fragments with broad trabeculae predominate. Discrete, varying- follicles are often present. The presence and the significance of microfollicles in thyroid aspirates has been over-emphasized and considered to be diagnostic of follicular neoplasms should be noted that the microfollicles are also seen in aspirates of nodular goiters. The differentiating feature is the nuclear size and arrangement and not the size of the follicle p se. The microfollicles from goiter show regularly arranged small nuclei while those from cell adenomas demonstrate crowded, overlapped, and enlarged nuclei with altered polarity. It i important to recognize this feature or else aspirates consisting of microfollicles will be interpreted as follicular neoplasms/adenomas.

Cellularity
Variable; low to high
Presentation
Cells mostly in syncytial tissue fragments or in loosely cohesive groups; scant or absent colloid
Architecture of Tissue Fragments
With or without follicular pattern; follicles may be discrete, vary in size, and may contain small amount of colloid; trabeculae with or without branching and anastomosis; considerable crowding and overlapping of nuclei
Cells
Poorly defined cell borders; N/C ratios favor the nucleus
Nucleus
Round, uniformly increased in size; smooth nuclear membranes; granular chromatin; nucleoli, grooves, or inclusions absent
Cytoplasm

Scant; pale

Colloid

Absent or scant

Background

Clean

TABLE 7.4 CYTOPATHOLOGIC FEATURES OF MICROFOLLICULAR/TRABECULAR-TYPE FOLLICULAR ADENOMA (CELLULAR FOLLICULAR ADENOMA)

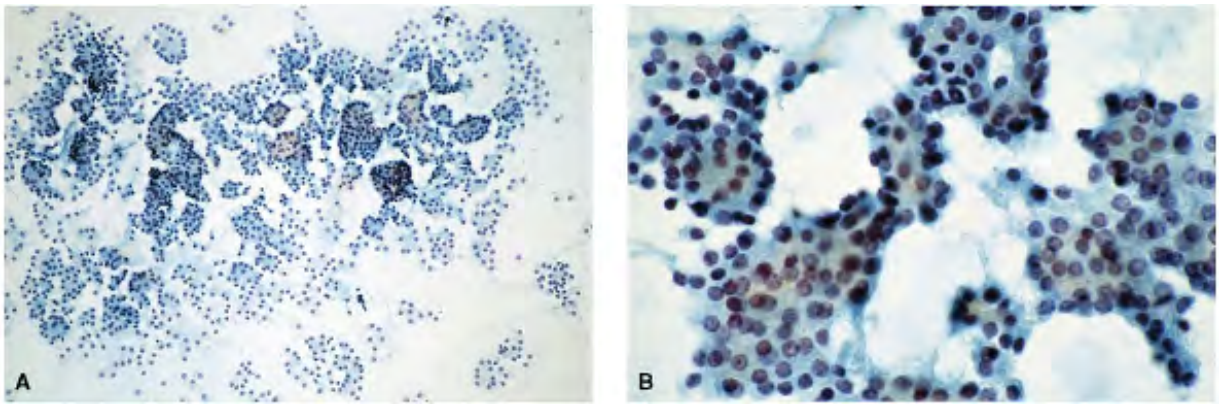

Figure 7.10. FNA of a cellular follicular adenoma. A. Hypercellular aspirate with several tis fragments of follicular cells in a clean background, with no colloid. B. Higher magnification showing syncytial architecture with a follicular pattern, uniformly enlarged, crowded and overlapped nuclei. The chromatin is granular, evenly dispersed. No nucleoli are present.

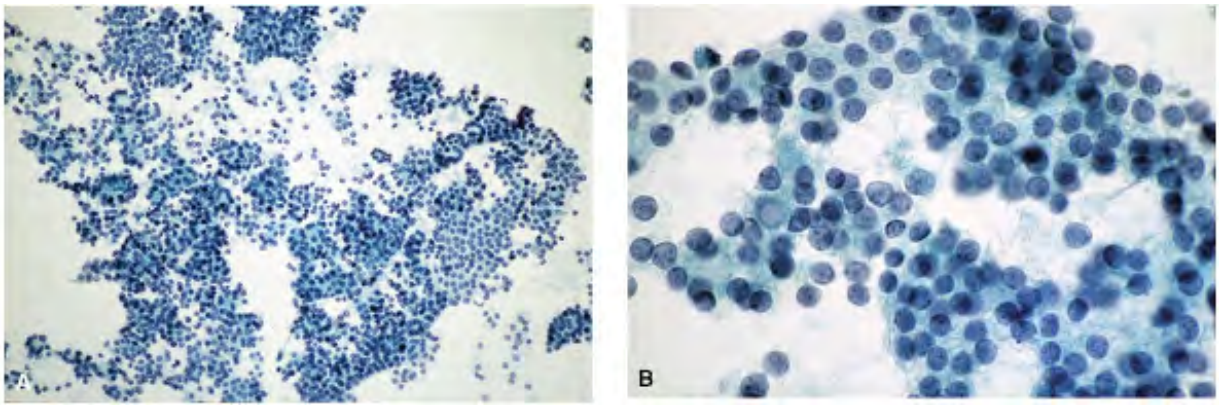

Figure 7.11. FNA of a cellular follicular adenoma. A. Hypercellular aspirate with several tis

fragments of follicular cells in a clean background, with no colloid, low power. B. Higher magnification showing syncytial architecture with a follicular pattern, uniformly enlarged, crowded and overlapped nuclei. The chromatin is granular, evenly dispersed. No nucleoli ar present.

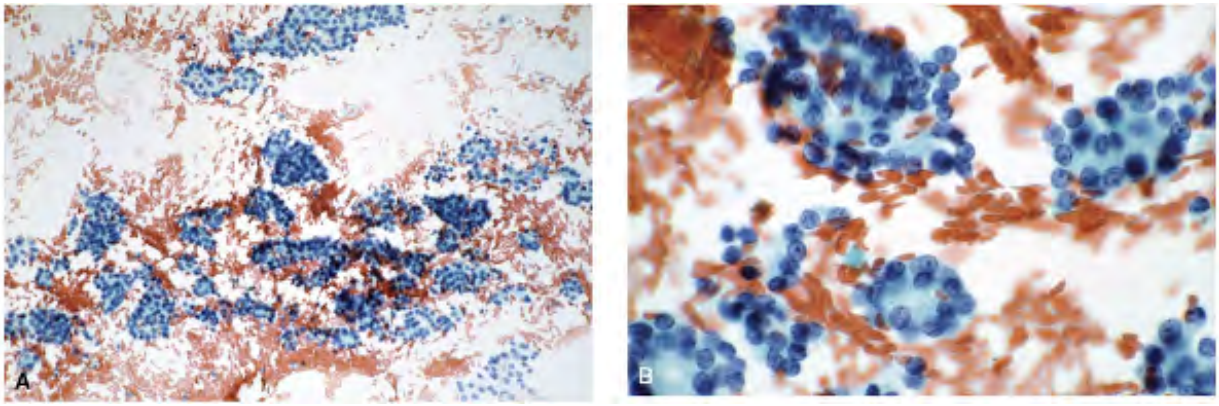

Figure 7.12. FNA of a cellular follicular adenoma. A. Hypercellular aspirate with several tis fragments of follicular cells in a clean background, with no colloid, low power. B. Higher magnification showing syncytial architecture with a follicular pattern, uniformly and moder enlarged, crowded and overlapped nuclei. The chromatin is granular, evenly dispersed. No nucleoli are present. The follicular cells contain scant, pale cytoplasm

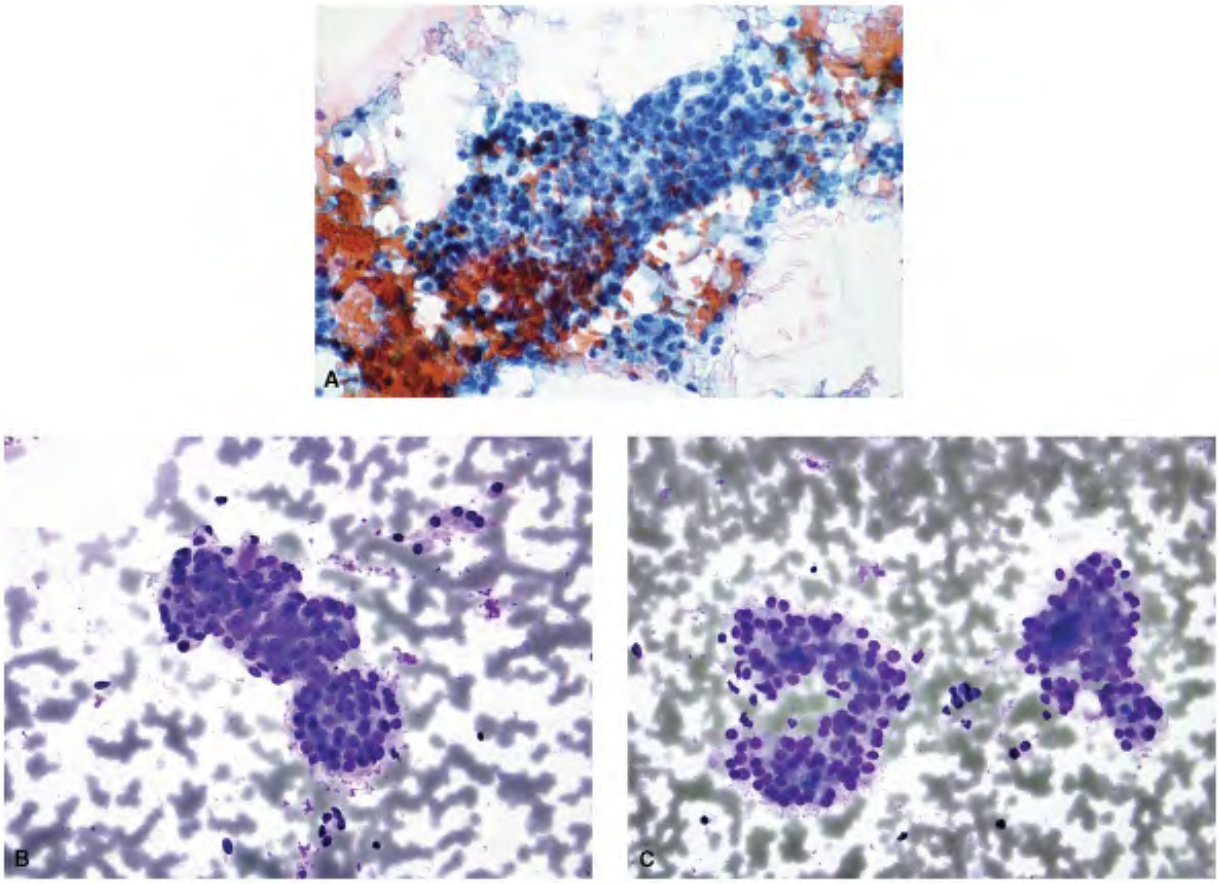

Figure 7.13. FNA of a cellular follicular adenoma. A. Large syncytial tissue fragment of folli cells. The follicular architecture is not evident. The nuclei are moderately but uniformly enlarged in size, crowded, and overlapped. No nucleoli are appreciated. The background is clean, devoid of colloid. Thyroidectomy revealed a cellular follicular adenoma. B, C. FNA of follicular adenoma. Note syncytial architecture with a follicular pattern, Diff-Quik. (Courtes Mithra Baliga, MD, University of Mississippi, Jackson, Mississippi.)

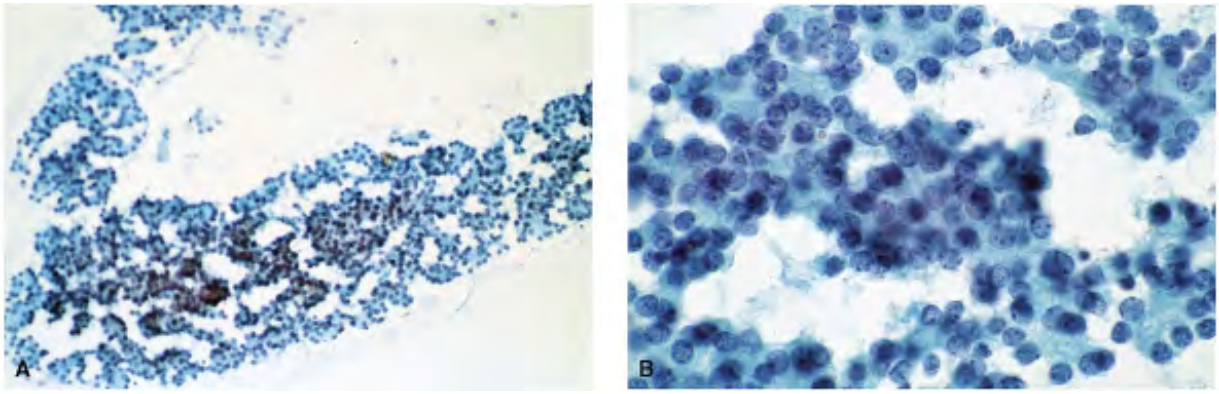

Figure 7.14. FNA of a cellular follicular adenoma. A. This aspirate is markedly cellular, consisting of several syncytial, anastomosing tissue fragments of follicular cells with follicul and trabecular pattern. Note the clean background and lack of colloid, low power. B. Highe magnification to highlight the microfollicular pattern, marked crowding, and overlapping of enlarged nuclei containing granular chromatin. An occasional nucleus contains micronucleol which suggest the possibility of invasive characteristics and warrants a suspicious diagnosis. Thyroidectomy showed an encapsulated microfollicular adenoma.

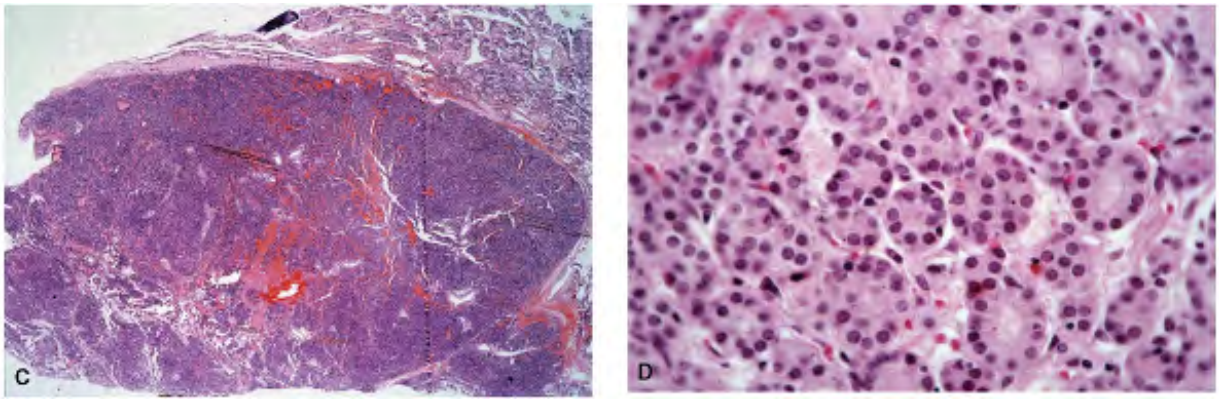

Figure 7.14. C. Low power of the encapsulated adenoma demonstrating a solid growth patt The small extension of the tumor is not considered enough evidence by the surgical patholo for justifying a diagnosis of follicular carcinoma. D. Higher magnification depicting the microfollicular adenoma.

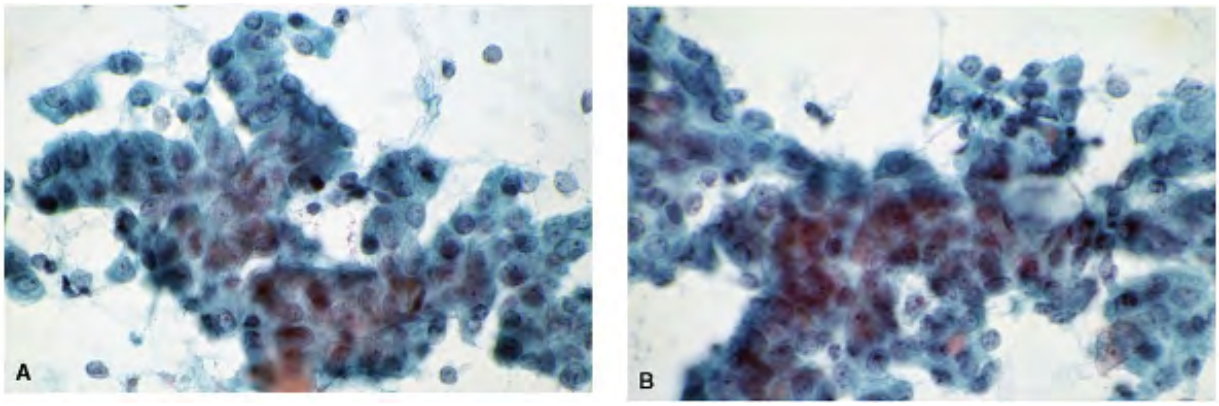

Figure 7.15. FNA of a cellular follicular adenoma with a trabecular pattern. This aspirate is markedly cellular, consisting of varying-sized, syncytial tissue fragments of follicular cells w trabecular pattern. The nuclei are considerably enlarged, crowded, and overlapped. Their

chromatin is granular and nucleoli are occasionally seen. Note the clean background, lackin colloid. Thyroidectomy revealed a follicular adenoma with a trabecular growth pattern.

The nuclear size in cellular follicular adenomas remains uniform in a given case, but is varia increased in size from tumor to tumor. The nuclei are crowded and overlapped. The cell bo are indistinct. The nuclear chromatin is granular and rather coarse but evenly distributed. Nucleoli are infrequent and the cytoplasm is variable but scanty, colorless to pale. Nuclear pleomorphism and the presence of nucleoli should raise the suspicion of follicular carcinoma

The background is usually clean, and colloid is rarely present but may be seen within the lu of the follicles.

Cellular follicular adenomas overlap with well-differentiated follicular carcinomas both cytologically and histologically, and the distinction between the two may be difficult. Additionally, the aspirates of cellular follicular adenomas present morphologic similarities w parathyroid adenomas and medullary thyroid carcinomas. The differentiating features are discussed in the respective chapters.

A summary of the cytopathologic features of conventional follicular adenomas is given in Ta 7.5 .

Cellularity
Low
Moderate
Moderate to marked
Moderate to marked
Presentation
Abundant colloid with follicular cells isolated appearing as bare nuclei often resembling lymphocytes or in loosely cohesive groups or in tissue fragments
Variable amounts of colloid; follicular cells in tissue fragments

Follicular cells in tissue fragments, scant to absent colloid

Follicular cells in tissue fragments, scant to absent colloid

Architecture

Small regular follicles or in monolayered sheets with honeycomb arrangement

Tissue fragments with both honeycomb and syncytial arrangement with or without follicular patterns; follicles small, some with evenly spaced nuclei, some with crowding and overlapping

Syncytial arrangement, mostly with follicular pattern; crowding and overlapping of nuclei

Syncytial arrangement mostly with trabecular pattern, follicular pattern infrequent, crowding and overlapping of nuclei

Nuclei

Small, pyknotic

Normal sized (7â€“9 Âµm) to slightly enlarged, evenly dispersed, finely granular chromatin; nucleoli absent

Variably enlarged but

	uniformly in a given neoplasm; fine to coarsely granular chromatin; nucleoli generally absent			
Variable enlarged, occasionally pleomorphic, fine to coarsely granular chromatin; nucleoli generally absent				
Significance				
Cannot be differentiated from hyperinvoluted goiter				
Difficult to differentiate from nodular goiter				
Difficult to differentiate from minimally invasive or well-differentiated follicular carcinoma				
Difficult to differentiate from minimally invasive or well-differentiated follicular carcinoma				
	Colloid or Macrofollicular Adenoma	Simple or Normofollicular	Microfollicular	Trabec

TABLE 7.5 COMPARISON OF CYTOPATHOLOGIC FEATURES (CONVENTIONAL FOLLICULAR ADENOMAS

Morphologic Variants of Follicular Adenoma

Hyalinizing Trabecular Adenoma

Hyalinizing trabecular adenoma, first described by Carney and associates16 and also referre

as "paraganglioma-like adenoma of thyroid" (PLAT),17 is a distinctive but uncommon subtype follicular adenoma with a female preponderance. These tumors generally behave in a benig fashion. Recurrence or metastasis is infrequent11 ; however, invasive hyalinizing trabecular carcinomas have been reported.18

Gross and Microscopic Features

Grossly the tumors are discrete, circumscribed, and solid; they are tan to gray-pink in color, with a granular texture.

Histologically, hyalinizing trabecular adenomas are characterized by encapsulation and an alveolar or trabecular growth pattern (Figs. 7.16 and 7.17).11 , 16 , 17 , 18 , 19 , 20 , 21 , The neoplastic cells are medium-sized, oval, polygonal to spindle-shaped, and either arrang solid masses or as trabeculae separated by dense hyaline stroma. The trabeculae are straigh sinuous, two to three layers thick. The neoplastic cells adjacent to the stroma are often mummified, and those within the trabeculae form a pseudofollicular pattern (Fig. 7.16), wi without colloid.

Another characteristic pattern consists of elongated neoplastic cells aligning with their base inserted vertically into the capillaries of the delicate fibrovascular stroma. The tumor cells contain variable pale to granular cytoplasm with perinuclear clearing. Their nuclei are roun mildly enlarged, with granular chromatin, micronucleoli, frequent inclusions, and grooves. T nuclear/cytoplasmic ratio is low. The stroma is variable, often increased, and with dense hy resembling amyloid. The stains for amyloid are negative.

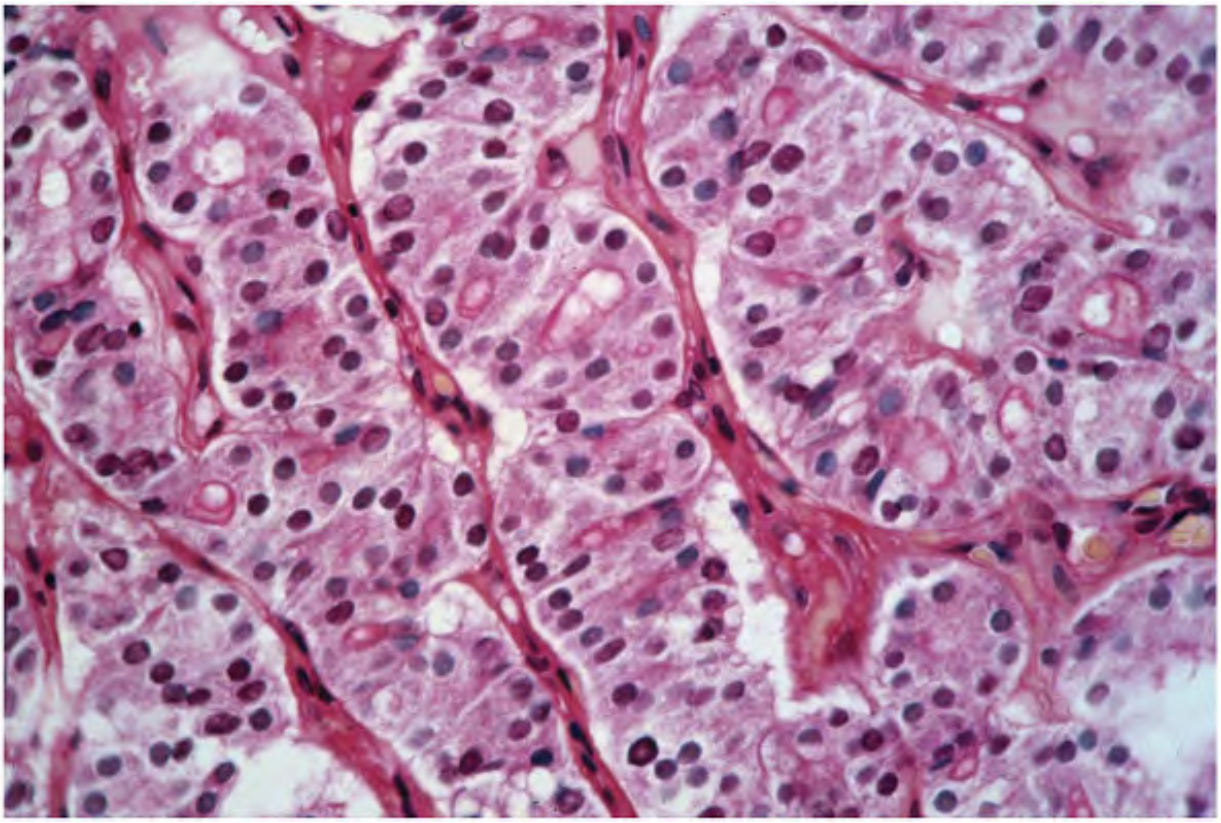

Figure 7.16. Hyalinizing trabecular adenoma. Histologic section showing trabeculae formed elongated cells.

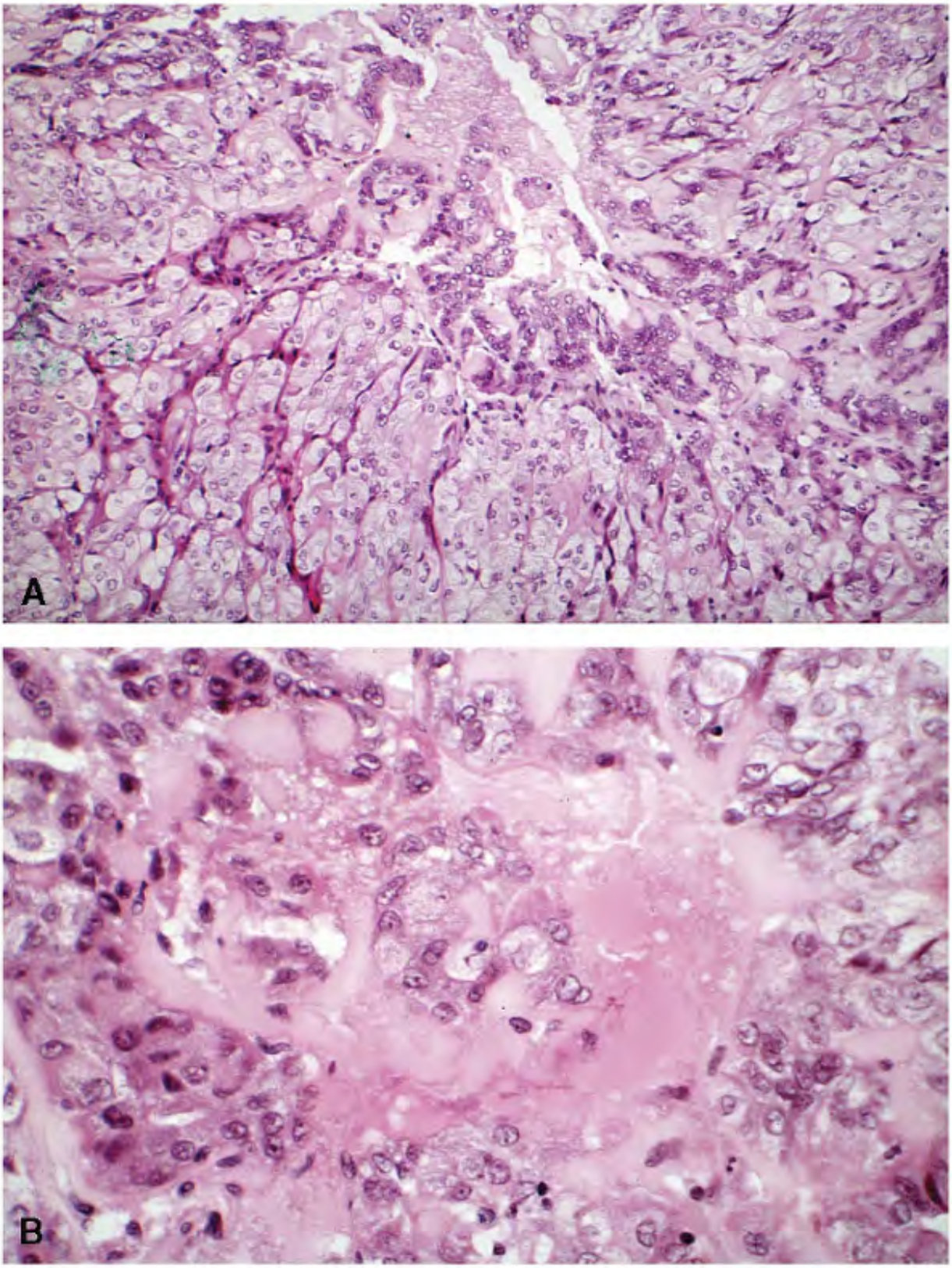

Figure 7.17. Histologic sections of hyalinizing trabecular adenoma. A. This field shows large

follicular cells forming trabeculae. Note focal area in the center, where nuclei appear very clear, similar to that seen in papillary carcinoma. Also note stromal hyalinization. B. Anothe field showing dense hyalinizing stroma separating the islands and trabeculae of neoplastic follicular cells.

Immunohistochemical findings23 , 24 , 25 include a positive reaction to thyroglobulin, TTT-1 cytokeratin, and vimentin; and a negative reaction to HBME-1, calcitonin, S-100 protein, an neurofilament. Neuroendocrine differentiation has been reported by some.25 A distinctive membrane staining with MIB-1 is described.23

Cytopathologic Features

Cytologically, hyalinizing trabecular adenomas show features common to both medullary an papillary carcinomas (Table 7.6 , Figs. 7.18 , 7.19 and 7.20). 26 , 27 , 28 , 29 , 30 , 31 , 32 , 34 , 35 The aspirates show oval to spindle-shaped cells, isolated, in loosely cohesive group in syncytial tissue fragments without any follicular or papillary architectural pattern. At tim the neoplastic cells are arranged in a sinuous parallel array and appear to radiate from a ce hyaline, acellular area (Fig. 7.20).

P.65

P.66

P.67

Bondeson and Bondeson32 have described neoplastic cells in a follicle-like or pseudofollicula arrangement around acellular material that stains metachromatically purplish red in Mayâ€“GrÃ¼nwaldâ€“Giemsa stain. The cytoplasm of these cells is pale to dense and variab sometimes filamentous, and not well visualized. Bipolar and triangular cells with long cytoplasmic processes may be present. Yellow cytoplasmic bodies 3 to 5 Âµm have been described both histologically and cytologically. Although Rothenberg and colleagues21 descr them in all 75 cases, the yellow cytoplasmic bodies are seen sparingly in any given case of hyalinizing trabecular adenoma. The nuclei tend to be round, oval to elliptical, and mildly pleomorphic in size have a smooth border and contain finely granular, evenly distributed chromatin with micronucleoli. Intranuclear inclusions and nuclear grooving are frequent. 26 , 34 , 35 Goellner and Carney35 described chromocenters with halo-like, clear zones arounc them. The perinuclear clearing appreciated in histologic sections may also be seen in cytolo samples. The background may contain amorphous hyaline material similar to amyloid, staini pink to gray-blue. Psammoma bodies have been described in both cytologic material and

histologic sections. 22 , 32 , 34

Cellularity
Variable
Presentation
Cells, discrete, in groups or in syncytial tissue fragments
Architecture of Tissue
Fragments
Syncytial without follicular pattern; papillary-like with branching; trabeculae; central cores of acellular hyaline material
Cells
Variably increased in size; round, oval, polygonal to elongated; poorly defined cell borders; N/C ratios low
Nucleus
Increased variably; often eccentric; round, oval to elongated, smooth nuclear membranes, f granular chromatin; micronucleoli present, intranuclear inclusions very frequent; grooves
Cytoplasm
Abundant, pale, fibrillar to finely granular; long, tapered cytoplasmic processes Â±; yellow cytoplasmic bodies Â±; perinuclear halo Â±
Psammoma Bodies
Â±
Background
Hyaline material, staining metachromatically purplish-red with Romanowsky stain; colloid al
Immunoprofile
Thyroglobulin, TTF-1, cytokeratin, and vimentin positive; distinctive cell membrane staining pattern with MIB-1, calcitonin, and chromogranin negative

TABLE 7.6 CYTOPATHOLOGIC FEATURES OF HYALINIZING TRABECULAR ADENOMA

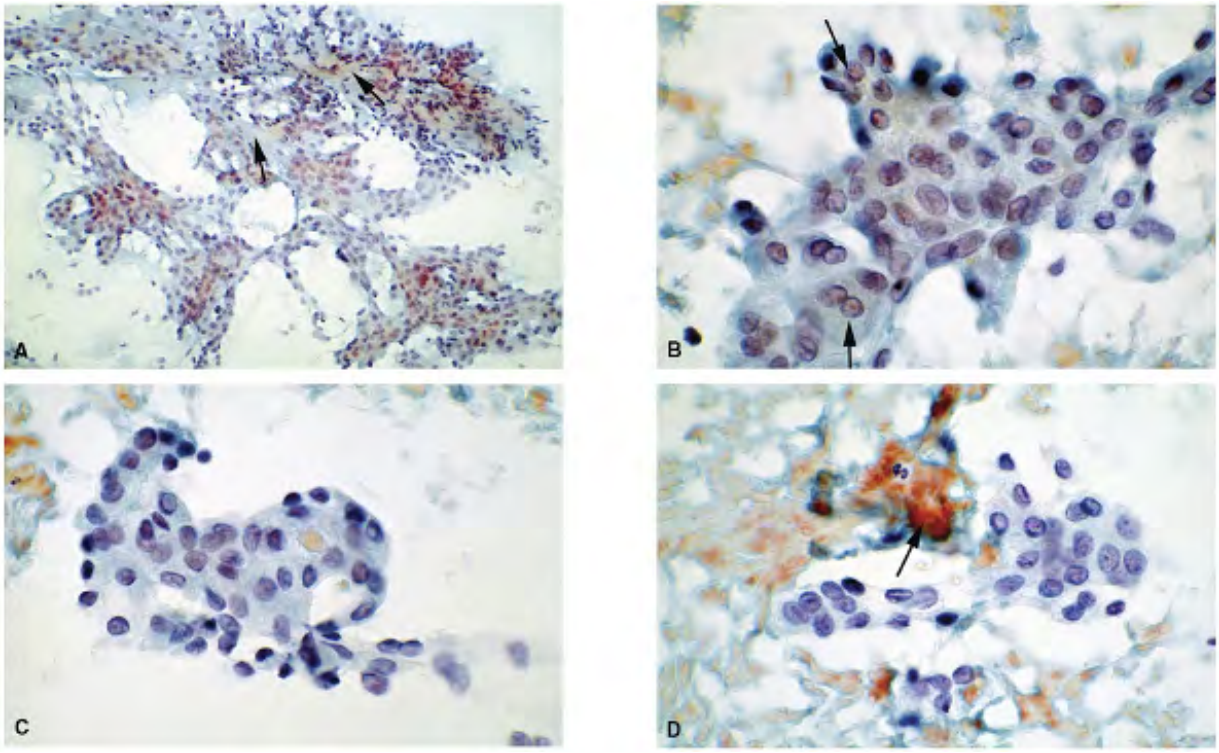

Figure 7.18. FNA of hyalinizing trabecular adenoma. Low power view showing anastomosing trabeculae. Hyaline stroma is seen between the follicular cells (arrows). B, C. Higher magnification showing syncytial fragments of follicular cells with a trabecular pattern. Thei nuclei are enlarged with pale granular chromatin. Note the intranuclear inclusions (arrows) nuclear grooves. D. This field shows stromal hyaline material (arrow).

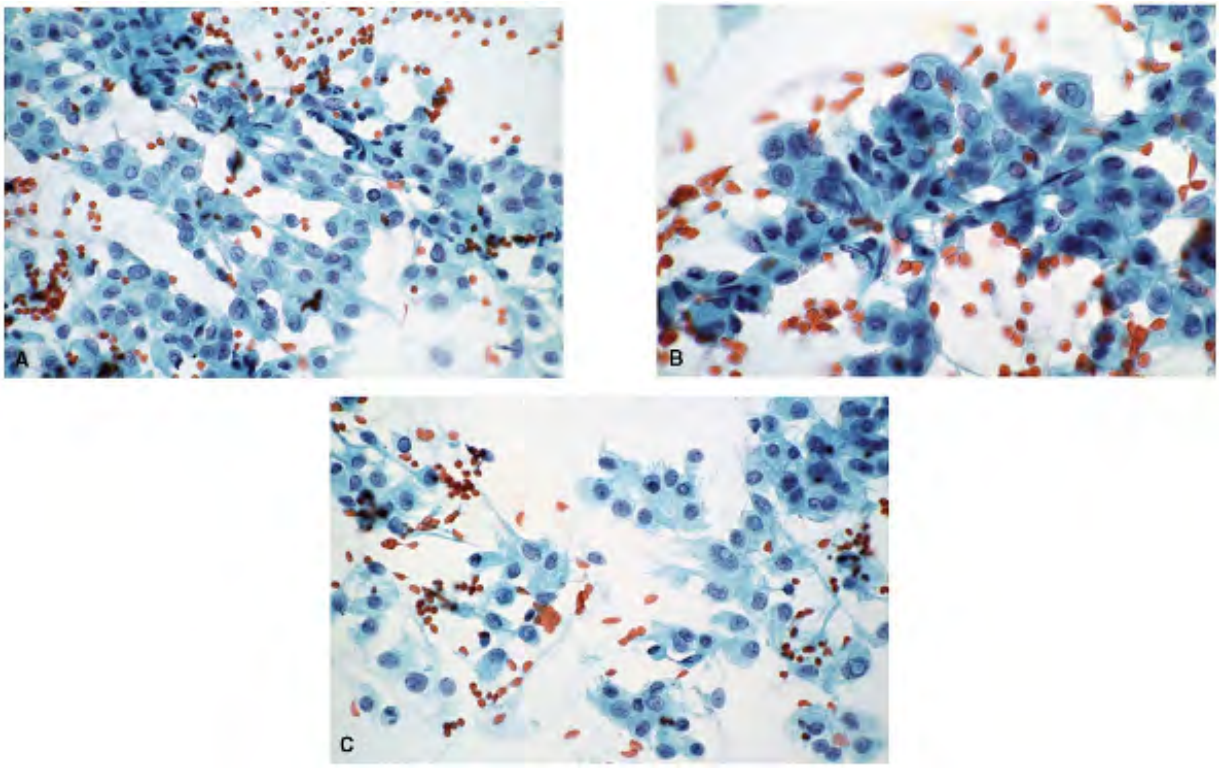

Figure 7.19. FNA of hyalinizing trabecular adenoma. A, B. The follicular cells are in syncyti
tissue fragments, forming trabeculae. Note the abundant granular cytoplasm. Their nuclei h
powdery chromatin, grooves and inclusions. C. The cells are discrete and loosely cohesive. T
are large and elongated, with some showing delicate filamentous cytoplasmic processes.

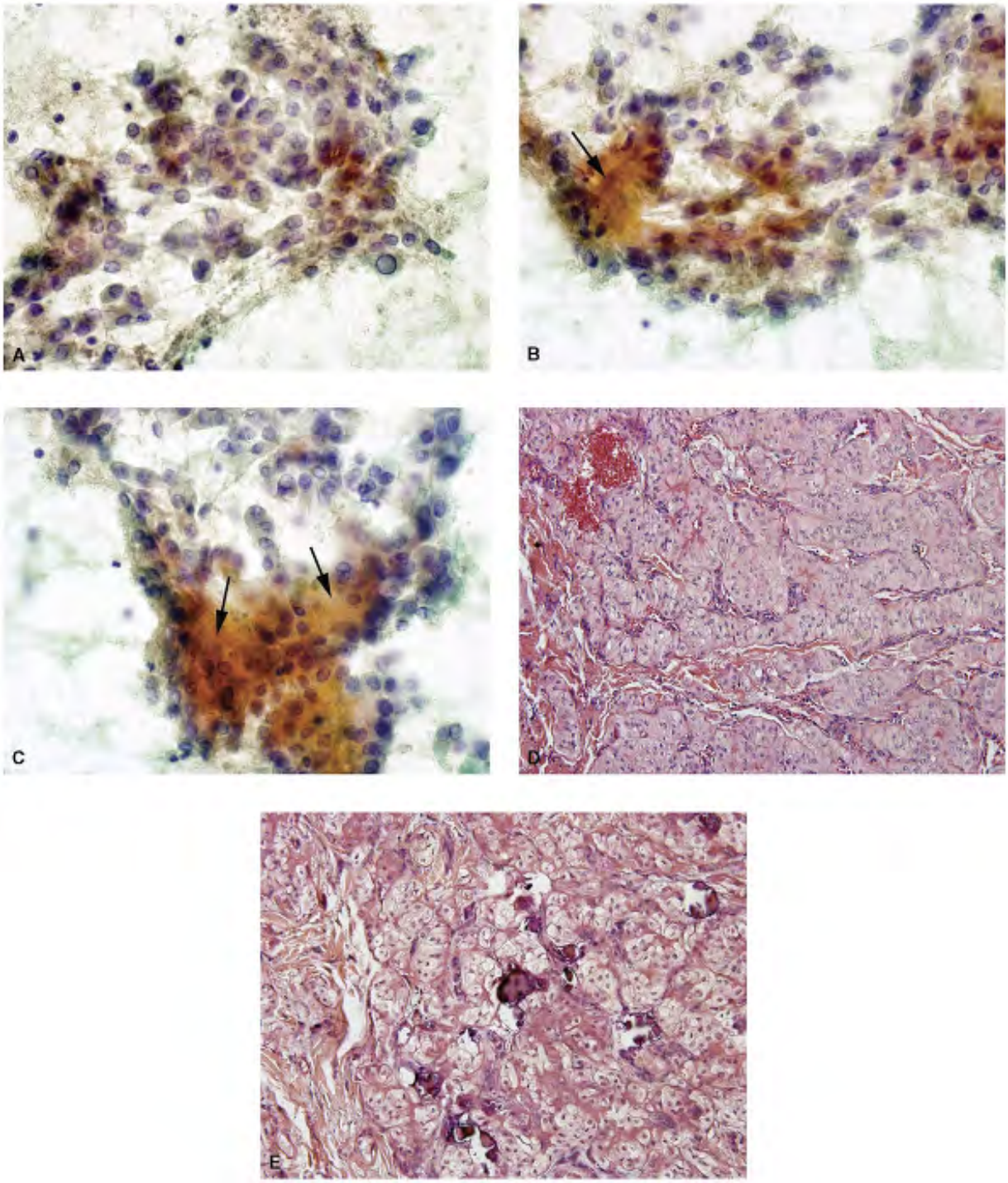

Figure 7.20. FNA of hyalinizing trabecular adenoma. A. Syncytial tissue fragments of follicu cells without any architectural configurations. The nuclei have finely granular chromatin, grooves, occasional micronucleoli, and frequent inclusions. B, C. These two images show intercellular hyaline material (arrows). The nuclei have powdery chromatin, and inclusions. Histologic section of the hyalinizing trabecular adenoma. E. Different field showing calcifica

and possible psammoma bodies. (Courtesy of Marizza de Peralta-Venturina, MD, William Beaumont Hospital, Royal Oak, Michigan.)

The cytologic recognition of hyalinizing trabecular adenomas is difficult because of the morphologic overlap with papillary and medullary carcinomas. Most of the reported series c with this observation. The differentiating features are listed in Chapter 9 on papillary carcir (Table 9.16) and Chapter 12 on medullary carcinoma (Table 12.7). Although very rare, prin paraganglioma of the thyroid may be considered in the differential diagnosis.36

Follicular Adenoma with Clear Cell Change

Follicular adenoma with a clear cell change is of uncommon occurrence. Its demographics, clinical presentation, and behavior are similar to the conventional-type adenomas.11 , 37 , 39 , 40

Histologically, follicular adenoma with clear cell change shows an encapsulated tumor with follicular or solid growth pattern formed by benign follicular cells containing abundant clear empty-looking cytoplasm. The nuclei are small and uniform.

Cytologically, the clear cell pattern is difficult to recognize when the cytoplasmic borders a indistinct or disrupted and the bare nuclei resemble lymphocytes (Fig. 7.21). The clear cytoplasm is difficult to appreciate in cytologic preparations.

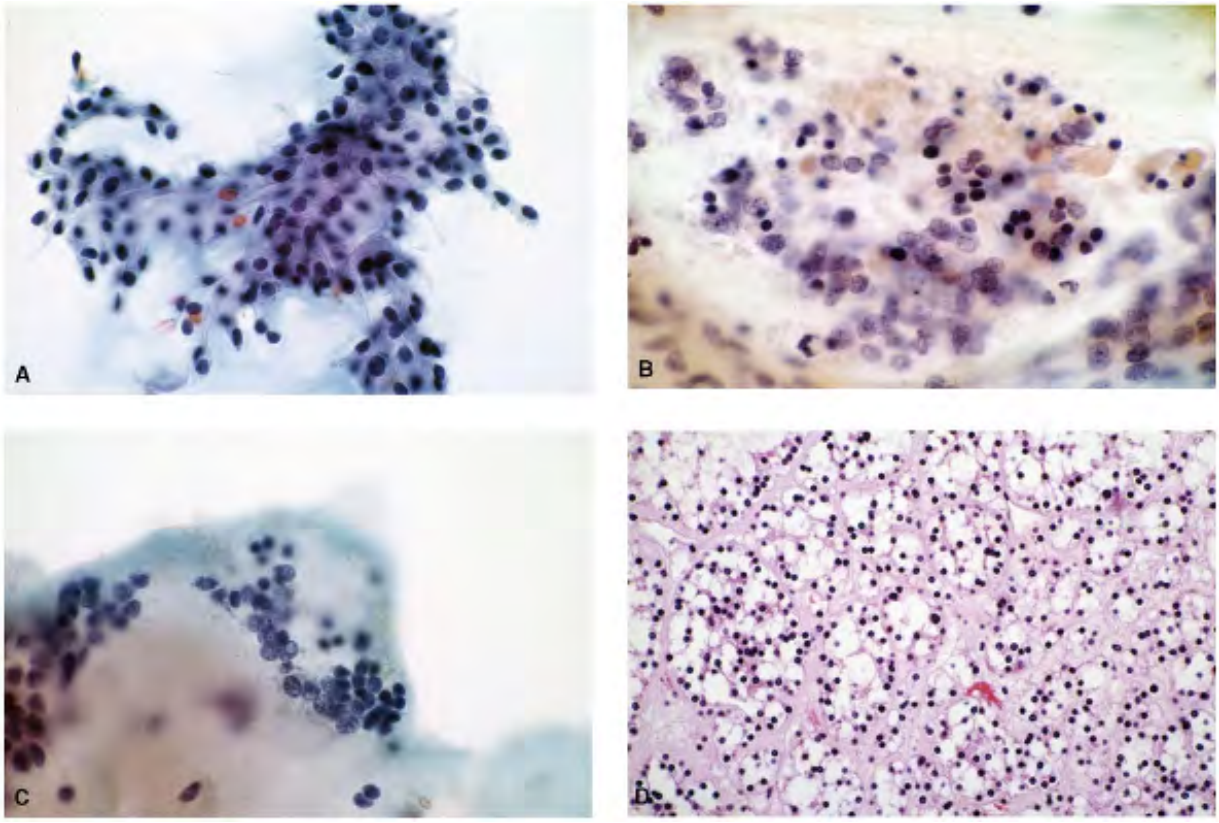

Figure 7.21. Follicular adenoma with clear cell change. Aâ€“C. FNA showing tissue fragmer
follicular cells with follicular pattern. Their cell borders are poorly defined and the nuclei
appear bare, resembling lymphocytes because of compact chromatin. D. Histologic section c
the resected follicular adenoma with a clear cell pattern.

The differential diagnosis includes metastatic renal cell carcinoma and intrathyroidal parathyroid adenoma.41

Follicular Adenoma, Oxyphil Cell Type

Follicular adenomas composed of oxyphil cells are considered by some as a morphologic vari
of follicular adenomas.10 , 12 , 42 Others refer to them as HÃ¼rthle cell tumors and consid
them a separate entity. They are described in detail in Chapter 8 .

Follicular Adenoma with Papillary Hyperplasia

Follicular adenomas with papillary hyperplasia or a papillary change are considered to be m

frequent in teenagers and young adolescents11 , 42 , 43 and are characterized by degenera changes with cyst formation and papillary change. The papillae are edematous, directed tov the center of the cyst, and lined by benign follicular epithelium containing basally located r with compact chromatin (Fig. 7.22 A and B, and Fig. 7.23 C to E). They lack the typical nucl morphology of papillary carcinoma.

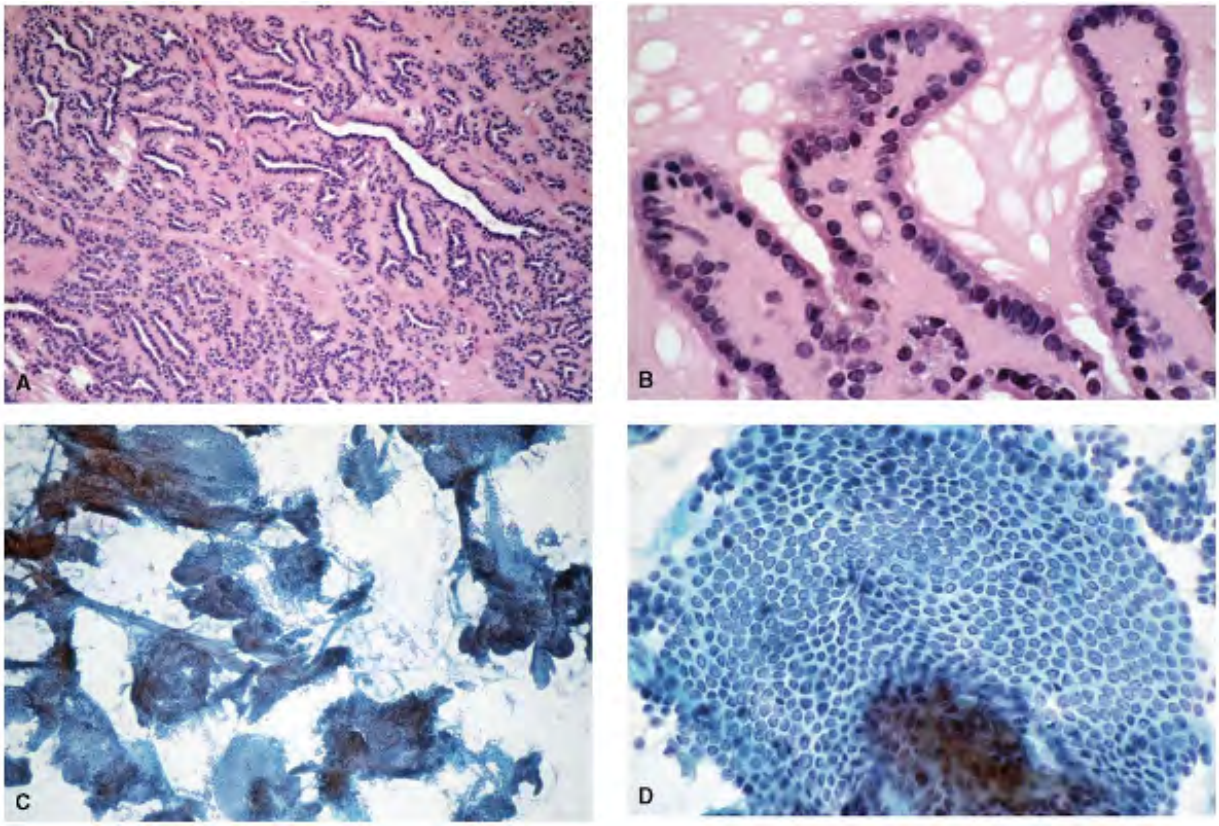

Figure 7.22. Follicular adenoma with papillary change. A. Histologic section of a follicular adenoma with large dilated follicles showing infolding of the lining follicular cells, suggestin papillary pattern (low power). B. Higher magnification shows papillary-like pattern with hyalinized stroma. The lining cells are single layered, lack stratification, have uniform nucle and do not demonstrate nuclear features of papillary carcinoma. C. FNA of this lesion was misinterpreted as papillary carcinoma because of highly cellular aspirate consisting of nume papillary-like tissue fragments. D. Higher magnification to highlight the honeycomb pattern uniform nuclei, a pattern not typical of papillary carcinoma.

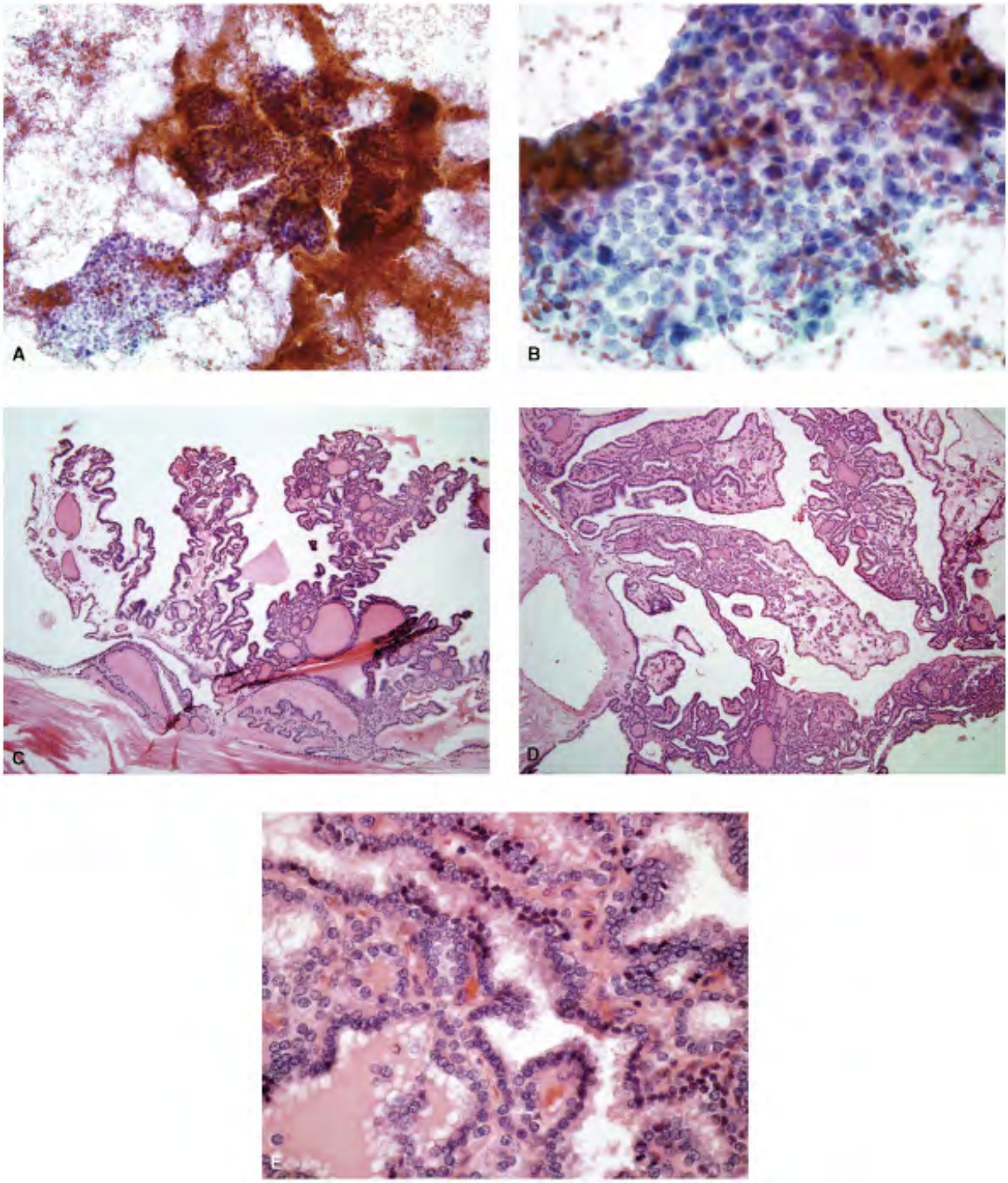

Figure 7.23. Follicular adenoma with papillary change. A. FNA showing branching large tissu fragments of follicular cell (low power). B. Higher magnification showing the large tissue fragment of follicular cells, folded over giving an appearance of syncytial arrangement. The nuclei are slightly but uniformly enlarged with granular chromatin. Some contain micronucle Thyroidectomy revealed a follicular adenoma with cystic degeneration and papillary change

Note the thick capsule and the papillary change. D. Different field showing papillary architecture (low power). E. Higher magnification showing lack of nuclear criteria for papill carcinoma.

Cytologically, follicular adenomas with papillary hyperplasia may be misinterpreted as papil carcinoma (Fig. 7.22 C and D, and Fig. 7.23 A and B). The aspirates are usually cellular, consisting of syncytial tissue fragments of follicular cells with a papillary-like pattern. The typical nuclear features of conventional papillary carcinoma are lacking. The diagnostic problems are discussed in detail in Chapter 9 .

Atypical Adenoma

Hazard and Kenyon44 coined the term "atypical adenoma" for those follicular adenomas tha histologically characterized by (i) hypercellularity, (ii) closely packed follicles often lacking lumina, (iii) back-to-back arranged trabeculae, (iv) solid areas, (v) areas with spindle-shape cells, (vi) mitotic figures, (vii) complete encapsulation and lack of invasive features, and (vi favorable outcome. It is apparent from this description that the atypical adenomas have the histomorphology of follicular carcinoma (Fig. 7.24) but lack invasive characteristics. The incidence of atypical adenoma is reported to be 9% by Lang and co-workers.45 They include cases with questionable invasive features.

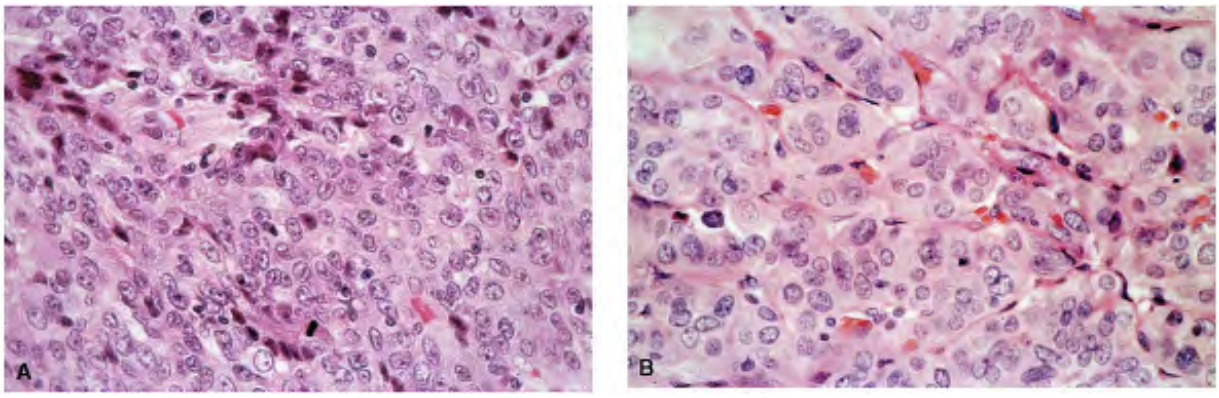

Figure 7.24. Histologic sections of two examples of atypical follicular adenomas. The neopl demonstrates a solid growth pattern with back-to-back follicles and trabeculae. The nuclei large with open chromatin and contain nucleoli. These tumors were confined to the capsule no evidence of capsular and vascular invasion.

Cytopathologic Features

Cytologically, the aspirates of atypical adenomas demonstrate marked cellularity, consisting syncytial tissue fragments of follicular epithelium (Figs. 7.25 and 7.26). They may exhibit a

P.69

P.70

P.71

follicular or a trabecular pattern or show branching without any architectural configurations with marked crowding and overlapping of enlarged, pleomorphic nuclei containing nucleoli. cytologic pattern is similar to that seen in follicular carcinoma (see Table 7.8).45 These aspirates are interpreted as follicular carcinomas and histologically diagnosed as atypical adenomas due to lack of invasion. Atypical adenoma is thus a histologic diagnosis and is nev made from cytologic samples.

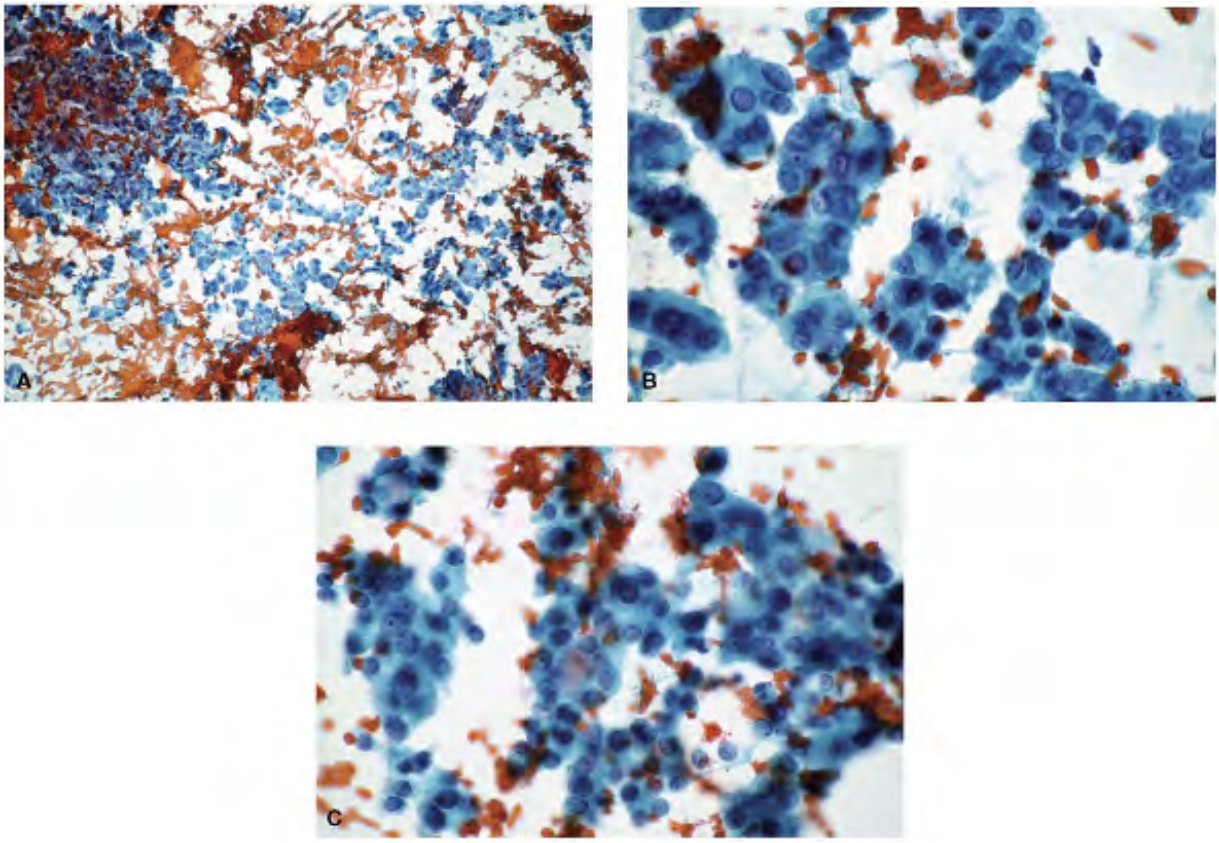

Figure 7.25. FNA of an atypical adenoma. A. The aspirate is markedly cellular, consisting of several tissue fragments of follicular cells in a background that is devoid of colloid, low pow B. Higher magnification showing syncytial tissue fragments, with and without a follicular pattern. The cells are large, pleomorphic in size, with appreciable cytoplasm. Their nuclei a

large, round, with granular chromatin, parachromatin clearing, and contain nucleoli. The pattern is consistent with follicular carcinoma. Thyroidectomy revealed an encapsulated follicular adenoma with no invasive characteristics and was interpreted as atypical adenoma FNA of a histologically confirmed follicular carcinoma showing similar cytologic pattern.

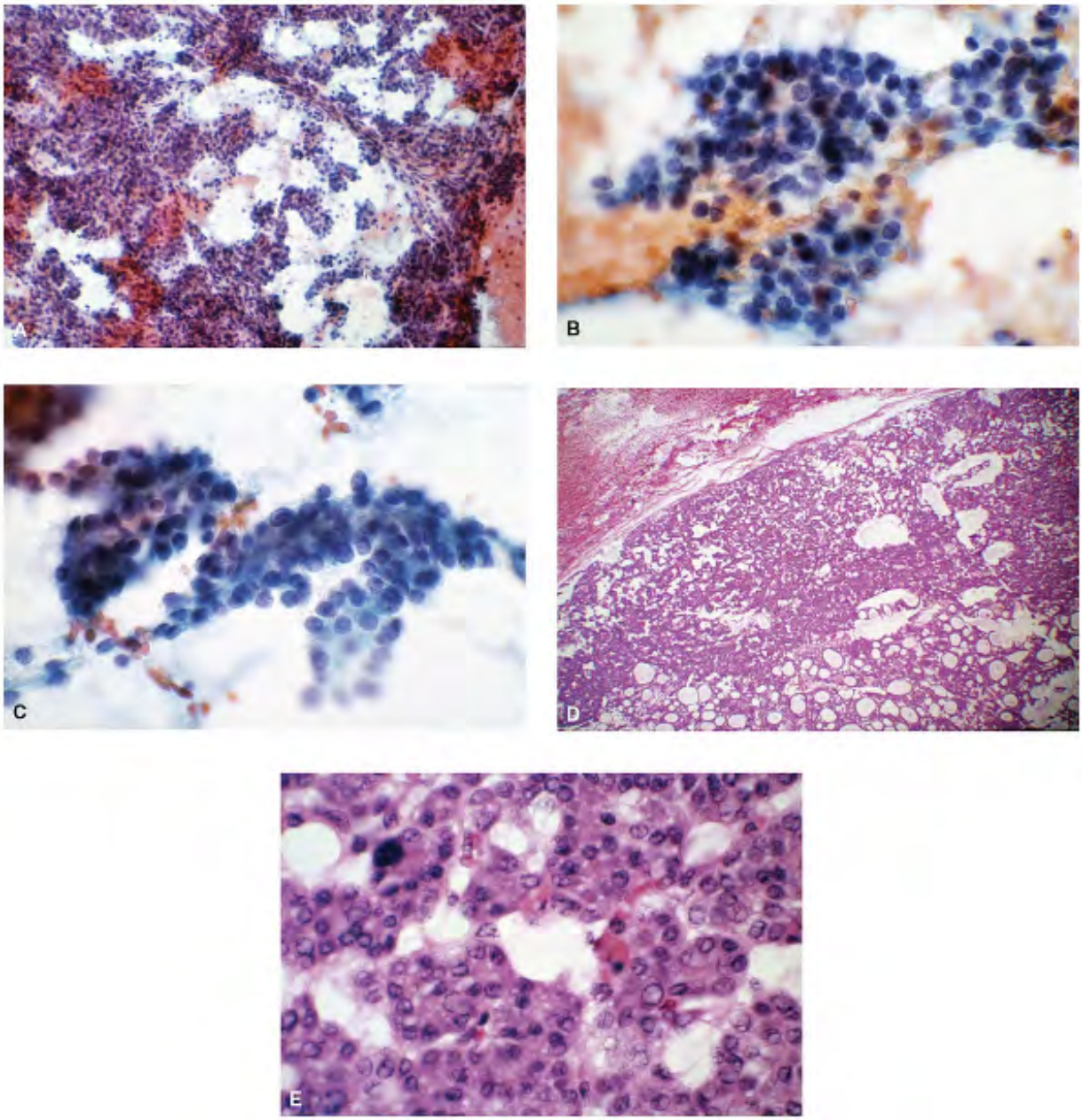

Figure 7.26. Atypical follicular adenoma. A. Low power of an overwhelmingly cellular aspira consisting of large branching tissue fragments of follicular cells. B, C. Higher magnification

showing syncytial tissue fragments with a trabecular pattern. The nuclei are extremely crow overlapped, and contain deep-staining, granular chromatin, and nucleoli. A diagnosis of follicular carcinoma was made. Thyroidectomy revealed an encapsulated cellular follicular adenoma with a thin capsule and no capsular or vascular invasion. E. The tumor showed a sc growth pattern and occasional mitosis and was interpreted as an atypical adenoma.

The other variants listed in Table 7.1 are of uncommon occurrence. The author has no persc experience with their cytologic features. The differential diagnoses of various types of follic adenomas are listed in Table 7.7

Macrofollicular Adenoma

- Nodular goiter
- Macrofollicular variant of papillary carcinoma

Simple or Normofollicular Adenoma

- Nodular goiter

Microfollicular and Trabecular Adenoma

- Hyperplastic goiter (cellular adenomatoid nodule)
- Follicular nodule from Hashimoto's thyroiditis
- Well-differentiated follicular carcinoma
- Follicular variant of papillary carcinoma
- Medullary carcinoma
- Parathyroid adenoma

Hyalinizing Trabecular Adenoma

- Papillary carcinoma
- Medullary carcinoma

Follicular Adenoma with Papillary Change

- Papillary carcinoma
- Nodular goiter

Follicular Adenoma with Clear Cell Change

- Metastatic renal cell carcinoma
- Parathyroid adenoma

Atypical adenoma
Follicular carcinoma

TABLE 7.7 DIFFERENTIAL DIAGNOSIS OF FOLLICULAR ADENOMAS

FOLLICULAR CARCINOMA

Follicular carcinomas11 , 46 , 47 , 48 are reported to represent 13% to 17% of thyroid carcinomas, although an incidence as low as 1% to 2% has been described.49 , 50 The report incidences vary depending on whether or not HÃ¼rthle cell carcinoma was included in the group. Follicular carcinomas are several times more common in women than in men, but the distribution differs from that of papillary carcinoma, being more frequent in middle and old age groups. A high incidence is reported in geographic areas with endemic goiters.13 Follicu carcinomas can be distinguished from papillary carcinomas in several ways. They are solitary lesions and rarely metastasize to cervical lymph nodes. They spread via the bloodstream to distant organs such as lungs, bone, brain, and liver. The prognosis is generally good, depend on the invasive characteristics of the tumor, but less favorable than for papillary carcinoma 12 , 51 , 52 , 53 , 54 , 55 , 56 , 57

Gross and Microscopic Features

Like adenomas, follicular carcinomas grossly are well circumscribed and sharply demarcated from adjacent parenchyma (Fig. 7.27). Poorly differentiated carcinomas are usually very la and may replace the entire lobe. The cut surface shows a varied pattern, including a bulging surface, fleshy areas, hemorrhage, necrosis, and calcification.

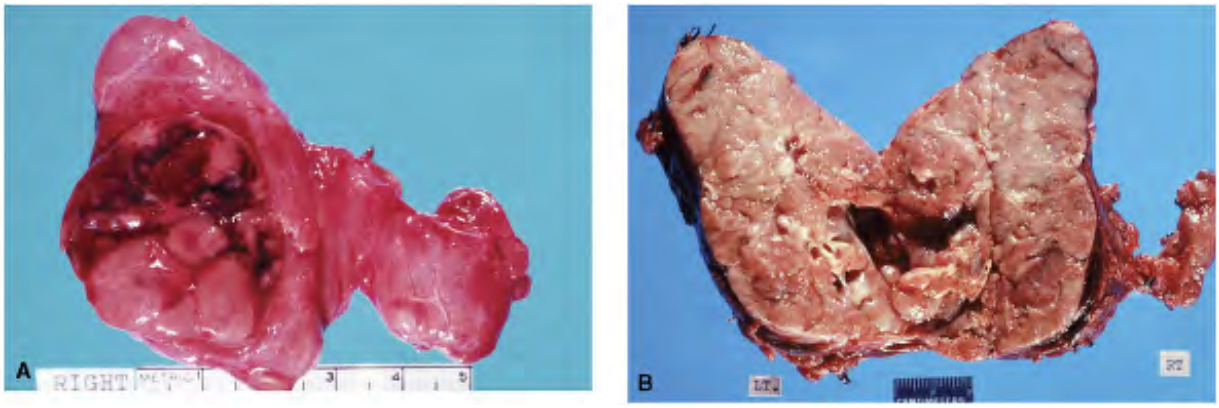

Figure 7.27. Follicular carcinoma, gross photographs. Follicular carcinomas are usually large bulky, and may involve the entire lobe. Their cut surfaces are fleshy, bulging with hemorrha and foci of necrosis.

The microscopic pattern is as varied as that of the adenomas, ranging from well-developed follicles to a solid pattern with no evidence of follicular cell differentiation (Figs. 7.28 and 7). The solid pattern may show trabeculae, alveoli, or large nests of carcinoma cells. Differer growth patterns may be seen in the same tumor. The follicular cells have larger nuclei with coarsely granular chromatin, often separated by clear parachromatin. Nucleoli are frequent Mitoses may be seen, especially in poorly differentiated carcinomas.

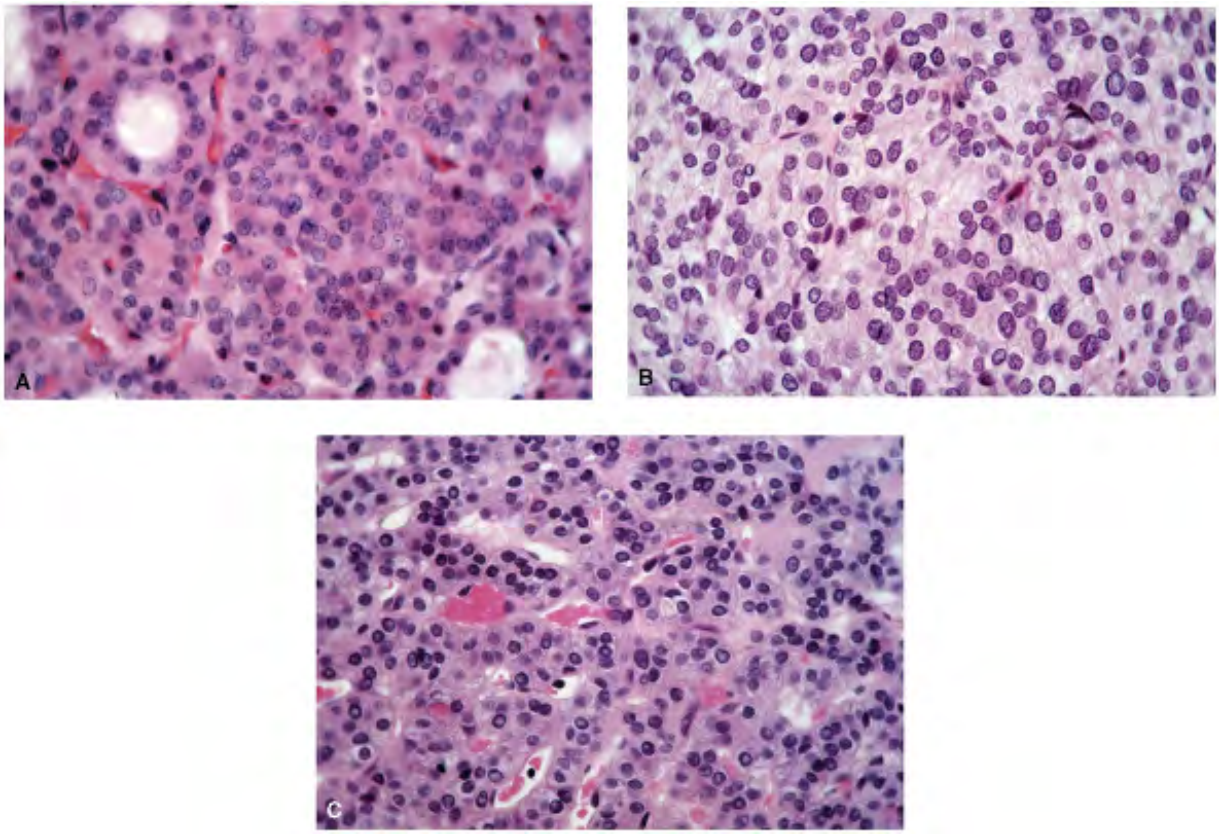

Figure 7.28. Histologic sections of well-differentiated or low-grade follicular carcinomas. A Microfollicular growth pattern. C. Trabecular growth pattern. These carcinomas show histol growth patterns similar to those of cellular follicular adenomas. The cells have uniform but enlarged nuclei. Cytologically, these low-grade carcinomas are difficult to differentiate fror cellular follicular adenomas unless micronucleoli are identified, which are present in carcin cells and usually not seen in adenomas.

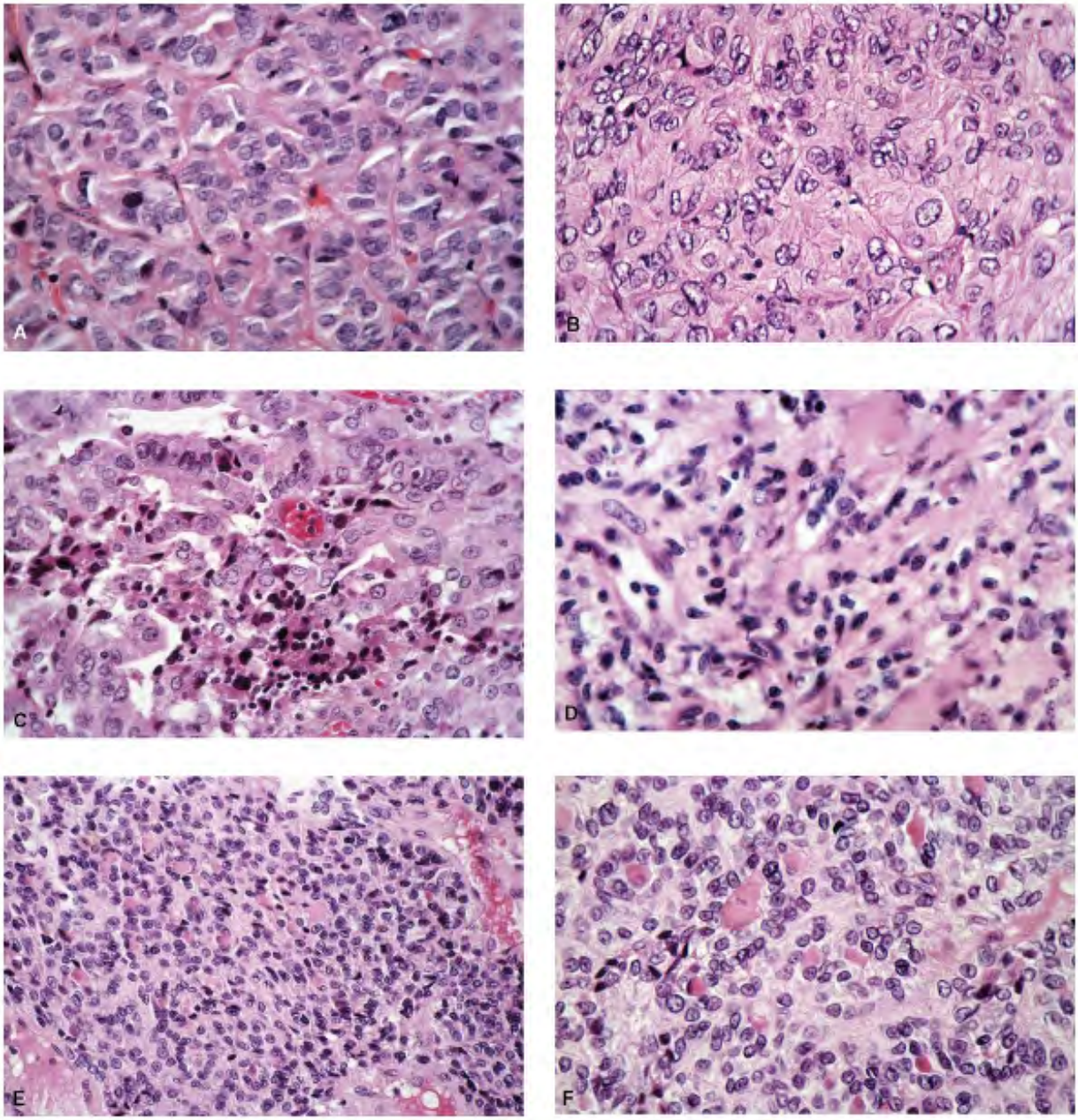

Figure 7.29. Spectrum of histologic patterns of poorly differentiated follicular carcinomas. Aâ€“D. These four images depict a solid growth pattern. The cells have large, pleomorphic nuclei with an open chromatin pattern and prominent nucleoli. Some show mitosis and foca necrosis. E, F. This follicular carcinoma shows sheets of follicular cells with only focal follic pattern. Their nuclei are hyperchromatic and pleomorphic.

Classification of follicular carcinomas may be based on differentiation (e.g., well differentia

or poorly differentiated) or on the extent of invasion (e.g., capsular or blood vessel invasior wide invasion of the surrounding parenchyma) regardless of the cytomorphology (Figs. 7.25 7.26 and 7.27).11 , 12 , 42 , 46 , 47 , 48 , 51 , 52 , 53 , 54 , 55 , 56 , 57 , 58 , 59 , 60 , 61 Usually well-differentiated carcinomas tend to be minimally invasive and the poorly differentiated carcinomas tend to be widely invasive.

A histologic diagnosis of follicular carcinoma is based on the presence of invasive characteri such as capsular or vascular invasion or invasion of the parenchyma outside the capsule and extent of it. Although everyone agrees that the demonstration of invasive features is absolu essential for the diagnosis of follicular carcinoma, considerable confusion, controversy, and debate exist over what constitutes a capsular or vascular invasion and how much invasion is significant. Thus, the interpretation becomes subjective, and the diagnosis of encapsulated follicular lesions varies greatly.58 , 59 , 60

Capsular Invasion

Some investigators feel that any degree of invasion of the capsule (Fig. 7.30 A to C) constitu the invasion qualifying for the diagnosis of follicular carcinoma.61 Others require complete transgression of the capsule to qualify as an invasive process (Fig. 7.30 D).62 Small nubbins the tumor into the capsule beyond its interface with the tumor are considered a feature of capsular invasion61 ; others totally discount it. Some consider this feature as a postâ€“fine-needle biopsy effect.

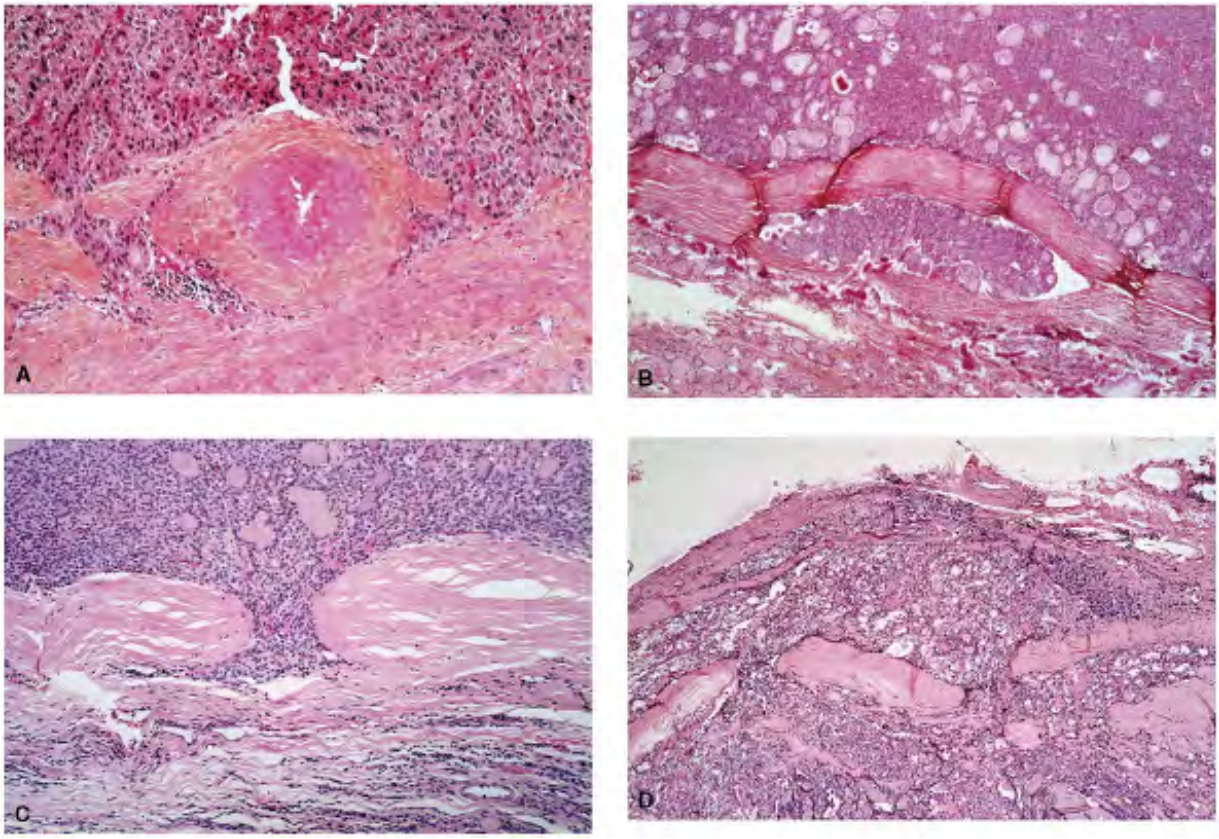

Figure 7.30. Follicular carcinoma with capsular invasion. A. These small foci of neoplastic c infiltrating the thick capsule but not completely penetrating it may not qualify for the diagr of follicular carcinoma according to some pathologists. B. The tumor has split the thick and fibrotic capsule. Again, this was not considered sufficient evidence for the diagnosis of folli carcinoma. C. The invasion in this image is seen as involving the entire capsule but not beyc it. D. The invasion of the tumor is seen as complete transgression of the capsule and beyonc

Vascular Invasion

The presence of vascular invasion is regarded as a reliable feature in favor of carcinoma. Th problem is what constitutes a vascular invasion. Mere presence of tumor within a small bloo vessel is not sufficient. The tumor must be attached to the vessel wall, subendothelial in location, and must be covered by the endothelium (Fig. 7.31). The invaded blood vessel mu within the capsule or outside and not intralesional.

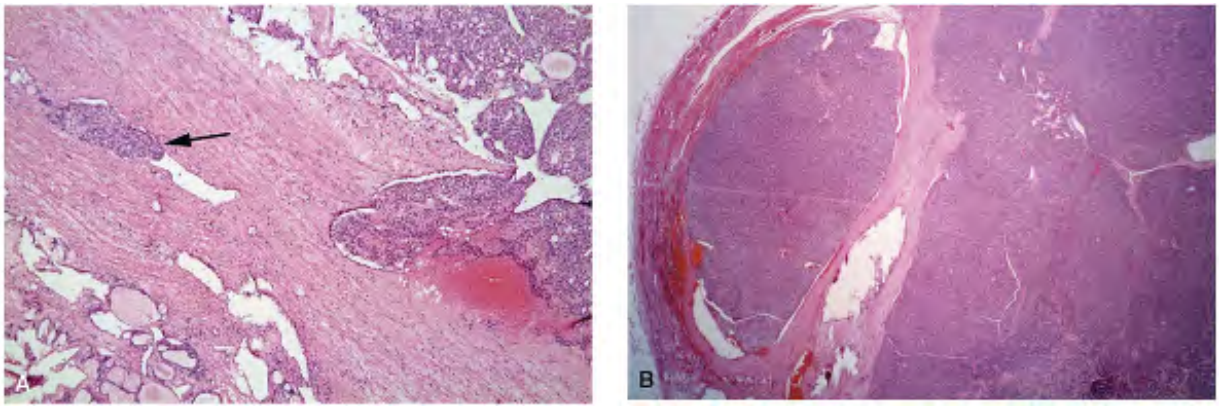

Figure 7.31. Follicular carcinoma. Vascular invasion. A. Tumor involving the small blood ves (arrow). There is capsular invasion as well. B. Follicular carcinoma with a larger blood vesse containing the tumor.

Wide Invasion of the Parenchyma

The tumor invades the capsule and invades the adjoining parenchyma widely (Fig. 7.32). Th tumor may form pushing nodules and incite fibrosis and should not be considered as separat nodules. Widely invasive tumors tend to be poorly differentiated.

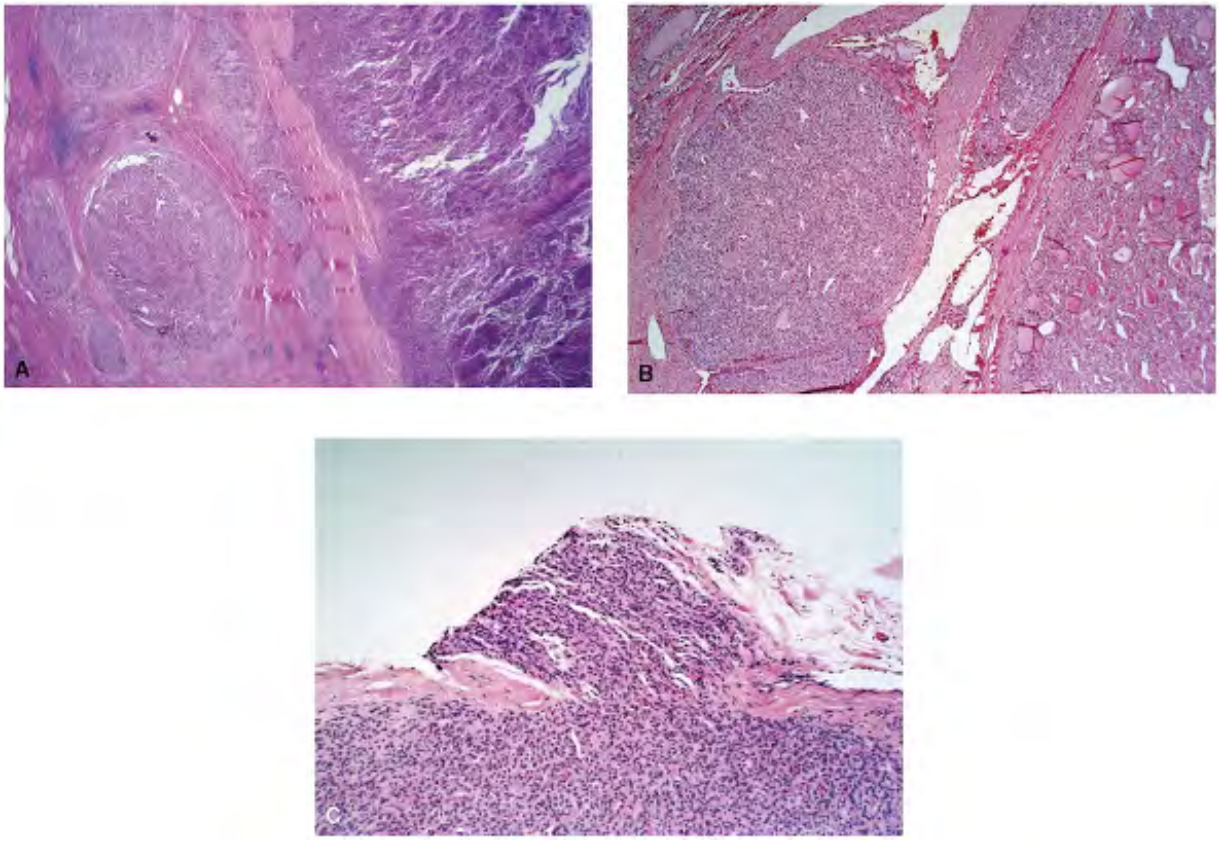

Figure 7.32. Follicular carcinomas with moderate to marked invasion. A, B. The carcinoma shows large islands of tumor outside the capsule, invading the thyroid parenchyma. C. The carcinoma has extended to the thyroid capsule and invaded the surrounding soft tissues.

Cytopathologic Features

The aspirates of follicular carcinomas present a spectrum of cytologic features (Table 7.8). one end of the spectrum, the cytologic pattern closely resembles that of cellular follicular adenomas. The other end of the spectrum represents poorly differentiated follicular carcinc where the neoplastic cells are clearly malignant. The cytologic recognition of well-different or low-grade follicular carcinomas may offer considerable difficulties because of the overla features with cellular adenomas. The poorly differentiated follicular carcinomas are readily identified.

Cellularity
Variable; usually high

Presentation

Cells mostly in syncytial tissue fragments or in loosely cohesive groups; scant or absent colloid

Architecture of Tissue Fragments

With or without follicular pattern; follicles may be discrete, irregular, vary in size, and may contain small amount of colloid; trabeculae with or without branching and anastomosis; marked crowding and overlapping of nuclei

Cells

Poorly defined cell borders; N/C ratios favor the nucleus

Nucleus

Round, considerably increased in size; smooth nuclear membranes; coarsely granular chromatin; nucleoli, parachromatin clearing; grooves or inclusions absent; pleomorphic size and clearly malignant in poorly differentiated carcinomas

Cytoplasm

Usually scant; pale but may be dense

Colloid

Absent or scant

Background

Usually clean, may show necrosis in poorly differentiated carcinomas

TABLE 7.8 CYTOPATHOLOGIC FEATURES OF FOLLICULAR CARCINOMA

Well-Differentiated Follicular Carcinoma

The cytopathologic features of follicular carcinomas are usually not described separately fro follicular adenomas, although

there are certain features that suggest the strong possibility, an observation made by Lang a associates63 several years ago. Well-differentiated follicular carcinomas are usually minima invasive. Their aspirates tend to be generally very cellular, composed of varying-sized syncy type tissue fragments of follicular epithelium, with or without a follicular pattern. Nuclei ar very crowded and overlapped, and their density within a given tissue fragment is much grea than that seen

in follicular adenomas (Figs 7.33 , 7.34 , 7.35 , 7.36 , 7.37 , 7.38 , 7.39 , 7.40 , 7.41 and 7.4
The architecture of the follicles can be strikingly irregular (Fig. 7.33). The nuclei are
considerably increased in size, round to oval, and either uniform or pleomorphic. The nucle
size is an important parameter and can be judged against an intact red blood cell in the
background. The nuclear chromatin is coarsely granular with parachromatin clearing. Micro-
and/or macronucleoli are almost always present, and intranuclear inclusions are almost nev
seen, although Glant and associates64 reported one case in which they were present. The c
of follicular carcinoma

tend to have more cytoplasm than those of adenoma. Colloid is very rarely seen in the
background, but it may be present within the follicular lumina. The background is clean. Th
cytologic features of well-differentiated follicular carcinomas are illustrated in Figures 7.33
7.42.

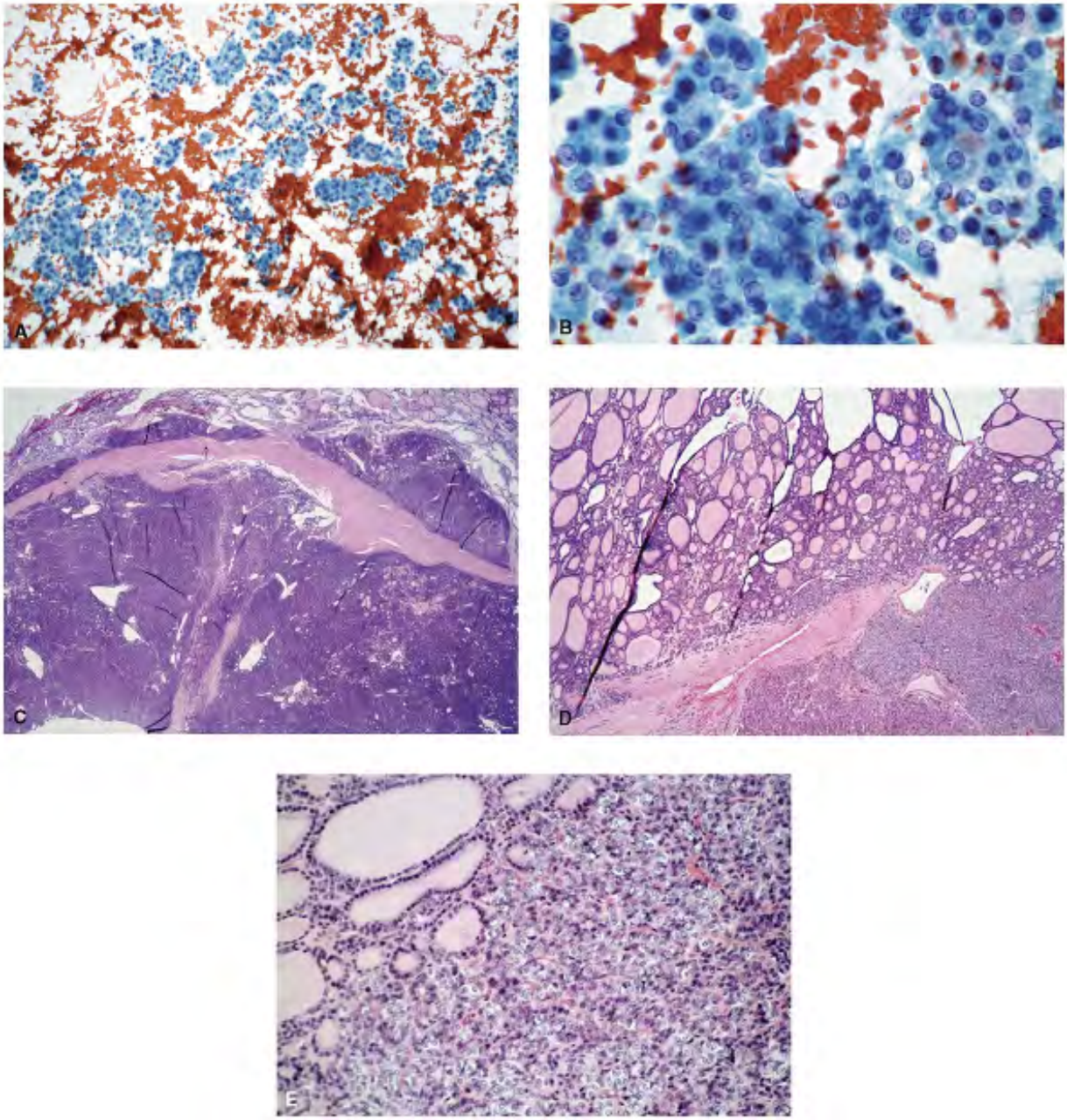

Figure 7.33. FNA of well-differentiated follicular carcinoma. A. Low power showing a hypercellular aspirate with several tissue fragments of follicular cells in a background that i clean and lacks colloid. B. Higher magnification showing syncytial tissue fragments of follicu cells with a follicular pattern. The nuclei are large, round, and vary in size. The chromatin i granular with micronucleoli, a feature that favors invasive characteristics. Thyroidectomy confirmed the diagnosis of follicular carcinoma. C. Follicular carcinoma showing invasion ou the capsule (low power). D. Higher magnification showing two patterns: a solid one on the r and the normofollicular one on the left. E. Higher magnification of the solid tumor.

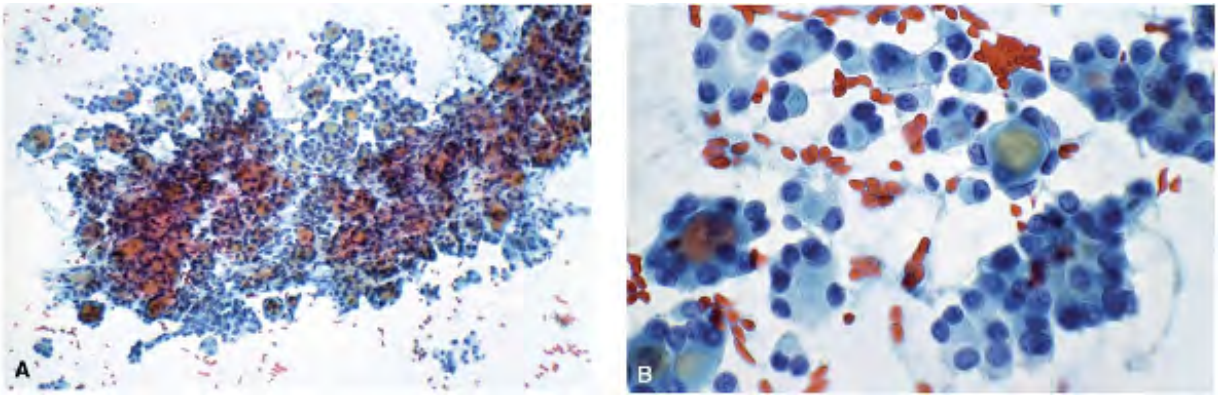

Figure 7.34. Well-differentiated follicular carcinoma. A. Low power of FNA showing a hypercellular aspirate with several tissue fragments in a background that is clean and lacks colloid. B. Higher magnification showing syncytial tissue fragments of follicular cells with follicular pattern. The cells are larger. Their nuclei are large, round, and vary in size. The chromatin is granular with micronucleoli, a feature that favors invasive characteristics. Thyroidectomy confirmed the diagnosis of follicular carcinoma

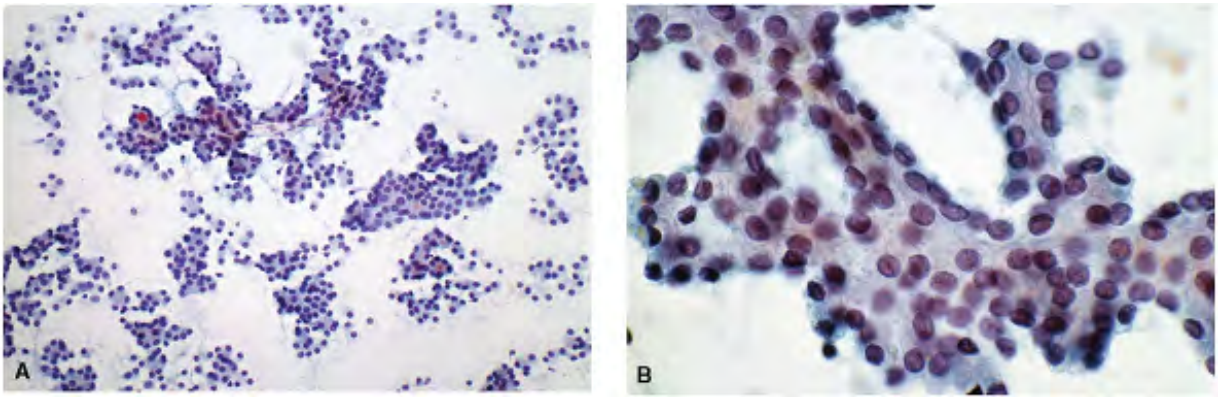

Figure 7.35. Well-differentiated follicular carcinoma. A. Low power depicting a cellular aspirate. B. Higher magnification showing anastomosing trabeculae of follicular cells with syncytial arrangement. The nuclei are enlarged with granular chromatin and contain nucleol colloid is present in the background. The cytologic diagnosis of follicular carcinoma was confirmed on histology.

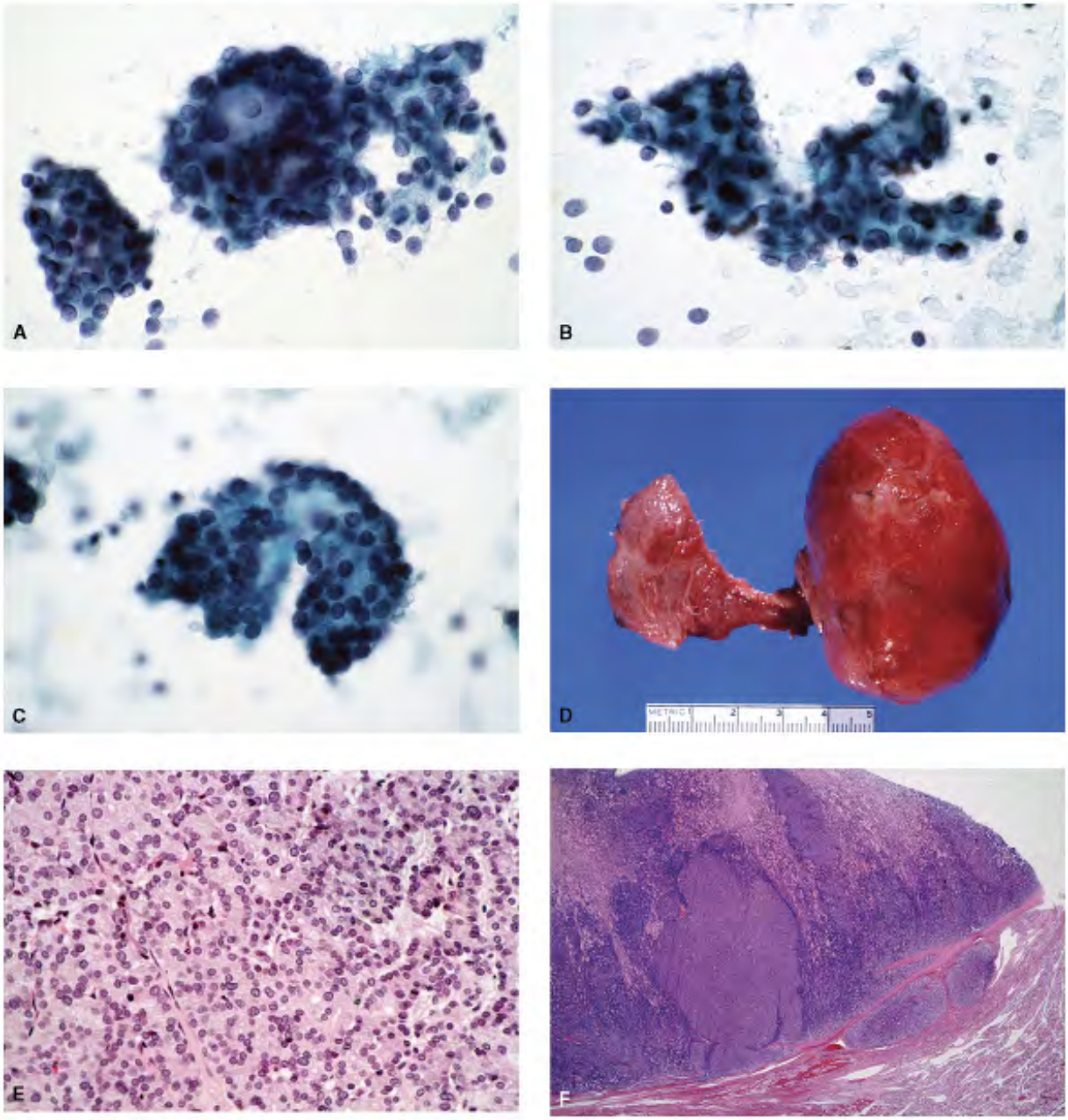

Figure 7.36. Well-differentiated follicular carcinoma. Aâ€“C. These three images show syn
tissue fragments with extreme crowding and overlapping of moderately enlarged nuclei. Bo
follicular and trabecular patterns are seen. The nuclear chromatin is coarsely granular and
staining. Nucleoli are occasionally seen. The cytologic diagnosis of follicular carcinoma was
confirmed on thyroidectomy. D. The resected thyroid showing a large left lobe completely
replaced by the tumor. E. Histologic section of the carcinoma. F. The carcinoma has invade
capsule and beyond.

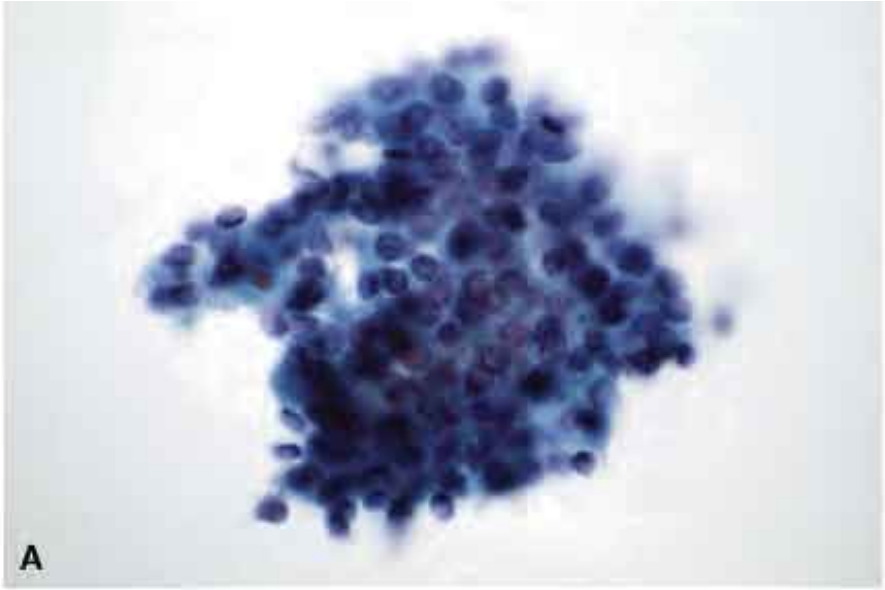
A

B

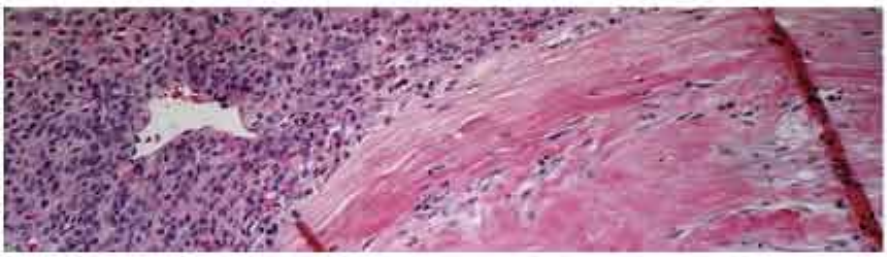

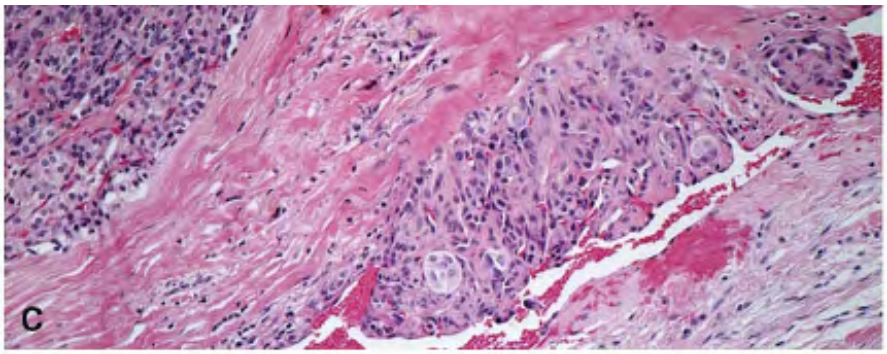

Figure 7.37. Well-differentiated follicular carcinoma. A, B. FNA showing syncytial tissue fragments of follicular cells with extreme crowding and overlapping of enlarged nuclei, pleomorphic in size. The nuclei are hyperchromatic with coarsely granular chromatin. The cytologic diagnosis of follicular carcinoma was confirmed at surgery. C. Histologic section of carcinoma showing vascular invasion.

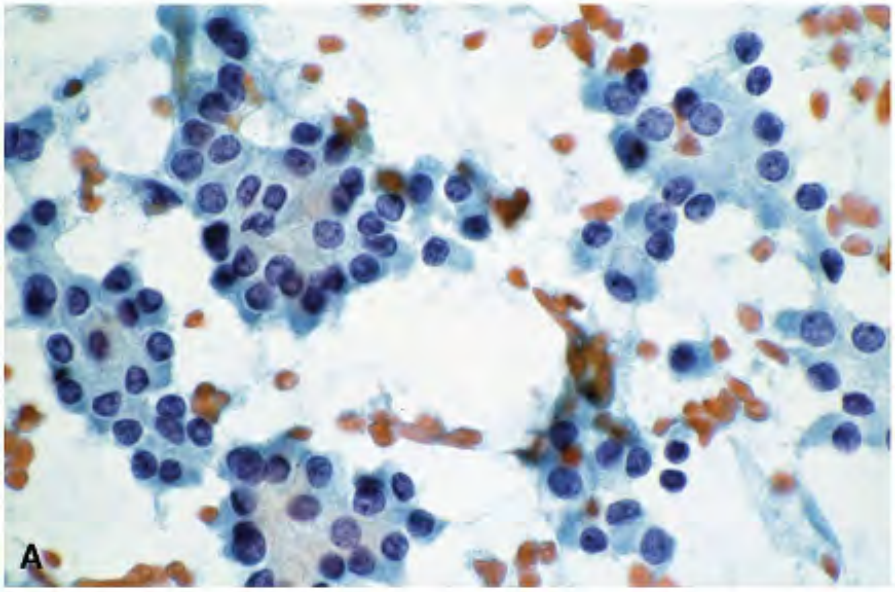

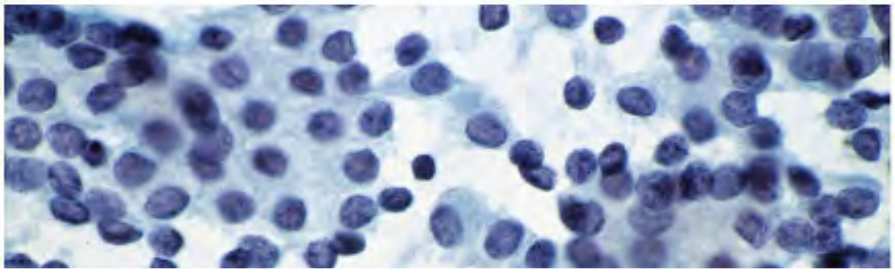

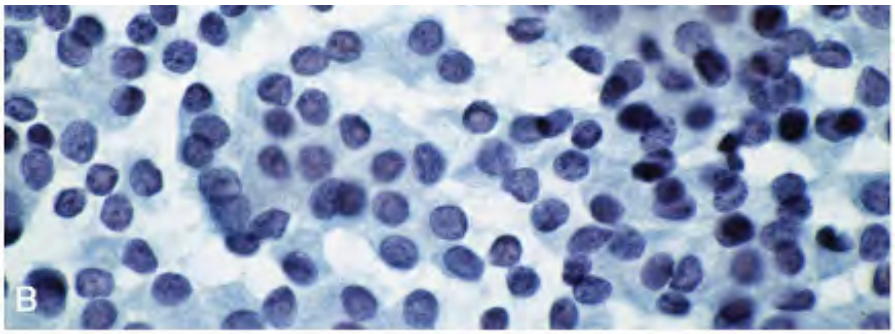

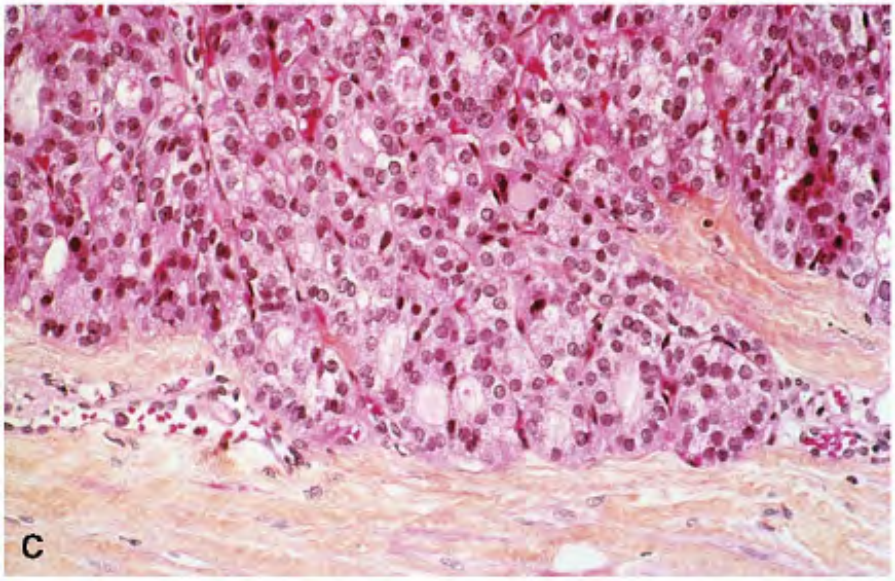

Figure 7.38. Well-differentiated follicular carcinoma. A, B. The aspirate is cellular, consisti syncytial tissue fragments of follicular cells with a follicular pattern. The nuclei are mildly enlarged, uniform, and with granular chromatin. No nucleoli are seen. The background is cl The cytologic diagnosis was cellular follicular adenoma. However, thyroidectomy revealed a follicular carcinoma with capsular invasion. C. Histologic section. This extent of invasion ma not be acceptable to some pathologists as enough evidence to justify a malignant diagnosis. that case, there will be a concordance between cytologic and histologic diagnoses.

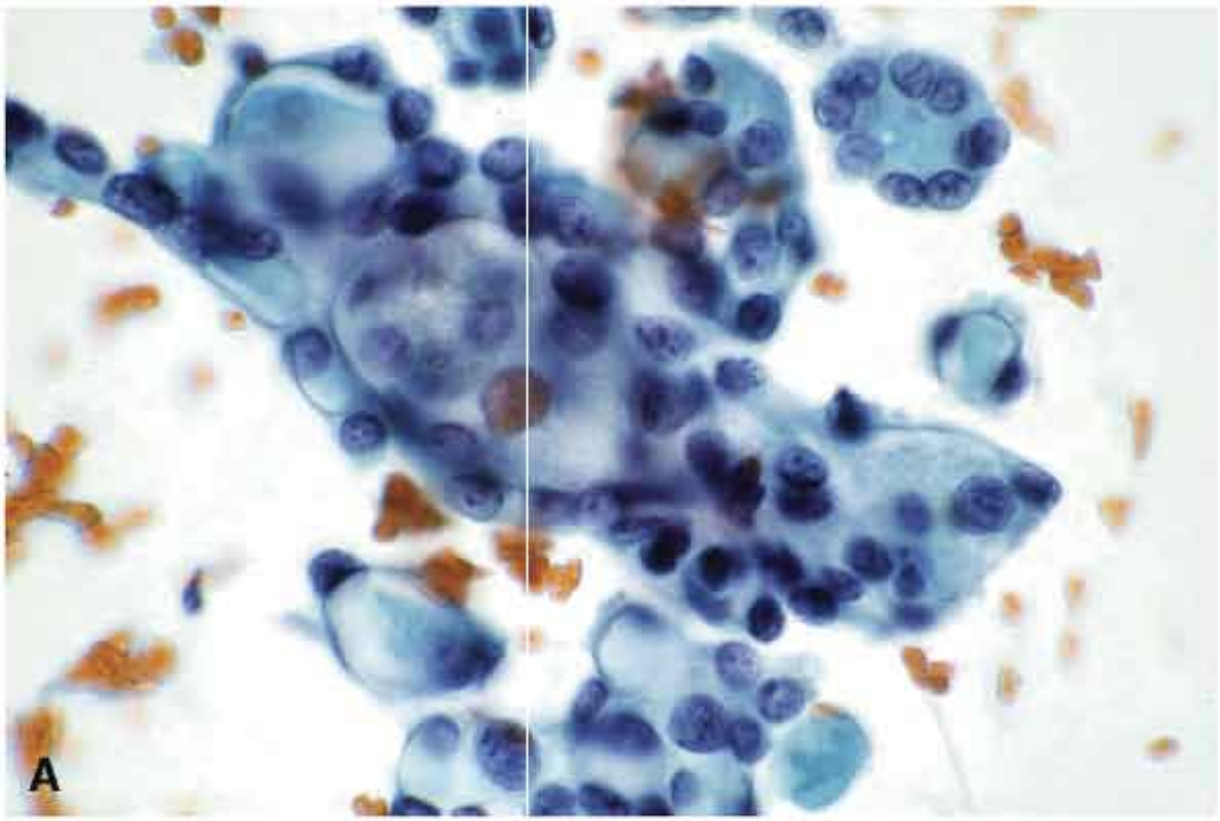
A

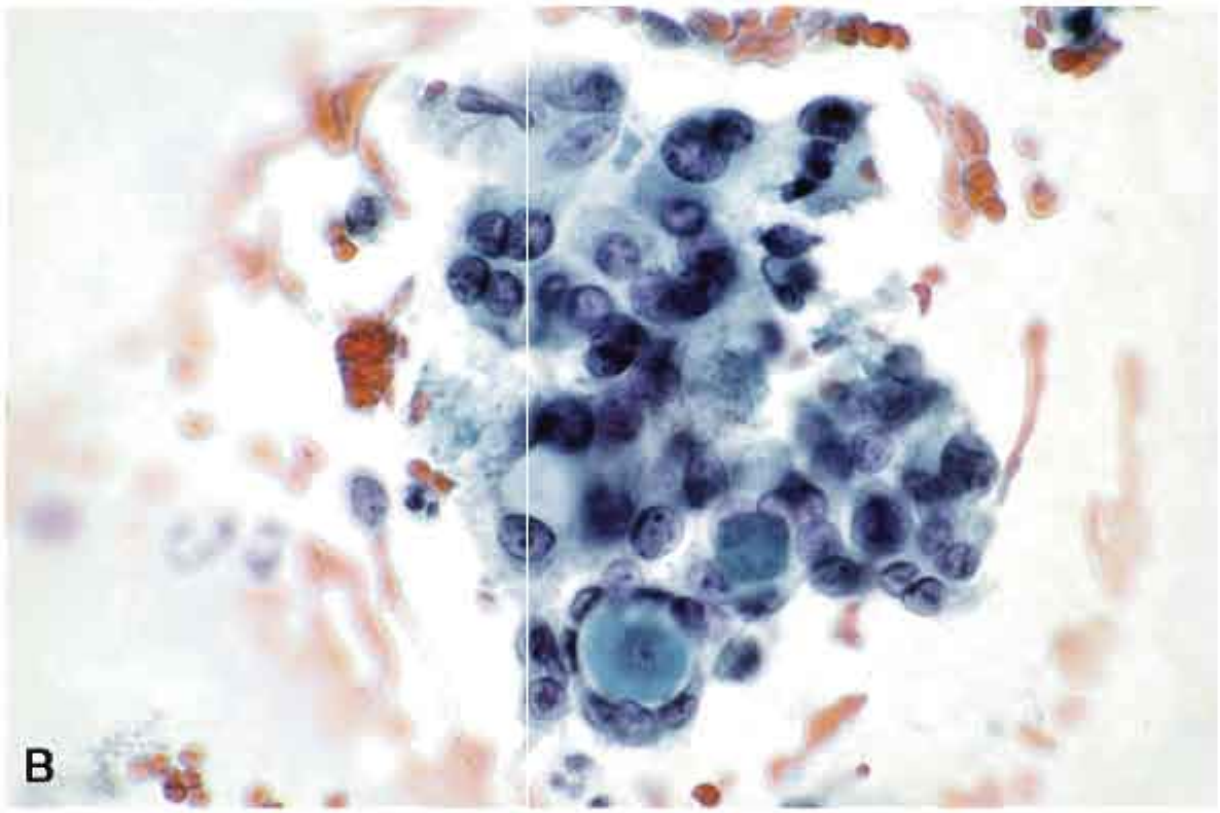
B

Figure 7.39. Well-differentiated follicular carcinoma. Syncytial architecture, follicular patt irregular follicles, large nuclei, pleomorphic in size, coarse chromatin with nucleoli, as depi here, are the cytologic features that favor the diagnosis of follicular carcinoma.

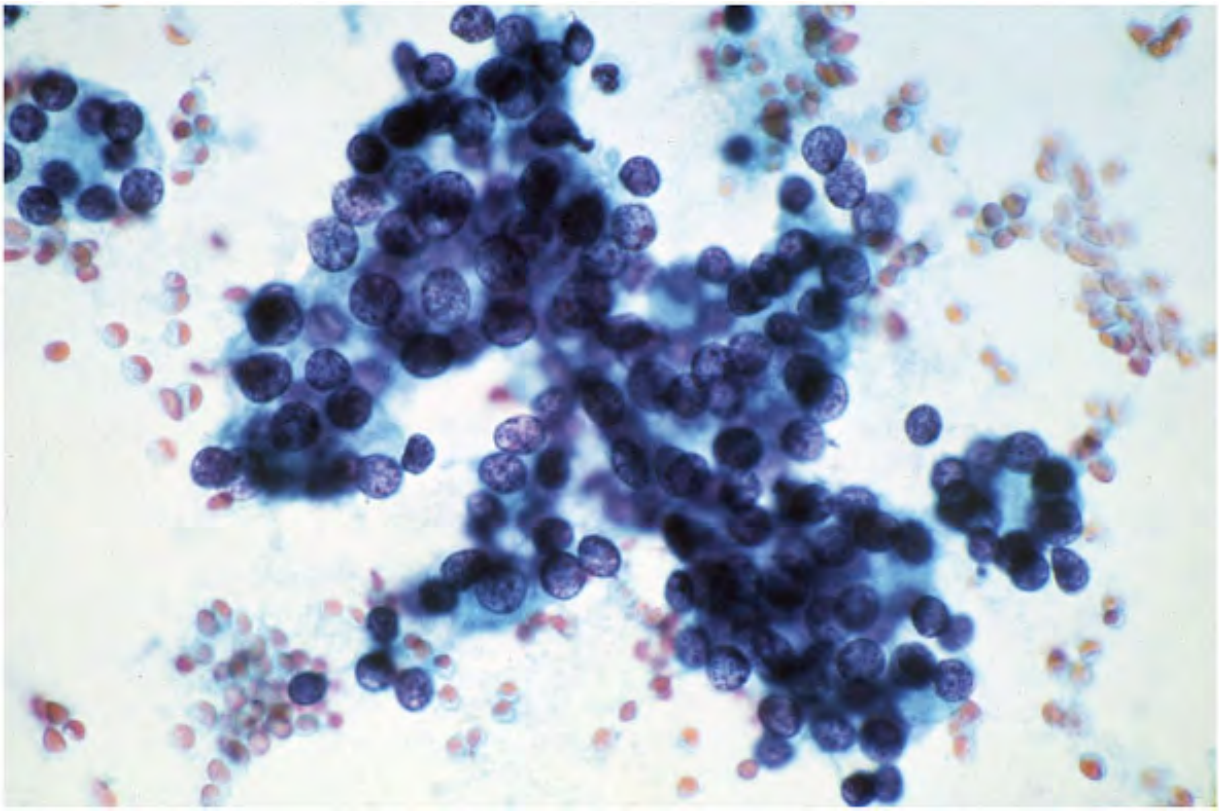

Figure 7.40. FNA of a follicular carcinoma. Syncytial architecture, extreme crowding and overlapping of enlarged nuclei, coarsely granular chromatin with parachromatin clearing, ar nucleoli are diagnostic of follicular carcinoma. Such extreme crowding of nuclei is generally seen in adenomas. Note the discrete follicles in the background. They are irregular with ext crowding of nuclei.

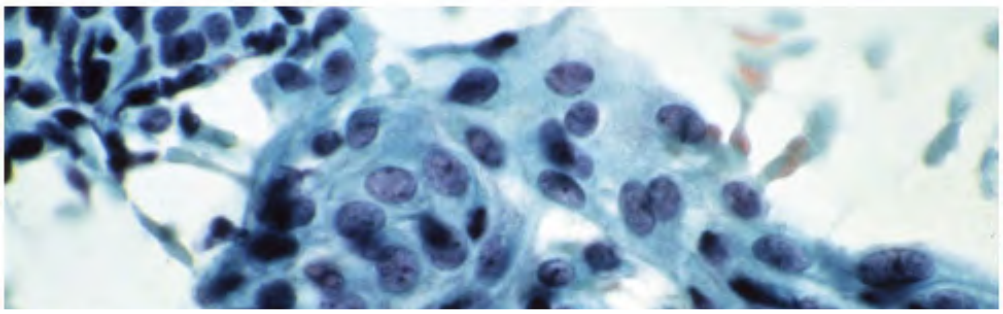

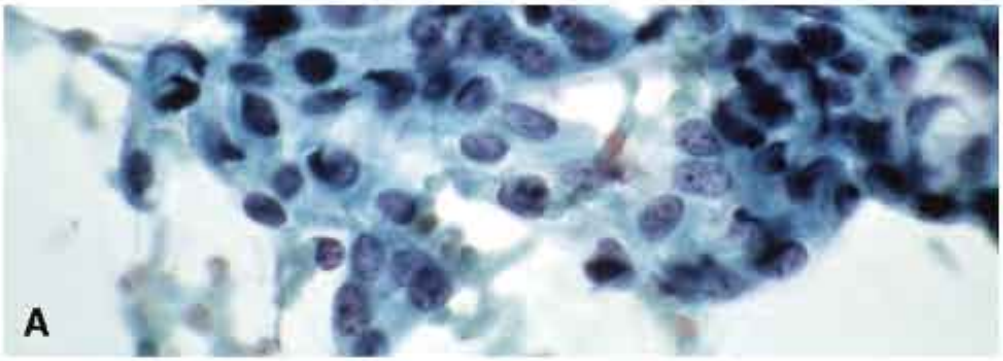
A

B

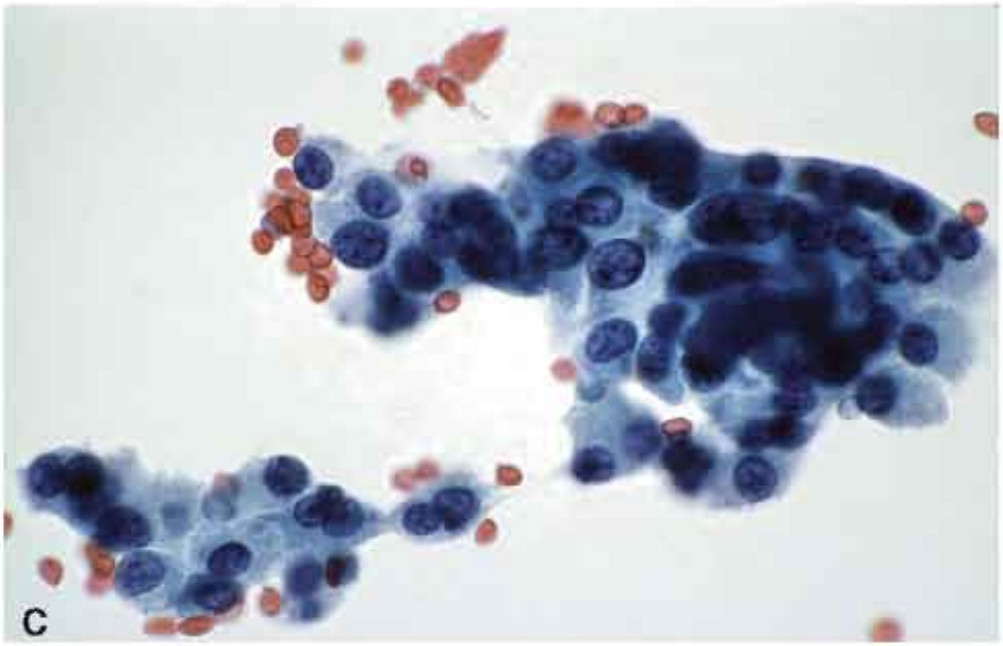
C

Figure 7.41. FNA of a follicular carcinoma showing syncytial tissue fragments with and with follicular pattern. The cells and their nuclei are pleomorphic, hyperchromatic, and contain nucleoli.

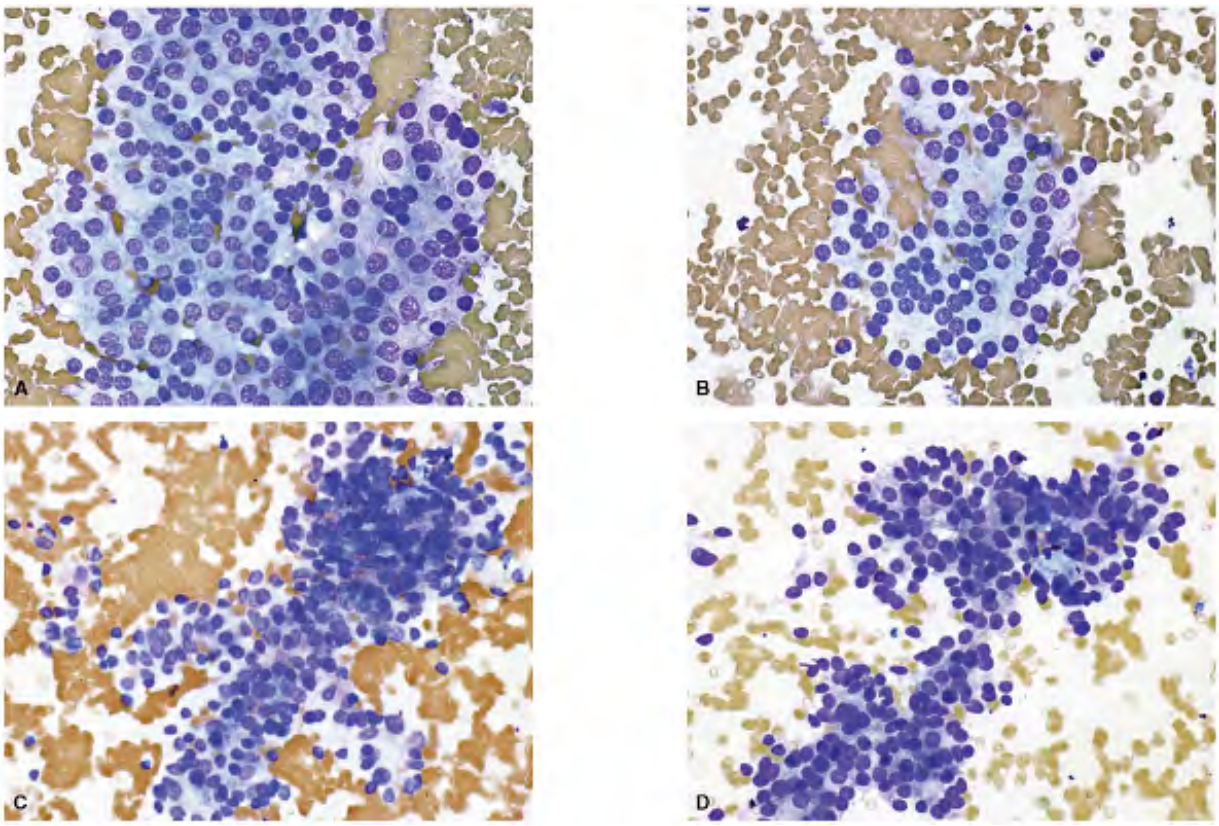

Figure 7.42. A till D. FNA of a follicular carcinoma (Diff-Quik preparation). Nuclear morphol is not as clear in Romanowsky-stained preparations as with Papanicolaou stain. (Courtesy of Mariza de Peralta-Venturina, MD, William Beaumont Hospital, Royal Oak, Michigan.)

The cytopathologic features of well-differentiated follicular carcinomas overlap with those o follicular adenomas, proliferating follicular nodules from Hashimoto's thyroiditis, and the follicular variant of papillary carcinoma (see "Differential Diagnosis of Follicular Lesions and Diagnostic Accuracy" later in the chapter, and Figs. 7.49 , 7.50 , 7.51 , 7.52 , 7.53 and 7.54 They may also overlap morphologically with medullary carcinoma8 , 65 and parathyroid adenoma.8

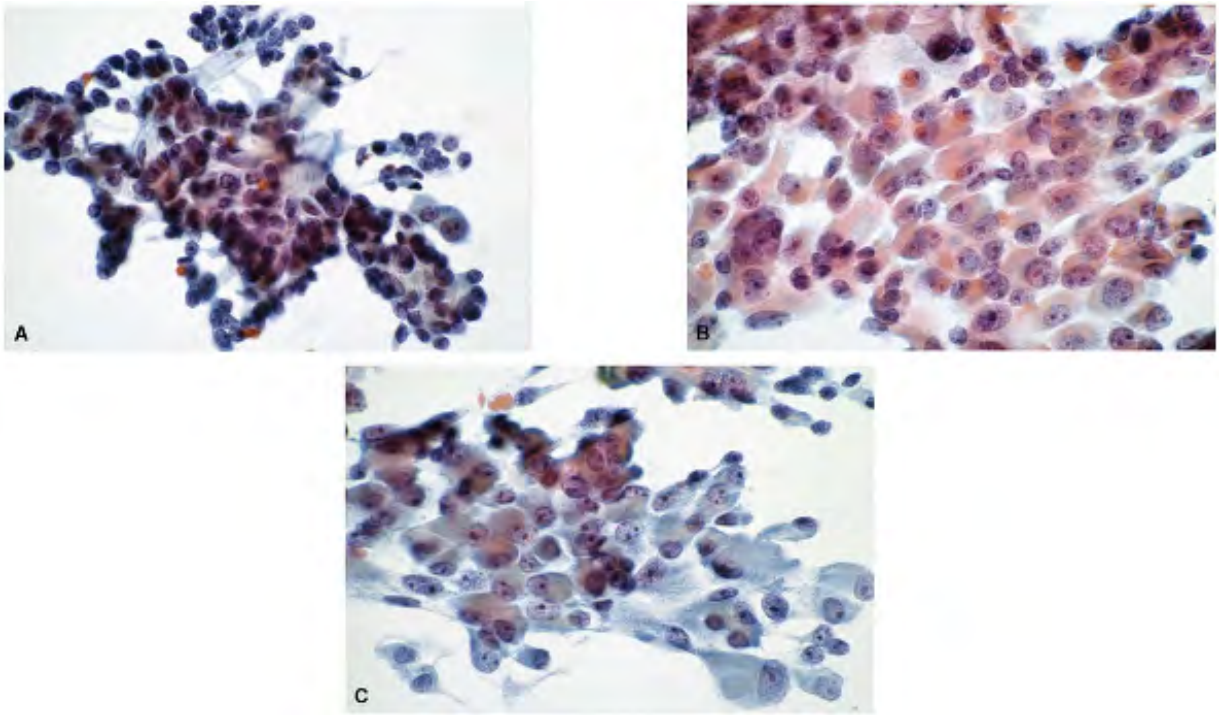

Figure 7.43. Aâ€“C. Poorly differentiated follicular carcinoma. FNA showing syncytial tissue fragments of clearly malignant follicular cells. Follicular pattern is evident. The nuclei conta granular chromatin with parachromatin clearing and prominent nucleoli. The thyroidectomy showed a widely invasive follicular carcinoma.

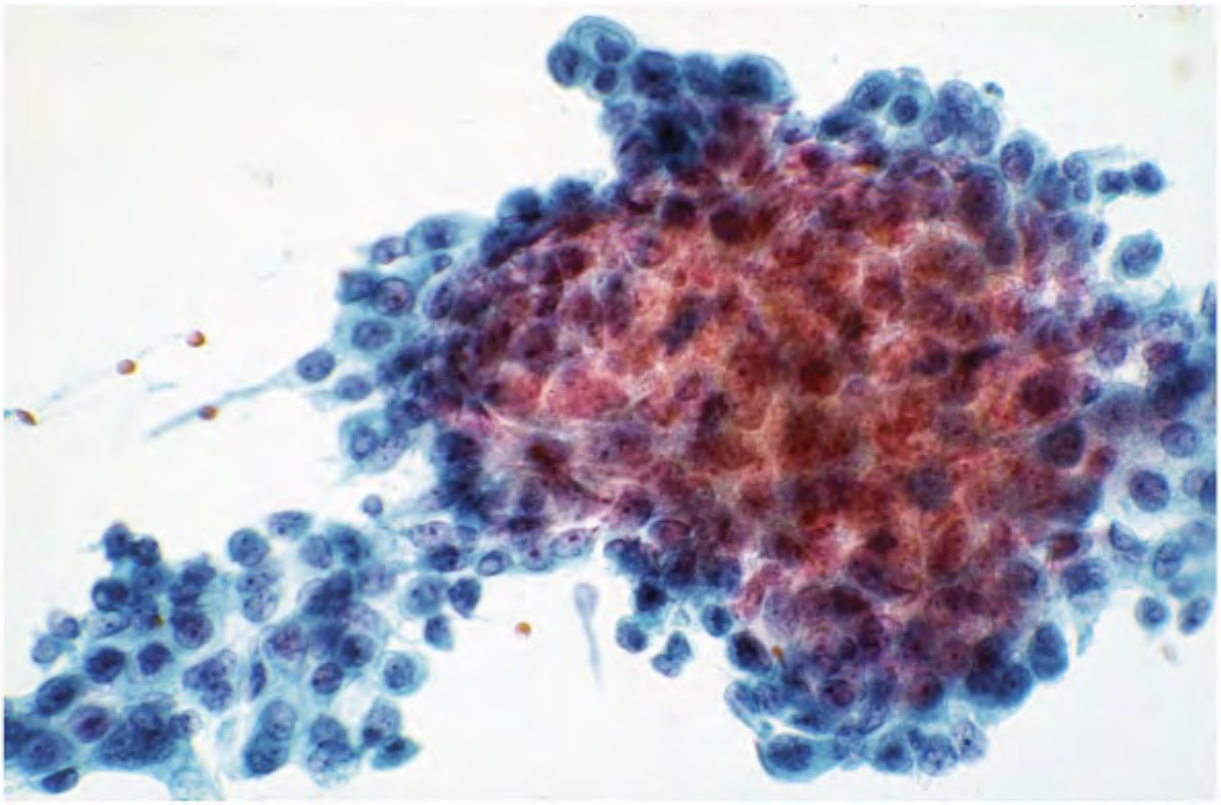

Figure 7.44. FNA of a poorly differentiated follicular carcinoma demonstrating syncytial tiss fragments of follicular cells without any architectural pattern. The malignant cell nuclei are pleomorphic, hyperchromatic, and contain nucleoli.

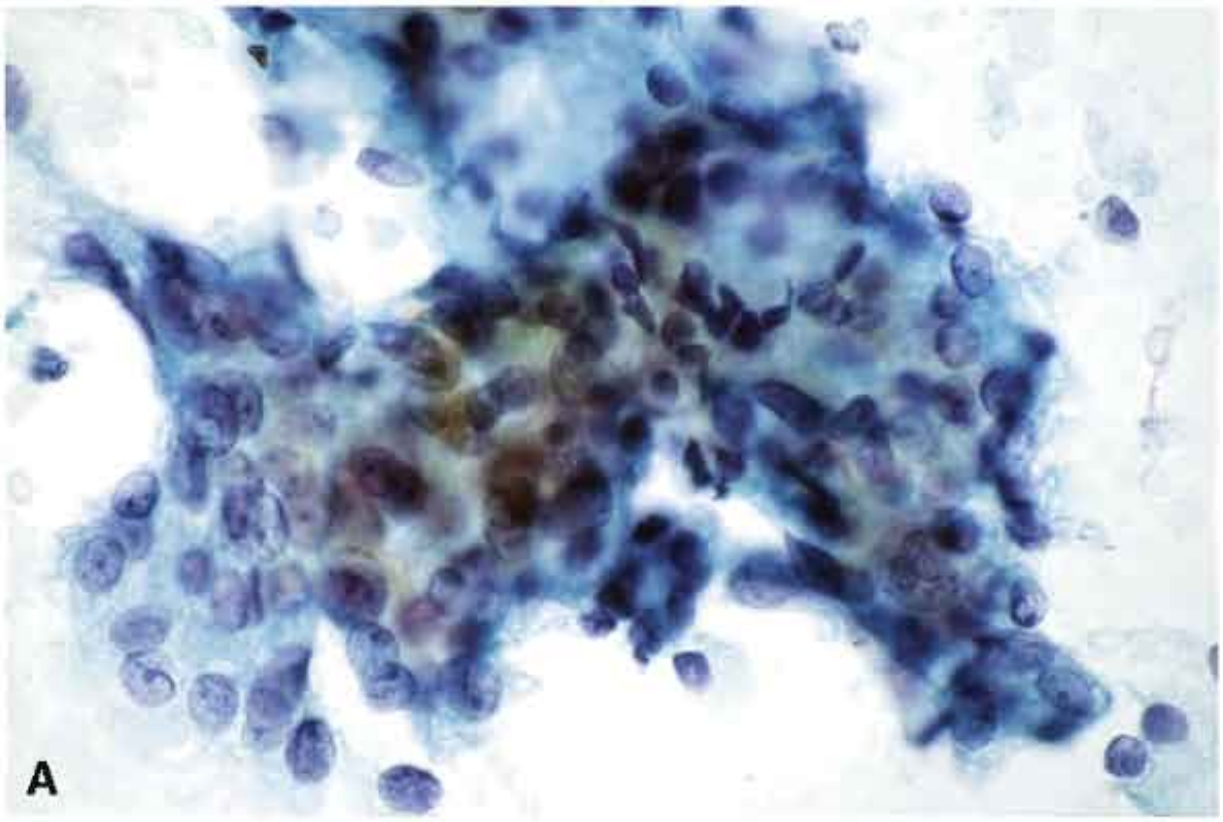
A

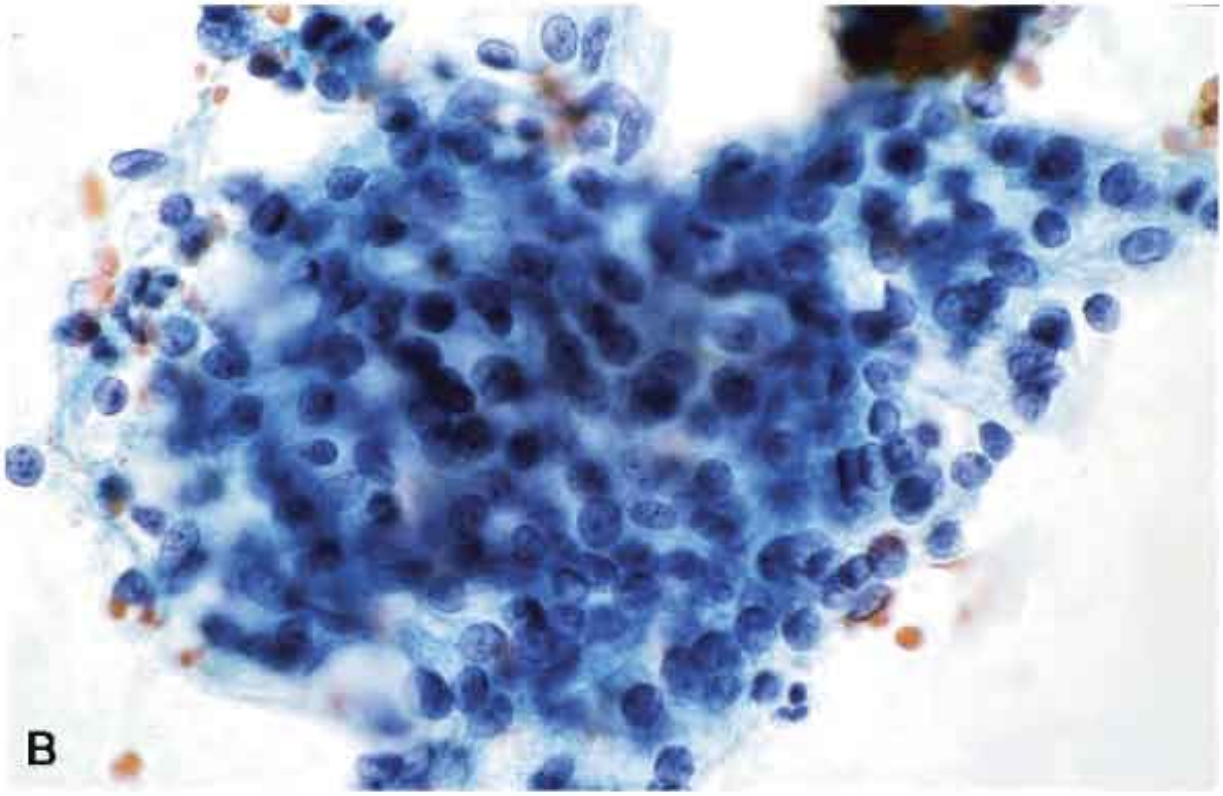
B

Figure 7.45. A and B. FNA of a poorly differentiated follicular carcinoma showing syncytial tissue fragments of follicular cells with and without a follicular pattern. The nuclei are enla hyperchromatic, pleomorphic, and contain nucleoli. The small cell size may represent an in: component.

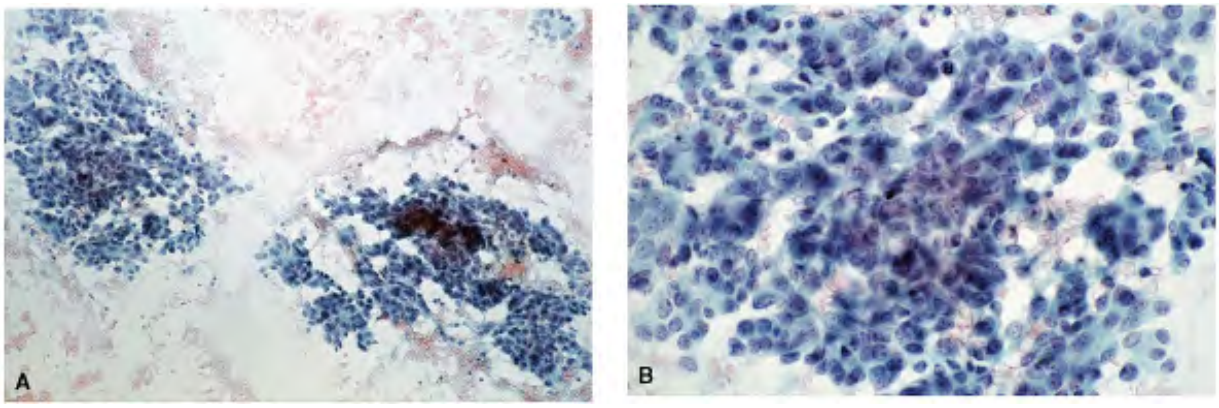

Figure 7.46. Poorly differentiated follicular carcinoma. A. FNA yielded an overwhelmingly cellular sample with syncytial tissue fragments. The background is clean and lacks colloid. L power. B. Medium power to show the pleomorphic malignant cells.

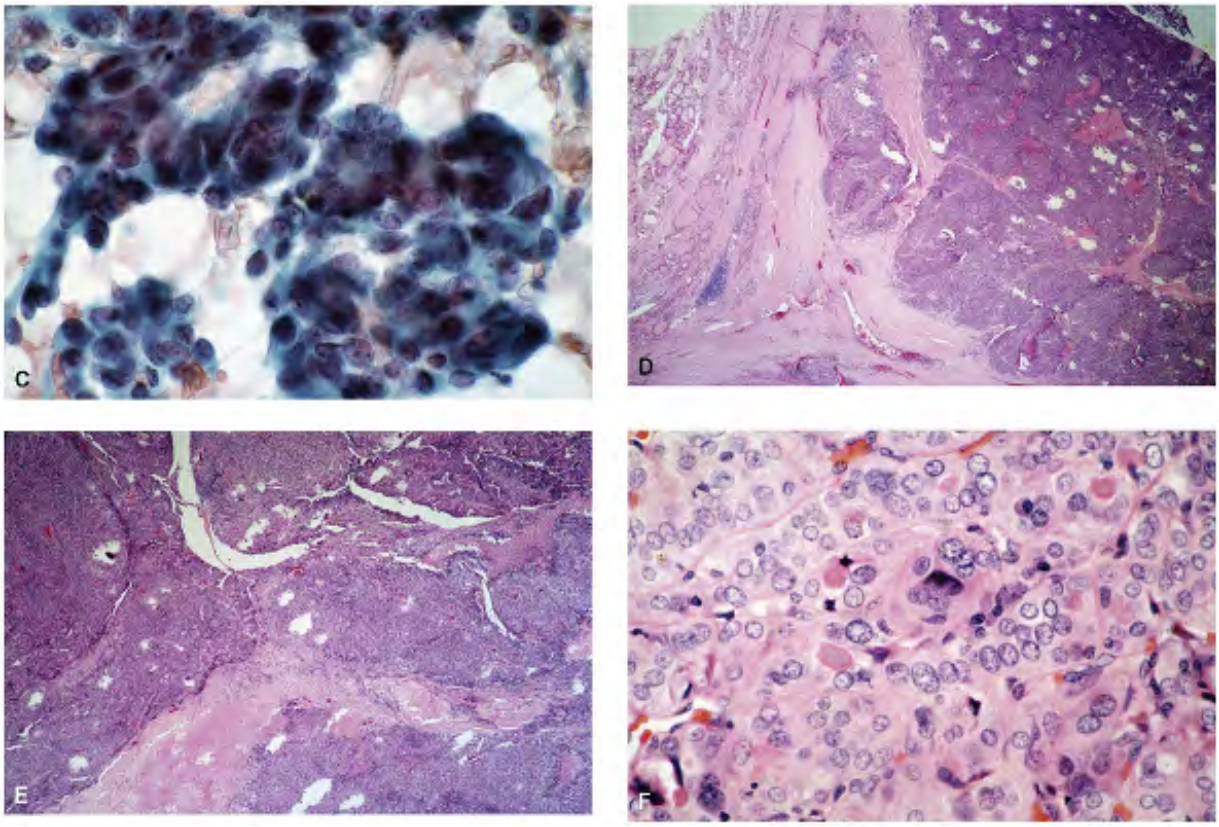

Figure 7.46. C. Higher magnification depicting clearly malignant cells forming syncytia with follicular pattern. Thyroidectomy confirmed a follicular carcinoma, which was widely infiltr the adjacent parenchyma. D, E. Histologic section showing marked invasion. F. Higher magnification of the poorly differentiated carcinoma.

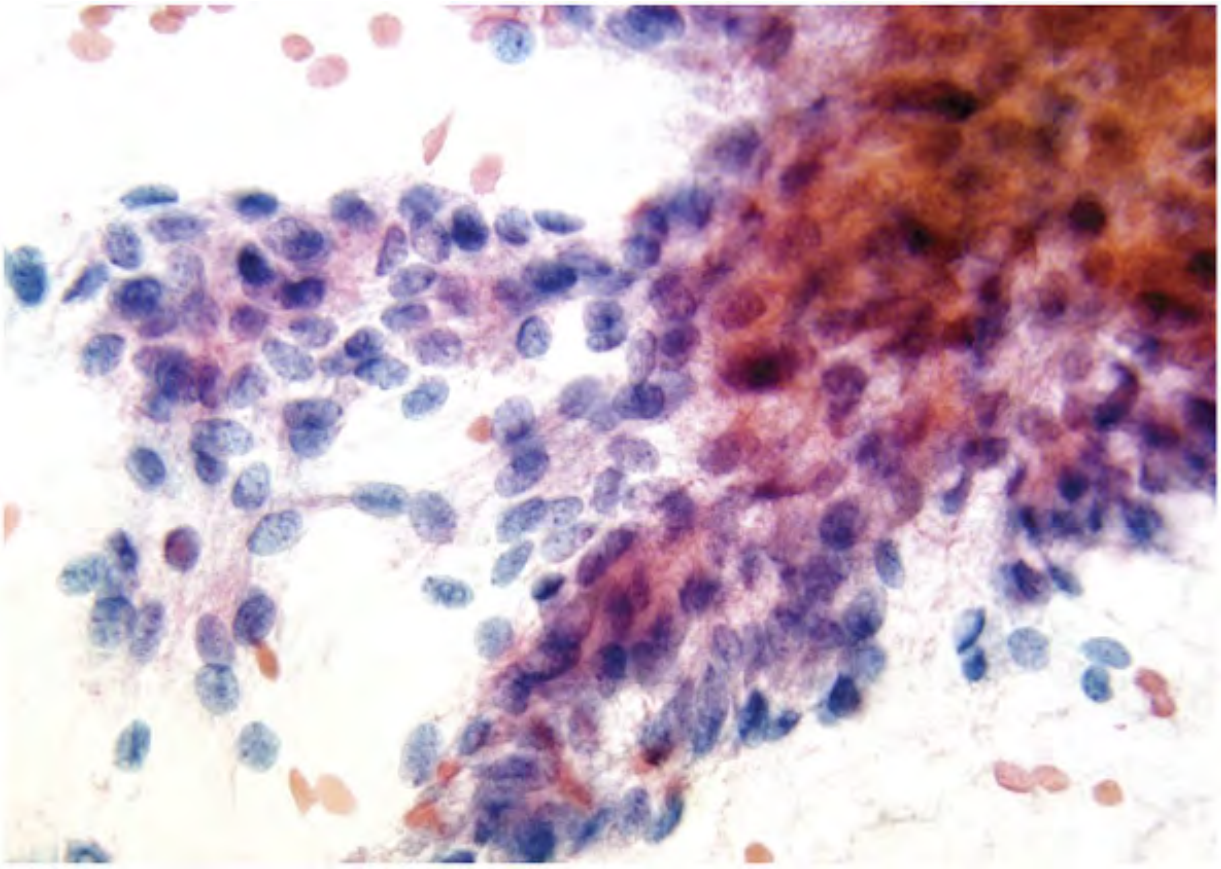

Figure 7.47. FNA of a poorly differentiated follicular carcinoma. The malignant cells are pleomorphic and enlarged, containing granular chromatin and nucleoli. The tissue fragment syncytial with no architectural pattern.

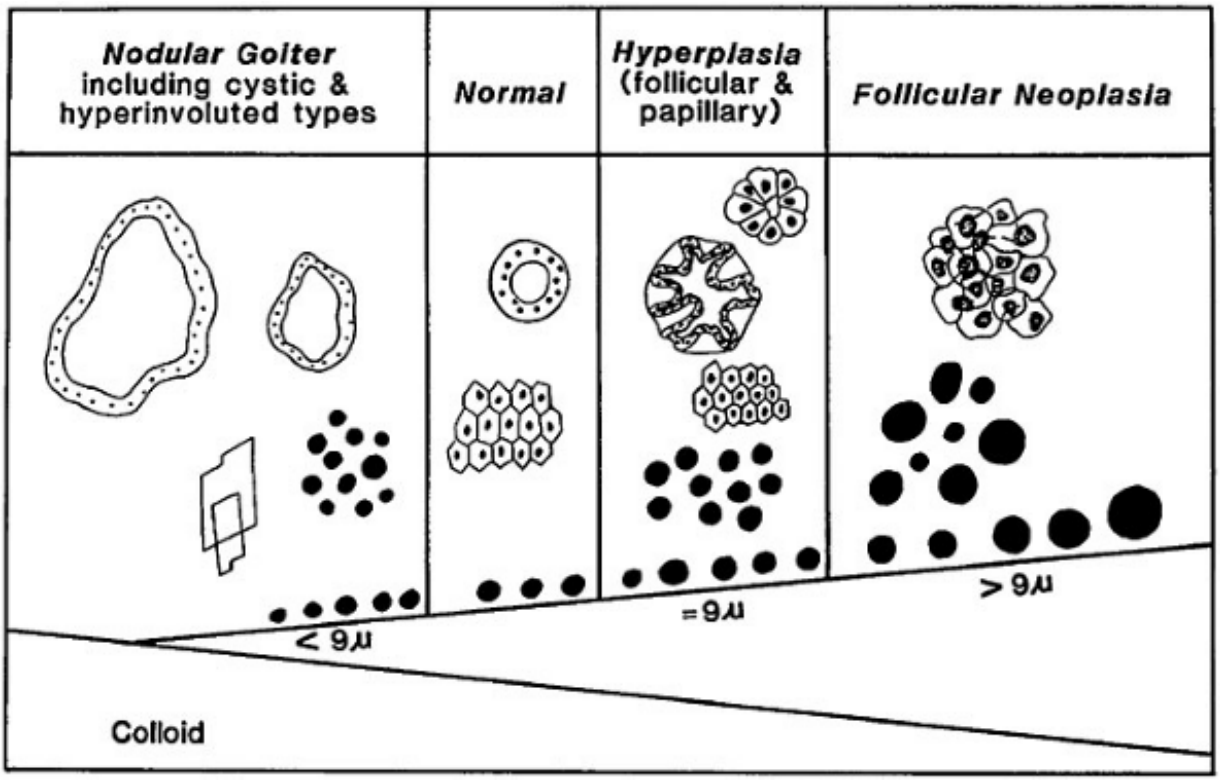

Figure 7.48. A spectrum of follicular nuclear size and amount of colloid in follicular lesions the thyroid. (Modified from Cervino JM, Paseyro P, Grosso O, et al. La exploracion citologica la glandula tirodes y sus correlaciones anatomoclinicas. An Facultad Medicina. 1962;47:128â€“143.)

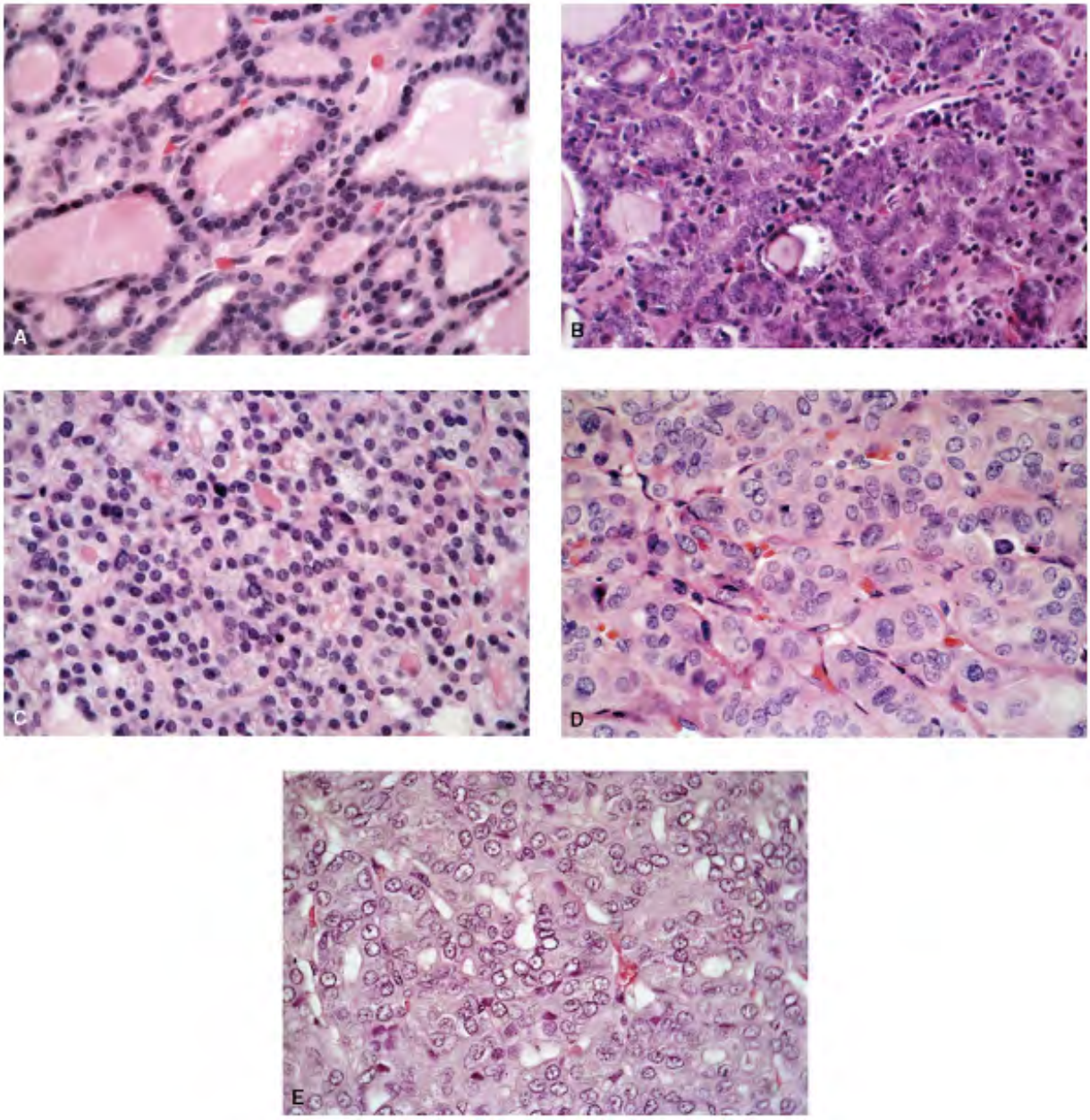

Figure 7.49. Differential diagnosis of follicular lesions. Histologic sections of follicular lesio (follicular-patterned). The common denominator here is the follicular growth pattern of follicular-derived cells. A. Nodular goiter. B. Follicular nodule in the background of Hashim thyroiditis. Note lymphoid cell infiltrate. C. Microfollicular adenoma. D. Follicular carcinom Follicular variant of papillary carcinoma.

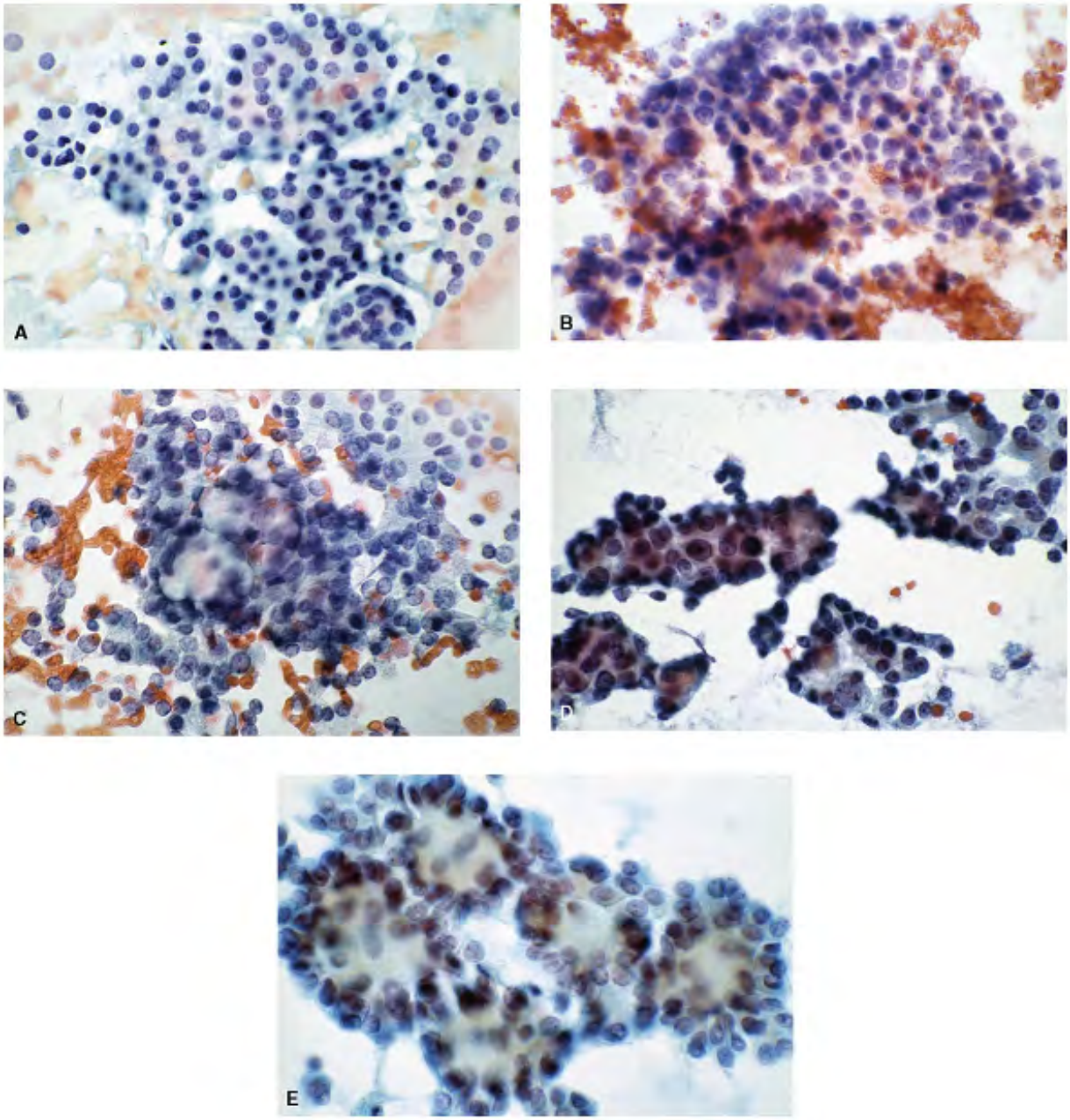

Figure 7.50. Differential diagnosis of follicular lesions. Cytologic features of follicular lesior (follicular-patterned). The common denominators here are: the follicular growth pattern, la colloid and hypercellularity. A. Nodular goiter. The follicular cells are small, forming honeyc sheets and regular follicles with evenly spaced small uniform nuclei, containing compact to finely granular chromatin. B. Follicular nodule in Hashimoto's thyroiditis. The tissue fragmer syncytial in architecture and resembles that of cellular follicular adenoma. Without lymphoc in the background, this will be interpreted as a follicular adenoma. C. Cellular follicular adenoma with syncytial tissue fragments of follicular cells, crowded, overlapped, uniformly

enlarged nuclei. Their chromatin is granular and evenly distributed. There are no nucleoli. D
Follicular carcinoma. Syncytial tissue fragments of clearly malignant cells. Note the follicula
pattern. E. Follicular variant of papillary carcinoma. The syncytial tissue fragments show a
follicular pattern. The component cells contain enlarged nuclei with pale, powdery chromat
micronucleoli, grooves, and inclusions, diagnostic of papillary carcinoma.

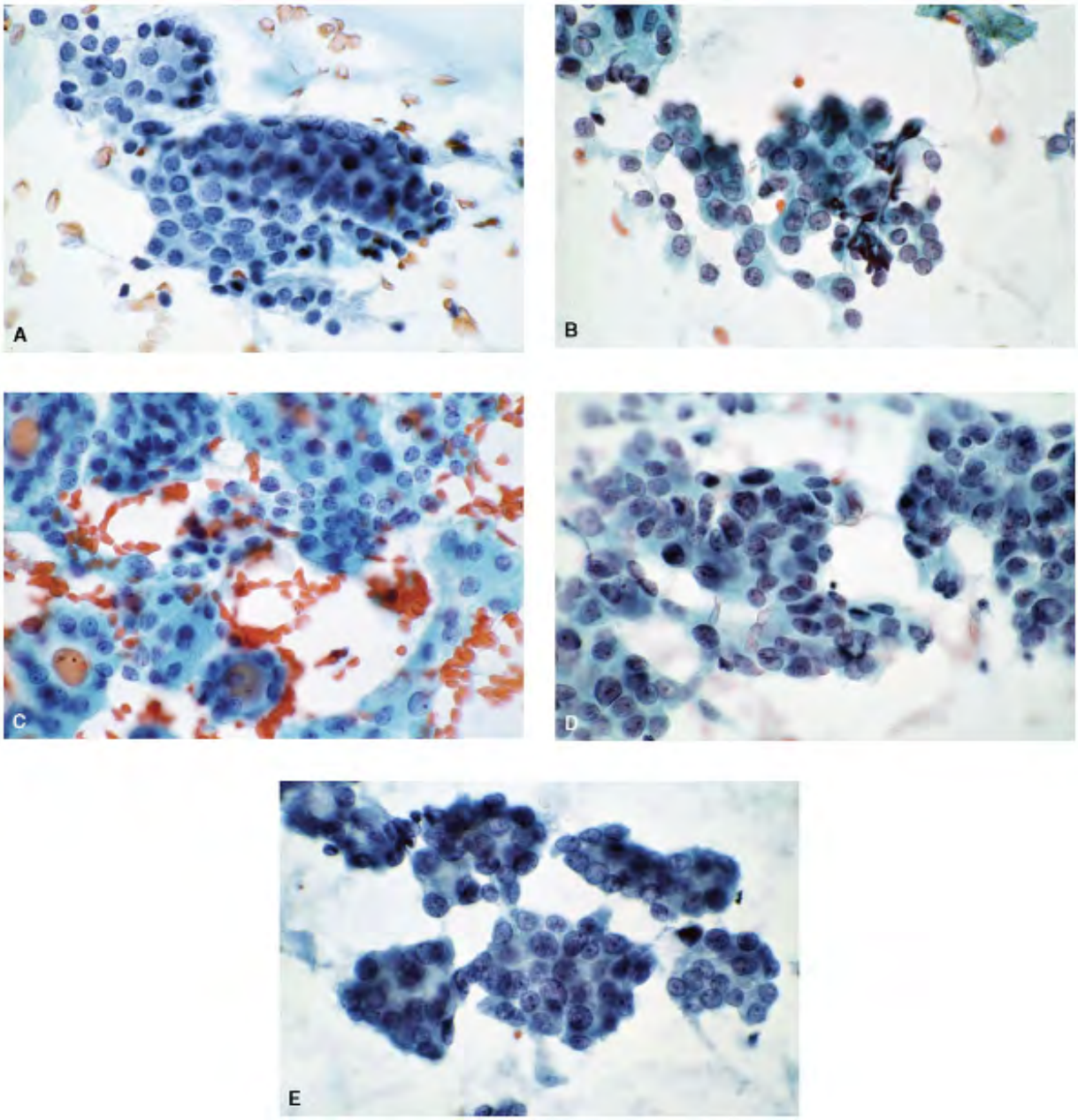

Figure 7.51. Differential diagnosis of follicular lesions. Cytologic features of follicular lesior

(follicular-patterned). The common denominators here are: the follicular growth pattern, la colloid and hypercellularity. A. Nodular goiter. The follicular cells are small, forming honeyc sheets and regular follicles with evenly spaced small uniform nuclei, containing compact to finely granular chromatin. B. Follicular nodule in Hashimoto's thyroiditis. The tissue fragmer syncytial in architecture and resembles that of cellular follicular adenoma. Note a few stretched-out lymphocytes that may serve as a clue for the diagnosis of Hashimoto's thyroidi C. Cellular follicular adenoma with syncytial tissue fragments of follicular cells, crowded, overlapped uniformly enlarged nuclei. Their chromatin is granular and evenly distributed. T are no nucleoli. D. Follicular carcinoma. Syncytial tissue fragments of clearly malignant cell Note the follicular pattern. E. Follicular variant of papillary carcinoma. The syncytial tissue fragments show a follicular pattern. The component cells contain enlarged nuclei with pale, powdery chromatin, micronucleoli, and grooves. Inclusions are not identified. This pattern i highly suggestive of papillary carcinoma.

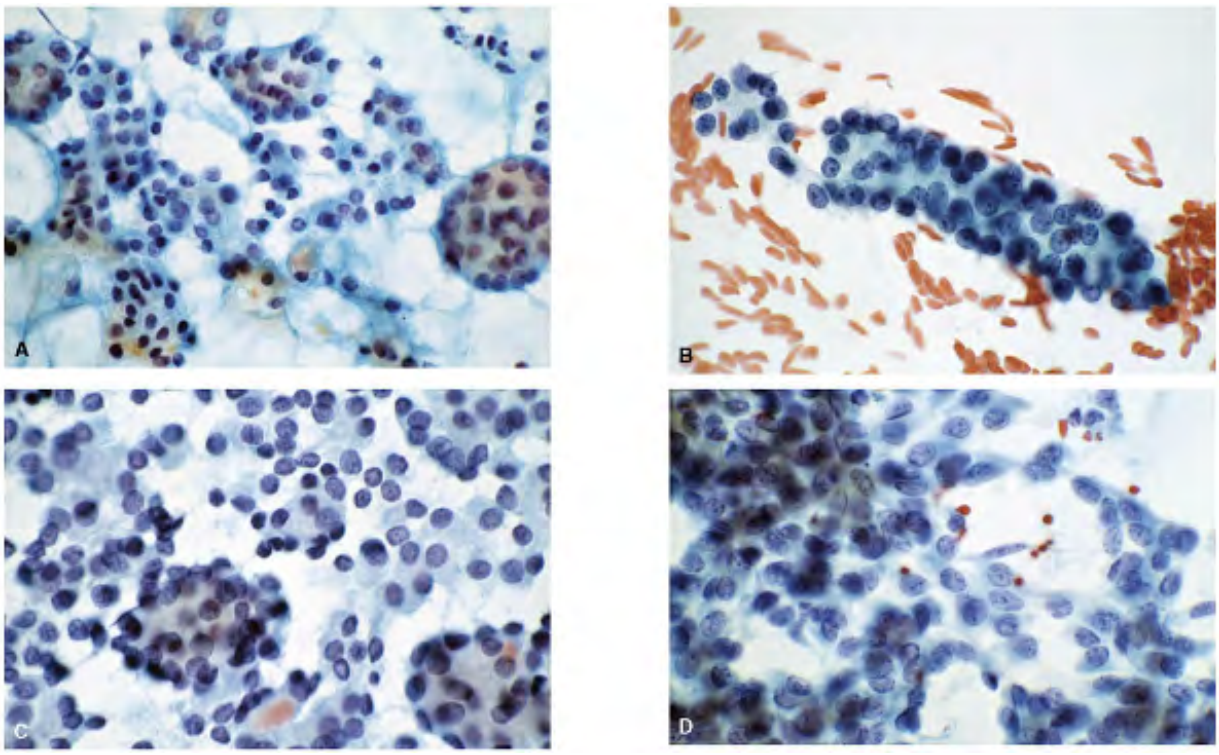

Figure 7.52. Differential diagnosis of follicular lesions. Cytologic features of follicular lesior (follicular-patterned). A. Nodular goiter. B. Cellular follicular adenoma. C. Follicular carcin D. Follicular variant of papillary carcinoma. Features that separate nodular goiter from the remaining three include lack of syncytial architecture and small uniform nuclei. All the thre

neoplasms depicted here, in B, C, and D, demonstrate syncytial architecture. Carcinoma ce
C contain nucleoli. D. The follicular cell nuclei here demonstrate features of papillary
carcinoma.

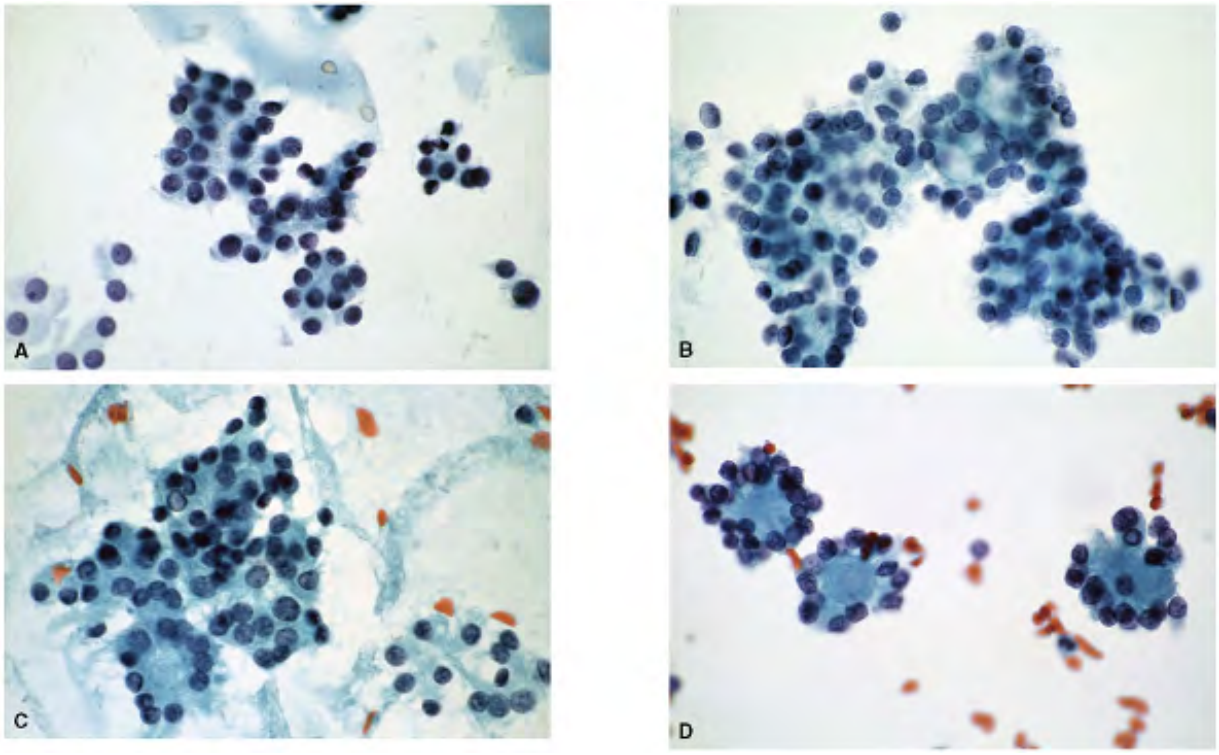

Figure 7.53. Differential diagnosis of follicular lesions. Cytologic features of follicular lesior
(follicular-patterned). A. Nodular goiter. B. Cellular follicular adenoma. C. Follicular carcin
D. Follicular variant of papillary carcinoma. All four lesions demonstrate a microfollicular
pattern. The presence of microfollicles by themselves is not indicative of a follicular neopla
unless the follicles are irregular; demonstrate crowded and overlapped nuclei, and syncytial
architecture.

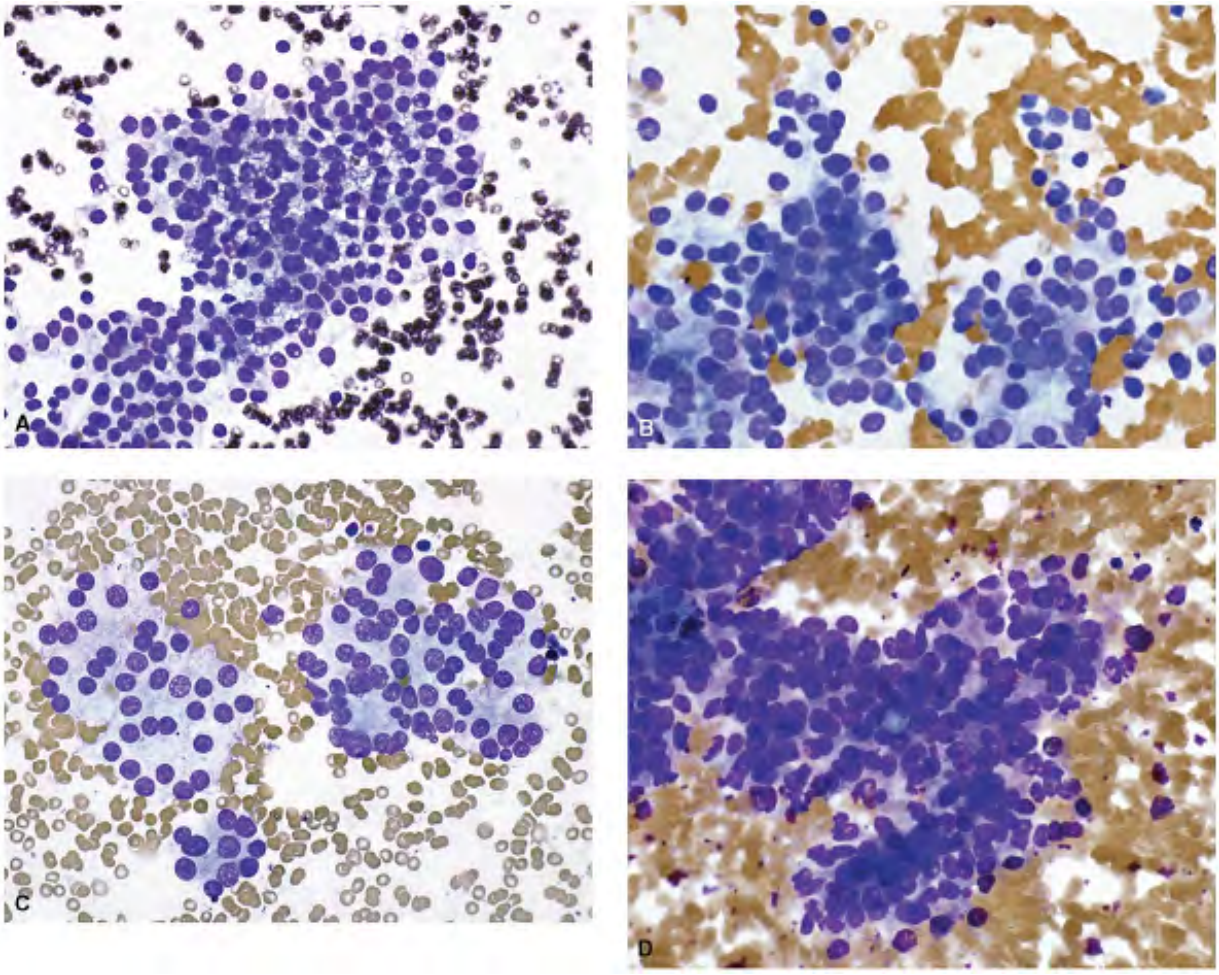

Figure 7.54. Differential diagnosis of follicular lesions. Cytologic features of follicular lesior (follicular-patterned). A. Hyperplastic goiter. B. Follicular adenoma. C. Follicular carcinoma Follicular variant of papillary carcinoma. The cytologic distinction of these various lesions is difficult from this type of preparation. (Diff-Quik preparations.) (Courtesy of Mariza de Pera Venturina, MD, William Beaumont Hospital, Royal Oak, Michigan.)

Poorly Differentiated Follicular Carcinoma

The aspirates of poorly differentiated follicular carcinomas pose no diagnostic problems. Th tend to be very cellular, consisting of large syncytial tissue fragments of malignant cells alo with loosely cohesive cells. The tissue fragments may exhibit a follicular pattern and often s branching, with a solid growth pattern. The malignant cells tend to be larger than those see well-differentiated carcinomas; are pleomorphic in size, with variable pale to dense cytopla and have large round nuclei with intensely stained coarsely granular chromatin and

parachromatin clearing. Nucleoli are easily identified. Colloid is generally not conspicuous. background may show necrosis. The cytologic features of poorly differentiated follicular carcinomas are illustrated in Figures 7.43 to 7.47.

The morphologic variants of follicular carcinomas include carcinomas with clear cell change with mucinous features, and with rhabdoid features.66 These are extremely uncommon. Th cytologic features of follicular carcinomas with clear cell and mucinous changes are describ Chapter 19 .

Immunocytohistochemical Profile

The cells of follicular neoplasms, including follicular adenomas and their morphologic variar as well as follicular carcinomas, demonstrate positive reactivity to thyroglobulin, the intens depending on the differentiation. A positive reaction

is also noted in the colloid. The neoplastic follicular cells also react to TTF-1 and to low-molecular-weight keratin but not to highâ€“molecular weight keratin. Vimentin is co-expres with keratin, and the cells show negative reactivity to carcinoembryonic antigen (CEA) and calcitonin. Follicular carcinomas consistently react negatively to CK 19 galectin-3 and RAT-oncogen.

Differential Diagnosis of Follicular Lesions and Diagnostic Accuracy

The follicular cell-derived lesions of the thyroid presenting a follicular growth pattern are referred to as follicular lesions or follicular-patterned lesions,67 and include the following.

Non-Neoplastic Entities

- Nodular goiters
- Proliferating follicular nodules from Hashimoto's thyroiditis

Neoplasms

- Follicular adenomas
- Follicular carcinomas
- Follicular variant of papillary carcinoma

The above-mentioned follicular lesions share several morphologic features, both cytological and histologically, causing

P.82

P.83

diagnostic difficulties. As noted in previous sections, the subject of cytopathology of follicul lesions has raised some key issues:

- Can the various follicular lesions be differentiated from cytologic samples? If so, wha are the differentiating features?
- If the cytologic differentiation is attempted, what is the diagnostic accuracy?
- For patient management, is the cytologic differentiation of follicular lesions better t grouping all lesions into one category, "indeterminate/suspicious," and recommendir surgery?
- Is the number of surgical removals of the thyroid for benign diseases reduced when cytologic differentiation is attempted?

Issue #1: Can Follicular Lesions Be Differentiated from Cytologic Samples? If So, What Are the Differentiating Features?

The answer to this question is yes. In most instances cytologic differentiation is achievable.

The common cytologic feature shared by the aspirates of follicular lesions is hypercellularity with a large population of follicular cells, in a clear background containing little or no colloi (Table 7.9). However, certain cytologic parameters are noticeable (Fig. 7.48)68 and can al be appreciated in

P.84

histologic sections if one looks for them (Figs. 7.49 and 7.50). As Rosai and Carcangiu state "It is not generally recognized that one of the classic papers70 on encapsulated angioinvasiv

carcinoma stated that microscopic atypia are nearly always present in these tumors." These atypical features in cytologic samples are represented by alterations in architectural patter the tissue fragments of follicular epithelium and their nuclear morphology. The following observations are useful:

Cellularity
Usually cellular
Usually cellular
Usually cellular
Usually cellular
Usually cellular
Presentation
Follicular cells mostly in tissue fragments
Follicular cells mostly in tissue fragments; sparse to abundant lymphoid cells
Mostly in tissue fragments
In tissue fragments, sometimes in loosely cohesive groups
In tissue fragments and in loosely cohesive groups
Architecture
Regular small follicles with evenly spaced nuclei; monolayered with honeycomb pattern; infrequently papillary configuration but with honeycomb arrangement of component nuclei
Tissue fragments with or without follicular pattern; nuclei often crowded and overlapped; permeated by mature lymphocytes

Syncytial tissue fragments with or without follicular pattern; follicles irregular with crowding and overlapping of nuclei; trabecular pattern Â±

Syncytial tissue fragments with or without follicular and trabecular pattern; follicles may be markedly irregular with intense crowding and overlapping of nuclei;

Syncytial tissue fragments with or without follicular pattern with crowding and overlapping of nuclei inspissated colloid within follicular lumina

Nuclear Size

Normal to slightly increased; uniform; 7â€“9 Âµm in diameter

Considerable variation in size

Variably enlarged but uniformly in a given neoplasm

Considerably enlarged with variation in size

Enlarged with variation in size

Chromatin

Finely granular, evenly distributed, sometimes compact; smooth nuclear membrane

Fine to coarsely granular; smooth nuclear membrane

Fine to coarsely granular;

smooth nuclear membrane
Fine to coarsely granular;
parachromatin clearing;
nuclear membrane may be
irregular
Dusty, powdery to finely
granular
Nucleolus
Micronucleoli Â±
Micronucleoli Â±
Micronucleoli Â±
Micronucleoli/macronucleoli
Micronucleoli Â±
Intranuclear
Inclusions
Absent
Rarely present
Absent
On rare occasions
Usually present
(a diagnostic clue)
Nuclear
Grooves
Rare
Absent
Absent
Absent
Present
Cytoplasm
Variable, clear to pale
Variable, clear to pale
Scant, pale
Variable, generally scant,
pale to dense

Usually scant to pale
Colloid
Scant to absent
Scant to absent
Scant to absent, may be present as droplets, within or outside follicular lumina
Scant to absent, may be present as droplets, within or outside follicular lumina
Often
Multinucleated Foreign Body Type Giant Cells
Absent
Rarely present
Absent
Absent
Present
Helpful Features
Cytologic changes of nodular goiter
HÃ¼rthle cell metaplasia and lymphoplasmacytoid cells in the background (high antimicrosomal or antithyroglobulin antibody titers)
â€”
â€”
Cytologic features of papillary carcinoma on other slides

Hyperplastic Nodular Goiter	Follicular Nodule in Hashimoto's Thyroiditis	Follicular Adenoma Cellular Type (Microfollicular and Trabecular)	Follicular Carcinoma	Follicular Vari of Papillary Carcinoma

TABLE 7.9 DIFFERENTIAL DIAGNOSTIC OF FOLLICULAR LESIONS

- The amount of colloid decreases from macrofollicular adenoma to hyperplastic goite cellular follicular adenoma and follicular carcinoma. Consequently, the cellularity ir aspirated material is more noticeable. *It is important to realize that the absence of colloid does not rule out a diagnosis of nodular or hyperplastic goiter. Mere absence colloid is not a criterion in favor of neoplasm.*
- The architectural patterns of the tissue fragments of follicular epithelium differ in n neoplastic follicular lesions from follicular neoplasms. The former display monolayer sheets with a honeycomb arrangement and regular follicles. The tissue fragments in neoplastic lesions are characterized by syncytial architecture. If the architectural pattern of the tissue fragments is disregarded and emphasis is placed on cellularity alone, differentiation of follicular lesions is not possible. *Hypercellularity of the asp does not equate with neoplasia* (Figs. 7.55 , 7.56 and 7.57).
- Follicular cell nuclei gradually increase in size from nodular goiter to follicular aden to follicular carcinomas.

P.85

P.86

The difference of nuclear size between goiters and follicular carcinomas is considera and can easily be appreciated. There is certainly an overlap between some cases of follicular adenomas and low-grade or well-differentiated carcinomas, where the nuc size approximates. The cytologic distinction in such cases is not possible.

- The compact chromatin pattern of follicular cell nuclei in nodular goiter changes to granular in cellular adenomas and to coarsely granular with the presence of nucleoli

parachromatin clearing in follicular carcinomas. The presence of nuclear pleomorphi with oval, oblong nuclear shapes, powdery chromatin, micronucleoli, grooves, and nuclear inclusions favors the follicular variant of papillary carcinoma. The nuclei in follicular adenomas and the low-grade follicular carcinomas tend to be uniformly enlarged in a given case.

- The aspirates of poorly differentiated follicular carcinomas demonstrate clearly malignant features and are not diagnostic problems.
- Nodular proliferations of follicular epithelium in Hashimoto's thyroiditis will yield cel samples exhibiting morphology very similar to that displayed by cellular follicular adenomas or follicular carcinomas. The presence of lymphocytes in the background supports the diagnosis of Hashimoto's thyroiditis. If the lymphoid cells are sparse, overlooked, or even absent, it is not possible to recognize the nature of the lesion a Hashimoto's thyroiditis and it will be interpreted as a follicular neoplasm. This constitutes an important diagnostic pitfall, causing a false-positive diagnosis. Differentiation of follicular nodules from follicular neoplasms in the background of Hashimoto's thyroiditis does not pose a problem in surgical pathology, where the ent lobe or a gland is available for examination.

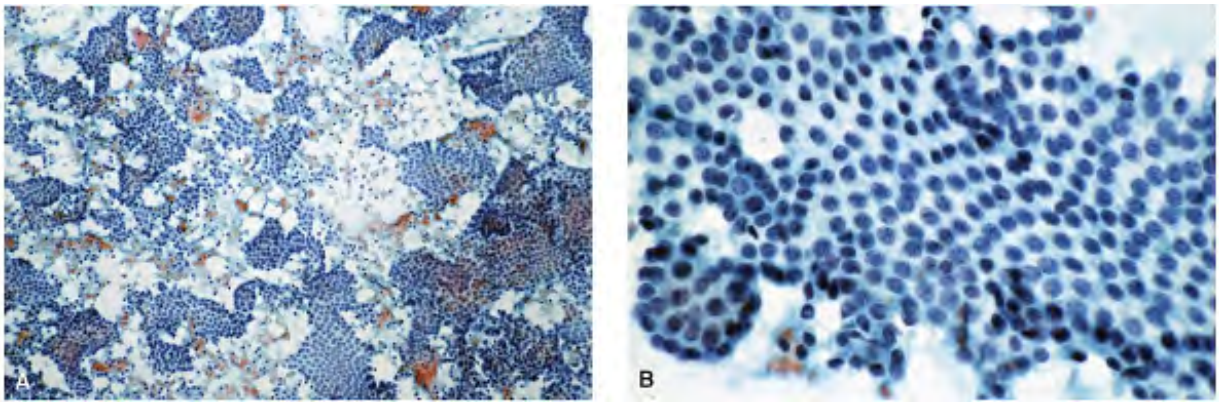

Figure 7.55. Hyperplastic goiter will yield a very cellular aspirate and no colloid in the background. Hypercellularity is not synonymous with neoplasia. Tissue fragments with a honeycomb architecture forming a two-dimensional sheets, regularly spaced, uniform small nuclei with finely granular, evenly spaced or compact chromatin indicate a benign non-neoplastic lesion. A. Low power of an aspirate from hyperplastic goiter. B. Higher magnifica

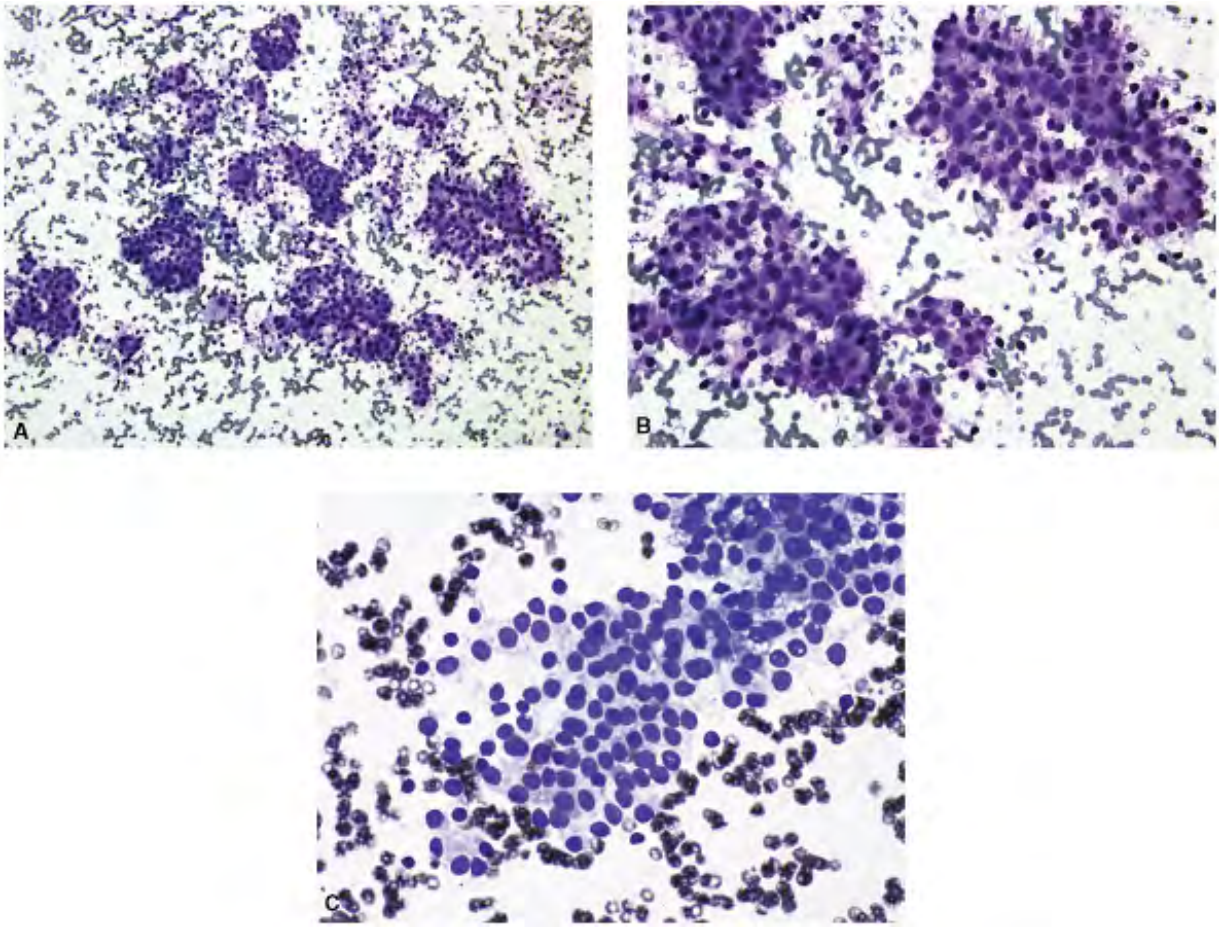

Figure 7.56. FNA of a hyperplastic goiter. The aspirate is very cellular, with no colloid in th background. The cellularity may lead to a diagnosis of a follicular neoplasm. (Diff-Quik). (Courtesy of Mithra Baliga, MD, University of Mississippi, Jackson.)

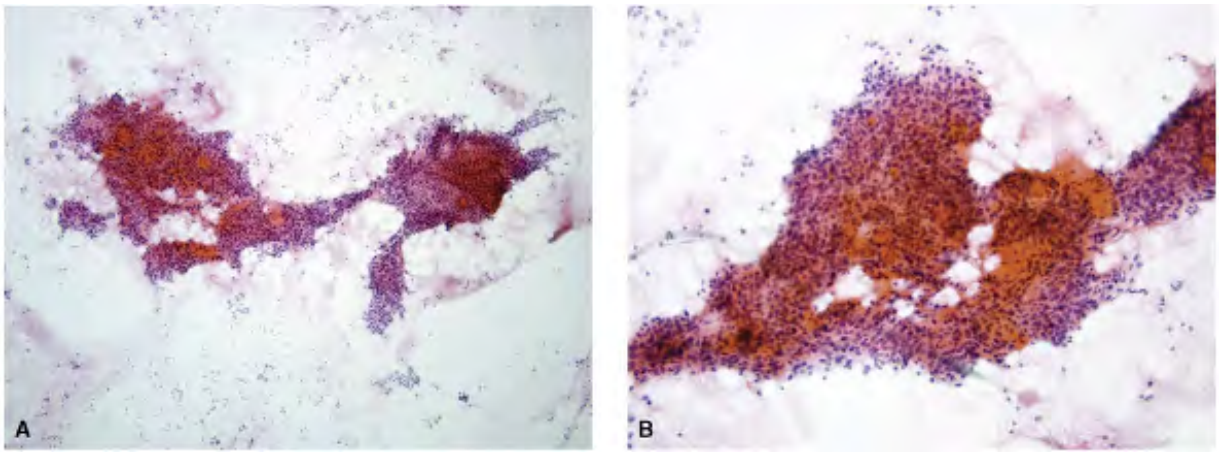

Figure 7.57. Simple type follicular adenoma, misinterpreted as nodular goiter. A. Low powe

FNA showing large tissue fragments of follicular epithelium. B. Medium power.

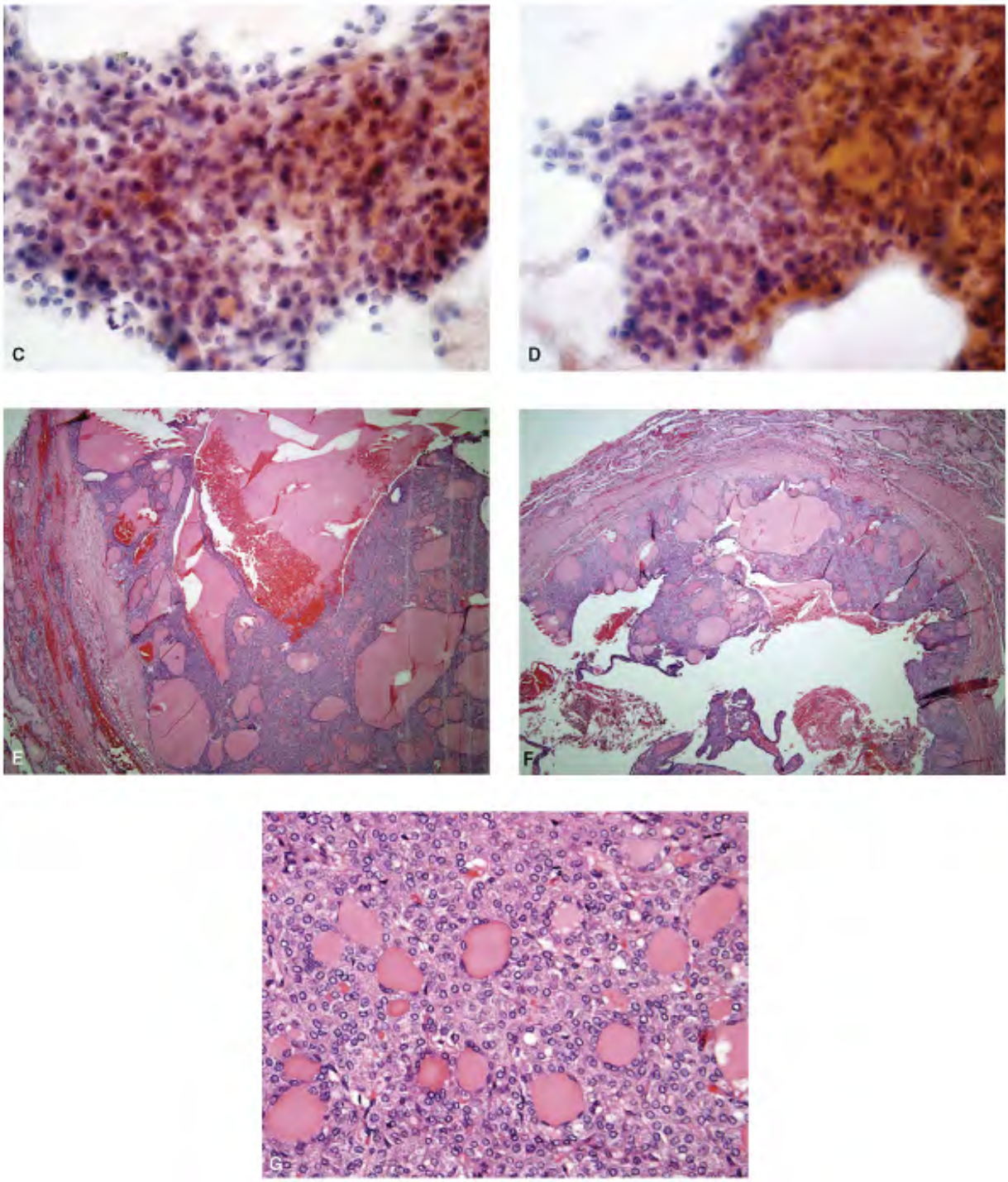

Figure 7.57. C, D. Higher magnification. The aspirate was interpreted as nodular goiter. Thyroidectomy revealed a large follicular adenoma with cystic change and multiple growth

patterns. E, F. Encapsulated tumor with solid areas mixed with large colloid filled follicles (power). G. Higher magnification. Sampling is the major problem in discrepancies.

If the above-mentioned factors are used as guidelines, the majority of the benign non-neopl diseases can be separated from neoplastic lesions. The differentiating features of various cellular follicular lesions are listed in Table 7.9 and illustrated in Figures 7.51 , 7.52 , 7.53 , , 7.55 , 7.56 to 7.57 .

Our observations and the criteria for separating various types of follicular lesions are echoe Suen71 and also supported by morphometric studies.5 , 72 , 76 Crissman and associates72 determined the morphometric parameters of the nuclear area (NA), the nuclear:cytoplasmi ratio and nuclear roundness (NR) in single cells and cell aggregates, the percentage of nucle overlap (NO), and the percentage of the nuclear area of overlap (NAO) in cellular aggregate (Tables 7.15 , 7.16 and 7.17), from the cytologic samples of 20 hyperplastic goiters, 21 folli adenomas, 5 encapsulated follicular carcinomas, and 22 invasive follicular carcinomas. All o cytologic diagnoses were subsequently confirmed by histologic examination. Cellular aggreg provided the maximum diagnostic information. Stepwise discriminant analysis revealed that nuclear size, nuclear roundness, and the percentage of nuclear area overlap (NAO) in syncy tissue fragments, allow optimum differentiation of hyperplasia, adenomas, and carcinoma. the poorly differentiated carcinomas (large NA, low NR, high NO, and high NAO) could be re diagnosed. Discriminant analysis allowed the differentiation of carcinoma from adenoma in 22 cases (91%) and correct identification of 19 of 21 adenomas (Table 7.15). The two cases follicular carcinomas misdiagnosed as adenoma by discriminant analysis represent insular carcinomas in which the malignant follicular cells are characteristically much smaller (see Chapter 10).

An overlap of cell and nuclear size in hyperplastic goiters and in some follicular adenomas explains the results of discriminant analysis in which two adenomas were incorrectly identif as hyperplasia and three hyperplasias as adenomas.

The study by Crissman and co-workers,72 as summarized in Tables 7.15 , 7.16 and 7.17 , concluded that (i) nuclear size remains an important criterion in differentiating hyperplastic nodules from follicular neoplasms, and is most important in separating follicular adenoma fr follicular carcinoma; and (ii) the nuclear area overlap (NAO) in syncytia demonstrates the greatest observed differences in separating hyperplasias, adenoma, and carcinoma. Table 7 lists similar observations reported in other studies.73 , 74 , 75 The morphometric analyses b

DeSantis and colleagues76 on histologic sections were similar to those reported by Crissman co-workers.72 DeSantis and associates76 reported a mean nuclear area of 22.6 Âµm^2 in norn thyroid, 30.9 Âµm^2 in goiters, 37.4 Âµm^2 in follicular adenomas, and 59.3 Âµm^2 in follicular carcinomas. These studies strongly support the cytologic observations. However, most cytopathologists are reluctant to attempt cytologic classification and separation of follicula lesions.3 , 4 , 9 , 15 , 77 , 78 , 79 , 80

Issue #2: If Cytologic Differentiation Is Attempted, What Is the Diagnostic Accuracy?

Our experience with cytohistologic correlation of all the follicular lesions and the incidence follicular carcinoma/follicular variant of papillary carcinoma during a 7-year period from 19 19836 is listed in Table 7.10 . The first 3 years of data reflects a learning curve as we ventu into fine-needle biopsy of the thyroid in late 1976. Using the criteria listed in Table 7.8 , at 70% to 75% of the follicular carcinomas were identified accurately (Tables 7.11 and 7.12).6 detection

P.87
P.88
P.89
P.90
P.91
P.92
P.93
P.94

rate was substantially lower when no attempts were made to differentiate follicular carcinc from other follicular lesions. As we gained experience with an increasing number of aspirate and their cytohistologic correlations, we attempted to separate various follicular lesions cytologically, which resulted in improved accuracy of the cytologic interpretations, as notec Table 7.12 . Fifty-three percent of the follicular carcinomas were identified cytologically in first 3 years as against 75% during the second 4-year period, which represents a substantial increase in the detection rate.

1
3
â€”
4
45
52
â€”
Follicular Adenoma
158
14
4
9
2
5
83
37
4
Suspected FCA
46
11
â€”
â€”
â€”
5
18
10
2
FCA
37
25
â€”
â€”
â€”
4

6
1
1
Suspected FVPC
7
â€”
4
â€”
â€”
â€”
2
1
â€”
FVPC
24
â€”
24
â€”
â€”
â€”
â€”
â€”
â€”
Totals
379
52
33
12
2
18
154
101
7
AA, atypical adenoma; FAD, follicular adenoma; FCA, follicular carcinoma; FVPC, follicular

variant of papillary carcinoma; HASH, Hashimoto's thyroiditis; MT, medullary carcinoma of tl thyroid; NG, nodular goiter; PCA, papillary carcinoma.

		Histologic Diagnosis							
Cytologic Diagnosis	No. Cases	FCA	FVPC	PCA	MCT	AA	FAD	NG	HA

TABLE 7.10 CYTOHISTOLOGIC CORRELATION OF FOLLICULAR LESIONS OF THE THYROID (EXCLUDING HÃœRTHLE CELL LESIONS)

Follicular carcinoma

25

70%

Suspected follicular carcinoma

11

Cellular follicular adenoma

14

Nodular goiter

2

TOTAL

52

TABLE 7.11 CYTOLOGIC DIAGNOSIS OF 52 HISTOLOGICALL CONFIRMED FOLLICULAR CARCINOMAS

Follicular carcinoma

7 (53%)

18 (75%)

Atypical adenoma

1

3

Nodular goiter

1
0
Follicular adenoma
3
3
Hashimoto's thyroiditis
1
â€”
TOTAL
13
24

Histologic Diagnosis	First 3 Years	Second 4 Years

TABLE 7.12 HISTOLOGIC DIAGNOSIS OF 37 CASES CYTOLOGICALLY INTERPRETED AS FOLLICULAR CARCINOM COMPARISON OF TWO TIME PERIODS

The incidence of follicular carcinoma among the cases cytologically interpreted as follicular adenomas was 18% cumulative for 7 years, but was considerably lower (14%) during the seco year period as compared to 21% during the first 3 years (Table 7.13), as experience was gai in recognizing the cytologic patterns of papillary carcinoma and its follicular variant.

Papillary carcinoma
7
2
9
Follicular variant of
papillary carcinoma
4
0
4
Follicular carcinoma
6
8

14
Medullary carcinoma
1
1
2
Atypical adenoma
1
5
6
Follicular adenoma
31
44
75
Nodular goiter
28 (45%)
14 (19%)
42
Hashimoto's thyroiditis
6
â€”
6
TOTAL
84
74
158
PERCENt(%) carcinoma
21
14
18

Histologic Diagnosis	First 3 Years (Oct. 1976â€“1979)	Second 4 Years (1980â€“1983)	Total

TABLE 7.13 HISTOLOGIC DIAGNOSIS OF 158 THYROID NODULES CYTOLOGICALLY INTERPRETED AS CELLULAR ADENOMA: COMPARISON OF FIRST 3 AND SECOND 4 YEAR

This trend has continued, as seen in a more recent review of follicular neoplasms during a p of 10 years from 1990 to 2000 (Table 7.14).81 The follicular neoplasms were subclassified ir five categories: (i) follicular adenoma when the cytologic features presented a micro-macrofollicular pattern, that is, a combination of cytologic features of nodular goiter as we features suggestive of cellular follicular adenomas; (ii) cellular adenoma when the pattern indicated microfollicular/trabecular adenoma but lacked nuclear features of follicular carcinoma; (iii) cellular follicular neoplasm that included a suspicious category; (iv) follicula carcinoma; and (v) follicular variant of papillary carcinoma. It is noteworthy that the cumul incidence of carcinoma when the first three categories were combined, corresponding to th indeterminate/suspicious group, was 16.5%. There was one follicular variant of papillary carcinoma and no follicular carcinoma in the group cytologically interpreted as cellular folli adenoma. Of the 13 cases cytologically interpreted as follicular carcinoma, 10 were proven malignant, 8 as follicular carcinoma, and 2 as the follicular variant of papillary carcinoma. C the 8 cases cytologically interpreted as the follicular variant of papillary carcinoma, 7 were histologically confirmed (87% concordance), and 1 was proven to be a follicular carcinoma. T presence of nuclear features of conventional papillary carcinoma allows the diagnosis of the follicular variant of papillary carcinoma with high degree of accuracy (Table 7.13).

Follicular adenoma
21
2
16
2
1
Cellular adenoma
22
5
1
15

1
Cellular follicular neoplasm
30
5
16
3
5
1[a]
Follicular carcinoma
13
2
1
8
2
Follicular variant of
papillary carcinoma
8
1
7
[a] Sampling error.
NG, nodular goiter; CG, colloid goiter; HASH, Hashimoto's hyroiditis; FA, follicular adenoma FCA, follicular carcinoma; FVPC, follicular variant of papillary carcinoma; PC, papillary carcinoma; AC, anaplastic carcinoma.
From Boboc L, Suterwala S, Kini SR, et al. Cytology can predict histology of follicular thyroic neoplasm. Presented at 74th Annual meeting of the American Thyroid Association, October 10â€“13, 2002.

Cytologic Diagnosis	NO	NG/CG	HASH	FA	FCA	FVPC/PC

TABLE 7.14 CYTO-HISTO CORRELATIONS OF 94 CASES WIT CYTOLOGIC DIAGNOSES OF FOLLICULAR NEOPLASTIC LESIONS

Correctly Predicted

17
Hyperplasia
Hyperplasia
26.49
0.93
2.98
19
Adenoma
Adenoma
35.56
0.94
14.19
20
Carcinoma
Carcinoma
47.66
0.92
14.19
Incorrectly Predicted
3
Hyperplasia
Adenoma
31.94
0.94
4.93
2
Adenoma
Hyperplasia
26.33
0.94
6.25
2
Carcinoma
Adenoma

34.60
0.94
13.65
From Crissman JD, Drozdowicz S, Johnson C, et al. Fine needle aspiration diagnosis of hyperplastic and neoplastic follicular nodules of the thyroid. Anal Quant Cytol Histol. 1991;13:321â€“328.

No.	Diagnosis	Discriminant Analysis	Mean Nuclear Area	Nuclear Roundness	Extent of Nuclear Area Overlap (%)

TABLE 7.15 MORPHOMETRIC PARAMETERS OF FOLLICULA LESIONS: DISCRIMINANT ANALYSIS

Hyperplasia (FH)
â€”
27.309
P value, FH vs. FA
<0.0001
Adenoma (FA)
41.007
35.584
P value, FA vs. EFC
-0.5842
-0.0035
Encapsulated carcinoma (EFC)
43.591
44.112
P value, EFC vs. IFC
-0.3398
-0.6219
Invasive (IFC)
49.524
44.478

P value, IFC vs. FA
41.007
35.584
Adenoma (FA)
41.007
35.584
[a] The two-tailed, unpaired t test was used.
FH, follicular hyperplasia; FA, follicular adenoma; EFC, encapsulated follicular carcinoma; I invasive follicular carcinoma.
From Crissman JD, Drozdowicz S, Johnson C, et al. Fine needle aspiration diagnosis of hyperplastic and neoplastic follicular nodules of the thyroid. Anal Quant Cytol Histol. 1991;13:321â€“328.

	Mean Nuclear Area (Âµm^2)	
Parameter	Single Cells	Sheets/Syncytia

TABLE 7.16 MORPHOMETRIC PARAMETERS OF FOLLICULA LESIONS: STATISTICAL EVALUATION[a]

No. patients
20
21
5
22
% of nuclei with overlap
21.170
30.262
42.926
57.466
% of nuclear area with
overlap
3.316
6.575

13.325

16.749

From Crissman JD, Drozdowicz S, Johnson C, et al. Fine needle aspiration diagnosis of hyperplastic and neoplastic follicular nodules of the thyroid. Anal Quant Cytol Histol. 1991;13:321â€“328.

Parameter	Hyperplasia	Adenoma	Encapsulated Carcinoma	Invasive Carcinom

TABLE 7.17 MORPHOMETRIC PARAMETERS OF FOLLICULA LESIONS: CELLS WITH NUCLEAR OVERLAP AND AN AREA O OVERLAP

Hyperplasia

25

56.1

35

43.6

â€”

27.3

Adenoma

74

66.4

42

50.1

41.0

35.6

Carcinoma

131

84.0

47

64.2

49.5

46.5

Measured only well-differentiated follicular carcinomas (five).
(a) From Crissman JD, Drozdowicz S, Johnson C, et al. Fine needle aspiration diagnosis of hyperplastic and neoplastic follicular nodules of the thyroid. Anal Quant Cytol Histol. 1991;13:321â€“328.

	Air-Dried Cytology Preparation (Âµm^2)		Fixed, Papanicolaou-Stained Preparation (Âµ)			
			Current Study			
Disease	Boon et al.[75] (1980)	Wright et al.[74] (1987)	Luck et al.[73] (1982)[a]	Wright et al.[74] (1987)	Single Cells	Sync (19

TABLE 7.18 MORPHOMETRIC PARAMETERS OF FOLLICULA LESIONS: MEAN NUCLEAR AREAâ€”COMPARISON WITH DAT FROM PUBLISHED STUDIES

Lately, the follicular variant of papillary carcinoma has generated considerable interest in t pathology community. The literature has focused on the difficulty in the diagnosis of the follicular variant of papillary carcinoma both cytologically and

P.95

P.96

P.97

histologically.58 , 59 , 82 , 83 , 84 , 85 , 86 , 87 , 88 , 89 , 90 , 91 , 92 , 93 , 94 , 95 Howev there seems to be wide variance in cytologic recognition of the follicular variant of papillar carcinoma. Some have reported very low sensitivity. Many cases of the follicular variant of papillary carcinoma are interpreted cytologically as either nodular goiter or follicular neopl The diagnostic problems very often arise from the fact that in some cases of the follicular variant of papillary carcinoma, the typical nuclear morphology may be limited to only a few focal areas within a tumor, or even in only one area depending on the sections taken. The surgical pathologist is often at a loss to make an unequivocal diagnosis of the follicular varia papillary carcinoma. Chan has recommended strict guidelines for histologic diagnosis of the follicular variant of papillary carcinoma.96 The follicular neoplasms continue to cause great

diagnostic concerns. LiVolsi and Baloch59 feel that even if the areas showing features of papillary carcinoma are focal, the neoplasm should be diagnosed as the follicular variant. If a single focus is identified, it should be referred to as follicular adenoma with a single focus papillary carcinoma. Williams and associates97 have proposed a scheme for addressing this i and recommend the term "well-differentiated tumor of uncertain malignant potential." The same holds true for cytologic samples. The absence of typical nuclear features in the cytolo samples in these cases may be related to sampling.

Issues # 3 and 4: For Patient Management, Is Cytologic Differentiation of Follicular Lesions Better than Grouping All Lesions into One Category ("Indeterminate/Suspicious") and Recommending Surgery for All? Is the Number of Surgical Remov of the Thyroid for Benign Disease Reduced when Cytologic Differentiation Is Attempted?

The purpose of the fine-needle biopsy is defeated if no attempt is made to differentiate nor neoplastic from neoplastic lesions. One must try to triage the hyperplastic goiters from folli neoplasms in order to avoid unnecessary surgeries. The incidence of benign non-neoplastic lesions in the group cytologically interpreted as indeterminate is 20% to 30%.3 , 4 The yield malignancy from the indeterminate/suspicious group is reported to be roughly 20%, of which represent follicular carcinomas.3 The majority of the remaining cases have proven to be follicular adenomas. These results parallel most other reported studies where all follicular neoplasms are cytologically grouped into one category.

SUMMARY

In conclusion, the various follicular lesions can be differentiated from cytologic samples wit fair degree of accuracy if an attempt is made. The prerequisites are an adequate specimen is wet-fixed and stained by the Papanicolaou technique, with the best results obtained by u spray fixatives. An alternative is hematoxylin and eosin stain.

The cytologic differentiation between cellular follicular adenomas and some low-grade or w differentiated follicular carcinomas is difficult. Poorly differentiated follicular carcinomas a easily recognized. Mere cellularity of the aspirate with abundance of follicular cells and lack colloid do not equate with neoplasia. Syncytial architecture of the tissue fragments and the nuclear size are important parameters in differentiating hyperplastic goiters from follicular

neoplasms. Increase in the nuclear size of the follicular cells and the presence of nucleoli fa
follicular carcinoma, while powdery chromatin, nuclear inclusions, grooves, and nucleoli fav
the follicular variant of papillary carcinoma.

REFERENCES

1.LÃ¶whagen T, Spencer E. Cytologic presentation of thyroid tumors in aspiration biopsy smear. *Acta Cytol* . 1974;18:192â€“197.

2.LÃ¶whagen T. Thyroid. In: Zajicek J, ed. *Aspiration Biopsy Cytology. Part I: Cytology of Supradiaphragmatic Organs.* New York: Karger; 1974:67â€“69.

3.Gharib H, Goellner JR. Fine-needle aspiration biopsy of the thyroid: An appraisal. *Ann Intern Med* . 1993;118:282â€“289.

4.Caruso D, Mazzaferri EL. Fine needle aspiration biopsy in the management of thyroid nodules. *Endocrinologist* . 1991;1:194â€“202.

5.Kelman AS, Rathan A, Leibowitz J, et al. Thyroid cytology and the risk of malignancy in thyroid nodules: importance of nuclear atypia in indeterminate specimens. *Thyroid* . 2001;11:271â€“277.

6.Kini SR, Miller JM, Hamburger JI, et al. Cytopathology of follicular lesions of the thyroid gland. *Diagn Cytopathol* . 1985;1:123â€“132.

7.Kini SR. Thyroid. In: Kline TS, ed. *Guides to Clinical Aspiration Cytology* . 2nd ed. Vol. 3 New York: Igaku Shoin; 1996.

8.Kini SR. *Color Atlas of Differential Diagnosis in Exfoliative and Aspiration Cytopatholog* Philadelphia: Lippincott Williams & Wilkins; 1999.

9.Ravinsky E, Safneck JR. Fine needle aspirates of follicular lesions of the thyroid gland.

Acta Cytol . 1990;34:813â€“820.

10.Chan JKC, Hirokawa M, Evans H, et al. Follicular adenoma. In: De Lellis, RA, Lloyd R, Heitz PU, et al., eds. *Pathology and Genetics of Tumours of Endocrine Organs* . *World Health Organization Classification of Tumors* . Lyon: IARC Press; 2004:57â€“66, 98â€“104.

11.Rosai J, Carcangiu ML, DeLellis RA. Tumors of the thyroid gland. *Atlas of Tumor Pathology.* Fascicle 5, 3rd series. Washington, DC: Armed Forces Institute of Pathology; 1993.

12.Meissner WA, Warren S. Tumors of the thyroid gland. *Atlas of Tumor Pathology.* Fascic 4, 2nd series. Washington, DC: Armed Forces Institute of Pathology; 1969.

13.Williams ED, Doniach I, Bjarnason O, et al. Thyroid cancer in an iodide rich area. *Canc* . 1977;39:215â€“222.

14.Cusick EL, McIntosh CA, Krukowski ZH, et al. Cystic change and neoplasia in isolated thyroid swellings. *Br J Surg* . 1988;75:982â€“983.

15.Abele JS, Miller TR. Fine needle aspiration of the thyroid nodule: clinical applications. Clark OH, ed. Firminger HI. *Endocrine Surgery of the Thyroid and Parathyroid Glands.* St. Louis: Mosby; 1985:293â€“335.

16.Carney JA, Ryan J, Goellner JR. Hyalinizing trabecular adenoma of the thyroid gland. *A J Surg Pathol* . 1987;11:583â€“591.

17.Bronner MP, LiVolsi VA, Jennings TA. Plat: Paraganglioma-like adenomas of the thyroid *Surg Pathol* . 1988;1:383â€“389.

18.Molberg K, Albores-Saavedra J. Hyalinizing trabecular carcinoma of the thyroid gland. *Hum Pathol* . 1994;25:192â€“197.

19.Carney JA, Volante M, Papotti M, et al. Hyalinizing trabecular adenoma. In: De Lellis, Lloyd R, Heitz PU, et al., eds. *Pathology and Genetics of Tumours of Endocrine Organs . World Health Organization Classification of Tumors.* Lyon: IARC Press; 2004:104â€“105.

20.LiVolsi VA. Hyalinizing trabecular adenoma of the thyroid: adenoma, carcinoma or neoplasm of uncertain malignant potential. *Am J Surg Pathol* . 2000;24:1683â€“1684.

21.Rothenberg HJ, Goellner JR, Carney JA. Hyalinizing trabecular adenoma of the thyroid gland. *Am J Surg Pathol* . 1999;23:118â€“125.

22.Sambade C, Franssila K, Camaselle-Teijeiro J, et al. Hyalinizing trabecular adenoma: a misnomer for a peculiar tumor of the thyroid gland. *Endocrinol Pathol* . 1991;2:83â€“91.

23.Hirokawa M, Carney JA. Cell membrane and cytoplasmic staining for MIB-1 in hyalinizin trabecular adenoma of the thyroid gland. *Am J Surg Pathol* . 2000;24:575â€“578.

24.Cerasoli S, Tabarri B, Farabegoli P, et al. Hyalinizing trabecular adenoma of the thyroi Report of two cases, with cytologic, immunohistochemical and ultrastructural studies. *Tumor* . 1992;78: 274â€“279.

25.Katoh R, Jasani B, Williams ED. Hyalinizing trabecular adenoma of the thyroid. A repor of three cases with immunohistochemical and ultrastructural studies. *Histopathology* . 1989;115:211â€“224.

26.Casey MB, Sebo TJ, Carney JA. Hyalinizing trabecular adenoma of the thyroid gland; cytologic features in 29 cases. *Am J Surg Pathol* . 2004;28:859â€“867.

27.Kuma S, Horokawa M, Miyauchi A, et al. Cytologic features of hyalinizing trabecular adenoma of the thyroid. *Acta Cytol* . 2003;47:399â€“404.

28.Boccato P, Mannara CM, La Rosa F, et al. Hyalinizing trabecular adenoma of the thyroi

diagnosed by fine-needle aspiration biopsy. *Ann Otol Rhinol Laryngol* . 2000;109:235â€“23

29.Akin MRM, Nguyen GK. Fine needle aspiration biopsy cytology of hyalinizing trabecular adenoma of the thyroid. *Diagn Cytopathol* . 1999;20:90â€“94.

30.Jayaram G. Fine-needle aspiration cytology of hyalinizing trabecular adenoma of the thyroid. *Acta Cytol* . 1999;43:978â€“980.

31.Kaleem Z, Davila RM. Hyalinizing trabecular adenoma of the thyroid. A report of two cases with cytologic, histologic and immunohistochemical findings. *Acta Cytol* . 1997;41:883â€“888.

32.Bondeson L, Bondeson AG. Clue helping to distinguish hyalinizing trabecular adenoma from carcinoma of the thyroid in fine needle aspirates. *Diagn Cytopathol* . 1994;10:25â€“2

33.LiVolsi VA, Gupta PK. Thyroid fine needle aspiration: intranuclear inclusions, nuclear grooves and psammoma bodies. Paraganglioma-like adenoma of the thyroid. *Diagn Cytopathol* . 1992;8:82â€“84.

34.Strong C, Garcia BM. Fine needle aspiration cytologic characteristics of hyalinizing trabecular adenoma of the thyroid. *Acta Cytol* . 1990;34:359â€“362.

35.Goellner JR, Carney JA. Cytologic features of fine needle aspirates of hyalinizing trabecular adenoma of the thyroid. *Am J Clin Pathol* . 1989;91:115â€“119.

36.LaGuette J, Matias-Guiu X, Rosai J. Thyroid paraganglioma: a clinicopathologic and immunohistochemical study of 3 cases. *Am J Surg Pathol* . 1997;21:748â€“753.

37.Sauer T, Olsholt R. Clear cell follicular adenoma of the thyroid: a case report. *Diagn Cytopathol* . 1996;15:124â€“126.

38.Orlando CA, Salman K, Miller JL, et al. Clear cell change in follicular adenoma mimicki HÃ¼rthle cell tumor on thyroid aspiration biopsy cytology. *Diagn Cytopathol* . 1991;7:273â€“276.

39.El-Sahrigy D, Zhang XM, Elhosseiny A, et al. Signet-ring follicular adenoma of the thyro diagnosed by fine needle aspiration. Report of a case with cytologic description. *Acta Cyt* 2004;48: 87â€“90.

40.Carcangui ML, Sibby RK, Rosai J. Clear cell change in primary thyroid tumors. A study c 38 cases. *Am J Surg Pathol* . 1985;9: 705â€“722.

41.Lasser A, Rothman JG, Calamia VJ. Renal cell carcinoma metastatic to the thyroid. Aspiration cytology and histologic findings. *Acta Cytol* . 1985;29:856â€“858.

42.LiVolsi VA. *Surgical Pathology of the Thyroid.* Philadelphia: Saunders; 1990.

43.LiVolsi VA. Papillary Neoplasms of the thyroid. Pathologic and prognostic features. *Am Clin Pathol* . 1992;97:426â€“434.

44.Hazard JB, Kenyon R. Atypical adenoma of the thyroid. *Arch Pathol* . 1954;58:554â€“56

45.Lang W, Georgi A, Staveh G, et al. The differentiation of atypical adenomas and encapsulated follicular carcinomas in the thyroid gland. *Virch Arch* . 1980;385:15â€“141.

46.Sobrinho-Somoes M, Asa SL, Kroll TG, et al. Follicular carcinoma. In: De Lellis RA, Lloyc R, Heitz PU, et al., eds. *Pathology and Genetics of Tumours of Endocrine Organs* . *World Health Organization Classification of Tumors* . Lyon: IARC Press; 2004:57â€“66, 67â€“72.

47.Thompson LD, Wieneke JA, Paal E, et al. A clinicopathologic study of minimally invasiv follicular carcinoma of the thyroid gland with a review of the English literature. *Cancer* . 2001;91: 505â€“524.

48.Hundahl SA, Fleming ID, Fremgen AM, et al. A national cancer data base on 53, 856 cas of thyroid carcinoma treated in us, 1985â€“1995. *Cancer* . 1998;83:2638â€“2648.

49.Demay RM. Follicular lesions of the thyroid. W(h)ither follicular carcinoma? *Am J Clin Pathol* . 2000;114:681â€“684.

50.LiVolsi VA, Asa SL. The demise of follicular carcinoma of the thyroid gland. *Thyroid* . 1994;4:233â€“236.

51.Heddinger CE, Williams ED, Sobin LH. Histologic typing of thyroid tumors. In: Heddinge CE, ed. *International Histologic Classification of Tumors* . Vol. 11. Berlin: Springer-Verlag 1988.

52.LiVolsi VA, Merino MJ. Histopathologic differential diagnosis of the thyroid. *Pathol Ann* 1981;16:357â€“406.

53.Vickery AL Jr. Needle biopsy pathology. In: Williams ED, ed. *Clinics in Endocrinology a Metabolism* . Vol. 10. Philadelphia: Saunders; 1981;275â€“292.

54.Selzer G, Kahn LB, Albertyn L. Primary malignant tumors of the thyroid gland: a clinicopathologic study of 254 cases. *Cancer* . 1977;40:1501â€“1510.

55.Meissner WA. Follicular carcinoma of the thyroid. *Am J Surg Pathol* . 1977;1:171â€“173

56.Franssila D. Is the differentiation between papillary and follicular thyroid carcinoma valid? *Cancer* . 1973;32:853â€“864.

57.Woolner LB. Thyroid carcinomas: pathologic classification with data on prognosis. *Sem Nucl Med* . 1971;1:481â€“502.

58.Suester S. Thyroid tumors with a follicular growth pattern: problems in differential

diagnosis. *Arch Pathol Lab Med* . 2006;130: 984â€“988,

59.LiVolsi VA, Baloch ZW. Follicular neoplasms of the thyroid. View, biases and experienc *Adv Anat Pathol* . 2004;11:279â€“287.

60.Mitsuyoshi H, Carney JA, Goellner JR, et al. Observer variation of encapsulated follicul lesions of the thyroid gland. *Am J Surg Pathol* . 2002;26:508â€“514.

61.Kahn NF, Perzin KH. Follicular carcinoma of the thyroid: an evaluation of the histologic criteria used for diagnosis. *Pathol Ann* . 1983;18:221â€“253.

62.Iida F. Surgical significance of capsule invasion of adenoma of the thyroid. *Surg Gynec Obstet* . 1977;144:710â€“712.

63.Lang W, Atay Z, Georgi A. The cytologic classification of follicular tumors in the thyroi gland. *Virch Arch* . 1978;378(A):199â€“211.

64.Glant MD, Berger EK, Davey DD. Intranuclear cytoplasmic inclusions in aspirates of follicular neoplasms of the thyroid. *Acta Cytol* . 1984;28:576â€“579.

65.Kini SR, Miller JM, Hamburger JI, et al. Cytopathologic features of medullary carcinom of the thyroid. *Arch Pathol Lab Med* . 1984;108:156â€“159.

66.Albores-Saavedra J, Sharma S. Poorly differentiated follicular thyroid carcinoma with rhabdoid phenotype: a clinicopathologic immunohistochemical and electron microscopic study of two cases. *Mod Pathol* . 2001;14:98â€“104

67.Baloch ZW, LiVolsi VA. Follicular-patterned lesions of the thyroid. The bane of the pathologist. *Am J Clin Pathol* . 2002;117: 143â€“150.

68.Cervino JM, Paseyro P, Grosso O, et al. La exploration citologic de la glandula tiroides

sus correlaciones anatomoclinices. *An Facultad Med* . 1962;47:128â€“143.

69.Rosai J, Carcangiu ML. Pathology of thyroid tumors, some recent and old questions. *Hu Pathol* . 1984;15:1008â€“1012.

70.Hazard JB, Kenyon R. Encapsulated angioinvasive carcinoma (angioinvasive adenoma) c the thyroid gland. *Am J Clin Pathol* . 1954;24:755â€“766.

71.Suen KC. How does one separate cellular follicular lesions of the thyroid by FNA's? *Diag Cytopathol* . 1987;4:78â€“81.

72.Crissman JD, Drozdowicz S, Johnson C, et al. Fine needle aspiration diagnosis of hyperplastic and neoplastic follicular nodules of the thyroid. *Anal Quant Cytol Histol* . 1991;13:321â€“328.

73.Luck JB, Mumaw VR, Frable WJ. Fine needle aspiration biopsy of the thyroid. Different diagnosis by a videoplan image analysis. *Acta Cytol* . 1982;26:793â€“796.

74.Wright RG, Castles H, Mortimer RH. Morphometric analysis of thyroid cell aspirates. *J C Pathol* . 1987;40:443â€“445.

75.Boon ME, LÃ¶whagen T, Williams JS. Planimetric studies on fine needle aspirates from follicular adenoma and follicular carcinoma of the thyroid. *Acta Cytol* . 1980;24:145â€“14

76.DeSantis M, Sciarretta F, Sudano L, et al. Morphometric evaluation of histologic sectior of the thyroid gland in benign and malignant follicular lesions. *Diagn Cytopathol* . 1987;3:60â€“67.

77.Busseniers AE, Oertel YC. Cellular adenomatoid nodules of the thyroid: review of 219 fine-needle aspirates. *Diagn Cytopathol* . 1993;9:581â€“589.

78.Humphrey AR, Gardner MB, Char B, et al. Predictive value of fine needle aspiration of the thyroid in the classification of follicular lesions. *Cancer* . 1993;71:2598â€“2603.

79.De Jong SA, Demeter JG, Castelli M, et al. Follicular cell predominance in the cytologic examination of dominant thyroid nodule indicates a sixty percent incidence of neoplasia. *Surgery* . 1990;108:794â€“800.

80.Atkinson B, Ernest CS, LiVolsi VA. Cytologic diagnosis of follicular tumors of the thyroid *Diagn Cytopathol* . 1986;2:1â€“3.

81.Boboc L, Suterwala S, Kini SR, et al. Cytology can predict histology of follicular thyroid neoplasms. Data presented at 74th annual meeting of the American Thyroid Association, October 2002.

82.Loyd RV, Erickson LA, Casey MB, et al. Observer-variation in the diagnosis of follicular variant of papillary thyroid carcinoma. *Am J Surg Pathol* . 2004;28:1336â€“1340.

83.Shih SR, Shun CT, Su DH, et al. Follicular variant of papillary thyroid carcinoma. Diagnostic limitations of fine needle aspiration cytology. *Acta Cytol* . 2005;49:383â€“386.

84.Zedan J, Karan D, Stein M, et al. Pure versus follicular variant of papillary thyroid carcinoma: clinical features, prognostic factors, treatment and survival. *Cancer* . 2003;97:1181â€“1185.

85.Wu HHJ, Jones JN, Grzbicki DM, et al. Sensitive cytologic criteria for the identification follicular variant of papillary thyroid carcinoma in fine-needle aspiration biopsy. *Diagn Cytopathol* . 2003;29:262â€“266.

86.Fulciniti F, Benincasa G, Vetrani A, et al. Follicular variant of papillary carcinoma: cytologic findings on FNAB samples-experience with 16 cases. *Diagn Cytopathol* . 2001;25:86â€“93.

87.Lin HS, Komisar A, Opher E, et al. Follicular variant of papillary carcinoma: the diagnos limitations of preoperative fine-needle aspiration and intraoperative frozen section evaluation. *Laryngoscope* . 2000;110:1431â€“1436.

88.Logani S, Gupta PK, LiVolsi VA, et al. Thyroid nodules with FNA cytology suspicious for follicular variant of papillary thyroid carcinoma: follow-up and management. *Diagn Cytopathol* . 2000; 23:380â€“385.

89.Baloch ZW, Gupta PK, Yu GH, et al. Follicular variant of papillary carcinoma. Cytologic and histologic correlation. *Am J Clin Pathol* . 1999;111:216â€“222.

90.Goodell WM, Saboorian MH, Ashfaq R. Fine-needle aspiration diagnosis of the follicular variant of papillary carcinoma. *Cancer Cytopathol* . 1998;84:349â€“354.

91.Zacks JF, Morenas A, Beazley RM, et al. Fine-needle aspiration cytology diagnosis of colloid nodule versus follicular variant of papillary carcinoma of the thyroid. *Diagn Cytopathol* . 1998;18: 87â€“90.

92.Mesonero CE, Jugle JE, Wilbur DC, et al. Fine-needle aspiration of the macrofollicular and microfollicular subtypes of the follicular variant of papillary carcinoma of the thyroid *Cancer Cytopathol* . 1998;84:235â€“244.

93.Sherman LJ, Chess Q. Fine-needle aspiration biopsy diagnosis of follicular variant of papillary thyroid cancer: Therapeutic implications. *Otolaryngol Head Neck Surg* . 1998;119:600â€“602.

94.Gallagher J, Oertel YC, Oertel JE. Follicular variant of papillary carcinoma of the thyro fine-needle aspirates with histologic correlation. *Diagn Cytopathol* . 1997;16:207â€“213.

95.Martinez-Parra D, Fernandez JC, Hierro-Guilmain C, et al. Follicular variant of papillar carcinoma of the thyroid: to what extent is fine-needle aspiration reliable? *Diagn Cytopat*

. 1996;15:12â€“16.

96.Chan JKC. Strict criteria should be applied in the diagnosis of encapsulated follicular variant of papillary carcinoma. *Am J Clin Pathol* . 2002;117:16â€“18.

97.Williams ED. Two proposals regarding the terminology of thyroid tumors. *Int J Surg Pat* . 2000;8:181â€“183.

Editors: Kini, Sudha R.
Title: *Thyroid Cytopathology: A Text and Atlas, 1st Edition*

Copyright Â©2008 Lippincott Williams & Wilkins

8

HÃ¼rthle cell Lesions

HÃ¼rthle cellsâ€”also called "oncocytes," "Askanazy cells," or "oxyphils"â€”are altered follic
Although the cells described originally by HÃ¼rthle were probably parafollicular cells, the t
"HÃ¼rthle cell" has become established in the medical literature. They are large polygonal c
8.1 and 8.2) with abundant granular cytoplasm, the granularity being the result of abundan
mitochondria (Fig. 8.3).1 , 2 HÃ¼rthle cells do not concentrate radioactive iodine.

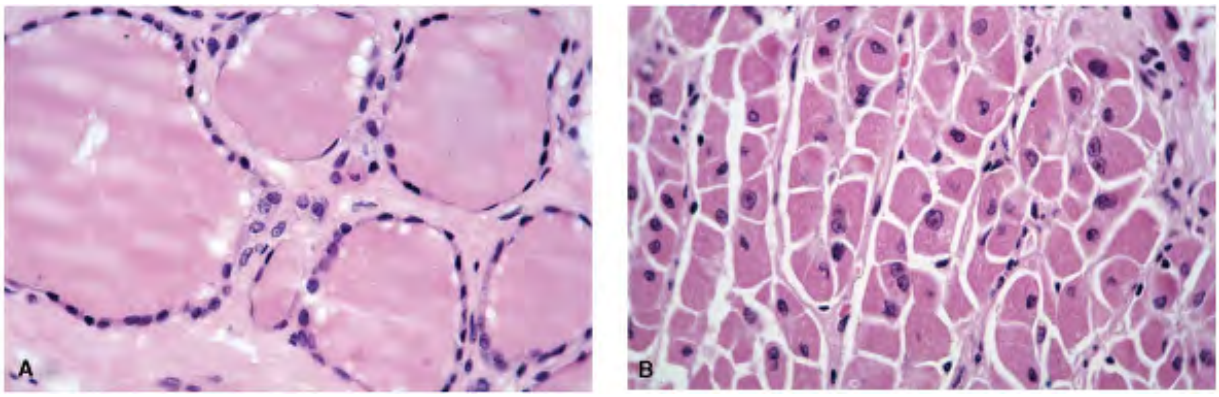

FIGURE 8-1. Comparison of normal follicular cells and HÃ¼rthle cells in histologic sections c
The follicular cells are small, cuboidal, and single layered, lining the follicles; they have sca
cytoplasm and round nuclei with compact to finely granular chromatin. Nucleoli are usually
B. The HÃ¼rthle cells are larger and variable in size with abundant granular cytoplasm due
accumulation of large numbers of mitochondria.

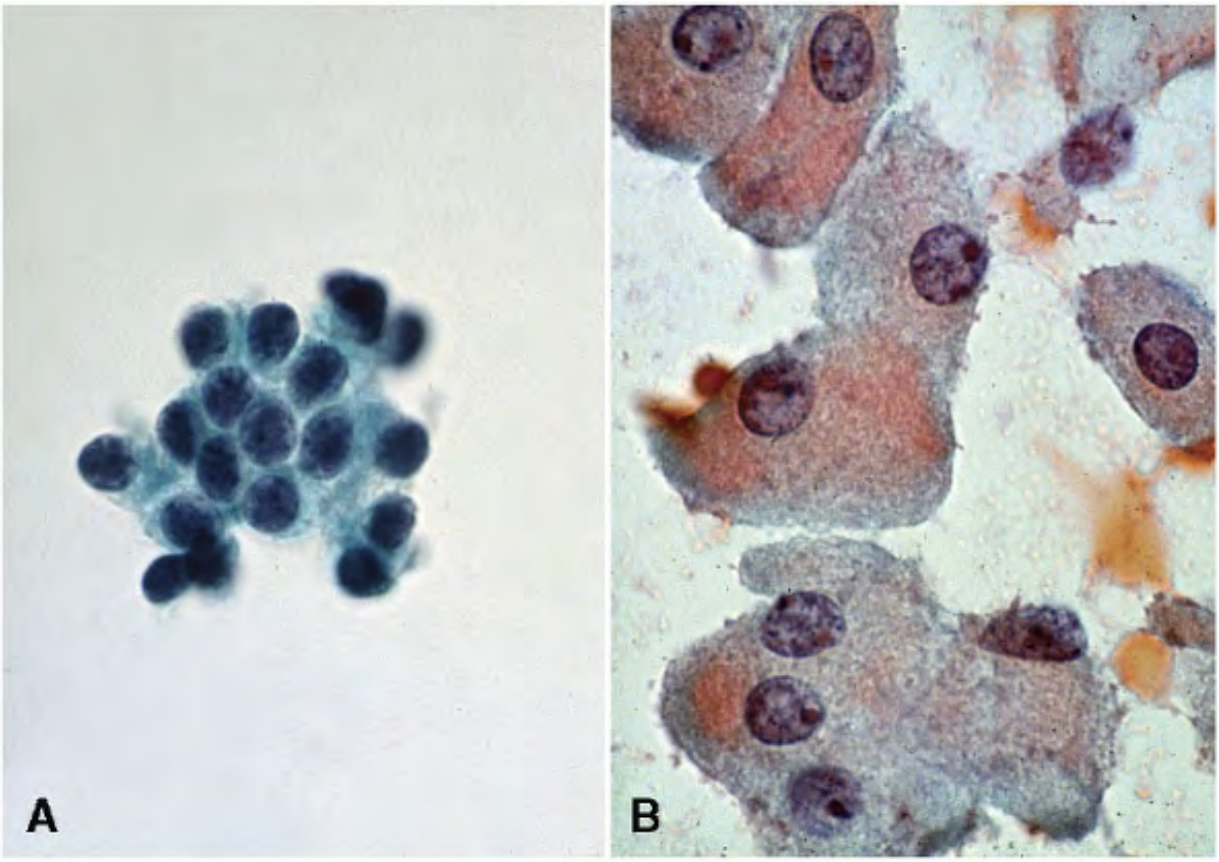

FIGURE 8-2. Comparison of normal follicular cells and HÃ¼rthle cells in cytologic samples o
The follicular cells are small and cuboidal with scant cytoplasm. Their nuclei are round with
finely granular chromatin. Nucleoli are usually absent (Ã— 1,000). B. The HÃ¼rthle cells are
polygonal with abundant granular cytoplasm and a slightly eccentric nucleus with a promine
macronucleolus in neoplastic cells (Ã— 1,000).

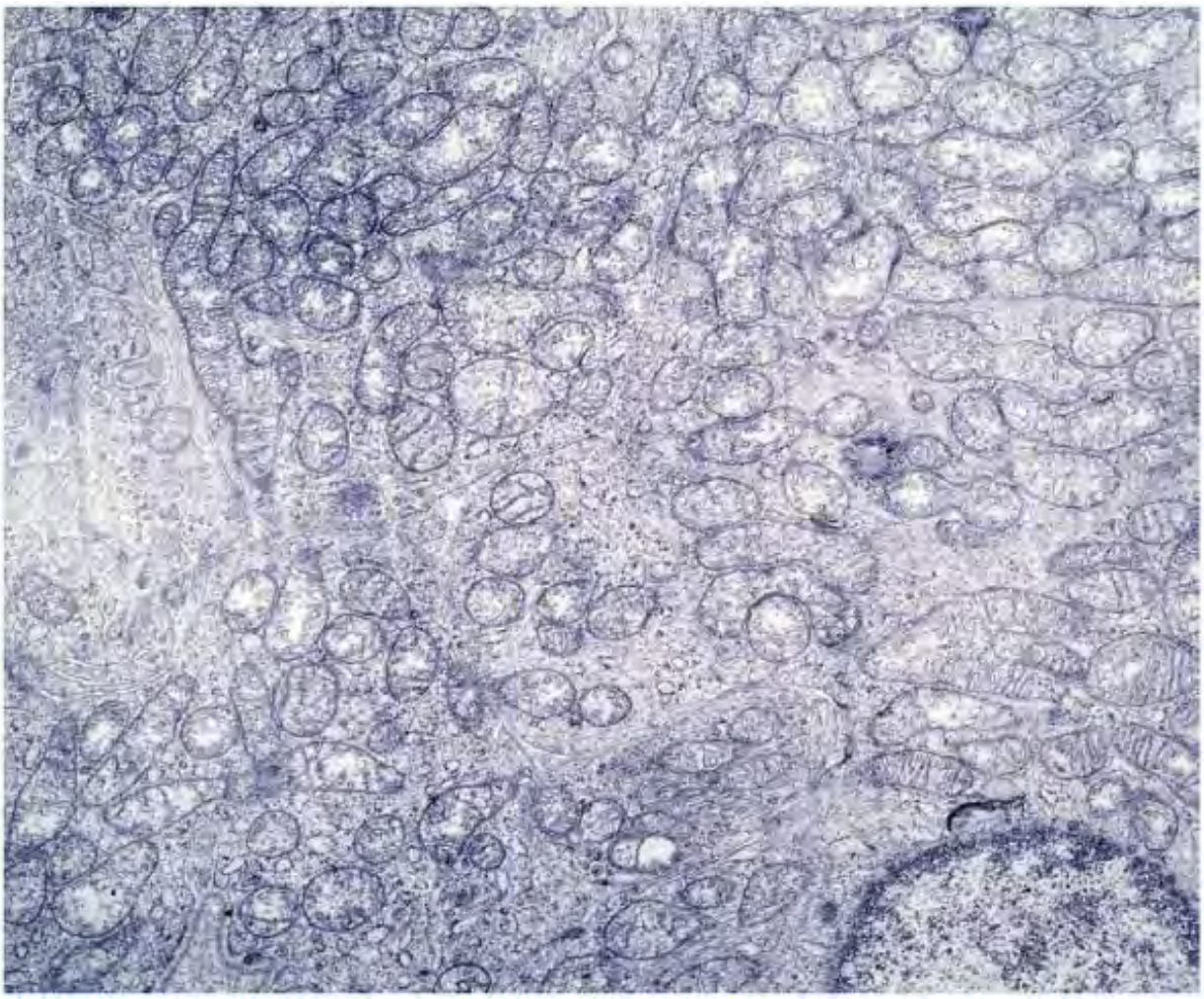

FIGURE 8-3. Ultrastructure of a HÃ¼rthle cell exhibiting abundant mitochondria in the cyto

The HÃ¼rthle cell metaplasia of follicular cells probably reflects a functional state labeled l Friedman3 as a "cellular involution." It is seen in several conditions affecting the thyroid, su Hashimoto's thyroiditis, adenomatous goiter, Graves disease, and others (Table 8.1). This cl extensive, resulting in the formation of nodules that are either palpable, or detected on ult They clinically cannot be differentiated from neoplasms, often necessitating fine-needle bic chapter deals with the cytopathology of HÃ¼rthle cell neoplasms and non-neoplastic HÃ¼rtl nodules, which together constitute HÃ¼rthle cell lesions of the thyroid (Table 8.2).

Hashimoto's thyroiditis
Adenomatous goiter
Graves disease

Radiation
Myxedema
Partial Thyroidectomy

TABLE 8.1 CONDITIONS ASSOCIATED WITH HÃœRTHLE C (OXYPHILIC) CHANGE

HÃ¼rthle cell neoplasms
Non-neoplastic HÃ¼rthle cell nodules
- Hashimoto's thyroiditis
- Adenomatous (nodular) goiter
- Graves disease

TABLE 8.2 DIFFERENTIAL DIAGNOSIS OF HÃœRTHLE CE LESIONS

HÃœRTHLE CELL NEOPLASMS

HÃ¼rthle cell neoplasms have generated considerable interest over the last several decades still do. The controversies and debates over almost every aspect of HÃ¼rthle cell neoplasms To begin with, HÃ¼rthle cell neoplasms are considered by many pathologists as morphologic follicular neoplasms; hence they are classified and referred to as "follicular adenoma, oxyph and "follicular cell carcinoma, oxyphil cell type." Proponents of this view believe that there justification for isolating HÃ¼rthle cell adenomas or carcinomas, because their morphologic behavior parallel that of follicular adenoma or carcinoma, respectively. It is felt that the or change is an inconsequential event that has no effect on the natural history.7 , 8 , 9 , 10 , 1 14 , 15 , 16 , 17 , 18 In sharp variance with this viewpoint, was the study of Thompson, et a authors reviewed 25 HÃ¼rthle cell neoplasms and found that their biological behavior was unpredictable, and that the distinction between an adenoma and carcinoma was not easily conventional criteria used. for follicular neoplasms. According to Thompson, et al.19 HÃ¼rt tumors followed an aggressive course with a frequent recurrence rate, distant metastasis, a incidence of fatal outcomes, regardless of their invasive characteristics. Therefore, they as term "HÃ¼rthle cell tumors" to all neoplasms comprising HÃ¼rthle cells and recommended t thyroidectomy. Gundry, et al.20 confirmed this observation several years later. Rosai,2 Car

al.21 Grant , et al.22 Tollefsen, et al.23 and many others believe that although HÃ¼rthle ce behave in a benign fashion, HÃ¼rthle cell carcinomas represent an entity distinct from folli carcinomas, with an aggressive behavior, as supported by the study of Carcangiu, et al.21

The above-mentioned controversy extends to the cytologic interpretation as well. Reasons a that for follicular lesions. The histologic criteria for the diagnosis of malignant HÃ¼rthle cel parallel those of follicular carcinomas. Needless to say, their interpretations have become v subjective, as already discussed in Chapter 7 . Many cytopathologists and therefore endocrinologists/surgeons believe that the cytologic differentiation of HÃ¼rthle cell adenor HÃ¼rthle cell carcinomas is not possible,24 , 25 , 26 , 27 , 28 , 29 , 30 because the diagnosi malignancy is made only from histologic examination. Along the same line, it is also believe cytopathologists that non-neoplastic HÃ¼rthle cell nodules cannot be differentiated from H neoplasms. Consequently, all aspirates composed of a HÃ¼rthle cell population are lumped HÃ¼rthle cell lesions and categorized as "indeterminate/suspicious" in the reporting scheme recommending surgical excision.24 , 25 , 26 , 27 , 28 , 29 , 30

The author disagrees with this approach, and strongly feels that the cytologic triage of HÃ¼ lesions into non-neoplastic and neoplastic, and benign and malignant, is possible.31 , 32 The observations are supported by other investigators.33 , 34 , 35

The author's clinical colleagues (endocrinologists and surgeons) believed and still believe tha cell neoplasms are a separate entity from follicular neoplasms. Therefore, HÃ¼rthle cell ne were cytologically placed in a separate category as HÃ¼rthle cell tumors, but without separ adenoma and carcinoma, when the FNA project was launched in the author's institution in 1 was in keeping with Thompson's recommendation.19 We gained the experience in cytologic presentations of HÃ¼rthle cell neoplasms from their

cytohistologic correlations as well as from misinterpreted cases. First, it became apparent t HÃ¼rthle cell adenomas can be separated from their malignant counterparts; second, the n neoplastic HÃ¼rthle cell lesions present a different morphologic pattern, allowing their rec from cytologic samples.

As in cytopathology of any other diseases of the thyroid, or for that matter of any other site 100% diagnostic accuracy cannot be achieved. Realizing this, we continue to triage HÃ¼rthl from the cytologic samples and offer the probabilities of neoplasia and malignancy with con success.

HÃ¼rthle Cell Adenoma

The synonyms for HÃ¼rthle cell adenoma are oncocytic-adenoma, oxyphilic-adenoma, and f adenoma with oncocytic features.

HÃ¼rthle cell adenomas are benign thyroid neoplasms, exclusively or predominantly compos HÃ¼rthle cells, or oncocytes (over 75%).2 , 14 , 21 , 22 , 136 , 137 , 138 , 139 Their true inc cannot be assessed, because they are often considered as the morphologic variants of follic adenomas. HÃ¼rthle cell adenomas are more frequent in women, with a male:female ratio Although HÃ¼rthle cell adenomas can occur at any age, they are more common between th fourth decades of life. The clinical presentation is same as follicular adenomas.

Gross and Histologic Features

HÃ¼rthle cell adenomas are usually solitary, discrete tumors that may reach a large size. M HÃ¼rthle cell tumors as well as bilaterality and the association with other diseases have bee reported.14 Their cut surfaces are bulging, and have characteristic mahogany-brown colora). HÃ¼rthle cell tumors are very vascular and have frequent hemorrhage and cystic changes

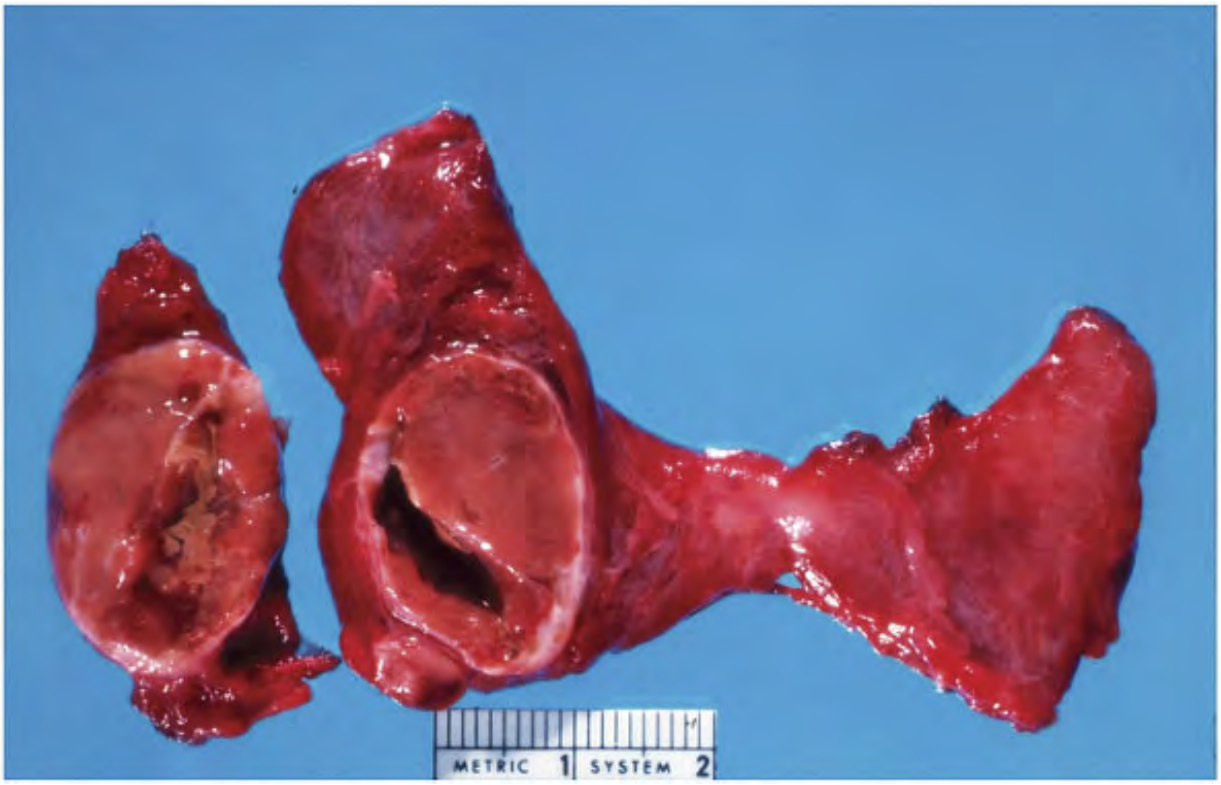

FIGURE 8-4. Gross photograph of a HÃ¼rthle cell neoplasm. Note the characteristic mahoga color on cut surface.

Histologically, HÃ¼rthle cell adenomas are completely encapsulated. The capsule is variabl tumor is composed entirely of large HÃ¼rthle cells with abundant, granular, consistently de eosinophilic cytoplasm (Figs. 8.5 and 8.6). The cell borders are distinct and well defined. T are round, uniform containing finely granular chromatin with a prominent macronucleolus. ratios are characteristically very low. The growth patterns of HÃ¼rthle cell adenomas vary follicular, solid, and trabecular to occasional papillary patterns (Figs. 8.5 , 8.6 and 8.7). Th vary in size and may contain abundant colloid (Figs. 8.6B and 8.7C). Cystic change is not un Psammoma bodies may be present in adenomas with a papillary growth pattern. HÃ¼rthle c adenomas may demonstrate nuclear pleomorphism. But the chromatin in these pleomorphic deep-staining, smudgy, and structureless, indicating degeneration; and the nuclei are not ir malignancy.

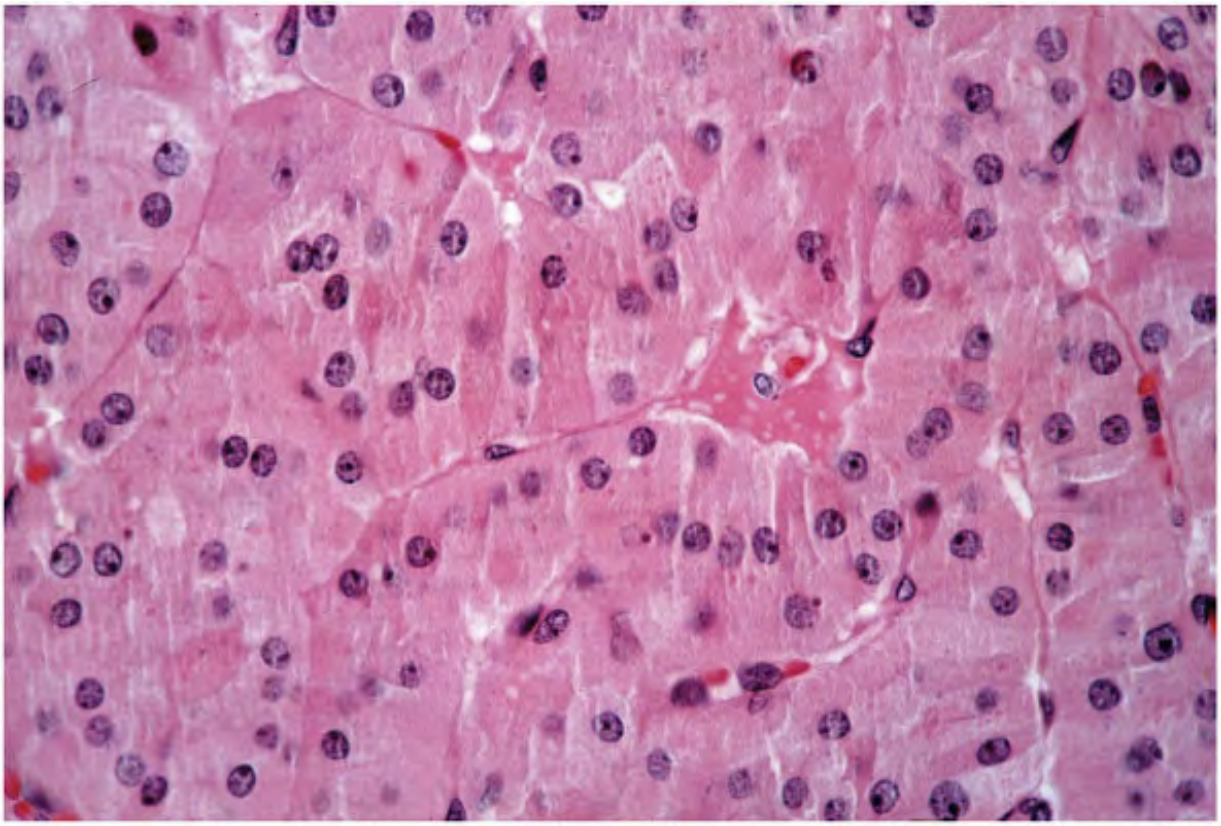

FIGURE 8-5. Histologic section of a HÃ¼rthle cell adenoma with a trabecular pattern, forme polygonal cells, containing abundant eosinophilic cytoplasm, and having uniform small nucle

prominent macronucleoli. The N/C ratios are low.

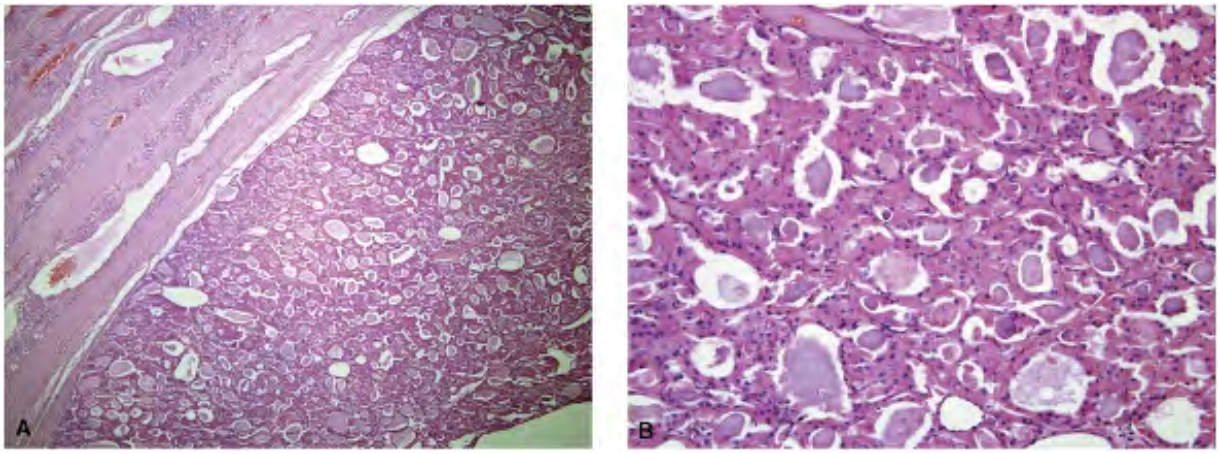

FIGURE 8-6. A . Histologic section of an encapsulated HÃ¼rthle cell adenoma, low power. E
magnification showing a follicular growth pattern. Note that the component cells are large v
defined cell borders. The cytoplasm is abundant, and deeply eosinophilic. The N/C ratios ar
nuclei are uniform. The follicles contain colloid. Aspirates of these lesions may contain a sig
amount of colloid.

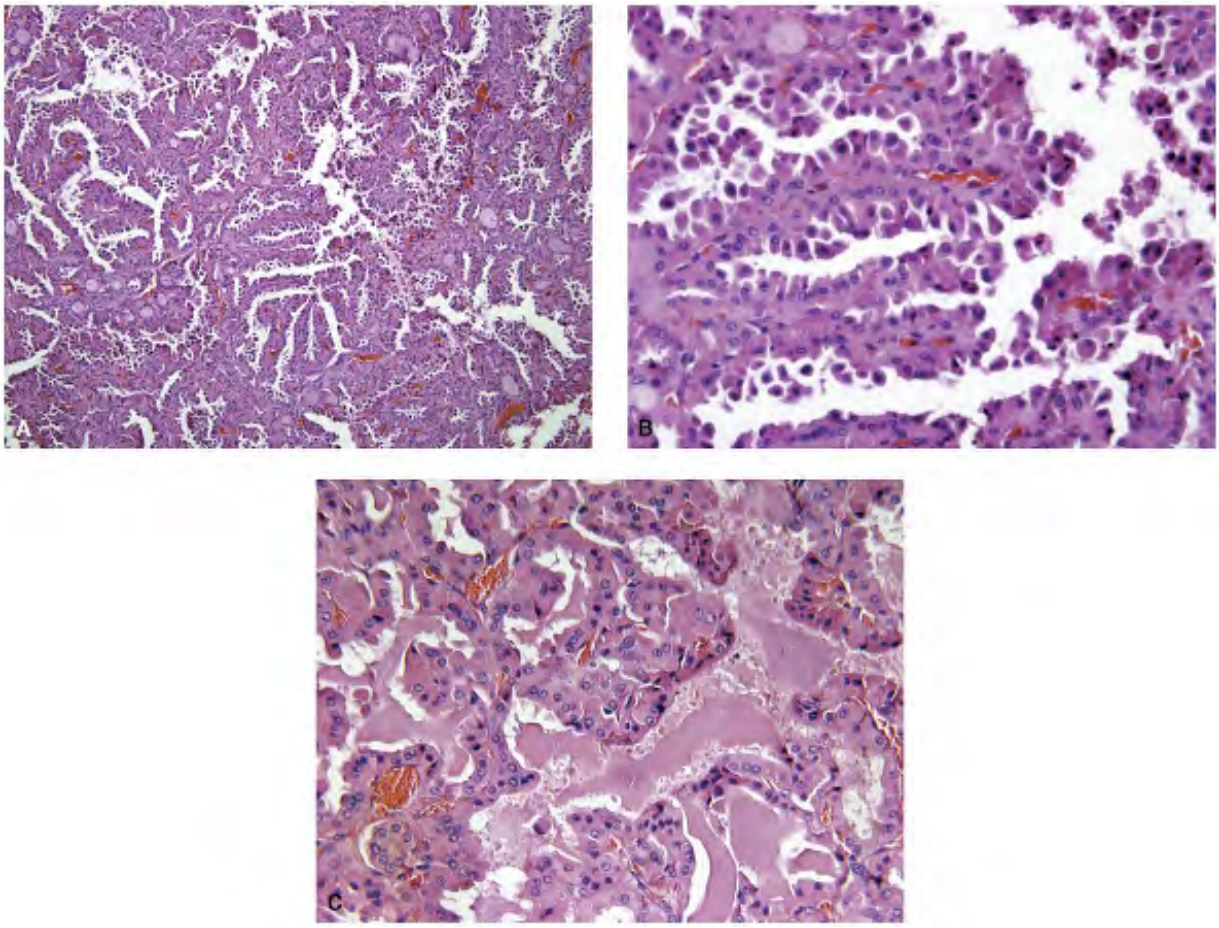

FIGURE 8-7. A. Histologic section of an encapsulated HÃ¼rthle cell adenoma with a papillar pattern, low power. B. Medium power view, showing papillary fronds lined by oncocytic cell round uniform nuclei with macronucleoli. Note the lack of characteristic nuclear morpholog conventional papillary carcinoma. C. Higher magnification. Note abundant colloid.

Cytopathologic Features of HÃ¼rthle Cell Adenoma

HÃ¼rthle cell adenoma cells present a very characteristic pattern on account of their abunc cytoplasm and prominent cherry-red macronucleus (Table 8.3 ; Figs. 8.8 , 8.9 , 8.10 , 8.11 , and 8.14).31 , 32 , 33 , 34 , 35 , 40 In general, the aspirates of HÃ¼rthle cell adenomas are cellular and demonstrate a strikingly monomorphic cell population. The neoplastic HÃ¼rthle to present themselves as isolated, in small groups, and in tissue fragments. A dispersed cell more commonly encountered. The tissue fragments are seen as sheets (two-dimensional) an follicles. Syncytial architecture is not a feature of HÃ¼rthle cell adenomas. A papillary patt occasionally be present. The tissue fragments of HÃ¼rthle cells often demonstrate transgre

vessels.41 , 42 , 43 Although we have noted this feature in HÃ¼rthle cell neoplasms, the fre
been low in our experience. The cells of HÃ¼rthle cell adenomas are usually very large, pol
round to oval, and with well-defined cell borders. Binucleation is frequent. The nuclei can b
eccentric. The cytoplasm is abundant and granular, resulting in very low N/C ratios. The sta
cytoplasm is dependent on the fixative and the stains used. With spray-fixed smears and Pa
stain, the cytoplasm stains eosinophilic, cyanophilic, or amphophilic (Figs. 8.8 , 8.9 , 8.10 ,
and 8.13) compared to smears wet-fixed with 95% alcohol; the HÃ¼rthle cells stain deep ec
similar to an H&E stained specimen (Fig. 8.14D). The HÃ¼rthle

P.103
P.104
P.105
P.106

cell cytoplasm stains lavender with Romanowsky stain (Fig. 8.14C). The nuclei of the HÃ¼rt
adenomas cells are always round, with smooth, crisp, nuclear membranes containing finely
evenly dispersed chromatin. A single cherry-red macronucleolus is the hallmark of neoplasti
cells, a feature that often helps differentiate HÃ¼rthle cell neoplasm from other thyroid fol
cell derived neoplasms and importantly from non-neoplastic HÃ¼rthle cell lesions. Intranucl
inclusions are not the feature of HÃ¼rthle cell adenomas. In a given neoplasm, the nuclei o
HÃ¼rthle cell adenoma cells tend to be of the same size and very uniform. Intracytoplasmic
lumina, have been described in neoplastic HÃ¼rthle cells.41 , 42 , 43 Rarely, psammoma bo
identified.

Cellularity
Generally very cellular
Presentation
Monomorphic, cells isolated, in loose groups or in tissue fragments, either monolayered or f
follicles; papillary configuration Â±; dispersed pattern more common; transgressing blood
within
the tissue fragments Â±
Cells
Generally large, round, oval to polygonal; tend to be of uniform shape in a given tumor; we
cell
borders; low N/C ratios
Nucleus

Single or binucleated, rarely multinucleated; central to eccentric; round with smooth nucle
membranes,
consistently uniform in size; finely granular, evenly dispersed chromatin, prominent, singl
macronucleolus; intranuclear cytoplasmic inclusions not present
Cytoplasm
Abundant, granular, may stain eosinophilic, cyanophilic, or amphophilic with Papanicolaou s
eosinophilic with hematoxylin-eosin stain; light purple to lavender with Romanowsky stain
Â±
Psammoma Bodies
Infrequently present
Background
Frequently bloody; colloid variable; usually clean; histiocytes Â±
Ultrastructure
Large numbers of mitochondria
Immunoprofile
Immunoreactive to thyroglobulin, TTF-1 Â±, low-molecular-weight keratin

TABLE 8.3 CYTOPATHOLOGIC FEATURES OF HÃœRTHLE ADENOMA

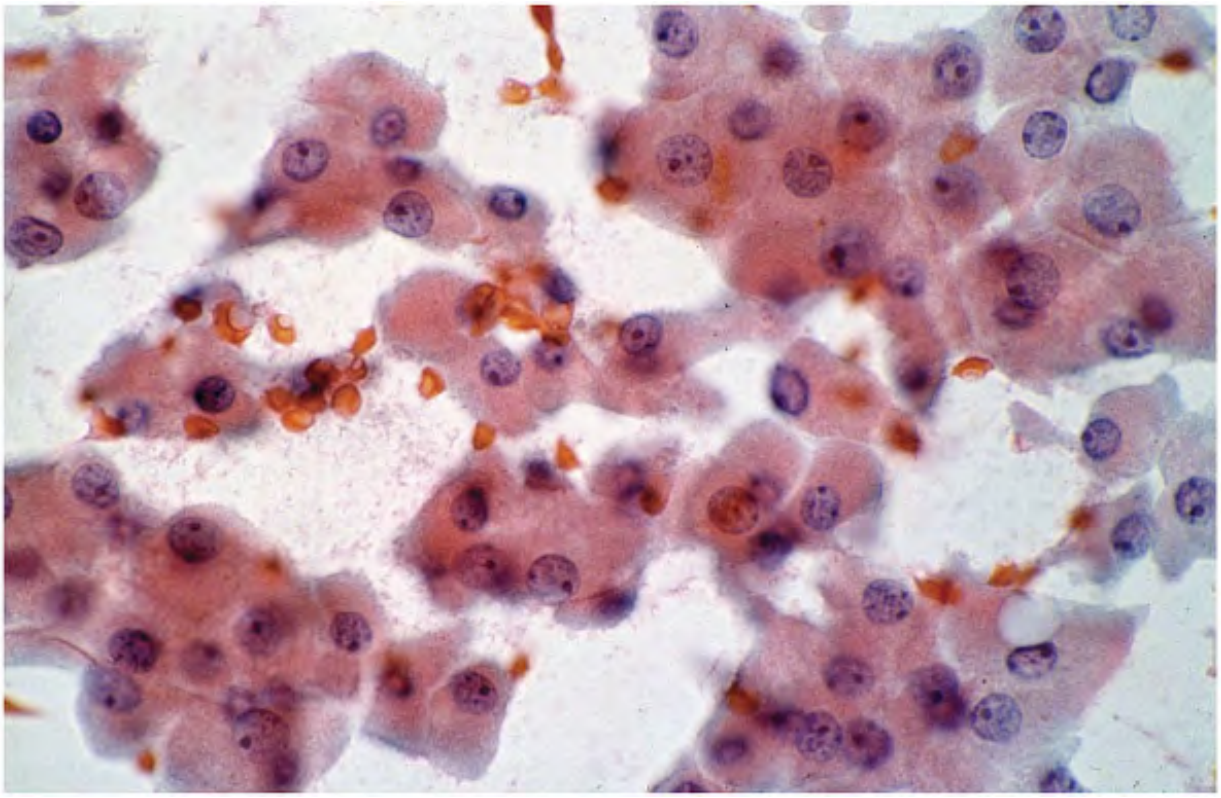

FIGURE 8-8. FNA of a HÃ¼rthle cell adenoma. The cellular aspirate shows large, round to p
cells with well-defined cell borders, arranged in sheets. Note the abundant granular eosinop
cytoplasm. The nuclei are uniform, round, central to eccentric, and with finely granular chr
cherry-red macronucleolus is the hallmark of neoplastic HÃ¼rthle cells. Note low N/C ratios
colloid in the background.

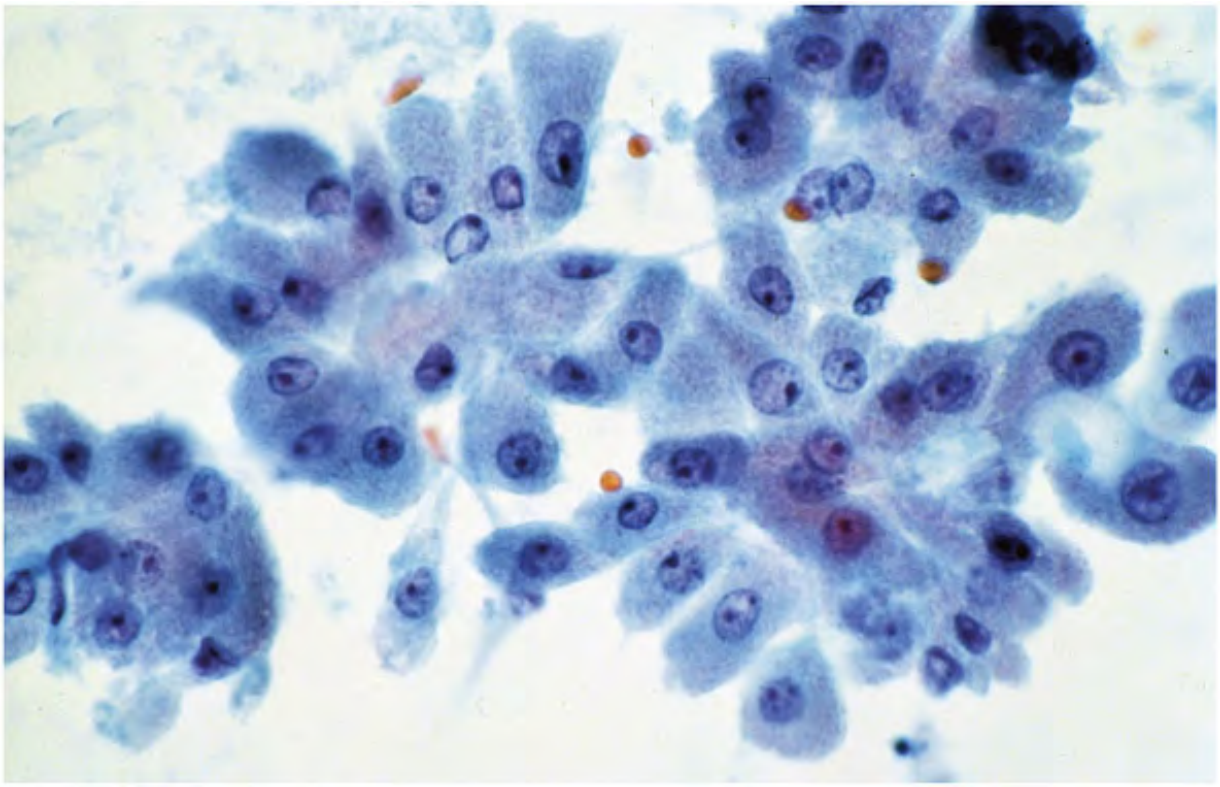

FIGURE 8-9. FNA of another HÃ¼rthle cell adenoma. The cellular aspirate shows large, rour polygonal cells with well-defined cell borders, occurring singly or arranged in sheets. Note t abundant granular cytoplasm is stained cyanophilic. The nuclei are uniform, round, and cen eccentric, with finely granular chromatin containing cherry-red macronucleolus.

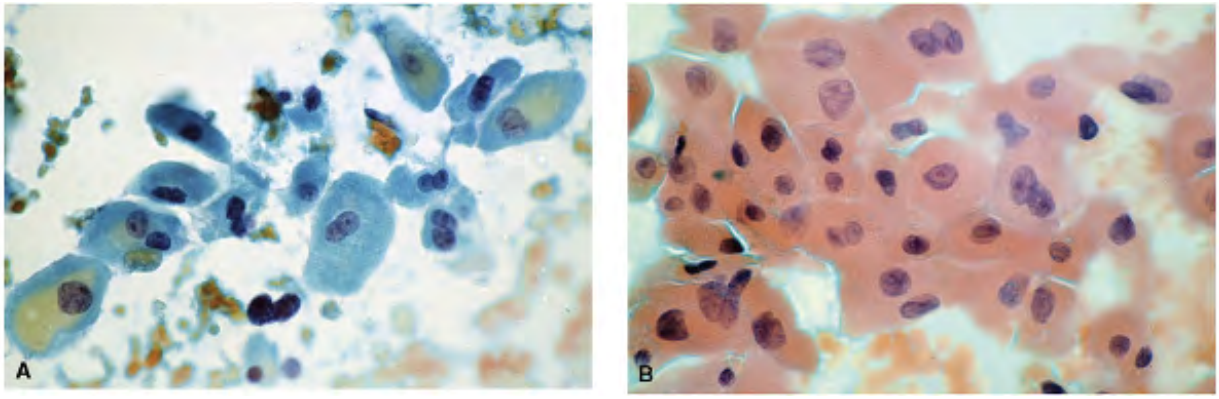

FIGURE 8-10. This FNA of a HÃ¼rthle cell adenoma shows neoplastic cells with either (A) ec (B) cyanophilic cytoplasm. The cells are pleomorphic in size and shape, but contain abundar cytoplasm with low N/C ratios. The nuclei are uniform.

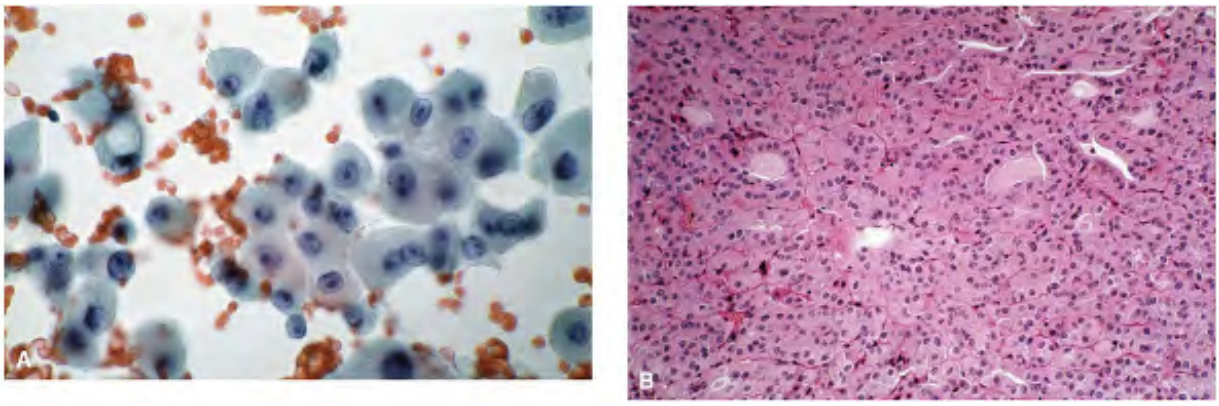

FIGURE 8-11. A. The neoplastic cells in FNA of this HÃ¼rthle cell adenoma are round but la seen isolated, in groups, or in sheets. The cytoplasm is abundant and granular. The nuclei a uniform, containing macronucleolus. Note the cytoplasmic vacuole. B. Histologic section of tumor showing a solid growth pattern with occasional follicular differentiation. Note the lar and low N/C ratios.

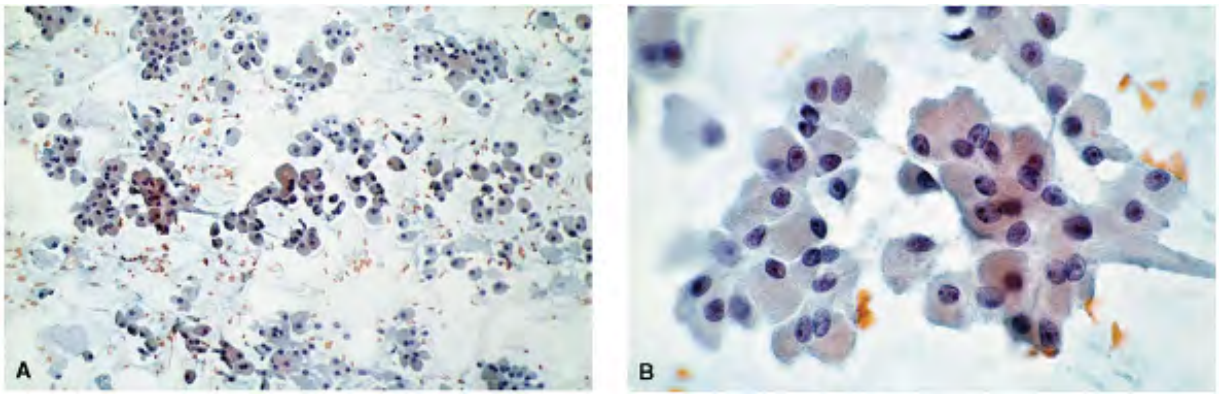

FIGURE 8-12. A. FNA of a HÃ¼rthle cell adenoma depicting marked cellularity and a clean b (low power). B. Higher magnification highlighting the characteristic cytomorphology. The ne HÃ¼rthle cells are round to oval, containing amphophilic cytoplasm. Some cells are binuclea Macronucleoli are conspicuous. The background is clean with no colloid.

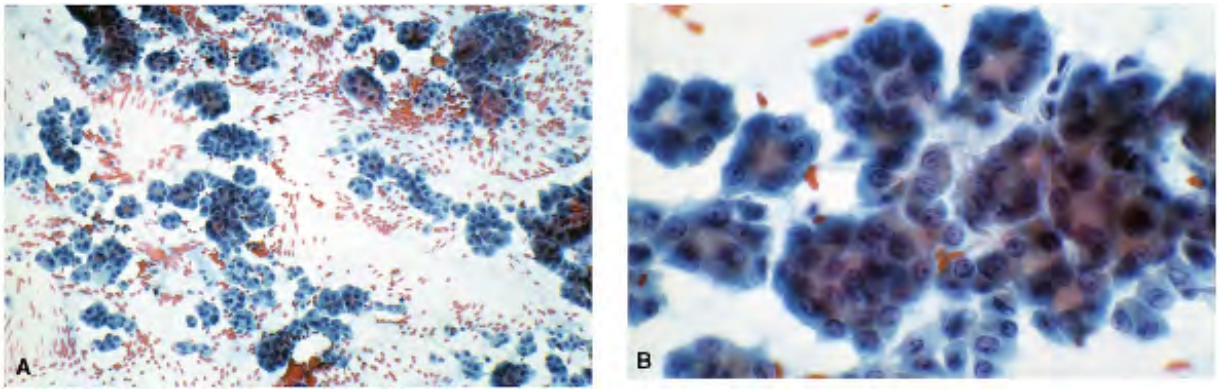

FIGURE 8-13. FNA of a HÃ¼rthle cell adenoma with follicular pattern. A. The aspirate is ve
with several tissue fragments in a clean background. B. Higher magnification demonstrating
to oval HÃ¼rthle cells forming follicles. Their granular cytoplasm is stained cyanophilic. No
nucleoli. Because of the high N/C ratios, malignancy was suspected. Thyroidectomy reveale
encapsulated HÃ¼rthle cell adenoma.

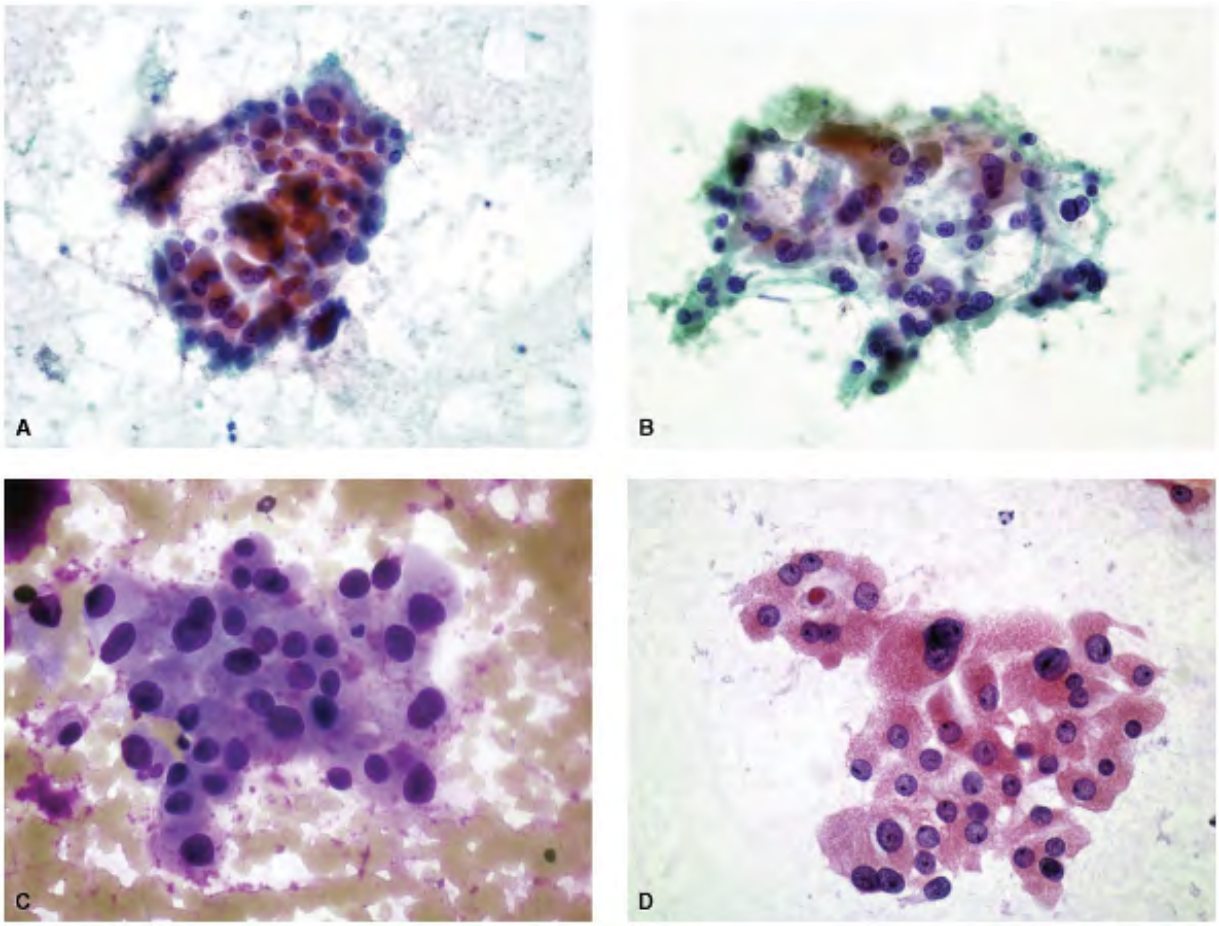

FIGURE 8-14. FNA of a HÃ¼rthle cell adenoma. A , B . Papanicolaou-stained preparation sh
round to polygonal cells with abundant cytoplasm. The nuclei are pleomorphic, with low N/
Same aspirate, Diff-Quik preparation. D . Same aspirate, hematoxylin-eosin preparation. (C
Mithra Baliga, MD, University of Mississippi, Jackson.)

The background is usually bloody. The amount of colloid is variable: it can be absent, scant,
appreciable. The presence of colloid is not a feature against the diagnosis of HÃ¼rthle cell
However, benign, regular-type, follicular cells are not present in the background. The occu
histiocytes with or without hemosiderin indicates old hemorrhage within the tumor and doe
out a neoplasm.

Being very vascular, HÃ¼rthle cell adenomas are prone to postbiopsy infarction (see Chapte
The importance of knowing this lies in the fact that infarction may compromise the final his
diagnosis, in the event that the surgical pathologist is not informed of the cytologic diagnos
case, the pathologist may overlook the viable tumor usually present as a thin rim at the per
Spontaneous infarction can also occur in HÃ¼rthle cell adenomas.44

HÃ¼rthle Cell Carcinoma

Synonyms for HÃ¼rthle cell carcinoma are oncocytic carcinoma, oxyphilic carcinoma, and f
carcinoma with oncocytic features.

HÃ¼rthle cell carcinomas are predominantly or exclusively composed of HÃ¼rthle cells. Ag
true incidence is not known, as they are often considered morphologic variants of follicular
carcinomas.7 , 8 , 9 , 10 , 11 , 12 , 13 , 14 , 15 , 16 , 17 , 18 They are considered uncommo
comprising 2% to 3% of all thyroid malignancies and 20% of follicular carcinomas.14 HÃ¼rthl
carcinomas are more common in women, and occur in the older age group, the mean age at
presentation being 55 years.

They present an aggressive clinical behavior, with a high degree of mortality.2 , 19 , 20 , 21
45 , 46 , 47 , 48 , 49 , 50 HÃ¼rthle cell carcinomas are locally invasive, frequently recur, a
follicular-carcinomas, metastasize to the cervical lymph nodes. They also metastasize to th
organs such as lungs, bones, and liver. HÃ¼rthle cell carcinomas do not take up radioactive
Large tumor size (> 4 cm), extrathyroidal extension, and nodal metastasis are factors associ
the worst outcome.

Gross and Histologic Features

Grossly, HÃ¼rthle cell carcinomas are large and bulky, replacing the entire lobe (Figs. 8.15 with a fleshy, brown, cut surface, and frequently with areas of necrosis and hemorrhage. Hi HÃ¼rthle cell carcinomas may be completely encapsulated with capsular or vascular invasio can be widely invasive. HÃ¼rthle cell carcinomas are characterized by solid, alveolar, trabe papillary growth patterns (Figs. 8.16 , 8.17D , 8.18C , 8.19B , 8.20E , 8.20F , 8.22C , 8.22D , 8.25F , 8.26C and 8.28B). The malignant HÃ¼rthle cells are usually of much smaller size co their benign counterpart. The N/C ratios are high, and macronucleoli are very prominent. T carcinoma demonstrates an increased proliferative activity with mitosis. HÃ¼rthle cell carc demonstrate a poorly differentiated pattern with large, pleomorphic, malignant cells contai malignant nuclei. The carcinoma frequently involves the perithyroidal soft tissues.

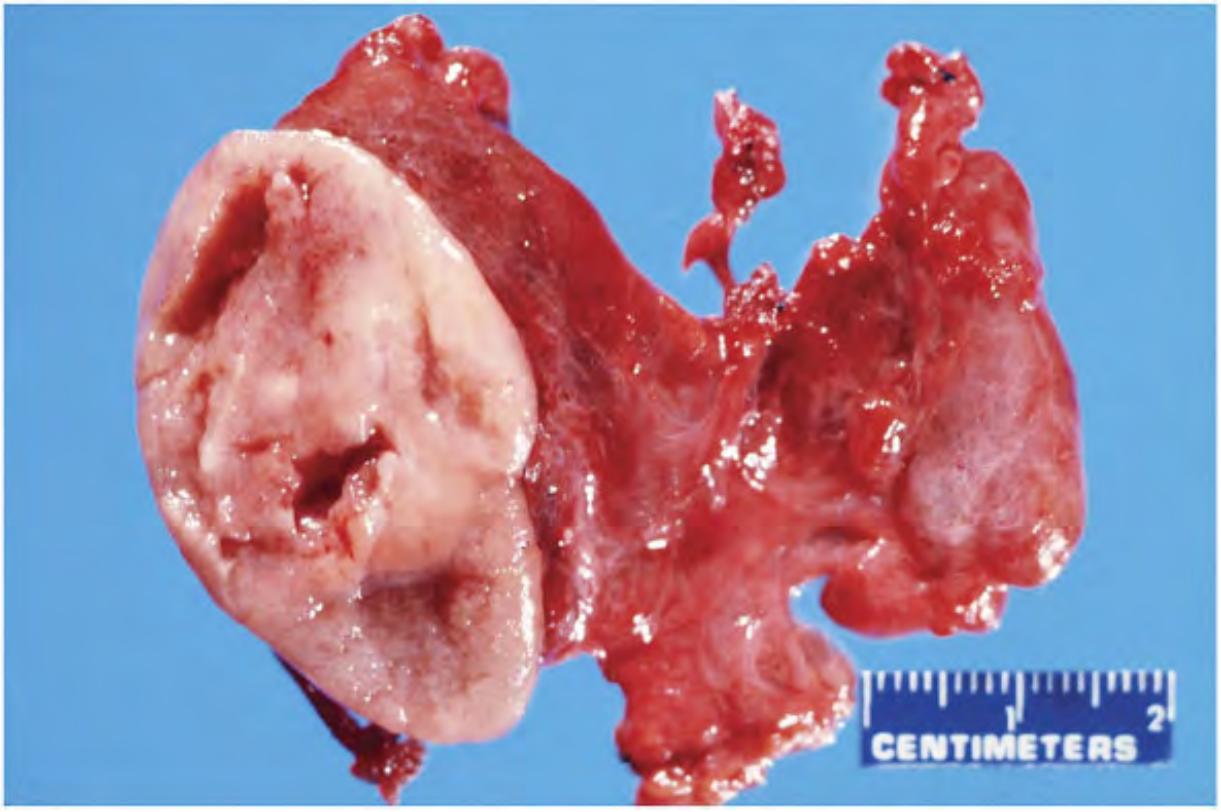

FIGURE 8-15. Gross photograph of a HÃ¼rthle cell carcinoma, involving the entire right lob thyroid. The tumor is bulky and fleshy with areas of hemorrhage and necrosis.

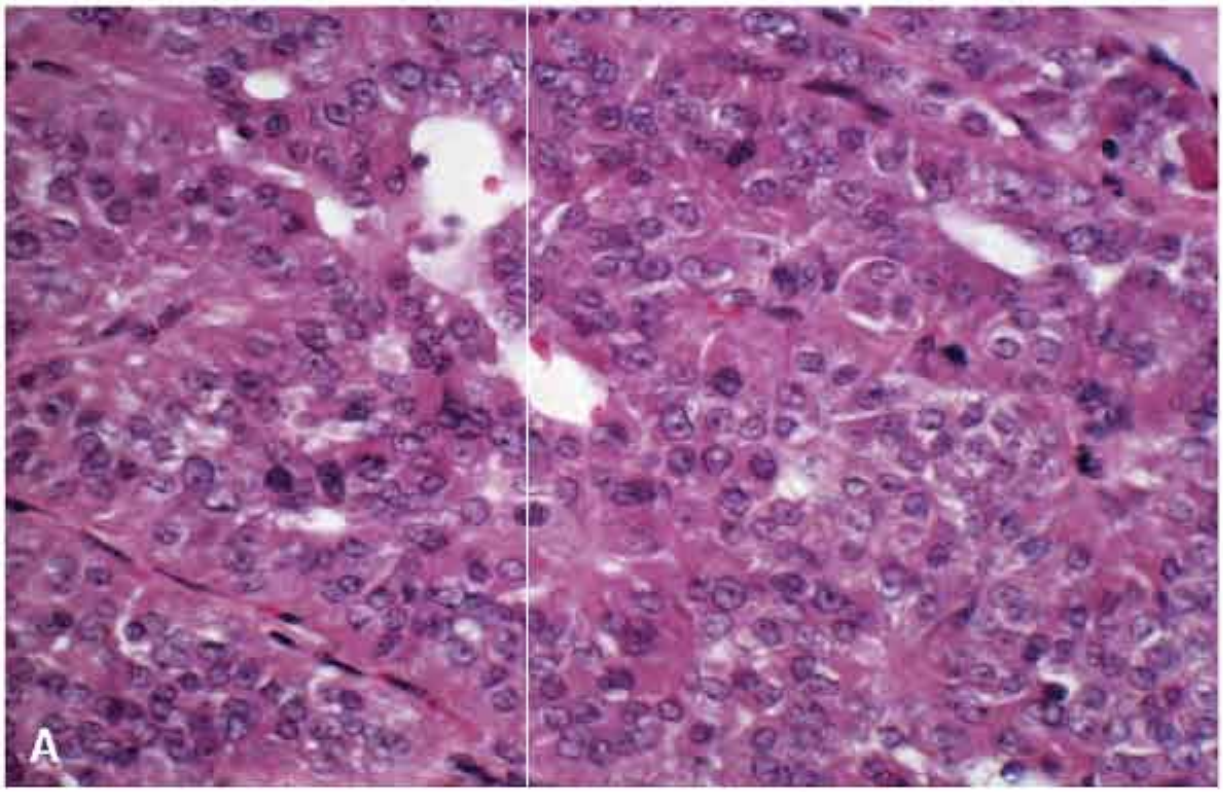
A

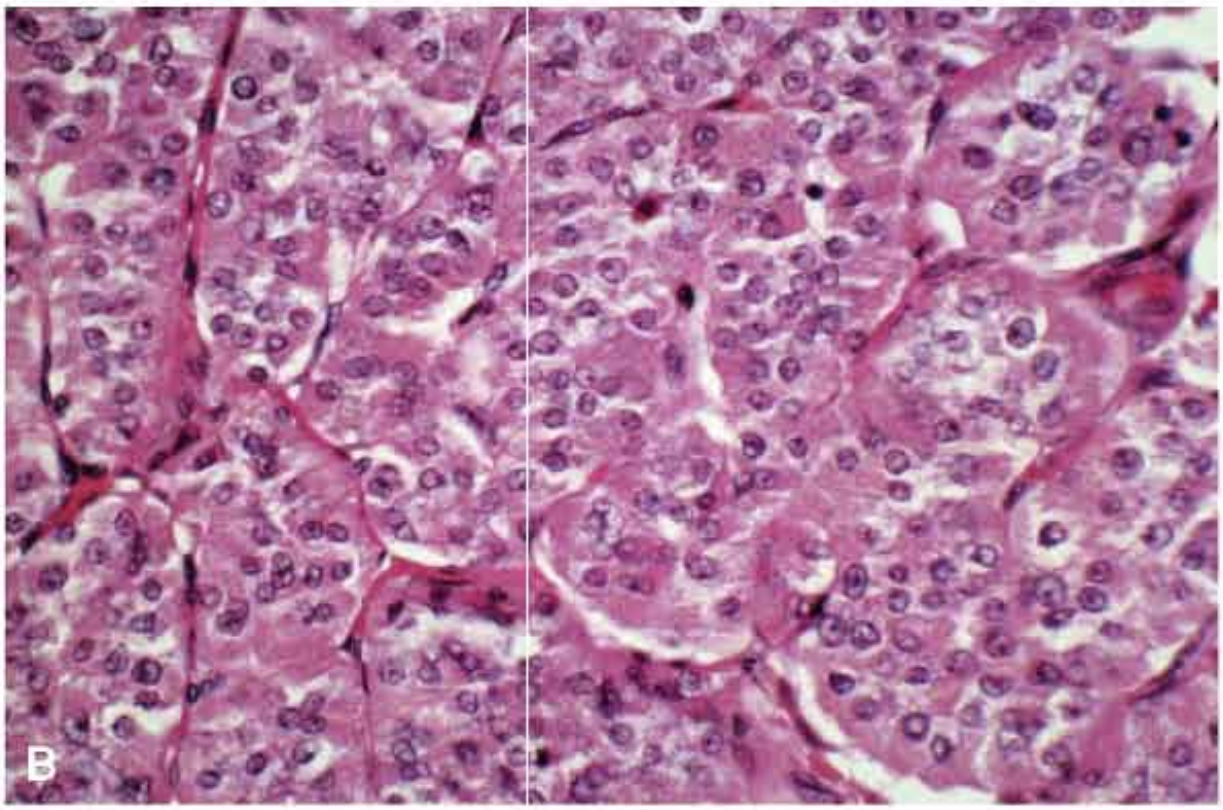
B

FIGURE 8-16. Histologic sections of a HÃ¼rthle cell carcinoma, showing a solid and a trabec formed by smaller neoplastic cells with very high N/C ratios.

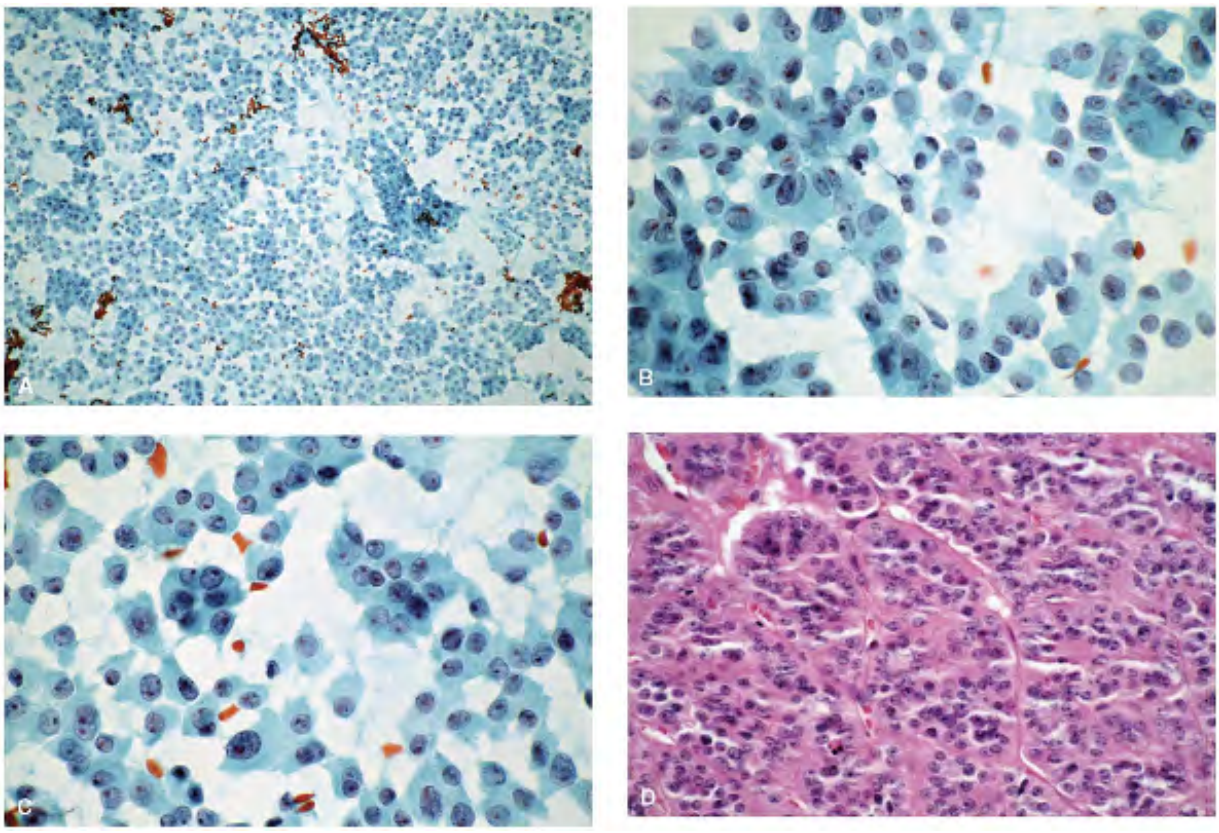

FIGURE 8-17. FNA of HÃ¼rthle cell carcinoma. A. The aspirate is markedly cellular with nec forming a dissociated pattern. The background is clean and lacks colloid (low power). B , C magnification showing much smaller cells, occurring singly, in loosely cohesive groups, or in tissue fragments. Smaller cell size, scant but dense cytoplasm, relatively large nucleus with ratios, and prominent macronucleoli characterize malignancy in HÃ¼rthle cell neoplasms. A plasmacytoid cells, resembling medullary-carcinoma cells. Thyroidectomy confirmed a HÃ¼ carcinoma. D . Histologic section showing a solid growth pattern with small to medium-sizec high N/C ratios.

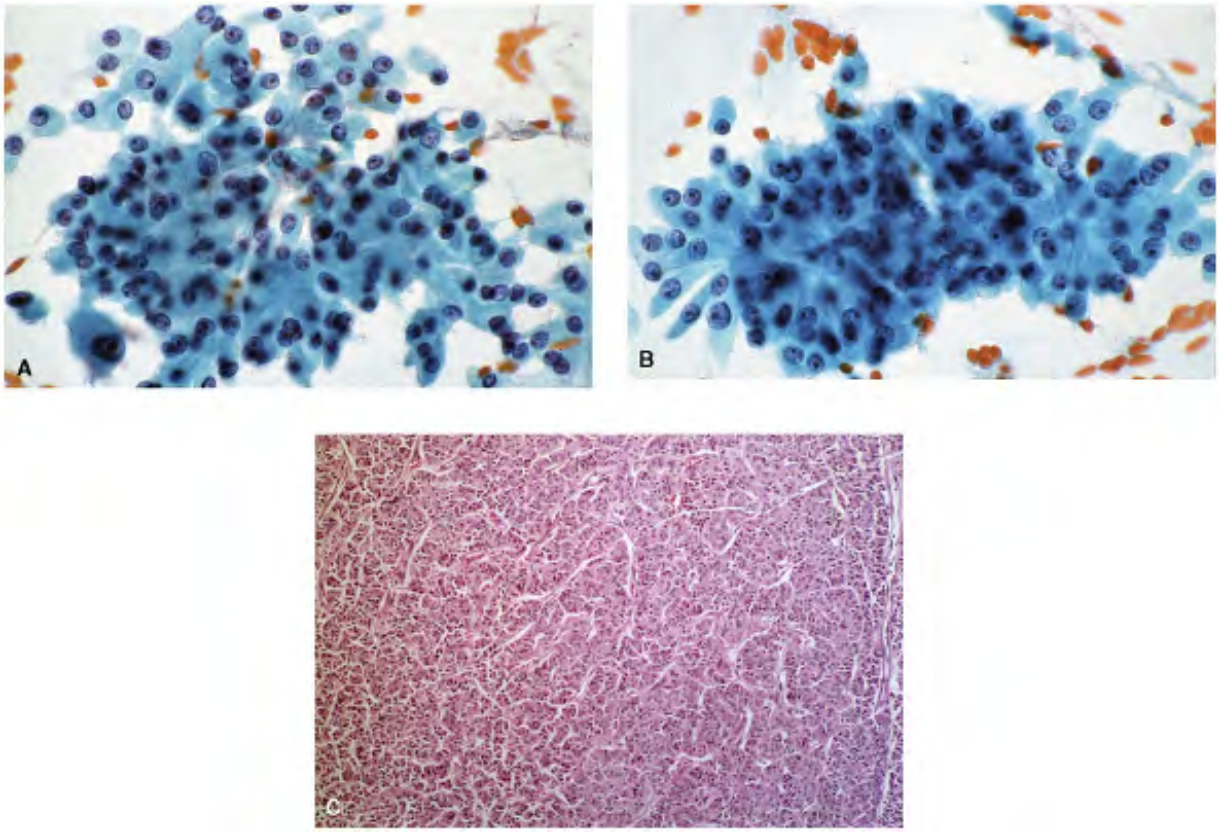

FIGURE 8-18. FNA of HÃ¼rthle cell carcinoma. A . The neoplastic HÃ¼rthle cells are presen syncytial tissue fragments. The malignant cells are medium-sized, round, oval to columnar, containing scant cytoplasm with high N/C ratios. Note the prominent macronucleoli. B . Anc showing syncytial arrangement with crowding and overlapping of nuclei. Their chromatin is granular, and single or multiple nucleoli are conspicuous. C . Histologic section of the carcir

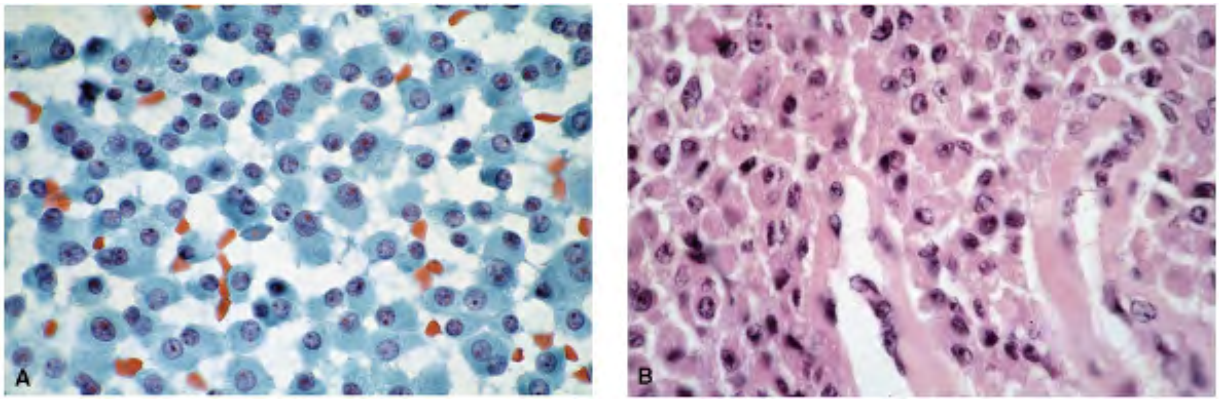

FIGURE 8-19. A . Another example of HÃ¼rthle cell carcinoma, showing a dispersed patterr small to medium-sized uniform cells with high N/C ratios. Note the characteristic nuclear m

with prominent macronucleoli. B . Histologic section of the excised tumor.

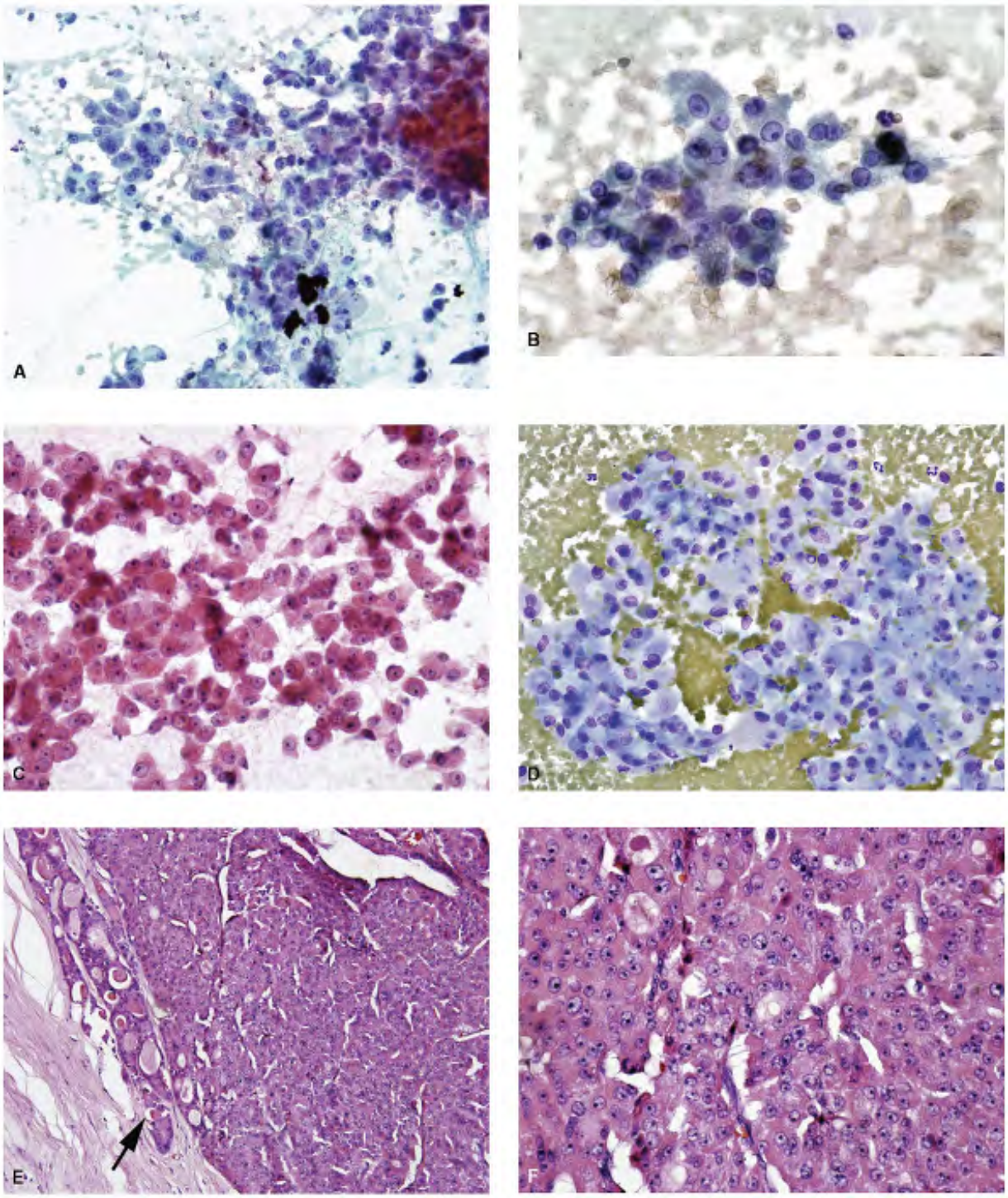

FIGURE 8-20. FNA of a HÃ¼rthle cell carcinoma. A, B . Papanicolaou-stained preparation sh
syncytial tissue fragments of small HÃ¼rthle cells with high N/C ratios. Note scant but granu

cytoplasm, round nuclei with macronucleoli. C . Smear stained with hematoxylin &eosin. Th in syncytial arrangement, containing eosinophilic cytoplasm. The nuclei are uniform, but co prominent macronucleoli. D . Diff-Quik-stained preparation showing a syncytial tissue fragm HÃ¼rthle cells. Note prominent nucleoli. E . Histologic section showing capsular invasion. F. magnification to show the solid growth pattern. (Courtesy of Mithra Baliga, MD, University o Jackson.)

The diagnosis of HÃ¼rthle cell carcinoma is entirely based on demonstrating invasive charac such as capsular and vascular invasion and invasion of the surrounding parenchyma, as descr conventional follicular carcinomas. The same diagnostic criteria are applicable and the sam controversies are also encountered.

Cytopathologic Features of HÃ¼rthle Cell Carcinoma

The aspirates of HÃ¼rthle cell carcinomas tend to be hypercellular and exhibit a spectrum c features (Table 8.4 ; Figs. 8.17 , 8.18 , 8.19 , 8.20 , 8.21 , 8.22 , 8.23 , 8.24 , 8.25 , 8.26 , and 8.29), which vary from small to medium-sized, uniform round, cuboidal, plasmacytoid c high N/C ratios, to a very pleomorphic cell pattern. The latter is only infrequently encounte the small to medium-sized cell pattern is more commonly observed in our experience. The r cells appear discrete, in loosely cohesive groups or in syncytial tissue fragments, the dispers pattern being more frequent. Malignant HÃ¼rthle cells are characterized by granular, some variable but scant cytoplasm, and larger, round nuclei with high N/C ratios (Figs. 8.17 , 8.18 8.22 , 8.23 , 8.24). In fact, a very cellular aspirate with a dispersed cell pattern formed by monomorphic small to medium-sized HÃ¼rthle cells with prominent cherry-red macronuclec striking presentation, even at low power (Figs. 8.17A and 8.24A). The neoplastic cells are o of their cytoplasm, resulting in naked nuclei 34 seen in the background.

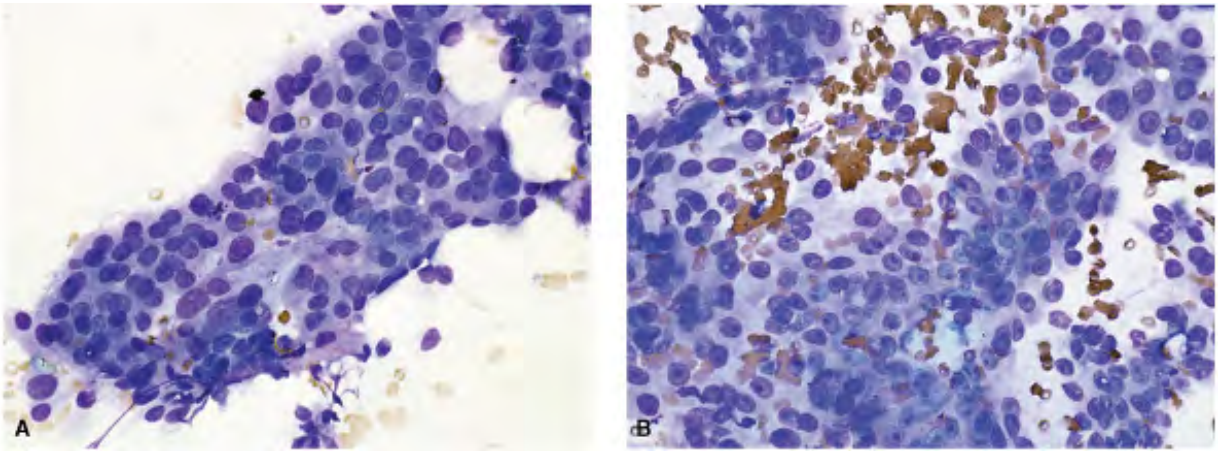

FIGURE 8-21. FNA of a HÃ¼rthle cell carcinoma stained by Diff-Quik. Note that nucleoli are visible. (Courtesy of Marizza de Peralta, MD, William Beaumont Hospital, Royal Oak, Michiga

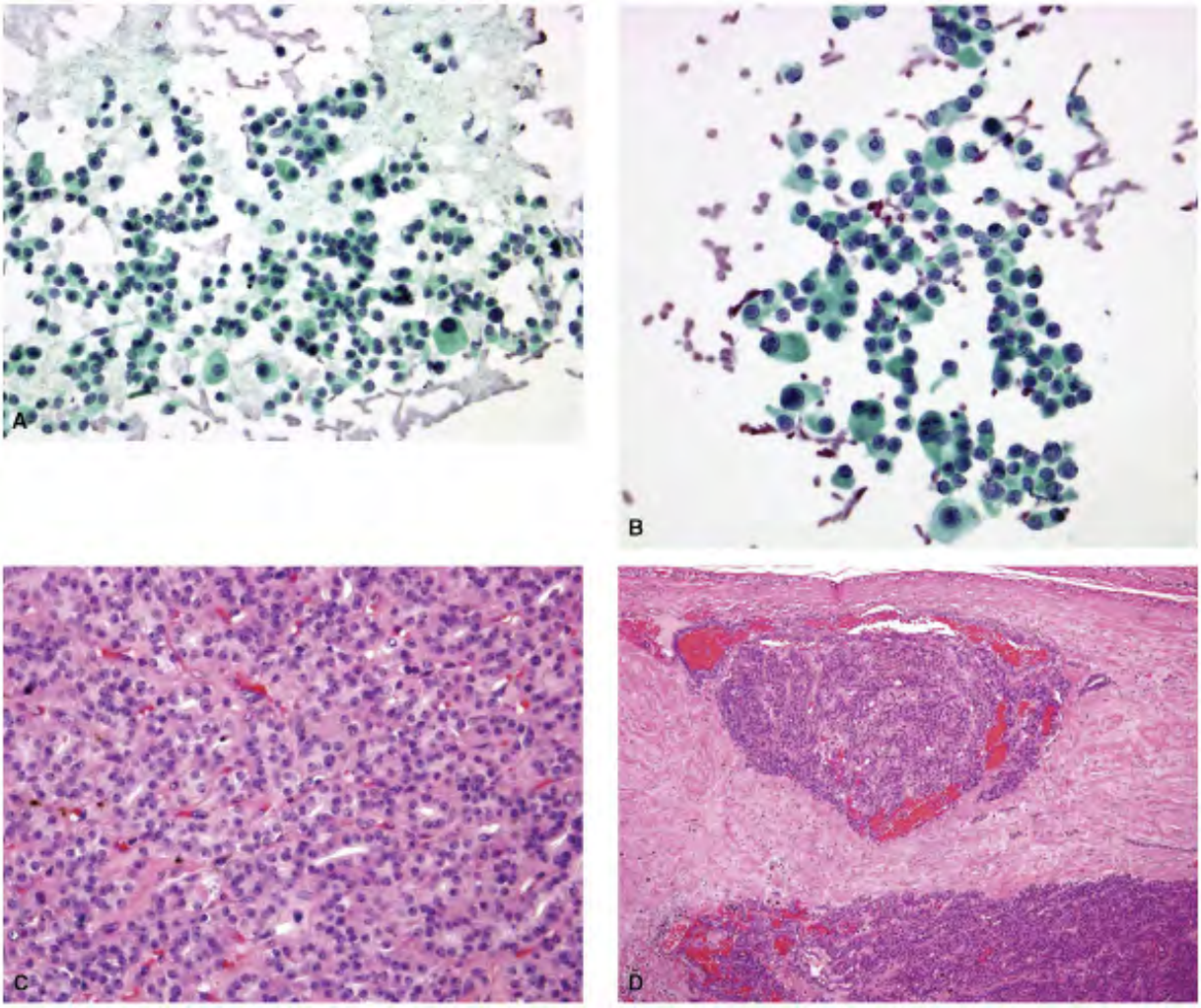

FIGURE 8-22. FNA of a HÃ¼rthle cell carcinoma. A, B . The cellular aspirate is composed of round to cuboidal cells, discrete and forming small syncytial tissue fragments. The cell bord poorly defined. N/C ratios are high, and macronucleoli are prominent. C . Histologic section carcinoma exhibiting a solid growth pattern. D . Invasion of the blood vessel.

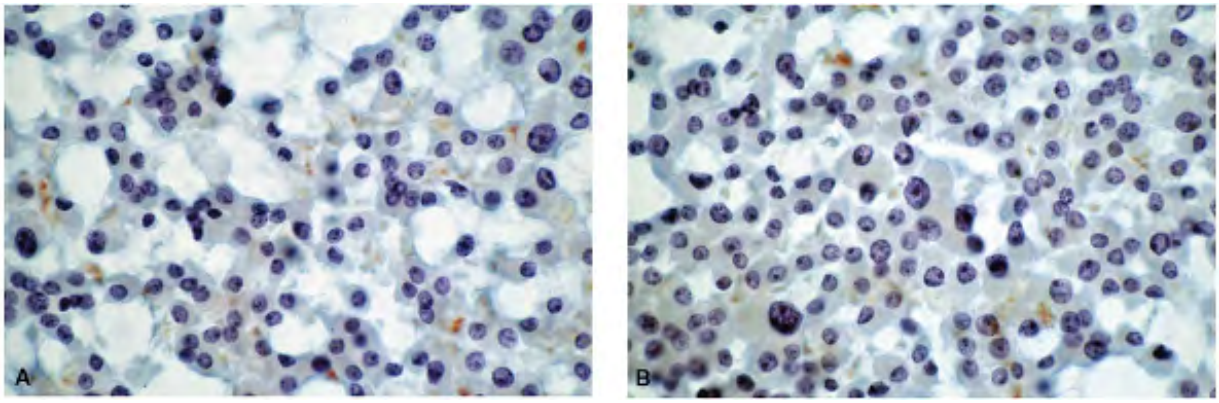

FIGURE 8-23. Another example of a HÃ¼rthle cell carcinoma, demonstrating a dispersed ce formed by small to medium-sized cells with high N/C ratios and containing a prominent mac

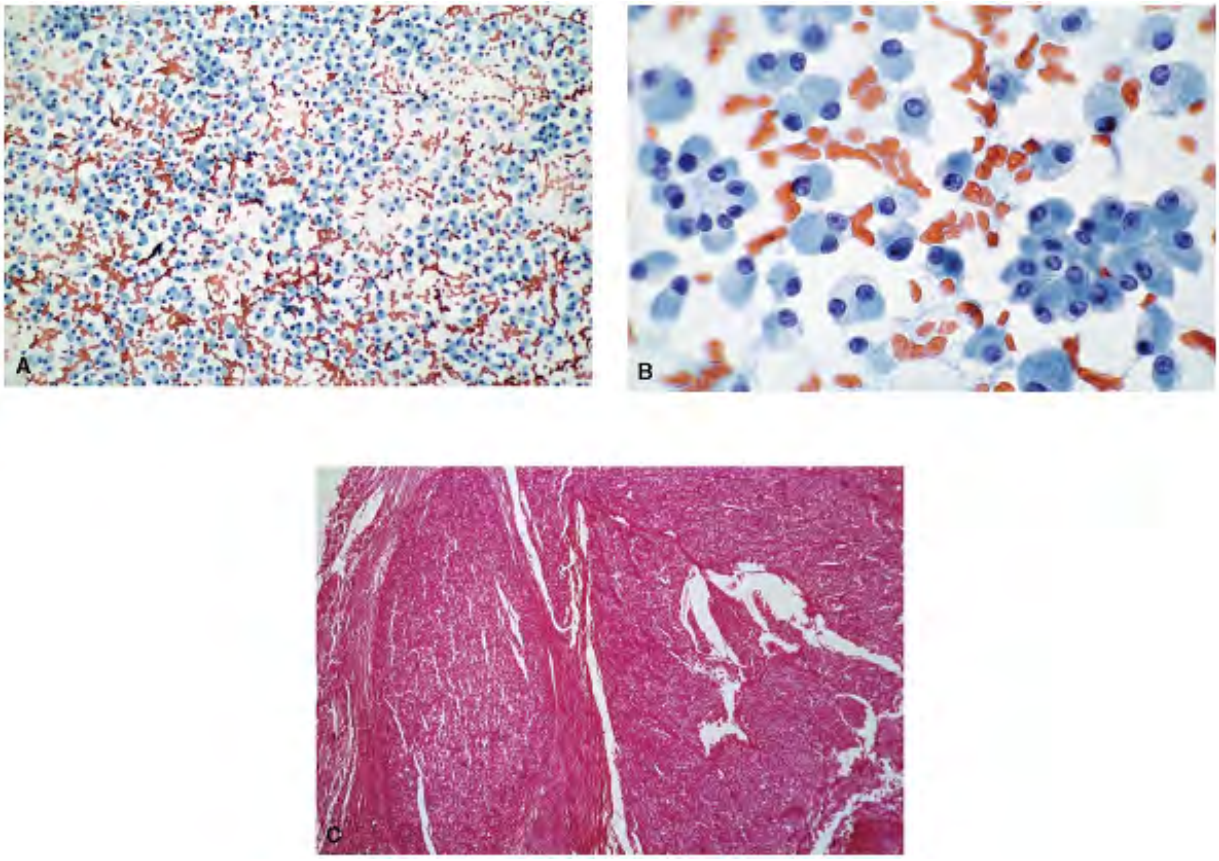

FIGURE 8-24. HÃ¼rthle cell carcinoma. A . Low-power view of the cellular aspirate with a c
pattern. The background is clean, lacking colloid. B . Higher magnification showing oval, un
to medium-sized cells. The nuclei are eccentric. But for their macronucleoli, these cells res
medullary-carcinoma cells. C . Histologic section showing invasion of the parenchyma outsid
capsule.

Cellularity

Usually very cellular

Presentation

Monomorphic, cells isolated, in loosely cohesive groups or in syncytial tissue fragments with
a follicular pattern; trabecular forms Â±; papillary configuration Â±; dispersed pattern mc
transgressing blood vessels within the tissue fragments Â±

Cells

Usually small to medium-sized, round, oval to cuboidal, increased N/C ratios, well to poorly
borders; cells tend to be uniform in size, but can be large and pleomorphic

Nucleus

Uniformly but slightly increased in size or can be pleomorphic; bimultinucleation Â±; centra
eccentric;
round with smooth nuclear membranes; finely granular chromatin, parachromatin clearing
micronucleoli or single to multiple macronucleoli; intranuclear cytoplasmic inclusions Â±
Cytoplasm
Variable; scant, more than seen in cells of follicular adenoma, or carcinoma to appreciable
generally much less compared to HÃ¼rthle cell adenoma cells, dense to granular; may sta
eosinophilic,
cyanophilic, or amphophilic with Papanicolaou stain; deep eosinophilic with hematoxylin-
light purple to lavender with Romanowsky stain
Psammoma Bodies
May be present in papillary variant
Background
Usually bloody; colloid generally absent; necrosis Â±
Ultrastructure
Large numbers of mitochondria
Immunoprofile
Positive reactivity to thyroglobulin, TTF-1 Â± low-molecular-weight keratin

TABLE 8.4 CYTOPATHOLOGIC FEATURES OF HÃœRTHLE CARCINOMA

The syncytial tissue fragments may show no architectural configurations, or demonstrate fo
trabecular patterns. Papillary architecture is encountered in the papillary variant. Many inv
have reported transgressing blood vessels in the tissue fragments of malignant cells to be co
key feature in the cytologic diagnosis.28 , 33 , 38 , 39 , 40 The nuclei are uniformly round a
slightly increased in size, compared to the benign counterpart (Fig. 8.37), with finely granu
chromatin and the characteristic macronucleolus. HÃ¼rthle cell carcinomas may also exhibi
pleomorphic pattern (Figs. 8.25 , 8.26 and 8.27). Multiple nucleoli are frequent,

along with intranuclear inclusions (Fig. 8.25B). The presence of intranuclear inclusions is nc consistent or a specific feature of HÃ¼rthle cell carcinomas. They were encountered infreq if present should raise a high index of suspicion for malignancy.

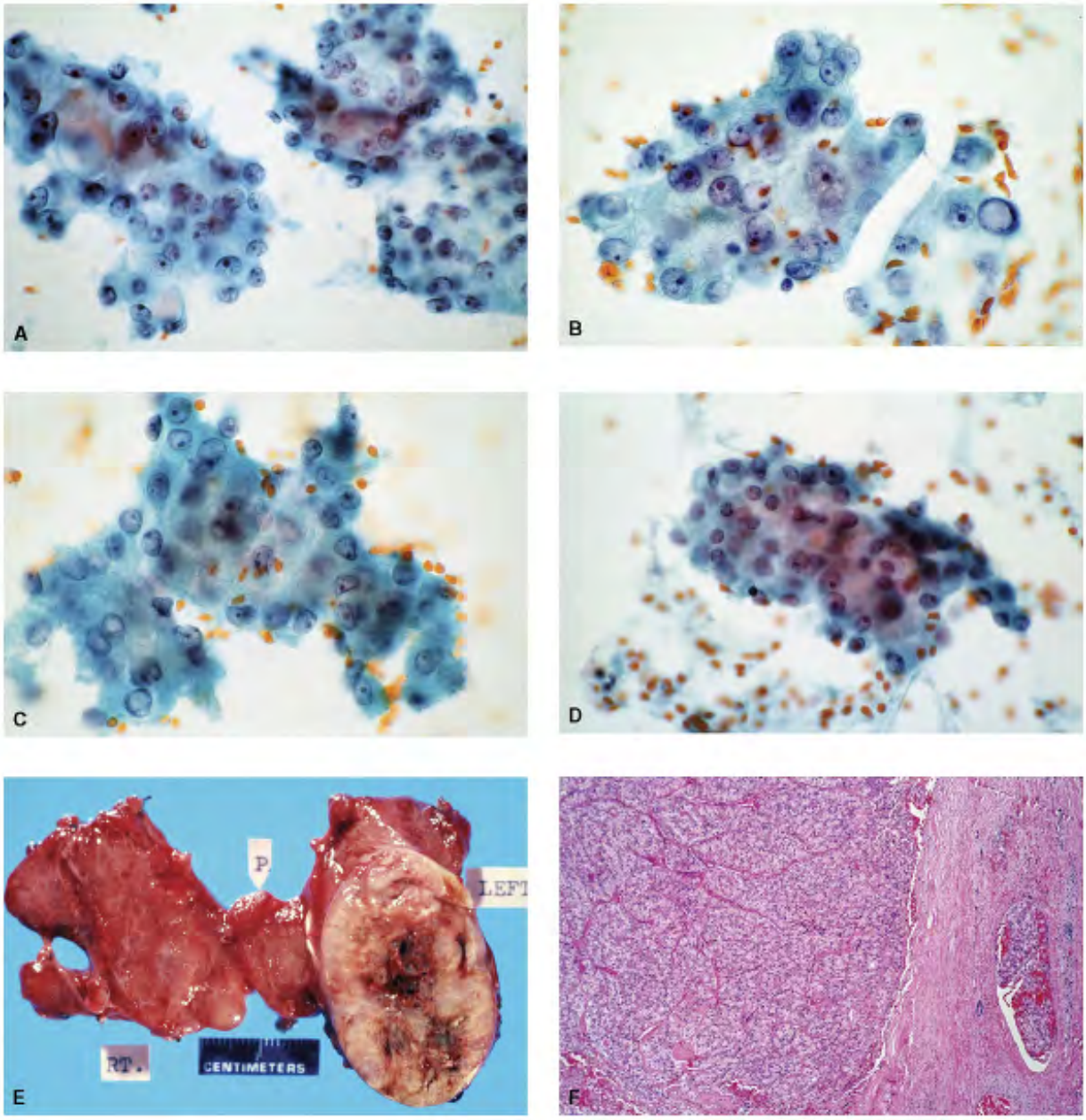

FIGURE 8-25. This HÃ¼rthle cell carcinoma initially presented as a destructive lesion of the Physical examination revealed a large thyroid nodule. Both lesions were biopsied which shov cytologic pattern. A, B . FNA of the vertebral mass showing syncytial tissue fragments of HÃ

Their cytoplasm is scant, and. macronucleoli are conspicuous. C, D . FNA of the thyroid mas are clearly malignant, arranged in syncytial tissue fragments with pleomorphic nuclei, prom nucleoli, and intranuclear inclusion. E . Gross photograph of the excised thyroid showing a l replacing the entire left lobe. F . Histologic section showing HÃ¼rthle cell carcinoma. Note invasion.

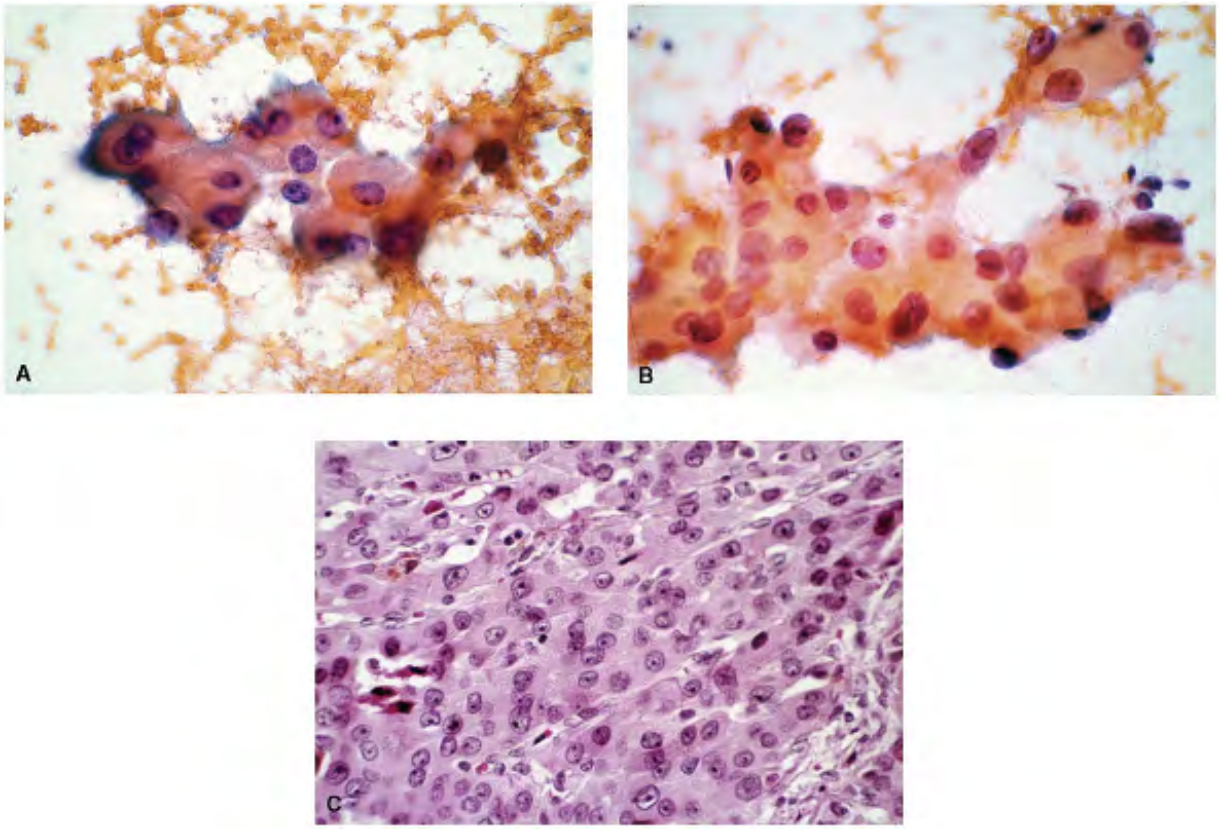

FIGURE 8-26. FNA of a HÃ¼rthle cell carcinoma. A, B . The malignant cells are large, conta abundant cytoplasm, and are arranged in syncytial fashion. However, note that their nuclei and very pleomorphic with prominent nucleoli. C . Histologic section of the carcinoma show growth pattern formed by pleomorphic malignant cells.

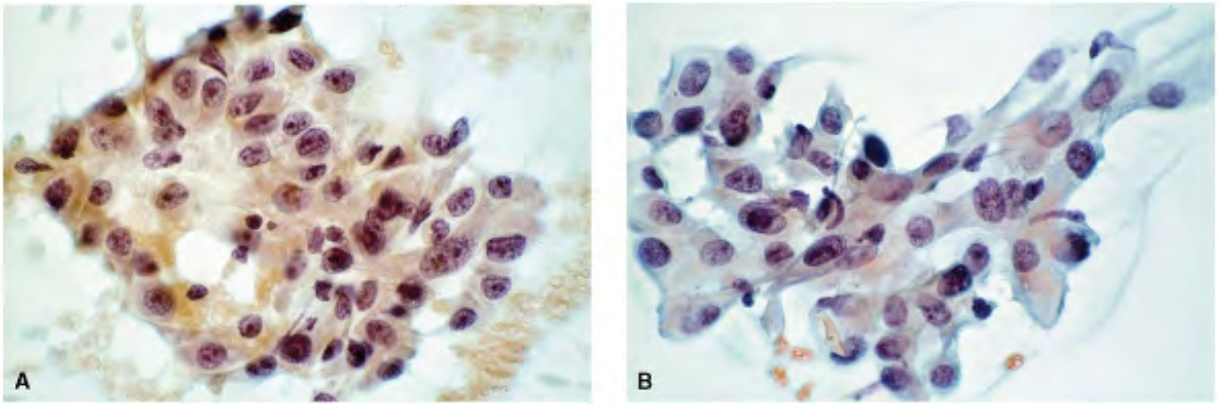

FIGURE 8-27. A different example of HÃ¼rthle cell carcinoma, showing syncytial tissue frag very pleomorphic nuclei.

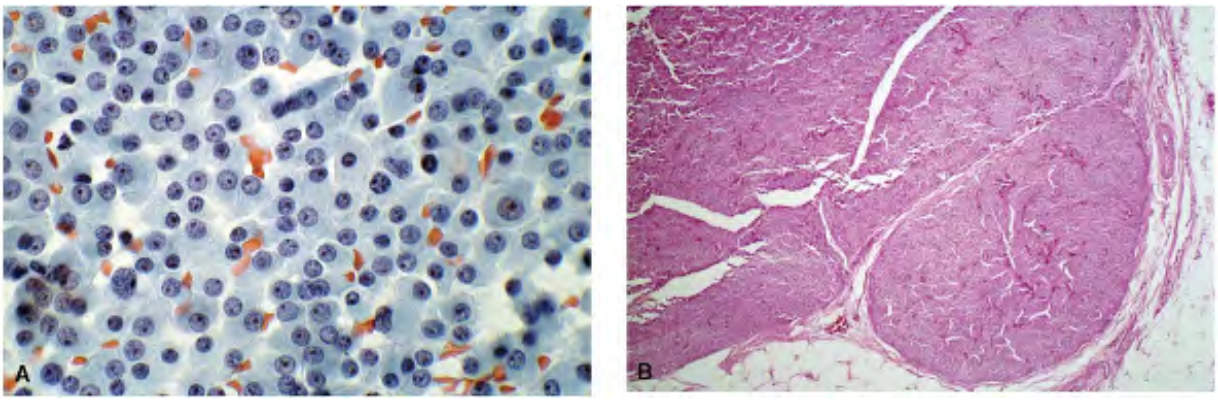

FIGURE 8-28. FNA of a locally recurrent HÃ¼rthle cell carcinoma. A . The cells are small, o singly, presenting a dispersed pattern. Note uniformity, scant cytoplasm, high N/C ratios an macronucleoli. B . Histologic section of the excised tumor showing a solid growth pattern. T neoplastic cells are smaller with high N/C ratios.

The background may be clean, necrotic, or bloody and devoid of colloid. The presence of hi with and without hemosiderin has been reported to be a feature against the diagnosis of HÃ tumors.29 Our experience, and that of others, states otherwise. Degeneration and hemorrh common in HÃ¼rthle cell neoplasms. Local recurrence is frequent with HÃ¼rthle cell carcin aspirates present the characteristic small to medium-sized cell pattern (Figs. 8.28 and 8.29

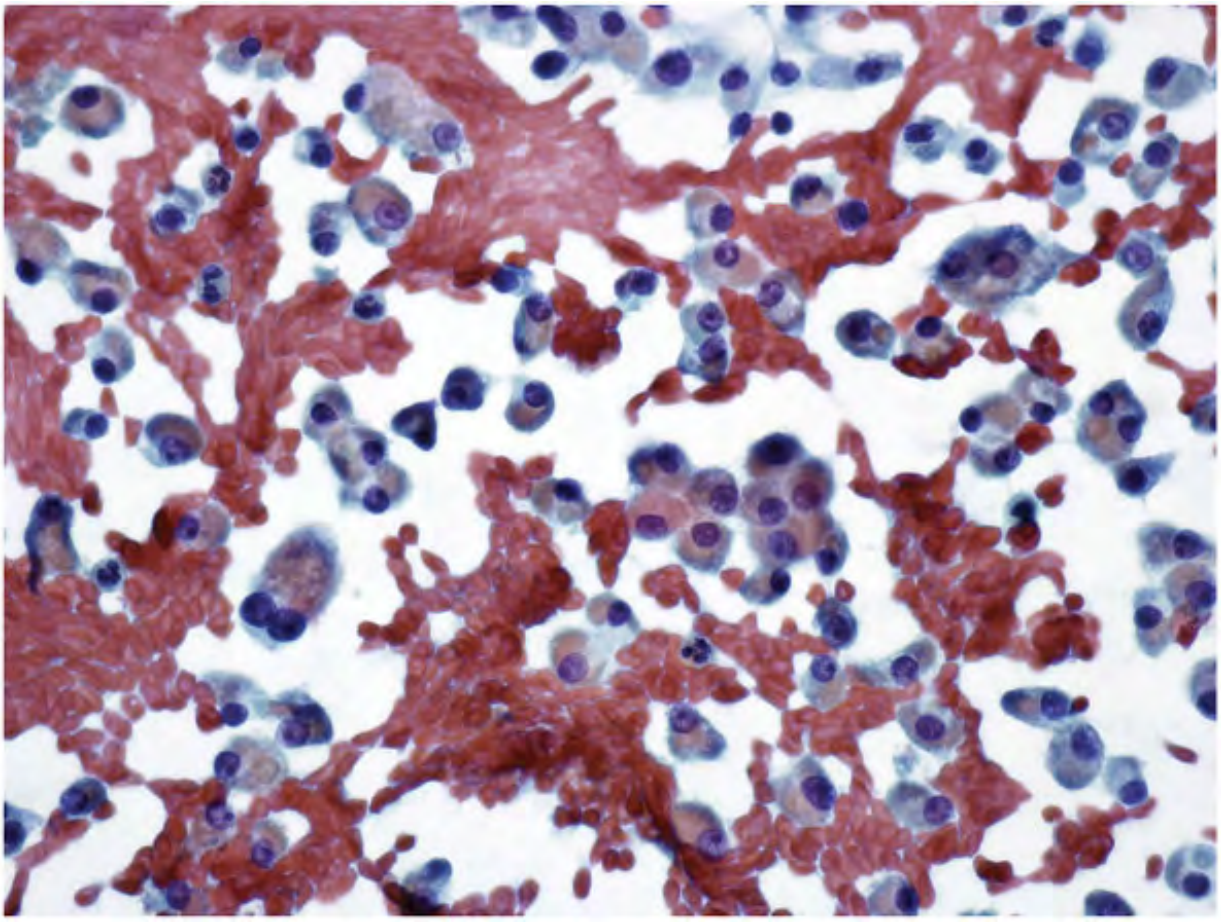

FIGURE 8-29. FNA of another example of locally recurrent HÃ¼rthle cell carcinoma, consist dispersed small cells with scant but dense cytoplasm, and nuclei with prominent nucleoli.

Papillary Variant of HÃ¼rthle Cell Carcinoma

Papillary variants of HÃ¼rthle cell carcinoma are very uncommon, and are characterized by growth pattern.2 , 4 , 51 , 52 , 53 , 54 , 55 , 56 , 57 , 58 , 59 The papillary fronds are lined to columnar oncocytic cells. Their nuclei contain granular chromatin and micronucleoli as w intranuclear inclusions. However, powdery, pale chromatin and nuclear grooves are not see Psammoma bodies are frequently identified. The clinical behavior is considered to be simila conventional papillary carcinomas, as was suggested by Horn.4 Barbuto, et al.55 and others reported an aggressive behavior.

Cytologically, the aspirates are cellular, and composed of syncytial tissue fragments of HÃ¼ with papillary configurations.57 , 58 , 59 The neoplastic cells are small to medium-sized wit

HÃ¼rthle cell morphology. This includes variable granular cytoplasm and nuclei containing p
nucleoli. Intranuclear inclusions are frequent. Psammoma bodies are present within the syn
fragments, but can be seen as naked.

Histologically and cytologically, the papillary variant of HÃ¼rthle cell carcinoma is difficult
differentiate from the oxyphilic, tall cell, and Warthin-like variants of papillary carcinomas.
differentiating feature between the carcinomas is the lack of typical nuclear pattern with g
watery nuclei in HÃ¼rthle cell carcinomas (Figs. 8.30 , 8.31 , 8.32 and 8.33).

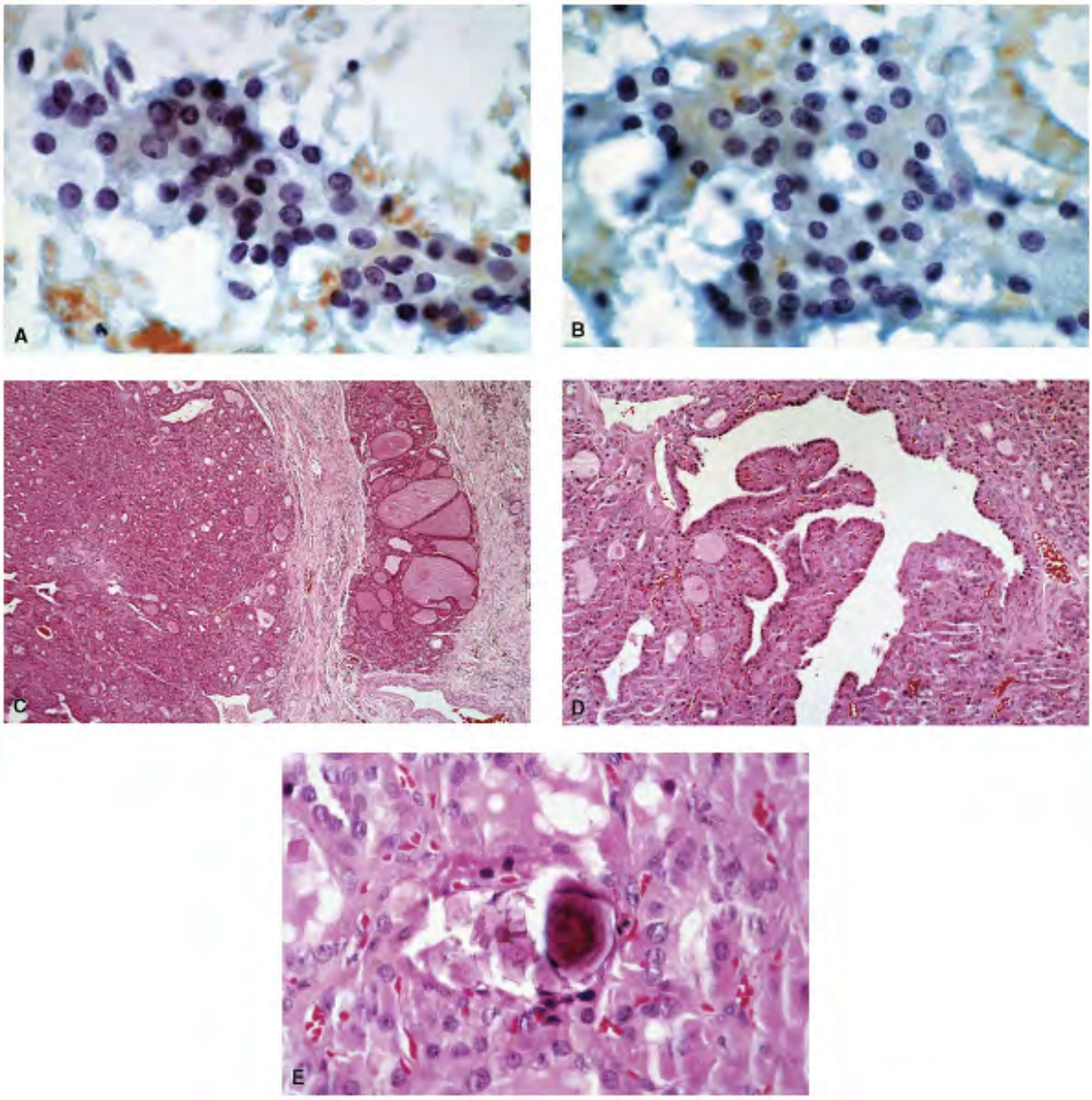

FIGURE 8-30. HÃ¼rthle cell carcinoma with a papillary growth pattern and psammoma bodi

FNA showing syncytial tissue fragments, with crowding and overlapping of nuclei with promi
nucleoli. C . Histologic section of the excised tumor showing vascular invasion. D . The tumc
showed a papillary growth pattern. E . Higher magnification of the papilla. Note that neopla
HÃ¼rthle cells lack the characteristic nuclear morphology of conventional papillary carcinor
the cells demonstrate the characteristic morphology of a HÃ¼rthle cell neoplasm. Note the
body.

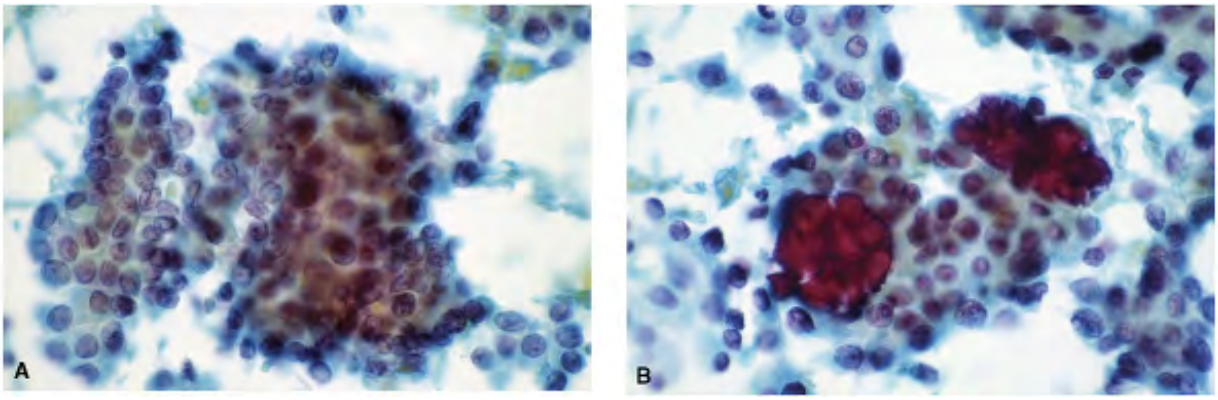

FIGURE 8-31. FNA of a papillary HÃ¼rthle cell carcinoma. A . The HÃ¼rthle cells are smalle
forming syncytial pattern. Note papillary-like architecture, with smooth external contours.
are crowded, overlapped, and contain macronucleoli. The cytoplasm is dense to granular, b
with high N/C ratios. B . These syncytial tissue fragments from a different field show multip
psammoma bodies. Note the lack of fine powdery chromatin.

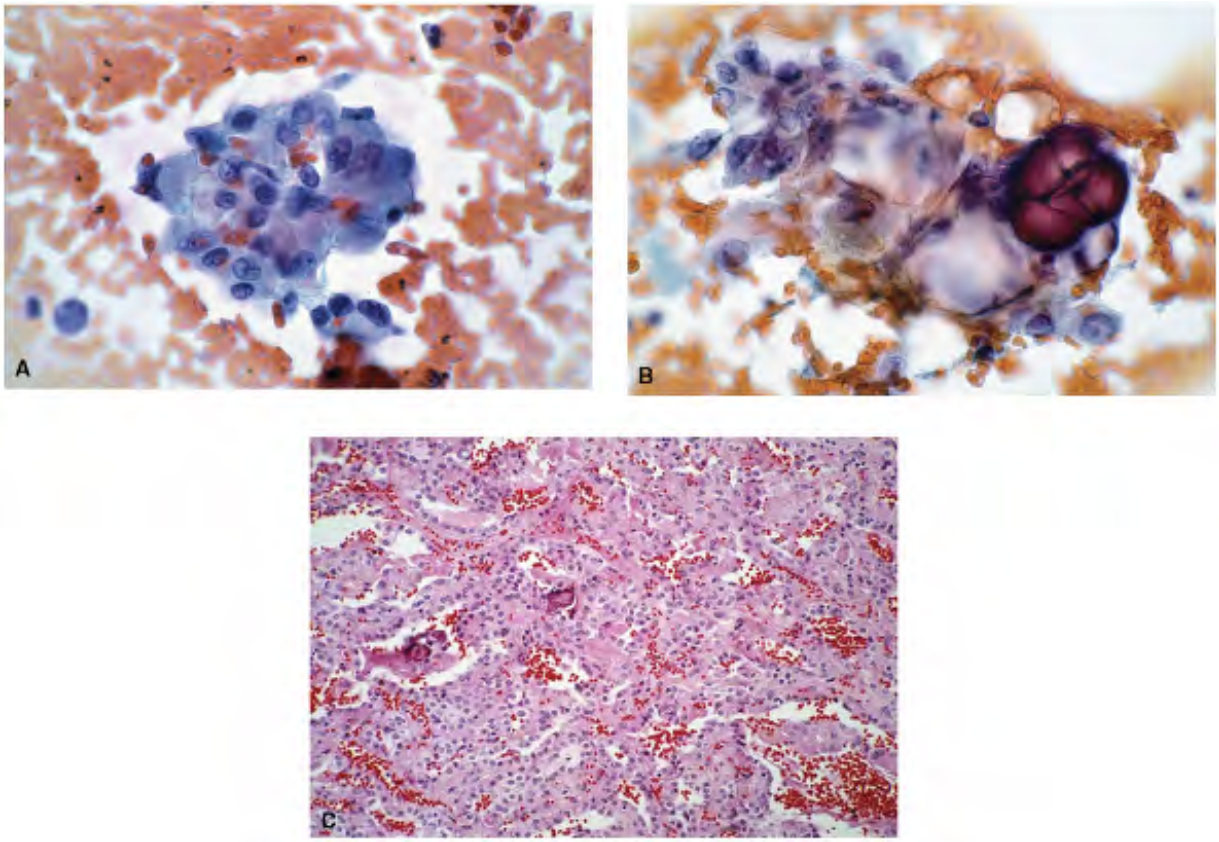

FIGURE 8-32. Papillary HÃ¼rthle cell carcinoma. A . The HÃ¼rthle cells are large, but in sy
arrangement and with altered nuclear polarity. B . This tissue fragment of HÃ¼rthle cells c
psammoma bodies. C . Histologic section of the HÃ¼rthle cell carcinoma demonstrating pap
architecture and psammoma bodies.

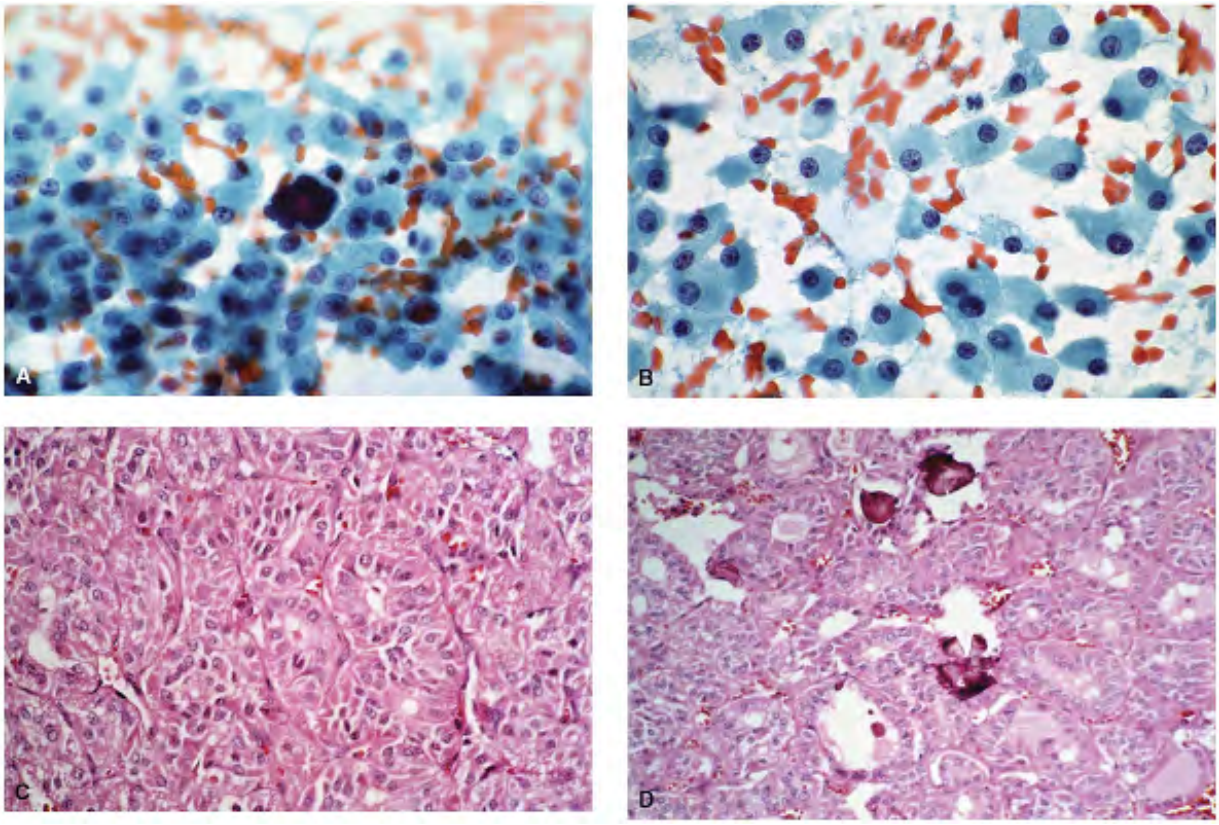

FIGURE 8-33. Locally recurrent papillary HÃ¼rthle cell carcinoma with psammoma bodies. T had a lobectomy in the past, with a diagnosis of papillary carcinoma that was based solely o presence of psammoma bodies. The oncocytic pattern was not taken into consideration. The developed a nodule in the area. A, B . FNA consisting of HÃ¼rthle cells, isolated and in sync fragments. Note the smaller size and high N/C ratios. C, D . The excision revealed a HÃ¼rth carcinoma with a papillary growth pattern and multiple psammoma bodies.

IMMUNOCYTOHISTOCHEMICAL PROFILE AND SPECIAL STUDIE

The cells of HÃ¼rthle cell or oncocytic neoplasms react positively to thyroglobulin, but less than their follicular counterparts. The cells show positive reactivity to TTF-1 in 30%, and to molecular-weight keratin, but not to calcitonin. Although reactivity to carcinoembryonic an is generally absent, Johnson, et al.62 reported consistent positivity to CEA. This observatior confirmed by Bronner and LiVolsi50 and Nesland et al.63 Galectin-3 is demonstrated in 95% cell neoplasms, and reactivity to HBME-1 in 55%, with a specificity of 88% when both marker used.64 , 65 Erickson et al. have demonstrated increased proliferative activity and cyclin D1 in HÃ¼rthle cell, or oncocytic-neoplasms.66 Ploidy analysis has proven to be of limited valu

diagnosis of HÃ¼rthle cell-neoplasms.67 , 68

Chiappetta and co-workers69 demonstrated RET/PTC in a significant number of both HÃ¼rtl adenomas and carcinomas, and its absence in cases with oncocytic hyperplasia. An unequivc gene rearrangement has also been demonstrated in papillary HÃ¼rthle cell carcinomas.70

DIAGNOSTIC ACCURACY AND DIFFERENTIAL DIAGNOSIS

Because of their characteristic cytomorphology, high diagnostic accuracy can be expected f cell neoplasms. However, in actual practice it is not so. The diagnostic accuracy cannot be a from the available data. An important limiting factor is that most institutions group all aspi consisting of a large population of HÃ¼rthle cells as "HÃ¼rthle cell lesions" without an atter differentiate non-neoplastic

entities from neoplastic ones, or benign from malignant lesions. In such an environment, the concordance or discordance between cytology and histology does not exist, because all are l cell lesions and the incidence of false-positive or false-negative diagnosis becomes irrelevan

Many investigators believe that HÃ¼rthle cell carcinomas present a very aggressive behavior recommend a total thyroidectomy. It makes sense, then, to provide the probabilities of neo specifically that of malignancy, and to identify non-neoplastic HÃ¼rthle cell lesions from th Patients with the non-neoplastic diagnosis can be managed conservatively. In the author's e as well as that of others,33 , 34 , 35 this is achievable with a considerable degree of succes noted in Table 8.5 , which lists the cytohistologic correlations of 125 histologically proven H neoplasms (81 adenomas and 29 carcinomas). Of the 81 HÃ¼rthle cell adenomas, 73 were cy interpreted as HÃ¼rthle cell tumors (according to the recommendation of

Thompson, et al.19 ; the distinction between adenoma and carcinoma was not attempted ir part of the biopsy experience). Twenty of thirty-five HÃ¼rthle cell carcinomas were correct from cytology, while only 3 of 17 cases cytologically suspected of carcinoma were confirmec neoplastic lesions were found in suspicious or positively diagnosed HÃ¼rthle cell cancer. On HÃ¼rthle cell neoplasm in the background of Hashimoto's thyroiditis did exhibit transcapsul but was interpreted histologically as an atypical HÃ¼rthle cell nodule (an example of contrc surgical pathological interpretation). The incidence of false-positive diagnoses (nodular goit Hashimoto's thyroiditis) was 12%. The majority of the misinterpretations occurred due to ine

HÃ¼rthle cell tumors
73
53
6
10
4
Suspected HÃ¼rthle cell carcinoma
17
14
3
0
0
HÃ¼rthle cell carcinoma
35
14
20
0
1[a]
TOTAL
125
81
29
10
5
88%
12%

[a] Final diagnosis was Hashimoto's thyroiditis with atypical HÃ¼rthle cell nodule.

	Histologic Diagnosis			
Cytologic Diagnosis	HÃ¼rthle Cell Adenoma	HÃ¼rthle Cell Carcinoma	Nodular Goiter	Hashimoto's Thyroiditis

TABLE 8.5 CYTOHISTOLOGIC CORRELATION OF HÃœRTHLI NEOPLASMS

HÃœRTHLE CELL ADENOMA VERSUS HÃœRTHLE CELL CARCI

Although we agree with the histologic criteria for HÃ¼rthle cell carcinoma, we have observe most instances, the cytologic patterns seen in aspirates of adenomas are strikingly different seen in carcinomas in Papanicolaou-stained preparations. The features are also appreciated sections, if one cares to look for them. Certain parameters are important in differentiating from carcinomas:

- In terms of >cell size , cells of HÃ¼rthle cell adenomas are distinctly larger than in
- >The nuclear size remains almost the same in adenomas and carcinomas, with mini variations in carcinomas. What is more striking is that the N/C ratios are markedly ir carcinoma cells as supported by morphometry (see below).
- Benign neoplastic cells are characterized by >abundant cytoplasm, in sharp contras scant cytoplasm of carcinoma cells.
- The diagnostic criteria listed in Table 8.4 for HÃ¼rthle cell carcinomas are extremel However, some cases of HÃ¼rthle cell carcinomas demonstrate larger cells with min deviation from the usual cytologic pattern seen in adenomas. McIvor, et al.35 report cases of HÃ¼rthle cell carcinomas to contain a bland pattern; these were not identi carcinoma from the aspirates. One of our cases of HÃ¼rthle cell adenomas showed a pattern indistinguishable from that seen in HÃ¼rthle cell carcinomas (Figs. 8.34 and

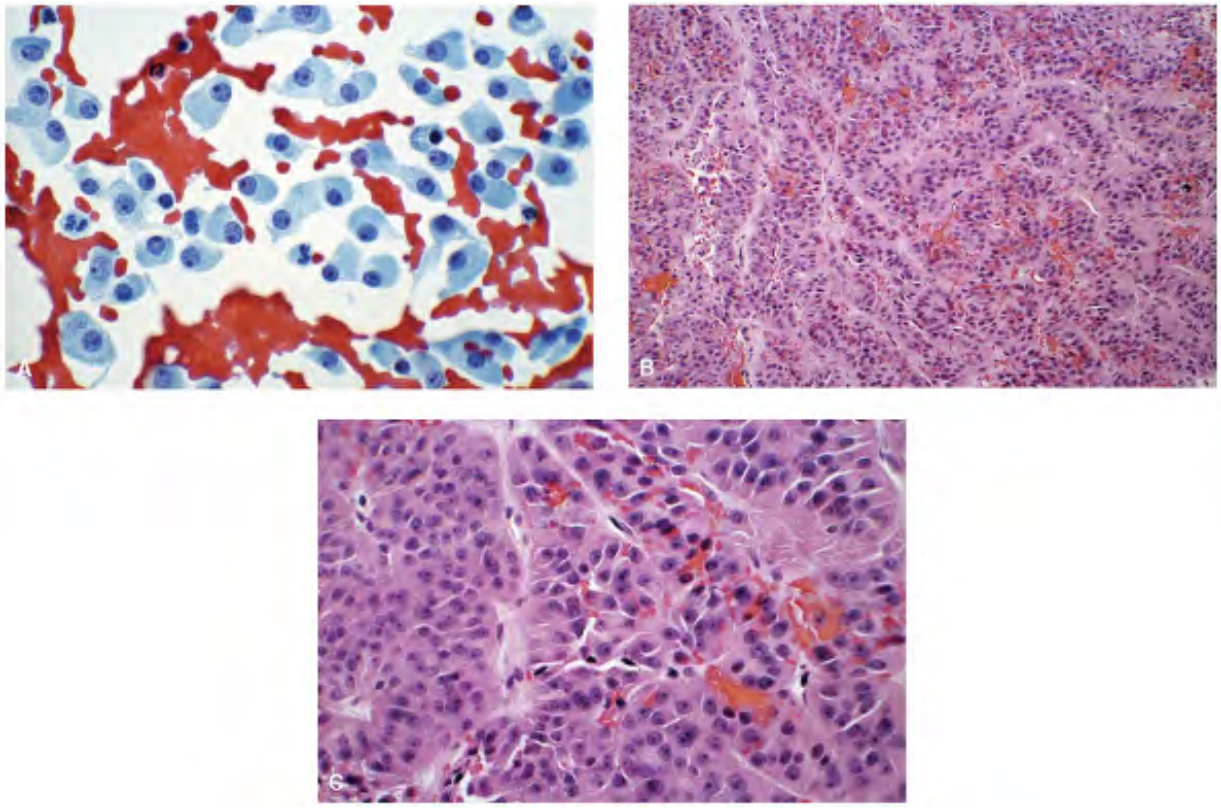

FIGURE 8-34. Aâ€“C . FNA of a HÃ¼rthle cell adenoma cytologically interpreted as
The cells are smaller, discrete. The scant cytoplasm is granular. The N/C ratios are l
macronucleoli are conspicuous. A thyroidectomy revealed an encapsulated tumor wi
invasion. Histologic section of the resected mass showing the solid and trabecular gr
pattern with smaller cells.

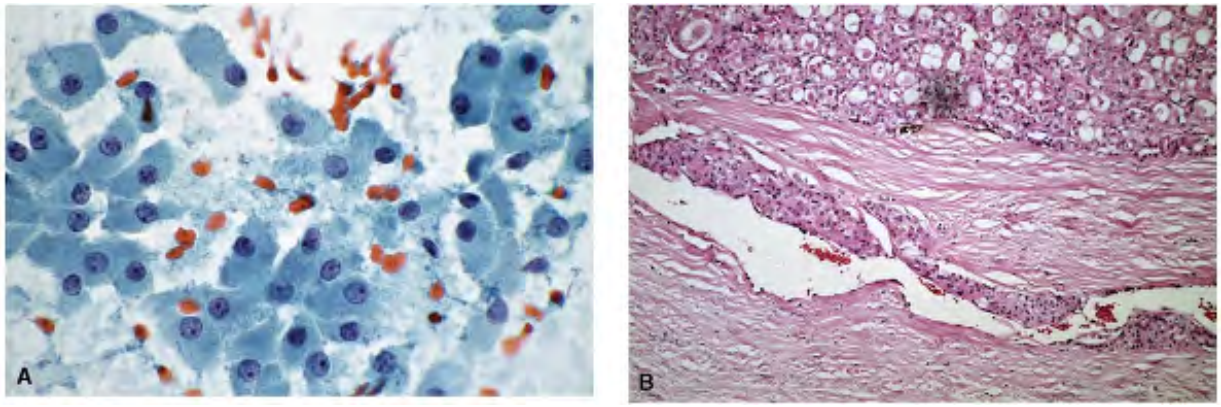

FIGURE 8-35. HÃ¼rthle cell carcinoma, cytologically interpreted as adenoma. A . Tl
HÃ¼rthle cells are discrete, large, and monomorphic, a pattern generally consistent

behavior, yet showed evidence of invasive characteristics in the excised thyroid. B . section showing vascular invasion.

- The cytohistomorphologic differences between HÃ¼rthle cell adenomas and carcino listed in Table 8.6 and illustrated in Figures 8.36 and 8.37 .

Cellularity
Cellular
Cellular
Presentation
Cells isolated, in loosely cohesive groups, or in two dimensional sheets; follicle formation infrequent; papillary tissue fragments in tumors with papillary architecture; dispersed cell pattern common
Cells isolated, in loosely cohesive groups or syncytial, usually without any architectural patterns; papillary tissue fragments present in papillary variant; dispersed cell pattern common
Cells
Large, well-defined cell borders; polygonal, round to oval; low N/C ratios
Usually small to medium-sized; round, oval to cuboidal; cytoplasmic borders well to poorly defined; very high N/C ratios
Nucleus
Central to eccentric; frequent binucleation; round, uniform, and monomorphic in a given case; thin, crisp nuclear membrane, finely granular, uniformly dispersed chromatin; single large cherry-red macronucleolus is characteristic; nuclear pleomorphism and pyknosis are rare
Central to eccentric; round, minimally pleomorphic in size; usually same size as that of benign counterpart or slightly enlarged; smooth nuclear membranes, finely granular

chromatin with prominent cherry-red macronucleous; nuclei may present clearly malignant features with coarse chromatin; parachromatin clearing, intranuclear inclusions in poorly differentiated, widely invasive tumors

Colloid

Variable

Absent

	HÃ¼rthle Cell Adenoma	HÃ¼rthle Cell Carcinom

TABLE 8.6 DIFFERENTIATING FEATURES BETWEE HÃœRTHLE CELL ADENOMA AND CARCINOMA

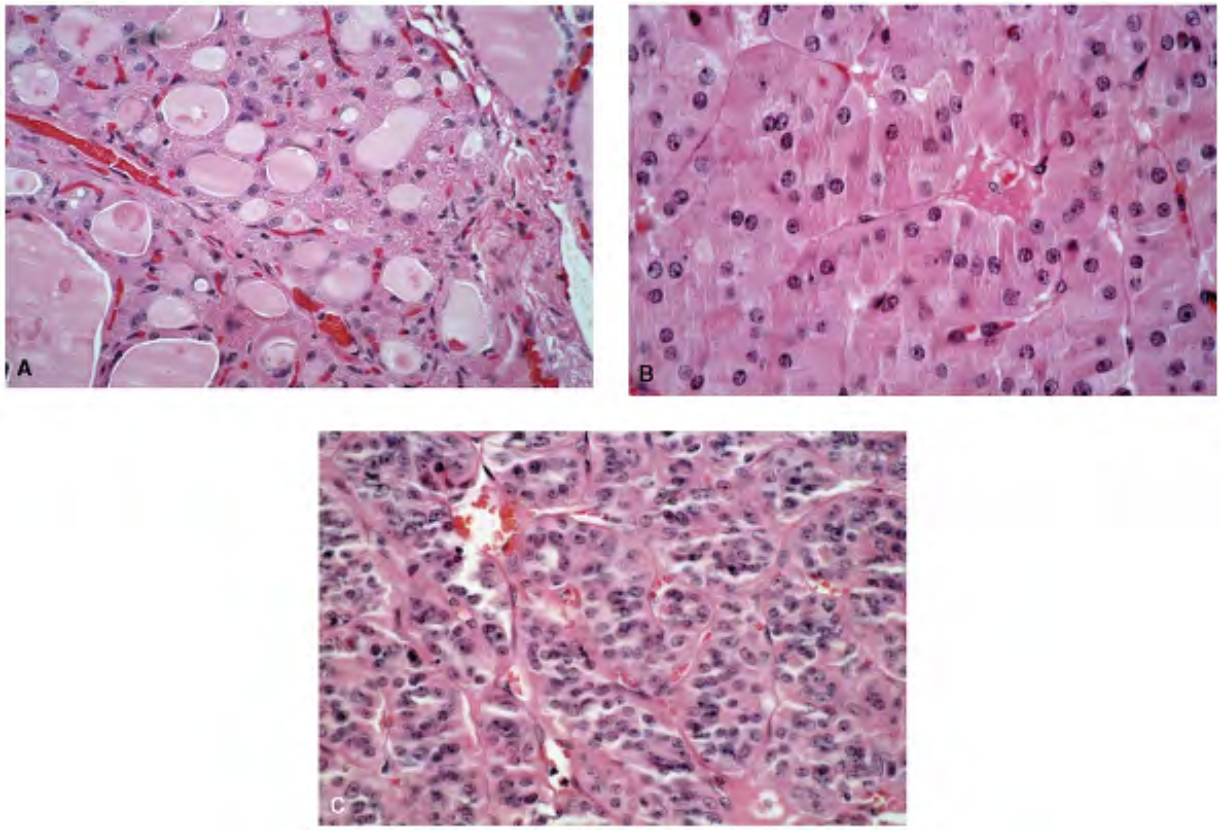

FIGURE 8-36. HÃ¼rthle cell adenoma versus carcinoma. A . Histologic section of HÃ adenoma showing a follicular pattern. Note abundant colloid. B . Histologic section adenoma with a solid growth pattern. The cells are large with abundant cytoplasm a ratios. C . Histologic section of a HÃ¼rthle cell carcinoma with a trabecular pattern

small cell size and higher N/C ratios.

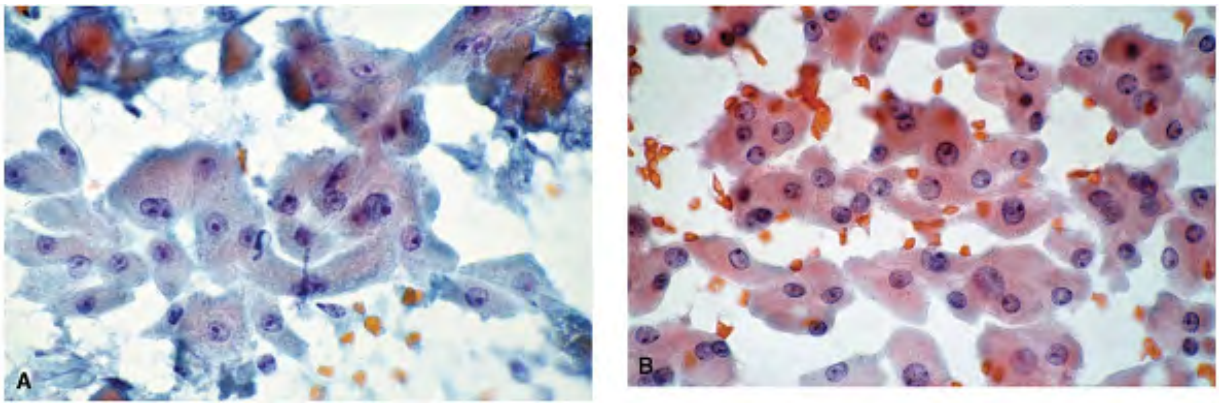

FIGURE 8-37. A, B . FNA of HÃ¼rthle cell adenomas. Note large discrete HÃ¼rthle cells, wi
ratios.

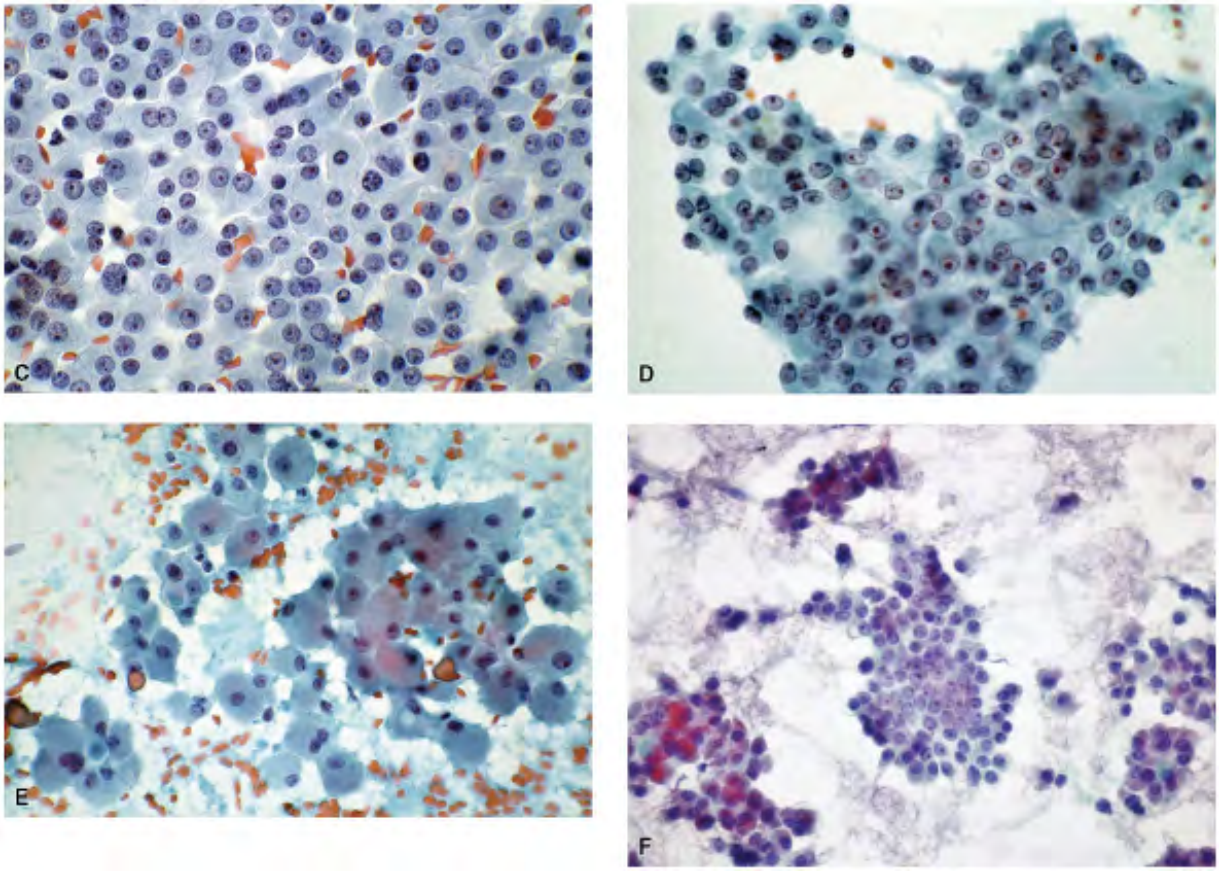

FIGURE 8-37. C . FNA of a HÃ¼rthle cell carcinoma for comparison. The cells are smaller, w ratios. D . A different example of HÃ¼rthle cell carcinoma showing syncytial tissue fragmen prominent cherry-red nucleoli. E . FNA of a HÃ¼rthle cell adenoma, consisting of large HÃ¼ with abundant cytoplasm, small uniform nuclei with low N/C ratios. F . These small carcino high N/C ratios appear strikingly different from adenoma cells.

Studies such as morphometric analysis have produced mixed results. Bondeson and co-worke their morphometric study of 26 oxyphilic thyroid tumors (13 benign and 13 malignant), foun difference between the nuclei of benign and malignant cells. Although mean nuclear size wa malignant neoplasms than in the benign group, there was considerable overlap. Bondeson et however, did not comment on the N/C ratios. Our experience with 29 HÃ¼rthle cell carcino that although the nuclei do not show much enlargement, the nuclear/cytoplasmic ratio is al favor of the nucleus in carcinomas. This is because the HÃ¼rthle cells in carcinomas are oft considerably smaller. This is an observation also made by Horn,4 and is confirmed by the stu by Benoit72 They performed morphometric analysis on fine-needle aspiration biopsy smears HÃ¼rthle cell lesions; 10 carcinomas, 10 adenomas, and 10 cases each of nodular proliferati chronic lymphocytic thyroiditis and nodular goiter. Their study proved that the cells of HÃ¼ carcinomas were smaller,

and had significantly higher nuclear/cytoplasmic ratios than those of adenomas or non-neop proliferations $p < 0.05$ (Fig. 8.38). The difference in the nuclear areas was not significant, a by Bondesson, et al.71

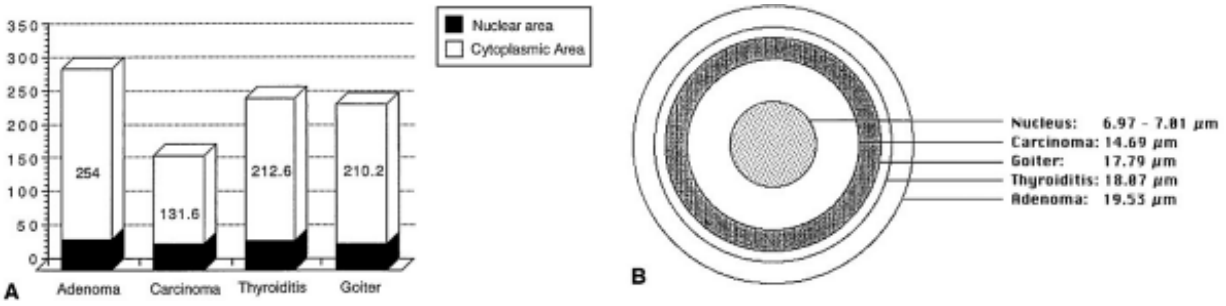

FIGURE 8-38. Morphometric analysis of HÃ¼rthle cell lesions.72 A . Comparison of cytoplas nuclear areas (square micrometers) in benign and malignant HÃ¼rthle cell neoplasms and n neoplastic nodule proliferations. B . An illustration of the calculated mean nuclear and cyto diameters in benign and malignant HÃ¼rthle cell neoplasms and non-neoplastic nodule proli

HÃœRTHLE CELL ADENOMA/CARCINOMA VERSUS NON-NEOP HÃœRTHLE CELL NODULES

Clinically palpable, or ultrasonically detected thyroid nodules formed entirely of HÃ¼rthle c nodular goiters, Hashimoto's thyroiditis, and sometimes following Graves disease. Clinically, imaging, these nodules cannot be differentiated from a neoplasm and are subjected to aspi biopsy. A large population of HÃ¼rthle cells in cytologic samples has caused considerable di difficulties in separating them from HÃ¼rthle cell neoplasms. Cytologically, these aspirates interpreted as HÃ¼rthle cell lesions or as indeterminate/suspicious, which has often resulte excision. The incidence of benign non-neoplastic HÃ¼rthle cell lesions in these groups is rep range of 17% to 50%. The cytologic criteria for differentiating HÃ¼rthle cell neoplasms from cell nodules are subtle, and recognizing them requires experience (Table 8.7).

Cellularity
Variable but generally high
Variable
Variable
Presentation
Neoplastic cells isolated, loosely cohesive, in two-dimensional sheets, follicular pattern Â±; small to large syncytial tissue fragments; usually without any architectural patterns; papillary pattern infrequent; monomorphic cell pattern[a]
HÃ¼rthle cells usually in varying-sized tissue fragments as sheets with honeycomb arrangement, follicular pattern may be present; isolated cell pattern infrequent; monomorphic cell pattern absent; varying numbers of benign

follicular cells

HÃ¼rthle cells isolated, or in varying-sized tissue fragments, syncytial architecture unusual, monomorphic cell absent

HÃ¼rthle cells

Large, polygonal or oval in adenomas; round to cuboidal, small to medium-sized in carcinomas; well to poorly defined cell borders; N/C ratios low in adenomas; high in carcinomas

Very pleomorphic in size; transition forms from normal benign follicular cells characteristic within a given tissue fragment; well-defined cell borders; low N/C ratios

Very pleomorphic in size; well-defined cell borders; low N/C ratios

Nucleus

Central to eccentric location, frequently binucleated; round with smooth nuclear membranes; finely granular chromatin; prominent, single cherry-red nucleolus; size uniform in a given case

Central location; bimultinucleation infrequent; variable in size from cell to cell with occasional giant forms; chromatin finely granular

to smudgy; may be pyknotic;
micronucleoli Â±; cherry-red
macronucleolus not observed
Central location;
bimultinucleation infrequent;
variable in size from cell to cell
with occasional giant forms;
chromatin finely granular to
smudgy; may be pyknotic;
micronucleoli Â±; cherry-red
macronucleolus very rare
Cytoplasm
Abundant, granular in adenomas;
stain eosinophilic, cyanophilic,
or amphophilic; scant in
carcinomas; intracytoplasmic
lumens Â±
Variable, granular, and
eosinophilicto cyanophilic
Variable; granular; eosinophilic
to cyanophilic
Regular type
follicular cells
Absent
Present with transition forms
Â±
Lymphoplasmacytic and
germinal center cells
Absent
Absent
Present in variable numbers; may
be sparse; lymphoid tangles Â±
Degenerative changes;
histiocytes with and

without Hemosiderin

Â±

Â±

Absent

Regular type

follicular cells

Absent

Present with transition forms

Â±

Transgressing blood

vessels in tissue

fragments of HÃ¼rthle

cells

Â±; Can be appreciated if the

tissue fragments are large

â€”

â€”

[a] A pleomorphic cell pattern seen in poorly differentiated or high-grade HÃ¼rthle cell carci
with clearly malignant nuclear features.

HÃ¼rthle Cell Neoplasms	HÃ¼rthle Cell Nodules in Nodular Goiter	HÃ¼rthle Cell Nodules in Hashimoto's Thyroiditis

TABLE 8.7 CYTOPATHOLOGIC DIFFERENTIATION BETWE
HÃœRTHLE CELL NEOPLASMS AND NON-NEOPLASTIC
(PROLIFERATIVE) HÃœRTHLE CELL NODULES

HÃœRTHLE CELL ADENOMA/CARCINOMA VERSUS HÃœRTHLE METAPLASIA IN NODULAR GOITER

HÃ¼rthle cell metaplasia is an extremely common feature in nodular goiters (Fig. 8.39). A f
scattered HÃ¼rthle cells along with benign follicular cells are often present in aspirates fro
goiter. However, nodules entirely composed of HÃ¼rthle cells will yield a large population c
cells that may be difficult to differentiate from a true neoplasm. We have found the cytolog
described below, and in Table 8.7 , very helpful.

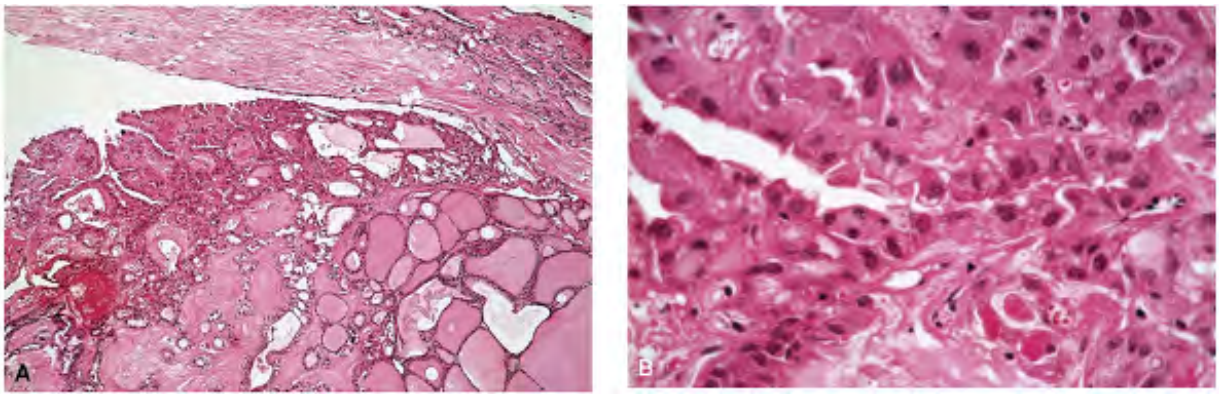

FIGURE 8-39. HÃ¼rthle cell metaplasia in nodular goiter. Histologic sections. A . Low powe
power.

HÃ¼rthle cells aspirated from non-neoplastic HÃ¼rthle cell nodules tend to be cohesive anc
sheets of epithelium

with a honeycomb arrangement, well-defined cell borders, and abundant cytoplasm that is
or granular and contains centrally placed nuclei (Figs. 8.40 , 8.41 , 8.42 , 8.43 , 8.44 and 8.
follicular pattern is not uncommon. Transitional forms from regular follicular cells to large,
cells are usually present (Figs. 8.40 , 8.41 and 8.42) and serve as important diagnostic clue
are almost always pleomorphic in size, and generally do not show macronucleoli. The nuclea
is coarsely granular and pyknotic forms are very frequent (Figs. 8.40 , 8.41 and 8.42). Collo
in the

background, but it is variable and can be abundant. Groups and tissue fragments of regular
follicular cells are often present in the background. Degenerative changes with histiocytes c
hemosiderin are features that favor nodular goiter. Papillary change in a nodular goiter with
HÃ¼rthle cell metaplasia is also a potential diagnostic pitfall (Fig. 8.45).

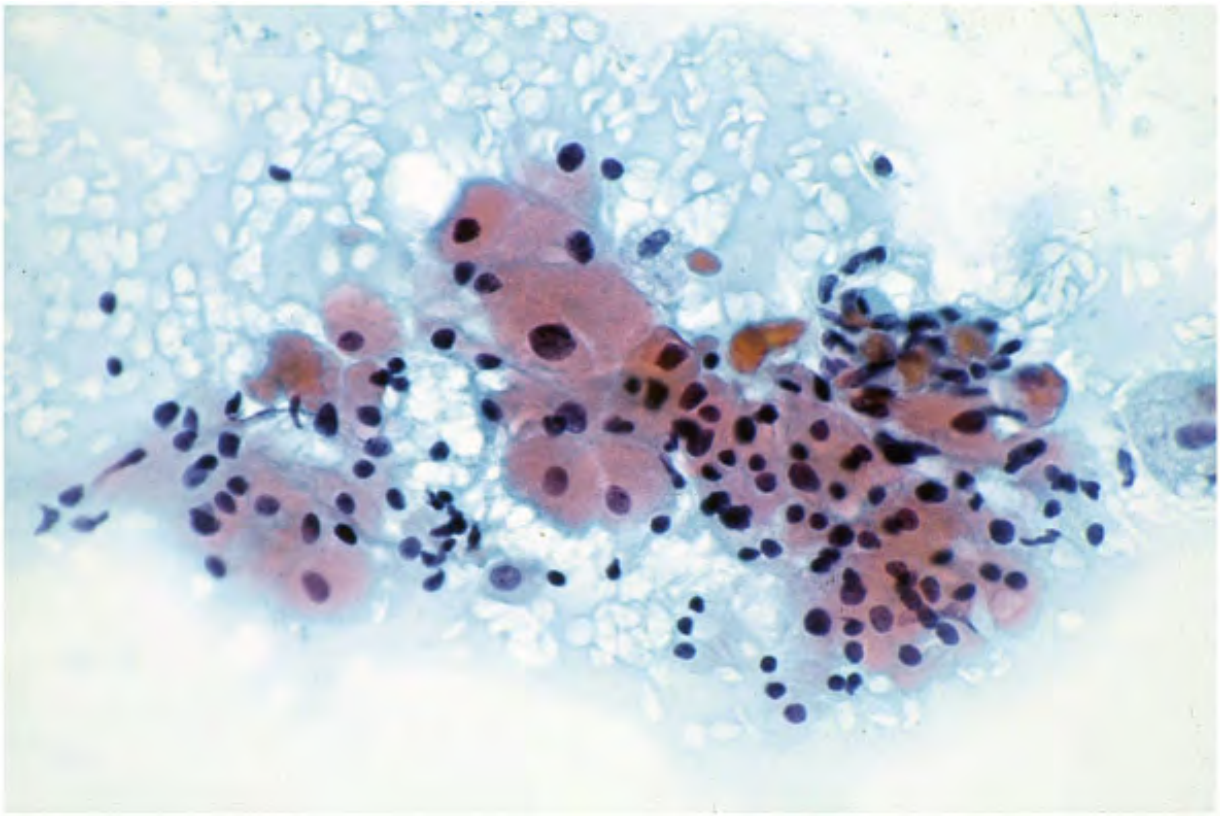

FIGURE 8-40. FNA of thyroid showing HÃ¼rthle cell metaplasia. The pleomorphic, large HÃ½
are admixed with benign follicular cells. They have abundant cytoplasm and small nuclei wi
chromatin. Macronucleoli are absent.

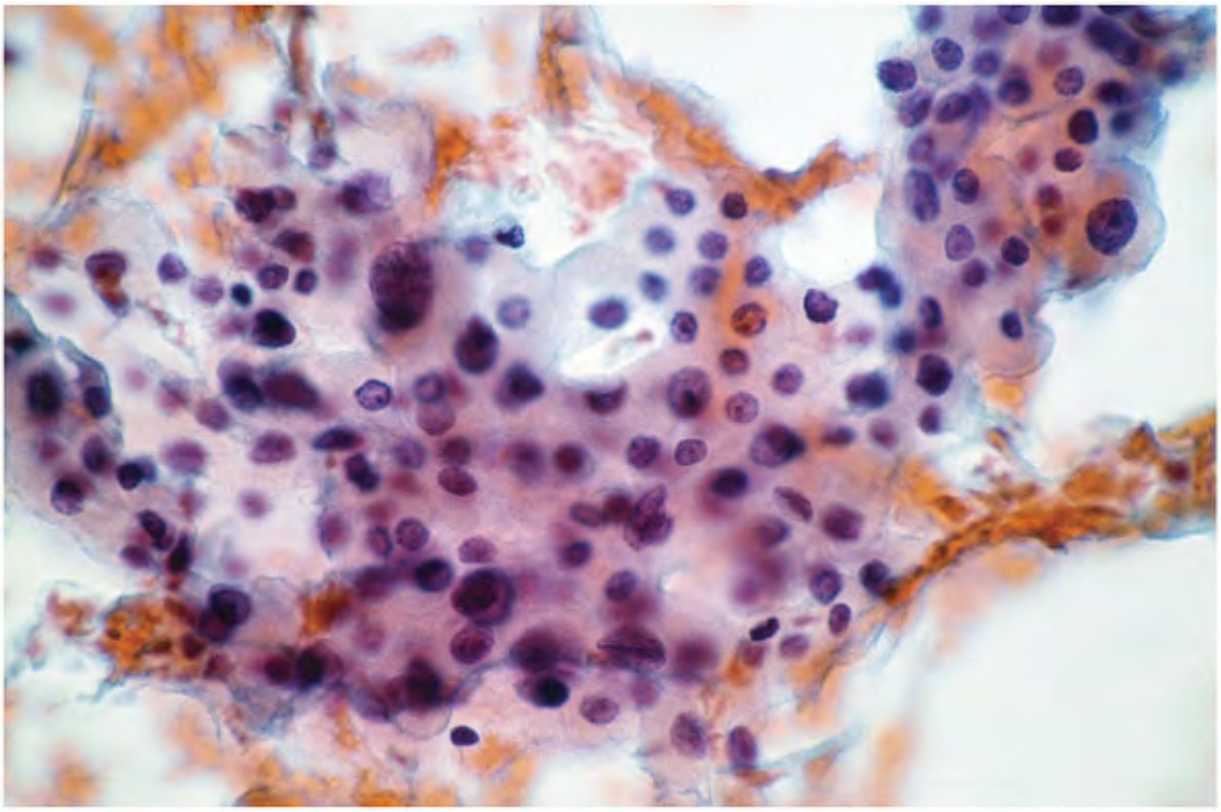

FIGURE 8-41. Sheets of pleomorphic HÃ¼rthle cells with variable deep eosinophilic cytopla
of uniformity and absence of macronuclei are features of metaplasia.

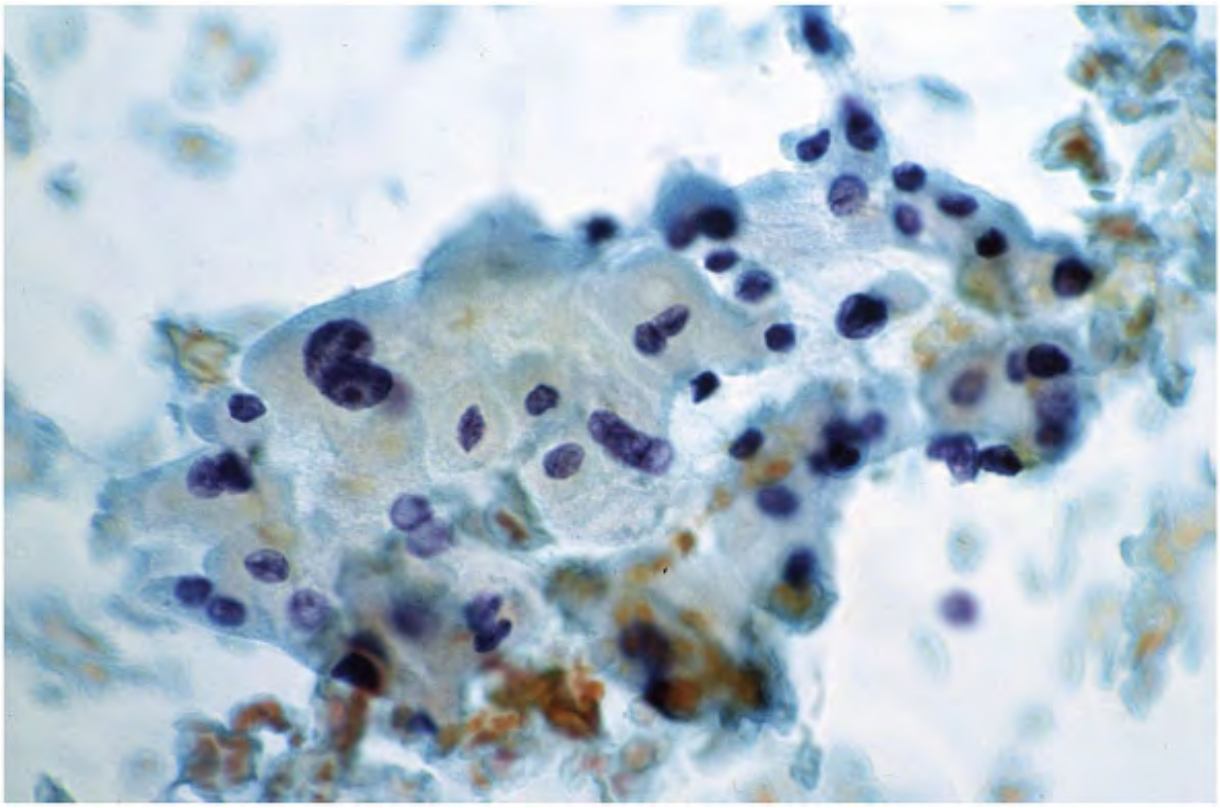

FIGURE 8-42. A large tissue fragment of benign follicular cells with transition forms to HÃ¼ metaplasia. Note abundant cytoplasm and large nuclei with smudgy chromatin.

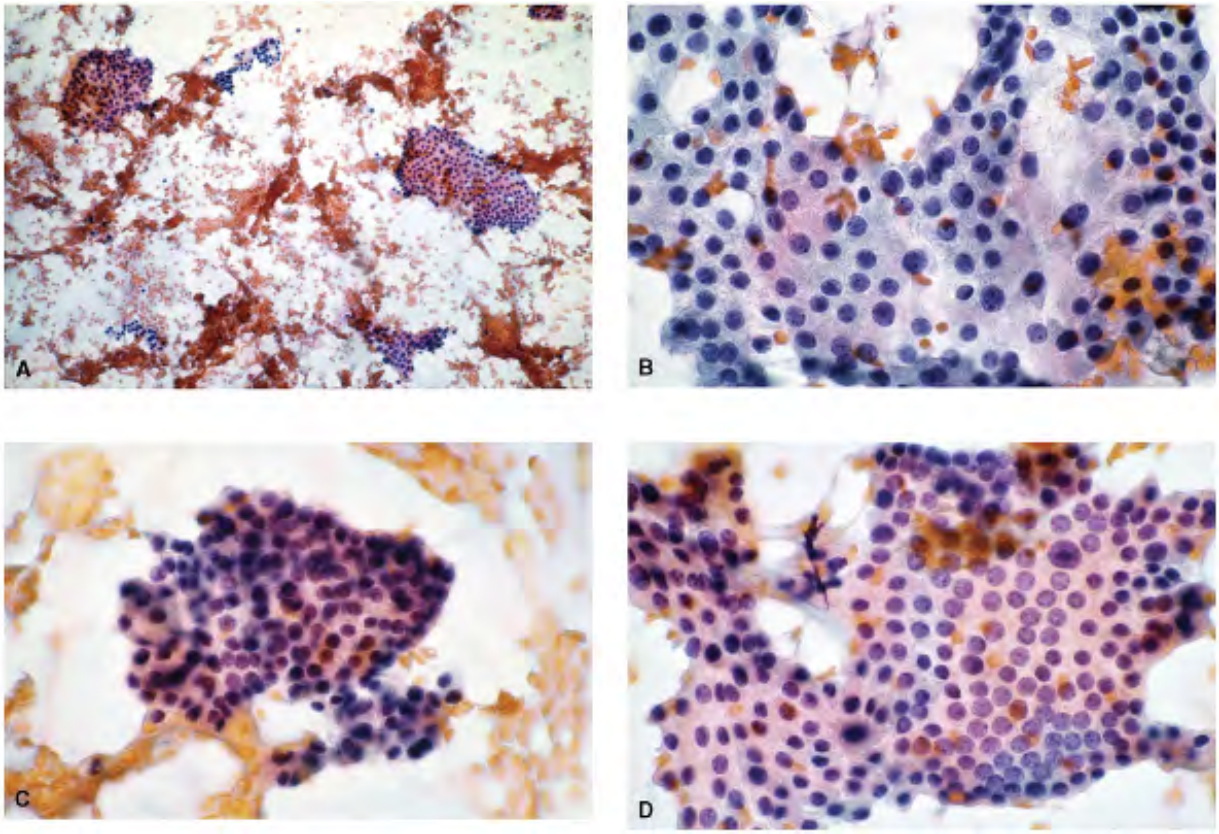

FIGURE 8-43. HÃ¼rthle cell metaplasia. A . The cellular aspirate reveals several tissue frag
HÃ¼rthle cells. Abundant eosinophilic cytoplasm is evident even at this low power. B . High
magnification, demonstrating sheets of HÃ¼rthle cells with a honeycomb arrangement. The
pleomorphic in size and lack macronucleoli. The cytoplasm is abundant. C . Another field, s
tissue fragment of metaplastic HÃ¼rthle cells. D . A tissue fragment of metaplastic HÃ¼rthl
variable but abundant granular cytoplasm, and pleomorphic nuclei with compact chromatin
absence of macronucleoli.

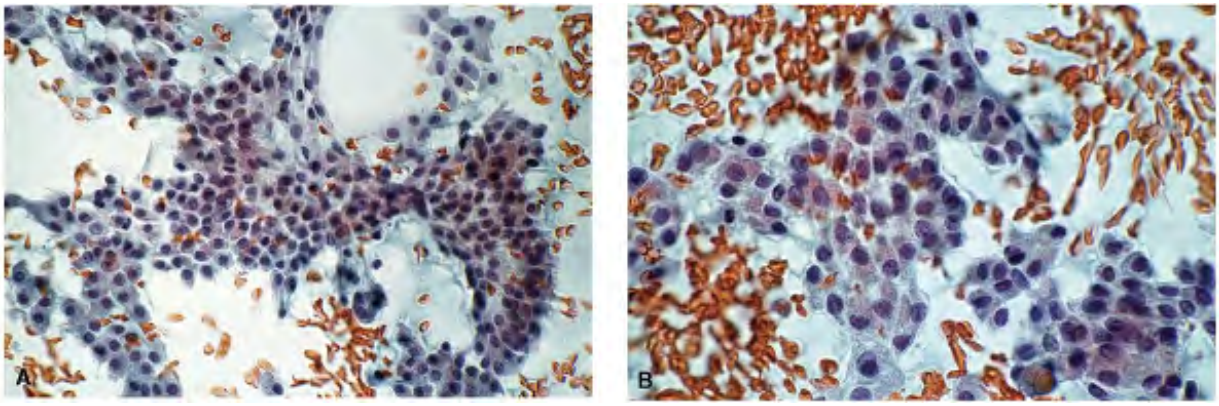

FIGURE 8-44. HÃ¼rthle cell metaplasia in nodular goiter. The aspirate is showing tissue frag
metaplastic HÃ¼rthle cells with a honeycomb pattern. The cells are larger than their norma
counterpart (benign follicular cells). The nuclei have compact chromatin and lack macronuc

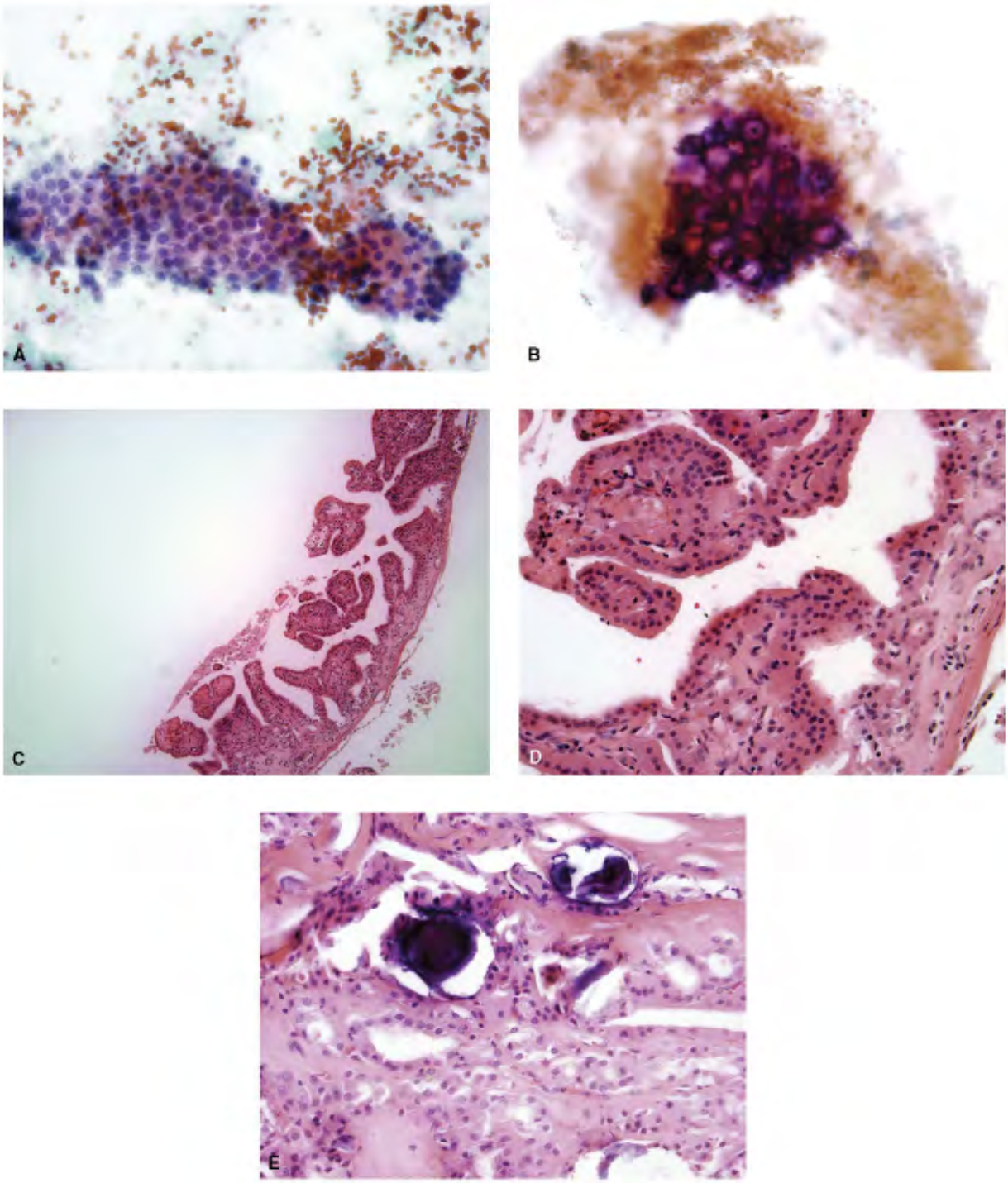

FIGURE 8-45. HÃ¼rthle cell metaplasia in nodular goiter with papillary change. A . Large tis
fragment of metaplastic HÃ¼rthle cells with appreciable, eosinophilic cytoplasm. Note the l
pattern. B . Naked psammoma bodies in the background. C . Thyroidectomy revealed a mult
goiter with cystic and papillary change, low power. D . Higher magnification showing pseudo
pattern with lining of HÃ¼rthle cells. E . Another field showing HÃ¼rthle cell metaplasia wi
psammoma bodies. The typical nuclear pattern of conventional papillary carcinoma is lackir

HÃœRTHLE CELL ADENOMA/CARCINOMA VERSUS HÃœRTHLE NODULES IN HASHIMOTO'S THYROIDITIS

HÃ¼rthle cell metaplasia is considered a hallmark of Hashimoto's thyroiditis. Varying-sized r
composed entirely of HÃ¼rthle cells, are a frequent histologic finding in

Hashimoto's thyroiditis. These nodules may reach a significant proportion and be palpable, p
a cold nodule, necessitating an FNA biopsy. They are also detected as incidental findings on
ultrasound performed for non-thyroid-related reasons. An aspirate of a cold nodule in the ba
a diffusely enlarged goiter showing many or predominantly HÃ¼rthle cells, with a few lymph
plasma cells, can be interpreted as a non-neoplastic HÃ¼rthle cell lesion. Experience is help
recognizing such lesions. A predominant HÃ¼rthle cell component in an aspirate will suggest
of a neoplasm (Figs. 8.46 , 8.47 , 8.48 and 8.49). A few stretched-out lymphocytes, and an
regular follicular cells with or without nuclear atypia and transition forms, serve as a clue to
diagnosis of Hashimoto's thyroiditis (Table 8.7). The problem of misinterpreting HÃ¼rthle c
thyroiditis as a HÃ¼rthle cell neoplasm is shared by many investigators.73 , 74 , 75 , 76 , 77
discussed in detail in Chapter 13 .

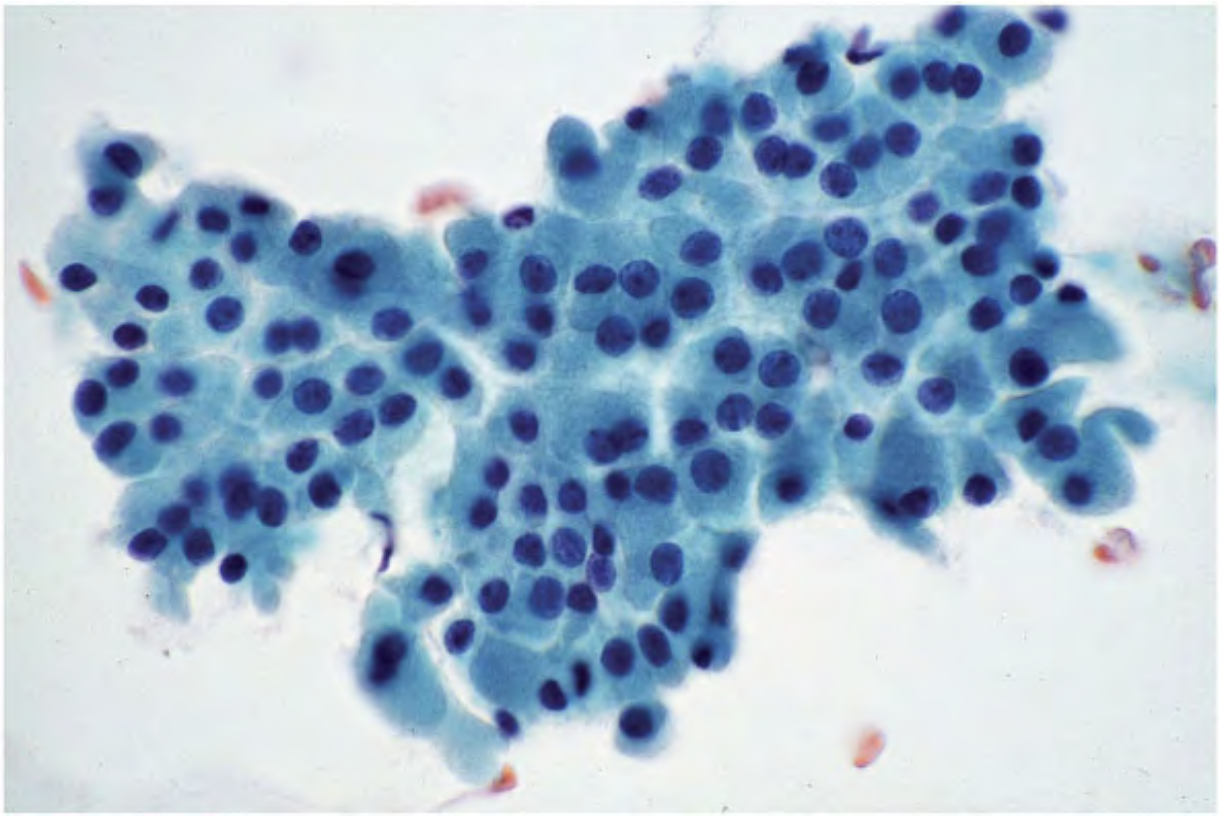

FIGURE 8-46. FNA of Hashimoto's thyroiditis, showing a large tissue fragment of HÃ¼rthle c
pleomorphic nuclei. The dispersed pattern of HÃ¼rthle cell neoplasms is lacking. The nuclei
smudgy chromatin and lack micronucleoli. Rare lymphocytes in intimate contact with the H
are difficult to identify. This aspirate was cytologically interpreted as HÃ¼rthle cell neoplas

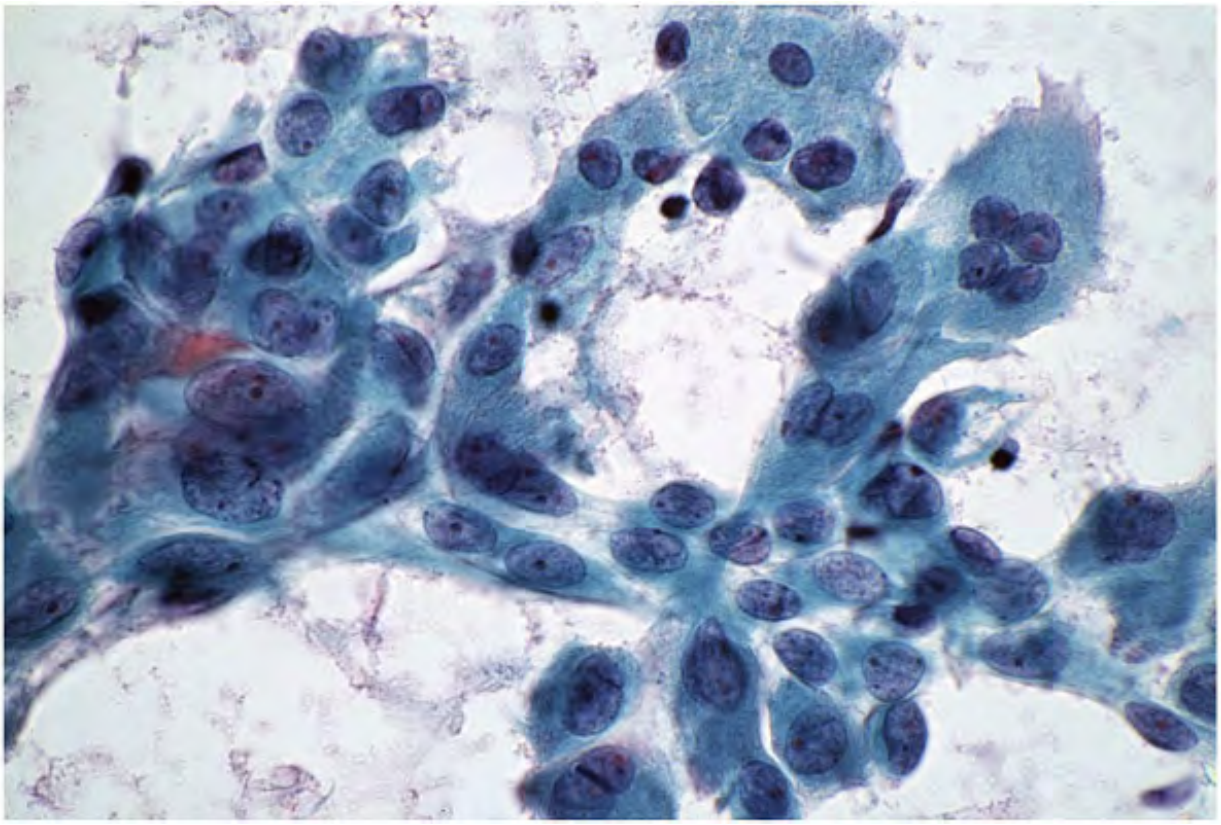

FIGURE 8-47. Another case of Hashimoto's thyroiditis with predominance of HÃ¼rthle cells. cells, large pleomorphic nuclei, and abundant cytoplasm. These cells, however, lack the cha nuclear morphology of neoplastic HÃ¼rthle cells. Rare lymphocytes are present in the backg

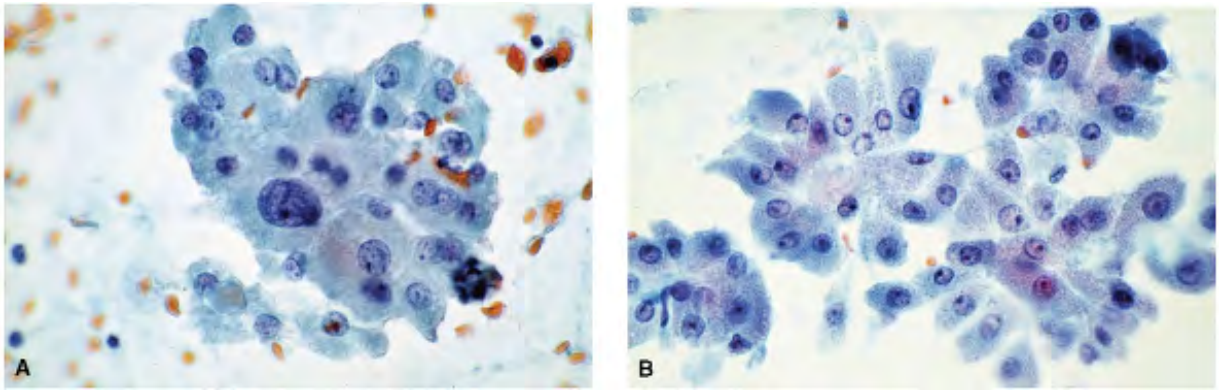

FIGURE 8-48. A . FNA of a nodule from Hashimoto's thyroiditis, showing HÃ¼rthle cells in a fragment and discrete. Note pleomorphic nuclei. This case was interpreted as HÃ¼rthle cell lymphocytes were present in the background but were overlooked. Note, however, that the the characteristic nuclear morphology of HÃ¼rthle cell neoplasm. B. FNA of HÃ¼rthle cell t

demonstrating the characteristic morphology for comparison.

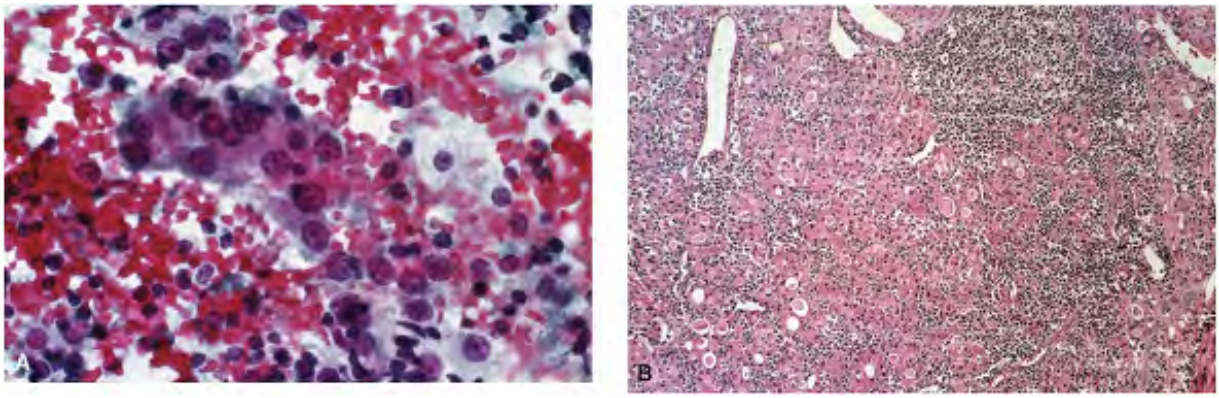

FIGURE 8-49. A . This bloody aspirate consisted of several tissue fragments of metaplastic H cells, containing pleomorphic, large, hyperchromatic nuclei, and was interpreted as malign Thyroidectomy revealed florid Hashimoto's thyroiditis. The interpretative error was due to i

P.125
P.126
P.127
P.128
P.129

HÃœRTHLE CELL CARCINOMA VERSUS OTHER NEOPLASMS

Several different types of neoplasms share morphologic similarities with HÃ¼rthle cell aden carcinomas. These include medullary carcinoma; oncocytic parathyroid adenoma, either in intrathyroid location or in close proximity to the thyroid; and metastatic renal cell carcinon

HÃœRTHLE CELL CARCINOMA VERSUS MEDULLARY CARCINO

HÃ¼rthle cell carcinomas share morphologic similarities with medullary thyroid carcinomas. their small size, round to oval shape, and a monomorphic pattern, HÃ¼rthle cell carcinoma strongly resemble medullary carcinoma when the latter presents a monomorphic pattern (Fi 8.51 and 8.52). Medullary carcinoma cells occasionally demonstrate abundant deep-staining and large pyknotic nuclei, a feature that is sometimes observed in HÃ¼rthle cell neoplasms. differentiating features include prominent cherry-red macronucleoli in HÃ¼rthle cell carcin

are characteristically absent in medullary-carcinoma cells. The nuclear chromatin is very co
medullary carcinomas, unlike the finely granular pattern of HÃ¼rthle cell carcinoma cells. I
cytologic preparations of HÃ¼rthle cell carcinoma fail to stain the macronucleoli, the differ
between the two may be difficult. Immunostains for thyroglobulin and calcitonin are require
confirm the diagnosis. The differentiating features are listed in Table 12.7.

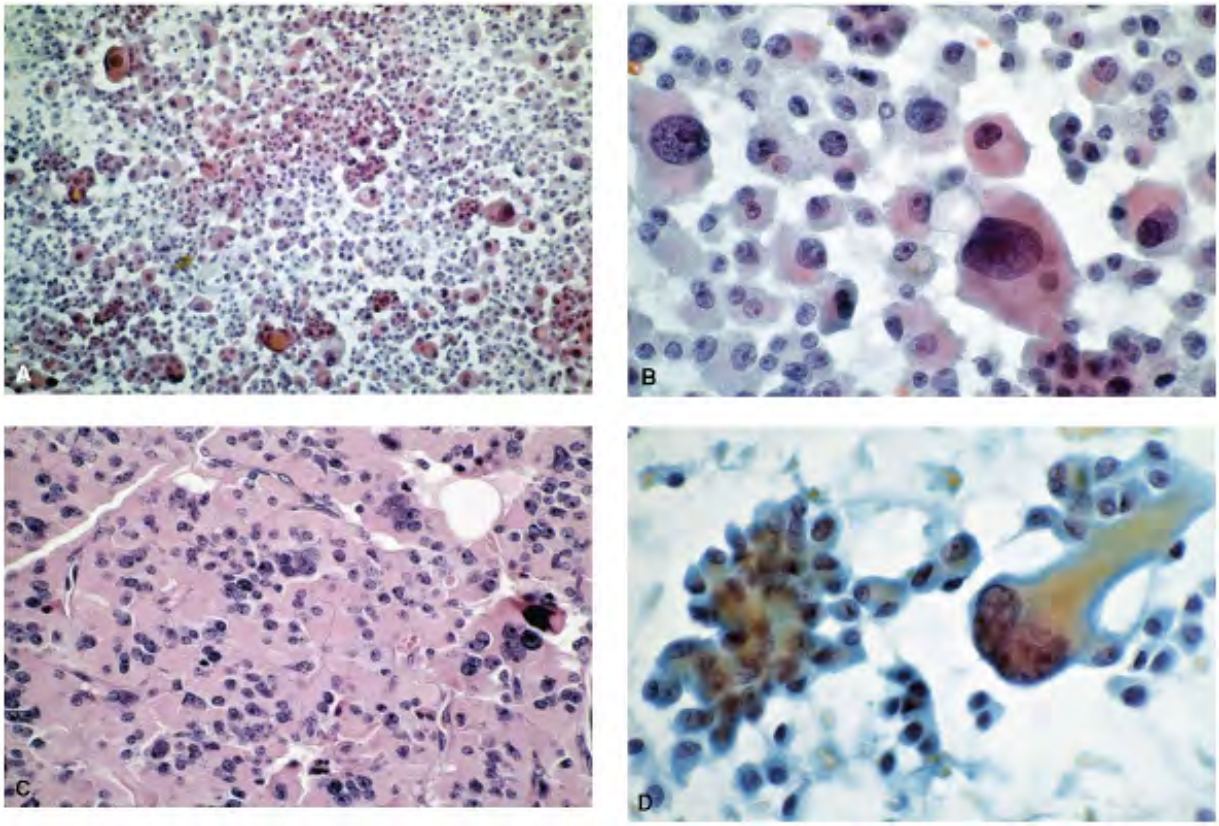

FIGURE 8-50. HÃ¼rthle cell carcinoma versus medullary thyroid carcinoma. HÃ¼rthle cell c
share morphologic similarity with medullary carcinomas, and may be interpreted as such. A
cellular aspirate with predominantly dispersed cells (low power). B . Higher magnification sl
discrete cells, markedly pleomorphic in size with eccentric nuclei. Macronucleoli were not p
differential diagnosis included HÃ¼rthle cell neoplasm and medullary carcinoma. Calcitonin
negative. C . Thyroidectomy revealed minimally invasive HÃ¼rthle cell carcinoma with a sol
pattern. Note nuclear pleomorphism corresponding to the cytologic presentation. D . Compa
of a medullary thyroid carcinoma, with a large cell, containing abundant cytoplasm and an e
nucleus with smudgy chromatin.

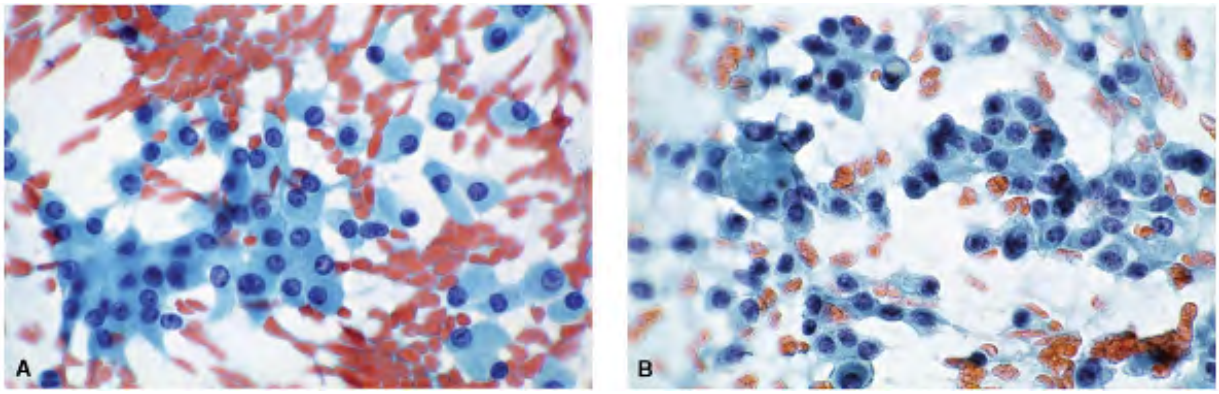

FIGURE 8-51. A . FNA of a HÃ¼rthle cell carcinoma with uniform, plasmacytoid cells contai eccentric nuclei strongly resembling medullary-carcinoma cells. Macronucleoli are only rare Calcitonin stain was negative. B . FNA of a medullary carcinoma for comparison.

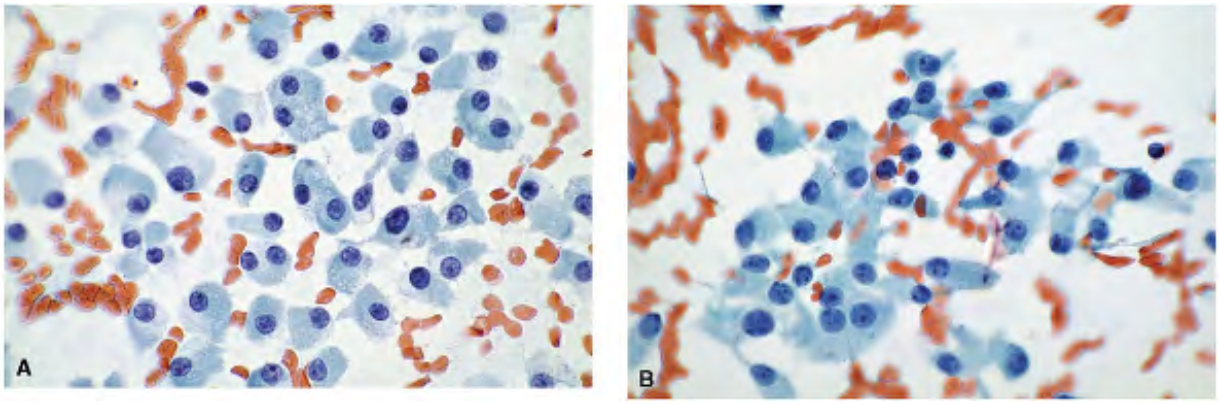

FIGURE 8-52. These two images present very similar morphologic pattern. A . HÃ¼rthle cell B . Medullary carcinoma. Cytologic differentiation sometimes is not possible, and requires i with thyroglobulin and calcitonin.

SUMMARY

HÃ¼rthle cell tumors with benign behavior (adenomas) often show large, loosely cohesive c well-defined cell borders; abundant, granular cytoplasm with variable staining characteristi central or eccentric nuclei with prominent cherry-red macronucleoli and a monomorphic pa HÃ¼rthle cell tumors with malignant behavior (carcinomas) can be recognized by their smal syncytial-type tissue fragments, and high nuclear/cytoplasmic ratios. Infrequent features in intranuclear, cytoplasmic inclusions, and psammoma bodies. HÃ¼rthle cell carcinoma may b

as medullary thyroid carcinoma. Important diagnostic pitfalls include metaplastic HÃ¼rthle in the background of nodular goiter or Hashimoto's thyroiditis.

References

1.Heiman P, Ljungren JH, LÃ¶whagen T, et al. Oxyphilic adenoma of the human thyroid, a morphological and biochemical study. *Cancer* . 1973;31:246â€“254.

2.Rosai J, Carcangiu ML, DeLellis RA. Tumors of the thyroid gland. Fascicle S, third Series, *Tumor Pathology* . Washington, DC: Armed Forces Institute of Pathology; 1993;161â€“182.

3.Friedman NB. Cellular involution in the thyroid gland: significance of HÃ¼rthle cells in r exhaustion atrophy. Hashimoto's disease and the "reactions to radiation," thiouracil therap subtotal resection. *J Clin Endocrinol* . 1949;9:874â€“882.

4.Horn RC. HÃ¼rthle cell tumors of the thyroid. *Cancer* . 1954;7: 234â€“244.

5.Chesky VE, Droese WC, Hellwig CA. HÃ¼rthle cell tumors of the thyroid gland: a report cases. *J Clin Endocrinol* . 1951;11: 1535â€“1548.

6.Frazell EI, Duffy BJ. HÃ¼rthle cell cancer of the thyroid, a review of forty cases. *Cancer* 1951;4:952â€“956.

7.Thompson LDR. *Endocrine Pathology* . Philadelphia: Churchill Livingstone; 2006.

8.Sobrinho-Somoes M, Asa SL, Kroll TG, et al. Follicular carcinoma. In: De Lellis, Lloyd R, Eng C, eds. *Pathology and Genetics of Tumours of Endocrine Organs* . *World Health Organ Classification of Tumors* . Lyon: IARC Press; 2004: 57â€“66, 67â€“72.

9.Evans HL, Vassilopoulou-Sellin R. Follicular and HÃ¼rthle cell carcinoma of the thyroid. comparative study. *Am J Surg Pathol* . 1998; 22:1512â€“1520.

10.Wenig BM, Heffess C, Adair CF. *Atlas of Endocrine Pathology* . Philadelphia: Saunders;

11.Hedinger CE, Williams ED, Cobin LH. Histological typing of thyroid tumours. In: Hedinge *International Histological Classification of Tumours* . Vol. 11. 2nd ed. Berlin: Springer-Ver 1988:9â€“11.

12.Rosen IB, Luk S, Katz I. HÃ¼rthle cell tumor behavior: dilemma and resolution. *Surger* 1985;98:777â€“778.

13.Saull SC, Kimmelman CP. HÃ¼rthle cell tumors of the thyroid gland. *Otolaryngol Head* 1985;93:58â€“62.

14.Watson RG, Brennan MD, Goellner JR, et al. Invasive HÃ¼rthle cell carcinoma of the th natural history and management. *Mayo Clin Proc* . 1984;59:851â€“855.

15.Caplan RH, Abellera M, Kisken W. HÃ¼rthle cell tumors of the thyroid gland: a clinicop review and long-term follow-up. *JAMA* . 1984;251:3114â€“3177.

16.Gusain AK, Clark OH. HÃ¼rthle cell neoplasms: malignant potential. *Arch Surg* . 1984;119:515â€“519.

17.Vickery AL JR. Needle biopsy pathology. In: Williams ED, ed. *Clinics in Endocrinology a Metabolism* . Vol. 10. Philadelphia: Saunders; 1981:283â€“292.

18.Bondeson L, Bondeson AG, Ljungberg O, et al. Oxyphil tumors of the thyroid. *Am Surg* 1981;196:677â€“680.

19.Thompson NW, Dunn EL, Batsakis JG, et al. HÃ¼rthle cell lesions of the thyroid gland. *Gynecol Obstet* . 1974;139:555â€“560.

20.Gundry SR, Burney RE, Thompson NW, et al. Total thyroidectomy for HÃ¼rthle cell nec
the thyroid. *Arch Surg* . 1983;188: 529â€“532.

21.Carcangiu ML, Branchi S, Savino D, et al. Follicular HÃ¼rthle cell tumors of the thyroid
study of 153 cases. *Cancer* . 1991;68:1944â€“1953.

22.Grant CS, Barr D, Goellner JR, et al. Benign HÃ¼rthle cell tumors: a diagnosis to be tru
World J Surg . 1988;12:488â€“495.

23.Tollefsen RH, Shah PJ, Juvos AG. HÃ¼rthle cell carcinoma of the thyroid. *Am J Surg* .
1974;130:390â€“394.

24.Pu RT, Yang J, Wasserman PG, et al. Does HÃ¼rthle cell lesion/neoplasm predict malig
more than follicular lesion/neoplasm on thyroid fine-needle aspiration? *Diagn Cytopathol*
330â€“334.

25.Elliott DD, Pittman MB, Bloom L, et al. Fine needle aspiration biopsy of HÃ¼rthle cell l
the thyroid gland. A cytomorphologic study of 139 cases with statistical analysis. *Cancer C*
. 2006;108:102â€“109.

26.Alaedeen D, Khiyani A, McHenry CR. Fine-needle aspiration biopsy specimen with a
predominance of HÃ¼rthle cells: a dilemma in the management of nodular thyroid disease
. 2005;138:650â€“657.

27.Kauffman PR, Dejax C, de Latour M, Daupiat J. The meaning and predictability of HÃ¼
in fine needle aspiration cytology for thyroid nodular disease. *Eur J Surg Oncol* . 2004;30:7

28.Giorgadze T, Rossi ED, Fadda G, et al. Does the fine needle aspiration diagnosis of HÃ¼
neoplasm/follicular neoplasm with oncocytic features denote increased risk of malignancy
Cytopathol . 2004;31:307â€“312.

29.Gonzalez JL, Wang HH, Ducatman BS. Fine needle aspiration of HÃ¼rthle cell lesions. *

cytomorphologic approach to diagnosis. *Am J Clin Pathol* . 1993;100:231â€“235.

30.Gharib H, Goellner JR, Johnson DA. Fine-needle aspiration cytology of the thyroid. A 1
experience with 11,000 biopsies. *Clinics Lab Med* . 1993;13:699â€“709.

31.Kini SR. *Color Atlas of Differential Diagnosis in Exfoliative and Aspiration Cytopatholo*
Philadelphia: Lippincott Williams &Wilkins; 1999.

32.Kini SR, Miller JM, Hamburger JI. Cytopathology of HÃ¼rthle cell lesions of the thyroid
fine needle aspiration. *Acta Cytol* . 1981;25:647â€“652.

33.Renshaw AA. HÃ¼rthle cell carcinoma is a better gold standard than HÃ¼rthle cell nec
fine-needle aspiration of thyroid: defining more consistent and specific cytologic criteria.
Cytopathol . 2002; 96:261â€“266.

34.Nguyen GK, Hussain M, Akin MR. Cytodiagnosis of benign and malignant HÃ¼rthle cell l
the thyroid by fine-needle aspiration biopsy. *Diagn Cytpathol* . 1999;20:261â€“265.

35.McIvor NP, Freeman JL, Rosen I, et al. Value of fine-needle aspiration in the diagnosis
HÃ¼rthle cell neoplasms. *Head Neck* . 1993;15:335â€“341.

36.Sugino K, Ito K, Mimura T, et al. HÃ¼rthle cell tumor of the thyroid: analysis of 188 ca
J Surg . 2001;25:1160â€“1163.

37.Flint A, Lloyd RV. HÃ¼rthle cell neoplasms of the thyroid gland. *Pathol Ann* . 1990; 25(
1):37â€“52.

38.Heppe H, Armin A, Calandra DB, et al. HÃ¼rthle cell tumors of the thyroid gland. *Surg*
1985;98:1162â€“1165.

39.Meissner WA, Warren S. Tumors of the thyroid gland. *Atlas of Tumor Pathology* . Fascic

series. Washington, DC: Armed Forces Institute of Pathology; 1969.

40.Vodanovic S, Crepinko I, Smoje J. Morphologic diagnosis of HÃ¼rthle cell tumors of the gland. *Acta Cytol* . 1993;37: 371â€“322.

41.Yang YJ, Khurana KK. Diagnostic utility of intracytoplasmic lumen and transgressing ves evaluation of HÃ¼rthle cell lesions by fine-needle aspiration. *Arch Path Lab Med* . 2001;125:1031â€“1035.

42.Bonilla AJ, Claudill il, Goellner JR. Neoplastic versus non-neoplastic HÃ¼rthle cell lesio diagnostic role of transgressing vessels and intracytoplasmic inclusions. *Acta Cytol* . 1999;

43.Silver SA, Busseniers AE. Cytologic criteria for differentiating neoplastic from non-neop HÃ¼rthle cell lesions by fine needle aspiration. In: *Abs US Can Acad Pathol.* 995;vol 8:242

44.Kini SR. Post-fine needle biopsy infarction of thyroid neoplasms. A review of 28 cases. *Cytopathol* . 1996;15:211â€“220.

45.Carcangiu ML. HÃ¼rthle cell carcinoma: clinical-pathological and biological aspects. *Tu* 2003;89:529â€“532.

46.Bhattacharyya N. Survival and prognosis in HÃ¼rthle cell carcinoma of the thyroid glan *Otolaryngol Head Neck Surg* . 2003;129:207â€“210.

47.Stojadinovic A, Ghossein RA, Marshall AH, et al. HÃ¼rthle cell carcinoma: a critical histopathologic appraisal. *J Clin Oncol* . 2001;19:2616â€“2625.

48.Yutan E, Clark OH. HÃ¼rthle cell carcinoma. *Curr Treat Oncol* . 2001;2:331â€“335.

49.Stojadinovic A, Hoos A, Ghossein R, et al. HÃ¼rthle cell carcinoma: a 60 year experien *Surg Oncol* . 1992;9:197â€“203.

50.Bronner MP, LiVolsi VA. Oxyphilic (Askanazy/HÃ¼rthle cell). Tumors of the thyroid: mi
features predict biologic behavior. *Surg Pathol* . 1988;1:137â€“150.

51.Berbo M, Suster S. The oncocytic variant of papillary carcinoma of the thyroid: a
clinicopathologic study of 15 cases. *Hum Pathol* . 1997;28:47â€“53.

52.Beckner M, Heffess CS, Oertel JE. Oxyphilic papillary thyroid carcinomas. *Am J Clin Pa*
1995;103:280â€“287.

53.Herrera MP, Hay ID, Wu PS, et al. HÃ¼rthle cell (oxyphilic) papillary carcinoma of the
variant with more aggressive behavior. *World J Surg* . 1992;16:669â€“675.

54.Wu PS-C, Hay ID, Hermann MA, et al. Papillary thyroid carcinoma (PTC), oxyphil cell ty
tumor misclassified by the world health organization (WHO). *Clin Res* . 1991;39:279.

55.Barbuto D, Carcangiu ML, Rosai J. Papillary HÃ¼rthle cell neoplasms of the thyroid gla
of 20 cases. *Mod Pathol* . 1990;3:7A.

56.Hill JH, Werkhaven JA, DeMay RM. HÃ¼rthle cell variant of papillary carcinoma of the
gland. *Otolaryngol Head Neck Surg* . 1988;98:338â€“341.

57.Khanum O, Wang S, Hameed A. Fine needle aspiration cytology of a papillary oncocytic
of the thyroid gland. *Acta Cytol* . 1999;43:976â€“978.

58.Dzieciok J, Musiatowicz B, Zimnoch L, et al. Papillary HÃ¼rthle cell tumor of thyroid. I
case with a cytomorphologic approach to diagnosis. *Acta Cytol* . 1996;40:311â€“314.

59.Chen KTK. Fine-needle aspiration cytology of papillary HÃ¼rthle cell tumors of thyroid
of three cases. *Diagn Cytopathol* . 1991;7:53â€“56.

60.Baloch ZW, LiVolsi VA. Fine-needle aspiration cytology of papillary HÃ¼rthle cell carci

lymphocytic stroma "Warthin-like tumor" of the thyroid. *Endocr Pathol* . 1998;4:317â€“323

61.Apel RL, Asa SL, LiVolsi VA. Papillary HÃ¼rthle cell carcinoma with lymphocytic stroma "Warthin-like tumor" of the thyroid. *Am J Surg Pathol* . 1995;19:810â€“814.

62.Johnson TL, Lloyd RV, Burney RE, et al. HÃ¼rthle cell thyroid tumors: an immunohisto study. *Cancer* . 1987;59: 107â€“112.

63.Nesland JM, Sobrinho-Somoes MA, Holm R, et al. HÃ¼rthle cell lesions of the thyroid: a study using transmission electron microscopy, scanning electron microscopy and immunocytochemistry. *Ultrastruct Pathol* . 1985;8:269â€“290.

64.Volante M, Bozzalla-Cassione F, DePompa R, et al. Galectin-3 and HBME-1 expression in tumors of the thyroid. *Virchows Arch* . 2004; 445:183â€“188.

65.Abu-Alfa AK, Straus FH, Montaf AG. An immunohistochemical study of thyroid HÃ¼rthle their neoplasms. The role of S-100 and HMB-45 proteins. *Mod Pathol* . 1994;7:529â€“532.

66.Erickson LA, Jin L, Goellner JR, et al. Pathologic features, proliferative activity, and cy expression in HÃ¼rthle cell neoplasms of the thyroid. *Mod Pathol* . 2000;13:186â€“192.

67.Bronner MP, Clevenger CV, Edmonds PR, et al. Flow cytometric analysis of DNA content HÃ¼rthle cell adenomas and carcinomas of the thyroid. *Am J Clin Pathol* . 1988;89:764â€“

68.Ryan JJ, Hay ID, Grant CS, et al. Flow cytometric DNA measurements in benign and ma HÃ¼rthle cell tumors of the thyroid. *World J Surg* . 1988;12:482â€“487.

69.Chiappetta G, Toti P, Santoro M, et al. The RET/PTC oncogene is frequently activated oncocytic thyroid tumors (HÃ¼rthle cell adenomas and carcinomas), but not in oncocytic hyperplastic lesions.*J Clin Endocrinol Metab* . 2002;87:364â€“369.

70.Cheung CC, Ezzat S, Ramyar L, et al. Molecular basis of HÃ¼rthle cell papillary carcino
Endocrinol Metab , 2000;85: 878â€“882.

71.Bondeson L, Bondeson AG, Ljungberg K, et al. Morphometric studies on nuclei in smear
needle aspirates from oxyphilic tumors of the thyroid. *Acta Cytol* . 1983;27:437â€“440.

72.Benoit JL, Chen D, Schultz DS, et al. Fine needle aspiration diagnosis of HÃ¼rthle cell
the thyroid: a morphometric analysis. *Acta Cytol* . 1994;38:850(A).

73.Kumarasinghe MP, De Silva S. Pitfalls in cytological diagnosis of autoimmune thyroiditis
Pathology . 1999;31:1â€“7.

74.Nguyen GK, Ginsberg J, Rockford PM, et al. Hashimoto's thyroiditis: cytodiagnosis, accu
pitfalls. *Diagn Cytopathol* . 1997;16:531â€“536.

75.Ravinsky E, Safneck JR. Differentiation of Hashimoto's thyroiditis from thyroid neoplasr
needle aspirates. *Acta Cytol* . 1988;32:854â€“861.

76.Jayaram G. Problems in the interpretation of HÃ¼rthle cell populations in fine needle
from the thyroid. *Acta Cytol* . 1983;27:84â€“85.

77.Kini SR, Miller JM, Hamburger JI. Problems in the cytologic diagnosis of the "cold" thyro
in patients with lymphocytic thyroiditis. *Acta Cytol* . 1981;25:506â€“512.

Editors: Kini, Sudha R.
Title: *Thyroid Cytopathology: A Text and Atlas, 1st Edition*

Copyright Â©2008 Lippincott Williams & Wilkins

9

Papillary Carcinoma

Papillary carcinoma, the most common differentiated malignant neoplasm of the thyroid, comprises up to 80% of all thyroid carcinomas in the United States.1 , 2 , 3 , 4 , 5 , 6 , 7 , 8 10 , 11 , 12 , 13 It occurs more frequently in women, with a female:male ratio of 3:1. Papil carcinomas are seen in all age groups, with a peak in the third to fourth decade. They have tendency for intraglandular spread, cervical lymph node metastasis, and local invasion, but demonstrate fewer predilections for hematogenous spread than follicular carcinomas. Distai metastases are uncommon and occur late in the disease. Relapses can occur as late as 30 ye after initial treatment.6 These tumors are slow growing, and follow an indolent course. The prognosis for papillary thyroid carcinoma is generally considered favorable; however, it dep on several risk factors such as the patient's age; the extension stage (e.g., occult, intrathyr or extrathyroidal), and the histologic differentiation. Mortality is very lowâ€"6.5% on long-te follow-up.5 A higher incidence of poorly differentiated and sclerosing types has been report children exposed to the radiation from Chernobyl studies.14 , 15 Risk factors for developing papillary thyroid carcinoma include prior exposure to ionizing radiation, genetic factors, an nodular disease of the thyroid.

RADIOLOGIC FINDINGS

Papillary carcinomas present as cold nodules on radionuclide imaging. On ultrasound, two patterns are described: (i) presence of a solid hypoechoic nodule with discrete echogenic fo and microcalcifications, and (ii) solid hypoechoic nodule with coarse echogenic foci.16

GROSS AND HISTOLOGIC FEATURES

The literature is rich in documentation of pathology of papillary thyroid carcinomas, with se excellent reviews on morphology including the ultrastructural findings.1 , 2 , 3 , 4 , 5 , 6 , 7 9 , 10 , 11 , 12 , 13 , 14 , 15 , 16 , 17 , 18 , 19 , 20 , 21 , 22 , 23 , 24 , 25 , 26 , 27

The gross appearance of papillary carcinoma varies with the size. Large tumors are typically fleshy, velvety, fragile, and may extend to the capsule of the thyroid (Figs. 9.1 , 9.2 and 9.3 They are usually invasive, but may be circumscribed. Papillary carcinomas are typically non-encapsulated, but have a tendency to develop fibrosis that results in partial encapsulation. Markedly desmoplastic carcinomas may appear like a scar tissue. Cystic changes due to degeneration are very common (Fig. 9.2). This can be extensive, with a prominent unicystic multicystic pattern. Calcification is frequent.

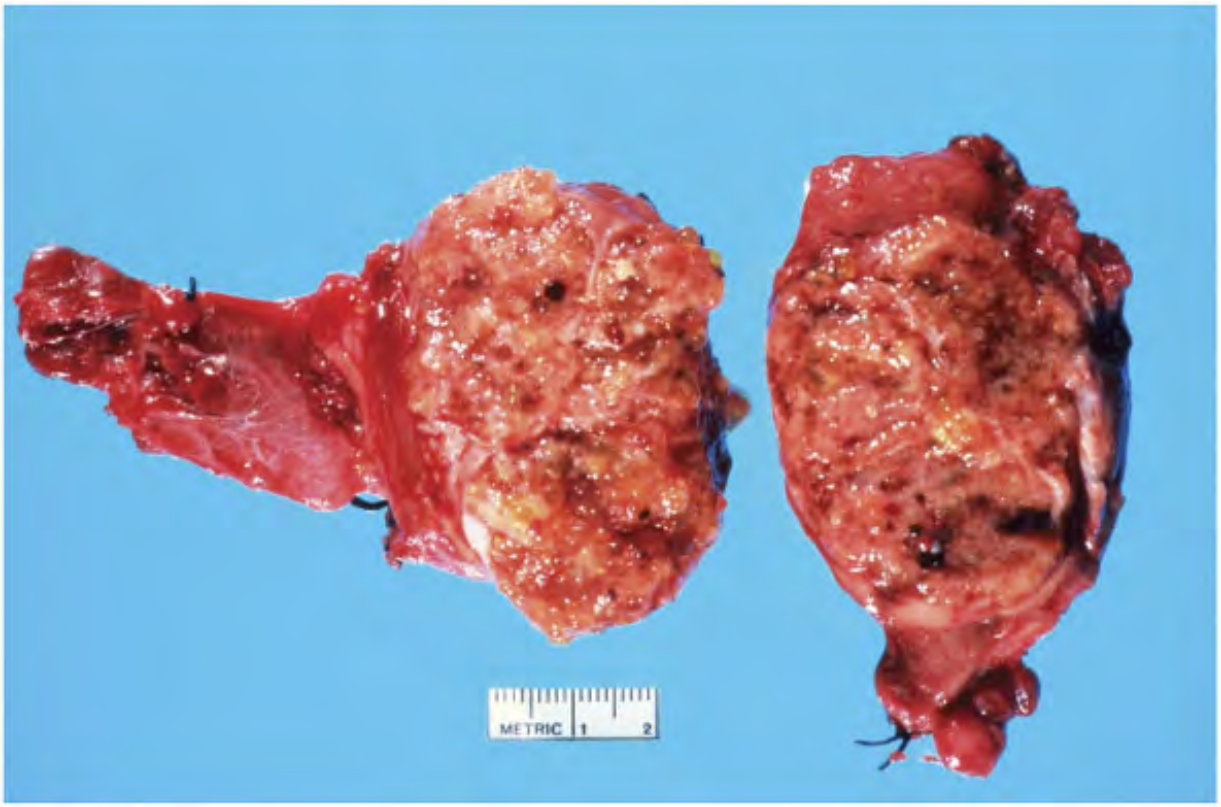

Figure 9.1. Papillary carcinoma of the thyroid. The tumor is fleshy, with a bulging, variegat cut surface, mottled by small cystic cavities and fibrosis.

Figure 9.2. Cystic papillary carcinoma. The tumor appears friable protruding into the cavity

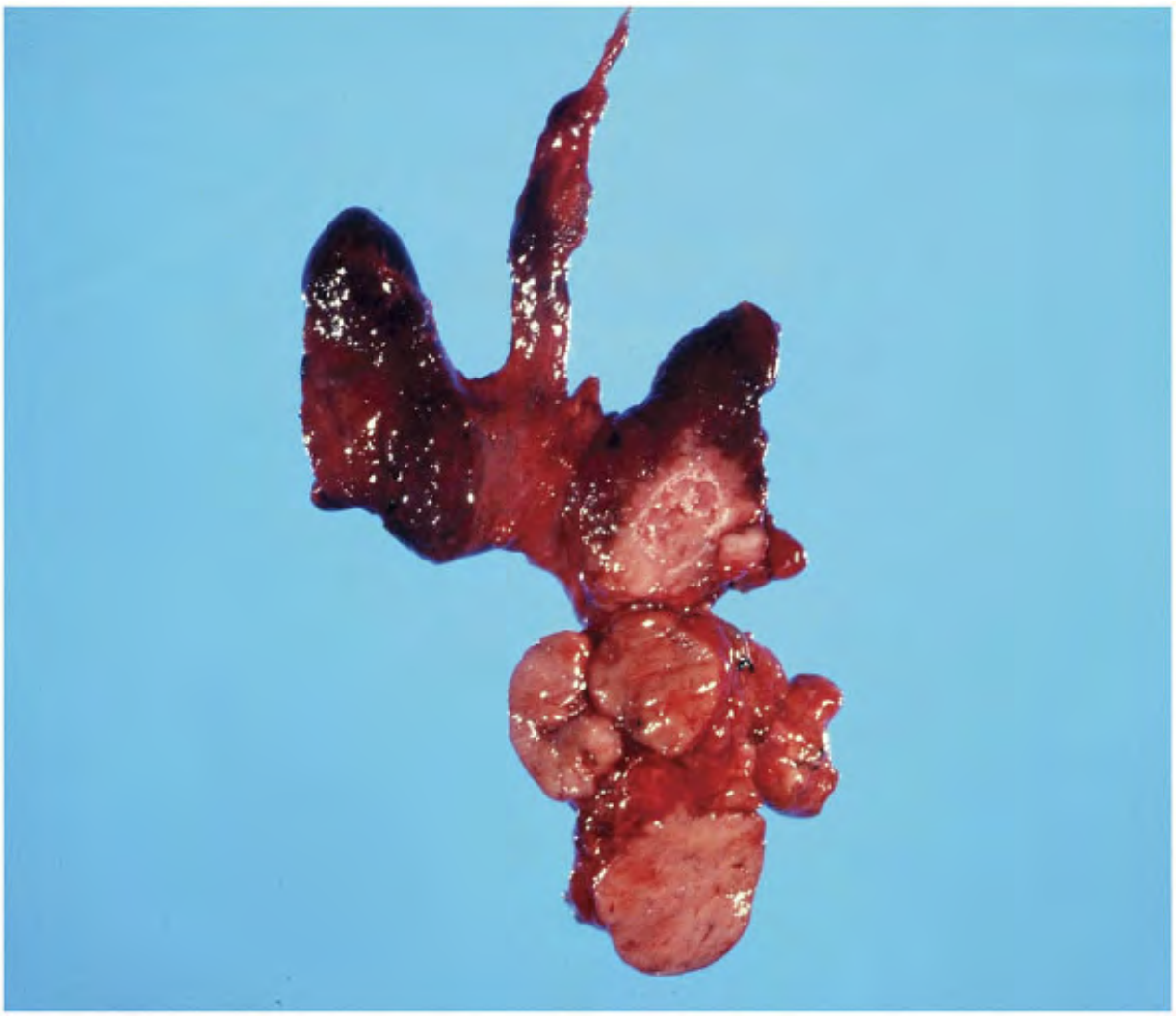

Figure 9.3. Papillary carcinoma of the left thyroid lobe with involvement of multiple lymph nodes.

Microscopically, papillary carcinomas present varied patterns (Figs. 9.4 , 9.5 , 9.6 , 9.7 , 9.8 9.9 , 9.10 , and 9.11). A typical papillary carcinoma is characterized by neoplastic epitheliu arranged on fibrovascular stalks (Figs. 9.4 and 9.5). The papillary fronds may be well devel with a complex branching pattern; or they may be rudimentary, without discernible fibrovascular stalks. Some fronds may be broad and edematous, and may contain foamy histiocytes. Generally, the covering epithelium is single-layered, although it may be multilayered, and the nuclei are stratified. The neoplastic cells can be cuboidal, columnar, squamoid, with variable cytoplasm surrounding a central ovoid nucleus. These nuclei have p chromatin, with peripheral condensation that gives a ground- glass or watery appearance, s

typical of papillary carcinoma.28 , 29 Intranuclear inclusions are readily identified in sectio conventional papillary carcinomas. Nuclear grooves are characteristic. Micronucleoli are alm always seen, especially with pale watery chromatin.30 , 31 Mitoses are extremely rare. Multifocal involvement of one or both lobes occurs in about 20% of cases,12 , 13 , 24 but ca higher if the whole gland is sectioned.11

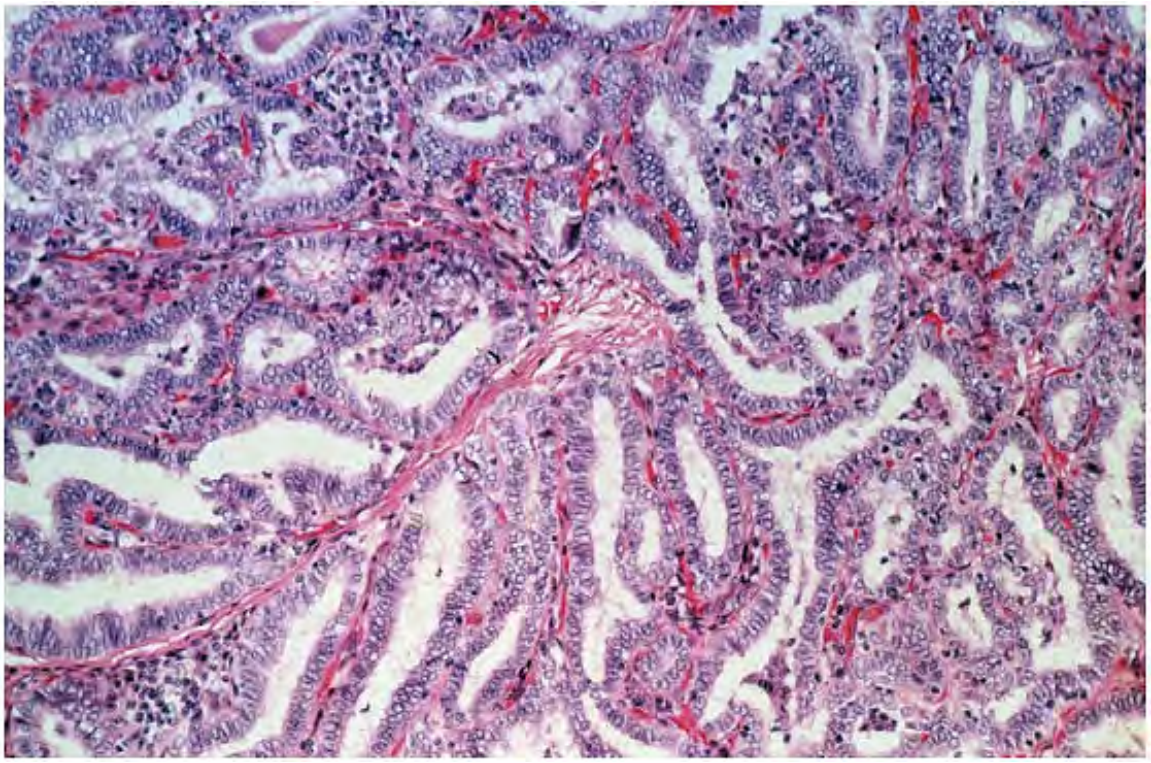

Figure 9.4. Histologic section. Papillary carcinoma with branching papillary fronds. The lini epithelium is single-layered, with ground-glass nuclei.

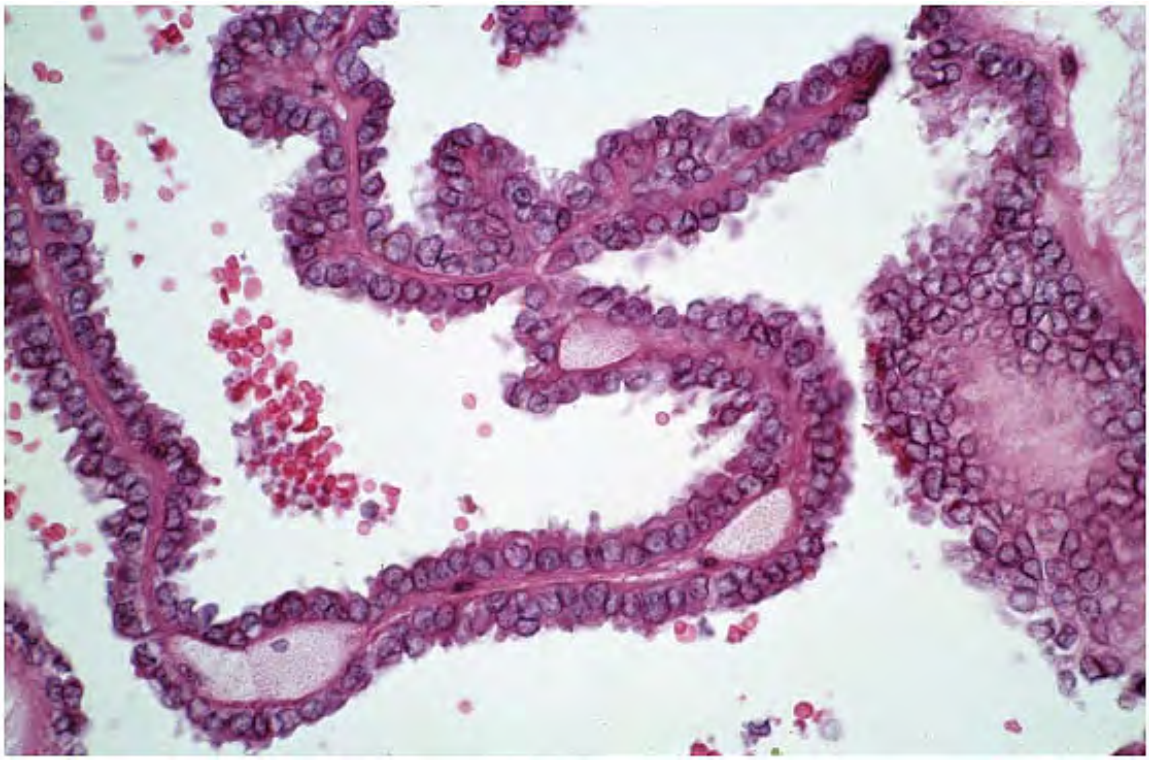

Figure 9.5. A delicate papillary frond covered by epithelium with stratified, empty-looking nuclei presenting "eggs in the basket" appearance.

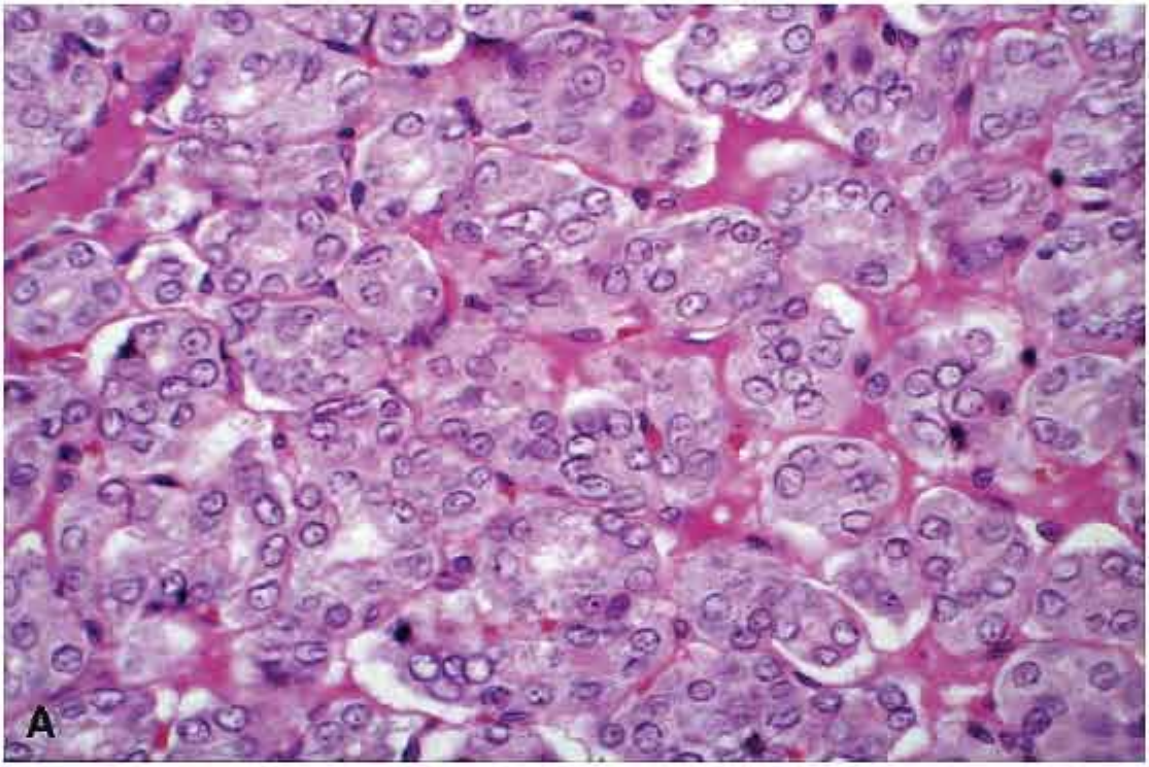
A

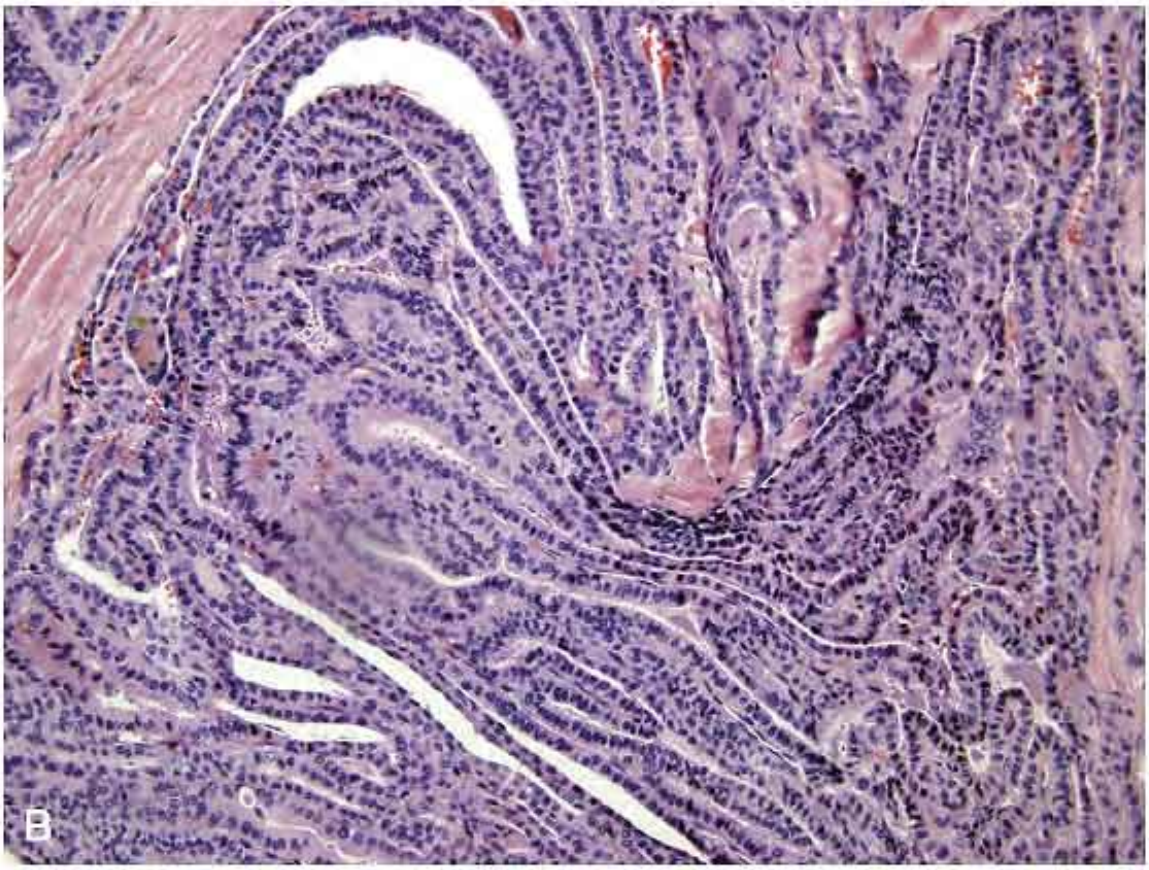
B

Figure 9.6. A. Papillary carcinoma exhibiting a follicular pattern. B. These follicles from a papillary carcinoma are elongated and are arranged in a parallel fashion (railroad tracks).

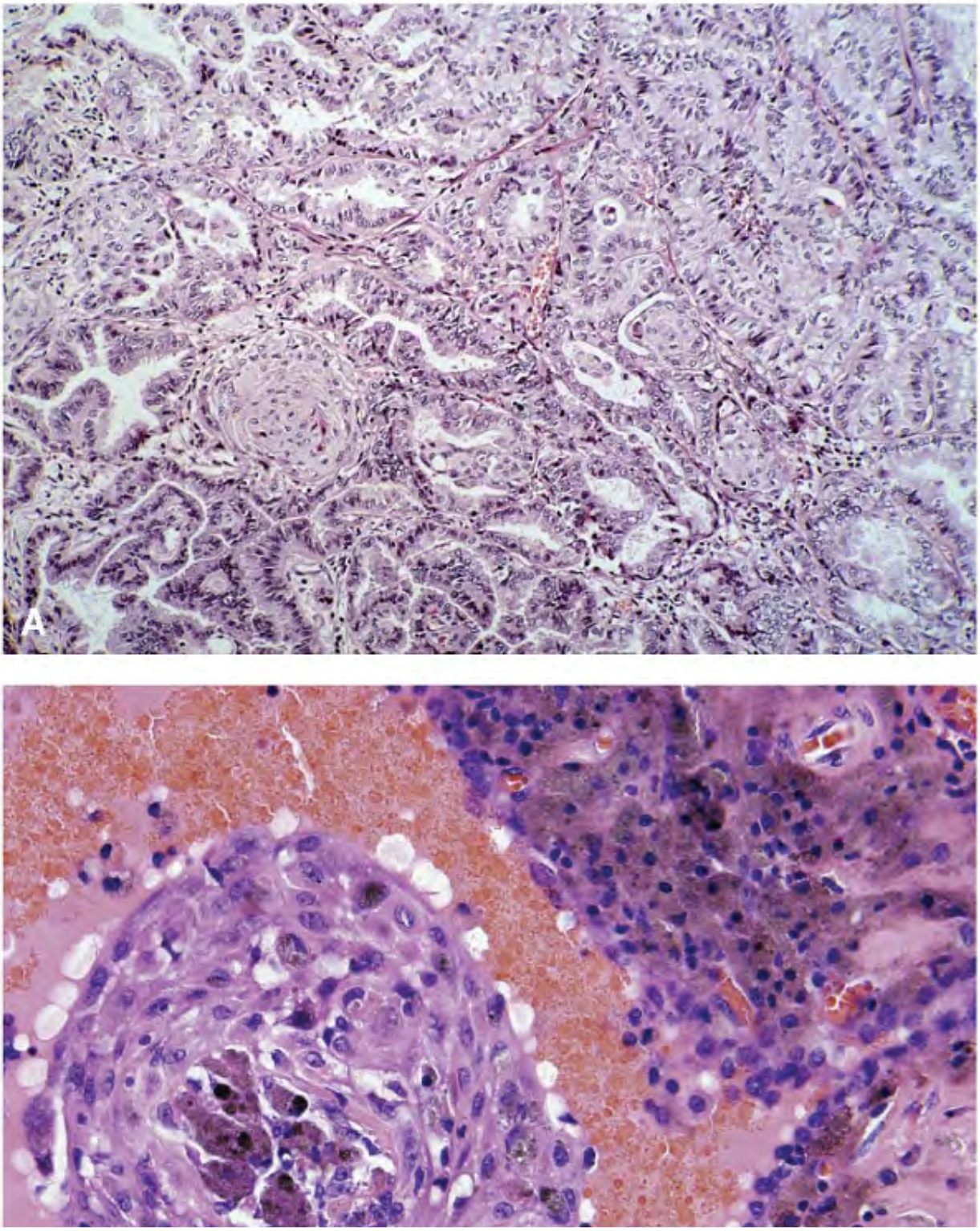

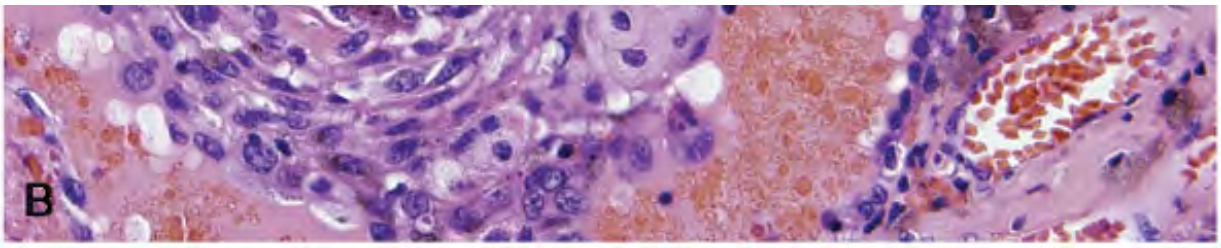

Figure 9.7. Papillary carcinoma with squamous metaplasia.

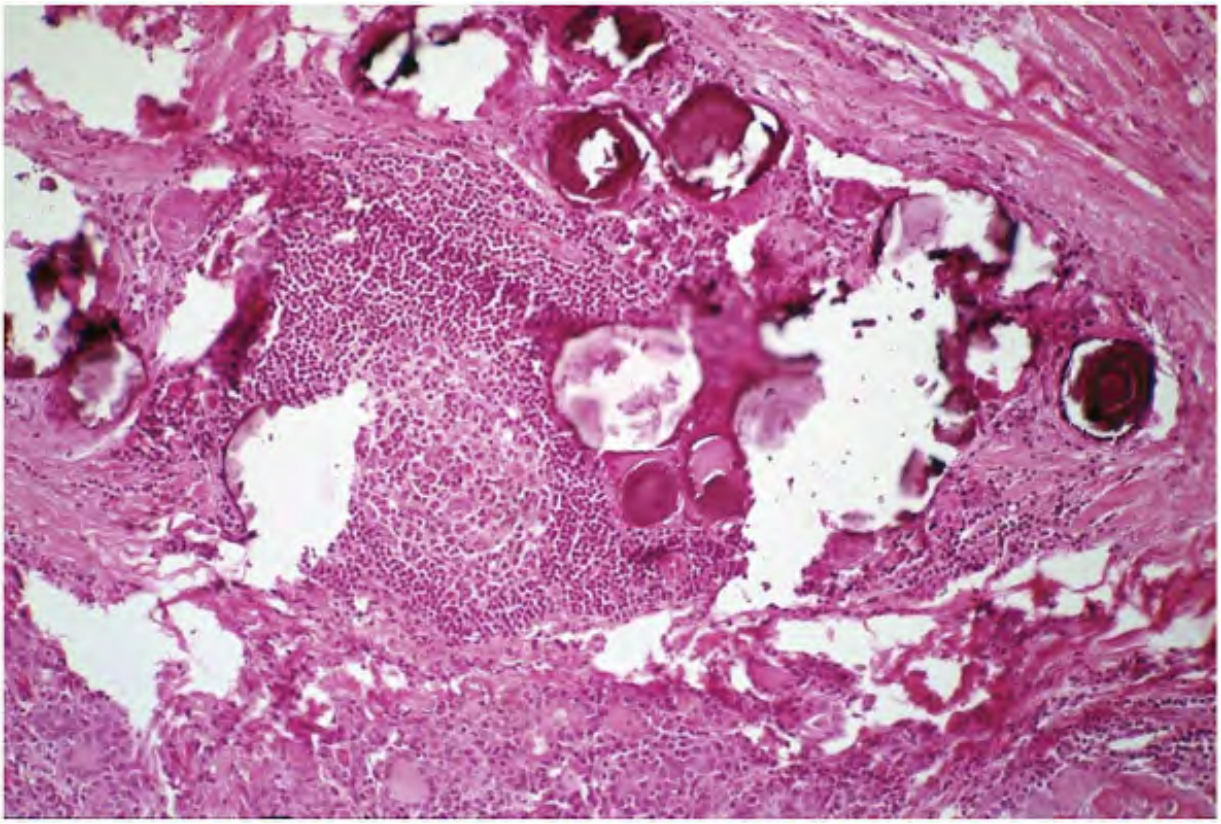

Figure 9.8. Multiple psammoma bodies in papillary carcinoma.

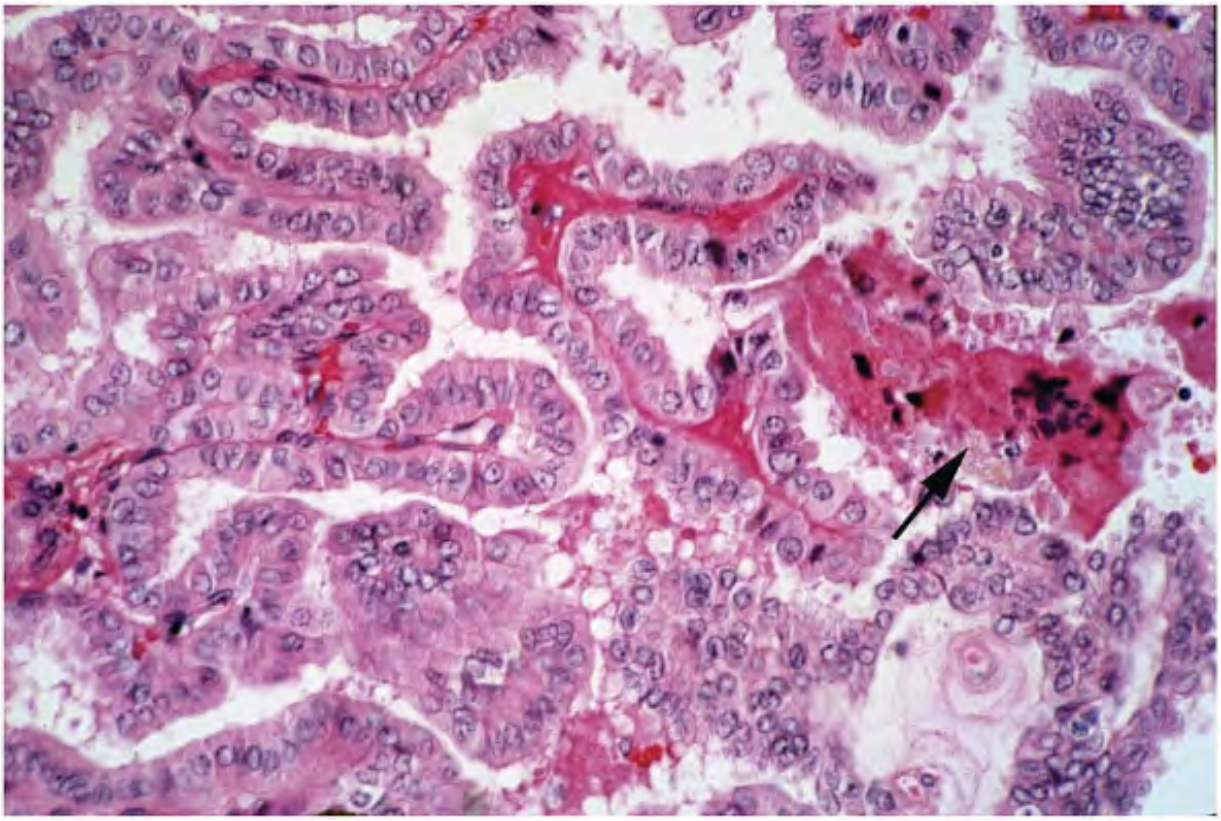

Figure 9.9. Papillary carcinoma with multinucleated foreign-body type giant cell (*arrow*).

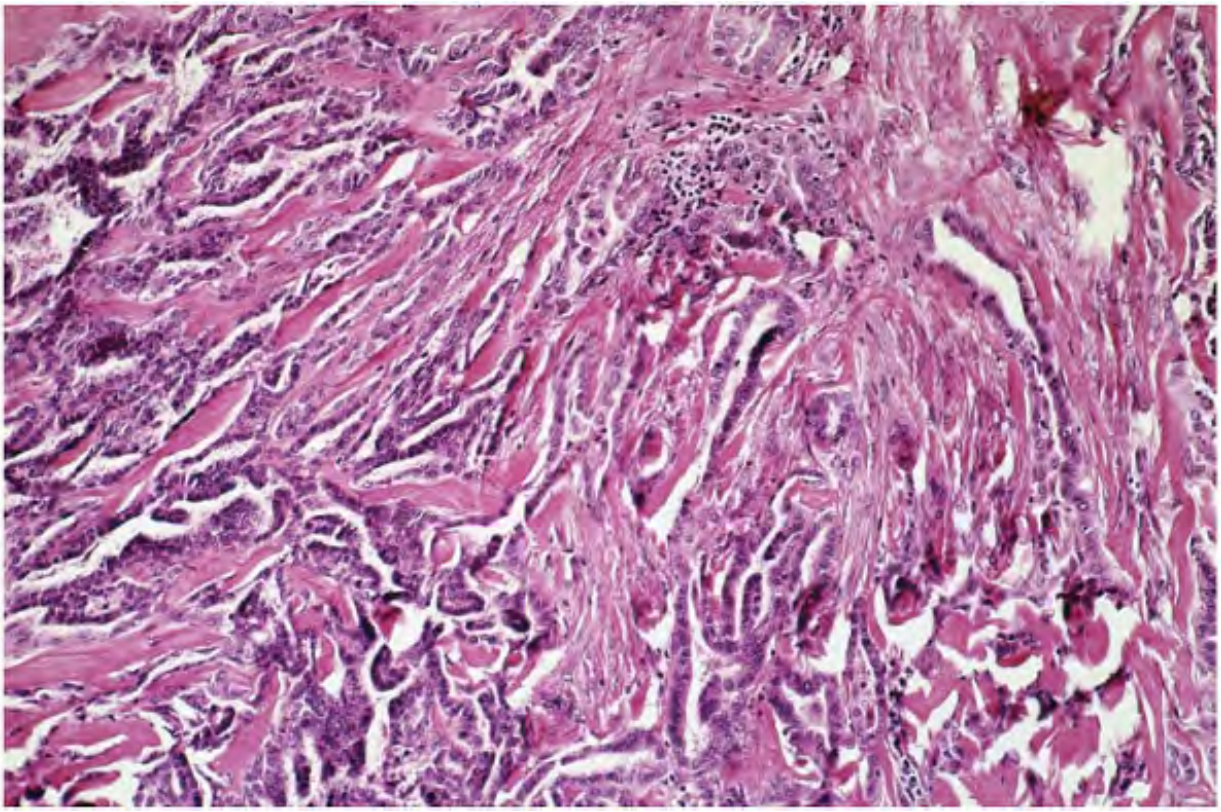

Figure 9.10. Papillary carcinoma with marked desmoplasia.

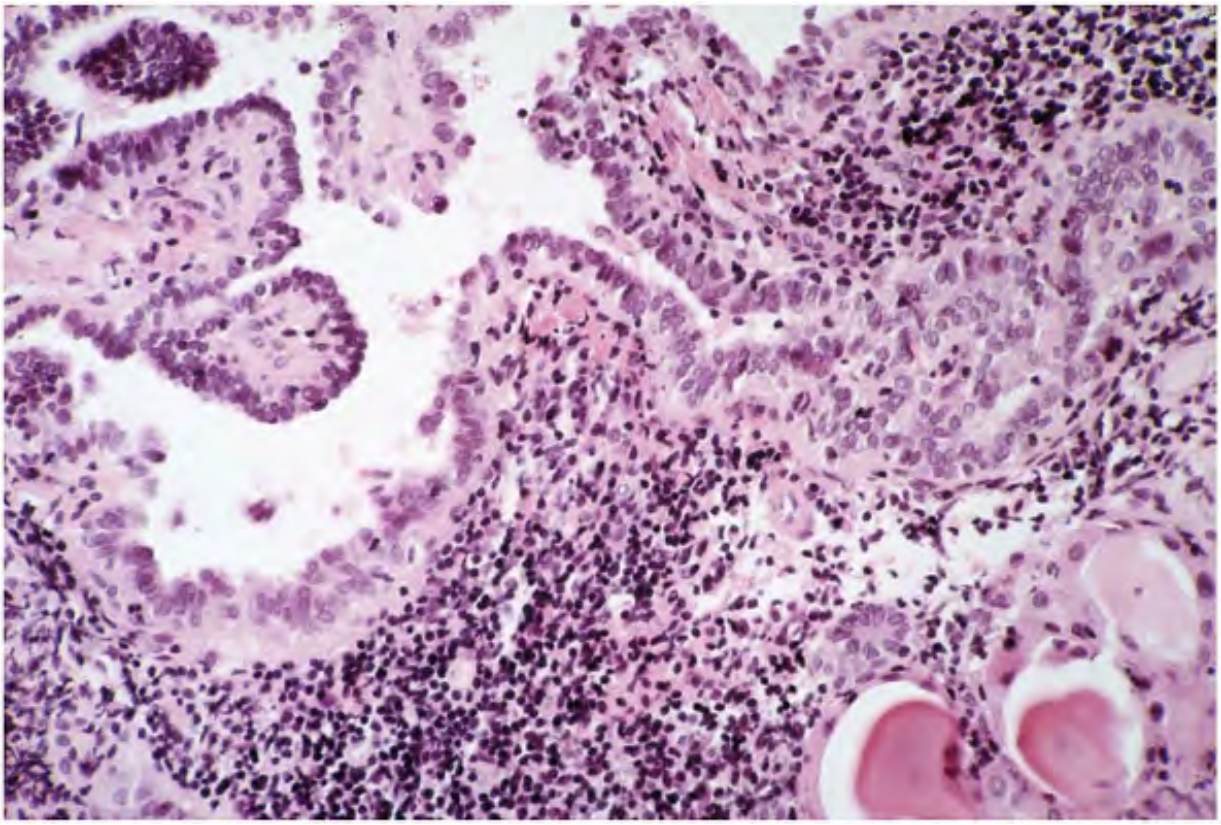

Figure 9.11. Papillary carcinoma with lymphocytic infiltrate.

Papillary carcinomas are often mixed, with areas of follicular differentiation in varying proportions (Fig. 9.6A). The follicles may be well developed, filled with colloid, or form clo packed narrow tubules (Fig. 9.6B). Areas of solid growth pattern may also be present. Squa metaplasia is quite common, present in up to 40% of cases.9 , 10 , 13 , 21 , 22 These foci of squamous differentiation appear as morulae within the follicles or against the papillae (Fig. and B). Spindle cell metaplasia has been described.32 Roughly 40% to 60% of papillary carcinomas have lamellated calcific spherules, called "psammoma bodies," "microliths," or "calcospherites" (Fig. 9.8).8 , 12 , 22 , 33 , 34 , 35 . These are basophilic, nonbirefringent, 100 Âµm in size, and seem to arise between epithelial cells. They are also found within hyalinized stroma at the tip of a papilla. "Naked" psammoma bodies may be found in thyroic tissue adjacent to, or even distant from, the cancer. The colloid in papillary carcinoma is de staining.21 Multinucleated giant cells are commonly seen (Fig. 9.9).

Cystic degeneration is very common. Carcangiu, et al.7 in their series of 241 papillary carcinomas, reported an incidence of 52.5%, with marked cystic changes in 9.1%. Cystic cha also develop in nodal metastasis; 19.7% of papillary carcinomas may present clinically with r metastasis.

The stroma in papillary carcinomas is often desmoplastic, which could be extensive (Fig. 9.1).20 , 36 Spindle cell metaplasia in papillary carcinomas is described, but is encountered on rarely.32

Lymphocytic infiltrate is frequent. Franssila9 reported this feature in 31% of his cases, and Carcangiu, et al.20 reported it in 26.7% (Fig. 9.11). Whether this infiltrate represents Hashimoto's thyroiditis or a reaction to the neoplasm is not certain.

Papillary carcinomas may coexist with poorly differentiated "insular" or undifferentiated are

CYTOPATHOLOGIC FEATURES OF CONVENTIONAL PAPILLAR CARCINOMA

The cytopathologic features of papillary carcinoma are amply reported in the literature.37 , 39 , 40 , 41 , 42 , 43 , 44 , 45 Kini, et al. (43) described them in great detail.43

Because of the diversity of morphologic patterns, the cytopathologic criteria, as reflected ir cytologic samples, are numerous and complex (Table 9.1). The diagnosis of papillary carcin cannot be based on just one criterion, because any feature listed in Table 9.1 can be seen i benign diseases. It is important, therefore, to be familiar with the typical cytopathologic features, in order to appreciate the variations and diagnostic pitfalls. For this reason, the u and typical cytopathologic features are first described individually, in detail, and then discu later in the chapter in terms of their significance.

Cellularity

Variable; overwhelmingly cellular to scant in tumors with desmoplasia, or with cystic chang

Presentation

Neoplastic cells isolated, in loosely cohesive groups or in syncytial tissue fragments with var architectural configurations

Architecture of the tissue fragments

Papillary, with or without complex branching, containing central fibrovascular cores; papilla

like without visible central cores but appearing as finger-like processes; monolayered (two dimensional, but syncytial) with or
without branching; syncytial with follicular pattern; syncytial without architectural patter appear as three-dimensional balls, onion-skin pattern or swirls;
nuclei variably crowded and overlapped

Cells

Wide range of size and shapes; small, medium-sized to very large; round, cuboidal, short columnar,
elongated, polygonal, spindle-shaped, cell borders well to poorly defined; N/C ratios varia

Nucleus

Pleomorphic in size and shape; round, oval, oblong; nuclear membranes smooth to irregular chromatin
characteristically, pale, dusty, powdery to finely granular; multiple micro/macronucleoli; longitudinal
grooves, single or multiple intranuclear inclusions; small to large occupying the entire nuc
bordered by condensed chromatin; mitosis rare to absent; degeneration may mask nuclear features

Cytoplasm

Variable, insignificant in conventional types to abundant in some morphologic variants; pale

Squamous metaplasia

Â±

Psammoma bodies

Often present; naked or incorporated in syncytial tissue fragments of neoplastic cells display nuclear
features of papillary carcinoma; single or multiple within any given tissue fragment; concentric
lamellated to star-burst appearance; basophilic to combination of multiple colors: brown, amber,
violet to purple; sometimes refractile; naked psammoma bodies not of diagnostic importa

Multinucleated foreign-
body-type
giant cells

Almost always present; variable in numbers and size, number of nuclei vary; round to oval w
finely granular chromatin and micronucleoli; grooves and inclusions not present; cytoplasm

abundant, dense and not phagocytic

Background

Usually clean without necrosis; evidence of recent or old hemorrhageâ€”histiocytes with or without

hemosiderin; lymphocytic infiltrate Â±; colloid variable; pale to dense, often stringy

Immunoprofile

Reactive to thyroglobulin, TTF-1; cytokeratin 19

TABLE 9.1 CYTOPATHOLOGIC FEATURES OF CONVENTIONA (USUAL TYPE) PAPILLARY CARCINOMA

Papillary carcinomas are generally soft, fragile, and when they have minimal stroma, they y very cellular aspirates. The cellularity is often overwhelming. A typical presentation at a ve low magnification includes a large number of tissue fragments with characteristic structural patterns, mixed with a large population of pleomorphic, isolated, and groups of neoplastic c (Fig. 9.12). The architectural patterns of the tissue fragments of follicular cells seen in aspirates of papillary carcinoma are multiple (Fig. 9.13). Their component cell nuclei prese the characteristic and diagnostic features. The carcinoma cells will be described first.

Figure 9.12. FNA. An overwhelmingly cellular aspirate of papillary carcinoma with many tis fragments exhibiting a complex branching pattern; some large ones appear monolayered. Th background is clean (low power).

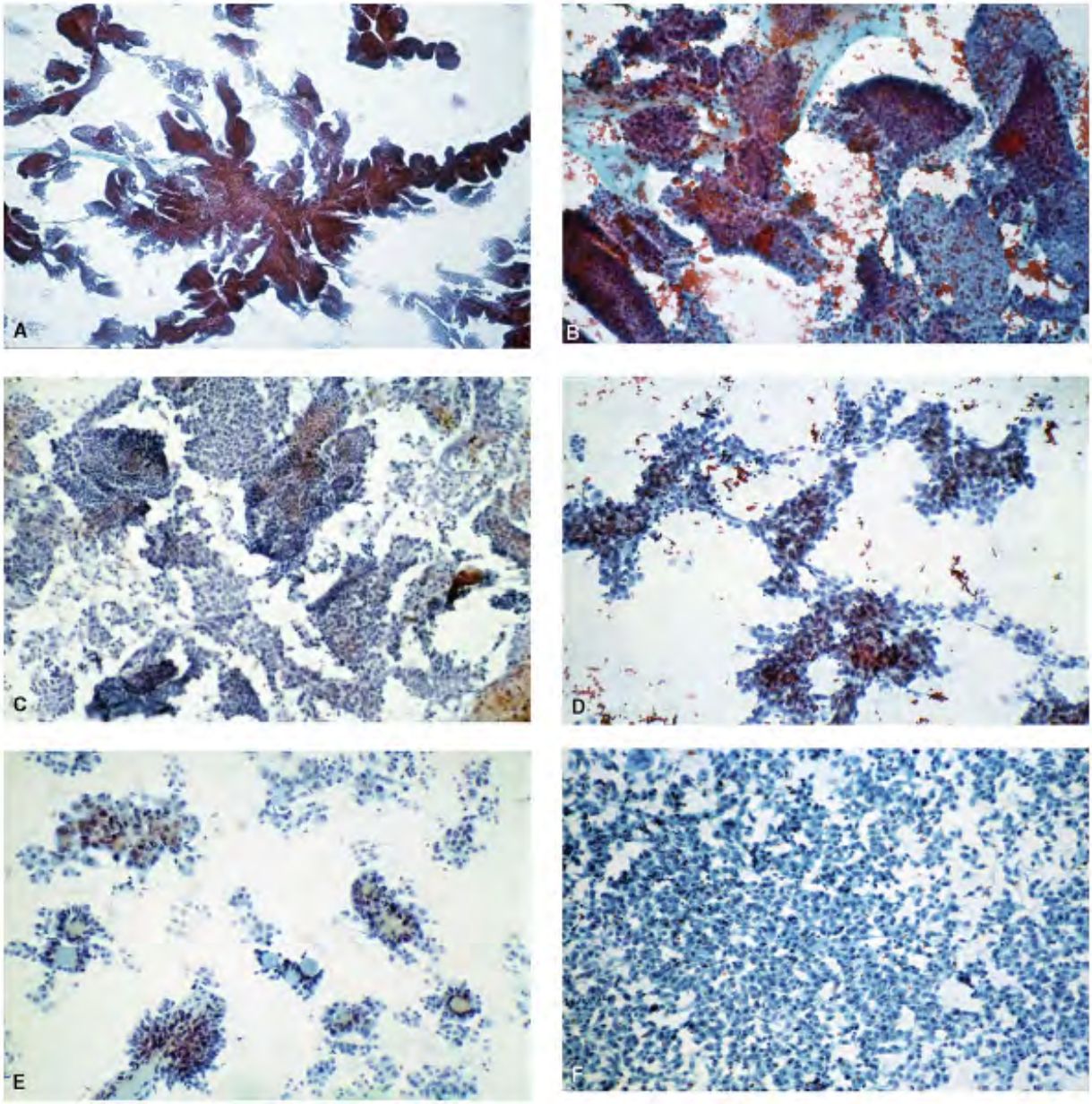

Figure 9.13. *General presentation.* A: cellular aspirate showing papillary tissue fragments v complex branching. B: Large numbers of papillary-like (without visible central cores) tissue fragments. C: Varying-sized monolayered tissue (two-dimensional) fragments. D: Syncytial t fragments with anastomosing trabeculae. E: A follicular pattern. F: Single cell pattern.

Cells of Papillary Carcinoma

Papillary carcinoma cells (Fig. 9.14) are so varied that practically any shape and size may b encountered. They may be cuboidal, columnar, ovoid, polygonal, squamoid, and even spind

shaped.

P.136

Papillary carcinoma cells may be medium-sized to large, sometimes exceeding 10 Âµm in diameter. The cell borders in single cells tend to be well defined. The cytoplasm is variable scant to abundant, and may be pale, foamy, vacuolated, granular, or dense. The carcinoma with abundant, dense cytoplasm appear HÃ¼rtheloid. Their nuclei are generally slightly eccentric in position; round, oval to ovoid, often irregular in shape, and varied in size. In we developed papillary fronds, the nuclei appear small because they are closely packed togethe monolayered tissue fragments, they appear considerably larger. The nuclear membranes are sharp, and may show irregularities. The chromatin is so finely granular, and dusty to powder that the nuclei appear clear, pale, or watery. Single or multiple micro- and or macronucleol always seen. Although not diagnostic by itself, nuclear groove is a consistent feature. It is se as a chromatin ridge along the long axis of the nucleus, and is probably due to irregular info of the nuclear membrane, as seen in electronmicrographs.25 Another characteristic aspect the presence of intranuclear cytoplasmic inclusions, a consistent feature in aspirates of pap carcinoma (Fig. 9.15), considered to be cytoplasmic invagination. They occur as sharply defined, clear, round inclusions, bordered by condensed chromatin. Intranuclear inclusions be large

P.137

P.138

and single, occupying the entire nucleus, or they may be small and multiple. The multiple inclusions within a single nucleus present a "soap-bubble" appearance. According to Abele a Miller,40 an intranuclear inclusion should take up at least 10% of the total nuclear surface a to distinguish it from nonspecific vacuoles, which are often seen in air-dried preparations. A the sharp border of these inclusions is a differentiating feature from the vacuoles seen in so degenerating nuclei, where the vacuoles merge with the chromatin.

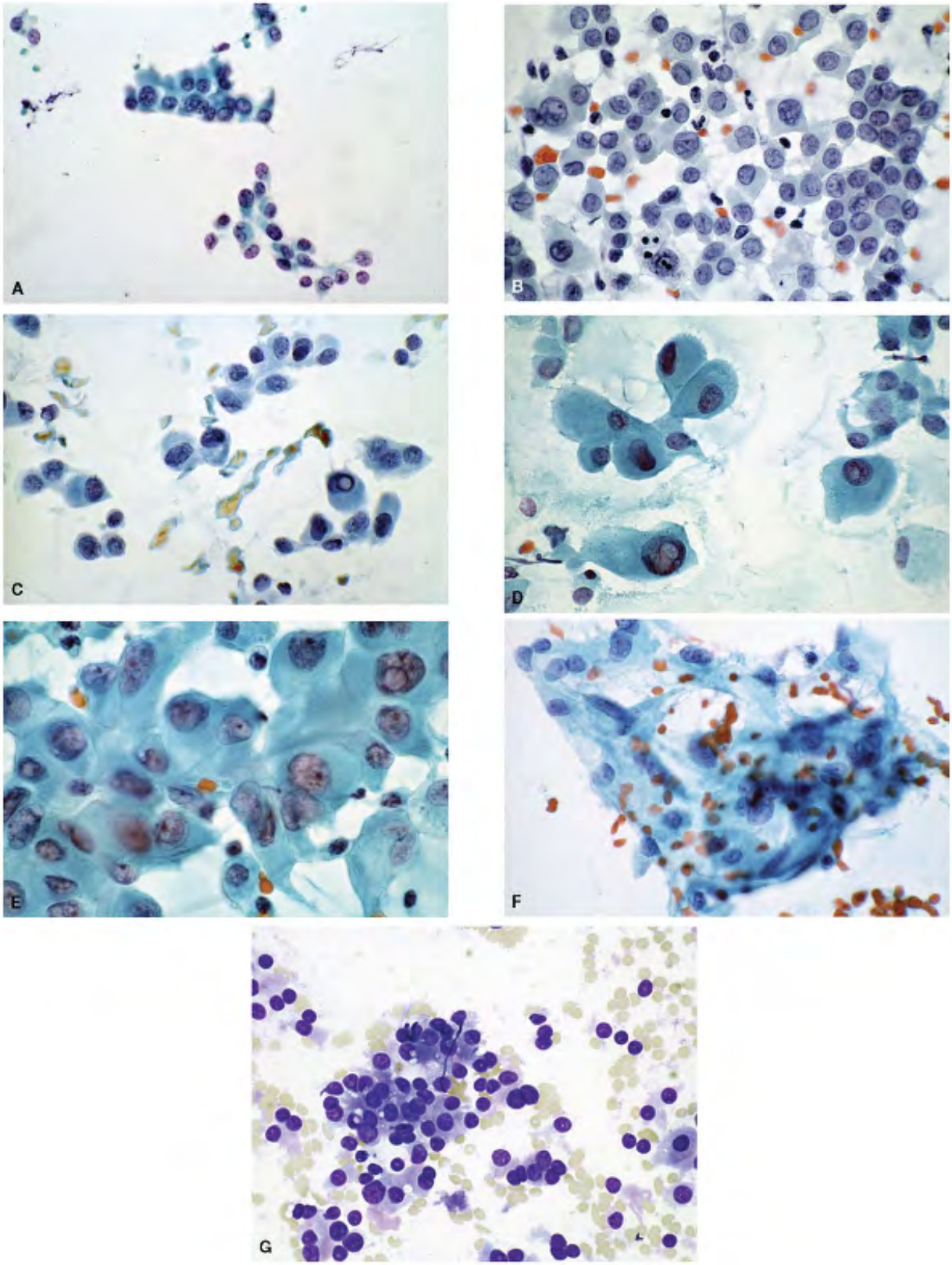

Figure 9.14. *Cells of papillary carcinoma* . A. Small, oval, and short columnar cells, poorly

defined cell borders; scant, indiscernible cytoplasm; powdery chromatin; intranuclear inclusions. B. Medium-sized cuboidal cells. C. Medium-sized oval to plasmacytoid cells with eccentric nuclei. D. Cells with dense cytoplasm resembling HÃ¼rthle cells. E. Tissue fragme very large cells with large, very pleomorphic nuclei and abundant dense cytoplasm. F. Pleomorphic, elongated, spindle to columnar cells with abundant dense cytoplasm. G. Cells papillary carcinoma (Diff-Quik stain). (Part G Courtesy of Mariza de Peralta-Venturina, MD, William Beaumont Hospital, Royal Oak, Michigan.)

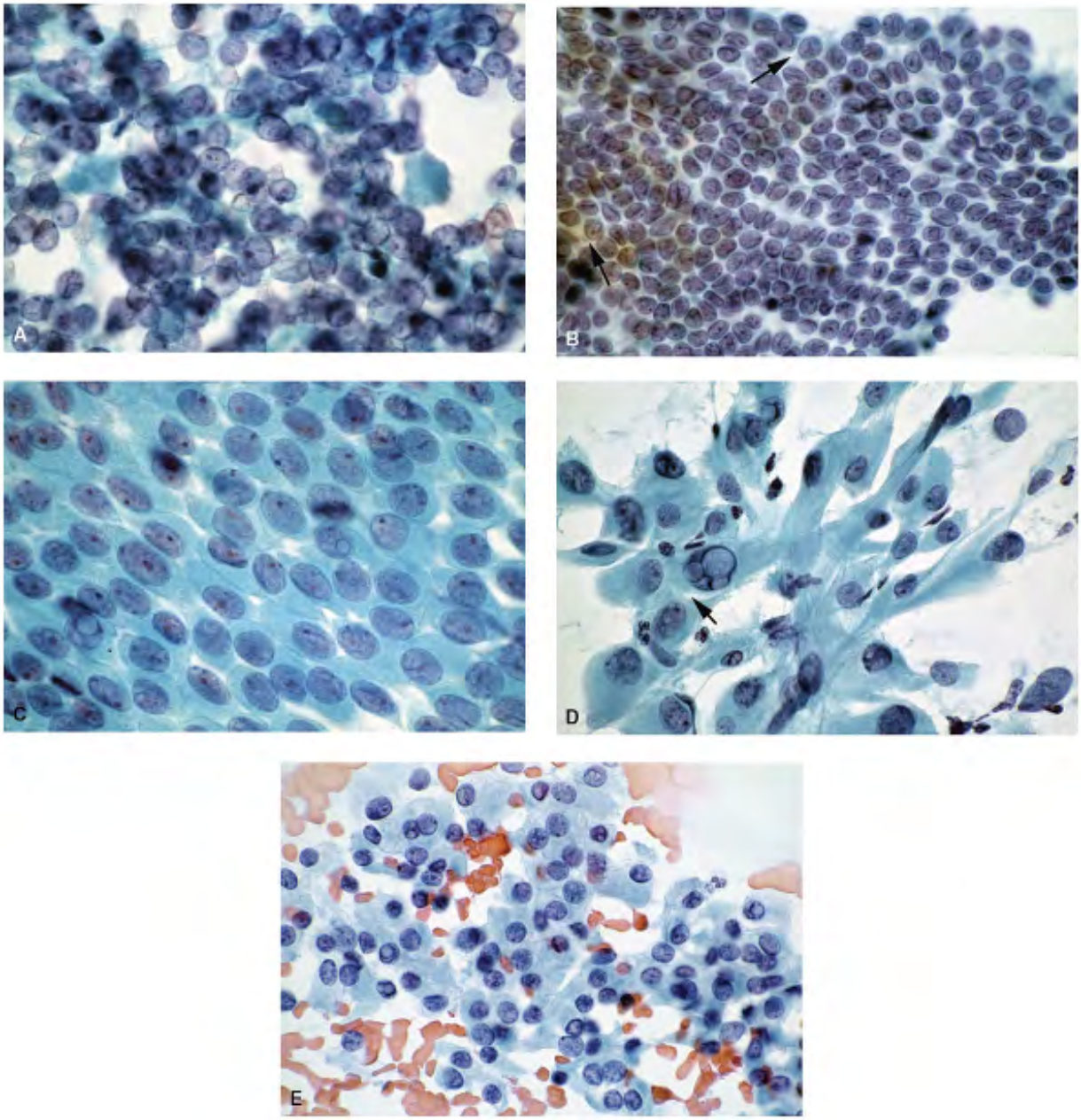

Figure 9.15. *Characteristic nuclear morphology of papillary carcinoma cells* . A. Round to c
nuclei with fine, dusty, powdery chromatin. B. Syncytial tissue fragment of cells. The nucle
oval or ovoid, many with irregular shapes. The chromatin is pale and powdery with multiple
micronucleoli, intranuclear inclusions (*arrow*), and frequent grooves. C. Syncytial arrangem
of cells. Nuclei are large and oval and have dusty powdery chromatin, micronucleoli, groove
and intranuclear inclusions. D. These papillary carcinoma cells are pleomorphic and elongat
Their nuclei demonstrate conspicuous inclusions that are sharp and bordered by condensed
chromatin. Some inclusions are single and some nuclei have multiple small inclusions like a s

bubble. E. Medium-sized round to cuboidal cells. The nuclei are slightly pleomorphic with fi granular chromatin, micronucleoli, grooves, and inclusions.

The nuclear characteristics of papillary carcinomas are diagnostic. In cytologic material, the tetrad of pale, enlarged nuclei with dusty chromatin, nucleoli, a chromatin ridge or groove, intranuclear cytoplasmic inclusions are virtually pathognomonic of papillary carcinoma (Fig.).

Syncytial-Type Tissue Fragments

Cancer cells grow irregularly. In cytologic specimens, they present themselves as syncytial-t tissue fragments (Fig. 9.16). The component cells may have ill-defined cell borders and alte nuclear polarity with crowded, overlapped nuclei. Syncytial architecture is seen in any type malignancy, and papillary carcinoma is no exception. Syncytial tissue fragments show a spec of architectural configurations in differentiated cancers, while in poorly differentiated neoplasms only syncytial tissue fragments without any architectural patterns predominate. I papillary carcinomas, the cells generally exhibit the typical nuclear morphology of conventi papillary carcinoma.

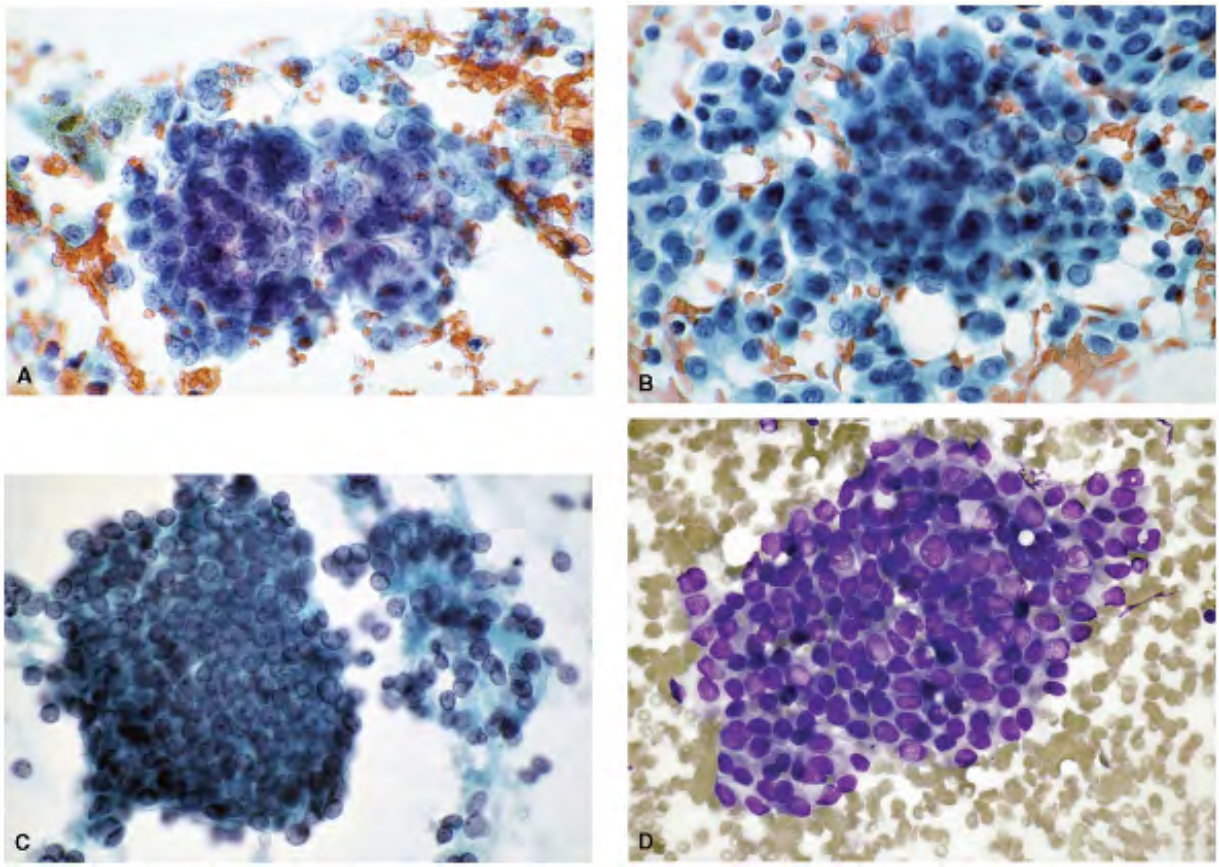

Figure 9.16. *Syncytial-type tissue fragments of papillary carcinoma without specific architectural configurations* . A. The tissue fragment is composed of carcinoma cells that ha poorly defined cell borders and marked crowding and overlapping of enlarged nuclei. The nuclear chromatin is fine, dusty, and powdery. Note micronucleoli and grooves. B,C. Syncyt tissue fragments with extreme crowding and overlapping of enlarged, round to oval nuclei. T chromatin is fine, powdery, and is condensed irregularly along the nuclear membranes. Note prominent micronucleoli and intranuclear inclusions. D. A syncytial tissue fragment of papill carcinoma cells (Diff-Quik stain).

Papillary Tissue Fragments

Papillary tissue fragments (Fig. 9.17) are syncytial, and have a simple or complex branching pattern that is characterized by a smooth external contour and peripheral palisading of the nuclei. The component cells are closely packed, have poorly defined cell borders, and their cytoplasm is hardly visible. The nuclei are crowded, overlapped, and exhibit characteristic morphology. The tips of the papillary fronds may be seen as three-dimensional clusters, with

smooth external boundaries. By definition, papillary tissue fragments must demonstrate cen fibrovascular cores. In well-fixed, well-stained preparations, the papillary tissue fragments demonstrate central fibrovascular stroma containing capillary loops. Neoplastic cells arising such a stromal core are low cuboidal or columnar and give a feathery pattern to the papillai fragment.

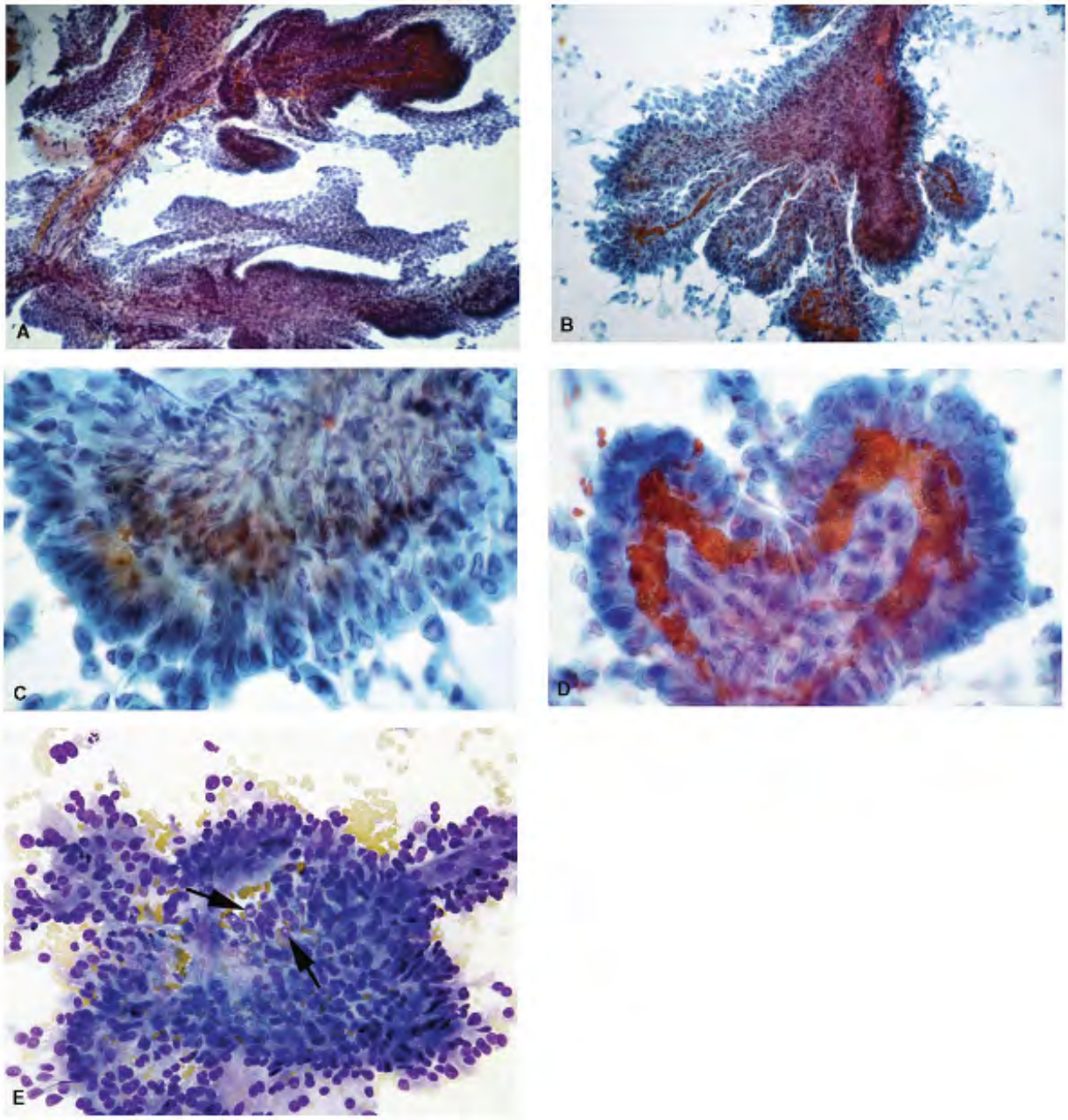

Figure 9.17. *Papillary architecture* . A. Tissue fragments with a complex branching pattern Branching papillary tissue fragments. The central fibrovascular cores are visible even at low

power. C. Higher magnification of tissue fragments in B showing a lining of columnar cells. N
the fibrovascular stroma. D. A papillary frond with clearly visible blood-filled capillaries in t
fibrovascular core. E. Branching papillary tissue fragments with central stromal cores.
Intranuclear inclusions are seen in some of the cells. Diff-Quik preparation. (Part E is courte
Mariza de Peralta-Venturina, MD, William Beaumont Hospital, Royal Oak, Michigan.)

Papillary-Like Tissue Fragments

When the central fibrovascular cores are not visualized, and the tissue fragments present fi
like processes with or without branching, they are referred to as "papillary-like" (Fig. 9.18).

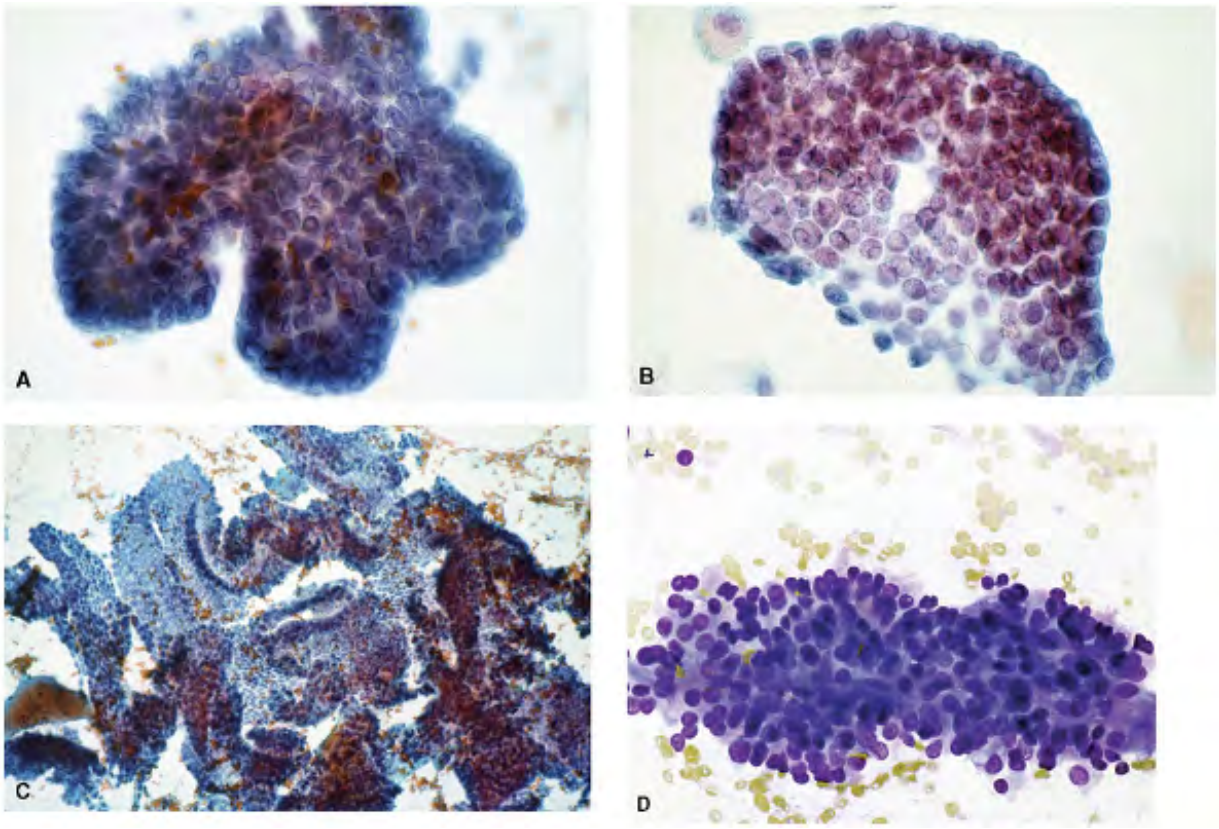

Figure 9.18. A. Branching papillary-like (without visible stromal core/cores) tissue fragmen
with a syncytial pattern. Note the smooth external contour and peripheral palisading of the
nuclei. B. A single syncytial tissue fragment with marked crowding and overlapping of small
nuclei. The chromatin is finely granular to powdery. Nuclear grooves, inclusions, and
micronucleoli are visible. Note the smooth external contour. C. Multiple branching papillary
tissue fragments. D. Papillary-like tissue fragment from papillary carcinoma in a Diff-Quik

preparation. (Fig. 9.18.D is courtesy of Mariza de Peralta-Venturina, M.D., William Beaumon Hospital, Royal Oak, Michigan.)

Syncytial Tissue Fragments with Follicular Pattern

These tissue fragments demonstrate multiple well-formed follicles, filled with colloid. The component nuclei show typical features of papillary carcinoma (Fig. 9.19).

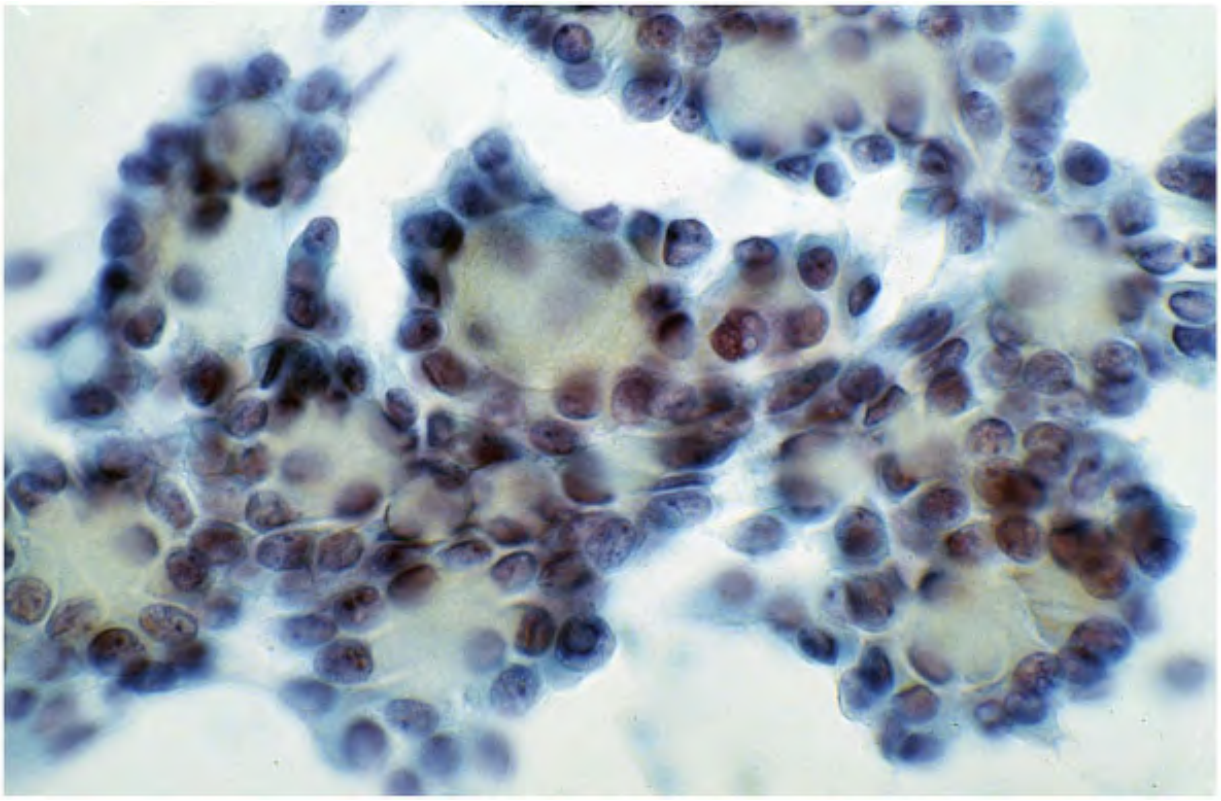

Figure 9.19. *Syncytial-type tissue fragments with a follicular pattern* . The nuclei have fine powdery chromatin with peripheral condensation, thus appearing pale or clear.

Syncytial Tissue Fragments with Three-Dimensional Architecture

It is not unusual to encounter three-dimensional cell clusters in aspirates of papillary carcinomas. They probably represent the tips of the papillary fronds (Fig. 9.20).

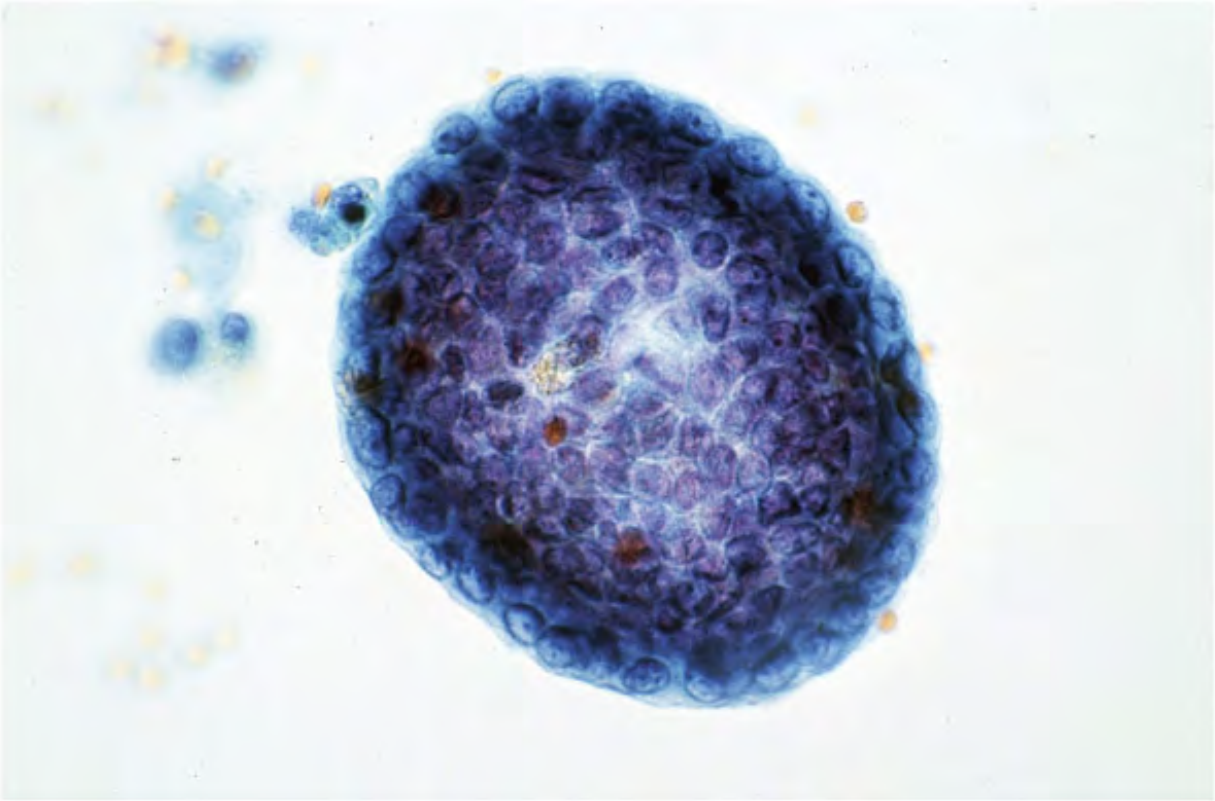

Figure 9.20. A syncytial tissue fragment from papillary carcinoma with extreme crowding of nuclei, smooth external contour, and appearing three-dimensional.

Monolayered (Two-Dimensional) Syncytial Tissue Fragmen

The presence of monolayered tissue fragments (Fig. 9.21) is characteristic of papillary carcinoma. These fragments probably represent the papillary fronds seen "en face" (see Cha 5). This impression is supported by the fact that many fragments are large, with branching, sweeping curves. They may aslo represent large neoplastic follicles seen "en face." The tissu fragments are commonly referred to as "monolayered sheets," because they often show a tw dimensional patternâ€”that is, the cells are in one plane of focus. The component cells usua have poorly defined cell borders with a syncytial pattern. Nuclei are generally large and pleomorphic, with altered polarity, and the nuclear chromatin is finely granular and powder Micro- and macronucleoli are frequently present. The nuclei show morphology characteristic papillary carcinoma. Intranuclear cytoplasmic inclusions are conspicuous. The cytoplasm is variable; generally abundant, pale, and foamy to dense, giving a HÃ¼rtheloid appearance.

Although, this dense cytoplasm is considered a diagnostic feature by Miller, et al.39 it is not of the requirements for the cytologic diagnosis of papillary carcinoma.

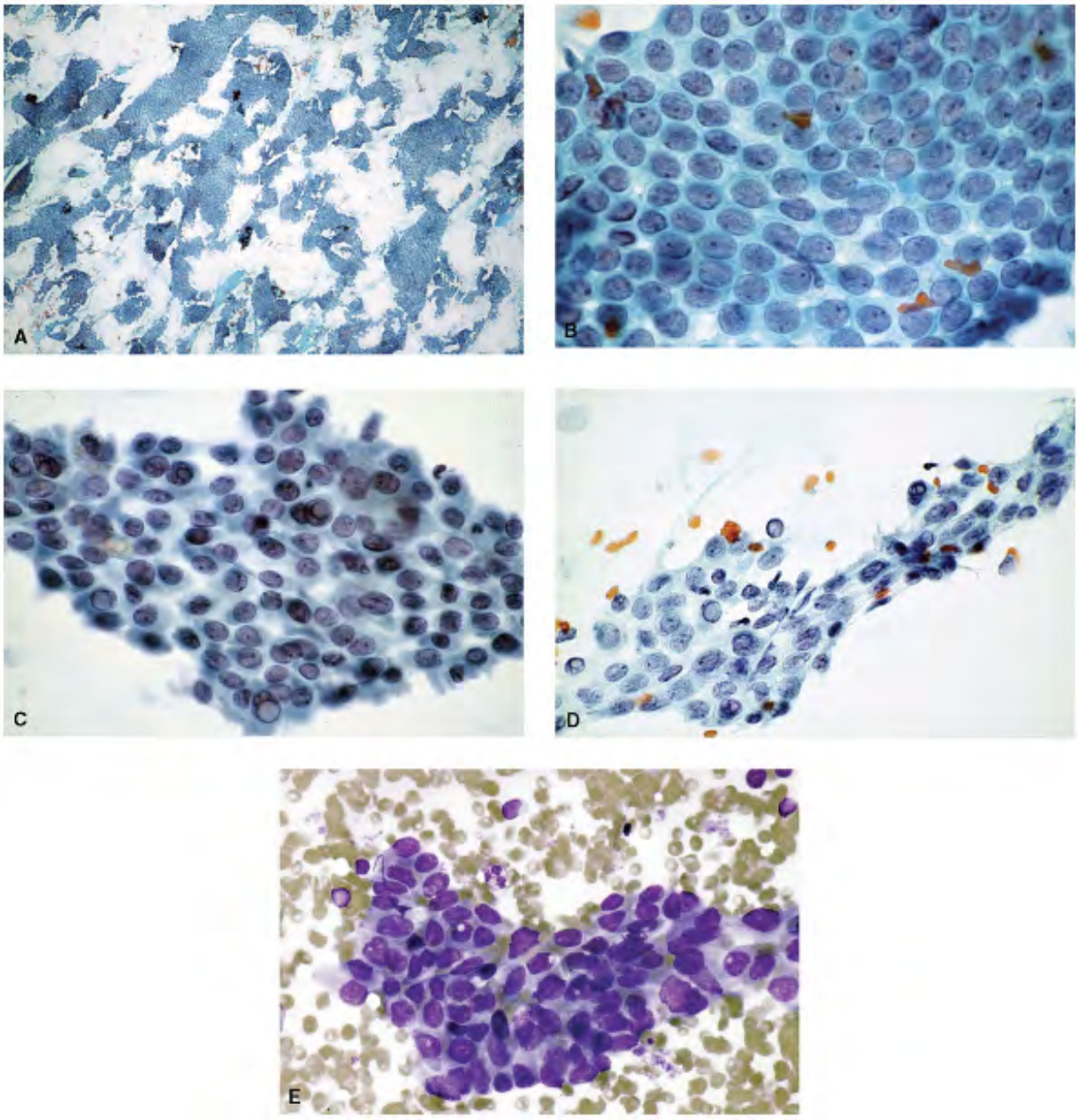

Figure 9.21. *Monolayered tissue fragments* . A. FNA of a papillary carcinoma showing monolayered (two-dimensional) tissue fragments with branching, sweeping curves (low powe B. Higher magnification. The cells are arranged in syncytial fashion with poorly defined cell borders and altered polarity. The nuclei are round to oval, enlarged, and have smooth nucle membranes. The chromatin is fine, dusty, and powdery. Note micronucleoli, grooves, and

inclusions. C,D. A monolayered but syncytial tissue fragment of papillary carcinoma cells wi several nuclei containing inclusions, micronucleoli, and grooves. E. A monolayered tissue fragment from papillary carcinoma (Diff-Quik stain).

Miscellaneous Architectural Patterns

At times, the tissue fragments of papillary carcinoma show a concentric arrangement of cell referred to as swirls46 (Fig. 9.22A and B), or an onion-skin pattern (Fig. 9.22C).46 This pat is specially noted in cystic carcinomas. It is perhaps due to a fluid environment that the cell ball up. Another pattern noted in the aspirates from cystic carcinoma is a "cartwheel" patte where the syncytial tissue fragment is composed of elongated cells, with one slender end directed centripetally and the wider ends projecting outwards, extending from centralized nuclei, giving a cartwheel appearance to the tissue fragment (Fig. 9.22D).

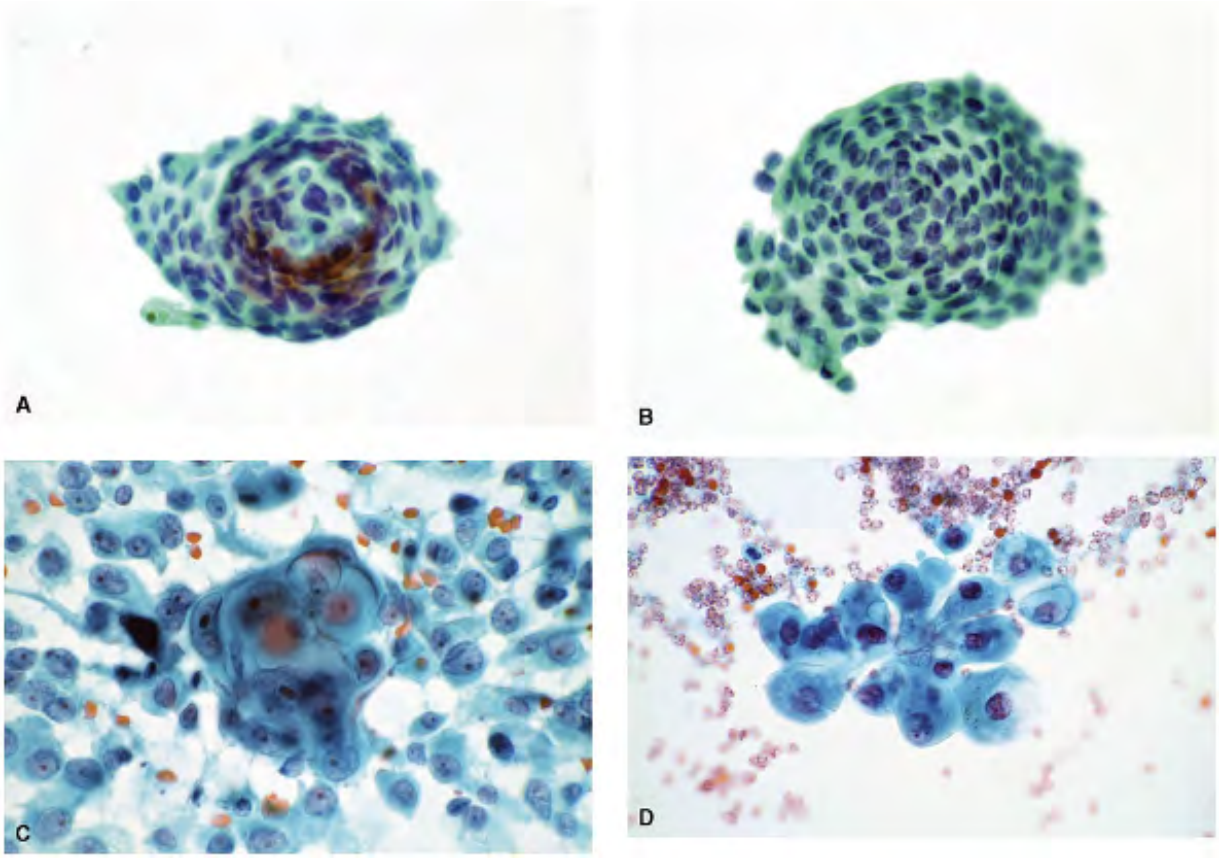

Figure 9.22. *Miscellaneous architectural patterns* . A,B. Cellular swirls in an FNA of papilla

carcinoma with tightly and concentrically arranged cells of papillary carcinoma. C. Tissue fragment of carcinoma cells with concentric arrangement like an onion-skin. D. Cartwheel pattern with cells radiating from the center.

Squamous Metaplasia

Although squamous metaplasia is frequently seen in histologic sections of papillary carcinom it is encountered only rarely in cytologic samples. Squamous metaplasia presents as tissue fragments of large cells with abundant cytoplasm, smaller, uniform nuclei, and a concentric arrangement (Fig. 9.23).

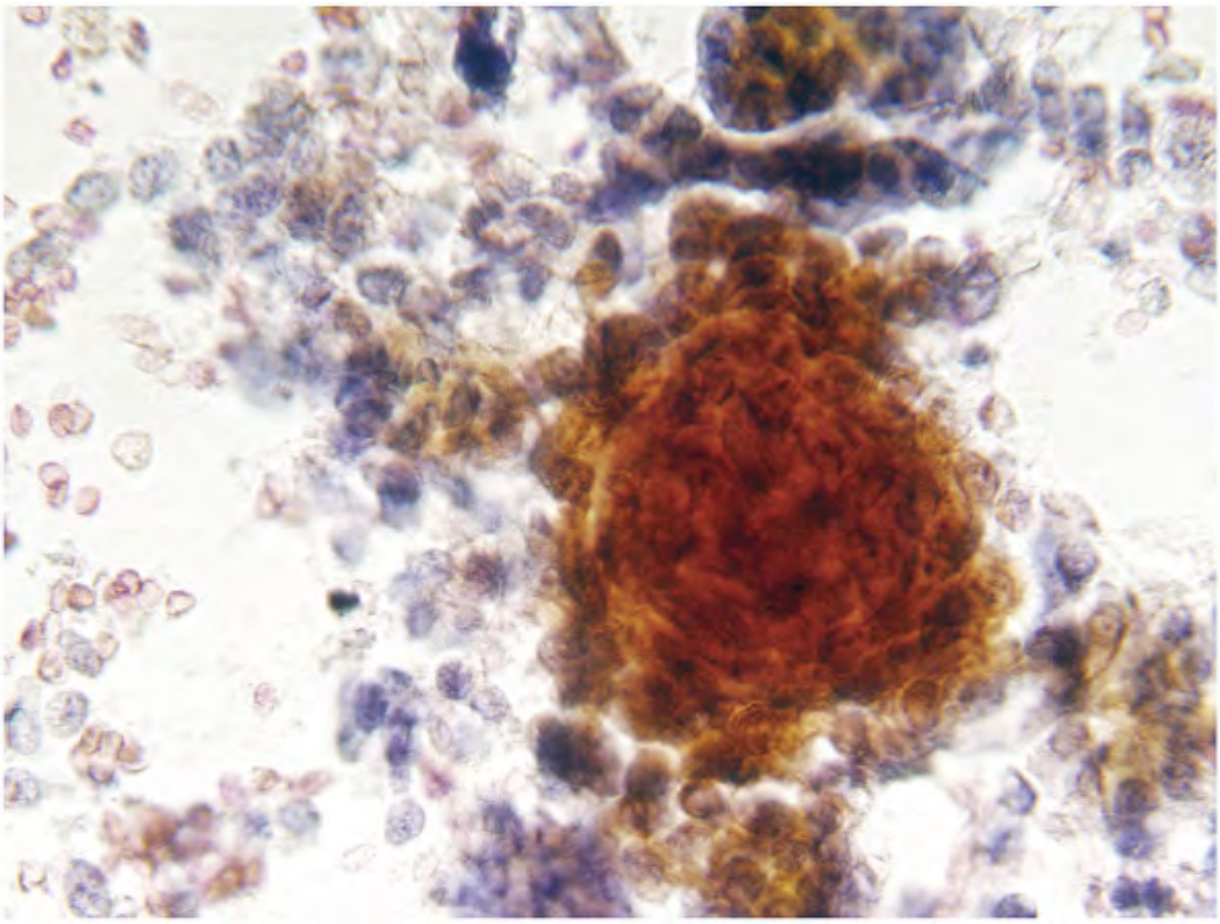

Figure 9.23. Squamous metaplasia in papillary carcinoma. Note the concentric arrangement the cells.

Psammoma Bodies

Psammoma bodies (Fig. 9.24) are a diagnostic feature of papillary carcinoma22 but are pre
in only 20% of the aspirates.43 They are easily recognized in histologic sections by their basophilic, concentric lamellation. In Papanicolaou-stained preparations of fine-needle aspirates, the psammoma

bodies not only stain basophilic, but also stain lavender, golden brown, or amphophilic. The architecture may also be different. In addition to concentric lamellation, they have a star-b and refractile appearance or may resemble a Maltese cross. The psammoma bodies vary in s may be seen naked or incorporated within a tissue fragment of follicular cells. They may be single or multiple within a given tissue fragment. Occasionally aspirates may contain a myria psammoma bodies with a striking display of various colors in Papanicolaou-stained preparati The nuclei of the cells forming the tissue fragments that incorporate the psammoma body sl the typical morphology of papillary carcinoma.

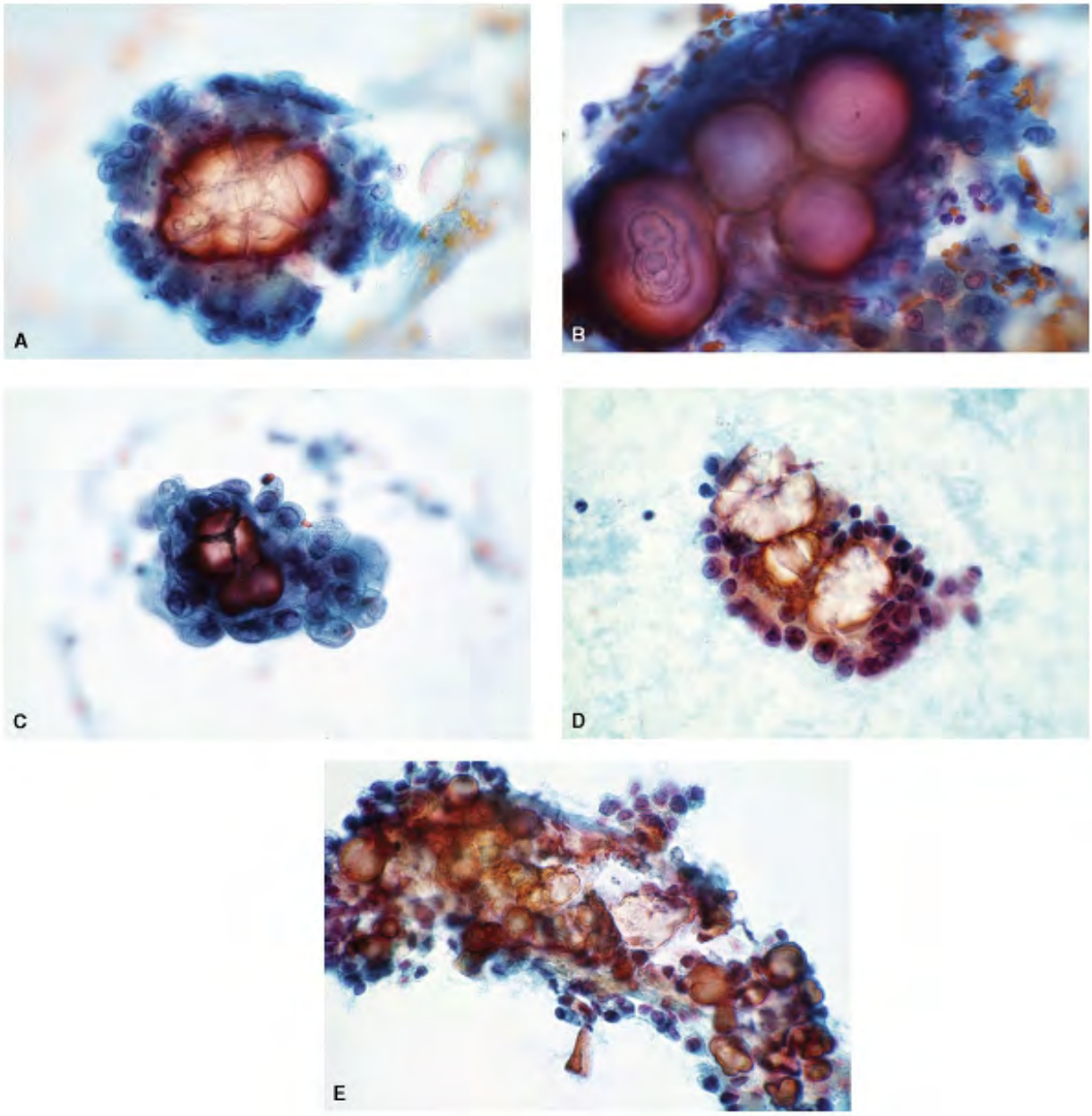

Figure 9.24. Psammoma bodies. A. Syncytial tissue fragment of malignant papillary carcino cells incorporating a single psammoma body. Note that concentric lamellation is not seen. T psammoma body has a refractile center with a starburst appearance. B. Multiple psammoma bodies with concentric lamellations. C. A syncytial tissue fragment incorporating three psammoma bodies. The component cells demonstrate nuclear features of papillary carcinom D. Psammoma bodies within this tissue fragment appear refractile. E. Myriad of psammoma bodies with a striking display of colors.

Multinucleated Foreign Body-Type Giant Cells

Although giant cells are not generally described in the literature on the histopathology of papillary carcinoma, their presence appears to be ubiquitous in cytologic and histologic mat (Fig. 9.25). They are seen in the absence of degeneration and do not seem to be phagocytic histiocytic in origin. These giant cells vary in size from small to enormous, and may fill an e high-power field. Their cytoplasm is dense and not dirty, granular, or vacuolated like that o histiocytic-type giant cells. The nuclei vary in number and often resemble those of carcinom cells. Giant cells are always intimately associated with papillary or monolayered fragments, feature appreciated in histologic material as well. Hidvegi et al.60 suggested that the giant are perhaps derived from cancer cells.

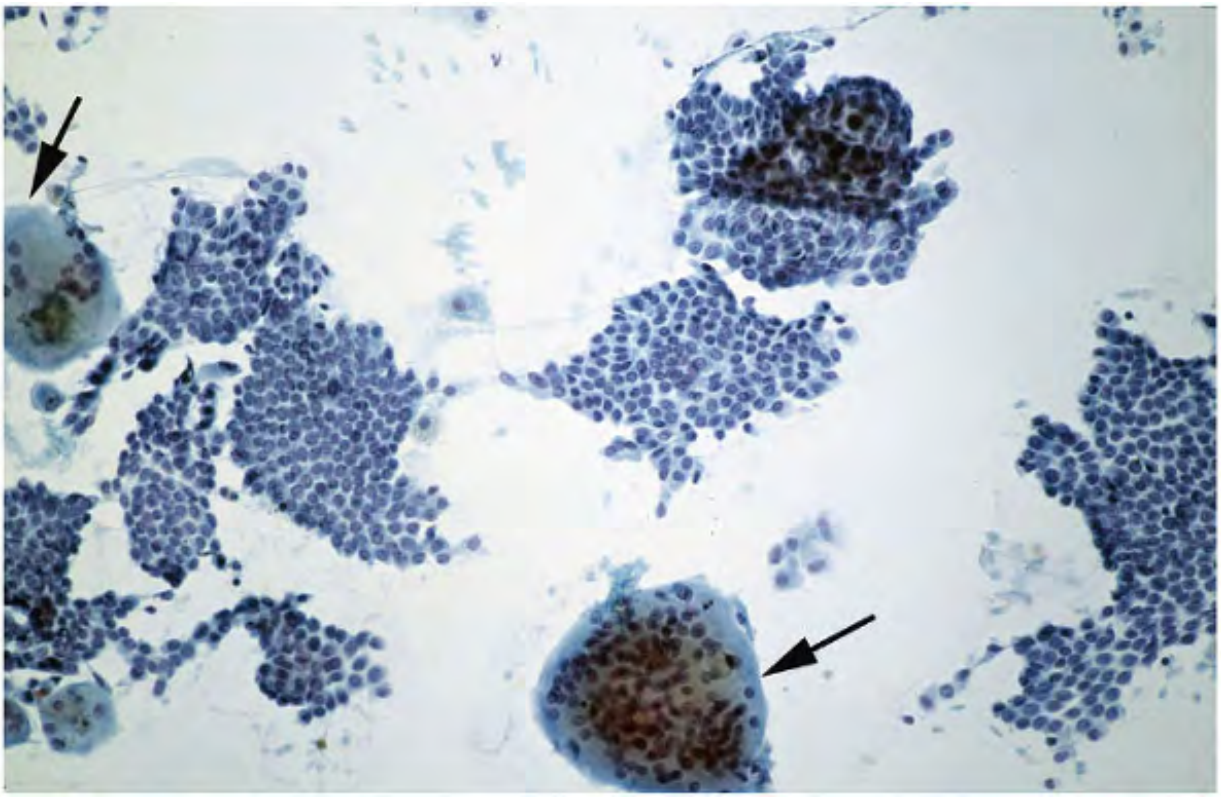

Figure 9.25. Multinucleated giant cells in papillary carcinoma, often seen in association wit tissue fragments of carcinoma cells.

Colloid Strands

As described by LÃ¶whagen et al.44 , 45 ropy strands of colloid (Fig. 9.26A to C) are often s in aspirates from papillary carcinoma. The colloid may also be dense staining and is frequen observed as blobs or follicular luminal casts (Fig. 9.26C).

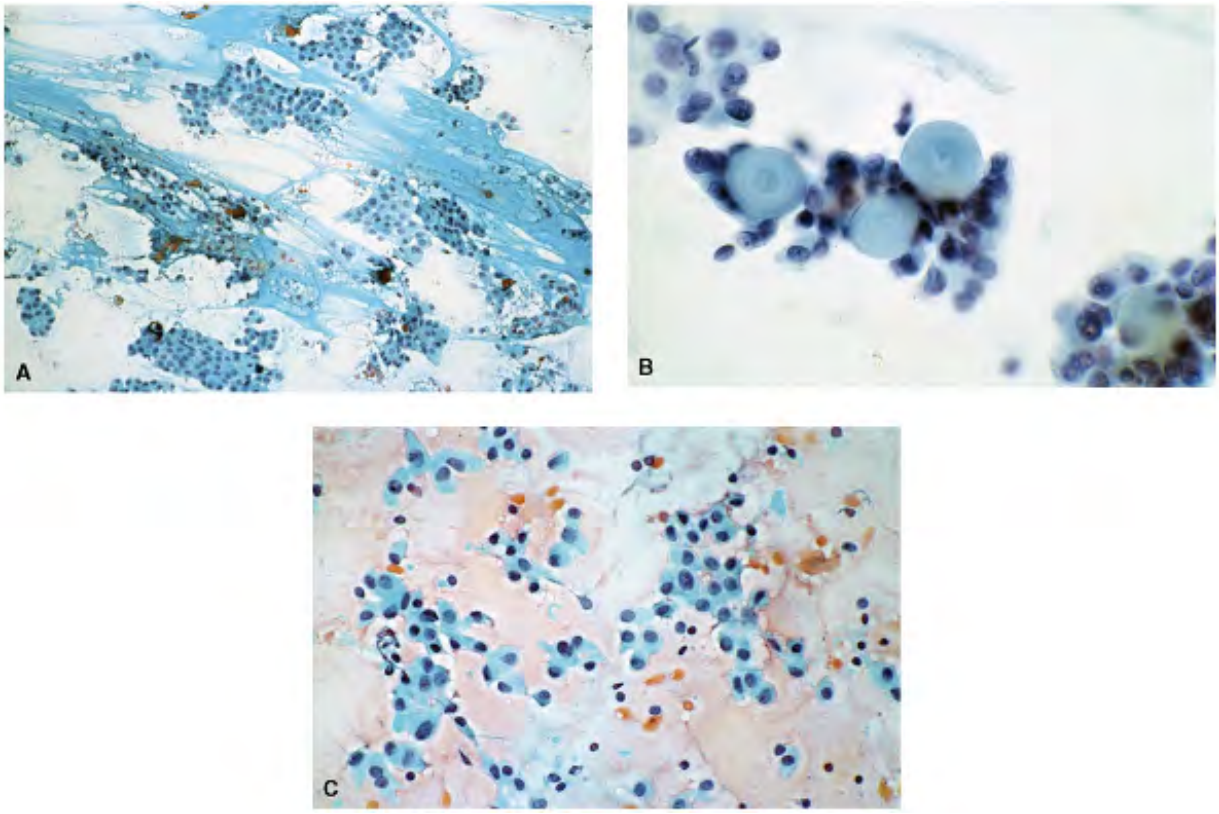

Figure 9.26. *Colloid in papillary carcinoma* . A. Strands of dense sticky colloid alongside th monolayered tissue fragments of papillary carcinoma. B. These spherical blobs of dense coll appear as luminal casts, typically seen in an aspirate of follicular variant of papillary carcin C. Thin, watery colloid in the background.

DEGENERATION

Degenerative changes with cyst formation (Fig. 9.27) are frequently observed in papillary carcinomas. They are manifested in the aspirate by the presence of histiocytes, with or wit hemosiderin.

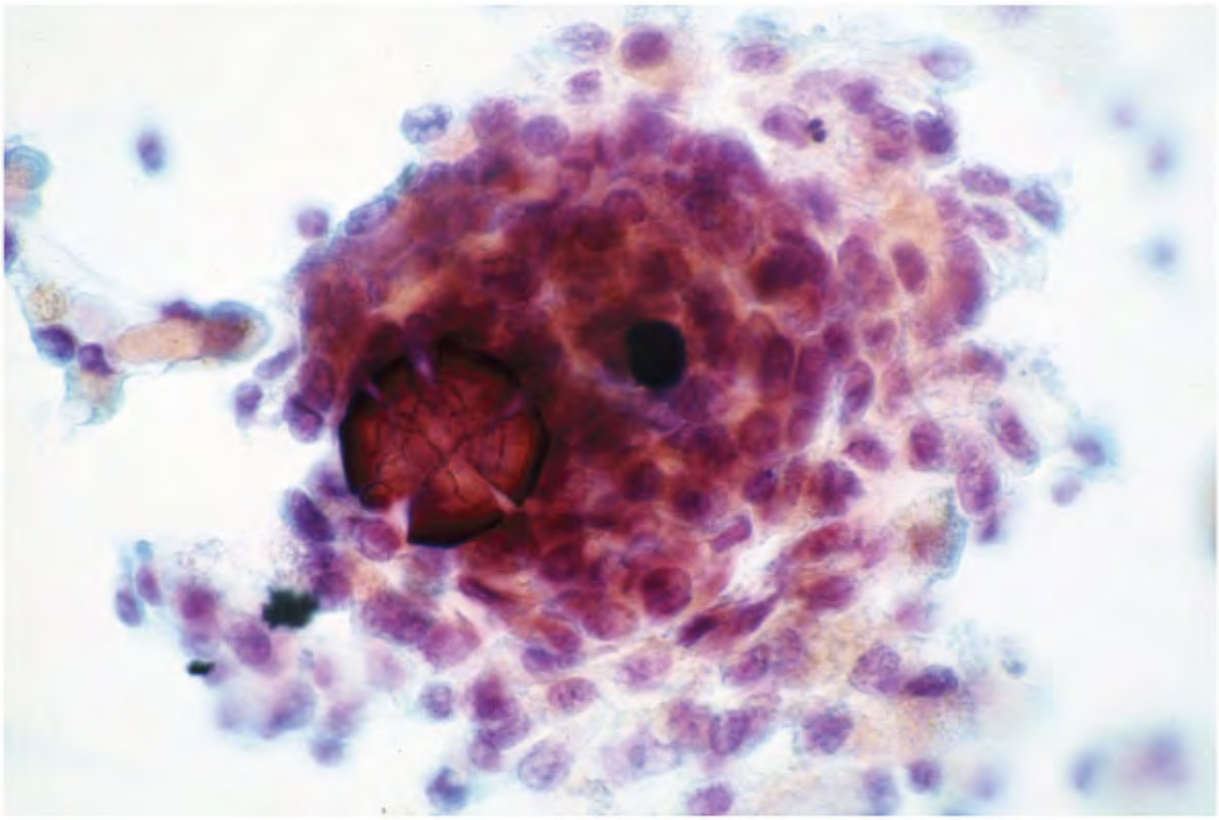

Figure 9.27. Papillary carcinoma cells with degeneration and hemorrhage. Such a pattern is often seen with cystic degeneration.

LYMPHOCYTIC INFILTRATE

The presence of lymphocytes indicates underlying or coexisting Hashimoto's thyroiditis, feat of which may be seen along with the cytologic features of papillary carcinoma (see Chapter According to some authors, papillary carcinomas elicit a host reaction characterized by a lymphocytic infiltrate,3 although Carcangiu and co-workers20 have disputed that concept.

IMMUNOCYTOHISTOCHEMICAL PROFILE

The cells of papillary carcinoma demonstrate positive reactivity to thyroglobulin in a consist fashion, except for the columnar cell variant. Wenig, et al. in their review of 17 cases of th columnar cell variant of papillary carcinoma, found reactivity to thyroglobulin in all their ca but in variable intensity. The papillary carcinoma cells also react to both low- and high-molecular-weight keratins, the latter indicating a tendency toward squamous metaplasia.

Positive reactivity is also noted with thyroid transcription factor-1 (TTF-1). Positive reactivi has been documented with vimentin but not with carcinoembryonic antigen (CEA) or with calcitonin. Strong reactivity to S-100 protein has also been reported.2 Other markers that ha been reported include CK-19, CD-15, HBME-1, and galectin-3.61 , 62 , 63 , 64 , 65 , 66

Molecular analysis has shown mutations in RAS proto-oncogenes, BRAF oncogenes, and *RET/*

gene rearrangement in

papillary carcinomas. The routine diagnostic application of these tests has not been establis as yet (see Chapter 22 for more information).

MORPHOLOGIC VARIANTS OF PAPILLARY CARCINOMA

Several histologic variants of papillary thyroid carcinomas have been described (Table 9.2). Some of the variants have a better prognosis than the conventional types, while others tend behave in an aggressive fashion, with a higher frequency of morbidity and mortality. Those aggressive behavior include the tall cell variant, diffuse sclerosing variant, diffuse follicular variant, and papillary thyroid carcinomas with dedifferentiated areas. The morphologic vari that are sometimes associated with an unfavorable outcome include the follicular variant, s variant, oncocytic variant, and those arising in the background of autoimmune thyroiditis.

Usual or conventional
Follicular
Macrofollicular
Diffuse follicular
Tall cell
Columnar cell
Oxyphil cell or oncocytic
Solid and trabecular
Diffuse sclerosing
Papillary carcinoma with nodular fasciitis-like stroma
Clear cell
Encapsulated
Warthin's-like tumor
Cribriform morular
Papillary microcarcinoma

TABLE 9.2 MORPHOLOGIC VARIANTS OF PAPILLARY CARCINOMA

The classification of the morphologic variants of papillary carcinomas is based on the architectural (growth) patterns and the cell types. Any variant must have more than 75% of tumor composed of a specific morphologic pattern to qualify for a specific designation. The common denominator for all the variants is the typical nuclear morphology characterized by nuclei, nucleoli, nuclear grooves, and intranuclear cytoplasmic inclusions, the exception bei the columnar cell variant. These nuclear features allow an accurate diagnosis of papillary carcinoma, both histologically and cytologically. It is very common to see multiple growth patterns in a given papillary carcinoma. The cytologic diagnosis thus depends on the area sampled and may not be representative of the major morphologic pattern.

Histologically, the morphologic variants of papillary thyroid carcinomas can be easily recogr but their identification from cytologic samples is generally not attempted, with the excepti the follicular variant. Features that characterize some of the variantsâ€"including encapsul (encapsulated variant), diffuse involvement (diffuse macrofollicular variant), desmoplastic nodular fasciitis-like stroma and micro papillary carcinomas (microcarcinoma)â€"cannot be appreciated in cytologic samples but only in histologic sections. Furthermore, the incidence most of these subtypes is low, and their cytopathologic features are documented only rarely With the exception of columnar cell carcinomas, all other subtypes have the same characte nuclear features, and a generic diagnosis of papillary thyroid carcinoma is easily made with high degree of accuracy. Cytologic recognition of morphologic subtypes may be unwarrante and insignificant in terms of the patient management. A total thyroidectomy is routinely performed with a diagnosis of papillary thyroid carcinoma, regardless of the morphologic subtypes. Several studies have attempted to subtype cytologic samples of papillary carcinon to predict the histologic variants but were not entirely successful.67 , 68 , 69 , 70 , 71 , 72 , 74

Follicular Variant of Papillary Carcinoma

First described by Lindsay75 and subsequently reported in detail by Chan and Rosai,76 the follicular variants comprise up to 12% of thyroid papillary carcinomas.2 , 13 , 76 The incider of cervical lymph node metastasis is stated to be high. Although the biologic behavior is usu that of the conventional type, a few reports have indicated a somewhat aggressive course,

a greater propensity to metastasize distally, especially to the lungs.2 , 3 , 7 , 77

The follicular variants of papillary carcinoma are completely or partially encapsulated or nonencapsulated and infiltrative. They vary in size, from microcarcinomas to large. Histologically, as the name implies, a predominantly or an exclusively follicular growth patt characterizes the follicular variant (Figs. 9.28 and 9.29). The follicles vary in size and shape from round to elongated, many distended with colloid. The lining epithelium may show infolding, forming rudimentary papillae. Their nuclei, however, exhibit the typical morphol of conventional papillary carcinoma. The colloid within the follicles is often dense (Fig. 9.2 deep-staining, and show peripheral scalloping. A clear cell pattern may be present (Fig. 9.3 The follicular variant may contain desmoplastic stroma. Psammoma bodies can be identifie

in the interfollicular stroma, and the multinucleated foreign-body type giant cells are some present. The metastatic foci from the follicular variant often show the typical morphology c conventional papillary carcinoma.

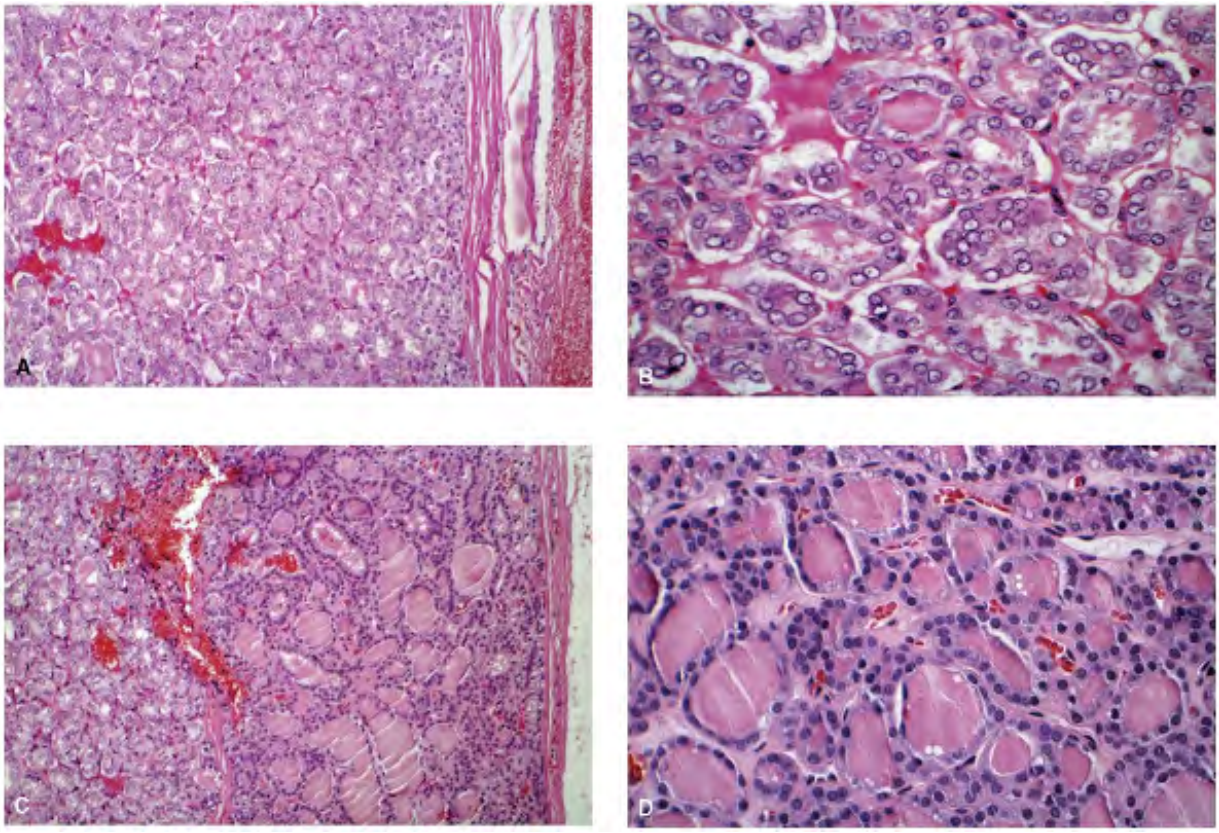

Figure 9.28. Histologic sections. A. An encapsulated neoplasm, medium power. B. Higher

magnification to show the follicular architecture. The lining epithelium shows typical nuclea features of papillary carcinoma. C. The carcinoma cells in the right half of the section show of clear nuclei. D. Higher magnification showing varying-sized follicles containing colloid. N the lining epithelium with dark hyperchromatic nuclei, resembling a follicular adenoma. Sampling from this area will not allow a specific diagnosis of the follicular variant of papilla carcinoma.

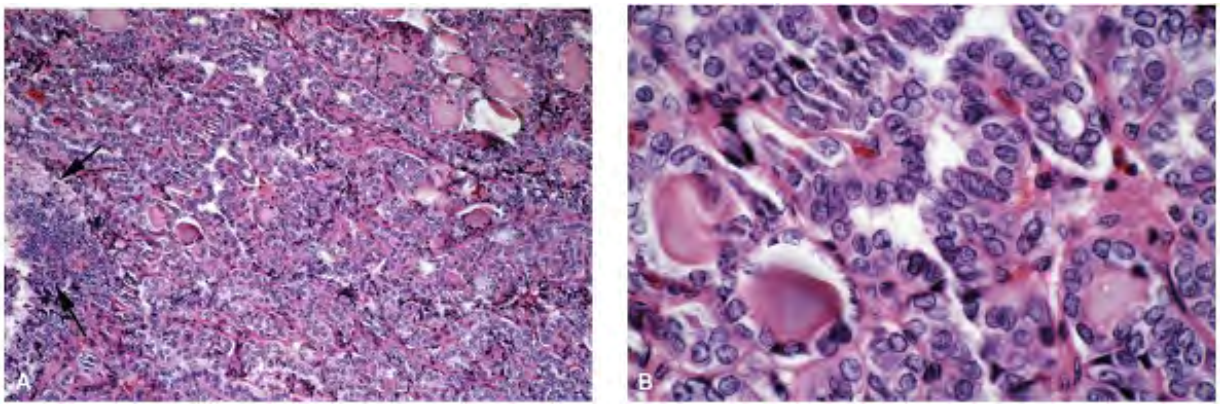

Figure 9.29. Follicular variant of papillary carcinoma. A. The carcinoma demonstrates a follicular growth pattern. At low power, the nuclear chromatin appears darkly stained. An a of typical papillary carcinoma cell nuclei is seen (*arrows*). B. Higher magnification to show follicular epithelium with granular chromatin. Intranuclear inclusions are present. The follic lumens contain dense, deep eosinophilic colloid.

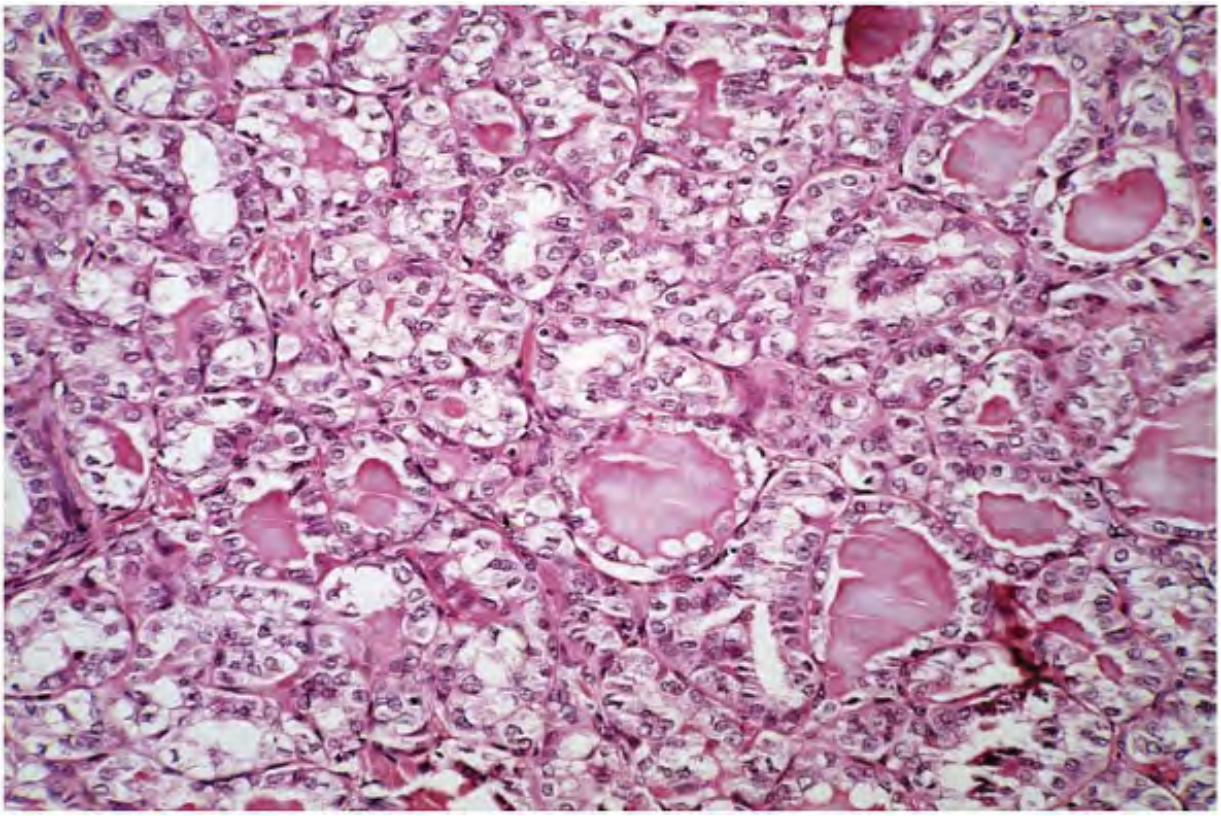

Figure 9.30. Follicular variant of papillary carcinoma. Histologic section showing clear cytoplasm. The colloid in the lumens shows peripheral scalloping.

Cytopathologic Features

The aspirates of follicular variant of papillary carcinoma tend to be cellular (Figs. 9.31A and 9.32A), but may be scanty in the presence of desmoplastic stroma. The typical cytologic appearance includes small to moderately enlarged follicular cells, in loosely cohesive groups in syncytial tissue fragments, with and without a follicular pattern (Figs. 9.31 , 9.32 , 9.33 , , 9.35 , 9.36 , 9.37 , 9.38 , 9.39 , 9.40 and 9.41). The neoplastic follicles may be seen discr (Fig. 9.34). Their enlarged, round to ovoid nuclei, containing pale, dusty, powdery chromat micronucleoli, grooves, and inclusions, clinch the diagnosis of the follicular variant (Table 9

The cytoplasm of the cells of this variant is scant or barely visible and the cell borders are p defined. The aspirates often show monolayered (two-dimensional), syncytial tissue fragmen which are often misinterpreted as indicative of nodular goiter, especially in Romanowsky-st preparations. The colloid is usually present as dense, rounded casts within the follicular lum

as well as in the background (Figs. 9.31B , 9.32B , 9.39). Gallagher, et al. 78 described the colloid in follicula variants of papillary carcinoma to be pink and dense. The dense-staining colloid in the follicular variant of papillary carcinomas is a characteristic feature that is alsc appreciated in histologic sections. Other cytologic features, such as papillary and papillary-l tissue fragments, are generally not observed, unless the needle also samples the focal papil growth pattern if present within the tumor. Psammoma bodies and multinucleated giant cel are sometimes present. The background is usually clean.

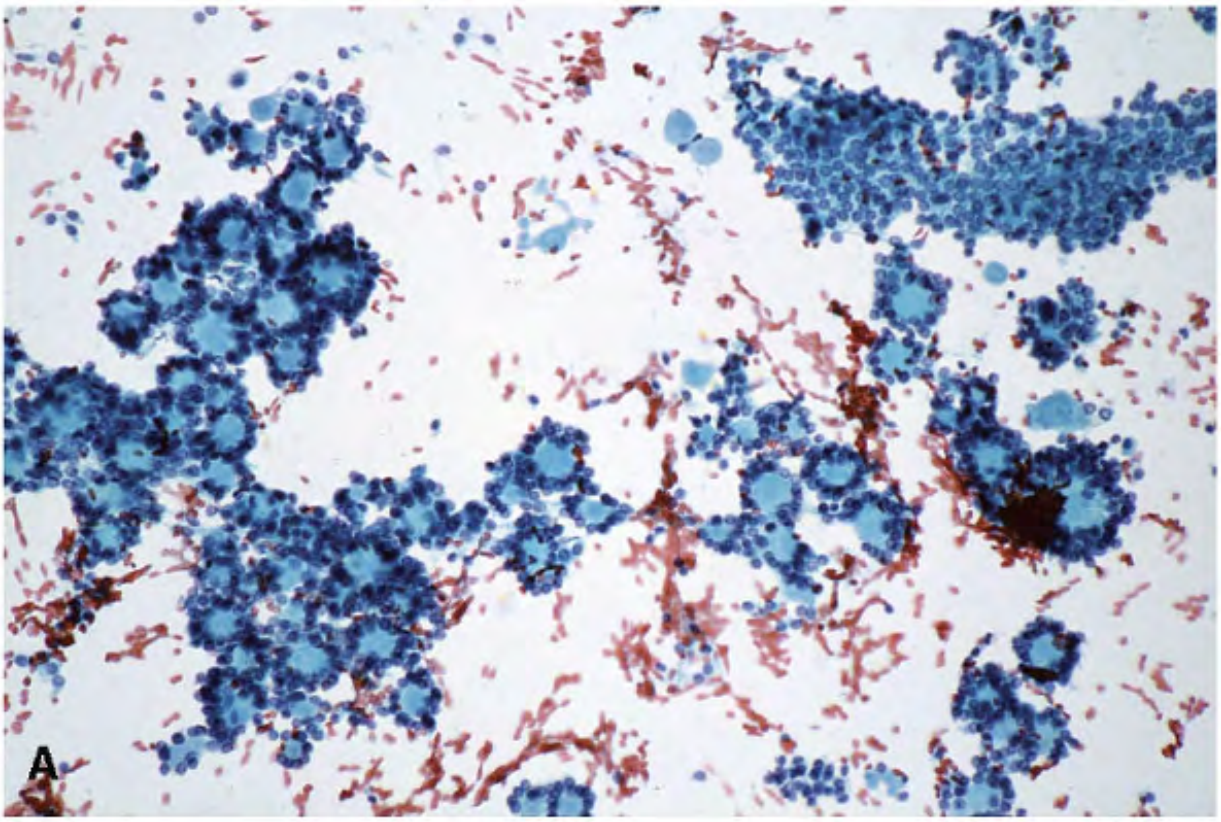

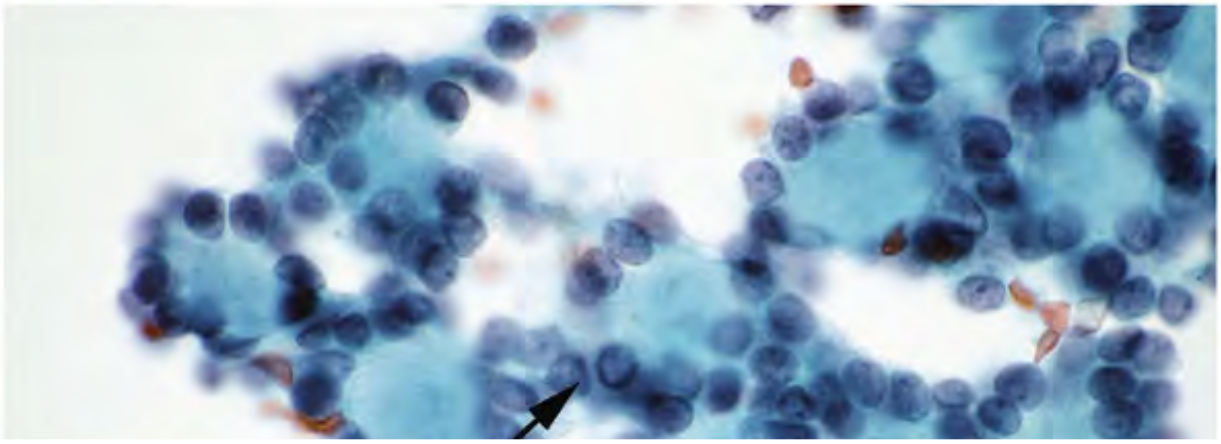

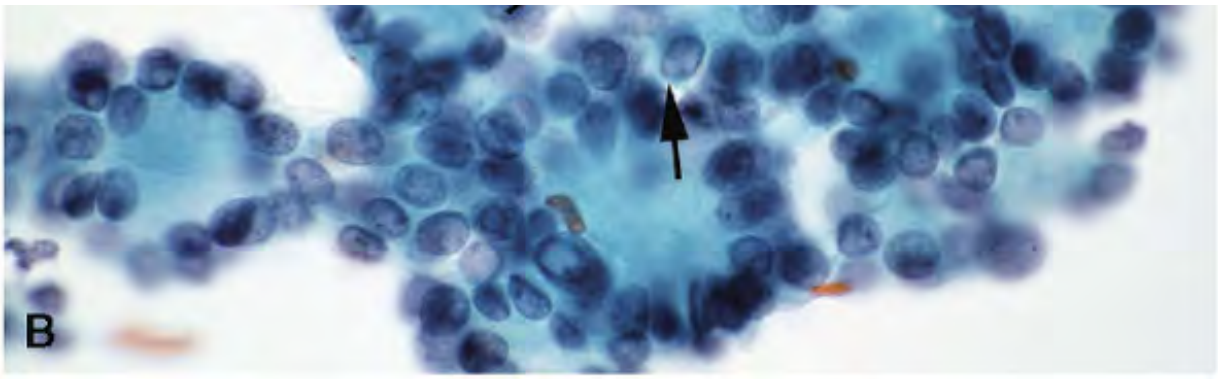

Figure 9.31. FNA. A. Follicular variant of papillary carcinoma. Note the hypercellularity anc striking follicular pattern (low power). B. Higher magnification demonstrates syncytial tissu fragments forming follicles. Their nuclei contain powdery chromatin and cytoplasmic inclusi The colloid within the follicles is dense.

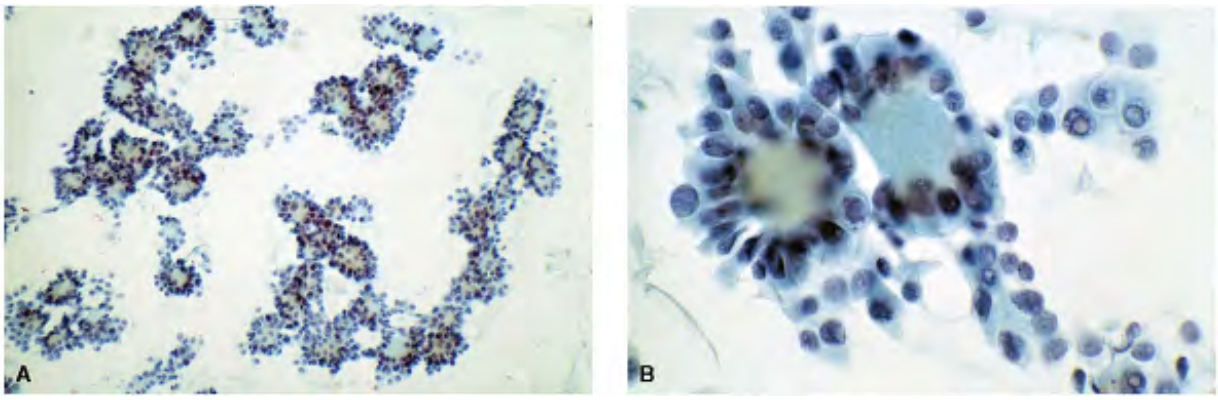

Figure 9.32. A. Follicular variant of papillary carcinoma. Note the hypercellularity and the striking follicular pattern (low power). B. Higher magnification. The lining cells of the follic present classic nuclear features of papillary carcinoma. Note that many nuclei have intranu inclusions. The colloid within the follicular lumina is dense.

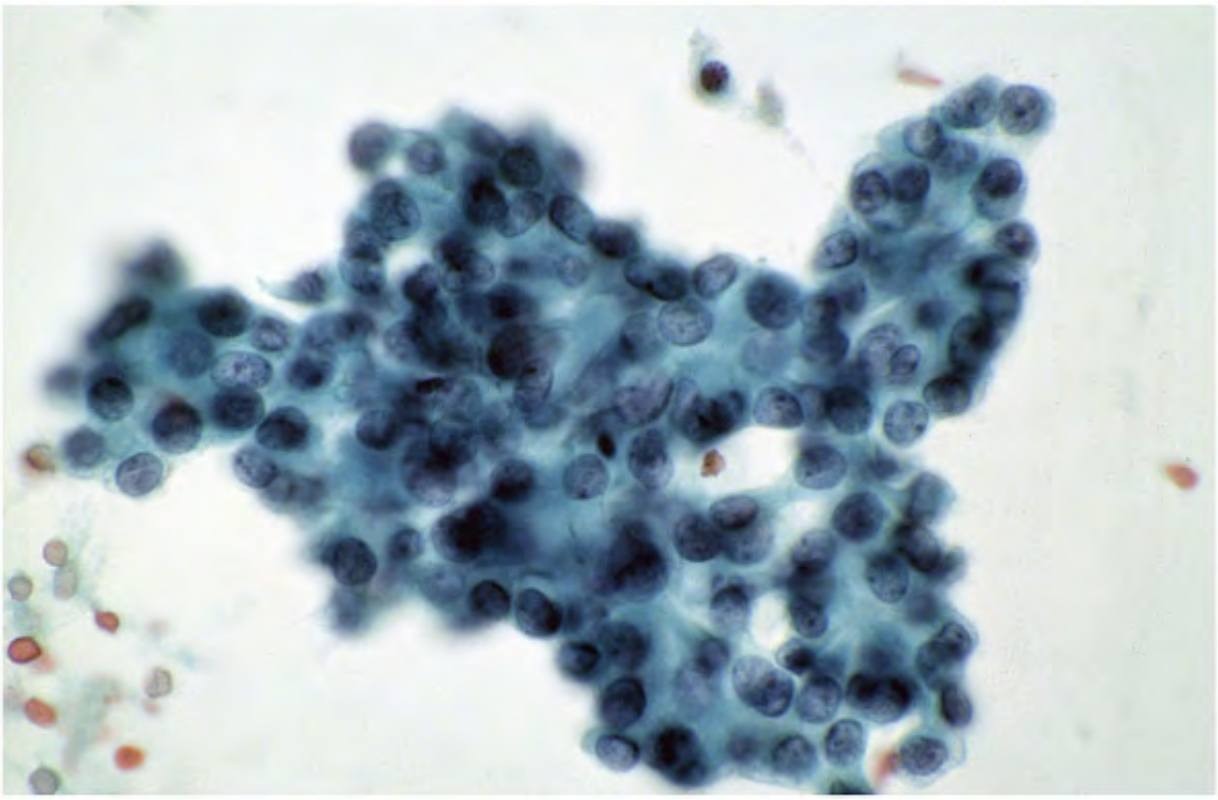

Figure 9.33. A syncytial tissue fragment with follicular architecture. The nuclei are enlarge round, and have finely granular to powdery chromatin. Nuclear inclusions and micronucleoli seen.

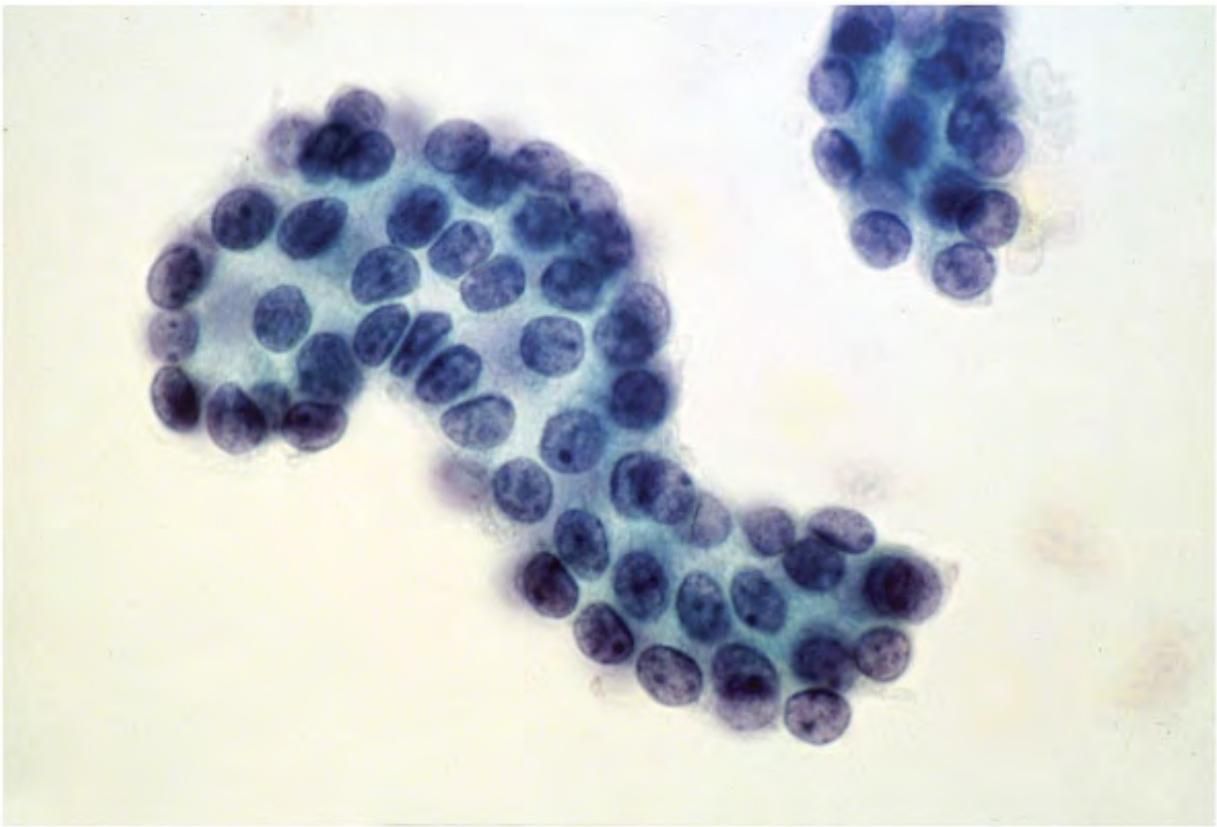

Figure 9.34. Angulated, curvaceous syncytial tissue fragment with component cells exhibiti
nuclear features of papillary carcinoma.

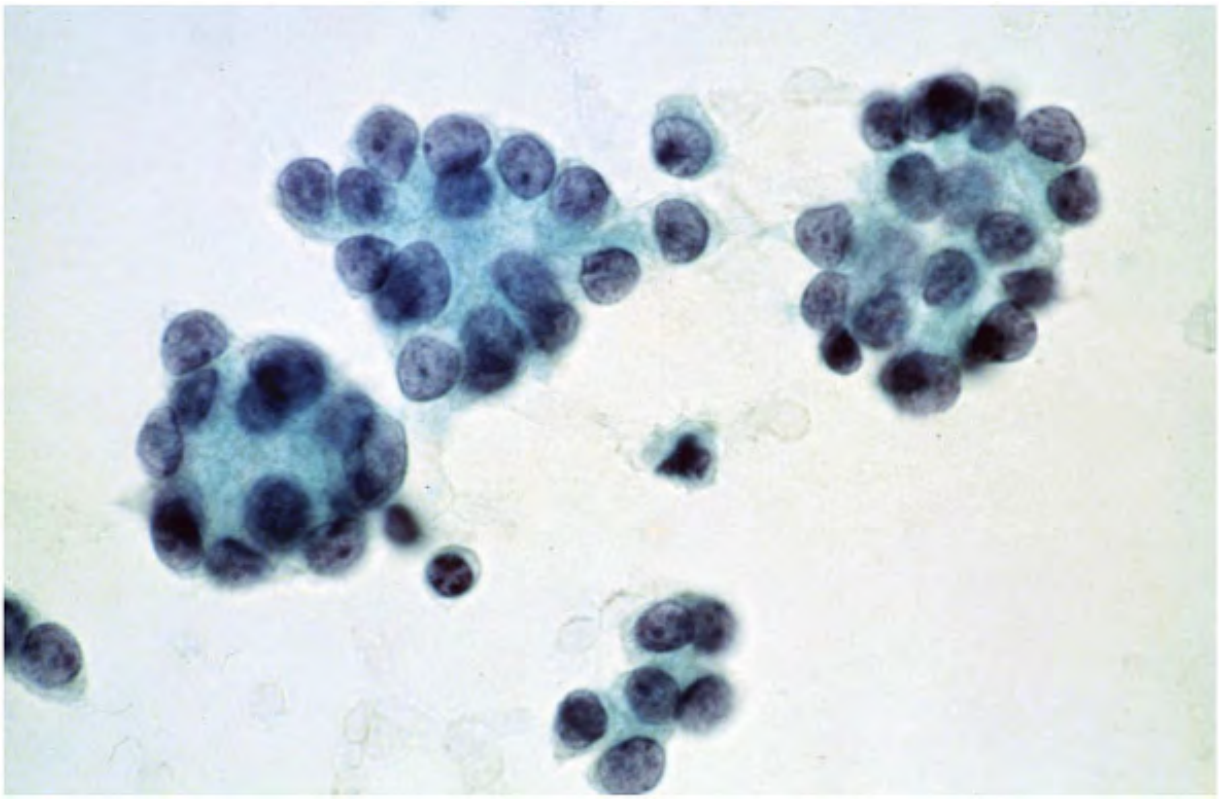

Figure 9.35. Discrete follicles lined by follicular cells. Their nuclei are enlarged, overlappe
with altered polarity and contain finely granular chromatin, micronucleoli, intranuclear
inclusions, and grooves.

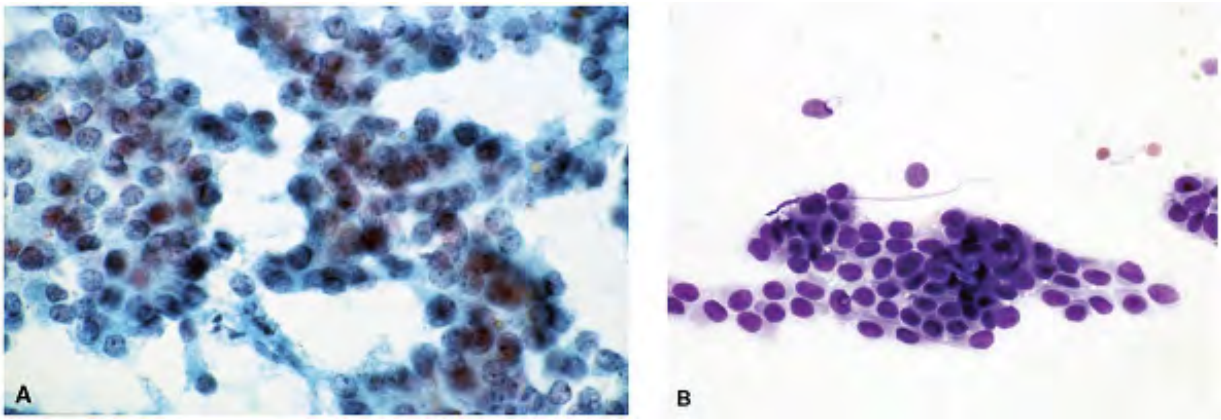

Figure 9.36. A. This syncytial tissue fragment of follicular cells shows a vague follicular pat
The component nuclei are enlarged, with finely granular chromatin, micronucleoli, grooves,
inclusions consistent with a follicular variant of papillary carcinoma. B. FNA of a follicular
variant of papillary carcinoma (Diff-Quik stain). (Part B is courtesy of Mariza de Peralta-

Venturina, MD, William Beaumont Hospital, Royal Oak, Michigan.)

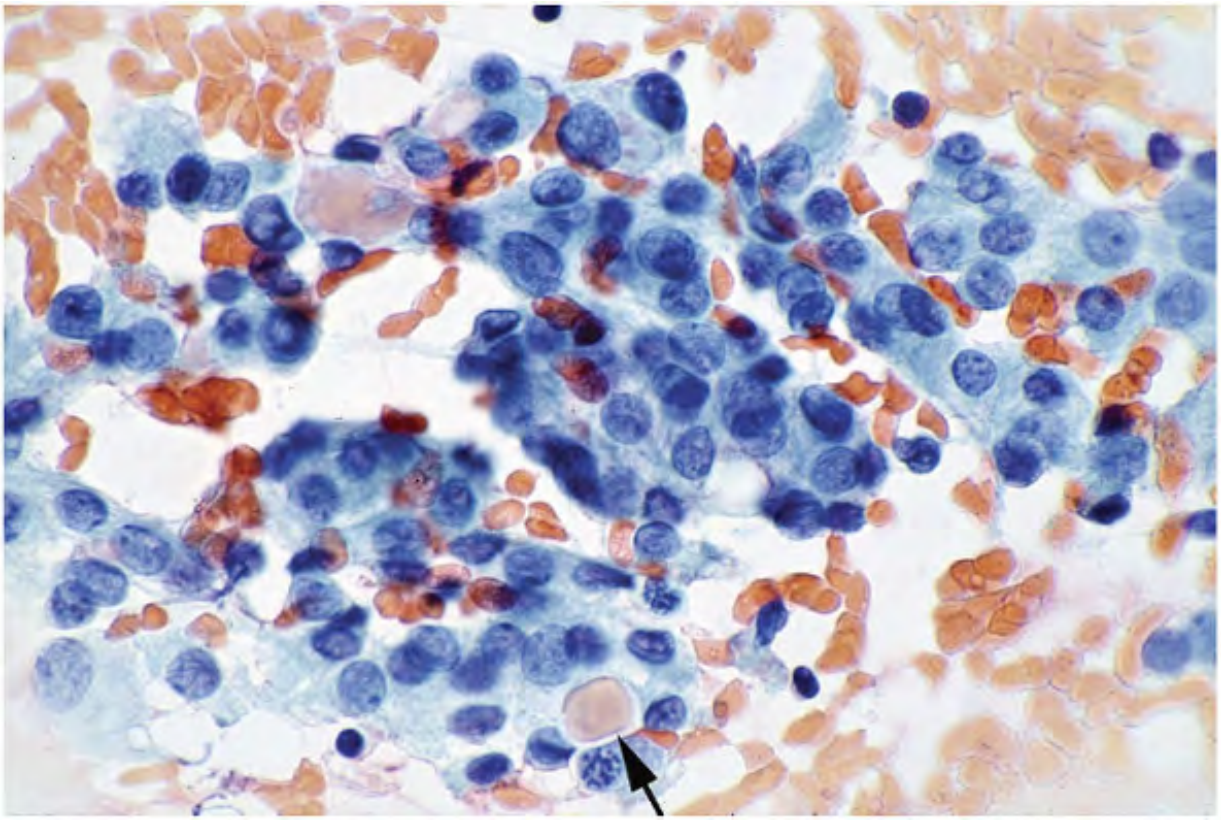

Figure 9.37. The syncytial tissue fragment of follicular cells shows minimal follicular architecture. Small amount of colloid is seen in the lumen. The nuclei, however, show typic features of papillary carcinoma.

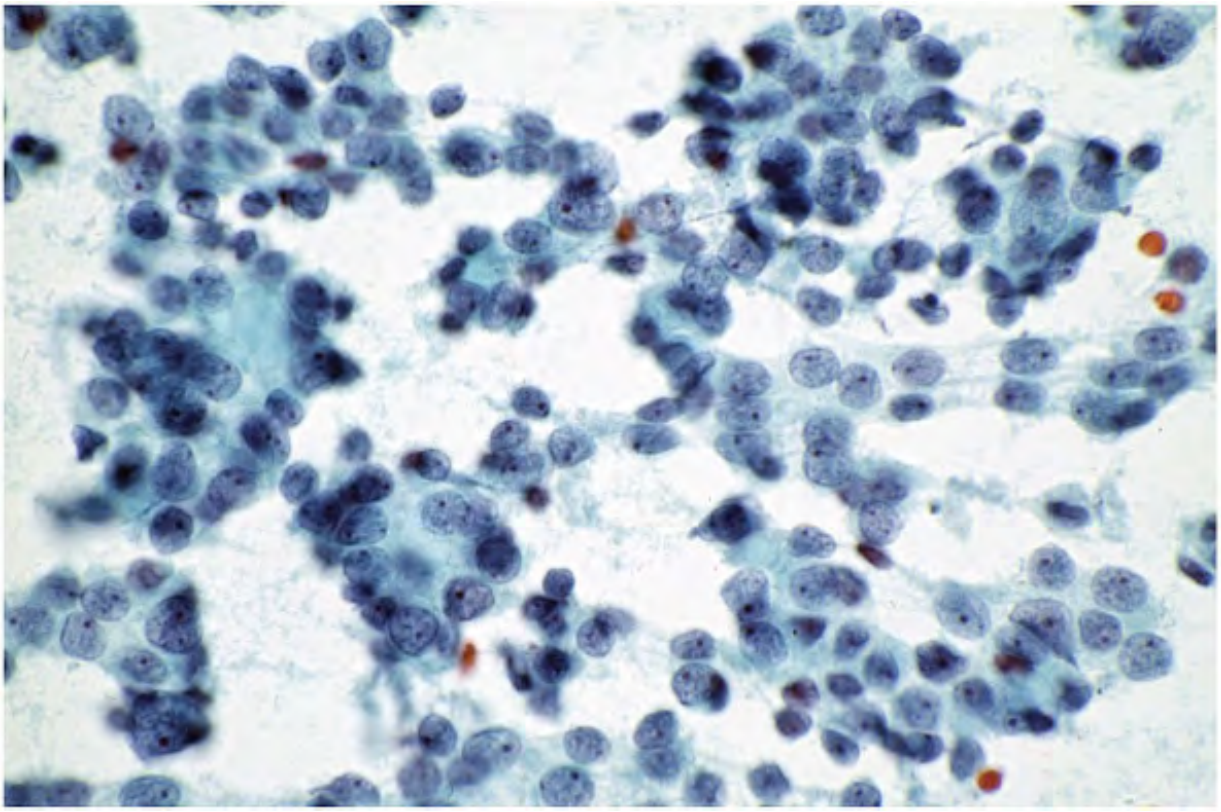

Figure 9.38. FNA of a follicular variant of papillary carcinoma. The cellular aspirate shows syncytial tissue fragments with follicular pattern. The nuclei have fine powdery chromatin a nucleoli. Nuclear grooves or inclusions are not present. A cytologic diagnosis of follicular va should be high on the list. Follicular neoplasms do not exhibit pale nuclei.

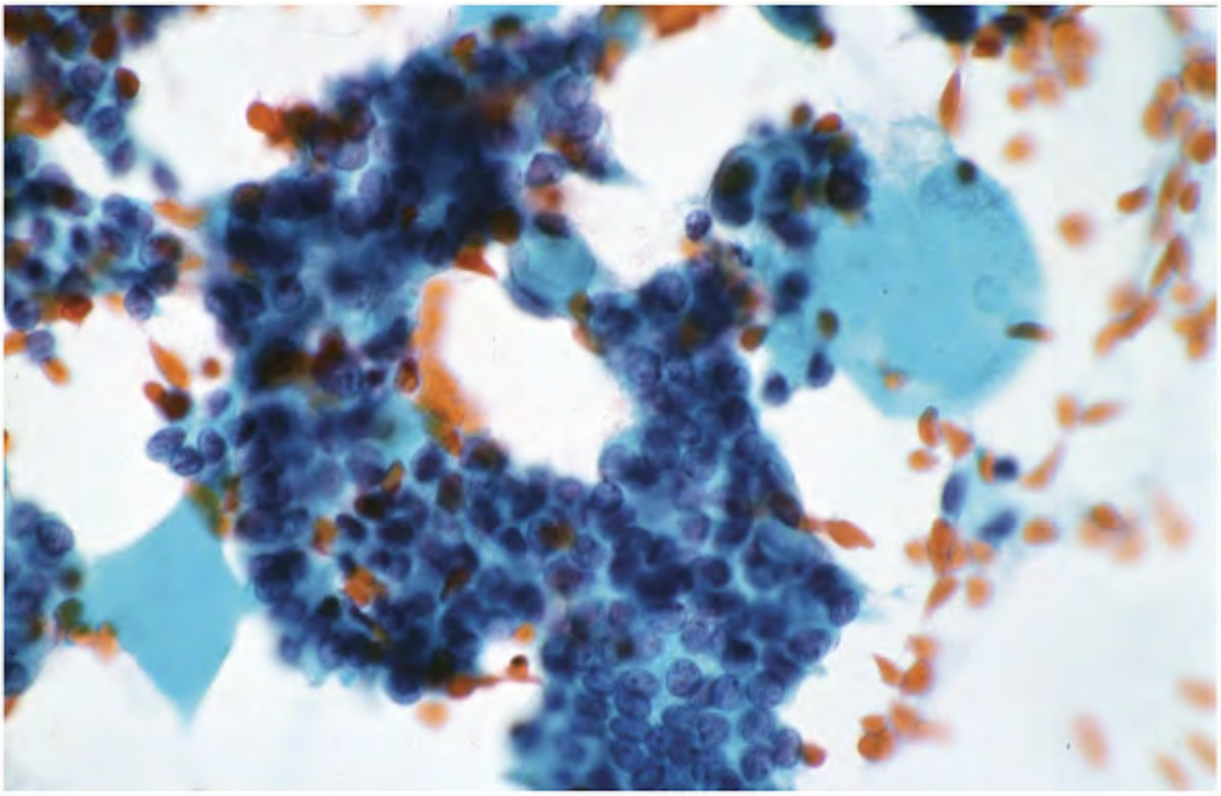

Figure 9.39. FNA of a follicular variant of papillary carcinoma. The syncytial tissue fragmen with a follicular pattern. The nuclei contain deep-staining granular chromatin. Lack of nucle grooves, and inclusions favors a follicular adenoma/carcinoma. A clue to the correct diagno may be the presence of dense colloid.

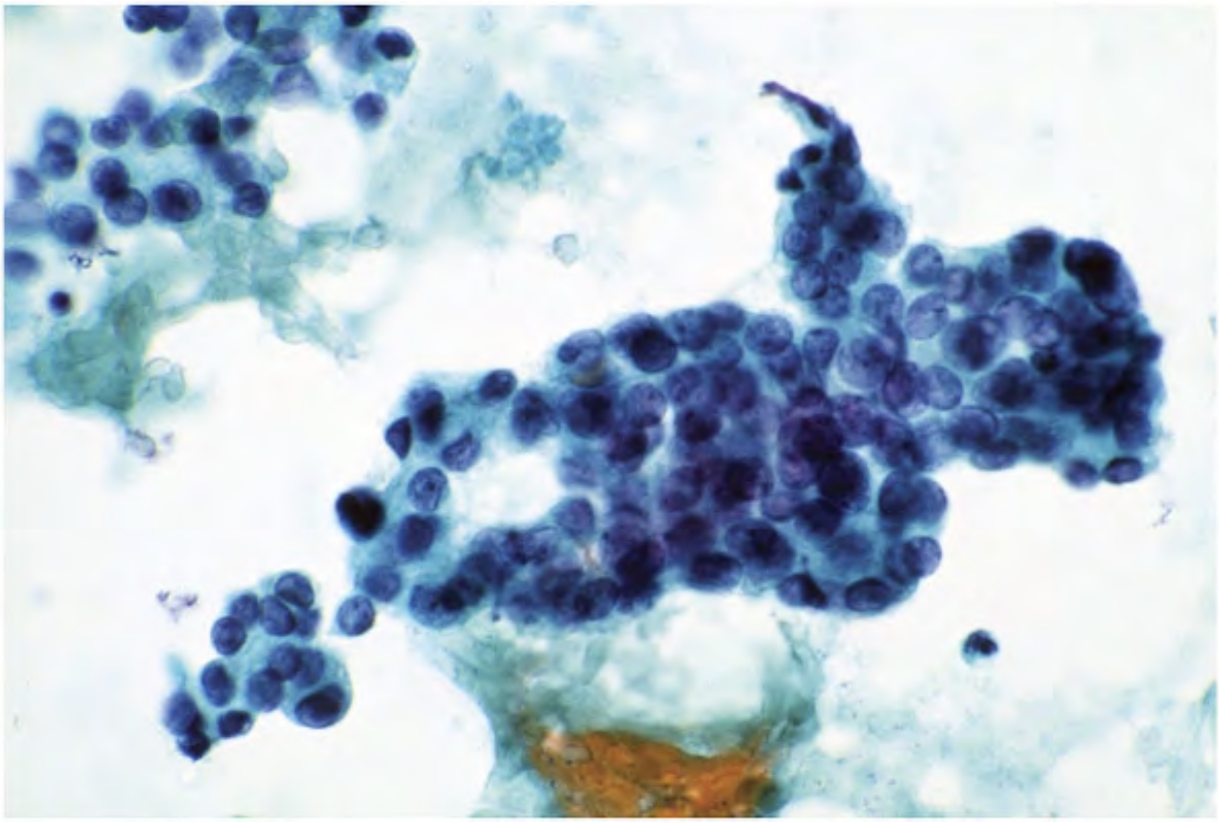

Figure 9.40. A syncytial tissue fragment of follicular cells with a follicular pattern. The enla nuclei are crowded and overlapped. The chromatin is deeply stained and granular. Grooves, inclusions, and nucleoli are not seen. This aspirate was interpreted as cellular follicular adenoma. It was histologically diagnosed as a follicular variant of papillary carcinoma.

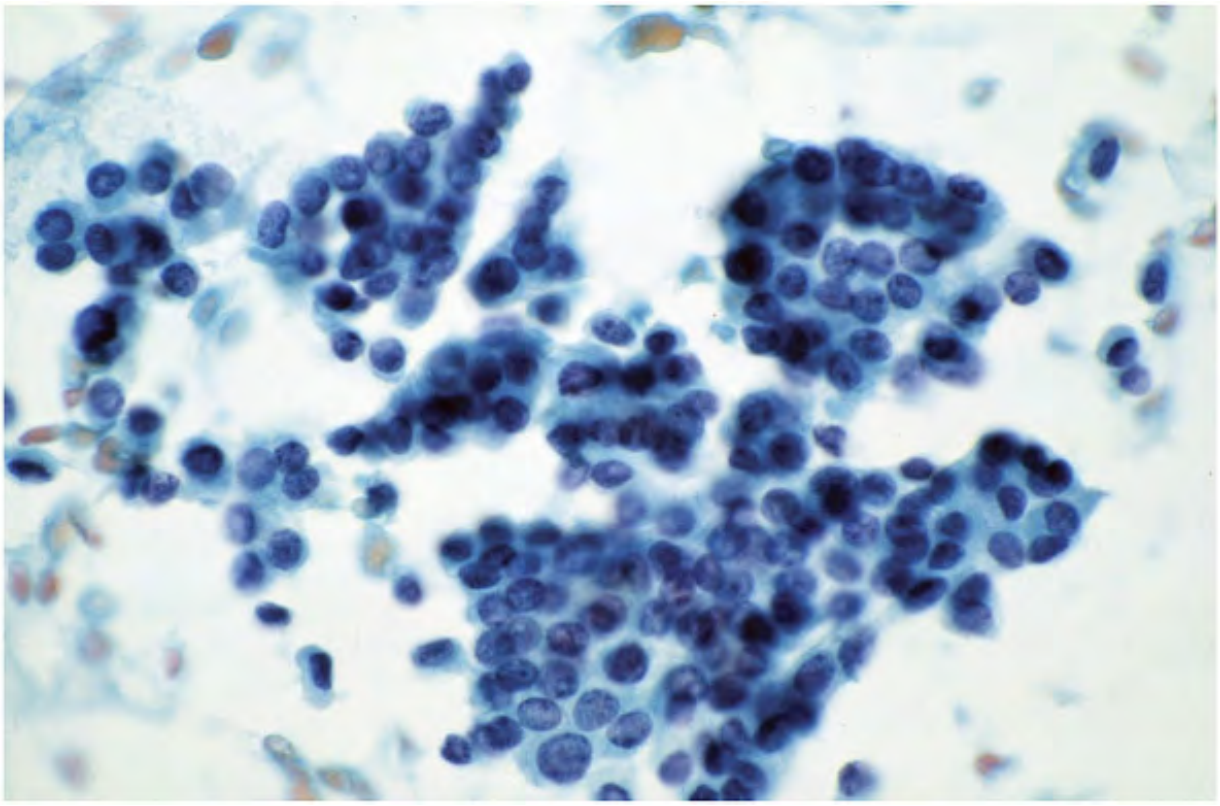

Figure 9.41. These tissue fragments of follicular cells are syncytial without any follicular pattern. The nuclei are uniformly enlarged, crowded, and overlapped. The chromatin is granular. Nucleoli, grooves, and inclusions are not present. The background is clean. The cytologic features are consistent with a cellular follicular adenoma. Thyroidectomy revealed follicular variant of papillary carcinoma.

Cellularity

Variable

Presentation

Neoplastic cells in loosely cohesive groups or in syncytial tissue fragments

Architecture of the tissue fragments

Syncytial tissue fragments with follicular pattern; varying sized individual follicles, empty or containing dense-staining globules of colloid; monolayered tissue fragments with or without branching; syncytial tissue fragments without any architectural patterns; twisted tubular structures; papillary or papillary architecture not present

Cells

Round to cuboidal; medium-sized; poorly defined cell borders; N/C ratios high

Nucleus

Variably enlarged, pleomorphic, round, oval, ovoid; nuclear membrane irregularity Â±; pale nuclei with powdery to finely granular chromatin; occasionally coarsely granular chromatin; micronucleoli, nuclear grooves, pseudoinclusions

Cytoplasm

Scant and pale

Psammoma bodies

Â±

Background

Dense-staining, stringy or globules of colloid, lymphocytes Â±; histiocytes Â±

TABLE 9.3 CYTOPATHOLOGIC FEATURES OF FOLLICULAR VARIANT OF PAPILLARY CARCINOMA

DIFFICULTIES WITH CYTOLOGIC DIAGNOSIS OF FOLLICULAR VARIANTS OF PAPILLARY CARCINOMA

This distinctive subtype of papillary carcinoma is correctly identified both histologically and cytologically when classic features, that is, the typical nuclear morphology of conventional papillary carcinoma, are present. However, recognition of these tumors has caused many problems at multiple levels, including aspiration cytology, intraoperative frozen sections,79 histologic interpretations. Many feel that these variants are overdiagnosed both cytologicall and histologically.80 , 81 , 82

The typical nuclear morphology of conventional papillary carcinomaâ€”such as powdery chromatin, micronucleoli, nuclear grooves, and inclusionsâ€”may not be a universal feature given case of the follicular variant of papillary carcinoma. If the fine needle targets the are lacking these classic nuclear features within a tumor, a correct diagnosis of the follicular va of papillary carcinoma is not possible. The follicular architecture and the lack of typical nuc morphology will lead to a diagnosis of a follicular lesion or a follicular neoplasm, especially the absence of intranuclear inclusions (Figs. 9.39 , 9.40 and 9.41 ; see also Figs. 7.50 , 7.51 7.52 , 7.53 and 7.54). A follicular variant of papillary carcinoma must always be considered the differential diagnosis, when an aspirate suggestive of a follicular neoplasm demonstrate

some of the nuclear features of papillary carcinoma.

In the last two decades, there has been a surge of reports on the cytologic diagnosis of the follicular variant of papillary carcinoma.78 , 83 , 84 , 85 , 86 , 87 , 88 , 89 , 90 , 91 , 92 , 9 94 , 95 , 96 , 97 Several reviews have attempted to analyze the cytologic features from histologically confirmed cases of the follicular variant of papillary carcinoma. The diagnostic accuracy of the follicular variant of papillary carcinoma reported varies from 40% to 86%.83 , 85 , 86 , 87 , 88 , 89 , 90 , 91 , 92 , 93 , 94 , 95 Many cases of follicular variants of papilla carcinoma have been interpreted as nodular goiter or follicular neoplasms. The problem is compounded by the fact that the histologic criteria used to identify this variant are also inconsistent.79 , 81 There is considerable interobserver variation in the histologic diagnosis the follicular variant of papillary carcinoma, indicating difficulties in a precise classification

Because of the tendency to overdiagnose the follicular variant of papillary carcinoma, Chan has proposed strict guidelines for the histologic diagnosis: (i) nuclei are ovoid rather than ro (ii) nuclei are crowded, often manifesting as lack of polarization in the cells lining the follic (iii) nuclei show a clear or pale chromatin pattern (nuclear clearing should not be confined the central portion of the tumor, which can happen due to poor fixation) or they exhibit prominent grooving; and (iv) psammoma bodies are found. If one of these four features is lacking, four or more of the following subsidiary features have to be present for a diagnosis FVPC: (i) presence of abortive papillae, (ii) predominantly elongated or irregularly shaped follicles, (iii) dark-staining colloid, (iv) presence of rare nuclear pseudoinclusions, and (v) multinucleated histiocytes in the lumens of the follicles.

Numerous studies have been conducted on the possible role of immunochemistry and molec analysis. None of the tests so far have been conclusive. In the absence of acceptable criteri recommended by Chan,81 the diagnostic scheme proposed by the Chernobyl group99 may be applicable: *"Well-differentiated tumor of uncertain malignant potential"* â€”an encapsulate tumor composed of well-differentiated follicles with questionable nuclear features of papill carcinoma and no vascular invasion and either absent or questionable capsular invasion.

Livolsi and Baloch100 present a different opinion. They prefer to address an encapsulated le with a follicular pattern but with multifocal distribution of nuclear features of papillary carcinoma as a follicular variant of carcinoma. If the encapsulated lesion shows only one foc papillary carcinoma, these authors designate the lesion as "follicular adenoma with a single of papillary carcinoma."

Tall Cell Variant of Papillary Carcinoma

First described by Hawk and Hazard,24 the tall cell variant comprises about 10% of papillary carcinomas of the thyroid.101 , 102 , 103 , 104 , 105 , 106 , 107 , 108 , 109 , 110 , 111 , 112 113 , 114 These tumors tend to occur in elderly patients, with a male:female ratio of 1:5. T tall cell variant is often large and bulky, frequently exceeding 6 cm in diameter, with areas necrosis, extrathyroidal extension, and vascular invasion (42%). The biologic behavior is mor aggressive101 than that of the conventional type, with a higher incidence of recurrences, cervical lymph node metastasis (75%), and distant metastasis (17%). Death occurs in 25% of t cases.1 , 2 , 101

Histologically, the growth pattern is papillary with complex branching (Fig. 9.42A and B). T follicles are elongated, often aligned in parallel lines referred to as "railroad tracks." The hallmark of tall cell carcinoma is neoplastic cells that are twice as tall as wide, containing abundant, eosinophilic, dense cytoplasm. Mitotic activity may be prominent. Colloid is scan and the carcinoma is frequently associated with lymphocytic infiltrate. Histologically, tall c carcinomas require at least 30% of the cell population to be of the tall cell type.101 , 104

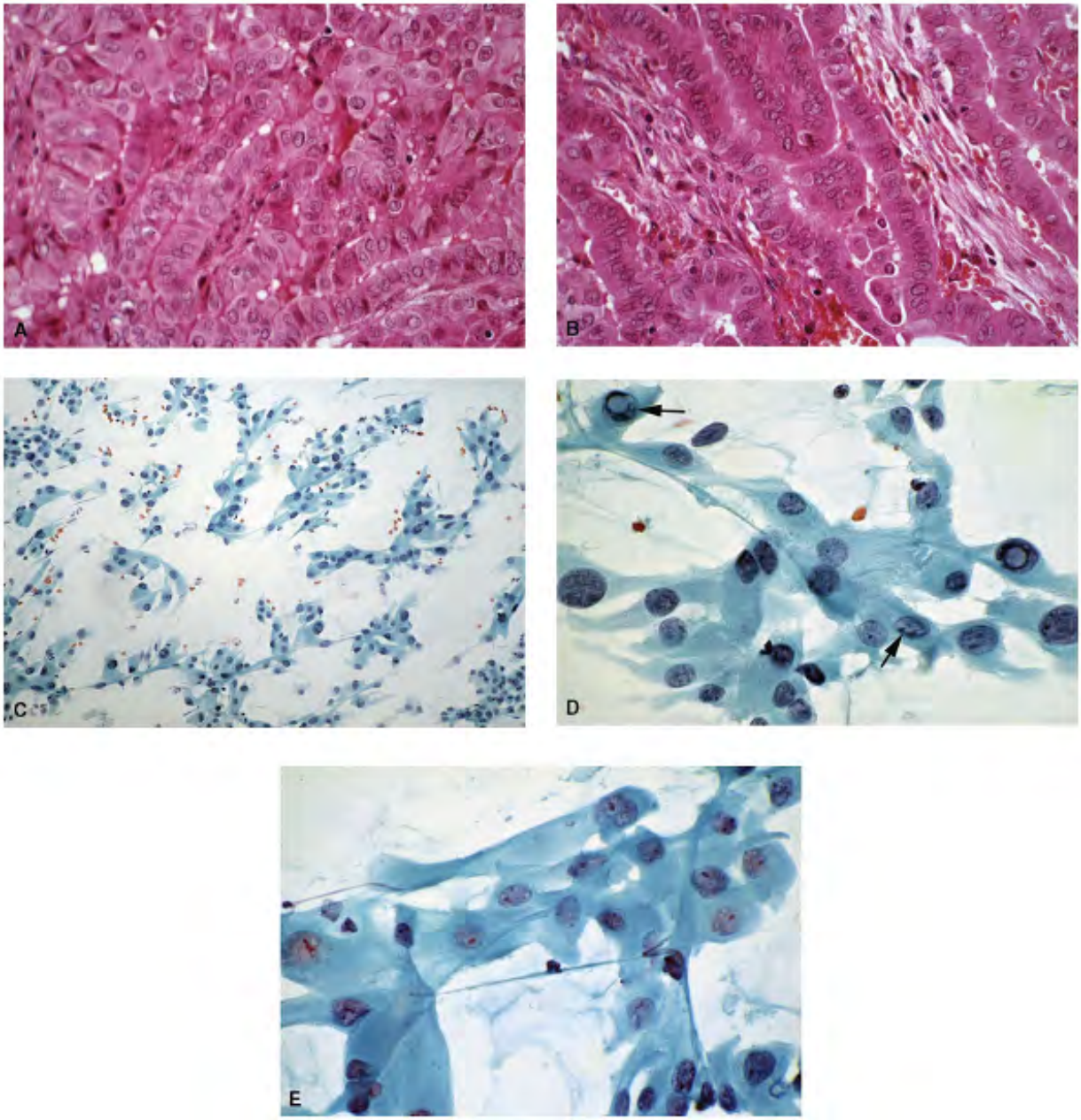

Figure 9.42. *Tall Cell Variant* . A. Histologic sections of the tall cell variant demonstrating branching papillae, lined by tall cells containing abundant eosinophilic cytoplasm. B. The neoplastic follicles are elongated and arranged in a linear fashion (railroad tracks), separate stroma. The lining follicular cells are tall columnar. C. FNA of this case showing several tissu fragments of malignant cells in a clean background. The elongated shapes of the cells are evident even at this low power. D,E. Higher magnification. The pleomorphic cells are loosel cohesive and discrete, large, elongated to columnar-shaped, with well-defined cell borders. Their cytoplasm is abundant and dense. Several nuclei contain sharp cytoplasmic inclusions,

some with a "soap-bubble appearance" (*arrows*).

Cytopathologic Features

Cytopathologic features have been described in the literature as case reports and as small s (Table 9.4).109 , 110 , 111 , 112 , 113 , 114 , 115 , 116 , 117 The aspirates

tend to be cellular, consisting of syncytial tissue fragments with various architectural configurations, in loosely cohesive groups and as isolated cells. The neoplastic cells are elongated, columnar, with well- defined cell borders, and containing abundant, oxyphilic to cyanophilic cytoplasm, which is often dense and sometimes pale and granular (Fig. 9.42C to Their resemblance to HÃ¼rthle cells is striking on account of the abundant cytoplasm. The may appear large and round instead of elongated when smeared in different planes (Figs. 9. and 9.44). Their nuclei are large, but the N/C ratios remain low due to abundant cytoplasm and the nuclei are eccentric in elongated cells but may be central. The nuclei are round to with smooth to irregular nuclear membranes, exhibiting typical cytologic features of conventional papillary carcinoma. Intranuclear inclusions are seen much more frequently in aspirates of tall cell variants of papillary carcinomas, an observation that was made by the author a decade ago118 and also supported by Soloman and co-workers.109 The nuclear inclusions can be multiple within any given nucleus, imparting a "soap-bubble appearance."1 Lymphoid infiltrate may be present (Fig. 9.45) Damiani and co-workers73 described the cytologic features, such as large cell size, oxyphilic to amphophilic cytoplasm, and a high nuclear/cytoplasmic ratio, as indicative of the tall cell variant. The differential diagnosis of tall cell variant of papillary carcinoma includes the oxyphilic variant of papillary or papillary HÃ¼rthle cell carcinoma.

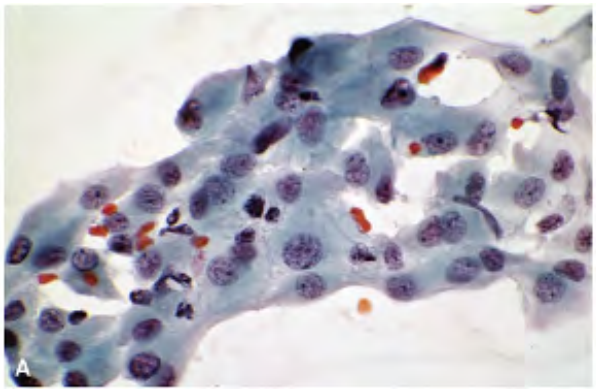

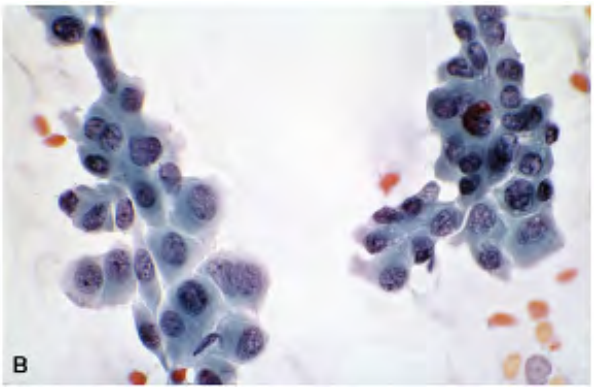

Figure 9.43. FNA of a different case of a tall cell variant of papillary carcinoma. The large, malignant cells with abundant granular to dense cytoplasm form a monolayered but syncytia tissue fragments. The nuclei demonstrate typical features of papillary carcinoma.

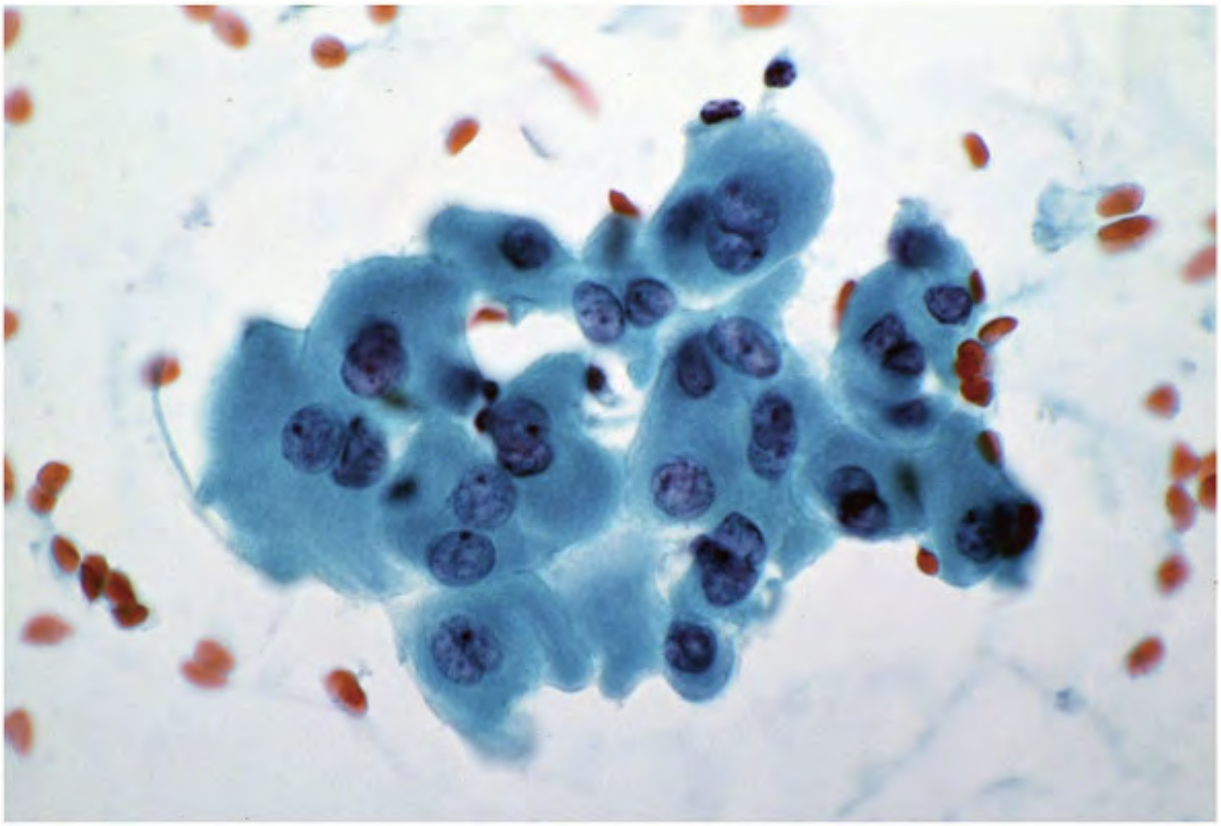

Figure 9.44. FNA of a tall cell variant of papillary carcinoma. The malignant cells are large, dense cytoplasm, forming a monolayered syncytial tissue fragment. Their nuclear morpholog typical of papillary carcinoma. Cells of a tall cell variant sometimes appear round to polygon instead of columnar or elongated and strongly resemble a HÃ¼rthle cell neoplasm.

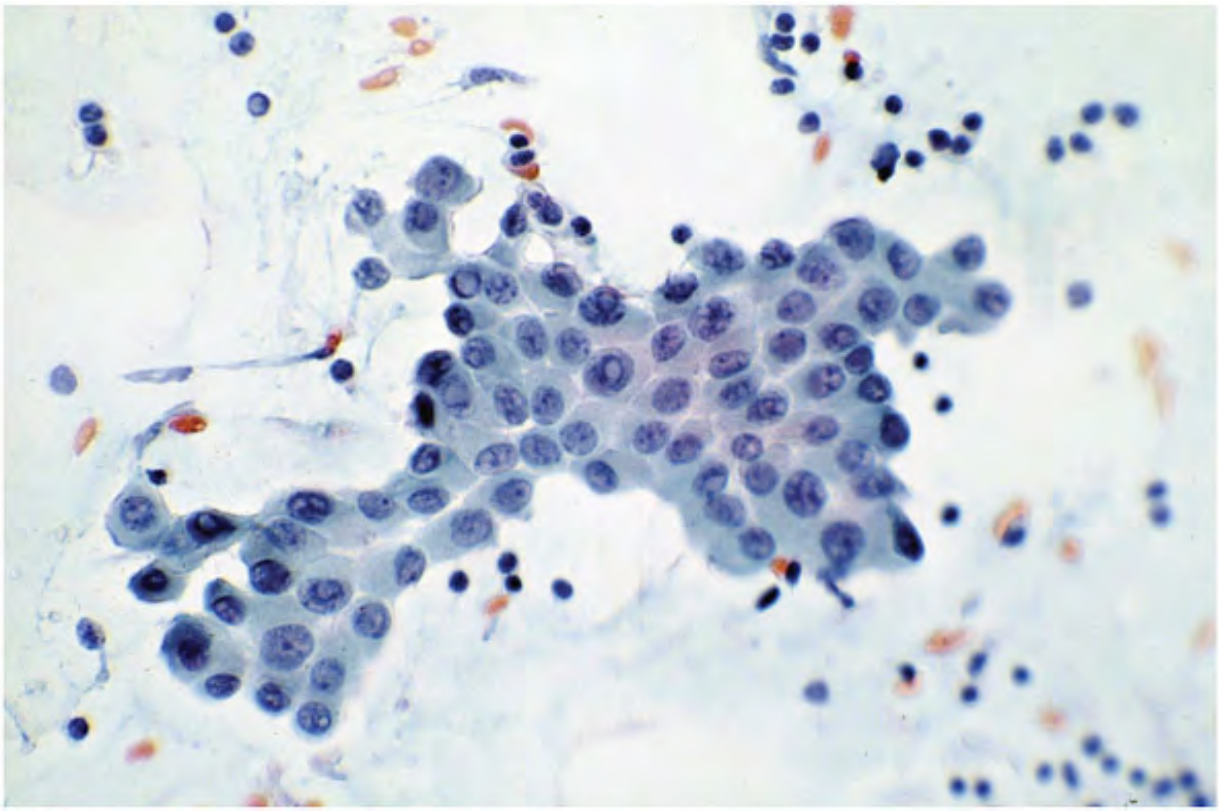

Figure 9.45. FNA of a tall cell variant of papillary carcinoma. The malignant cells are large, dense cytoplasm, forming a monolayered syncytial tissue fragment. Their nuclear morpholog typical of papillary carcinoma. Lymphocytes are present in the background.

Cellularity

Usually very cellular

Presentation

Cells isolated, in loosely cohesive groups and in syncytial tissue fragments

Architecture of the tissue fragments

Predominantly papillary with or without branching, monolayered, follicular pattern infrequent

Cells

Large, elongated to columnar, appear round to polygonal when seen on cross-section; well-defined cell borders; N/C ratios lower than cells of conventional or follicular variant carcinoma cells

Nucleus

Usually eccentric, may be central; large, round to oval, with smooth to irregular mem-

branes; chromatin dusty, powdery to finely granular; micro-macronucleoli; grooves; intranuclear inclusions present in larger numbers than other variants; multiple inclusions within a single nucleus giving a "soap-bubble" appearance; rare mitosis

Cytoplasm

Abundant, dense staining cyanophilic or oxyphilic; may be pale and granular and amphophilic

Psammoma bodies

Very rare

Background

Colloid infrequent, lymphocytic infiltrate Â±

TABLE 9.4 CYTOPATHOLOGIC FEATURES OF TALL CELL VARIANTS OF PAPILLARY CARCINOMA

Columnar Cell Variant of Papillary Carcinoma

The columnar cell variant is an extremely rare, morphologically distinct type of papillary carcinoma. First described by Evans119 and later by Sobrinho-Simoes et al.,120 the columna variant is considered to be an aggressive tumor. All of their patients died of the disease. However, in a large series by Wenig et al.67 this view is contradicted. According to this rep the behavior depends on the presence or absence of extrathyroidal extension rather than th morphologic type alone. Literature on the columnar cell variant of papillary carcinoma is limited,119 , 120 , 121 , 122 , 123 , 124 , 125 , 126 , 127 , 128 , 129 , 130 with only a few ca reports on cytopathologic findings.125 , 126 , 127 , 128 , 129 , 130

The histologic features of the columnar cell variant of papillary carcinoma are characterize an extreme papillary growth pattern, tall columnar cells, and nuclear stratification, present strong morphologic resemblance to endometrioid carcinoma (Figs. 9.46A , 9.46B , 9.47G , 9.). Also present are elongated follicles, arranged in parallel lines.67 Columnar cell papillary carcinomas may be associated with other growth patterns. The neoplastic cells are twice as as they are wide, and contain clear, vacuolated to eosinophilic cytoplasm, sometimes exhib subnuclear vacuoles. The nuclei, aligned perpendicular to the surface, are darker and lack t empty look of classic papillary carcinoma cells (Figs. 9.46C to 9.46E , 9.47A to 9.47D). Incre mitotic activity may be present, but necrosis is rare. The colloid is minimal to absent and

psammoma bodies are rare. The immunoprofile includes positive reactivity to cytokeratin. Although all cases described by Wenig et al.67 showed positive reactivity to thyroglobulin, i inconsistent, varying from strong to weak to focally negative within a given tumor and was absent in metastatic tumor. In the cases described by Evans,119 the carcinoma cells did not react with antithyroglobulin antibodies. Two cases of columnar cell variants of papillary carcinoma from the author's files showed negative reactivity.

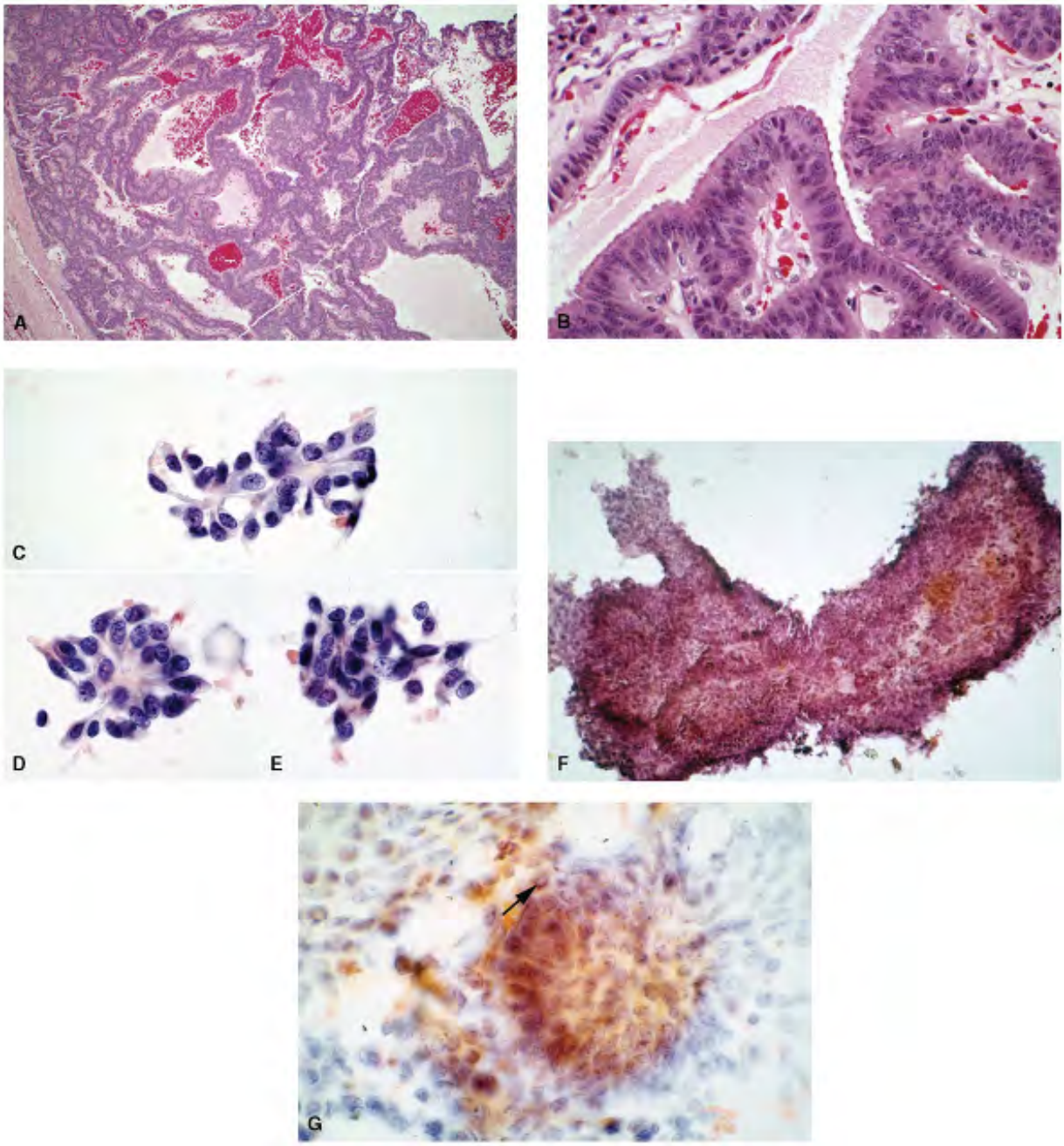

Figure 9.46. *Columnar cell variant of papillary carcinoma* . A. Histologic section. The tumo shows a complex papillary pattern with tall columnar cells and nuclear stratification and resembles an endometroid adenocarcinoma. B. Higher magnification. Note the tall columna tumor cells with hyperchromatic, stratified nuclei. Câ€“E. Fine-needle biopsy of this colum cell variant of papillary carcinoma. The tumor cells are delicate and columnar, with pale cytoplasm and tapered ends, round to oblong nuclei with coarse chromatin, and micronucle Intranuclear inclusions or grooves are not identified. F. A large tissue fragment consisting of closely packed cells with elongated nuclei with peripheral palisading. Nuclear details are difficult to assess due to thickness of the tissue fragment. G. The syncytial tissue fragment shows stratified elongated nuclei at the periphery. The chromatin is granular. Micronucleoli occasional inclusions are present (*arrow*).

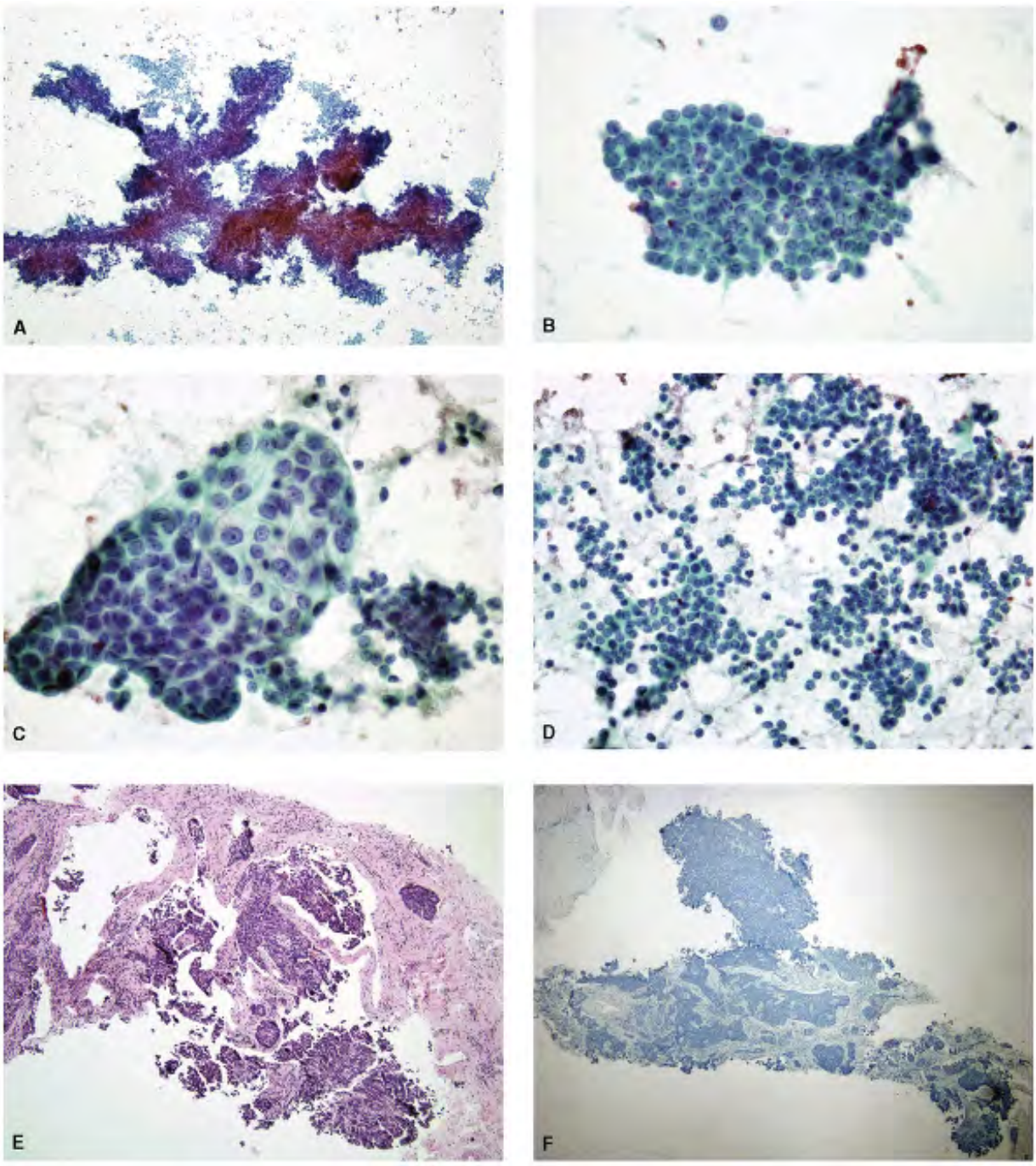

Figure 9.47. *Columnar cell variant of papillary carcinoma* . FNA of a massively enlarged thy
with multiple enlarged cervical lymph nodes. A. Overwhelmingly cellular aspirate consisting
several papillary tissue fragments with complex branching. The background shows single cel
and groups of cells, low power. B. Higher magnification of the tissue fragment shows minim
enlarged round nuclei with granular chromatin and micronucleoli; their cytoplasm is scant.
Different field showing a tissue fragment of malignant cells with papillary-like pattern. Thei

nuclei have deep-staining coarsely granular chromatin. Some exhibit nucleoli. The cells demonstrate variable cytoplasm. D. The neoplastic cells are small to medium-sized, are pre isolated and in syncytial tissue fragments. Their cell borders are poorly defined and the cytoplasm is scant. The nuclei are round and uniform, containing granular chromatin and micronucleoli. E. Core needle biopsy of the neck mass showing a papillary carcinoma. F. Immunostain with thyroglobulin. The neoplastic cells are nonreactive. Thyroidectomy revea columnar cell carcinoma, widely infiltrating the adjacent tissues and involving multiple cerv lymph nodes.

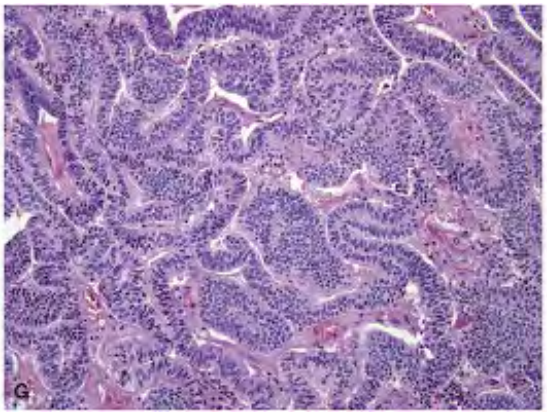

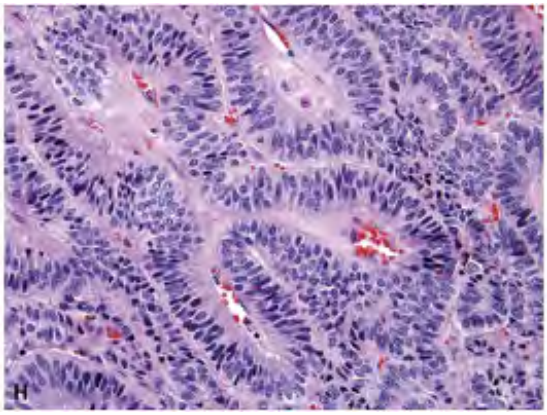

Figure 9.47. G. Histologic section demonstrating typical architecture of the columnar cell variant of papillary carcinoma, resembling an endometrioid carcinoma. H. Higher magnifica highlighting the columnar cells, stratification, and pale cytoplasm.

Cytopathologic Features

The aspirate of the columnar cell variant shows syncytial tissue fragments with a papillary pattern comprised of elongated columnar cells that may show pale, tapering cytoplasm at o end (Figs. 9.46 and 9.47). The nuclei show stratification and palisading at the periphery of tissue fragments. They are hyperchromatic, oval to oblong nuclei with micronucleoli, contra sharply with the dusty, powdery chromatin of the cells seen in conventional or other morphologic variants. Intranuclear inclusions or nuclear grooves are usually absent. The cell the columnar cell variant possess scant, pale to clear cytoplasm. The ancillary featuresâ€”su as psammoma bodies, multinucleated foreign-bodyâ€“type giant cells, and colloidâ€”are no described or seen in these tumors.

The lack of typical nuclear features of papillary carcinoma may lead to diagnostic difficultie and may be mistyped as other neoplasms such as medullary carcinoma.125 The columnar ce pattern was misinterpreted as possible contamination by respiratory columnar cells, in their initial evaluation of the case reported by Jayaram.127 Columnar cell carcinoma morphologic resembles tall cell carcinoma. But the cytoplasm in tall cell carcinomas is dense and eosinop and the nuclei demonstrate typical features of papillary carcinoma.

Oncocytic or Oxyphil Cell Variant

The oncocytic variant of papillary carcinoma is uncommon, the reported incidence ranging f 3.5% to 11%.131 , 132 , 133 , 134 , 135 , 136 , 137 , 138 , 139 , 140 There are two types of oncocytic papillary carcinomas. Both have a papillary growth pattern.

The oncocytic variant of papillary carcinoma demonstrates typical nuclear features of conventional papillary carcinoma such as powdery chromatin, micronucleoli, grooves, and inclusions. These may also demonstrate a follicular growth pattern. These are usually encapsulated and may or may not show capsular invasion. The biologic behavior of the oxyp variant parallels that of a conventional papillary carcinoma.

The papillary HÃ¼rthle cell carcinomas demonstrate a papillary growth pattern, but lack so nuclear features such as powdery chromatin and micronucleoli, yet show a prominent cherry macronucleolus. Inclusions are present in both and do not serve as a differentiating feature. These are more aggressive clinically with 16% mortality and are in keeping with HÃ¼rthle ce carcinomas.

Cytologic specimens from the oncocytic variant of papillary carcinomas show a HÃ¼rthle cel population (Figs. 9.48

and 9.49). The neoplastic cells are variable in size, may be discrete, and occur in loosely cohesive groups and syncytial tissue fragments, with a papillary configuration; a follicular pattern may be evident (Fig. 9.49). Their nuclei demonstrate nuclear features seen in papil carcinomas such as powdery, dusty chromatin, micronucleoli, grooves, and inclusions. The oxyphilic cells contain abundant granular cytoplasm similar to that seen in cells of the tall c variant. Psammoma bodies may or may not be present in the background. A papillary HÃ¼rt cell carcinoma is illustrated in Figure 9.50 for comparison.

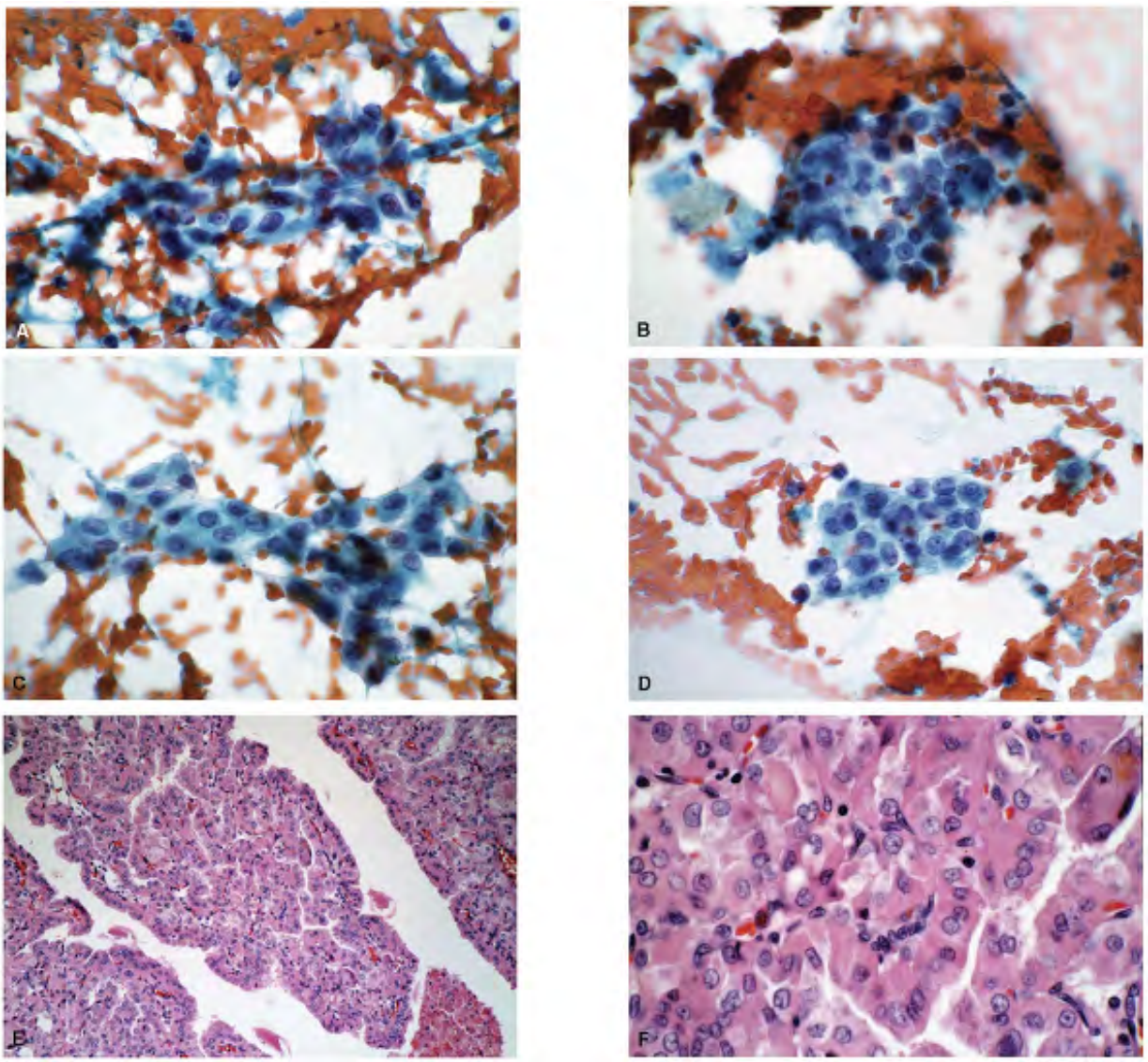

Figure 9.48. *Oxyphilic variant of papillary carcinoma* . Aâ€“D. FNA of a cystic thyroid nodu
The syncytial tissue fragments consist of cells with abundant cyanophilic cytoplasm. The nu
contain finely granular chromatin, micronucleoli, grooves, and inclusions. Thyroidectomy
revealed a large cystic tumor with residual in the wall. E. Histologic section showing an oxy
variant of papillary carcinoma with branching papillary fronds. F. Higher magnification of th
papillary frond. The lining cells are columnar with abundant eosinophilic cytoplasm. The nu
are uniform in size, round, and with granular chromatin containing nucleoli. Nuclear inclusi
are also seen.

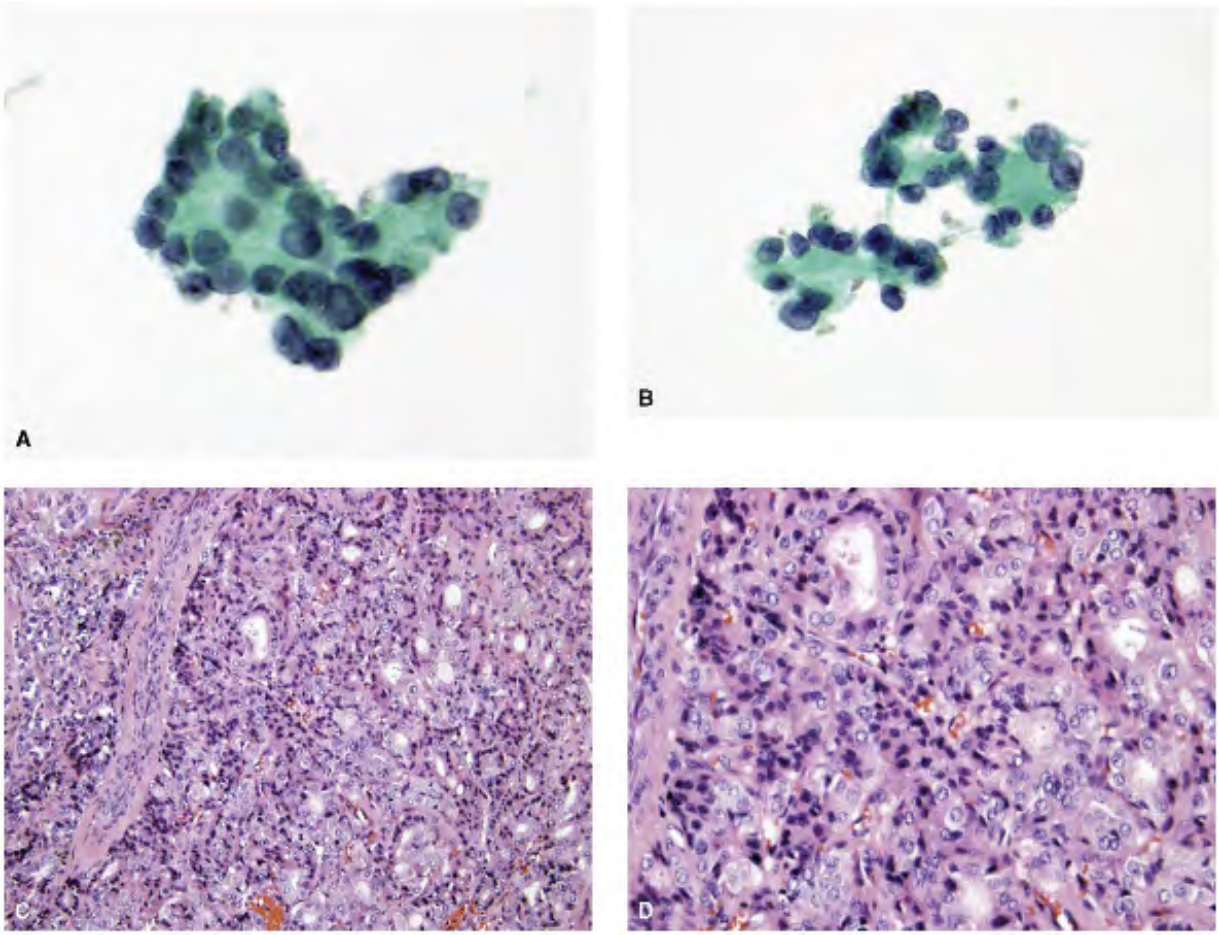

Figure 9.49. *Oxyphilic variant with a follicular pattern* . A,B. Syncytial tissue fragments wi follicular pattern. The nuclei are round with granular chromatin and nucleoli. Intranuclear inclusions are easily identified. The appreciable amount of cytoplasm is dense. The cytologi diagnosis was a follicular variant of papillary carcinoma. The oxyphilic nature of the cells wa not recognized. C. Histologic sections of the resected tumor showing a follicular growth pat formed by oncocytic cells. D. Higher magnification. The follicles are lined by HÃ¼rthle cells uniform nuclei, some containing inclusions. Macronucleoli are not seen.

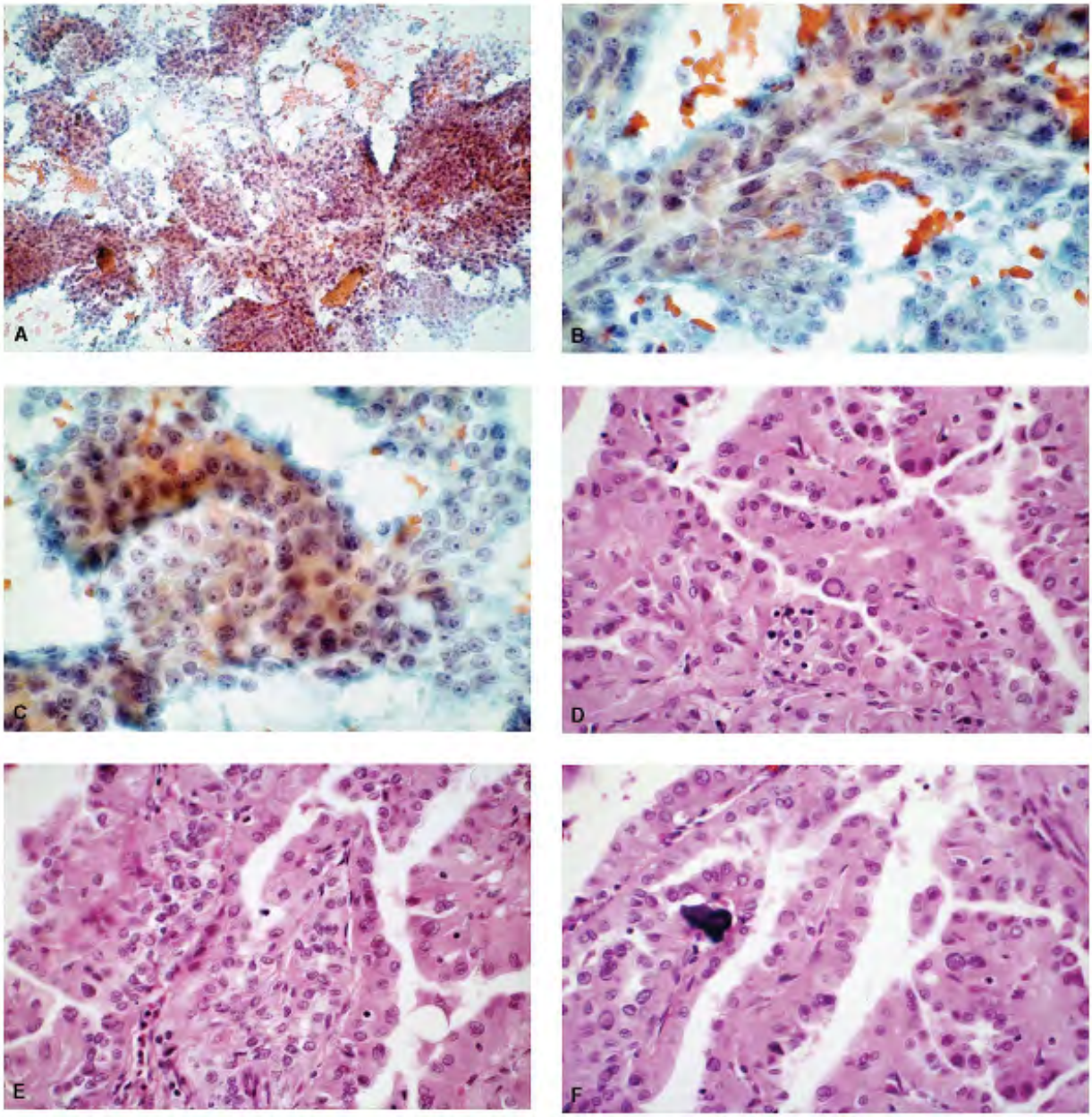

Figure 9.50. *HÃ¼rthle cell carcinoma, papillary type* . A. Markedly cellular aspirate with syncytial tissue fragments exhibiting a papillary and monolayered patterns. B. Higher magnification showing cells lining a papillary core demonstrating typical nuclear features of HÃ¼rthle cell tumor with prominent macronucleoli. C. Syncytial tissue fragments of small HÃ¼rthle cells presenting with uniform round nuclei containing characteristic macronucleol Nuclear grooves or inclusions are not seen. D,E. Histologic section showing a HÃ¼rthle cell carcinoma with papillary growth pattern. F. Note the psammoma body. Note that the nucle pattern is that of a HÃ¼rthle cell carcinoma and not a conventional papillary carcinoma.

P.156
P.157
P.158

Solid and Trabecular Variants

As the name implies, these subtypes are characterized by a solid growth pattern composed o polygonal cells with abundant pink cytoplasm and nuclei with typical characteristics of conventional papillary carcinoma (Fig. 9.51A). The solid pattern comprising 70% of the tumo usually associated with common morphologic types and blends with the papillary and follicu areas and with squamous metaplasia. These tumors with solid growth pattern must be differentiated from poorly differentiated or undifferentiated carcinomas. The features that favor papillary carcinoma include irregular fibrous trabeculae within the tumor and occasior psammoma body and most important, the nuclear morphology.2 , 141

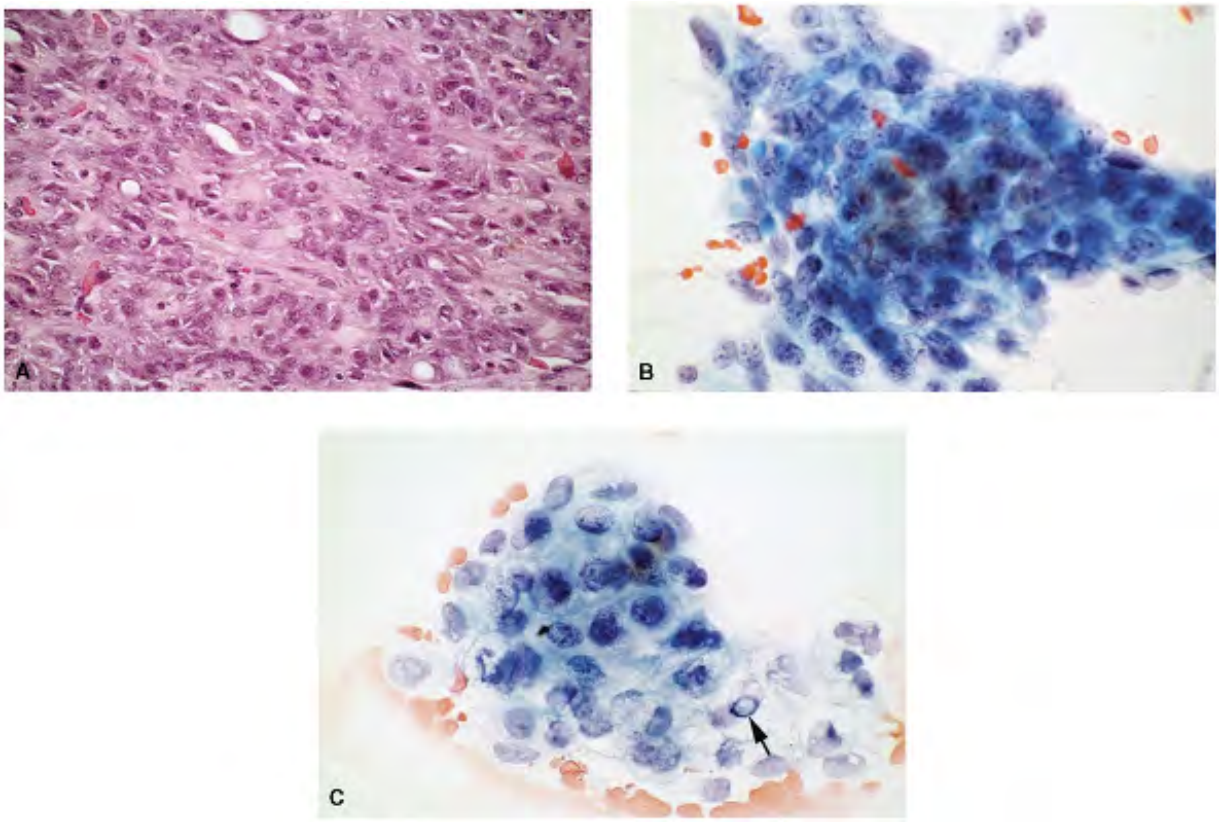

Figure 9.51. *Solid variant of papillary carcinoma* . A. Histologic section. The growth patter solid with an attempt at follicle formation. B,C. FNA showing syncytial tissue fragments of la cells without any architectural configurations. Their nuclei are large and show an occasiona

intranuclear inclusion (*arrow*).

Cytologically, these carcinomas contain malignant cells, isolated and in syncytial tissue fragments, without any papillary or a follicular architecture However, the nuclear morpholo characteristic (Fig. 9.51B and C).

Diffuse Sclerosing Variant

First reported by Vickery et al. 22 the diffuse sclerosing variant is more frequently seen in children and adolescents.142 , 143 , 144 , 145 , 146 , 147 , 148 , 149 , 150 , 151 , 152 It accounts for 2.3% of all thyroid papillary carcinomas. The characteristic features include dif involvement of one or both lobes rather than a dominant nodule, numerous small papillary formations within cleft-like spaces, probably lymphatics, extensive squamous metaplasia, m psammoma bodies, marked lymphocytic infiltration, and prominent fibrosis (Fig. 9.52). Cha al.148 and others145 described the presence of S-100 protein-containing cells in the stroma variant shows a greater incidence of cervical lymph node involvement and pulmonary metas The metastatic deposits are not as distinctive as primary tumor and resemble classic-type papillary carcinoma.148

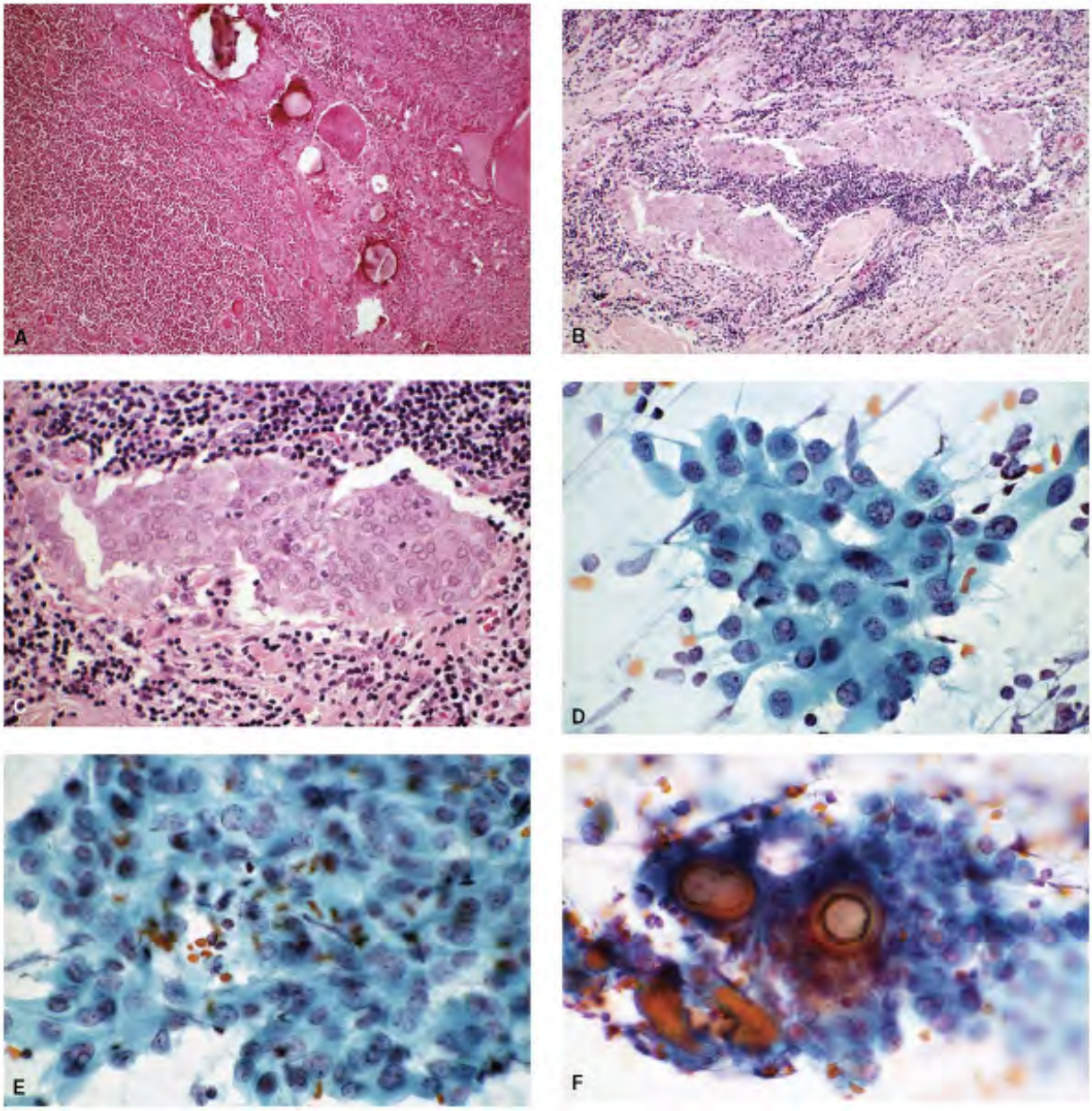

Figure 9.52. *Diffuse sclerosing variant of papillary carcinoma* . A. Histologic section of the diffuse sclerosing variant of papillary carcinoma with a heavy lymphoid infiltrate and numer psammoma bodies. B. Another field showing a solid growth pattern in the background of a lymphocytic infiltrate. C. Higher magnification of part B, showing tumor cells in an endothe lined space. The component cells are uniform appearing squamoid. D,E. Fine-needle biopsy the same case shown in parts A to C. The malignant cells are pleomorphic, with the characteristic nuclear features of papillary carcinoma. Lymphocytes are present in the background. F. A tissue fragment of malignant cells incorporating psammoma bodies.

Cytopathologic features of diffuse sclerosing variant are documented in only three case reports.150 , 151 , 152 One personally examined

case showed syncytial tissue fragments of medium-sized cells containing nuclei with the typ features of papillary carcinoma. Many psammoma bodies were conspicuous in the backgrour heavy lymphocytic cells (Fig. 9.52). This morphologic variant cannot be detected from the cytologic samples, since areas of fibrosis are not visualized and the samples will be interpre as papillary carcinoma in the background of lymphocytic thyroiditis. Abundant psammoma b may be present.

Papillary Carcinoma with Exuberant Nodular Fascitis-Like Stroma

Papillary carcinoma with nodular fasciitis-like stroma was first described by Chan et al. in 1991.153 Since then a few case reports have appeared in the literature on histologic and cytologic presentations.154 , 155 , 156 , 157 , 158

This variant of papillary carcinoma is characterized by abundant fasciitis-like stroma consist of spindle cells arranged in fascicles in a background of vascularized fibrovascular stroma wi histiocytes and inflammatory cells (Fig. 9.53). The stromal spindle cells have plump nuclei v a finely granular, bland chromatin pattern. The amount of stroma can be extensive and exuberant. The papillary carcinoma may present follicles, papillae, and trabeculae separate variable stroma. The nuclear features are those of a typical conventional papillary carcinom Psammoma bodies may occasionally be seen (Fig. 9.53C). The spindle cell component is immunoreactive to vimentin and negative to cytokeratin.

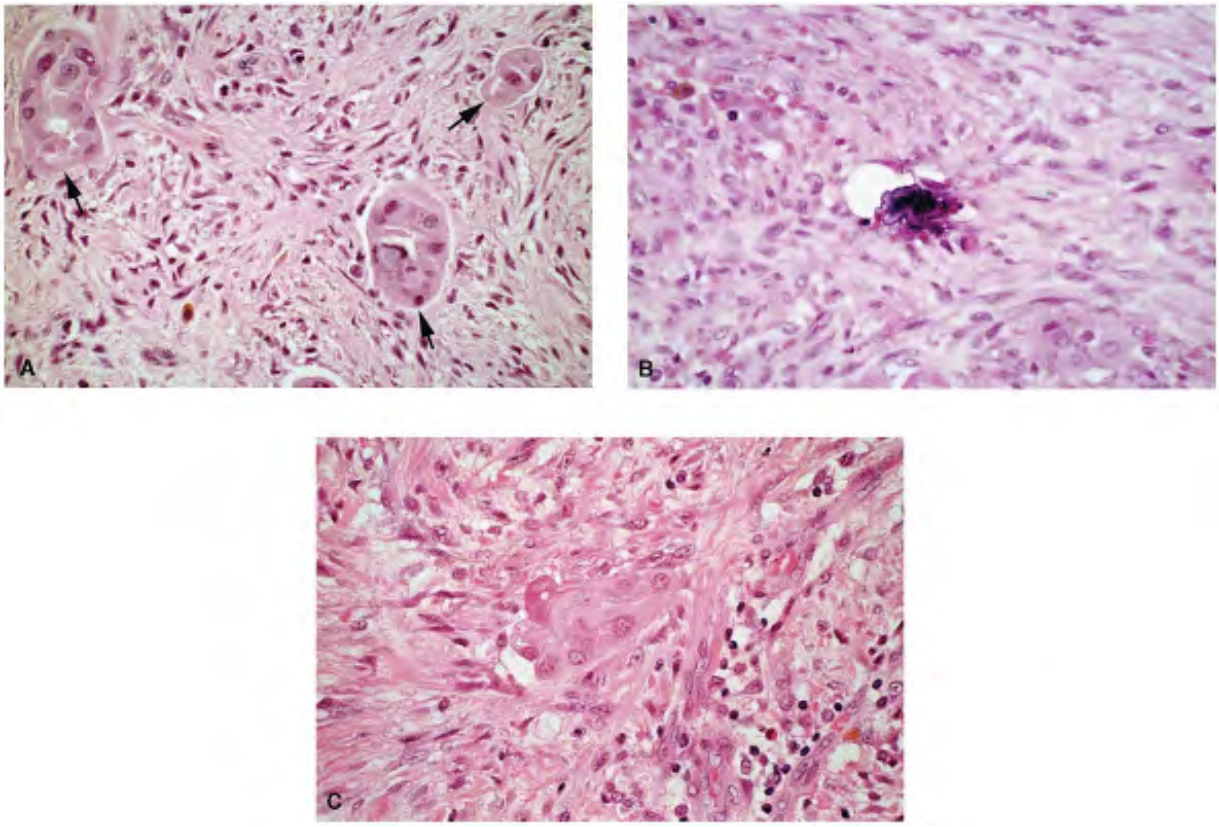

Figure 9.53. Papillary carcinoma with nodular fasciitis-like stroma. A. Histologic section of papillary carcinoma with nodular fasciitis-like stroma. Note the exuberant proliferating stro with trapped neoplastic follicles and cells (*arrows*). The follicles are lined by epithelium wi features of conventional papillary carcinoma. B. Proliferating stroma composed of spindle c with small nuclei presenting a bland chromatin pattern. A psammoma body is embedded in exuberant stroma. C. Exuberent stroma and a single follicle lined by cells with typical morphology of papillary carcinoma. Because of the increased stroma, the fine-needle biopsi this variant will tend to be poorly cellular but will show features of either the conventional follicular variant of papillary carcinoma. FNA in this case was inadequate for cytologic evaluation.

Cytopathologic Features

Because of the fibrous stroma, the aspirates tend to be paucicellular with minimal epithelia component. Cytologic presentations are sparsely reported.157 , 158 This subtype cannot be identified from cytologic samples due to the absence of the stromal component. The aspirat however, exhibit the typical cytopathologic features of the conventional or follicular varian

papillary carcinoma. Most published reports highlight the diagnostic difficulties. Yang et al.:
reported a case of papillary carcinoma with nodular fasciitis-like stroma that was cytologica
interpreted as malignant neoplasm suggestive of myxoid sarcoma because of the large
population of spindle cells with a bland chromatin pattern. The diagnosis of papillary carcin
was established at open biopsy.

Macrofollicular Variant

As a morphologic variant of papillary carcinoma, macrofollicular papillary carcinoma was fir
described by Albores-Saavedra and co-workers.159 It is characterized by the presence of lar
varying-sized colloid-filled macrofollicles mixed with the follicular variant of papillary carci
(Fig. 9.54). The colloid within the follicles is often scalloped or vacuolated. The nuclei of tl
cells lining the follicles may be hyperchromatic. The classic nuclear pattern of conventional
papillary

carcinoma is seen in foci scattered throughout the tumor. The large colloid-filled follicles m
also contain abortive papillae lined by atypical cells. Due to the presence of large, distende
follicles with abundant colloid, this variant may be easily confused with multinodular goiter
macrofollicular adenoma, both grossly and histologically. Albores-Saavedra et al.159 , 161 a
Ashfaq and co-workers160 have reported a higher incidence of insular component associatec
with the macrofollicular variant of papillary carcinoma.

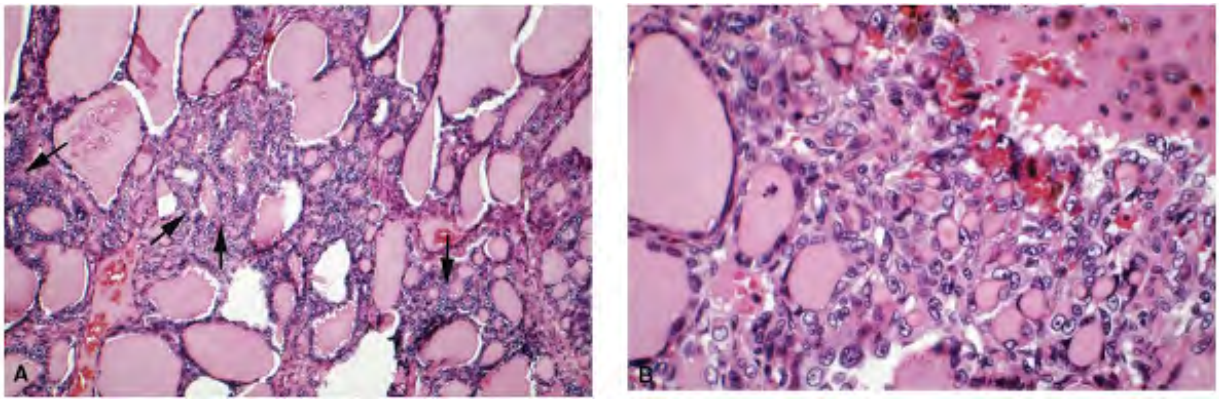

Figure 9.54. *Macrofollicular variant of papillary carcinoma* . Histologic section. A. The larg
varying-sized follicles distended with colloid present a deceptively bland pattern, strongly
resembling a nodular goiter or a macrofollicular adenoma. Focally the follicles are lined by
epithelium (*arrows*) with typical nuclear features of conventional papillary carcinoma, whic
can be appreciated only at high power. B. Higher magnification to highlight the nuclear

morphology. This carcinoma metastasized to the shoulder 4 years later with dedifferentiatic into an insular pattern (see Figure 15.10 in Chapter 15).

The cytologic features162 , 163 , 164 are similar to those of the conventional or follicular variant, with abundant colloid in the background (Figs. 9.54 , 9.55 and 9.56). This variant r be differentiated from a nodular goiter with abundant colloid or a macrofollicular adenoma

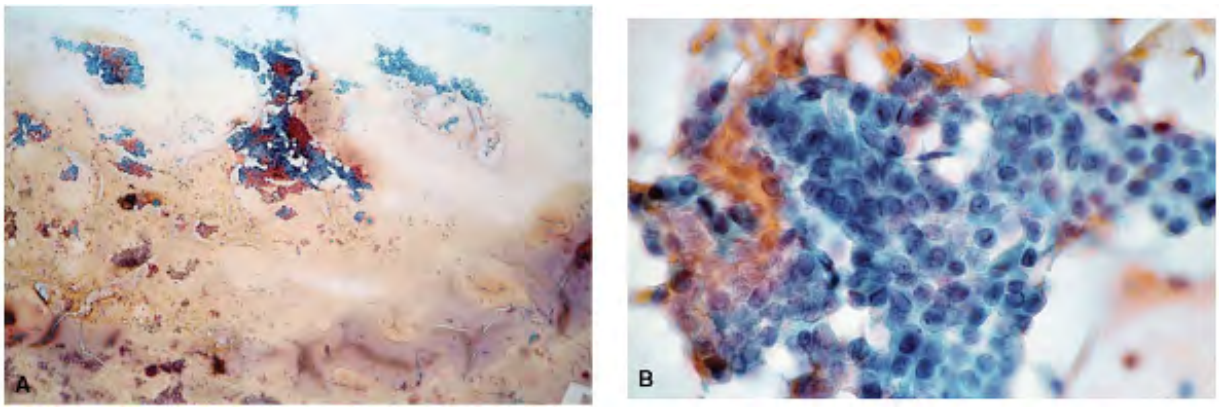

Figure 9.55. *Macrofollicular variant of papillary carcinoma* . A. Marginally cellular specime with few tissue fragments in the background of abundant colloid, low power. B. Higher magnification showing syncytial architecture with nuclei exhibiting typical feature of papilla carcinoma.

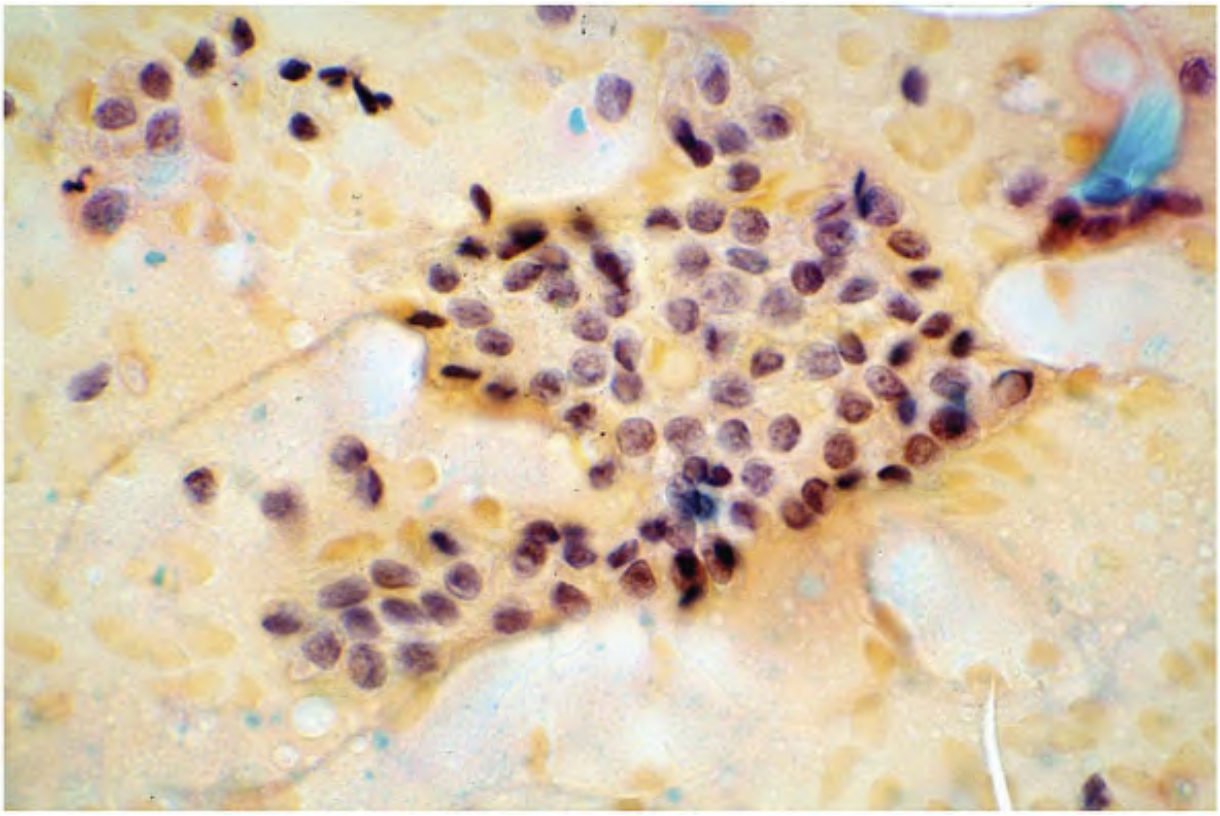

Figure 9.56. *Macrofollicular variant of papillary carcinoma* . Different example showing sm monolayered tissue fragments with component nuclei containing powdery chromatin and intranuclear inclusions. Note abundant colloid in the background.

P.162
P.163

Diffuse Follicular Variant

Originally described by Sobrinho-Simoes et al.165 the diffuse follicular variant occurs predominantly in women who may be hyperthyroid and presents grossly as a goiter. The enla thyroid gland is diffusely involved by a neoplasm showing the follicular pattern and nuclear morphology of papillary carcinoma. The clinical course is described as aggressive, with dista metastasis.166 Although the cytologic features have not been reported, they conceivably wi present the cytomorphology of papillary carcinoma.

Encapsulated Variant

The encapsulated variant is characterized by total encapsulation, with or without invasion c

capsule by the tumor.167 , 168 , 169 Because of this encapsulation, it was referred to as "papillary adenoma." The histomorphology may be typical of the conventional variant or the follicular variant, with corresponding cytologic features.

This morphologic variant is strictly based on complete encapsulation identified only in a surgically excised specimen, and hence can be interpreted only as papillary carcinoma from cytologic samples.

Papillary Carcinoma with Clear Cell Change

Some consider papillary carcinomas with clear cell change as an expression of morphologic variance.170 , 171 Rosai et al.2 state that this feature in papillary carcinomas is rare and inconsequential. Meissner and Adler13 reported clear cell change in 28% of their 224 cases c papillary carcinoma. The clear cytoplasm is a result of glycogen accumulation or vesicular formation.172

Histologically, clear cell change is more frequent with the follicular variant (Fig. 9.57 A and but can also be seen with the papillary pattern (Fig. 9.57D). Cytologically, the cells with cl change show poorly defined cell borders, tend to appear discrete, and frequently appear as stripped nuclei. Their cytoplasm is barely discernible; the enlarged nuclei exhibit the typica features of a papillary carcinoma. Because of the single cell pattern, these aspirates may be misinterpreted as medullary carcinoma (Fig. 9.57C).

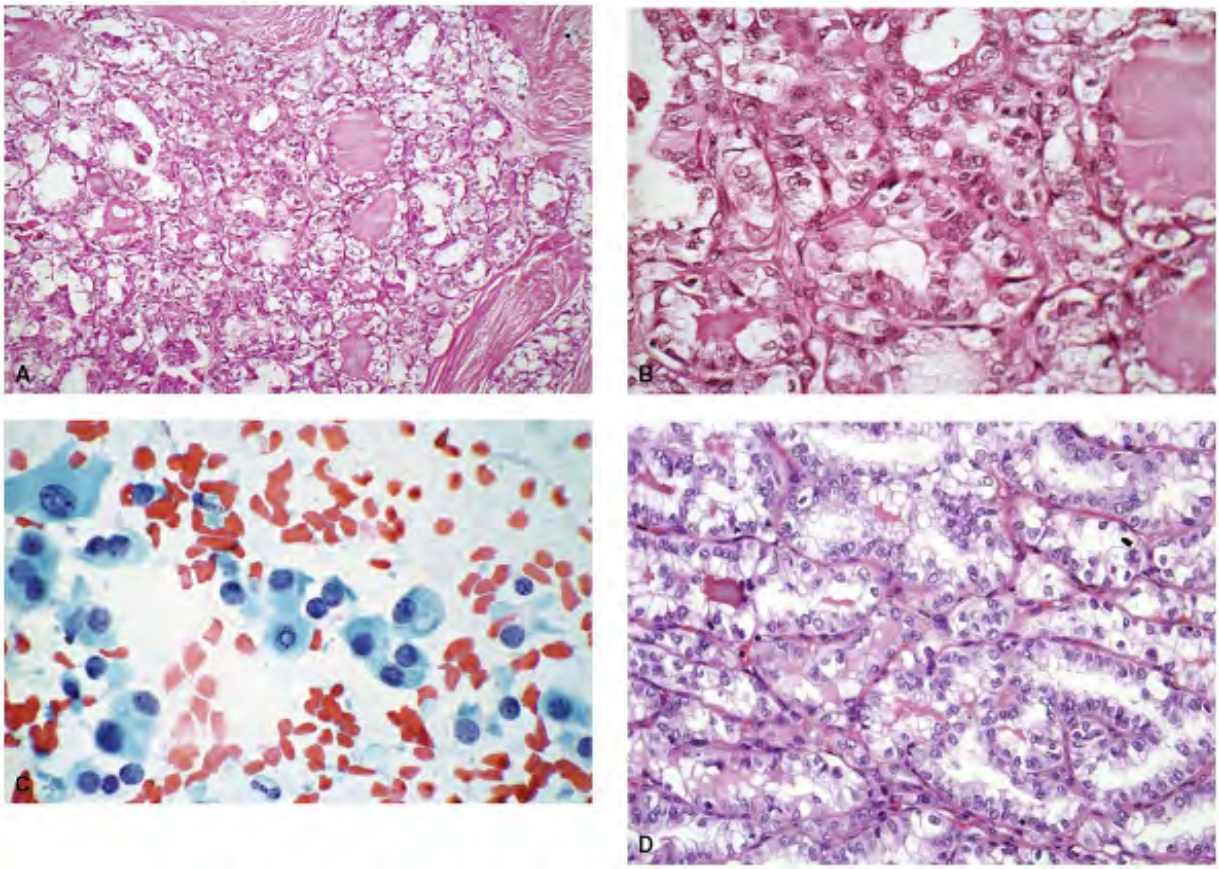

Figure 9.57. *Papillary carcinoma with clear cell change* . Histologic section. A. Follicular pattern with follicular cells exhibiting clear cytoplasm. B. Higher magnification. C. FNA. Th aspirated cells tend to be isolated and possess poorly defined cell borders. The nuclei demonstrate typical features of papillary carcinoma. D. Histologic section of papillary carci with clear cell change.

Cribriform-Morular Variant

The cribriform-morular variant as a distinct variety of papillary carcinoma was first describe Harach et al.173 in association with familial adenomatous polyposis syndrome. This associat has been confirmed in other studies.

Histologically, the cribriform-morular variant is characterized by an intricate blending of cribriform, follicular, papillary, trabecular, and solid patterns with morular (squamoid) area (Fig. 9.58).173 , 174 , 175 , 176 , 177 The cribriform pattern is formed by anastomosing ba and arches of cells without intervening stroma and resembles breast-duct carcinoma. Discre cribriform structures are scattered in sclerotic stroma. The follicular structures are usually

devoid of colloid. The neoplastic cells are tall with abundant eosinophilic cytoplasm and frequent pseudostratification. Also present is a trabecular arrangement of spindle cells reminiscent of hyalinizing trabecular adenoma.

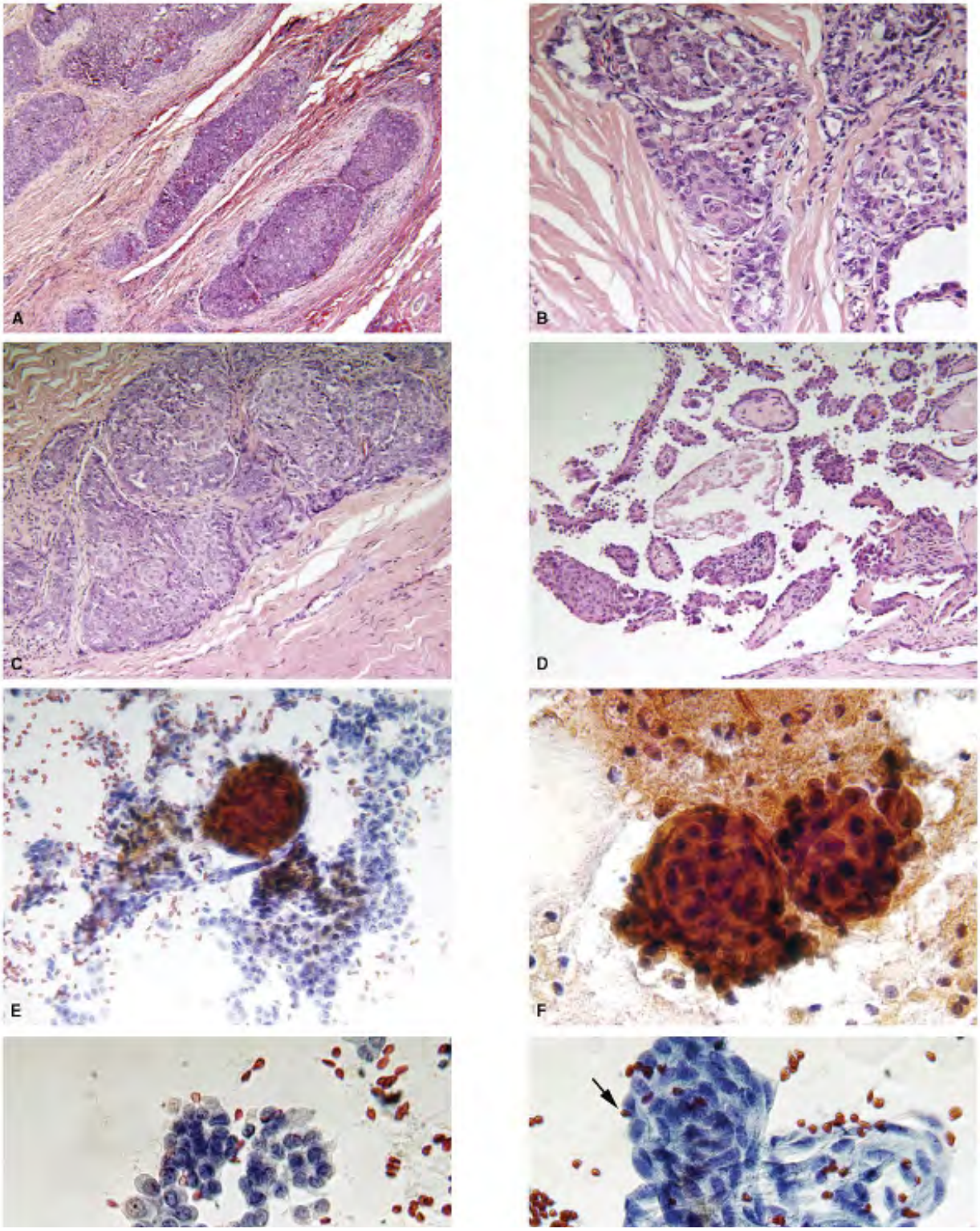

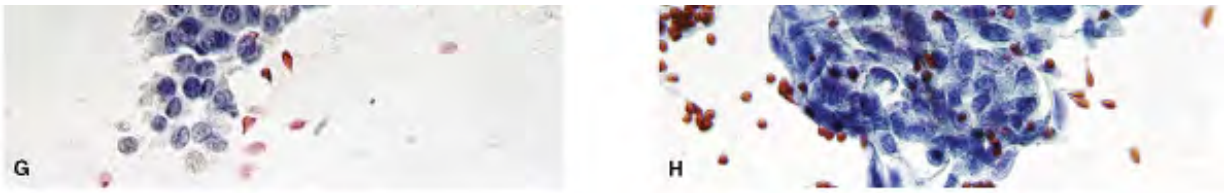

Figure 9.58. *Cribriform-morular variant.* A. Histologic section (low power). Lobules of neoplastic tissue surrounded by sclerotic stroma. Note the cribriform pattern and squamous morula. B. Medium power view showing a cribriform pattern C. Extensive squamous metapla seen as large morulae. D. Areas of conventional papillary carcinoma with squamous metapla E. FNA of this case. Tissue fragments of papillary carcinoma cells with a large morula of squamous cells. F. Two large squamous morulae presenting with a typical whorled pattern. Tissue fragments of carcinoma cells with typical cytomorphology of papillary carcinoma. H. Tissue fragment of spindle cells and a squamous morula (*arrow*).

Colloid is scant to absent. The cells vary from cuboidal to columnar and display typical nucl morphology of papillary thyroid carcinoma. The tumor is immunoreactive to thyroglobulin.

Cytologic Features

The cytologic findings of the cribriform-morular variant as described by Chuah and co-workers,174 Kuma et al.,175 and Chong et al.176 include the usual features of papillary carcinoma with typical nuclear characteristics. The syncytial tissue fragments may show a cribriform pattern and cellular whirls or morulae may be present. Cytologic features of one from the author's laboratory are illustrated in Figure 9.58 .A to F.

Papillary HÃ¼rthle Cell Carcinoma with Lymphocytic Stro (Warthin's-Like Tumor of the Thyroid)

A recent addition to the long list of morphologic variants of papillary carcinoma, this varian characterized by papillary growth pattern, intimately mixed with heavy lymphoid infiltrate, bearing a striking resemblance to Warthin's-like tumor of the salivary gland. Since first desc by Apel et al.,178 there have been several cases reported with histologic and cytologic findings.179 , 180 , 181 , 182 , 183 , 184 , 185

Histologically, papillary HÃ¼rthle cell carcinoma with lymphocytic stroma consists of papill architecture formed by cuboidal to columnar HÃ¼rthle cells containing abundant eosinophil

cytoplasm (Fig. 9.59 A to C). The fibrous stalks of the papillary fronds are packed with lymp cells. The neoplastic cells demonstrate typical nuclear morphology of conventional papillary carcinoma.

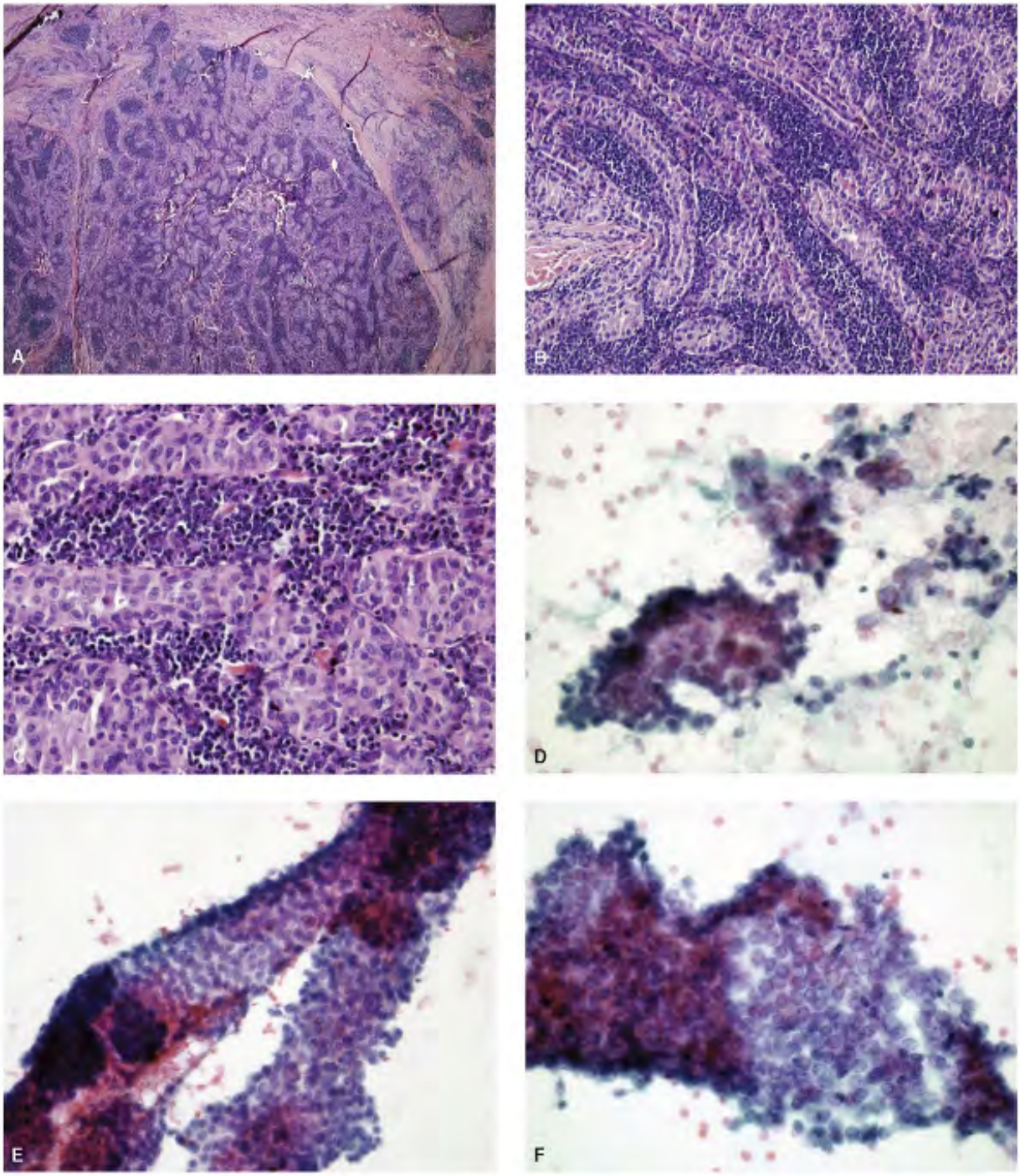

Figure 9.59. *Papillary carcinoma with Warthin's tumor-like features* . A. Histologic section showing well-defined lobules of tumor, consisting of papillary fronds of epithelium with the

fibrovascular stalks densely infiltrated by lymphocytes, medium power. B,C. Higher magnification. The papillary fronds and elongated tubules show oncocytic epithelium. There dense lymphocytic infiltrate. D. FNA of this case. Medium power showing a cellular aspirate branching tissue fragments. E. Higher magnification. The tissue fragments are monolayered long with small, uniform, crowded, and overlapped nuclei. The chromatin is finely granular micronucleoli. F. These syncytial tissue fragments show nuclei with micronucleoli and intranuclear inclusions. Their cytoplasm is scant. The oxyphilic nature is not seen. Few lymphocytes are present in the background.

Cytologic Features

There are four case reports documenting the cytologic findings.182 , 183 , 184 , 185 The aspirates contain discrete and syncytial tissue fragments of HÃ¼rthle cells with or without papillary architecture. The neoplastic cells exhibit typical features of conventional papillary carcinoma. The background shows variable numbers of lymphoid cells. One personally encountered case illustrated in Figure 9.59 did not contain HÃ¼rthle cells. The lymphoid infiltrate was sparse. However, the cellular aspirate showed diagnostic features of conventi papillary carcinoma (Fig. 9.59 D to F).

PAPILLARY MICROCARCINOMA AND OCCULT CARCINOMA

The terms "microcarcinoma" and "occult carcinoma" are frequently used synonymously, crea considerable confusion among pathologists, endocrinologists, and surgeons alike.

P.165

P.166

P.167

Papillary microcarcinoma is defined as tumor less than 10 mm in size (WHO).1 Lesions rangir from 5 to 10 mm are visible to the naked eye; visualized by ultrasound, they can be palpate an endocrinologist (unless deeply situated) and even biopsied.

An occult carcinoma is refers to a carcinoma discovered subsequent to its presentation at a metastatic site, which is more often to the cervical lymph nodes. An occult carcinoma is no necessarily a microcarcinoma. Papillary thyroid carcinomas discovered incidentally in thyroidectomy specimens or at autopsy should be considered latent carcinomas.18 Like occu carcinoma, a latent carcinoma is not necessarily a microcarcinoma. A common incidental fir

in several series based on autopsy studies, the incidence of latent (incidental) carcinoma va from 4% to as high as 35% to 60%.186 , 187 , 188 , 189 , 190

Papillary occult carcinomas usually manifest as cervical lymph node metastases. The latter present as cystic lesions in the neck. Fine-needle biopsy is able to establish a correct diagnc a majority of cases. Several studies on microcarcinomas have supported this observation.19 192 , 193 , 194

Microcarcinoma may be solitary, multifocal, unilateral or bilateral, circumscribed, and well defined with or without encapsulation. It may be infiltrative in the surrounding parenchyma be sclerotic and sharply defined from the adjacent normal parenchyma.18 Very small microcarcinoma may be missed on gross examination. A small microcarcinoma may resemble scar due to desmoplasia.

Histologically, microcarcinomas may present features of conventional papillary carcinoma o follicular variant (Fig. 9.60). They may be seen as microscopic foci formed by aggregates of follicles exhibiting typical nuclear features of papillary carcinoma (Fig. 9.58B) and are frequently observed in thyroidectomy specimens as incidental findings. Lymph node metasta can occur with microcarcinoma (see Figure 15.8 in Chapter 15) and distant metastases are reported.195 , 196 , 197 , 198 , 199 Kasai and Sakamoto200 suggested subgrouping of microcarcinoma as minute (0â€“5 mm) and tiny (5â€“10 mm), because of difference in the incidence of lymph node metastases, 13% versus 59%, and extrathyroidal extension, 3% versu 10%. Fine-needle biopsy may be diagnostic if the carcinomas are accessible to aspiration an dependent on the size.201 , 202

As mentioned earlier, cytologic detection of the various morphologic variants depends upon sampled areas. Some variants may be identified while some do not lend themselves for typi Table 9.5 summarizes the cytologic features of some of the morphologic variants of papillar carcinoma.

Cytopatho
logic features
Conventional
FVPC
Tall Cell
Diffuse
Sclerosing

Macrofollicular
Oxyphilic
Solid
Columnar
Papillary
Carcinoma
Cribriform-
Morular Type[a]
Warthin's-Like
Tumor of
Thyroid[a]
Tissue fragments
Syncytial with
or without a
follicular
pattern
Syncytial with
or without a
follicular
pattern
Syncytial
without a
follicular
pattern
Syncytial
without a
follicular
pattern
Syncytial with
or without a
follicular
pattern
Syncytial with
or without a

follicular
pattern
Syncytial
without a
follicular
pattern
Syncytial
without a
follicular
pattern
Syncytial with a
cribriform
pattern
Syncytial
without a
follicular
pattern
Papillary with
or without a
central core of
fibrovascular
tissue
Papillary
fragments
not present
Papillary
without
central cores
Papillary
uncommon
Not present
Papillary with
or without core
Not present

Papillary
without
a core
Papillary with
or without
central cores
Papillary
with or without
central cores
Monolayered
Â±
Monolayered
Monolayered
Monolayered
Monolayered
Rare
Not present
Monolayered
tissue fragments
not present
Monolayered
tissue
fragments Â±
Cells
Pleomorphic
Round to
cuboidal
Large
polygonal,
squamoid or
HÃ¼rthleoid
Medium-sized,
round
Round to

cuboidal
Round to polygonal
Medium-sized, round to cuboidal
Columnar
Round to cuboidal; spindle cells frequent
Round to cuboidal
Cytoplasm
Variable in quality and quantity
Scanty, pale
Abundant, dense
Variable
Scanty, pale
Abundant, granular
Variable, pale to dense
Clear with cytoplasmic tailing
Variable in quality and quantity
Variable in quality and

quantity;
abundant
eosinophilic
cytoplasm,
resembling
HÃ¼rthle cells
Nucleus size
Enlarged
Enlarged
Enlarged
Enlarged
Enlarged
Enlarged
Enlarged
Enlarged
Enlarged
Enlarged
Chromatin
Fine, powdery
to granular
Fine, powdery
to granular
Fine, powdery
to granular
Fine, powdery
to granular
Fine, powdery
to granular
Fine, powdery
to granular
Fine, powdery
to granular
Coarse
Powdery to finely

granular
Powdery to
finely granular
Nucleoli
Micro/macro
Micro
Micro/macro
Micro/macro
Micro
Macro
Micro/macro
Micro
Micro/macro
Grooves
Present
Present
Present
Present
Present
Present
Present
Not present
Present
Present
Inclusions
Present
Present
Present
Present
Present
Present
Present
Â±
Present

Present
Squamous
Metaplasia
(Morulae)
Â±
Â±
Generally not
present
Marked
Generally not
present
Not present
Â±
Not present
Morulae
characteristic
Not present
Colloid
Ropy strands Â±
Blobs of
dense viscous
colloid Â±
Generally not
present
Â±
Abundant
Generally not
present
Not present
Not present
Not conspicuous
Absent
Psammoma
Bodies

Â±
Â±
Â±
Abundant
Rare
Â±
Rare
Not present
Â±
Not described
Lymphocytes
Â±
Â±
Â±
Abundant
Not present
Not present
Not present
Not present
Not present
Present in variable numbers
Differential Diagnoses
Hyperplastic nodular goiter; papillary hyper plasia in follicular adenoma; Hashimoto's thyroiditis
Follicular

adenoma/
follicular
carcinoma
HÃ¼rthle cell
carcinoma
Hashimoto's
thyroiditis in
the absence of
psammoma
bodies
Nodular goiter;
follicular
adenoma/
follicular
carcinoma
HÃ¼rthle cell
carcinoma
Medullary
carcinoma;
follicular
carcinoma
Adenocarcinoma,
metastatic
Adenocarcinoma,
metastatic
Oxyphilic
variant;
papillary
HÃ¼rthle cell
carcinoma;
tall cell variant
These variants are rare, with sparse documentation of cytologic features.

TABLE 9.5 CYTOPATHOLOGIC FEATURES OF SOME MORPHOLOGIC VARIANTS OF PAPILLARY THYROID CARCINOMA

P.168
P.169
P.170

DIAGNOSTIC DIFFICULTIES IN PAPILLARY CARCINOMAS

An adequate cellular sample with the characteristic cytopathologic features of papillary carcinoma facilitates a correct diagnosis in most instances. Diagnostic difficulties do arise ir several settings listed in Table 9.6 . The first two settings represent a typing problem. Some the subtypes of papillary carcinoma share morphologic similarities with other thyroid neopla both benign and malignant. The remaining three represent major diagnostic dilemmas and constitute important reasons for both false-positive and false-negative diagnoses. Each of tl settings is discussed in detail below.

1. Morphologic subtypes
   - Follicular variant
   - Oxyphilic variant
   - Columnar cell variant
   - Macrofollicular variant
2. Papillary carcinoma with single cell pattern
3. Papillary carcinoma with cystic change
4. Papillary carcinoma coexistent with Hashimoto's thyroiditis
5. Inadequate sample/unsatisfactory cytopreparation

TABLE 9.6 DIFFICULTIES IN CYTOLOGIC DIAGNOSIS OF PAPILLARY CARCINOMA

Morphologic Subtypes PresentingDiagnostic Difficulties

The morphologic subtypes that present diagnostic problems include:

- The follicular variant, which may be interpreted as a follicular lesion or a follicular neoplasm.
- The oxyphil variant, typed as HÃ¼rthle cell tumor.
- The columnar cell variant, where identification as thyroid in origin is difficult on a routinely stained specimen.
- The macrofollicular variant, which may be interpreted as nodular goiter or a colloid adenoma.

The diagnostic problems with the follicular variant of papillary carcinoma are already discus in detail in Chapter 7 . The differentiating features are listed in Table 7.13 .

The cells of the oxyphilic variant lack powdery chromatin and micronucleoli but exhibit typi features of HÃ¼rthle cell carcinoma (see Chapter 8). The exact designation, whether an oxyphilic variant of papillary thyroid carcinoma or HÃ¼rthle cell carcinoma, is probably not significant for patient management.

The cells of the columnar cell variant not only lack the nuclear features of papillary carcino but may be nonreactive to thyroglobulin.119 This subtype is extremely rare and may be interpreted cytologically as a carcinoma not otherwise specified.

The macrofollicular variant of papillary carcinoma can be a diagnostic problem because (bo grossly and microscopically) it resembles involuted goiter, except for the nuclei, which shov characteristics of conventional papillary carcinoma. The macrofollicular pattern may be see parts of the tumor as well and may yield abundant colloid. Many believe that the abundance colloid is a diagnostic feature of nodular goiter. Thus, they consider it a feature of benignity consequently, the nuclear morphology is overlooked.

PAPILLARY CARCINOMA WITH A SINGLE CELL PATTERN

Papillary carcinomas often have solid areas with or without clear cell change. Aspirates fron these foci yield mostly single cells ranging from round to cuboidal to short columnar forms. Architectural patterns of tissue fragments seen in the conventional type may not be present However, the neoplastic cells do exhibit powdery chromatin and intranuclear inclusions. Be

of a single cell dispersed pattern with intranuclear inclusions, a diagnosis of medullary thyrc carcinoma may be rendered (Fig. 9.61).203 Immunostain for calcitonin is negative, while th for thyroglobulin is positive.

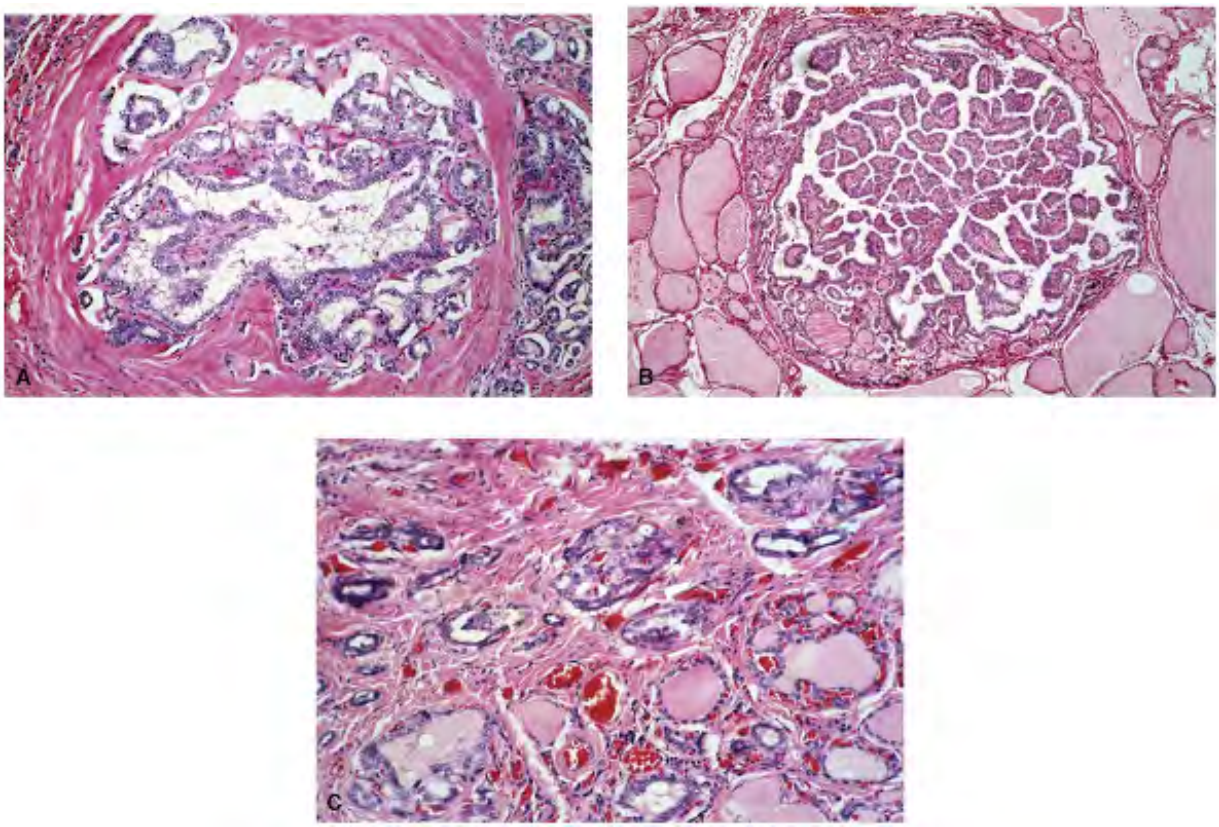

Figure 9.60. *Papillary microcarcinoma* . A,B. Histologic sections. Papillary microcarcinoma than 2 mm. C. Microcarcinoma consisting of aggregates of follicles lined by cells typical of papillary carcinoma.

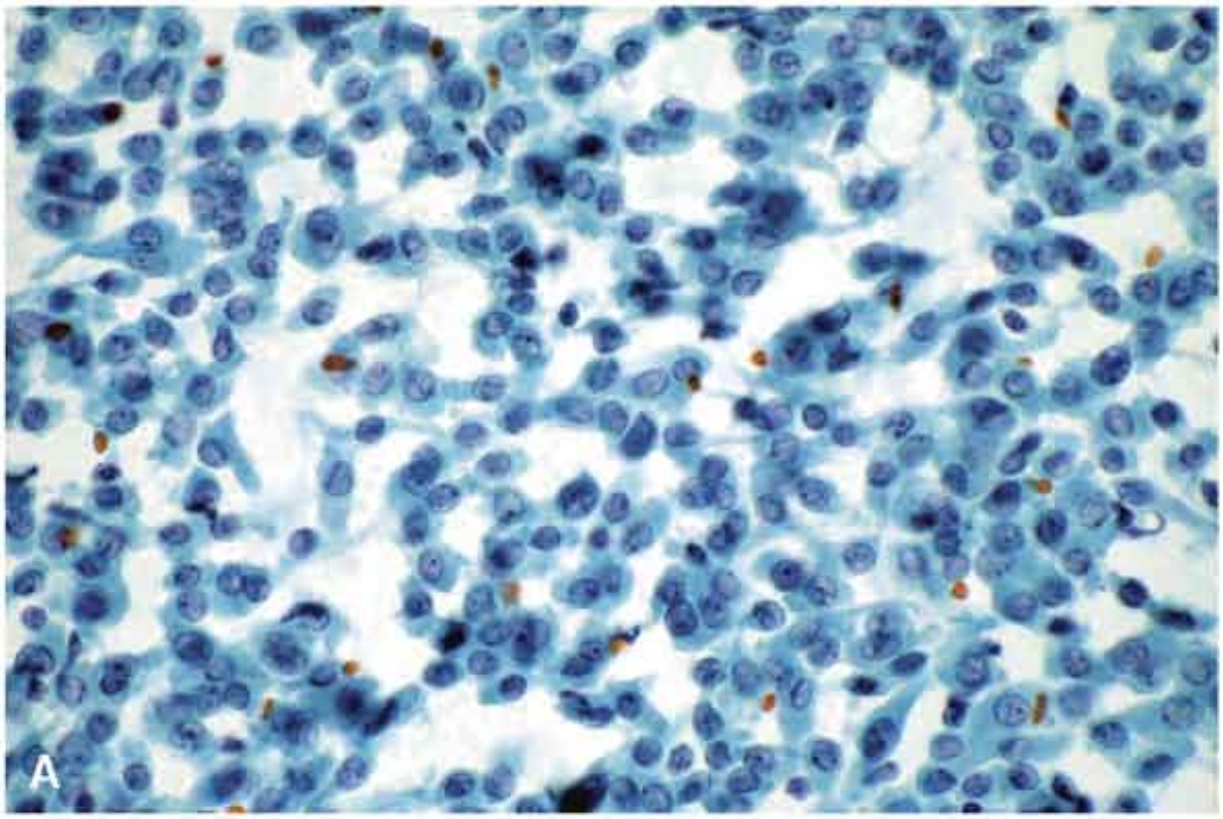
A

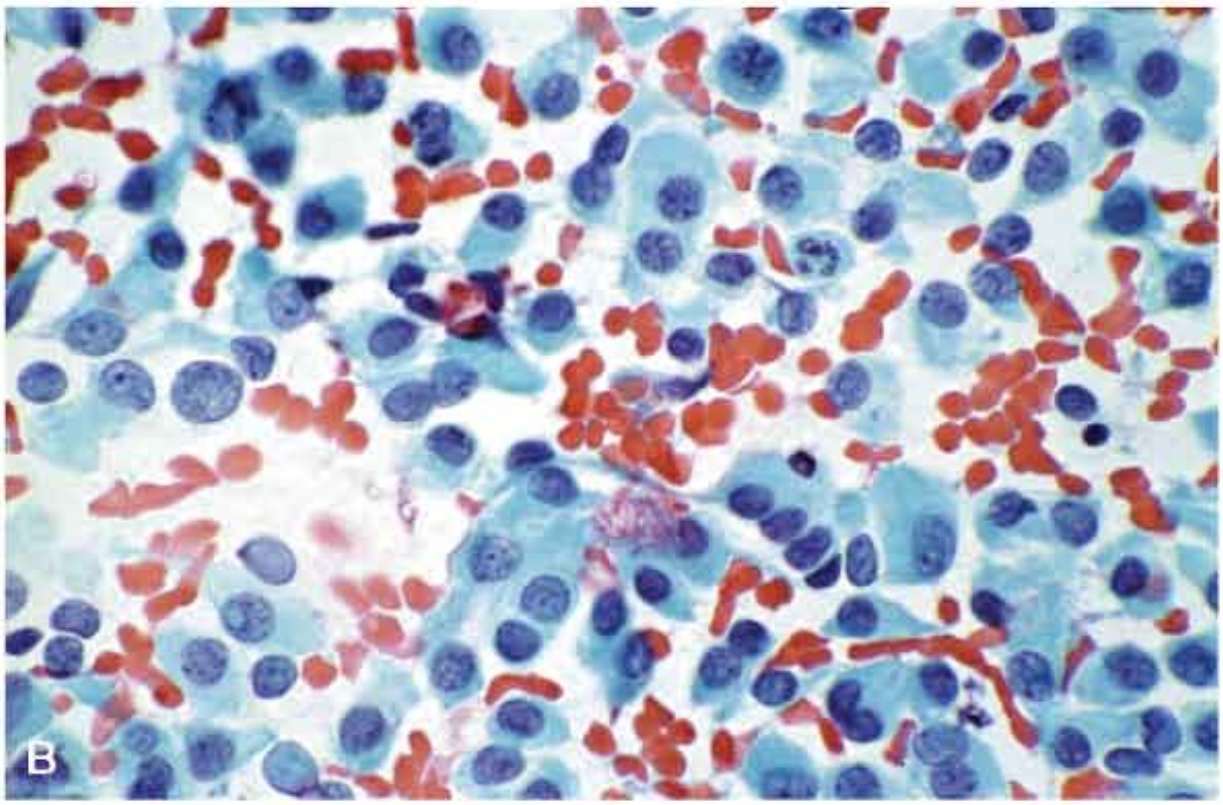
B

Figure 9.61. FNA. Two separate examples of papillary carcinomas with a single cell pattern aspirates. The nuclear chromatin is finely granular with micronucleoli and inclusions. This pattern may be mistaken for medullary thyroid carcinoma.

CYSTIC PAPILLARY CARCINOMA

The most common malignant neoplasm of the thyroid to undergo cystic change is papillary carcinoma.7 In a study by Goellner and Johnson,204 16.6% of papillary carcinomas were cyst The carcinoma may be purely cystic or partially cystic, unilocular or multilocular, thin walle thick walled, and may contain residual in the wall (Figs. 9.61 , 9.62 , 9.63 and 9.64). Follov an aspiration biopsy of any cystic nodule, it is desirable to palpate for a residual mass in the and aspirate it, if present. The reaspiration often provides a diagnostic specimen.

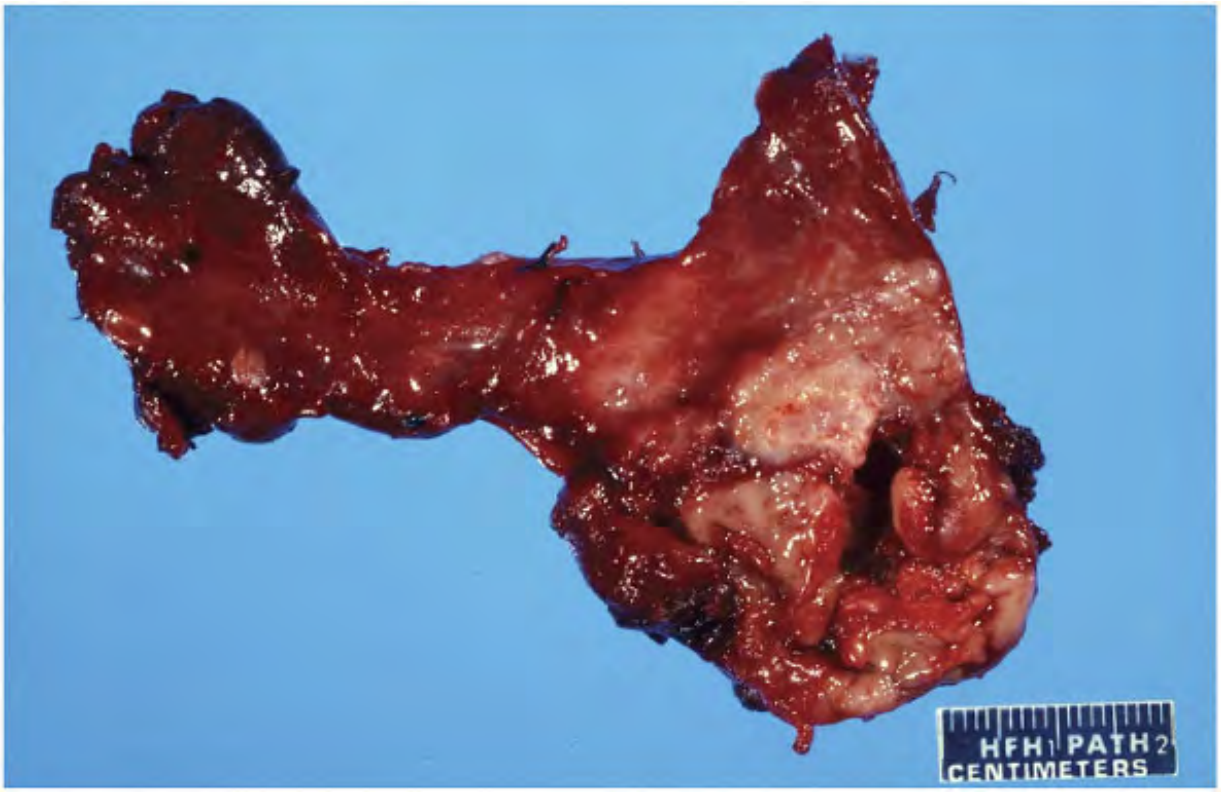

Figure 9.62. Gross photograph of a cystic papillary carcinoma.

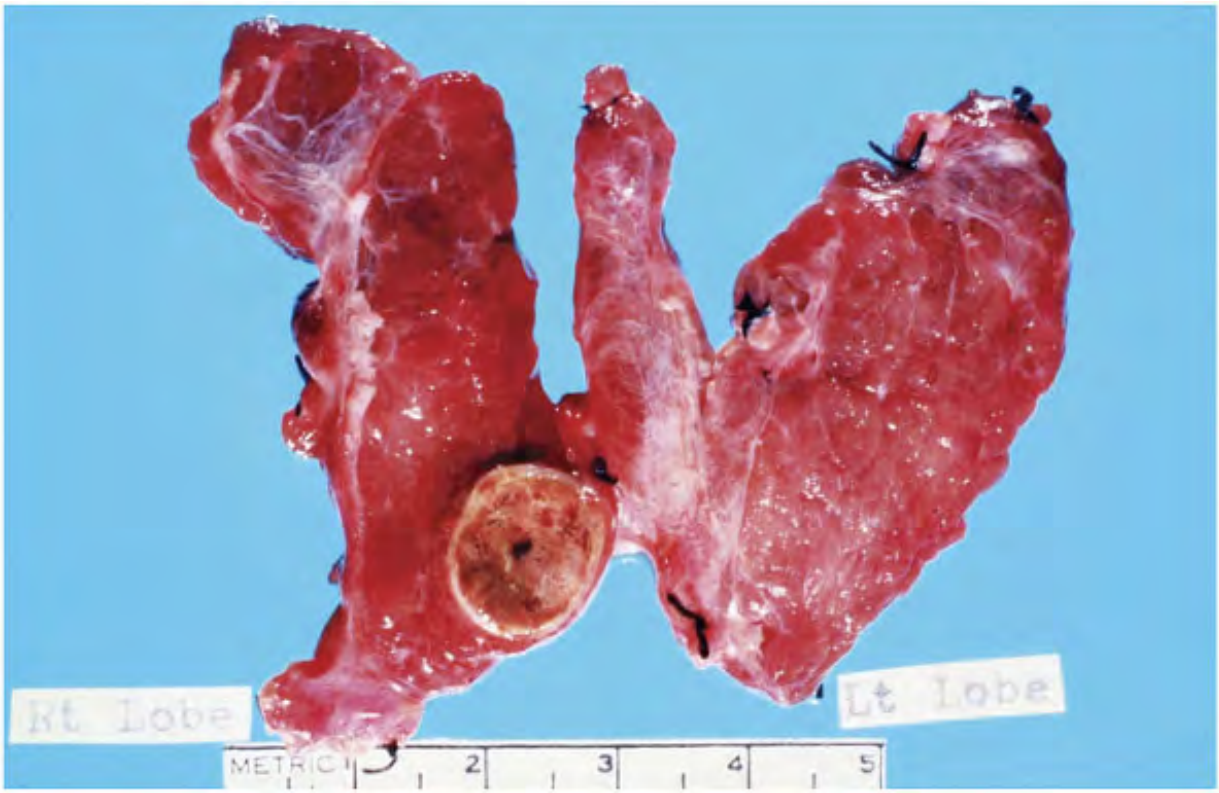

Figure 9.63. Gross photograph of a unilocular cystic papillary carcinoma bordered by a thicl capsule.

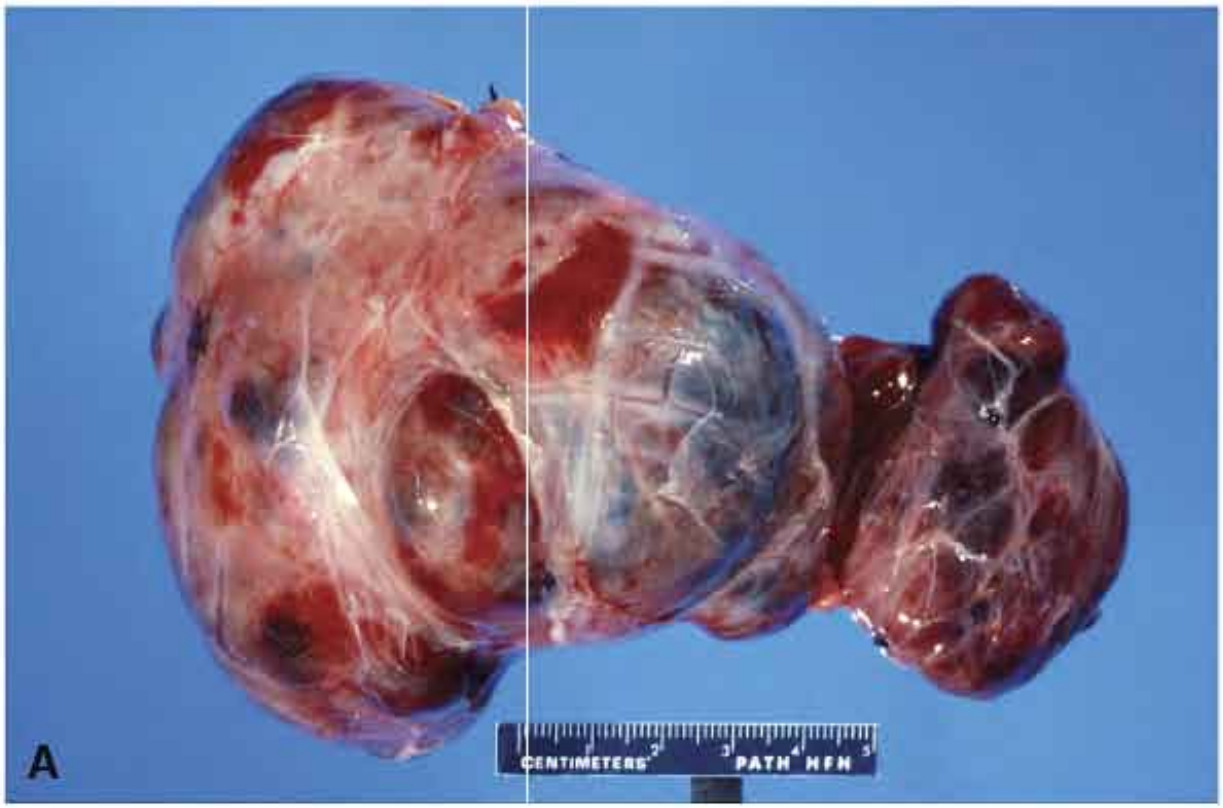
A
CENTIMETERS
PATH HFH

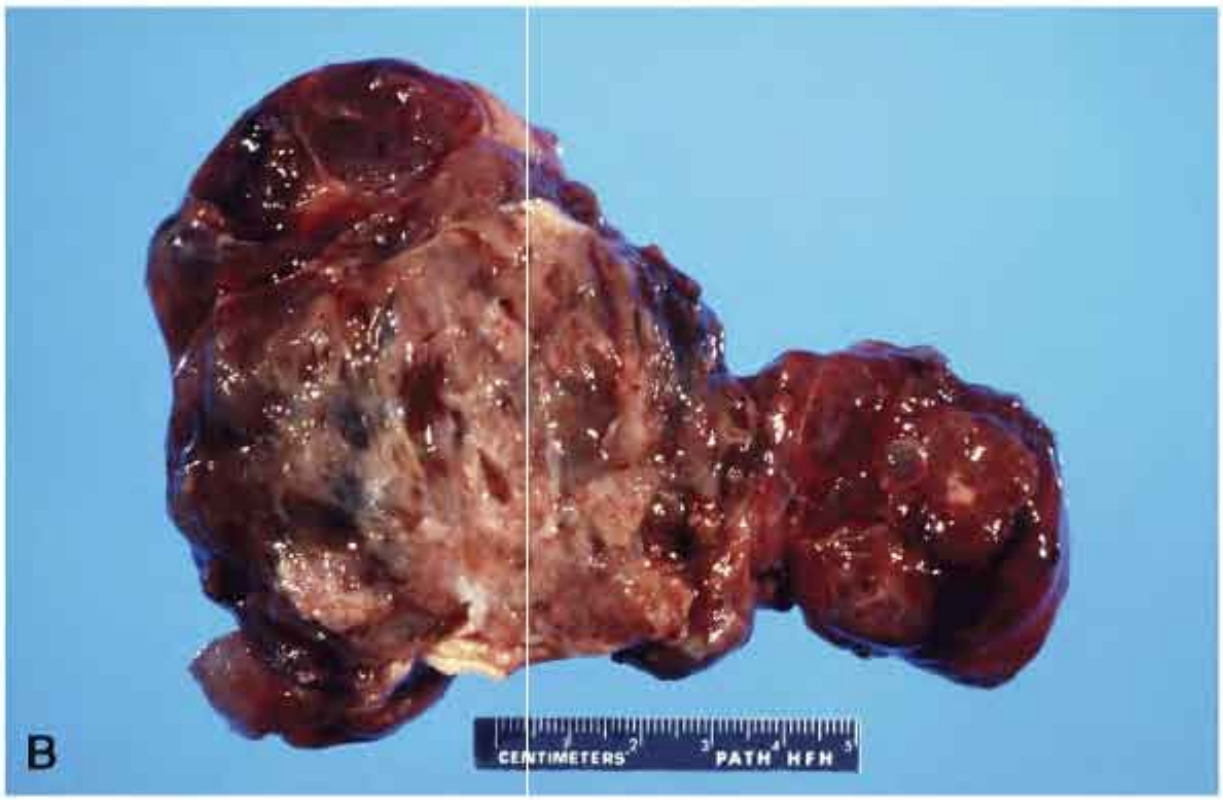
B
CENTIMETERS
PATH HFH

Figure 9.64. The patient presented with a cystic neck mass that was aspirated and interpre as papillary carcinoma. A. Gross photograph of the excised multilocular cystic neck mass, w histologically confirmed the lymph node metastasis. B. Thyroidectomy revealed a large cyst papillary carcinoma.

Histologically, cystic carcinomas show papillary fronds projecting into the cystic cavity. The latter is often filled with old and new blood, varying numbers of histiocytes, with and witho hemosiderin pigment, cellular and calcific debris, as well as detached papillary fronds (Figs. , 9.66 and 9.67).

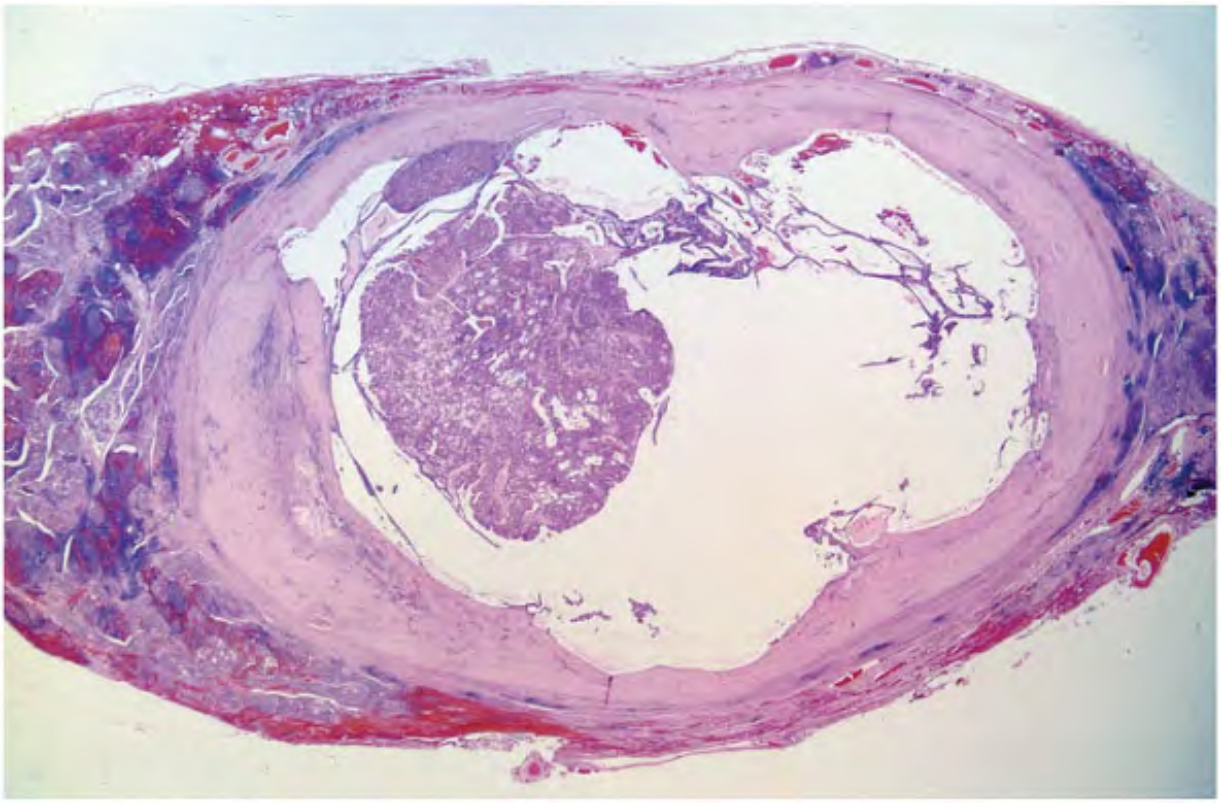

Figure 9.65. Histologic section of a cystic papillary carcinoma. Note the thick fibrotic capsu

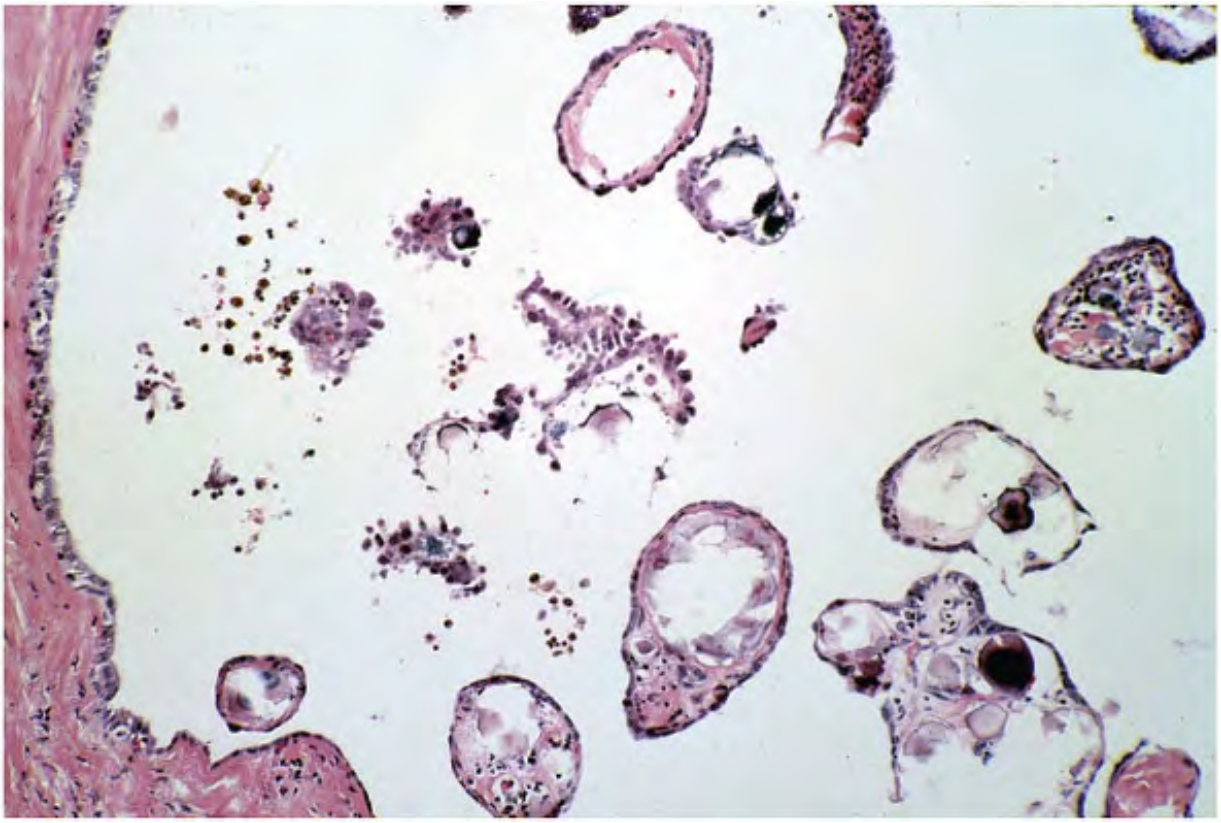

Figure 9.66. Histologic section of a cystic papillary carcinoma filled with detached papillae psammoma bodies.

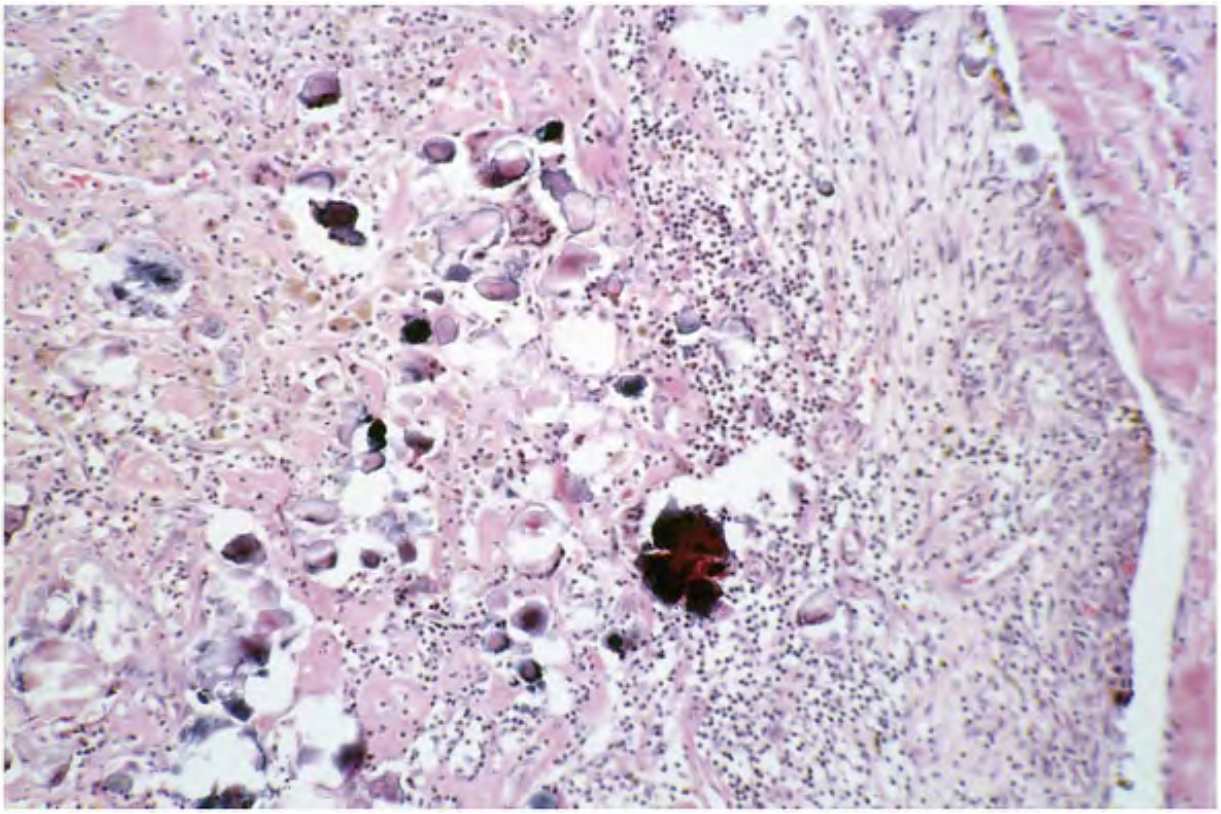

Figure 9.67. Histologic section of a cystic papillary carcinoma filled with inflammatory, cell and calcific debris. An aspirate of such a lesion is apt to present diagnostic difficulties due t degenerative changes and cellular debris obscuring the morphology.

The aspirates of the cystic carcinomas are often diagnostic problems.204 , 205 , 206 , 207 T diagnosis of cystic papillary carcinoma will be accurate in the presence of cellular material classic cytologic features (Fig. 9.68). However, in cystic papillary carcinomas, the cytologic features present a broad spectrum, which are to a great extent modified by the degenerati changes occurring in the fluid milieu. Besides the typical pattern of conventional papillary carcinoma, the cells in the cystic environment present a number of features that are not commonly encountered in aspirates of noncystic papillary carcinomas (Figs. 9.68 , 9.69 , 9.7 9.71 , 9.72 , 9.73 , 9.74 , 9.75 and 9.76 , Table 9.7):

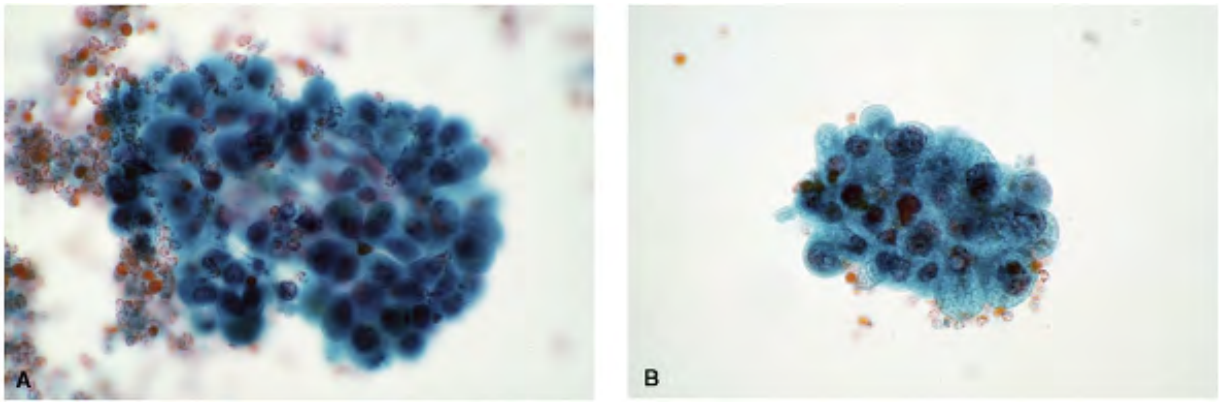

Figure 9.68. Thyroid cyst fluid with diagnostic features of papillary carcinoma. Syncytial tis
fragments with intranuclear inclusions.

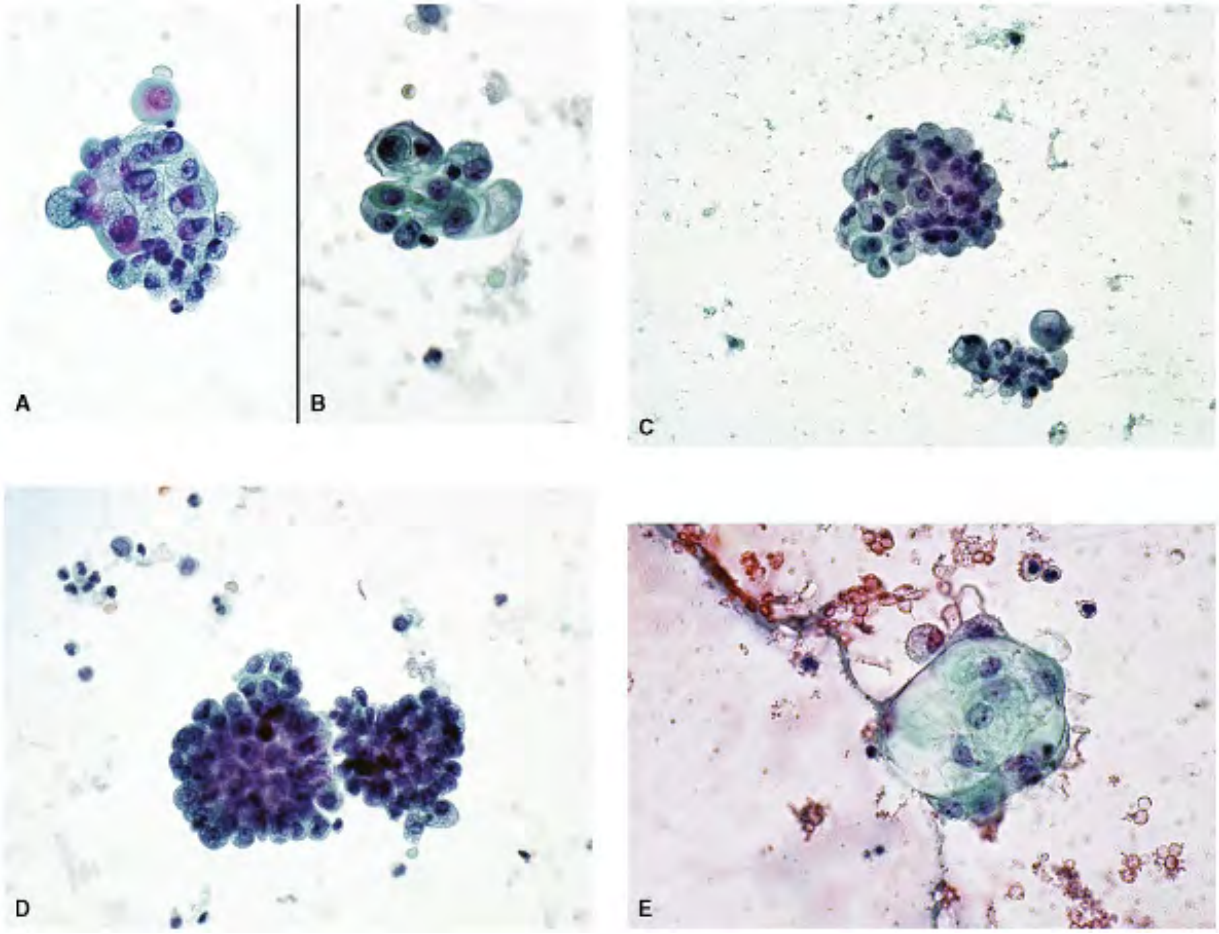

Figure 9.69. FNA of a cystic papillary carcinoma. Aâ€“C. These tissue fragments are syncyti
The cells are pleomorphic with well-defined cell borders and contain variable but abundant
cytoplasm that is bubbly and vacuolated as well as dense. The nuclei are pleomorphic in siz

containing deep-staining chromatin and prominent nucleoli. Grooves or inclusions are not present. These cells are difficult to differentiate from the cells of nodular goiter. D. These syncytial tissue fragments appear three dimensional with scalloped borders. The nuclear chromatin is intensely hyperchromatic and morphology is not visualized. The cells at the periphery have bubbly vacuolated cytoplasm. E. This syncytial tissue fragment of follicular c show marked vacuolization of the cytoplasm (bubble-gum vacuoles). This feature should ser a red flag to examine the specimen more carefully. Thyroidectomy confirmed a cystic papill carcinoma.

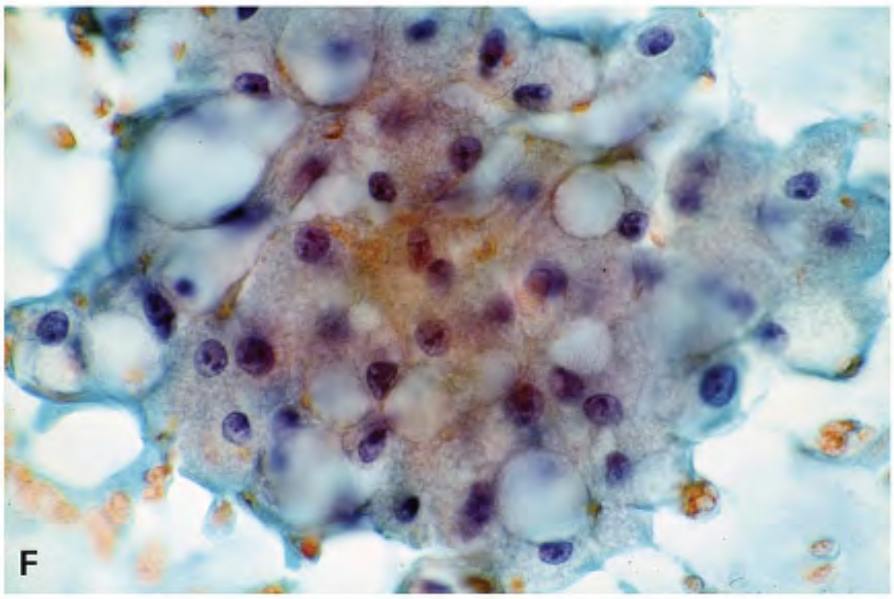

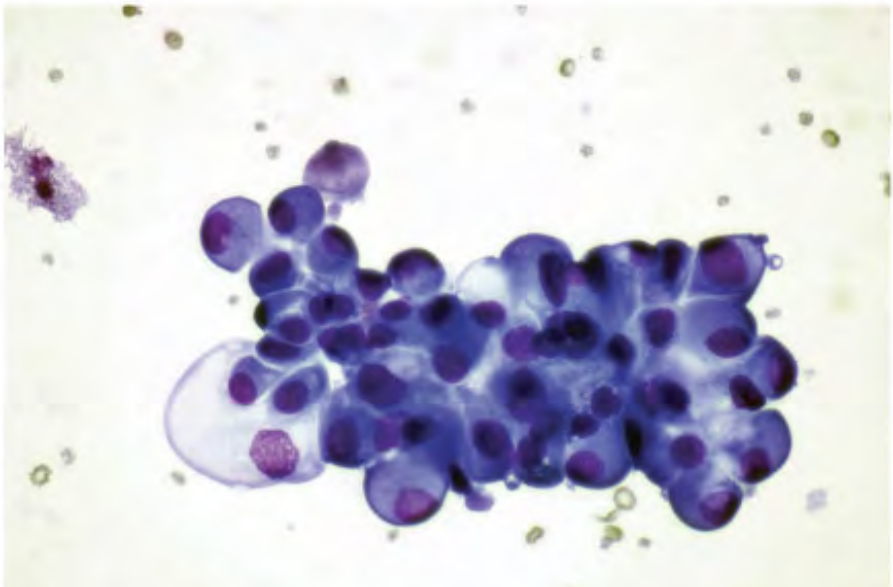

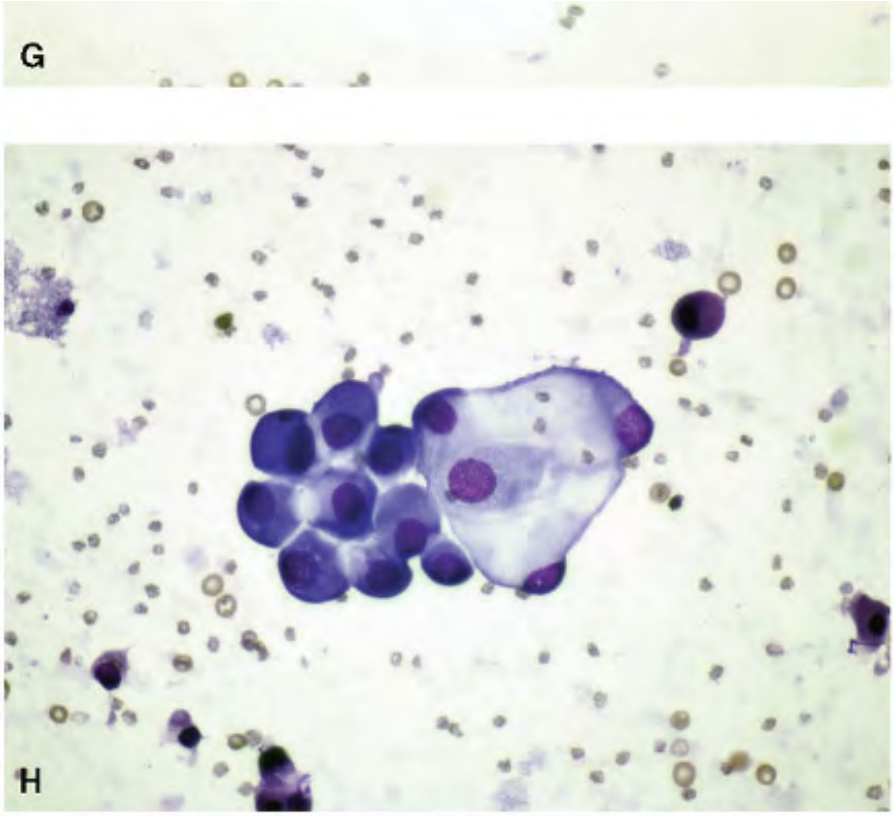

Figure 9.69. F. Degenerating follicular cells from nodular goiter. Although the cytoplasm is bubbly, the nuclei are small and very uniform. These histiocytoid cells may cause diagnostic difficulties. G,H. Cystic papillary carcinoma. Note syncytial arrangement of cells and large cytoplasmic vacuoles (Diff-Quik stain).

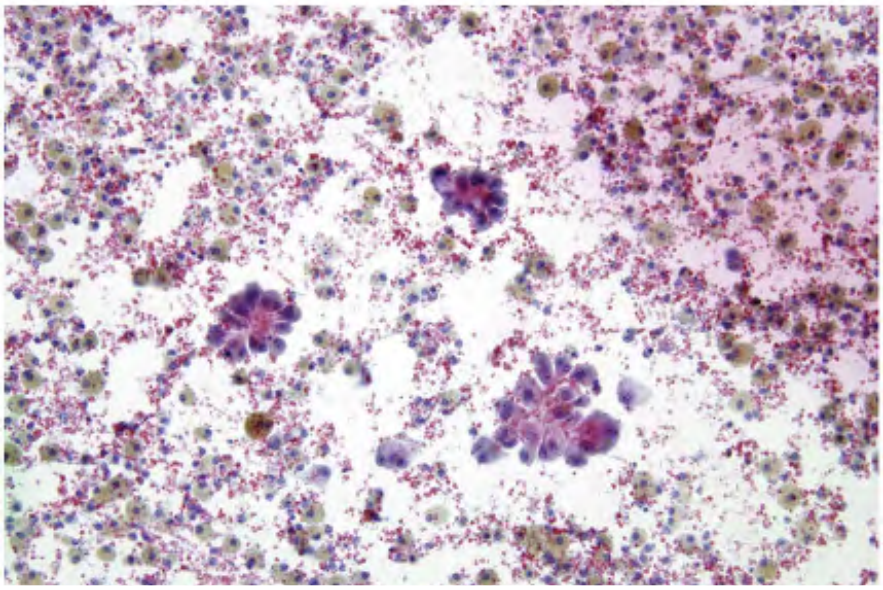

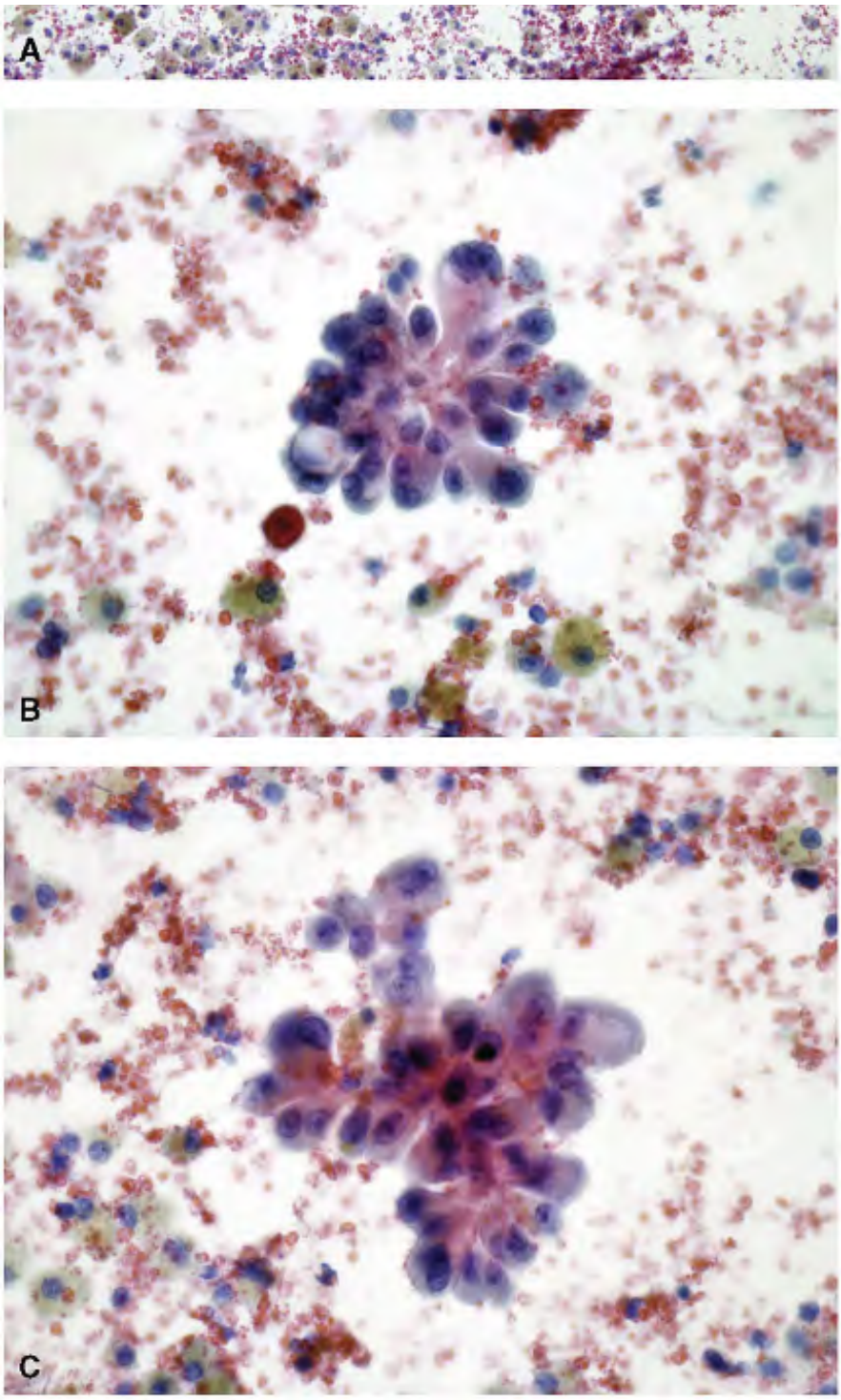

Figure 9.70. FNA of a cystic papillary carcinoma. The fluid was grossly blood-tinged. A. Aga
the background of blood and a large number of histiocytes, these three syncytial tissue
fragments of follicular cells depict scalloped borders. Many cells at the periphery demonstra
vacuolated cytoplasm. B,C. The syncytial tissue fragments are composed of elongated cells

one slender end that is directed centripetally and the wider outer ends house the nuclei, gi
a cartwheel appearance to the tissue fragment. Some nuclei contain nucleoli. Inclusions anc
grooves are not present and the chromatin appears dense. Although minimal criteria were n
observed, this aspirate was interpreted as suspicious for papillary carcinoma. Thyroidectom
confirmed papillary carcinoma.

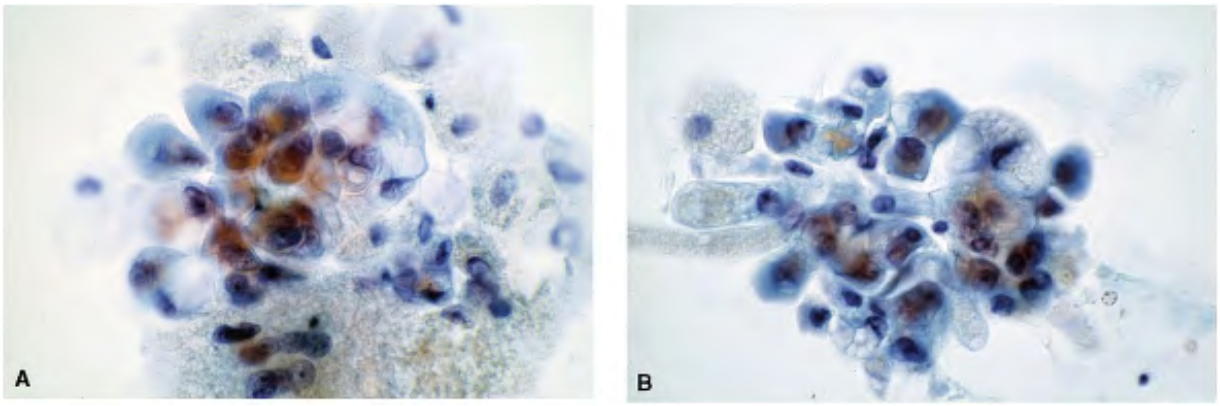

Figure 9.71. Cystic papillary carcinoma. These tissue fragments are composed of large cells
abundant pale, vacuolated to dense cytoplasm. Their nuclei are large and round, many
containing nucleoli. No grooves or inclusions were seen. The syncytial architecture and high
ratios, with nucleoli raised the possibility of papillary carcinoma and a suspicious diagnosis
rendered. Papillary carcinoma was confirmed following thyroidectomy.

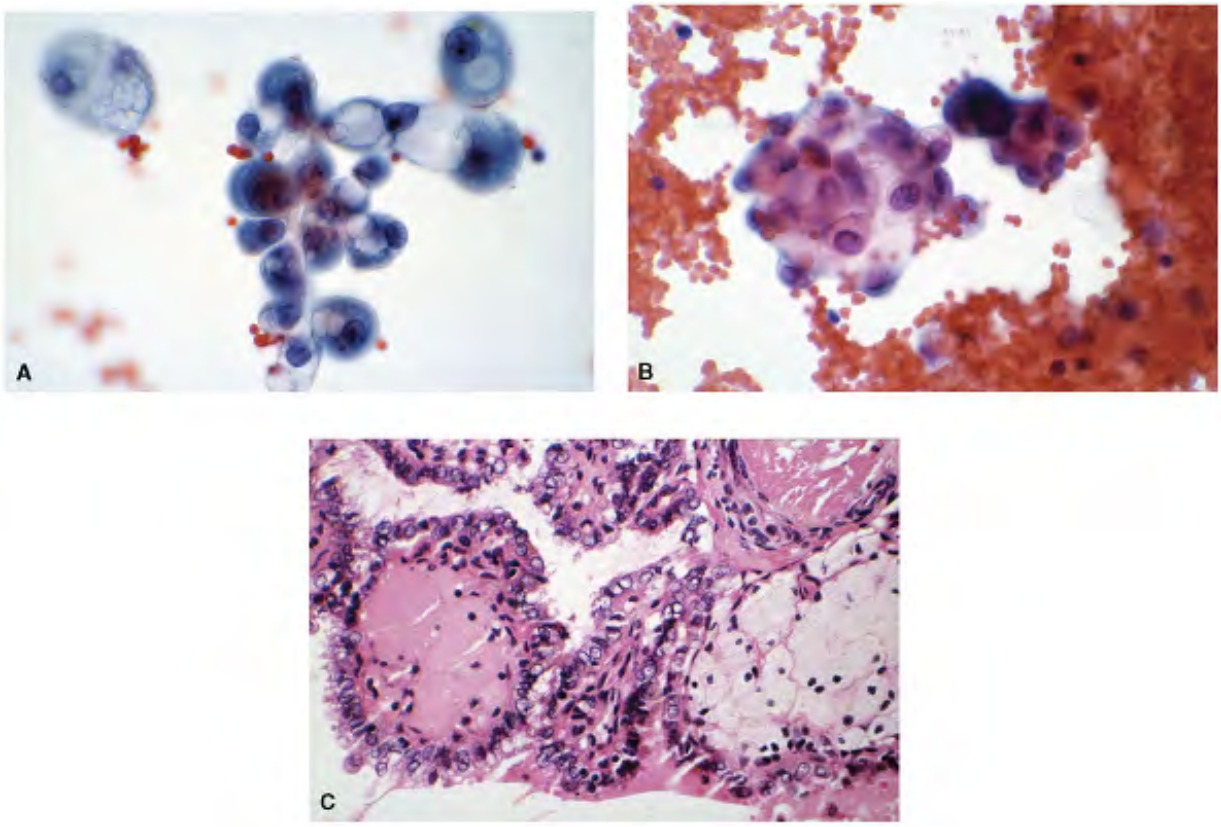

Figure 9.72. Cystic papillary carcinoma. A. The papillary carcinoma cells in a fluid medium expand due to abundant vacuolated cytoplasm. These cells also demonstrate well-defined c borders and dense cytoplasm. The nuclei are large, pale, eccentric, and lack features of papillary carcinoma. The presence of such cells should serve as a red flag for the possibility papillary carcinoma. B. These cells forming a syncytial tissue fragment show nuclear feature papillary carcinoma. Note cytoplasmic vacuoles. The second tissue fragment contains a psammoma body. C. Histologic section of the resected papillary carcinoma. Note the follicu cells lining the papillary fronds show cytoplasmic vacuoles.

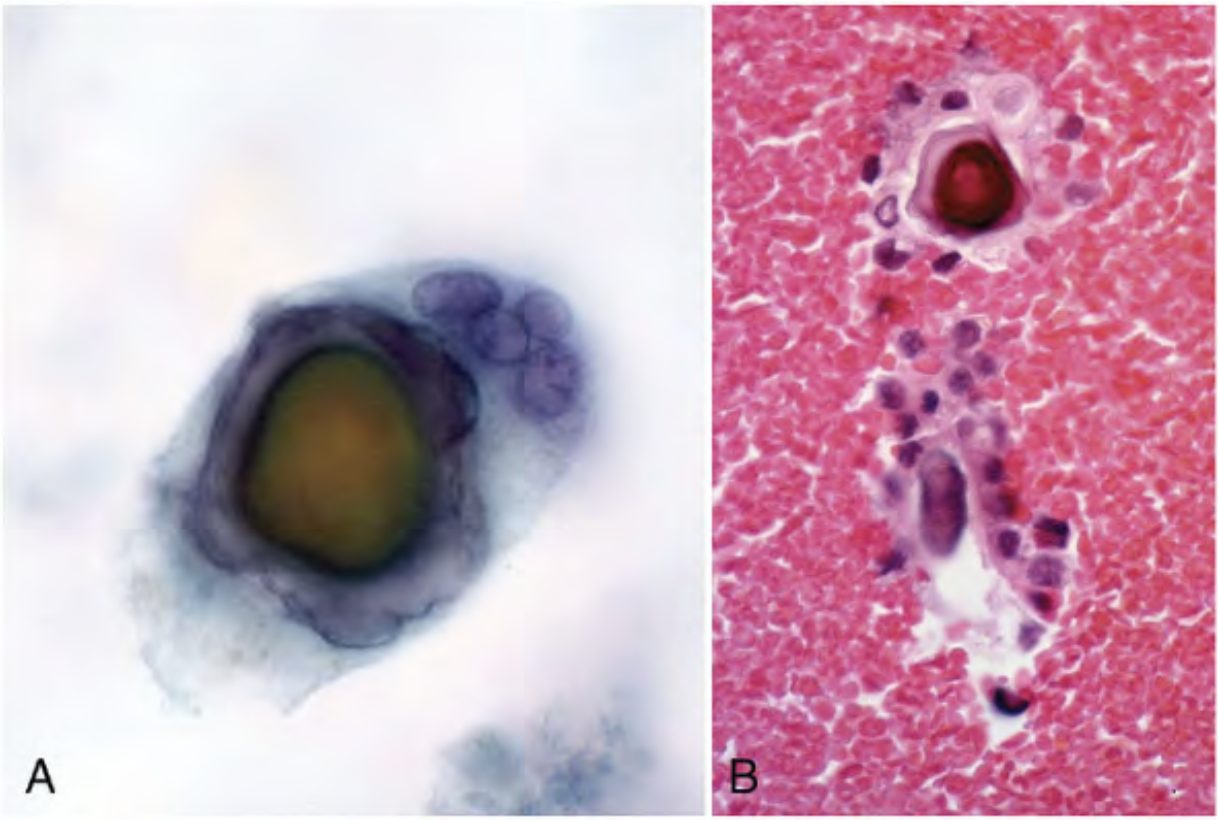

Figure 9.73. A. The fluid aspirated from this carcinoma was practically acellular except for single psammoma body incorporated in a tissue fragment. Note pale nuclear chromatin. B. A block preparation of the sediment showed similar features suggesting the diagnosis of papill carcinoma.

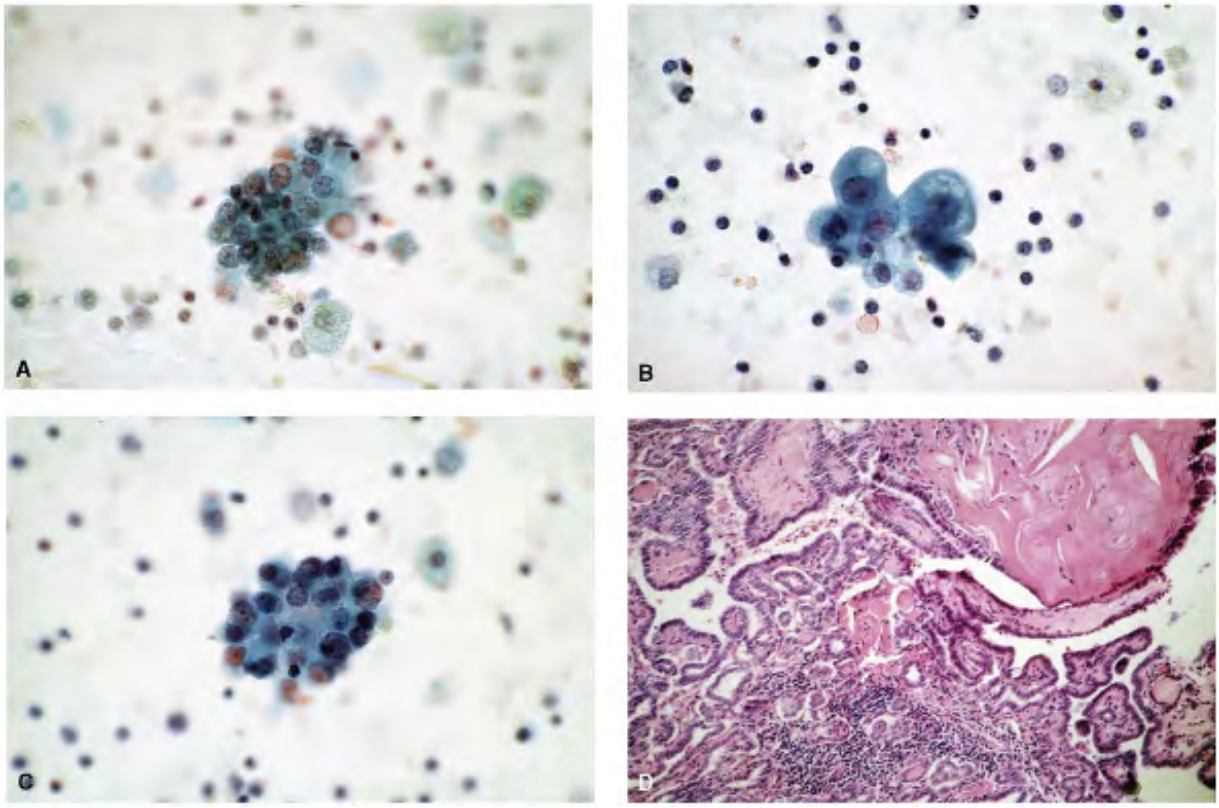

Figure 9.74. Aâ€“C. The aspirated fluid from this cystic thyroid lesion was grossly clear. A cytospin preparation salvaged few syncytial tissue fragments with scalloped borders. The nu chromatin is pale with micronucleoli. Note dense cytoplasm and eccentric nuclei. These fea are suspicious for papillary carcinoma. D. Thyroidectomy confirmed a cystic papillary carcin

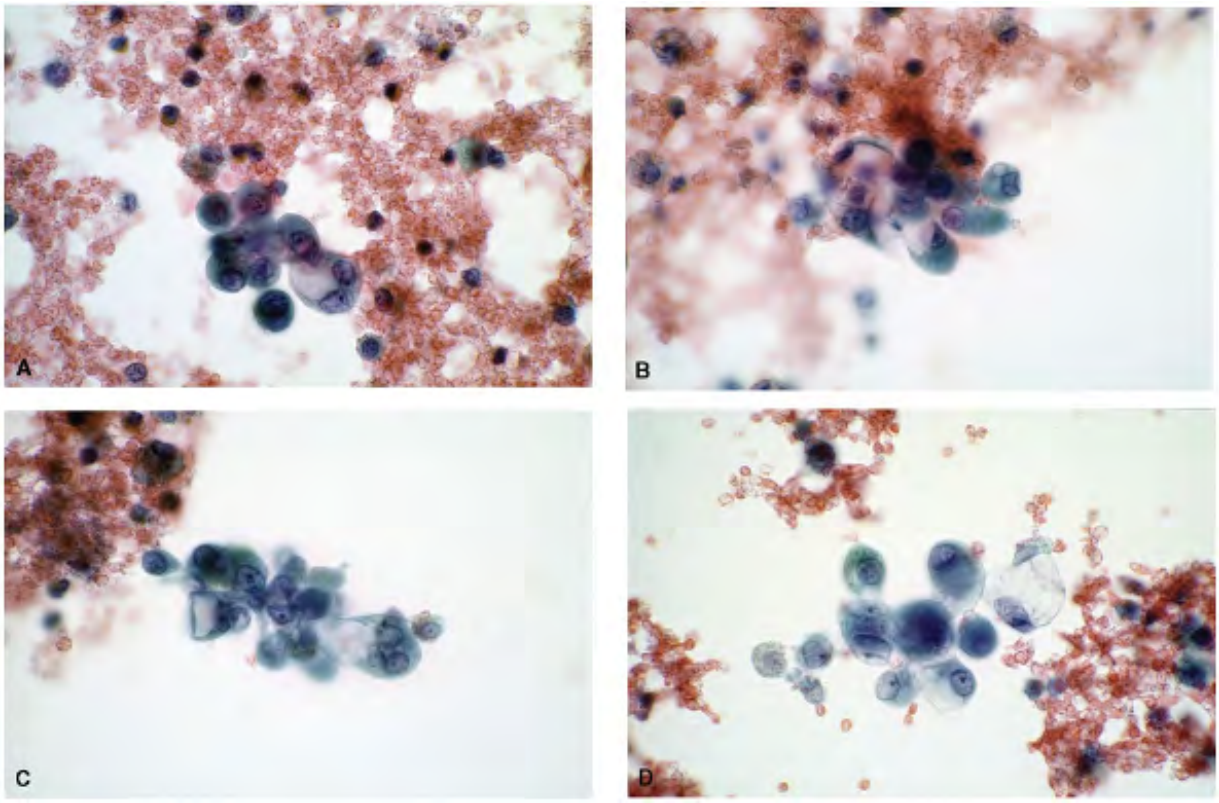

Figure 9.75. The aspirated bloody fluid from a cystic thyroid nodule was marginally cellular showed groups and tissue fragments of moderately enlarged follicular cells. Common featur exhibited by all these cells include well-defined cell borders; variable, dense to vacuolated cytoplasm; and round, moderately enlarged nuclei with micronucleoli. Inclusions and groove rarely seen. These features are not seen in degenerating follicular cells of nodular goiter an warrant a suspicious diagnosis. Thyroidectomy confirmed a cystic papillary carcinoma.

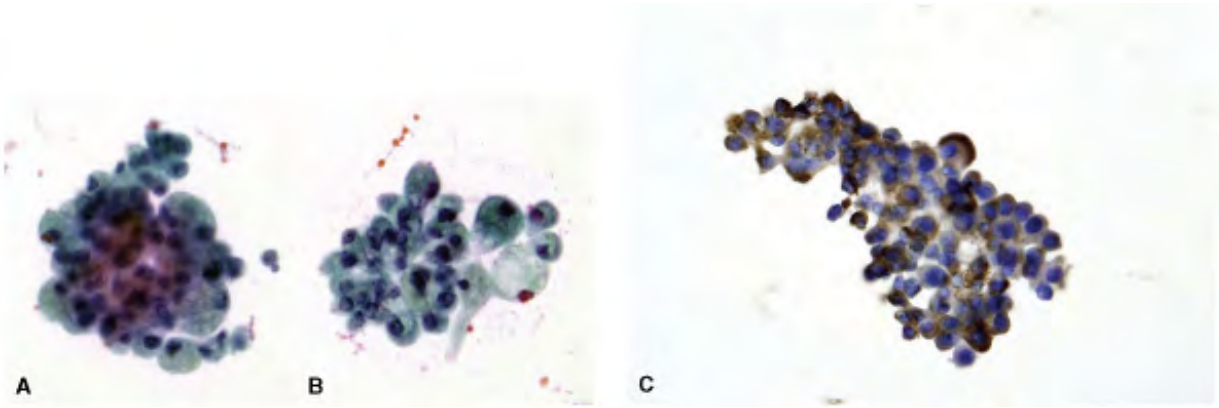

Figure 9.76. FNA of a cystic metastasis in neck from a papillary thyroid carcinoma. The cyt

features of cystic metastases and primary cystic carcinoma were identical. A,B. FNA of the cystic neck mass. The syncytial tissue fragments are composed of pleomorphic cells with abundant foamy, vacuolated to dense cytoplasm and eccentric nuclei. The nuclear chromati intensely basophilic due to degeneration and lacks the features of papillary carcinoma. Note scalloped borders of the tissue fragments. C. The cells reacted strongly to thyroglobulin, confirming the thyroid origin.

Cellularity
Variable, but frequently marginal
Presentation
Biopsy may yield fluid contents; clear to bloody; cells isolated, in loosely cohesive groups and in syncytial tissue fragments, may be obscured by histiocytes and blood
Architecture of the tissue fragments
Marked variation; syncytial tissue fragments; may present all the architectural configurations; cells tend to form tight groups in fluid medium, frequently forming a whorled pattern; cartwheel pattern with nuclei along the outer margin
Cells
Broad range of size; small to large; well-defined cell borders; N/C ratios variable
Nucleus
Round to oval, variable in size; often eccentric; powdery chromatin, micro/macronucleoli, grooves and inclusions
Cytoplasm
Scant to abundant; pale, vacuolated, bubbly; single to multiple vacuoles; strongly resemble histiocytes (histiocytoid carcinoma cells); must be differentiated from histiocytes
Psammoma bodies
Â±
Background
Clean to bloody; colloid absent; histiocytes with or

without hemosiderin

TABLE 9.7 CYTOPATHOLOGIC FEATURES OF CYSTIC PAPILLARY CARCINOMA

- The specimens are frequently poorly cellular, and inadequate for interpretation. Th cellularity may be the result of failure of the needle to penetrate the thick, fibrous, often calcified capsule found in cystic carcinomas (Figs. 9.63 and 9.65).
- The cellular and inflammatory debris resulting from hemorrhage and necrosis obscur the cytomorphology of

P.172

neoplastic cells (Fig. 9.67). Interpretation of scanty cellular material in the backgro of extensive cellular debris can be very challenging (Figs. 9.65 , 9.65 , 9.66 , 9.67 , 9 , 9.74 , 9.75).

- The tissue fragments of malignant cells ball up in the fluid medium, appearing three dimensional (Fig. 9.69D), and often show an onion-skin pattern.
- The tissue fragments of malignant cells often exhibit scalloped borders and also tend arrange themselves in a cartwheel pattern with nuclei at the outer perimeter (Fig. 9 B and C).
- Degenerating carcinoma cells acquire abundant cytoplasm that can be bubbly or vacuolated (Figs. 9.69A , 9.69B , 9.69E , 9.69H , 9.71 , 9.72 , 9.75 , 9.76). The vacu may be small, multiple, or large occupying the entire cell and pushing the nucleus to periphery but not indenting it (Fig. 9.69 E and H).

P.173

P.174

P.175

P.176

- The degenerating papillary carcinoma cells may be discrete (Figs. 9.72 , 9.74A , 9.75 in groups, or in syncytial tissue fragments. The single cells are difficult to differentia from the histiocytes. The diagnostic clues are well-defined, almost rigid cell borders dense cytoplasm (Figs. 9.72A , 9.74 , 9.75 , 9.76). The nuclear/cytoplasmic ratios a

favor of the nucleus. Also, histiocytes are never seen in tissue fragments, unlike carcinoma cells. The foamy carcinoma cells referred to as histiocytoid carcinoma cells204 may be misinterpreted as benign. On the other hand, the histiocytic aggrega may be misinterpreted as carcinoma cells (Fig. 9.69F).208 , 209 The carcinoma cells with foamy cytoplasm must also be differentiated from degenerating cells from nodu goiter (Fig. 9.69F).

- The chromatin of papillary carcinoma cell nuclei have a tendency to stain intensely to degeneration (Fig. 9.69C). The characteristic fine powdery chromatin may not be retained.
- Long-standing cystic fluid may be clear and poorly cellular. Proper cytopreparation i critical to salvage the few neoplastic

cells. The author's laboratory prefers to process clear fluids by cytocentrifugation (F 9.74).

- Cyst fluids are often bloody. Processing the specimen by removing the blood will ass proper cytologic evaluation.

Poorly cellular, clear fluids as well as bloody specimens are likely to result in both false-negative208 , 209 , 210 and false-positive interpretations. Colloid is absent from aspirates o cystic papillary carcinoma. Syncytial architecture with a follicular pattern is also unusual. T presence of psammoma bodies

favors a malignant diagnosis. However, care must be taken to evaluate the nuclear features the cells forming the tissue fragments. Naked psammoma bodies or calcific debris are of no significance, except that careful examination of all the smears is in order when they are encountered. Any visible sediment in a cyst fluid may be cell-blocked. Although routine cell block preparations of thyroid aspirates is not recommended, it can be of diagnostic help in of cyst fluids (Fig. 9.73).

The cells from cystic nodular goiters mimic cytologic features of papillary carcinoma and ma difficult to differentiate from carcinoma cells (Fig. 9.77). Table 9.8 lists the differences between cells of papillary carcinoma and atypical cells in nodular goiter. This problem is als addressed in Chapters 6 and 17 .

Presentations

Predominantly histiocytic cell population mixed with variable numbers of papillary carcinoma cells; (malignant cells rarely absent); malignant cells discrete, in groups or in syncytial tissue fragments

Predominantly histiocytic cell population mixed with variable numbers of benign follicular cells, discrete, in groups or in syncytial tissue fragments

Architecture of the Tissue Fragments

Tissue fragments with varying architectural configurations: papillary or papillary-like, with scalloped borders; swirls, cartwheel pattern; three dimensional

Small regular follicles; loosely cohesive groups or in varying sized tissue fragments; large papillary-like tissue fragments unusual; when present demonstrate honeycomb arrangement

Cells

Considerable pleomorphism in size; small to large; well-defined cell borders; N/C ratios variable

Follicular cells without degenerative changes; small, round to cuboidal; degenerating cells larger in size; cell

borders well to poorly defined

Nucleus

Variably enlarged; round with smooth nuclear membranes; often eccentric; nuclei located at the periphery in tissue fragments with cartwheel pattern; chromatin granular; smudgy in degenerating cells; nucleoli Â±; grooves and inclusions Â±

Nucleus normal-sized to minimally enlarged; round, usually centrally located; smooth nuclear membranes; granular to smudgy chromatin; nucleoli Â±

Cytoplasm

Variable; pale, bubbly, finely vacuolated to multiple small vacuoles or a single large bubble-gum type vacuole pushing the nucleus to the periphery but not indenting it; dense cytoplasm is characteristic; hemosiderin Â±

Variable; scant to abundant, granular in degenerating cells; hemosiderin Â±; nuclear grooves and inclusions rare

HÃ¼rthle Cell Metaplasia

Not present

Â±

Psammoma Bodies

Â±; Naked psammoma bodies not diagnostic; must be incorporated in tissue fragments

Very rare

Background

Often bloody; calcific debris Â±; colloid absent

May be bloody; colloid Â±; calcific debris rare

Cytologic Feature	Cystic Papillary Carcinoma	Cystic Nodular Goiter

TABLE 9.8 CYTOPATHOLOGIC FEATURES DIFFERENTIATIN CYSTIC PAPILLARY CARCINOMA AND CYSTIC NODULAR GOITER

P.179
P.180
P.181

PAPILLARY CARCINOMA COEXISTENT WITH HASHIMOTO'S THYROIDITIS

The differentiation of papillary hyperplasia from papillary carcinoma in the background of lymphocytic (Hashimoto's) thyroiditis is often very difficult and challenging. The cells derive from the hyperplastic process may present some of the nuclear features of papillary carcino Both false-positive and false-negative diagnoses may be rendered. Minimal cytologic criteria must be demonstrated before interpreting an aspirate as diagnostic of papillary carcinoma. problem is discussed in the section on differential diagnosis, later in this chapter and also in Chapter 13 on Hashimoto's thyroiditis.

Inadequate Sample

Inadequate samples and poor cytopreparation (Figs. 9.78 , 9.79 , 9.80 , 9.81 and 9.82) prob account for most of the diagnostic errors. Attempting to provide an unequivocal diagnosis o basis of suboptimal preparations is risky. Partial or complete air-drying of cells in a Papanic

preparation reveals very pale, clear nuclei mimicking those of papillary carcinoma (Fig. 9.78

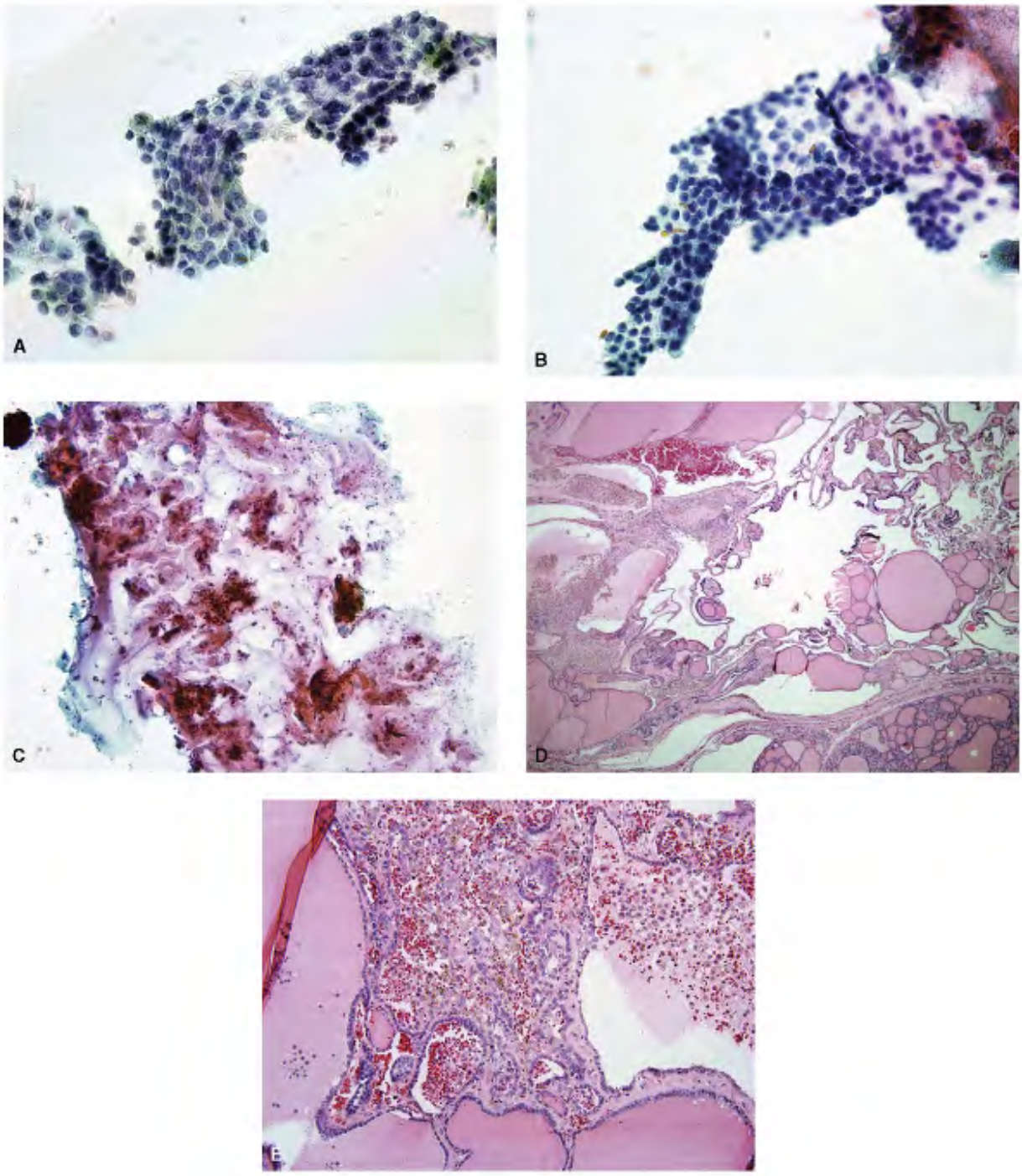

Figure 9.77. FNA of a cystic nodular goiter misinterpreted as suspicious for papillary carcinc
A,B. Monolayered tissue fragments with minimal nuclear overlapping and crowding. The nuc
are slightly enlarged, with granular chromatin and micronucleoli. An occasional nucleus
suggested the presence of intranuclear inclusion. C. The background features were those of

nodular goiter with abundant colloid. The aspirate was interpreted as atypical; papillary carcinoma cannot be ruled out. Thyroidectomy showed cystic nodular goiter. D. Histologic section of the thyroid showing features of nodular goiter with cystic degeneration. E. Higher magnification showing mild nuclear atypia.

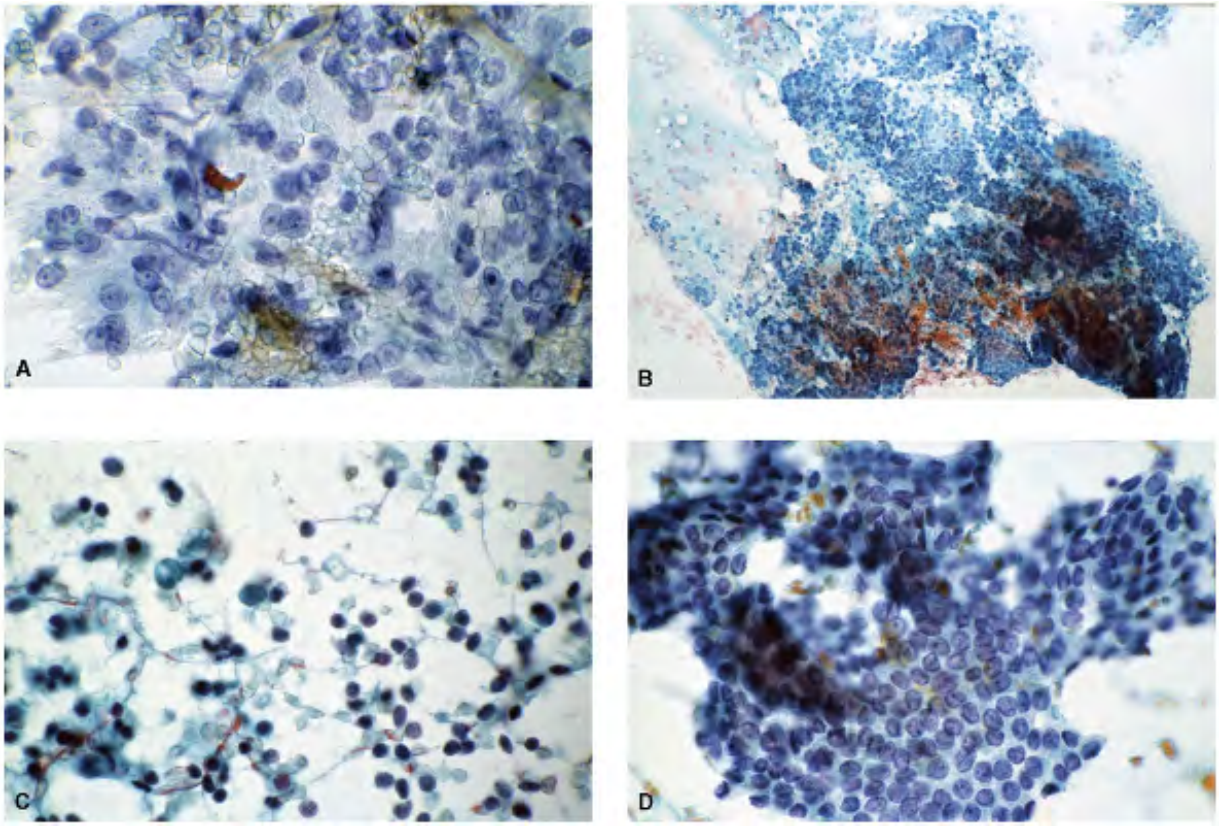

Figure 9.78. A. This aspirate shows partially air-dried cells with pale chromatin misinterpre as suggestive of papillary carcinoma. Thyroidectomy failed to confirm the malignancy. B. Th smear from a papillary carcinoma is hypercellular but totally air-dried, rendering the specin unsatisfactory for evaluation. C. This case represents a false-negative diagnosis due to samp error. The aspirate of the thyroid nodule revealed only lymphocytes. D. Repeat biopsy one y later showed classic features of papillary carcinoma. Thyroidectomy confirmed the carcinon a background of Hashimoto's thyroiditis.

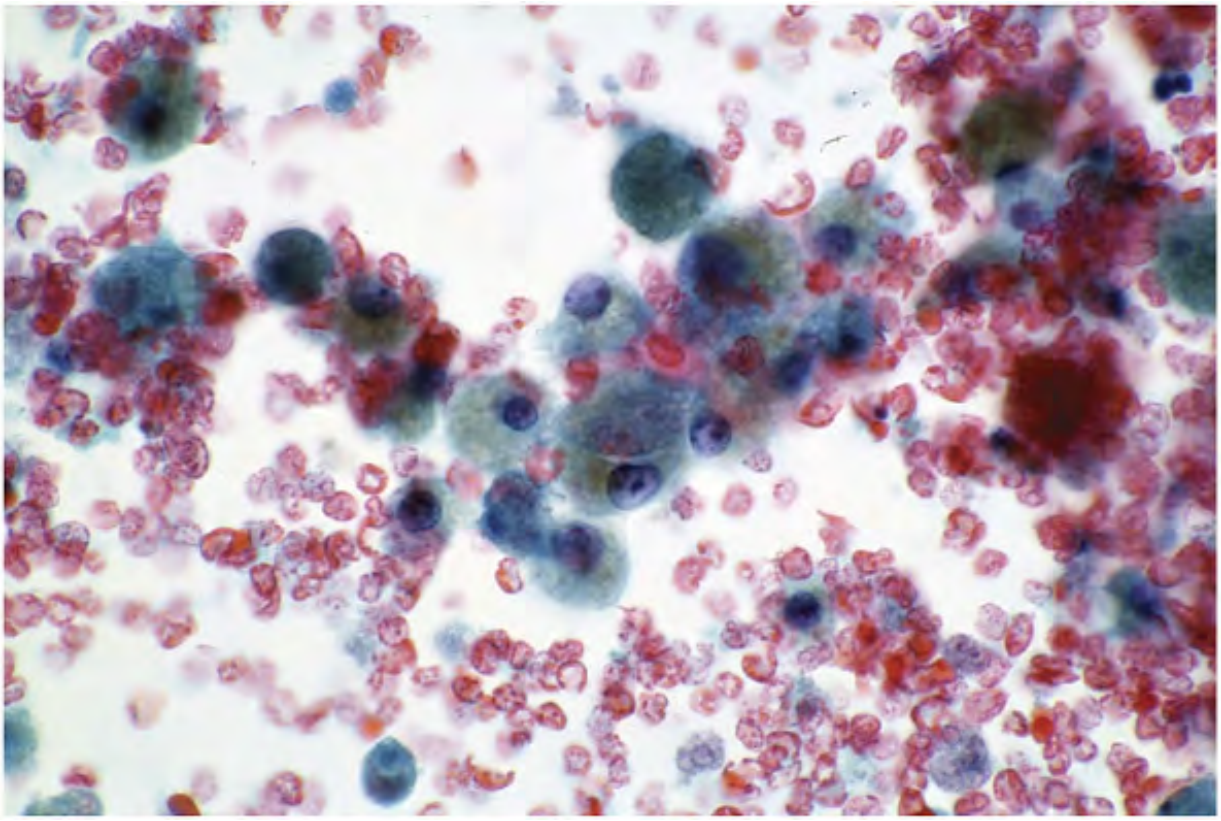

Figure 9.79. An example of a true false-negative aspirate of papillary carcinoma. Three attempts at the fine-needle biopsy yielded only hemorrhagic fluid containing histiocytes. Thyroidectomy revealed a cystic papillary carcinoma.

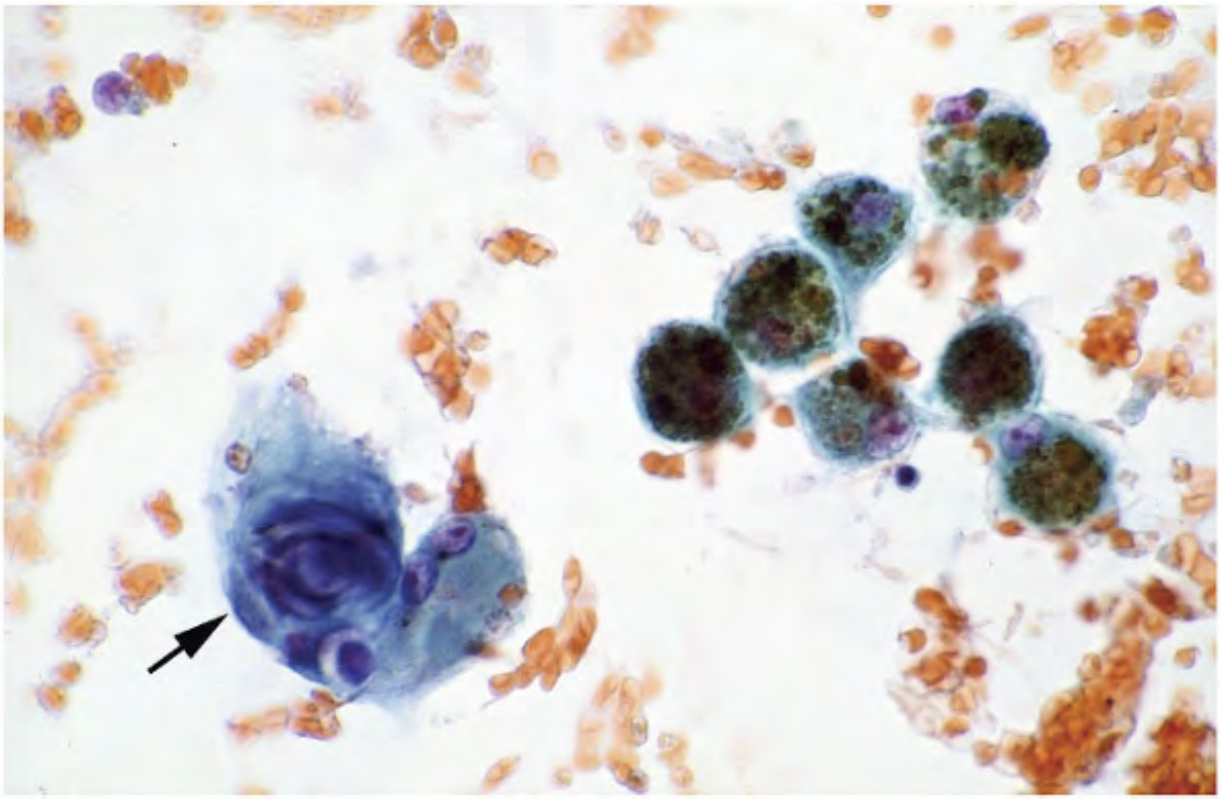

Figure 9.80. This aspirate from a papillary carcinoma consisted of hemosiderin-containing macrophages and extensive calcific debris. There were no well-preserved follicular cells. Th structure seen here (*arrow*) suggests a formation of psammoma body. This aspirate was interpreted as negative but should have been interpreted as inadequate. A repeat aspiratio biopsy was in order.

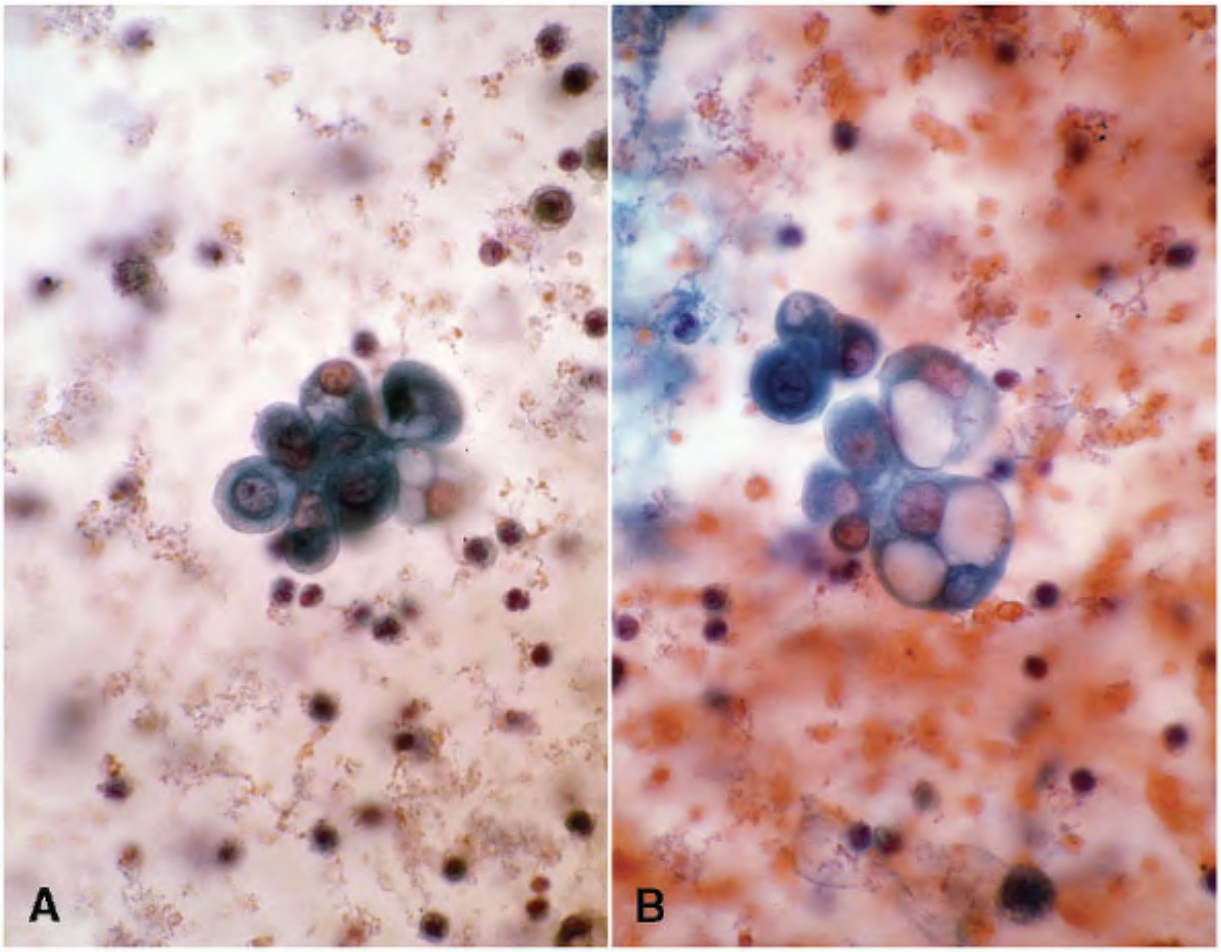

Figure 9.81. A hemorrhagic fluid from a cystic carcinoma, showing rare groups of atypical follicular cells interpreted as benign. Note that they have features such as dense and vacuol cytoplasm and well-defined cell borders that should have raised the suspicion of papillary carcinoma (refer to Figure 9.75).

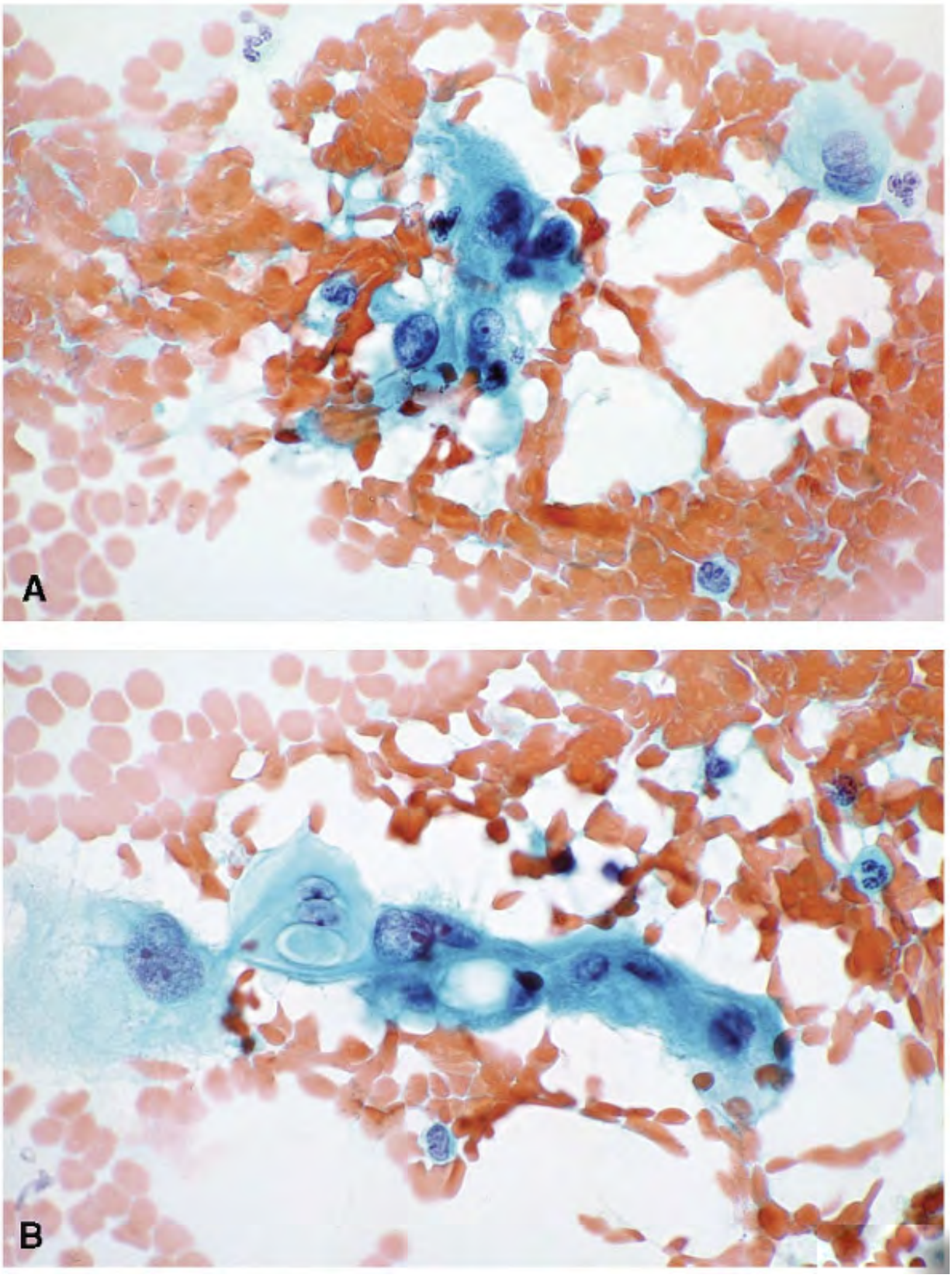

Figure 9.82. This aspirate was poorly cellular and showed a rare group of large pleomorphic

cells that were interpreted as negative. Note that dense cytoplasm and pleomorphic nuclei nucleoli should have been reported as abnormal but scant, and a repeat biopsy requested. T patient was biopsied again several years later only to confirm a papillary carcinoma.

DIAGNOSTIC ACCURACY

The diagnostic accuracy of papillary carcinoma should approach 90% to 94% (Table 9.9), provided the aspirate obtained by fine-needle biopsy is adequate for cytologic interpretatio

Papillary carcinoma
303[a]
Suspected papillary carcinoma
18
Medullary carcinoma
2
Cellular follicular adenoma
13
Benign (nodular goiter)
4
Unsatisfactory
9
Total
349
[a] Two cases were initially benign (lymphocytic thyroiditis). However repeat biopsies reveale papillary carcinoma in both. Sampling error was the reason for the discrepancy.

TABLE 9.9 CYTOLOGIC DIAGNOSIS OF 349 PAPILLARY CARCINOMAS

Errors in the cytologic diagnosis of papillary carcinoma can be grouped into three categories

- False-negative results.
- False-positive results.

- Typing errors.

False-Negative Results

The cytologic diagnosis of papillary carcinoma may be missed only if the specimen is acellul poorly cellular, demonstrating insufficient diagnostic criteria or if there is a sampling error (Tables 9.9 and 9.10).

1
Cyst fluid; cellular debris; histiocytes, calcospherites
No well-preserved follicular epithelium present; calcospherites, some surrounded by cellular and hemorrhagic debris
2
Few groups of follicular cells
Partially air-dried and scant cellularity; intranuclear inclusions overlooked; inadequate but suspicious for papillary carcinoma
3
Rare group of follicular cells
Inadequate for diagnosis; only one syncytial tissue fragment of follicular cells; large, atypical nuclei not appreciated due to inexperience
4
Bilateral nodules, both aspirated with similar findings; few tissue fragments with follicular cells containing pale nuclei

Few groups of atypical follicular cells in the background of nodular goiter; possibly sampling error

5

Hemorrhagic cyst fluid; only histiocytes

True false-negative diagnosis

6â€“13

Acellular specimens

True false-negative diagnoses

Case No.	Cytologic Findings	Comments

TABLE 9.10 ANALYSIS OF 13 FALSE-NEGATIVE DIAGNOSES OF PAPILLARY CARCINOMA

Acellular aspirates or a poor cellular yield on a fine-needle biopsy are inevitable in some instances, such as large cystic

papillary carcinoma, marked desmoplasia, or a thick, fibrous, calcified capsule.

Three false-negative cases of papillary carcinoma in our series (Table 9.10) reflected a combination of poorly cellular specimens and inexperience in recognizing certain cytologic atypia as possibly indicative of papillary carcinoma. In one case of papillary carcinoma in wł repeated attempts at fine-needle biopsy were madeâ€”including one on a "residual" palpabl massâ€”only histiocytes were found. A large-needle biopsy on the residual mass confirmed t diagnosis. Of 349 papillary carcinomas, 9 were acellular on fine-needle biopsy (2.5%) (Table). If fine-needle biopsies on large nodules are unsuccessful and there are strong clinical suggestions of carcinoma, a cutting-needle biopsy may be diagnostic.

A false-negative diagnosis may also occur as a result of sampling error. Two of our cases wer initially and correctly diagnosed as lymphocytic thyroiditis. One year later, repeat biopsy in cases showed all the criteria of papillary carcinoma coexistent with lymphocytic thyroiditis 9.78 C and D). The initial biopsies had sampled the parenchyma adjacent to the carcinoma. this reason, a few unremarkable follicular cells aspirated from a thyroid containing a large

nodule should not be considered adequate and benign.

False-Positive Results

False-positive diagnoses of papillary carcinoma are common errors in the practice of thyroid cytopathology and involve misinterpretation of aspirates from benign, non-neoplastic diseas the thyroid as malignant neoplasms when the cytologic features mimic some of the cytologic criteria of papillary carcinoma (Table 9.11).215 , 216 , 217 , 218 , 219 , 220 , 221 , 222 , 22 224 , 225 , 226 , 227 , 228 , 229 The same problem occurs with cellular aspirates from a follicular adenoma, especially with degeneration and pseudopapillary change. Most often, t errors are made if too much emphasis is placed on just one cytologic feature, especially wh the aspirate is overwhelmingly cellular. Of 316 cytologic diagnoses of papillary carcinoma, 1 were false positive and 18 aspirates were interpreted as suspicious for papillary carcinoma (Table 9.12).

Tissue Fragments
Papillary

- Hyperplastic goiter
- Papillary changes in follicular nodules or follicular adenoma
- Hashimoto's thyroiditis

Monolayered

- Hyperplastic goiter
- Follicular adenoma
- Follicular hyperplasia in Hashimoto's thyroiditis

Nuclear Features
Powdery chromatin with micronucleoli

- Hyperplastic goiter or nodular goiter with degeneration and cyst formation
- Hashimoto's thyroiditis
- Follicular adenoma

Pseudoinclusions

- Hyalinizing trabecular adenoma
- Hashimoto's thyroiditis
- Nodular goiter

Grooves

- Hyalinizing trabecular adenoma

Ancillary Features
Psammoma bodies

- Hyalinizing trabecular adenoma
- Nodular goiter
- Hashimoto's thyroiditis
- Follicular adenoma

Inspissated Colloid Simulating
psammoma body

- Nodular goiter

Cytologic Findings	Disease Entities Misinterpreted as PTC

TABLE 9.11 FALSE-POSITIVE DIAGNOSES OF PAPILLARY CARCINOMA

Papillary carcinoma
303
Medullary carcinoma
2
Follicular adenoma
4
Nodular goiter

4

Hashimoto's thyroiditis

3

Total

316

TABLE 9.12 HISTOLOGIC DIAGNOSIS OF 316 CASESWITH CYTOLOGIC DIAGNOSIS OF PAPILLARY CARCINOMA

A diagnosis of suspected papillary carcinoma (Figs. 9.83 , 9.84 , 9.85 , 9.86 and 9.87) is generally given when:

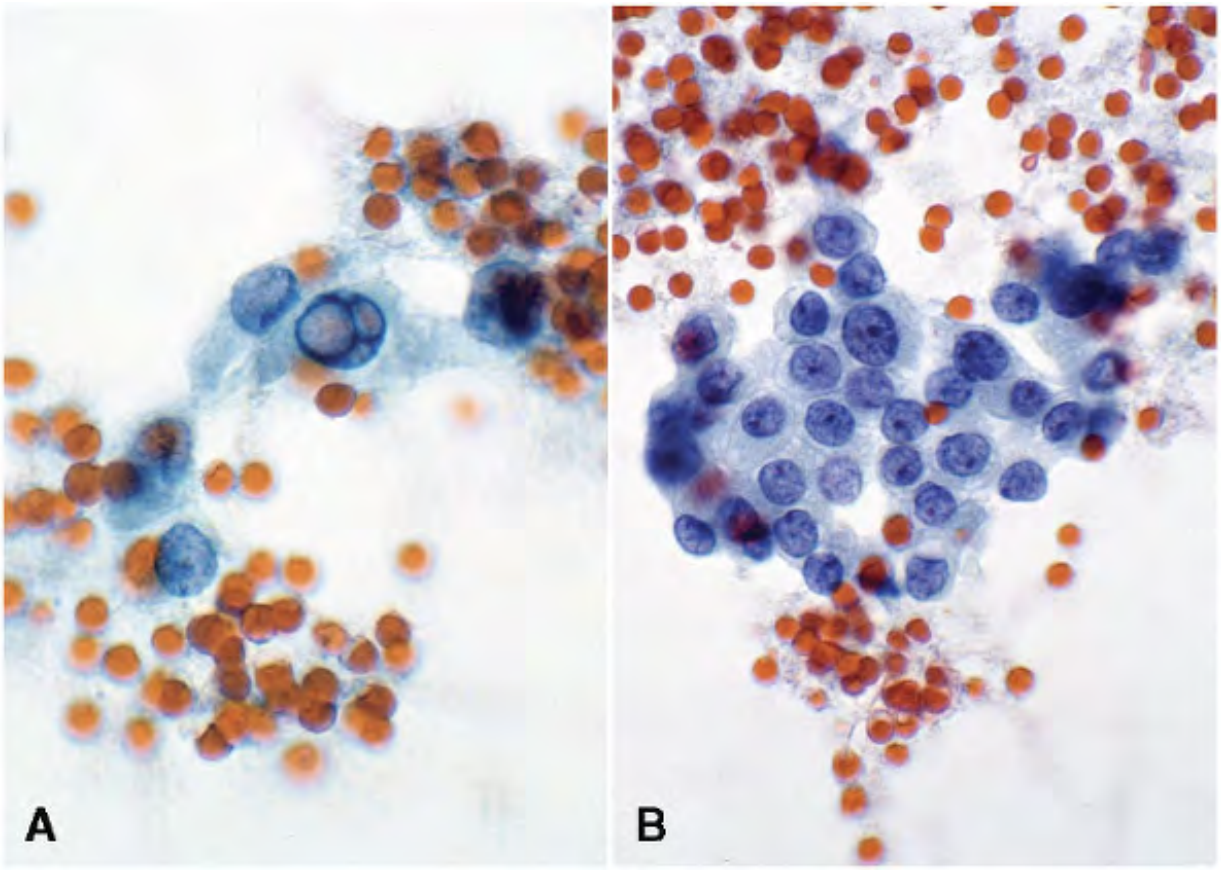

Figure 9.83. This aspirate was poorly cellular but showed rare tissue fragments of follicular that demonstrated atypical nuclear features. Note sharp intranuclear inclusions. The cytolo interpretation was suspicious for papillary carcinoma. A repeat biopsy confirmed the diagno

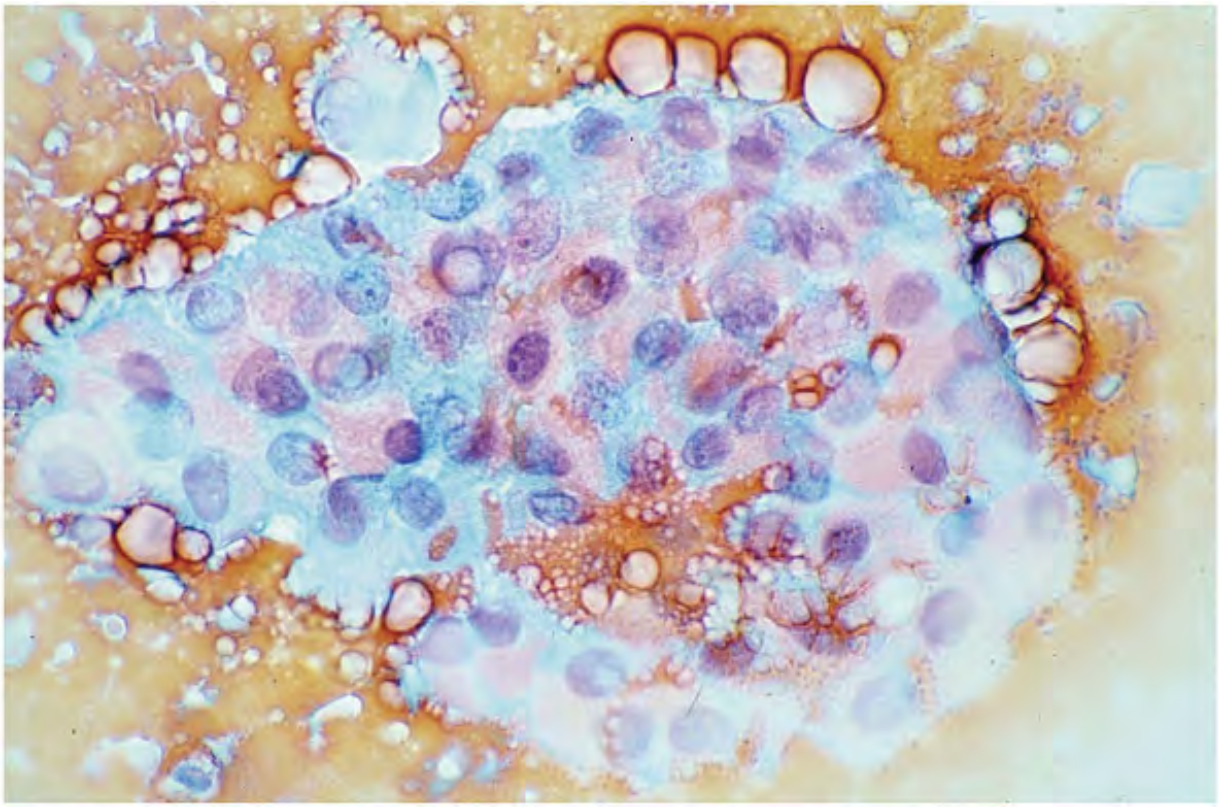

Figure 9.84. Air-dried cells in a syncytial arrangement with enlarged nuclei containing intranuclear inclusions. The quantity was insufficient and was interpreted as suspicious for papillary carcinoma, later confirmed on thyroidectomy.

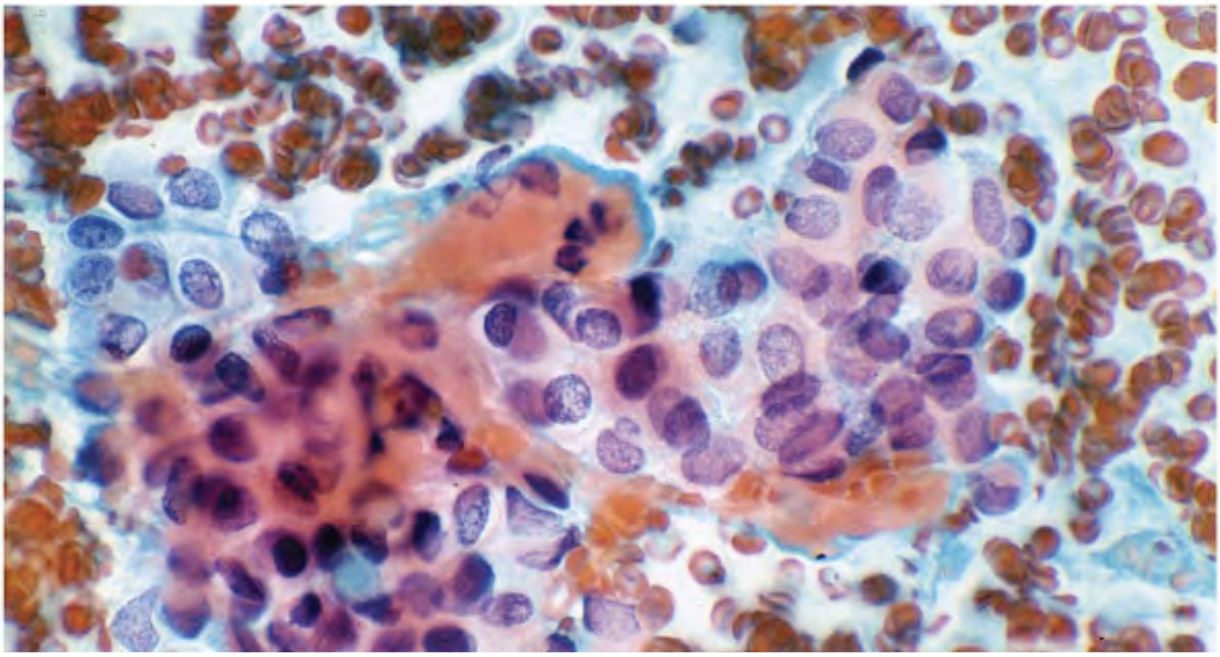

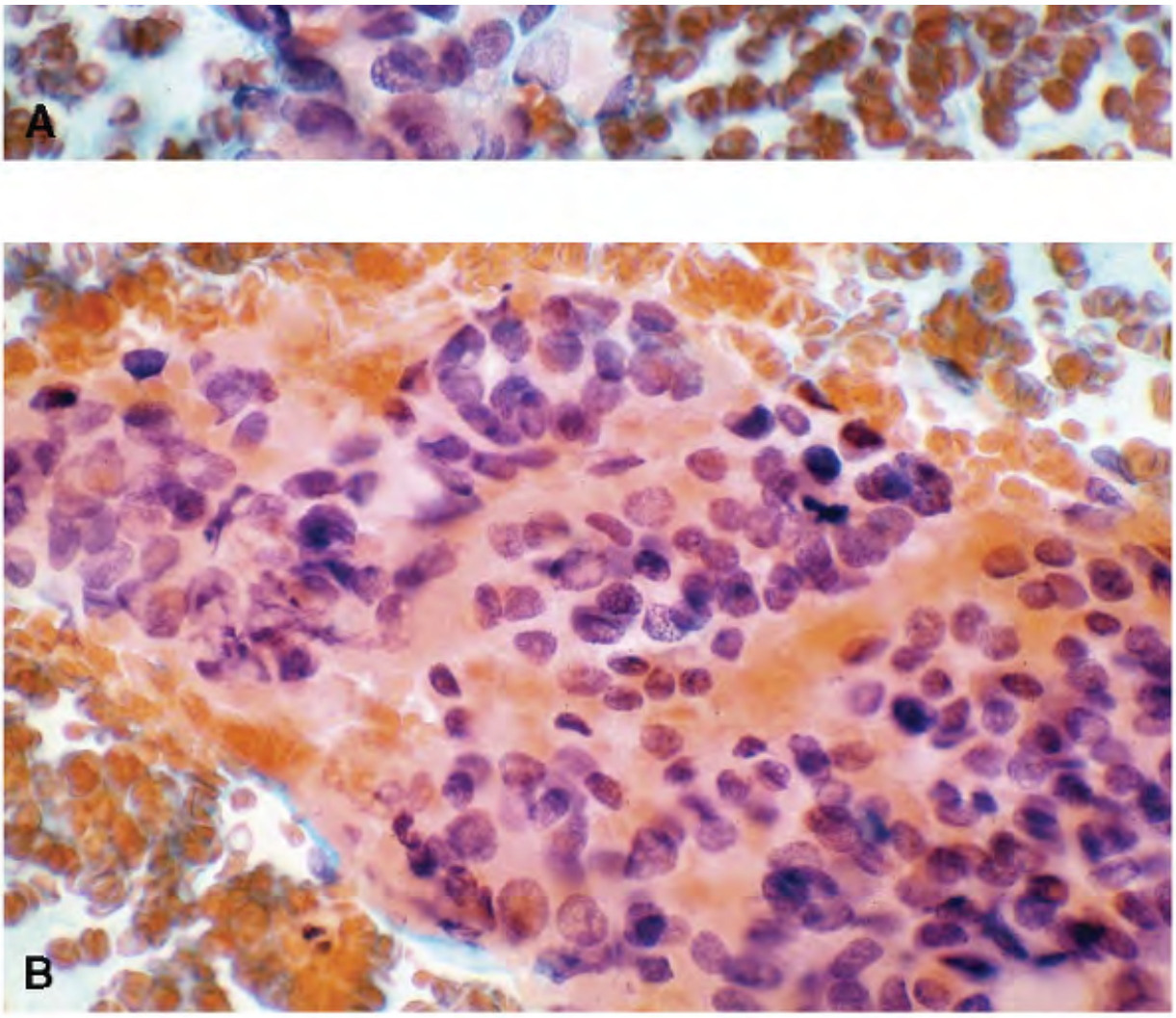

Figure 9.85. This aspirate is adequately cellular but air-dried with poor cellular details. The syncytial architecture and suggestion of intranuclear inclusions render this aspirate suspicio for papillary carcinoma, confirmed on surgery.

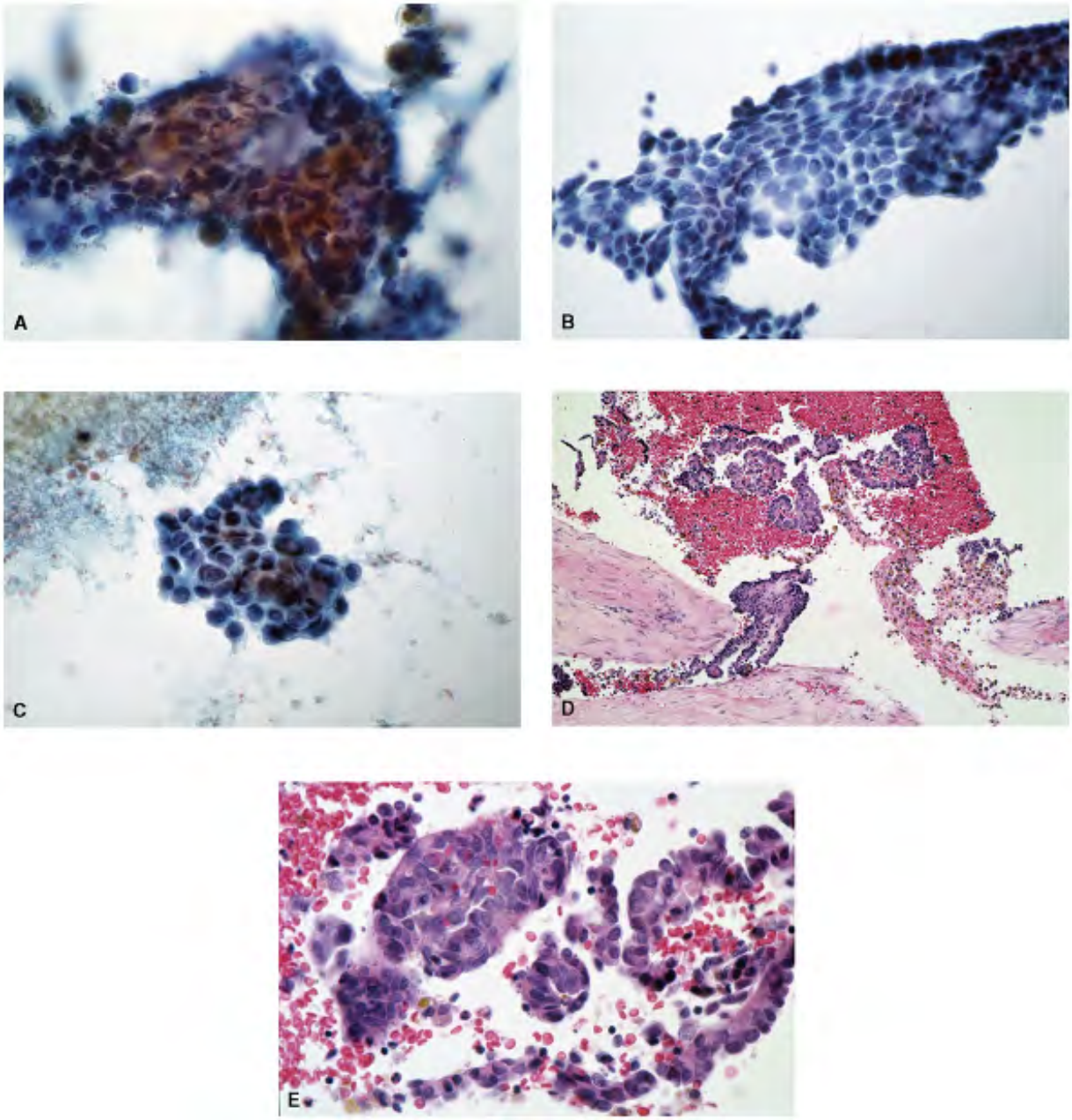

Figure 9.86. Aâ€“C. An adequately cellular specimen with several syncytial tissue fragment follicular cells with hyperchromatic nuclei. The papillary-like architecture and pleomorphic nuclei rendered this specimen suspicious for papillary carcinoma. Note that the minimal crit are not present. Thyroidectomy confirmed a cystic papillary carcinoma. D. The detached fragments of papillary fronds were floating within the cystic cavity. E. Higher magnification

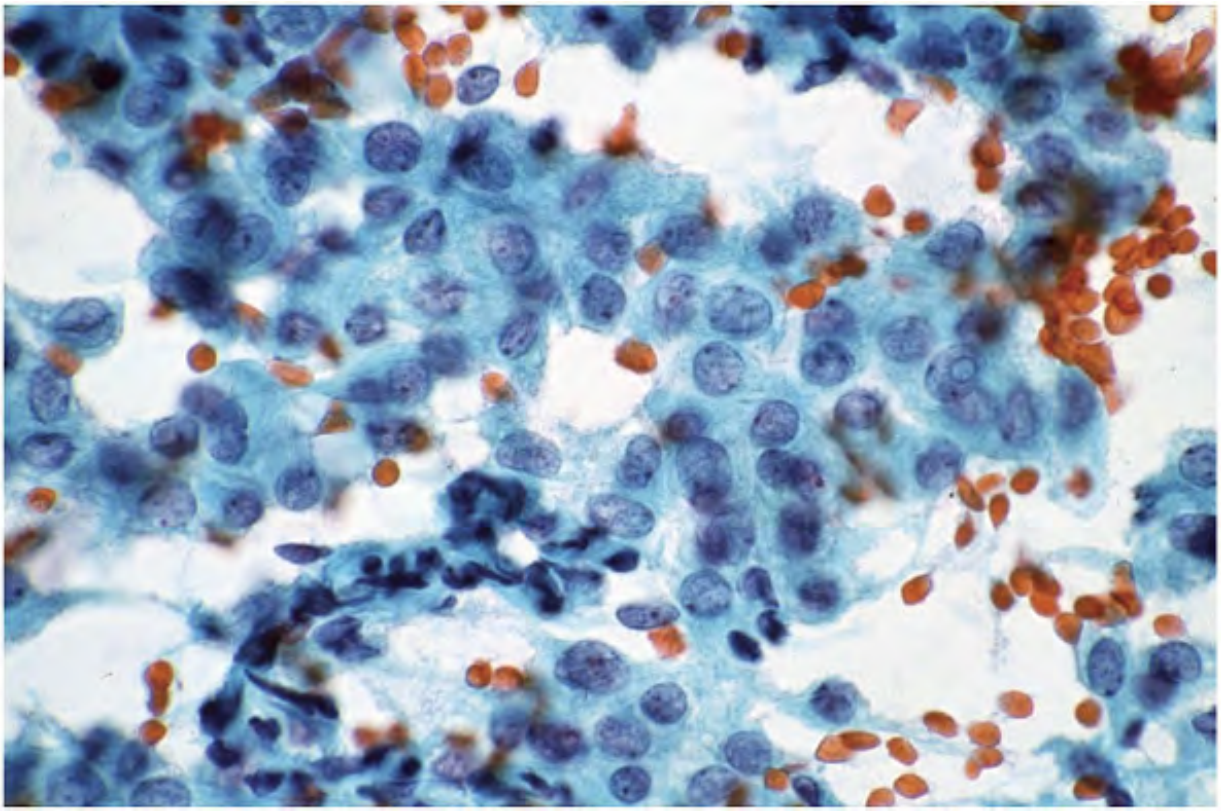

Figure 9.87. The syncytial tissue fragments of follicular cells demonstrate all the nuclear features of papillary carcinoma. Thyroidectomy showed a hyalinizing trabecular adenoma.

- The aspirate is marginally cellular and exhibits atypical features suggestive, but not diagnostic, of papillary carcinoma.
- The aspirate is adequately cellular, with features of a benign disease (nodular goiter Hashimoto's thyroiditis, follicular adenoma) but in addition shows a few follicular ce with atypia (Table 9.11).

The features that may be mistaken for papillary carcinoma are (i) an occasional monolayere tissue fragment of follicular cells, with abundant dense cytoplasm and large, irregular nucle with powdery chromatin and nucleoli; (ii) an occasional follicular cell showing intranuclear cytoplasmic inclusions; (iii) a rare papillary tissue fragment with crowded nuclei; (iv) tissue fragments of spindle cells forming a whorled pattern, with atypical nuclei; or (v) a rare psammoma body.

These isolated findings, as listed in Table 9.11 , by themselves may be extremely worrisome when present in the background of a benign disease, they should be judged with extreme caution. Table 9.13 analyzes the cases with false-positive diagnoses of papillary carcinoma.

1	
Single psammoma body; papillary tissue fragments; background features of nodular goiter; repeat fine-needle biopsy; nodular goiter	Total thyroidectomy; nodular goiter with papillary hyperplasia
Diagnosis of papillary carcinoma based on single psammoma body, architectural pattern (papillary) of the tissue fragment; cells lacked typical cytomorphology of papillary carcinoma	
2	
Single psammoma body; rare group of atypical follicular cells; several monolayered tissue fragments of follicular epithelium with honeycomb pattern	Total thyroidectomy; multiple follicular adenomas
Tissue fragment containing psammoma body lacked typical cytomorphology of papillary carcinoma; other features of papillary carcinoma not present; tissue fragments of follicular epithelium suggested diagnosis of	

nodular goiter
3
Cyst fluid; hemorrhagic, large
papillary tissue fragments;
psammoma bodies
Total thyroidectomy;
HÃ¼rthle cell adenoma
with cystic degeneration
Cytomorphology altered by the
hemorrhage; psammoma bodies
were atypical, perhaps colloid
4
Multiple psammoma bodies
Total thyroidectomy;
multiple follicular
adenomas
Inspissated colloid within
follicular simulated psammoma
bodies
5
Hypercellular aspirate; large
numbers of monolayered sheets
of follicular epithelium
Right lobectomy; simple
adenoma
Emphasis on cellularity and
architectural pattern of tissue
fragments without cytomorphology
of papillary carcinoma
6
Hypercellular aspirate; papillary
tissue fragments
Total thyroidectomy;
diffuse hyperplasia

Emphasis on cellularity and
architectural pattern;
cytomorphology of papillary
carcinoma lacking
7
Extremely cellular aspirate;
branching papillary tissue
fragments; crowded nuclei
with nucleoli
Total thyroidectomy;
follicular adenoma with
atypical papillary
change
Papillary fragments; crowded nuclei
with nucleoli, chromatin not
powdery; intranuclear inclusions
and chromatin ridge
8
Papillary tissue fragments
with powdery chromatin
Total thyroidectomy;
nodular goiter with
papillary hyperplasia,
one focus of atypical
hyperplasia
Marginal cellularity, partial
air-drying with suboptimal
cytomorphology; insufficient
criteria for diagnosis of
papillary carcinoma
9
Syncytial-type tissue fragments;
enlarged; crowded nuclei with
nucleoli; chromatin finely granular;

	features of lymphocytic thyroiditis; history of lobectomy for carcinoma papillary	Lobectomy; Hashimoto's thyroiditis	Insufficient criterial for diagnosis of papillary carcinoma; history of carcinoma influenced the diagnosis
10	Features of lymphocytic thyroiditis; occasional papillary fragment of follicular epithelium	Total thyroidectomy; Hashimoto's thyroiditis with papillary hyperplasia	Typical nuclear cytomorphology absent
11	Features of lymphocytic thyroiditis; occasional papillary fragment of follicular epithelium	Total thyroidectomy; Hashimoto's thyroiditis with papillary hyperplasia	Typical nuclear cytomorphology absent

Patient No.	Cytologic Findings	Surgery	Comme

TABLE 9.13 ANALYSIS OF 11 FALSE-POSITIVE DIAGNOSES C PAPILLARY CARCINOMA

Of 42 patients with suspected papillary carcinoma, 36 underwent surgery (Table 9.14). Eigh

cases were confirmed. Two were follicular carcinomas and two were follicular adenomas, indicating a typing error (see Chapter 7). Thirteen were benign, non-neoplastic diseases of thyroid. Surgery was not recommended for six patients because the cytologic features on re biopsy were diagnostic of benign disease. As the diagnostic accuracy of papillary carcinoma an adequate aspirate is very high, it is advisable to have a definitive diagnosis before surger The decision to recommend a surgical excision after a cytologic diagnosis of suspicious papil carcinoma depends on such factors as the age and sex of the patient, size of the nodule, lymphadenopathy, and a history of radiation to the head and neck and unsatisfactory attem at repeat fine-needle biopsy.

Papillary carcinoma
18
Follicular carcinoma
2
Follicular adenoma
3
Nodular goiter
11
Hashimoto's thyroiditis
2
Total
36

TABLE 9.14 HISTOLOGIC DIAGNOSIS OF 36 CASES CYTOLOGICALLY SUSPECTED OFPAPILLARY CARCINOMA

Typing Errors

Typing errors are not as consequential as false-positive results because surgery is recommen for most thyroid neoplasms. Tumors that may be confused with papillary carcinomas include follicular neoplasmsâ€”follicular adenoma and its special variant, the hyalinizing trabecular adenoma, as well as follicular carcinoma. The cytologic features differentiating follicular adenoma, follicular carcinoma, and the follicular variant of papillary carcinoma are listed ir Table 7.13 .

Hyalinizing trabecular adenoma is a subtype of follicular adenoma (see Chapter 7) that disp almost all the nuclear features of papillary carcinoma (Fig. 9.87). Cytologic differentiation between the two neoplasms is very difficult, (Table 9.15).213 , 215

Pattern
Cells mostly isolated, in loose aggregates
with cells radiating from acellular material;
syncytial tissue fragments without any
architectural patterns
Cells isolated, in loosely cohesive groups or in
syncytial tissue fragments with various
architectural pattern
Cells
Mildly pleomorphic in size; oval to spindle
shaped; bipolar and triangular forms;
cytoplasmic processes present
Marked variation in size and shape; spindle cells,
rare to absent; cytoplasmic processes not
present
Nucleus
Size & shape
Round, oval to elliptical; minimal variation
in size
Round to oval with marked variation in size
Chromatin
Finely granular, occasional prominent
chromocenter with clearing around
Dusty, powdery
Nucleoli
Micronucleoli
Micro/macronucleoli
Nuclear grooving
Frequent
Frequent
Intranuclear

inclusions

Frequent

Frequent

Cytoplasm

Variable; pale to dense, sometimes filamentous; intracytoplasmic hyaline deposit

Variable; clear pale to dense, sometimes vacuolated

Psammoma bodies

Absent

May be present

Background

Amorphous/Hyaline material

Present in variable amount, stain purplish-pink with Romanowsky stain

Absent

Colloid

Absent

Present

Multinucleated giant cells

Absent

Present

	Hyalinizing Trabecular Adenoma	Papillary Carcinoma

TABLE 9.15 CYTOPATHOLOGIC DIFFERENTIATION BETWEE PAPILLARY CARCINOMAAND HYALINIZING TRABECULAR ADENOMA

Papillary carcinoma is also mistyped as medullary carcinoma, especially when there is a sing cell pattern. Both of these malignant tumors have morphologic similarities (see Table 12.6) Other uncommon lesions in the differential diagnosis include parathyroid adenoma and metastatic bronchioloalveolar carcinoma.

A critical analysis of 16 cases cytologically suspected of papillary carcinoma is given in Table 9.16 .

1

Hypercellular aspirate; large, monolayered sheets of follicular epithelium; occasional papillary pattern; multiple micronucleoli

Nodular goiter with infarct

Emphasis on hypercellularity as well as architectural pattern; lacked typical cytomorphology of papillary carcinoma

2

Features of nodular goiter; few groups of atypical follicular cells with large nuclei and multiple nucleoli

Nodular goiter

Few groups of atypical cells in a background of nodular goiter, generally of no significance; misinterpretation due to inexperience

3

Cyst fluid; histiocytes and tissue fragments of follicular epithelium with foamy cytoplasm, enlarged nuclei and nucleoli

Nodular goiter with cyst

Degenerative changes in epithelium from cyst
fluid mimicking neoplasia; important
diagnostic pitfall
4
One group of pleomorphic
cells with atypical nuclei; one
psammoma body; one very
large monolayered sheet of
follicular epithelium; nucleoli
present
Nodular goiter
Marginal cellularity; cytomorphology of papillary
carcinoma not present
5
Hypercellular aspirate; many
monolayered sheets of
follicular epithelium
Simple adenoma
Emphasis on only one criterion, i.e.,
monolayered sheets; typical nuclear
morphology of papillary carcinoma absent
6
Hypercellular aspirate; many
monolayered sheets of
follicular epithelium
Simple adenoma
Emphasis on only one criterion, i.e.,
monolayered sheets; typical nuclear
morphology of papillary carcinoma absent
7
Occasional papillary tissue
fragment (?), psammoma body
Simple adenoma
Pseudopsammoma body (inspissated

colloid simulating psammoma body)

8

Few tissue fragments of atypical cells; spindle forms; nucleoli; swirling arrangement suggesting a papillary configuration; background of nodular goiter

Hyperplastic goiter

Adequate aspirate with features of nodular goiter; only a few tissue fragments of atypical cytomorphology; nuclei did not show cytoplasmic inclusions; mostly coarse chromatin

9

Few tissue fragments of atypical follicular epithelium; two psammoma bodies; many histiocytes and giant cells

Nodular goiter

Psammoma bodies not surrounded by cells that exhibit typical cytomorphology of papillary carcinoma; features of papillary carcinoma not present

10

Cystic hemorrhage with cellular debris; few fragments of follicular epithelium; vacuolated cytoplasm

Nodular goiter

Poorly cellular specimen; nuclear cytomorphology not seen; degenerated follicular cells with nuclear atypia

11

Psammoma bodies and
features of nodular goiter
Hyperplastic goiter
with single
psammoma
True psammoma body, but lacked nuclear
features of papillary carcinoma
12
Psammoma body; few groups
of atypical cells; occasional
monolayered tissue
fragments
Nodular goiter
Marginal cellularity; typical cytomorphology of
papillary carcinoma absent; emphasis only on
psammoma body
13
Features of nodular goiter;
calcific debris and multinu-
cleated giant cells; rare
psammoma body
Nodular goiter
Features of papillary carcinoma not present;
emphasis only on calcospherites
14
Cytologic features of lympho-
cytic thyroiditis; occasional
papillary tissue fragment
with overlapping nuclei
Hashimoto's
thyroiditis
Papillary tissue fragments; lacked typical
cytomorphology
15

Features of lymphocytic thy-
roiditis; occasional tissue
fragment with papillary con-
figuration; discrete cells with
intranuclear inclusions
Hashimoto's
thyroiditis
Except for intranuclear inclusions, papillary tissue
fragments lacked nuclear morphology of
papillary carcinoma
16
Cellular debris and hemor-
rhage; (?) syncytial-type
tissue fragments
Hypec goiter
Only (?) syncytial-tissue fragments; typical
nuclear cytomorphology not present

Patient No.	Cytologic Findings	Surgery	Comme

TABLE 9.16 CRITICAL ANALYSIS OF 16 CASES CYTOLOGICALLY SUSPECTED OF BEING PAPILLARY CARCINOMA WITH HISTOLOGIC DIAGNOSES OF BENIGN DISEASES FOLLOWING SURGERY

MINIMAL CRITERIA FOR CYTOLOGIC DIAGNOSIS

Cytologic preparations of papillary carcinoma have several diagnostic features, but not all m
be present in aspirates of every case. Some features are essential, whereas others are adjur
Their frequency also depends on the histologic pattern of the tumor.

In a review and analysis of cytopathologic features of 329 cases of papillary carcinoma, all o
features listed in Table 9.1 were present in only 27 cases. Tables 9.17 and 9.18 indicate the
frequency of occurrence of various cytologic features of papillary carcinoma in adequately

cellular (329 cases) and marginally cellular specimens (65 cases), respectively. These Figure differ somewhat from those reported in our earlier review of 87 cases of papillary carcinom perhaps because of better cytologic preparation in subsequent years and more careful revie Usually one or two features predominated. The most consistent features were enlarged nucl containing fine, powdery, dusty chromatin that appeared pale or watery (100%); a linear chromatin ridge or groove (88%); single or multiple micro- and/or macronucleoli (100%); anc intranuclear cytoplasmic inclusions (93%).

Syncytial tissue fragments
329
100
Papillary tissue fragments
283
86
Monolayered tissue fragments
198
60
Syncytial tissue fragments with
follicular pattern
174
50
Powdery chromatin
320
100
Micro- and/or macronucleoli
320
100
Nuclear inclusions
308
93
Nuclear grooves
290
88
Psammoma bodies
68

20
Multinucleated foreign-bodyâ€“type
giant cells
200
60
Colloid Strands
100
30

Cytologic Criteria	No.	Percent

TABLE 9.17 FREQUENCY OF OCCURRENCE OF VARIOUS CYTOLOGIC CRITERIA IN 329 CASES OF PAPILLARY CARCINOMA

Syncytial tissue fragments with or
without follicular pattern
65
100
Papillary tissue fragments
34
52
Monolayered tissue fragments
13
20
Powdery chromatin
65
100
Micro- and/or macronucleoli
65
100
Nuclear inclusions
55
84.5

Nuclear grooves
54
83
Psammoma bodies
15
23
Multinucleated foreign-body type
giant cells
19
29
Colloid strands
2
3

Cytologic Criteria	No.	Percent

TABLE 9.18 FREQUENCY OF OCCURRENCE OF VARIOUS CYTOLOGIC CRITERIA IN 65 CASES OF PAPILLARY CARCINOMA WITH MARGINAL CELLULARITY

The minimal criteria for the diagnosis of papillary carcinoma thus include a syncytial-type tissue fragment of follicular epithelium that, regardless of the architectural pattern, show typical nuclear morphology, that is, pale-appearing enlarged nuclei with fine, dusty, powde chromatin; a chromatin bar or ridge; single or multiple micro- and/or macronucleoli; and intranuclear cytoplasmic inclusions (Fig. 9.88 , Table 9.19).

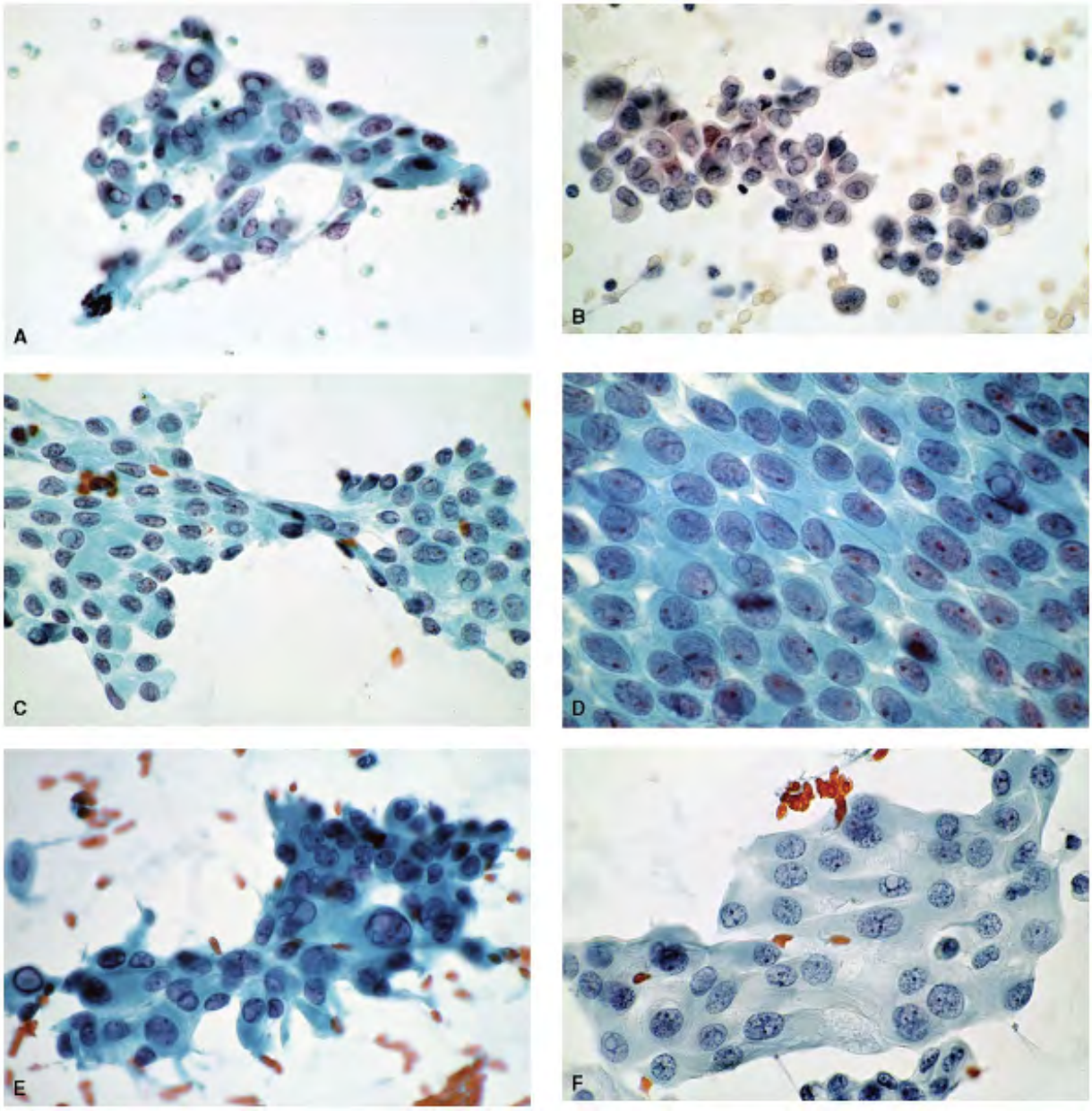

Figure 9.88. Minimal criteria. All six images show syncytial tissue fragments without any spe architectural configuration. The cells display varied types, but their nuclei are enlarged anc contain fine, powdery chromatin with nucleoli, grooves, and inclusions.

1. Syncytial tissue fragments with or without any architectural configurations
2. Enlarged nuclei with very fine, dusty powdery chromatin
3. Multiple micro- and/or macronucleoli

4. Intranuclear cytoplasmic inclusions
5. Nuclear grooves

TABLE 9.19 MINIMAL CRITERIA FOR THE CYTOLOGIC DIAGNOSIS OF PAPILLARY CARCINOMA

The results of an analysis of cytologic preparations of 65 papillary carcinomas with marginal cellularity (Table 9.18) were similar to those for the overall analysis of 329 cases, thus substantiating the minimal criteria of the cytologic diagnosis of papillary carcinoma (Fig. 9.8 Abele and Miller40 have subclassified cytopathologic features in primary and secondary grou Their primary features include intranuclear cytoplasmic inclusions (92%), cells with dense cytoplasm (89%), and papillary fronds (92%). Their secondary features included septate cytoplasmic vacuoles (64%), huge multinucleated giant cells (50%), psammoma bodies (36%),

P.188
P.189
P.190

monolayered sheets with atypical nuclei (36%), and "bubble-gum" colloid (14%).

No single cytopathologic feature is diagnostic of papillary carcinoma. A diagnosis based on c feature will often prove to be a false-positive result (Tables 9.11 and 9.16). The cases wher the atypical cytologic features lead us to interpretive traps in all three categories are listed Tables 9.13 and 9.16 and illustrated in Figures 9.89 , 9.90 , 9.91 , 9.92 , 9.93 , 9.94 , 9.95 , , 9.97 , 9.98 , 9.99 , 9.100 , 9.101 , 9.102 , 9.103 , 9.104 , 9.105 , 9.106 , 9.107 , 9.108 , 9.1 9.110 and 9.111 .

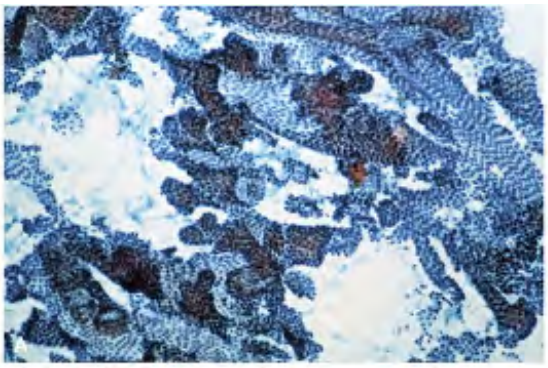

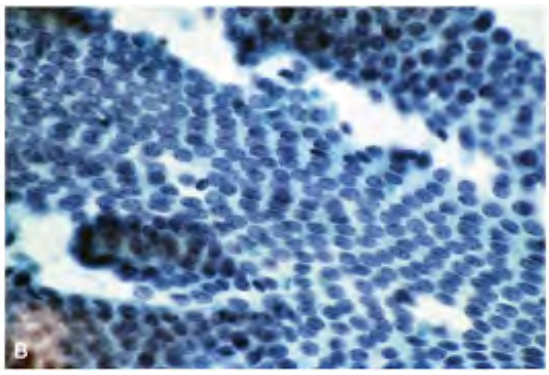

Figure 9.89. *Papillary tissue fragments in nodular goiter versus papillary carcinoma* A. Extremely cellular aspirate. The large numbers of tissue fragments with papillary-like and

monolayered architecture are very striking at this medium-power view. The background is c and devoid of colloid. B. The honeycomb arrangement of small cells with uniform round nuc containing granular chromatin supports the diagnosis of hyperplastic goiter.

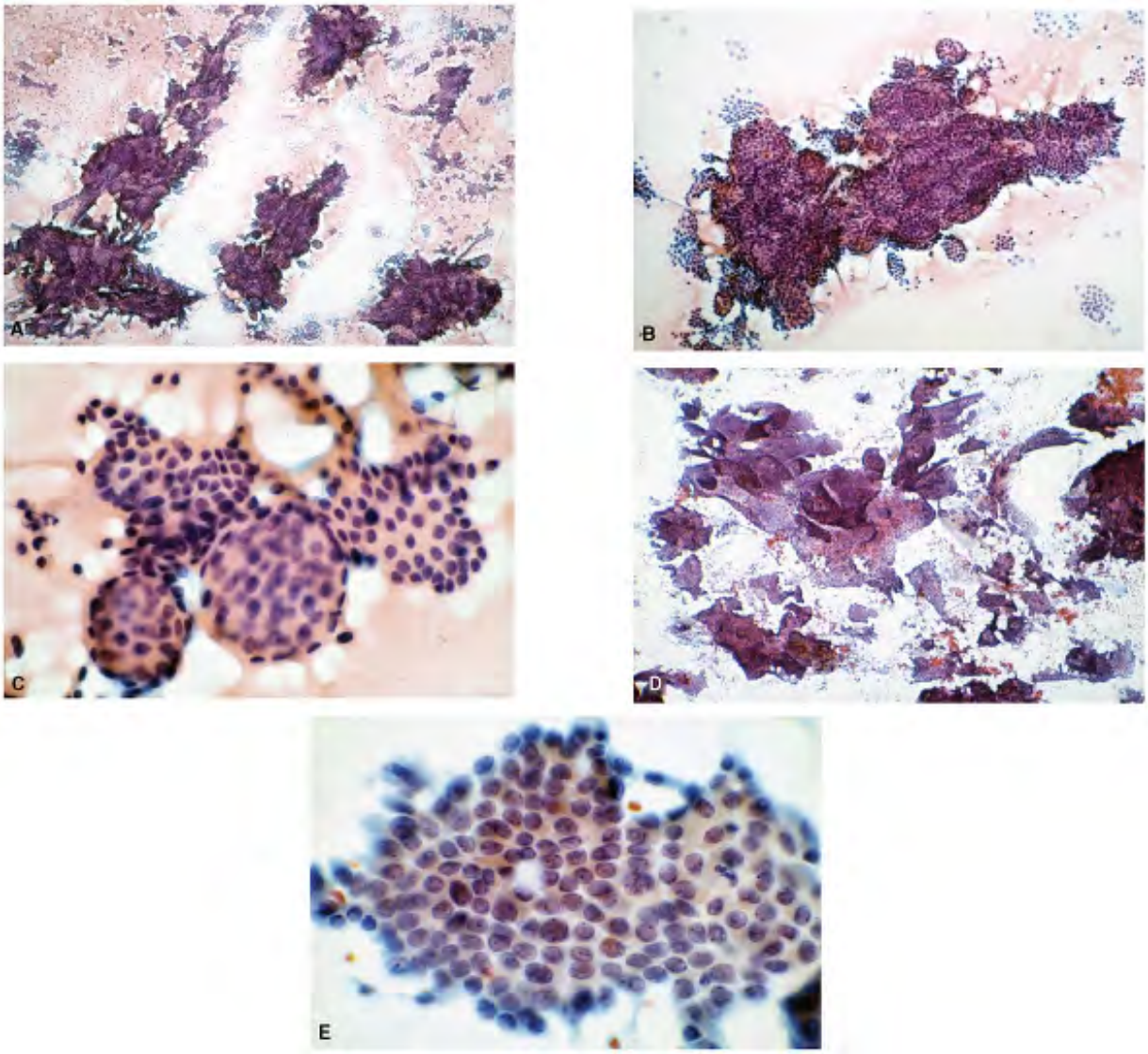

Figure 9.90. *Papillary tissue fragments in nodular goiter versus papillary carcinoma.* A. Extremely cellular aspirate. The large numbers of tissue fragments with papillary and monolayered architecture are highly suggestive of neoplasia at this low power. Note abunda colloid in the background. B. At medium power, the tissue fragments show papillary-like architecture. However, the honeycomb arrangement is quite evident. C. The honeycomb arrangement of small cells with uniform round nuclei, containing compact chromatin suppor

the diagnosis of hyperplastic goiter. D. FNA of a papillary carcinoma for comparison. The extreme cellularity is formed by several large, branching tissue fragments of follicular cells clean background (low power). E. Higher magnification shows a monolayered syncytial tissue fragment with characteristic features of papillary carcinoma cell nuclei. Compare this with C.

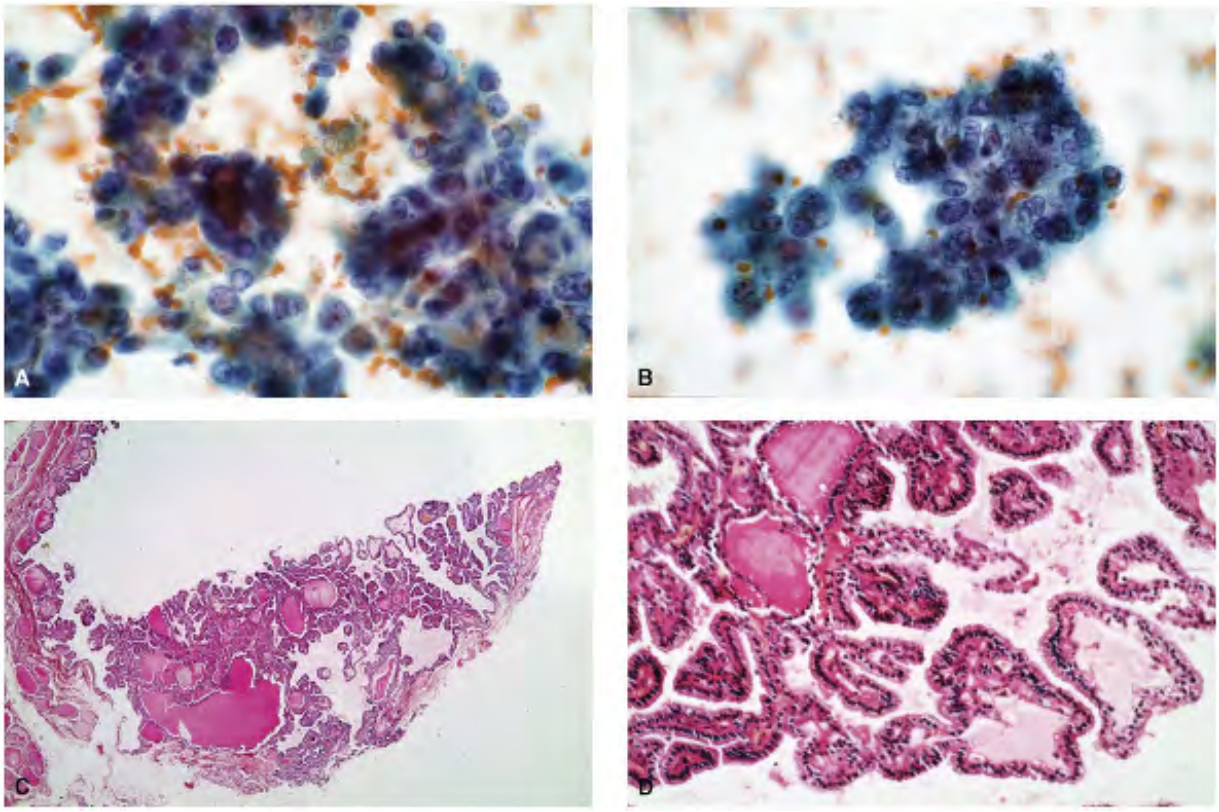

Figure 9.91. *Papillary tissue fragments in a cystic nodular goiter versus papillary carcinoma.* The cellular aspirate consists of several tissue fragments of follicular cells that appear to be syncytial arrangement with crowding and overlapping. The nuclei are round, with coarsely granular chromatin and occasional nucleoli. B. These two tissue fragments of follicular cells demonstrate similar morphology. The background is bloody. A large number of degenerating follicular cells were present in the background (not illustrated). A suspicious diagnosis of papillary carcinoma was rendered. Thyroidectomy revealed a cystic nodular goiter with pap hyperplasia. C. Histologic section at low power showing a cystic lesion. Papillary architectur readily apparent. D. Higher magnification showing edematous papillae lined by follicular cel containing hyperchromatic nuclei and lacking the characteristics of conventional papillary carcinoma.

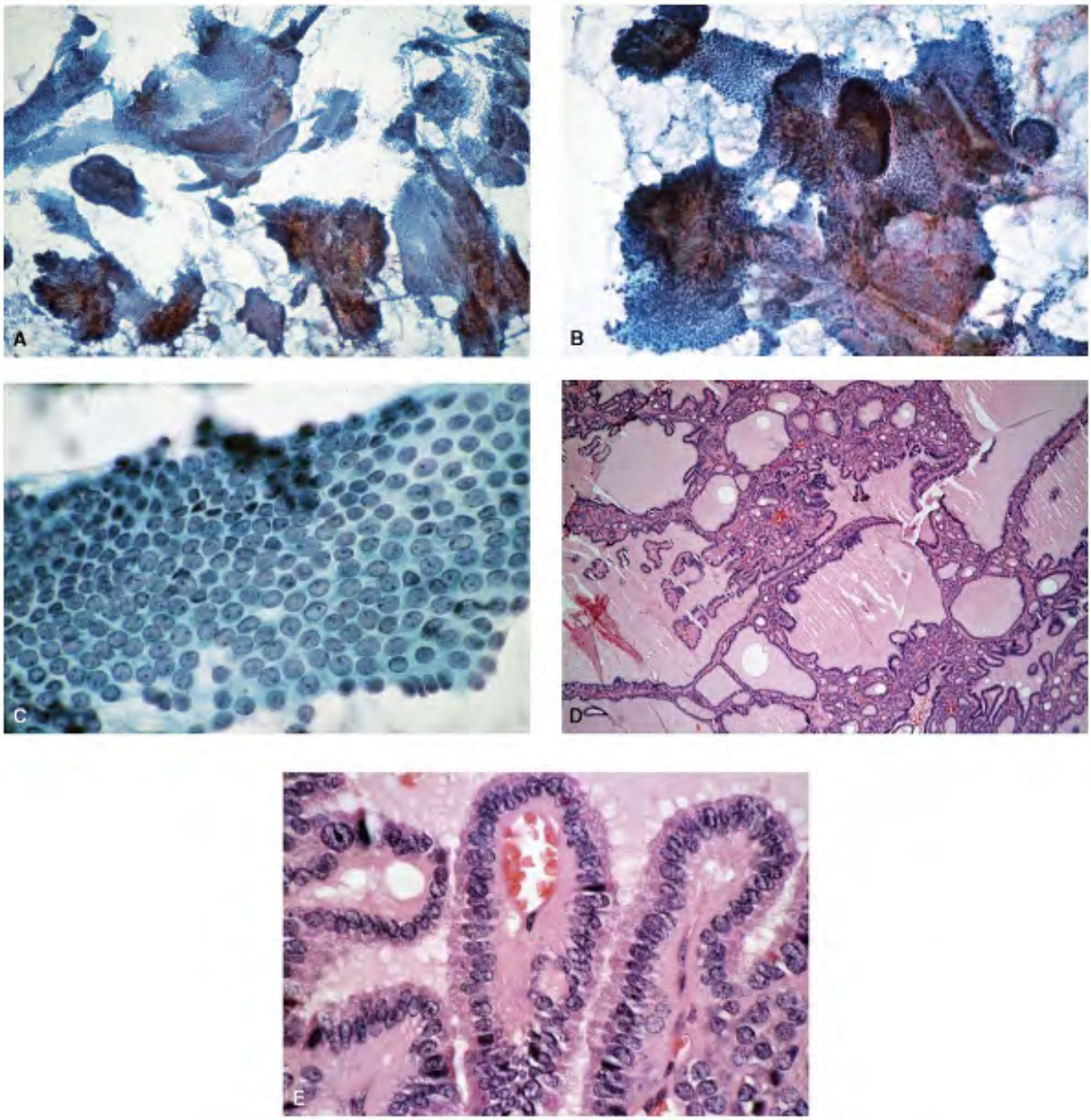

Figure 9.92. *Papillary tissue fragments in follicular adenoma with papillary change versus papillary carcinoma.* FNA of a thyroid nodule. A. The cellularity of this aspirate is impressiv The tissue fragments appear papillary and monolayered. B. At medium power, the tissue fragments appear monolayered and papillary-like, lacking central cores of fibrovascular tiss C. Higher magnification demonstrating a honeycomb arrangement of uniform, small round n with granular chromatin. The overwhelming cellularity and the architecture of the tissue fragments lead to a positive diagnosis of papillary carcinoma. Thyroidectomy revealed a

follicular adenoma with papillary change. D. Histologic section with several dilated follicles showing short papillae protruding in the lumen. E. Higher magnification of the papillae cove by uniform follicular cells, lacking stratification and pale watery nuclei.

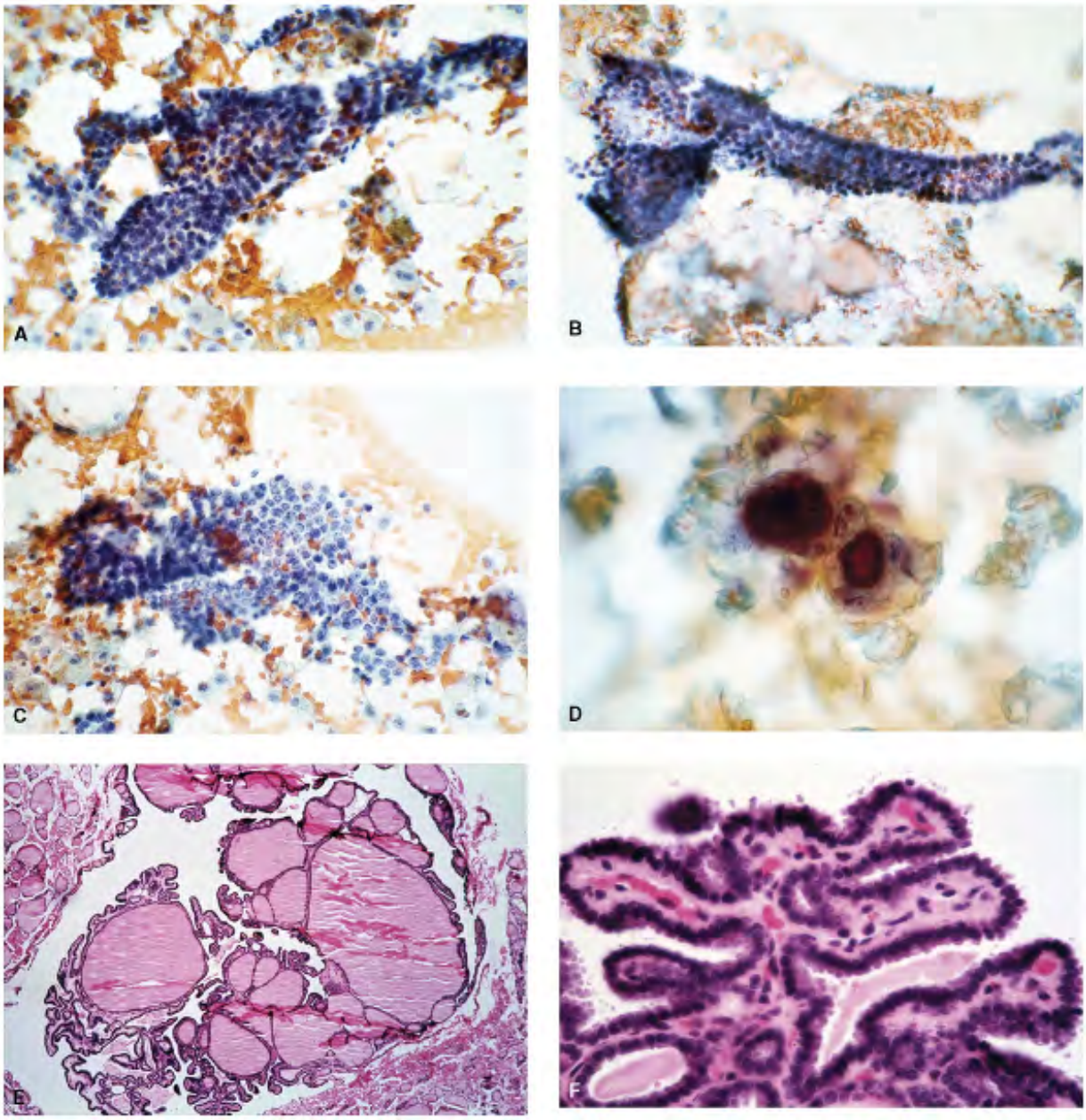

Figure 9.93. *Papillary tissue fragments in follicular adenoma with papillary change versus papillary carcinoma* . Another example of a false-positive cytologic diagnosis. FNA of an isth nodule. A,B. An adequately cellular aspirate showing tissue fragments of follicular epitheliu with papillary-like architecture. The honeycomb arrangement is apparent at this power. C.

monolayered tissue fragment with honeycomb arrangement. The follicular cell nuclei are uniform, small, and hyperchromatic. No grooves or inclusions are present. D. This tissue fragment contains a psammoma body. Note that the component cells lack the characteristic features of papillary carcinoma. Based on the architecture and psammoma body, papillary carcinoma was diagnosed. Thyroidectomy confirmed an encapsulated cystic follicular adeno E. Histologic section at low power to illustrate the nodule with arborizing papillae, directed towards the center of the cavity. F. Higher magnification. Note the lack of typical features papillary carcinoma.

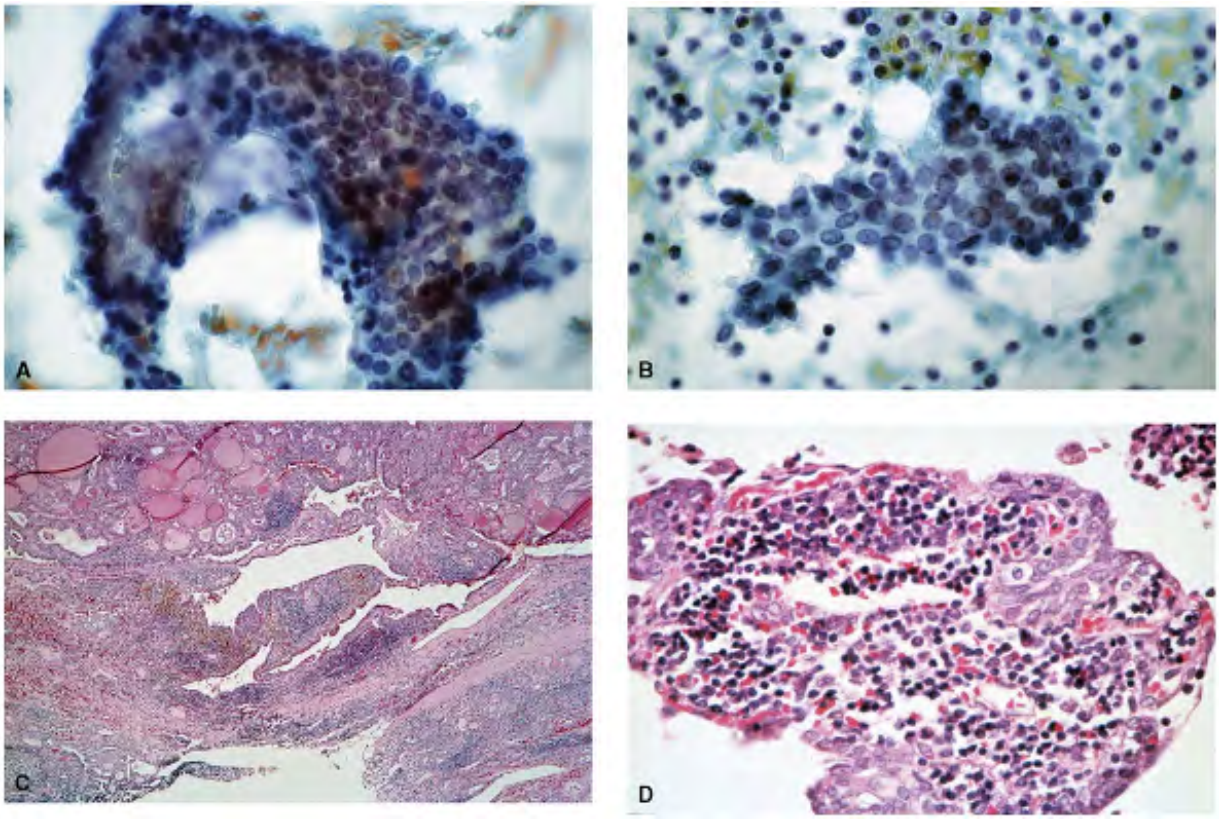

Figure 9.94. *Nuclear atypia and papillary hyperplasia in the background of Hashimoto's thyroiditis versus papillary carcinoma in the background of thyroiditis* . A. This syncytial tis fragment shows a papillary-like configuration. The component cell nuclei are minimally enlarged, round, and with granular chromatin. Besides the architecture, nuclear characteris of papillary carcinoma are lacking. B. Syncytial tissue fragment with small, minimally enlarg nuclei and some suggestion of intranuclear inclusions. With a suspicious diagnosis for papilla carcinoma, a thyroidectomy was performed, which failed to confirm a papillary carcinoma. Histologic section showing features of Hashimoto's thyroiditis with papillary hyperplasia. D.

lining epithelium is atypical, with nuclei containing pale chromatin.

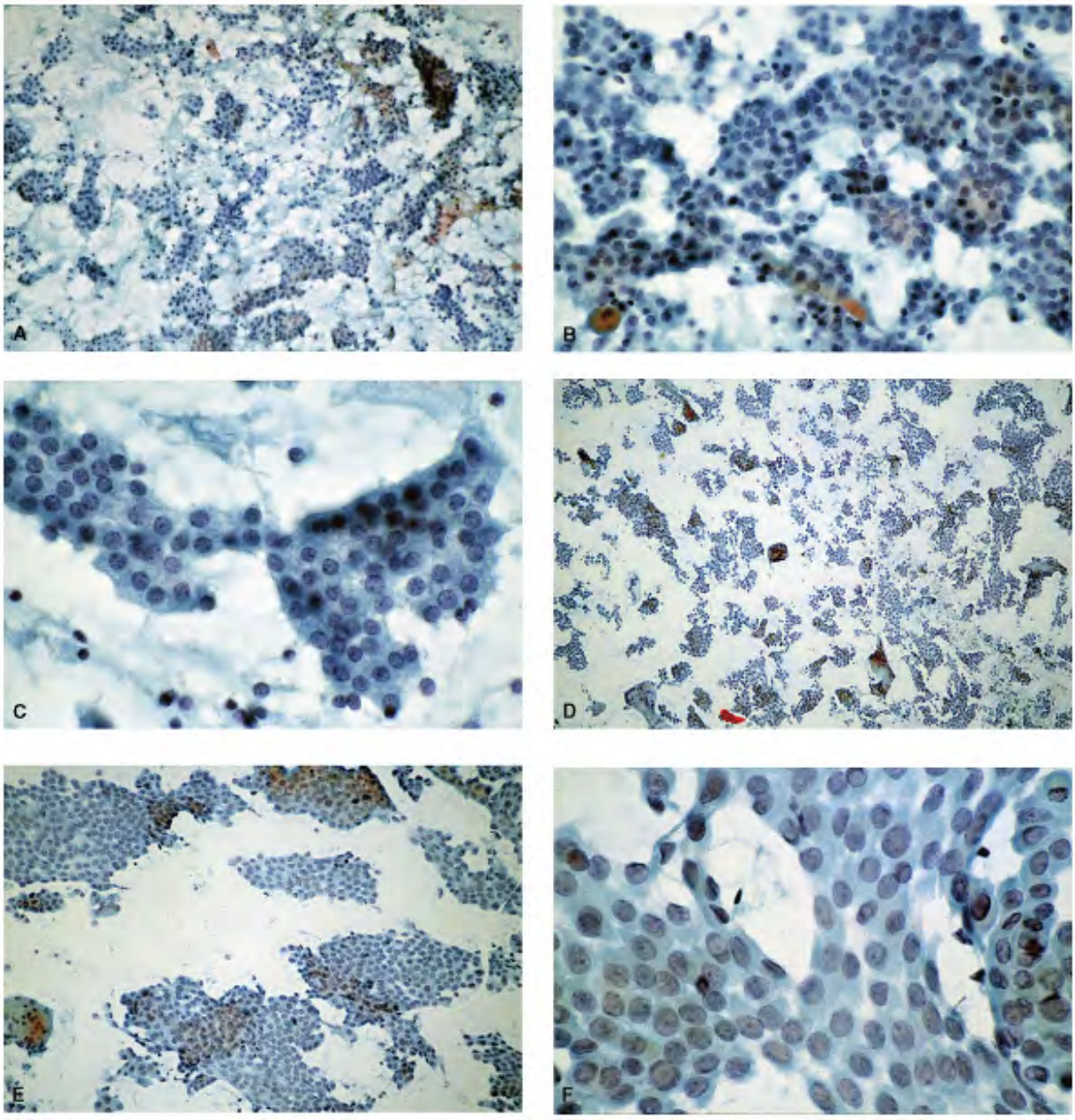

Figure 9.95. *Differential Diagnosis of monolayered tissue fragments* . A. FNA of a hyperpla
nodular goiter, low power. The aspirate is overwhelmingly cellular, consisting of several tiss
fragments of follicular cells. B. Medium-power view demonstrating monolayered tissue fragments. C. Higher magnification highlights the lack of nuclear features of papillary carcinoma. The cellularity by itself may tempt a diagnosis of follicular neoplasm. Dâ€“F. FN

a papillary carcinoma consisting of predominantly monolayered tissue fragments, for compa
with the case illustrated in parts A to C. D. The cellular aspirate shows several tissue fragme
This low-power view is very similar to part A. E. Medium-power view. F. Higher magnificatic
The tissue fragment is syncytial, with altered polarity of enlarged nuclei. The chromatin is p
fine, and powdery. Note micronucleoli, grooves, and intranuclear inclusions.

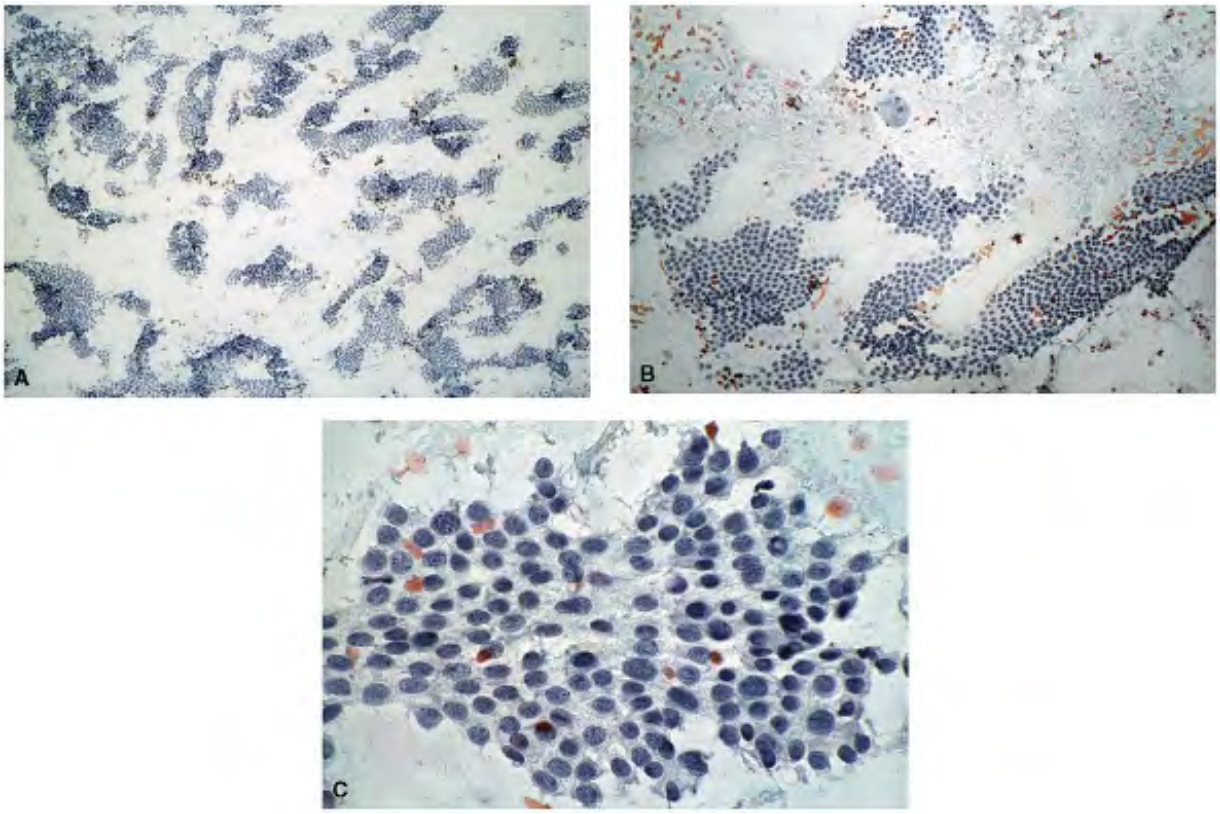

Figure 9.96. Another example of hyperplastic goiter with a cellular aspirate consisting of a number of monolayered tissue fragments that may lead to a false-positive diagnosis of papil carcinoma. A. Low power to demonstrate the cellularity and large number of tissue fragmer B. Medium power view to show the monolayered tissue fragments with honeycomb arrangen The nuclei are minimally but uniformly enlarged with granular chromatin. C. Higher magnification highlights the lack of nuclear features of papillary carcinoma.

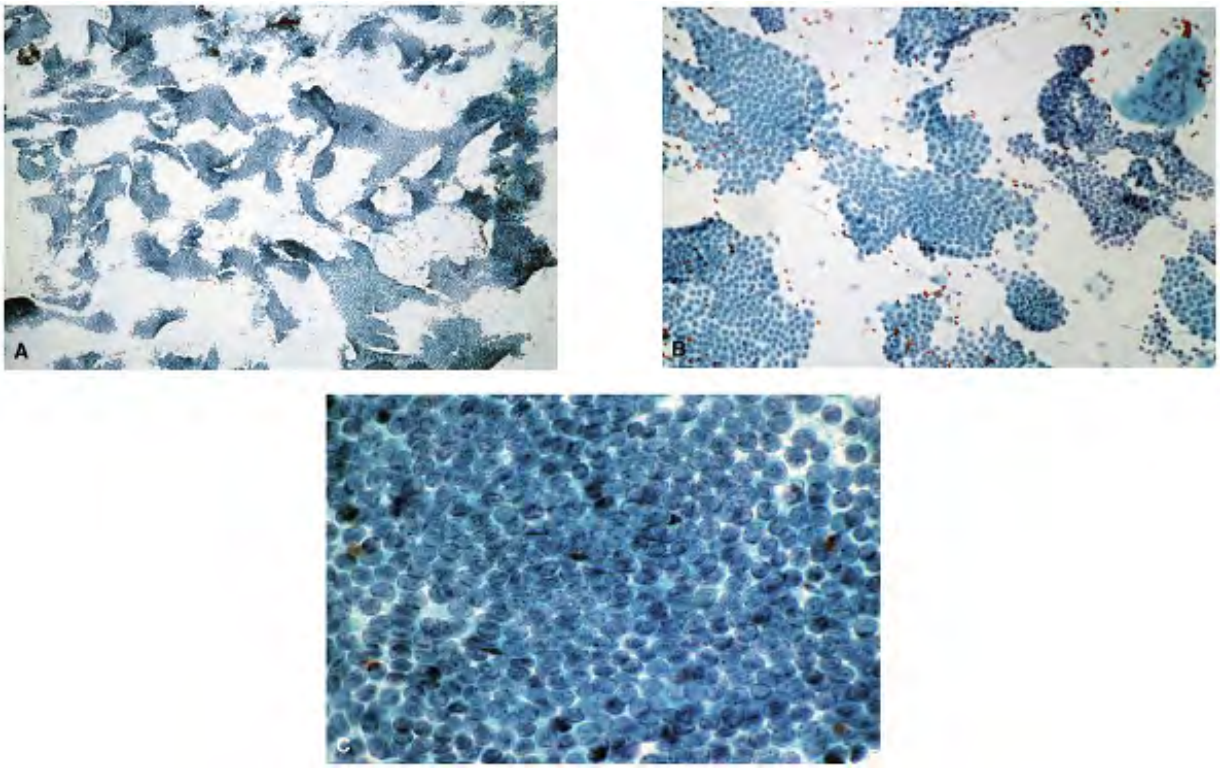

Figure 9.97. FNA of a papillary carcinoma consisting of predominantly monolayered tissue fragments for comparison with the case illustrated in Figure 9.96. A. The cellular aspirate sl several tissue fragments. This low-power view is very similar to Figure 9.96A. B. Medium-pov view to show the monolayered architecture. C. Higher magnification. The tissue fragment is syncytial, with altered polarity of enlarged nuclei. The chromatin is pale, fine, and powdery Note micronucleoli, grooves, and intranuclear inclusions.

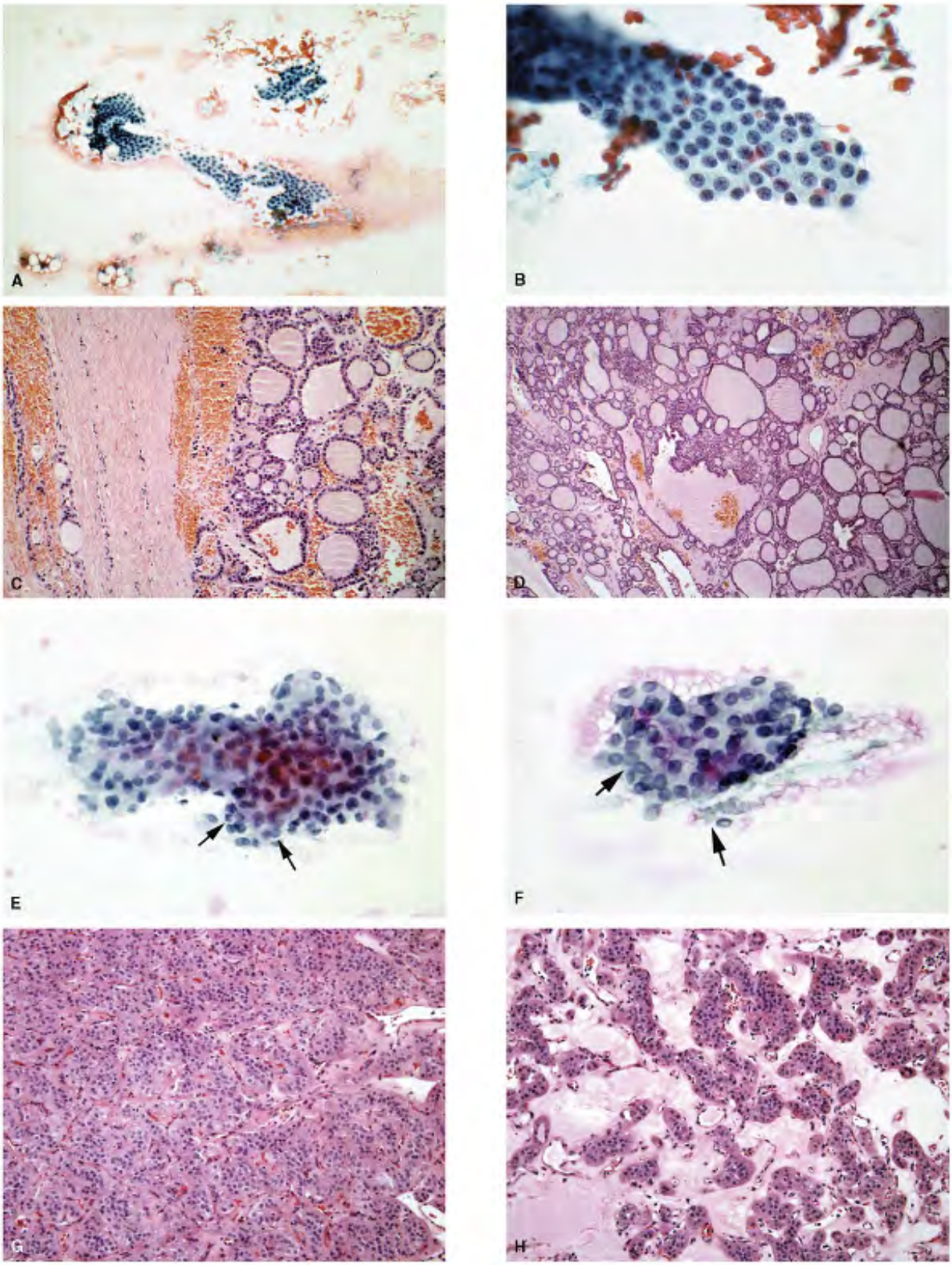

Figure 9.98. *Follicular adenoma versus papillary carcinoma* . A. FNA of a thyroid nodule sho

several large monolayered tissue fragments of follicular epithelim, low power. B. Higher magnification showing a monolayered tissue fragment lacking features of papillary carcinom The case was misinterpreted as suspicious for papillary carcinoma. C,D. Thyroidectomy reve an encapsulated simple-type follicular adenoma. E,F. Another example of cellular follicular adenoma, interpreted as suspicious for papillary carcinoma. FNA showing syncytial tissue fragments of follicular epithelium without any architectural pattern. The nuclei are enlarge Their chromatin appears pale with some suggestion of intranuclear inclusions (*arrows*). Part air-drying has rendered the nuclei pale looking. G. Thyroidectomy showed an encapsulated cellular follicular adenoma with a solid growth pattern. H. Higher magnification showing a trabecular adenoma.

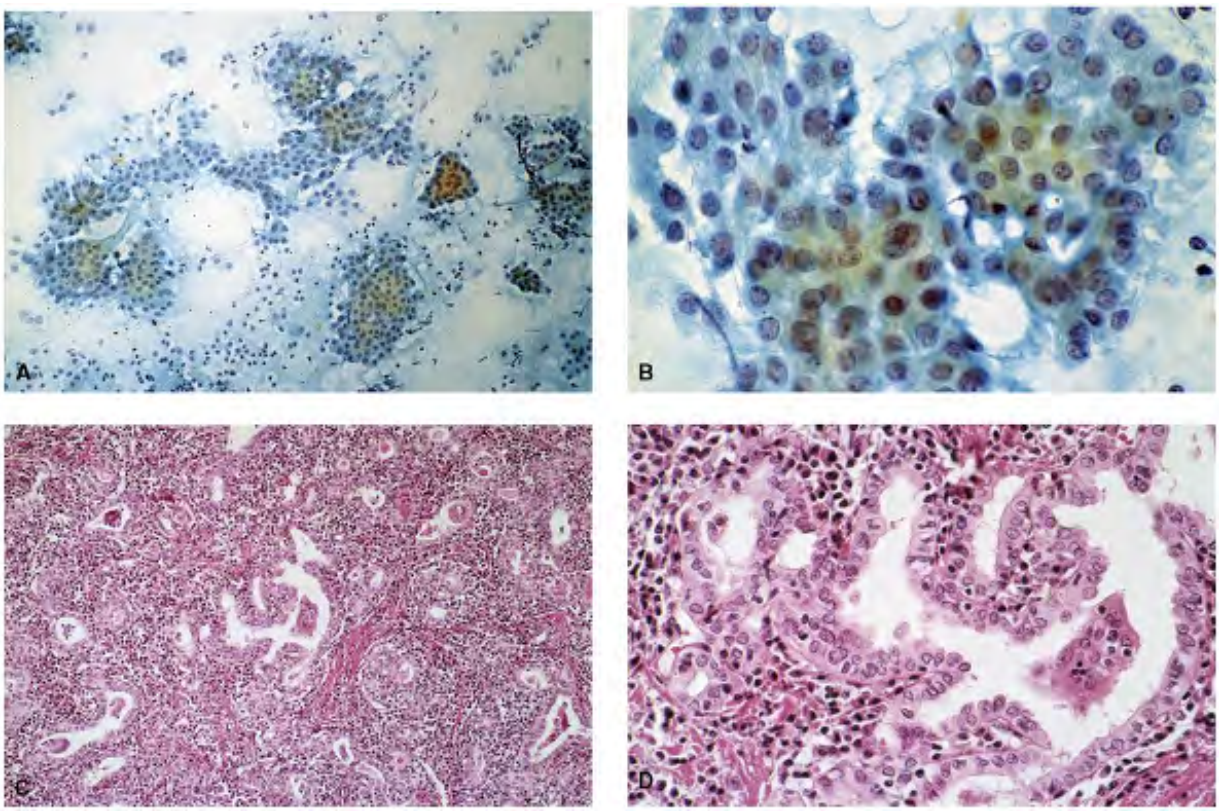

Figure 9.99. *Papillary hyperplasia in Hashimoto's thyroiditis presenting monolayered tissue fragments, misinterpreted as papillary carcinoma.* A. The cellular aspirate shows several la tissue fragments (low power). B. Higher magnification showing a monolayered tissue fragme with syncytial arrangement. The cells are large, with abundant cytoplasm and appear HÃ¼rtheloid. The nuclei are round and enlarged, with micro- and macronucleoli. The chrom is granular. Nuclear grooves or inclusions are not present. Lymphocytes are present in the

background. Thyroidectomy failed to show a papillary carcinoma. C. Histologic section show features of Hashimoto's thyroiditis with diffuse papillary hyperplasia. D. Higher magnificatio The follicular cells lining these short papillae lack nuclear characteristics of papillary carcin

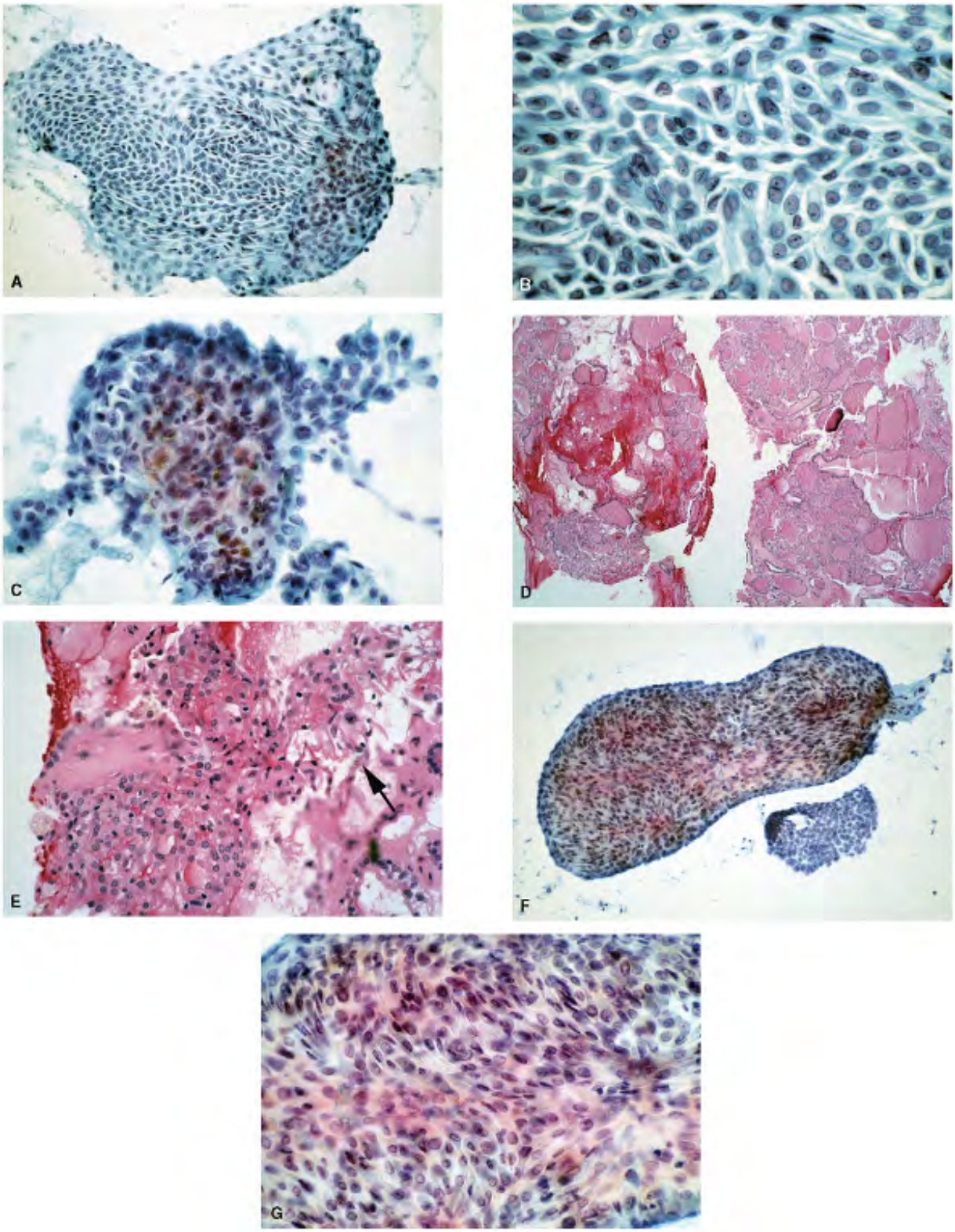

Figure 9.100. *Squamous metaplasia in nodular goiter and papillary carcinoma.* FNA of a no
goiter. A. A large tissue fragment with smooth external contour with papillary-like pattern,

medium power. B. Higher magnification showing the spindle cell architecture. The nuclei ar round and uniform, with granular chromatin and some containing nucleoli. C. Some tissue fragments of follicular cells exhibited mild nuclear atypia. Grooves and inclusions are not present. With a suspicious diagnosis of papillary carcinoma, a thyroidectomy was performed which showed nodular goiter with cystic change. D. Histologic section of the goiter, low pov E. This image depicts degeneration of the follicular cells with spindle cell change (*arrow*). I FNA of a papillary carcinoma to illustrate squamous metaplasia. Note the large tissue fragm with cytomorphology similar to that seen in part A. Also note the monolayered tissue fragme of papillary carcinoma in the field. G. Higher magnification of the tissue fragment with squamous metaplasia.

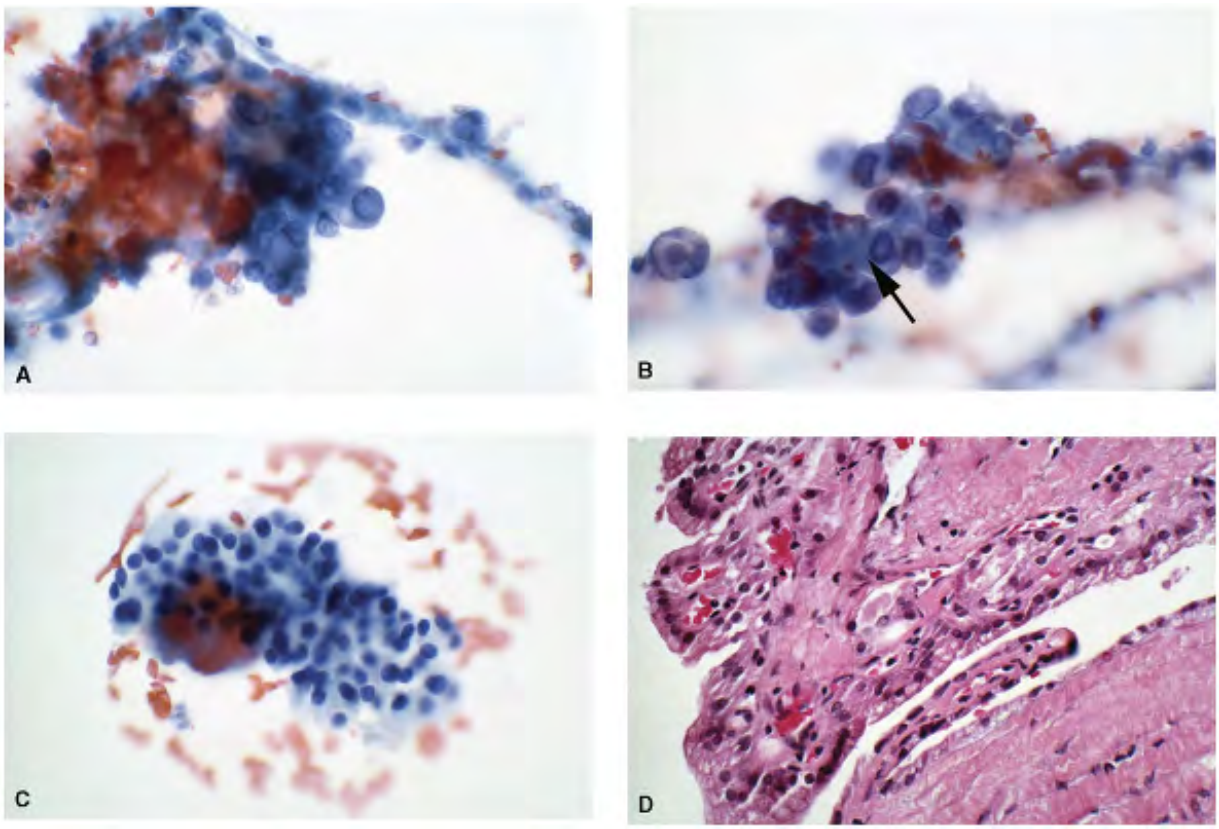

Figure 9.101. *Atypical nuclear changes in nodular goiter mimicking papillary carcinoma.* A Poorly preserved tissue fragments of follicular epithelium with crowding and overlapping of hyperchromatic nuclei. There is some suggestion of intranuclear inclusions (*arrow*). C. Feat of nodular goiter were present elsewhere in the aspirate. D. Thyroidectomy revealed cystic nodular goiter with papillary change.

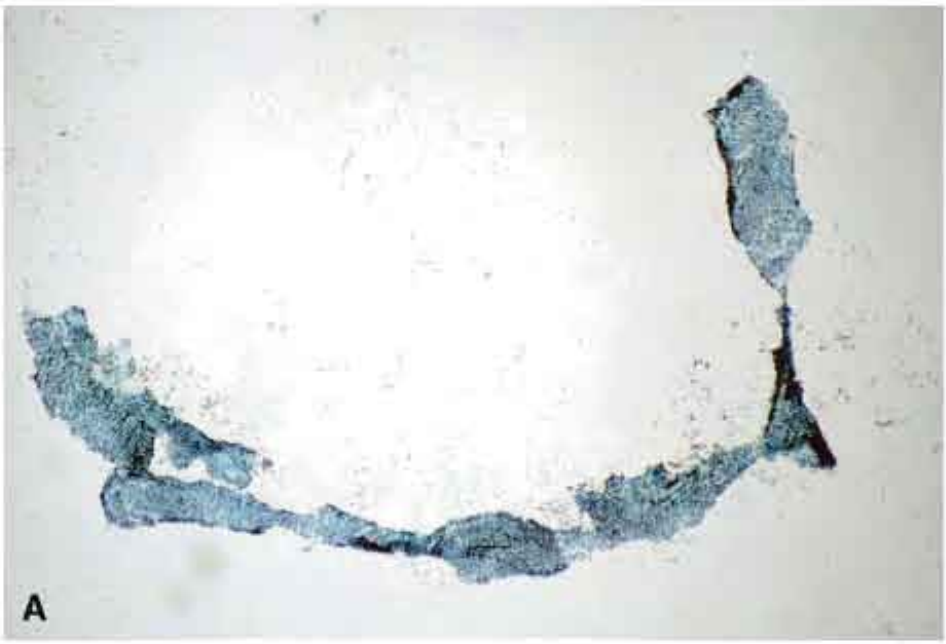
A

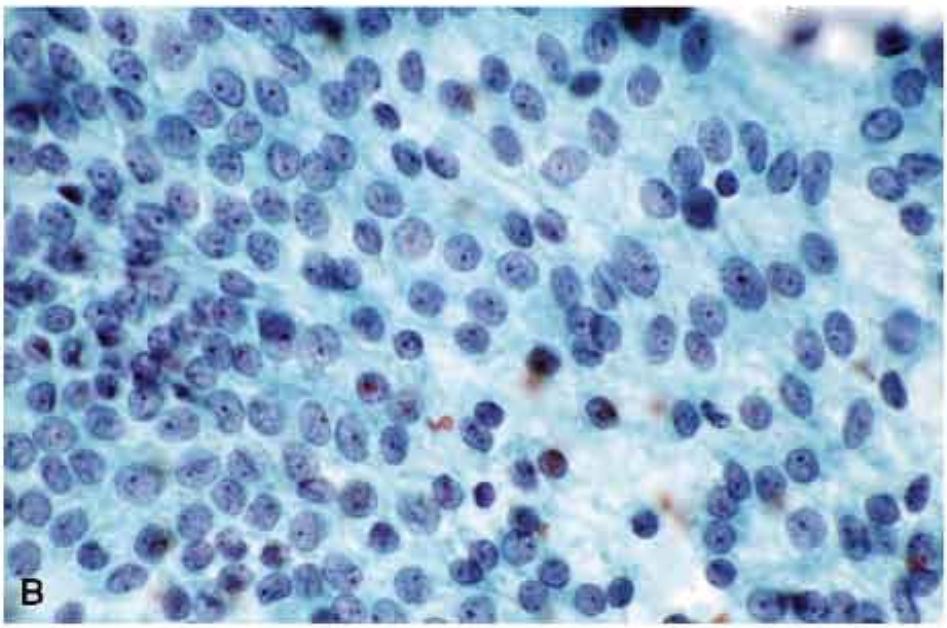
B

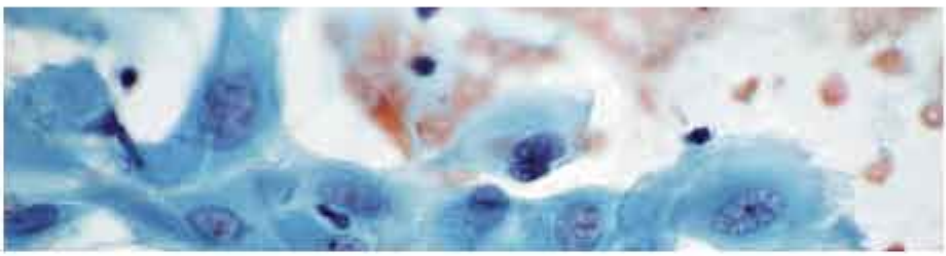

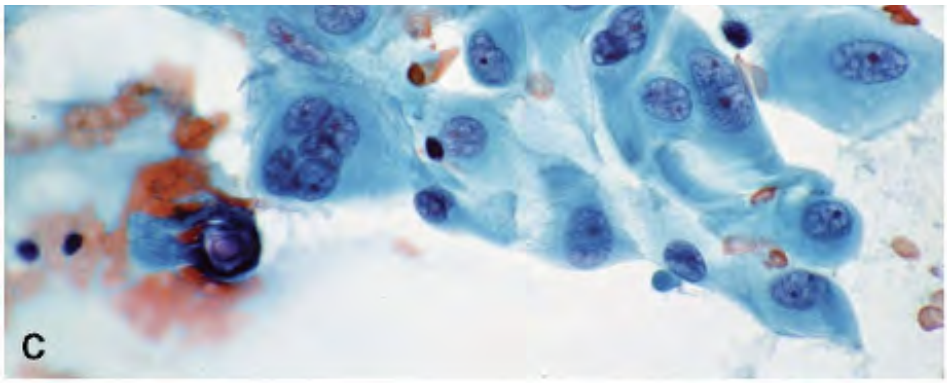

Figure 9.102. *Atypical nuclear changes with post 131I therapy mimicking papillary carcinor* A. Low power showing a very large branching tissue fragment of follicular cells. B. Higher magnification showing a monolayered tissue fragment. The nuclei are enlarged, mildly pleomorphic with frequent micronucleoli and grooves. No inclusions are identified. C. These cells are much larger, pleomorphic, and with abundant dense cytoplasm. Their nuclei are enlarged with nucleoli. Also note the bubbly appearance of the chromatin due to radiation. psammoma body is also present. A papillary carcinoma was suspected. Thyroidectomy failec confirm the malignancy. History of prior radiation was not available at the time of biopsy.

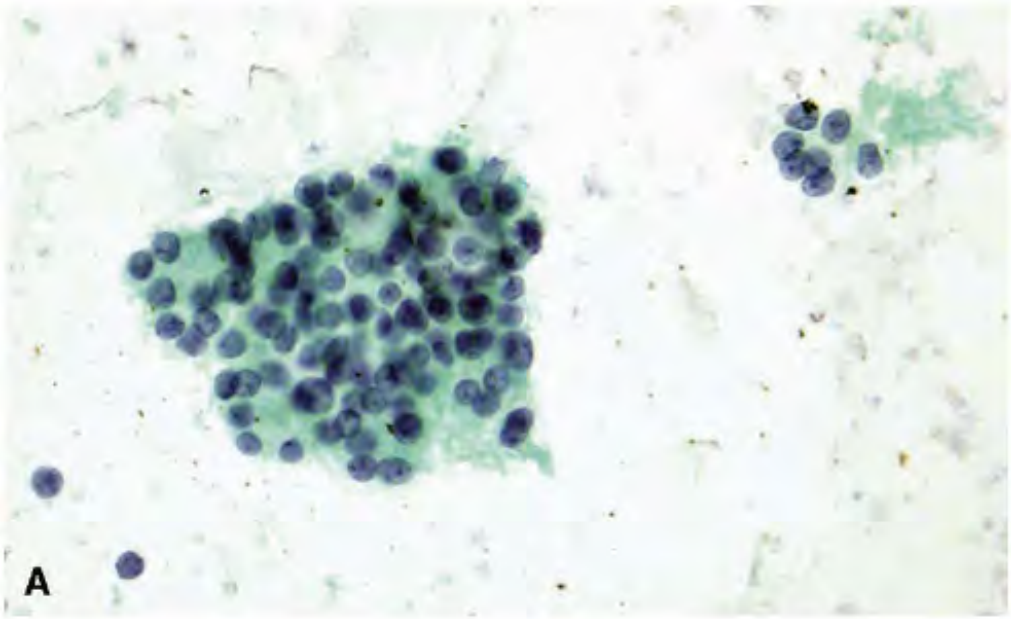

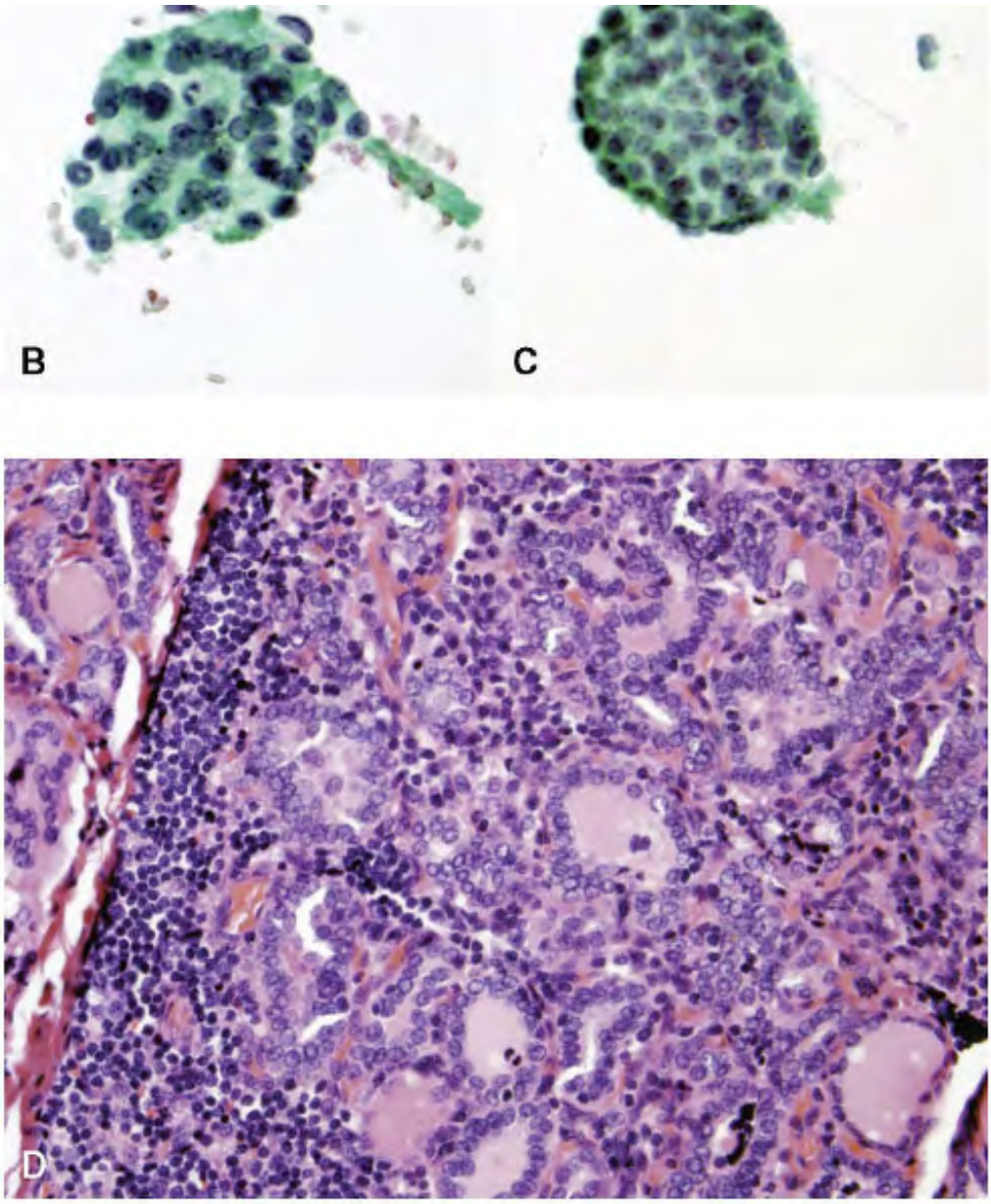

Figure 9.103. *Atypical nuclear changes in Hashimoto's thyroiditis mimicking papillary carcinoma.* Aâ€“C. All three tissue fragments are syncytial with marked crowding and overlapping of nuclei. The chromatin is pale, and some suggest the presence of intranuclear inclusions. No lymphocytes are present in the background. The aspirate was interpreted as suspicious for papillary carcinoma. D. Thyroidectomy revealed Hashimoto's thyroiditis with follicular cell atypia, mimicking changes of papillary carcinoma.

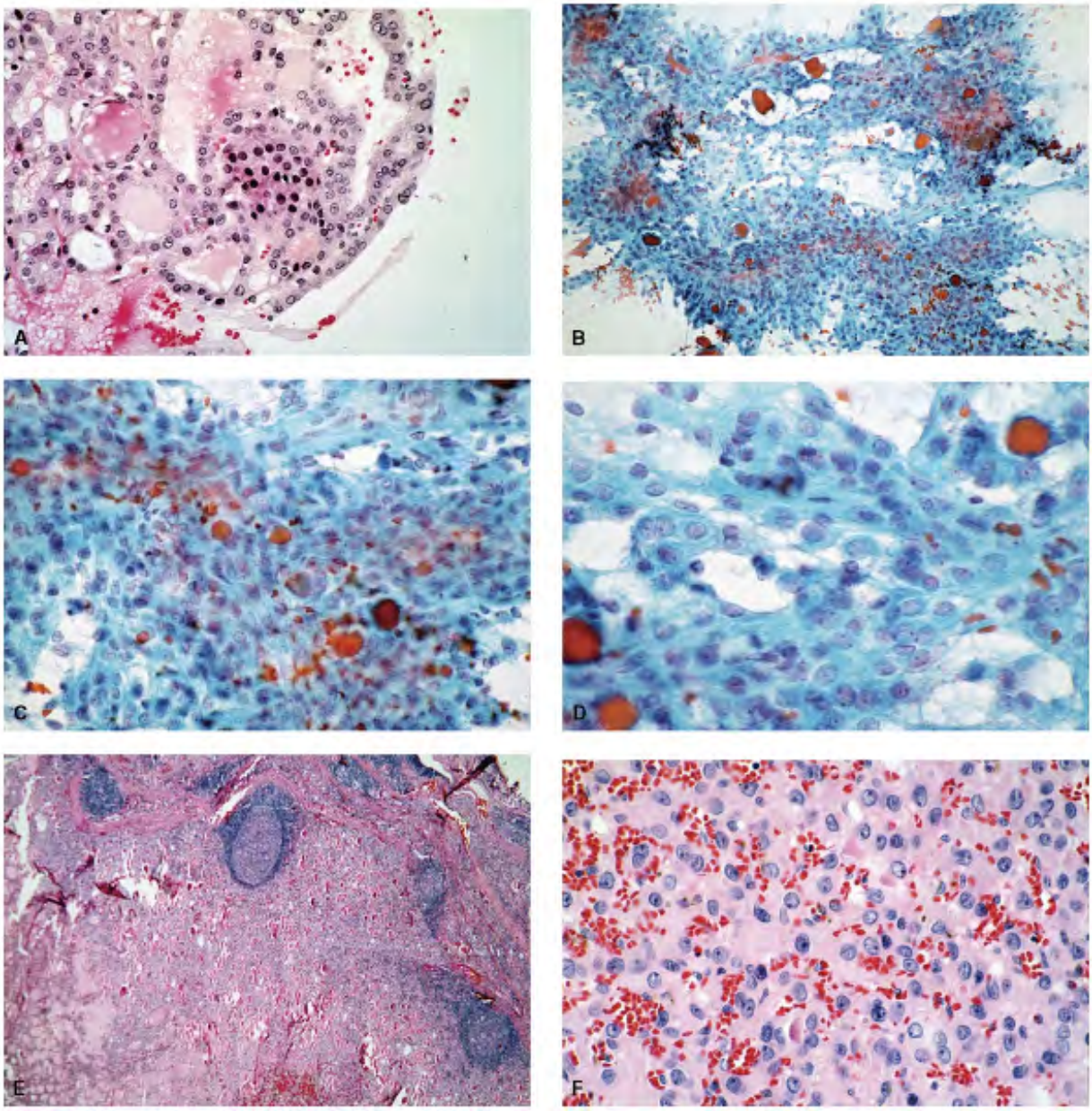

Figure 9.104. Reactive changes in nodular goiter or Hashimoto's thyroiditis with pale nuclei micronucleoli may lead to false-positive diagnosis. A. Histologic section of nodular goiter showing focal area with pale, watery nuclei. B. FNA of a thyroid nodule showed marked cellularity. The tissue fragments of follicular cells are large with branching. C,D. Higher magnification to show nuclei with fine, powdery chromatin and prominent micronucleoli. A papillary carcinoma was suspected. Thyroidectomy showed Hashimoto's thyroiditis with folli cell nuclear atypia. E. Histologic section showing features of Hashimoto's thyroiditis. F. Higl magnification depicting follicular cells with pale chromatin and micronucleoli.

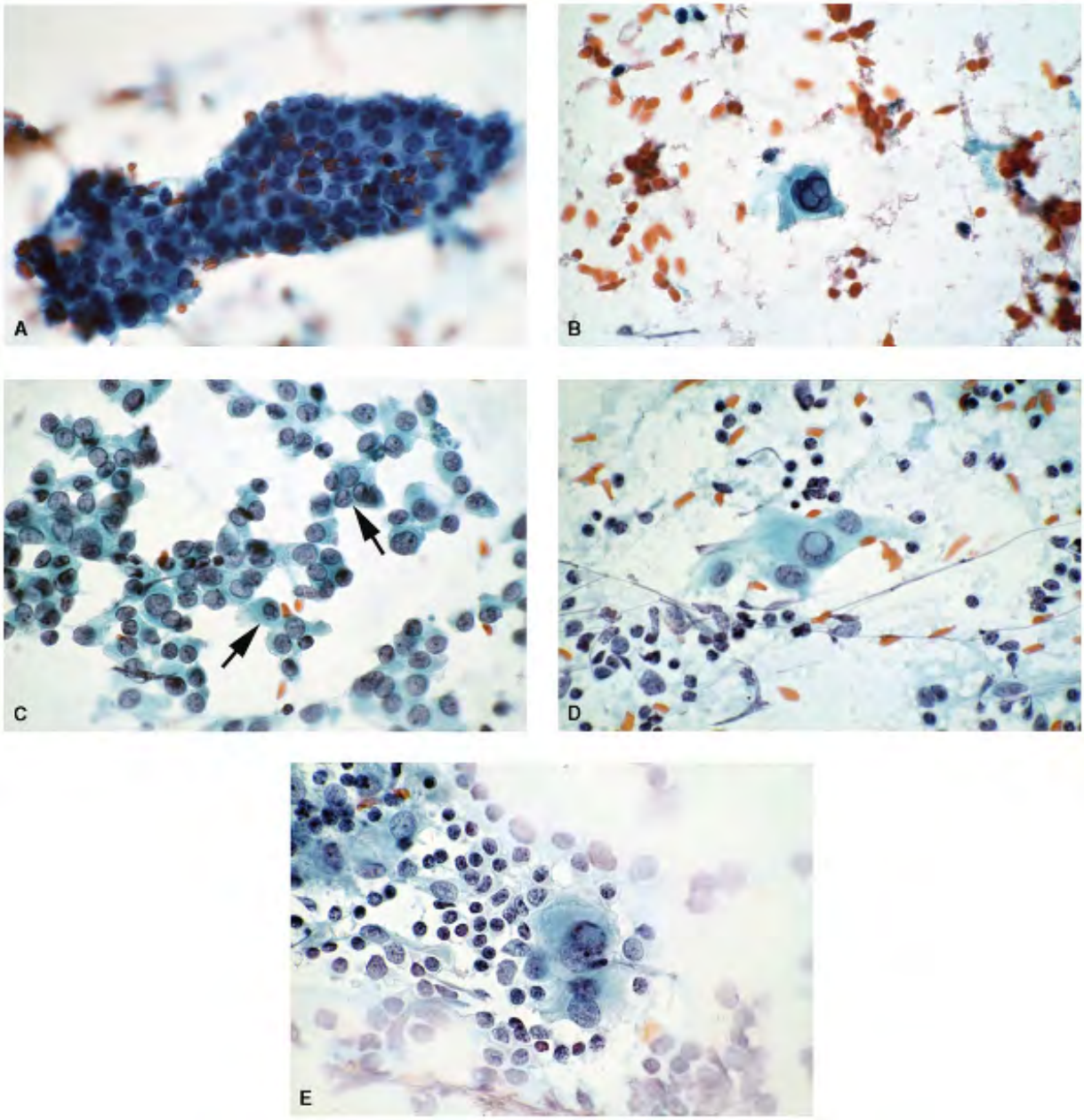

Figure 9.105. The presence of intranuclear inclusion by itself is not a diagnostic criterion fc papillary carcinoma. A. FNA of Hashimoto's thyroiditis with a papillary-like tissue fragment c follicular cells. The nuclei are crowded and overlapped. B. A single cell containing an intranuclear inclusion. A suspicious diagnosis resulted in a thyroidectomy, which showed onl Hashimoto's thyroiditis. C. FNA of Hashimoto's thyroiditis interpreted as suspicious for a folli variant of papillary carcinoma. Note the intranuclear inclusions (*arrows*). Lymphoid cells ar seen in this field. Papillary carcinoma was not confirmed. D. An intranuclear inclusion shoul sharp and bordered by condensed chromatin, as seen here. E. The follicular cell depicted in

image shows a suggestion of intranuclear inclusion that blends with the peripheral chromati and probably represents a degenerative change.

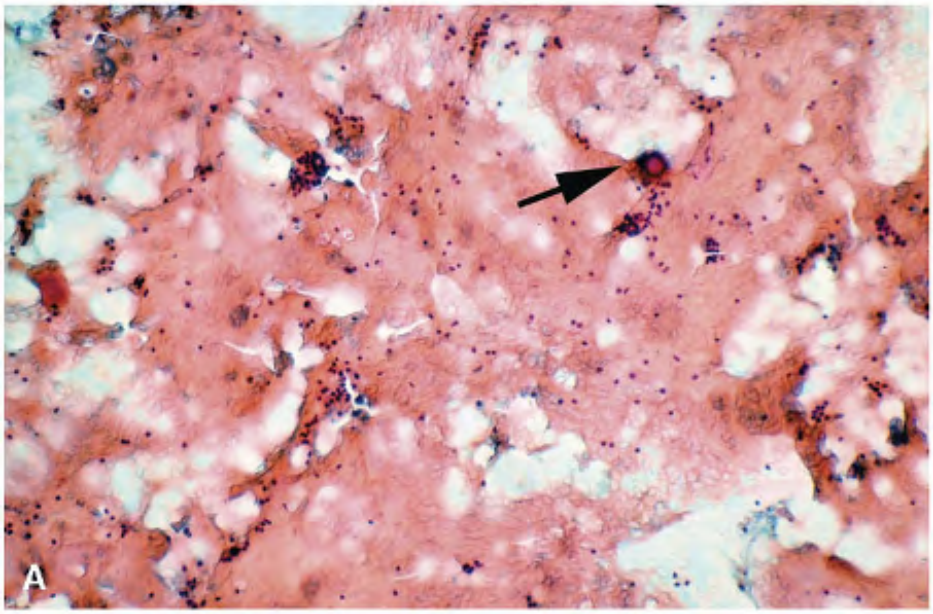

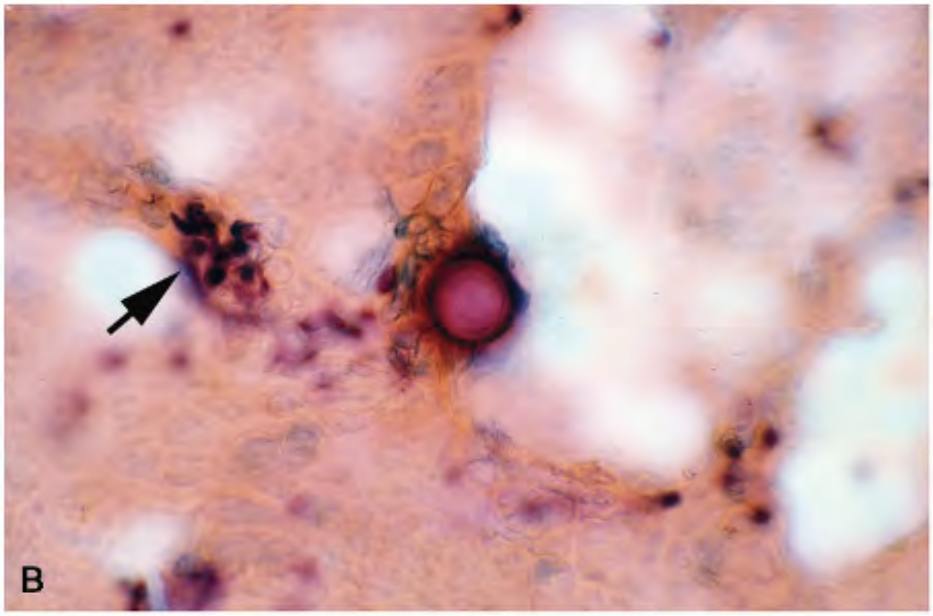

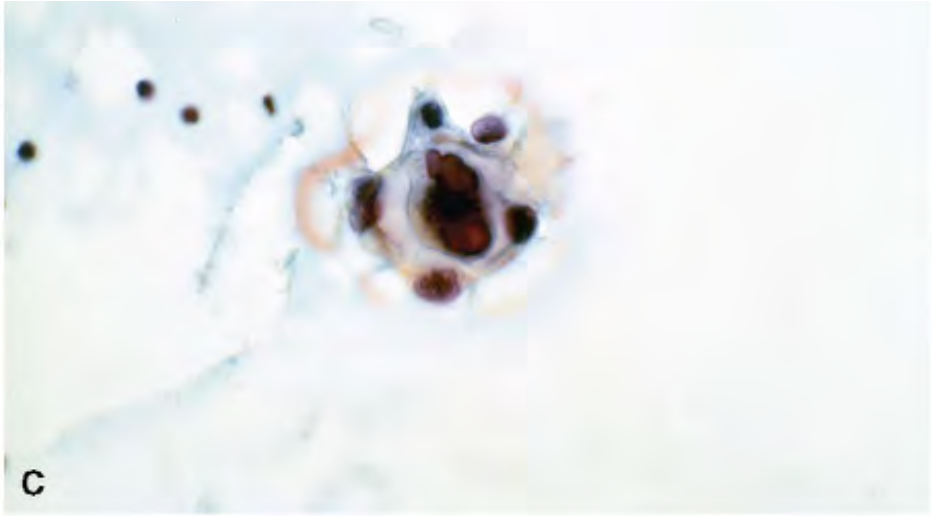

Figure 9.106. *Significance of psammoma bodies* . A. FNA of a nodular goiter. This low-powe view shows abundant colloid, few groups of follicular cells, and a small psammoma body (*ar*), low power. B. Higher magnification highlighting the psammoma body. The follicular cell r are small with compact chromatin. Note another group of benign follicular cells (*arrow*). C. different field from the same case showing a single psammoma body incorporated in a tissue fragment of benign follicular cells. The background features were those of a nodular goiter the aspirate was considered benign. A regular follow-up and possibly a repeat biopsy should recommended.

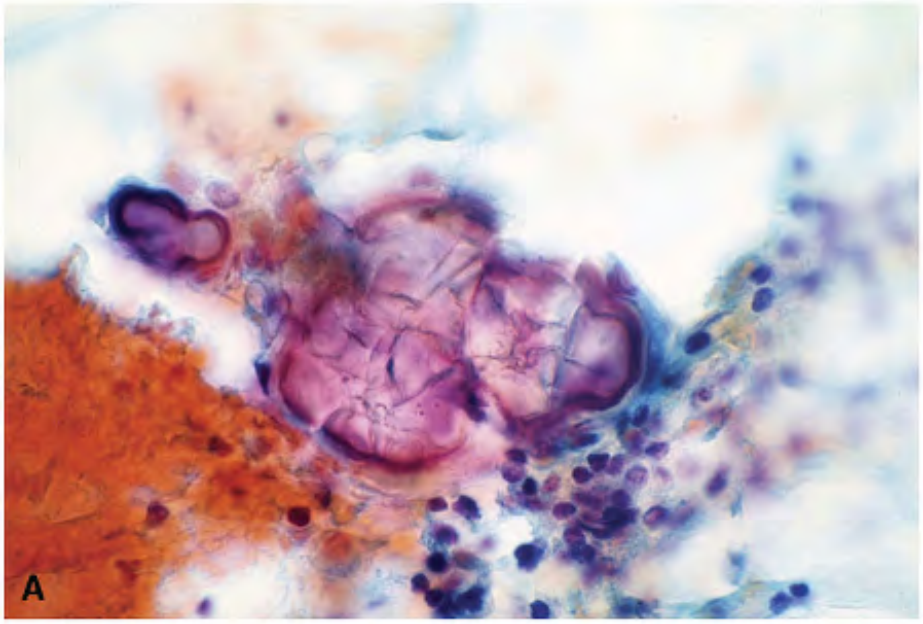

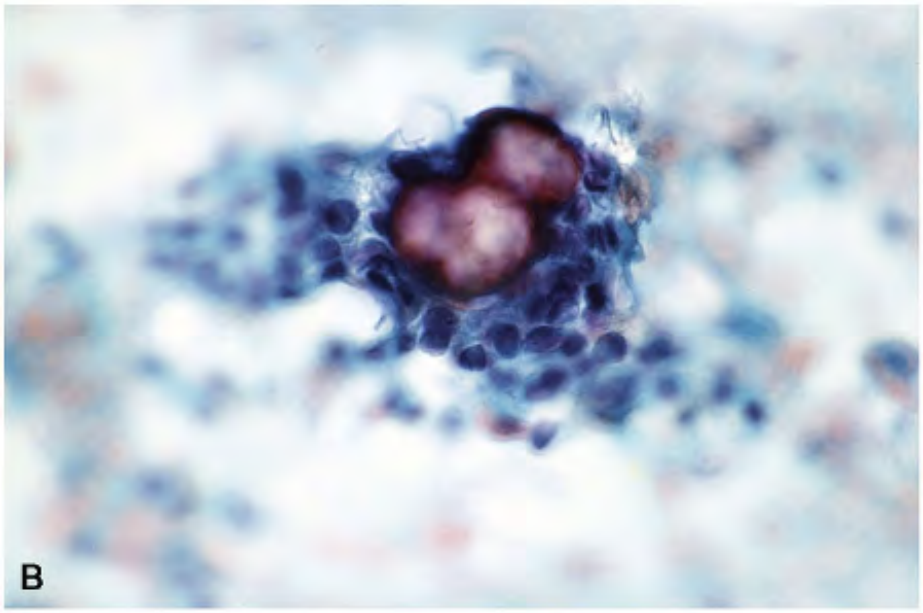

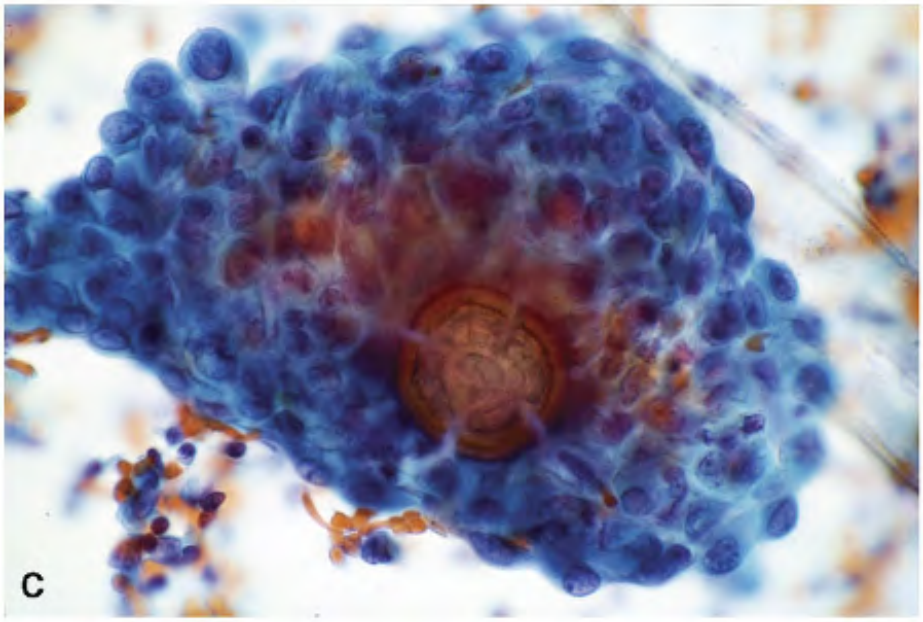

Figure 9.107. A. FNA of a nodular goiter showing a tissue fragment of benign follicular cells containing small nuclei with compact chromatin, incorporating three psammoma bodies. B. of a different case of nodular goiter depicting psammoma bodies incorporated in a tissue fragment of benign follicular cells. C. Psammoma body from a papillary carcinoma for comparison. The component cell nuclei exhibit features of papillary carcinoma.

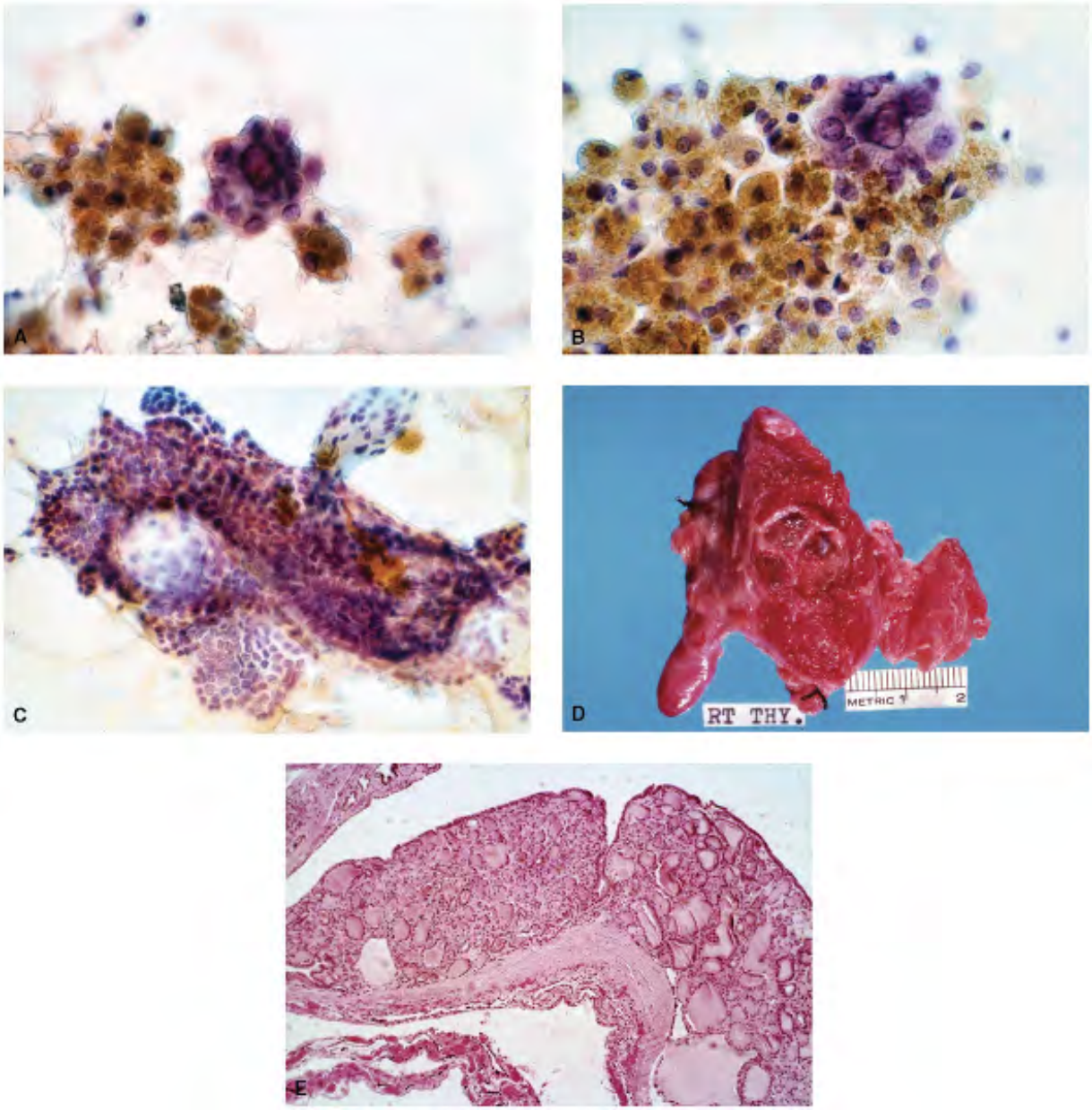

Figure 9.108. An example of a false-positive diagnosis of papillary carcinoma that was base the presence of psammoma bodies. A,B. These two images depict degenerating follicular ce containing hemosiderin pigment and psammoma bodies. Note the absence of nuclear featur papillary carcinoma. C. A large tissue fragment of benign follicular cells with papillary-like configuration. The component cells are arranged in honeycomb fashion and have small nucl with compact chromatin. A suspicious diagnosis for papillary carcinoma was rendered. D. Thyroidectomy revealed a multinodular goiter with cystic degeneration. There was no papill carcinoma. E. Histologic section of the nodular goiter.

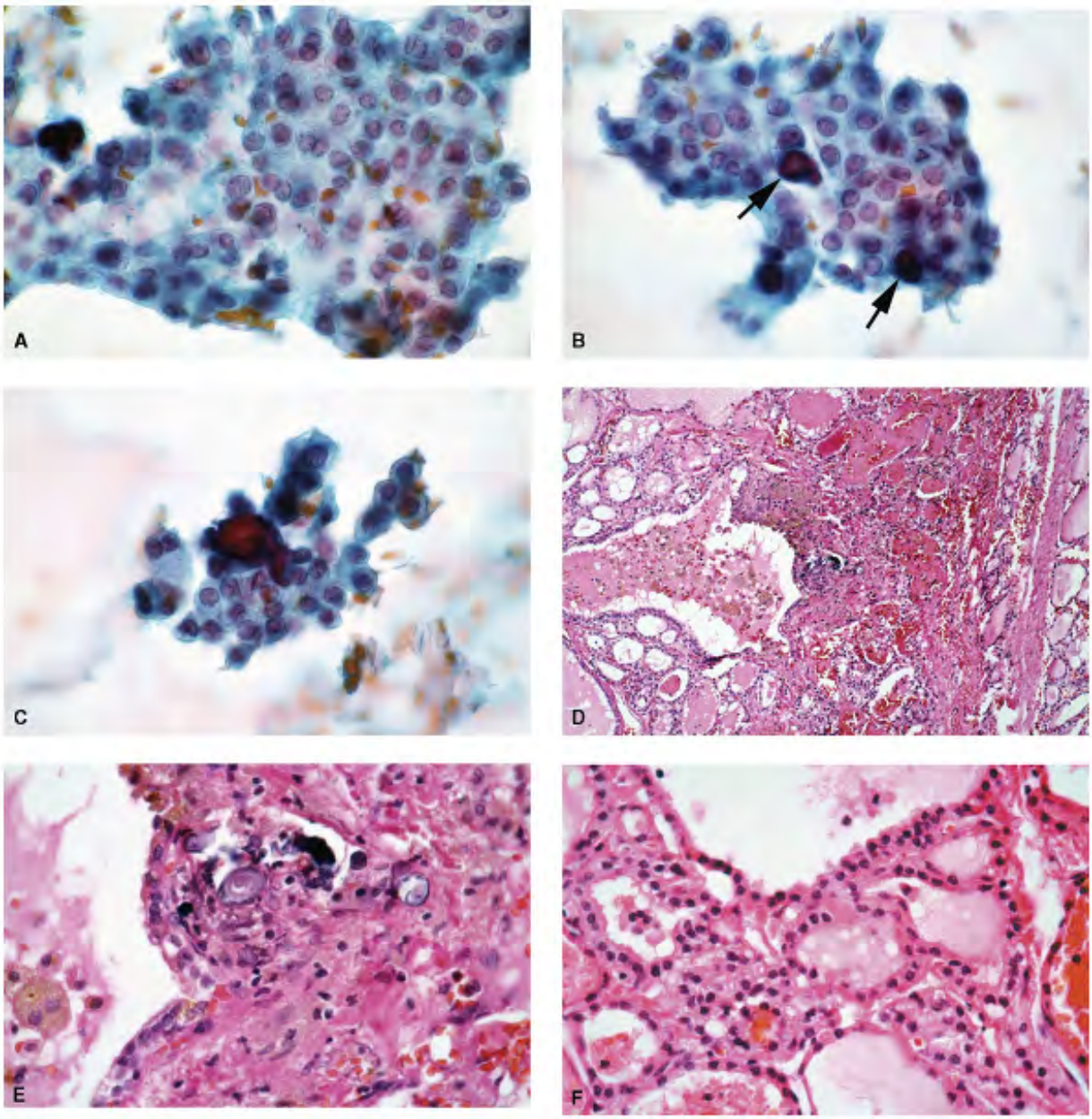

Figure 9.109. Psammoma body in aspirate of follicular adenoma. FNA of a follicular adenom with monolayered tissue fragments and psammoma bodies. A,B. These tissue fragments of follicular epithelium are syncytial type with follicular pattern. The nuclei are enlarged with granular chromatin and contain micronucleoli. Grooves or inclusions are not present. Note s psammoma bodies (*arrows*). C. Same aspirate showing a syncytial tissue fragment with a psammoma body. Although micronucleoli are present, no grooves or inclusions are present. Thyroidectomy revealed an encapsulated follicular adenoma with cystic change. E. Higher magnification to demonstrate multiple small psammoma bodies surrounded by hemosiderin-

containing histiocytes. F. Histologic section of the follicular adenoma showing follicles lined epithelium and lacking features of papillary carcinoma.

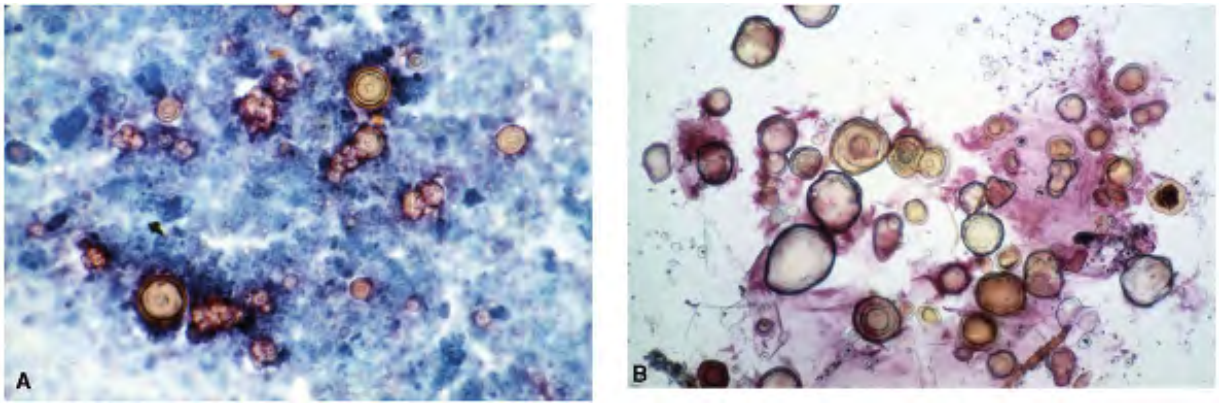

Figure 9.110. Naked psammoma bodies are not diagnostic of papillary carcinoma. A. FNA of nodular goiter showing multiple naked psammoma bodies. B. FNA of a papillary carcinoma. Naked psammoma bodies can also occur in papillary carcinoma. To be diagnostic, they must incorporated in tissue fragments with cells presenting nuclear features of papillary carcinom

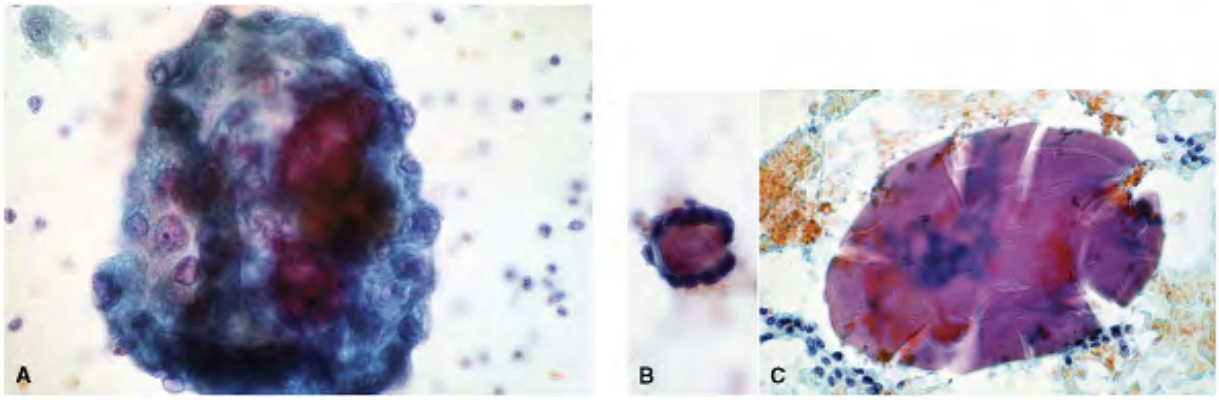

Figure 9.111. Mimics of psammoma body. A. FNA of a nodular goiter with extensive HÃ¼rth cell metaplasia and cystic degeneration. This tissue fragment of follicular cells contains an inspissated colloid-simulating psammoma body. The follicular cell nuclei contain micronucle but lack grooves and inclusions, B. Dense colloid within a microfollicle mimicking a psammo body. C. Inspissated colloid with cracks resembling a naked psammoma body.

PAPILLARY CARCINOMA VERSUS PAPILLARY HYPERPLASIA; DIFFERENTIAL DIAGNOSIS OF PAPILLARY TISSUE FRAGMENT

Papillary or papillary-like architecture can be seen in several conditions affecting the thyroi gland that present clinically as cold nodules (Figs. 9.89 , 9.90 , 9.91 , 9.92 , 9.93 and 9.94 , Table 9.20).215 Fine-needle aspirates of thyroid nodules of any of these diseases yield papi tissue fragments of follicular epithelium. Their occurrence in lesions other than papillary carcinoma, however, is infrequent. The papillary tissue fragment is one of the most commo features in the cytologic material of papillary carcinoma. Of 329 papillary carcinomas, 283 aspirates showed either only papillary or predominantly papillary tissue fragments (Table 9. Such a pattern was not appreciated in only 46 cases.

1. Papillary carcinoma
2. Papillary hyperplasia in nodular goiter
3. Papillary change in follicular adenoma
4. Hashimoto's thyroiditis

[a] Although papillary hyperplasia is seen in Graves disease, it is not included here as no fine-needle biopsies were performed on functioning nodules.

TABLE 9.20 TISSUE FRAGMENTS WITH PAPILLARY OR PAPILLARY-LIKE ARCHITECTURE IN CYTOLOGIC SAMPLES[a]

Despite its frequency, the diagnosis of papillary carcinoma based on papillary architecture a is difficult both cytologically and histologically. This problem is covered in several articles t offer criteria helpful for differentiating between benign and malignant lesions on a histologi basis.22 Carcangiu et al.20 stressed the cytologic criteria in the diagnosis of papillary carcinoma. The cytomorphology of the cells forming the papillary tissue fragment is critical important. Papillary hyperplasia occurring in follicular nodules or lymphocytic thyroiditis contitutes an important diagnostic pitfall.215 , 216 , 217 , 218

Papillary Hyperplasia in Follicular Nodules

Papillary hyperplasia can occur in follicular adenoma or in an adenomatous nodule with hyperplastic change. These hyperplastic nodules are well circumscribed, with or without

encapsulation (Figs. 9.89 , 9.90 , 9.91 , 9.92 , 9.93 and 9.94), and may show cystic change centrally. The follicular epithelium is hyperplastic papillary, with the papillae directed towa the center of the nodule. The papillae may be edematous and contain follicles. Their nuclei

are basally located, round, and do not exhibit the cytologic criteria of papillary carcinoma. encountered 11 cases of follicular nodules with papillary hyperplasia, 5 interpreted cytologi as diagnostic of papillary carcinoma and 6 as suspicious. The patients ranged from 14 to 51 y of age; 10 were female and 1 was male. The aspirates yielded fluid in 4 cases.

The diagnosis of papillary carcinoma was based on the presence of one or more of the follov features: papillary or syncytial tissue fragments; mildly enlarged nuclei with powdery to gra chromatin; and micronucleoli, intranuclear inclusions (1/11), nuclear grooves (1/11), and a psammoma body (1/11). None of these cases showed the minimal criteria

of papillary carcinoma. Furthermore, 5 specimens were only marginally cellular. Thyroidect in all 11 patients failed to show papillary carcinoma. Four were follicular adenomas and 7 w nodular goiter (Table 9.21).

Cystic (fluid aspirated)
4/11
Nuclear chromatin
Cellularity
  Powdery
1/11
  Hypercellular
1/11
  Finely granular
7/11
  Adequate
5/11
  Coarsely granular
3/11
  Marginal
5/11

Micronucleoli
11/11
Tissue fragments
Nuclear groove
1/11
Papillary
8/11
Monolayered
5/11
Intranuclear inclusion
1/11
Syncytial
4/11
Background
Follicular cells (round to cuboidal)
11/11
Histiocytes
8/11
Nuclei
Bloody
5/11
Mildly enlarged
7/11
Moderately enlarged
2/11

TABLE 9.21 CYTOLOGIC FEATURES IN 11 CASES OF PAPILLARY HYPERPLASIA IN FOLLICULAR NODULES

The cytologic differentiation between benign and papillary fragments and papillary carcinor listed in Table 9.22 .

Cellularity
Generally high

Generally high
Generally high
Presentation
Papillary tissue fragments
Papillary tissue fragments
Papillary tissue fragments
Architecture of tissue
fragments
Component cells with
honeycomb arrangement;
well-defined cell borders;
nuclear polarity maintained;
peripheral palisading of
nuclei present
Syncytial arrangement with
crowding and overlapping
of nuclei, altered polarity
peripheral palisading of
nuclei; central fibrovascular
core may be visible
Honeycomb arrangement; well-
defined cell borders; nuclear polarity
maintained, peripheral palisading of
nuclei may be present
Nucleus
size
Small uniform to slight
enlargement (7â€“9 Âµm) round;
finely granular chromatin
Enlarged, pleomorphic in size,
round, dusty powdery chromatin
Slightly enlarged; uniform, round,
finely granular chromatin
Nucleolus

Multiple micronucleoli
Multiple micro/macronucleoli
Miconucleoli
Groove
Rare in nodular goiter;
absent in adenoma
Present
Absent
Intranuclear
inclusions
Rare in nodular goiter;
absent in follicular
adenoma
Present
Rare
Psammoma Bodies
Rare
25% of the cases
Rare
Background
histiocytes with
Â±
Â±
-
or without
hemosiderin
Multinuclear
giant cells
-
Present
Present
lymphoid cells
-
Â±

+

TABLE 9.22 CYTOPATHOLOGIC DIFFERENTIATION BETWEE PAPILLARY HYPERPLASIA AND PAPILLARY CARCINOMA

Papillary Carcinoma versus Follicular Hyperplasia: Differential Diagnosis of Monolayered Tissue Fragments

Monolayered tissue fragments of carcinoma cells (Figs. 9.95 , 9.96 , 9.97 , 9.98 and 9.99) w seen in 60% of the aspirates of papillary carcinoma in our series (Table 9.17). As described earlier, they probably represent either the papillary fronds or large follicles seen en face. B single layered, they exhibit a two-dimensional pattern and share a morphologic similarity to tissue fragments of nodular goiter. An overwhelmingly cellular aspirate of hyperplastic goite with a myriad of monolayered tissue fragments may be mistaken for papillary carcinoma, especially when viewed under a low-power objective (Figs. 9.95A and 9.96A). However, clos examination will reveal a different cytomorphology. The monolayered tissue fragments of nodular goiter have a honeycomb pattern, with well-defined cell borders; uniform, small nu with regular polarity; and compact chromatin. They do not show all of the nuclear features exhibited by monolayered tissue fragments of cancer cells seen in papillary carcinoma (Fig. 9.95C , Table 9.23).

Presentation
Large number of monolayered tissue fragments; scant or absent colloid
Large numbers of monolayered tissue fragments; colloid variable

Large numbers of monolayered tissue fragments; colloid variable in blobs or strings

Large number of monolayered tissue fragments; scant to absent colloid, lymphoid cells in the background

Component follicular cells

Honeycomb arrangement with well-defined cell borders; nuclear polarity maintained

Honeycomb arrangement with well-defined cell borders; some crowding and overlapping; with nuclear polarity maintained or slightly altered

Lack of honeycomb arrangement; some crowding and overlapping; cell borders may or may not be well-defined; altered nuclear polarity

Honeycomb arrangement with well-defined cell borders; nuclear polarity either maintained or slightly

altered
Cell size
Normal
Normal to slightly
increased
Slight to considerable
enlargement
Slightly enlarged
Nucleus
Normal, uniform 7â€“9 Âµm;
chromatin finely granular,
evenly distributed;
miconucleoli Â±
Slightly enlarged
uniform; chromatin
finely granular,
evenly distributed;
miconucleoli Â±
Considerably enlarged; dusty
powdery to finely granular
chromatin; single/multiple
micronucleoli/
macronucleoli
Slightly enlarged;
finely granular chromatin;
multiplemicronucleoli
Intranuclear
inclusions
Extremely rare
Extremely rare
Present
Rarely present
Nuclear grooves
Â±

Absent

Present

Â±

Cytoplasm

Variable, pale

Variable, generally scant and pale

Variable, may be abundant and dense

Variable, pale

Psammoma bodies

Rarely present

Rarely present

Present in up to 25% of the cases

Rarely present

Background

Multinucleated giant cells absent

Multinucleated giant cells absent

Multinucleated giant cells present

Multinucleated giant cells may be present; features of Hashimoto's thyroiditis present

Hyperplastic Nodular Goiter	Simple Follicular Adenoma	Papillary Carcinoma	Hashimoto's Thyroi

TABLE 9.23 CYTOPATHOLOGIC DIFFERENTIATION BETWEE MONOLAYERED TISSUE FRAGMENTS IN THYROID ASPIRATE

Monolayered tissue fragments may also be seen in simple follicular adenomas or Hashimoto's thyroiditis with papillary hyperplasia, but they lack the typical nuclear morphology of papill carcinoma (Figs. 9.98C and 9.99).

FALSE-POSITIVE DIAGNOSIS OF PAPILLARY CARCINOMA DUE SQUAMOUS METAPLASIA

Squamous metaplasia in both papillary carcinoma and nodular goiters is not a frequent occurrence in cytologic samples. When encountered in cytologic samples, this may cause a diagnostic dilemma (Fig. 9.100)

P.196

FALSE-POSITIVE CYTOLOGIC DIAGNOSIS OF PAPILLARY CARCINOMA DUE TO ATYPICAL NUCLEAR FEATURES

The nuclei of papillary carcinoma cells present a characteristic morphology consisting of enlargement, pale to powdery chromatin, micro/macronucleoli, grooves, and inclusions. On more but not all of these features may be present in benign diseases and may lead to false-positive interpretation. Nodular goiter is a prime example. Degeneration, hemorrhage, and cystic changes result in retrogressive as well as reactive/reparative changes that mimic nucl morphology of papillary carcinoma cells. Hyperplasia in nodular goiters or Hashimoto's thyro may show micronucleoli as well as

P.197

P.198

P.199

pale chromatin. Nuclear grooves are also rarely observed in nodular goiters. Intranuclear inclusions may occasionally be seen in follicular cell nuclei in nodular goiters and in Hashim thyroiditis. These diagnostic difficulties are illustrated in Figures 9.101 , 9.102 and 9.103 .

SIGNIFICANCE OF INTRANUCLEAR INCLUSIONS

Intranuclear cytoplasmic inclusions were first noted by SÃ¶derstrÃ¶m and Bjorklund52 to be

important criterion of malignancy in fine-needle aspirate smears of papillary carcinoma of t thyroid. They were present in 308 of 329 cases (93%) of papillary carcinoma in our series. LÃ¶whagen and Sprenger45 found them in 5 of 10 (50%), Christ and Haja48 in 20 of 22 (91%) Frable41 in 7 of 7 (100%). Intranuclear inclusions are often considered synonymous with the ground-glass or "Orphan Annie" appearance of the nuclei of papillary thyroid carcinoma. However, ground-glass or watery nuclei is more or less a generalized finding in papillary carcinomas involving the entire nucleus due to finely granular, powdery chromatin. Intranuc inclusions are morphologically different, seen in both cytologic and histologic sections, but i small proportion of cells. Ultrastructurally, they are seen as membrane-bound, spheroidal masses of cytoplasm intruding into the nuclei27 , 28 that contain cytoplasmic organelles.

Although a frequent feature of papillary carcinoma, intranuclear inclusions are also present other thyroid malignancies. They are a remarkably consistent finding in hyalinizing trabecul adenomas, medullary carcinoma,43 and are sometimes seen in HÃ¼rthle cell carcinomas49 well as in anaplastic carcinoma. Glant et al.50 reported their presence in follicular neoplasr both adenoma and carcinoma, and Droese42 found them in benign, nonneoplastic condition have seen three aspirates from Hashimoto's thyroiditis with follicular cell nuclei containing cytoplasmic

inclusions (Fig. 9.105). Intranuclear cytoplasmic inclusions are not only present in cells of thyroid neoplasms but are also observed in several different types of malignancies, includin malignant melanoma, liver cell carcinoma, adenocarcinoma of the lung, breast carcinomas, soft-tissue sarcomas.

Intranuclear cytoplasmic inclusions are diagnostically important only when present in a prop setting. In thyroid aspirates, syncytial-type tissue fragments of any architectural pattern, w nuclei containing powdery chromatin and cytoplasmic inclusions, may be diagnostic of papil carcinoma. On the other hand, aspirates showing only isolated cells with intranuclear inclus may be a medullary carcinoma203 of the thyroid, a papillary carcinoma (see Chapter 12), o benign lesion. For this reason, a diagnosis of papillary carcinoma should never be based on t presence of intranuclear cytoplasmic inclusions alone.

SIGNIFICANCE OF PALE, WATERY NUCLEI

Hapke and Dehner29 described the incidence and discussed the significance of optically clea

nuclei in thyroid lesions, stating that they occur in a variety of nonneoplastic and neoplastic conditions (Figs. 9.103 to 9.104). They concluded that the mere presence of optically clear nuclei must not be considered diagnostic of papillary carcinoma. Aspirates from nodular goi Hashimoto's thyroiditis, and follicular adenoma may all show a few groups of follicular cells dusty, powdery chromatin and micronucleoli resembling the cells of papillary carcinoma. However, these pale nuclei lack the other features (e.g., grooves and inclusions) are not diagnostic of papillary carcinoma.

SIGNIFICANCE OF NUCLEAR GROOVES

A nuclear groove or crease is a frequent finding in the cells of papillary carcinoma.30 , 54 , 56 , 57 , 58 , 59 Seen as a linear crease or a fold along the long axis of the nucleus (Fig. 9.1 it probably represents an irregular infolding of the nuclear membrane, as observed ultrastructurally.27 , 28 Its presence is by no means diagnostic of papillary thyroid carcinom even though some authors have reported it in 100% of their cases reviewed.57 Studies have shown nuclear grooving in cells of other nonneoplastic and neoplastic thyroid lesions.57

P.202

P.203

FALSE-POSITIVE CYTOLOGIC DIAGNOSIS OF PAPILLARY CARCINOMA DUE TO THE PRESENCE OF PSAMMOMA BODIES

Psammoma bodies (Fig. 9.24) are considered a pathognomonic feature of papillary carcinoma.22 The reported incidence in histologic material varies from 40% to 60%, but they not seen with such frequency in cytologic material (Table 9.16). We found them in 20% of t aspirates from papillary carcinomas. Psammoma bodies are so rarely seen in benign disorder the thyroid35 , 225 , 226 , 227 , 228 , 229 that their presence in an otherwise normal-appea thyroid gland or even in a cervical lymph node should be regarded as evidence for the prese of carcinoma until proved otherwise.13 Because of

P.204

P.205

P.206

P.207

P.208

such views, the presence of psammoma bodies in aspirates of thyroid nodules causes a diagr dilemma if other cytologic features of papillary carcinoma are not present. Can a diagnosis

papillary carcinoma be made unequivocally in the above situations? Should a surgical procec be recommended to confirm the diagnosis of papillary carcinoma? As indicated earlier, mini criteria for the diagnosis of papillary carcinoma do not include a psammoma body. Initially, placed considerable emphasis on psammoma bodies alone in making a diagnosis of papillary carcinoma, but later it was noted that they might not be of diagnostic importance in the absence of other features of papillary carcinoma. "Naked" psammoma bodies (Fig. 9.110) or rare psammoma body incorporated in a tissue fragment without minimal criteria of papillary carcinoma must be interpreted with

P.209
P.210
P.211
P.212

caution, as these may be seen in nodular goiter. Two of our false-positive cases fell in to thi category (Table 9.11). A diagnosis of suspected papillary carcinoma was given in nine cases solely because of the presence of psammoma bodies. Five patients underwent surgery, with final diagnosis of adenomatous goiter. The other four cases had a diagnosis of nodular goiter based on the results of a repeat fine-needle or large-needle biopsy. All nine cases had featu of nodular goiter in the background, and the typical cytomorphology of papillary carcinoma either lacking or insufficient. The cellular material exhibited insufficient criteria for the diagnosis of papillary carcinoma (Table 9.13). A psammoma body is diagnostic only if it is incorporated in a tissue fragment of follicular cells that exhibit minimal criteria of malignar Table 9.24 lists the difference between psammoma bodies seen in papillary carcinoma and t seen in nodular goiters.

Number of psammoma bodies
Generally an isolated finding or few
in numbers; multiple psammoma bodies
in a single tissue fragment uncommon
Usually in significant numbers
when present; multiple psammoma
bodies in a single tissue fragment common
Naked forms
Present
Present

Size
Usually small
Variable, small to large
Characteristics of tissue fragment
incorporating the psammoma
body(ies)
Component cells of the tissue
fragment have small uniform nuclei
with compact to finely granular
chromatin, lack the typical nuclear
features of papillary carcinoma;
syncytial arrangement absent.
Syncytial arrangement of cells
with enlarged nuclei demonstrating
the typical features of papillary carcinoma
Calcific Debris in the Background
Â±
Â±
Background
Background features of nodular goiter
Features of papillary carcinoma

Psammoma Bodies in Nodular Goiter	Psammoma Bodies in Papillary Carcinoma

TABLE 9.24 DIFFERENTIATING FEATURES BETWEEN PSAMMOMA BODIES IN NODULAR GOITER AND PAPILLARY CARCINOMA

A psammoma body can be mimicked by dense, inspissated colloid within a follicle or becaus its tendency to crack in a linear fashion (Fig. 9.111).

Having described in detail the cytopathologic features of papillary carcinoma, the diagnosti difficulties, and analyzing the errors, the author would like to pose a philosophical question surgical pathology always the gold standard against which an accuracy of cytologic diagnosis

papillary carcinoma is judged? Is it taken for granted that the histologic diagnosis rendered every case is accurate?

Figures 9.112 , 9.113 , 9.114 and 9.115 represent some such examples. The reader is reques to make his or her own judgment.

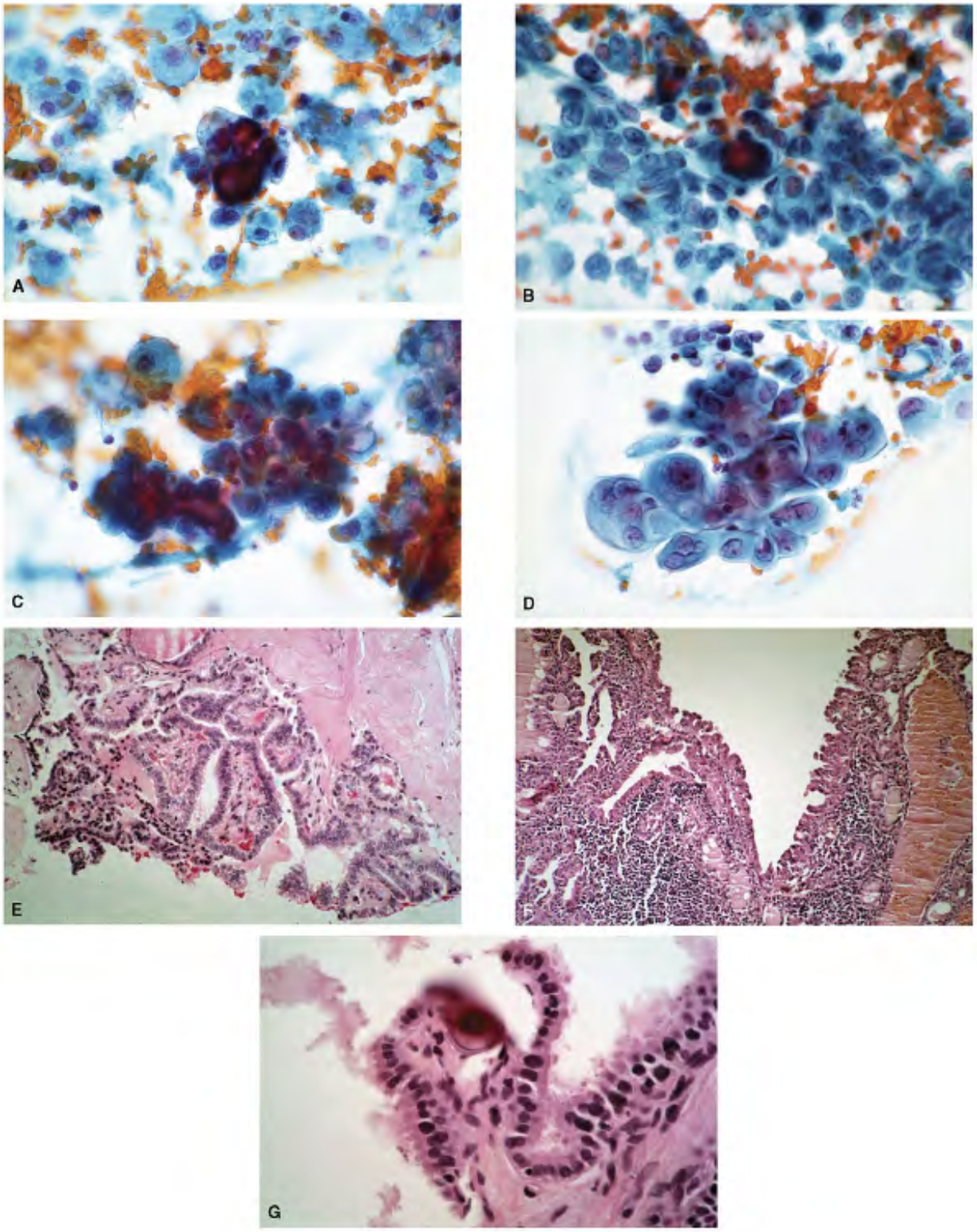

Figure 9.112. *Is surgical pathology always a gold standard? Positive cytology for papillary carcinoma, histology interpreted as benign.* Aâ€“D. FNA of a thyroid nodule. These four ima depict syncytial tissue fragments of follicular cells with psammoma bodies. The pleomorphic

enlarged nuclei show features of papillary carcinoma. Note the intranuclear inclusions and grooves. The background contains a large number of histiocytes, suggesting a cystic lesion. T cytologic diagnosis was papillary carcinoma. Thyroidectomy at another hospital was interpre as Hashimoto's thyroiditis. E. Histologic section showing a cystic papillary carcinoma. F. Ano section revealing lymphoid infiltrate in the wall of the cystic cavity showing papillary carcin lining the cyst. G. Higher magnification of the papilla with psammoma body. Lack of typical nuclear features in this lining epithelium lead the pathologist to interpret this lesion as beni Is this lesion Hashimoto's thyroiditis or papillary carcinoma in the background of thyroiditis?

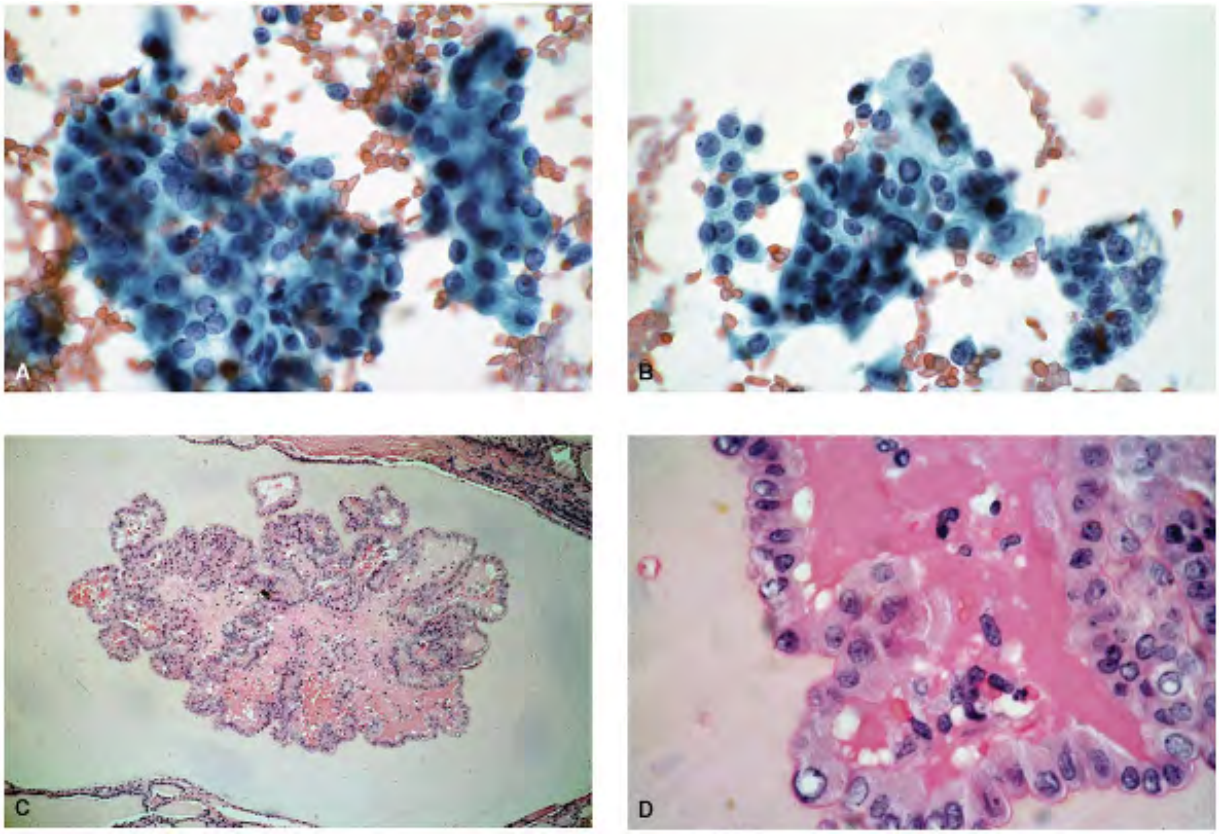

Figure 9.113. *Is surgical pathology always a gold standard? Positive cytology for papillary carcinoma, histology interpreted as benign.* FNA of a thyroid nodule. A,B. FNA of a cold noc These syncytial tissue fragments of follicular cells. The nuclear chromatin is granular with occasional intranuclear inclusions and micronucleoli. Cytologic interpretation was suspicious papillary carcinoma. Thyroidectomy revealed a small cystic lesion in the background of nodu goiter. C. Histologic section showing the cystic cavity containing a detached, small but comp branching papillary structure. D. Higher magnification demonstrates pale, watery nuclei wit

intranuclear inclusions. The final histologic diagnosis was nodular goiter. Does this lesion represent a microcarcinoma?

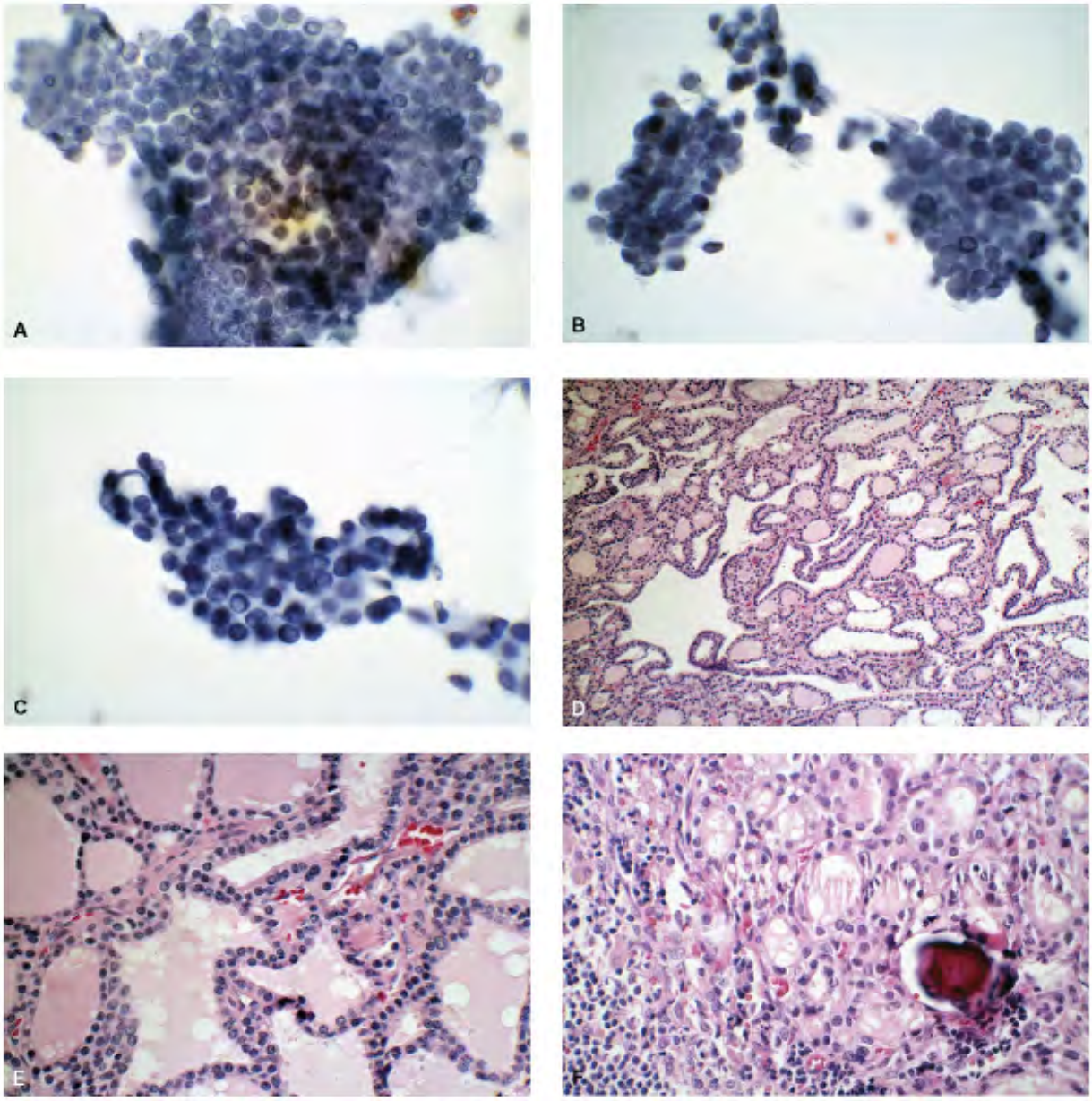

Figure 9.114. *Is surgical pathology always a gold standard? Positive cytology for papillary carcinoma, histology interpreted as benign.* Aâ€“C. Hypercellular aspirate showing syncytia tissue fragments of follicular cells. The nuclear chromatin is pale with frequent intranuclear inclusions. Papillary carcinoma was suspected. Thyroidectomy showed a massively enlarged multinodular thyroid with features of nodular goiter. D,E. Histologic sections of the nodular

goiter. F. Cervical lymph nodes showed thyroid tissue and psammoma bodies. Typical nuclea features of papillary carcinoma were not present. Was a papillary carcinoma overlooked on examination of the thyroid and not sampled because of the large size of the thyroid? Was th psammoma body considered insignificant and the thyroid tissue in the cervical nodes consid as lateral aberrant thyroid valid?

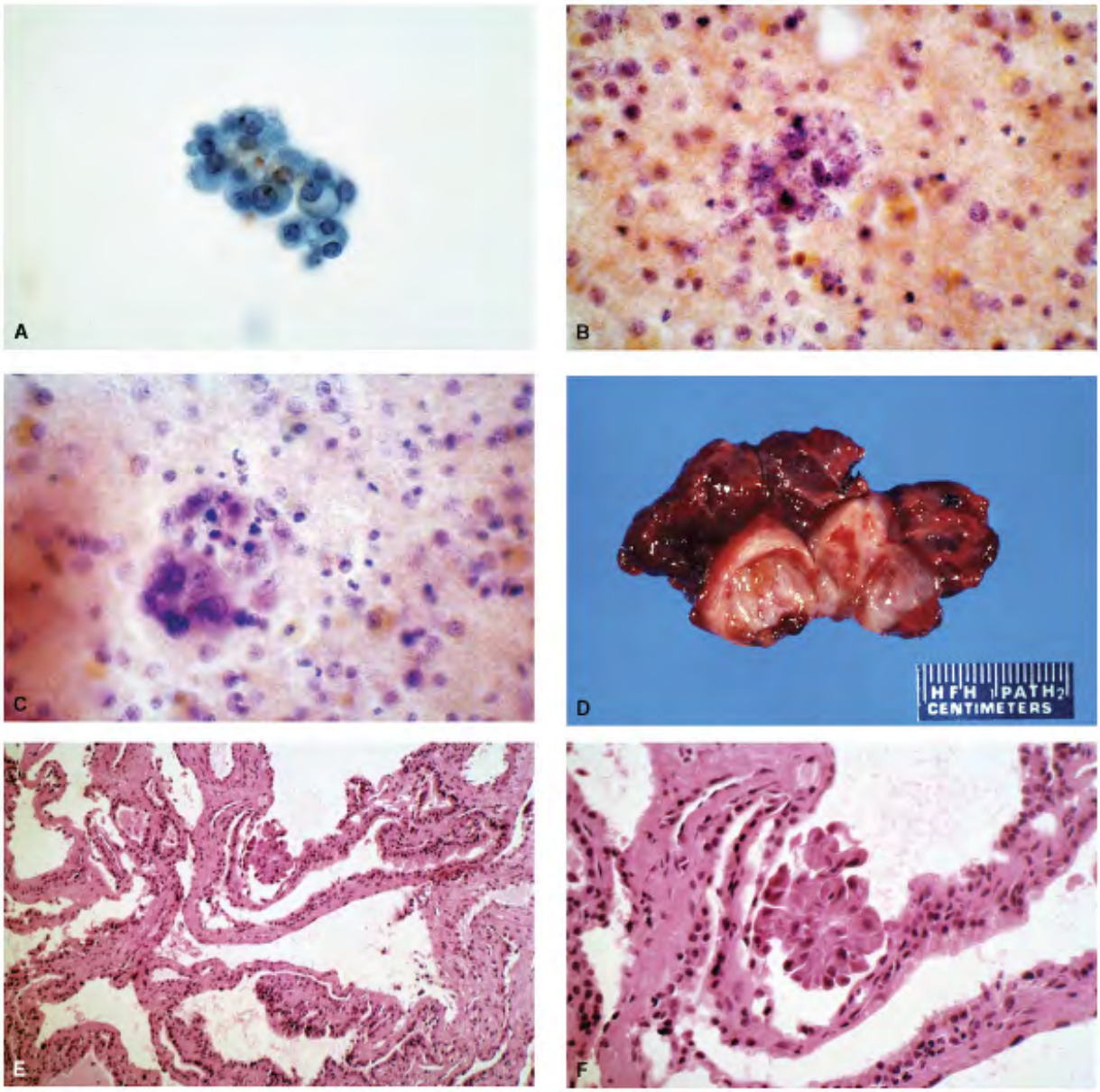

Figure 9.115. *Is the surgical pathology always a gold standard? Positive cytology for papilla carcinoma, histology interpreted as benign* . Fine-needle biopsy of a thyroid nodule from a year-old girl. Aâ€“C. FNA yielded several milliliters of hemorrhagic fluid. The cytospin

preparation was marginally cellular, with rare tissue fragments of follicular epithelium obsc by blood and cellular debris. These tissue fragments show follicular cells with nuclei contair powdery chromatin and prominent nucleoli. The aspirate was diagnosed as suspicious of papillary carcinoma. A repeat fine-needle biopsy again yielded hemorrhagic fluid and very f cells containing pleomorphic nuclei with pale chromatin. D. Thyroidectomy revealed a 2-cm cystic lesion. E,F. Histologic sections were interpreted as nodular goiter with cystic change papillary hyperplasia. Is this a nodular goiter or a microcarcinoma?

SUMMARY

Papillary carcinoma of the thyroid is the most common differentiated thyroid malignancy. It also the least difficult to diagnose from cytologic samples, provided the *aspirate is adequat* has a diagnostic accuracy of over 90%. Although there are several cytologic features, the minimal criteria include a syncytial-type tissue fragment that, irrespective of the architectu pattern, shows typical nuclear morphology of pale, watery nuclei due to powdery, dusty chromatin; micro- and/or macronucleoli; a chromatin ridge; and intranuclear cytoplasmic inclusions. False-positive diagnoses result from interpretations based on insufficient criteria and/or placing emphasis on few but not all the described cytologic features of papillary carcinoma.

REFERENCES

General

1.LiVolsi VA, Albores-Saavedra J, Asa SL, et al. Papillary carcinoma. In: De Lellis, Lloyd R, Heitz PU, Eng C, eds. *Pathology and Genetics of Tumours of Endocrine Organs . World Health Organization Classification of Tumors* . Lyon: IARC Press; 2004.

2.Rosai J, Carcangiu ML, DeLellis RA. Tumors of the thyroid gland. *Atlas of Tumor Patholo* . Fasicle five, 3rd series. Washington, DC: Armed Forces Institute of Pathology; 1993.

3.LiVolsi VA. *Surgical Pathology of the Thyroid* . Philadelphia: Saunders; 1990.

4.Hay ID. Papillary thyroid carcinoma. *Endocrinol Metab Clin North Am* . 1990;19:545â€“5

5.McConahey WM, Hay ID, Woolner LB. Papillary thyroid cancer treated at the Mayo Clinic 1946 through 1970: initial manifestations, pathologic findings, therapy and outcome. *Mayo Clin Proc* . 1986;61:978â€“996.

6.Tubiana M, Schlumberger M, Rougher P, et al. Long-term results and prognostic factors patients with differentiated thyroid carcinoma. *Cancer* . 1985;55;794â€“804.

7.Carcangiu ML, Zampi G, Pupi A, et al. Papillary carcinoma of the thyroid. A clinicopathologic study of 241 cases treated at the University of Florence, Italy. *Cancer* . 1985;55:805â€“828.

8.Selzer G, Kahn LB, Albertyn L. Primary malignant tumors of the thyroid gland: a clinicopathologic study of 254 cases. *Cancer* . 1977;40:1501â€“1510.

9.Franssila KO. Is the differentiation between papillary and follicular thyroid carcinoma valid? *Cancer* . 1973;32:853â€“864.

10.Woolner LB. Thyroid carcinoma: pathologic classification with data on prognosis. *Semin Nucl Med* . 1971;1:481â€“502.

11.Russel WD, Ibanez ML, Clark RL, et al. Thyroid carcinoma: classification, intraglandular dissemination and clinicopathologic study based upon whole organ section of 80 glands. *Cancer* . 1963;11:1425â€“1460.

12.Hirabayashi RN, Lindsay S. Carcinoma of the thyroid gland: a statistical study of 390 patients. *J Clin Endocrinol Metab* . 1961;21:1596â€“1610.

13.Meissner WA, Adler A. Papillary carcinoma of the thyroid: a study of the patients in 22
cases. *Arch Pathol* . 1958;66:518â€“525.

14.Ito M, Yamashita S, Ashizawa K, et al. Histopathologic characteristics of childhood thyroid cancer in Gomel, Belarus. *Int J Cancer* . 1996;65:29â€“33.

15.Nikiforov Y, Gnepp DR. Pediatric thyroid cancer after the Chernobyl disaster: patholog
study of 84 cases (1991â€“1992) from the Republic of Belarus. *Cancer* . 1994:74:748â€“76

16.Reading CC, Charboneau JW, Hay ID, et al. Sonography of thyroid nodules: a "classic pattern" diagnostic approach. *Ultrasound Q* . 2005;21:157â€“165.

17.Al-Brahim N, Asa SL. Papillary thyroid carcinoma. An overview. *Arch Path Lab Med* . 2006;130:1957â€“1062.

18.Chan JKC. Papillary carcinoma of thyroid: classical and variants. *Histol Histopathol* . 1990;5:241â€“257.

19.Heddinger CE, Williams ED, Sobin LH. Histologic typing of thyroid tumors. In: Heddinge
CE, ed. *International Histologic Classification of Tumors* . Vol. 11. Berlin: Springer-Verlag
1988.

20.Carcangiu ML, Zampi G, Rosai J. Papillary thyroid carcinoma: a study of its many morphologic expressions and clinical correlates. In: Sommers S, Rosen PD, eds. *Pathology Annuals* . Part 1. Norwalk, CT: Appleton-Century-Crofts; 1985;20:1â€“44.

21.Rosai J, Zampi G, Carcangiu ML. Papillary carcinoma of the thyroid: a discussion of the
several morphologic expressions with particular emphasis on the follicular variant. *Am J S*
Pathol . 1983;7:809â€“817.

22.Vickery AL Jr. Thyroid papillary carcinoma: pathological and philosophical controversie
Am J Surg Pathol . 1983;7:797â€“807.

23.Tscholl-Durommun J, Hedinger CE. Papillary thyroid carcinomas: morphology and prognosis. *Virchows Arch (A)* . 1982;396:19â€“39.

24.Hawk WA, Hazard JB. The many appearances of papillary carcinoma of the thyroid. *Cle Clin Q* . 1976;43:207â€“216.

25.Kaneko C, Shamoto M, Niimi H et al. Studies on intranuclear inclusions and nuclear grooves in papillary thyroid cancer by light, scanning electron and transmission electron microscopy. *Acta Cytol* . 1996;40:417â€“422.

26.Oyama T. A histopathological, immunohistochemical and ultrastructural study of intranuclear inclusions in thyroid papillary carcinoma. *Virchows Arch (A)* . 1989;414:91â€“104.

27.Albores-Saavedra J, Altamirano-Dimas M, Alcurta-Anguizola B, et al. Fine structure of human papillary thyroid carcinoma. *Cancer* . 1971;28:763â€“744.

28.Gray A, Doniach J. Morphology of the nuclei of papillary carcinoma of the thyroid. *Br J Cancer* . 1969;23:49â€“51.

29.Hapke M, Dehner L. The optically clear nucleus: a reliable sign of papillary carcinoma o the thyroid? *Am J Surg Pathol* . 1979;3: 31â€“58.

30.Scopa CD, Melachrinou M, Saradopoulou C, et al. The significance of the grooved nucle in thyroid lesions. *Mod Pathol* . 1993;6:691â€“694.

31.Chan JKC, Saw D. The grooved nucleus, a useful diagnostic criterion of papillary carcinoma of the thyroid. *Am J Surg Pathol* . 1986;10:672â€“679.

32.Vergilio JA, Baloch ZW, LiVolsi VA. Spindle cell metaplasia of the thyroid arising in association with papillary carcinoma and follicular adenoma. *Am J Clin Pathol* .

2002;117:199â€“204.

33.Johannessen JV, Sobrino-Simoes M. The origin and significance of thyroid psammoma bodies. *Lab Invest* . 1980;43:287â€“296.

34.Batsakis JG, Nishiyama RH, Rich CR. Microlithiasis (calcospherites) and carcinoma of th thyroid gland. *AMA Arch Pathol* . 1960,69:493â€“498.

35.Klinck GH, Winship T. Psammoma bodies and thyroid cancer. *Cancer* . 1959;12:656â€“662.

36.Isarangkul W. Dense fibrosis. Another diagnostic criterion for papillary carcinoma. *Arch Pathol Lab Med* . 1993;117:645â€“646.

37.Ito M, Yamashita S, Ashizawa K, et al. Childhood thyroid diseases around Chernobyl evaluated by ultrasound examination and fine needle aspiration cytology. *Thyroid* . 1995;5:365â€“368.

38.Aktar M, Ali MA, Huq M, et al. Fine needle aspiration biopsy of papillary carcinoma of t thyroid. Cytologic, histologic and ultrastructural correlations. *Diagn Cytopathol* . 1991;7:373â€“379.

39.Miller TR, Bottles K, Holly EA, et al. A step-wise logistic regression analysis of papillary carcinoma of the thyroid. *Acta Cytol* . 1986;30:285â€“292.

40.Abele JS, Miller TR. Fine needle aspiration of the thyroid nodule: clinical applications. Clark OH, ed. *Endocrine Surgery of the Thyroid and Parathyroid Glands* . St. Louis: Mosby 1985:293â€“365.

41.Frable W. Thin needle aspiration biopsy. In: Bennington JL, ed. *Major Problems in Pathology* . Vol. 14. Philadelphia: Saunders; 1983:162,170â€“171.

42.Droese M. *Cytological Aspiration Biopsy of the Thyroid Gland* . Stuttgart: Schattauer Verlag; 1980.

43.Kini SR, Miller JM, Hamburger JI, et al. Cytopathology of papillary carcinoma of the thyroid. *Acta Cytol* . 1980;24:511â€“521.

44.LÃ¶whagen T, Giremberg PO, Lundell G. Aspiration biopsy cytology (ABC) in nodules of the thyroid gland suspected to be malignant. *Surg Clin North Am* . 1979;59:3â€“18.

45.LÃ¶whagen T, Sprenger E. Cytologic presentation of thyroid tumors in aspiration biopsy smear: a review of 60 cases. *Acta Cytol* . 1974;18:192â€“197.

46.Szporn AH, Yuan S, Wu M, et al. Cellular swirls in fine needle aspirates of papillary thyroid carcinoma: a new diagnostic criterion. *Mod Pathol* . 2006;19:1470â€“1473.

47.Das DK. Intranuclear cytoplasmic inclusions in fine-needle aspiration smears of papillar thyroid carcinoma: a study of its morphological forms, association with nuclear grooves, a mode of formation. *Diagn Cytopathol* . 2005;32:264â€“268.

48.Christ M, Haja J. Intranuclear cytoplasmic inclusions (invaginations) in thyroid aspirations, frequency and specificity. *Acta Cytol* . 1979;23:327â€“331.

49.O'Morchoe PJ, Lee DC. Intranuclear cytoplasmic inclusions in carcinoma of the thyroid gland. *Acta Cytol* . 1984;28:621. Letter.

50.Glant MD, Berger EK, Davey DD. Intranuclear cytoplasmic inclusions in aspirates of follicular neoplasms of the thyroid. *Acta Cytol* . 1984;28:576â€“579.

51.Lew W, Orell S, Henderson DW. Intranuclear vacuoles in nonpapillary carcinoma of the thyroid. *Acta Cytol* . 1984;28:581â€“586.

52.SÃ¶derstrÃ¶m M, Bjorklund A. Intranuclear cytoplasmic inclusions in some types of thyroid cancer. *Acta Cytol* , 1973,17:191â€“197.

53.Yang YJ, Demirci SS. Evaluating the diagnostic significance of nuclear grooves in thyroi fine needle aspirates with a semiquantitative approach. *Acta Cytol* . 2003:47:563â€“570.

54.Fracis IM, Das KD, Sheikh ZA, et al. Role of nuclear grooves in the diagnosis of papillary thyroid carcinoma. A quantitative assessment on fine needle aspiration smears. *Acta Cyto* 1995;39:409â€“415.

55.Bhambhani S, Kashyap V, Das KD. Nuclear grooves: valuable diagnostic feature in May-GrÃ¼nwald-Giemsa stained fine needle aspirates of papillary carcinoma of the thyroid. *Ac Cytol* . 1990;34:809â€“912.

56.Gould E, Watzak L, Chamizo W, et al. Nuclear grooves in cytologic preparations. A stuc of the utility of this feature in the diagnosis of papillary carcinoma. *Acta Cytol* . 1989;33:16â€“21.

57.Rupp M, Ehya H. Nuclear grooves in the aspiration cytology of papillary carcinoma of th thyroid. *Acta Cytol* . 1989;33:21â€“26.

58.Shurbaji MS, Gupta PK, Frost JK. Nuclear grooves: a useful criterion in the cytopatholo diagnosis of papillary thyroid carcinoma. *Diagn Cytopathol* . 1988;4:91â€“94.

59.Deligeorgi-Piloti H. Nuclear crease as a cytodiagnostic feature of papillary thyroid carcinoma in fine needle aspiration biopsies. *Diagn Cytopathol* . 1987;3:307â€“310.

60.Hidvegi DF, Heltgren S, Gallagher L. Origin of giant cells from papillary carcinoma of th thyroid: immunologic, enzymatic and ultrastructural aspects of cytopreparations. *Acta Cy* . 1982;26 :742.

61.Saggiorato E, Aversa S, Deandreis D, et al. Galectin-3: presurgical marker of thyroid follicular epithelial cell-derived carcinomas. *J Endocrinol Invest* . 2004;27:311â€“317.

62.Khurana KK, Truong LD, LiVolsi VA, et al. Cytokeratin 19 immunolocalization in cell blo preparation of thyroid aspirates. An adjunct to fine-needle aspiration diagnosis of papillar carcinoma. *Arch Pathol Lab Med* . 2003;127:579â€“583.

63.Aratake Y, Umeki K, Kiyoyama K. Diagnostic utility of Galectin-3 and CD26/DPPIV as preoperative diagnostic markers for thyroid nodules. *Diagn Cytopathol* . 2002;26:366â€“37

64.Cheung C, Ezzat S, Freeman J, et al. Immunohistochemical diagnosis of papillary thyro carcinoma. *Mod Pathol* . 2001;14: 338â€“342.

65.Hirokawa M, Inagaki A, Sonoo H. Expression of cytokeratin 19 in cytologic specimens of thyroid. *Diagn Cytopathol* . 2000;22:197â€“198.

66.Baloch ZW, Abraham S, Roberts S, et al.. Differential expression of cytokeratin in follicular variant of papillary carcinoma: an immunohistochemical study and its diagnostic utility. *Hum Pathol* . 1999;10:1166â€“1171.

67.Wenig BM, Thompson LDH, Adair CF, et al. Thyroid papillary carcinoma of columnar ce type. A clinicopathologic study of 16 cases. *Cancer* . 1998;82:40â€“53.

68.van Hoeven KH, Kovatich AJ, Mietttinen M. Immunocytochemical evaluation of HBME-1 CA19-9 and CD-15 (Leu-M1) in fine needle aspirates of thyroid nodules. *Diagn Cytopathol* . 1997;8:83â€“97.

Morphologic Variants

69.Gupta S, Sodhani P, Jain S, et al. Morphologic spectrum of papillary carcinoma of the thyroid. Role of cytology in identifying the variants. *Acta Cytol* . 2004;48:795â€“800.

70.Das DK, Mallik MK, Sharma P, et al. Papillary thyroid carcinoma and its variants in fine needle aspiration smears. *Acta Cytol* . 2004;41:325â€“336.

71.Nair M, Kapila K, Verma K. Papillary carcinoma of the thyroid and its variants: a cytohistological correlation. *Diagn Cytopathol* . 2001;24:167â€“173.

72.Akslen LA, LiVolsi VA. Prognostic significance of histologic grading compared with subclassification of papillary thyroid carcinoma. *Cancer* . 2000;88:1902â€“1908.

73.Damiani S, Dina R, Eusebi V. Cytologic grading of aggressive and nonaggressive variants papillary thyroid carcinoma. *Am J Clin Pathol* . 1994;101:651â€“655.

74.Leung CS, Hartwick RW, Bedard YC. Correlation of cytologic and histologic features in variants of papillary carcinoma of the thyroid. *Acta Cytol* . 1993;37:645â€“650.

Follicular Variant

75.Lindsay S. *Carcinoma of the Thyroid Gland: A Clinical and Pathologic Study of 293 Patients at the University of California Hospital* . Springfield, IL: Thomas; 1960.

76.Chan KTK, Rosai J. Follicular variant of thyroid papillary carcinoma: a clinicopathologi study of six cases. *Am J Surg Pathol* . 1977;1:123â€“130.

77.Tielens ET, Sherman SL, Hruban RH, et al. Follicular variant of papillary carcinoma. A clinicopathologic study. *Cancer* . 1994;73:424â€“431.

78.Gallagher J, Oertel YC, Oertel JE. Follicular variant of papillary carcinoma of the thyro fine-needle aspirates with histologic correlation. *Diagn Cytopathol* . 1997;16:207â€“213.

79.Suster S. Thyroid tumors with a follicular growth pattern. Problems in differential diagnosis. *Arch Path Lab Med* . 2006;130:984â€“988.

80.Lin HS, Komisar A, Opher E, et al. Follicular variant of papillary carcinoma: the diagnos limitations of preoperative fine-needle aspiration and intraoperative frozen section evaluation. *Laryngoscope* . 2000;110:1431â€“1436.

81.Chan JKC. Strict criteria should be applied in the diagnosis of encapsulated follicular variant of papillary carcinoma. *Am J Clin Pathol* . 2002;117:16â€“18.

82.Renshaw AA, Gould EW. Why there is the tendency to "overdiagnose" the follicular vari of papillary carcinoma. *Am J Clin Pathol* . 2002;117:19â€“21.

83.Shih SR, Shun CT, Su DH, et al. Follicular variant of papillary thyroid carcinoma. Diagnostic limitations of fine needle aspiration cytology. *Acta Cytol* . 2005;49:383â€“386.

84.Zedan J, Karan D, Stein M, et al. Pure versus follicular variant of papillary thyroid carcinoma: clinical features, prognostic factors, treatment and survival. *Cancer.* 2003;97:1181â€“1185.

85.Wu HH-J, Jones JN, Grzbicki DM, et al. Sensitive cytologic criteria for the identificatio of follicular variant of papillary thyroid carcinoma in fine-needle aspiration biopsy. *Diagn Cytopathol* . 2003;29:262â€“266.

86.Fulciniti F, Benincasa G, Vetrani A, et al. Follicular variant of papillary carcinoma: cytologic findings on FNAB samplesâ€”experience with 16 cases. *Diagn Cytopathol* . 2001;25:86â€“93.

87.Yan Z, Yang GCH, Waisman J. A low power, "architectural" clue to the follicular varian papillary thyroid adenocarcinoma in aspiration biopsy. *Acta Cytol* . 2000;44:211â€“217.

88.Logani S, Gupta PK, LiVolsi VA, et al. Thyroid nodules with FNA cytology suspicious for follicular variant of papillary thyroid carcinoma: follow-up and management. *Diagn Cytopathol* . 2000;23:380â€“385.

89.De Micco C, Vassko V, Henry JF. The value of thyroid peroxidase immunohistochemistry for preoperative fine-needle aspiration diagnosis of the follicular variant of papillary thyro cancer. *Surgery* . 1999;126:1200â€“1204.

90.Baloch ZW, Gupta PK, Yu GH, et al. Follicular variant of papillary carcinoma. Cytologic and histologic correlation. *Am J Clin Pathol* . 1999;111:216â€“222.

91.Goodell WM, Saboorian MH, Ashfaq R. Fine-needle aspiration diagnosis of the follicular variant of papillary carcinoma. *Cancer (Cancer Cytopathol)* . 1998;84:349â€“354.

92.Zacks JF, Morenas A, Beazley RM, et al. Fine-needle aspiration cytology diagnosis of colloid nodule versus follicular variant of papillary carcinoma of the thyroid. *Diagn Cytopathol* . 1998;18:87â€“90.

93.Mesonero CE, Jugle JE, Wilbur DC, et al. Fine-needle aspiration of the macrofollicular and microfollicular subtypes of the follicular variant of papillary carcinoma of the thyroid *Cancer (Cancer Cytopathol)* . 1998;84:235â€“244.

94.Sherman LJ, Chess Q. Fine-needle aspiration biopsy diagnosis of follicular variant of papillary thyroid cancer: therapeutic implications. *Otolaryngol Head Neck Surg* . 1998;119:600â€“602.

95.Martinez-Parra D, Fernandez JC, Hierro-Guilmain C, et al. Follicular variant of papillar carcinoma of the thyroid: to what extent is fine-needle aspiration reliable? *Diagn Cytopat* . 1996;15:12â€“16.

96.Harach HRZS. Cytologic findings in the follicular variant of papillary carcinoma of the thyroid. *Acta Cytol* . 1992;36:142â€“146.

97.Hugh JC, Duggan MA, Chang-Poon V. The fine needle aspiration appearance of the follicular variant of thyroid papillary carcinoma. A report of three cases. *Diagn Cytopatho* 1988;4:196â€“201.

98.Loyd RV, Erickson LA, Casey MB, et al. Observer-variation in the diagnosis of follicular variant of papillary thyroid carcinoma. *Am J Surg Pathol* . 2004;28:1336â€“1340.

99.Williams RD. Guest editorial: Two proposals regarding the terminology of thyroid tumo *Int J Surg Pathol* . 2000;8:181â€“183.

100.LiVolsi VA, Baloch ZW. Follicular neoplasms of the thyroid. Views, biases and experiences. *Adv Anat Pathol* . 2004;11:279â€“287.

Tall Cell Variant

101.Johnson TL, Lloyd RV, Thompson NW, et al. Prognostic implications of the tall cell variant of papillary thyroid carcinoma. *Am J Surg Pathol* . 1988;12:22â€“27.

102.Filie A, Chiesa A, Bryant BR, et al. The tall cell variant of papillary carcinoma of the thyroid. *Cancer* . 1999;87:238â€“242.

103.Van den Brekel MW, Hekkenberg RJ, Asa SL, et al. prognostic features in tall cell papillary carcinoma and insular thyroid carcinoma. *Laryngoscope* . 1997;107:254â€“260.

104.Merino MJ. Monteagudo C. Tall cell carcinoma of the thyroid: an aggressive variant of papillary carcinoma. *Pathol Case Rev* . 1997;2:196â€“199.

105.Ostrowski N, Merino MJ. Tall cell variant of papillary thyroid carcinoma. A reassessme and immunohistochemical study with comparison to the usual type of papillary carcinoma the thyroid. *Am J Surg Pathol* . 1996; 20:964â€“974.

106.Terry J, St. John S, Karkowski F, et al. Tall cell papillary thyroid cancer: incidence an prognosis. *Am J Surg* . 1994;168:459â€“461.

107.Hicks MJ, Batsakis JG. Tall cell carcinoma of the thyroid gland. *Ann Otol Rhinol Laryn* . 1993;102:402â€“403.

108.Flint A, Davenport RD, Lloyd RV. The tall cell variant of papillary carcinoma of the thyroid gland. *Arch Pathol Lab Med* . 1991;115:196â€“171.

109.Soloman A, Gupta PK, LiVolsi VA, et al. Distinguishing tall cell variant of papillary thyroid carcinoma from usual variant of papillary thyroid carcinoma in cytologic specimen *Diagn Cytopathol* . 2002;27:143â€“148.

110.Pisani T, Giovagnoli MR, Intrieri FS, et al. Tall cell variant of papillary carcinoma coexisting with chronic lymphocytic thyroiditis. A case report. *Acta Cytol* . 1999;43:435â€“438.

111.Bocklage T, DiTomasso JP, Ramzy I, et al. Tall cell variant of papillary thyroid carcinoma: cytologic features and differential diagnostic considerations. *Diagn Cytopatho* 1997;17:25â€“29.

112.Gamboa-Dominguez A, Candanedo-Gonzalez F, Uribe-Uribe N, et al. Tall cell variant c papillary thyroid carcinoma. A cytohistologic correlation. *Acta Cytol* . 1997;41:672â€“676.

113.Cameselle-Teijeiro J, Febles-Perez C, Cameselle-Teijeiro JE, et al. Cytologic clues fo distinguishing the tall cell variant of thyroid papillary carcinoma. A case report. *Acta Cytc* 1997; 41:1310â€“1316.

114.Cameselle-Teijeiro J, Cameselle-Teijeiro JE, Uribe-Uribe N, et al. Tall cell variant of papillary thyroid carcinoma. A cytohistologic correlation. *Acta Cytol* . 1997;41:671â€“676.

115.De Rizzolo EB, Prytyka A, Leale MJ. Thyroid gland: tall cell variant of papillary carcinoma and papillary oncocytic carcinoma. *Acta Cytol* . 1995;39:280.

116.Kaw YT. Fine needle aspiration cytology of the tall cell variant of papillary carcinoma

the thyroid. *Acta Cytol* . 1994;38: 282â€“283.

117.Harach HR, Zusman SB. Cytopathology of the tall cell variant of papillary thyroid carcinoma. *Acta Cytol* , 1992;36:895â€“899.

118.Kini SR. Thyroid. In: Kline TS, ed. *Guides to Clinical Aspiration Biopsy* . Vol. 3. 2nd ec New York: Igaku Shoin; 1996:152.

Columnar Cell Variant

119.Evans HL. Columnar cell carcinoma of the thyroid: a report of two cases of an aggress variant of thyroid carcinoma. *Am J Clin Pathol* . 1986;88:77â€“80.

120.Sobrino-Simoes M, Nesland JM, Johannessen JV. Columnar cell carcinoma: another variant of poorly differentiated carcinoma of the thyroid. *Am J Clin Pathol* . 1988;89:264â€“267.

121.Chen J-H, Pinkus GS, Faquin WC, et al. Papillary thyroid carcinoma, columnar cell variant: a clinicopathologic and molecular study. *Mod Pathol* . 2007;20:100(A).

122.Ferreiro JA, Hay ID, Lloyd RV. Columnar cell carcinoma of the thyroid: report of three additional casesâ€”a review. *Hum Pathol* . 1996;27:1156â€“1160.

123.Evans HL. Encapsulated columnar cell neoplasms of the thyroid: a report of four cases suggesting a favorable prognosis. *Am J Surg Pathol* . 1996;20:1205â€“1211.

124.Mizukami Y, Nonomura A, Michigishi T, et al. Columnar cell carcinoma of the thyroid gland: a case report and review of the literature. *Hum Pathol* . 1994;25:1098â€“1101.

125.Akslen L, Varhaug JE. Thyroid carcinoma with mixed tall cell and columnar cell features. *Am J Clin Pathol* . 1990;94:442â€“445.

126.Ylagan LR, Dehner LP, Huettner PC, et al. Columnar cell variant of papillary thyroid carcinoma. Report of a case with cytologic findings. *Acta Cytol* . 2004;48:73â€“77.

127.Jayaram G. Cytology of columnar cell variant of papillary thyroid carcinoma. *Diagn Cytopathol* . 2000;22:227â€“229.

128.Perez F, Llobel M, Gario G, et al. Fine-needle aspiration cytology of columnar cell carcinoma of the thyroid: report of two cases with cytohistologic correlation. *Diagn Cytopathol* . 1998;18:352â€“356.

129.Putti TC, Bhuiya TA, Wasserman PC. Fine needle aspiration cytology of mixed tall and columnar cell papillary carcinoma of the thyroid: a case report. *Acta Cytol* . 1998;42:387â€“390.

130.Hui PK, Chan JK, Cheung PS, et al. Columnar cell carcinoma of the thyroid: fine needl aspiration findings in a case. *Acta Cytol* . 1990;34:355â€“358.

Oncocytic Variant

131.Livolsi VA, Asa SL. *Endocrine Pathology* . New York: Churchill Livingstone; 2002.

132.Berbo M, Suster S. The oncocytic variant of papillary carcinoma of the thyroid: a clinicopathologic study of 15 cases. *Hum Pathol* . 1997;28:47â€“53.

133.Beckner M, Heffess CS, Oertel JE. Oxyphilic papillary thyroid carcinomas. *Am J Clin Pathol* . 1995;103:280â€“287.

134.Herrera MP, Hay ID, Wu PS, et al. HÃ¼rthle cell (oxyphilic) papillary carcinoma of the thyroid: a variant with more aggressive behavior. *World J Surg* . 1992;16:669â€“675.

135.Wu PSC, Hay ID, Hermann MA, et al. Papillary thyroid carcinoma (PTC), oxyphil cell type: a tumor misclassified by the World Health Organization (WHO). *Clin Res* . 1991;39:27

136.Barbuto D, Carcangiu ML, Rosai J. Papillary HÃ¼rthle cell neoplasms of the thyroid gland: a study of 20 cases. *Mod Pathol* . 1990;3:7A.

137.Hill JH, Werkhaven JA, DeMay RM. HÃ¼rthle cell variant of papillary carcinoma of the thyroid gland. *Otolaryngol Head Neck Surg* . 1988;98:338â€“341.

138.Khanum O, Wang S, Hameed A. Fine needle aspiration cytology of a papillary oncocyti neoplasm of the thyroid gland. *Acta Cytol* . 1999;43:976â€“978.

139.Dzieciok J, Musiatowicz B, Zimnoch L, et al. Papillary HÃ¼rthle cell tumor of thyroid. Report of a case with a cytomorphologic approach to diagnosis. *Acta Cytol* . 1996;40:311â€“314.

140.Chen KTK. Fine-needle aspiration cytology of papillary HÃ¼rthle cell tumors of thyroi a report of three cases. *Diagn Cytopathol* . 1991;7:53â€“56.

Solid Variant of Papillary Carcinoma

141.Nikiforov YE, Erickson LA, Nikiforov MN, et al. Solid variant of papillary thyroid carcinoma. Incidence, clinical-pathologic characteristics, molecular analysis and biologic behavior. *Am J Surg Pathol* . 2001;25:1478â€“1484.

Diffuse Sclerosing Variant

142.Carcangiu ML, Sianchi S. Diffuse sclerosing variant of papillary thyroid carcinoma: clinicopathologic study of 15 cases. *Am J Surg Pathol* . 1989;13:1041â€“1049.

143.Imamura Y, Kasahara Y, Fukuda M. Multiple brain metastases from a diffuse sclerosing variant of papillary carcinoma of the thyroid. *Endocr Pathol* . 2000;11:97â€“108.

144.Gomez-Morales M, Alvaro T, Munoz M, et al. Diffuse sclerosing papillary carcinoma of the thyroid: immunohistochemical analysis of the local host response. *Histopathology* .

1991;18: 427â€“433.

145.Schroder S, Bay V, Dumke K, et al. Diffuse sclerosing variant of papillary carcinoma of the thyroid: S100 protein immunohistochemistry and prognosis. *Virch Arch A Pathol Anat* . 1990;416: 367â€“371.

146.Fujimoto Y, Obara T, Ito Y, et al. Diffuse sclerosing variant of papillary carcinoma of thyroid. *Cancer* . 1990;66:2306â€“2312.

147.Sores J, Limbert E, Sobrinho-Simoes M. Diffuse sclerosing variant of papillary thyroid carcinoma: a clinicopathologic study of 10 cases. *Pathol Res Pract* . 1989;185:200â€“206.

148.Chan JKC, Tsui MS, Tse CH. Diffuse sclerosing variant of papillary thyroid carcinoma o thyroid: a histological and immunohistological study of three cases. *Histopathology* . 1987;11:191â€“202.

149.Hayashi Y, Sasao T, Takeichi N, et al. Diffuse sclerosing variant of papillary carcinoma the thyroid: a histopathological study of four cases. *Acta Pathol Jpn* . 1990;40:193â€“198.

150.Triggiani V, Ciampolillo A, Maiorano E. Papillary thyroid carcinoma, diffuse sclerosing variant, with abundant psammoma bodies. *Acta Cytol* . 2003;47:1141â€“1143.

151.Kumarasinghe MP. Cytomorphologic features of diffuse sclerosing variant of papillary carcinoma of the thyroid. A report of two cases in children. *Acta Cytol* . 1998;42:983â€“98

152.Caruso G, Tabarri B, Lucchi I, et al. Fine needle aspiration cytology in a case of diffus sclerosing carcinoma of thyroid. *Acta Cytol* . 1990;34:352â€“354.

Papillary Carcinoma with Nodular Fasciitis-Like Stroma

153.Chan JK, Carcangiu ML, Rosai J. Papillary carcinoma of thyroid with exuberant nodula

fasciitis-like stroma: report of three cases. *Am J Clin Pathol* . 1991;95:309â€“314.

154.Terayama K, Toda S, Yonemitsu N, et al. Papillary carcinoma of thyroid with exuberar nodular fasciitis-like stroma. *Virchows Arch* . 1997;431:291.

155.Michael M, Chlumska A, Faken F. Papillary carcinoma of thyroid with exuberant nodul fasciitis-like stroma. *Histopathology* . 1992;21:577.

156.Andres L, Etxegarai L, Ibarrola R, et al. Fasciitis like papillary carcinoma of the thyroi gland. *Acta Cytol* . 2005;49:462â€“463.

157.Yang YJ, LiVolsi VA, Khurana KK. Papillary thyroid carcinoma with nodular fasciitis-lik stroma: pitfalls in fine needle aspiration cytology. *Arch path Lab Med* . 1999;123:838â€“8

158.Us-Krasovec M, Golouh R. Papillary thyroid carcinoma with exuberant nodular fasciitis like stroma in a fine needle aspirate. *Acta Cytol* . 1999;43:1101â€“1104.

Macrofollicular Variant of Papillary Carcinoma

159.Albores-Saavedra J, Housini I, Vuitch F, et al. Macrofollicular variant of papillary thyr carcinoma with minor insular component. *Cancer* . 1997;80:1110â€“1116.

160.Ashfaq R, Vuitch F, Delgado R, et al. Papillary and follicular thyroid carcinomas with a insular component. *Cancer* . 1994;73:416â€“423.

161.Albores-Saveedra J, Gould E, Vardman C, et al. The macrofollicular variant of papillar thyroid carcinoma: a study of 17 cases. *Hum Pathol* . 1991;22:1195â€“1205.

162.Mesonero CE, Jugle JE, Wilbur DC, et al. Fine-needle aspiration of the macrofollicular and microfollicular subtypes of the follicular variant of papillary carcinoma of the thyroid *Cancer (Cancer Cytopathol)* . 1998;84:35â€“44.

163.Hirokawa M, Shimizu M, Terayama K, et al. Macrofollicular variant of papillary thyroic carcinoma. Report of a case with fine needle aspiration biopsy findings. *Acta Cytol* . 1998;42:1441â€“1443.

164.Woyke S, Al-Jassar A, Al-Jazzaf H. Macrofollicular variant of papillary thyroid carcinor Diagnosed by fine needle aspiration biopsy. *Acta Cytol* . 1998;42:1184â€“1188.

Diffuse Follicular Variant of Papillary Carcinoma

165.Sobrinho-Simoes M, Soares L, Carneiro F, et al. Diffuse follicular variant of papillary carcinoma of the thyroid: report of eight cases of a distinct aggressive type of thyroid tumor. *Surg Pathol* . 1990;3:189â€“203.

166.Ivanova R, Soares P, Castro P, et al. Diffuse (or multinodular) follicular variant of papillary thyroid carcinoma: a clinicopathologic and immunohistochemical analysis of ten cases of an aggressive form of differentiated thyroid carcinoma. *Virchows Arch* . 2002;440:418â€“420.

Encapsulated Follicular Variant

167.Evans HL. Encapsulated papillary neoplasms of the thyroid: a study of 14 cases followe for a minimum of 10 years. *Am J Surg Pathol* . 1987;11:592â€“597.

168.Schroder S, Bocker W, Drallie H, et al. The encapsulated papillary carcinoma of the thyroid. A morphologic subtype of the papillary thyroid carcinoma. *Cancer* . 1984;54:90â€“93.

169.Baloch ZW, LiVolsi VA. Encapsulated follicular variant of papillary thyroid carcinoma with bone metastases. *Mod Pathol* . 2000;13:861â€“865.

Clear Cell Variant

170.Schroder S, Bocker W. Clear cell carcinomas of the thyroid. A clinicopathologic study

13 cases. *Histopathology* . 1986;10:75â€“89.

171.Carcangui ML, Sibby RK, Rosai J. Clear cell change in primary thyroid tumors. A study 38 cases. *Am J Surg Pathol* . 1985;9:705â€“722.

172.Cirantos F, Albores-Saavedra J, Nadyi M, et al. Clear cell variant of thyroid carcinoma *Am J Surg Pathol* . 1984;8:187â€“192.

Cribriform-Morular Variant of Papillary Carcinoma

173.Harach HR, Williams GT, Williams DE. Familial adenomatous polyposis associated thyr carcinoma: a distinct type of follicular cell neoplasm. *Histopathology* . 1994;25:549â€“561

174.Chuah KL, Hwang JS, Ng SB, et al. Cribriform-morular variant of papillary carcinoma c the thyroid: a case report. *Acta Cytol* . 2005;49:75â€“80.

175.Kuma S, Hirokawa M, Xu B, et al. Cribriform-morular variant of papillary carcinoma. Report of a case showing morules with peculiar nuclear clearing. *Acta Cytol* . 2004:48:431â€“436.

176.Chong J, Koshilshi N, Kurihara K, et al. Aspiration and imprint cytopathology of thyroi carcinoma associated with familial adenomatous polyposis. *Diagn Cytopathol* . 2000;23: 101â€“105.

177.Cameselle-Teijeiro J, Chan JKC. Cribriform-Morular variant of papillary carcinoma: A distinctive variant representing the sporadic counterpart of familial adenomatous polypos associated thyroid carcinoma? *Mod Pathol* . 1999;12:400â€“411.

Papillary HÃ¼rthle Cell Carcinoma with Lymphocytic Strom (Warthin-Like Tumor of the Thyroid)

178.Apel RL, Asa SL, LiVolsi VA. Papillary HÃ¼rthle cell carcinoma with lymphocytic strom

"Warthin-like tumor" of the thyroid. *Am J Surg Pathol* . 1995;19:810â€“814.

179.Ludvikova M, Ryska A, Korabeena M, et al. Oncocytic papillary carcinoma with lymphc stroma (Warthin-like tumor) of the thyroid: a distinct entity with favorable prognosis. *Histopathology* . 2001;39:17â€“24.

180.Urano M, Abe M, Mizoguchi Y, et al. Warthin-like tumor variant of papillary thyroid carcinoma: case report and literature review. *Pathol Int* . 2001;81:707â€“712.

181.Vera-Sampere FJ, Prieto M, Camanas A. Warthin-like tumor of the thyroid: a papillary carcinoma with mitochondria-rich cells and abundant lymphoid stroma. A case report. *Pathol Res Pract* . 1998;194:341â€“347.

182.Vasei M, Kumar PV, Malekhoseini SA, et al. Papillary HÃ¼rthle cell carcinoma (Warthi like tumor) of the thyroid. Report of a case with fine needle aspiration findings. *Acta Cytc* 1998;42: 1437â€“1440.

183.Fadda G, Mule A, Zannoni GF, et al. Fine needle aspiration of Warthin-like thyroid tumor: report of a case with differential diagnostic criteria vs other lymphocytic-rich thyr lesions. *Acta Cytol* . 1998;42:998â€“1002.

184.Baloch ZW, LiVolsi VA. Fine-needle aspiration cytology of papillary HÃ¼rthle cell carcinoma with lymphocytic stroma "Warthin-like tumor" of the thyroid. *Endocr Pathol* . 1998;4:317â€“323.

185.Yousef O, Dichard A, Bocklage T. Aspiration cytology features of the Warthin-like vari of papillary thyroid carcinoma. *Acta Cytol* . 1997;41:1361â€“1368.

Microcarcinoma

186.Lang W, Borrusch H, Bauer L. Occult carcinomas of the thyroid. Evaluation of 1,102 sequential autopsies. *Aur J Clin Pathol* . 1988;90:72â€“76.

187.Harach HR, Franssila KO, Wasenius VM. Occult papillary carcinoma of the thyroid. A "normal" finding in Finland. A systematic autopsy study. *Cancer* . 1985;56:531â€“538.

188.Bondeson L, Ljungberg O. Occult papillary thyroid carcinoma in the young and the age *Cancer* . 1984;53:1790â€“1792.

189.Hubert JP JR, Kiernan PD, Bearhs OH, et al. Occult papillary carcinoma of the thyroid *Arch Surg* . 1980;115:394â€“398.

190.Sampson RJ, Oka H, Key CR, et al. Metastasis from occult thyroid carcinoma. An autop study from Hiroshima and Nagasaki, Japan. *Cancer* . 1970;25:803â€“811.

191.Nasir A. Chaudhary AZ, Gillespi J, et al. Papillary microcarcinoma of the thyroid: a clinicopathologic and prognostic review. *In Vivo* . 2000;14:367â€“376.

192.Bramley MD, Harrison BJ. Papillary microcarcinoma of the thyroid gland. *BRJ Surg* 1996;83:1674â€“1683.

193.Ha ID, Grant CS, van Heerden IA, et al. Papillary thyroid microcarcinoma. A study of 5 cases observed over a 50 year period. *Surgery* . 1992;12:1130â€“1146.

194.Ilda F, Sugenoya A, Murmatsu A. Clinical and pathologic properties of small differentiated carcinomas of the thyroid gland. *World J Surg* . 1991;15:511â€“515.

195.Hoie J, Stenwig AE, Kullmann G, et al. Distant metastases in papillary thyroid cancer. review of 91 patients. *Cancer* . 1988; 61:1â€“6.

196.Strate SM, Lee EL, Childers JM. Occult papillary carcinoma of the thyroid with distant metastasis. *Cancer* . 1984;54:1093â€“1100.

197.Naruse T, Koike A, Kanemitsu T, et al. Minimal thyroid carcinoma: a report of nine ca discovered by cervical node metastasis. *Jpn J Surg* . 1984;14:118â€“121.

198.Harach RH, Franssila KO. Occult papillary carcinoma of the thyroid appearing as lung metastasis. *Arch Pathol Lab Med* . 1984;108: 529â€“530.

199.Laskin WB, James PL. Occult papillary carcinoma of the thyroid with pulmonary metastases. *Hum Pathol* . 1983;31:83â€“85.

200.Kasai N, Sakamoto A. New sub grouping of small thyroid carcinomas. *Cancer* 1987;60:1767â€“1770.

201.Renshaw AA. Papillary carcinoma of the thyroid { 1.0 cm. Rarely incidental or occult a more. *Cancer (Cancer Cytopathol)* . 2005;105:217â€“219.

202.Yang GC, LiVolsi VA, Baloch ZW. Thyroid microcarcinoma: fine needle aspiration diagnosis and histologic follow-up. *Int J Surg Pathol* . 2002;10:133â€“139.

203.Kini SR, Miller JM, Hamburger JI. Cytopathological features of medullary carcinoma of the thyroid. *Arch Pathol Lab Med* . 1984;108:156â€“159.

Cystic Carcinoma

204.Goellner JR, Johnson DA. Cytology of cystic papillary carcinoma of the thyroid. *Acta Cytol* , 1982;26:787â€“799.

205.Castro-Gomez L, Cordova-Ramirez S, Duarie-Torres R, et al. Cytologic criteria of cysti papillary carcinoma of the thyroid. *Acta Cytol* . 2003;47:590â€“594.

206.Renshaw AA. Histiocytoid cells in fine needle aspirates of papillary carcinoma of the thyroid: frequency and significance of an under-diagnosed cytologic pattern. *Cancer (Can Cytopathol)* . 2002;96:240â€“243.

207.de las Santos ET, Keyhani-Rofagha S, Cunningham JJ, et al. Cystic thyroid nodules. Th dilemma of malignant lesions. *Arch Intern Med* . 1990;150:1422â€“1427.

208.Faquin WC, Cibas ES, Renshaw AA. Atypical cells in fine-needle aspiration biopsy specimens of benign thyroid cysts. *Cancer (Cancer Cytopathol)* . 2005;105:71â€“79.

209.Nassar A, Gupta PK, LiVolsi VA, et al. Histiocytic aggregates in benign nodular goiters mimicking cytologic features of papillary thyroid carcinoma (PTC). *Diagn Cytopathol* . 2003;29: 243â€“245.

210.Meko JB, Norton JA. Large cystic/solid thyroid nodules: a potential false-negative fine needle aspiration. *Surgery (St. Louis)* . 1995;118:996â€“1003.

211.Muller N, Cooperburg PL, Suen KCH, et al. Needle aspiration in cystic papillary carcinoma of the thyroid. *Am J Radiol* . 1985;144:251â€“253.

212.Walfish, PG, Hazani E, Strawbridge HTH, et al. Combined ultrasound and needle aspiration cytology in the assessment and management of hypofunctioning nodule. *Ann Intern Med* . 1971;87:270â€“274.

Diagnostic Accuracy

213.LiVolsi VA, Gupta PK. Thyroid fine-needle aspiration of intranuclear inclusions, nuclea grooves and psammoma bodiesâ€”paraganglioma-like adenoma of the thyroid. *Diagn Cytopathol* . 1992;8:82â€“84.

214.Goellner JR, Carney JA. Cytologic features of fine-needle aspirates of hyalinizing trabecular adenoma of the thyroid. *AM J Clin Pathol* . 1989;91:115â€“119.

215.LiVolsi VA. Papillary neoplasms of the thyroid. Pathologic and prognostic features. *Am Clin Pathol* . 1992;97:426â€“434.

216.Faser CR, Marley EF, Oertel YC. Papillary tissue fragments as a diagnostic pitfall in fin needle aspirations of thyroid nodule. *Diagn Cytopathol* . 1997;16:454â€“459.

217.Renshaw AA, Wang E, Haja J, et al. Fine-needle aspiration of papillary thyroid carcinoma. Distinguishing between cases that performed well and those that performed poorly in the College of American Pathologists Non gynecologic Cytology Program. *Arch Pa Lab Med* . 2006;130:452â€“455.

218.Harach HR, Zusman SB, Day S. Nodular goiter: a histocytological study with some emphasis on pitfalls of fine-needle aspiration cytology. *Diagn Cytopathol* . 1993;8:409â€“419.

219.Caraway NP, Sneige N, Samaan NA. Diagnostic pitfalls in thyroid fine-needle aspiratio A review of 394 cases. *Diagn Cytopathol* . 1993;9:345â€“350.

220.Fiorella RM, Isky W, Miller L, et al. Multinodular goiter of the thyroid mimicking malignancy. Diagnostic pitfalls in fine-needle aspiration biopsy. *Diagn Cytopathol* . 1993;9:351â€“354.

221.Hall TL, Layfield LJ, Philippe A, et al. Sources of diagnostic error in fine needle aspiration of the thyroid. *Cancer* . 1989; 63:718â€“725.

222.Ravinsky E, Safneck JR. Differentiation of Hashimoto's thyroiditis from thyroid neopla in fine needle aspirates. *Acta Cytol* . 1988;32:854â€“861.

223.Kumarasinghe MP, De Silva S. Pitfalls in cytological diagnosis of autoimmune thyroidit *Pathology* . 1999;31:1â€“7.

224.Wortsman J, Dietrich J, Apesus J, et al. Hashimoto's thyroiditis simulating cancer of t thyroid. *Arch Surg* . 1981;116:386â€“388.

225.Hunt JL, Barnes EL. Non-tumor associated psammoma bodies in the thyroid. *Am J Clir Pathol* . 2000;119:90â€“94.

226.Ellison E, Lapueria P, Martin SE. Psammoma bodies in fine-needle aspirates of the thyroid. Predictive value for papillary carcinoma. *Cancer (Cancer Cytopathology)* . 1998;84:169â€“175.

227.Riazmontazer N, Bedayat G. Psammoma bodies in fine needles aspirates from thyroids containing nontoxic hyperplastic goiters. *Acta Cytol* . 1991;35:563â€“566.

228.Dugan JH, Atkinson BF, Avitabile A, et al. Psammoma bodies in FNA of thyroid in lymphocytic thyroiditis. *Acta Cytol* . 1987;31: 330â€“334.

229.Patchefsky AS, Hoch WS. Psammoma bodies in diffuse toxic goiter. *Am J Clin Pathol* . 1972;57:551â€“556.

Editors: Kini, Sudha R.
Title: *Thyroid Cytopathology: A Text and Atlas, 1st Edition*

Copyright Â©2008 Lippincott Williams & Wilkins

10

Poorly Differentiated "Insular" Carcinoma

In 1984, Carcangiu et al.1 reported 25 cases of a distinctive type of thyroid carcinoma characterized by the formation of solid masses or islands (insulae) of small monomorphic tu cells with aggressive clinical behavior, distant metastases, and death in most instances. The authors believed that this carcinoma occupies a place intermediate between well-differenti follicular/papillary carcinomas and the usually fatal anaplastic carcinoma. They referred to morphologic type as poorly differentiated carcinoma, and coined the term "insular" because the characteristic histologic appearance.

Insular carcinomas are uncommon, comprising 4% to 7% of all thyroid malignancies, with a male:female ratio of 1:2.2 Insular carcinoma usually occurs in older individuals, the mean a being 55 years. But it has also been described in the pediatric age group.3 , 4 , 5 These tum follow an aggressive course and have a high mortality rate. Most patients demonstrate local distant metastases at the time of presentation.

Since the introduction of this aggressive subtype of thyroid carcinomas by Carcangiu and co-workers,1 several small series and case reports have been published in the literature,3 , 4 , , 7 , 8 , 9 , 10 , 11 , 12 , 13 , 14 , 15 , 16 , 17 , 18 , 19 , 20 , 21 , 22 , 23 , 24 , 25 , 26 , 27 , 29 , 30 , 31 including a few on their cytologic presentations.21 , 22 , 23 , 24 , 25 , 26 , 27 , 29 , 30 , 31

GROSS AND HISTOLOGIC FINDINGS

Grossly, insular carcinomas are usually large and bulky, often exceeding 5 cm in dimension. are solid and grayish white, with foci of necrosis (Fig. 10.1). Gross extrathyroidal extension frequently present.

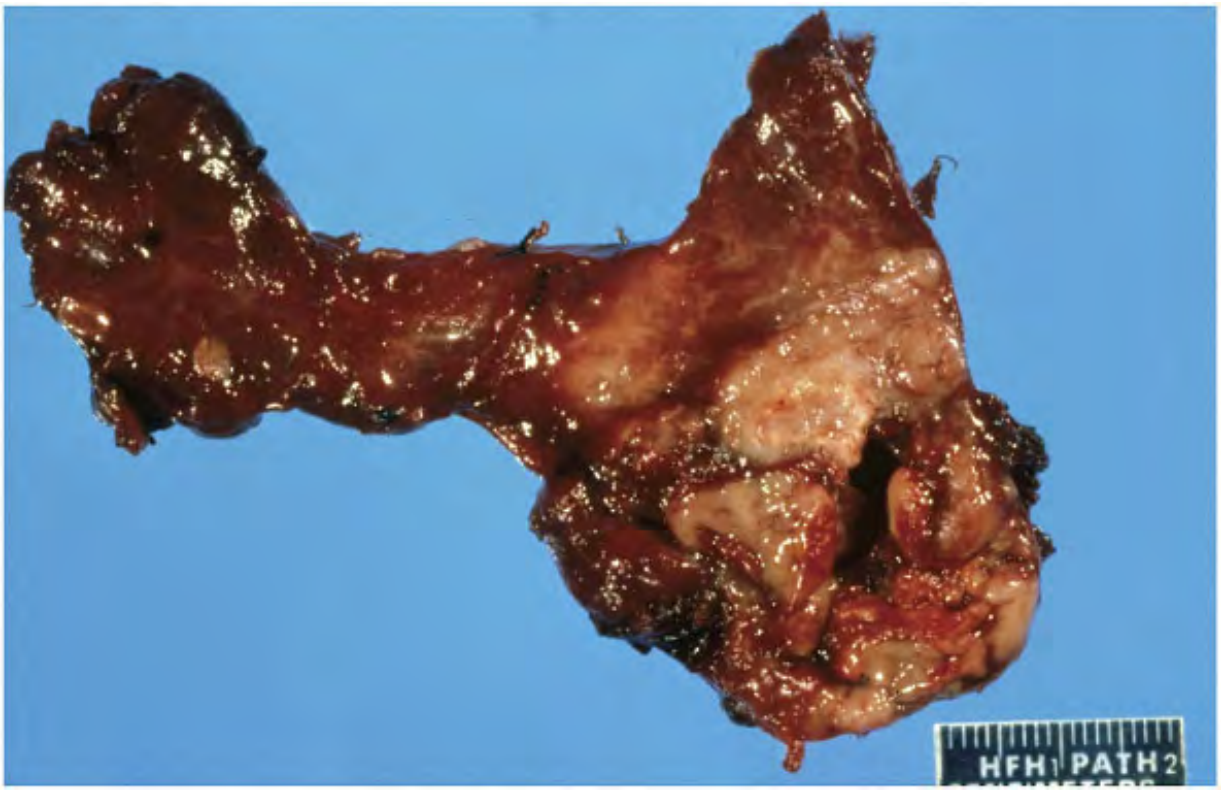

Figure 10.1. Gross photograph of an insular carcinoma involving the left lobe of the thyroid tumor is large, bulky with areas of necrosis and is replacing almost the entire left lobe.

Insular carcinomas demonstrate a distinctive histologic appearance (Figs. 10.2 , 10.3 and 10 characterized by a solid growth pattern consisting of well-defined nests or insulae of round oval, small follicular cells averaging up to 10 Âµm in diameter. The nests of the tumor cells well demarcated, vary in size, and are separated by thin connective-tissue septae containin delicate blood vessels. The nests of tumor cells may be solid, or show a follicular pattern, o with abortive follicles or a trabecular pattern. Large areas of necrosis are frequent (Fig. 10. Sparing of malignant cells around the blood vessels imparts a peritheliomatous pattern. Mitc are frequent. Droplets of colloid may be present in the abortive follicles.

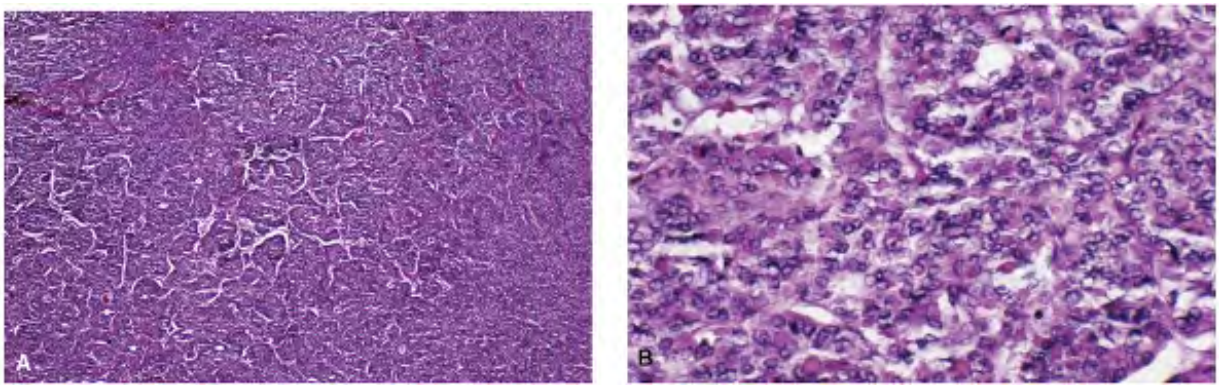

Figure 10.2 A. Histologic section of an insular carcinoma with a solid growth pattern and prominent vascularization (low power). B. Higher magnification showing small uniform malig cells with scant cytoplasm and hyperchromatic nuclei.

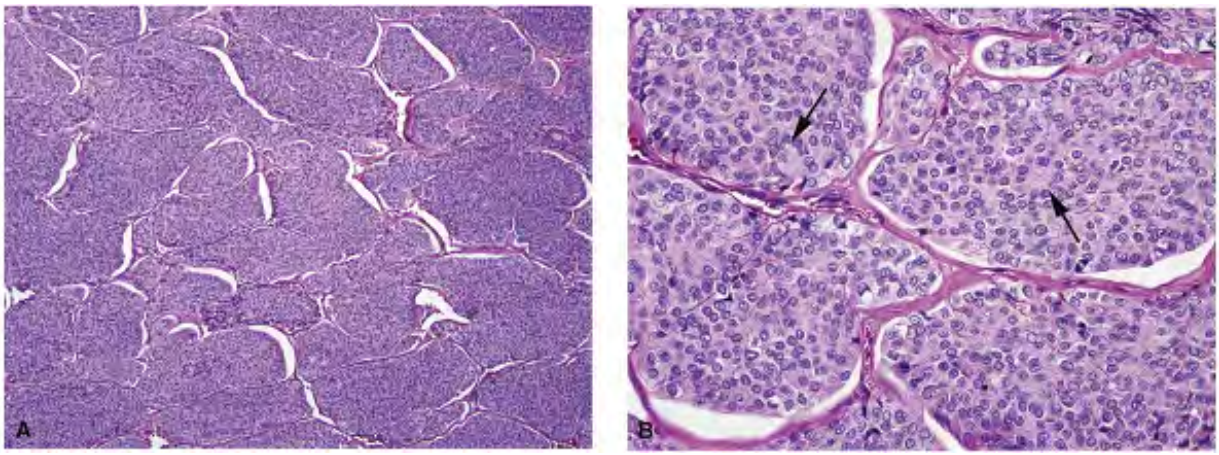

Figure 10.3. Histologic sections of insular carcinoma. A. Note a solid growth pattern with la islands of uniform malignant cells (insulae), delineated by delicate fibrous septae, low powe Higher magnification highlighting the small uniform malignant cells. Note the abortive follic (arrows).

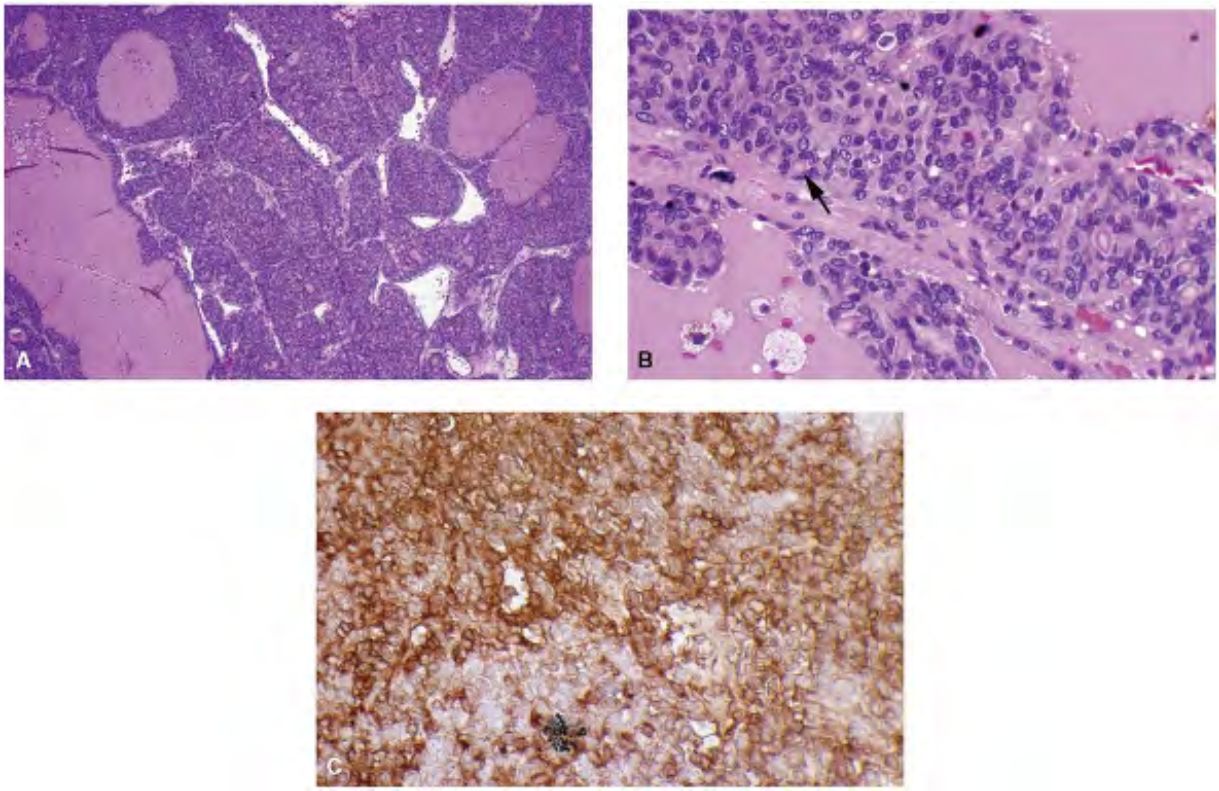

Figure 10.4. A. Histologic section of insular carcinoma showing a solid growth pattern with areas of necrosis (low power). B. Higher magnification highlighting the small monotonous ce and abortive follicles (arrow), some containing colloid. C. Positive reactivity of the insular carcinoma cells to thyroglobulin.

Insular carcinomas may be associated with well-differentiated follicular/papillary carcinoma anaplastic carcinomas.2 , 17 , 18 , 19 The macrofollicular variant of papillary carcinoma in particular has been described as associated with an insular component.18 , 19 An insular pa is also observed in metastases from differentiated follicular/papillary carcinomas.

CYTOPATHOLOGIC FEATURES

The cytopathologic findings of insular carcinomas are sparsely documented.21 , 22 , 23 , 24 , 26 , 27 , 28 , 29 , 30 , 31 Their presentation varies, the common denominator being the consistent small cell size. The aspirates are generally cellular, consisting of a large populati small, very uniform malignant cells occurring singly, in loosely cohesive groups, and in syncy tissue fragments (Figs. 10.5 , 10.6 , 10.7 , 10.8 , 10.9 , 10.10 , 10.11 and 10.12). The latter occur as nests, masses, or trabeculae with intense crowding and overlapping of nuclei. The

are often rounded and sharply defined, corresponding to the insulae seen in the histologic sections. Some syncytial tissue fragments may demonstrate a microfollicular pattern, with t lumens at times containing droplets of colloid (Fig. 10.10C). A dispersed pattern is also occasionally seen (Fig. 10.7). The cells of the insular carcinoma are round, with poorly defi cell borders, and are much smaller than cells of the differentiated (follicular/papillary) thyr cancers, averaging 9 to 10 Âµm in diameter. Plasmacytoid features causing difficulties in differentiating the tumor from medullary carcinoma have been described.22 Their cytoplasr scant, indiscernible, occasionally pale and vacuolated with extremely high N/C ratios. The nuclear contours are smooth and the chromatin is coarsely granular and deep-staining. Exce parachromatin clearing is also appreciated and micronucleoli are usually conspicuous. Mitot figures may be present. Insular carcinomas, dedifferentiated from papillary carcinomas, ma demonstrate features of papillary carcinoma such as powdery chromatin, nuclear grooves, a intranuclear

inclusions. Those dedifferentiated from follicular carcinomas may demonstrate a follicular pattern. As mentioned in histologic findings, a metastatic carcinoma from a differentiated thyroid cancer may present as an insular carcinoma (Figs. 10.10 and 10.11). The backgroun may be clean or necrotic. Mitosis may be a prominent feature. No colloid is appreciated in t background. The cytologic features of insular carcinoma are listed in Table 10.1 and illustra in Figures 10.5 to 10.12 .

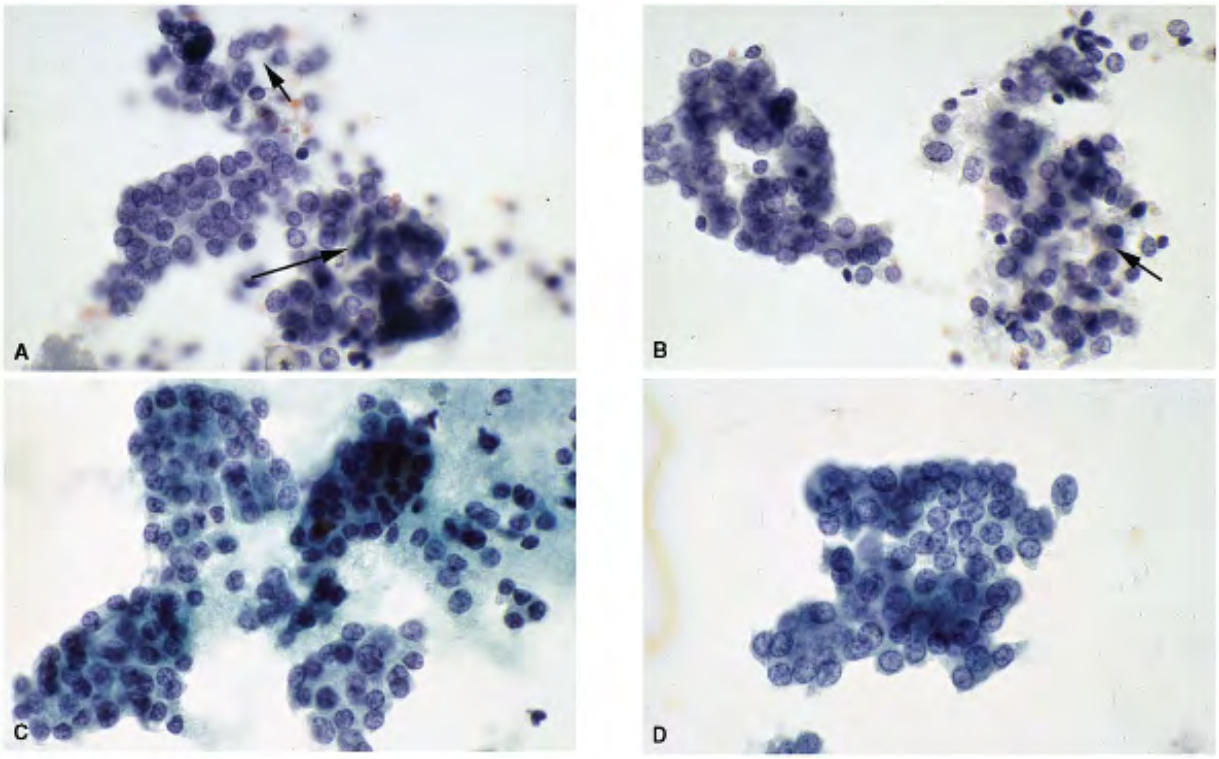

Figure 10.5. A,B. FNA of an insular carcinoma consisting of syncytial tissue fragments of sm uniform, round cells with scant to indiscernible cytoplasm. Note the follicular pattern (arrov C,D. Scrape cytology of sternal metastasis of the insular carcinoma depicted in A and B, sho similar cytomorphology. The patient initially presented with a pulsatile mass with destructic the sternum.

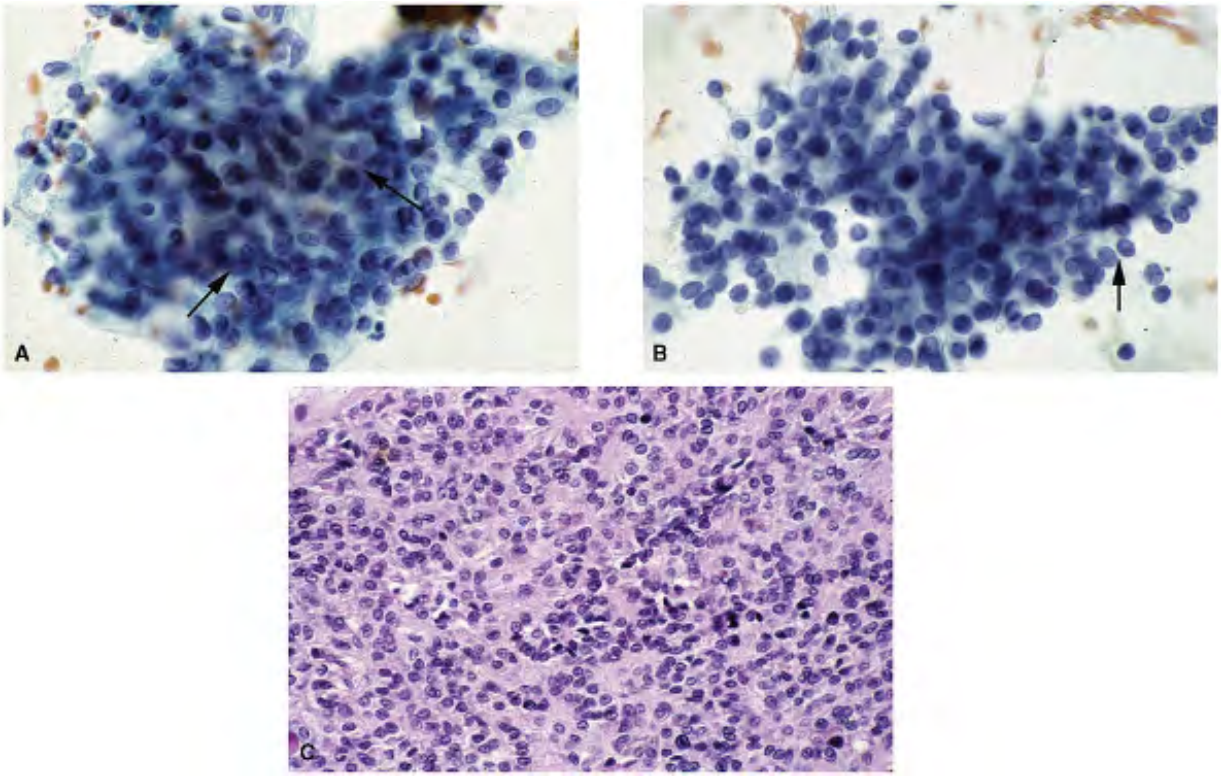

Figure 10.6. A,B. FNA of an insular carcinoma showing large syncytial tissue fragments of sr uniform malignant cells with extreme crowding and overlapping. Note a vague follicular pat (arrows). "Insular" nature may not be recognized from the cytologic samples and the carcinc may be interpreted as poorly differentiated follicular carcinoma. C. Histologic section of th resected insular carcinoma.

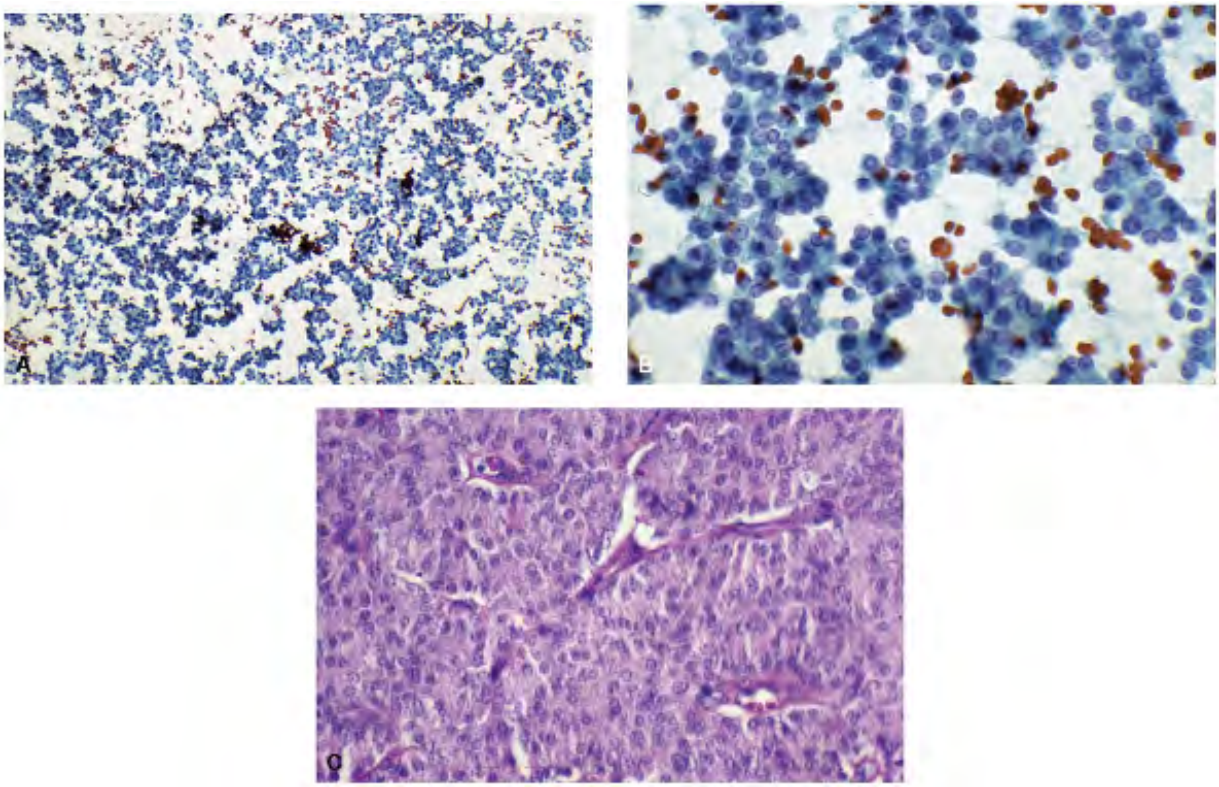

Figure 10.7. A. FNA of another case of an insular carcinoma. The cellular aspirate consists c small malignant cells, in syncytial tissue fragments with a follicular pattern. Note the disper pattern (low power). B. Higher magnification showing small uniform malignant cells with sca cytoplasm, high N/C ratios, and granular chromatin with micronucleoli. Note the clean background. C. Histologic section of the insular carcinoma.

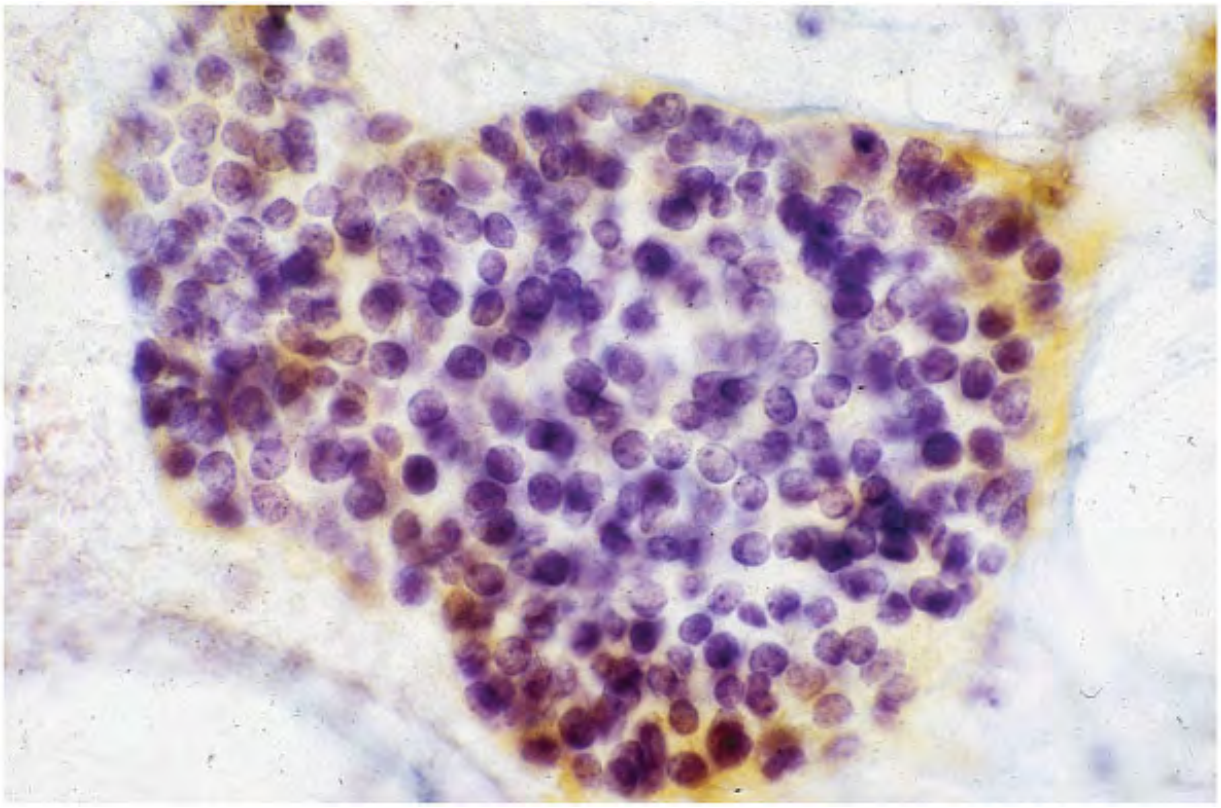

Figure 10.8. FNA of an insular carcinoma metastatic to the vertebra. Note the characteristi insula formed by small uniform cells. There is an attempt at follicular growth pattern.

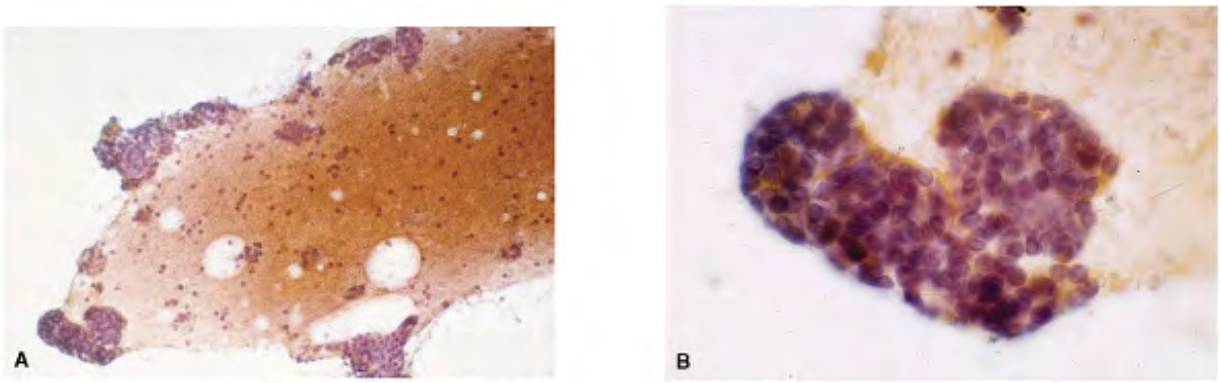

Figure 10.9. A. FNA of an insular carcinoma metastatic to the lung. Note syncytial tissue fragments forming insulae with well-defined outlines (low power). B. Higher magnification demonstrating monomorphic small follicular cells with high N/C ratios, presenting a follicula pattern.

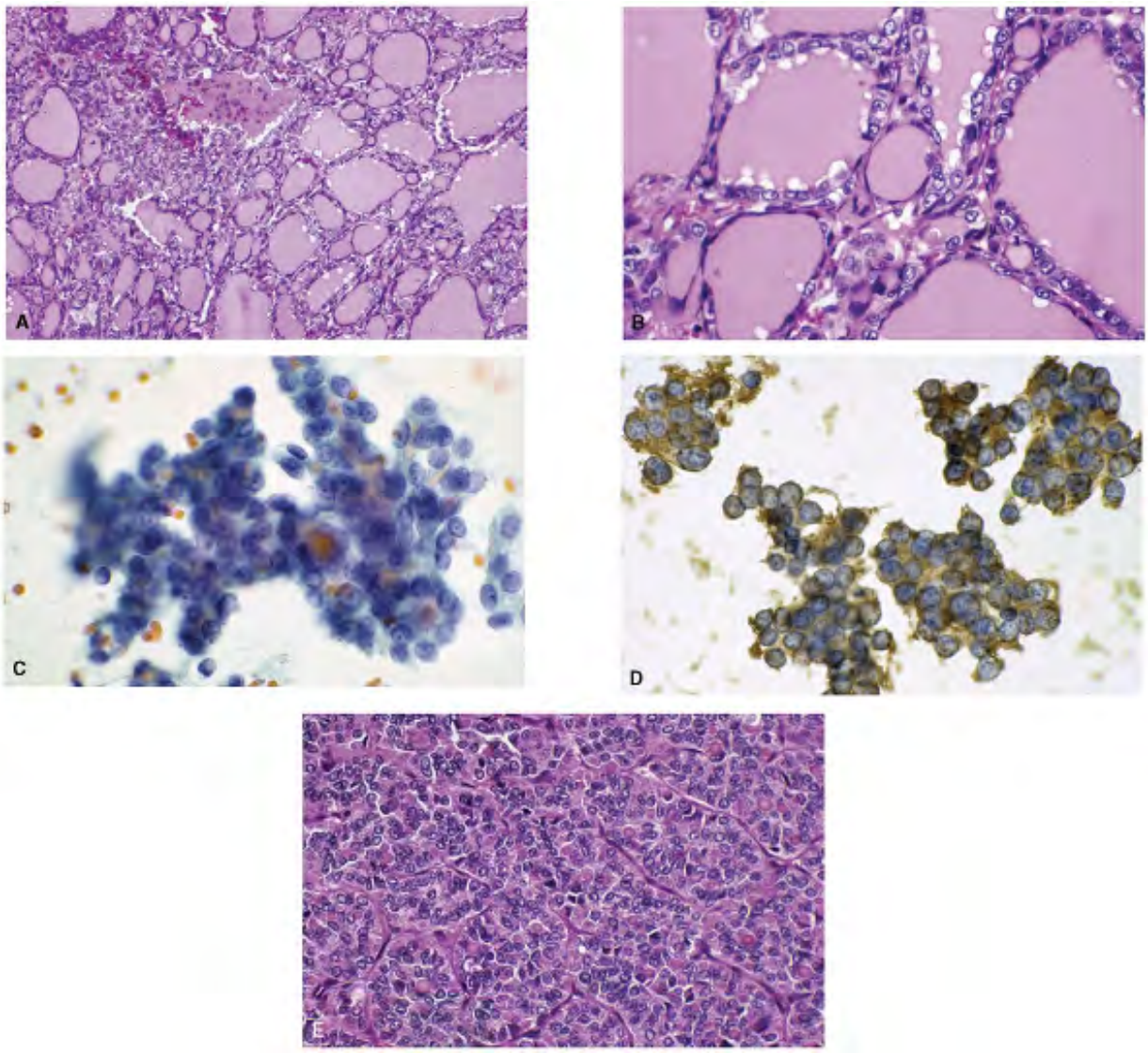

Figure 10.10. This case represents a macrofollicular papillary carcinoma, which metastasize years later to the shoulder with dedifferentiation. FNA of the shoulder mass showed an insul carcinoma that was confirmed on surgical excision. A. Histologic section of the macrofollicu papillary carcinoma. Note large follicles distended with colloid. The lining epithelium demonstrates classic nuclear features of a conventional papillary carcinoma. B. Higher magnification to highlight the classic nuclear features of a conventional papillary carcinoma FNA of the shoulder mass showing small uniform malignant follicular cells. Note occasional follicle formation and colloid in their lumens. D. Positive reactivity of the malignant cells to thyroglobulin. E. Histologic section of the excised shoulder mass showing insular carcinoma.

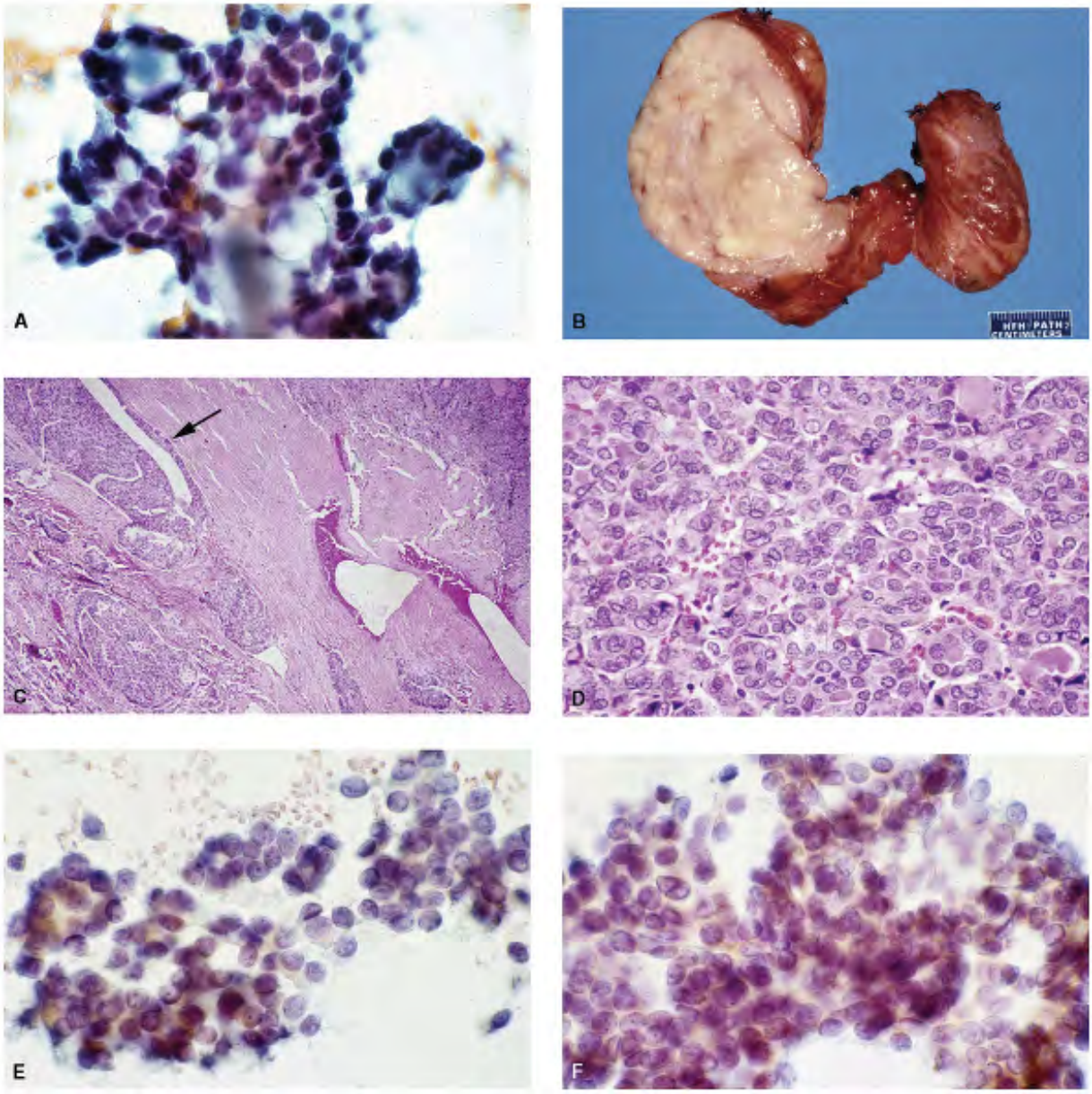

Figure 10.11. This case represents a follicular carcinoma that metastasized 11 years later t lung as an insular carcinoma. A. FNA of the follicular carcinoma performed preoperatively. I syncytial tissue fragments with a follicular pattern. The component cells have intensely hyperchromatic, enlarged nuclei. B. The thyroidectomy revealed a very large fleshy tumor replacing the entire right lobe. C. Histologic section showed a widely invasive follicular carcinoma. Note vascular invasion (arrow). D. Higher magnification of the follicular carcinoı E,F. FNA of the pulmonary metastasis showing a characteristic cytologic pattern of insular carcinoma with a follicular pattern. Compare the cell size in this metastatic tumor with the original tumor as depicted in A.

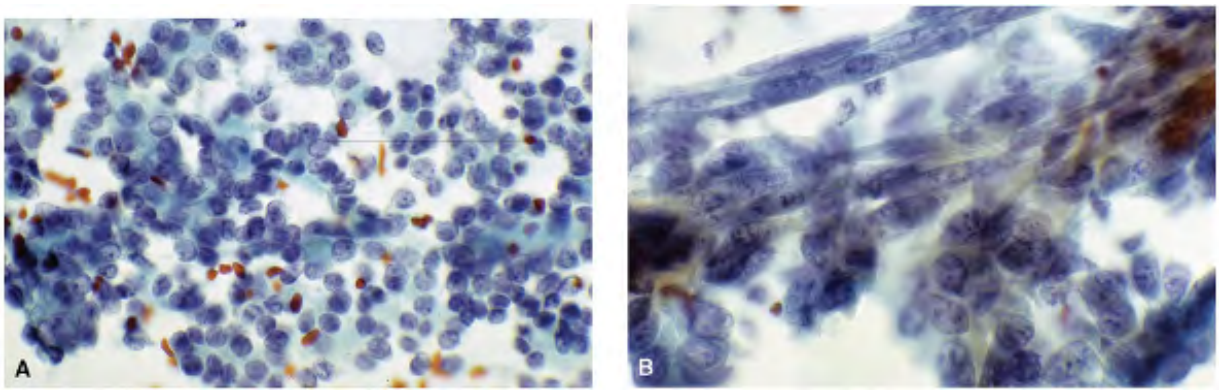

Figure 10.12. This case represents an anaplastic thyroid carcinoma with a coexistent insula component. Both components were present in the fine-needle aspirates and were confirmec histologic examination following the excision. A. FNA showing a cellular aspirate with a larg population of small cells, isolated and in syncytial tissue fragments, some with a follicular pattern. The follicular cell nuclei are uniformly round with finely granular chromatin, parachromatin clearing, and contain micronucleoli. The cytologic pattern is consistent with poorly differentiated carcinoma. An interpretation of insular carcinoma is difficult. B. Anotl smear of the same aspirate showing spindle and giant malignant cells, characteristic of anaplastic carcinoma. Recognition of both the components depends on sampling.

Cellularity and
presentation
Generally very cellular, malignant cells isolated, in loosely
cohesive groups or in syncytial tissue fragments;
a dispersed pattern is frequent
Architecture
Syncytial tissue fragments of small malignant cells with follicular
pattern, or forming insulae, nests or trabeculae; intense
crowding and overlapping of nuclei; peripheral palisading
not present in the tissue fragments
Cells
Small, monomorphic
Nucleus
Approximately 10 Âµm in diameter; round, deep-staining, granular

chromatin with parachromatin clearing; single/multiple micronucleoli; no nuclear molding; mitoses Â±; no stretch artifacts

Cytoplasm

Scant, indiscernible; pale; vacuoles Â±

Background

Clean to necrotic; features of pre-existing follicular or papillary carcinoma Â±

Immunocytochemical profile

Usually react positively with antibodies to thyroglobulin and TTF-1, occasionally negative; positive reactivity to cytokeratin; negative reactivity to calcitonin, neuroendocrine markers, leukocyte common antigen (LCA)

TABLE 10.1 CYTOPATHOLOGIC FEATURES OF POORLY DIFFERENTIATED"INSULAR CARCINOMA"

IMMUNOPROFILE

The insular carcinoma cells usually react positively to thyroglobulin and TTF-1. Negative reactivity to thyroglobulin is occasionally observed. Insular carcinomas also react positively cytokeratins.

P.222

P.223

P.224

DIAGNOSTIC ACCURACY AND DIFFERENTIAL DIAGNOSIS

The diagnostic accuracy of insular carcinoma is difficult to assess. These are uncommon thyı neoplasms, and since first described over two decades ago in 1984, cytologic findings of insu carcinoma have been described only infrequently, usually as individual case reports or as sm case series.21 , 22 , 23 , 24 , 25 , 26 , 27 , 28 , 29 , 30 , 31 In most of these reports, the ca were interpreted as poorly differentiated carcinomas, and the insular nature was appreciate following the histologic examination. An accurate cytologic diagnosis of insular carcinoma is difficult to make, unless the aspirate shows insulae formed by small, uniform malignant cell

, 25 Most cases of insular carcinomas are cytologically interpreted as poorly differentiated follicular carcinoma because of the follicular architecture or papillary carcinomas if feature papillary carcinoma are coexistent. Presence of insulae is not a very common feature. Recognition

P.225
P.226
P.227

also depends on the experience of the interpreter, as most cytopathologists have limited experience with the cytologic presentation of this uncommon thyroid neoplasm. The small s of the malignant cells, however, is the key to the diagnosis. Conventional follicular carcinor cells are much larger (Fig. 10.11). Also, many insular carcinomas are associated with differentiated carcinomas of follicular cell origin, such as the follicular or papillary type. Th aspiration biopsy may sample only the differentiated component and the diagnosis of insula carcinoma will be evident only following the surgical excision. On rare occasions however, multiple sampling of the neoplasm may demonstrate the coexistence of both components (F 10.12).

Differential Diagnosis

The differential diagnosis of insular carcinoma includes neoplasms composed of small malig cells such as medullary thyroid carcinoma with a small cell pattern, other neuroendocrine tumors including carcinoid tumors or the recently described nonâ€“calcitonin-producing neuroendocrine carcinoma,32 , 33 , 34 malignant lymphoma, metastatic malignancy such as small cell carcinoma, or poorly differentiated metastatic malignancy composed of a small ce pattern (Table 10.2). Immunostains are often required to establish a correct diagnosis. The cytologic differentiating features are listed in Table 10.3 .

Medullary carcinoma with a small cell pattern
Other neuroendocrine tumors with small cells
Malignant lymphoma
Metastatic small cell malignancy
- Small cell carcinoma
- Basaloid squamous cell carcinoma

TABLE 10.2 DIFFERENTIAL DIAGNOSIS OF INSULAR CARCINOMA

Presentation

Dispersed cell pattern or cells in syncytial tissue fragments forming nest, insulae or trabeculae; microfollicular pattern Â±; intense crowding and overlapping of nuclei

Neoplastic cells discrete, in loosely cohesive groups, infrequently in syncytial tissue fragments; pseudofollicular pattern Â±

Cells mostly isolated with dispersed pattern; rare syncytial tissue fragment

Neoplastic cells isolated, in loosely cohesive groups and in syncytial tissue fragments without any architectural patterns

Neoplastic cells

isolated, in loosely cohesive groups or in syncytial tissue fragments without any architectural pattern

Cells

Small in size, monomorphic, round, poorly defined cell borders; high N/C ratios

Small, monomorphic poorly defined cell borders; high N/C ratios

Small, monomorphic poorly defined cell borders; high N/C ratios

Small pleomorphic in size, poorly defined cell borders; high N/C ratios

Small, pleomorphic in size, poorly defined cell borders; high N/C ratios

Nucleus

Approximately 10 Âµm in diameter, round,

smooth nuclear
membrane, finely
granular chromatin
with parachromatin
clearing; micronu-
cleoli Â±; no nuclear
molding; no stretch
artifacts; mitosis Â±;
intranuclear inclu-
sions Â±; nuclear
groove Â±; karyor-
rhexis not observed
round; smooth
nuclear membrane;
coarsely granular
chromatin; nucleoli Â±;
nucleus often eccen-
tric; no nuclear
molding; no stretch
artifacts; mitosis -;
intranuclear inclu-
sions Â±; nuclear
groove -; karyor-
rhexis -
Round; smooth to
irregular nuclear
membrane; finely
granular chromatin
with parachromatin
clearing; micronucle-
oli +; no nuclear
molding; mitosis +;
stretch artifacts +;
intranuclear inclu-

sions -; nuclear groove -; karyorrhexis +

Round, oval, oblong to short spindle shape; smooth nuclear membrane; compact chromatin; nucleoli not appreciated; nuclear molding characteristics; mitosis +; stretch artifacts +; intranuclear inclusions -; nuclear groove +; karyorrhexis +

Rounds, oval to oblong; smooth nuclear membrane; chromatin coarsely granular and deep staining; nucleoli Â±; no nuclear molding; mitosis -; stretch artifacts -; intranuclear inclusions -; nuclear grooves -

Cytoplasm

Scant, insignificant; may contain small vacuoles

Scant, insignificant;
rudimentary cyto-
plasmic tailing
Scant, indiscernible
Scant, indiscernible
Scant; indiscernible
Colloid
Absent
Absent
Absent
Absent
Absent
Amyloid
Absent
Â±
Absent
Absent
Absent
Background
Clean or necrosis
Clean
Clean or necrotic
debris
Necrosis
Necrosis Â±
Immunoprofile
Thyroglobulin
+
â€”
â€”
â€”
â€”
TTF-1
+

â€”
â€”
â€”
â€”
Cytokeratin
+
+
â€”
+
+
Calcitonin
â€”
+
â€”
â€”
â€”
Neuroendocrine
â€”
+
â€”
â€”
â€”
Markers
LCA
â€”
â€”
+
â€”

	Insular Carcinoma	Medullary Carcinoma, Small Cell Type	Malignant Lymphoma	Metastatic Small Cell-Carcinoma	Metastat Basaloic Squamous Carcinom

TABLE 10.3 DIFFERENTIAL DIAGNOSIS OF POORLY DIFFERENTIATED "INSULAR" CARCINOMA

Insular Carcinoma versus Medullary Thyroid Carcinoma

The aspirate of a medullary carcinoma consisting of small uniform cells is very difficult to distinguish from insular carcinoma of the thyroid without the help of immunostains (Figs. 10 and 10.14). Insular carcinomas often show necrosis and increased proliferative activity, a feature generally not observed with medullary carcinomas. Calcitonin will be strongly positi with medullary carcinoma cells. A rare primary neuroendocrine tumor referred to as calcito free oat cell carcinoma34 will be extremely difficult to differentiate from either a medullar carcinoma or a metastatic small cell carcinoma. An example is illustrated in Figure 10.15 .

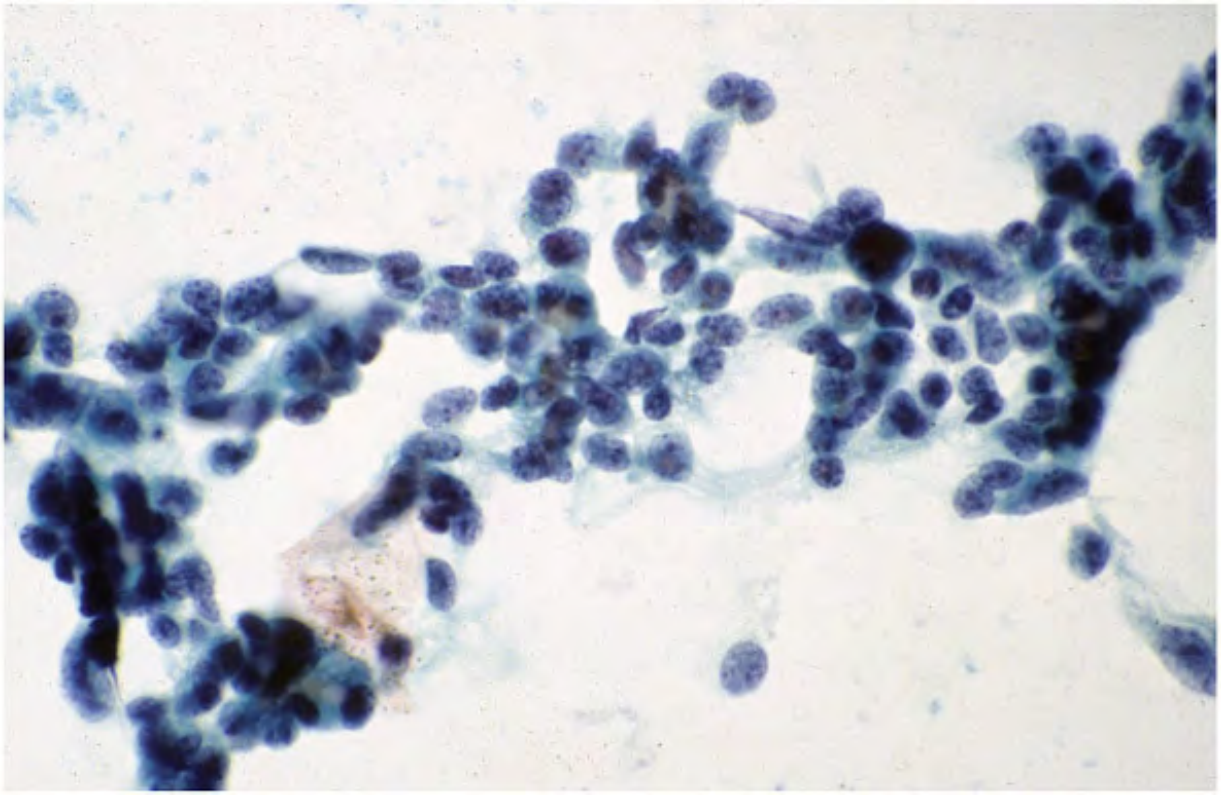

Figure 10.13. FNA of a medullary thyroid carcinoma depicting syncytial tissue fragments composed of monomorphic small cells with hyperchromatic nuclei. In the absence of a typic pleomorphic cell pattern of a medullary carcinoma, a diagnosis of insular carcinoma must b considered. A positive calcitonin stain will establish the diagnosis.

A

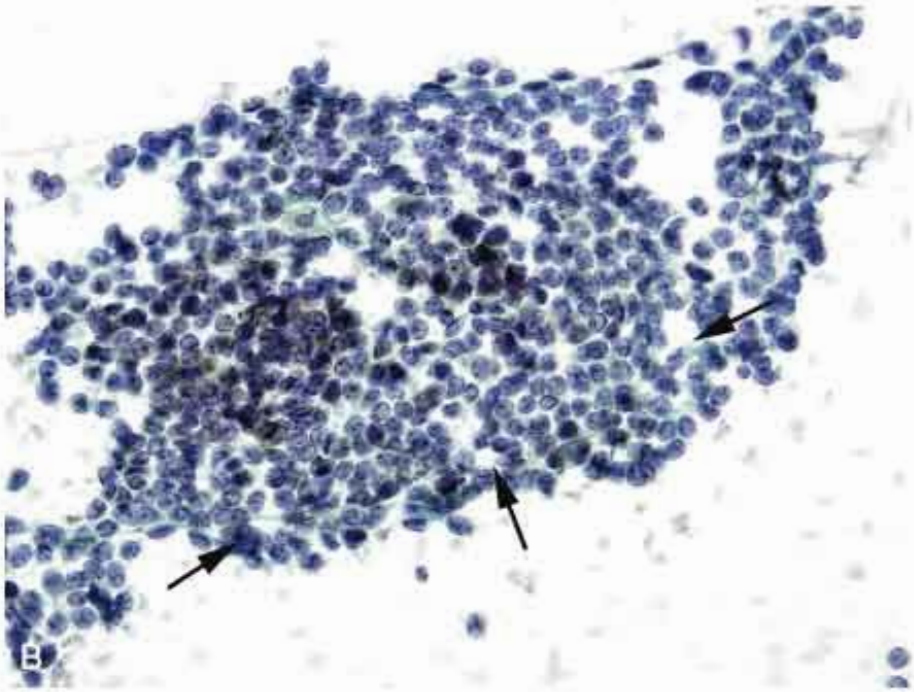
B

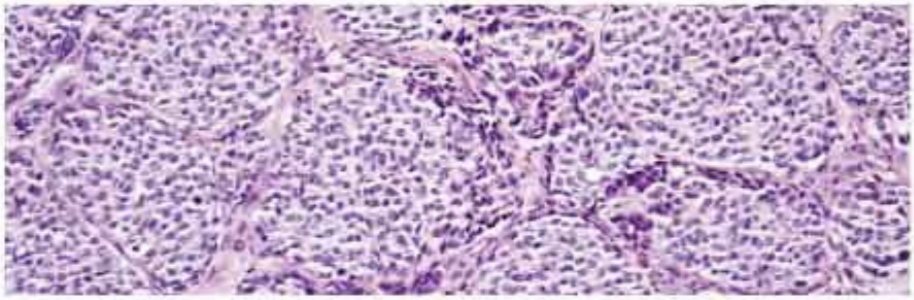

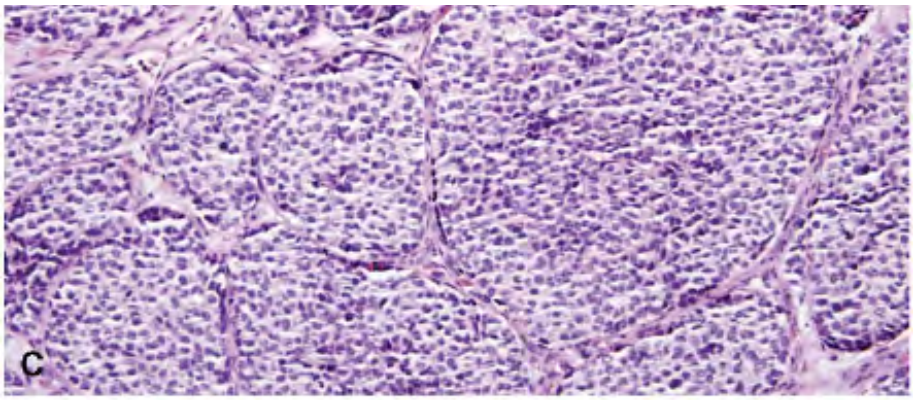

Figure 10.14. A. Medium power view of an aspirate of a medullary thyroid carcinoma showi small monomorphic malignant cells appearing discohesive and in syncytial tissue fragments resembling insulae. B. Higher magnification. The malignant cells are small with insignificant cytoplasm, high N/C ratios. Note pseudofollicular pattern (arrows). Such a pattern with sma cells may be mistaken for an insular carcinoma. C. Histologic section of the medullary carci showing nests of small, round to cuboidal cells. The tumor cells strongly reacted to calcitoni

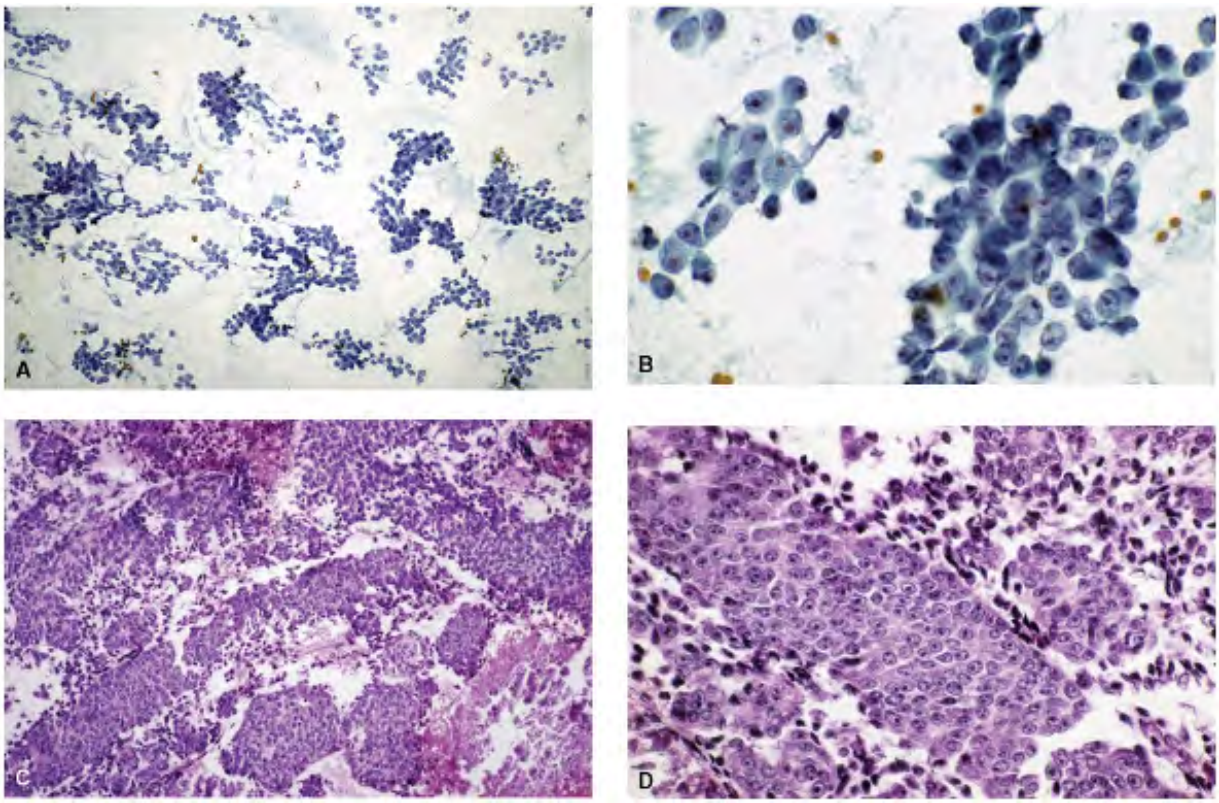

Figure 10.15. A. FNA of a thyroid mass. The aspirate is markedly cellular, consisting of seve

syncytial tissue fragments as well as loosely cohesive cells (low power). B. Higher magnifica showing the syncytial tissue fragment of the malignant cells without any architectural patte The malignant cells have scant undifferentiated cytoplasm. Their nuclei are slightly larger t the usual insular carcinoma cells and bear a strong resemblance to neuroendocrine carcinon cells. C. The cell block of the aspirate showing several tissue fragments forming insulae. The marked necrosis in the background, medium power. D. Higher magnification demonstrating insular pattern. The tumor cells did not express thyroglobulin, TTF-1, calcitonin, or any neuroendocrine markers. Only cytokeratin was positive. The neoplasm strongly resembles a cell neoplasm but the exact morphologic type remains undetermined. This may represent ar endocrine carcinoma (clinically serum calcitonin levels were not elevated).

Insular Carcinoma versus Malignant Lymphoma

A dispersed pattern of small malignant cells in an insular carcinoma of the thyroid may be misinterpreted as malignant lymphoma (Figs. 10.16 and 10.17). Nuclear molding and stretcl artifacts are not present in either of the two malignancies. The presence of increased proliferative activity, frequent mitotic figures, and necrotic background are features comm both. Without immunostains such as thyroglobulin and lymphoid markers, their differentiati may be very difficult.

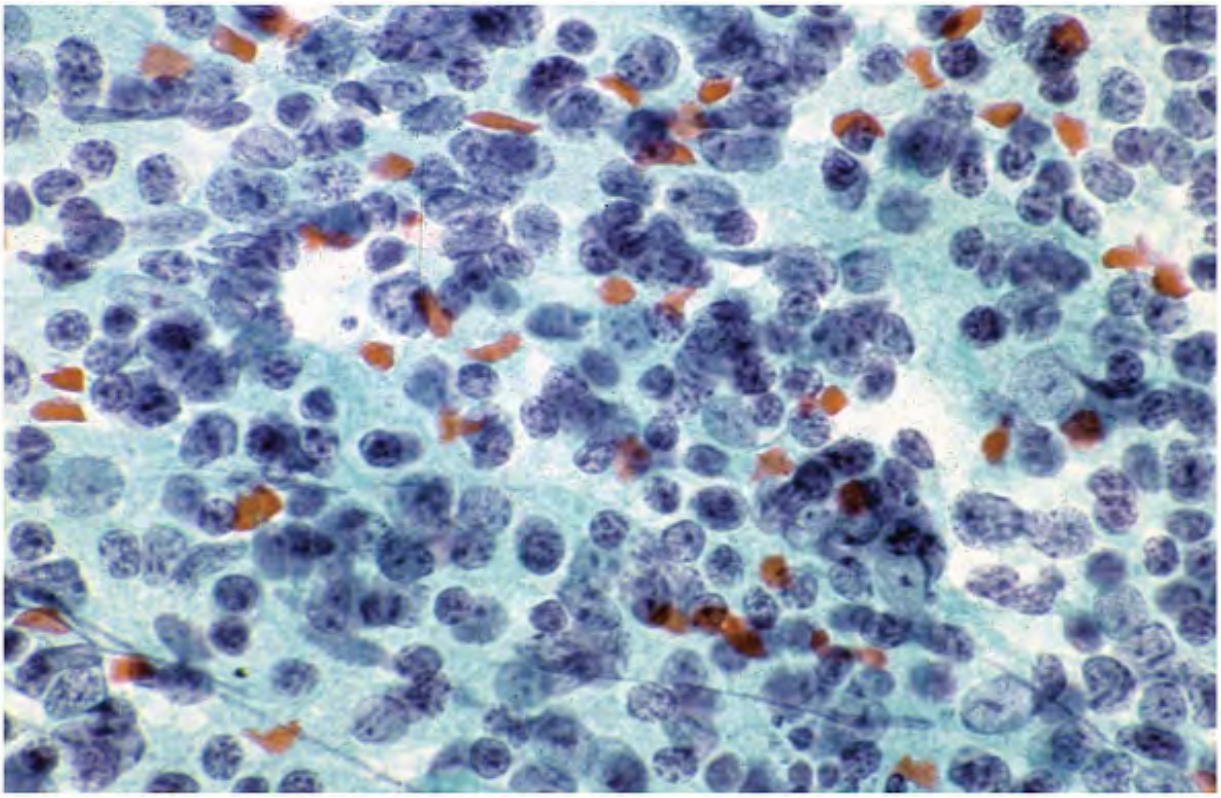

Figure 10.16. FNA of a primary malignant lymphoma of the thyroid. The monomorphic cell population of poorly differentiated lymphoid cells closely resembles cells of insular carcinor The malignant lymphoma cells will react positively with leukocyte common antigen (LCA).

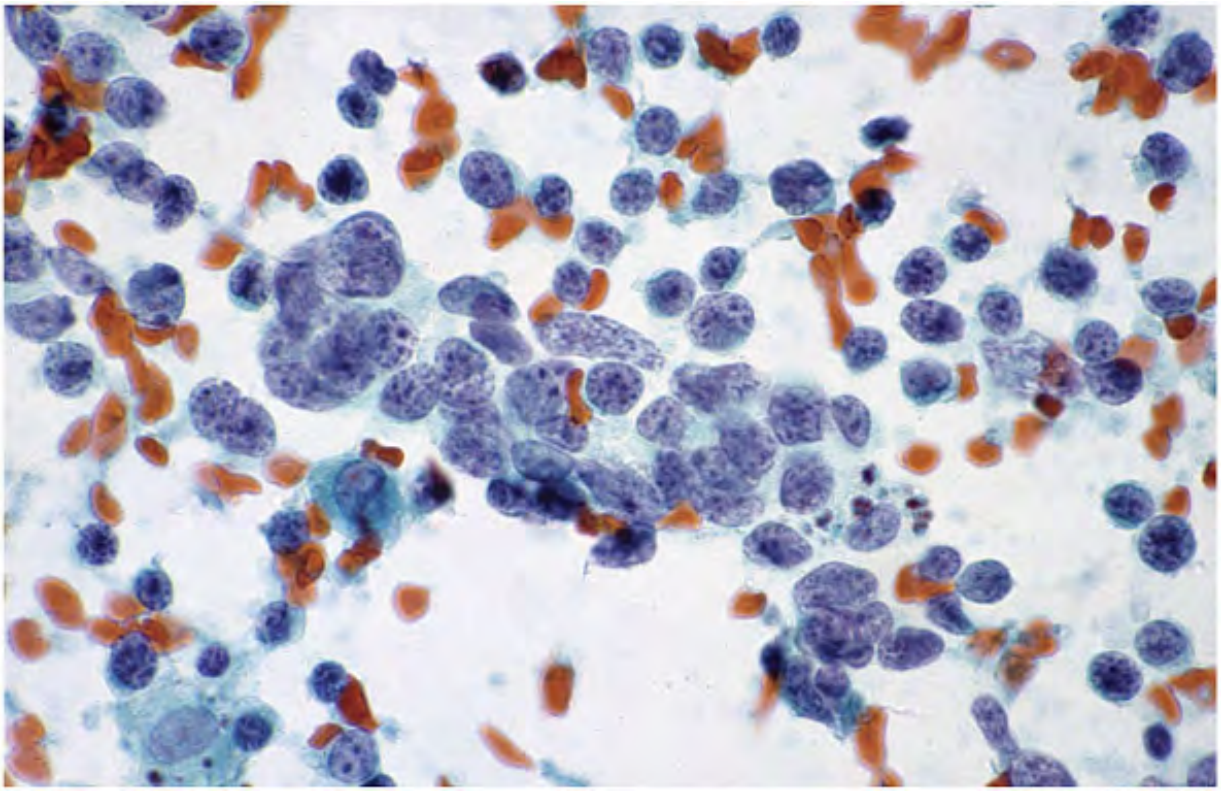

Figure 10.17. FNA of a primary malignant lymphoma of the thyroid showing a syncytial tissu fragment bearing morphologic resemblance to insular carcinoma.

Insular Carcinoma versus MetastaticSmall Cell Carcinoma

Small cell carcinomas of the lung often metastasize to the thyroid (Fig. 10.18). Not infrequently, a rapidly growing thyroid mass may be the only initial presenting sign of lung carcinoma. Although the common denominator for both entities is the small cell size, insula carcinoma cells lack the nuclear molding and stretch artifacts, a hall mark of small cell carcinomas; but extensive necrosis and frequent mitoses are common to both. Also, small ce carcinoma cells usually have a pleomorphic nuclear pattern with round, oval, and oblong sha while insular carcinoma cells are round. Insular carcinomas as well as small cell carcinomas TTF-1 and cytokeratin positive; however, thyroglobulin is strongly expressed by insular carcinomas most of the time.

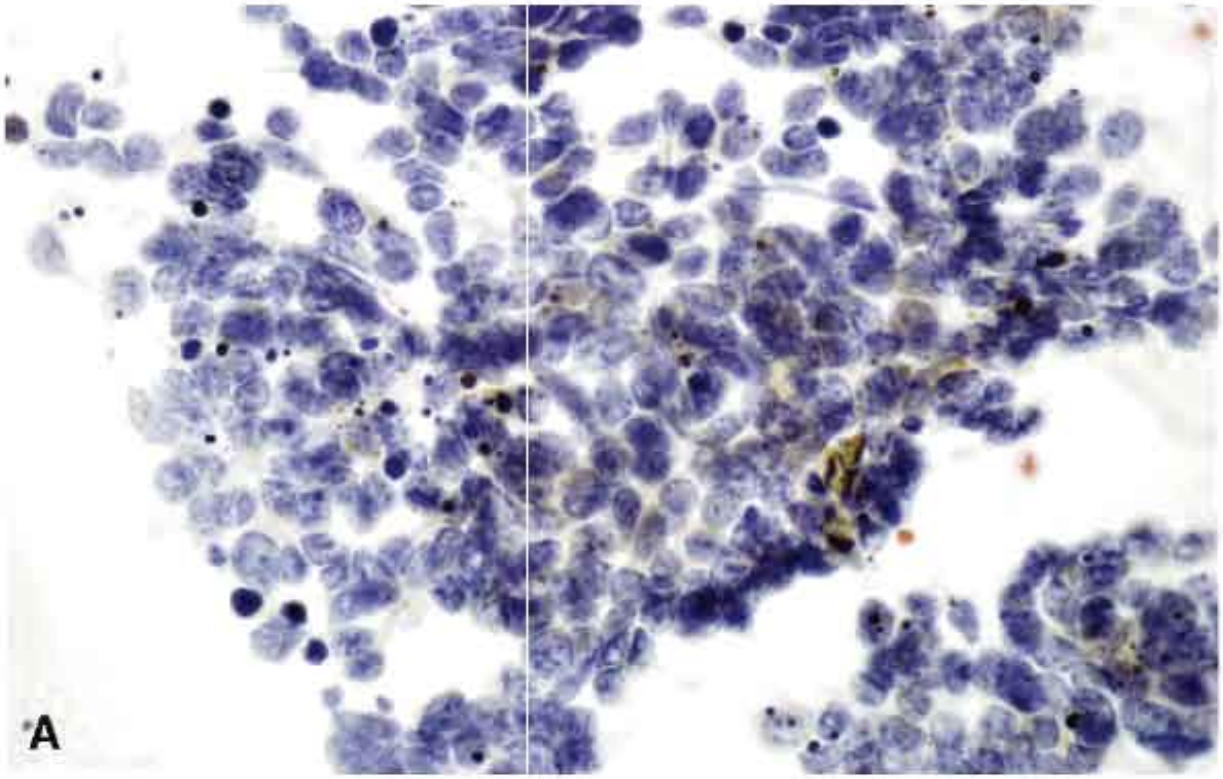
A

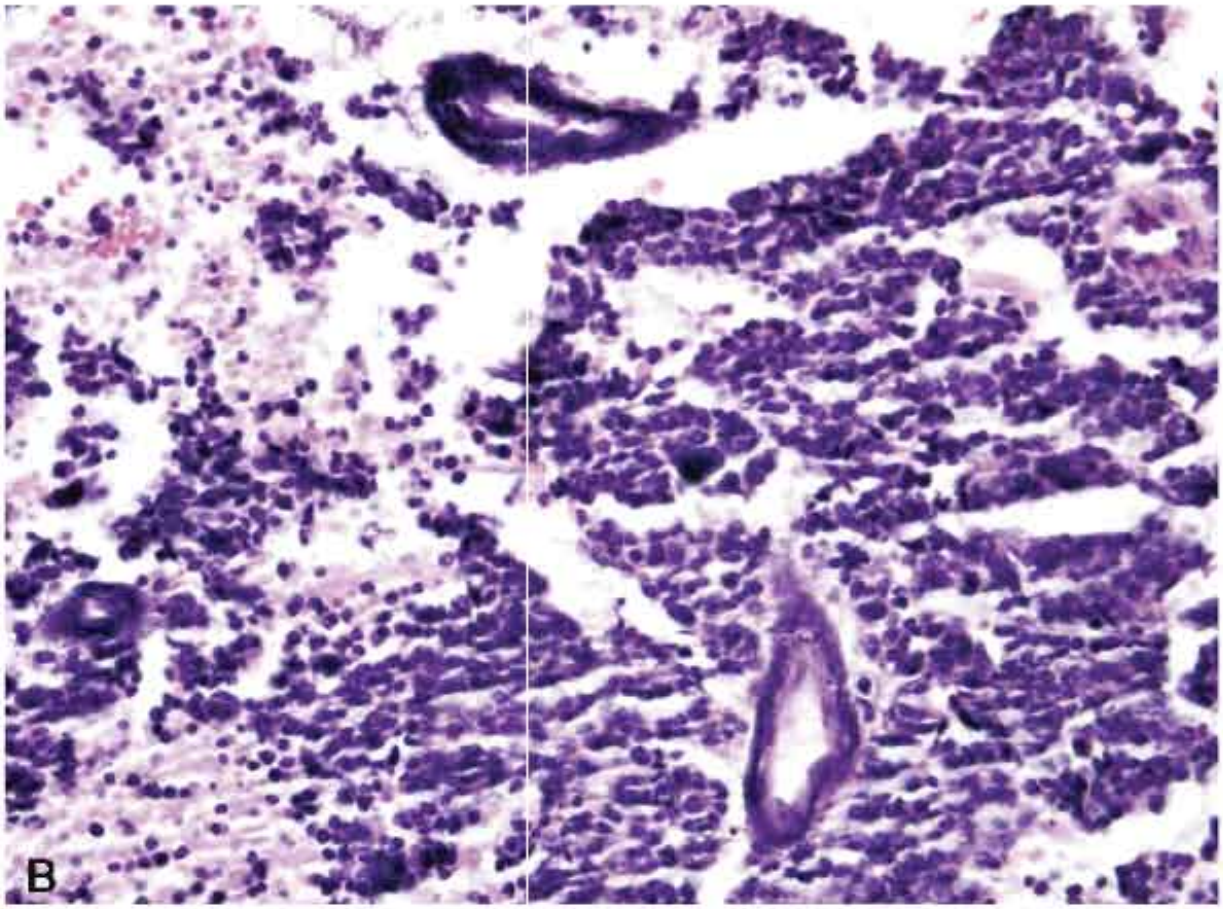
B

Figure 10.18. A. FNA of a metastatic small cell carcinoma of the lung that presented as a thyroid mass. The malignant cells exhibit a typical cytologic pattern of small cell carcinoma Note round, oval, oblong nuclei with molding. The cytoplasm is insignificant. Also note stret artifacts and karyorrhexis. B. The cell block of the aspirate confirming small cell carcinoma

Insular Carcinoma versus Poorly Differentiated Metastatic Malignancy

Poorly differentiated malignancy such as basaloid squamous cell carcinoma may be extreme difficult to differentiate from an insular carcinoma of the thyroid. Figure 10.19 gives an exa of such a case, where both the cytologic and histologic presentations appeared to closely resemble those of an insular carcinoma. The diagnosis of insular carcinoma was not supporte the negative reactivity to follicular cell markers such as thyroglobulin or TTF-1. An extensive workup confirmed a basaloid squamous cell carcinoma arising in the esophagus that had inva the thyroid and presented itself as a thyroid mass.

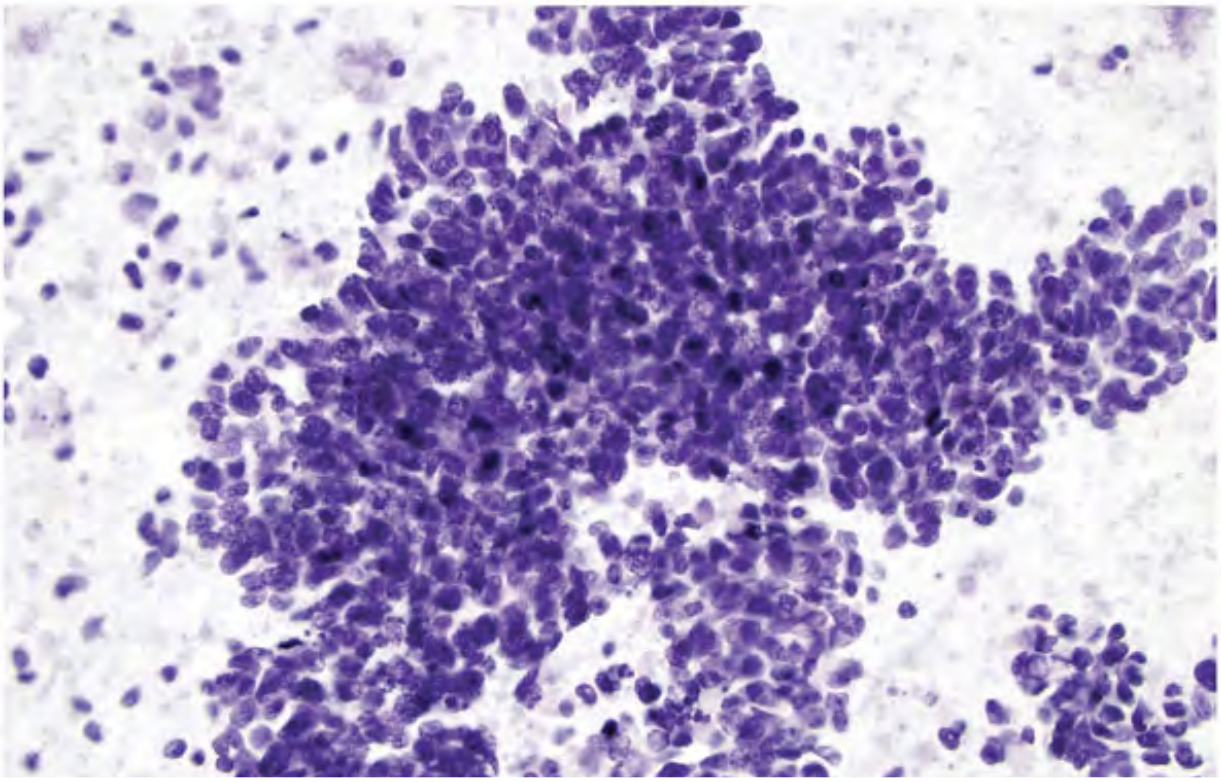

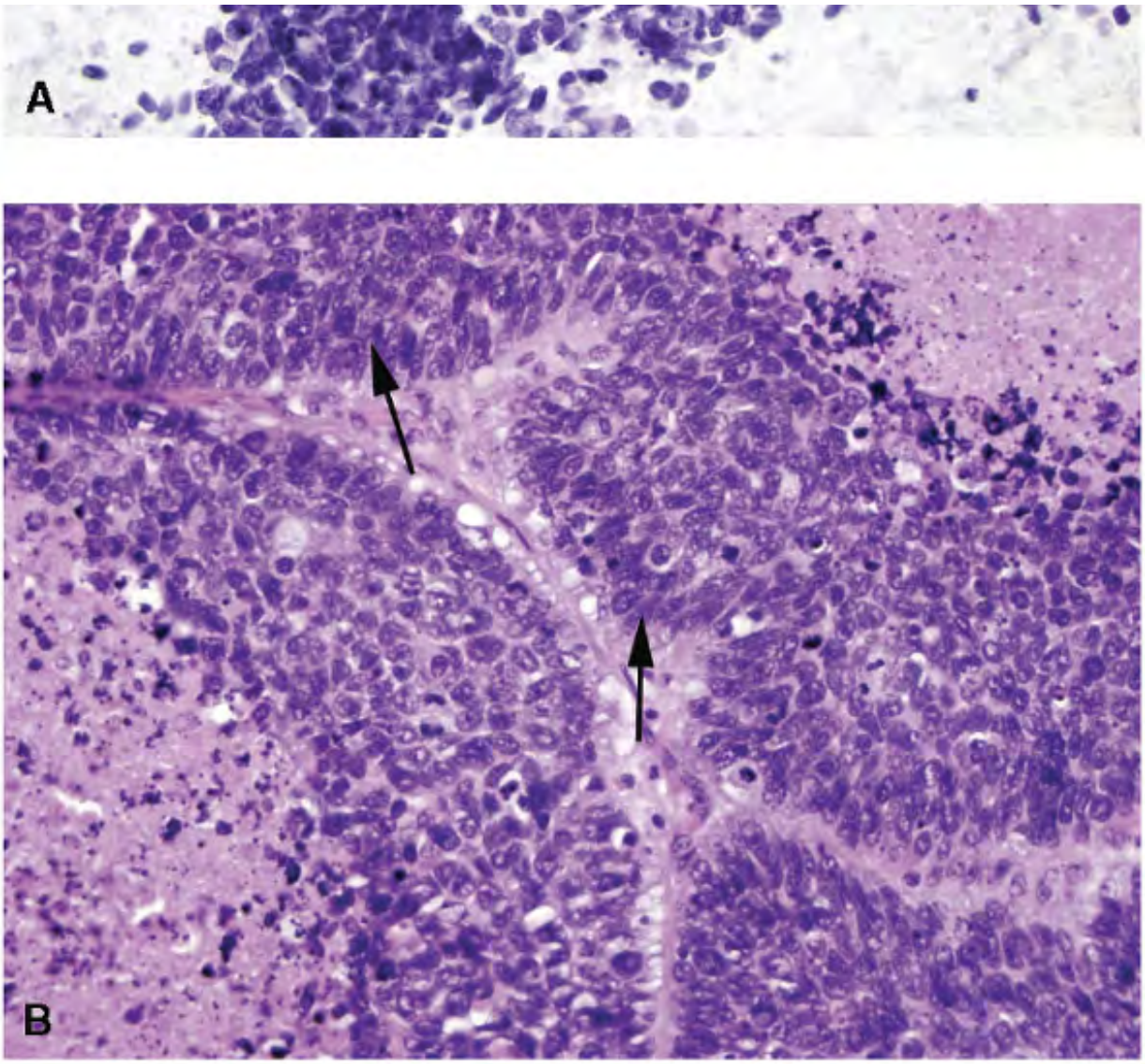

Figure 10.19. A. FNA of a metastatic basaloid squamous cell carcinoma of the esophagus th presented as a rapidly growing thyroid mass. The aspirate is cellular, showing syncytial tissu fragments of small uniform malignant cells with scant cytoplasm and high N/C ratios. Note necrosis in the background. The pattern is highly suggestive of an insular carcinoma. B. The block of the aspirate showed malignant cells presenting an insular pattern and considerable necrosis. Note the peripheral palisading (arrows) of nuclei, which is not a feature of insular carcinoma. The differential diagnosis included insular carcinoma, medullary carcinoma, and metastatic small cell carcinoma. The tumor cells expressed only cytokeratin. Further investigations revealed an infiltrating basaloid squamous carcinoma of the esophagus that infiltrated the thyroid presenting as a goiter. (Courtesy of Mithra Baliga, MD, University of Mississippi, Jackson.)

SUMMARY

Insular carcinomas constitute a subset of poorly differentiated thyroid carcinomas with aggressive behavior, and they present a characteristic cytopathologic pattern. Criteria help correct identification include small monomorphic cells with a high nuclear/cytoplasmic rati syncytial tissue fragments with and without a follicular pattern, and granular chromatin wit micronucleoli.

REFERENCES

1.Carcangiu ML, Zampi G, Rosai J. Poorly differentiated ("insular") thyroid carcinoma. A reinterpretation of Langhans' "wuchernde Struma." *Am J Surg Pathol* . 1984;8:655â€“668.

2.Rosai J, Caracngiu ML, DeLellis RA. Tumors of the thyroid gland. *Atlas of Tumor Patholo* . Fascicle 5, 3rd series. Washington, DC: Armed Forces Institute of Pathology; 1993.

3.Rijhwani A, Satish GN. Insular carcinoma of the thyroid in a 10-year-old child. *J Pediatr Surg* . 2003;38:1083â€“1086.

4.Yusuf K, Reyes-Mugica M, Carpenter TO. Insular carcinoma of the thyroid in an adolesce a case report and review of the literature. *Curr Opin Pediatr* . 2003;15:512â€“515.

5.Hassoun AA, Hay ID, Goellner JR, et al. Insular thyroid carcinoma in adolescents: a potential lethal endocrine malignancy. *Cancer* . 1997;79:1044â€“1048.

6.Cometta AJ, Burchard A, Edmund A, et al. Insular carcinoma of the thyroid. *Ear Nose Throat J* . 2003;82:384â€“393.

7.Chao TC, Lin JD, Chen MF. Insular carcinoma: infrequent subtype of thyroid cancer with aggressive clinical course. *World J Surg* . 2003;28:393â€“396.

8.Ganly J, Crowther J. Insular carcinoma of thyroid presenting as cervical cord compressic

J Laryngol Otol . 2000;114:808â€“810.

9.Nishida T, Katayama ST, Sujimoto M, et al. Clinicopathologic significance of poorly differentiated thyroid carcinomas. *Am J Surg Pathol* . 1999;23:205â€“211.

10.Rodriguez JM, Parrilla P, Moreno A, et al. Insular carcinoma: an infrequent subtype of thyroid cancer. *J Am Coll Surg* . 1998;187:503â€“508.

11.Pilotti S, Collini P, Mariana L, et al. Insular carcinoma: a distinct de novo entity among follicular carcinomas of the thyroid gland. *Am J Surg Pathol* . 1997;21:1466â€“1473.

12.Mizukami Y, Nonomura A, Michigishi T, et al. Poorly differentiated ("insular") carcinom of the thyroid. *Pathol Int* . 1996;45:663â€“668.

13.Justin EP, Seabold JE, Robinson RA, et al. Insular carcinoma: a distinct thyroid carcino with associated iodine-131 localization. *J Nucl Med* . 1991;32:1358â€“1363.

14.Johnson HW, Hunicott JW, Bilboa JE, et al. Poorly differentiated thyroid carcinoma wi focal insular pattern: clinicopathological correlation. *Am J Clin Pathol* . 1990;94:497A.

15.Kilian R, Barnes L, Watson C, et al. Poorly differentiated ("insular") thyroid carcinoma: report of two cases and review of the literature. *Arch Otolaryngol Head Neck Surg* . 1990;116:1082â€“1086.

16.Flynn SD, Forman BH, Stewart AF, et al. Poorly differentiated carcinoma ("insular") of t thyroid gland: an aggressive subset of differentiated thyroid neoplasms. *Surgery* . 1988;104:963â€“970.

17.Sasaki A, Daa T, Kashima K, et al. Insular component as a risk factor of thyroid carcinoma. *Pathol Int* . 1996;46: 939â€“946.

18.Albores-Saavedra J, Housini I, Vuitch F, et al. Macrofollicular variant of papillary thyro carcinoma with minor insular component. *Cancer* . 1997;80:1110â€“1116.

19.Ashfaq R, Vuitgh F, Delgado R, et al. Papillary and follicular thyroid carcinomas with a insular component. *Cancer* . 1994;73:416â€“423.

20.Papotti M, Micca FB, Favero A, et al. Poorly differentiated thyroid carcinoma with primordial cell component: a group of aggressive lesions sharing insular, trabecular and sc patterns. *Am J Surg Pathol* . 1993;17:291â€“301.

21.Oertel YC, Miyahara-Felipe L. Cytologic features of insular carcinoma of the thyroid: a case report. *Diagn Cytopathol* . 2006;34:572â€“575.

22.Gong Y, Krishnamurthy S. Fine-needle aspiration of an unusual case of poorly differentiated insular carcinoma of the thyroid. *Diagn Cytopathol* . 2005;32:103â€“107.

23.Jain S, Kumar N, Gupta S, et al. Insular carcinoma of the thyroid with a predominant microfollicular pattern: a diagnostic pitfall on cytology. *Acta Cytol* 2004;48:111â€“113.

24.Nguyen G-K, Akin MRM. Cytopathology of insular carcinoma of the thyroid. *Diagn Patho* 2001;25:325â€“330.

25.Layfield LJ, Gopez EV. Insular carcinoma of the thyroid: report of a case with intact insulae and microfollicular structures. *Diagn Pathol* . 2000;23:409â€“413.

26.Guiter GE, Aufer M, Ali SZ, et al. Cytopathology of insular carcinoma of the thyroid. *Cancer (Cancer Cytopathol)* . 1999;87: 196â€“202.

27.Kuhel WI, Kutler DL, Santos-Buch CA. Poorly differentiated insular thyroid carcinoma. case report with identification of intact insulae with fine needle aspiration biopsy. *Acta Cytol* . 1998;42:991â€“997.

28.Sironi M, Collini P, Cantaboni A. Fine needle aspiration cytology of insular carcinoma. A report of four cases. *Acta Cytol* . 1992;36:435â€“439.

29.Pereira EM, Maeda SA, Alves F, et al. Poorly differentiated (insular carcinoma) of the thyroid diagnosed by fine-needle aspiration (FNA). *Cytopathology* . 1996;7:61â€“65.

30.Zakowski MF, Schlesinger K, Mizrach HH. Cytologic features of poorly differentiated "insular" carcinoma of the thyroid. A case report. *Acta Cytol* . 1992;36:523â€“526.

31.Pietribiassi F, Sapino A, Papotti M, et al. Cytologic features of poorly differentiated "insular" carcinoma of the thyroid, as revealed by fine needle aspiration biopsy. *Am J Clin Pathol* . 1990;94:687â€“692.

32.Harach HR, Bergholm U. Small cell variant of medullary carcinoma of the thyroid with neuroblastoma-like features. *Histopatholgy* . 1992;21:378â€“380.

33.Mendelsohn G, Bigner SH, Eggleston JC, et al. Anaplastic variants of medullary thyroid carcinoma. A light-microscopic and immunohistochemical study. *Am J Surg Pathol* . 1980;4:333â€“341.

34.Eusebi V, Damiani S, Riva C, et al. Calcitonin free oat cell carcinoma of the thyroid gland. *Virchows Arch* . 1990;417:262Aâ€“271A.

Editors: Kini, Sudha R.
Title: *Thyroid Cytopathology: A Text and Atlas, 1st Edition*

Copyright Â©2008 Lippincott Williams & Wilkins

11

Anaplastic Carcinoma

Anaplastic thyroid carcinoma (ATC) is one of the most aggressive malignancies, with a rapid onset and fatal outcome in a short period of time.1 , 2 , 3 , 4 , 5 , 6 , 7 , 8 , 9 , 10 , 11 , 12 comprises 2% to 5% of thyroid malignancies; however, a higher incidence is reported in area with endemic goiters.1 Anaplastic thyroid carcinomas are more frequent in women, with a male:female ratio of 1:3 to 1:4. It commonly occurs in older individuals, with a median age years, although anaplastic carcinomas can occur in younger individuals. Some patients have long history of goiter or a thyroid nodule. Patients with anaplastic carcinomas present with rapidly growing, painful neck mass and pressure symptoms, such as dysphagia, dyspnea, and hoarseness of voice. The thyroid gland is firm to hard and fixed. The tumor is widely infiltra locally and metastasizes to distant organs and is rapidly fatal.

GROSS AND HISTOLOGIC FEATURES

Grossly, anaplastic carcinomas are large, bulky tumors extensively infiltrating the thyroid. T cut surfaces are soft, fleshy, and lobulated with areas of necrosis, hemorrhage, and cystic degeneration (Figs. 11.1 and 11.2). The tumor often infiltrates the perithyroidal soft tissue neighboring organs.

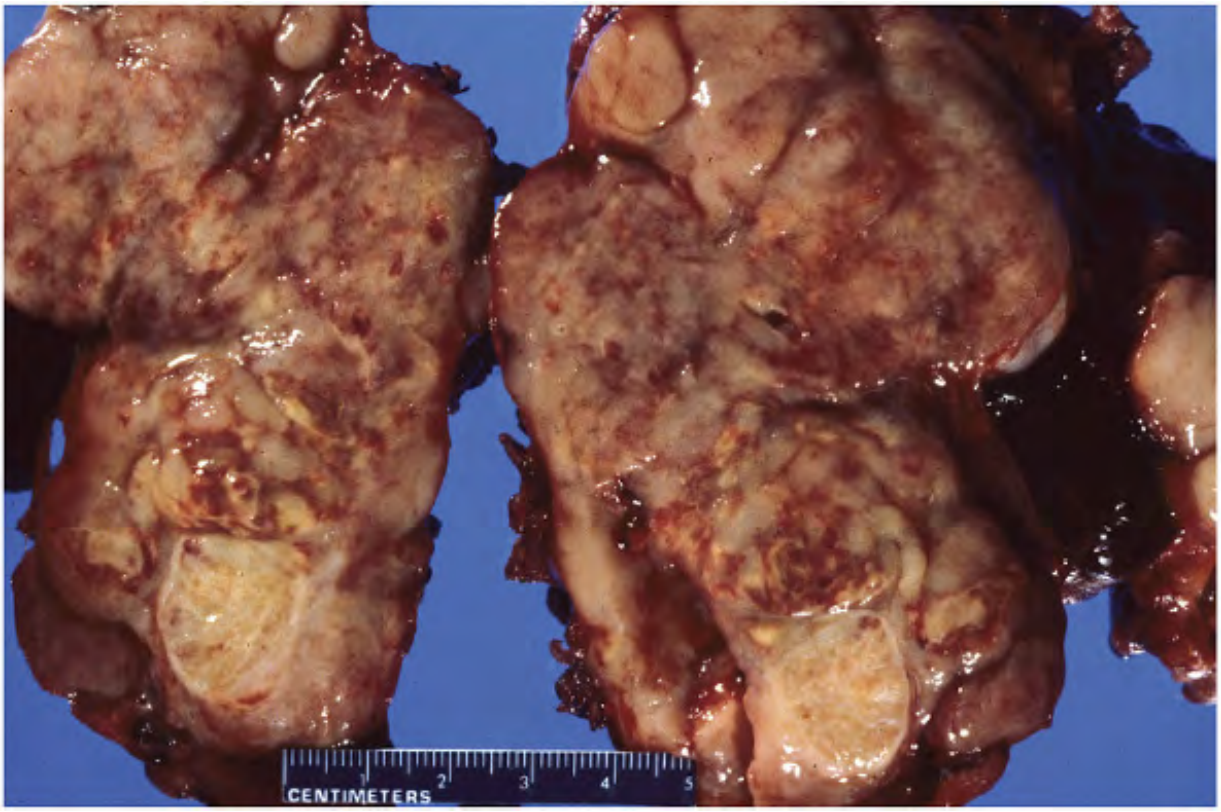

Figure 11.1. Gross photograph of an anaplastic carcinoma. The tumor is large, bulky, replac
the entire lobe of the thyroid. Note the fleshy cut surface with necrosis and hemorrhage.

Figure 11.2. Another example of an anaplastic carcinoma. The tumor is bulky and fleshy, w cystic change, and is infiltrating the surrounding soft tissues.

The histomorphology of anaplastic carcinoma varies widely from tumor to tumor and someti within the same tumor (Figs. 11.3 , 11.4 , 11.5 , 11.6 , 11.7 , 11.8 , 11.9 , 11.10 , 11.11 and 11.12).6 , 8 Three basic patterns have been described: giant cell type, spindle cell type, an squamoid.6 One of these patterns may predominate, although a combination of varied types frequent.

The giant cell type (Fig. 11.3) is characterized by a solid growth pattern consisting of marke pleomorphic round to oval, large to giant-sized malignant cells containing single to multiple bizarre nuclei with prominent nucleoli. Normal as well as abnormal mitoses are commonly observed (Fig. 11.4). Their cytoplasm is variable, scant to abundant, pale to dense to granu or clear. The giant tumor cells are often mixed with smaller mononuclear tumor cells.

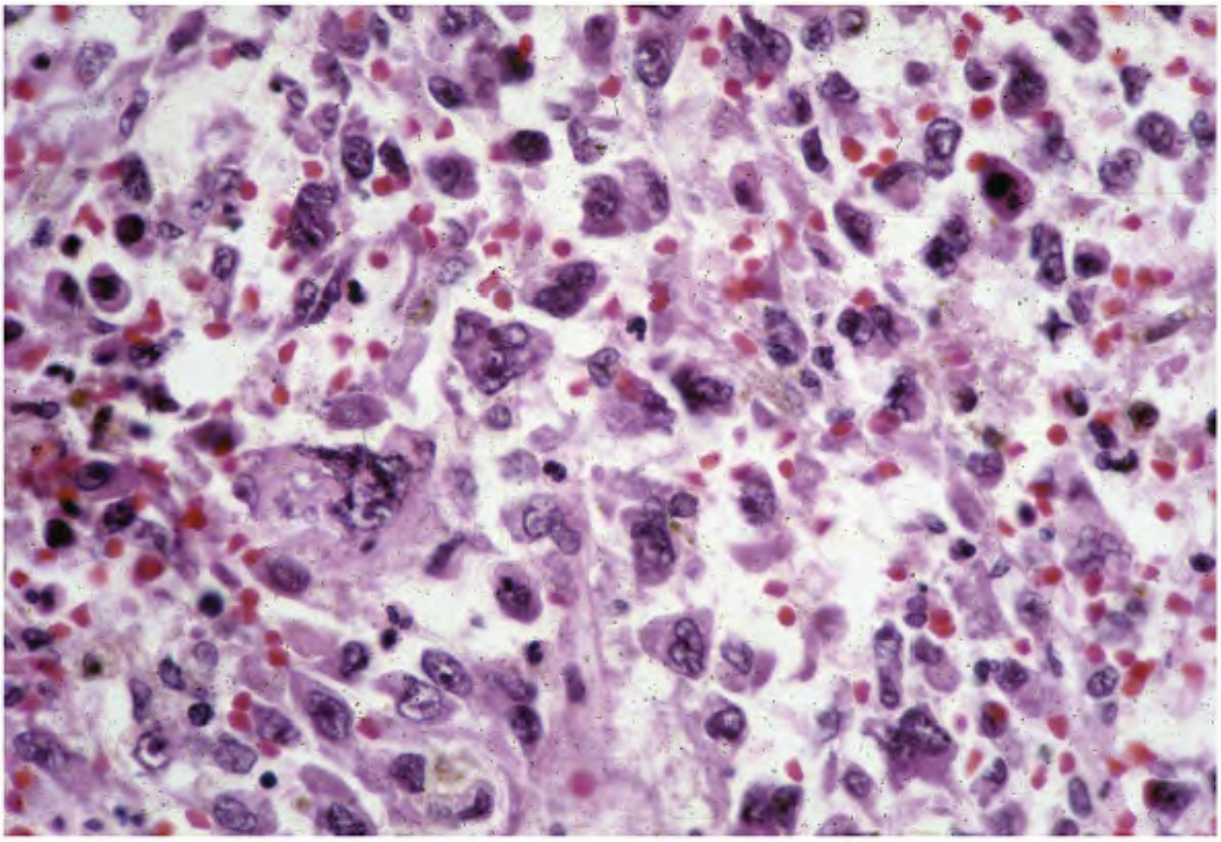

Figure 11.3. Histologic section of anaplastic carcinoma showing a giant cell pattern. Note tl pleomorphic tumor cells giant with bizarre nuclei.

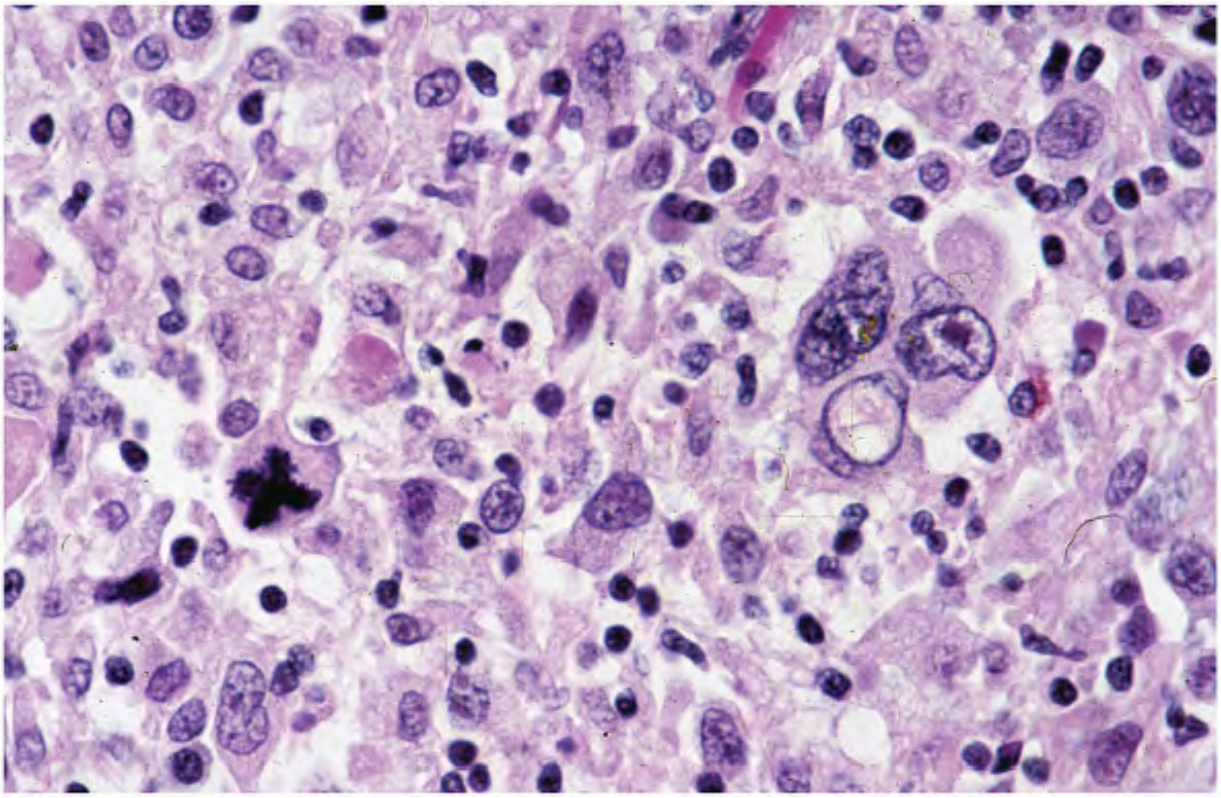

Figure 11.4. Histologic section of anaplastic carcinoma. The pleomorphic malignant cells ha bizarre nuclei. Note the intranuclear inclusion and quadripolar mitosis. Inflammatory cells a present in the background.

The squamoid type of anaplastic carcinoma is composed of large, round to polygonal cells, resembling the cells of non-keratinizing, poorly differentiated squamous carcinoma, forming solid growth pattern (Fig. 11.5). They are more uniform, occasionally showing keratinizatio and lack the typical giant tumor cells. The squamoid type anaplastic carcinoma cells contai abundant eosinophilic cytoplasm. Both giant cell and squamoid types show prominent vasculature with curvaceous capillaries within the neoplasm.

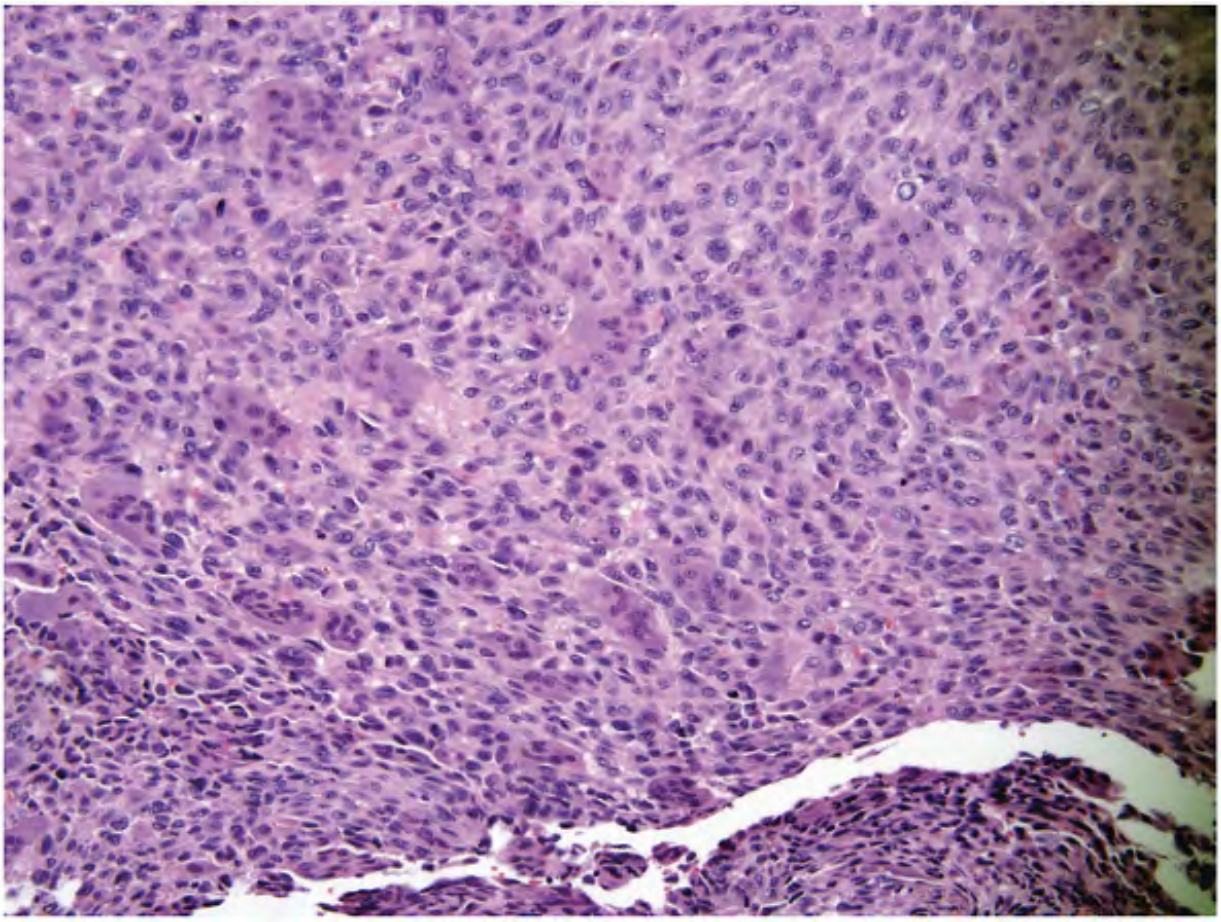

Figure 11.5. Histologic section of anaplastic carcinoma depicting a squamoid cell pattern.

The spindle cell pattern strongly resembles a soft-tissue sarcoma and is composed of pleomorphic spindle cells with bizarre nuclei. Fascicles of tumor cells, a storiform pattern, scattered tumor giant cells, and inflammatory infiltrate mimic the pattern of malignant fibr histiocytoma (Fig. 11.6). Elongated spindle-shaped tumor cells separated by collagen resem fibrosarcoma. Anaplastic carcinomas often consist of a mixed giant cell and spindle cell pat (Fig. 11.7). Squamous differentiation may be present (Fig. 11.8).

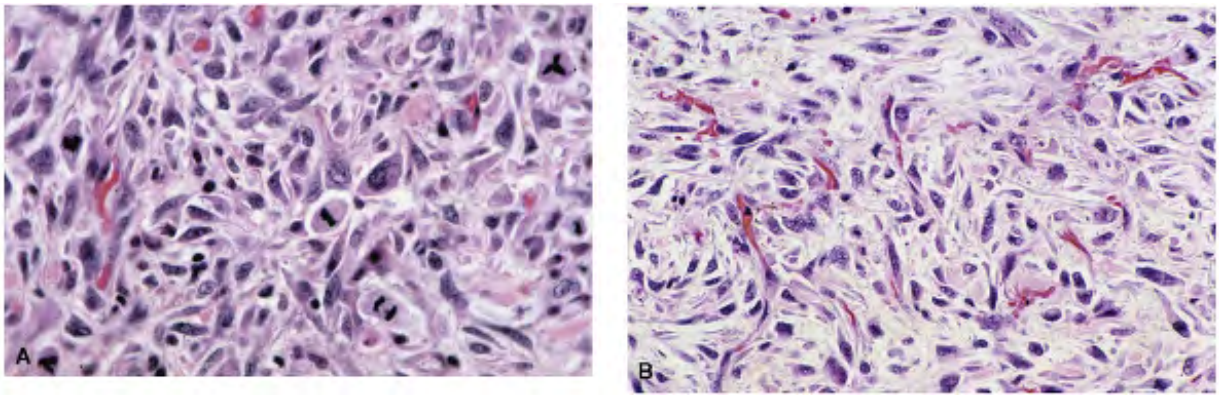

Figure 11.6 A and B. Histologic sections of anaplastic carcinoma with a spindle cell pattern reminiscent of a soft-tissue sarcoma.

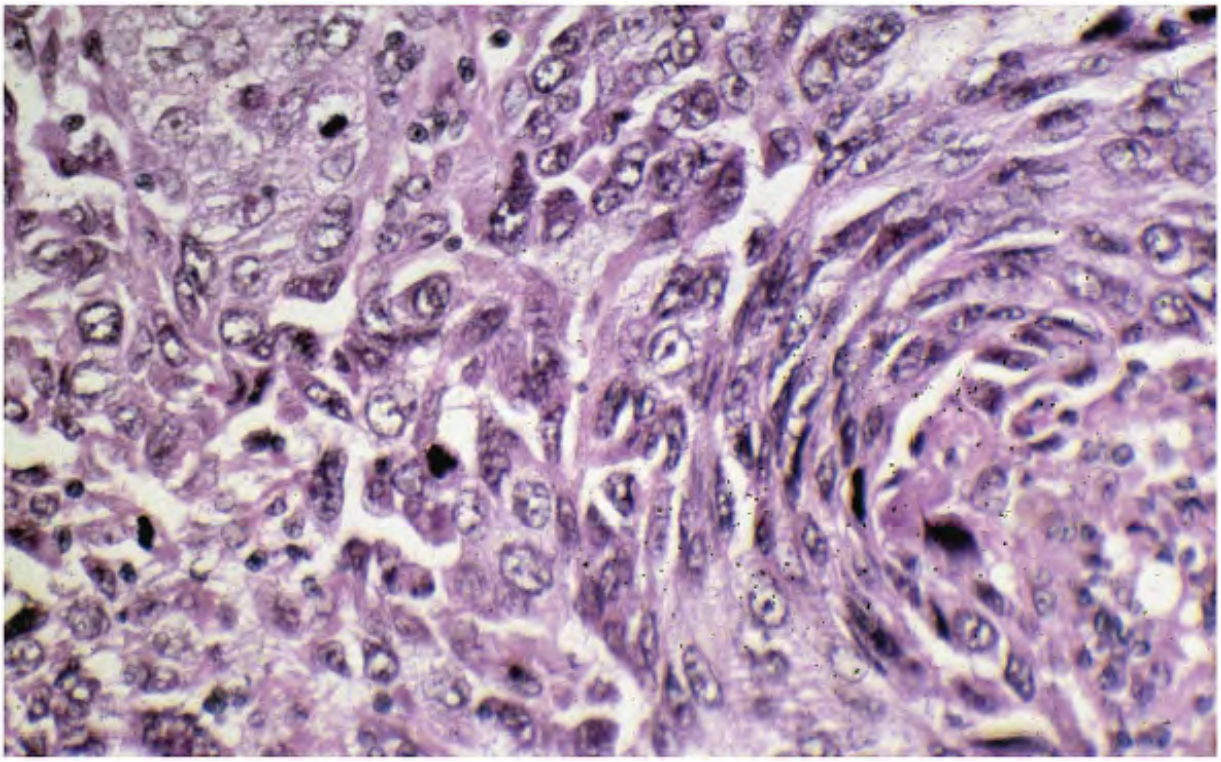

Figure 11.7. Histologic section of anaplastic carcinoma showing a mixed spindle cell and gia cell pattern.

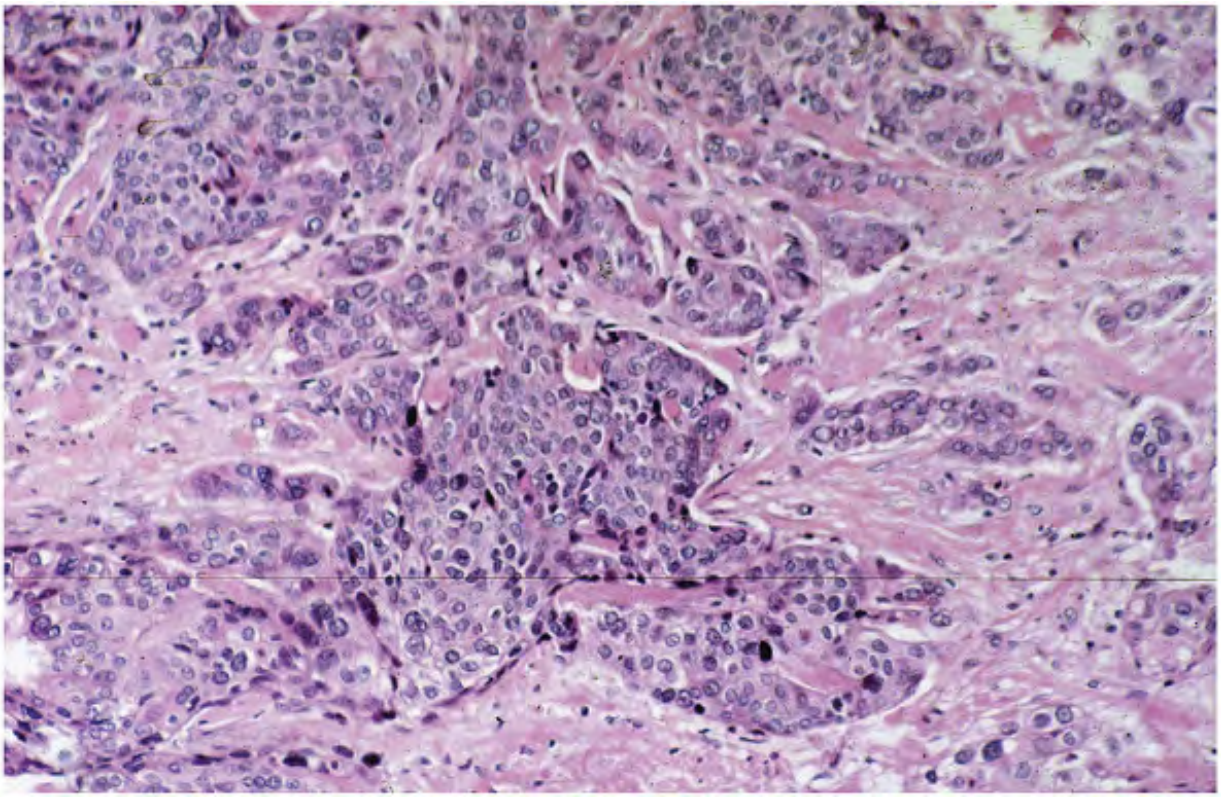

Figure 11.8. Anaplastic carcinoma with focal squamous differentiation.

Hemorrhage, necrosis, and inflammatory cell infiltrate may be seen with all cell patterns. Anaplastic carcinomas frequently contain osteoclast-like multinucleated giant cells (Fig. 11.).13 , 14

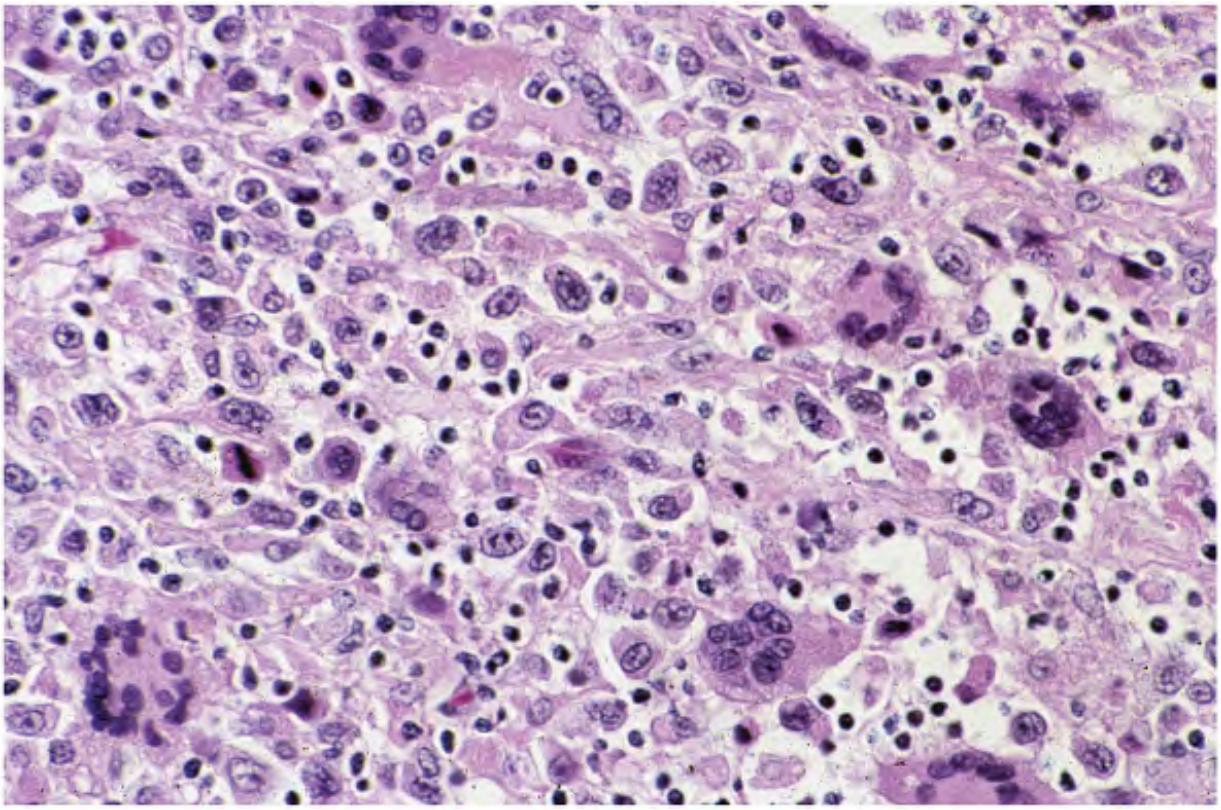

Figure 11.9. Numerous osteoclast-type giant cells in an anaplastic carcinoma.

Anaplastic carcinomas generally develop from differentiated follicular/papillary thyroid can
Evidence of pre-existing follicular or papillary carcinoma may be seen (Figs. 11.10 and 11.11
, 16 , 17 Anaplastic carcinomas may develop from dedifferentiation of HÃ¼rthle cell carcinc
Coexistence of insular and anaplastic carcinomas is also described.

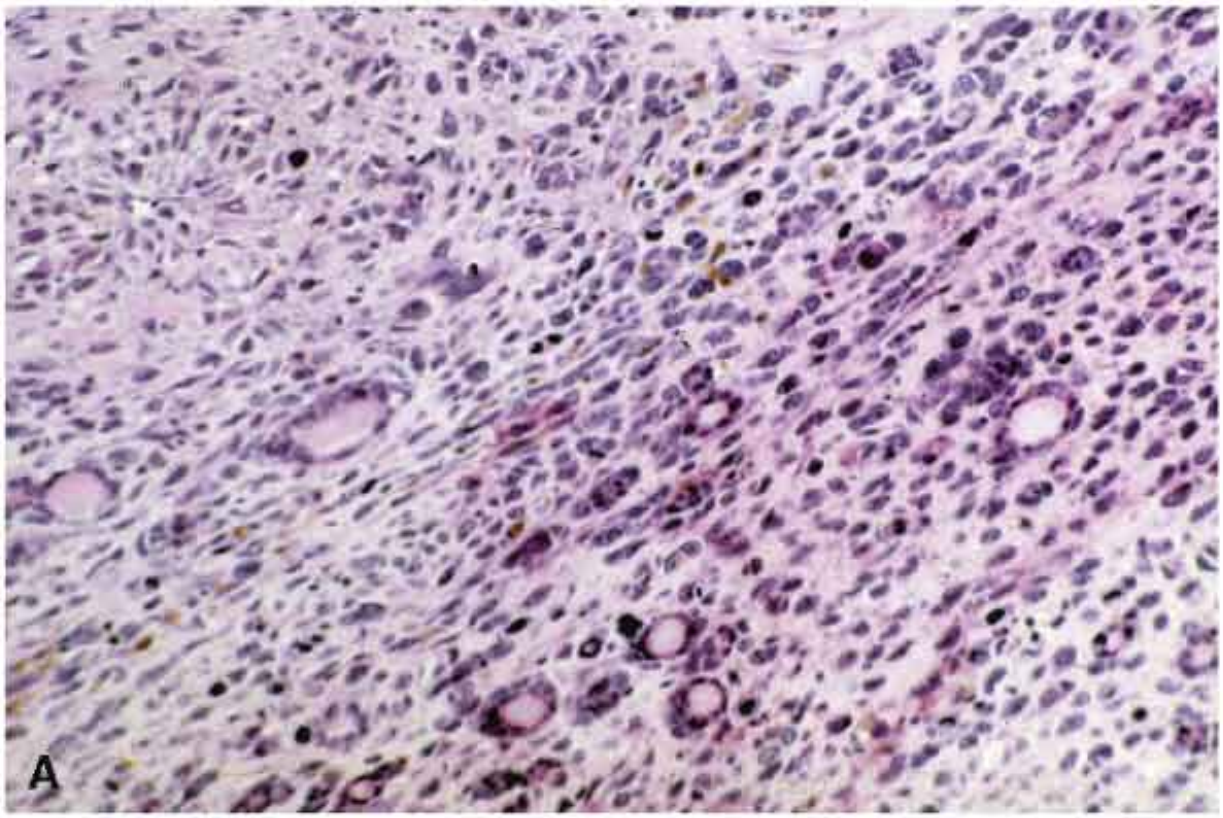
A

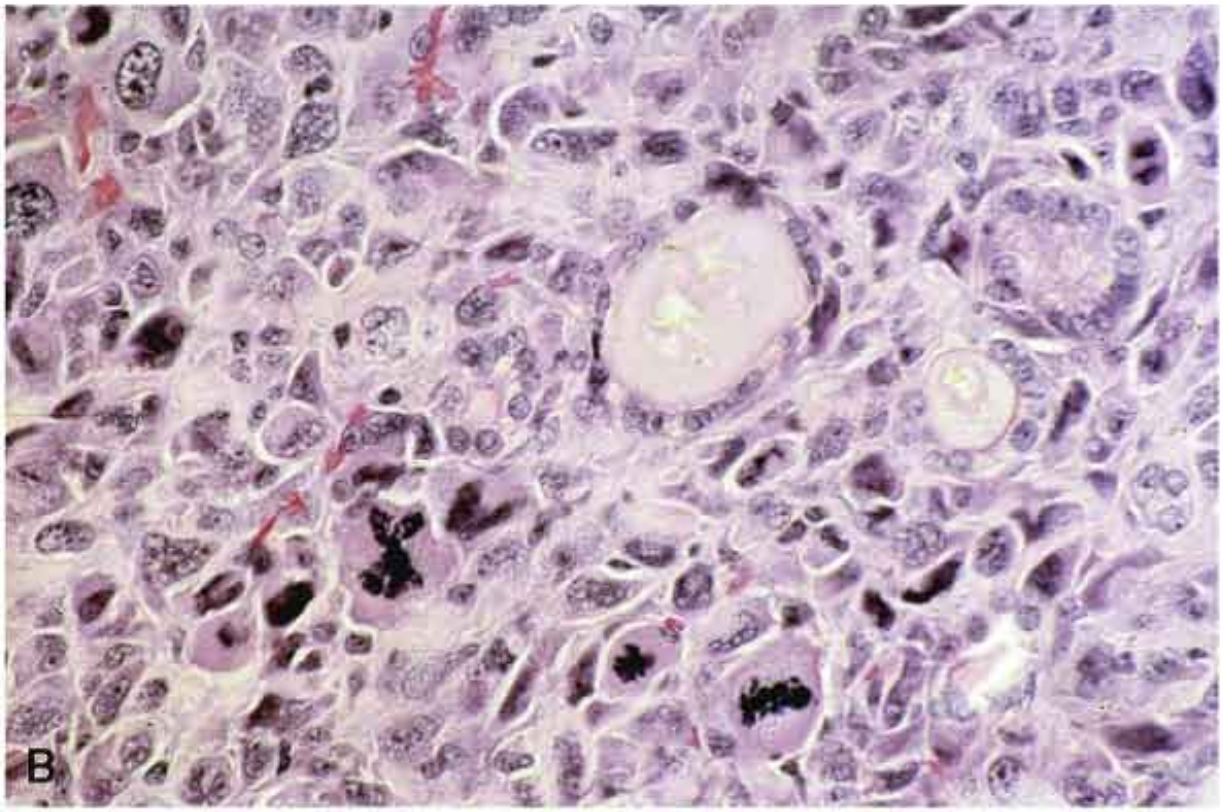
B

Figure 11.10. A. Histologic section of anaplastic carcinoma with remnants of pre-existing follicular carcinoma. B. Higher magnification showing malignant cells with numerous abnorr mitoses and malignant follicles containing colloid.

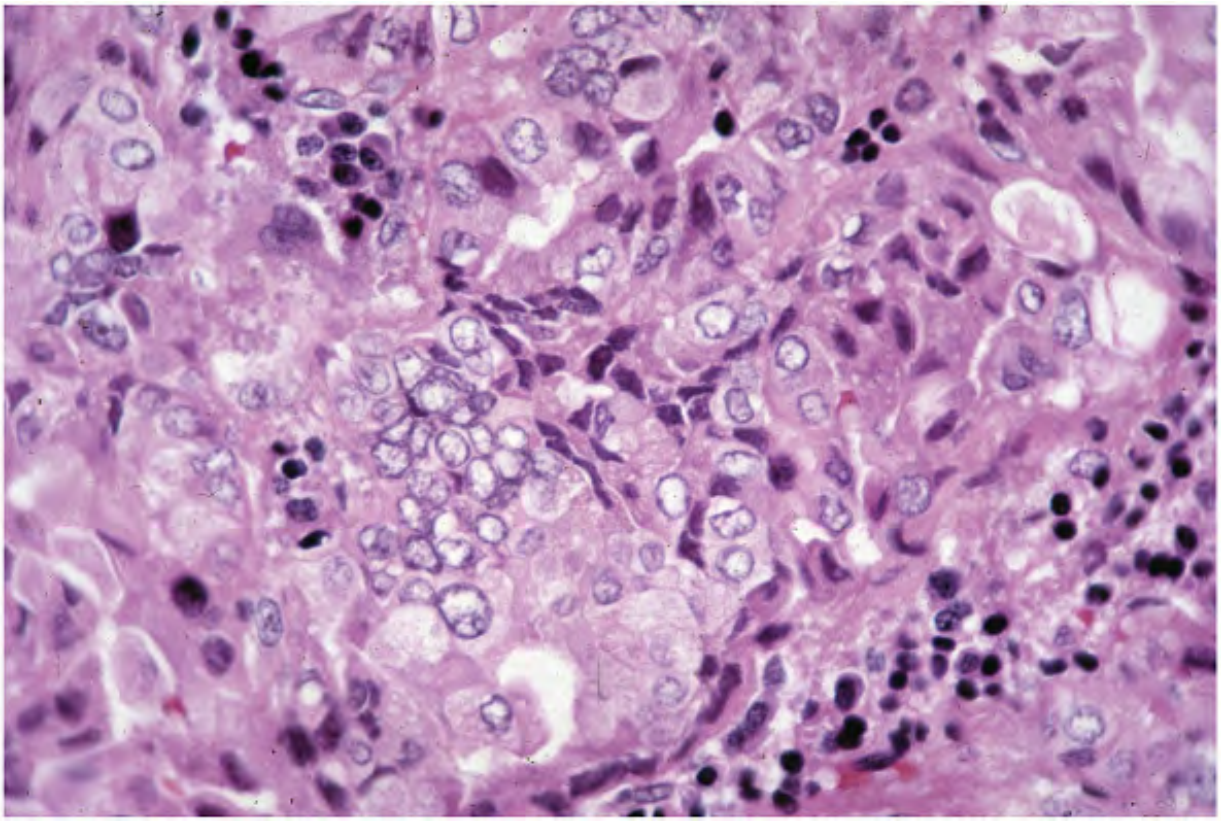

Figure 11.11. Anaplastic carcinoma showing a focal area consisting of typical nuclei of a conventional papillary carcinoma, indicating a pre-existing papillary carcinoma.

Morphologic variants of anaplastic carcinoma include the paucicellular (Fig. 11.12)18 and rhabdoid types.19 The paucicellular variants are characterized by extensive desmoplasia wi wide areas of collagenized fibrous tissue. Malignant cells usually of the spindle cell type are in number, often seen scattered within the fibrous stroma. Areas of necrosis and infarction also present. The paucicellular variant clinically as well as grossly mimics Riedel's thyroiditis Extensive fibrosis is common in both lesions. Needle biopsies, both fine and large, tend to b either acellular or poorly cellular due to fibrosis.

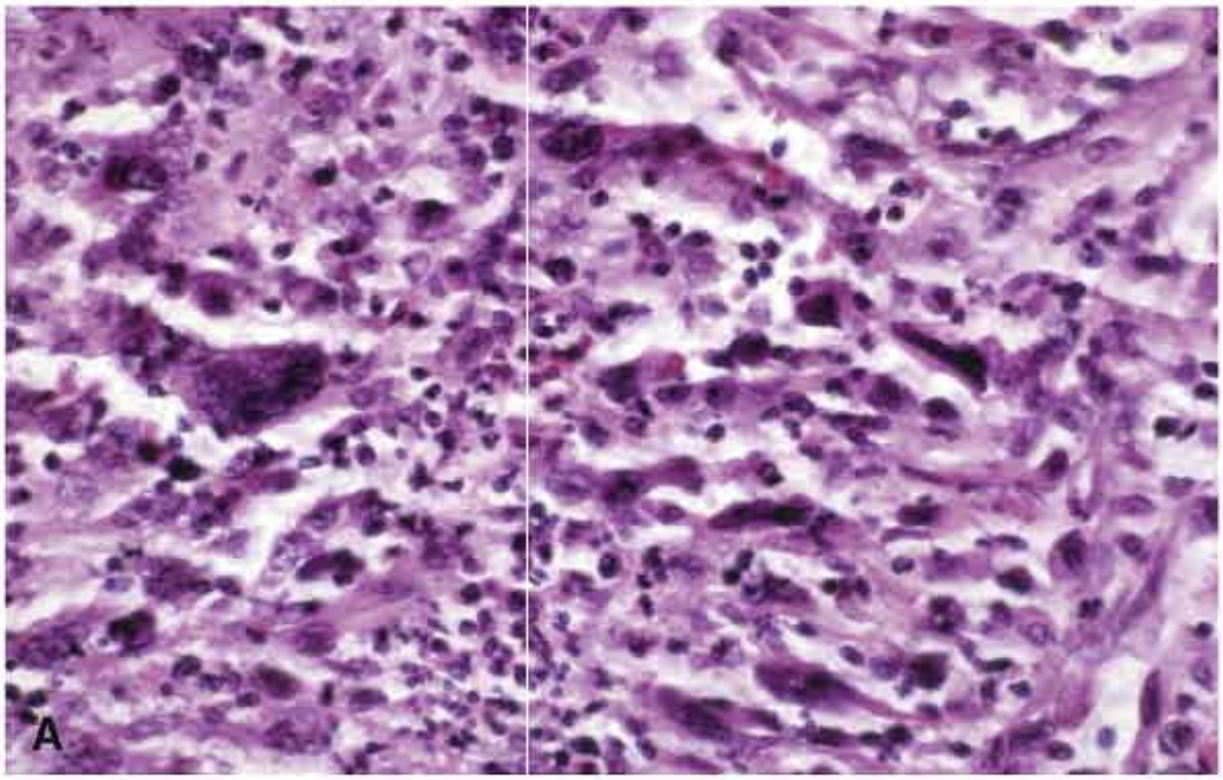
A

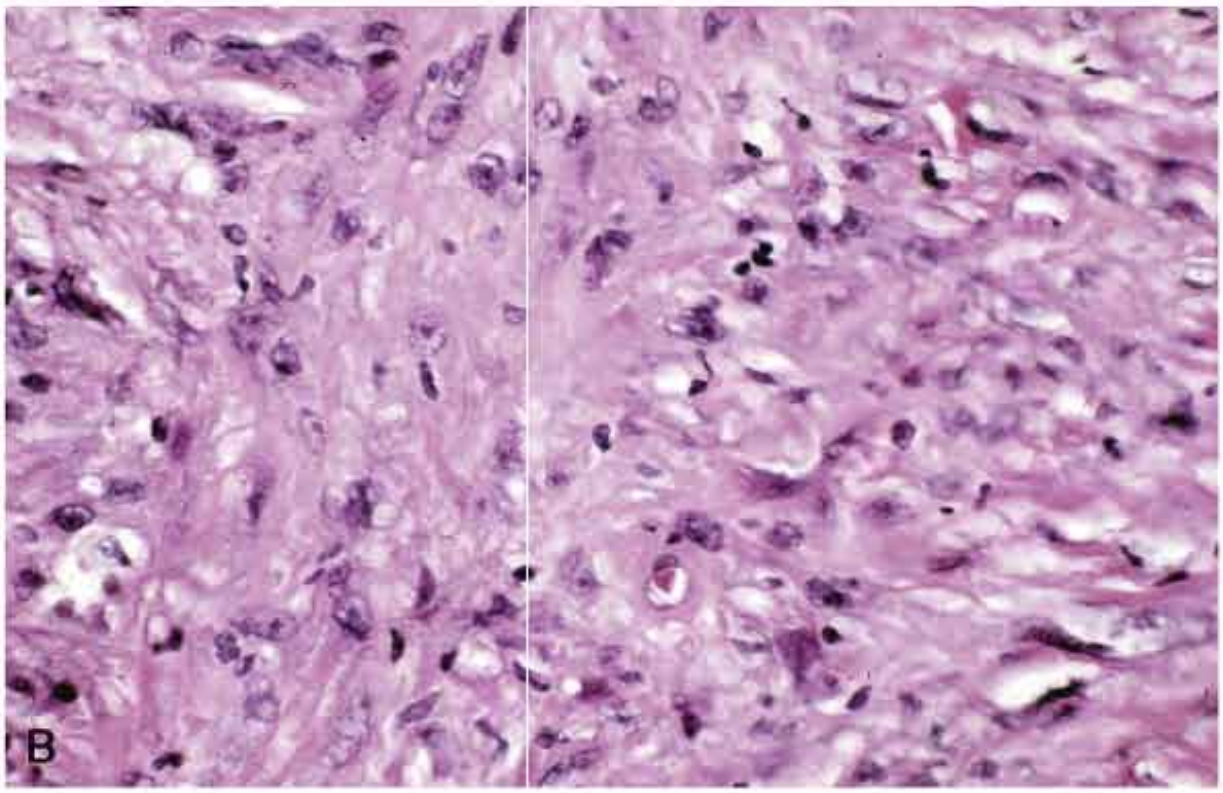
B

Figure 11.12. Histologic sections of a paucicellular variant of anaplastic carcinoma with desmoplastic stroma. A. The malignant sells are pleomorphic and separated by collagen. B. carcinoma shows extensive fibrosis widely separating few malignant spindle cells.

The rhabdoid type is a rare morphologic variant, with only a few cases reported in the literature. The reported cases consisted of foci of papillary or follicular carcinomas. Histologically, the rhabdoid variant of anaplastic carcinoma shows a solid growth pattern wi uniform, large, round cell population containing eccentric nuclei. The cytoplasm of the malignant cells contains eosinophilic globules that are shown to contain intermediate filame ultrastructurally. These also stain positively with desmin and muscle-specific actin. The sma cell variant of anaplastic carcinomas described in the literature probably represents malign lymphoma, medullary carcinoma, or poorly differentiated "insular" carcinomas.20 , 21 , 22 , 24 , 25

CYTOPATHOLOGIC FEATURES

The cytopathologic features of anaplastic carcinoma are usually diagnostic on account of neoplastic cells that present obvious malignant criteria (Figs. 11.13 , 11.14 , 11.15 , 11.16 , 11.17 , 11.18 , 11.19 , 11.20 , 11.21 , 11.22 , 11.23 , 11.24 , 11.25 , 11.26 , 11.27 , 11.28 , 1 , 11.30 , 11.31 , 11.32 , 11.33 and 11.34).

The cellularity of the aspirates of anaplastic carcinomas depends on the histologic type as w as the presence and extent of tumor necrosis.26 , 27 , 28 , 29 , 30 , 31 Carcinomas with a spindle cell pattern and abundant collagenous stroma tend to be paucicellular or even acell while the giant cell and squamoid types yield overwhelmingly cellular aspirates. Carcinomas extensive necrosis may yield unsatisfactory samples. With adequate cellularity, the cytologi diagnosis of anaplastic carcinoma is obvious even to a novice (Fig. 11.13). The spectrum of cytologic features is extremely wide, although the anaplastic nature is conspicuously appare

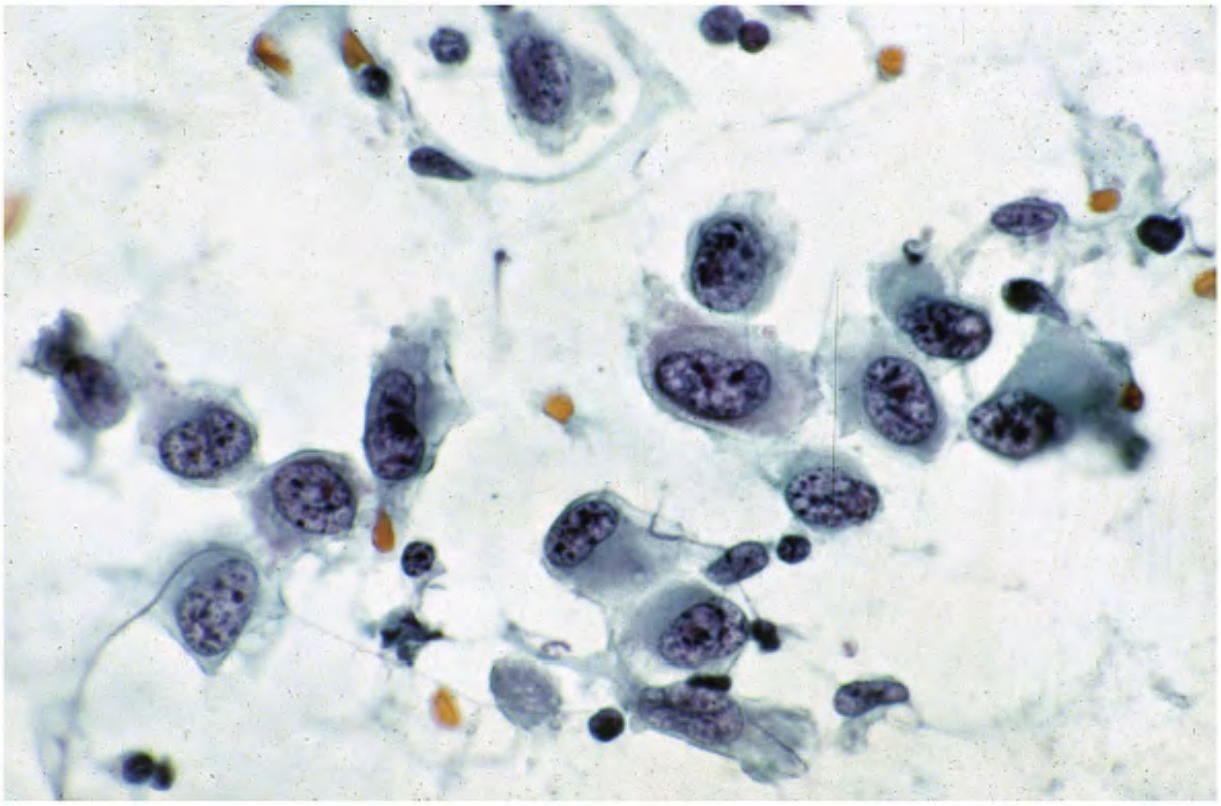

Figure 11.13. FNA of an anaplastic carcinoma, giant cell type. The neoplastic cells are disc
markedly pleomorphic, and clearly malignant.

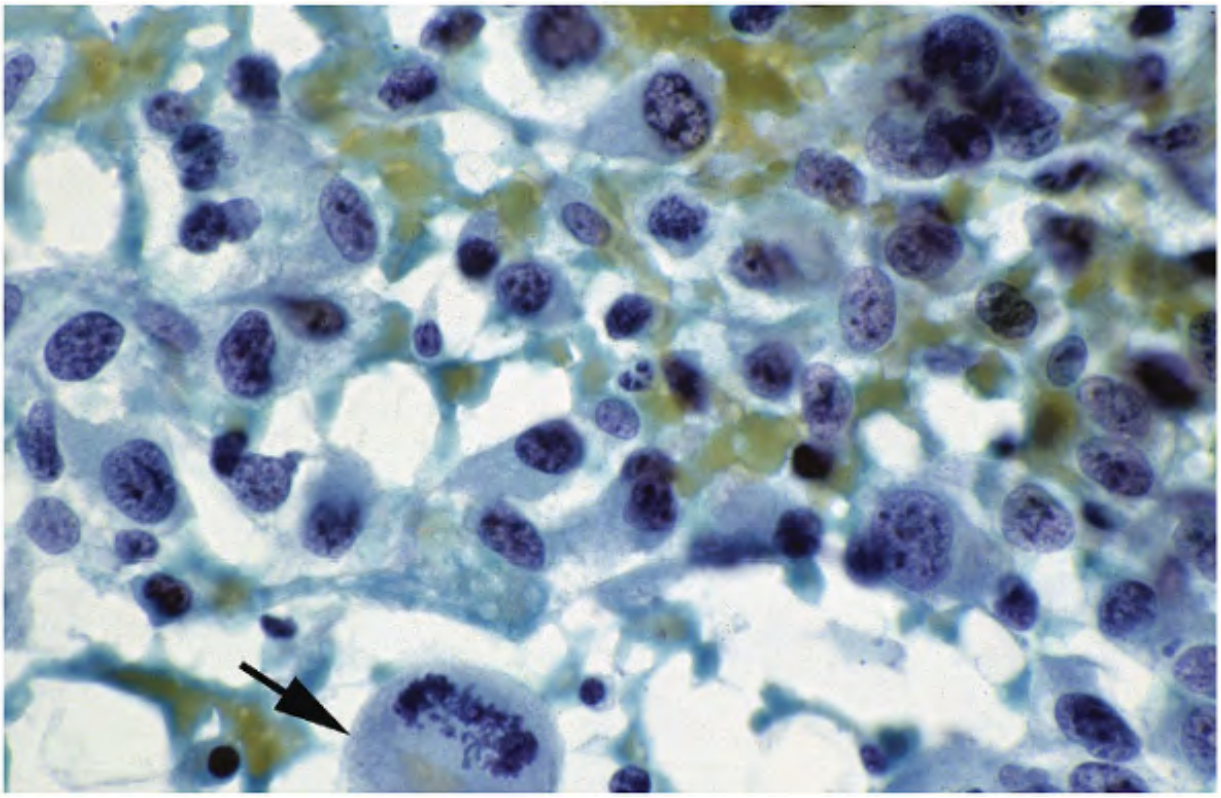

Figure 11.14. FNA of an anaplastic carcinoma. The malignant cells are discrete and widely pleomorphic. Note multinucleation and an abnormal mitosis (*arrow*).

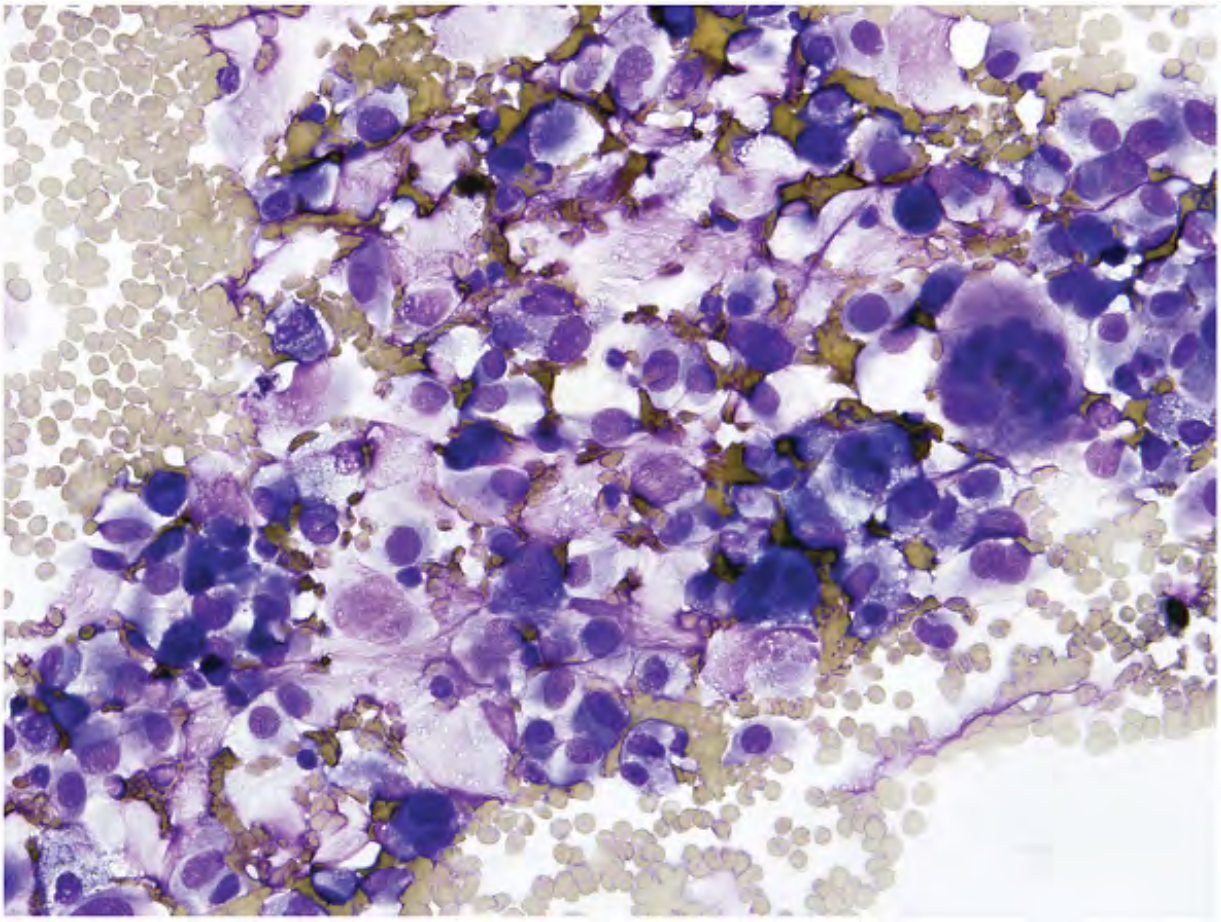

Figure 11.15. FNA of a giant cell type anaplastic carcinoma. The malignant cells are discret
and markedly pleomorphic (Diff-Quik Stain).

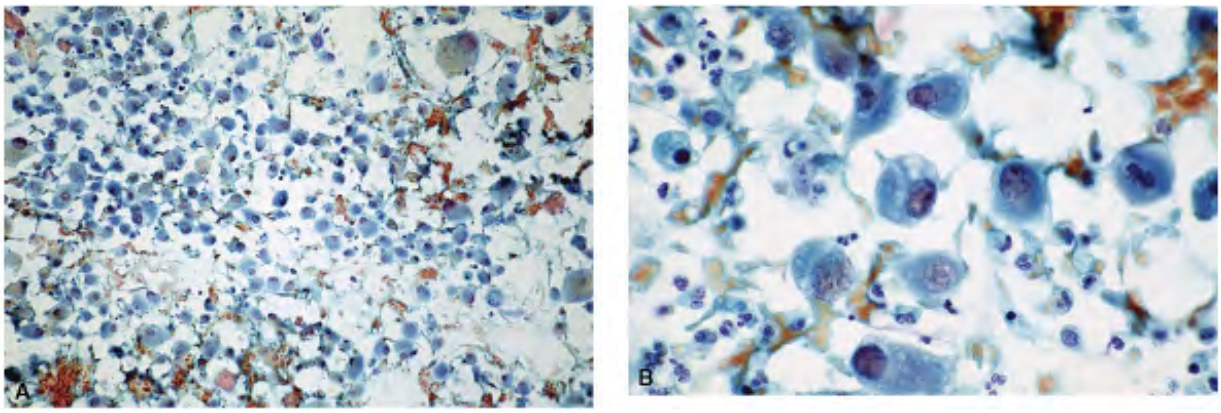

Figure 11.16. A. This cellular aspirate consists of a large population of discrete malignant c
The pleomorphic nature and the giant cell pattern are evident even at this low power. B. Hi
magnification showing giant malignant tumor cells with inflammatory cells in the backgroun

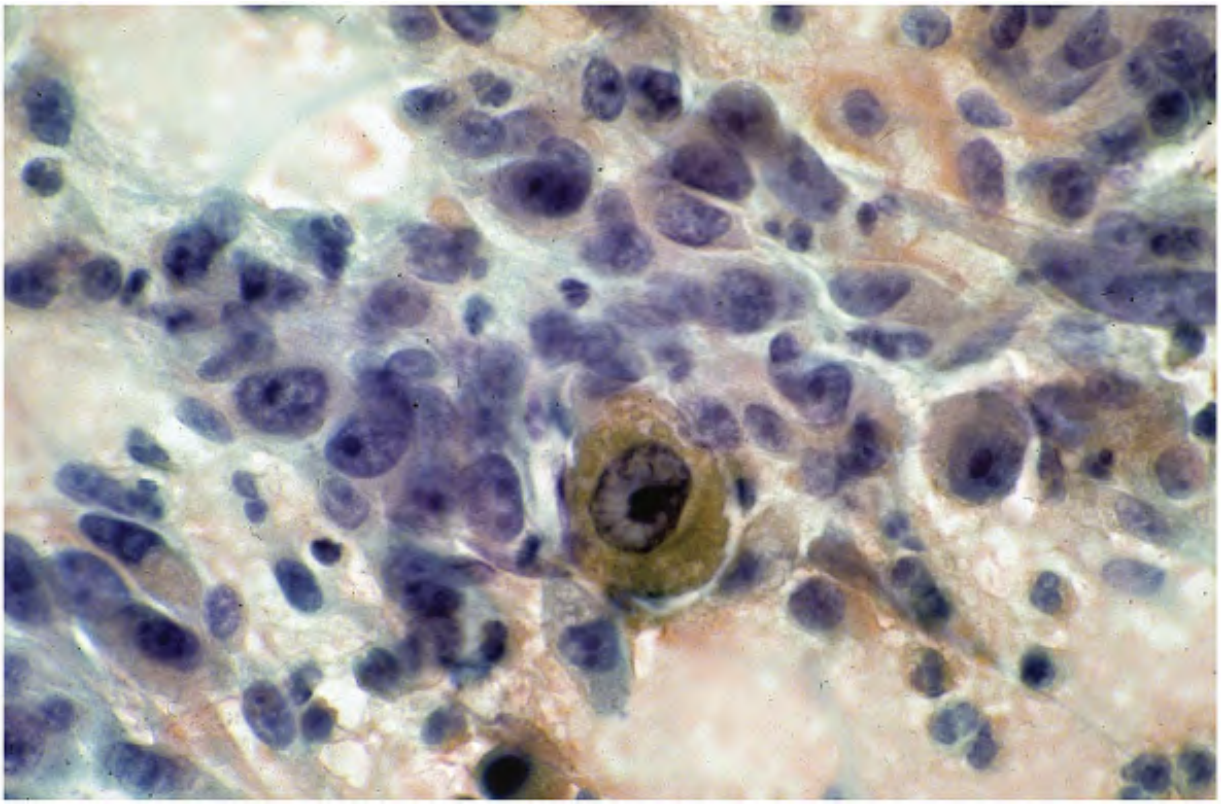

Figure 11.17. FNA of an anaplastic carcinoma showing loosely cohesive, pleomorphic maligr cells. Note occasional cells with dense cytoplasm, rigid cell borders, and central nuclei suggesting squamous differentiation.

P.236
P.237
P.238
P.239

The malignant cells range in size from small to giant forms reaching enormous dimensions (F 11.18 , 11.19 and 11.20). Their shape likewise demonstrates extreme variation from round, oval, plasmacytoid, polygonal, caudate, racket shaped, to spindle type. The malignant cells usually discrete, in discohesive groups, or infrequently in syncytial tissue fragments without architectural patterns. Arborizing blood vessels may be seen in the background. A given aspi may present only one cell pattern or a combination of one or more patterns.

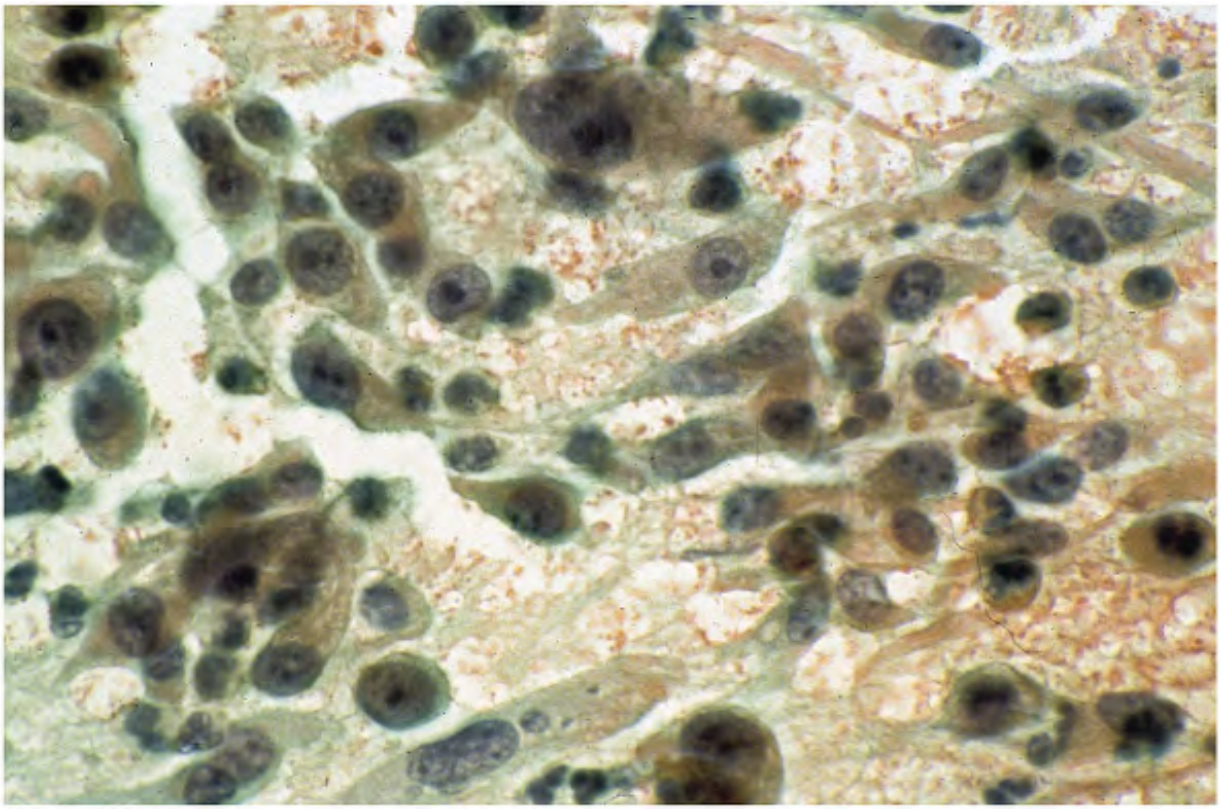

Figure 11.18. An admixture of malignant cells exhibiting wide variation in their size and sh
Some are multinucleated. The background is dirty due to proteinaceous material and amorp
debris.

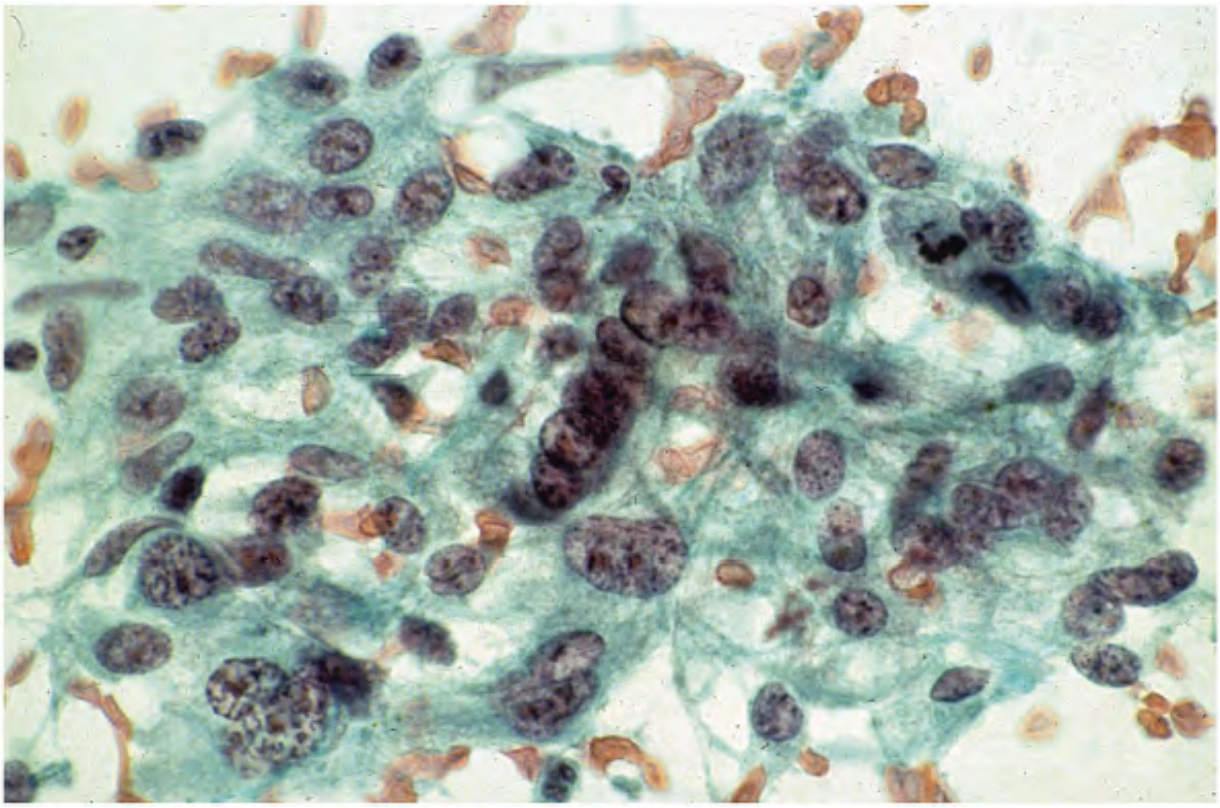

Figure 11.19. These anaplastic carcinoma cells are very pleomorphic in size and shape. Son are multinucleated. Their cytoplasm is variable and abundant. Several malignant cells are spindle shaped.

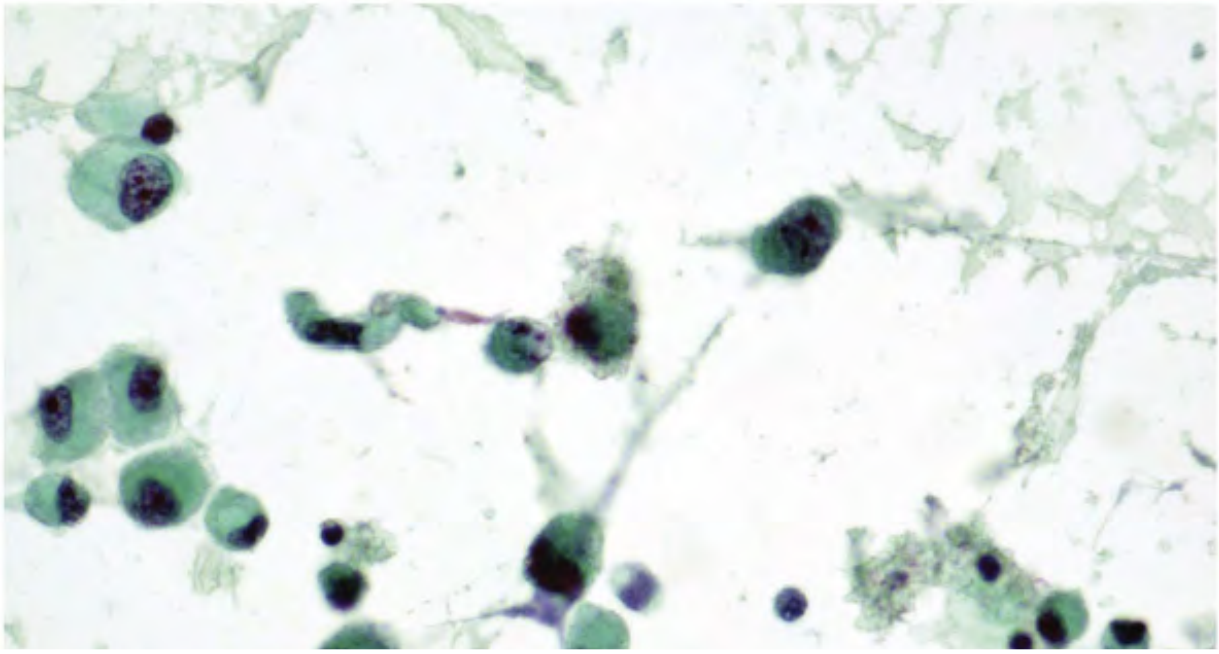

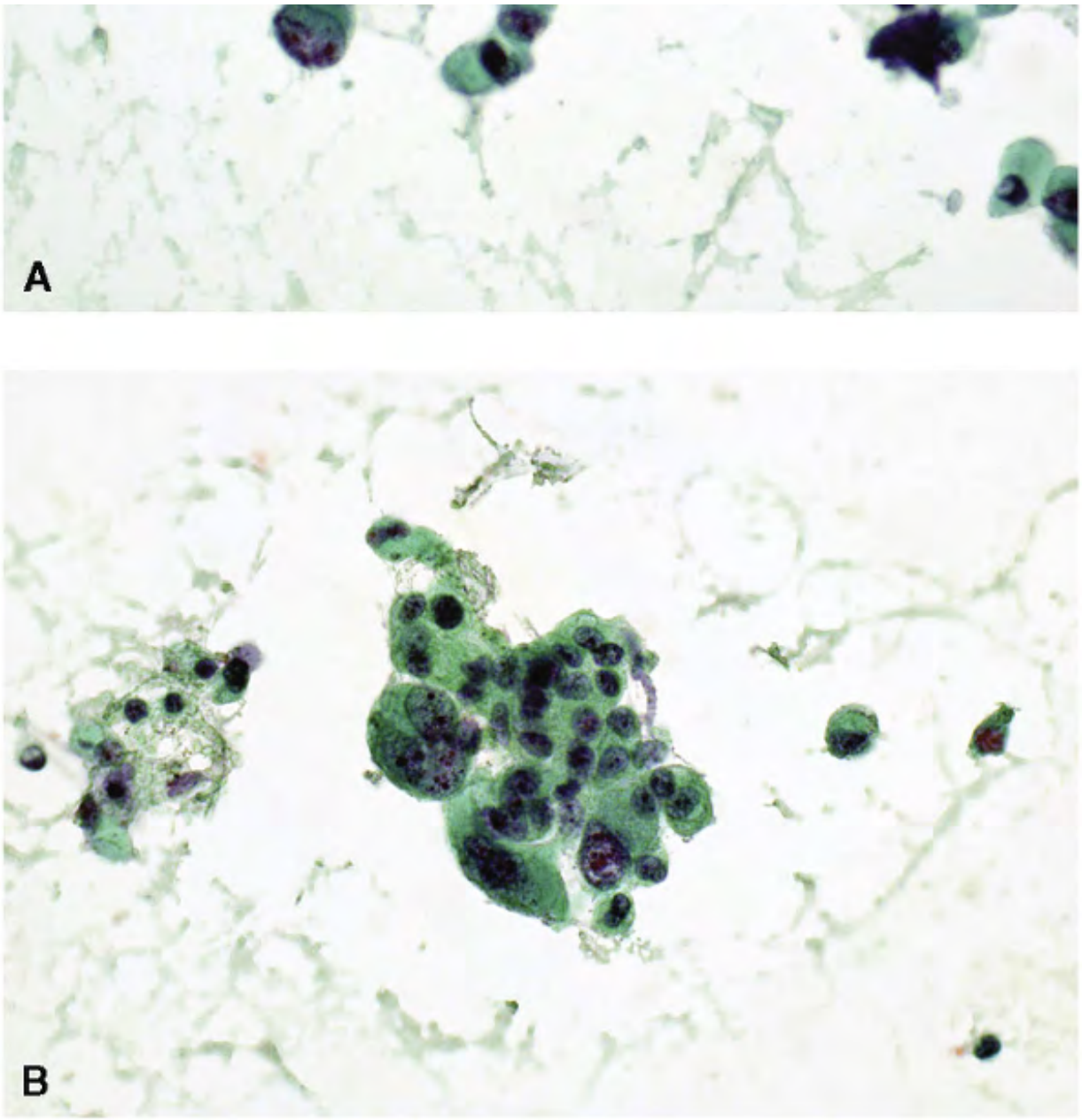

Figure 11.20. A and B. FNA of an anaplastic carcinoma showing an admixture of small, medi sized, and large to giant malignant cells.

The aspirates of giant cell anaplastic carcinomas show pleomorphic giant tumor cells contai bizarre nuclei with irregular nuclear membranes with scalloping (Figs. 11.13 , 11.14 , 11.15 11.16 , 11.17 , 11.18 , 11.19 , 11.20 , 11.21 , 11.22 , 11.23 and 11.24). The nuclei are large coarsely granular to clumped, deep-staining chromatin and excessively clear parachromatin Nucleoli are prominent and intranuclear inclusions are often present. Exuberant mitotic act

is reflected by the presence of both normal and abnormal mitotic figures. Multilobulation ar multinucleation are very common. The malignant cells of the giant cell type contain abunda pale to dense and sometimes clear cytoplasm and may demonstrate emperipolesis. The den cytoplasm imparts a HÃ¼rthaloid appearance (Figs. 11.24 and 11.25). However, ultrastructurally, mitochondria are few or absent. An admixture of pleomorphic smaller malignant cells is often noted (Fig. 11.20A and B).

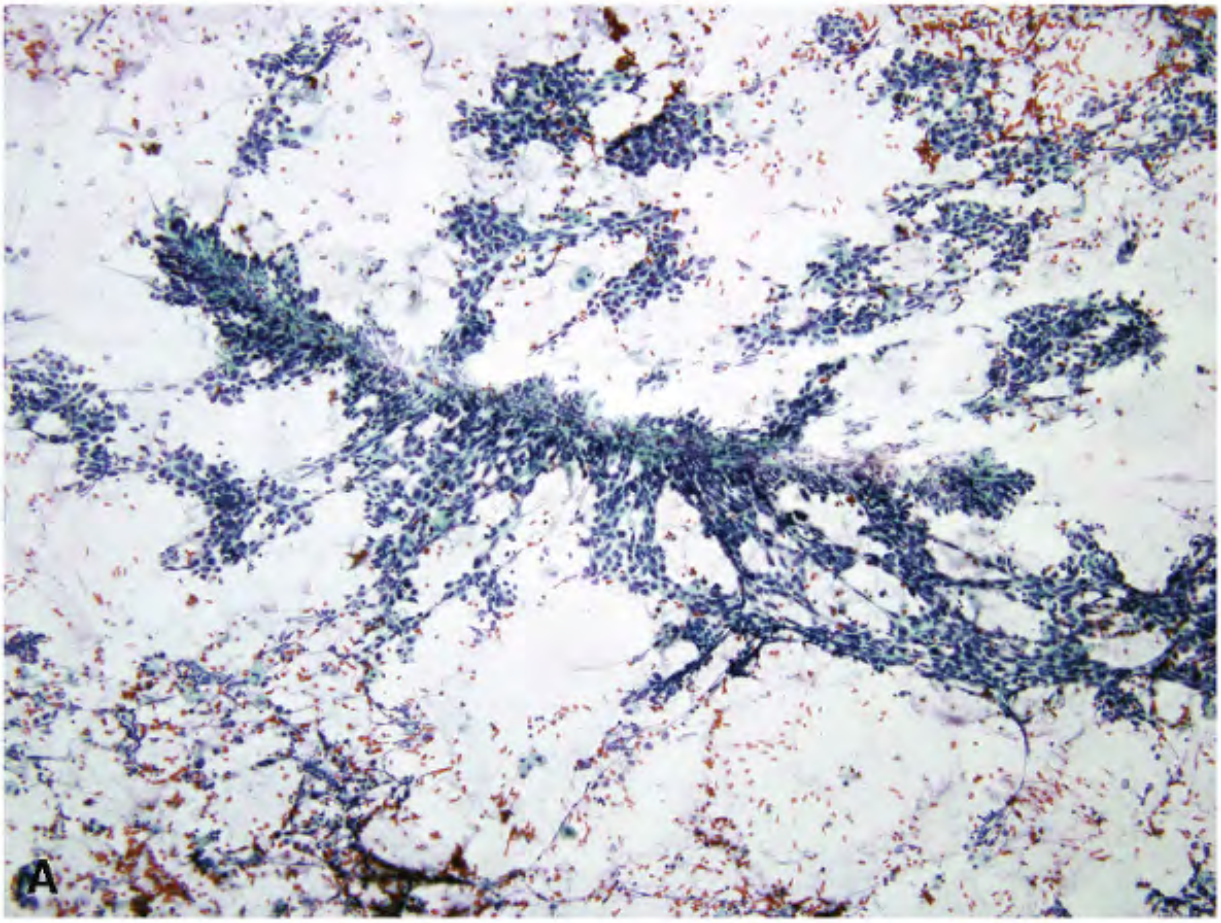

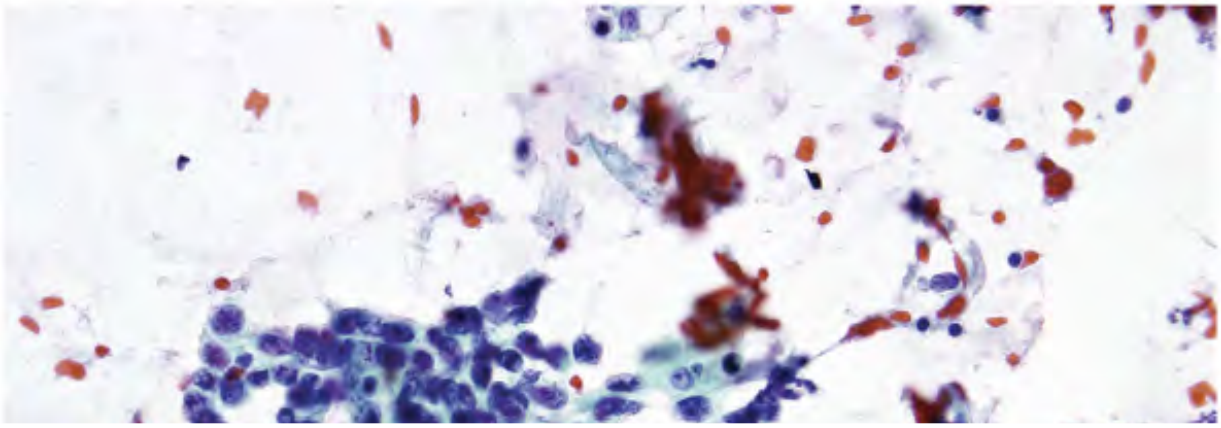

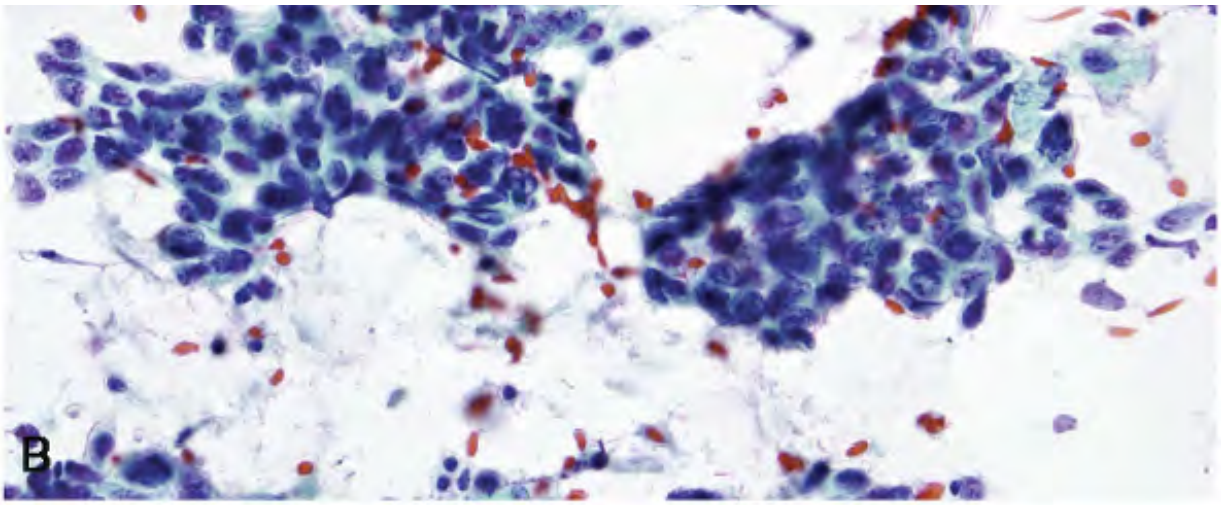

Figure 11.21. A. The aspirate is overwhelmingly cellular, consisting of large tissue fragmen malignant cells with dispersed cells in the background (low power). B. Higher magnification Note large round to spindle malignant cells with high N/C ratios. The nuclei are intensely hyperchromatic, and irregular with multiple nucleoli.

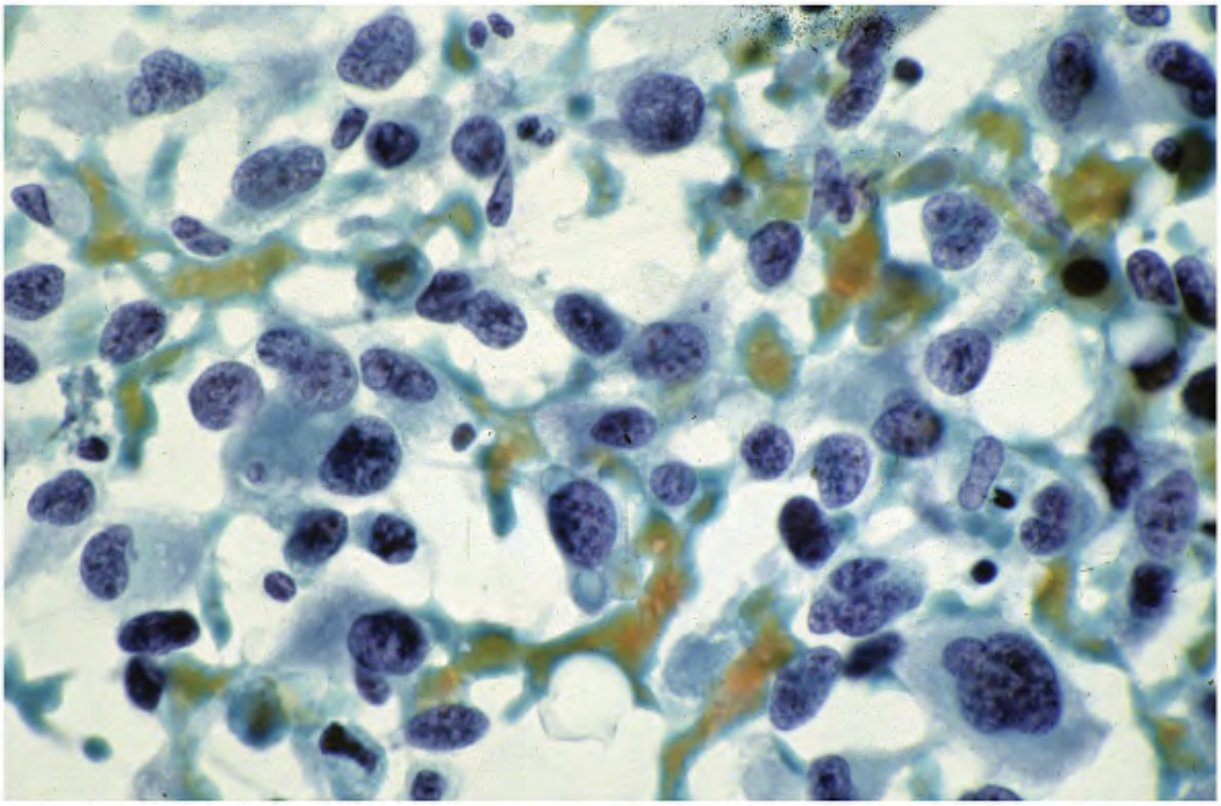

Figure 11.22. FNA of a squamoid-type anaplastic carcinoma showing discrete large, round

malignant cells with variable cytoplasm.

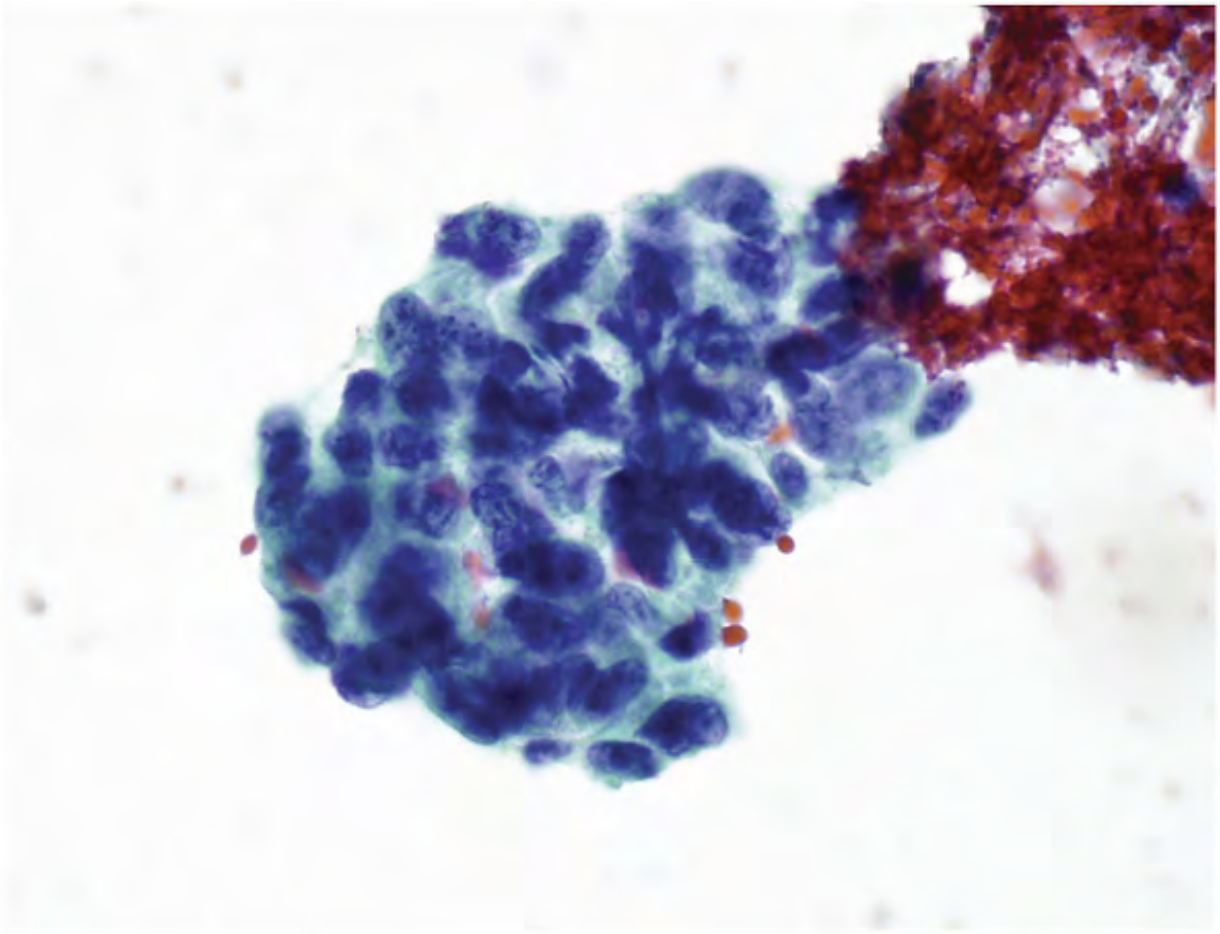

Figure 11.23. FNA of a squamoid-type anaplastic carcinoma showing a syncytial tissue fragr of malignant cells containing large nuclei and variable cytoplasm.

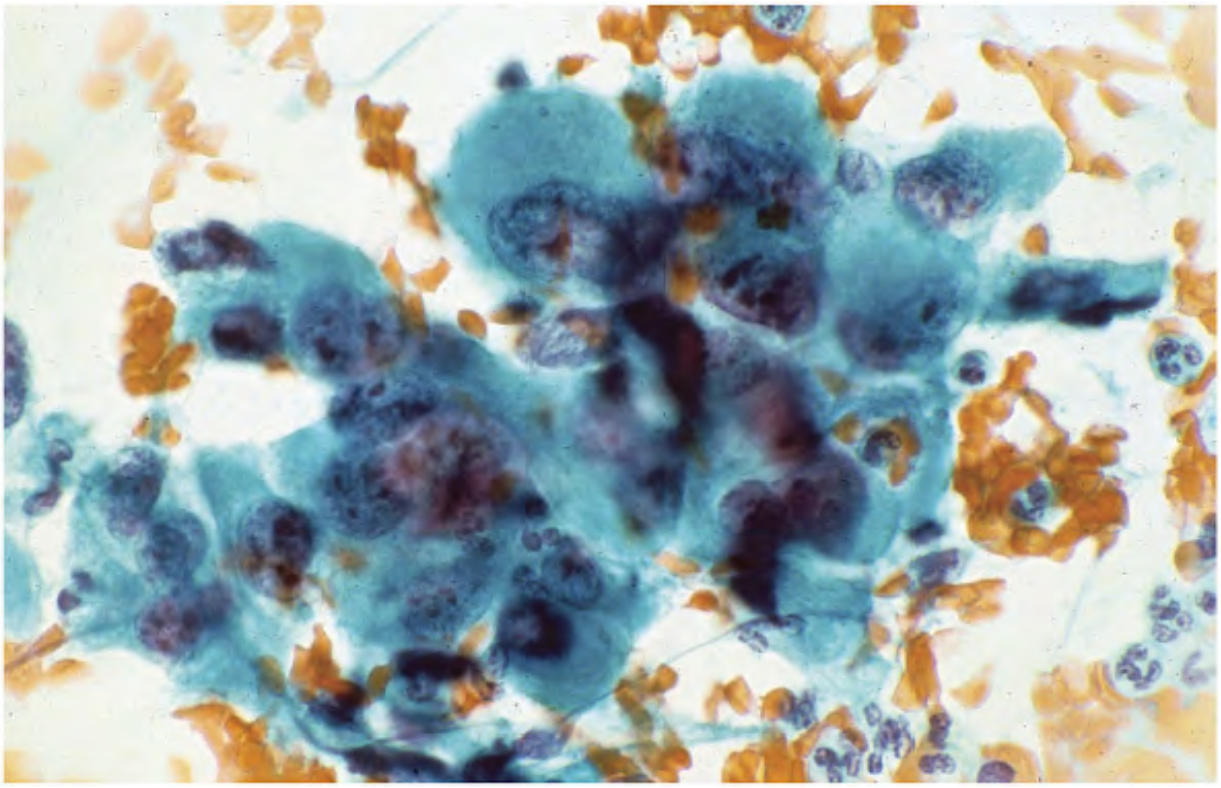

Figure 11.24. These malignant cells from an anaplastic carcinoma are giant sized and conta
abundant dense cytoplasm with a HÃ¼rtheloid appearance.

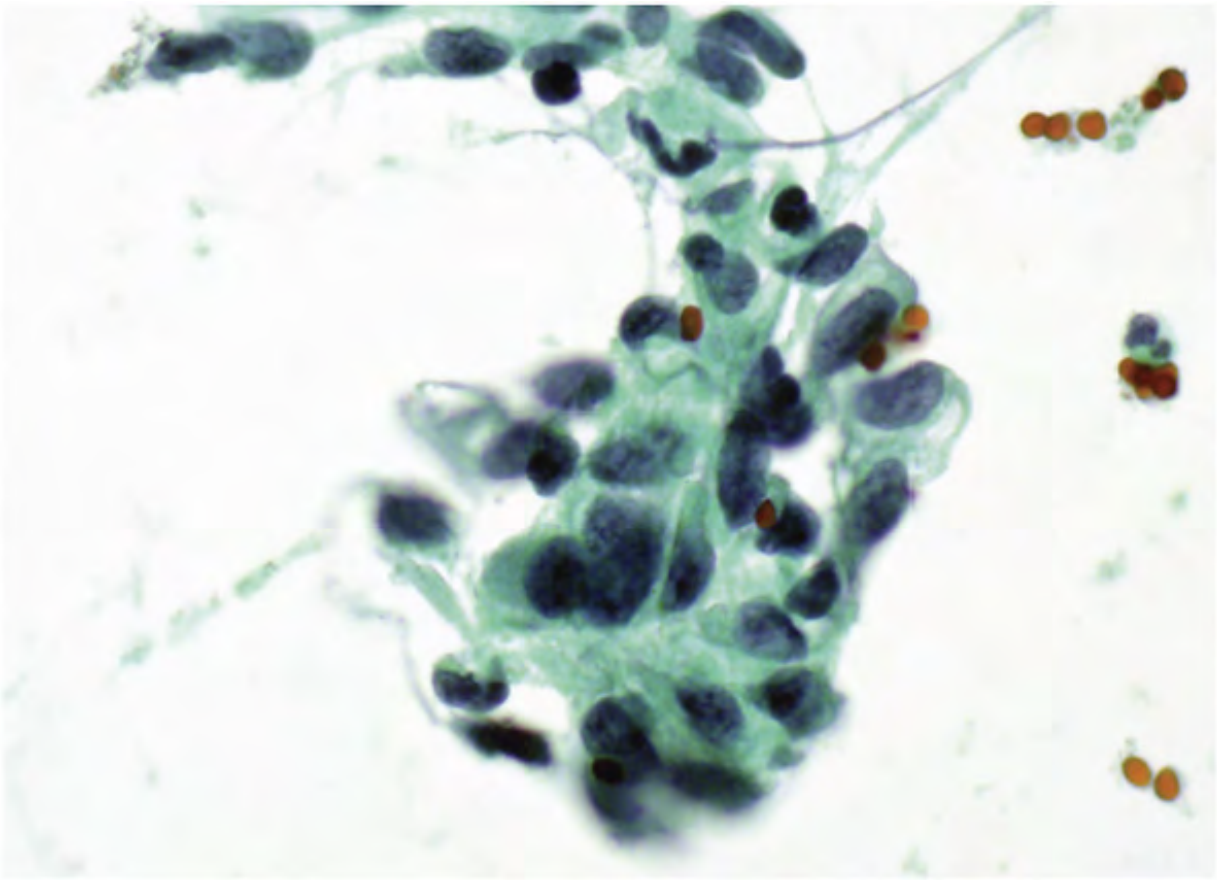

Figure 11.25. Another example of anaplastic carcinoma cells with dense cytoplasm present HÃ¼rtheloid appearance.

The squamoid type of anaplastic carcinomas yield cellular aspirates composed of medium to large, malignant cells occurring discrete, in loosely cohesive groups, or in syncytial tissue fragments without any architectural patterns (Figs. 11.22 and 11.23). The malignant cells a round to polygonal with appreciable pale to dense cytoplasm. Squamous differentiation and keratinization may be focally evident.

The carcinoma cells in the spindle cell type of anaplastic carcinoma vary in numbers and ma present as discrete cells, in aggregates, or as syncytial tissue fragments occasionally forming fascicles (Figs. 11.26. , 11.26. and 11.28). The cell borders may be poorly to well defined. T nuclei vary from round, oval, and elongated to spindle shape, often with irregular nuclear membranes. The nuclear features are similar to those seen in the giant cell type. With mark desmoplasia, the aspirate may yield fragments of collagenized stroma in which discrete

malignant cells are embedded and may be difficult to recognize (Fig. 11.27C and D).

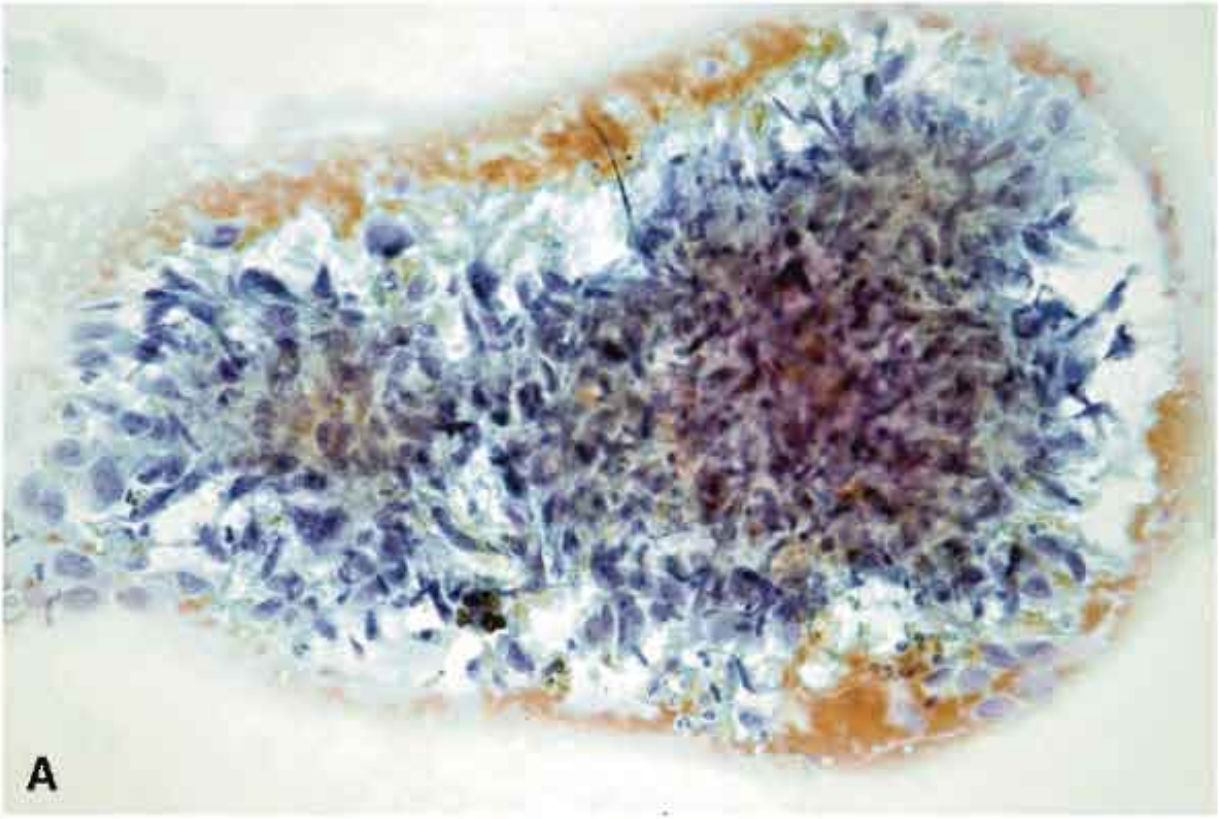
A

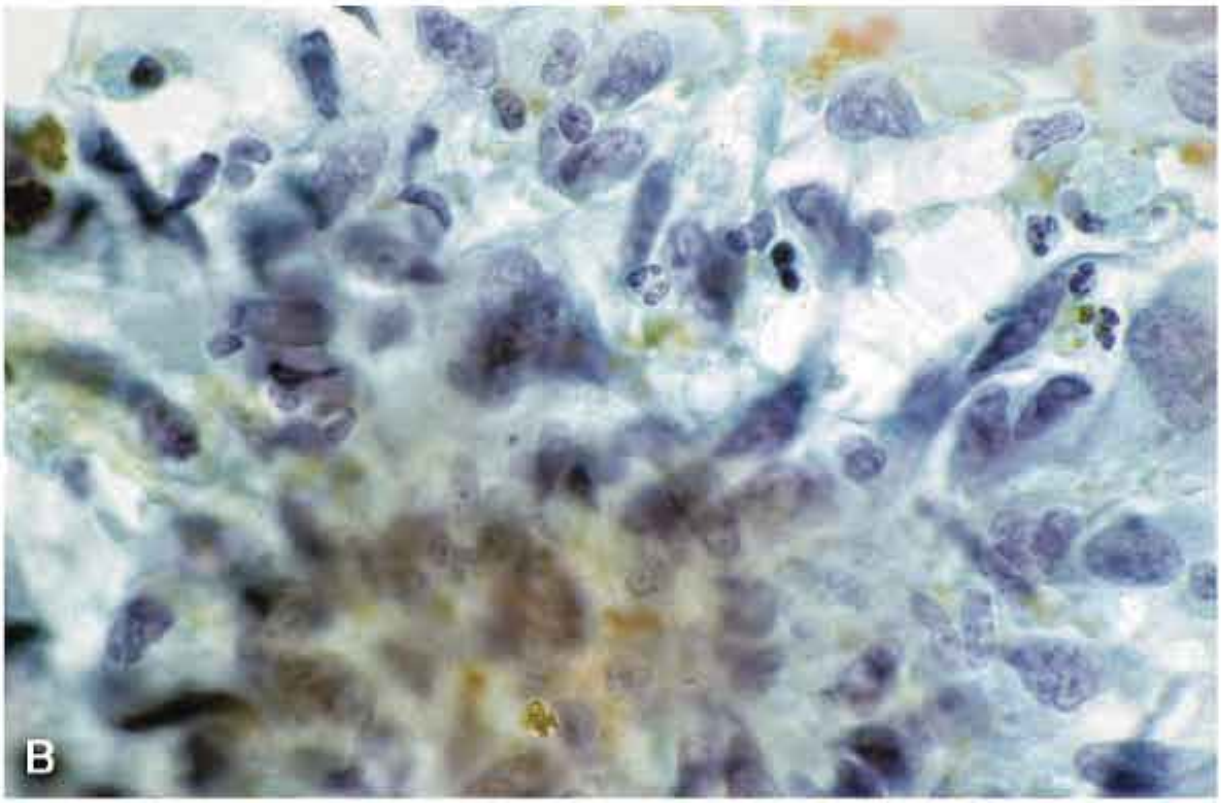
B

Figure 11.26. A. This marginally cellular aspirate from a spindle cellâ€“type anaplastic carcinoma showed only a few tissue fragments of malignant cells (low power). B. Higher magnification demonstrating malignant spindle cells varying widely in size. Note bizarre nuc pattern, variable cytoplasm and cytoplasmic processes. The cytomorphologic pattern is reminiscent of a soft-tissue sarcoma.

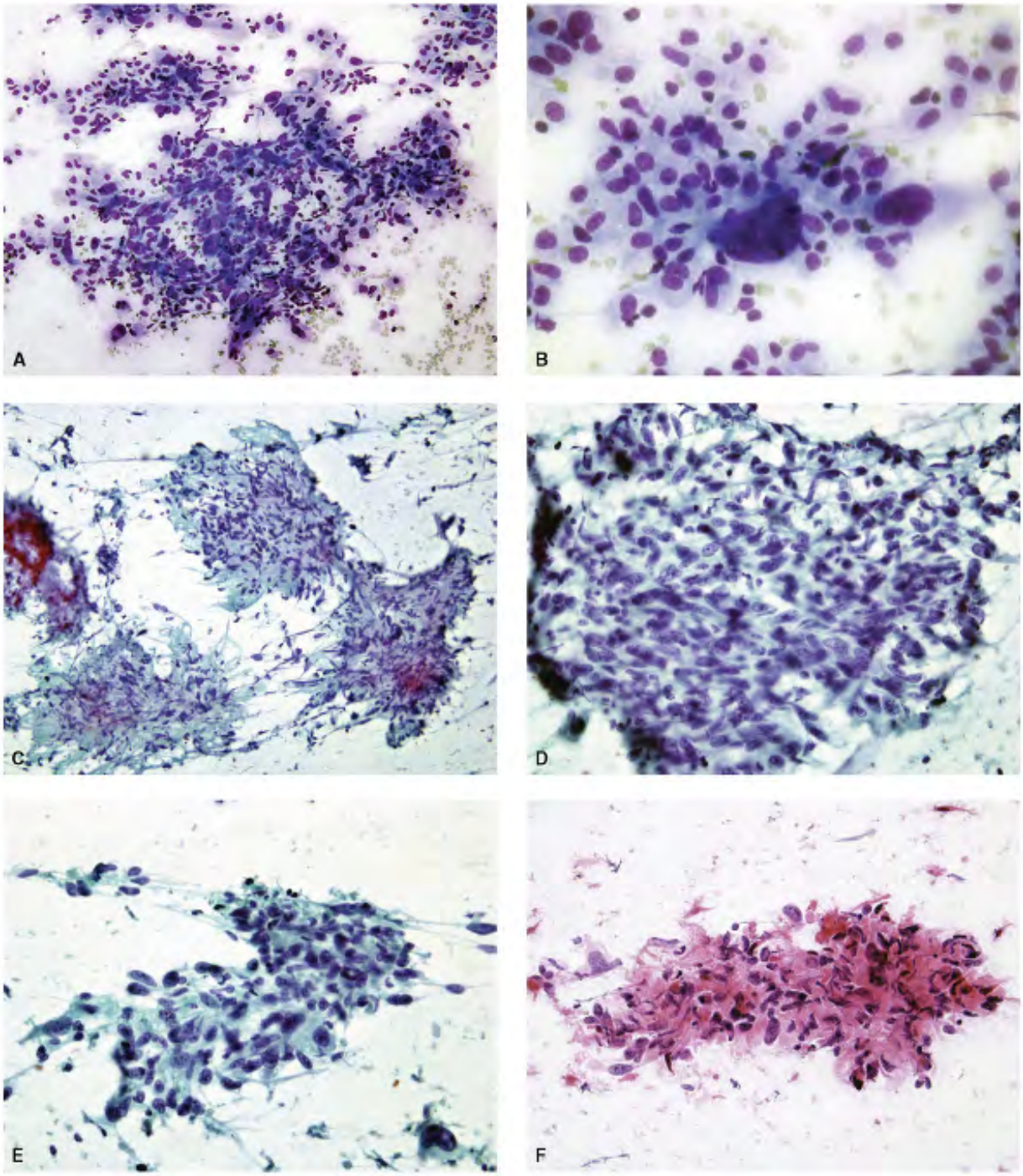

Figure 11.27. A. FNA of a spindle cell anaplastic carcinoma consisting of several tissue fragments of malignant cells. B. Higher magnification depicting pleomorphic malignant cells with numerous spindle forms (Diff-Quik stain). C. Same aspirate stained by Papanicolaou sta depicting several large tissue fragments of stromal tissue with spindle-shaped malignant cell embedded in the collagenized tissue. D,E. Different fields showing more cellular areas with

pleomorphic malignant spindle cells. F. Same aspirate stained by hematoxylin and eosin. No collagen separating the neoplastic spindle cells with bizarre nuclei. (Courtesy of Mithra Bali MD, University of Mississippi, Jackson.)

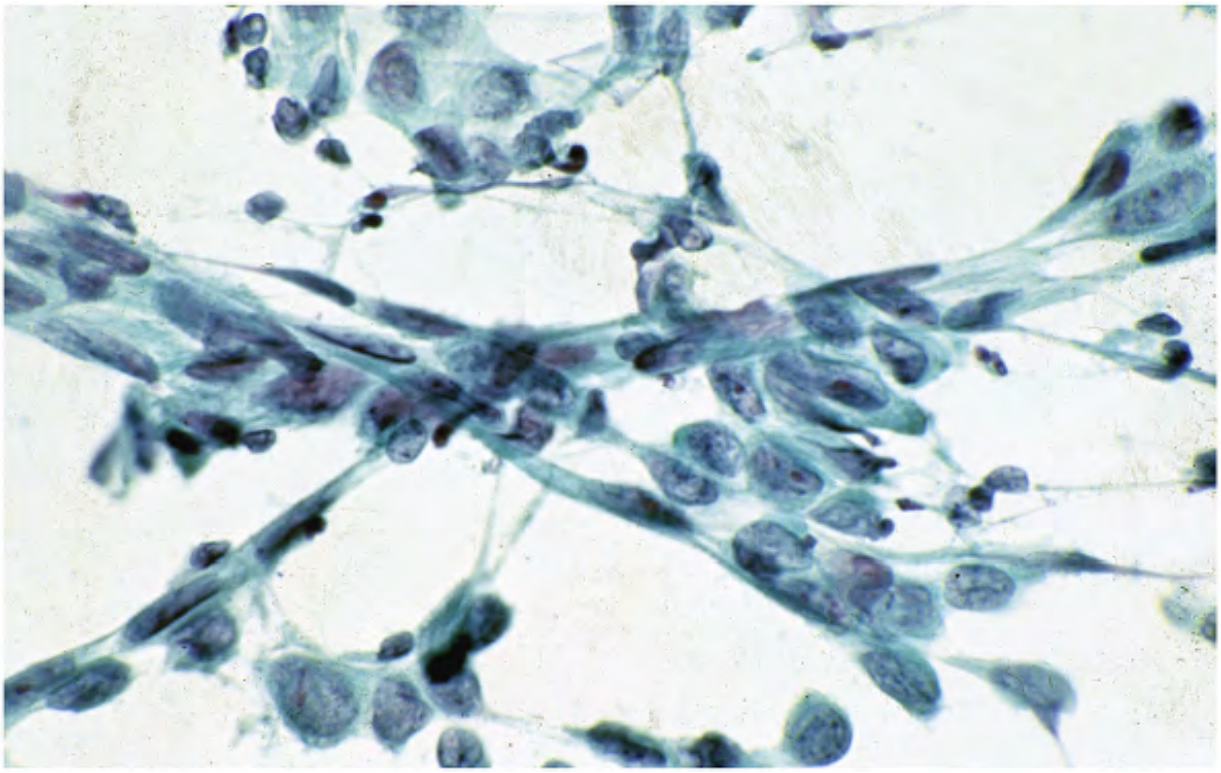

Figure 11.28. FNA of a poorly cellular aspirate of a spindle cell anaplastic carcinoma. The malignant cells are pleomorphic with long cytoplasmic processes. The nuclei are clearly malignant.

Osteoclast-type multinucleated giant cells have been described in some anaplastic carcinom (Fig. 11.29).32 , 33 , 34 , 35 The background usually shows necrosis, inflammation, and tun diathesis with cellular debris. Extensive necrotic debris may obscure the isolated malignant and result in a false-negative diagnosis (Fig. 11.34).

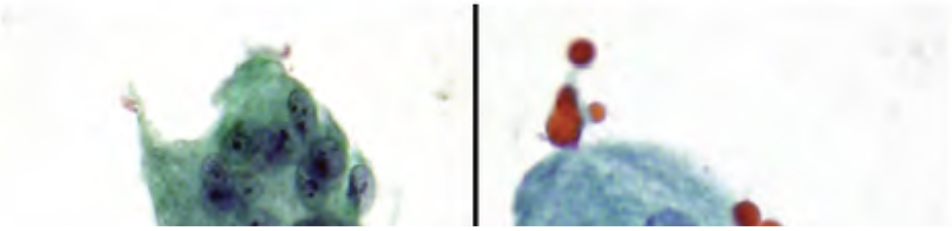

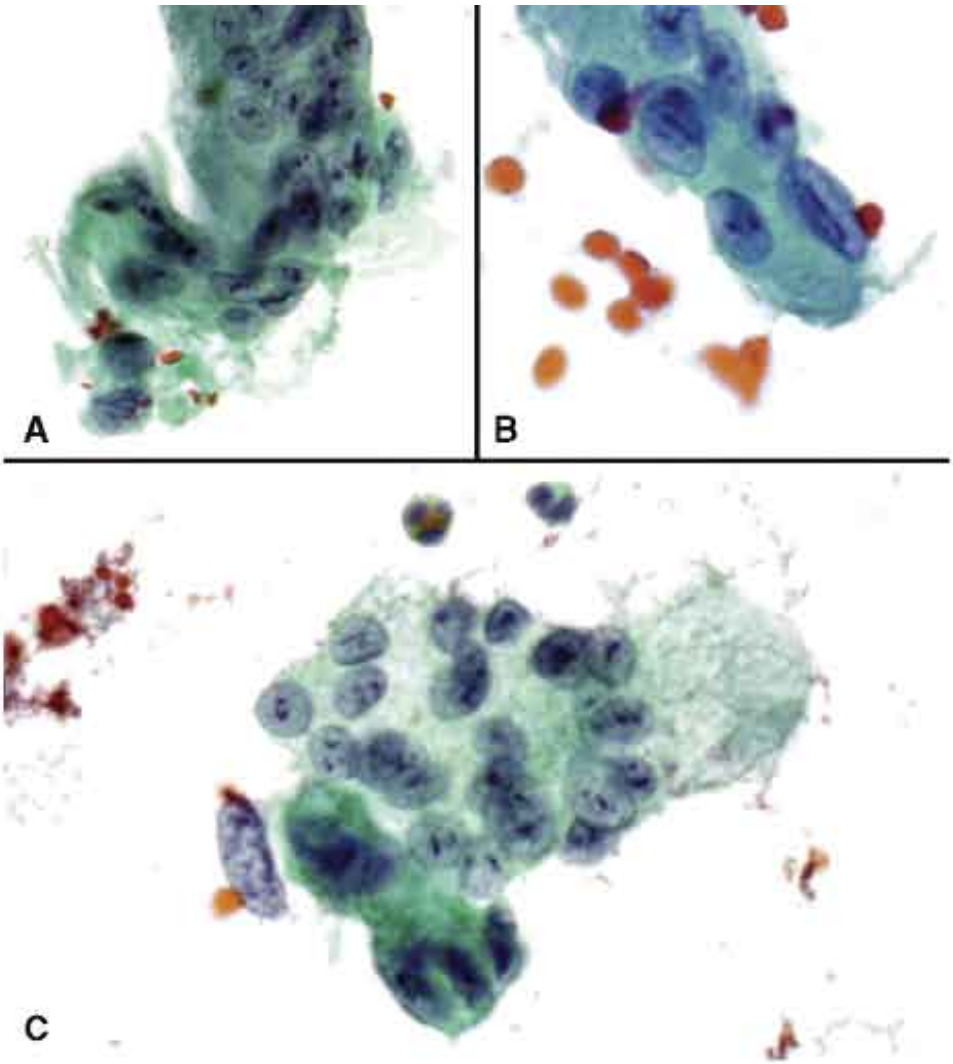
A
B
C

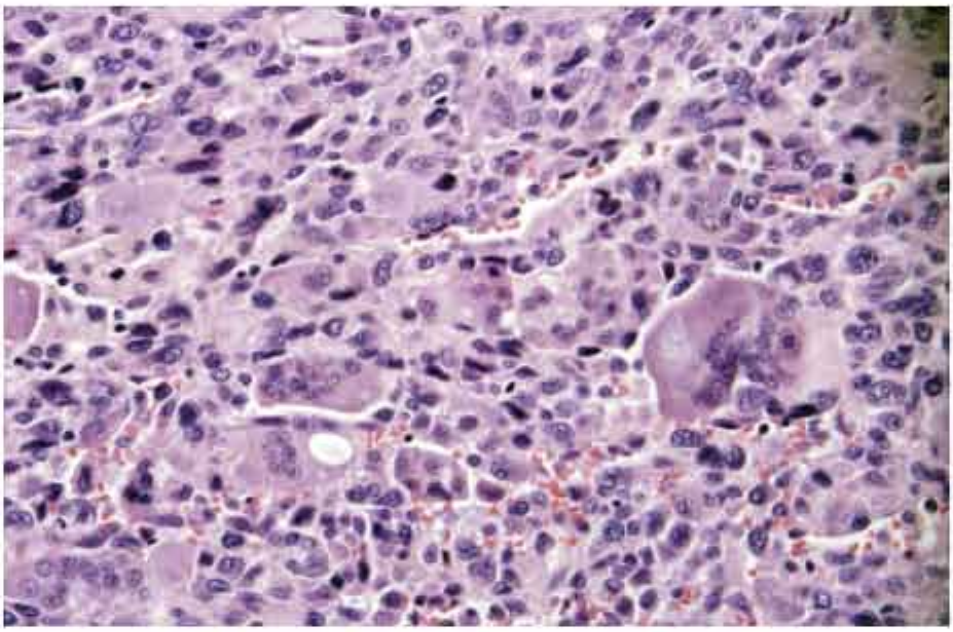

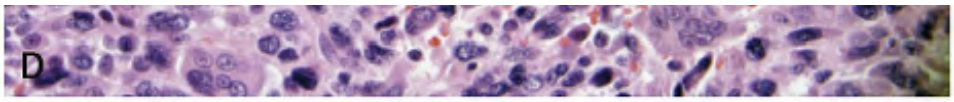

Figure 11.29. Aâ€“C. FNA of an anaplastic carcinoma depicting osteoclast-like multinuclea giant cells. Note that their nuclei are small, round to oval, uniform, with finely granular chromatin, and appearing very bland. D. Histologic section of the anaplastic carcinoma shov the osteoclast-like multinucleated giant cells.

The clear cell variant (Fig. 11.30) demonstrates malignant cells with cytologic features of g cell type anaplastic carcinoma with clear cytoplasm, appreciated better in histologic sectio than in cytologic preparations. Their nuclei are often seen as naked due to disruption of the membranes and cleared cytoplasm. The cytoplasm is abundant and often very pale.

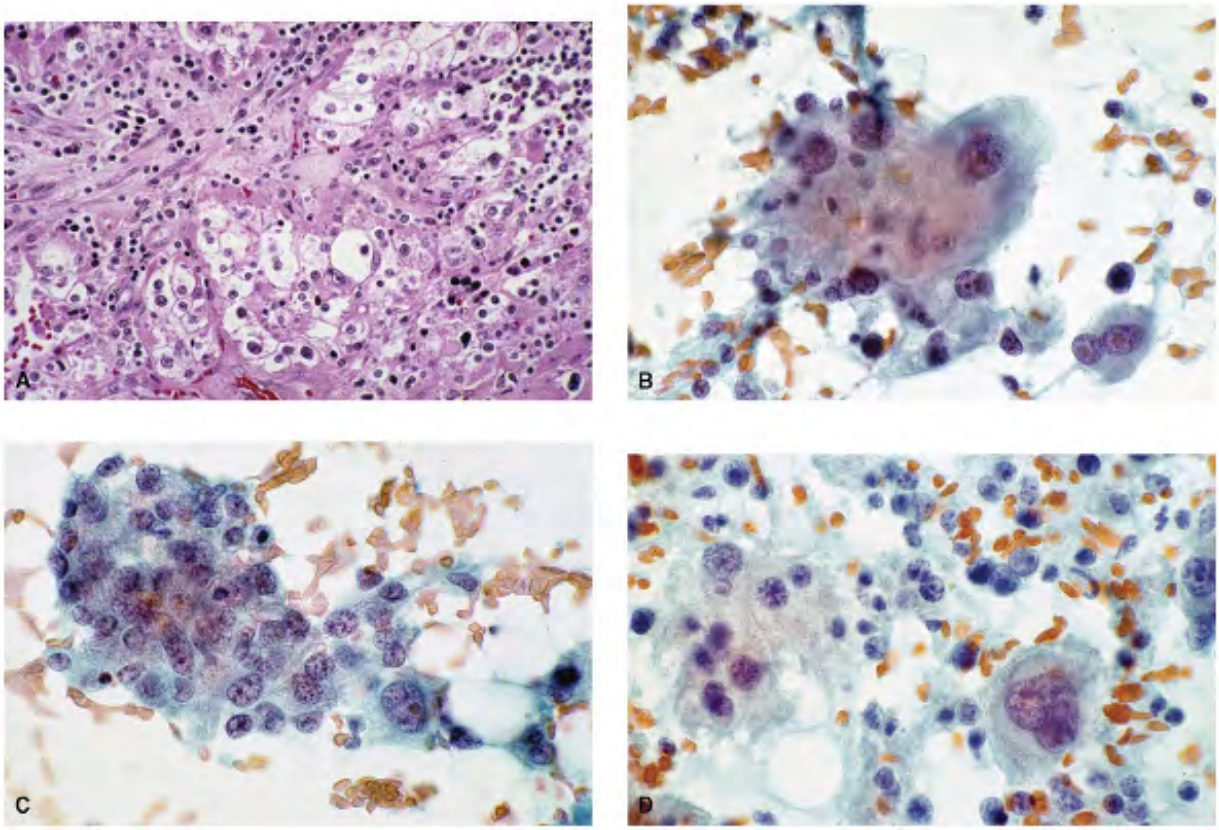

Figure 11.30. A. Histologic section of an anaplastic carcinoma with a clear cell pattern. Bâ FNA of this carcinoma. The malignant cells contain variable, pale to clear cytoplasm with bi nuclei. Because of the clear cytoplasm, some cells appear as bare nuclei.

The paucicellular variant, because of the extensive desmoplastic stroma, tends to yield poo cellular aspirate, predominantly consisting of pleomorphic spindle-shaped malignant cells (F 11.31).36 The rhabdoid type shows undifferentiated malignant cells containing abundant cytoplasm with vimentin-positive globules (Fig. 11.32), which ultrastructurally contain who filaments (Fig. 11.32D and E).37 The aspirates may also include cellular features of a pre-existing follicular/ HÃ¼rthle cell, papillary carcinoma, or an insular carcinoma (Fig. 11.33). 18 , 37 , 38

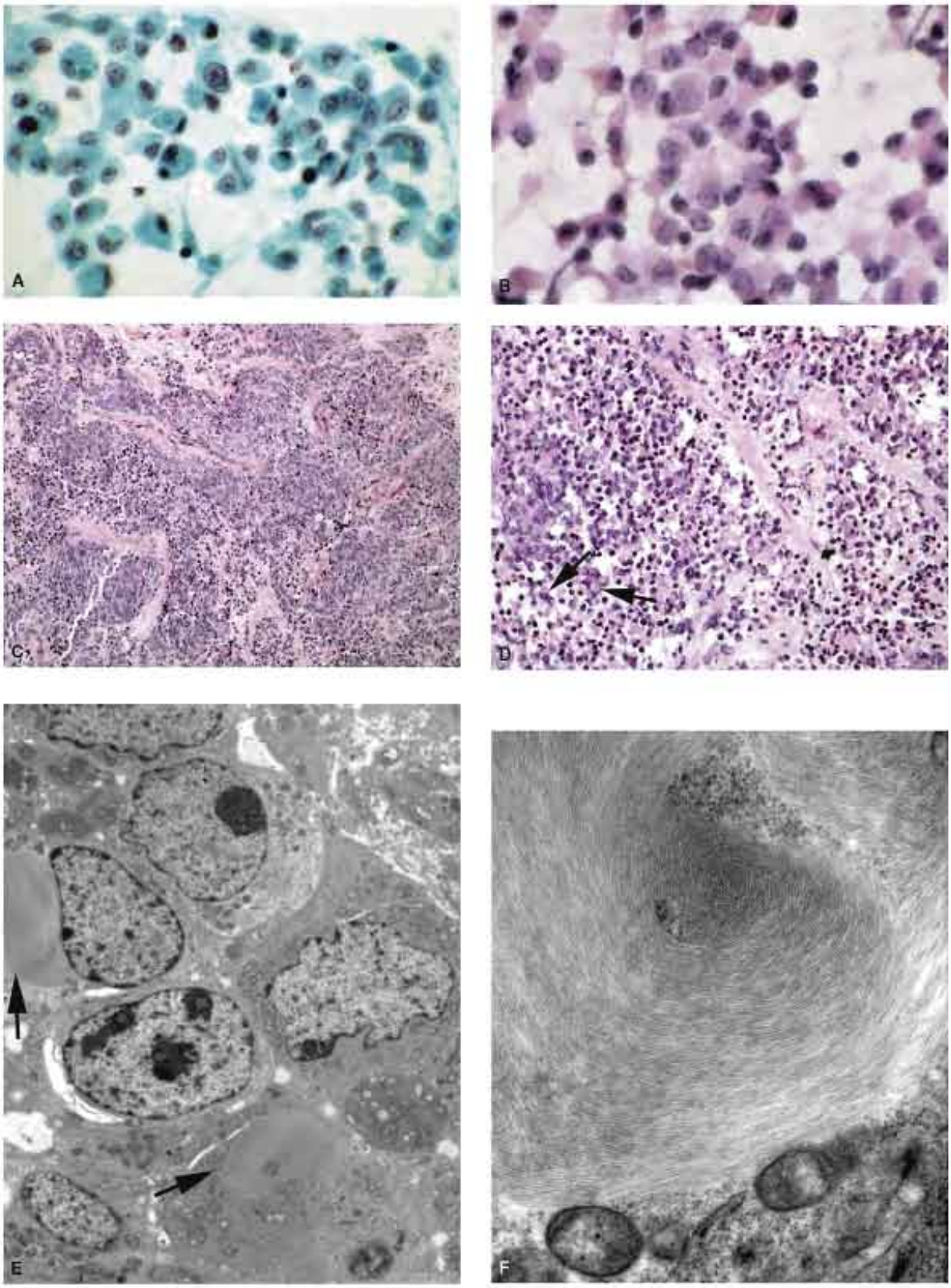
A
B
C
D
E
F

Figure 11.31. Anaplastic carcinoma, rhabdoid variant. A. Cellular aspirate depicting discret malignant cells with large pleomorphic eccentric nuclei and variable dense cytoplasm. B. Sc cytology of the resected tumor showing medium to large-sized plasmacytoid malignant cells dense cytoplasm. The cells appear uniform. H&E stain. C. Histologic section of the resected tumor. Medium-power view, showing a solid growth pattern. D. Higher magnification. The malignant cells are medium sized, round to polygonal, with an appreciable amount of eosinophilic cytoplasm. Note eosinophilic cytoplasmic globules (*arrows*). E. Ultrastructure showing cytoplasmic globule of filaments (*arrows*). F. Higher magnification showing intermediate filaments with a whorled pattern.

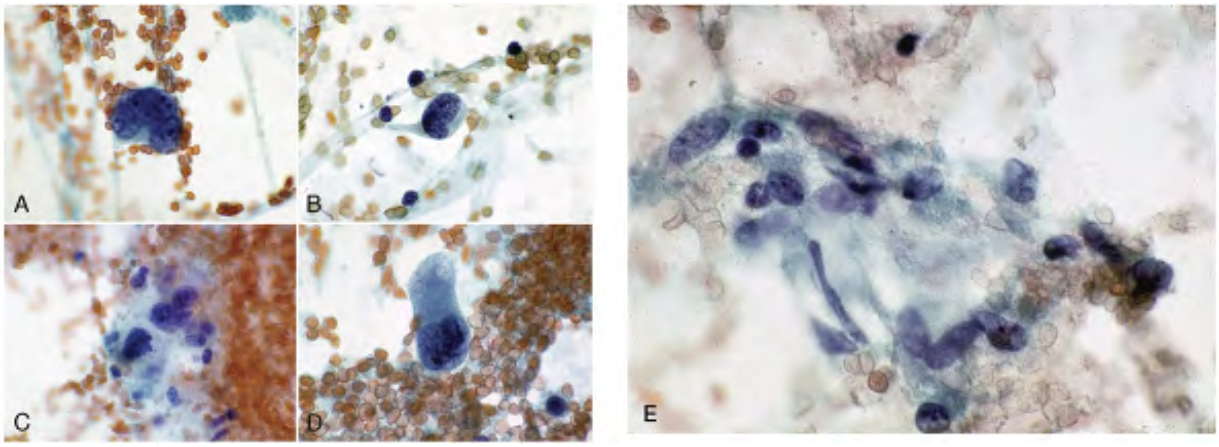

Figure 11.32. Paucicellular variant of anaplastic carcinoma. Three attempts at fine-needle biopsy of the hard, fixed enlarged thyroid in a 41-year-old male failed to yield an adequate aspirate. From over 40 smears from three aspirates, rare but pleomorphic spindle and giant were identified that raised a question of anaplastic carcinoma. The surgical resection showe paucicellular anaplastic carcinoma with considerable desmoplasia, explaining the difficultie obtaining an adequate aspirate. Aâ€“D. The malignant cells are discrete, highly pleomorphi with variable cytoplasm, spindle to giant forms. E. An aggregate of pleomorphic spindle cell was the only finding in one of the aspirates. Histologic section of the resected tumor confirr anaplastic carcinoma with marked desmoplasia (please refer to Fig. 11.12).

The cytologic features of anaplastic carcinoma are listed in Table 11.1 and illustrated in Fig 11.13 , 11.14 , 11.15 , 11.16 , 11.17 , 11.18 , 11.19 , 11.20 , 11.21 , 11.22 , 11.23 , 11.24 , 1 , 11.26 , 11.27 , 11.28 , 11.29 , 11.30 , 11.31 , 11.32 , 11.33 and 11.34 .

Cellularity

Variable; usually very cellular; low in paucicellular variant or necrotic tumors

Presentation

Malignant cells isolated, in loosely cohesive groups, or in syncytial tissue fragments without any architectural patterns

Cells

Extremely pleomorphic in size and shape; small to giant forms; round, polygonal, spindle shaped, caudate, tadpoles; well to poorly defined cell borders; N/C ratios variable, usually high

Nucleus

Large to giant sized; round, elongated to spindle shaped; bizarre forms; bi-multinucleation frequent; deep staining coarsely granular to clumped chromatin with excessive parachromatin clearing; multiple micro-macronucleoli; intranuclear cytoplasmic inclusions; mitotic figures +

Cytoplasm

Variable; scant to abundant; clear, pale, vacuolated to dense; emperipolesis frequent

Background

Cellular and necrotic debris; acute inflammatory cells Â±; osteoclast-like giant cells Â±

Features of pre-existing papillary, follicular, or insular carcinoma

May be present, depending on the sampling

Immunoprofile

Almost always negative reactivity to thyroglobulin and TTF-1; positive reactivity to cytokeratin and vimentin

TABLE 11.1 CYTOPATHOLOGIC FEATURES OF ANAPLASTIC CARCINOMA

IMMUNOPROFILE

Several studies on reactivity of various antibodies have indicated that anaplastic carcinoma fail to react to thyroglobulin in almost all cases.39 , 40 , 41 , 42 , 43 , 44 Keratin is the mos useful marker, as it is consistently positive. Carcinoembryonic agent (CEA) and epithelial membrane antigen (EMA) are of limited diagnostic value. Anaplastic carcinoma cells are also non-reactive to calcitonin and leukocyte common antigen (LCA). However, all these stains a useful in differentiating anaplastic carcinomas from several other poorly differentiated neoplasms.

DIAGNOSTIC ACCURACY AND DIFFERENTIAL DIAGNOSIS

With adequate cellularity, the cytologic presentation of anaplastic carcinomas in fine-needl aspirates usually offers no diagnostic challenge. The diagnostic accuracy is reported in the r of 85% to 90%.26 False-negative diagnosis results from inadequate aspirate usually from paucicellular spindle cell variants containing excessive collagenized stroma.45 Extensive ne may also result in a false-negative diagnosis, as the single malignant cells obscured by the inflammatory and cellular debris preclude the diagnosis. Sampling of only a pre-existing differentiated cancer in anaplastic carcinoma is another reason for a missed diagnosis. Up t of anaplastic carcinomas arise as dedifferentiation of an existing differentiated carcinoma, either follicular or papillary.7 , 16 , 17 The cytologic samples may or may not contain both components (Fig. 11.33).16 , 37 , 38 Unlike a surgically resected specimen that allows care inspection and examination of multiple areas, cytologic interpretation is based only on the a sampled by the biopsy needle, an important limitation of fine-needle biopsy.

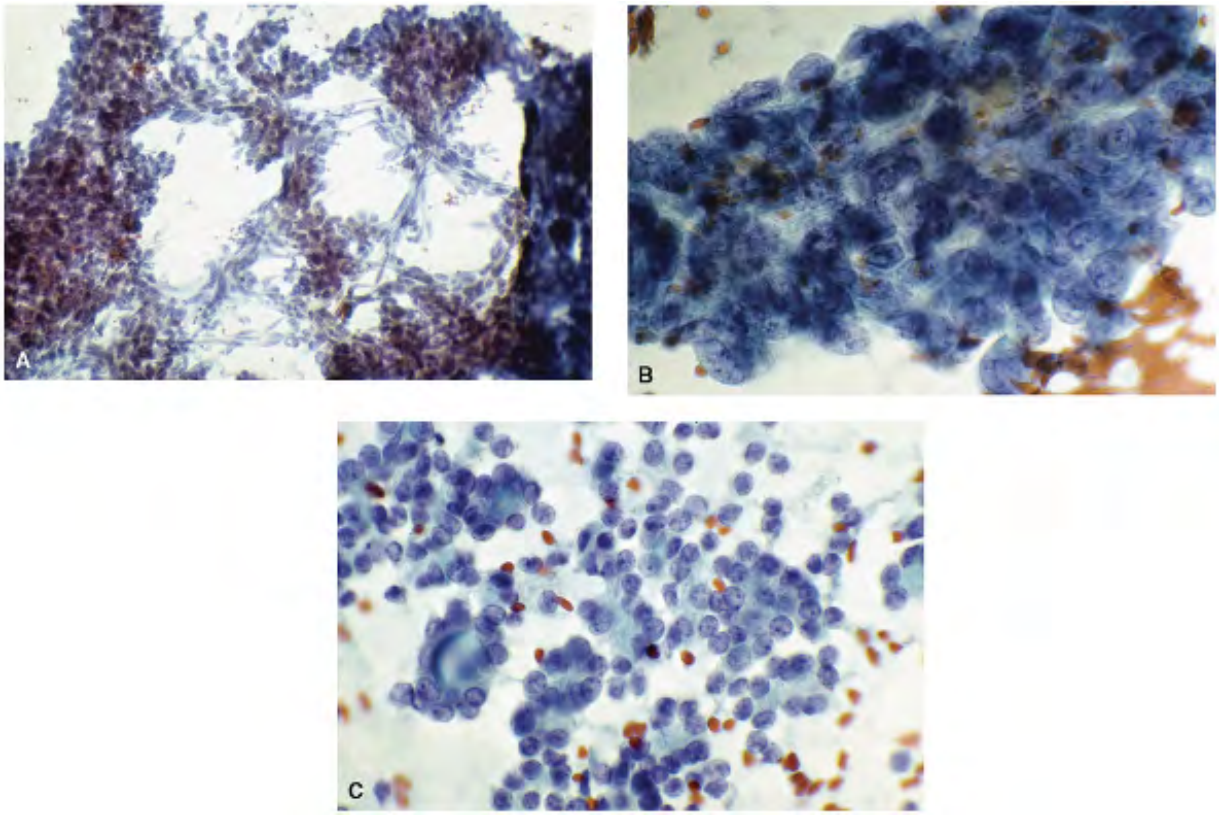

Figure 11.33. FNA of an anaplastic carcinoma that de-differentiated from a follicular carcinoma. The aspirate contained both components, which were correctly identified. A. Lo power view of the overwhelmingly cellular aspirate showing large tissue fragments of maligr cells with branching and anastomosing. The spindle cell nature is apparent at this magnifica B. A different field from the same case showing a syncytial tissue fragment of large undifferentiated malignant cells. C. Yet another field showed a very different cytologic pat Note a very cellular field containing smaller cells, discrete and in syncytial tissue fragments a follicular pattern. Their enlarged, crowded, and overlapped nuclei contain granular chrom and nucleoli. The background is clean. The cytologic presentation is consistent with follicula carcinoma. The surgical resection showed an anaplastic carcinoma with varied histologic patterns that included follicular carcinoma, an insular pattern, and anaplastic carcinoma wi mixed spindle cell and giant cell pattern.

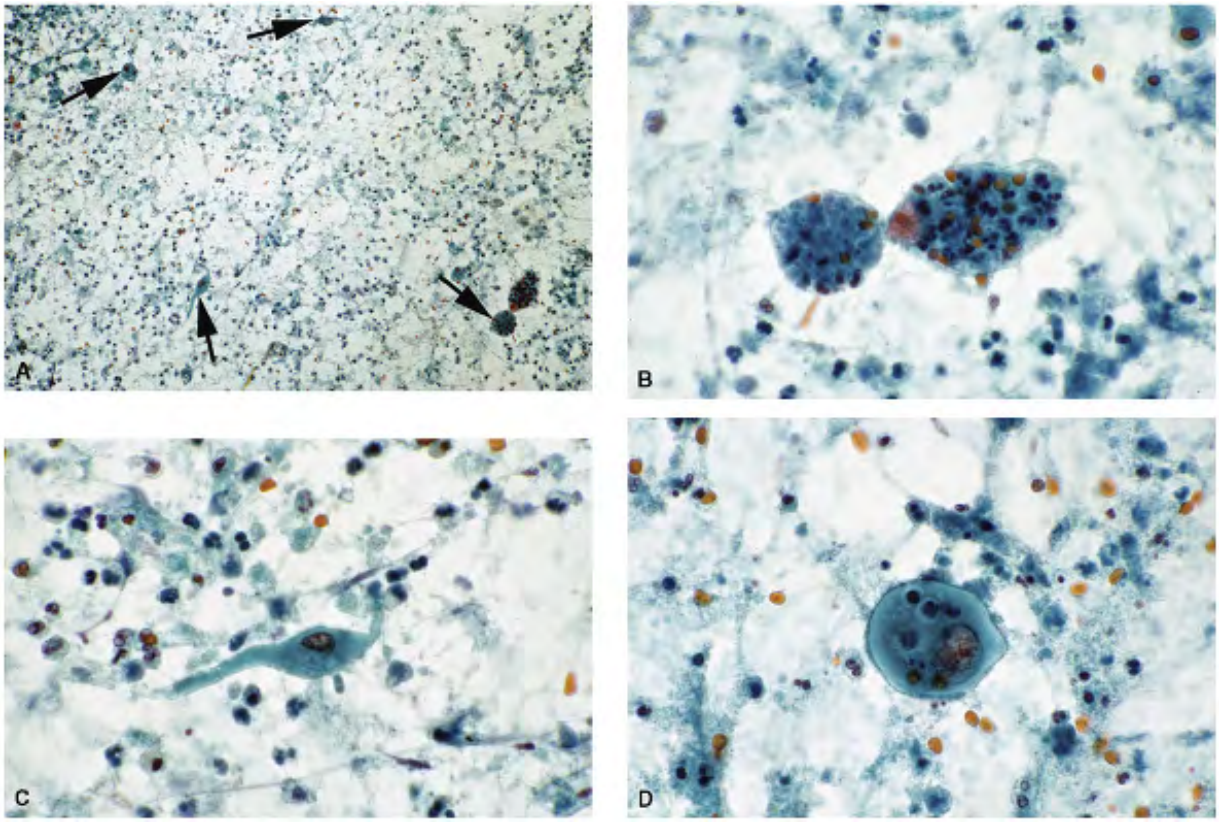

Figure 11.34. A. FNA of a rapidly growing thyroid mass in an elderly woman with a history c long-standing goiter, contained predominantly inflammatory and cellular debris obscuring ra pleomorphic malignant cells (*arrows*) (low power). B. Two malignant cells with cytoplasm distended with neutrophils referred to as emperipolesis. The neutrophils have completely masked the nuclei. C. A discrete racket-shaped malignant cell in the background of inflammatory cells. D. An isolated giant tumor cell with abundant dense cytoplasm and rigic border. The surgical excision confirmed an anaplastic carcinoma with extensive necrosis.

In general, the characteristic cytomorphology of anaplastic carcinoma with extreme pleomorphism of the malignant cells containing bizarre nuclei lends itself to accurate diagn and cannot be misinterpreted as any other neoplasm. The converse is not true. Several type benign cells46 as well as some malignant neoplasms may be misinterpreted as anaplastic carcinoma (Table 11.2). Benign cells that can be misinterpreted as anaplastic carcinoma in proliferating fibroblasts and stromal tissue fragments in Riedel's as well as subacute thyroidi (see Chapter 18 for a detailed discussion on spindle cells in thyroid aspirates). Degenerative changes in the benign follicular cells in nodular goiters, or radiation-induced changes, may a mimic anaplastic carcinoma cells.

Thyroiditis
- Acute thyroiditis with abscess
- Subacute or granulomatous thyroiditis
- Fibrous variant of Hashimoto's thyroiditis
- Riedel's thyroiditis

Nodular goiter
- Proliferating fibroblasts from granulation tissue
- Degenerating follicular cells in nodular goiter

Radiation-induced changes
Megakaryocytes from ossified cartilage
Medullary thyroid carcinoma
Poorly differentiated primary squamous cell carcinoma
Poorly differentiated metastatic carcinomas
Malignant lymphoma
Malignant melanoma
Soft-tissue sarcomas (primary and secondary)

TABLE 11.2 DIFFERENTIAL DIAGNOSIS OF ANAPLASTIC CARCINOMA

P.243
P.244
P.245
P.246

Acute infections with abscess are uncommon examples that masquerade clinically as anapla carcinoma. Rarely, megakaryocytes aspirated from the laryngeal or thyroid cartilage may be mistaken for anaplastic carcinoma. Malignant neoplasms mistyped as anaplastic carcinoma include medullary thyroid carcinoma, malignant lymphoma, poorly differentiated primary squamous carcinoma, poorly differentiated metastatic carcinomas, metastatic malignant melanoma, and soft-tissue tumors. The cytologic features of various diagnostic entities in th differential diagnosis of anaplastic carcinoma are listed in Table 11.3 .

Acute thyroiditis
Acute inflammatory (neutrophilic) exudate; histiocytes;

cellular and necrotic debris

11.35

Subacute (granulomatous thyroiditis)

Large numbers of multinucleated foreign-body type giant cells, some enormously large with multiple, uniform nuclei in tens and hundreds; often seen in the vicinity of blobs of colloid, forming granuloma, epithelioid cells Â±; varying numbers of spindle cells with bland nuclei, tissue fragments of stroma; benign follicular and HÃ¼rthle cells with or without nuclear atypia; lymphocytes in the background; neutrophils and cellular debris in acute phase

11.36

Riedel's thyroiditis

Acellular aspirate; no follicular cells; stromal tissue fragments; spindle cells, lymphocytes

Nodular goiter

Degenerating follicular cells with marked nuclear atypia,

11.39

with pyknosis; spindle shaped cells with bland nuclear chromatin; nuclear inclusions and grooves Â±

11.40

Radiation-induced

Pleomorphic follicular cells with spindle shapes; stromal

11.41

changes

spindle cells, bland nuclear chromatin or with degenerative changes with pyknosis; bare nuclei in the background

11.42

Megakaryocytes

Pleomorphic, large with multilobulated (not multinucleated) nuclei with clumped chromatin; hematopoietic cells in

the background

11.43

Medullary thyroid

Pleomorphic cell pattern with spindle and large polygonal

11.44

carcinoma

cells; spindle cells may be in fascicles; high N/C ratios; dense cytoplasm; coarsely granular chromatin; nuclear inclusions +; nucleoli inconsistent; grooves â€“; mitotic activity not present; background clean; amyloid +; neoplastic cells reactive to calcitonin

11.45

Poorly differentiated

primary squamous

carcinoma

Medium to large malignant cells, isolated, in loosely cohesive groups and in syncytial tissue fragments; undifferentiated cytoplasm; clearly malignant nuclei with nucleoli; mitotic activity +; cellular and necrotic debris Â±; negative reactivity to thyroglobulin; positive reactivity to cytokeratin

11.46

Poorly differentiated metastatic

carcinomas

Malignant cells pleomorphic; clearly malignant nuclei; mitotic activity +; cytoplasm with no differentiating features; immunostains necessary to identify the origin

11.47 to 11.49

Malignant large cell

lymphoma

Medium-sized round cells with scant cytoplasm; round nuclei with granular chromatin, parachromatin clearing, multiple nucleoli; mitotic activity brisk; karyorrhexis +; LCA +

11.53
Malignant melanoma
Pleomorphic malignant cell population; fine to coarsely
granular chromatin; macronucleoli; mitosis +, nuclear
inclusions +; melanin pigment in the cytoplasm Â±; HMB
45-positive reactivity
11.52
Soft-tissue sarcomas (primary
or secondary)
Spindle cell population, cells discrete or in fascicles;
pleomorphism common; nuclear morphology depending
on the type of neoplasm and range from bland to clearly
malignant; mitotic activity Â±; negative reactivity
to thyroglobulin and cytokeratin; positive to vimentin
and soft-tissue tumor markers (muscle-specific actin,
HHF 35, Desmin)
11.54
Anaplastic carcinoma
Extremely pleomorphic malignant cell population, ranging
11.13
from medium-sized to large and giant forms; round,
11.16
polygonal, to spindle shape; discrete, in groups, or in
11.17
syncytial tissue fragments with no architectural patterns;
large nuclei, often with irregular outlines; coarsely granular
chromatin with excessive parachromatin clearing; multiple
micro/macronucleoli; mitotic activity +; intranuclear inclusions +
11.26

Diagnostic Entity	Cytopathologic Features	See Fig(s).

TABLE 11.3 DIFFERENTIAL DIAGNOSIS OF ANAPLASTIC CARCINOMA CYTOLOGIC FEATURES

Anaplastic Carcinoma versus Acute Thyroiditis with Absce

Acute infection of the thyroid with an abscess formation is not a common occurrence. Both acute infection, as well as anaplastic carcinoma may be extremely painful and especially in older individuals anaplastic carcinoma is certainly a consideration. FNA biopsy will show acu inflammatory exudate and must be differentiated from a necrotic anaplastic carcinoma witl inflammatory and cellular debris (Fig. 11.35). The aspirate of the abscess will not contain a epithelial cells. However, the plump histiocytes may offer some diagnostic difficulties. Acti proliferating fibroblasts from the granulation tissue in these cases may also be a diagnostic problem.

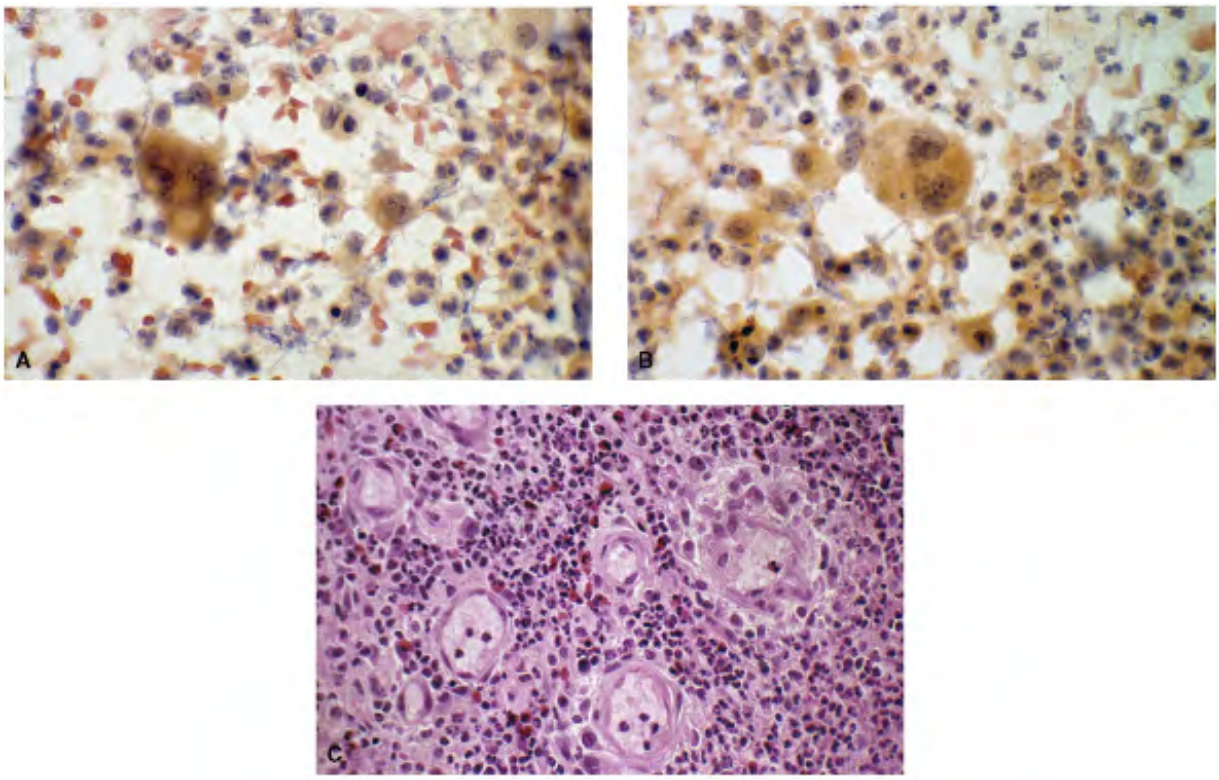

Figure 11.35. *Anaplastic carcinoma versus an acute abscess* . A,B. FNA of a painful thyroid showing heavy neutrophilic infiltrate and a large multinucleated cell, and histiocytes. C. Th surgical excision revealed an abscess and granulation tissue.

Anaplastic Carcinoma versus Riedel's Thyroiditis

The paucicellular variant of anaplastic carcinoma with excessive collagenized stroma will m

Riedel's thyroiditis. Both are hard to palpate and fixed to the deeper and surrounding tissue
Aspirates of both lesions may yield only fragments of fibrous tissue. The stromal spindle cell
from Riedel's thyroiditis will show a bland nuclear pattern in contrast to anaplastic carcinom
cells.18

Anaplastic Carcinoma versus Subacute or Granulomatous Thyroiditis

Subacute or granulomatous thyroiditis, a self-limiting condition, presents with severe discor
in the thyroid area. The onset is usually sudden. When the condition occurs in an elderly
patient, a fine-needle biopsy may be performed to exclude an anaplastic carcinoma. Fascicl
spindle cells of stromal origin (Fig. 11.36) may be misleading, and the multinucleated forei
body type giant cells may be interpreted as osteoclast-type giant cell, thus supporting the
diagnosis of spindle cell type anaplastic carcinoma. The benign stromal cells do not possess
bizarre nuclei that are so characteristic of anaplastic carcinoma.

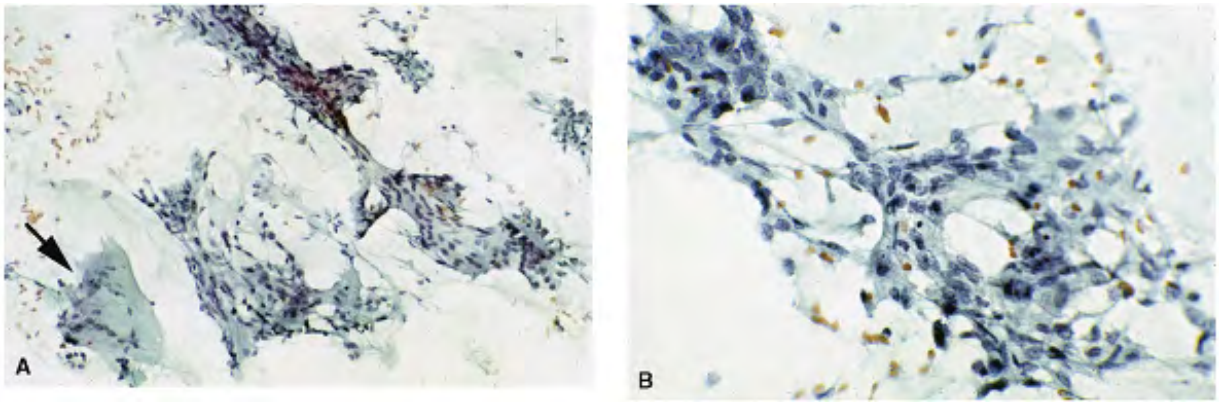

Figure 11.36. *Anaplastic carcinoma versus subacute or granulomatous thyroiditis* . FNA of a
painful, extremely tender, diffusely enlarged thyroid in a 70-year-old woman. A. The large
anastomosing bundles of spindle cells suggested anaplastic carcinoma. The large multinuclea
giant cell (*arrow*) was overlooked. B. The bland nuclear pattern is inconsistent with the
diagnosis of anaplastic carcinoma. Higher magnification. Two weeks following the biopsy, th
thyroid enlargement subsided and the tenderness disappeared.

Anaplastic Carcinoma versus Degenerating Follicular Cells from Nodular Goiter

Degenerating follicular cells in nodular goiters may exhibit conspicuous cellular changes tha

include cytokaryomegaly with bizarre nuclear pattern (Figs. 11.37 and 11.38). These change are usually focal and occur in the background features of nodular goiter.

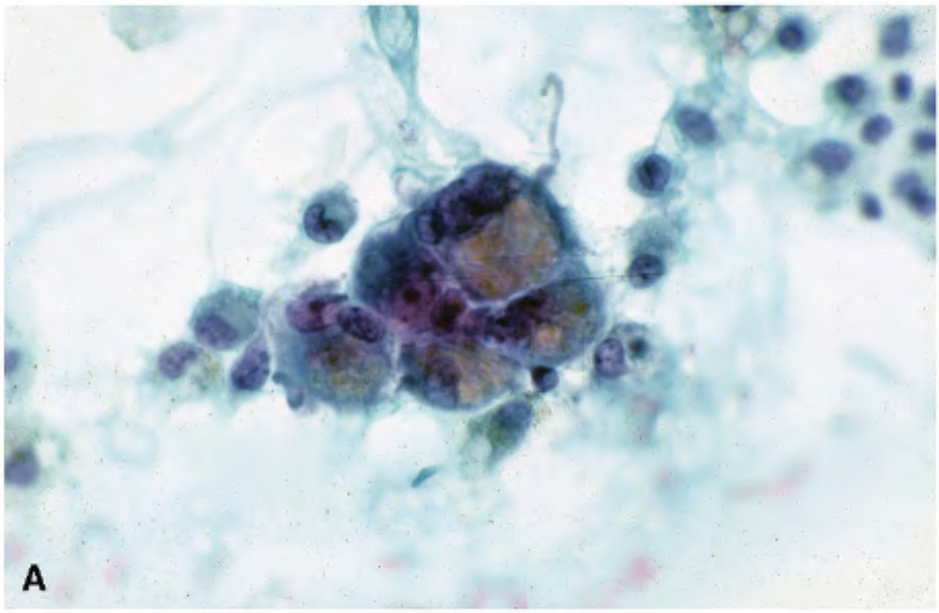

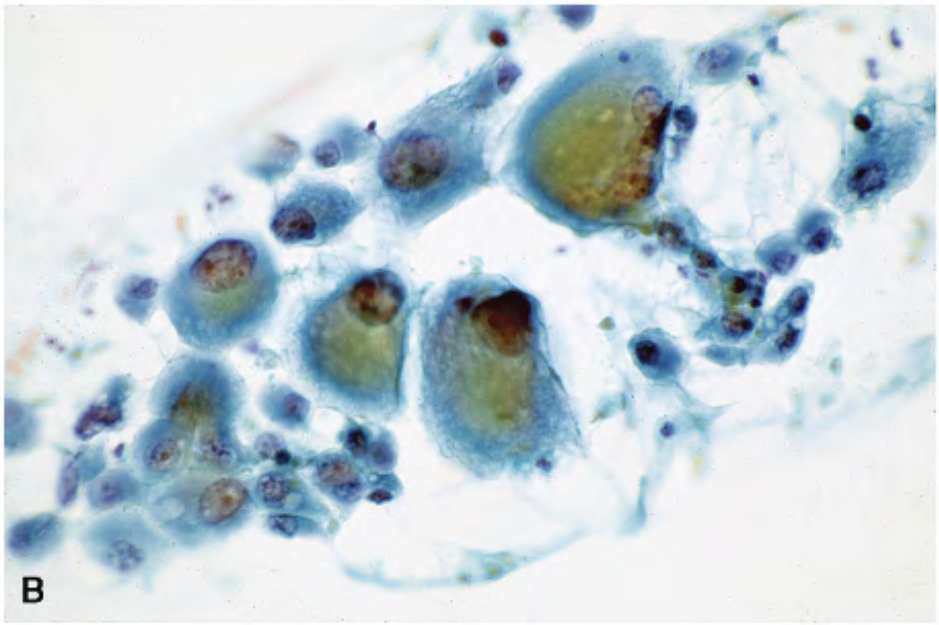

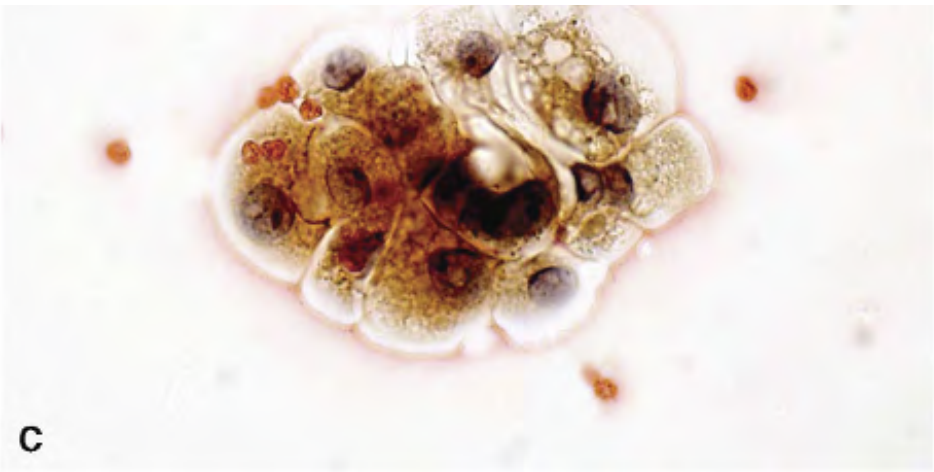

Figure 11.37. *Anaplastic carcinoma versus nodular goiter* . A. Degenerating follicular cells exhibit cellular and nuclear enlargement with micronucleoli and may appear worrisome. Suc cells are usually small in numbers and occur in the background of benign follicular cells. B. anaplastic carcinoma cells for comparison. Note the morphologic similarity to the degenerat follicular cells. Anaplastic carcinomas do not show features of nodular goiter in the backgro C. FNA of a nodular goiter showing an isolated group of large round cells with atypical nucle Some contain intranuclear inclusions. Their cytoplasm is abundant and foamy.

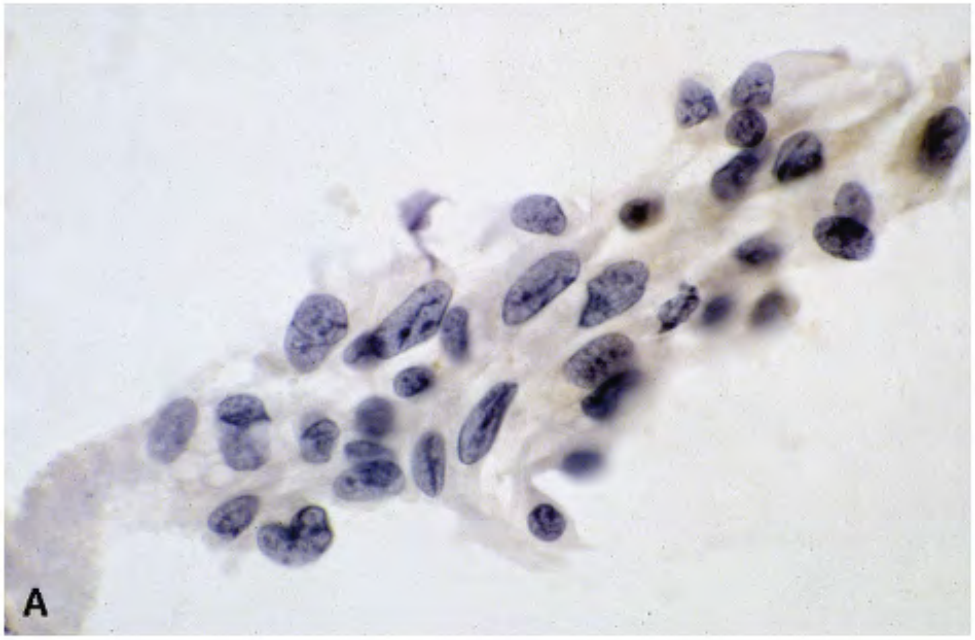

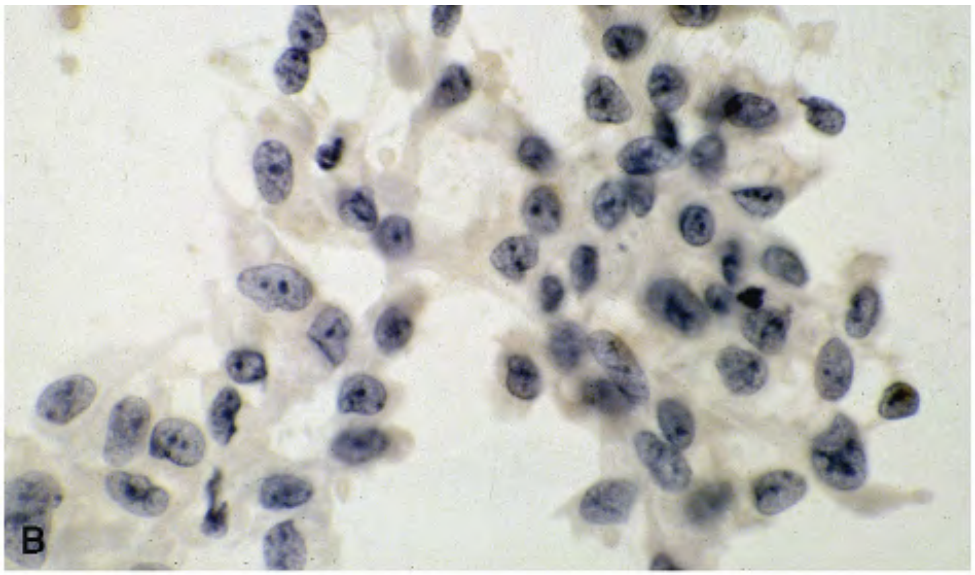

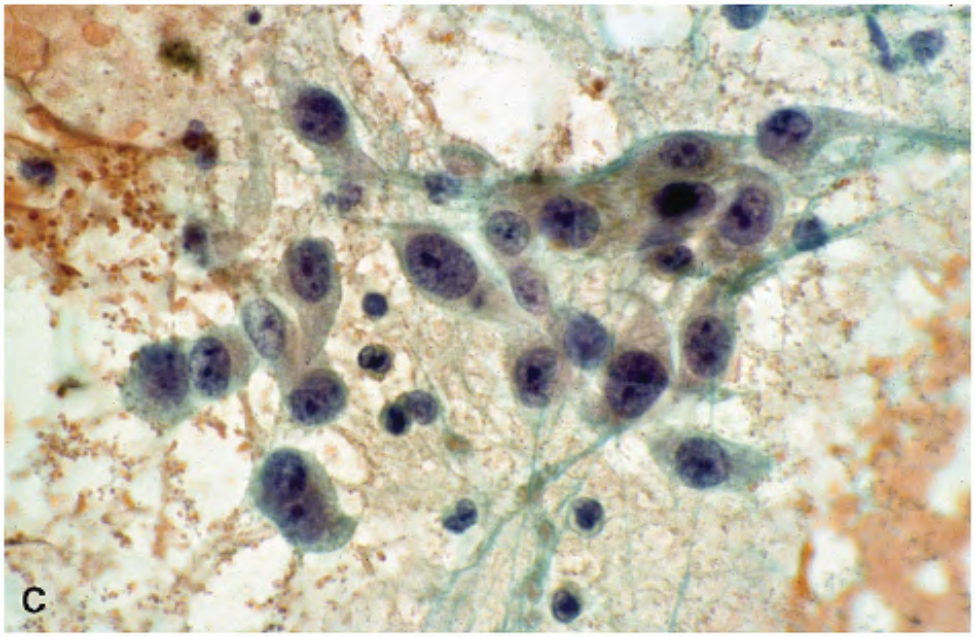

Figure 11.38. *Anaplastic carcinoma versus nodular goiter* . A. FNA of an enlarged nodular thyroid lobe in a 70-year-old woman with a history of contralateral thyroid lobectomy in the remote past for a nodular goiter. The aspirate was paucicellular, consisting of a few groups pleomorphic cells. Note small to large cells with an occasional giant form. Their nuclei are likewise pleomorphic, ranging from round, oval, and oblong to short and spindle shaped wit some exhibiting nuclear notches. The chromatin is granular and nucleoli can be appreciated exact origin of these cells is uncertain but may represent an admixture of reactive follicular cells and stromal cells. B. Another group from the same smear is more consistent with stron

cells. With a cytologic diagnosis of anaplastic carcinoma, lobectomy was performed, which f
to confirm the diagnosis. C. An aspirate of anaplastic carcinoma for comparison.

Anaplastic Carcinoma versus Proliferating Fibroblasts fro Granulation Tissue in a Nodular Goiter with Hemorrhage

The actively proliferating spindle-shaped fibroblasts sometimes present an alarming cytolog appearance that may lead to a malignant diagnosis such as anaplastic carcinoma of spindle type. Their nuclei, however, contain finely granular chromatin and contain micronucleoli. T cytoplasm of fibroblasts is usually abundant with low N/C ratios. Anaplastic carcinoma cells more pleomorphic with clearly malignant features (Figs. 11.39 and 11.40).

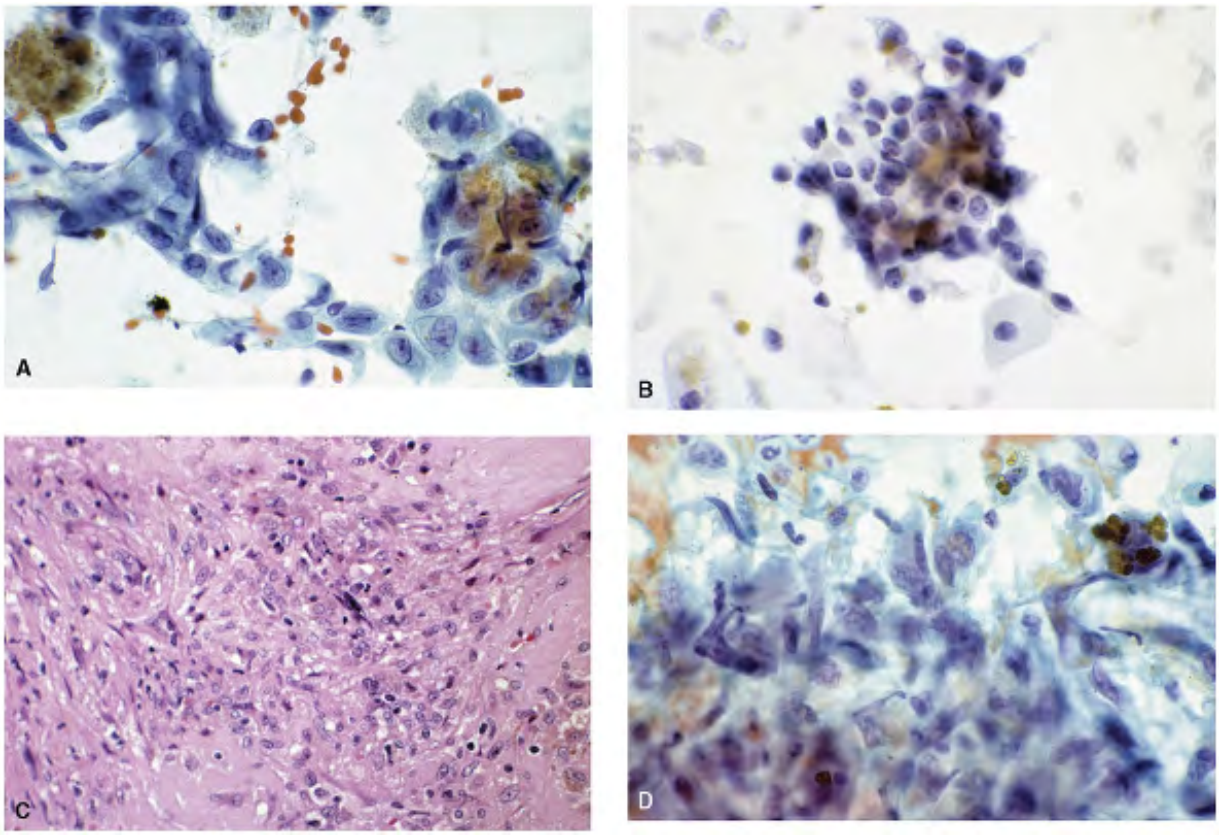

Figure 11.39. *Anaplastic carcinoma versus proliferating granulation tissue* . A. FNA of pain solitary thyroid nodule with rapid enlargement. Note very pleomorphic cells highly suggestiv anaplastic carcinoma. B. The presence of benign follicular cells in the background should ha been a clue for exercising caution in rendering a malignant diagnosis. C. Thyroidectomy rev hemorrhage, organization with proliferating fibroblasts, in a nodular goiter. D. Anaplastic

carcinoma with a spindle cell pattern for comparison. Hemorrhage within a nodule is a freq
cause for painful thyroid.

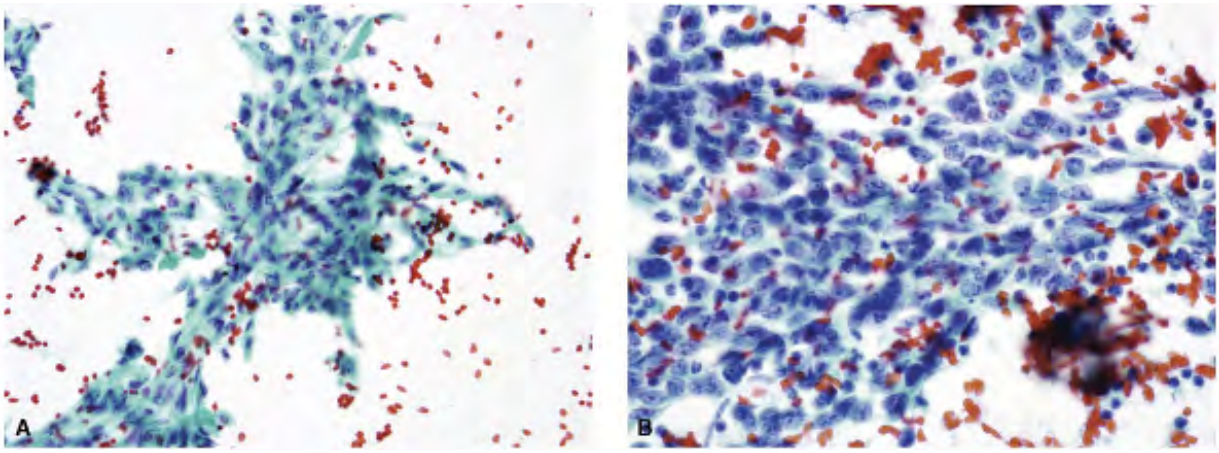

Figure 11.40. *Anaplastic carcinoma versus proliferating granulation tissue* . A. FNA of a no
goiter representing another example of actively proliferating fibroblasts. The spindle-shape
cells are in fascicles, containing round to oval nuclei with finely granular chromatin and
micronucleoli. The N/C ratios are low. Note the uniformity, clean background. The other sm
from the same aspirate showed features of nodular goiter. B. Anaplastic carcinoma for
comparison. The malignant cells are round to spindle shaped, less cohesive, and with larger
nuclei and high N/C ratios. The chromatin is coarsely granular and hyperchromatic. Note th
inflammatory background.

Anaplastic Carcinoma versus Radiation-Induced Changes ir Benign Follicular Cells

Radioactive iodine used for treating Grave disease may have residual effect on the follicula
cells. These changes include cytokaryomegaly, with clumped chromatin, intranuclear inclus
presence of nucleoli, and leukophagocytosis (Figs. 11.41 and 11.42). These changes may be
pronounced, mimicking anaplastic carcinoma.

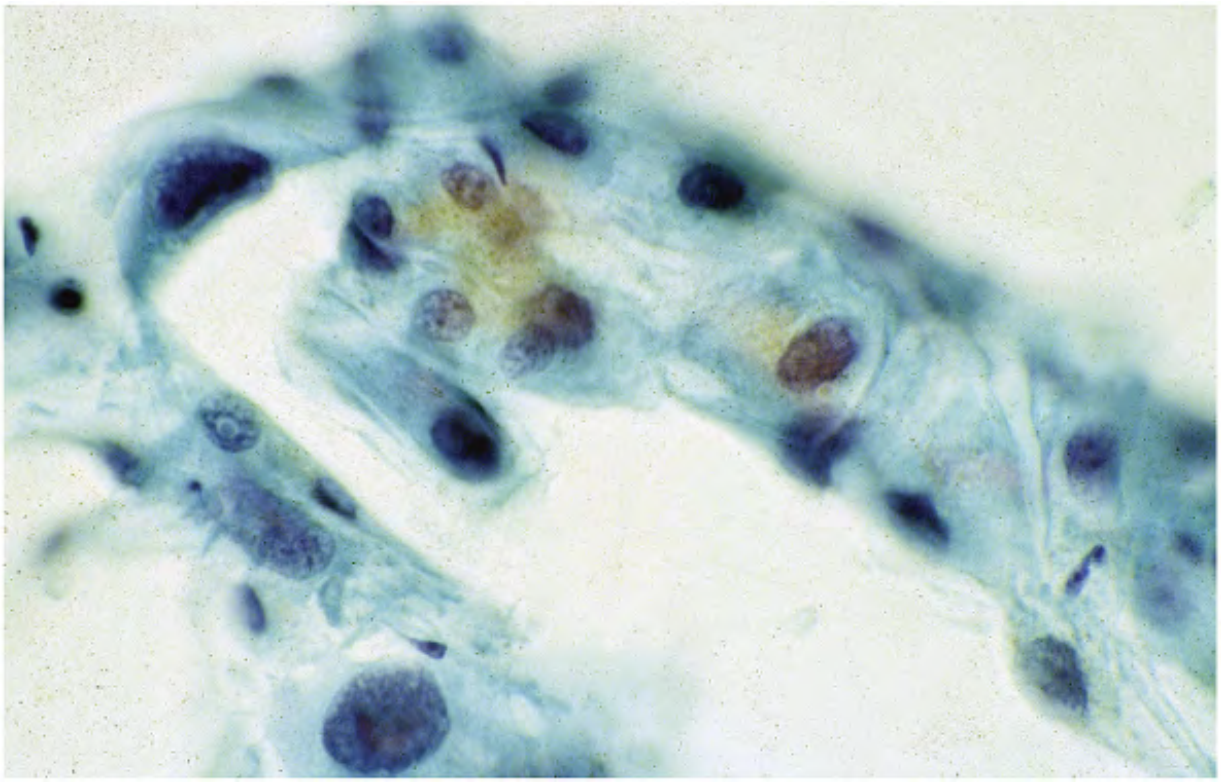

Figure 11.41. *Anaplastic carcinoma versus radiation induced changes* . Pleomorphic follicul cells with bizarre nuclei. The patient had ^{131}I therapy for Graves disease. Without taking th clinical information into account, these cells may be interpreted as anaplastic carcinoma.

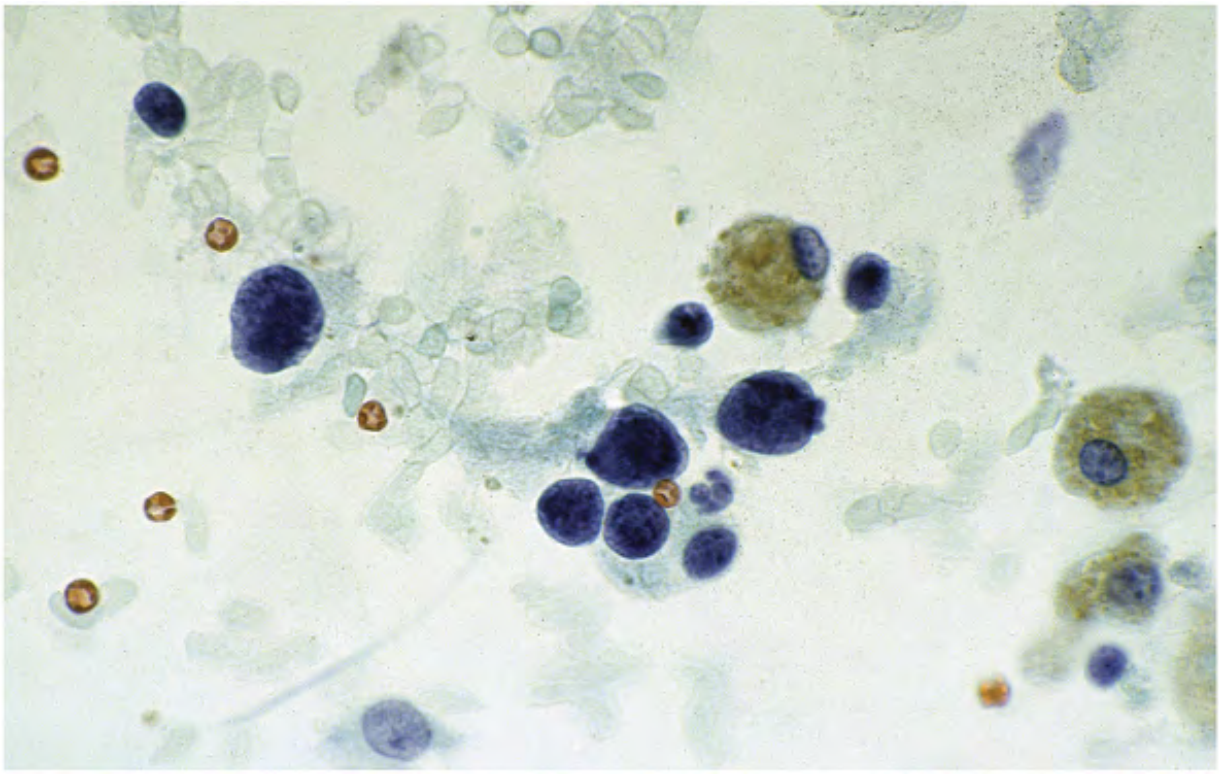

Figure 11.42. *Anaplastic carcinoma versus radiation-induced changes* . Another example of radiation-induced changes. The naked nuclei of the follicular cells are enlarged and contain smudgy chromatin. They appear similar to the bare nuclei seen in an aspirated anaplastic carcinoma with clear cell change (Fig. 11.30 D).

Anaplastic Carcinoma versus Megakaryocytes

On rare occasions, the needle may inadvertently target the ossified thyroid cartilage contai hematopoietic tissue. The dispersed megakaryocytes with their giant size and lobulated nuc mimic anaplastic carcinoma cells (Fig. 11.43). The megakaryocytes, however, lack the malignant criteria exhibited by anaplastic carcinoma cells (Fig. 11.43). Also, the clinical da and the presenting symptoms are not consistent with the diagnosis of anaplastic carcinoma.

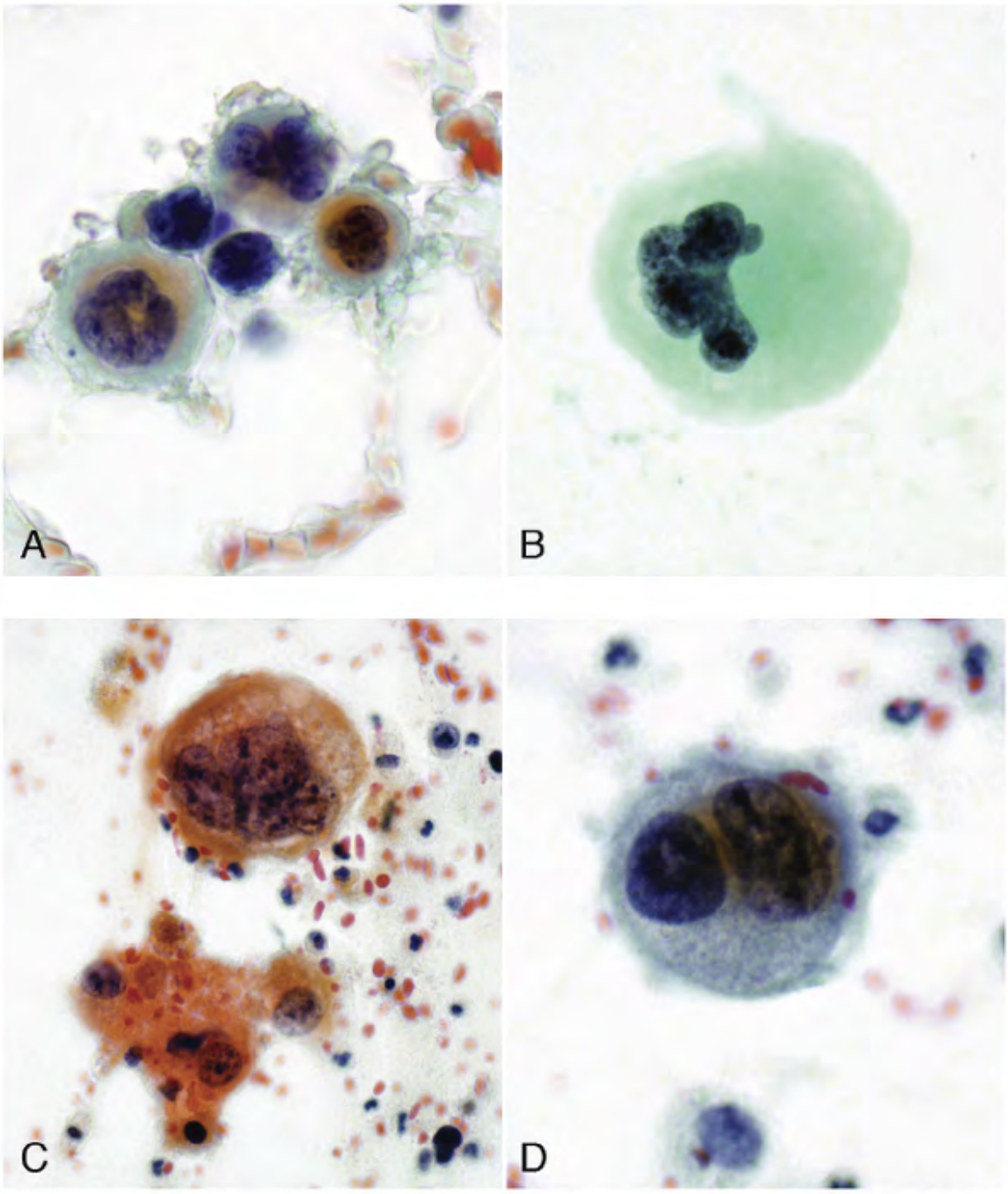

Figure 11.43. *Anaplastic carcinoma versus hematopoietic cells* . A,B. An FNA of a large thy mass in an 80-year-old man yielded a marginally cellular aspirate predominantly consisting c varying-sized large to giant cells with single to multilobulated nuclei. These are megakarycy inadvertently aspirated from ossified thyroid cartilage, which has developed foci of hematopoietic tissue. These megakaryocytes are easily interpreted as anaplastic carcinoma

right clinical setting as in this case. C,D. Discrete anaplastic carcinoma cells for comparison Note the nuclei are clearly malignant with coarsely granular chromatin, excessive parachror clearing and macronucleoli.

P.247
P.248
P.249
P.250
P.251

Anaplastic Carcinoma Versus Medullary Thyroid Carcinom

Medullary carcinoma of the thyroid presents a characteristic cytologic pattern allowing an e recognition. The nuclei of the medullary carcinoma cells have a typical neuroendocrine chromatin pattern that is rather uniform. Occasionally, medullary carcinoma cells may be ve pleomorphic, simulating a pattern of anaplastic carcinoma (Figs. 11.44 and 11.45).39 Immunostains are required for establishing a correct diagnosis.

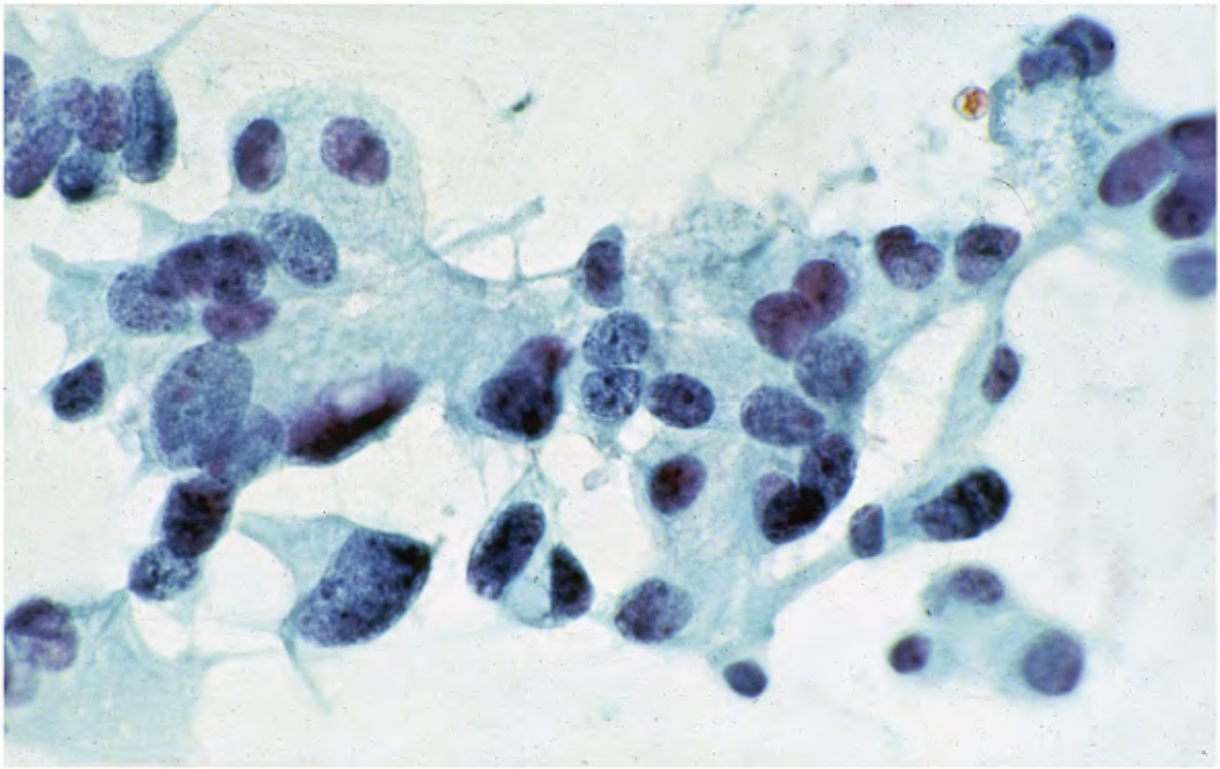

Figure 11.44. *Anaplastic carcinoma versus medullary carcinoma* . FNA of a medullary carcir

depicting a very pleomorphic cell pattern that can be misinterpreted as anaplastic carcinom

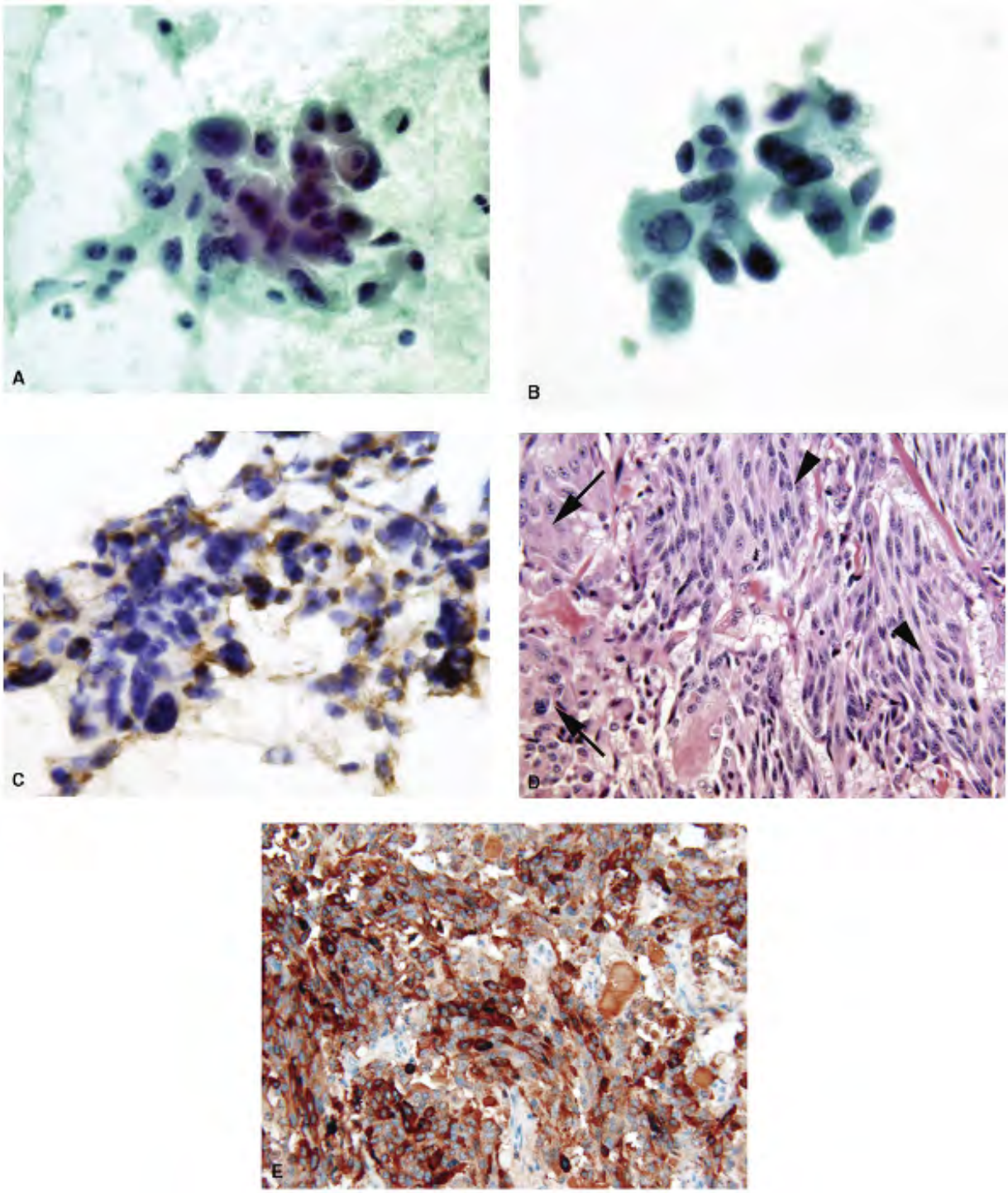

Figure 11.45. *Anaplastic carcinoma versus medullary carcinoma* . A. FNA of an irregularly a
massively enlarged thyroid in an 80-year-old man showing pleomorphic cell pattern with spi

and large round cells suggesting the diagnosis of anaplastic carcinoma. The differential diag included anaplastic and medullary carcinomas. B. Another field from the same case reveale malignant cells with eccentric nuclei, intranuclear inclusions, and appreciable cytoplasm, ra the possibility of a medullary carcinoma. C. A strongly positive calcitonin stain on the aspira smear confirmed the diagnosis of medullary carcinoma. D. Histologic section of the resectec thyroid with medullary carcinoma demonstrating a round cell pattern (*arrows*) and a predominant spindle cell pattern (*arrowheads*). E. Histologic section with strong positive reactivity to calcitonin.

Anaplastic Carcinoma versus Poorly Differentiated Primar Squamous Carcinoma

Primary squamous carcinomas of the thyroid are very uncommon. However, when they do o an accurate typing is difficult especially when squamous differentiation is not apparent in tl malignant cells (Fig. 11.46). Immunostains are not helpful in differentiating the two neopla because both will be strongly reactive to cytokeratin and anaplastic thyroid carcinomas are usually nonreactive to thyroglobulin.1

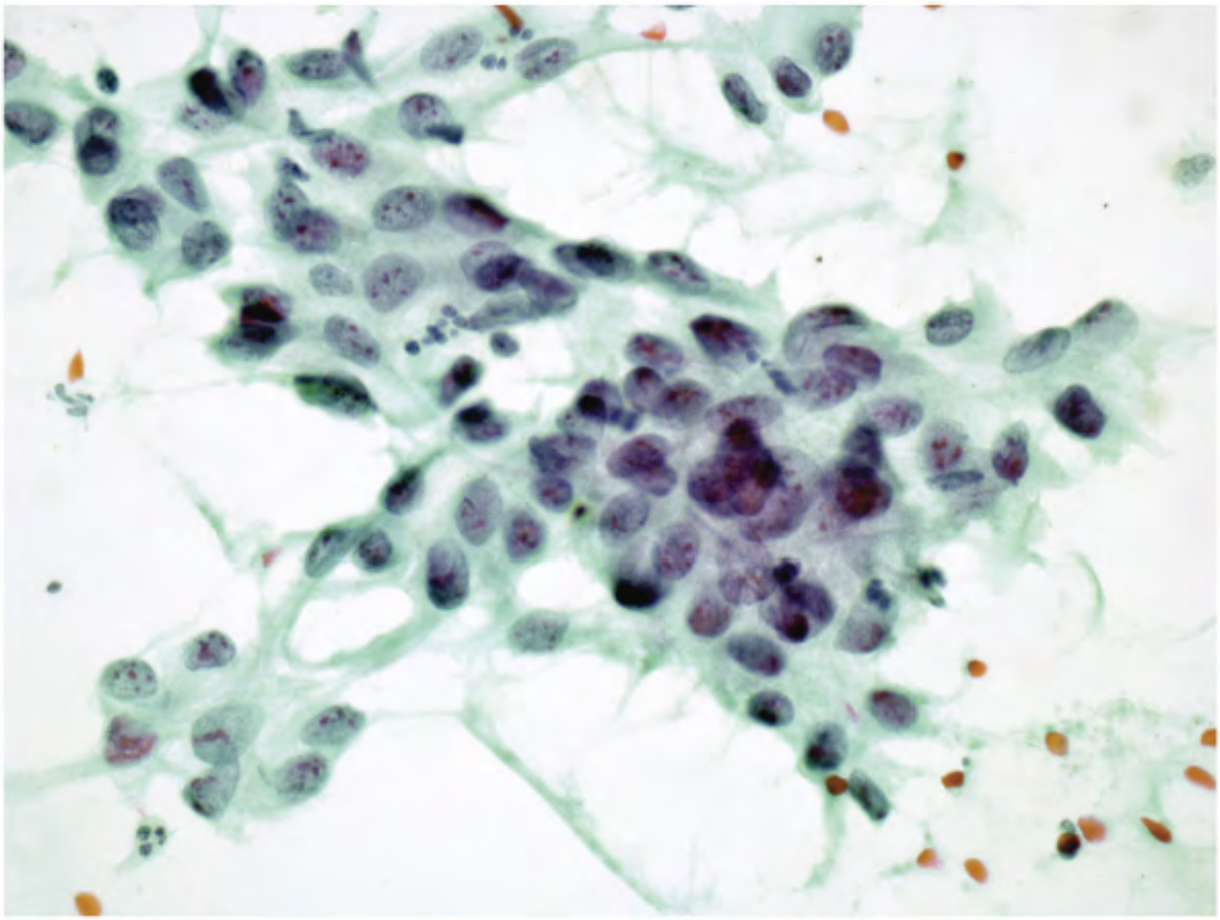

Figure 11.46. *Anaplastic carcinoma versus primary poorly differentiated squamous carcino*
FNA of a primary poorly differentiated squamous cell carcinoma of the thyroid showing pleomorphic malignant cells that do not exhibit any architectural or cytoplasmic squamous differentiation. These cannot be differentiated from an anaplastic carcinoma.

Anaplastic Carcinoma versus Metastatic Poorly Differentiated Carcinomas

Metastatic poorly differentiated carcinomas, whether squamous or adenocarcinomas, may p diagnostic dilemma, especially when a primary site is not known (Figs. 11.47 and 11.48). Pc differentiated carcinomas arising from the neighboring organs such as esophagus or larynx m clinically present as thyroid masses and may be misinterpreted as anaplastic carcinomas (Fig 11.49 , 11.49 and 11.51). Differentiation between the two is not possible from cytomorphol alone.

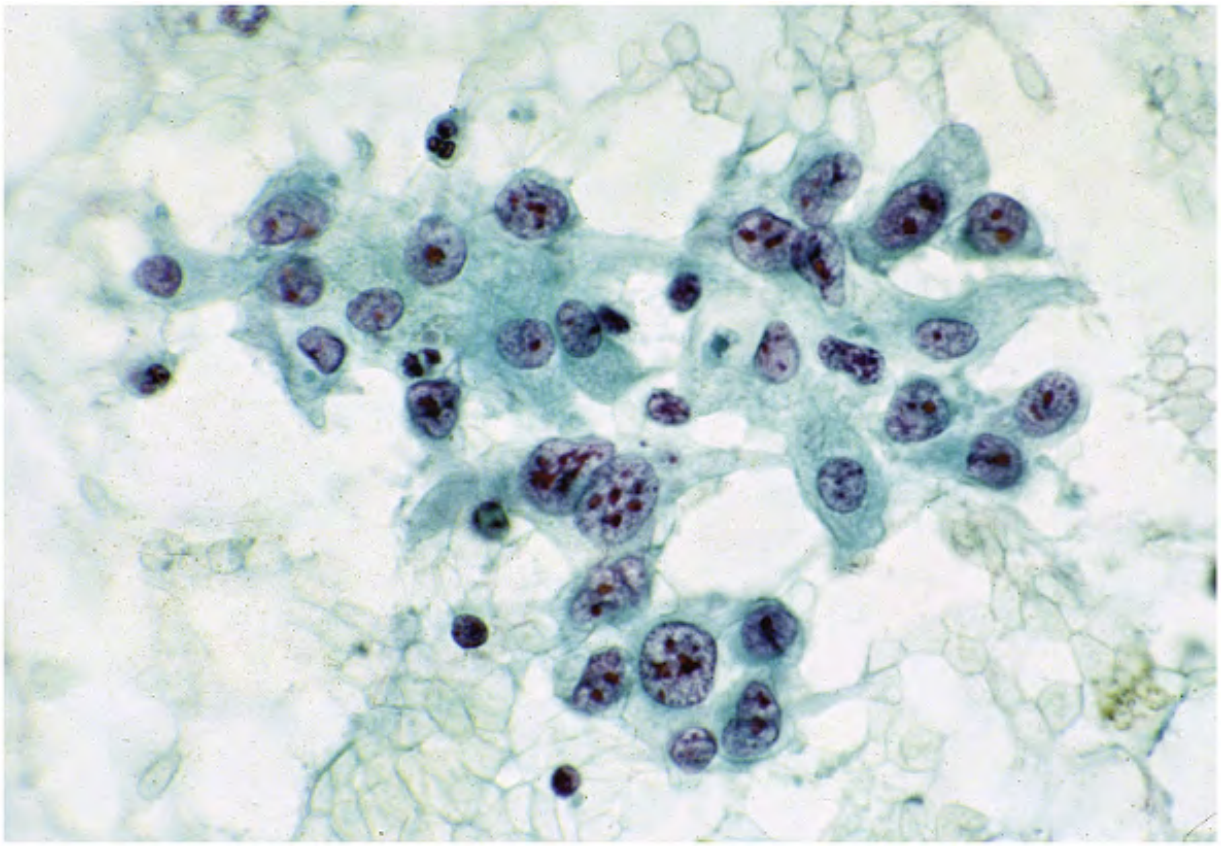

Figure 11.47. *Anaplastic carcinoma versus metastatic malignancy* . FNA of a poorly differentiated metastatic adenocarcinoma of the lung presenting as a thyroid nodule. In the absence of benign follicular cells in the background, these cells must be differentiated from anaplastic thyroid carcinoma.

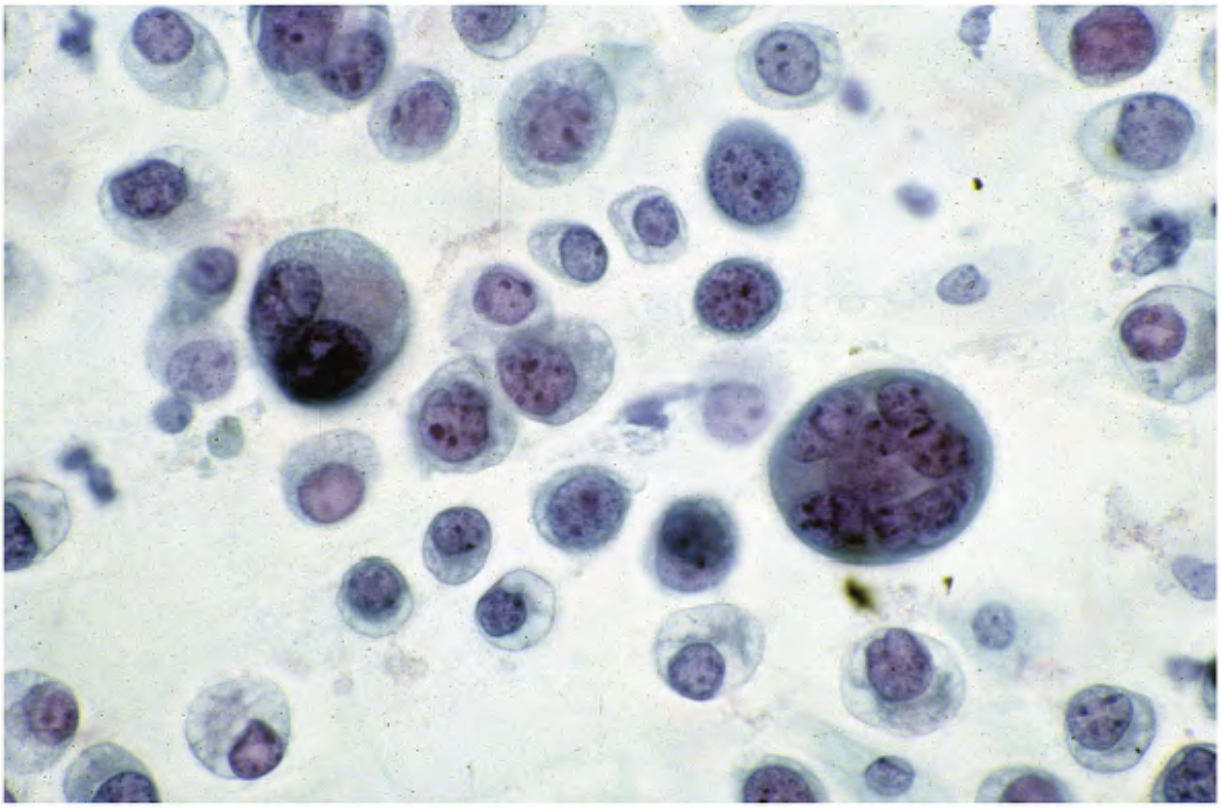

Figure 11.48. *Anaplastic carcinoma versus metastatic malignancy* . Another example of a p differentiated adenocarcinoma of the lung metastatic to the thyroid.

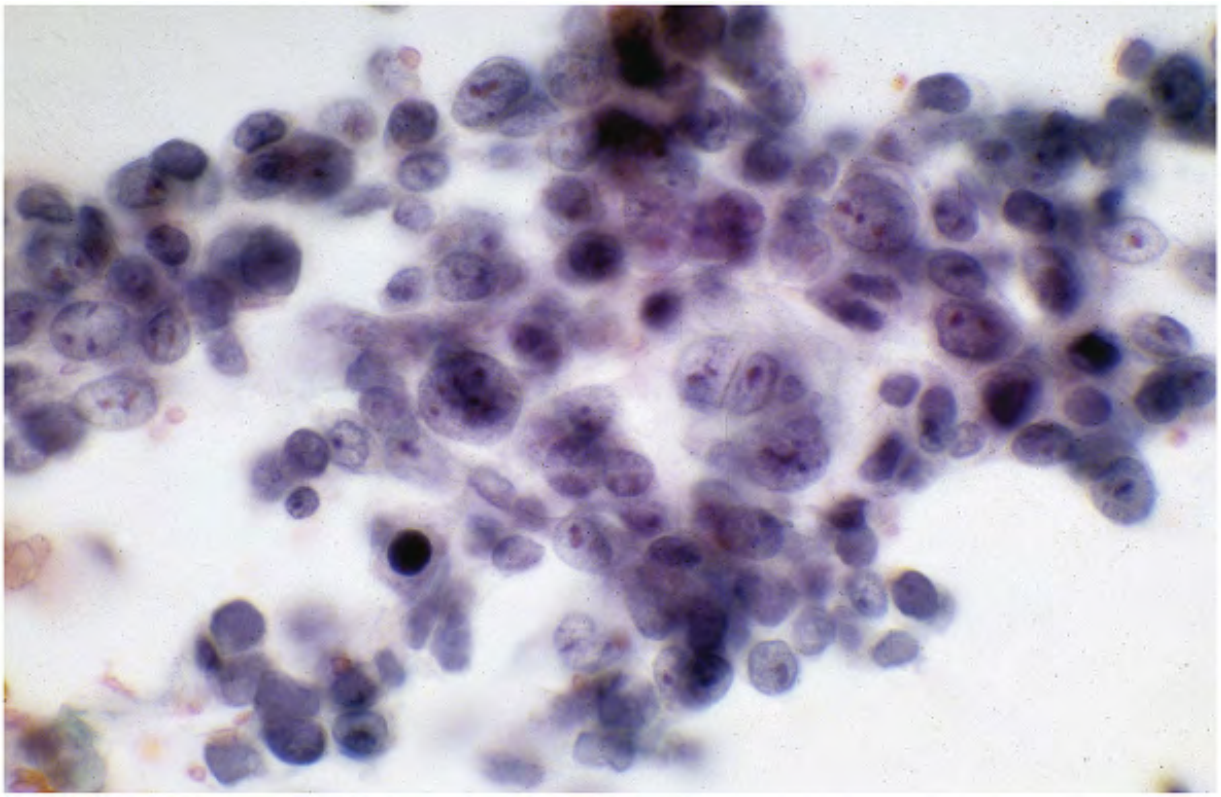

Figure 11.49. *Anaplastic carcinoma versus metastatic malignancy* . Poorly differentiated metastatic squamous cell carcinoma presenting as a solitary nodule. From cytology alone, th poorly differentiated malignant cells cannot be differentiated from anaplastic thyroid carcinoma. The patient had a history of squamous carcinoma of the upper aerodigestive tra

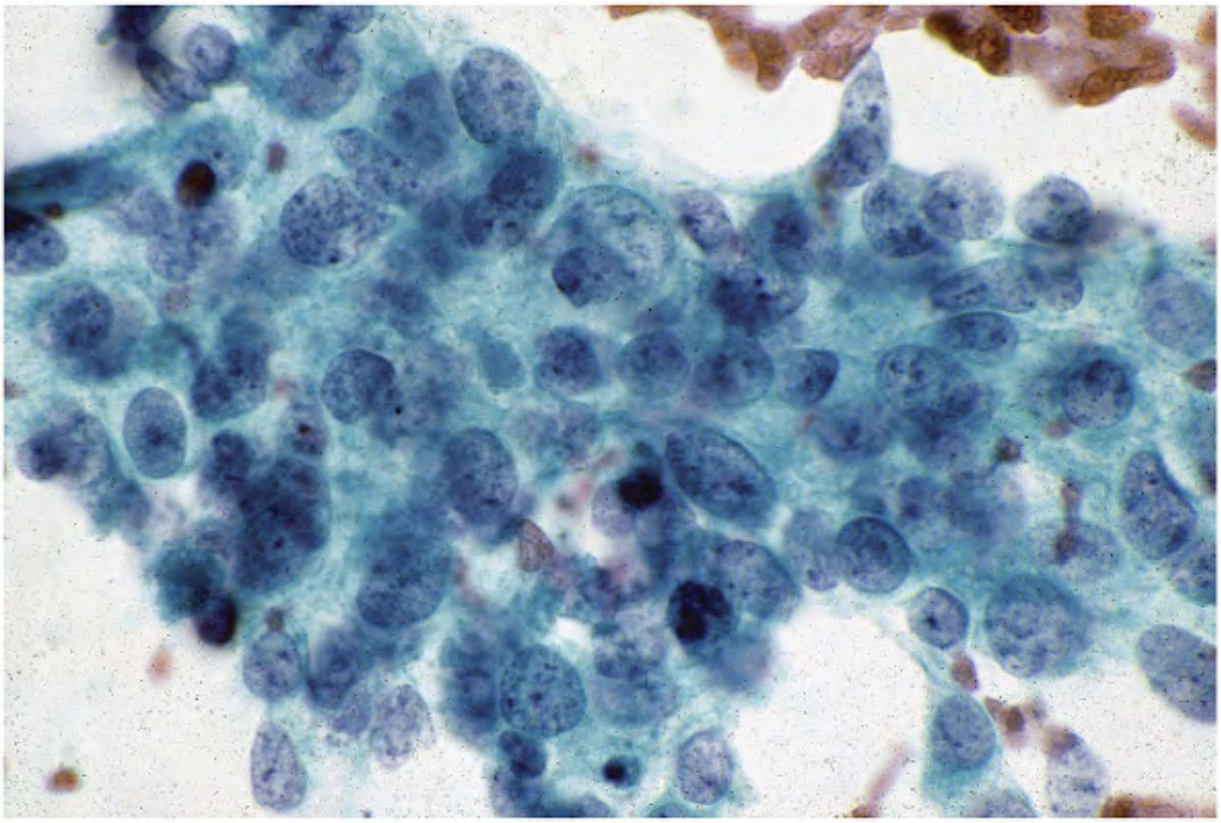

Figure 11.50. *Anaplastic carcinoma versus metastatic malignancy* . Poorly differentiated squamous carcinoma of the esophagus extending into and infiltrating the thyroid clinically presenting as a thyroid mass. FNA biopsy depicting pleomorphic malignant cells with no cytoplasmic differentiation.

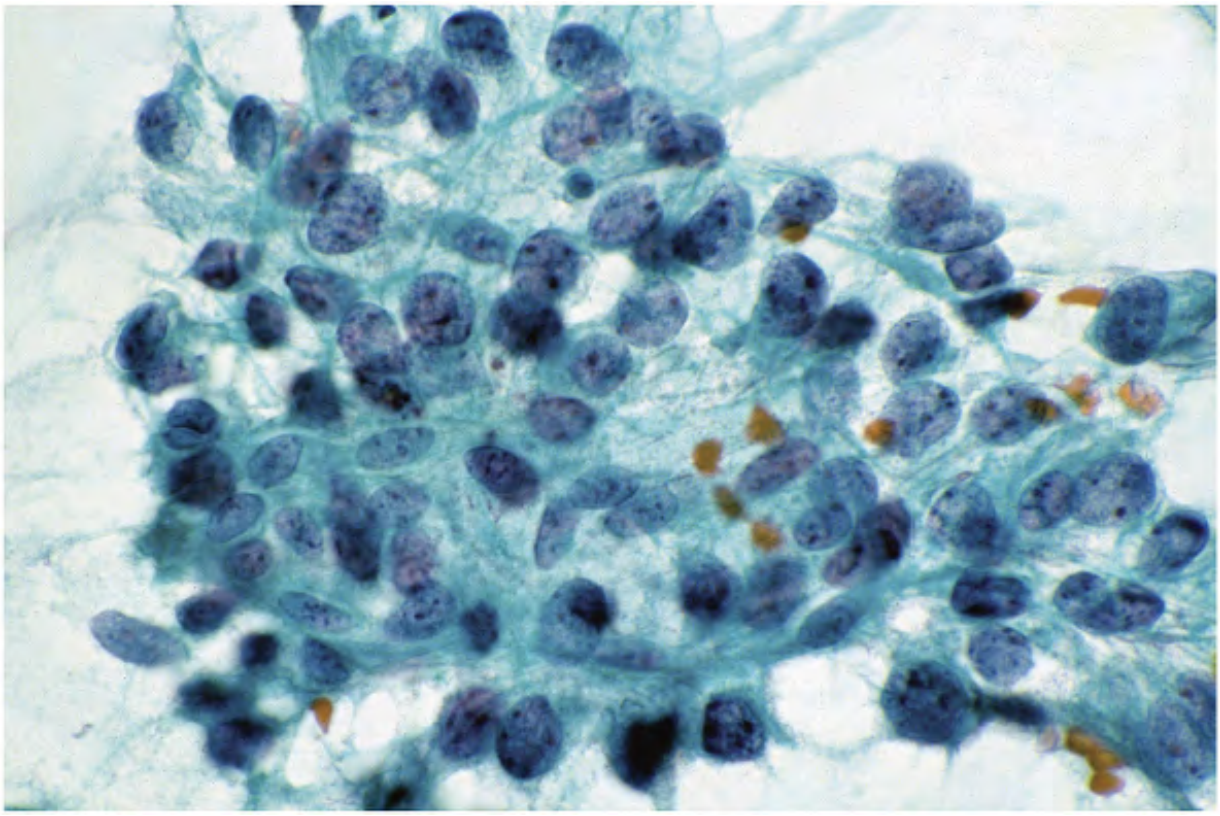

Figure 11.51. *Anaplastic carcinoma versus metastatic malignancy* . FNA of a carcinosarcom the esophagus infiltrating into the thyroid, presenting primarily as a thyroid mass. A combin of spindle-shaped and large round malignant cells suggested the diagnosis of anaplastic thyr carcinoma. Further workup identified the esophageal primary.

Anaplastic Carcinoma versus Malignant Melanoma

Malignant melanoma commonly metastasizes to the thyroid. Melanin pigment and a history o melanoma allow accurate diagnosis. The problem arises when the melanoma cells are amelanotic and cytologically difficult to separate from anaplastic thyroid carcinomas (Fig. 1).

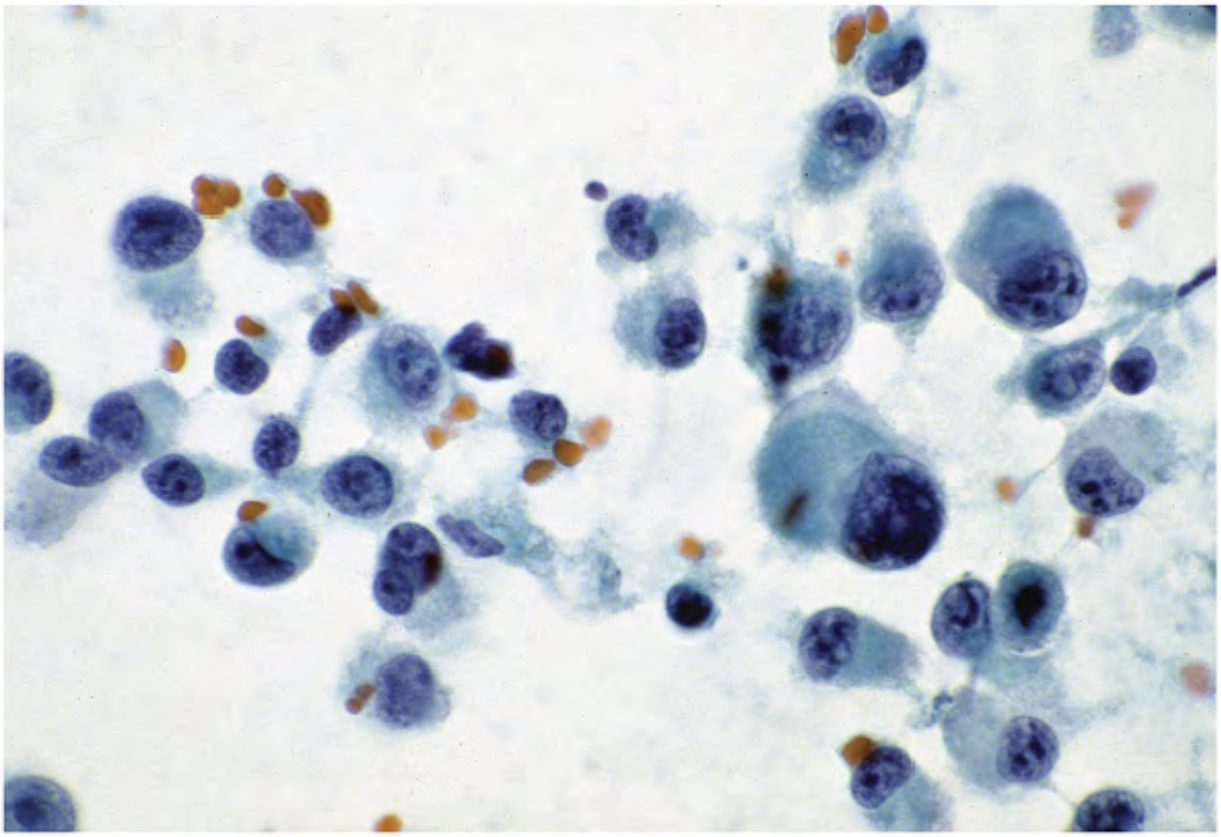

Figure 11.52. *Anaplastic carcinoma versus metastatic malignant melanoma* . FNA of metast melanoma to the thyroid. Melanoma cells can be very pleomorphic with bizarre nuclei. In th absence of melanin pigment, melanoma cells cannot be differentiated from anaplastic carcinoma cells without the aids of ancillary tests.

Anaplastic Carcinoma versus Malignant Lymphoma

Anaplastic carcinomas are known for their wide spectrum of cytomorphology. One of the patterns include small to medium-sized cells with scant cytoplasm and high N/C ratios,

a pattern difficult to differentiate from that of a large cell malignant lymphoma (Fig. 11.53 Shvero and co-workers39 reclassified 3 of 26 anaplastic carcinomas as malignant lymphomas Ancillary tests such as immunostains and flow cytometry are necessary to establish a correct diagnosis.

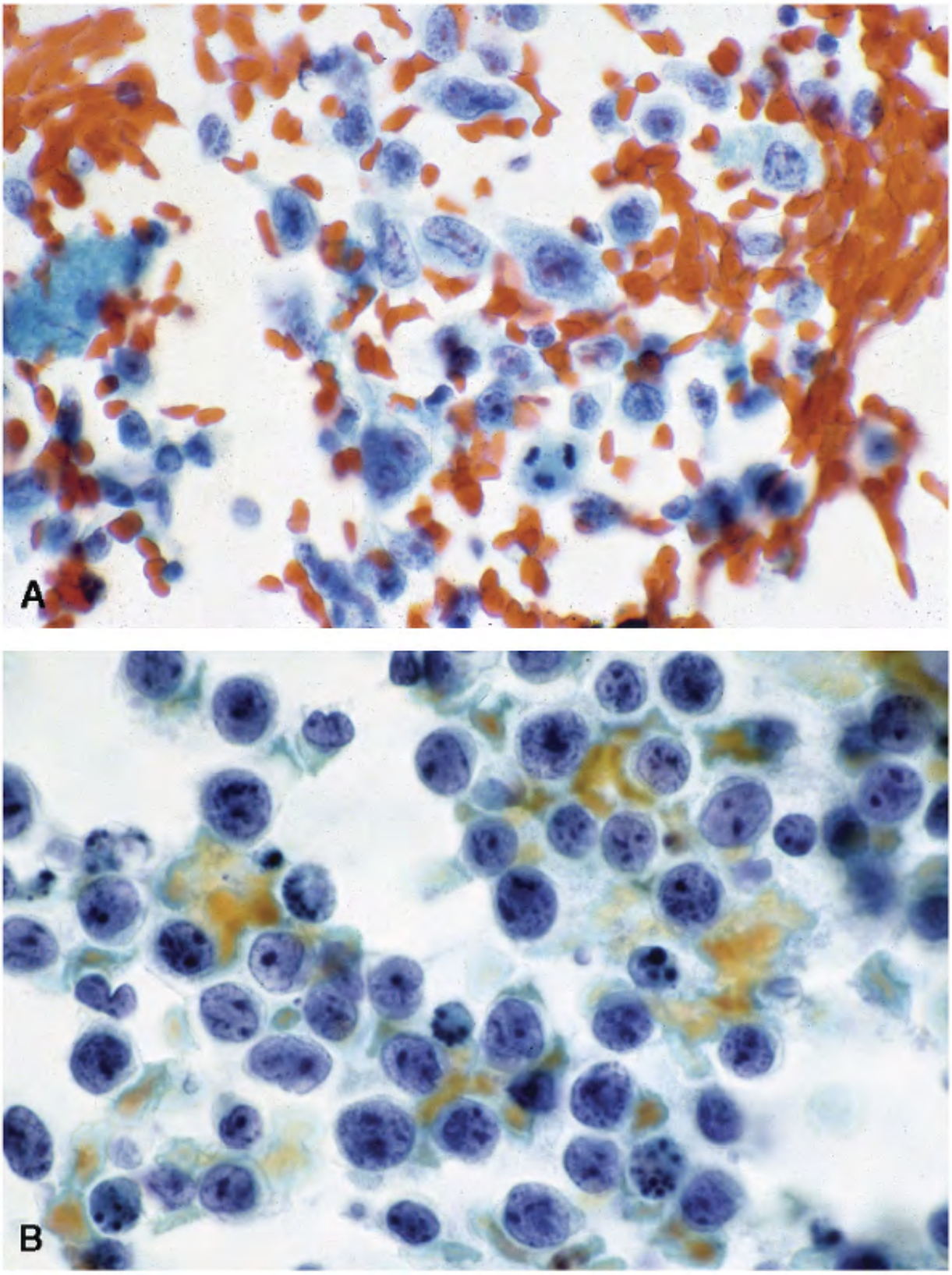

Figure 11.53. *Anaplastic carcinoma versus malignant lymphoma* . A,B. Two separate examp

of large cell malignant lymphomas of the thyroid. These discrete large lymphoma cells must differentiated from anaplastic carcinoma by immunostains and flow cytometry.

Anaplastic Carcinoma versus Soft-Tissue Sarcomas (Primar and Secondary)

Anaplastic carcinomas with a spindle cell pattern simulate cytologic features of soft-tissue malignancy, both primary and secondary. Shvero et al.39 reclassified 1 of 26 cases of anapla carcinoma as hemangioendothelioma. Primary soft-tissue sarcomas of the thyroid are extrer rare. A history of sarcoma is helpful for proper cytologic evaluation (Figs. 11.54 and 11.55).

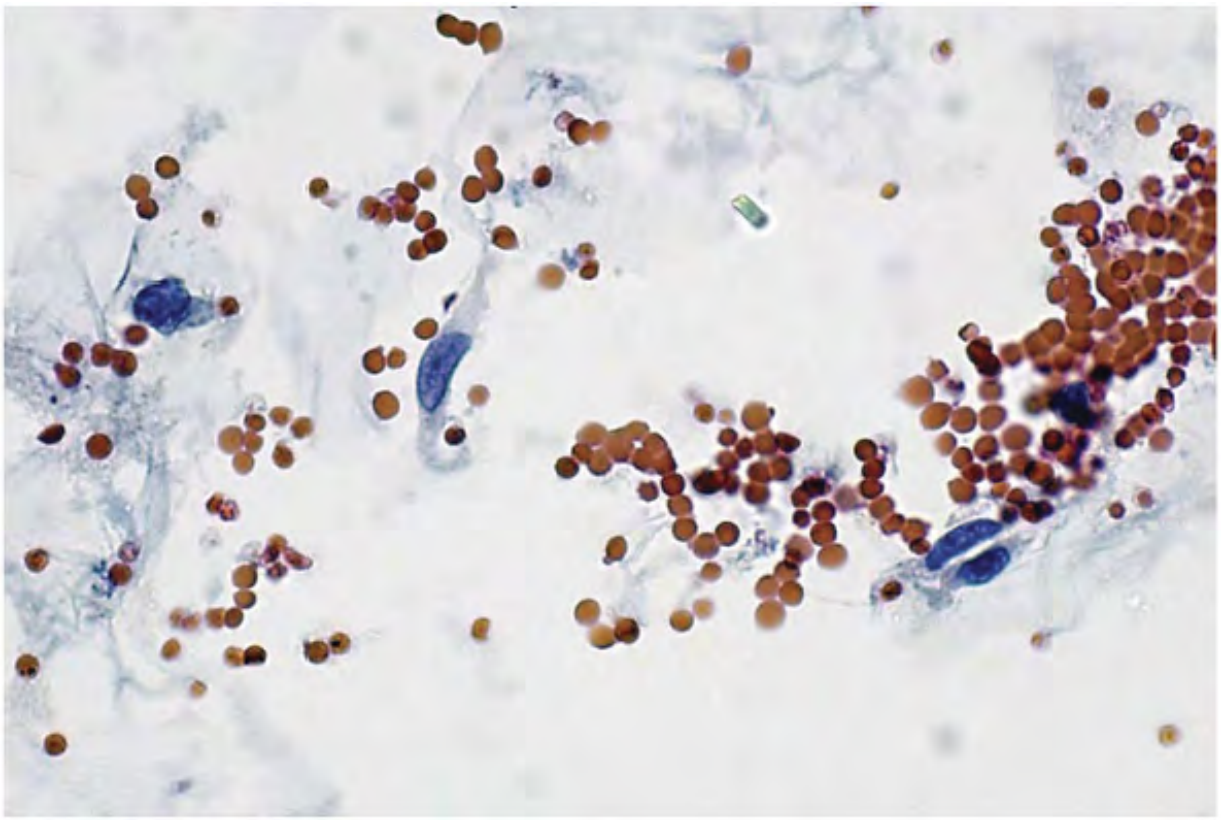

Figure 11.54. *Anaplastic carcinoma versus soft-tissue tumors (primary and metastatic)* . FN a metastatic retroperitoneal malignant fibrous histiocytoma. The isolated spindle-shaped ce mimic the cytologic pattern of a paucicellular anaplastic carcinoma.

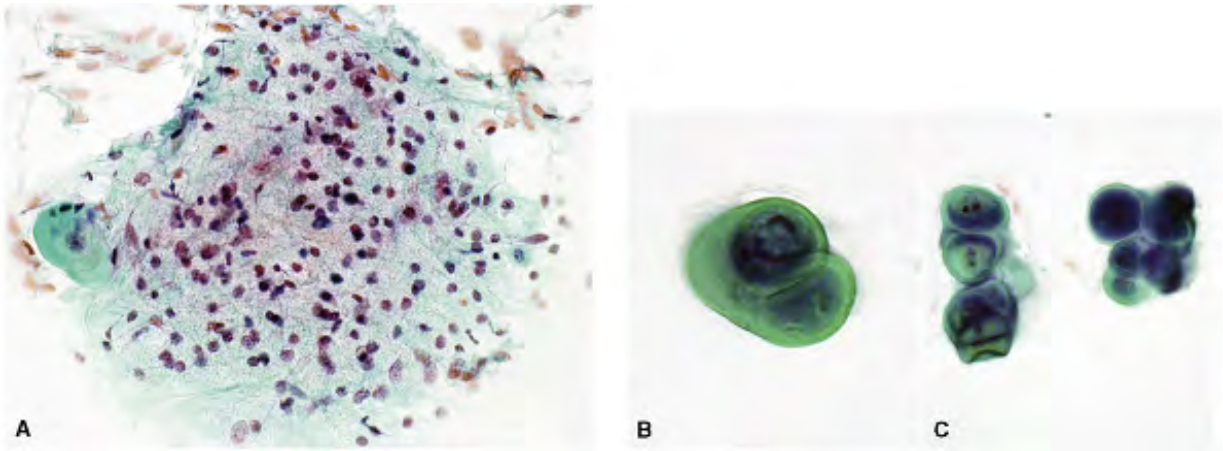

Figure 11.55. *Anaplastic carcinoma versus soft-tissue tumors (primary and metastatic)* . FN
a laryngeal chondrosarcoma clinically presenting as a thyroid nodule. A. Delicate spindle ce
a myxoid stroma. B,C. Bizarre, pleomorphic giant malignant cells with dense cytoplasm stro
resemble an anaplastic carcinoma. The excision confirmed a chondrosarcoma.

SUMMARY

Anaplastic or undifferentiated carcinoma of the thyroid is one of the most lethal malignanci
which follows a rapid, aggressive course with fatal outcome. The cytologic features are easi
recognized, causing no diagnostic problems. However, many other poorly differentiated
neoplasms and non-neoplastic disease entities may be cytologically mistaken for anaplastic
carcinoma. Anaplastic carcinomas usually do not react to thyroglobulin antibodies, but do r
to cytokeratin.

REFERENCES

1.Ordonez N, Baloch ZW, Matias-Guiu X, et al. Undifferentiated (anaplastic) carcinoma. Ir
DeLellis RA, Lloyd RV, Heitz PU, et al., eds. *Pathology and Genetics of Tumors of Endocri*
Organs . World Health Organization Classification of Tumors. Lyon: IARC Press;
2004;77â€“81.

2.Giuffrida D, Gharib H. Anaplastic thyroid carcinoma: current diagnosis and treatment. *A*
Oncol . 2002;11:1083â€“1089.

3.McIver B, Hay ID, Giuffrida D, et al. Anaplastic thyroid carcinoma: a 50-year experience a single institution. *Surgery* . 2001;130:1028â€“1034.

4.Nilson O, Lindsberg JI, Zedenius J, et al. Anaplastic giant cell carcinoma of the thyroid gland: treatment and survival over a 25-year period. *World J Surg* . 1998;22:725â€“730.

5.Lo CY, Lam KY, Wan KY. Anaplastic carcinoma of the thyroid. *Am J Surg* . 1999;177:337â€“339.

6.Rosai J, Carcangiu ML, DeLellis RA. Tumors of the thyroid gland. *Atlas of Tumor Patholo* . Fascicle 5, 3rd series. Washington, DC: Armed Forces Institute of Pathology; 1993.

7.Venkatesh YSS, Ordonez NG, Schultz PN, et al. Anaplastic carcinoma of the thyroid. A clinicopathologic study of 121 cases. *Cancer* . 1990;66:321â€“330.

8.Carcangiu ML, Steeper T, Zampi G, et al. Anaplastic thyroid carcinoma. A study of 70 cases. *Am J Clin Pathol* . 1985;83:135â€“158.

9.Nel CJC, Van Heerden JA, Goellner JR, et al. Anaplastic carcinoma of the thyroid: a clinicopathologic study of 82 cases. *Mayo Clin Proc* . 1985;60:51â€“58.

10.Kapp DS, LiVolsi VA, Sanders ME. Anaplastic carcinoma: etiological considerations. *Yale Biol Med* . 1982;55:521â€“528.

11.McConahey WM, Taylor WF, Gorman CA, et al. Retrospective study of 820 patients treated for papillary carcinoma of the thyroid at the Mayo Clinic between 1946 and 1971. Andreoli M, Monaco F, Robbins J, eds. *Advances in Thyroid Neoplasia* . Rome: Field Educational Italia; 1981:245â€“262.

12.Aldinger KA, Samaan NA, Ibanez M, et al. Anaplastic carcinoma of the thyroid: a review of 84 cases of spindle and giant cell carcinoma of the thyroid. *Cancer* . 1978;41:2267â€“2275.

13.Esmaili JM, Hafez GR, Warner TFCS. Anaplastic carcinoma of the thyroid with osteoclas like giant cells. *Cancer* . 1983;52: 2112â€“2128.

14.Hashimoto H, Koga S, Watanabe H, et al. Undifferentiated carcinoma of the thyroid gla with osteoclast-like giant cells. *Acta Pathol Jpn* . 1980;30:323â€“334.

15.Brooke PK, Hameed M, Zakowski M. Fine needle aspiration of anaplastic thyroid carcinoma with varied cytologic and histologic patterns. A case report. *Diagn Cytopathol* . 1994;11:60â€“63.

16.Vinette DSJ, MacDonald LL, Yazdi HM. Papillary carcinoma of the thyroid with anaplast transformation: diagnostic pitfalls in fine-needle aspiration biopsy. *Diagn Cytopathol* . 1991;7:75â€“78.

17.Spires JR, Schwartz MR, Miller RH. Anaplastic thyroid carcinoma association with differentiated thyroid cancer. *Arch Otolaryngol Head Neck Surg* . 1988;114:40â€“44.

18.Wan S-K, Chan JKC, Tang SK. Paucicellular variant of anaplastic thyroid carcinoma. A mimic of Riedel's thyroiditis. *Am J Clin Pathol* . 1996;105:388â€“393.

19.Lai ML, Faa G, Serra S, et al. Rhabdoid tumor of the thyroid gland: a variant of anaplas carcinoma. *Arch Pathol Lab Med* . 2005;129:55â€“57.

20.Burt AD, Kerr DJ, Brown IL, et al. Lymphoid and epithelial markers in small cell anaplastic thyroid tumors. *J Clin Pathol* . 1985;38: 893â€“896.

21.Nishiyama RH, Dunn LL, Thompson NW. Anaplastic spindle cell and giant cell tumors of the thyroid gland. *Cancer* . 1972;30:113â€“127.

22.Cameron RG, Seemayer TA, Wang NS, et al. Small cell malignant tumors of the thyroid light and electron microscopic study. *Hum Pathol* . 1975;6:731â€“740.

23.Kruseman ACN, Bosman FT, Henegouw JCV, et al. Medullary differentiation of anaplast thyroid carcinoma. *Am J Clin Pathol* . 1982;77:541â€“547.

24.Meissner WA. Tumors of the thyroid gland. *Atlas of Tumor Pathology* . Fascicle 4, 2nd series. Supplement. Washington, DC: Armed Forces Institute of Pathology; 1984.

25.Rayfield EJ, Nishiyama RH, Sisson JC. Small cell tumors of the thyroid: a clinicopatholc study. *Cancer* , 1971;28:1023â€“1030.

26.Us-Krasovecs? M, Golouh R, Auersperg M, et al. Anaplastic thyroid carcinoma in fine needle aspirates. *Acta Cytol.* 1996;40:953â€“958.

27.Das DK, Gupta SK, Francis IM, et al. Fine-needle aspiration cytology diagnosis of non-Hodgkin's lymphoma of thyroid: a report of four cases. *Diagn Cytopathol* . 1993;9:639â€“6

28.Luze T, Totsch M, Banger I, et al. Fine needle aspiration cytology of anaplastic carcino and malignant hemangioendothelioma of the thyroid in an endemic goiter area. *Cytopathology* . 1990;1:305â€“310.

29.Guarda LA, Peterson CE, Hall W, et al. Anaplastic thyroid carcinoma: cytomorphology a clinical implications of fine-needle aspiration. *Diagn Cytopathol* . 1991;7:63â€“67.

30.Schneider V, Frable WJ. Spindle and giant cell carcinoma of the thyroid. *Acta Cytol* . 1980;24:184â€“189.

31.Lai ML, Faa G, Serra S, et al. Rhabdoid tumor of the thyroid gland: a variant of anaplas carcinoma. *Arch Pathol Lab Med* . 2005;129:55â€“57.

32.Kumar PV, Torabinejad S, Omrani GH. Osteoclastoma-like anaplastic carcinoma of the thyroid gland diagnosed by fine needle aspiration cytology. Report of two cases. *Acta Cyto*

1997;41:1345â€“1348.

33.Berry B, Macfarlane J, Chan N. Osteoclastoma-like anaplastic carcinoma of the thyroid Diagnosis by FNA cytology. *Acta Cytol* . 1990;34:248â€“250.

34.Lee JS, Lee MC, Park CS, et al. Fine needle aspiration cytology of anaplastic carcinoma with osteoclast-like giant cells of the thyroid. A case report. *Acta Cytol* . 1996;40:1309â€“1312.

35.Willems JS, LÃ¶whagen T, Palombini L. The cytology of giant cell osteoclastoma-like malignant thyroid neoplasm: A case report. *Acta Cytol* . 1979;23:214â€“216.

36.Deshpande AH, Munshi MM, Bobhate SK. Cytological diagnosis of paucicellular variant o anaplastic carcinoma of thyroid: report of two cases. *Cytopathology* . 2001;12:203â€“208.

37.Mai DD, Mai KT, Shamji FM. Fine needle aspiration biopsy of anaplastic carcinoma developing from a HÃ¼rthle cell tumor: a case report. *Acta Cytol* . 2001;45:761â€“764.

38.Bauman ME, Tao L-C. Cytopathology of papillary carcinoma of thyroid with anaplastic transformation. A case report. *Acta Cytol.* 1995;39:525â€“529.

39.Shvero J, Gal R, Avidor I, et al. Anaplastic carcinoma: a clinical, histologic and immunohistochemical study. *Cancer* . 1988;62: 319â€“325.

40.Ordonez NG, El-Naggar AK, Hickey RC, et al. Anaplastic thyroid carcinoma. Immunocytochemical study of 32 cases. *Am J Clin Pathol* . 1991;96:15â€“24.

41.Albores-Saavedra J, Nadji M, Civantos F, et al. Thyroglobulin in anaplastic carcinoma o the thyroid: an immunohistochemical study. *Hum Pathol* . 1983;14:62â€“66.

42.Livolsi VA, Brooks JJ, Arendash-Durand B. Anaplastic thyroid tumors Immunohistology.

J Clin Pathol . 1987:434â€“442.

43.Burt AD, Kerr DJ, Brown IL, et al. Lymphoid and epithelial markers in small cell anaplastic thyroid tumors. *J Clin Pathol* , 1985;38:893â€“896.

44.Mambo NC, Irwin S. Anaplastic small cell neoplasm of the thyroid: an immunoperoxidas study. *Hum Pathol* . 1964;15:55â€“60.

45.Miller JM, Kini SR, Hamburger JI. *Needle Biopsy of the Thyroid* . New York: Praeger; 1983.

46.Anderson RJ, Pragasam PJ, Nazar T. Atypical, retrogressive and metaplastic changes in nodular goiters. Potential pitfalls in aspiration cytology of the thyroid. *Acta Cytol* . 1990;3 715Aâ€“716A.

Editors: Kini, Sudha R.
Title: *Thyroid Cytopathology: A Text and Atlas, 1st Edition*

Copyright Â©2008 Lippincott Williams & Wilkins

12

Medullary Carcinoma

Medullary carcinoma of the thyroid arises from the calcitonin-producing "C-cells," "parafollic cells," or "clear cells."1 In 1951, Horn2 recognized this thyroid carcinoma as a distinct and separate entity from other differentiated carcinomas by noting the differences in histologic patterns and their biologic behavior. Hazard et al.3 identified the amyloid in the stroma of neoplasm and coined the term *medullary carcinoma* . Williams,1 later in 1965, identified th cell of origin. A considerable interest in this tumor, leading to extensive studies and advanc understanding the pathogenesis of medullary carcinoma, followed this observation.4 , 5 , 6 8 , 9 , 10 , 11 , 12 , 13 , 14 , 15 , 16 , 17 , 18

Medullary carcinoma comprises 3% to 10% of all thyroid malignancies.4 , 5 , 6 It occurs in tw forms; roughly 20% are familial forms and the remaining are sporadic forms. The hereditary of medullary carcinoma, transmitted as an autosomal dominant trait, includes three types: IIA, MEN IIB, and non-MEN familial type. The MEN II syndromes are associated with tumors o other endocrine organs.4 , 5 , 6 , 15 , 16 , 17

The sporadic form of medullary carcinoma occurs more commonly in women, primarily in th older individuals with the mean age of 5 to 6 decades. They clinically present as a unilatera palpable nodule and have a high incidence (up to 50%) of cervical lymph node metastases.6 Distant metastases via hematogenous spread to liver, lungs, bone, and occasionally to brain occur in roughly 15% of the cases. Occult medullary carcinomas with local metastatic diseas involving the cervical lymph nodes have been described.7

The familial forms are common in males and occur at a younger age. The non-MEN familial medullary carcinoma is slightly more common in women.5 Medullary carcinomas in general

project good clinical outcome, especially in sporadic forms. Aggressive clinical behavior wit fatal outcome is described in some hereditary forms.

Medullary carcinomas arise from C-cells, which originate from the neural crest via migration through the ultimobranchial body.1 The ultimobrancial body is located in the middle and up thirds of the lateral lobes, and so medullary carcinomas are only found in these locations an not in the isthmus or the extreme uppe r or lower thirds of the lateral lobes. C-cells are not visualized in routinely stained histologic or cytologic preparations.

The main secretory product of the C-cells is the hormone calcitonin, increased levels of whi serve as a sensitive marker for the presence of medullary carcinomas.1 , 18 C-cell hyperplas considered a precursor lesion for medullary carcinomas (Fig. 12.4).

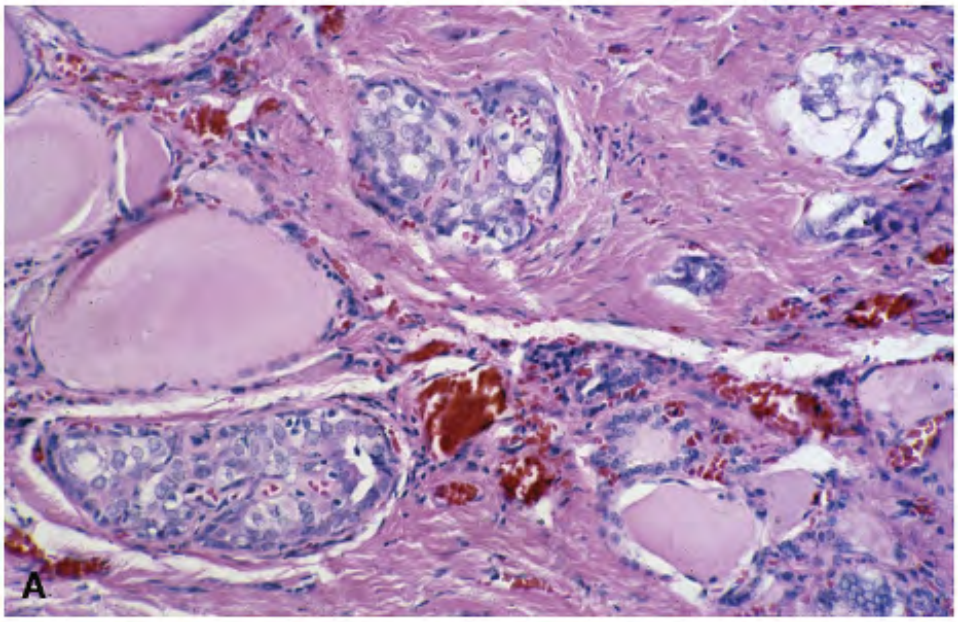

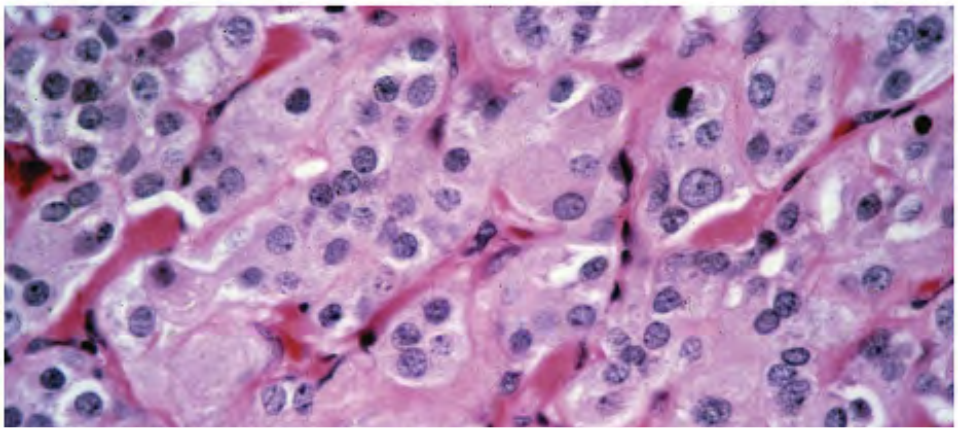

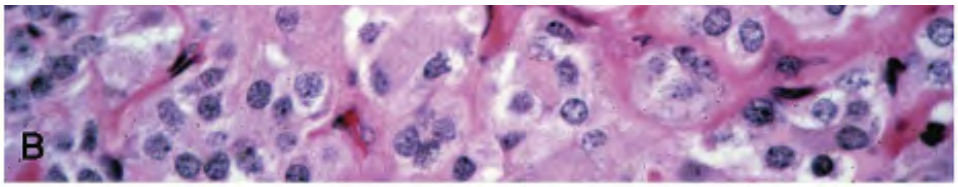

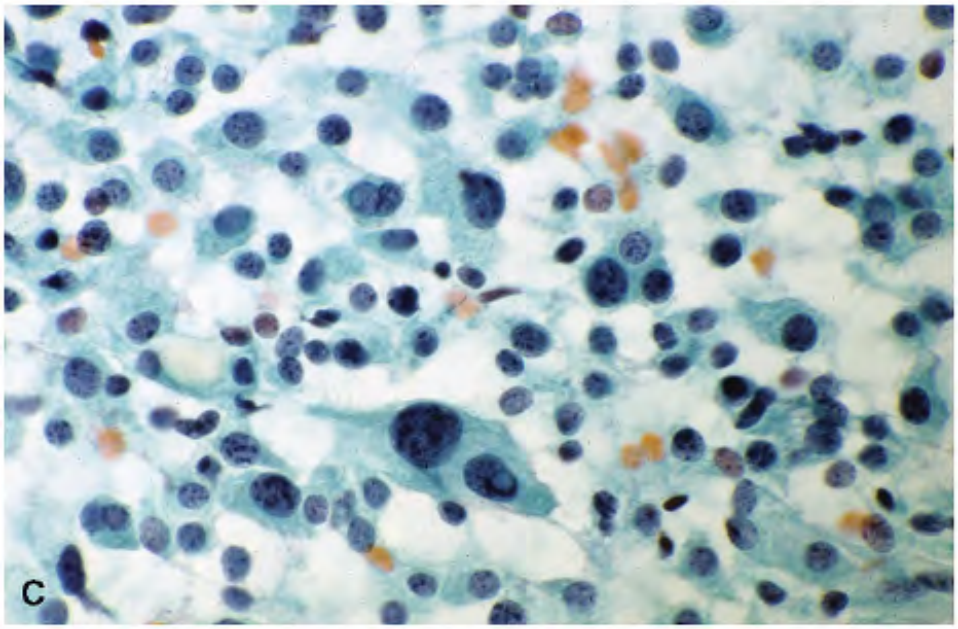

Figure 12.4. A. Histologic section of a thyroid demonstrating C-cell hyperplasia. Note well-defined nests of cuboidal to polygonal cells in between the thyroid follicles. There was no gı visible tumor. The patient had several members of the family with hereditary-type medullar carcinoma. B. Higher magnification. These cells have abundant eosinophilic cytoplasm. C. Imprint of the surgically resected specimen showing discrete C-cells with plasmacytoid appearance.

RADIOLOGIC FINDINGS

Medullary carcinomas present as hypofunctioning cold nodules. The plain x-rays of the neck show dense calcification. Ultrasound shows hypoechoic mass. Imaging with ultrasonography using^{131} I metaiodobenzylguanidine (MIBG) demonstrates a positive uptake and is a useful diagnostic tool.5

Gross and Histologic Features

The sporadic form of medullary carcinoma occurs as a unilateral, well-defined, nonencapsul solitary nodule variable in size, ranging from less than 1 cm to several centimeters and may replace the entire lobe (Figs. 12.1 and 12.2). Its cut surface is tan-white to gray or pink, us flat. The consistence is soft to firm, at times gritty, and without areas of hemorrhage and necrosis. Calcification may be present. The hereditary forms are usually multifocal and bila (Fig. 12.3).

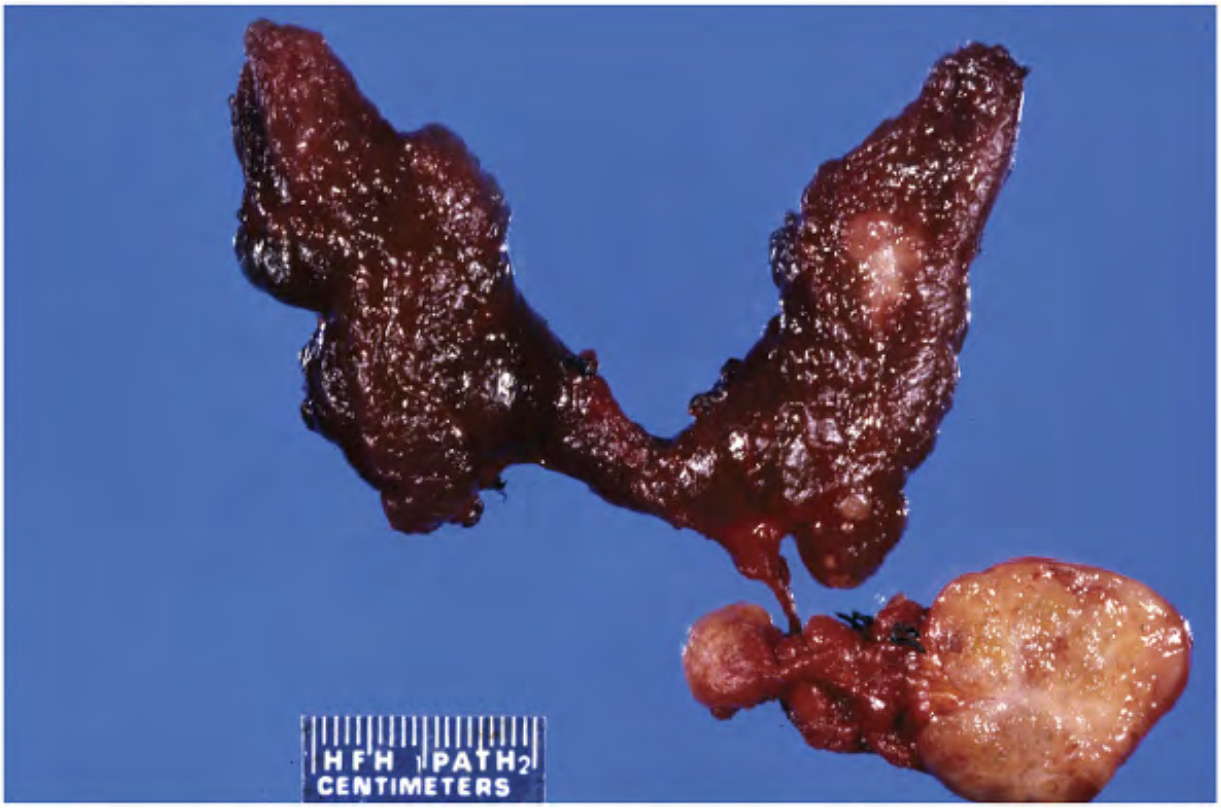

Figure 12.1. A gross photograph of a nonfamilial (sporadic) form of medullary thyroid carcir located in the middle third of the lobe and lymph node metastasis.

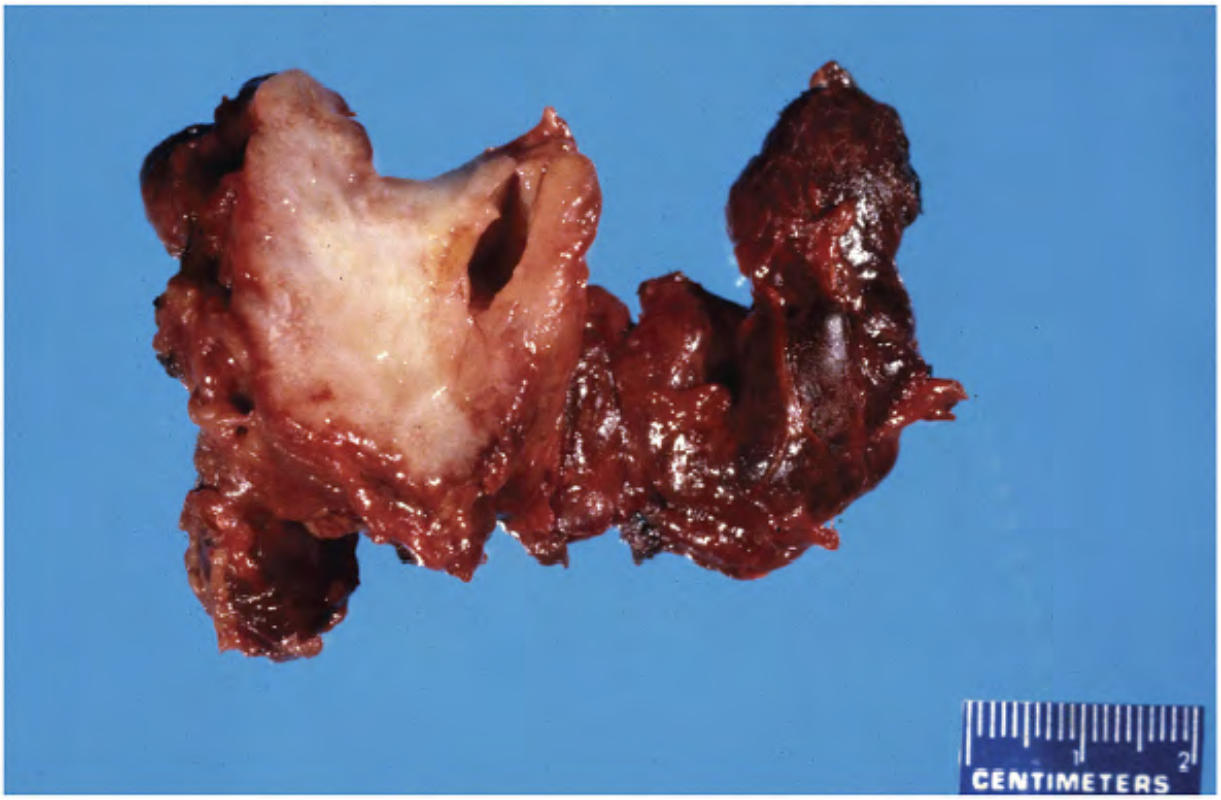

Figure 12.2. This nonfamilial medullary carcinoma is large, replacing the entire right lobe. tumor presents a flat cut surface.

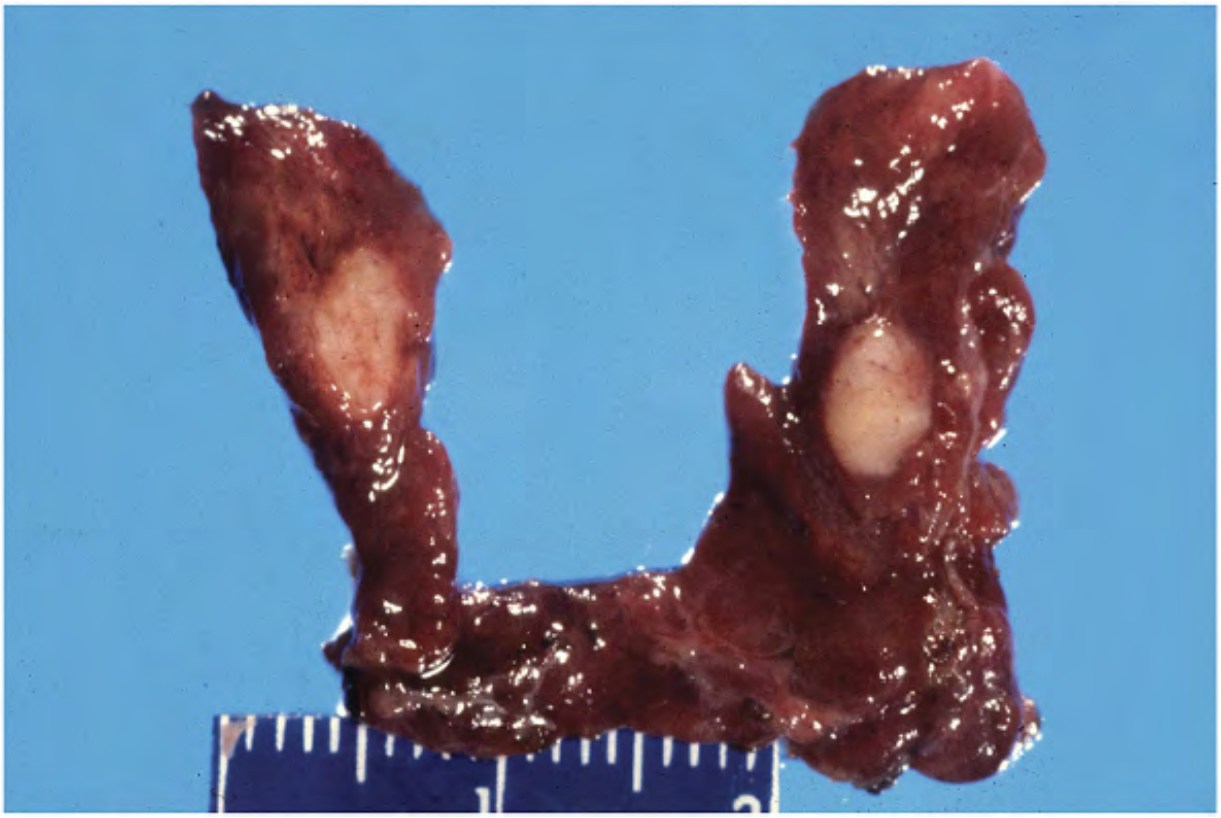

Figure 12.3. An example of hereditary medullary carcinoma. Note that the tumor is located the middle third of the lobe and bilateral.

The histologic spectrum of medullary carcinoma is extremely wide and varies from tumor to tumor and within the same tumor, often mimicking other types of follicular cellâ€“derived tumors such as follicular, papillary, insular, HÃ¼rthleâ€“cell, or anaplastic carcinomas (Figs 12.5 , 12.6 , 12.7 , 12.8 , 12.9 , 12.10 , 12.11 , 12.12 , 12.13 , 12.14 , 12.15 , 12.16 , 12.17 12.18 , 12.19 , 12.20 and 12.21).4 , 5 , 6 , 7 , 8 , 9 , 10 , 11 , 12 , 13 , 14 , 15 , 16 , 17 , 18 , 20 , 21 , 22 , 23 , 24 , 25 , 26 , 27 , 28 , 29 , 30 The histologic patterns are similar in both familial type and the sporadic type. Medullary carcinoma shows multiple growth patterns su lobular, insular, trabecular, solid, and rarely follicular or papillary. The spindle cells form fascicles, simulating a sarcomatous pattern. The nests of tumor cells vary in size, separated stromal tissue, imparting an organoid pattern. The cell types vary as well, and include small round to oval carcinoid-like cells, polygonal, or epithelioid, plasmacytoid to spindle shape, a vary considerably in size from small to large with occasional giant forms. Their cell borders well to poorly defined, and the cytoplasm varies from scant to abundant, clear,

pale to dense. Some may contain mucin.5 , 6 , 28 The nuclei are pleomorphic, round, oval, oblong to spindle shape with stippled to coarsely granular chromatin and sometimes contain cytoplasmic inclusions. Hemorrhage, necrosis, and mitotic activity are infrequent findings. A given tumor may show a predominant cell type or pattern; mixed patterns are more frequer with several cell types. However, a monomorphic pattern is also encountered.

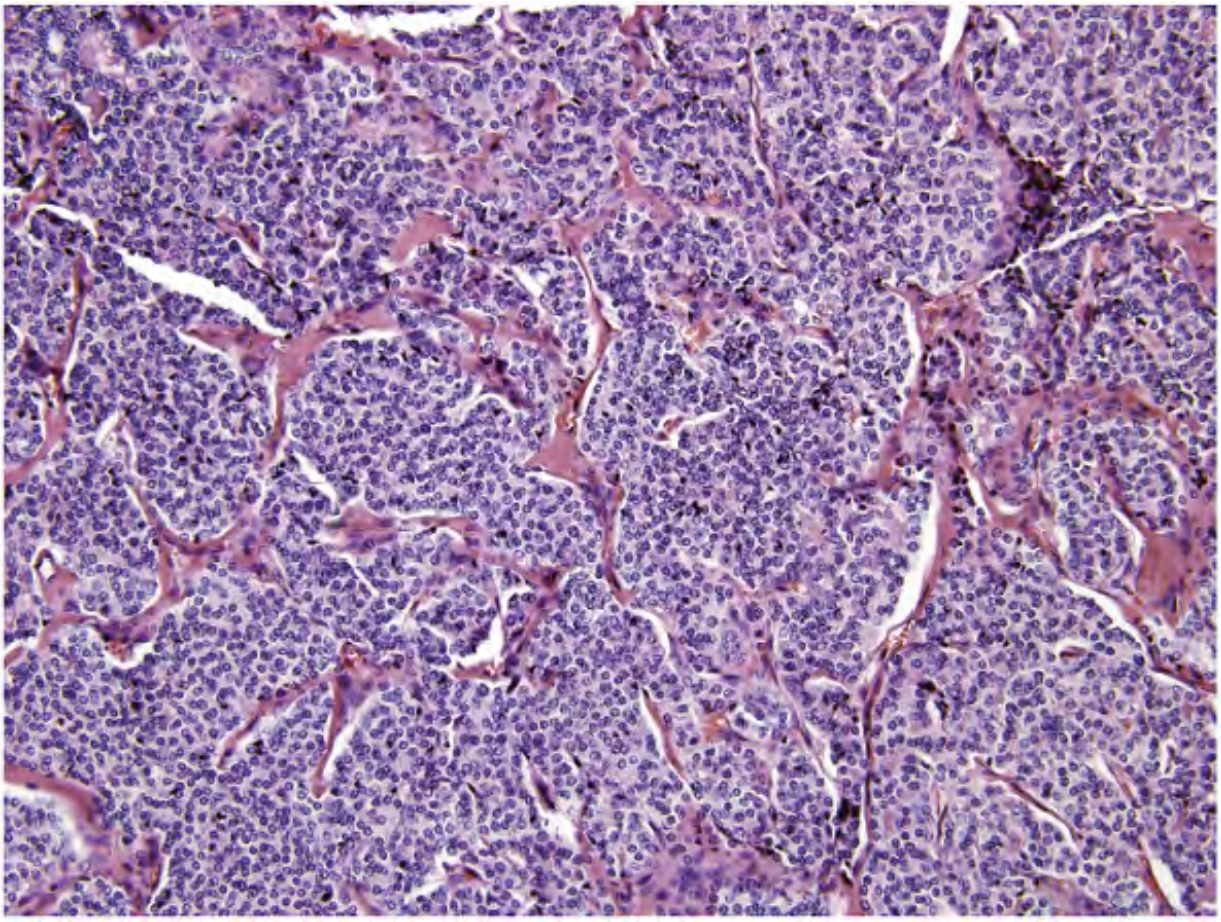

Figure 12.5. Medullary carcinoma showing a lobular growth pattern and is composed of sma round cells.

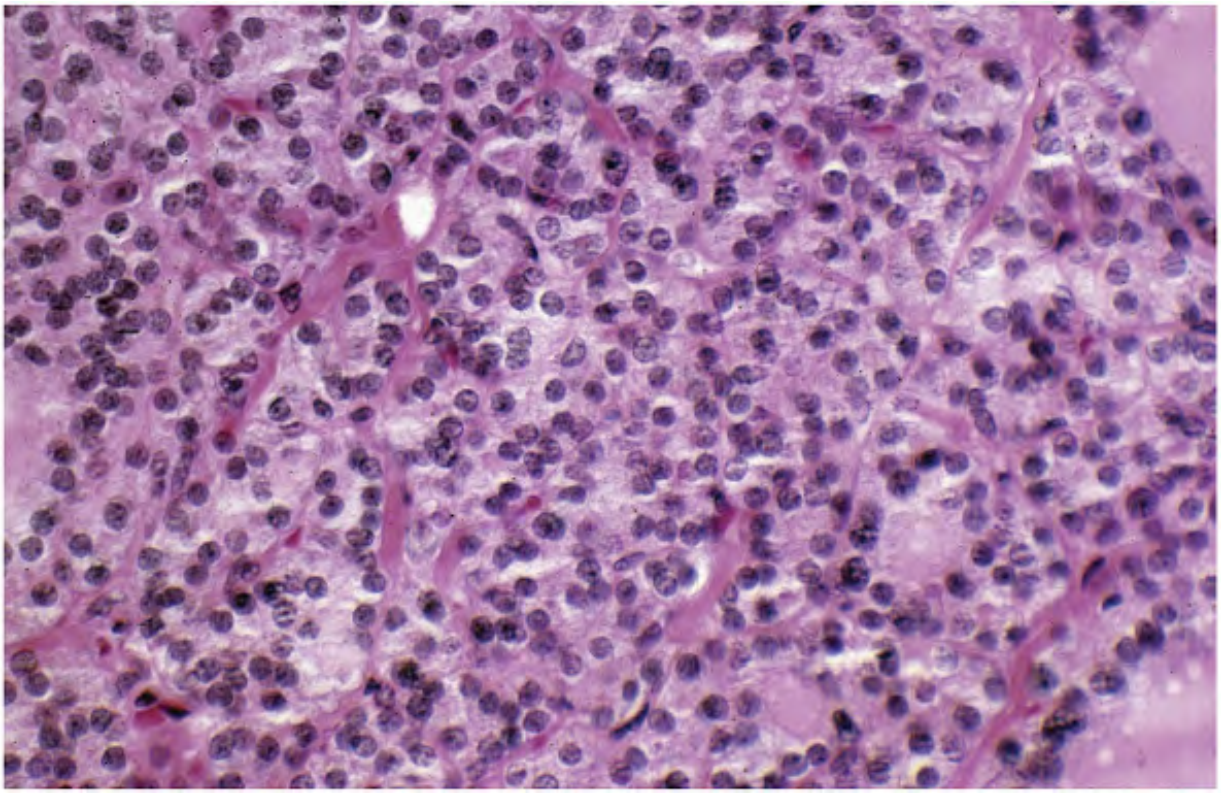

Figure 12.6. Medullary thyroid carcinoma showing a predominantly uniform, cuboidal cell pattern. The neoplastic cells have appreciable eosinophilic cytoplasm.

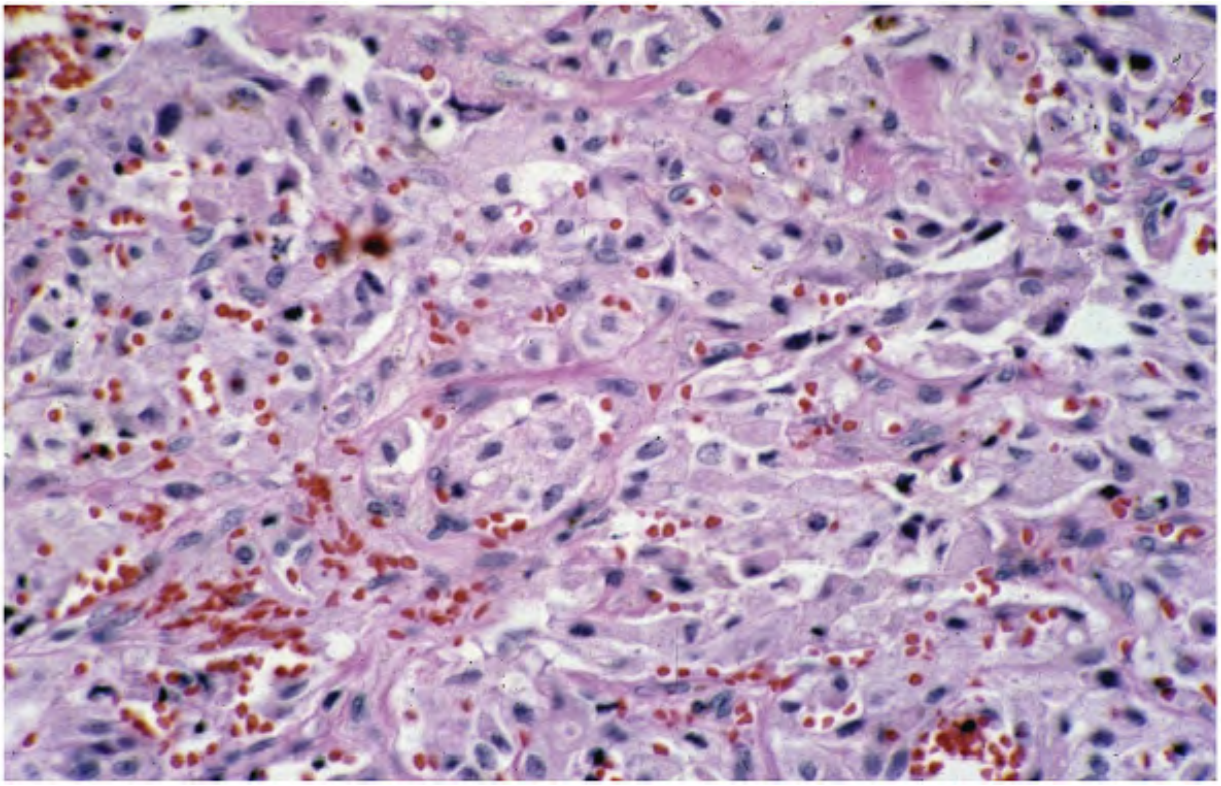

Figure 12.7. Medullary carcinoma is composed of large polygonal cells with abundant eosinophilic cytoplasm bearing a morphologic resemblance to oncocytes.

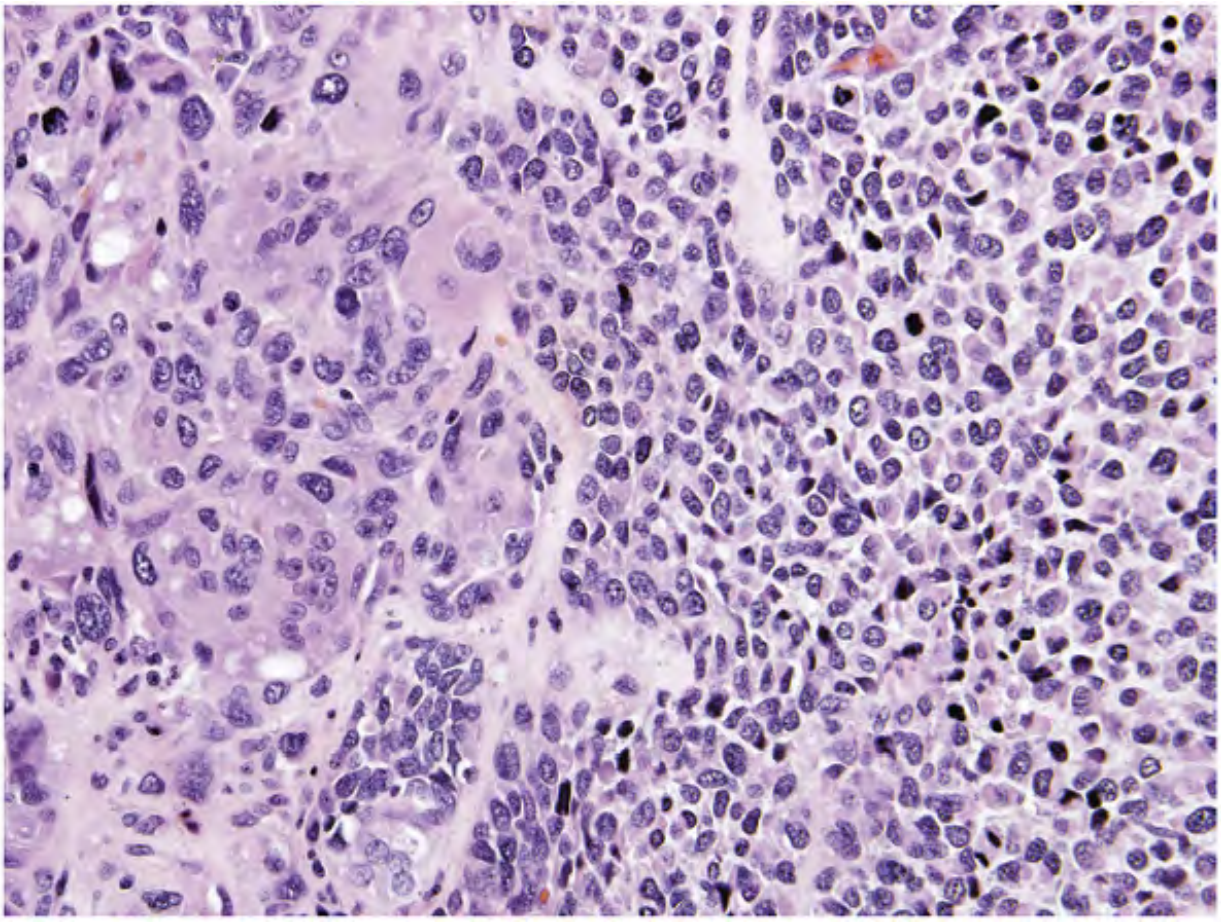

Figure 12.8. Medullary thyroid carcinoma. The left half of the section shows tumor compose large polygonal cells with abundant eosinophilic cytoplasm, while the rest consists of smalle round to cuboidal cells.

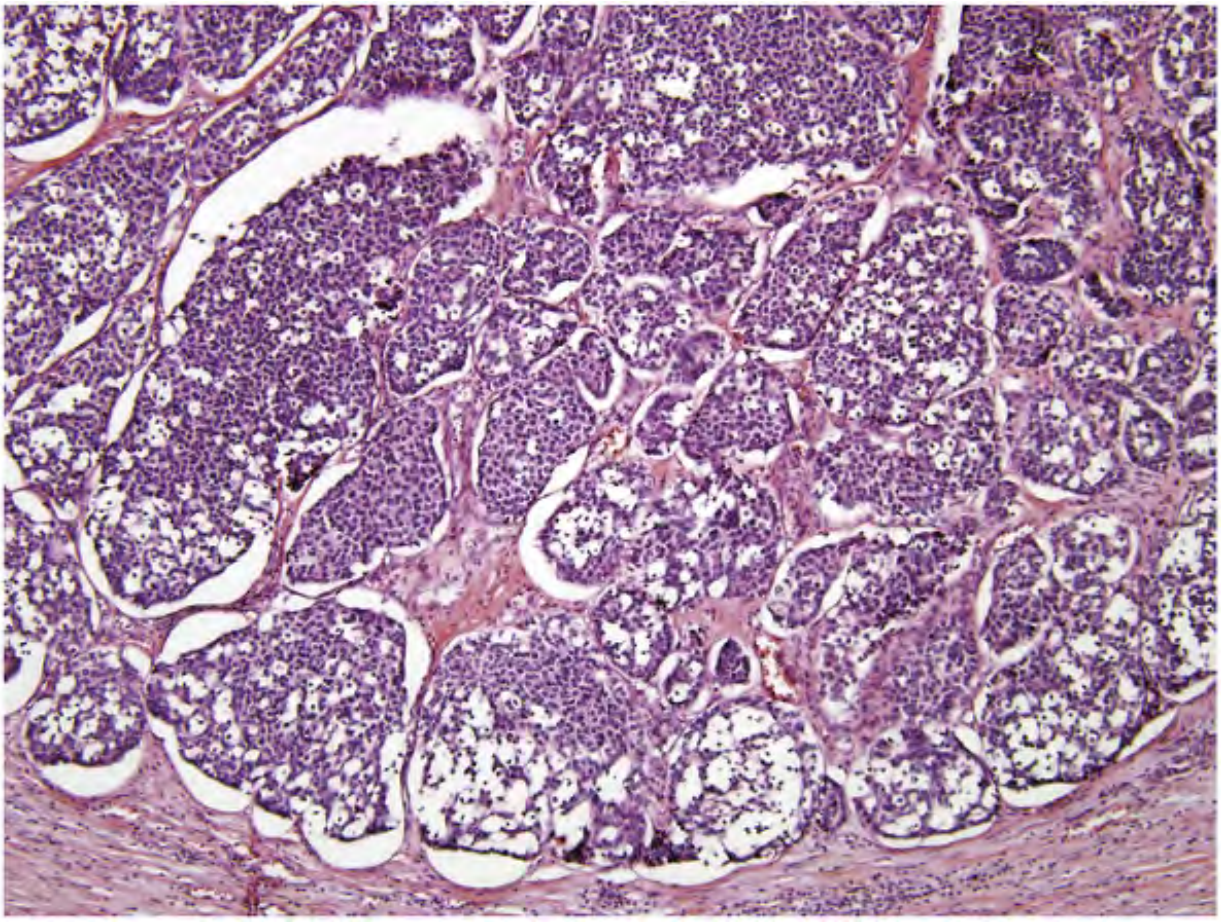

Figure 12.9. Histologic section of a medullary carcinoma showing a lobular pattern. The lob vary in size, separated by bands of fibrous tissue septae. Also note clear change in the cytoplasm.

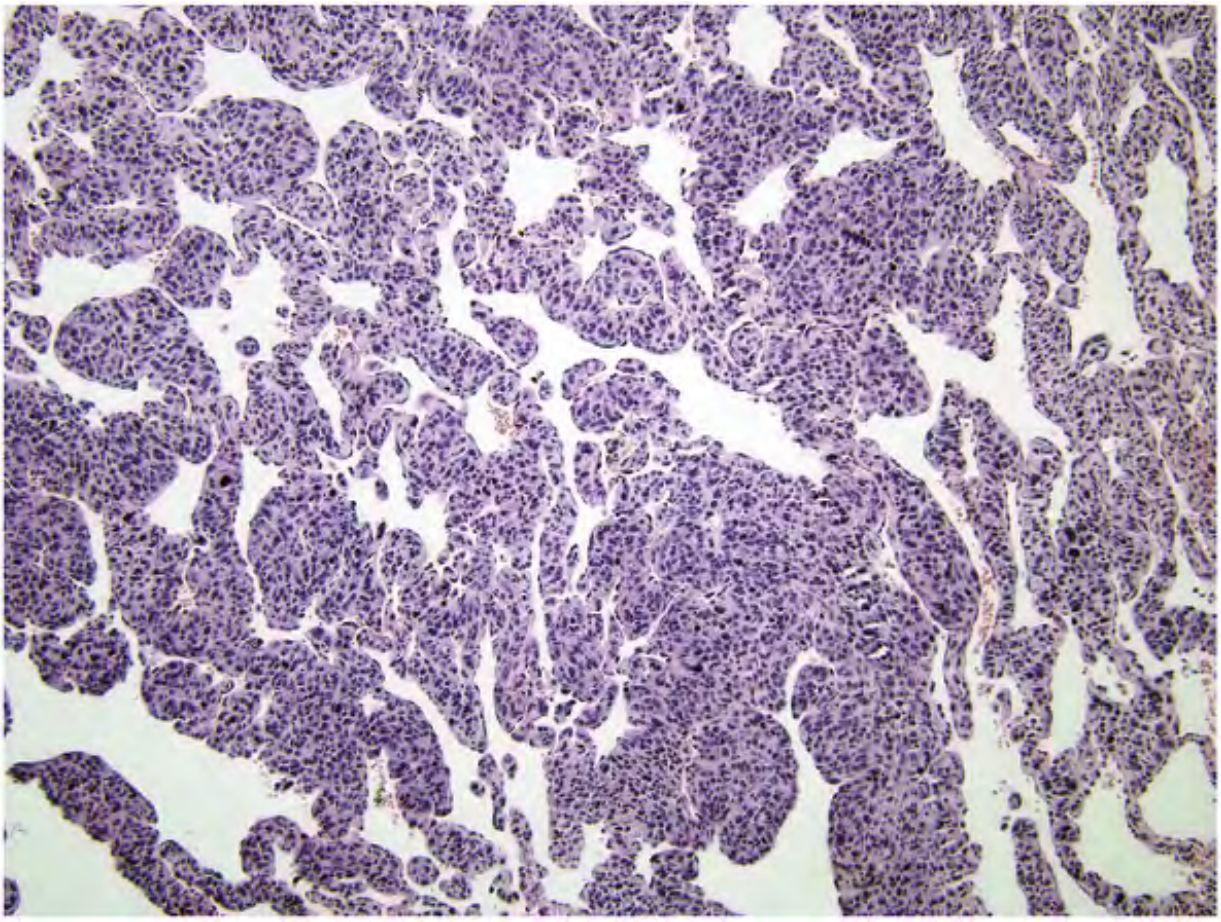

Figure 12.10. Medullary carcinoma exhibiting a trabecular growth pattern. The trabeculae
in thickness from slender to broad and are interdigitating, medium power.

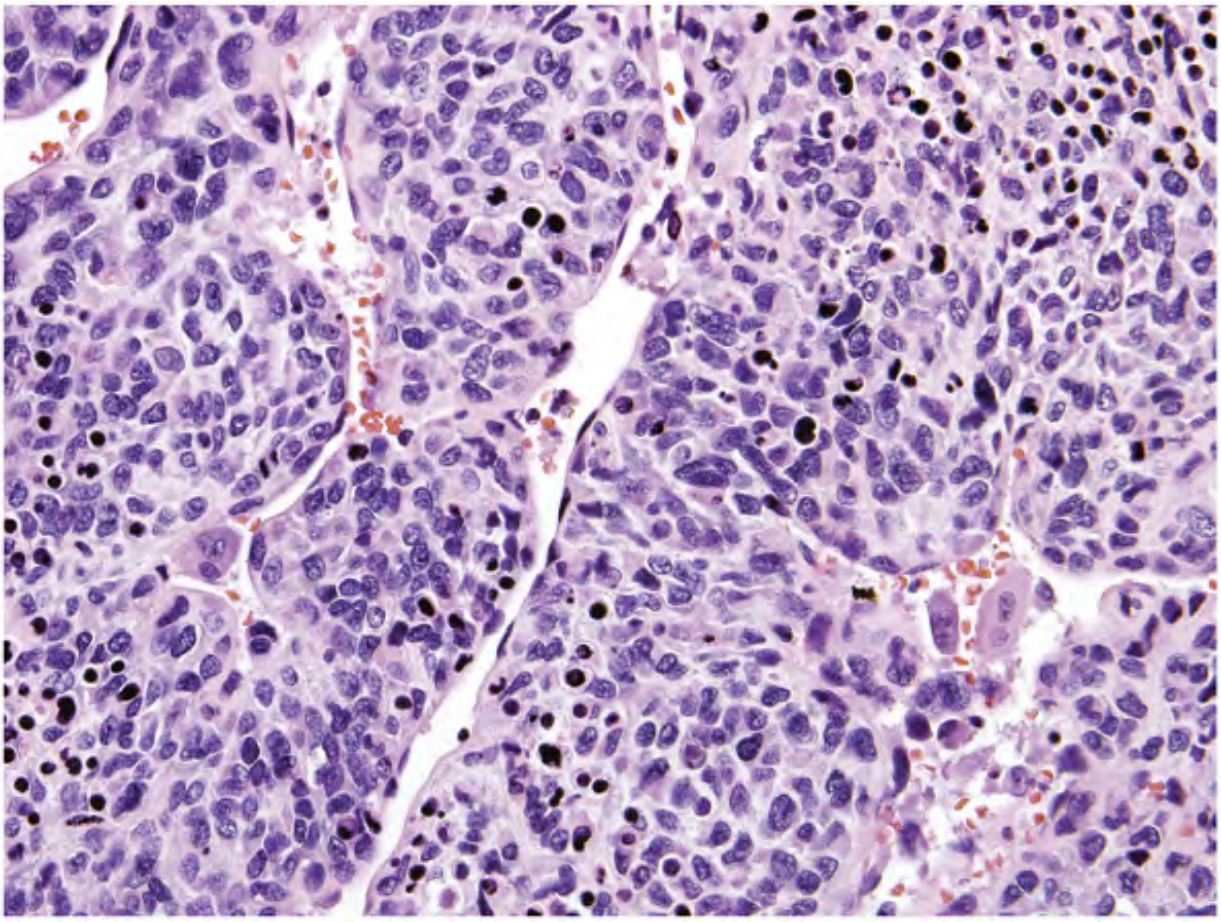

Figure 12.11. FNA of a medullary carcinoma showing broad trabeculae consisting of very pleomorphic, round to short spindle-shaped cells.

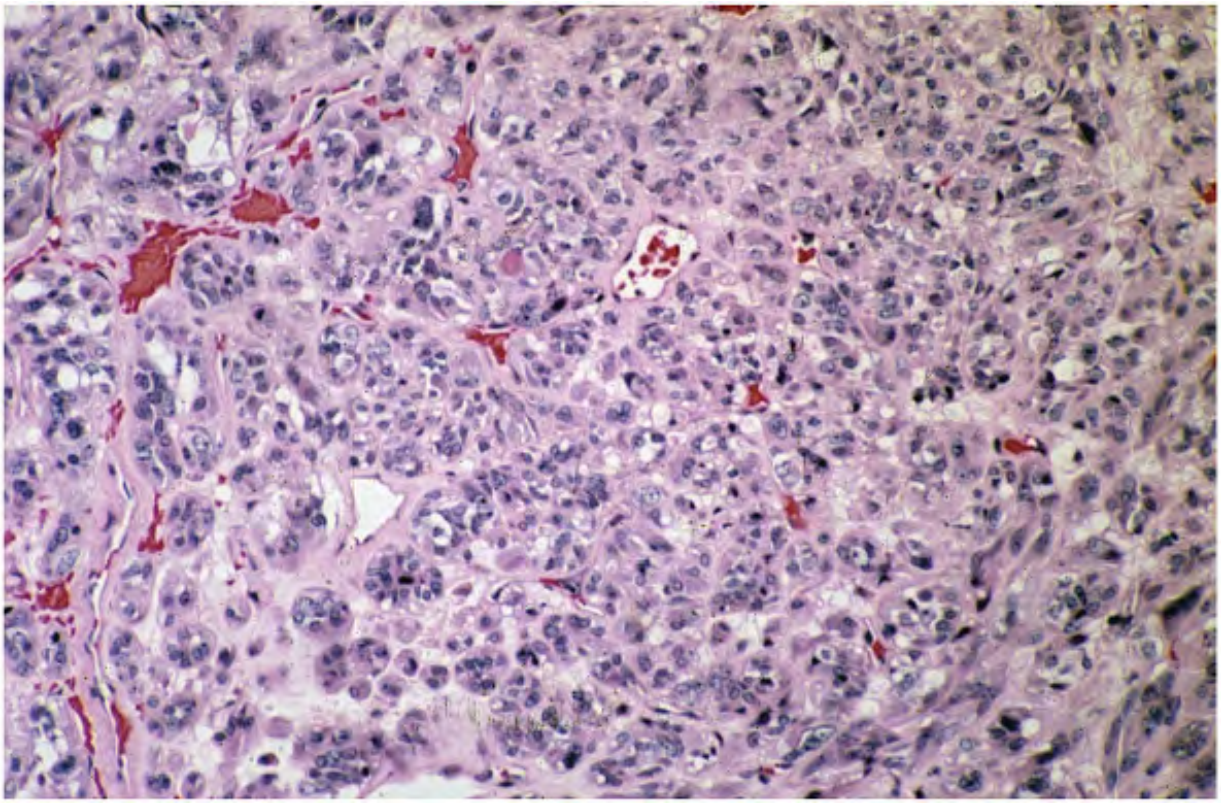

Figure 12.12. This medullary carcinoma is composed of cells forming small nests with a follicular growth pattern.

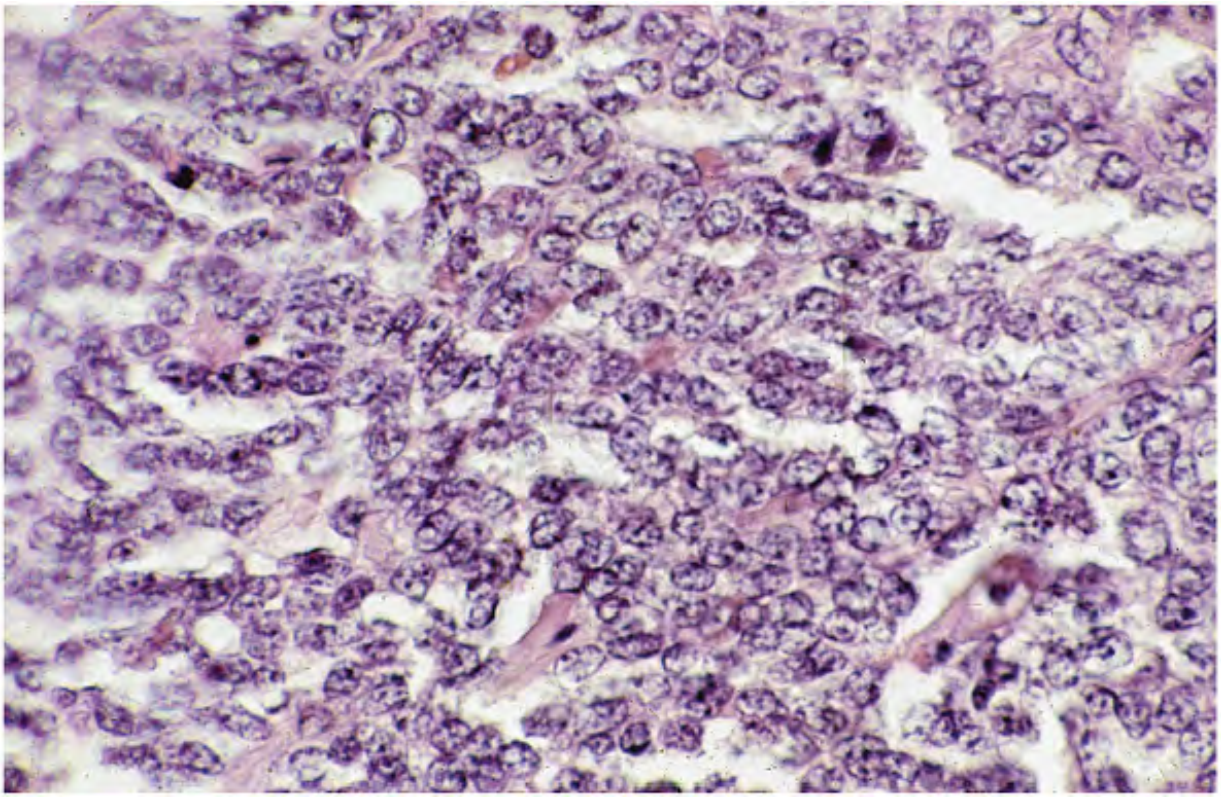

Figure 12.13. A solid growth pattern of medullary carcinoma. The cells contain scant to indiscernible cytoplasm

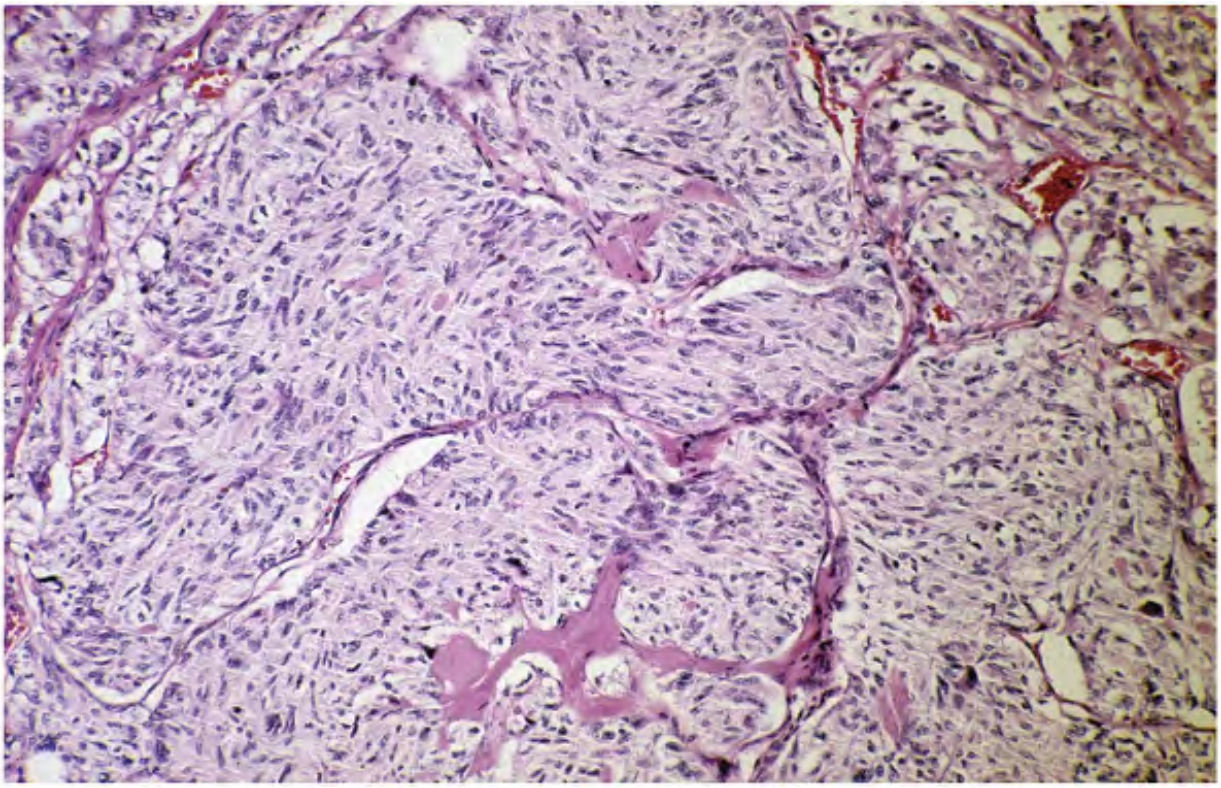

Figure 12.14. Medullary carcinoma with a spindle cell pattern. The spindle cells are formin
large nests, separated by fibrous tissue septae.

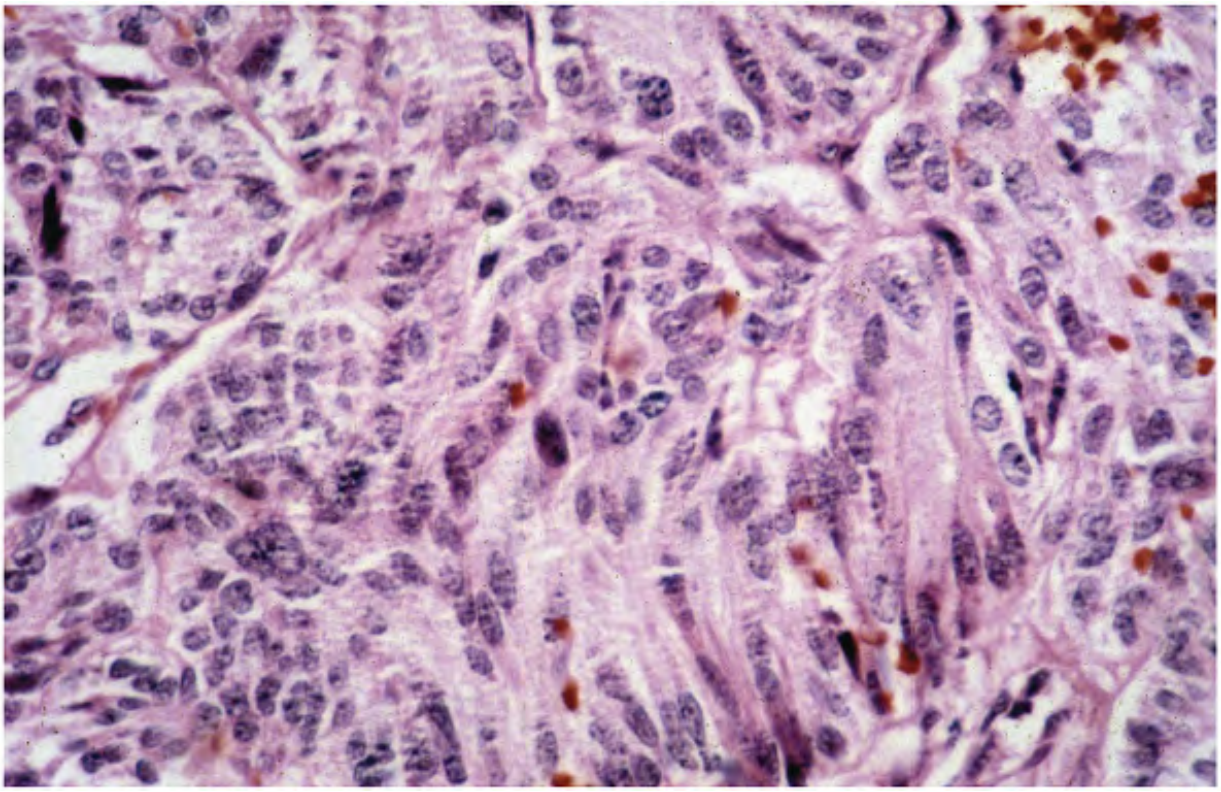

Figure 12.15. The histologic pattern of this medullary carcinoma with nests of elongated sp
cells resembles a paraganglioma.

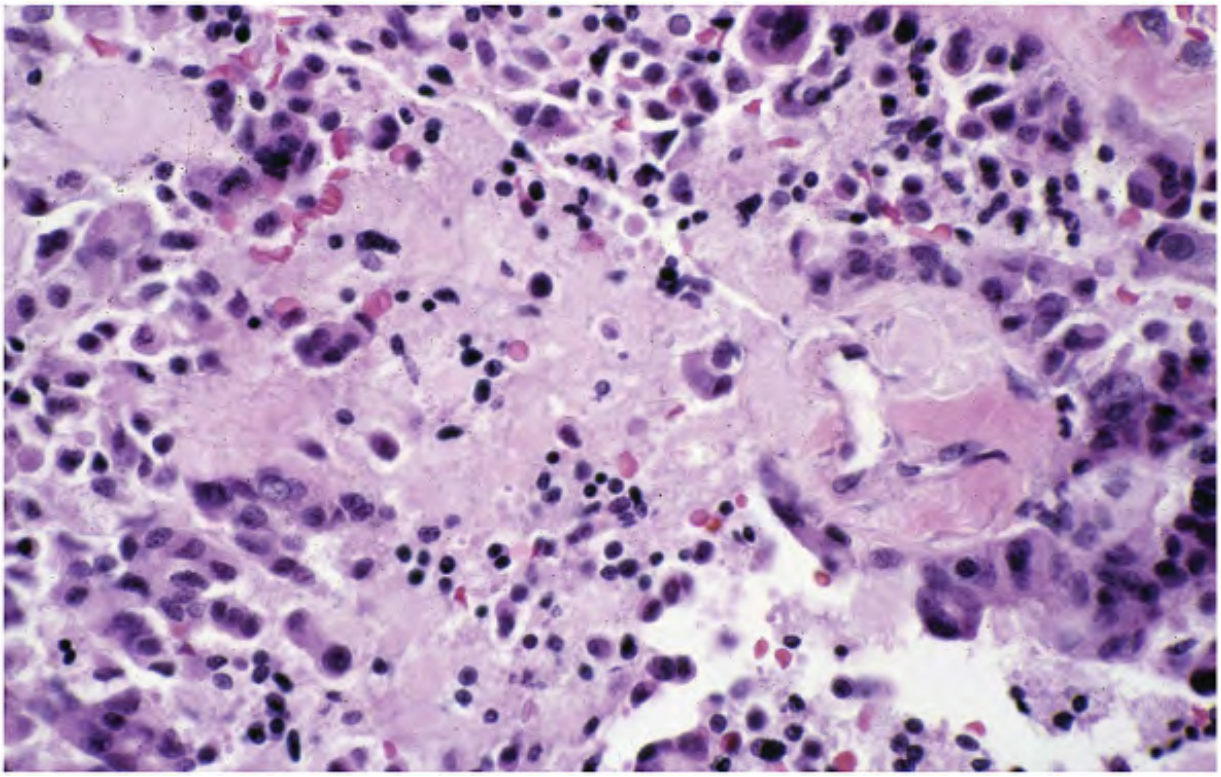

Figure 12.16. Histologic section of medullary carcinoma exhibiting a pleomorphic cell patte
with amyloid in the stroma.

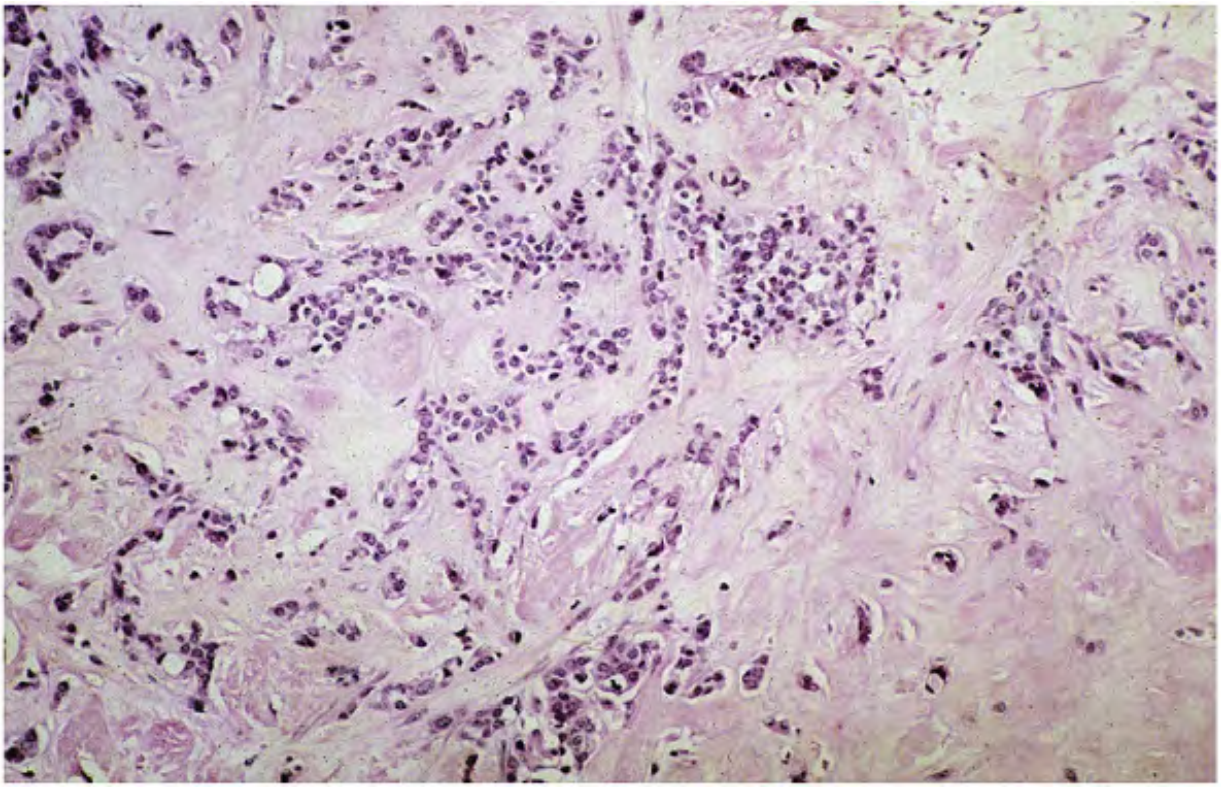

Figure 12.17. Medullary carcinoma with abundant amyloid in the stroma.

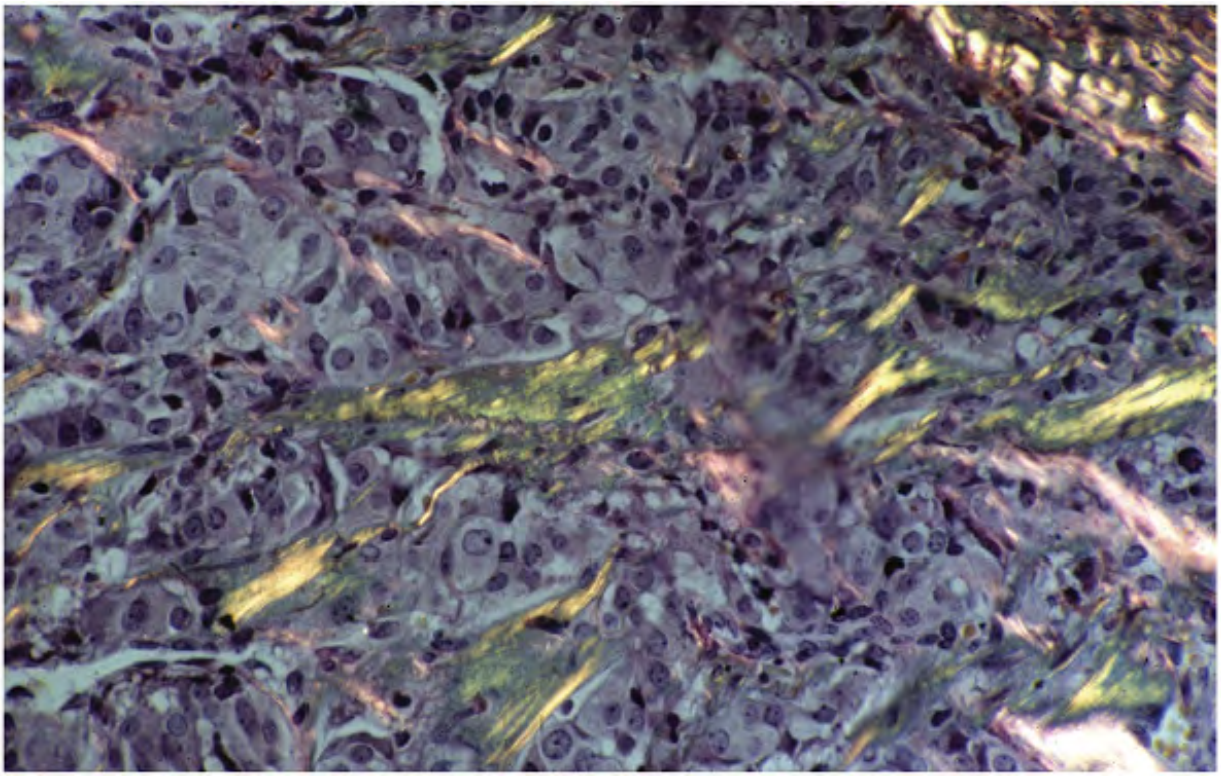

Figure 12.18. Histologic section of medullary carcinoma, showing apple green birefringence amyloid stained with Congo red.

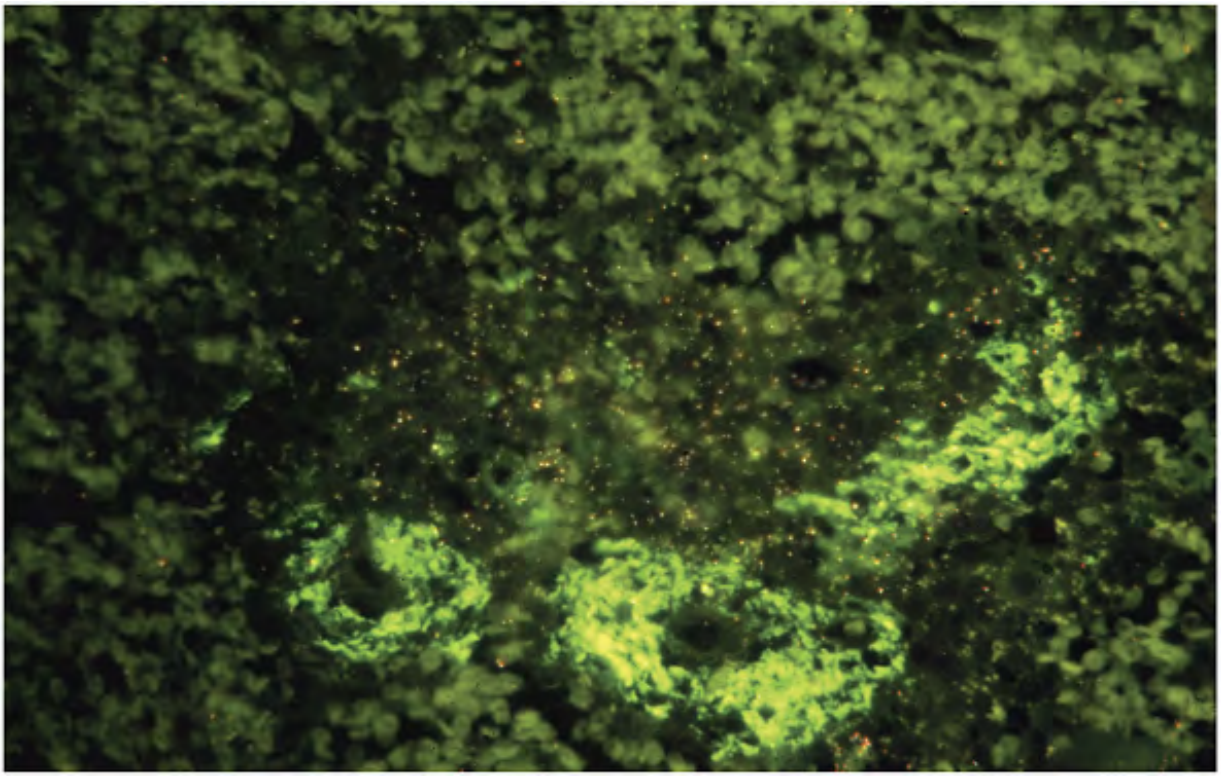

Figure 12.19. Bright green fluorescence of amyloid when stained with thioflavin T and view under ultraviolet light.

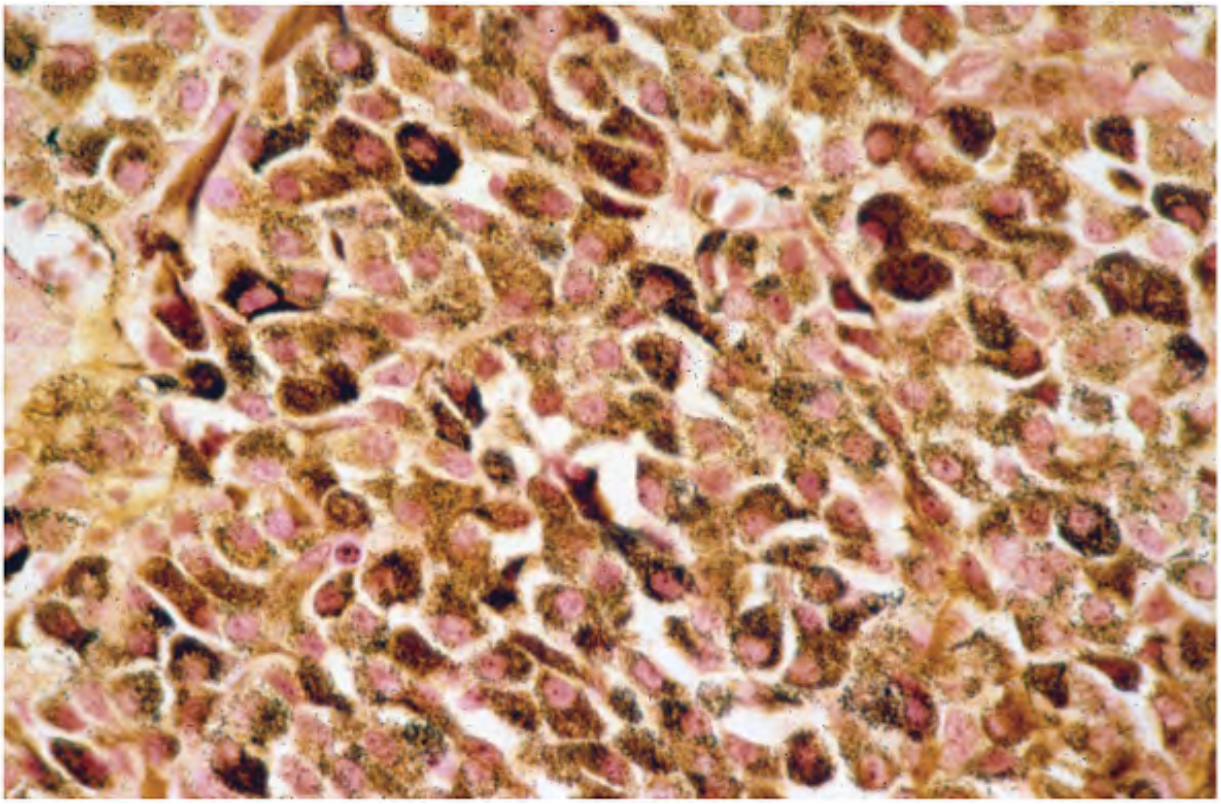

Figure 12.20. Medullary carcinoma demonstrating a strong positive reactivity with calcitoni stain.

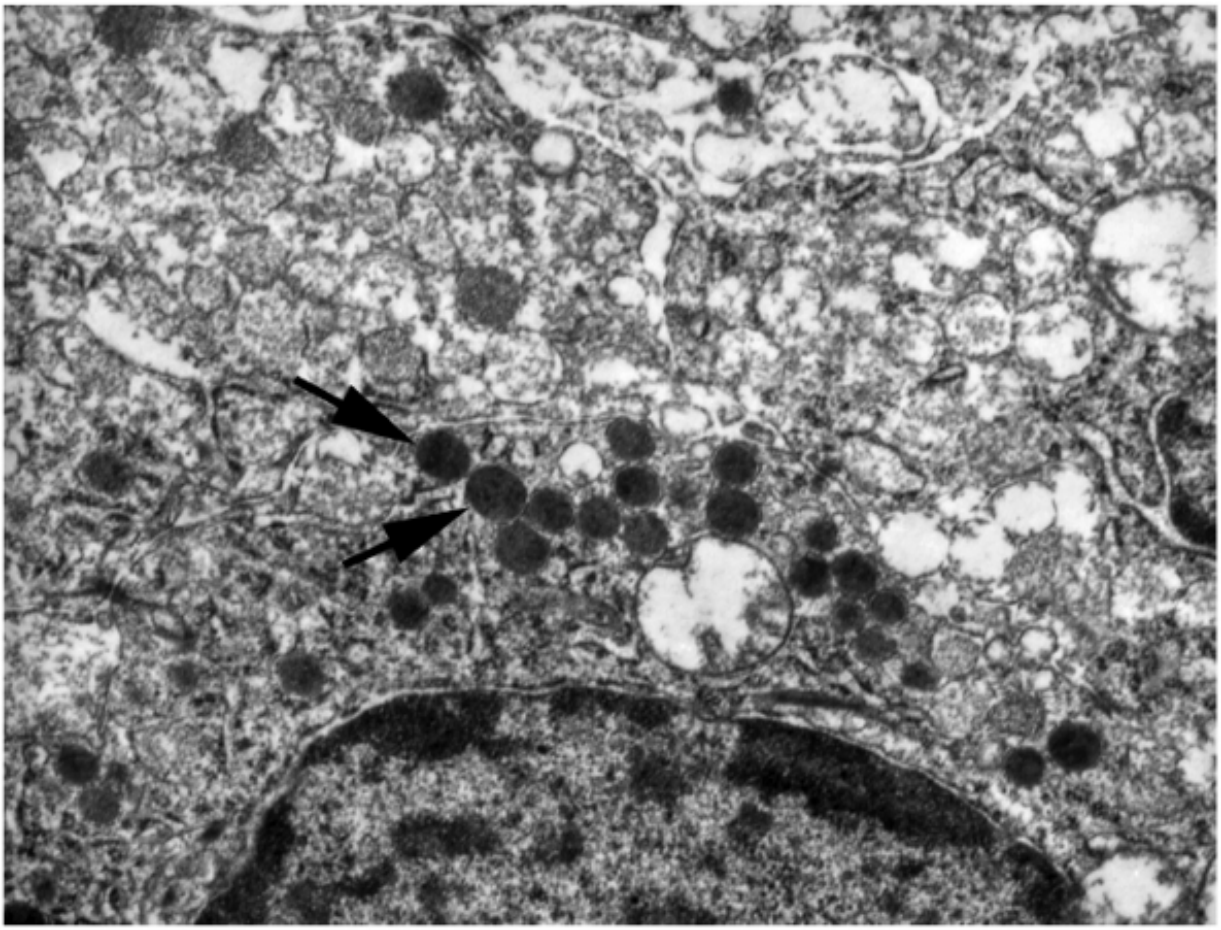

Figure 12.21. Electron micrograph of medullary carcinoma showing membrane-bound, sphe neurosecretory granules with an electron-dense core (*arrows*). Uranyl acetate and lead citr preparation (42,000).

Medullary carcinoma is characterized by the presence of amyloid deposits in the stroma in u 80% of cases (Figs. 12.16 and 12.17). The amyloid shows green birefringence under crossed polarized light when stained by Congo red (Fig. 12.18) and green fluorescence under ultrav light when stained by thioflavin T (Fig. 12.19). The carcinoma may also contain a significan amount of collagenous stroma, with or without calcification.

P.260

P.261

P.262

Several morphologic variants have been described.19 , 20 , 21 , 22 , 23 , 24 , 25 , 26 , 27 , 29 , 30 These include follicular or tubular, papillary, small cell, giant cell, clear cell, melan

(pigmented), oncocytic, squamous, amphicrine (composite calcitonin and mucin-producing), paraganglioma-like.

Histochemistry

Argyrophilia as demonstrated by silver stain (Grimelius) is present in 90% of medullary carcinomas.6 The stroma shows PAS and Alcian blue positivity. Both intra- and extracellular mucin is demonstrated by mucicarmine stain in a high proportion of cases.6 , 28

Ultrastructure

Ultrastructurally, medullary carcinoma cells demonstrate characteristic membrane-bound secretory granules (Fig. 12.21).

Cytopathologic Features

The cytopathologic features of medullary carcinoma are documented in several publications 32 , 33 , 34 , 35 , 36 , 37 , 38 , 39 , 40 , 41 , 42 , 43 , 44 They encompass a broad spectrum (Table 12.1 ; Figs. 12.22 , 12.23 , 12.24 , 12.25 , 12.26 , 12.27 , 12.28 , 12.29 , 12.30 , 12.3 12.32 , 12.33 , 12.34 , 12.35 , 12.36 , 12.37 , 12.38 , 12.39 , 12.40 , 12.41 , 12.42 , 12.43 , 1 , 12.45 , 12.46 , 12.47 , 12.48 , 12.49 and 12.50), depending on the histomorphology: monomorphic if only one pattern is evident and pleomorphic if a combination of different morphologic patterns is seen. The pleomorphic pattern is more frequently observed.

Cellularity

Usually very cellular

Presentation

Cells mostly isolated, in aggregates and rarely in tissue fragments forming nests and trabeculae; follicular or papillary architecture not present; pseudofollicular pattern rarely present; dispersed pattern characteristic; aggregates of spindle cells may present a "fish-school" pattern or occur in fascicles

Cells

Uniform to markedly pleomorphic; size ranging from small to large with frequent giant forms; varied shapes: round, cuboidal, plasmacytoid, polygonal, caudate, racket-shaped, triangular, short to elongated spindle shaped; unipolar cells; admixture of various types is characteristic; cell borders well to poorly defined; variable N/C ratios

Nucleus

Location

Always eccentric with extreme marginal location

Numbers

Bi-multinucleation frequent

Shape

Round, oval, oblong to spindle shaped; smooth nuclear membranes

Chromatin

Deep-staining, coarsely granular to chunky

Parachromatin clearing

Not common

Nucleoli

Â±

Nuclear grooves

Not observed

Intranuclear inclusions

Almost always present

Mitotic activity

Generally absent

Cytoplasm

Variable; scant, indiscernible to abundant; clear, pale, granular to dense; drawn into cytoplasmic processes; rudimentary tailing to delicate intertwining processes; azurophilic cytoplasmic granules in Romanowsky-stained preparations

Psammoma bodies

Rare

Background

Hyaline, amorphous, fluffy acellular material staining positive for amyloid (Congo red or thioflavin T); strongly resembles colloid; usually clean; necrosis generally absent

Histochemistry

Argyrophilic granules in the cytoplasm

Immunoprofile

Positive reactivity to: calcitonin, low-molecular-weight keratin, CEA, neuroendocrine markers (chromogranin A, synaptophysin, somatostatin, neuron-specific enolase)

and TTF-1; negative reactivity to thyroglobulin

Ultrastructure

Electron dense, membrane-bound neurosecretory granules

TABLE 12.1 CYTOPATHOLOGIC FEATURES OF MEDULLARY CARCINOMA

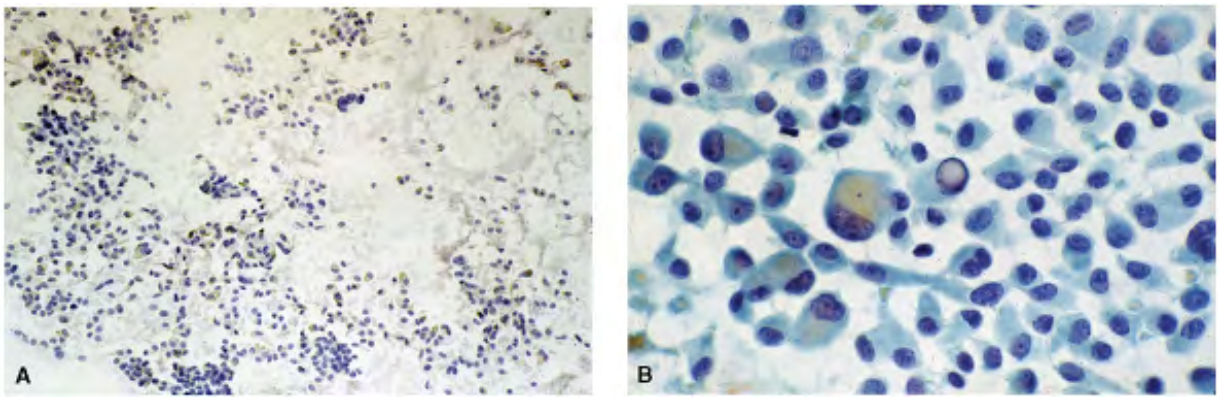

Figure 12.22. A. FNA of a medullary thyroid carcinoma showing the characteristic dispersed pattern (low power). B. Higher magnification showing the discrete, medium-sized, pleomorp and plasmacytoid neoplastic cells.

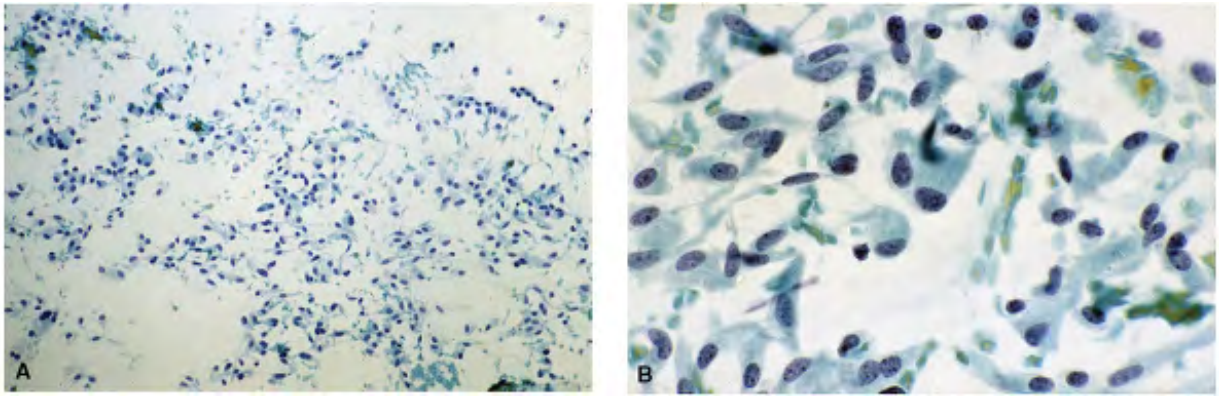

Figure 12.23. A. FNA of a medullary carcinoma depicting a dispersed cell pattern formed by spindle-shaped cells (low power).B. Higher magnification. Note eccentric nuclei.

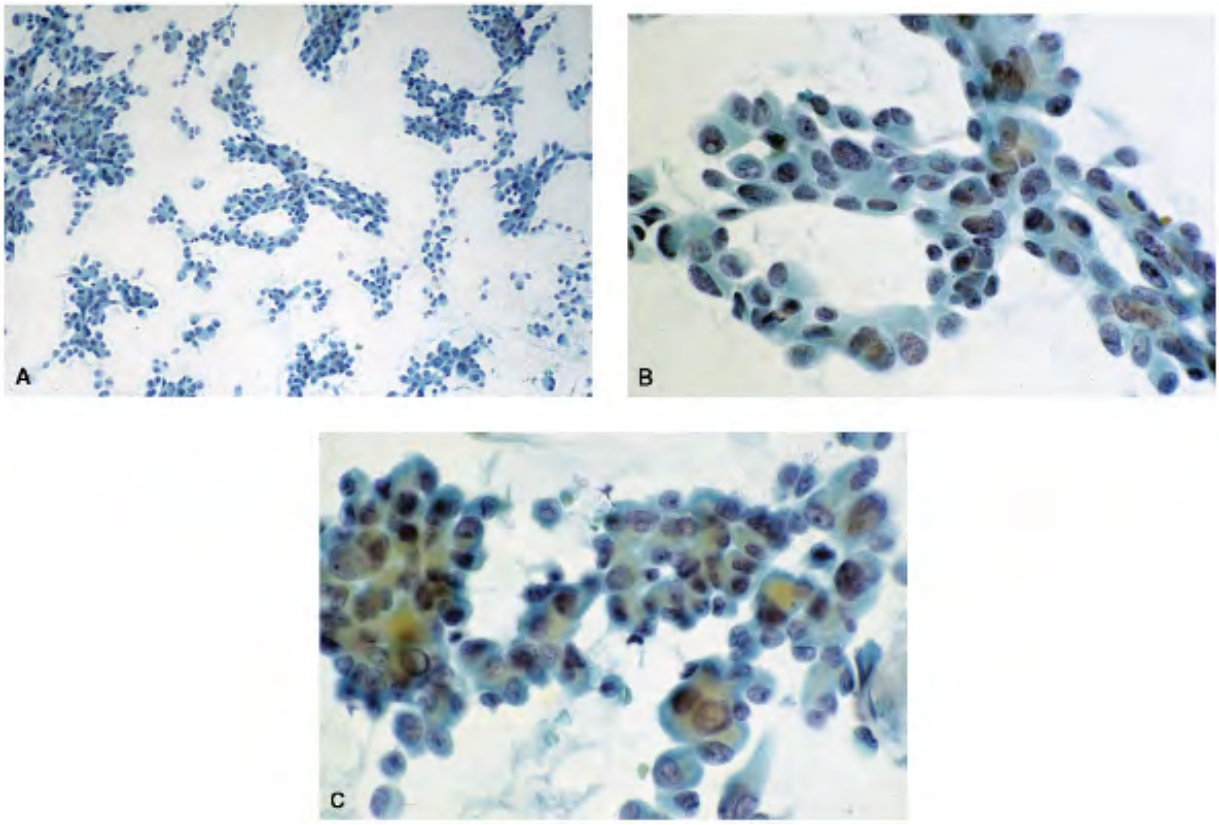

Figure 12.24. The presence of syncytial tissue fragments in FNA of medullary carcinoma is r very common. A. Low power showing several tissue fragments. B,C. Higher magnification. T tissue fragments are syncytial. Note that the component cells are pleomorphic.

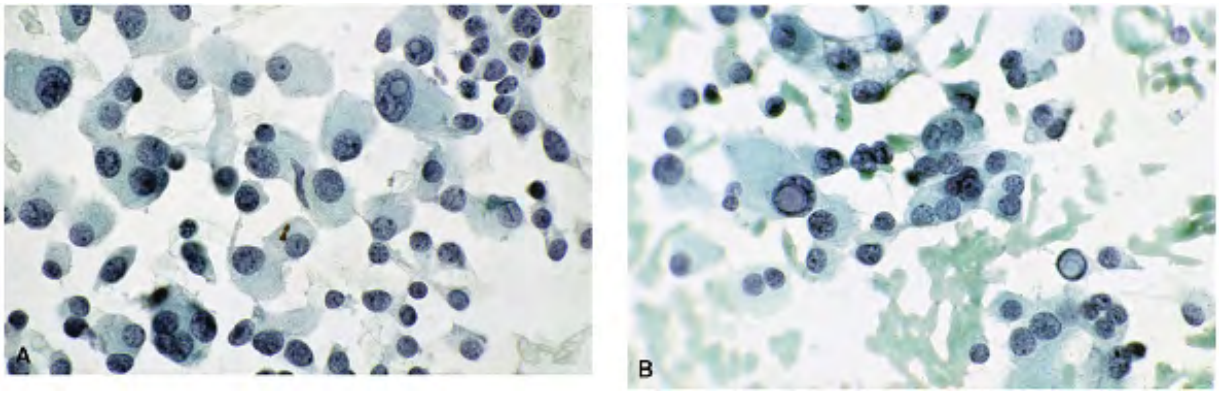

Figure 12.25. A. Medullary carcinoma cells exhibiting marked pleomorphism in cell size anc shape. Note the admixture of small, round carcinoid-type cells, plasmacytoid cells, polygona cells, and triangular cells. The nuclei are consistently eccentric. Also note the multinucleati B. Pleomorphic cell pattern with intranuclear inclusions.

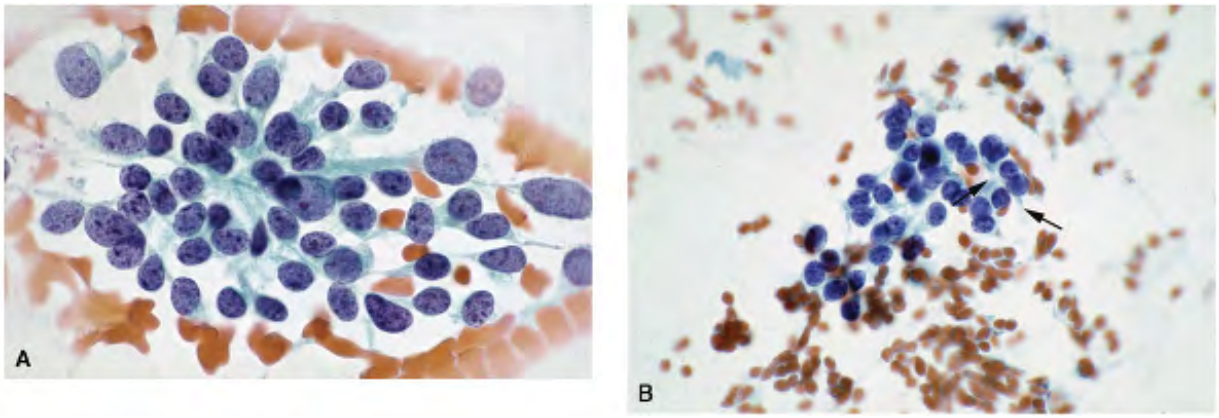

Figure 12.26. A. FNA of a medullary carcinoma. These cells are very small with scant cytop and compact nuclei. Note rudimentary cytoplasmic processes, Ã— 1,000. B. These medullar carcinoma cells are very small with hyperchromatic nuclei and indiscernible cytoplasm. The larger cells have scant cytoplasm with thin and rudimentary cytoplasmic processes.

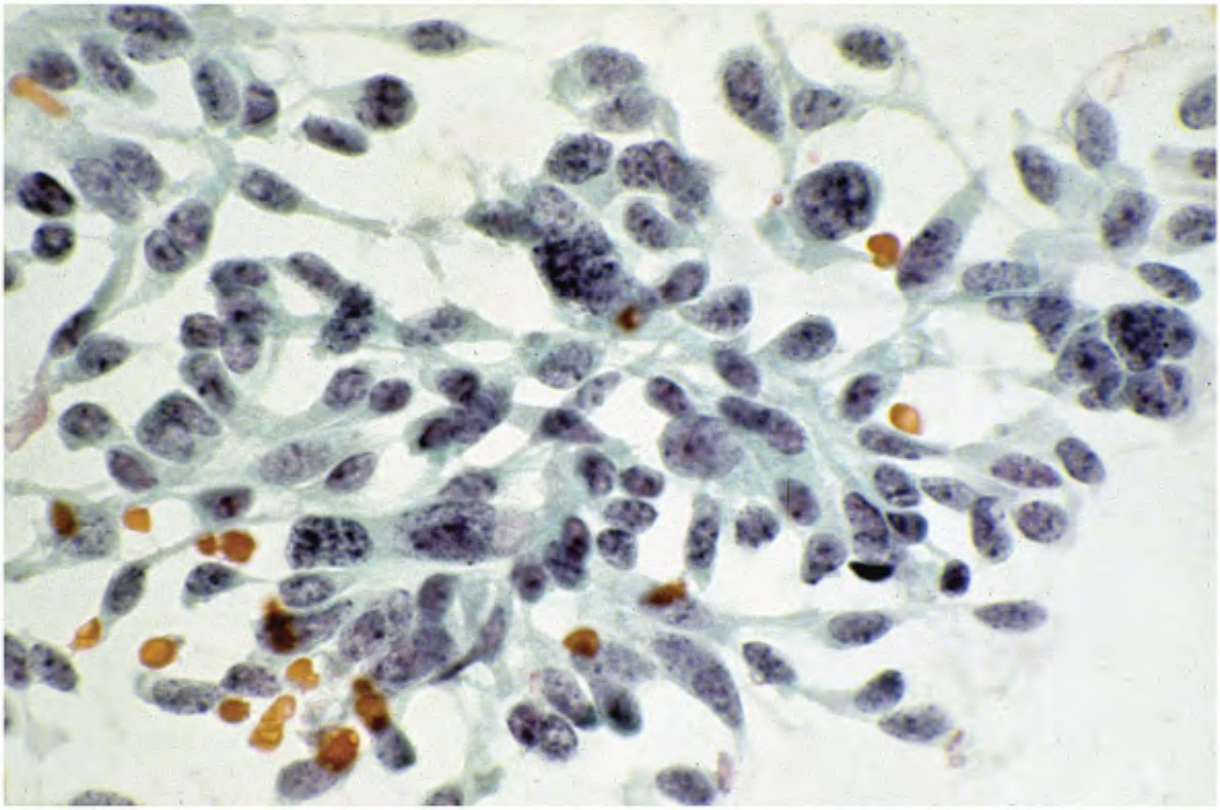

Figure 12.27. FNA of a medullary carcinoma. The neoplastic cells are spindle shaped, with cytoplasmic processes. Note the salt-and-pepper chromatin pattern of the nuclei.

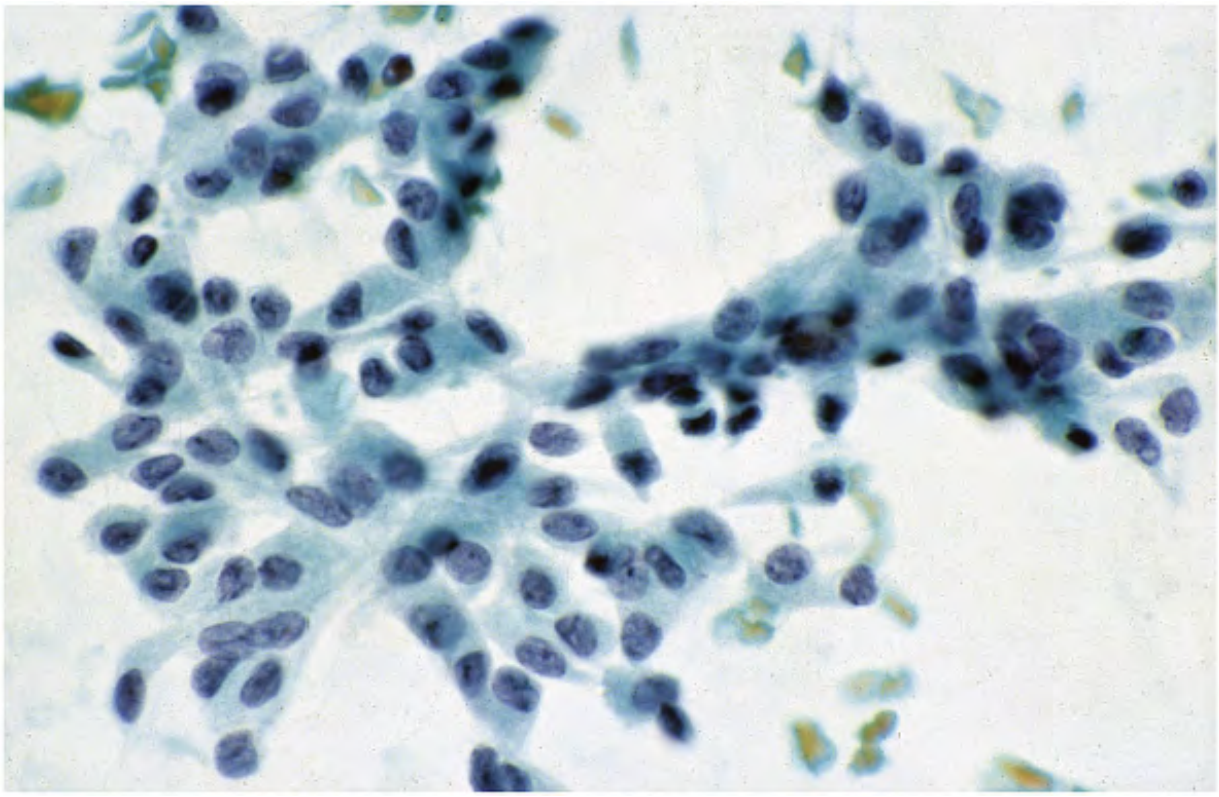

Figure 12.28. Another case of medullary carcinoma. The carcinoma cells are loosely cohesi and discrete. They are round, cuboidal to spindle shaped. The cytoplasm is moderate in am and dense. The background is clean.

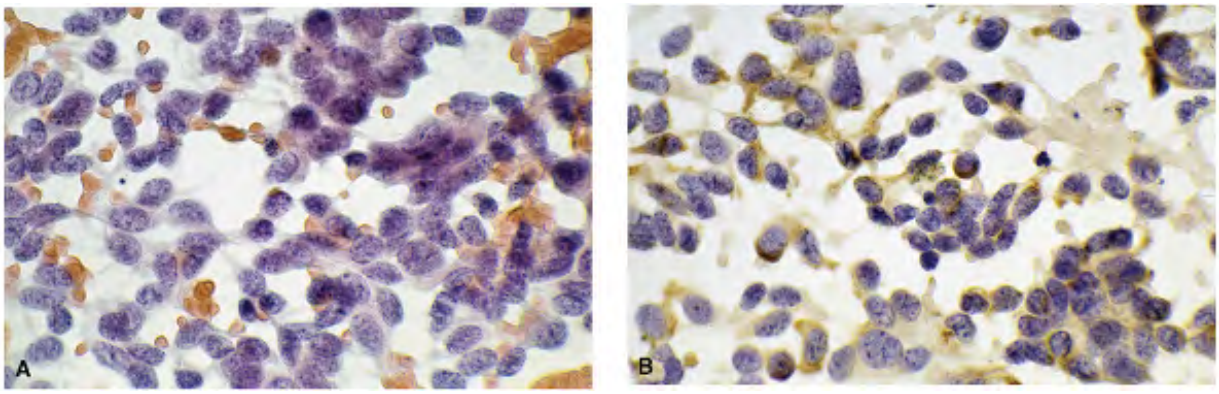

Figure 12.29. A. Medullary carcinoma cells exhibiting the nuclear chromatin pattern so characteristic of a neuroendocrine tumor. The nuclei are round, ovoid to spindle shaped, wi salt-and-pepper chromatin. Note that nucleoli are not seen. The cells possess delicate

cytoplasmic processes. B. Smear stained for calcitonin showing positive reactivity to calcito

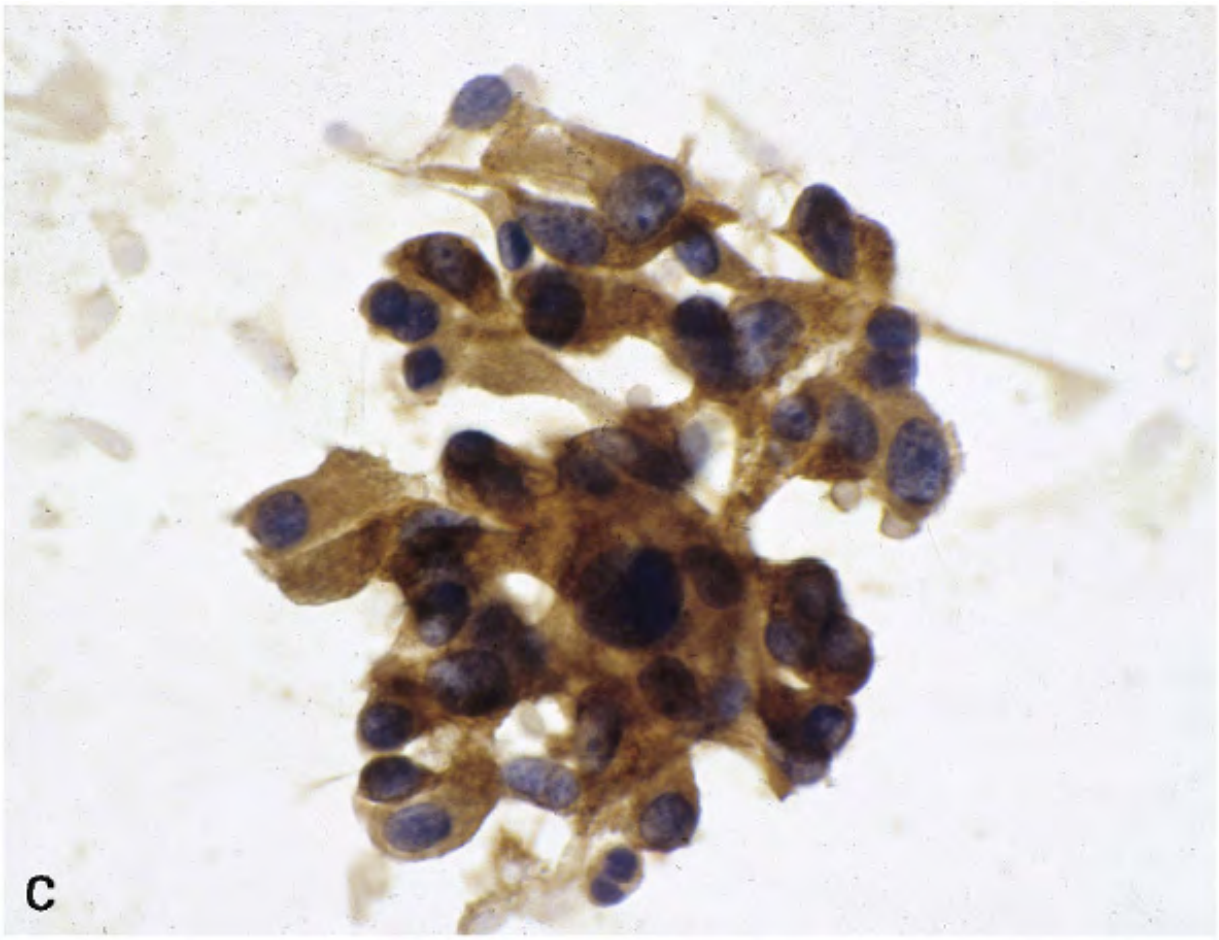

Figure 12.29. C. Reactivity to calcitonin is usually very strong as demonstrated by these medullary carcinoma cells.

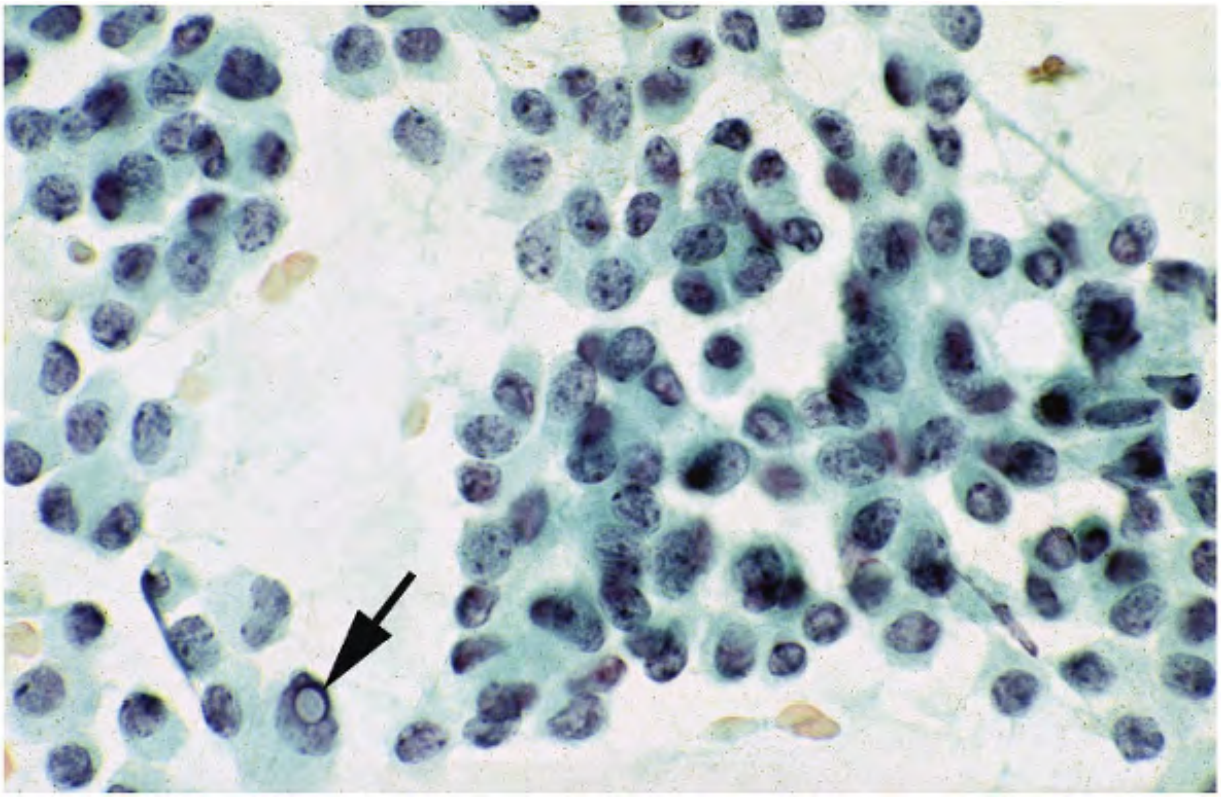

Figure 12.30. FNA of medullary carcinoma showing a monomorphic cell pattern of plasmacy cells. Note intranuclear inclusions (*arrow*).

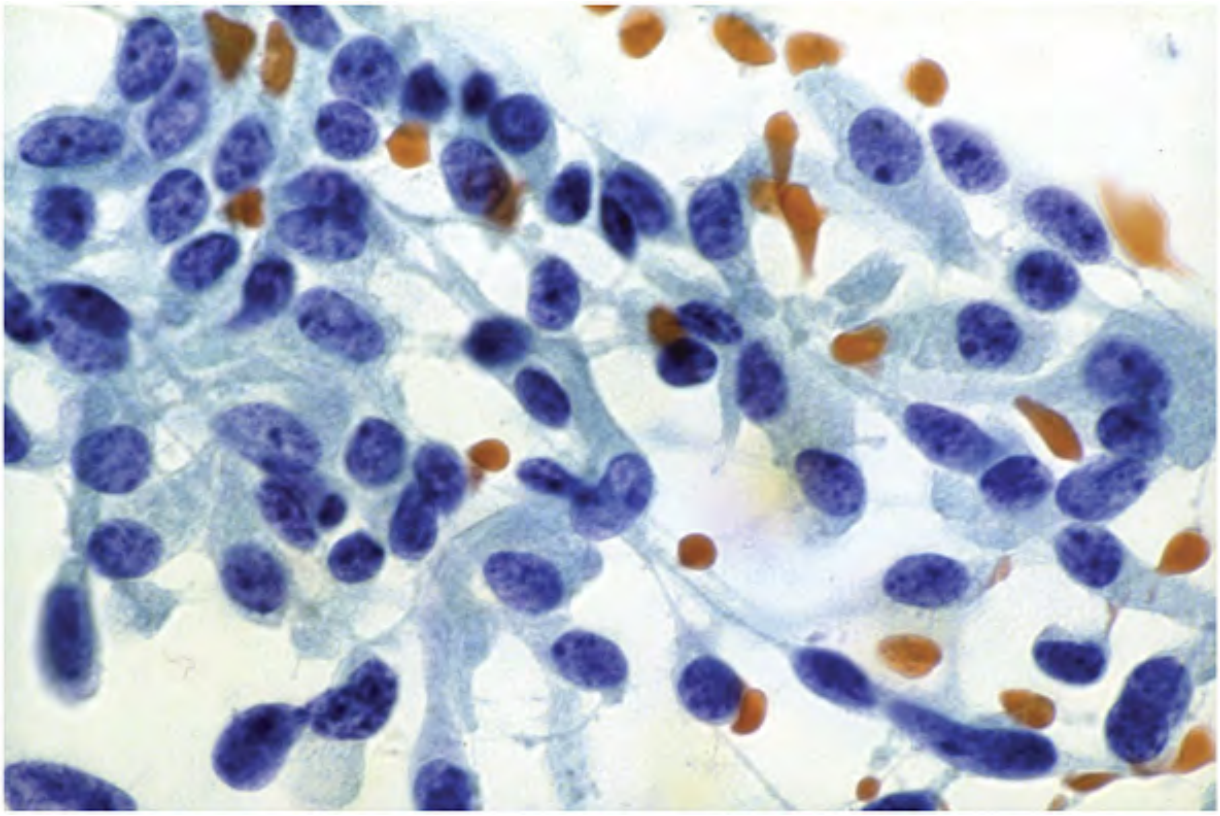

Figure 12.31. A pleomorphic cell pattern as seen here is the hallmark of medullary carcinor

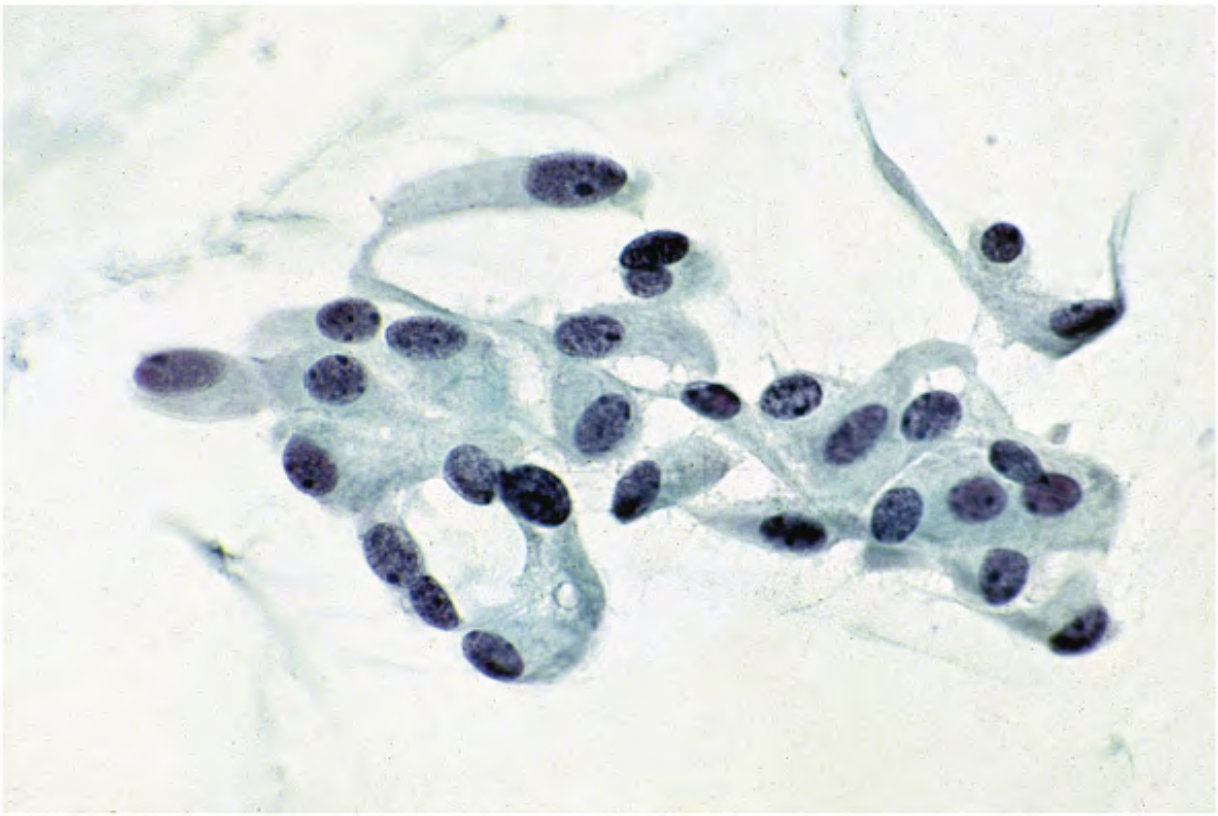

Figure 12.32. Medullary carcinoma cells with pleomorphic spindle cells, eccentric bland nu
and fibrillar cytoplasm with processes.

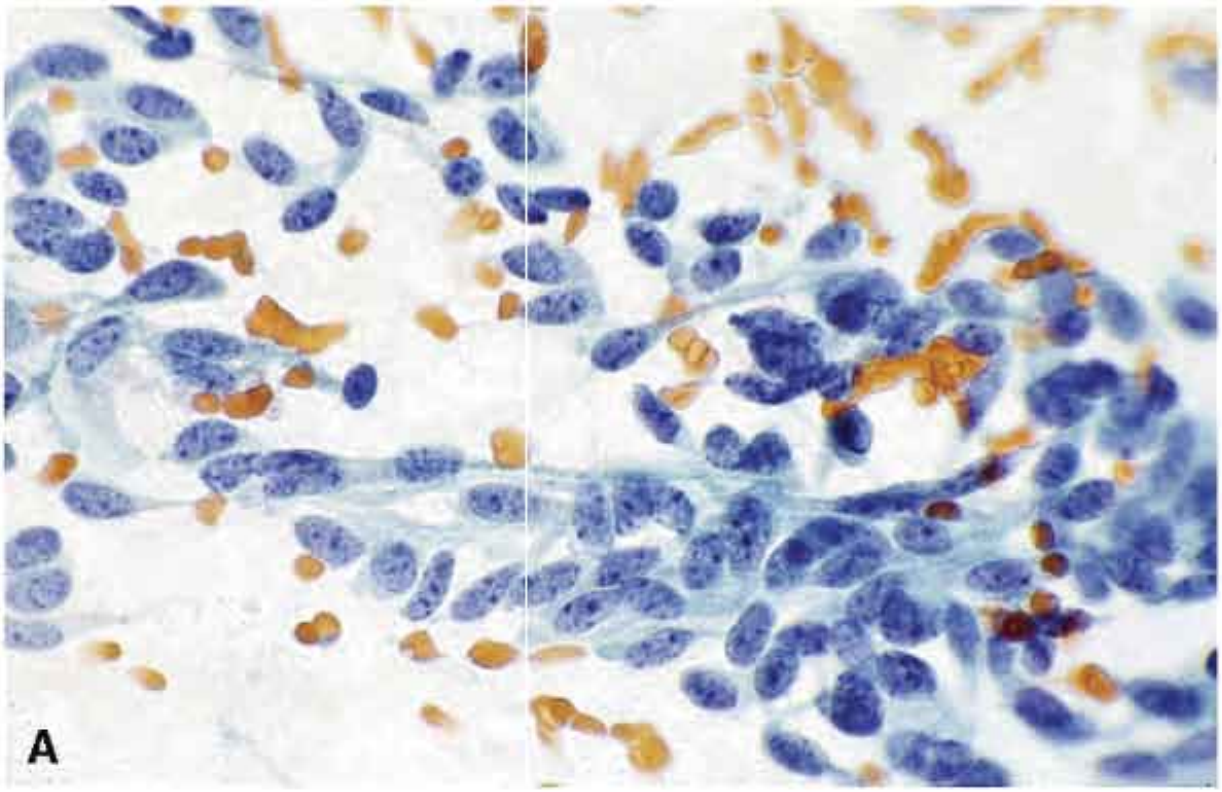
A

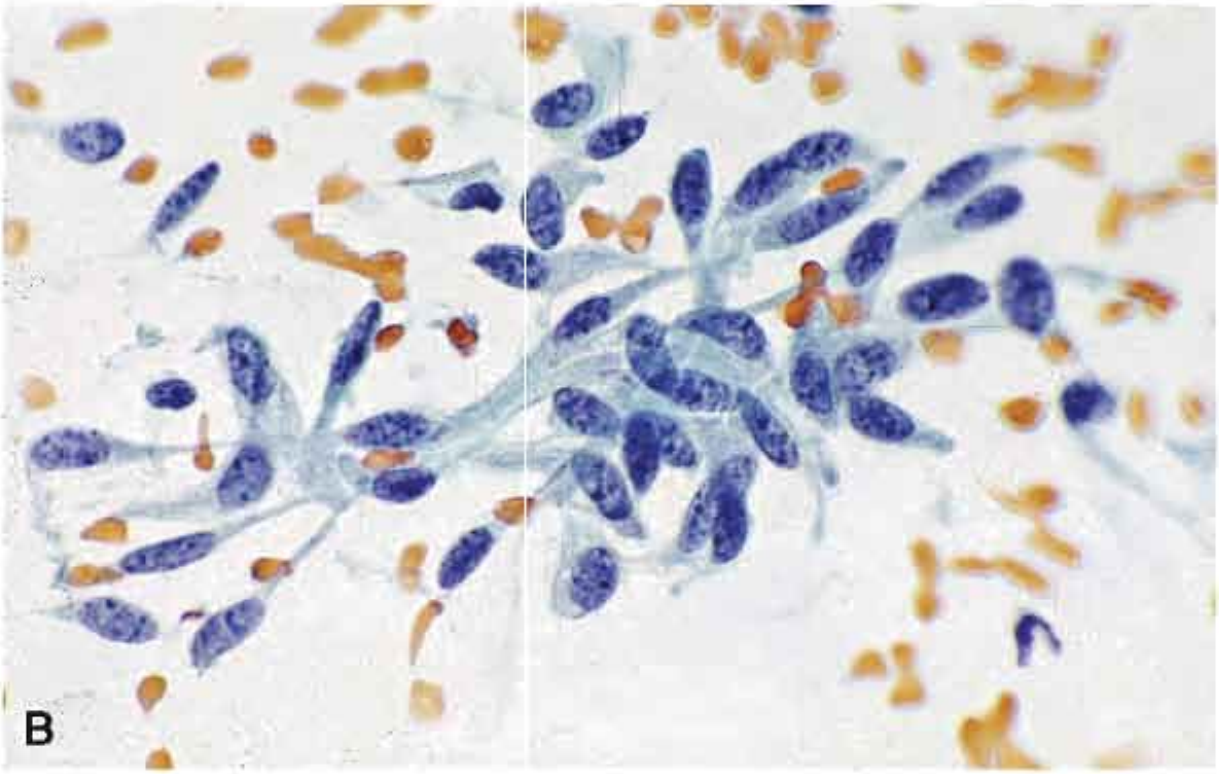
B

Figure 12.33. Medullary carcinoma with a dominant spindle cell pattern. The carcinoma cel are discohesive and possess delicate cytoplasmic processes.

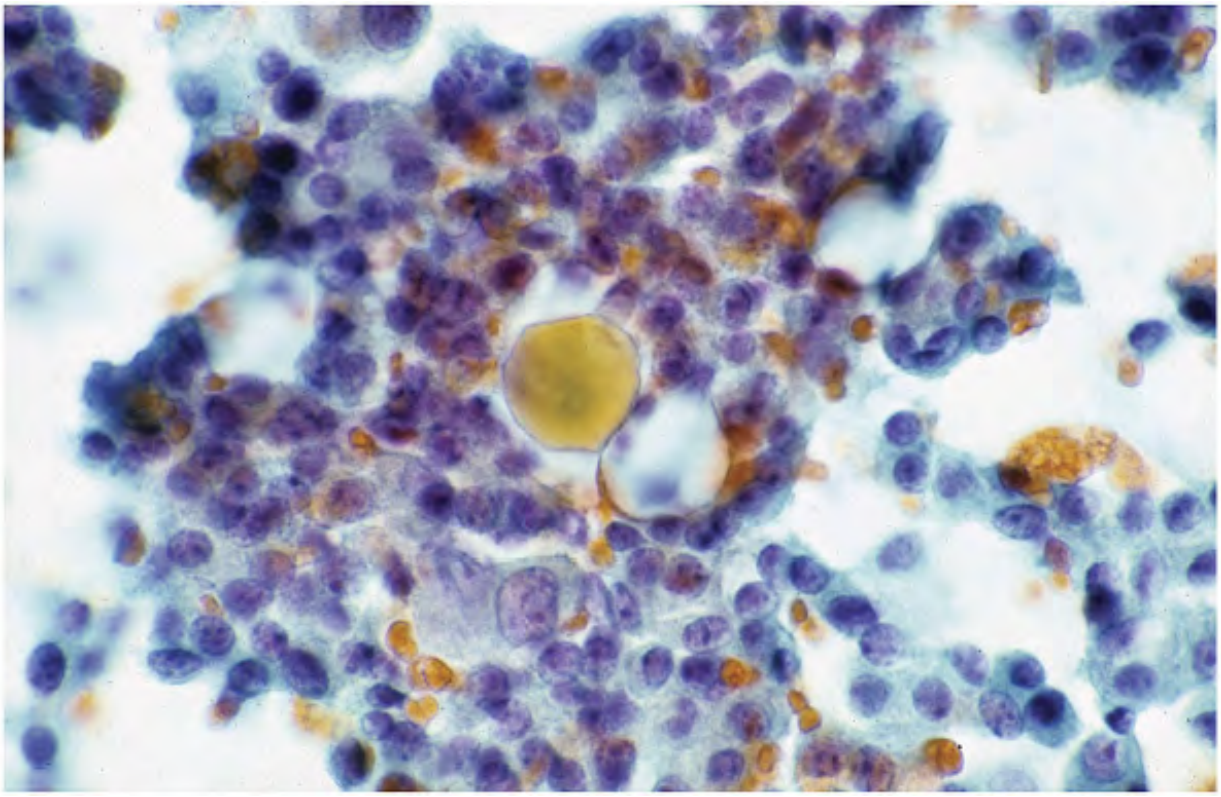

Figure 12.34. Medullary carcinoma cells are medium-sized, cuboidal, with a modest amoun cytoplasm. Lack of pleomorphism may cause typing difficulties. This pattern may be mistake for a follicular neoplasm.

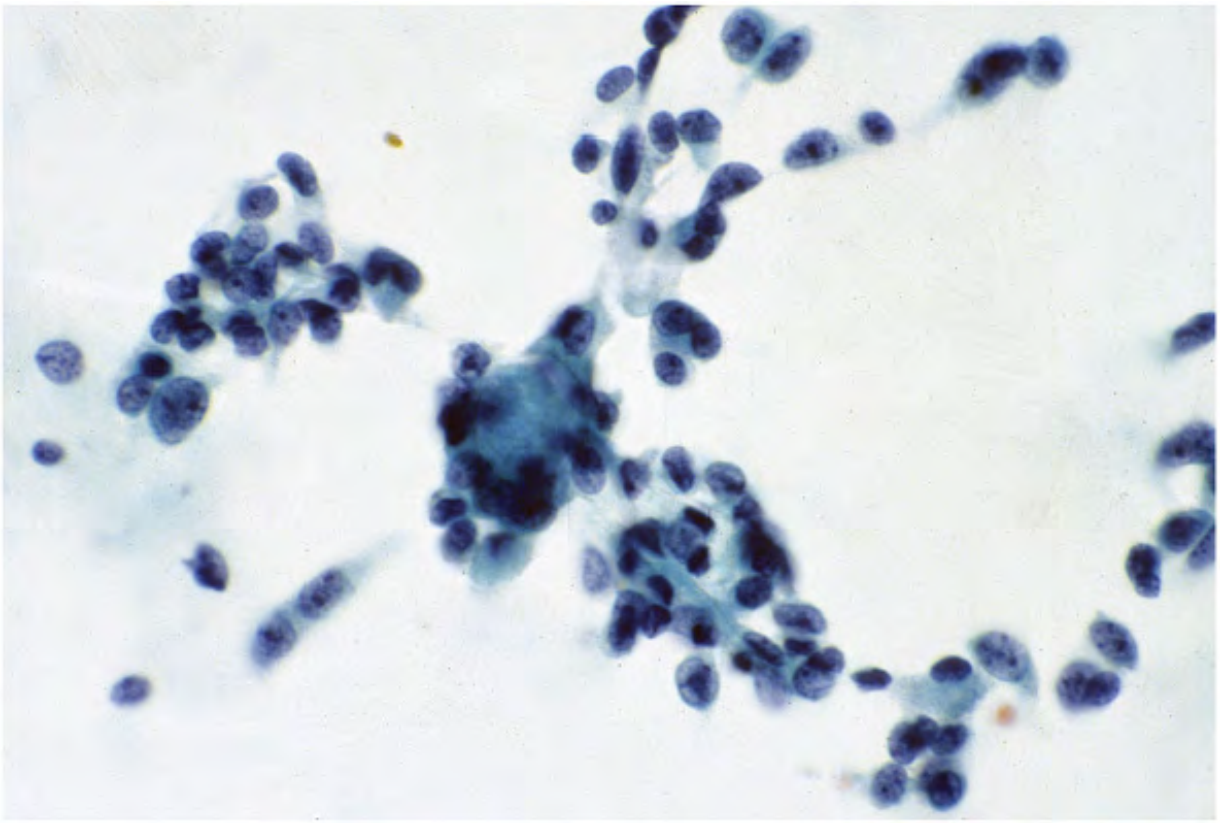

Figure 12.35. Medullary carcinoma with a small cell pattern. The carcinoma cells have scar indiscernible cytoplasm and deep-staining nuclei. This pattern may be misinterpreted as a s cell carcinoma.

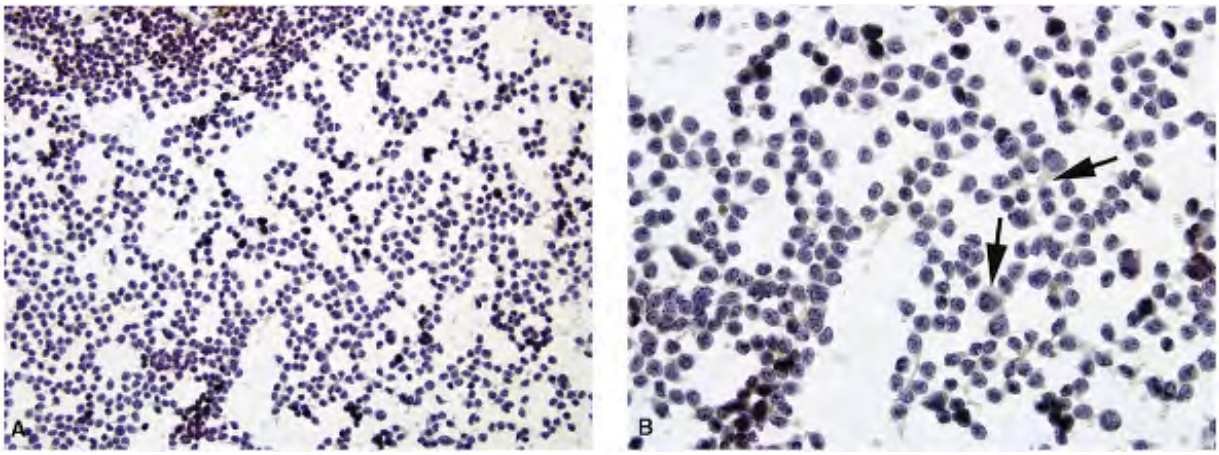

Figure 12.36. A. FNA of a medullary thyroid carcinoma showing marked cellularity with a dispersed cell pattern (low power). B. The isolated neoplastic cells are small, round, and sli pleomorphic in size. The cell borders are well defined and the cytoplasm is scant, indiscerni

to dense, with cyanophilic thin rim (*arrows*). The nuclei are round with coarsely granular chromatin. There is no nuclear molding. With a monomorphic pattern of small cells, malign lymphoma must be considered in the differential diagnosis.

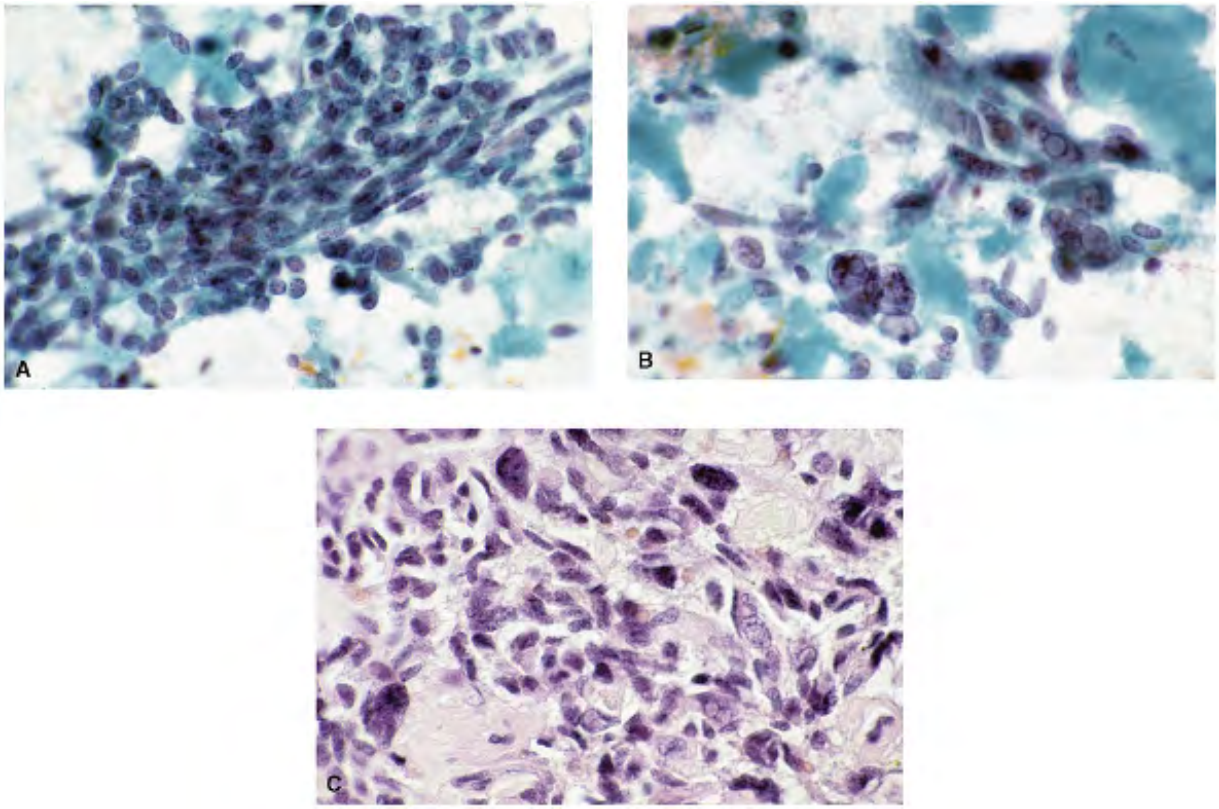

Figure 12.37. A. The carcinoma cells are spindle shaped and in fascicles. Note the acellula cyanophilic material in close association with carcinoma cells, which probably represents amyloid. B. A different field showing pleomorphic malignant cells. Note multinucleation an intranuclear inclusion. The background shows abundant dense acellular material that proba represents amyloid. In Papanicolaou-stained smears, amyloid resembles colloid. C. The cell block of the aspirate showing a very pleomorphic, diagnostic cell pattern of medullary carcinoma.

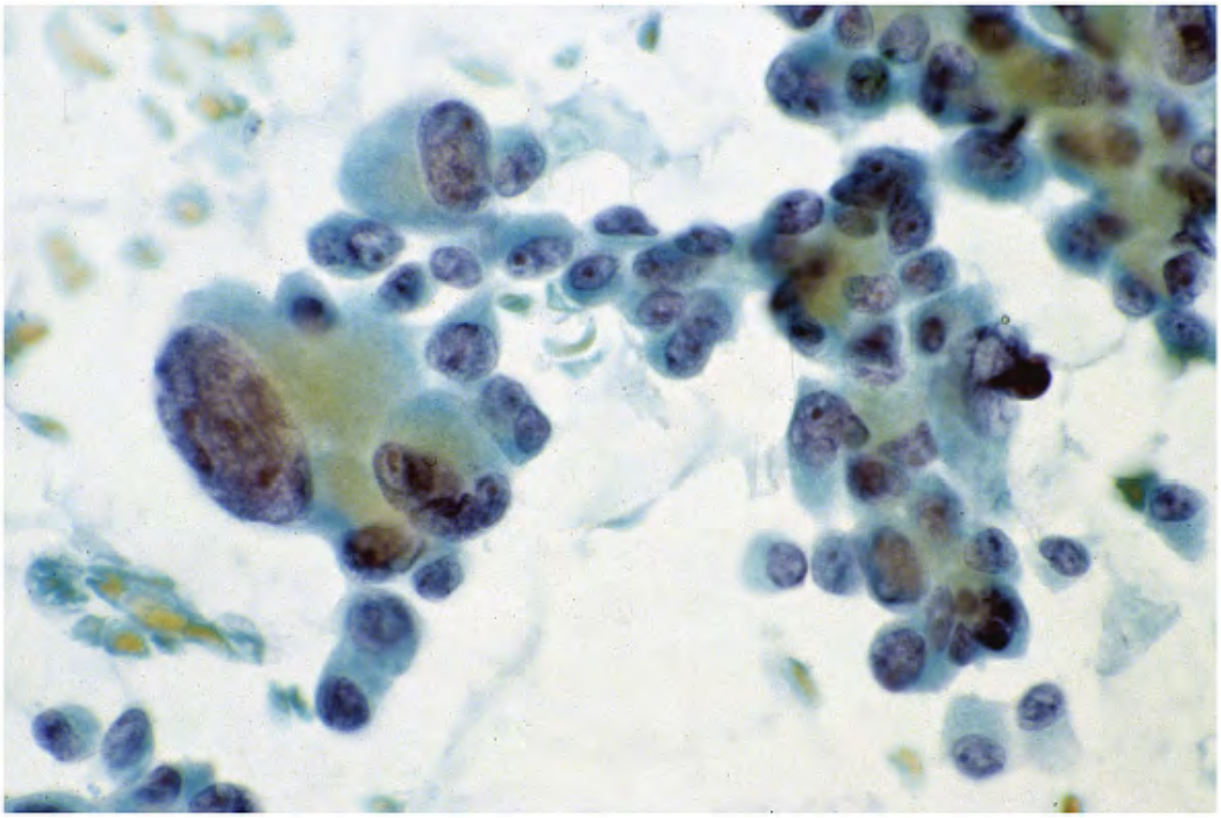

Figure 12.38. FNA of a medullary carcinoma showing a giant tumor cell with bizarre nucleu

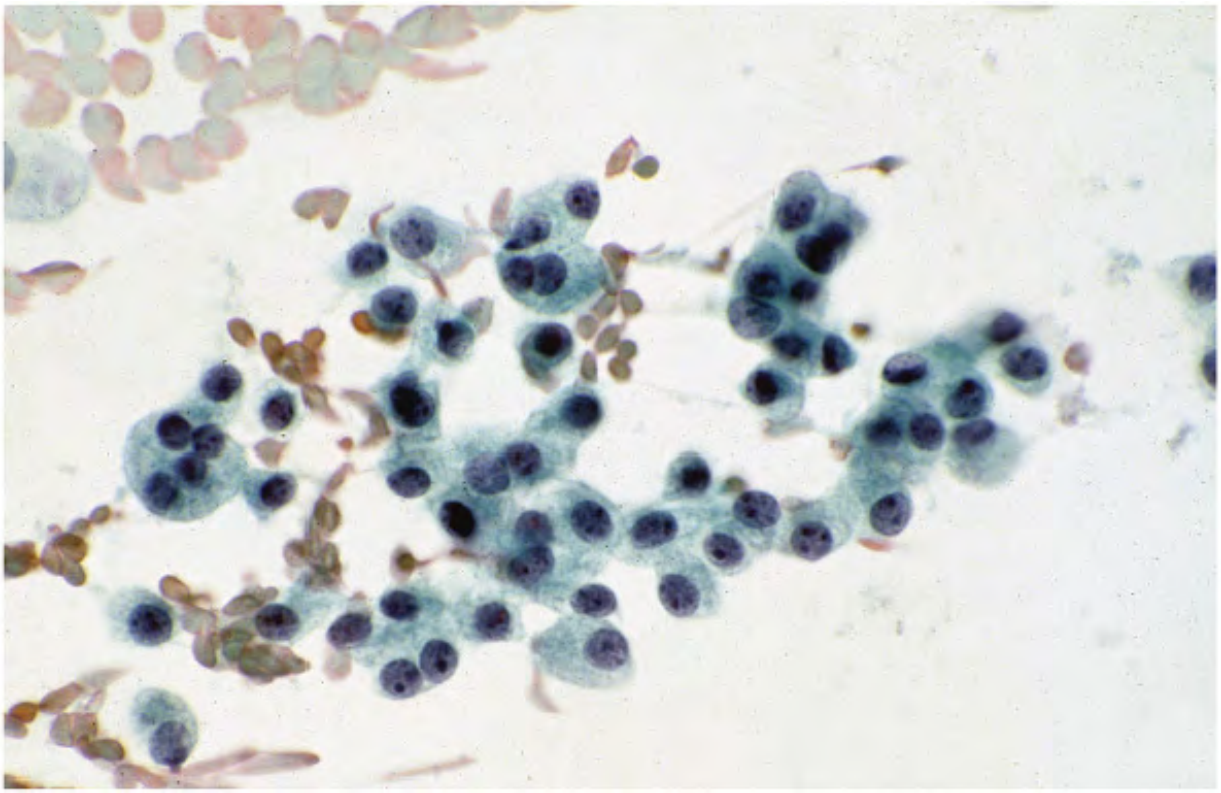

Figure 12.39. The medullary carcinoma cells are small, discrete, and in tissue fragments. T are monomorphic with eccentric, bland nuclei and contain modest amount of cytoplasm. Th pattern may be mistaken for a follicular neoplasm.

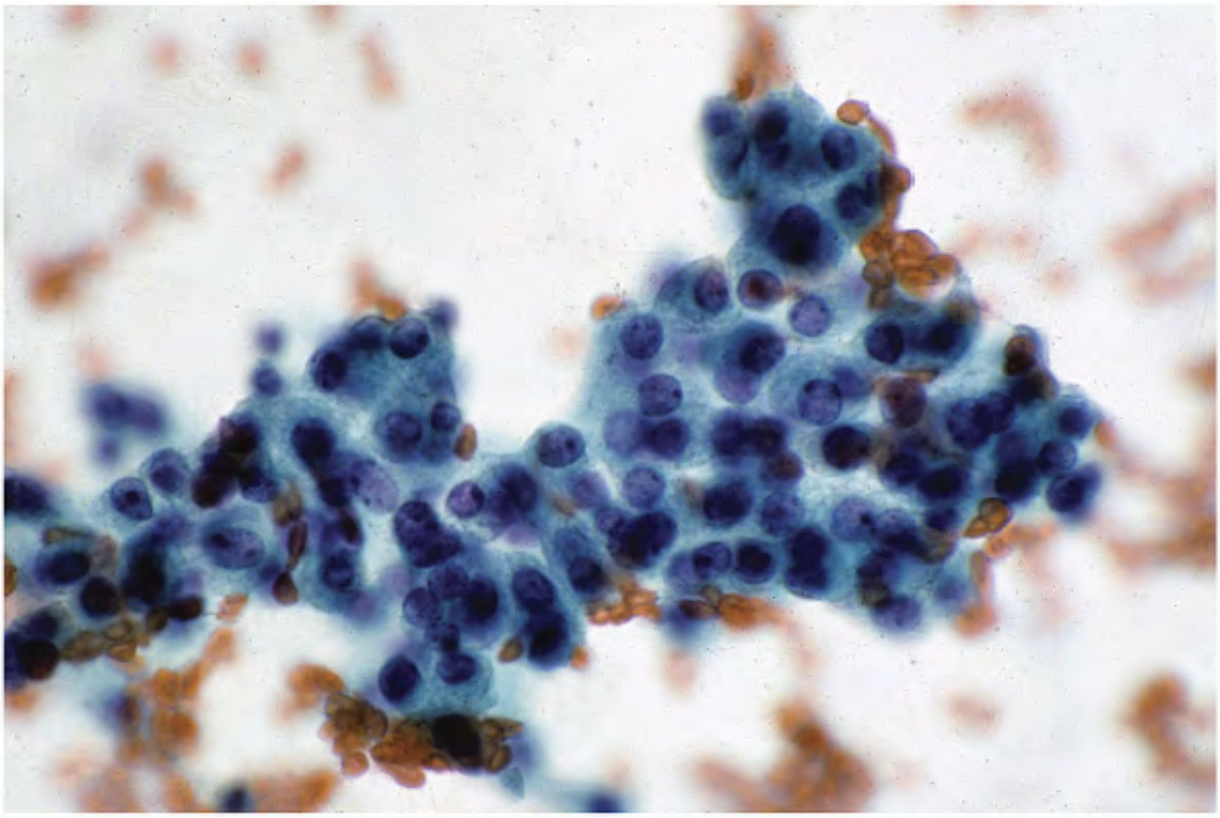

Figure 12.40. The medullary carcinoma cells in this aspirate are compactly arranged in a ti fragment and offer no clue as to their type. This pattern may be mistaken for a follicular neoplasm.

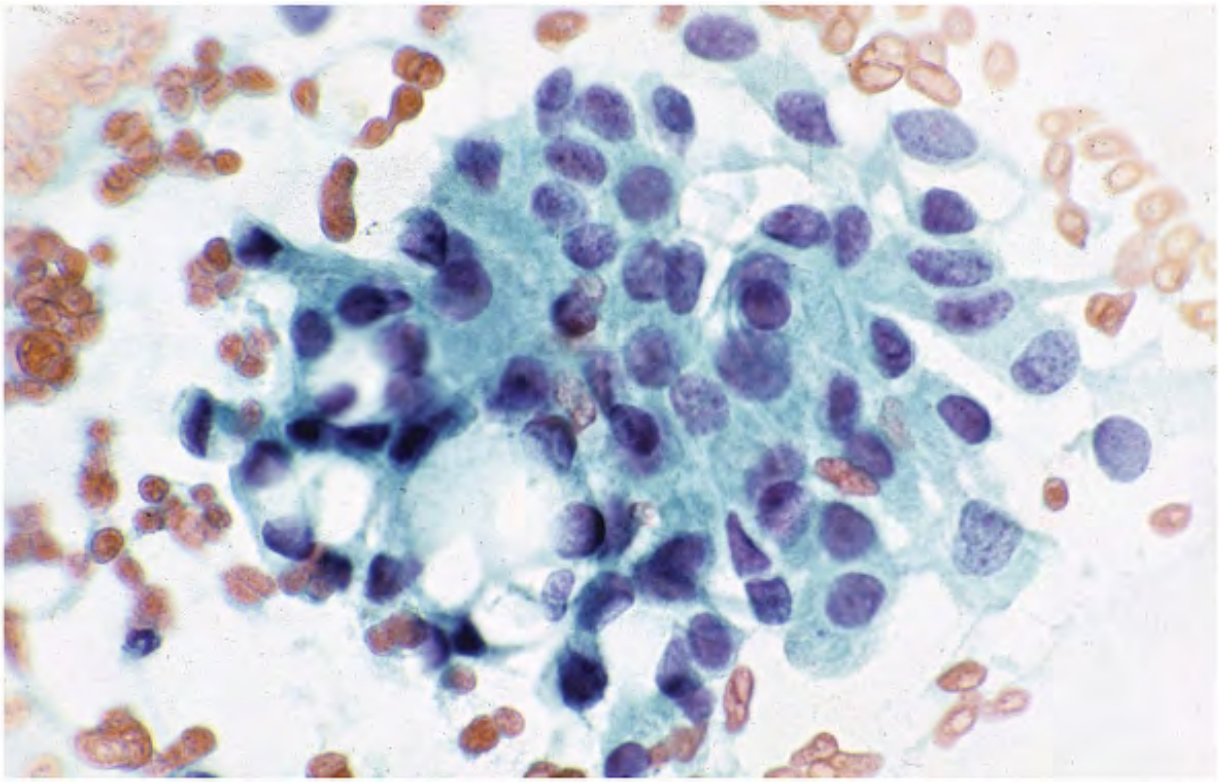

Figure 12.41. These medullary carcinoma cells are pleomorphic but contain abundant dens
cytoplasm.

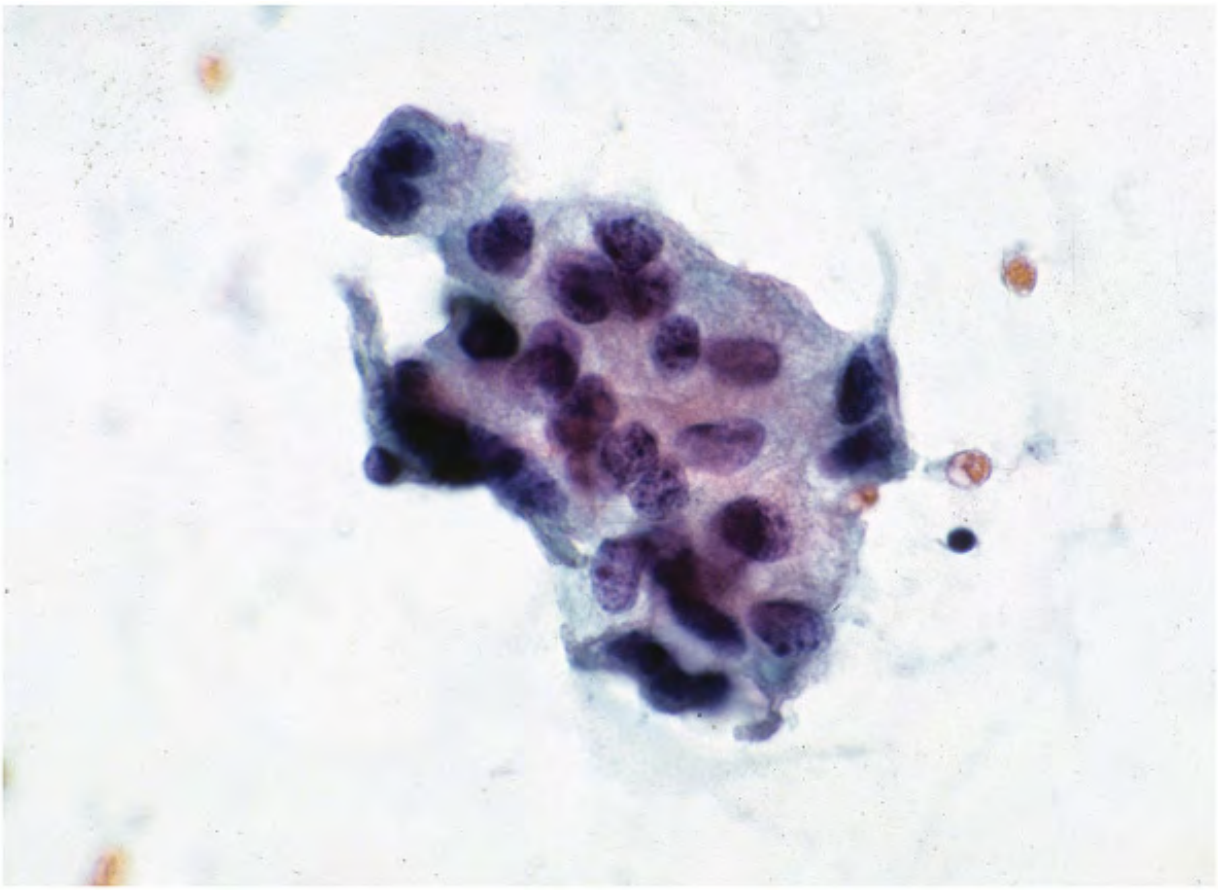

Figure 12.42. These medullary carcinoma cells resemble oncocytes because of their abunda
dense cytoplasm.

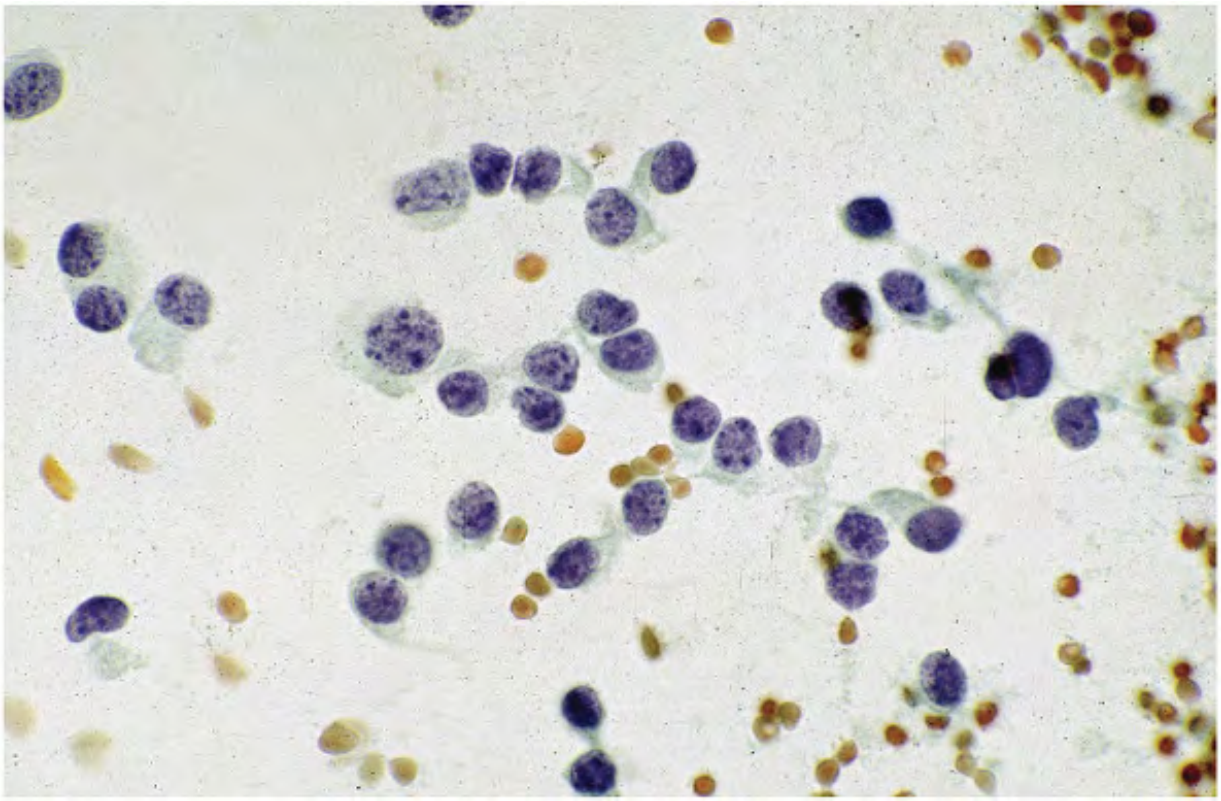

Figure 12.43. Medullary carcinoma. The aspirate is poorly cellular and partially air-dried. T only clue to the diagnosis of medullary carcinoma is the pleomorphic nuclei. A medullary carcinoma with abundant amyloid may yield a poorly cellular aspirate.

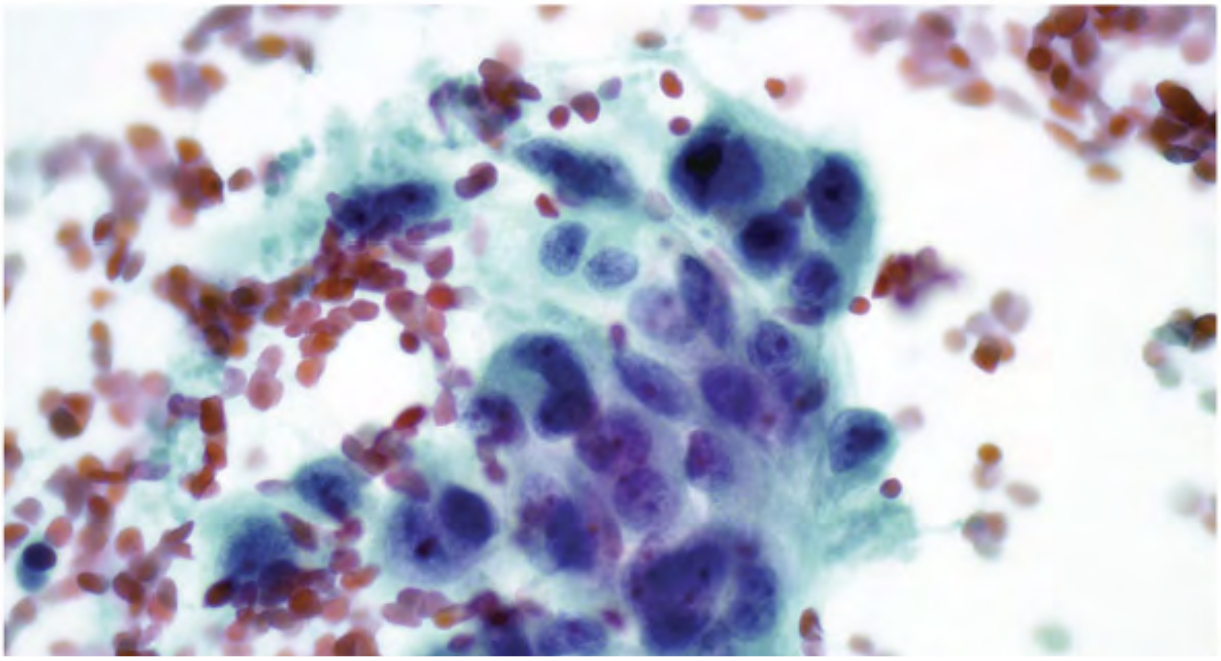

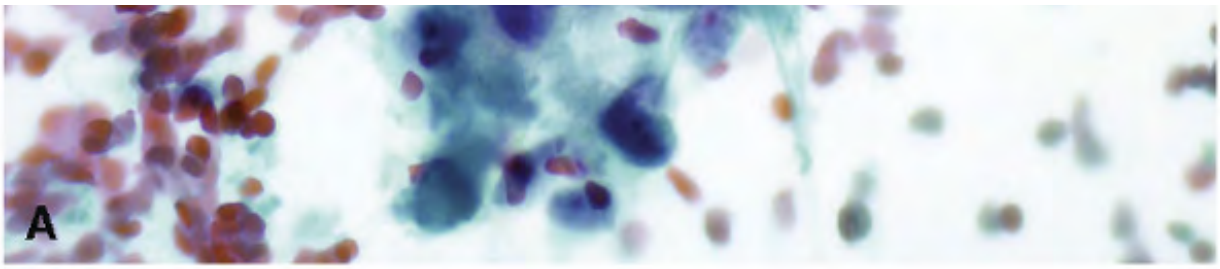

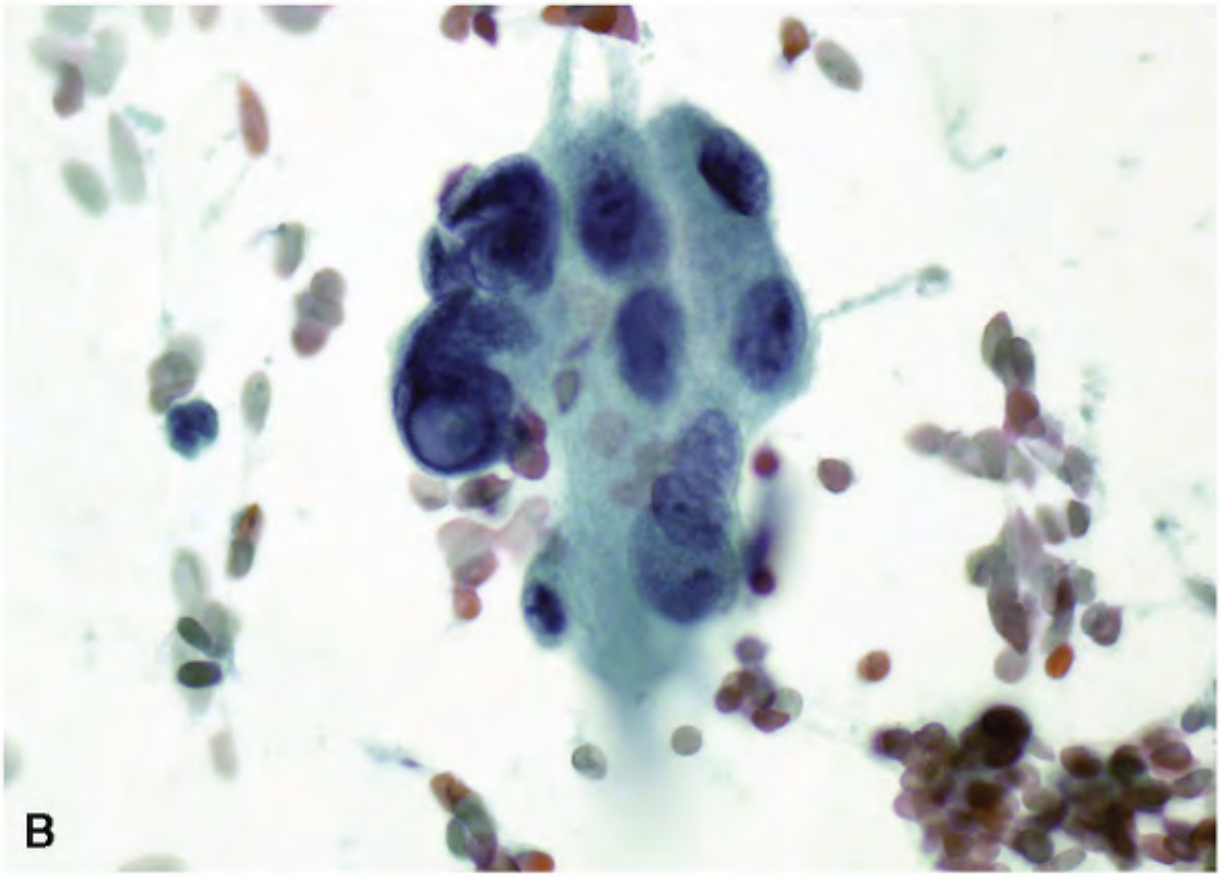

Figure 12.44. A. FNA of a medullary carcinoma cells with extremely pleomorphic cells containing large nuclei resembling anaplastic carcinoma. B. Another field showing similar ce Note large intranuclear cytoplasmic inclusion.

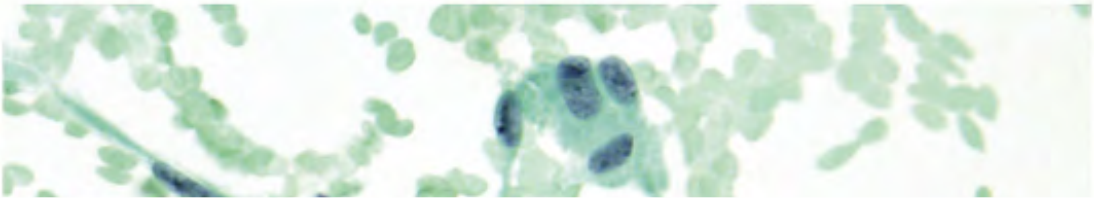

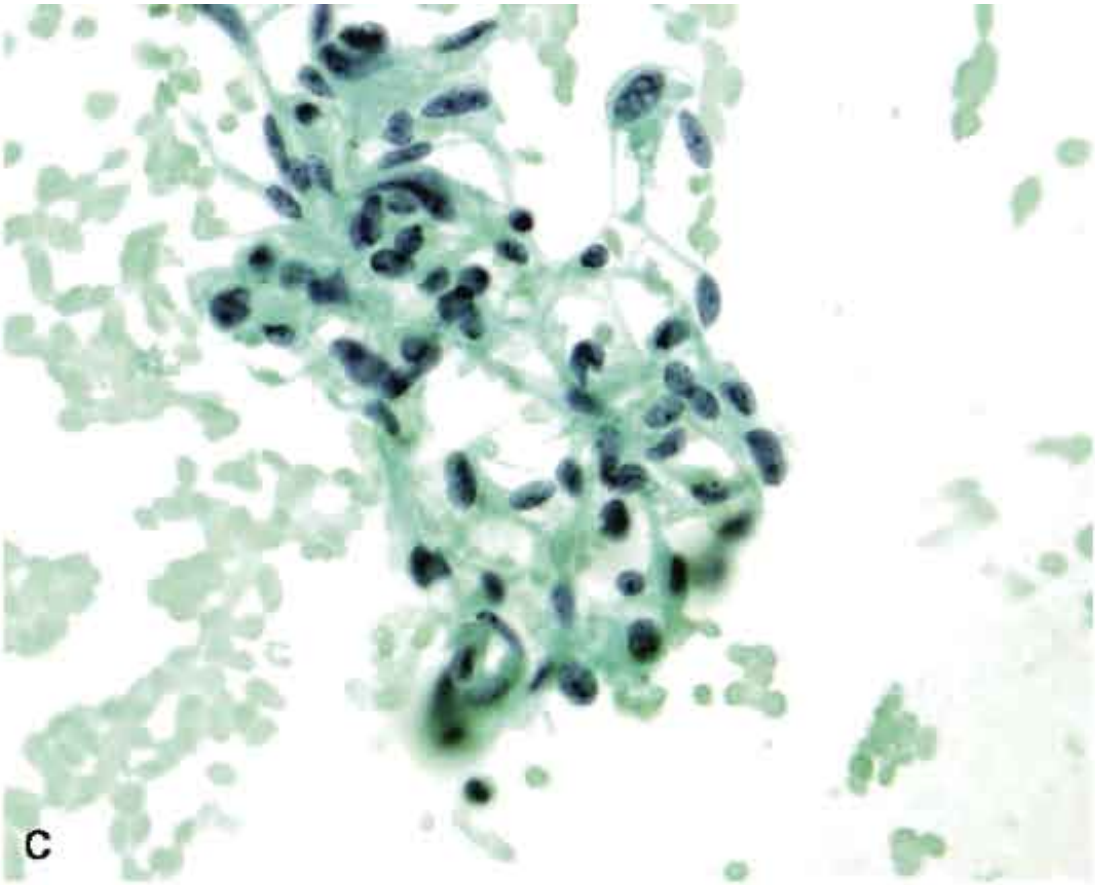
C

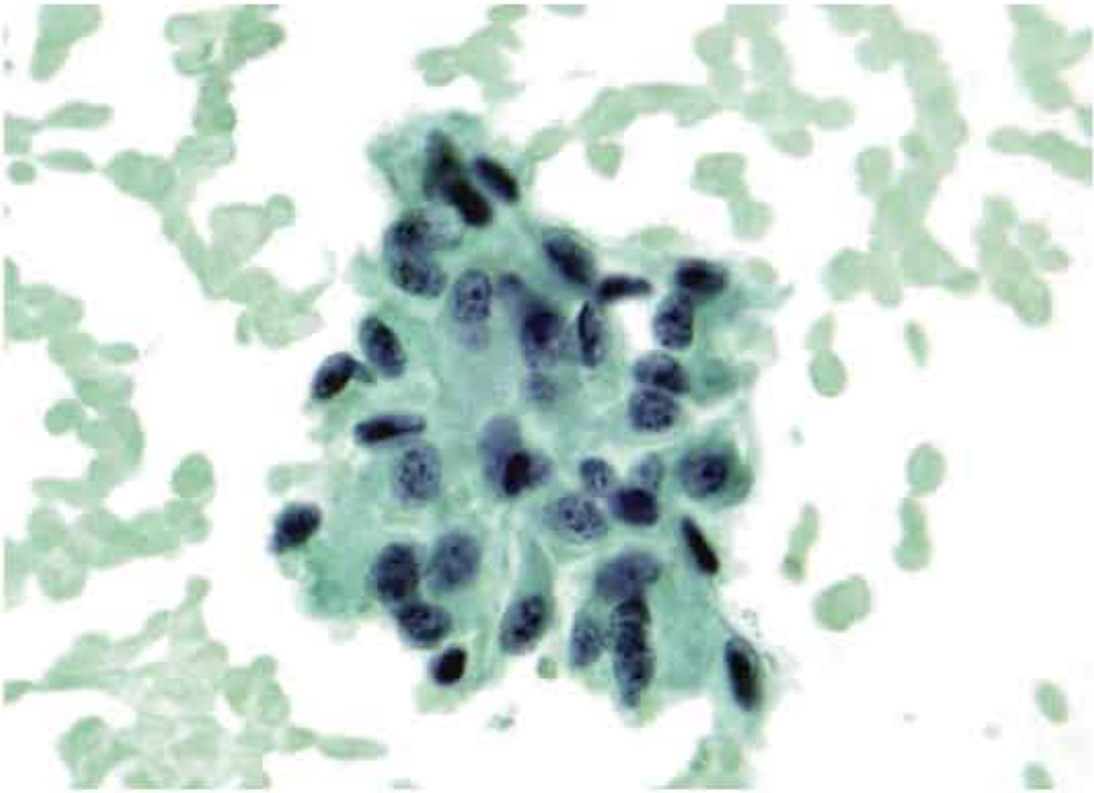

Figure 12.44. C,D. The aspirate also revealed aggregates of spindle-shaped cells. The calci
stain was strongly positive.

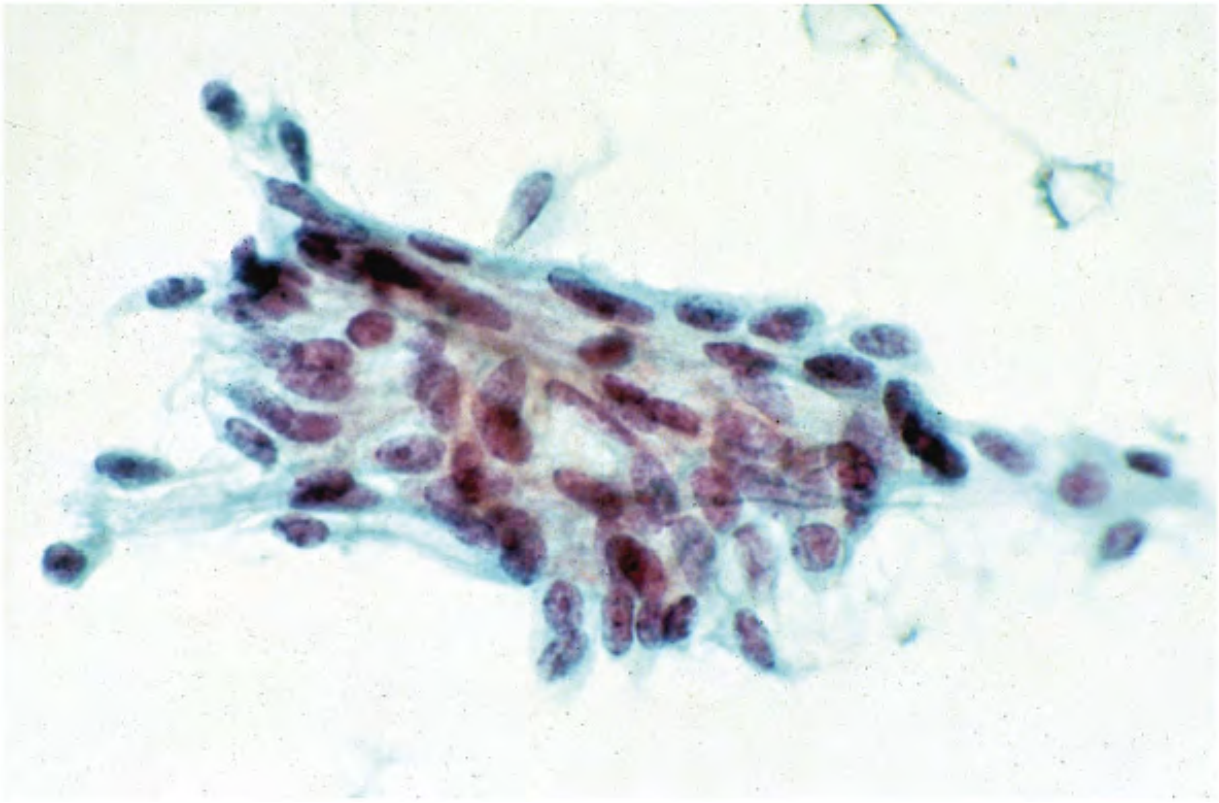

Figure 12.45. Spindle-shaped cells from an aspirate of medullary carcinoma. Note the typic
salt-and-pepper nuclear chromatin.

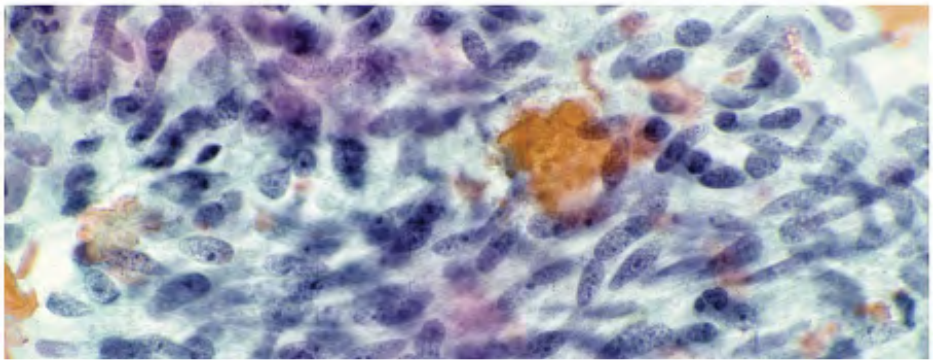

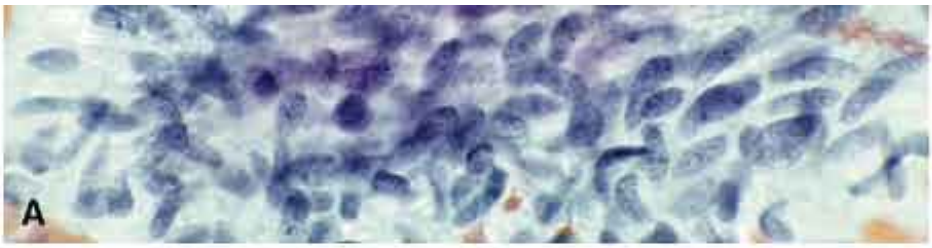
A

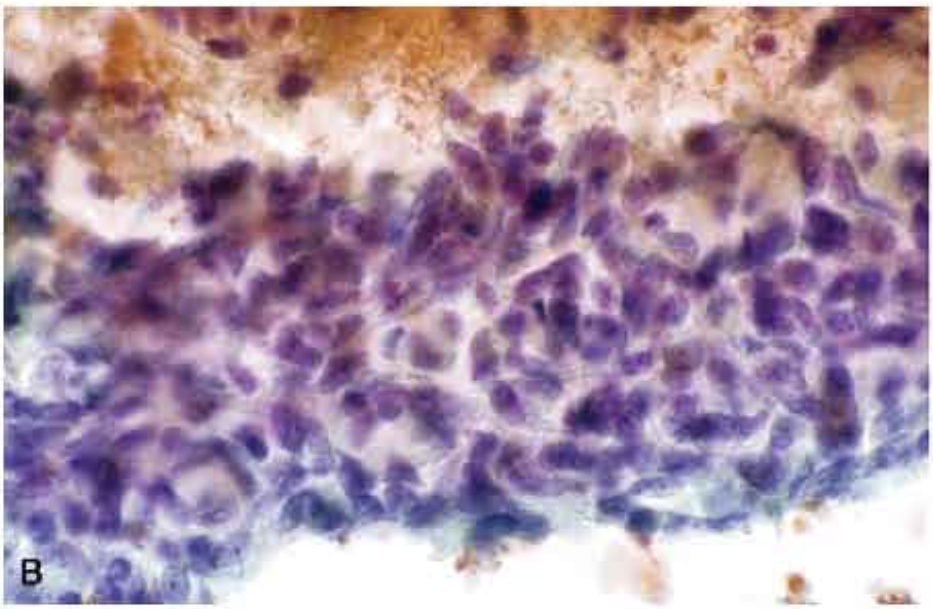
B

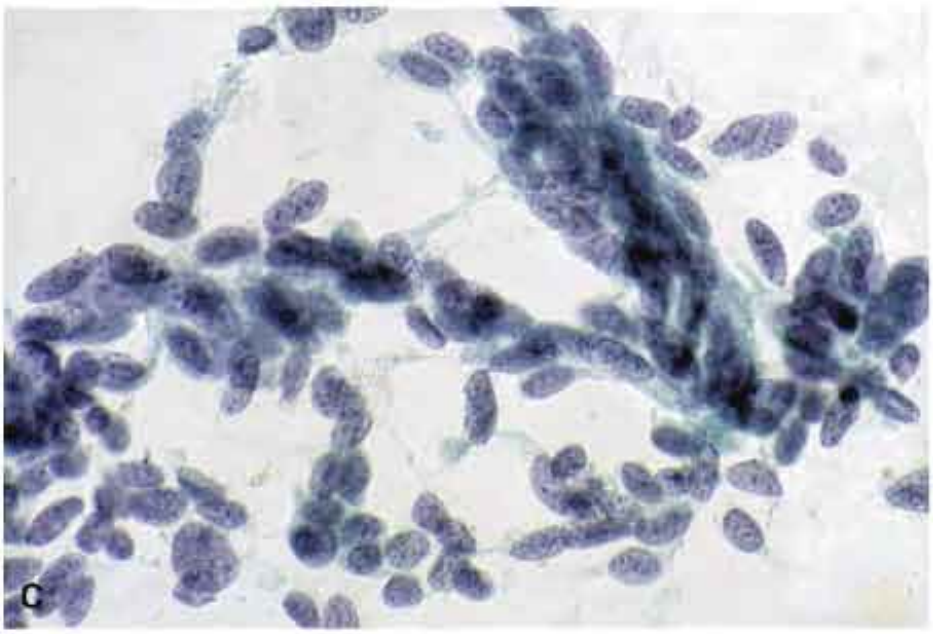
C

Figure 12.46. A,B. FNA of a medullary thyroid carcinoma, with an exclusive spindle cell pat raising the possibility of a soft-tissue tumor. Calcitonin stain was positive. Medullary carcinc was confirmed on thyroidectomy. C. Spindle cells in fascicles from another case of medullar carcinoma.

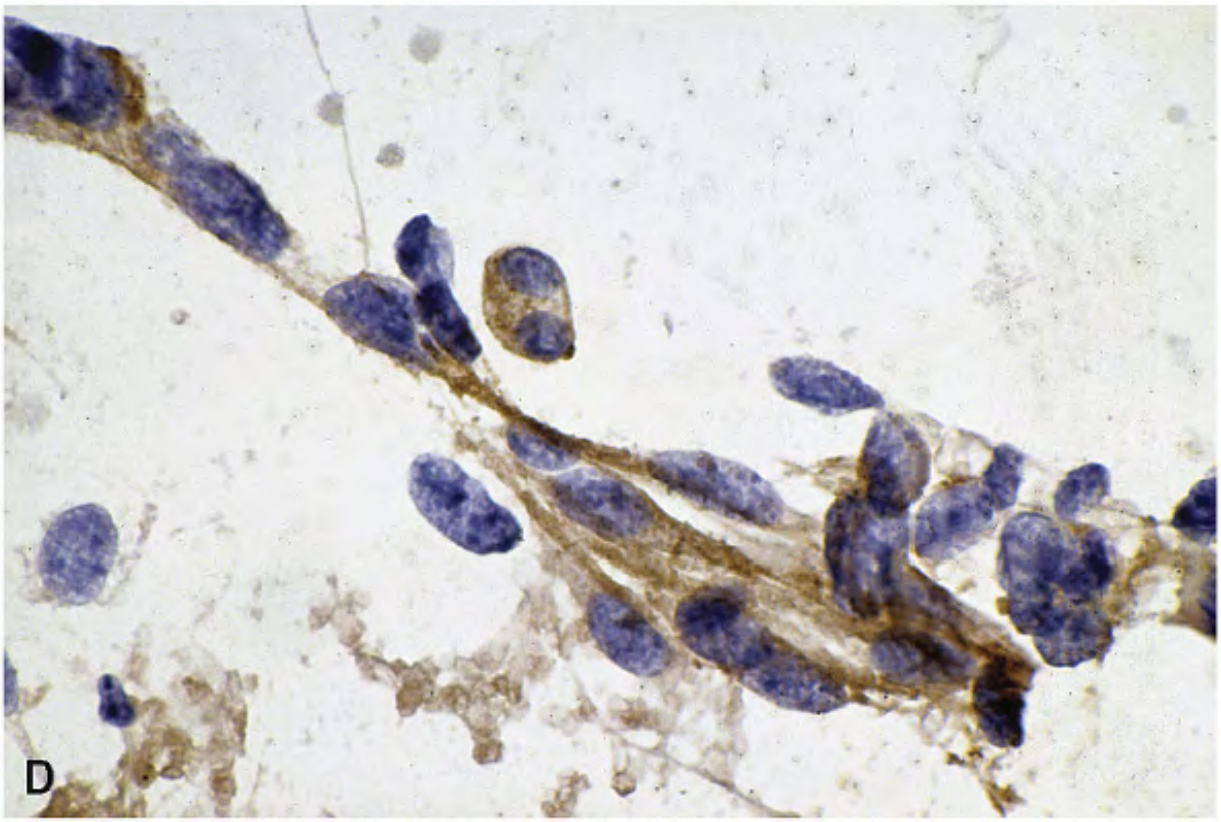

Figure 12.46. D. Positive reactivity to calcitonin.

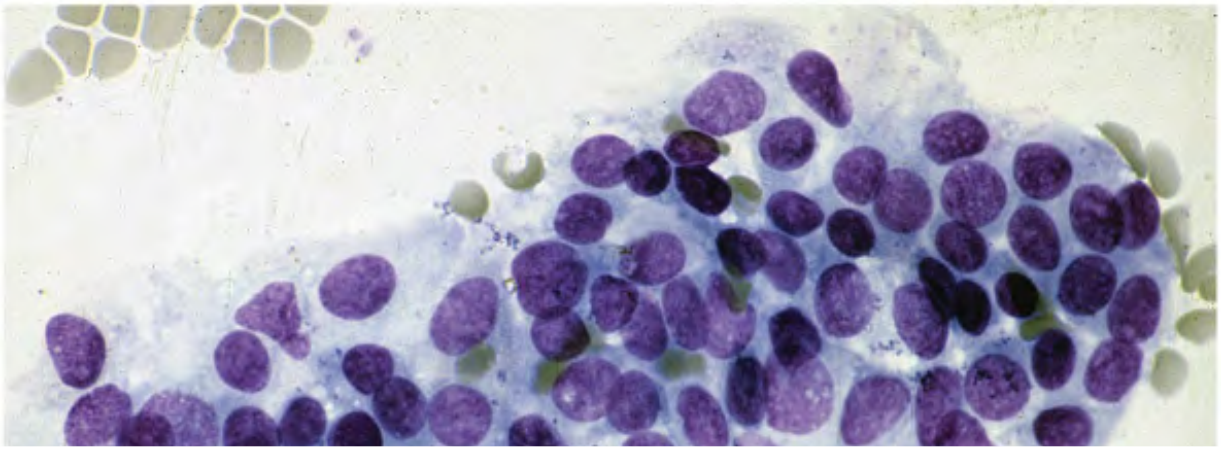

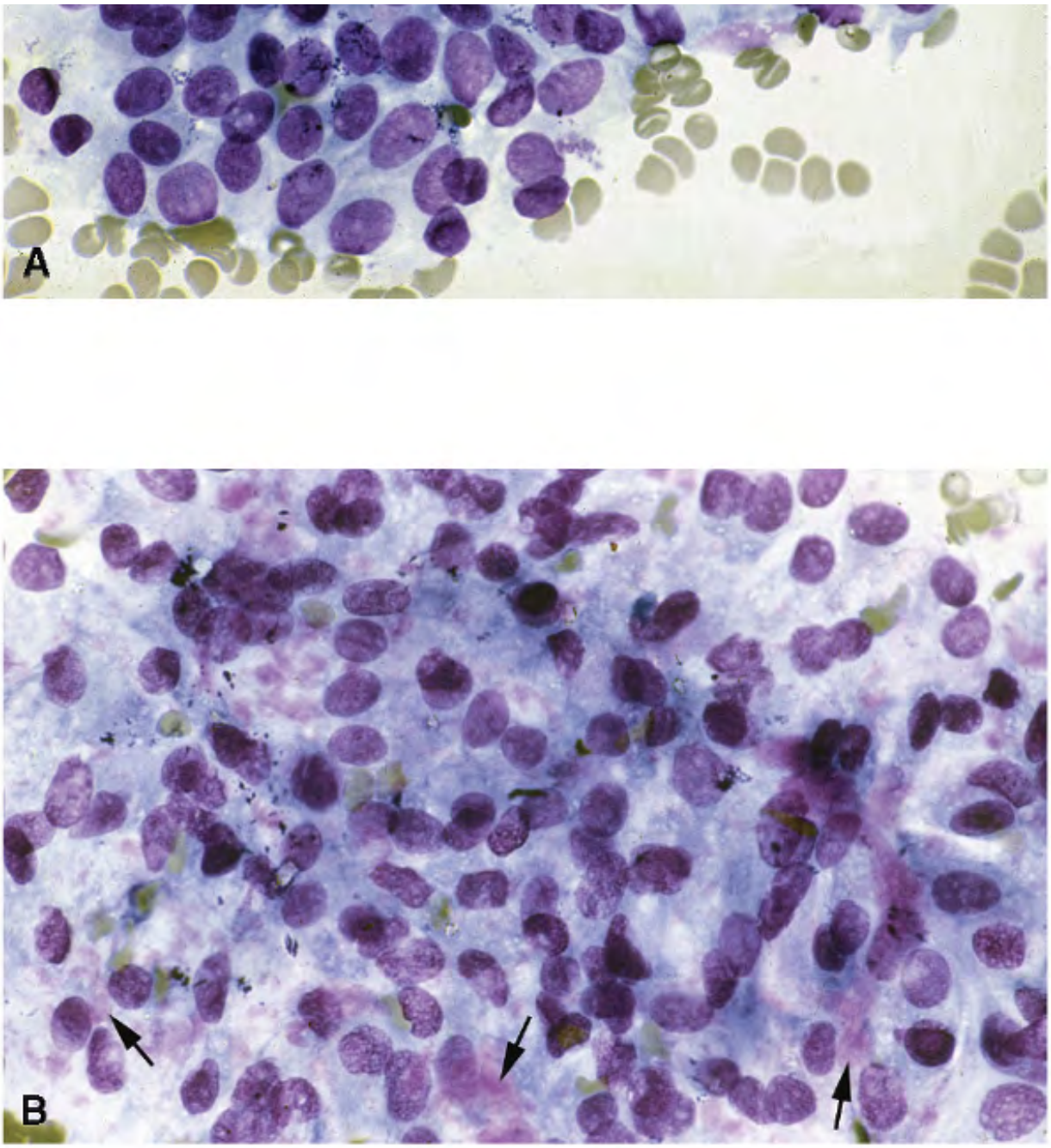

Figure 12.47. FNA of a medullary carcinoma stained with Romanowsky stain. A. The cells a
syncytial tissue fragments. B. Pleomorphic medullary carcinoma cells. Some contain azuropl
granules in their cytoplasm (*arrow*).

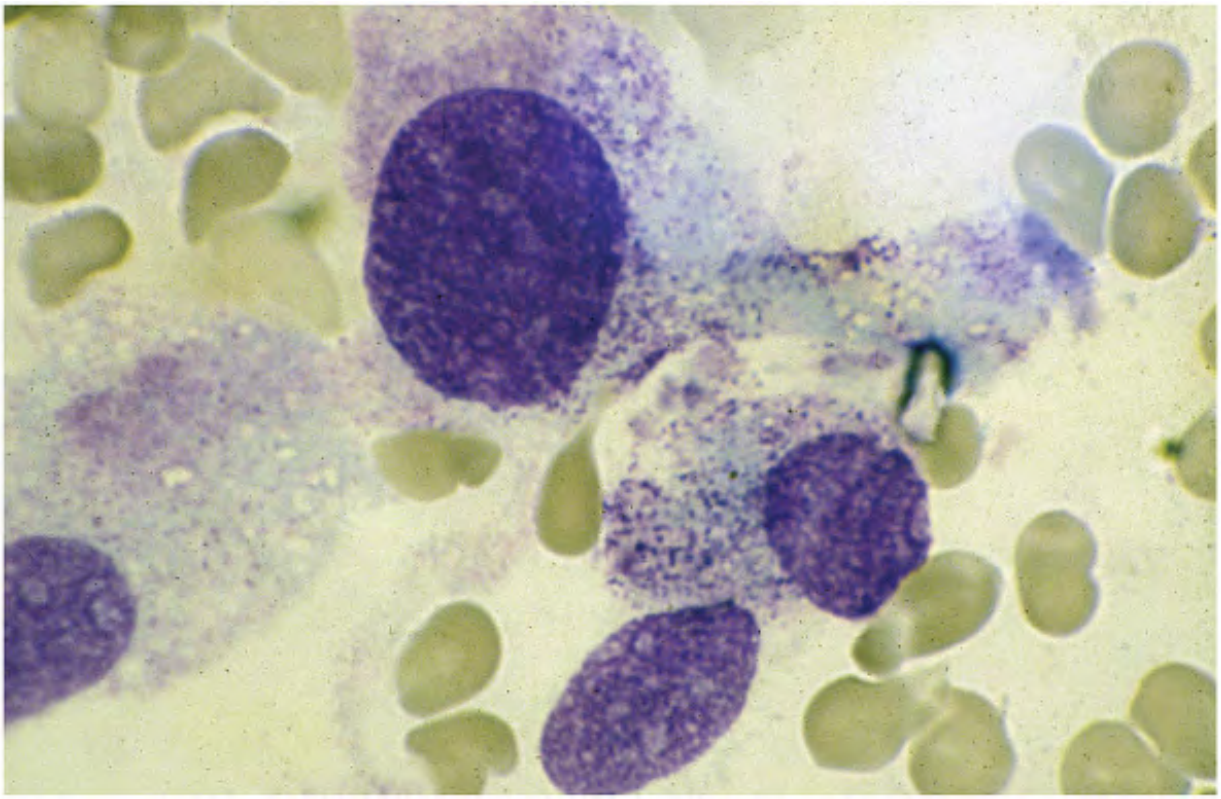

Figure 12.48. These medullary carcinoma cells contain the characteristic azurophilic granu their cytoplasm Romanowsky stain.

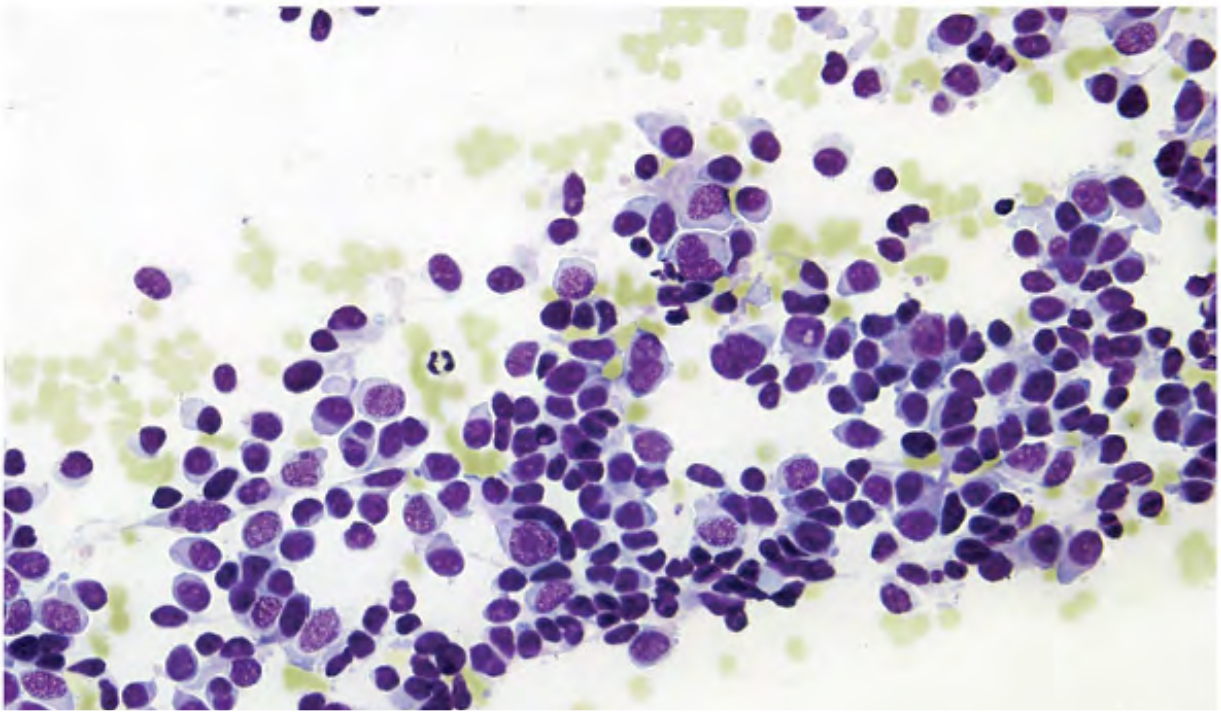

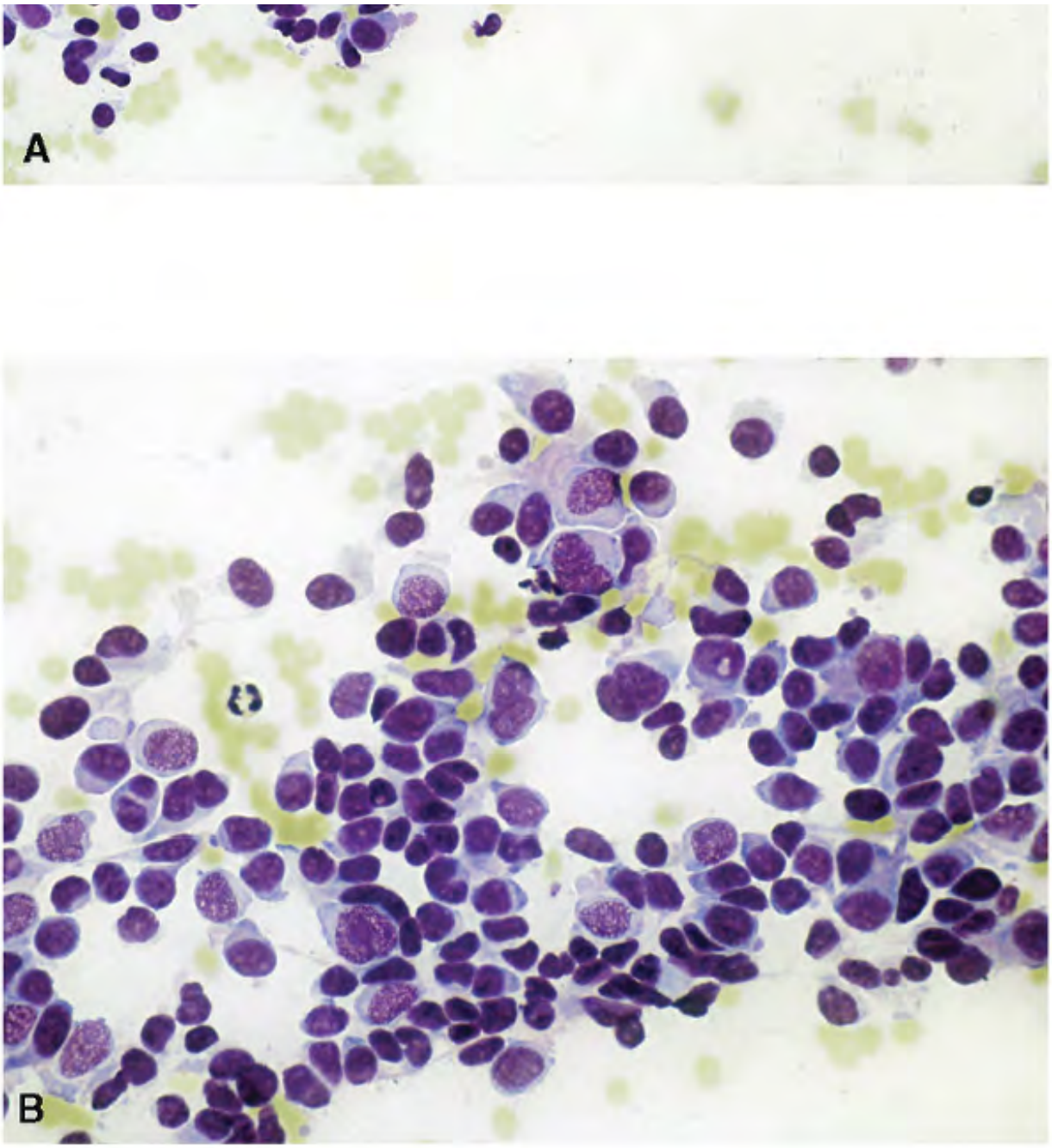

Figure 12.49. Aâ€“C. FNA of a medullary carcinoma presenting a very pleomorphic cell pat Many cells are plasmacytoid. Romanowsky stain.

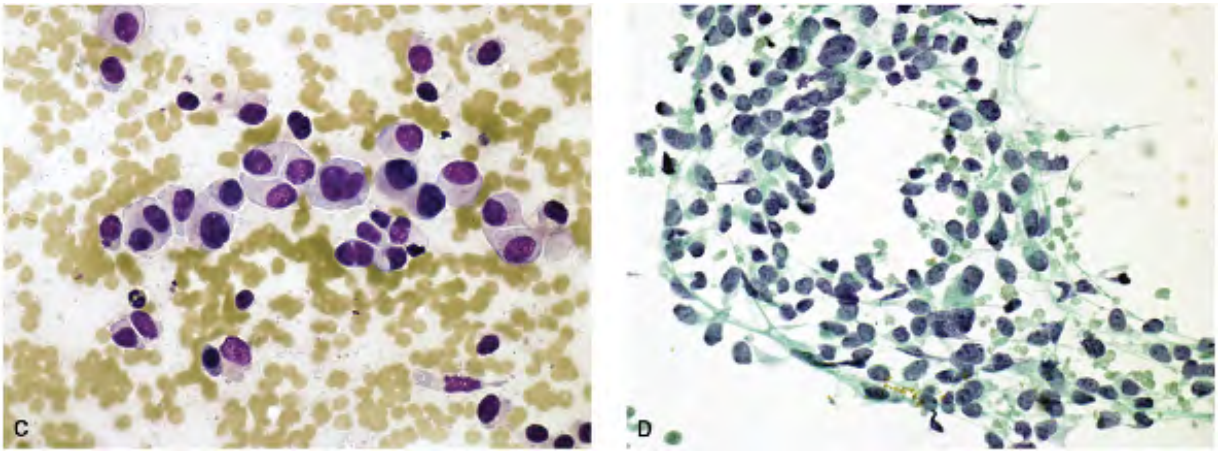

Figure 12.49. D. Same aspirate with Papanicolaou stain. (Courtesy of Mithra Baliga, MD, University of Mississippi, Jackson.)

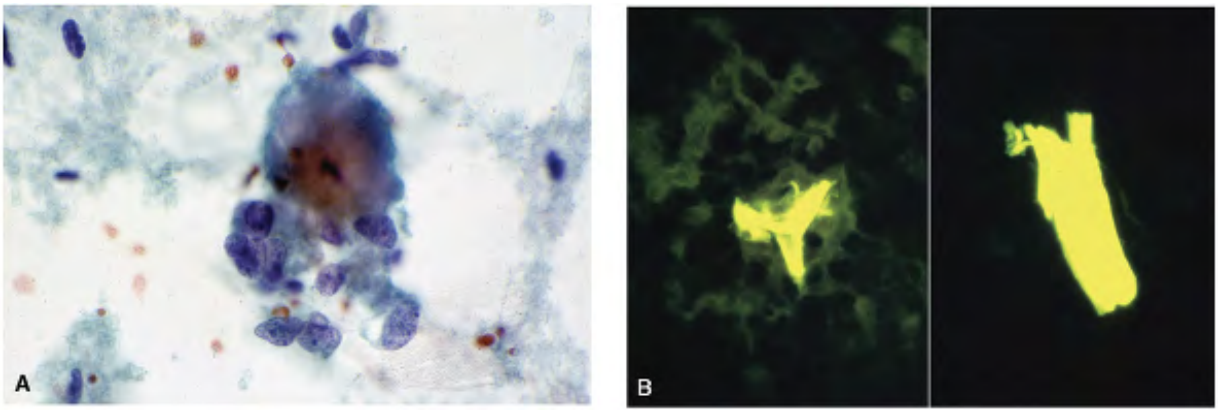

Figure 12.50. A. Dense acellular material in FNA of medullary carcinoma, probably represe amyloid. Note the resemblance to colloid. B. Cell block of an aspirate of medullary carcinor stained with thioflavin T, to demonstrate bright green fluorescence under ultraviolet light.

P.263
P.264
P.265
P.266
P.267
P.268
P.269
P.270

The aspirates are usually cellular; scant cellularity is encountered with carcinomas containi extensive amyloid deposits and calcification.

The smear of an aspirate from medullary carcinoma of the thyroid generally shows malignan cells, either isolated or in loosely cohesive groups (Figs. 12.22 and 12.23) presenting a dispe cell pattern. Syncytial-type tissue fragments are infrequent (Fig. 12.24) and a papillary or follicular pattern is not identified. However, a pseudofollicular pattern may rarely be seen (Fig. 12.56). The spindle cells may be present in fascicles, dispersed, or in aggregates with intertwining cytoplasmic processes (Figs. 12.27 , 12.32 , 12.33 , 12.45 , and 12.46).

Medullary carcinoma cells are very pleomorphic; any size or shape may be present (Figs. 12. 12.26 , 12.27 , 12.28 , 12.29 , 12.30 , 12.31 , 12.32 , 12.33 , 12.34 , 12.35 , 12.36 , 12.37 , 1 , 12.39 , 12.40 , 12.41 , 12.42 and 12.43). The carcinoma cells can be small, round to cuboi reminiscent of carcinoid cells, or oval to plasmacytoid. They may be triangular, polyhedral, racket-shaped, or spindle-shaped. Their size also varies: the small, round cells are slightly la than the follicular cells, and the larger cells are several microns in their largest dimension. cellular aspirate with a dispersed cell pattern formed by pleomorphic cells is virtually pathognomonic of medullary carcinoma (Figs. 12.25 , 12.26 , 12.27 , 12.28 and 12.29), whe a monomorphic pattern comprising only one type of cell is not frequently observed (Figs. 12 12.39 , and 12.40). The latter does cause typing difficulties.

The nuclei of medullary carcinoma cells are always eccentric, regardless of the cell shape, c size, or number of nuclei. Extreme marginal location of the nucleus is characteristic of the plasmacytoid cell type, and bi- and multinucleation occur very frequently (Fig. 12.25). The nuclei are round, sometimes oval and occasionally oblong or elongated in spindle-shaped ce Their chromatin is coarse, stippled with a salt-and-pepper pattern, so characteristic of neuroendocrine tumors (Figs. 12.27 , 12.28 and 12.29). The presence of nucleoli is not a consistent finding. Bizarre nuclei, such as those seen in anaplastic

carcinomas, are rare. A remarkable and consistent feature is the presence of intranuclear cytoplasmic inclusions (Figs. 12.25 , 12.30 , and 12.37).40

The cytoplasm of medullary carcinoma cells is variable. In small round cells, it is very scant hardly discernible (Figs. 12.26 , 12.35 , and 12.36), whereas in plasmacytoid or large polyhe cells it is abundant (Figs. 12.25 , 12.41 , and 12.42). It generally stains pale and has a fibril

quality (Fig. 12.25). The cytoplasm is often drawn out in a delicate process, which may be rudimentary in cuboidal cells (Fig. 12.26 A). SÃ¶derstrÃ¶m et al.43 called these "dendritic processes." The spindle cells of medullary carcinoma are usually and characteristically unipo with eccentric nuclei. A group of spindle cells with delicate intertwined cytoplasmic process a characteristic finding in smears from medullary carcinoma (Fig. 12.33).

Another feature of diagnostic importance is the presence of azurophilic granules in the cytoplasm of medullary carcinoma cells which are seen only in air-dried preparations staine the Romanowsky method (Figs. 12.48 and 12.49), and not in Papanicolaou-stained preparati These granules are present in about 5% to 10% of the neoplastic cell population and probabl represent cytoplasmic calcitonin.

One of the characteristic features of medullary carcinoma is the presence of stromal amyloi can be seen in cytologic preparations as fluffy, finely granular, or dense acellular material i background (Figs. 12.37 and 12.50 A). The amyloid has the same staining characteristics as t colloid in Papanicolaou-stained preparations and cannot be differentiated from it without special stains such as Congo red or thioflavin T (Fig. 12.50 B). Although the presence of intracellular cytoplasmic amyloid has been described by SÃ¶derstrÃ¶m et al.,43 it is not appreciated by Papanicolaou stain. The use of special stains to identify amyloid in cytologic preparations is time-consuming and not recommended. It is best performed on cell-block preparations.

Immunocytohistochemical Profile of Medullary Carcinoma

Positive reactivity to calcitonin is very specific,6 , 45 , 46 although rare negative reactivity been reported.6 , 45 The stain works well on alcohol-fixed cytologic preparations. In our experience, medullary thyroid carcinomas reveal positive reactivity to calcitonin on cytolog smears and have correlated 100% with increased serum calcitonin levels and histologic findi Goellner et al.45 however, reported a positive reaction in 60% of their cytologic preparatior in 93% of histologically proven medullary carcinomas. Bose et al.37 found positive reactivity 55% of their cases. Medullary carcinoma cells show positive reactivity to low-molecular-weig cytokeratin but very rarely to high-molecular-weight keratin. Reactivity to vimentin is varia The carcinoma cells react positively to a host of antibodies such as chromogranin and synaptophysin, aimed at neuroendocrine differentiation (Table 12.2).

Calcitonin

Positive
Low-molecular-weight cytokeratin
Positive
Highâ€“molecular-weight cytokeratin
Rarely expressed
Vimentin
Variable
Neuron-specific enolase
Positive
Synaptophysin
Positive
Chromogranin
Positive
Carcinoembryonic antigen
Positive
Thyroglobulin
Negative
Thyroid transcription factor-1
Positive

Antibodies	Reactivity

TABLE 12.2 IMMUNOPROFILE OF MEDULLARY CARCINOMA

Diagnostic Accuracy

The cytologic typing of medullary carcinoma can be achieved with a high degree of accurac However, it can be mistyped as various different types of thyroid cancers, both histologicall and cytologically.

In our first 9 years of experience with fine-needle aspirates of the thyroid nodules, 571 case were diagnosed as primary thyroid malignancies by surgery, of which 27 (4.5%) were medulla carcinomas. Of these 27 cases, 20 were accurately typed from cytologic specimens. Three w interpreted as undifferentiated carcinoma, one as a follicular variant of papillary carcinoma and two as cellular follicular adenomas (Table 12.3). Typing errors are generally due to

inexperience and unfamiliarity with the varied cytopathologic features of medullary carcinc
Our errors were made within the first 2 years of our experience in interpreting biopsy specimens. In the largest study of cytologic features of medullary carcinomas, Papaparaskev al.32 reviewed fine-needle aspiration biopsy specimens from 91 histologically confirmed medullary carcinomas. Accurate cytologic typing of medullary carcinoma was reported in 89 the cases (81 of 91). Five cases were cytologically mistyped as follicular neoplasms, and 4 ca were typed as papillary carcinoma, 4 as neuroendocrine carcinoma, 4 as carcinoma NOS, an as spindle cell tumor. There was one false-negative case, interpreted as follicular hyperplas

Medullary carcinoma
20
8
6
1
HÃ¼rthle cell carcinoma
0
0
0
0
Undifferentiated carcinoma
3
0
0
0
Papillary carcinoma
1
0
0
0
Follicular adenoma
2
0
0
0
Acellular

1
0
0
0

	Histologic Diagnosis			
Cytologic Diagnosis	Medullary Carcinoma (n = 27)	HÃ¼rthle Cell Carcinoma (n = 8)	Papillary Carcinoma (n = 8)	Nod Goi (n =

TABLE 12.3 CYTOHISTOLOGIC CORRELATION OF MEDULLAR CARCINOMA OF THE THYROID

Medullary carcinoma also tends to be over diagnosed cytologically. The monomorphic cell population of HÃ¼rthle cell carcinomas, the single cell pattern in papillary carcinomas, and spindle cells in anaplastic carcinomas all may be mistaken for medullary carcinoma. In our series, 33 cases were typed cytologically as medullary carcinoma, of which 20 were confirm were diagnosed as HÃ¼rthle cell carcinoma, 4 as papillary carcinoma, and 1 as nodular goit (Table 12.3). In the series reported by Papaparaskeva et al.,32 14 cases cytologically typed diagnostic or suspicious for medullary carcinoma were histologically proven to be follicular neoplasms (4), papillary carcinoma (4), metastatic carcinoid tumor (2), paraganglioma (2), metastatic renal cell carcinoma (1), and nodular goiter (1).

A cytologic diagnosis of medullary carcinoma must be confirmed by other means, such as:

- Immunostain for calcitonin.
- Serum calcitonin levels.
- Large-needle biopsy (size of the thyroid nodule permitting).47 , 48

Poor cellularity is likely to result in a false-negative diagnosis (Fig. 12.43). A diligent search necessary in poorly cellular specimens with abundant amyloid to identify medullary carcinor cells. Immunostains for calcitonin, as well as serum calcitonin levels, should help confirm th

diagnosis.

Differential Diagnosis

The pleomorphic cell pattern is characteristic and diagnostic of medullary carcinoma. It is n frequently encountered, allowing an accurate cytologic diagnosis. A monomorphic cell patte comprised of only one cell type such as small round cells, plasmacytoid cells, or spindle-sha cells, is not common and may be mistaken for other types of thyroid neoplasms, and vice ve (Table 12.4).51 , 52 , 53 , 54 , 55 , 56 , 57 , 58 , 59 , 60 , 61 , 62 , 63 Neoplasms such as HÃ¼rthle cell carcinomas are often confused with medullary carcinoma because of the plasmacytoid cells. Bourtsos et al.63 reported a case of primary plasmacytoma of the thyroi that was interpreted as medullary carcinoma. Follicular neoplasms (e.g., hyalinizing trabecu adenoma and follicular adenomas and carcinomas) have been misinterpreted as medullary carcinomas. Extreme pleomorphism with bizarre nuclei or a spindle cell pattern may be mistaken for anaplastic carcinoma. A spindle cell pattern can also be confused with soft-tiss tumors. Medullary carcinomas demonstrate morphologic overlap with other neuroendocrine tumors such as carcinoid tumors,23 paragangliomas,19 , 20 , 21 or the rare "oat- cell carcin of the thyroid.57 The small cell pattern may also be mistyped as poorly differentiated "insul thyroid carcinoma, metastatic small cell carcinoma, or a malignant lymphoma. Benign cond may also cause diagnostic pitfalls. The presence of benign spindle cells of stromal origin in c of nodular goiters when present in large numbers may mimic the cytologic pattern of medul carcinoma. The rare cases of amyloid goiter in patients with systemic amyloidosis are anoth example of diagnostic pitfall. Hyperplastic nodular goiters were interpreted as medullary carcinoma as reported by Papaparaskeva,32 Forrest,33 and their colleagues.

Nodular goiter
- Follicular cell hyperplasia
- Spindle-shaped stromal cells

Amyloidosis or amyloid goiter
Follicular neoplasms
- Hyalinizing trabecular adenoma
- Cellular follicular adenoma
- Follicular carcinoma

HÃ¼rthle cell carcinoma
Papillary carcinoma

Poorly differentiated "insular carcinoma"
Anaplastic (undifferentiated) carcinoma
Other neuroendocrine tumors
  Carcinoid tumor
  Paraganglioma
  Calcitonin-free oat cell carcinoma (neuroendocrine carcinoma)
Soft-tissue tumors (primary or metastatic)
Malignant lymphoma
Malignant melanoma

TABLE 12.4 DIFFERENTIAL DIAGNOSIS OF MEDULLARY CARCINOMA

Medullary Carcinoma versus Stromal Cells in Nodular Goiter

Occasionally, in a nodular goiter, the fibroblasts from the supporting stroma or the granulat tissue from an old hemorrhage appear very similar to the spindle cells of medullary carcinor (Figs. 12.51 , 12.52 and 12.53). Features of nodular goiter, if present in other areas of the smears, should aid in correct interpretation. Also, the stromal fibroblasts are bipolar with central nuclei while medullary carcinoma cells are unipolar with eccentric nuclei.

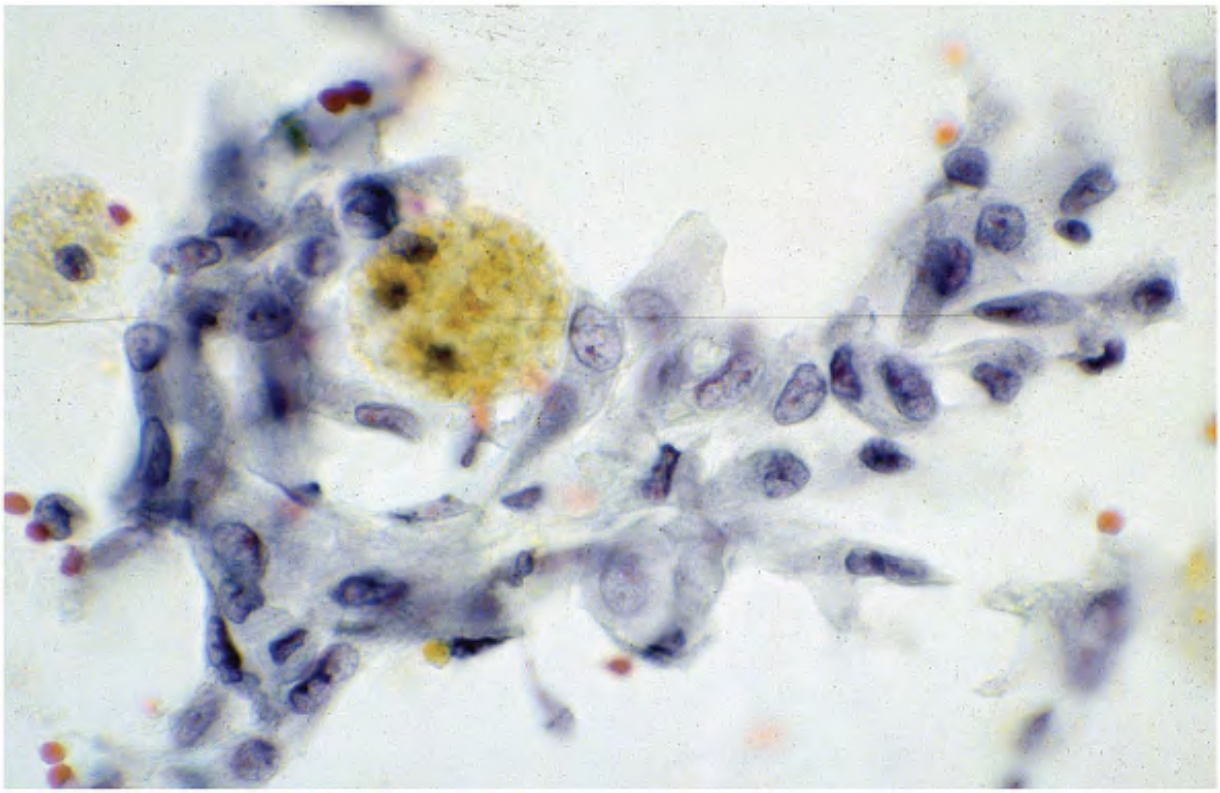

Figure 12.51. *Medullary carcinoma versus nodular goiter* . Spindle-shaped stromal cells fro nodular goiter may be mistaken for medullary carcinoma. The delicate, slender spindle cells bear a strong resemblance to medullary carcinoma cells. The stromal cells, however, are fe number and occur in the background of nodular goiter. The spindle-shaped stromal cells are bipolar while the medullary carcinoma cells are unipolar.

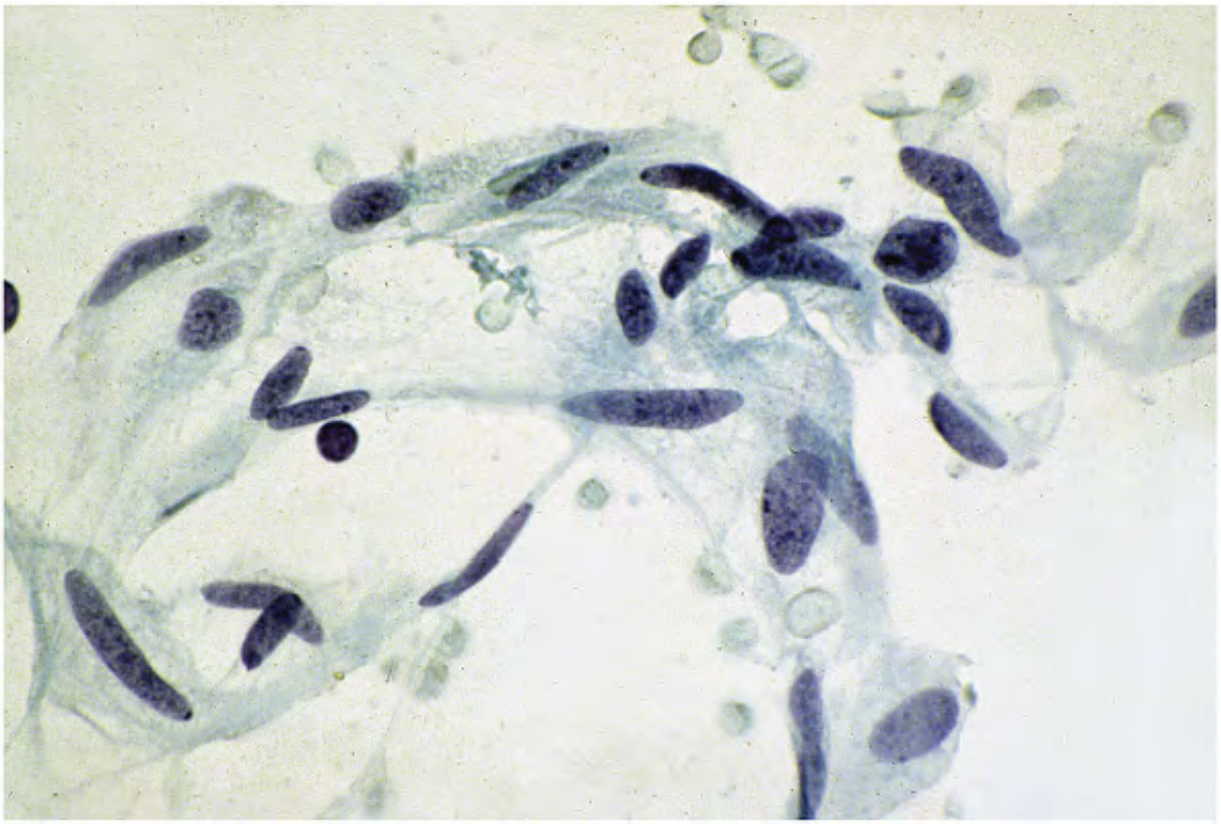

Figure 12.52. *Medullary carcinoma versus nodular goiter* . Another example of pleomorphic stromal cells from an aspirate of nodular goiter. Note that the stromal cells are bipolar with central nuclei, unlike medullary carcinoma cells, which are usually unipolar with eccentric nuclei.

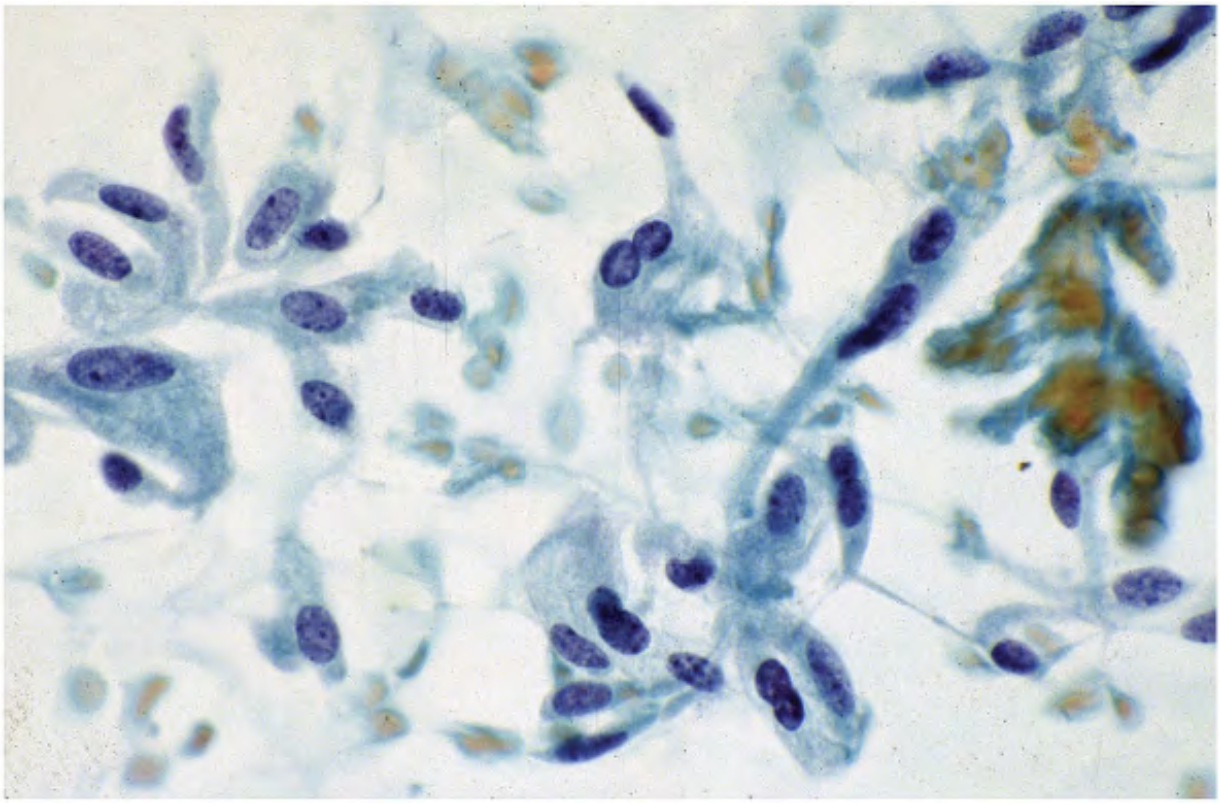

Figure 12.53. FNA of a medullary carcinoma showing unipolar spindle-shaped cells for comparison.

Medullary Carcinoma versus Hyperplastic Nodular Goiter

Follicular hyperplasia in a nodular goiter has been misinterpreted as medullary thyroid carcinoma.32 , 33 The hypercellular specimens composed of round to cuboidal follicular cel may be responsible for mistyping.

Medullary Carcinoma versus Amyloid Goiter

Systemic amyloidosis involving the thyroid gland rarely presents as a goiter (Fig. 12.54).49 Extensive amyloid deposits in a cellular sample may be misinterpreted as medullary carcino as reported by Kapila and Verma.49

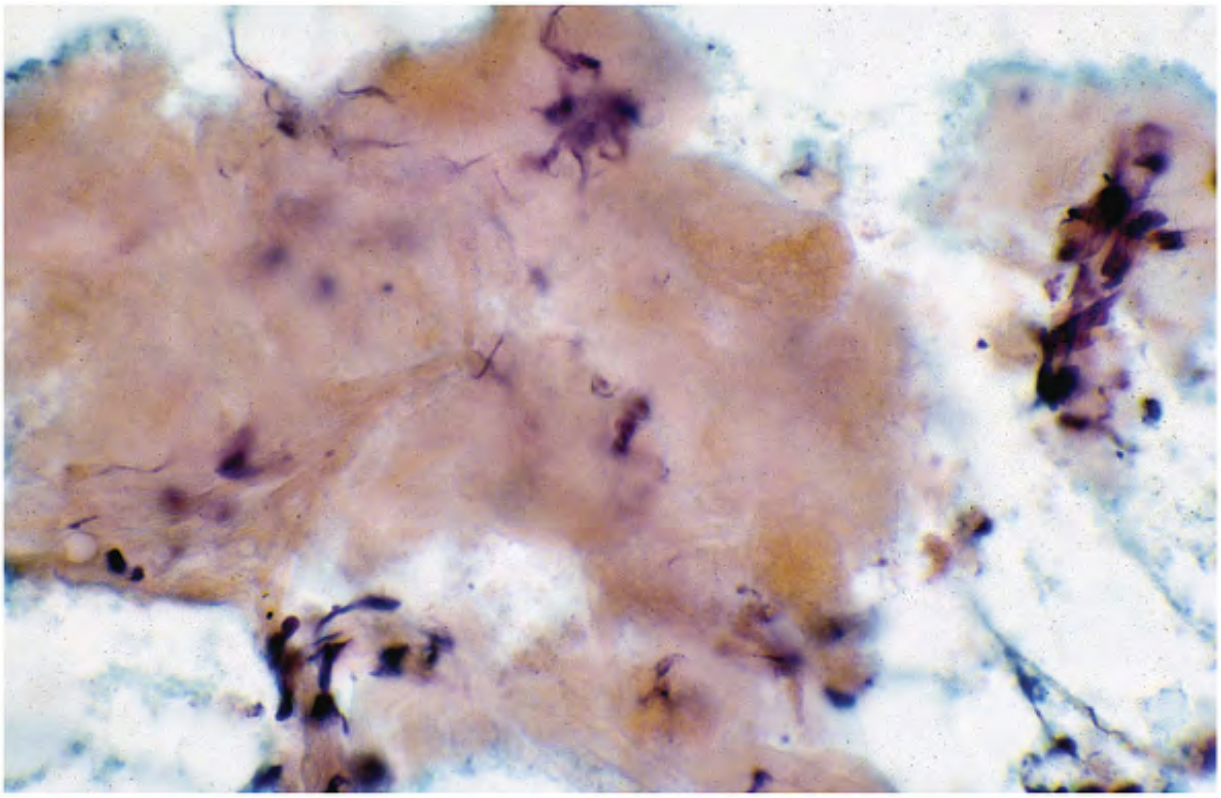

Figure 12.54. *Medullary carcinoma versus amyloid goiter* . FNA of amyloid goiter. The aspir is poorly cellular, consisting of predominantly acellular material that is proven histochemica as amyloid. (Courtesy of John F. Goellner, MD, Previously of Department of Pathology, Mayo Clinic, Rochester, Minnesota.)

Medullary Carcinoma versus Hyalinizing Trabecular Adenoma

Hyalinizing trabecular adenoma is an infrequent subtype of follicular adenoma that strongly resembles medullary carcinoma both cytologically and histologically (Fig. 12.55).51 , 52 , 5 54 , 55 , 56 The distinction between the two may be very difficult without the aid of immunocytohistochemical stains for calcitonin and thyroglobulin. Table 12.5 lists the cytolo features of both medullary carcinoma and hyalinizing trabecular adenoma.

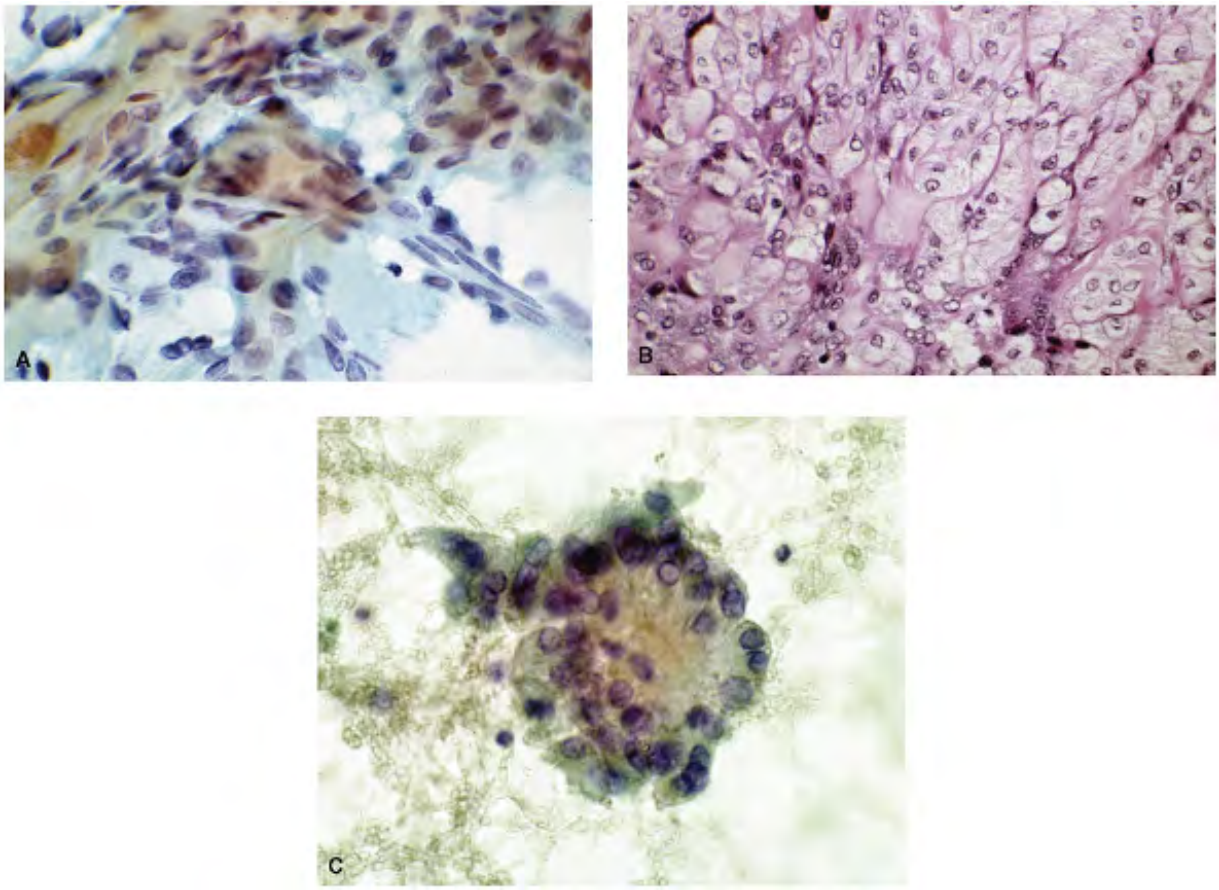

Figure 12.55. *Medullary carcinoma versus hyalinizing trabecular adenoma* . A. FNA of a hyalinizing trabecular adenoma. The cells are elongated, spindle-shaped, and have bland nu The pattern has a strong resemblance to medullary thyroid carcinoma cells and is interprete such. B. Histologic section of the lesion showing a characteristic pattern of hyalinizing trabecular adenoma. C. FNA of a hyalinizing trabecular adenoma showing a pseudofollicular pattern. The collagen seen in the center may be mistaken for amyloid. (Part C is courtesy o Marizza de Peralta-Venturina, MD, William Beaumont Hospital, Royal Oak, Michigan.)

Cellularity
Variable, usually cellular
Variable
Presentation
Cells mostly isolated or in loosely cohesive
groups with a dispersed pattern; syncytial tissue
fragments not common; no architectural

configurations

Cells isolated, in loosely cohesive groups and in syncytial tissue fragments, some with central acellular hyaline material with cells springing from it; trabecular with branching

Cells

Monomorphic to markedly pleomorphic; round, plasmacytoid, spindle shaped with unipolar cytoplasmic processes; well-defined to poorly defined cell borders; N/C ratios variable

Round, oval, elongated, spindle shape with bipolar cytoplasmic processes; well to poorly defined cell borders; N/C ratios low

Nucleus

Eccentric with extreme marginal location; bi- and multinucleation frequent; giant forms Â±; pleomorphic, round, oval, oblong to spindle shaped, smooth nuclear membranes; salt-and-pepper type granular chromatin, sometimes chunky; nucleoli usually not seen; intranuclear inclusions always present; grooves not appreciated

Central to eccentric; round to oval, smooth nuclear membranes; bi- and multinucleation not seen; finely granular chromatin; micronucleoli; perinucleolar halo +; intranuclear inclusions always present; nuclear grooves +

Cytoplasm

Variable; scant to abundant; pale, granular to dense; intracytoplasmic azurophilic granules with Romanowsky stain

Abundant, pale

Background

Clean; amorphous, acellular, hyaline material confirmed as amyloid with Congo red stain or

thioflavin T

Clean; amorphous, acellular, hyaline material; negative staining for amyloid; hyaline material of basement membrane origin

Immunoprofile

Positive reactivity to calcitonin; negative reactivity to thyroglobulin

Negative reactivity to calcitonin; positive reactivity to thyroglobulin

Medullary Carcinoma	Hyalinizing Trabecular Adenoma

TABLE 12.5 DIFFERENTIATING FEATURES BETWEEN MEDULLARY CARCINOMA AND HYALINIZING TRABECULAR ADENOMA

Medullary Carcinoma versus Follicular Adenoma/Carcinoma

A common cytologic presentation of medullary carcinoma is that of isolated or loosely cohes cells. The infrequent cytologic presentation of syncytial-type tissue fragments with a pseudofollicular pattern and small, round to cuboidal cells with nuclei containing coarse chromatin may be mistyped as

follicular adenoma or carcinoma. The presence of intranuclear cytoplasmic inclusions favors diagnosis of medullary carcinoma or a follicular variant of papillary carcinoma. Recognition medullary carcinoma may be extremely difficult unless cytoplasmic processes are identified (Table 12.6 , Figs. 12.56 , 12.57 , 12.58 and 12.59). Appropriate immunostains will confirm diagnosis.

Cellularity

Usually cellular

Variable

Presentation

Cells mostly isolated or in loosely cohesive groups with a dispersed pattern; syncytial tissue

fragments not common; no architectural configurations; pseudofollicular pattern Â±

Cells arranged in syncytial tissue fragments with and without follicular pattern; isolated and loosely cohesive groups less frequent

Cells

Small, round to cuboidal; ill-defined to well-defined cell borders; high N/C ratios

Small, round to cuboidal; ill-defined cell borders; high N/C ratios

Nucleus

Eccentric; round, oval; smooth nuclear membranes; salt-and-pepper type granular chromatin, sometimes chunky; nucleoli usually not seen; intranuclear inclusions always present

Central location; round with smooth nuclear membranes; coarsely granular chromatin; micronucleoli Â±; intranuclear inclusions absent

Cytoplasm

Scant, pale to dense; cytoplasmic tailing (rudimentary process) Â±

Scant indiscernible cytoplasm; no cytoplasmic processes

Amyloid

Â±

Absent

Colloid

Absent

Â±; May be present in the background or within the follicular lumens

Immunoprofile

Positive reactivity to calcitonin; negative reactivity to thyroglobulin

Negative reactivity to calcitonin; positive reactivity

to thyroglobulin

Medullary Carcinoma	Follicular Adenoma/Carcinoma

TABLE 12.6 DIFFERENTIATING FEATURES BETWEEN MEDULLARY CARCINOMA WITH ROUND CELL PATTERN AN FOLLICULAR ADENOMA/FOLLICULAR CARCINOMA

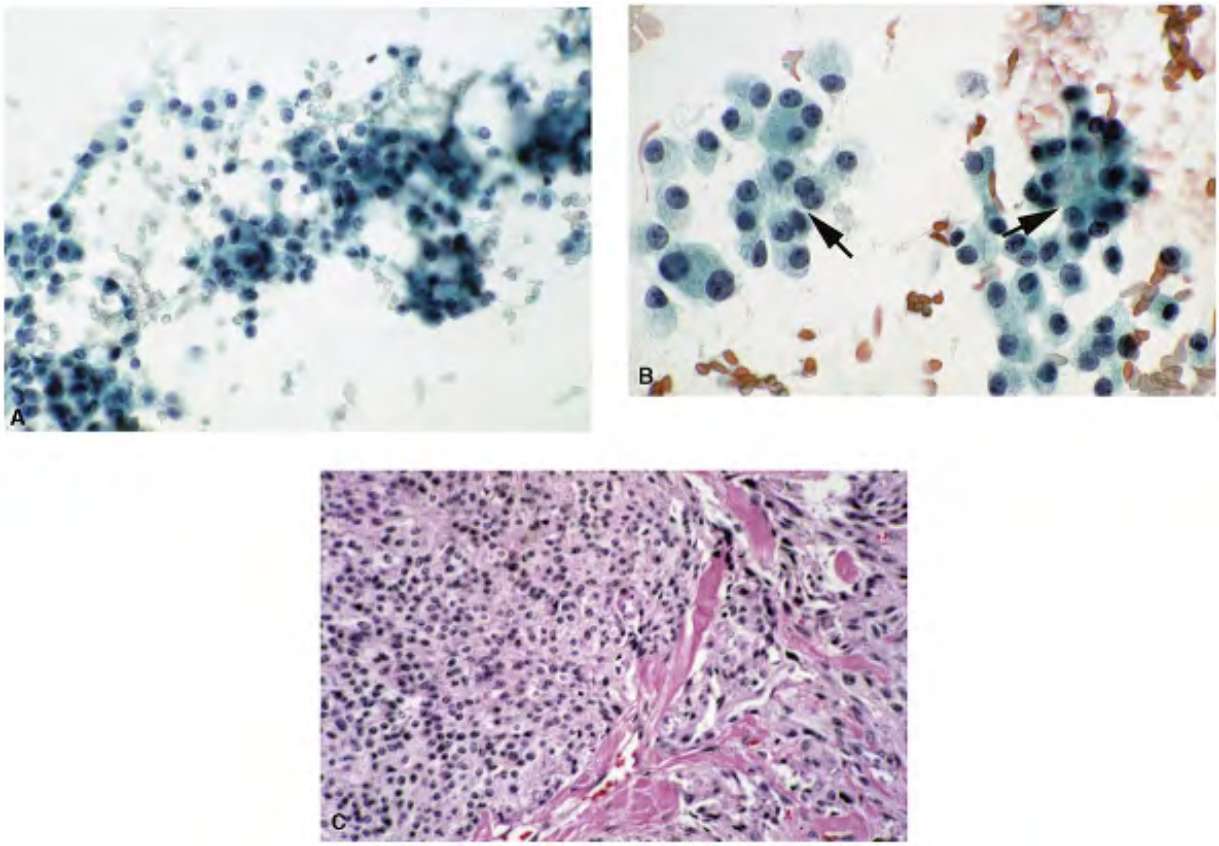

Figure 12.56. *Medullary carcinoma versus follicular adenoma/carcinoma* . A. This cellular aspirate showed a monomorphic population of small to medium-sized cells, discrete and in s tissue fragments with a pseudofollicular pattern (medium power). B. Higher magnification demonstrated eccentric nuclei and minimal pleomorphism. Note the pseudofollicular patter (*arrows*). The aspirate was interpreted as a cellular follicular adenoma. C. Thyroidectomy revealed a medullary carcinoma, confirmed by positive calcitonin stain.

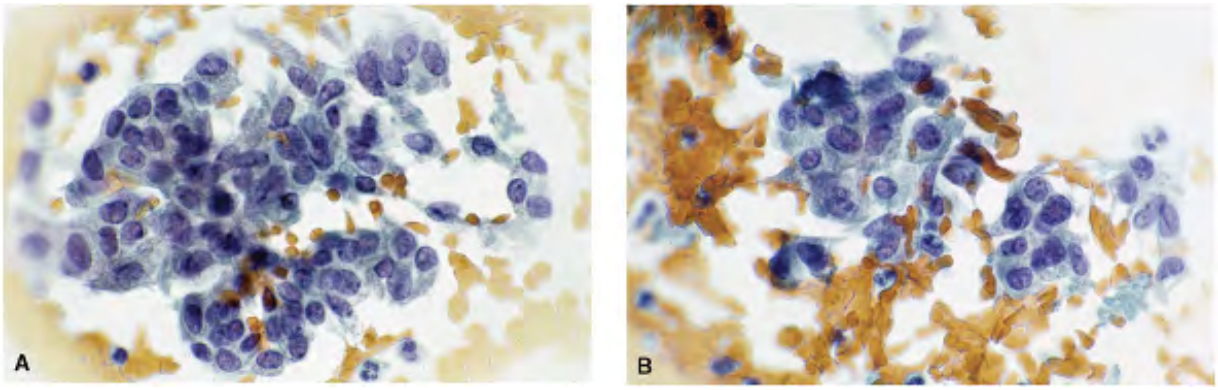

Figure 12.57. *Medullary carcinoma versus follicular adenoma/carcinoma* . Another exampl medullary carcinoma cytologically interpreted as cellular follicular adenoma. The syncytial arrangement of cuboidal cells favored the diagnosis of follicular neoplasm. The short spindl cells, rudimentary cytoplasmic processes, and intranuclear inclusions were not appreciated the time of examination. Thyroidectomy revealed a medullary carcinoma.

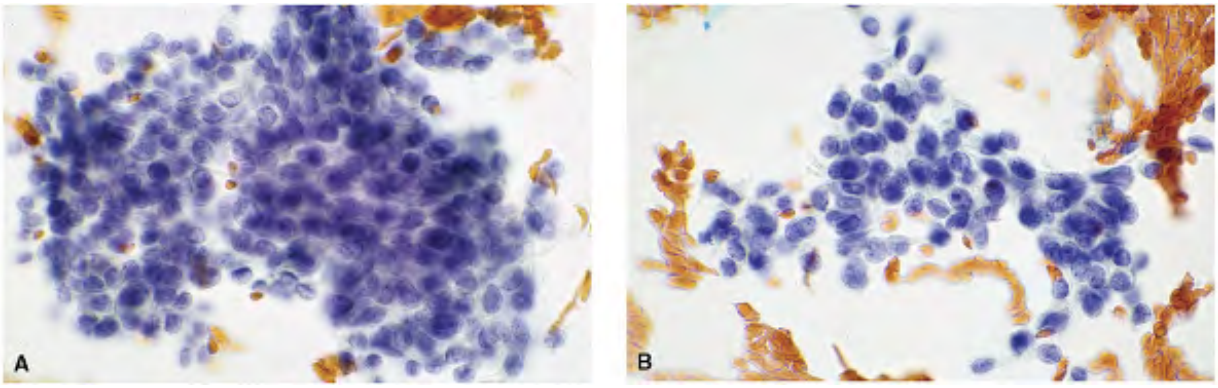

Figure 12.58. *Medullary carcinoma versus follicular adenoma/carcinoma* . This cellular asp consisted of syncytial tissue fragments of round to cuboidal cells with scant cytoplasm. The nuclear chromatin was uniform and bland, lacking the coarse granularity of medullary carci cell nuclei. Absence of pleomorphism led to the diagnosis of a follicular neoplasm. Thyroidectomy revealed a medullary carcinoma.

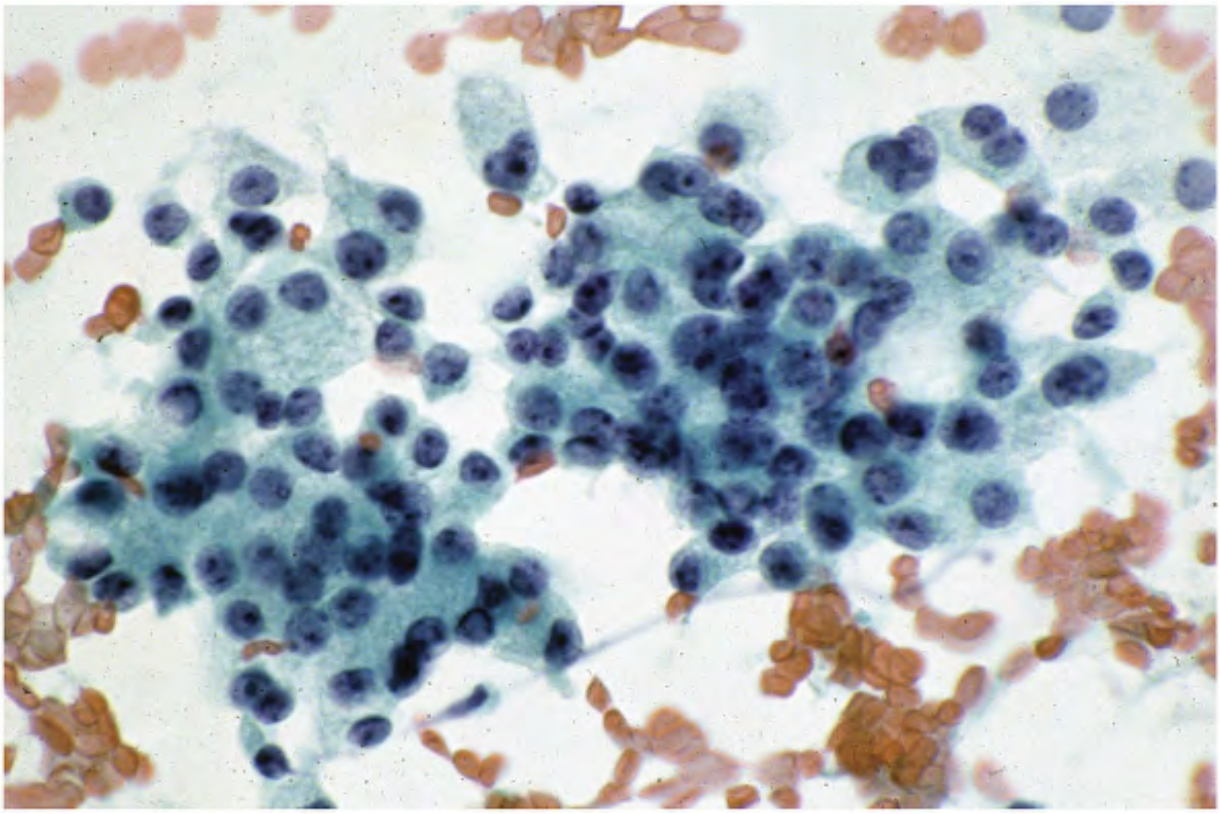

Figure 12.59. *Medullary carcinoma versus follicular adenoma/ carcinoma* . Uniform, mediu sized cells in syncytial tissue fragment with coarsely granular chromatin, can be misinterpre as a follicular neoplasm.

Medullary Carcinoma versus HÃ¼rthle Cell Carcinoma

In our experience, cells aspirated from some HÃ¼rthle cell carcinomas exhibit a morphologi resemblance to plasmacytoid cells of medullary carcinoma. This observation is shared by Fo et al.33 and SÃ¶derstrÃ¶m and co-workers,43 but not by Geddie et al.41 However, SÃ¶derst et al.43 believe that the distinction between a HÃ¼rthle cell neoplasm and a medullary thy carcinoma could be made easily by the dusty blue granulation of HÃ¼rthle cells in Romanow stained preparations and the cytoplasmic pink granules of medullary carcinoma cells. A prominent cherry-red macronucleolus favors the diagnosis of HÃ¼rthle cell carcinoma. Whenever an aspirate shows a monomorphic pattern of oval to plasmacytoid cells with no o cytologic features of medullary carcinoma or HÃ¼rthle cell carcinoma, it is prudent to recommend tests to rule out medullary carcinoma (Table 12.7 , Figs. 12.60 , 12.61 and 12.6

Cellularity

Highly cellular

Highly cellular

Pattern

Cells mostly discrete, in groups, rarely in syncytial tissue fragments; without any architectural patterns, dispersed pattern frequent and characteristic

Cells discrete, in groups, or in syncytial tissue fragments; a dispersed pattern is frequent

Cells

Medium-sized, round, oval, plasmacytoid, mildly pleomorphic; cell borders well-defined to poorly defined; N/C ratios variable

Medium-sized, round, oval to plasmacytoid, uniform in a given case; cell borders well defined in discrete cells; N/C ratios very high

Nucleus

Almost always eccentric, binucleation frequent; round, variably sized; smooth nuclear membranes, coarsely granular chromatin to salt-and-pepper type chromatin; nucleoli not conspicuous; intranuclear inclusions frequent

Central to eccentric; binucleation frequent; round, mostly uniform with little variation in size; smooth nuclear membranes, finely granular chromatin; macro nucleoli conspicuous; intranuclear inclusions Â±

Cytoplasm

Variable; pale, lacy to dense; azurophilic granules in Romanowsky-stained preparations

Variable, usually scant; granular to dense; azurophilic granules in Romanowsky-stained preparations not present

Background

Colloid absent; amyloid present;
clean with no necrosis

Colloid Â±; amyloid absent; necrosis Â±

Immunoprofile

Calcitonin +; Thyroglobulin

Calcitonin -; thyroglobulin +

Ultrastructure

Neurosecretory granules

Abundant mitochondria

Medullary Carcinoma	HÃ¼rthle Cell Carcinoma

TABLE 12.7 DIFFERENTIATING FEATURES BETWEEN MEDULLARY CARCINOMA WITH MONOMORPHIC ROUND, OV TO PLASMACYTOID CELLS AND HÃœRTHLE CELL CARCINOM

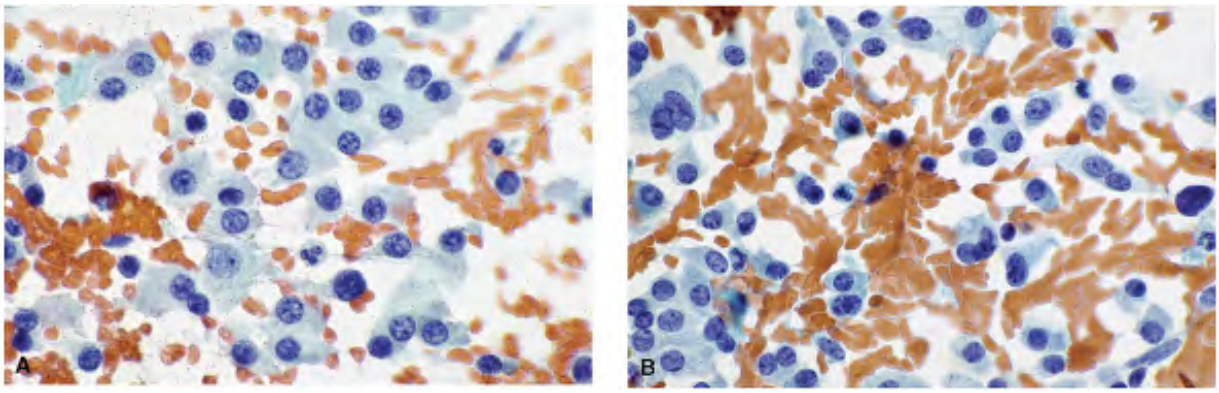

Figure 12.60. *Medullary carcinoma versus HÃ¼rthle cell carcinoma* . A. FNA of a HÃ¼rthle carcinoma. The cells are monomorphic with eccentric nuclei. A differential diagnosis of HÃ¼rthle cell carcinoma and medullary carcinoma was considered. Immunostain for thyroglobulin was positive and negative for calcitonin. Thyroidectomy confirmed a HÃ¼rthle carcinoma. B. FNA of a medullary carcinoma demonstrating cytomorphology similar to a HÃ¼rthle cell neoplasm.

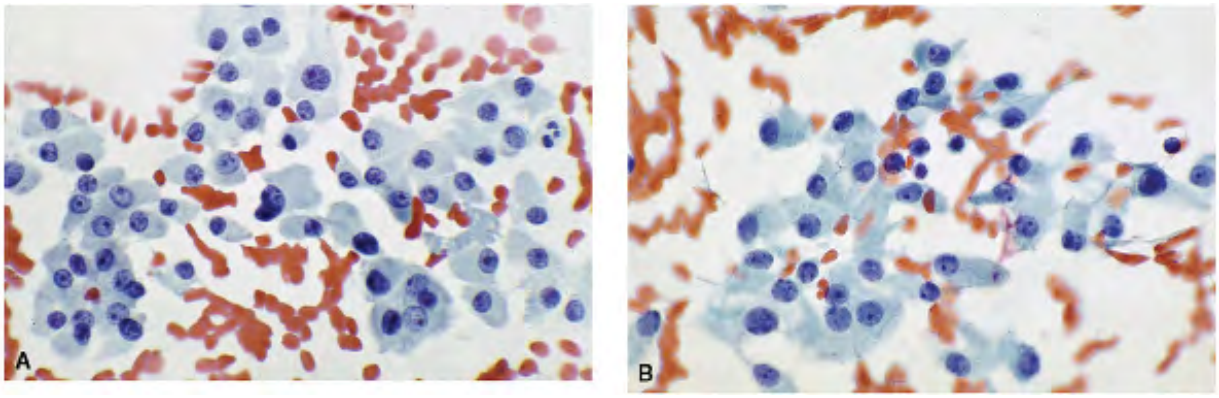

Figure 12.61. *Medullary carcinoma versus HÃ¼rthle cell carcinoma* . A. FNA of a HÃ¼rthle carcinoma showing plasmacytoid cells resembling the cells of medullary carcinoma. Macronucleoli in some cells suggested the diagnosis of HÃ¼rthle cell neoplasm. A calcitonin was nondiagnostic. Thyroidectomy revealed a HÃ¼rthle cell carcinoma. B. FNA of a medulla carcinoma showing cells with morphology similar to HÃ¼rthle cell carcinoma.

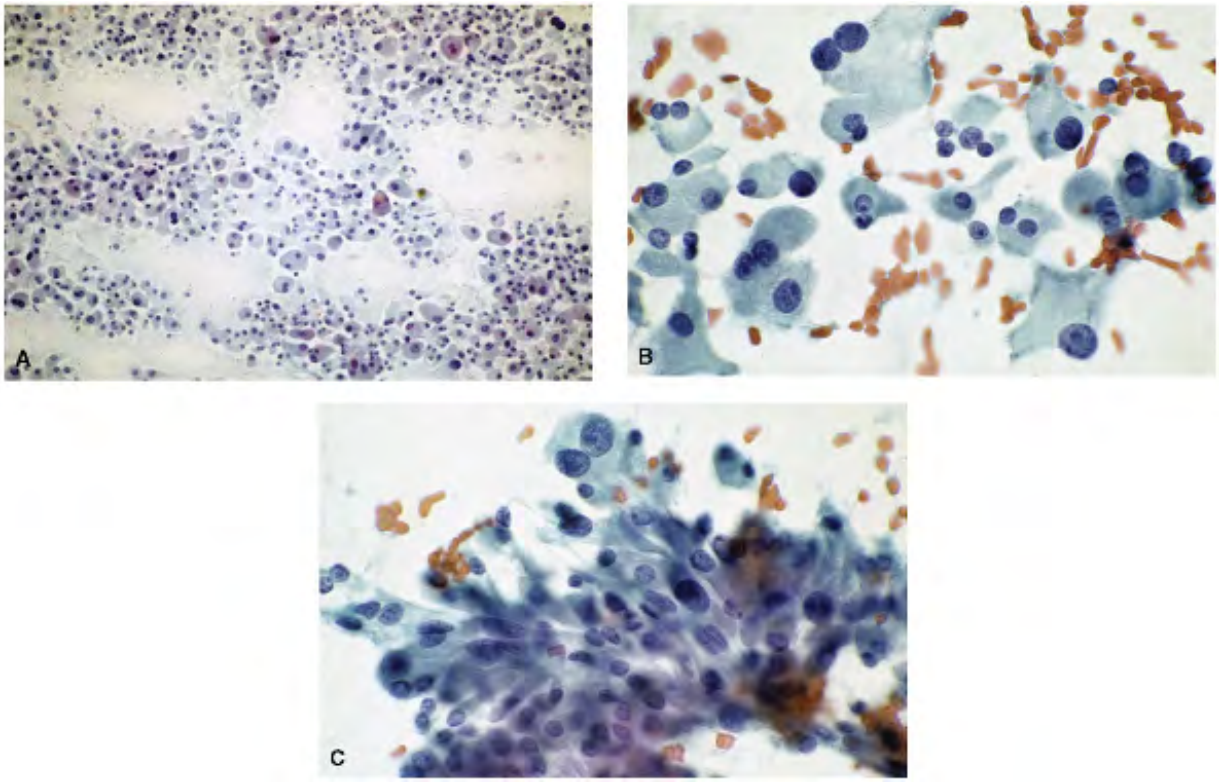

Figure 12.62. FNA of a HÃ¼rthle cell carcinoma. A. The aspirate is very cellular consisting discrete, pleomorphic cells (low power). B. Higher magnification showing plasmacytoid shap with eccentric nuclei. The chromatin is coarsely granular and macronucleoli are not

appreciated. C. A different field showing a syncytial tissue fragment of similar cells with abundant dense cytoplasm; some cells are short spindle shaped. A differential diagnosis of HÃ¼rthle cell neoplasm and medullary carcinoma was considered. A calcitonin stain was negative while the cells were reactive to thyroglobulin. Thyroidectomy confirmed a HÃ¼rth cell carcinoma.

Medullary Carcinoma versus Papillary Carcinoma

Most papillary carcinomas of thyroid are easily recognized by the varied architectural patte the tissue fragments and the characteristic nuclear morphology. Very infrequently, aspirate from papillary carcinomas present a single cell pattern with a large population of cuboidal, columnar, or spindle-shaped cells similar to those seen in medullary carcinomas. Other diagnostic features of papillary carcinoma may not be

P.277
P.278
P.279
P.280

present in the aspirated sample. Intranuclear cytoplasmic inclusions are seen in both carcin and are not helpful in differentiating the two. Powdery nuclear chromatin, micronucleoli, a chromatin ridge or the groove, if present, suggests papillary carcinoma (Table 12.8 , Figs. 1 , 12.64 and 12.65).

Cellularity
Highly cellular
Highly cellular
Pattern
Cells mostly discrete, in groups, rarely in syncytial tissue fragments; without any architectural patterns, dispersed pattern frequent and characteristic
Cells mostly discrete, in groups, rarely in syncytial tissue fragments without any architectural patterns, dispersed pattern
Cells
Small, round to cuboidal; ill-defined to well-defined

	Medullary Carcinoma	Papillary Carcinoma
	cell borders; high N/C ratios	
	Small, round to cuboidal, to short columnar; ill-defined to well-defined cell borders; high N/C variable	
Nucleus		
	Eccentric; round, oval; smooth nuclear membranes; salt-and-pepper type granular chromatin, sometimes chunky; nucleoli usually not seen. binucleation frequent; intranuclear inclusions always present	
	Eccentric to central; round, oval; smooth nuclear membranes; salt-and-pepper type granular chromatin; nucleoli usually not seen; binucleation not a feature; intranuclear inclusions always present	
Cytoplasm		
	Scant, pale to dense; cytoplasmic tailing (rudimentary process) Â±; azurophilic granules in Romanowsky-stained preparations	
	Variable, pale clear or vacuolated; azurophilic granules in Romanowsky-stained preparations not present	
Background		
	Colloid absent; amyloid present	
	Colloid Â±; amyloid absent	
Immunoprofile		
	Calcitonin +; thyroglobulin -	
	Calcitonin -; thyroglobulin +	

TABLE 12.8 DIFFERENTIATING FEATURES BETWEEN MEDULLARY CARCINOMA AND PAPILLARY CARCINOMA WIT A SINGLE CELL PATTERN

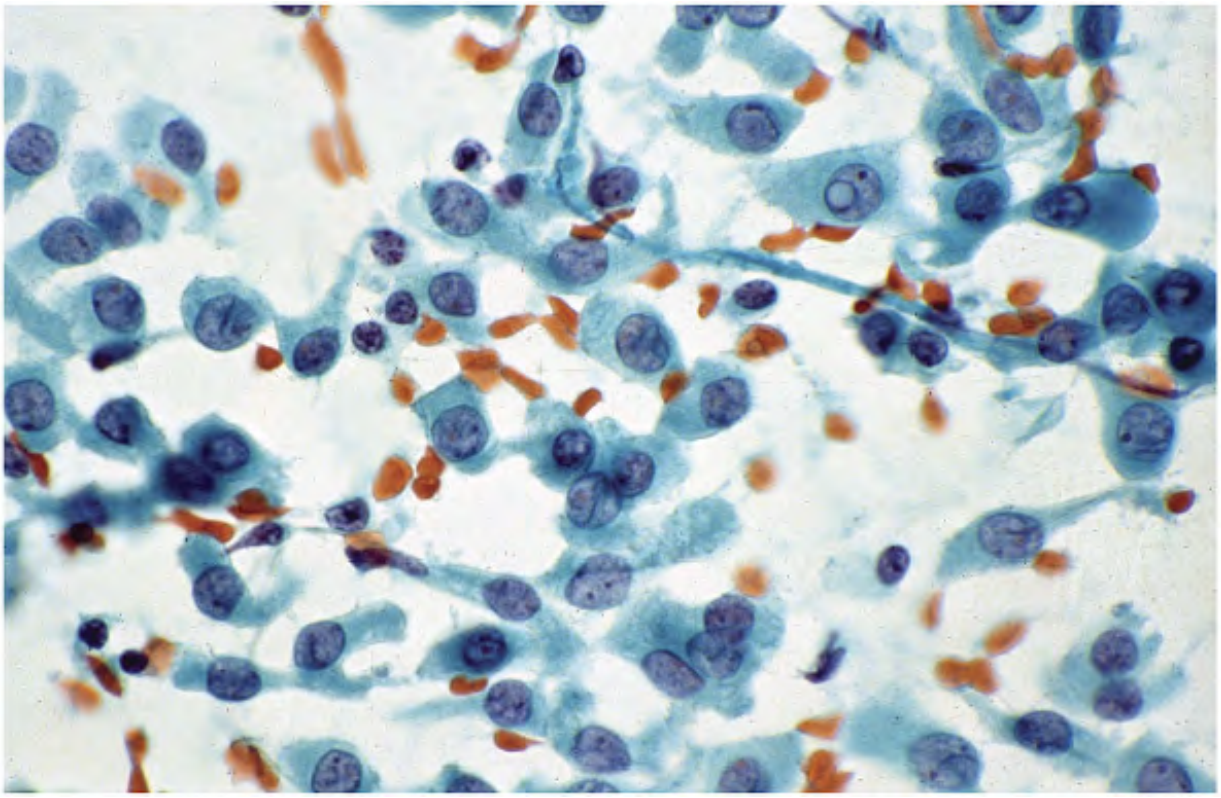

Figure 12.63. *Medullary carcinoma versus papillary carcinoma* . FNA of a papillary thyroid carcinoma showing a single cell pattern. The neoplastic cells are pleomorphic, round to spir shaped, and with cytoplasmic processes. Note the intranuclear inclusions. The differential diagnosis in this case includes papillary carcinoma, hyalinizing trabecular adenoma, and medullary carcinoma. Immunostains are necessary for the diagnosis. Thyroidectomy confirm papillary carcinoma.

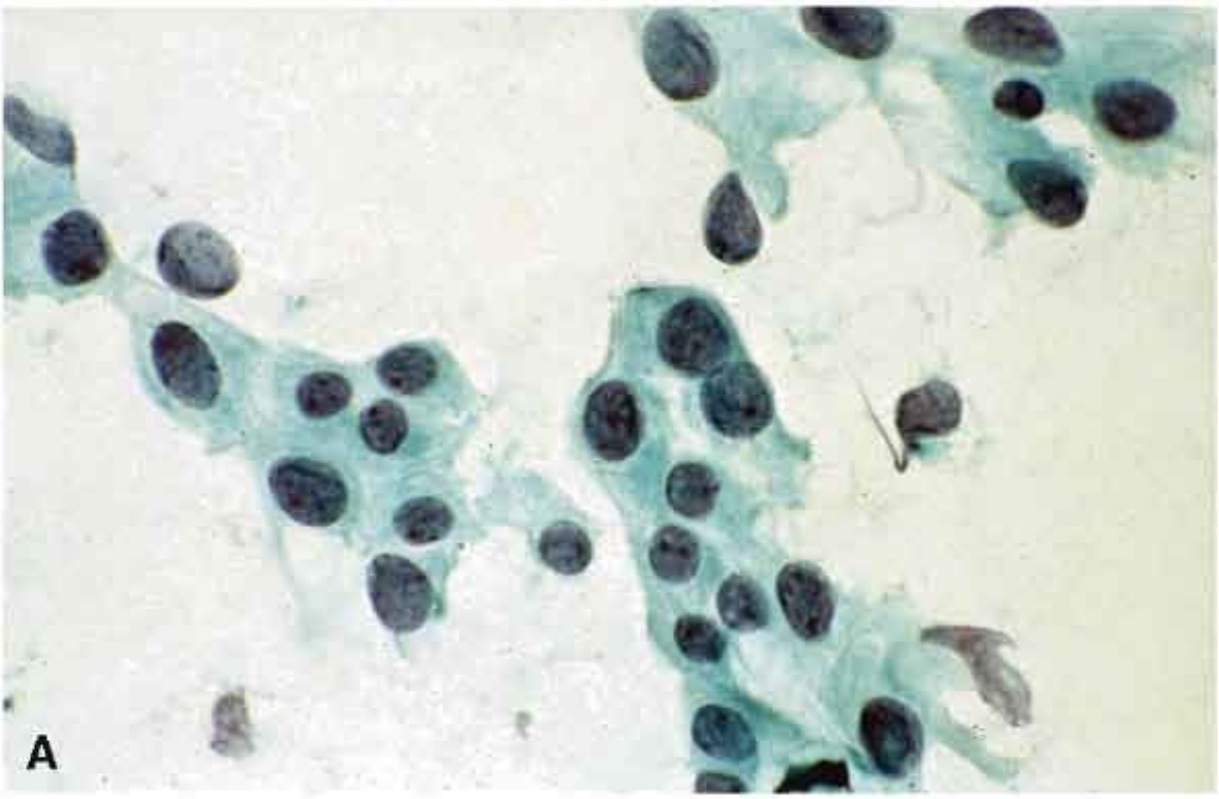
A

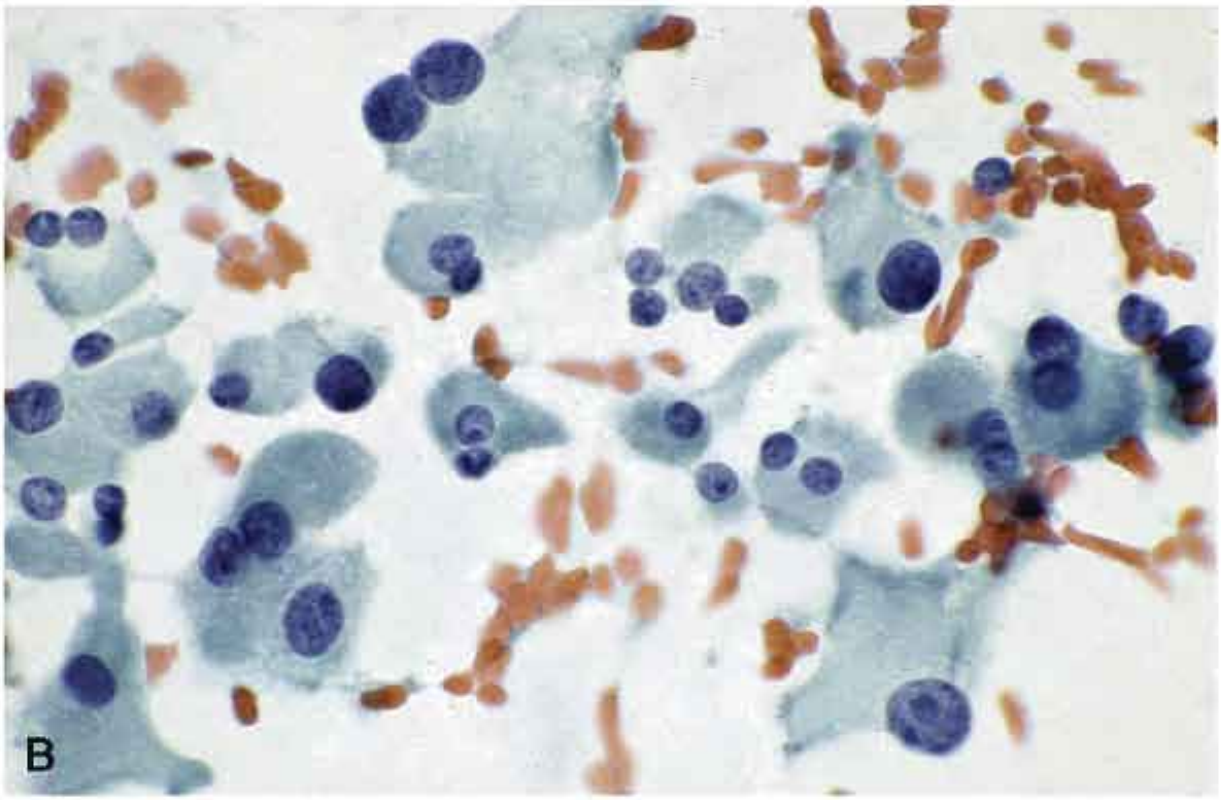
B

Figure 12.64. A. *Medullary carcinoma versus papillary carcinoma* . FNA of a papillary carci composed of large polygonal cells with abundant cytoplasm and eccentric nuclei. The coars thready chromatin favored medullary carcinoma. Other smears from the same aspirate show features suggestive of papillary carcinoma and were confirmed on thyroidectomy. B. FNA of medullary thyroid carcinoma showing similar cytomorphology to that seen in part A.

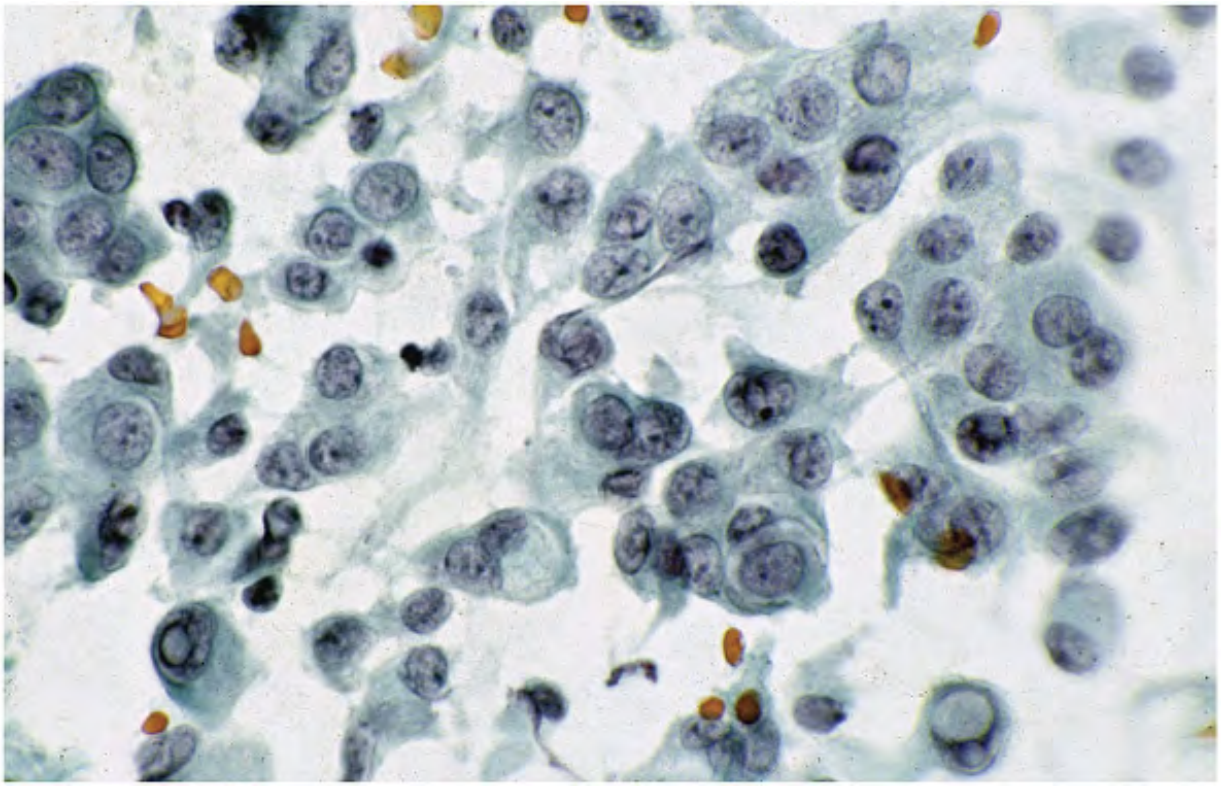

Figure 12.65. *Medullary carcinoma versus papillary carcinoma* . Another example of papilla carcinoma with a single cell pattern. The round, cuboidal, and plasmacytoid cells with ecce nuclei containing intranuclear inclusions raise the possibility of medullary carcinoma. When doubt, immunostains for calcitonin will confirm the diagnosis of medullary carcinoma.

Medullary Carcinoma versus Insular Carcinoma

The small cell variant of medullary carcinoma shows morphologic overlap with other small c malignancies such as poorly differentiated or insular carcinoma of the thyroid as well as malignant lymphoma and metastatic small cell carcinoma. The aspirate of medullary carcin consisting of small uniform cells is very difficult to distinguish from insular carcinoma of the

thyroid without the help of immunostains (Fig. 12.66). Insular carcinomas often show necro and increased proliferative activity, a feature generally not observed with medullary carcinomas. Calcitonin will be strongly positive with medullary carcinoma cells. A rare prim neuroendocrine

P.281

P.282

P.283

tumor referred to as calcitonin-free oat cell carcinoma will be extremely difficult to differentiate from either a medullary carcinoma or a metastatic small cell carcinoma. The differential diagnosis of thyroid aspirates with small cells is discussed in Chapter 10 and liste Table 10.3 .

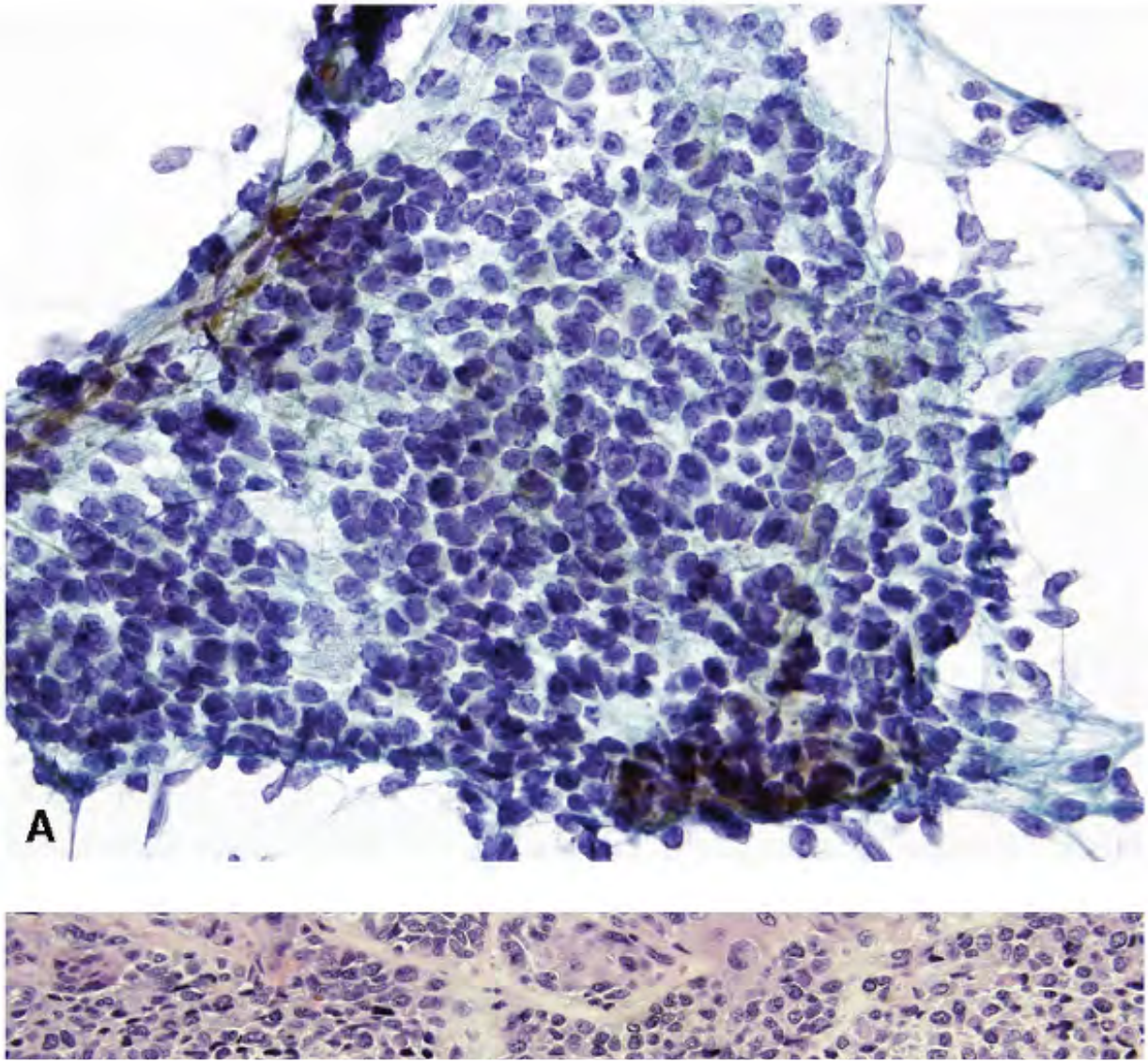

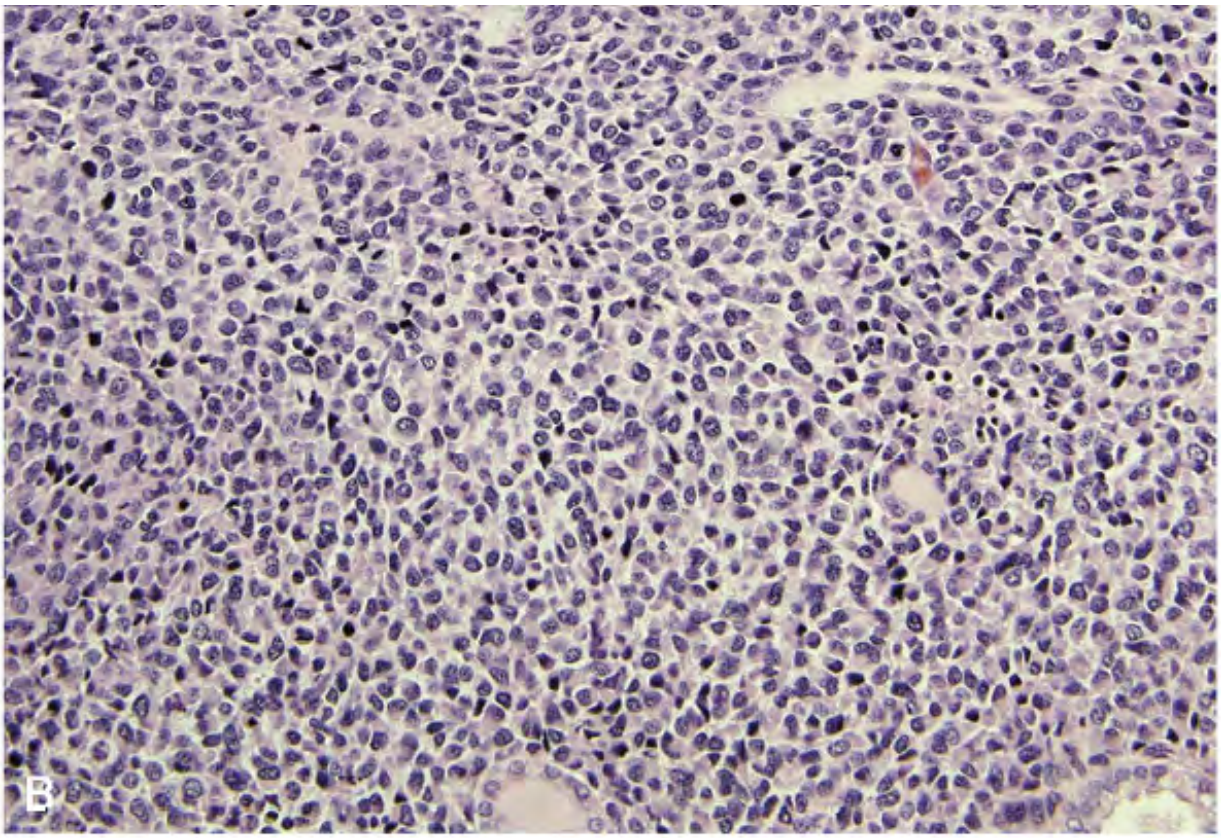

Figure 12.66. *Medullary carcinoma versus insular carcinoma* . A. FNA of a medullary carcin A small cell pattern forming sharply defined tissue fragments resembling insulae of insular carcinoma. B. Thyroidectomy confirmed medullary carcinoma. Histologic section showing a lobular pattern formed by small round cells and is reminiscent of an insular carcinoma.

Medullary Carcinoma versus Carcinoid Tumor

The small cell pattern of medullary thyroid carcinoma with salt-and-pepper nuclear chroma morphologically resembles a carcinoid tumor. Fine-needle aspirates of carcinoid tumor metastatic to the thyroid may be interpreted as medullary carcinoma.32 There have been isolated case reports of metastases from extra-thyroidal carcinoid tumor to the thyroid glan that may be confused with medullary carcinomas.

Medullary Carcinoma versus Anaplastic Carcinoma

The monomorphic spindle cell pattern of medullary carcinoma may be mistyped as anaplasti carcinoma, particularly when occasional nuclei appear bizarre (Fig. 12.67). On the other ha

in the absence of the usual cytopathologic features, such as pleomorphic and bizarre nuclei tumor diathesis, the aspirate of anaplastic carcinoma may be mistyped as medullary carcinc Intranuclear cytoplasmic inclusions are seen in both types of cancer cells. The presence of c features of medullary carcinoma, as described earlier, is helpful in making a correct diagnos Intertwining cytoplasmic processes are not a feature of anaplastic carcinoma (Table 12.9). Immunostains for calcitonin are necessary to confirm the diagnosis of medullary carcinoma.

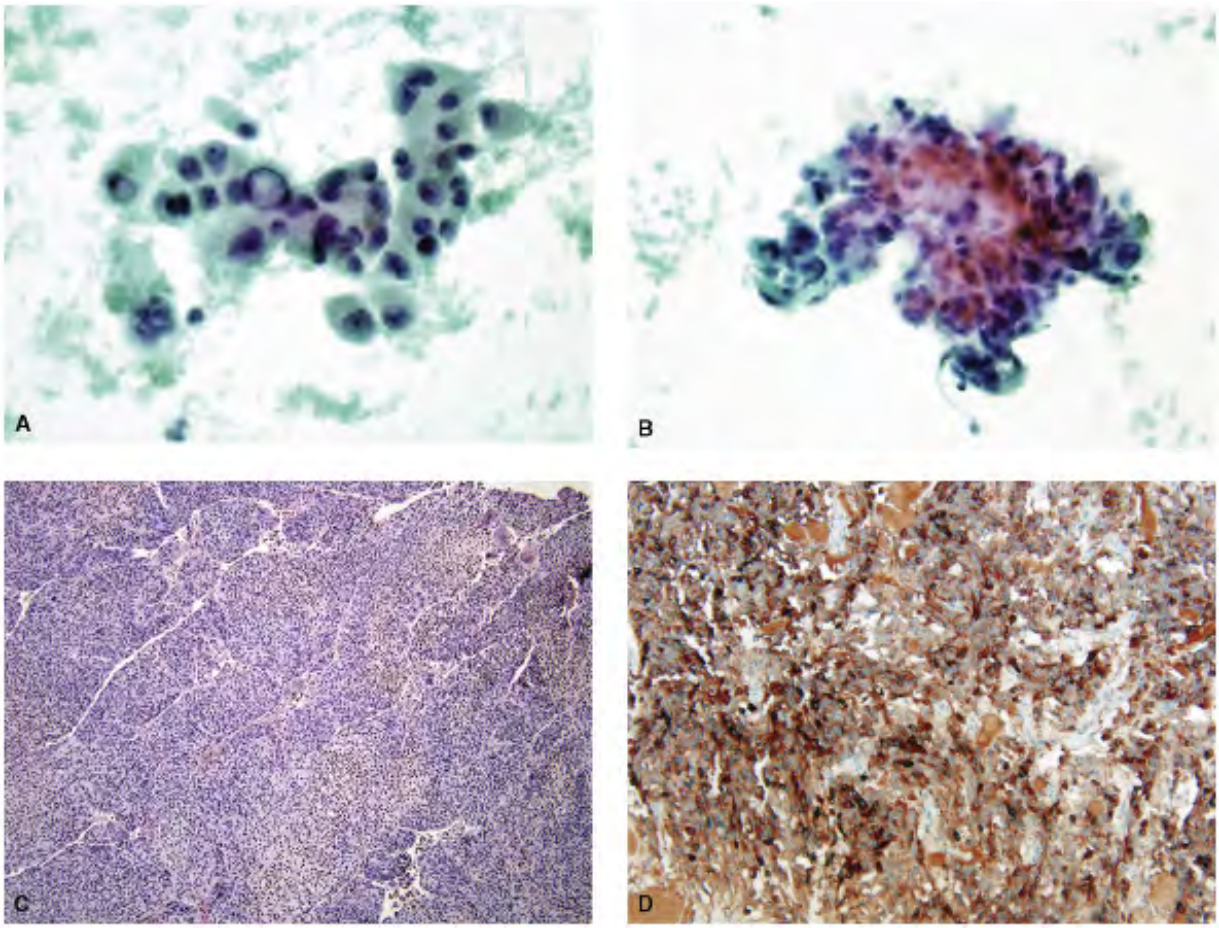

Figure 12.67. *Medullary carcinoma versus anaplastic carcinoma* . A,B. FNA of a medullary carcinoma showing syncytial tissue fragments of markedly pleomorphic cells, which reacted strongly to calcitonin. Thyroidectomy confirmed the medullary carcinoma. C. Histologic sec of the medullary carcinoma. D. Strong positive reaction to calcitonin.

Cellularity
Generally high

Generally high, can be low with markedly desmo plastic cancer

Pattern

Cells mostly discrete, in groups, presenting a fish-school pattern; rarely in fascicles

Isolated, loosely cohesive; in syncytial tissue fragments;

Cells

Variably sized, spindle shaped; delicate slender; well-defined cell borders; N/C ratios variable

Variably sized, slender to plump spindle shaped, well-defined cell borders; N/C ratios variable; giant forms frequent

Nucleus

Eccentric, round to oval, short spindle shaped; pleomorphism may be pronounced; smooth nuclear membranes; coarsely granular chromatin; nucleoli not conspicuous; intranuclear inclusions present; mitosis -

Central to eccentric; very pleomorphic; multinucleation +; coarsely granular chromatin with excessively cleared parachromatin; smooth to irregular nuclear membranes; bizarre forms frequent; multiple micro/macronucleoli with irregular forms; intranuclear inclusions +; mitotic activity + with normal and abnormal mitoses

Cytoplasm

Variable; pale lacy to dense; unipolar with delicate cytoplasmic processes often intertwining

Variable, can be abundant and dense; cytoplasmic processes rare

Background

Clean; amyloid +; necrosis absent; stromal tissue fragments not present

Amyloid +; necrosis frequent; stromal tissue fragments Â±		
Immunoprofile		
Calcitonin +; thyroglobulin -		
Calcitonin -; thyroglobulin usually negative		
Ultrastructure		
Electron dense, membrane-bound; neurosecretory granules		
No neurosecretory granules		

	Medullary Carcinoma	Anaplastic Carcinoma

TABLE 12.9 DIFFERENTIATING FEATURES BETWEEN MEDULLARY CARCINOMA AND ANAPLASTIC CARCINOMA

Medullary Carcinoma versus Malignant Lymphoma

Medullary carcinomas may consist predominantly of small cells that present a dissociated pattern (Fig. 12.68). With uniform, small, round cells, scant cytoplasm, and high N/C ratios malignant lymphoma must be considered in the differential diagnosis. Cytoplasmic tailing, la of nucleoli, and coarsely granular chromatin are the features that help differentiate medull carcinomas from malignant lymphomas. The latter exhibit malignant cells with nucleoli, hig proliferative activity, karyorrhexis, and necrosis. Ancillary diagnostic tests are required for accurate diagnosis. Please refer to Chapter 10 , Table 10.3 , on cytologic features of small c neoplasms of the thyroid gland.

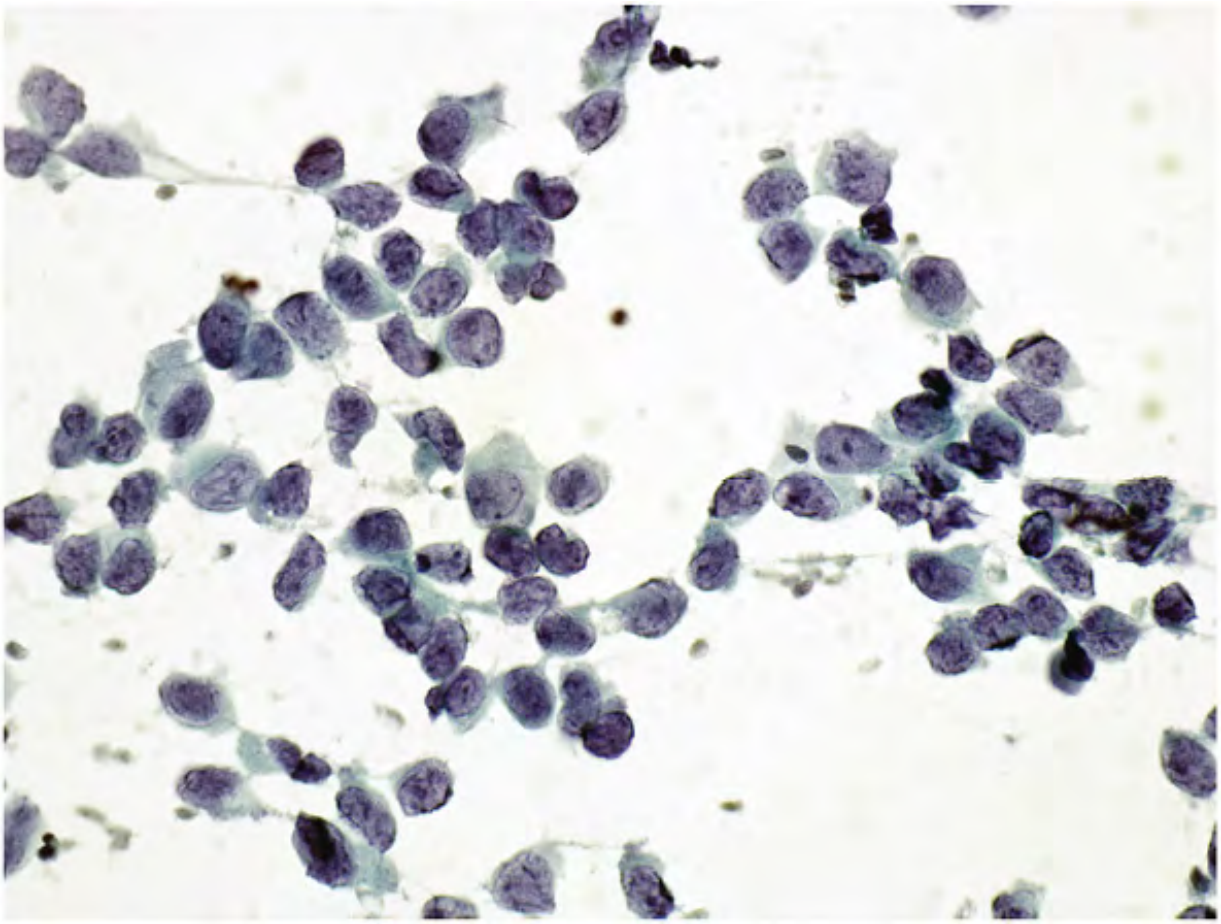

Figure 12.68. *Medullary carcinoma versus malignant lymphoma* . FNA of a medullary thyroi carcinoma consisting of discrete small to medium-sized cells with high N/C ratios and scant cytoplasm. These cells strongly resemble large cell lymphoma.

Medullary Carcinoma versus Paraganglioma

Medullary carcinomas with a histologic pattern similar to that of a paraganglioma has been described in the literature.19 , 20 , 21 It is possible to misinterpret the cells of primary paraganglioma of the thyroid as a medullary carcinoma (Fig. 12.69), as reported by Vodvnik and Papaparaskeva et al.32

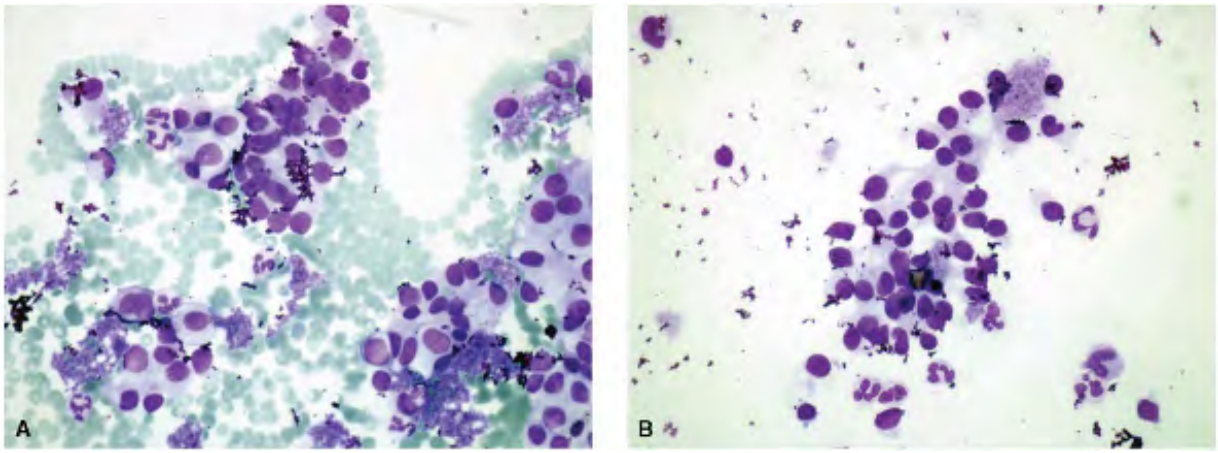

Figure 12.69. *Medullary carcinoma versus paraganglioma* . FNA of a histologically confirme primary paraganglioma of the thyroid. The marginally cellular aspirate demonstrates mediu sized to large cells with poorly defined cell borders. The nuclei are moderately pleomorphic large, round to oval, and with evenly dispersed chromatin. Nucleoli are only occasionally present. These cells have insignificant to scant, pale, bluish cytoplasm. A cytologic diagnosi paraganglioma is not possible from this morphology alone, as the cells also bear similarities medullary carcinoma cells. Romanowsky stain. (Courtesy of A. Vodovnik, MD, Calderdale Ro Hospital, HX3 OPW Halifax, England.)

Medullary Carcinoma versus Soft-Tissue Tumors

An exclusive spindle cell pattern is unusual for medullary carcinoma and when present may mistyped as soft-tissue tumor (Fig. 12.70). Medullary carcinoma cells tend to be discohesive unipolar. Spindle cells running in fascicles like the ones seen in leiomyoma or fibrous histiocytomas are very unusual. Again, a differential diagnosis must be rendered, and appropriate ancillary tests need to be performed for accurate typing.

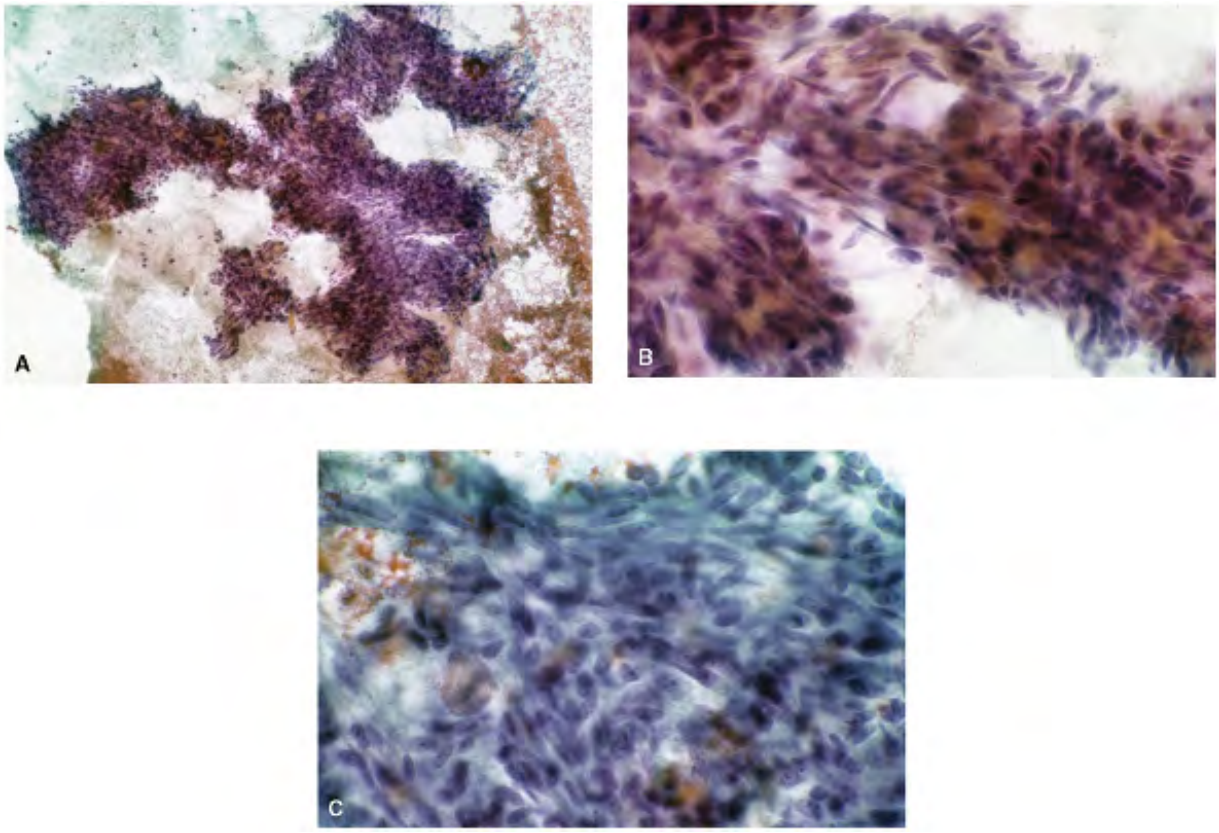

Figure 12.70. *Medullary carcinoma versus soft-tissue tumors* . An exclusive spindle cell pat as seen here in an FNA of medullary carcinoma is unusual. Also, the neoplastic cells in medu carcinomas tend to be discohesive and unipolar. Spindle cells running in fascicles like the or seen in leiomyoma or fibrous histiocytomas are very unusual. A differential diagnosis must b rendered and appropriate ancillary tests need to be performed for accurate typing.

Medullary Carcinoma versus Plasmacytoma

The medullary carcinoma cells may be predominantly plasmacytoid in shape and resemble a plasmacytoma. A case of plasmacytoma of the thyroid interpreted as medullary carcinoma v reported by Bourtsas et al. (63).

Medullary Carcinoma versus Malignant Melanoma

Malignant melanoma is a great mimicker and must always be considered in any differential diagnosis. With a broad spectrum

of morphologic patterns, it is conceivable that a melanoma may be diagnosed as medullary carcinoma in thyroid aspirates. On the other hand, medullary carcinoma will be typed as melanoma if such a past history is available.

Mixed Medullary, Follicular, and Composite Carcinomas

These tumors show both parafollicular and follicular differentiation in the same tumor.64 , 66 , 67 , 68 , 69 Two types are described, mixed carcinoma and composite carcinoma.64

Mixed tumors demonstrates both medullary (C-cell) and follicular cell differentiation, the la with a follicular or papillary growth pattern. The tumor cells express reactivity to both calcitonin and thyroglobulin.

The composite tumors of the thyroid show two distinct cell populations, thyroglobulin react papillary carcinoma and calcitonin reactive medullary carcinoma. Composite tumors differ f mixed tumors in that the parafollicular and follicular cell origin can be demonstrated in two distinct cell populations rather than within the same tumor of mixed type.64

These tumors are uncommon, and only three reports document their cytologic features,70 , 72 This author has no personal experience with them.

SUMMARY

Medullary thyroid carcinoma presents a characteristic cellular pattern with a wide variety o shapes and sizes. The eccentric nuclear position, intranuclear cytoplasmic inclusions, fibrill cytoplasm, cytoplasmic processes, and azurophilic granules in the cytoplasm (by Romanowsk stain) are diagnostic. The cytologic interpretation can be confirmed by demonstrating positi reactivity to calcitonin, and by serum calcitonin levels.

REFERENCES

1.Williams ED. Histogenesis of medullary carcinoma of the thyroid. *J Clin Pathol* . 1965;19:114â€“118.

2.Horn RC Jr. Carcinoma of the thyroid. Description of a distinctive morphologic variant: a report of seven cases. *Cancer* . 1951; 4: 697â€“707.

3.Hazard JB, Hawk WA, Crile G Jr. Medullary (solid) carcinoma of the thyroid: a clinicopathological entity. *J Clin Endocrinol Metab* . 1959;19:152â€“161.

4.Matias-Guiu X, DeLellis RA, Moley JF, et al. Medullary thyroid carcinoma. In: DeLellis RA Lloyd RV, Heitz PU, et al, eds. *Pathology and Genetics of Tumors of Endocrine Organs* . *World Health Organization Classification of Tumors* . Lyon: IARC Press; 2004;86â€“91.

5.Wenig BM, Heffess C, Adair CF. *Atlas of Endocrine Pathology* . Philadelphia: Saunders; 1997.

6.Rosai J, Carcangiu ML, DeLellis RA. Tumors of the thyroid gland. In: *Atlas of Tumor Pathology* . Fascicle 5, 3rd series. Washington, DC: Armed Forces Institute of Pathology; 1993.

7.Aldabagh SM, Trujillo YP, Taxy JB. Occult medullary thyroid carcinoma: unusual histolog variant presenting with metastatic disease. *Am J Clin Pathol* . 1986; 85:247â€“250.

8.Papotti M, Sambataro O, Pacchioni C, et al. The pathology of medullary carcinoma of th thyroid: review of the literature and personal experience on 62 cases. *Endocr Pathol* . 1996;7:1â€“20.

9.Colson YL, Carty SE.Medullary thyroid carcinoma. *Am J Otolaryngol* . 1993;14:73â€“81.

10.Laimore TC, Wells SA. Medullary carcinoma of the thyroid: current diagnosis and management. *Semin Diagn Oncol* 1991; 7:92â€“99.

11.Albores-Saavedra S, LiVolsi VA, Williams ED. Medullary carcinoma. *Semin Diagn Pathol* 1985;2:137â€“146.

12.Uribe M, Fenogh-Prciser CM, Grimes M, et al. Medullary carcinoma of the thyroid gland *Am J Surg Pathol* . 1983, 9:577â€“594.

13.Williams ED. Medullary carcinoma of the thyroid. In: Harrison CV, Weinbrank K, eds. *Recent Advances in Pathology* . New York: Churchill Livingstone; 1975:152â€“164.

14.Ibanez ML. Medullary carcinoma of the thyroid gland. In: Sommers SC, ed. *Pathology Annu* al. New York: Appleton-Century-Crofts; 1974:263â€“290.

15.Fletcher JR. Medullary (solid) carcinoma of the thyroid gland: a review of 249 cases. *A Surg* . 1970;100:257â€“262.

16.Williams ED, Pollack DJ. Multiple mucosal neuromata with endocrine tumors: a syndror allied to von Recklinghausen's disease. *J Pathol Bacteriol* . 1966; 91:71â€“89.

17.Steiner AL, Goodman AD, Powers SF. Study of a kindred with pheochromocytoma, medullary thyroid carcinoma, hyperparathyroidism and Cushing's disease: multiple endocr neoplasia type 2. *Medicine* . 1968;47:371â€“409.

18.LiVolsi VA. Calcitonin: The hormone and its significance. *Prog Surg Pathol* . 1980;1:71â€“109.

19.Bockhorn M, Sheu SY, Frilling A, et al. Paraganglioma-like medullary thyroid carcinoma rare entity. *Thyroid* . 2005; 15:1363â€“1367.

20.Ikeda T, Satoh M, Azuma K, et al. Medullary carcinoma with a paraganglioma-like patte and melanin production: a case report with ultrastructural and immunohistochemical studies. *Arch Path Lab Med* . 1998;122:555â€“558.

21.Huss LJ, Mendelsohn G. Medullary carcinoma of the thyroid gland: An encapsulated variant resembling the hyalinizing trabecular (paraganglioma-like) adenoma of the thyroic *Mod Pathol* . 1990;3:581â€“585.

22.Papotti M, Sapino A, Abbone GC, et al. Pseudosarcomatous features in medullary carcinoma of the thyroid. Report of two cases. *Int J Surg Pathol* . 1996;3:29â€“34.

23.Harach HR, Bergholm U. Medullary carcinoma of the thyroid with carcinoid-like feature *J Clin Pathol* . 1993;45:113â€“117.

24.Harach HR, Bergholm U. Small cell variant of medullary carcinoma of the thyroid with neuroblastoma-like features. *Histopatholgy* . 1992;21:378â€“380.

25.Dominguez-Malagon HM, Delgado-Chavez B, Torres-Najare M, et al. Oxyphil and squam variants of medullary thyroid carcinoma. *Cancer* . 1989;63:1183â€“1188.

26.Harach HR, Bergholm U. Medullary (C-cell) carcinoma of the thyroid with features of follicular oxyphilic cell tumors. *Histopathology* . 1988;13:645â€“656.

27.Harach HR, Williams ED. Glandular (tubular and follicular variant of medullary carcino of the thyroid. *Histopathology* . 1983;7:83â€“89.

28.Zatari GS, Saigo PE, Huvos AG. Mucin production in medullary carcinoma of the thyroi *Arch Path Lab Med* . 1983;107:70â€“74.

29.Kakudo K, Miyauchi A, Ogihana T, et al. Medullary carcinoma of the thyroid, giant cell type. *Arch Pathol Lab Med* . 1978; 102:445â€“447.

30.Mendelsohn G, Bignes SH, Eggleston JC, et al. Anaplastic variants of medullary thyroid carcinoma: a light microscopic and immunohistochemical study. *Am J Surg Pathol* . 1980;4 333â€“341.

31.Chang TC, Wu SL, Hsiao YL. Medullary thyroid carcinoma. Pitfalls in diagnosis by fine needle aspiration cytology and relationship of cytomorphology to RET Proto-oncogene mutations. *Acta Cytol* . 2005;49:477â€“482.

32.Papaparaskeva K, Nagel H, Droese M. Cytologic diagnosis of medullary carcinoma of the thyroid gland. *Diagn Cytopathol* . 2000;22:351â€“358.

33.Forrest CH, Frost FA, Bastiaan de Boer D, et al. Medullary carcinoma of the thyroid. Accuracy of diagnosis by fine-needle aspiration cytology. *Cancer (Cancer Cytol)* . 1998;84:295â€“302.

34.Green I, Ali SZ, Allen EA, et al. A spectrum of morphologic variations in medullary thyr carcinoma. *Cancer* . 1997;81:40â€“44.

35.Collins BT, Cramer HM, Tabatowski, et al. Fine needle aspiration of medullary carcinor of the thyroid: Cytomorphology, immunocytochemistry and electron microscopy. *Acta Cyt* . 1995;39:920â€“930.

36.Das A, Gupta SK, Banerjee AK, et al. Atypical cytologic features of medullary carcinom of the thyroid: A review of 12 cases. *Acta Cytol* . 1992;36:137â€“141.

37.Bose S, Kapila K, Verma K. Medullary carcinoma of the thyroid: a cytological, immunocytochemical and ultrastructural study. *Diagn Cytopathol* . 1992; 8:28â€“32.

38.Mendonca ME, Ramos S, Soaves J. Medullary carcinoma of thyroid: a reevaluation of th cytologic criteria of diagnosis. *Cytopathology* . 1991;2:93â€“102.

39.Zeppa P, Vetrani A, Marino M, et al. Fine-needle aspiration cytology of medullary thyro carcinoma: a review of 18 cases. *Cytopathology* . 1990;1:35â€“44.

40.Kini SR, Miller JM, Hamburger JI, et al. Cytopathology of medullary carcinoma of the thyroid. *Arch Pathol Lab Med* . 1984;108:156â€“159.

41.Geddie WR, Bedard YC, Staawbridge HTG. Medullary carcinoma of the thyroid in fine needle aspiration biopsies. *Am J Clin Pathol* . 1984;82:552â€“558.

42.Schaffer R, Miller HA, Pfeifer U, et al. Cytological findings in medullary carcinoma of t

thyroid. *Pathol Res Pract* . 1984;178:461â€“466.

43.SÃ¶derstrÃ¶m N, Telenius-Berg M, Ackerman M. Diagnosis of medullary carcinoma of th thyroid by fine needle aspiration biopsy. *Acta Med Scand* . 1975; 197:71â€“76.

44.De Lima MA, Dias Mediros J, Rodrigues Da Cunha L, et al. Cytological aspects of melanc variant of medullary thyroid carcinoma. *Diagn Cytopathol* . 2001;24:206â€“208.

45.Goellner JR, Nelson SN, Humphrey S. A study of calcitonin immunostains in medullary carcinoma of the thyroid. *Acta Cytol* . 1991;35:621A.

46.Pacini F, Basolo F, Elisei R, et al. Medullary thyroid cancer: an immunohistochemical a humoral study using six separate antigens. *Am J Clin Pathol* . 1991;95:300â€“308.

47.Hamburger JI, Miller JM, Kini SR.Clinical-pathological evaluation of thyroid nodules. In: *Handbook and Atlas* . Southfield, Michigan: Private Publication; 1979;10â€“12.

48.Miller JM, Kini SR, Hamburger JI. *Needle Biopsy of the Thyroid* . New York: Praeger; 1983.

49.Kapila K, Verma K. Amyloid goiter in fine needle aspirates. *Acta Cytol.* 1993;37:256â€“257.

50.Gharib M, Goellner JR. Diagnosis of amyloidosis by fine needle aspiration biopsy of the thyroid. *N Engl J Med* . 1981;305:586.

51.Casey MB, Sebo TJ, Carney JA. Hyalinizing trabecular adenoma of the thyroid gland. Cytologic features in 29 cases. *Am J Surg Pathol* . 2004;28:850â€“867.

52.Bondeson L, Bondeson AG. Clue helping to distinguish hyalinizing trabecular adenoma from carcinoma of the thyroid in fine-needle aspirates. *Diagn Cytopathol* . 1994;10:25â€“

53.Sambade C, Franssila K, Camaselle-Teijeiro J, et al, Hyalinizing trabecular adenoma: a misnomer for a peculiar tumor of the thyroid gland. *Endocrinol Pathol* . 1991;2:83â€“91.

54.Goellner JR, Carney JA. Cytologic features of fine needle aspirates of hyalinizing trabecular adenoma of the thyroid. *Am J Clin Pathol* . 1989;91:115â€“119.

55.Bronner MP, LiVolsi VA, Jennings TA. PLAT: Paraganglioma-like adenomas of the thyroi *Surg Pathol* . 1988;1:383â€“389.

56.Carney JA, Ryan J, Goellner JR. Hyalinizing trabecular adenoma of the thyroid gland. *A J Surg Pathol* . 1987;11:583â€“591.

57.Eusebi V, Damiani S, Riva C, et al. Calcitonin free oat cell carcinoma of the thyroid gland. *Virchows Arch (A)* . 1990;417:262â€“271.

58.Matias-Guiu X, LlaGuette J, Puras-Gil AM, et al. Metastatic neuroendocrine tumors to t thyroid gland mimicking medullary carcinoma: a pathologic and immunohistochemical stu of six cases. *Am J Surg Pathol* . 1997;21:754â€“762.

59.Maly A, Meir K, Maly B. Isolated carcinoid tumor metastatic to the thyroid gland. Repo of a case initially diagnosed by fine needle aspiration cytology. *Acta Cytol* . 2006;50:84â€“87.

60.Loo CK, Burchett IJ. Fine needle aspiration biopsy of neuroendocrine breast carcinoma metastatic to the thyroid. A case report. *Acta Cytol* . 2003;47:83â€“87.

61.LaGuette J, Matias-Guiu X, Rosai J. Thyroid paraganglioma: a clinicopathologic and immunohistochemical study of 3 cases. *Am J Surg Pathol* . 1997;21:748â€“753.

62.Vodvnik A. Fine needle aspiration cytology of primary thyroid paraganglioma. Report o case with cytologic, histologic and immunohistochemical features and differential diagnos

considerations. *Acta Cytol* . 2002;46:1133â€“1137.

63.Bourtsos E, Bedrossian CWM, De Frias DVS, et al. Thyroid plasmacytoma mimicking medullary carcinoma. A potential pitfall in aspiration cytology. *Diagn Cytopathol* . 2000;23:354â€“358.

64.Baloch ZW, LiVolsi VA. Pathology of the thyroid gland. In: *Endocrine Pathology* . LiVolsi VA, Asa SA eds. Philadelphia: Churchill Livingston; 2002;83.

65.Papotti M, Bussolati G, Komminoth P, et al. Mixed medullary and follicular cell carcinoma. In: DeLellis RA, Lloyd RV, Heitz PU, et al, eds. *Pathology and Genetics of Tum of Endocrine Organs* . *World Health Organization Classification of Tumors* . Lyon: IARC Press; 2004;92â€“93.

66.Rossi S, Fugazzola L, De Pasquale L, et al. Medullary and papillary carcinoma of the thyroid gland occurring as a collision tumor: report of three cases with molecular analysis and review of the literature. *Endocr Relat Cancer* . 2005;28:281â€“289.

67.Papotti M, Negro F, Carney JA, et al. Mixed medullary-follicular carcinoma of the thyr A morphological, immunohistochemical and in situ hybridization analysis of 11 cases. *Virchows Arch* . 1997;430:397â€“405.

68.Apel RL, Alpert LC, Rizzo A, et al. A metastasizing composite tumor of the thyroid wit distinct medullary and papillary components. *Arch Pathol Lab Med* . 1994;118:1143â€“114

69.Sambade C, Baldaque-Faria A, Cardoso-Oliveira CA, et al. Follicular and papillary varia of medullary carcinoma of the thyroid. *Pathol Res Prac* . 1988;184:98â€“107.

70.Luboshitzky R, Dharan M. Mixed follicular-medullary thyroid carcinoma: a case report. *Diagn Cytopathol* . 2004;30:122â€“124.

71.Duskova J, Janotova D, Svobodova E, et al. Fine needle aspiration biopsy of mixed

medullary-follicular thyroid carcinoma. A report of two cases. *Acta Cytol* . 2003;47:71â€“

72.Merchant FH, Hirschowitz SL, Cohan P, et al. Simultaneous occurrence of medullary an papillary carcinoma of the thyroid gland identified by fine needle aspiration. A case repor *Acta Cytol* . 2002; 46:762â€“766.

Editors: Kini, Sudha R.
Title: *Thyroid Cytopathology: A Text and Atlas, 1st Edition*

Copyright Â©2008 Lippincott Williams & Wilkins

13

Thyroiditis

Thyroiditis, an inflammatory condition of the thyroid, can be classified according to its etio
classification by morphology and duration is accepted by most (Table 13.1).7

TABLE 13.1 CLASSIFICATION OF THYROI

Acute thyroiditis
Subacute or granulomatous thyroiditis
Chronic thyroiditis
Infectious thyroiditis
Fibrosing thyroiditis (Riedel's thyroiditis)
Hashimoto's thyroiditis (chronic lymphocytic thyroiditis)

Any type of thyroiditis can be mistaken clinically for a neoplasm. Clinical and gross features both inflammation and neoplasms. Without a biopsy, the distinction between thyroiditis anc

INFECTIOUS THYROIDITIS

Infectious diseases of the thyroid gland are rare. A detailed review was reported by Berger e infectious processes is attributed to its unique anatomic location and its rich system of drair

Acute bacterial thyroiditis is rapid in onset, with fever, pain, and tenderness; is most comm suppurative thyroiditis is very uncommon in the cytopathology practice of thyroid aspirates. bacterial thyroiditis were encountered. Fine-needle biopsy is useful in the diagnosis of acut the differential diagnosis includes anaplastic carcinoma as well as granulomatous thyroiditis

CHRONIC INFECTIOUS THYROIDITIS

Among the types of chronic infectious thyroiditis, mycobacterial and fungal infections and, *Pneumocystis carinii* infections have been reported. Parasitic infestations, such as with *Wuc*

Tuberculosis of the thyroid is extremely rare.6, 8, 12, 13, 14 Das et al.13 reported eight cas lymphadenitis, one had pulmonary tuberculosis, and four had no known focus. Involvement lesions presenting as a cold abscess. The aspirates show necrotic acellular debris and granul special stains.

MYCOTIC INFECTIONS

Among the fungal diseases involving the thyroid gland, infection caused by *Aspergillus* sp. is approximately 20% of patients, the thyroid gland is infected with disseminated aspergillosis 17, 18, 19, 20

We have encountered one case of *Aspergillus* thyroiditis in an immunosuppressed patient wi identified by aspiration biopsy and later confirmed following thyroidectomy (Fig. 13.1).

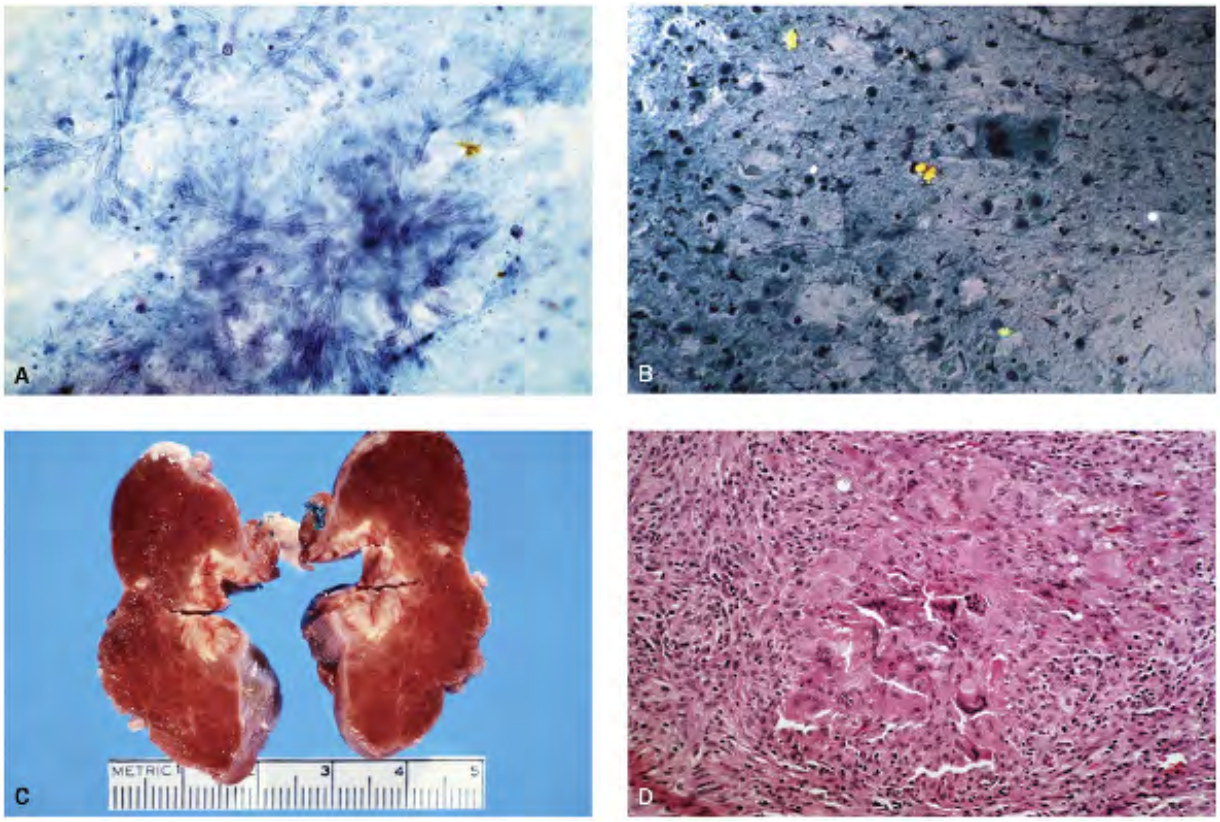

Figure 13.1. A. Aspiration biopsy specimen of a cold nodule in an immunosuppressed pati
smear showing calcium oxalate crystals when viewed under crossed polarized light. C. Th
granulomatous inflammation.

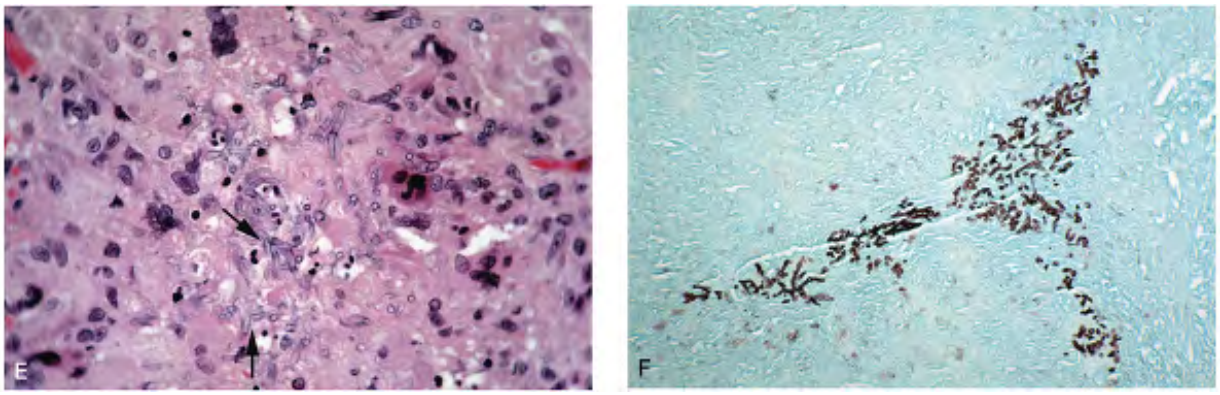

Figure 13.1. E. Higher magnification showing *Aspergillus* hyphae within a granuloma (*arr*

Other mycotic infections of the thyroid reported in the literature include *Candida* and crypt

HIV INFECTION

Opportunistic infections involve the thyroid in patients with human immunodeficiency virus gland involved by HIV infection shows multiple cysts.32, 33

PNEUMOCYSTIS *CARINII* INFECTIONS OF THE THYROID

Thyroid gland involvement by *P. carinii* infection has generally been reported in immunosup infection.24, 25, 26, 27, 28, 29, 30, 31

Patients with *Pneumocystis carinii* infection may present with a tender unilateral thyroid m Aspiration biopsies showed large amounts of granular, frothy material associated with bland silver stain demonstrated the presence of *Pneumocystis carinii* organisms in the frothy mate

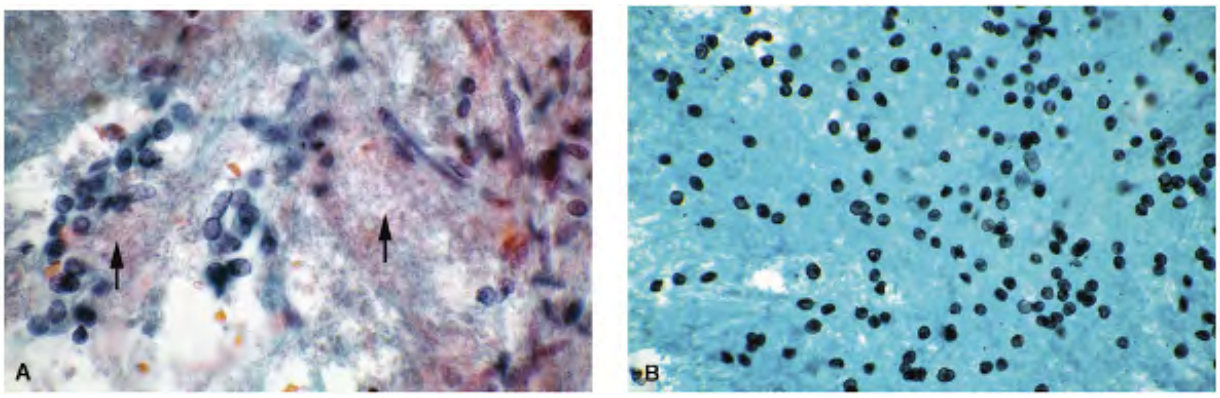

Figure 13.2. A. Fine-needle biopsy of a thyroid nodule in a patient with AIDS. There is gr
through them. B. Methenamine silver stain on the smear showed organisms with morpholc

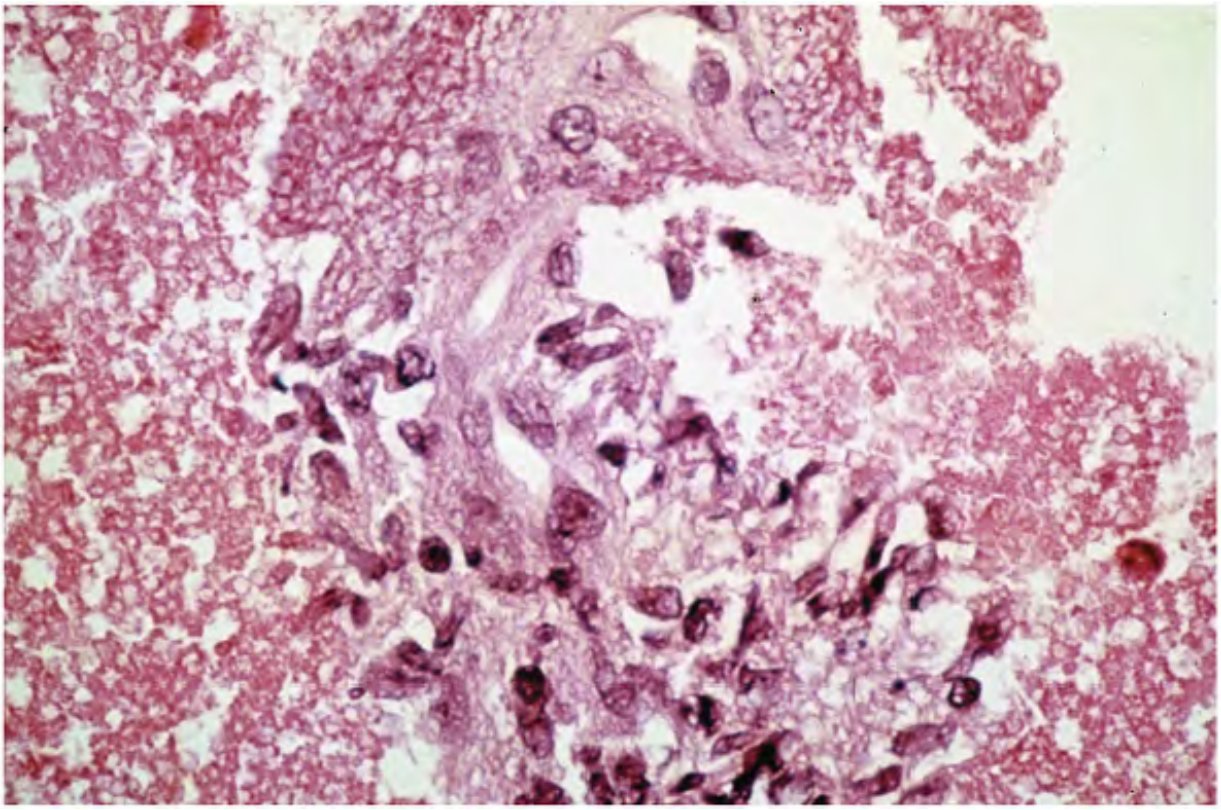

Figure 13.3. A cell block preparation from an aspirate of a thyroid nodule in a patient wi
pattern. (Courtesy of Sedigheh-Keyhani-Rafagha, MD, FIAC, Professor of Clinical Pathology

PARASITIC INFESTATION

In developing countries with endemic infestation by *Wucheria bancrofti*, microfilaria has be
echinococcal cyst involving the thyroid is reported by Sodhani and co-workers.39

SARCOIDAL THYROIDITIS

Sarcoidosis of thyroid is rare and usually presents as a manifestation of a generalized diseas
related to the thyroid disease, such as a diffuse asymmetrical enlargement or nodular goite

Histologically, there are interfollicular non-caseating granulomas consisting of epithelioid ce
contain asteroids or Schaumann bodies.

Fine-needle aspiration biopsy is not a diagnostic modality for sarcoidosis of the thyroid. The
sarcoidosis. The cytologic presentation is that of characteristic non-caseating granulomas of

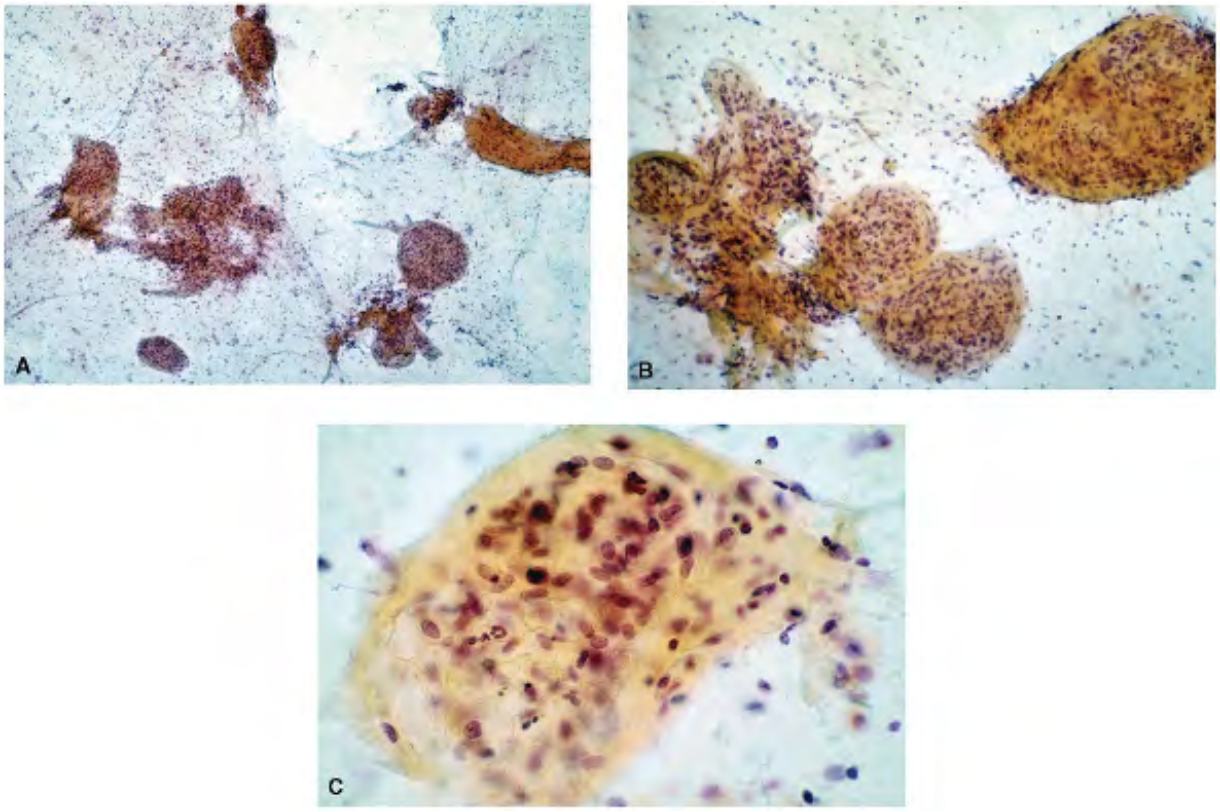

Figure 13.4. A. FNA of a thyroid nodule from a patient with a history of sarcoidosis. The
granulomas. C. Higher magnification showing aggregates of epithelioid cells, forming a no

SUBACUTE GRANULOMATOUS THYROIDITIS

Subacute or granulomatous thyroiditis is a spontaneously remitting inflammatory disease co
pseudotuberculous thyroiditis, viral thyroiditis, nonsuppurative thyroiditis, struma granulom

cell thyroiditis. It is reportedly common in women from the second to the fifth decades. Pat
the thyroid gland to an abrupt onset with chills, fever, severe neck pain, and symptoms of h
blood cell count, and low radioiodine level. There may be increased blood levels of thyroxin
although recurrence is common. However, it is self-limiting, and thyroid functions gradually

Usually the entire gland is involved, but initially the disease may be focal. In such circumsta
nodular involvement. The characteristic

microscopic features show destruction of the thyroid parenchyma with foreign body-type gia
infiltrate consists of neutrophils and eosinophils, as well as lymphocytes and plasma cells. L

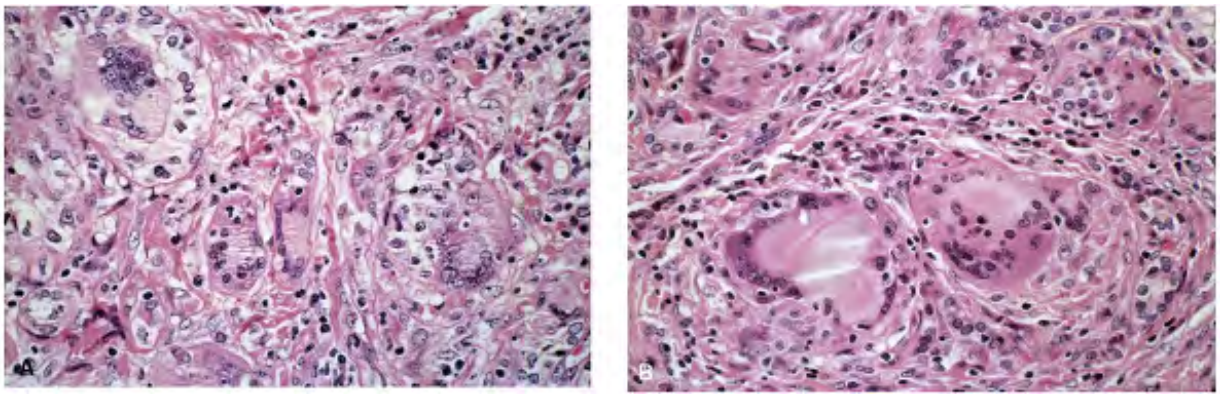

Figure 13.5. A. Histologic section of a thyroid involved by subacute (granulomatous) thyr
granulomas with large multinucleated foreign body-type giant cells.

Cytopathologic Findings

Fine-needle biopsy as a diagnostic technique is not routinely used to confirm the diagnosis c
Biopsies are performed in patients with an unusual presentation to rule out suppurative thyı
one rarely encounters a case in routine cytopathology practice; our experience is limited to
review is presented by Chang et al.52

The cytopathologic features of subacute thyroiditis (Figs. 13.6, 13.7, 13.8) are presented in
the aspirate is cellular, characterized by several

large multinucleated foreign body-type giant cells containing up to several hundred nuclei (
generally uniform, small, round to oval, with sharp nuclear membranes, finely granular chro
often seen in the vicinity of either follicular epithelial cells or colloid droplets (Fig. 13.6D).
cells (Fig. 13.7).

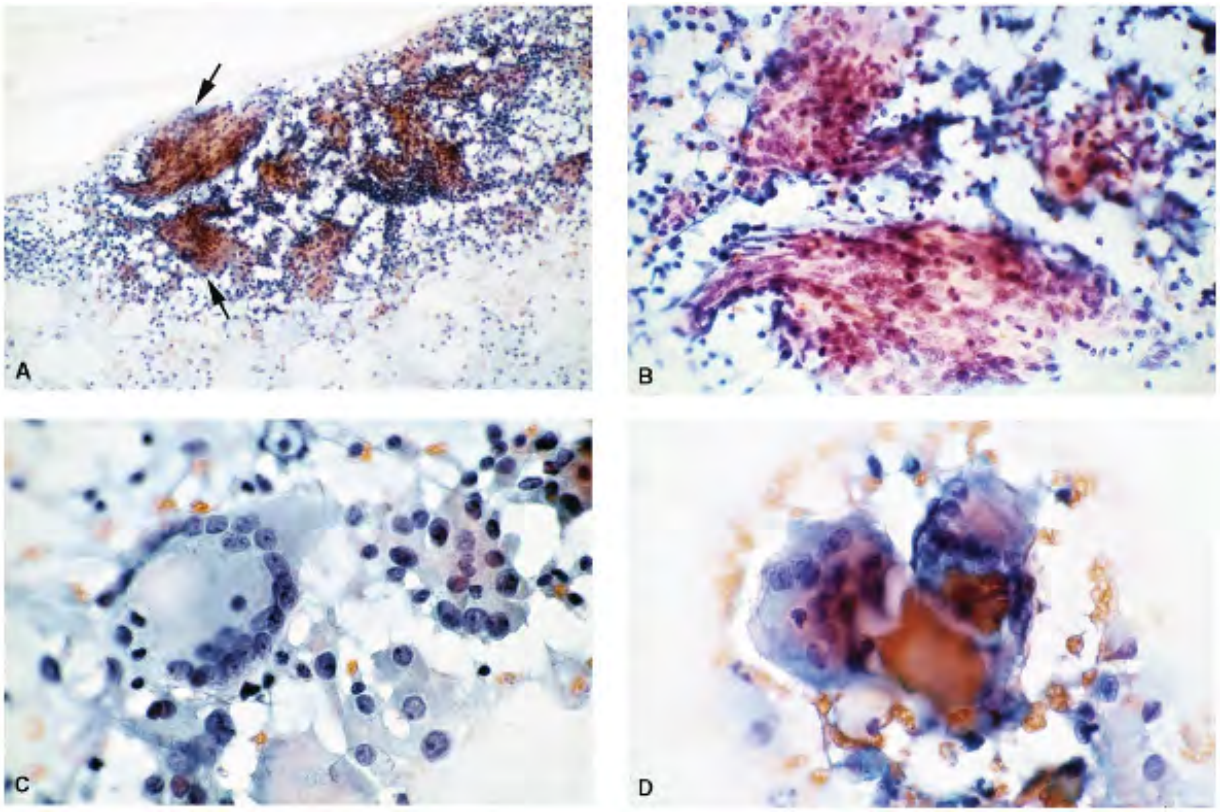

Figure 13.6. FNA from subacute (granulomatous) thyroiditis. A. Cellular aspirate with infl
Higher magnification highlighting the multinucleated foreign body-type giant cells. C. A L
giant cells surrounding a blob of colloid.

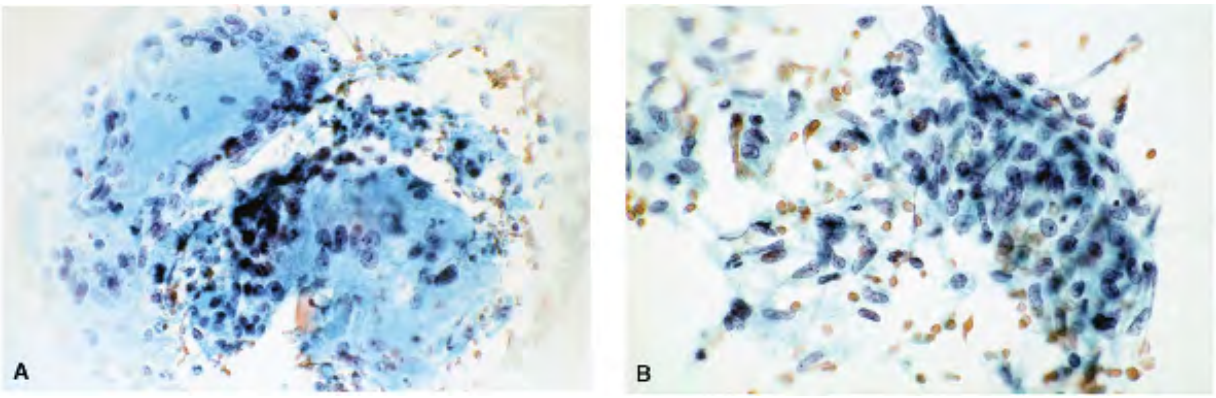

Figure 13.7. A. Subacute (granulomatous) thyroiditis. A granuloma formed by epithelioid

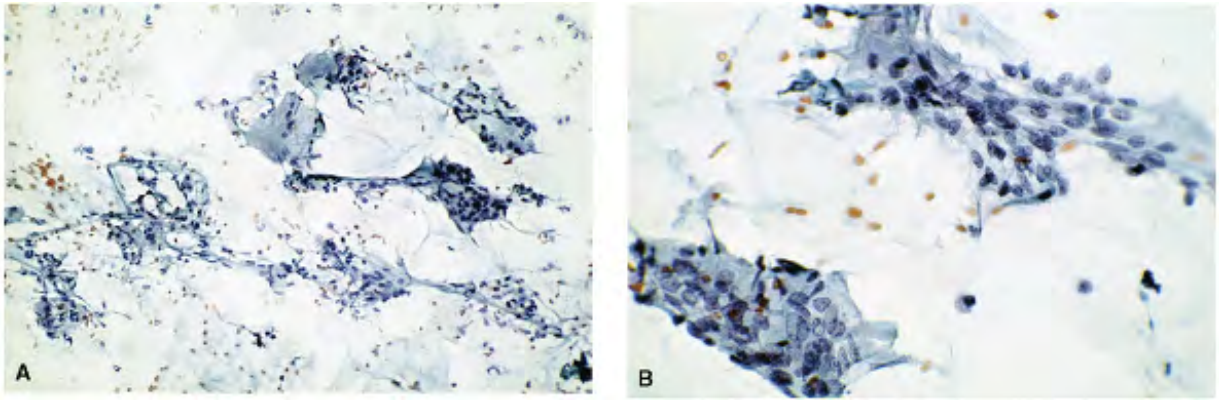

Figure 13.8. FNA of a painful thyroid mass in an older individual. A. Several fragments of showing stromal spindle-shaped cells and multinucleated giant cell.

TABLE 13.2 CYTOPATHOLOGIC FEATURES OF SUBACUTE (G

Cellularity	Variable; can be highly cellular
Presentation	Varying numbers of large multinucleated foreign-body-type giant cel propor- tions; contain large numbers of nuclei scattered throughout the cy perimeter; multinucleated cells discrete or in groups, often around colloid for usu- ally identified; epithelioid cells Â±; lymphocytes in varying numbe tingible body histiocytes not present; neutrophils in acute stages
Epithelial cells	Follicular and HÃ¼rthle cells with or without nuclear atypia in varyir
Background	Spindle cells of stromal origin; stromal tissue fragments may be seer inflammatory debris in acute stages

Other inflammatory cells include spindle-shaped and/or plump epithelioid cells, lymphocyte be seen, along with cellular and inflammatory debris. Stromal cells are often aspirated, esp absent during the healing phase.

Differential Diagnosis

The cytologic pattern of an aspirated sample from subacute or granulomatous thyroiditis ha also be seen in several conditions affecting the thyroid gland (see "Multinucleated Giant Cel thyroiditis and subacute (granulomatous) thyroiditis are discussed later in this chapter, in th

Anaplastic carcinoma is important as a differential diagnosis clinically because both disease

Occasionally, proliferating stromal fibroblasts may be mistaken for spindle cell-type anaplas
Anaplastic Carcinoma versus Granulomatous Thyroiditis).

SUBACUTE LYMPHOCYTIC THYROIDITIS

This relatively recently recognized entity is also referred to as "painless thyroiditis."56, 57,
lymphocytic infiltrate. This type of thyroiditis is very common in the United States and is fre
debatable. More information can be found in the literature.

RIEDEL'S THYROIDITIS (INVASIVE FIBROUS THYROIDITIS)

Invasive fibrous thyroiditis, the rarest form of thyroiditis,1, 2, 3, 59, 60, 61, 62, 63 primaril
struma. Originally described by Riedel in 1896, it is a progressive disease characterized by c
process causes pressure symptoms in the neck, with fixation of the neck organs. Clinically, t
granulomatous thyroiditis.

Grossly, the thyroid is rock-hard in consistency. The cut surface shows a loss of normal redd
is total destruction of the thyroid parenchyma, which is replaced by dense collagenized fibr

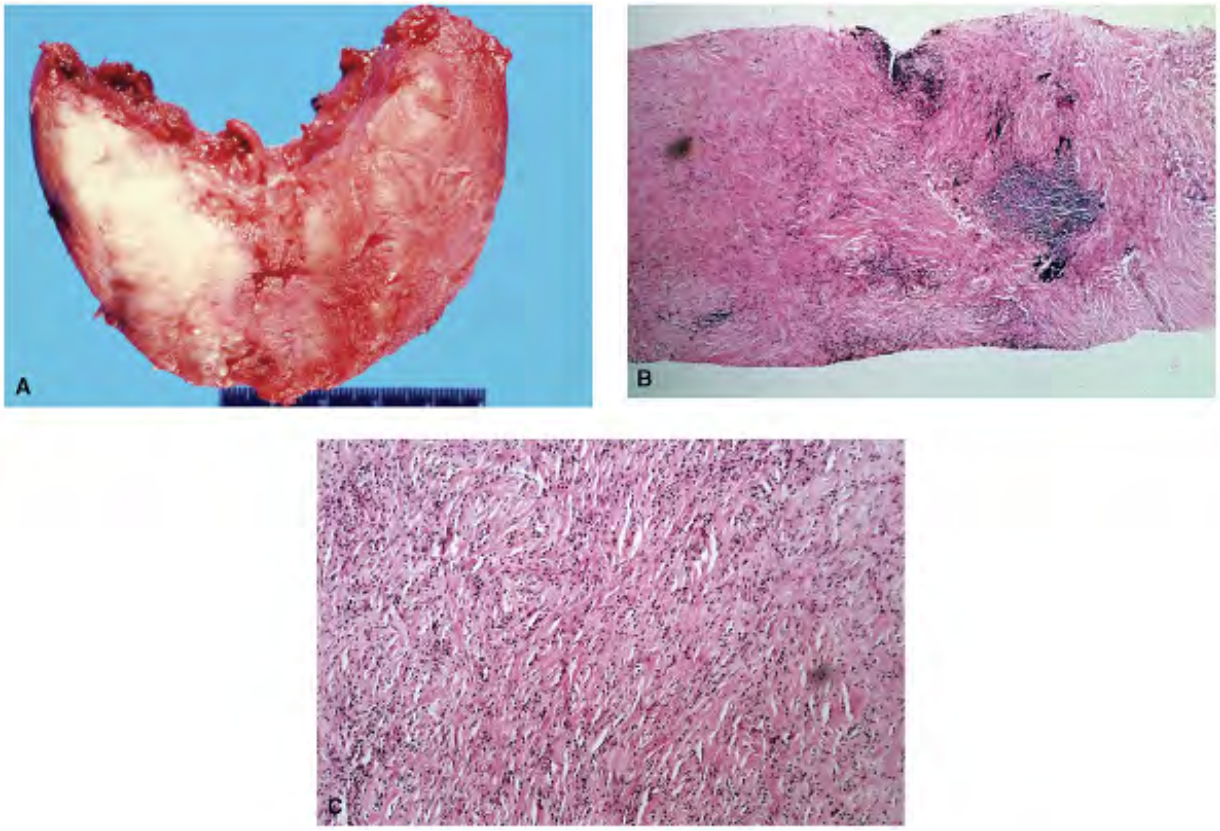

Figure 13.9. A. Gross photograph of Riedel's thyroiditis. The cut surface of the right lobe
lobulation. A fine-needle biopsy from such a lesion is likely to be unsatisfactory. B. Core-
infiltrate. C. Higher magnification to show dense fibrosis.

Fine-needle biopsy yields no thyroid follicular cells. Rare documented cases with fine-needl
65, 66

CHRONIC LYMPHOCYTIC (HASHIMOTO'S) THYROIDITIS

Hashimoto's thyroiditis, first described in 1912, is the most common form of thyroiditis.1, 2,
goiter, autoimmune thyroiditis, and chronic lymphocytic thyroiditis. It commonly occurs in f
reported occurrence of this disease a decade earlier in areas of endemic goiter. Hashimoto's
are at risk of developing malignant lymphoma, stated to be 67- to 80-fold.76, 77

Clinically, the disease is characterized by a diffuse firm, nontender goiter with or without n

thyroiditis is an autoimmune disease with high titers of antithyroglobulin antibodies, antimi
Hashimoto's thyroiditis may be progressive, and it is an important cause of hypothyroidism.

Radiologic Findings

Imaging quite often shows patchy uptake or cold defects. Innumerable tiny hypoechoic nodu

Gross and Histologic Features

Grossly, the thyroid is symmetrically enlarged, 2 to 4 times the normal size (Fig. 13.10), anc
also occur. The capsule is smooth and tense. The gland feels firm and rubbery. The cut surf

Figure 13.10. Gross photograph of a thyroid with both lobes involved by Hashimoto's thyr

Microscopically (Figs. 13.11, 13.12, 13.13, 13.14, 13.15, 13.16, 13.17, 13.18, 13.19, 13.20, 1
tissue. Progressive destruction of the thyroid parenchyma is seen, along with interlobular ar
82, 83 The lymphoid infiltrate varies significantly from gland to gland and within the same g
The lymphoplasmacytic infiltrate may obscure the thyroid follicles.

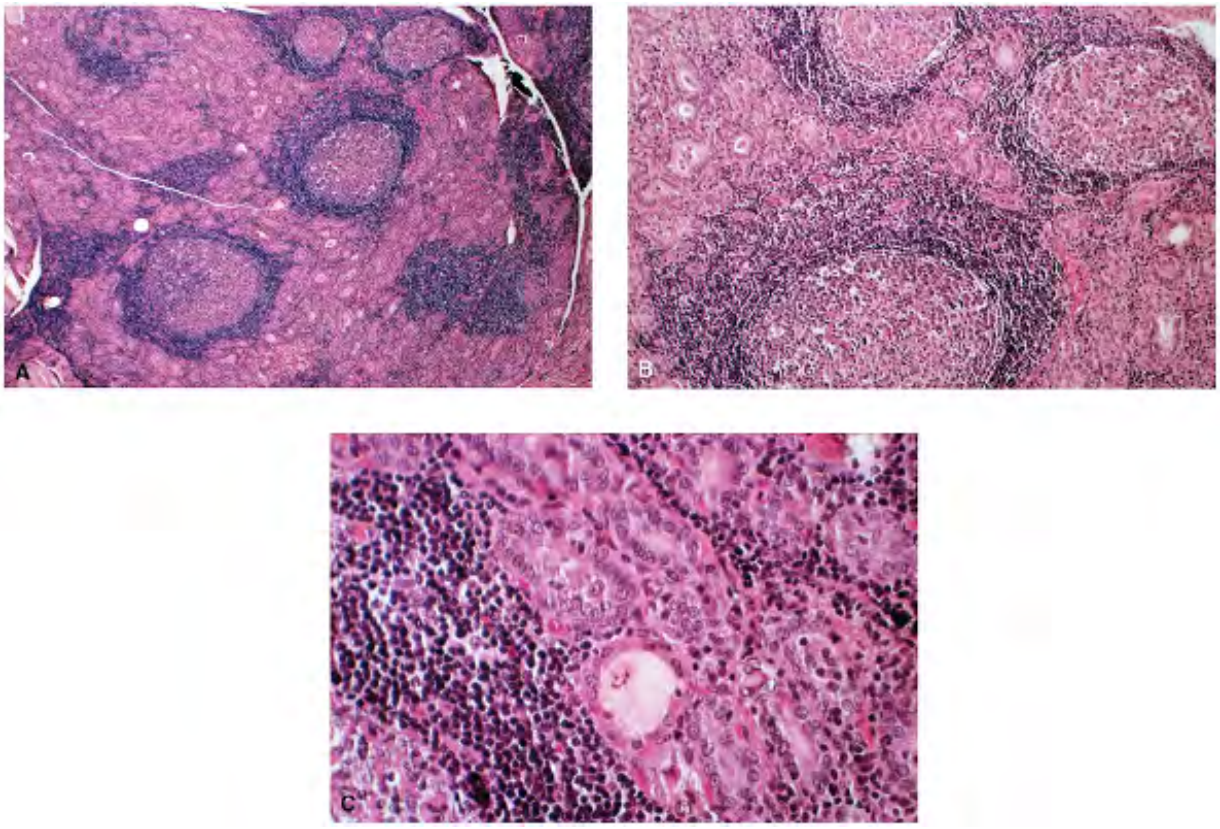

Figure 13.11. Histologic sections of Hashimoto's thyroiditis. A. Low power showing heavy lymphoid follicles with expanded germinal centers. C. Higher magnification to show inter

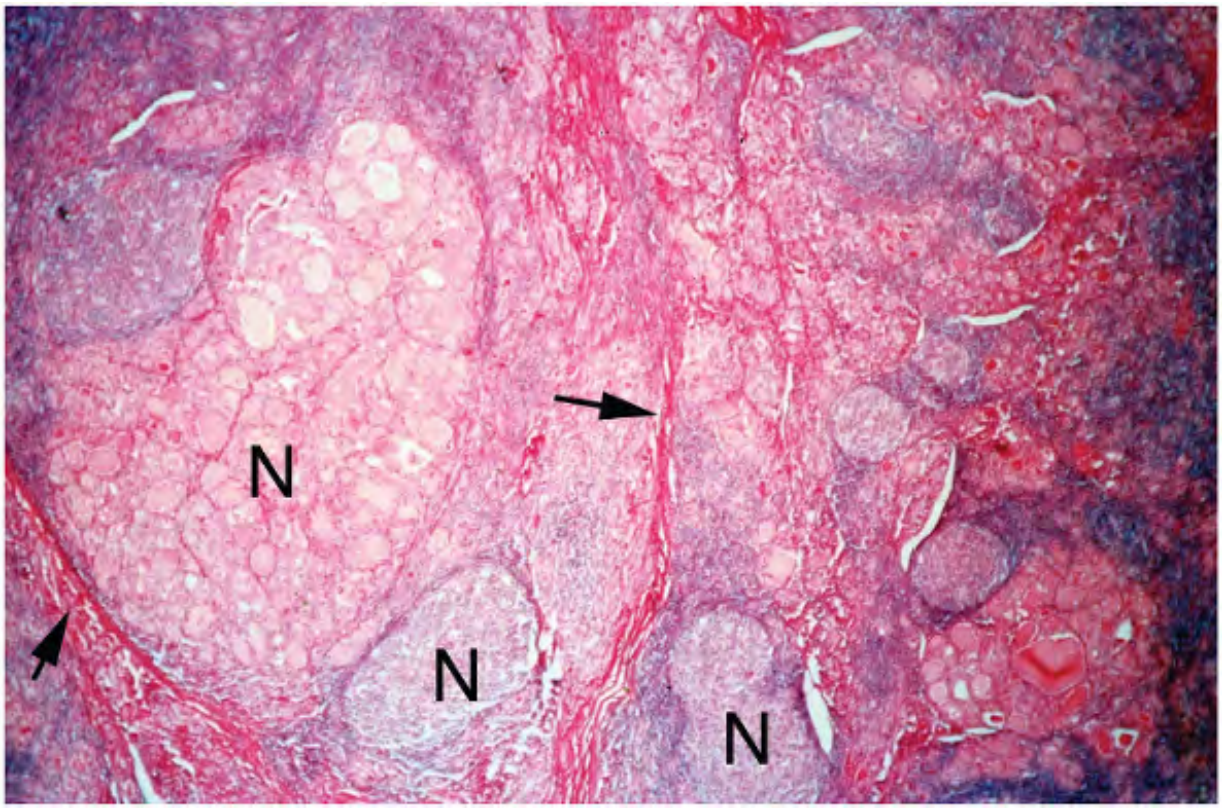

Figure 13.12. Hashimoto's thyroiditis. Heavy inflammatory infiltrate, lymphoid follicles w

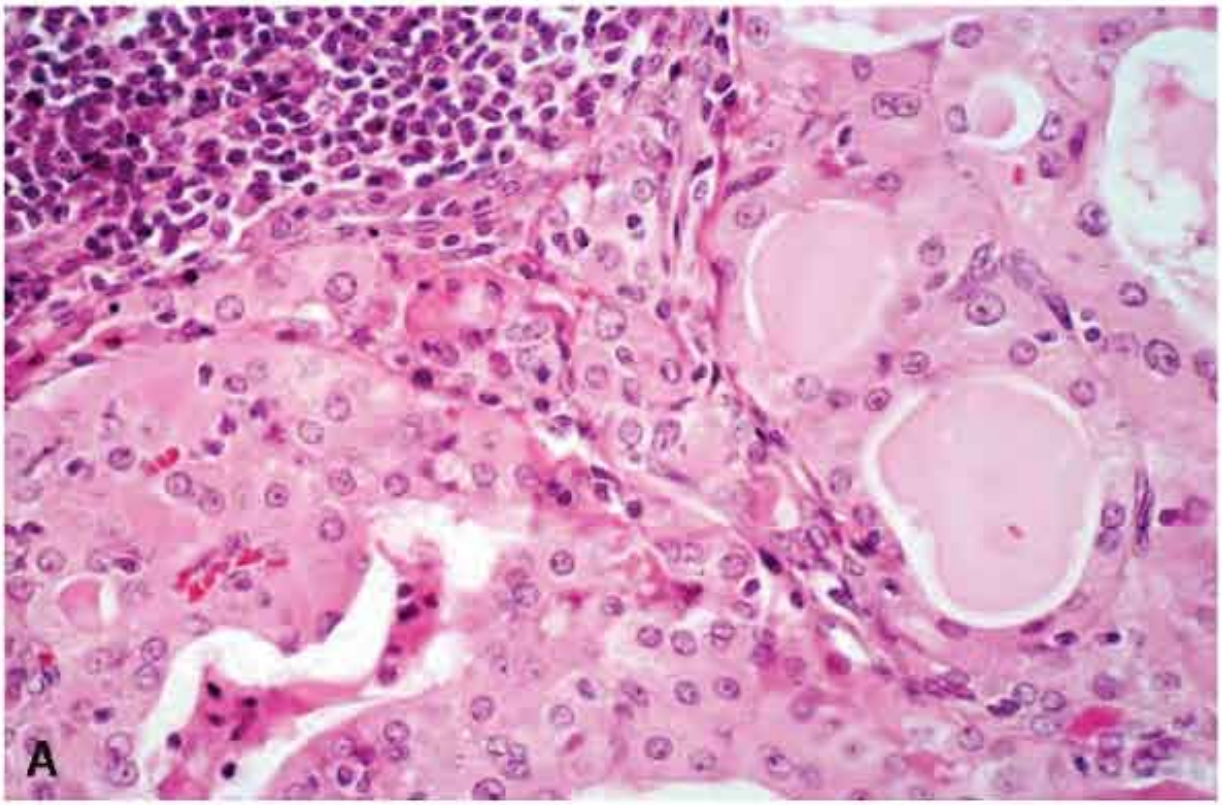
A

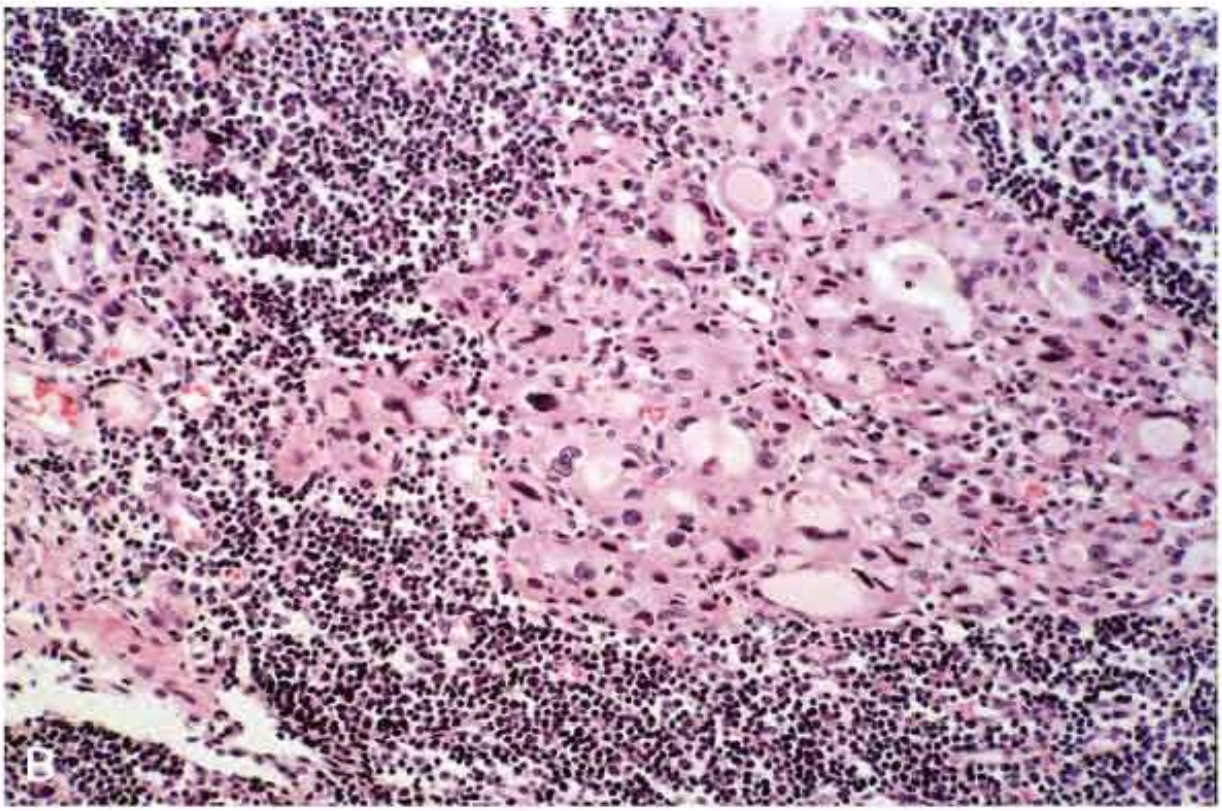
B

Figure 13.13. Hashimoto's thyroiditis with prominent HÃ¼rthle cell metaplasia and lympl

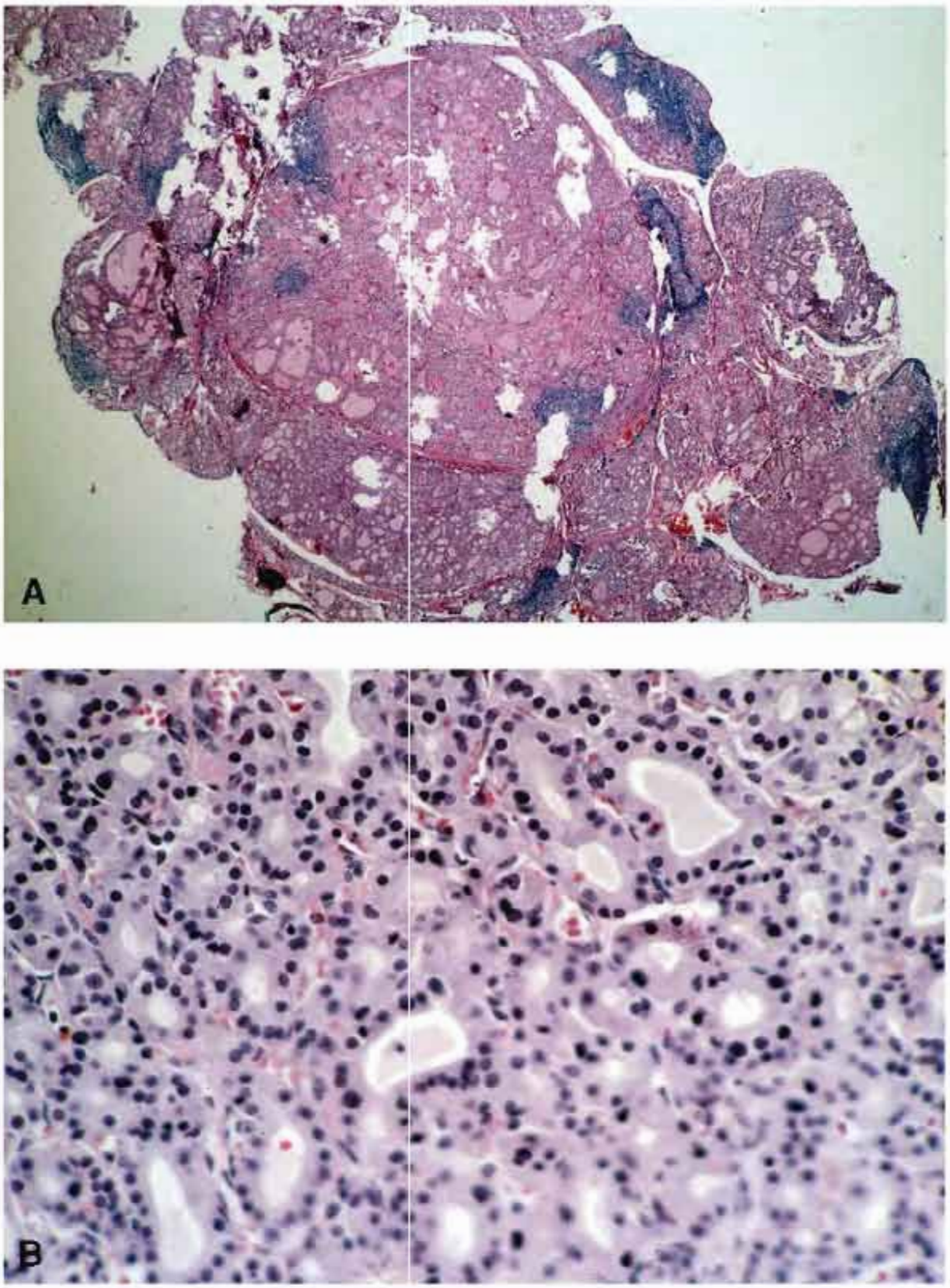
A
B

Figure 13.14. Hashimoto's thyroiditis. A. Low power. Note multiple epithelial nodules an
lymphoid infiltrate. FNA biopsy of such an area is likely to show a predominant or an excl

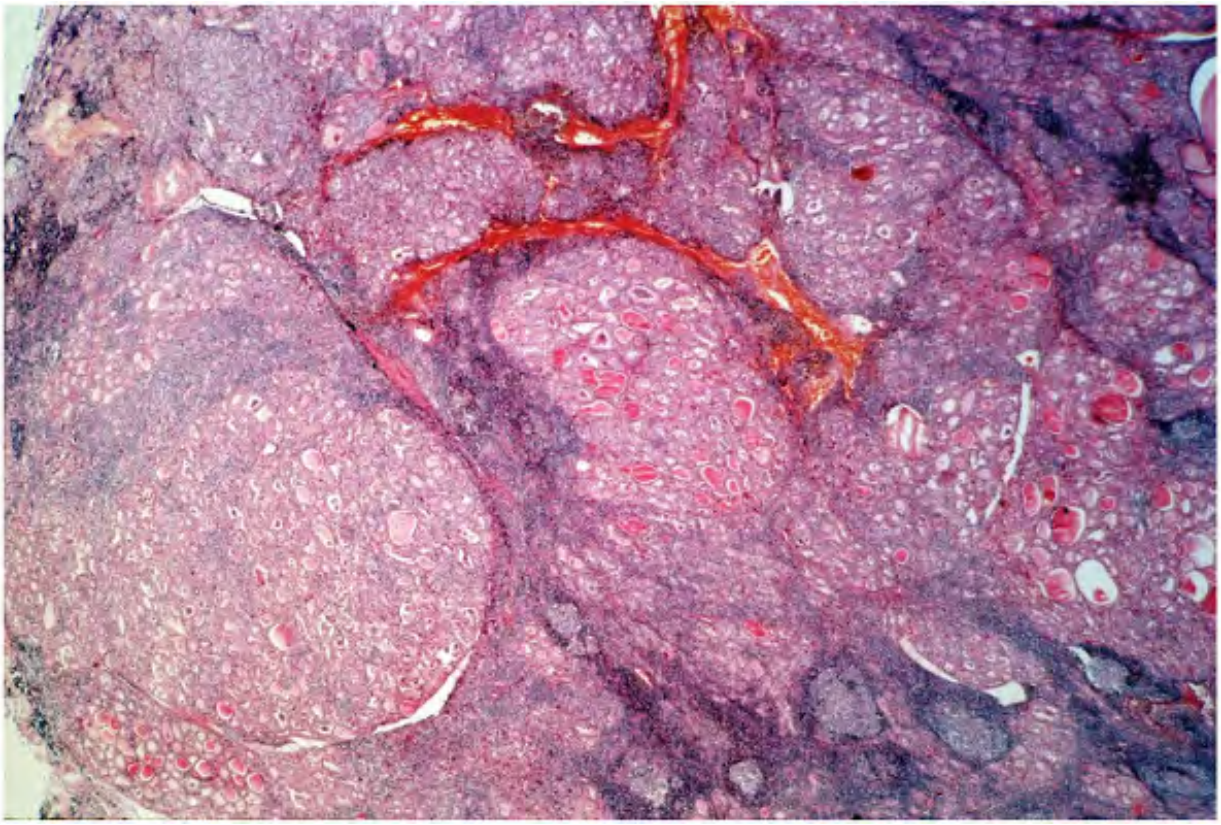

Figure 13.15. Hashimoto's thyroiditis medium-power view demonstrating varying-sized fo

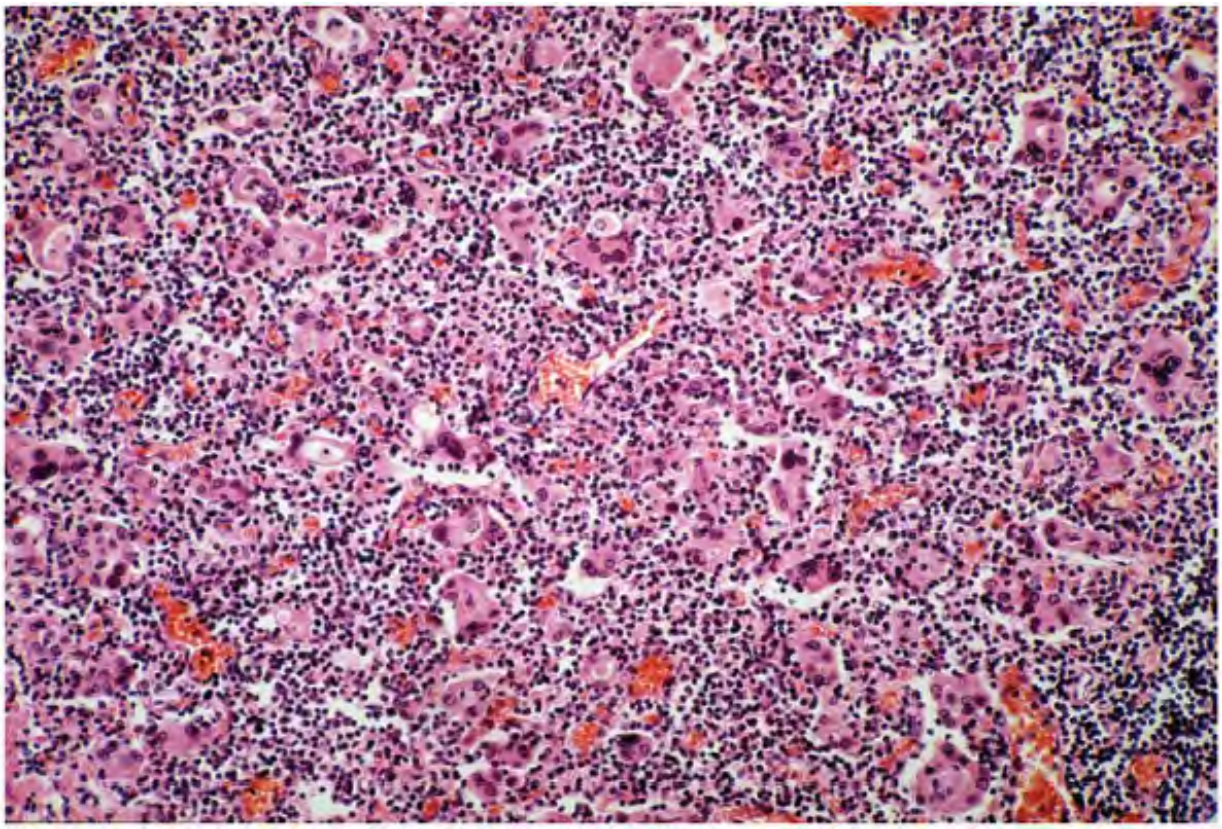

Figure 13.16. Hashimoto's thyroiditis. Histologic section highlighting extensive HÃ¼rthle
likely to show an admixture of HÃ¼rthle cells and lymphoplasmacytic cells. The nuclear a
typical change in Hashimoto's thyroiditis.

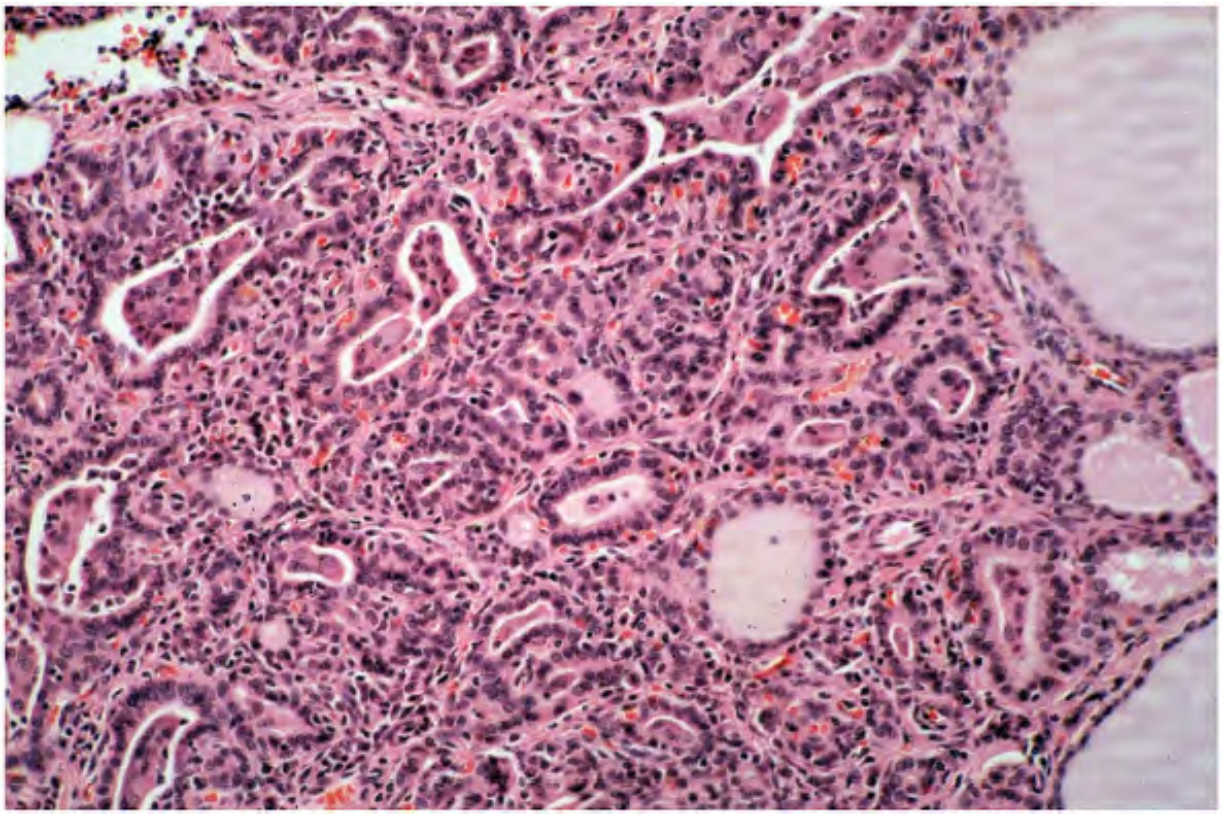

Figure 13.17. Another example of Hashimoto's thyroiditis with irregular follicles, some di significant perifollicular fibrosis.

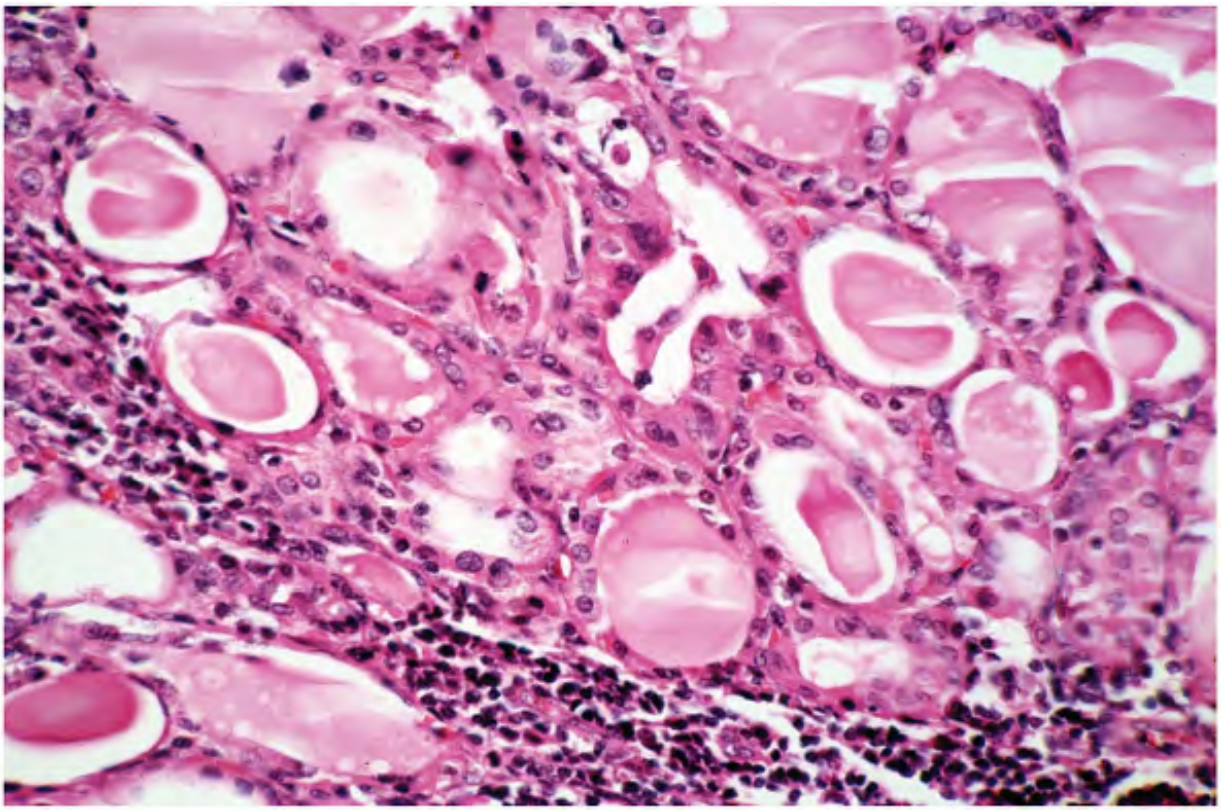

Figure 13.18. Hashimoto's thyroiditis. An infrequent finding, showing dilated follicles fille

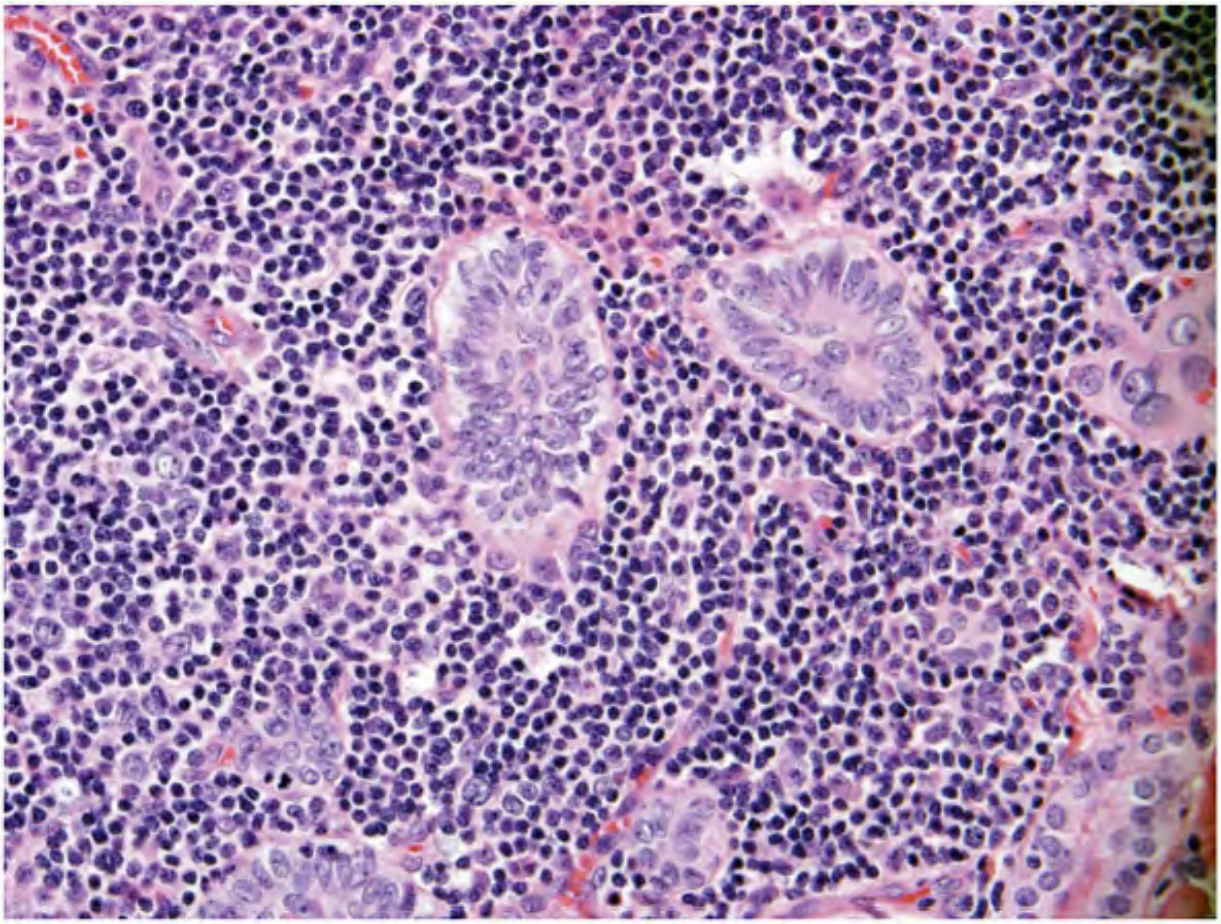

Figure 13.19. Hashimoto's thyroiditis. Embedded in the pools of lymphoplasmacytic infilt resembling the nuclei of conventional papillary carcinoma.

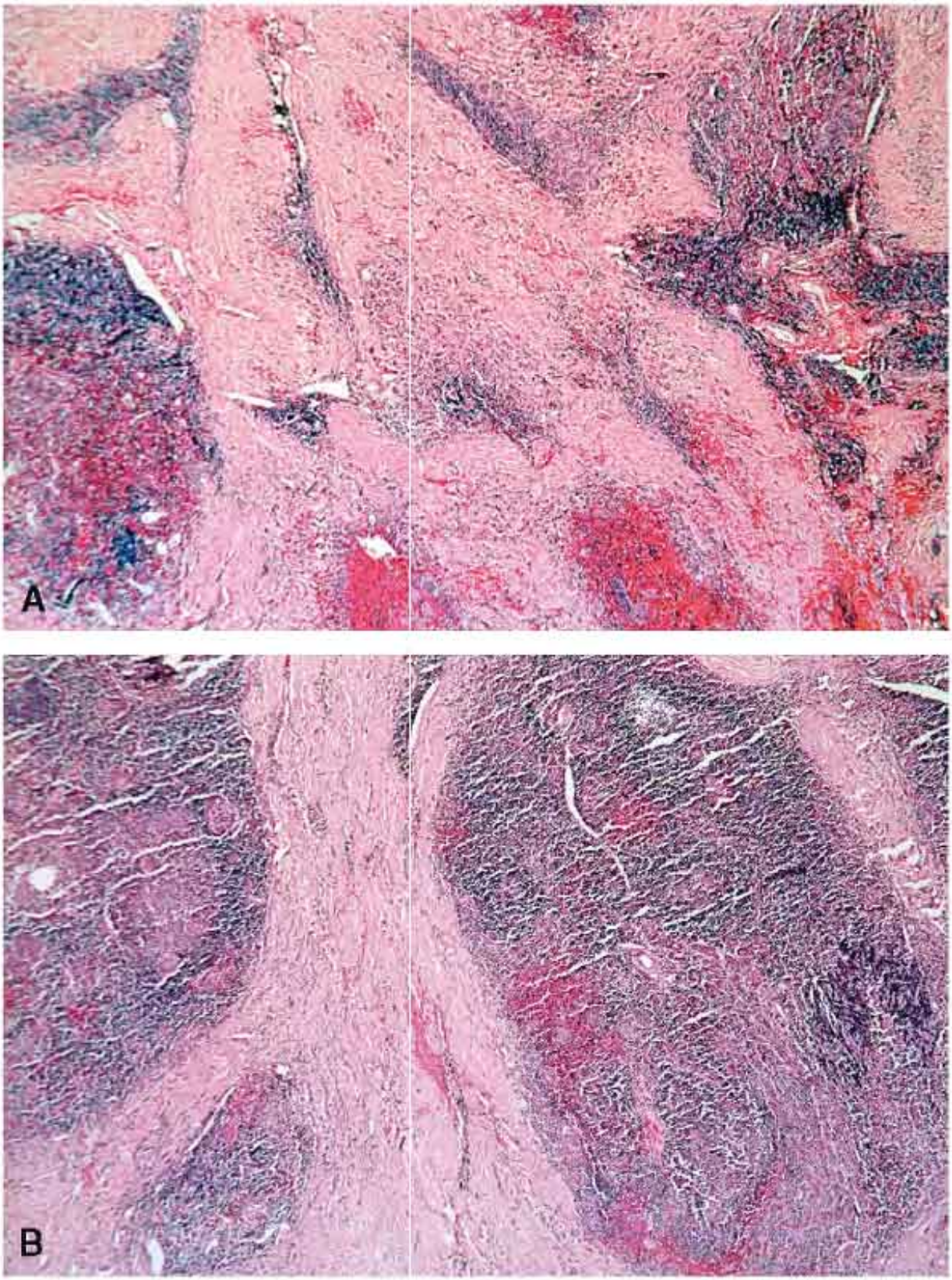
A
B

Figure 13.20. A. Hashimoto's thyroiditis with extensive fibrosis, separating large areas of

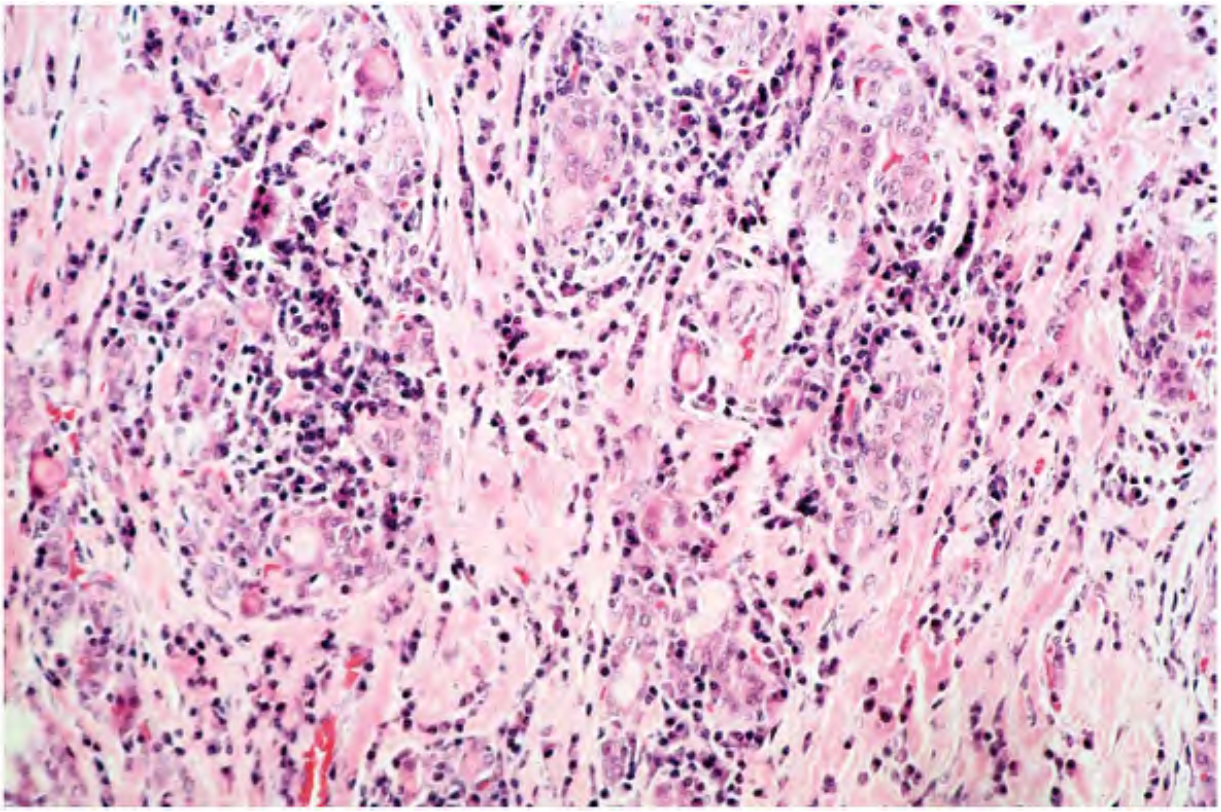

Figure 13.21. Fibrous variant of Hashimoto's thyroiditis with extensive fibrosis. The thyro

The epithelial changes are varied and are characterized by oxyphilic change in the follicular formations. Oxyphilic change in the epithelium is considered a hallmark of Hashimoto's disea However, these nodules are non-encapsulated. Papillary hyperplasia is also present. The foll regular follicular epithelium often show considerable atypia. The follicular cell nuclei may p

changes of papillary carcinoma. In some instances, the thyroid may contain aggregates of th carcinoma (Fig. 13.19)81, 82 Multinucleated foreign-body-type giant cells may be seen infre part of the lobe may be seen. In later stages, there may be marked fibrosis with considerabl

infrequent occurrence. Still more rarely, thyroids may show squamous lined cysts referred t

The intensity of the changes described above varies from lobe to lobe, as well as within a lo prominent feature, but the lymphocytic infiltration is diffuse and extensive. This is referred

FIBROUS VARIANT OF HASHIMOTO'S THYROIDITIS

The fibrous variant of Hashimoto's thyroiditis represents approximately 10% of cases.2 It occ pressure symptoms. Grossly the gland is more fibrotic, larger. Histologically, it maintains th Features such as lymphoid follicles with germinal centers, and HÃ¼rthle cell metaplasia, ar thyroiditis.

Cytopathologic Features

Aspirates of the thyroid gland involved by Hashimoto's disease show an admixture of polymo 13.26, 13.27, 13.28, 13.29, 13.30, 13.31, 13.32, 13.33, 13.34, 13.35, 13.36, 13.37).55, 84, 8 of involvement. Usually the inflammatory cells are comprised of lymphocytes, plasma cells, transforming lymphocytes, including immunoblasts and histiocytes with phagocytic debris (F

distorted and are seen as stretched fibers, frequently in dark, tangled masses (Fig. 13.24B). centrifuged blood. Cytologic preparations of such aspirates show a dense population of lymp aspirated may remain as tight groups of cells and may mimic a tissue fragment of follicular discrete lymphocytes are not visualized. The author has encountered this problem on two o lymphoid cells (Fig. 13.27C and 13.27D). The inflammatory infiltrate in Hashimoto's thyroidi are polyclonal for heavy-and light-chain immunoglobulins.

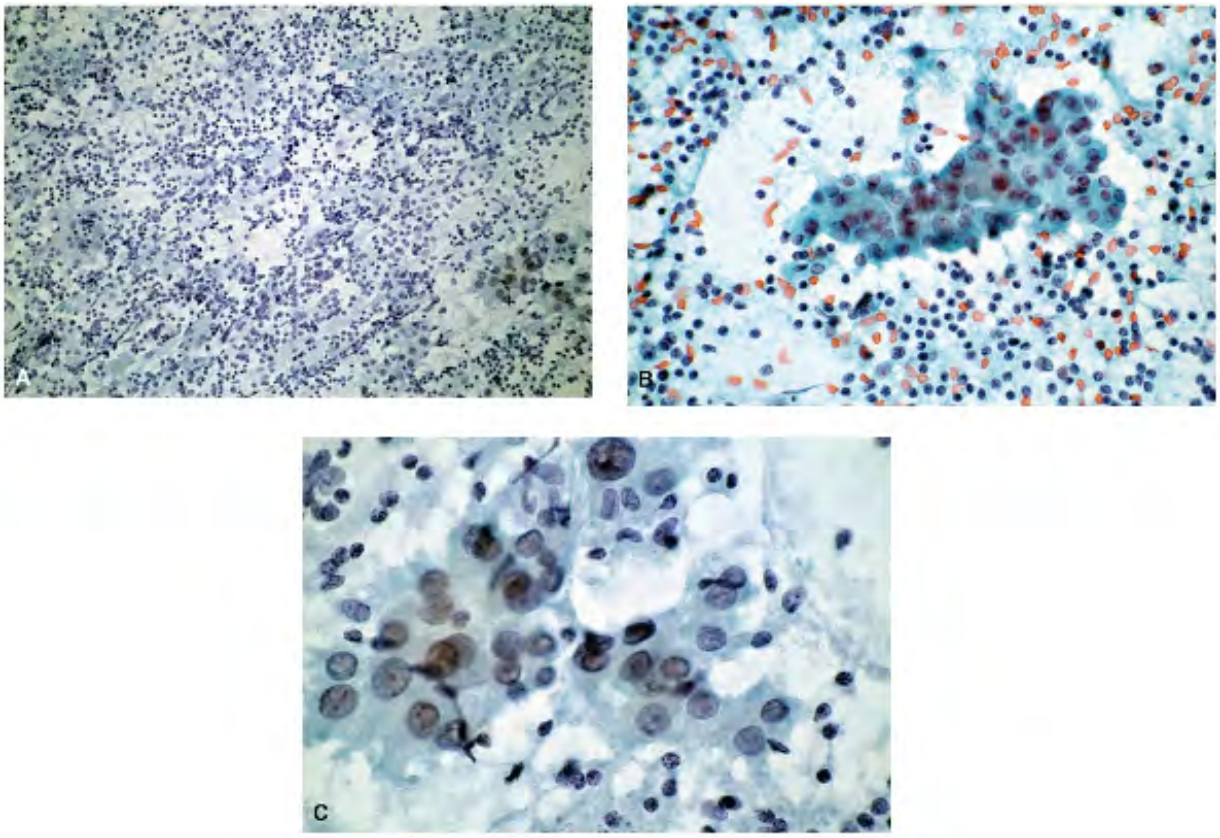

Figure 13.22. A. FNA of Hashimoto's thyroiditis, showing a mixture of inflammatory and e
background of lymphoplasmacytic cells. C. These HÃ¼rthle cells demonstrate considerabl

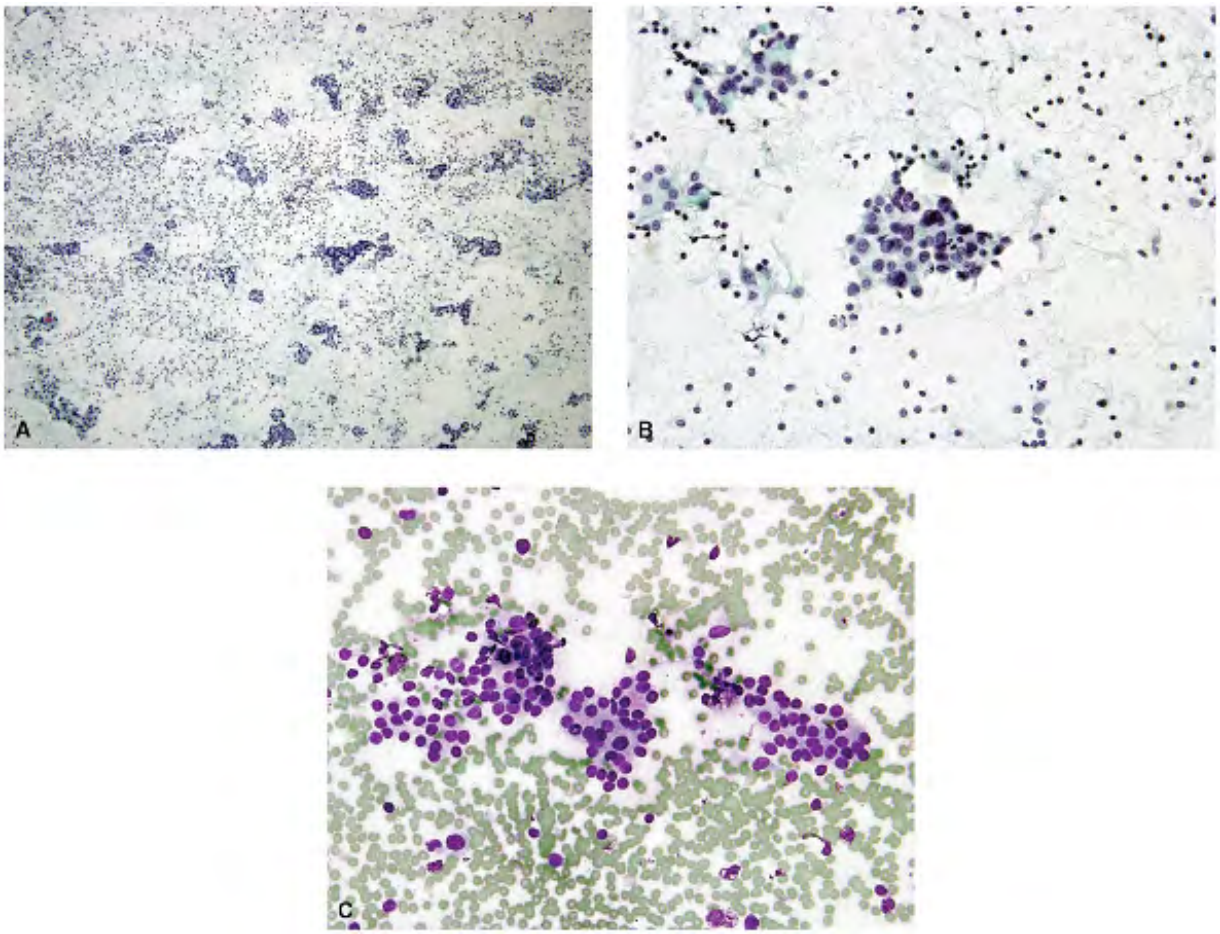

Figure 13.23. FNA of Hashimoto's thyroiditis. A. A characteristic pattern with cellular asp
magnification. C. Diff-Quik stain.

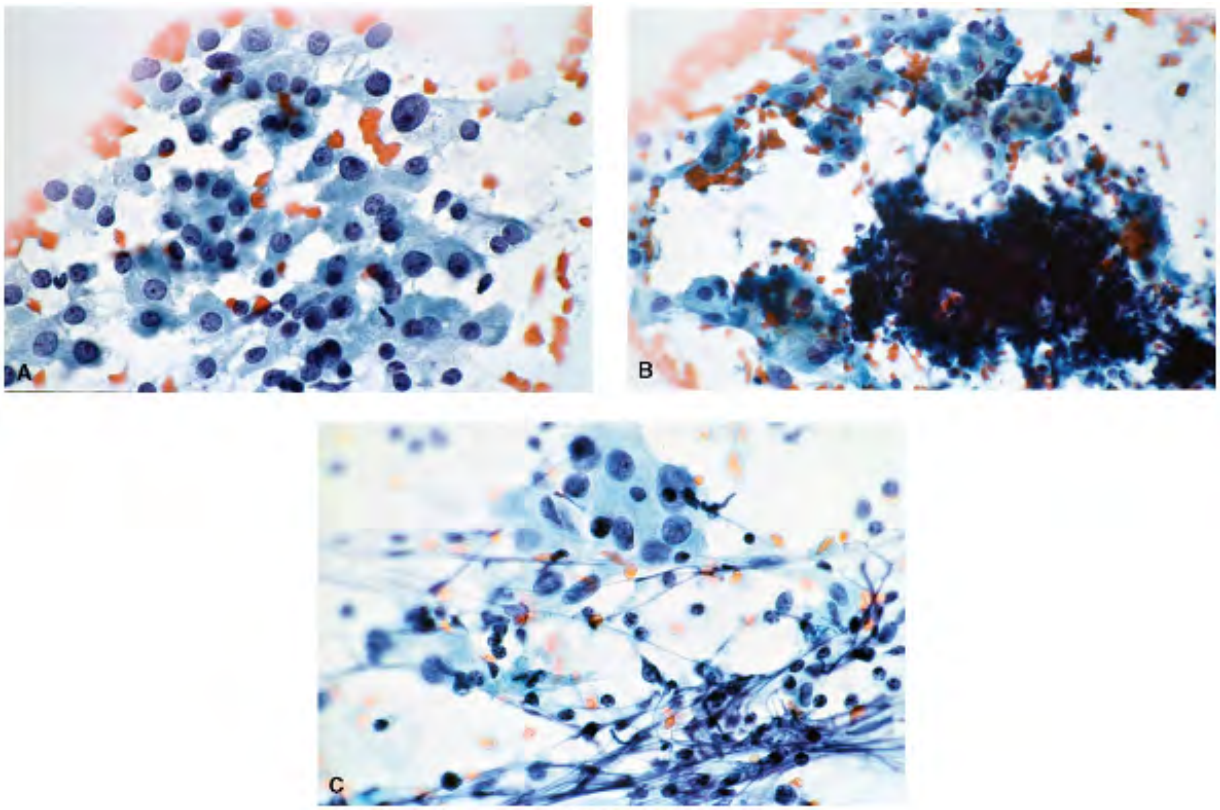

Figure 13.24. A. This smear from an FNA of Hashimoto's thyroiditis shows loosely cohesiv
identified. B. Another field from the same case showing several tissue fragments of HÃ¼r
lymphocytes.

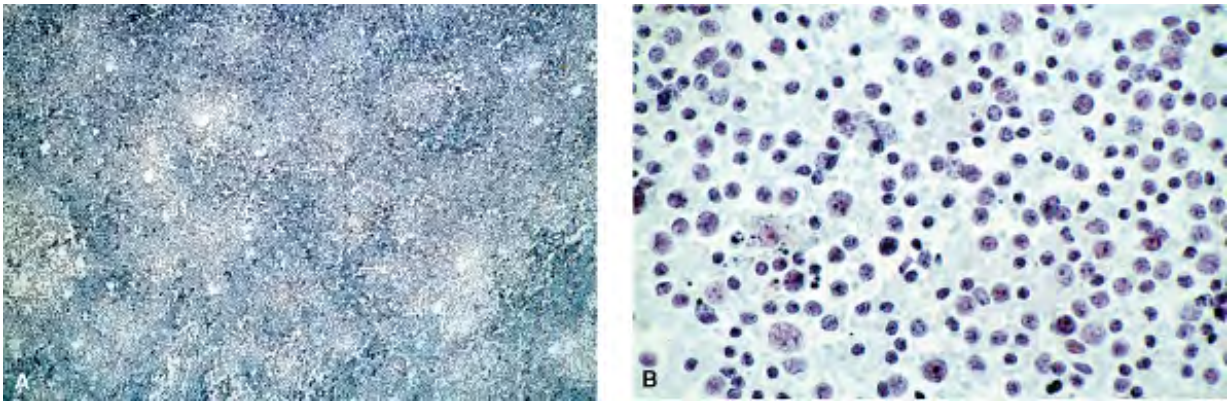

Figure 13.25. A. Hashimoto's thyroiditis, lymphoid variety, showing a heavy inflammatory
of the lymph node. B. Higher magnification depicting polymorphic cell population represe

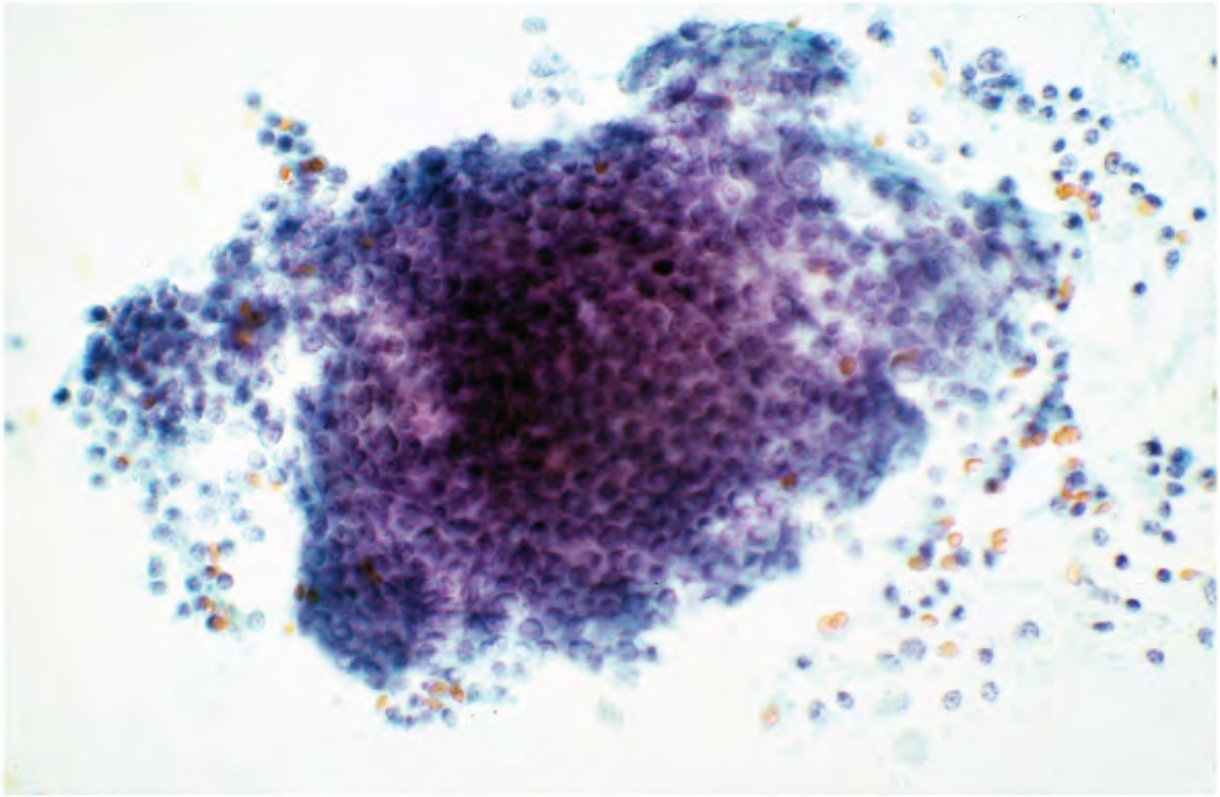

Figure 13.26. FNA of Hashimoto's thyroiditis. This large aggregate of tightly packed lymp
follicular neoplasm. This may represent lymphocytes totally obscuring the follicular cells.

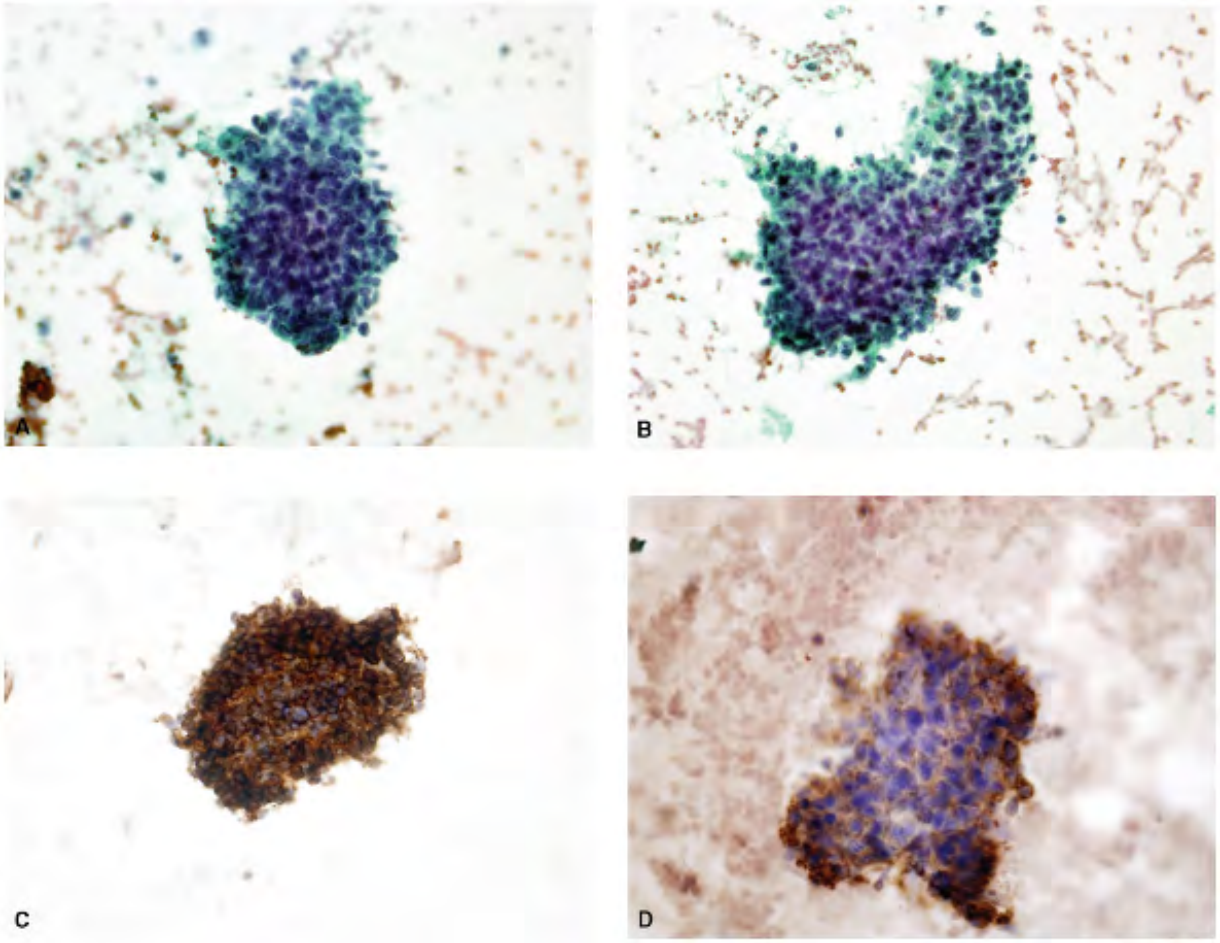

Figure 13.27. A,B. FNA of Hashimoto's thyroiditis showing a large aggregate of tightly pa
pattern. This was misinterpreted as a follicular neoplasm. Thyroidectomy revealed typica
these cells raised the possibility of being lymphoid cells. C. Immunostain for leukocyte co
fragment shows central follicular cells, not reacting to leukocyte common antigen (LCA),

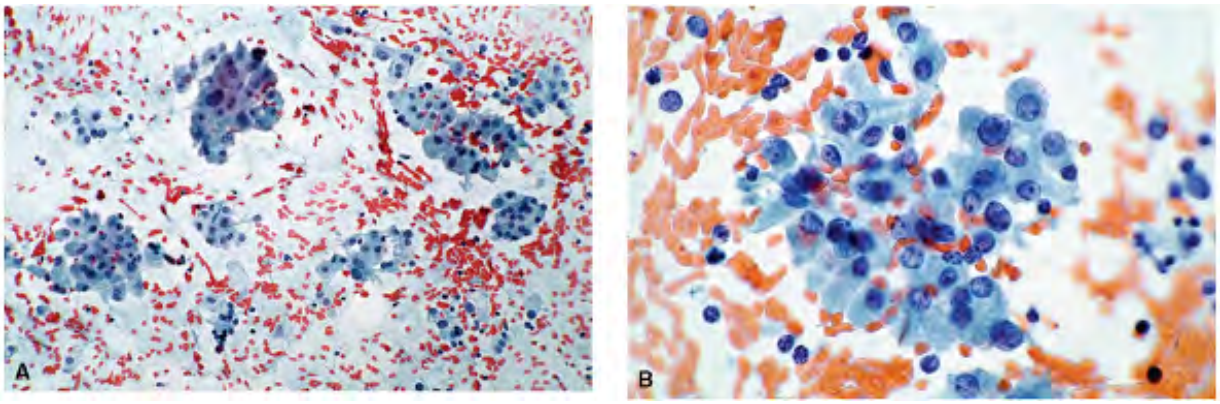

Figure 13.28. A. Low-power view of a cellular aspirate from a case of Hashimoto's thyroi
neoplasm. B. Higher magnification demonstrating HÃ¼rthle cells with atypical but marke
diagnosis of thyroiditis. These HÃ¼rthle cells lack the typical nuclear morphology of HÃ¼

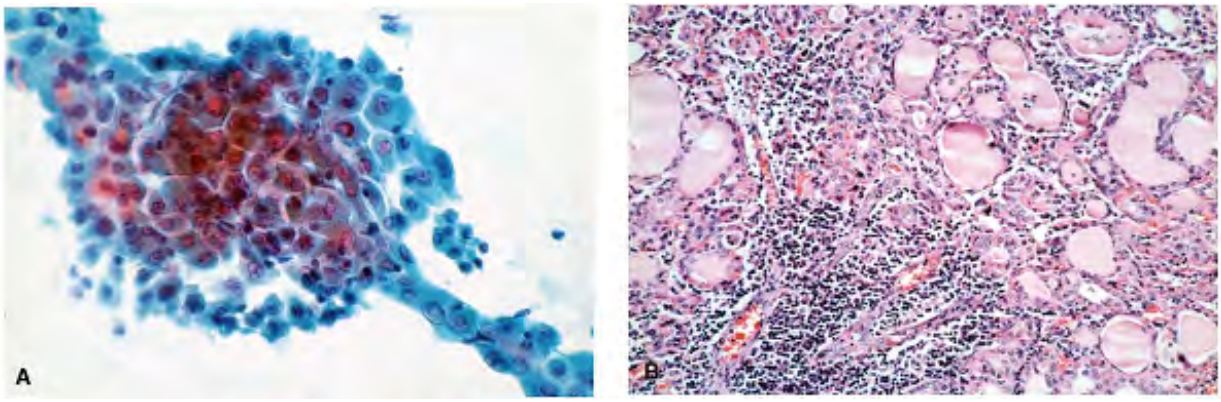

Figure 13.29. A. Hashimoto's thyroiditis showing a large tissue fragment of HÃ¼rthle cell
contain prominent nucleoli. HÃ¼rthle cell neoplasm was suspected. B. The core-needle b

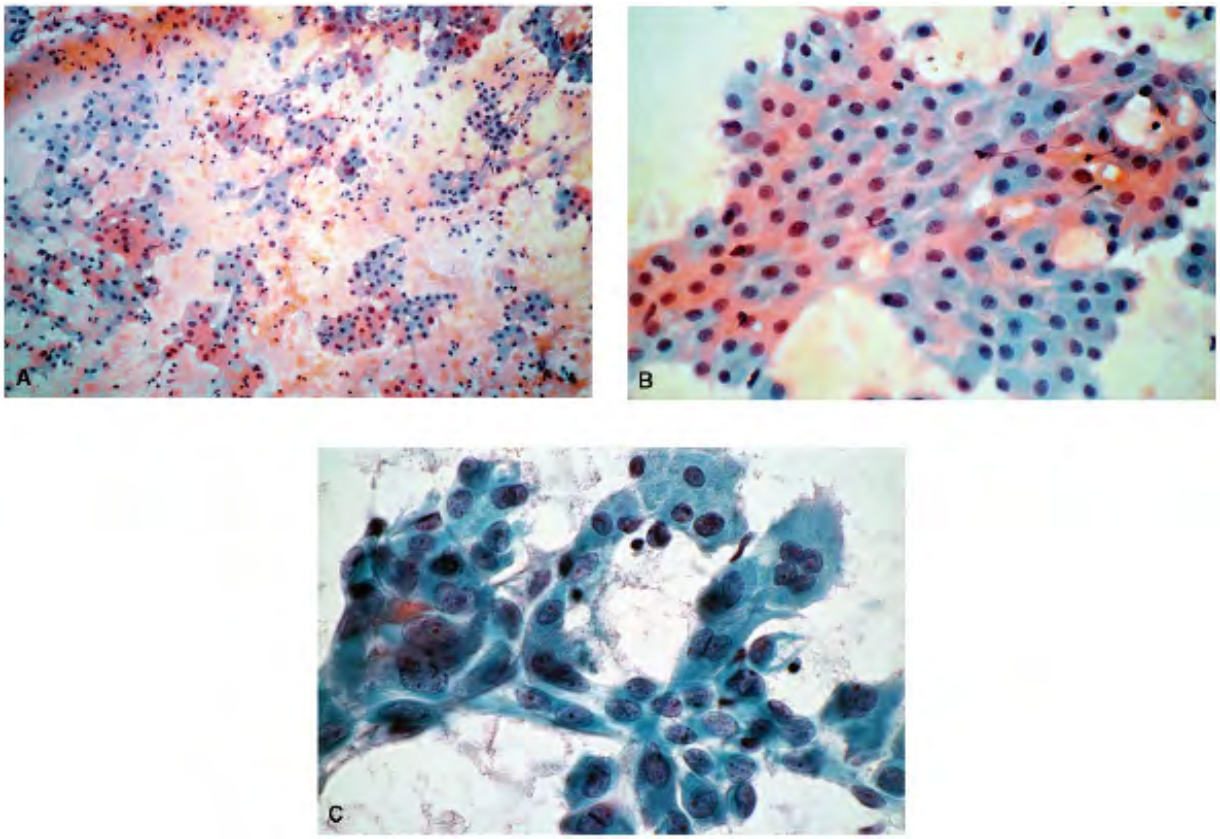

Figure 13.30. A. This aspirate from a case of Hashimoto's thyroiditis contained several tis
magnification showing a monolayered sheet of HÃ¼rthle cells with uniform nuclei, lackin
HÃ¼rthle cells with bizarre nuclei. Such a presentation is not consistent with a HÃ¼rthle

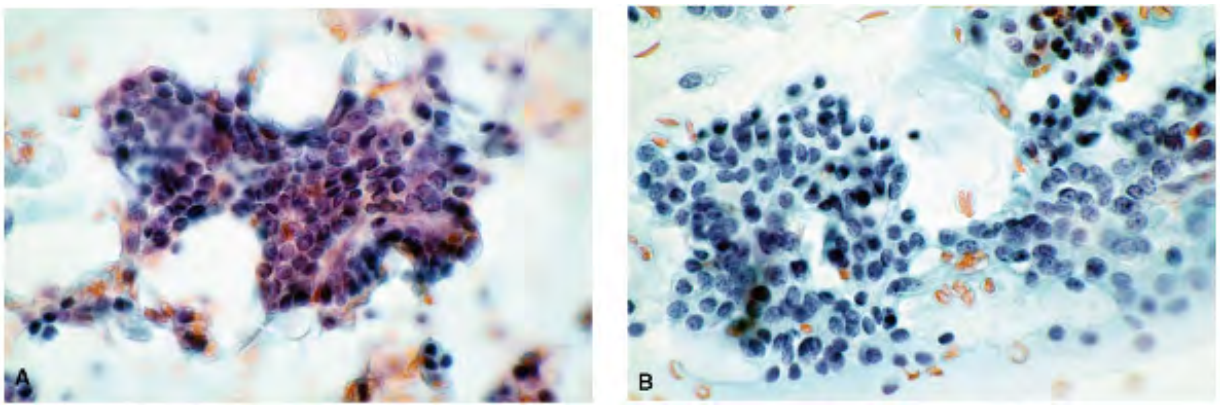

Figure 13.31. FNA of Hashimoto's thyroiditis showing a syncytial tissue fragment of follicu
to be interpreted as a follicular neoplasm.

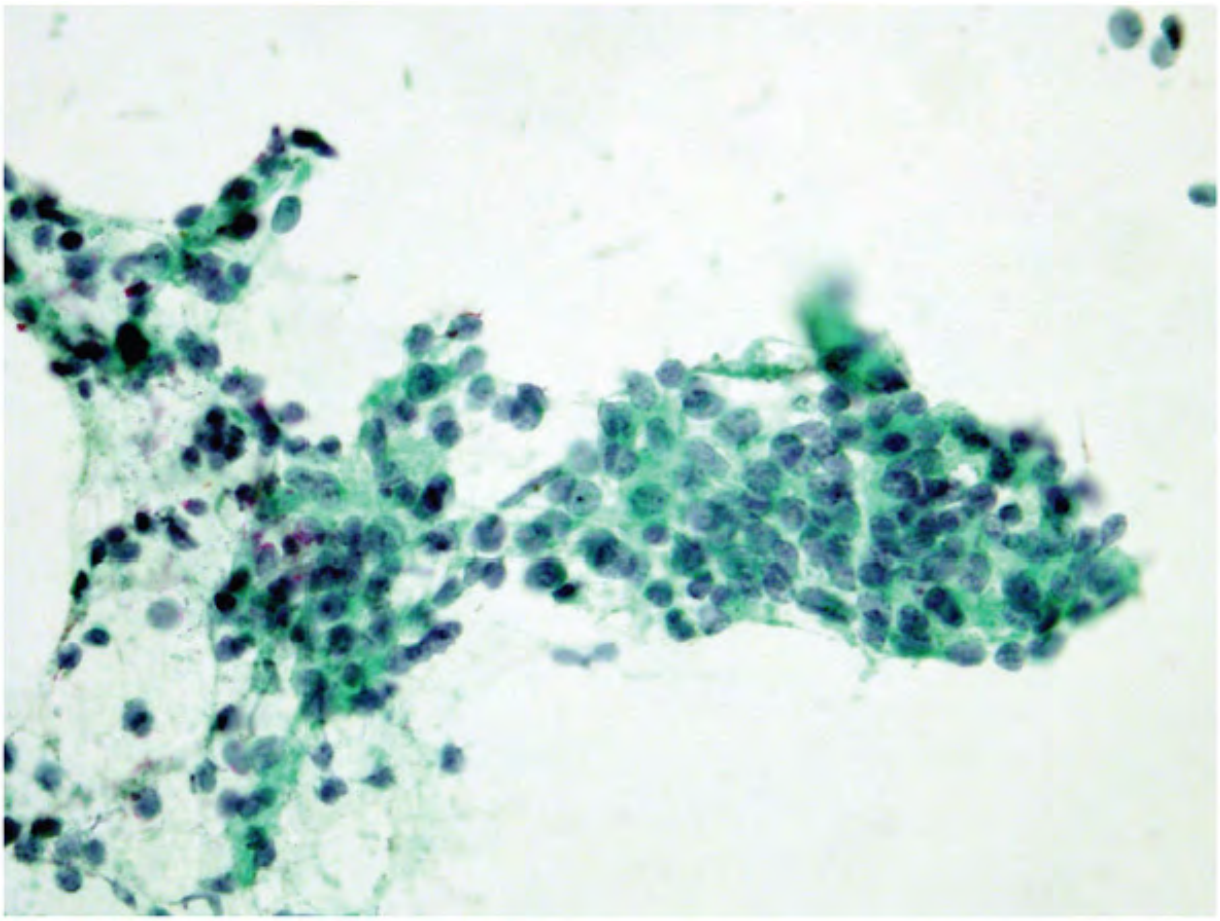

Figure 13.32. FNA of a thyroid nodule. The aspirate is cellular, with syncytial tissue fragr
few lymphocytes are present in the background, suggesting Hashimoto's thyroiditis.

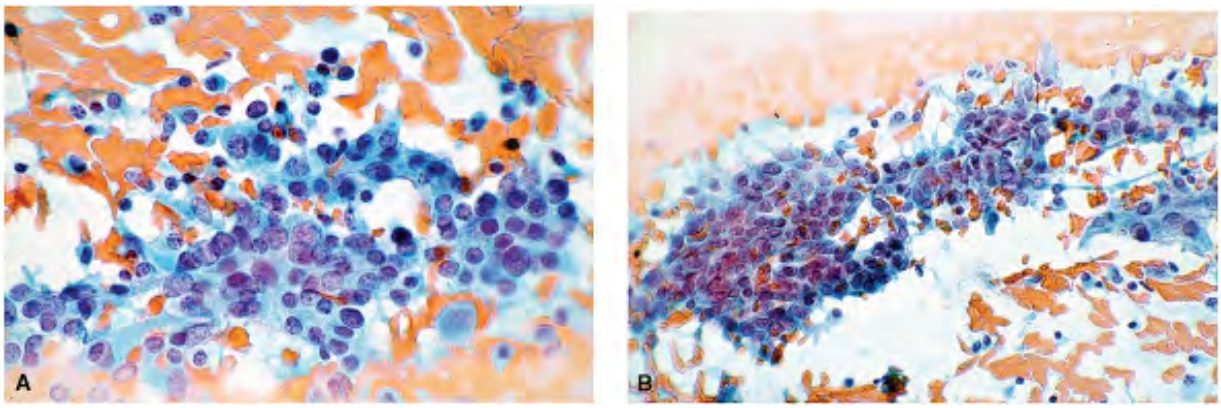

Figure 13.33. FNA of another case of Hashimoto's thyroiditis showing tissue fragments of cells in the background were overlooked and a diagnosis of follicular neoplasm was rende

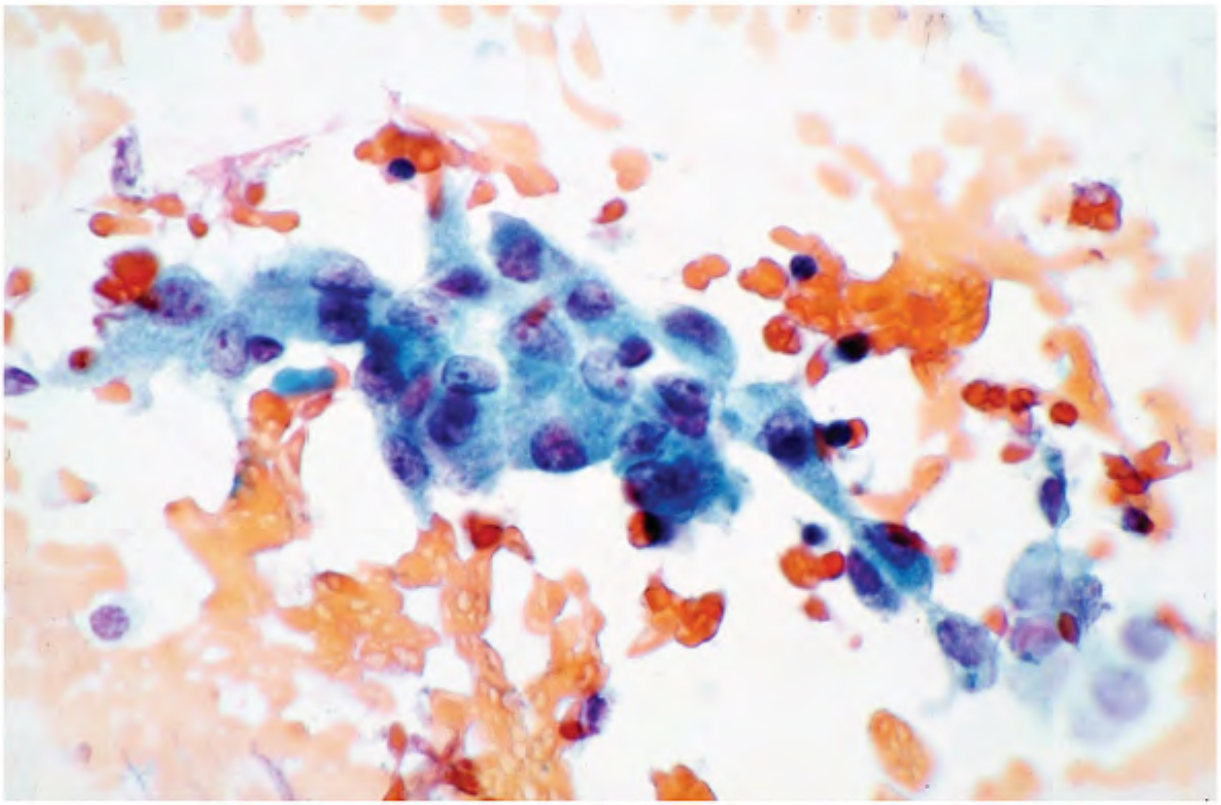

Figure 13.34. FNA of a thyroid, with a clinical diagnosis of Hashimoto's thyroiditis. Note t

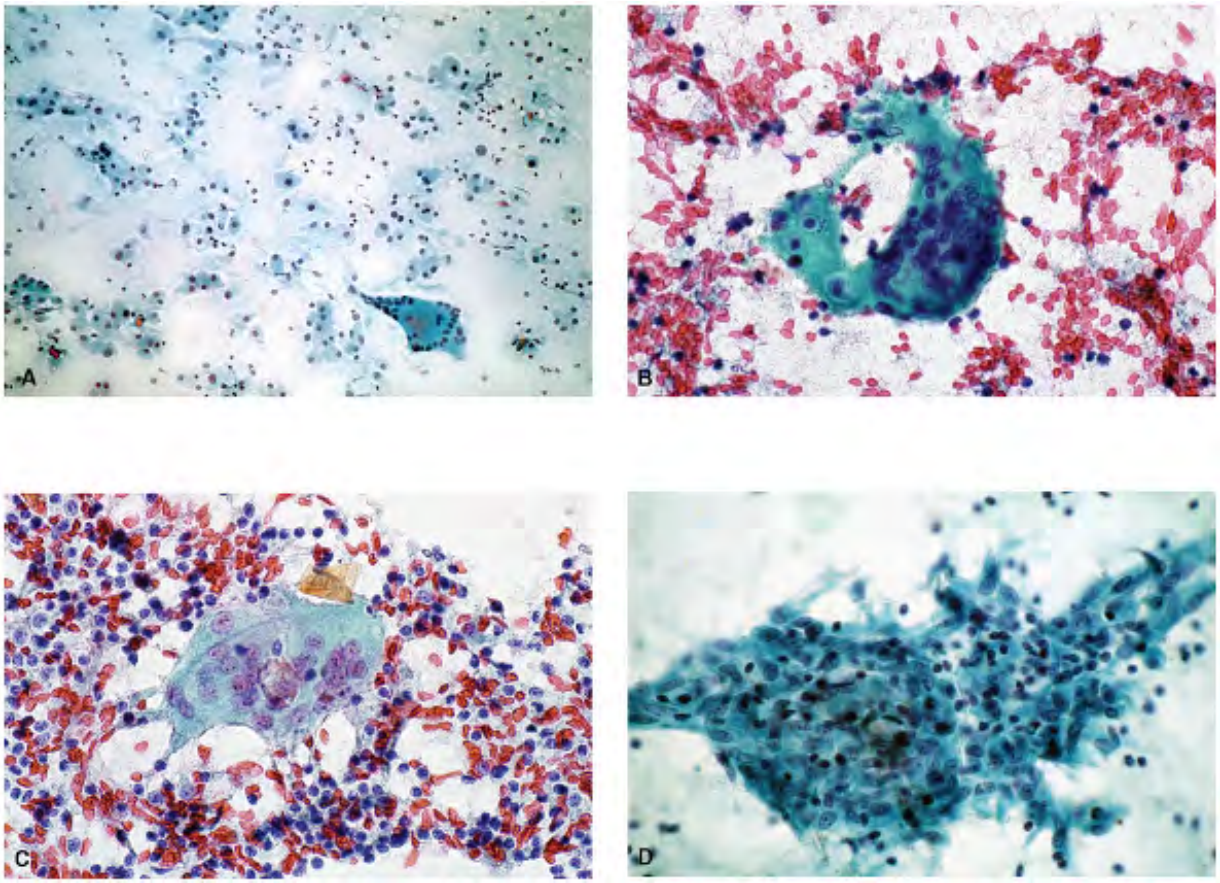

Figure 13.35. A. FNA of Hashimoto's thyroiditis showing multinucleated foreign-body-type seen only infrequently in aspirates of Hashimoto's thyroiditis. D. A stromal tissue fragmen

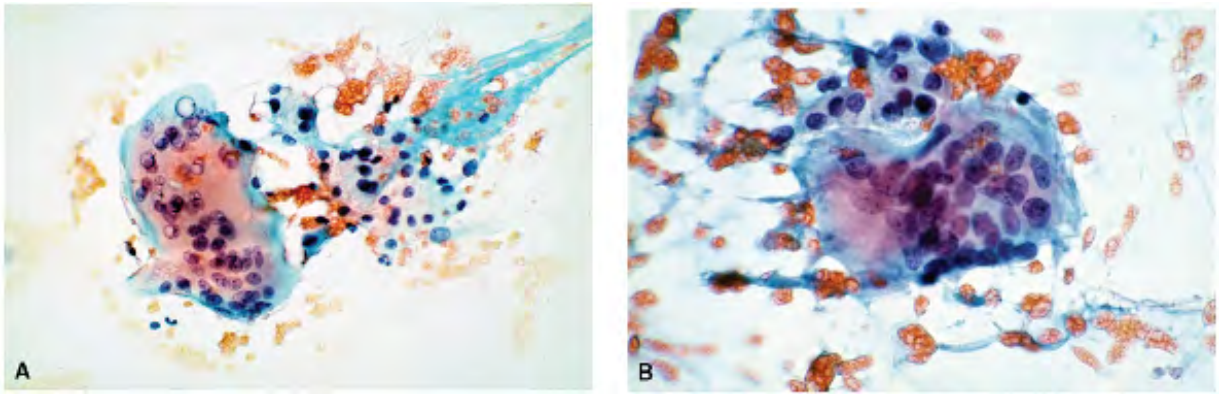

Figure 13.36. *Hashimoto's thyroiditis versus subacute (granulomatous) thyroiditis.* A. FN
significance. The presence of multinucleated giant cell alone does not favor the diagnosis
demonstrate multinucleated giant cells.

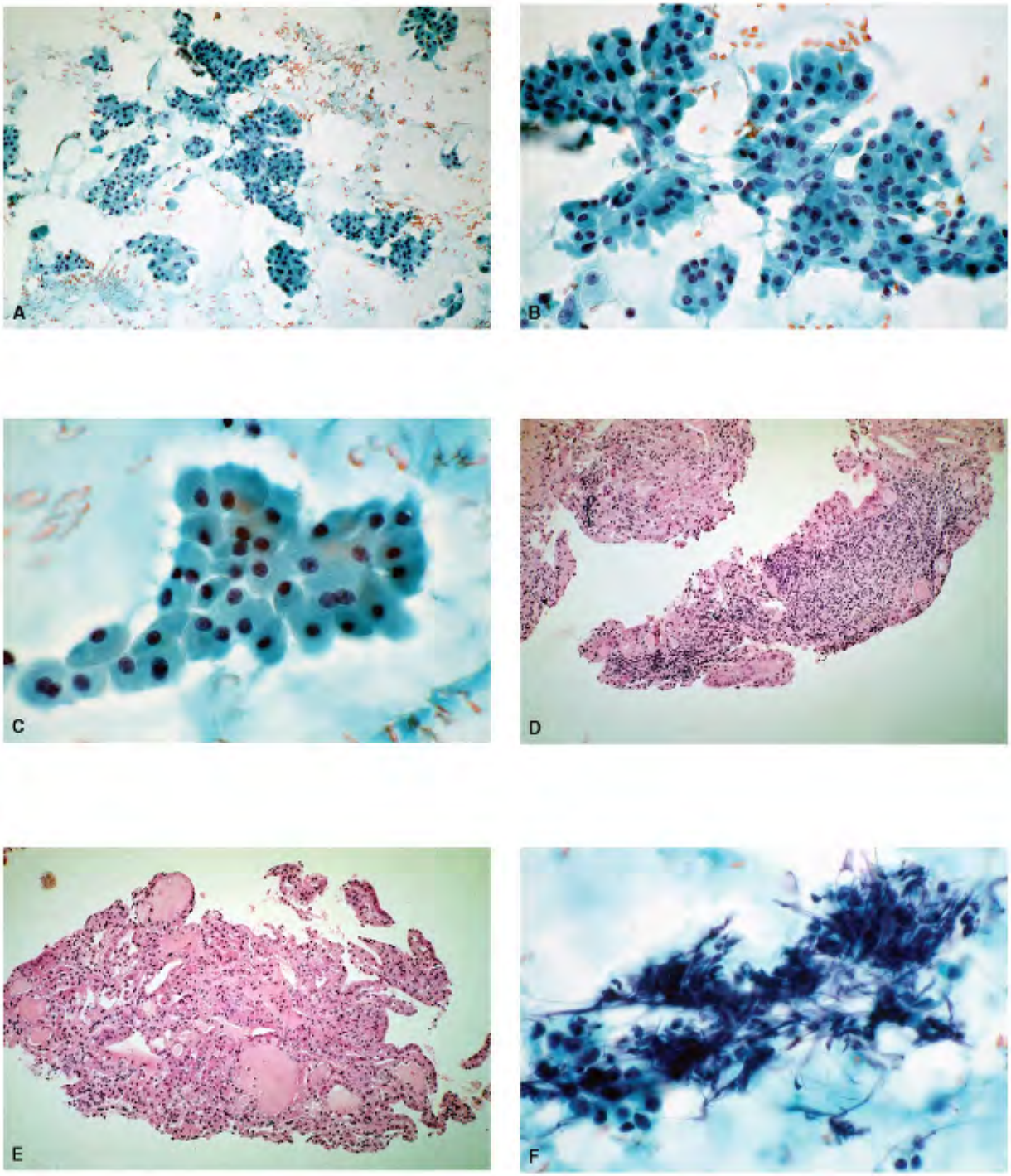

Figure 13.37. *Hashimoto's thyroiditis versus HÃ¼rthle cell neoplasm.* A. FNA of a thyroic
The background is clean. B,C. Higher magnification showing HÃ¼rthle cells lacking macro
HÃ¼rthle cell tumor was rendered. D. A large-needle biopsy revealed Hashimoto's thyroid
lymphoid tangles such as these in different smears should have suggested the diagnosis of

TABLE 13.3 CYTOPATHOLOGIC FEATURES OF CHRONIC LYM

Cellularity	Variable, generally highly cellular; paucicellular in late stages d
Presentation	An admixture of inflammatory and epithelial cells in varying pro
Epithelial cells	
Hurthle cells	Isolated, in loosely cohesive groups and in tissue fragments (in s size; well-defined cell borders; abundant granular cytoplasm; nucle granular chromatin; the characteristic macronucleoli seen in Hurthle c infrequently; tissue fragments may be permeated and/or obscured by lympl
Follicular cells	In loosely cohesive groups and in tissue fragments (in sheets anc infrequent; papillary-like pattern Â±; nuclei round, variable in size; fine t micronucleoli Â±; intranuclear inclusions rare; nuclear grooves Â± tissue fragme by lymphoplasmacytic infiltrate
Inflammatory cells	Lymphocytes, plasma cells, and the entire range of transformin plasma cells; tingible body histiocytes; lymphoid tangles and stretche packed aggre- gates of lymphocytes difficult to differentiate from follicular giant cells Â±

Background	Clean; scant or absent colloid; stromal cells, tissue fragments o

Epithelial cells, generally seen in tissue fragments, can also occur isolated and in aggregates component cells of the follicular or HÃ¼rthle cell tissue fragments are very cohesive and ra

The HÃ¼rthle cells are pleomorphic in size and shape (Figs. 13.22B, 13.22C, 13.24A, 13.24C cherry-red nucleolus, a feature so characteristic of HÃ¼rthle cell neoplasms, is usually not s

The follicular cells may be their usual size or hyperplastic and are aspirated in tight clusters aggregates of lymphocytes (Figs. 13.26 and 13.27). Tissue fragments of follicular epithelium pleomorphism in size and hyperchromasia with the occasional presence of grooves and nucle nuclear pattern of both HÃ¼rthle cells and regular follicular cells is more common in Hashir even obscured by them. On the other hand, the follicular and/or HÃ¼rthle cells may predor disease with increasing

fibrosis, the aspirate is often acellular or poorly cellular, showing only a few lymphocytes.

Other nonspecific findings include the presence of multinucleated foreign bodyâ€“type gian occasionally seen (Fig. 13.35D).

There are frequent deviations from the usually encountered patterns described above that r of this chapter.

Diagnostic Accuracy and Differential Diagnosis

Hashimoto's thyroiditis as a disease entity presents complex diagnostic problems, not only b mimic various types of neoplasia, but also because benign and malignant thyroid neoplasms nodularity of the thyroid gland are seen in Hashimoto's thyroiditis, with or without a coexist of Hashimoto's thyroiditis with coexisting neoplasm from those that do not harbor any tumor unique and specific problem in cytologic specimens from Hashimoto's thyroiditis, because in presence or absence of Hashimoto's disease does not appear as a problem. The cytologic eva

The incidence of neoplasia in the background of Hashimoto's thyroiditis is variably reported number of patients with thyroiditis were subjected to surgery110, 111 because of high

P.303

incidence of malignancy in surgical specimens. Hashimoto's thyroiditis, with its characteristi
In doubtful cases, aspiration biopsy is very useful.

It is most difficult to judge the diagnostic accuracy of Hashimoto's thyroiditis because, in ou
thyroiditis, an aspiration biopsy is performed primarily to rule out a neoplastic process unde
imaging defects; and (iii) enlarging tender goiter.

Also, some patients are asymptomatic and present with clinically palpable or ultrasonically
cytologic basis after an aspiration biopsy has been performed, and subsequently confirmed

Cytologic errors in Hashimoto's thyroiditis can be grouped into two main categories:

- False-positive diagnoses: diagnoses of neoplastic disease made when the cytologic cl
- False-negative diagnoses: failure to identify a neoplastic process coexistent with thy

P.304

P.305

P.306

P.307

P.308

Our initial experience in this field revealed many false-positive as well as false-negative res
features. In later years, errors have been considerably minimized. Thus the statistics presen

TABLE 13.4 CYTOHISTOLOGIC DATA ON 117 PATI

Cytologic Diagnosis
Lymphocytic thyroiditis
Lymphocytic thyroiditis and papillary carcinoma
Lymphocytic thyroiditis and cellular adenoma
Lymphocytic thyroiditis and possible lymphoma
Cellular adenoma
HÃ¼rthle cell tumor
Suspected follicular carcinoma
Total

[a]One patient developed malignant lymphoma 7 years after the diagnosis of lymphocytic thyroiditis.

The first period includes 117 cases (Table 13.4) in which aspiration biopsy was performed be histologically. Thirteen cases were misinterpreted as follicular or HÃ¼rthle cell neoplasms. thyroiditis was identified easily and accurately.

During the second period (Table 13.5), 398 patients had a cytologic diagnosis of Hashimoto's
a small number of patients (Table 13.5). It is noteworthy that coexistent diagnoses of follicu
lymphoma or papillary carcinoma in the presence of Hashimoto's thyroiditis was made more

TABLE 13.5 CYTOHISTOLOGIC DATA ON 398 PATIENTS WIT

Cytologic Diagnosis	No. Patients	No. Patients with Large-Needle Biopsy	No. Patients with Surgery	
Lymphocytic thyroiditis	307	45		
Lymphocytic thyroiditis and papillary carcinoma	18		18	1 thyroid
Lymphocytic thyroiditis and suspected papillary carcinoma	9	1	3	thyroid
Lymphocytic thyroiditis and malignant lymphoma	21	21	18	1 thyroid

Lymphocytic thyroiditis and suspected	10	9	4	thyroid
malignant lymphoma				
Lymphocytic thyroiditis and cellular	1		1	
adenoma				thyroid
Lymphocytic thyroiditis and (?) cellular	15	4		
adenoma				
Lymphocytic thyroiditis and follicular	2	2	2	thyroid
carcinoma				thyroid
Lymphocytic thyroiditis and (?) HÃ¼rthle	11	2		
cell tumor				
Lymphocytic thyroiditis and HÃ¼rthle cell	1	1	1	

carcinoma			HÃ¼rth
Lymphocytic thyroiditis and carcinoma,	1	1	1
type unknown			
Cellular adenoma	1	1	
HÃ¼rthle cell tumor	1	1	
Total	398		

False-negative diagnoses of epithelial neoplasms in the background of thyroiditis are more c
and may be missed (Table 13.4).

HASHIMOTO'S THYROIDITIS VERSUS OTHER DISEASES

Diagnostic difficulties can occur when Hashimoto's thyroiditis is mistaken for other diseases.
presents lymphoplasmacytic cells along with epithelial cells and both components are prese
predominates, and the usual presentation is absent. Thus, cytologic changes of Hashimoto's
differentiating features are summarized in Table 13.7.

TABLE 13.6 DIFFERENTIAL DIAGNOSIS OF HASHIMOTO'S TH

Subacute or granulomatous thyroiditis

HÃ¼rthle cell neoplasms

Follicular neoplasms (adenoma/carcinoma)

Papillary carcinoma

Malignant Lymphoma

TABLE 13.7 DIFFERENTIAL DIAGNOSIS OF H

	Chronic Lymphocytic Thyroiditis (Hashimoto's type)	Granulomatous (Subacute) De Quervain Thyroiditis	HÃ¼rthl
Cellularity	Variable	Variable	Variable, g moderate marked
Presentation	Admixture of lymphoid and epithelial cells in varying proportions; follicular cells	Admixture of lymphoid cells, epithelioid, histiocytes, large multinucleated foreign-body-	Neoplastic in loosely cohesive tissue frag ments

	isolated, in loosely cohe- sive groups, and in tissue fragments	type giant cells, epithelial cells in varying proportions; follicular cells isolated, in loosely cohesive groups, and in tissue fragments	
Architecture of tissue fragments	Mostly in monolayered sheets, occasionally with syncytial arrangement	In monolayered sheets	In monolay occasional follicula
Epithelial cell	Either regular follicular cell type or HÃ¼rthle cell type; pleomorphic in size	Either regular follicular cell type or HÃ¼rthle cell type; pleomorphic in size	Monomorp oval to polygona neoplasm
Epithelial cell nuclei	Pleomorphic in size; round; fine to coarsely granular chromatin; smooth nuclear membrane; nucleoli Â±; rare intranuclear inclusions;	Round, uniform in a given neo- plasm; finely to granular chro- matin; prominent cherry-red macronucleoli; intranuclear inclusions absent; generally	Round to c enlarged b niform; s membrane finely gr chromatin inconsist intranucle absent; g absent (pr

	nuclear grooves absent	absent (present in carcinoma); nuclear grooves absent	carcinon grooves ab
Psammoma bodies	Exceptionally rare	Absent	Rare
Lymphoid cells	With germinal center cells and plasma cells	Mature lymphocytes; plasma cells absent	Absent
Foreign-body-type giant cells	Occasionally present; granu-lomas absent	Hallmark of the disease, enor-mous size with several nuclei or Langhans type	Absent
Epithelioid-type histiocytes	Absent	Present, especially around blobs of colloid-forming granuloma	â€”

Hashimoto's Thyroiditis versus Granulomatous Thyroiditis

Multinucleated foreign-body-type giant cells are seen infrequently in aspirates of Hashimoto cells, granulomatous thyroiditis may be suspected. In the latter, giant cells are enormous in fewer nuclei (Fig. 13.36). Lymphocytes are present in both, but germinal center cells are no data are necessary to corroborate the cytologic findings.

Hashimoto's Thyroiditis versus HÃ¼rthle Cell Neoplasm

A pronounced HÃ¼rthle cell change in Hashimoto's thyroiditis can give rise to palpable nodu 13.37 and 13.38). Aspiration biopsy specimen of such nodules will show a large population o pitfall sometimes extends to histologic specimens as well.

HÃ¼rthle cells in aspirates of Hashimoto's thyroiditis are more often seen in cohesive groups lacking the prominent macronucleolus of neoplastic HÃ¼rthle cells. The monomorphic patte exceptions do occur (Fig. 13.38). HÃ¼rthle cell neoplasms, on the other hand, have been in

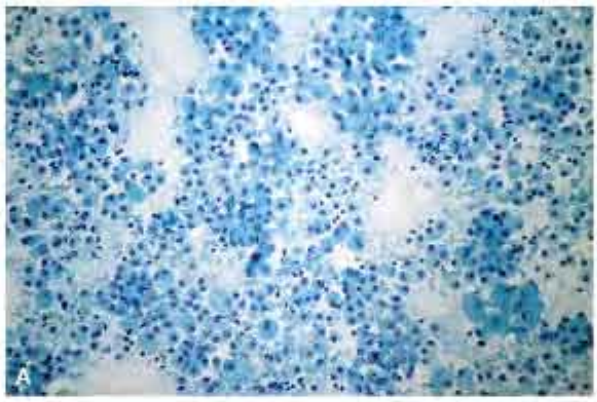
A

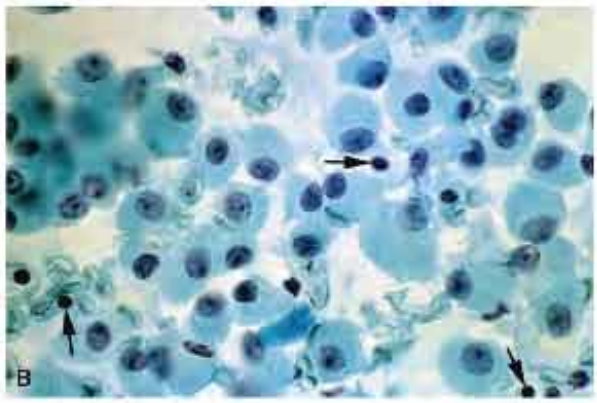
B

C

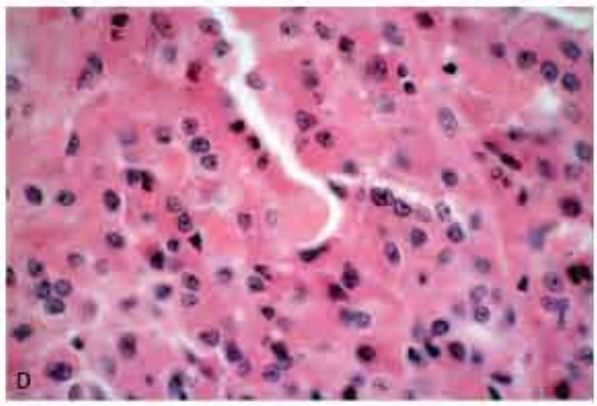
D

E

F

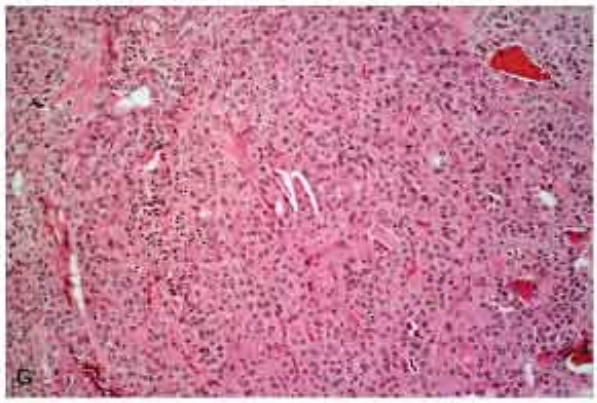
G

Figure 13.38. *Hashimoto's thyroiditis versus HÃ¼rthle cell neoplasm*. A. Low-power view These HÃ¼rthle cells with high nuclear/cytoplasmic ratios and prominent macronucleoli v needle biopsy specimen was equally indicative of HÃ¼rthle cell carcinoma. D. Higher mag with multiple HÃ¼rthle cell nodules. F. This HÃ¼rthle cell nodule was encapsulated with that seen in the core biopsy with a solid growth pattern and forming trabeculae. Final dia

P.309
P.310

Hashimoto's Thyroiditis versus Follicular Neoplasm

Follicular hyperplasia in Hashimoto's thyroiditis often results in nodule formation (Figs. 13.3 infiltrate in these nodules may be focal or sparse, and the fine-needle biopsy specimens of s cells appear very cohesive and are architecturally difficult to differentiate from syncytial-ty presence of any inflammatory cells, such as lymphocytes or plasmacytes, suggests a nonneop identification of the aspirate as that of Hashimoto's thyroiditis.

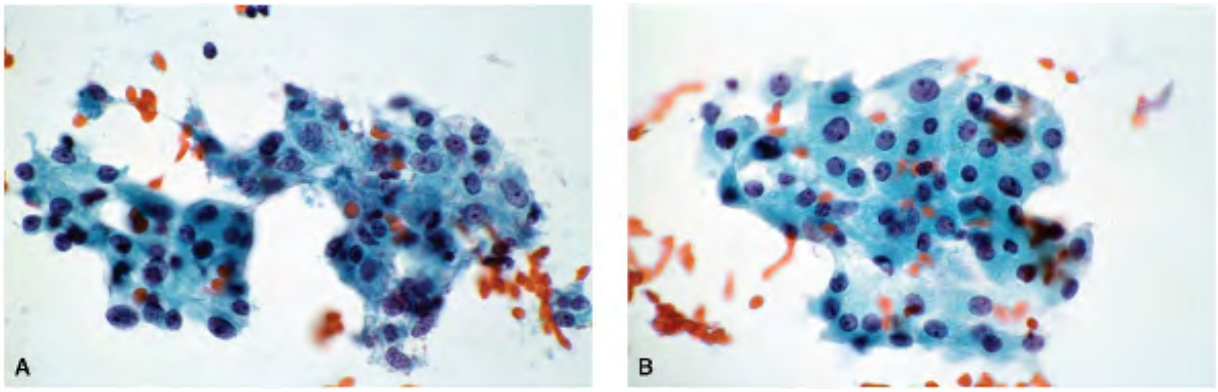

Figure 13.39. *Hashimoto's thyroiditis versus follicular neoplasm.* FNA of thyroid nodule. No lymphocytes are appreciated in the background. A cytologic diagnosis of follicular neo

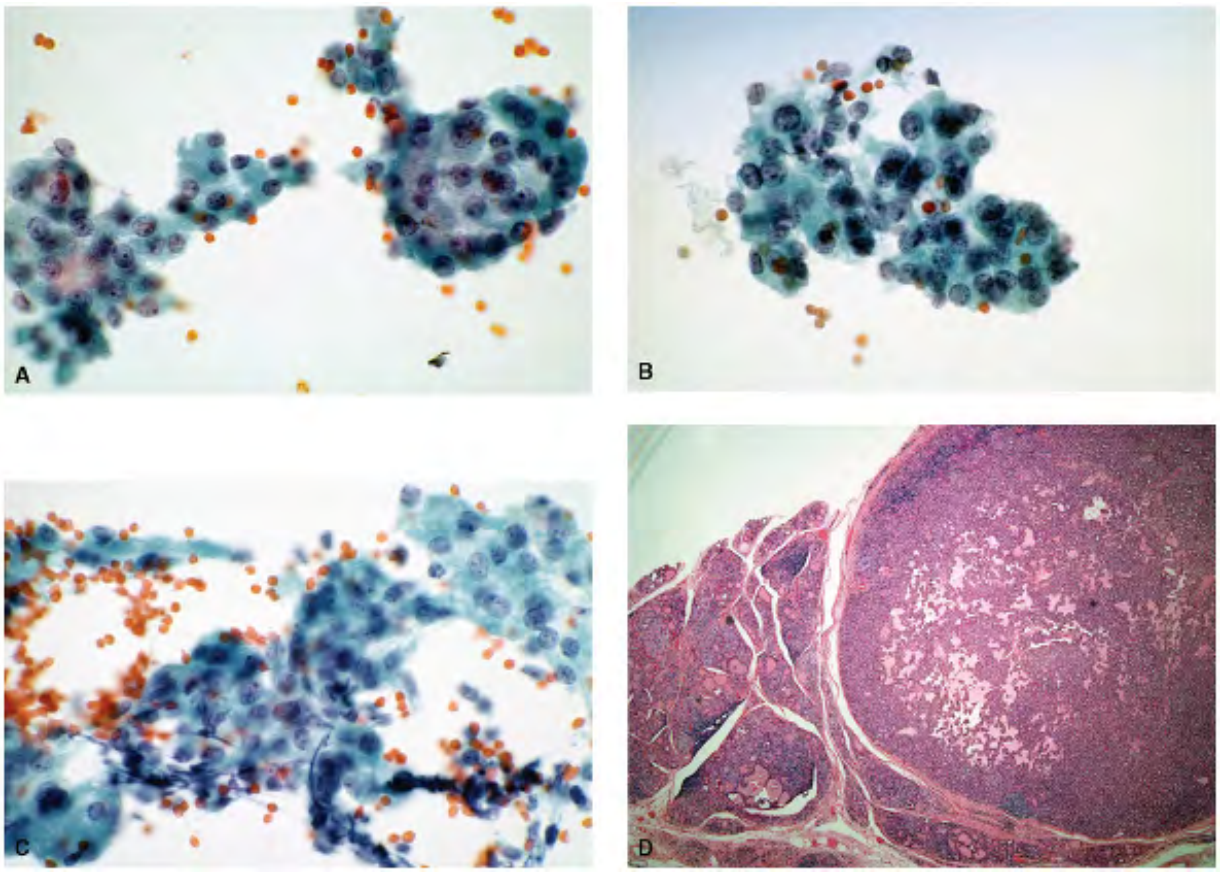

Figure 13.40. *Hashimoto's thyroiditis versus follicular neoplasm.* Another example of Ha
tissue fragments of enlarged follicular cells with pleomorphic nuclei. The cytologic interp
failed to show any neoplasm but revealed Hashimoto's disease. D. Histologic section show

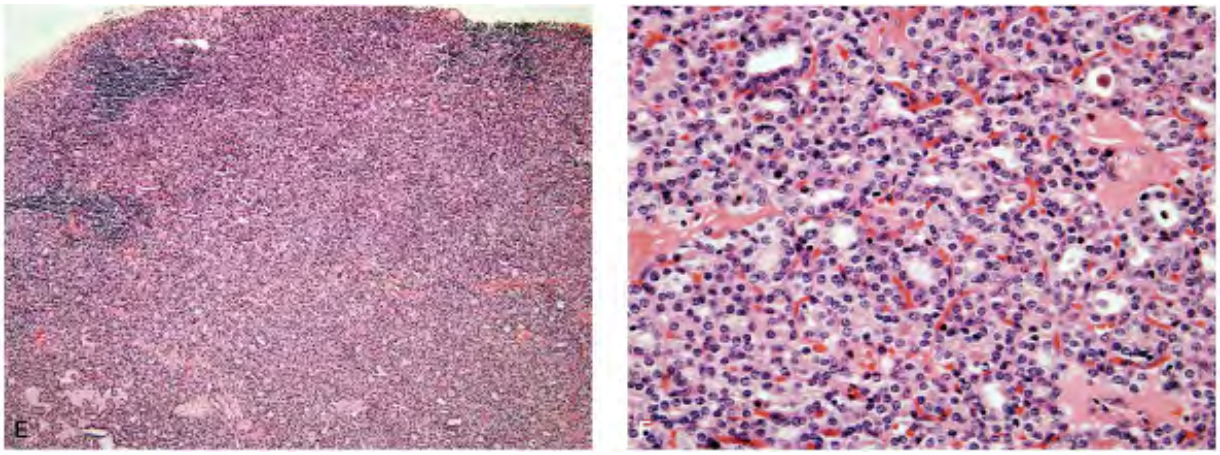

Figure 13.40. E. Medium power view showing a proliferative nodule. Note lymphoid aggr

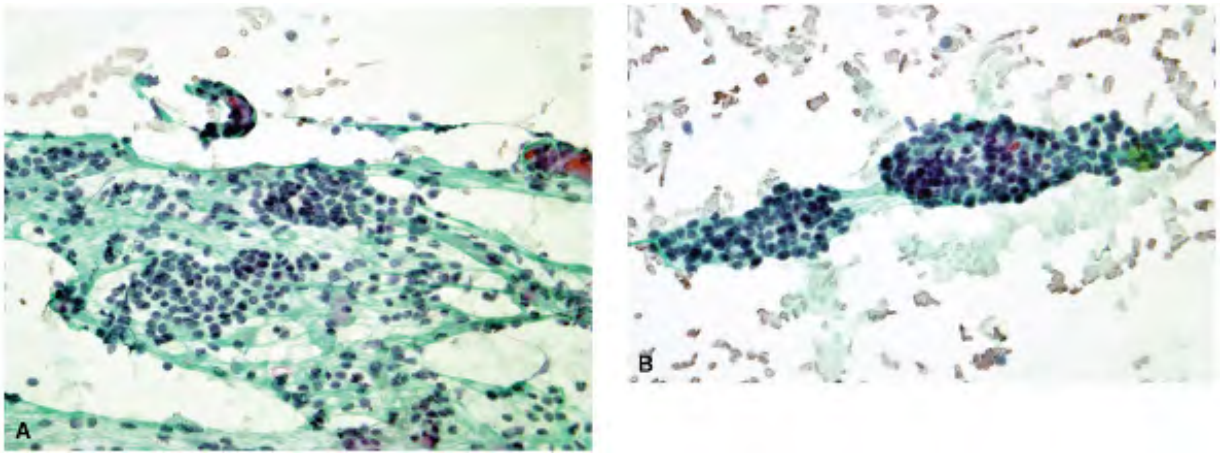

Figure 13.41. A,B. *Hashimoto's thyroiditis versus follicular neoplasm.* FNA of a thyroid n
and overlapping of mildly but uniformly enlarged nuclei. No HÃ¼rthle cells or lymphocyte
thyroiditis.

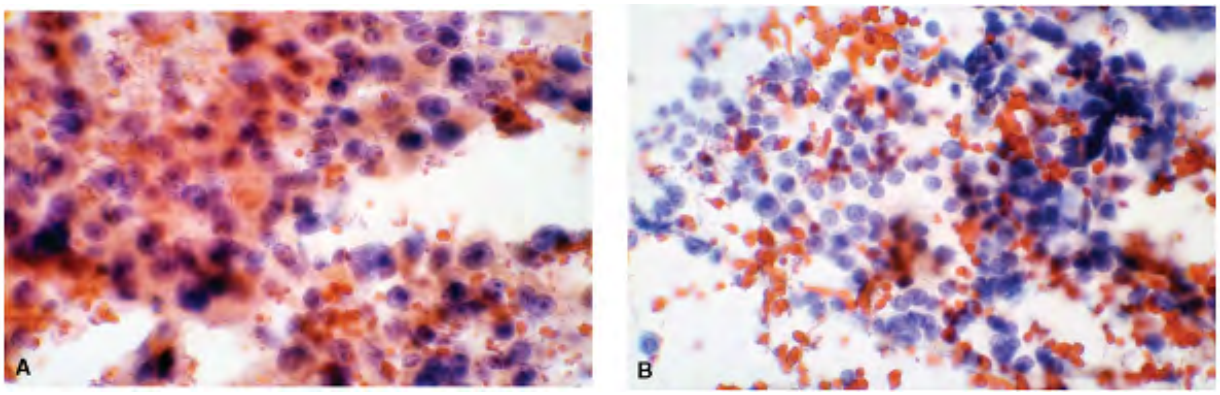

Figure 13.42. *Hashimoto's thyroiditis versus follicular neoplasm.* A,B. Aspirate showing t
cannot be differentiated from a follicular neoplasm.

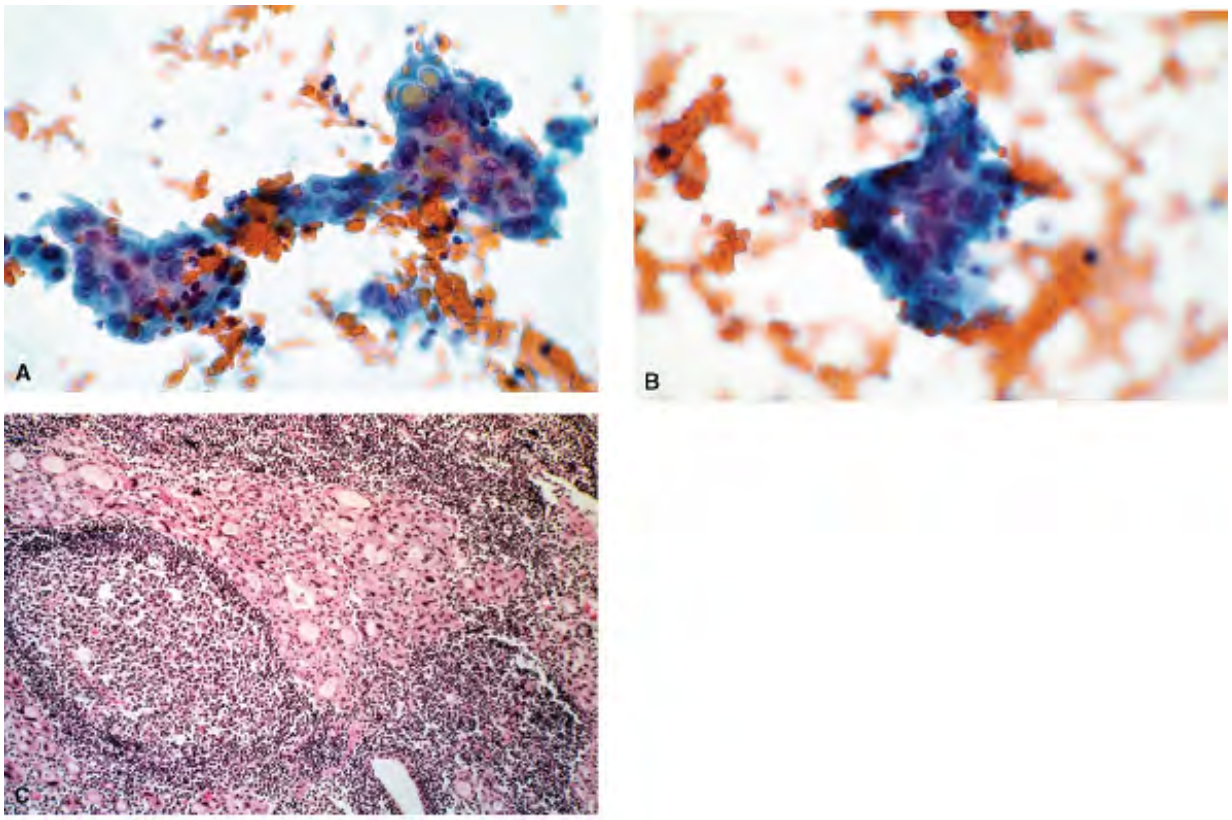

Figure 13.42. C,D. Thyroidectomy showed features of Hashimoto's thyroiditis. There wer
as a non-neoplastic lesion. It is not clear whether the biopsy sampled this nodule.

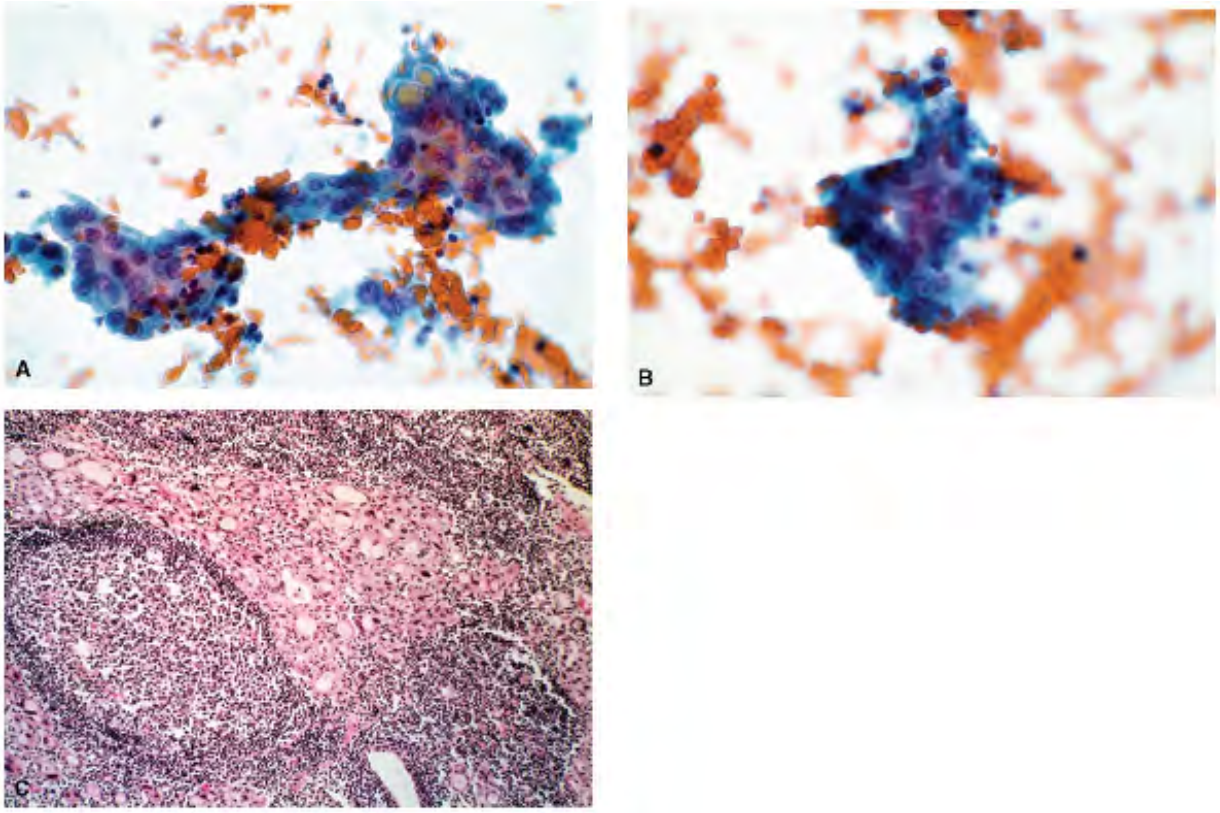

Figure 13.43. *Hashimoto's thyroiditis versus follicular neoplasm.* FNA of a thyroid nodule
show marked nuclear atypia leading to a diagnosis of follicular carcinoma. The presence o
on the part of the interpreter led to the misinterpretation. C. Thyroidectomy revealed Ha

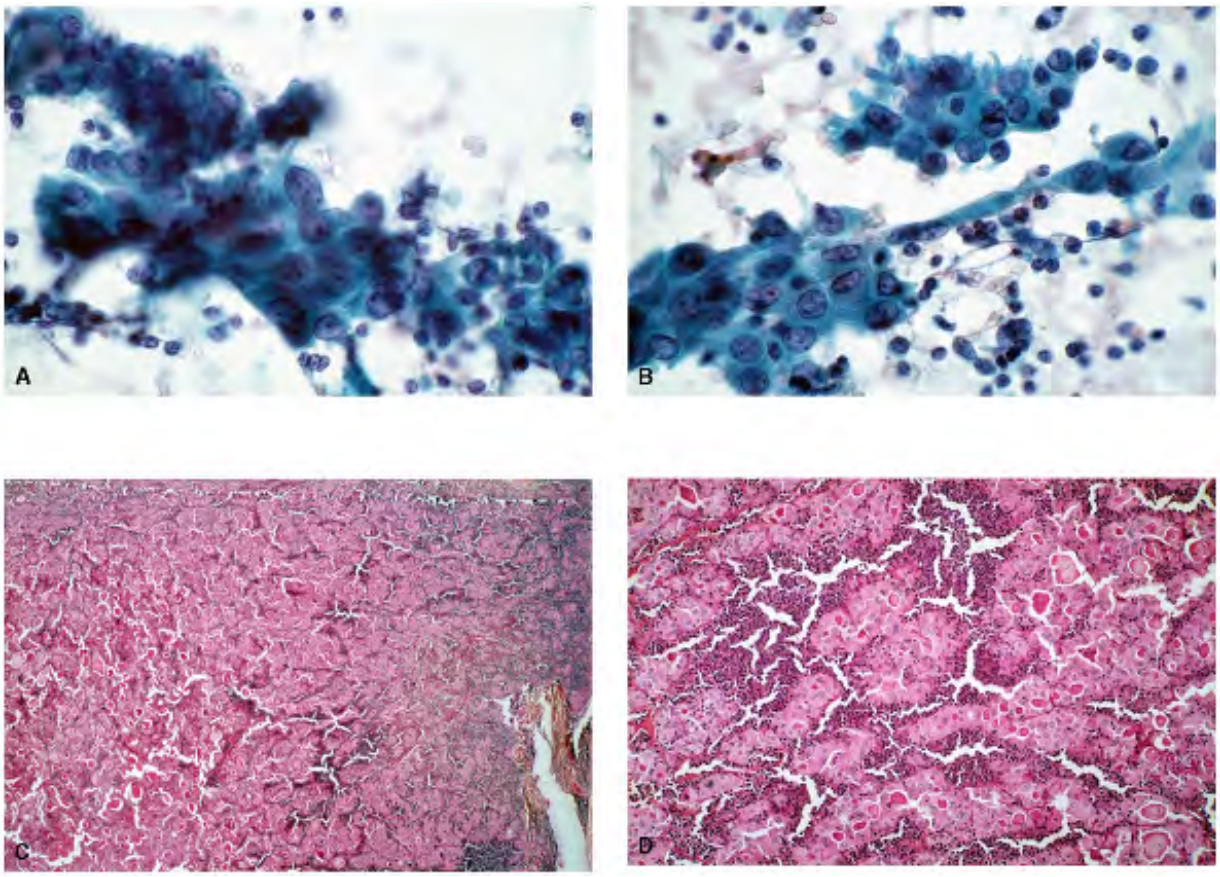

Figure 13.44. *Hashimoto's thyroiditis versus papillary carcinoma.* A,B. An example of asp
lobe of thyroid from a patient who had undergone left thyroid lobectomy and right subtot
syncytial tissue fragments of follicular cells with enlarged and pleomorphic nuclei in the b
these cells do not exhibit minimal cytologic criteria of papillary carcinoma, the clinical hi
surgery. C. Histologic section of the resected lobe, showing HÃ¼rthle cell proliferation. D

One of the diagnostic clues for differentiating non-neoplastic proliferation of HÃ¼rthle cells
unlike with a neoplasm.

Hashimoto's Thyroiditis versus Papillary Carcinoma

Epithelial changes in Hashimoto's thyroiditis may be misinterpreted as papillary carcinoma f
changes include syncytial tissue fragments of follicular epithelium with papillary-like or mor
carcinoma. Berbo and Suster82 reported cases of Hashimoto's thyroiditis with microscopic fo

case where few tissue fragments in the aspirated sample were interpreted as papillary carci
papillary carcinoma, but there was no discrete tumor. It is not unusual to see occasional nu
giant cells must not be considered a feature of papillary carcinoma, in the absence of minin
papillary carcinoma are not met. This diagnostic problem is discussed in detail in Chapter 9.

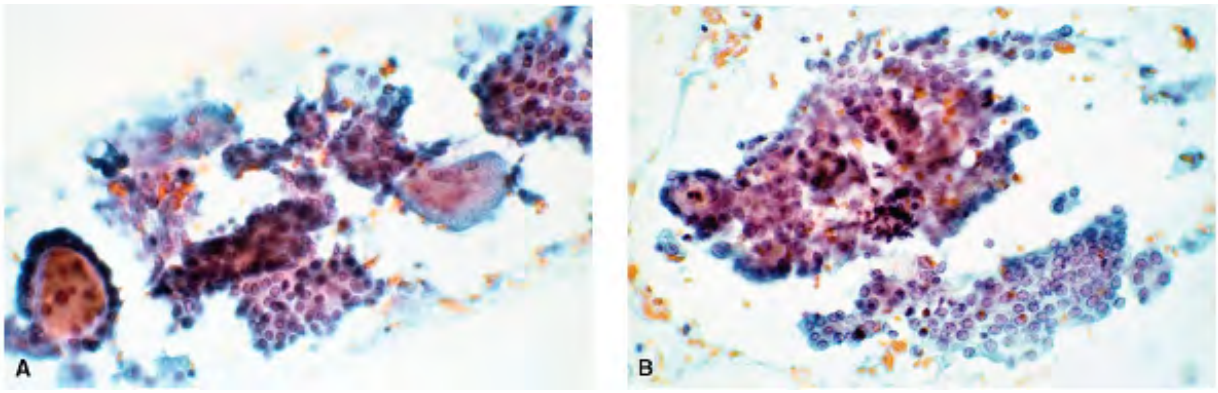

Figure 13.45. *Hashimoto's thyroiditis versus papillary carcinoma.* Another example of a r
of the tissue fragments and the presence of multinucleated giant cells. The nuclei did no
thyroiditis.

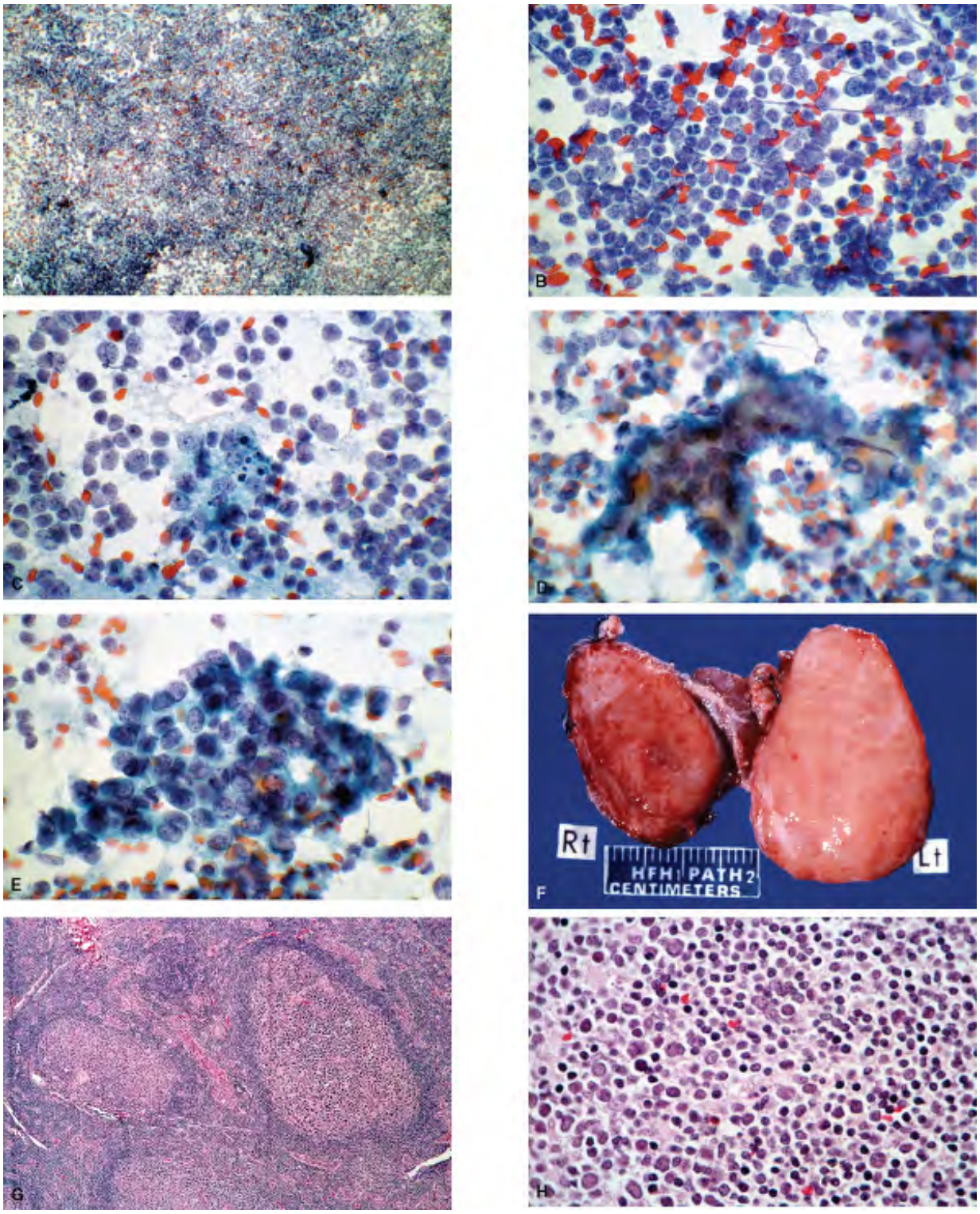

Figure 13.46. *Hashimoto's thyroiditis versus malignant lymphoma.* FNA of a massively en
showing a diffuse lymphoid infiltrate. B. Higher magnification showing a monomorphic sm

lymphoid infiltrate with tingible body histiocytes. D. Some smears demonstrated a typical background of lymphoid cells. E. This syncytial tissue fragment of follicular cells show enl performed. The thyroid was massively enlarged, the left lobe larger than the right. The c right lobe shows a nodule in the upper pole. G. Histologic sections showed florid, lymphoi magnification showing a heterogenous cell population. No papillary carcinoma was identif Hashimoto's thyroiditis.

Hashimoto's Thyroiditis versus Malignant Lymphoma

Aspiration biopsy of the lymphoid variety of Hashimoto's thyroiditis will yield an aspirate cor differentiation between the two disease entities is not possible without ancillary testing (Fig

Hashimoto's Thyroiditis and Associated Neoplasms

There is considerable controversy over the causal relationship between Hashimoto's thyroidi thyroiditis and other thyroid neoplasms (Table 13.8).104 The controversy stems from severa among pathologists.

TABLE 13.8 INCIDENCE OF NEOPLASMS IN HASHIM

Reference (Year)	Hashimoto's Thyroiditis	Hashimoto's Thyroiditis plus Benign and Malignant Neoplasms	Hashimoto's Thyroiditis plus Carcinoma	Hashimoto's Thyroiditis plus Malignant Lymphoma
Dailey et al.[109] (1954)	278	73 (36.2%)	35 (17.7%)	
Woolner et al.[73] (1959)	605		18 (3%)	12 (2%)

Schlicke et al.[107] (1960)	103		9 (8.7%)	
Shands[108] (1960)	44	18 (32%)	3 (7%)	
Chesky[106] (1962)	432	48	43 (10%)	5 (1.1%)
Hirabayashi and Lindsay[105] (1965)	752		169 (22.5%)	(22.5%
Holmes et al.[76] (1977)	60	10 (6.6%)	2 (3.3%)	(3.5%)
Crile[104] (1978)	373			1 (0.37%)
Ott et al.[103] (1985)	146		47 (32%)	
Pollock and Sprang[110] (1985)	52	6 (11.5%)	5 (10%)	(1.2%)
Ott et al.[101] (1987)	161		61 (38%)	
Sclafani et al.[109](1993)	48		8 (17%)	
McKee et al.[99] (1993)	115	16 (14%)	5 (4 %)	7 (6%)

Carson et al.[98] (1996)	90	7 (4%)	1 (1%)
Nguyen et al.[92] (1997)	134	7	2 (1.5%)

In a review of 1,150 surgical pathology reports on thyroidectomies from our series, a lympho
thyroiditis, chronic lymphocytic thyroiditis, nonspecific lymphocytic infiltrate, or nonspecifi
concluded that the disease process can be diffuse or focal and that HÃ¼rthle cell change m
diagnosis of Hashimoto's thyroiditis. Because antibody titers from all patients who undergo t
correlated. LiVolsi and Marino112 have justly remarked that adequate serologic and clinical
direct correlation of the clinical level of thyroid-stimulating hormone, free thyroxine index
in papillary thyroid carcinomas to the host response, but Carcangiu and co-workers113 have

Although a detailed discussion of this debate is beyond the scope of this monograph, suffice
is to identify the coexistence of two disease processes. Although we believe that malignant
we cannot say the same about HÃ¼rthle cell neoplasm or follicular cell neoplasm. The latte
component of thyroiditis are almost identical to those seen in follicular/HÃ¼rthle cell neop
hand, papillary carcinoma presents specific diagnostic criteria that can be appreciated even
the basis of insufficient criteria (see Chapter 9). A malignant lymphoma, large cell type can

P.311
P.312
P.313
P.314
P.315
P.316
P.317
P.318

thyroiditis if sampled. The cytologic features and diagnostic pitfalls are described in Chapte

The apparent ease with which a papillary carcinoma or diffuse large B-cell lymphoma can b
by follicular or HÃ¼rthle cell neoplasms, is understandable and may be explained by the mo
neoplastic processes (Fig. 13.47A). Involvement is, at times, diffuse and multicentric. Thus

of papillary carcinoma allow easy recognition of both or coexistent disease processes. On th
Aspiration biopsy will sample only the lesion bordered by the capsule, not the adjacent pare
identified only in surgically removed specimens. Metaplastic HÃ¼rthle cell nodules or hyper
and large. They almost always contain a lymphocytic infiltrate and even germinal centers. T
be few in number and easily overlooked. Hence, we recommend extreme caution in the diag
practice to alert the clinician and suggest additional investigations. These include laborator
Because thyroid neoplasms are slow-growing, it is not necessary to hasten surgical intervent

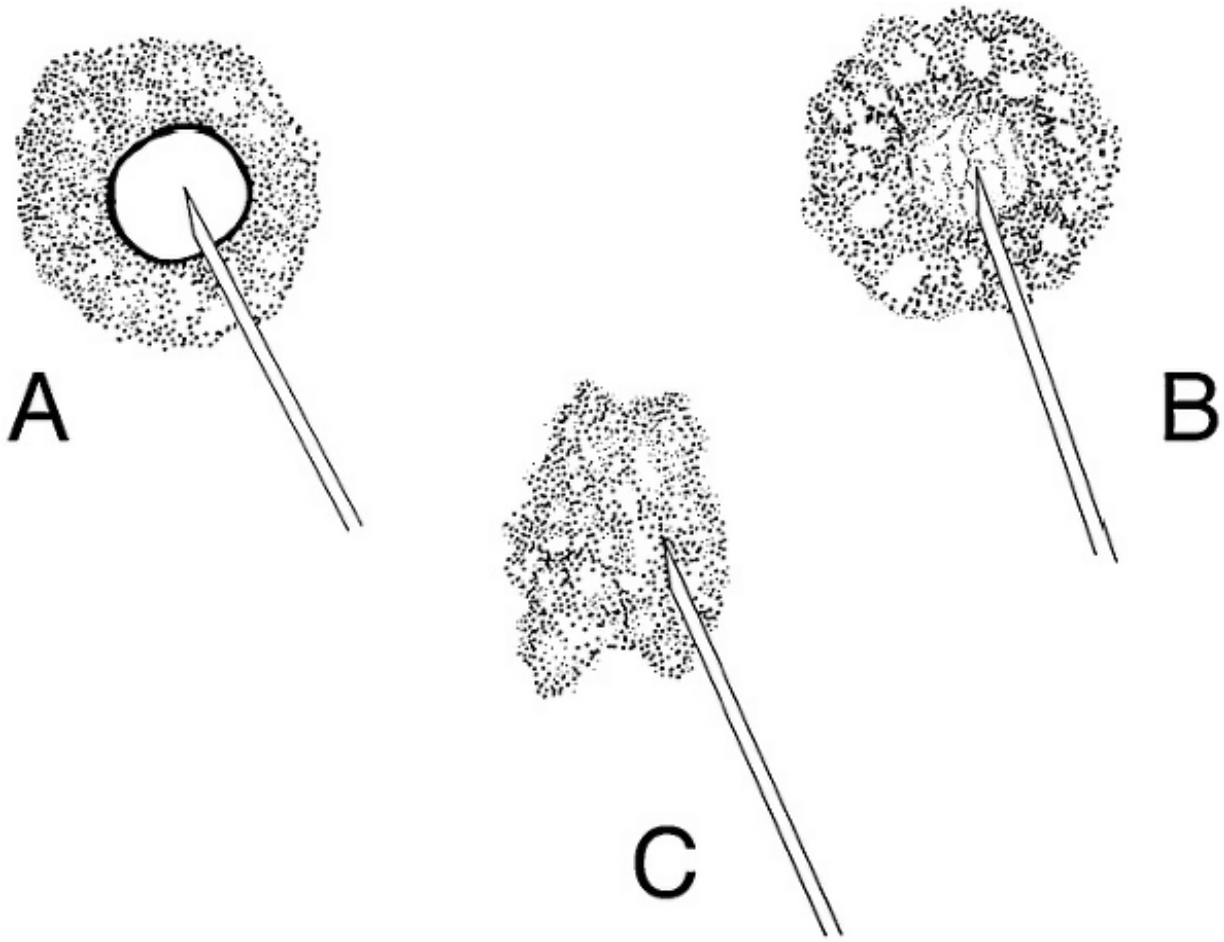

Figure 13.47. A model to demonstrate the significance of lymphoid cells when follicular
A. Hashimoto's thyroiditis coexistent with discrete encapsulated neoplasms, such as follic
papillary carcinoma. The aspirates will represent only the neoplasm, not the surrounding
external to the capsule is not sampled. Thyroiditis is diagnosed only after thyroidectomy.
these appear discrete and palpable when enlarged, they are non-encapsulated and often

shows a large population of epithelial cells (follicular or HÃ¼rthle) and a few lymphoplas
with malignant lymphoma or papillary carcinoma. The neoplastic process is quite often di
processes.

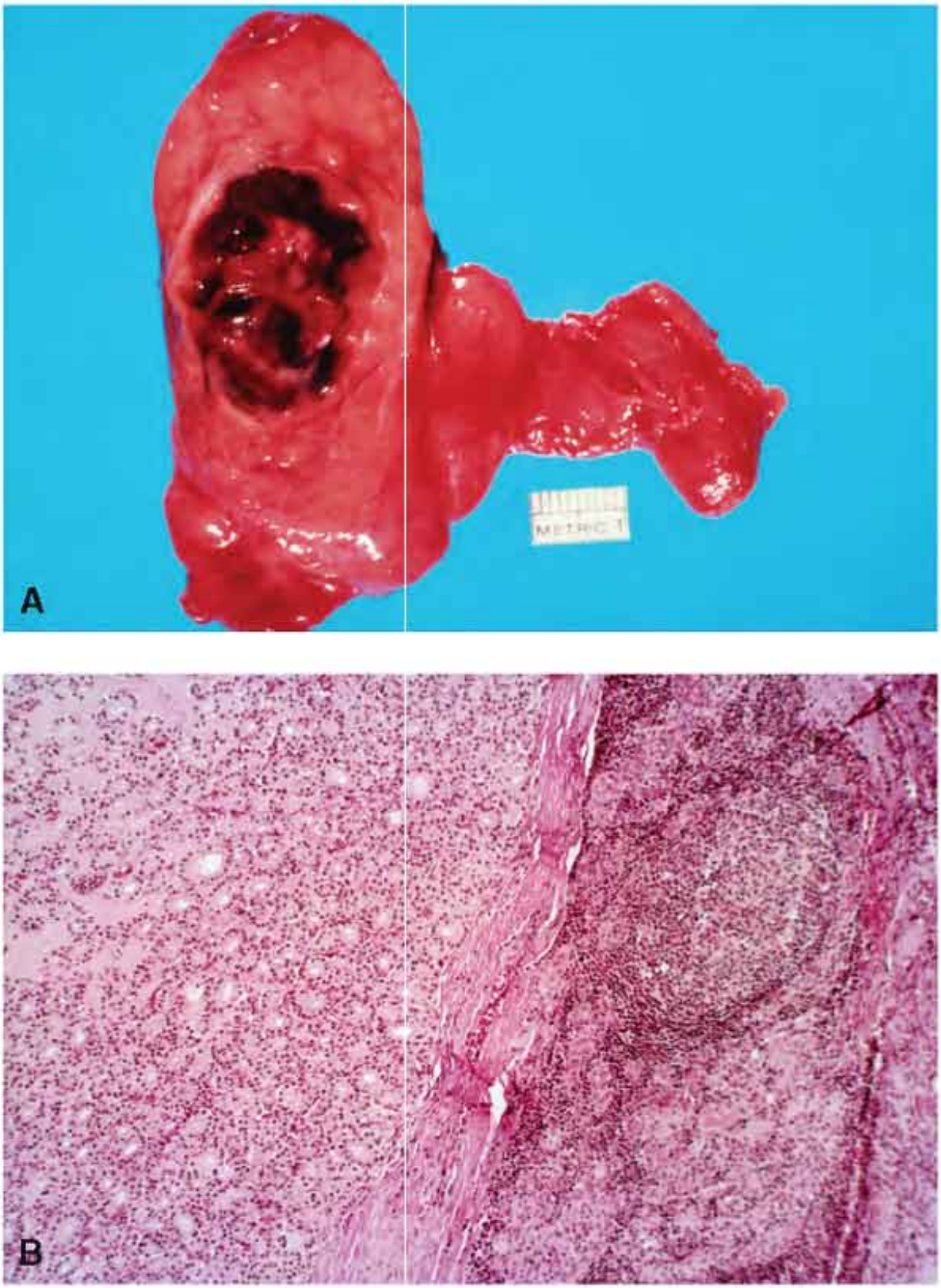
A
METRIC 1
B

Figure 13.48. A. Gross photograph of a thyroid involved by Hashimoto's disease. The righ
confirmed as an encapsulated microfollicular adenoma. This corresponds to Figure 13.47A
surrounding parenchyma.

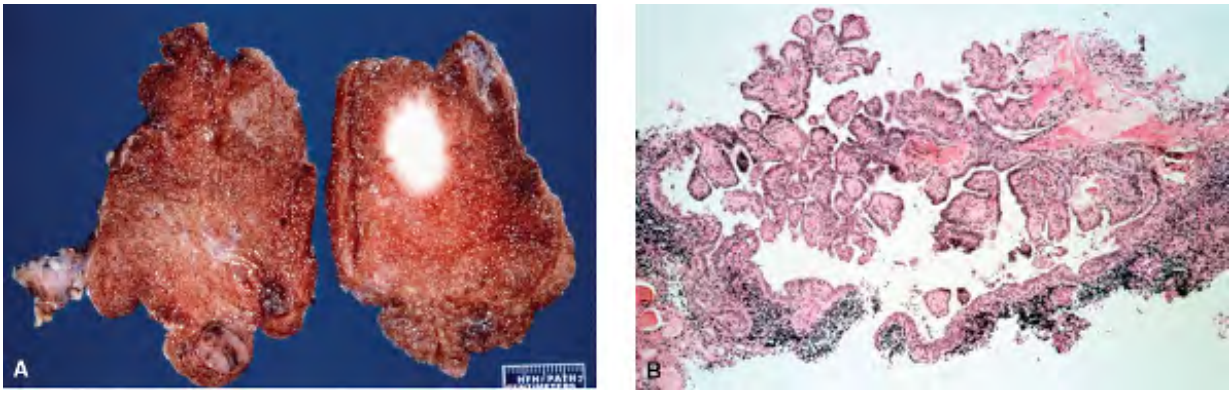

Figure 13.49. A. Gross photograph of a thyroid involved by Hashimoto's thyroiditis and a
Figure 13.47C of the model. B. Histologic section of papillary carcinoma on a core-needle

Hashimoto's Thyroiditis and Papillary Carcinoma

Of the malignant neoplasms associated with Hashimoto's thyroiditis, papillary carcinoma (Fi
author's laboratory, lymphocytic infiltration was noted cytologically in 36 cases (10%), and

histologically in 92 cases (28%). This disparity is explained by the fact that the parenchymal
needle biopsy (Fig. 13.47A). With adequate cellularity showing several of the cytologic featu

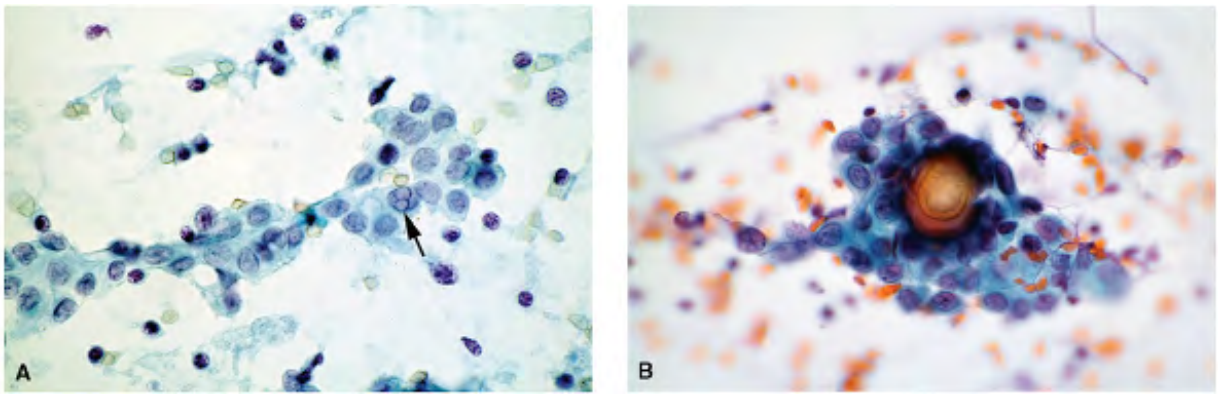

Figure 13.50. Papillary carcinoma coexistent with Hashimoto's thyroiditis. A. FNA showin cytoplasmic inclusions (*arrow*), and lymphocytes in the background. B. Characteristic psa background of lymphocytes,

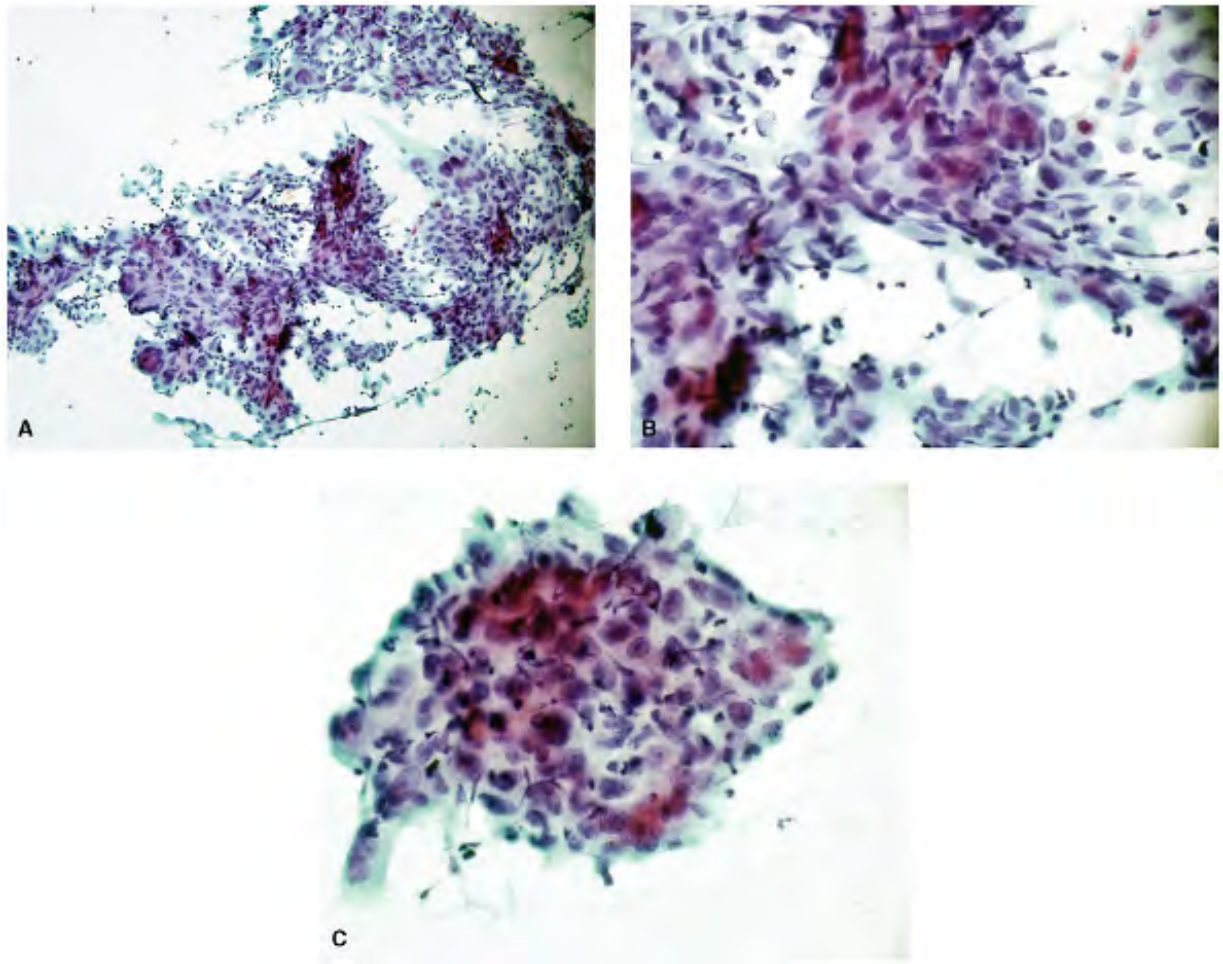

Figure 13.51. Anaplastic carcinoma arising in the background of Hashimoto's thyroiditis. A
magnification to demonstrate marked nuclear atypia and is consistent with malignancy. T
neoplastic epithelial type, seen in Hashimoto's thyroiditis. Thyroidectomy confirmed an a

Hashimoto's Thyroiditis and Malignant Lymphoma

The association between these two diseases has been recognized by most authors. Cytologic
differentiated lymphoid cells without a mixture of polymorphic germinal center cells should
features of Hashimoto's thyroiditis. Diagnosis of MALT lymphoma may be extremely difficult.

Other types of malignant neoplasms associated with Hashimoto's thyroiditis are not well doc
the background of Hashimoto's thyroiditis (refer to Chapter 19). We have seen one case of a

Hashimoto's Thyroiditis and Benign Neoplasms

Most of the literature has focused on the association between Hashimoto's thyroiditis and m adenoma or HÃ¼rthle cell tumors.90, 91, 94

We find it difficult to diagnose follicular or HÃ¼rthle cell neoplasms cytologically in the pre neoplasm. Without clinical or laboratory data, the association between the neoplasm and ly

SUMMARY

Hashimoto's thyroiditis is a clinical disease entity that presents with a diffusely enlarged goi may be seen in conditions other than Hashimoto's thyroiditis, cytologically the aspirates may Not only is it a great imitator of various neoplasms, but the latter are frequently present in

Hashimoto's thyroiditis is a common disease entity, characterized by progressive destruction varying degrees of nuclear atypia and heavy lymphoplasmacytic infiltrate with germinal cen

The aspiration biopsies are performed to identify co-existant neoplasms that occur with high malignant neoplasms.

REFERENCES

1.Thompson LDR. *Endocrine Pathology.* Philadelphia: Churchill Livingstone; 2006:8â€“28.

2.Lloyd RV, Douglas BR, Young WE. Endocrine diseases. In: *Atlas of Non-Tumor Pathology.*

3.Wenig BM, Heffess C, Adair CF. Non-autoimmune thyroiditis. In: *Atlas of Endocrine Path*

4.Farwell AP, Braverman LE. Inflammatory thyroid disorders. *Otolaryngol Clin North Am*. 1

5.Singer PA. Thyroiditis, acute, subacute and chronic. *Med Clin North Am*. 1991;75:61â€“

6.Livolsi VA. *Surgical Pathology of the Thyroid.* Philadelphia: Saunders; 1990:37â€“67.

7.Hay ID. Thyroiditis: A clinical update. *Mayo Clin Proc*. 1985;60:836â€“843.

8.Berger SA, Zonstein J, Villamena P, et al. Infectious diseases of the thyroid gland. *Rev I*

9.Jeng HBB, Lin JD, Chen MF. Acute suppurative thyroiditis: a ten-year review in Taiwane

10.Singh SK, Agrawal JK, Kumar M, et al. Fine needle aspiration cytology in the managem

11.Millar MW. Acute suppurative thyroiditis: a case report. *S Afr Med J*. 1980;58:617â€“61

12.Harach HR, Williams ED. The pathology of granulomatous disease of the thyroid. *Sarcoi*

13.Das DK, Pant CS, Chachra KL, et al. Fine needle aspiration cytology, diagnosis of tuber

14.Sachs MK, Dickinson G, Amazon K. Tuberculous adenitis of the thyroid mimicking subac

15.Solary E, Rafle G, Chalopin JM. Disseminated aspergillosis revealed by thyroiditis in a r

16.Kakudo K, Kanokogs M, Mitsunobu M, et al. Acute mycotic thyroiditis. *Acta Pathol Jpn*.

17.Jang KS, Han HX, Oh YH. Aspergillosis of the thyroid gland diagnosed by fine needle as

18.Torres AM, Agarwal S, Peters S, et al. Invasive aspergillosis diagnosed by fine-needle a

19.Winzelberg GG, Grose J, Yu D, et al. Aspergillus flavus as a cause of thyroiditis in an i

20.Halazun JF, Lukens JN. Thyrotoxicosis associated with aspergillus thyroiditis in chronic

21.Kaw TY, Brunnemer C. Initial diagnosis of disseminated cryptococcosis and acquired i
38:427â€“430.

22. Vaidya KP, Lomvardias S. Cryptococceal thyroiditis: report of a case diagnosed by fine-

23. Szporn AH, Topper S, Watson CW. Disseminated cryptococcosis presenting as thyroiditi

24. Heufelder AE, Hofhauer LC. Human immunodeficiency virus infection and the thyroid g

25. Keyhani-Rofagha S, Piquero C. *Pneumocystis carinii* thyroiditis diagnosis by fine needle

26. Guttler R, Singer PA. *Pneumocystis carinii* thyroiditis. Report of three cases and review

27. Patel A, Sowden D, Kemp R, et al. Pneumocystis thyroiditis. *Med J Aust*. 1992;156:136â

28. Rogrii MV, Dekker A, DeRubertis FR, et al. *Pneumocystis carinii* infection presenting as

29. Battan R, Mariuz P, Raviglione MC, et al. *Pneumocystis carinii* infections of the thyroid 1991;72:724â€“726.

30. Watts AE, Pichon HE. Pneumocystis carinii in FNA of the thyroid. *Diagn Cytopathol*. 199

31. Gallant JE, Enriquez RE, Cohen KL, et al. *Pneumocystis carinii* thyroiditis. *Am J Med*. 1

32. Mittledorf CATS, de Oliveira Misiara AC, de Carvalho IE. Multicystic autoimmune thyroi

33. Mishalani SH, Lones MA, Said JW. Multilocular thyroid cyst. A novel thyroid lesion assoc

34. Mohanty SK, Patnaik S, Dey P, et al. Microfilaria in thyroid aspirate. *Diagn Cytopathol*.

35. Mehrotra R, Lahiri VL, Hazra DK. Microfilaria identified in fine needle aspirate of thyro

36. Pandit AA, Prayag AS. Microfilaria in thyroid aspirate. An unusual finding. *Acta Cytol*. 1

37. Das DK, Khanna CM, Tripathi RP, et al. Microfilaria *Wuchereria bancrofti* in the fine ne

38. Sodhani P, Nayar M. Microfilaria in a thyroid aspirate. *Acta Cytol*. 1989;33:942â€“943.

39. Sodhani P, Gupta S, Jain S. Unusual presentation of disseminated Echinococcus with th
2002;46:75â€“76.

40. Valati A, Marena C, Aristia L, et al. Sarcoidosis of the thyroid. Repot of a case and a re

41. Cilley RE, Thompson NW, Lloyd RV, et al. Sarcoidosis of the thyroid presenting as a pai

42. Kitchener MI, Chapman JM. Subacute thyroiditis: a review of 105 cases. *Clin Nucl Med*.

43. Volpe R. Subacute thyroiditis. *Prog Clin Biol Res*. 1981;4:115â€“134.

44. Greene JN. Subacute thyroiditis. *Am J Med*. 1971;51:97â€“108.

45. Lindsay S, Dailey ME. Granulomatous or giant cell thyroiditis: a clinical and pathologic

46. Lu CP, Chang TC, Wang CY, et al. Serial changes in ultrasound-guided fine needle aspir

47. Shabb NS, Salti Ibrahim S. Subacute thyroiditis: fine-needle aspiration cytology of 14 c

48. Solano JG, Bascunana BG, Perez DM, et al. Fine-needle aspiration of subacute granulor
1997;16:214â€“220.

49. Tabbara SO, Acoury N, Siadwy MK. Multinucleated giant cells in thyroid neoplasms. A c

50. Orell SR, Walters MNI, Sterrett GF, et al. *Manual and Atlas of Fine Needle Aspiration C*

51. Guarda LA, Baskin HJ. Inflammatory and lymphoid lesions of the thyroid gland. *Am J C*

52. Chang FC, Chan FE, Kau S. Diagnostic criteria of granulomatous thyroiditis by needle a

53. Droese M. *Cytological Aspiration of the Thyroid.* Stuttgart: Schattauer-Verlag; 1980.

54. Kini SR. *Differential Diagnosis in Exfoliative and Aspiration Cytopathology*. Philadelphi

55. Kini SR, Miller JM, Hamburger JI. Problems in the cytologic diagnosis of the "cold" thyr

56. Mizukami Y, Michigishi T, Nonomura A, et al. Postparum thyroiditis. A clinical, histolog

57. Mizukami Y, Michigishi T, Hashimoto's T, et al. Silent thyroiditis: a histologic and immu

58. Hamburger JI, Meier DA. Are silent thyroiditis and postpartum silent thyroiditis forms c
York: Springer-Verlag; 1981:21â€“67.

59. Belsing Z, Rasmussen U, Bendtzen K. Case report. Riedel's thyroiditis: an autoimmune

60. Fontan JP, Carballido PC. A case report: Riedel's thyroiditis. US, CT, and MR evaluation

61. Taubenberger JK, Merini MJ, Medeiros J, et al. A thyroid biopsy with histologic feature
1992;9:1072â€“1075.

62. Schwaegerie SM, Bauer TW, Esselstyn CB Jr. Riedel's thyroiditis. *Am J Clin Pathol*. 1988

63. Harach HR, Williams ED. Fibrous thyroiditisâ€”an immunological study. *Histopathology*

64. Harigopal M, Sahoo S, Recant WM. Fine-needle aspiration of Riedel's thyroiditis: report

65. Blumenfeld W. Correlation of cytologic and histologic findings in fibrosing thyroiditis. *A*

66. Clark DP, Faquin WC. *Thyroid Cytopathology.* New York: Springer-Verlag; 2005.

67. Kumar N, Ray C, Jain S. Aspiration cytology of Hashimoto's thyroiditis in an endemic ar

68. Dayan CM, Daniels GH. Chronic autoimmune thyroiditis. *N Engl J Med*. 1996;335:99â€“1

69. Schubert MF, Kountz DS. Thyroiditis: a disease with many faces. *Postgrad Med*. 1995;98

70. Weetman AP, McGregor AM. Autoimmune thyroiditis: further developments in our unde

71. Weetman AP. Autoimmune thyroiditis: Predisposition and pathogenesis. *Clin Endocrino*

72. Volpe R. Hashimoto's thyroiditis. *Curr Ther*. 1977;3:68â€“76.

73. Woolner LB, McConahey WM, Beh OH. Struma lymphomatosa and related thyroidal diso

74. Rallison ML, Dobyns EM, Keating FR, et al. Occurrence and natural history of chronic ly

75. MÃ¤npÃ¤Ã¤ J, Raatikka M, RÃ¤Ã¤sanen J, et al. Natural course of juvenile autoimmur

76. Holmes LE, Blomgren H, LÃ¶whagen T. Cancer risks in patients with chronic lymphocyt

77. Kato I, Tajima K, Sucha T, et al. Chronic thyroiditis as a risk factor of B-cell lymphoma

78. Reading CC, Charboneau JW, Hay ID, et al. sonography of thyroid nodules: a "classic pa

79. LiVolsi VA. The pathology of autoimmune thyroid disease: a review. *Thyroid*. 1994;4:33

80. Mizukami Y, Michigishi T, Kawato M, et al. Chronic thyroiditis: thyroid function and his

81. Di Pasquale M, Rothstein JL, Palazzo JP. Pathologic features of Hashimoto's thyroiditis,

82. Berbo M, Suster S. Clear nuclear changes in Hashimoto's thyroiditis: a clinicopathologic

83. Louis DN, Vickery AL Jr, Rosai J, et al. Multiple branchial cleft-like cysts in Hashimoto's

84. Poropatich C, Marcus D, Oertel YC. Hashimoto's thyroiditis: fine needle aspirations of 5

85. Tseieni-Balafouta S, Kyroudi-Voulgari A, Paizi-Biza P, et al. Lymphocytic thyroiditis in

86. Tani E, Skoog L. Fine-needle aspiration cytology and immunochemistry in the diagnosis

87. Jayaram G, Marwaha RK, Gupta RK, et al. Cytopathologic aspects of thyroiditis: a study

88. Baker BA, Gharib H, Markowitz H. Correlation of thyroid antibodies and cytologic featu

89. Friedman M, Shimauka F, Roo U, et al. Diagnosis of chronic lymphocytic thyroiditis (no

90. McDonald L, Yazdi HM. Fine needle aspiration biopsy of Hashimoto's thyroiditis: sources

91. Kumarasinghe MP, De Silva S. Pitfalls in cytological diagnosis of autoimmune thyroiditis

92. Nguyen GK, Ginsberg J, Rockford PM, et al. Hashimoto's thyroiditis: cytodiagnosis, accu

93. Ravinsky E, Safneck JR. Differentiation of Hashimoto's thyroiditis from thyroid neoplasm

94. Kini SR, Miller JM, Hamburger JI. Cytopathology of HÃ¼rthle cell lesions of the thyroid

95. Lerma E, Arguelles R, Rigla M, et al. Comparative findings of lymphocytic thyroiditis ar

96. Kollur S, Sayed E, El Hag I. Follicular thyroid lesions coexisting with Hashimoto's thyroi

97. Kebebew E, Treseler PA, Iturate PH, et al. Coexisting chronic lymphocytic thyroiditis a

98. Carson HJ, Castelli MJ, Gattuso P. Incidence of neoplasia in Hashimoto's thyroiditis: a f

99. Mckee RF, Krukowski ZH, Matheson NA. Thyroid neoplasia coexistent with chronic thyr

100. Sclafani AP, Valdes M, Cho H. Hashimoto's thyroiditis and carcinoma of the thyroid: o

101. Ott RA, McCall AR, McHenry C, et al. The incidence of thyroid carcinoma in Hashimot

102. Mauras N, Zimmerman D, Goellner JR. Hashimoto's thyroiditis associated with thyroid

103. Ott RA, Calandra DB, McCall A, et al. The incidence of thyroid carcinoma in patients v

104. Crile G Jr. Struma lymphomatosa and carcinoma of the thyroid. *Surg Gynecol Obstet*.

105. Hirabayashi RN, Lindsay S. The relation of thyroid carcinoma and chronic thyroiditis.

106. Chesky VE, Hellwig CA, Welch JW. Cancer of the thyroid associated with Hashimoto's

107. Schlicke CP, Hill JE, Schultz GF. Carcinoma in chronic thyroiditis. *Surg Gynecol Obste*

108. Shands WC. Carcinoma of the thyroid in association with struma lymphomatosa (Hashi

109. Dailey WE, Lindsay S, Shahen R. Relation of the thyroid neoplasms to Hashimoto's dise

110. Pollock WF, Sprang DH Jr. The rationale of thyroidectomy for Hashimoto's thyroiditis:

111. Thomas CG, Rutledge R. Surgical intervention in chronic (Hashimoto's) thyroiditis. *Am*

112. LiVolsi VA, Marino MJ. Histopathologic differential diagnosis of the thyroid. *Pathol An*

113. Carcangiu ML, Zampi G, Rosai V. Papillary thyroid carcinoma: a study of its many mor

Editors: Kini, Sudha R.
Title: *Thyroid Cytopathology: A Text and Atlas, 1st Edition*

Copyright Â©2008 Lippincott Williams & Wilkins

14

Malignant Lymphoma

Primary malignant lymphomas of the thyroid are considered to be uncommon malignant neoplasms of the thyroid. The reported incidence varies from 2% to 5% of all thyroid malignancies.1 , 2 , 3 , 4 , 5 , 6 , 7 A higher incidence of 8% to 10% has been reported.8 , 9 Primary malignant lymphomas of the thyroid almost always arise in the background of Hashimoto's thyroiditis1 , 2 , 3 , 4 , 5 , 6 , 7 , 8 , 9 , 10 , 11 , 12 , 13 , 14 and are of B-cell lineage. The relative risk of developing malignant lymphomas in patients with Hashimoto's thyroiditis is reported to be up to 67 to 80 times higher than with a normal individual.15 , 1 takes on an average of 20 to 30 years for lymphoma to develop after the onset of lymphocyt thyroiditis.17 Primary malignant lymphomas have attracted considerable interest.1 , 2 , 3 , , 6 , 7 , 8 , 9 , 10 , 11 , 12 , 13 , 14 , 15 , 16 , 17 , 18 , 19 , 20 , 21 , 22 , 23 , 24 , 25 , 26 , 28 , 29 , 30 , 31 , 32 , 33 , 34 Over the last few decades there have been substantial advanc our understanding of the development of primary lymphomas of the thyroid. A great deal of information is now available in the literature, and it is beyond the scope of this monograph include the details. Some salient features are described below that may help understand th mechanism of development of primary lymphomas in the thyroid, their cytohistologic patte diagnostic features, limitations, and the use of ancillary tests in aid of diagnosis.

Primary lymphomas of the thyroid are basically of two types, referred to as extranodal marg zone B-cell lymphoma (ENMZBL) and diffuse large B-cell lymphoma (DBCLL). Isaacson and W in 198435 noted the morphologic similarity between low-grade lymphomas of the stomach, l salivary glands and thyroid (organs lacking native lymphoid tissue), which recapitulated thos mucosa-associated lymphoid tissue (MALT), typified by Peyer patches in the intestine. They coined the term MALT lymphoma to describe this group of extranodal lymphomas. Subseque

it was appreciated that the common denominator for these extranodal lymphomas is that th arise from the acquired lymphoid tissue in the setting of autoimmune disorders and demons features of MALT, which include lymphoid follicles and adjacent epithelium referred to as lymphoepithelium.

MALT lymphomas are low-grade lymphomas, remain localized for a long period of time, and show progression to high grade. They have a tendency to involve the "mucosal" (extranodal) and spare the bone marrow. It is felt by some5 that lymphomas of the thyroid referred to as follicular lymphoma, diffuse small cleaved lymphoma, lymphocytic lymphoma, monocytoid B lymphoma, and plasmacytoma, that arise in the setting of Hashimoto's thyroiditis indeed represent variants MALT lymphoma. The Revised European-American Classification of Lymph Neoplasms (REAL)36 and the World Health Organization (WHO) Classification for Neoplastic Diseases of the Lymphoid Tumors37 have referred to primary thyroid lymphomas as margina zone B-cell lymphoma of MALT type (MZBL) and diffuse large B-cell lymphoma (DLBCL).

Primary malignant lymphomas occur in elderly individuals in the sixth to seventh decades of and are more frequent in women, with a female:male ratio of 4:1 although this differs in younger age groups.8 , 26 The youngest patient reported was 11 years old,33 but the averag age is 63 to 65 years. Patients generally give a history of pre-existing goiter of variable dura Presenting symptoms include a rapidly enlarging, tender mass in the neck, often with pressu symptoms such as dysphagia, hoarseness, or tracheal compression. These symptoms clinicall mimic those of anaplastic carcinomas.

Patients often have a history of Hashimoto's thyroiditis with a goiter. Derringer et al.3 repor evidence of Hashimoto's thyroiditis in 94% of their cases. Antithyroid antibody levels are oft elevated.

RADIOLOGIC FINDINGS

Imaging shows cold nodules, cold areas in diffuse goiters, or patchy uptake.

GROSS AND HISTOLOGIC FEATURES

The lymphomas are often large, bulky, and involving a single lobe or both lobes of the thyro but may present as a solitary nodule (Figs. 14.1 , 14.2 , 14.3 and 14.4). The gland is enlarge often several centimeters in the longest dimensions. The cut surface is

bulging, smooth, homogeneous, pale, and pearly-white to pink with a "fish-flesh" appearanc

and may show areas of hemorrhage and necrosis (Fig. 14.4). They feel firm and rubbery on palpation. Malignant lymphomas may extend beyond the thyroid capsule, involving the surrounding soft tissues and skeletal muscle.

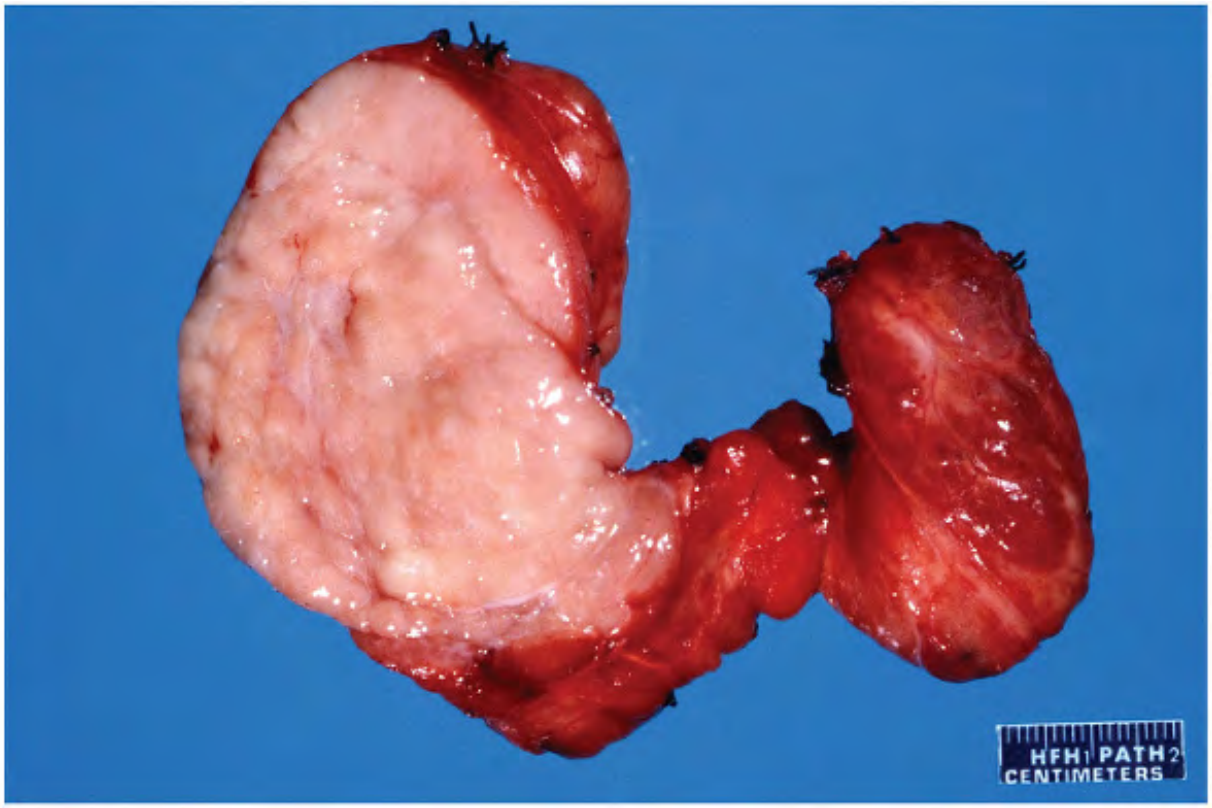

Figure 14.1. Gross photograph of thyroid with massive enlargement of the right lobe due to involvement by malignant lymphoma. The tumor is bulky with a bulging cut surface presenti fish-flesh appearance.

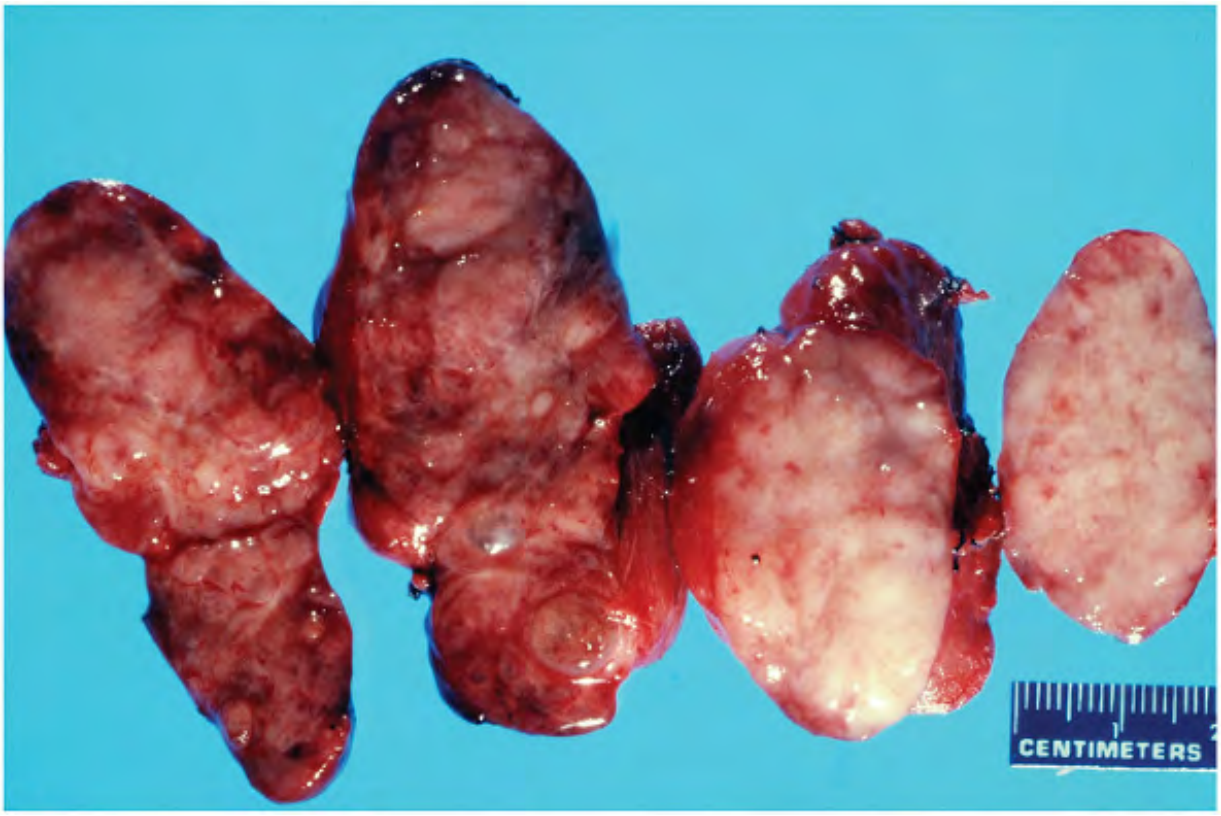

Figure 14.2. Gross photograph of the thyroid with both lobes involved by malignant lymphoı

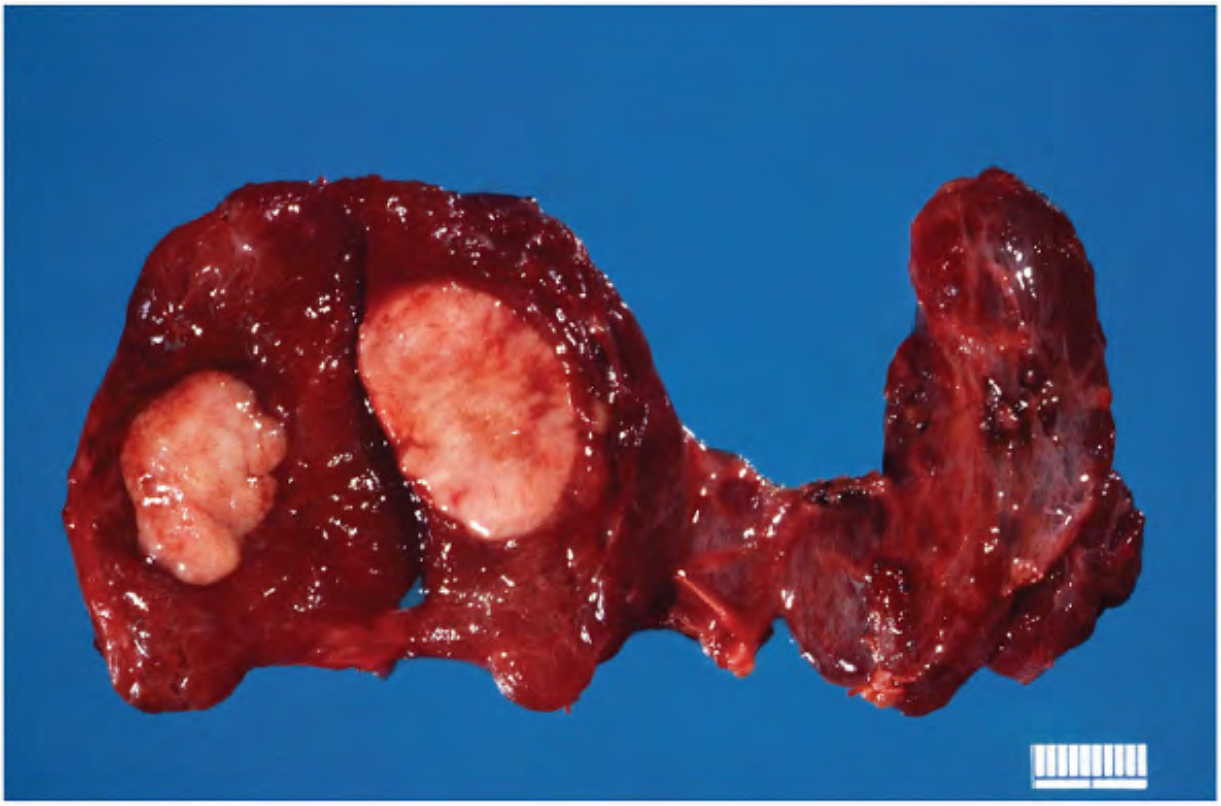

Figure 14.3. This malignant lymphoma presented grossly as a discrete nodule.

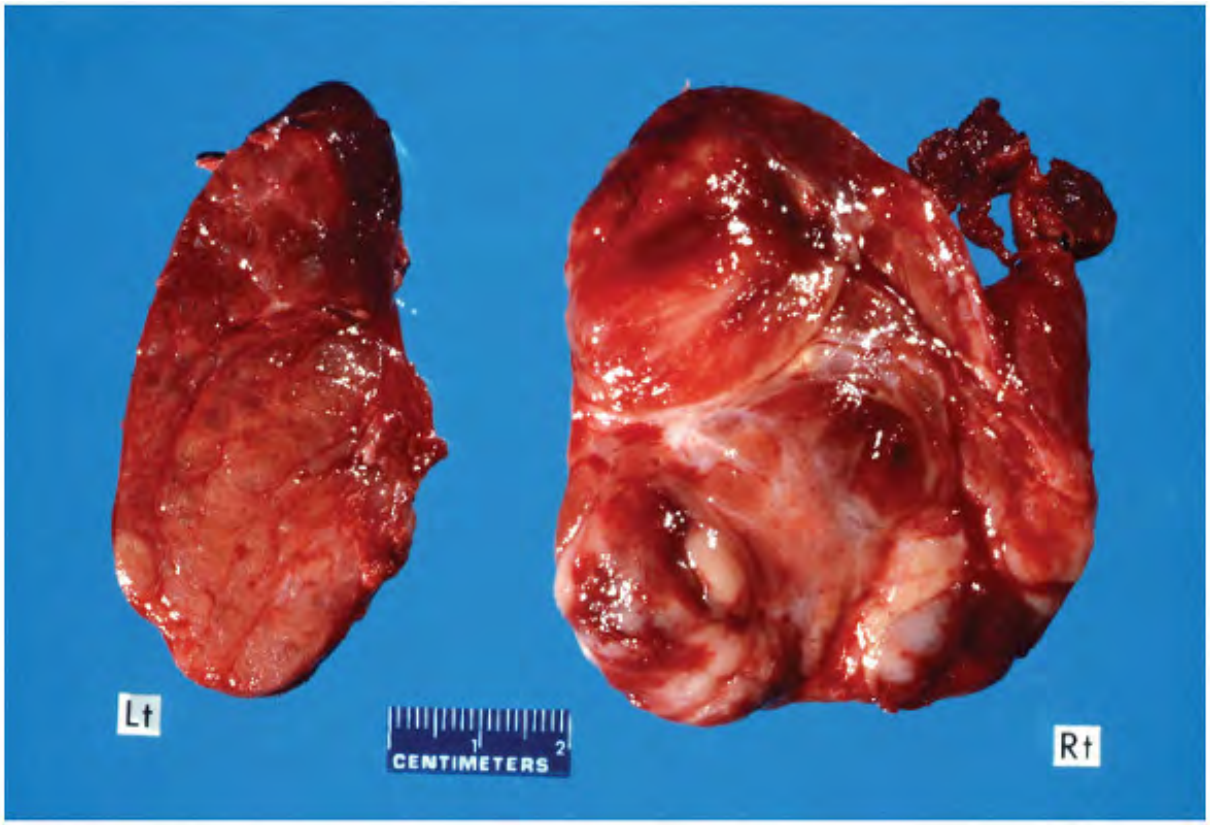

Figure 14.4. Gross photograph of malignant lymphoma with areas of hemorrhage and necro

Histologically, malignant lymphomas of the thyroid are grouped into two types:

- Marginal zone B-cell lymphoma (MZBL).
- Diffuse large B-cell lymphoma or DLBCL.

All thyroid primary lymphomas arise in the setting of Hashimoto's thyroiditis, features of wh may be identified in the biopsy specimens or excised glands depending on the extent of involvement by lymphoma.

MARGINAL ZONE B-CELL LYMPHOMA (MZBL)

Histologically, extranodal marginal zone B-cell lymphoma (MZBL) shows either focal or diffu areas of confluent dense lymphoid infiltration with effacement of thyroid follicles. Reactive lymphoid follicles are always present and may be extremely prominent. The lymphomatous infiltrate is seen in between the lymphoid follicles replacing and pushing the thyroid

parenchyma peripherally (Fig. 14.5A). This infiltrate is heterogenous or polymorphic, characterized by an admixture of predominantly small lymphoid cells with variable proporti of centrocyte-like cells, monocytoid B-cells, plasma cells, and dispersed large transformed lymphocytes or immunoblasts (Figs. 14.5B). Another feature of these lymphomas is the colonization of the germinal centers of the lymphoid follicles by the lymphoma cells, often completely replacing them. This colonization mimics the follicular pattern of reactive lympl nodes (Fig. 14.6). However, they lack the starry-sky pattern of the germinal centers.

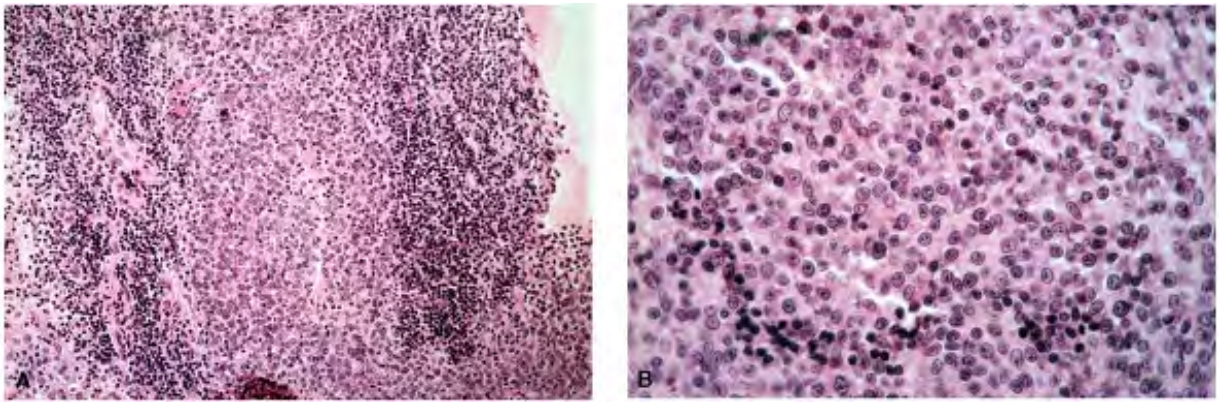

Figure 14.5. MALT lymphoma. Core-needle biopsy of thyroid. A. The malignant lymphoma c are infiltrating the interfollicular area (medium power). Note the darker area represents lymphoid cells of the marginal zone. B. Higher magnification showing a heterogenous cell population representing a mixture of lymphocytes, centrocyte-like cells, monocytoid Bâ€“ce and plasma cells.

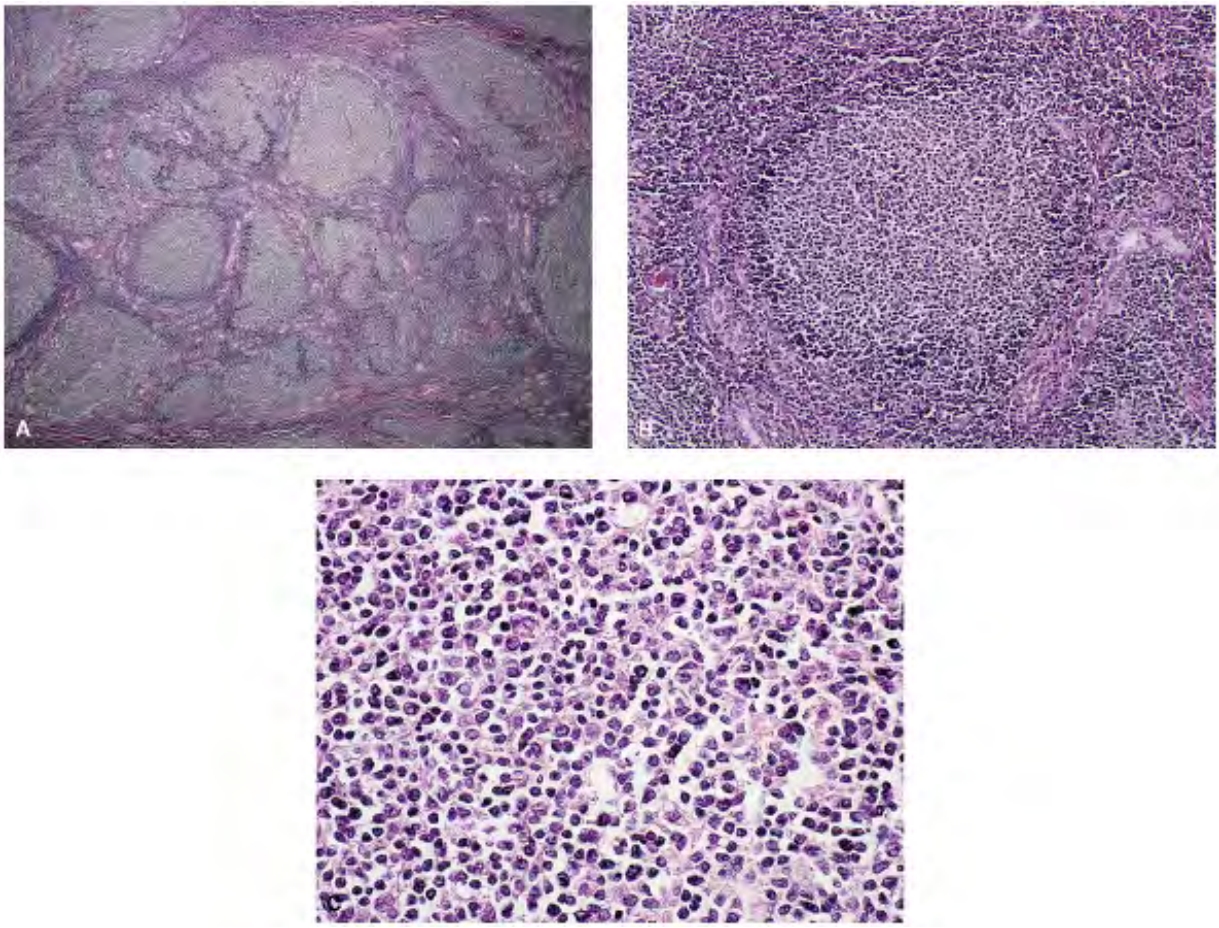

Figure 14.6. Histologic section of MALT lymphoma. A. Low power showing a nodular patterr to colonization of the germinal center. B. Note the loss of starry-sky pattern. The lymphoma cells are infiltrating the thyroid parenchyma extensively (medium power). C. Higher magnification highlighting the polymorphic nature of the lymphoma cells.

Lymphoepithelial lesions are always present and are characteristic of MALT lymphoma. Two types of lymphoepithelial lesions are described, one where the lymphoma cells are infiltrati and growing into the thyroid follicles (Fig. 14.7A) and the other consisting of lymphoma cel filling the lumens and expanding the follicles, referred to as "MALT balls" (Fig. 14.7B). Plasr cell differentiation is more frequent in thyroid MZBL. It may be so pronounced as to suggest diagnosis of plasmacytoma.

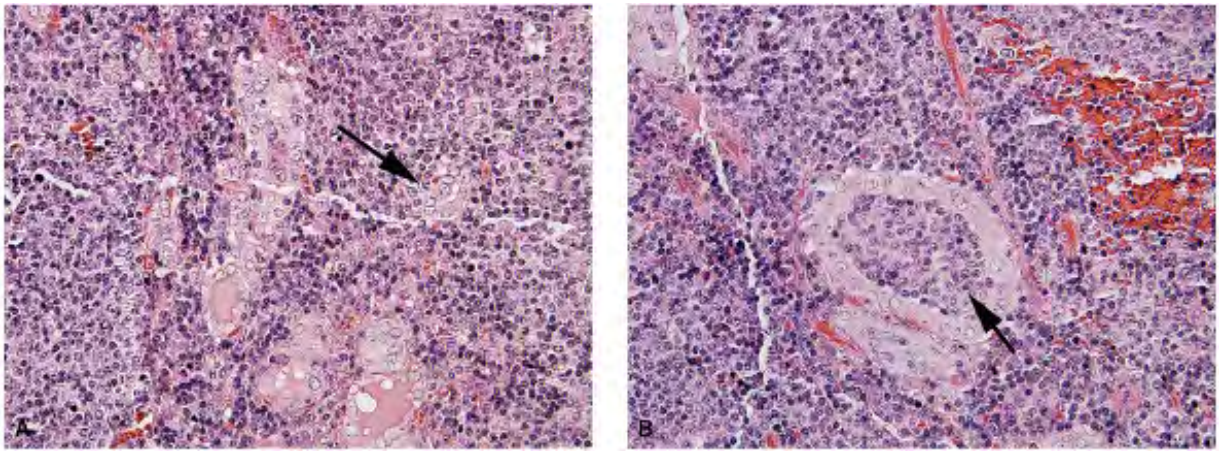

Figure 14.7. MALT lymphoma, lymphoepithelial lesions. A. The thyroid parenchyma is diffus infiltrated by lymphoma cells involving the follicles, forming a lymphoepithelial lesion (*arro* B. The lymphoma cells are packed in the follicular lumen, referred to as "MALT balls" (*arrow*

P.326
P.327

DIFFUSE LARGE B-CELL LYMPHOMA (DLBCL)

The diffuse large B-cell lymphomas are high-grade lesions and occur more commonly than marginal-zone B-cell lymphomas, showing massive replacement of thyroid parenchyma by sh of poorly differentiated lymphoid cells representing the variants of large B-cell lymphomas, including centroblast-like cells, immunoblasts, monocytoid B-cells, and plasma cell differentiation. Focal Reedâ€“Sternberg-like cells or Burkitt-like cells with brisk mitotic acti apoptosis, and starry sky pattern may be seen (Fig. 14.8). Lymphoepithelial lesions are usua not present. Morphologic evidence of Hashimoto's thyroiditis is present in existing thyroid ti (Fig. 14.9). Some malignant lymphomas present prominent sclerosis (Fig. 14.10).

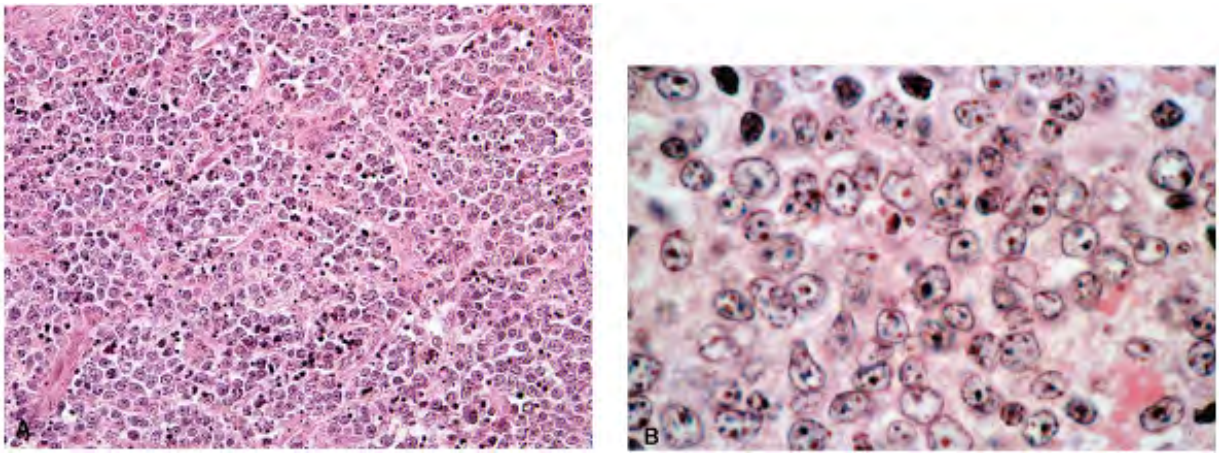

Figure 14.8. Histologic section of diffuse large B-cell lymphoma. A. The lymphoma cells are large, monomorphic with an open chromatin pattern and contain nucleoli. B. Diffuse large E lymphoma (Ã— 1,000).

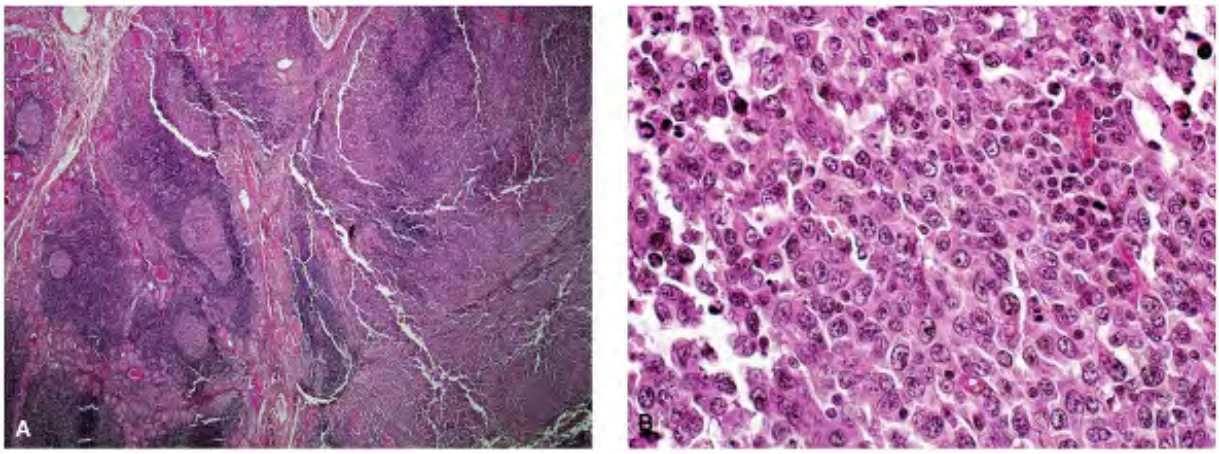

Figure 14.9. A. Histologic section of malignant lymphoma of the thyroid, in the background Hashimoto's thyroiditis seen in the right half of the field. B. Higher magnification, to highlig homogeneous population of large lymphoma cells.

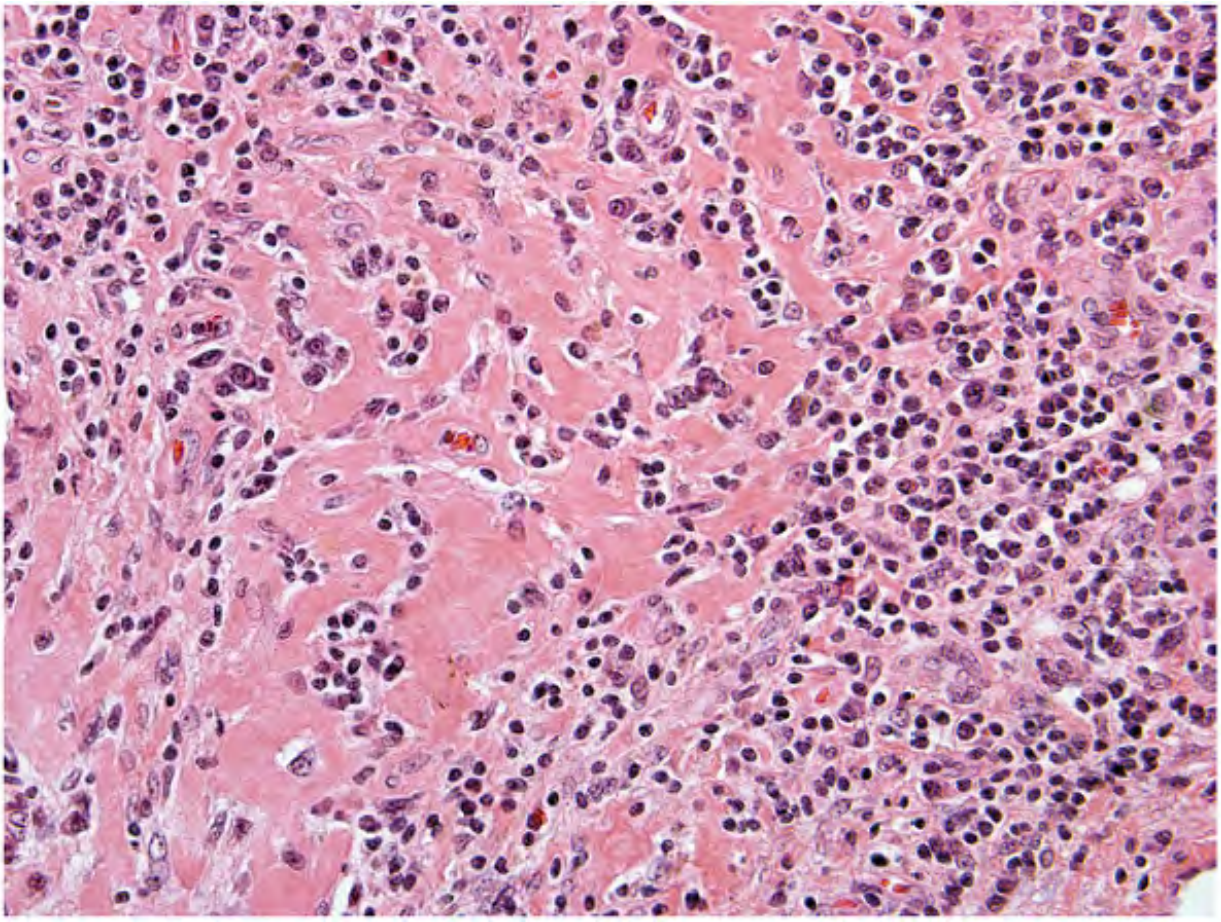

Figure 14.10. Malignant lymphoma with sclerosis.

Lymphoma cells have a tendency to invade the walls of the blood vessels and extend into th perithyroidal soft tissues and skeletal muscles (Fig. 14.11).3 , 11 Areas of progression to dif large B-cell lymphoma from MALT lymphomas may be identified.

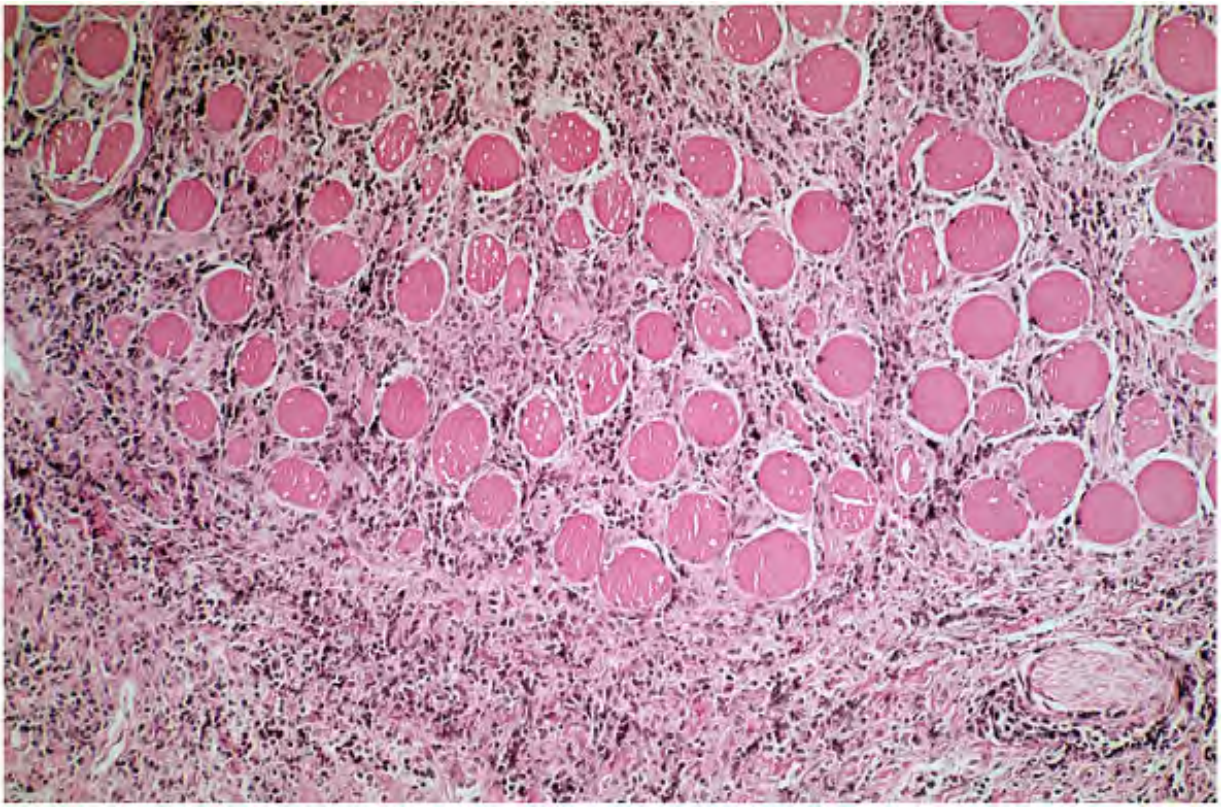

Figure 14.11. Malignant lymphoma of the thyroid, infiltrating the skeletal muscles of the ne

Cytopathologic Features of Marginal Zone B-Cell Lymphom (MZBL)

The MALT-type malignant lymphomas are not very common and their cytopathologic feature sparsely documented (Table 14.1 , Figs. 14.12 , 14.13 , 14.14 and 14.15).36 , 37 , 38 , 39 , 41 , 42 , 43 , 44 , 45 The aspirates of marginal-zone B-cell lymphoma of MALT type consist c heterogenous population of lymphoid cells characterized by an admixture of centrocyte-like cells, monocytoid B-cells and plasma cells. The centrocyte-like cells are medium-sized lymp cells (1.5 times the small lymphocyte), have deep-staining nuclei with condensed chromatin with irregular outlines. The monocytoid B-cells are larger and contain appreciable amounts pale cytoplasm. Plasma cells may be present in large numbers. Features suggestive of lymphoepithelial lesions cannot be appreciated in cytologic samples.

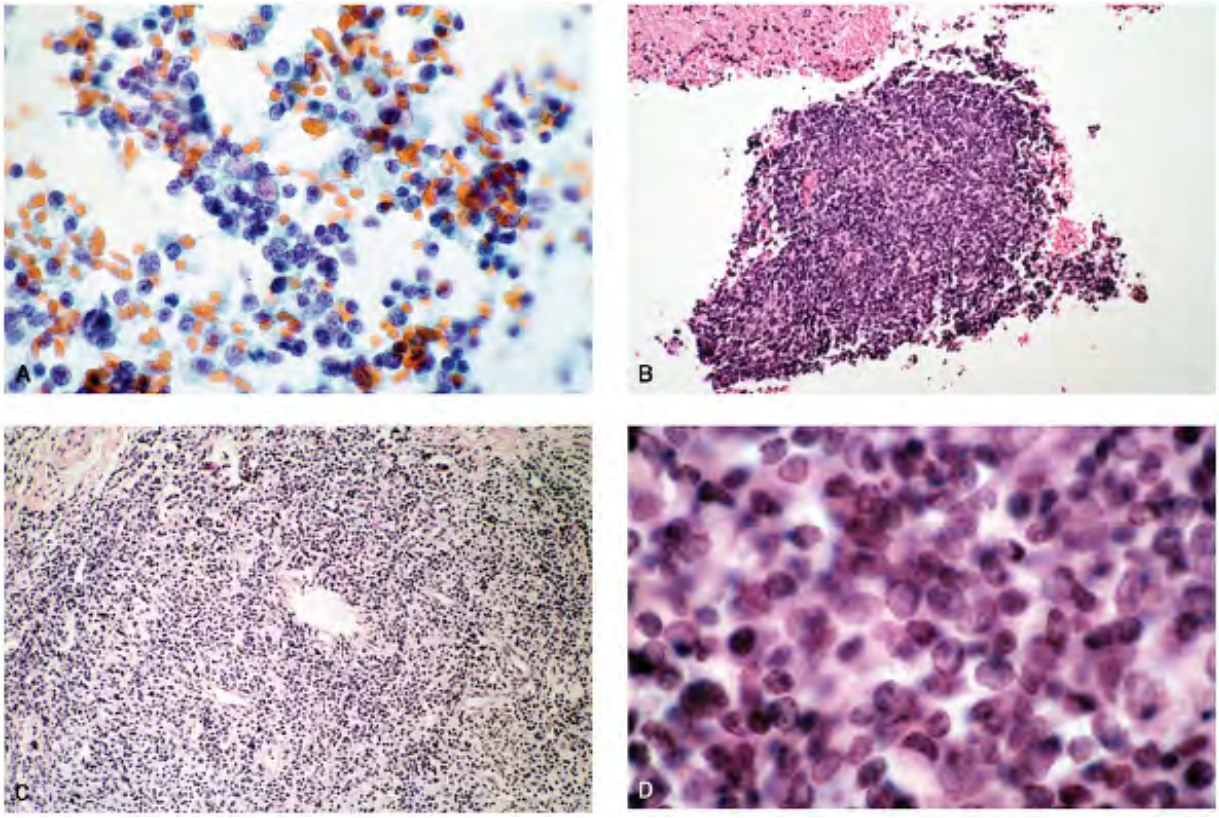

Figure 14.12. MALT lymphoma. FNA of a diffusely enlarged thyroid. A. Polymorphic small lymphoid cell infiltrate, lacking tingible body histiocytes. A malignant lymphoma can only be suggested. B. Core biopsy of the thyroid showing a fragment of thyroid parenchyma heavily infiltrated by lymphoid cells, low power. C. Medium power to show the effacement of thyro parenchyma by the lymphoid infiltrate. D. Higher magnification highlighting the cell compos representing a heterogenous lymphoid population including some immature forms (Ã— 1,000

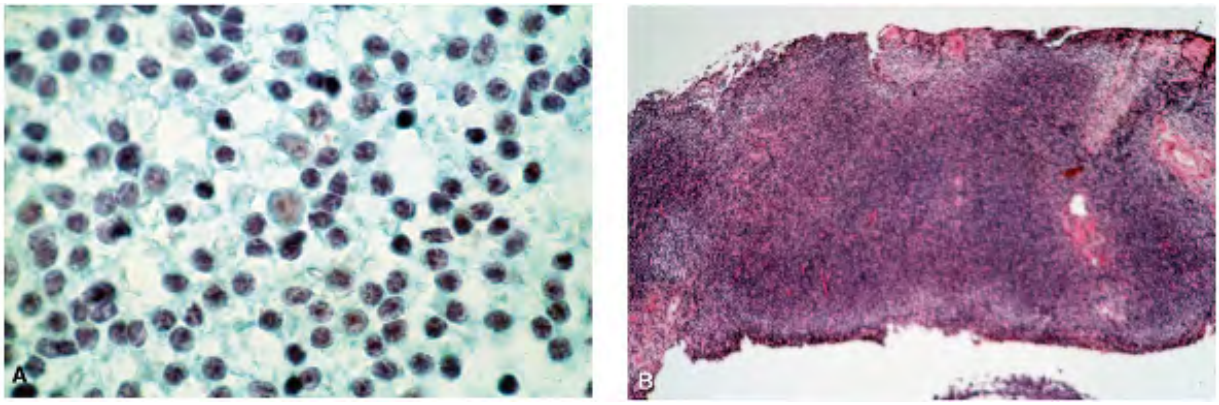

Figure 14.13. MALT lymphoma. A. FNA of an enlarged thyroid. This infiltrate composed of s

lymphoid cells was interpreted at an outside hospital as Hashimoto's thyroiditis. Note that tl cells are heterogenous, consisting of small lymphocytes some larger and occasional monocyt B-cells. A diagnosis of lymphoma can only be suggested as no tingible body histiocytes or follicular/HÃ¼rthle component were present. B. Core-needle biopsy showed heavy lymphoi infiltrate, low power.

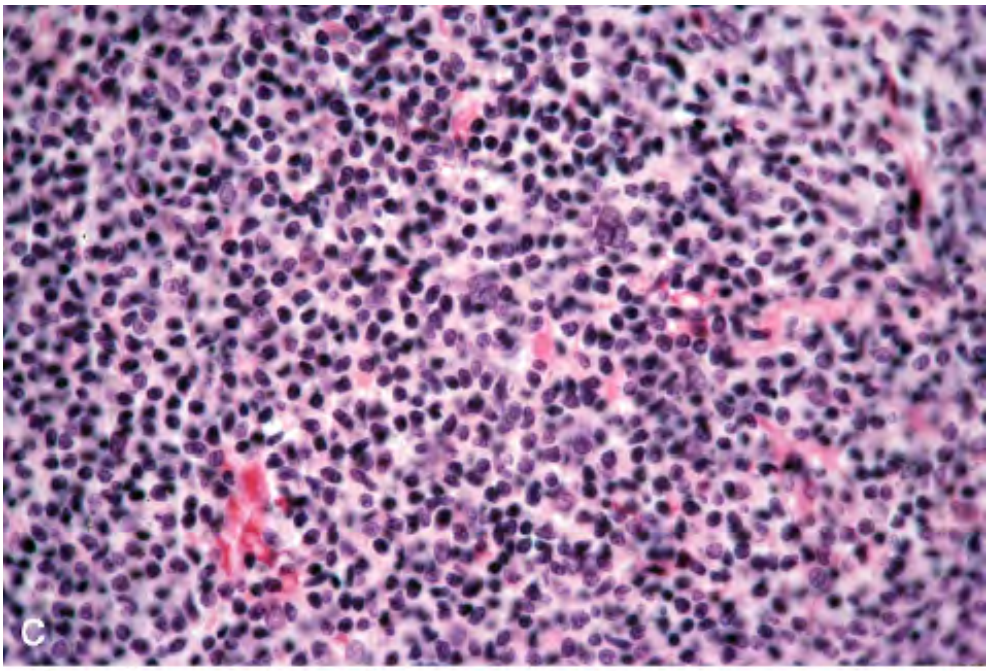

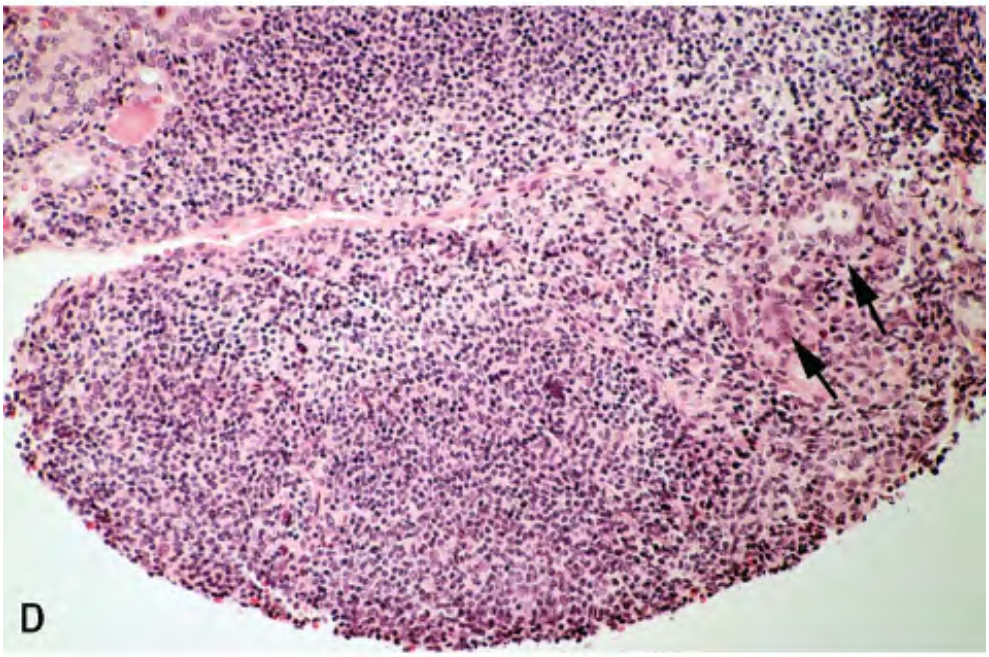

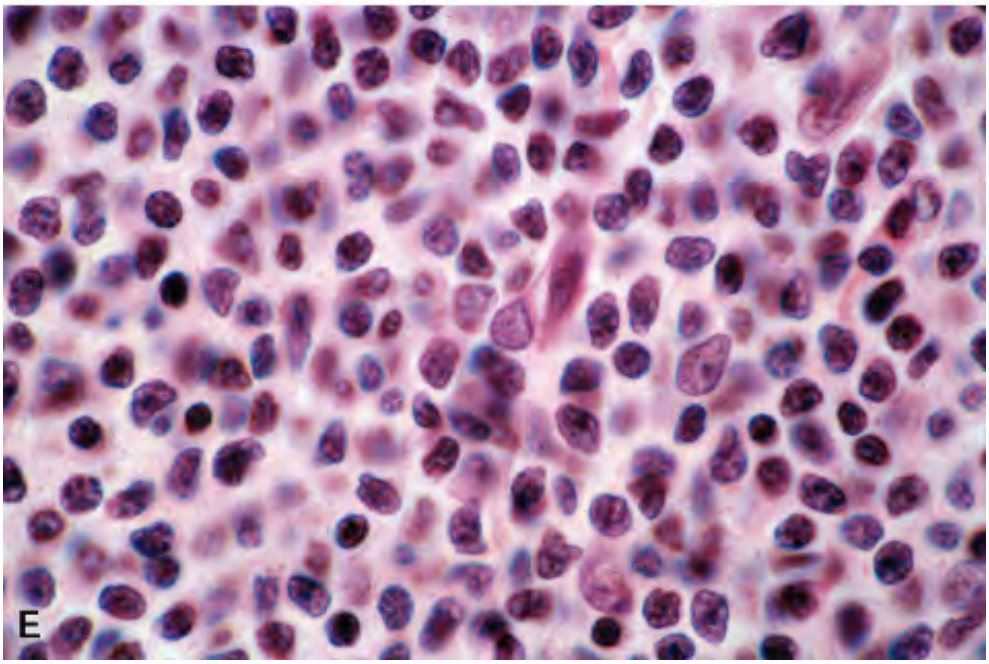

Figure 14.13. C. Higher magnification showing diffuse lymphoid infiltrate replacing the thyı parenchyma. D. Histologic section of the thyroid confirming malignant lymphoma. Note lymphoepithelial lesions (*arrows*). E. Higher magnification to highlight the cell composition

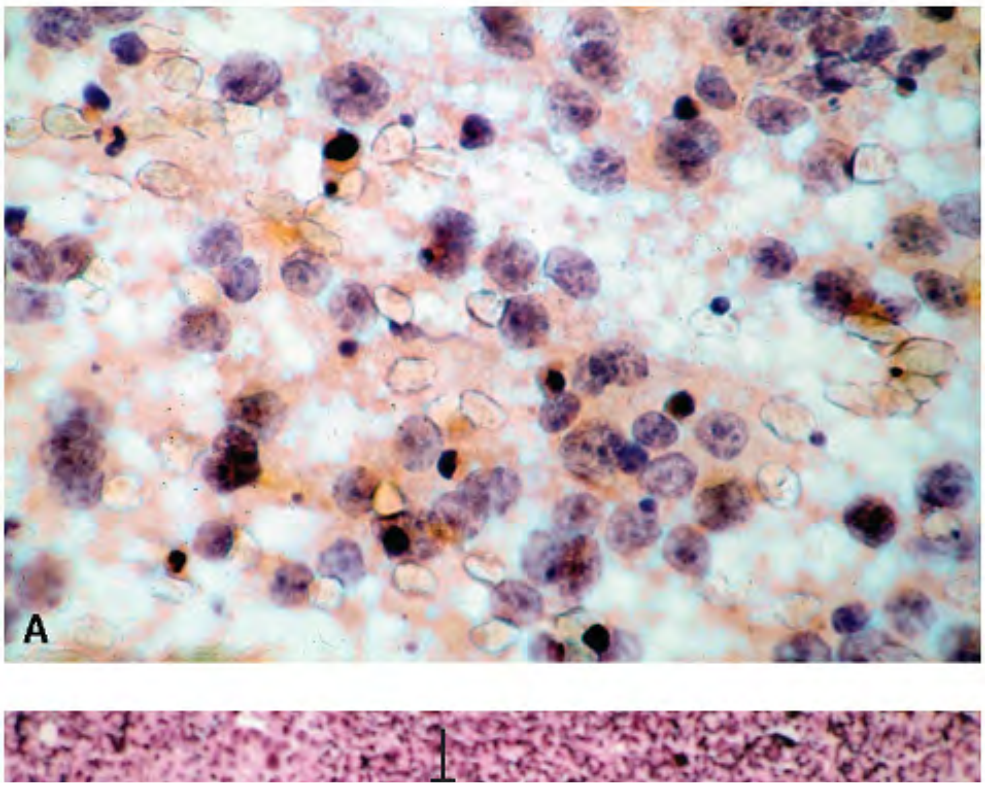

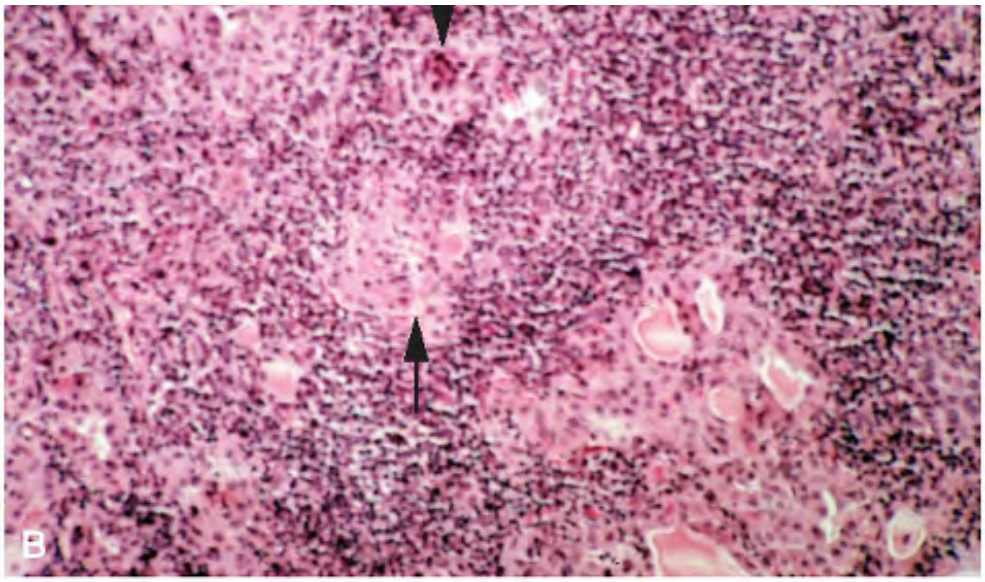

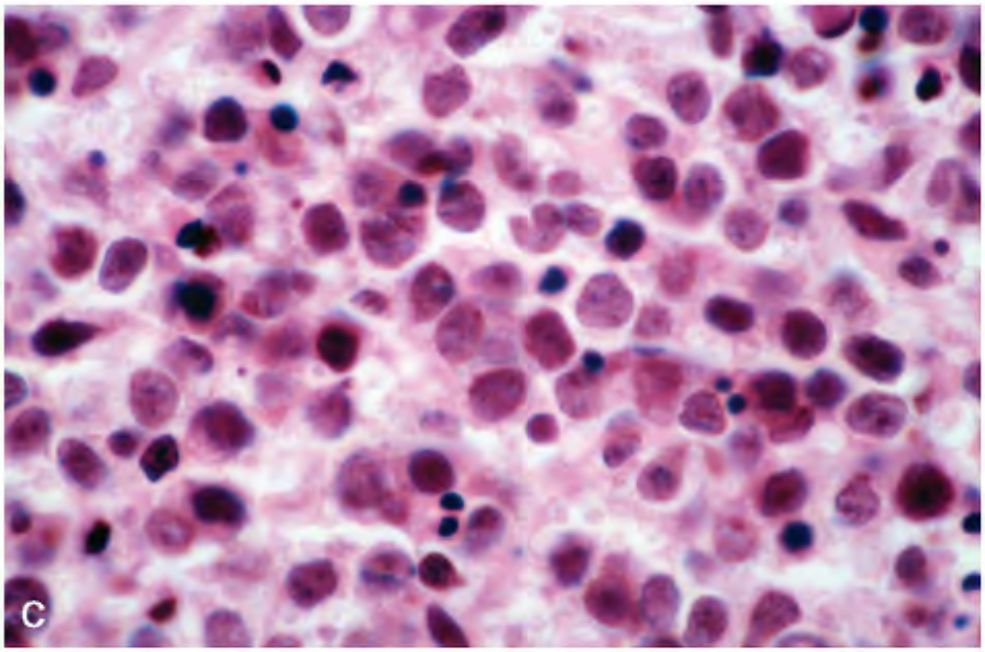

Figure 14.14. MALT lymphoma. An FNA of a 5-cm thyroid mass, enlarging over a period of 1 in an 80-year-old woman. Antibody titers were extremely high. A. The aspirate shows predominantly immature lymphoid cells with karyorrhexis. Thyroidectomy confirmed MALT lymphoma. B. Histologic section showing diffuse lymphoid infiltrate replacing the thyroid parenchyma. Lymphoepithelial lesions can be identified (*arrow*). C. Higher magnification showing heterogenous lymphoid cell population (Ã— 1,000).

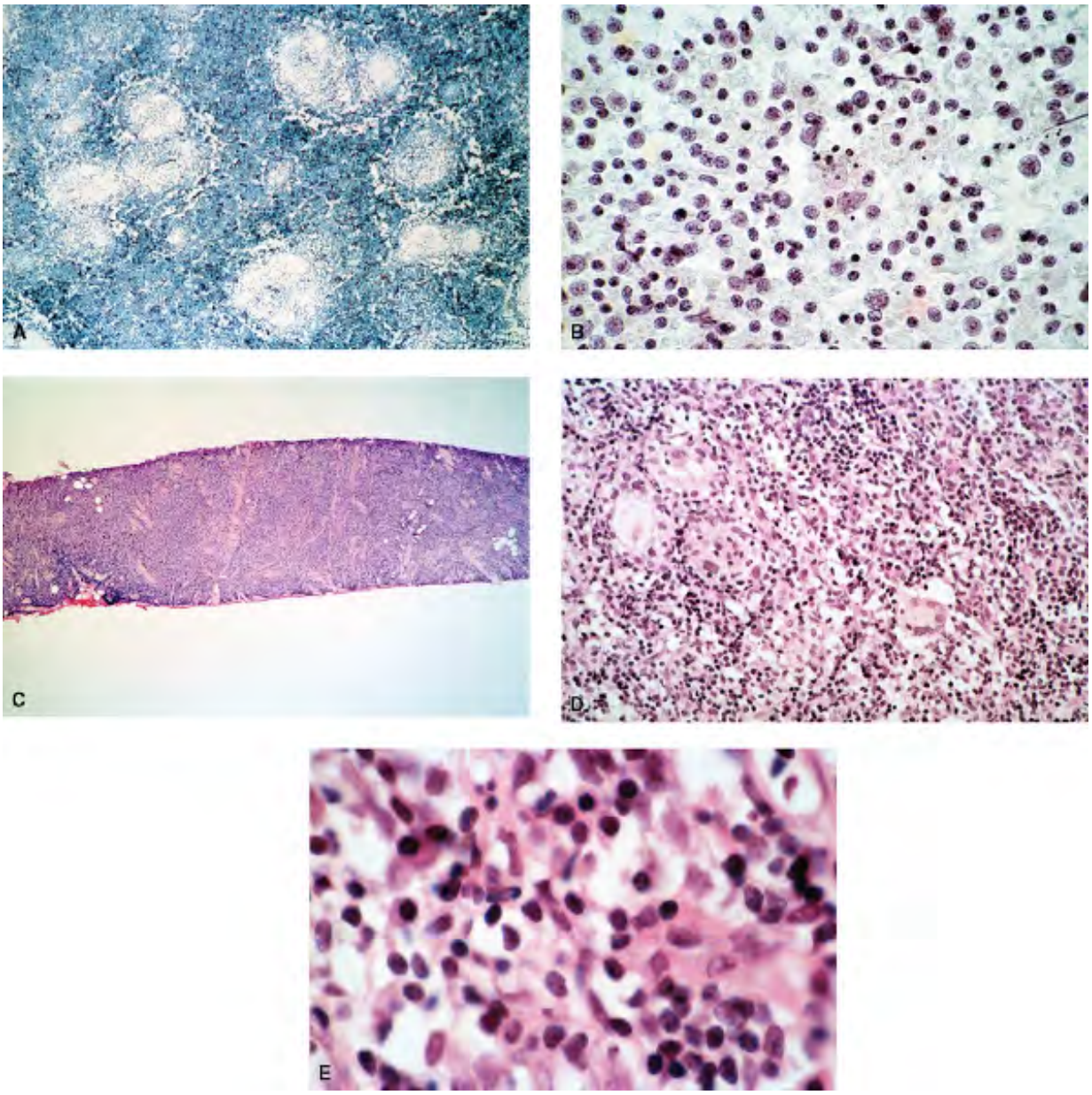

Figure 14.15. MALT lymphoma developed 7 years after the diagnosis of Hashimoto's thyroid A. FNA showing massive lymphoid infiltrate. No epithelial component is identified. B. Highe magnification showing germinal center cells including tingible body histiocytes. A diagnosis Hashimoto's thyroiditis was rendered. The patient was lost to follow-up for 7 years and was at an outside facility for rapidly enlarging thyroid, where an FNA was interpreted as Hashim thyroiditis. The patient was referred for a cutting needle biopsy. C. Core needle biopsy at l power shows a dense lymphoid infiltrate. D. Higher magnification showing lymphoid cells infiltrating and destroying the thyroid parenchyma. Note lymphoepithelial lesions. E. Heterogeneous cell population consistent with MALT Lymphoma (Ã— 1,000).

Cellularity

Variable, usually very cellular

Presentation

Heavy lymphoid cell population, with or without epithelial cell component

Characteristics of lymphoid cell population

Heterogenous population representing an admixture of small lymphocytes, centrocyte-like cells (1.5 times the size of resting lymphocyte) with deep-staining chromatin and irregular nuclear membranes; monocytoid B-cells with appreciable pale cytoplasm; plasma cells; scattered centroblasts and immunoblasts; mitotic activity insignificant; karyorrhexis Â±; lymphoglandular bodies Â±

Features of Hashimoto's thyroiditis

May be present in the same smear or in smears representing different sampled areas

Background

Usually clean

Immunoprofile

CD 20 +, CD 79a +, CD 5 -, CD 10 -; occasional coexpression of CD43 with CD 20; express IgM, less often than IgA or IgG with light-chain restriction

Flow cytometry

Monoclonal

TABLE 14.1 CYTOPATHOLOGIC FEATURES OF MARGINAL ZONE B-CELL LYMPHOMA (MZBL)

The aspirates of marginal zone B-cell lymphoma may also demonstrate features of underlyin Hashimoto's thyroiditis, specifically an epithelial cell component characterized by HÃ¼rthle and follicular cells along with lymphoplasmacytic

P.328

P.329

P.330

cells. This polymorphic lymphoid infiltrate of Hashimoto's thyroiditis is practically impossibl differentiate from the heterogenous neoplastic infiltrate of MZBL without the aid of ancillar diagnostic techniques. Identification of fair numbers of transformed lymphocytes may serve diagnostic clue.

Cytopathologic Features of Diffuse Large B-Cell Lymphoma (DLBC)

Diffuse large B-cell lymphomas are more common than MALT-type lymphomas, and so the cytologic features have been reported more frequently.39 , 40 , 41 , 42 , 43 , 44 , 45 , 46 , 48 Aspirates of DLBCL tend

P.331

to be very cellular (Table 14.2 , Fig. 14.16). The cell spreads show a dense and homogeneou population of poorly differentiated lymphoid cells, larger than the normal lymphocytes. The morphology depends on the morphologic variant (Figs. 14.16 , 14.17 , 14.18 , 14.19 , 14.20 , 14.21 , 14.22 , 14.23 and 14.24). The lymphoma cells are usually discrete and round, with scanty, pale cytoplasm. The nuclei are large, with high N/C ratios and contain finely granula chromatin that gives an open pattern, in contrast to the compact nuclei of the mature lymphocytes. Nucleoli are always present, either small and multiple in a marginal location (centroblast), or large in a central position (immunoblast). Mitotic activity is frequent. Karyorrhexis is a common feature of high-grade malignant lymphoma. Fragmented nuclei ar often seen in the background and also as phagocytized debris in the histiocytes. Another characteristic feature seen only in Romanowsky-stained preparations is the presence of detached fragments of the cytoplasm of lymphoma cells, about the size of platelets. They s basophilic and are referred to as "lymphoglandular

P.332

P.333

bodies." In exfoliative cytology, lymphoma cells are characterized by a discrete pattern. But the material obtained by an aspiration biopsy, it is not unusual to find a tissue fragment of lymphoma cells (Figs. 14.19B and 14.24). These fragments of small, round cells with scanty cytoplasm should not be mistaken for carcinoma. Tumor diathesis is often seen in the background. Lymphoma cells are usually seen in large aggregates or masses. Being very frag they may appear as lymphoid tangles (Fig. 14.22C). In such areas, features of Hashimoto's disease (germinal center cells or epithelial cells) are conspicuously absent.

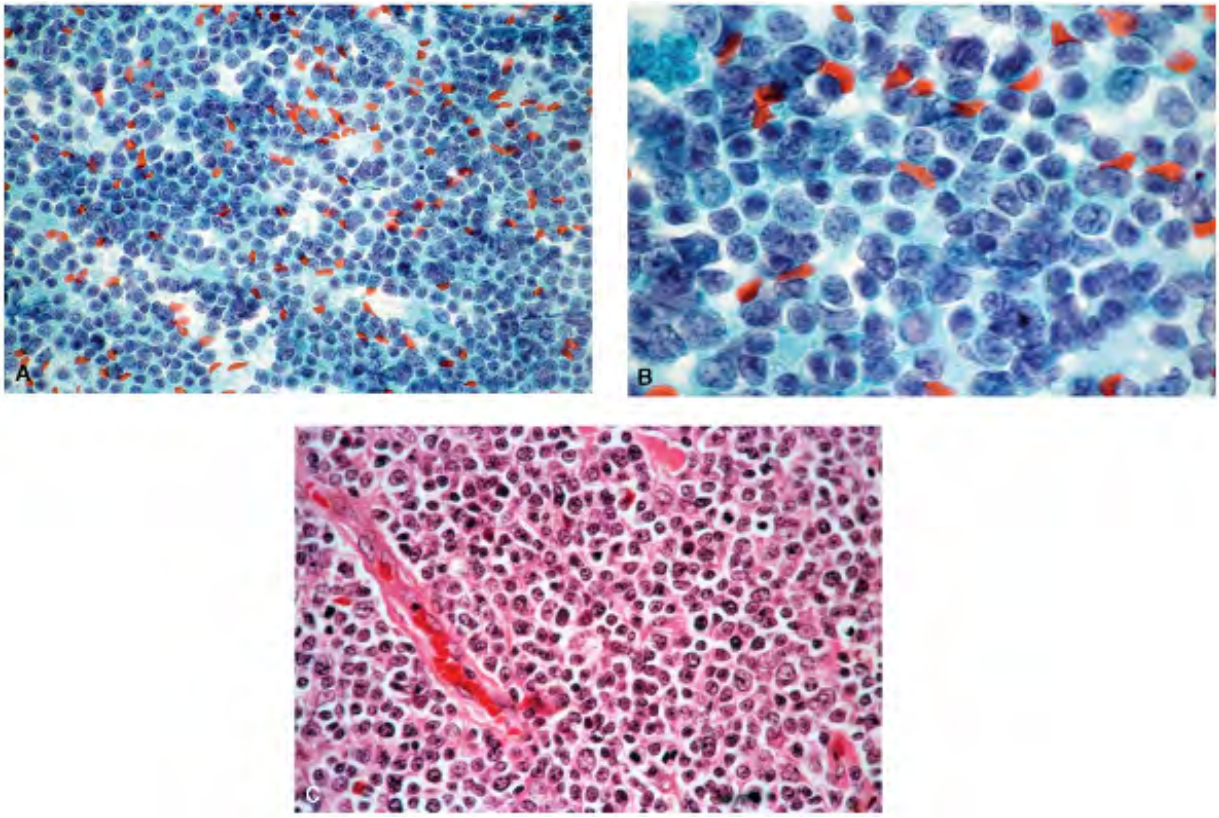

Figure 14.16. A. FNA of malignant lymphoma showing a dense population of lymphoid cells (medium power). B. Higher magnification to depict the monomorphic population of poorly differentiated lymphoid cells (Ã— 1,000). C. Histologic section of thyroid showing malignant lymphoma, diffuse large cell type.

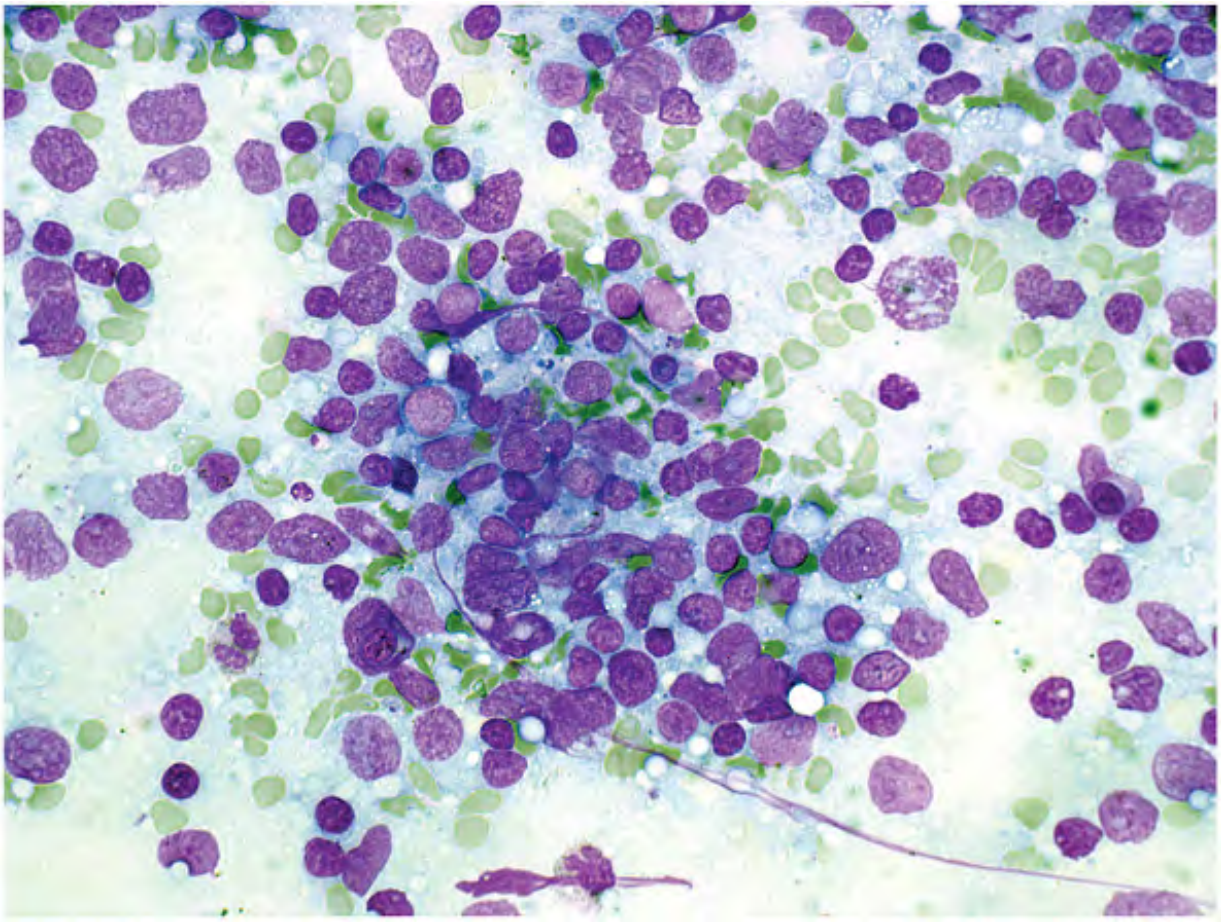

Figure 14.17. FNA of a diffuse large B-cell lymphoma (Diff-Quik stain).

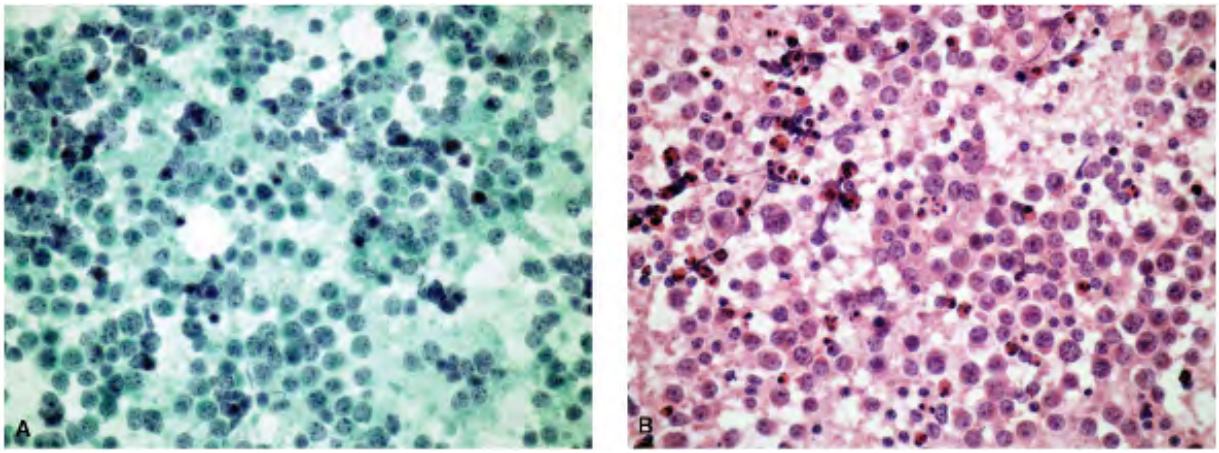

Figure 14.18. FNA of a diffuse large B-cell lymphoma. A. Monomorphic population of poorly differentiated lymphoid cells. B. Imprint of the lymphoma stained by hematoxylin and eosin

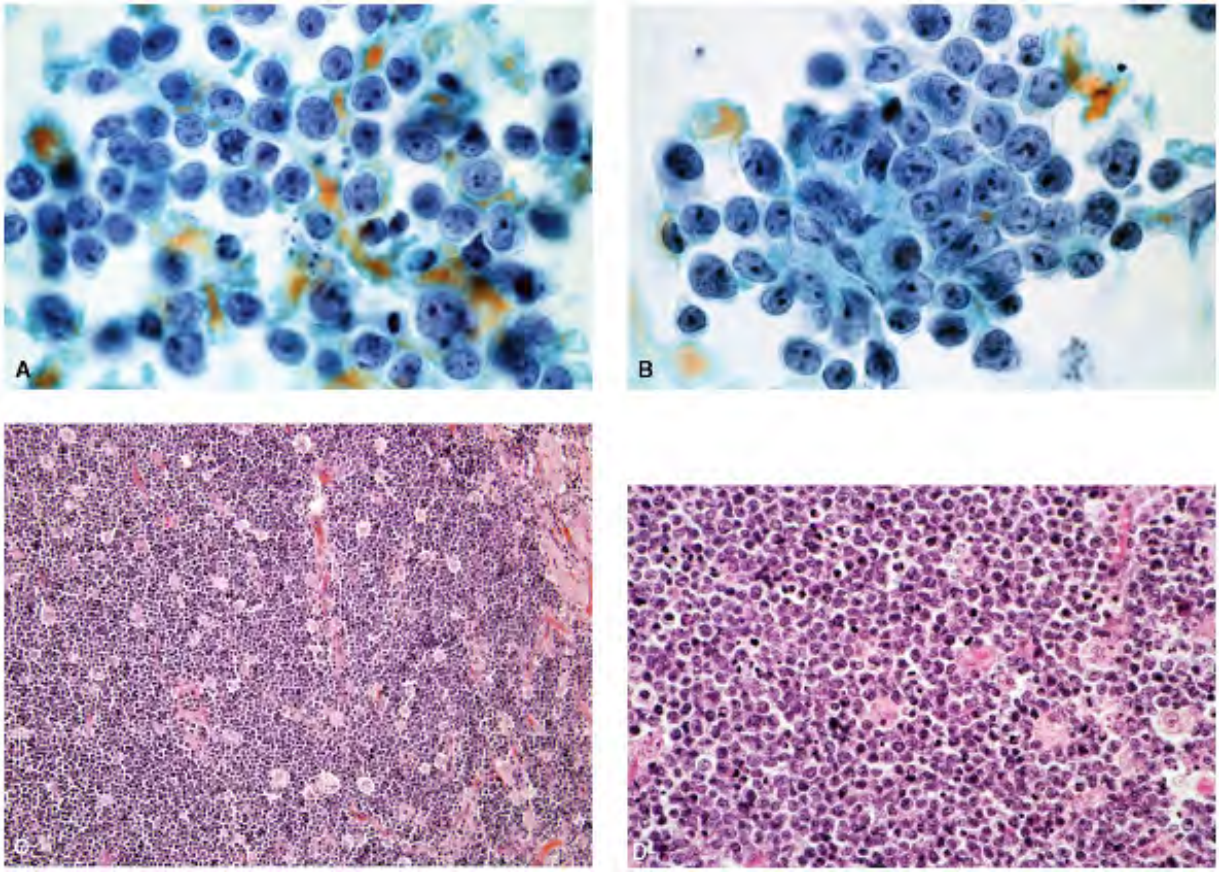

Figure 14.19. FNA of diffuse large B-cell lymphoma. A. Discrete large, poorly differentiatec lymphoid cells with scanty cytoplasm, large nuclei with an open chromatin pattern, and mul nucleoli (Ã— 1,000). B. Another field from the smear showing mitosis and karyorrhexis (Ã— 1,000). Thyroidectomy confirmed malignant lymphoma, Burkitt type, and associated Hashim thyroiditis. C. Histologic section of the lymphoma, showing a typical "starry-sky" pattern. D. Higher magnification.

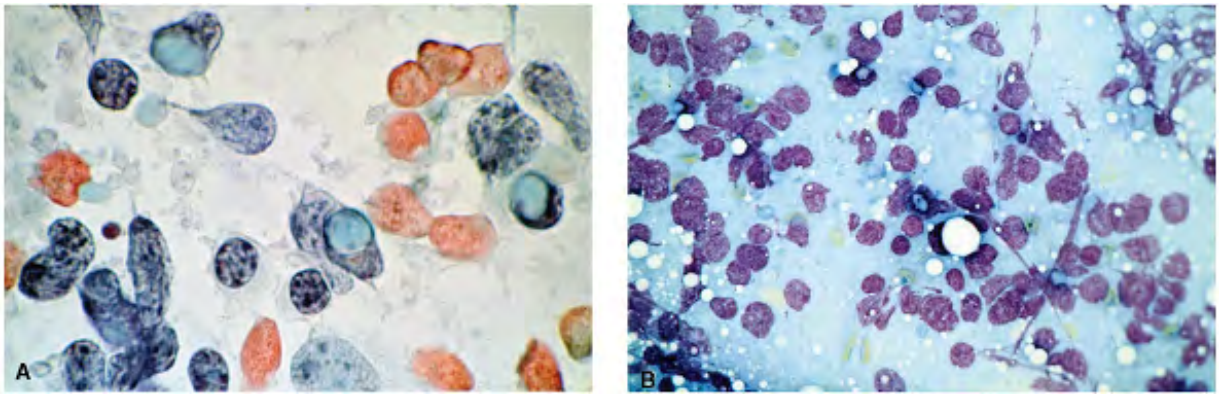

Figure 14.20. Aspiration biopsy specimen of malignant lymphoma, signet ring cell type. A. I the cytoplasmic secretions (Ã— 1,000). B. Romanowsky-stained preparation (Ã— 1,000). Thyroidectomy revealed a signet ring cell lymphoma in the background of Hashimoto's thyroiditis.

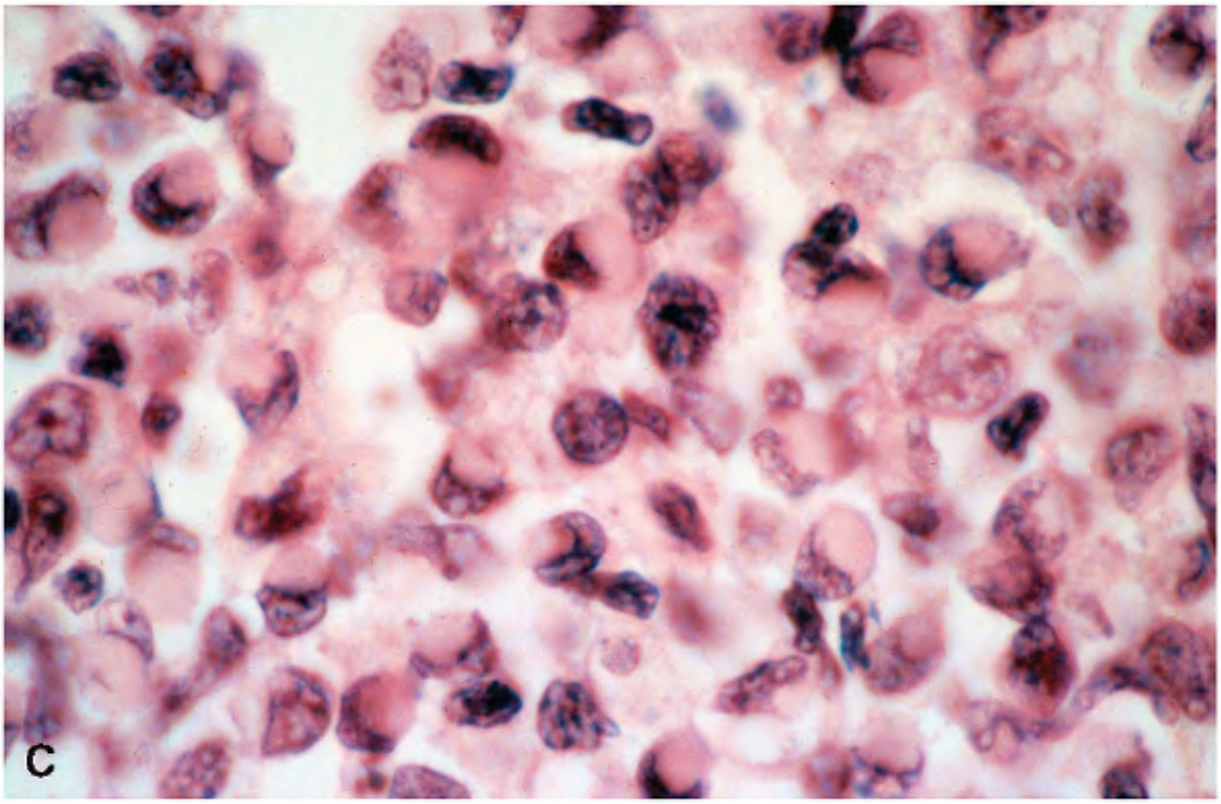

Figure 14.20. C. Section of the thyroid showing signet ring cell lymphoma (Ã— 1,000).

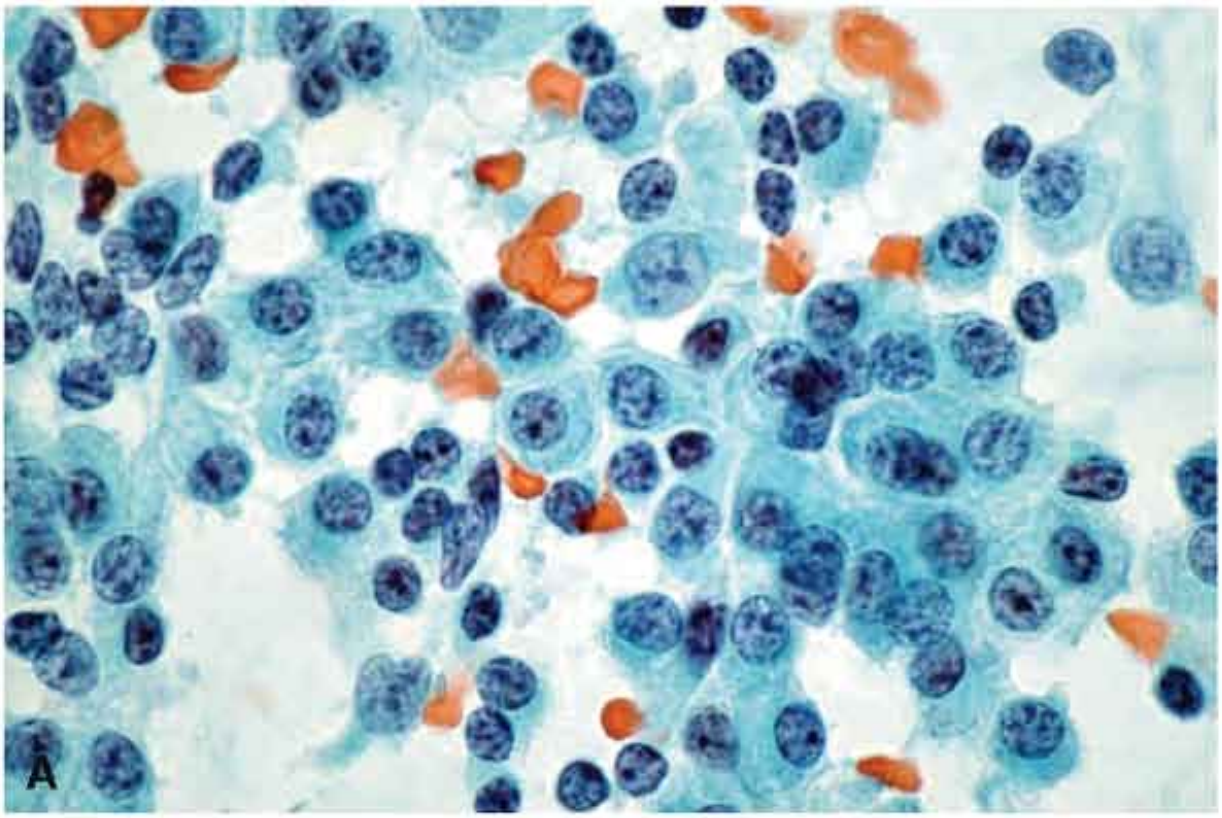
A

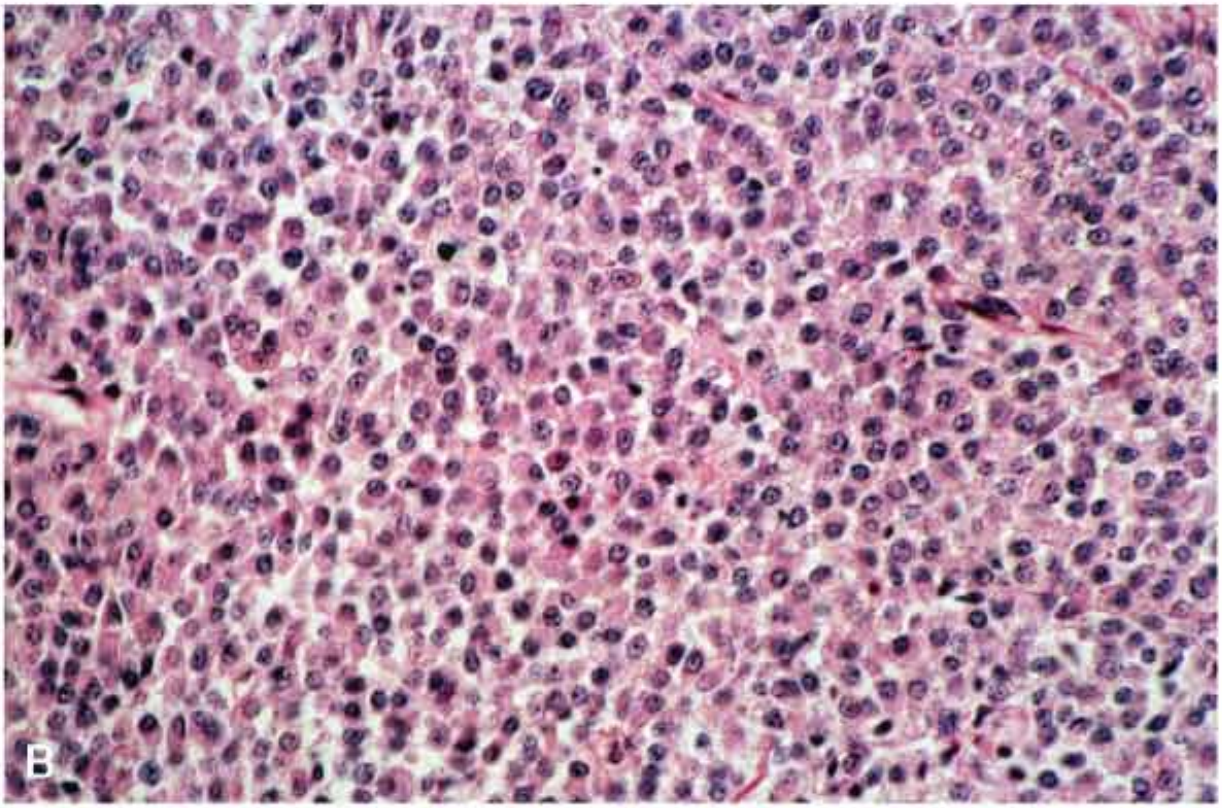
B

Figure 14.21. A. FNA of malignant lymphoma with extreme plasmacytic differentiation (plasmacytoma of the thyroid) with a large population of poorly differentiated plasma cells 1,000). B. Large-needle biopsy specimen confirmed plasmacytoma.

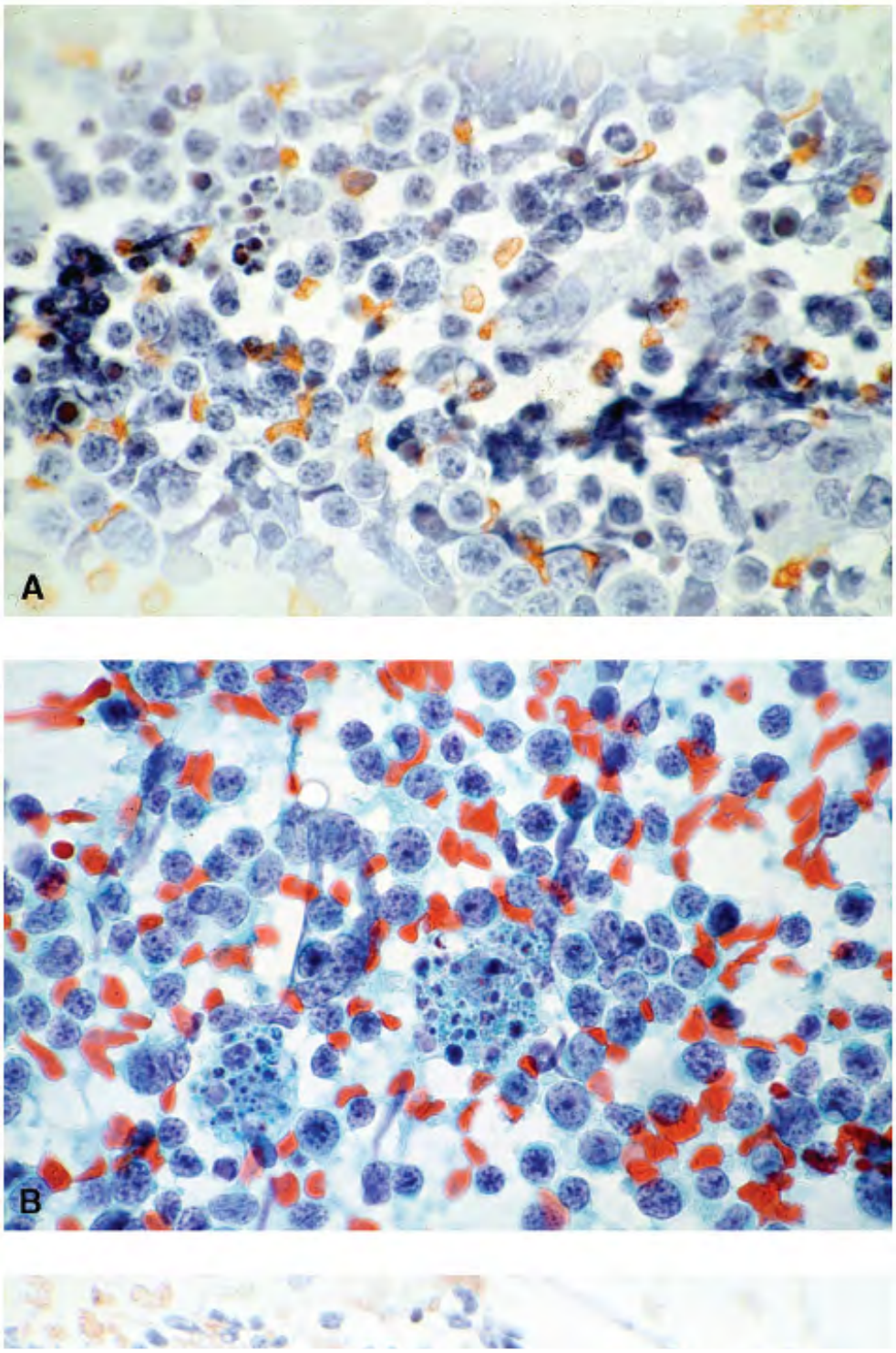

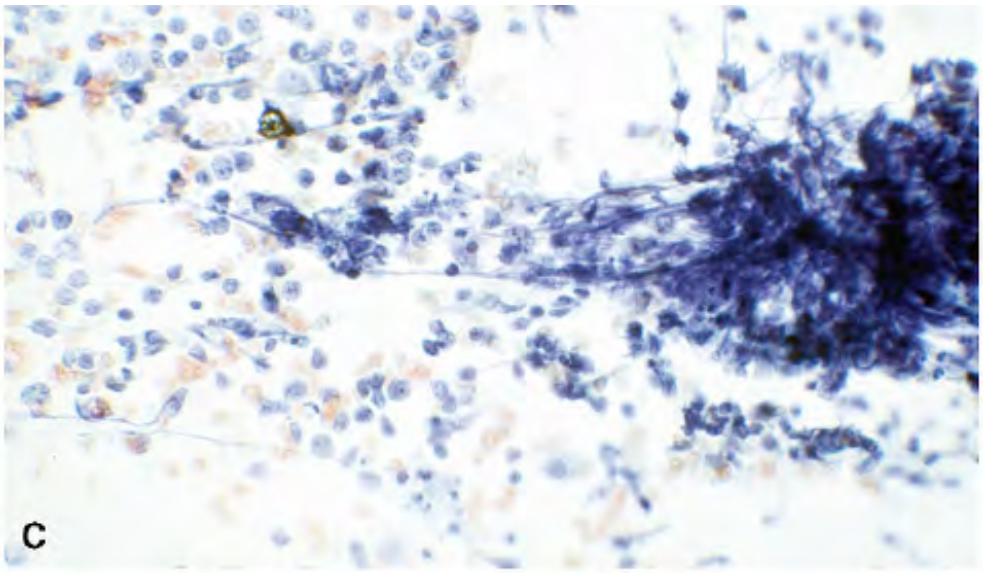

Figure 14.22. A. Diffuse large B-cell lymphoma with histiocytes containing karyorrhectic de
These are not indicative of tingible body histiocytes as seen in germinal centers. The backgr
cell population is monomorphic and represents poorly differentiated lymphoid cells. An oper
biopsy specimen revealed diffuse large cell lymphoma infiltrating the soft tissues of the nec
Another example of diffuse large B-cell lymphoma with histiocytes containing karyorrhectic
debris. C. This aspirate of a large cell lymphoma is partially air-dried and poorly preserved.
lymphoid tangles. Such a preparation will not allow the diagnosis of malignant lymphoma.

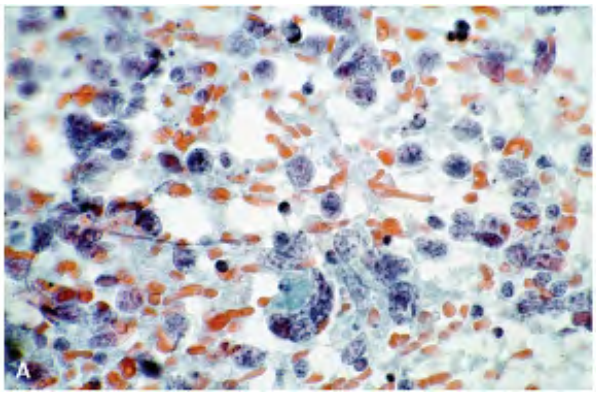

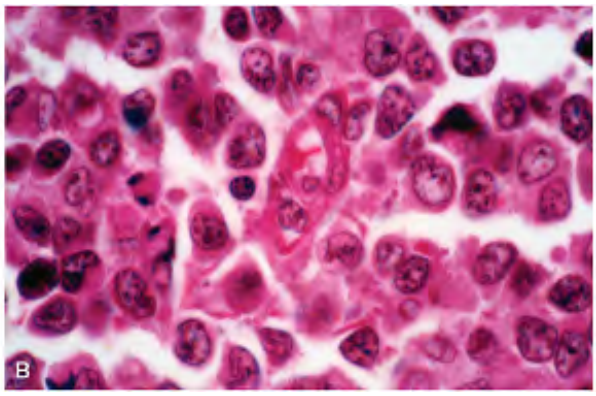

Figure 14.23. Malignant lymphoma large cell type. A. The tumor diathesis and large nuclear
suggested the differential diagnosis of poorly differentiated carcinoma and malignant lymph
Thyroidectomy confirmed diffuse large cell lymphoma and associated Hashimoto's thyroiditis
Section of the thyroid showing large cell lymphoma (Ã— l,000).

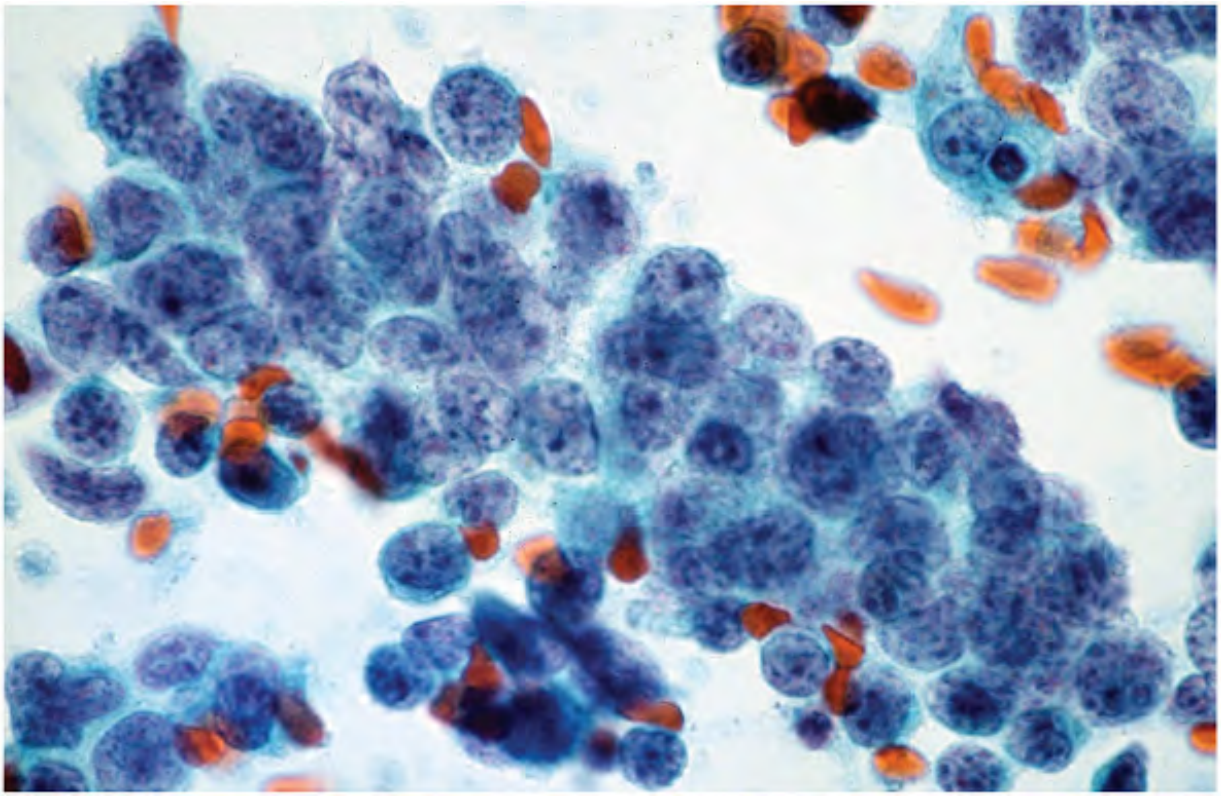

Figure 14.24. FNA of malignant lymphoma with tissue fragments of lymphoma cells. A diagr of poorly differentiated carcinoma was also considered (Ã— 1,000). Thyroidectomy revealed diffuse, large cell lymphoma and associated Hashimoto's thyroiditis.

Cellularity
Variable, usually very cellular
Presentation
Sheets of homogeneous cell population; cells discrete but rare
tissue fragments may be present
Characteristics of lymphoid
cell population
Poorly differentiated lymphoid cell (transformed lymphocytes)
with features of specific morphologic variant: centroblastic;
immunoblastic; plasmacytoma; Burkitt type; signet-ring type,
anaplastic; brisk mitotic activity; lymphoglandular bodies in
Romanowsky-stained preparations; karyorrhexis; histiocytes
with karyorrhectic debris

Features of Hashimoto's thyroiditis

May be present in smears representing other sampled areas

Background

Often dirty with cellular and necrotic debris

Immunoprofile

CD 20 + , CD 79a + , CD 5 - , CD 10 -; express IgM, less often IgA or IgG with light-chain restriction

Flow cytometry

Monoclonal

TABLE 14.2 CYTOPATHOLOGIC FEATURES OF DIFFUSE LARGE B-CELL LYMPHOMA (DLBCL)

Dependent on the sampling, however, cytologic features of Hashimoto's thyroiditis may be present, either separately from lymphoma cells on the same smear or on different smears representing other areas of the thyroid. Such a varied pattern is not infrequent when the th is focally involved or when the malignant lymphoma is of the nodular type. Thyroid epithelia neoplasms, especially papillary carcinoma, can occur in the background of thyroiditis and malignant lymphoma (refer to "Multiple Neoplasms in the Thyroid" in Chapter 19).

IMMUNOCYTOHISTOCHEMICAL PROFILE

Cytologic diagnosis of malignant lymphoma can be confirmed by immunocytochemical stains the smears.1 , 2 , 3 , 4 , 28 , 39 , 45 , 49 If a diagnosis of malignant lymphoma is clinically suspected, and if an immediate diagnosis is available on-site, additional cellular material ca obtained for the ancillary diagnostic techniques to further type the malignant lymphoma.

Malignant lymphoma cells are positive for leukocyte common antigen, which helps different lymphoma from carcinoma. Cytokeratin can be used for the same purpose because of its negative reactivity in malignant lymphoma cells. However, antibodies to cytokeratin will highlight the epithelial remnants in the lymphoepithelial lesions.

Because primary thyroid lymphomas are B-cell derived, pan B-cell markers are useful.28 Malignant lymphomas can be confirmed by their positive reactivity to light-chain immunoglobulins, either kappa or lambda, and establish the clonality. B-cell lymphomas are

reactive to CD20 and or CD79a. Coexpression of CD43 with CD20 is seen in a small percentag marginal zone B-cell lymphomas. They are nonreactive to CD5, CD10, and CD23.

The histologic and cytologic recognition of diffuse large B-cell lymphoma is facilitated becau of the homogeneous and diffuse population of poorly differentiated lymphoid cells, unlike tl of MALT lymphoma. Their cytohistologic differentiating features are listed in Table 14.3 .

FNA: Cellularity
Variable
Usually high
Cell population
Heterogenous, composed of small lymphocytes, centrocyte-like cells, monocytoid B-cells, plasma cells, scattered centroblasts and immunoblasts in varying proportions; mitotic activity -
Homogeneous population of poorly differentiated lymphoid cells, dependant on the morphologic type; high mitotic activity; karyorrhexis; lymphoglandular bodies in Romanowsky-stained smears
Histology:
Location of the infiltrate
In the marginal zone of reactive B-cell follicles, extending into the interfollicular region, and involve parenchyma; effacement of the architecture Â±; colonization of the germinal centers, eventually replacing it entirely with lymphoma cells resembling nodular lymphoma; transition to large cell lymphoma may be present
Diffuse sheets and islands of malignant cells with effacement of the architecture; necrosis Â±; high mitotic rate
Lymphoepithelial lesions

1. Involvement of the follicles
2. Formation of "MALT" balls

Not present
Vascular invasion
Â±
Easily identified
Evidence of Hashimoto's
disease in the thyroid
Present
Present in the remnants
Extrathyroidal extension
Â±
Frequent
Immunoprofile
CD 20 + , CD 79a + ,
CD 5 - , CD 10 -
CD 20 + , CD 79a + ,
CD 5 - , CD 10 -
Immunoglobulin
Express IgM, less often IgA or
IgG with light-chain restriction
Express IgM, less often IgA or
IgG with light-chain restriction
Flow cytometry
Monoclonal
Monoclonal
Differential diagnosis
Hashimoto's thyroiditis
Neoplasms composed of small cells:
Anaplastic carcinoma
Medullary thyroid carcinoma with small pattern
Insular carcinoma
Metastatic small cell carcinoma
Clinical behavior

Indolent, slow to recurrences, may involve other extranodal sites

Very aggressive

Extranodal Marginal Zone B-Cell Lymphoma | Diffuse Large B-Cell Lymphom

TABLE 14.3 CYTOHISTOLOGIC FEATURES OF PRIMARY MALIGNANT LYMPHOMAS OF THE THYROID

DIAGNOSTIC ACCURACY

Accuracy of cytopathologic diagnosis of primary malignant lymphoma of the thyroid depends several factors, such as adequacy of the specimen and proper cytopreparatory technique, as well as the interpreter's familiarity with their cytopathologic patterns. Lymphoma cells are v fragile and dry quickly unless wet-fixed immediately for Papanicolaou stain. Drying artifacts prevent proper cytopathologic evaluation. The literature on the cytologic features of prima malignant lymphomas of the thyroid

P.334

P.335

P.336

and their diagnostic pitfalls is very limited. 38 , 39 , 40 , 41 , 42 , 43 , 44 , 45 , 46 , 47 , 48 Inadequate specimens and/or inexperience are prime reasons for false-negative results. Due inexperience, our first three cases of malignant lymphoma were interpreted as lymphocytic thyroiditis (Table 14.4).7 The polymorphic lymphoid infiltrate of MALT is extremely difficul differentiate from the infiltrate of Hashimoto's thyroiditis, both histologically and cytologica Hyjek et al.,14 in a retrospective review of Hashimoto's thyroiditis, identified five out of 21 cases as MALT lymphoma. Saangalli et al.40 interpreted three out of 10 MALT lymphomas as Hashimoto's thyroiditis. Others have reported similar experience.7 , 26 , 43 , 49 , 50 , 51 , 5 53 , 54 , 55 , 56 , 57

Malignant lymphoma

23

20

2

1

(?) Malignant lymphoma,
(?) carcinoma
2
2
â€”
â€”
Suspicious malignant
lymphoma
10
3
â€”
7

		Histologic Diagnosis		
			Atypical	
Cytologic Diagnosis	No.	Malignant Lymphoma	Lymphoid Hyperplasia	Hashimoto's Thyroiditis

TABLE 14.4 HISTOLOGIC DIAGNOSES OF 35 CASES OF CYTOLOGICALLY DIAGNOSED MALIGNANT LYMPHOMA OR SUSPECTED MALIGNANT LYMPHOMA

In the author's laboratory, 35 cases were cytologically interpreted as either diagnostic or suspicious for lymphoma. Of 23 cases cytologically interpreted as diagnostic of malignant lymphoma, 20 were confirmed by large-needle biopsy, thyroidectomy, or both. Two were difficult to interpret histologically, but had a final diagnosis of atypical lymphoid hyperplasi and one was Hashimoto's thyroiditis. Of the 10 cases of suspected malignant lymphoma, only three were confirmed (Table 14.4). Ancillary tests were either not available or not perform which would have been immensely helpful.

Of 32 histologically confirmed malignant lymphomas, 20 cases were correctly interpreted fr fine-needle aspirates (Table 14.5). Typing errors are occasionally involved between large c lymphomas and poorly differentiated carcinomas. Two cases had a differential diagnosis of

malignant lymphoma and poorly differentiated carcinoma (Table 14.5).

Malignant lymphoma
2
Malignant lymphoma and lymphocytic thyroiditis
18
Suspected malignant lymphoma and lymphocytic thyroiditis
3
(?) Carcinoma, (?) malignant lymphoma, lymphocytic thyroiditis
2
Lymphocytic thyroiditis[a]
3
Unsatisfactory (acellular)[a]
4
Total
32
[a] Diagnosis of malignant lymphoma based on large-needle biopsy specimen.

TABLE 14.5 CYTOLOGIC DIAGNOSES OF 32 PRIMARY NON-HODGKIN'S MALIGNANT LYMPHOMA OF THE THYROID

Some false-positive results must be anticipated in the cytologic diagnosis of malignant lymp if false-negative results are to be avoided, and in order to maintain a high sensitivity for its diagnosis. With the aid of immunocytochemistry and flow cytometry, the diagnosis of malig lymphoma can be readily established.

DIAGNOSTIC DIFFICULTIES AND DIFFERENTIAL DIAGNOSIS

Just as the diagnosis of malignant lymphoma of the thyroid is difficult histologically, either large-needle biopsy specimen50 or in surgically excised specimens, cytologic diagnosis51 , 5 53 , 54 , 55 , 56 , 57 , 58 , 59 , 60 may pose similar problems, for the following reasons:

- The aspirates from MALT lymphomas show heterogenous population of small lymphocytes, centrocyte-like cells, monocytoid B-cells, and plasma cells with variab numbers of transformed lymphocytes. These cells are difficult to differentiate from

lymphoid cells of Hashimoto's thyroiditis. A large number of transformed lymphocyte well as very heavy lymphoid infiltrate should raise the suspicion of MALT lymphoma. diagnostic concern should be followed by ancillary tests. A repeat aspiration biopsy i order if the initial specimen is inadequate. A large-needle biopsy can be quite helpf 26 , 50

- Lymphomas, when involvement is focal, multiple samples may show lymphoma cells some cell spreads and evidence of Hashimoto's thyroiditis on others. Such a diverse pattern is often present. A cytologic pattern of Hashimoto's disease on one of the specimens should not be a deterrent to rendering a diagnosis of lymphoma.

P.337

P.338

- Phagocytic histiocytes with karyorrhectic debris are seen frequently in large cell lymphomas (Fig. 14.22B). These should not be mistaken for germinal-center cells.
- Lymphoma cells, especially of the large cell type, are large and may be mistaken fo carcinoma
- Aspiration biopsy may yield a few tissue fragments of neoplastic lymphoid cells. The traditional diagnostic criteria of malignant lymphoma in exfoliative cytopathology include a single cell pattern; the presence of a tissue fragment should not be consid a feature contradicting the diagnosis of malignant lymphoma (Fig. 14.24).

The differential diagnoses of MALT lymphoma include Hashimoto's thyroiditis with florid lymphoid infiltrate (lymphoid verity) (Table 14.7). The diffuse large B-cell lymphoma may b typed as anaplastic carcinoma or poorly differentiated insular carcinoma of the thyroid, medullary carcinoma with small cell pattern, and a metastatic small cell carcinoma (Table 1 and Table 14.8 ; also refer to Table 10.3 and Figures 10.15 , 10.16 , 10.17 , 10.18 and 10.19

Extranodal marginal zone B-cell lymphoma
  Hashimoto's thyroiditis
Diffuse large B-cell lymphoma
  Anaplastic carcinoma
  Insular carcinoma
  Medullary carcinoma, small cell type
  Metastatic small cell carcinoma

TABLE 14.6 DIFFERENTIAL DIAGNOSIS OF PRIMARY MALIGNANT LYMPHOMA OF THE THYROID

Cellularity

Variable, generally highly cellular; paucicellular in late stages due to atrophy and fibrosis

Variable, usually very cellular

Presentation

An admixture of inflammatory and epithelial cells in varying proportions

Heavy lymphoid cell population; epithelial cells Â±

Characteristics of lymphoid cell population

Heterogenous cell population, consisting of lymphocytes, plasma cells, and the entire range of transforming lymphocytes (germinal center cells); plasma cells; tingible body histiocytes; lymphoid tangles and stretched out lymphocytes; large closely packed aggregates of lymphocytes difficult to differentiate from follicular cells;

Heterogenous population representing an admixture of small lymphocytes, centrocyte-like cells (1.5 times the size of resting lymphocyte) with deep-staining chromatin and irregular nuclear membranes; monocytoid B-cells with appreciable pale cytoplasm; plasma cells; scattered centroblasts and immunoblasts; mitotic activity insignificant; karyorrhexis Â±;

Characteristics of epithelial component (follicular and HÃ¼rthle cells)

	Hashimoto's Thyroiditis	Extranodal Marginal Zone B-Cell Lymphoma (MALT Lymphoma)
	In variable proportions; one type may predominate; in groups or in tissue fragments, with or without nuclear atypia; may be obscured by lymphocytes	Same as Hashimoto's thyroiditis if present in the aspirated sample
Background	Clean; multinucleated foreign body-type giant cells Â±; scant or absent colloid; stromal cells, tissue fragments of fibrous tissue Â±; endothelial cells	Clean; no colloid; no multinucleated foreign-body type giant cells; stromal cells or tissue fragments of stroma Â±
Flow cytometry	Polyclonal	Monoclonal

TABLE 14.7 DIFFERENTIATING FEATURES BETWEEN HASHIMOTO'S THYROIDITIS AND MARGINAL ZONE B-CELL LYMPHOMA (MALT LYMPHOMA)

Large B-cell lymphoma	Dispersed cell pattern; syncytial tissue fragment very rare; monomorphic population of immature lymphoid cells; poorly defined cell borders; high N/C ratios; large nucleus with smooth to irregular nuclear membrane, finely granular chromatin; parachromatin clearing, nucleoli +; mitosis karyorrhexis +; nuclear molding absent; scant cytoplasm; lymphoglandular bodies in Romanowsky-stained preparations; LCA +; thyroglobulin, TTF-1, and calcitonin negative
Anaplastic Carcinoma	

(Small round cell type)

Variable cellularity; malignant cells isolated and in tissue fragments; size variable; high N/C ratios;
nucleus round with smooth to irregular membranes; granular chromatin with parachromat clearing;
single to multiple nucleoli; mitosis with atypical forms Â±; karyorrhexis +; lymphoglandula bodies
absent; leukophagocytosis +/-; scant, nondescript cytoplasm; cytokeratin +; negative reactivity
to LCA, thyroglobulin, TTF-1, calcitonin, and neuroendocrine markers

Medullary carcinoma with
a small cell pattern

Neoplastic cells discrete, in loosely cohesive groups; syncytial tissue fragments infrequent; pseudofol-
licular pattern Â±; small size, monomorphic, poorly defined cell borders; high N/C ratios; eccentric
nuclei; round with smooth nuclear membranes; coarsely granular to chunky chromatin; nucleoli usu-
ally absent; mitosis unusual; karyorrhexis -; no nuclear molding; no stretch artifacts; intranuclear
inclusions Â±; nuclear grooves -; scant cytoplasm with rudimentary cytoplasmic tailing; co
absent in the background; amyloid Â±; positive reactivity to calcitonin, neuroendocrine markers,
cytokeratin; negative reactivity to LCA, thyroglobulin, TTF-1

Metastatic small cell
carcinoma

Marked cellularity; small cells; round to oval; indiscernible cytoplasm; poorly defined cell borders; high
N/C ratios; coarse, deep-staining chromatin; nucleoli absent or not appreciated; mitosis frequent;
nuclear molding characteristic; mitosis frequent; stretch artifacts +; karyorrhexis -; positi reac-
tivity to cytokeratin, TTF-1, and neuroendocrine markers; negative reactivity to LCA and calcitonin

Tumor Type	Cytopathologic Features

TABLE 14.8 DIFFERENTIAL DIAGNOSIS OF DIFFUSE LARGE CELL LYMPHOMA

Malignant Lymphoma versus Hashimoto's Thyroiditis

In the lymphoid variety of Hashimoto's thyroiditis, the aspirates generally exhibit a dense population of lymphoid cells, without an admixture of epithelial cells. The presence of polymorphic germinal center cells favors the diagnosis of Hashimoto's thyroiditis. However, sometimes very difficult to rule out a malignant lymphoma from the cytologic or histologic specimens without the aid of immunocytohistochemistry and flow cytometry. These cases a interpreted as atypical lymphoid hyperplasia. Whether atypical lymphoid hyperplasia repres an early stage in the evolution of malignant lymphoma in the background of thyroiditis is a subject beyond the scope of this text. Compagno and Oertel11 have also referred to this problem. Cytologically, such cases may be diagnosed as malignant lymphoma or suspected malignant lymphoma and must be followed by ancillary testing. Figures 14.25 and 14.26 illustrate two examples of such cases from our experience.

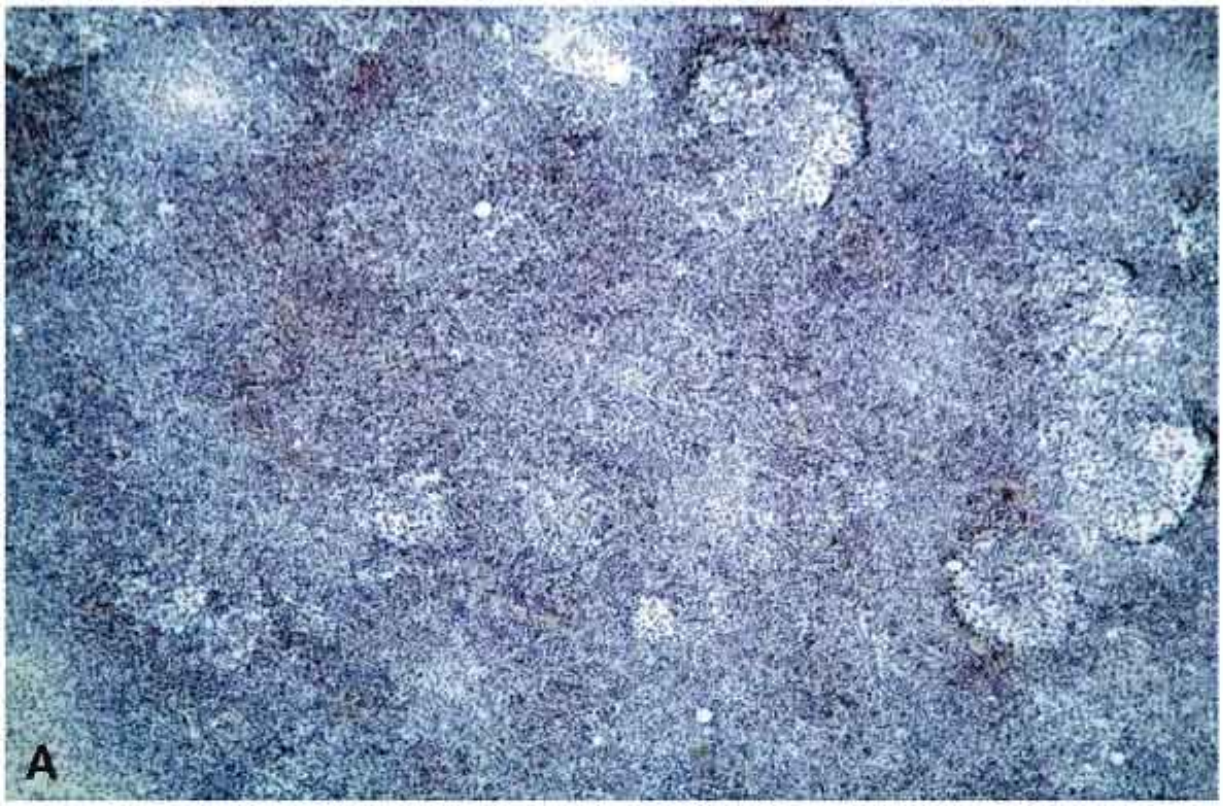
A

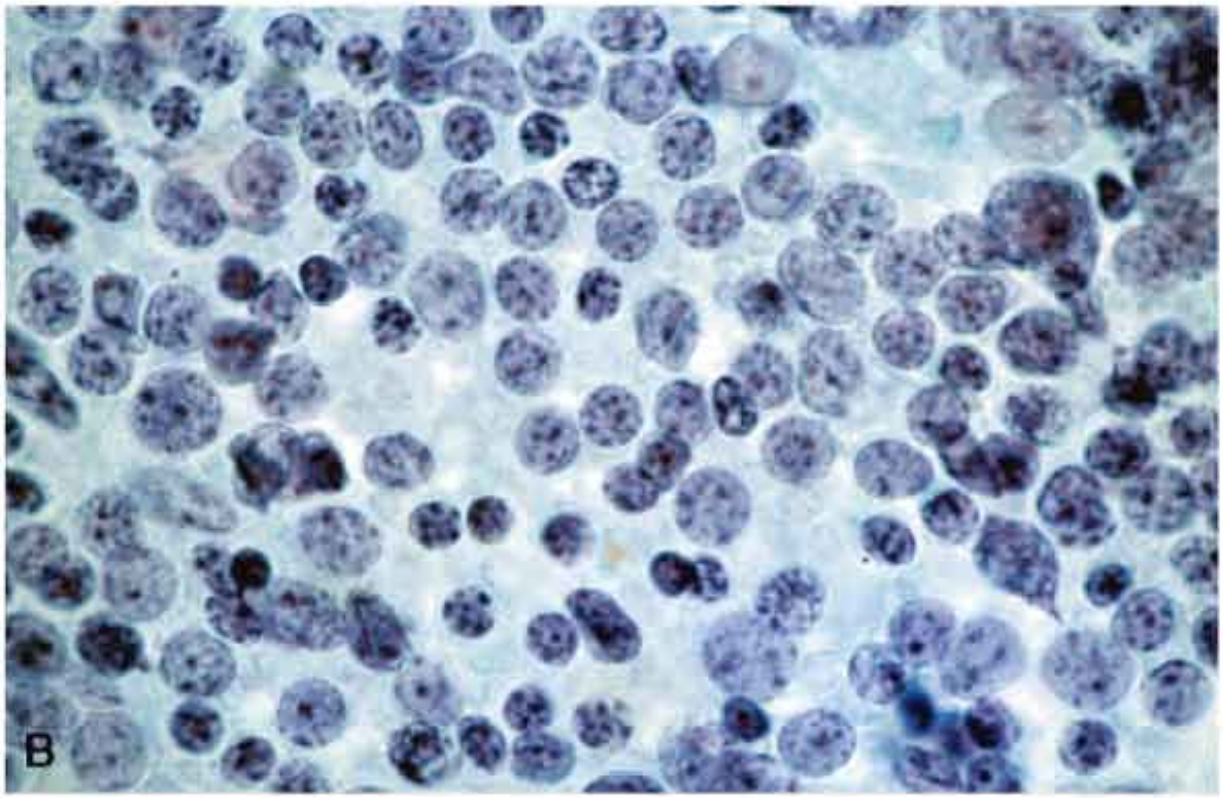
B

Figure 14.25. A. FNA showing a dense population of lymphoid cells. No follicular/HÃ¼rthle are seen (low power). B. Higher magnification showing a mixed cell population with many plasma cells.

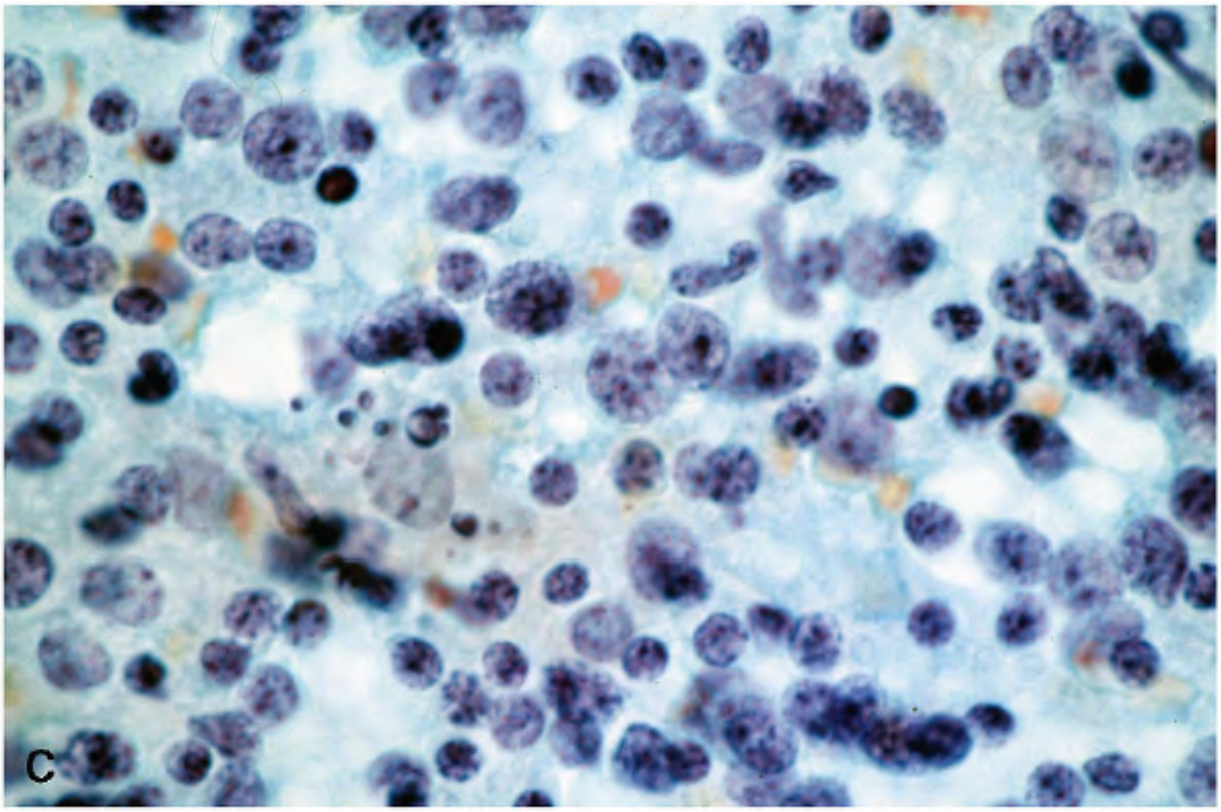

Figure 14.25. C. This field shows a tingible body histiocyte. Because of the dense lymphoid infiltrate, malignant lymphoma was suspected. Thyroidectomy showed florid Hashimoto's thyroiditis and no malignant lymphoma. Immunostains and flow cytometry would have been helpful in confirming or ruling out malignant lymphoma.

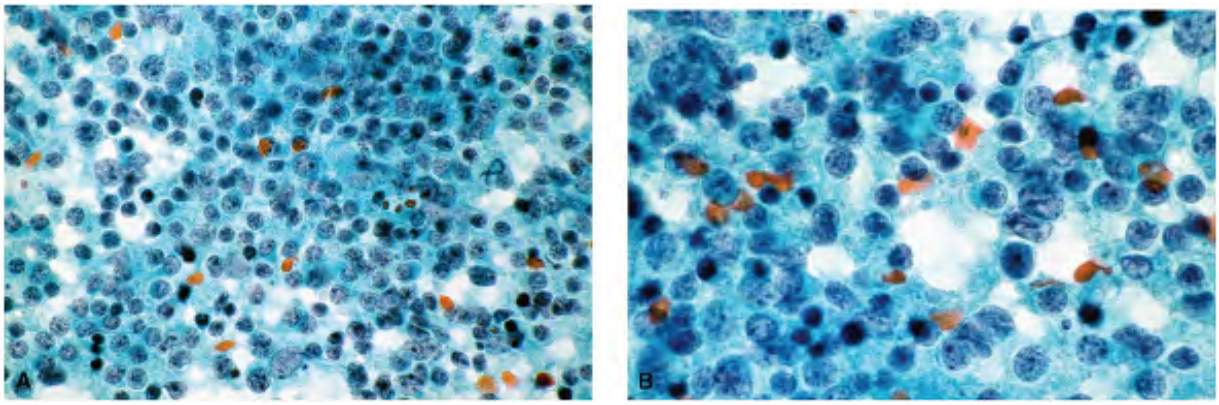

Figure 14.26. Another example of atypical lymphoid infiltrate on cytology suspected of malignant lymphoma. A large-needle biopsy did not confirm the cytologic diagnosis.

P.339
P.340

Malignant Lymphoma versus Anaplastic Carcinoma

Malignant lymphomas have been mistyped as anaplastic carcinomas both histologically and cytologically.41 , 61 The large size of the lymphoma cells (Figs. 14.23A and 14.27), as well the presence of tissue fragments (Fig. 14.24)â€"a feature common to epithelial neoplasms, were reasons for mistyping the malignant lymphoma as anaplastic carcinoma. Immunocytochemical stains and flow cytometry are required to confirm the diagnosis.

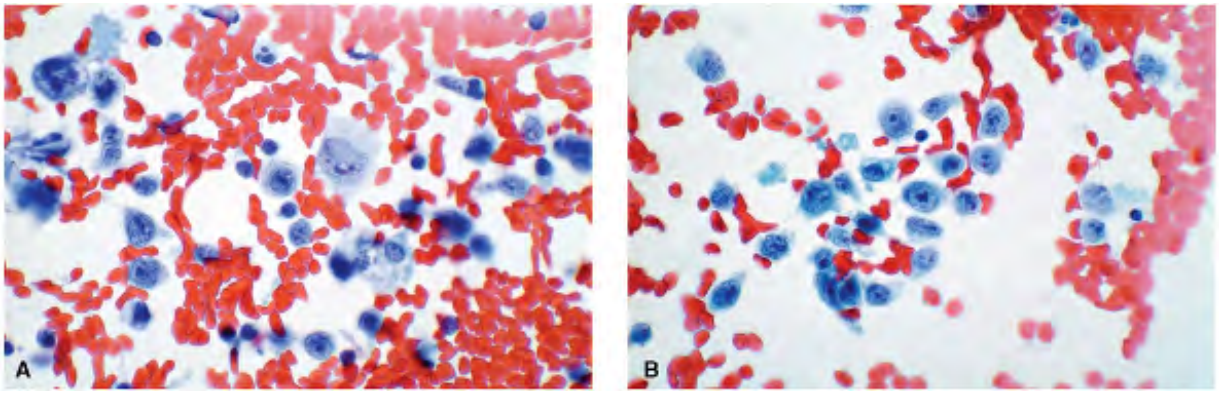

Figure 14.27. Fine-needle aspiration biopsy of a rapidly enlarging thyroid in a 51-year-old n
A,B. The aspirate showed a homogeneous population of medium-sized, pleomorphic discrete cells with high N/C ratios. Note the mitotic figures. Anaplastic carcinoma and malignant lymphoma were considered in the differential diagnoses. Thyroidectomy confirmed a diffuse

large B-cell lymphoma.

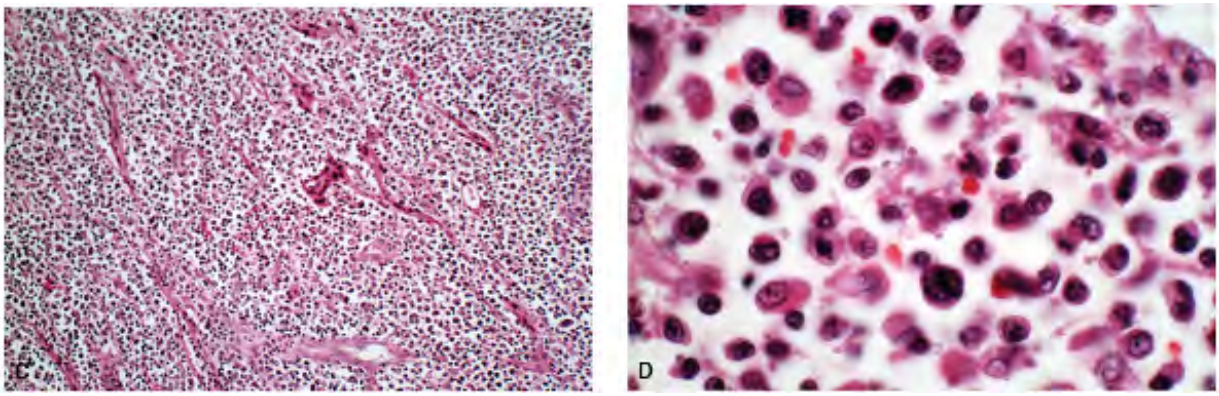

Figure 14.27. C. Histologic section of the lymphoma. D. Higher magnification (Ã— 1,000).

Malignant Lymphoma versus Metastatic Undifferentiated Small Cell Carcinoma

On rare occasions, small cell carcinoma of the lung metastatic to the thyroid may be mistak for malignant lymphoma. The clinical history and other diagnostic studies, including a large needle biopsy, are necessary for establishing a diagnosis.

Plasmacytoma

Plasmacytomas are rare in thyroid.59 , 60 , 61 It is suggested that these lesions probably represent MALT lymphomas with predominant plasma cell differentiation.

Secondary Involvement of Thyroid by Malignancy of Hematopoietic System

The thyroid gland is reported to be frequently involved by malignancies of the lymphoid tiss In a series of 300 autopsies on patients dying of lymphomas, of either the Hodgkin's or non-Hodgkin's type, Naylor62 found that leukemias and multiple myelomas formed an overall incidence of thyroid involvement in 17.7%. None of the patients in Naylor's series experience thyroid enlargement during life; the secondary involvement was identified only on microsco examination. However, on occasion, secondary involvement does present as thyroid nodules which are biopsied, as illustrated in Figures 14.28 , 14.29 and 14.30 .

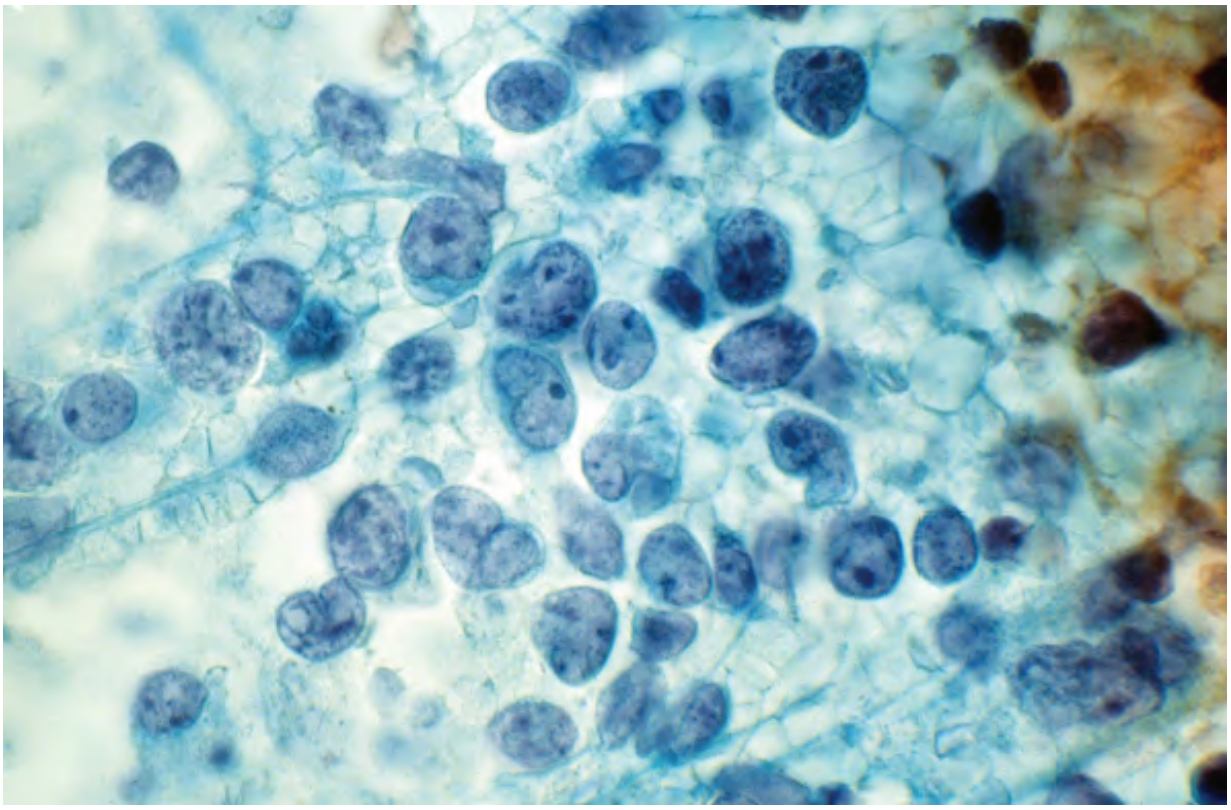

Figure 14.28. FNA of a large cell lymphoma, metastatic to the thyroid. The patient had generalized lymphadenopathy and a large retroperitoneal mass (Ã— 1,000).

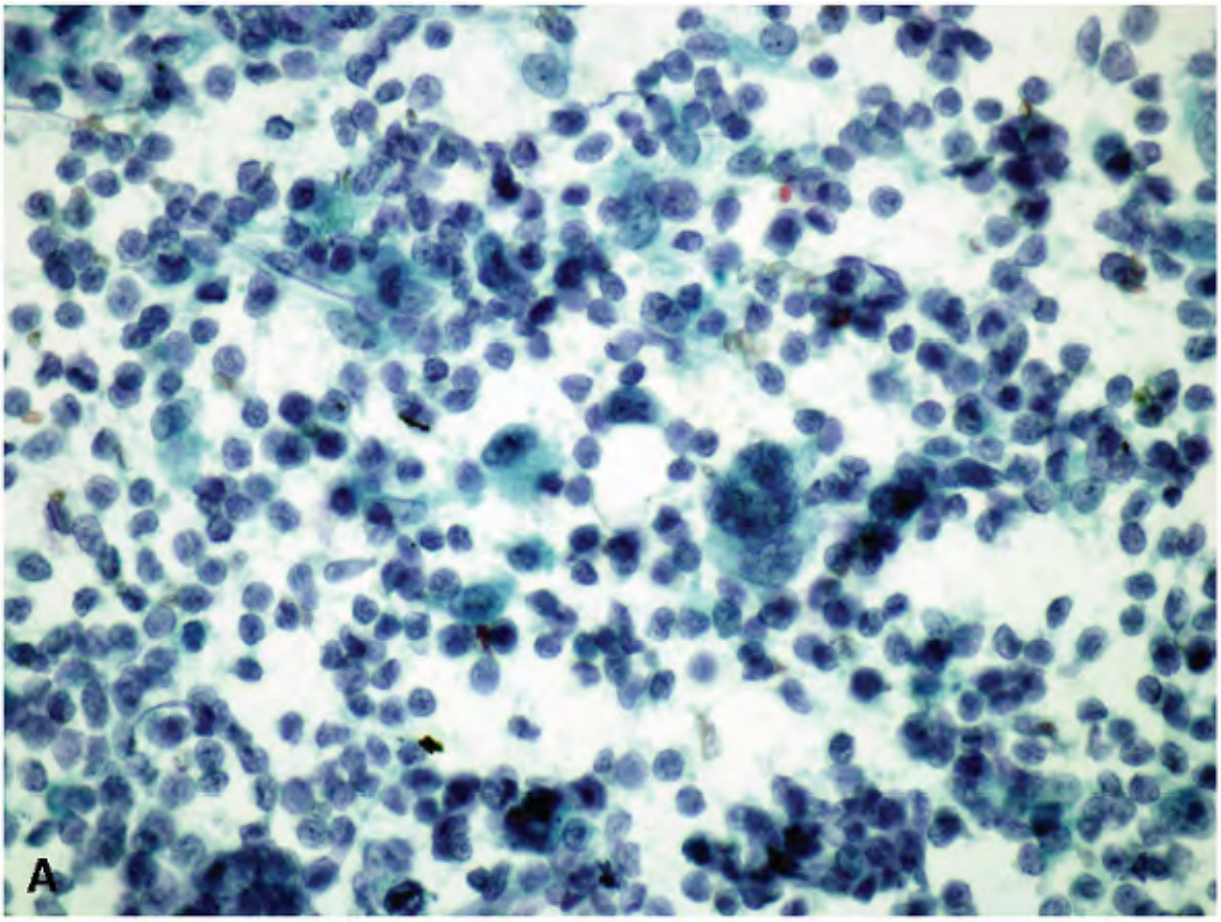

Figure 14.29. Hodgkin's lymphoma metastatic to thyroid. A. FNA showing Reedâ€“Sternberg cells, obscured by heavy lymphoid cell population.

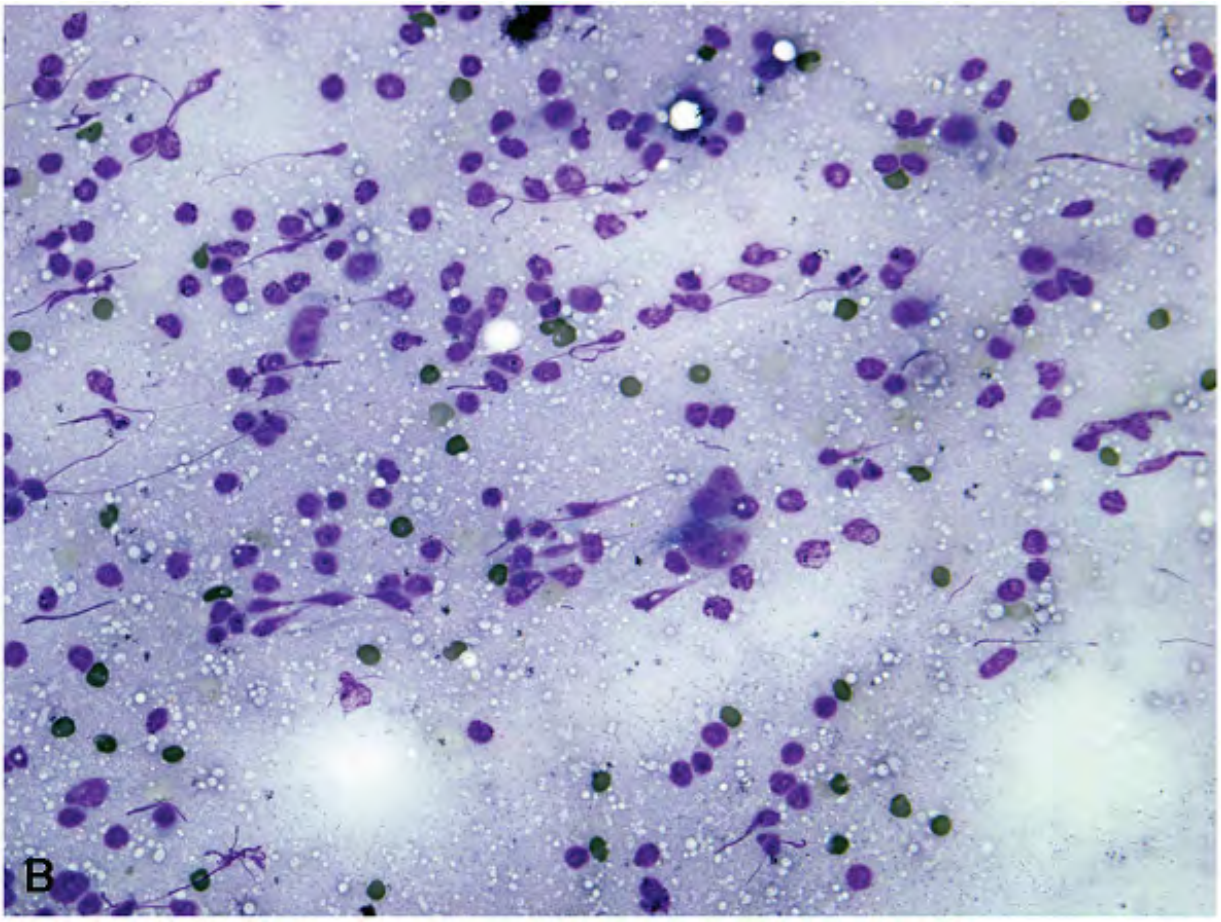

Figure 14.29. B. Diff-Quik stain.

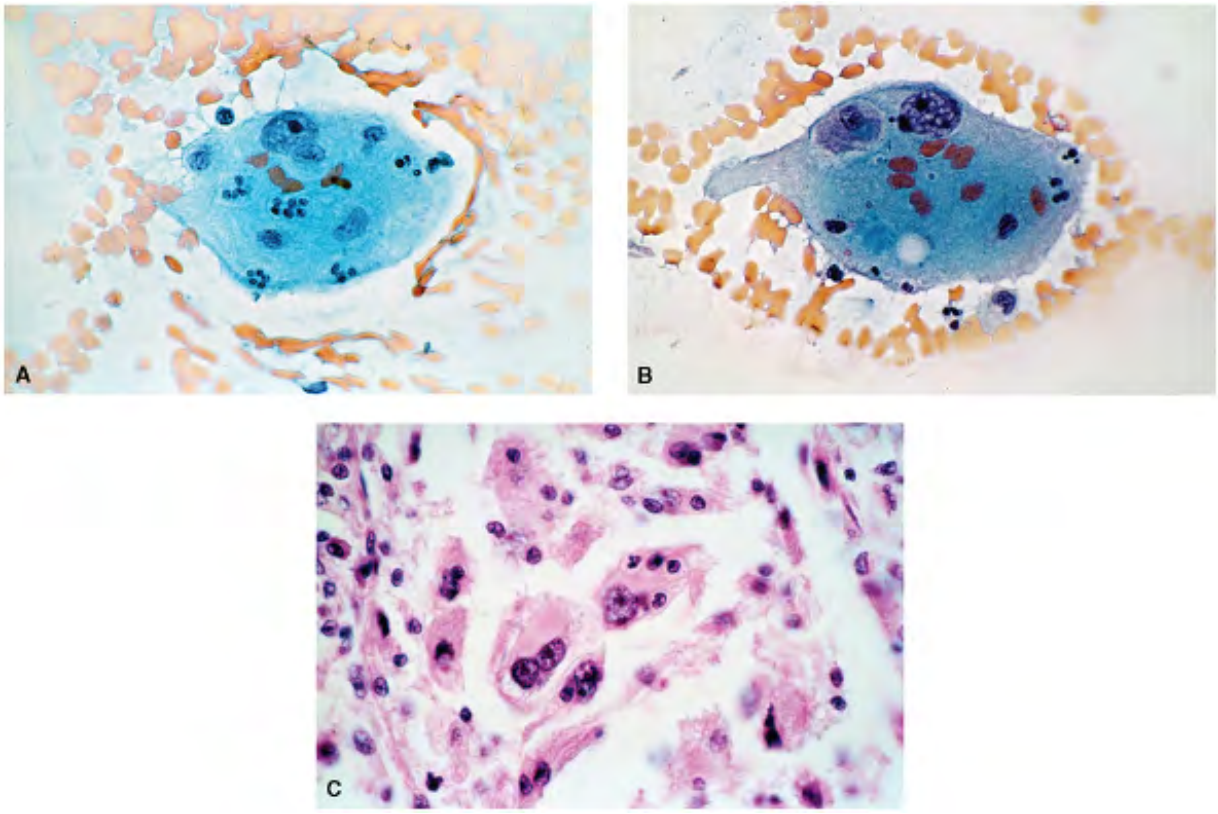

Figure 14.30. Aspiration biopsy specimen of thyroid involved by generalized malignant histiocytosis. A,B. Large, malignant histiocyte with erythroleukophagocytosis. C. Histologic section of the cervical lymph node showing sinusoids filled with malignant histiocytes exhibi erythroleukophagocytosis.

P.341
P.342
P.343

SUMMARY

The increasing incidence of primary malignant lymphomas of the thyroid has been recognize only in recent years. An early diagnosis of this disease made possible by aspiration cytology, certainly accomplish the goals of early cancer detection, i.e., effective treatment and cont the disease. This is one of the greatest contributions of aspiration cytology of the thyroid.

REFERENCES

1.Thompson LDR. Thompson LDR. *Endocrine Pathology.* Philadelphia: Churchill Livingstone 2006;123â€“131.

2.Abbondanzo S, Aozasa K, Boerner S, et al. Primary lymphoma and plasmacytoma. In: DeLellis RA, Lloyd RV, Heitz PU, et al. eds. *Pathology and Genetics of Tumors of Endocrin Organs. World Health Organization Classification of Tumors* . Lyon: IARC Press; 2004:77â€“81.

3.Derringer GA, Thompson LD, Frommelt RA, et al. Malignant lymphoma of the thyroid gland: a clinicopathologic study of 108 cases. *Am J Surg Pathol* . 2000;24:623â€“639.

4.Kossev P, LiVolsi VA. Lymphoid lesions of the thyroid in light of the revised European-American Lymphoma Classification and upcoming World Health Organization Classification *Thyroid* . 1999;9:1273â€“1280.

5.Isaacson PG. Lymphoma of the thyroid gland. In: KW, Bocker W, eds. *Current Topics in Pathology* . New York: Springer Verlag; 1997.

6.Livolsi VA. *Surgical Pathology of the Thyroid* . Philadelphia: Saunders; 1990.

7.Miller FM, Kini SR, Rebuck J, et al. Is lymphoma of the thyroid a disease which is increas in frequency? In: Hamburger JI, Miller JM, eds. *Controversies in Clinical Thyroidology* . Ne York: Springer-Verlag; 1981;267â€“297.

8.Heimann R, Vannineuse A, DeSloover C, et al. Malignant lymphomas and undifferentiate small cell carcinoma of the thyroid: a clinicopathological review in the light of the Kiel classification for malignant lymphomas. *Histopathology* . 1978;2:201â€“213.

9.Singer JA. Primary lymphoma of the thyroid. *Am Surg* . 1998;64:334â€“337.

10.Williams ED. Malignant lymphoma of the thyroid. *J Clin Endocrinol Metab* . 1981;10:379â€“398.

11.Compagno J, Oertel JE. Malignant lymphoma and other lymphoproliferative disorders c the thyroid gland. A clinico-pathologic study of 245 cases. *Am J Clin Pathol* . 1980;74:1â€“11.

12.Woolner LB, McConahey WM, Beahrs OH, et al. Primary malignant lymphoma of the thyroid. *Am J Surg* . 1966;111:502â€“523.

13.Hsi ED, Singleton TP, Svolboda SM, et al. Characteristics of the lymphoid infiltrate in Hashimoto's thyroiditis by immunohistochemistry and polymerase chain reaction for immunoglobulin heavy chain gene rearrangement. *Am J Clin Pathol* . 1998;110: 327â€“333

14.Hyjek E, Smith WZ, Isaacson PG. Primary B-cell lymphoma of the thyroid and its relationship to Hashimoto's thyroiditis. *Hum Pathol* . 1988;19:1315â€“1326.

15.Holm LE, Blomgren H, LÃ¶whagen T. Cancer risks in patients with chronic lymphocytic thyroiditis. *N Engl J Med* . 1985;312:601â€“604.

16.Kato I, Tajima K, Sucha T, et al. Chronic thyroiditis as a risk factor of B-cell lymphoma the thyroid gland. *Jpn J Cancer Res* . 1985;76:1085â€“1090.

17.Pedersen RK, Pedersen NT. Primary Non-Hodgkin's lymphoma of the thyroid gland: a population based study. *Histopathology* . 1996;28:25â€“32.

18.Chetty R. Thyroid lymphomas. *Cancer Treat Res* . 2004;122:69â€“86.

19.Widder S, Pasieka JL. Primary thyroid lymphomas. *Curr Treat Oncol* . 2004;4:309â€“31

20.Ansell SM, Grant CS, Habermann TM. Primary thyroid lymphomas. *Semin Oncol* . 1999;26:316â€“323.

21.Lam KY, Lo CY, Kwong DLW, et al. Malignant lymphoma of the thyroid: a 30 year clinicopathologic experience and an evaluation of the presence of Epstein-Barr virus. *Am J Clin Pathol* . 1999;112:263â€“270.

22.Logue JP, Hale RJ, Stewart AL, et al. Primary malignant lymphoma of the thyroid: a clinicopathologic analysis. *Int J Radiat Oncol Biol Phys* . 1992;22:929â€“933.

23.Mizukami Y, Michigishi T, Nonomura A, et al. Primary lymphoma of the thyroid: a clinic histological and immunohistochemical study of 20 cases. *Histopathology* . 1990;17:201â€“209.

24.Oertel JE, Heffess CS. Lymphoma of the thyroid and related disorders. *Semin Oncol* . 1987;14:333â€“342.

25.Anscombe AM, Wright DH. Primary malignant lymphoma of the thyroid: a tumour of mucosa-associated lymphoid tissue. Review of seventy-six cases. *Histopathology* . 1985;9:81â€“97.

26.Hamburger JI, Miller JM, Kini SR. Lymphoma of the thyroid. *Ann Intern Med* . 1983;99:685â€“693.

27.Devine RM, Edis AJ, Banks PM. Primary lymphoma of the thyroid: a review of the Mayo Clinic experience through 1978. *World J Surg* . 1981;5:33â€“38.

28.Schwarze EW, Papadimetriou CS. Non-Hodgkin's lymphoma of the thyroid. *Pathol Res P* . 1980;167:346â€“362.

29.Sirota DK, Segal RL. Primary lymphomas of the thyroid gland. *JAMA* . 1979;242:1743â€“1746.

30.Burke JS, Butler JJ, Fuller LM. Malignant lymphomas of the thyroid: a clinicopathologic study of 35 patients including ultrastructural observations. *Cancer* . 1977;39:1587â€“1602.

31.Selzer G, Kahn L, Albertyn L. Primary malignant tumors of the thyroid gland: a clinicopathologic study of 254 cases. *Cancer* . 1977;40:1501â€“1510.

32.Taylor I. Malignant lymphoma of the thyroid. *Br J Surg* . 1976;63:932â€“933.

33.Cox M. Malignant lymphoma of the thyroid. *J Clin Pathol* . 1964;17:591â€“601.

34.Lindsay S, Dailey ME. Malignant lymphoma of the thyroid gland and its relation to Hashimoto's disease: a clinical and pathologic study of 8 patients. *J Clin Endocrinol Metab* 1955;15:1332â€“1353.

35.Isaacson PG, Wright DH. Extranodal malignant lymphoma arising from mucosa-associate lymphoid tissue. *Cancer* . 1984;53:2515â€“2524.

36.Harris NL, Jaffe ES, Stein H, et al. A revised European-American Classification of lymphoid neoplasms: a proposal from the International Lymphoma Study Group. *Blood* . 1994;84:1361â€“1392.

37.Jaffe ES, Harris NL, Diebold J, et al. World Health Organization Classification of neoplastic diseases of the hematopoietic and lymphoid tissue. *Am J Clin Pathol* . 1999;111:S8â€“S12.

38.Al Marzooq YM, Chopra R, Younis M, et al. Thyroid low grade B-cell lymphoma (MALT type) with extreme plasmacytic differentiation: report of a case diagnosed by fine-needle aspiration and flow cytometric study. *Diagn Cytopathol* . 2004;31:52â€“56.

39.Van den Bruel A, Drijkoningen M, Oyen P, et al. Diagnostic fine needle aspiration cytol and immunocytochemistry analysis of a primary thyroid lymphoma presenting as an anator emergency. *Thyroid* 2002;12:169â€“173.

40.Saangalli G, Serio G, Zampati C, et al. Fine needle aspiration cytology of primary

lymphoma of the thyroid: a report of 17 cases. *Cytopathology* . 2001;12:257â€“263.

41.Higgins JPT, Warnke RA. Large B-cell lymphoma of thyroid. Two cases with marginal zo distribution of the neoplastic cells. *Am J Clin Pathol* . 2000;114:264â€“270.

42.Das DK, Gupta SK, Francis I, et al. Fine needle aspiration cytology diagnosis of non-Hodgkin's lymphoma of thyroid: a report of four cases. *Diagn Cytopathol* . 1993;9:639â€“6

43.Detweiler RD, Katz RL, Alapat C, et al. Malignant lymphoma of the thyroid. A report of two cases diagnosed by fine needle aspiration. *Diagn Cytopathol* . 1991;7:163â€“171.

44.Jayaram G, Rani S, Raina V, et al. B-cell lymphoma of the thyroid in Hashimoto's thyroiditis monitored by fine needle aspiration cytology. *Diagn Cytopathol* . 1990;6:130â€“133.

45.Tani E, Skoog L. Fine needle aspiration cytology and immunocytochemistry in the diagnosis of lymphoid lesions of the thyroid gland. *Acta Cytol* . 1989;33:48â€“52.

46.Guarda LA, Baskin HJ. Inflammatory and lymphoid lesions of the thyroid gland. Cytopathology by fine-needle aspiration. *Am J Clin Pathol* . 1987;87:14â€“22.

47.Matsuda M, Sone H, Koyami M, et al. Fine-needle aspiration cytology of malignant lymphoma of the thyroid. *Diagn Cytopathol* . 1987;3:244â€“249

48.Allevato PA, Kini SR, Rebuck JW, et al. Signet ring cell lymphoma of the thyroid: a case report. *Hum Pathol* . 1985;16:1066â€“1068.

49.Young NA, Al-Saleem T. Diagnosis of lymphoma by fine needle aspiration cytology using the Revised European-American classification of lymphoid neoplasms. *Cancer (Cancer Cytopathol)* . 1999;87:325â€“345

50.Vickery AL Jr. Needle biopsy pathology. *J Clin Endocrinol Metab* . 1981;10:275â€“293.

51.Kini SR, Miller JM, Hamburger JI. Problems in cytologic diagnosis of the "cold" thyroid nodule in patients with lymphocytic thyroiditis. *Acta Cytol* . 1981;25:506â€“512.

52.Lerma E, Arguelles R, Rigla M, et al. Comparative findings of lymphocytic thyroiditis ar thyroid lymphoma. *Acta Cytol* . 2003;47:575â€“580.

53.Kumarasinghe MP, De Silva S. Pitfalls in cytological diagnosis of autoimmune thyroiditis *Pathology* . 1999;31:1â€“7.

54.McDonald L, Yazdi HM. Fine needle aspiration biopsy of Hashimoto's thyroiditis: source diagnostic errors. *Acta Cytol* . 1999;43:400â€“405.

55.Nguyen GK, Ginsberg J, Rockford PM, et al. Hashimoto's thyroiditis: cytodiagnosis, accuracy and pitfalls. *Diagn Cytopathol* . 1997;16:531â€“536.

56.Ravinsky E, Safneck JR. Differentiation of Hashimoto's thyroiditis from thyroid neoplasr in fine needle aspirates. *Acta Cytol* . 1988;32:854â€“861.

57.Droese M. *Cytological Aspiration Biopsy of the Thyroid Gland* . Stuttgart: Schattauer-Verlag; 1980.

58.Shvero J, Gal R, Avidor I, et al. Anaplastic thyroid carcinoma. A clinical histologic and immunohistochemical study. *Cancer* . 1988;62:319â€“325.

59.Lopez M, DiLauro L, Marolla P, et al. Plasmacytoma of the thyroid gland. *Clin Oncol* . 1983;9:61â€“66.

60.Bourtsos EP, Bedrossian CW, De Frias DV, et al. Thyroid plasmacytoma mimicking medullary carcinoma: a potential pitfall in aspiration cytology. *Diagn Cytopathol* .

2000;23:354â€“358.

61.Kovacs CS, Mant MJ, Nguyen GK, et al. Plasma cell lesions of the thyroid: report of a ca of solitary plasmacytoma and a review of the literature. *Thyroid* . 1994;4:65â€“71.

62.Naylor B. Secondary lymphoblastomatous involvement of the thyroid gland. *Arch Patho* 1959;67:432â€“437.

Editors: Kini, Sudha R.
Title: *Thyroid Cytopathology: A Text and Atlas, 1st Edition*

Copyright Â©2008 Lippincott Williams & Wilkins

15

Thyroid Carcinomas Metastatic to Other Body Sites

Thyroid carcinomas are infrequent compared to malignancies arising in other body sites or organs, comprising less than 1% of all cancers diagnosed in the United States.1 , 2 Most primary thyroid carcinomas are low-grade, well-differentiated, and follow a protracted clinical course with excellent prognosis. Although cervical lymph node metastases are common with papillary carcinomas, distant metastases of differentiated thyroid cancer are infrequent and reported to be in the range of 7% to 23%.3 , 4 , 5 , 6 The great majority of metastatic thyroid cancers offer few diagnostic difficulties, but on occasion may cause a diagnostic dilemma.

The pattern of spread differs with the type of thyroid cancer. They also have different predilections for metastatic sites. For example, anaplastic carcinomas are known for extensive local as well as widespread involvement of multiple organs and sites.1 , 7 Metastasis to distant organs such as lungs, bones, liver, and brain are more frequent with follicular, poorly differentiated or insular, medullary, and HÃ¼rthle cell carcinomas, and less frequent with papillary carcinomas.1 , 7 , 8 , 9 , 10 , 11 On the other hand, cervical lymph node metastases are extremely common with papillary carcinomas1 , 12 but can also occur with HÃ¼rthle cell, medullary, and anaplastic carcinomas.1 Involvement of the serous membranes with effusions are associated with papillary and anaplastic carcinomas and not documented with other types of thyroid cancers.

The metastatic involvement of different body sites by primary thyroid carcinomas can be observed in one of the several settings described next.

- A known history of thyroid cancer with a clinical diagnosis of local or distant metastasis at a later date. A new disease process or a neoplasm in the organ suspected of involvement by the metastatic thyroid cancer is often a possibility, which must be ruled out (Fig. 15.1).

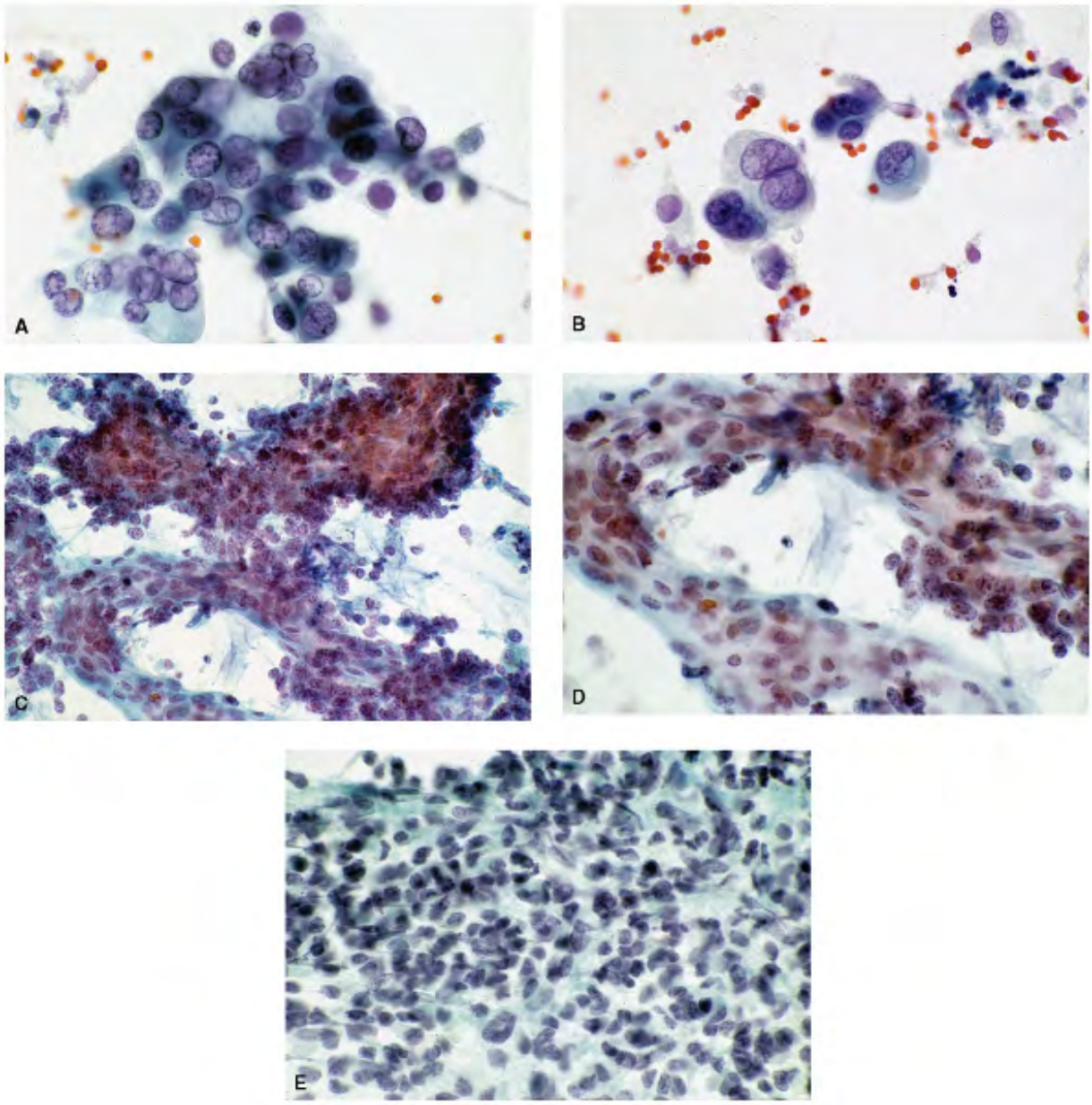

Figure 15.1. A,B. *Recurrence/metastasis versus a different neoplastic process* . Metastatic papillary carcinoma. Smears of bronchial brushings from a patient with a past history of papillary thyroid carcinoma, who presented with hemoptysis 4 years later. The morphology of these malignant cells is consistent with metastatic

papillary carcinoma. Since both carcinomas will be reactive to TTF-1, immunostain with thyroglobulin is recommended to rule out primary adenocarcinoma of the lung. C,D. Bronchial brushings from a woman in her 30s with a history of papillary thyroid carcinoma resected several years earlier, who now presented with obstructive pulmonary symptoms. Bronchoscopy was done to rule out metastatic carcinoma. A lesion was found in the bronchus. The neoplastic cells are forming syncytial tissue fragments. Their cytoplasm is scanty, and the nuclear chromatin is very granular. A cytologic diagnosis of carcinoid tumor was made and confirmed by lobectomy. E. FNA of a mediastinal mass suspected of metastatic carcinoma, in a 56-year-old woman with thyroidectomy, 6 years earlier for papillary carcinoma. The aspirate shows a large population of immature plasma cells, suggesting a diagnosis of multiple myeloma, which was later confirmed.

- Patients present with a palpable thyroid mass associated with cervical lymphadenopathy. This pattern is more frequent with papillary and medullary thyroid carcinomas. Sometimes both sites are biopsied simultaneously, with the thyroid biopsy offering nondiagnostic results. In such instances the thyroid origin must be determined (Fig. 15.2).

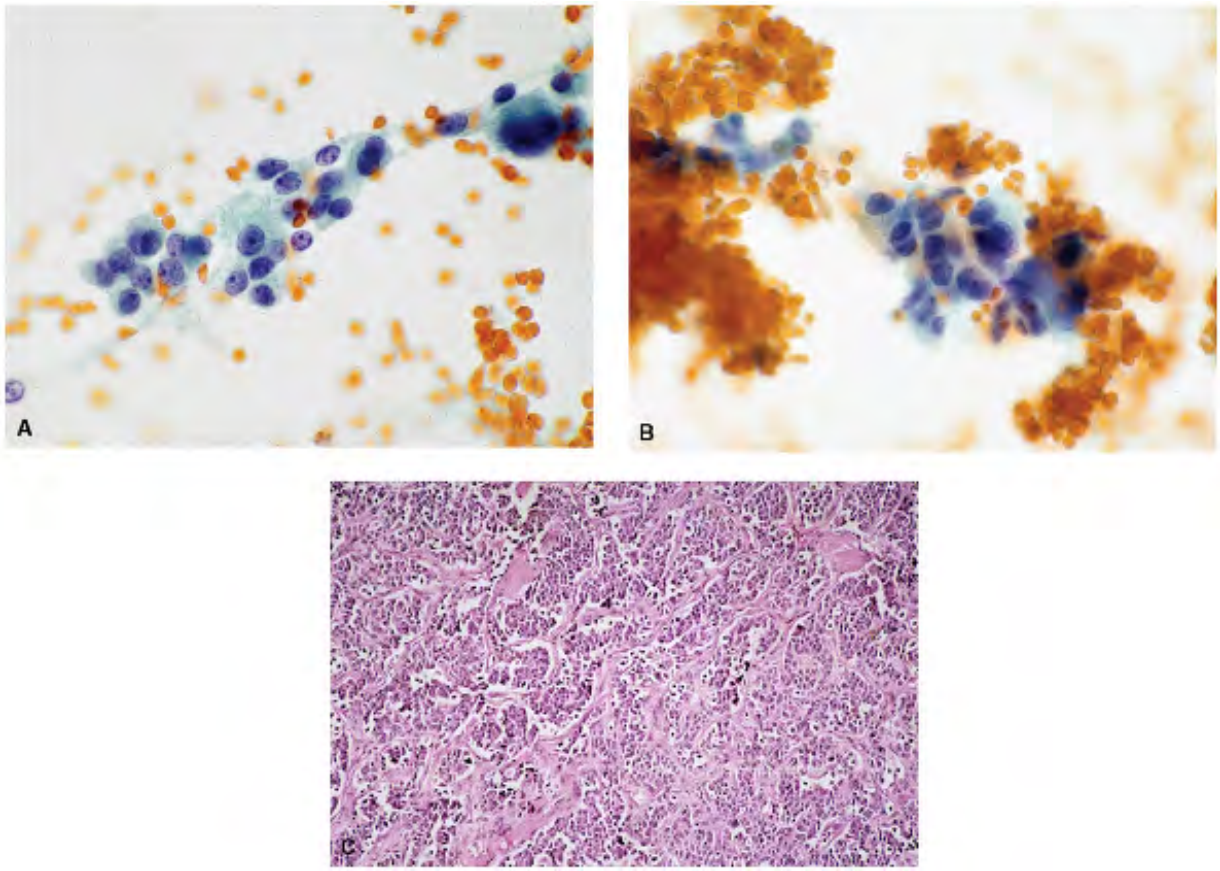

Figure 15.2. *Simultaneous aspiration biopsies of thyroid nodule and cervical lymph node.* This patient had a palpable thyroid nodule and cervical lymphadenopathy. Fine-needle aspiration biopsy of the thyroid was unsatisfactory. A,B. Aspiration biopsy of the cervical lymph node showing cells with cytomorphology consistent with medullary carcinoma. C. Histologic section of the thyroidectomy showing medullary carcinoma. Metastases were present in the lymph nodes.

- Recurrent thyroid cancer at the thyroidectomy site, a frequent occurrence with HÃ¼rthle cell carcinomas (Fig. 15.3).

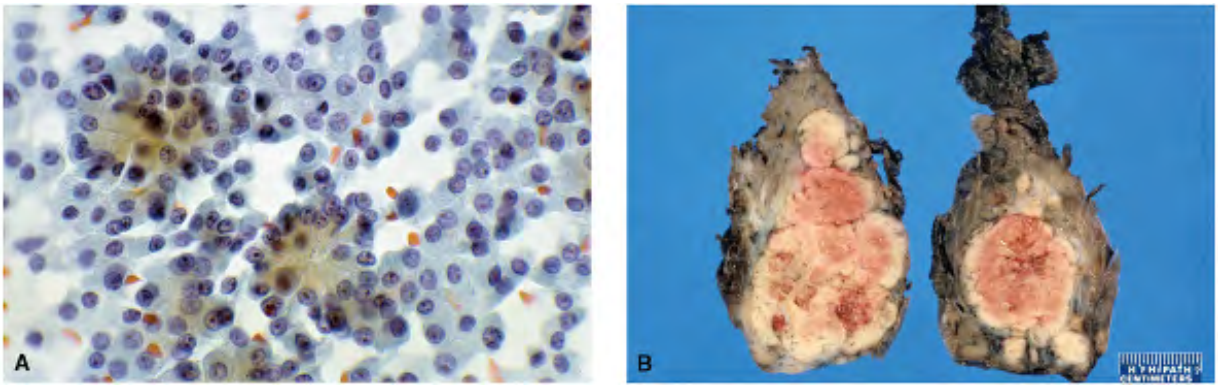

Figure 15.3. A. FNA of mass in the thyroid area in a patient with a history of thyroidectomy for HÃ¼rthle cell carcinoma. The aspirate is cellular, consisting of discrete and syncytial tissue fragments of small HÃ¼rthle cells with high N/C ratios and prominent macronucleoli, consistent with the recurrent HÃ¼rthle cell carcinoma. B. Gross photograph of the resected large, bulky tumor.

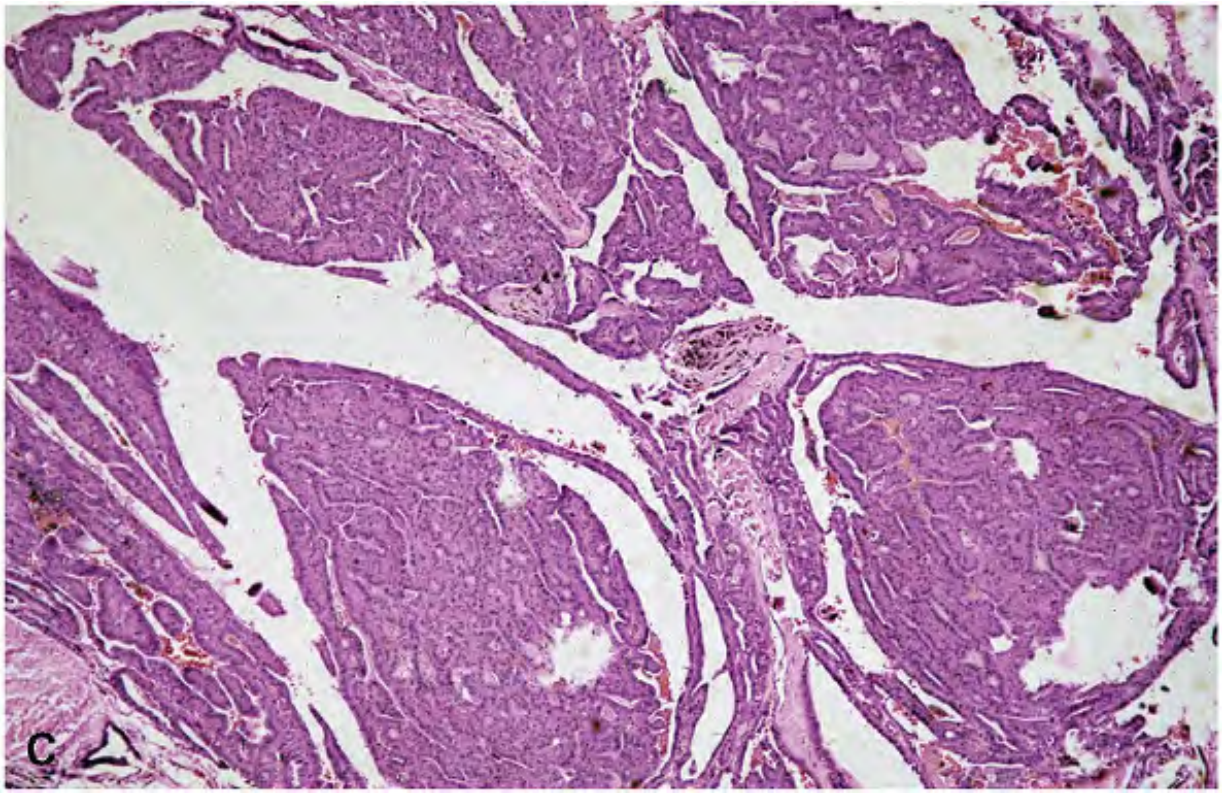

Figure 15.3. C. Histologic section of HÃ¼rthle cell carcinoma.

- The patient presents with metastatic thyroid malignancy at a distant site with subsequent discovery of a palpable thyroid nodule. These thyroid cancers are generally silent. The patient presents with signs and symptoms related to the site of metastasis, such as bone pain, weakness hemoptysis and cough (Figs. 15.4 , 15.5 , 15.6 and 15.7).

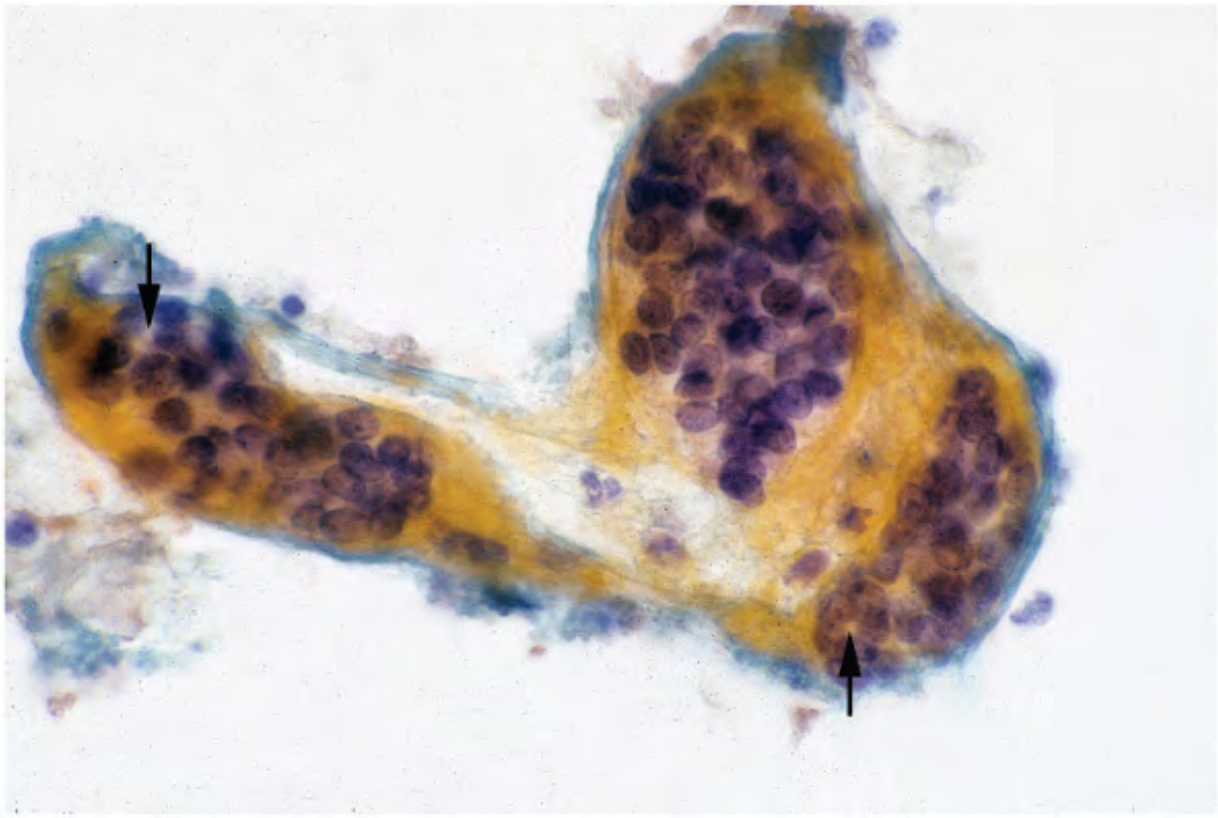

Figure 15.4. *Silent thyroid malignancy presenting with distant metastases* . Fine-needle biopsy of a lytic lesion involving the cervical vertebra in a 47-year-old man. The malignant cells are small and closely packed. Their nuclei have coarse chromatin showing a follicular pattern (*arrows*). Although the cytomorphology is strongly suggestive of a thyroid neoplasm, other sources, such as the lung or prostate, must be ruled out. Immunostain for thyroglobulin was strongly positive. A thyroidectomy confirmed an insular carcinoma.

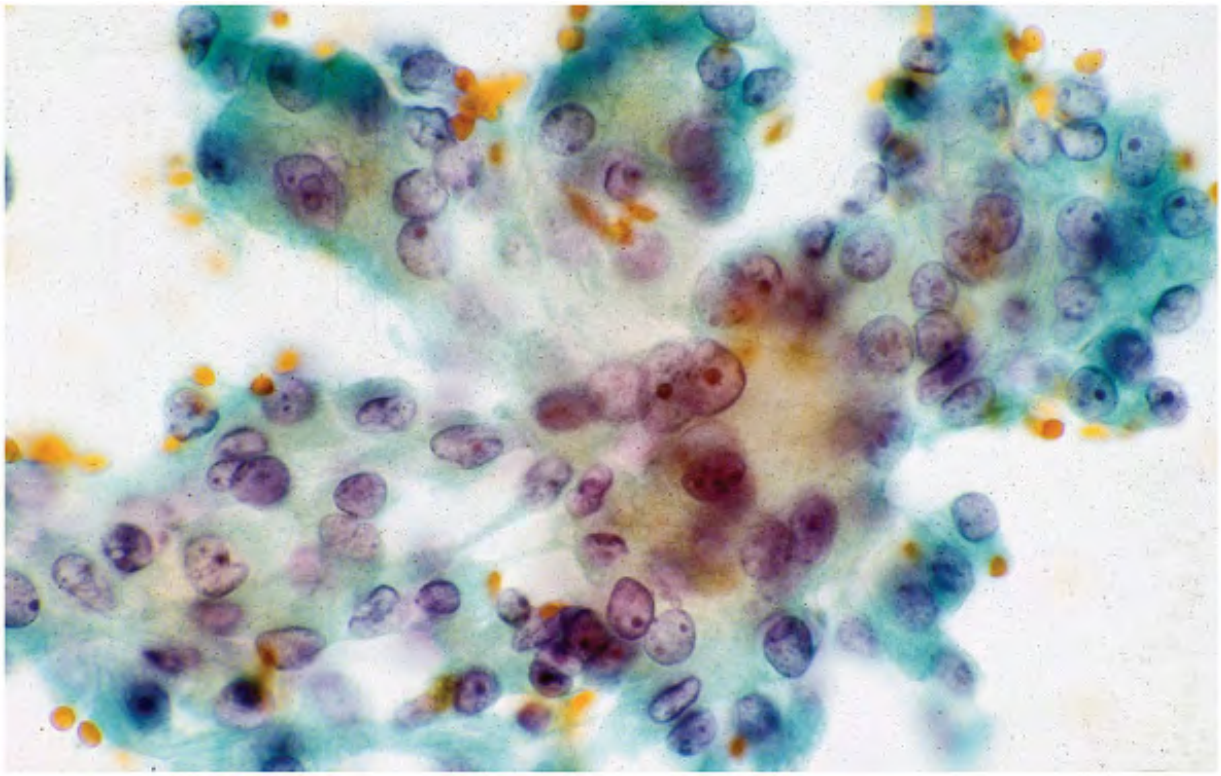

Figure 15.5. *Silent thyroid malignancy presenting with distant metastases* . Fine-needle biopsy of a lytic lesion of the vertebra with a paraspinal mass showing pleomorphic malignant cells with prominent macronucleoli. The cytomorphology resembles that of a malignant melanoma or a liver cell carcinoma. The patient was found to have a large thyroid nodule. Fine-needle aspiration biopsy showed HÃ¼rthle cell carcinoma. The malignant cells are forming syncytial tissue fragments with and without a follicular pattern. The nuclei are large, with prominent macronucleoli.

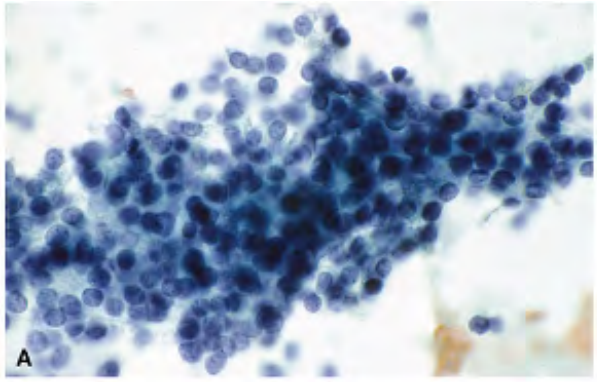

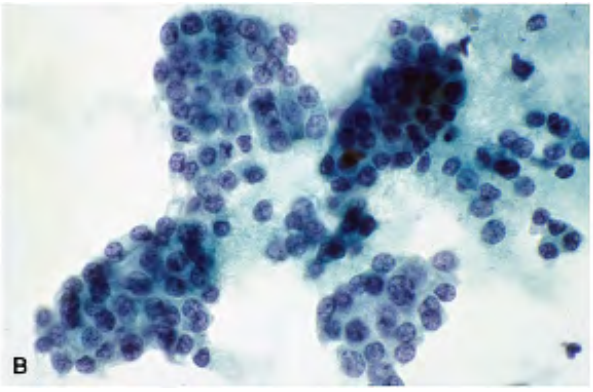

Figure 15.6. *Silent thyroid malignancy presenting with distant metastases.* Poorly differentiated "insular" carcinoma presenting as a pulsatile mass involving the sternum in a 69-year-old woman. The patient was later found to have a large thyroid mass. A. FNA of the thyroid showing a syncytial-type tissue fragment of small follicular cells with enlarged, crowded nuclei consistent with the diagnosis of insular carcinoma. B. Imprint of the resected sternal mass with cells similar to those seen in thyroid carcinoma.

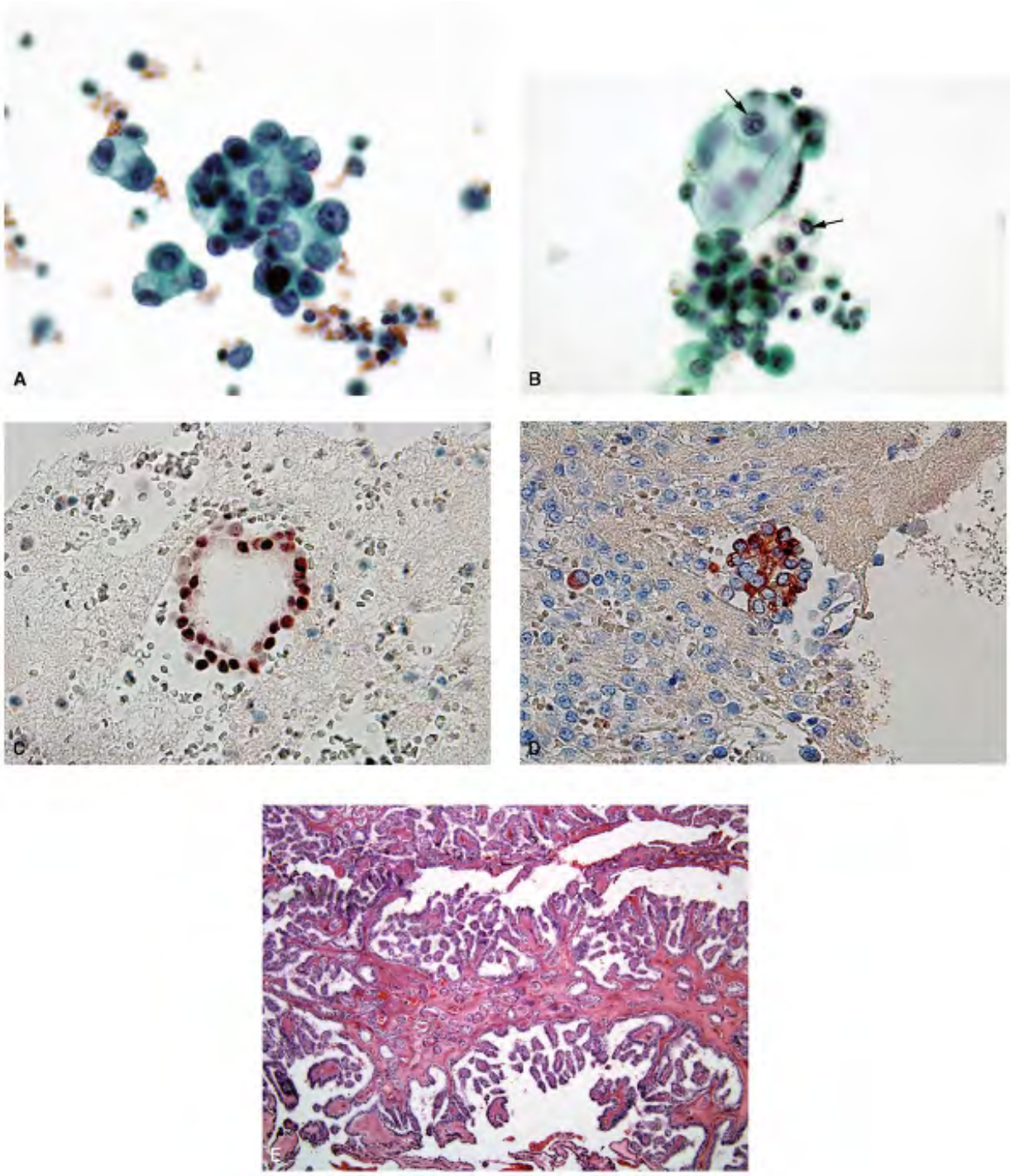

Figure 15.7. *Silent thyroid malignancy presenting with distant metastases* . Sixty-five-year-old male with a low-grade prostate adenocarcinoma, was found to have multiple lung nodules and a large pleural effusion on CT scan during the follow up examination. The scan also revealed a superior mediastinal mass extending superiorly and involving the left lower pole of the thyroid. The serum

PSA levels were within normal limits. A. These smears from the aspirated pleural fluid show malignant cells in syncytial tissue fragments with an acinar patten. B. These malignant cells demonstrate large cytoplasmic vacuoles. Note the intranuclear inclusions (*arrows*). C. Positive reactivity to TTF-1 supports both the lung adenocarcinoma and thyroid papillary carcinoma. D. Positive reactivity to thyroglobulin confirms thyroid origin. E. Histologic section of a 1-cm papillary carcinoma that infiltrated the extrathyroidal soft tissues.

- Initial presentation of thyroid malignancy at a metastatic site, either local or distant. The thyroid shows no palpable nodules. The cancers are occult and may or may not be detected by ultrasonography or imaging.[13] , [14] , [15] , [16] , [17] , [18] , [19] , [20] , [21] , [22] , [23] This presentation is more frequently associated with papillary carcinomas and is usually associated with cervical lymphadenopathy with extensive cystic change (Fig. 15.8). The cystic metastasis may be misinterpreted clinically as branchial cleft cysts. Occult thyroid carcinomas with distant metastases are rare.[24] , [25] , [26] , [27] , [28] , [29] , [30]

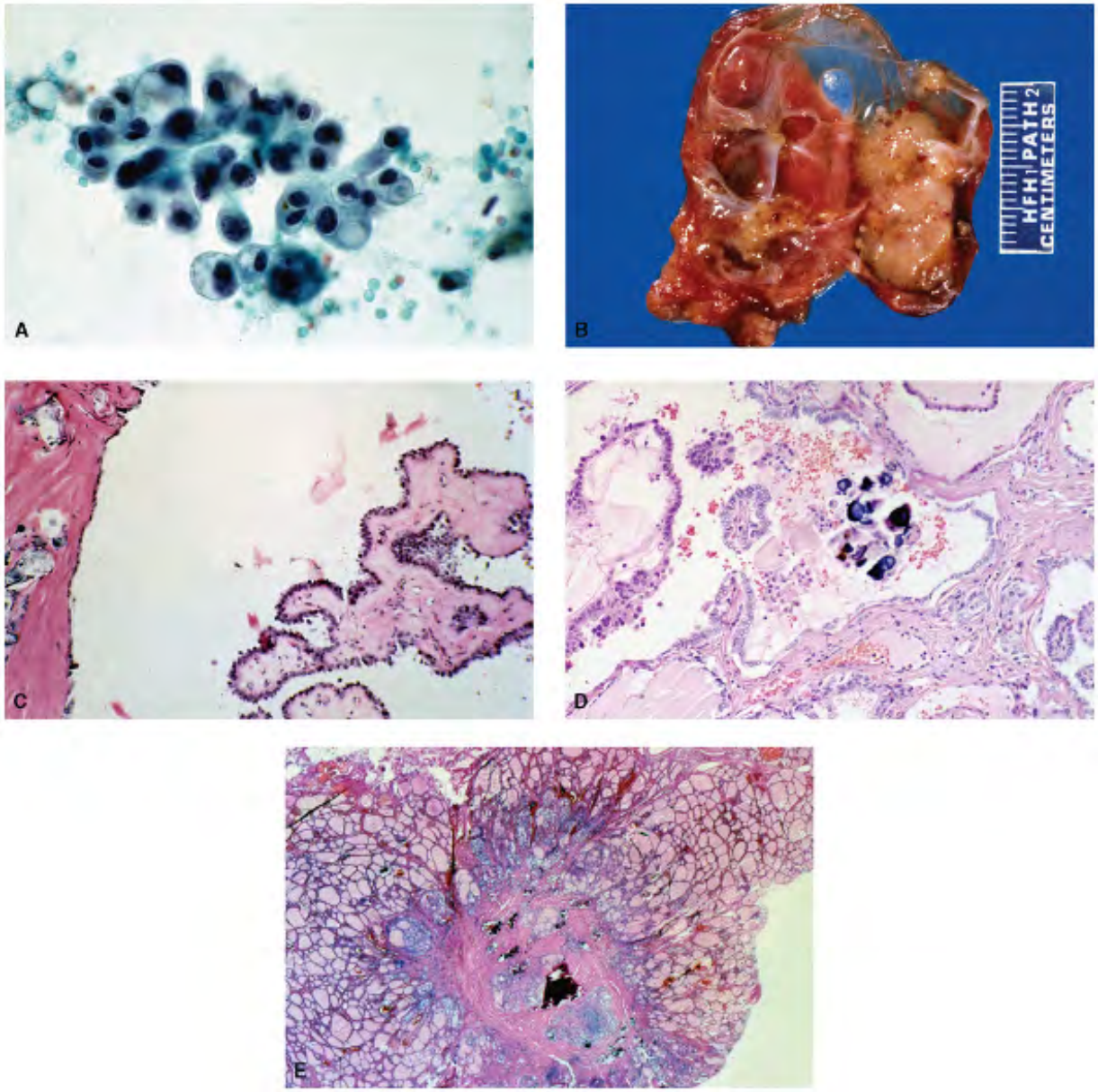

Figure 15.8. *Metastatic carcinoma in cervical lymph node with occult papillary carcinoma.* A. Fluid aspirated from a lateral neck cyst. The tissue fragments of epithelial cells are syncytial. The cells are pleomorphic, with vacuolated cytoplasm. Their nuclei show degenerative changes and appear compact. Immunostain for thyroglobulin was positive. B. Excision of the neck mass revealed a thin-walled, multiloculated cystic lesion. C,D. Histologic section showing metastatic papillary thyroid carcinoma. No nodule was palpated in the thyroid or detected by imaging. E. Thyroidectomy showed a 2-mm papillary microcarcinoma.

- Previous needle biopsy or surgery for a thyroid lesion misinterpreted as benign and metastasis occurring at a later date (Fig. 15.9).

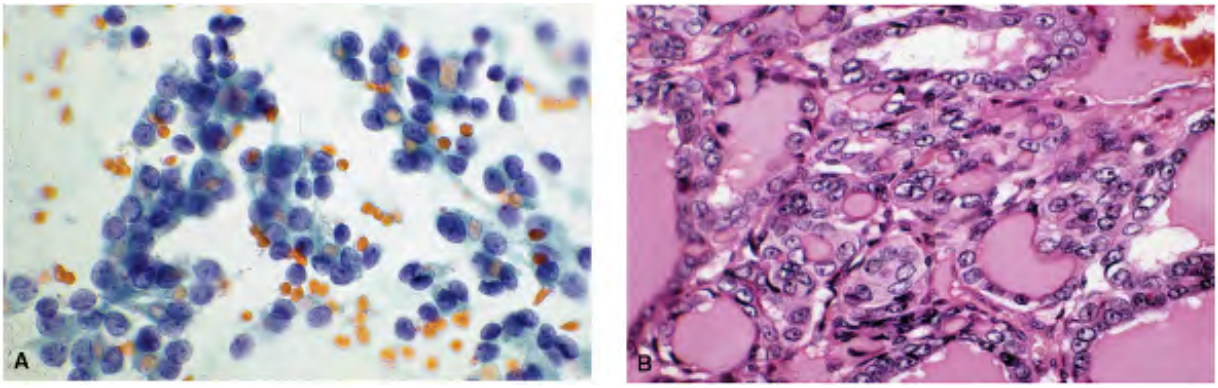

Figure 15.9. *Distant metastasis in a patient with thyroidectomy for an apparent benign disease.* A. Fine-needle aspiration biopsy of a large shoulder mass with lytic lesions of the humerus. The patient had a history of large (200-g) multinodular goiter resected 4 years earlier. The cellular aspirate shows small malignant cells in syncytial tissue fragments with and without a follicular pattern. The chromatin is powdery. The nuclei contain grooves, inclusions, and nucleoli. Immunostain for thyroglobulin was strongly positive, confirming metastatic thyroid carcinoma. B. Review of the thyroidectomy specimen showed a macrofollicular variant of papillary carcinoma.

- The metastasis from a differentiated thyroid cancer may dedifferentiate into insular or anaplastic types (Fig. 15.9) and may require extensive workup to determine the primary source.

The following paragraphs describe cytologic features of metastatic thyroid cancer in different organs or sites.

P.346
P.347
P.348
P.349
P.350

LYMPH NODES

Papillary carcinomas show a great propensity for cervical lymph node involvement, reported to be in the range of 46% to 47%.1 , 2 This involvement may be ipsilateral, contralateral, or bilateral. The metastatic process may also involve the mediastinal lymph nodes. A lateral neck mass or cervical lymphadenopathy is the initial presenting sign in about 21% of papillary thyroid carcinomas.12 , 13 , 31 , 32 Many are associated with occult lesions a few mm in size, neither palpable nor detectable on imaging or ultrasound (Fig. 15.8). Fine-needle biopsy of the enlarged lymph nodes involved by papillary carcinoma offers an accurate diagnosis, especially when the lesion is solid, but tends to be a diagnostic problem with cystic degeneration. Clinically cystic lesions in the lateral neck are often diagnosed as branchial cleft cysts.33 With extensive cystic degeneration, the cyst fluid consists of predominantly or solely histiocytes with or without hemosiderin pigment. The

carcinoma cells when present show pronounced degenerative changes, precluding an accurate diagnosis. Immunostains with thyroglobulin are often confirmatory. False-negative diagnoses are frequent with extensive cystic degeneration.

It must be realized, however, that not all papillary carcinomas in cervical lymph nodes are thyroidal in origin. The differential diagnosis for metastatic papillary carcinomas includes primary sites such as lungs, kidneys, or ovaries. Homan et al. [15] reported three cases of metastatic renal cell carcinomas in cervical lymph nodes interpreted as papillary thyroid carcinoma from the cytologic samples obtained by fine-needle biopsy. Immunostains for thyroglobulin in all three cases were nondiagnostic and thyroidectomies in all three cases failed to show papillary carcinomas. Our experience with metastatic papillary cystadenocarcinoma of the ovary to the cervical lymph nodes, histologically misinterpreted as metastatic papillary thyroid cancer, is illustrated in Figure 15.10 . Thyroidectomy had failed to confirm the papillary carcinoma. The tumor subsequently recurred in the neck and was aspirated which showed cytologic pattern inconsistent with the primary thyroid. A past history of ovarian cystadenocarcinoma was later made available. Bronchogenic or bronchioloalveolar adenocarcinomas metastatic to the cervical lymph nodes also present a cytologic pattern identical to that of papillary thyroid carcinomas, including psammoma bodies.34 Both papillary thyroid carcinomas and pulmonary adenocarcinomas react positively to TTF-1; however, papillary thyroid carcinomas will react to thyroglobulin.

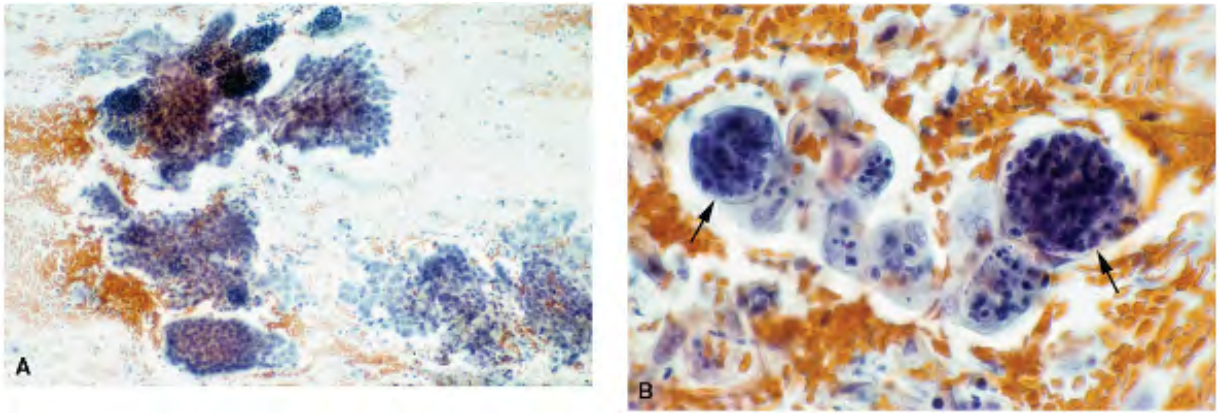

Figure 15.10. A. Aspiration biopsy specimen of a lateral neck mass in a 67-year-old woman with a history of ovarian adenocarcinoma, showing large, branching papillary tissue fragments. B. Higher magnification showing secretory vacuoles in the cytoplasm filled with neutrophils (*arrows*). This suggested a mucin-producing carcinoma not originating in the thyroid.

Medullary thyroid carcinomas frequently metastasize to the cervical lymph nodes (Fig. 15.2). Occasionally, cervical lymphadenopathy may be the presenting sign. A characteristic pleomorphic cell pattern in cytologic samples obtained by fine-needle biopsy offers correct diagnosis (see Chapter 12). However, a monomorphic pattern with small cells may mimic a small cell carcinoma. Cervical paraganglioma must also be considered with large polyhedral cells. Positive immunostains for calcitonin and increased serum calcitonin levels will support the diagnosis of medullary carcinoma. The involvement of cervical lymph nodes by follicular carcinoma is an exceptional event.

HÃ¼rthle cell carcinomas may involve the cervical lymph nodes but rarely present as an initial sign. Local recurrences are very frequent with HÃ¼rthle cell carcinomas (Fig. 15.3).1 Poorly differentiated or insular carcinoma and anaplastic thyroid carcinoma do metastasize to the cervical lymph nodes and are not diagnostic problems.

RESPIRATORY SYSTEM

With generalized widespread involvement, lungs are frequent sites for metastatic anaplastic carcinomas, and less frequently for insular carcinomas, HÃ¼rthle cell carcinomas, and medullary carcinomas. Pulmonary involvement in differentiated thyroid

cancers (follicular and papillary) is reported to be 10% for follicular carcinomas and 2% to 14% for papillary carcinomas.5 , 6 Metastases to the lungs denote advanced disease. Rarely do thyroid carcinomas initially manifest with signs and symptoms of pulmonary involvement.22 , 24 , 35 These range from cough, hemoptysis, fever, and pleural effusion to opacities in lung fields on chest x-rays. Both miliary infiltrates36 and macronodular densities have been described. Direct extension into the trachea may occur. Metastatic thyroid cancer can be identified from cytologic samples such as sputum, bronchial brushings and washings, transbronchial or transthoracic percutaneous fine-needle biopsy (Figs. 15.11 , 15.12 and 15.13), and pleural fluid (Fig. 15.7). Primary lung cancer must be ruled out when papillary carcinoma is identified from the respiratory specimens, since primary lung cancers are more common than metastatic thyroid cancers. Follicular carcinomas also spread to the lungs (Fig. 15.14), and with poorly differentiated types ancillary studies are needed to confirm the diagnosis. HÃ¼rthle cell carcinomas are known to involve the lungs. When occurring as an endobronchial lesion (Fig. 15.15A), HÃ¼rthle cell carcinomas may be difficult37 , 38 to differentiate from granular cell tumors since both show cells with abundant granular cytoplasm (Fig. 15.15).

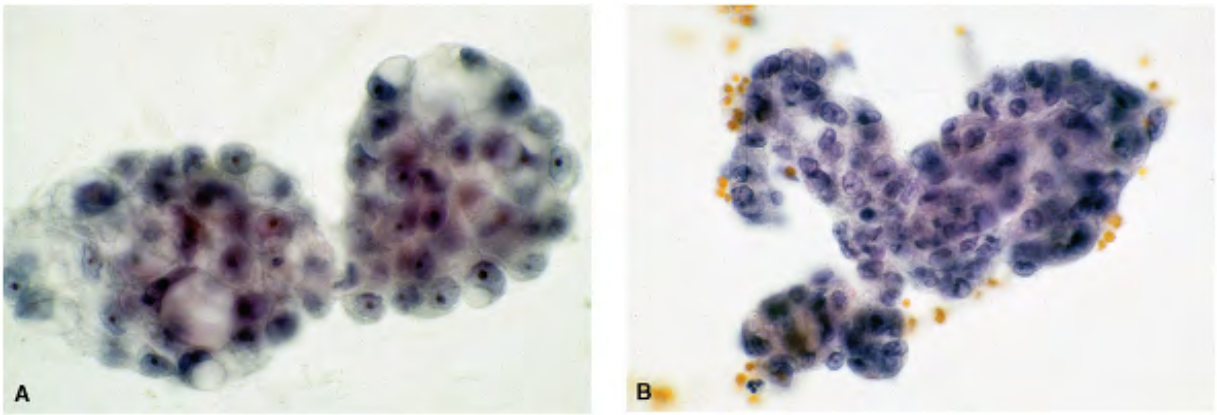

Figure 15.11. Sputum preparation from a woman in her 60s who presented with hemoptysis. The large papillary tissue fragments of malignant cells, with crowded and overlapped nuclei containing powdery chromatin and multiple micronucleoli, are diagnostic of adenocarcinoma. The patient was subsequently found to have multiple lung lesions and a thyroid nodule, which harbored a papillary carcinoma. Immunostains with thyroglobulin and TTF-1 will both be positive and diagnostic in this case.

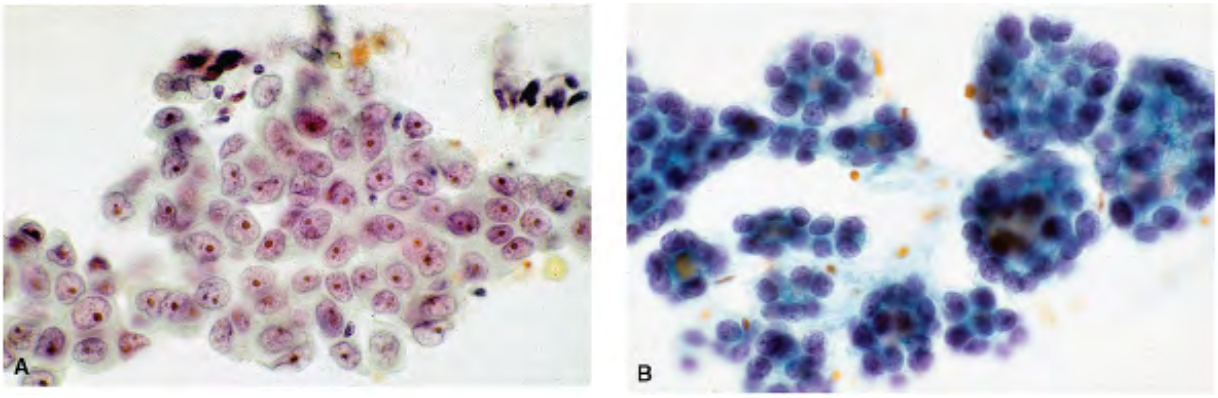

Figure 15.12. A. Bronchial brushings from a patient with a history of papillary thyroid carcinoma and a lung mass on chest x-ray. The malignant cells have large nuclei, some with irregular contours, very fine powdery chromatin, and prominent nucleoli. Intranuclear inclusions or grooves are not present. The differential diagnosis includes metastatic papillary thyroid carcinoma and bronchogenic adenocarcinoma. Immunostain for thyroglobulin was positive. B. Bronchial brushings of a metastatic follicular variant of papillary carcinoma. These cells must be differentiated from pulmonary adenocarcinoma.

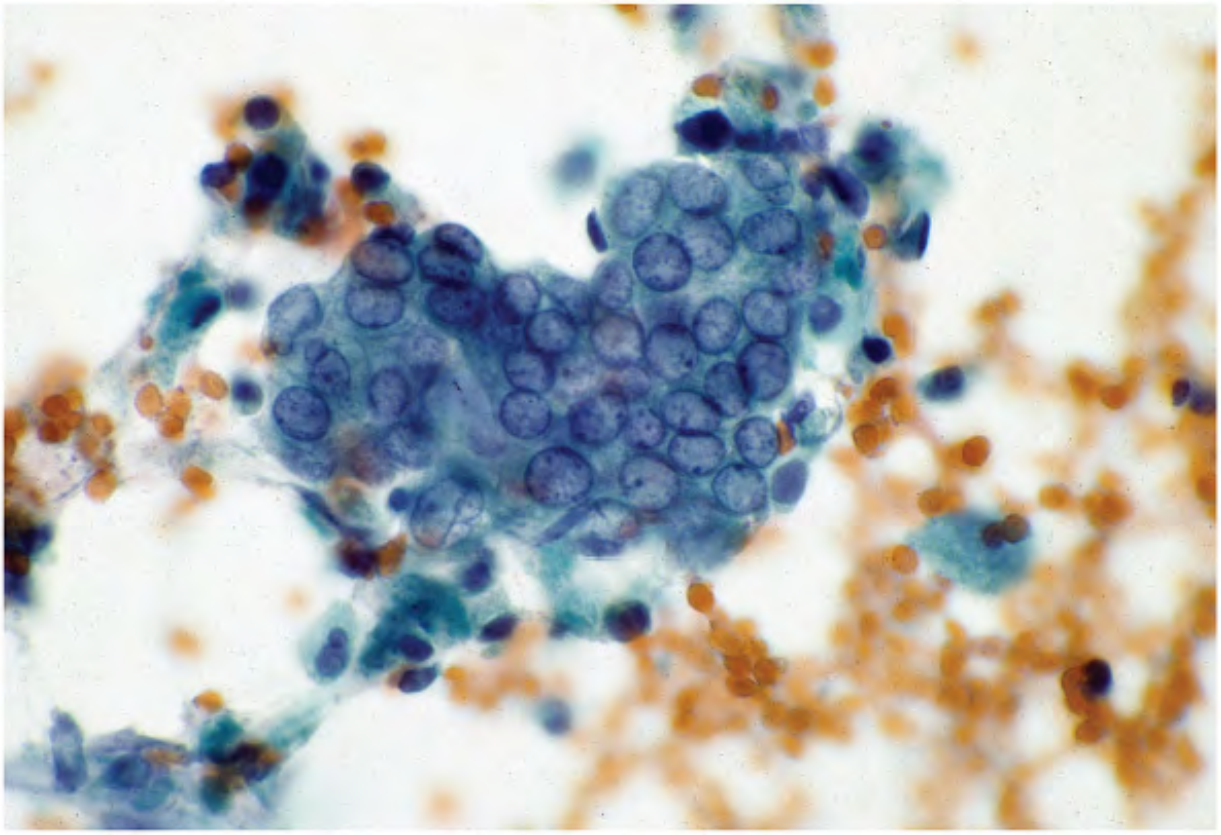

Figure 15.13. FNA of a metastatic papillary thyroid carcinoma to the lung. The syncytial tissue fragment is composed of crowded nuclei with powdery chromatin, grooves, micronucleoli, and inclusions. These features are also shared by bronchioloalveolar carcinoma. Immunostains with thyroglobulin and TTF-1 are required to establish a diagnosis. Both will be positive with papillary thyroid carcinoma.

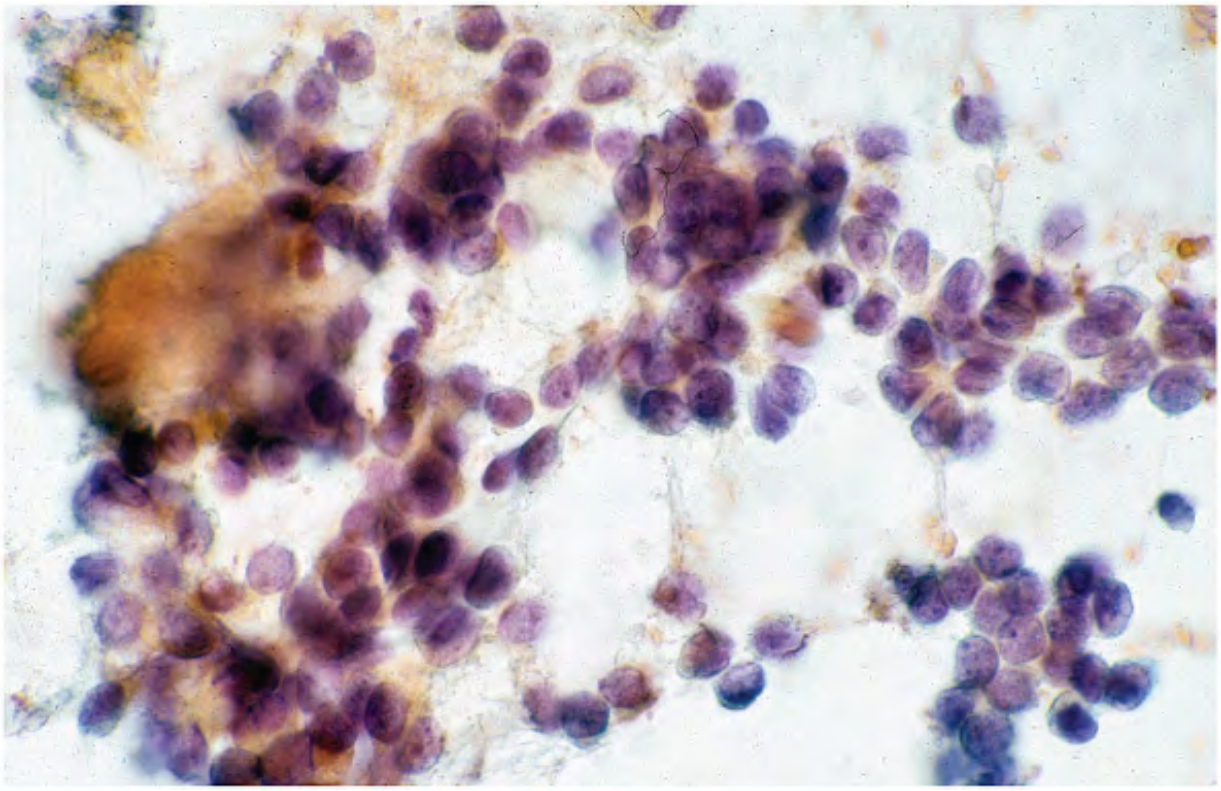

Figure 15.14. FNA of a metastatic follicular carcinoma to the lung. The patient had thyroidectomy for a follicular carcinoma 9 years prior to the development of metastasis.

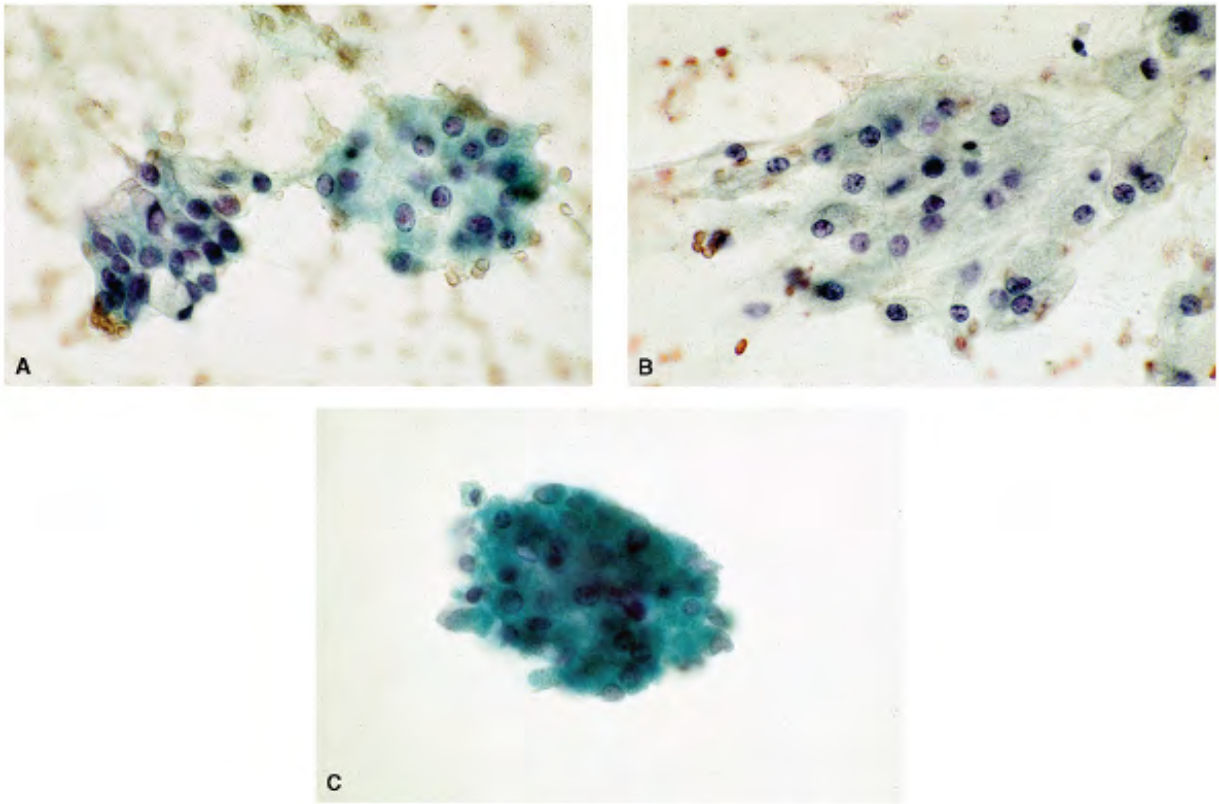

Figure 15.15. A,B. Bronchial brushings showing a metastatic HÃ¼rthle cell carcinoma. The differential diagnosis includes granular cell tumor. C. Bronchial brushings of a granular cell tumor. Note the morphologic similarities.

P.353

P.354

Medullary carcinomas may metastasize to the lungs (Fig. 15.16A). With a spindle cell pattern, medullary carcinoma must be differentiated from a spindle cell carcinoid tumor of the lung (Fig. 15.16B).

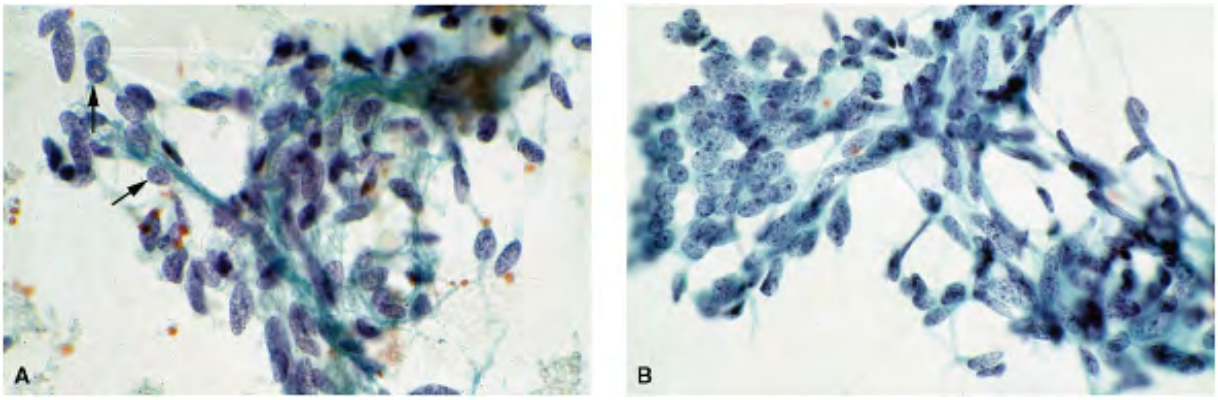

Figure 15.16. A. FNA of a metastatic medullary thyroid carcinoma to the lung. Note the intranuclear cytoplasmic inclusions in malignant cells (*arrows*). B. FNA of a spindle cell carcinoid tumor of the lung demonstrating morphologic similarity to the medullary carcinoma cells.

BODY CAVITY FLUIDS

Metastatic thyroid cancers are rarely encountered in body cavity fluids.39 , 40 , 41 Among the thyroid cancers, anaplastic and papillary carcinomas tend to metastasize to the pleural cavities (Figs. 15.7 and 15.17 , 15.18 and 15.19). Their cytologic presentation may cause some diagnostic difficulties, as the fluid medium may initiate regressive changes such as marked cytoplasmic vacuolization, resulting in considerable deviation from the usual cytologic patterns. Also papillary carcinoma in pleural cavities must be differentiated from either primary lung adenocarcinomas or papillary carcinomas from other body sites.

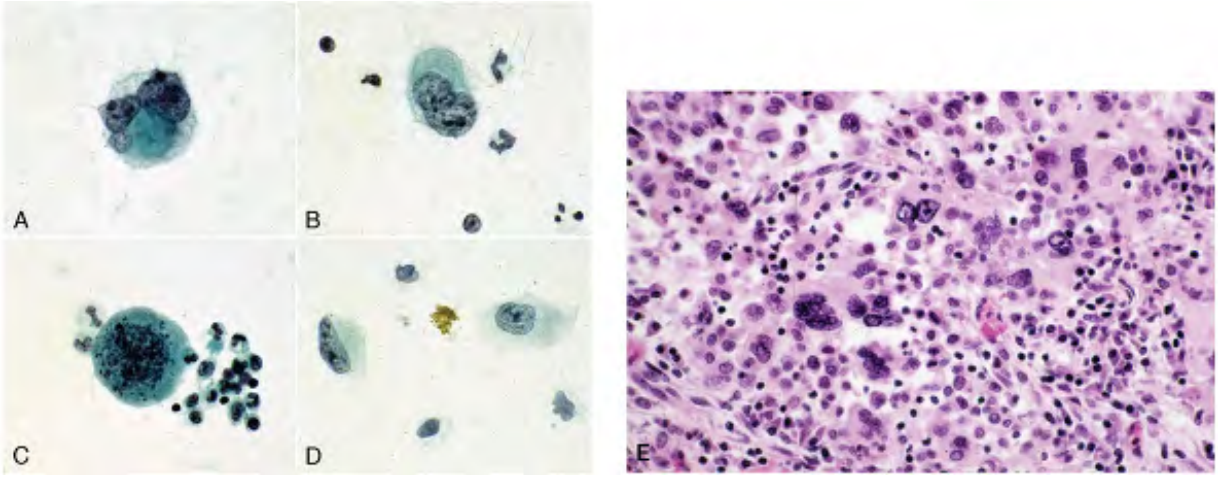

Figure 15.17. Anaplastic carcinoma metastatic to the pleura. Aâ€“D. Bizarre isolated malignant cells in pleural fluid. E. Cell block preparation of the pleural fluid showing similar malignant cells.

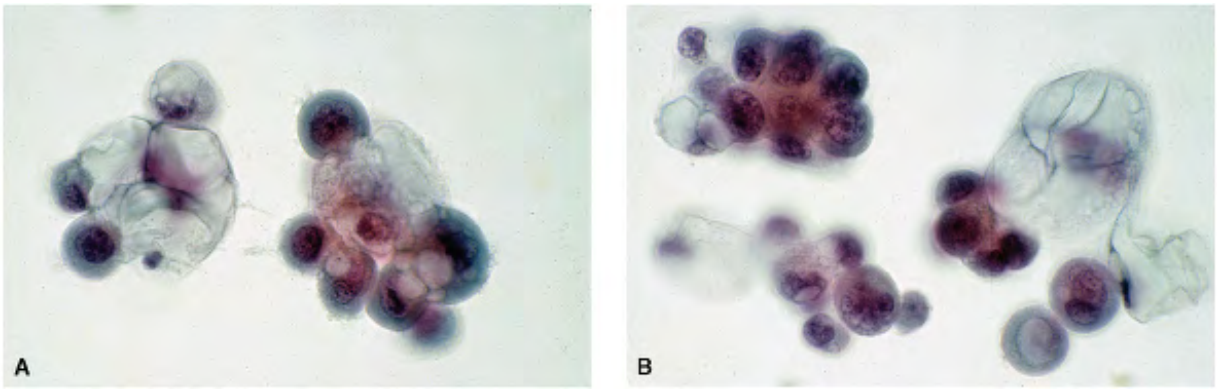

Figure 15.18. Papillary carcinoma metastatic to the pleura. The carcinoma cells in pleural fluid have bizarre nuclei and marked cytoplasmic vacuolization, resembling mucin-producing adenocarcinoma. The Alcian blue stain on the cell block preparation did not reveal the presence of mucin, indicating that the cytoplasmic vacuoles represent degenerative changes in the fluid medium.

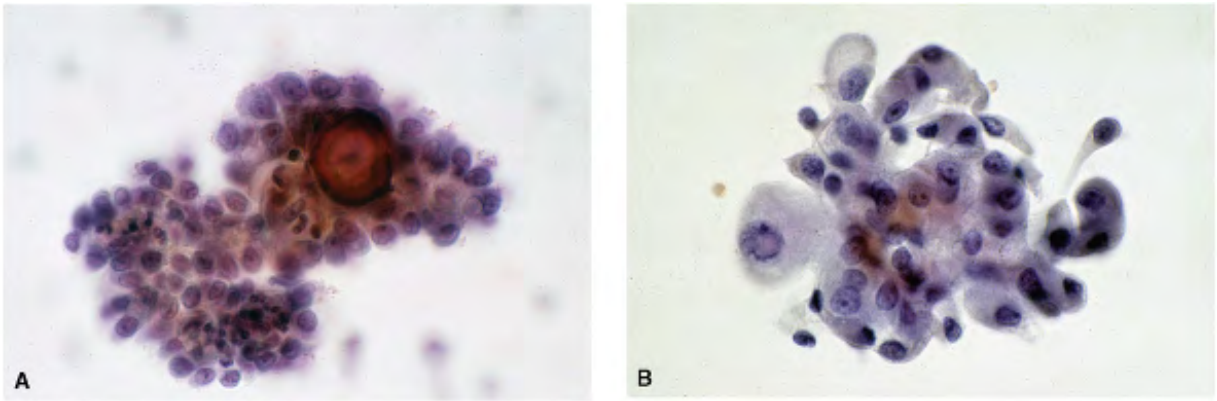

Figure 15.19. A. Metastatic papillary carcinoma in pleural fluid showing a syncytial tissue fragment with a psammoma body. B. Different example of metastatic papillary carcinoma in pleural fluid from a patient with a history of thyroid carcinoma. Note marked cytoplasmic vacuolization and intranuclear cytoplasmic inclusion.

SKELETAL SYSTEM

The skeletal system is a frequent site for metastatic thyroid cancer, especially follicular, HÃ¼rthle cell, insular and anaplastic types.1 , 9 , 42 The incidence is reported to be 9%. The osseous lesions are often osteolytic, involving long bones as well as flat bones such as the pelvis and sternum. Pulsatile lesions are described as a characteristic feature of metastatic follicular carcinomas to the bones. The presenting signs and symptoms include bone pain, weakness, and pathologic fractures may occur. The metastatic tumor may extend into the adjacent soft tissues. Fine-needle biopsy is a helpful diagnostic technique (Figs. 15.4 , 15.5 and 15.6 , 15.20) but may present interpretative difficulties if the tumor is less differentiated.

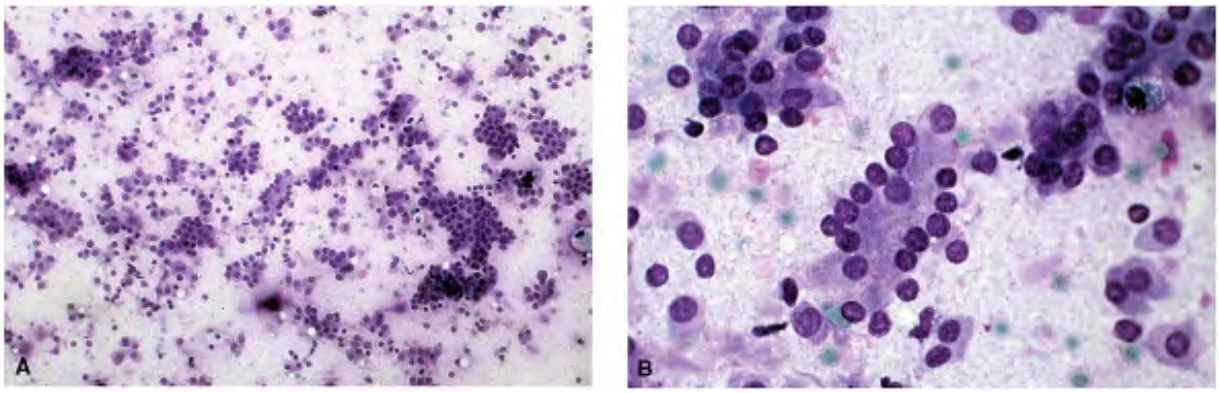

Figure 15.20. FNA of metastatic follicular carcinoma to the bone. A. Low power showing a cellular aspirate composed of syncytial tissue fragments of malignant cells with a follicular pattern. B. Higher magnification highlighting the neoplastic follicles with enlarged nuclei. Romanowsky stain.

MISCELLANEOUS SITES

Other organs or sites involved less frequently by thyroid cancer include breast,43 , 44 liver,45 , 46 , 47 and central nervous system.48 , 49 Single case reports have appeared of various types of thyroid cancers involving rare and uncommon sites such as uvea,50 skin,51 , 52 , 53 , 54 spleen,55 parotid gland,56 and urinary bladder.57 A case of metastatic medullary carcinoma metastasizing to the thigh seen in consultation is illustrated in Figure 15.21 .

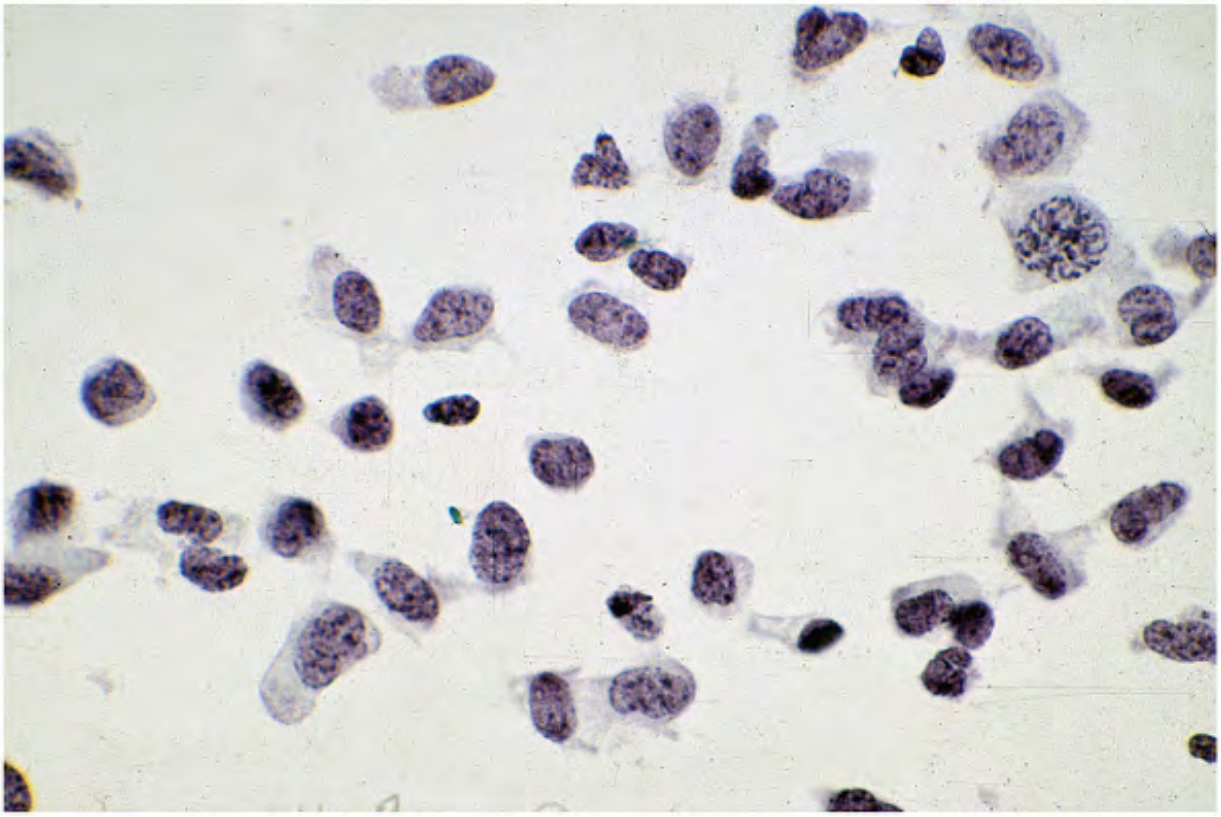

Figure 15.21. Metastatic medullary thyroid carcinoma to the thigh. (Courtesy of Ami J. Walloch, MD and Rashead Hammadeh, MD, Christ Hospital, Oaklawn, Illinois.)

SUMMARY

The majority of thyroid cancers are of the differentiated type and metastasize to distant organs only infrequently. Cervical lymph node involvement is common with papillary carcinomas. A history of thyroid cancer is necessary for correct identification of a metastatic tumor and can be confirmed by immunostains such as thyroglobulin, TTF-1, or calcitonin, especially in the presence of overlapping patterns.

REFERENCES

1.Rosai J, Carcangiu ML, DeLellis RA. Tumors of the thyroid gland. *Atlas of Tumor Pathology* . Fascicle 5, 3rd series. Washington, DC: Armed Forces Institute of Pathology; 1993:61,90â€“94, 150, 327.

2.Wenig BM, Heffess C, Adair CF. *Atlas of Endocrine Pathology* . Philadelphia: Saunders; 1997:83.

3.Ruegemer IJ, Hay ID, Bergstralh EJ, et al. Distant metastases in differentiated thyroid carcinomas: a multivariate analysis of prognostic variables. *J Clin Endocrinol* . 1988;67:501â€“508.

4.Schlumberger M, Tubiana M, De Vathaire F, et al. Long term results of treatment of 283 patients with lung and bone metastases from differentiated thyroid carcinomas. *J Clin Endocrinol Metab* . 1986;63:376â€“381.

5.Massin JP, Savoie JC, Garnier H, et al. Pulmonary metastases in differentiated thyroid carcinoma. *Cancer* . 1984;53:982â€“992.

6.Samaan NA, Schultz PN, Hayne TP, et al. Pulmonary metastasis of differentiated carcinoma: treatment results in 101 patients. *J Clin Endocrinol Metab* . 1985;65:376â€“380.

7.Albores-Saavedra J, Nadji M, Civantos F, et al. Thyroglobulin in carcinoma of the thyroid: an immunohistochemical study. *Hum Pathol* . 1983;14:62â€“66.

8.Aldinger KA, Samaan NA, Ibanez M, et al. Anaplastic carcinoma of the thyroid: a review of 84 cases of spindle and giant cell carcinoma of the thyroid. *Cancer* . 1978;41:2267â€“2275.

9.Tikko SK, Pittas AG, Adler M, et al. Bone metastases from thyroid carcinoma: a histopathologic study with clinical correlates. *Arch Pathol Lab Med* . 2000;124:1440â€“1447.

10.Uribe M, Grimes M, Fenoglio-Preiser CM, et al. Medullary carcinoma of the thyroid gland: clinical, pathological, and immunohistochemical features with review of the literature. *Am J Surg Pathol* . 1985;9:577â€“594.

11.Williams ED, Brown CL, Doniach I. Pathological and clinical finding in a series of 67 cases of medullary carcinoma of the thyroid. *J Clin Pathol* . 1966;19:103â€“113.

12.Carcangiu ML, Zampi G, Pupi A, et al. Papillary carcinoma of the thyroid: a clinicopathologic study of 241 cases treated at the University of Florence, Italy. *Cancer* . 1985;55:805â€“828.

13.DeJong SA, Demetter JC, Jarosz H, et al. Primary papillary thyroid carcinoma presenting as cervical lymphadenopathy. *Am Surg* . 1993;59:172â€“177.

14.Levy I, Barki Y, Tovi F. Cystic metastases of the neck from occult thyroid adenocarcinoma. *Am J Surg* . 1992;163:298â€“300.

15.Homan MR, Gharib H, Goellner JR. Metastatic papillary cancer of the neck. A diagnostic dilemma. *Head Neck* . 1992;14:113â€“118.

16.Hwang C-F, Wu C-M, Su C-Y, et al. A long-standing cystic lymph node metastasis from occult thyroid carcinomaâ€“-report of a case. *J Laryngol Otol* . 1992;106:932â€“934.

17.Matsuda M, Najumo S, Koyama H, et al. Occult thyroid cancer discovered by fine-needle aspiration cytology of cervical lymph node: a report of three cases. *Diagn Cytopathol* . 1991;299â€“303.

18.Lang N, Borrusels H, Bayer L. Occult carcinomas of the thyroid. Evaluation of 1020 sequential autopsies. *Am J Clin Pathol* . 1988;90:72â€“76.

19.Kasai N, Sakamoto A. New subgrouping of small thyroid carcinomas. *Cancer* . 1987;60:1767â€“1770.

20.Aldabagh SM, Trujillo YP, Taxy JB. Occult medullary thyroid carcinoma: unusual

histologic variant presenting with metastatic disease. *Am J Clin Pathol* . 1986;85:247â€“250.

21.Maceri DR, Babyak J, Ossakow S. Lateral neck mass. Sole presenting sign of metastatic thyroid cancer. *Arch Otolaryngol Head Neck Surg* . 1986;112:47â€“49.

22.Harach RH, Franssila KO. Occult papillary carcinoma of the thyroid appearing as lung metastasis. *Arch Pathol Lab Med* . 1984;108:529â€“530.

23.Naruse T, Koike A, Kanemitsu T, et al. Minimal thyroid carcinoma: a report of nine cases discovered by cervical node metastasis. *Jpn J Surg* . 1984;14:118â€“121.

24.Laskin WB, James PL. Occult papillary carcinoma of the thyroid with pulmonary metastases. *Hum Pathol* . 1983;31:83â€“85.

25.Lloyd RV, Beierwaltes WH. Occult sclerosing carcinoma of the thyroid. Potential for aggressive biologic behaviour. *South Med J* . 1983;76:437â€“439.

26.Hoie J, Stenwig AE, Kullmann G, et al. Distant metastases in papillary thyroid cancer. A review of 91 patients. *Cancer* . 1988;61:1â€“6.

27.Strate SM, Lee EL, Childers JH. Occult papillary carcinoma of the thyroid with distant metastasis. *Cancer* . 1984;54:1093â€“1100.

28.Brodner RA, Berman AJ, Wisniewski M, et al. Thyroid carcinoma presenting as epidural metastasis with spinal cord compression. *Mt Sinai J Med* . 1975;42:307â€“315.

29.Patchefsky AS, Keller LB, Mansfield CM. Solitary vertebral column metastasis from occult sclerosing carcinoma of the thyroid gland. *Am J Clin Pathol* . 1970;53:596â€“601

30.Sampson R, Olea H, Kay CR, et al. Metastasis from occult thyroid carcinoma: an autopsy study from Hiroshima and Nagasaki, Japan. *Cancer* . 1970;25:803â€“811.

31.Park CS, Min JS. Lateral neck mass as the initial manifestation of thyroid carcinoma. *Head Neck* . 1989;11:410â€“413.

32.Vassilopoulou-Sellin R, Weber RS. Metastatic thyroid cancer as an incidental finding during neck dissection: significance and management. *Head Neck* . 1962;14:451â€“463.

33.Cinberg JZ, Silver CE, Molnar JJ, et al. Cervical cysts: cancer until proven otherwise. *Laryngoscope* . 1982;92:27â€“30.

34.Silverman JF, Finley JL, Park KH, et al. Psammoma bodies and optically clear nuclei in bronchioloalveolar cell carcinoma: diagnosis by fine needle aspiration biopsy with histologic and ultrastructural confirmation. *Diagn Cytopathol* . 1985;1:205â€“215.

35.Weiland JE, de Los Santos E, Mazzafari EL, et al. Hemoptysis as the presenting manifestation of thyroid carcinoma. *Arch Intern Med* . 1989;149:1693â€“1694.

36.Chariot P, Feliz A, Honnet I. Miliary opacities diagnosed as lung metastases of a thyroid carcinoma after 13 years of stability. *Chest* . 1993;104:981â€“982.

37.Hanta I, Akali S, Kuleci S, et al. A rare case of HÃ¼rthle cell carcinoma with endobronchial metastasis. *Endocr J* . 2004;51:155â€“157.

38.Kintanar EB, Giordano T, Thompson NW, et al. Granular cell tumor of trachea masquerading as HÃ¼rthle cell neoplasm on fine-needle aspirate: a case report. *Diagn Cytopathol* . 2002;22:379â€“382.

39.Vernon AN, Sheelar LR, Biscotti CV, et al. Pleural effusion resulting from metastatic papillary carcinoma of the thyroid. *Chest* . 1992;101:1448â€“1450.

40.Hyman MP. Papillary and undifferentiated thyroid carcinoma presenting as a metastatic papillary serous effusion: a case report. *Acta Cytol* . 1979;23:483â€“486.

41.Woolner LB, Lemmon ML, Beahrs OH, et al. Occult papillary carcinoma of the thyroid gland: a study of 140 cases observed in a 30-year period. *J Clin Endocrinol* . 1960;20:89â€“105.

42.Heimann A, Moll U. Spinal metastasis of a thyroglobulin-rich HÃ¼rthle cell carcinoma detected by fine needle aspiration. Light and electron microscopic study of an unusual case. *Acta Cytol* . 1989;33:639â€“644.

43.Pritchett DD, Ali SZ. Metastatic medullary thyroid carcinoma in a breast fine needle aspiration: cytopathologic findings. *Acta Cytol* . 1998;42:446â€“448.

44.Ordonez NG, Katz RL, Luma MA, et al. Medullary thyroid carcinoma metastatic to breast diagnosed by fine needle aspiration biopsy. *Diagn Cytopathol* . 1988;4:254â€“257.

45.Salvatori M, Perotti G, Rufini V, et al. Solitary liver metastasis from HÃ¼rthle cell thyroid cancer: a case report and review of the literature. *J Endocr Invest* . 2004;27:52â€“56.

46.de Andres IC, Castellano Megias VM, Ballestin CC, et al. Hepatic metastases from the spindle cell variant of medullary thyroid carcinoma: report of a case with diagnosis by fine needle aspiration biopsy. *Acta Cytol* . 2001;45:1022â€“1026.

47.Bonetto S, Pagano F, Bianco R, et al. Hepatic metastases from medullary thyroid carcinoma after the eradication of primitive tumor: cytologic and radiologic aspects. *Diagn Cytopathol* . 1999;21:43â€“45.

48.McWilliams RR, Giannini C, Hay ID, et al. Management of brain metastases from thyroid carcinoma. A study of 10 pathologically confirmed cases over 25 years. *Cancer* . 2003;98:356â€“363.

49.Kapusta LR, Taylor M, Ang LC, et al. Cytologic diagnosis of a solitary brain metastasis from papillary carcinoma of the thyroid. *Acta Cytol* . 1999;43:432â€“434.

50.Dutton JJ, Barbour HI. HÃ¼rthle cell carcinoma metastatic to uvea. *Cancer* . 1994;73:163â€“167.

51.Prasson D. Follicular carcinoma of the thyroid presenting as scalp metastasis. *Acta Cytol* . 1998;42:451â€“452.

52.de Erenchun R, Esphana A, Idoate MA, et al. Cutaneous metastasis from a follicular carcinoma of the thyroid. *Arch Derm Venereol* . 1993;73:154â€“156.

53.Vives R, Valcayo A, Menendez E, et al. Follicular carcinoma metastatic to the skin. *J Am Acad Dermatol* . 1992;27:276â€“277.

54.Doutre MS, Beylot C, Baquey A, et al. Cutaneous metastasis from papillary carcinoma of the thyroid. A case confirmed by monoclonal antithyroglobulin antibody. *Dermatologica* . 1988;177: 241â€“243

55.Mayayo E, Blazquez S, Gomez-Aracil V, et al. Spleen metastasis from thyroid carcinoma. Report of a case with diagnosis by fine needle aspiration cytology. *Acta Cytol* . 2003;47:1116â€“1168.

56.Kini H, Pai RR, Kalpana S. Solitary parotid metastasis from columnar cell carcinoma of the thyroid: a diagnostic dilemma. *Diagn Cytopathol* . 2003;28:72â€“75.

57.Kaplan AS, van Heerden JA, McMahon MM, et al. Follicular carcinoma of the

thyroid presenting with hematuria: a case report. *Surgery* . 1986;100:572â€“575.

Editors: Kini, Sudha R.
Title: *Thyroid Cytopathology: A Text and Atlas, 1st Edition*

Copyright Â©2008 Lippincott Williams & Wilkins

16

Metastatic Malignancyto the Thyroid

The thyroid gland is a rare site for metastatic malignancy. Clinically significant metastatic disease is not commonly encountered,1, 2, 3, 4, 5, 6, 7, 8, 9 but the incidence of thyroid involvement in patients with extensive malignant disease is reported to be in the range of 0.19% to 24.2% as discovered at autopsy.10, 11, 12, 13 At the Mayo Clinic,14 only 30 cases of metastatic thyroid cancers were reported from a series of 1,161 thyroid cancers over a period of 25 years. Our own series15 included 22 cases of 593 thyroid cancers over a period of 9 years. Chacho et al.16 reported 8 metastatic tumors out of 61 malignant thyroid lesions, while the incidence of 0.1% or 25 metastatic cancers out of 25,000 aspiration biopsies reported by Schmidt et al.17 is extremely low.

A thyroid nodule occurring in a patient with a history of extrathyroidal cancer may be a diagnostic problem, because it could represent a metastasis from an extrathyroidal malignancy, a primary thyroid cancer, or a benign thyroid lesion. Fanning and Katz18 reported 63 extrathyroidal cancer patients with thyroid nodules over a period of 8 years who had fine- needle biopsy procedures. Their data revealed 46 benign lesions, 4 primary malignancies, 11 metastases, and 2 inconclusive results. This study not only revealed a higher incidence of metastatic disease in patients with a history of extrathyroidal malignancy, but also that the primary thyroid cancer occurs in a significant number of these patients.

Metastases to the thyroid are most often multifocal and variable in size in autopsy series. In clinical series, they are more commonly solitary and present as a nodule, and may attain large dimensions. Malignancy originating in neighboring organs tends to

involve a single lobe and tend to present as a large mass.1 The great majority of the patients with metastatic disease to the thyroid are asymptomatic. Rarely, a metastatic malignancy may masquerade as primary thyroid cancer or present with symptoms of hyperthyroidism or subacute thyroiditis.19, 20, 21, 22, 23, 24, 25, 26, 27 The thyroid gland can harbor metastatic tumor from any part of the body, but four primary sites are listed as the most common source: kidney, 28, 29, 30, 31, 32, 33, 34 lung,35 breast,36, 37 and melanoma.38, 39, 40 The other sites42, 43, 44, 45, 46, 47, 48, 49 include the gastrointestinal tract, especially the colon41, 42; genital and urothelial malignancies salivary glands43; neuroendocrine tumors44, 45, 46; malignant lymphomas47; and soft- tissue sarcomas.48 The incidence of these primary sources involving the thyroid varies considerably in different studies. The thyroid gland may also be involved by direct spread from the cancers originating in the neighboring organs such as esophagus, larynx, pharynx, or trachea.1 These are usually squamous carcinoma or its morphologic variants. FNA has been valuable in the diagnosis of metastatic disease and the management, especially when the patients have had a history of extrathyroidal cancer and an advanced disease.49, 50, 51, 52, 53

MICROSCOPIC FEATURES

Willis13 described three histologic patterns of metastatic tumors to the thyroid: (i) multiple small but discrete foci less than 2 mm, (ii) a single discrete clinically palpable nodule; and (iii) diffuse widespread parenchymal involvement.

CYTOPATHOLOGIC FEATURES

The cytologic pattern of a metastatic tumor depends upon the manner in which the thyroid is involved by the secondary neoplasms (Table 16.1, Figs. 16.1, 16.2 and 16.3) and on the histologic type of the tumor as well as their stage of differentiation (Figs. 16.4, 16.5, 16.6, 16.7, 16.8, 16.9, 16.10, 16.11, 16.12, 16.13, 16.14, 16.15, 16.16, 16.17, 16.18, 16.19 and 16.20). The aspirated sample reveals two basic cytologic patterns. With metastatic foci less than 2 mm in size, the cytologic samples show an admixture of malignant cells and benign follicular cells (Fig. 16.1) Tumor diathesis is rare or absent. With a single, discrete, large palpable nodule or with diffuse widespread involvement, the aspirate shows only malignant cells (Figs. 16.2 and 16.3). The thyroid follicular cells are not present in the background and tumor diathesis is frequent, particularly in large tumors. Necrosis is also a characteristic of metastatic

colon carcinomas.

TABLE 16.1 CYTOHISTOLOGIC PATTERNS OF METASTATIC MALIGNANCY TO THE THYROID AND THEIR DIFFERENTIAL DIAGNOSIS

Histologic Pattern	Cytologic Pattern	Differential Diagnosis
A. Multiple small foci of metastatic tumor, less than 2 mm	Admixture of malignant cells and benign follicular cells; tumor diathesis absent	Degenerating follicular cells in nodular goiter
B. Single large discrete nodule	Large population of malignant cells; no thyroid follicular cells in the background; tumor diathesis frequent;	
	I. Malignant cells with squamous or glandular differentiation	Consistent with metastatic malignancy
	II. Medium- sized to	1. Anaplastic thyroid

Histologic Pattern	Cytologic Pattern	Differential Diagnosis
	large, round to polyg-onal malignant cells with no functional or architectural differentiation	carcinoma 2. Poorly differentiated primary or metastatic squamous cell-carcinoma 3. Poorly differentiated adenocarcinoma 4. Malignant melanoma 5. Malignant large cell lymphoma
	III. Small malignant cells	1. Anaplastic thyroid carcinoma with small cell pattern 2. Medullary thyroid carcinoma 3. Basaloid squamous cell carcinoma 4. Metastatic neuroendocrine carcinomas including small cell carcinomas 5. Malignant lymphoma 6. Malignant melanoma
	III. Spindle cell pattern	1. Anaplastic thyroid carcinoma, spindle cell pattern

Histologic Pattern	Cytologic Pattern	Differential Diagnosis
		2. Medullary thyroid carcinoma 3. Soft- tissue sarcoma 3. Metastatic carcinosarcoma 4. Malignant melanoma
	IV. Clear cell pattern	1. Anaplastic thyroid carcinoma 2. Metastatic renal cell carcinoma
C. Diffuse and widespread involvement	Same as above	Same as above

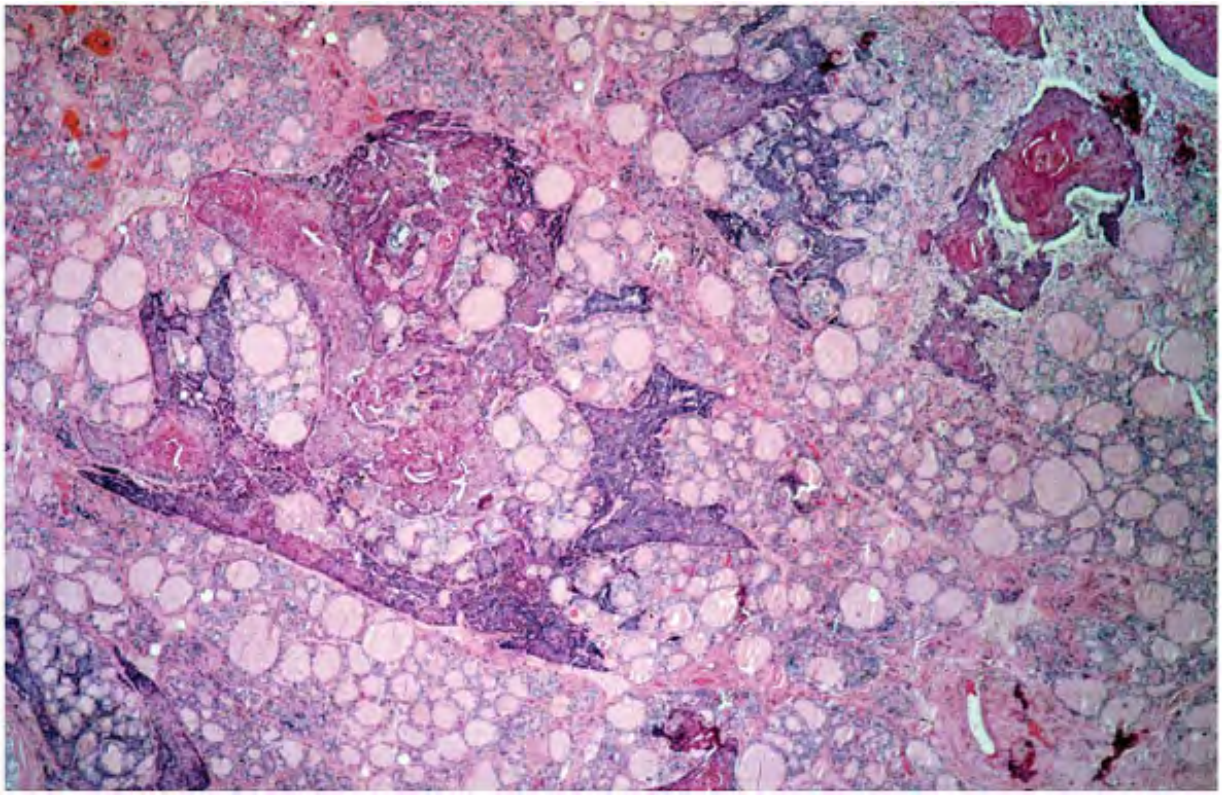

Figure 16.1. Metastatic squamous cell carcinoma of the lung infiltrating in the form of multiple foci less than 2 mm. Note intact thyroid follicles in between the infiltrating tumor.

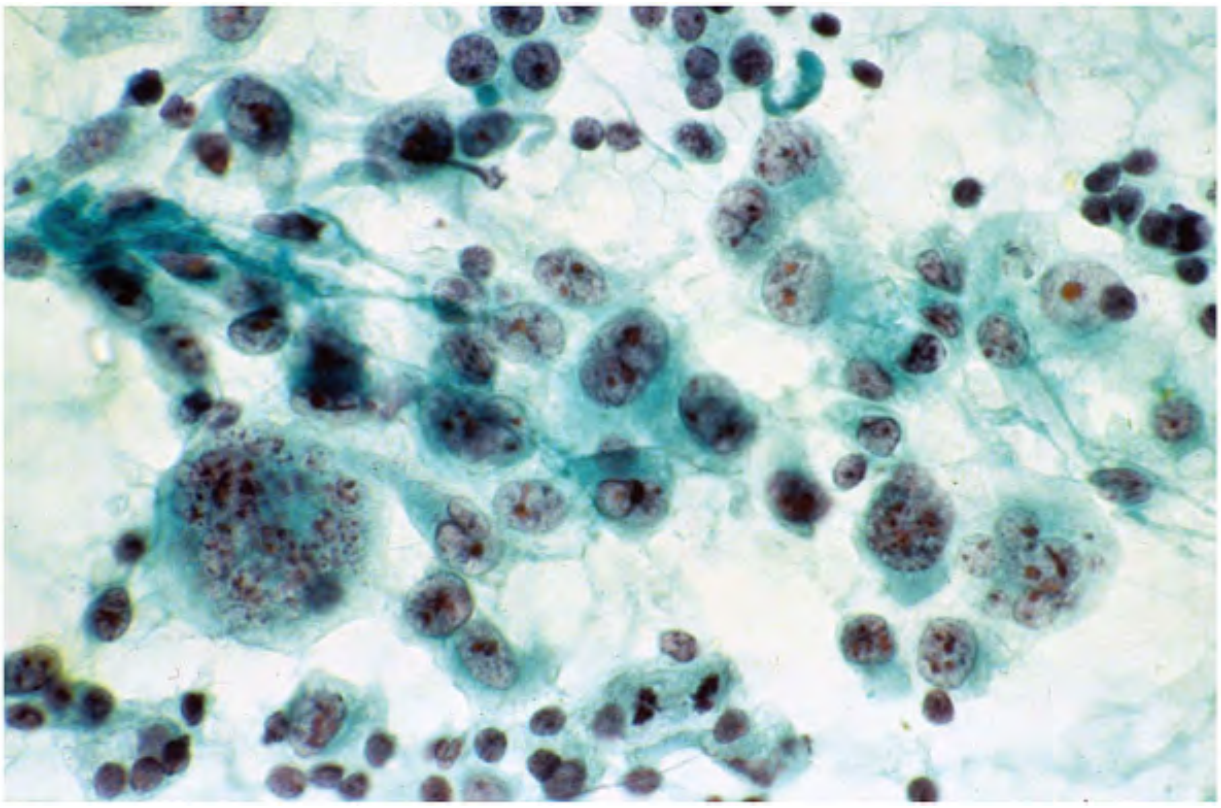

Figure 16.2. Cytologic pattern of the metastases, smaller than 2 mm, generally includes an admixture of cancer cells and the benign follicular cells. Note very pleomorphic malignant cells with benign follicular cells in the background.

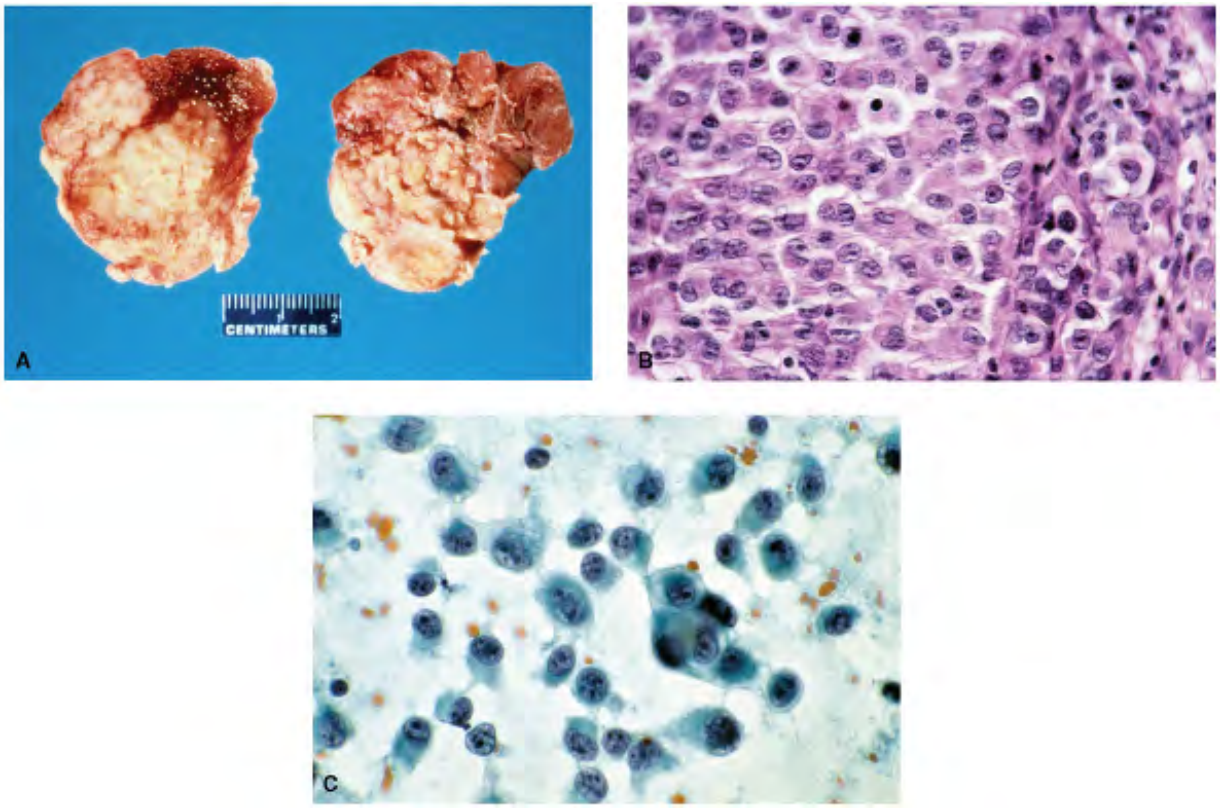

Figure 16.3. A. Metastatic tumor occurring as a distinct large, palpable nodule. Fine- needle biopsy is utilized to differentiate between a benign thyroid lesion, primary thyroid cancer, or metastasis. This is a metastatic malignant melanoma in a young male with a history of melanoma. B. The histologic section of the resected thyroid showing a solid growth pattern of poorly differentiated malignant cells, consistent with malignant melanoma. C. FNA of the mass showing amelanotic melanoma cells. Without a history of primary malignancy, these undifferentiated malignant cells must be differentiated from a primary anaplastic carcinoma.

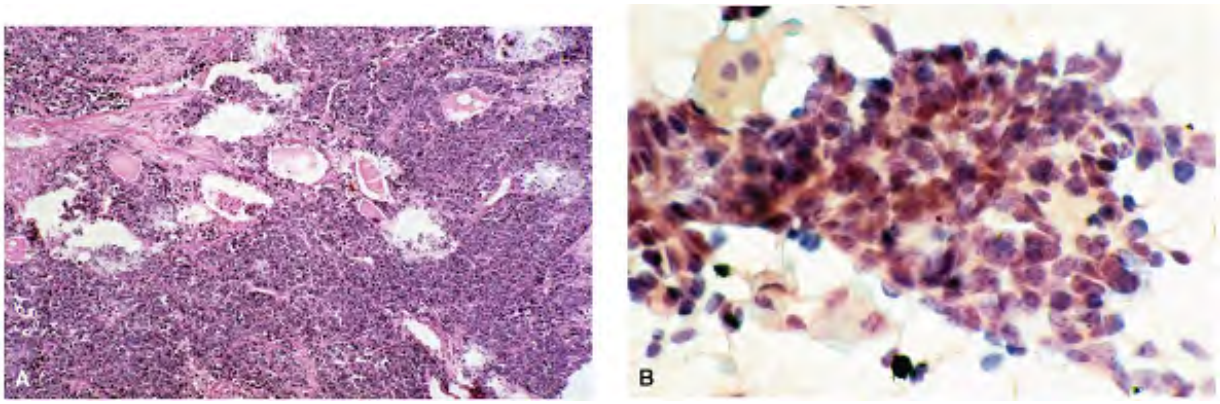

Figure 16.4. A. Metastatic carcinoma diffusely involving the thyroid parenchyma. This pattern will yield only malignant cells in FNA biopsy. B. FNA of the above thyroid mass showing small cell carcinoma cells originating from the lung. This tumor first presented as a thyroid nodule.

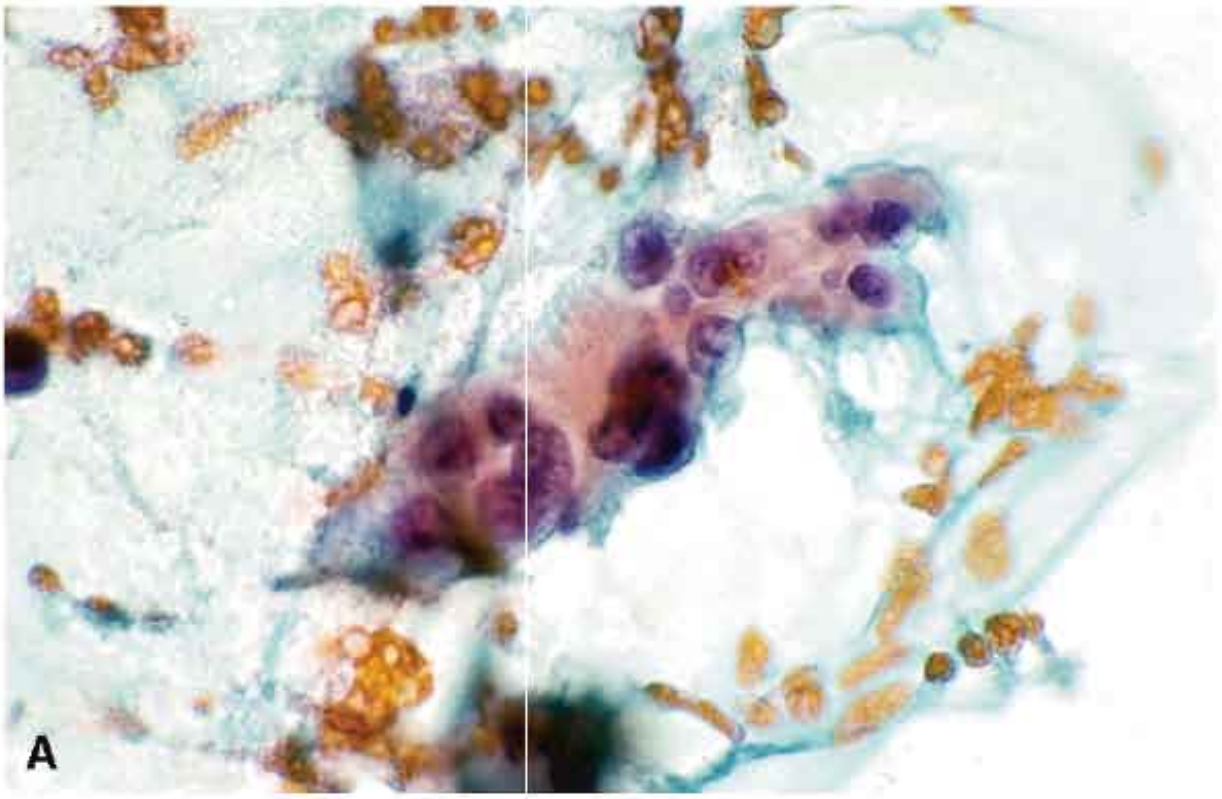
A

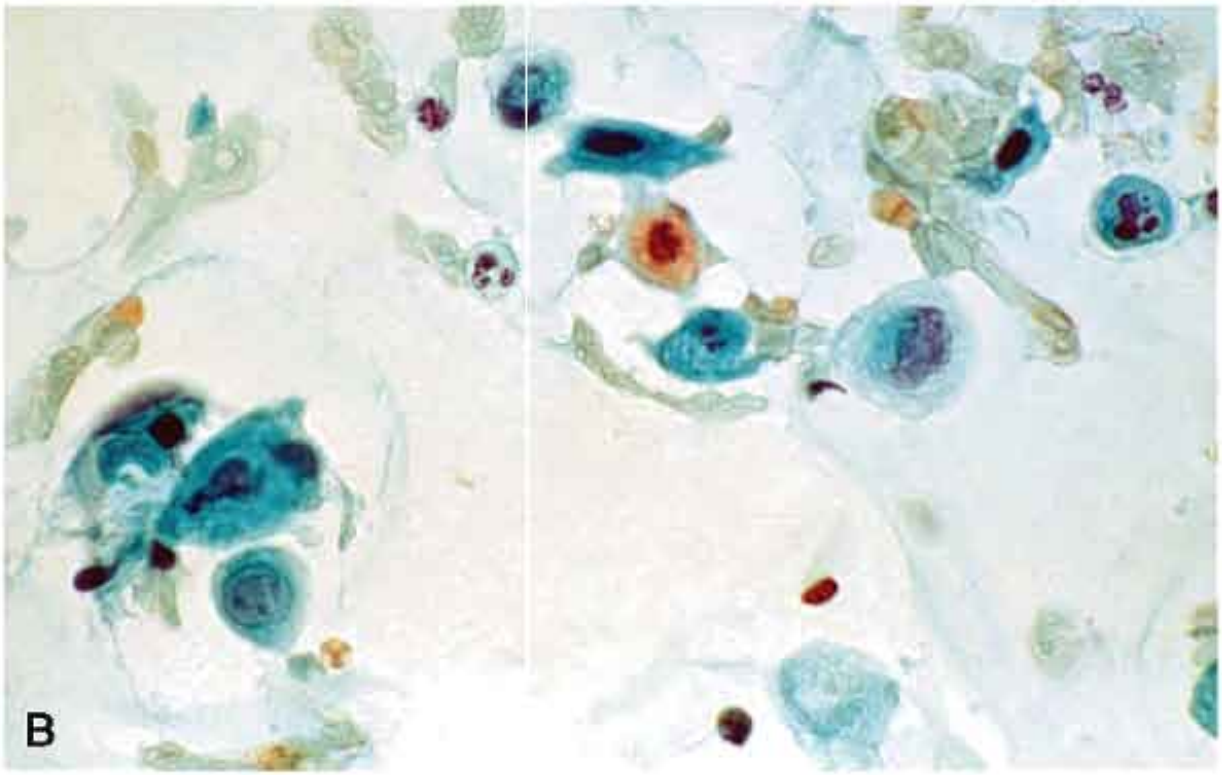
B

Figure 16.5. A and B. Well- differentiated squamous carcinomas of the lung, metastatic to the thyroid. A cytologic pattern of well- differentiated squamous cancer cells with keratinization is more consistent with the diagnosis of metastasis because a primary squamous cancer of the thyroid is very uncommon. A history of primary cancer elsewhere is critical.

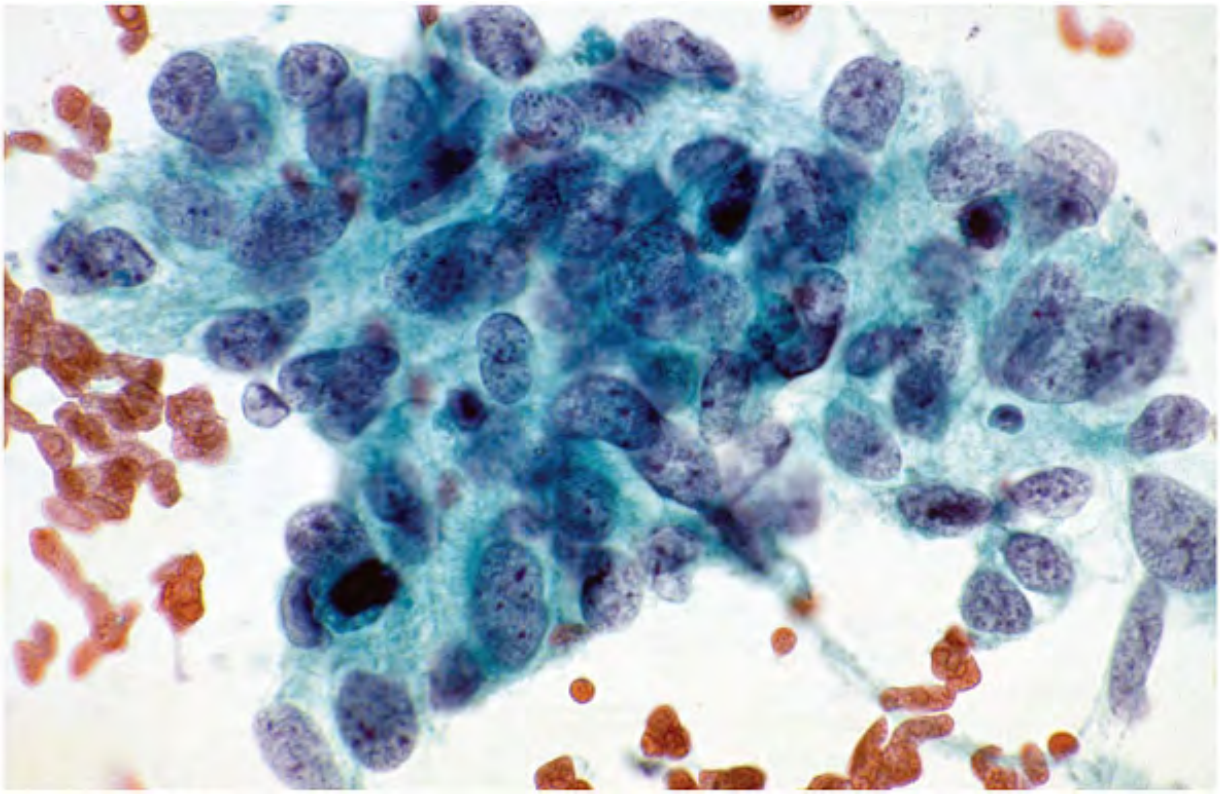

Figure 16.6. FNA of a poorly differentiated squamous cell carcinoma of the esophagus masquerading as goiter. These malignant cells must be differentiated from anaplastic carcinoma of the thyroid.

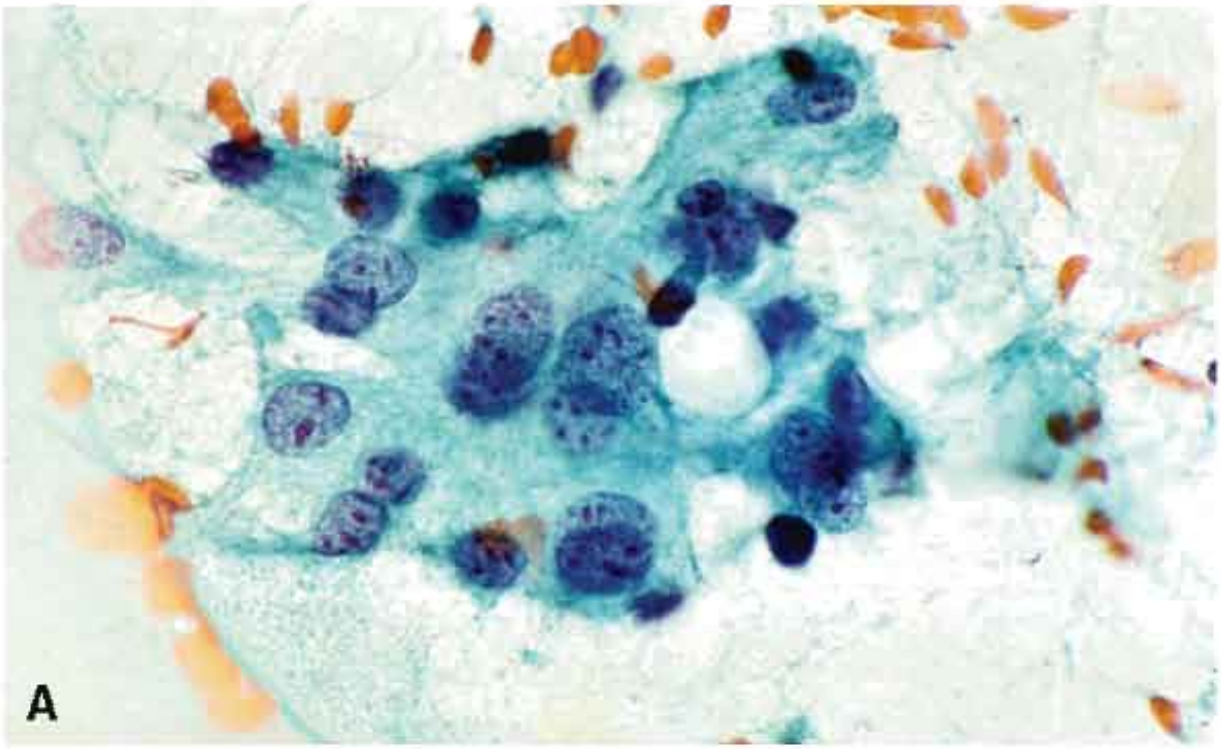
A

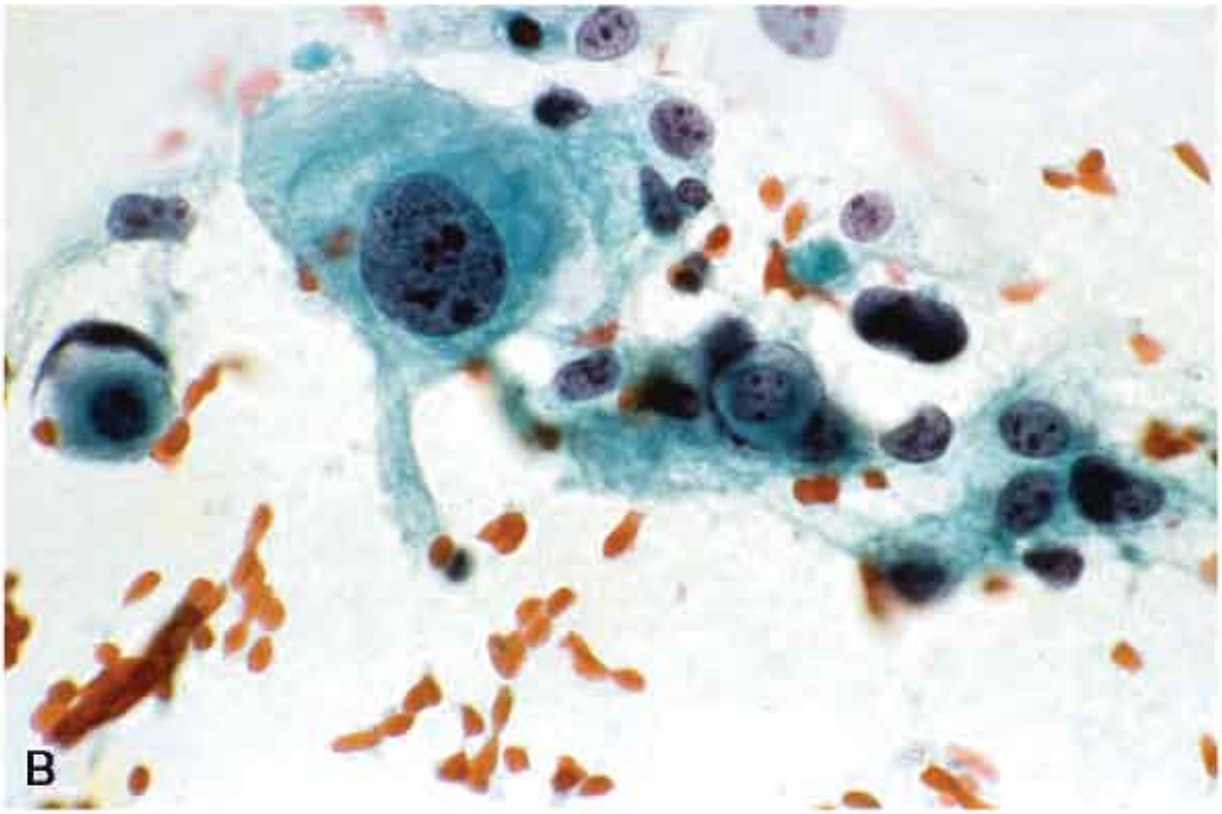
B

Figure 16.7. FNA of a poorly differentiated squamous carcinoma of the esophagus that infiltrated the thyroid and clinically presented as goiter.

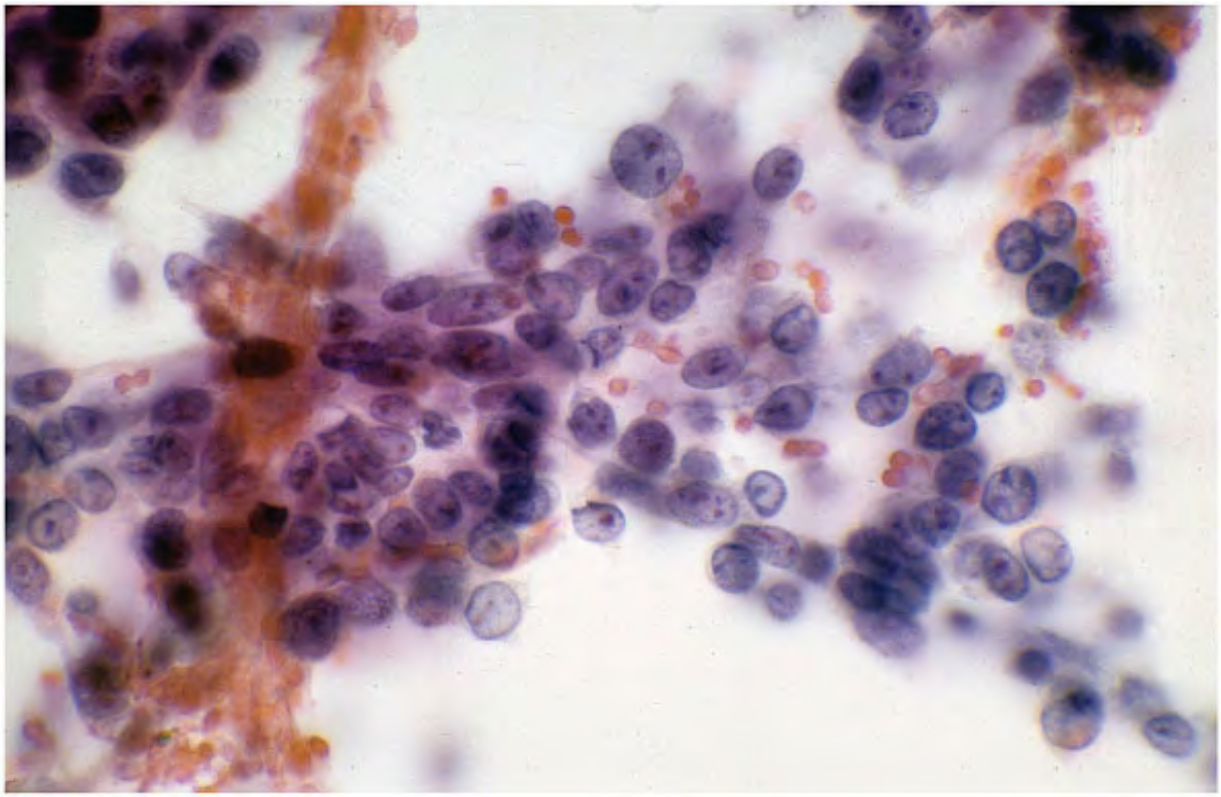

Figure 16.8. FNA of a solitary thyroid nodule in a patient with a history of squamous carcinoma of the upper aerodigestive tract, showing poorly differentiated malignant cells. There was no evidence of tumor metastasis anywhere else in the body. This case is difficult to differentiate from a primary squamous cell carcinoma.

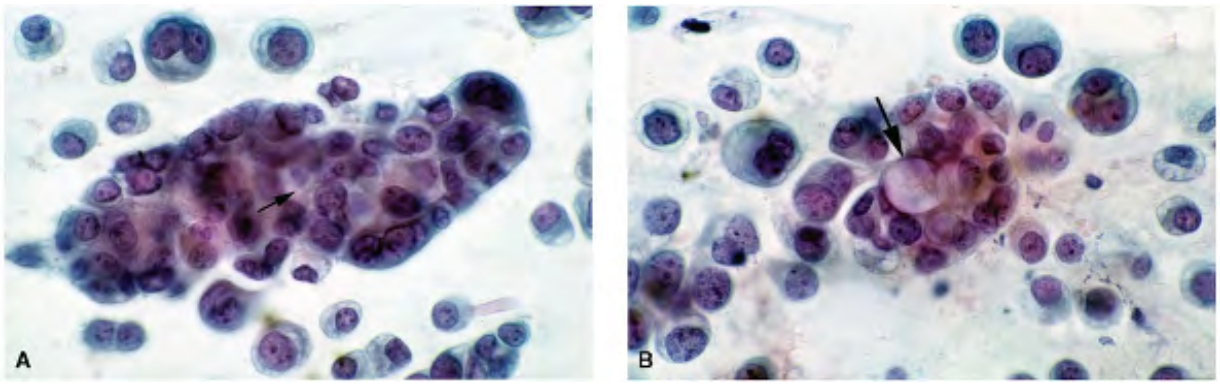

Figure 16.9. FNA of a metastatic pulmonary adenocarcinoma. The malignant cells are extremely pleomorphic. The architecture of the tissue fragments with acinar pattern (*arrows*) suggests an adenocarcinoma.

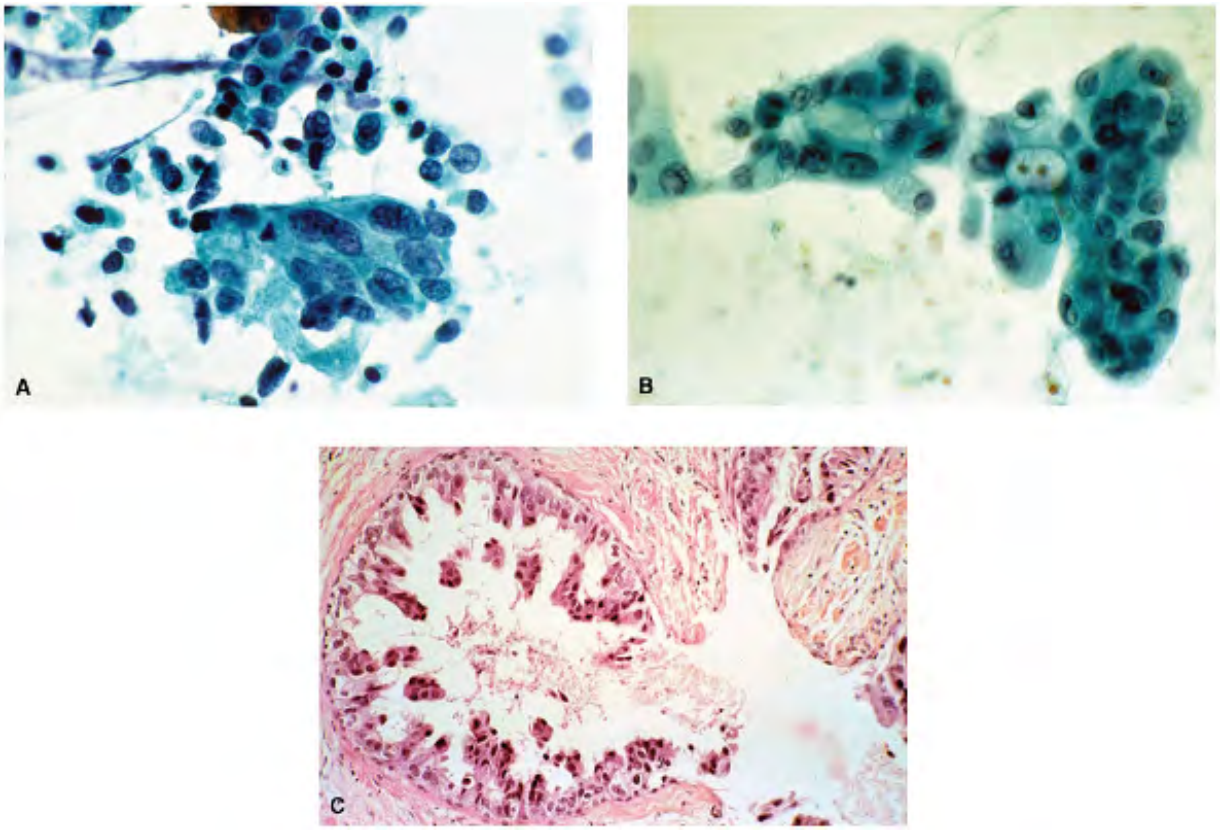

Figure 16.10. FNA of a metastatic adenocarcinoma of the colon to the thyroid. A. The syncytial type tissue fragment of malignant cells containing elongated nuclei in a picket fence arrangement is characteristic of colonic adenocarcinoma. Note benign follicular cells in the background. B. Another field showing syncytial tissue fragments of malignant cells with acinar pattern. Note cytoplasmic vacuoles. C. Histologic section of the excised tumor confirming colonic origin.

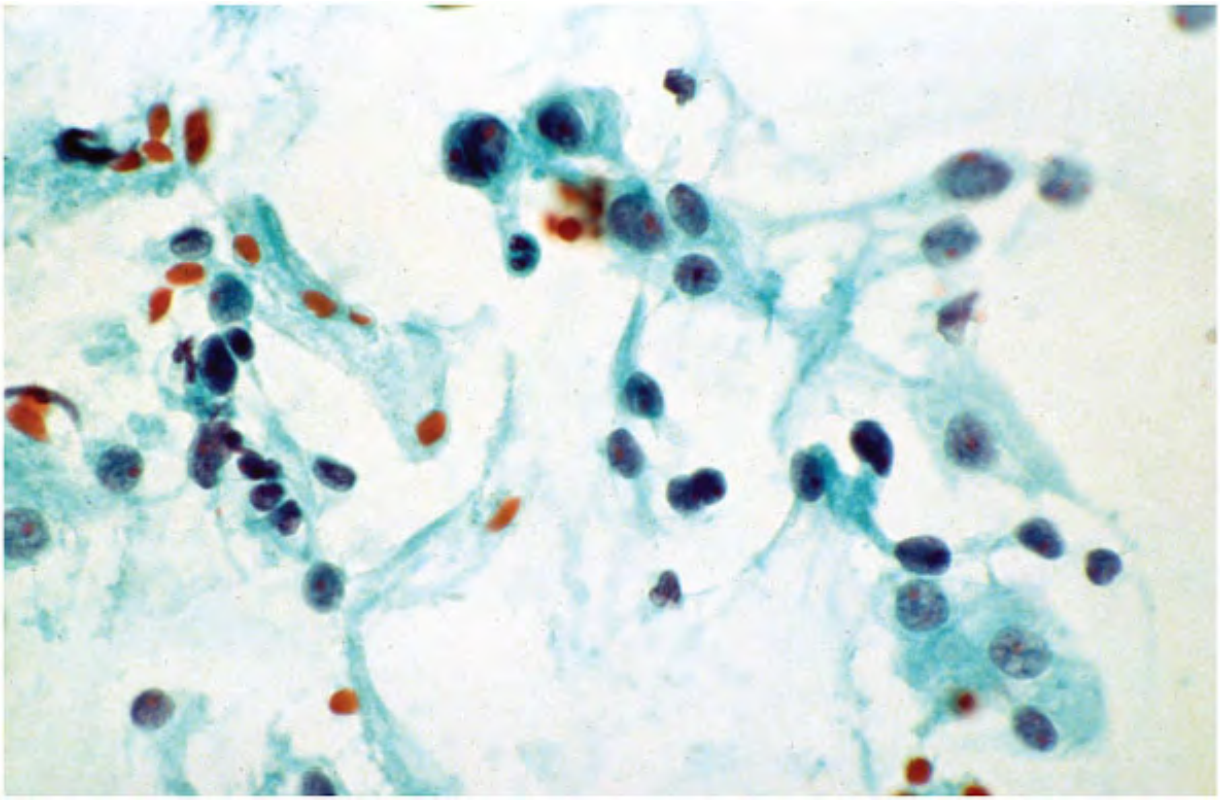

Figure 16.11. Metastatic renal cell carcinoma. The carcinoma is clear cell type, as noted by pale cytoplasm and disrupted cell borders resulting in bare nuclei that are small and uniform.

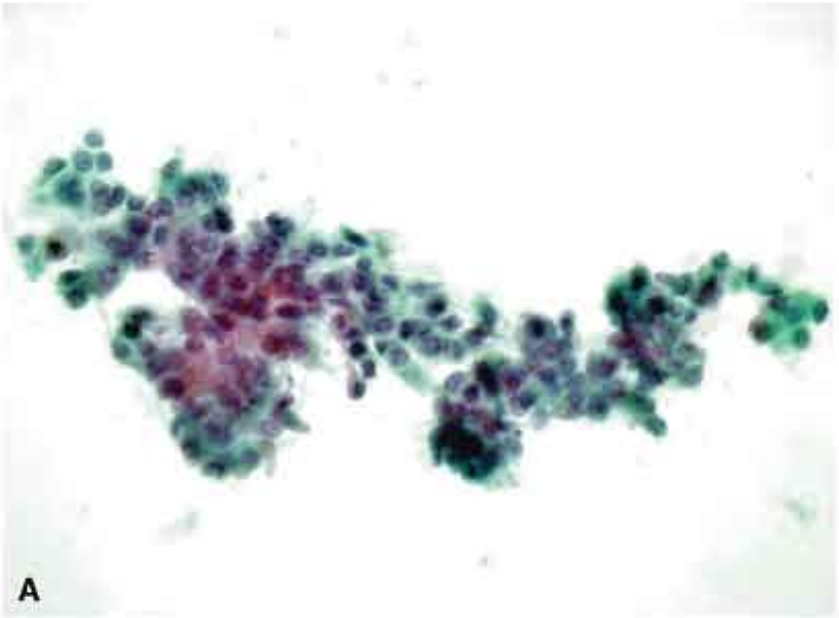
A

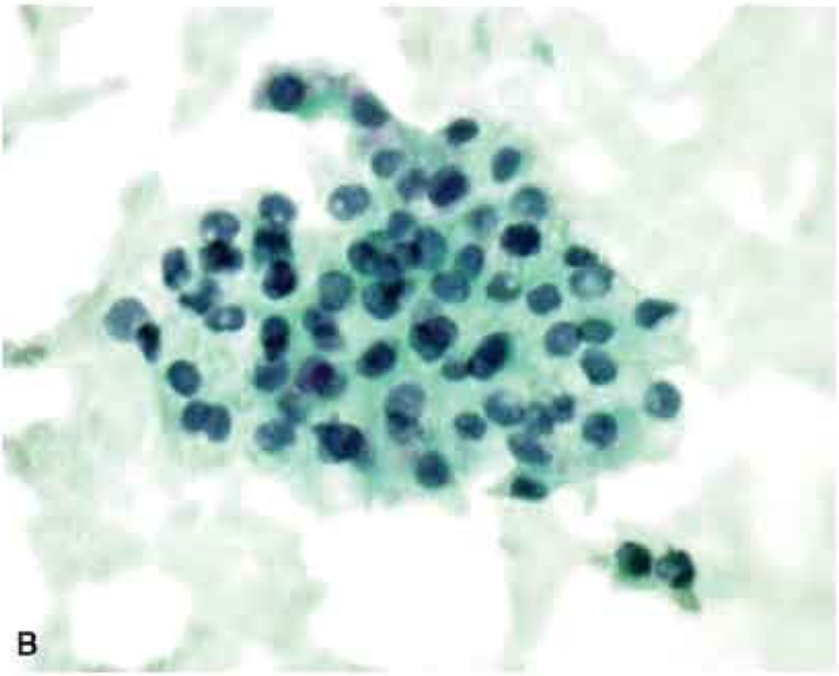
B

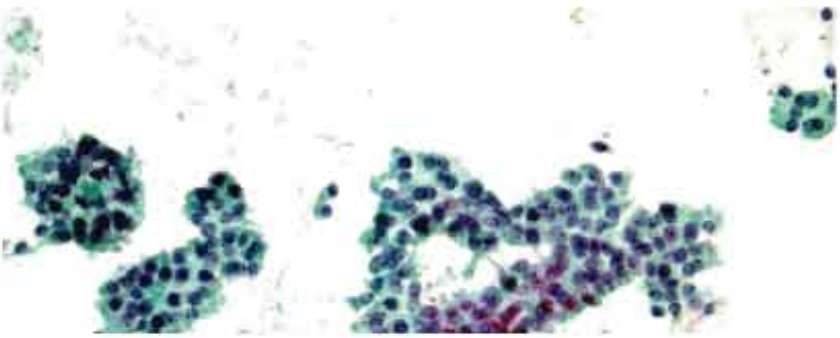

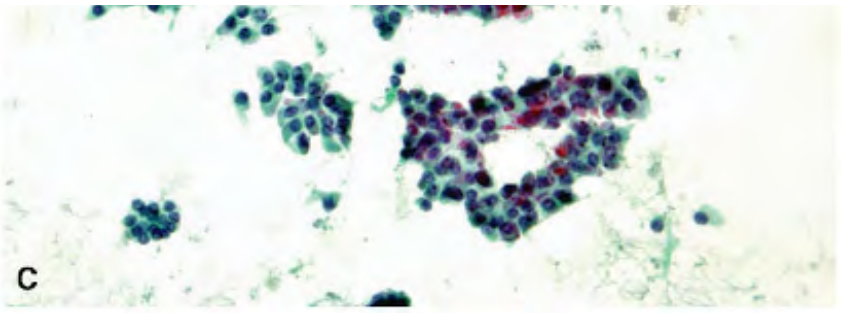

Figure 16.12. A,B. Another example of metastatic renal cell carcinoma to the thyroid. The history of nephrectomy for renal cell carcinoma, in the remote past, was not available at the time of FNA biopsy of the solitary thyroid nodule. The malignant cells are in syncytial arrangement and have appreciable granular cytoplasm with uniform nuclei. Note the morphologic resemblance to HÃ¼rthle cell tumors. C. FNA of a HÃ¼rthle cell carcinoma for comparison.

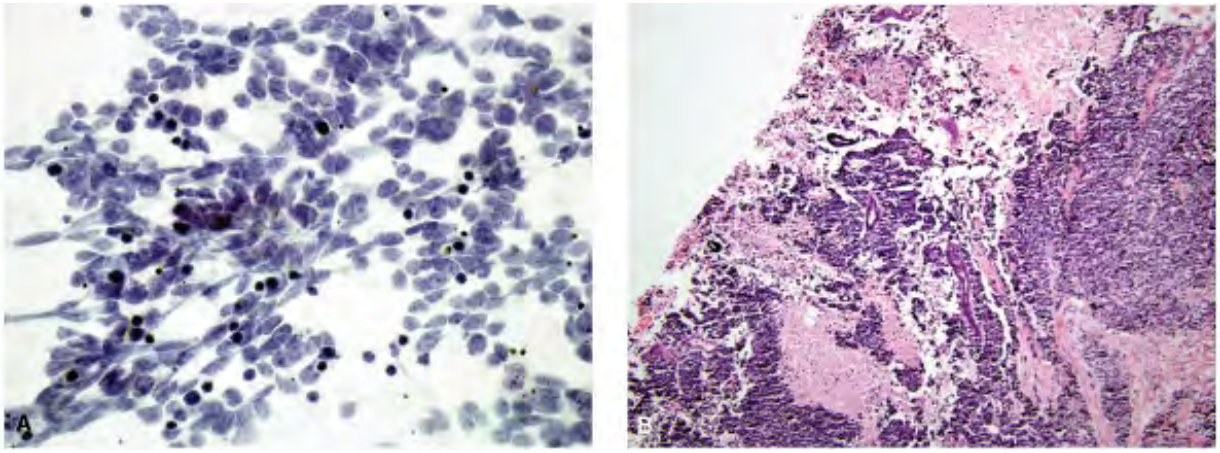

Figure 16.13. A. FNA of a small cell carcinoma of the lung clinically presenting as goiter. The aspirate is cellular, demonstrating the typical cytomorphologic pattern of small cell carcinoma. Note oval to oblong nuclei with dense chromatin, nuclear molding, and karyorrhexis. B. Cell block preparation of the aspirate confirming the cytologic diagnosis of small cell carcinoma.

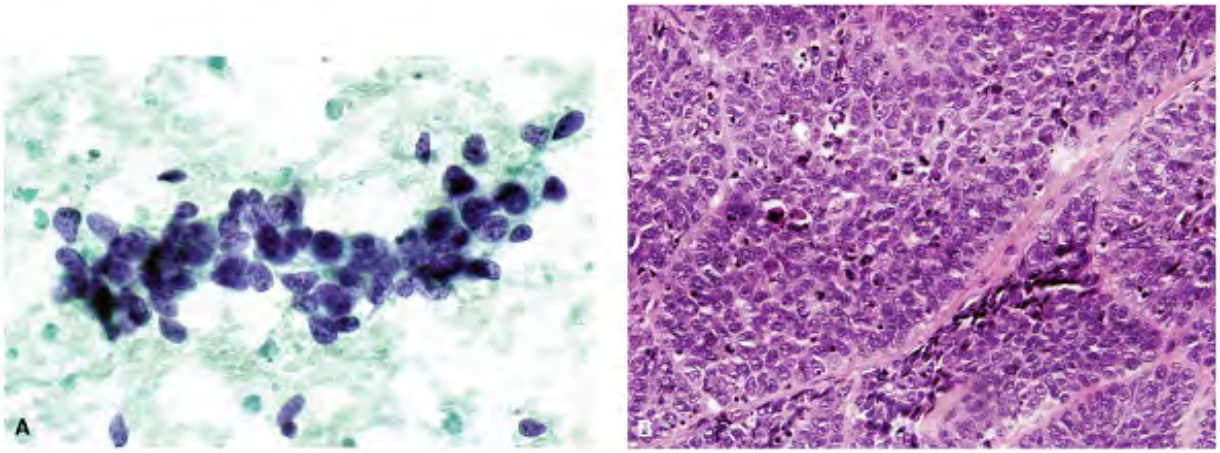

Figure 16.14. A. FNA of a rapidly growing large thyroid mass. The malignant cells are small with very high N/C ratios and scant indiscernible cytoplasm. There is necrosis in the background. The differential diagnoses include: Insular carcinoma, metastatic small cell carcinoma, medullary carcinoma and malignant lymphoma. A large panel of immunostain performed was nondiagnostic except for cytokeratin. A surgical exploration revealed a large malignant neoplasm of the esophagus extending into the thyroid. B. Histologic section of the tumor showing basaloid squamous carcinoma. (Courtesy of Mithra Baliga, MD, University of Mississippi, Jackson.)

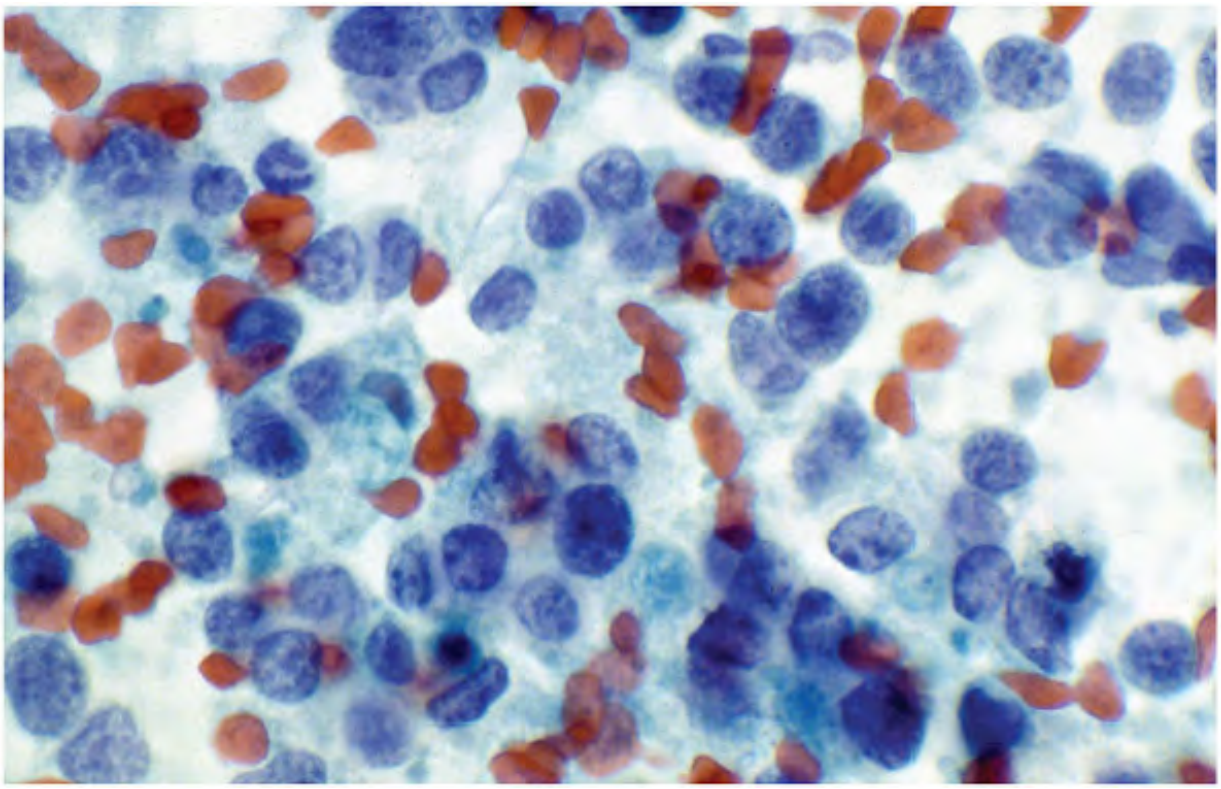

Figure 16.15. FNA of a thyroid nodule showing metastatic malignant non-Hodgkin's lymphoma. The aspirate shows poorly differentiated lymphoid cells consistent with the diagnosis of large cell lymphoma. Patient was subsequently found to have a generalized lymphadenopathy and an abdominal mass. Thyroid is more often involved by secondary lymphoma than a primary one.

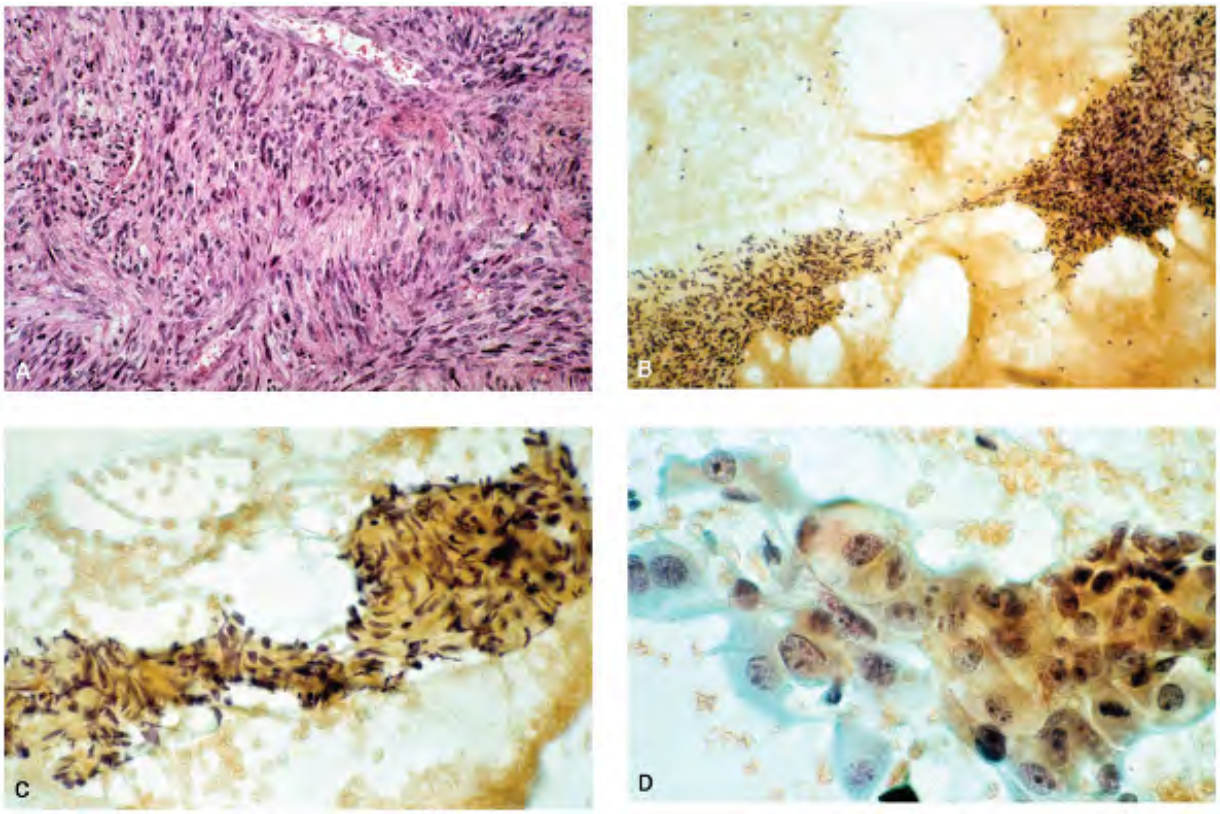

Figure 16.16. A patient with a history of leiomyosarcoma of the inferior vena cava and a mastectomy for duct adenocarcinoma of the breast developed a cold thyroid nodule. A. Histologic section of the leiomyosarcoma. B. FNA of the thyroid nodule showing large tissue fragments of spindle- shaped cells. C. Higher magnification highlighting the spindle cells in fascicles consistent with leiomyosarcoma. D. These malignant cells from the same aspirate appear epithelial in origin and suggest metastatic breast adenocarcinoma. The patient also had cutaneous metastases from leiomyosarcoma. Whether this case represents double metastases is not known, because histologic confirmation is not available and no ancillary tests were performed on cytologic material.

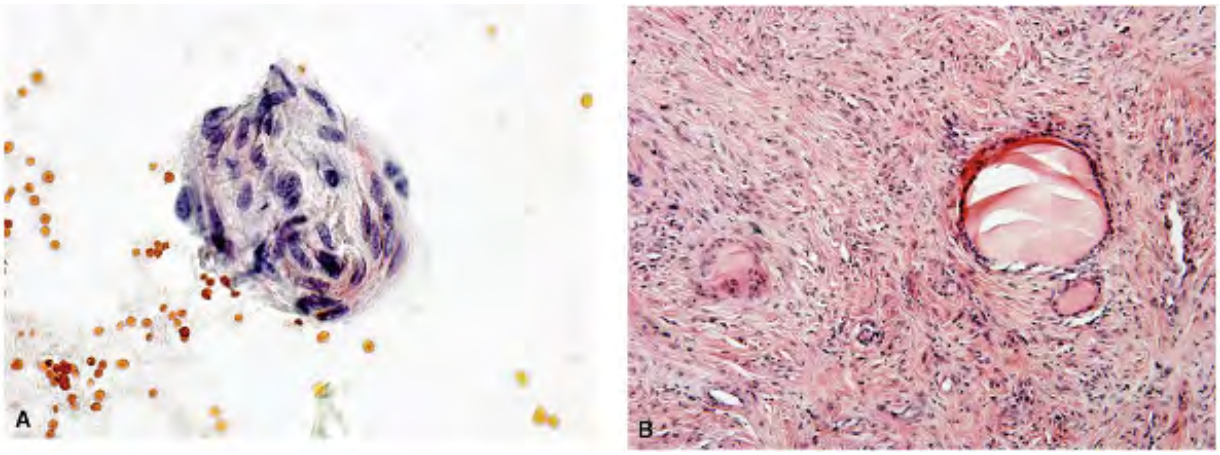

Figure 16.17. A. FNA of a metastatic malignant fibrous histiocytoma of the retroperitoneum to the thyroid. B. Histologic section of the resected thyroid showing a spindle cell tumor consistent with malignant fibrous histiocytoma.

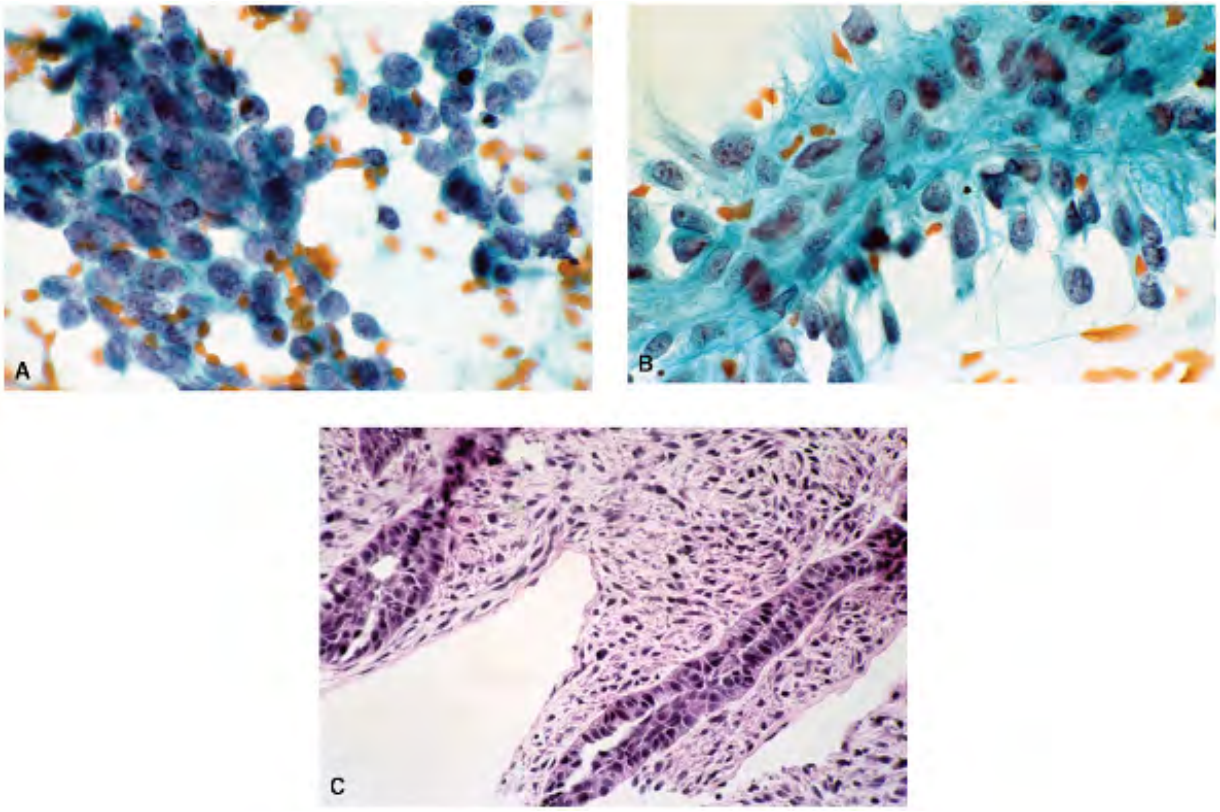

Figure 16.18. Metastatic carcinosarcoma of the esophagus infiltrating the thyroid, masquerading as goiter. A. Syncytial tissue fragment of malignant cells with glandular differentiation. B. A different field from the same case showing spindle- shaped malignant cells, suggesting sarcomatous differentiation. C. Histologic section of the excised tumor showing carcinosarcoma exhibiting both glandular and stromal components.

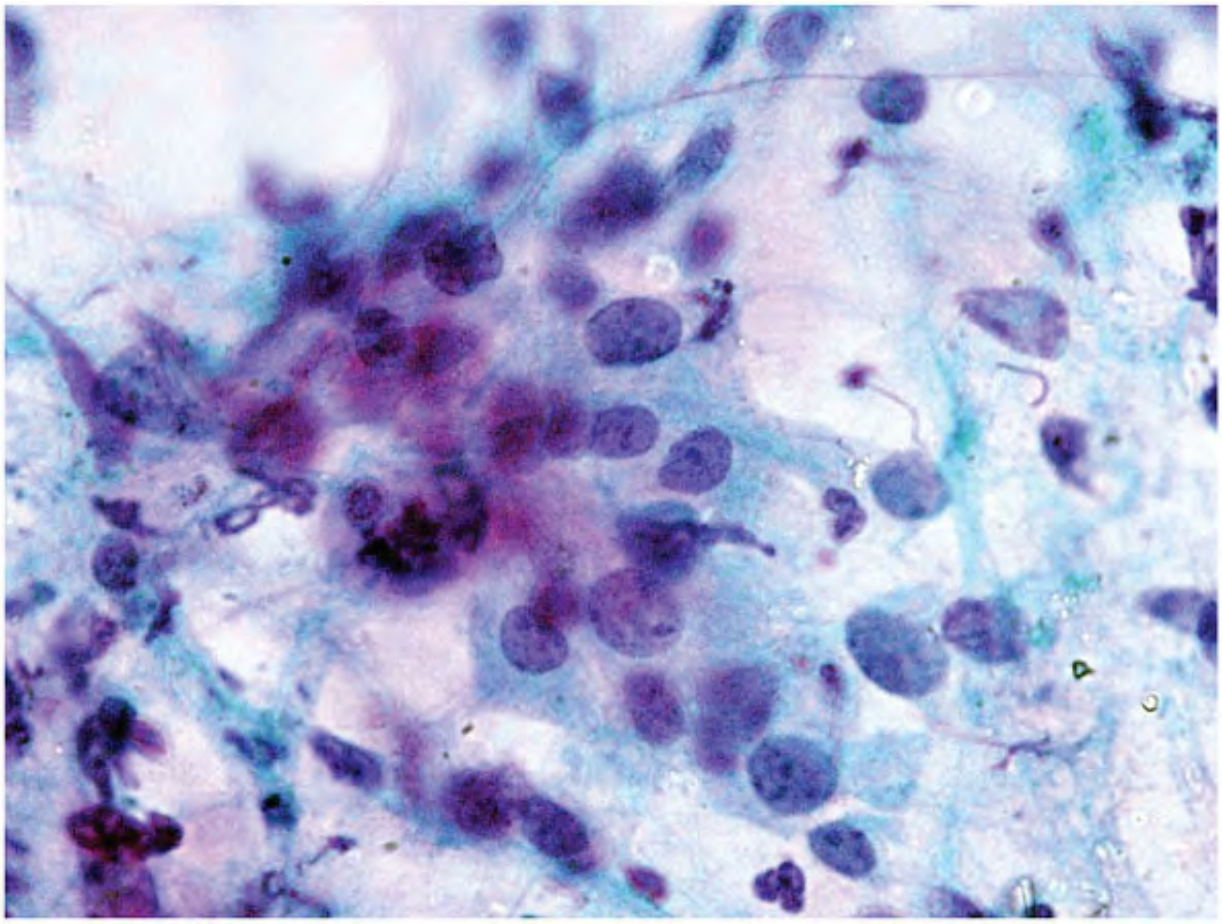

Figure 16.19. FNA of a metastatic carcinoma of the breast, metaplastic type to the thyroid. The cytologic pattern consists of a pleomorphic cell population with spindle cells. Positive reactivity to cytokeratin confirmed the epithelial nature of the tumor. (Courtesy of Yun Gong, MD, University of Texas, M.D. Anderson Cancer

Center, Houston.)

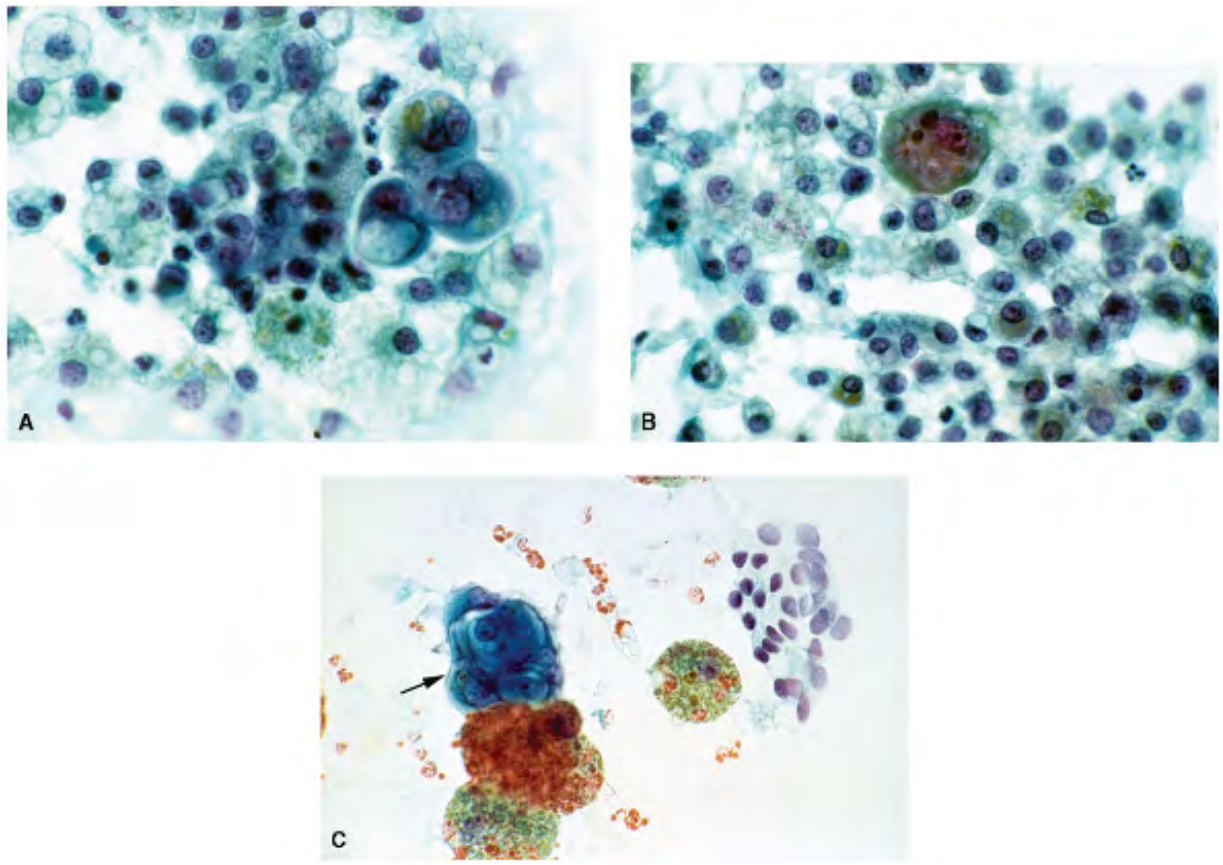

Figure 16.20. A,B. FNA of a thyroid nodule in an elderly woman. These degenerating follicular cells with atypical nuclei were considered to be metastatic carcinoma. Thyroidectomy did not confirm the diagnosis. C. Metastatic breast adenocarcinoma (*arrow*) in a background of benign follicular cells and hemosiderin- containing macrophages.

Metastatic squamous carcinomas are easily recognized when the malignant cells exhibit evidence of functional differentiation

such as keratin (Fig. 16.4) but the poorly differentiated ones must be distinguished from primary anaplastic carcinomas (Figs. 16.5, 16.6 and 16.7). Similarly, the acinar pattern and the presence of cytoplasmic vacuoles (Fig. 16.8) are diagnostic of adenocarcinomas. The presence of melanin pigment supports the diagnosis of malignant melanoma. However, amelanotic melanomas must be differentiated from primary anaplastic thyroid carcinomas (Fig. 16.2). The typical architectural patterns displayed by the tissue fragments of malignant cells, such as palisading or picket fence arrangement of nuclei, are highly indicative of colonic carcinomas (Fig. 16.9). Renal cell carcinomas are the most common malignant tumor to involve the thyroid secondarily (Figs. 16.10 and 16.11). Their cytologic presentation may pose problems if the history is not available.

P.361
P.362
P.363

The characteristic cytomorphology of small cell carcinoma of the lung depicting small cell size; round to oval nuclei; molding; compact chromatin; frequent mitotic figures; and karyorrhexis in the background allows easy identification of the primary source (Fig. 16.12). In fact, small cell carcinomas of the lung are known to present clinically as thyroid nodules before the primary malignancy is clinically evident. Small cell carcinomas should be differentiated from small cell medullary carcinomas, insular carcinomas, metastatic basaloid squamous carcinoma (Fig. 16.13), and malignant lymphomas (Fig. 16.14).

Soft- tissue sarcomas very rarely involve the thyroid gland. Since primary sarcomas of the thyroid are extremely rare, a primary spindle cell- type anaplastic thyroid carcinoma must be first ruled out when a spindle cell tumor is encountered. Metastatic sarcomas occur more frequently than the primary lesions (Figs. 16.15, 16.16, 16.17 and 16.18).

In general, metastatic tumors to the thyroid offer diagnostic difficulties when (i) the malignant cells are undifferentiated, (ii) the primary tumor is unknown, (iii) the primary cancer is remote or the history is unknown, or (iv) when there is cytomorphologic overlap between the metastatic tumor and primary thyroid cancers.

If the distinguishing cytologic features are absent, as is the case in most poorly differentiated cancers, their separation from primary anaplastic carcinoma of the

thyroid may cause a diagnostic dilemma (Figs. 16.3, 16.6, 16.7 and 16.8, 16.18). Ancillary diagnostic techniques such as histochemical or immunocytohistochemical stains are necessary to establish the diagnosis.[54]

The cytohistologic patterns of metastatic tumors and their differential diagnoses are listed in Table 16.1 and illustrated in Figures 16.4, 16.5, 16.6, 16.7, 16.8, 16.9, 16.10, 16.11, 16.12, 16.13, 16.14, 16.15, 16.16, 16.17, 16.18, 16.19 and 16.20. The features that help differentiate primary from secondary tumors are listed in Table 16.2. When the history of prior non- thyroidal malignancy is available, a review of previous cytologic/surgical material is extremely useful.

TABLE 16.2 DIFFERENTIATING FEATURES FOR PRIMARY VERSUS SECONDARY THYROID TUMORS

- History of primary cancer elsewhere in the body
- Presence of unremarkable thyroid follicular cells mixed with cancer cells favors a metastatic process
- Functional differentiation of cytoplasm of cancer cells (e.g., keratin or mucin secretions, melanin)
- Characteristic cytomorphology of ceratin types of neoplasms:
  - Small cells with compact nuclear chromatin, molding, frequent mitoses, and karyorrhexis (small cell carcinoma)
  - Small cells, uniform, round nuclei, with open chromatin pattern and nucleoli, high N/C ratios, and scant cytoplasm favor malignant lymphoma
  - Salt- and- pepper nuclear chromatin
- Architectural patterns of the tissue fragments of malignant cells:
  - Acinar or glandular pattern
  - Palisading of elongated nuclei with a picket- fence pattern

Metastatic tumors to the thyroid that share morphologic similarities with primary

thyroid cancers include renal cell carcinoma, neuroendocrine tumors, and malignant lymphomas. Renal cell carcinomas are known to metastasize several years

P.364

P.365

P.366

P.367

after the initial detection. Without the clinical history, the neoplasm may be mistyped. For example, cells of metastatic renal cell carcinoma with granular and clear cytoplasm morphologically resemble HÃ¼rthle cell carcinoma (Fig. 16.12).

A metastatic bronchioloalveolar carcinoma of the lung to the thyroid is very difficult to differentiate morphologically from a primary thyroid papillary carcinoma without appropriate immunostains.35 Likewise, metastases from neuroendocrine tumors to the thyroid gland, although rare, may be misinterpreted as medullary carcinoma.42, 43

False- positive diagnosis of metastatic malignancy is a possibility when the degenerating follicular cells containing atypical nuclei in nodular goiter mimic the cytologic presentation of small metastatic foci, as with benign follicular cells and malignant cells (Fig. 16.20).

P.368

REFERENCES

1.DeLellis R. In: DeLellis RA, Lloyd RV, Heitz PU, et al., eds. *Pathology and Genetics of Tumors of Endocrine Organs*. *World Health Organization Classification of Tumors*. Lyon; IARC Press; 2004;122â€“123.

2.Chen H, Nicol TL, Udelsman R. Clinically significant isolated metastatic disease to the thyroid gland. *World J Surg*. 1999;23;172â€“180.

3.Lin JD, Weng HF, Ho YS. Clinical and pathological characteristics of secondary thyroid cancer. *Thyroid*. 1998;8:149â€“153.

4.Lam KY, Lo CY. Metastatic tumors of the thyroid gland: a study of 79 cases in Chinese patients. *Arch Pathol Lab Med*. 1998;122:37â€“41.

5.Lin J- D, Weng H- F, Ho Y- S. Clinical and pathological characteristics of secondary thyroid cancer. *Thyroid*. 1998;8:149â€“153.

6.Nakhjavani MK, Gharib H, Goellner JR, van Heerden JA. Metastasis to the thyroid gland: a report of 43 cases. *Cancer*. 1997;79:574â€“578.

7.Wenig BM, Heffess C, Adair CF. *Atlas of Endocrine Pathology*. Philadelphia: Saunders; 1997:149â€“151.

8.Rosai J, Carcangiu ML, DeLellis RA. Tumors of the thyroid gland. In: Rosaij, Sobin LH, eds. *Atlas of Tumor Pathology*. Washington, DC: Armed Forces Institute of Pathology; 1993;289â€“296.

9.Watts NB. Carcinoma metastatic to the thyroid: prevalence and diagnosis by fine needle aspiration cytology. *Am J Med Sci*. 1987;293:13â€“17.

10.Shimaoka K, Sokal JE, Pickren JW. Metastatic neoplasms in the thyroid gland. Pathologic and clinical findings. *Cancer*. 1962;15:557â€“565.

11.Mortensen JD, Woolner LB, Bennett WA. Secondary malignant tumors of the thyroid gland. *Cancer*. 1956;9:306.

12.Silverberg SG, Vidone RA. Metastatic tumors in the thyroid. *Pacific Med Surg*. 1954;68:117â€“119.

13.Willis RA. *The Spread of Tumors in the Human Body*. London: Butterworth; 1951:271â€“275.

14.Ivy HK. Cancer metastatic to the thyroid: a diagnostic problem. *Mayo Clin Proc*. 1984;59:856â€“859.

15.Kini SR, Smith MJ, Miller JM. Fine needle aspiration cytology of tumors metastatic to the thyroid gland. *Acta Cytol*. 1982;26:743.

16.Chacho MS, Greenbaum E, Moussouris HP, et al. Value of aspiration cytology of the thyroid in metastatic disease. *Acta Cytol*. 1987;31:705â€“712.

17.Schmid KW, Hittmair A, Ofner C, et al. Metastatic tumors in fine needle aspiration biopsy of the thyroid. *Acta Cytol*. 1991;35:722â€“724.

18.Fanning TV, Katz RI. Evaluation of thyroid nodules in cancer patients. *Acta Cytol*. 1986;30:572. Letter.

19.Miyakawa M, Sato K, Hasegawa M, et al. Severe thyrotoxicosis induced by thyroid metastasis of lung adenocarcinoma: a case report and review of the literature. *Thyroid*. 2001;11:883â€“888.

20.Treadwell T, Alexander BB, Owen M, et al. Clear cell renal carcinoma, masquerading as a thyroid nodule. *South Med J*. 1981;74:878â€“879.

21.Rosen IB, Bedard YC, Walfish PG, et al. Metastasis of cancer to the thyroid gland as a cause of goiter. *Can Med Assoc J*. 1978; 118:1265â€“1268.

22.Trokoudes KM, Rosen IB, Strawbridge HTG, et al. Carcinomatous pseudothyroiditis: a problem in differential diagnosis. *Can Med Assoc J*. 1978;119:896â€“898.

23.Pillary SP, Angarn IB, Baker LW. Tumor metastasis to the thyroid gland. *S Afr Med J*. 1977;51:509â€“512.

24.Thomson JA, Kennedy JS, Browne MK, et al. Secondary carcinoma of the thyroid gland. *Br J Surg*. 1975;62:692â€“693.

25.Gault EW, Leung THW, Thomas DP. Clear cell renal carcinoma masquerading as thy roid enlargement. *J Clin Pathol*. 1974; 113:21â€“25.

26.Harcourt- Webster JN. Secondary neoplasm of the thyroid presenting as a goiter. *J Clin Pathol*. 1965;18:282â€“287.

27.Elliott RHE Jr, Frantz VK. Metastatic carcinoma masquerading as primary thyroid can cer. *Am J Surg*. 1960;151:551â€“556.

28.Koo HL, Jang J, Hong SJ, et al. Renal cell carcinoma metastatic to follicular adenoma of the thyroid gland. A case report. *Acta Cytol*. 2004;48:64â€“68.

29.Ryska A, Cap J. Tumor- to- tumor metastasis of renal cell carcinoma into oncocytic carcinoma of the thyroid. Report of a case and review of the literature. *Path Res Pract*. 2003;199;101â€“106.

30.Heffess CS, Wenig BM, Thompson LD. Metastatic renal cell carcinoma to the thyroid gland: a clinicopathologic study of 36 cases. *Cancer*. 2002;95:1869â€“1878.

31.Sant F, Moysset I, Badal JM, et al. Fine- needle aspiration of chromophobe renal cell carcinoma metastatic to the thyroid gland. *Diagn Cytopathol*. 2001;24:193â€“194.

32.Haulbauer M, Kardum- Skelin I, Vranesic D, et al. Aspiration cytology of renal cell carcinoma metastatic to the thyroid. *Acta Cytol*. 1991;35:443â€“445.

33.Lasser A, Rothman JG, Calamia VJ. Renal cell carcinoma metastatic to the thyroid. *Acta Cytol*. 1984;28:856â€“858.

34.Friberg S Jr, Kinnman J. Renal adenocarcinoma with metastasis to the thyroid gland. *Acta Otolaryngol*. 1969;67:552â€“562.

35.Parwani AV, Erozan YS, Ali SZ. Metastatic bronchioloalveolar carcinoma presenting as a solitary thyroid nodule: report of a case with fine- needle aspiration cytopathology. *Diagn Cytopathol*. 2004;31:43â€“47.

36.Owens CL, Basaria S, Nicol TL. Metastatic breast carcinoma involving the thyroid gland diagnosed by fine- needle aspiration: a case report. *Diagn Cytopathol*. 2005;33:110â€“115.

37.Gong Y, Jalali M, Staerkel G. Fine needle aspiration cytology of a thyroid metastasis of metaplastic breast carcinoma. A case report. *Acta Cytol*. 2005;49:327â€“330.

38.Miiji LO, Nguyen G- K. Metastatic melanoma of the thyroid mimicking a papillary carcinoma in fine- needle aspiration. *Diagn Cytopathol*. 2005;32:374â€“376.

39.Bozbora A, Barbaros U, Kaya H, et al. Thyroid metastasis of malignant melanoma. *Am J Clin Oncol*. 2005;28:642â€“643.

40.Baloch ZN, Sack MJ, Yu GH, et al. Papillary formation in metastatic melanoma. *Diagn Cytopathol*. 1999;20:148â€“151.

41.Hanna WC, Ponsky TA, Trachiotis GD, et al. Colon cancer metastatic to the lung and thyroid. *Arch Surg*. 2006;141:93â€“96.

42.Witt RL. Colonic adenocarcinoma metastatic to thyroid HÃ¼rthle cell carcinoma presenting with airway obstruction. *Del Med J*. 2003;75:285â€“288.

43.Jayaram G, Kakar A, Natarajan V. Clear cell carcinoma of the minor salivary gland metastasizing to the thyroid. *Diagn Cytopathol*. 1995;12:85â€“86.

44.Maly A, Meir K, Maly B. Isolated carcinoid tumor metastatic to the thyroid gland. Report of a case initially diagnosed by fine needle aspiration cytology. *Acta Cytol*. 2006;50:84â€“87.

45.Loo CK, Burchett IJ. Fine needle aspiration biopsy of neuroendocrine breast carcinoma metastatic to the thyroid. A case report. *Acta Cytol*. 2003;47:83â€“87.

46.Matias- Guiu X LlaGuette J, Puras- Gil AM, Rosai J. Metastatic neuroendocrine tumors to the thyroid gland mimicking medullary carcinoma: a pathologic and immunohistochemical study of six cases. *Am J Surg Pathol*, 1997;21:754â€“762.

47.Naylor B. Secondary lymphoblastomatous involvement of the thyroid gland. *Arch Pathol*. 1959;67:432â€“437.

48.Gattuso P, Castelli MJ, Reyes CV. Fine needle aspiration cytology of metastatic sarcoma involving the thyroid gland. *South Med J*. 1989;82;1158â€“1160.

49.Aron M, Kapila K, Verma K. Role of fine- needle aspiration cytology in the diagnosis of secondary tumors of the thyroidâ€”twenty years experience. *Diagn Cytopathol*. 2006;34:240â€“245.

50.Kim TY Kim WB, Gong G, et al. Metastasis to the thyroid diagnosed by fine-needle aspiration biopsy. *Clin Endocrinol (Oxf)*. 2005;2:236â€“241.

51.Michelow PM, Leiman G. Metastases to the thyroid gland: diagnosis by aspiration cytology. *Diagn Cytopathol*. 1995;13:209â€“213.

52.Smith SA, Gharib H, Goellner JR. Fine- needle aspiration usefulness to diagnosis and management of metastatic carcinoma to the thyroid. *Arch Intern Med*. 1987;147:311â€“312.

53.Lernard TWJ, Wadehra V, Farndon JR. Fine needle aspiration biopsy in

diagnosis of metastasis to thyroid gland. *J R Soc Med*. 1984;77:196â€“197.

Editors: Kini, Sudha R.
Title: *Thyroid Cytopathology: A Text and Atlas, 1st Edition*

Copyright Â©2008 Lippincott Williams & Wilkins

17

Cysts and Cystic Lesions of the Thyroid

The term "cysts" or "cystic" implies a fluid-filled, epithelium-lined space; those without epit lining are referred to as "pseudocysts." True cysts occur as a result of dilatation of the ducts tubules lined by epithelium, although the latter may be denuded secondary to inflammatior Pseudocysts lack epithelial lining. They develop following degeneration, necrosis, and hemorrhage into the parenchyma or soft tissues with fluid accumulation. In the thyroid glan the term "cyst" is used loosely to denote any fluid-containing lesion, usually detected by ultrasound or during the aspiration biopsy procedure when the fluid is aspirated. The incide of cysts in solitary thyroid nodules removed surgically is reported to be as high as 37%.1 Vari types of cystic lesions are identified in the thyroid gland (Table 17.1), the most common be cystic degeneration in nodular goiters.

- Simple cyst
- Lymphoepithelial cyst in Hashimoto's thyroiditis
- Intrathyroidal thyroglossal duct cyst or branchial cleft cyst
- Colloid-filled giant mMacrofollicle in nodular goiter or a macrofollicular adenoma
- Cystic degeneration in nodular goiter
- Degenerating neoplasms
  - Follicular or HÃ¼rthle cell adenomas
  - Malignant neoplasms
    - Papillary carcinoma
    - Anaplastic Carcinoma

TABLE 17.1 CYSTS OF THYROID: MORPHOLOGIC TYPES

The majority of the thyroid cysts are benign. The incidence of malignancy in thyroid cysts reported in various series ranges from 0% to 33% (Table 17.2).1 , 2 , 3 , 4 , 5 , 6 , 7 , 8 , 9 , 11 , 12 , 13 , 14 , 15 Cystic change is more frequent with thyroid lesions greater than 4 cm. , 5 , 6 , 7 , 8

Crile[15] (1966)
0/5
0
Miller et al.[14] (1974)
2/303
0.6
Ma and Ong[13] (1975)
1/62
1.6
Jensen and Rasmussen[12] (1976)
0/288
0
Walfish et al.[11] (1977)
3/13
23.0
Goellner and Johnson[9] (1982)
9/158
5.6
Hammer et al.[10] (1982)
16/48
33.0
Suen and Quenville[8] (1983)
2/59
3.0
Rosen et al.[7] (1986)
15/60

25.0
Cusick et al.[1] (1988)
15/106
14.0
Sarda et al.[1] (1988)
5/78
6.4
de las Santos et al.[5] (1990)
10/71
14.0
Mecko et al.[4] (1995)
39/90
29.0
McHenry et al.[3] (1999)
6/70
8.6
Abbas et al.[2] (2001)
4/34
12.0

Author (Year)	No.	Percent

TABLE 17.2 INCIDENCE OF CARCINOMA IN CYSTS OF THYROID

Clinically, thyroid cysts can be suspected by a rounded nodule that appears tense or taut on palpation.15 The sudden appearance of a rapidly enlarging thyroid nodule, causing discomfo nearly always a cyst with acute hemorrhage.15

RADIOLOGIC FINDINGS

Ultrasound has been helpful in identification of the cystic lesions.16 , 17 , 18 , 19 , 20 , 21 The high-resolution ultrasonography can determine the characteristics of the nodule such as size, whether solid or cystic or complex, although distinguishing benign from malignant is no possible.

Ultrasound findings that favor benign non-neoplastic nodules include small cystic nodules, w or without internal echogenic foci; multiple cystic spaces separated by thin septations in a "honeycomb" pattern; and a large cyst.16 Papillary carcinomas with cystic component rarely reach the dimensions of a large benign cyst.

GENERAL CHARACTERISTICS OF CYSTIC LESIONS

The most commonly encountered cystic lesions are nodular goiters. Benign cysts such as tho arising from the nodular goiters collapse after being drained. A small number may re-accum or bleed immediately following an aspiration biopsy necessitating re-aspiration. Recurrence hemorrhagic contents should be a warning of the possibility of malignancy.

Aspiration biopsy has been found to be very useful for (i) identifying the lesion as a cyst, an differentiating between benign and malignant cysts based on cytologic examination of the c fluids.23 , 24

The volume of the aspirated fluid varies from a few milliliters to 20 mL or more. The gross characteristics of the fluid reflect the duration as well as the nature of the cystic lesion. So after the hemorrhage into the nodule, the specimen resembles the venous blood. Subsequer the cyst contents change from a chocolate-colored fluid to opaque to an olive, translucent a ultimately to yellow, amber-colored transparent fluid. A nodule that has undergone degeneration and necrosis may yield a small amount of turbid, thick fluid. The gross characteristics have no bearing on the nature of the lesions. Rehak et al.25 performed biochemical analysis of thyroid cyst fluids for several analytes. They did not identify any ana that would differentiate between benign and malignant cysts.

The cytopreparation of the cyst contents varies according to the gross characteristics of the fluid. The cytopathologic features of the aspirated fluid specimen depends on several facto including the type of cyst; whether non-neoplastic or neoplastic; whether it is hemorrhagic, if so, recent or old hemorrhage; and the extent of necrosis. The cytologic evaluation too depends greatly on the quality of the cytopreparation (see Chapter 3). A poor cytopreparat of a bloody specimen is likely to be unsatisfactory and nondiagnostic, even if the lesion is malignant, unless the blood is removed prior to making the smears. At the same time, a clea transparent fluid

from a cystic papillary carcinoma is likely to be poorly cellular and may result in a false-neg diagnosis and must be processed by the cytocentrifugation method to salvage the few malig

cells (see Fig. 17.23). The fluid medium to which

the exfoliated cells are exposed may initiate retrogressive changes that simulate neoplasia i benign cells, thereby constituting an important diagnostic pitfall. Conversely, true neoplasi be masked by retrogressive changes, resulting in false-negative diagnoses.2 , 4 , 11 , 14

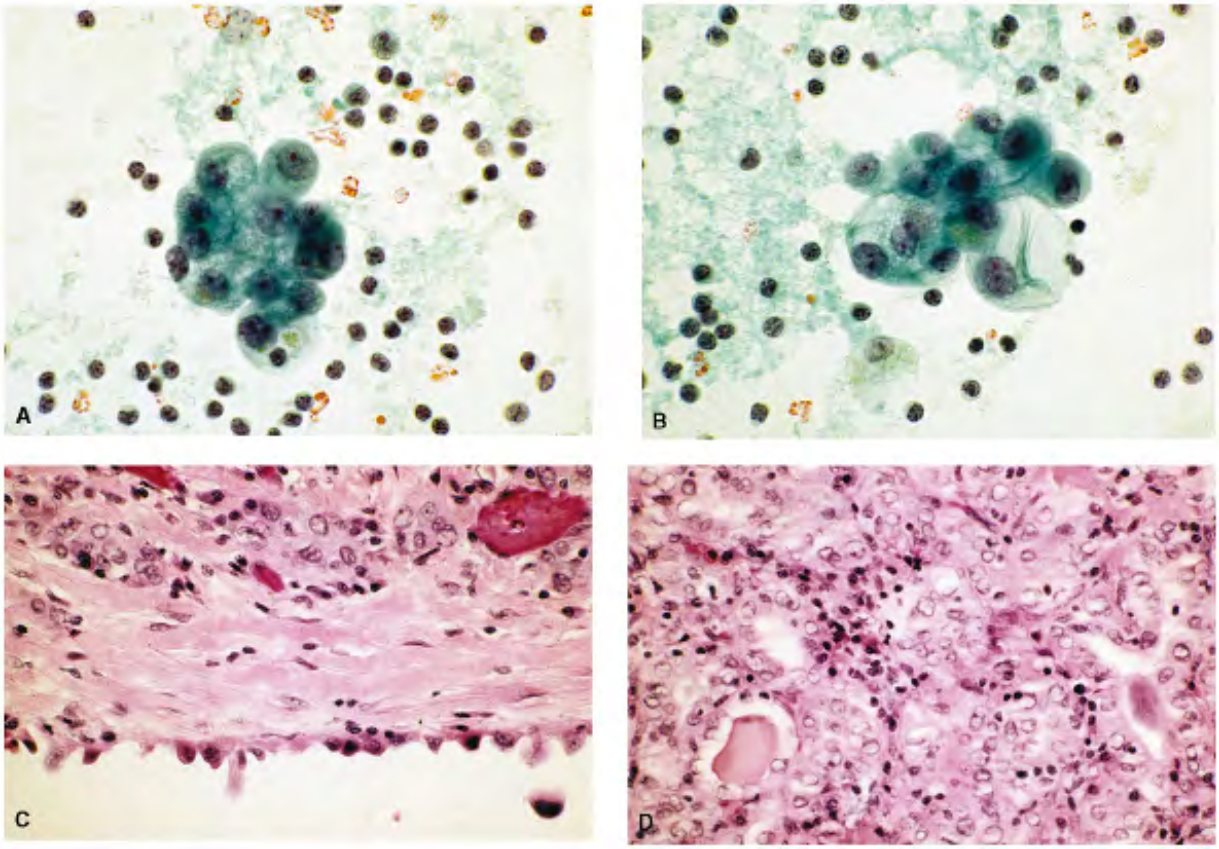

Figure 17.23. A,B. Cytospin preparation of a clear fluid aspirated from a cystic papillary carcinoma. The aspirate is poorly cellular with a rare syncytial tissue fragment of enlarged follicular cells with scalloped margin and with well-defined cell borders. The nuclei are enl with finely granular chromatin with prominent nucleoli. Their cytoplasm is foamy to vacuol The morphology is suspicious for papillary carcinoma. The thyroidectomy confirmed a cystic papillary carcinoma. C. The cyst lining composed of a single layer of atypical follicular cells not typical of papillary carcinoma. D. A conventional papillary carcinoma was present focall the cyst wall.

SIMPLE CYSTS

Simple epithelium-lined cysts are extremely rare and their etiology is uncertain.26 , 27 , 28 The epithelial lining may be squamous type. The case illustrated in Figure 17.1 represents a example of a simple cyst with squamous lining. The aspirated sample showed atypical cells, which were interpreted as suspicious for malignancy. The thyroidectomy revealed a simple squamous epithelium-lined cyst with atypical features.

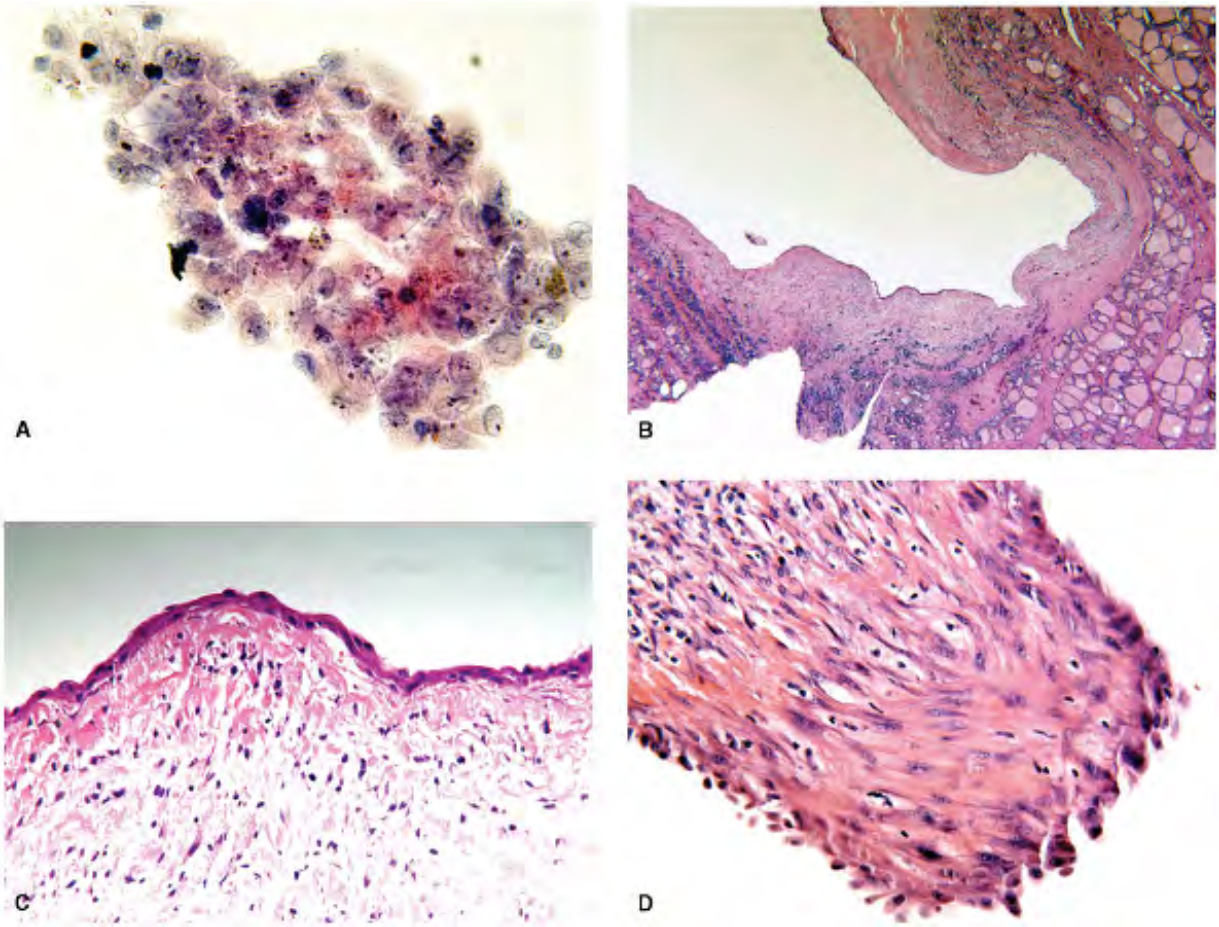

Figure 17.1. A. The smears prepared from the aspirated cyst fluid were almost acellular ex for this syncytial tissue fragment of cells with large, atypical nuclei containing nucleoli. The cells were interpreted as suspicious for papillary carcinoma. B. Thyroidectomy revealed a fi walled cyst and no papillary carcinoma. C,D. Higher magnification showing lining epithelium with nuclear atypia, which is the source of atypical cells in the cyst fluid.

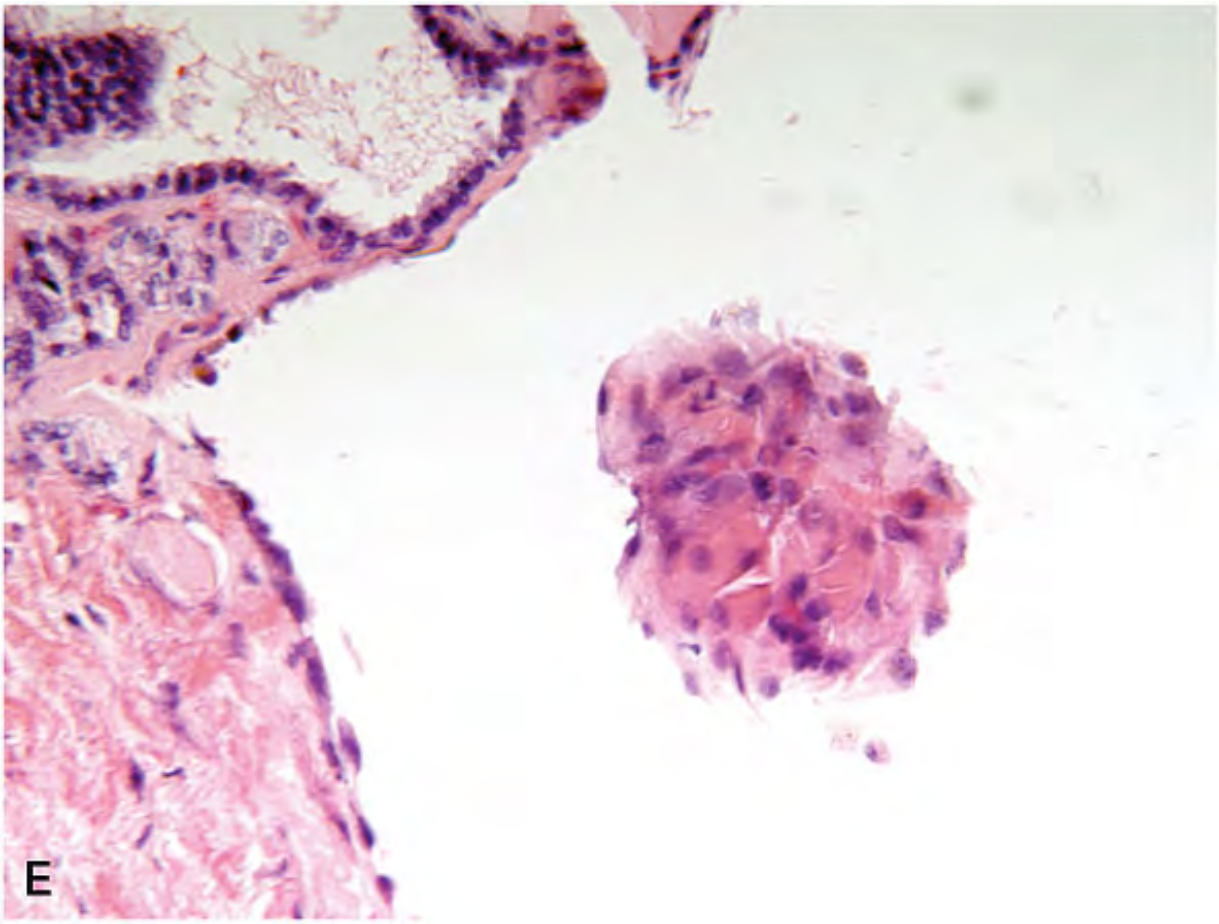

Figure 17.1. E. A tissue fragment of atypical squamoid cells floating in the cystic cavity.

LYMPHOEPITHELIAL CYSTS

Small cysts lined by squamous epithelium have been described in Hashimoto's thyroiditis,26 are referred to as lymphoepithelial cysts or lymphoepithelial-like cysts as they bear resembl to

lymphoepithelial cysts encountered in parotid glands. They are extremely rare and only a fe cases are reported in the surgical pathology literature (Fig. 17.2).30 , 31 , 32 , 33 Louis et described two cases of multiple cysts in patients with Hashimoto's thyroiditis. These cysts, l mostly by squamous epithelium and focally by columnar epithelium, were surrounded by lymphoid tissue with follicles and germinal centers and contained a fibrous capsule. They referred to these as branchial cleft-like cysts. Apel et al.31 reported 6 cases of intrathyroid lymphoepithelial cysts, all associated with Hashimoto's thyroiditis. The cysts were lined by

squamous epithelium and contained heavy lymphoid tissue in their walls. In 5 of their cases, solid cell nests (please refer to Chapter 19) were found in the vicinity of the cysts. The aut postulated that these branchial cleft-like cysts may have resulted from squamous metaplasi degeneration or may have been derived from cystic change within the solid cell nests. The squamous lining of these cysts may demonstrate cytologic atypia leading to a malignant diag (Fig. 17.2). Rys?ks et al.35 reported 2 cases of intrathyroidal lymphoepithelial cysts that we not associated with Hashimoto's thyroiditis. Carney28 reported 2 cases of branchial cleft-lik cysts in thyroid, not associated with Hashimoto's thyroiditis. In both instances, the cysts we single and the extra cyst parenchyma showed islands and strands of basaloid epithelium, associated with lymphoid infiltrate as seen with lymphoepithelial lesions. Lymphoepithelial of thyroid have also been documented in patients with HIV infection,33 , 34 with one repor describing the cytologic findings on aspiration biopsy.34

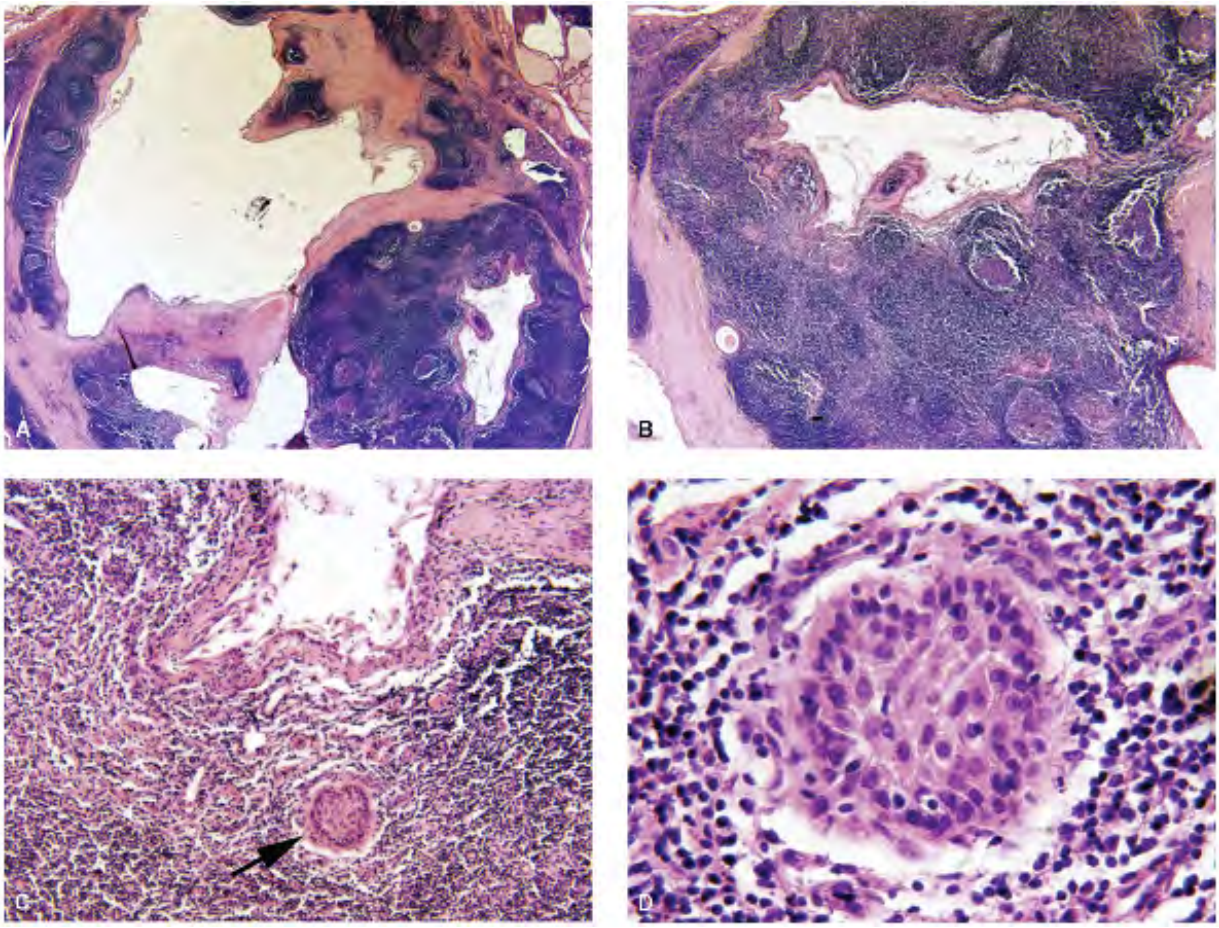

Figure 17.2. A. Histologic sections of a thyroid with Hashimoto's disease. Note multiple cyst spaces, some within lymphoid follicles, low power. B. Higher magnification of the cyst withi

the lymphoid follicle, lined by squamous epithelium. C. A different field showing a cystic ca lined by stratified squamous epithelium. Note squamous metaplasia within the lymphoid tiss (*arrow*). D. Higher magnification of C highlighting the squamous metaplasia.

INTRATHYROIDAL THYROGLOSSAL DUCT CYST AND INTRATHYROIDAL BRANCHIAL CLEFT CYST

Both thyroglossal duct cysts36 , 37 , 38 and branchial cleft cysts39 , 40 have been describec the intrathyroidal location as discrete cystic structures within the thyroid parenchyma and l by stratified squamous epithelium. No other disease process in the surrounding thyroid parenchyma, such as thyroiditis, was described. Aspiration biopsy of the above-reported intrathyroidal cysts showed only benign squamous cells. The cytohistologic features were consistent with both thyroglossal duct cysts and branchial cleft cysts. We recently came acr such cases of intrathyroidal cysts (confirmed by ultrasound). Their aspirates contained matu squamous cells with and without keratinization, and large numbers of anucleated squames (17.3 , 17.4 and 17.5). One cyst aspirate also contained benign follicular cells along with squamous cells (Fig. 17.5). The cytologic patterns strongly resembled those of branchial cle cyst or thyroglossal duct cysts. Since the benign cytologic features of these cases did not wa surgical excision, there was no surgical follow-up and their etiology remains unknown.

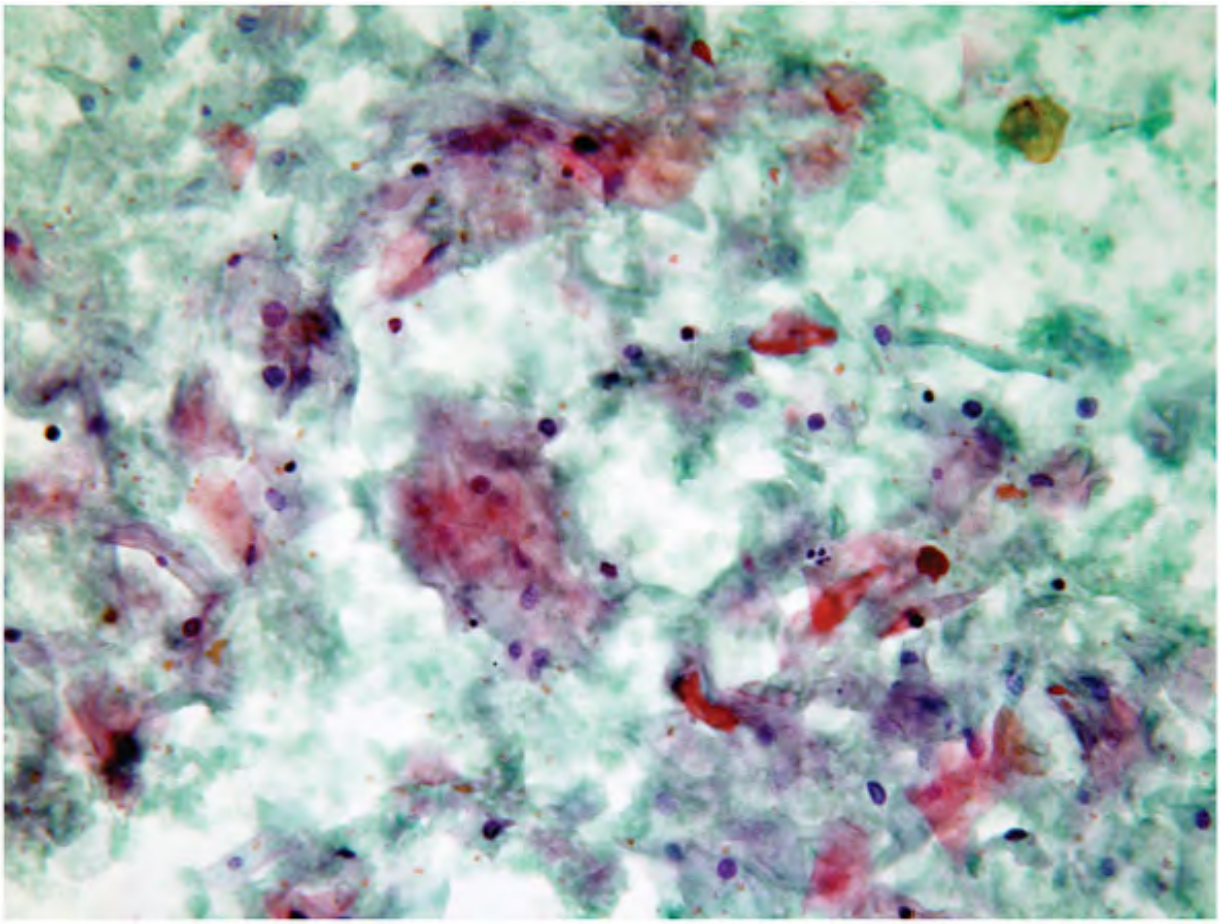

Figure 17.3. Case #1. Cyst aspirate of an intrathyroidal cyst with mature squamous cells an
anucleated squames.

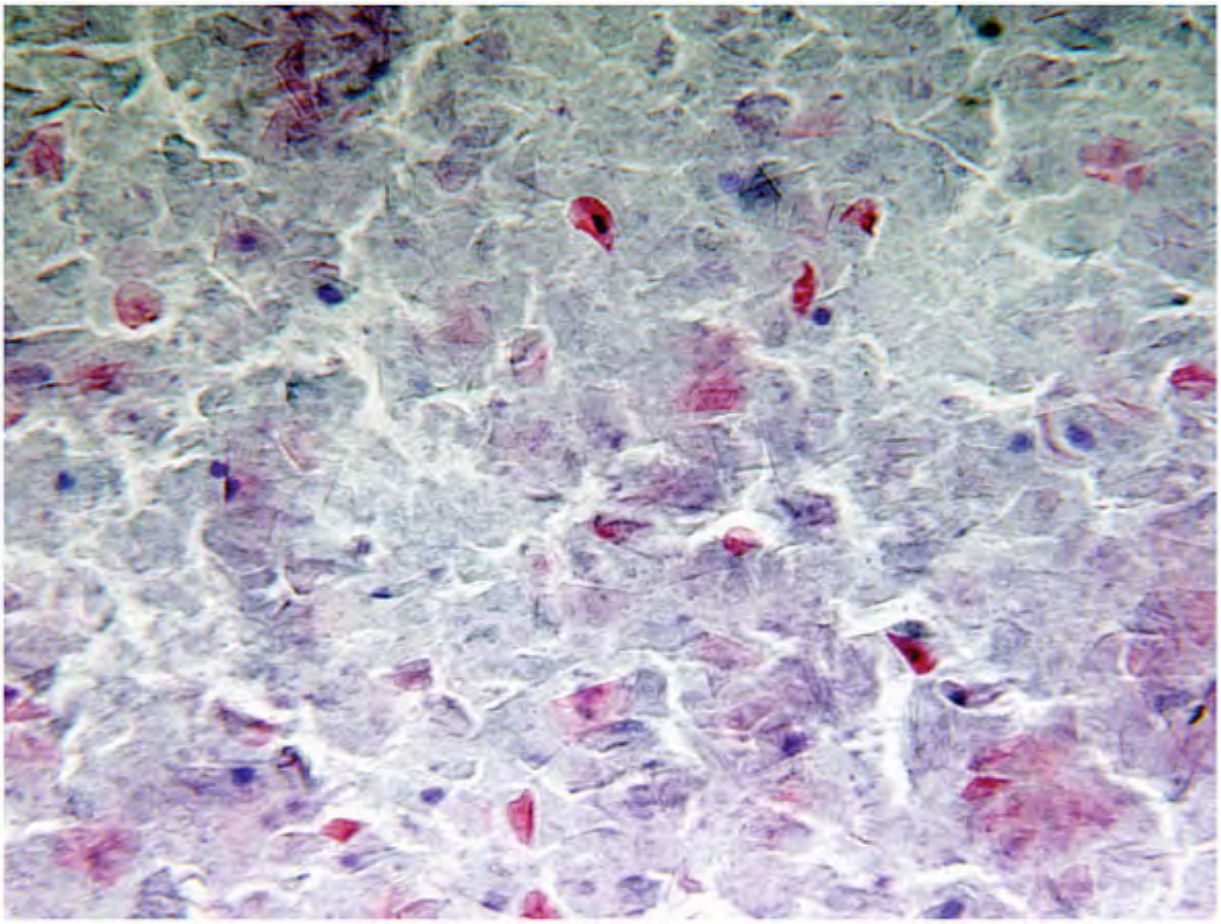

Figure 17.4. Case #2. Cyst aspirate of an intrathyroidal cyst with mature squamous cells an
anucleated squames. Note some cells with keratinization.

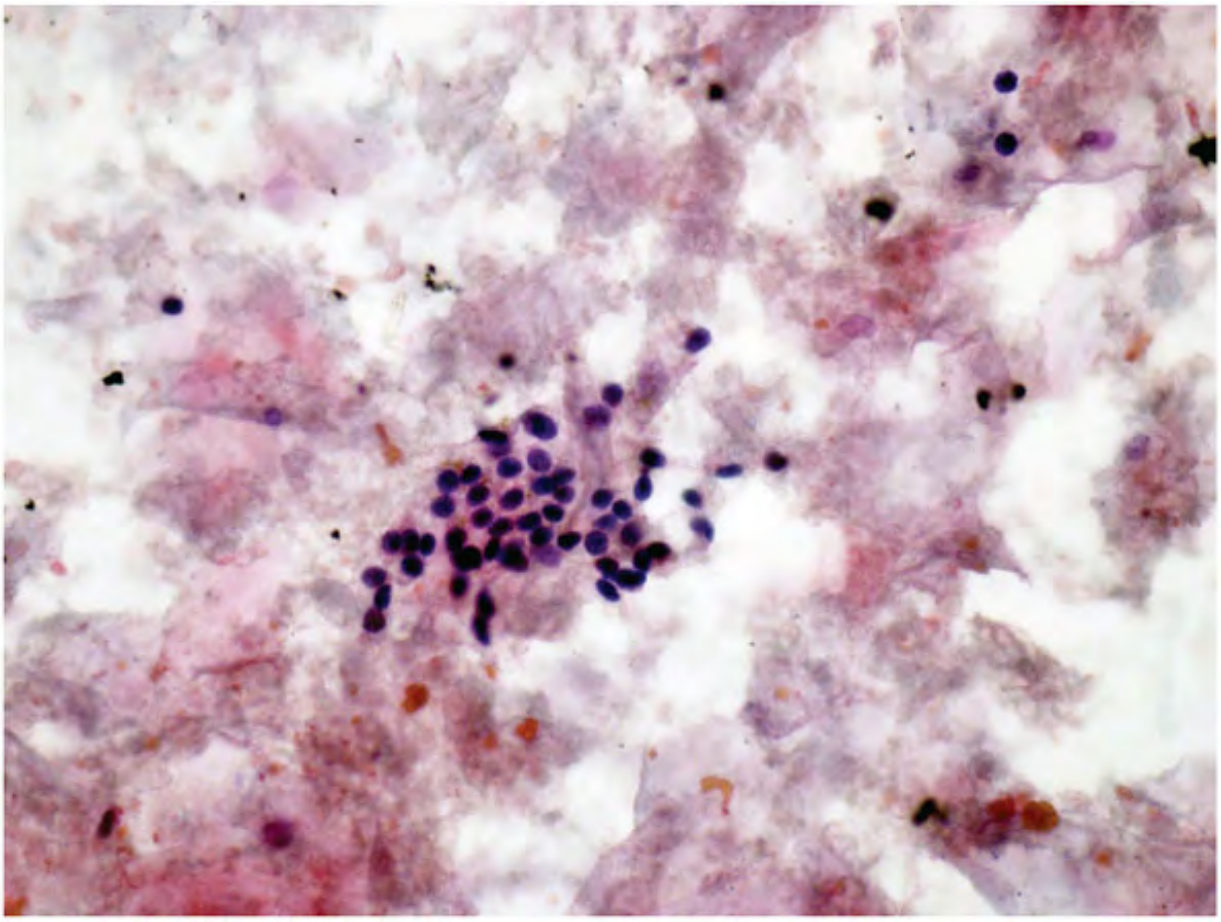

Figure 17.5. Case #3. Cyst aspirate of an intrathyroidal cyst with mature squamous cells an anucleated squames. Note a group of benign follicular cells, suggesting the diagnosis of thyroglossal duct cyst.

COLLOID CYST OR GIANT COLLOID-FILLED FOLLICLE

It is not uncommon to aspirate several milliliters of watery to viscous colloid during the aspiration biopsy procedure of thyroid nodules. The prepared smears generally demonstrate abundant colloid with no or rare small follicular cells containing

pyknotic nuclei (Fig. 17.6). The colloid stains dense and shows cracks or fissures and tends fall off the slide during the fixation (in 95% ethyl alcohol) and processing. These aspirates w abundant colloid generally represent hyperinvoluted goiter or a macrofollicular adenoma.

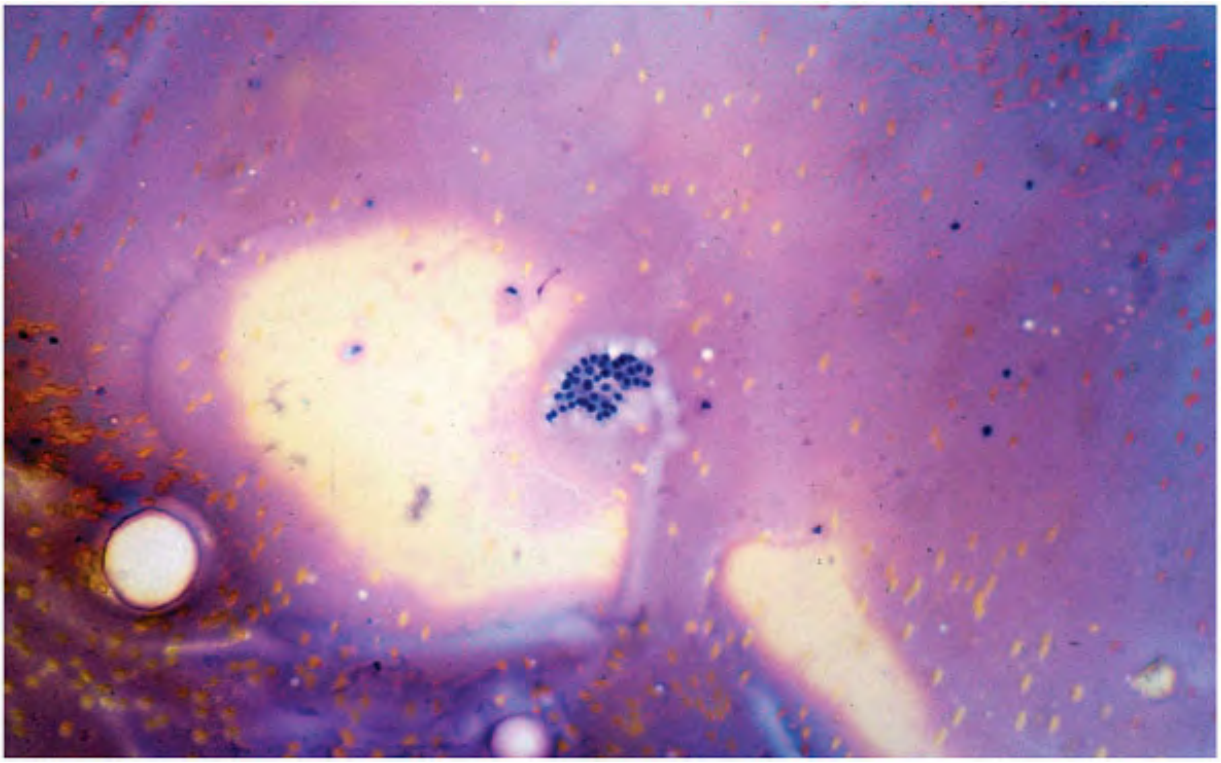

Figure 17.6. Fine-needle aspiration biopsy of a colloid cyst (nodule), showing abundant coll
with a few benign follicular cells.

CYSTIC DEGENERATION IN NODULAR GOITER

Cyst formation is a frequent occurrence in nodular goiters. The cysts vary in size and can at
large dimensions (Fig. 17.7). Depending on their duration, the fine-needle biopsy of these c
will yield varying amounts of fluid, from frankly hemorrhagic to thick, sticky contents, refer
to by one of our endocrinologists as "gruel." The fluid from a long-standing cyst is usually thi
clear, transparent, and practically acellular. The absence of well-preserved follicular cells s
to be the rule in such cases rather than an exception.

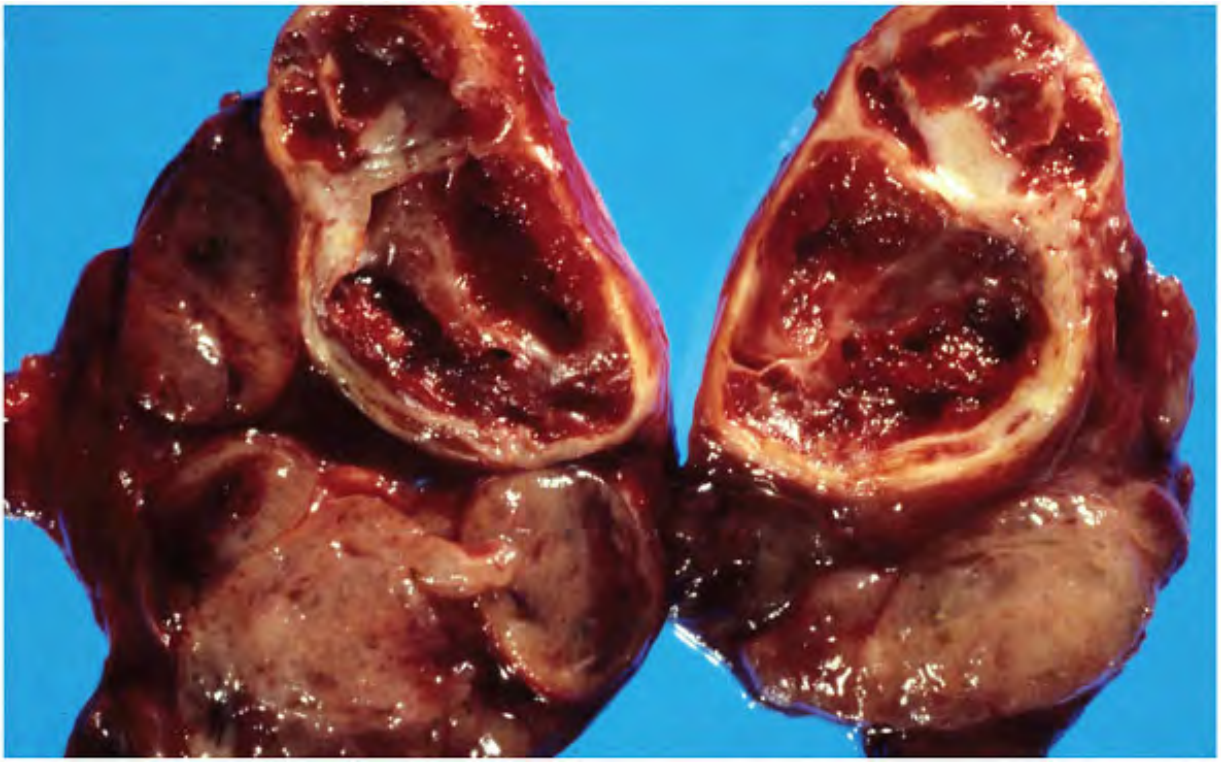

Figure 17.7. A gross photograph of a large cystic nodular goiter.

Generally, the smears prepared from the sediment of the cyst fluid almost always contain variable numbers of histiocytes with or without hemosiderin pigment (Fig. 17.8). These histiocytes or macrophages possess abundant, granular to foamy cytoplasm, and round nucle that are central to slightly eccentric. Their N/C ratios are low and their cell borders are wel defined but not rigid or sharp, unlike the discrete papillary carcinoma cells (see Fig. 17.23) nuclear chromatin is finely granular and micronucleoli may be present. Multinucleated histiocytic foreign-body-type giant cells are frequent; some contain hemosiderin pigment. Cholesterol crystals are often identified (Fig. 17.9) in a toluidine blue-stained preparation the fresh fluid sediment (wet mount; see Chapter 3). A paraffin cell block preparation of th sediment is highly recommended. On rare occasions, it will provide a diagnostic result. The fluid may

contain follicular cells, their numbers as well as their morphology dependent on the duratio the cyst.

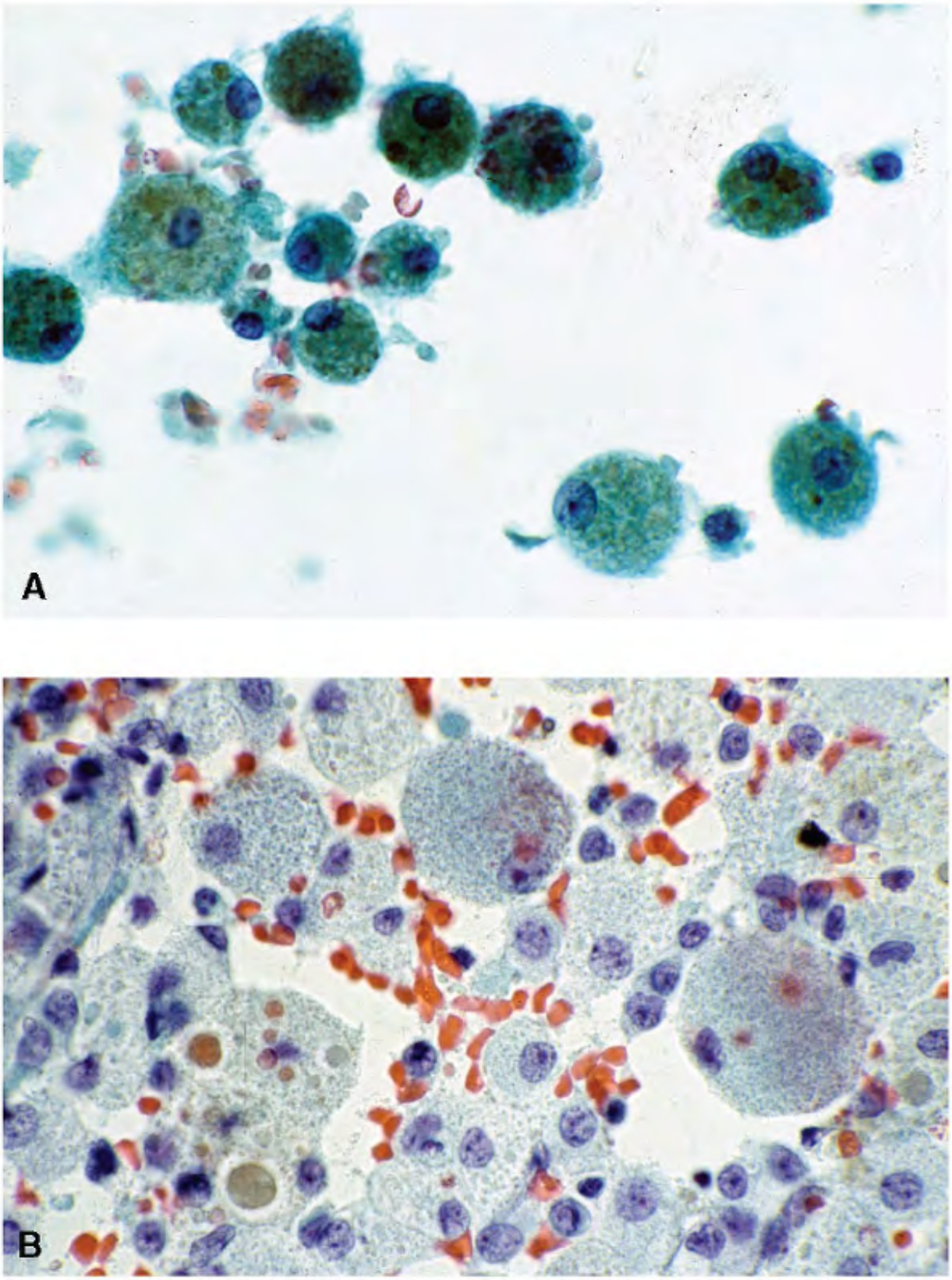

Figure 17.8. Usual cytopathologic pattern of cyst fluid showing several hemosiderin-contair

histiocytes.

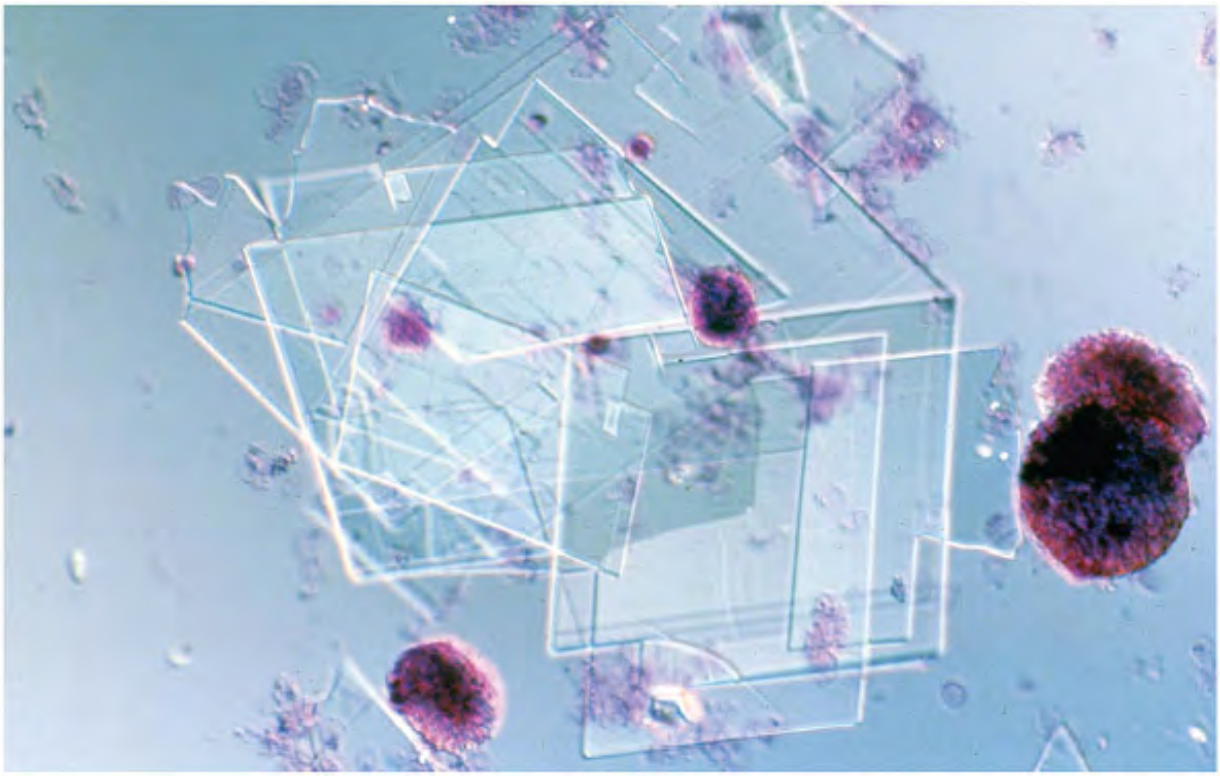

Figure 17.9. Cyst fluid from a degenerated nodular goiter with cholesterol crystals and hemosiderin-containing histiocytes. Wet mount, Toluidine blue preparation.

Degenerating follicular cells exhibit various morphologic alterations. They may enlarge and acquire abundant granular cytoplasm, resembling histiocytes, and they may even be phagoc containing hemosiderin. Although they resemble histiocytes, follicular cells are almost alwa tissue fragments (Fig. 17.10) unlike the macrophages.

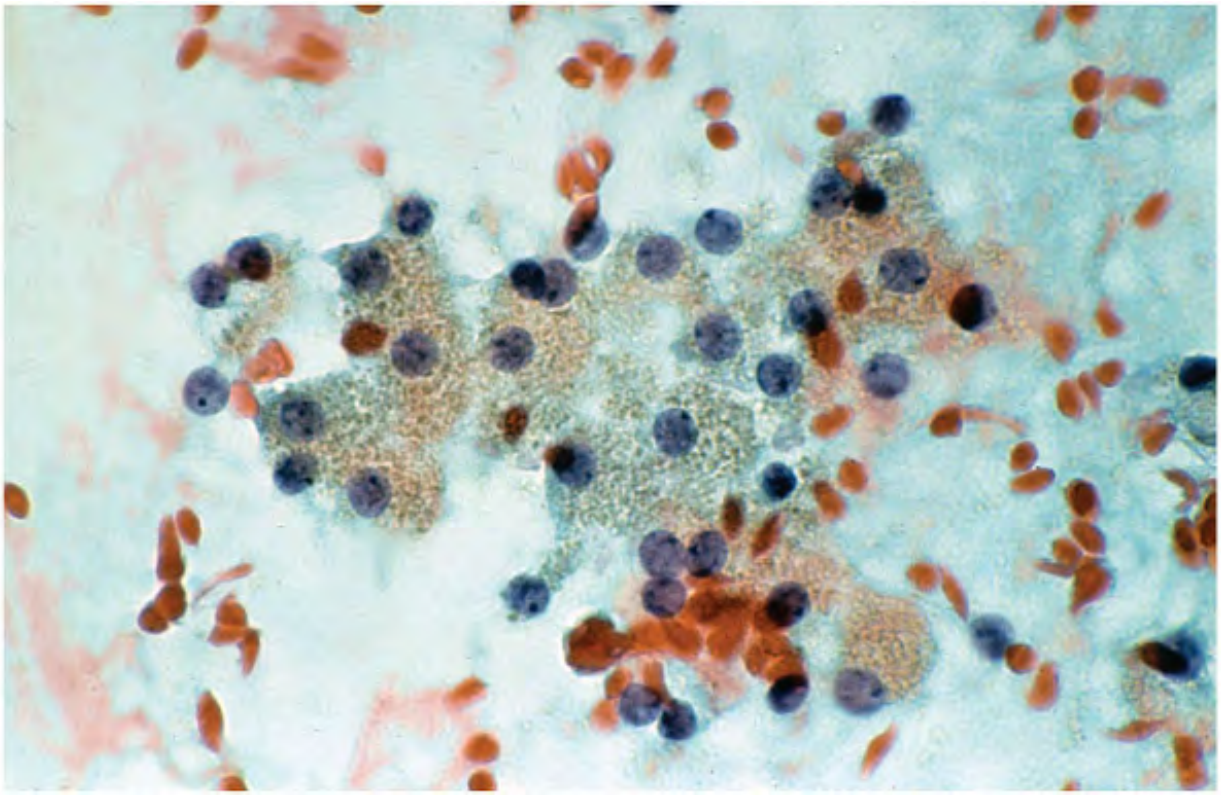

Figure 17.10. A tissue fragment of degenerating follicular cells with hemosiderin pigment.

In long-standing cysts, the follicular cell nuclei demonstrate variable degrees of atypia (Figs 17.11 , 17.12 , 17.13 , 17.14 , 17.15 and 17.16).41 , 42 , 43 The nuclei show enlargement a may contain prominent nucleoli. Nuclear grooves are occasionally present as are intranuclea inclusions. Their cytoplasm may be vacuolated or may even contain a single vacuole.

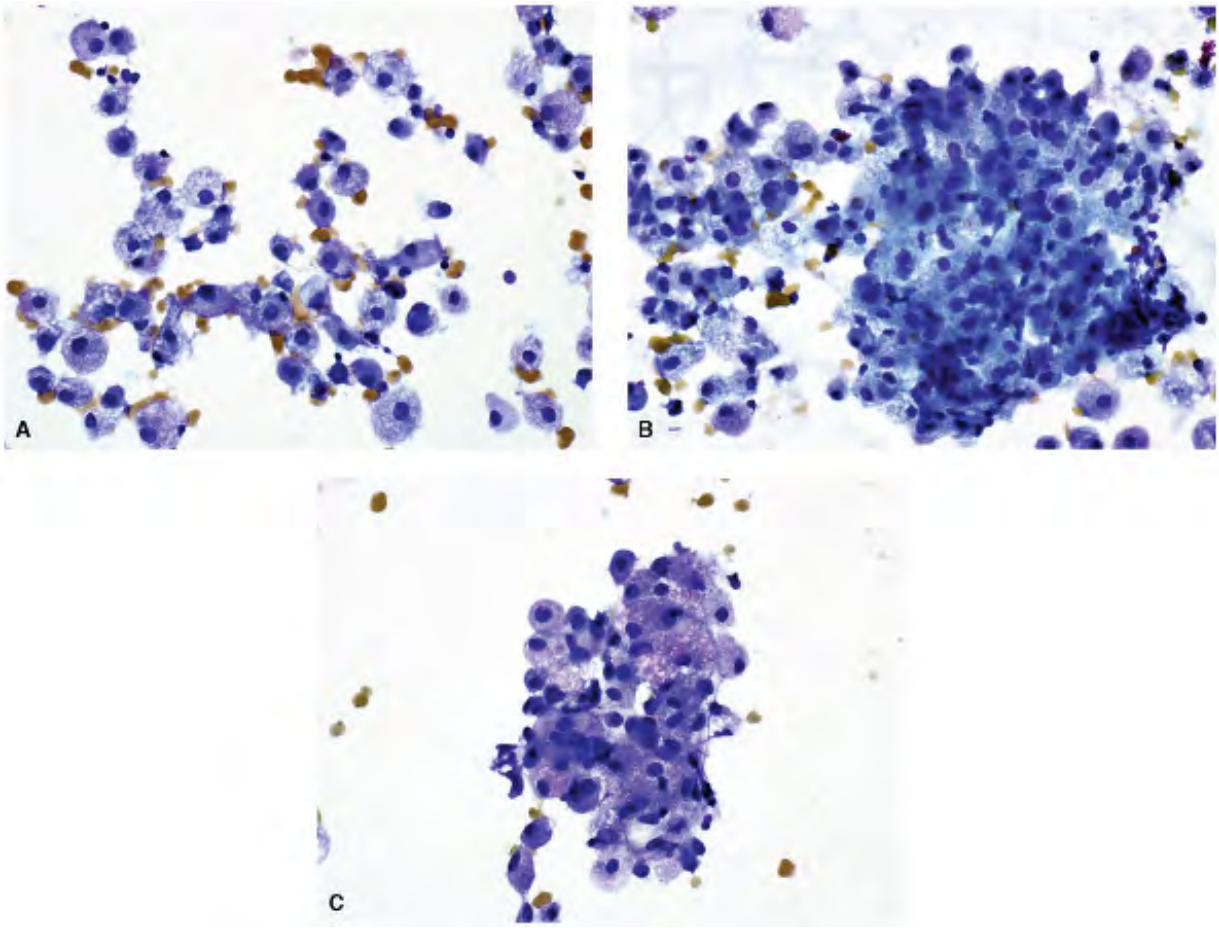

Figure 17.11. FNA of a cystic nodule.A. Degenerating follicular cells and histiocytes. B,C. T fragments of follicular cells with mild nuclear enlargement. The nuclear atypia suggesting a neoplasm, possibly papillary carcinoma.. Thyroidectomy showed nodular goiter. Diff-Quik preparation. (Courtesy of Mariza de Peralta-Venturina, MD, William Beaumont Hospital, Roy Oak, Michigan.)

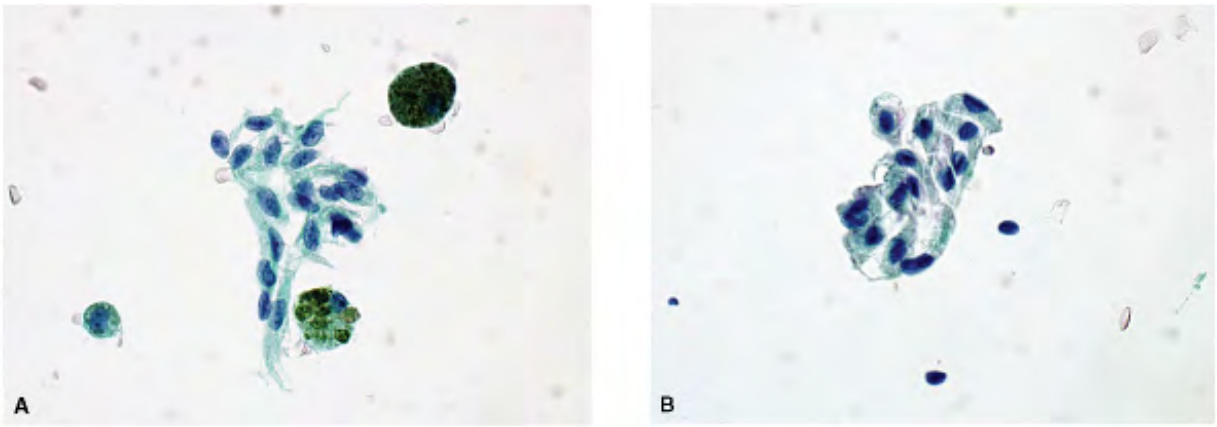

Figure 17.12. FNA of cystic nodular goiter. A. This group of follicular cells has assumed spin shape with nuclear enlargement. Note hemosiderin-containing macrophages. B. A different group exhibiting similar morphology. A small number of these types of cells in a background nodular goiter are usually of no significance.

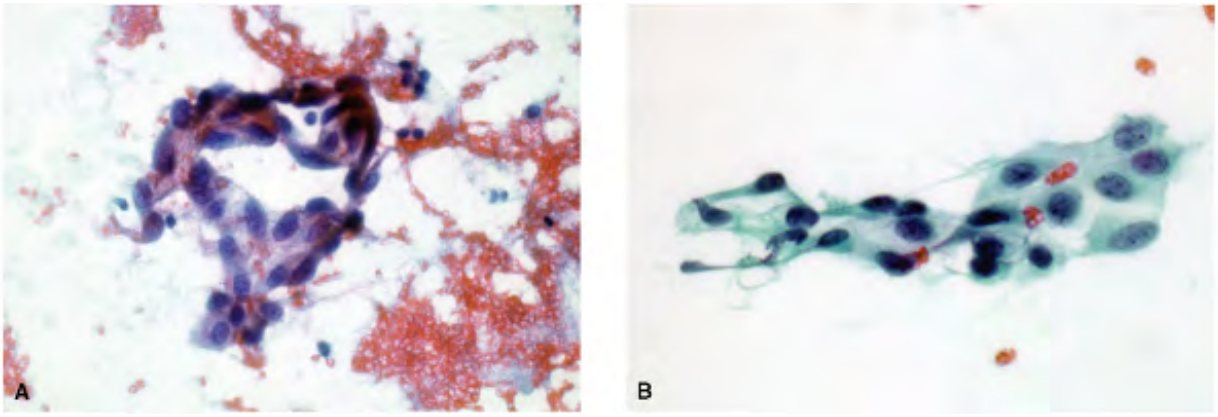

Figure 17.13. FNA of a cystic nodular goiter. Tissue fragments of enlarged follicular cells w pleomorphic and enlarged nuclei with granular to compact chromatin and occasional micronucleoli. Nuclear grooves or inclusions are not appreciated. These cells were few in numbers, in the background of typical features of cystic nodular goiter and do not justify a surgical procedure.

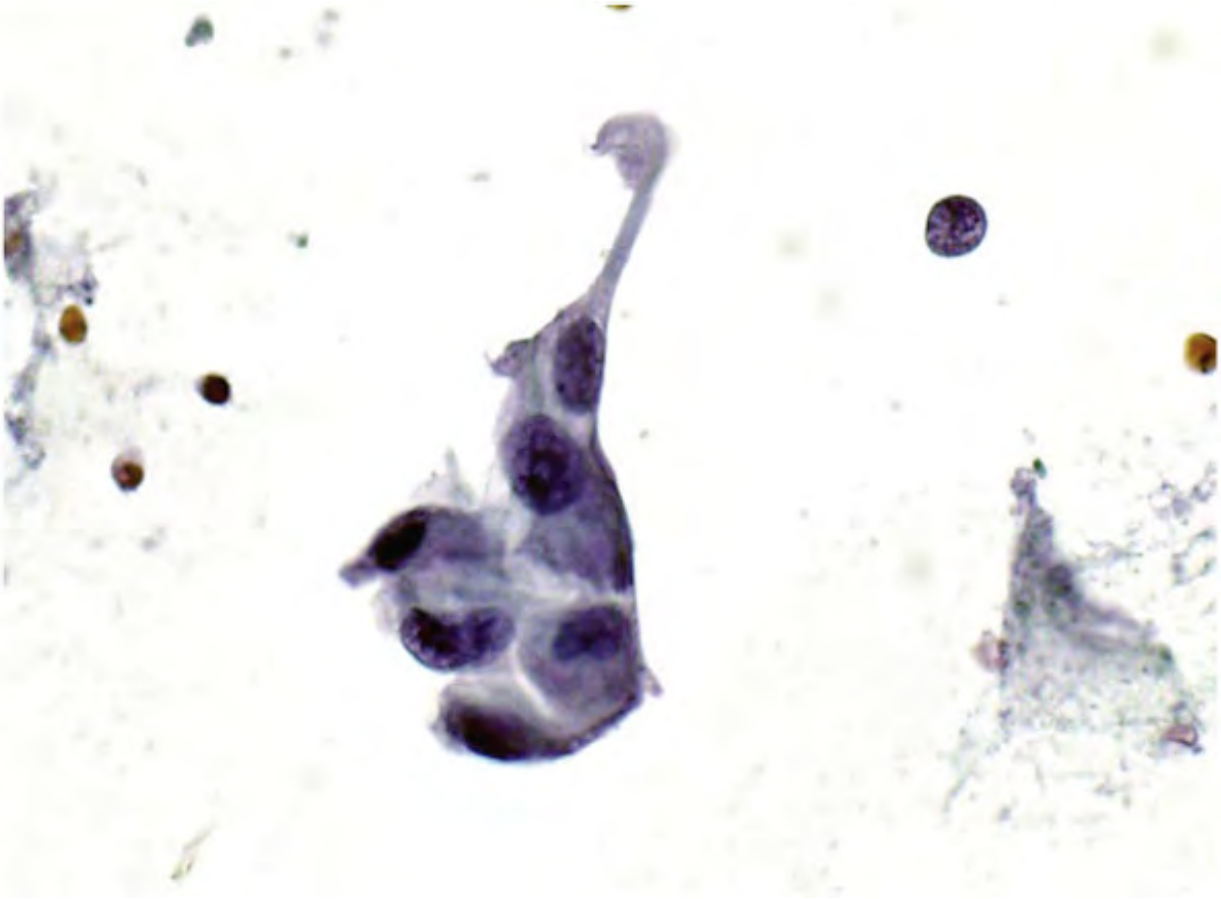

Figure 17.14. FNA of a cystic nodule showing a single group of enlarged follicular cells with markedly pleomorphic, hyperchromatic nuclei and high N/C ratios, in the background featu nodular goiter.

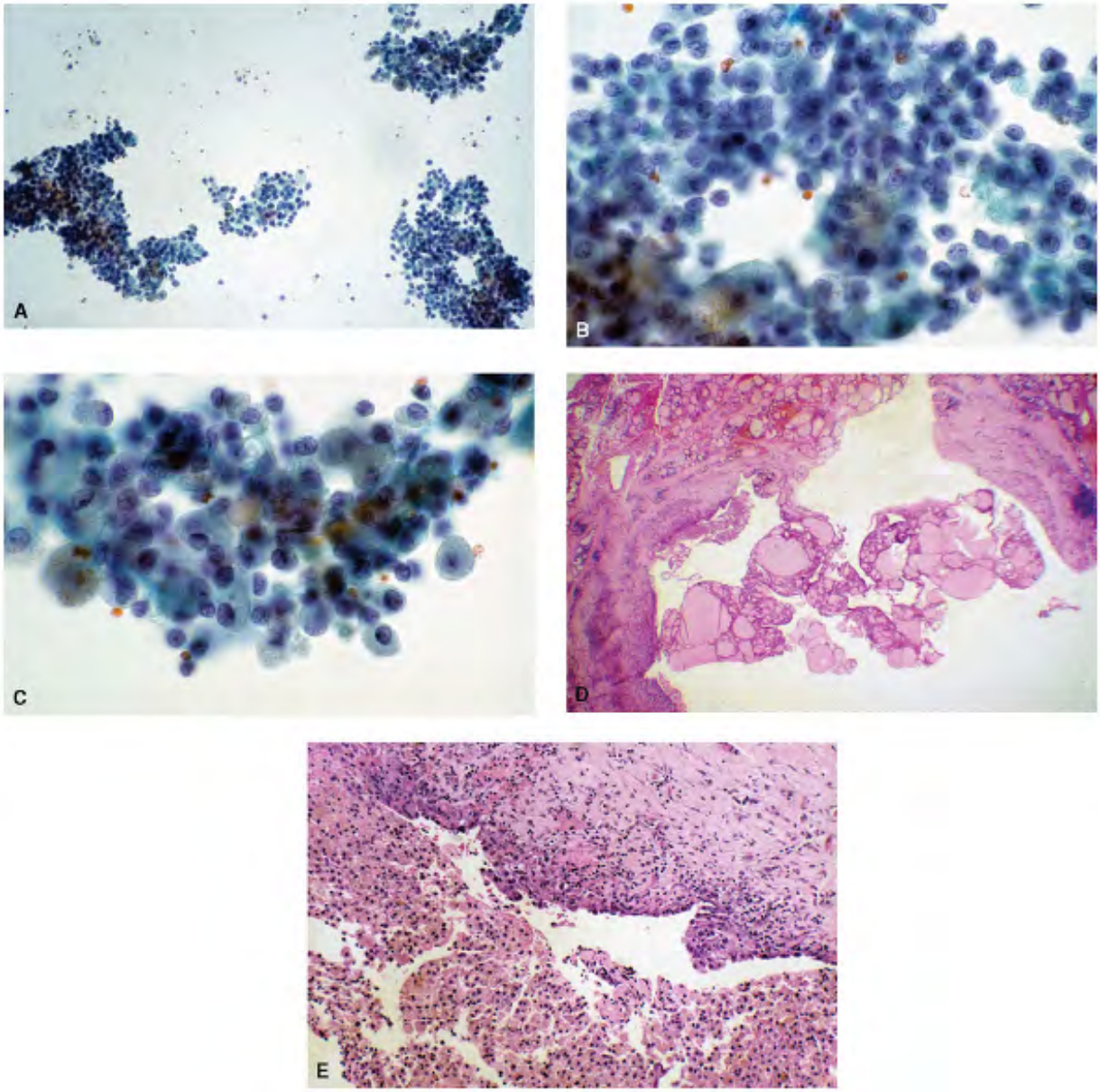

Figure 17.15. A. Cytospin preparation of clear cyst fluid showing several large tissue fragme of follicular cells, low power. B,C. Higher magnification demonstrating follicular cells in tiss fragments with follicular pattern and in loosely cohesive groups. Their cell borders are poor defined and the cytoplasm is pale, vacuolated to dense. The nuclei are enlarged, crowded nuclei, some containing micronucleoli. The cytologic diagnosis was suspicious for papillary carcinoma. D. The thyroidectomy confirmed nodular goiter with cystic change. E. The cystic cavity is filled with hemosiderin-containing histiocytes. No papillary carcinoma was identifie

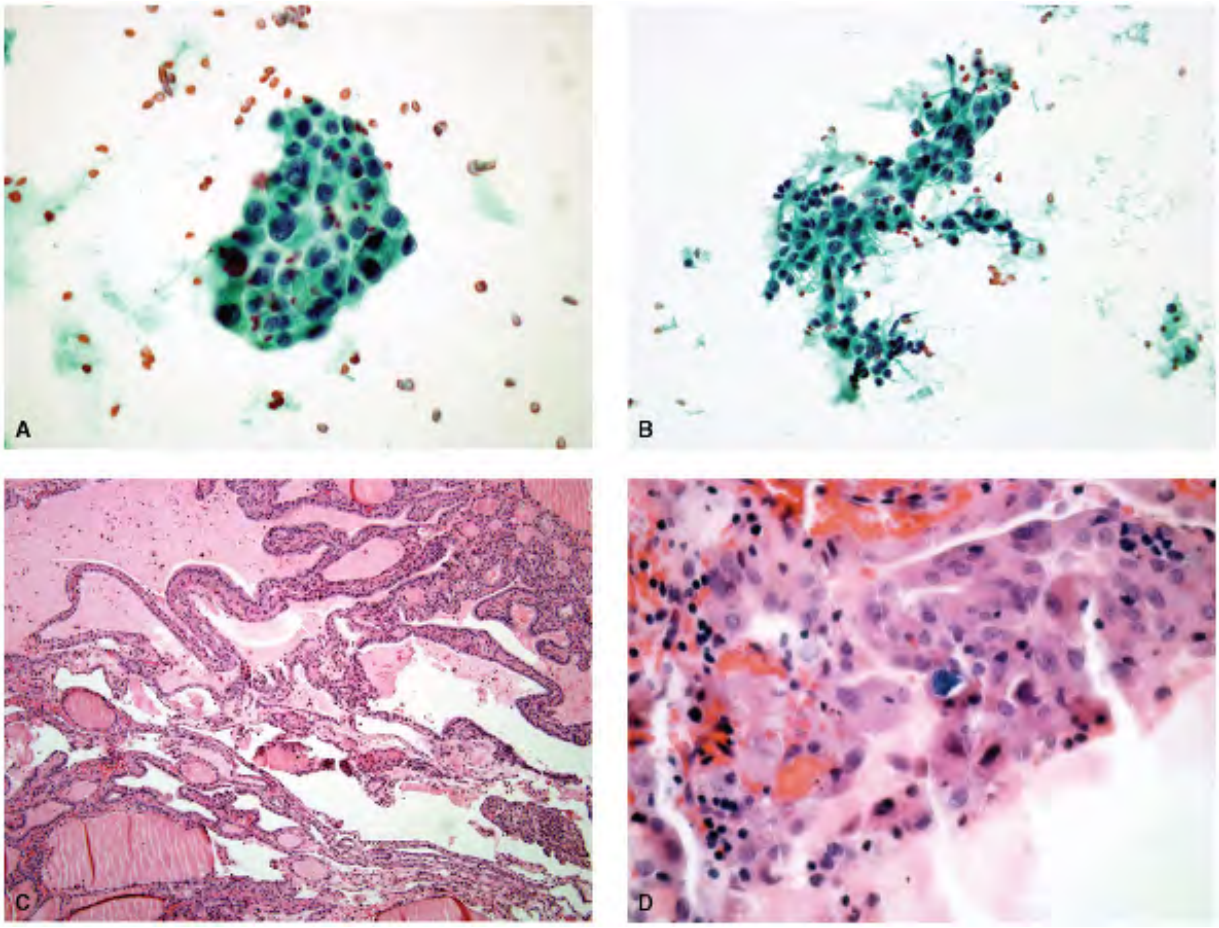

Figure 17.16. Different example of a cystic nodular goiter that was cytologically interprete "atypical cells, papillary carcinoma cannot be ruled out." A,B. These two images depict tissu fragments of follicular cells with pleomorphic nuclei, granular chromatin, and occasional nu grooves. C. The thyroidectomy revealed a cystic nodular goiter. No papillary carcinoma was identified. D. The follicular cells in focal areas demonstrated nuclear atypia, representing tl source of atypical cells.

Large tissue fragments of benign follicular cells within the cystic cavity exposed to the fluid environment may resemble syncytial-type tissue fragments from papillary carcinoma. The atypical follicular cells in a cystic nodular goiter may acquire a spindle shape and abundant cytoplasm, and may present a directional flow similar to that seen in repair squamous metaplasia.44

The morphologic alterations in follicular cells in cystic nodular goiters represent a frequent

source of diagnostic problems as they mimic malignant cells and constitute a major cause fo false-positive diagnosis of papillary carcinoma.

Various examples of disturbing morphologic alterations in follicular cells in cyst fluids are illustrated in Figures 17.11 , 17.12 , 17.13 , 17.14 , 17.15 , 17.16 . The diagnostic difficulties differentiating atypical follicular cells of the cystic nodular goiters from cystic papillary carcinoma cells are discussed in detail in Chapter 9 and listed in Table 9.8 .

CYSTIC DEGENERATION IN NEOPLASMS

The cystic degeneration may also occur in both benign and malignant thyroid neoplasms. Th larger the size of the neoplasm, the greater the chances of degeneration, necrosis, and cyst formation. Large follicular and HÃ¼rthle cell adenomas

are frequently cystic. The incidence of cystic change in follicular adenomas is reported to b high as 37% (Fig. 17.17).1 De las Santos et al.5 reported 25% of 71 cystic lesions to be follicu adenomas and 3% HÃ¼rthle cell adenomas. The cyst fluid show features of the respective be neoplasm in the background of histiocytes and foreign-body-type multinucleated giant cells 17.18).

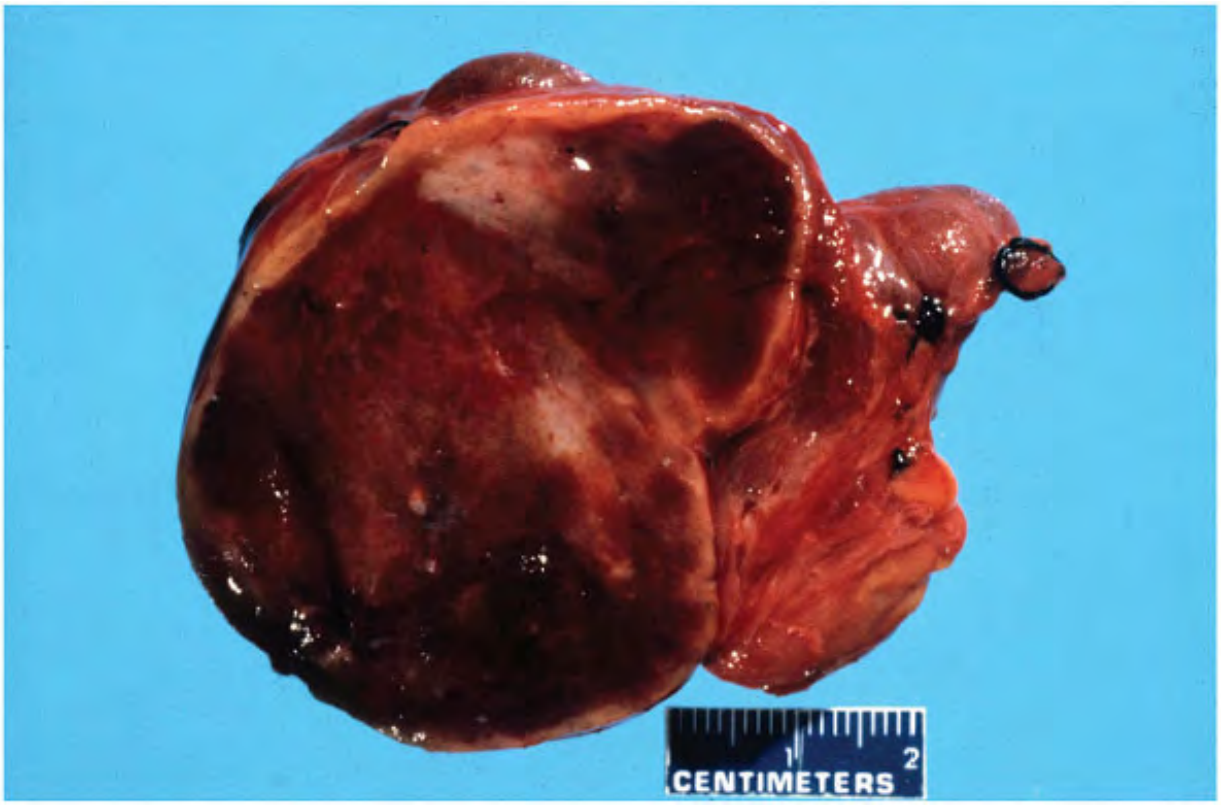

Figure 17.17. Gross photograph of a large cystic follicular adenoma.

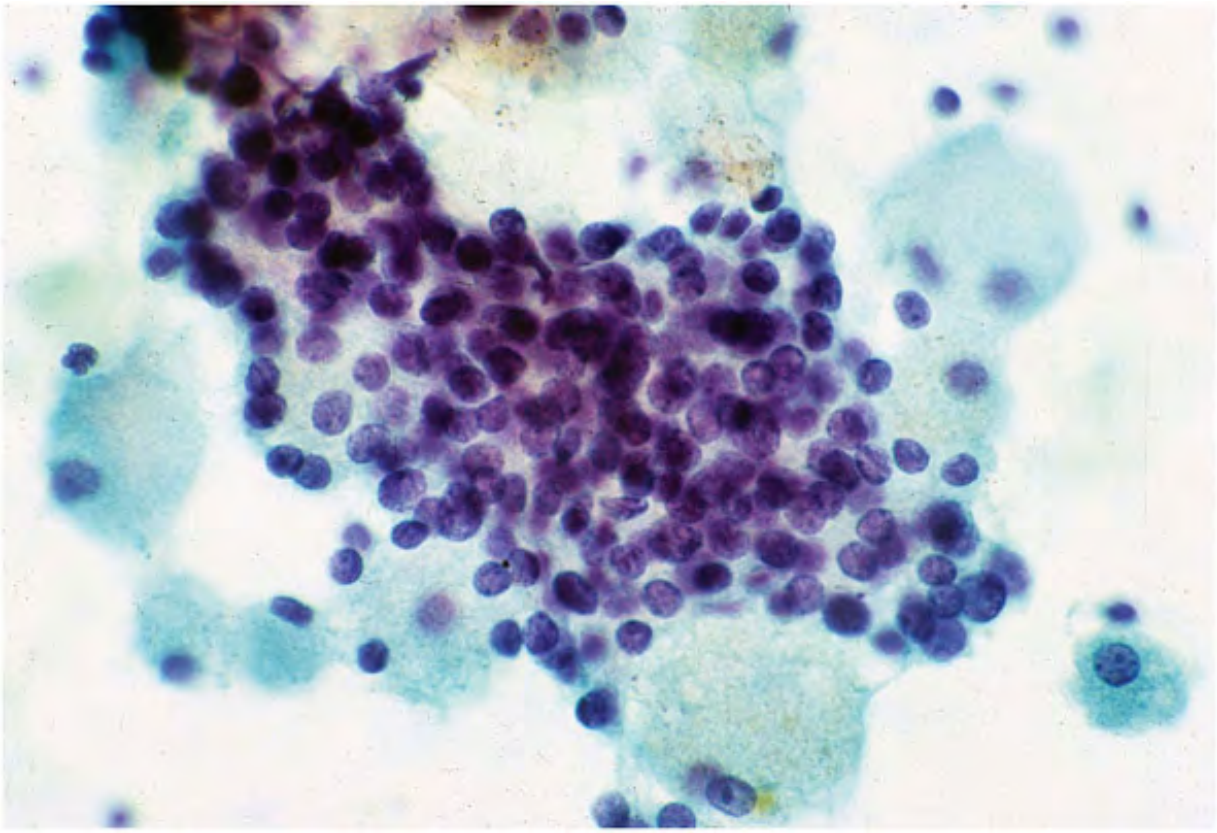

Figure 17.18. FNA of a cystic follicular adenoma consisting of a syncytial tissue fragment of follicular cells with a follicular pattern. The nuclei are mildly enlarged. Note macrophages i background.

CYSTIC PAPILLARY CARCINOMA

The most common malignant neoplasm of the thyroid to undergo cystic change is papillary carcinoma.45 In a study reported by Goellner,9 16.6% of papillary carcinomas were cystic. T carcinoma may be purely cystic or partially cystic and may contain residual in the wall (Fig. 17.19). The diagnosis of

P.377

P.378

P.379

P.380

cystic papillary carcinoma will be accurate in the presence of cellular material with classic cytologic features (Fig. 17.20). However, considerable diagnostic difficulties are faced with cytologic diagnosis of cystic papillary carcinoma due to a poorly cellular sample, regressive

changes in the neoplastic cells masking the malignant criteria, and the cellular debris, blood and large numbers of macrophages in the background (Figs. 17.21 , 17.22 , 17.23 , 17.24 , 1 and 17.26). Their differentiation from reactive/reparative follicular cells in cystic nodular goiter is a major diagnostic problem. Castro-Gomez46 described the features helpful in identifying papillary carcinoma cells that included tridimensional tissue fragments, anisonucleosis, nuclear bars, powdery chromatin, metaplastic cytoplasm, and cytoplasmic vacuoles.

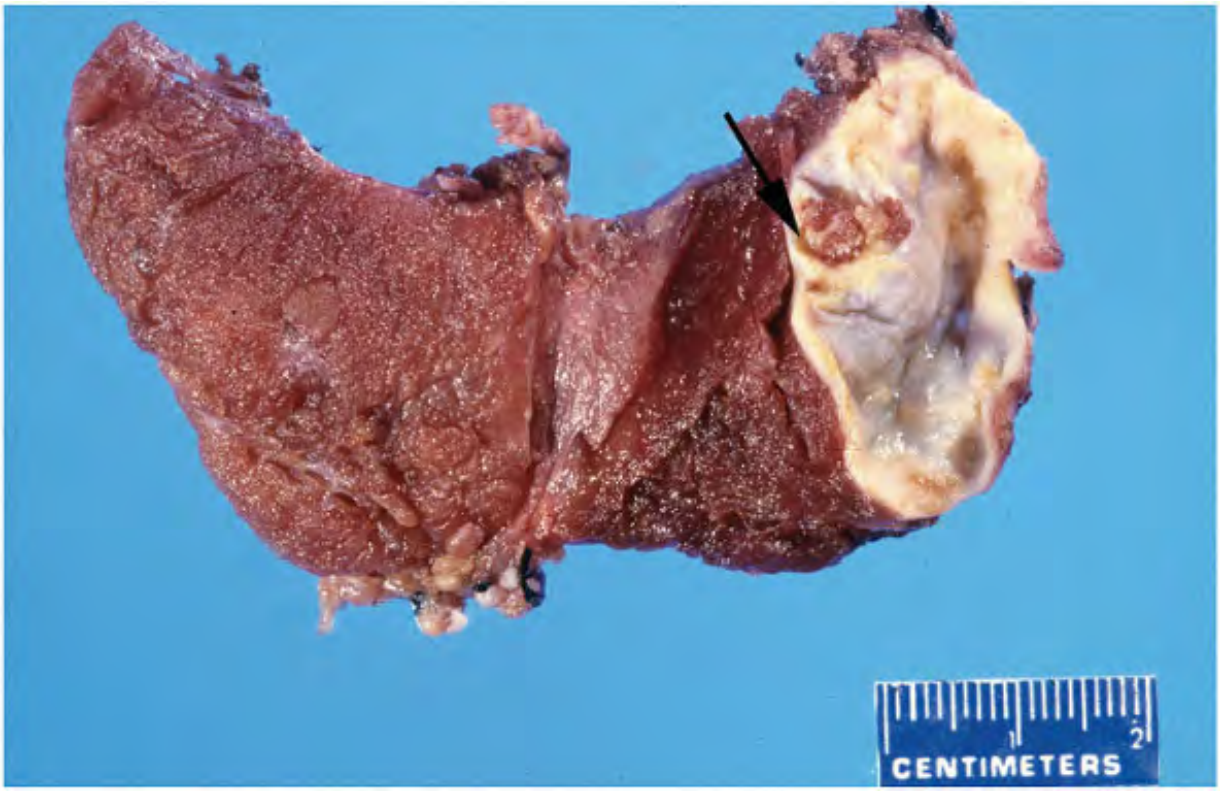

Figure 17.19. Gross photograph of a cystic papillary carcinoma. The cystic cavity is large w thick wall. Note residual tumor in the wall (*arrow*). After aspirating a cystic lesion, the resi tumor if palpable should be aspirated.

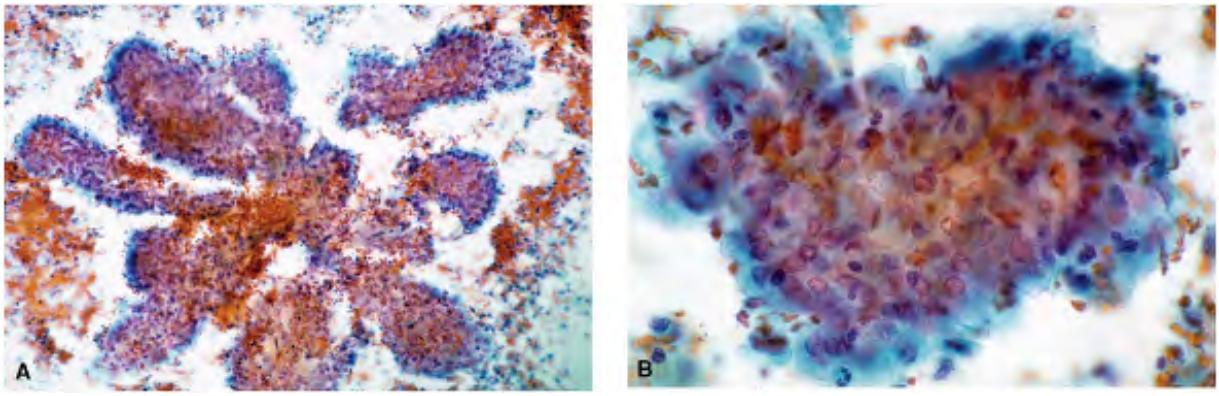

Figure 17.20. A. Fine-needle aspirate of a cystic papillary carcinoma may be diagnostic as s here with branching papillary tissue fragments. B. Higher magnification showing features of papillary carcinoma.

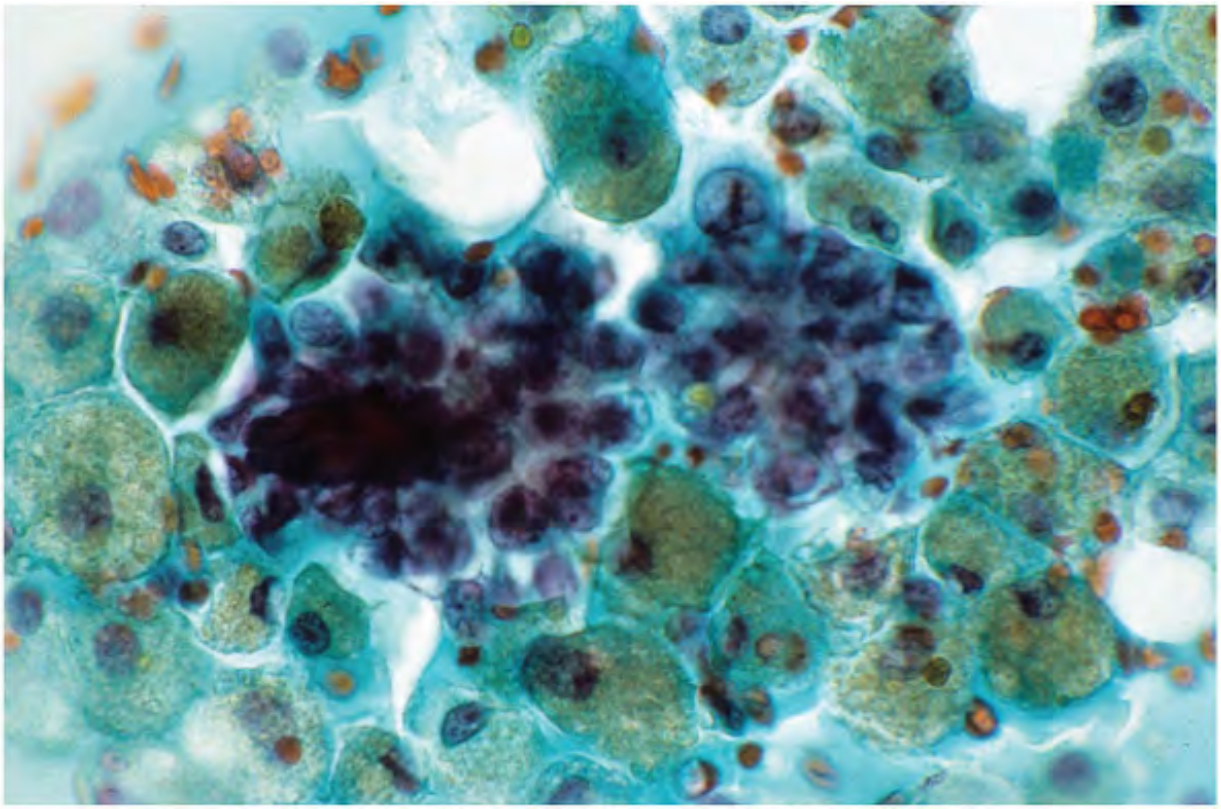

Figure 17.21. This aspirate from a cystic papillary carcinoma consists of tissue fragments of malignant cells obscured by hemosiderin-containing macrophages. Note a psammoma body. cellular details will preclude an unequivocal diagnosis of papillary carcinoma.

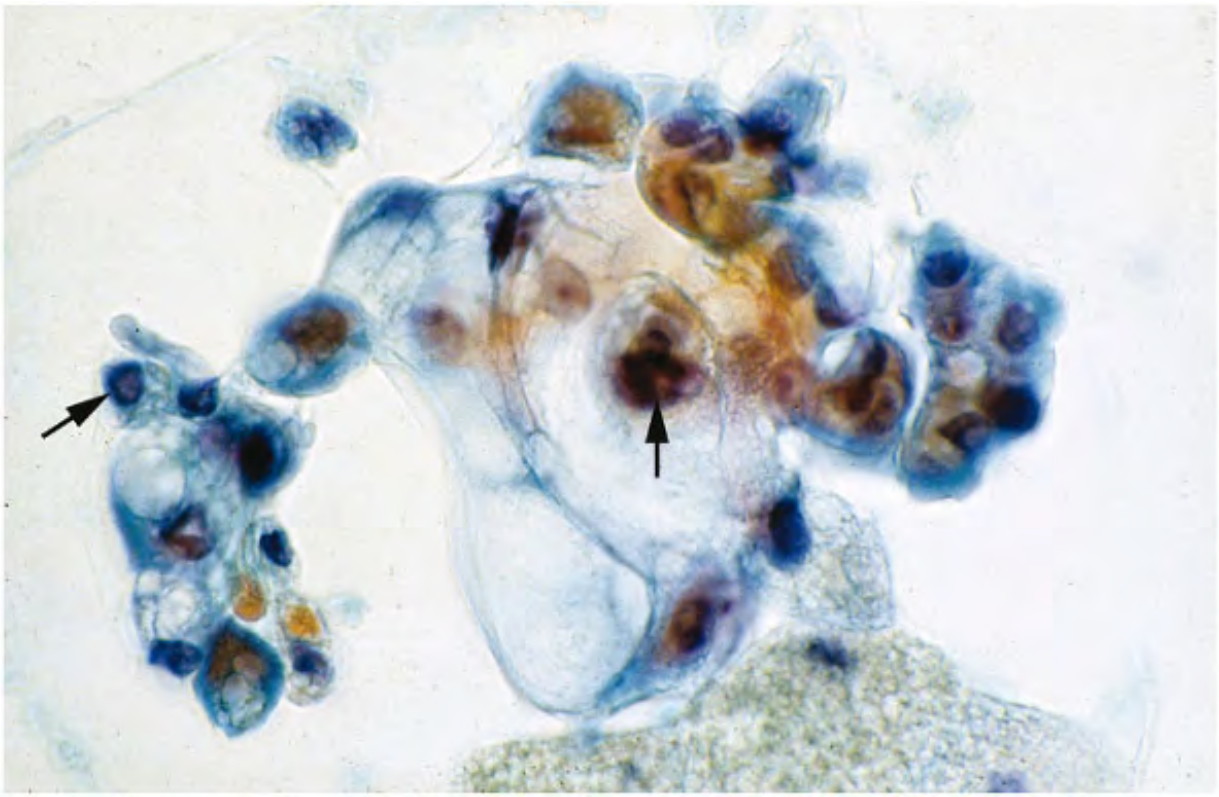

Figure 17.22. Another example of degenerating carcinoma cells from a cystic papillary carcinoma. Their cytoplasm is markedly vacuolated. The nuclei have smudgy chromatin with suggestion of intranuclear inclusions (*arrows*). An unequivocal diagnosis of papillary carcinc cannot be given from this cytologic pattern.

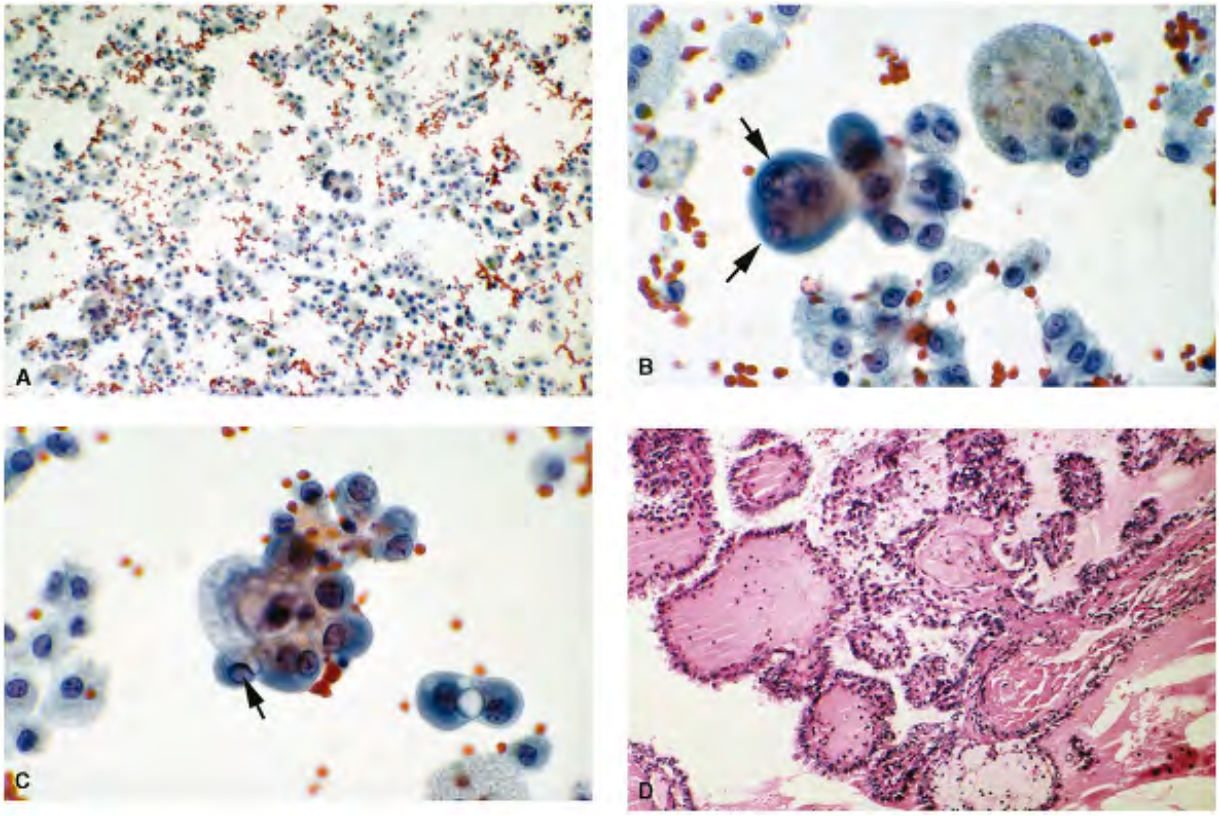

Figure 17.24. A. Fine-needle biopsy of cystic papillary carcinoma. The smear shows a large number of degenerating follicular cells and histiocytes (low power). B,C. Higher magnificati The follicular cells are large and pleomorphic, with cytoplasmic vacuoles. The nuclear chror appears smudgy, but pseudoinclusions are seen (*arrows*). D. Thyroidectomy confirmed a cys papillary carcinoma.

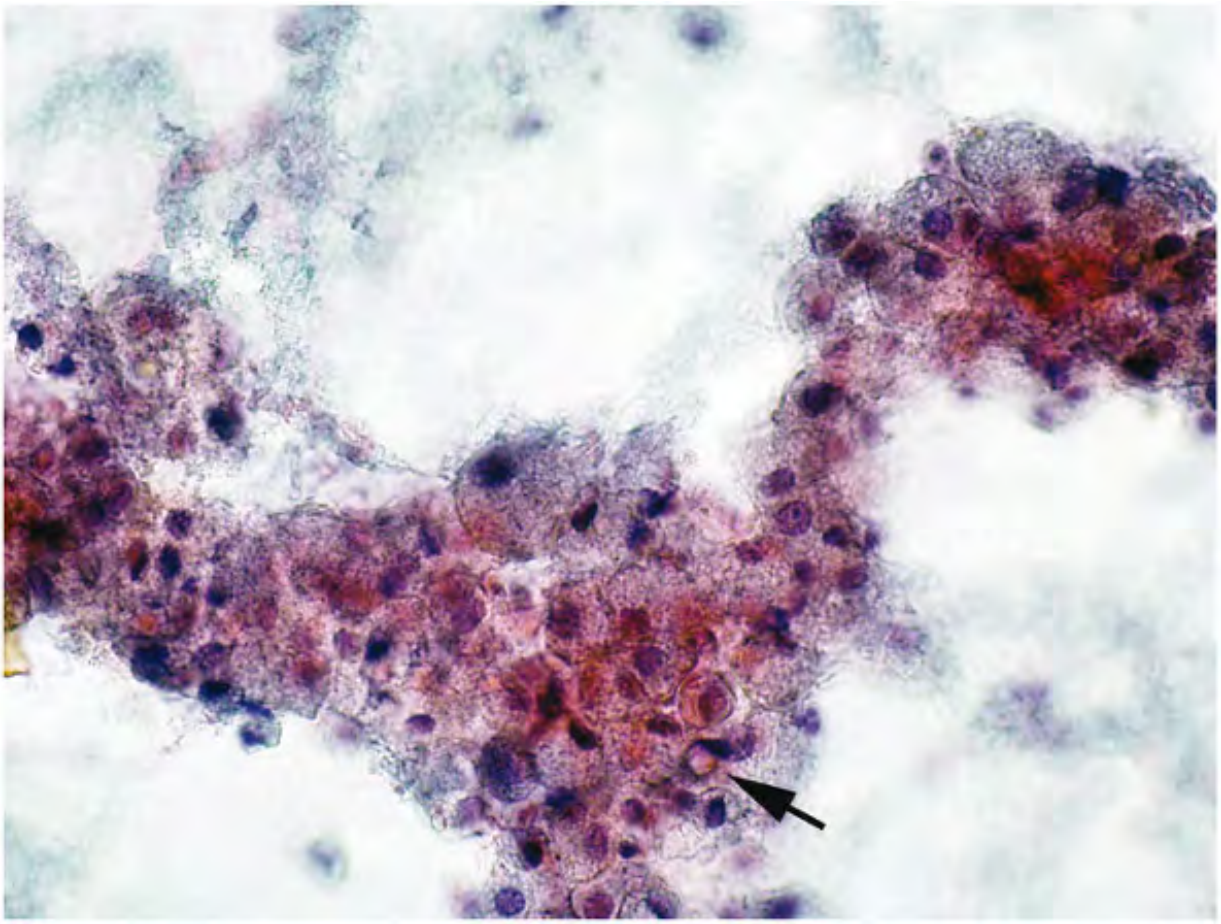

Figure 17.25. FNA of a surgically proven cystic papillary carcinoma showing hemorrhagic background and tissue fragments of enlarged follicular cells containing abundant finely vacuolated cytoplasm. Their nuclei present degenerative changes and are difficult to evalua Note a suggestion of intranuclear inclusion (*arrow*). These cells appear histiocytoid but are suspicious for papillary carcinoma.

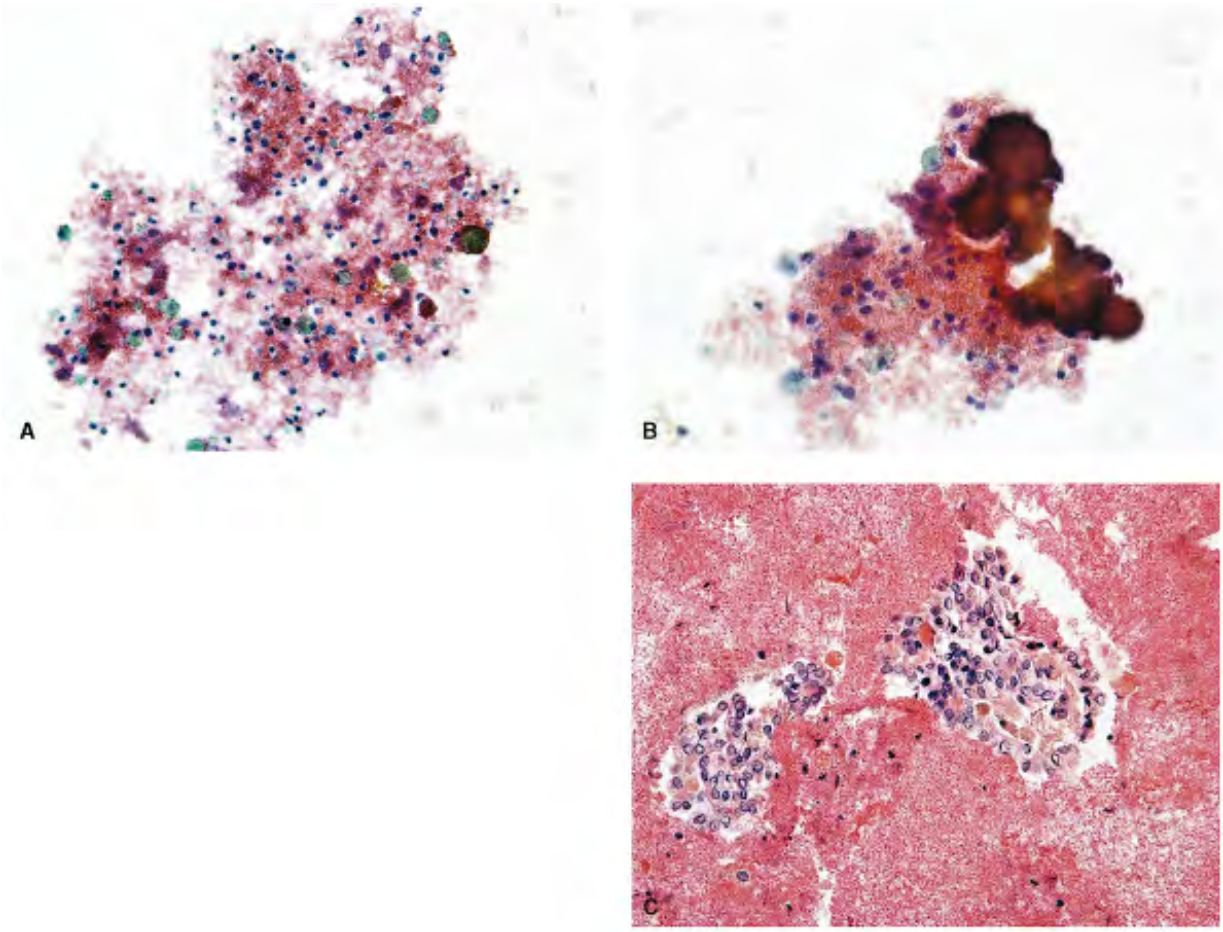

Figure 17.26. FNA of a cystic papillary carcinoma. A. The aspirate is bloody and the smear i practically acellular, containing few histiocytes. B. This field shows a naked psammoma bod The smear is nondiagnostic. C. The cell block, however, revealed fragments of papillary carcinoma. Thyroidectomy confirmed the papillary carcinoma.

We rely very heavily on minimal criteria for the cytologic diagnosis of papillary carcinoma (s Chapter 9), which are similar to those described by Castro-Gomez et al.46

Cystic change is unusual in follicular carcinomas but may be pronounced in anaplastic carcinomas due to extensive necrosis (Fig. 17.27). The cellular and necrotic debris obscures malignant cells and may preclude a correct diagnosis.

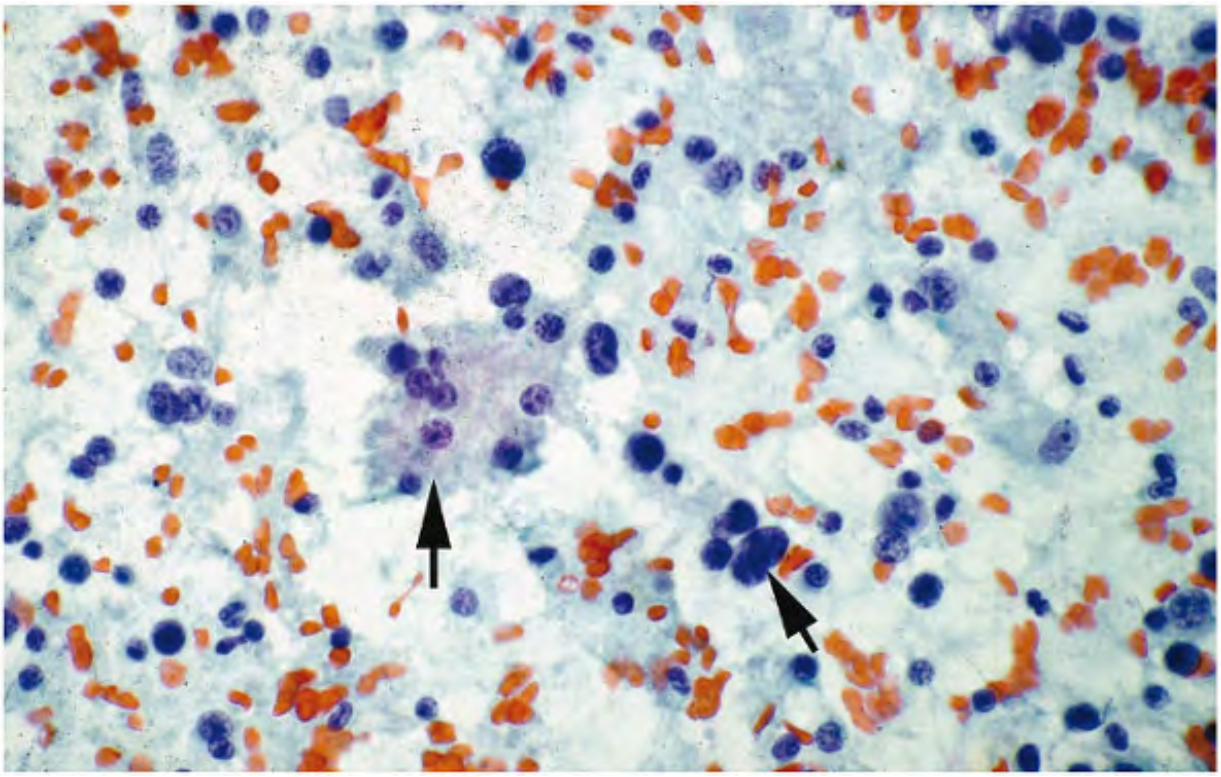

Figure 17.27. Cystic anaplastic carcinoma showing inflammatory and necrotic background. malignant cells (*arrows*) have poorly defined cell borders and are obscured by the cellular debris.

Very rarely a branchial cleft cyst (Fig. 17.28) or a parathyroid cyst enters the differential diagnosis. Unless clinically and radiologically suspected, the cytologic differentiation of a parathyroid cyst from a cystic nodular goiter is not possible without ancillary tests (see Cha 21). The differential diagnostic features of various cystic thyroid lesions are listed in Table

Simple cyst
Usually squamous epithelial lined cyst; variable cellularity; epithelial cells may be atypical
17.1
Lymphoepithelial cyst
Uncommon multiple cysts in the background of Hashimoto's thyroiditis; may be present without underlying disease process; lined by squamous epithelium with or without atypia; associated squamous metaplasia

17.2

Intrathyroidal thyroglossal duct cyst or branchial cleft cyst

Squamous or columnar epithelial lining; aspirated specimen with benign, mature squamous cells; metaplastic squamous cells Â±; anucleated squames; thyroid follicular cells Â±

17.3 to 17.5

Colloid cyst

Abundant colloid; absent or few follicular cells with small pyknotic nuclei

17.6

Cystic nodular goiter

Aspirated fluid variable in quantity; thin, clear to amber colored, or thick, turbid, "gruel-like"; or hemorrhagic to chocolate colored; variable cellularity, usually few or no well-preserved follicular cells; occasionally large tissue fragments; degenerative changes in follicular cells, with cellular and nuclear enlargement, granular to compact chromatin; micronucleoli Â±; appreciable cytoplasm, with or without hemosiderin; repair/regenerative changes with atypical features such as nuclear grooves, intranuclear inclusions, squamous metaplasia., spindle forms; HÃ¼rthle cells Â±; variable numbers of macrophages with and without hemosiderin; multinucleated foreign-body-type giant cells; calcific debris, stromal cells; oxalate crystals with supravital stain (wet mount)

17.8 to 17.16

Cystic follicular adenoma

Syncytial tissue fragments of follicular cells with or without follicular pattern, with mild to moderately enlarged nuclei, containing granular chromatin; histiocytes with and without hemosiderin in the background

17.18

Cystic HÃ¼rthle cell tumor

Neoplastic HÃ¼rthle cells discrete, in groups, or in tissue fragments, uniform nuclei with prominent macronucleoli; transition forms not present; follicular cells or colloid not present in the background; histiocytes with and without hemosiderin

Cystic papillary carcinoma

Aspirated contents may be clear to turbid, grossly hemorrhagic to chocolate colored; cellularity variable; carcinoma cells well-preserved and clearly diagnostic of papillary carcinoma or with degenerative changes such as cytoplasmic vacuoles, foamy, bubbly cytoplasm appearing histiocytoid, hemosiderin Â±; psammoma body Â±; histiocytes with and without hemosiderin in large numbers; may obscure carcinoma cells; colloid absent

17.20 to 17.26

Anaplastic carcinoma with cystic degeneration and necrosis

Profuse inflammatory infiltrate, obscuring carcinoma cells; identification of malignant cells may be difficult

17.27

Branchial cleft cyst in the neck

Aspirated fluid clear to turbid; polymorphic cell population composed of benign squamous cells with frequent anucleated forms; ciliated columnar cells Â±; thyroid follicular cells Â±; mucoid background; inflammatory cells Â±; macrophages Â±; cholesterol crystals Â±

17.28

Parathyroid cyst

Clear fluid, acellular to poor cellularity; small cuboidal epithelial cells with uniform, round nuclei; coarsely granular chromatin; difficult to differentiate from thyroid follicular cells; macrophages Â±; positive immunoreactivity to parathyroid antibody; high levels of parathyroid hormone

See Fig. 21.4 (Chapter 21)

Disease Entity	Cytopathologic Features	See Fig(s).

TABLE 17.3 DIFFERENTIAL DIAGNOSIS OF CYSTIC LESIONS O THE THYROID

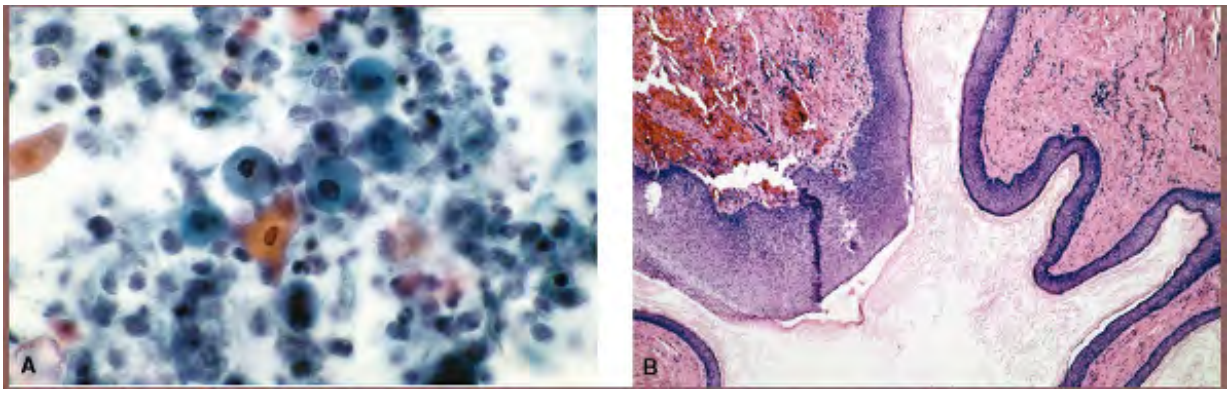

Figure 17.28. A. Branchial cleft cyst fluid showing benign mature squamous cells anucleate squames and cellular debris in the background. B. Histologic section of a branchial cleft cyst lined by stratified squamous epithelium.

P.382
P.383

SUMMARY

The most common cystic lesion of the thyroid is cystic nodular goiter. The follicular cells in cystic background often demonstrate degenerative and/or reparative-regenerative changes cause diagnostic difficulties. They are often misinterpreted as suspicious or diagnostic of papillary carcinoma, leading to unnecessary surgical procedures. It is prudent not to render cytologic diagnosis of papillary carcinoma unless minimal cytologic criteria are present. Degenerative changes may also result in a false-negative diagnosis. Clinically suspicious cyst those that recur or those with a residual mass by palpation or by ultrasonography after aspiration. Repeat aspiration or excision of suspicious cysts is indicated because of the risk cancer.

References

1.Cusick EL, McIntosh CA, Krukowski ZH, et al. Cystic change and neoplasia in isolated thyroid swellings. *Br J Surg* . 1988;75:982â€“983.

2.Abbas G, Heller KS, Khoynezhad A, et al. The incidence of carcinoma in cytologically benign thyroid cysts. *Surgery* . 2001; 130:1035â€“1038.

3.McHenry CR, Slusarczk SJ, Khiyami A. Reccomendations for management of cystic thyroi disease. *Surgery* . 1999;126:1167â€“1172.

4.Meko JB, Norton JA. Large cystic/solid thyroid nodules: a potential false-negative fine needle aspiration. *Surgery (St. Louis)* . 1995;118:996â€“1003.

5.de las Santos ET, Keyhani-Rofagha S, Cunningham JJ, et al. Cystic thyroid nodules. The dilemma of malignant lesions. *Arch Intern Med* . 1990;150:1422â€“1427.

6.Sarda AK, Bal S, Dutta Gupta S, et al. Diagnosis and treatment of cystic disease of the thyroid by aspiration. *Surgery* . 1988; 103:593â€“596.

7.Rosen IB, Provias JP, Walfish PG. Pathologic nature of cystic thyroid nodules selected fo surgery by needle aspiration biopsy. *Surgery* . 1986;100:606â€“612.

8.Suen KC, Quenville NF. Fine needle aspiration biopsy of the thyroid gland: a study of 304 cases. *J Clin Pathol* . 1983;36:1036â€“1045.

9.Goellner JR, Johnson DA. Cytology of cystic papillary carcinoma of the thyroid. *Acta Cyt* . 1982;26:787â€“799.

10.Hammer M, Wortsman J, Folse R. Cancer in cystic lesions of the thyroid. *Arch Surg* . 1982;117:1020â€“1023.

11.Walfish PG, Hazani E, Strawbridge HTH, et al. Combined ultrasound and needle aspirat cytology in the assessment and management of hypofunctioning thyroid nodule. *Ann Inter Med* . 1977;87:270â€“274

12.Jensen F, Rasmussen SN. The treatment of thyroid cysts by ultrasonically guided fine needle aspirate. *Acta Chir Scand* . 1976;142:209â€“211.

13.Ma MKG, Ong B. Cystic thyroid nodules. *Br J Surg* . 1975;62:205â€“206.

14.Miller JM, Zafar S, Karo JJ. The cystic thyroid nodule. *Diagn Radiol* . 1974;110:257â€“2

15.Crile G Jr. Treatment of thyroid cysts by aspiration. *Surgery* . 1966;59:210â€“212.

16.Reading CC, Charboneau JW, Hay ID, et al. Sonography of thyroid nodules: a "classic pattern" diagnostic approach. *Ultrasound Q* . 2005;2:1â€“19.

17.Khati N, Adamson T, Johnson KS, et al. Ultrasound of the thyroid and parathyroid glanc *Ultrasound Q* . 2003;19:162â€“176.

18.Rosen IB, Wallace C, Strawbridge HG, et al. Re-evaluation of needle aspiration cytolog in detection of thyroid cancer. *Surgery* . 1981;90:747â€“756.

19.Thijs LG, Winer JD. Ultrasonic examination of the thyroid glandâ€“-possibilities and limitations. *Am J Med* . 1976;60:96â€“105.

20.Rosen IB, Walfish PG, Miskin M. The use of B-mode ultrasonography in changing indications for thyroid operations. *Surg Gynecol Obstet* . 1974;139:193â€“197.

21.Ashcraft NW, Van Herle AJ. Management of thyroid nodules, II. Scanning techniques, thyroid suppression therapy and fine needle aspiration. *Head Neck Surg* . 1981;3:297â€“32

22.Clark OH, Greenspan FS, Coggs GC, et al. Evaluation of solitary cold thyroid nodules by echography and thermography. *Am J Surg* . 1975;130:206â€“211.

23.Crockford PM, Bain G. Fine needle aspiration biopsy of the thyroid. *Can Med Assoc J* . 1974;110:1029â€“1032.

24.Miller JM, Hamburger JI, Taylor CL. Is needle aspiration of the cystic thyroid nodule

effective and safe treatment? In: Hamburger JI, Miller JM, eds. *Controversies in Thyroidology* . New York: Praeger; 1983:209â€“236.

25.Rehak NN, Oertel YC, Herp A, et al. Biochemical analysis of thyroid cyst fluid obtained fine needle aspiration. *Arch Pathol Lab Med* . 1993;117:625â€“630.

26.Wenig BM, Heffess C, Adair CF. *Atlas of Endocrine Pathology* . Philadelphia: Saunders; 1997:39â€“40.

27.Goldburg HM, Harvey P. Squamous cell cysts of the thyroid with special reference to th etiology of squamous epithelium in the human thyroid. *Br J Surg* . 1956;43:565â€“569.

28.Carney JA. Thyroid cysts. *Am J Surg Pathol* . 1989;13:1072â€“1074.

29.Hsu C, Boey J. Diagnostic pitfalls in the fine needle aspiration of thyroid nodules: a stu of 555 cases in Chinese patients. *Acta Cytol* . 1987;31:699â€“704.

30.Louis DN, Vickery AL Jr, Rosai J, et al. Multiple branchial cleft-like cysts in Hashimoto's thyroiditis. *Am J Surg Pathol* . 1989;13:45â€“49.

31.Apel RL, Asa SL, Chalvardlian A, et al. Intrathyroidal lymphoepithelial cysts of probable branchial origin. *Hum Pathol* . 1994;25:1238â€“1242.

32.Watanabe I, Kobayashi K, Yamaguchi M, et al. Multilocular lymphoepithelial cyst in the thyroid accompanied with a minute thyroid carcinoma. *Patholgy Int* . 1995;45:965â€“970.

33.Mittledorf CATS, de Oliveira Misiara AC, de Carvalho IE. Multicystic autoimmune thyroiditis-like disease associated with HIV infection. A case report. *Acta Cytol* . 1999;43:862â€“866.

34.Mishalani SH, Lones MA, Said JW. Multilocular thyroid cyst. A novel thyroid lesion associated with human immunodeficiency virus infection. *Arch Pathol Lab Med* . 1995;119:467â€“470.

35.Ry?sks A, Vokurka J, Michal M, et al. Intrathyroidal lymphoepithelial cyst. A report of t cases not associated with Hashimoto's thyroiditis. *Pathol Res Pract* . 1997;193:777â€“781.

36.North JH Jr. Foley AM, Hamill RL. Intrathyroid cysts of thyroglossal duct origin. *Am Sur* 1998;64:886â€“888.

37.Hatada T, Ichii S, Sagayama K, et al. Intrathyroid thyroglossal duct cyst simulating a thyroid nodule. *Tumori* . 2000;86:250â€“252.

38.McHenry CY, Danish r, Murphy T, et al. Atypical thyroglossal duct cyst: a rare cause for solitary thyroid nodule in childhood. *Am J Surg* . 1993;59:223â€“228.

39.Desmet J, DeWolf-Oeeters C, Cappelle L, et al. Branchial cleft-like cysts of the thyroid *Am J Surg Path* ol. 1990;14:1165â€“1171.

40.Lim-Tio SW, Judson R, Busmanis I, et al. An intra-thyroidal branchial cyst: a case repor *Aust NZ J Surg* . 1992;62:826â€“828.

41.Nassar A, Gupta PK, LiVolsi VA, et al. Histiocytic aggregates in benign nodular goiters mimicking cytologic features of papillary thyroid carcinoma (PTC). *Diagn Cytopathol* . 2003;29:243â€“245.

42.Faqin WC, Cibas ES, Renshaw AA. Atypical cells in fine-needle aspiration biopsy specimens of benign thyroid cysts. *Cancer (Cancer Cytopathol)* . 2005;105:71â€“79.

43.Renshaw AA. Histiocytoid cells in fine needle aspirates of papillary carcinoma of the thyroid: frequency and significance of an under-diagnosed cytologic pattern. *Cancer (Can Cytopathol)* . 2002; 96:240â€“243.

44.Ohashi H, Sato A, Tanagbe Y, et al. Cystic goiter with squamous cell metaplasiaâ€“-cas
report and comment on origin of squamous cell cyst. *Acta Pathol Jpn* . 1976;26:503â€“508

45.Carcangiu ML, Zampi G. Pupi A, et al. Papillary carcinoma of the thyroid: a clinicopathological study of 241 cases treated at the University of Florence, Italy. *Cancer* 1985;55:805â€“808.

46.Castro-Gomez L, Cordova-Ramirez S, Duarie-Torres R, et al. Cytologic criteria of cystic papillary carcinoma of the thyroid. *Acta Cytol* . 2003;47:590â€“594.

Editors: Kini, Sudha R.
Title: *Thyroid Cytopathology: A Text and Atlas, 1st Edition*

Copyright Â©2008 Lippincott Williams & Wilkins

18

Spindle Cells in Thyroid Aspirates

The normal thyroid gland contains limited stromal component. The presence of spindle-shap cells of mesenchymal origin in fine-needle aspirates of epithelial lesions of the thyroid is no common occurrence. Infrequently, the epithelial cells, in non-neoplastic as well as both ber and malignant neoplastic lesions acquire spindle shape. The stromal and epithelial spindle c originate from diverse sources (Table 18.1). They present considerable diagnostic difficulti when encountered in aspirated specimens from thyroid nodules, and may result in false-posi diagnosis of malignancy because of several cytologic abnormalities. The problem caused by presence of spindle cells in thyroid aspirates has not received much attention and only a fev reports document the diagnostic difficulties.1 , 2 , 3 This chapter describes various conditio which spindle cells are present in the thyroid aspirates including their diagnostic pitfalls anc cytologic features differentiating benign spindle cells from malignant ones (Table 18.2).

Stromal
Non-neoplastic
Nodular goiter
Chronic lymphocytic thyroiditis
Granulomatous thyroiditis
(subacute and infectious)
Riedel's thyroiditis (extremely rare)
Post^{131}I therapy
Proliferating granulation tissue with
fibroblastic and endothelial proliferation
Leiomyocytes (blood vessel)

Desmoplastic stroma of papillary or
anaplastic carcinoma
Neoplastic
Soft-tissue neoplasms, primary
or metastatic
Epithelial
Non-neoplastic
Reparative/regenerative follicular cells in
nodular goiter
Squamous metaplasia
Nodular goiter
Hashimoto's thyroiditis
Papillary carcinoma
Neoplastic
Hyalinizing trabecular adenoma
Papillary carcinoma
Medullary thyroid carcinoma
Anaplastic carcinoma
Poorly differentiated squamous carcinoma
(sarcomatoid type)
Spindle cell thyroid tumor with thymus-like
elements (SETTLE)
Spindle cell type, intrathyroidal thymoma
Metastatic carcinosarcoma

TABLE 18.1 SPINDLE CELLS IN THYROID ASPIRATES

Presentation
In tissue fragments or loosely cohesive groups; iso-
lated cells infrequent
In tissue fragments, loosely cohesive groups or isolated cells; may be in fascicles
Arrangement
In fascicles with palisading of nuclei, directional
flow to the cytoplasm; swirling arrangement;

cells may be separated by collagen

May be in fascicles, swirling arrangement or stori form pattern Â±

Cells

Large, mildly pleomorphic

Markedly pleomorphic

Cytoplasm

Abundant, pale

Variable with high N/C ratios

Nuclei

Round, oval, oblong, spindle to cigar-shaped, uni form to mildly pleomorphic, smooth nuclear mem branes, notch on the membrane Â± , compact to evenly dispersed, finely granular chromatin; multi ple micro- macronucleoli Â±; intranuclear inclusions Â±; mitosis regular Â±

Marked anisonucleosis with bizarre shapes, irregular nuclear membranes, coarsely granular chromatin with excessive parachromatin clear ing; multiple, irregular, micro-macronucleoli; intranuclear inclusions Â±; mitosis regular and irregular Â±

Background

Clean to inflammatory; features of nodular goiter or Hashimoto's thyroiditis

Clean to necrotic

Benign Spindle Cells	Malignant Spindle Cells

TABLE 18.2 DIFFERENTIATING FEATURES BETWEEN BENIG AND MALIGNANT SPINDLE CELLS

NON-NEOPLASTIC SPINDLE CELLS OF MESENCHYMAL ORIGIN

Benign spindle cells of mesenchymal or stromal origin are encountered in nodular goiters, ir

Hashimoto's thyroiditis, and from desmoplastic stroma in papillary or anaplastic carcinomas (Table 18.1 , Figs. 18.2 , 18.3 , 18.4 , 18.5 and 18.6). In nodular goiters they may be derive from fibrosis occurring as a result of episodes of hemorrhage, necrosis and subsequent organization of the granulation tissue (Figs. Figs. 18.1 and 18.2). They may also be derived reparative processes especially in cases of cystic degeneration. The cystic change and the fibrotic lesions are a frequent source of stromal cells in thyroid aspirates. Anderson et al.3 reported an incidence of 49% of nodular goiters with retrogressive changes to contain fibroblastic proliferations. Van Hooven et al.2 described 3 cases with fibrotic nodules that resulted in surgery because of significant population of spindle cells. Fibrosis has also been described in large follicular adenomas,2 although it is not very common. The thyroid parenchyma along the needle biopsy track or from the infarcted lesions (Figs. Fig. 18.3) ma show fibroblastic proliferation and may be seen in aspirated samples. Desmoplastic stroma i papillary or anaplastic carcinoma is yet another source of benign spindle cells (Figs. Figs. 18 and 18.5).

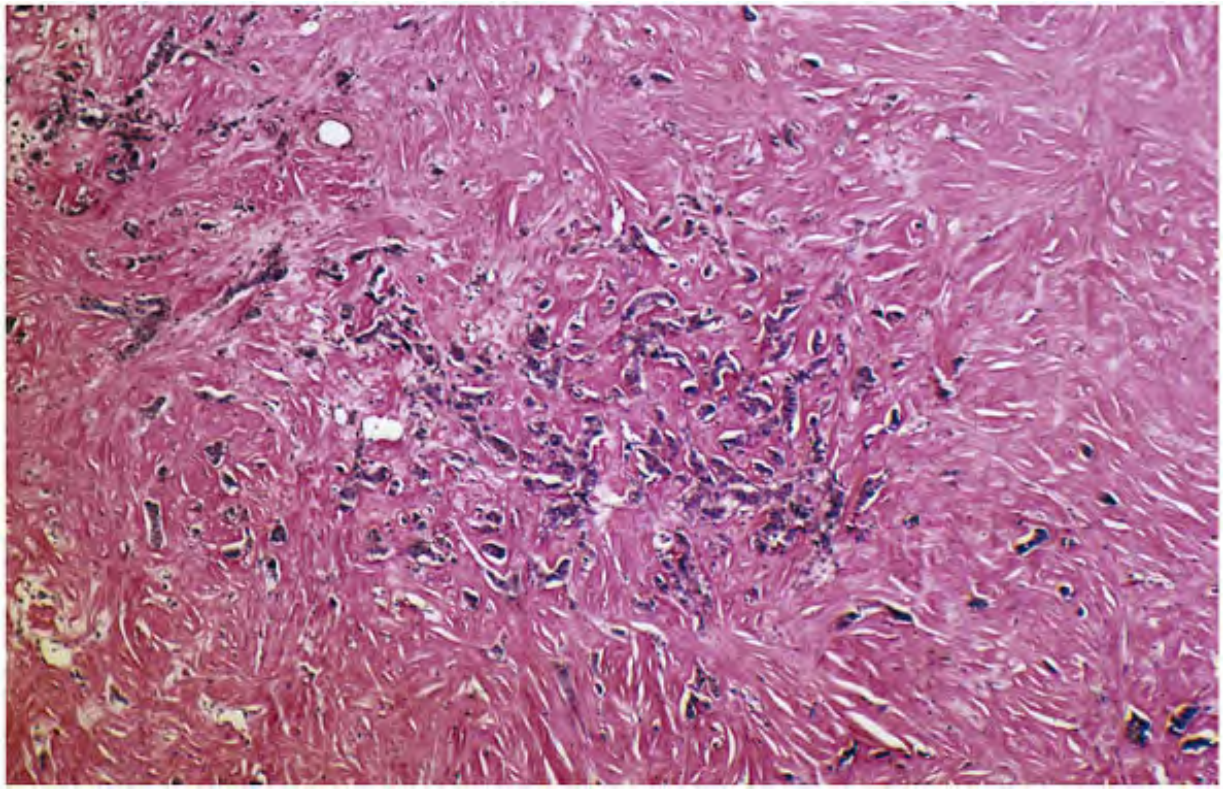

Figure 18.1. Histologic section of a fibrotic nodule from a case of nodular goiter. Note the collagenized stroma. Aspirate of such a lesion will be paucicellular with few stromal cells.

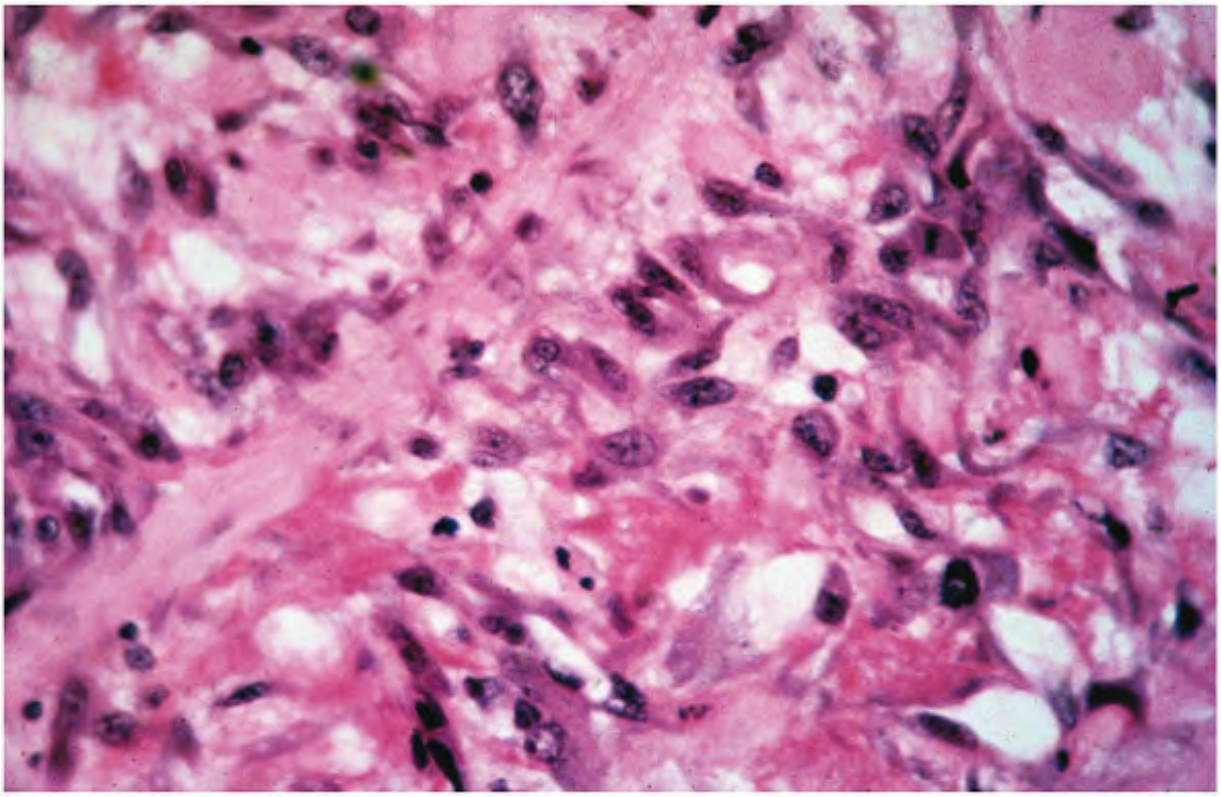

Figure 18.2. Histologic section showing granulation tissue with actively proliferating fibrobl FNA of this lesion may yield spindle cells with atypical nuclei.

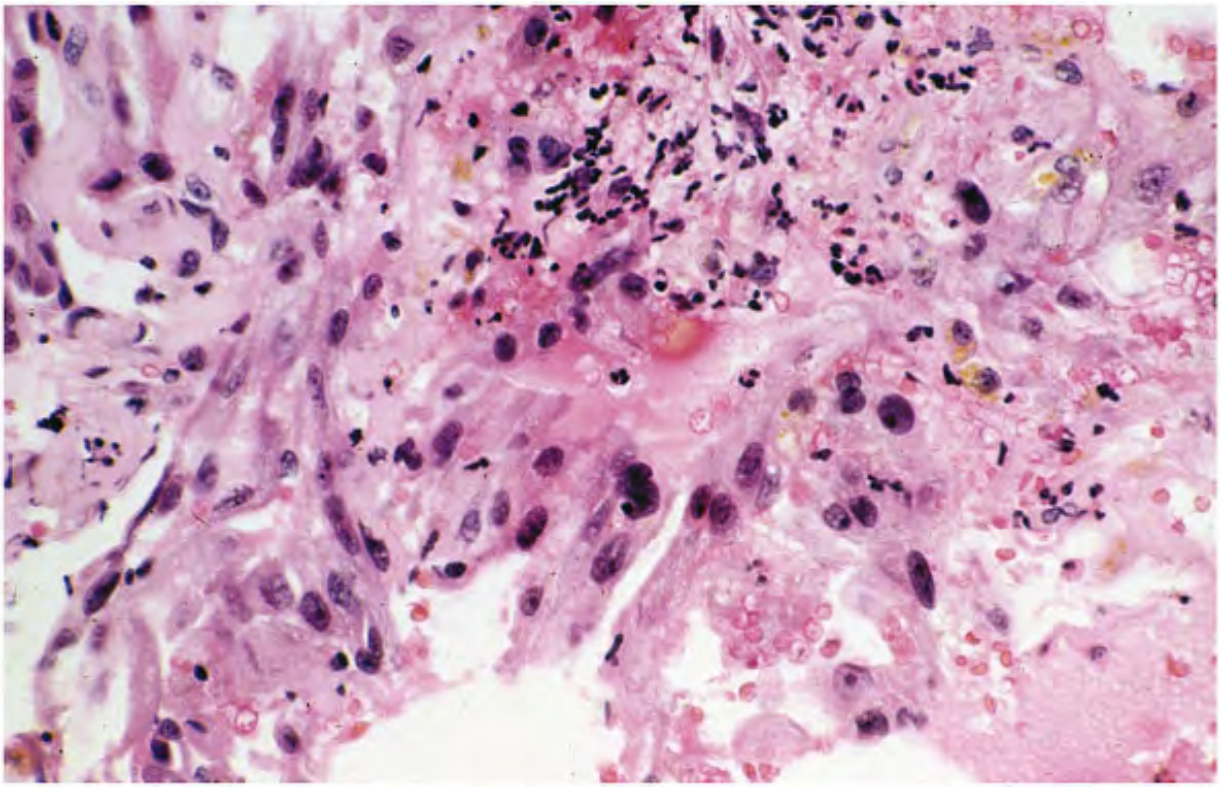

Figure 18.3. Histologic section of granulation tissue along the perimeter of an infarcted tun

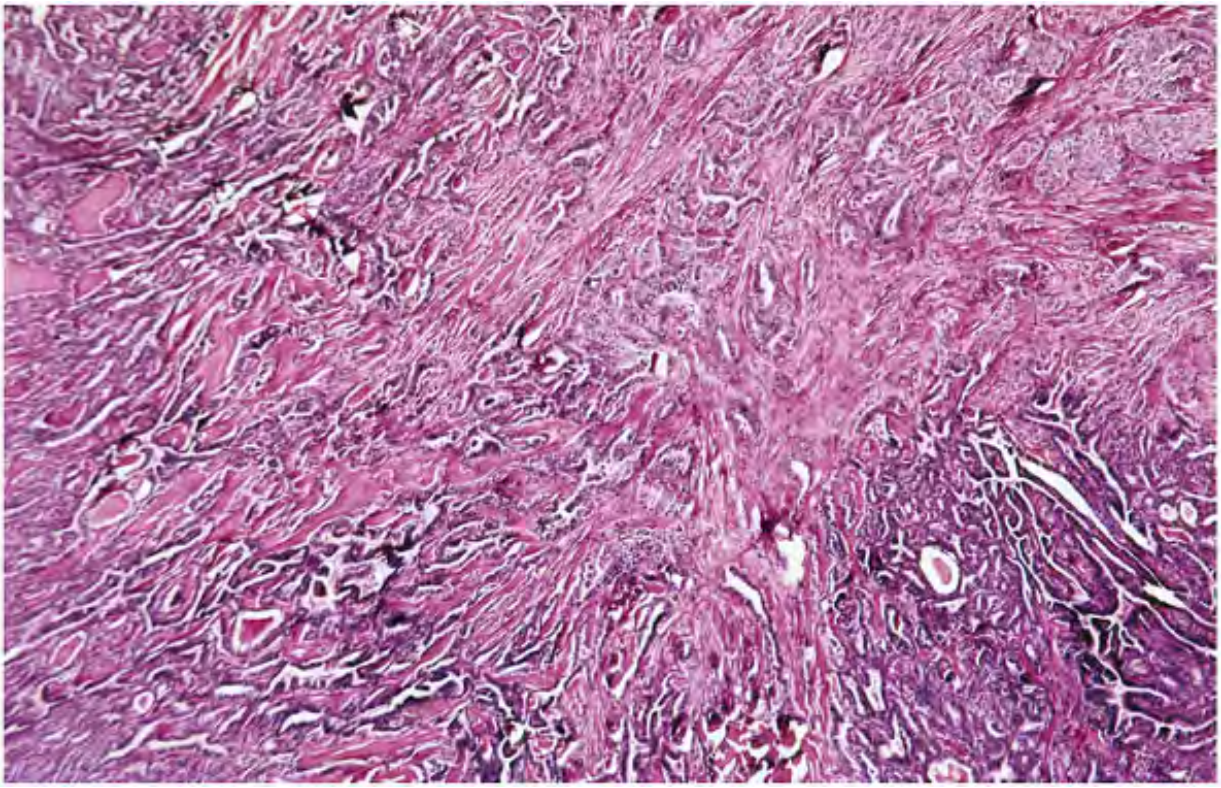

Figure 18.4. Histologic section of a papillary carcinoma with marked desmoplasia. FNA of th areas may be poorly cellular with only stromal cells leading to a false negative diagnosis.

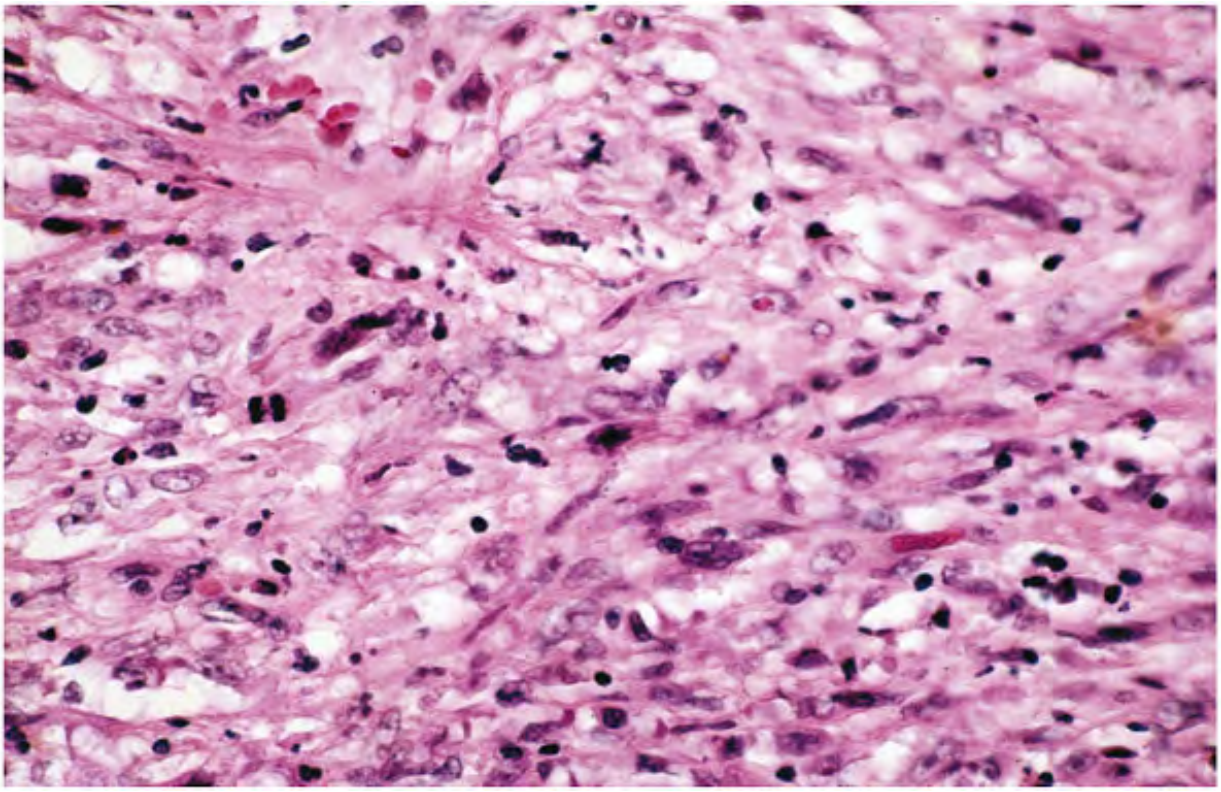

Figure 18.5. Histologic section of a paucicellular variant of anaplastic carcinoma with desmoplastic stroma. FNA of these areas may be poorly cellular, and may contain only strom cells, leading to a false-negative diagnosis.

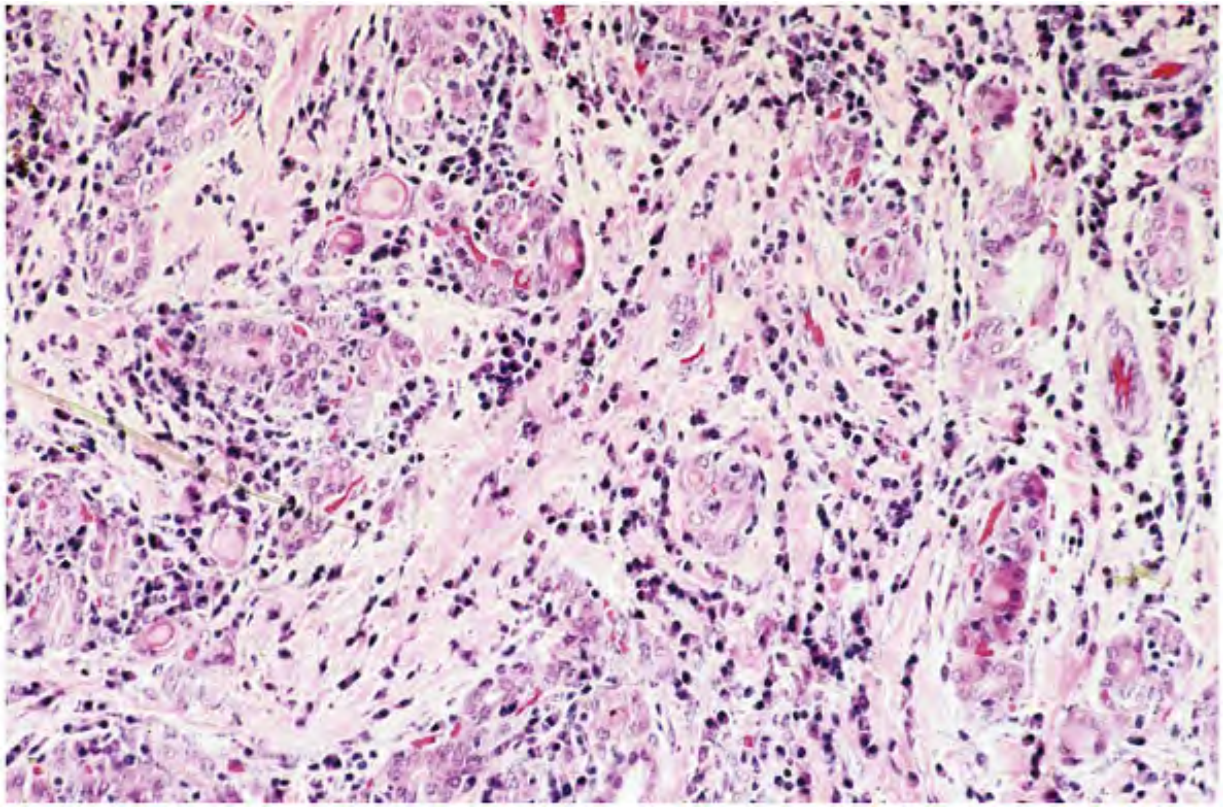

Figure 18.6. Histologic section of a thyroid involved by Hashimoto's disease demonstrating parenchymal atrophy and increased fibrosis.

Tissue fragments of connective tissue stroma may also be seen in aspirates of Hashimoto's thyroiditis (Fig. 18.6), especially in late stages of the disease.

Cytopathologic Features

The spindle cell of stromal origin in thyroid aspirates present a diverse morphology (Figs. 18 18.8 , 18.9 , 18.10 , 18.11 , 18.12 , 18.13 , 18.14 , 18.15 , 18.16 , 18.17 , 18.18 , 18.19 , 18. 18.21 , 18.22 , 18.23 and 18.24). The latter depends on whether the area biopsied is an old fibrotic nodule, or an actively organizing stroma with proliferating fibroblasts and capillarie The spindle cells from the fibrotic nodule usually are few in numbers and have bland nuclei, while those from organizing stroma show atypical nuclei with pleomorphism and nucleoli. Th spindle cells by their sheer presence cause diagnostic concern, more so with atypical morphology, and are often misinterpreted as neoplastic.

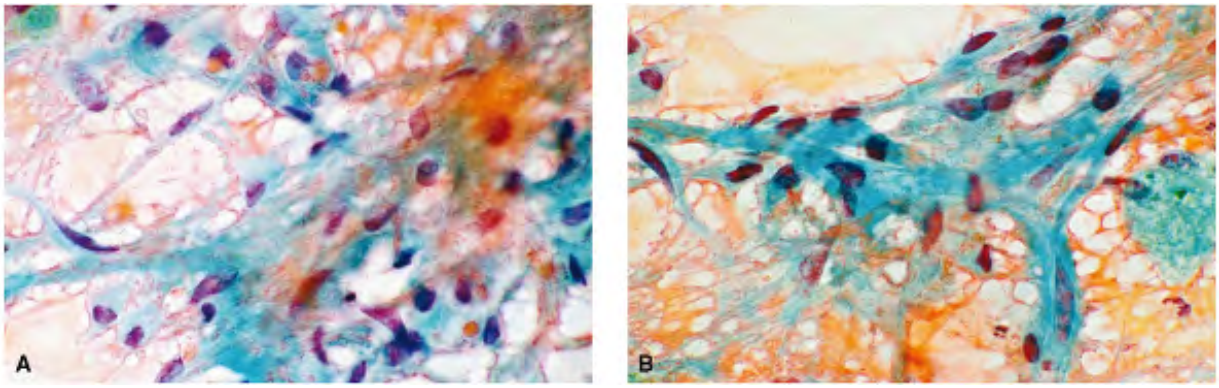

Figure 18.7. FNA of a nodular goiter showing several elongated spindle-shaped stomal cells separated by collagen. Note the nuclei are oblong to spindle shaped, containing bland chromatin.

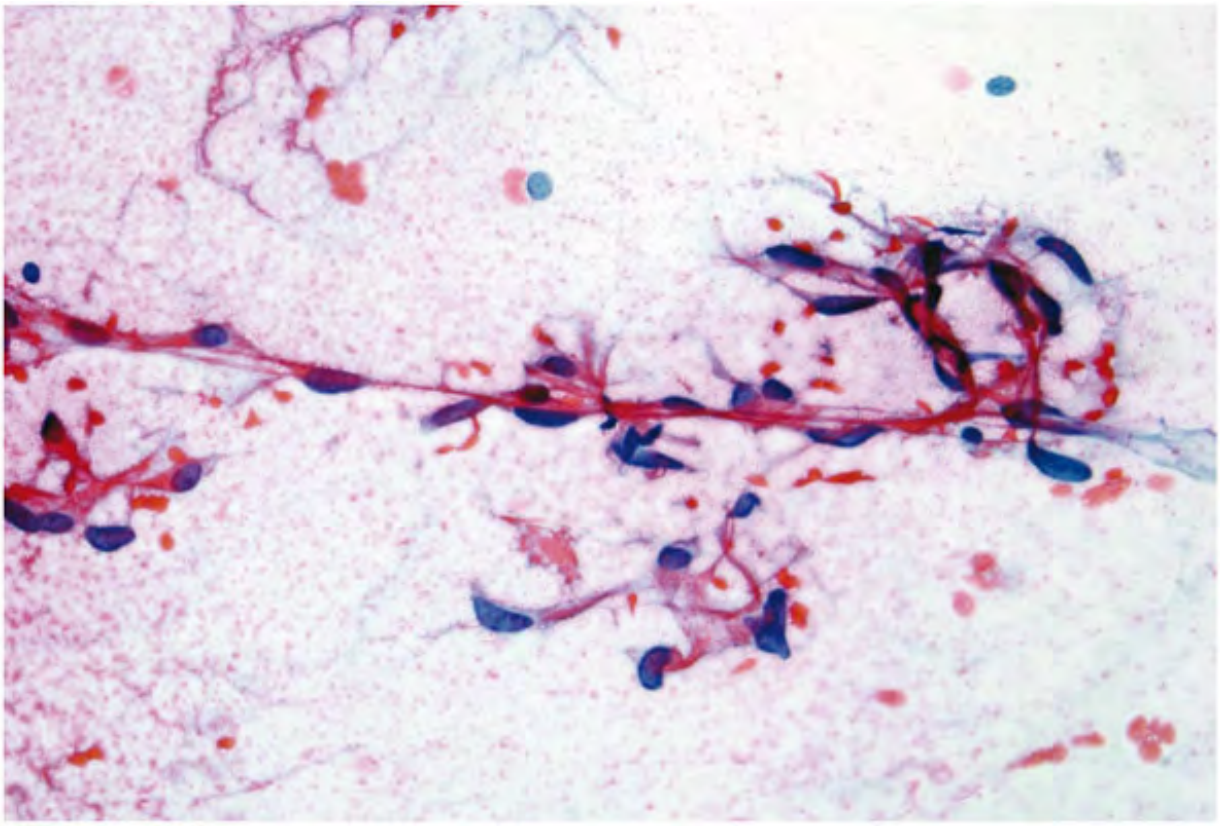

Figure 18.8. FNA of a nodular goiter showing a string of elongated stromal fibrocytes with lo cytoplasmic processes. The spindle-shaped nuclei have a bland chromatin pattern.

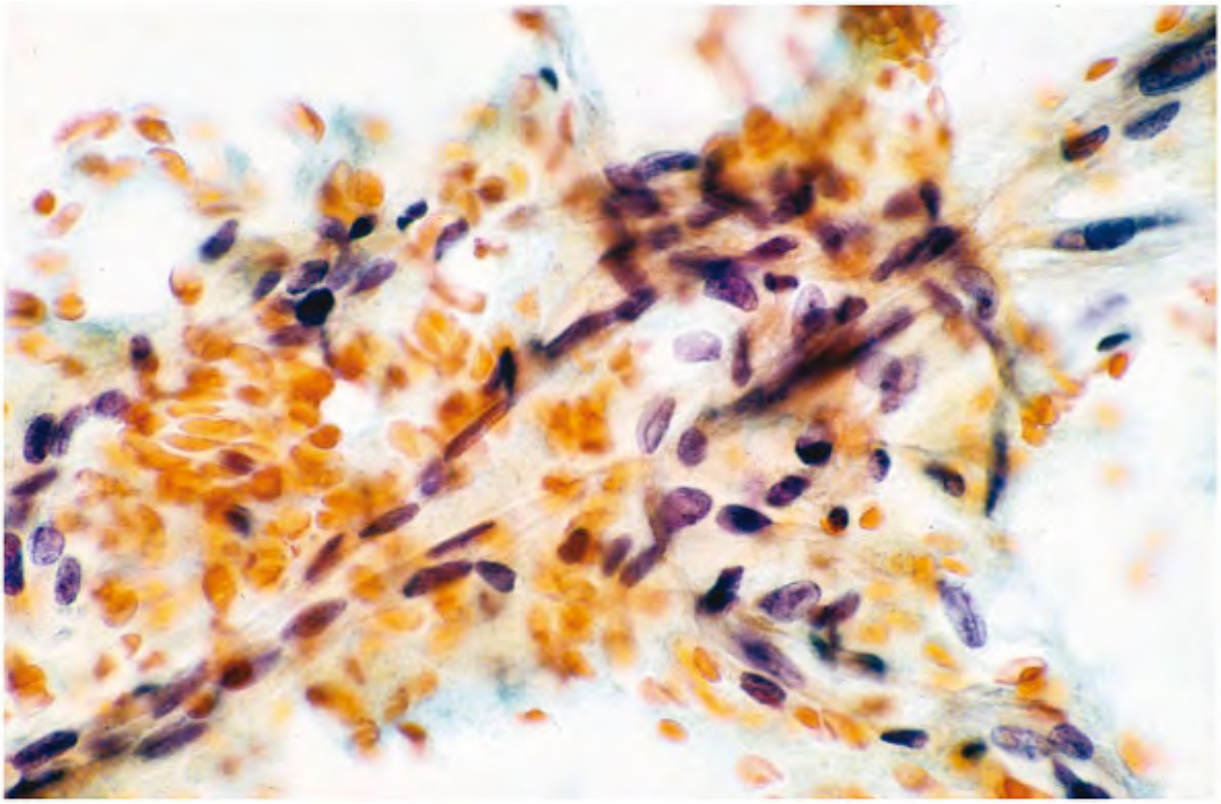

Figure 18.9. This aspirate from a case of nodular goiter shows a large population of spindle cells, isolated and in aggregates. The cells appear monomorphic with bland nuclei. This patt may be misinterpreted as a soft-tissue tumor or a medullary carcinoma.

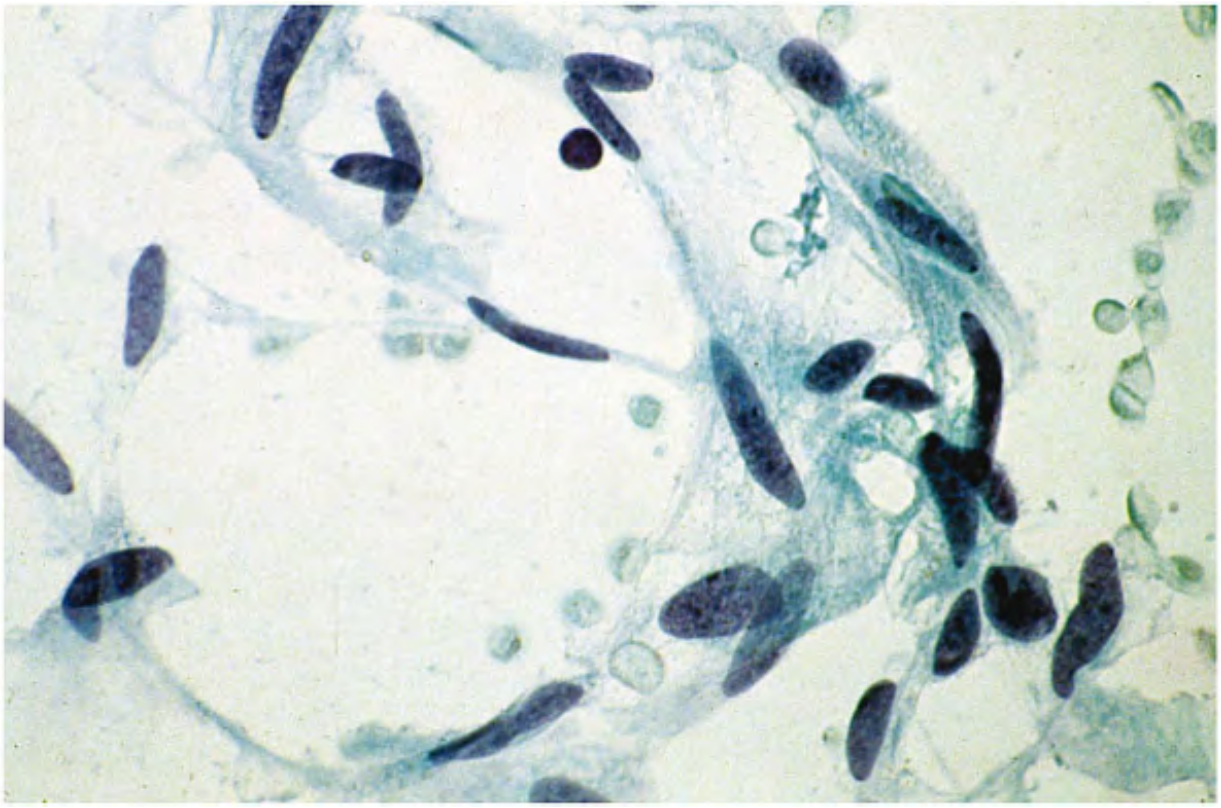

Figure 18.10. A group of delicate stromal spindle cells with long cytoplasmic processes and spindle-shaped nuclei. A small number of these types of cells in the background of nodular g should cause no concern.

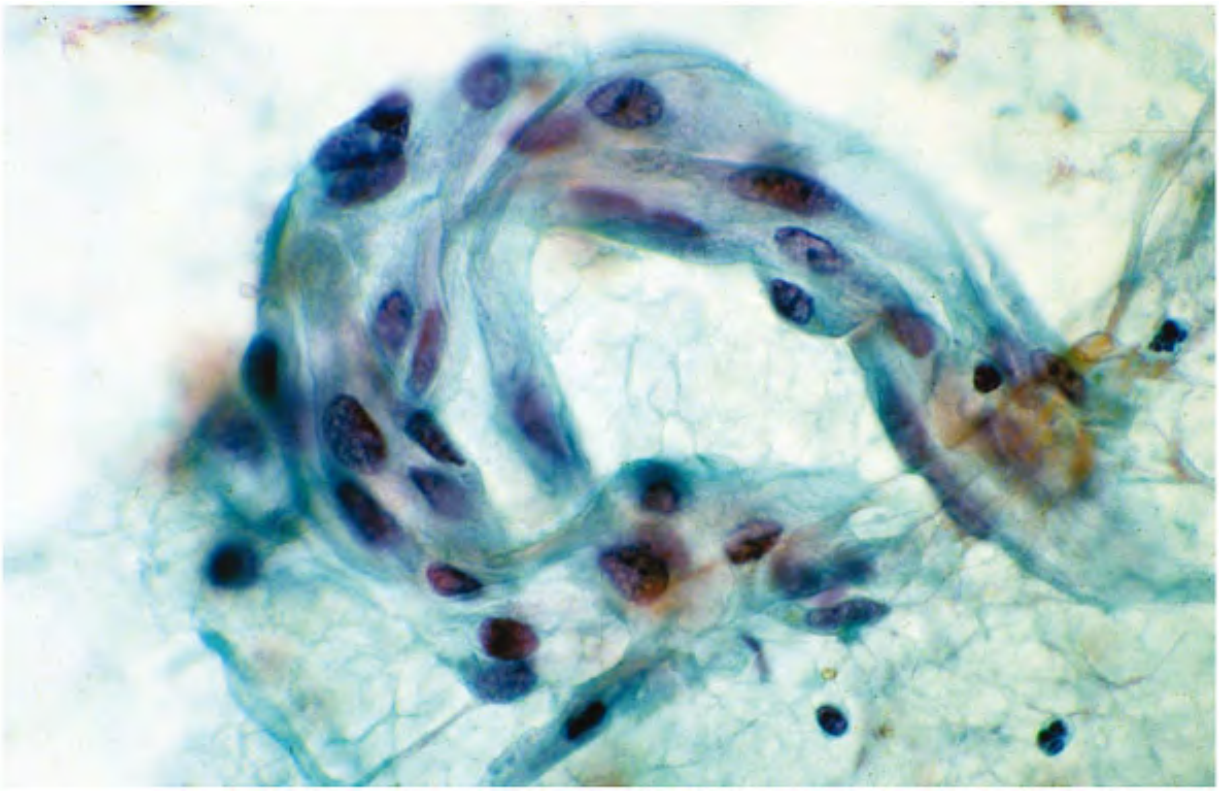

Figure 18.11. A fascicle of spindle-shaped stromal cells identified in an aspirate of nodular goiter. These stromal cells have abundant pale cytoplasm and impart a directional flow simi to that seen in repair. The nuclei are plump but with uniformly distributed finely granular chromatin.

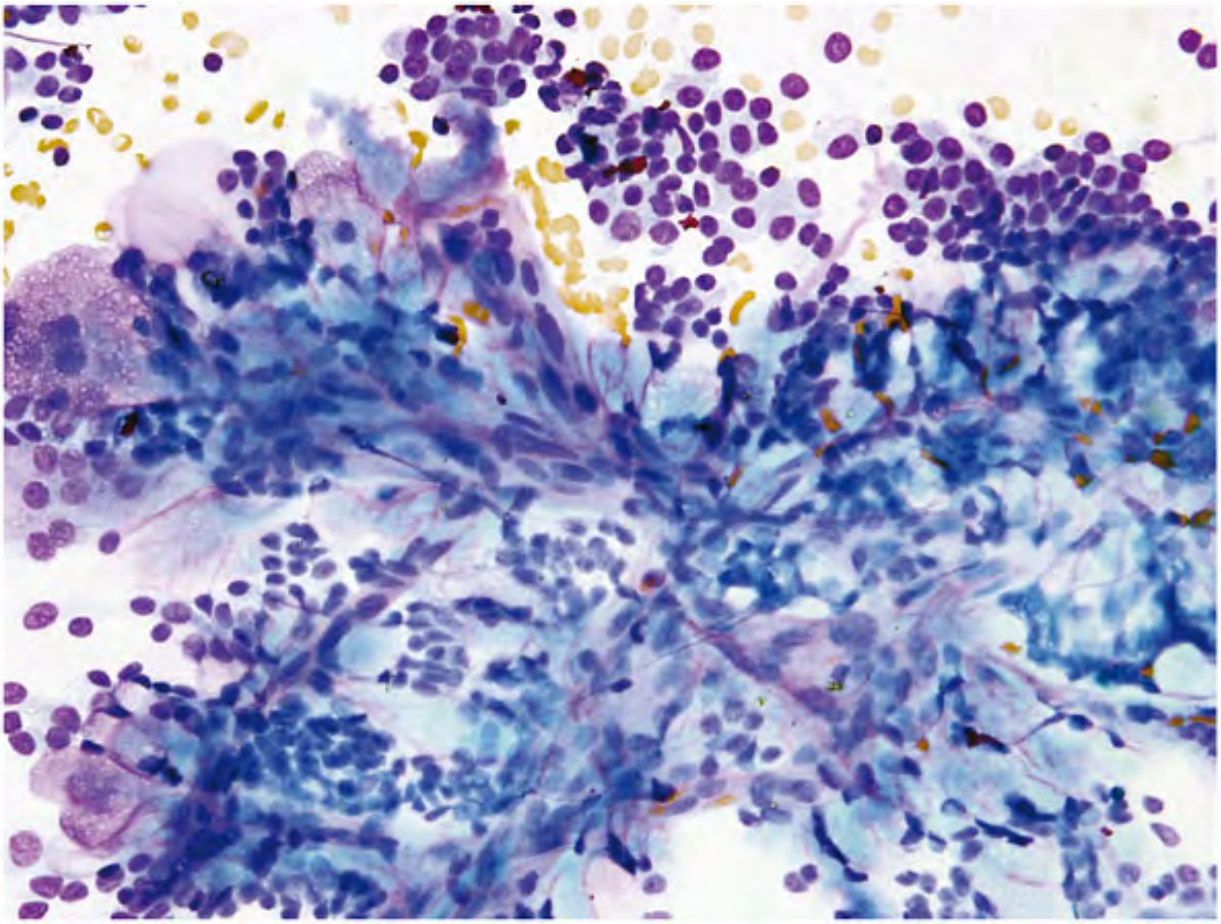

Figure 18.12. FNA of nodular goiter showing a branching stromal tissue fragment. Note ben follicular cells and colloid in the background (Diff-Quik stain). (Courtesy of Mariza de Peralt Venturina, MD, William Beaumont Hospital, Royal Oak, Michigan.)

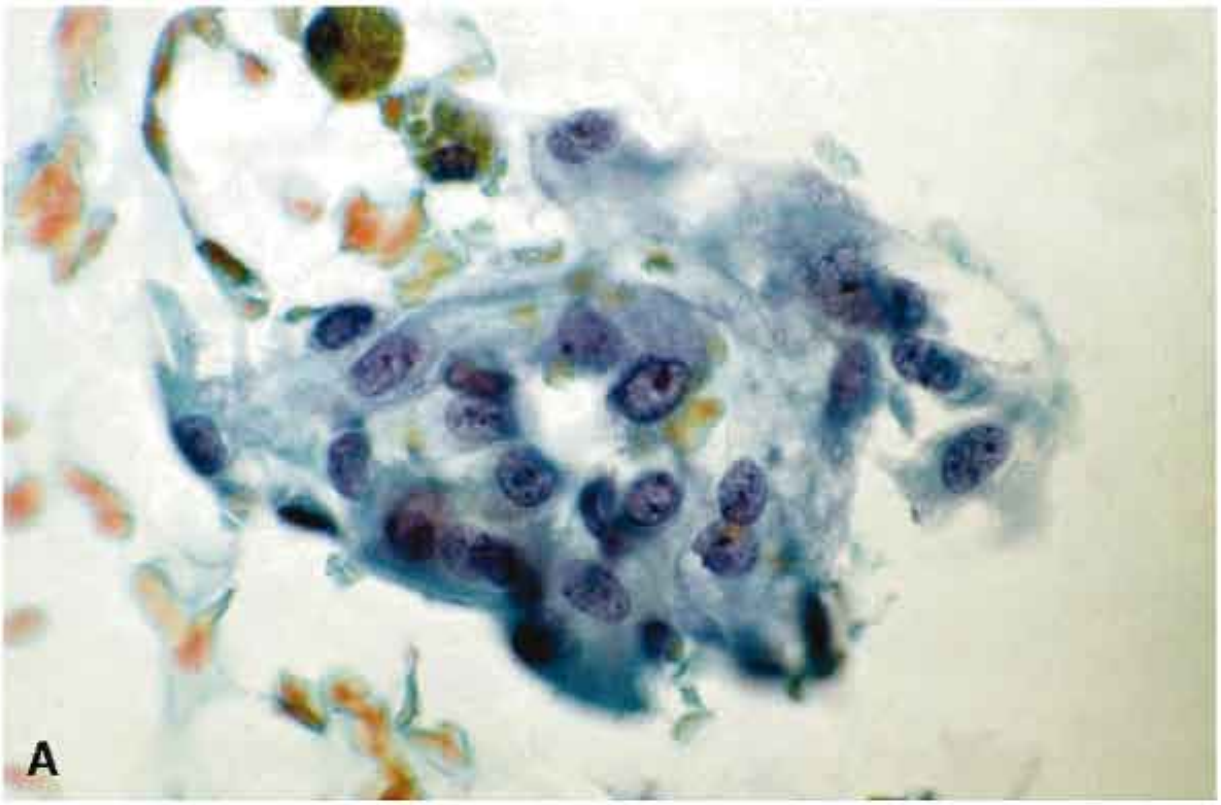
A

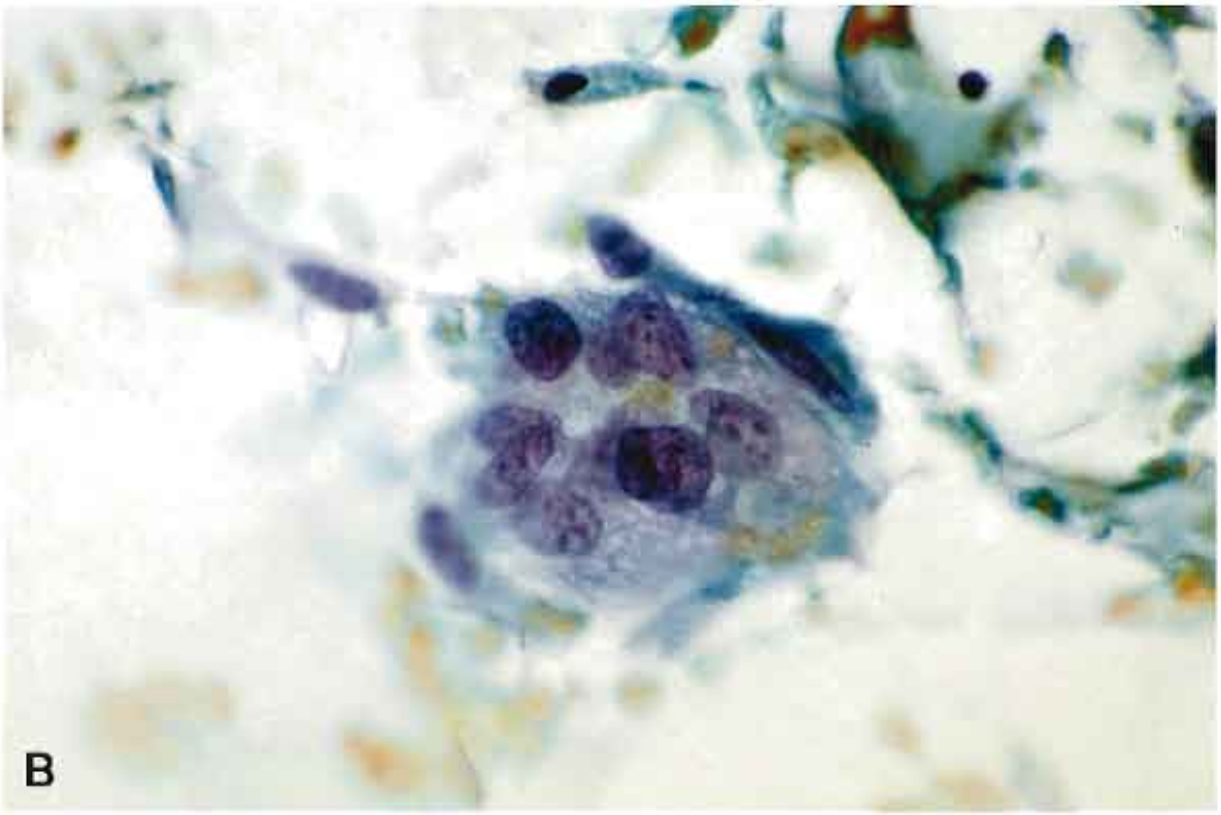
B

Figure 18.13. FNA of a nodular goiter showing a group of spindle-shaped cells with atypical nuclei. The background showed features of nodular goiter.

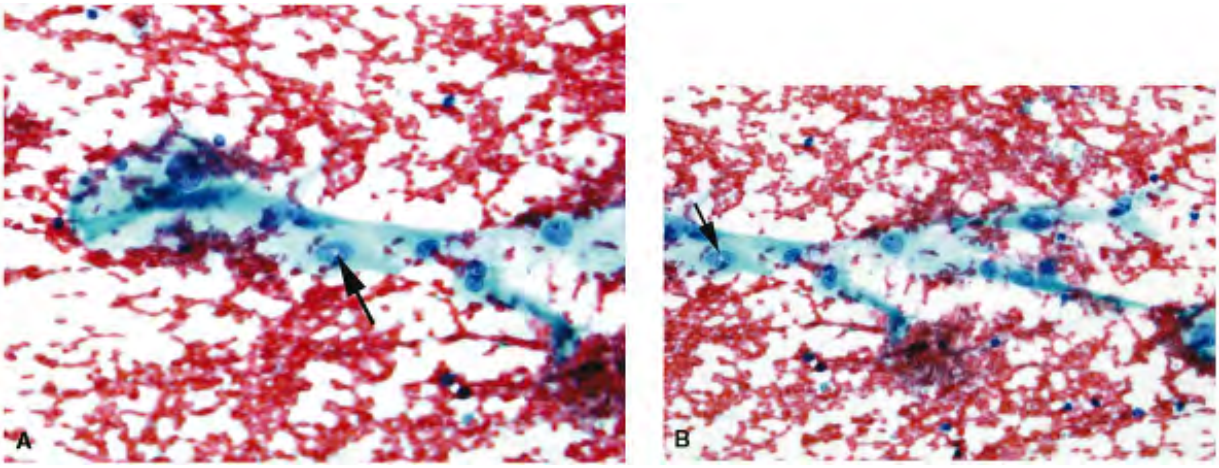

Figure 18.14. FNA of a nodular goiter showing few tissue fragments of elongated spindle-sh stromal cells with abundant cytoplasm and varying-sized enlarged nuclei. Note prominent nucleoli and intranuclear inclusions (*arrows*).

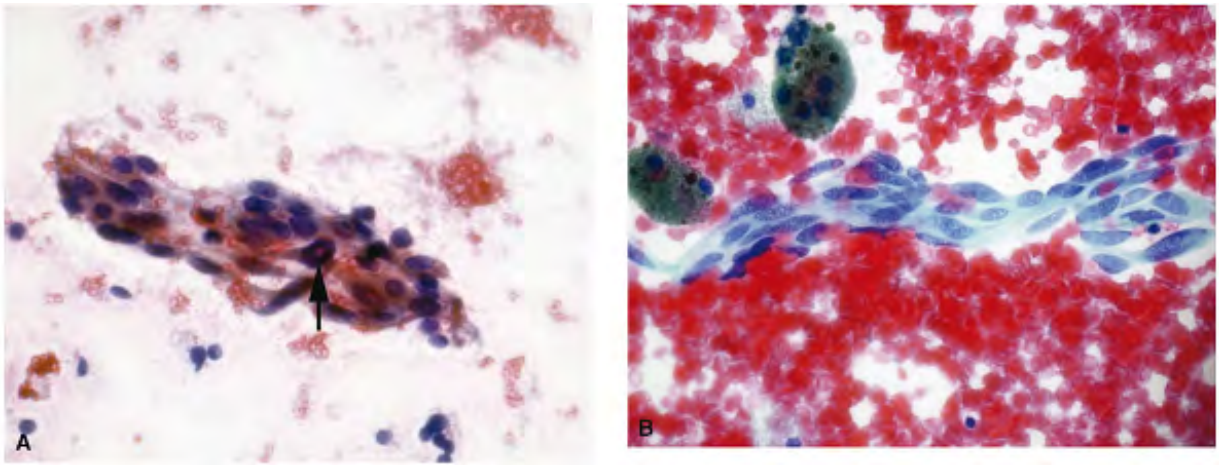

Figure 18.15. FNA of a cystic nodular goiter. A. This fascicle of spindle cells was present in background of benign follicular cells and histiocytes containing hemosiderin. Note that their nuclei are elongated with bland chromatin and contain intranuclear inclusion (*arrow*). B. Different field showing a fascicle of spindle cells with elongated nuclei. These strongly resei medullary carcinoma cells.

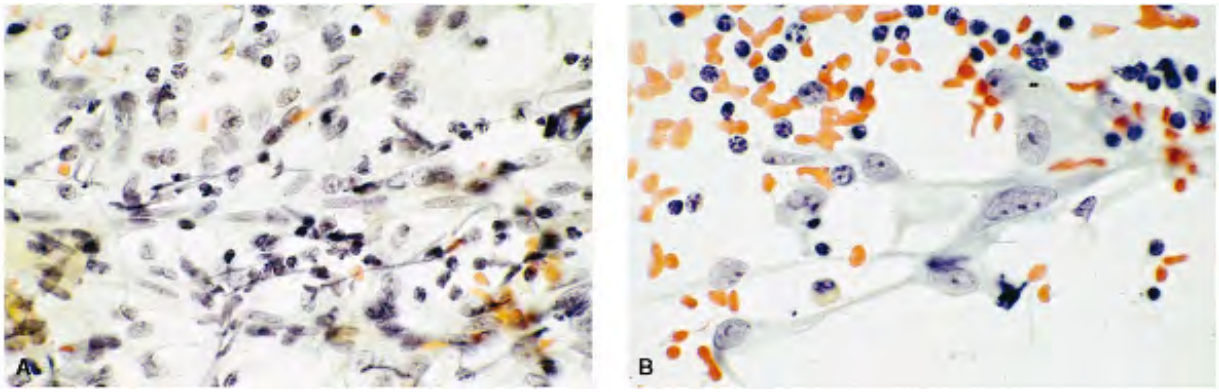

Figure 18.16. FNA of Hashimoto's thyroiditis. Note spindle-shaped stromal cells in a backgrc of inflammatory cells.

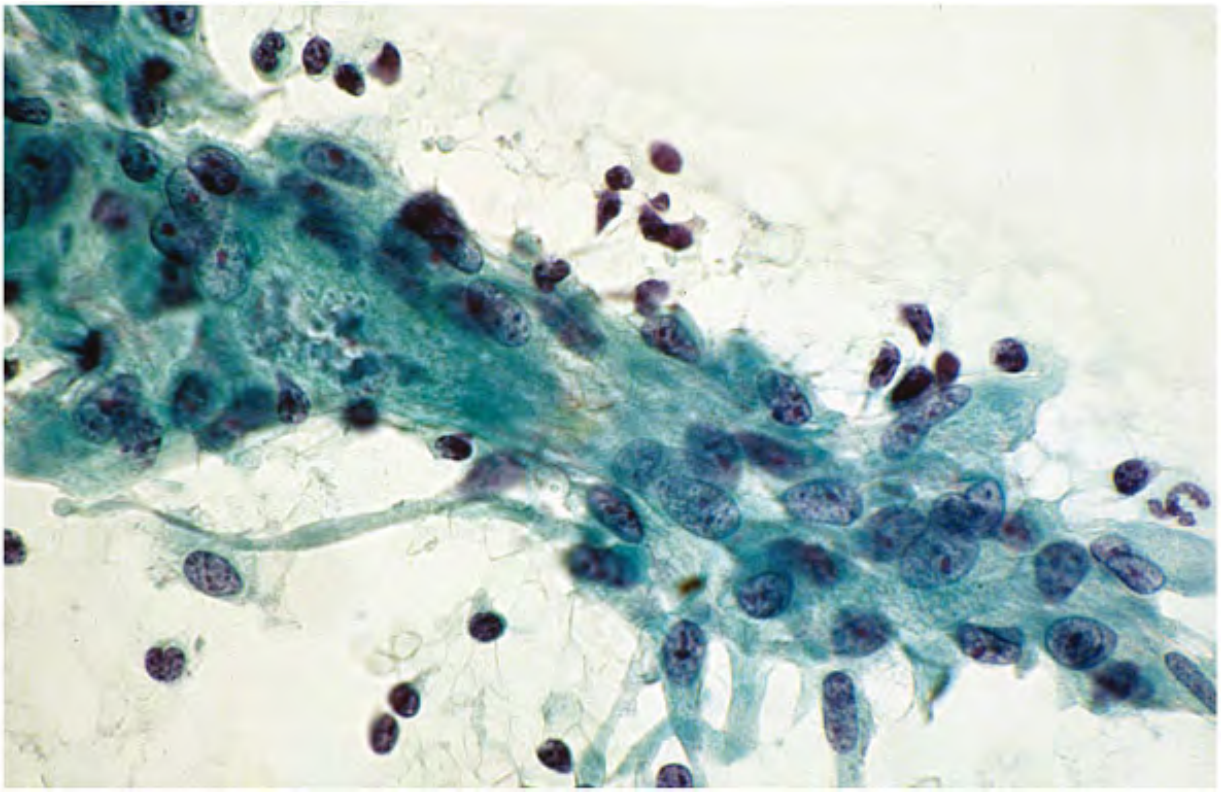

Figure 18.17. Another example of a tissue fragment of stromal cells from Hashimoto's thyroiditis.

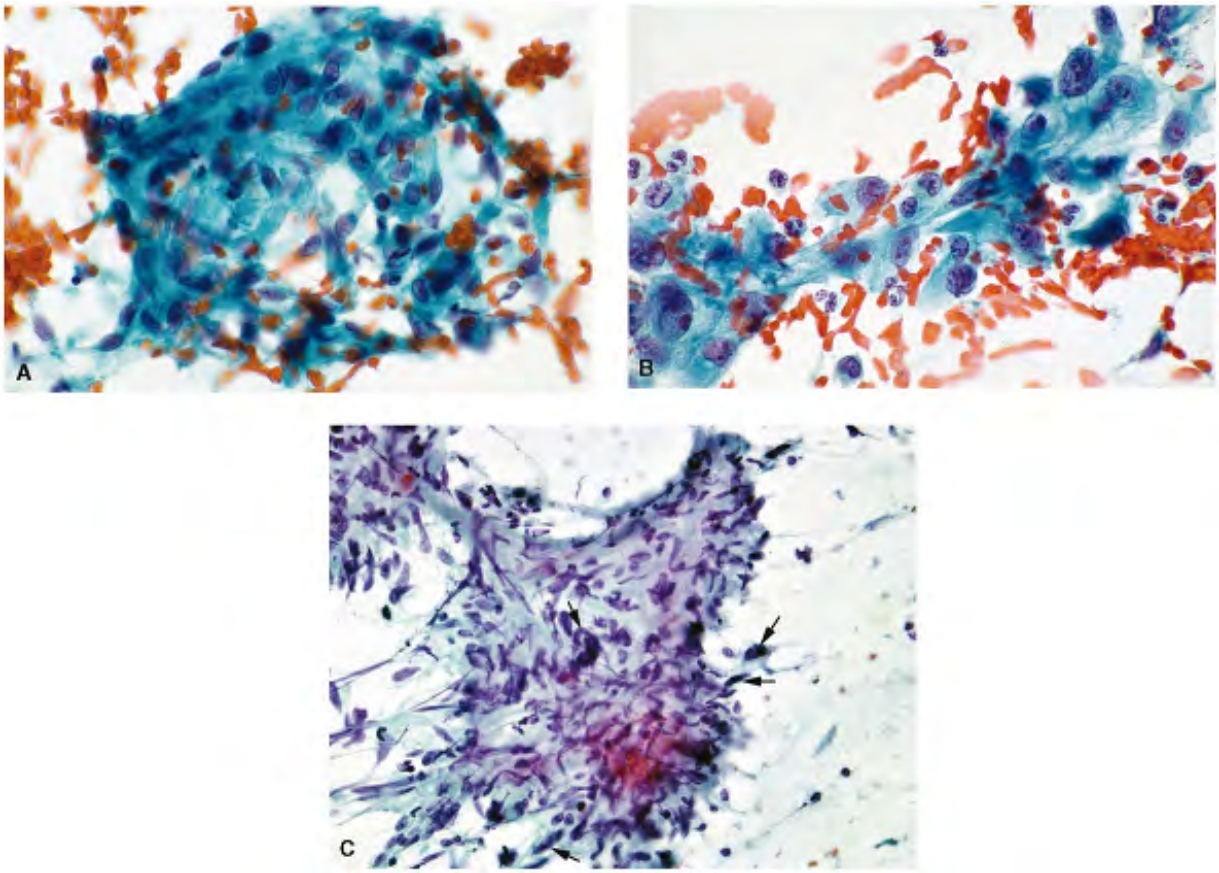

Figure 18.18. A. FNA of an anaplastic carcinoma showing a tissue fragment of benign strom Note that the nuclei are uniform, small, containing granular chromatin and lack malignant features. B. Malignant cells of anaplastic carcinoma from the same case as A. Compare the benign stromal cells to these malignant cells, which appear clearly malignant. It is not unus to aspirate benign stromal tissue from malignant lesions. C. FNA of a spindle cell type anapl carcinoma. Note occasional malignant cell (*arrows*) embedded in this dense fibrous tissue.

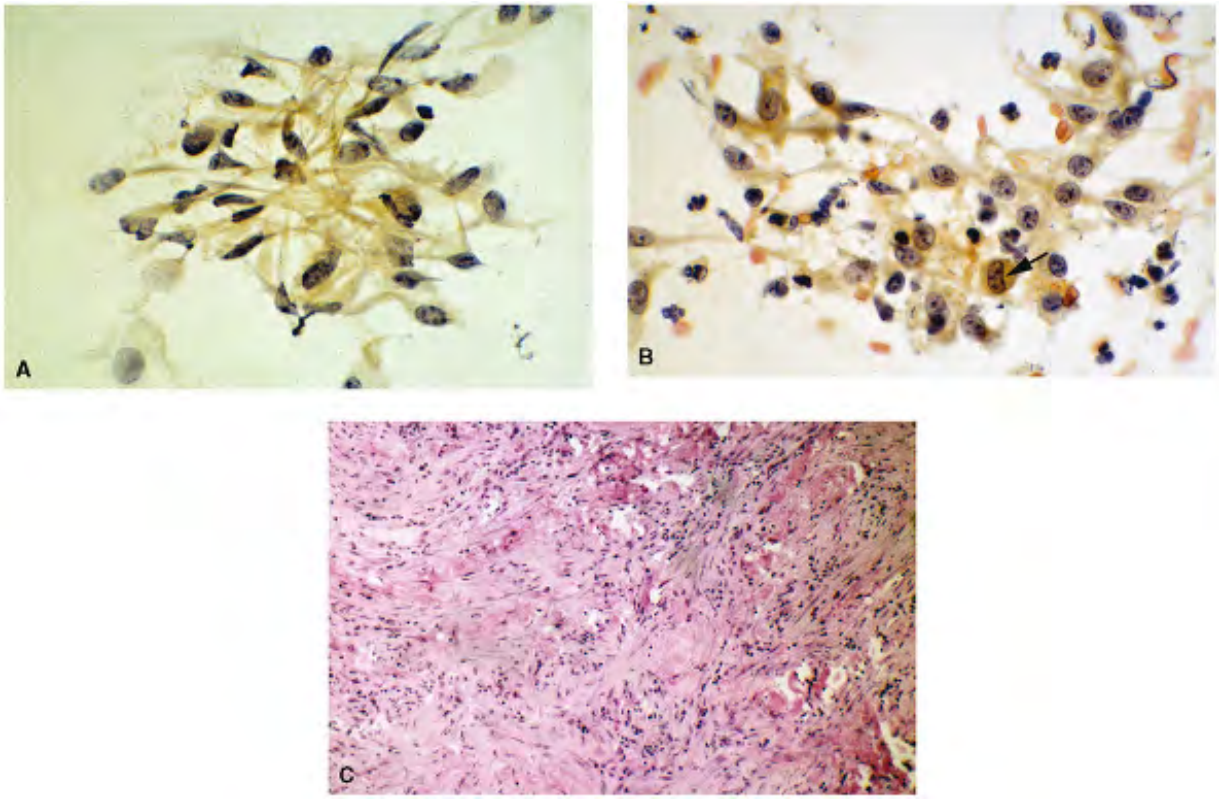

Figure 18.19. FNA of a mass considered being of thyroid origin. A. Spindle-shaped, actively proliferating fibroblasts with delicate cytoplasmic processes. The nuclei are uniform with fi granular chromatin. B. A different field showing round, plump histiocytes with nuclei contai a notch (*arrow*) as well as intranuclear inclusion. Note spindle-shaped fibroblasts and inflammatory cells. A malignant diagnosis was suspected. C. Excision of the mass revealed granulation tissue in the region of prior neck surgery unrelated to the thyroid.

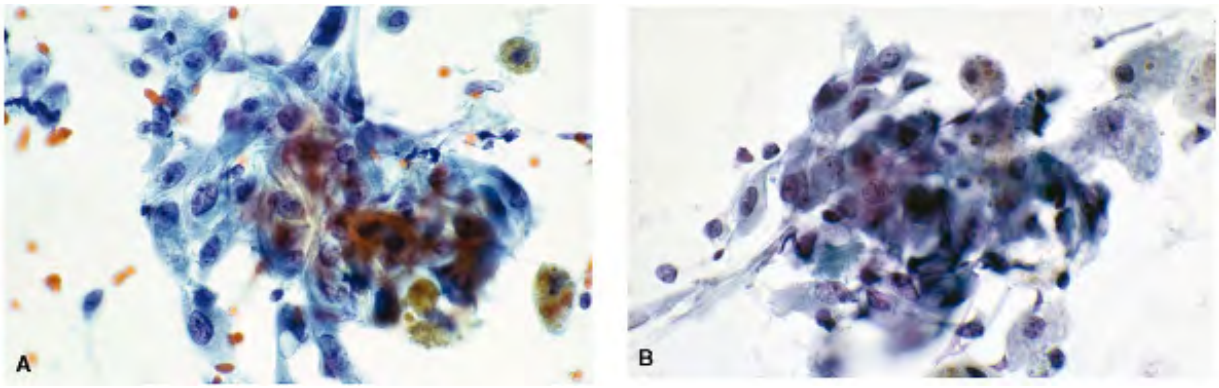

Figure 18.20. FNA of a cold thyroid nodule. A,B. The cells are spindle shaped, with very pleomorphic, atypical nuclei. Malignant diagnosis was rendered.

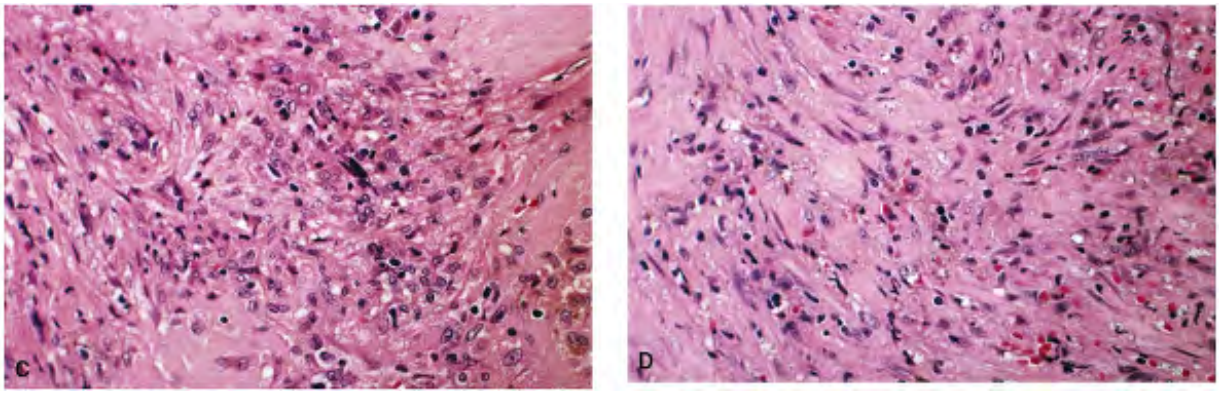

Figure 18.20. C,D. The thyroidectomy revealed the nodule to be totally composed of proliferating granulation tissue, probably representing an organizing hematoma. Note the actively proliferating fibroblasts and capillaries.

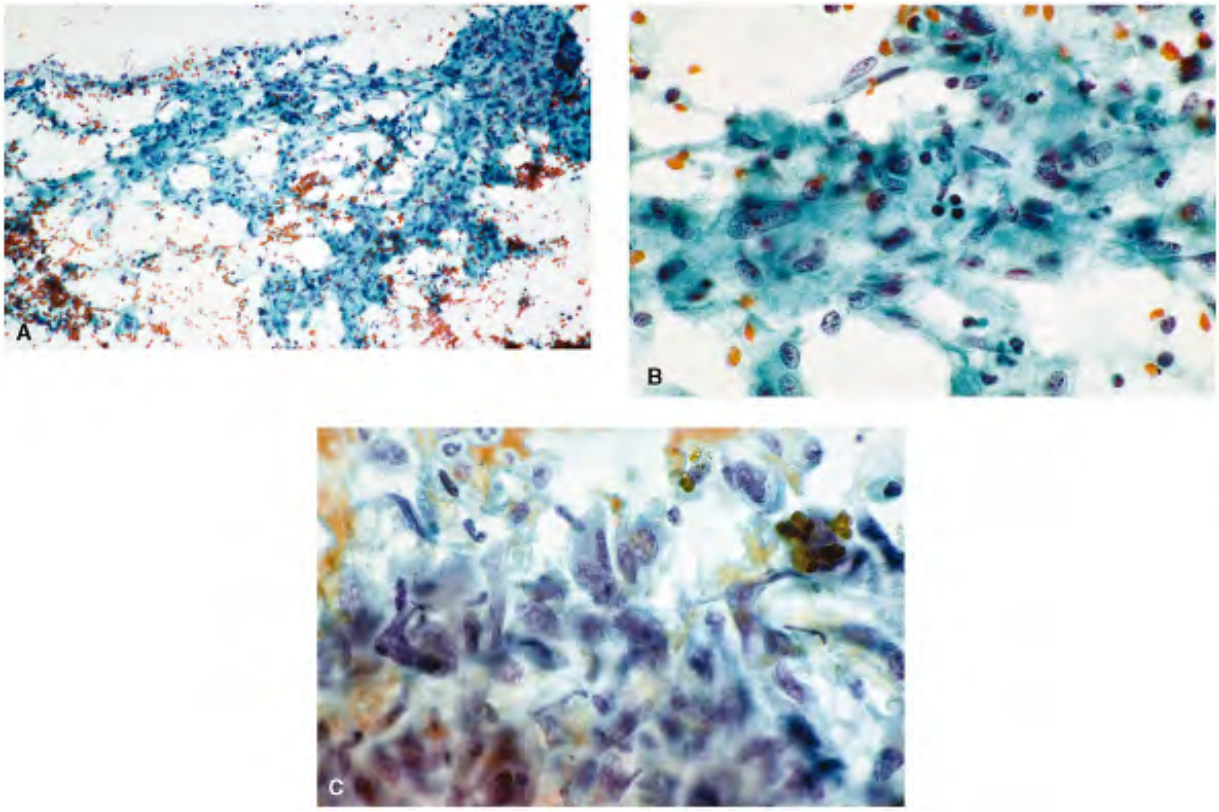

Figure 18.21. FNA of a nodular goiter. A. One of the passes of needle biopsy contained thes large anastomosing tissue fragments of spindle cells (low power). B. Higher magnification depicted stromal cells with abundant cytoplasm, low N/C ratios, and uniform nuclei. These

stromal cells probably represent proliferating granulation tissue. Most of the cellular materi this case was diagnostic of nodular goiter. C. FNA of an anaplastic thyroid carcinoma for comparison. Note that the nuclei are clearly malignant with high N/C ratios.

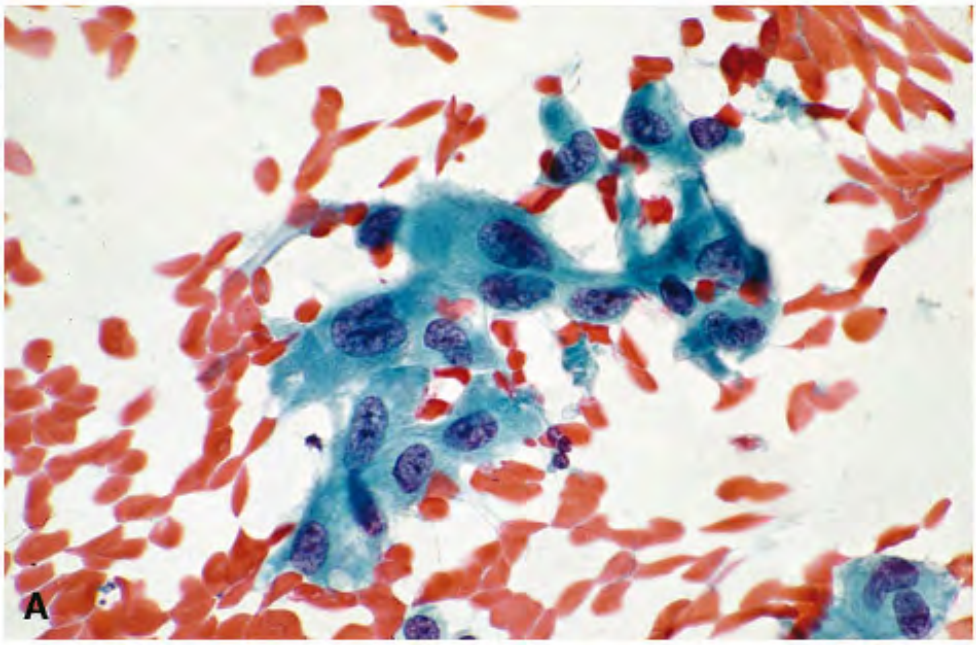

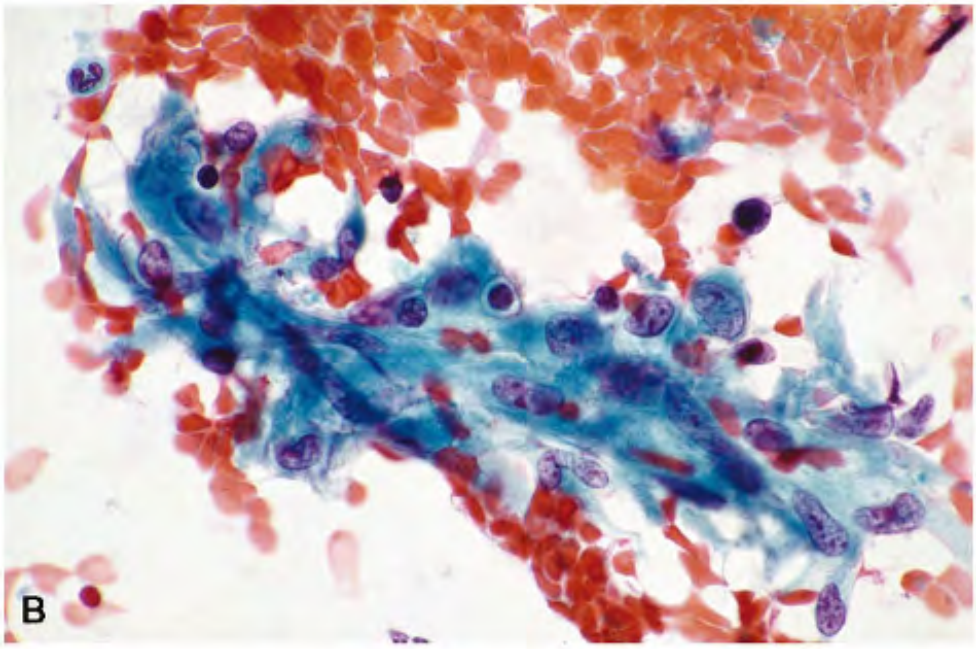

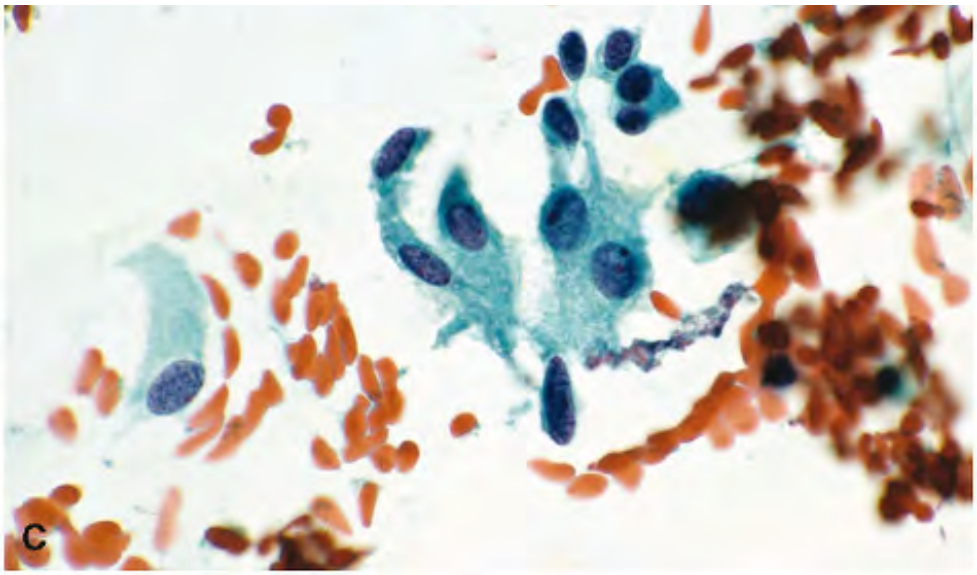

Figure 18.22. A,B. Another example of very atypical stromal cells from nodular goiter with morphologic similarity to medullary carcinoma cells. C. FNA of a medullary thyroid carcinom demonstrating discrete spindle-shaped carcinoma cells. Compare these with the benign stro cells in A and B.

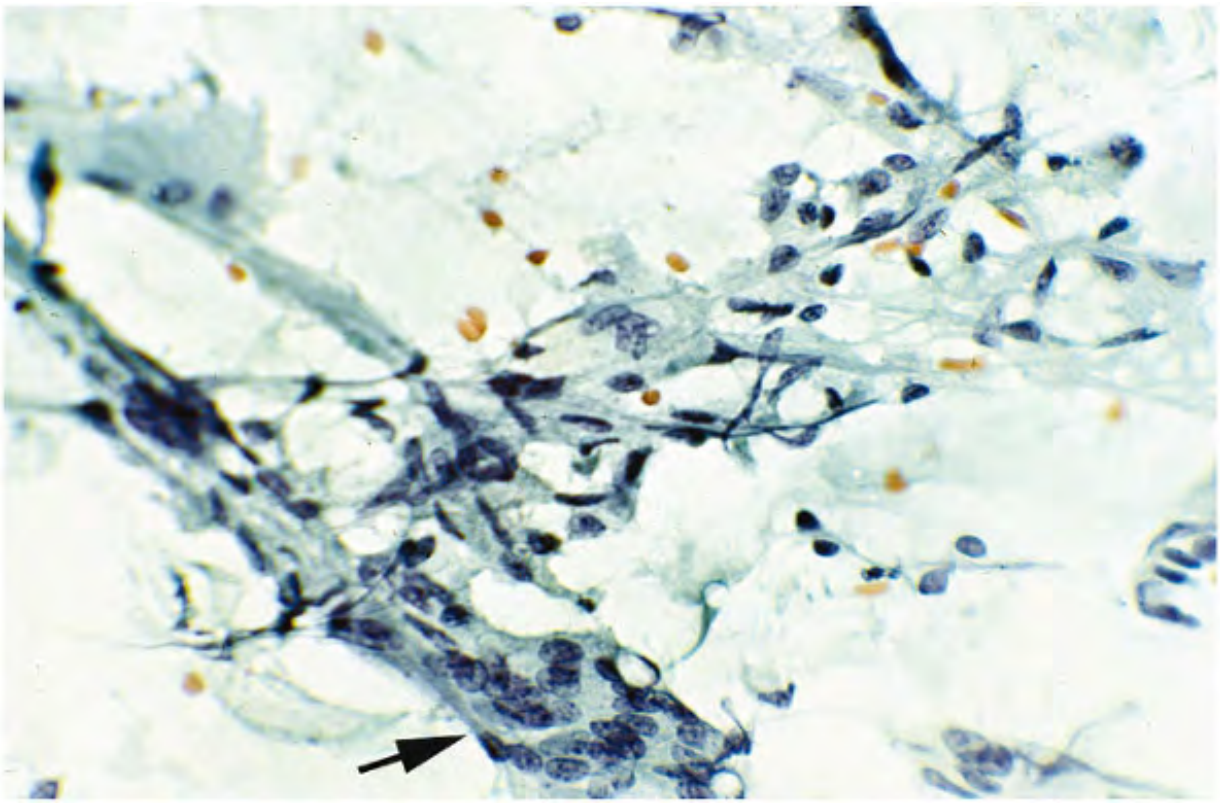

Figure 18.23. FNA of subacute (granulomatous) thyroiditis depicting fascicles of stromal spi cells. Note a multinucleated giant cell (*arrow*).

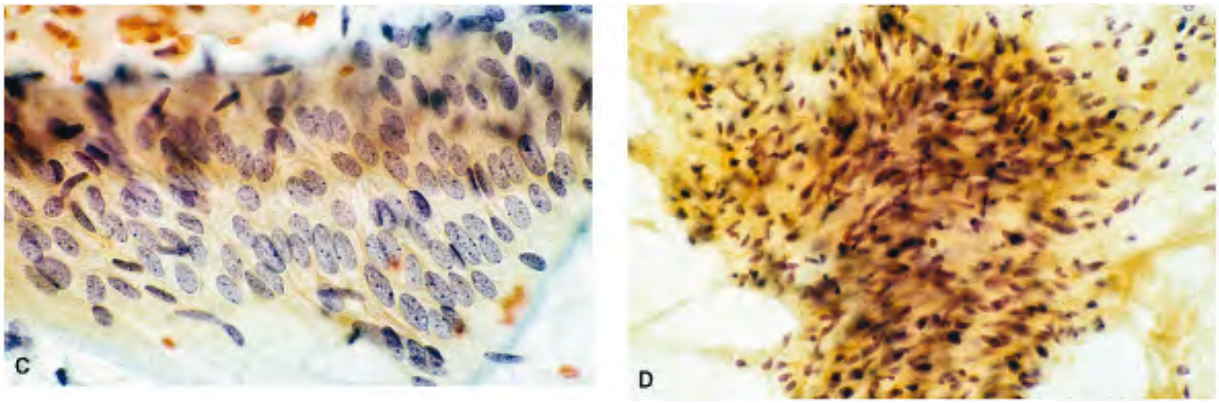

Figure 18.24. A. FNA of a nodular goiter showing longitudinally sectioned blood vessel (low power). B,C. Higher magnification showing palisading, uniform cigar-shaped nuclei consister with leiomyocytes.

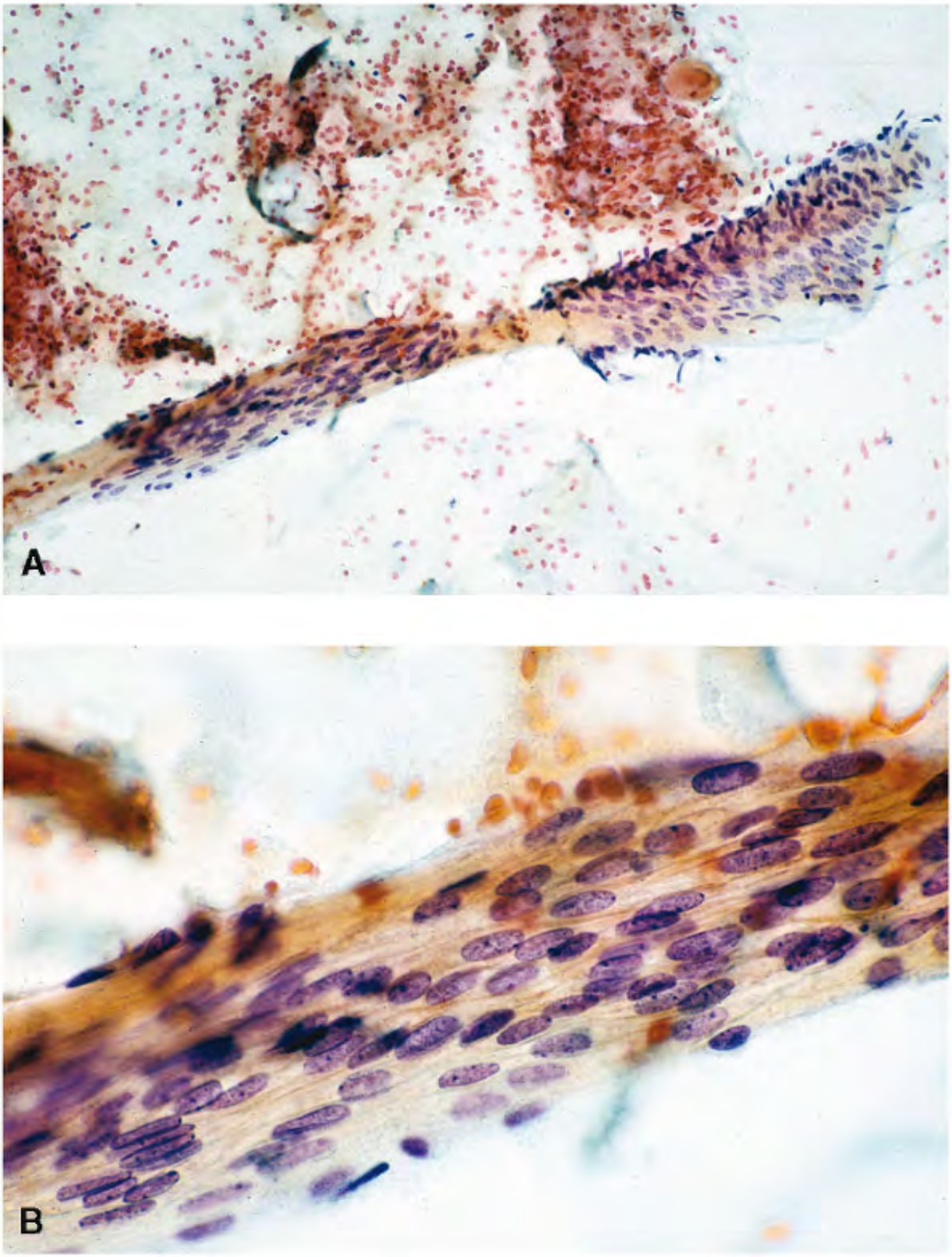

Figure 18.24. B,C. Higher magnification showing palisading, uniform cigar-shaped nuclei

consistent with leiomyocytes. D. FNA of thyroid showing malignant smooth-muscle cells fron metastatic leiomyosarcoma, for comparison.

In thyroid aspirates of nodular goiters or Hashimoto's thyroiditis, the stromal cells or fibrocy are generally present in small numbers, isolated, in groups, or in tissue fragments separatec collagen (Figs. Fig. 18.7). They have elongated, spindle-shaped nuclei with pale, uniformly distributed finely granular chromatin, occasionally containing micronucleoli (Figs. 18.7 , 18. 18.9 , 18.10 , 18.11 , 18.12 , 18.13 , 18.14 , 18.15 , 18.16 , 18.17 and 18.18). The nuclear membrane is smooth, thin, and may show a notch as well as intranuclear inclusions (Figs. 18 and 18.15). The stromal cells or fibrocytes are bipolar with variable, pale cytoplasm that m extend into processes. The N/C ratios are low. At times, the stromal cells are displayed in s fascicles that appear flat with a directional flow to the cytoplasm (Fig. 18.11). The collage appears fibrillar or homogeneous in Papanicolaou-stained preparations (Fig. 18.7), while it appears as ragged, membranous fragments staining metachromatically red in air-dried Romanowsky-stained preparations.4 The background often shows hemosiderin-containing histiocytes and inflammatory cells.

The benign spindle cells of stromal origin are frequently present in aspirates from Hashimot thyroiditis (Figs. 18.16

P.386

P.387

P.388

and 18.17). Again, the morphology of these cells is very similar to that seen in stromal cells from nodular goiters.

It is not uncommon to find benign stromal tissue fragments in aspirates from papillary carci or anaplastic carcinomas. They originate from the desmoplastic stroma (Fig. 18.18). Morphologically, the benign stromal cells are distinctly benign as compared to the malignan cells from the same aspirate, which demonstrate obvious malignant features.

The aspirate from an actively organizing granulation tissue yields proliferating fibroblasts ar endothelial lining cells of the proliferating capillaries. These present as elongated, or large, round cells that are loosely cohesive, sometimes arranged in fascicles that may interdigitate (Figs. 18.19 , 18.20 , 18.21 , 18.22 and 18.23). Their elongated to oblong nuclei are enlarge with a moderate increase in the N/C ratios. The nuclear membrane is smooth, thin and cris the chromatin finely granular and evenly distributed. The micronucleoli may be conspicuous

These spindle cells have abundant pale cytoplasm, with distinct long cytoplasmic processes. Because of the increased N/C ratios and prominent nucleoli, the proliferating fibroblasts or endothelial lining cells may be misinterpreted as malignant, especially anaplastic thyroid carcinoma, or medullary carcinoma or a soft-tissue tumor. Anderson et al.3 reported 299 ca of nodular goiters of which 73 (24%) of cases displayed atypical, retrogressive, or metaplasti changes.

P.389

P.390

Of these, 36 (49%) contained fibroblastic proliferations characterized by elongated to round bizarre cells with atypical nuclei.

Systemic administration of radioactive iodine (^{131}I) can induce changes in both the follicula cells and the stromal tissue of the thyroid. Aspiration biopsy shows both epithelial and stron type spindle cells with karyocytomegaly and deep-staining smudgy, structureless chromatin occasional intranuclear inclusions.5 Their cytoplasm is variable, sometimes abundant and vacuolated, and may contain neutrophils. Bare, pleomorphic, but pyknotic nuclei are also se frequently (see "Radiation-Induced Cellular Changes" in Chapter 19).

Another source of benign spindle cells is granulomatous or subacute thyroiditis. Aggregates epithelioid and stromal spindle cells may be present with or without accompanying multinucleated giant cells (Fig. 18.23).4 , 6 Cytologic identification is generally easy especi when considered in context with the clinical features, laboratory data, and radionuclide ima findings. Riedel's thyroiditis, or fibrosing thyroiditis, an extremely rare condition of the thyr

P.391

P.392

P.393

will yield scant aspirate on needle biopsy, represented by only stromal cells.4 , 7

Spindle cells in thyroid aspirates may also originate from the smooth-muscle wall of the bloc vessels. The smooth-muscle cells are arranged in a palisading fashion and are aligned in para rows. Their nuclei are cigar shaped with blunt ends and a bland chromatin pattern (Fig. 18.2

P.394

NEOPLASTIC SPINDLE CELLS OF MESENCHYMAL ORIGIN

The spindle cell pattern is one of the morphologic characteristics of both benign and malign soft-tissue tumors. These primary soft-tissue neoplasms8 , 9 , 10 , 11 , 12 , are very rare in

thyroid gland. The reported cases include schwannoma, leiomyosarcoma, liposarcoma, hemangioendothelioma, synovial sarcoma,8 and osteosarcoma, to mention a few. The thyro gland may also be the site of metastatic sarcoma (Fig. 18.24D).13 Soft-tissue tumors in the may clinically simulate thyroid nodules and be aspirated.

NON-NEOPLASTIC SPINDLE CELLS OF EPITHELIAL ORIGIN

Non-neoplastic spindle cells of epithelial origin include reactive/reparative follicular cells ir nodular goiters and squamous cell metaplasia. The reactive follicular cells in nodular goiters with degeneration may acquire a spindle shape, enlarge in size, and may contain pleomorph nuclei. These cells usually occur in small numbers, seen either isolated or in loosely cohesiv groups (Figs. 18.25 , 18.26 , 18.27 , 18.28 , 18.29 and 18.30). Their nuclei have finely granu chromatin and micronucleoli, and also exhibit occasionally inclusions and grooves, causing a great deal of concern. Faquin et al.1 described atypical cells from 75 benign cysts of the thy associated with nodular goiter with histologic follow-up. The cytologic features of the atypi cells included flat tissue fragments, distinct cell borders, nuclear enlargement, nuclear groo dense granular cytoplasm, small distinct micronucleoli, fine chromatin, and elongation to spindle cytomorphology. These cells were immunoreactive to cytokeratin and thyroglobulin while negative for CD68 and smooth-muscle actin, suggesting a follicular origin.

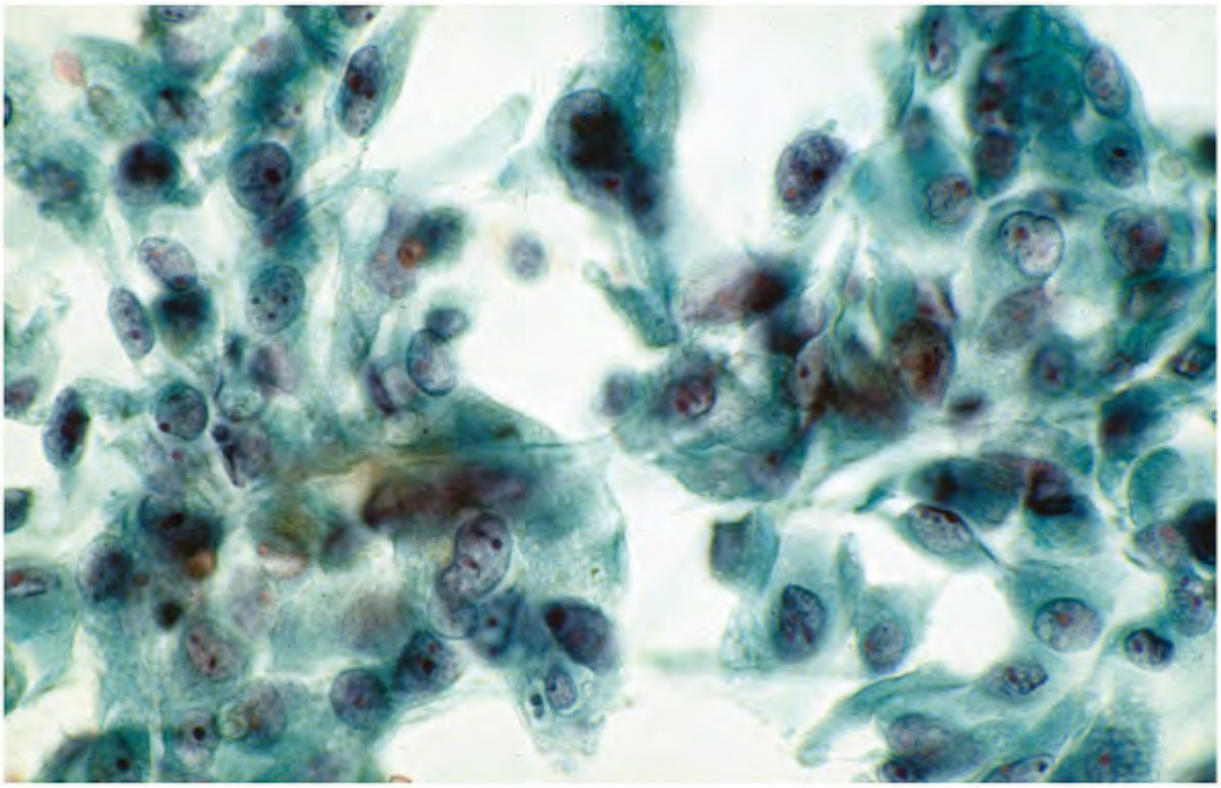

Figure 18.25. FNA of a nodular goiter with retrogressive changes, showing an admixture of reactive, enlarged follicular cells with spindle and round forms. A papillary carcinoma was suspected. The thyroidectomy revealed multinodular goiter.

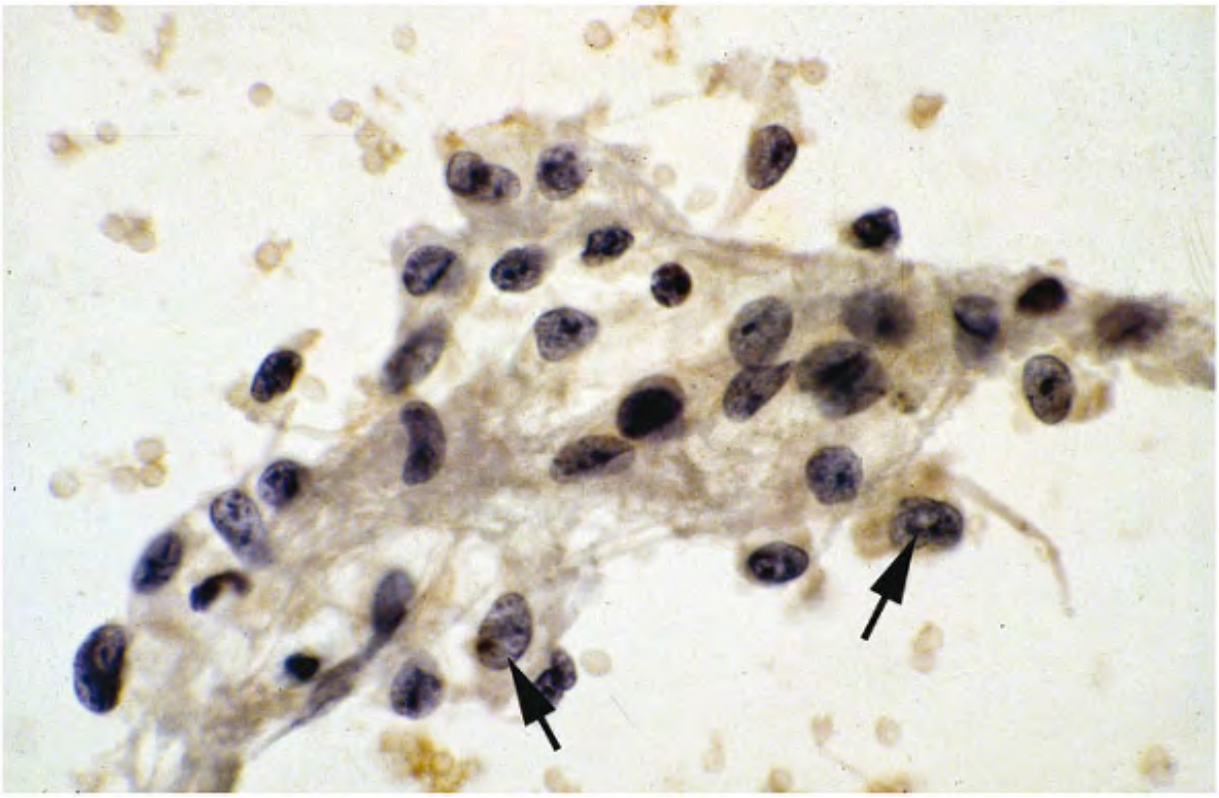

Figure 18.26. A group of very abnormal-appearing spindle and round cells with enlarged nu containing finely granular chromatin. Note intranuclear inclusion (*arrows*). A malignant diagnosis was rendered. Thyroidectomy showed nodular goiter.

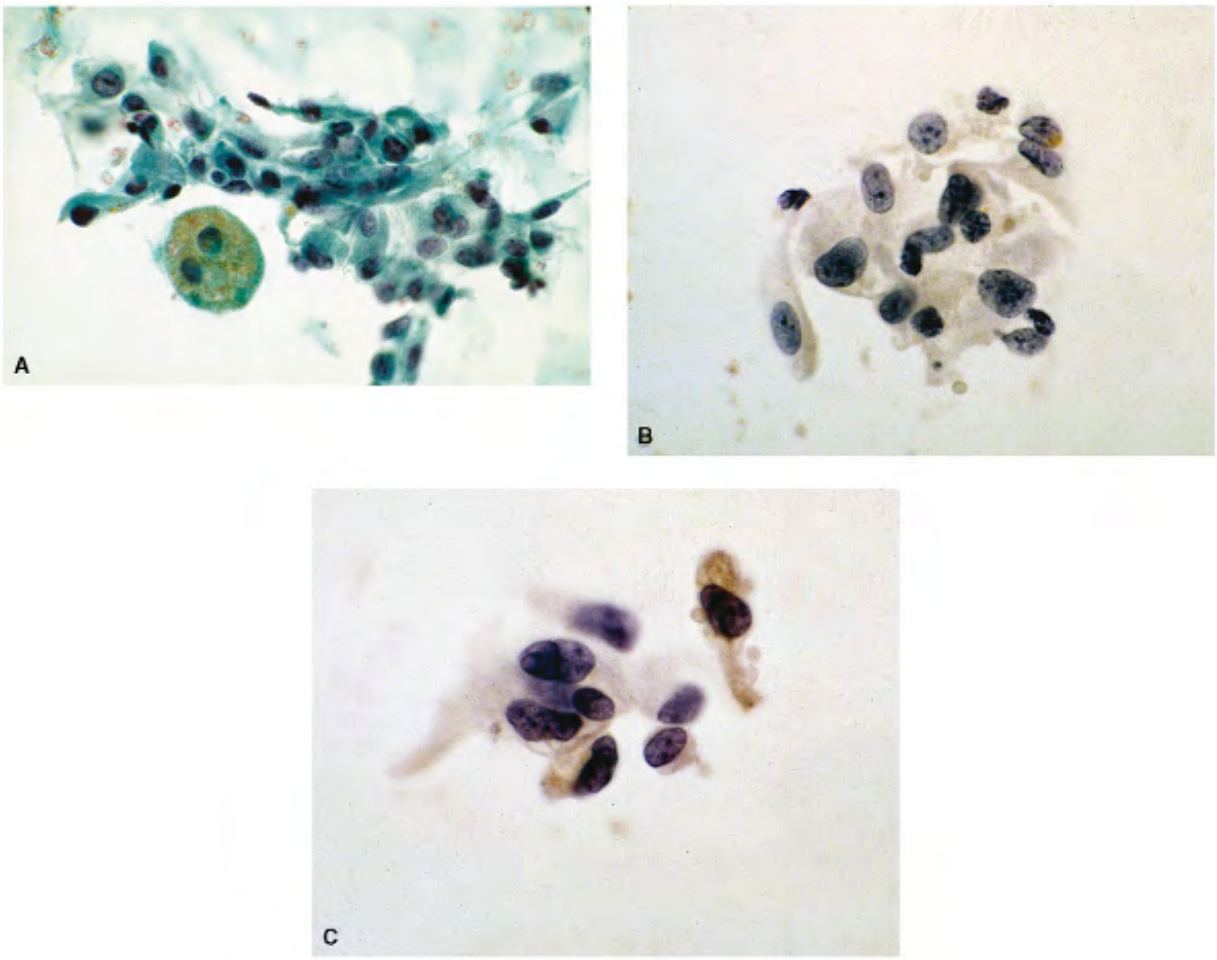

Figure 18.27. FNA of a nodular goiter with retrogressive changes. This group of spindle and round cells probably represents reactive/reparative follicular cells and may offer diagnostic difficulties. A hemosiderin-containing macrophage is present in the background.

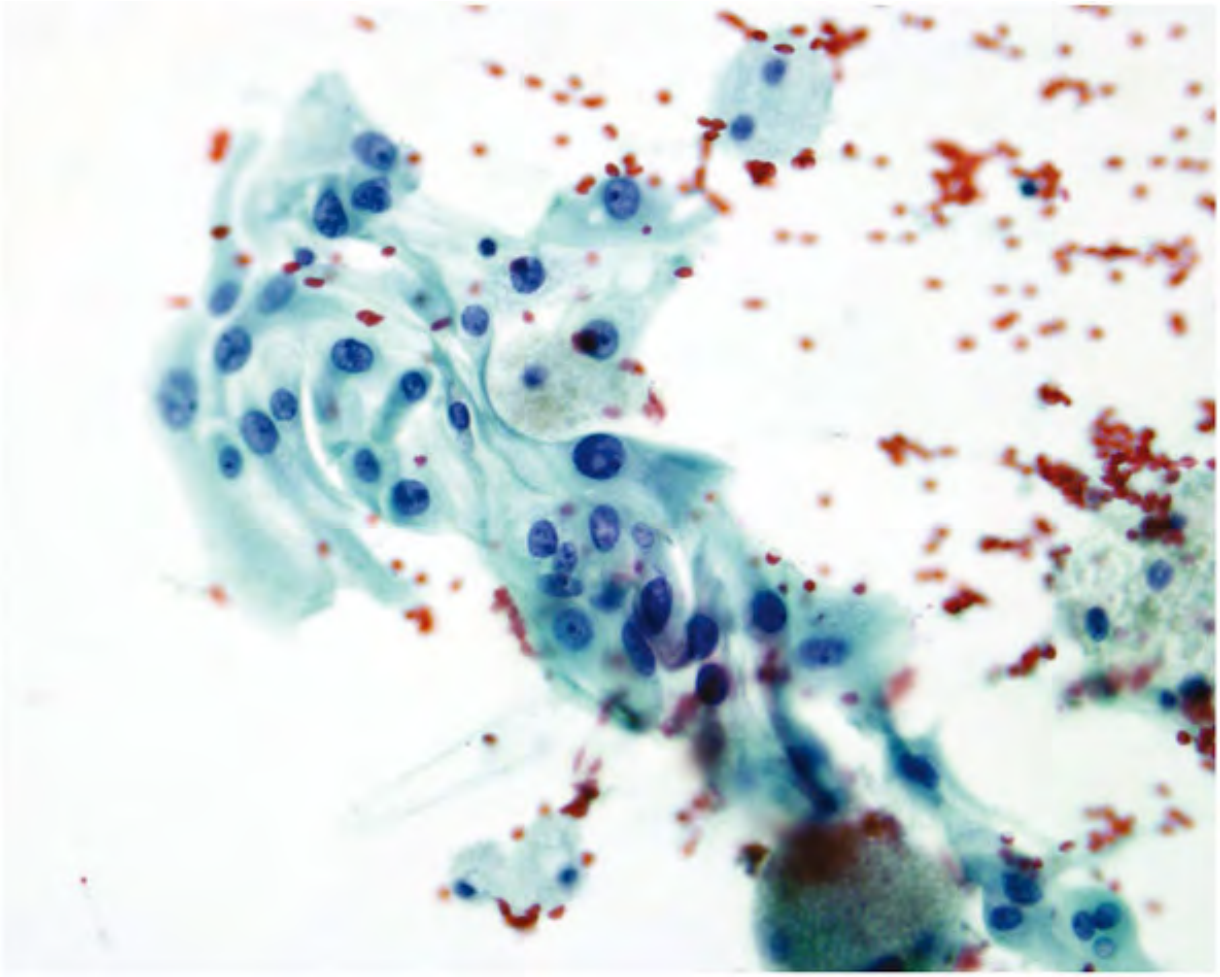

Figure 18.28. Squamous metaplastic cells occurring in the background of nodular goiter oft display spindle shape. They may be present as isolated cells.

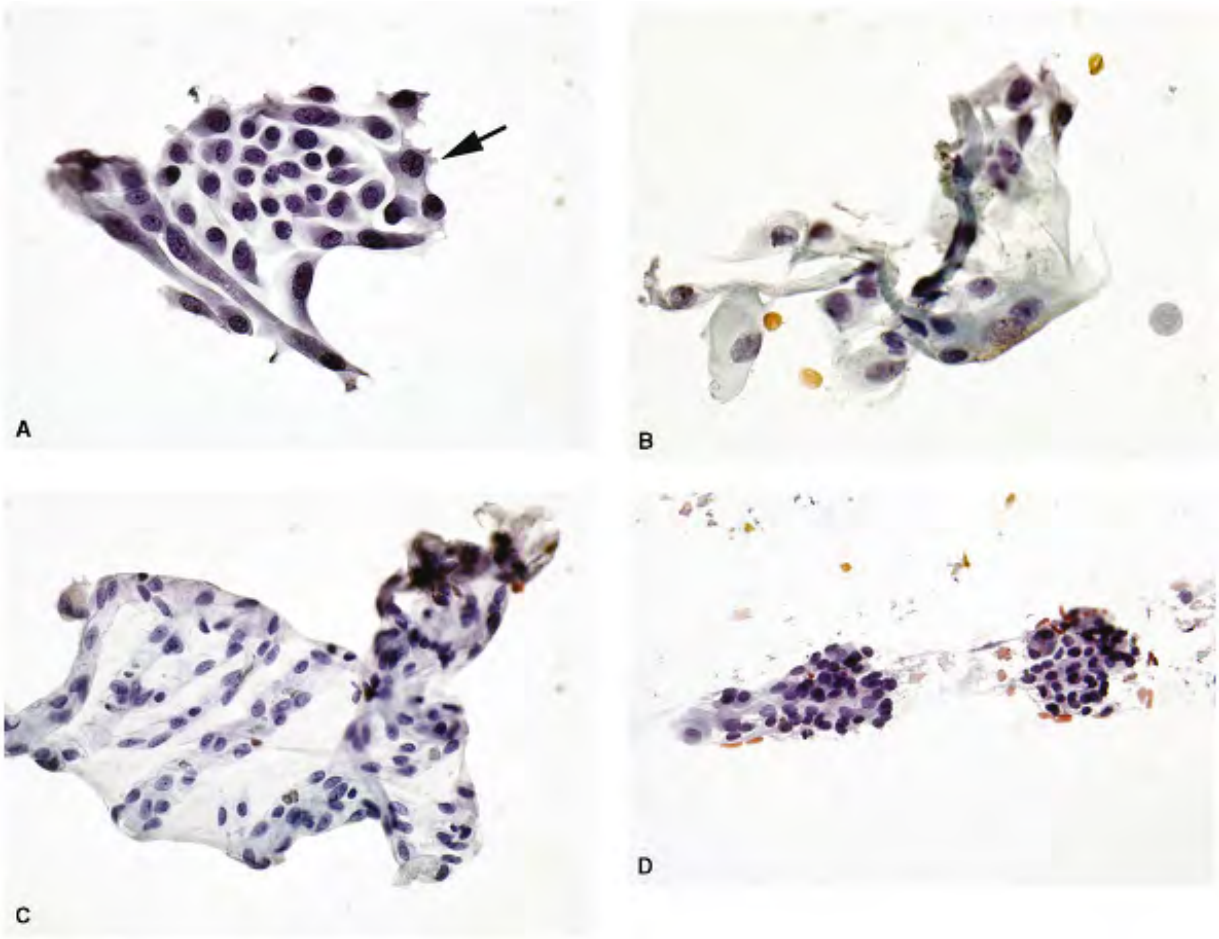

Figure 18.29. A. An excellent example of squamous metaplasia in FNA of nodular goiter. Th tissue fragment of follicular cells exhibit enlarged nuclei, containing coarsely granular chromatin. Note the transition to spindle and polygonal forms with cytoplasmic processes resembling spider cells (*arrow*) described for metaplastic squamous cells. B. A different fie from the same case showing squamous metaplasia. The follicular cells are large, with abund pale cytoplasm. C. A different field showing several spindle-shaped and round cells in the sa aspirate. The morphology resembles that of stromal cells. It is not unusual to see spindle ce both stromal and epithelial origin in the same aspirate. D. Same aspirate showing tissue fragments of benign follicular cells consistent with nodular goiter.

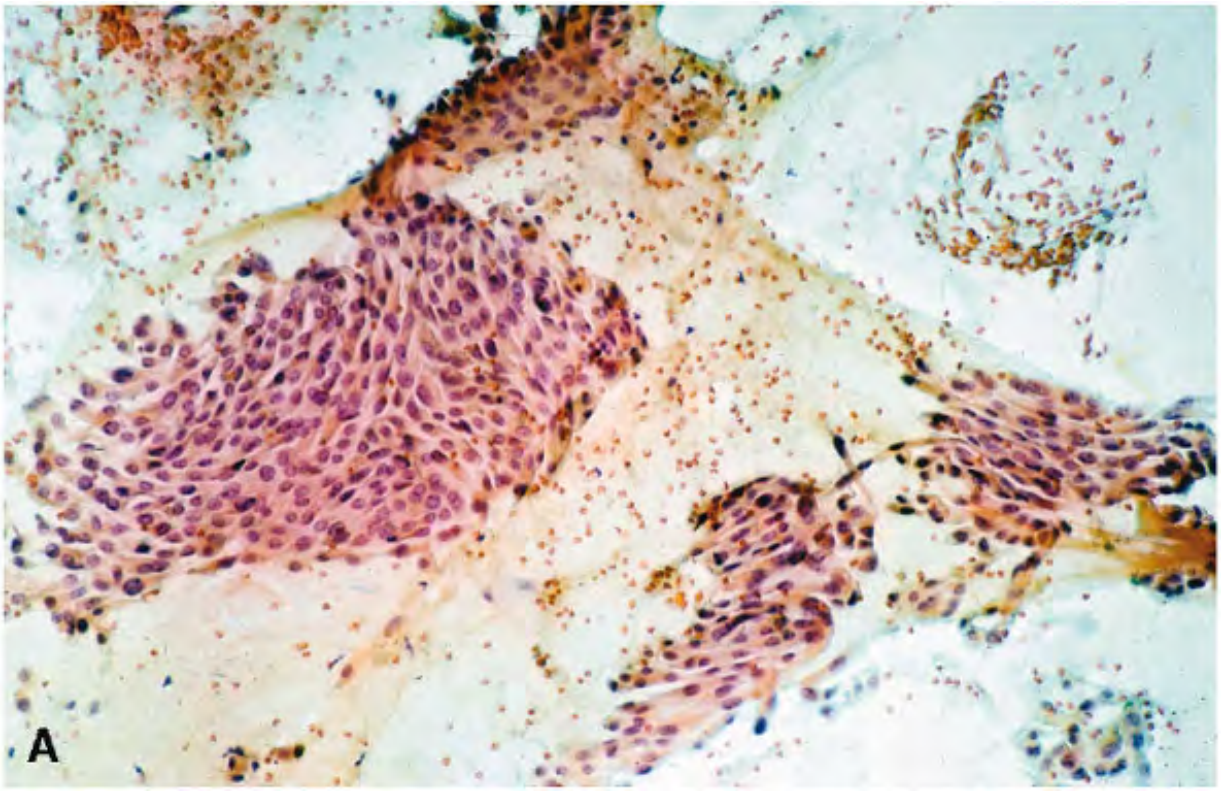

Figure 18.30. A. FNA of a nodular goiter showing large tissue fragments of metaplastic squamous cells (low power).

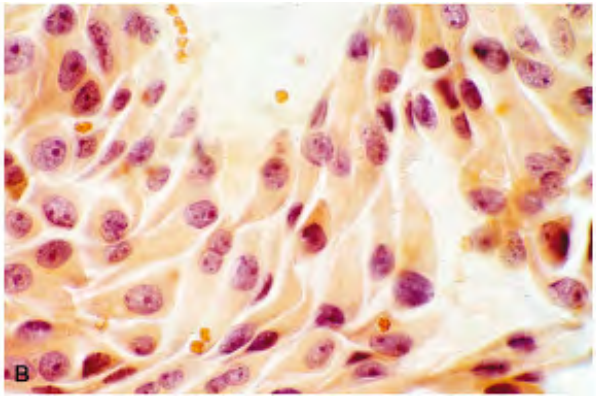

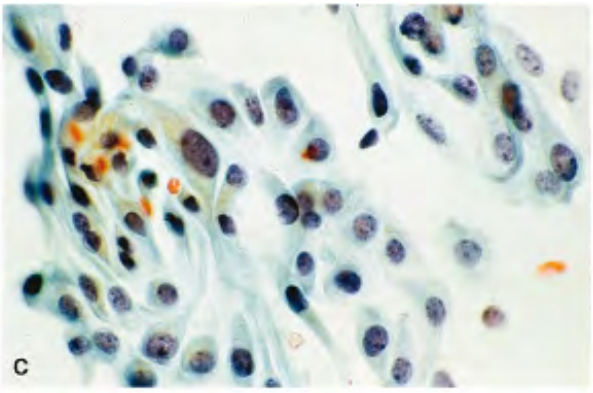

Figure 18.30. B,C. Higher magnification demonstrating spindle shapes with abundant cytop smaller nuclei with low N/C ratios, and finely granular chromatin.

The metaplastic squamous cells are sometimes encountered in the aspirates of thyroid lesio such as with nodular

goiter, especially with cystic change; in thyroids subjected to ^{131}I therapy; and in chronic lymphocytic thyroiditis of the Hashimoto's type. Squamous metaplasia is also reported in 10% 50% of papillary carcinomas14 , 15 and may be present in cytologic specimens from papillary carcinomas. The metaplastic squamous cells occur as tight groupings of cells forming morula with a whirled arrangement (see Figs. 19.29 and 19.30), or as loosely cohesive, elongated c with abundant cytoplasm and tapered ends (Figs. 18.28 , 18.29 and 18.30). Occasionally, squamous metaplasia presents as large monolayered tissue fragments (Fig. 18.30). The nucl are centrally located, containing granular chromatin and low N/C ratios. The presence of micronucleoli is not consistent. The metaplastic squamous cells are large, polygonal to spin shaped, with well-defined cell borders. Multiple cytoplasmic processes referred to as spider as described in cervical smears may also be encountered (Fig. 18.29A). Their cytoplasm is variable but abundant and pale to dense.

NEOPLASTIC SPINDLE CELLS OF EPITHELIAL ORIGIN

Neoplastic spindle cells of epithelial origin may be seen in benign neoplasms such as hyaliniz trabecular adenoma,16 or in malignant neoplasms, that is, papillary carcinomas17 (Fig. 18.3 medullary carcinoma (Fig. 18.32), or anaplastic carcinoma (Fig. 18.33). Some very infreque examples of thyroid epithelial neoplasms with a spindle cell pattern include intrathyroidal thymomas, referred to as thyroid carcinoma showing thymus-like element (CASTLE), and spi epithelial tumor of thyroid with thymus-like elements (SETTLE) (see "Unusual and Uncommo Neoplasms of the Thyroid" in Chapter 19). Other rare examples include primary or metastat poorly differentiated squamous carcinomas, sarcomatoid type, and metastatic carcinosarco

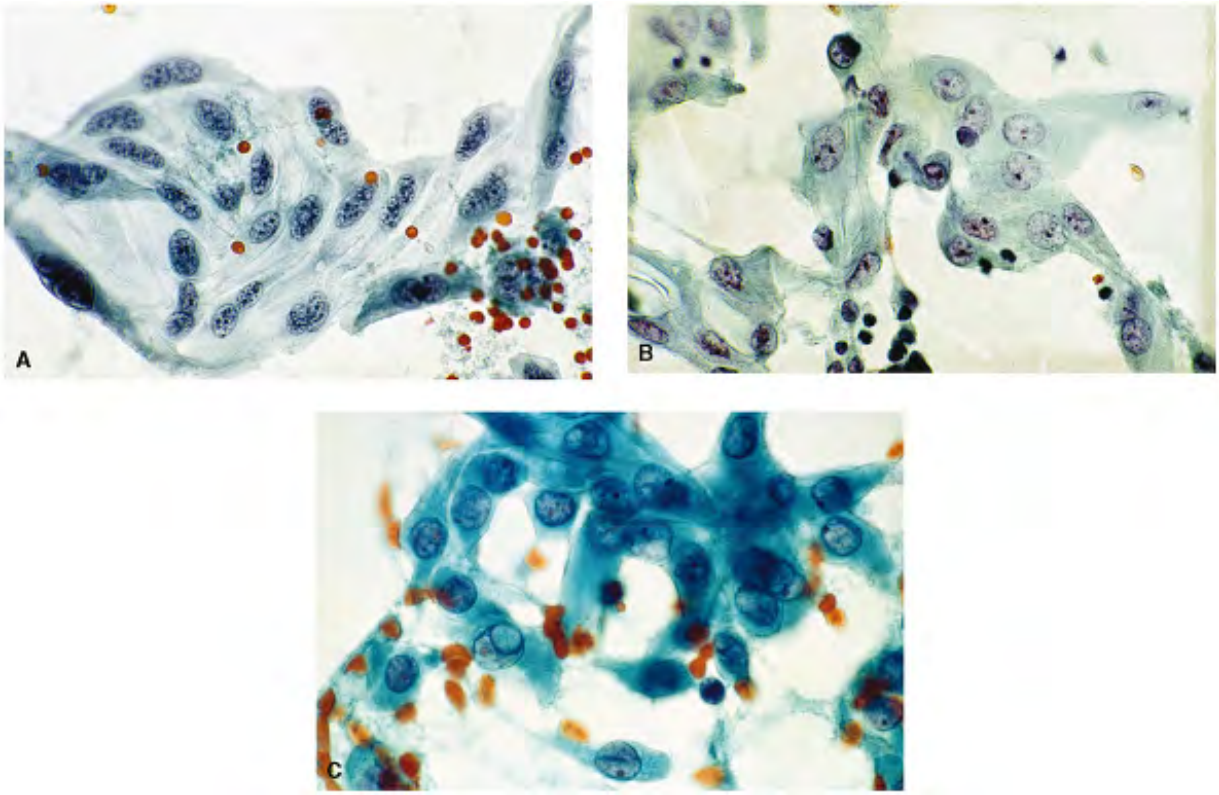

Figure 18.31. Three separate cases of papillary thyroid carcinomas with spindle-shaped carcinoma cells with their nuclei demonstrating features of papillary carcinoma.

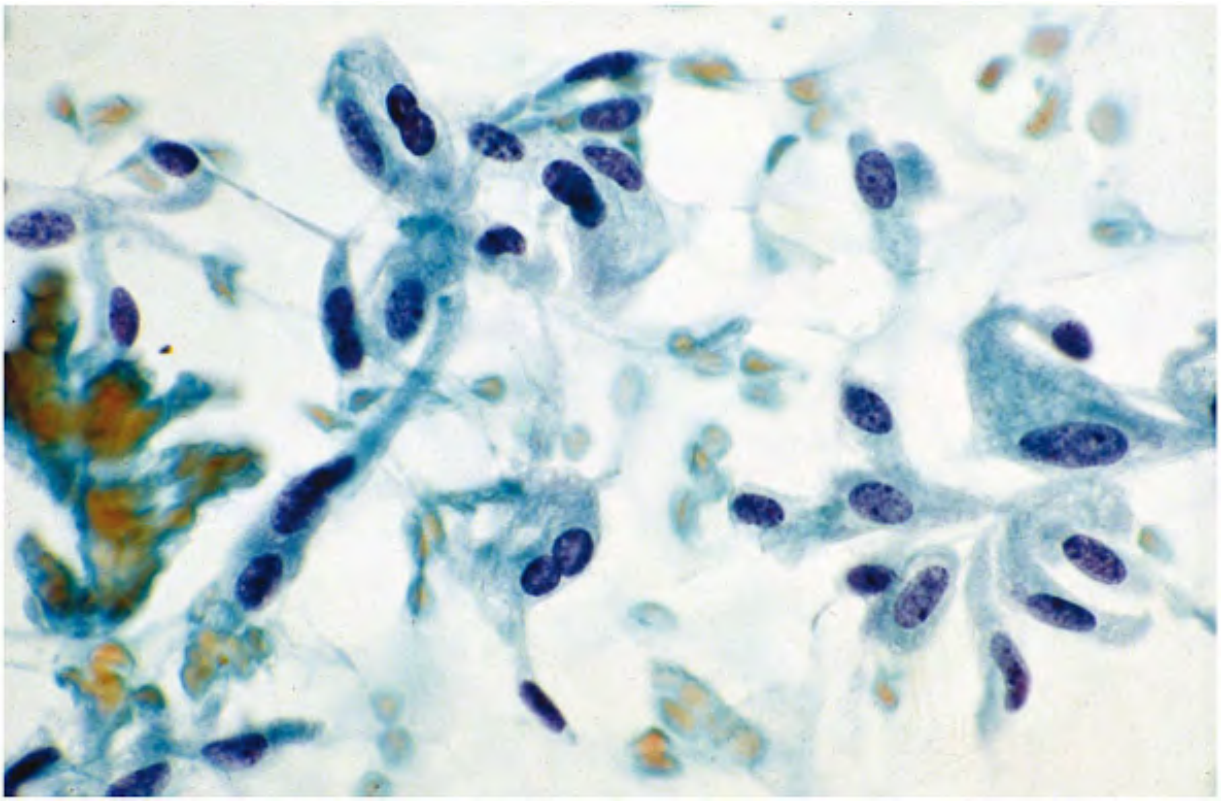

Figure 18.32. FNA of a medullary thyroid carcinoma showing spindle-shaped cells. Their nu
chromatin is typical salt-and-pepper type.

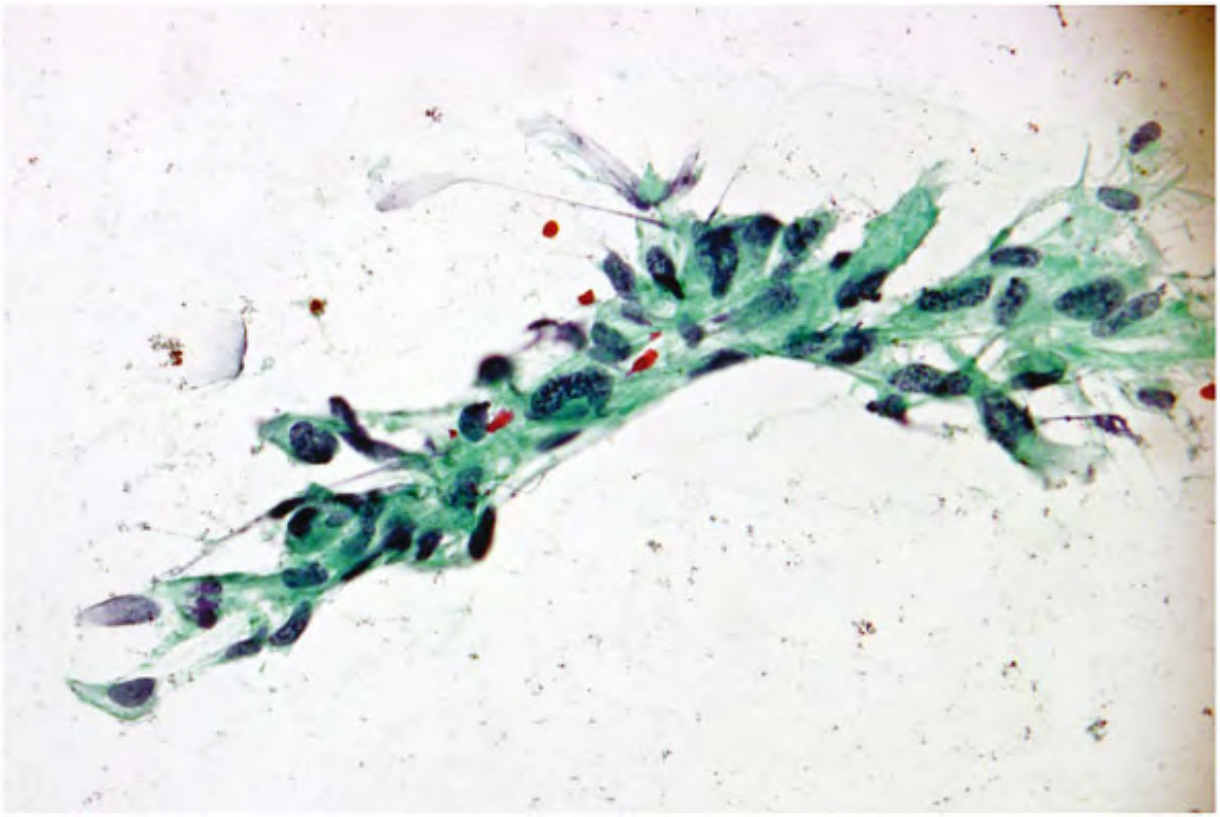

Figure 18.33. FNA of an anaplastic thyroid carcinoma, exhibiting spindle-shaped malignant cells.

SUMMARY

The presence of few spindle-shaped cells in thyroid aspirates originating from stromal tissue altered follicular cells may cause a great concern. Usually, they are of no diagnostic significance. The background features of the aspirate are generally those of nodular goiter \ retrogressive changes. It is important to recognize them as benign and of stromal origin or reactive/reparative follicular cells so that over-diagnosis and unnecessary surgery is avoidec

REFERENCES

1.Faquin WC, Cibas ES, Renshaw AA. Atypical cells in fine-needle aspiration biopsy specimens of benign thyroid cysts. *Cancer (Cancer Cytopathol)* . 2005;105:71â€“79.

2.van Hoeven KH, Dookhan DB. Cytology of the thyroid gland: pitfalls in aspiration of the fibrotic nodule. *Diagn Cytopathol* . 1996;14:362â€“366.

3.Anderson RJ, Pragasam PJ, Nazeer T. Atypical retrogressive and metaplastic changes in nodular goiter: potential pitfalls in aspiration cytology of the thyroid. *Acta Cytol* . 1990;34:715Aâ€“716A.

4.Droese M. *Cytological Aspiration Biopsy of the Thyroid Gland.* Stuttgart: Schattauer Verlag; 1980:57,62,81â€“85.

5.Centeno BA, Szyfelbein WM, Daniels GH, et al. Fine needle aspiration biopsy of the thyr gland in patients with prior Grave's disease treated with radioactive iodine: Morphologic findings and potential pitfalls. *Acta Cytol* . 1996;40:1189â€“1197.

6.Ofner C, Hittmair A, Kroll I, et al. Fine needle aspiration cytodiagnosis of subacute (de Quervain's) thyroiditis in an endemic goiter area. *Cytopathology* . 1994;5:33â€“40.

7.Clark DP, Faquin WC. *Thyroid Cytopathology* . New York: Springer Verlag; 2005:40â€“41

8.Kikuchi I, Anbo J, Nakamura S, et al. Synovial sarcoma of the thyroid. Report of a case with aspiration cytology findings and gene analysis. *Acta Cytol* . 2003;47:495â€“500.

9.Jayaram G. Neurilemmoma (schwannoma) of the thyroid diagnosed by fine needle aspiration cytology. *Acta Cytol* . 1999;47:743â€“744.

10.Andrion A, Mazzucco G, Torchio B. FNA cytology of thyroid neurilemmoma (schwannom *Diagn Cytopathol* . 1992;8:311â€“312.

11.Andrion A, Bellis D, Delsedime L, et al. Leiomyoma and neurilemmoma: report of two unusual non-epithelial tumors of the thyroid gland. *Virchows Arch* . 1988;413:367Aâ€“372A

12.Andrion A, Gaglio A, Dogliani N, et al. Liposarcoma of the thyroid gland. Fine needle aspiration cytology, immunohistology and ultrastructure. *Am J Clin Pathol* . 1991;95:675â€“679.

13.Wojcik EM. Fine needle aspiration of metastatic malignant schwannoma to the thyroid. *Diagn Cytopathol* . 1997;16:94â€“95.

14.LiVolsi VA. Papillary neoplasms of the thyroid: pathologic and prognostic features. *Am Clin Pathol* . 1992;97:426â€“434.

15.Carcangiu ML, Zampi G, Pupi A, et al. Papillary carcinoma of the thyroid: a clinicopathologic study of 241 cases treated at the University of Florence, Italy. *Cancer* . 1985;55:805â€“828.

16.Casey MB, Sebo TJ, Carney JA. Hyalinizing trabecular adenoma of the thyroid gland. Cytologic features in 29 cases. *Am J Surg Pathol* . 2004;28:850â€“867.

17.Woyke S, Al-Jassar AK, Al-Jarallah M, et al. Papillary carcinoma of the thyroid with numerous spindle-shaped tumor cells in fine needle aspiration smears. A case report. *Acta Cytol* . 1996;38:226â€“230.

Editors: Kini, Sudha R.
Title: *Thyroid Cytopathology: A Text and Atlas, 1st Edition*

Copyright Â©2008 Lippincott Williams & Wilkins

19

Miscellaneous Lesions of the Thyroid

This chapter is a potpourri of cytopathologic features of a broad range of uncommon and un rare neoplastic and non-neoplastic lesions of the thyroid. They represent some unexpected cytopathologic patterns encountered in aspiration biopsy specimens of thyroid nodules or ne lesions that masquerade as thyroid nodules.1 Some are related to the thyroid gland; others thyroidal. Interestingly enough, lesions that occur in the lateral neck not only masquerade a thyroid lesions but can also occur within the thyroid, although on extremely rare occasions (soft-tissue tumors and Hodgkin's lymphoma). With increasing use of fine-needle biopsy proce these patterns may be encountered more frequently. The cytopathologist needs to be cogni the diverse lesions that can occur in the thyroid gland and adjacent region so that their reco can be easy or at least differential diagnoses can be offered. Every attempt is made to inclu illustrate cytologic presentations of uncommon, unusual, and rare lesions. Several case repo describing rare entities in thyroid aspirates can be found in the current literature. An illustr every example is beyond the scope of this book. The reader may refer to the literature for f information.

NON-NEOPLASTIC CELLS OF NON-THYROID ORIGIN

Aspiration biopsy of the thyroid gland may yield cells that are non-thyroidal in origin (Table Most often these include fragments of epidermis, skeletal muscle, or subcutaneous fibroadip tissue (Figs. 19.1 and 19.2). An inadvertently placed needle in the trachea may aspirate res columnar cells, dust cells, carbon-containing multinucleated histiocytes, and mucus (Figs. 1 19.4). The presence of respiratory columnar cells has no significance and represents a minc complication of the biopsy procedure. Jayaram2 reported an incidence of 0.2% of thyroid as

(42/18,847) containing respiratory columnar cells, while the incidence reported by Kumar3 v
of the thyroid aspirates (3/339). The biopsy needle may also aspirate the chondrocytes origi
from the laryngeal cartilage1 (Fig. 19.5). The laryngeal cartilage may get ossified and deve
hematopoietic tissue.4 , 5 Aspiration biopsy of these foci may contain megakaryocytes in th
background of other hematopoietic cells.4 , 5 The large to giant-sized multilobated megaka
are an important source of diagnostic pitfalls as they can be misinterpreted as cells of anapl
carcinoma (Figs. 19.6A to C and 19.7 ; see also Fig. 11.43). Rarely, the thyroid gland may be
involved by agnogenic myeloid metaplasia,6 , 7 , 8 , 9 and may clinically present as a thyroi
nodule. The aspiration biopsy findings in such a case with the presence of megakaryocytes h
been documented.6 The cytologic diagnosis in these cases was assisted by the clinical inforr
of an existing disease.

Epidermis
Adipose tissue
Skeletal muscle
Tracheal contents
  Respiratory columnar cells
  Dust cells and macrophages
Chondrocytes
Hematopoietic cells including megakaryocytes
  (from the hematopoietic tissue developed in ossified
  laryngeal cartilage) or agnogenic myeloid metaplasia
  involving the thyroid

TABLE 19.1 NON-NEOPLASTIC CELLS OF NON-THYROID ORI

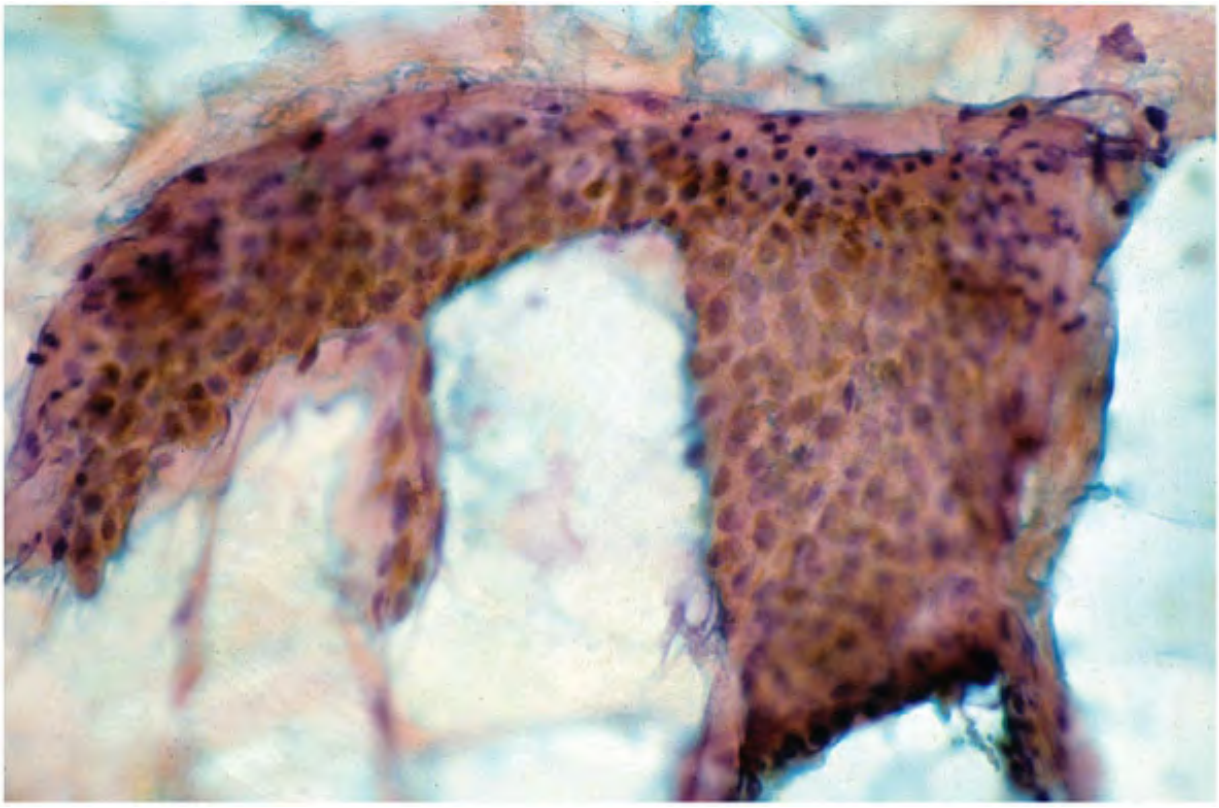

Figure 19.1. Strips of epidermis as seen here are sometimes present as contaminants in thy aspirates, and are easily recognized.

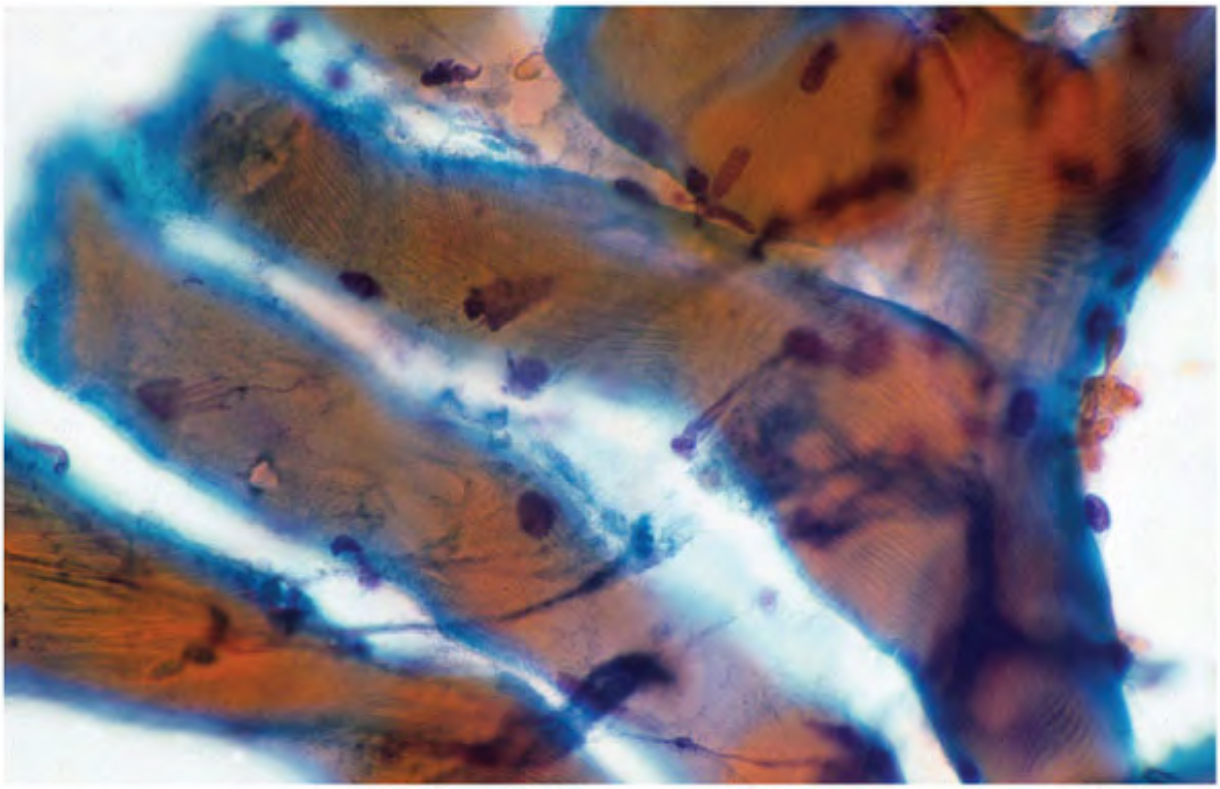

Figure 19.2. Fragments of skeletal muscle may also be present.

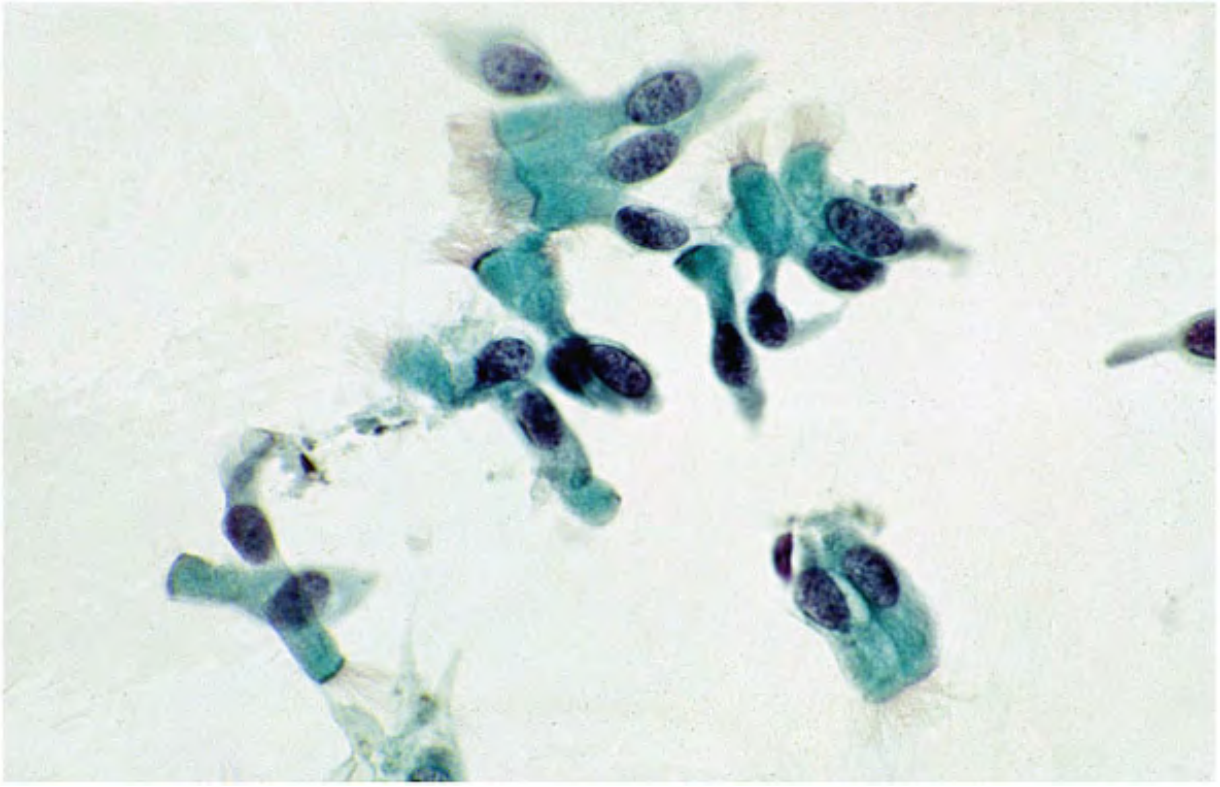

Figure 19.3. Ciliated respiratory columnar cells from trachea are rarely encountered if nee
enters the trachea.

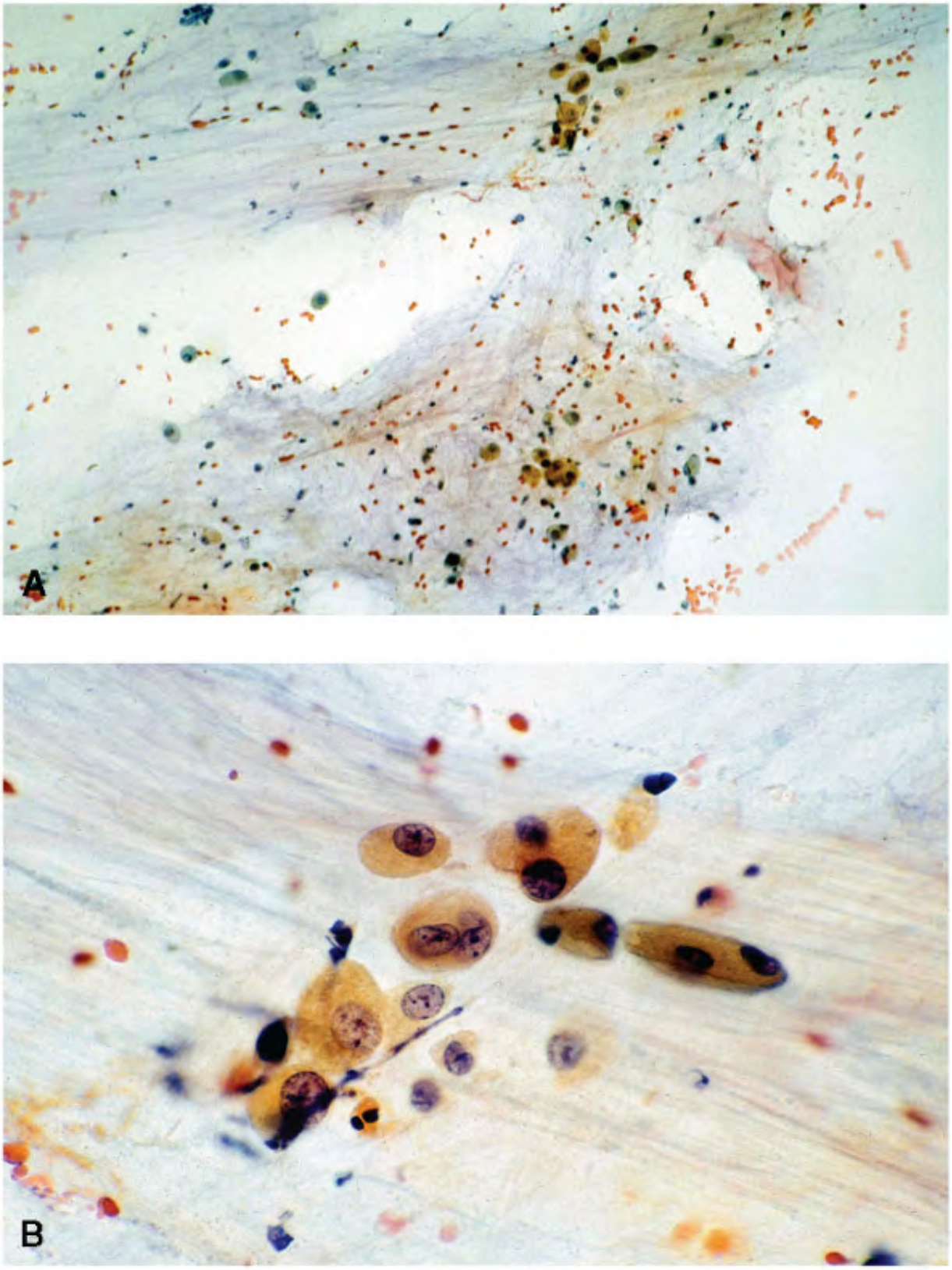

Figure 19.4. During the biopsy procedure the needle inadvertently entered the trachea and

aspirated mucus along with dust cells. A. Mucus and dust cells (low power). B. Higher magni
showing the dust cells.

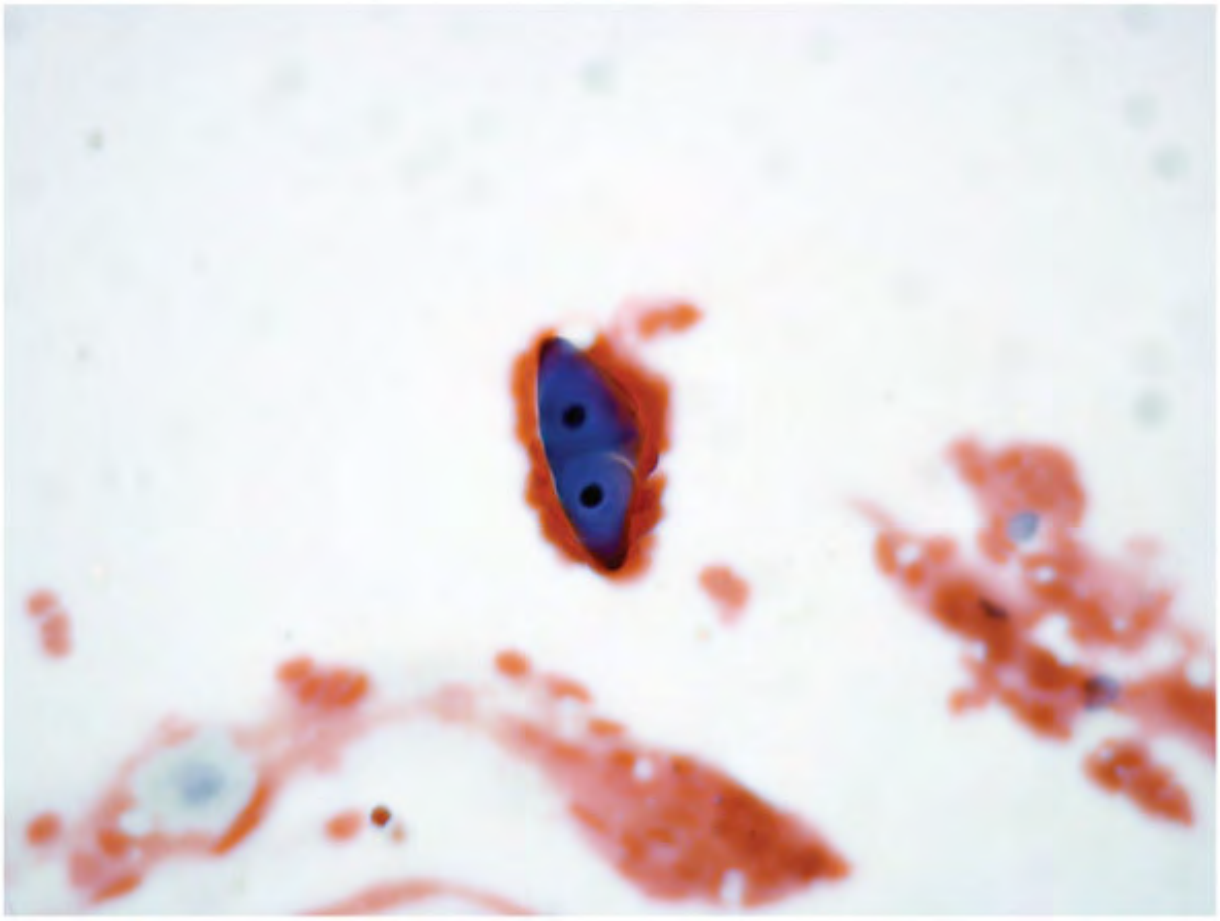

Figure 19.5. Normal chondrocytes may also be aspirated.

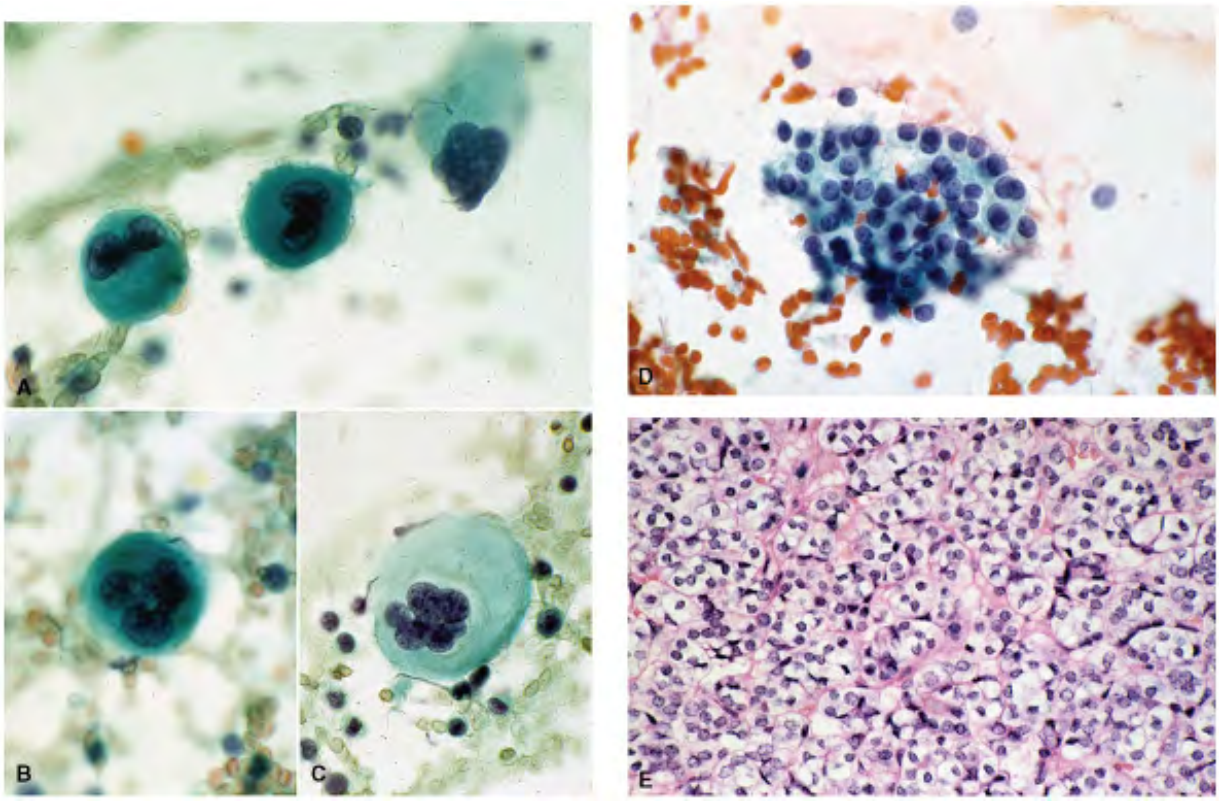

Figure 19.6. Hematopoietic cells in a thyroid aspirate from a 30-year-old woman with a soli cold nodule. Aâ€“C. Large, giant cells with multilobated nuclei. These cells were not recog megakaryocytes at the time of biopsy. Follicular cells were absent. A cytologic diagnosis of anaplastic carcinoma was made. D. A repeat FNA biopsy showed features of a cellular follic adenoma. The follicular cells are in syncytial tissue fragment with moderately enlarged nuc containing granular chromatin. The megakaryocytes were not present in the repeat biopsy s E. Histologic section of the surgically excised thyroid nodule confirming a cellular follicular adenoma.

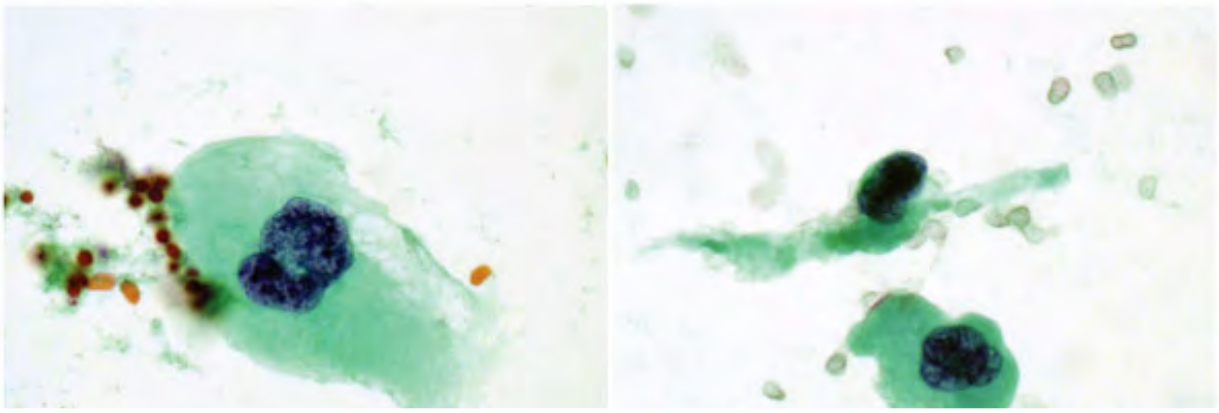

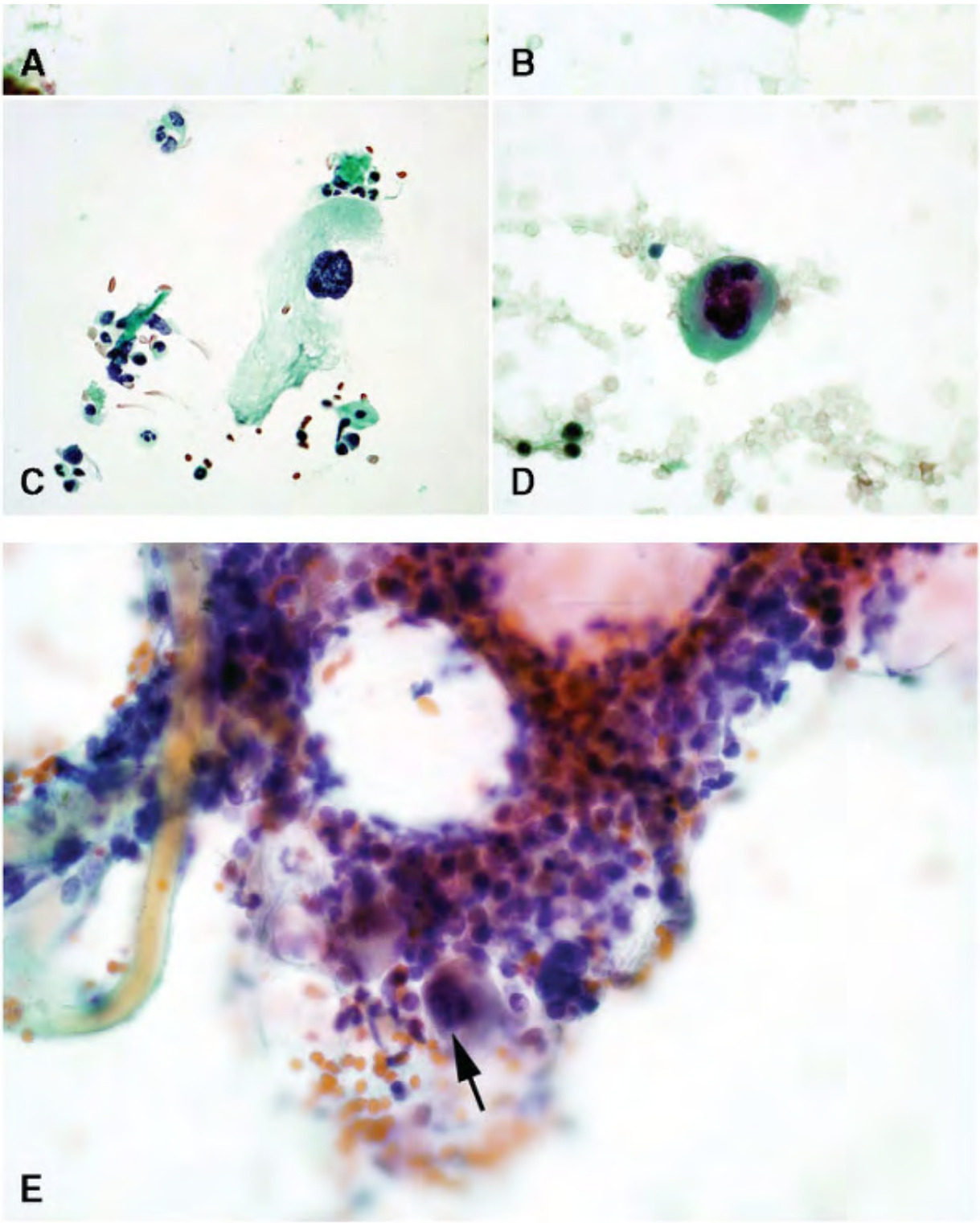

Figure 19.7. Another example of hematopoietic cells in thyroid aspirate. FNA of a large thy nodule with cervical lymphadenopathy. A to D. The smears showed only megakaryocytes in background of other hematopoietic cells. Follicular cells were not present. E. A megakaryoc

the background of other hematopoietic cells (*arrow*). Thyroidectomy subsequently revealec papillary carcinoma with metastasis to cervical lymph nodes.

MULTINUCLEATED GIANT CELLS IN THYROID ASPIRATES

The presence of multinucleated giant cells is a frequent but a nonspecific finding in fine-ne aspirates of the thyroid. These multinucleated giant cells originate from a wide variety of d processes10 (Table 19.2). Their cytomorphology differs in different conditions.11 , 12 Some multinucleated giant cells present characteristic features that are highly suggestive of the diseaseâ€”for example, subacute (granulomatous) thyroiditis; while the majority of multinu giant cells present nonspecific features (Table 19.3 , Figs. 19.8 , 19.9 , 19.10 , 19.11 , 19.12 , 19.14 , 19.15 , 19.16 and 19.17).

Multinucleated foreign-body-type histiocytic giant cells
- Nodular goiter and neoplasms with degeneration

Multinucleated foreign-body-type giant cells
- Subacute or granulomatous thyroiditis
- Hashimoto's thyroiditis
- Chronic infectious granulomatous thyroiditis
- Sarcoidosis
- Foreign-body giant cells (e.g., Teflon granuloma)
- Associated with radiation induced changes

Multinucleated giant cells associated with papillary carcinoma

Multinucleated malignant tumor giant cells
- Anaplastic thyroid carcinoma and poorly differentiated carcinomas (primary and secondary)
- Hodgkin's lymphoma

Osteoclast-type multinucleated giant cells associated with anaplastic carcinoma

Megakaryocyte

TABLE 19.2 MULTINUCLEATED GIANT CELLS IN THYROII ASPIRATES

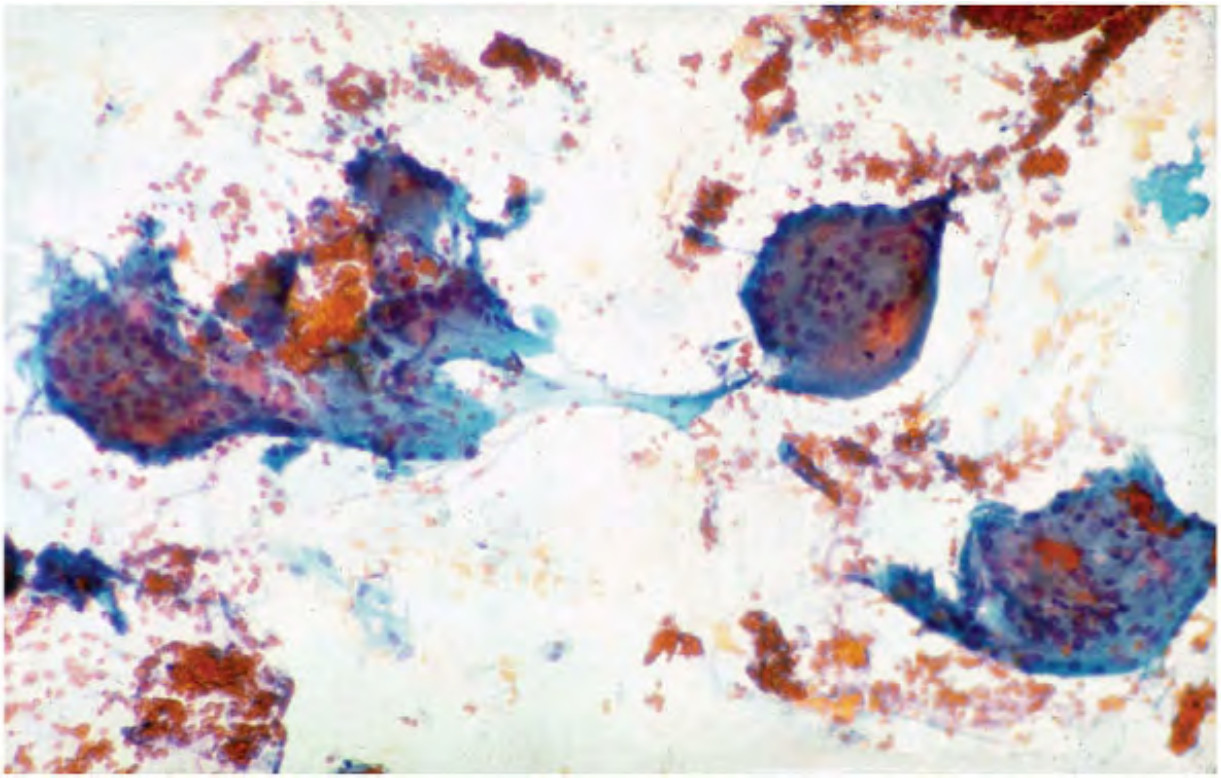

Figure 19.8. Multinucleated foreign body-type histiocytic giant cells in FNA of nodular goite degeneration. Similar giant cells may be seen in benign and malignant neoplasms of thyroid cystic degeneration.

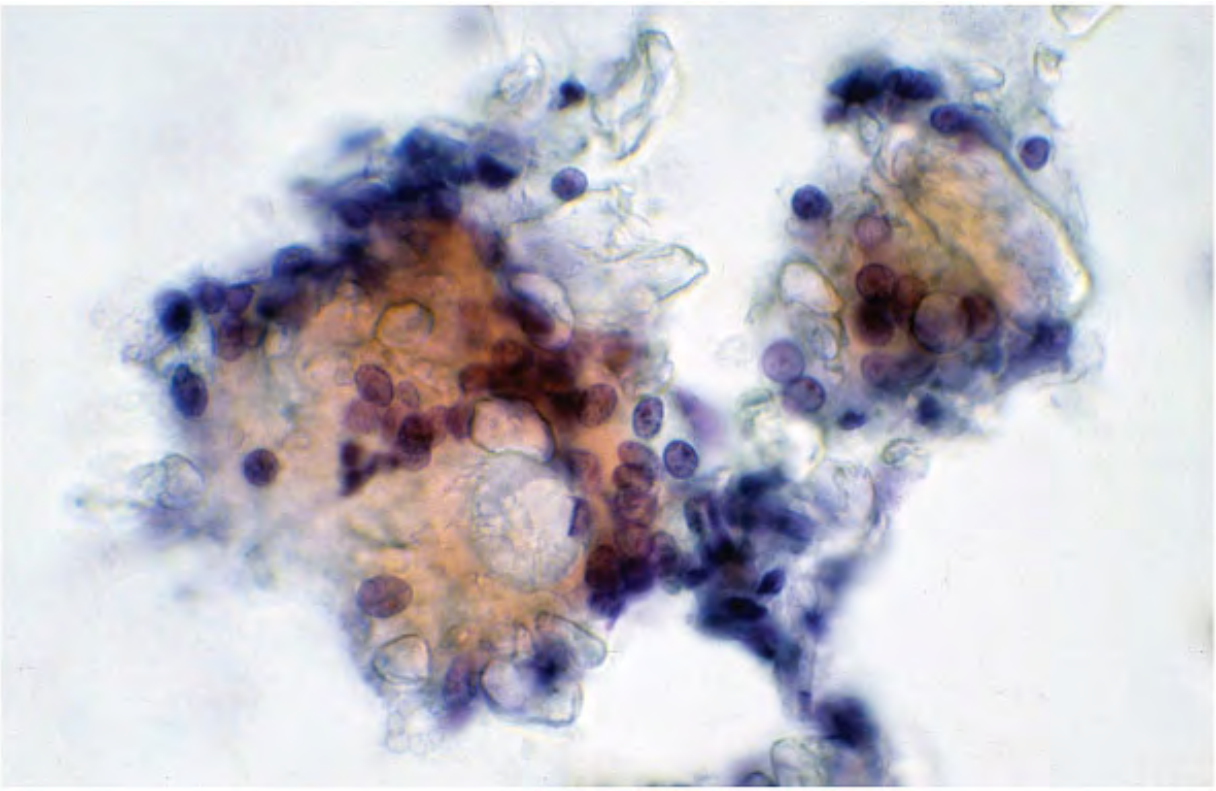

Figure 19.9. Multinucleated foreign-body giant cells from Teflon granulomas of the thyroid. refractile foreign material in the giant cells. (Courtesy of David B. Kaminsky, MD, Palm Sprir Pathology Associates, Palm Springs, California.)

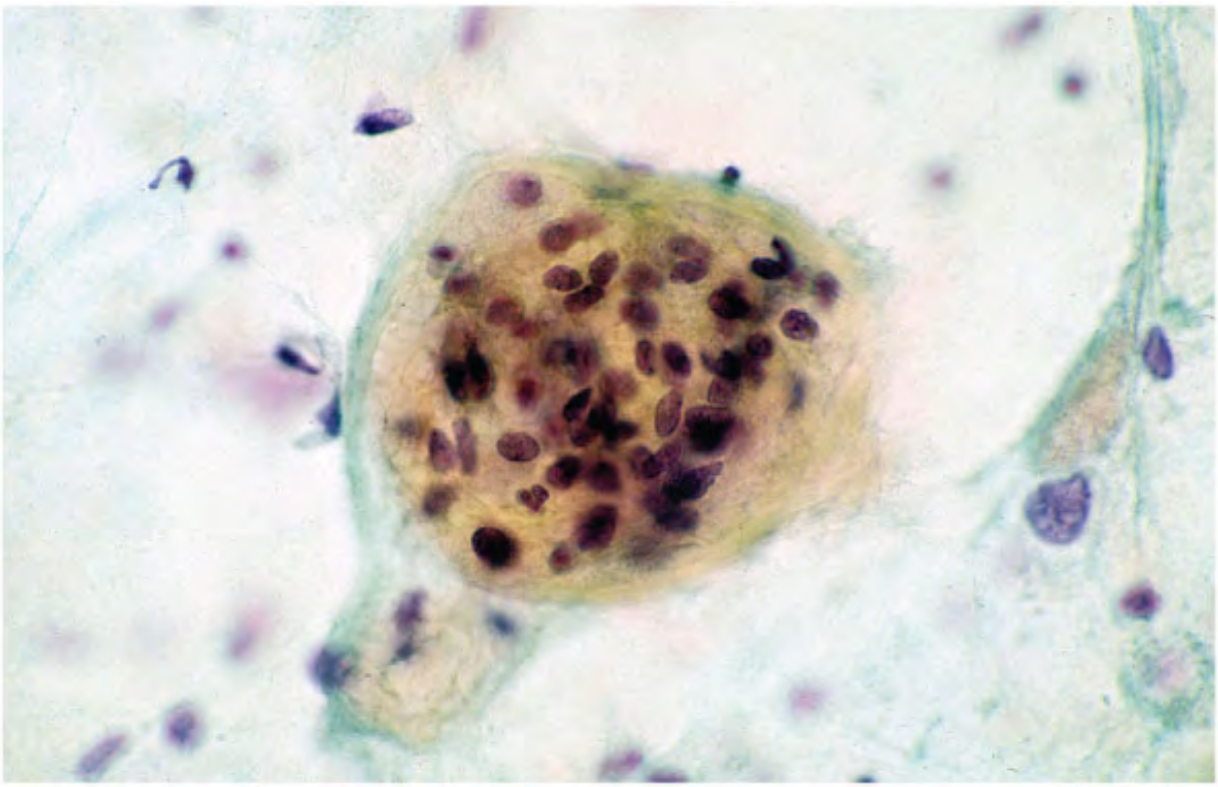

Figure 19.10. Multinucleated giant cell from a sarcoid granuloma.

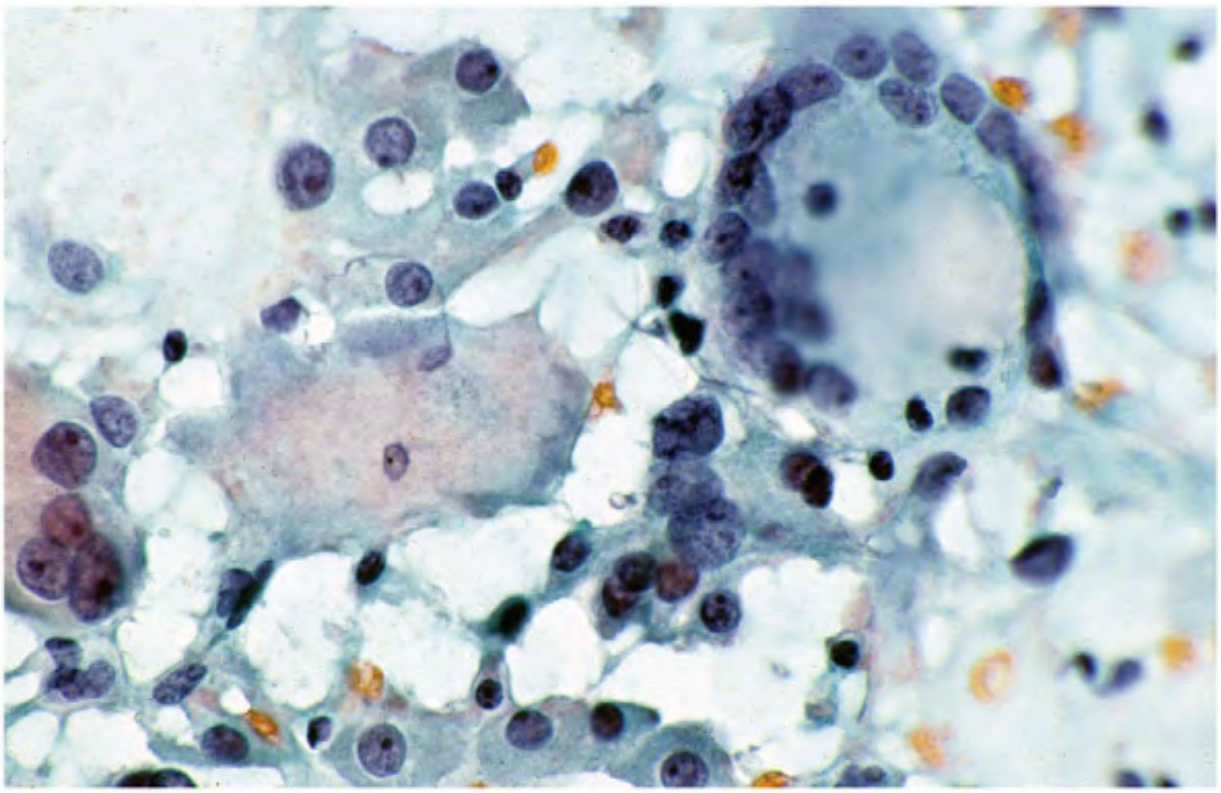

Figure 19.11. Multinucleated giant cells from FNA of a case of subacute or granulomatous thyroiditis.

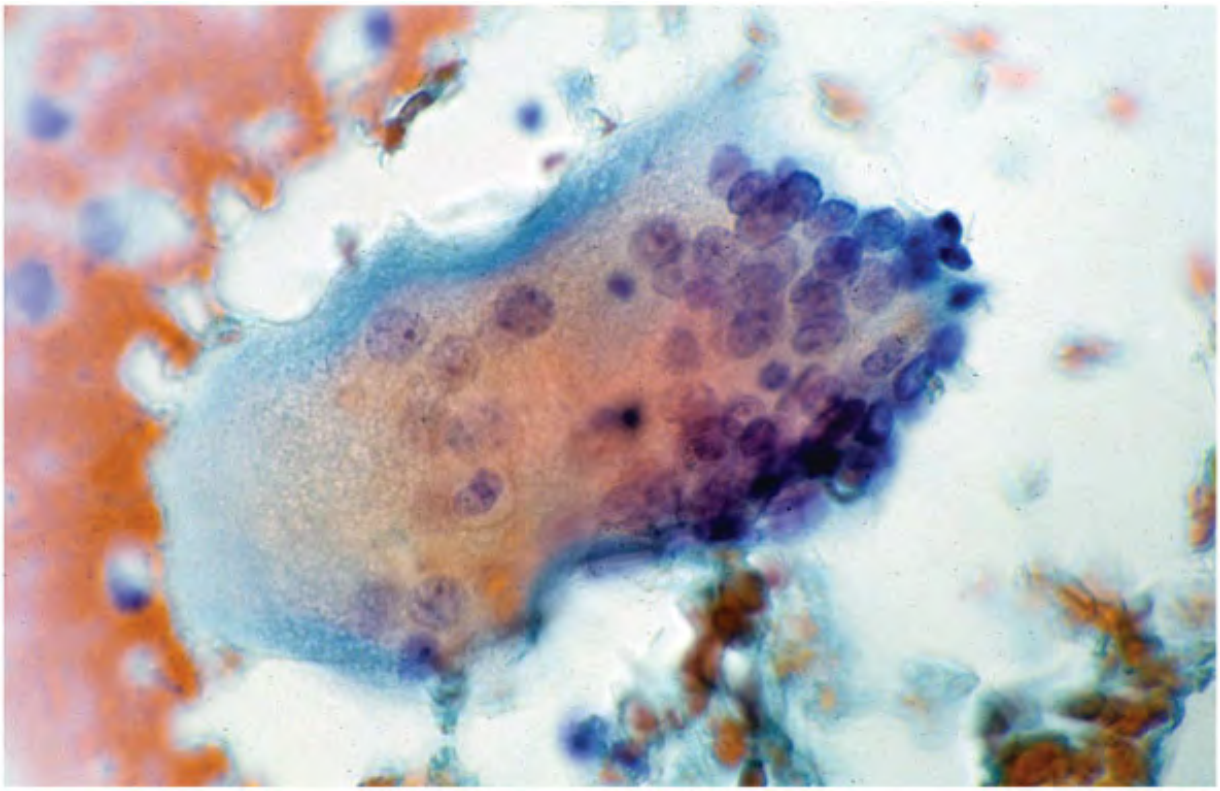

Figure 19.12. Nondescript multinucleated giant cells from FNA of a case of chronic lymphoc
thyroiditis of the Hashimoto's type.

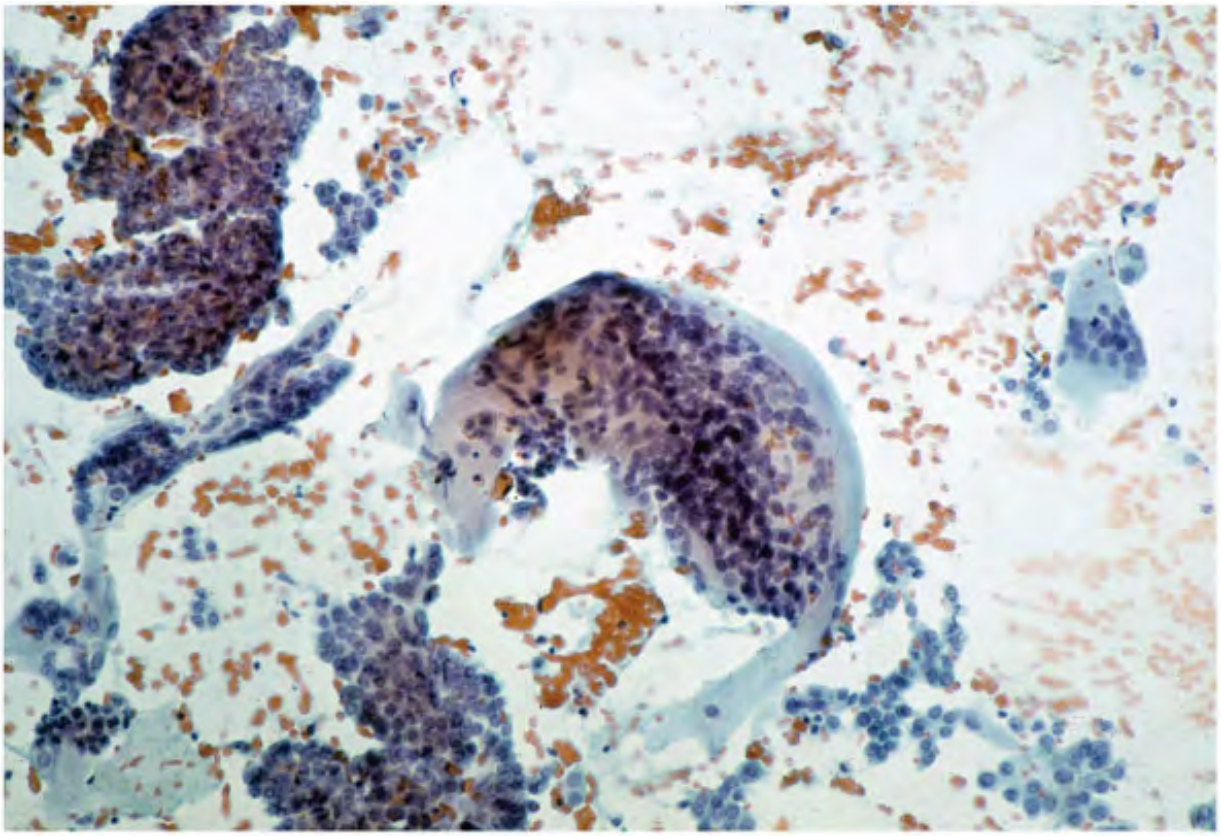

Figure 19.13. Multinucleated giant cells in FNA of a papillary carcinoma.

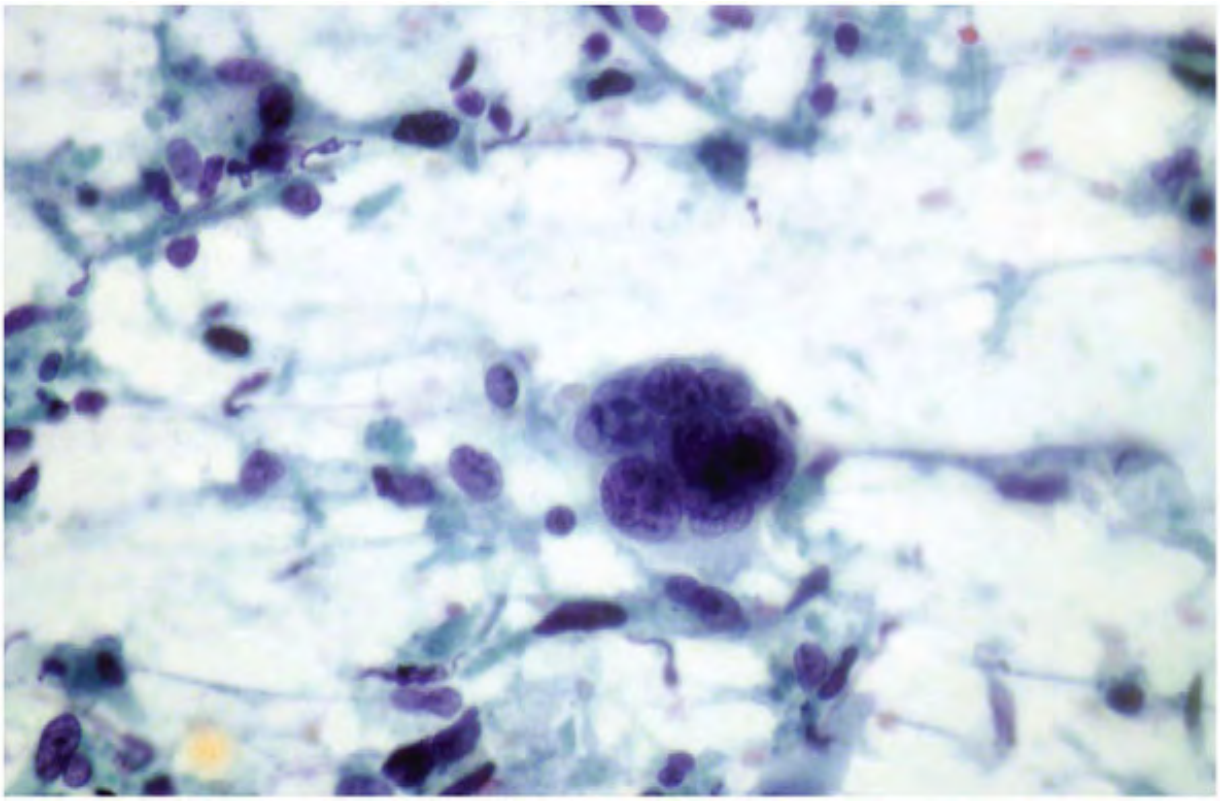

Figure 19.14. A multinucleated malignant cell with bizarre nuclei in FNA of an anaplastic carcinoma.

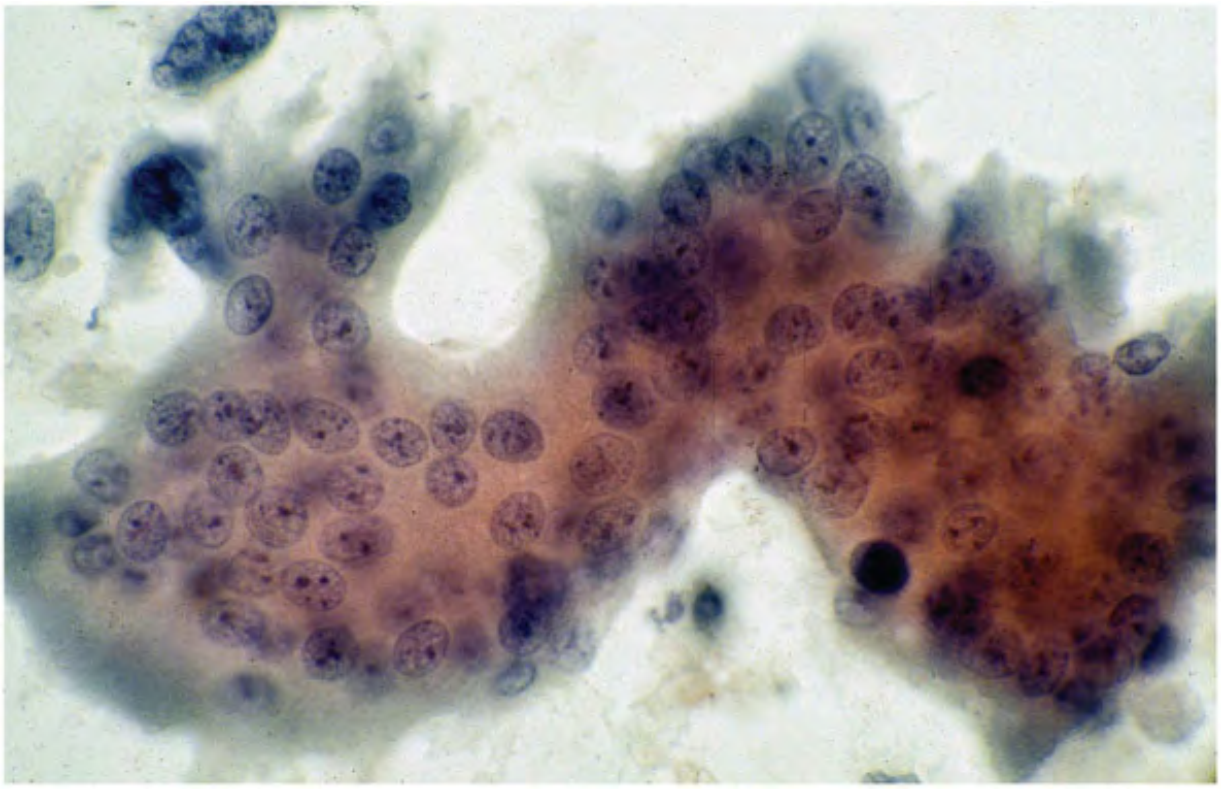

Figure 19.15. An osteoclast type giant cell in anaplastic carcinoma.

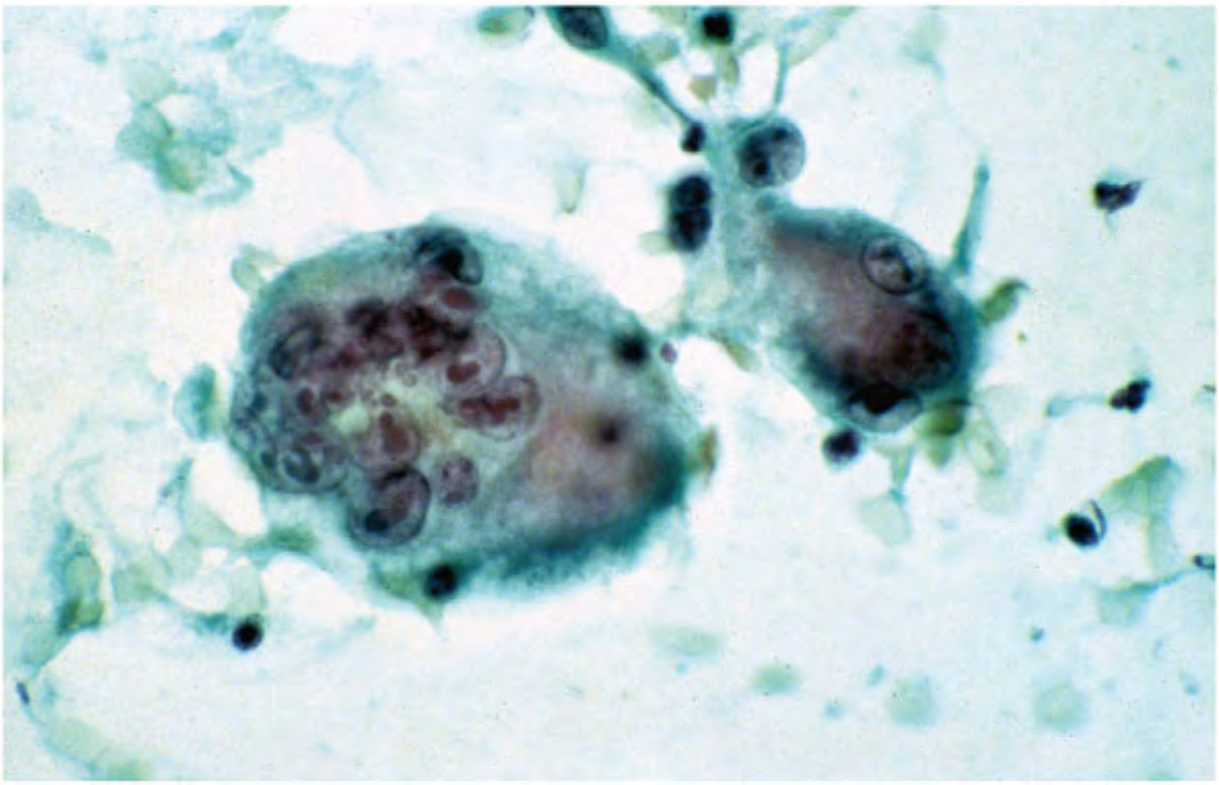

Figure 19.16. Multinucleated Reedâ€“Sternberg cell from Hodgkin's lymphoma.

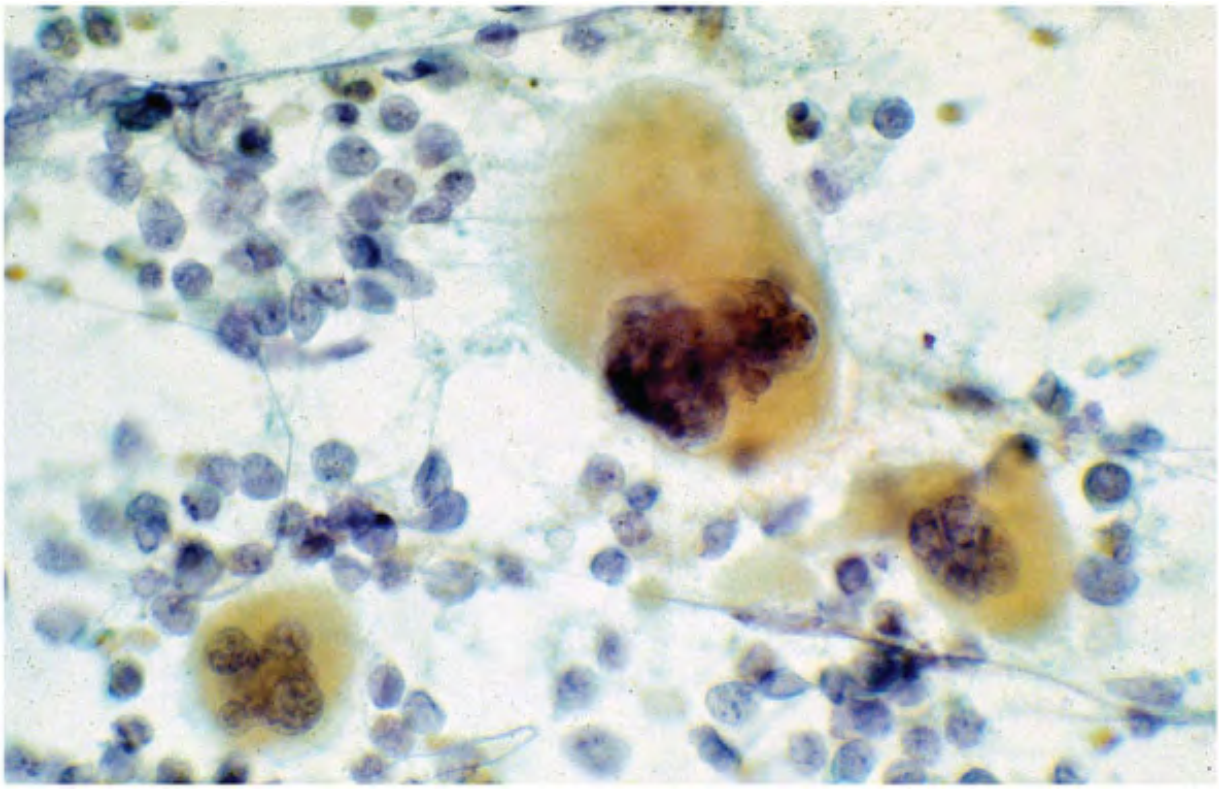

Figure 19.17. Megakaryocytes with multilobulated nucleus. Note the compact smudgy chro

Foreign body
histiocytic type
Nodular goiter or thyroid
neoplasms with degeneration
and with cystic change
Variable in size; nuclei uniform and usually
small in numbers; cytoplasm dirty, granular,
with or without hemosiderin
19.8
Multinucleated foreign-
body type
Subacute or granulomatous
thyroiditis
Considerable variation in size; may be present
in large numbers; the giant cells can be

enormous in size with multiple, uniform nuclei in tens and hundreds; often seen in the vicinity of blobs of colloid, forming granuloma, epithelioid cells Â±; associated featuresâ€”spindle-shaped stromal cells

19.11

Multinucleated giant cell

Hashimoto's thyroiditis

Infrequent occurrence; nondescript morphology; fewer nuclei, associated features of Hashimoto's thyroiditis; of no diagnostic significance

19.12

Multinucleated giant cell

Papillary carcinoma

Variable in size; can be very large, often angulated; abundant, dense cytoplasm; no phagocytosis; isolated or in the vicinity of follicular tissue fragments; rare intranuclear inclusions and grooves

19.13

Multinucleated tumor giant cell

Anaplastic carcinoma; poorly differentiated metastatic carcinomas

Bizarre nuclei with malignant criteria

19.14

Osteoclast-type

Anaplastic carcinoma

Rarely present in anaplastic carcinomas, variable numbers of uniform small nuclei

19.15

Multinucleated foreign-body giant cells

Infectious granulomatous lesions; sarcoidosis

Langhans-type giant cells characteristic in tuberculous granulomas; associated with epithelioid cells and granulomas

19.10

Megakaryocytes

Inadvertent aspiration of thyroid or thyroid cartilage

Variable in size; multilobulated nuclei; smudgy chromatin, abundant dense cytoplasm; other hematopoietic cells in the background; may be mistaken for malignant cells

19.17

Multinucleated foreign body giant cells

Teflon granuloma

Varying-sized multinucleated foreign-body giant cells containing refractile Teflon

19.11

Multinucleated giant cells in Hodgkin's lymphoma

Hodgkin's lymphoma

Varying-sized, large to giant forms; mirror-image nuclei or multinucleated with prominent nucleoli

19.16

Type of Giant Cell	Present In	Cytologic Characteristics	See Fi

TABLE 19.3 MULTINUCLEATED GIANT CELLS IN THYROII ASPIRATES: DIFFERENTIATING FEATURES

The multinucleated giant cells associated with degeneration and cystic change in nodular go usually occur in smaller numbers, are not significantly enlarged, and contain fewer nuclei. T cytoplasm is dirty, granular to foamy, and phagocytic, often containing hemosiderin (Fig. 19 The multinucleated giant cells in foreign-body granulomas often contain foreign bodies, for example, Teflon granuloma in thyroid aspirates (Fig. 19.9). Infectious granulomatous inflan of the thyroid is also associated with the presence of multinucleated giant cells. Sarcoidosis involves the thyroid gland. The multinucleated giant cells in sarcoidosis are often associated epithelioid granulomas and may resemble Langhans-type giant cells or be nonspecific (Fig. 1 They have been reported to contain Schumann bodies or asteroid bodies.

In subacute or granulomatous thyroiditis, the multinucleated giant cells are enormous in siz contain tens and hundreds of nuclei11 , 12 , 13 (Fig. 19.11). Multinucleated giant cells are seen in aspirates of Hashimoto's thyroiditis14 (Fig. 19.12).

The presence of multinucleated giant cells is a nonspecific but a consistent finding in aspira papillary carcinomas (Fig. 19.13).15 , 16 , 17 , 18 , 19 , 20 The origin of the giant cells in p carcinomas is uncertain. Anaplastic carcinomas demonstrate tumor giant cells with obvious malignant criteria (Fig. 19.14). Anaplastic carcinomas may also be associated with osteocla multinucleated giant cells (Fig. 19.15).20 , 21 , 22

Multinucleated tumor giant cells (Reedâ€“Sternberg cells) are also encountered in aspirates Hodgkin's lymphoma (Fig. 19.16). The presence of megakaryocytes in thyroid aspirates is a occurrence. They are inadvertently aspirated from the ossified laryngeal cartilage that has developed hematopoiesis. The megakaryocytes resemble multinucleated giant cells. Howeve nuclei are multilobulated rather than multiple in numbers and the chromatin is smudgy. The multiple lobulations and smudgy chromatin should aid the identification (Fig. 19.17 ; see als Neoplastic Cells of Non-Thyroid Origin" earlier in the chapter).

BLACK THYROID ASSOCIATED WITH MINOCYCLIN THERAPY

Certain drugs such as minocyclin are known to cause black pigmentation of the thyroid. Min is an antibiotic related to the tetracycline group, used for bacterial infection and acne. Its l term use has been associated with black pigmentation of the skin, nails, teeth, and rarely th thyroid gland.23 , 24 There is uncertainty as to the nature of the black

pigment.25 , 26 , 27 , 28 , 29 Thyroid involvement is uncommon. So far, only 62 cases are r
in the literature, of which 15 cases had fine-needle aspiration biopsies.30 Most cases of blac
thyroid have been diagnosed as incidental findings either at autopsy or at surgical resection
brown to jet black pigmentation involves the thyroid parenchyma (Fig. 19.18A and B). Howe
pigmentation of the nodular lesions is not consistent. Cases reported by Oertel et al. ,30 Je
et al.,31 and Pastolero et al.32 did not show pigmentation of the nodular lesions, either in t
needle biopsy specimens or in their histologic sections. Keyhani-Rofagha et al.33 reported a
where the aspirate of the thyroid nodule showed follicular cells containing dark brown pigm
their cytoplasm, which was also observed in macrophages (Fig. 19.18C and D). The black
pigmentation is of no clinical significance.

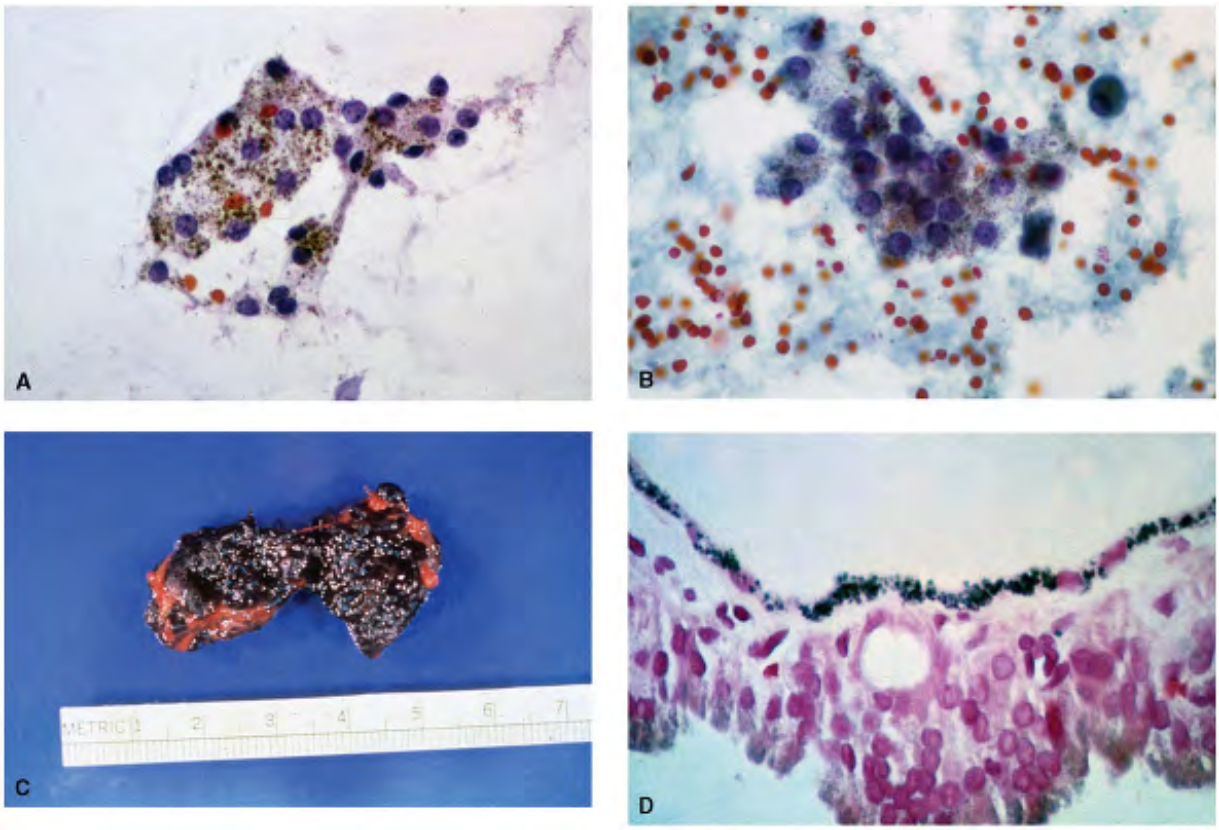

Figure 19.18. A,B. FNA of a thyroid nodule in a patient with a long history of minocycline t
The follicular cells contain abundant cytoplasmic black granules. C. Thyroidectomy revealec
black discrete nodule. D. Histologic section of the nodule showing jet-black pigment in the t
cells. (Courtesy of Sedigheh-Keyhani, MD, FIAC, Professor of Clinical Pathology, Ohio State
University Hospital, Columbus.)

TEFLON GRANULOMA OF THE THYROID

Polytef (polytetrafluoroethylene), or Teflon, is sometimes injected into the larynges of pati with unilateral vocal cord paralysis to improve phonation. Teflon particles are known to mig into the soft tissues and to distinct sites including the thyroid gland, eliciting a granulomato reaction.34 The granulomas show refractile, irregular, angular particles ranging from 4 to 1(This reaction can cause nodularity of the thyroid.35 , 36 , 37 Wilson and Gartner35 reportec of fine-needle biopsy of a thyroid nodule containing Teflon granuloma that was initially misinterpreted as suspicious for malignancy. The author has seen one case in consultation, illustrated in Figure 19.19 .

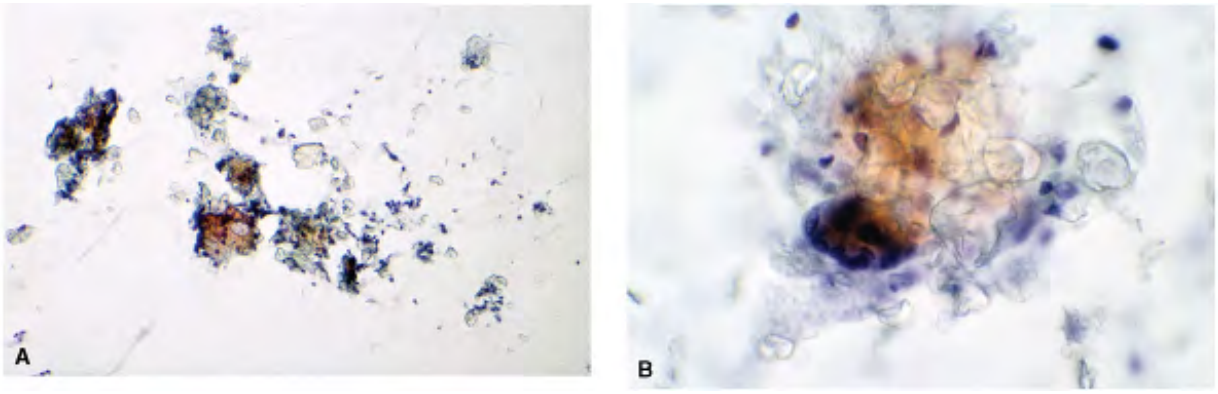

Figure 19.19. A. FNA of a thyroid involved by Teflon granuloma. Low-power view showing n granulomas. The refractile Teflon granules can be appreciated even at low power. B. Highe magnification showing the refractile Teflon granules in the multinucleated foreignâ€"body- giant cells. (Courtesy of David B. Kaminsky, MD, Palm Springs Pathology Associates, Palm Sp California.)

AMYLOID GOITER

Amyloid goiter is a rare condition and occurs as a result of amyloid deposits in the thyroid o patients with primary or secondary systemic amyloidosis.38 , 39 Amyloid deposits produce a progressive enlargement of the thyroid gland that may be clinically misdiagnosed as carcino

Diagnosis of amyloid by fine-needle aspiration biopsy has been reported in several reports.4
42 , 43 Gharib and Goellner43 described two cases of amyloid goiter diagnosed by fine-neec
biopsy; one patient presented with diffuse goiter, not responding to the treatment, and the
one with a firm, discrete nodule. In both cases, rectal biopsies confirmed systemic amyloidc
Nijhwan et al.42 reported 4 cases of amyloid goiter and Lucas et al.42 reported 2 cases, all
correctly diagnosed by cytology.

The aspirates of amyloid goiters are sparsely cellular consisting predominantly of large depo
acellular material in the background of spindle-shaped stromal cells and few lymphocytes (F
19.20). Multinucleated foreign-body-type giant cells may be present. Presence of follicular
unusual. Mature fat has been described in fine-needle aspirates of amyloid goiters.40

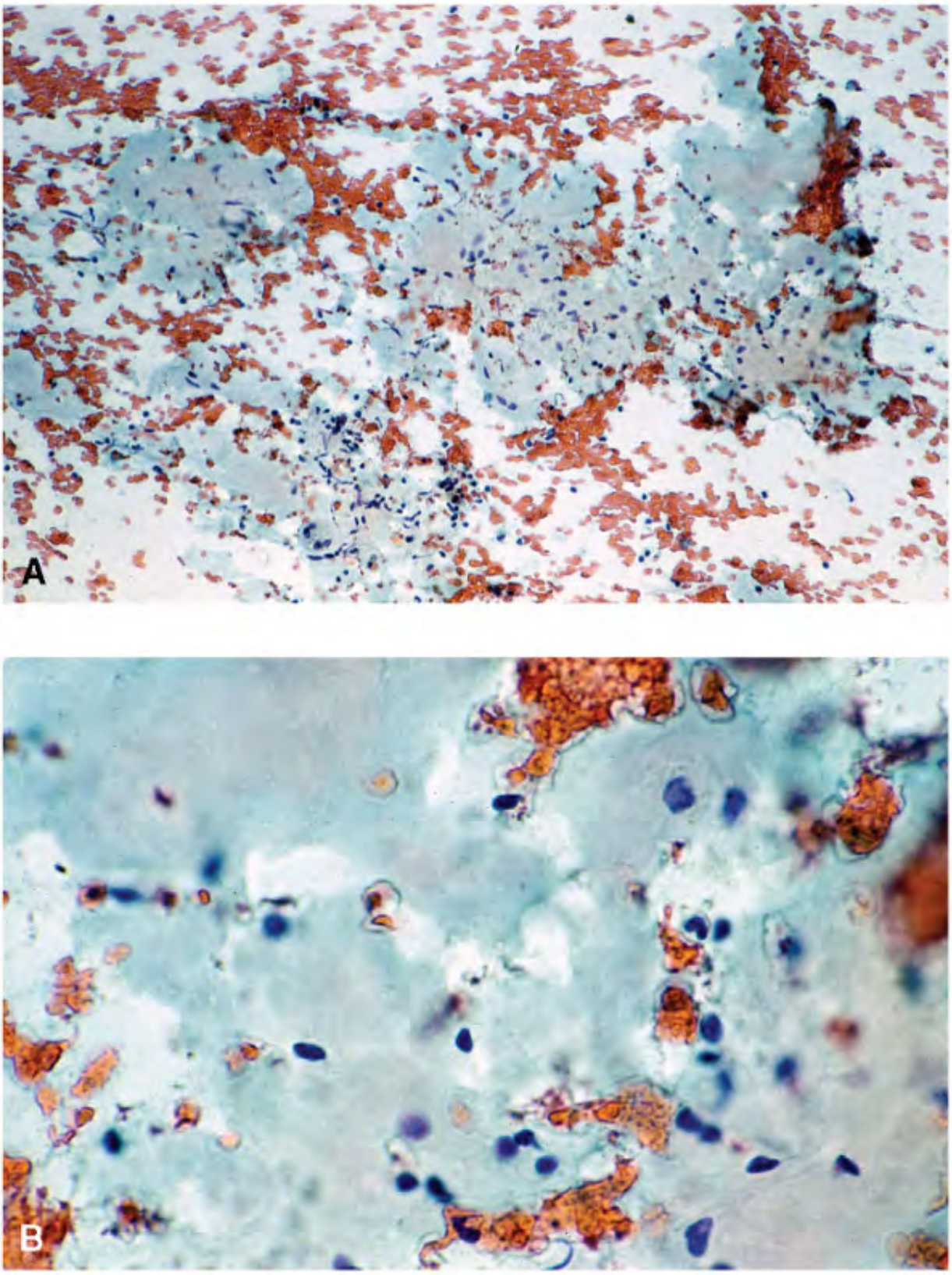

Figure 19.20. A. FNA of an amyloid goiter. Medium-power view showing large deposits of ac

material. B. Higher magnification showing the hyaline quality of the amyloid deposit with fe spindle-shaped stromal cells. The presence of amyloid must be confirmed by special stains. (Courtesy of John F. Goellner. MD, formerly of Department of Pathology, Mayo Clinic, Roche Minnesota.)

The amyloid appears as irregular deposits of pale cyanophilic to eosinophilic, amorphous ma more solid and hyaline than colloid with artifactually stretched and distorted nuclei of the s cells. Amyloid may be confirmed with special stains such as Congo red, which shows apple-g birefringence or with thioflavin T, which demonstrates bright green fluorescence under ultra light. The differential diagnosis of amyloid deposits in thyroid aspirates includes medullary carcinoma. Kapila and Verma41 described a case of amyloid goiter that was cytologically dia as medullary thyroid carcinoma.

RADIATION-INDUCED CELLULAR CHANGES

Morphologic alterations in thyroid parenchyma secondary to radioactive iodine (131 I) therap in the treatment of Graves disease or secondary to external radiation are well described in literature.44 , 45 , 46 , 47 , 48 , 49 , 50 , 51 , 52

Histopathologic changes in thyroid parenchyma following radioactive iodine 131 I are varied depending on the dose of radiation and the duration of the treatment. The morphologic cha include initially a neutrophilic infiltrate, necrosis of follicular cells, and a giant cell reactior followed by parenchymal atrophy and fibrosis, loss of colloid, oxyphilia of the follicular cells cytoplasmic degeneration, and variable degree of nuclear atypia. The latter is characterized pleomorphism in nuclear size and shape and chromatin pattern (Fig. 19.21). Morphologic ch similar to those of Hashimoto's thyroiditis and development of adenomatous nodules have al described. HÃ¼rthle cell change is often pronounced, leading to nodule formations. A detai description of histologic changes can be found in the literature.44 , 45 , 46 , 47 , 48 , 49 , 5 52 High-dose external radiation (greater than 1,500 rad) to the head and neck area has beer reported to cause significant morphologic changes in thyroid.47

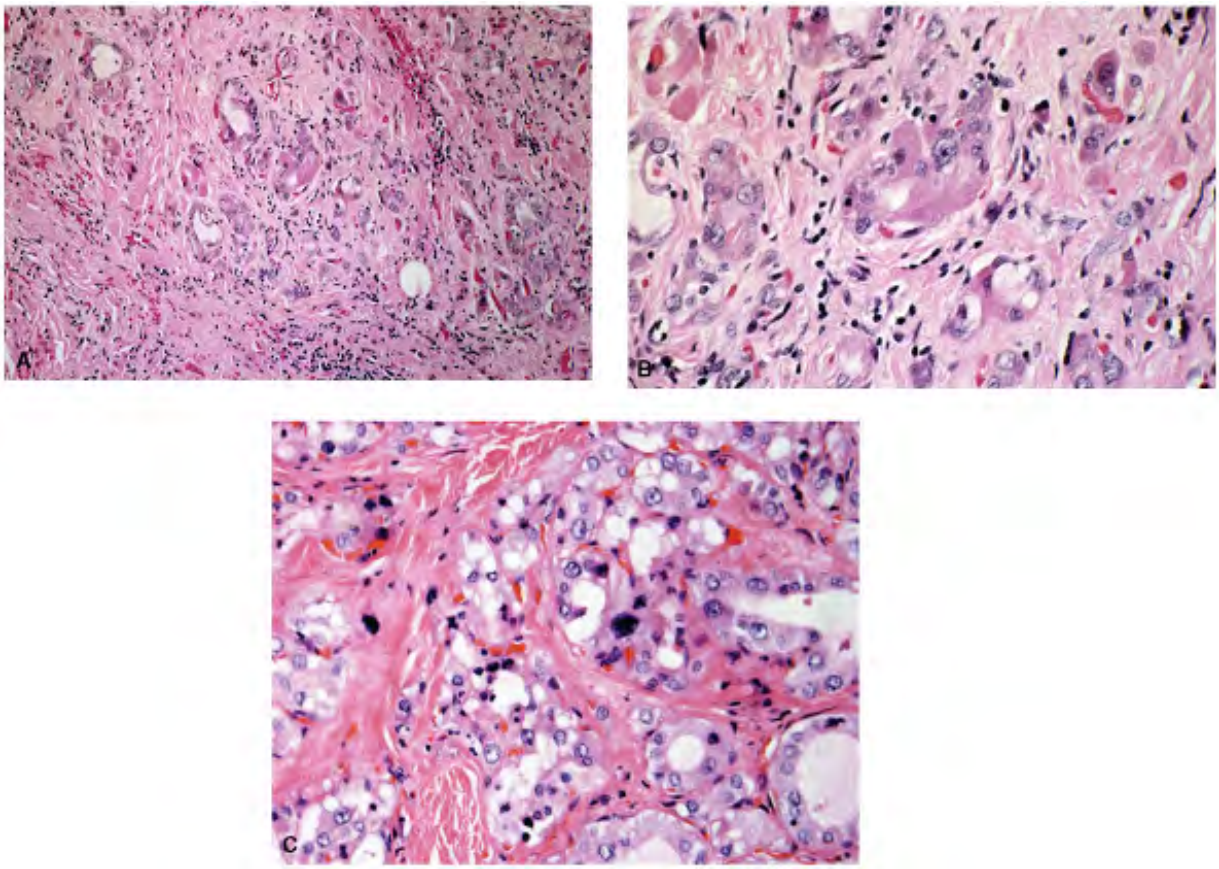

Figure 19.21. A. Histologic section of the thyroid from a patient with history of 131 I therap
There is marked parenchymal atrophy, distorted follicles lined by variably enlarged cells, wi
considerable nuclear atypia. Note extensive interfollicular fibrosis (medium power). B. High
magnification highlighting the marked nuclear atypia and the fibrosis. C. Histologic section o
different thyroid gland, treated with 131 I for Graves disease. Note extensive HÃ¼rthle cell
with nuclear atypia.

Cytopathologic Features

The cytologic findings are variable but can be significant enough to cause diagnostic difficul
that have resulted in malignant diagnoses.53 , 54 , 55 , 56 , 57 , 58 , 59 , 60 A wide spectru
cellular changes is noted in fine-needle aspirates (Table 19.4 , Figs. 19.22 , 19.23 , 19.24 an
). The aspirates show tissue fragments of follicular epithelium with varying degrees of cellul
nuclear atypia. The follicular cells are enlarged and may contain abundant cytoplasm that n
vacuolated and contain neutrophils. Their nuclei are enlarged, pleomorphic in size, with a c
staining, often smudgy, structure less chromatin. Similar but varyiably sized, bare nuclei ma

present in the background (Fig. 19.22). Large tissue fragments of follicular cells with papill configurations have been described in the literature (Fig. 19.24), leading to misinterpretati papillary carcinoma. Intranuclear inclusions and nuclear grooves may be present (Fig. 19.23 further causing diagnostic difficulties. Stromal cells are often seen, either isolated or in tiss fragments, and may demonstrate nuclear atypia. The background often shows inflammatory and occasionally psammoma bodies.

Cellularity
Variable, scant in cases with increased fibrosis
Composition
Admixture of follicular cells and spindle cells of
stromal origin
Follicular Cells
Discrete, in groups or in tissue fragments with or without
HÃ¼rthle cell metaplasia, markedly pleomorphic
in size and shape; round to spindle shaped; enlarged
nuclei with deep-staining, smudgy chromatin; may
contain prominent nucleoli and intranuclear inclusions;
nuclear grooves; varying-sized, bare nuclei containing
structureless chromatin scattered throughout;
cytoplasm may be abundant with intracytoplasmic
neutrophils, vacuolated, or disintegrated; and the
Hurthle cell metaplasia
Stromal Cells
Pleomorphic, isolated, or in fascicles; atypical nuclei with
variation in size; granular chromatin; prominent nucleoli Â±
Background
Colloid scant to absent; inflammatory cells +; neutrophils
in early stages; lymphocytes and macrophages with or
without hemosiderin; karyorrhexis, cellular and calcific
debris; psammoma bodies Â±

TABLE 19.4 CYTOLOGIC FEATURES OF RADIATION-ASSOCIA CHANGES

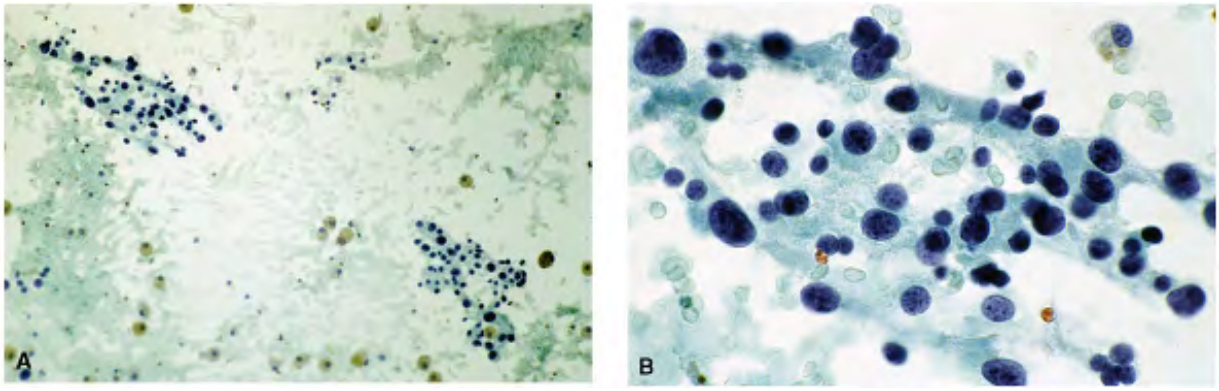

Figure 19.22. A. FNA of a thyroid subjected to 131 I therapy. A low-power view showing tiss fragments of pleomorphic follicular cells. The background shows proteinaceous debris, macrophages, and pyknotic bare follicular cell nuclei. B. Higher magnification, showing mar varying-sized bare follicular cell nuclei. Note the structureless dense-staining chromatin.

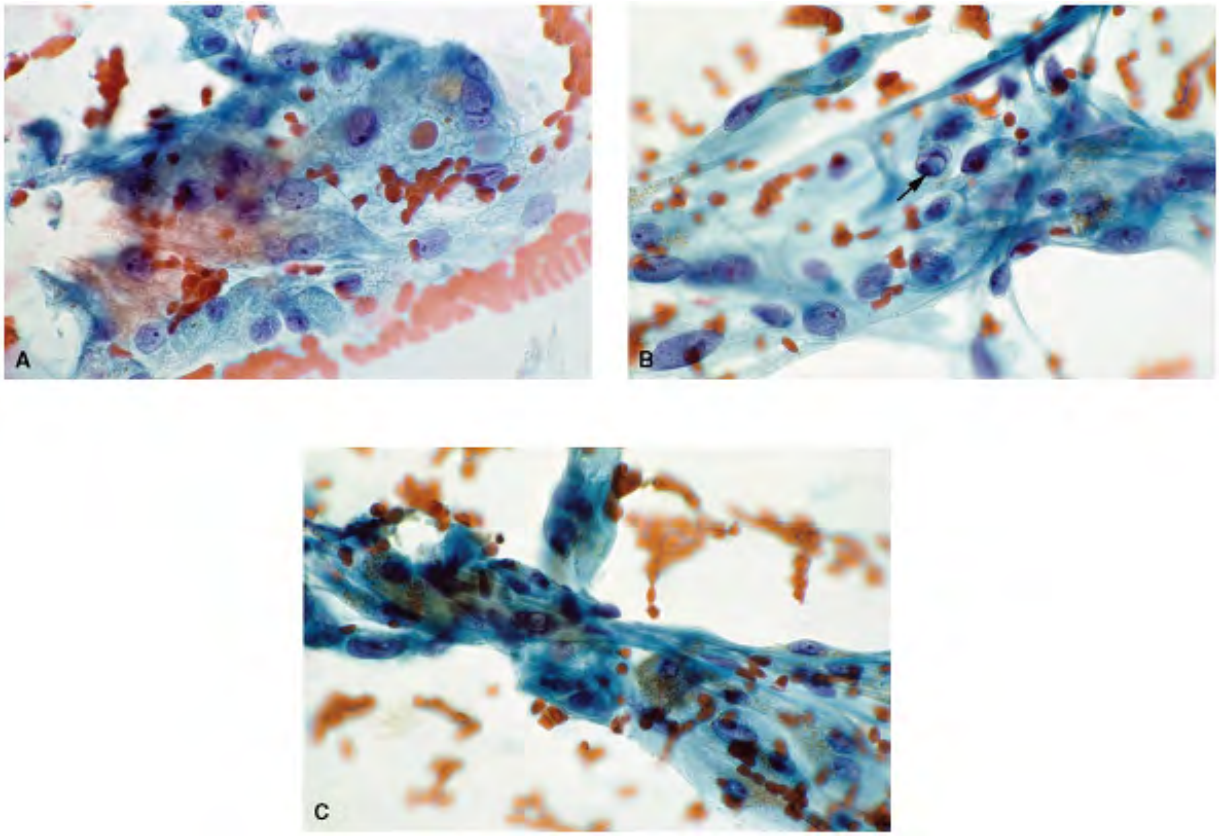

Figure 19.23. FNA of a thyroid subjected to 131 I therapy. A. The follicular cells are in a tis fragment, and contain abundant granular cytoplasm. The nuclei are likewise enlarged and c

nucleoli. B. The cells here are large, pleomorphic, predominantly spindle shaped, and may l
stromal origin. Their nuclei have coarse chromatin and are round to spindle shaped. Also pre
are intranuclear cytoplasmic inclusions (*arrow*). C. These cells are probably stromal in origi
present bizarre shapes. They have abundant cytoplasm and enlarged pleomorphic, hyperchr
nuclei.

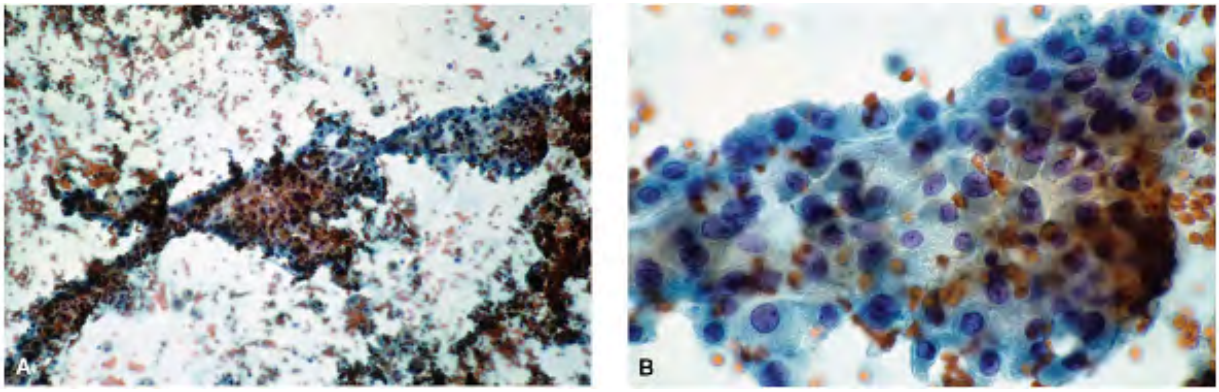

Figure 19.24. A. Another example of radiation-induced changes in thyroid with a history of
therapy for Graves disease. This low-power view shows a cellular aspirate consisting of large
branching tissue fragments of follicular cells. B. Higher magnification showing a syncytial
arrangement with crowded and enlarged nuclei, suggesting a diagnosis of a follicular neopla

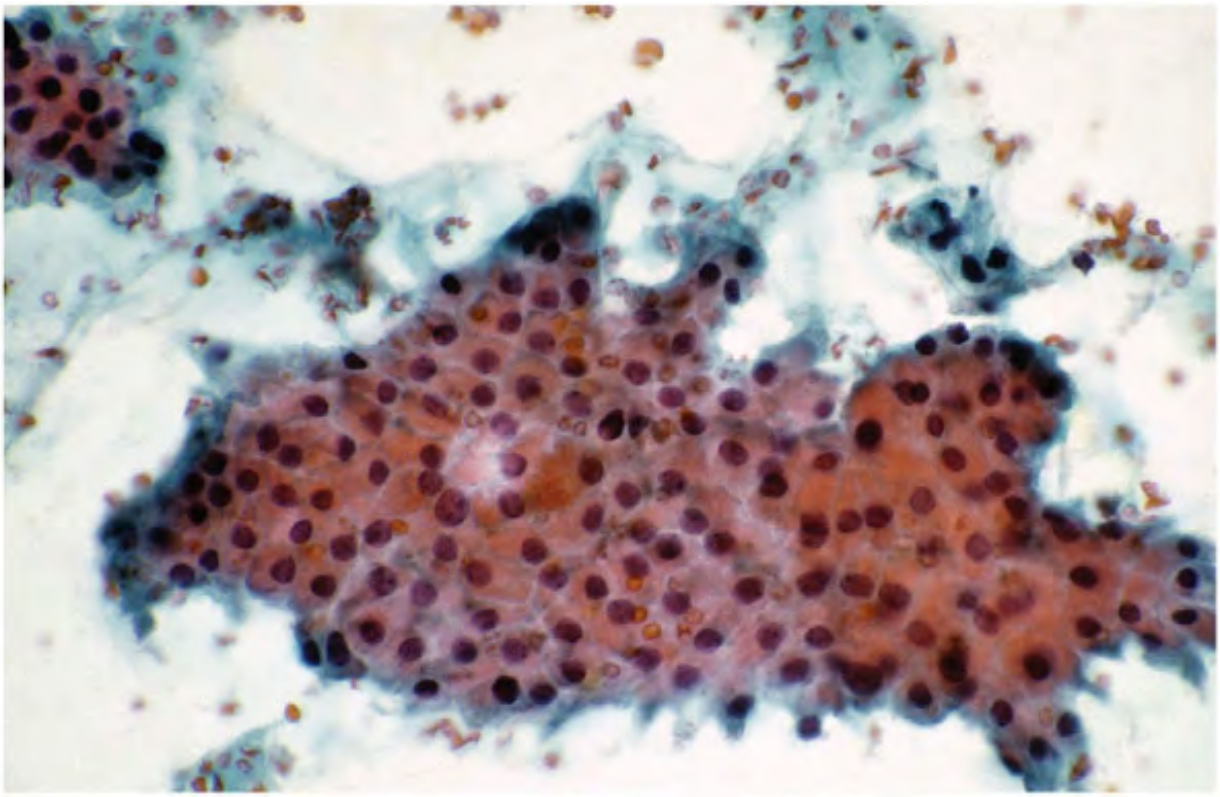

Figure 19.25. FNA of a thyroid nodule in a patient with a history of Graves disease treated
I. The aspirate was very cellular consisting of a tissue fragment of HÃ¼rthle cells with a hon
arrangement.

The varied cytologic changes induced by 131 I therapy for Graves disease can be significantl
abnormal, leading to diagnosis of malignant neoplasms. Centeno et al.57 reported cytologic
in 6 cases with 131 I therapy. One case was interpreted as diagnostic of papillary carcinoma
other

P.408

P.409

P.410

was suspected of papillary carcinoma. Saqi et al.53 and Sturgis54 reported similar findings.
Roza et al.55 reported a case of post-131 I therapy where the severe atypia lead to a diagnc
anaplastic carcinoma. Without a clinical history of such a therapy, the cytologic interpretat
lead to a false-positive diagnosis. Extensive HÃ¼rthle cell change with nodule formation ma
interpreted as HÃ¼rthle cell neoplasm (Fig. 19.25).

"INCLUSIONS" IN THE THYROID

The thyroid gland may be a seat for branchial and pharyngeal pouch-derived endodermal an mesodermal structures, such as parathyroid tissue, thymic tissue, and salivary gland tissue. also contain remnants of ultimobranchial body (Table 19.5).61 , 62 , 63 , 64 , 65 , 66 , 67 T embryologic remnants are incidental findings in the histologic sections of the thyroid and ar identified but are not expected to be present in aspirates of the thyroid lesions. However, "inclusions" are discussed here briefly, because some of the lesions of the thyroid originate f such inclusions.

Intrathyroidal islands of ectopic thymus
Intrathyroidal parathyroid
Intrathyroidal salivary gland tissue
Ultimobranchial body
Mesenchyme-derived structures: adipose tissue
skeletal muscle, cartilage, bone

TABLE 19.5 INCLUSIONS IN THYROID

Thymic tissue can be seen in 1.8% of thyroid glands (Fig. 19.26).63 Occasionally these thym may give rise to neoplasms (thymoma). Similarly, parathyroid gland hyperplasia and adenom arise in an intrathyroid location.

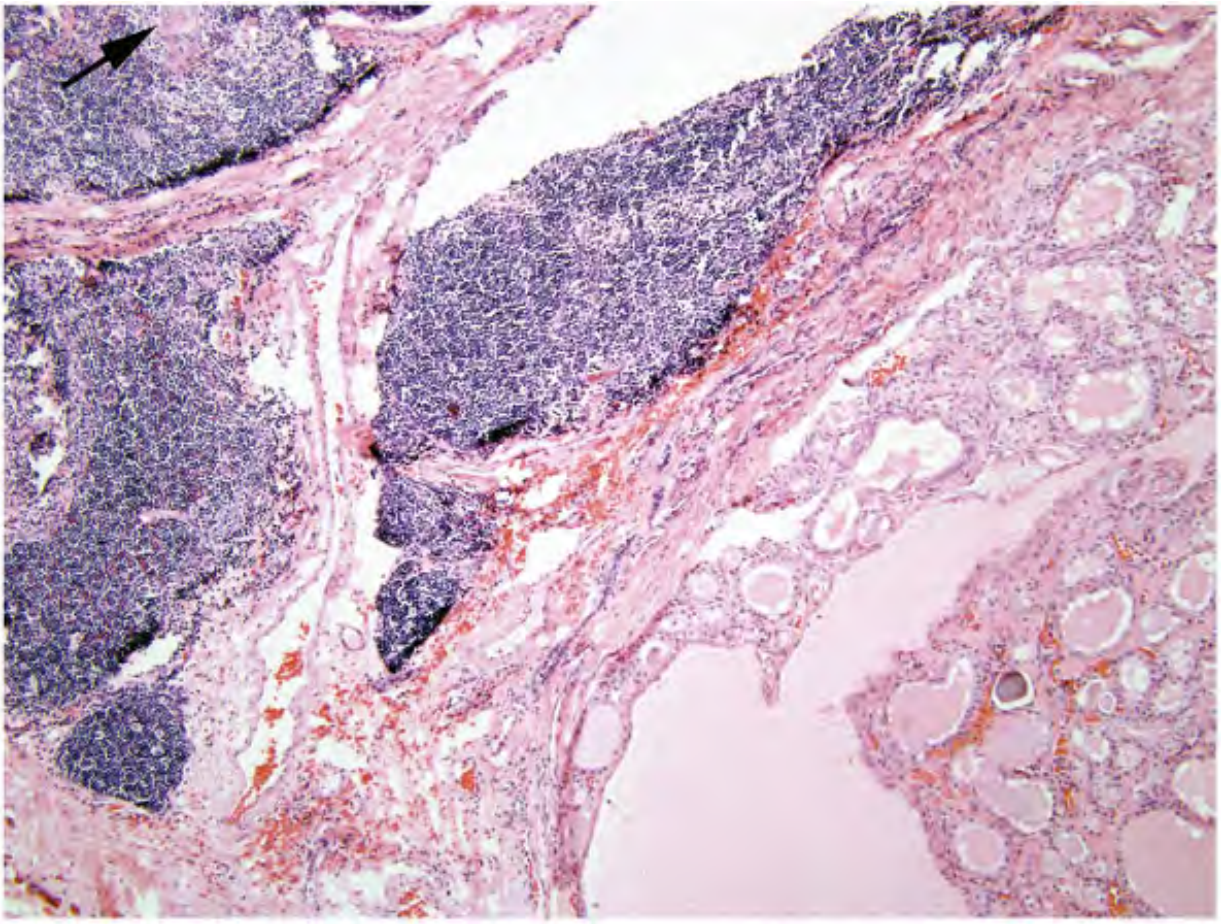

Figure 19.26. Histologic section of intrathyroidal thymic rests with Hassall's corpuscles.

The ultimobranchial thyroid solid cell nests (SCNs) are irregular structures roughly 1 mm in t longest dimension, usually found in the middle third of the thyroid lateral lobes. SCN are fou 20% to 30% of thyroids.64 They are composed of nonkeratinizing polygonal to elongated squa cells, which lack intercellular bridges and are arranged in solid clusters or nests. Their nucle uniform centrally located round to oval or short and spindle-shaped (Fig. 19.27). These cell often have cystic spaces that may contain mucinous material. SCN may be associated with lymphocytic aggregates. The cells of SCN are immunoreactive to high and low molecular we cytokeratins, as well as to CEA and calcitonin, and are negative to thyroglobulin. The SCN m misinterpreted as medullary carcinoma, C cell hyperplasia or nodules, foci of squamous cells occult papillary carcinoma. SCN is less likely to be encountered in cytologic material. The cy presentation of cells of ultimobranchial body cyst is illustrated by Clark and Faquin.67

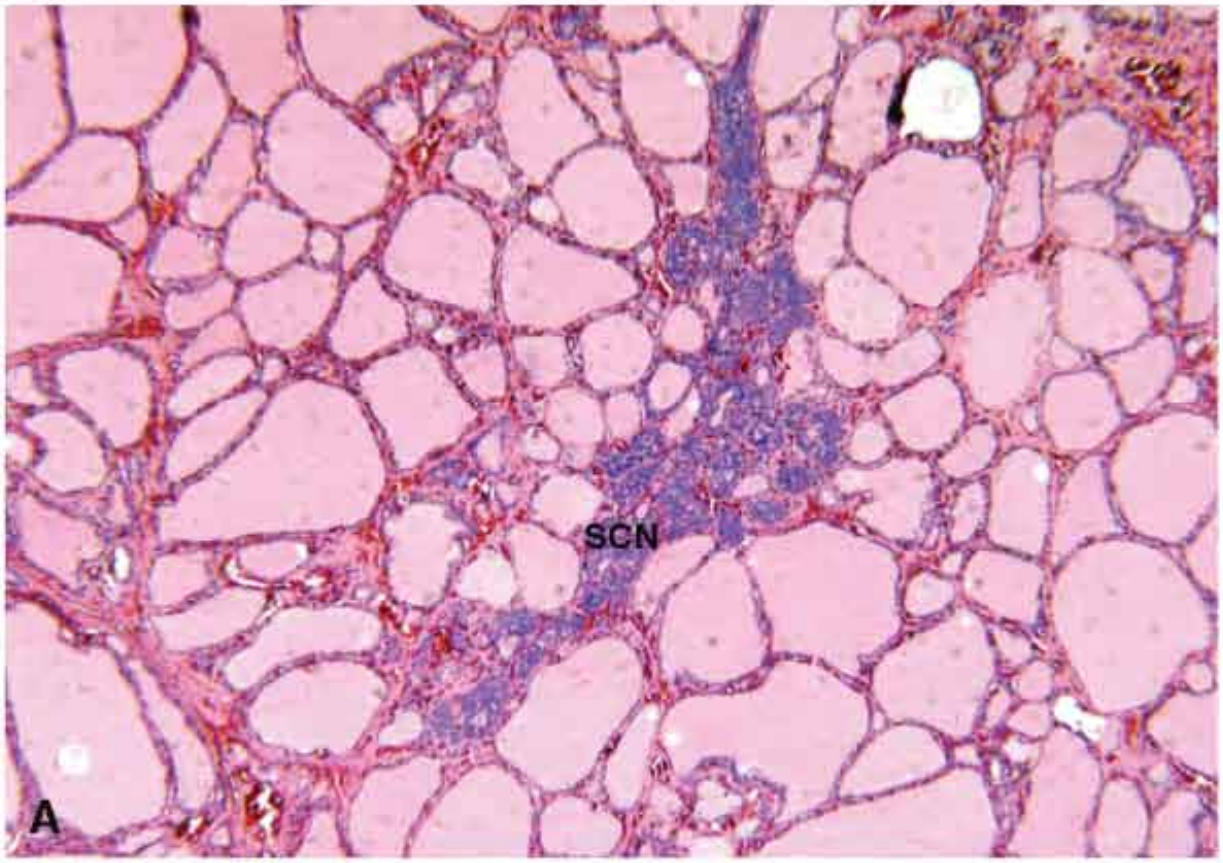
SCN
A

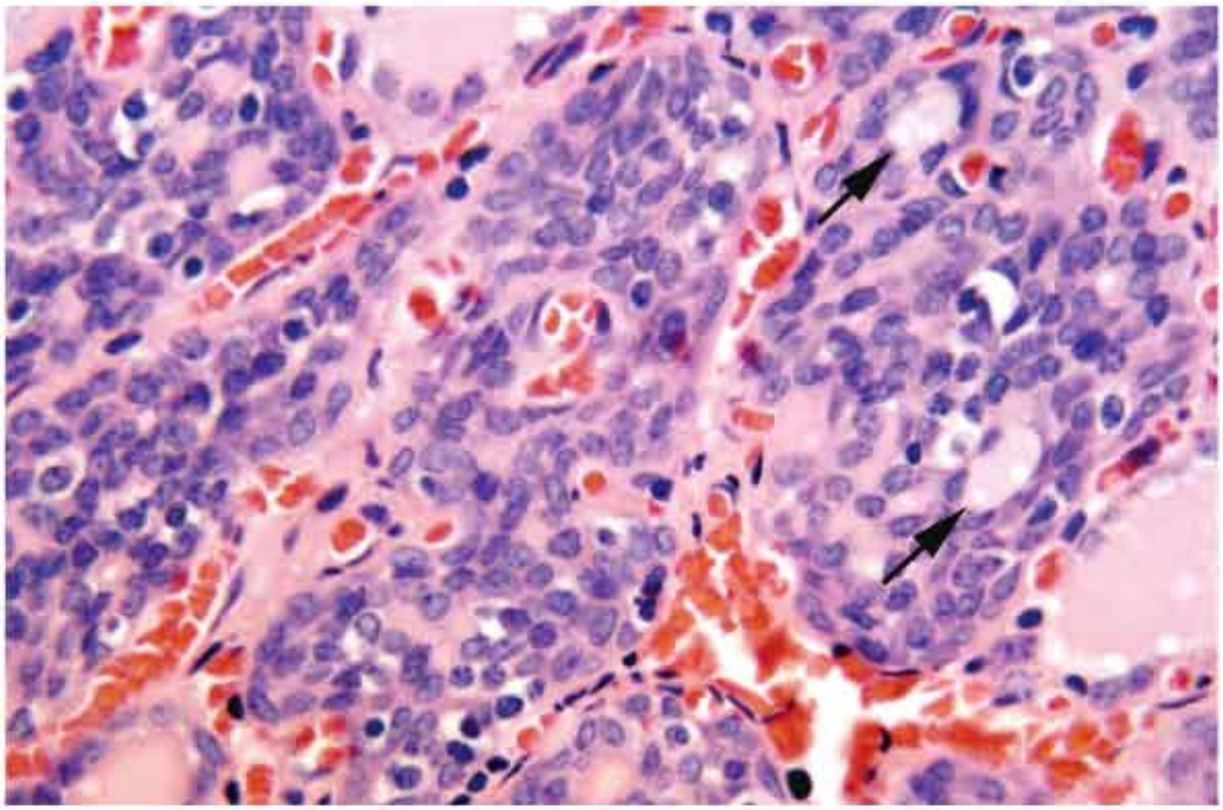

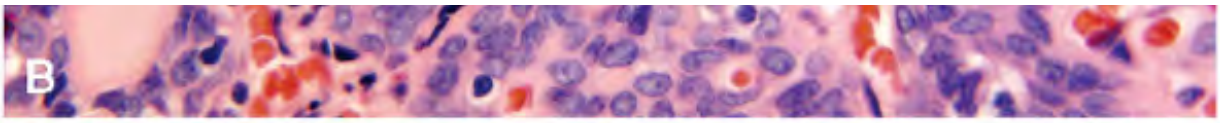

Figure 19.27. A. Histologic section of the thyroid showing an ultimobranchial body or solid
nests (SCN) (low power). B. Higher magnification. The cells of SCN are round, oval to short
shaped with uniform nuclei. Note multiple small cystic structures (*arrows*).

FAT IN THE THYROID

Synonyms for fat in the thyroid are hamartomatous adiposity and adenolipomatosis.

Rarely, mature adipose tissue is found within the thyroid gland under normal conditions as v
associated with pathologic conditions such as amyloid goiter, lymphocytic thyroiditis, thyroi
atrophy, follicular adenoma (adenolipoma), papillary carcinoma, follicular carcinoma, and r
diffuse hyperplasia and dyshormonogenetic goiter.61 The presence of adipose tissue within
thyroid parenchyma is an incidental finding. The normal or benign adipose tissue varies in a
and is found intimately admixed with the thyroid tissue (Fig. 19.28). The mature adipocytes
as fairly uniform cells with some variation in size and shape. They are characterized by the
presence of a clear to vacuolated cytoplasm that compresses and eccentrically displaces the
nucleus. The nuclei have bland chromatin.

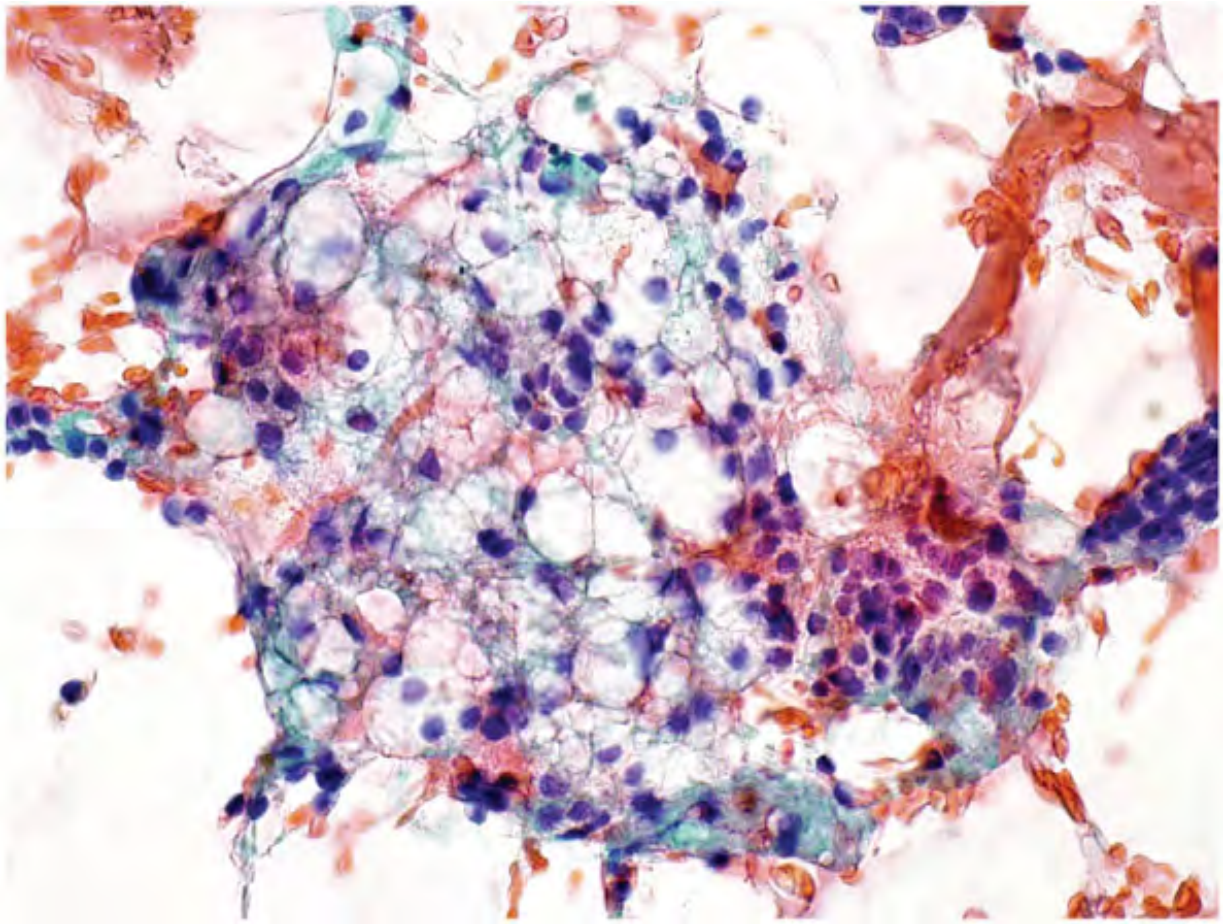

Figure 19.28. FNA of a thyroid nodule showing small tissue fragments of benign follicular ce admixed with adipose tissue.

The other mesenchymal derived inclusions include skeletal muscle and cartilage and bone.6

SQUAMOUS CELLS, SQUAMOUS METAPLASIA, AND SQUAMOU CARCINOMA

Squamous Cells in Thyroid

The squamous cells in thyroid occur in several different settings such as developmental rest inflammatory conditions, and neoplasms.68 , 69 , 70 , 71

The developmental rests associated with squamous cells include thymic remnants, thyroglos remnants, and ultimobranchial body rests or solid cell nests (see "'Inclusions'in the Thyroid" e in the chapter).

Squamous Metaplasia

Squamous metaplasia is a benign process whereby the follicular cells change and acquire fea squamous epithelium. It occurs in a wide variety of situations. Squamous metaplasia is most common with chronic lymphocytic thyroiditis of the Hashimoto's type71 and in nodular goite retrogressive changes. Squamous metaplasia is also encountered in thyroids subjected to fin needle aspiration biopsies, in the vicinity of the needle track. Among the neoplasms, squam metaplasia is seen in papillary carcinomas (20% to 40%), either conventional types or in the sclerosing and cribriform-morular types.72

Histologically and cytologically, squamous metaplasia appears as nests of round to oval cells appearing as "morulae" (Figs. 19.29 , 19.30 , 19.31 and 19.32). The metaplastic squamous c characteristically arranged in whorls. The squamous cells have abundant cytoplasm with low ratios; keratinization and intercellular bridges may occasionally be seen. The nuclei are unif with a bland chromatin pattern. Metaplastic squamous cells often assume a spindle shape, appearing elongated. They usually contain nuclei with bland chromatin pattern.

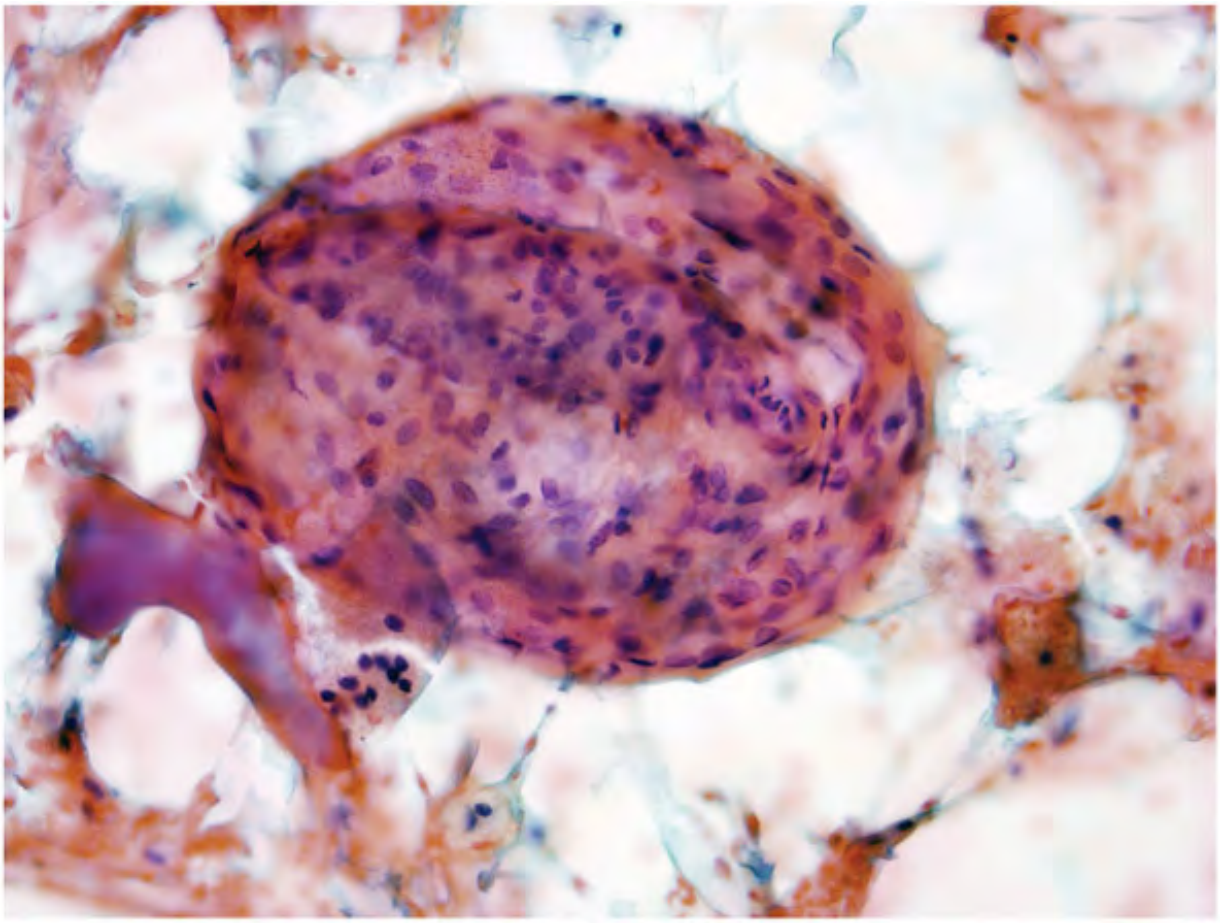

Figure 19.29. FNA of a nodular goiter showing squamous cells in a whorled pattern. The metaplastic cells have abundant cytoplasm and bland nuclei.

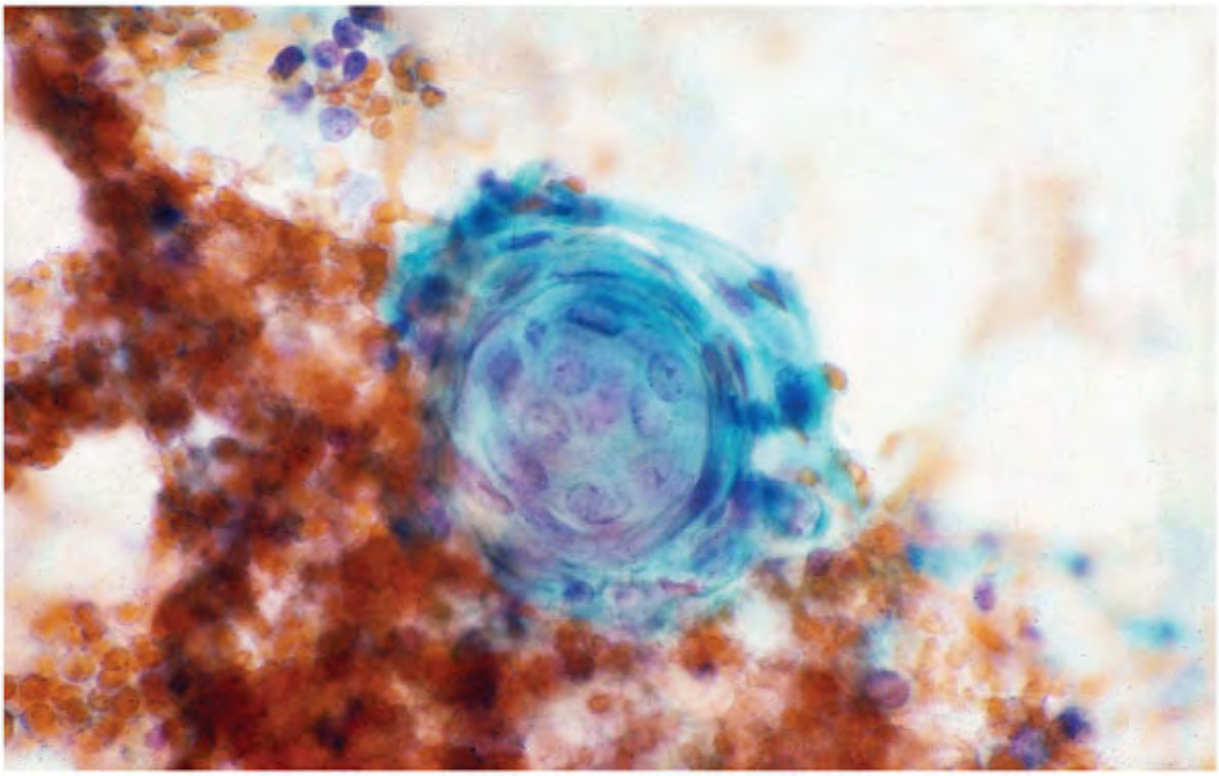

Figure 19.30. Another example of squamous metaplasia in a case of nodular goiter. The cel arranged in a whorled pattern.

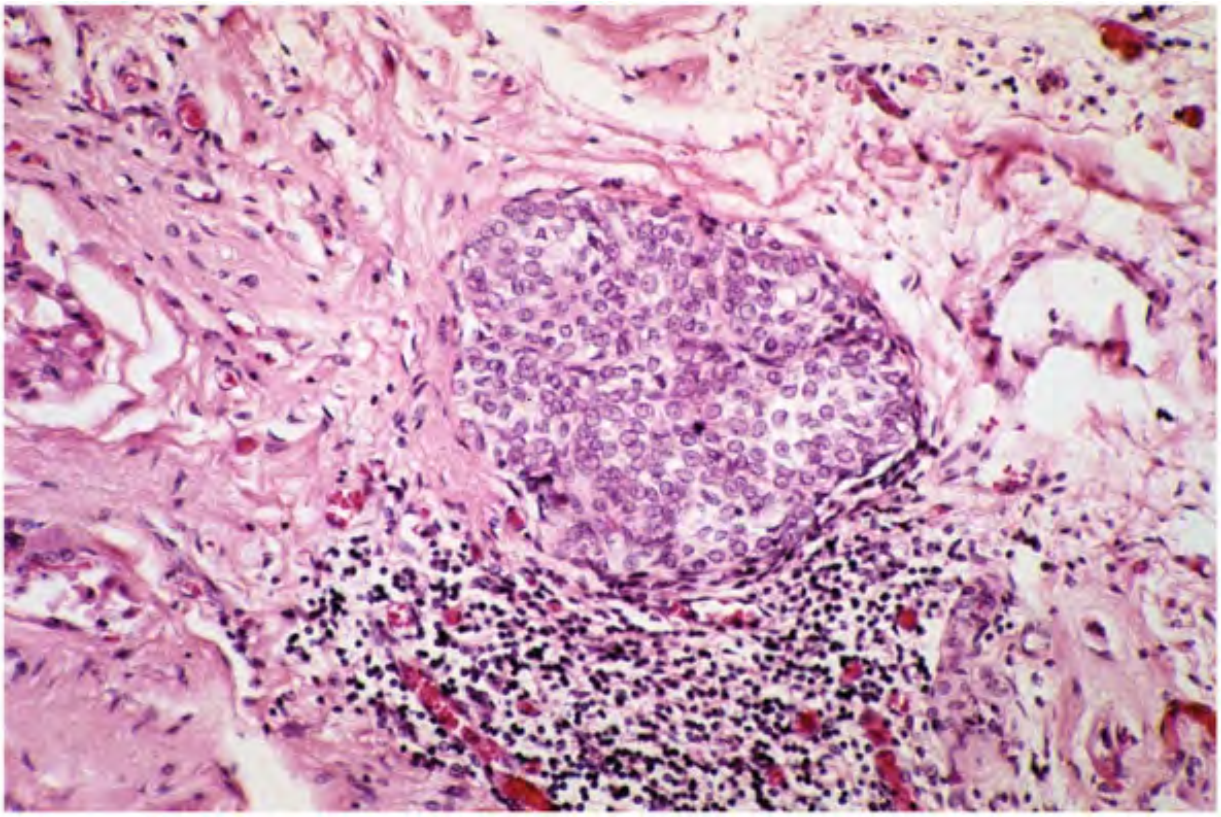

Figure 19.31. Histologic section of Hashimoto's thyroiditis with squamous metaplasia.

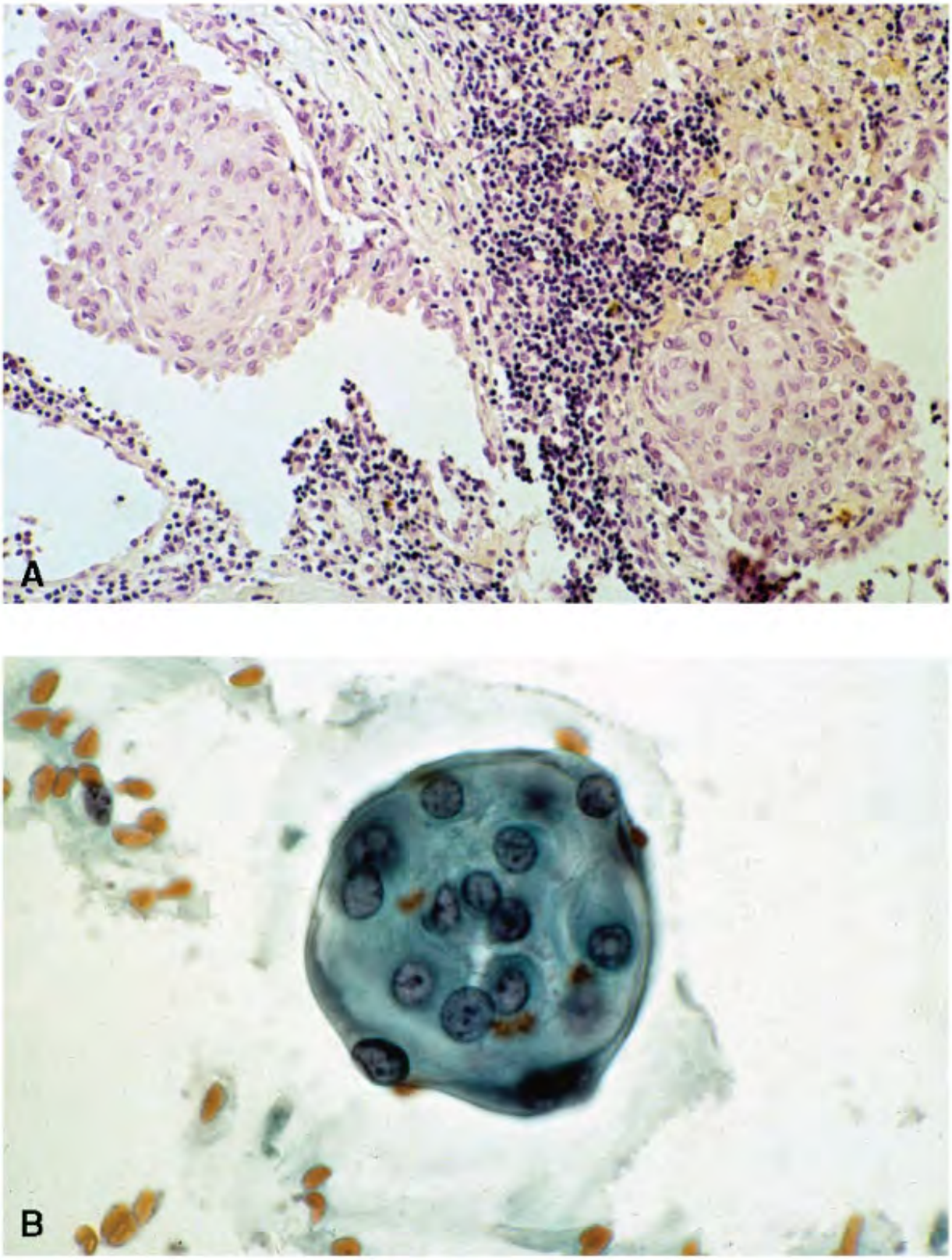

Figure 19.32. A. Histologic section of papillary carcinoma with squamous metaplasia. B. FN

papillary carcinoma showing cells with squamous metaplasia.

Primary Squamous Carcinoma of the Thyroid

Primary squamous carcinomas of the thyroid are rare, accounting for 1% of all thyroid malignancies.72 Very few cases with histologic and cytologic findings are documented in the literature.72 , 73 , 74 , 75 , 76 , 77 , 78 , 79 It occurs in elderly individuals and is more com females. Squamous carcinomas arise from the squamous epithelium present in the normal gl which is derived from developmental remnants such as ultimobranchial body or thyroglossal remnant. It may also arise from metaplastic squamous cells, seen in nodular goiter, and Has thyroiditis as well as papillary and follicular carcinomas.

Squamous carcinoma clinically presents as a rapidly growing mass with pressure symptoms a follows an aggressive course. Imaging studies are necessary to exclude a metastatic process primary squamous carcinoma occurring at other sites and to study the extent of the disease tumor grows rapidly, spreading locally, and metastasizes widely. The prognosis is poor.

Gross and Microscopic Features

Squamous cell carcinomas are typically large bulky tumors, grayish-white in color, with area necrosis. Histologically, the carcinoma is exclusively the squamous type, predominantly poo differentiated with focal keratinization. Squamous carcinomas may occur in combination wi papillary carcinomas, follicular carcinomas, or anaplastic carcinomas

Immunoprofile

Squamous carcinomas are strongly immunoreactive to CK-19 but negative for CK1, CK4, CK1 and CK20, and focally positive for CK7 and CK18. They are negative for thyroglobulin.73

Cytopathologic Features

The cytopathologic features of primary squamous carcinomas are no different than their me counterpart from other sources. The aspirates of squamous carcinomas are usually very cell consisting of a large population of malignant squamous cells, isolated, in loosely cohesive gr and in syncytial tissue fragments (Figs. 19.33 , 19.34 , 19.35 and 19.36). The malignant cell usually large with appreciable cytoplasm that occasionally shows keratinization. Necrosis is

frequent and the malignant cells may be obscured by the cellular and necrotic debris (Figs. and 19.36).

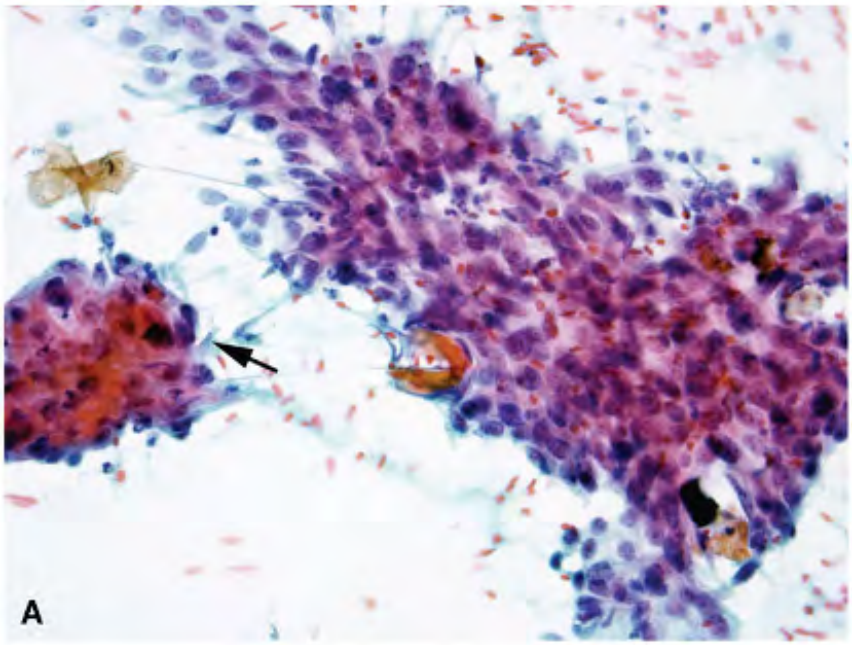

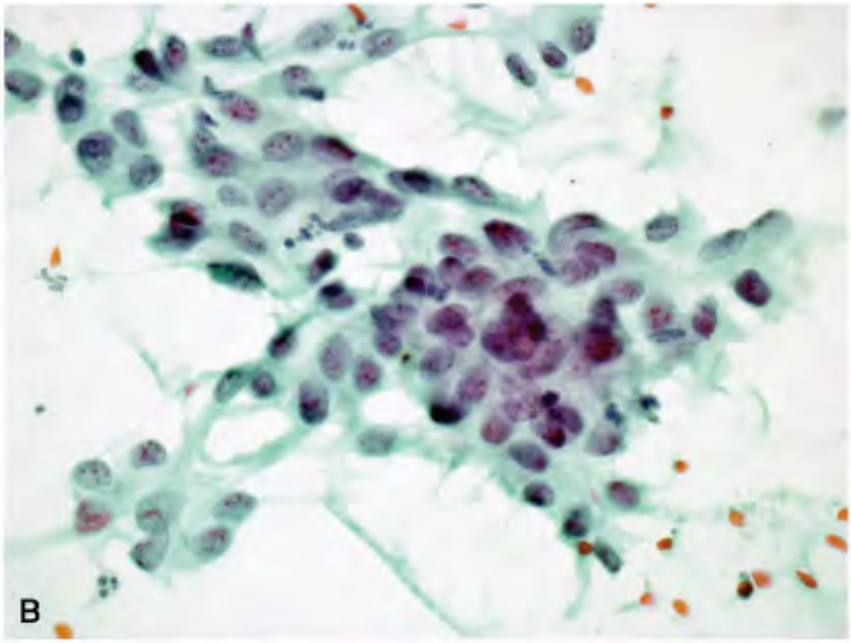

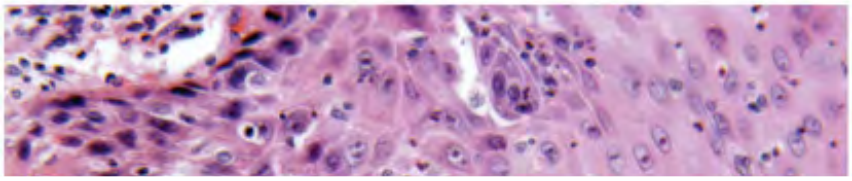

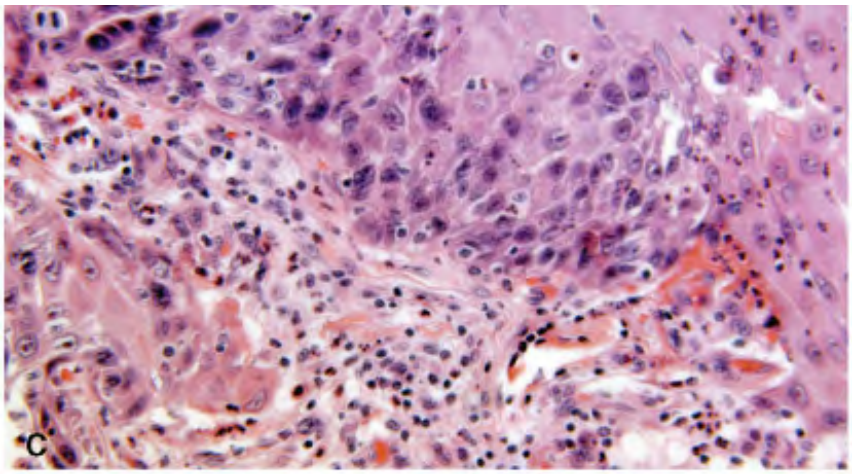

Figure 19.33. A. FNA of primary squamous cell carcinoma of the thyroid. The malignant cel
a syncytial tissue fragment and are poorly differentiated. There is focal squamous differenti
with keratinization (*arrow*). B. A different field from the same case showing poorly differer
malignant cells with no squamous differentiation. C. Histologic section of the excised tumor
confirming the squamous cell carcinoma.

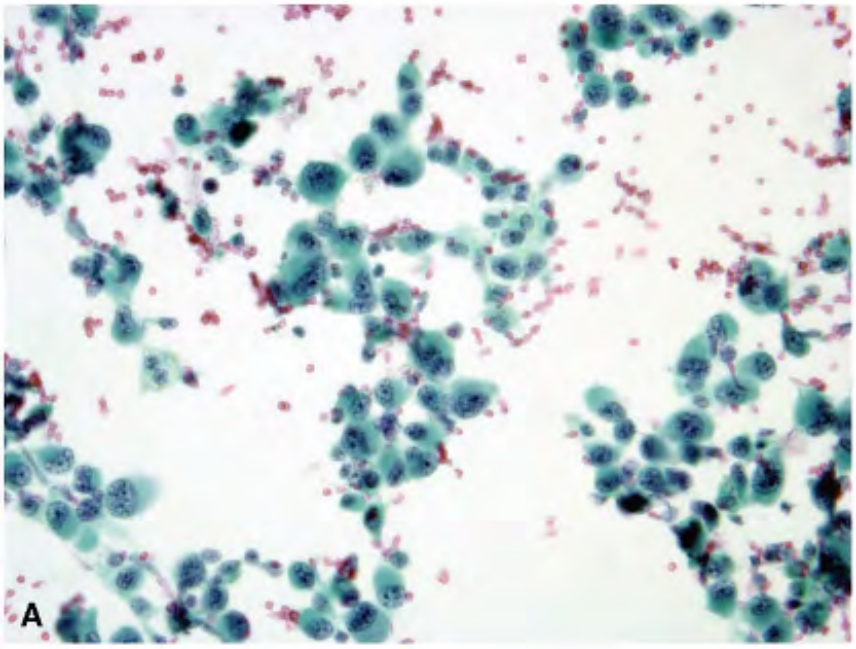

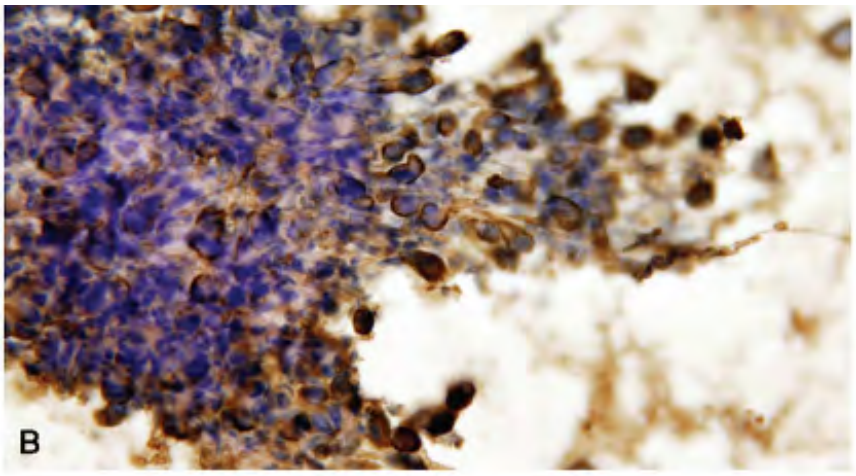

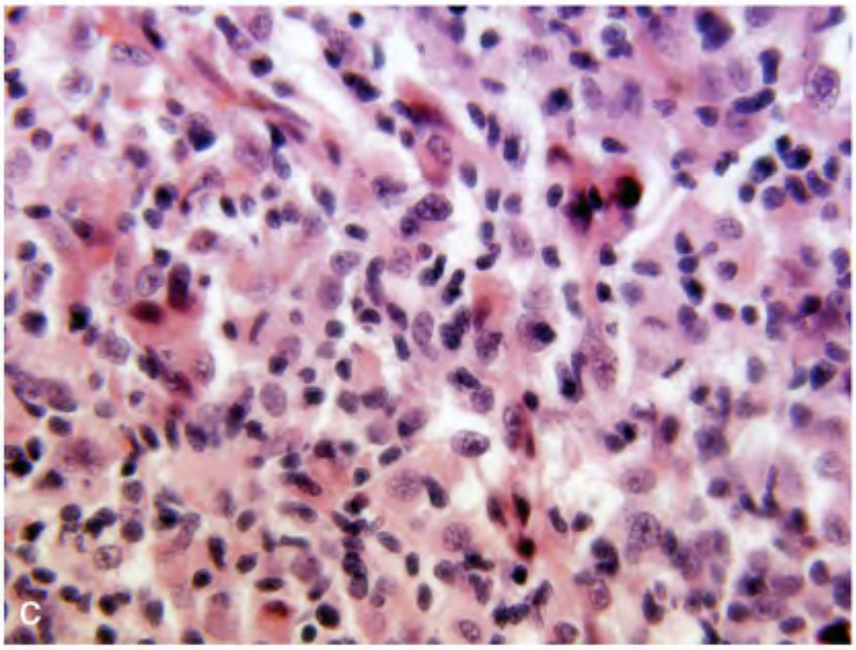

Figure 19.34. A. FNA of a thyroid mass showing a large population of undifferentiated malig cells suggesting a diagnosis of anaplastic carcinoma. B. The malignant cells reacted strongly cytokeratin but not to thyroglobulin. C. Thyroidectomy revealed a poorly differentiated car with focal squamous differentiation.

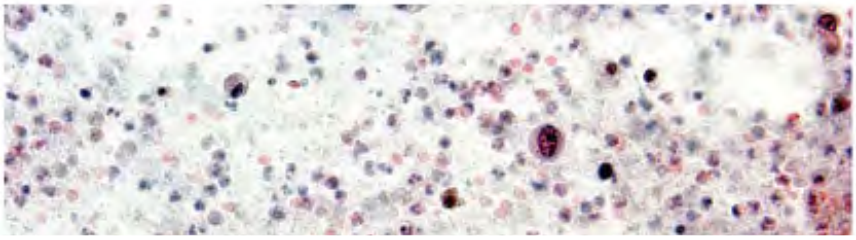

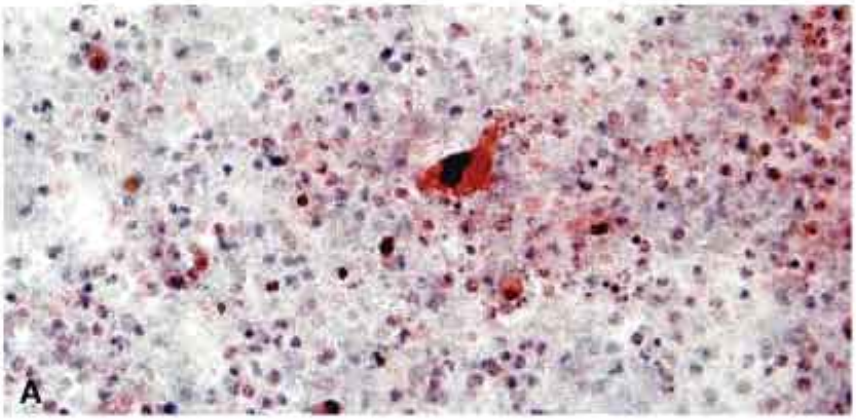
A

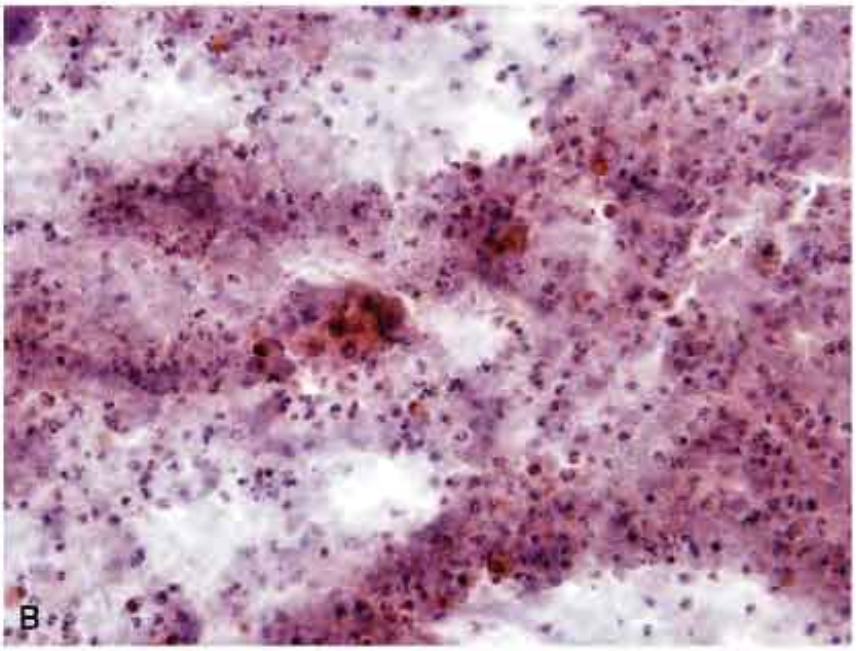
B

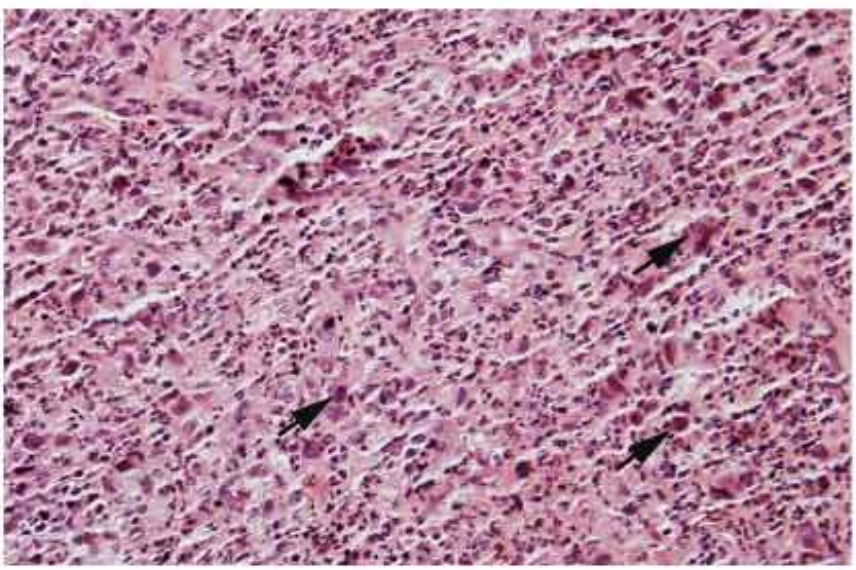

Figure 19.35. A,B. FNA of a primary squamous carcinoma of the thyroid with extensive nec
Note scattered keratinized individual squamous cells obscured by inflammatory and necrotic
C. Thyroidectomy showed a poorly differentiated squamous cell carcinoma. Note isolated ce
keratinization (*arrows*).

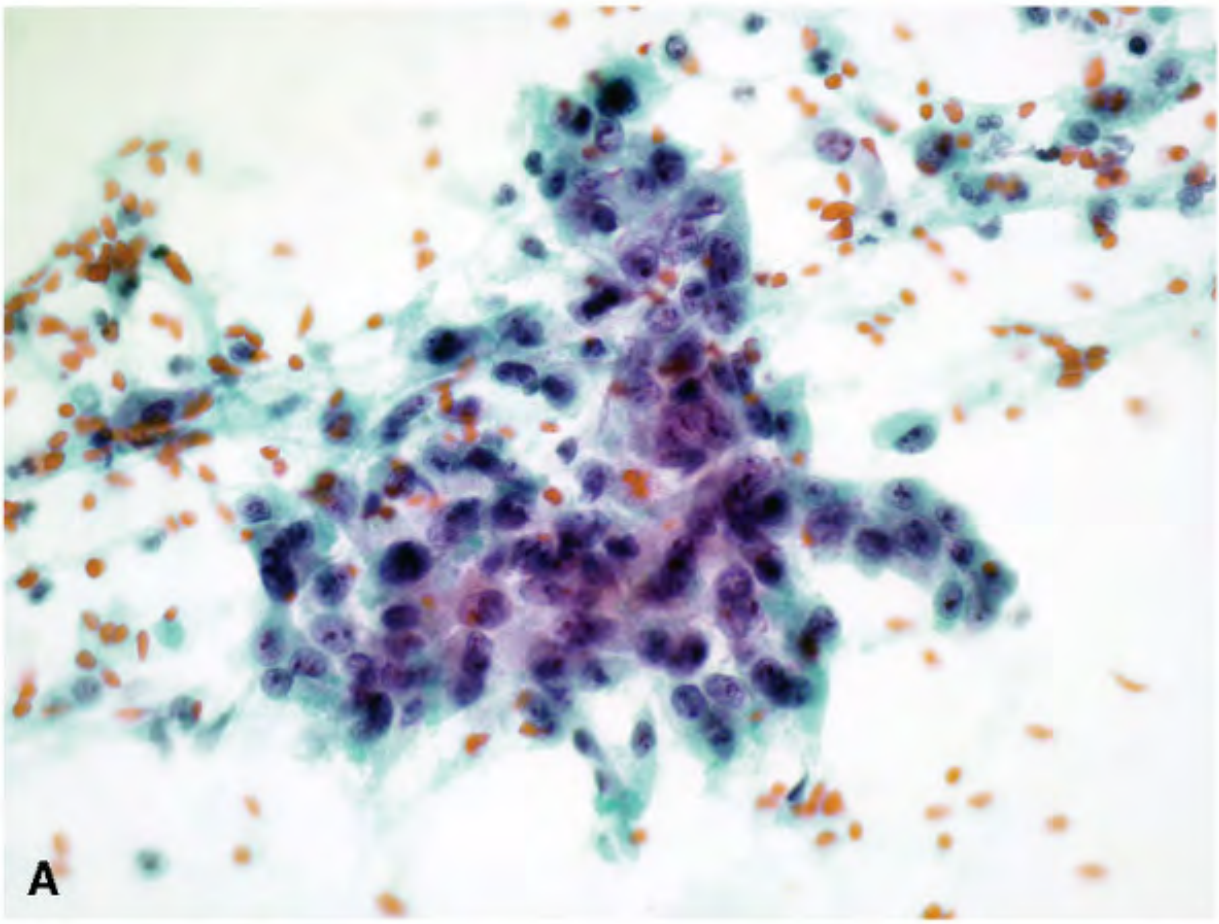

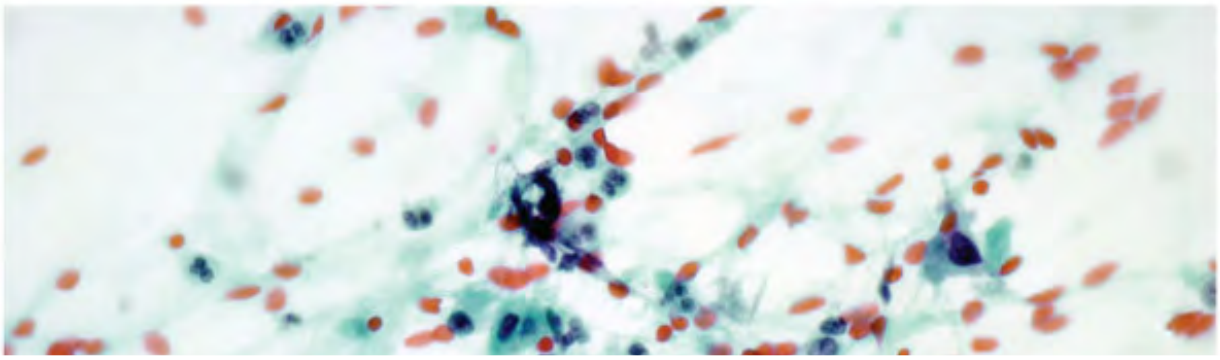

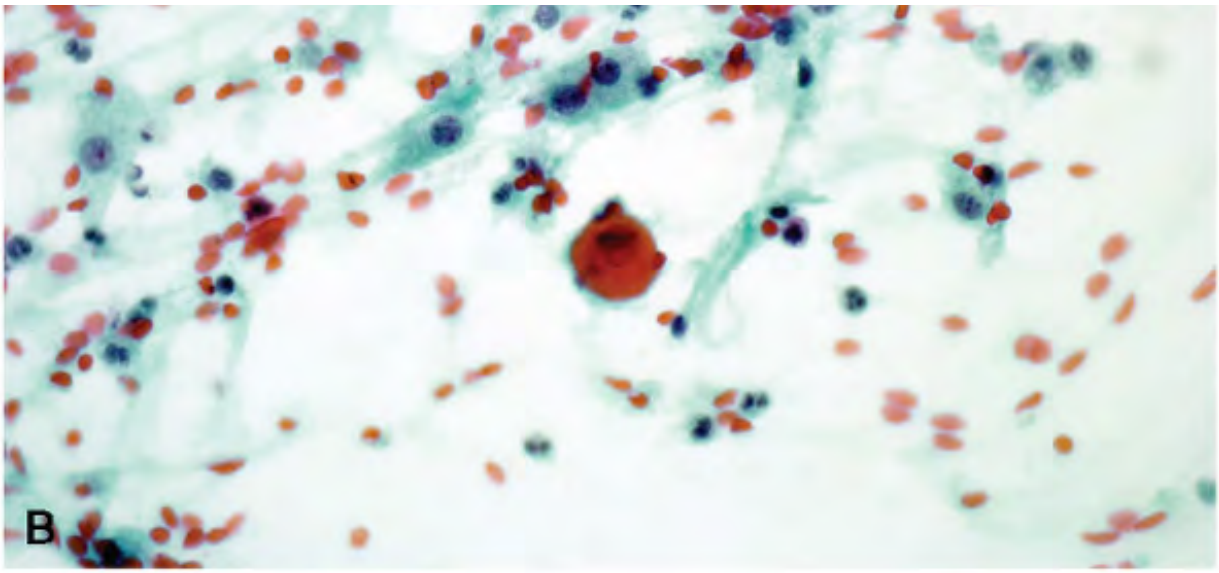

Figure 19.36. A. FNA of a large cystic mass of the thyroid that yielded a large amount of st
colored fluid. The smears showed necrosis and a rare syncytial tissue fragment of poorly
differentiated malignant cells. B. There were individual cells scattered in the background, s
exhibiting keratinization. Thyroidectomy confirmed a primary squamous carcinoma.

The metastatic squamous carcinomas are more common in thyroid and must be ruled out be
rendering the diagnosis of a primary squamous carcinoma, especially in the event of a remo
primary cancer elsewhere (Fig. 19.37). Poorly differentiated squamous carcinomas are also
difficult to differentiate from anaplastic carcinomas. The primary thyroid squamous carcino
are non-reactive to thyroglobulin and the anaplastic carcinomas tend to be negative in majo
the cases. Both display positive reactivity to cytokeratin. The differential diagnosis also incl
poorly differentiated metastatic adenocarcinomas, malignant melanomas, and high-grade
mucoepidermoid carcinoma.

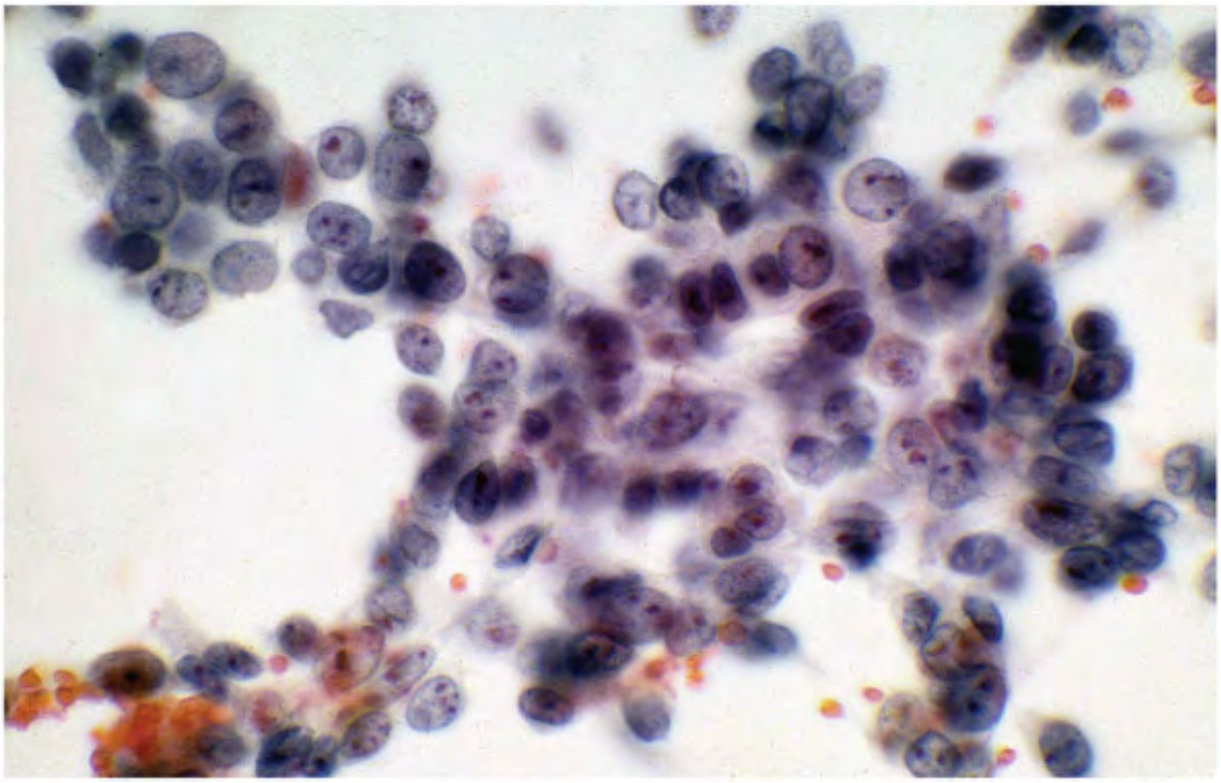

Figure 19.37. FNA of a solitary thyroid nodule showing poorly differentiated malignant cells Squamous differentiation with keratinization was focally present suggesting the diagnosis of differentiated squamous carcinoma. Since there were no other lesions detected anywhere e the body, a diagnosis of primary squamous carcinoma was suggested. The thyroidectomy co a squamous cell carcinoma. It was later found out that the patient had a remote history of squamous cell carcinoma of the upper aerodigestive tract. In the light of the history, this le must be considered as a metastatic cancer.

P.414
P.415

ECTOPIC THYROID

The presence of thyroid tissue in abnormal locations as a result of developmental anomaly i referred to as "thyroid ectopia."80 , 81 , 82 Thyroid tissue can be found at the base of the t (lingual thyroid), beneath the tongue (sublingual thyroid), in and around the hyoid bone (as the thyroglossal duct cyst), and in the mediastinum. Other locations for ectopia include the trachea, larynx, aortic arch, heart and diaphragm, lateral neck ("lateral aberrant thyroid"), ovary ("struma ovarii").

These ectopic foci may be the seat of non-neoplastic as well as neoplastic lesions similar to arising in the thyroid gland. Fine-needle biopsy is useful in identifying these lesions.83 , 84 , 87

THYROGLOSSAL DUCT CYSTS

Thyroglossal duct cyst results from the failure of obliteration of the thyroglossal duct follow descent of the thyroid in the early fetal life and cystic dilatation.88 , 89 , 90

Thyroglossal duct cysts can occur at any age from the first to eighth decades of life, and are frequent in childhood.91 They are slightly more common in males, with a male to female ra 1.4:1. Most often they presents as a painless, midline mass, in front of the neck, that moves with swallowing. The thyroglossal duct cyst is always connected to the hyoid bone. Thyroglo duct cysts typically occur in the midline but can occur laterally and rarely within the thyroi , 90 , 91 , 92 , 93 , 94

Radiologic findings include a solitary, well-defined thin-walled anechoic cystic lesion in the just under the hyoid bone.

Gross and Microscopic Features

Grossly, the thyroglossal duct cysts are cystic structures with a smooth lining and range from 5 cm in diameter. The cyst contents range from clear, mucinous to turbid, to thick and puru infected cysts. Histologically, the cyst wall is lined by columnar, simple cuboidal, or squamo epithelium (Fig. 19.38). The epithelium may be denuded as a result of acute and chronic inflammation (Fig. 19.39). Lymphoid tissue or thyroid follicular cells may be present in the wall, which is often fibrotic. Chow and Lee95 described cholesterol granulomas in the wall o cyst.

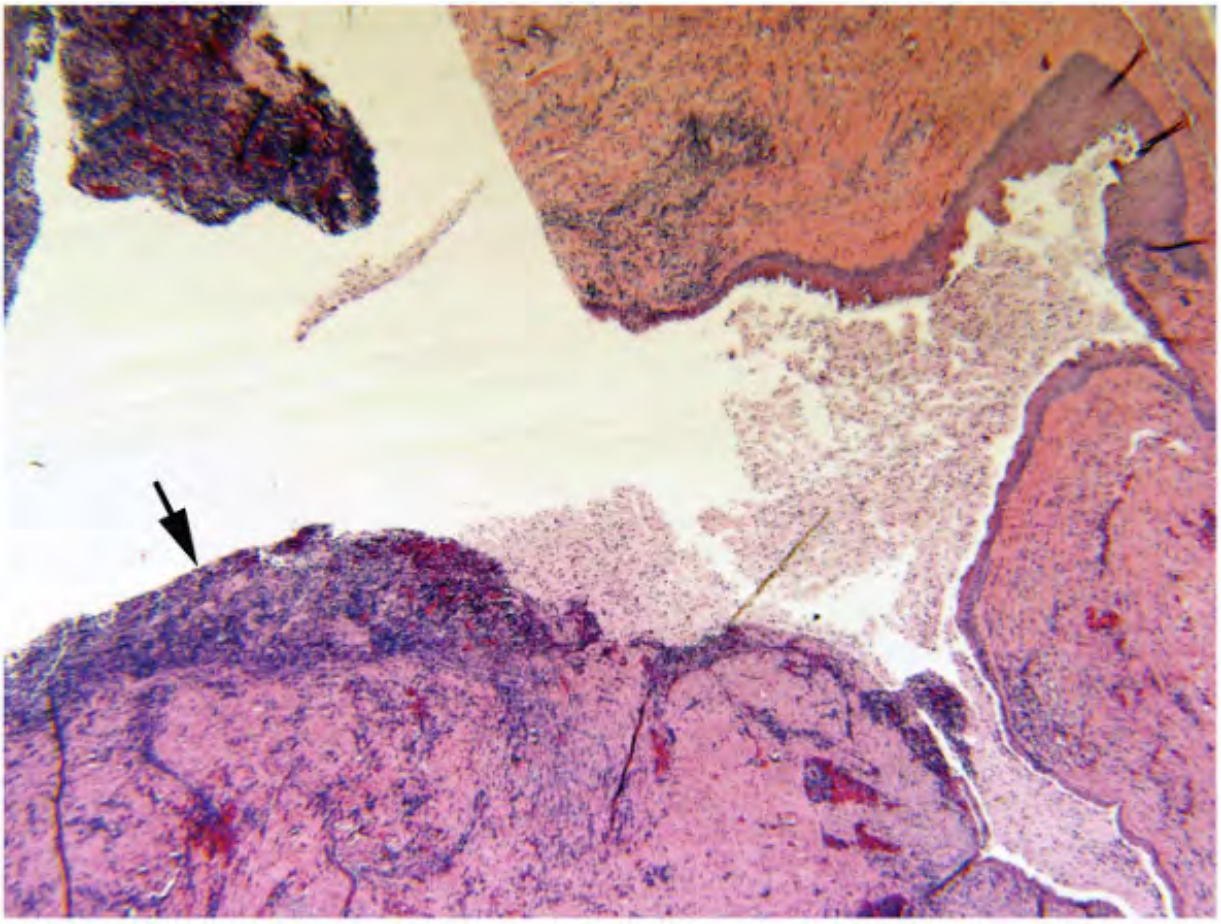

Figure 19.38. Histologic section of a thyroglossal duct cyst, lined by stratified squamous epithelium. The lining is focally denuded with inflammation of the cyst wall (*arrow*).

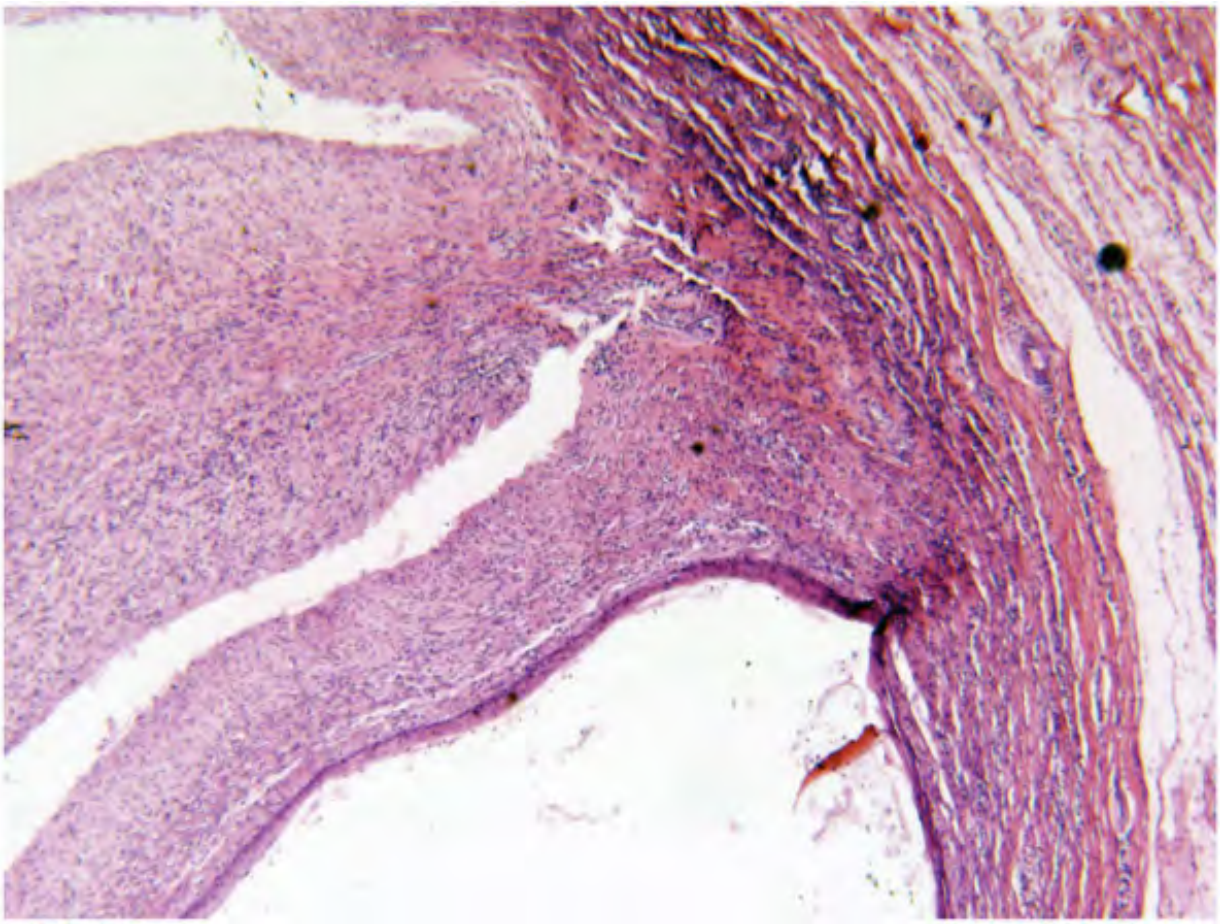

Figure 19.39. Histologic section of a thyroglossal duct cyst showing a fibrous wall, which is inflamed.

Cytopathologic Features

The cytologic findings are variable depending on whether the cyst is infected.95 , 96 , 97 , 9
The aspiration biopsy of the cyst yields variable amounts of thin, clear, and watery to viscid mucoid contents, ranging from a few to several milliliters. The contents may be purulent if is infected. The cellularity of the cyst fluid is variable but usually sparse, consisting of a predominantly inflammatory cell component comprised of neutrophils, lymphocytes, and his with or without hemosiderin (Fig. 19.40). The epithelial component is represented by ciliat nonciliated columnar cells and squamous cells (Figs. 19.41 and 19.42). Benign thyroid follicu cells (Fig. 19.41) are reported to be present in 3% to 20% of cases.96 , 97 The squamous cel usually of mature type with frequent anucleated as well as keratinized forms. Metaplastic s

cells are also encountered. The background shows cellular debris, thick mucoid material, so inspissated colloid, and only occasionally cholesterol crystals.95 Lymphoid cells are generall numbers because the lymphoid tissue is in the subepithelial area. They may be present in la numbers if the epithelial lining gets ulcerated (Fig. 19.43). Also described are the presence foamy histiocytes and multinucleated foreign-body-type giant cells originating from choleste granulomas (Fig. 19.43F). The usual cytologic features of thyroglossal duct cysts, described detail in two large series, are summarized in Table 19.6 .

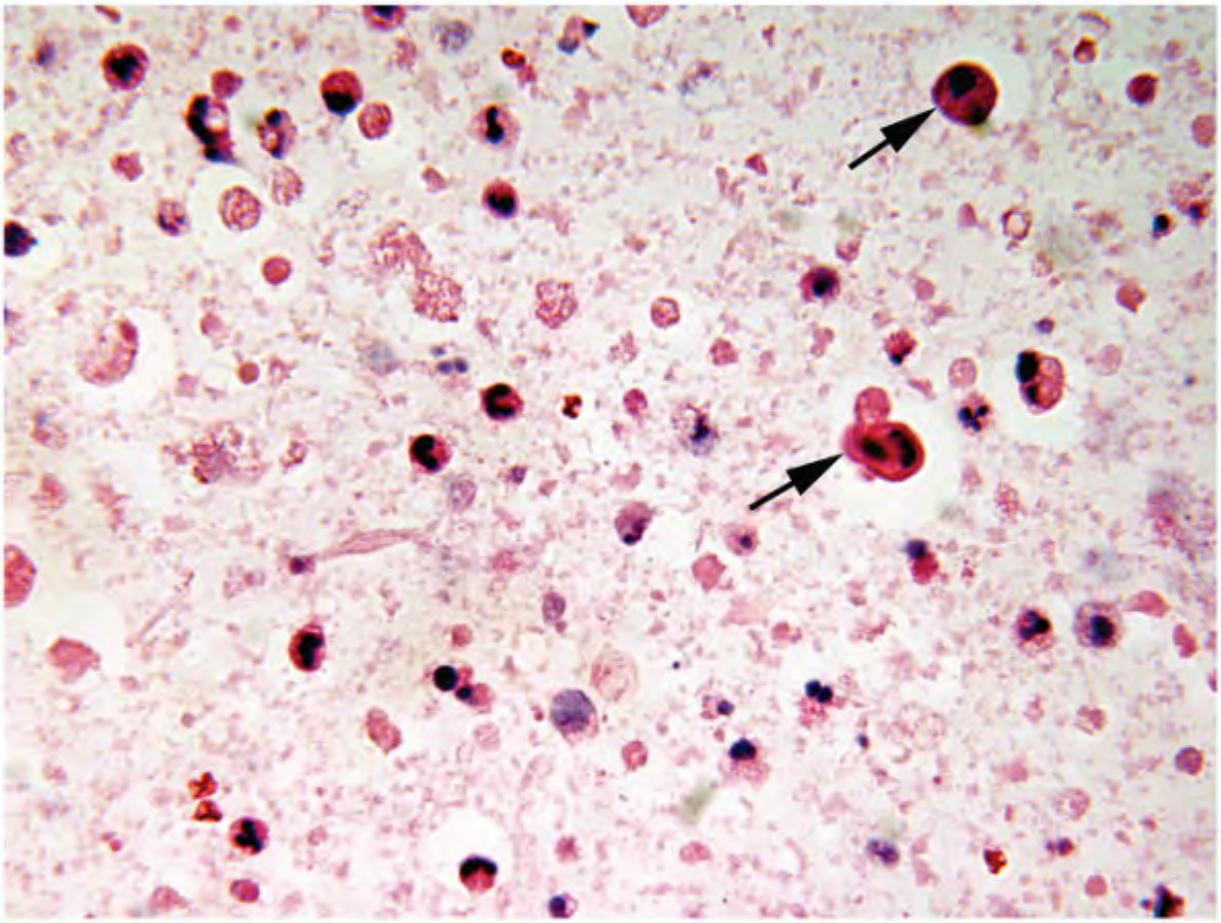

Figure 19.40. FNA of thyroglossal duct cyst showing sparse cellularity. Note rare squamous (arrows), histiocytes, and inflammatory cells. The background shows cellular debris.

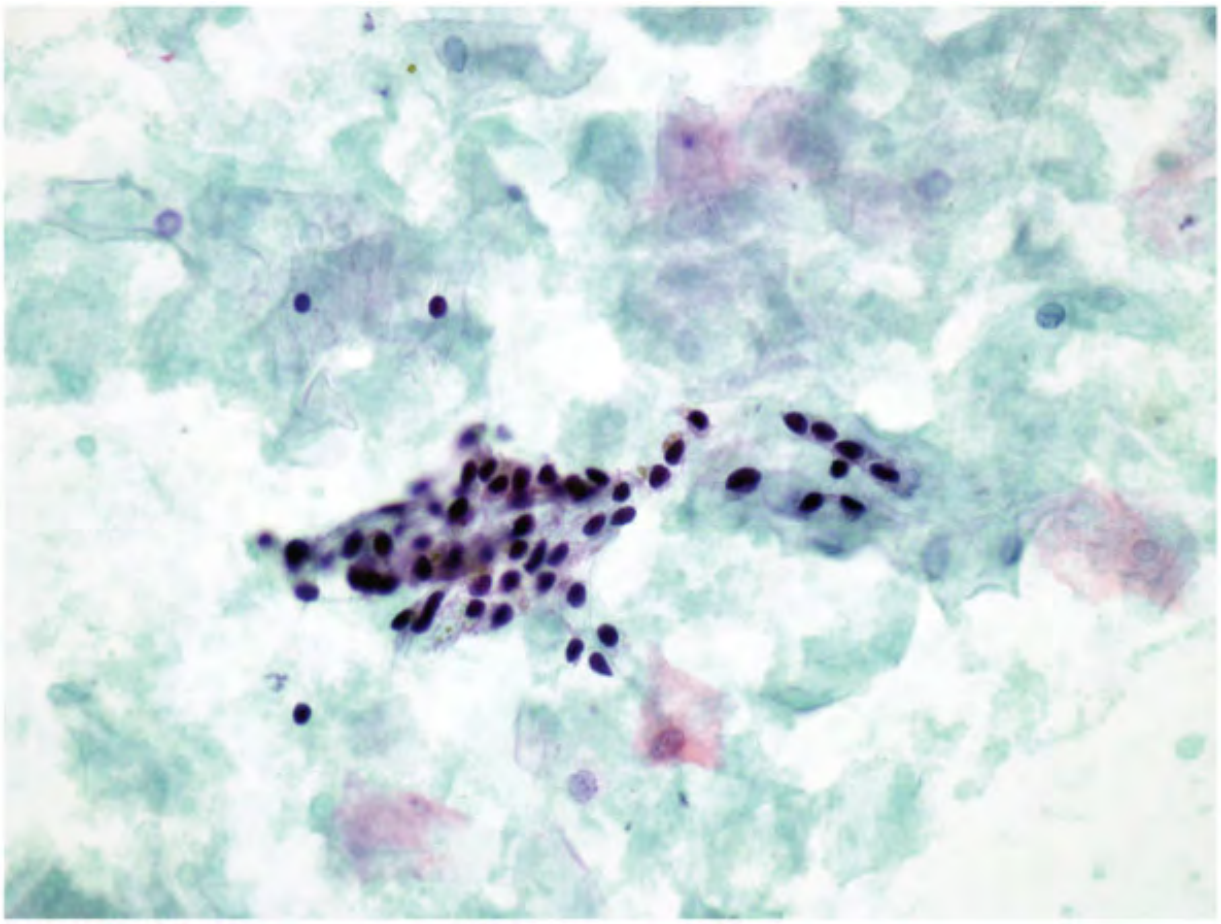

Figure 19.41. This aspirate from a different case of thyroglossal duct cyst shows benign thy follicular cells, mature squamous cells, and anucleated squames.

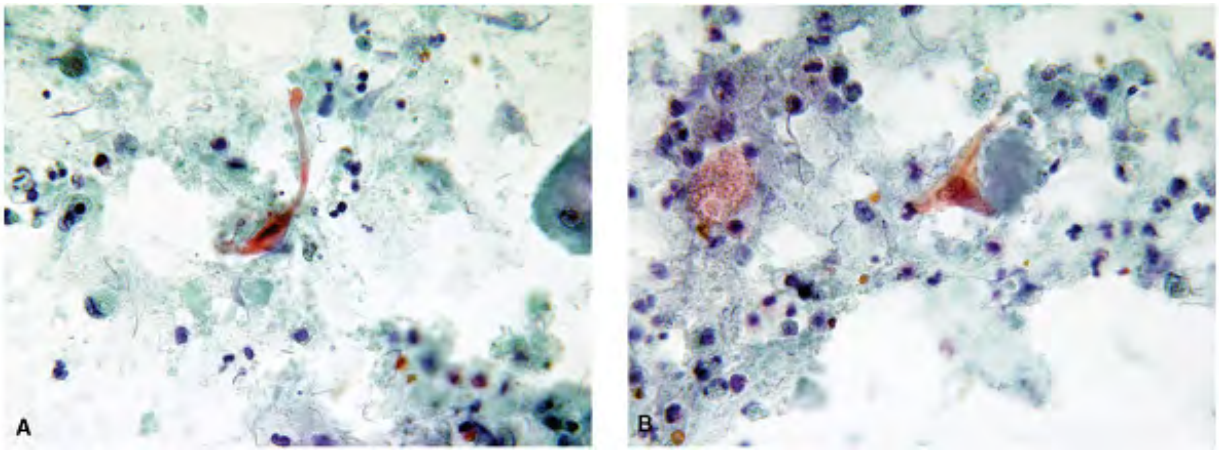

Figure 19.42. A and B . FNA of a thyroglossal duct cyst showing mature squamous cell popu Note the keratinized squamous cells with mildly atypical nuclei.

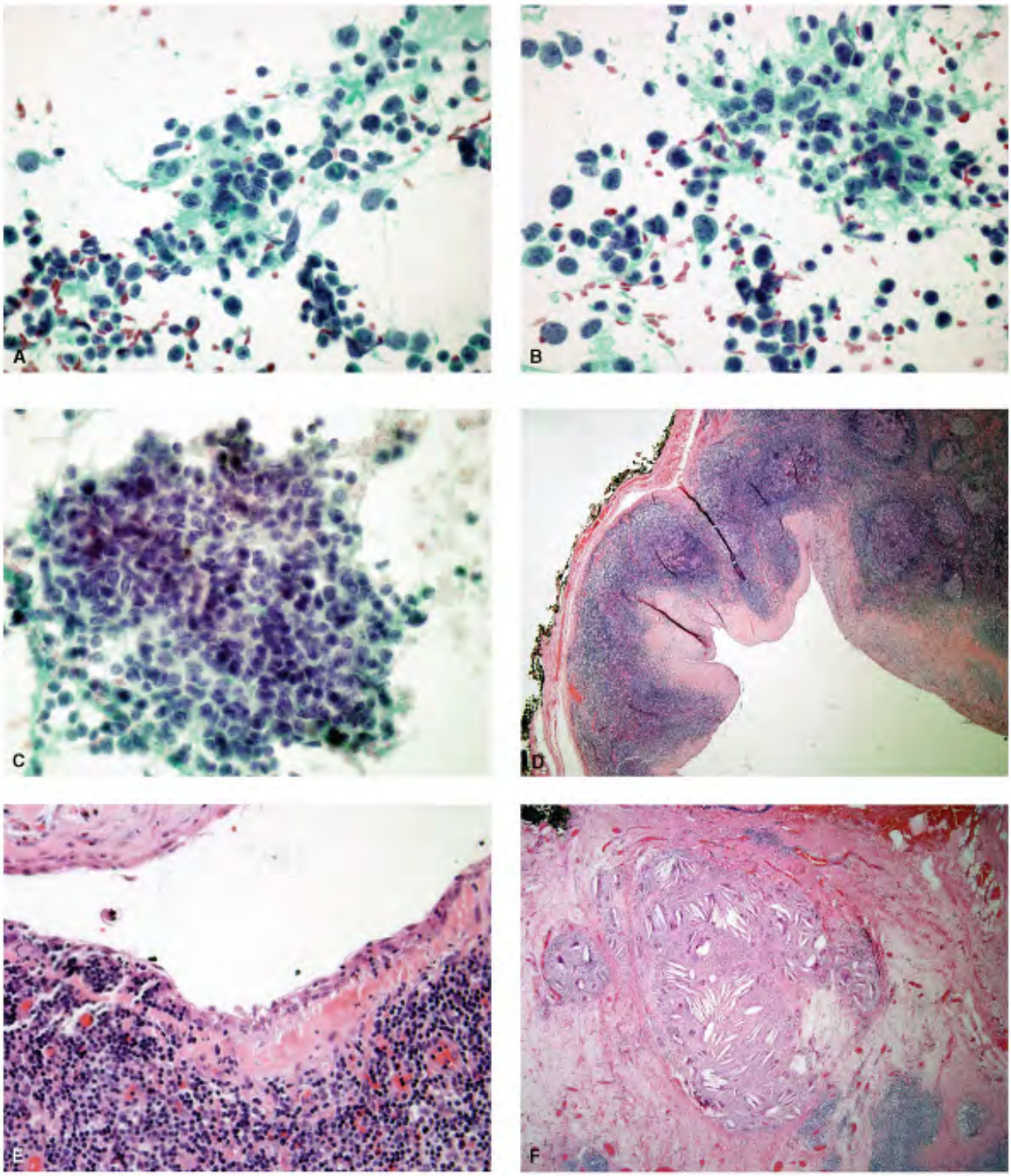

Figure 19.43. Aâ€“C. An aspirate from a 2.5-cm cyst in the isthmus in a 31-year-old womar hypothyroidism. The smears showed a large population of lymphoid cells with focal aggregat immature forms, raising the suspicion for a malignant lymphoma in the background of Hashi thyroiditis. A repeat aspirate with flow cytometry did not confirm the diagnosis of malignan

lymphoma. An MRI requested by the surgeon, following the FNA diagnosis of possible lympho suggested the lesion as a possible thyroglossal duct cyst. D,E. The surgical excision confirme thyroglossal duct cyst. There is extensive lymphoid tissue containing prominent germinal ce the wall of the cyst. The cyst lining is of squamous type. This case illustrates the fact that t diagnosis of thyroglossal duct cyst can be accurately made only in the right clinical context. cyst wall also contained cholesterol granulomas.

Macrophages, with or without hemosiderin
85
89
Colloid
68
61
Squamous epithelial cells including anucleated
and metaplastic and keratinized forms
65
88
Neutrophils
56
61
Lymphocytes
â€”
72
Cholesterol crystals
50
â€”
Mucoid or proteinaceous debris
44
16
Ciliated columnar cells
18
33
Thyroid follicular cells
3

11

[a] Shaffer M, Ortel Y. Thyroglossal duct cysts: criteria by fine needle aspiration. *Am J Clin Pa* 1994;102:52(A).

[b] Shahin A, Burroughs FH, Kirby JP, et al. Thyroglossal duct cyst: a cytopathologic study of 2 *Diagn Cytopathol.* 2005;33:365â€“369.

Cytomorphologic Feature	Shaffer et al.[a] %	Shahin et al.[b] %

TABLE 19.6 CYTOPATHOLOGIC FEATURES OF FLUID ASPIRATED FROM THYROGLOSSAL DUCT CYSTS

The differential diagnosis of thyroglossal duct cysts includes branchial cleft cyst, thyroid cys cystic papillary carcinomas, and metastatic squamous carcinoma.

Neoplasms Arising in Thyroglossal Duct Cysts

Both benign and malignant neoplasms can occur in the thyroglossal duct cysts.88 , 89 , 90 , 101 , 102 , 103 Their occurrence, however, is rare. Benign neoplasms include follicular and HÃ¼rthle cell adenomas.104 , 105 Of the various types of malignant neoplasms reported to from thyroglossal duct cysts, papillary carcinomas (Fig. 19.44) are the most common, comp 87% to 94%.105 , 106 , 107 , 108 , 109 Other malignancies include HÃ¼rthle cell carcinoma, anaplastic carcinoma,111 , 112 and squamous carcinomas.113 , 115 Fine-needle biopsy is ef in the preoperative diagnosis of malignancy, although the origin from a thyroglossal duct cys determined only after excision.

Figure 19.44. A gross photograph of a papillary carcinoma arising in a thyroglossal duct cyst was correctly diagnosed as papillary carcinoma from the aspirated specimen. However, the was determined only after the surgery.

UNUSUAL AND UNCOMMON NEOPLASMS OF THE THYROID

The thyroid gland can be a seat for several unusual and uncommon primary neoplasms, whic rarely encountered in fine-needle aspirates of the thyroid. Because of the rarity

and unusual cytopathologic features, they do cause diagnostic difficulties. This section will
some of these neoplasms.

THYROID CARCINOMA SHOWING THYMUS-LIKE ELEMENT (CASTLE)

Chan and Rosai116 introduced the term CASTLE for thyroid carcinomas showing thymus-like differentiation. This tumor was described as an intrathyroidal thymoma by Miyachi et al.117 other terms used for this tumor include lymphoepithelioma-like carcinoma of the thyroid gl intrathyroid epithelial thymoma, and primary thyroid thymoma. This unusual thyroid neopla sparsely documented in the literature.116 , 117 , 118 , 119 , 120 , 121 , 122 , 123

CASTLE usually arises in the middle to lower third of the thyroid and occurs in adults 40 to 5 of age. It often extends into the extrathyroidal soft tissues. The tumors are circumscribed, demarcated from the surrounding thyroid, and show a lobulated firm and gray cut surface (19.45A).

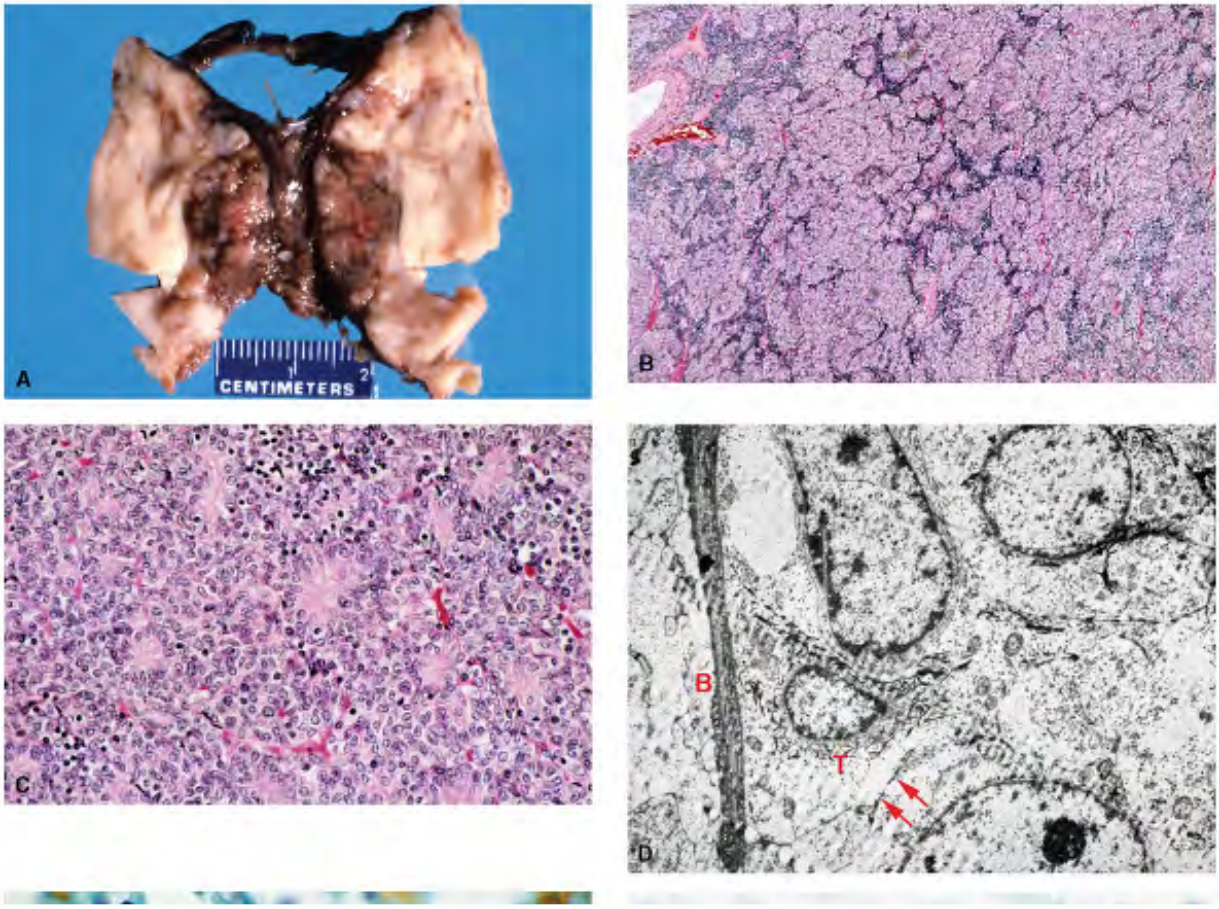

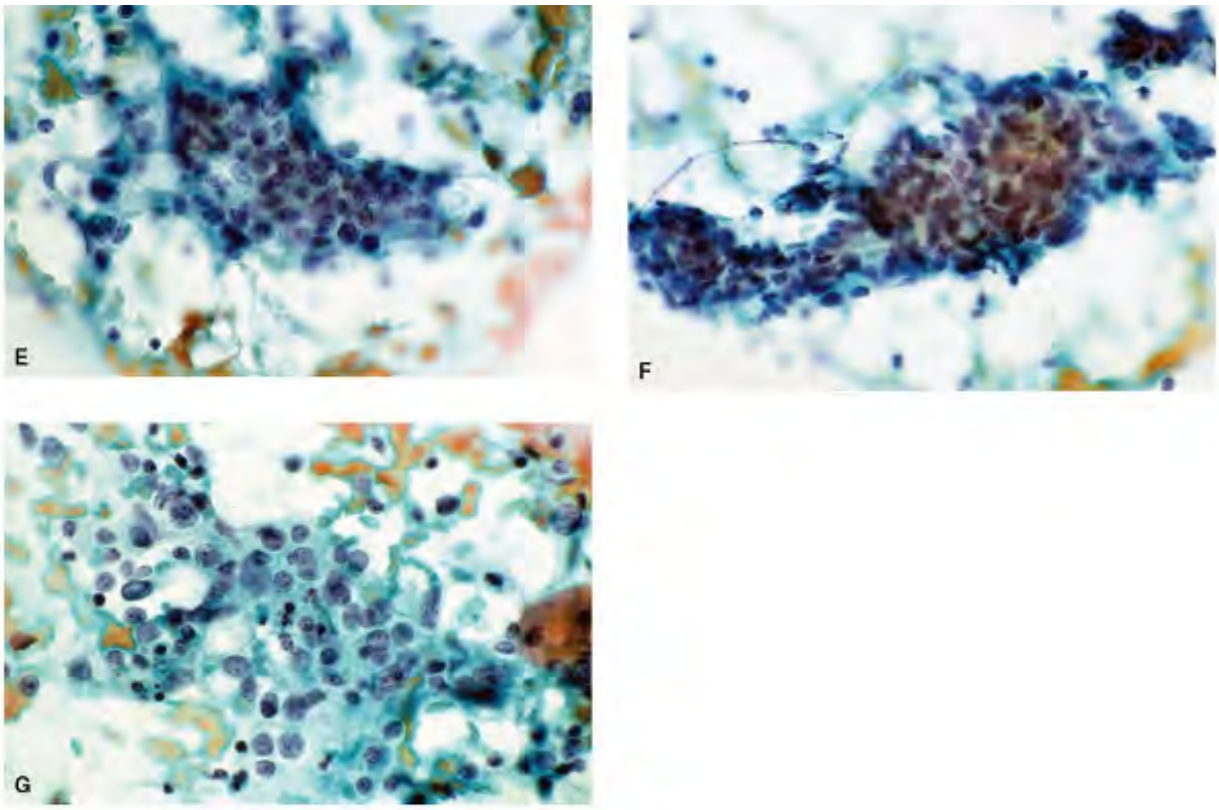

Figure 19.45. A. Gross photograph of an intrathyroidal thymoma or CASTLE. The left thyroi totally replaced by a white fleshy lobulated tumor. B. Histologic section of the tumor showi masses of tumor cells separated by strands of lymphoid cells. C. Higher magnification showi medium-sized cells with poorly defined cell borders, amphophilic cytoplasm, and large vesic nuclei containing nucleoli. D. Ultrastructurally, the neoplastic cells showed features of thym This electron micrograph shows a group of squamous epithelial cells invested by a basement membrane (*B*). The cells have numerous perinuclear bundles of tonofilaments (*T*) and desm (arrows). Uranyl acetate and lead citrate preparation âˆž 43,2000. Eâ€“G. FNA of the above illustrated thyroid tumor. The aspirate is cellular showing syncytial tissue fragments of mali cells with no architectural patterns. The component cells are medium-sized with poorly def borders, scant pale to dense cytoplasm, and round to oval nuclei. Note lymphocytes in the background. These malignant cells offer no clue as to their differentiation. A diagnosis of th or CASTLE is difficult from cytologic samples.

Histologically, CASTLE closely resembles thymic carcinoma by histologic features and immunoprofile. The tumor shows a solid growth pattern consisting of sheets and lobules of p differentiated malignant cells intermingled with mature lymphocytes (Fig. 19.45B and C). Tl

tumor lobules are separated by fibrous septae. The malignant cells contain large nuclei and granular, open chromatin pattern with prominent nucleoli. They have abundant cytoplasm. are sparse. Focal squamous differentiation may be present. The tumor cells are positive for cytokeratin, and negative for thyroglobulin and calcitonin as well as CD5 antibody, similar t tumors. Positivity to *bcl-2 and mcl-1* has been recorded in both thymic carcinomas and CAST Ultrastructurally (Fig. 19.45D), thymoma cells demonstrate prominent, multiple desmosome tonofilaments, often in bundles arranged in garland-like fashion around the nucleus.

Cytopathologic Features

The cytologic findings of CASTLE are sparsely documented.123 , 124 , 125 Our experience w case of CASTLE is illustrated in Figure 19.45 . Cytologically, the lymphoid cells mixed with malignant epithelial cells (Fig. 19.45E to G) suggested a carcinoma in the background of lymphocytic thyroiditis. The malignant cells exhibited no architectural or cytoplasmic differentiation precluding accurate typing.

Most cases described in the literature represent CASTLE with lymphoepithelioma-like patter 19.46). Gerhard et al.125 described a case of intrathyroidal thymoma with a predominant s cell pattern (Fig. 19.47).

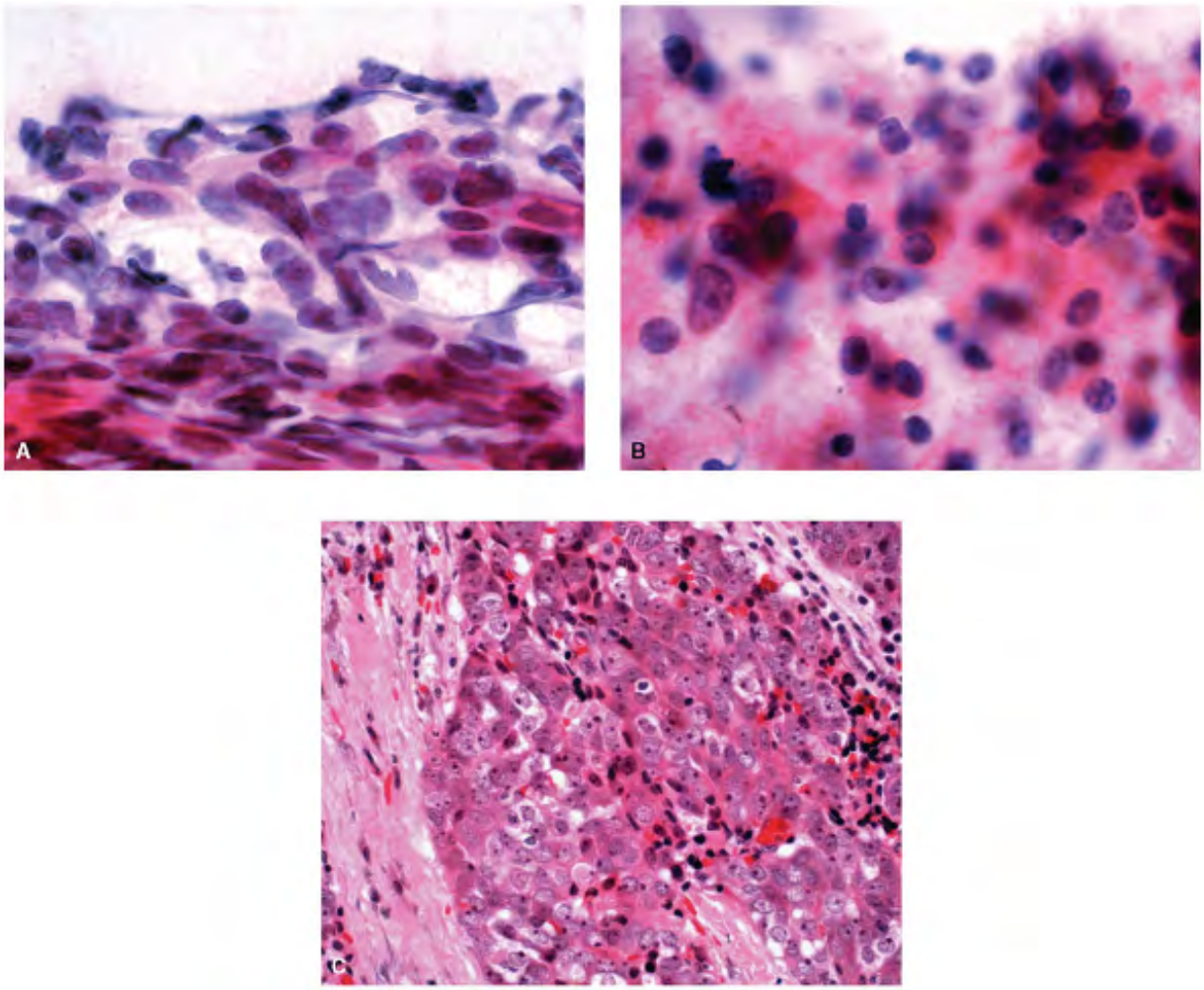

Figure 19.46. A,B. FNA of a different case of CASTLE of thyroid, showing undifferentiated malignant cells. Lymphocytes are not easily appreciated in the background. C. Surgical exci showed a malignant neoplasm with features of CASTLE. Note that the morphology resemble lymphoepithelial carcinoma. (Courtesy of W.K. Ng, MD, Department of Pathology, University Hongkong, Queen Mary Hospital, Hong Kong.)

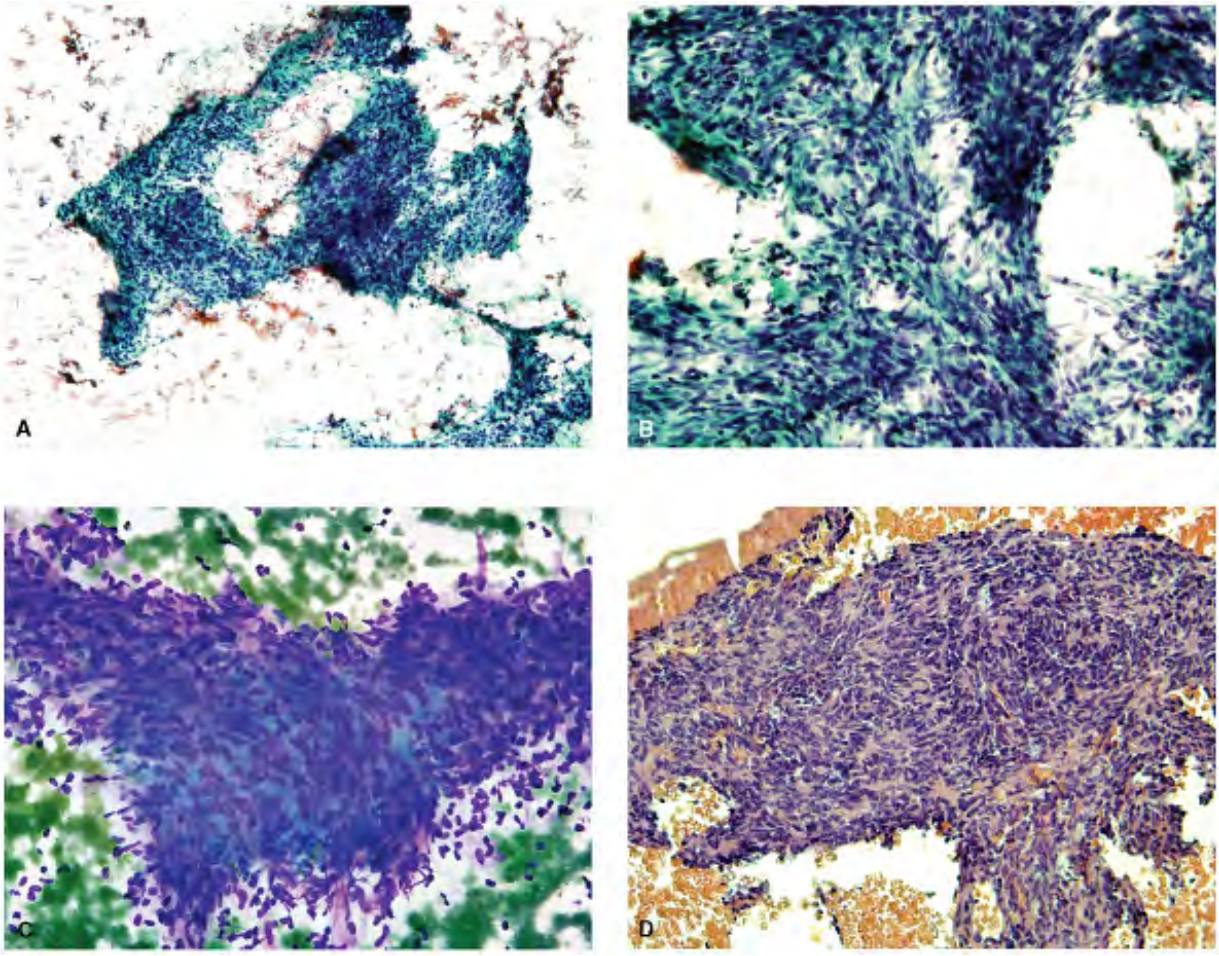

Figure 19.47. A. FNA of a left lower lobe thyroid mass showing interdigitating fascicles of s cells (low power). B. Higher magnification showing spindle cells with bland nuclei. The patt suggestive of a spindle cell neoplasm and the diagnosis of medullary thyroid carcinoma was considered. C. Same aspirate stained by Diff-Quik. The tissue fragment is composed of spinc with some suggestion of epithelioid forms. D. Histologic section of the excised thyroid tumo confirming spindle cell thymoma. (Courtesy of RenÃ© Gerhard, MD, Department of Patholog Hospital das Clinicas, University of Sao Paulo, SP, Brazil.)

Differential Diagnosis

The epithelial predominant tumors must be differentiated from lymphoepitheliomas, poorly differentiated squamous carcinomas. and malignant lymphomas. The spindle cell type thym (CASTLE) must be differentiated from medullary carcinoma or spindle epithelial tumor with like differentiation (SETTLE) and soft-tissue tumors.

SPINDLE EPITHELIAL TUMOR WITH THYMUS-LIKE DIFFERENTIATION (SETTLE)

The term spindle epithelial tumor with thymus-like differentiation (SETTLE) was first coined Chen and Rosai126 to describe malignant neoplasms occurring in children and young adults v distinctive histologic pattern consisting of a biphasic cellular composition and featuring spir shaped epithelial cells that merge into glandular structures.126 , 127 , 128 These tumors ar referred to as thyroid spindle cell tumors with mucus cysts, malignant teratoma, and thyroi thymoma in childhood.129 , 130 , 131 , 132 SETTLE is an extremely uncommon neoplasm of thyroid with very few cases being reported in the literature.132 , 133 , 134 , 135 The cytolo features are documented still more rarely.133 , 136 , 137

SETTLE usually affects children, adolescents, and young adults with a mean age of 19 years range of 4 to 59 years. Male predominance is reported. They present as solitary thyroid mas are characterized by slow growth, late local recurrences, and distant metastases.126

Histologically, the tumor shows a lobular growth pattern, with lobules encircled by thick scl bands. The neoplasm demonstrates a mixture of spindle cells and epithelial cells, the forme predominating. The spindle cells occur in fascicles

forming a whorled or storiform pattern. They usually have bland chromatin pattern. The epi cells show glandular, papillary, trabecular, or solid growth patterns (Figs. 19.48D to F and 1 Occasionally, squamous differentiation reminiscent of Hassall's corpuscles can be seen. Cyst changes can be seen both grossly and microscopically. The cysts are small, lined by squamou columnar epithelium or goblet cells. Interstitial mucin can be demonstrated in the majority cases.

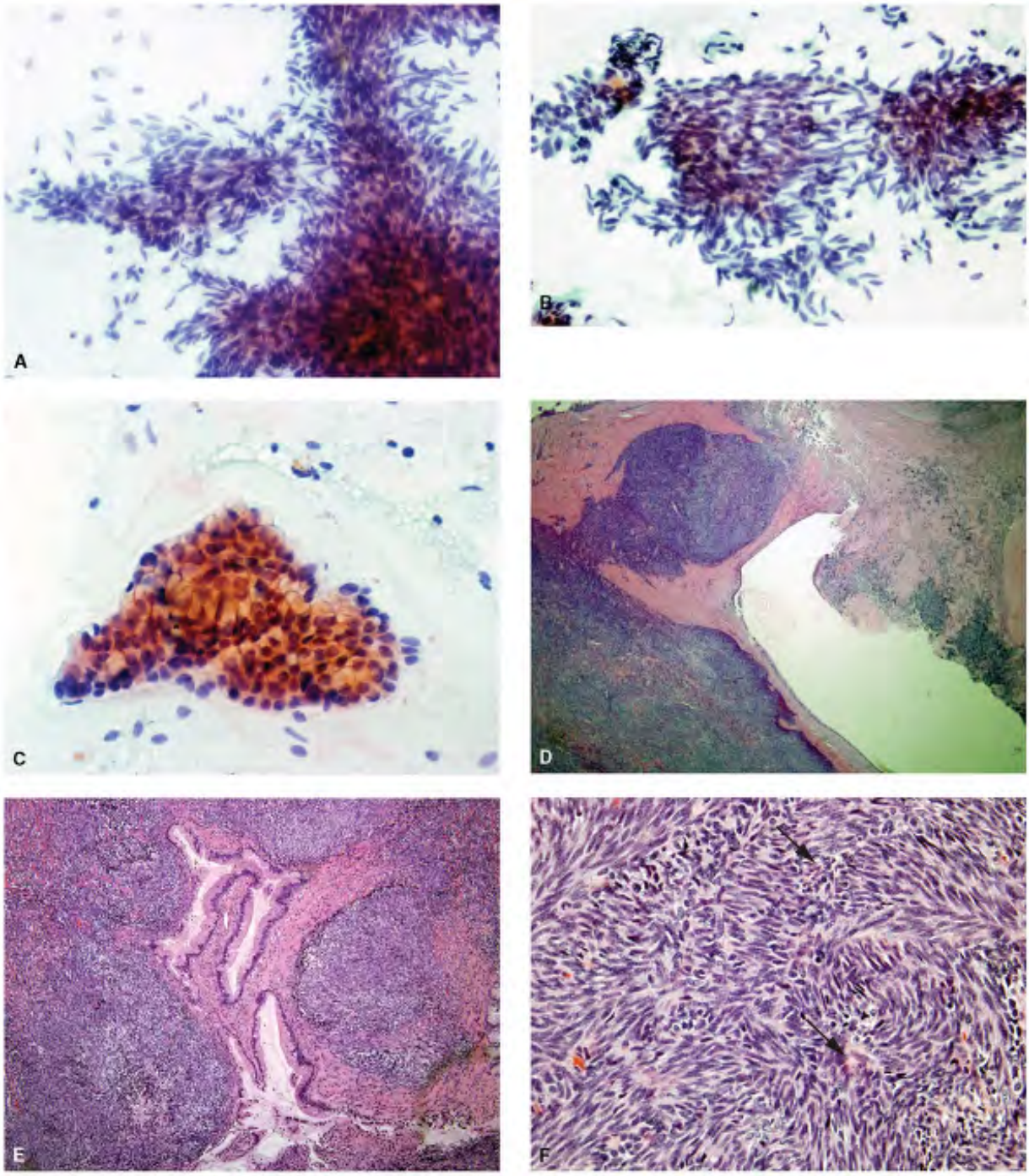

Figure 19.48. A. FNA of a thyroid mass from a 15-year-old. The aspirate is cellular showing fragments of closely packed spindle cells. Discrete spindle cells are seen dispersed in the background (low power). B. Higher magnification showing the spindle cells to be very unifor monotonous with scant to indiscernible cytoplasm. Their nuclei are elongated with bland chromatin. C. The aspirate also contained tissue fragments of cuboidal epithelial cells with acinar pattern, suggesting glandular differentiation. The cytoplasm is vacuolated and some

appear to be the goblet cell type. D. The surgically excised mass was lobulated and multicys cysts contained greenish to white turbid fluid. The tumor showed a biphasic pattern consisti spindle cells with varying-sized cysts, lined by goblet cells (low power). E. Higher magnifica highlighting the spindle cell component and the goblet cell-lined cysts. F . Another section demonstrating the monomorphic spindle cells. Note a rudimentary glandular structure merg imperceptibly with the spindle cells (*arrow*). (A to C are courtesy of Edward Bernecki, MD, Beaumont Hospital, Royal Oak, Michigan. D to F are courtesy of Claire Michael, MD, Universi Michigan Hospital, Ann Arbor.)

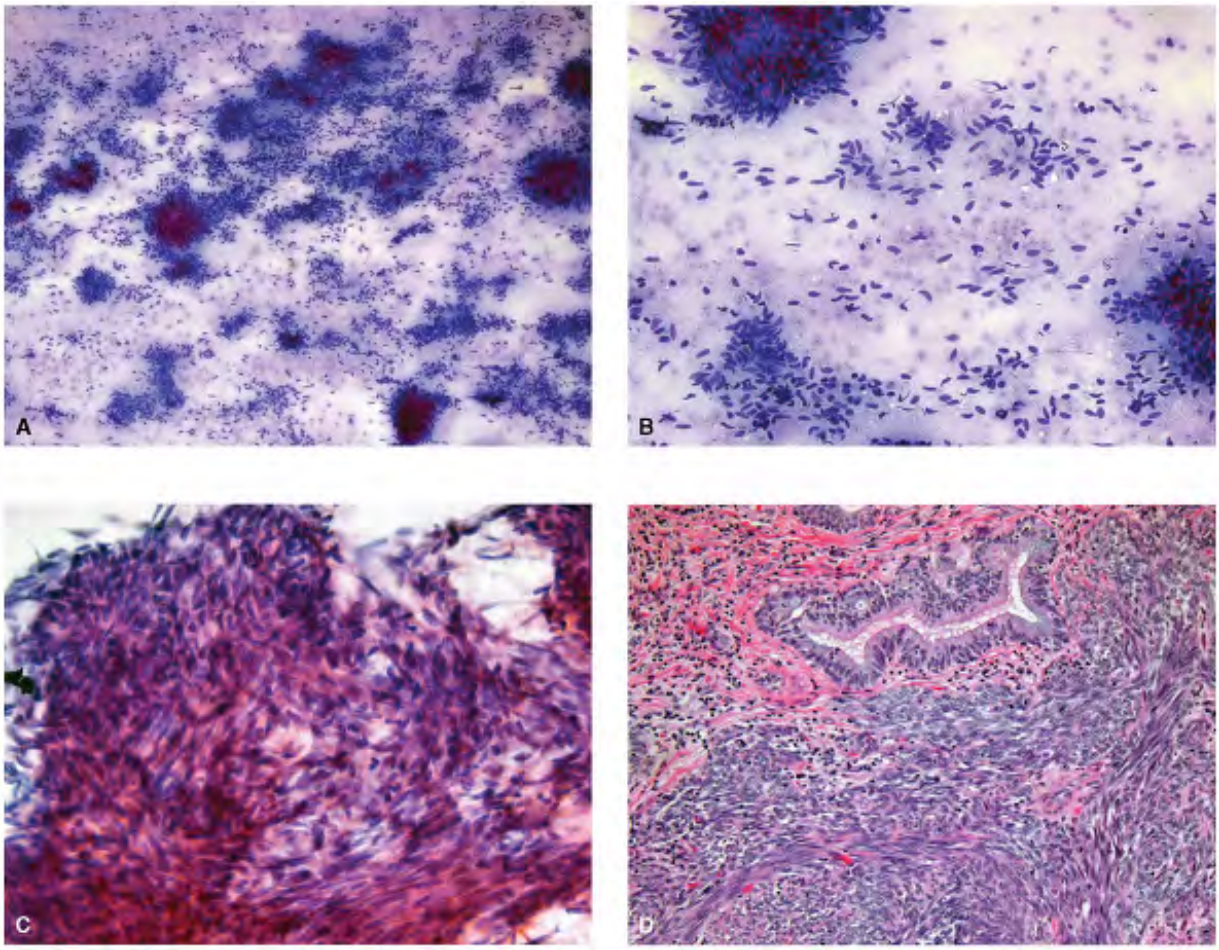

Figure 19.49. A. FNA of another case of SETTLE. A low-power view showing a very cellular consisting of tissue fragments, loosely cohesive groups and dispersed cells, the spindle form apparent even at this power. Diff-Quik stain. B. Medium power showing the monomorphic, small spindle cells presenting a dispersed pattern. Diff-Quik stain. C. Same aspirate, stainec Papanicolaou. A tissue fragment of monomorphic small to medium-sized spindle cells. D. His

section of the excised tumor showing a biphasic pattern with a spindle cell component form fascicles and a glandular component. (Courtesy of Chris Jenson, MD, University of Iowa Hosp Iowa City.)

The spindle cells stain positive with cytokeratins, smooth-muscle actin, and muscle-specific and stain negative with thyroglobulin and calcitonin.119 Ultrastructurally, the neoplastic ce encased by well-defined basal lamina and the cytoplasm contains tonofilaments and few desmosomes.

Cytologically, SETTLE is characterized by spindle cells with scant cytoplasm present in tissue fragments or in dispersed fashion. They contain scant cytoplasm, uniform nuclei with finely chromatin, and indistinct nucleoli (Figs. 19.48 and 19.49). The epithelial component is pres tissue fragments of mucin-producing columnar cells.136 , 137

Differential diagnosis of SETTLE includes intrathyroid thymoma and mesenchymal tumors of thyroid, especially synovial sarcoma, medullary thyroid carcinoma, and anaplastic carcinom

PRIMARY MUCOEPIDERMOID CARCINOMA OF THE THYROID

Primary mucoepidermoid carcinoma, first described in 1977,138 is a malignant tumor of the with only a few cases reported in the literature.139 , 140 , 141 , 142 , 143 , 144 , 145 , 146 characterized by a combination of squamous and mucin-secreting features. Mucoepidermoid carcinomas have been also reported to be associated with papillary carcinomas.145 , 146 , 1 148 It is more common in females, with an age range of 10 to 56 years.

Histologically, both low-grade and high-grade mucoepidermoid carcinomas have been report mucoepidermoid carcinomas are comprised of solid islands and sheets of malignant squamou The glandular component is seen as mucin-producing cells lining duct-like formations. Both cells are intimately associated. Cyst formations are present in the low-grade tumors. Intracytoplasmic and intraluminal mucin stains positive with mucicarmine and is PAS diastas resistant. Immunoprofile includes positivity to cytokeratin and often to thyroglobulin. The n secreting component reacts positively to CEA.

Cytopathologic Features

The cytologic findings of mucoepidermoid carcinomas of the thyroid are identical to those c

in salivary glands149 or

P.423

P.424

other extrasalivary gland sites. The cytologic features are dependent on the grade. The low tumor shows tissue fragments of squamous to intermediate cells with mucin-producing cells must be differentiated from metastatic mucoepidermoid carcinoma originating in salivary g (Fig. 19.50).

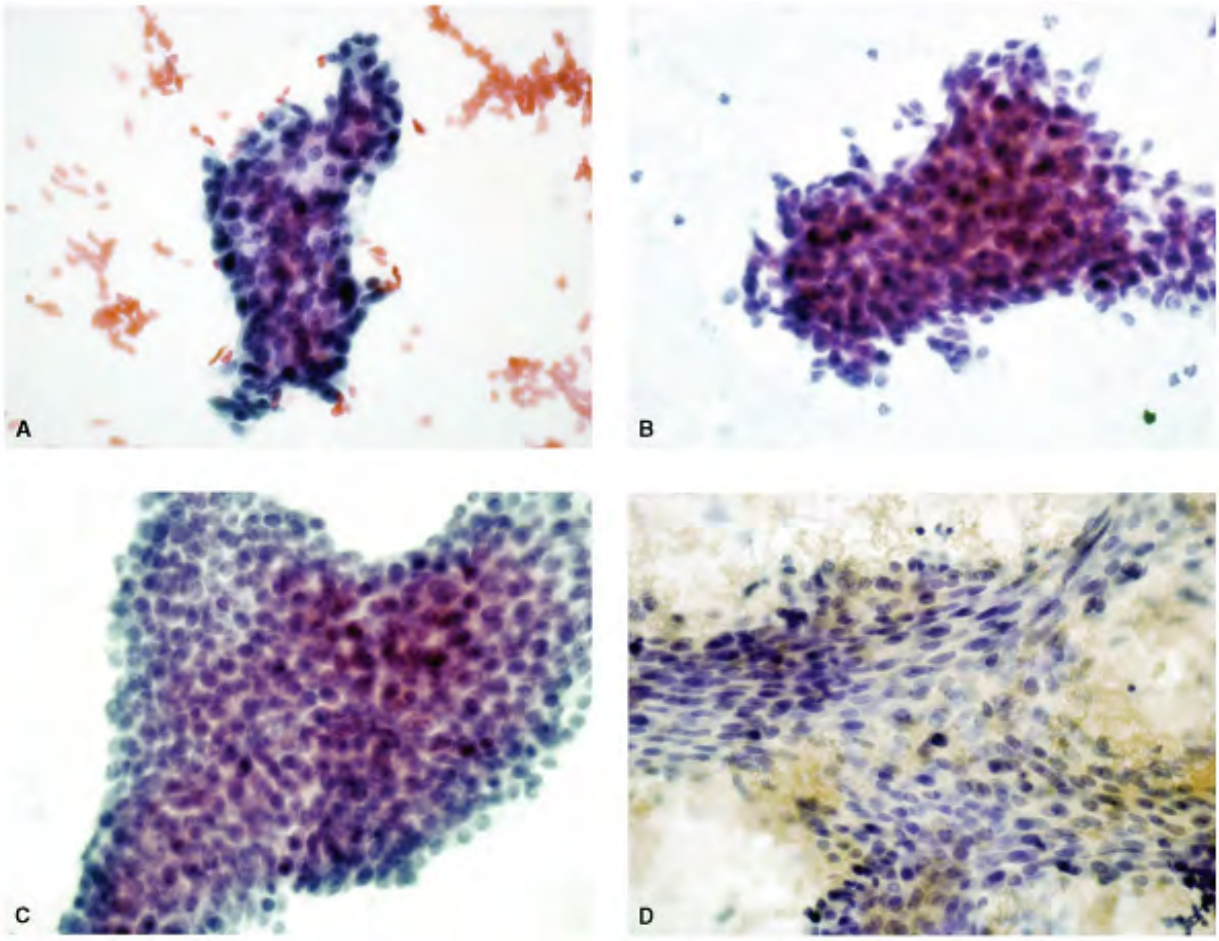

Figure 19.50. A,B. FNA of a thyroid nodule from a patient with the history of mucoepiderm carcinoma of the minor salivary glands at the base of the tongue. The syncytial tissue fragm composed of malignant cells with hyperchromatic nuclei and variable but scant cytoplasm. (Another field showing syncytial tissue fragment of malignant cells. Lack of architectural pat scant, indiscernible cytoplasm does not allow typing. D. The malignant cells show negative reactivity to thyroglobulin, ruling out the possibility of a thyroid follicular cell-derived neop The cytomorphology is similar to primary mucoepidermoid carcinoma of the minor salivary g

The high-grade tumors show clearly malignant cells but offer difficulties in typing, since the be differentiated from squamous, anaplastic or metastatic carcinoma (Fig. 19.51). A low-gr mucoepidermoid carcinoma cannot be differentiated from a metastatic mucoepidermoid ca without a clinical history. A high-grade carcinoma needs to be differentiated from a poorly differentiated primary or metastatic squamous carcinoma.

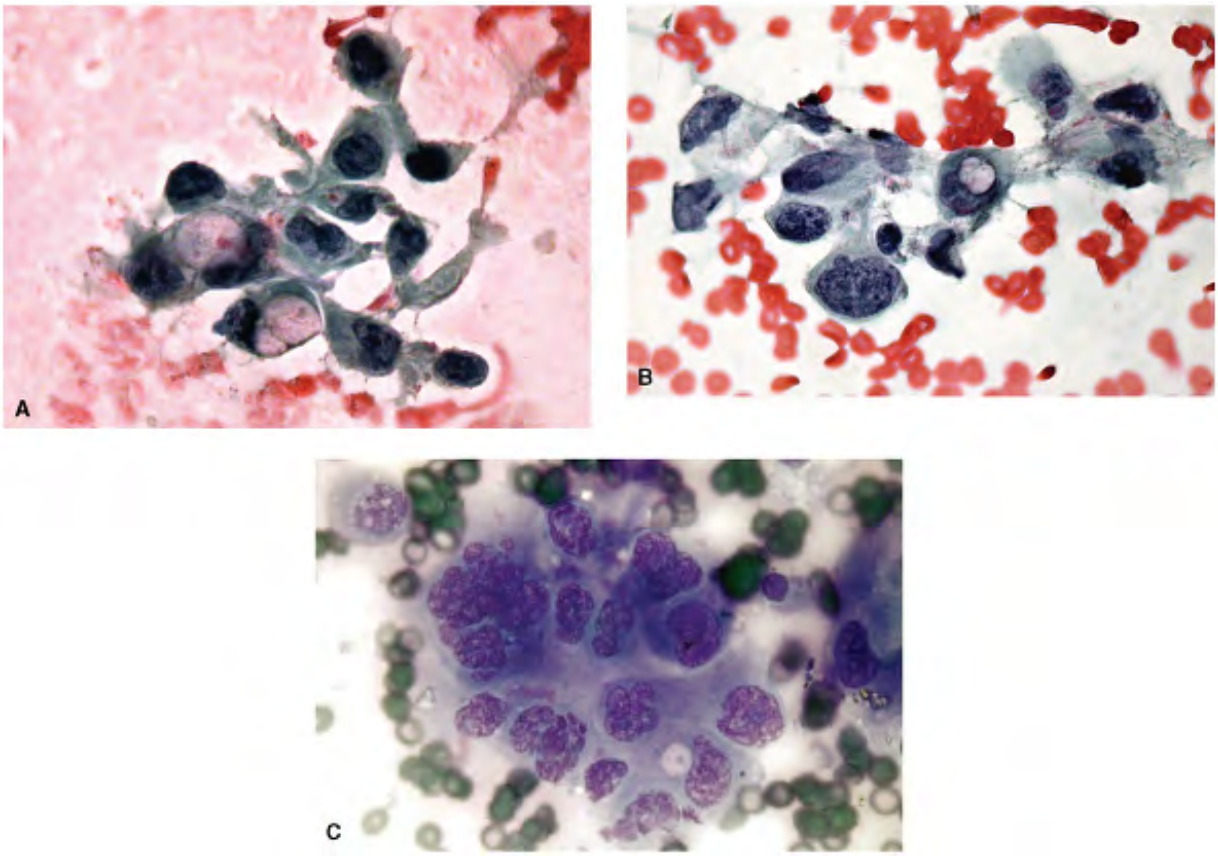

Figure 19.51. A,B. FNA of a high-grade histologically confirmed primary mucoepidermoid carcinoma of the thyroid. The malignant cells are large, round, and polygonal with hyperchr nuclei and abundant dense cytoplasm. Note occasional cells containing cytoplasmic vacuole Same aspirate stained with Romanowsky stain. (Courtesy of Ricardo Gonzalez-Campora, MD, Department of Pathology, Faculty of Medicine, University of Seville.)

SCLEROSING MUCOEPIDERMOID CARCINOMA WITH EOSINOPH

Sclerosing mucoepidermoid carcinoma with eosinophilia is a morphologically distinctive mal neoplasm of the thyroid showing epidermoid and glandular differentiation, sclerosis with pr

eosinophilia and lymphocytic infiltrate. The tumor occurs in adults and affects women almo exclusively. It occurs in the background of Hashimoto's thyroiditis, often of the fibrous type. 151 , 152 , 153 , 154 , 155 , 156 , 157 , 158 , 159

Histologically, sclerosing mucoepidermoid carcinoma with eosinophilia is characterized by a sclerotic stroma extensively infiltrated by eosinophils, lymphocytes, and plasma cells. The t cells form anastomosing cords and nests of polygonal

cells with mild to moderate nuclear atypia and distinct nucleoli. Also present are mucinous and small pools of mucin. The background almost always shows Hashimoto's thyroiditis.

The tumor is immunoreactive to cytokeratin, and negative for thyroglobulin and calcitonin. 50% of the cases have demonstrated immunoreactivity to TTF-1. The mucin-containing cells positive to CEA.

Cytologic Features

The cytologic features of sclerosing mucoepidermoid carcinoma with eosinophilia are sparse documented and correspond to the histologic pattern. They are characterized by tissue frag of squamous cells with varying degrees of differentiation, intimately associated with glandu mucin-producing cells. The background shows prominent eosinophilia and lymphoid cells (Fi).

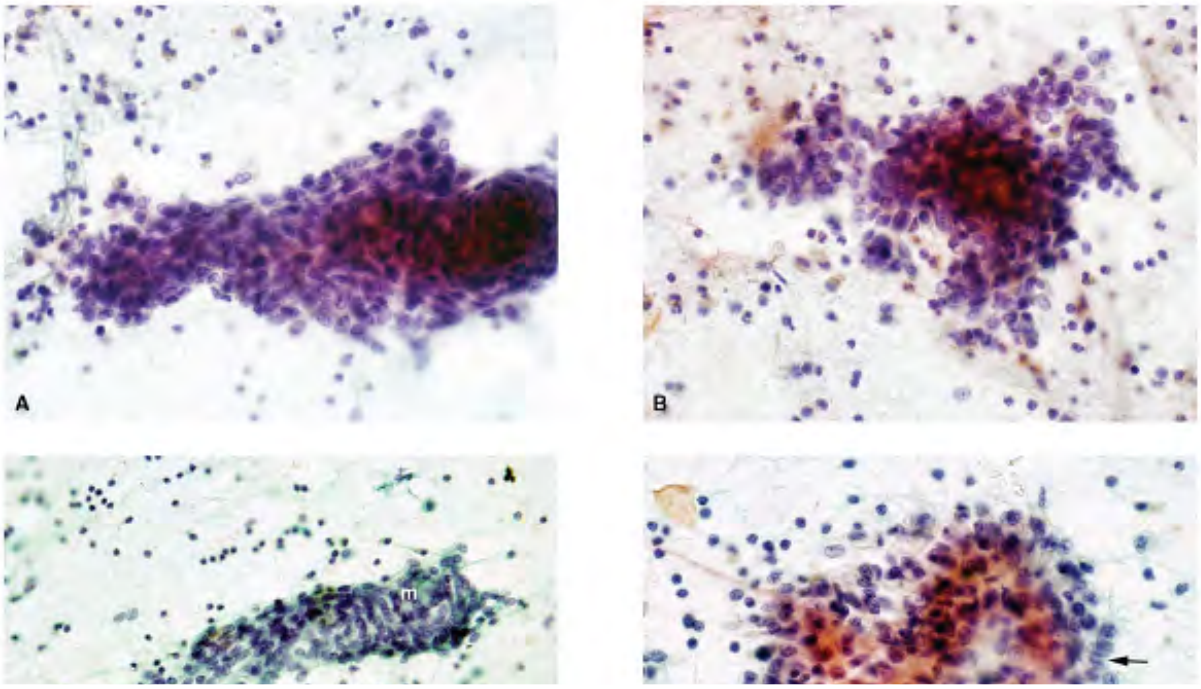

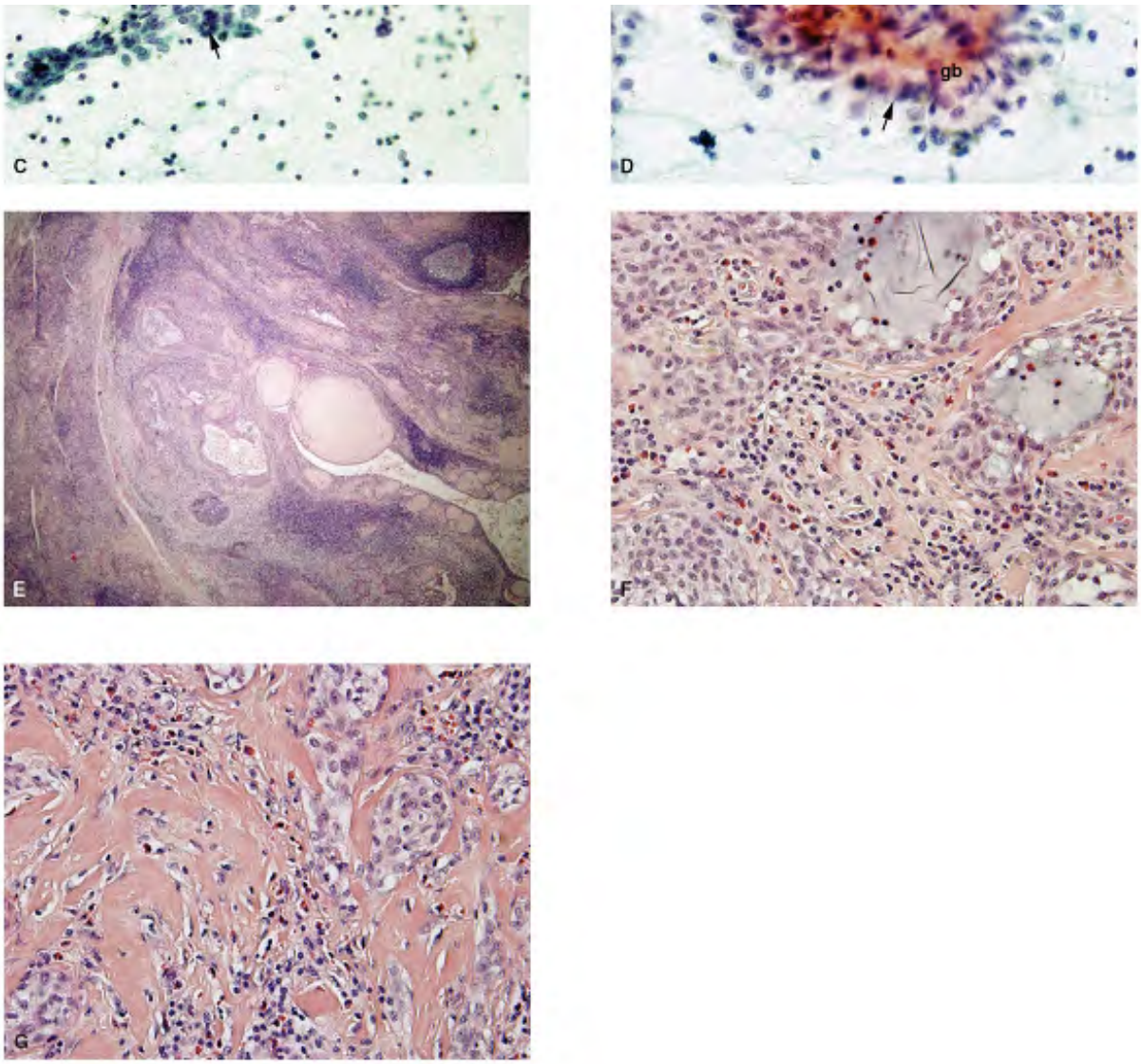

Figure 19.52. A,B. FNA of a sclerosing mucoepidermoid carcinoma with eosinophilia, depict syncytial tissue fragment of small malignant cells without any architectural pattern. Their c borders are poorly defined and the cytoplasm is scant to indiscernible. The nuclei are large high N/C ratios, crowded, and overlapped. The chromatin is coarsely granular. Note several eosinophils in the background. C. These syncytial tissue fragments of malignant cells demon an acinar pattern (*arrow*). Note mucin in the lumen (m). There are many lymphocytes in th background. D. The malignant cells in this syncytial tissue fragment contain appreciable pal foamy cytoplasm. The cells at the periphery appear columnar (*arrows*). The malignant cells this syncytial tissue fragment show cytoplasmic vacuoles (*arrow*). Occasional goblet cells ar present (gb). E. The surgical excision revealed a multicystic tumor in the background of Has thyroiditis. F. Higher magnification showing glandular structures lined by goblet cells and isl

squamoid cells in the background of lymphoid cells and marked eosinophilia. Note mucin wi
glandular space. G. Note stromal sclerosis (Courtesy of Mariza de Peralta-Venturina, MD, Wi
Beaumont Hospital, Royal Oak, Michigan.)

PRIMARY PARAGANGLIOMA OF THE THYROID

Primary paragangliomas of the thyroid are extremely rare and very few cases are document
the surgical pathology literature.160 , 161 , 162 , 163 , 164 , 165 , 166 Morphologically they
a pattern typically seen in paragangliomas at the other sites. Only one

case of cytologic findings from fine-needle aspirate of primary paraganglioma of the thyroid
documented in the literature (Fig. 19.53).166

The differential diagnosis of paraganglioma includes hyalinizing trabecular adenoma, which
morphologic similarity to paraganglioma. In fact, hyalinizing trabecular adenomas are some
referred to as paraganglioma-like follicular adenoma. Other possible differential diagnostic
include medullary carcinoma, metastatic neuroendocrine neoplasms, HÃ¼rthle cell carcinor
insular carcinoma.

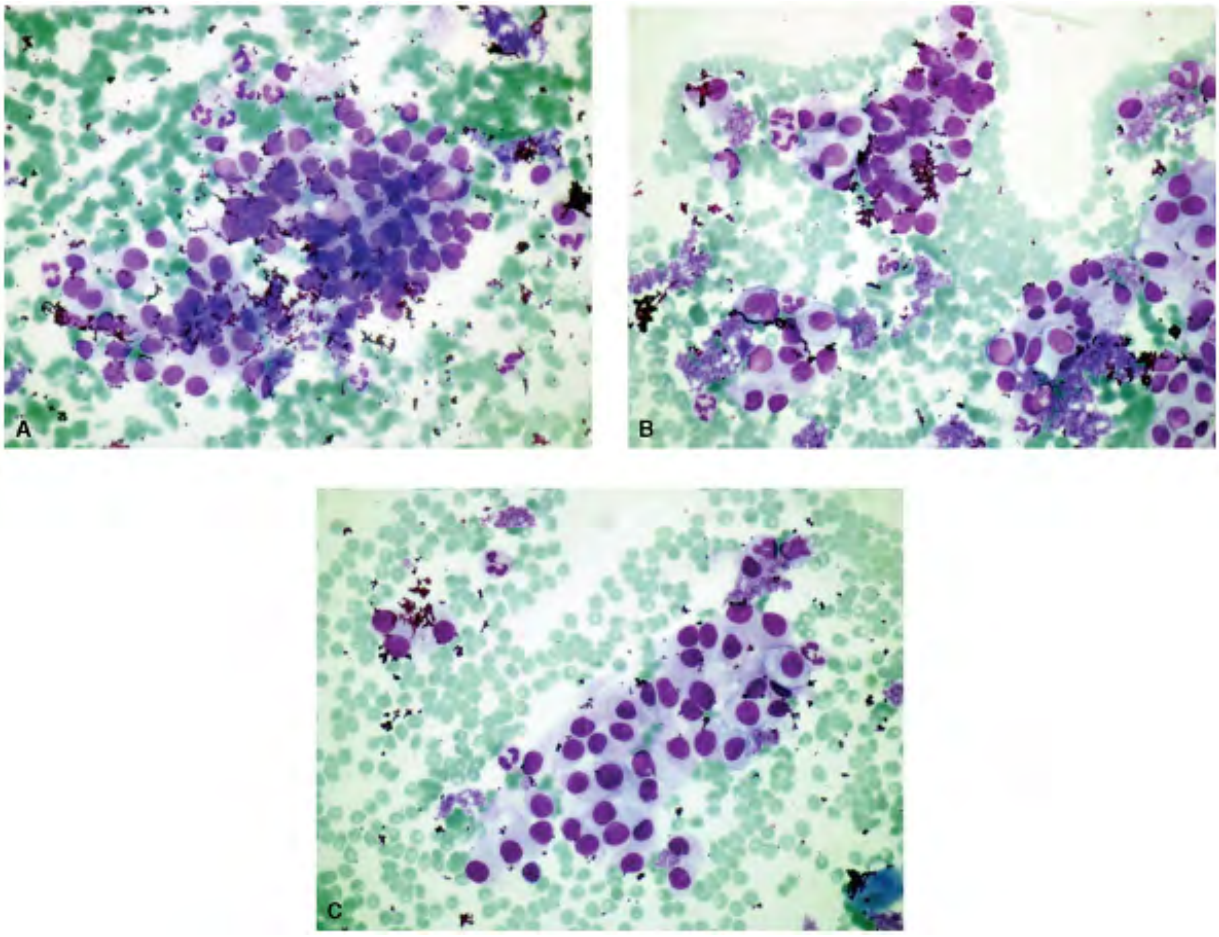

Figure 19.53. FNA of a histologically confirmed primary paraganglioma of the thyroid. The marginally cellular aspirate demonstrates tissue fragments of medium-sized to large cells wi poorly defined cell borders. The neoplastic cells are also present as discrete and in loosely c groups. The nuclei are moderately pleomorphic, large, round to oval, and with evenly dispe chromatin. Nucleoli are only occasionally present. These cells have insignificant to scant, pa bluish cytoplasm. A cytologic diagnosis is of paraganglioma is not possible from this morphol they also bear similarities to medullary carcinoma cells. Romanowsky stain. (Courtesy of A. Vodovnik, MD, Calderdale Royal Hospital, HX3 OPW Halifax, England.)

LANGERHANS' CELL HISTIOCYTOSIS (HISTIOCYTOSIS X)

Langerhans' cell histiocytosis is an uncommon disorder affecting children and adolescents, a involves multiple systems in the body, such as skin, bone, lung, lymph nodes, and the centra nervous system. Involvement of thyroid is rare, and the isolated involvement presenting as a nodule or goiter is still rarer.167 , 168 , 169 , 170 , 171 Cytologic diagnoses of Langerhans' c

histiocytosis by fine-needle aspiration biopsy in such cases have been described.172 , 173 , 175 , 176 A clinical history of Langerhans' cell histiocytosis and the presence of characteristi Langerhans' cells allow an accurate diagnosis and can be confirmed by immunostains. The Langerhans' cells are round to polygonal, with poorly defined cell borders, and contain abun pale to granular cytoplasm. The nuclei are oval to kidney-shaped with characteristic deep g (Fig. 19.54A). Nucleoli are often present. The Langerhans' cells are often associated with eosinophils, lymphocytes, multinucleated foreign-body-type giant cells, and macrophages. Ultrastructurally, Langerhans' cells demonstrate characteristic Birbeck granules. Their immunoprofile includes positive reactivity to S100 protein (Fig. 19.54B), CD1, CD 11, and Cl

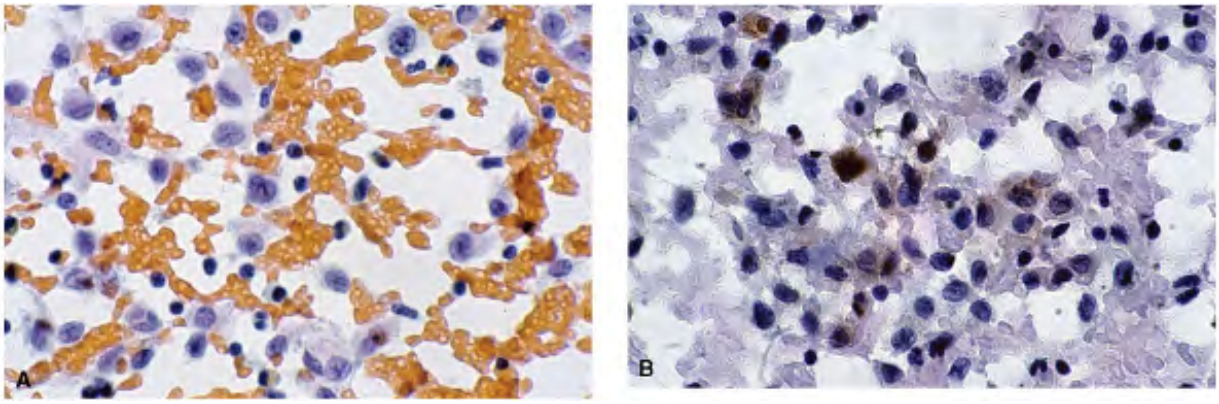

Figure 19.54. A. FNA of the thyroid. The aspirate is cellular, consisting of numerous Langer cells with abundant granular cytoplasm and low N/C ratios. Their nuclei have prominent gro and indentations. B. Same case as above showing positive immunoreactivity of Langerhans' histiocytosis cells with S-100 protein. (Courtesy of Fadi Abdul-Karim, MD, Institute of Pathol University Hospitals of Cleveland.)

PRIMARY SOFT-TISSUE TUMORS OF THE THYROID

Both benign and malignant soft-tissue and mesenchymal tumors arise in the thyroid gland, a very rarely.177 , 178 The benign tumors include vascular tumors such as hemangioma or lymphangioma, schwannoma,177 , 178 , 179 , 180 , 181 leiomyoma,181 lipoma,182 and solit fibrous tumors.183 , 184 , 185 An aspirate of hemangioma may yield only blood, resulting in unsatisfactory aspirate and the diagnosis established only after surgical excision (Fig. 19.55

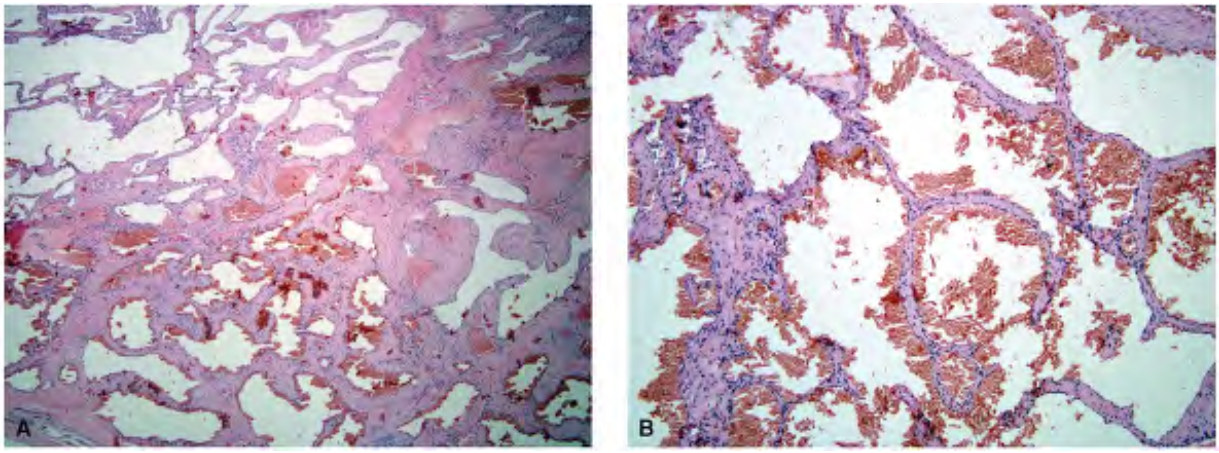

Figure 19.55. A. Histologic section of a cavernous hemangioma of the thyroid. The fine-nee aspiration biopsy of this lesion was bloody and acellular. The section shows anastomosing th walled blood spaces, some filled with blood. B. Higher magnification highlighting the structu hemangioma.

The malignant mesenchymal tumors of the thyroid are extremely rare and include angiosarcomas,186 , 187 leiomyosarcomas,188 , 189 malignant peripheral nerve-sheath tum synovial sarcoma,190 liposarcoma, fibrosarcoma, osteosarcoma, and chondrosarcoma. The c presentation of these extremely rare primary neoplasms is almost non-existent. A case of sy sarcoma is illustrated in Figure 19.56 . Metastatic soft-tissue sarcomas may be more frequer encountered than the primary ones.

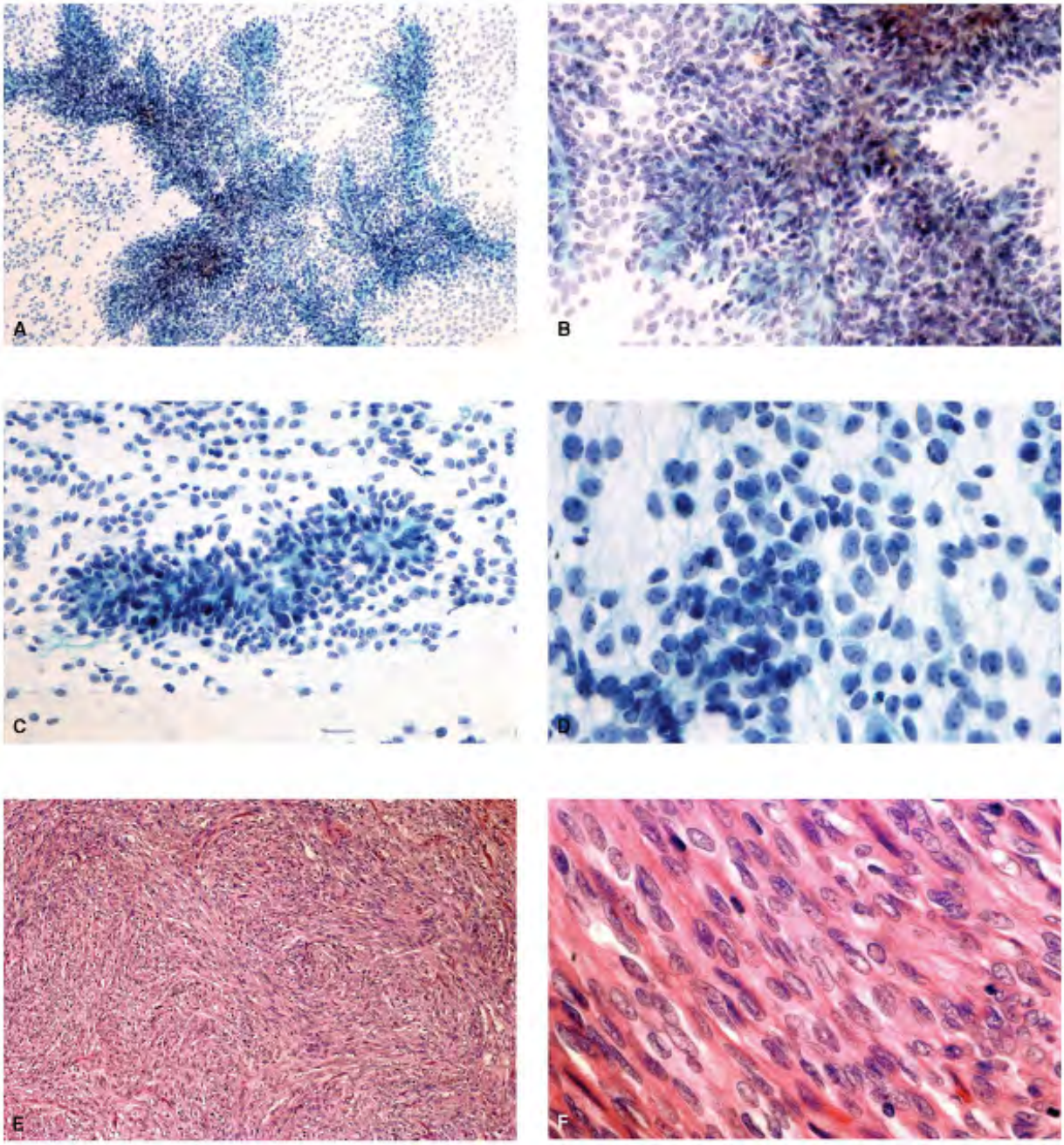

Figure 19.56. FNA of a primary synovial sarcoma of the thyroid. A. The cellular aspirate co branching tissue fragments of delicate spindle cells. These spindle cells are also present in a dispersed fashion. B. Higher magnification showing the spindle cells with uniform round to elongated nuclei with a finely granular, bland chromatin. The cell borders are poorly define scant cytoplasm. C. Another field showing a tissue fragment of spindle cells in the backgrou discrete round cells. D. These tumor cells appear epithelioid. E. Histologic section of the sy sarcoma showing fascicles of spindle cells. F. Higher magnification of the synovial sarcoma s

spindle cells with uniform elongated nuclei. (Courtesy of Ms. I. Kikuchi, CT (IAC), Departmer Pathology, Central Clinical Laboratory, Iwate Medical University, Morioka, Japan.)

PRIMARY HODGKIN'S LYMPHOMA OF THE THYROID

Primary extranodal Hodgkin's disease of the thyroid gland is extremely rare. Cases so diagno generally found to be a secondary involvement. Some bona fide cases have been

P.429

reported in the surgical pathology literature.191 , 192 , 193 , 194 However, only 2 cases hav described with a cytologic diagnosis made following aspiration biopsy.192 , 193

CLEAR CELL CHANGE IN THYROID NEOPLASMS

Clear cell change can occur in several types of thyroid neoplasms. Carcangiu et al.195 prese excellent review of 38 cases including 10 cases of HÃ¼rthle cell tumors, 17 cases of follicula neoplasms, 7 cases of papillary carcinomas, and 4 cases of anaplastic carcinomas. All of the exhibited extensive clear cell change involving over 50% of the tumor. In the past, clear cell had prompted a separate category of the tumors such as clear cell carcinoma. Carcangiu et claim from their study that the clear cell change is a secondary event in different types of t and a separate designation of clear cell carcinoma is not indicated.196 , 197 , 198 The clear cytoplasmic change occurs due to a variety of reasons, including (i) formation of medium-siz vesicles, many of mitochondrial derivation, a common cause in

P.430

P.431

HÃ¼rthle cell and follicular neoplasms; (ii) glycogen accumulation in papillary and anaplasti carcinomas; and (iii) deposition of intracellular thyroglobulin in a subgroup of follicular neop with a signet ring or lipoblast-like appearance. The clear cell change is also described in me carcinomas.199

Cytologic Features

The cytologic findings of clear cell change in thyroid tumors are reported infrequently.200 , 202 , 203 , 204 , 205 The characteristic clearing of the cytoplasm seen in histologic sections by hematoxylin and eosin is not replicated in cytologic preparations stained by the Papanicc method. The cytoplasm of the clear cells stains very pale to granular, cyanophilic to eosinop Their cell borders are often poorly defined and the cells appear as naked nuclei (Figs. 19.57

and 19.59) due to rupture of the cell membranes. The pale eosinophilic granular cytoplasm cells may lead to a diagnosis of HÃ¼rthle cell neoplasm.201

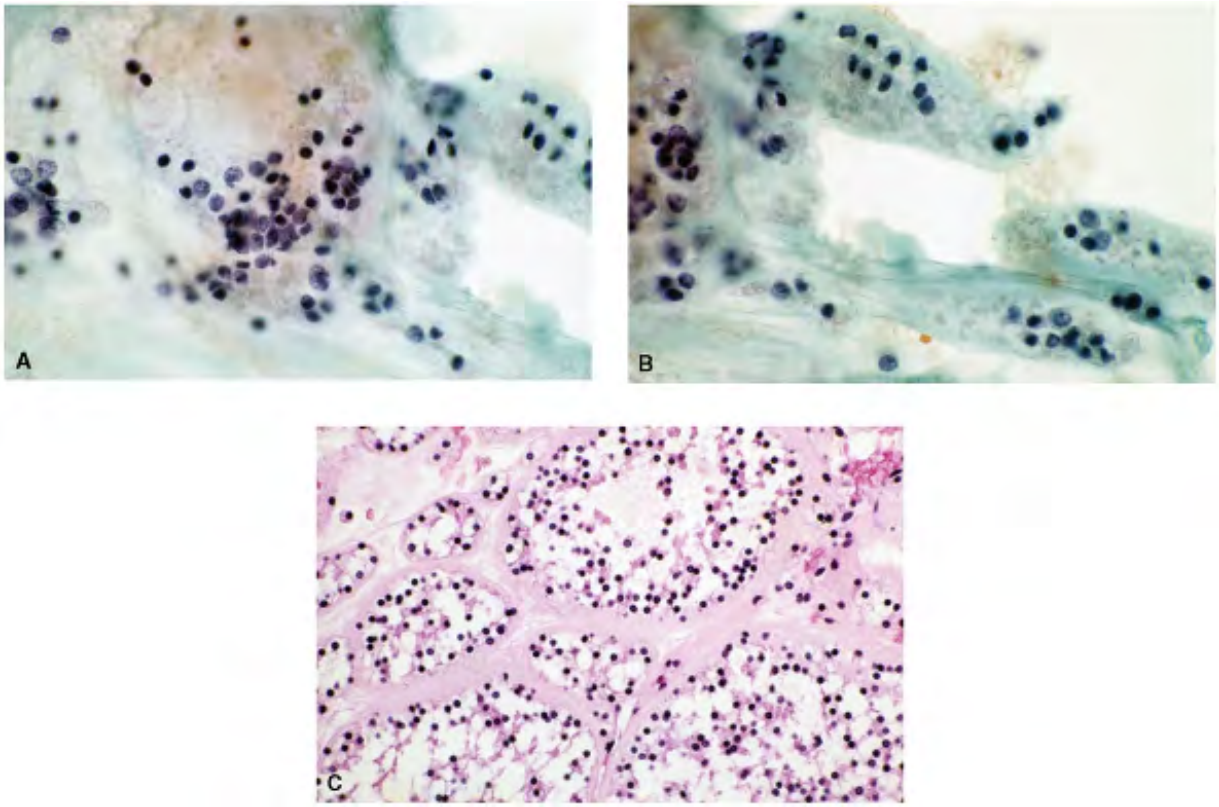

Figure 19.57. A,B. FNA of a follicular adenoma with clear cell change. The follicular cells a syncytial arrangement and have poorly defined cell borders and are probably ruptured. The are crowded and overlapped and appear naked. C. Histologic section of the thyroid tumor sl follicular adenoma with a clear cell pattern.

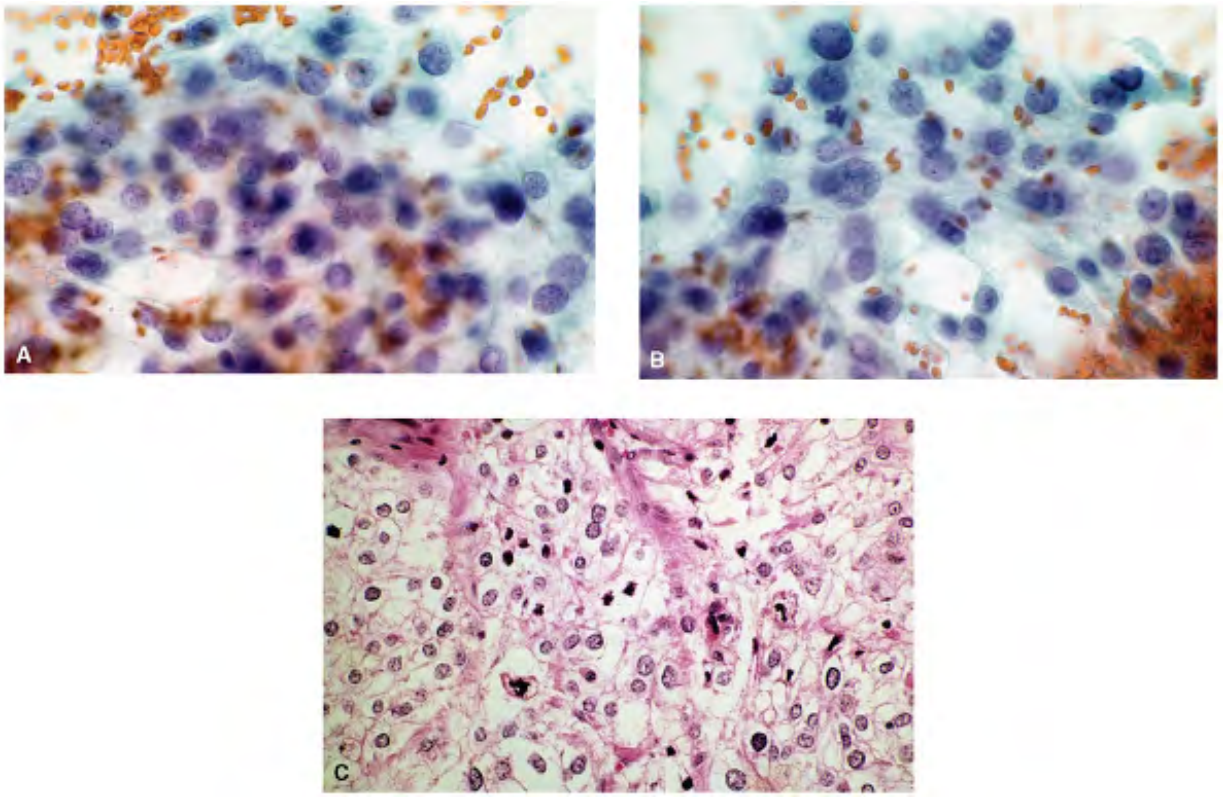

Figure 19.58. A,B. FNA of a poorly differentiated follicular carcinoma showing syncytial tis fragments without any follicular pattern. The nuclei are considerably enlarged, pleomorphic and with granular chromatin and nucleoli. The moderate amount of cytoplasm is pale to cle The surgical excision showed a poorly differentiated follicular carcinoma with extensive cle change.

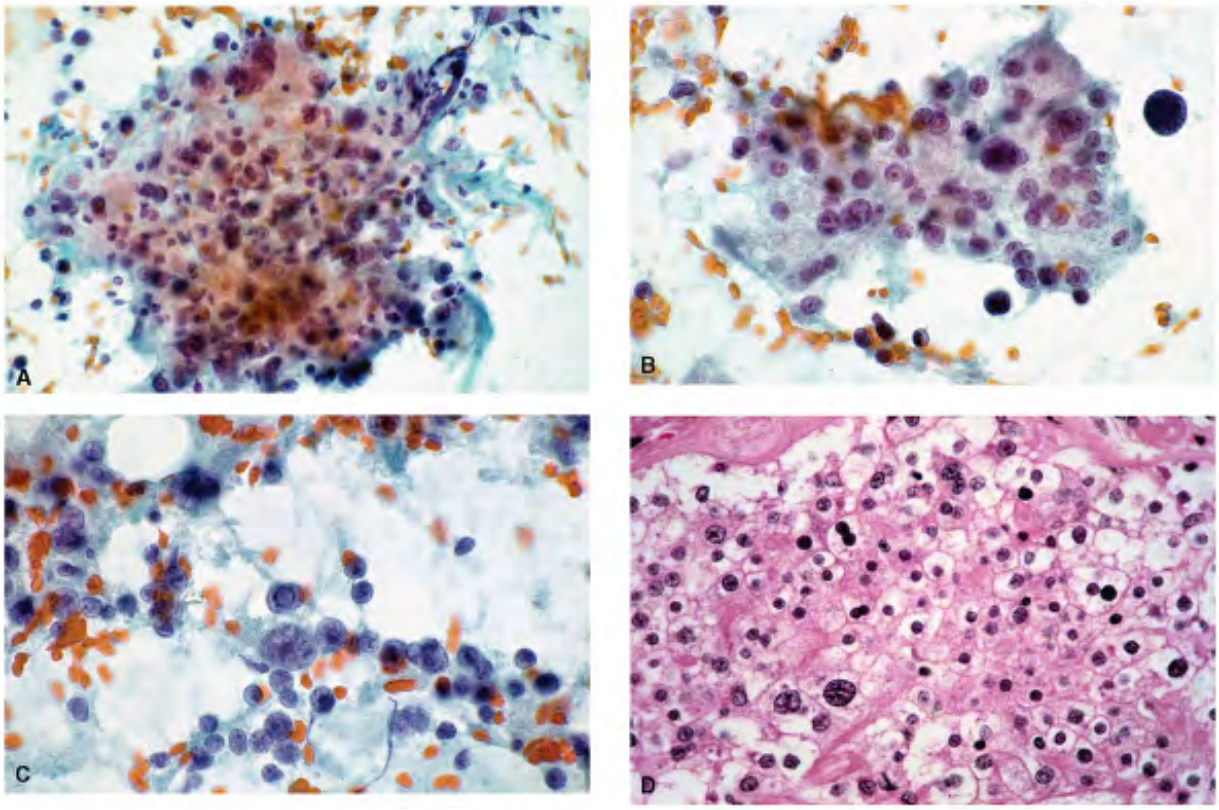

Figure 19.59. Aâ€“C . FNA of an anaplastic carcinoma. Note that the variable but abundan cytoplasm is very pale and some nuclei appear bare. D . Histologic section of the anaplastic carcinoma showing clear cell change.

The differential diagnosis tumors with clear cell change include metastatic clear cell carcin the kidney to the thyroid. El-Sahrigy et al.203 reported a signet-ring-type follicular adenom was interpreted as metastatic adenocarcinoma on fine-needle aspiration biopsy.

THYROID TUMORS WITH MUCINOUS FEATURES

The presence of cytoplasmic mucin in thyroid tumors is not uncommon.206 , 207 , 208 , 209 211 , 212 It has been described in follicular adenomas of the signet ring type, follicular carc (Fig. 19.60), mucoepidermoid carcinoma, sclerosing mucoepidermoid carcinoma with eosin and spindle epithelial tumor with thymus-like differentiation (SETTLE). Other malignant thy neoplasms associated with mucin production include papillary carcinomas, where Chan210 described the presence of mucin in 17% of the cases; anaplastic carcinomas; medullary carc and metastatic adenocarcinomas.

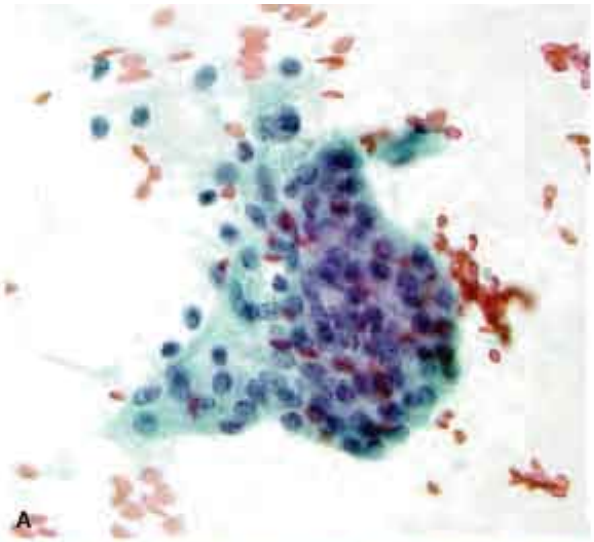
A

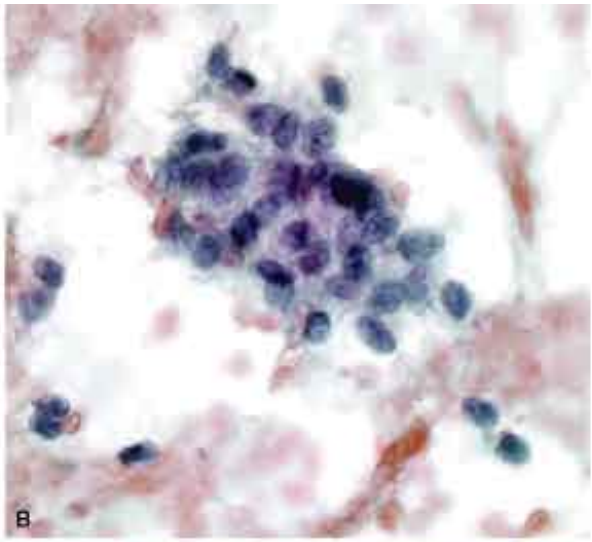
B

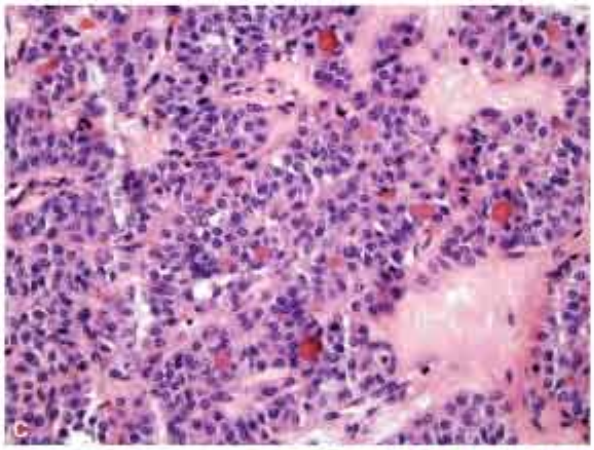
C

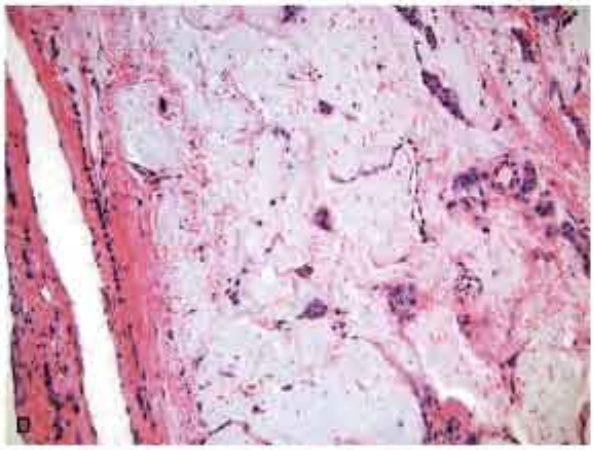
D

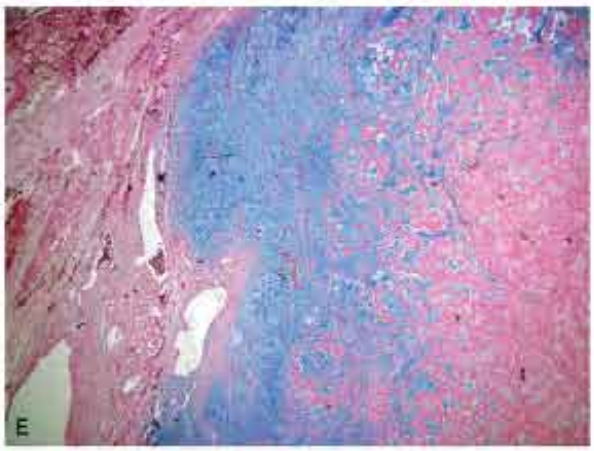
E

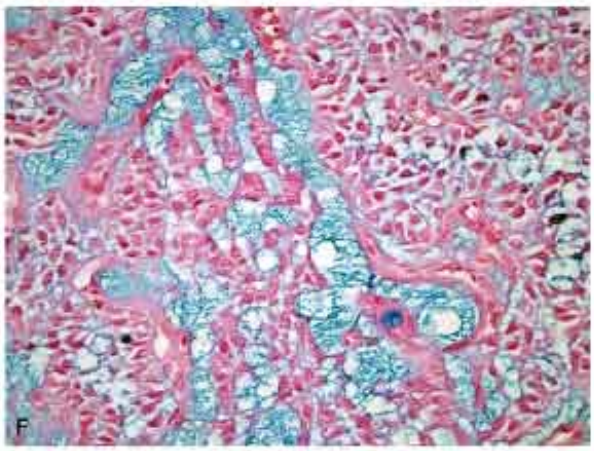
F

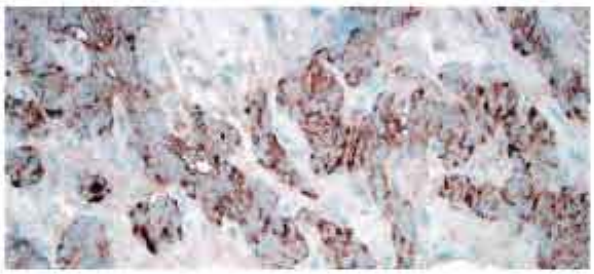

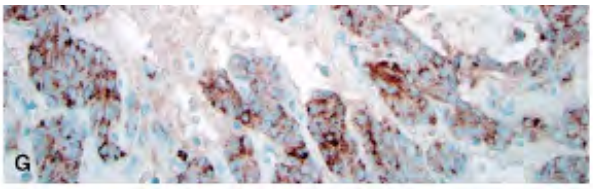

Figure 19.60. A,B. FNA of a follicular carcinoma with mucinous features. The aspirate was
cellular, consisting of several syncytial tissue fragments of follicular cells with and without
pattern. Their nuclei are considerably enlarged in size, pleomorphic, crowded, and overlap
containing coarsely granular chromatin and nucleoli. The cytoplasm is variable and occasion
abundant and foamy. C. Thyroidectomy revealed a large follicular carcinoma with a solid gr
pattern. D. Several areas of the carcinoma showed abundant mucin. E. Strongly positive alc
stain, 2.5 pH confirmed the mucin. F . The mucin was present within the malignant cells an
between the cells. Alcian blue, 2.5 pH. G. Strong positive reactivity to thyroglobulin.

P.432
P.433

The mucin can be demonstrated by histochemical stains such as alcian blue or mucicarmine.
documentation of cytologic findings of thyroid tumors with mucin production is sparse, limit
very few reports.213 , 214 , 215 A case of mucin-producing follicular carcinoma from the au
files is illustrated in Figure 19.60 .

MULTIPLE NEOPLASMS IN THE THYROID

The presence of multiple tumors, benign and malignant, occult or apparent, in the same th
not uncommon,216 , 217 , 218 , 219 , 220 , 221 , 222 but the incidence is not known due to
sparsity of literature on the subject. O'Neill and Lomas218 and Lamberg et al.221 reported
concurrent medullary carcinoma and papillary carcinoma. Ayala et al.222 described a case
Hashimoto's thyroiditis with follicular carcinoma and malignant lymphoma. These reported
were identified following surgery. Cytologic diagnosis of multiple malignancies has not been
reported. Our experience includes 2 cases of Hashimoto's thyroiditis with papillary carcinom
malignant lymphoma (Fig. 19.61) and one case of HÃ¼rthle cell carcinoma and papillary ca
identified in cytologic samples (Fig. 19.62).

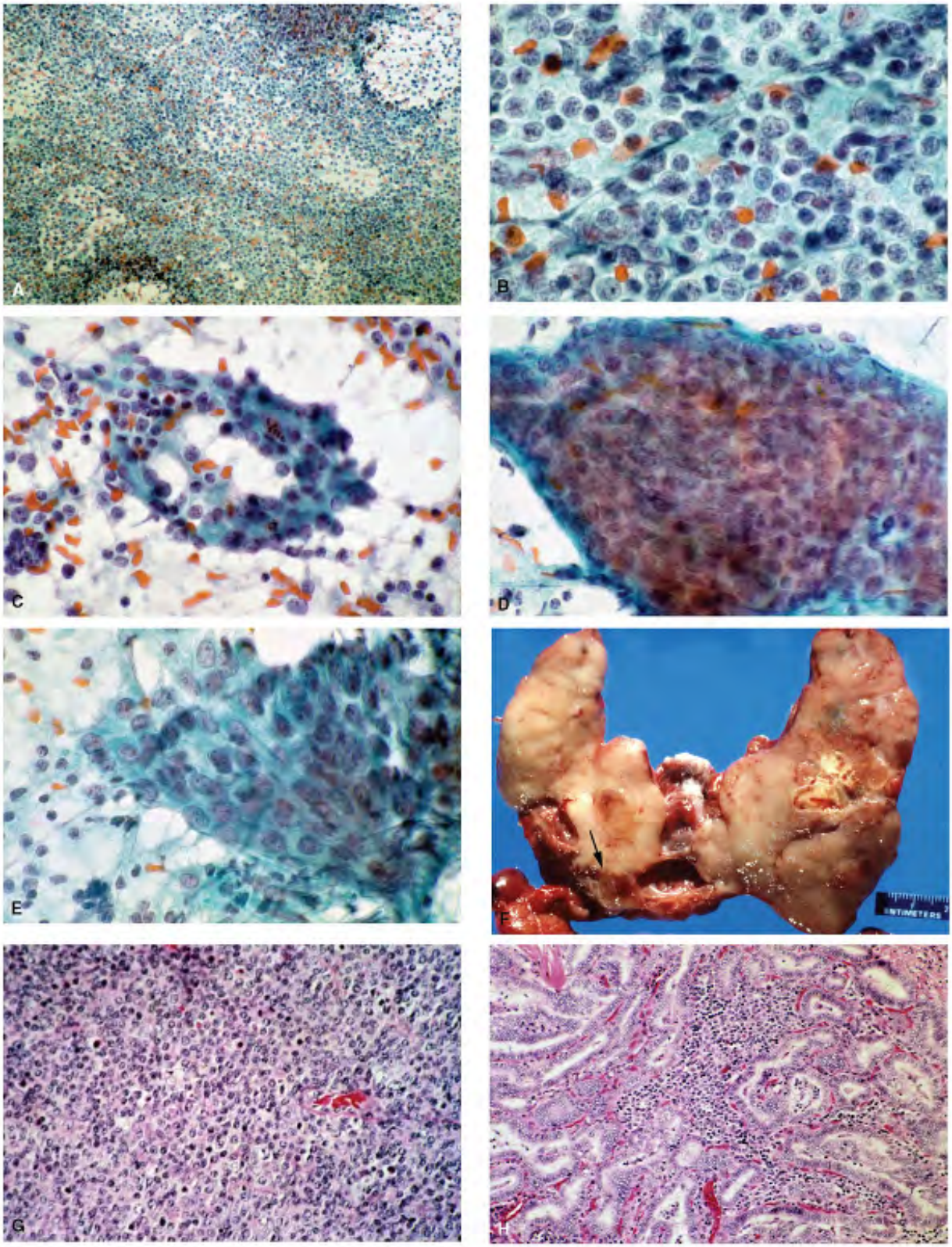

Figure 19.61. FNA of a diffusely enlarged thyroid with nodularity, from a 30-year-old woma

homogeneous population of immature lymphoid cells, low power. B. Higher magnification, consistent with malignant lymphoma. C. Smears from other areas of the thyroid showing fea lymphocytic (Hashimoto's) thyroiditis. D,E. Aspirate also showed syncytial-type tissue fragme with typical nuclear morphology of papillary carcinoma. F. Total thyroidectomy revealed bo enlarged and replaced by a white, fleshy tumor. Note the discrete nodule in the right lobe (G. Histologic section confirming malignant lymphoma, diffuse mixed lymphocytic and large type. H. Section of the discrete nodule showing a papillary carcinoma.

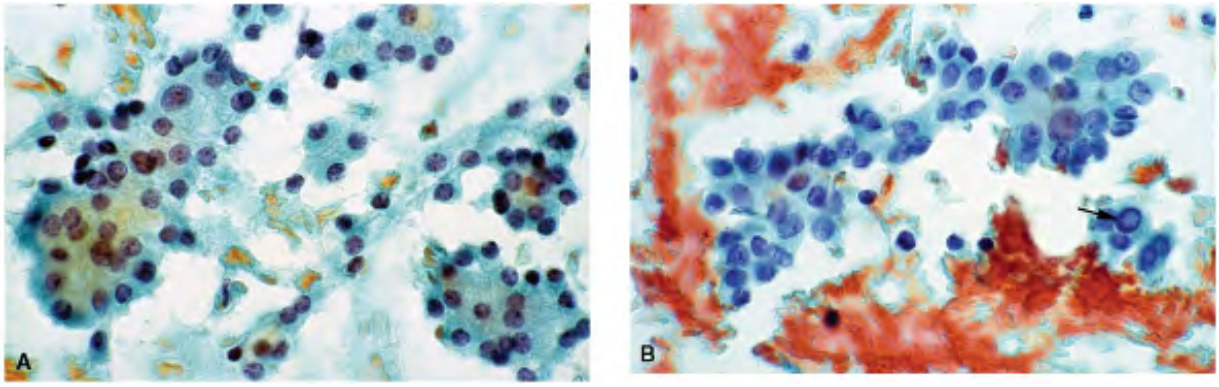

Figure 19.62. A. Aspirate of a cold thyroid nodule showing small HÃ¼rthle cells, discrete ar tissue fragments, suggesting a diagnosis of HÃ¼rthle cell carcinoma. B. Another field from t smear as in a showing syncytial-type tissue fragments, with nuclei exhibiting typical morpho papillary carcinoma. Note the intranuclear cytoplasmic inclusions. Thyroidectomy confirmec HÃ¼rthle cell carcinoma and papillary carcinoma.

NON-THYROID MASSES PRESENTING AS THYROID NODULES

Lesions in front of the neck, or those that move with deglutition, are not necessarily thyroic origin.223 , 224 , 225 , 226 , 227 , 228 , 229 , 230 , 231 , 232 Enlarged cervical lymph nodes tissue tumors along the lateral borders of the thyroid, lesions of the larynx and trachea, thyroglossal duct cysts, branchial cleft cysts, parathyroid lesions, and dermal adnexal tumor all appear clinically to originate in the thyroid gland. Lesions of the tail of the parotid gland clinically appear to be a thyroid nodule at its upper pole. Anterior mediastinal masses exter proximally into the neck may also appear to arise from the thyroid gland. Clinically, radiolo and even on radionuclide scanning, these lesions may simulate cold thyroid nodules. The FN biopsies of such lesions present wide-spectrum cytologic patterns representing a host of lesi

Some are illustrated in the following sections.

MALIGNANT LYMPHOMA, HODGKIN'S AND NON-HODGKIN'S T INVOLVING THE CERVICAL LYMPH NODES

Because cervical lymph nodes often move with the thyroid, they are sometimes clinically an on imaging (Fig. 19.63A) mistaken for thyroid nodules. The same holds true for an anterior mediastinal mass that extends into the neck, covering the thyroid. An aspiration biopsy spec provides an accurate diagnosis in such instances. We have diagnosed 5 cases of Hodgkin's lyr that presented clinically as thyroid masses (Figs. 19.63B and C and 19.64). One case of poor differentiated lymphocytic lymphoma arising from the anterior mediastinum, extended in fr the neck, and presented as goiter. It was correctly identified following an aspiration biopsy 19.65).

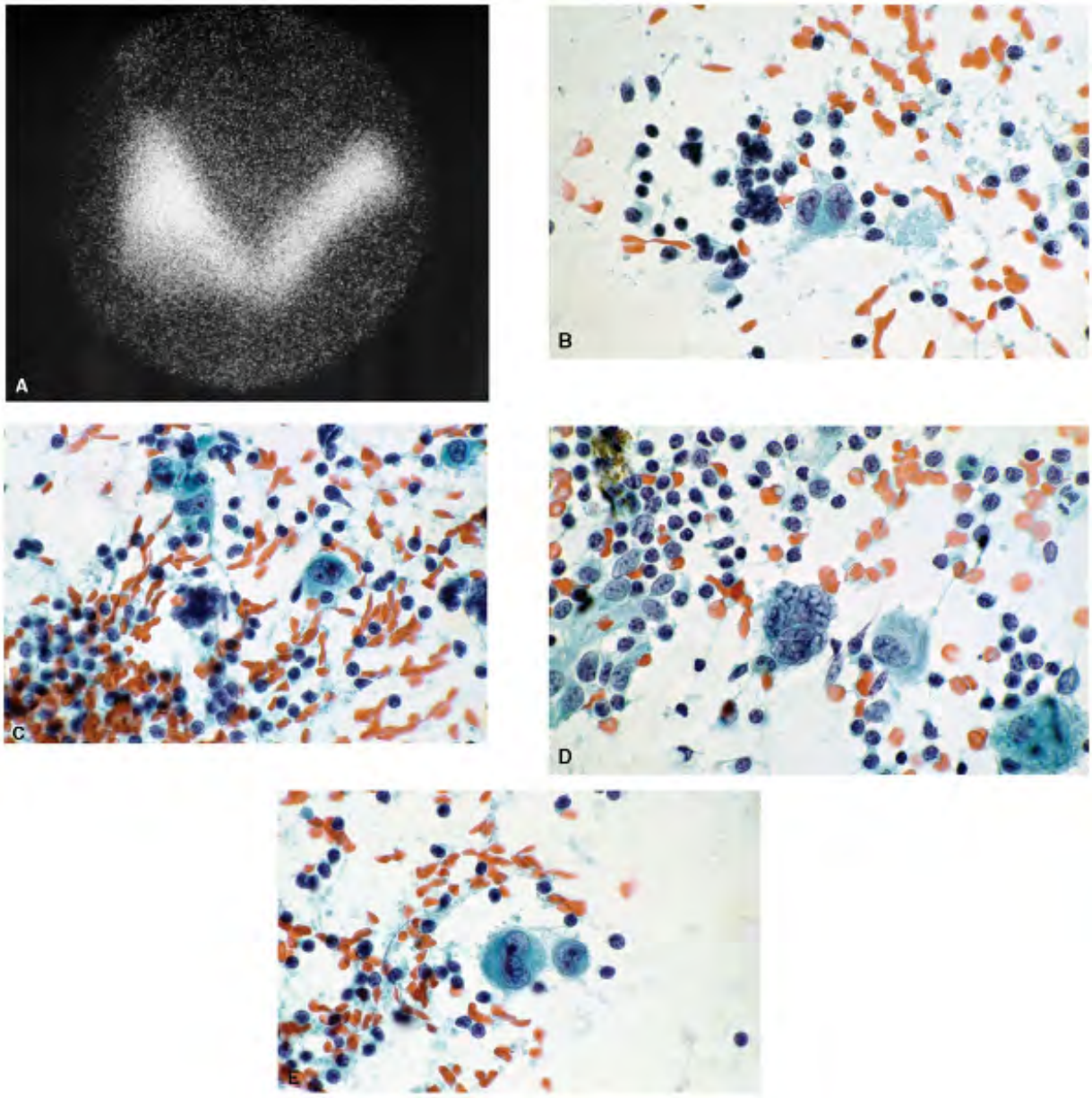

Figure 19.63. A. Radionuclide scan showing an area of decreased uptake in the left lobe of thyroid. Bâ€“E. FNA of the mass showing typical Reedâ€“Sternberg cells. The surgical excisi confirmed Hodgkin's lymphoma involving the cervical lymph node.

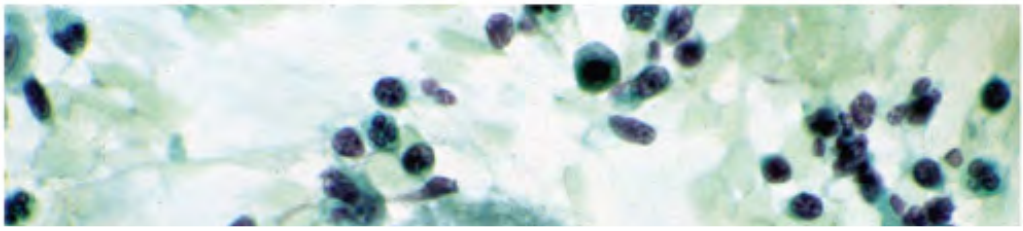

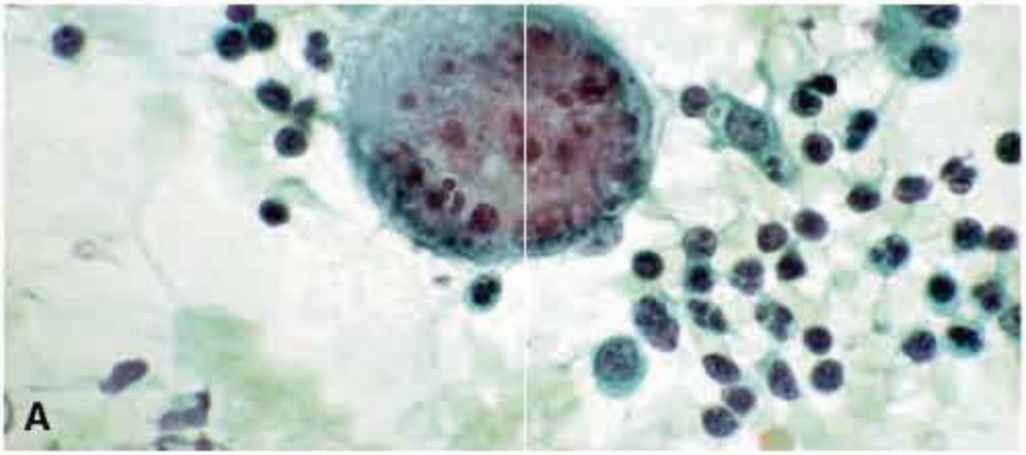
A

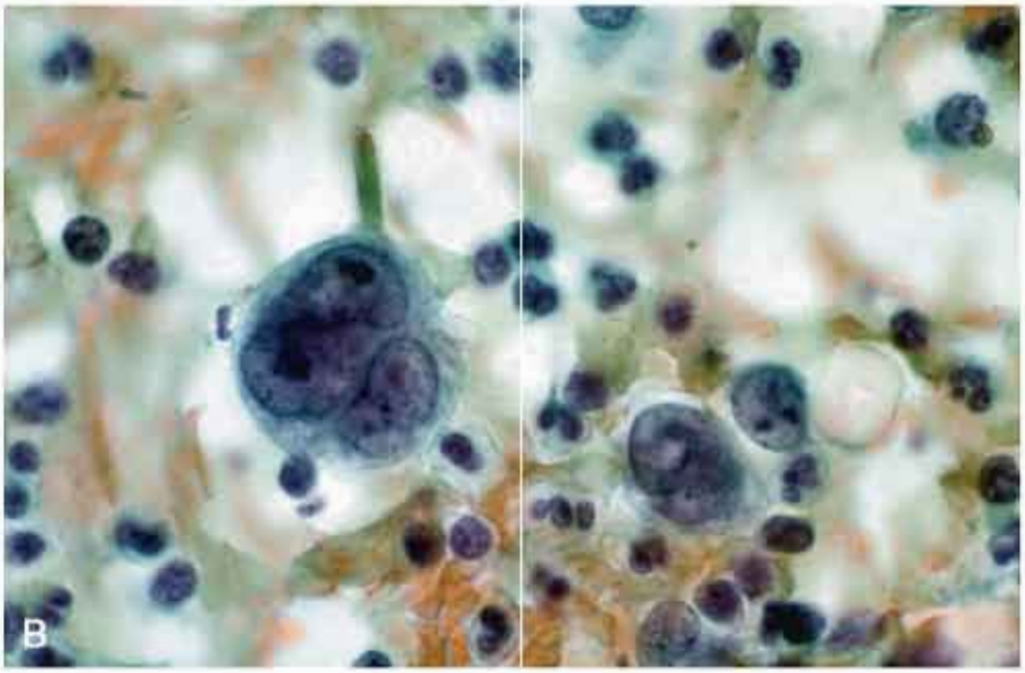
B

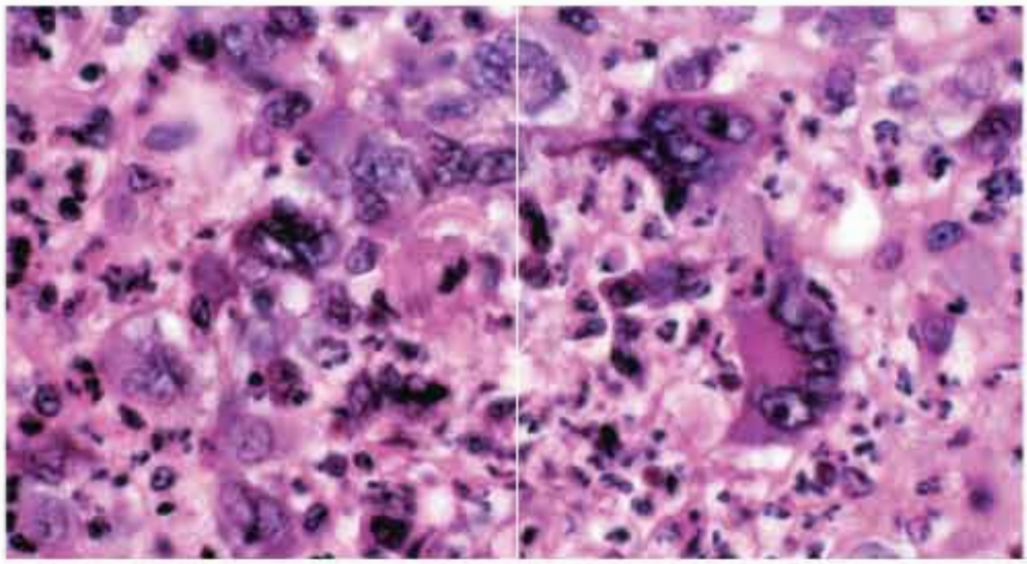

Figure 19.64. A,B. Bizarre tumor giant cells from an aspirate of massively enlarged cervical node. C. Histologic section of the excised lymph node confirmed Hodgkin's lymphoma.

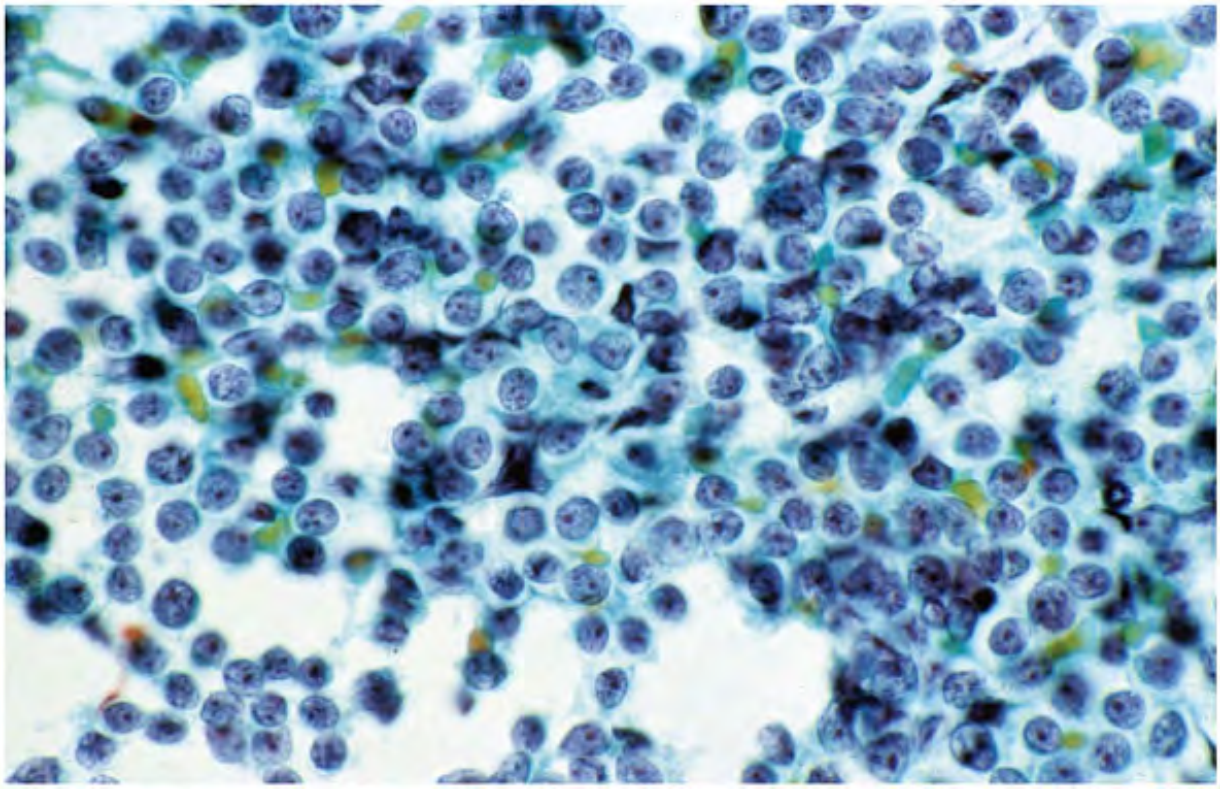

Figure 19.65. FNA of a mediastinal non-Hodgkin's malignant lymphoma poorly differentiatec lymphocytic type. The mediastinal mass extended proximally in the neck and presented as a The smear shows a homogeneous population of poorly differentiated lymphoid cells.

TUMORS OF THE LARYNX AND TRACHEA

Rarely, tumors of the larynx or trachea may involve the thyroid and clinically present as thy nodules. Aspiration biopsies of these lesions may cause diagnostic difficulties because of the unsuspected cytologic features in "thyroid" aspirates. A case of low-grade chondrosarcoma o larynx, an uncommon neoplasm223 , 224 presenting as a thyroid nodule, is illustrated in Figu 19.66 .

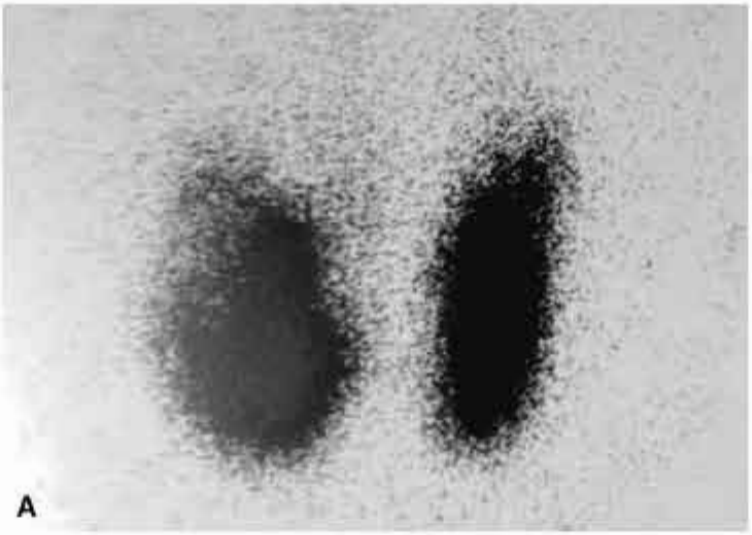
A

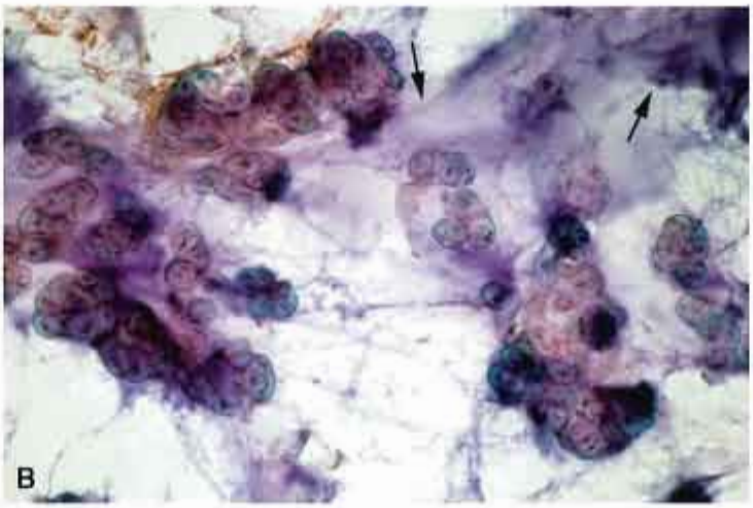
B

C

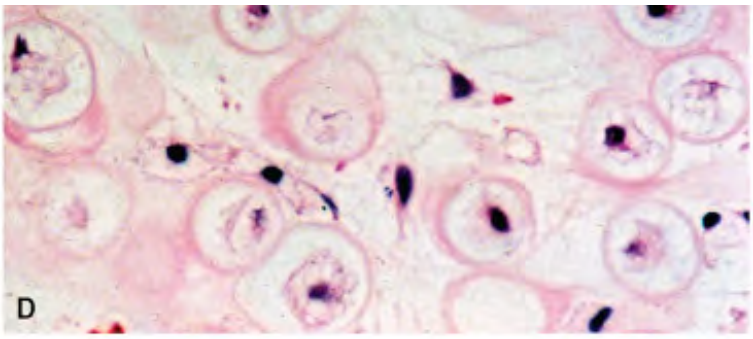

Figure 19.66. A. Radionuclide imaging of a thyroid nodule, present for 2 years in a 70-year-
male with recent enlargement. Note the area of decreased uptake at the right upper pole, v
corresponded to the palpable mass. B. FNA of this "thyroid" nodule showing tissue fragments
large round cells with chondroid stroma (*arrows*) (medium power). C. Higher magnification
clusters of markedly enlarged neoplastic chondrocytes, containing more than one, atypical r
D. Histologic section of the core needle biopsy of the mass showed this mass to be a low-gra
chondrosarcoma.

Natarajan et al.225 reported cytologic findings of a case of adenoid cystic carcinoma of the
that mimicked a thyroid mass. Na et al.226 also reported primary adenoid cystic carcinoma
trachea mimicking thyroid tumor.

SOFT-TISSUE TUMORS IN THE NECK

Soft-tissue tumors in the neck in close proximity to the thyroid gland may mimic thyroid noc
both clinically and on radionuclide imaging. Fine-needle aspiration biopsy will present unusu
cytologic patterns that often present a diagnostic challenge.

Butler and Oertel reported lipomas that simulated thyroid nodules (Fig. 19.67).227 We enco
2 cases of cervical schwannomas that presented as thyroid nodules. One case had an unsatis
fine-needle biopsy but the core-needle biopsy was diagnostic for schwannoma (Fig. 19.68).
second case showed a cellular aspirate consisting of spindle cells in anastomosing fascicles.
nuclei were pleomorphic. The surgical excision confirmed a peripheral malignant nerve-shea
tumor (Fig. 19.69). A spindle cell pattern in a thyroid aspirate must always be differentiate
medullary thyroid carcinoma.228

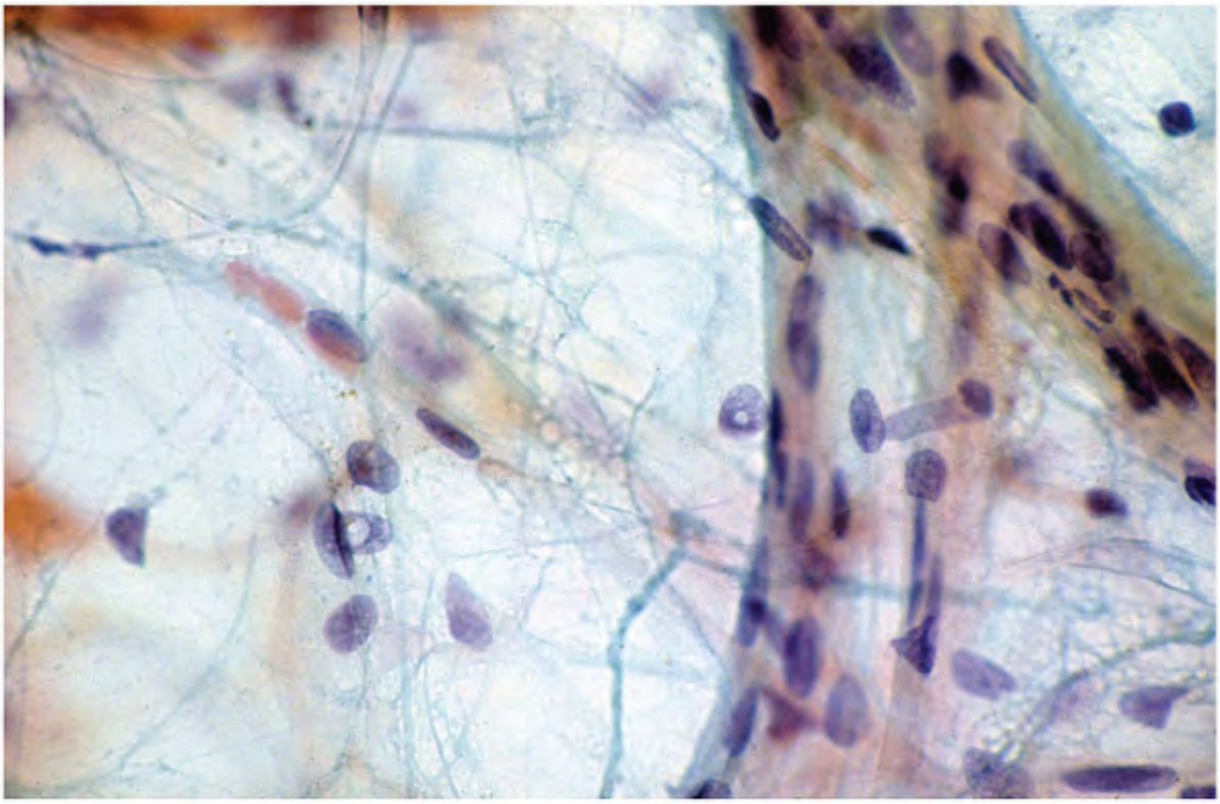

Figure 19.67. FNA of a neck mass clinically appeared to be a thyroid nodule. FNA consisted mature adipose tissue, consistent with lipoma.





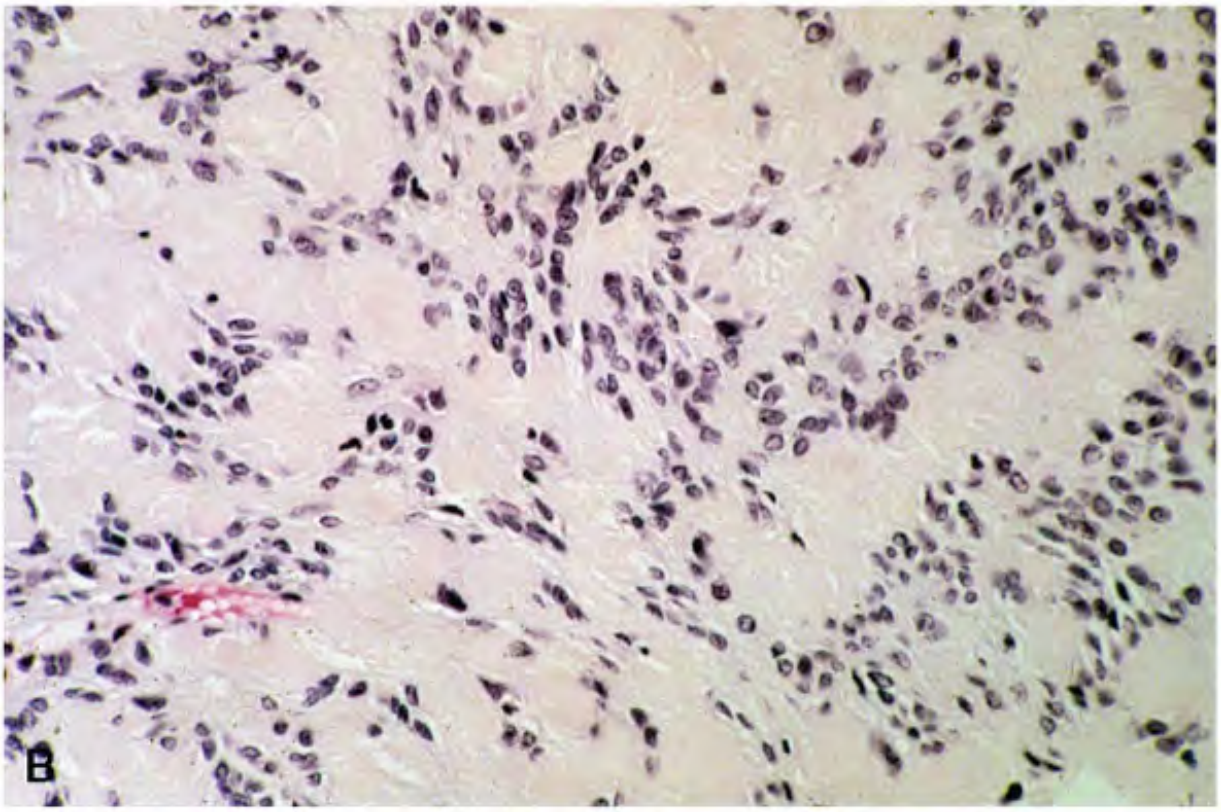

Figure 19.68. A. Thyroid scan from a 16-year-old female, who was found to have a 2-cm fir nodule that seemed to be located at the right upper pole of the thyroid. Note the area of decreased function in the upper pole of the right lobe. The fine-needle biopsy was acellular Large-needle biopsy showed a typical histologic pattern of schwannoma with fascicles of de spindle cells separated by collagenized stroma.

A

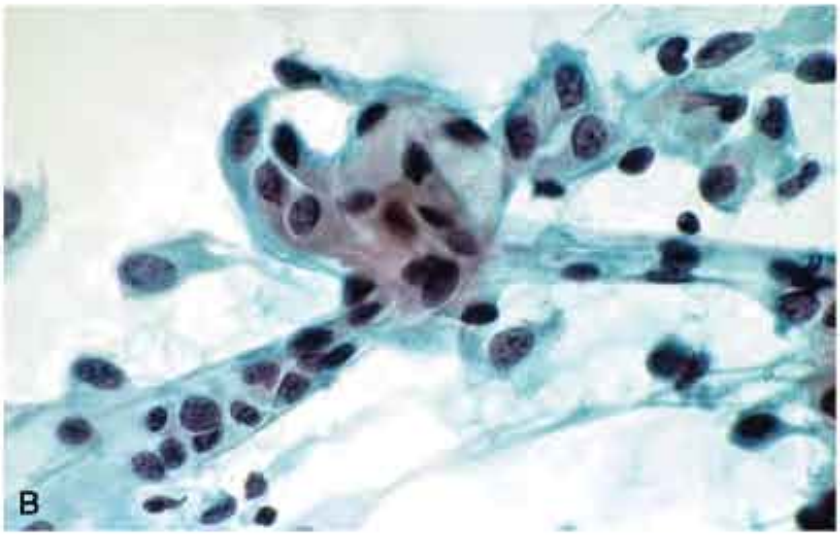
B

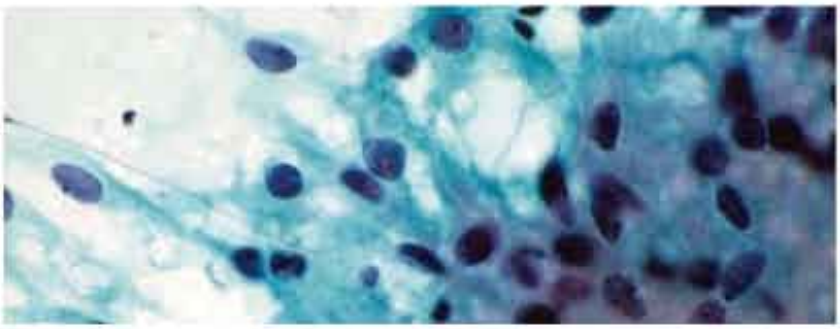

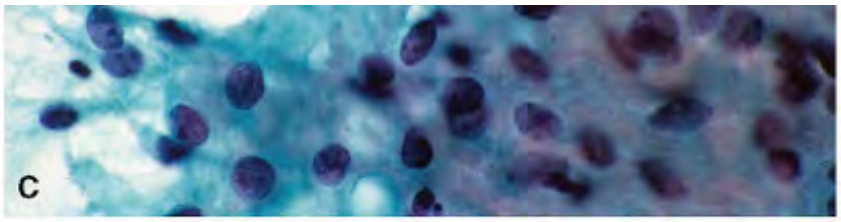

Figure 19.69. A. Fine-needle aspiration biopsy of a nodule, felt to be thyroidal in origin. Th aspirate is cellular, showing several interdigitating tissue fragments of spindle-shaped cells power). B. Higher magnification showing spindle cells with pleomorphic nuclei with low nuclear/cytoplasmic ratios and variable cytoplasm. C. Another field showing a mixture of ro spindle-shaped cells, some with delicate cytoplasmic processes. Exploration of the neck rev nodule in the soft tissues. Histologic examination showed features of a neurogenic tumor.

Some other lesions in the neck reported as masquerading as thyroid nodules include cervica chordoma229 and cervical thymoma.230 , 231 , 232

DERMAL ADNEXAL TUMORS OVER THE THYROID AREA, MIMIC A THYROID LESION

Chondroid Syringoma (Mixed Tumor) of the Skin in the Thy Area

Lesions involving the skin overlying the thyroid gland move with deglutition and may be diag clinically as thyroid nodule. Aspiration biopsy may be of value in recognizing the exact natu lesion. Our experience with a case of chondroid syringoma arising in the skin over the thyroi isthmus is illustrated in Figure 19.70 . The nodule was clinically felt to be thyroidal. The fin aspiration biopsy revealed loosely cohesive groups of delicate small spindle cells that sugges diagnosis of medullary thyroid carcinoma. The neoplastic cells were nonreactive to calciton to thyroglobulin. Surgical excision proved to be a chondroid syringoma.

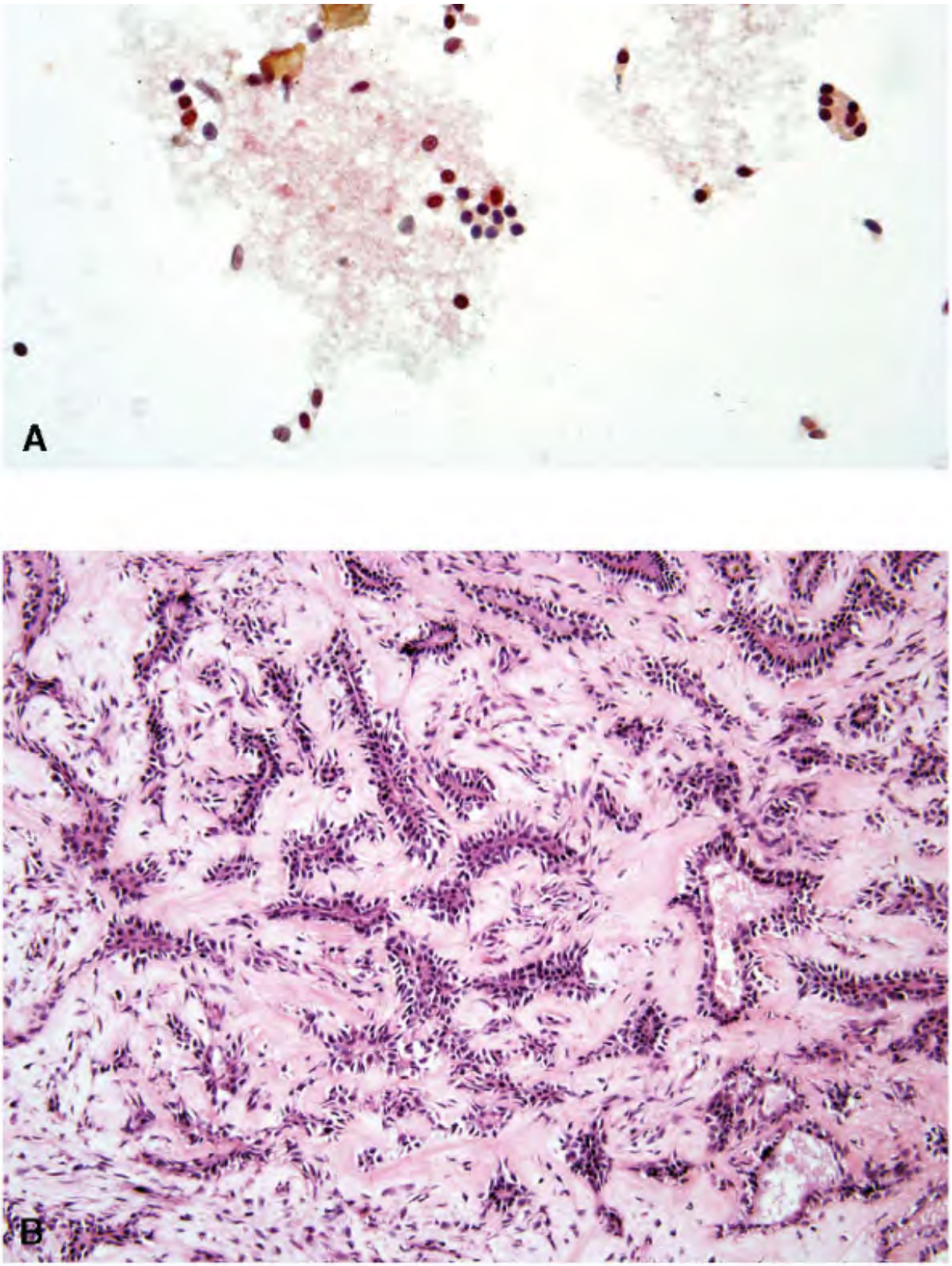

Figure 19.70. A. FNA of a nodule in the thyroid isthmic region that moved with swallowing

thought to be thyroidal in origin. The aspirate is cellular, showing very uniform short spindle with oval to spindle-shaped bland nuclei. The cytologic pattern was suggestive of medullary carcinoma. The calcitonin stain performed on the smear was negative. B. Surgical excision s a benign mixed tumor (chondroid syringoma) of the dermal adnexa.

P.434
P.435
P.436
P.437
P.438
P.439

Salivary Gland Lesions Mimicking Cytologic Patterns of Th Neoplasms

Based on their cytologic features, some salivary gland lesions may occasionally be interprete thyroid origin. We had misinterpreted a case of Warthin's tumor of the parotid gland that wa submitted by an endocrinologist as an aspirate from a nodule, located in the upper pole of t thyroid. The presence of oncocytic cells and the clinical data led to the diagnosis of HÃ¼rth tumor and the patient was referred to the surgeon for the excision (Fig. 19.71A). Immunost performed at the request of the surgeon, since he clinically questioned the thyroid origin, w nonreactive to thyroglobulin (Fig. 19.71B). Surgical exploration resulted in a superficial parotidectomy for Warthin's tumor (Fig. 19.71C).

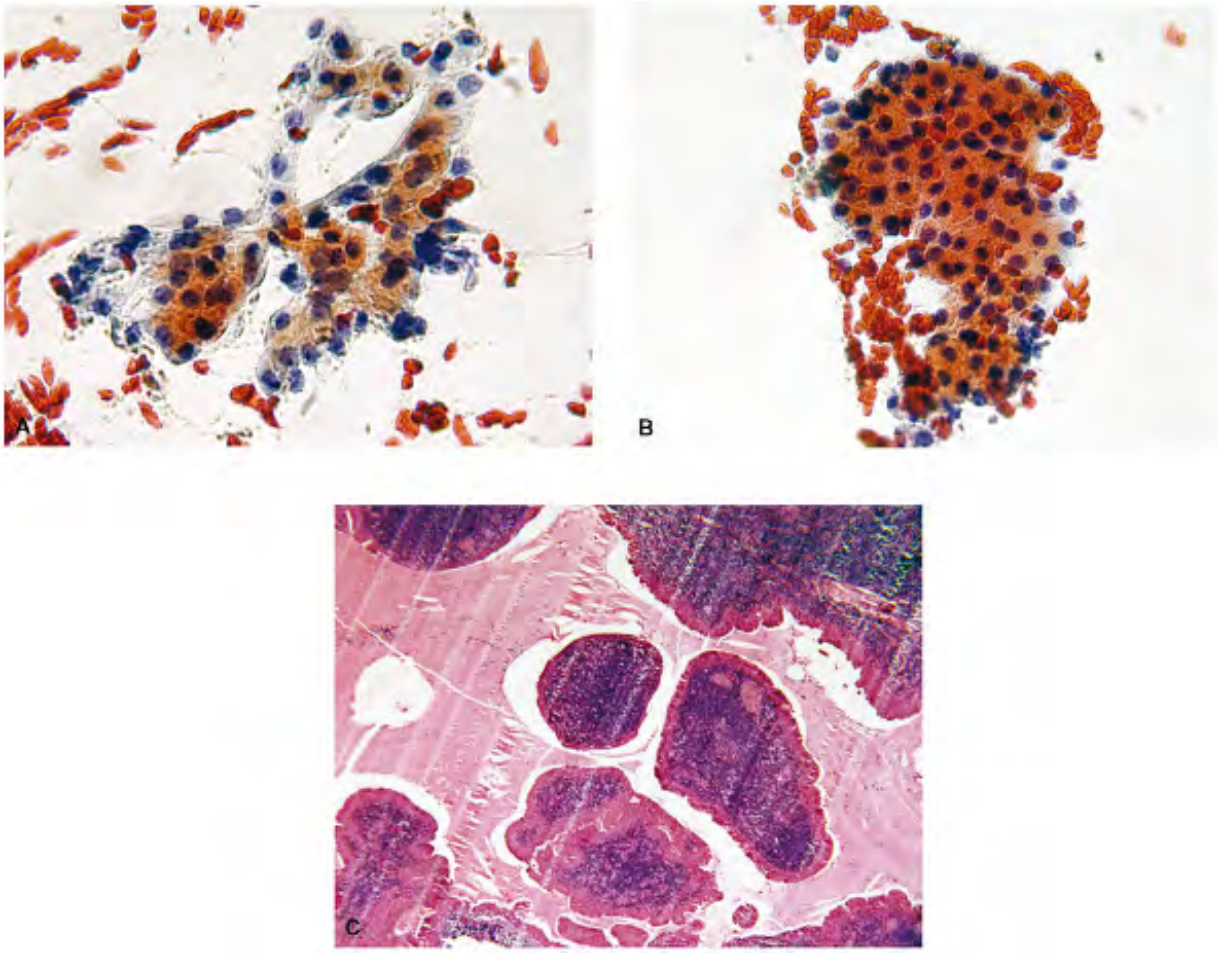

Figure 19.71. A,B. Fine-needle biopsy of a mass in the lateral neck submitted by an endocr as being of thyroidal origin. These oncocytic cells, some in a sheet with a low nuclear/cytop ratio and few lymphocytes in the background, were interpreted as a HÃ¼rthle cell nodule. T patient was referred to an endocrine surgeon who doubted the site of the lesion as thyroid. Immunostain for thyroglobulin was performed which was negative. C. Surgical exploration of area revealed a lesion at the lower pole of the parotid gland. Histologic examination showed Warthin's tumor. Note the oncocytic papillary structure and the lymphoid stroma.

Another case of a mucoepidermoid carcinoma of the submandibular gland was interpreted a metastatic papillary carcinoma of the thyroid. The specimen was submitted as FNA of the submandibular lymph node. The smears of the aspirate revealed several monolayered syncy tissue fragments of neoplastic cells with enlarged nuclei, powdery chromatin, nucleoli, and intranuclear inclusions (Fig. 19.72A to C). A diagnosis of metastatic papillary carcinoma was rendered. The mucoid background was overlooked (Fig. 19.72A). The thyroid gland failed to

any lesion either on palpation or imaging. Surgical exploration showed a mucoepidermoid ca
of the submandibular salivary gland (Fig. 19.72D and E).

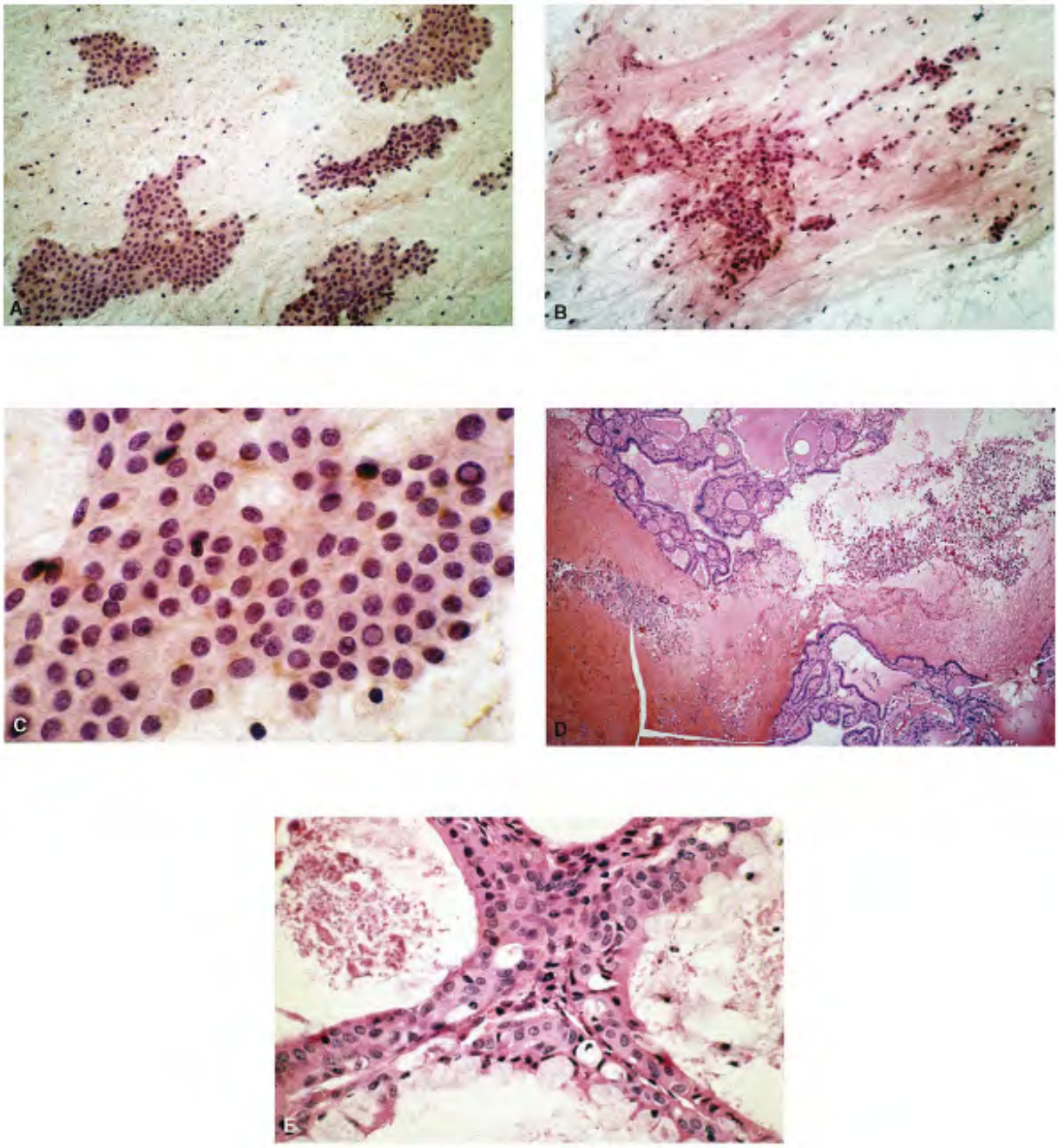

Figure 19.72. A. Fine-needle aspiration of a mucoepidermoid carcinoma of the submandibu
gland. The specimen was submitted as that of a submandibular lymph node. Note the tissue
fragments of neoplastic cells in the background of abundant mucin (low power). B. Another
from this case with several monolayered tissue fragments of neoplastic cells (low power). C.

magnification showing a monolayered but syncytial tissue fragment. The nuclei are enlargec finely granular chromatin, nucleoli, and intranuclear inclusions. A diagnosis of metastatic pa thyroid carcinoma was given. D. Surgical exploration revealed a mass involving the submand salivary gland. Histologic sections revealed a low-grade cystic mucoepidermoid carcinoma. E Higher magnification showing a mucinous component.

COLD THYROID NODULES IN CHILDREN AND ADOLESCENTS

The prevalence of nodular thyroid disease in the adult population is high, reported to be ab by palpation, up to 35% by ultrasound, and almost 50% at autopsy. However, its prevalence i children and adolescents (age up to 18 years) is considerably lower. Towbridge et al.233 fou goiters in 6% of 7,785 children aged 9 to 16 years, while Rallison et al.234 detected goiters i of 5,179 children aged 11 to 18 years. The incidence of diffuse and nodular goiters was foun equal frequency in the Rallison et al.234 study. Most diffusely enlarged thyroid glands durin adolescence are due to Hashimoto's thyroiditis, Graves disease, and multinodular goiter.235 solitary cold nodules of the thyroid are still infrequent in the pediatric and adolescent age groups.233 , 235 This incidence could be higher if the age group was extended to 21 years.2

The incidence of cancer in solitary nodules in this age group is considerably higher as compa the adults and is reported to be anywhere from 2% to 50%.234 , 235 , 236 , 237 , 238 , 239 , 241 , 242 , 243 , 244 , 245 , 246 , 247 , 248 As in adults, clinical evaluation, laboratory data imaging techniques are not very helpful in differentiating non-neoplastic from neoplastic an benign from malignant thyroid nodules. Fine-needle biopsy, an indispensable diagnostic tool evaluation of cold nodules in adults, is underutilized in pediatric population. The manageme cold nodules in children without a preoperative diagnosis is a subject of controversy.243 , 2 , 251 Some authors suggest surgical removal of all solitary nodules, whereas others recomme somewhat conservative approach, based on clinical, laboratory, and imaging data. In recent FNA biopsy has been utilized more frequently in pediatric patients with a high degree of accuracy.238 , 239 , 240 , 242 , 252 , 253 , 254 , 255 , 256 , 257 , 258 Ultrasound guidance l of particularly great help in performing the fine-needle biopsy. A study by Amrikachi et al.2 concluded that only FNA significantly contributed in detecting thyroid malignancies in childl and adolescence, offering the best sensitivity, specificity, and accuracy in detecting malign compared to other conventional methods. Their observation is supported by other studies as well.238 , 239 , 240 , 242 , 252 , 253 , 254 , 255 , 256 , 257 , 258 Some have used large-nee biopsy of the thyroid nodules with success.259

Our experience with 175 children and adolescents aged 9 to 21 years with cold thyroid nodu
proved that the fine-needle biopsy is as useful in this age group as it is in adults

(Table 19.7).242 Nonsurgical diseases, such as nodular goiter or chronic lymphocytic thyroi
(Hashimoto's thyroiditis), are readily identified by aspiration-biopsy specimen. Nodular goite
constituted 36% while lymphocytic thyroiditis represented 12% of the aspirates. A study by R
al.240 reported a higher incidence of benign diagnosis (77%). These results are at variance v
ours, where the incidence of neoplasia was higher. Table 19.8 lists the cytohistologic correl
69 patients from our study who underwent surgery.

Nodular goiter
64
Lymphocytic thyroiditis
21
Cellular follicular adenoma
14
HÃ¼rthle cell tumor
5
Papillary carcinoma
45
Suspected papillary carcinoma
2
Medullary carcinoma
1
Follicular carcinoma
1
Abscess
1
Unsatisfactory
21
TOTAL
175

TABLE 19.7 CYTOLOGIC DIAGNOSES OF 175 PATIENTS AG TO 21 YEARS WITH COLD NODULES

Hashimoto's thyroiditis is the most common cause of thyroid enlargement in the pediatric ag group.260 , 261 Fine-needle biopsy is also very useful in differentiating nodular goiters from lymphocytic thyroiditis. The risk of developing hypothyroidism is higher with the latter, and cytologic diagnosis is complimentary to the other diagnostic procedures. It is also associatec higher incidence of papillary carcinoma.262

The information on benign thyroid neoplasms in the pediatric age group is limited. We enco 17 cases that included 12 follicular adenomas and 5 HÃ¼rthle cell neoplasms among 69 thyroidectomies (Table 19.8), an incidence of 24%.

Nodular goiter
1
1
Cellular adenoma
14
12
1
1
HÃ¼rthle Cell tumor
5
5
Suspected papillary
carcinoma
2
1
1
Papillary
carcinoma
45
1
44

Follicular
carcinoma
1
1
Medullary
carcinoma
1
1
Total
69

Histologic Diagnosis

Cytologic Diagnosis	No. Patients	Nodular Goiter	Follicular Adenoma	Follicular Carcinoma	HÃ¼rthle Tumor	Papillary Carcinoma	Mec Car of T

TABLE 19.8 CYTOHISTOLOGIC CORRELATION OF 69 PEDIAT PATIENTS WITH COLD NODULES

Thyroid cancer is the third most common solid malignant tumor in children and adolescents. incidence of neoplasia in our series was 36% and that of malignancy was 25% (Table 19.8). T majority of thyroid carcinomas in childhood are of the differentiated type, with papillary th carcinomas the most common malignant tumor in this age group, followed by follicular carcinomas.264 , 265 , 266 , 267 , 268 , 269 , 270 , 271 , 272 , 273 , 274 , 275 The risk facto developing carcinomas include radiation exposure.

Papillary carcinomas top the list among childhood thyroid cancers. Although most are conve type papillary carcinomas, a higher incidence of poorly differentiated and sclerosing types h been reported in children exposed to the radiation from Chernobyl studies.277 , 278 , 279 Coexistence of Hashimoto's thyroiditis and papillary carcinomas is frequent.262 Fifteen of 45 papillary carcinomas in our series were associated with Hashimoto's thyroiditis, an incidence Cervical lymph node metastasis is more frequent in children (87.7%) than in adults (34.7%),

postoperative node recurrence and distant metastasis are seen with equal frequency in chil
adults.268 , 273 Survival is comparable to that of adults up to 30 years of age. Other differe
cancers include follicular carcinomas and medullary carcinomas.277 Most children with thyr
cancers fare well, with rare fatalities.272 , 274 , 276

Poorly differentiated malignancies such as insular carcinomas in the pediatric age group hav
documented.280 , 281 Other rare malignancies in this age group include the spindle epithel
tumor with thymus like differentiation (SETTLE)282 , 283 and teratomas.284

DYSHORMONOGENETIC GOITER

Dyshormonogenetic goiters are genetically determined thyroid hyperplasias due to enzyme
in thyroid hormone synthesis.285 , 286 The resulting negative feedback to the pituitary is
responsible for hypersecretion of TSH leading to continuous stimulation and hyperactivity. I
in newborns to adults with a median age of 16 years. Patients present with goiters and are
diagnosed as hypothyroid. The thyroid glands are enlarged, multinodular, and weigh up to 6
Histologically, dyshormonogenetic goiters are characterized by cellular nodules with various
patterns and nuclear atypia, mimicking various types of thyroid neoplasms. Fibrosis is comm
excellent morphologic review is presented by Ghossein et al.285

Fine-needle biopsy is not a recommended test for dyshormonogenetic goiters. A single case
describes cytologic findings.287

REFERENCES

1.Kini SR, Miller JM, Smith-Purslow J. Unusual and uncommon encounters in thyroid aspira
Acta Cytol , 1986;30:571.

Non-Neoplastic Cells of Non-Thyroid Origin

2.Jayaram G. Respiratory epithelial cells in fine needle aspirates of thyroid. *Acta Cytol* .
1995;39:834â€“835.

3.Kumar PV, Omrani G. Respiratory epithelium in aspirates of thyroid gland lesions. *Acta*
1993;37:257.

4.Gay JD, Bjornsson J, Goellner JR. Hematopoetic cells in thyroid fine needle aspirates fo cytologic study: report of two cases. *Mayo Clin Proc* . 1985;60:123â€“124.

5.Micijevic E. Megakaryocytes in a fine needle aspirate of the thyroid gland. *Acta Cytol* . 1990;34:764Aâ€“765A.

6.Ambrogio F, Fedeli U, Borsato S. Extramedullary hematopoesis of the thyroid gland diag by FNA cytology. A case report. *Acta Cytol* . 1999;43:1181â€“1183.

7.Lazzi S, Als C, Mazzucchelli L, et al. Extensive extramedullary hematopoesis in a thyroid nodule. *Mod Pathol* . 1996;9:1062â€“1065.

8.Leoni F, Fabbri R, Pascarella A, et al. Extramedullary hematopoesis in thyroid multinodu goiter preceding clinical evidence agnogenic myeloid metaplasia. *Histopathology* . 1996;28:559â€“561.

9.Schmid C, Beham A, Seewann HL. Extramedullary hematopoesis in the thyroid gland. *Histopathology* . 1989;15:423â€“425.

Multinucleated Giant Cells in Thyroid Aspirates

10.LiVolsi VA. *Surgical Pathology of Thyroid* . Philadelphia: Saunders; 1990.

11.Shabb NS, Tawil A, Gergaos F, et al. Multinucleated giant cells in fine-needle aspiratio thyroid nodules: their diagnostic significance. *Diagn Cytopathol* . 1999;21:307â€“312.

12.Tabbara SO, Acoury N, Siadwy MK. Multinucleated giant cells in thyroid neoplasm. A cytologic, histologic and immunochemical study. *Acta Cytol* . 1996;40:1184â€“1188.

13.Solano JG, Bascunana BG, Perez DM, et al. Fine-needle aspiration of subacute granulomatous thyroiditis (De Quervain's thyroiditis): a clinicopathologic review of 36 case

Diagn Cytopathol . 1997;16:214â€“220.

14.Kini SR, Miller JM, Hamburger JI. Problems in the cytologic diagnosis of the "cold" thyro nodule in the patients with lymphocytic thyroiditis. *Acta Cytol* . 1981;25:506â€“512.

15.Guiter GE, DeLellis RA. Multinucleated giant cells in papillary carcinoma: a morphologi immunohistochemical study. *Am J Clin Pathol* . 1996;106:765â€“768.

16.Orell SR, Walters MNI, Sterrett GF, et al. *Manual and Atlas of Fine Needle Aspiration Cytology* . New York: Churchill-Livingstone; 1996:121â€“122.

17.Leung C-S, Hartwick RWJ, Bedard YC. Correlation of cytologic and histologic features i variants of papillary carcinoma of the thyroid. *Acta Cytol* . 1993;37:645â€“649.

18.Hidvegi DF, Heltgren S, Gallagher L. Origin of giant cells from papillary carcinoma of th thyroid: immunologic enzymatic and ultrastructural aspects of cytopreparations. *Acta Cyt* 1982;26:742.

19.Kini SR, Miller JM, Hamburger JI, et al. Cytologic features of papillary carcinoma of the thyroid. *Acta Cytol* . 1980;24:511â€“521.

20.Kumar PV, Torabinejad S, Omrani GH. Osteoclastoma-like anaplastic carcinoma of the thyroid gland diagnosed by fine needle aspiration cytology. Report of two cases. *Acta Cyto* 1997;41:1345â€“1348.

21.Lee JS, Lee CS, Park CS, et al. Fine needle aspiration cytology of anaplastic carcinoma osteoclast-like giant cells of the thyroid: a case report. *Acta Cytol* . 1996;40:1309â€“1312

22.Berry B, Macfarlane J, Chan N. Osteoclastoma like anaplastic carcinoma of the thyroid diagnosis by FNA cytology. *Acta Cytol* . 1990; 34:248â€“250.

Black Thyroid Associated with Minocyclin Therapy

23.Reid JD. The black thyroid associated with minocycline therapy. *Am J Clin Pathol* . 1983;79:738â€“746.

24.Attwood HD, Dennett X. A black thyroid and minicyclin treatment. *BMJ* . 1976;2:1109â€“1110.

25.Landas SK, Schelper RL, Tio FO, et al. Black thyroid syndrome, exaggeration of a norma process? *Am J Clin Pathol* . 1986;85:411â€“418.

26.Bell CD, Kovacs K. Horvath E, et al. Histologic, immunohistochemical and ultrastructur findings in a case of minocycline-associated "black-thyroid." *Endocr Pathol* . 2002;12:443â€

27.Veinot JP, Ghadially FN. Melanosis thyroid. *Ultrstruct Pathol* . 1998;22:401â€“406.

28.Hecht DA, Wenig BM, Sessions RB. Black thyroid: a collaborative series. *Otolaryngol He Neck Surg* . 1999;121:293â€“296.

29.Wenig BM, Heffess C, Adair CF. *Atlas of Endocrine Pathology* . Philadelphia: Saunders; 1997:42â€“43.

30.Oertel YG, Oertel JE, Dalal K, et al. Black thyroid revisited: cytologic diagnosis in fine-needle aspirates is unlikely. *Diagn Cytopathol* . 2006;34:106â€“111.

31.Jennings TA, Sheehan CE, Chodos RB. Follicular carcinoma associated with minocyclin-induced black thyroid. *Endocr Pathol* . 1996;7:345â€“348.

32.Pastolero GC, Asa SL. Drug-related pigmentation of the thyroid associated with papilla carcinoma. *Arch Pathol Lab Med* . 1994;118:79â€“83.

33.Keyhani-Rofagha S, Kooner DS, Landas SK, et al. Black thyroid: A pitfall for aspiration

cytology. *Diagn Cytopathol* , 1991;7:640â€“643.

Teflon Granuloma of the Thyroid

34.LiVolsi VA. *Surgical Pathology of Thyroid* . Philadelphia: Saunders; 1990:60,64.

35.Wilson RA, Gartner WS. Teflon granuloma mimicking a thyroid tumor. *Diagn Cytopatho* 1987;3:156â€“158.

36.Sanfilippo F, Shlburne J. Analysis of Polytef granuloma mimicking a cold thyroid nodule months after laryngeal injection. *Ultrastruct Pathol* . 1980;1:471â€“470.

37.Walsh FM, Castelli JB. Polytef granuloma clinically simulating carcinoma of the thyroid *Otolaryngol* . 1975;101:262â€“263.

Amyloid Goiter

38.Hamed G, Heffess CS, Shmookler BM, et al. Amyloid goiter. A clinicopathologic study o cases and review of the literature. *Am J Clin Pathol* . 1995;104:306â€“312.

39.LiVolsi VA. *Surgical Pathology of Thyroid* . Philadelphia: Saunders; 1990:111.

40.Nijhawan VS, Marwaha RK, Sahoo M, et al. Fine needle aspiration cytology of amyloid g A report of four cases. *Acta Cytol* . 1997;41:830â€“834.

41.Kapila K, Verma K. Amyloid goiter in fine needle aspirate. *Acta Cytol* . 1993;37:256â€“

42.Lucas A, Sanmarti A, Salinas I, et al. Amyloid goiter. Diagnosis by fine-needle aspiratio biopsy of the thyroid. *J Endocrinol Invest* . 1989;12:43â€“46.

43.Gharib M, Goellner JR. Diagnosis of amyloidosis by fine needle aspiration biopsy of the thyroid. *N Engl J Med* . 1981;305:586.

Radiation-Induced Cellular Changes

44.Wenig BM, Heffess C, Adair CF. *Atlas of Endocrine Pathology* . Philadelphia: Saunders; 1997:57,58.

45.Mizukami Y, Michigishi T, Nonomura A, et al. Histologic changes in Grave's thyroid glan after ^{131} I therapy for hyperthyroidism. *Acta Pathol Jpn* . 1992;42:420â€“426.

46.LiVolsi VA. *Surgical Pathology of Thyroid* . Philadelphia: Saunders; 1990:107â€“111.

47.Carr RF, LiVolsi VA. Morphologic changes in the thyroid after irradiation for Hodgkin's a non-Hodgkin's lymphoma. *Cancer* . 1989;64: 825â€“829.

48.Pretorius HT, Katikeni M, Kinsella, TJ, et al. Thyroid nodules occurring after high-dose external radiotherapy: fine needle aspiration cytology in diagnosis and management. *JAM* 1982;247:3217â€“3220.

49.Kennedy JS, Thomson JA. The changes in the thyroid gland after irradiation with ^{131} I c partial thyroidectomy for thyrotoxicosis. *J Pathol* . 1974;112:65â€“81.

50.Murphy E, Zervantes C. Atypical changes in thyroid follicular cells secondary to radioio *Am J Roentgenol* . 1970;109:724â€“728.

51.Vickery AL Jr. Thyroid Alterations Due to Irradiation. In: Hazard BJ, Smith DE, eds. *The Thyroid* . International Academy of Pathology monograph no. 5. Baltimore: Williams & Wil 1964:183â€“205.

52.Dailey MZ, Lindsay S, Miller ER. Histologic lesions in the thyroid glands of patients rece radioiodine for hyperthyroidism. *J Clin Endocrinol Metab* . 1953;13:1513â€“1529.

53.Saqui A, Hoda R, Kuhel WJ, et al. Cytologic changes mimicking papillary carcinoma of

thyroid after ^{131} I treatment. *Acta Cytol* . 1999;43:971â€“972.

54.Sturgis CD. Radioactive iodine-associated cytomorphologic alterations in thyroid follicu epithelium: is recognition possible in fine-needle aspiration specimens? *Diagn Cytopathol* 1999;21:207â€“210.

55.De la Roza G, Burke KC, Dumlar JS, et al. Aspiration cytology of ^{131} I-induced thyroiditi case report. *Acta Cytol* . 1997;41:1369â€“1372.

56.Granter SR, Cibas ES. Cytologic findings in thyroid nodules after ^{131} I treatment of hyperthyroidism. *Am J Clin Pathol* . 1997;107:200â€“205.

57.Centeno BA, Szyfelbein WM, Daniels GH, et al. Fine needle aspiration biopsy of the thy gland in patients with prior Grave's disease treated with radioactive iodine: Morphologic findings and potential pitfalls. *Acta Cytol* . 1996;40:1189â€“1197.

58.Oz F, Urganicoglu I, Uslu I, et al. Cytologic changes induced by ^{131} I in the thyroid glan patients with hyperthyroidism: results of fine needle aspiration cytology. *Cytopathology* . 1994;5:154â€“163.

59.Verma RN, Dhananjayan G, Saini JS, et al. Fine needle aspiration biopsy: a critical investigation in thyrotoxicosis. *Ind J Pathol Microbiol* . 1992;35:209â€“218.

60.Droese M. *Cytological Aspiration Biopsy of the Thyroid Gland* . Sttutgart: Schattauer; 1980:55â€“62.

Inclusions in Thyroid

61.Wenig BM, Heffess C, Adair CF. *Atlas of Endocrine Pathology* . Philadelphia: Saunders; 1997:37,38.

62. LiVolsi VA. In: *Surgical Pathology of the Thyroid* . Major Problems in Pathology, Vol. 22
Philadelphia: Saunders; 1990:289â€“291.

63. Livolsi VA, Asa SL. *Endocrine Pathology* . New York: Churchill Livingstone; 2002:85.

64. Harach HR. Solid cell nests of thyroid. *J Pathol* . 1988;155:191â€“200.

65. Mizukami Y, Nonomura A, Michigishi T, et al. Solid cell nests of thyroid. A histologic ne
the thyroid. *Am J Clin Pathol* . 1994;101:186â€“191.

66. Feliciano DV. Parathyroid pathology in an intrathyroid position. *Am J Surg* .
1992;164:496â€“500.

67. Clark DP, Faquin WC. *Thyroid Cytopathology* . New York: Springer Verlag; 2005:114â€“

Squamous Cells, Squamous Metaplasia, and Squamous Carcinoma

68. Wenig BM, Heffess C, Adair CF. *Atlas of Endocrine Pathology* . Philadelphia: Saunders;
1997:37,38.

69. LiVolsi VA. Squamous Lesions of the Thyroid. In: *Surgical Pathology of the Thyroid* . *Ma*
Problems in Pathology, vol. 22. Philadelphia: Saunders; 1990:289â€“302.

70. LiVolsi VA, Merino MJ. Squamous cells in the human thyroid gland. *Am J Surg Pathol* .
1978;2:133â€“140.

71. Dube VE, Joyce TG. Extreme squamous metaplasia in Hashimoto's thyroiditis. *Cancer* .
1971;27:434â€“437.

Squamous Carcinoma

72.Rosai J, Carcangiu ML, DeLellis RA. Tumors of the thyroid gland. In: Rosai J, Sobin LH, *Atlas of Tumor Pathology* . Washington, DC: Armed Forces Institute of Pathology; 1993:19

73.Lam KY, Sakamoto A.. Squamous cell carcinoma. In: DeLellis RA, Lloyd RV, Heitz PU, e eds. *Pathology and Genetics of Tumors of Endocrine Organs* . *World Health Organization Classification of Tumors* . Lyon: IARC Press; 2004:81.

74.Baloch ZW, LiVolsi VA. Chapter 4, *Pathology of Thyroid.* In eds. Livolsi VA Asa SL. Endo Pathology New York, Churchill Livingstone 2002:84â€“85.

75.Lam KM, Lo CY, Lie MC. Primary SCC of the thyroid gland: an entity with aggressive bel and distinctive cytokeratin expression profiles. *Histopathology* . 2001;39:279â€“286.

76.Kleer CG, Giordano TJ, Merino MJ. Squamous cell carcinoma of the thyroid: an aggress tumor associated with tall cell variant of papillary carcinoma. *Mod Pathol* . 2000;13:742â€

77.Sahoo M, Bel CS, Bhatnagar D. Primary squamous carcinoma of the thyroid: new eviden support of follicular epithelial cell origin. *Diagn Cytopathol* . 2002;27:227â€“231.

78.Kumar PV, Malekhusseini SA, Talei AR. Primary squamous cell carcinoma of the thyroid diagnosed by fine needle aspiration cytology. A report of two cases. *Acta Cytol* . 1999;43:659â€“662.

79.Mai KT, Yazdi HM. Fine needle aspiration biopsy of primary squamous cell carcinoma o thyroid gland. *Acta Cytol* . 1999;43:1194â€“1196.

Ectopic Thyroid

80.Wenig BM, Heffess C, Adair CF. *Atlas of Endocrine Pathology* . Philadelphia: Saunders; 1997:32â€“34.

81.Rosai J, Carcangiu ML, DeLellis RA. Tumors of the thyroid gland. In: Rosai J, Sobin LH,

Atlas of Tumor Pathology . Washington, DC: Armed Forces Institute of Pathology; 1993;317â€“318.

82.LiVolsi VA. Squamous lesions of the thyroid. In: *Surgical Pathology of the Thyroid* . *Maj Problems in Pathology* , Vol. 22. Philadelphia: Saunders; 1990:7â€“8.

83.Bhadani PP, Agarwal A, Sah SP, et al. Fine needle aspiration diagnosis of ectopic thyro with laboratory features of hyperthyroidism. *Acta Cytol* . 2005;49:228â€“229.

84.Kumar PV, Akbari HM, Arjmand F. Lingual thyroid diagnosed by fine needle aspiration cytology. *Acta Cytol* . 1996;42:387â€“389.

85.Wang CY, Chang TC. Preoperative thyroid ultrasonography and fine needle aspiration cytology in ectopic thyroid. *Am Surg* . 1995;61:1029â€“1031.

86.Stanek J, Busseniers AE. Fine needle aspiration diagnosis of ectopic thyroid: report of case. *Diagn Cytopathol* . 1991;9:59â€“62.

87.Zerkin HJ, Hertzanu Y, Gal R. Fine needle aspiration cytology and immunocytochemist case of intrathoracic thyroid goiter. *Acta Cytol* . 1987;31:694â€“698.

Thyroglossal Duct Cysts

88.Wenig BM, Heffess C, Adair CF. *Atlas of Endocrine Pathology* . Philadelphia: Saunders; 1997:32â€“33.

89.Rosai J, Carcangiu ML, DeLellis RA. Tumors of the thyroid gland. In: Rosai J, Sobin LH, *Atlas of Tumor Pathology* . Washington, DC: Armed Forces Institute of Pathology; 1993;317â€“320.

90.LiVolsi VA. *Surgical Pathology of Thyroid* . Philadelphia: Saunders; 1990:107â€“111.

91.Soloman JR, Rangecroft L. Thyroglossal-duct lesions in childhood. *J Pediatr Surg* . 1984;19:555â€“556.

92.North JH Jr. Foley AM, Hamill RL. Intrathyroid cysts of thyroglossal duct origin. *Am Sur* 1998;64:886â€“888.

93.McHenry CY, Danish R, Murphy T, et al. Atypical thyroglossal duct cyst: a rare cause fo solitary thyroid nodule in childhood. *Am J Surg* . 1993;59:223â€“228.

94.Hatada T, Ichii S, Sagayama K, et al. Intrathyroid thyroglossal duct cyst simulating a th nodule. *Tumori* . 2000;86:250â€“252.

95.Chow LT-C. Cholesterol-rich thyroglossal cyst: report of a case diagnosed by fine needl aspiration. *Acta Cytol* . 1996;40:377â€“379.

96.Shahin A, Burroughs FH, Kirby JP, et al. Thyroglossal duct cyst: a cytopathologic study cases. *Diagn Cytopathol* . 2005;33:365â€“369.

97.Chang TJ, Chang TC, Hsiao YL. Fine needle aspiration cytology of thyroglossal duct cys analysis of 10 cases. *Acta Cytol* . 1999;43:321â€“322.

98.Shaffer M, Ortel Y. Thyroglossal duct cysts: criteria by fine needle aspiration. *Am J Cli Pathol* . 1994;102:52A.

99.Shaffer M, Ortel Y, Ortel JE. Thyroglossal duct cysts. Diagnostic criteria by fine-needle aspiration. *Arch Path Lab Med* . 1996;120:1039â€“1043.

100.Heshmati HM, Fatoutrechi V, van Heerden JA, et al. Thyroglossal duct carcinoma: rep 12 cases. *Mayo Clin Proc* . 1997;72:315â€“319.

101.Boswell WC, Zoller M, Williams J, et al. Thyroglossal duct carcinoma. *Am Surg* .

1996;60:650â€“655.

102.Chen F, Sheridan B, Nankervis J. Carcinoma of the thyroglossal duct: case reports and literature review. *Aust NZ J Surg* . 1993;63:614â€“616.

103.Trail ML, Zeringue GP, Chicola JP. Carcinoma in the thyroglossal duct remnants. *Laryngoscope* . 1977;84:1685â€“1691.

104.Lyos AT, Schwartz MR, Malpica A, et al. HÃ¼rthle cell adenoma arising in a thyrogloss duct cyst. *Head Neck* . 1993;15:348â€“351.

105.Tovi F, Fliss DM, Inbar-Yanari J. HÃ¼rthle cell adenoma of the thyroglossal duct remn *Head Neck Surg* . 1988;10:346â€“349.

106.Yang YJ, Haghir S, Wanamaker JR, et al. Diagnosis of papillary carcinoma in a thyrogl duct cyst by fine needle aspiration biopsy. *Arch Pathol Lab Med* . 2000;124:139â€“142.

107.Chen KTK. Cytology of thyroglossal cyst papillary carcinoma. *Diagn Cytopathol* . 1993;9:318â€“321.

108.Weiss SD, Orlich CC. Primary papillary carcinoma of a thyroglossal duct cyst: report o case and literature review. *Br J Surg* . 1991;78:87â€“89.

109.Kashkari S. Identification of papillary carcinoma in a thyroglossal cyst by fine needle aspiration biopsy. *Diagn Cytopathol* . 1990;6:267â€“270.

110.Adler M, Freeman H. HÃ¼rthle cell carcinoma of the thyroglossal duct. *Head Neck Sur* 1991;13:446â€“449.

111.Nouds R, Saunders JR, Pearlman S, et al. Anaplastic carcinoma arising in a thyroglossa

tract. *Otolaryngol Head Neck Surg* . 2003;109:945â€“949.

112.Nussbaum M, Buckwald RP, Ribna A, et al. Anaplastic carcinoma arising from median ectopic thyroid thyroglossal duct remnant. *Cancer* . 1981;48:2724â€“2728.

113.Ranieri E, D'Andrea MR, Veechione A. Fine needle aspiration cytology of squamous carcinoma arising in a thyroglossal duct cyst: a case report. *Acta Cytol* . 1996;40:747â€“75

114.Hanna E. Squamous cell carcinoma in a thyroglossal duct cyst (TGDC): clinical present diagnosis and management. *Am J Otolaryngol.* 1996;17:353â€“357.

115.Yanagisawa K, Eisen RN, Sasaki CT. Squamous cell carcinoma arising in thyroglossal du cyst. *Arch Otolaryngol Head Neck Surg* . 1992;116:538â€“541.

Thyroid Carcinoma Showing Thymus-Like Element (CASTLE

116.Chan JK, Rosai J. Tumors of the neck showing thymic or related branchial pouch differentiation: A unifying concept. *Hum Pathol* . 1991;22:349â€“367.

117.Miyachi A, Kuma K, Matsuzuka F, et al. Intrathyroid epithelial thymoma: an entity dis from squamous carcinoma of the thyroid. *World J Surg* . 1985;9:128â€“135.

118.Cheuk W, Chan JKC, Dorfman DM, et al. Spindle cell tumour with thymus-like differentiation. In: DeLellis RA, Lloyd RV, Heitz PU, et al, eds. *Pathology and Genetics of Tumors of Endocrine Organs* . *World Health Organization Classification of Tumors* . Lyon: Press; 2004:964â€“995.

119.Livolsi VA, Asa SL. *Endocrine Pathology* . New York: Churchill Livingstone; 2002:85â€“

120.Rosai J, Carcangiu ML, DeLellis RA. Tumors of the thyroid gland. In: Rosai J, Sobin LH, *Atlas of Tumor Pathology* . Washington, DC: Armed Forces Institute of Pathology; 1993.

121.Damiani S, Filotico M, Eusebi V. Carcinoma of the thyroid showing thymoma-like featu
Virchows Arch . 1991;418:463Aâ€“466A.

122.Asa SL, Dardick I, Van Norstrand AW, et al. Primary thyroid thymoma: a distinct clinicopathologic entity. *Hum Pathol* . 1988;19:1463â€“1467.

123.Nasser A, Saqui A, Baloch Z, et al. Carcinoma showing thymus-like element of the thy
Acta Cytol . 2003;47:313â€“315.

124.Ng WK, Collins RJ, Shek WH, et al. Cytologic diagnosis of "CASTLE" of thyroid gland: re
of a case with histologic correlation. *Diagn Cytopathol* . 1996;15:224â€“227.

125.Gerhard R, Kanashiro EH, Kliemann CM, et al. Fine-needle aspiration biopsy of ectopi
cervical spindle cell thymoma: a case report. *Diagn Cytopatol* . 2005;32:358â€“362.

Spindle Epithelial Tumor with Thymus-Like Differentiation

126.Chan JK, Rosai J. Tumors of the neck showing thymic or related branchial pouch differentiation a unifying concept. *Hum Pathol* . 1991;22:349â€“367.

127.Cheuk W, Chan JKC, Dorfman DM, et al. Spindle cell tumor with thymus-like differentiation. In: DeLellis RA, Lloyd RV, Heitz PU, et al., eds. *Pathology and Genetics of Tumors of Endocrine Organs* . *World Health Organization Classification of Tumors* . Lyon: Press; 2004:94.

128.Rosai J, Carcangiu ML, DeLellis RA. Tumors of the thyroid gland. In: Rosai J, Sobin LH,
Atlas of Tumor Pathology . Washington, DC: Armed Forces Institute of Pathology; 1993:28

129.Harach HR, Seravia D, Franssila KO. Thyroid spindle cell tumor with mucous cysts. An intrathyroid thymoma? *Am J Surg Pathol* . 1985;9:525â€“530.

130.Levey M. An unusual tumor in a child. *Laryngoscope* . 1976;86:1864â€“1868.

131.Weigensberg C, Dalsey H, Asa SL, et al. Thyroid thymoma in childhood. *Endocr Pathol* 1990;1:123â€“127.

132.Cheuk W, Jacobson AA, Chan JKC. Spindle epithelial tumor with thymus-like different (SETTLE): a distinctive malignant thyroid neoplasm with significant metastatic potential. *Pathol* . 2000;13:1150â€“1155.

133.Kirby PA, Ellison WA, Thomas PA. Spindle epithelial tumor with thymus-like differenti (SETTLE) of the thyroid with prominent mitotic activity and focal necrosis. *Am J Surg Pat* 1999;23:712â€“716.

134.Chetty R, Goetsch S, Nayler S, et al. Spindle epithelial tumor with thymus-like differentiation (SETTLE): the predominantly monophasic variant. *Histopathology* .1998;33:71â€“74.

135.Saw D, Wu D, Chess Q, et al. Spindle epithelial tumor with thymus-like differentiatior (SETTLE): a primary thyroid tumor. *Int J Surg Pathol* . 1997;4:169â€“174.

136.Bradford CR, Devaney KO, Lee JL, et al. Spindle epithelial tumor with thymus-like differentiation (SETTLE): a case report and review of the literature. *Otolaryngol Head Ne Surg* . 1999;120:603â€“606.

137.Su L, Beals T, Bernecki EG, et al. Spindle epithelial tumor with thymus-like differenti (SETTLE): a case report and cytologic, histologic, immunohistologic and ultrastructural fir *Mod Pathol* . 1997;10:510â€“514.

Primary Mucoepidermoid Carcinoma of the Thyroid

138.Rhafigan RM, Rogue H, Bucher RI. Primary mucoepidermoid carcinoma in the thyroid a case report including ultrastructural and biochemical studies. *Cancer* . 1977;39:210â€“2

139.Cameselle-Teijeiro J, Wenig B, Sobrinho-Simoes, et al. Mucoepidermoid carcinoma. Ir
DeLellis RA, Lloyd RV, Heitz PU, et al, eds. *Pathology and Genetics of Tumors of Endocrin*
Organs . *World Health Organization Classification of Tumors* . Lyon: IARC Press; 2004:82â

140.Wenig BM, Adair CF, Heffess CS. Primary mucoepidermoid carcinoma of the thyroid gl
report of six cases and a review of the literature of a follicular epithelial-derived tumor. *I*
Pathol . 1995;26:1099â€“1108.

141.Rosai J, Carcangiu ML, DeLellis RA. Tumors of the thyroid gland. *Atlas of Tumor Patho*
3rd series, fascicle 5. Washington DC: Armed Forces Institute of Pathology;1993:105,196.

142.Vasquez-Ramirez F, Otal SC, Arguesta MO, et al. Fine needle aspiration cytology of hi
grade mucoepidermoid carcinoma of the thyroid. A case report. *Acta Cytol* .
2000;44:259â€“254.

143.Cameselle-Teijeiro J, Sobrinho-Simoes M. Cytomorphologic features of mucoepidermo
carcinoma of the thyroid. *Am J Clin Pathol* . 1999;111:134â€“136.

144.Larson RS, Wick M. Primary mucoepidermoid carcinoma of the thyroid: diagnosis by fi
needle aspiration biopsy. *Diagn Cytopathol* . 1993;9:438â€“443.

145.Viviana ML, Galera-Davidson H, Martin-Lacave, et al. Papillary carcinoma of the thyro
with mucoepidermoid differentiation. *Arch Path Lab Med* . 1996;120:397â€“398.

146.Miranda RN, Myint M, Gnepp DR. Composite follicular variant of papillary carcinoma a
mucoepidermoid carcinoma of the thyroid. Report of a case and review of the literature.
Surg Pathol . 1995;19:1209â€“1215.

147.Cameselle-Teijeiro J, Febles-Perez C, Sobrinho-Simoes M. Cytologic features of fine n
aspirates of papillary and mucoepidermoid carcinoma of the thyroid with anaplastic
transformation. A case report. *Acta Cytol* . 1997;41:1356â€“1360.

148.Bondeson L, Bondeson AG, Nissborg A, et al. Papillary carcinoma of the thyroid with mucoepidermoid features. *Am J Clin Pathol* . 1991;95:175â€“179.

149.Kini SR, Dardick I. *Atlas of Salivary Gland Cytopathology, Oral and Surgical Pathology* Ottawa: Pathology Images; 2006.

Sclerosing Mucoepidermoid Carcinoma with Eosinophilia

150.Chan JKC, LiVolsi VA, Bondeson L, et al. Sclerosing mucoepidermoid carcinoma with eosinophilia. In: DeLellis RA, Lloyd RV, Heitz PU, et al., eds. *Pathology and Genetics of Tu of Endocrine Organs* . *World Health Organization Classification of Tumors* . Lyon: IARC Pr 2004:84.

151.Shehadeh NJ, Vernick J, Lonardo F, et al. Sclerosing mucoepidermoid carcinoma with eosinophilia of the thyroid: a case report and review of the literature. *Am J Otolaryngol* . 2004;25:48â€“53.

152.Albores-Saavedra J, Gu X, Luna MA. Clear cells and thyroid transcription factor I reac in sclerosing mucoepidermoid carcinoma of the thyroid gland. *Ann Diagn Pathol* . 2003;7:348â€“353.

153.Sim SJ, Ro JY, Ordonez NG, et al. Sclerosing mucoepidermoid carcinoma with eosinop of the thyroid: report of two patients, one with distant metastasis, and review of the literature. *Hum Pathol* . 1997;28:1091â€“1096.

154.Rosai J, Carcangiu ML, DeLellis RA. Tumors of the thyroid gland. In: Rosai J, Sobin LH, *Atlas of Tumor Pathology* . Washington, DC: Armed Forces Institute of Pathology; 1993:196â€“197.

155.Chen JK, Albores-Saavedra J, Battifora H, et al. Sclerosing mucoepidermoid thyroid carcinoma with eosinophilia. A distinctive low-grade malignancy arising from the metapla

follicles of Hashimoto's thyroiditis. *Am J Surg Pathol* . 1991;15:438â€“448.

156.Baloch ZW, LiVolsi VA. Primary mucoepidermoid carcinoma and sclerosing mucoepide carcinomas with eosinophilia of the thyroid gland: a report of nine cases. *Mod Pathol* . 2000;13:802â€“807.

157.Geisinger KR, Steffee CH, McGee RS, et al. The cytomorphologic features of sclerosin mucoepidermoid carcinoma of the thyroid gland with eosinophilia. *Am J Clin Pathol* . 1998;109:294.

158.Bondesson L, Bondesson AG. Cytologic features in fine-needle aspirates from a scleros mucoepidermoid thyroid carcinoma with eosinophilia. *Diagn Cytopathol* . 1996;15:301â€“3

159.Soloman AC, Baloch ZW, Salhany KE, et al. Thyroid sclerosing mucoepidermoid carcin with eosinophilia: mimic of Hodgkin's disease in nodal metastases. *Arch Path Lab Med* . 2000;124:448â€“449.

Paraganglioma

160.DeLellis RA. Paraganglioma. In: DeLellis RA, Lloyd RV, Heitz PU, et al, eds. *Pathology Genetics of Tumors of Endocrine Organs. World Health Organization Classification of Tum* Lyon: IARC Press; 2004:117.

161.Kronz JD, Argani P, Udelsman R, et al. Paraganglioma of the thyroid: two cases that c and expand the clinical spectrum. *Head Neck* . 2000;22:621â€“625.

162.LaGuette J, Matias-Guiu J, Rosai J. Thyroid paraganglioma: a clinicopathologic and immunohistological study of three cases. *Am J Surg Pathol* . 1997;21:748â€“753.

163.Hughes JH, El-Mofty S, Sessions D, et al. Primary intrathyroidal paraganglioma with metachronous carotid body tumor: report of a case and review of the literature. *Path Res* . 1997;193:791â€“796.

164.Brownlee RE, Shockley WW. Thyroid paraganglioma. *Ann Otol Laryngol* . 1992;101:293â€“299.

165.Haegert DG, Wang NS, Farrer PA, et al. Non-chromaffin paragangliomatosis manifestir cold thyroid nodule. *Am J Clin Pathol* . 1974;61:561â€“569.

166.Vodvnik A. Fine needle aspiration cytology of primary thyroid paraganglioma. Report c case with cytologic, histologic and immunohistochemical features and differential diagnos considerations. *Acta Cytol* . 2002;46:1133â€“1137.

Langerhans' Cell Histiocytosis (Histiocytosis X)

167.Thompson LDR. Langerhans' cell histiocytosis X. In: DeLellis RA, Lloyd RV, Heitz PU, et eds. *Pathology and Genetics of Tumors of Endocrine Organs. World Health Organization Classification of Tumors* . Lyon: IARC Press; 2004:121.

168.Coode PE, Shaikh MU. Histiocytosis X of the thyroid masquerading as thyroid carcinom *Hum Pathol* . 1998;19:230â€“241.

169.Lahey ME, Rallison ML, Hilding DA, et al. Involvement of thyroid in histiocytosis X. *Am Pediatr Hematol Oncol* . 1986;8:257â€“258.

170.Teja K, Sabio H, Langdon DR, et al. Involvement of the thyroid gland in histiocytosis X *Pathol* . 1981;12:1137â€“1139.

171.Thompson LDR, Wenig BM, Adair CF, et al. Langerhans' cell histiocytosis of the thyroic series of seven cases and a review of the literature. *Mod Pathol* . 1996;9:145â€“149.

172.Dey P, Luthra UK, Sheikh ZA. Fine needle aspiration cytology of Langerhans' cell histiocytosis of the thyroid. *Acta Cytol* . 1999;43:429â€“431.

173.Sahoo M, Karak AK, Bhatnagar D, et al. Fine-needle aspiration cytology in a case of isc involvement of thyroid with Langerhans' cell histiocytosis. *Diagn Pathol* . 1998;19:33â€“37

174.Gomez-Plaza MC, Castella E, Lucas A, et al. Histiocytosis X of the thyroid. *Acta Cytol* 1996;40:618â€“619. Letter.

175.Kirchgraber PRN, Weaver MG, Arafah BM, et al. Fine needle aspiration cytology of Langerhans' cell histiocytosis involving the thyroid: a case report. *Acta Cytol* . 1994;35:424â€“426.

176.Goldstein N, Layfield LJ. Thyromegaly secondary to simultaneous papillary carcinoma histiocytosis X: report of a case and review of the literature. *Acta Cytol* . 1991;35:422â€“4

Primary Soft-Tissue Tumors of the Thyroid

177.Wenig BM, Heffess C, Adair CF. *Atlas of Endocrine Pathology* . Philadelphia: Saunders 1997.

178.Rosai J, Carcangiu ML, DeLellis RA. Tumors of the thyroid gland. In: Rosai J, Sobin LH, *Atlas of Tumor Pathology* . Washington, DC: Armed Forces Institute of Pathology; 1993.

179.Thomson LDR. Peripheral nerve sheath tumor. In: DeLellis RA, Lloyd RV, Heitz PU, et eds. *Pathology and Genetics of Tumors of Endocrine Organs. World Health Organization Classification of Tumors* . Lyon: IARC Press; 2004.

180.Andrion A, Mazzucco G, Torchio B. FNA cytology of thyroid neurilemmoma (schwanno *Diagn Cytopathol* . 1992;8:311â€“312.

181.Andrion A, Bellis D, Delsedime L, et al. Leiomyoma and neurilemmoma: report of two unusual non-epithelial tumors of the thyroid gland. *Virchows Arch* . 1988;413:367Aâ€“372

182.Rollins SD, Flinner RL. Thyrolipoma: Diagnostic pitfalls in the cytologic diagnosis and r

of the literature. *Diagn Cytopathol* . 1991;7:150â€“154.

183.Sobrinho-Simoes M, Cameselle-Teijeiro J. Solitary fibrous tumor. In: DeLellis RA, Lloyd
Heitz PU, et al., eds. *Pathology and Genetics of Tumors of Endocrine Organs. World Healt*
Organization Classification of Tumors . Lyon: IARC Press; 2004:118.

184.Parwani AV, Galindo R, Steinberg DM, et al. Solitary fibrous tumor of the thyroid:
cytopathologic findings and differential diagnosis. *Diagn Cytopathol* . 2003;28:213â€“216.

185.Rodriguez I, Ayala E, Caballero C, et al. Solitary fibrous tumor of the thyroid gland: re
of seven cases. *Am J Surg Pathol* . 2001;25:1424â€“1428.

186.Eusebi V. Angiosarcoma. In: DeLellis RA, Lloyd RV, Heitz PU, et al, eds. *Pathology and*
Genetics of Tumors of Endocrine Organs. World Health Organization Classification of Tum
Lyon: IARC Press; 2004:113.

187.Lin O, Gerhard R, Siqueira SAC, et al. Cytologic findings of epithelioid angiosarcoma c
thyroid. A case report. *Acta Cytol* . 2002;46:767â€“771.

188.Thomson LDR. Smooth muscle tumors. In: DeLellis RA, Lloyd RV, Heitz PU, et al., eds.
Pathology and Genetics of Tumors of Endocrine Organs . *World Health Organization*
Classification of Tumors . Lyon: IARC Press; 2004:115.

189.Thompson L, Wenig B. Adair C, et al. Primary smooth muscle tumors of the thyroid gla
Cancer . 1997;79:579â€“587.

190.Kikuchi I, Anbo J, Nakamura S-I, et al. Synovial sarcoma of the thyroid. Report of a ca
with aspiration cytology findings and gene analysis. *Acta Cytol* . 2003;47:495â€“500.

Primary Hodgkin's Lymphoma

191.Grandos R, Pinkus GS, West P, et al. Hodgkin's disease presenting as an enlarged thyro

gland. *Acta Cytol* . 1991;35:439â€“442.

192.Jayaram G. Hodgkin's disease beginning as a thyroid nodule. *Acta Cytol* . 1993;37:256â€“257.

193.Shimaska K, Sokal JE, Pickren JW. Metastatic neoplasms in the thyroid gland. *Cancer* 1962;15:557â€“565.

194.Abel WG, Finnerly J. Primary Hodgkin's disease of thyroid. *NY State J Med* . 1969;69:314â€“315.

Clear Cell Change in Thyroid Tumors

195.Carcangui ML, Sibby RK, Rosai J. Clear cell change in primary thyroid tumors. A study cases. *Am J Surg Pathol* . 1985;9:705â€“722.

196.Schroder S, Bocker W. Clear cell carcinomas of the thyroid. A clinicopathologic study cases. *Histopathology* . 1986;10:75â€“89.

197.Yang GCH, Yao JL, Feiner HD, et al. Lipid-rich follicular carcinoma of the thyroid in a patient with McCune-Albright syndrome. *Mod Pathol* . 1999;12:969â€“973.

198.Jayaram G. Cytology of clear cell carcinoma of the thyroid. *Acta Cytol* . 1989;33:135â€“136.

199.Landon G, Ordonez NG. Clear cell variant of medullary carcinoma of the thyroid. *Hum Pathol* . 1985;8:844â€“847.

200.Sauer T, Olsholt R. Clear cell follicular adenoma of the thyroid: a case report. *Diagn Cytopathol* . 1996;15:124â€“126.

201.Orlando CA, Salman K, Miller JL, et al. Clear cell change in follicular adenoma mimick HÃ¼rthle cell tumor on thyroid aspiration biopsy cytology. *Diagn Cytopathol* . 1991;7:273â€“276.

202.Ropp BG, Solomides C, Palazzo J, et al. Follicular carcinoma of the thyroid with exter clear cell differentiation: a potential diagnostic pitfall. *Diagn Cytopathol* . 2000;23:222â€

203.El-Sahrigy D, Zhang XM, Elhosseiny A, et al. Signet-ring follicular adenoma of the thyr diagnosed by fine needle aspiration. Report of a case with cytologic description. *Acta Cyt* 2004;48:87â€“90.

204.Harach HR. Cytopathology of follicular tumors of thyroid with clear cell change. *Cytopathology* . 1991; 2:125â€“135.

205.Lasser A, Rothman JG, Calamia VJ. Renal cell carcinoma metastatic to the thyroid. Aspiration cytology and histologic findings. *Acta Cytol* . 1985;29:856â€“858.

Thyroid Tumors with Mucinous Features

206.Rosai J, Carcangiu ML, DeLellis RA. Tumors of the thyroid gland. *Atlas of Tumor Patho* 3rd series, fascicle 5. Washington, DC: Armed forces Institute of Pathology; 1993:203â€“2

207.Cruz MC, Marques LP, Sambade CC, et al. Primary mucinous carcinoma of the thyroid. *Pathol* . 1991;4:266â€“273.

208.Sobrinho-Simoes M, Stenwig AE, Holm R, et al. A mucinous carcinoma of the thyroid. *Res Pract* . 1986;181:464â€“469.

209.Mlynek ML, Richter HJ, Leder LD. Mucin in carcinomas of the thyroid. *Cancer* . 1985;56:2647â€“2650.

210.Chan JK, Tse CC. Mucin production in metastatic papillary carcinoma of the thyroid. *A*

Pathol . 1988;19:195â€“200.

211.Deligdisch L, Subhani Z, Gordon R. Primary mucinous carcinoma of the thyroid gland. Report of a case and ultrastructural study. *Cancer* . 1980;45:2564â€“2567.

212.Harada T, Shimaoka K, Hiratsuka M, et al. Mucin-producing carcinoma of the thyroid glandâ€”a case report and review of the literature. *Jpn J Clin Oncol* . 1984;14:417â€“424.

213.Morrison C, Wakely P Jr. Aspiration cytopathology of metastatic mucinous papillary th carcinoma. *Mod Pathol* . 2001;14:361â€“365.

214.Levin TS, Hore L, Stearns M, et al. Cytological findings in a mucin-secreting follicular carcinoma of the thyroid. *Cytopathology* . 2000;11:185â€“190.

215.Haleem A, Akhtar M, Ali MA, et al. Fine needle aspiration biopsy of mucus-producing medullary carcinoma of thyroid: report of a case with cytologic, histologic and ultrastruct correlation. *Diagn Cytopathol* . 1990;6:112â€“117.

Multiple Malignancies in Thyroid

216.Welch W, Helwig CA. Multiple malignant tumors of the thyroid. *J Int Coll Surg* . 1963;40:492â€“497.

217.Campara-Gonzalez R, Garrido-Lopez J, LaCave-Martin L, et al. Concurrence of a symptomatic encapsulated follicular carcinoma, an occult papillary carcinoma and a medu carcinoma in the same patient. *Histopathology* . 1992;21:380â€“382.

218.O'Neill ME, Lomas FE. Medullary and papillary thyroid carcinoma. *Med J Aust* . 1984;140:747.

219.Merchant FH, Hirschowitz SL, Cohan P, et al. Simultaneous occurrence of medullary a papillary carcinoma of the thyroid gland identified by fine needle aspiration. A case repor

Acta Cytol . 2002;46:762â€“766.

220.Motoyama T, Watanabe H. Simultaneous squamous cell carcinoma and papillary adenocarcinoma of the thyroid gland. *Hum Pathol* . 1983;14:1009â€“1010.

221.Lamberg BA, Reissel P, Steman S, et al. Concurrent medullary and papillary thyroid carcinoma in the same thyroid lobe and in siblings. *Acta Med Scand* . 1981;209:421â€“424

222.Ayala A, Sloane J, Woling FJ Jr. Coexistent lymphomas, adenocarcinoma, and struma lymphomatosa. *JAMA* . 1968;204:819â€“831.

Tumors of the Larynx and Trachea Masquerading as Thyroid Nodules

223.Burggraaf BA, Weinstein GS. Chondrosarcoma of the larynx. *Ann Otol Rhinol Laryngol* 1992;101:183â€“184.

224.Hyams VJ, Rabuzzi DD. Cartilaginous tumors of the larynx. *Laryngoscope* . 1970;80:755â€“767.

225.Natarajan S, Greaves TS, Raza AS, et al. Fine-needle aspiration of an adenoid cystic carcinoma of the larynx mimicking a thyroid mass. *Diagn Cytopathol* . 2004;30:115â€“118.

226.Na DG, Moon HH, Kim KH, et al. Primary adenoid cystic carcinoma of the cervical trac mimicking thyroid tumor: CT evaluation. *J Comp Assist Tomogr* . 1995;19:559â€“563.

Soft-Tissue Tumors in the Neck Masquerading as Thyroid Nodules

227.Butler SL, Oertel YC. Lipomas of anterior neck simulating thyroid nodules. Diagnosis b fine-needle aspiration. *Diagn Cytopathol* . 1992;8:528â€“531.

228.Kini SR, Miller JM, Hamburger JI, et al. Cytopathology of medullary carcinoma of the thyroid. *Arch Pathol Lab Med* . 1984, 108:156â€“159.

229.Saqui A, LiVolsi VA, Mandel SJ. Cervical chordoma masquerading as a thyroid neoplasr case report. *Diagn Cytopathol* . 2005;32:296â€“298.

230.Oh YL, Ko yh, Ree HJ. Aspiration cytology of ectopic cervical thymoma mimicking a tl mass. A case report. *Acta Cytol* . 1998;42:1167â€“1171.

231.Miller WT, Gefter WB, Miller WT. Thymoma mimicking a thyroid mass. *Radiology* 1992;184:75â€“76.

232.Vengrove MA, Schimmel M, Atkinson BF, et al. Invasive cervical thymoma masqueradi solitary thyroid nodule. *Acta Cytol* . 1991;35:431â€“433.

Thyroid Nodules in Pediatric and Adolescent Age Group

233.Towbridge FL, Matovinovich J, McLaren GD, et al. Iodine and goiter in children. *Pedia* 1975;56:82â€“86.

234.Rallison ML, Dobyns EM, Keating FR, et al. Thyroid nodularity in children. *JAMA* . 1975;233:1069â€“1072.

235.Mahone CP. Differential diagnosis of goiter. *Pediatr Clin North Am* . 1987:34:891.

236.Kirkland RT, Kirkland JL, Rosenberg HS, et al. Solitary thyroid nodules in 30 children a reports of a child with a thyroid abscess. *Pediatrics* . 1973;51:85â€“90.

237.Committee on Adolescence: On the terminology of adolescent/adolescence, 1977â€“1 American Academy of Pediatrics. *Pediatrics* . 1978;62:838.

238.Hosler GA, Clark I, Zakowski MF, et al. Cytopathologic analysis of thyroid lesions in th

pediatric population. *Diagn Cytopathol* . 2006;34:101â€“105.

239.Khurana KK, Labradore E, Izquierdo R, et al. The role of fine needle aspiration biopsy management of thyroid nodules in children, adolescents and young adults: a multi-institut study. *Thyroid* . 1999;9:383â€“385.

240.Raab SS, Silverman JF, Elsheikh TM, et al. Pediatric thyroid nodules: disease demogra and clinical management as determined by fine-needle aspiration biopsy. *Pediatrics* . 1995;95:46â€“49.

241.Ceccarelli C, Pacini F, Lippa F, et al. Thyroid cancer in children and adolescents. *Sur* 1988;104:1143â€“1148.

242.Kini SR, Miller JH, Kini R, et al. Fine needle aspiration biopsy of cold thyroid nodules i children and adolescents. *Lab Invest* . 1987;56:41A.

243.Hung W, August GP, Randolph JG, et al. Solitary thyroid nodules in children and adolescents. *J Pediatr Surg* . 1982;17:225â€“229.

244.Nishiyama RH, Schmidt RW, Batsakis JG. Carcinoma of the thyroid gland in children a adolescents. *JAMA* . 1982;181:1036â€“1038.

245.Silverman SH, Nussbaum M, Rausen AR. Thyroid nodules in children: a ten-year experi at one institution. *Mt Sinai J Med* . 1979;46:460â€“463.

246.Tawes RL, Delorimier AA. Thyroid carcinoma during youth. *J Pediatr Surg* . 1968;3:21

247.Hayles AB, Johnson ML, Beahrs OH, et al. Carcinoma of the thyroid in children. *Am J* 1965;106:735â€“743.

248.Crile G Jr. Carcinoma of the thyroid in children. *Ann Surg* . 1959;150:959.

249.Hung W, Sarlis NJ. Current controversies in the management of pediatric patients wit well-differentiated non-medullary thyroid cancer: a review. *Thyroid* . 2002;12:683â€“702.

250.Van Vilet G, Glinoer D, Verelst J, et al. Cold thyroid nodules in childhood: is surgery a necessary? *Eur J Pediatr* . 1987;146:378â€“382.

251.Fisher DA. Thyroid nodules in childhood and their management. *J Pediatr* . 1976;89:866â€“868.

252.Amrikachi M, Ponder TB, Wheeler TM, et al. Thyroid fine-needle aspiration biopsy in children and adolescents: experience with 218 aspirates. *Diagn Cytopathol* . 2005:32:189â€“192.

253.Corrias A, Einaudi S, Chiorboli E, et al. Accuracy of fine-needle aspiration biopsy of th nodules in detecting malignancy in childhood: comparison with conventional, clinical, laboratory and imaging approaches. *J Clin Endocrinol Metab* . 2001;86:4644â€“4648.

254.Arda IS, Yildirim S, Demirhan B, et al. Fine needle aspiration biopsy of thyroid nodule *Arch Dis Child* . 2001;85:313â€“317.

255.Al-Shaikh A, Ngen DL, Danerman, A, et al. Fine-needle aspiration biopsy in the manag of thyroid nodules in children and adoescents. *J Pediatr* . 2001;138:140â€“142.

256.Lugo-Vicente H, Ortiz VN, Irizarry H, et al. Pediatric thyroid nodules: management in era of fine-needle aspiration. *J Pediatr Surg* . 1998;33:1302â€“1305.

257.Degan BM, McMClellan DR, Frands GL. An analysis of fine needle aspiration biopsy of t thyroid in children and adolescents. *J Pediatr Surg* . 1996;32:903â€“907.

258.Verdeguer A, Castel V, Torres V, et al. Fine-needle aspiration biopsy in children:

Experience in 70 cases. *Med Pediatr Oncol* . 1988;16:98â€“100.

259.Weitzman JJ, Ling SM, Kaplar SA, et al. Percutaneous needle biopsy of goiter in childl *J Pediatr Surg* . 1970;5:251â€“255.

260.Rallison ML, Dobyns EM, Keating FR, et al. Occurrence and natural history of chronic lymphocytic thyroiditis in childhood. *J Pediat* . 1975;86:675â€“682.

261.MÃ¤enpÃ¤Ã¤ J, Raatikka M, RÃ¤Ã¤sanen J, et al. Natural course of juvenile autoimmu thyroiditis. *J Pediatr* . 1985;107:898â€“904.

262.Mauras N, Zimmerman D, Goellner JR. Hashimoto's thyroiditis associated with thyroid cancer in adolescent patients. *J Pediatr* . 1985;106:895â€“899.

263.Feinmesser R, Lubin E, Segal K, et al. Carcinoma of the thyroid in children: a review. *Pediatr Endocrinol Metab* . 1997;10: 561â€“568.

264.Halac I, Zimmerman D. Thyroid nodules and cancers in children. *Endocrinol Metab Cli North Am* . 2005;34:725â€“744.

265.Skinner MA. Cancer of the thyroid gland in infants and children. *Semin Pediatr Surg* . 2001;10:561â€“568.

266.Lafferty AR, Batch JA. Thyroid nodules in childhood and adolescence: Thirty years of experience. *J Pediatr Endocrinol Metab* . 1997;10:479â€“486.

267.Geiger JD, Thompson NW. Thyroid tumors in children. *Otolaryngol Clin North Am* . 1995;29:711â€“719.

268.Leavitt A, Vuitch F. Clinicopathologic study of thyroid neoplasms in children. *Am J Cli Pathol* . 1991;4:410(A).

269.Gorlin JB, Allan SE. Thyroid carcinoma in children. *Endocrinol Metab Clin North Am* . 1990;19;649â€“662.

270.Tallroth E, Backdahl M, Einhorn J, et al. Thyroid carcinoma in children and adolescen *Cancer* . 1986;58:2329â€“2332.

271.Gow KW, Lensing S, Hill DA, et al. Thyroid carcinoma presenting in childhood or after treatment of childhood malignancies: an institutional experience and review of the litera *Pediatr Surg* . 2003;38:1574â€“1580.

272.Raju U, Kini SR. Follicular neoplasms in children and adolescents. *Mod Pathol* . 1988;1:18P(A).

273.Zimmerman D, Hay JD, Gough IR, et al. Papillary thyroid carcinoma in children and ac long-term follow-up of 1039 patients conservatively treated at one institution during thre decades. *Surgery* . 1988;104:1157â€“1166.

274.Schlumberger M, DeVathaire F, Travagli JP, et al. Differentiated thyroid carcinoma in childhood. Long-term follow-up of 72 patients. *J Clin Endocrinol Metab* . 1987;65:1088â€“

275.Withers EH, Rosenfeld L, O'Neil J, et al. Long-term experience with childhood thyroid carcinoma. *J Pediatr Surg* . 1979;14: 3322â€“3325.

276.Raju R, Kini SR, Jackson CE. Clinicopathological features of medullary thyroid carcino children and adolescents. *Mod Pathol* . 1988;1:17P(A).

277.Ito M, Yamashita S, Ashizawa K, et al. Histopathologic characteristics of childhood thy cancer in Gomel, Belarus. *Int J Cancer* . 1996;65:29â€“33.

278.Nikiforov Y, Gnepp DR. Pediatric thyroid cancer after the Chernobyl disaster: patholo study of 84 cases (1991â€“1992) from the Republic of Belarus. *Cancer* . 1994:74:748â€“76

279.Ito M, Yamashita S, Ashizawa K, et al. Childhood thyroid diseases around Chernobyl evaluated by ultrasound examination and fine needle aspiration cytology. *Thyroid* . 1995;5:365â€“368.

280.Hassoun AA, Hay ID, Goellner JR, et al. Insular thyroid carcinoma in adolescents: a potential lethal endocrine malignancy. *Cancer* . 1997;79:1044â€“1048.

281.Rijhwani A, Satish GN. Insular carcinoma of the thyroid in a 10-year-old child. *J Pedia Surg* . 2003;38:1083â€“1086.

282.Cheuk W, Jacobson AA, Chan JKC. Spindle epithelial tumor with thymus-like different (SETTLE): a distinctive malignant thyroid neoplasm with significant metastatic potential. *Pathol.* 2000;13:1150â€“1155.

283.Weigensberg C, Dalsey H, Asa SL, et al. Thyroid thymoma in childhood. *Endocrinol Pa* 1990;1:123â€“127.

284.Riedlinger WFJ, Lack EE, Robson CD, et al. Primary thyroid teratomas in children. A r of 11 cases with a proposal of criteria for their diagnosis. *Am J Surg Pathol* . 2005;29:701â€“706.

Dyshormonogenetic Goiters

285.Ghossein RA, Rosai J, Heffess C. Dyshormonogenetic goiters: a clinicopathologic study cases. *Endocrinol Pathol* . 1998;8:283â€“292.

286.Rosai J, Carcangiu ML, DeLellis RA. Tumors of the thyroid gland. In: Rosai J, Sobin LH, *Atlas of Tumor Pathology* . Washington, DC: Armed Forces Institute of Pathology; 1993:30

287.Deshpande AH, Bobhate SK. Cytological features of dyshormonogenetic goiter. *Diagn Cytopathol* . 2005;33:252â€“254.

Editors: Kini, Sudha R.
Title: *Thyroid Cytopathology: A Text and Atlas, 1st Edition*

Copyright Â©2008 Lippincott Williams & Wilkins

20

Infarction of Thyroid Neoplasms Following Fine-Needle Biopsy

Necrosis along the needle tract is not unusual following a cutting needle biopsy of a thyroid neoplasm with Vim-Silverman or Tru-Cut needles (Fig. 20.1), whereas fine-gauge needles us for aspiration biopsy procedures are generally atraumatic.1 Considering the widespread use the fine-needle aspiration biopsy in evaluating thyroid nodules, tissue damage is an infreque occurrence. However, a wide range of morphologic changes in thyroids with preoperative FN biopsy has been described in the recent literature,1 , 2 , 3 , 4 , 5 , 6 , 7 , 8 , 9 , 10 , 11 , 12 , 14 , 15 , 16 partial or complete infarction of the neoplasms being one of them. LiVolsi and Merino5 compiled an impressive list of postâ€“fine-needle biopsy changes in 300 thyroidecto from a total of 3,000 cases, an incidence of 10%. The authors referred the changes as "worri histologic alterations following fine needle aspiration biopsy (WHAFFT)" and grouped them in two categories, acute and chronic.

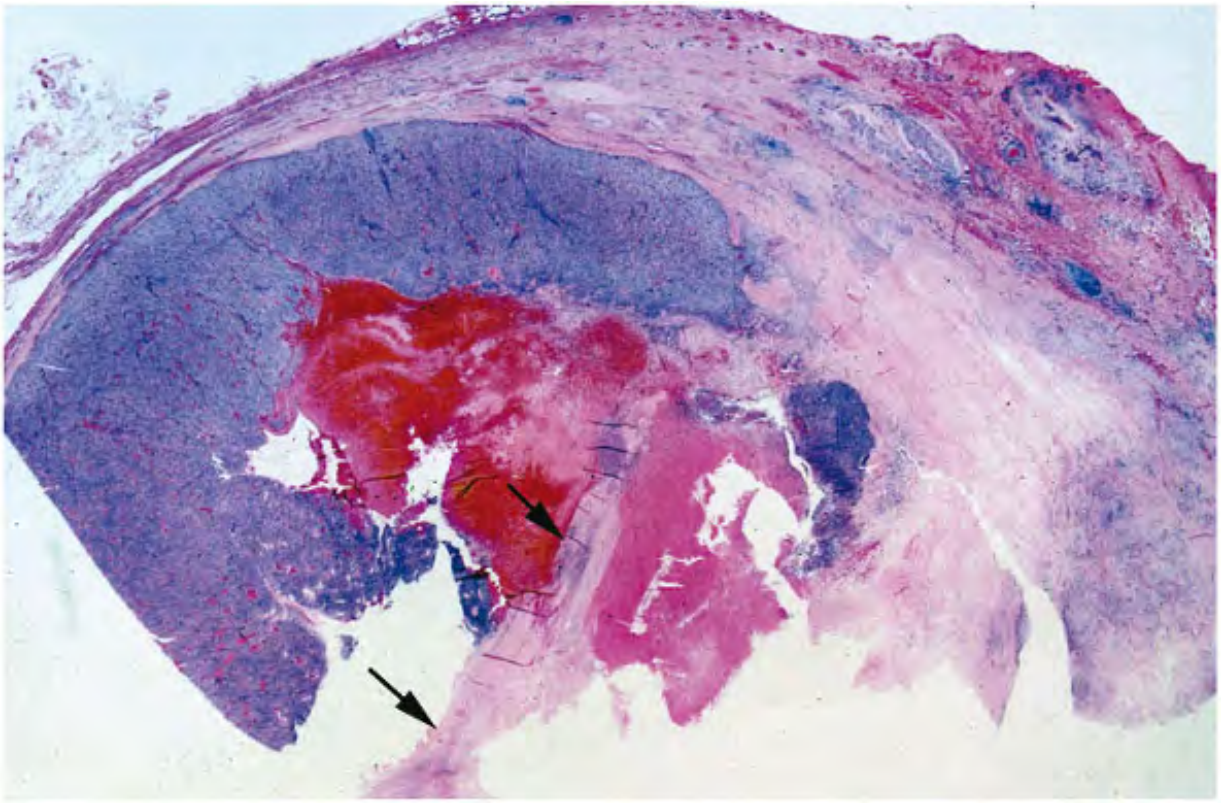

Figure 20.1. Follicular adenoma of the thyroid showing a needle tract caused by the Tru-Cu needle (*arrows*). Note the linear fibrosis and hemorrhage.

The acute changes *were* observed within 3 weeks of fine-needle aspiration biopsy and inclu hemorrhage, granulation tissue, giant cells and siderophages, mitoses and necrosis, nuclear clearing, poorly formed granuloma, capsular distortion, and, rarely, infarction. The chronic changes included linear fibrosis near siderophages, metaplasia (oncocytic, spindle cell, and squamous types), infarction, pseudo-invasion of the capsule, significant random nuclear aty cyst formation, papillary degeneration, and calcification.

The etiology of such changes can only be speculated on. Reasons offered include interruptic the microvascular supply, compromised vascular supply from the extraction of large amount tissue, traumatic venous thrombosis, rough needle use, and multiple passes with vigorous aspiration.4 , 5 , 6 , 7 , 8 , 9 , 10 , 11 , 12 , 13 , 14 , 15 , 16 , 17 , 18

Of the changes described above, infarction, either partial or complete, is the most dramatic (Fig. 20.2). The incidence of infarction, previously published in our series,13 was 1.4% (22 c 1,150 thyroidectomies). However, an incidence as high as 10% (8 of 82) was reported by Gor

et al.6

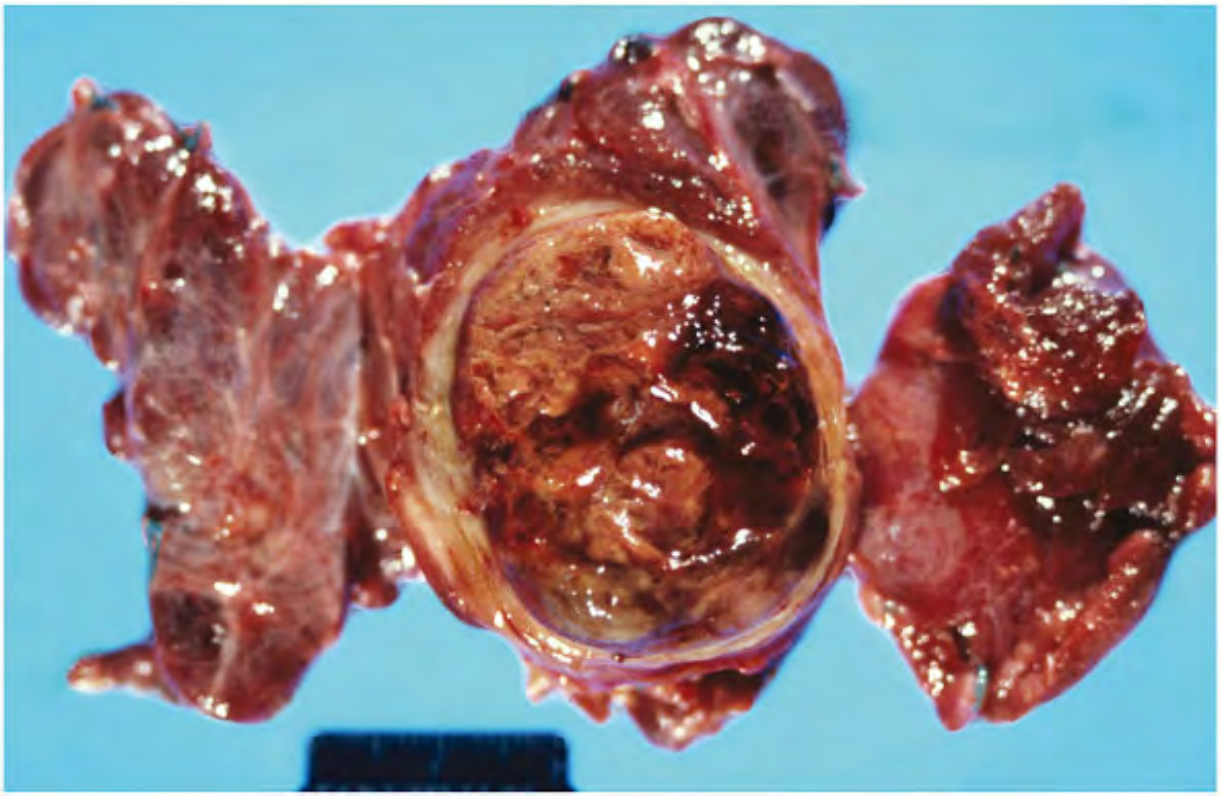

Figure 20.2. Gross photograph of the thyroid showing an acutely infarcted papillary carcino (case 4 in Table 20.2).

Our initial experience with a total of 28 cases of thyroid neoplasms that showed partial to t infarction was reported in 1996.14 Their cytologic diagnoses were 15 HÃ¼rthle cell tumors, papillary carcinomas, and 5 follicular neoplasms; 10 of these also had large-needle biopsy procedures, 2 concurrent and the remaining 8 within 3 weeks of fine-needle aspiration biop Three showed infarction, one within 24 hours of the biopsy, indicating that infarction could occur within a short period. Since our last publication,14 we have encountered 13 additiona cases of post-fine needle biopsy infarction of the thyroid neoplasms, which included 9 HÃ¼r cell tumors, 2 papillary carcinomas, 1 follicular carcinoma, and 1 follicular adenoma, bringi the total to 41 cases (Table 20.1). None of these additional 13 cases had large-needle biop procedures. However, one case had a repeat fine-needle biopsy, which revealed infarcted c The time period between the fine-needle biopsy and the surgical resection varied from 1 we to 7 months (case 38 in Table 20.2). The higher incidence of infarction of HÃ¼rthle cell neoplasms (24/41) after fine-needle aspiration biopsy, is perhaps due to their increased

vascularity. Table 20.2 lists the cytologic diagnosis of all 41 cases, large-needle biopsy diagr if performed, the time period between the two biopsy procedures, time between fine/large needle biopsy and thyroidectomy, and the histologic diagnoses rendered by the surgical pathologists. Some examples of infarction are illustrated in Figures 20.3 , 20.4 , 20.5 , 20.6 20.7 , 20.7 , 20.8 , 20.9 , 20.10 and 20.11 . Pathologists, if not aware of the cytologic diagn may overlook the thin rim of viable-appearing tumor at the periphery.

HÃ¼rthle cell neoplasms
24
Papillary carcinomas
10
Follicular neoplasms
7
Total
41

TABLE 20.1 CYTOLOGIC DIAGNOSIS OF 41 CASES OF INFARCTED THYROID NEOPLASMS

1
6/27/78
HÃ¼rthle cell
tumor
6/28/78
HÃ¼rthle-
cell
tumor
1
7/25/98
HÃ¼rthle cell tumor
with total necrosis
in the center
28
2

5/17/79
Follicular
carcinoma
5/31/79
Consistent with
follicular
neoplasm
14
8/9/79
Infarcted nodule
with fibrosis; no
specific diagnosis
90
3
8/22/79
HÃ¼rthle cell
tumor
9/21/79
Marked degeneration;
histologic evaluation
difficult
30
4
6/22/80
Papillary
carcinoma
6/27/80
Papillary
carcinoma
Concurrent
7/7/80
Almost total
infarction with
organizing

hematoma;
papillary
carcinoma at
the periphery
10
5
6/30/80
HÃ¼rthle-
cell tumor
7/9/80
Degeneration and
necrosis of the
nodule; no specific
diagnosis
9
6
12/10/81
HÃ¼rthle cell
carcinoma
1/10/81
Infarcted nodule; no
specific diagnosis
30
7
1/20/81
HÃ¼rthle-
cell
tumor
2/4/81
HÃ¼rthle-
cell
tumor
14
3/19/81

Follicular adenoma
with infarction,
recent and
organizing
hemorrhage;
HÃ¼rthle cells along
the tract
60
8
4/22/81
HÃ¼rthle-
cell
carcinoma
5/21/81
Benign necrotic nodule
(review diagnosis:
a thin rim of HÃ¼rthle cell
tumor at the periphery)
28
9
5/26/81
Papillary
carcinoma
10/22/81
Necrotic papillary
carcinoma
30
10
9/1/81
HÃ¼rthle-
cell tumor
9/23/81
Necrotic tissue
22

10/12/81
Infarcted nodule; no
specific diagnosis
35
11
6/17/81
Cellular
follicular
adenoma
8/7/87
Follicular adenoma,
partial infarction
50
12
2/8/82
Papillary
carcinoma
2/22/82
Infarcted nodule
(revised diagnosis:
PTC with infarction
and metastasis to
cervical lymph node)
14
13
6/4/82
HÃ¼rthle cell
tumor
9/15/82
Extensive necrosis
and hemorrhage, no
recognizable tumor
90
14

6/8/82
Papillary carcinoma
7/14/82
Degenerating nodule (revised diagnosis: papillary carcinoma with extensive necrosis)
35
15
9/28/82
HÃ¼rthle cell tumor
11/5/82
Extensive area of degeneration colloid nodule with areas of HÃ¼rthle-cell differentiation
50
16
6/25/82
HÃ¼rthle cell tumor
8/11/82
Encapsulated nodule with diffuse coagulative necrosis (review diagnosisâ€”a thick rim of HÃ¼rthle-cell tumor of the periphery)
45

17
1/21/82
Cellular
follicular
adenoma
1/12/83
Infarcted
tissue
11
No surgical follow-up
18
3/21/83
HÃ¼rthle-
cell tumor
3/31/83
Infarcted HÃ¼rthle-
cell tumor
10
19
5/11/83
HÃ¼rthle-
cell
tumor
5/18/83
? Follicular
adenoma
7
6/9/83
Extensive hemorrhage
and necrosis, no
specific diagnosis
28
20
3/11/85

Suspicious for follicular carcinoma
4/2/85
Partial infarction; follicular adenoma
22
21
9/3/85
HÃ¼rthle-cell tumor
9/12/85
Necrotic tissue
9
10/15/85
HÃ¼rthle cell tumor with massive infarction
35
22
4/30/86
Papillary carcinoma
4/30/86
Papillary carcinoma
Concurrent
6/5/86
Totally infarcted nodule, metastatic PTC in lymph

nodes
35
23
2/2/87
Papillary
carcinoma
3/24/87
Total infarction with
rim of PTC at the
periphery
50
24
5/4/87
HÃ¼rthle cell
tumor
5/25/87
Infarcted adenoma
compatible with
HÃ¼rthle cell type
21
25
5/29/87
HÃ¼rthle cell
tumor
6/19/87
Infarcted nodule
(review diagnosis:
HÃ¼rthle cell tumor

of the periphery)
21
26
7/8/87
Suspicious for

PTC papillary carcinoma
9/10/87
Infarcted nodule and fibrosis; no specific diagnosis
60
27
7/11/91
Cellular adenoma
7/18/91
Follicular adenoma, partial infarction
17
28
3/23/92
Follicular variant of papillary carcinoma
4/30/92
Infarction, fibrosis squamous metaplasia (revised diagnosis: focal PTC)
35
29
10/10/96
HÃ¼rthle cell tumor
12/6/96
HÃ¼rthle cell tumor, almost total infarction

56
30
1/22/99
Suspicious for follicular carcinoma
3/17/99
Minimally invasive follicular carcinoma, partial infarction
25
31
4/14/99
HÃ¼rthle-cell tumor
5/19/99
HÃ¼rthle cell tumor, partial infarction
35
32
1/3/00
HÃ¼rthle-cell tumor
1/10/00
HÃ¼rthle cell tumor, acute infarction
7
33
Not known
HÃ¼rthle-cell tumor
HÃ¼rthle cell tumor, almost total

infarction
35
34
Not
known
Papillary
carcinoma
Papillary carcinoma,
almost total
infarction
Not
known
35
7/16/01
HÃ¼rthle-
cell tumor
8/3/01
HÃ¼rthle cell tumor
almost total
infarction
7
36
2/6/03
HÃ¼rthle cell
tumor under-
going infarction
(repeat
biopsy?
1 week
between
two FNBs)
12/22/03
No surgical
follow-up

35
37
11/17/03
Scant,
nondiagnostic
12/22/03
Follicular adenoma
with infarction
35
38
1/13/04
HÃ¼rthle-
cell tumor
8/9/04
HÃ¼rthle cell neoplasm,
extensive infarction
210
39
1/26/06
Suspicious for
HÃ¼rthle cell
carcinoma
2/21/06
Minimally invasive
HÃ¼rthle cell carcinoma,
massive infarction
36
40
4/4/06
HÃ¼rthle-
cell
carcinoma
5/12/06
Total infarction; few

foci of HÃ¼rthle cells, suggestive of neoplasia

38

41

5/18/06

Papillary carcinoma

6/22/06

Total infarction of papillary carcinoma; metastasis to lymph nodes

40

	Fine-Needle Biopsy (FNB)		Large-Needle Biopsy (LNB)			Surgery		
Case	Date	Cytologic DX	Date	Histologic DX	Days between FNB and LNB	Date	Histologic DX	Day betw FNB Surg

TABLE 20.2 CYTOHISTOLOGIC CORRELATION OF 41 CASES OF INFARCTED THYROID NEOPLASMS

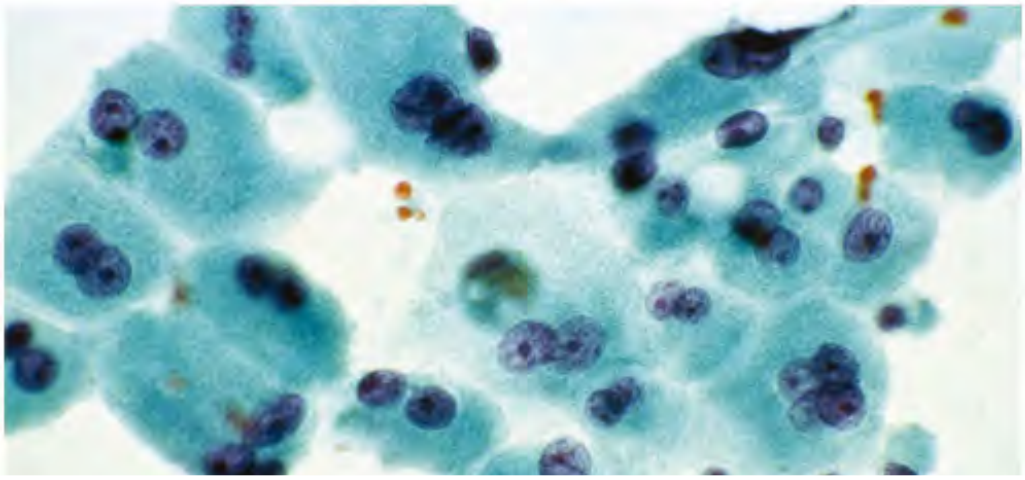

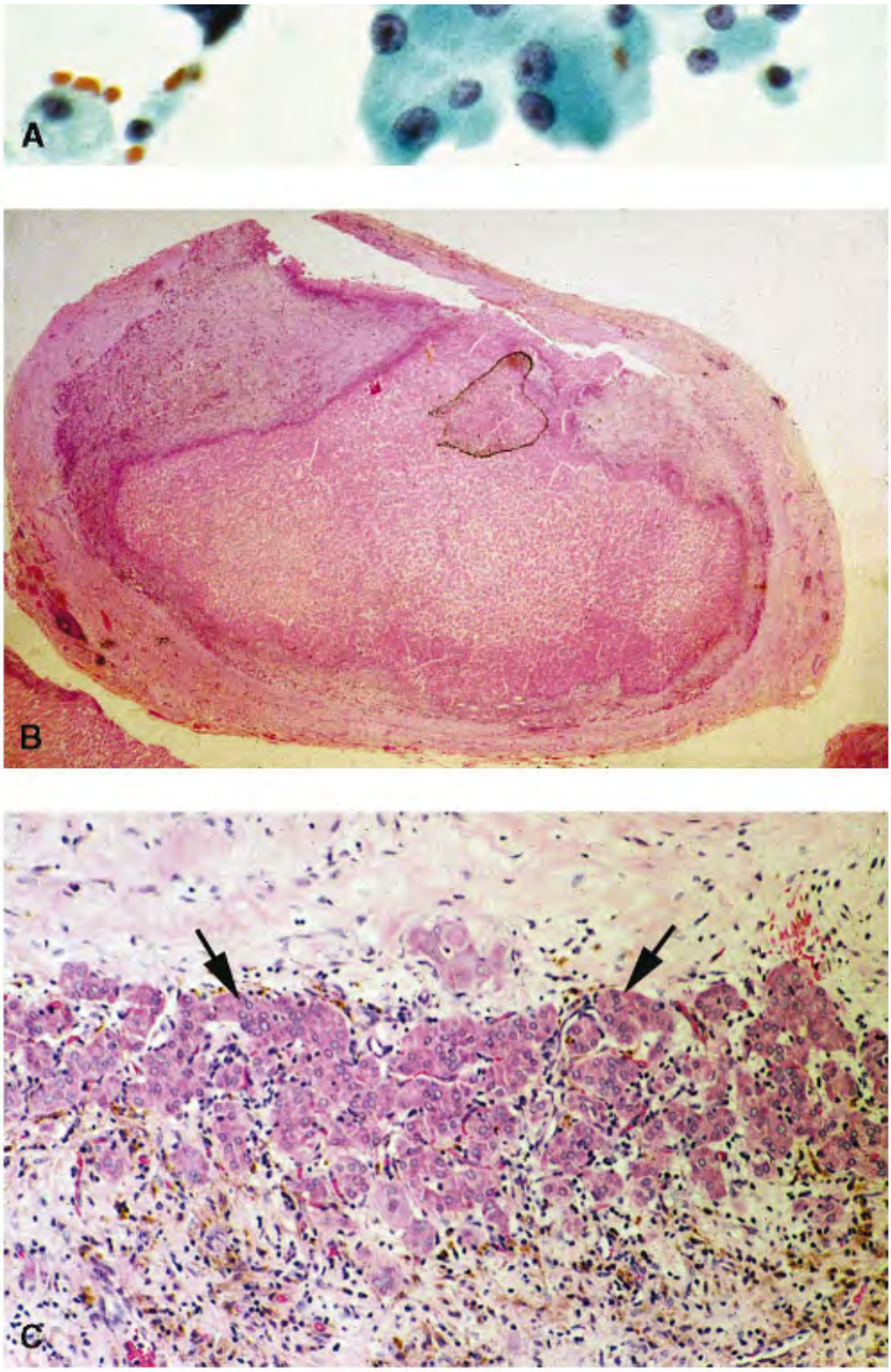

Figure 20.3. A. This aspirate, characteristic of HÃ¼rthle cell neoplasm (adenoma), shows la
discrete HÃ¼rthle cells with eccentric nuclei and prominent macronucleoli. B. A total

thyroidectomy was performed. The 1.5-cm tumor is almost completely infarcted (low power
Higher magnification showing only a thin rim of HÃ¼rthle cell tumor at the periphery, borde
the granulation tissue (*arrows*) around the infarcted tumor (case 16 in Table 20.2).

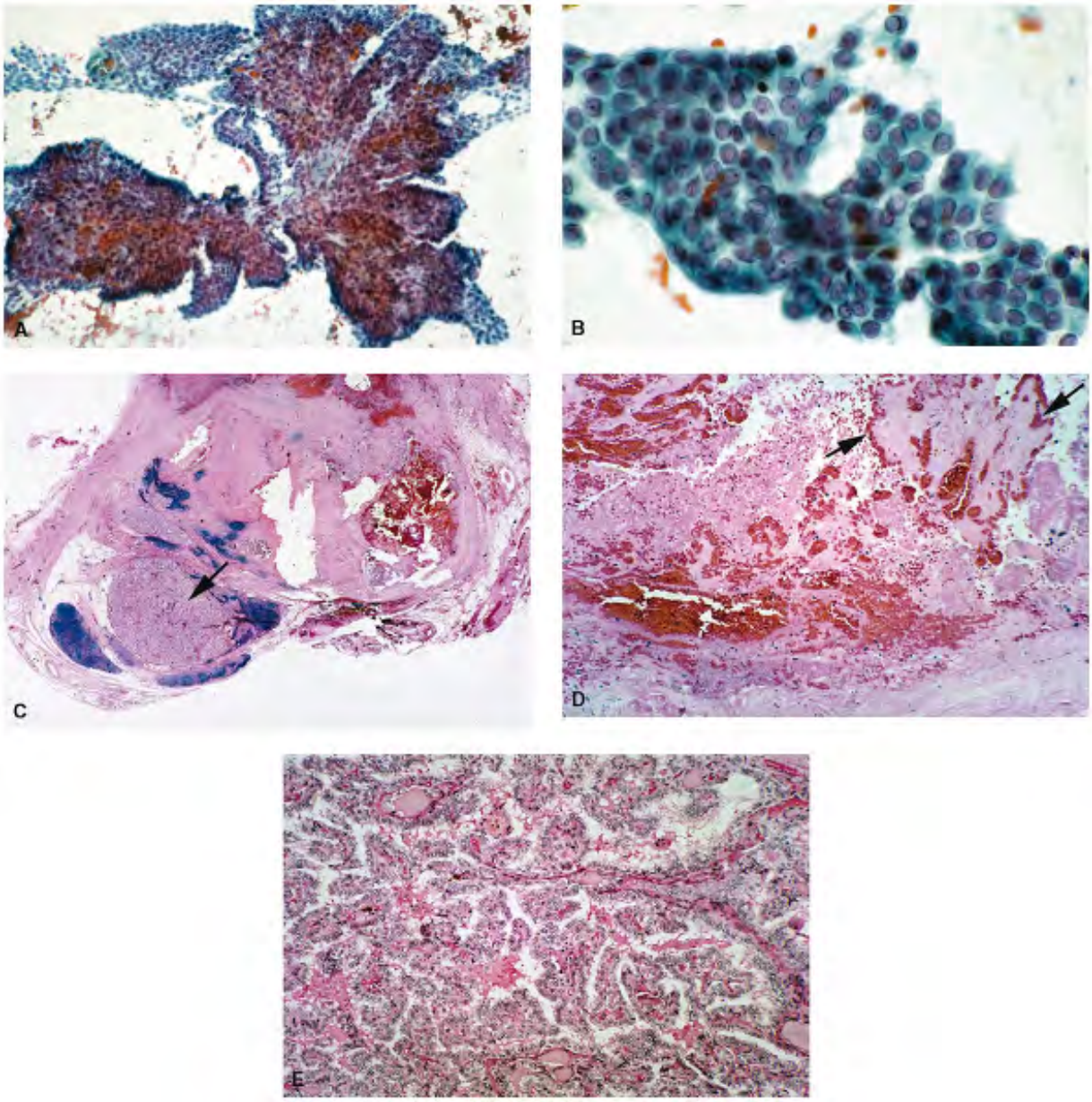

Figure 20.4. A. FNA presenting the characteristic cytopathologic pattern of papillary carcin
with branching papillary tissue fragments, medium power. B. Higher magnification showing
syncytial tissue fragment of follicular cells with enlarged, pleomorphic nuclei, finely granula
chromatin, micronucleoli, intranuclear inclusions, and nuclear grooves. C. Total thyroidecto

revealed an almost totally infarcted hemorrhagic nodule, interpreted as such. Subsequent examination of the thyroid gland showed tumor extending beyond the capsule (*arrow*). D. Section of the hemorrhagic nodule showing the ghost appearance of papillary fronds (*arrows* E. Section of tumor beyond the capsule demonstrating the papillary carcinoma. Note also th extension of the carcinoma into the lymph node (see part A), which was overlooked by the pathologist (case 12 in Table 20.2).

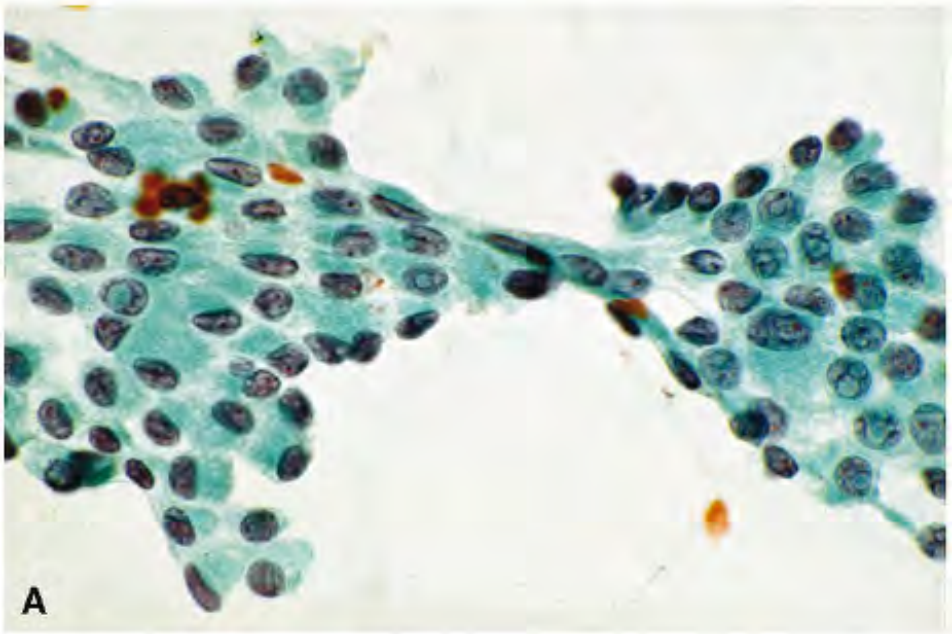

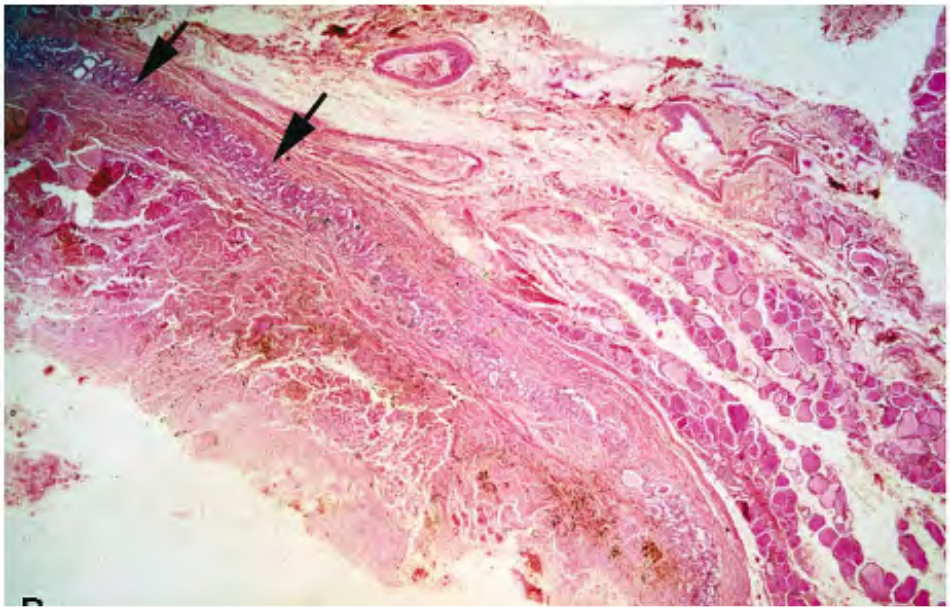

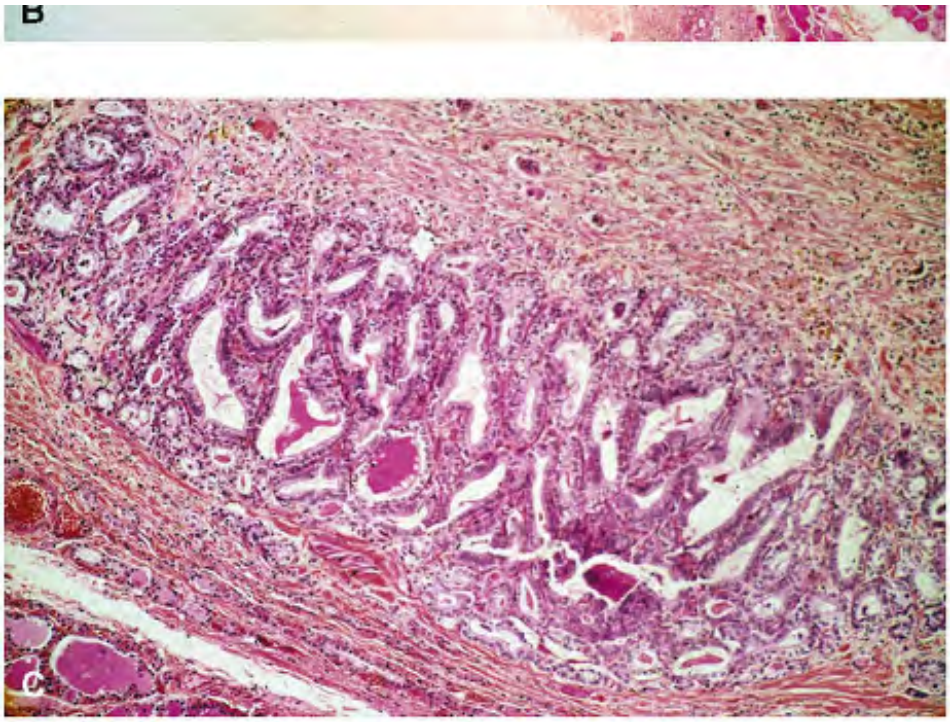

Figure 20.5. A. FNA showing monolayered tissue fragments of follicular cells with enlarged nuclei, finely granular chromatin, micronucleoli, nuclear grooves, and nuclear inclusions, diagnostic of papillary carcinoma. B. A total thyroidectomy revealed a hemorrhagic nodule represented almost total infarction of the papillary carcinoma with a peripheral, narrow rim viable tumor (*arrow*). C. Higher magnification of the viable papillary carcinoma. The histol diagnosis initially was a cyst, but later amended after a second review (case 14 in Table 20.

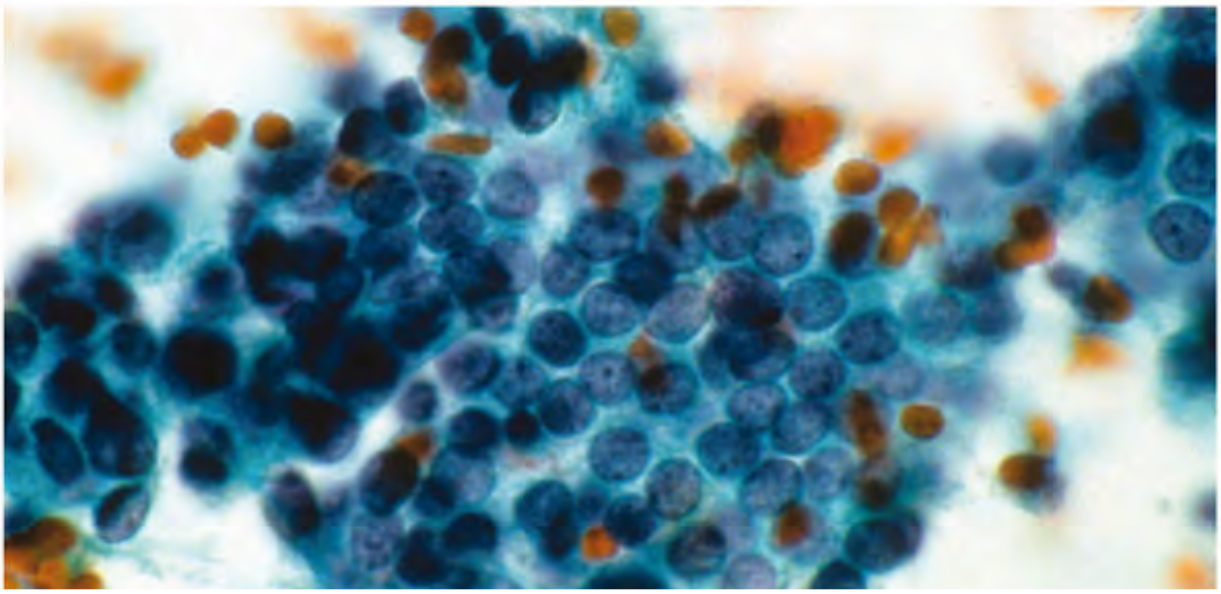

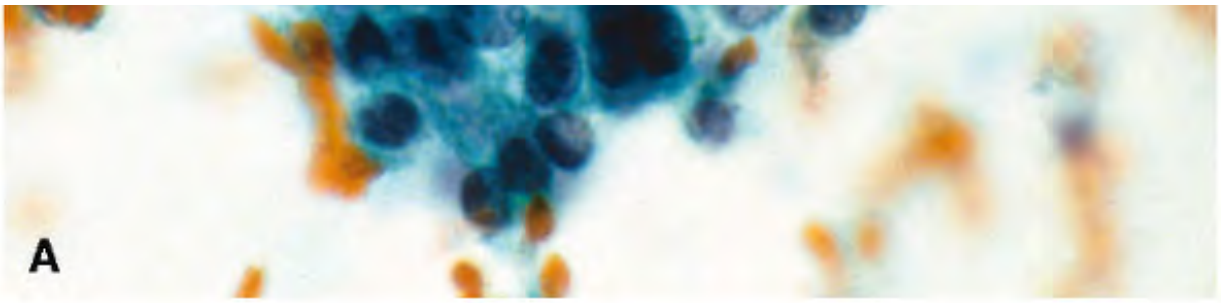

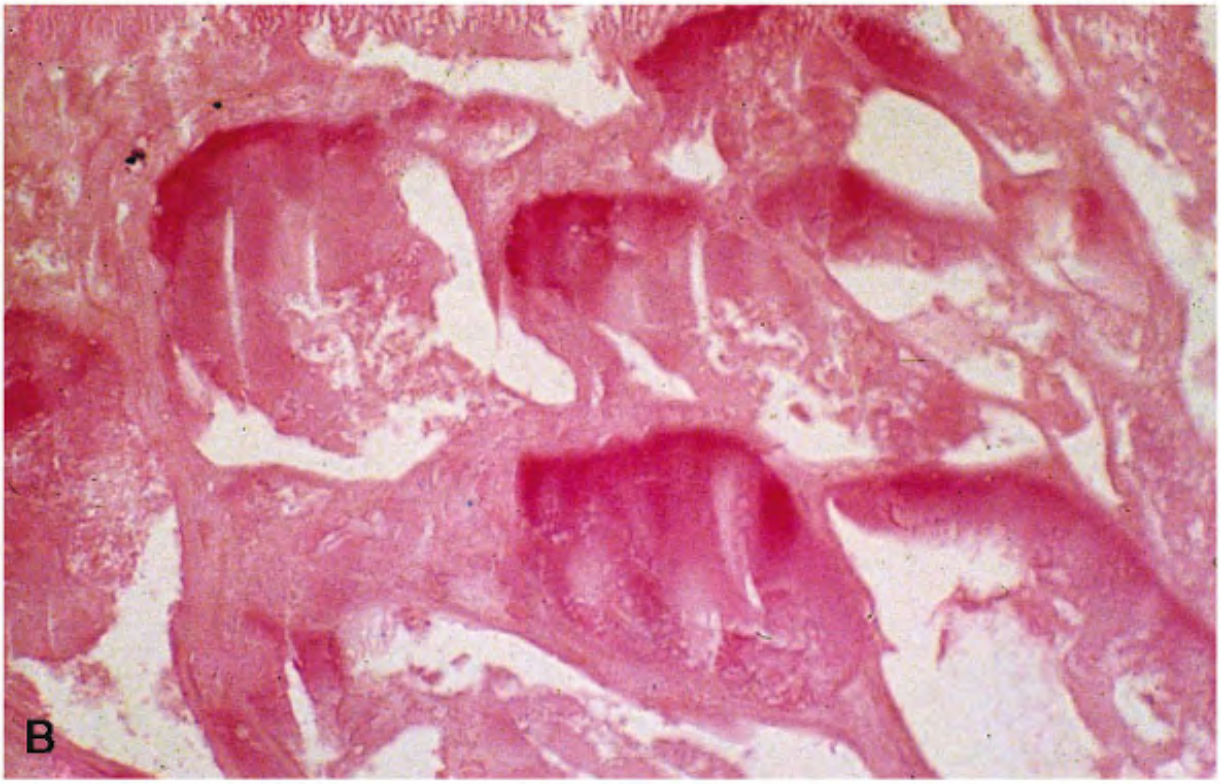

Figure 20.6. A. FNA of a thyroid nodule demonstrating syncytial tissue fragments of follicul cells with and without follicular pattern. Their nuclei are moderately enlarged, crowded, ar overlapped. The chromatin is granular and nucleoli are not appreciated. The cytologic patte that of a cellular follicular adenoma. B. A core-needle biopsy performed 11 days after the F biopsy revealed several fragments of infarcted tissue with no recognizable pattern or struct (case 17 in Table 20.2).

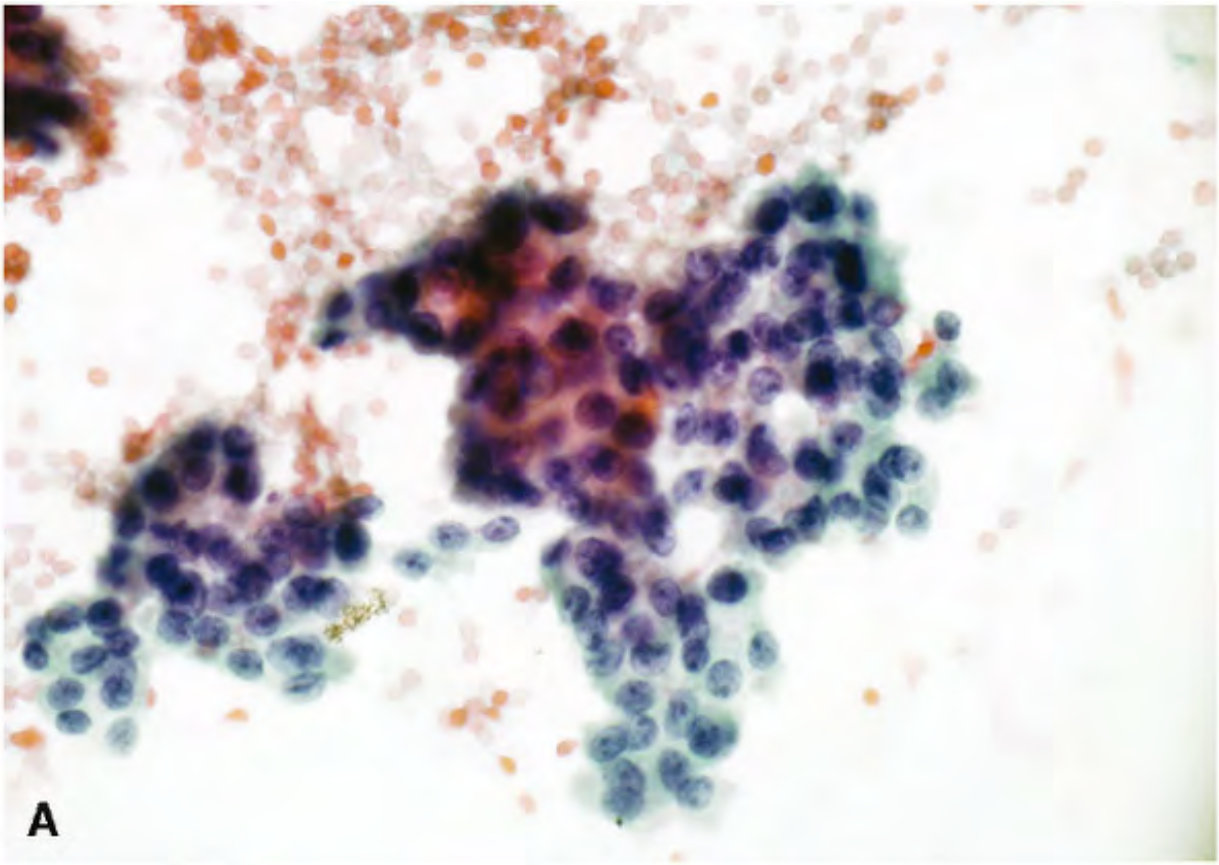

Figure 20.7. A. FNA of a thyroid nodule consisting of syncytial tissue fragments of follicular with and without a follicular pattern. The nuclei are enlarged, crowded, containing granula chromatin and micronucleoli. A cytologic diagnosis of follicular carcinoma was rendered.

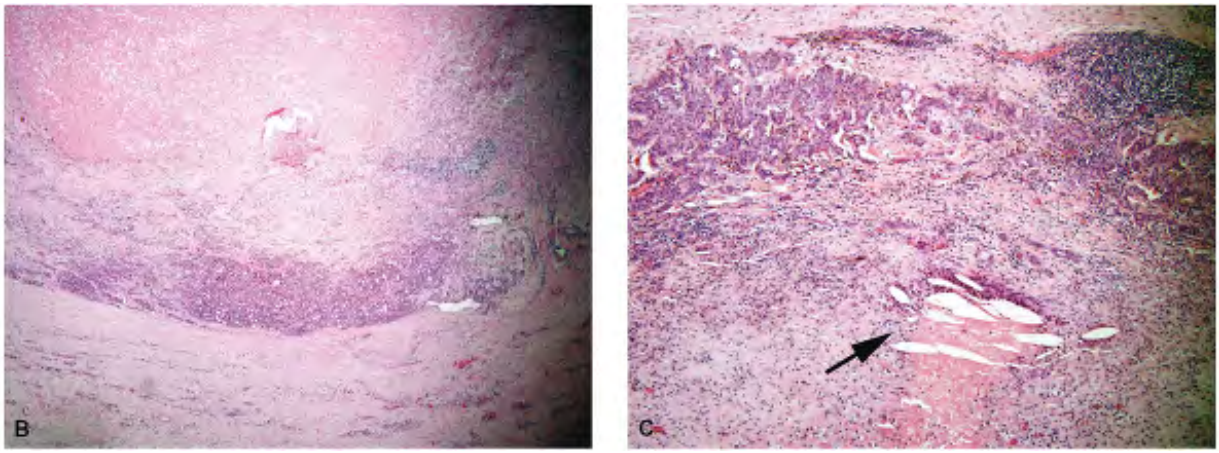

Figure 20.7. B. A total thyroidectomy performed 25 days later, revealed a minimally invasi follicular carcinoma with over 90% of the infarction with organization. C. Note the biopsy tr

and cholesterol crystals (*arrow*) (case 30 in Table 20.2).

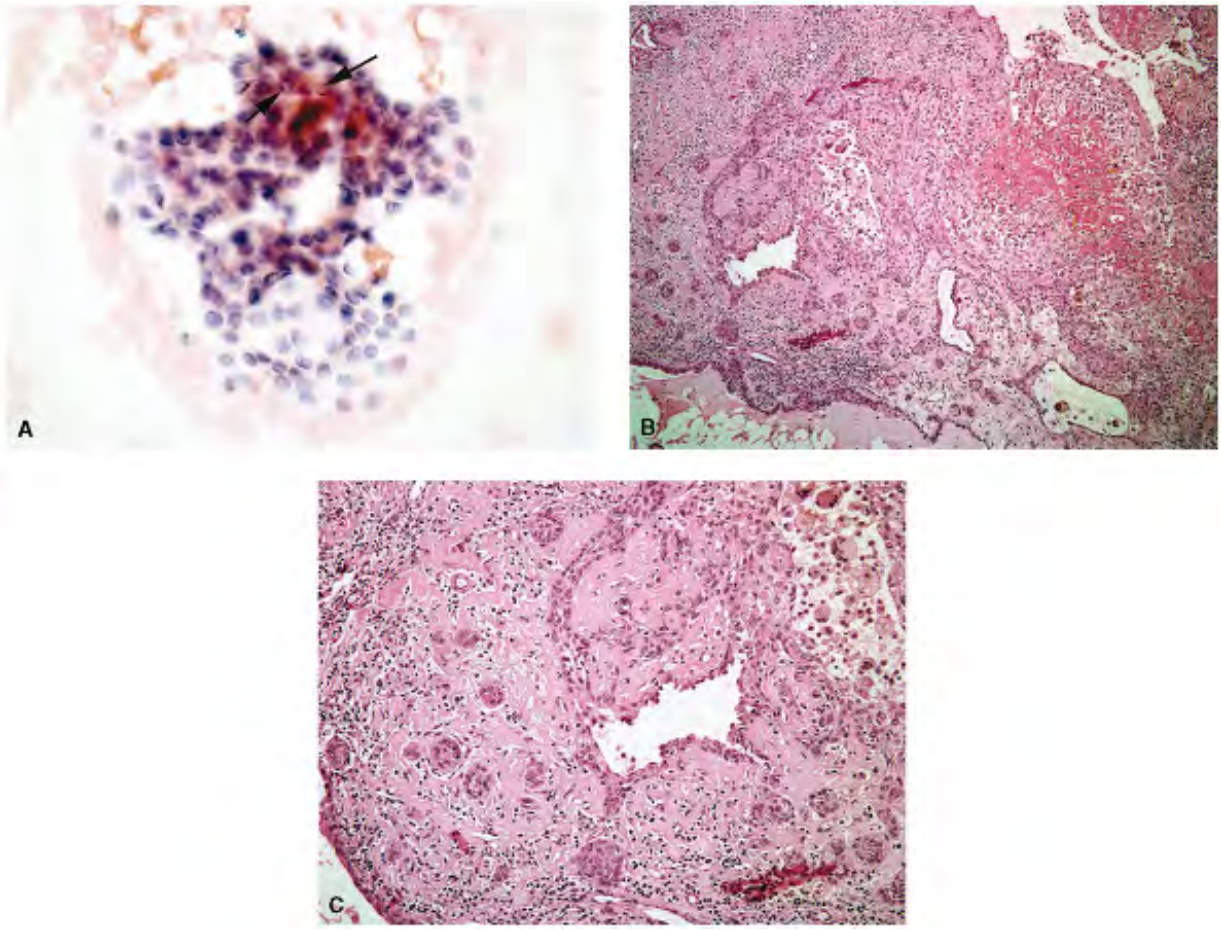

Figure 20.8. A. Fine-needle aspiration biopsy of a papillary carcinoma showing syncytial tiss fragments of follicular epithelium with enlarged nuclei, finely granular chromatin, and intranuclear inclusions (*arrows*) (case 28 in Table 20.2). B and C. A total thyroidectomy performed 35 days post-FNA showed a fibrotic nodule with considerable squamous metaplas There were a few trapped dilated follicles, lined by follicular cells with features of papillary carcinoma cells (case 28 in Table 20.2).

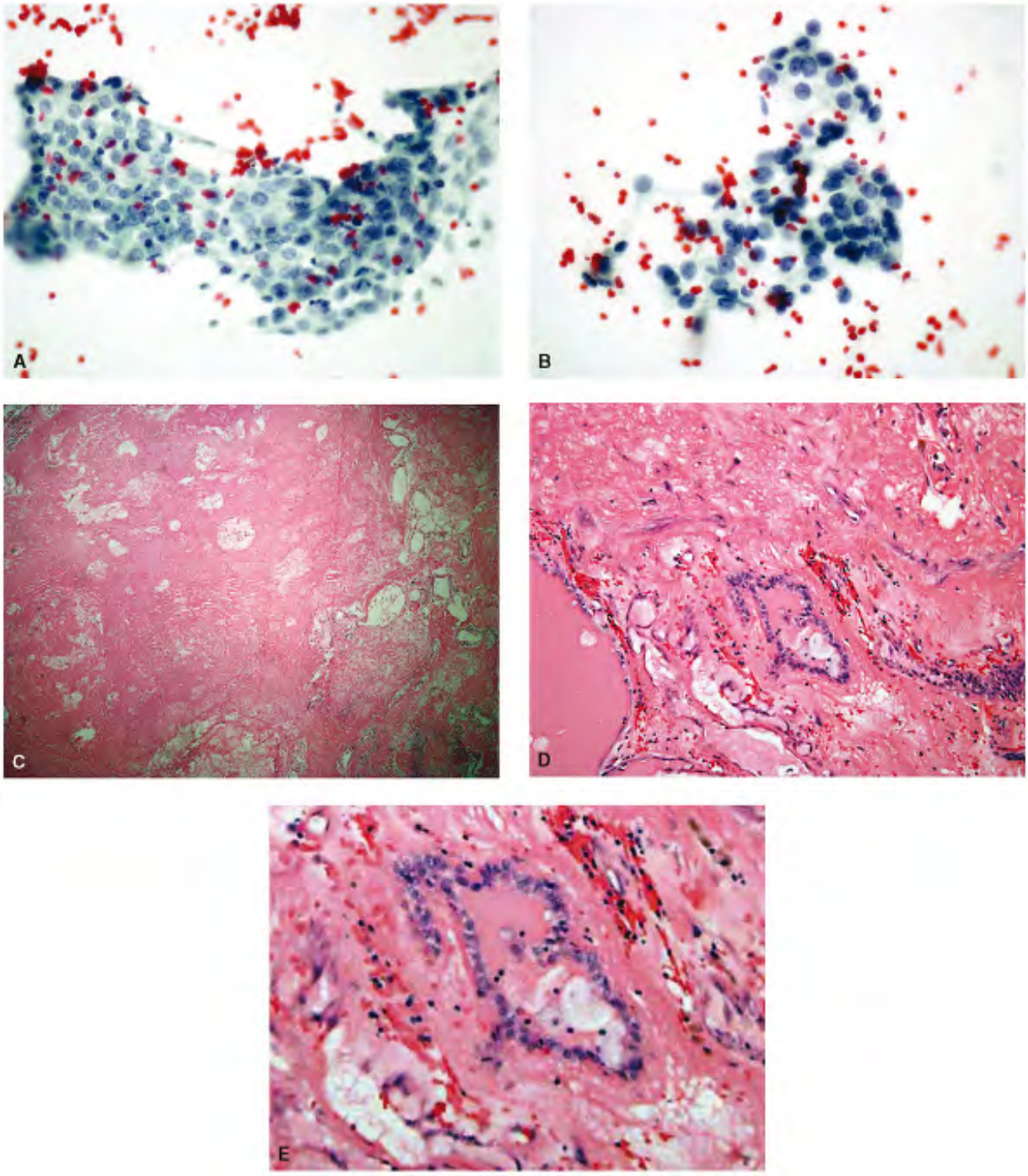

Figure 20.9. An example of a totally fibrotic nodule with no residual tumor. A,B. FNA showi syncytial tissue fragments of follicular cells with enlarged, mildly pleomorphic nuclei, conta finely granular chromatin, micronucleoli, and some suggestion of intranuclear inclusions. Th cytologic diagnosis was suspicious for papillary carcinoma. The repeat aspirate was unsatisfactory. C. A total thyroidectomy performed 60 days later revealed a large (3 cm), encapsulated, totally fibrotic nodule with no identifiable neoplasm. Note several dilated blc

vessels. D. Rarely, few trapped follicles were noted. E. Higher magnification highlighting th
lining follicular epithelium. No histologic diagnosis of a neoplasm was rendered in this case (
26 in Table 20.2).

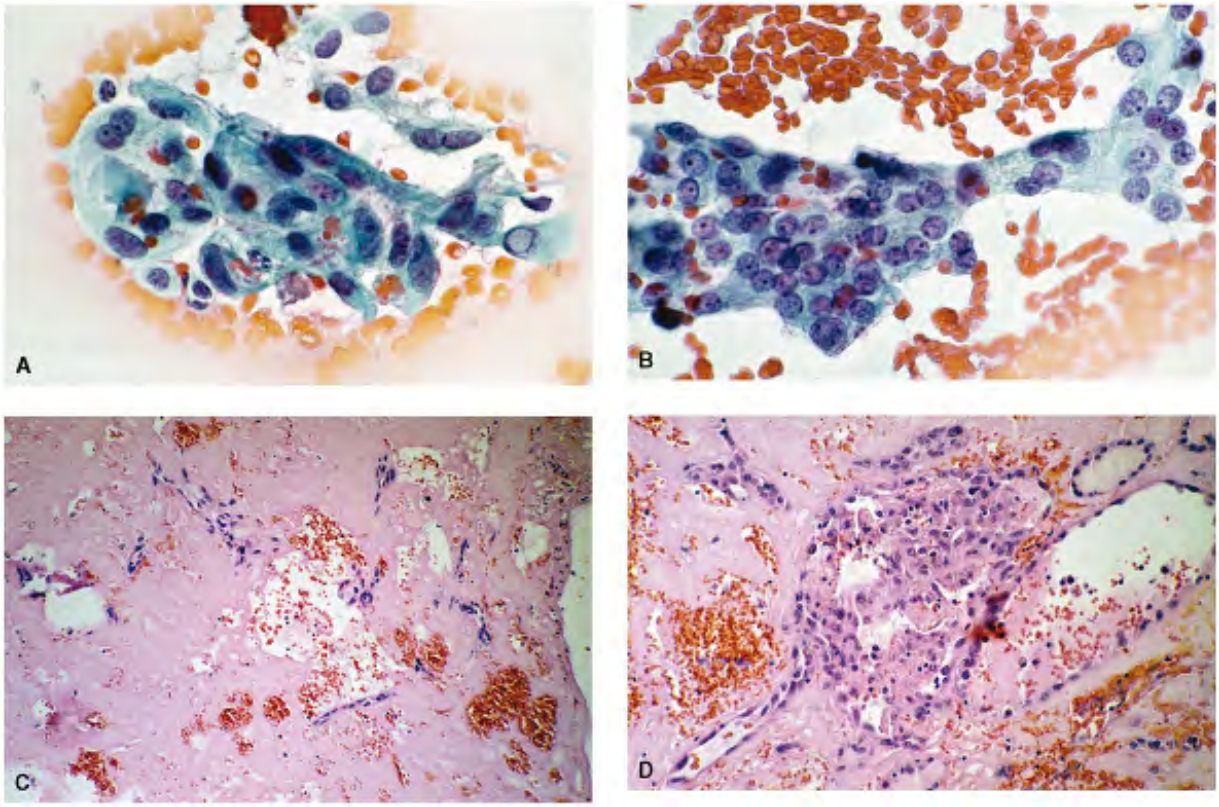

Figure 20.10. Another example of a nondiagnostic thyroidectomy. A. FNA of a thyroid nodu
consisting of enlarged cells containing very pleomorphic nuclei with nucleoli. Note an
intranuclear inclusion. The cells have variable, dense cytoplasm. B. A different field showin
syncytial tissue fragment of follicular cells with enlarged nuclei, containing granular chroma
and micronucleoli. A cytologic diagnosis of carcinoma was rendered. C. Thyroidectomy 90 d
later revealed a fibrotic nodule with no features suggestive of malignancy. D. A focal area w
the fibrotic area showed these trapped follicular cells with oncocytic features. No histologic
diagnosis of a neoplasm was rendered on this case (case 2 in Table 20.2).

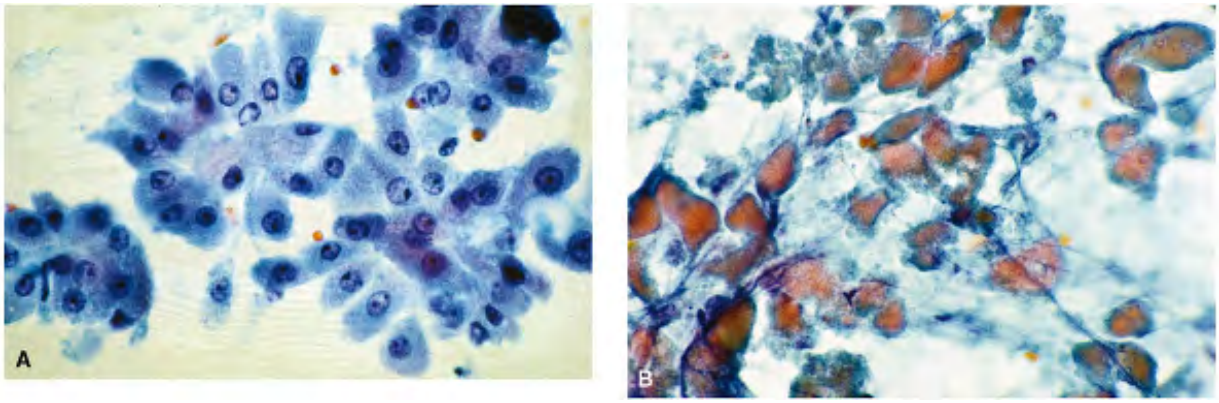

Figure 20.11. Spontaneous infarction. A. Fine-needle biopsy specimen of a HÃ¼rthle cell tu Note the characteristic cytomorphology with large polygonal, loosely cohesive cells, with abundant granular cytoplasm and uniform nuclei with prominent macronucleoli. B. A differe smear from the same case showing infarcted cells. HÃ¼rthle cell tumor was confirmed on surgery.

The long-term sequelae, such as fibrosis, endothelial proliferation, atypical nuclei along the needle tract, metaplasias, and entrapment of neoplastic tissue in the capsule, are worrisom changes that may offer diagnostic difficulties in histopathologic evaluation.2 , 3 , 4 , 5 , 6 , Completely infarcted neoplasm may undergo total fibrosis, which would prevent a surgical pathologist from rendering a meaningful diagnosis. These events are encountered with a lon time span between the fine-needle biopsy and the surgical excision. The prolonged interval between the procedures allows sufficient time for the development of fibrosis. Two such ca are illustrated in Figures 20.9 and 20.10 . The case of spontaneously disappearing HÃ¼rthle adenoma reported by Bauman and Strawbridge17 probably represents an extreme example the late effect of an infarcted neoplasm.

The importance of these post-fine-needle biopsy sequelae is that extensive necrosis and infarction will obscure the true nature of the neoplasm, and the cytologic diagnosis of the neoplasm may not be confirmed histologically. Widespread necrosis/infarction in a neoplasn should alert the histopathologist to evaluate the specimen more carefully. The accuracy of cytologic diagnoses of papillary carcinomas, HÃ¼rthle cell tumors, and follicular neoplasms quite high. An unequivocal cytologic diagnosis of neoplasia, especially of malignancy, shoulc be taken lightly in the presence of hemorrhage and necrosis of the neoplasm (Fig. 20.5). It imperative that the surgical pathologist be provided with the information on preoperative fi

needle aspiration biopsy diagnosis. Lack of information or the knowledge on the part of the surgical pathologist may result in a benign diagnosis. In

P.451

P.452

P.453

P.454

the light of positive cytologic results, and a careful examination of both the gross and microscopic specimens, a neoplasm can be usually be recognized in focal areas along the perimeter of the lesion. Judkins et al.18 performed immunohistochemical studies on infarct neoplasms. Their study demonstrated that the infarcted tissue of the thyroid neoplasm reac positively to thyroglobulin and not to cytokeratin.

It must be noted, however, that spontaneous hemorrhage, necrosis, organization, fibrosis, a cyst formation do occur in nodular goiters and also in neoplasms. Fine-needle biopsy will demonstrate necrotic debris with ghost cells in the background (Fig. 20.5). Spontaneous necrosis/infarction is also reported in several other organs, and readers may refer to the literature for their review.19 , 20 , 21 , 22 , 23 , 24

P.455

P.456

P.457

P.458

P.459

SUMMARY

In summary, partial or complete infarction of the thyroid neoplasm is an infrequent complic following fine/large-needle biopsies. Of the various types of benign and malignant neoplasm HÃ¼rthle cell tumors are more prone to post-biopsy infarction. The final histologic diagnosis the infarcted neoplasm may be compromised, resulting in non-confirmation of the cytologic diagnosis if the cytologic diagnosis is not taken into consideration.

REFERENCES

1.Miller JM, Kini SR, Hamburger JI. *Needle Biopsy of the Thyroid* . New York: Praeger; 198

2.Baloch ZW, LiVolsi VA. Post fine-needle aspiration histologic alterations of thyroid revisited. *Am J Clin Pathol* . 1999;112:311â€“316.

3.Baloch ZW, LiVolsi VA. Post FNA spindle cell nodules of the thyroid (PSCNT). *Am J Clin Pathol* . 1999;111:70â€“74.

4.Ersoz C, Soylu L, Erkocak E, et al. Histologic alterations in the thyroid gland after fine-needle aspiration. *Diagn Cytopathol* . 1997;16:230â€“232.

5.LiVolsi VA, Merino MJ. Worrisome histologic alterations following fine needle aspiration thyroid. *Pathol Ann* . 1994;29:99â€“120.

6.Gordon DL, Gattuso P, Castelli M, et al. Effect of fine needle aspiration biopsy on the histology of thyroid neoplasms. *Acta Cytol* . 1993;37:651â€“654.

7.Tsang K, Duggan MA. Vascular proliferation of the thyroid: a complication of fine-needle aspiration. *Arch Pathol Lab Med* . 1992;116:1404â€“1042.

8.Us-Krasovec M, Golauth R, Auesperg M, et al. Tissue damage after fine needle aspiration biopsy. *Acta Cytol* . 1992;36:456â€“457.

9.Axiots AC, Merino MJ, Ain K, et al. Papillary endothelial hyperplasia in the thyroid following fine-needle aspiration. *Arch Pathol Lab Med* . 1991;115:240â€“242.

10.Kini SR. Post fine needle biopsy infarction of thyroid neoplasms. A review of 28 cases. *Diagn Cytopathol* . 1996;15:211â€“220.

11.Layfield LJ, Lones MA. Necrosis in thyroid nodules after fine needle aspiration biopsy. Report of two cases. *Acta Cytol* . 1991;35:427â€“430.

12.Alejo M, Matias-Guiu X, de las Heras Duran P. Infarction of a papillary thyroid carcinom

after fine needle aspiration. *Acta Cytol* . 1991;35:478â€“479.

13.Keyhani-Refagha S, Kooner DS, Keyhani M, et al. Necrosis of a HÃ¼rthle cell tumor of t thyroid following fine needle aspiration. Case report and literature review. *Acta Cytol* . 1990;34: 805â€“808.

14.Kini SR, Miller SM, Abrash MP, et al. Post-fine needle aspiration biopsy infarction in thyroid nodules. *Mod Pathol* . 1988;1:14A.

15.Jayaram G, Aggarwal S. Infarction of thyroid nodule: a rare complication following fine needle aspiration. *Acta Cytol* . 1989:33:940â€“941.

16.Jones JD, Pittman DL, Sander LR. Necrosis of thyroid nodules after fine needle aspirati *Acta Cytol* . 1985;29:29â€“32.

17.Bauman A, Strawbridge HTG. Spontaneous disappearance of an atypical HÃ¼rthle cell adenoma. *Am J Clin Pathol* . 1983;80: 399â€“402.

18.Judkins AR, Roberts SA, LiVolsi VA. Sensitivity of antibodies on necrotic thyroid nodules *Mod Pathol* . 1998;11:57A.

19.Tsang WYW, Chan JKC. Spectrum of morphologic changes in lymph nodes attributable t fine needle aspiration. *Hum Pathol* . 1992;23:562â€“565.

20.Layfield LJ, Reznick M, Low M, et al. Spontaneous infarction of a parotid gland pleomorphic adenoma. *Acta Cytol* . 1992;36: 381â€“385

21.Dekmezian RH, Sneige N, Katz RL. The effect of fine needle aspiration of lymph node morphology in lymphoproliferative disorders. *Acta Cytol* . 1989;33:732â€“733.

22.Davies JD, Webb AJ. Segmental lymph node infarction after fine needle aspiration. *J C*

Pathol . 1982;35:855â€“857.

23.Kern SB. Necrosis of a Warthin's tumor following fine needle aspiration. *Acta Cytol* . 1988;32:207â€“208.

24.Lucey JJ. Spontaneous infarction of the breast. *J Clin Pathol* . 1975;28:937â€“943.

Editors: Kini, Sudha R.
Title: *Thyroid Cytopathology: A Text and Atlas, 1st Edition*

Copyright Â©2008 Lippincott Williams & Wilkins

21

Lesions of the Parathyroid Glands

Fine-needle aspiration biopsy is not routinely performed in evaluation of the parathyroid gla lesions. Consequently, information on their cytopathologic findings is limited. The literature includes mostly individual case reports, small case series, and very few reviews of large num of cases. The cytologic criteria for parathyroid cysts, hyperplasia, and adenoma described ir chapter are based on limited personal experience and also culled from the literature.1 , 2 , , 5 , 6 , 7 , 8 , 9 , 10 , 11

Although specimens from the parathyroid lesions are not received in routine cytopathology practice, it is important to be familiar with their cytologic presentations. This is because th parathyroid glands, either in their usual or in ectopic locations, may clinically and/or radiologically appear to be of thyroidal origin.12 , 13 , 14 , 15 , 16 , 17 Thus specimens submitted as thyroidal lesions may indeed be parathyroidal in origin. Furthermore, the specimens from these parathyroid lesions are difficult to recognize accurately because of th morphologic overlap between thyroid and parathyroid lesions, which constitutes a common diagnostic problem.

Some reasons for the infrequent use of fine-needle biopsy in the diagnosis of parathyroid les may be as follows:

- Functioning parathyroid lesions are subjected to surgical exploration following a clir diagnosis supported by the laboratory data. Preoperative fine-needle biopsies are nc performed or required in these instances.
- Although ultrasonography is popularly used10 , 11 , 18 , 19 , 20 in localizing the

parathyroid lesions, its sensitivity varies widely, ranging from 34% to 92%, while the specificity is reported to be high, up to 97%. But the difficulties in differentiating between thyroid nodules, parathyroid glands, and lymph nodes still exist (Fig. 21.2)

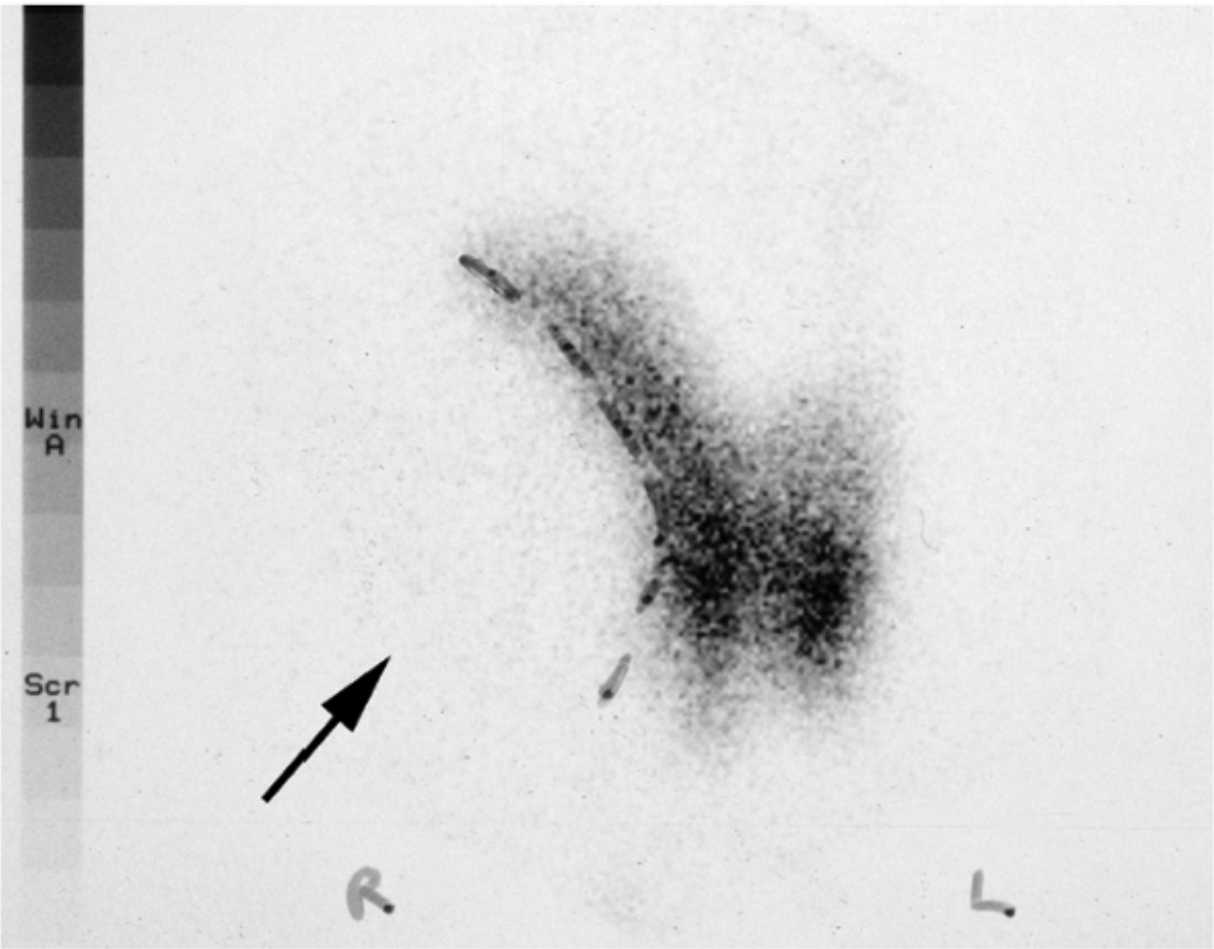

Figure 21.2. Thyroid radionuclide image. The large, discrete, clear area *(arrow)* wa interpreted as a cold nodule of the right lobe of the thyroid. A fine-needle biopsy specimen was diagnosed as carcinoma but was not typed (see Fig. 21.14). Thyroidectomy revealed a large, encapsulated nodule grossly thought to be involving right thyroid lobe. Only the histologic examination confirmed the parathyroid adeno This is an example of a parathyroid lesion being mistaken for a thyroid nodule on radionuclide scan.

- Small functioning parathyroid lesions may not be detected by ultrasonography.
- Accurate cytologic identification of parathyroid glands offers difficulties because of

morphologic overlap between thyroid and parathyroid lesions.

Fine-needle biopsies of parathyroid gland lesions have been performed in following situatior

- Enlarged parathyroid glands visualized during routine ultrasonography of the neck fo thyroid.21
- Patients with hyperparathyroidism with ultrasound localization of the parathyroid glands.5 , 10 , 11
- Ultrasonography of thyroid bed following thyroidectomy.22
- Suspected parathyroid lesion following unsuccessful parathyroid exploration, under ultrasound guidance.4 , 23 , 24

NORMAL PARATHYROID GLANDS

The parathyroid glands are small red-brown, flattened, ovoid structures generally measurin 6 mm in length, 2 to 4 mm in width, and 1 to 2 mm in thickness. The average combined wei 120 Â± 3.5 mg in males and 142 Â± 5.2 mg in females.25 Most normal adults have four parathyroid glands, the superior pair located about 1 cm above the intersection of the recu laryngeal nerve and the inferior thyroid artery. The inferior parathyroids are typically found inferior, posterior, or lateral to the lower pole of the thyroid and sometimes high up on the anterior aspect of the thyroid lobe. Due to their intimate anatomic location in thyroid area, lesions of the parathyroid may masquerade as thyroidal lesions. The parathyroid glands are highly vascularized and thinly encapsulated. Histologically, the parathyroid gland shows a mixture of parenchyma and adipose tissue (Fig. 21.1A). The parathyroid parenchyma consis chief cells, varying numbers of oncocytic cells, and transitional oncocytic cells (Fig. 21.1B). parenchymal cells are often arranged in a lobular pattern. The chief cells are polyhedral, 8 Âµm in diameter,26 with round central nuclei containing sharp nuclear membrane with coa chromatin. Their cytoplasm is eosinophilic to amphophilic and often appears clear or vacuol in formalin-fixed tissues. The cells are rich in glycogen and contain variable amounts of neu lipid in the form of two or three sudanophilic fat droplets per cell.25 The chief cells may fo solid sheets, branching anastomosing cords, and sometimes small acinar structures. Eosinop periodic acidâ€“Schiff (PAS)â€“positive material resembling colloid may be present within t acinar structures. The oncocytic cells

measure 12 to 20 Âµm in diameter and contain deep eosinophilic cytoplasmic granules. Thei nuclei are slightly larger than those of chief cells. The stroma contains mature fat cells, blo vessels, and varying amounts of connective tissue, the proportion of which changes with age The immunoprofile of parathyroid parenchymal cells includes positive reactivity to parathormone and chromogranin.

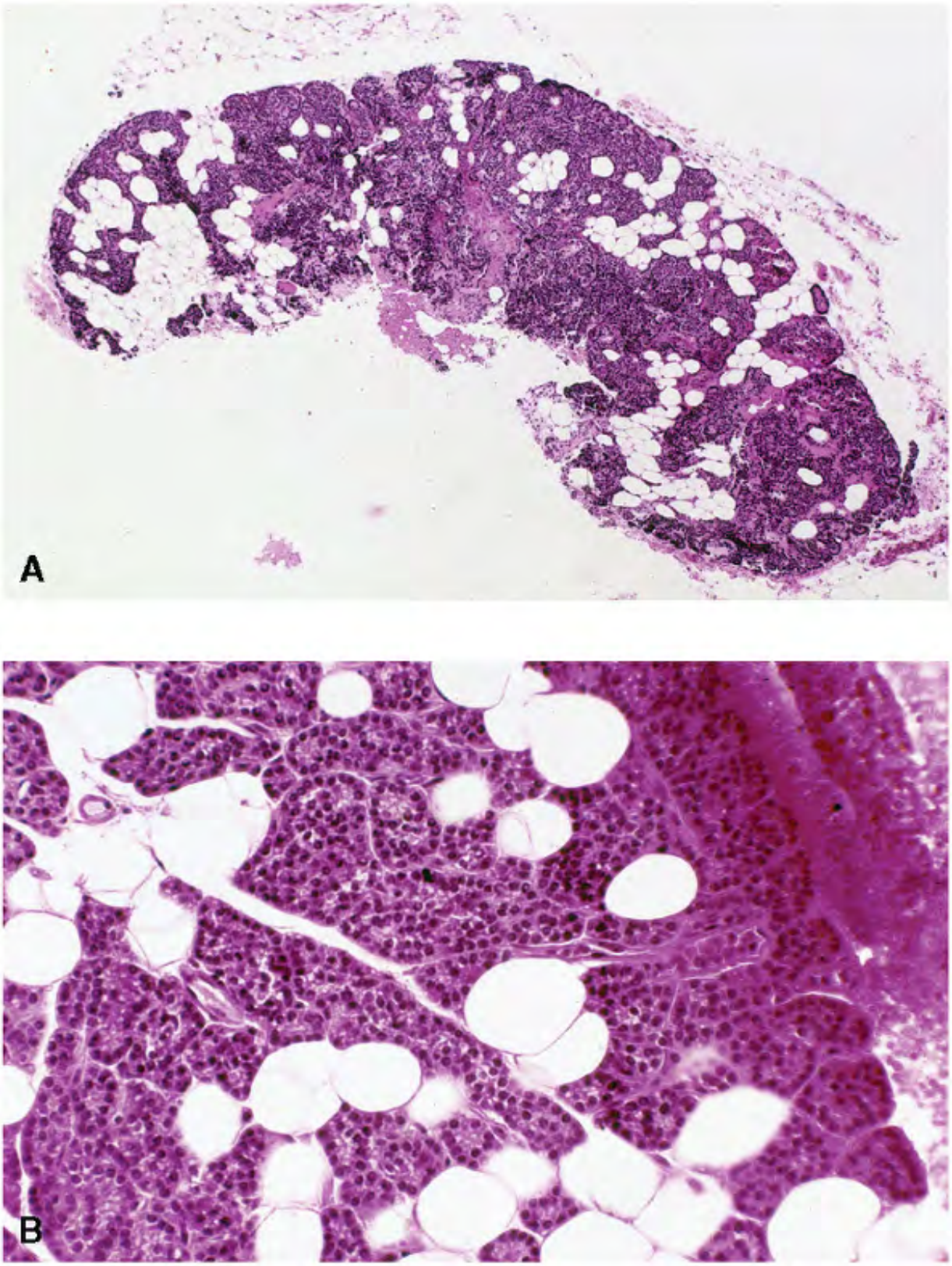

Figure 21.1. A. Histologic section of the normal parathyroid gland with a mixture of parenc

and adipose tissues (low power). B. Higher magnification showing islands of chief cells with intervening adipose tissue.

The parathyroid cells secrete parathyroid hormone, which along with the hormones calcitric (produced in the kidney) and calcitonin (produced in the thyroid), regulates calcium and phosphorus levels.25

RADIOLOGIC FINDINGS

Several imaging modalities are used to localize parathyroid gland lesions. These include ultrasonography, CT scanning, magnetic resonance imaging (MRI), thallium substation scann and the recent technetium-99m sestamibi imaging. Ultrasonography is the most frequently u modality for primary parathyroidism. A normal parathyroid gland is typically not seen with ultrasound. A parathyroid adenoma or a carcinoma is seen as a round, elliptical, or oblong hypoechoic mass. These may contain cysts and calcifications. Hyperplastic glands are usually much smaller than adenomas. Ultrasound cannot localize ectopic parathyroids. Thyroid nod and lymph nodes may be mislabeled as parathyroids.

PARATHYROID CYSTS

Parathyroid cysts are rare,25 , 27 , 28 , 29 , 30 , 31 , 32 , 33 , 34 , 35 , 36 , 37 , 38 , 39 , 4 41 with fewer than 300 cases reported to date in the literature. The incidence of parathyroi cysts among cystic neck lesions is stated to be less than 1% of patients undergoing neck exploration for parathyroid and thyroid lesions.

Most parathyroid cysts are located in the lower cervical neck region in proximity to the infe parathyroid glands; 13% are found in the anterior superior mediastinum.13 , 25 , 30 , 36 Parathyroid cysts are generally asymptomatic, but the larger ones may cause symptoms due compression of the trachea, esophagus, or recurrent laryngeal nerve. Up to 11% of parathyr cysts may be associated with hyperparathyroidism.25 Nonfunctional cysts are more common women. Clinically, the parathyroid cysts may present as cervical nodules often mistaken for those of thyroidal origin. The results of radionuclide thyroid imaging are often misleading in diagnosis of parathyroid cysts.6 , 7 , 9 , 10 , 11 However, ultrasonography has been quite successful in detecting parathyroid cysts, allowing for the fine-needle biopsy procedures.2 , , 6 , 7 , 10 , 11 , 35 , 43 The origin of parathyroid cysts includes:

- Embryologic remnants of the third and fourth branchial clefts.
- Coalescence of microcysts.
- Degeneration in a hyperplastic gland or in an adenoma.

Gross and Microscopic Features

Grossly, parathyroid cysts vary in size and may be as large as 10 cm in diameter. They are loosely attached to the thyroid (Fig. 21.3A). They can be uni- or multilocular. The cyst wall typically thin, translucent, membranous, and gray-white.

Histologically, the wall is fibrous and lined by flattened epithelial cells, some containing cle cytoplasm and resembling chief cells. Trapped islands of chief cells may also be present in t wall (Figs. 21.3B and C).

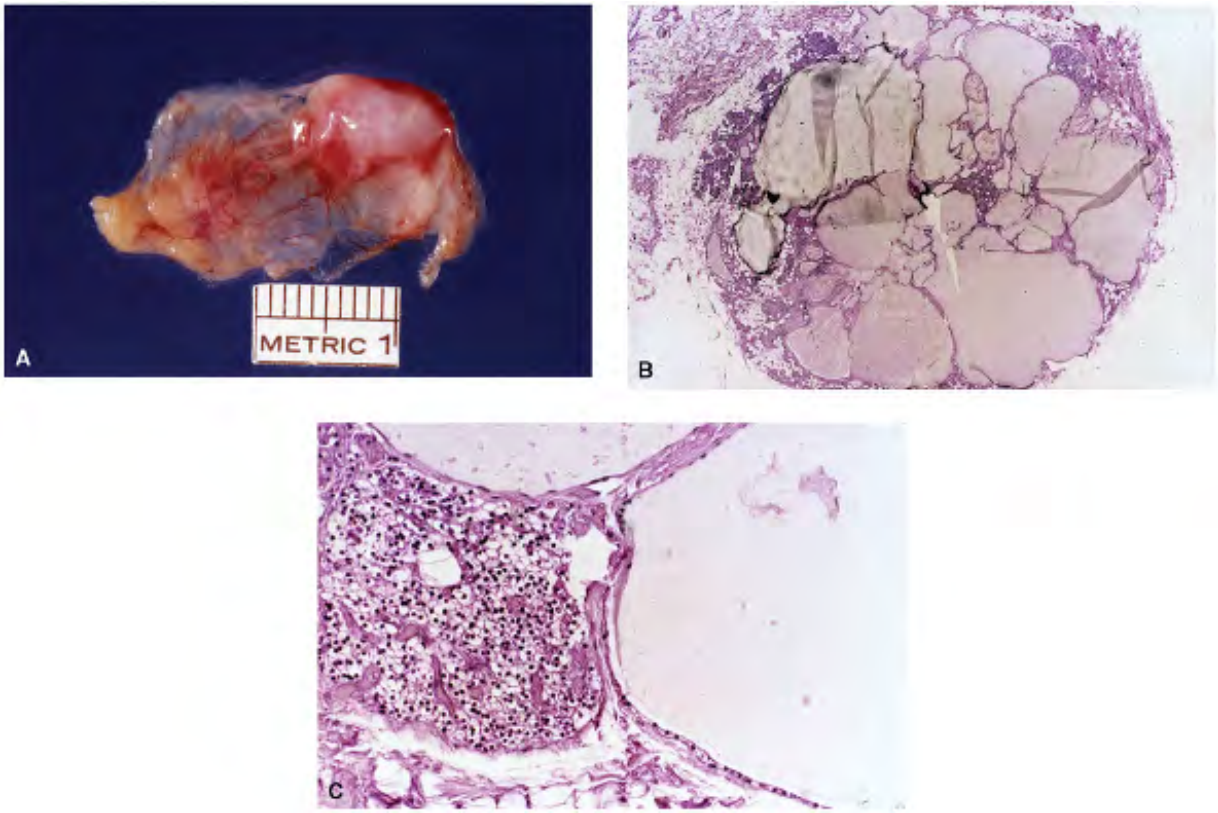

Figure 21.3. A. Gross photograph of a thin-walled parathyroid cyst. B. Low-power view of t histologic section of a multiloculated parathyroid cyst with thin walls. C. Higher magnificati showing an island of parathyroid cells in the wall.

Cytopathologic Features

Aspirated cyst fluid can measure up to several milliliters; and is characteristically clear, wat and occasionally golden brown, in contrast to thyroid cyst fluid, which is straw-colored, aml hemorrhagic, dark brown, or viscous. The fluid is often acellular2 or poorly cellular, consisti tissue fragments of small cuboidal cells with round nuclei containing granular to compact chromatin (Fig. 21.4). The cells are arranged in regular microfollicles or honeycomb sheets. Oncocytic cells and histiocytes are rarely seen, and colloid is absent. The background shows proteinaceous debris. The

parathyroid hormone levels in cyst fluids are always elevated, supporting their parathyroid c and serving as a differentiating feature from thyroid cysts.2 , 4 , 33

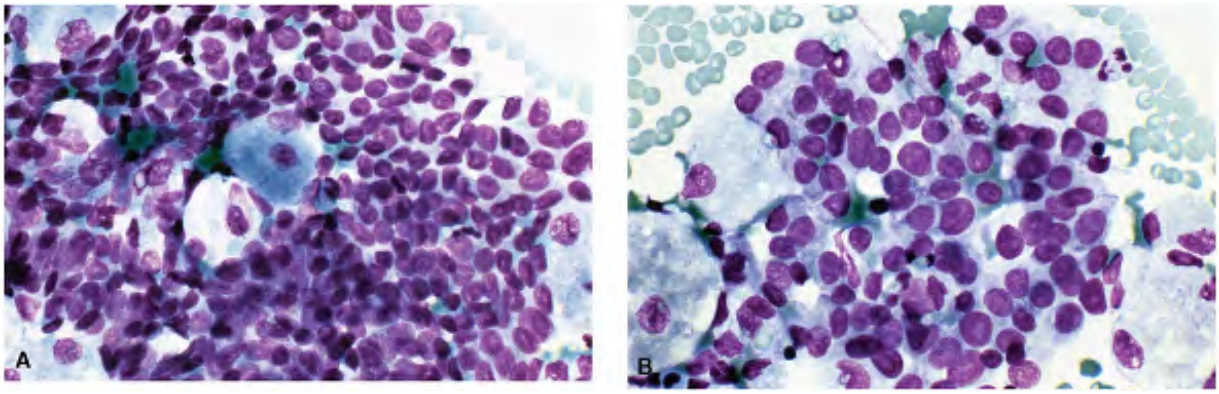

Figure 21.4. Parathyroid cyst fluid. A,B. Monolayered tissue fragments of small cuboidal cel a honeycomb arrangement. The nuclei are small and uniform, with compact chromatin. Not their strong resemblance to thyroid follicular cells. The empty spaces within the tissue fragr probably represent fat cells.

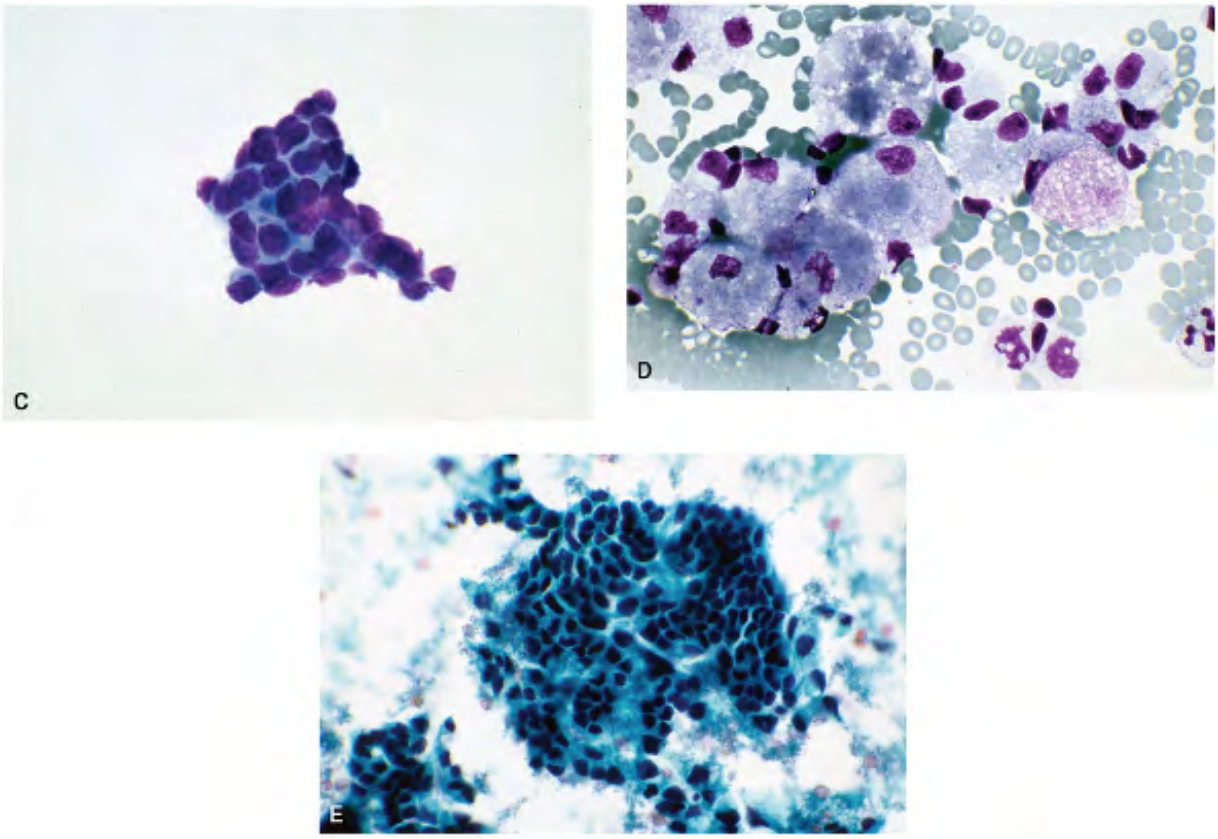

Figure 21.4. C. A tissue fragment of tightly packed small parathyroid cells with scant cytopl and high N/C ratios. D. A group of histiocytes. Heme-3 stain. E. Same specimen as A to D, stained by Papanicolaou stain. Tissue fragments of small cuboidal cells with crowding and overlapping of small, uniform, nuclei with compact chromatin. Note their strong resemblanc thyroid follicular cells. The background shows proteinaceous precipitate. (Courtesy of Micha Glant, MD, director, Diagnostic Cytology Clinic, Indianapolis.)

Diagnostic Accuracy and Differential Diagnosis

Both clinically and cytologically, parathyroid cysts are often mistaken for thyroidal cysts of degenerating nodular goiters (Figs. 21.5 and 21.6). Parathyroid cells resemble thyroid follic cells in size and in architectural configurations. The main differentiating features between two cysts include the gross characteristics of the parathyroid cyst fluid and the elevated parathormone levels. The parathyroid cells will react positively to parathyroid antibody and negatively to thyroglobulin.42 , 43 Table 21.1 lists the differentiating features between parathyroid cysts and cysts of nodular goiter. The other differential diagnostic entities inclu cystic lesions of the neck such as branchial cleft, thymic, or thyroglossal duct cysts.

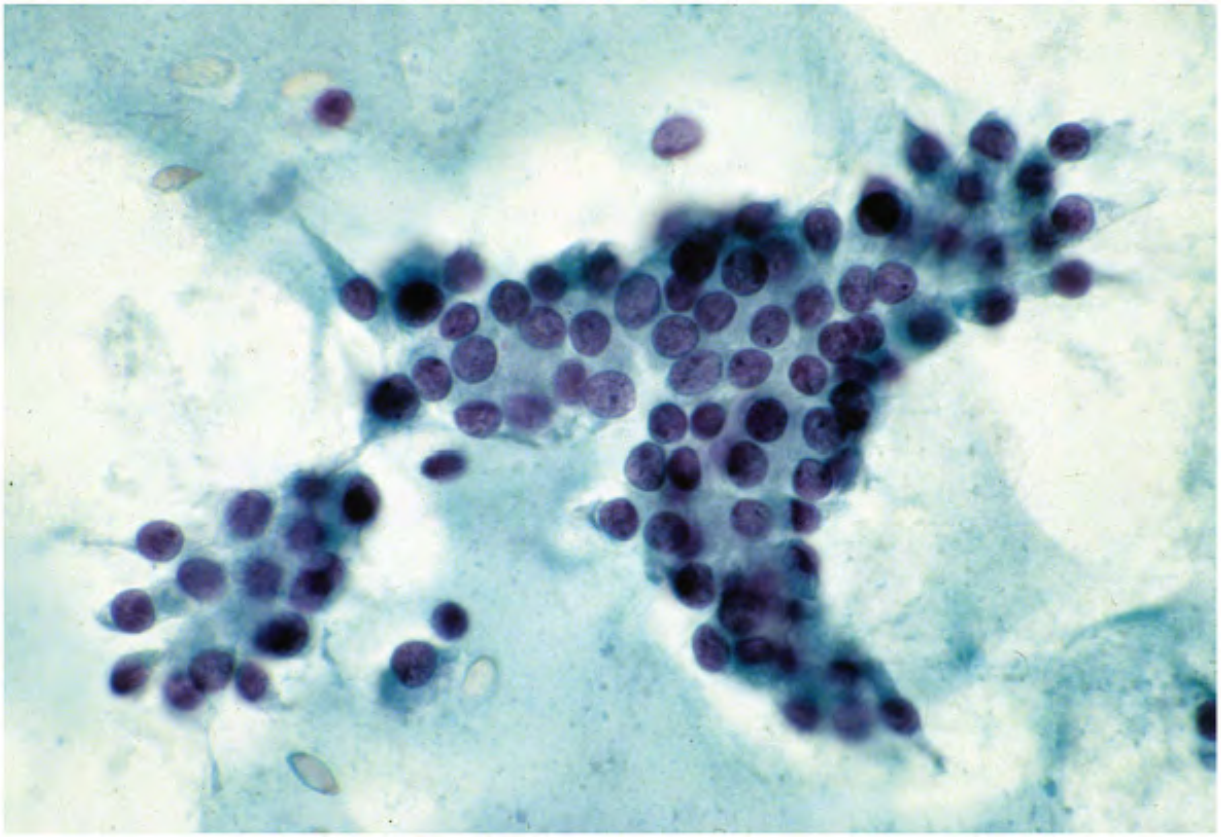

Figure 21.5. FNA of a nodular goiter. The tissue fragment of benign follicular cells with a honeycomb pattern, lacking extreme crowding and overlapping of nuclei. The nuclear size is slightly larger than the parathyroid cells. Note the morphologic overlap between thyroid follicular cells and parathyroid cells.

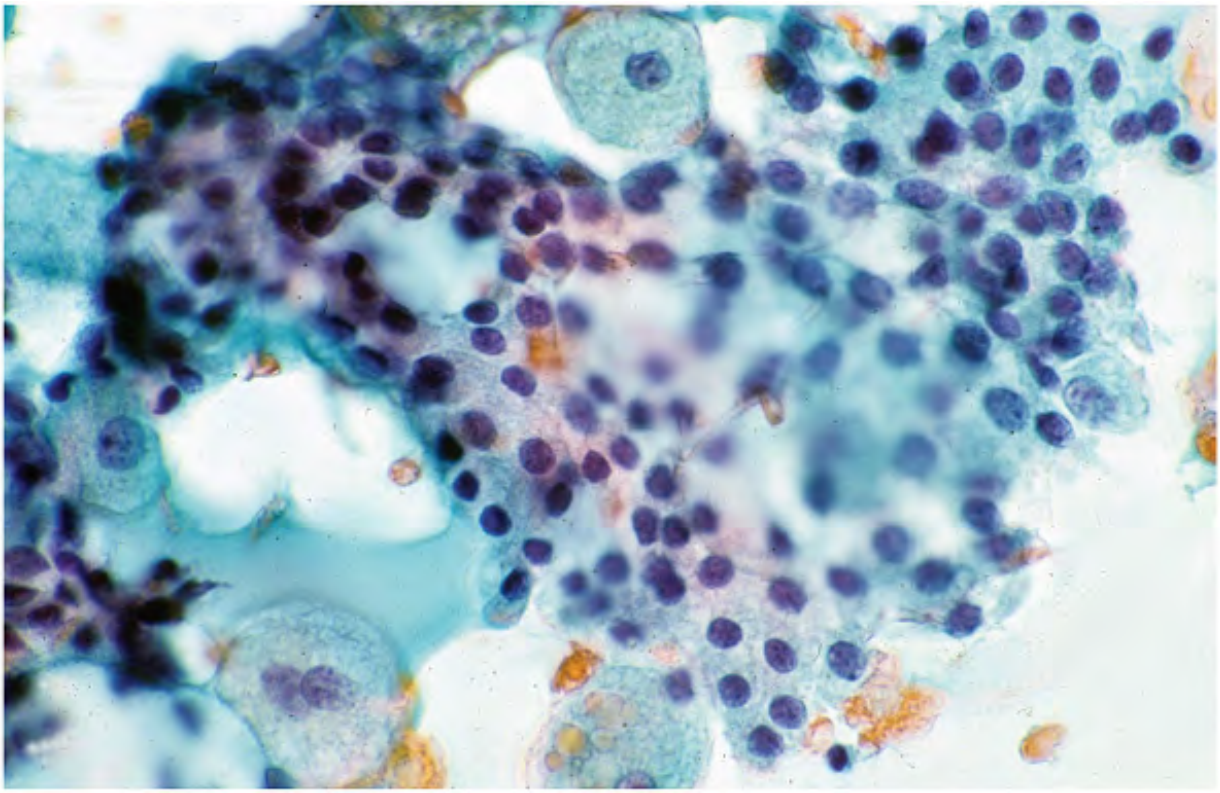

Figure 21.6. FNA of a cystic nodular goiter showing macrophages and benign follicular cells. cytologic pattern is indistinguishable from that of a parathyroid cyst.

Presentation

Aspirated fluid water: clear, thin, occasionally straw-colored or red-brown

Clear, straw-colored, amber, red-brown to hemorrhagic, to thick, sticky

Cellularity

Acellular to poorly cellular

Variable

Epithelial cells

Rare group or a tissue fragment of very small round to cuboidal cells; microfollicular pattern or sheets, poorly defined cell borders; scant cytoplasm with high N/C ratios; round nuclei with deep-staining compact chromatin

Follicular epithelial cells in varying numbers; regular follicles or honeycomb sheets with well-defined cell borders; uniform round nuclei with compact to granular chromatin; degenerative changes frequent

HÃ¼rthle Cell metaplasia

Absent

Â±

Histiocytes

Â±

Usually present in variable numbers; with or without hemosiderin; multinucleated foreign-body-type giant cells Â±

Colloid

Absent

Variable

Immunoprofile

Positive reactivity to parathyroid hormone and chromogranin

Positive reactivity to thyroglobulin

Parathyroid hormone levels

High

Nil

Parathyroid Cyst	Thyroid Cyst (Nodular Goiter)

TABLE 21.1 CYTOPATHOLOGIC FEATURES OF PARATHYRO CYSTS AND THYROID CYSTS IN NODULAR GOITER

PARATHYROID HYPERPLASIA AND ADENOMA

Parathyroid hyperplasia and adenoma may be associated with primary hyperparathyroidism characterized by excess production of parathyroid hormone and hypercalcemia, along with

certain bone changes.25 Solitary adenoma is the most frequent cause (80% to 85% of cases) hyperparathyroidism. Primary hyperplasia accounts for up to 15% of primary hyperparathyroidism. It can also be associated with the dominantly inherited multiple endo neoplasia (MEN) syndrome. The incidence of primary hyperparathyroidism has increased ove last several years,25 , 27 primarily because of the improved radiologic modalities and sophisticated laboratory studies.

Secondary hyperplasia of the parathyroid glands occurs as a result of certain systemic disorders.25

PARATHYROID HYPERPLASIA

Gross and Microscopic Features

Proliferation of parenchymal cells of the parathyroid is referred to as hyperplasia,25 , 27 ar often takes the form of nodules. Generally, all four parathyroid glands are involved but not uniformly. The size and weight of each enlarged gland are variable features, and not all gla are visualized by ultrasound. Histologically, the hyperplasia involves chief cells as well as oncocytic cells (Figs. 21.7 and 21.8). It can be diffuse or nodular and sometimes can form glandular patterns. The stromal adipose tissue is reduced or absent.

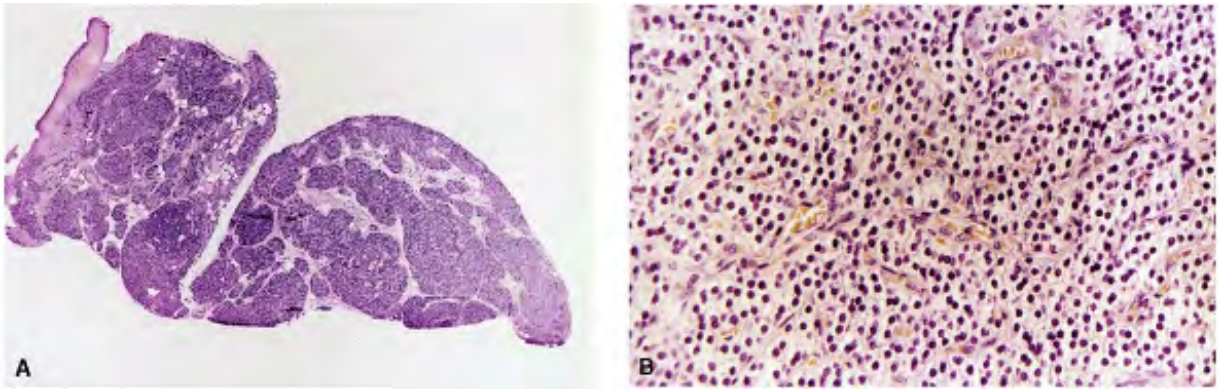

Figure 21.7. A. Histologic section of a hyperplastic parathyroid gland with reduced amount adipose tissue (low power). B. Higher magnification showing chief cell hyperplasia with a follicular growth pattern.

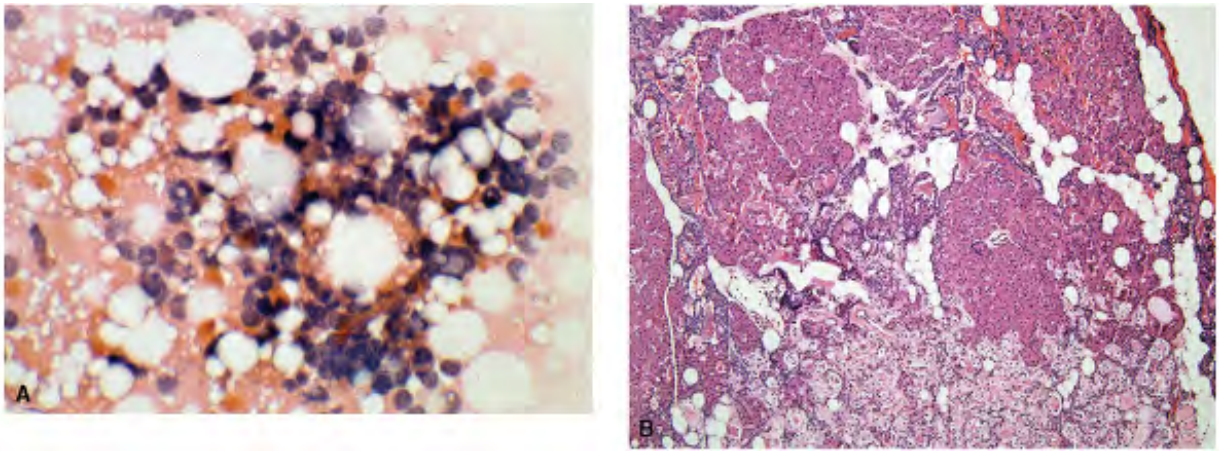

Figure 21.8. A. Scrape preparation of a hyperplastic parathyroid gland. The parathyroid cel are small with poorly defined cell borders, scant cytoplasm, and containing round nuclei. Th chromatin is compact. The cells are in aggregates or small tissue fragments and are separat fat cells. B. Histologic section of the excised hyperplastic parathyroid gland revealing hyperplasia of both chief and oncocytic cells.

Cytopathologic Features

The smears are variably cellular, showing tissue fragments of small parathyroid cells with ro uniform nuclei, containing finely granular chromatin. The cytoplasm of the chief cells is sca pale, or may be finely vacuolated. The oncocytic cells are slightly larger and contain apprec slightly denser cytoplasm. The stromal fat if identified in the aspirate will favor the diagnos hyperplasia (Fig. 21.8).

PARATHYROID ADENOMA

Gross and Microscopic Features

In contrast to hyperplasia, parathyroid adenoma involves a single gland. A typical parathyro adenoma is a thinly encapsulated, tan to reddish brown neoplasm, homogeneous in consiste with a smooth external surface. Adenomas vary considerably in size and shape. They may be round, ellipsoid, bean- or kidney-shaped, or flattened and elongated (Fig. 21.9).18 , 19 Lar adenomas may undergo cystic change and the aspiration biopsy may yield fluid contents.

Figure 21.9. Gross photograph of a large parathyroid adenoma.

Histologically, adenomas are encapsulated neoplasms with compressed normal parenchyma outside the capsule. The dominant cell type is chief cells often larger than their normal counterpart. The cell outlines are indistinct. Their cytoplasm ranges from faintly eosinophili clear, and contains abundant

glycogen deposits. The nuclei are round and central, with dense chromatin and occasional nucleoli. A few cells may contain large, hyperchromatic nuclei. The growth patterns consist closely packed chief cells arranged in anastomosing cords, nests, glandular formations, and sheets separated by a delicate network of sinusoids (Fig. 21.10).

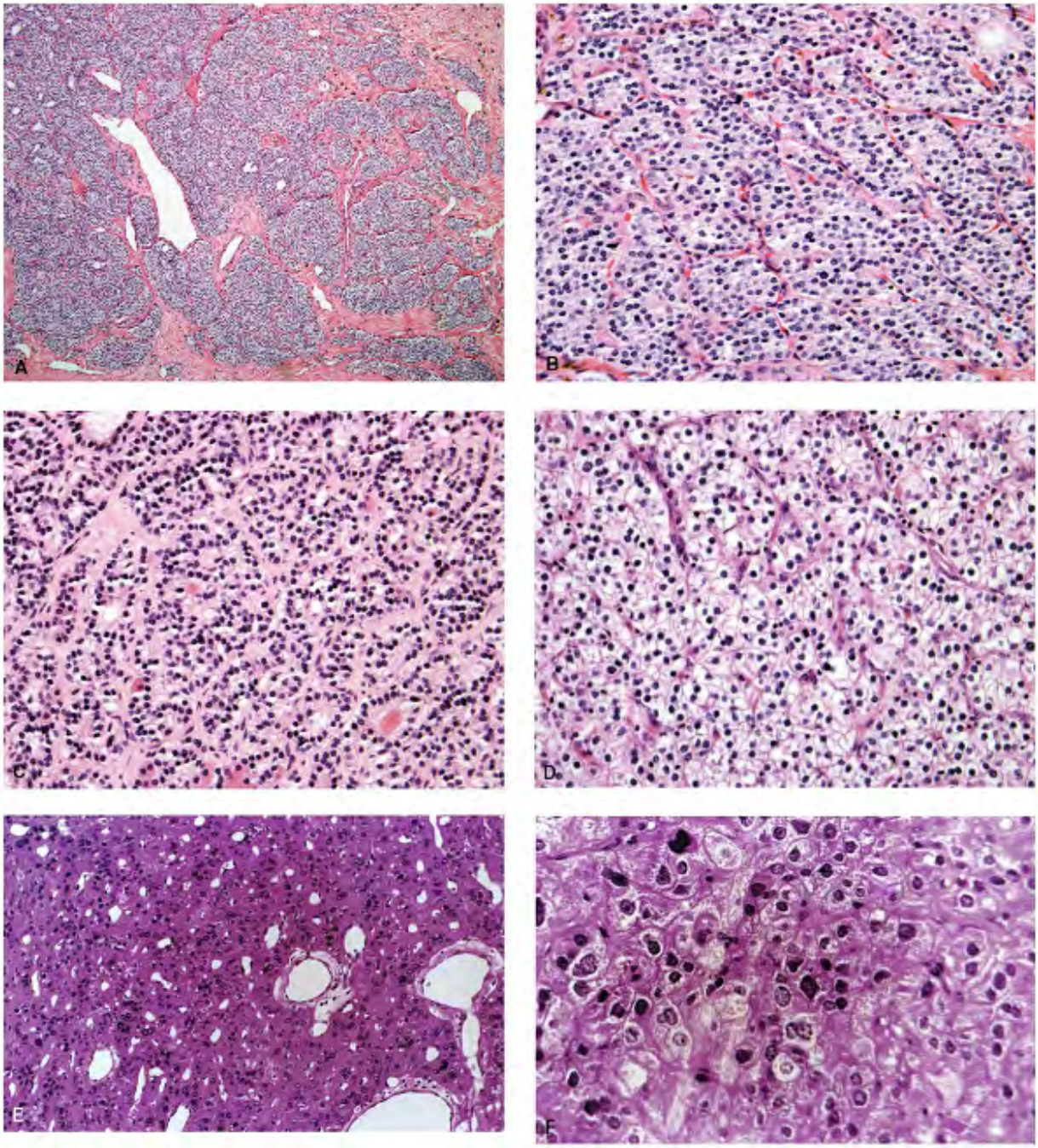

Figure 21.10. *Histologic sections demonstrating various cell types and growth patterns of parathyroid adenomas.* A. Parathyroid adenoma showing nests and insulae of cells. B. Trabecular growth pattern of chief cells. Note the rich sinusoidal network. C. Follicular grov pattern. D. Clear cell pattern. E. Oncocytic cell pattern. F. Note marked nuclear atypia tha sometimes present in parathyroid adenomas.

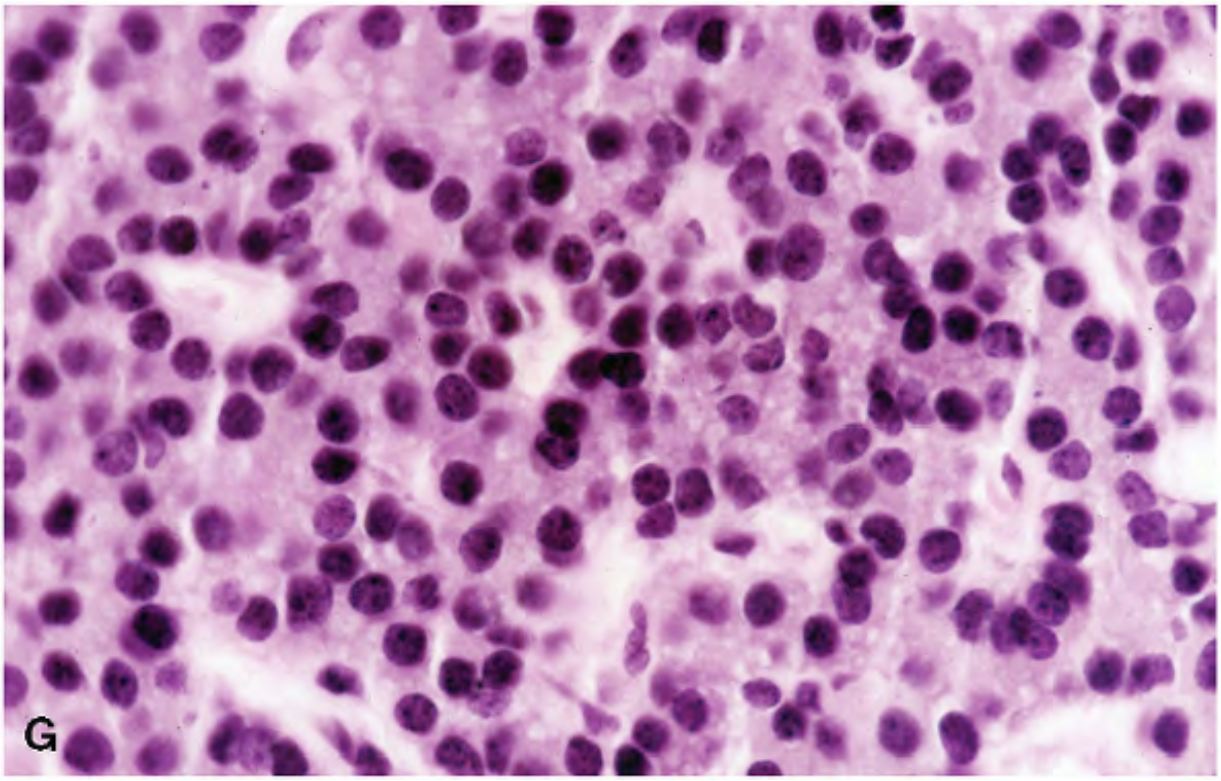

Figure 21.10. G. Higher magnification of an adenoma composed of chief cells depicting a follicular pattern, small cuboidal cells with uniform nuclei.

The adenomas frequently contain cystic structures, which may be empty or filled with PAS-positive, eosinophilic, homogeneous material that strongly resembles colloid. The cells cont glycogen and fat. Argyrophilic granules in the cytoplasm of adenoma cells have been described.10

Immunoprofile

The cells of parathyroid hyperplasia or adenoma exhibit positive reactivity to parathyroid hormone, chromogranin A, and low-molecular-weight cytokeratin; and negative reactivity t thyroglobulin and vimentin.2 , 4 , 25 , 42 , 43

Cytopathologic Features

Cytologically, a parathyroid adenoma cannot be distinguished from parathyroid hyperplasia because both present similar cytologic features.8 When adequate, the cytologic material

consists of a large population of small round to cuboidal epithelial cells displayed singly, in loosely cohesive groups, or in thick syncytial-type tissue fragments (Figs. 21.11 , 21.12 , 21.
21.14 and 21.15). A dispersed cell pattern is also characteristic (Fig. 21.13). The tissue fragments present various architectural configurations. They may be monolayered (two-dimensional), trabecular with branching and interdigitating to enclose spaces (Fig. 21.11).
tissue fragments may present a follicular pattern (Fig. 21.11E) or appear papillary-like with complex branching and frayed edges. Frequently, the extreme crowding and overlapping of nuclei within a tissue fragment result in a three-dimensional pattern (Figs. 21.11 and 21.12

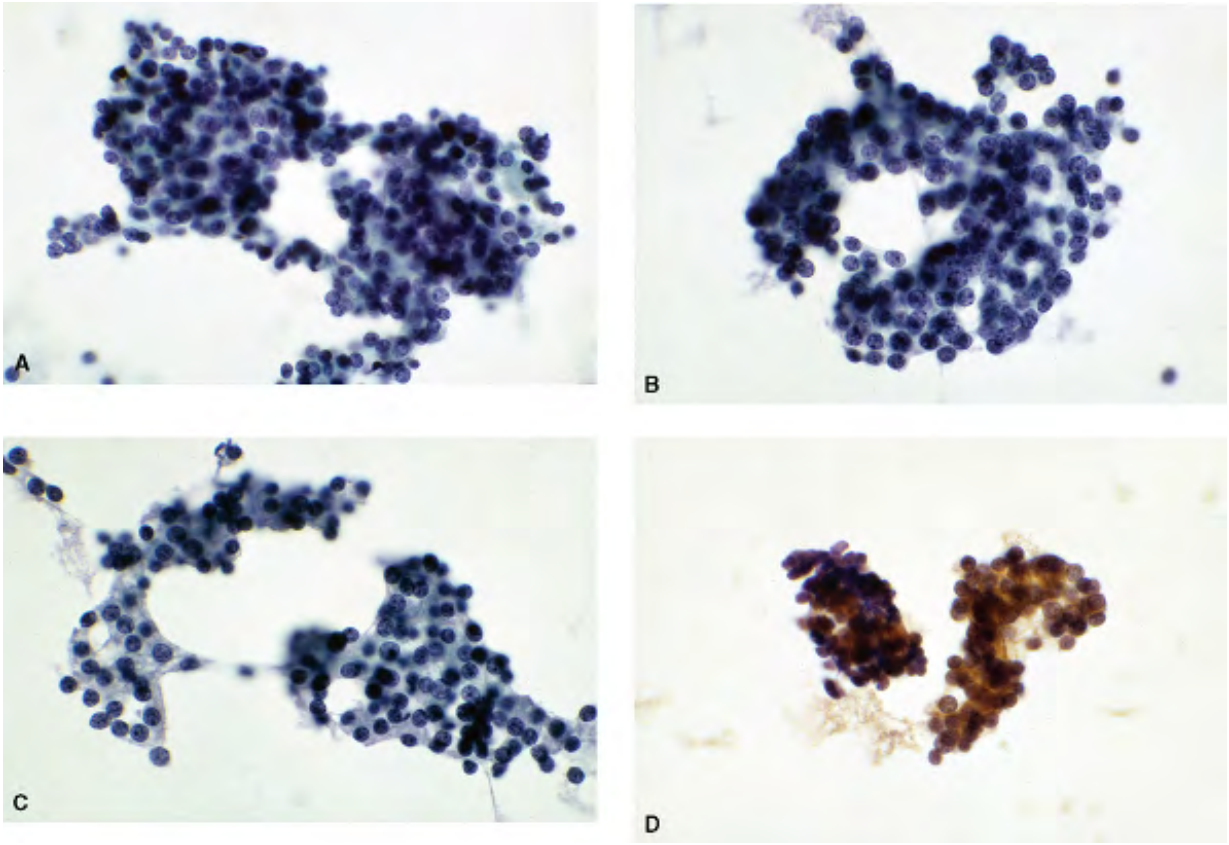

Figure 21.11. *Scrape smears of a parathyroid adenoma.* A. The syncytial tissue fragment consists of small cells with extreme crowding and overlapping of uniform, round nuclei with granular chromatin. The N/C ratios are very high. The cell borders are indistinct and the cytoplasm is pale, scant but variable. B. The syncytial tissue fragments of small cells presen trabecular pattern. C. Syncytial tissue fragments with a follicular pattern. D. Positive reacti to parathyroid hormone antibody.

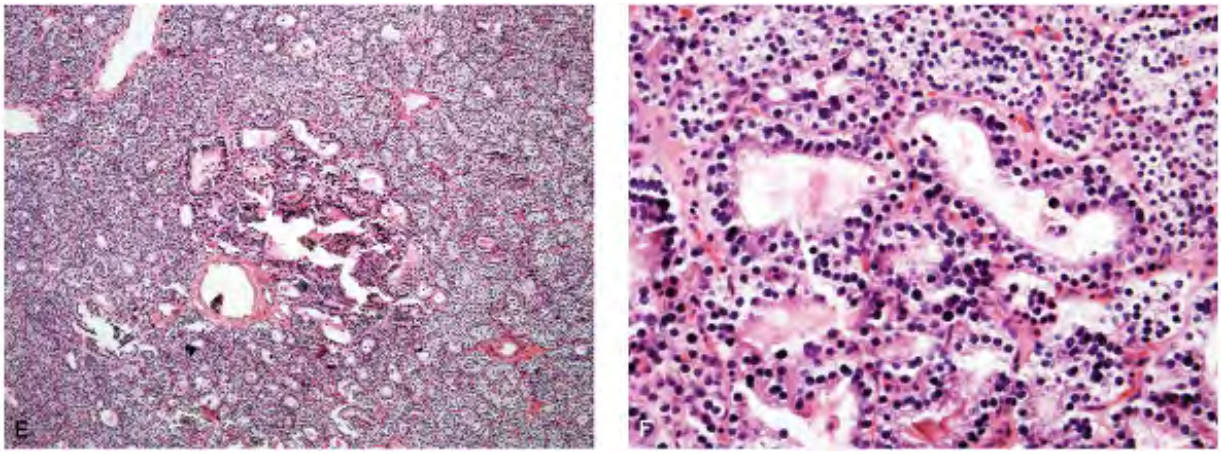

Figure 21.11. E. Histologic section of the resected specimen showing a variegated growth pattern such as insular, trabecular, and follicular. Medium power. F. Higher magnification showing chief cells.

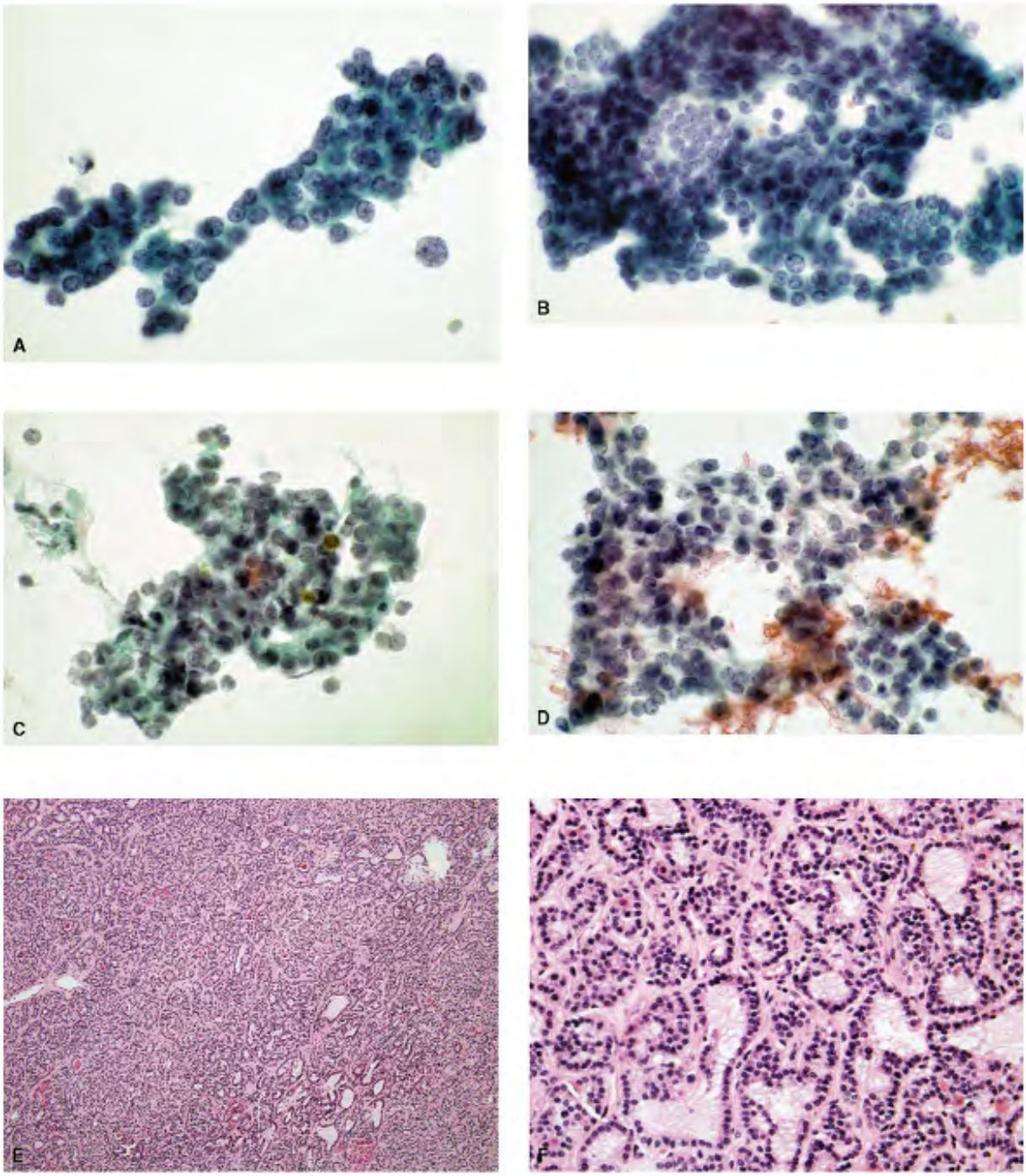

Figure 21.12. A,B. FNA of a parathyroid gland adenoma. The specimen was submitted as th from a thyroid nodule and interpreted as a cellular follicular adenoma. The parathyroid cell in syncytial tissue fragments forming anastomosing chords and trabeculae, enclosing spaces. component cells demonstrate extreme crowding and overlapping of small uniform nuclei wit finely granular chromatin. The background is clean. C,D. Some of the neoplastic cells conta scant, pale cytoplasm. Their nuclei are uniform with granular chromatin. E. Histologic secti

of the parathyroid adenoma composed of chief cells presenting a follicular growth pattern.
power. F. Higher magnification.

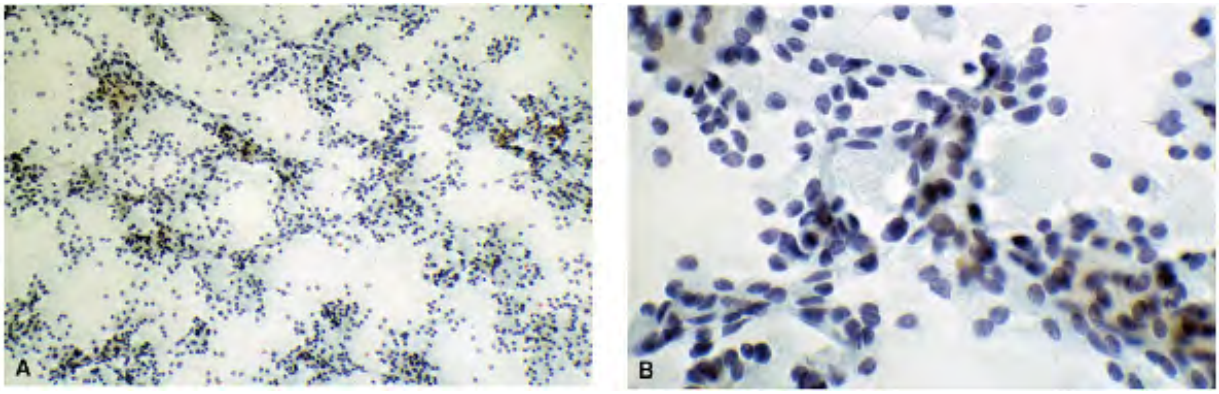

Figure 21.13. A. Low-power view of a cellular aspirate from parathyroid adenoma, showing dispersed cell pattern and tissue fragments. B. Higher magnification showing loosely cohesiv and discrete epithelial cells with poorly defined cell borders. The nuclei are mildly pleomor and many appear to be stripped of their cytoplasm.

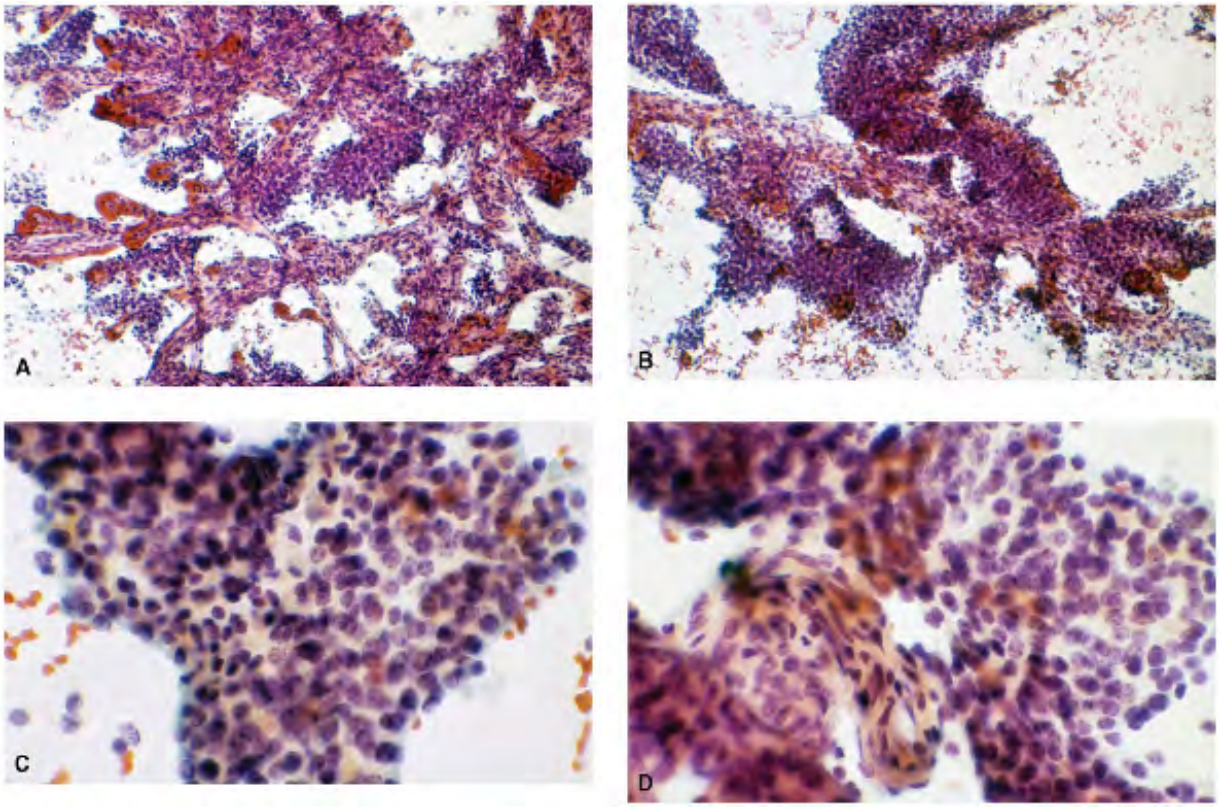

Figure 21.14. Fine-needle biopsy of a parathyroid adenoma submitted as thyroid nodule, se as a defect on imaging studies (Fig. 21.2) A. The aspirate is very cellular consisting of large branching tissue fragments of epithelial cells, and fibrovascular stroma (low power) B. Anot field showing very large tissue fragments of epithelial cells. C,D. Higher magnification. The syncytial tissue fragments of epithelial cells demonstrate no architectural configurations. Th nuclei are round, with granular chromatin, and contain nucleoli. The cell borders are poorly defined, and the cytoplasm is scant.

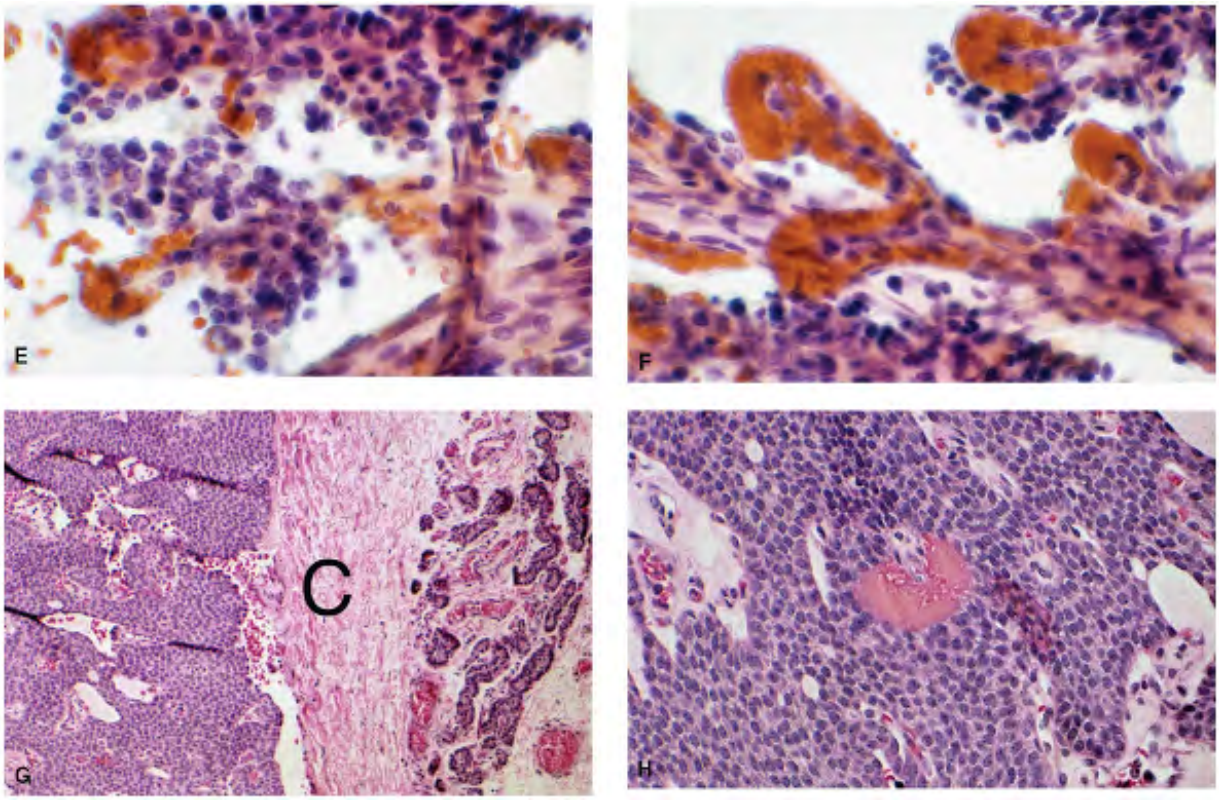

Figure 21.14. E. The neoplastic cells show a characteristic perivascular location. F. Note th branching capillaries. The neoplastic cells are aligned along the capillaries. G. Histologic se of the encapsulated parathyroid adenoma (low power) demonstrating a thick capsule (*C*). H Higher magnification showing a solid growth pattern composed of uniform cells. Note that t tumor is richly vascular.

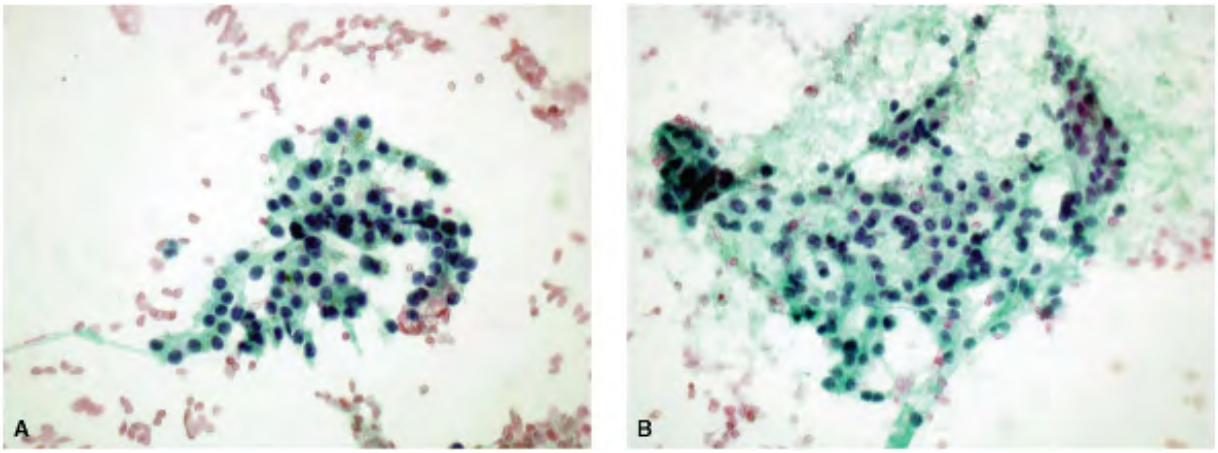

Figure 21.15. An example of intrathyroidal parathyroid adenoma. A,B. This aspirate, submi as that from a thyroid nodule, was marginally cellular, consisting of syncytial tissue fragmen small cells with uniform nuclei containing finely granular chromatin. The cell borders are vaguely appreciated. The cytoplasm is scant and appears pale to foamy.

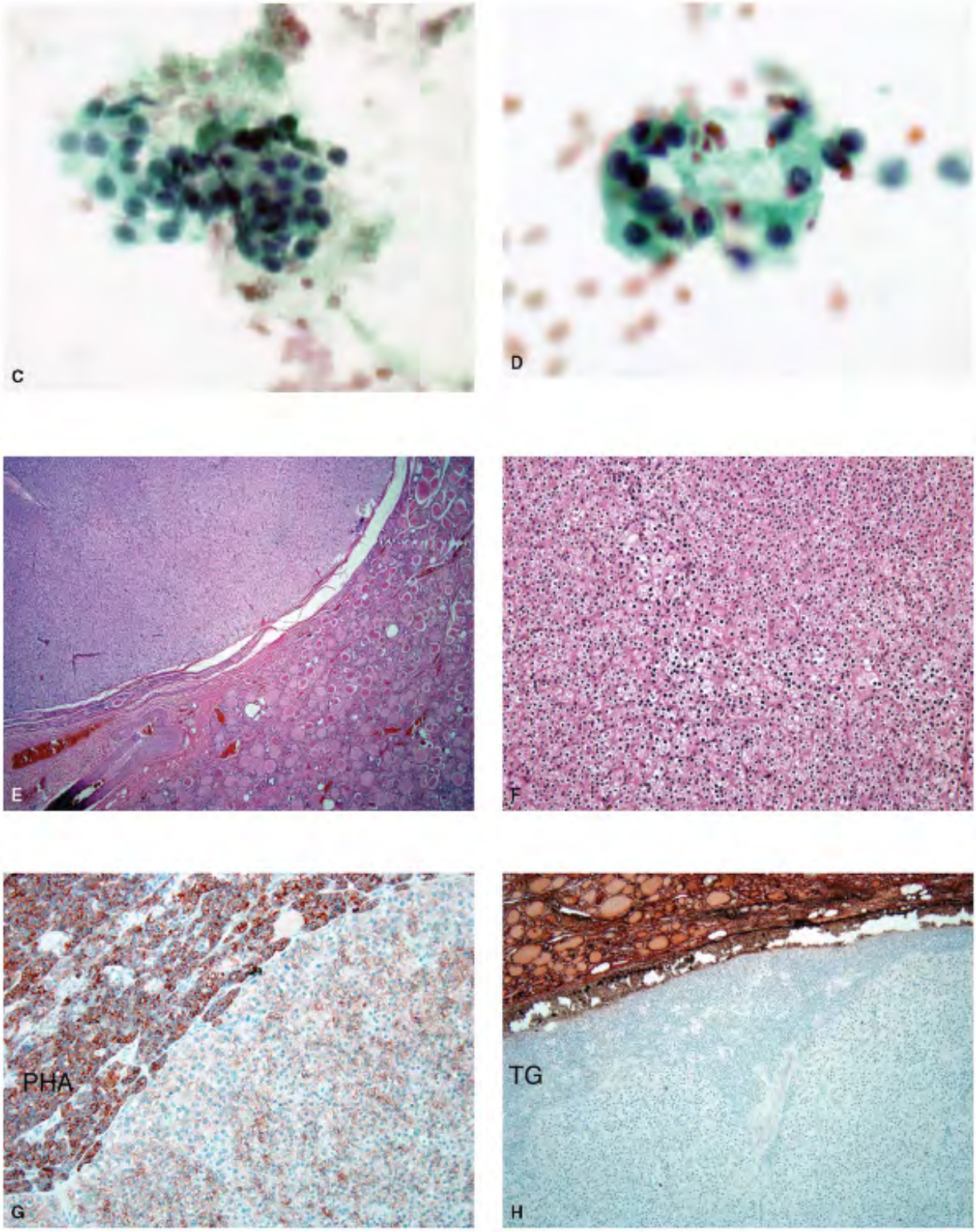

Figure 21.15. (*continued*) C,D. These cells are slightly larger and possess granular cytoplas and probably represent an oncocytic component. The aspirate was interpreted as nondiagnostic/unsatisfactory due to poor cellularity. E. Total thyroidectomy revealed a 2-cr

encapsulated nodule with compressed normal parathyroid parenchyma external to the capsu
F. The neoplasm is predominantly composed of chief cells and showed areas with clear cells
oncocytic cells. G. The neoplasm showed positive reactivity to parathyroid hormone antiboc
The neoplastic cells exhibited negative reactivity to thyroglobulin.

Another characteristic feature of parathyroid adenomas is the branching network of capillar
and the neoplastic cells often seen along the capillaries (Fig. 21.14A). The parathyroid ader
cells are round to cuboidal, slightly smaller than normal thyroid follicular cell nuclei, measu
6 to 7 Âµm in diameter. Their nuclei are round, uniform, containing coarsely granular chrom
and micronucleoli. Nuclear pleomorphism is occasionally present. Nuclear molding has been
described as a hitherto undescribed but diagnostic feature2

but not documented by others. The parathyroid chief cells have scanty, pale cytoplasm with
defined cell borders and are frequently displayed as stripped nuclei, presenting a lymphocy
like pattern. Occasionally single vacuoles are noted within the cytoplasm. The oncocytic cel
contain appreciable amounts of granular cytoplasm. Although a monomorphic pattern is
commonly seen in adeno-mas, pleomorphic size and shapes may occasionally be encountere
Mitoses or karyorrhexis is not present. The background contains delicate, branching,
vascularized stromal tissue fragments. Histiocytes are rarely present, and fat globules are n
identified. The presence of fat globules favors hyperplasia. The background may contain
proteinaceous fluid or colloid-like material. The cytologic features of parathyroid
hyperplasia/adenoma are summarized in Table 21.2 .

Cellularity
Generally hypercellular
Presentation
Cells isolated or discrete, in loosely cohesive groups or in tissue fragments; dispersed cell pattern frequent; network of branching capillaries with tissue fragments of epithelial cells in perivascular location; lymphocyte-like pattern due to naked nuclei of chief cells
Architecture of the tissue fragments
Syncytial tissue fragments, without any architectural patterns with extreme crowd-ing and overlapping of nuclei, often appearing three dimensional; trabecular arrangement with branching and interdigitating, enclosing varying sized spaces,

mimicking acinar pattern; monolayered small to large tissue fragments; microfollicular pattern; papillary-like architecture

Cells

Small, round to cuboidal; poorly defined, indistinct cell borders; 7â€“9 Âµm in diameter

Nucleus

Usually round, with high N/C ratios; smooth nuclear membranes; coarsely granular to compact, deep-staining chromatin; micronucleoli Â±; usually uniform but occasionally pleomorphic; size slightly larger than the normal counterpart; intranuclear inclusions extremely rare

Cytoplasm

Insignificant to moderate; clear, pale to granular, single cytoplasmic vacuole Â±

Background

Usually clean; naked nuclei; colloid-like material Â±; fat globules Â± in hyperplasia but absent in adenoma; lymphocytes rare; macrophages with or without hemosiderin Â±

Histochemistry

Argyrophilic granules in the cytoplasm

Immunoprofile

Positive reactivity to parathyroid hormone, chromogranin A, and low-molecular-weight cytokeratin; negative to thyroglobulin

TABLE 21.2 CYTOPATHOLOGIC FEATURES OF PARATHYRO HYPERPLASIA AND ADENOMA

P.469
P.470
P.471
P.472
P.473

Diagnostic Accuracy and Differential Diagnosis

Recognition of parathyroid lesions from cytologic samples has historically presented difficult , 3 , 9 , 12 , 15 , 29 , 44 , 45 , 46 , 47 , 48 , 49 The diagnostic difficulties are compounded

the location is intrathyroidal (Fig. 21.14) or if the specimen is submitted as a thyroid nodul (Figs. 21.12 , 21.13 and 21.14). Cytologically, many aspirates from parathyroid lesions are interpreted as thyroid neoplasms, only to find parathyroid pathology on surgically excised specimens. There is considerable cytomorphologic overlap between thyroid lesions and parathyroid lesions. There are no definite cytologic criteria that help accurately identify th parathyroid lesions without the help of ancillary diagnostic techniques, coupled with clinica radiologic data. However, some authors have claimed that cytologic differentiation betwee thyroidal and parathyroidal lesions is possible.11 , 24 , 50

LÃ¶whagen and Sprenger46 reported 5 cases of parathyroid adenomas cytologically diagnose follicular neoplasms. Friedman et al.47 described a case of parathyroid adenoma with the cytologic diagnosis of papillary carcinoma. The presence of oncocytic cells in large numbers potential diagnostic pitfall and will lead to misinterpretation of the aspirates as thyroidal lesions.15 , 45 Auger et al. reported a case of intrathyroidal parathyroid adenoma that was interpreted as lymphocytic thyroiditis. The naked nuclei of the chief cells with the clumped chromatin along with oncocytic-type cells lead to the diagnosis of lymphocytic thyroiditis. Lymphoid infiltrate has been described in parathyroid adenomas.15

The small cell size of parathyroid adenoma cells, and their presentation in tight, three-dimensional clusters, resembles the cytologic pattern of insular carcinoma of the thyroid an potential diagnostic pitfall. The same holds true for medullary thyroid carcinoma with a sma cell pattern.

Differentiation of parathyroid lesions from thyroid lesions may be attempted based on the current knowledge of parathyroid cytopathologic features of hyperplasia/adenomas, as liste Tables 21.1 and 21.2 , and the special stains. Parathyroid cells contain glycogen and argyrop granules that can be demonstrated by the PAS reaction and the sliver stain, respectively.7

Immunoreactivity to parathyroid hormone will confirm the origin of the cells.4 , 42 , 43 Rysl al.44 reported high levels of parathyroid hormone in the needle rinsing of the aspirate. Also morphometric analysis of parathyroid cells and thyroid cells has been reported to be helpful Presence of fat cells will favor parathyroid origin and a hyperplastic lesion. The accuracy of diagnosing parathyroid lesions from cytologic specimens is low in general, but can be maxim if the parathyroid location is known or suspected, in which case ancillary tests will offer conclusive results.

Parathyroid adenomas may also on occasion be difficult to differentiate from oncocytic, or

cell, neoplasms of the thyroid; they also share morphologic similarities with metastatic rena carcinoma.

PARATHYROID HYPERPLASIA/ADENOMA VERSUS FOLLICULAR ADENOMA/CARCINOMA

In cytologic samples, follicular neoplasms of the thyroidâ€"follicular adenoma and follicular carcinomaâ€"share morphologic similarities with parathyroid lesions (Table 21.3 , Fig. 21.16 Syncytial-type tissue fragments and coarse nuclear chromatin are characteristic of both parathyroid hyperplasia/adenoma and follicular neoplasms (adenoma/carcinoma). However thyroid follicular cell nuclei in adenoma/carcinoma are considerably enlarged. Colloid is usu scant or absent in cellular follicular neoplasms. The differentiation between parathyroid les and thyroid follicular neoplasms is extremely difficult. The diagnostic dilemma may be solve immunostains with either thyroglobulin or parathyroid hormone.

Cellularity
Generally hypercellular
Generally hypercellular
Generally hypercellular
Pattern
Cells isolated, in loose aggregates, or in syncytial tissue fragments; bare nuclei frequent
Cells isolated, in loosely cohesive groups and in syncytial tissue fragments with various different architectural patterns, bare nuclei is not a feature
Cells in syncytial tissue fragments; bare nuclei is not a feature
Architecture of the tissue fragments
Small to large tissue fragments

with or without branching; trabecular pattern frequent; follicular pattern Â±; extreme crowding and overlapping of nuclei; perivascular arrangement of neoplastic cells; branching network of delicate capillaries characteristic

Architectural patterns include papillary with or without branching, papillary-like, with or without follicular pattern, monolayered, three- dimensional clusters; swirls

Syncytial with or without follicular patterns; slim to broad trabeculae, with or without branching; crowding and overlapping of nuclei, intense in carcinomas

Cells

Small, round to cuboidal, poorly defined cell borders; 6â€“9 Âµm in diameter

Variable size; pleomorphic; larger than parathyroid cells; well to poorly defined cell borders

Larger than parathyroid cells; variable in size; poorly defined cell borders

Nucleus

Round; smooth nuclear membranes; coarsely granular chromatin; micronucleoli; high N/C

ratios
Enlarged; demonstrate nuclear criteria of papillary carcinoma (powdery to pale granular chromatin; micro/macronucleoli; nuclear grooves and intranuclear inclusions)
Variably enlarged, smooth nuclear membranes; fine to coarsely granular chromatin; nucleoli Â± in adenomas but present in carcinomas
Cytoplasm
Scant, indiscernible to modest; clear, granular, occasionally oxyphilic
Variable
Scant
Psammoma bodies
Absent
May be present
Absent
Background
Clean to proteinaceous material; fat globules in hyperplasia
No proteinaceous material or fat globules; macrophages Â±
No proteinaceous material or fat globules
Colloid
Absent
Colloid Â±; dense blobs to stringy
Colloid Â±; may be present in fol-

licular lumens

Immunoprofile

Parathyroid hormone

+

-

-

Thyroglobulin

-

+

+

Chromogranin

+

-

-

	Parathyroid Hyperplasia/Adenoma	Papillary Thyroid Carcinoma	Thyroid Cellular Follicular Adenoma/Follicular Carcinoma

TABLE 21.3 CYTOPATHOLOGIC FEATURES OF PARATHYRO HYPERPLASIA, PAPILLARY THYROID CARCINOMA, AND FOLLICULAR NEOPLASMS

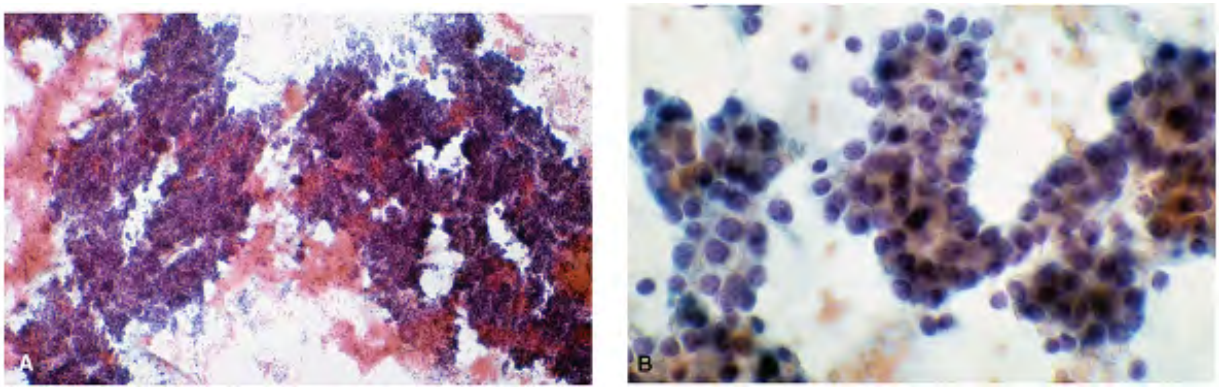

Figure 21.16. *Parathyroid adenoma versus follicular neoplasm.* A. FNA of a cellular follicul

adenoma. Note the cellularity and large tissue fragments of follicular cells. B. Higher magnification showing syncytial architecture, with and without a follicular pattern. The cell slightly larger than those seen in parathyroid adenoma. The chromatin is granular. This cyto presentation is very similar to that of parathyroid adenoma.

PARATHYROID HYPERPLASIA/ADENOMA VERSUS PAPILLARY THYROID CARCINOMA

Aspirates of parathyroid adenoma have been misinterpreted as papillary thyroid carcinoma (Table 21.3). The latter presents a wide spectrum of cytologic features with several

characteristics that are not seen in parathyroid lesions. Branching tissue fragments of epithe cells with a papillary-like pattern alone, which are seen in cytologic specimens of parathyro adenomas, must not be considered a diagnostic feature of PTC unless accompanied by nucle features (e.g., enlargement, powdery chromatin, micronucleoli, nuclear grooves, and intranuclear inclusions; Fig. 21.17). Positive immunostains for parathyroid hormone will cor the parathyroid origin.

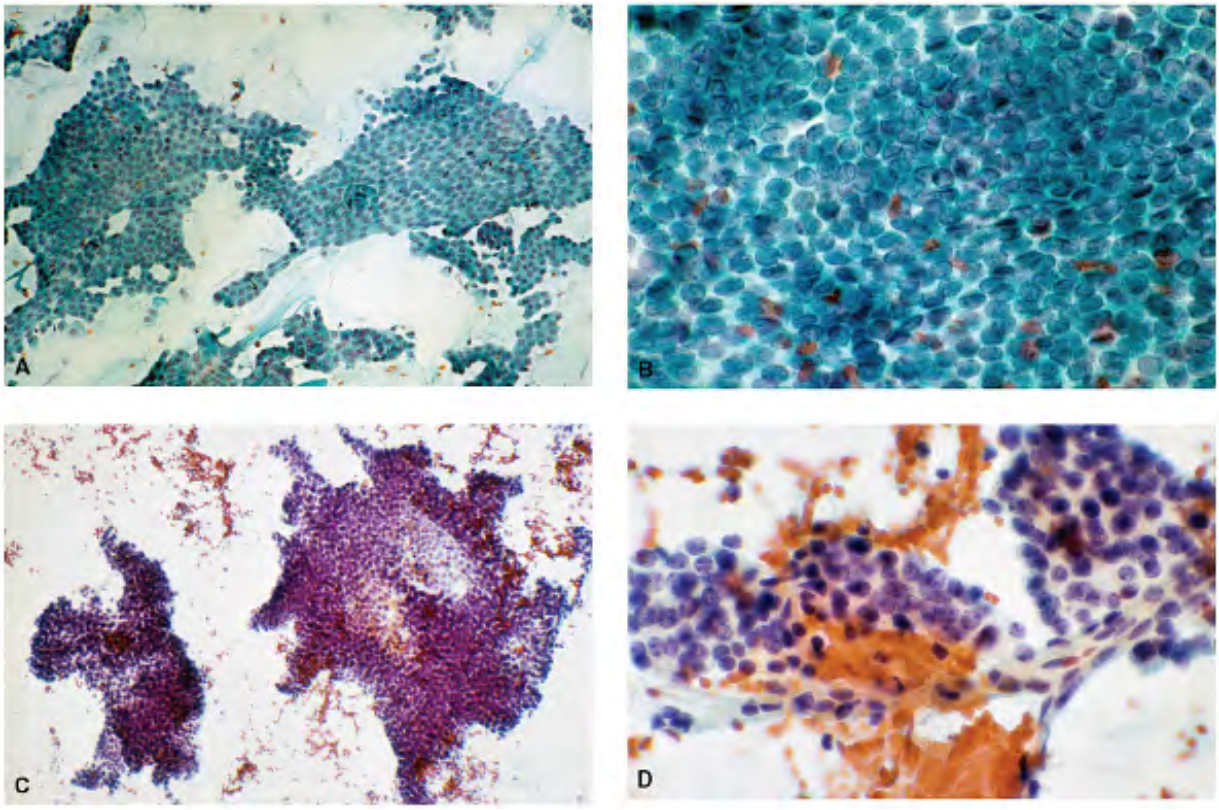

Figure 21.17. *Parathyroid adenoma versus papillary carcinoma.* A. FNA of a papillary thyroi carcinoma depicting large monolayered tissue fragments. B. Higher magnification showing a syncytial arrangement with enlarged nuclei, powdery chromatin, micronucleoli, nuclear gro and intranuclear inclusions. C. FNA of a parathyroid adenoma depicting large monolayered t fragments. D. Higher magnification showing the syncytial arrangement of uniform nuclei, la minimal criteria for papillary carcinoma.

PARATHYROID CARCINOMA

The cytopathologic features of parathyroid carcinoma are sparsely documented as individua case reports.50 , 51 , 52 , 53 , 54 The cytologic features described are extremely variable, ranging from uniform small cells with regular nuclei to a pleomorphic cell pattern; evenly dispersed chromatin to coarsely granular; single to multiple macronucleoli; and dispersed pattern to syncytial tissue fragments. It is a general opinion

that parathyroid hyperplasia/adenoma and carcinoma are difficult to separate cytologically

SUMMARY

Fine-needle aspiration biopsy may be helpful in recognizing parathyroid lesions in the follow circumstances: (i) size sufficient for ultrasonic localization, (ii) adequate cytologic material clinical data favoring parathyroid dysfunction, and (iv) familiarity with the cytologic feature

REFERENCES

1.Tseng TU, Hsiao YL, Chang TC. Ultrasound guided fine needle aspiration cytology of parathyroid lesions. A review of 72 cases. *Acta Cytol* . 2002;46:1029â€“1036.

2.Absher K, Truong LD, Khurana K, et al. Parathyroid cytology: avoiding diagnostic pitfalls *Head Neck* . 2002;24:187â€“164.

3.Bondeson L, Bondeson AG, Nissbong A, et al. Cytopathological variables in parathyroid lesions: a study based on 1,600 cases of hyperparathyroidism. *Diagn Cytopathol* . 1997;16:476â€“482.

4.Abati A, Skarulis MC, Shaeker T, et al. Ultrasound-guided fine-needle aspiration of parathyroid lesions: a morphological and immunocytochemical approach. *Hum Pathol* . 1995;26: 238â€“243.

5.Tikkakoski T, Stenfors LE, Typpo T, et al. Parathyroid adenomas: preoperative localizati with ultrasound combined with fine-needle biopsy. *J Laryngol Otol* . 1993;107:543â€“545.

6.Kini U, Shariff S, Thomas JA. Ultrasonically guided fine-needle aspiration of the parathyroid. A report of two cases. *Acta Cytol* . 1992;37:747â€“751.

7.Halbauer, M, Crepinko I, Brzae HT, et al. Fine-needle aspiration cytology in the preoperative diagnosis of ultrasonically enlarged parathyroid tumors. *Acta Cytol* . 1991;35:728â€“735.

8.Davey DD, Giant MD, Berger EK. Parathyroid cytopathology. *Diagn Cytopathol* .

1986;2:76â€“80.

9.Mincione GP, Borrelli D, Ciechi P, et al. Fine-needle aspiration cytology of parathyroid adenoma. A review of seven cases. *Acta Cytol* . 1986;30:65â€“69.

10.Rastad J, Johansson H, Lindgren PG, et al. Ultrasonic localization and cytologic identification of parathyroid tumors. *World J Surg* . 1984;8:501â€“508.

11.Solbiati L, Grangrande A, DePra L, et al. Parathyroid tumors detected by fine-needle aspiration biopsy under ultrasonic guidance. *Radiology* . 1983;148:783â€“797.

12.Rossi ED. Mule A, Zannoni GF, et al. Asymptomatic intrathyroidal parathyroid adenoma Report of a case with a cytologic differential diagnosis including thyroid neoplasms. *Acta Cytol* . 2004;48:437â€“440.

13.Pitsilos SA, Webster R, Baloch ZW, et al. Ectopic parathyroid adenoma initially suspect to be a thyroid lesion. *Arch Pathol Lab Med* . 2002;126:1541â€“1542.

14.Kirstein LJ, Ghosh BL. Intrathyroidal parathyroid carcinoma. *J Surg Oncol* . 2001;77:136â€“138.

15.Auger M, Charbonneau M, Huttner J. Unsuspected intrathyroidal parathyroid adenoma: mimic of lymphocytic thyroiditis in fine needle aspiration specimensâ€”a case report. *Diag Cytopathol* . 1999;21:276â€“279.

16.Crescenzo DG, Shabahang M, Garvin D, et al. Intrathyroidal parathyroid cancer present as a left neck mass. *Thyroid* . 1998;2:652â€“657.

17.Galloway A, Jarmer S, Moinuddin S. Fine needle aspiration cytology of an ectopic parathyroid adenoma. *Acta Cytol* . 1996;40: 315â€“318.

18.Huppert BJ, Reading CC. The parathyroid glands. In: Rumack CM, Wilson SR, Charbonea JW, eds. *Diagnostic Ultrasound* . St. Louis: Elsevier Mosby; 2005;771â€“794.

19.Khati N, Adamson T, Johnson KS, et al. Ultrasound of the thyroid and parathyroid glanc *Ultrasound Q* . 2003;19:162â€“176.

20.Clark OH, Gooding G, Ljund BM. Locating a parathyroid adenoma by ultrasound and aspiration biopsy cytology. *West J Med* . 1981;135:154â€“158.

21.Frasoldati A, Pesenti M, Toschi E, et al. Detection and diagnosis of parathyroid incidentomas during thyroid sonography. *J Clin Ultrasound* . 1993;27:492â€“498.

22.Krishnamurthy S, Bedi DG. Ultrasound guided fine-needle aspiration biopsy of the thyrc bed. *Cancer (Cancer Cytopathol)* . 2001;93:199â€“205.

23.MacFarlane MP, Fraker DL, Shawker TH, et al. Use of preoperative fine-needle aspirati in patients undergoing reoperation for primary hyperparathyroidism. *Surgery* . 1994;116:959â€“965.

24.Gooding GAW, Clark OH, Stark DD, et al. Parathyroid aspiration biopsy under ultrasoun guidance in the postoperative hyperparathyroid patient. *Radiology* . 1985;155:193â€“196.

25.DeLellis RA. Tumors of the parathyroid gland. *Atlas of Tumor Pathology* . Fascicle 6, 3r series. Washington, DC: Armed Forces Institute of Pathology; 1993:1â€“13,16,93.

26.Banek T, Banek L, Pezerovic-Panijan R. Morphology of healthy human parathyroid glan in cytologic smears. *Acta Cytol* . 2005;49:627â€“633.

27.Wenig BM, Heffess C, Adair CF. *Atlas of Endocrine Pathology* . Philadelphia: Saunders; 1997:173.

28.Lerud KS, Tabbara SO, DelVecchio DM, et al. Cytomorphology of cystic parathyroid lesions: report of four cases evaluated preoperatively by fine-needle aspiration. *Diagn Cytopathol* . 1996; 15:306â€“311.

29.Layfield LJ. Fine-needle aspiration cytology of cystic parathyroid lesions. A cytomorphologic overlap with cystic lesions of the thyroid. *Acta Cytol* . 1991;35:447â€“45

30.Petri N, Holten I. Parathyroid cyst: Report of case in the mediastinum. *J Laryngol Otol* 1990;104:56â€“57.

31.Prinz RA, Peters JR, Kane JM, et al. Needle aspiration of non-functioning parathyroid cysts. *Am Surgeon* . 1990;56:420â€“422.

32.Turner A, Lampe HB, Cramer H. Parathyroid cysts. *J Otolaryngol* . 1989;18:311â€“313.

33.Silverman JF, Khazanie PG, Norris T, et al. Parathyroid hormone (PTH). Assay of parathyroid cysts examined by fine-needle aspiration biopsy. *Am J Clin Pathol* . 1986;86:776â€“780.

34.Pacini F, Antonelli A, Lari R, et al. Unsuspected parathyroid cysts diagnosed by measurement of thyroglobulin and parathyroid hormone concentration in fluid aspirates. *Ann Int Med* . 1985;102:793â€“794.

35.Katz A, Dunkleman D. Needle aspiration of nonfunctioning parathyroid cyst. *Arch Surg* 1984;119:307â€“308.

36.Marco V, Carrasco MA, Marco C, et al. Cytomorphology of a mediastinal parathyroid cy report of a case mimicking malignancy. *Acta Cytol* . 1983;27:688â€“692.

37.Calandra DB, Shab KH, Prinz RA, et al. Parathyroid cysts: a report of eleven cases including two associated with hyperparathyroid crisis. *Surgery* . 1983;94:887â€“892.

38.Rosenberg J, Orlando R, Ludwig M, et al. Parathyroid cysts. *Am J Surg* . 1982;143:473â€“480.

39.Miyauchi A, Kakudo K, Fujimoto, et al. Parathyroid cyst: analysis of the cyst fluid and ultrstructural observationa. *Arch Pathol Lab Med* . 1981;105:497â€“499.

40.Clark OH. Parathyroid cysts. *Am J Surg* . 1978;135;395â€“402.

41.Ginsberg J, Young JEM, Walfish PG. Parathyroid cysts. Medical diagnosis and management. *JAMA* . 1978;240:1506â€“1507.

42.Chang TC, Tung CC, Hsiao YL, et al. Immunoperoxidase staining in the differential diagnosis of parathyroid from thyroid origin in fine needle aspirates of suspected parathyr lesions. *Acta Cytol* . 1998;42:619â€“624.

43.Winkler B, Gooding GAW, Montgomery CK, et al. Immunoperoxidase confirmation of parathyroid origin of ultrasound-guided fine-needle aspirates of the parathyroid glands. *A Cytol* . 1987;31:40â€“44.

44.Ryska A, Kereska Z. Aspiration cytology of parathyroid adenoma: radioimmunoassay of parathormone in aspirate as a helpful diagnostic tool. *Acta Cytol* . 1998;42:826â€“827.

45.Giorgadza T, Stratton B, Baloch ZW, et al. Oncocytic parathyroid adenoma: problem in cytological diagnosis. *Diagn Cytopathol* . 2004;31:276â€“280.

46.LÃ¶whagen T, Sprenger E. Cytologic presentations of thyroid tumors in aspiration biops smear. A review of 60 cases. *Acta Cytol* . 1974;18:192â€“197.

47.Friedman M, Shimaoka K, Lopez CA, et al. Parathyroid adenoma diagnosed as papillary carcinoma of thyroid on needle aspiration smears. *Acta Cytol* . 1983;27:37â€“40.

48.Tsai TH, Chang TC, Chiang CP. Comparison of nuclear measurements on parathyroid adenoma, parathyroid hyperplasia and thyroid follicular adenoma. *Anal Quant Cytol Histo* 1997;19: 45â€“48.

49.Glenthoj A, Karstrup S. Parathyroid identification by ultrasonically guided aspiration cytology. Is correct cytologic identification possible? *APMIS* . 1989;97:497â€“502.

50.Guazzi A, Gatriella M. Bucologni G. Cytologic features of a functioning parathyroid carcinoma. A case report. *Acta Cytol* . 1982;26:709â€“713.

51.Sulak LE, Brown RW, Butler DB. Parathyroid carcinoma with occult bone metastasis diagnosed by fine-needle aspiration cytology. *Acta Cytol* . 1989;33:645â€“659.

52.Hara H, Oyama T, Kimura M, et al. Cytologic characteristics of parathyroid carcinoma: case report. *Diagn Cytopathol* . 1998;18: 193â€“198.

53.Garza S, Garza EF, Batres FH. Functional parathyroid carcinoma: cytology, histology, a ultrastructure of a case. *Diagn Cytopathol* . 1985;1:232â€“235.

54.Ikeda K, Tate G, Suzuki T, et al. Cytologic comparison of a primary parathyroid cancer and its metastatic lesions: a case report. *Diagn Cytopathol* . 2006;34:50â€“55.

Editors: Kini, Sudha R.
Title: *Thyroid Cytopathology: A Text and Atlas, 1st Edition*

Copyright Â©2008 Lippincott Williams & Wilkins

22

Ancillary Diagnostic Techniques

Osama Alassi

Sudha R. Kini

Milena Cankovic

Claire W. Michael

Ancillary diagnostic techniques have become an integral part of pathology practice and are utilized to confirm or support the diagnostic impression made on routinely stained (H&E or Papanicolaou-stained) preparations or to identify a lesion from several diagnostic possibilities. These tests range from simple histochemical stains to immunochemistry, electron microscopy, tissue cultures, flow cytometry, and image analysis. Some of these tests are sparingly used because of their limited application; some have only historical value, while technique such as immunochemistry has become an indispensable diagnostic tool. The quest for more information beyond the diagnosis, in terms of better understanding of the disease process, improving the diagnostic abilities, expanding the therapeutic options, and improving prognostication, has led to the development of more sophisticated tests at molecular level.

APPLICATION OF ANCILLARY TECHNIQUES IN THE DIAGNOSIS OF THYROID DISEASES

Most of the thyroid lesions are relatively easy to interpret. But as alluded to earlier (Chapters 7 to 9), the histologic diagnoses of certain thyroid lesions continue to cause difficulties because the interpretation of the criteria established for various follicular and HÃ¼rthle cell lesions has turned out to be very subjective, at times causing

controversies in the diagnoses and patient management. The controversies hover around separation of hyperplastic nodular goiter from follicular and HÃ¼rthle cell neoplasms, and follicular adenomas from follicular carcinomas. The diagnostic difficulties involve both cytopathology and histopathology. Another major problem is differentiating the follicular variant of papillary carcinoma (FVPC) from follicular lesions, especially when the FVPC demonstrates nuclear morphology of conventional papillary carcinoma only in focal areas. The cytologic diagnoses of follicular lesions rendered are often ambiguous and grouped into one broad category as "indeterminate." Most of these diagnostic difficulties affect the management decisions and the extent of surgical procedures. The inability to make a precise diagnosis of a follicular lesion has led the investigators to seek the assistance of ancillary diagnostic techniques. It is also hoped that the newer techniques would offer more information regarding the biologic behavior, including the prognosis of the disease, and help in patient management. The ancillary diagnostic techniques applicable to thyroid lesions include histochemical and immunocytohistochemical stains, flow cytometry, and image analysis. Currently the attention is focused on molecular testing, which has generated a great deal of interest, with several studies being conducted for possible routine use in thyroid lesions.1, 2, 3, 4, 5, 6, 7, 8

This chapter will briefly describe the application of these ancillary tests in the diagnosis of thyroid disease. A detailed discussion is beyond the scope of this chapter. The interested reader is requested to refer to the vast literature available on the subject. Also included in this chapter is a section on liquid-based cytology, since many laboratories currently process the aspirates by using liquid-based preparations in addition to the conventional methods.

Simple histochemical stains have been to a large extent replaced by immunostains. Their application in thyroid pathology has been limited and will not be further discussed.

IMMUNOCHEMISTRY

The technique of detecting tissue antigens by utilizing specific antibodies and tagging them with chromogens so as to visualize the antigenâ€“antibody reaction, referred to as immunochemistry, is a major milestone in surgical pathology. That it has revolutionized the practice of surgical/cytopathology is an understatement. Practice

without the use of immunochemistry is now unimaginable. Hundreds of antibodies are currently available for any diagnostic workup. Only a few are applicable to thyroid diseases. The stains can be performed on tissues as well as on fine-needle aspirates, both on smears and cell blocks.

In immunocytochemistry, as in any other technical procedure, strict qualitative and quantitative controls are required.[9, 10, 11]

Results may vary and greatly depend on proper fixation, processing, and immunocytochemical methods. Interpretative variability in agreement on the pattern of staining (e.g., cytoplasmic or nuclear, cutoff level of positivity, and what part of the tumor) may also affect the test results. Attention must be paid to nonspecific staining due to diffusion of the antigens as well as coexpression by tissues other than the intended lesion.

Immunochemical stains for thyroid lesions are useful in following situations:

- To differentiate follicular cell-derived tumors from C cell derived neoplasms such as medullary carcinoma. The use of thyroglobulin and calcitonin are diagnostic.
- To differentiate parathyroid lesions, either in intrathyroidal location or in close proximity of thyroid, simulating thyroid origin (e.g., parathyroid hormone).
- To distinguish poorly differentiated primary thyroid cancer from a poorly differentiated metastatic cancer to the thyroid of known extrathyroidal malignancy.
- To confirm metastatic malignant neoplasm of thyroid origin to other body sites.
- To differentiate non-neoplastic lesions from the neoplastic ones; e.g., thyroiditis from malignant lymphoma.
- As additional prognostic markers in thyroid carcinoma.

Besides the traditional markers such as thyroglobulin, TTF-1, and calcitonin, several new markers have been studied in order to differentiate non-neoplastic lesions from

neoplastic ones, follicular adenomas from follicular carcinomas, and follicular carcinomas from papillary carcinomas, as described in the following sections.

Thyroglobulin

The thyroglobulin antibody is specific for follicular cell-derived lesions and is extremely useful in confirming the thyroid origin of a metastatic lesion, or in distinguishing a poorly differentiated carcinoma in aspirates of the thyroid from extra-thyroidal malignancy. The frequency and intensity of thyroglobulin positivity in thyroid carcinomas depends on the degree of tumor differentiation and the histologic subtype.10 Generally, poorly differentiated carcinomas contain less thyroglobulin than better-differentiated tumors. Most anaplastic carcinomas do not express thyroglobulin.12, 13 Poorly differentiated thyroid carcinoma of the insular type is usually thyroglobulin positive, although the extent of cellular staining is usually weak and focal.13

Thyroid Transcription Factor-1

Thyroid transcription factor-1 (TTF-1) is expressed in the thyroid, diencephalon, and lung. TTF-1 regulates the expression of thyroperoxidase and thyroglobulin genes in the thyroid. TTF-1 immunoreactivity has been reported in almost all follicular-derived neoplasms: 96% of papillary, 100% of follicular, 20% of HÃ¼rthle cell, 100% of insular, and 90% of medullary carcinomas16 and about 34 % of anaplastic carcinoma.14, 15, 16

Cytokeratin Subtypes

Cytokeratins are intermediate filaments of different molecular weights, present in thyroid follicular cells.10 CK1, CK4, CK10, and CK13 are high-molecular-weight cytokeratins, detected in the stratified squamous epithelium. The normal follicular cells react positively to low-molecular-weight cytokeratins such as CK7, CK8, CK18, and CK19, which are present in the simple or glandular epithelium, but not to high-molecular-weight keratins.10, 17, 18 Broad-spectrum keratin antibodies such as AE1/AE3 and CAM5.2 react with normal and hyperplastic follicular cells, chronic thyroiditis, and all tumor types.10 High molecular-weight keratins are positive in 100% of papillary carcinomas. CK19, a low-molecular-weight keratin, is especially useful in the diagnosis of papillary carcinoma, including the follicular variant.10, 17, 18, 19, 20, 21, 22, 23, 24, 25, 26 Studies have shown that strong, diffuse staining with CK19 is

characteristic of papillary carcinoma including the follicular variant. It is also found to be positive in follicular carcinomas. The reactivity is weak and focal in nodular goiter and other benign lesions.19 Follicular adenoma may have some immunoreactivity, although it tends to be focal and weaker than in papillary carcinoma.19 Although reactivity to CK19 is reported to be 92% to 100% for papillary carcinomas by some investigators,21, 23 others recommend caution in interpretation because some reactivity is noted in other thyroid lesions as well.24, 25

HBME-1

HBME-1 is one of the most useful markers to differentiate benign thyroid lesions from carcinoma, either follicular or papillary. This antibody recognizes an unknown epitope present on the microvilli of mesothelial cells. Most of the studies are done on paraffin-embedded histologic sections and few are on cell blocks from fine-needle aspiration.27, 28, 29, 30, 31 Both follicular (up to 40%) and papillary carcinomas (85% to 100%) show diffuse positive staining. Benign lesions, (nodular goiter and follicular adenoma) may show focal positive staining (20% to 60%). There are few studies that questioned the ability of this stain to diagnose follicular carcinoma.28 A negative reactivity, however doesn't rule out carcinoma.27, 28, 29, 30, 31, 32

Galectin 3

Galectin 3 is a beta galactosil-binding protein involved in regulating cell cycle and apoptosis, thyroid cell transformation, and tumor progression. Many studies have reported encouraging results with this marker.33, 34, 35, 36, 37, 38, 39, 40, 41, 42, 43, 44, 45, 46, 47 Others, however, found this marker to be of no or limited use in differentiating benign from malignant thyroid nodules. Aron et al.33 found galectin 3 to be strongly expressed in papillary carcinomas; however, they also found it to be expressed in 60% of benign nodules, and therefore its role as a presurgical marker for differentiating benign from malignant thyroid nodules is limited.32, 36 Mills et al.35 concluded that galectin 3 does not reliably distinguish benign from malignant nodules and also many thyroid aspirates are of low cellularity and are not suitable for reliable immunohistochemical stain. Nascimenti et al.44 reported positive reactivity in 59% of HÃ¼rthle cell carcinomas as against 7.1% of adenomas, indicating that galectin 3 may be used to differentiate adenoma from carcinoma. On the other hand, studies by Saggiorato et al.36 and Maruta et al.38 indicated that galectin 3 and HBME-1 do not

appear to be useful in differentiating adenoma from carcinoma in oncocytic cell tumors.

Carcinoembryonic Agent (CEA)

CEA is generally absent from follicular cell-derived lesions.10, 48, 49 Medullary carcinoma cells demonstrate positive reactivity to CEA.10 With the availability of calcitonin as a specific marker for medullary carcinoma, the utility of CEA is limited.

Calcitonin and Neuroendocrine Markers

Calcitonin is a specific marker for medullary carcinoma cells with a high degree of sensitivity and specificity in both histologic and cytologic samples. Other routinely used endocrine markers include chromogranin, synaptophysin, and neuron-specific enolase, which are useful in the workup of medullary carcinoma and other neuroendocrine tumors of the thyroid.10

Vimentin is often coexpressed with cytokeratins.10 S-100 protein has been reported in 100% of papillary carcinomas, 75% of follicular carcinomas, 37.5% of follicular adenomas, and 28.5% of papillary hyperplasias.10 Parathyroid hormone is diagnostic in identifying intraparathyroidal parathyroid lesions.

CD15 (Leu-M1)

CD15 (Leu-M1) is a marker for adenocarcinomas. It is expressed in a significant number of cases of papillary carcinomas.50 The cellular distribution of reactivity is largely cytoplasmic, with some cases demonstrating membranous accentuation. The immunoreactivity of CD15 appears similar to HBME-1, although with less frequency and strength in papillary carcinomas (30%).

CD57 (Leu-7)

CD57, also known as Leu-7, a marker of NK lymphocytes and glucose transporter-1, is a facilitative cell-surface transport protein expressed in a wide variety of epithelial malignancy. Ghali et al.51 reported strong CD57 positivity in 100% of papillary and follicular carcinomas, whereas focal and weak staining was present in 25% of colloidal goiters and 21% of follicular adenomas. Other authors, however, have questioned the

specificity of CD57 as a marker for malignancy in thyroid tumors.52, 53, 54

CD44

CD44, also known as Hermes antigen, H-CAM, Pgp-1, and ECM-III, is a glycosylated cartilage-linked protein associated with extracellular matrix adhesion and lymphocyte homing.55, 56, 57, 58 Chhieng et al.56 described intense staining in 14 of 16 papillary carcinomas and only 1 case of nonpapillary carcinoma (HÃ¼rthle cell tumor) displayed focal weak staining.

The preferential expression of CD44 antigen in papillary carcinomas was demonstrated by Ross et al. in aspiration biopsy specimens57 and by Figge et al.58 in tissue sections. Positive immunostaining is characterized by cytoplasmic staining.

Some other markers studied for thyroid neoplasms include CA15-3, CA19-9, CA125, and lectoferrin. CA15-3 is present in 100% of papillary carcinomas while CA19-9 has been reported in 70% of the papillary carcinomas but absent in follicular carcinomas.59 CA125 has been reported in 40% of papillary carcinomas.60 Lectoferrin is suggested to be useful in differentiating benign from malignant lesions in cytologic smears.61 Steroid receptors are variably expressed with 21% in papillary carcinomas and none in HÃ¼rthle cell neoplasms. Reactivity to progesterone was described in 33% of papillary carcinomas, 40% of follicular neoplasms (adenomas and carcinomas), and 53% of HÃ¼rthle cell neoplasms.62

Proliferation Markers (Ki-67, p-27kip1, Bcl-2)

The proliferative activity in tumors is considered an important prognostic indicator. Many antibodies raised against various antigens present in proliferating cells have been developed over the years. Antibodies tested include KI-67 (MIB-1), p-27kip1, and Bcl-2, with variable results.63, 64, 65, 66

Lymphoid Markers

The lymphoid markers used in other areas of pathology are also applicable with the thyroid, in differentiating Hashimoto's thyroiditis from malignant lymphoma. Flow cytometry is the technique of choice.

p53

The mutations of the p53 tumor-suppression gene play an important role in carcinomas of the colon, breast, and urinary bladder. However, its role has been examined in cases of thyroid carcinoma. In the series reported by Soares et al.,67p53 was absent from 14 cases of goiter and follicular adenomas and from 12 cases papillary carcinomas. p53 was present in 20% of follicular carcinomas (predominantly of the widely invasive type), 16% of poorly differentiated carcinoma, and 67% of undifferentiated carcinoma. In the series reported by Holm and Nesland,68 6 of 32 (19%) of papillary carcinomas, 5 of 29 (17%) of follicular carcinomas, and 18 of 24 (75%) of undifferentiated carcinoma were p53 positive; in contrast, the retinoblastoma (Rb) gene product was present in all thyroid carcinomas.71

A wealth of literature is available on the application of newer markers to thyroid lesions with variable degrees of success. The reported sensitivities and specificities of the above-described new markers vary from study to study. To date, none of the recently introduced makers are considered as diagnostically specific for any particular thyroid lesion. As a result, many investigators have recommended a panel of three or more markers to increase the specificity.30, 32, 39, 69, 70, 71, 72

FLOW CYTOMETRY

Flow cytometry measures different cellular parameters73 of cells in suspension, as they flow in a single file, in a controlled space with application of laser light. Currently, the computer-interfaced flow cytometers are very sophisticated, capable of six or more simultaneous measurements on each of the cells in the sample. There are two important clinical applications: (i) measuring the DNA content of tumor cells to distinguish diploid from aneuploid tumors and to display tumor cell-cycle distribution, that is, proliferative activity; and (ii) diagnosis and classification of leukemias and lymphomas by expression of cellular antigens.63 An excellent review on technical as well

as practical aspects of flow cytometry is provided by Melamed73 and is highly recommended.

Application of Flow Cytometry to Thyroid Lesions

The application of flow cytometry to thyroid lesions is very limited as reported by

several studies.74, 75, 76, 77, 78, 79, 80, 81, 82, 83, 84, 85, 86, 87, 88 Tsuchiya et al.74 found the majority of thyroid carcinomas (92%) to be diploid and 7.4%, aneuploid. Nodular goiters were found to be aneuploid in 13% by Castro et al.75 and in 10% by Mizukami et al.76 Many thyroid adenomas were found to be aneuploid.77, 78, 79 On the other hand, several investigators found various thyroid malignancies to be diploid.75, 78, 80 In addition, the presence of aneuploidy does not signify malignant potential. Cuscik et al.81 found similar proportions of benign and malignant follicular lesions to be aneuploid. Some studies, however, have shown an improvement in diagnostic accuracy when combining the use of flow cytometric determination with fine-needle aspiration biopsy cytology. Sturgis et al.82 and Yamashita et al.83 found significant association between aneuploidy and death from the disease in cases of papillary carcinomas. Joensuu et al.84 also detected aneuploidy more frequently in the recurrent (40%) and in the deceased (33.3%) groups than in the nonrecurrent group (4.3%).

Schelfhout85 found a high frequency and degree of aneuploidy in undifferentiated carcinomas, which is in agreement with the very poor survival rate in these patients. However, the occurrence of highly aneuploid adenomas and (near)-diploid undifferentiated carcinomas does not point to a direct causal relationship between DNA-ploidy changes and clinical behavior of these thyroid tumors.

Aneuploidy increases with undifferentiated carcinomas and is more common with advancing age, which may explain why carcinomas in the elderly tend to have a worse prognosis. From the diagnostic point of view, poorly differentiated thyroid carcinoma is easy to diagnose on a morphologic basis, and using DNA ploidy, other than for academic interest, seems redundant.

As part of a nationwide study of thyroid carcinoma in Iceland, Jonasson and Hrafnkelsson86 measured DNA ploidy in 424 tumors and found aneuploid populations in approximately 10% of papillary carcinoma, 24% of follicular carcinoma, 43% of medullary carcinoma, and 79% of anaplastic carcinomas. They also measured S-phase fraction, which was somewhat lower in papillary carcinoma than in other histologic classes. When taking into account known prognostic variables of thyroid carcinoma in a multivariate analysis, however, neither ploidy status nor S-phase value proved significant. They concluded that neither DNA ploidy nor S phase fraction were of independent prognostic significance. In this large study, and other studies, the

controversial results indicate that ploidy has no prognostic significance in thyroid carcinomas.

Studies on HÃ¼rthle cell tumors did not show surprising results either. El-Naggar et al.80 found that nuclear DNA ploidy alone does not distinguish benign from malignant HÃ¼rthle cell tumors; however, aneuploid HÃ¼rthle cell carcinoma had a more aggressive clinical course and a worse outcome. Therefore, ploidy studies are not helpful in diagnosis, but may give an insight on clinical outcome.

MORPHOMETRY OR IMAGE ANALYSIS

Static cytometry, or morphometry in contrast to flow cytometry, is performed on a variety of cell preparations, including cytologic smears, touch imprints, and cytocentrifuge processed preparations of nuclei disaggregated from tissue paraffin blocks as well as paraffin tissue sections. The instrument consists of an optical light microscope, a video camera that captures the image, an image frame buffer, and a computer system for analysis. The absorption values are represented as a range of "gray levels" and digitized into a series of tiny squares called "pixels." The system is known as digital image analysis.

In contrast to flow cytometry, static image analysis does not necessarily require single cell suspensions, and has the added advantage that direct cell identification is possible. The major drawback of image analysis is that only a small number of cells are examined, and the procedure is slow and cumbersome. It can also suffer from an inadequate selection of cells to examine, with poor randomization and selection of subgroups by the operator. The quality of DNA histograms obtained in image analysis, in comparison to flow cytometry, is not as refined. This limitation is secondary to the small numbers of cells evaluated. Therefore, in contrast to flow cytometric analysis, examination of the different cell-cycle phases is not possible. In a prospective comparative study of DNA quantitation by image and flow cytometry performed by Baur et al.,88 a relatively good correlation between both methods was reported, with only a few aneuploid peaks missed by image analysis or flow cytometry.

From the cytologic viewpoint, image analysis can also be used to quantify micromorphometric data on nuclear and cellular details. These include nuclear volumes, areas, contours, shapes, nuclear:cytoplasmic ratios, and chromatin texture (see Chapters 7 and 8).

MOLECULAR TECHNIQUES

Milena Cankovic

Cancer is a complex disease that occurs as a result of progressive accumulation of genetic aberrations and epigenetic modification that enables cancer cells to escape from normal control mechanisms. Cancer cells may have many acquired genetic abnormalities such as chromosomal rearrangements, amplifications, deletions, and point mutations, which result in gain of function or loss of function in affected genes. Additionally, epigenetic modifications in certain genes act to promote tumor growth. The genetic alterations in oncogenes generally lead to an increased function of the protein product, while tumor-suppressor genes are inactivated during carcinogenesis with apparent loss of function of the protein product.

Molecular genetic testing is well established as an ancillary method in surgical pathology. It encompasses well-established technologies such as immunohistochemistry and flow cytometry. In recent years, nucleic acid-based techniques have become an integral part of surgical pathology practice. The use of genetic biomarkers relevant to each of the main cancer types is helping to better define individual cancer types, provide information for more accurate diagnosis and staging, give a measure of risk assessment, and aid in therapy monitoring.

Molecular genetic techniques can be divided in two types: (i) hybridization-based technologies and (ii) amplification-based technologies. The commonly used hybridization techniques in clinical settings include fluorescent in situ hybridization (FISH) and Southern blot analysis. Microarray techniques, which are currently used mainly in research settings, include gene profiling and comparative genomic hybridization (CGH). Hybridization-based technologies use signal amplification as a method of detection.

Amplification-based technologies rely on copy number amplification of the gene of interest. Well established in the clinical arena are techniques such as polymerase chain reaction (PCR), where isolated genomic DNA is used as a target; and reverse transcriptase PCR (RT-PCR), which uses RNA as an amplification target. PCR and RT-PCR products can be detected by a variety of methods such as gel electrophoresis, capillary electrophoresis, real-time quantitative PCR, and DNA sequencing. Some of

the detection methods include use of fluorescent primers and probes that enhance the sensitivity of detection.

Thyroid Cancer

Thyroid cancer is the most common malignant tumor of the endocrine system and accounts for approximately 1% of all newly diagnosed cancer cases.89 When diagnosed early, thyroid cancer is generally curable. Consequently, accurate differentiation of malignant from benign thyroid nodules is very important. This is currently accomplished by cytologic evaluation of thyroid needle aspirated materials. While cytologic assessment is diagnostic in the majority of patients, approximately 15% to 20% of biopsies have an insufficient amount of tissue for assessment, and an additional 15% to 20% have indeterminate cytologic findings.90 Identification of more aggressive tumors preoperatively would permit more extensive surgery when indicated. Over the past few years, a number of laboratories have started using genomic approaches to address issues in thyroid pathology, such as understanding pathogenesis and improving diagnosis and prognosis.91 Molecular diagnostic techniques, while still lacking the sensitivity and specificity needed to make them an effective preoperative screening tool, nevertheless offer additional help in characterizing difficult to diagnose thyroid nodules.

Papillary Thyroid Carcinoma

Papillary thyroid carcinoma (PTC) accounts for about 80% of all thyroid malignancies. With PTC, prognosis is generally dependent on the patient's age and tumor stage at the time of diagnosis. However, the aggressiveness of individual tumors cannot always be predicted from the initial clinical features, making it difficult to consistently identify patients who will die from their disease. While the traditional morphologic classification of thyroid neoplasms into follicular, papillary, medullary, and anaplastic subtypes remains valid for most lesions, subclassification, particularly of variant papillary lesions and lesions showing mixed morphology, can be problematic.

Papillary carcinomas frequently have genetic alterations that lead to the activation of the mitogen-activated protein kinase (MAPK) signal pathway. These include two general types of mutations: (i) chromosomal rearrangements of the tyrosine kinase proto-oncogenes *RET* (located on chromosome 10q11.2) and *NTRK* (located at 1q22)92,

93 and (ii) point mutations of the serine-threonine kinase *BRAF* (located at 7q34)94, 95 and RAS on multiple genes.96 Mutations of one of these genes are found in over 70% of papillary carcinomas, and they rarely overlap in the same tumor.97 The *RET/RAS/BRAF* mitogen-activated protein kinase signal transduction pathway is central to PTC development via mitogenic signaling to the nucleus and uncontrolled cell division.

BRAF

Point mutations of the *BRAF* gene are found in about 45% of thyroid papillary carcinomas.94, 97 Most of them involve nucleotide 1,799 and result in a valine to glutamate substitution at residue 600 (V600E).95, 98 In addition to papillary carcinomas, *BRAF* mutations are found in thyroid anaplastic and poorly differentiated carcinomas, typically in those tumors that also contain areas of well-differentiated papillary carcinoma.99, 100, 101

BRAF mutations are highly prevalent in classical papillary carcinomas and in the tall cell variant, but are rare in the follicular variant.102, 103 Mutant *BRAF* has been shown to play a role in tumor dedifferentiation. Mutant *BRAF* is also likely to be associated with tumor recurrence and resistance to conventional radioactive therapy. In some studies, the presence of *BRAF* mutation has been associated with an older age of patients, advanced tumor stage at presentation, and tumor recurrence. *BRAF* mutations have also been associated with the decreased ability of tumors to trap I-131 and treatment failure of the recurrent disease.104, 105

Most recent efforts in developing targeted therapy for papillary thyroid carcinomas have focused on *BRAF* inhibitors. Several new drugs that act as RAF kinase inhibitors are currently undergoing clinical trials for use as potential targeted therapeutic agents. The initial results with these agents have been encouraging.106 Assuming that further studies demonstrate the efficacy of these therapeutic agents, and provided that a link between *BRAF* V600E and clinical outcome does exist, *BRAF* mutational analysis may become a routine part of the evaluation of papillary thyroid carcinomas.107

RET/PTC

The *RET* tyrosine kinase is involved in rearrangements with a number of different partner genes in *PTC*.92, 108, 109 At least 11 types of *RET/PTC* have been reported to

date.93, 110 The two most common rearrangement types are *RET/PTC*1 and *RET/PTC*3, which account for the majority of all rearrangements found in papillary carcinomas. *RET/PTC*1 is formed by fusion of *RET* with the H4 (D10S170) gene, and *RET/PTC*3 by fusion of *RET* with the NCOA4 (ELE1) gene.111, 112 The *RET/PTC* fusion products act as oncoproteins that activate the *RAS-RAF-MAPK* cascade.113, 115

NTRK

A much smaller subset of papillary thyroid carcinomas shows rearrangements in the *NTRK*1 gene,116 and the percentage of tumors that harbor *NTRK*1 rearrangements does not seem to be increased in Chernobyl-associated tumors.117

RAS

The *RAS* genes (H-*RAS*, K-*RAS*, and N-*RAS*) encode highly related G-proteins that are located at the inner surface of the cell membrane and play a central role in the intracellular transduction of signals arising from tyrosine kinase and G-protein-coupled cell-surface receptors.

In many human neoplasms, point mutations occur in the discrete domains of the *RAS* gene, which result in either an increased affinity for GTP or inactivation of the autocatalytic GTPase function. As a result, the downstream signaling pathways become permanently activated.

In papillary carcinomas, activating *RAS* mutations are relatively infrequent, being detected in 10% to 15% of these tumors.93, 118 Papillary carcinomas with *RAS* mutations almost always have the follicular variant histology. This mutation also correlates with significantly less prominent nuclear features, more frequent encapsulation, and a low rate of lymph node metastases.103, 119 Some studies have reported the association between *RAS* mutations and more aggressive behavior of papillary carcinoma and a higher frequency of distant metastases.120, 121

Morphologic Variants of Papillary Thyroid Carcinoma

Between 3% and 25% of cases of the follicular variant of PTC contain *RET/PTC*1 or *RET/PTC*3 mutations,119, 122 and a larger group of 20% to 43% of cases harbors RAS mutations.119, 123 The tall cell variant of PTC typically harbors the *RET/PTC*3 variant,

which has been demonstrated in 100% of cases.122

BRAF mutations have been detected in about 40% of cases of the oncocytic variant of PTC, and in about 75% of cases of Warthin-like PTC.102

Follicular Thyroid Carcinoma

Follicular thyroid carcinoma (FTC), the second most common thyroid malignancy, accounts for 5% to 15% of malignant thyroid neoplasms, depending on the criteria used for diagnosis. FTC is an aneuploid tumor with a high loss of heterozygosity (LOH) and high frequency of *RAS* mutations and *PAX8-PPARÎ³* rearrangement.124

PAX8-PPARÎ³

PAX8-PPARÎ³ fusion gene rearrangement results from t(2;3)(q13;p25) translocation. The *PAX*8 gene at 2q13 encodes a transcription factor that is essential for development of the thyroid follicular epithelial cell lineage,125 and the *PPARÎ³*1gene at 3p25 encodes a ligand-dependent nuclear transcription factor that is a member of the perioxysome proliferator-activator receptor family.126

Functionally, the *PAX8-PPARÎ³*1 fusion protein is a dominant negative suppressor of wild-type *PPARÎ³*1 function,127 but the mechanism by which suppression of *PPARÎ³* promotes follicular carcinoma formation is not well understood.

RAS

In follicular thyroid carcinoma, *RAS* mutations are found in 40% to 50% of tumors,128, 129, 130 and they may also correlate with tumor dedifferentiation and a less favorable prognosis.120

Molecular Testing in Thyroid Cancer

With the completion of the Human Genome Project and recent advances in technology, it is now possible to examine a person's entire genome in order to provide individualized risk predictions and treatment decisions. With the advances in molecular diagnostics, we are now in a position to characterize health and disease states by molecular fingerprinting and to develop meaningful stratification for patient populations to elucidate mechanistic pathways based on genome-wide data, and to develop new preventive, diagnostic, and therapeutic strategies that will completely

shift patient care from reactive to proactive. Several tasks lie ahead in molecular technologies. First, correlation of genetic testing with diseases needs to be validated. Most of the molecular signatures are based on retrospective studies, and additional prospective studies are needed to fully understand the connection between molecular markers and disease. Second, consideration should be given to whether a new marker meets the criteria for being a valuable and practical clinical tool. To have utility in general usage, a biomarker should be detected relatively easily, reproducibly, and reliably, and should have value in guiding patient treatment decisions.

Real-Time Quantitative RT-PCR

There are several issues to consider, such as RNA quality issues, clinicopathologic correlates, cellular heterogeneity even in small tissue samples, and microarray data validation by other available molecular methods.

Validation of select genes by quantitative RT-PCR is often performed to validate microarray data. Giordano et al.131 studied *PPARG* and four additional genes (*ANGPTL*4, *AQP*7, *ENO*3, and *PGF*) with increased expression in the PPFP(+) follicular carcinomas. Overall, their study demonstrated that the RT-PCR results validated the microarray data.

Microarrays

Application of microarray technology to analysis of tumor biology has provided new opportunities to study and understand cancer biology, including the identification of new genes involved in carcinogenesis. Based on their individual gene expression profiles, tumors can be classified as high risk or low risk.

Many studies have examined the potential of molecular profiling for thyroid cancer. While none of the studies have resulted in a clinically available and validated diagnostic assay, the results are generally encouraging.

A cluster analysis study of a group of 62 samples was performed to determine whether molecular profiling can discriminate between benign and malignant thyroid nodules.132 The study group included 11 papillary thyroid carcinomas, 13 of the follicular variant of papillary thyroid carcinomas, 9 follicular thyroid carcinomas, and 26 benign tumors. Hierarchical cluster analysis of oligonucleotide microarray data reliably distinguished between benign and malignant follicular thyroid tumors, as well

as benign thyroid nodules and papillary thyroid carcinomas. Additionally, the study demonstrated that molecular profiling of thyroid nodules can be used to classify tumors as high risk or low risk, indicating that microarray-based expression profile analysis is a powerful tool

that can distinguish benign from malignant thyroid tumors, as well as risk-stratify carcinomas into high and low risk.

Using commercially available oligonucleotide microarrays, a gene expression data set was generated that corresponded to the common types of benign and malignant thyroid tumors.133 The investigators applied various clustering methods to the study set and were able to show that the clustering studies provided molecular classification that recapitulated the overall morphologic classification of thyroid tumors. Examination of the papillary thyroid carcinoma cohort revealed a molecular classification that was a reflection of both tumor morphology and an underlying activating mutation. They found a large degree of heterogeneity within the papillary thyroid carcinoma cohort, consistent with the numerous morphologic variants associated with papillary thyroid carcinoma and with several different activating mutations (*BRAF, RET/PTC,* and *RAS*). Examination of the papillary thyroid carcinoma cohort revealed a molecular classification that was a reflection of tumor morphology as well as underlying activation mutation.

The study further showed that the clustering divided the study cohort into tumors with papillary architecture and follicular architecture. Additionally, papillary thyroid carcinoma follicular variants formed two subclusters within the follicular-patterned tumors, and these tumors had a predominance of *RAS* mutations.

Follicular thyroid carcinoma (FTC) with the *PAX8-PPAR*Î³ translocation formed a distinct subcluster within the follicular patterned lesions.131 Other studies confirmed the finding that these tumors display a characteristic gene expression profile, where FTC with *PAX8-PPAR*Î³ translocation has a gene expression profile that is a function of the activity of the fusion protein PPFP.134 These studies imply the role of the PPFP fusion protein in the pathogenesis of FTC with *PAX8-PPAR*Î³ and suggest that this fusion protein might present an important therapeutic target.

In terms of using gene expression profiling in the clinical laboratory, it has to be kept in mind that microarray data contains biological information imbedded in a lot of

technical and biological noise. Methods of experimental design and data analysis must be carefully selected in order to reliably identify biological effects of interest while at the same time removing extra noise. One drawback of moving this technology into the clinical arena is the fact that only fresh and frozen tissues can be used for analysis. Additionally, since expression profiling of a large numbers of genes gets evaluated, this necessitates a large amount of isolated RNA. Both of these requirements make the microarray technology unsuitable for analysis of archival specimens, as well as fine-needle biopsies, where only a small amount of tissue is available for analysis.

Comparative Genomic Hybridization (CGH)

Comparative genomic hybridization (CGH) is a technique for analyzing genomic information by focusing on the differences in DNA copy numbers between tumor and normal tissue.

MicroRNA Profiling

The discovery of microRNAs (miRNAs) and the growing appreciation of the importance of miRNAs in the regulation of gene expression are driving increasing interest in miRNA expression profiling. MicroRNA profiling represents a complimentary approach to messenger RNA profiling.

MicroRNAs are small RNA molecules that are thought to function as negative regulators of gene expression.135, 136 Early studies have suggested prominent roles for these genetically encoded regulatory molecules in a variety of normal biological processes and diseases, particularly cancer.137, 138, 139, 140 MicroRNA profiling represents a complimentary approach to gene expression profiling using messenger RNA. Microarray experiments studying miRNA expression changes in thyroid cancers hold an interesting promise.141, 142, 143, 144 Studies have shown that these small-molecular-weight RNAs play a regulatory role in both papillary and follicular thyroid carcinoma.

Methylation Profiles in Thyroid Cancer

DNA methylation is another potential marker for thyroid cancer, and real-time quantitative methylation-specific PCR techniques on blood samples preoperatively have been found to differentiate benign from malignant lesions. When five genes were analyzed, this method of detecting aberrant DNA methylation had a preoperative

sensitivity for detecting thyroid cancer of 68%, specificity of 95%, accuracy of 77%, positive predictive value of 96%, and negative predictive value of 60%.145

SUMMARY

Of the several ancillary diagnostic techniques utilized in the practice of pathology, only a few are of diagnostic value in thyroid. Immunochemistry is indispensable in confirming thyroid follicular cell origin. Similarly, calcitonin is a very specific marker for medullary thyroid carcinoma. Of the large number of newly introduced markers aimed at differentiating follicular lesions, none has shown the diagnostic sensitivity and specificity to be used in the routine practice. Flow cytometry has only a limited application, especially in the diagnosis of lymphoproliferative disorders. DNA measurements have not been helpful in differentiating benign from malignant thyroid lesions. Molecular diagnostics have shown a lot of promise. Currently, molecular testing is performed in research settings with limited practical application.

REFERENCES

1.Krishnamurthy S. Applications of molecular techniques to fine needle aspiration *Biopsy*. *Cancer (Cancer Cytopathol)*. 2006;111:106â€“122.

2.Raphael SJ. The meanings of markers. Ancillary techniques in diagnosis of thyroid neoplasms. *Endocrinol Pathol*. 2002;13: 301â€“311.

3.Puxeddu E, Nanni S, Pontecorvi A. Genetic markers in thyroid neoplasia. *Endocrinol Metab Clin North Am*. 2001;30:493â€“513.

4.Ringel MD. Molecular diagnostic tests in the diagnosis and management of thyroid carcinoma. *Rev Endocrinol Metab Disorder*. 2000;1:173â€“181.

5.Rimm DL. Molecular biology in cytopathology. Current applications and future directions. *Cancer (Cancer Cytopathol)*. 2000; 90:1â€“9.

6.Fagin JA. Molecular genetics of tumors of thyroid follicular cells. In: Braverman

LE, Utiger RD, eds. *Werner & Ingbar's The Thyroid*. Philadelphia: Lippincott Williams & Wilkins; 2000:886â€“898.

7.Abati A, Fetsch P, Fille A. If cells could talk: the application of new technologies to cytopathology. *Clin Lab Med*. 1998;18:561â€“583.

8.Farid NR, Molecular pathogenesis of thyroid cancer: the significance of oncogenes, tumor suppressor genes and genomic instability. *Exp Clin Endocrinol Diabetes*. 1996(suppl 4);104:1â€“12.

9.Yaziji H, Barry T. Diagnostic immunochemistry: what can go wrong? A*dv Anat Pathol*. 2006;13:238â€“246.

10.DeLellis RA, Shin SI. Chapter 9; Immunohistology of endocrine tumors. In: Dabbs JD, ed. *Diagnostic Immunohistochemistry*. New York: Churchill Livingstone; 2006:267â€“276.

11.Seidal T, Balaron aj, Batifora H. Interpretation and quantification of immunostains. *Am J Surg Pathol*. 2001;25:1204â€“1207.

12.Carcangiu ML, Steeper T, Zampi G, et al. Anaplastic thyroid carcinoma. A study of 70 cases. *Am J Clin Pathol*. 1985;83:135â€“158.

13.Ordonez NG, eL-Naggar K, Hickey RC, et al. Anaplastic thyroid carcinoma: Immunocytochemical study of 32 cases. *Am J Clin Pathol*. 1991;96:15â€“24.

14.Katoh R, Kawaoi A, Miyagi E, et al. Thyroid transcription factor-1 in normal, hyperplastic and neoplastic follicular thyroid cells examined by hybridization. *Mod Pathol*. 2000;13:576.

15.Bejarano PA, Nikiforov YE, Swenson ES, et al. Thyroid transcription factor-1,

thyroglobulin, cytokeratin 7 cytokeratin 20 in thyroid neoplasms. *Appl Immunochem Mol Morphol*. 2000;8:189â€“194.

16.Ordonez NG. Thyroid transcription factor 1 is a marker of lung and thyroid carcinoma. *Adv Anat Pathol*. 2000;7:123â€“127.

17.Cameron BR, Berean KW. Cytokeratin subtypes in thyroid tumors: immunohistochemical study with emphasis on the follicular variant of papillary carcinoma. *J Otolaryngol*. 2003;32: 319â€“322.

18.Lam KY, Lui MC, Lo CY. Cytokeratin expression profiles in thyroid carcinomas. *Eur J Surg Oncol*. 2001;27:631â€“635.

19.Saggiorato E, De Pompa R, Volanti M, et al. Characterization of thyroid "follicular neoplasms" in fine needle aspiration cytological specimens using a panel of immunohistochemical markers: a proposal for clinical application. *Endocr Relat Cancer*. 2005;12: 305â€“317.

20.Nasr MR, Mukhopadhyay S, Zhang S, et al. Immunohistochemical markers in diagnosis of papillary thyroid carcinoma: utility of HMBE-1 combined with CK19 immunostaining. *Mod Pathol*. 2006;19:1631â€“1637.

21.Khurana KK, Truong LD, LiVolsi VA, et al. Cytokeratin 19 immunolocalization in cell block preparation of thyroid aspirates. An adjunct to fine-needle aspiration diagnosis of papillary carcinoma. *Arch Pathol Lab Med*. 2003;127:579â€“583.

22.Hirokawa M, Inagaki A, Sonoo H. Expression of cytokeratin 19 in cytologic specimens of thyroid. *Diagn Cytopathol*. 2000;22: 197â€“198.

23.Baloch ZW, Abraham S, Roberts S. LiVolsi VA. Differential expression of cytokeratins in follicular variant of papillary carcinoma: an immunohistochemical study and its diagnostic utility. *Hum Pathol*. 1999;10:1166â€“1171.

24.Miettinen M, Kovatich AJ, Karkkainen P. Keratin subsets in papillary and follicular thyroid lesions. A paraffin section analysis with diagnostic implications. *Virchows Arch*. 1997;431:407â€“413.

25.Sahoo S, Hoda SA, Rosai J, et al. Cytokeratin 19 immunoreactivity in the diagnosis of papillary thyroid carcinoma: A note of caution. *Am J Clin Pathol*, 2001;116:696â€“702.

26.Nasser SM, Pitman MB, Pilch BZ, et al. Fine needle aspiration biopsy of papillary thyroid carcinoma: diagnostic utility of cytokeratin 19 immunostaining. *Cancer*. 2000;90:307â€“311.

27.Sack MJ, Astengo-Osuna C, Lin BT, et al. HBME-1 immunostaining in thyroid fine needle aspirations: a useful marker in the diagnosis of carcinoma. *Mod Pathol.* 1997;10:668â€“674.

28.Papotti M, Rodriguez J, De Pompa R, et al. Galectin-3 and HBME-1 expression in well-differentiated thyroid tumors of uncertain malignant potential. *Mod Pathol*. 2005;18:541â€“546.

29.Ito Y, Yoshida H, Tomoda C, et al. HBME-1 immunostaining in follicular tumor of the thyroid: an investigation of whether it can be used as a marker to diagnose follicular carcinoma. *Anticancer Res*. 2005;25:179â€“182.

30.Miettinen M. Differential reactivity of HBME-1 and CD15 antibodies in benign and malignant thyroid tumors. Preferential reactivity with malignant tumors. *Virchows Arch*. 1996;429: 213â€“219. See comment.

31.Mase T, et al. HBME-1 immunostaining in thyroid tumors especially in follicular neoplasm. *Endocrine J*. 1997;18:173â€“177.

32.van Hoeven KH, Kovatich AJ, Mietttinen M. Immunocytochemical evaluation of HBME-1, CA19-9 and CD-15 (Leu-M1) in fine needle aspirates of thyroid nodules. *Diagn Cytopathol*. 1997;8:83â€“97.

33.Aron M K, Kapila K, Verma K. Utility of galectin-3 expression in thyroid aspirates as a diagnostic marker in differentiating benign from malignant thyroid neoplasms. *Ind J Pathol Microbiol*. 2006; 49:376â€“380.

34.Kim MJ, Kim HJ, Hong SJ, et al. Diagnostic utility of galectin-3 in aspirates of thyroid follicular lesions. *Acta Cytol*. 2006;50:28â€“34.

35.Mills LJ, Poller DN, Yiangou C. Galectin-3 is not useful in thyroid FNA. *Cytopathol*. 2005;16:132â€“138.

36.Saggiorato E, Aversa S, Deandreis D, et al. Galectin-3: pre-surgical marker of thyroid follicular epithelial cell-derived carcinomas. *J Endocrinol Invest*. 2004;27:311â€“317.

37.Mehrotra P, Okpokam A, Bouhaidur R. Gelectin-3 does not reliably distinguish benign from malignant thyroid neoplasms. *Histopathology*. 2004;45:493â€“500.

38.Maruta J, Hashimoto's H, Yamashita H, et al. Immunostaining of galectin-3 and C44v6 using fine needle aspiration for distinguishing follicular carcinoma from adenoma. *Diagn Cytopathol*. 2004;31:392â€“396.

39.Volante M, Bozzalla-Cassione F, DePompa R, et al. Galectin-3 and HBME-1 expression in oncocytic cell tumors of the thyroid. *Virchows Arch*. 2004;445:183â€“188.

40.Cvejic D, Savin S, Petrovic I, et al. Differential expression of Galectin-3 in papillary projections of malignant and non-malignant hyperplastic thyroid lesions. *Acta Chir Iugol*. 2003;50:67â€“70.

41.Aratake Y, Umeki K, Kiyoyama K. Diagnostic utility of galectin-3 and CD26/DPPIV as preoperative diagnostic markers for thyroid nodules. *Diagn Cytopathol*. 2002;26:366â€“372.

42.Herrmann ME, LiVolsi VA, Pasha TL, et al. Immunohistochemical expression of galectin-3 in benign and malignant thyroid lesions. *Arch Pathol Lab Med*. 2002;126:710â€“713.

43.Saggiorato E, Cappia S, De Giuli P, et al. Galectin-3 as a pre-surgical marker of minimally invasive follicular thyroid carcinoma. *J Clin Endocrinol Metab*. 2001;89:5152â€“5158.

44.Nascimento MSPA, Bisi H, Alves VAF, et al. Differential reactivity for galactin-3 IN Hurthle cell adenomas and carcinomas. *Endocrine Pathol*. 2001;12:275â€“279.

45.Orlandi F, Saggioato E, Pivano G, et al. Galectin-3 is a pre-surgical marker of human thyroid carcinoma. *Cancer Res*. 1998;58: 3015â€“3020.

46.Cvejic D, Savin S, Paunovic I, et al. Immunohistochemical localization of galectin-3 in malignant and benign thyroid tissue. *Anticancer Res*. 1998;18:2637â€“2641.

47.Fernandez PL, Merino MJ, Gomez M, et al. Galectin-3 and laminin expression in neoplastic and non-neoplastic thyroid tissue. *J Pathol*. 1997;181:80â€“86.

48.Dasovic-Knezevic M, Bormer O, Holm R, et al. Carcinoembryonic antigen in medullary thyroid carcinoma: an immunohistochemical study applying six novel monoclonal antibodies. *Mod Pathol*. 1989;2:610â€“617.

49.Wilson NW, Pambakian H, Richardson TC, et al. Epithelial markers in thyroid carcinoma: an immunoperoxidase study. *Histopathology*. 1986;10:815â€“829.

50.Schroder S, Schwarz W, Rehenning W, et al. Prognostic significance of Leu-M-1 immunostaining in papillary carcinomas of the thyroid gland. *Virchows Arch A Pathol Anat Histopathol*. 1987;411:435â€“439.

51.Ghali VS, Jimenez JS, Garcia RL. Distribution of Leu-7 (HNK-1) in thyroid tumors: its usefulness as a diagnostic marker for follicular and papillary carcinomas. *Hum Pathol*. 1992;23:21â€“25.

52.Loy TS, Darkow GV, Spollen LE, et al. Immunostaining for Leu-7 in the diagnosis of thyroid carcinoma. *Arch Path Lab Med*. 1994;118:172â€“174.

53.Ostrowski ML, Brown RW, Wheeler TM, et al. Leu-7 immunoreactivity in cytologic specimens of thyroid lesions with an emphasis on follicular neoplasms. *Diagn Cytopathol*. 1995;12:297â€“312.

54.Chandan VS, Faquin WC, Wilbur DG, et al. The role of immunolocalization of CD57 and GLUT-1 in cell blocks in fine needle aspiration diagnosis of papillary thyroid carcinoma. *Cancer (Cancer Cytopathol)*. 2006;108:331â€“336.

55.Kim JY, Cho H, Rhee BD, et al. Expression of CD44 and cyclin D1 in fine needle aspiration cytology of papillary thyroid carcinoma. *Acta Cytol*. 2002;46:679â€“683.

56.Chhieng DC, Ross JS, McKenna BJ. CD44 immunostaining of thyroid fine-needle aspirates differentiates thyroid papillary carcinoma from other lesions with nuclear grooves and inclusions. *Cancer (Cancer Cytopathol)*. 1997;81:157â€“162.

57.Ross JS, del Rosario AD, Sanderson B, et al. Selective expression of CD44 cell adhesion molecules in thyroid papillary carcinomas fine needle aspirates. *Diagn Cytopathol*. 1995;14:287â€“291.

58.Figge J, del Rosario AD, Gerasimov G, et al. Preferential expression of the cell

adhesion molecule CD 44 in papillary thyroid carcinoma. *Exp Mol Pathol*. 1994;61:203â€“211.

59.Gatalica Z, Miettenton M. Distribution of carcinoma antigen CA19-9 and CA15-3: an immunochemical study of 400 tumors. *Appl Immunochem Mol Morphol*. 1994;2:205â€“211.

60.Keen CE, Szakaca S, Okon E, et al. CA125 and thyroglobulin staining in papillary carcinomas of thyroid and ovarian origin is not entirely specific for site of origin. *Histopathology*. 1999;34: 113â€“117.

61.Asato de Camargo RY, Longatto FA, Alves VA, et al. Lectoferrin in thyroid lesions. Immunoreactivity in fine needle aspiration biopsy samples. *Acta Cytol*. 1996;40:408â€“413.

62.Bur M, Shiraki W, Masood S. Estrogen and progesterone receptor detection in neoplastic and non-neoplastic thyroid tissue. *Mod Pathol*. 1993;6:469â€“472.

63.Pelosi G, Zamboni G. Proliferation markers and their uses in the study of endocrine tumors. *Endocr Pathol*. 1996;7:103â€“119.

64.Muller-Hocker J. Immunoreactivity of p53, Ki-67, and Bcl-2 in oncocytic adenomas and carcinomas of the thyroid gland. *Hum Pathol*. 1999;30:926â€“933.

65.Pestereli HE, Ogus M, Oren N, et al. Bcl-2 and p53 expression in insular and in well-differentiated thyroid carcinomas with an insular pattern. *Endocrine Pathol*. 2001;12:301â€“305.

66.Erickson LA, Jin L, Wollan PC, et al. Expression of p27kip1 and Ki-67 in benign and malignant thyroid tumors. *Mod Pathol*. 1998;11:169â€“174.

67.Soares P, Camiselle-Teijeiro J. Sobrinho-Simoes M. Immunohistochemical

detection of p53 in differentiated, poorly differentiated and undifferentiated carcinomas of the thyroid. *Histopathology*. 1994;24:205â€“210.

68.Holm R, Nesland JM. Retinoblastoma and p53 tumor suppressor gene protein expression in carcinomas of the thyroid gland. *J Pathol*. 1994;172:267â€“272.

69.Prasad ML, Pellegata NS, Huamg Y, et al. Galectin-3, fibronectin-1, CITED-1, HBME-1 and cytokeratin 19 immunohistochemistry is useful for the differential diagnosis of thyroid tumors. *Mod Pathol*. 2005;18:48â€“57.

70.Cheung CC, Ezzat S, Freeman JL, et al. Immunohistochemical diagnosis of papillary thyroid carcinoma. *Mod Pathol*. 2001;14: 338â€“342.

71.Mai KT, Ford JC, Yazdi HM, et al. Immunohistochemical study of papillary thyroid carcinoma and possibly papillary thyroid carcinoma-related benign thyroid nodules. *Pathol Res Pract*. 2000;196:533â€“540

72.Guyetant S, Michalak S, Valo I, et al. Diagnosis of the follicular variant of papillary thyroid carcinoma. Significance of immunohistochemistry. *Ann Pathol*. 2003;23:11â€“20.

73.Melamed MR. Flow cytometry. In: Koss LG, Melamed MR, eds. *Koss' Diagnostic Cytology and its Histopathologic Bases*. 5th ed. Philadelphia: Lippincott-Williams & Wilkins; 2006:1708â€“1751.

74.Tsuchiya A, Sekikawa K, Ando Y, et al. Flow cytometric DNA analysis of thyroid carcinoma. *Jpn J Surg*. 1990;20:510â€“514.

75.Castro P, Sansonetty F, Soares P, et al. Fetal adenomas and minimally invasive follicular carcinomas of the thyroid frequently display a triploid DNA pattern. *Virchows Arch*. 1991;438:336â€“342.

76.Mizukami Y, Nonomuta A, Michigishi T, et al. Flow cytometric DNA measurement in benign and malignant thyroid tissues. *Anticancer Res*. 1992;12:2213â€“2217.

77.Greenbaum E, Koss LG, Elequin F, et al. The diagnostic value of flow cytometric DNA measurements in follicular tumors of the thyroid gland. *Cancer*. 1985;56:2011â€“2018.

78.Joensuu H, Klemi PJ, Erola E. Diagnostic value of flow cytometric DNA determination combined with fine needle aspiration biopsy in thyroid tumors. *Ann Quant Cytol Histol*. 1987;9:328â€“334.

79.Czyz W, Joensuu H, Pylkanen L, et al. p53 protein, PCNA staining and DNA content in follicular neoplasms of the thyroid gland. *J Pathol*. 1994;174:267â€“274.

80.el-Naggar AK, Batsakis JG, Luna MA, et al. Hurthle cell tumors of the thyroid. A flow cytometric DNA analysis. *Arch Otolaryngol Head Neck Surg*. 1988;114:520â€“521.

81.Cuscik EL, MacIntosh CA, Krukowski ZH, et al. Comparison of flow cytometry with static densitometry in papillary carcinoma of thyroid. *Br J Surg*. 1990;77:813â€“916.

82.Sturgis CD, Caraway NP, Johnston DA, et al. Image analysis of papillary thyroid carcinoma in fine needle aspirates: significant association between aneuploidy and death from disease. *Cancer*. 1999;87:155â€“160.

83.Yamashita T, Hirayama A, Obara T, et al. Flow cytometric DNA analysis of papillary carcinoma of the thyroid using paraffin-embedded specimens. *Gan No Rinsho*. 1990;36:569â€“573.

84.Joensuu H, Klemi PJ, Erola E. Influence of cellular DNA content on survival in differentiated thyroid cancer. *Cancer*. 1986;58; 2462â€“2467.

85.Schelfhout S, Cornelisse CJ, Goslings BM. Frequency and degree of aneuploidy in benign and malignant thyroid neoplasms. *Int J Cancer*. 1990;45:16â€“20.

86.Jonasson JG, Hrafnkelsson J. Nuclear DNA analysis and prognosis in carcinoma of the thyroid gland. A nationwide study in Iceland on carcinomas diagnosed 1955â€“1990. *Virchows Arch*. 1994;425:349â€“355.

87.el-Naggar AK, Batsakis JG, Luna MA, et al. Hurthle cell tumors of the thyroid. A flow cytometric DNA analysis. *Arch Otolayngol Head Neck Surg*. 1988;114:520â€“521.

88.Bauer TW, Tubbs RR, Edinger MG, et al. Measurement of nuclear DNA quantitation by image and flow cytometry. *Am J Clin Pathol* 1990;93:322â€“326.

MOLECULAR TECHNIQUES

89.Hundahl SA, Fleming ID, Fremgen AM, et al. A national cancer database report on 53,856 cases of thyroid carcinoma treated in the U.S. *Cancer*. 1998;83:2638â€“2648.

90.Kim N, Lavertu P. Evaluation of a thyroid nodule. *Otolaryngol Clin North Am*. 2003;36:17â€“33.

91.Pfeifer JD. Endocrine system. In: *Molecular Genetic Testing in Surgical Pathology* ed Pfiefer JD. Philadelphia: Lippincott Williams & Wilkins; 2006:232â€“249.

92.Smanik PA, Furminger TL, Mazzafferi EL, et al. Breakpoint characterization of the RET/PTC oncogene in human papillary thyroid carcinoma. *Hum Mol Genet*.

1995;4:2313â€“2318.

93.Nikiforov YE. RET/PTC rearrangement in thyroid tumors. *Endocr Pathol*. 2002;13:3â€“16.

94.Cohen Y, Xing M, Mambo E, et al. BRAF mutation in papillary thyroid carcinoma. *J Natl Cancer Inst*. 2003;95:625â€“627.

95.Xing M. BRAF mutation in thyroid cancer. *Endocr Relat Cancer*. 2005;12:245â€“262.

96.Namba H, Rubin SA, Fagin JA. Point mutations of RAS oncogenes are an early event in thyroid tumorigenesis. *Mol Endocrinol*.1990;4:1474â€“1479.

97.Kimura ET, Nikiforova MN, Zhu Z, et al. High prevalence of BRAF mutations in thyroid cancer: genetic evidence for constitutive activation of the RET/PTC-RAS-BRAF signaling pathway in papillary thyroid carcinoma. *Cancer Res*. 2003;63:1454â€“1457.

98.Ciampi R, Nikiforov YE. Alterations of the BRAF gene in thyroid tumors. *Endocr Pathol*. 2005;16:163â€“172.

99.Namba H, Nakashima M, Hayashi T, et al. Clinical implication of hot spot BRAF mutation, V599E, in papillary thyroid cancers. *J Clin Endocrinol Metab*. 2003;88:4393â€“4397.

100.Nikiforova MN, Kimura ET, Gandhi M, et al. BRAF mutations in thyroid tumors are restricted to papillary carcinomas and anaplastic or poorly differentiated carcinomas arising from papillary carcinomas. *J Clin Endocrinol Metab*. 2003;88: 5399â€“5404.

101.Begum S, Rosenbaum E, Henrique R, et al. BRAF mutations in anaplastic

thyroid carcinoma: implications for tumor origin, diagnosis and treatment. *Mod Pathol*. 2004;17:1359â€“1363.

102.Trovisco V, Vieira de Castro I, Soares P, et al. BRAF mutations are associated with some histological types of papillary thyroid carcinoma. *J Pathol*. 2004;202:247â€“251.

103.Adeniran AJ, Zhu Z, Gandhi M, et al. Correlation between genetic alterations and microscopic features, clinical manifestations, and prognostic characteristics of thyroid papillary carcinomas. *Am J Surg Pathol*. 2006;30:216â€“222.

104.Xing M, Westra WH, Tufano RP, et al. BRAF mutation predicts a poorer prognosis for papillary thyroid cancer. *J Clin Endocr Metab*. 2005;90:6373â€“6379.

105.Riesco-Eizaguirre G, Gutierrez-Martinez P, Garcia-Cabezas MA, et al. The oncogene BRAF V600E is associated with a high risk of recurrence and less differentiated papillary thyroid carcinoma due to the impairment of Na+/I- targeting to the membrane. *Endocr Relat Cancer*. 2006;13:257â€“269.

106.Ouyang b, Knauf JA, Smith EP, et al. Inhibitors of RAF kinase activity block growth of thyroid cancer cells with RET/PTC or BRAF mutations in vitro and in vivo. *Clin Cancer Res*. 2006;12:1785â€“1793.

107.Chiloeches A, Marais R. Is BRAF the Achilles' heel of thyroid cancer? *Clin Cancer Res*. 2006;12:1661â€“1664.

108.Giannini R, Salvatore G, Monaco C, et al. Identification of a novel subtype of H4-RET rearrangement in a thyroid papillary carcinoma and lymph node metastasis. *Int J Oncol*. 2000;16: 485â€“489.

109.Elisei R, Romei C, Soldatenko P, et al. New breakpoints in both the H-4 and

RET genes create a variant of PTC-1 in a post-Chernobyl papillary thyroid carcinoma. *Clin Endocrinol*. 2000;53:131â€“136.

110.Tallini G, Asa SL. RET oncogene activation in papillary thyroid carcinoma. *Adv Anat Pathol*. 2001;8:345â€“354.

111.Grieco M, Santoro M, Berlinigieri MT, et al. PTC is a novel rearranged form of the ret proto-oncogene and is frequently detected in vivo in human thyroid papillary carcinomas. *Cell*. 1990;60:557â€“563.

112.Santoro M, Dathan NA, Berlinigieri MT, et al. Molecular characterization of RET/PTC3; a novel rearranged version of the RET proto-oncogene in a human thyroid papillary carcinoma. *Oncogene*. 1994;9:509â€“516.

113.Knauf JA, Kuroda H, Basu S, Fagin JA. RET/PTC-induced dedifferentiation of thyroid cells is mediated through Y1062 signaling through SHC-RAS-MAP kinase. *Oncogene*. 2003;22: 4406â€“4412.

114.Melillo RM, Castellone MD, Guarino V, et al. The RET/PTC-RAS-BRAF linear signaling cascade mediates the motile and mitogenic phenotype of thyroid cancer cells. *J Clin Invest*. 2005;115:1068â€“1081.

115.Mitsutake N, Knauf JA, Mitsutake S, et al. Conditional BRAF V600E expression induces DNA synthesis, apoptosis, dedifferentiation, and chromosomal instability in thyroid PCCL3 cells. *Cancer Res*. 2005;65:2465â€“2473.

116.Bongarzone I, Vigneri P, Mariani L, et al. *RET/NTRK*1 rearrangements in thyroid gland tumors of the papillary carcinoma family: correlation with clinicopathological features. *Clin Cancer Res*. 1998;4:223â€“228.

117.Beimfohr C, Klugbauer S, Demidchik EP, et al. *NTRK*1 rearrangement in papillary thyroid carcinomas of children after the Chernobyl reactor accident. *Int*

J Cancer. 1999;80: 842â€“847.

118.Ezzat S, Zheng L, Kolenda J, et al. Prevalence of activating RAS mutations in morphologically characterized thyroid nodules. *Thyroid*. 1996;6:409â€“416.

119.Zhu Z, Gandhi M, Nikiforova MN, et al. Molecular profile and clinical-pathologic features of the follicular variant of papillary thyroid carcinoma. An unusually high prevalence of RAS mutations. *Am J Clin Pathol*. 2003;120:71â€“77.

120.Garcia-Rostan G, Zhao H, Camp RL, et al. RAS mutations are associated with aggressive tumor phenotypes and poor prognosis in thyroid cancer. *J Clin Oncol*. 2003;21:3226â€“3235.

121.Hara H, Fulton N, Yashiro T, et al. N-RAS mutation: an independent prognostic factor for aggressiveness of papillary thyroid carcinoma. *Surgery*. 1994;116:1010â€“1016.

122.Basolo F, Giannini R, Monaco C, et al. Potent mitogenicity of the RET/PTC3 oncogene correlates with its prevalence in tall cell variant of papillary thyroid carcinoma. *Am J Pathol*. 2002;160: 247â€“254.

123.De Micro C, Vasco V, Ferrand M, et al. N-RAS oncogene mutations in the follicular variant of papillary thyroid carcinomas. *Cancer Detec Prev*. 2000;24:S74.

124.Sobrinho-Simoes M, Preto A, Sofia Rocha A, et al. Molecular pathology of well differentiated thyroid carcinomas. *Virchows Arch*. 2005;447:787â€“793.

125.Mansouri A, Chowdhury K, Gruss P. Follicular cells of the thyroid gland require Pax8 gene function. *Nature Genet*. 1998;19:87â€“90.

126.Fajas L, Auboeuf D, Raspe E. The organization, promoter analysis, and expression of the human PPAR*g* gene. *J Biol Chem*. 1997;272:18779â€“18789.

127.Kroll TG, SarrafP, Pecciarini L, et al. PAX8-PPAR*g*1 fusion oncogene in human thyroid carcinoma. *Science*. 2000;289:1357â€“ 1360.

128.Lemoine NR, Mayall ES, Wyllie FS, et al. High frequency of RAS oncogene activation in all stages of human thyroid tumorigenesis. *Oncogene*. 1989;4:159â€“164.

129.Suarez HG, du Villard JA, Severino M, et al. Presence of mutations in all three RAS genes in human thyroid tumors. *Oncogene*. 1990;5:565â€“570.

130.Motoi N, Sakamoto A, Yamochi T, et al. Role of RAS mutation in the progression of thyroid carcinoma of follicular epithelial origin. *Pathol Res Pract*. 2000;196:1â€“7.

131.Giordano TJ, Au AYM, Kuick R, et al. Delineation, functional validation, and bioinformatics evaluation of gene expression in thyroid follicular carcinomas with the *PAX8-PPARG* translocation. *Clin Cancer Res*. 2006;12:1983â€“1993

132.Finley DJ, Zhu B, Barden CB, Fahey TJ. Discrimination of benign and malignant thyroid nodules by molecular profiling. *Ann Surg*. 2004;240:425â€“437.

133.Giordano TJ, Kuick R, Thomas DG, et al. Molecular classification of papillary thyroid carcinoma: distinct BRAF, RAS, and RET/PTC mutation-specific gene expression profiles discovered by DNA microarray analysis. *Oncogene*. 2005;24: 6646â€“6656.

134.Lui WO, Foukakis T, Liden J, et al. Expression profiling reveals a distinct transcription signature in follicular thyroid carcinomas with a PAX8-PPAR (gamma) fusion oncogene. *Oncogene*. 2005;24: 1467â€“1476.

135.Shivdasani RA. MicroRNAs: regulators of gene expression and cell

differentiation. *Blood*. 2006;108:3646â€“3653.

136.Pasquinelli AE, Hunter S, Bracht J. MicroRNAs: a developing story. *Curr Opin Genet Dev*. 2005;15:200â€“205.

137.Calin GA, Croce CM. MicroRNA signatures in human cancers. *Nat Rev Cancer*. 2006;6:857â€“866.

138.Cummins JM, Velculescu VE. Implications of micro-RNA profiling for cancer diagnosis. *Oncogene*. 2006;25:6220â€“6227.

139.Garzon R, Fabri M, Cimmino A, et al. MicroRNA expression and function in cancer. *Trends Mol Med*. 2006;12:580â€“587.

140.Wu W, Sun M, Zou GM, Chen J. MicroRNA and cancer: current status and perspective. *Int J Cancer*. 2007;120:953â€“960.

141.Cahill S, Smyth P, Finn SP, et al. Effect of RET/PTC1 rearrangement on transcription and post-translational regulation in a papillary thyroid carcinoma model. *Mol Cancer*. 2006;5:70.

142.He H, Jazdzewski K, Li W, et al. The role of microRNA genes in papillary thyroid carcinoma. *Proc Natl Acad Sci USA*. 2005;102: 19075â€“19080.

143.Pallante P, Visone R, Ferracin M, et al. MicroRNA deregulation in human papillary carcinomas. *Endocr Relat Cancer*. 2006;13: 497â€“508.

144.Weber F, Teresi RE, Broelsch CE, et al. A limited set of human microRNA is deregulated in follicular thyroid carcinoma. *J Clin Endocrinol Metab*. 2006;91:3584â€“3591.

145.Hu S, Ewertz M, Tufano RP, et al. Detection of serum deoxyribonucleic acid methylation markers: a novel diagnostic tool for thyroid cancer. *J Clin Endocrinol Metab*. 2006;91:98â€“104.

APPENDIX TO CHAPTER 22

Liquid-Based Cytopathology for Thyroid Aspirates

Claire W. Michael

The liquid-based preparation (LBP) technique for cytopathology samples has been gaining popularity in the last decade, particularly for cervical specimens and selected non-gynecologic specimens. However, its utilization for fine-needle aspirations (FNA) has been controversial, particularly thyroid FNA, where architecture and colloid play a significant role in diagnostic accuracy. Despite that concern, LBP assumed a significant role in our cytopathology practice, especially in small private practices, community hospitals, or large reference laboratories that sought an opportunity to improve the specimen quality and preservation without investing in the resources needed for on-site adequacy assessment or technical support. To date, two of the preparations that received FDA approval, ThinPrep and SurePath, are widely used for non-gynecologic specimens. While both represent LBP, they are completely different in methodology. ThinPrep harvests the cells through filtration while SurePath relies on sedimentation of cells at one times gravity (1 g) on a lysine-coated slide. For more detailed comparison of the two procedures, please refer to Michael et al.1 The author has more extensive experience with ThinPrep, and with the exception of few publications1, 2 all the literature has focused on ThinPrep for FNA. Therefore, while the following discussion will focus on ThinPrep, SurePath will be cited whenever possible for completion of the discussion.

ADVANTAGES OF LIQUID-BASED PREPARATIONS (LBP)

- The slides are easier to examine due to the elimination of many of the obscuring elements such as blood, mucous and obscuring inflammation.
- The immediate wet fixation allows for optimal cellular preservation and eliminates air-drying artifacts.
- Lack of manual spreading results in elimination of crushing artifact that may obscure examination.
- During the cell- transfer stage, the cells are evenly deposited on the slide within a defined circular area, which allows more efficient screening.
- Decrease in number of unsatisfactory specimens.3 This is a result of the elimination of obscuring elements and the cellular concentration achieved by filtration in the case of ThinPrep and cell enrichment by SurePath.
- Reduced number of slides needed to prepare per specimen.4, 5

METHODOLOGY

*ThinPrep (Cytyc Corporation, Boxborough, MA)*6, 7

The needle is rinsed in CytoLyt solution (20% buffered methanol-based solution), which acts as the collecting medium. At the laboratory, the specimen in centrifuged, the supernatant is discarded, and 3 to 5 drops of the cell pellet are transferred to PreservCyt (50% methanol-based fixative, Cytyc Corporation, Boxborough, MA) and should be fixed for at least 20 minutes. If the pellet is small, it can be transferred in its entirety to PreservCyt. The vial is then introduced into the Cytyc 2000 in which processing is done.

Processing

Cell Dispersion

A cylinder with attached TransCyt filter is inserted into the vial and rotated to create currents within the fluid that disperse mucuos and cell debris.

Cell Collection

A gentle vacuum is created within the filter, thus collecting the cells on its exterior surface. The processor software monitors the rate of cell flow and collection. Collection stops when the filter saturation reaches a preset density set by the machine software, or in scantly cellular specimens, when the specimen is depleted.

Cell Transfer

The TransCyt filter is inverted and pressed against the slide. A slight positive pressure through the cylinder ensures optimal transfer of cells and adherence within a defined circular area in a thin layer.

Slide Staining

The slides are then dropped in 95% ethanol and stained by the Papanicolaou stain based on the laboratory protocol of staining, whether automated or manual. The slides can also be spray fixed and stained at a later time. While in the United States Papanicolaou staining for ThinPrep is the standard of practice, in Europe, May-GrÃ¼nwald-Giemsa staining has been

practiced with success on air dried ThinPrep, where the 95% ethanol fixation step is bypassed.8

ThinPrep-Related Issues7

- Filtration induces concentration of the sample, allowing easier identification of the different components. However, this also alters the ratio of these components in relation to one another (e.g., the ratio of colloid to follicular cells cannot be relied on to favor hyperplasia versus neoplasia).
- Blood undergoes hemolysis during processing, leaving behind scattered fibrin fragments and inflammatory cells in the background. Few red blood cells (RBCs) may still be detected in significantly bloody samples.
- Small cells such as lymphocytes and neutrophils may be considerably reduced in number. Remaining lymphocytes may migrate towards the periphery of the ring.
- Colloid is altered in both quality and quantity. Watery colloid does not

withstand processing well and becomes difficult to recognize or distinguish from fibrin. Hard colloid tends to survive processing better and presents as small droplets.

- There is a uniform decrease in cellular size when compared to conventional smears as a result of wet fixation in methanol.
- Large and complex cellular fragments such as papillae tend to break into smaller and simpler groups.
- Nuclear features are well preserved; however, intranuclear pseudo-inclusions are markedly reduced in number.
- The nucleoli appear more prominent than their counterpart on conventional smears
- The cytoplasm acquires a denser quality due to the wet fixation.
- Filters may get clogged by highly inflamed or bloody specimens resulting in an empty prep in the center with a peripheral ring of red blood cells or neutrophils, the "halo effect."

*SurePath (TriPath Imaging, Burlington, NC)*9

Specimen Concentration

Mix the specimen well and remove any large visible blood clots or mucous. Transfer to 50-mL centrifuge tube, centrifuge for 10 minutes at 600 g, and decant supernatant.

Specimen Fixation

Add 30 mL CytoRich Red and centrifuge for 10 minutes at 600 g, then decant supernatant and vortex.

Specimen Washing

In a 12-mL tube containing 10 mL water, transfer the entire pellet if not visible or small. Otherwise, add a representative sample (1 to 5 drops) and centrifuge the tube for 5 minutes at 600*g*. Decant the supernatant and vortex to homogenize the specimen

Processing and Staining

Load the labeled 12-mL tubes onto the PrepStain. The cells are allowed to settle on the slide at 1*g* and stained by Papanicolaou stain within the same cycle.

TriPath-Related Issues1

Blood, inflammatory cells, and colloid are usually adequately represented regardless of their original amount.

- Cellular preservation is excellent and with minimal shrinkage. Cells will ball up as a result of liquid fixation and may appear smaller.
- Large complex fragments retain their complex architecture and assume a three-dimensional configuration that may be pronounced at times and interfere with examination of such clusters. In those cases, smaller groups with more spread-out cells may be easier to evaluate.
- Cells and clusters are in different planes of focus. This is a result of sedimentation with gravity without applied pressure.

Specimen Adequacy

Two issues are worthy of consideration when discussing thyroid aspirates in the setting of liquid base cytology. The first is what constitutes an adequate sample? The second is how many preps are needed to achieve adequacy? Recently we evaluated these two questions in our institution. In one study we reviewed 218 thyroid aspirates prepared by one ThinPrep each; all had a surgical pathology correlation. The number of cells and clusters were counted, and each case was given a definitive diagnosis based on a standardized classification developed by the group and modified from that of the Papanicolaou Society Guidelines.11 Based on statistical analysis of the data, samples with 180 cells or less had an agreement rate of 50% or less. The agreement rate increased to 80% when the cellularity was 180 to 320. Therefore we now require a minimum of 200 cells to establish a definitive diagnosis. While most adequacy guidelines on conventional smears are based on a minimum number of clusters, we were surprised that the total number of clusters per case/prep did not play an independent role in explaining diagnostic agreement. However, we found that the

number of cells per cluster had a significant correlation and that a 25-cell increase in average cells per cluster increased the odds of diagnostic agreement by 65%.12

Knowing that the ThinPrep is a random representative sample, and that frequently additional material is left behind after the first ThinPrep is prepared, we wanted to test whether additional preps possibly containing additional clusters would improve diagnostic accuracy. We reviewed 100 consecutive aspirates prepared by two ThinPreps. Each ThinPrep was reviewed separately and then together. We found that in 97 of 100 cases the two preps were similar. In only three scantly cellular cases, the second prep contained a few atypical cells that were lacking in the first prep; however, they were not sufficient to achieve adequacy or establish a definitive diagnosis.5 In our laboratory we choose to do ThinPrep in cases that we do not provide immediate assessment for. In such cases we vortex the CytoLyt vial well and divide the sample in two 50- mL tubes. One tube is used to prepare the ThinPrep and the other for a cell block. In another study,4 where four ThinPreps were initially prepared for each case; the authors concluded that 1.4 preps were adequate to achieve diagnostic accuracy.

Benign Cystic Lesions

Simple Thyroid Cysts

The aspirate usually consists of variable number of foamy histiocytes in a clear background. Hemorrhagic cysts may present with numerous hemosiderin-laden macrophages, and the background may be surprisingly clear except for scattered fibrin fragments and few red blood cells either trapped within the fibrin or singly scattered.

Thyroglossal Duct Cyst

These aspirates are usually clear and contain few columnar cells and few anucleated squamous cells. Ciliated cells are easily recognized when present.

Autoimmune Thyroiditis

Hashimoto's Thyroiditis-HT (Chronic Lymphocytic Thyroiditis)

Chronic lymphocytic thyroiditis (CLT) and nonspecific lymphocytic thyroiditis (NSLT) were the lesions mostly reported to be missed by ThinPrep. Cochand-Priolellet et al.8 reported missing 2 cases, diagnosing them as suspicious for malignancy; while Frost et al.4 reported missing 10 out of 26 cases by ThinPrep compared to only 2 out of 26 by direct smears. Meanwhile, 9 of the 85 adenomatoid nodules in their series were misdiagnosed as CLT. Tulecke et al.10 reported predicting the correct diagnosis in 3 of 19 cases with CLT on follow-up resection (2 HT and 1 NSLT), while falsely diagnosing HT/ NSLT in 11 cases. Malle et al.3 correctly classified 3 out of 9 cases and misdiagnosed the remaining 6 cases as follicular/HÃ¼rthle neoplasms. It has also been our experience that CLT could be misclassified or not recognized, particularly if the reviewer is not familiar with the ThinPrep presentation.

*ThinPrep Features (*Fig. 22.1*)*

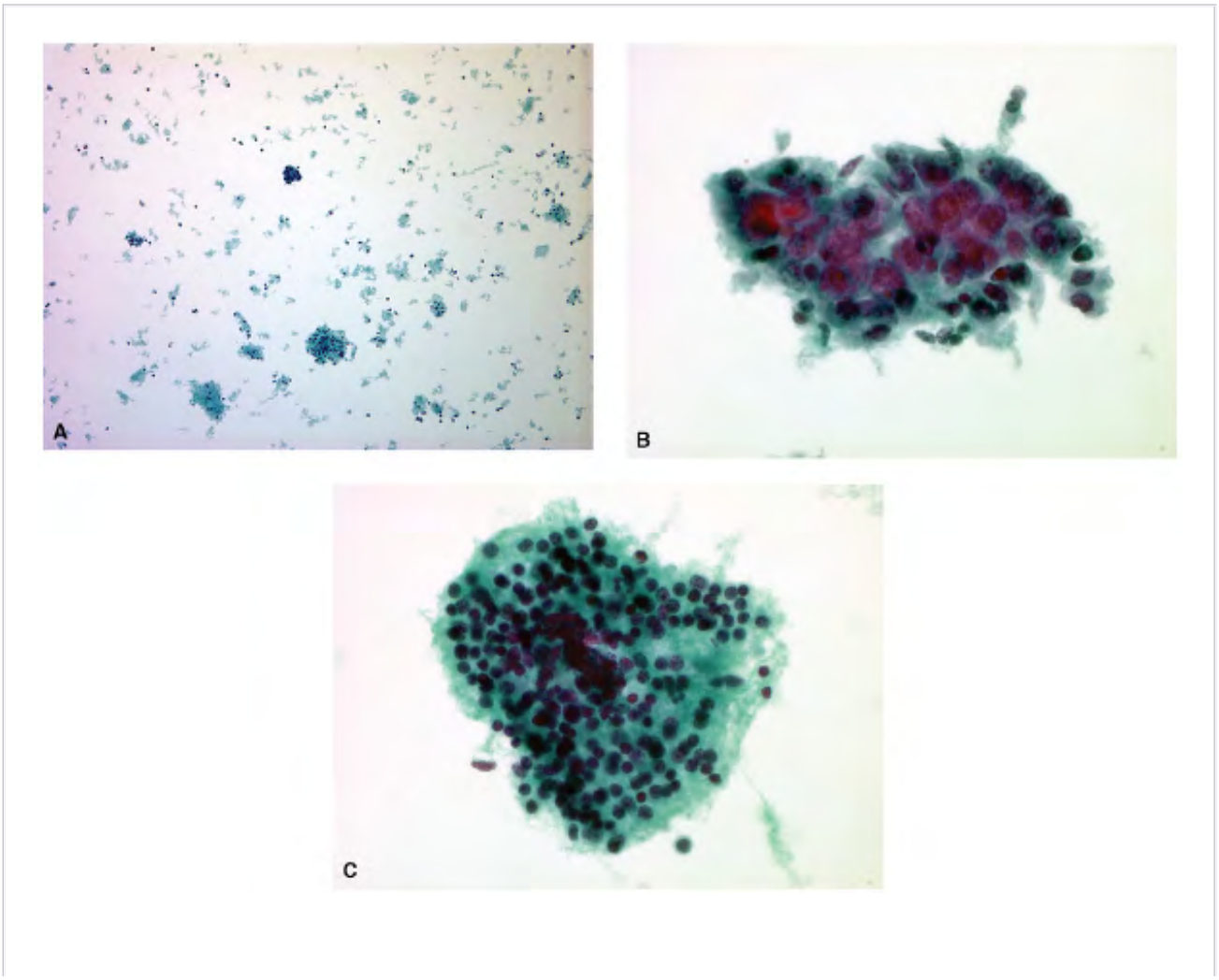

Figure 22.1. Chronic lymphocytic thyroiditis. A. Low power showing singly scattered lymphocytes in the background, mostly away from the epithelial clusters. Some lymphocytes appear as aggregates when entrapped by fibrin. B. A tight cluster of HÃ¼rthle cells with infiltrated lymphocytes. The cells are tightly cohesive with overcrowded pleomorphic nuclei, coarse chromatin, and prominent nucleoli.C. Aggregated polymorphous population of lymphocytes admixed with plasmacytoid cells (ThinPrep).

- As the blood undergoes hemolysis during processing, some of the white blood cells (WBCs) left behind appear as scattered cells in the background or are entrapped within the fibrin, giving the false impression that inflammatory cells are increased. However, upon closer examination it is clear that those cells are not associated with the epithelial clusters and are composed of a mixture of lymphocytes and

  neutrophils. Few red blood cells may be retained if the aspirate was bloody, giving a clue to the cells origin.
- By its nature, the ThinPrep was designed to filter obscuring inflammatory cells. Consequently, it had been our experience that in the majority of CLT, lymphocytes are markedly decreased when compared with conventional smears. When present, the lymphocytes tend to pool away from the epithelial clusters or migrate to the periphery of the ring, especially when present as single cells.
- Background giant cells are easily detected.
- At low magnification, most cases present with scattered small clusters of follicular/HÃ¼rthle cells, some of which may be infiltrated by lymphocytes. The background may vary widely from one case to another. Rarely, there would be numerous lymphocytes but most commonly the lymphocytic component is scant to moderate. The lymphocytes tend to pool together away from the clusters or get entrapped within the fibrin fragments.

*SurePath Features (*Fig. 22.2*)*

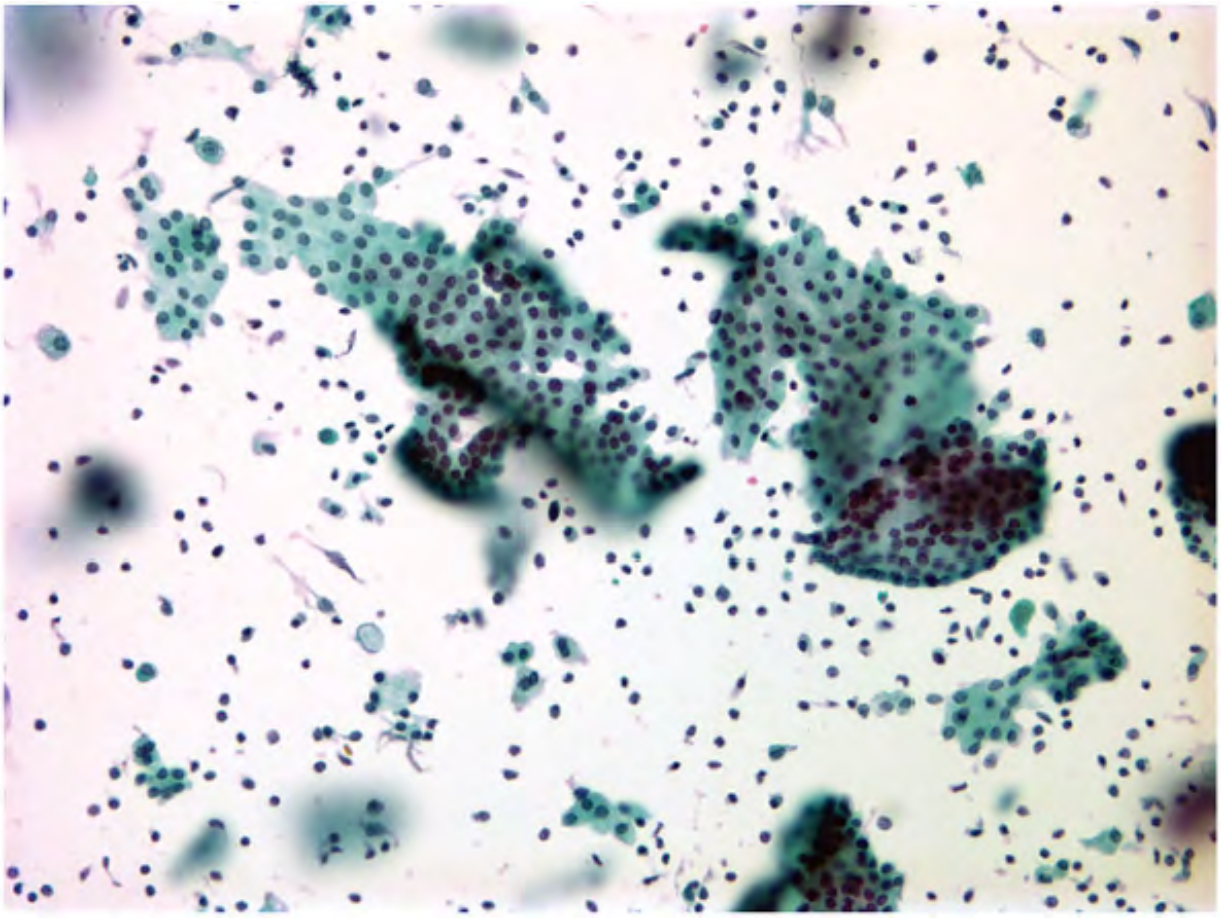

Figure 22.2. Hashimoto's thyroiditis showing sheets of HÃ¼rthle cells surrounded by numerous singly scattered lymphocytes. Notice the three-dimensional appearance and presence of cellular components at different planes of focus, medium power (SurePath).

Lymphocytes are usually adequately represented throughout the Prep making them easier to recognize. However, similar to ThinPrep, inflammatory cells from hemolyzed blood could also be present and should be distinguished from the polymorphous lymphocytic population characteristic of CLT.

The diagnostic pitfalls and clues for chronic lymphocytic thyroiditis are listed in Table

22.1.

TABLE 22.1 DIAGNOSTIC PITFALLS AND CLUES FOR HASHIMOTO'S THYROIDITIS (HT)/CHRONIC LYMPHOCYTIC THYROIDITIS

Diagnostic Pitfalls	Diagnostic Clues
Subtle lymphocytic infiltrate	Look for lymphocytes infiltrating or close to epithelial clusters; lymphocytes may pool as small aggregates away from clusters Look for lymphocytes towards the periphery of the ring
Bare follicular nuclei or white blood cells from hemolyzed blood can be confused with lymphocytes	Polymorphous population of lymphocytes and plasma cells
Follicular/HÃ¼rthle cells are increased in number and can be mistaken for nodular hyperplasia or neoplasia	HÃ¼rthle cells in HT appear as small, cohesive, syncytial aggregates
	Cells are enlarged and may exhibit cytologic atypia
	Chromatin pattern is not as crisp as that of

	HÃ¼rthle cell neoplasms and single cells are rare

Nodular Colloid Goiter (NCG)

In a comparison between conventional smears (CS) and ThinPrep of 41 surgical bench aspirates, Biscotti et al.13 accurately diagnosed 19 of 25 goiters by ThinPrep versus 20 of 25 cases by CS. On the other hand, Frost et al.,4 in their study of split samples, reported missing 10 of 85 of their goiter cases, contributing to half of their discrepant cases. Low cellularity and cystic degeneration accounted for these errors. Almost all studies described colloid as markedly diminished and appearing as small dense droplets rather than a diffuse layer or film. Tulecke et al.10 described two forms of colloid, the dense droplets and tissue-paper-like material corresponding to abundant watery colloid on correlating histology. It is worth noting that in their 37 goiters on surgical follow-up, 2 were accurately diagnosed by cytology as goiters, 11 diagnosed as benign, 24 cases were considered indeterminate, and 4 were diagnosed as follicular/HÃ¼rthle cell neoplasm on ThinPrep. Of the 23 cases they diagnosed as benign by ThinPrep, only 11 were goiters, and 12 were follicular adenomas on surgical follow-up. While I agree that some of the watery colloid may appear as thin tissue-like sheets, I found it very difficult to reliably distinguish that type of colloid from fibrin fragments in many cases.

ThinPrep Features (Fig. 22.3)

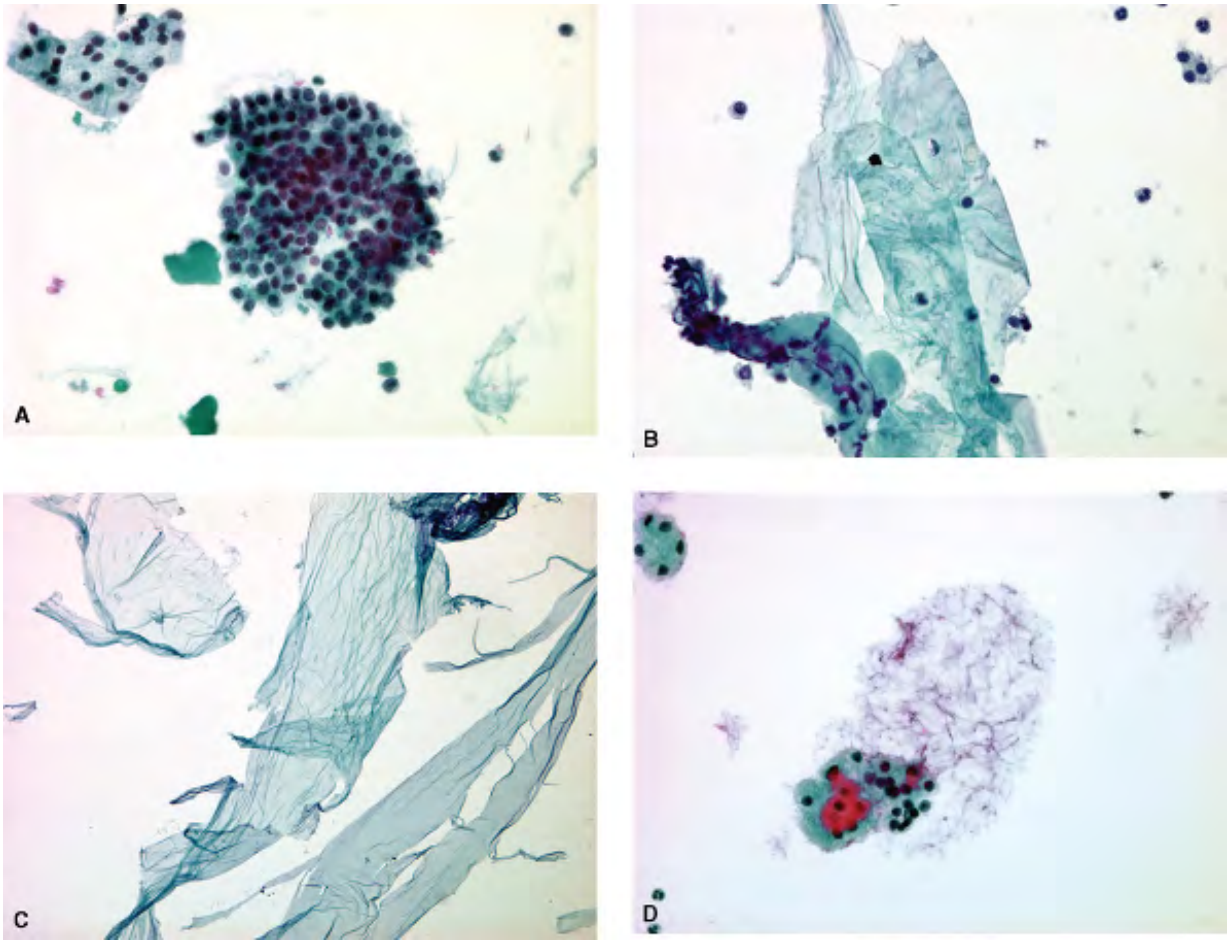

Figure 22.3. Multinodular goiter. A. Cluster of follicular cells with uniform, orderly arranged cells adjacent to small droplets of dense colloid. B. Thin colloid appearing as a thin folded tissue paper with semi-translucent quality. This appearance can be difficult to distinguish from fibrin produced by hemolyzed blood. C. Fibrin fragments seen in a ThinPrep from cerebrospinal fluid. Notice the similarity to watery colloid (medium power). D. Transmission gel may mimic colloid. However, it has a purple color and more transparent quality (ThinPrep).

- Small sheets of follicular/HÃ¼rthle cells in a honeycomb arrangement. The cells have well-defined cell borders, no crowding or overlapping of cells, and the nuclei are equally spaced.

- Large fragments and spherules are less frequent.
- Some follicular cells exhibit degenerative changes.
- Scattered histiocytes, some may contain hemosiderin.
- Small droplets of thick colloid.
- Thin paper-like sheets with homogeneous transparent quality (not commonly found).

SurePath Features (Fig. 22.4)

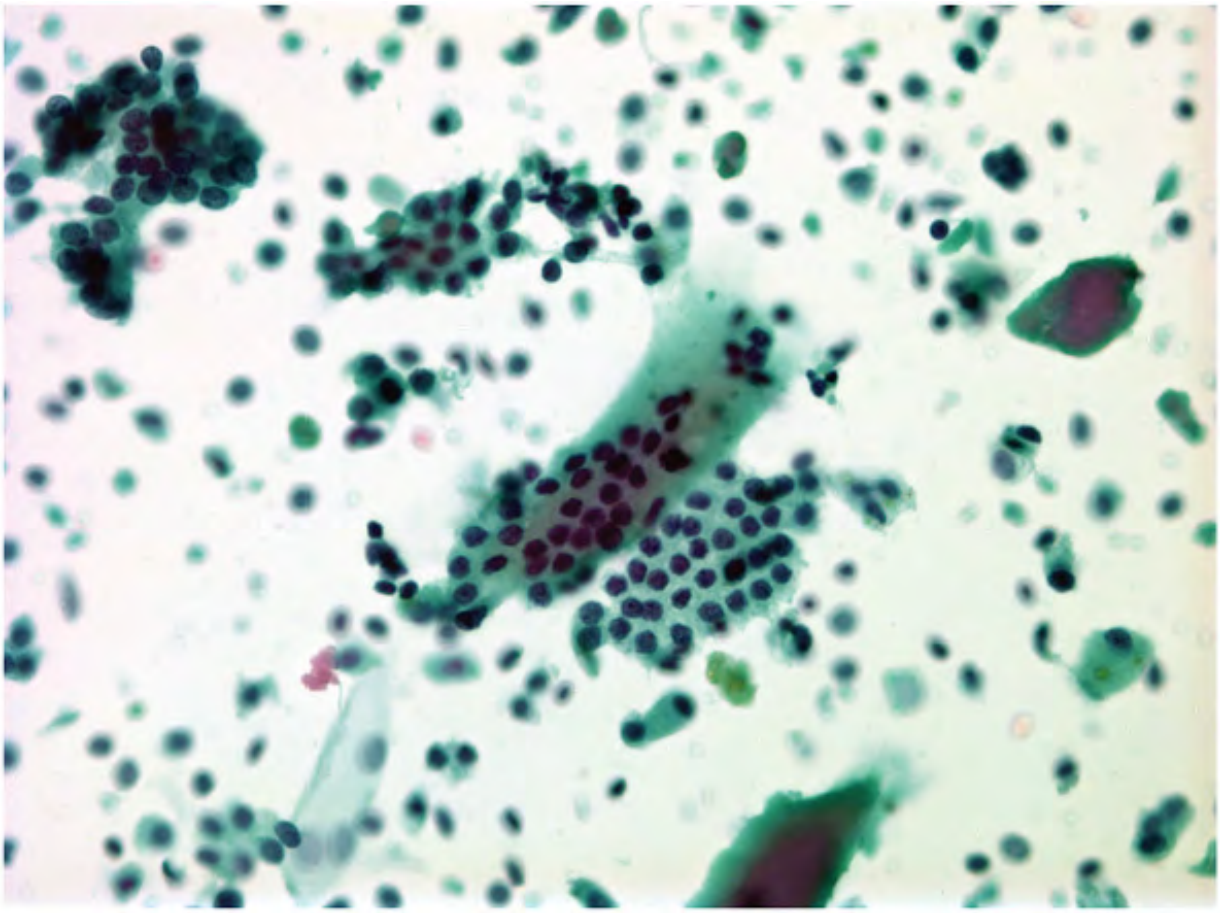

Figure 22.4. Multinodular goiter showing several clusters of follicular cells and easily identifiable colloid fragments presented in a range of sizes (SurePath).

The honeycomb arrangement is easily visualized despite the three-dimensional appearance. Colloid is easier to identify and adequately represented. Thin colloid acquires a denser quality than that seen on CS.

The diagnostic pitfalls and clues for nodular colloid goiter are listed in Table 22.2.

TABLE 22.2 DIAGNOSTIC PITFALLS AND CLUES FOR NODULAR COLLOID GOITER (NCG)

Diagnostic Pitfalls	Diagnostic Clues
Colloid is markedly reduced	Appears as small dense cyanophilic droplets; sometimes thick droplets acquire two-tone staining
Ultrasound transmission gel mimic colloid	Gel has a purplish hue and has a more transparent texture
Cellularity of follicular cells may be exaggerated	Watch out! Ratio of colloid to cells is not accurate and may be reversed Diagnosis should depend on the organization of follicular cells within the aggre-gates (i.e., honeycomb arrangement rather than syncytial sheets)

Follicular Cell Neoplasms (FCN)

The high cellularity, disturbed architecture, and numerous microfollicles are characteristic of these lesions. Caution should be exercised when reviewing the literature regarding follicular/HÃ¼rthle cell lesions, since the reporting criteria varied among the studies. Some studies included macrofollicular adenomas with benign lesions,8 while others included in this differential all follicular/HÃ¼rthle cell rich lesions mainly including floridly hyperplastic nodular goiters, adenomas, and carcinomas. In our institution we diagnose FCN when we are considering adenoma or carcinoma. Generally the rates of false negative in this category by ThinPrep is less than that of CS,3 and in all reported studies, neoplastic lesions, including follicular adenomas (FCA) and carcinomas (FCca), were correctly classified as neoplastic or suspicious for malignancy.4, 10, 13 However, there were some false-positive cases in several studies, where multinodular goiters were erroneously classified as hypercellular follicular lesions/neoplasia. In the study by Tulecke et al.,10 almost 60% of the nodular goiters were misclassified as indeterminate or neoplastic. It has also been our experience that this error is particularly prevalent among new reviewers who are not very familiar with changes unique to ThinPrep and that it declines with experience.

ThinPrep Features (Figs. 22.5 and 22.6)

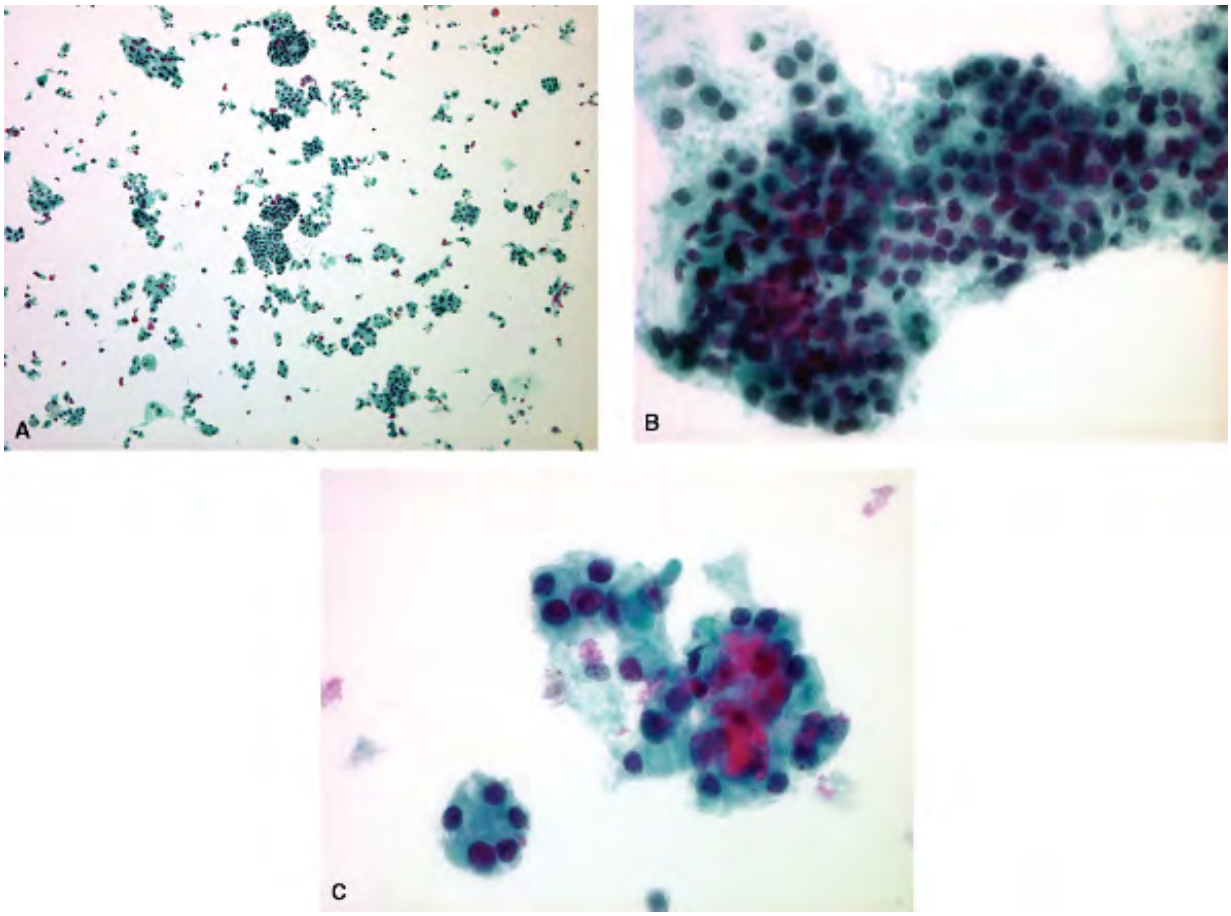

Figure 22.5. Follicular cell adenoma. A. Cellular prep containing numerous variably sized clusters of follicular cells, numerous scattered microfollicles and some single cells, medium power. B. Syncytium of follicular cells showing irregularly spaced cells with no distinct cell borders. The nuclei are relatively larger and hyperchromatic when compared with those seen in Figure 22.3A. C. Several microfollicles appearing as an aggregate with irregular borders or singly scattered. Small droplets of inspissated colloid may sometimes be seen within the microfollicles (ThinPrep).

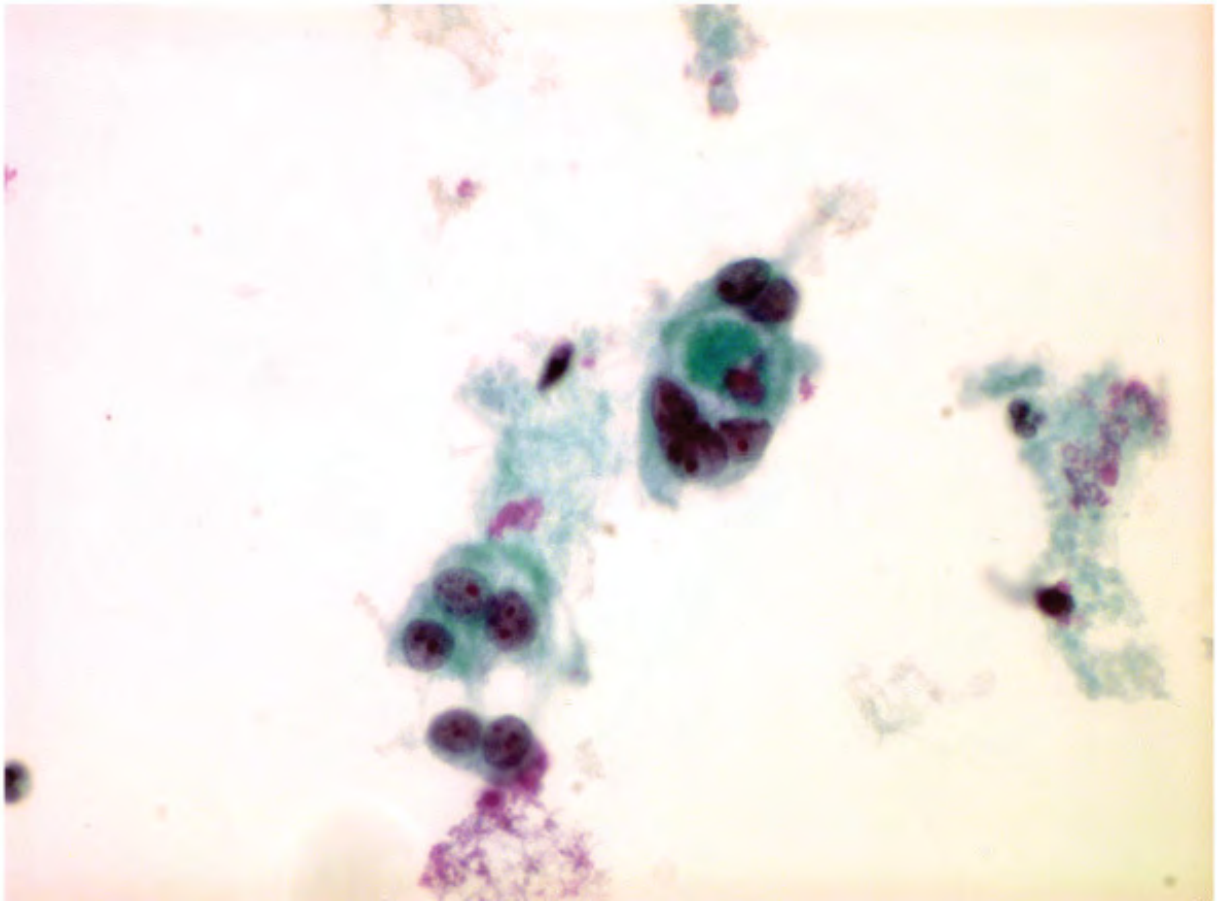

Figure 22.6. Follicular cell carcinoma showing small scattered microfollicles and single cells. The nuclei are large with coarse chromatin and prominent nucleoli (ThinPrep).

- Cellular preps with small syncytial sheets, exhibiting loss of orderly arrangement, crowding of cells, irregular spacing of nuclei, and lack of well-defined cell borders.
- Numerous microfollicles (a small flower-like arrangement of follicular cells with or without inspissated colloid) and small clusters with scalloped contours.
- Variable number of colloid droplets but usually few and small in microfollicular neoplasms.

- Follicular carcinomas may show more nuclear enlargement, nuclear pleomorphism, predominantly microfollicular pattern, and numerous singly scattered cells. The cells may appear relatively more crowded.

SurePath Features (Fig. 22.7)

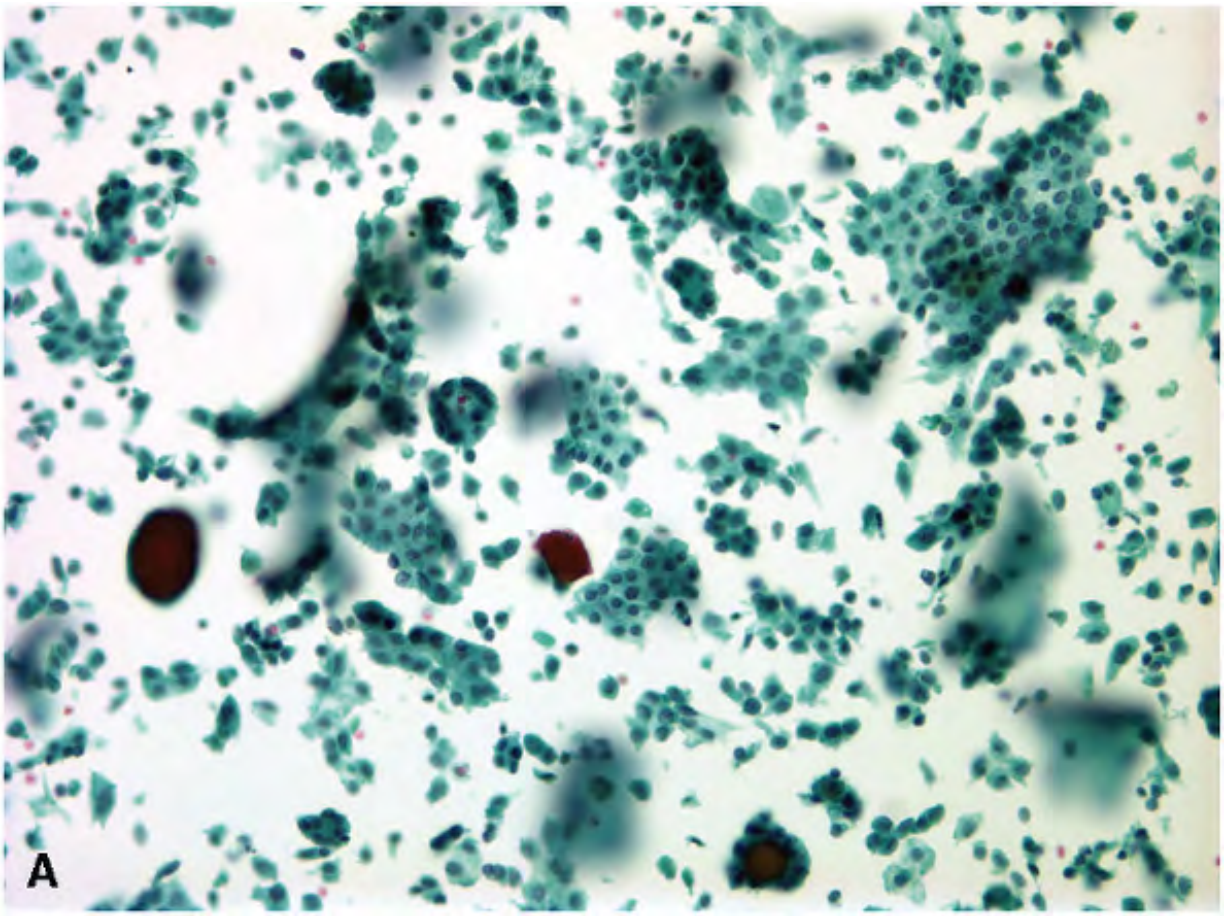

Figure 22.7. Follicular cell adenoma. A. Cellular prep containing numerous sheets, clusters, and microfollicles appearing in several focal planes and three-dimensional configuration.

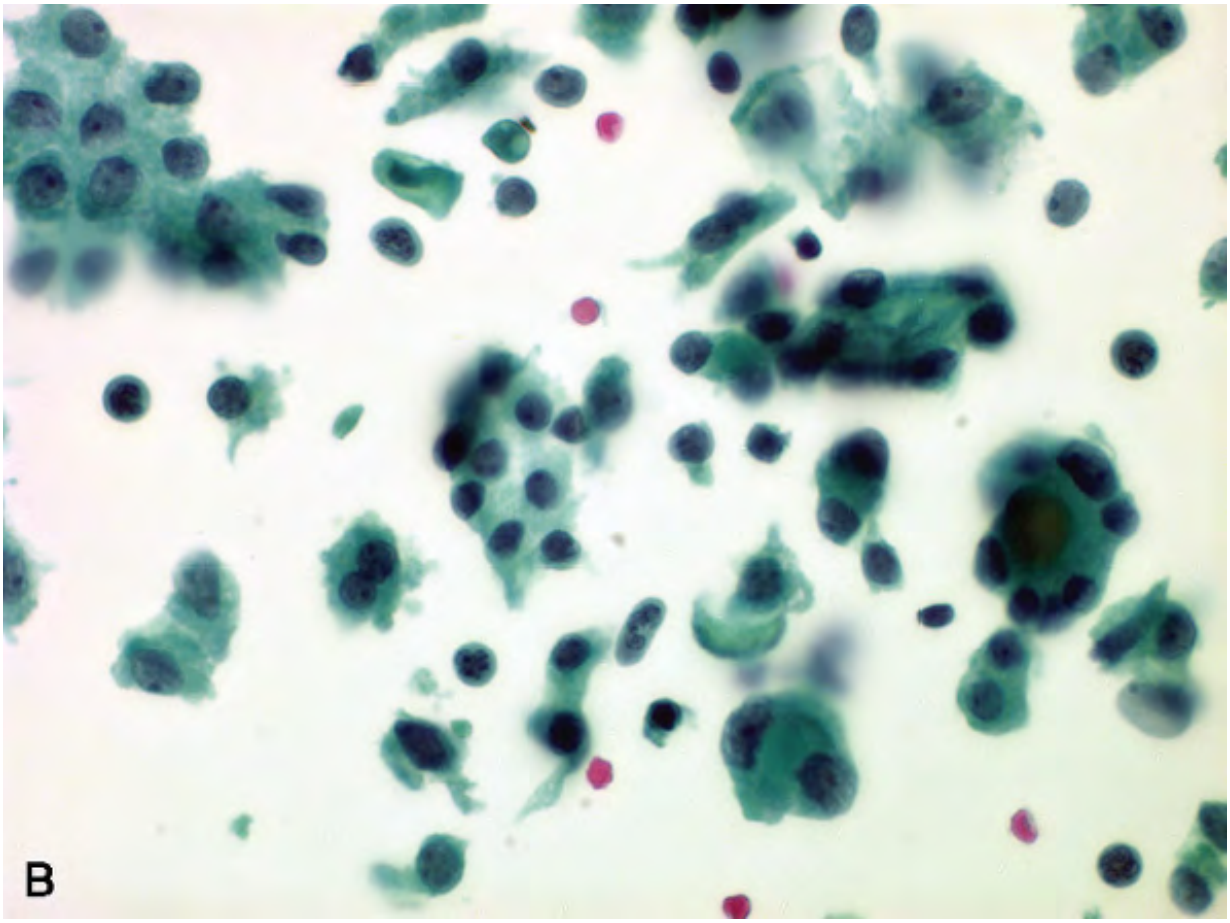

Figure 22.7. B. Microfollicles with inspissated colloid and discohesive follicular cells with enlarged nuclei and small nucleoli (SurePath). (Courtesy of Paul Wakely, MD, Ohio State University, Columbus.)

Generally, the cytologic presentation is very similar to that of ThinPrep. The SurePath is highly cellular and is comprised of a mixture of small sheets, clusters, and some microfollicles in a background of numerous singly scattered and evenly distributed cells. Fragments of very dense colloid may also be seen.

The diagnostic pitfalls and clues for follicular cell neoplasm are listed in Table 22.3.

TABLE 22.3 DIAGNOSTIC PITFALLS AND CLUES FOR FOLLICULAR CELL NEOPLASM (FCN)

Diagnostic Pitfalls	Diagnostic Clues
Exaggerated cellularity and reduced colloid may result in mistaking NCG for FCN	Diagnosis is based on organization of cells within sheets or aggregates (i.e., honeycomb versus syncytium) Follicular clusters have irregular or scalloped contours rather than the smooth surface seen in intact follicles Look for microfollicles singly scattered or within the cellular clusters
Microfollicular pattern tend to be overestimated (3)	Numerous microfollicles that do not exceed 10-15 cells are not a characteristic feature of NCG When present in FCN colloid droplets are usually smaller and fewer against a highly cellular background.
Papillary carcinoma misclassified as FCN	Although the syncytial arrangement may be a common feature and micro follicles may be seen in the follicular variant, the chromatin is almost always coarser in FCN

HÃ¼rthle Cell Neoplasms (HCN)

This category includes HÃ¼rthle cell adenoma (HCA) and carcinoma (HCca). The numbers of these cases are very few in ThinPrep reported literature, and most studies

reported no problems with correctly recognizing them. Cochand-Priollet et al.8 reported that 50% (2 of 4 cases) were missed by ThinPrep. Similar to FCN, false-negative cases are not common for these neoplasms in our experience; however, false-positive cases do occur. As with CS, aspirates rich in HÃ¼rthle cells from hyperplastic nodules within Hashimoto's thyroiditis or extensive HÃ¼rthle cell change in NCG could be misdiagnosed as HCN.3, 8 FCA and papillary carcinomas with considerable HÃ¼rthle cell change may be misclassified as HCN.

ThinPrep Features (Figs. 22.8 and 22.9)

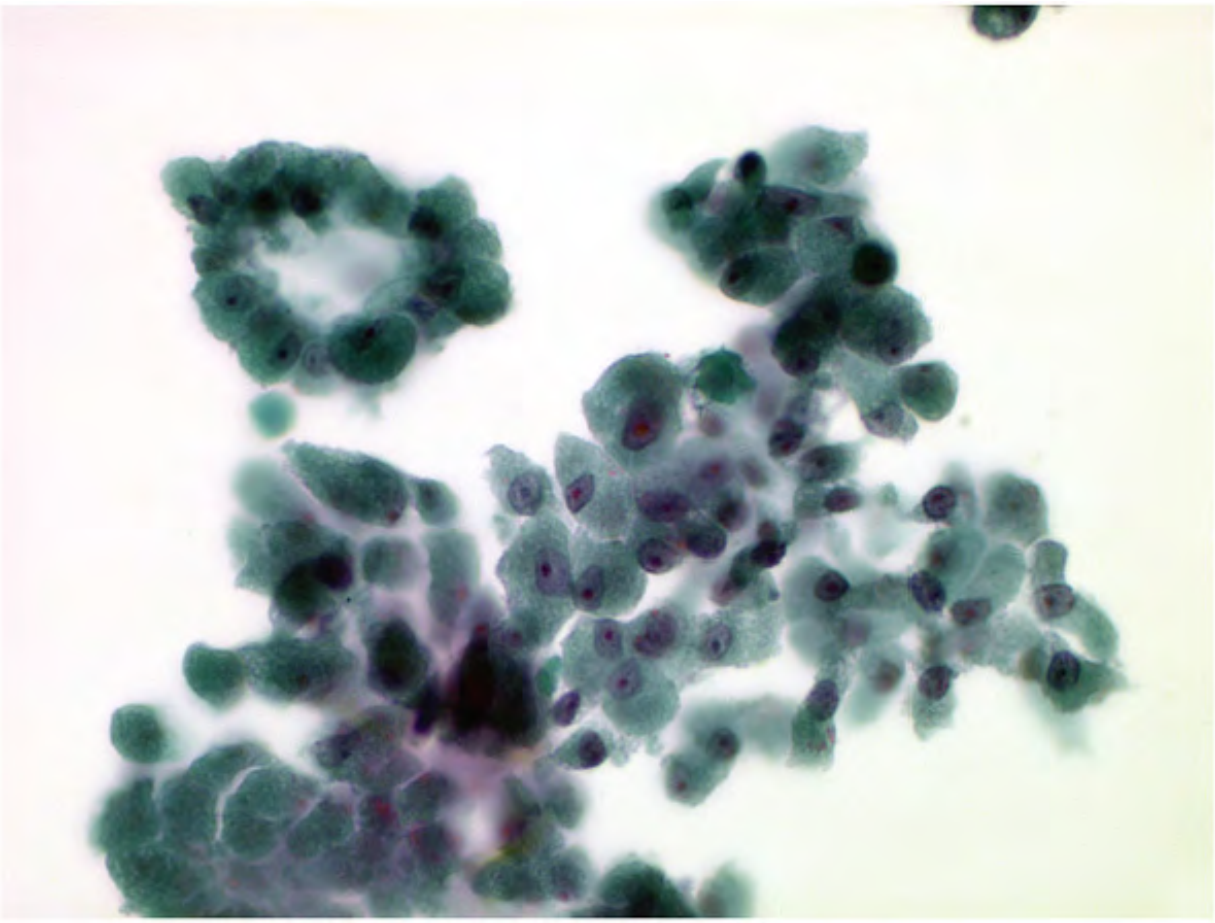

Figure 22.8. HÃ¼rthle cell adenoma showing a predominantly discohesive and monotonous cell population and occasional microfollicle. The cells are enlarged and contain abundant granular cytoplasm. Despite the enlarged nuclei, the N/C

ratio remains relatively low (ThinPrep).

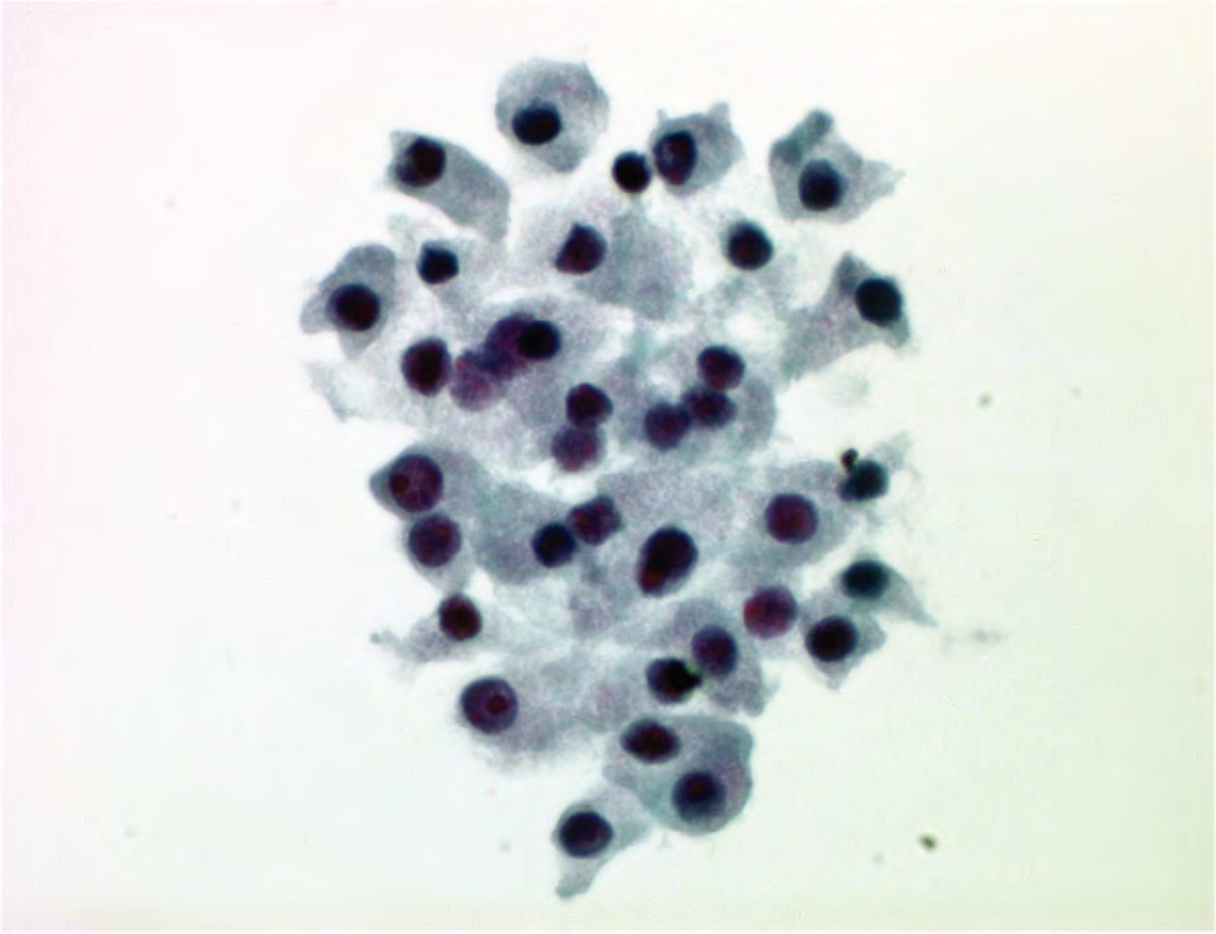

Figure 22.9. HÃ¼rthle cell carcinoma showing a predominantly single cell population with uniform size. The nuclei are enlarged and the nucleoli are very prominent (ThinPrep).

- Cellular Preps consisting predominantly of small clusters or single cells. Few microfollicles may be detected.
- The cells are markedly enlarged and monomorphic in size and appearance

within the same sample.

- The cells are widely spaced by their abundant granular or slightly vacuolated cytoplasm.
- The nuclei are large with prominent frequently cherry red nucleoli. They are slightly eccentric and the nuclear to cytoplasmic ratio (N/C) is usually low, particularly in adenomas.
- HCca may present with larger fragments and prominent nuclear atypia such as coarse chromatin and irregular or multiple nucleoli.

SurePath Features (Fig. 22.10)

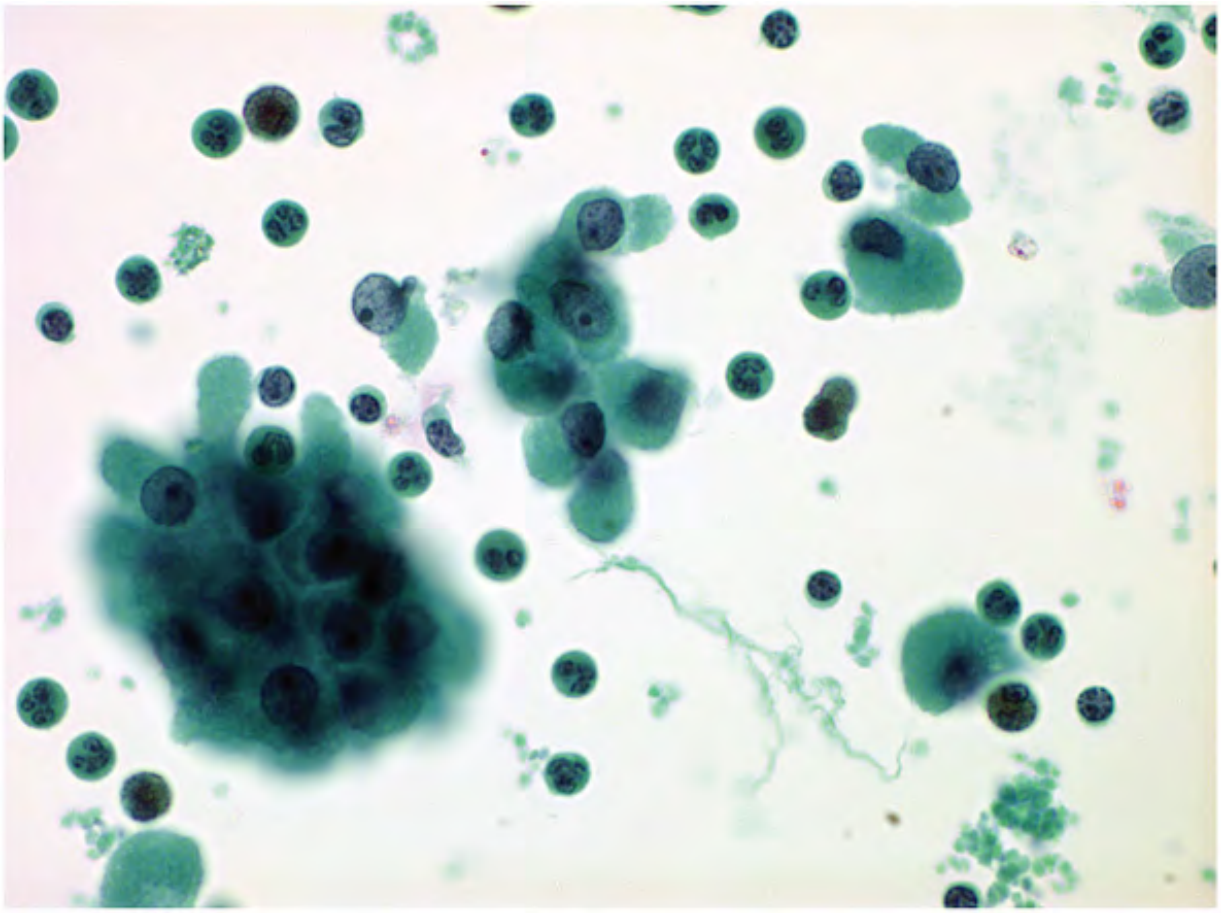

Figure 22.10. HÃ¼rthle cell adenoma showing small clusters of monotonously

enlarged cell with abundant cytoplasm, large nucleoli, and prominent nucleoli (SurePath). (Courtesy of Paul Wakely, MD, Ohio State University, Columbus.)

The features on SurePath are very similar to those described above. The extent of discohesion may, however, be less prominent.

P.493
P.494
P.495

The diagnostic pitfalls and clues for HÃ¼rthle cell neoplasm are listed in Table 22.4.

TABLE 22.4 DIAGNOSTIC PITFALLS AND CLUES FOR HÃœRTHLE CELL NEOPLASM (HCN)

Diagnostic Pitfalls	Diagnostic Clues
Hyperplastic HÃ¼rthle cell nodules within HT may dominate the aspirate and mimic HCN	Clusters are tightly cohesive and commonly infiltrated by lymphocytes Cytologically atypical with nuclear variation and pleomorphism Nuclei centrally located and frequently show degenerative changes
Papillary carcinoma with HÃ¼rthle cell change lack nuclear crowding and overlap	Nuclear grooves and powdery chromatin are present
FCN with considerable HÃ¼rthle cell change exhibits many overlapping features	FCN presents predominantly as microfollicles in contrast to the sheets or single cells seen in HCN

Hyperplastic NCG with HÃ¼rthle cell change	Sheets of HÃ¼rthle cells admixed with sheets of follicular cells, colloid droplets, and histiocytes Cells are orderly arranged in a honeycomb pattern with centrally located nuclei and small nucleoli The granular cytoplasm is far less abundant than in FCN
Granular cell tumor (GCT) in the vicinity of thyroid gland may mimic HCN[15]	Be aware that the loose background granules commonly seen in the CS are absent in ThinPrep Cells of GCT show some spindling, less defined cytoplasm, and relatively inconspicuous nucleoli Cells of GCT are reactive to neuro specific enolase and nonreactive to pancytokeratin

Papillary Carcinoma (PCA)

Two studies correctly identified all 7 PCA in their reports,4, 8 and one identified 5 out of 6 cases and diagnosed the sixth case as a hypercellular follicular neoplasm.13 In a study dedicated to PCA by ThinPrep, Zhang et al.14 statistically analyzed 40 cases of PCA and 17 cases of other lesions for 10 characteristics with assigned scores. They found that high cellularity, presence of papillary clusters and large sheets, nuclear grooves, nuclear molding, powdery chromatin, and small nucleoli were significant. However, none of these features could absolutely predict PCA by itself. Not surprisingly, intranuclear inclusions had the highest predictive power while cellularity and small nucleoli had the least predictive power. They found that the presence of intranuclear inclusions is essential to achieve 100% specificity, and recorded many inclusions in 12 of 40 cases and rare inclusions in 18 of 40 cases. In a pilot study in our institution, we accurately diagnosed 22 of 38 adequately cellular cases with surgical

follow-up. Fifteen of these 22 cases showed inclusions, but it is worth noting that in 10 of 15 cases, the intranuclear inclusions were rare and only detected after scrutiny under high magnification. In our experience, the presence of numerous nuclear grooves within crowded irregular nuclei is highly correlated with PCA.

ThinPrep Features (Fig. 22.11)

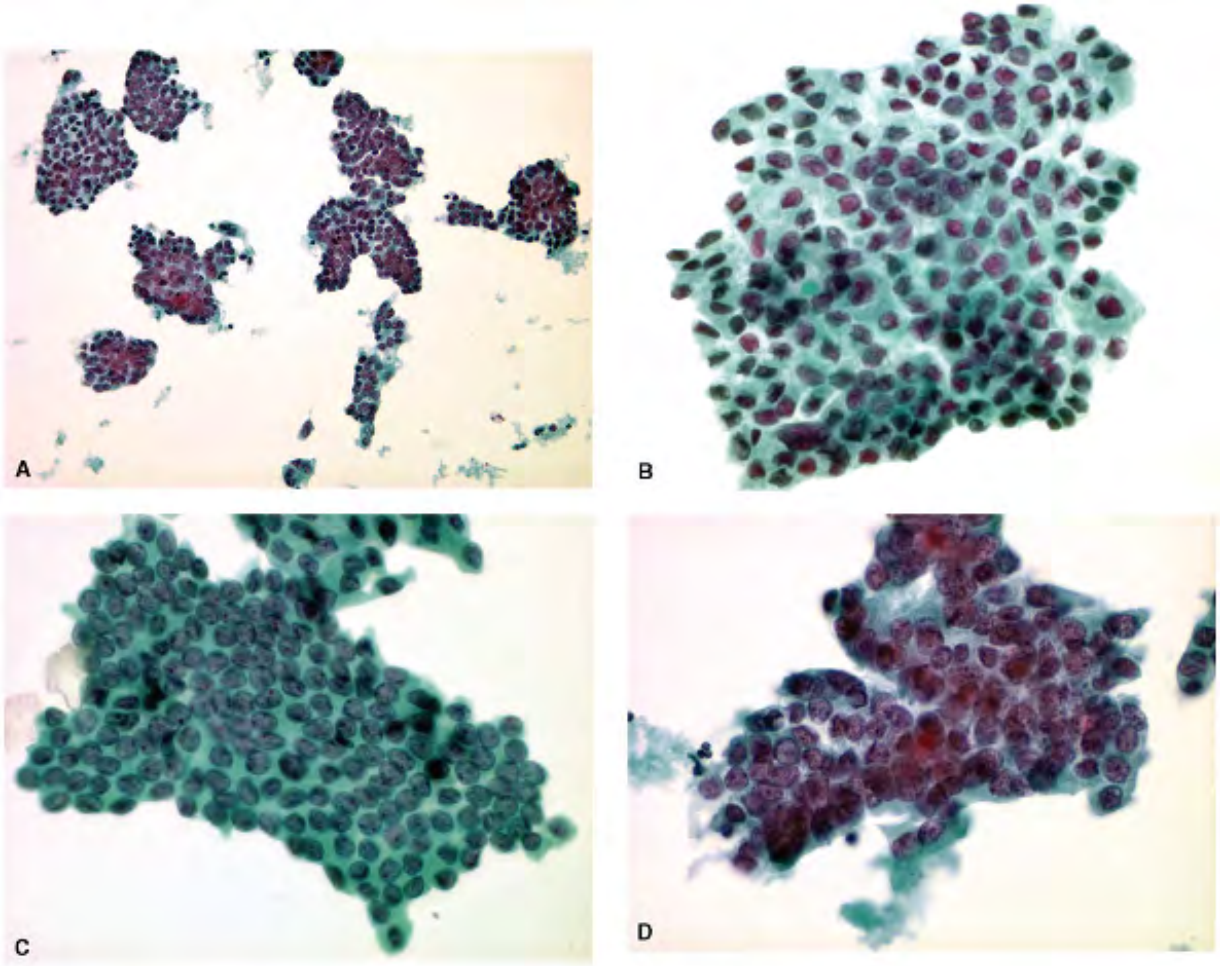

Figure 22.11. Papillary carcinoma. A. Cellular prep with small cellular clusters and simple papillae. The nuclei are densely packed within the clusters when compared to those of nodular goiter, medium power. B. Uniformly enlarged cells that are slightly crowded. Notice the marked wrinkling of the nuclear membrane. The nuclear chromatin is evenly distributed and several nuclear grooves can be

detected. C. A sheet of monotonous more or less orderly arranged cells with smooth nuclear membranes can be mistaken for hyperplasia. However, notice the powdery chromatin, small nucleoli, and numerous nuclear grooves. D. Intranuclear pseudoinclusions are occasionally detected (ThinPrep).

- Cellular preps containing numerous sheets and clusters.
- Papillary architecture may need some experience to recognize, since papillae may be broken down into finger-like clusters and rarely retain the complex architecture seen on CS.
- The cells are crowded and nuclear molding could be prominent.
- Uniformly enlarged nuclei with powdery chromatin and small nuclei.

- Nuclear grooves and coffee-bean-like nuclei. Nuclear membranes may be markedly wrinkled.
- Intranuclear inclusions are not easily visualized and may be absent.
- Hard colloid appears as very thick fragments.
- Squamous metaplasia may be focally present as small clusters or single cells with larger nuclei and thick cyanophilic cytoplasm.
- Psammoma bodies when present are well preserved.

SurePath Features (Fig. 22.12)

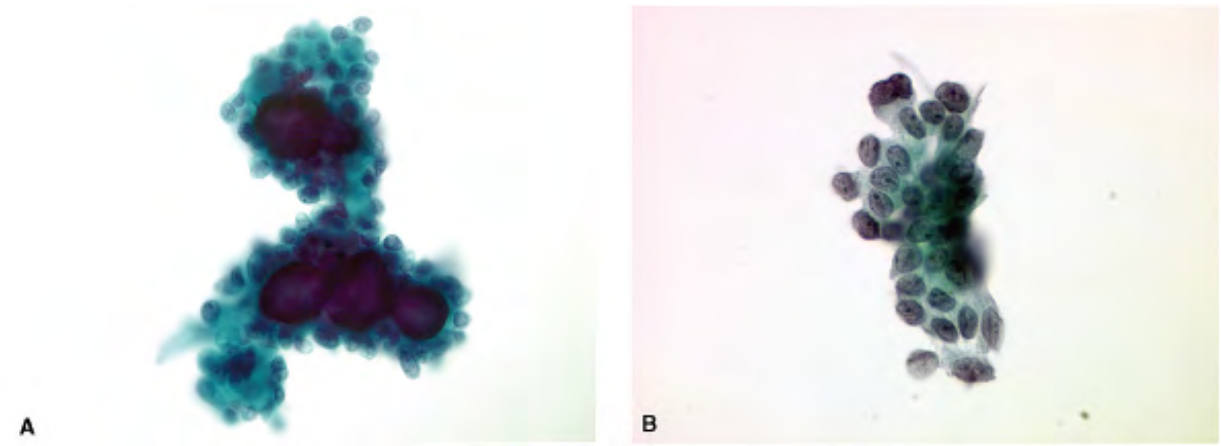

Figure 22.12. Papillary carcinoma. A. Papillary clusters with central psammoma bodies. B. Evenly spread cluster of enlarged cells with oval nuclei, powdery chromatin, nuclear grooves, and small nucleoli (SurePath). (Courtesy of Michael Henry, MD, Mayo Clinic, Rochester, Minnesota.)

The complex papillae are usually preserved and assume a three-dimensional architecture. About 50% of cases manifest intranuclear inclusions (personal communication). Examination of cells lining the periphery of these three-dimensional papillae and clusters reveals all the characteristic nuclear features. Psammoma bodies are well preserved.

The diagnostic pitfalls and clues in papillary carcinoma are listed in Table 22.5.

TABLE 22.5 DIAGNOSTIC PITFALLS AND CLUES IN PAPILLARY CARCINOMA (PCA)

Diagnostic Pitfalls	Diagnostic Clues
Monolayer sheets can be deceptively uniform with subtle nuclear features; this could be mistaken for NCG, especially in cases with cystic degeneration	The aspirate is usually very cellular with large sheets The nuclei are crowded and wrinkled when viewed at higher magnification The chromatin is pale and finely granular Colloid fragments are relatively larger and denser than those of NCG
PCA with HÃ¼rthle cell change lack the nuclear crowding and overlap and may be mistaken for HCN	Characteristic nuclear features such as grooves and membrane irregularity Powdery, finely granular chromatin Present predominantly as sheets or clusters and not as single cells as in FCN
Follicular variant may mimic FCN	Characteristic nuclear changes
Some FCA may manifest focal nuclear crowding and groves	Focal changes are not sufficient for unequivocal diagnosis of PCA

Anaplastic Carcinoma

Only one study reported 9 anaplastic carcinoma cases, all correctly diagnosed by ThinPrep.3 In the several cases we have seen in our institution, mostly of the giant cell

type, all cases were easily identified.

ThinPrep Features of Giant Cell Type (Fig. 22.13)

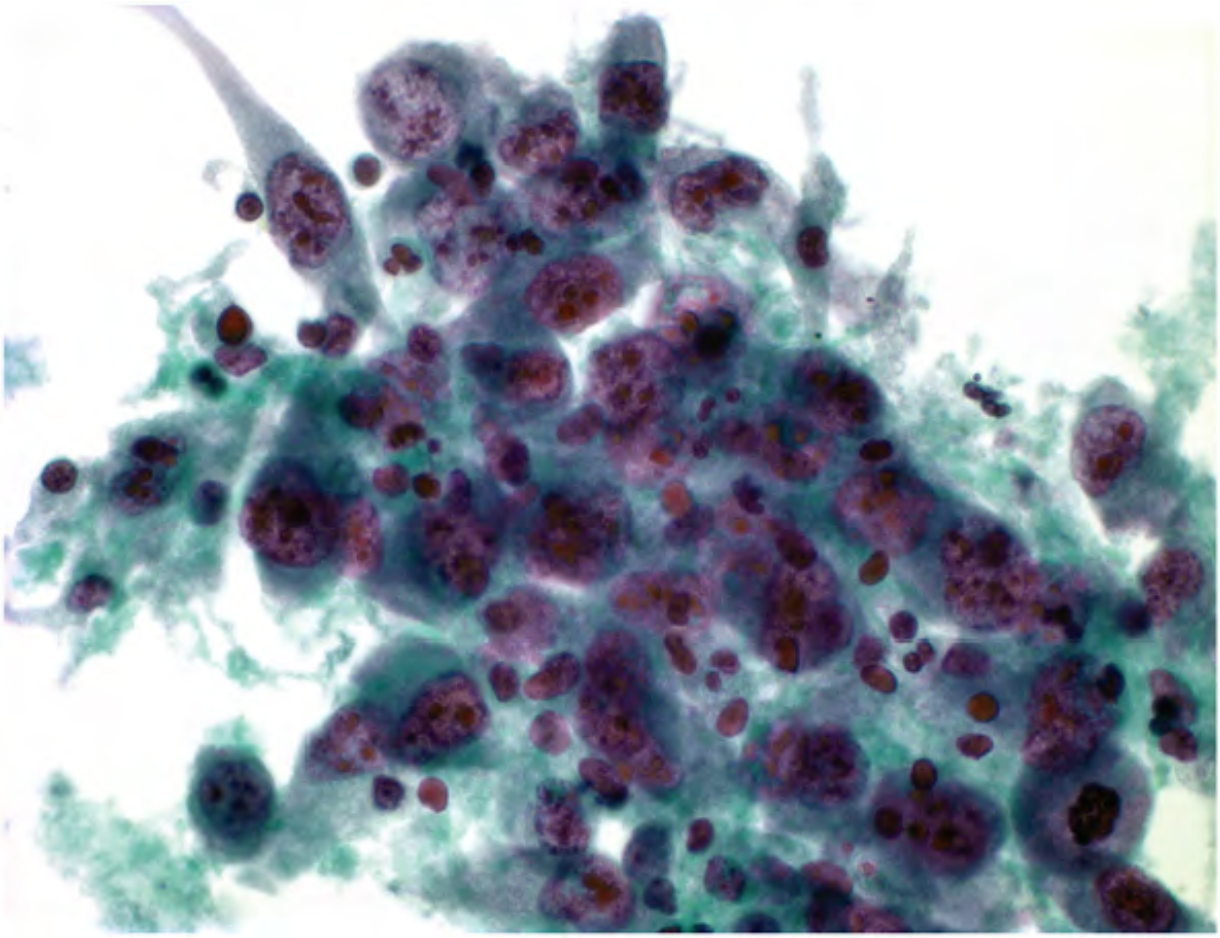

Figure 22.13. Anaplastic carcinoma. Gigantic cells with markedly large nuclei, high N/C ratio, course clumpy chromatin and macronucleoli. Phagocytosis of neutrophils by the malignant cells is prominent (ThinPrep).

- Predominantly single cells and few small cell aggregates.
- Extremely pleomorphic cells with wide variation of size and shape.

- Bizarre nuclei with prominent nucleoli and irregular nuclear membranes
- Fibrin fragments with entrapped cellular debris represent background necrosis
- Cytoplasmic leukophagocytosis
- Nuclear inclusions are rarely detected unlike those on conventional smears.

ThinPrep Features of Spindle Cell Type

- Aspirates are usually scant in cellularity
- Singly scattered or small groups of spindled cells with variable degree of pleomorphism. Some may mimic medullary carcinoma with spindle cell features and require confirmation by immunostains.

Medullary Carcinoma

Only 2 cases were reported by ThinPrep.7, 8 Over the years we have encountered several cases with variable amounts of amyloid. Congo red stain can be performed on a cell block or on an additional ThinPrep with success. We have also routinely applied thyrocalcitonin with excellent results. However, we have encountered occasional HÃ¼rthle cell lesions collected in CytoLyt that would falsely react to calcitonin and therefore recommend that it is interpreted in conjunction with thyroglobulin as a negative control.

ThinPrep Features (Fig. 22.14)

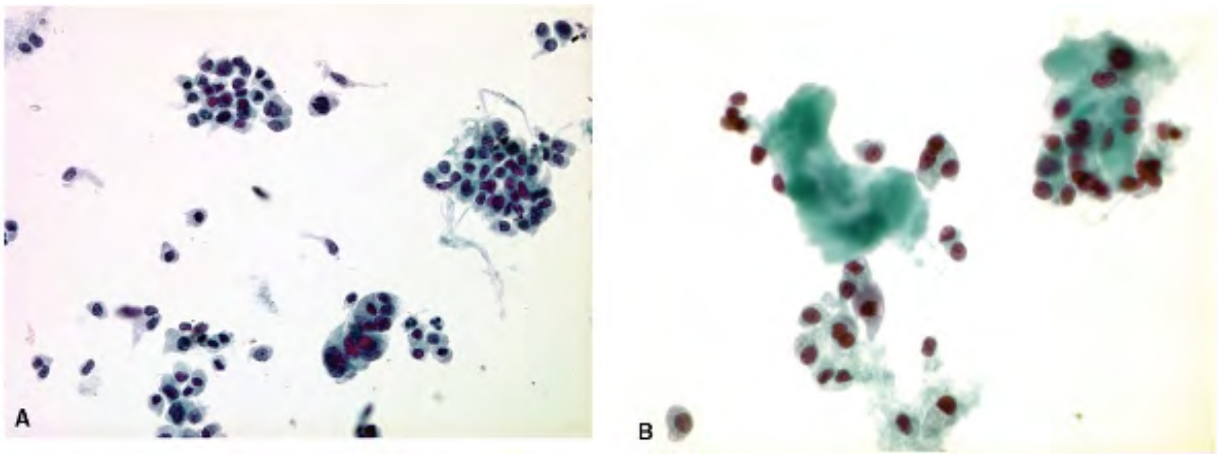

Figure 22.14. Medullary carcinoma. A. Loosely cohesive clusters of cells with eccentric nuclei, slight nuclear membrane irregularity, evenly distributed chromatin and small nucleoli. B. Loosely cohesive clusters and single plasmacytoid cells. Two dense fragments with waxy quality are consistent with amyloid (ThinPrep).

- Small singly scattered and in small cohesive groups, cells are cuboidal, columnar, polygonal, or plasmacytoid in shape.
- Cells may vary from monomorphic to pleomorphic, and occasional bizarre cells are not unusual.
- Eccentric nuclei, coarsely granular chromatin and small nucleoli.
- Cytoplasm is moderate in amount, dense, with well-defined borders.
- Amyloid when present appears as small dense fragments with waxy quality.

REFERENCES

1.Michael CW, McConnell J, Pecott J, et al. Comparison of the ThinPrep and AutoCyte liquid based preparations in non-gynecologic specimens. *Diagn Cytopathol*. 2001;25:177â€“184.

2.Nicol TL, Kelly D, Reynolds L, et al. Comparison of TriPath thin-layer technology with conventional methods on non-gynecologic specimens. *Acta Cytol*. 2000;44:567â€“575.

3.Malle D, Valeri RM, Panajiotou, et al. Use of a thin-layer technique in thyroid fine needle aspiration. *Acta Cytol*. 2006;50:23â€“17.

4.Frost AR, Sidawy MK, Ferfelli M, et al. Utility of thin-layer preparations in thyroid fine needle aspiration. Diagnostic accuracy, cytomorphology and optimal sample preparation. *Cancer Cytopathol*. 1998;84:17â€“25.

5.Hasteh F, Pang Y, Pu RT, et al. Do we need more than one ThinPrep to obtain adequate cellularity in fine needle aspirates? *Cancer Cytopathol*. 2006;108:424A.

6.CYTYC Corporation. *Operator's Manual. ThinPrep Processor*. Marlborough, MA: CYTYC; 1992.

7.Michael CW, Hunter B. Interpretation of fine needle aspirates processed by the ThinPrep technique: cytologic artifacts and diagnostic pitfalls. *Diagn Cytopathol*. 2000;23:6â€“13.

8.Cochand-Priollet B, Prat JJ, Polivka M, et al. Thyroid fine needle aspiration: the morphological features on ThinPrep slide preparations. Eighty cases with histological control. *Cytopathology*. 2003;14:343â€“349.

9.TriPath Imaging Inc. *Operator's Manual. General Non-Gynecologic Procedure*. Burlington, NC: TriPath Imaging; 2006.

10.Tulecke MA, Wang HH. ThinPrep for cytologic evaluation of follicular thyroid lesions: Correlation with histologic findings. *Diagn Cytopathol*. 2004;30:7â€“13.

11. The Papanicolaou Society of Cytopathology Task Force on Standards of Practice. Guidelines of the Papanicolaou Society of Cytopathology for examination of fine-needle aspiration specimens from thyroid nodules. *Diagn Cytopathol*. 1996;15:84â€“89.

12. Michael CW, Pang Y, Pu RT, et al. Cellular adequacy for thyroid aspirates prepared by ThinPrep: how many cells are needed? *Mod Pathol.* 2006;19:292A.

13. Biscotti CV, Hollow JA, Toddy SM, et al. ThinPrep versus conventional smear cytologic preparations in the analysis of thyroid fine-needle aspiration specimens. *Am J Clin Pathol*. 1995;104: 150â€“153.

14. Zhang Y, Fraser JL, Wang HH. Morphologic predictors of papillary carcinoma on fine-needle aspiration of thyroid with ThinPrep preparations. *Diagn Cytopathol*. 2001;24:378â€“383.

15. Kintanar BK, Giordano TJ, Thompson NW, et al. Granular cell tumor of trachea masquerading as HÃ¼rthle cell neoplasm on fine needle aspirate: a case report. *Diagn Cytopathol*. 2000;22:379â€“382.

Editors: Kini, Sudha R.
Title: *Thyroid Cytopathology: A Text and Atlas, 1st Edition*

Copyright Â©2008 Lippincott Williams & Wilkins

23

Application of Needle Biopsy Data to Managemen Decisions

A PHILOSOPHICAL APPROACH

J. Martin Mille

Deceased.

The primary consideration in the application of needle biopsy data to the management of thyroid nodules is the perception of thyroid cancer by the responsible physician. When thyro nodules were selected for lobectomy by noninvasive means, it was recognized that some ca were missed. (Just how many were missed was not appreciated until we began doing thyroi biopsies.) The problem, however, was not failure to identify cancers that later proved letha but a plethora of operations for removal of benign disease. Simply stated, in the minds of m physicians, the consequences of observing some cancerous thyroid nodules did not justify th removal of all thyroid nodules. Consider this example of a translation of this perception of thyroid cancer into aspiration biopsy language: A cytologic diagnosis that admits to a small (chance of a nodule's being a mini-invasive thyroid cancer is not synonymous with a surgical mandate. Under certain circumstances, even a definite diagnosis of carcinoma might not be surgical mandate. For example, a 65-year-old man with congestive heart failure, previous myocardial infarction, and a 1-cm isthmus nodule diagnosed as papillary carcinoma by fine-needle biopsy is probably not a surgical candidate.

The cytopathologist and the thyroidologist must understand each other's objectives.

The former has been justifiably trained never to miss a diagnosis of cancer. The thyroidolog

however, places maximum emphasis on being certain that the morbidity and mortality of th thyroid lesion in question exceed those of the anesthesia and surgery for a particular patien The cytopathologist appreciates that a diagnosis other than outright malignancy may repres very small chance of a lethal cancer. When the cytopathologist perceives that the clinician favors conservative management, he or she is free to note the presence of small numbers of abnormal cells or to vacillate between a diagnosis of benign tumor and adenoma without provoking early, and usually unnecessary, surgery. The clinician will respond to such a diagn by prescribing observation with thyroid-stimulating hormone suppression, repeat biopsy afte to 12 months, or a large-needle biopsy before considering lobectomy. For the clinician, a definitive diagnosis is not required. A needle biopsy diagnosis is needed that is more accura the average than that from noninvasive diagnostic methods. The needle biopsy diagnosis mu identify all cancers with proximate lethal potential and, utilizing previous biopsy diagnoses correlated with surgical data, provide a statement of the probability of a nodule's being a le aggressive differentiated cancer. It must also reliably select nodules that may be safely observed; if this is at variance with clinical judgment, selection must be almost 100% accura When clinical and biopsy data both suggest a diagnosis of benign disease but both are in erro the delay in making a proper diagnosis should not prove catastrophic. When the physical description or behavior of a nodule suggests malignancy and the diagnosis by needle biopsy i benign, the tissue diagnosis must be correct or a therapeutic opportunity may be lost. It is t responsibility of the physician who correlates the biopsy diagnosis and the clinical findings t make sure that the biopsy diagnosis adequately explains the total clinical picture. This has b our guideline for 10 years of needle biopsy use. Abele and Miller1 have expressed this philos very well.

The approach of many physicians to nodule management is quite simple. If the biopsy diagno is benign, observe it or treat it by thyroid-stimulating hormone suppression. If the biopsy diagnosis is anything else (and, therefore, does not exclude cancer), remove the nodule. As clinicians, our opinion is that such a therapeutic philosophy results in too many diagnostic surgical lobectomies. If the pathologist member of the biopsy team is aware that all nodules diagnosed as non-benign will be removed anyway, much of the incentive for attempting spe diagnoses has been eliminated. This applies mostly to follicular lesions for which the specifi of the diagnosis is less than that for papillary lesions. The specificity varies with

the exact cytologic diagnosis made. Therefore, we encourage the cytopathologist to make a accurate a diagnosis as possible on all lesions and for selective removal to be employed. If t

presence of cancer is highly probable, surgery is usually advised. If it is only possible, other factors are considered.

In our experience, 10% to 15% of fine-needle biopsy specimens are diagnosed as cellular adenoma. Perhaps 25% of these are false-positive results, as the correct pathologic diagnosi nodular goiter. If the nodule is 2 cm or larger, a large-needle biopsy is done, and the histolc specimen often enables us to screen out the nodular goiters. If the fine-needle biopsy diagn of cellular adenoma is confirmed, or if the nodule is too small for large-needle biopsy, the decision for or against surgery is based on several factors. These include the length of time risk (the patient's age), the presence of diseases that increase the operative risk, the perce of risk based on the cytopathology, and the perception of risk based on the clinical features the nodule. It is important to note that follicular cancers identified by the diagnosis of cellu adenoma have consistently been mini-invasive, in our experience. All aggressive cancers hav been easily diagnosed as such.

Different cytopathologists have different classifications for fine-needle biopsy diagnoses bas on different microscopic criteria. Therefore, decisions made by one biopsy team may not be applicable to the experience of another team. Consider the differences in diagnoses made c the first 2,000 satisfactory fine-needle biopsy specimens interpreted at the Mayo Clinic2 in Rochester, Minnesota, and the first 2,000 diagnoses made from a combination of fine- and la needle biopsy specimen interpretations at the Henry Ford Hospital in Detroit. Table 23.1 summarizes the percentage of diagnoses in each diagnostic classification.

Malignant
5
Malignant or suspected
malignancy
15
Suspected
17
Abnormal; cellular
adenoma or HÃ¼rthle cell adenoma
18
Benign
78
Benign

Mayo Clinic	Percent	Henry Ford Hospital	Perc

TABLE 23.1 PERCENTAGE OF DIAGNOSES BY DIAGNOSTIC CLASSIFICATION AT THE MAYO CLINIC AND THE HENRY FOR HOSPITAL

When the middle categories are compared, nonequivalence of microscopic criteria is sugges by the number and type of cancers identified. At the Mayo Clinic, 253 of 333 patients were operated on who had a diagnosis of suspected malignancy. Of these, 60 cancers were foundâ€”32 papillary, 14 follicular, 4 medullary, 1 anaplastic, 2 metastatic, and 7 assorted cancers including malignant lymphoma. Among the Henry Ford Hospital group diagnosed as abnormal (possible cancer), 224 of 354 nodules underwent operation. Only 20 were cancerâ€ HÃ¼rthle cell variant of follicular carcinoma, 6 follicular, 5 papillary, and 1 medullary carcinoma. It appears that the management of a diagnosis of suspected malignancy in Minne and a diagnosis of possible cancer in Michigan should not be the same.

It is appropriate to close the discussion of needle biopsy management of thyroid nodules wit restatement of the goals of such management. They are, first, to remove all potentially leth thyroid cancers and, second, to remove as few benign nodules as possible in achieving the fi goal. Continued refinement of diagnostic biopsy criteria is necessary for maximum approximation of these objectives.

AN ENDOCRINOLOGIST'S PERSPECTIVE

Max Wisgerhof

The endocrinologist is ever more dependent upon the skill and experience of the cytopathol for the diagnostic assessment of thyroid nodularity, because the aspiration of thyroid nodule rapidly increasing, in large part as a result of the detection, incidentally, of nodules by ultrasound, computerized tomography, and magnetic resonance imaging, performed for indications not related to the thyroid.

The characteristics of thyroid nodularity shown by imaging are not sufficiently reliable to distinguish cancerous from benign nodularity. Assessment by molecular genetic markers hold promise, but one that has not as yet been fulfilled. Immunostaining, excepting in medullary

thyroid cancer, has not been helpful.

Defining Ambiguities in the Management of Thyroid Nodularity

Clinical recommendations for the management of thyroid nodularity can be linked to the res of the cytological examination of the aspirates, and those links are made in the next sectior

Two challenges can be highlighted in attempting to link a cytologic report and a clinical recommendation:

- The inadequate aspirate.
- The cytopathology report for an abnormal or indeterminate thyroid nodule.

For the inadequate cytologic specimen, the endocrinologist faces a dilemmaâ€”was the sam inadequate because of the nature of the nodule or the technique of the aspiration? Ultrasou guidance has enhanced aspiration technique (and tempted aspiration of small nodules with problematic cytologic yield), and the endocrinologist often falls back on the

premise that neoplastic thyroid nodules should yield sufficient cells for cytopathologic evaluationâ€”"no (few) cells, no cancer." This is plagued with risk, and clinical suspicion tru the premise. Whatever, thyroid surgery can usually await a cytological diagnosis, or suspect diagnosis, from repeated aspiration(s) of nodules initially inadequate cytologically, or can w upon clinical acumen.

For the cytopathology report for an abnormal or indeterminate nodule, the endocrinologist little room to maneuver by judgment. If the cytology interpretation cannot be more specific there are fewâ€”really noâ€”reliable clinical or ultrasound characteristics to place the abnc follicular nodule in the benign or malignant camp. Thus, the value of the labored experienc interpretation cytologically of the follicular-patterned lesions to reach the diagnosis of folli adenoma, or follicular carcinoma.

These two highlighted ambiguities are included in Table 23.2 , linking clinical recommendat and cytopathology reports, and in the next section.

Unsatisfactory for cytologic evaluation

Consider whether thyroid follicular cells were not obtained because of:
â€¢ Aspiration technique, or
â€¢ Characteristics of the nodule or tissue.
Reaspiration can resolve this, although clinical monitoring is often appropriate because the technique is straightforward, readily learned, and usually not faulty; and morbid follicular nodules are expected to yield cells
Consider the presence of:
â€¢ Colloid nodularity (frequent), or
â€¢ Cystic papillary carcinoma
Reaspiration to resolve this is indicated, particularly if colloid is scant; ultrasound guidance for placement of the needle tip in tissues can be helpful.
Inadequate for cytologic evaluation
Attempt to obtain the findings to support not proceeding to thyroid surgery (no finding itself is reliable):
â€¢ Soft, homogeneous by palpation
â€¢ "Benign" ultrasound characteristics (full "halo," not vascular, homogeneous, ovoid, smooth, regular borders)
â€¢ Small size, less than 2 cm
â€¢ Absence of radiation exposure, autoimmune thyroid disease, and family history of thyroid cancer, or
â€¢ Upon review with the cytopathologist, malignant cells are not suggested
Reaspirate if some or all of the above not obtained, or if the patient or physician requires diagnosis
Monitor nodule size for rapid growth, which would indicate reaspiration; or thyroid surgery, to detect more serious thyroid cancer
Negative for malignant cells (Benign)
Set aside considerations for thyroid surgery or reaspiration, unless:
â€¢ Nodularity is markedly vascular
â€¢ Neither colloid goiter nor chronic thyroiditis present clinically
â€¢ Nodularity is large (greater than 2 cm; "sampling error"), and/or
â€¢ Apparently rapidly enlarging
Abnormal cytology
follicular adenoma

Monitor for rapid growth, an indication for surgery; use clinical factors tâ€¢ recommend monitoring:
â€¢ Small size (less than 2 cm)
â€¢ Older patient age
â€¢ Patient and physician preference
This conundrum requires discussion among patient, physician, cytopathologist, endocrinologist, and surgeon
Strongly consider thyroid surgery, because the natural history of this thyroid disease cannot be reliably predicted
HÃ¼rthle Cell neoplasm
Review with the cytopathologist the diagnosis for degree of certainty, because though unusual, it is challenging diagnostically and therapeutically
Suspicious for malignancy
Recommend thyroid surgery, accepting that:
â€¢ Predictability of papillary thyroid carcinoma can be as low as 50%
â€¢ The potential for morbidity and mortality for other types of thyroid cancer is greater than the risks from thyroid surgery, anesthesia, and resulting hypothyroidism
â€¢ Reaspiration cannot reasonably set aside this report
â€¢ Monitoring suspected HÃ¼rthle cell cancer or lymphoma, for positive indicators, is not helpful because such do not exist
Positive for or diagnostic of malignancy
differentiated thyroid cancers
Thyroid surgery (unless the patient's surgical risk is great, and then there would have been little indication for the aspiration)
â€¢ Consider that the false-positive incidence is low (less than 5%)
Thyroidectomy is the opportunity for cure, and is important for palliation
Poorly differentiated or anaplastic thyroid
cancers

Thyroidectomy and tumor excision-for cure and palliation
Medullary thyroid cancer
Malignant lymphoma
Attempt confirmation of diagnosis by flow cytometry, and consider nonsurgical

intervention

Metastasis from nonthyroid cancer
Consider staging for the primary cancer to direct interventions, unless palliation indicated, to protect the airway, for example

For cystic thyroid nodules:
Inadequate (nondiagnostic)
Nodular goiter
Suspicious or diagnostic of papillary cancer
For follicular-patterned thyroid lesions with cystic degeneration

Monitor for recurrence or enlargement, and reaspirate
Reevaluate if symptomatic
Total thyroidectomy

Review the cytology with the cytopathologist to attempt a specific diagnosis and/or estimate of risk of cancer. Otherwise, offer for discussion close monitoring to detect suspicion for cancer or its progression, though no finding is sensitive

Cytopathology Report	Clinical Recommendation

TABLE 23.2 PROPOSALS FOR CLINICAL MANAGEMENT

Refining the Ambiguity

In an attempt to refine the clinical ambiguity that can reside in management decisions abou thyroid nodularity, the endocrinologist can propose, to the patient or the patient's physician reasonable links between the cytopathology report and a clinical recommendation. Some lin are based on sound experience, and others on sound communication among the cytopathologist(s), endocrinologist, surgeon, physician, and most importantly, the patient.

The proposals for clinical management in Table 23.2 are organized by the reporting categori

for the cytopathology result from thyroid aspirate (see "Reporting Scheme for Thyroid Aspira in Chapter 4).

Accepting the Ambiguity

The value of these clinical recommendations is fundamentally dependent upon the cytopathologic interpretation and the clarity of the report. Frequent collegial discussion an review of the cytology are essential, among the cytopathologist, endocrinologist, and surge for recommendations to approach success. With that, the inherent ambiguity in predicting histology or clinical outcome from cytology can be tolerable for all.

A SURGEON'S PERSPECTIVE

Vinod Narra

In 1973 there were approximately 7,500 cases of thyroid cancer reported whereas in 2007, b on the Surveillance Epidemiology and End Result (SEER) database, there will be 30,000.3 Wi this unprecedented rise in the incidence of thyroid cancer over the last 30 years and with li indication that this steady increase will cease, our ability to accurately diagnose these lesio preoperatively is critical to formulation of an appropriate treatment plan. It remains unclea whether the true incidence has increased or increase is associated with greater awareness c disease and/or an increased detection of subclinical nodules. Regardless of the reason, the for an accurate evaluation differentiating benign from malignant lesions is required.

In the management of thyroid nodules, the interaction between the endocrinologist, cytopathologist, and surgeon is critical to the achievement of an optimal treatment plan. W there is tremendous reliance on the expertise of the endocrinologist to clinically categorize thyroid nodules based on history, physical, and radiographic appearance, it is the precision adequacy of the fine-needle aspirate and the subsequent cytopathologist's interpretation of fine-needle aspirate that drives not only the decision to operate but also the extent of surg Any uncertainty or vacillation can lead to suboptimal treatment, potentially exposing the patient to unnecessary harm.

Interpretation of the Fine-Needle Aspirate and Its Therapeutic Implicationsâ€"Minimizing Risk and Maximizi Benefit

Papillary thyroid cancer, including its variants, accounts for 85% to 90% of all thyroid cancer

more prevalent in iodine-rich areas, and is often multifocal with regional lymph node involvement. Follicular thyroid cancers are often solitary, arise in iodine-deficient areas, ar show minimal extension to the regional lymph nodes. HÃ¼rthle cell carcinomas, like papilla carcinoma, are often multifocal, and to a lesser extent than papillary thyroid cancers, they spread to regional lymph nodes; but in contrast they rarely trap iodine. Medullary thyroid cancers are sporadic 70% of the time, multifocal, and also have a propensity for regional no involvement.

When a diagnosis of cancer can be established, we advocate a total thyroidectomy. In experienced hands, the risk of recurrent laryngeal nerve injury ranges from 0.5% to 1.5% anc risk of hypoparathyroidism is 2% to 4% for a total thyroidectomy. The benefits of total thyroidectomy include the following.

- Improves the ability to perform postoperative radioiodine scanning and ablation.
- Allows for the initiation of hormone-suppression therapy. When performing a hemithyroidectomy, there is an assumption that replacement hormone therapy is no necessary. However, there is a risk of hypothyroidism leading to a rise in thyroid-stimulating hormone (TSH), which is mitogenic.
- Permits the use of thyroglobulin levels to detect persistent or recurrent disease. Thi particularly important in the case of HÃ¼rthle cell carcinomas, which infrequently t iodine.
- Eliminates the risks of an undetected or untreated contralateral lesion.

The adjuvant treatment options for thyroid cancer remain limited. Therefore, the primary r of cure remains surgical. If a clear diagnosis of malignancy can be established preoperativel then a central neck dissection can be advantageous both for staging purposes and cytoreduc when metastases are present. The lymphatic clearance of the central or lateral neck can be particularly valuable in the case of HÃ¼rthle cell carcinoma, where radioiodine uptake is pc and there is a need for surgical extirpation of all thyroid tissue.

P.502

P.503

With accurate preoperative assessment, the need for reoperation and subjecting the patien an unnecessary second operation can be limited. We find intraoperative frozen section only

benefit in cases when fine-needle aspiration is deemed inadequate or unsatisfactory and suspicion remains for malignancy based on the nodule's growth or ultrasound characteristics Particularly with follicular or HÃ¼rthle cell neoplasms, there is a need for multiple sections this generally is not practical in the settings of frozen section. In addition, postbiopsy chang that may occur within the lesion can mimic cytologic changes of malignancy as well as invas of the capsule. These changes may mislead to a malignant diagnosis at frozen section.

By stringently applying our center's reporting scheme (Table 4.4) to each fine-needle aspira the uncertainty of certain cytopathology reports as recommended in other reporting scheme eliminated. Our reporting scheme does not include the phrase "favor goiter but cannot rule neoplasm." This latter terminology is exceedingly confusing and lacks any standardization. A unanticipated consequence of our reporting schema has been the significant decrease in the number of surgical specimens consisting of nodular goiter when there was concern for malignancy. Our experience with nodular goiters is mainly isolated to those patients with la nodular goiters exhibiting compressive symptoms. We continue to advocate that surgical management of large multinodular goiters requires a total thyroidectomy even with a unilat enlargement because of the risk for hypertrophy of the contralateral side, the incidence of hypothyroidism developing despite sparing adequate thyroid tissue, and particularly in youn individuals there is a significant risk for recurrent disease or occult and latent papillary microcarcinomas.

SUMMARY

A multidispiciplinary approach to the management of thyroid nodulesâ€”involving an experienced endocrinologist, cytopathologist, and surgeon, in which constant feedback and evaluation of the efficacy and quality of the fine-needle aspirates as well as the interpretat of the fine-needle aspirate with respect to the surgical pathologyâ€”should be followed to improve outcome. The classification schema as discussed in earlier sections has improved th positive predictive value of fine-needle aspirate diagnosis and final surgical specimens, minimizing unnecessary operations or the need to perform completion thyroidectomies. Wh total thyroidectomy can be done with minimal morbidity, it should be the treatment of cho for patients with thyroid cancer, because persistent or recurrent disease can be readily det using serum thyroglobulin levels and localized with either radioiodine or FDG-PET. This is predicated on the center's ability to identify suspicious nodules, obtain adequate fine-needl aspirates, and appropriately distinguish the characteristic features within the samples.

REFERENCES

A Philosophical Approach

1.Abele JS, Miller TR. Fine needle aspiration of the thyroid nodule: clinical application. In Clark OH, ed. *Endocrine Surgery of the Thyroid and Parathyroid Glands.* St Louis: Mosby;1985:293.

2.Gharib H, Goellner JR, Zinsmeister AR, et al. Fine-needle aspiration biopsy of the thyroi the problem of suspicious cytological findings. *Ann Intern Med* . 1984;101:25.

A Surgeon's Perspective

3.Davies L, Welch HG. Increasing incidence of thyroid cancer in the United States, 1973â€“2002. *JAMA* . 2006;296:2164â€“2167.

APPENDIX TO CHAPTER 23

Observations on Pathophysiology of the Thyroid

J. Martin MillerKINI

Deceased.

The raison d'Ä›tre for needle biopsy of the thyroid is the palpable nodule of uncertain natur The term "nodule" is defined for our purposes as an area within or adjacent to a thyroid lobe that has a consistency other than that of normal thyroid tissue. Theoretically, a portion of a different from the remaining tissue should be included only because of its increased thickne The palpatory differences may be related to the cellularity, vascularity, amount of fluid or colloid, or any combination of these factors.

There is no perfect experimental model for studying the pathogenesis of thyroid nodules. Us the rat as an imperfect experimental model, it seems that most thyroid nodules appear as a result of thyroid-stimulating hormone or thyroid-growth immunoglobulin stimulation, remitt

or intermittent. The nodule represents an area of hyperinvolution remaining after the rema of the thyroid-stimulating hormoneâ€“stimulated hyperplastic tissue has returned to normal it begins as a group of follicles that partially or totally escapes from thyroid-stimulating hor control and grows and/or functions independently of the trophic hormone. In many instance these nodules are multiple, although one may be dominant and palpable and the others sma microscopic and not felt.

The hyperinvolution hypothesis of nodule formation was well described by Marine1 based on material from patients with endemic goiter. A diffuse enlargement of the gland preceded th formation of palpable nodules. Miller et al.2 observed, by autoradiographic studies, single follicles or groups of follicles that escaped thyroid-stimulating hormone control as the genes for autonomous functioning nodules.

When a nodule enlarges to approximately 1 cm, an important classification can be made by radionuclide imaging. About 10% of nodules will appear to be functioning. On a second study with the patient taking triiodothyronine to suppress thyroid-stimulating hormone, the nodul will continue to function whereas the extranodular tissue will suppress and take up less radionuclide. This identifies the nodule as a true functioning tumor of the thyroid. These tu are composed of a spectrum of histologic structures ranging from large, colloid-filled follicle small, hyperplastic follicles. The latter may have nuclear chromatin patterns that can be confused with those of malignant neoplasia. Of the thousands of these tumors surgically removed, only two of those reported in the literature were probably well-differentiated carcinomas.3 , 4 Most patients with thyroid nodules have radionuclide imaging before biopsy and the autonomous functioning tumors are not evaluated cytologically. The possibility of interpretive error must be kept in mind when looking at the cytology of patients whose nodu have not been imaged.

On radionuclide image, 90% of thyroid nodules localize to an area of decreased function. At two-thirds of these are involutional nodules, or have been diagnosed as nodular goiter rathe than follicular adenoma (a true tumor) by a thyropathologist. The other one-third is usually grossly solitary tumors, with a well-defined capsule, composed of follicular cells of varying patterns. Autoradiographically, these nodules collect little radioactive iodine, which accour for their appearance on scintiphoto.

As most nodules subject to biopsy do not trap or bind pertechnetate or iodine radionuclide, epithelium that the pathologist calls "benign" or "nodule goiter" is composed of functionally inactive cells, as judged by iodine metabolism. Nuclei of normal follicles appear much more

active. This difference might prove confusing, except that normal thyroid follicles are rarel aspirated through a fine needle. The evidence for this is circumstantial. We routinely make separate slides from each nodule using six different needles. In studies of over 6,000 nodule have virtually never found tumor on one slide and diagnostic numbers of normal-appearing on another. As most of the 1- to 2-cm tumor nodules are at least partially surrounded by no tissue, this is a remarkable observation. We have, however, diagnosed Hashimoto's thyroidit one slide and tumor on another when the paranodular tissue had features of autoimmune thyroiditis. We hypothesize, therefore, that we usually get an unsatisfactory aspirate and a acellular smear when the fine needle is placed in normal thyroid tissue. It is probable that t structural integrity of normal tissue is far greater than that of tumor. This is in keeping with observation we have made on 16-gauge aspirations of follicular tumors: The ease of sample aspiration is inversely proportional to the follicular size.

Hashimoto's thyroiditis, generally recognized as an autoimmune process, is of concern in sev different ways to the pathologist interpreting biopsies. If the cytotoxic antibodies destroy th follicular epithelium without producing a hyperplastic reaction, or if thyroid-stimulating-hormoneâ€“blocking antibodies prevent the formation of a goiter, the associated hypothyro is of concern only to the clinician. If compensatory hyperplasia of the damaged epithelium a the lymphocytic infiltrate combine to produce palpable thyroid enlargement, then it is poss that the needle biopsy specimen will supply information of value for the physician making management decisions. Diffuse thyromegaly is not usually considered an indication for need

biopsy, but in the following instances, biopsy may follow a clinical diagnosis of Hashimoto's thyroiditis:

- Thyromegaly does not regress with thyroid-stimulating hormone suppression.
- Thyromegaly increases despite thyroid-stimulating hormone suppression, either in th initial treatment period or after a period of stable gland size.
- Diffuse thyroid enlargement or abnormality is accompanied by an area different eno in size or consistency to be described as a nodule.

In each instance, the original diagnosis may be questioned as to correctness or completenes the enlargement either totally or partially from lymphocytic thyroiditis? If it is partial, what the other pathologic entity?

Two diseases coexist in the thyroid with lymphocytic thyroiditis often enough to recommenc their inclusion in its differential diagnosis. The first disease is papillary carcinoma. Carcinon has been reported as occurring in as many as 3% of thyroids operated on for Hashimoto's thyroiditis.5 The majority of these tumors are papillary. The tumor may present as a nodule may be palpable or may present with multiple microscopic foci throughout a lobe. These ad the lobe's size but are not individually identifiable. Our series of 593 cancers did not include follicular carcinoma in a palpable, diffusely abnormal gland of lymphocytic thyroiditis.

The second disease associated with lymphocytic thyroiditis is malignant lymphoma. In our practice, we have noted an increase in the occurrence of malignant lymphoma of the thyroi Although malignant lymphoma is rare in patients with lymphocytic thyroiditis, about 75% of patients with malignant lymphoma have an underlying lymphocytic thyroiditis.7 As malignan lymphoma of the thyroid is easily curable when diagnosed early and almost incurable when diagnosed late, it behooves the clinician and the cytopathologist to have a high index of suspicion for this disease in patients with Hashimoto's thyroiditis. For the clinician, this mea abandoning the picture of malignant lymphoma of the thyroid as a massive, rapidly enlargin goiter in an elderly female and substituting any suspicious enlargement (or lack of regressio patients with Hashimoto's thyroiditis, regardless of their age or sex. For the cytopathologist, means reporting any suspected coexisting malignant lymphoma and determining false-positi results by histologic examination of a large-needle biopsy specimen.

The occurrence of medullary carcinoma of the thyroid has special significance for the physic interpreting or performing biopsies. This tumor may be sporadic (80%) or familial (20%). The familial variety may be associated with a parathyroid adenoma or pheochromocytoma, and presence of either will alter surgical planning. Therefore, a specific biopsy diagnosis is of gr importance. A good cytologic specimen should rarely be interpreted as other than cancer, a there is any suspicion that this might be a medullary carcinoma, immunoperoxidase and seru calcitonin studies should be done. This will ensure proper determination of the presence or absence of ancillary tumors.

Most of the statistics concerning cancer metastatic to the thyroid are based on autopsy mat In our 10 years of biopsy experience, we have observed cancer of the lung, esophagus, color kidneys, sebaceous glands, and breast, as well as malignant melanoma presenting as a thyro nodule. Most were not the primary site of identification of the tumor, although the metasta nature was sometimes unsuspected.

Undifferentiated cancer of the thyroid may occur in an otherwise normal gland, and even

modest growth makes the patient aware of its presence. (In such situations, dedifferentiatic a papillary or follicular cancer may be present, which might have been prevented by early biopsy, identification, and removal of the differentiated cancer.) Undifferentiated cancer o thyroid may also arise in a multinodular goiter that has been present for many years. This possibility presents two caveats for the biopsy physician. First, the physician must remembe very limited information provided by fine-needle biopsy of large multinodular goiters and m perform repeat biopsy of any areas of anatomic change. Second, the physician must carefull avoid giving the patient the impression that carcinoma has been ruled out by a benign biops

CYSTIC NODULES

The number of thyroid nodules that are partially or totally cystic at the time of presentatior been estimated to be about 20%.8 The thin-walled veins in many nodules are susceptible to minor trauma, with subsequent hemorrhage, tissue necrosis, and cyst formation. The poten for such change depends on the vascularity of the lesion. Most thyroid cancers are less vascu than benign lesions; this accounts for the unusual presentation of cancer as a cystic lesion. the other end of the spectrum is the autonomous functioning thyroid nodule, which frequen presents with partial cystic change. The degree of vascularity apparently relates to the degi of metabolic activity. Judging from our experience4 with cyst aspiration, hemorrhagic cysts present in two different ways. In one, following bleeding, hemoglobin is absorbed. At initial aspiration, straw-colored fluid is found. In the other, it is hypothesized that partial reabsorb of the cyst contents decreases the pressure on the vein from which the original bleeding toc place, and hemorrhage recurs. At initial aspiration, the cyst content is always that of recen bleeding. Although cytologic examination of most cyst aspirates identifies only histiocytes, t recent bloody contents are more apt to contain viable follicular cells than are straw-colorec residue from bleeding that occurred at least 6 to 8 weeks previously.

Some thyroid cysts contain viscous, clear material that has the same appearance as aspirate from a tendon sheath cyst or ganglion. This material stains like colloid with Papanicolaou st and may well be colloid. Rare lesions of this sort that have been removed have been endoth lined cavities (simple cysts).

Hemorrhagic cysts are turgid and quite firm on palpation, as bleeding has been stopped by t pressure of the capsule. Cysts that are spongy or soft almost invariably contain water-clear gray-opalescent fluid. These are parathyroid cysts, and their etiology is established by a lev cyst fluid parathormone at least three times that of blood serum.

We do not routinely examine cyst fluid for either thyroxine or parathormone, as neither contributes to management decisions. Patients with parathyroid cysts diagnosed from the al description are routinely checked for hyperparathyroidism.

Certain clinical observations are relevant for pathologists interpreting or performing thyroid biopsies. Even with palpable residual after initial aspiration, obtaining a satisfactory fine-ne biopsy specimen is difficult. Efforts made at the second or third aspiration are more apt to l rewarding. Partial or complete recurrence of the cyst is considered presumptive evidence o existence of part of the original nodule. Aspiration biopsy may be attempted in the suspect area, as well as in palpable residual tissue. On second and third biopsies of nonpalpable or barely palpable residuals of small cysts, we have identified four papillary carcinomas.

REFERENCES

1.Marine D. Etiology and prevention of simple goiter. *Medicine* . 1924;3:453.

2.Miller JM, Horn RC, Bloch MA. The autonomous functioning thyroid nodule in the evoluti of nodular goiter. *J Clin Endocrinol Metab* . 1267;27:1264.

3.Abdel-Razzak M, Christie JH. Thyroid carcinoma in an autonomously functioning nodule. *Nucl Med* . 1979;20:1001.

4.Hopwood NJ, Carrol RG, Kinney FM, et al. Functioning thyroid masses in children and adolescence. *J Pediatr* . 1976;89:710â€“718.

5.Woolner LB, McConahey WM, Beahrs OH. Struma lymphomatosa (Hashimoto's thyroiditis) and related thyroid disorders. *J Clin Endocrinol Metab* . 1959;19:53â€“58.

6.Miller JM, Kini SR, Rebuck J, et al. Is lymphoma of the thyroid a disease which is increas in frequency? In: Hamburger JI, Miller JM, eds. *Controversies in Clinical Thyroidology* . Ne York: Springer-Verlag; 1981:267â€“297.

7.Hamburger JI, Miller JM, Kini SR. Lymphoma of the thyroid. *Ann Intern Med* . 1983;99:685â€“693.

8.Miller JM, Zafar S, Karo JJ. The cystic nodule: recognition and management. *Radiology* . 1965;85:702â€“710.