

OXFORD SPECIALIST HANDBOOKS IN PAEDIATRICS

# PAEDIATRIC NEUROLOGY

Edited by

Rob Forsyth

Richard Newton

SECOND EDITION



PAEDIATRICS

OXFORD MEDICAL PUBLICATIONS

# Paediatric Neurology

## Oxford Specialist Handbooks

### General Oxford Specialist Handbooks

A Resuscitation Room Guide  
Addiction Medicine  
Day Case Surgery  
Perioperative Medicine, 2e  
Postoperative Complications, 2e  
Renal Transplantation

### Oxford Specialist Handbooks in Anaesthesia

Anaesthesia for Medical and Surgical Emergencies  
Cardiac Anaesthesia  
Neuroanaesthesia  
Obstetric Anaesthesia  
Ophthalmic Anaesthesia  
Paediatric Anaesthesia  
Regional Anaesthesia, Stimulation and Ultrasound Techniques  
Thoracic Anaesthesia

### Oxford Specialist Handbooks in Cardiology

Adult Congenital Heart Disease  
Cardiac Catheterization and Coronary Intervention  
Cardiac Electrophysiology and Catheter Ablation  
Cardiovascular Computed Tomography  
Cardiovascular Magnetic Resonance  
Echocardiography, 2e  
Fetal Cardiology  
Heart Failure  
Hypertension  
Inherited Cardiac Disease  
Nuclear Cardiology  
Pacemakers and ICDs  
Pulmonary Hypertension  
Valvular Heart Disease

### Oxford Specialist Handbooks in Critical Care

Advanced Respiratory Critical Care

### Oxford Specialist Handbooks in End of Life Care

End of Life Care in Cardiology  
End of Life Care in Dementia  
End of Life Care in Nephrology  
End of Life Care in Respiratory Disease  
End of Life in the Intensive Care Unit

### Oxford Specialist Handbooks in Neurology

Epilepsy  
Parkinson's Disease and Other Movement Disorders  
Stroke Medicine

### Oxford Specialist Handbooks in Paediatrics

Paediatric Dermatology  
Paediatric Endocrinology and Diabetes  
Paediatric Gastroenterology, Hepatology, and Nutrition  
Paediatric Haematology and Oncology  
Paediatric Intensive Care  
Paediatric Nephrology, 2e  
Paediatric Neurology, 2e  
Paediatric Radiology  
Paediatric Respiratory Medicine  
Paediatric Rheumatology

### Oxford Specialist Handbooks in Pain Medicine

Spinal Interventions in Pain Management

### Oxford Specialist Handbooks in Psychiatry

Child and Adolescent Psychiatry  
Forensic Psychiatry  
Old Age Psychiatry

### Oxford Specialist Handbooks in Radiology

Interventional Radiology  
Musculoskeletal Imaging  
Pulmonary Imaging  
Thoracic Imaging

### Oxford Specialist Handbooks in Surgery

Cardiothoracic Surgery  
Colorectal Surgery  
Hand Surgery  
Hepatopancreatobiliary Surgery  
Neurosurgery  
Operative Surgery, 2e  
Oral Maxillofacial Surgery  
Otolaryngology and Head and Neck Surgery  
Paediatric Surgery  
Plastic and Reconstructive Surgery  
Surgical Oncology  
Urological Surgery  
Vascular Surgery

**Oxford Specialist  
Handbooks in  
Paediatrics**

**Paediatric  
Neurology**

Second edition

Edited by

**Rob Forsyth**

Consultant and Senior Lecturer in Child Neurology  
Great North Children's Hospital, Newcastle, UK

**Richard Newton**

Consultant Paediatric Neurologist  
Royal Manchester Children's Hospital, UK

**OXFORD**  
UNIVERSITY PRESS

# OXFORD

UNIVERSITY PRESS

Great Clarendon Street, Oxford, OX2 6DP,  
United Kingdom

Oxford University Press is a department of the University of Oxford. It furthers the University's objective of excellence in research, scholarship, and education by publishing worldwide. Oxford is a registered trade mark of Oxford University Press in the UK and in certain other countries

© Oxford University Press 2012

The moral rights of the authors have been asserted

First Edition published 2007

Second Edition published 2012

Impression: 1

All rights reserved. No part of this publication may be reproduced, stored in a retrieval system, or transmitted, in any form or by any means, without the prior permission in writing of Oxford University Press, or as expressly permitted by law, by licence or under terms agreed with the appropriate reprographics rights organization. Enquiries concerning reproduction outside the scope of the above should be sent to the Rights Department, Oxford University Press, at the address above

You must not circulate this work in any other form  
and you must impose this same condition on any acquirer

British Library Cataloguing in Publication Data

Data available

Library of Congress Cataloging in Publication Data

Data available

ISBN 978-0-19-960363-3

Printed in Great Britain  
on acid-free paper by  
Ashford Colour Press Ltd, Gosport, Hampshire

Oxford University Press makes no representation, express or implied, that the drug dosages in this book are correct. Readers must therefore always check the product information and clinical procedures with the most up-to-date published product information and data sheets provided by the manufacturers and the most recent codes of conduct and safety regulations. The authors and the publishers do not accept responsibility or legal liability for any errors in the text or for the misuse or misapplication of material in this work. Except where otherwise stated, drug dosages and recommendations are for the non-pregnant adult who is not breast feeding.

Links to third party websites are provided by Oxford in good faith and for information only. Oxford disclaims any responsibility for the materials contained in any third party website referenced in this work.

# **Dedication**

**For our families:**

Pip, Beth, and Ellen; Judith, Sarah, Michael, and Jennifer

**And from all the contributors:**

Thanks to our own families, and those we meet through our work,  
who support us and teach us so much.

# Preface to the second edition

The very gratifying response to the first edition of this book has justified our belief in the value of a team approach: contributors with their fingers on the pulse of advances in our field, steadied at the helm by two editors with experience and perspective. It has, again, been a great privilege: never has Lord Acton's advice to 'learn as much from writing books as from reading them' been better heeded!

We have appreciated the very constructive suggestions for improvement of the first edition and followed them where we can. We have added respiratory consults to Chapter 5, and included more neuroradiology, diagrams, and images in situations where they offer clarity. A section on late-onset metabolic disease is added with an emphasis on how this group of disorders might catch us out.

With an ever-increasing list of genes and autoantibodies to think about it is important to remember those everyday skills we carry, honed as juniors in our specialty: listening to what is truly being said, careful clinical examination, focused investigation, and above all the communication of understanding, reassurance, and hope to families and young people facing challenges they never dreamed existed. You will find due emphasis on this in the text.

We trust this book will become a trusted companion. Please continue to tell us how it can be improved!

RF  
RN  
2012



# Preface to the first edition

Medicine is a communal discipline, and this book has benefited greatly from being written in community by trainees (who remember the recent struggle to grasp a complex area) and older colleagues who can add particular emphases and perspective. We have striven to provide a combination of practical advice on clinical approach, and 'at a glance' oversights and *aides-memoire* to topic areas. We also wanted to address a number of practical issues that occupy a lot of time in practice, but that are rarely addressed in more conventional textbooks.

RF  
RN  
2007



# Acknowledgements

We are grateful to colleagues Hilary Cass and Chris O'Brien for their contributions to the sections on  p. 114 and  p. 254, respectively. Robert MacFarland reviewed the section on mitochondrial disease and Simon Bailey commented on the CNS tumour section. We thank Susan Kafka, Clinical Pharmacist at Royal Manchester Children's Hospital for her expert review of the pharmacopoeia. Stavros Stivaros, also of Royal Manchester Children's Hospital provided some MR images. Hilary Reidpath, Senior Technician in the Neurophysiology Department at the Royal Hospital for Sick Children Glasgow and Dr Ming Lai, Consultant Neurophysiologist at the Royal Victoria Infirmary, Newcastle kindly supplied EEG illustrations.

We are very grateful to Nuno Cordeiro, Christian de Goede, and Omar Kwaja who contributed so generously to the first edition. We are particularly grateful to Anna Basu, Ram Kumar, and Kate Riney for detailed proof-reading but any remaining errors are of course our responsibility.

RF  
RN  
2012

# Contents

Detailed contents *xi*

Contributors *xv*

Symbols and abbreviations *xvi*

1	Clinical approach	1
2	Neurodiagnostic tools	51
3	Signs and symptoms	103
4	Specific conditions	209
5	Consultation with other services	469
6	Emergencies	533
7	Pharmacopoeia	573

Index *621*

*This page intentionally left blank*

# Detailed contents

Contributors *xv*

Symbols and abbreviations *xvi*

---

## **1 Clinical approach** **1**

The consultation *2*

What, where, and when *4*

History taking *6*

Examination *8*

Higher cognitive function *13*

Cranial nerves *16*

Peripheral nervous system *25*

Neonatal neurological examination *41*

Real world examination sequences *45*

Synthesis *49*

---

## **2 Neurodiagnostic tools** **51**

Principles of investigation *52*

Principles of neuroradiology *54*

Neuroradiological anatomy *64*

Brainstem anatomy *69*

Principles of neurophysiology *70*

Peripheral neurophysiological tests *76*

Neurophysiological testing of central sensory pathways *82*

Specialist investigations *85*

Practical procedures *94*

Neuropsychological testing *99*

---

## **3 Signs and symptoms** **103**

Agitation and confusion *104*

Back pain *106*

Behaviour disorders *107*

Developmental impairment *109*

Exercise limitation and muscle pain *117*

Eye movement abnormalities *119*

- Facial movement abnormalities 126
  - Facial sensation abnormalities 130
  - The floppy infant 132
  - Foot deformities 135
  - Funny turns: episodic events 136
  - Funny turns: likely epilepsy? 141
  - Gait abnormalities 144
  - Head shape abnormalities 146
  - Head size abnormalities 148
  - Headache 151
  - Hearing loss 155
  - Incontinence 157
  - Movement abnormalities 159
  - Magnetic resonance imaging and brain development 163
  - Unexpected findings on magnetic resonance imaging 167
  - White matter abnormalities on magnetic resonance imaging 170
  - Numbness, pain, tingling, and sensory disturbance 174
  - Peripheral weakness 176
  - Psychomotor regression 179
  - School failure 186
  - Sleep disturbance 188
  - Speech difficulties 192
  - Swallowing and feeding problems 194
  - Toe walking 196
  - Unsteadiness and falls 197
  - Visual disturbances 200
- 

#### 4 Specific conditions

209

- Acquired brain injury 210
- Acquired spinal cord injury 215
- Autoimmune disease of the central nervous system 218
- 'Autoinflammatory' conditions 223
- Autoimmune encephalitides 224
- Cerebral palsies 227
- Care of the disabled child 240
- Feeding 248
- Communication 251

- Special senses 252
  - Respiratory disease in neurodisability 254
  - Demyelinating disease 257
  - Epilepsy 262
  - Investigating epilepsy 275
  - Am I missing an underlying cause? 280
  - Treatment of epilepsy 286
  - Epilepsy and daily life 298
  - Non-epileptic paroxysmal phenomena 304
  - Functional illness 311
  - Headache 317
  - Hydrocephalus 324
  - Spina bifida and related disorders 329
  - Idiopathic ('benign') intracranial hypertension 334
  - Infection of the central nervous system 336
  - Congenital infection 355
  - Late-onset metabolic disease 365
  - Mitochondrial disease 369
  - Movement disorders 375
  - Neuromuscular conditions: introduction 390
  - Neuropathies 392
  - Disorders of muscle 399
  - Anterior horn cell disease 410
  - Myasthenic syndromes 411
  - Management of neuromuscular disease 416
  - Neurocutaneous syndromes 418
  - Neurodegenerative conditions 425
  - Neurotransmitter disorders 435
  - Sleep disorders 439
  - Stroke 446
  - Cerebral haemorrhage 452
  - Tumours of the central venous system 454
  - Vitamin-responsive conditions 462
- 

## 5 Consultation with other services

469

- General principles 470
- Cardiology consultations 471

Endocrinology consultations	474
Gastroenterology consultations	476
Neonatal neurology	480
Neonatal encephalopathy	487
Neurosurgical consultations	500
Oncology consultations	502
PICU consultations	507
Psychiatry consultations	517
Neuropsychiatric liaison work	520
Renal consultations	523
Respiratory consultations	526
Rheumatology consultations	531

---

## **6 Emergencies** **533**

Acute agitation	534
Emergency management of coma	536
Traumatic coma	541
Status epilepticus	544
Status dystonicus	551
Sudden onset visual loss	558
The child who suddenly stops walking	559
Acute ataxia	572

---

## **7 Pharmacopoeia** **573**

Pharmacopoeia: A–Z	574
Acute sedation protocols	619
Interactions of anti-epileptic drugs	619

Index	621
-------	-----

# Contributors

## **Anna Basu**

Clinical Lecturer, Newcastle University and Specialist Registrar, Great North Children's Hospital, Newcastle upon Tyne, UK

## **Rob Forsyth**

Senior Lecturer, Newcastle University and Consultant Paediatric Neurologist, Great North Children's Hospital, Newcastle upon Tyne, UK

## **Cheryl Hemingway**

Consultant Paediatric Neurologist, Great Ormond Street Hospital, London, UK

## **Imelda Hughes**

Consultant Paediatric Neurologist, Royal Manchester Children's Hospital, UK

## **Rachel Kneen**

Consultant Paediatric Neurologist, Alder Hey Children's Hospital, Liverpool, UK

## **Ram Kumar**

Consultant Paediatric Neurologist, Alder Hey Children's Hospital, Liverpool, UK

## **Andrew Lux**

Consultant Paediatric Neurologist, Bristol Royal Hospital for Children, UK

## **Richard Newton**

Consultant Paediatric Neurologist, Royal Manchester Children's Hospital, UK

## **Ki Pang**

Consultant Paediatric Neurologist, Great North Children's Hospital, Newcastle upon Tyne, UK

## **Kate Riney**

Consultant Paediatric Neurologist, Mater Children's Hospital, Brisbane, Australia

## **Sophia Varadkar**

Consultant Paediatric Neurologist, Great Ormond Street Hospital, London, UK

## **Grace Vassallo**

Consultant Paediatric Neurologist, Royal Manchester Children's Hospital, UK



# Symbols and abbreviations

5FU	5-fluorouracil
5HIAA	5-hydroxyindoleacetic acid
5MTHF	5-methyl tetrahydrofolate
AAC	assistive/augmentative communication
AASA	L-alpha-aminoadipic semialdehyde
ABC	airway, breathing, circulation
ABG	arterial blood gases
ABI	acquired brain injury
ACE	angiotensin converting enzyme
AChE	anticholinesterase
AChR	acetylcholine receptor
ACTH	adrenocorticotrophic hormone
AD	autosomal dominant
ADANE	autosomal dominant acute necrotising encephalopathy
ADC	apparent diffusion coefficient (in MRI)
ADEM	acute disseminated encephalomyelopathy
ADHD	attention deficit hyperactivity disorder
ADP	adenosine diphosphate
ADI/ADOS	Autism Diagnostic Inventory/Observation Schedule
A&E	Accident and Emergency
AED	anti-epileptic drug
AFB	acid-fast bacilli
AFP	alpha-foeto protein
AGS	Aicardi–Goutières syndrome
AIDP	acute inflammatory demyelinating neuropathy
AIDS	acquired immunodeficiency syndrome
ALL	acute lymphoblastic leukaemia
ALT	alanine amino-transaminase
ALTE	acute life-threatening events
AMAN	acute motor axonal neuropathy
AMC	arthrogryposis multiplex congenital
AMP	adenosine monophosphate
AMPA(-R)	$\alpha$ -amino-3-hydroxy-5-methyl-4-isoxazole propionic acid (receptor)
AMSAN	acute motor and sensory axonal neuropathy
ANA	antinuclear antibody

ANCA	antineutrophil cytoplasmic antibodies
AOA	ataxia oculomotor ataxia
AP	anteroposterior
APD	afferent pupillary defect
AR	autosomal recessive
ART	anti-retroviral treatment
ASOT	anti-streptolysin O titre
AST	aspartate aminotransferase
AT	ataxia telangiectasia
ATM	ataxia telangiectasia mutated protein
ATP	adenosine tri-phosphate
AV	arterioventricular
AVED	ataxia with vitamin E deficiency
AVM	arteriovenous malformation
BAERP	brainstem auditory evoked response/potential
BAS	British Ability Scales
BBB	blood–brain barrier
BCNU	bis-chloroethylnitrosourea or carmustine
BCG	Bacillus Calmette–Guérin
bd	twice daily
BECTS	benign epilepsy with centrotemporal spikes
BFNS	benign familail neonatal seiures
BIND	bilirubin-induced neurological dysfunction
BIPAP	bilevel positive airway pressure
BM	(inf.) glucose monitoring strip
BMEI	benign myoclonic epilepsy of infancy
BMD	Becker muscular dystrophy
BMT	bone marrow transplant
BNF-C	British National Formulary for Children
BNS	benign neonatal syndrome
BP	blood pressure
BSD	brainstem death
CACH	childhood ataxia with CNS hypomyelination (Vanishing White Matter disease)
CADASIL	cerebral autosomal dominant arteriopathy with subcortical infarcts and leukoencephalopathy
CAE	childhood absence epilepsy
CAMHS	child and adolescent mental health services
CBF	cerebral blood flow
CBT	cognitive-behavioural therapy
CBZ	carbamazepine

CD	controlled drug
CDG	congenital disorder of glycosylation (also known as carbohydrate deficient glycoprotein syndrome)
CEOP	childhood epilepsy with occipital paroxysms
CFAM	cerebral function analysing monitor
CFEOM	congenital fibrosis of extraocular muscles
CFS/ME	chronic fatigue syndrome/myalgic encephalomyelopathy
CGD	chronic granulomatous disease
CGH	comparative genome hybridisation
CHARGE	coloboma, heart defects, (choanal) atresia, (growth) retardation, genital/urinary and ear abnormalities (syndrome)
CHAT	checklist for Autism in Toddlers
CIDP	chronic inflammatory demyelinating neuropathy
CINCA	chronic infantile neurological cutaneous and articular (syndrome)
CIS	clinically isolated syndrome
CJD	Creutzfeld-Jakob disease
CK	creatinine (phospho)kinase
CKMB	muscle-brain isoenzyme of CK
CMAP	compound muscle action potential
CMD	congenital muscular dystrophy
CMS	congenital myaesthetic syndrome
CRMCC	cerebro-retinal microangiopathy with calcification and cysts
CMT	Charcot-Marie tooth Disease
CMV	cytomegalovirus
CNS	central nervous system
CNV	copy number variant
COACH	cerebellar vermis hypo- or aplasia, oligophrenia, congenital ataxia, ocular coloboma and hepatic fibrosis
COX	cytochrome oxidase
CPEO	chronic progressive external ophthalmoplegia
CP	cerebral palsy
CPP	cerebral perfusion pressure
C/R	controlled-release
CRMCC	cerebroretinal microangiopathy with calcification and cysts
CRP	C-reactive protein
CRPS	complex regional pain syndrome
CSE	convulsive status epilepticus
CSF	cerebrospinal fluid

CSI	craniospinal irradiation
CSW	cerebral salt wasting
CSWS	continuous spike-wave discharges during slow wave sleep
CT	computed tomography
CTA	computed tomographic angiography
CTG	cardiotocograph
CVA	cerebrovascular accident
CVI	cerebral (or cortical) visual impairment
CVID	common variable immunodeficiency
CVP	central venous pressure
CVVH	continuous veno-venous haemofiltration
CXR	chest X-ray
DA	dopamine
DAMP	disorders of attention, motor processing, and perception
DCD	developmental co-ordination disorder
DDAVP	desmopressin
DEXA	dual-energy X-ray absorptiometry
DI	diabetes insipidus
DIDMOAD	diabetes insipidus, diabetes mellitus, optic atrophy and deafness.
DIPG	diffuse intrinsic brainstem gliomas
DKA	diabetes ketoacidosis
DM	myotonic dystrophy
DMD	Duchenne muscular dystrophy
DML	distal motor latency
DNET	dysembryoplastic neuroepithelial tumour
DRD	L-DOPA responsive dystonia
DRPLA	dentato-rubral-pallido-luysian atrophy
DSA	digital subtraction angiography
DSM-IV	diagnostic and statistical manual of mental disorders—Fourth edition
DTI	diffusion tensor imaging (MRI)
DTR	deep tendon reflex
DWI	diffusion-weighted image (MRI)
EBV	Epstein–Barr virus
ECG	electrocardiogram
ECMO	extra-corporeal membrane oxygenation
EDH	extra-dural haemorrhage
EEG	electroencephalography
EIEE	early infantile epileptic encephalopathy (Ohtahara syndrome)

ELISA	enzyme-linked immunosorbent assay
EM	electron microscopy
EMA	epileptic absence syndrome
EMAS	epilepsy with myoclonic-astatic seizures
EMD	Emery–Dreyfuss muscular dystrophy
EME	early myoclonic encephalopathy
EMG	electromyography
ENT	ear, nose, and throat
EOG	electrooculogram
EOS	early onset sarcoid
EPC	epilepsia partialis continua
EPI	epinephrine
ERG	electroretinogram
ESES	electrical status during slow-wave sleep (synonymous with CSWS)
ESR	erythrocyte sedimentation rate
ET	endotracheal tube
EVD	extra-ventricular drain
FA	Friedreich ataxia
FAC	fatty acid
FEES	functional endoscopic evaluation of swallowing
FII	factitious or induced illness
FBC	full blood count
FCMD	Fukuyama congenital muscular dystrophy
FDG-PET	fluorodeoxy-glucose positron emission tomography
FIM	functional independence measure
FISH	fluorescent in-situ hybridisation
FLAIR	fluid attenuated inversion recovery–MRI sequence
fMRI	functional MRI
FRAX	fragile X–locus
FSH	facioscapulohumeral muscular dystrophy
FTA-ABS	fluorescence trepanema antibody-absorbed syndrome
FTT	failure to thrive
FVC	forced vital capacity
GA	general anaesthesia
GAA	guanidinoacetate
GABA	gamma amino-butyric acid
GAG	glycosaminoglycans
GAMT	guanidinoacetate methyltransferase
GBS	Guillain-Barré syndrome
GC-MS	gas chromatography mass spectroscopy

GCS	Glasgow coma score
GCT	germ cell tumour
GEFS+	generalized epilepsy with febrile seizures plus
GHB	gamma hydroxy-butyrate
GI	gastrointestinal
GIT	gastrointestinal tract
GLUT1 DS	glucose transporter enzyme 1 deficiency syndrome
GM	ganglioside
GM-CSF	granulocyte-macrophage colony-stimulating factor
GMFCS	gross motor function classification syndrome
GMFM	gross motor function measure
GMH	germinal matrix haemorrhage
GMPM	gross motor performance measure
GORD	gastro-esophageal reflux disease
GSD	glycogen storage disease
GTC	generalized tonic-clonic (seizure)
HAART	highly active anti-retroviral therapy
HCG	human chorionic gonadotrophin
HDU	high dependency unit
HELLP	haemolysis, elevated liver enzymes with low platelet count
HHV	Herpes hominis virus
HIE	hypoxic-ischaemic encephalopathy
HIV	human immunodeficiency virus
HLH	haemophagocytic lymphohistiocytosis
HLA	human leucocyte antigen
HMN	hereditary motor neuropathy
HMSN	hereditary sensory motor neuropathy
HNPP	hereditary neuropathy with liability to pressure palsies
HOCUM	hypertrophic obstructive cardiomyopathy
HPE	HIV-associated progressive encephalopathy
HSAN	hereditary sensory and autonomic neuropathy
HSV	Herpes simplex virus
HUS	haemolytic uraemic syndrome
HVA	homo-vanilic acid
IBD	inflammatory bowel disease
ICD-10	International Classification of Diseases v.10
ICF	International classification of Functioning, Disability and Health
ICP	intracranial pressure
ICU	intensive care unit

ID	infectious diseases
IDDM	insulin dependent diabetes mellitus
IEF	iso-electric focusing
IEM	inborn errors of metabolism
IFN $\alpha$	interferon- $\alpha$
IIH	idiopathic intracranial hypertension
ILAE	International League against Epilepsy
IM	intramuscular
INAD	infantile neuraxonal dystrophy
INO	internuclear ophthalmoplegia
INR	international normalization ratio
IOP	intraocular pressure
IPH	intraparenchymal haemorrhage
IS	infantile spasms
IT	intrathecal
IUGR	intrauterine growth retardation
IV	intravenous
IVA	isovaleric acidaemia
IVH	intraventricular hemorrhage
IVIG	intravenous immunoglobulin
JAE	juvenile absence epilepsy
JEV	Japanese encephalitis virus
JIA	juvenile idiopathic arthritis
JME	juvenile myoclonic epilepsy
JRA	juvenile rheumatoid arthritis
KD	Kawasaki disease
KF	Kaiser-Fleischer (ring)
KSS	Kearn-Sayre syndrome
LCMV	lymphocytic choriomeningitis virus
L-DOPA	L-3,4-dihydroxyphenylalanine (levodopa)
LD	learning difficulty
LDH	lactate dehydrogenase
LE	lupus erythematosus (also a particular cell seen in blood film in lupus erythematosus)
LEV	levetiracetam
LFT	liver function test
LGMD	limb girdle muscular dystrophy
LGS	Lennox-Gastaut syndrome
LHON	Leber's hereditary optic neuropathy
LKS	Landau-Kleffner syndrome

LMN	lower motor neurone
LMP	last menstrual period
LMWH	low molecular weight heparin
LP	lumbar puncture
MABC	movement assessment battery for children
MAO	mono-amine oxidase
MAP	mean arterial pressure
MCA	middle cerebral artery
MCAD	medium chain acyl coenzyme A
MC&S	microscopy, culture, and sensitivity
MCT	medium chain triglyceride
MD	muscular dystrophy
MEB	muscle eye brain disease
MECP2	methyl-CpG-binding protein 2 gene—common Rett syndrome gene
MELAS	mitochondrial encephalomyopathy, lactic acidosis, and stroke-like episodes
MERRF	myoclonic epilepsy and ragged-red fibre
MGUS	monoclonal gammopathy of unknown significance
MH	malignant hyperthermia
MIBG	meta-iodobenzyl guanidine (Iodine123)
MLD	metachromatic leucodystrophy
MLF	medial longitudinal fasciculus
MLPA	multiplex ligation-dependent probe amplification
MLST	multiple sleep latency test
MMA	methylmalonic acidemia
MMF	mycophenylate mofetil
MMR	mumps, measles and rubella
MMSE	mini mental state examination
MNGIE	myopathy and external ophthalmoplegia; Neuropathy; Gastro-Intestinal; Encephalopathy
MPGR	multi-planar gradient echo sequence—on MRI
MPS	mucopolysaccharidosis
MRA	magnetic Resonance Angiography
MRC	Medical Research Council
MRI	magnetic resonance imaging
MRS	magnetic resonance spectroscopy
MRV	magnetic resonance venography
MS	multiple sclerosis
MS/MS	tandem mass spectroscopy
MSUD	maple syrup urine disease



MTHFR	methylene tetrahydrofolate
MUP	motor unit potential
MuSK	musculo-specific kinase
MWT	maintenance of wakefulness test
NADH	nicotinamide adenine dinucleotide
NADH-TR	NADH-tetrazolium reductase
NAI	non-accidental injury
NARP	neuropathy, ataxia and retinitis pigmentosa
NBIA	neurodegeneration with brain iron accumulation
NCC	neurocysticercosis
NCL	neuronal ceroid lipofuscinosis
NCSE	non-convulsive status epilepticus
NCV	nerve conduction velocity
NE	norepinephrine
NEC	necrotizing enterocolitis
NEAD	non-epileptic attack disorder
NF	neurofibromatosis
NGT	nasogastric tube
NICE	National Institute of Clinical Excellence
NICU	neonatal intensive care unit
NIH	National Institutes of Health
NIPPV	non-invasive positive pressure ventilation
NKH	non-ketotic hyperglycinemia
NMD	neuromuscular disease
NMDA(-R)	N-methyl-D-aspartate (receptor)
NMO	neuromyelitis optica
NPV	negative predictive value
NSAID	non-steroidal anti-inflammatory
NTD	neural tube defect
OCD	obsessive compulsive disorder
OCP	oral contraceptive pill
od	once daily
OFC	occipitofrontal circumference
OGB	oligoclonal bands
OGD	oesophago-gastro-duodenoscopy
OKN	optokinetic nystagmus
OMS	opsoclonus-myooclonus syndrome (Kinsbourne)
ON	optic neuritis
OSA	obstructive sleep apnoea
OT	occupational therapist

PACNS	primary arteritis of the CNS
PANDAS	paediatric autoimmune neuropsychiatric disorders associated with streptococcal infection
PCH	pontocerebellar hypoplasia
PCR	polymerase chain reaction
PCWP	pulmonary capillary wedge pressure
PDA	patent ductus arteriosus
PDD	pervasive developmental disorder
PDE	pyridoxine-dependent epilepsy
PDH	pyruvate dehydrogenase
PE	phenytoin equivalent
PECS	picture exchange communication system
PEDI	Paediatric Evaluation of Disability Inventory
PEG	percutaneous endoscopic Gastrostomy
PEHO	progressive encephalopathy with oedema, hysarrhythmia and optic atrophy
PERM	progressive encephalomyelitis with rigidity and myoclonus
PET	positron-emission tomography
PFO	patent foramen ovale
PHT	phenytoin
PICU	paediatric intensive care unit
PKAN	pantothenate kinase-associated neurodegeneration
PKU	phenylketonuria
PLAN	phospholipase-associated neurodegeneration
PLEDS	periodic lateralized epileptiform discharges
PLP	pyridoxal 5-phosphate
PMD	Pelizaeus–Merzbacher disease
PME	progressive myoclonus epilepsy
PML	progressive multifocal leucoencephalopathy
PNDC	progressive neuronal degeneration of childhood with liver disease (Alpers)
PNET	primitive neuroectodermal tumor
PNPO	pyridoxine 5'-phosphate oxidase
PNS	peripheral nervous system
PPHN	persistent pulmonary hypertension of the newborn
PPT	palmitoyl-protein thioesterase
PPV	positive predictive value
pr	per rectum
PRES	posterior reversible encephalopathy syndrome
prn	pro re nata
PROMM	proximal myotonic myopathy

PRP	penicillin-resistant pneumococci
PTA	post-traumatic amnesia
PTH	parathyroid hormone
PTSD	post-traumatic stress disorder
PVC	polyvinyl chloride
PVL	periventricular leucomalacia
qds	four times a day
QUEST	quality of upper extremity skills test
RANS	rapid antigen screen
RAPD	relative afferent pupillary defect
RAS	reflex asystolic syncope/reflex anoxic seizure
RBC	red blood cells
RCDP	rhizomelic chondrodysplasia punctata
RCPCH	Royal College of Paediatrics and Child Health
RCT	randomized controlled trial
RDS	respiratory distress syndrome
REM	rapid eye movement
RICP	raised intracranial pressure
RR	relative risk
SA	sino-atrial
SAH	sub-arachnoid hemorrhage
SALT	Speech and Language Therapist
SCA	spinocerebellar ataxia
ScDH	succinate dehydrogenase
SCID	subacute combined immunodeficiency
SCIWORA	spinal cord injury without radiological abnormality
SDH	subdural haemorrhage
SEGA	sub-ependymal giant cell astrocytoma (in tuberous sclerosis)
SFEMG	single fibre electromyography
SIADH	syndrome of inappropriate antidiuretic hormone secretion
SLE	systemic lupus erythematosus
SMA	spinal muscular atrophy
SMARD	spinal muscular atrophy with respiratory distress
SMEI	severe myoclonic epilepsy of infancy
SNAP	sensory nerve action potential
SPECT	single photon emission computerised tomography
SSADH	succinic semi-aldehyde dehydrogenase
SSEP	somatosensory evoked potentials
SSPE	subacute sclerosing panencephalitis
SSRI	selective serotonin reuptake inhibitor

STD	sexually transmitted diseases
SUDEP	sudden unexpected death in epilepsy
SWI	susceptibility-weighted imaging (MRI)
SWS	Sturge–Weber syndrome
SXR	skull X-ray
TB	tuberculosis
TBI	traumatic brain injury
TBM	tuberculous meningitis
TCA	trichloroacetic acid
tds	three times a day
TFT	thyroid function test
TGA	transposition of the great arteries
TIA	transient ischaemic attack
TORCH	toxoplasmosis, rubella, cytomegalovirus, herpes virus (congenital infection syndrome)
TPO	thyroid peroxidase (antibody to)
TRMU	(mitochondrial) tRNA-specific 2-thiouridylase
TS	tuberous sclerosis
TSH	thyroid-stimulating hormone
TTP	thrombotic thrombocytopenic purpura
U&E	urea & electrolytes
UBE3A	ubiquitin protein ligase gene–Angelman syndrome
UCH	University College Hospital (type of muscle biopsy needle)
UI	utility indices
UKISS	UK Infantile Spasm Study
ULD	Unverricht-Lundborg disease
ULN	upper limit of normal
UMN	upper motor neurone
URTI	upper respiratory tract infection
USS	ultrasound scan
UTI	urinary tract infection
UV	ultraviolet
VATER	vertebral defects, anal atresia, tracheoesophageal fistula, esophageal atresia, radial and renal anomalies
vCJD	variant Creutzfeldt-Jakob disease
VDRL	venereal disease reference laboratory
VEP	visual evoked potential
VGKC	voltage-gated potassium channel (target in autoimmune encephalitides)
VHL	von Hippel–Lindau disease

VI	visual impairment
VLCFA	very long chain fatty acid
VMA	vanillylmandelic acid
VMI	visual-motor integration
VNS	vagal nerve stimulation
VP	ventriculo-peritoneal
VPA	valproate
VST	venous sinus thrombosis
vWF	von Willebrand factor
VWM	“vanishing white matter” leukodystrophy (=CACH, q.v.)
VZV	Varicella zoster virus
WCC	white cell count
WCE	white-cell enzymes
WISC	Wechsler Intelligence Scale for Children
WM	white matter
WPPSI	Wechsler Preschool and Primary Scale of Intelligence
WPW	Wolff–Parkinson–White
WWS	Walker Warburg syndrome
X-ALD	X-linked adrenoleucodystrophy

# Clinical approach

The consultation	2
What, where, and when	4
History taking	6
Examination	8
Higher cognitive function	13
Cranial nerves	16
Peripheral nervous system	25
Neonatal neurological examination	41
Real world examination sequences	45
Synthesis	49

## The consultation

'I've learned that people will forget what you said, people will forget what you did, but people will never forget how you made them feel.'  
*Maya Angelou*

### For the family

This is an eagerly or apprehensively awaited time—to hear the worst, dispel fears, learn more, get tests, get help, find a cure.

### For doctors

This is often a severely time-limited interchange—to meet the family's agenda, diagnose, arrange a management plan, to **form a relationship**.

### Setting the scene

Make people feel welcome, greet them at the door, welcome them in. Arrange furniture appropriately. In a ward setting, avoid talking across the bed. Use a setting conducive to communication.

### Seeing a child for the first time

- Read the notes before seeing the child!
- Introduce yourself.
- Make sure you know who everyone is (is that mother or grandmother? Aunt or social worker? Father or mothers' boyfriend?)
- Establish what the child likes to be called (and if necessary check how to pronounce their name).
- Establish what the family is expecting to be discussed—this may not be your agenda or that of the referring clinician.
- Encourage parents to ask questions. Consider providing open question sheets before the appointment with question prompts. Consider how life would be for you in similar circumstances—it will help you pinpoint solutions:
  - 'What do **you** want to get from this time together?'
  - Demonstrating your clinical acumen and confirming an esoteric diagnosis may be less important to the family than getting basic understanding and services.
- Make sure the child understands what is to be discussed (occasionally families will not have divulged the purpose of the hospital visit).
- Explain how much time is available for the consultation. In complex situations, it may be helpful to be able to reassure everyone that this will be the first of several opportunities to talk together.
- Explain what will not be happening. Children may be dreading a venesection that may not be planned.
- The child is why you are all there—include them as much as possible.

### Review appointment issues

► Again, encourage questions from the family to establish the consultation agenda.

- Is the diagnosis right?
- Is the medication list right?
- Update the problem list.
- Chase any outstanding results.

- Check for any investigations that ought to have been sent (e.g. in a 'legacy' case).
- Ensure the addressing of the family's practical needs is not overshadowed by the hunt for a diagnosis.

### Special circumstances

#### *Giving the news of disability*

Parents want news on diagnosis:

- Together.
- As soon as possible.
- Sympathetically and in private.
- With accuracy.

They also want:

- Help with how to pass on news to family and friends.
- To have the child present.

*Language to use, language to avoid*

Remember parents will hang on to every word. **Do not be too negative.**

Compare:

'I am very sorry but I have some very bad news for you. Your child has cerebral palsy.'


with:

'I have some news you were not expecting. Your child has cerebral palsy. This may be something you have heard of but know little about. I shall do the best I can to explain something about it to you and then explain how we can help.'

**Do not be too positive.** Present a balanced view on therapies. It is easy for parents to hope that remedial therapy may 'heal'. Present it rather as maximizing developmental potential and limiting secondary complications. Remember that parents will recall little of what you said at a first consultation and misunderstand half of that. Try always to see both parents together at important interviews. See if an advocate is available for them (health visitor, social worker, ward nurse, or a friend they know well).

❗ If you have been trying to give 'bad' news, and parents are not clearly upset: consider whether they really heard what you were trying to say.

#### *The dying child*

- Acknowledge that parents feel the loss before death actually occurs.
- Address parents' feelings, as well as, and separately from, day-to-day management issues.
- Respect parental wishes in difficult end-of-life decisions (but see  p. 513).

#### *Seeing parents after their child has died*

- Discuss the post-mortem examination.
- Re-explain the cause of the illness in the light of the findings.
- Dispense with misconceptions about the illness, death, or care.
- Alleviate guilt.
- Give counselling on bereavement behaviour of parents and siblings.
- Arrange genetic counselling if appropriate.
- Give an update on the transplant recipient if relevant.
- Accept thanks, donations, and offers to help with research.




## What, where, and when

### 'Where's the lesion? What's the lesion?'

This is the catch-phrase of the classical (adult) neurological approach: its applicability to children is limited only by the greater frequency of diffuse, rather than focal neurological disease in this age group.

Examination gives the 'where'; history gives the 'what'.

### Examination findings, plus some neuroanatomical knowledge, locate the problem (the 'where?')

A clinical assessment of the site(s) of involvement is crucial to the planning of further investigation, such as where to direct neuroimaging studies. It can also prevent the chance finding of an unexpected imaging abnormality (an 'incidentaloma', see  p. 167) distracting evaluation, if its location means that the abnormality cannot be responsible for the presenting symptoms or signs. The signs you elicit at examination, evaluated in light of neuroanatomical knowledge and pattern recognition, indicate the site(s) of the problem.

#### Examples

- The cause of a spastic hemiparesis will lie in the contralateral corticospinal tract:
  - if there is also an ipsilateral visual field defect the lesion probably involves the subcortical white matter (and/or very extensive cortical infarction);
  - an associated aphasia, or seizures, makes cortical grey matter involvement likely.
- Ipsilateral fourth, fifth, and sixth cranial nerve signs imply cavernous sinus pathology.
- Unilateral hypoglossal nerve involvement and ipsilateral ataxia are hallmarks of the lateral medullary syndrome—the lesion is localized as precisely as by any magnetic resonance imaging (MRI) scan!

Even in the more common situation of more widespread involvement (e.g. in the evaluation of a child with possible psychomotor regression) it is important to try to define the system(s) involved based on examination, e.g. cortical grey matter (seizures, cognitive impairments) vs. central white matter (pyramidal signs).

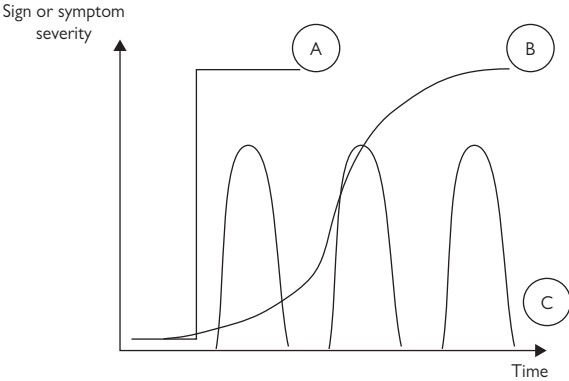
### The history tells you the pathology (the 'what?')

Recall the classic 'surgical sieve' of causes: infective, inflammatory, neoplastic, paraneoplastic, iatrogenic, toxic, metabolic, etc. The 'what?' of the diagnosis comes from history, particularly the *time-course of the onset* of symptoms and signs.

Consider any sign (e.g. hemiparesis) or symptom (e.g. headache):

- Near-instantaneous onset (Figure 1.1 A) suggests a *vascular* cause: haemorrhage or infarction.
- Gradual development (B) over days might suggest inflammation. Evolution over weeks may be due to expansion of a space-occupying lesion.

- Paroxysmal symptoms or signs occurring episodically with intervals of complete normality (C) are most commonly due either to *epilepsy* or to *migrainous* processes. Both are capable of a wide repertoire of phenomena. Again the time-course can be helpful: epileptic events tend to last seconds to a few minutes; migrainous events tend to evolve over tens of minutes and to last up to several hours.



**Fig. 1.1** Time courses.

### 'When' was the process?

The effects of lesions depend both on age at insult and time since insult in complex ways. Lesions acquired *before* the establishment of the normal function of the affected region can be relatively silent (e.g. neonatal infarction of the dominant hemisphere 'language' cortex) if adjacent or homologous contralateral brain regions can take on that function. Conversely, the effects of a lesion acquired in early childhood to a region of the brain still developmentally 'silent' may remain hidden until the region's function can be assessed clinically (see [p. 212](#)).

A less common perspective relates to the classical concept of the 'momentum' of a lesion. A very slowly developing lesion (such as a low grade tumour) may be clinically very silent as the surrounding brain has time to 'accommodate' its presence. Conversely, pronounced clinical manifestations imply a 'high momentum' lesion of recent onset and rapid evolution. This can be a useful consideration when, for example, considering an extensive infiltrative abnormality on MRI. If such an extensive lesion is relatively clinically silent, it has been there a long time and developed slowly.

## History taking


Listen to the patient, he is trying to tell you the diagnosis. *William Osler*

Specific questions relevant to particular presentations are dealt with in Chapter 3.

### Some general points

- An accurate history often contributes far more to successful diagnosis and management than either examination or investigation.
- History taking should be *interactive*:
  - ‘Have I got this right? You’re saying . . .’;
  - ‘No, that’s not quite right—try again’.
- History taking can be *iterative*. It may be important to revisit aspects of the history in light of the examination or investigation findings.
- The experience of giving a history (as a child or a parent) can be an emotionally charged one. Done well, it can itself be therapeutic. Hearing your experiences retold as a coherent story can help make sense of the experience. Knowing that the story is similar to others that the doctor has heard, and that he/she will be able to make additional ‘sense’ of it is a bonus.
- Children as young as 3 can give useful first-hand history, even if their language is limited. Young children can, however, be very influenced by perceptions of what they ‘ought’ or ‘ought not’ to be saying.
- School age children deserve an opportunity to speak to you alone, although this must be balanced against the reassurance a child gains from observing a good rapport between physician and parent, and against the opportunity for indirect observation of the child that talking to the parent offers.
- A child’s *inability* to give a history may itself be informative.

### History of presenting complaint

- Hear what was said, not what you thought was said!
  - Families do not complain of ataxia, or dystonia; they report poor coordination or balance.
  - If the mother said ‘he keeps falling over’, but you heard ‘ataxia’ you have already closed your mind to a range of non-cerebellar causes of balance problems, weakness, and other causes of falls.
- Occasionally a well-intentioned parent will use quasi-medical language (‘He’s having *petit mals*: that’s what you call them isn’t it, doctor?’), which must be gently discouraged and unpacked.
- The family will see the presenting complaint as the most important part of the history. If, for some reason, other aspects are important in your assessment you need to explain why.
- For acute presentations, it is usually possible to start at the beginning of the story (‘Tell me when your child was last entirely well’) and take the story forward. For very long-term pictures, it may be more useful to start with the present situation and fill in backwards.
- The time-course of symptom onset is crucial to determining pathology (see  p. 4).
- Evaluating whether very long-term/insidious onset symptoms were present from birth or appeared after a few months can be challenging.

- Likewise, it can be difficult to distinguish static from slowly progressive symptoms.
- ❗ Static ability is rarely normal. If ability is not demonstrably improving with time, consider whether it may be regressing.

### Developmental history

Some less commonly emphasized, but useful, developmental milestones, particularly of early cognitive/linguistic development:

- *Hand regard* (*prolonged periods of fascinated observation of hands*): an important prelude to the establishment of hand use, seen at about 3–5 months, followed by foot regard (holding feet and bringing them into view) several weeks later.
- Distinguishes familiar carers and strangers, from 9 months.
- *Object permanence*: the understanding that objects continue to exist even if they cannot currently be seen; makes ‘peek-a-boo’ a game and prevents distraction hearing tests (they are aware of the examiner behind them). From 9–10 months.
- *Theory of mind*: the recognition that there is another ‘I’ in my mother whom the child can interest in the things that interest them. Typically, established by 18 months and demonstrated by *shared attention*, e.g. bringing an interesting object for mother to look at, or by glancing at mother for a reaction to my actions (e.g. ones the child knows will meet with disapproval).
- *Proto-linguistic pointing behaviour*: pointing, again as a demonstration of shared attention, often with vocalizations meaning either ‘get me that’ (proto-imperative) or ‘look at that interesting aeroplane/bus/cat, etc.’ (proto-declarative). From ~18 months.
- *Symbolic play*: using representational toys in imitative play (making cups of tea for dolls using toy tea set). From ~18 months.
- *Naming body parts*: e.g. ‘where’s Amy’s nose?’ from ~18 months.
- Cooperative play including turn-taking, from ~3 years.
- Piaget (1898–1980) created a very influential model of child cognitive development based on sequential stages:
  - the Sensorimotor stage (0–2 years);
  - the Pre-operational stage (2–7 years);
  - the Concrete Operational stage (7–11 years); and the
  - Formal Operations stage (>11 years).

The model is undoubtedly somewhat over-simplistic, and more relevant to educational theory than clinical development assessment. However, some insights (such as the prevalence of ‘magical thinking’ and the imbuing of inanimate objects with personalities in the pre-operational phase) are clinically valuable.

❗ A boy not walking independently by 18 months’ age must have a creatine kinase (CK) checked (see 📖 p. 111).



▶ For early developmental milestones in the context of autism spectrum concerns see 📖 p. 115.

▶ For early visual developmental milestones see Table 3.16.

▶ For early hearing and language developmental milestones see 📖 p. 112.

## Examination (Table 1.1)

**Table 1.1** Diagnostic clues in external appearance

Big head	Most commonly familial; see  p. 148 for evaluation
Small head	Any cause of cerebral atrophy; see  p. 150 for evaluation
Big fontanelle	Zellweger
Hair abnormalities	<i>Stiff, wiry:</i> trichopoliodystrophy (Menkes)
	<i>Hirsutism:</i> infantile GM gangliosidosis, Hurler, Hunter, Sanfilippo, I-cell disease <i>Grey:</i> ataxia telangiectasia, Cockayne, Chédiak–Higashi, progeria
Skin findings	<i>Telangiectasia:</i> ataxia telangiectasia, hereditary haemorrhagic telangiectasia
	<i>Angiokeratoma:</i> Fabry, juvenile fucosidosis, sialidosis with chondrodystrophy
	<i>Icthyosis:</i> Refsum, Sjögren–Larsson
	<i>Hypopigmentation:</i> trichopoliodystrophy (Menkes), Chédiak–Higashi, tuberous sclerosis (ash-leaf macules), hypomelanosis of Ito
	<i>Hyperpigmentation:</i> Niemann–Pick, adrenoleukodystrophy, Farber, neurofibromatosis 1 ( <i>café au lait</i> ), xeroderma pigmentosum
	<i>Thin atrophic skin:</i> ataxia telangiectasia, Cockayne disease, xeroderma pigmentosum, progeria
	<i>Thick skin:</i> I-cell disease, mucopolysaccharidoses I, II, III, infantile fucosidosis
	<i>Subcutaneous nodules:</i> Farber, neurofibromatosis 1, cerebrotendinous xanthomatosis <i>Xanthomas:</i> Niemann–Pick <i>Blotching:</i> dysautonomia
Enlarged nodes	Farber, Niemann–Pick, juvenile Gaucher, Chédiak–Higashi, ataxia telangiectasia (lymphoma)
Stridor, hoarseness	Infantile adrenoleukodystrophy, Farber, infantile Gaucher, Pelizaeus–Merzbacher, Chiari II malformation
Big (orange) tonsils	Tangier disease
Severe swallowing problems	All severe bulbar, pseudobulbar, cerebellar, basal ganglia pathology
	Infantile Gaucher
Dysautonomia	Pantothenate kinase-associated neurodegeneration (Hallervorden–Spatz), dystonia musculorum deformans, infantile adrenoleukodystrophy, Zellweger

**Table 1.1** (Continued)

Heart ab-normalities	Pompe, Hurler and other mucopolysaccharidoses, Fabry, infantile fucosidosis, Refsum, Friedreich, abetalipoproteinaemia, tuberous sclerosis, progeria, Zellweger
Strokes	MELAS; Fabry, trichopoliodystrophy (Menkes), progeria
Organomegaly	Mucopolysaccharidoses (most), infantile GM1 gangliosidosis, Niemann–Pick, Gaucher, Zellweger, galactosaemia, Pompe, mannosidosis
GI problems	<i>Malabsorption:</i> MNGIE syndrome (myopathy and external ophthalmoplegia; neuropathy; gastrointestinal; encephalopathy), Wolman disease, abetalipoproteinaemia <i>Non-functioning gallbladder:</i> metachromatic leukodystrophy, infantile fucosidosis <i>Jaundice:</i> infantile Niemann–Pick, Zellweger, galactosaemia, Niemann–Pick <i>Vomiting:</i> dysautonomia urea-cycle defects <i>Diarrhoea:</i> Hunter syndrome
Kidney problems	<i>Renal failure:</i> Fabry, nephrosialidosis <i>Cysts:</i> Zellweger, von Hippel–Lindau, tuberous sclerosis <i>Stones:</i> Lesch–Nyhan <i>Aminoaciduria:</i> specific aminoacidurias, Lowe syndrome, Wilson
Bone and joint abnormalities	<i>Stiff joints:</i> mucopolysaccharidoses (all but type I-S), mucopolipidoses (most), fucosidoses, Farber disease, sialidoses (some), Zellweger, Cockayne <i>Scoliosis:</i> Friedreich, Rett, ataxia telangectasia, dystonia musculorum deformans, all chronic illnesses with muscle weakness especially anterior horn cell involvement <i>Kyphosis:</i> mucopolysaccharidoses
Endocrine dysfunction	<i>Adrenals:</i> adrenoleukodystrophy, Wolman <i>Hypogonadism:</i> xeroderma pigmentosum, ataxia telangectasia, some spinocerebellar degenerations <i>Diabetes:</i> ataxia telangectasia <i>Short stature:</i> Morquio, other mucopolysaccharidoses, Cockayne, progeria, diseases with severe malnutrition
Neoplasms	Ataxia telangectasia, xeroderma pigmentosum, neurofibromatosis (1 and 2), von Hippel–Lindau, tuberous sclerosis, basal cell nevus syndrome (Gorlin)
Hearing loss	Hunter disease, other mucopolysaccharidoses, adrenoleukodystrophy, Cockayne disease, Kearns–Sayre, Leigh and other mitochondrial disease, other spinocerebellar degenerations, Usher syndrome



Adapted with permission from Traeger EC, Rapin I (2000). Differential diagnosis. In: L. P. Rowland (Ed.) *Merritt's Neurology*. Lippincott Williams & Wilkins, Philadelphia. Copyright (2000) Wolters Kluwer Health.

**Dysmorphic appearances**

Dysmorphology is a demanding discipline. Beyond the easily recognized gestalts of Down, Angelman, and other syndromes, it is probably wisest to seek specialist opinions from clinical genetics colleagues. Computer databases of neurogenetic and dysmorphic syndromes can be useful, but require care to ensure the most informative 'handles' have been entered.

Deciding whether a child is 'subtly dysmorphic' is a dangerous business (!) and cannot happen without having met both parents. Hypertelorism is a particularly 'hard' and useful finding if present.

**Head circumference measurement**

See the relevant sections for assessment of abnormal head size (see  p. 148 and Figures 1.2 and 1.3) or shape (see  p. 146).








## Higher cognitive function

A conceptual framework is very useful in interpreting and organizing informal impressions of higher cognitive function gained incidentally during examination.

### Conscious level

Consciousness infers both arousal (not asleep) and awareness of events. These can be dissociated: see  p. 210.

### Orientation

In time, place, and person. Orientation also implies return of awareness, registration and recall of events around one ('who came to visit you this morning?'). In the context of acquired brain injury, return of full orientation marks the end of *post-traumatic amnesia* (PTA), the duration of which is a sensitive indicator of severity of injury.

### Attention and concentration

Two-, three- and four-year-olds should be able to recall immediately 2, 3 and 4 digit sequences (forward), respectively. Between 5 and 10 yrs of age, 5–6 digits forward and 3–4 digits reversed are typical. Over 10 yrs of age, <5 digits forward or <3 digits reversed should be concerning. Also serial 7s subtracted from 100 should be assessed.

### Memory

- *Retrograde*: recall of birthdays, ages, family member, and pet names, meanings of simple words.
- *Anterograde (registration)*: recall three words after 3min.

### Frontal lobe function

Relatively selective impairment of executive function is common after traumatic brain injury and may be an early indicator of cognitive regression. It is not normally fully established until mid-adolescence, however, so these tests are not useful in younger children.

- In what ways are these similar? An apple and a banana? A coat and a dress? Praise and punishment? A poem and a statue?
- Understanding of proverbs ('a rolling stone gathers no moss', 'too many cooks spoil the broth', 'still waters run deep', 'a bird in the hand is worth two in the bush') is reassuring, although they are culturally dependent.
- Demonstrate the Luria 'fist-edge-hand' sequence. Put your dominant hand down on the table or your thigh repeatedly, first in a fist, then ulnar side down with extended fingers, then palm down. Demonstrate once and ask the child to repeat five times.
- *Cognitive estimates*: 'What's the largest object normally found in a house?'

### Praxis

- *Constructional*: 'Draw a clock face'.
- *Ideomotor/ideational*: 'Imitate brushing your teeth', 'wave bye-bye', copy the examiner's arbitrary gesture.

**Communication****Verbal expression**

Spontaneous speech. Immediate repetition of a simple sentence. Naming items. Dysphasia or dysarthria. Word generation ('name as many animals/ words beginning with F as you can in 1 min').

**Verbal comprehension**

Understanding 1-, 2-, or 3-stage requests.

**Non-verbal**

Use of gestures.

**Cognitive 'syndromes'****Frontal lobe function**

Deficits in attention, impulsivity, perseveration ('stuck in a groove'), misconstrues sarcasm, irony. Literal interpretation of figurative language. Good at superficial social 'chit-chat' (over-learned), but poor 'emotional intelligence'. Poor executive skills (i.e. organizing, prioritizing, or problem solving) in adolescents: can reflect frontal or subcortical white matter damage. In extreme situations (e.g. large frontal tumour), incontinence and inappropriate defecation/urination, or sexualized behaviour may be seen.

**Temporal lobe dysfunction**

- *Language dysfunction (receptive or expressive dysphasia) in dominant temporal lobe disease:* visual field defect (superior, contralateral quadrantanopia).
- *Memory deficits:* poor anterograde memory due to hippocampal injury typical of traumatic brain injury.

**Parietal lobe dysfunction**

Poor 2-point discrimination, graphaesthesia (interpretation of letters drawn on the hand) or shape discrimination (identification of a coin or paper clip in the contralateral hand particularly in non-dominant lobe disease). Apraxia. Inferior contralateral quadrantanopia.

**Global dementia**

There are very few causes of new-onset dementia in children old enough to perform the Mini-Mental State Examination (MMSE); however, such instruments may be a useful reassurance, where apparently deteriorating school performance is due to depression or other emotional factors. It is, however, very language-orientated, with relatively limited testing of memory, visuospatial function, or executive skills (see Box 1.1).

**Box 1.1 Mini-Mental State Examination****Orientation**

- What is the Time/Day/Month/Year/Season? (5 points).
- What is the name of this Ward/Hospital/Town/County/Country? (5 points).

**Registration**

Name three objects (e.g. car, dog, book) and ask the child to repeat them (3 points).

**Attention and calculation**

Subtract serial 7s backward from 100. Scoring 1 point for each of the first five subtractions correct. Alternatively, spell 'world' backwards.

**Recall**

Name the three objects repeated in the registration test (3 points).

**Language**

- Name two objects (e.g. a pencil and a watch) (2 points). Repeat a short phrase (e.g. 'No ifs, ands, or buts') (1 point). Execute a 3-stage command, scoring 1 point for each stage (e.g. 'With the index finger of your left hand touch the tip of your nose and then your left ear').
- Read and obey the following sentence 'Close your eyes' (1 point).
- Write a sentence of your own choice (the sentence must make sense, and contain a subject and verb) (1 point).
- Copy a diagram showing two intersecting pentagons (1 point).

► Maximum score 30, adult cut-off score <24.

## Cranial nerves

### Olfactory nerve (I)

Not routinely examined. The most common cause of 'anosmia' is rhinitis! To assess this formally, first check nostril patency (sniff with the other nostril occluded) then use pleasant odours (chocolate, etc.). Very irritant odours can be detected somatically by the nasal mucosa (trigeminal nerve).

### Optic nerve (II)

For an approach to the evaluation of visual disturbances, see Table 1.2.

#### Acuity

Assess informally using books for the appropriate reading age. In pre-literate children, note the ability to reach for small items (e.g. tiny 'hundreds and thousands' cake decorations, which are safe if ingested!) Formal techniques, such as preferential looking can assess visual acuity accurately even in infants.

#### Fields

In older children, visual fields can be tested by confrontation with both eyes open. Isolated nasal visual field defects (without temporal field defects) are rare other than in relation to chronic vigabatrin use (see [p. 616](#)), thus a binocular approach is an effective screen. If deficits are identified, then test each eye separately. In infants, gross field preservation can be inferred by the refixation reflex: the child refixing on a target as it moves from central into peripheral vision in each direction.

#### Fundoscopy

'The eye is anatomically an extension of the brain; it is almost as if a portion of the brain were in plain sight' *EH Hess*.

In younger children (age 5–7 yrs), make a game of having them sit in your (swivelling!) clinic chair watching mummy behind you and asking them to 'tell mummy off if she makes funny faces' to help them fix on her and not your ophthalmoscope. Fundoscopy in toddlers requires an assistant to attempt to secure attention, and patience! In neonates get the mother to hold the child against her with head on her shoulder looking to the side, whilst quietly awake.

Perform fundoscopy in the child's right eye with your right eye and vice versa so as not to block the view of the non-examined eye with your head and so prevent their fixing on a distant target. Keep your glasses on if worn, but remove the child's. Darkening the room (e.g. drawing curtains) helps pupillary dilatation, but a very dark room may cause distress and prevent the child fixing on the target.

► Optic neuritis (papillitis) and papilloedema have very similar appearances, but distinguishing them should not be difficult. Visual loss is prominent in papillitis and is the usual presenting complaint (only in the mildest cases is it confined to loss of colour vision). Visual impairment is only ever a very late feature of papilloedema.

### **Red reflex**

View from arm's length distance with the lens at 0. Observe the corneal light reflex at the same time. Normal red reflex appearances vary in different ethnic groups: if in doubt, check appearances in parents. An abnormal red reflex can be absent (dark pupil), partially obscured (by an opacity in lens or media) or of an abnormal colour or brightness (e.g. typically near-white in retinoblastoma).

### **Venous pulsation**

Retinal veins are thicker than arteries. Pulsation, if seen, confirms normal intracranial pressure, which can be very useful reassurance but is absent in 10% of the normal population. Rest your thumb on the eyebrow and stabilize the ophthalmoscope on your thumb: this minimizes confusing parallax effects due to movement of the ophthalmoscope relative to the eye. Pulsation is best seen at the 'knuckle' where the vessel turns perpendicular to view to enter optic cup (A), as a pulsation of the vein profile particularly at tortuosities (B), or as in Figure 1.4, movement of the light reflex on the surface of the vein.



**Fig. 1.4** Venous pulsation.

**Pupil reactions***Anisocoria*

Deciding which is the abnormal pupil can be difficult!

- A dilated pupil may be due to a partial third cranial nerve lesion. Usually associated with eye deviation inferolaterally and/or eyelid closure.
- A small pupil again associated with ipsilateral ptosis is likely to represent a unilateral Horner syndrome. Asymmetry will be more marked in the dark. 0.5% apraclonidine eye drops will reverse the miosis (i.e. pupil dilates). Test for the ipsilateral anhidrosis by sliding a clean metal teaspoon lightly over the forehead and noting the slight drag on crossing to the stickier, normal side. For an approach to the evaluation of Horner syndrome see 📖 p. 124.
- Isolated anisocoria is usually benign, although often a cause of anxiety:
  - Tonic pupil is a common benign cause of anisocoria. The affected pupil is larger and reacts poorly to light (thus, asymmetry may be more marked in, or on initially moving to, brighter conditions), but contracts briskly on accommodating to a near target.
  - Hyoscine patches (used to control drooling) can cause anisocoria if the child touches the patch and then rubs his/her eye!

*Afferent pupillary defect*

A non-reactive pupil can arise from a lesion either in the afferent (optic nerve) or the efferent (third nerve) limb of the pupillary light reflex. Due to the bilateral consensual nature of the pupillary light reflex, an eye with an interrupted optic nerve, but intact third nerve will still constrict when the opposite eye is illuminated, but both pupils will dilate when the injured eye is illuminated.

Partial afferent pupillary defects (APDs) can be subtle and hard to identify reliably. Key to accurate assessment is careful timing in the 'swinging penlight test'. Swing onto one pupil for 5s then promptly swing over to the other pupil for another 5s then back, and continue repeatedly until a consistent impression is gained of whether one pupil is dilating as the torch swings onto it.


⚠️ Head trauma is one context where recognition of an APD is crucial: the optic nerve can be involved in orbital fractures and give rise to a fixed dilated pupil *due to an APD* that might otherwise be interpreted as a third nerve lesion and a sign of ipsilateral uncal herniation (see 📖 p. 537). The difference will be that the consensual response will be present: the pupil will constrict when the other eye is illuminated.

**Table 1.2** Eye findings in neurological disease

Telangectasia	Ataxia telangectasia, Fabry
Corneal opacity	Wilson (KF ring) Mucopolysaccharidoses I, III, IV, VI; mucopolysaccharidoses III, IV; Zellweger (inconstant); Fabry; sialidosis with chondrodystrophy; Cockayne; xeroderma pigmentosum
Lens opacity	Wilson, galactosaemia, Marinesco–Sjögren Lowe, sialidosis (rarely significant clinically); mannosidosis; cerebrocutaneous xanthomatosis
Glaucoma	Mucopolysaccharidosis I, Zellweger (infrequent)
Cherry red spot	Tay–Sachs; sialidosis (usually); infantile Niemann–Pick (50%); infantile GM1 gangliosidosis (50%); Farber (variable); multiple sulphatase deficiency (metachromatic leukodystrophy variant)
Macular and retinal pigmentary degeneration	Most NCLs; mucopolysaccharidoses I–H and I–S, II, III; mucopolysaccharidoses I; abetalipoproteinaemia; Refsum; some spinocerebellar syndromes Kearns–Sayre syndrome; PKAN/Hallervorden–Spatz (some); Cockayne; Sjögren–Larsson (some); Usher
Optic atrophy	Krabbe; metachromatic leukodystrophy; most sphingolipidoses (late); adrenoleukodystrophy; Alexander Spongy degeneration, Pelizaeus–Merzbacher; neuraxonal dystrophy; Alpers; Leber; some spinocerebellar degenerations
Nystagmus	Sensory nystagmus; Pelizaeus–Merzbacher; metachromatic leukodystrophy; Friedreich and spinocerebellar degenerations; neuraxonal dystrophy, ataxia telangectasia; Leigh syndrome (inconstant); Marinesco–Sjögren syndrome Chédiak–Higashi; opsoclonus-myoclonus (jerky eye movements may be mistaken for nystagmus), GLUT1 (jerky eye movements may be mistaken for nystagmus)
Ophthalmoplegia	Kearns–Sayre and Leigh; Niemann–Pick with vertical ophthalmoplegia; abetalipoproteinaemia; Ataxia telangectasia; Infantile Gaucher; Tangier





*Abbreviations:* KF, Kayser–Fleischer ring; NCL, neuronal ceroid lipofuscinosis. Adapted with permission from Traeger EC, Rapin I (2000). *Differential Diagnosis*. In: L. P. Rowland (Ed.) *Merritt's Neurology*, 10th edn. Lippincott Williams & Wilkins, Philadelphia with permission. Copyright (2000) Wolters Kluwer Health.

### Cranial nerves III, IV and VI

For an approach to the evaluation of abnormal eye movements, see  'Eye movements', p. 119 and Figure 1.5.

► The 3rd, 4th, and 6th cranial nerve nuclei and their interconnections span the pons; it is rare for significant pontine pathology to spare eye movements.



Cranial nerve	Ocular muscle	Function	Palsy		Aetiology	
III	Oculomotor nerve Medial rectus Superior rectus Inferior rectus Inferior oblique	Adduction Elevation, intorsion, adduction Depression, extorsion, adduction Elevation, extorsion, abduction	Normal 	Palsied 	Looking straight ahead: ptosis, dilated pupil, eye 'down-and-out' (not myasthenia if pupil dilated)	<b>Congenital</b> : rare, 50% have associated neurological abnormalities <b>Acquired</b> : Trauma Tumour Raised intracranial pressure Vascular (migraine: posterior communicating artery aneurysms—pupil dilates first) Inflammation or infection (ADEM, meningitis)
IV	Trochlear nerve Superior oblique	Depression, intorsion, abduction			Head tilt-and-turn away from paralysed side. To test, tilt head toward affected side (shown here): see defect in depression	<b>Congenital</b> : commonest of ocular palsies, rarely due to birth trauma or perinatal events <b>Acquired</b> : Trauma (closed head injury) Tumour (brainstem glioma) Myasthenia
VI	Abducens nerve Lateral rectus	Abduction			Looking left: left eye fails to abduct	<b>Congenital</b> : usually isolated, rare, spontaneous recovery <b>Acquired</b> : Trauma (commonest) Tumour (brain-stem glioma, histiocytosis) Raised intracranial pressure Vascular (AVM) Inflammation (ADEM)

#### Congenital cranial dysinnervation disorders

Möbius syndrome: congenital facial weakness accompanied by abduction deficit in one or both eyes. Other cranial nerve palsies also may occur.

Duane retraction syndrome: on attempted adduction, limitation or absence of abduction, variable limitation of adduction and palpebral fissure narrowing because of globe retraction. Aplasia of one or both VI nuclei. Mostly sporadic. 50% have associated brain-stem deficits (e.g. crocodile tears, sensorineural deafness).

**Fig. 1.5** Cranial nerve palsies.

### Inspection

- Note the presence of broad epicanthic folds or a nasal bridge that can give the appearance of a pseudo-squint.
- Observe for ptosis.
- Note pupil size (small on the side of Horner); aniridia; colobomata.
- Note symmetry of position of the light reflex (the dot of light due to the reflection of the ophthalmoscope light on the iris when examining for red reflex). This is very useful in detecting subtle non-alignment of eyes in the neutral position.

### Eye movements

- In an older child, test smooth pursuit of a slowly moving target and saccadic eye movements ('Look at mummy . . . now look at me') separately.
  - In a younger child, observe spontaneous eye movements.
  - In an infant, eye movements can be observed by inducing nystagmus. A rotating striped drum will induce optokinetic nystagmus (OKN) confirming the integrity of horizontal eye movements and indirectly indicating sufficient visual acuity to track stripes.
  - In the absence of an OKN drum, standing holding the child in front of your face and turning repeatedly on the spot induces nystagmus (again confirming the integrity of horizontal eye movements). If the child's visual acuity is adequate to fix on your face, the motion-induced nystagmus will be rapidly suppressed despite continuing rotation.
- Distinguish a paralytic disorder of eye movement from non-paralytic squint (where each eye considered separately is capable of a full range of movement, but binocular movement is dysconjugate).

### Abnormal conjugate eye movements

- Down (sunsetting in raised intracranial pressure).
- To one side: 'away from' an irritative lesion (seizures, frontal lobe lesion); 'toward' an old lesion (stroke) in part due to associated visual field deficits or visual inattention in the contra-lesional visual field.
- Nystagmus (can also be dysconjugate).

### Abnormal dysconjugate eye movements

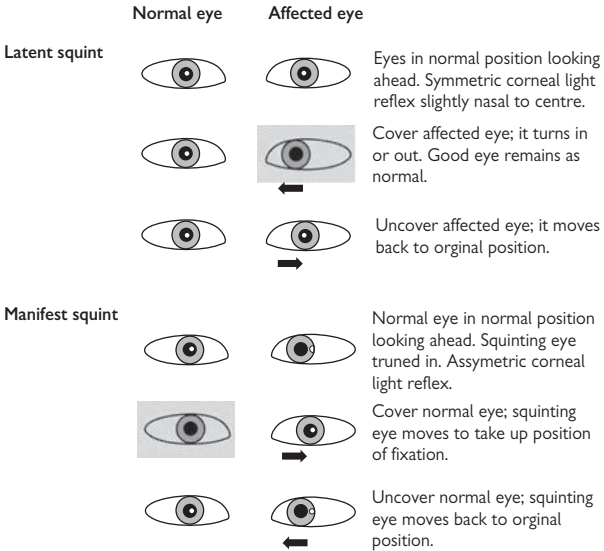
- Squint (Figure 1.6).
- Cranial nerve palsies.
- Head tilt (to compensate for squint; posterior fossa tumour).

### Diplopia

Paralytic eye movement abnormalities, particularly if acute give rise to subjective diplopia. Diplopia will be worst (i.e. image separation greatest) when attempting to look in the direction of the affected eye movement. The false image (the most lateral one) will be from the affected eye and will disappear when the affected eye is occluded, although younger children will struggle to report this reliably. Covering one eye with red glass and asking children to consider the red image can help.

Diplopia is often distressing; children may cover or occlude one eye, and dislike having it open.

- Reported double vision that persists with one eye covered is almost certainly non-organic. Only a readily identifiable and rare ocular cause, such as lens dislocation could otherwise give rise to this.

**Cover test****Fig. 1.6** Cover test.**Cranial nerve V**

For an approach to the evaluation of disturbances of facial sensation, see Table 3.4.

Examine perception of light touch and temperature in the normal manner. Note whether boundaries of any reported area of altered perception correspond to the anatomical boundaries of the divisions of the trigeminal nerve (see Figure 3.1).

**Corneal reflex**

Approach with a wisp of cotton wool from the side to avoid a blink due to visual threat. Touch the cornea over the inferolateral quadrant of the iris (i.e. the coloured part of the eye). Note whether a blink is elicited and also ask whether the sensation felt similar on each side. Informally, observing the blink produced by brushing eyelashes elicits similar information.


**Motor functions of trigeminal nerve**

Test the ability to resist attempted jaw closure (lateral pterygoid).


**Jaw jerk**

Elicit by asking the child to let their mouth fall open, gently holding their chin and tapping your own thumb: explain what you are going to do before approaching the child's face with a tendon hammer! Not normally detectable. A readily elicited, exaggerated jaw jerk confirms that an upper motor neuron picture is of cerebral, rather than high cervical spine origin.

## Cranial nerve VII

For an approach to the evaluation of abnormal facial movement, see  p. 126.

Ask the child to imitate facial expressions (grimace, frown, smile, forced eye closure). Examine the symmetry of movements. The child should normally be able to bury their eyelashes in forced eye closure: distinguish upper motor neuron involvement of the seventh cranial nerve (minimal effect on eye closure or eyebrow elevation) from lower motor neuron cranial nerve lesions (typically marked effect on eye closure).

**!** Do not mistake asymmetric crying facies of a newborn for a unilateral lower motor neuron facial nerve injury! (See  p. 126).

## Hearing

For an approach to the evaluation of hearing loss, see  p. 155.


Middle ear disease (chronic serous otitis media; 'glue ear') is a common cause of conductive hearing loss in younger children, also in children with Down syndrome and any disorder of palatal function (including acquired palatal palsies, as well as cleft palate).

Rinne tuning fork testing is reliable in children as young as 5 if performed carefully.


- 'This is behind' (press base of fork against mastoid); 'and this is in front' (hold next to ear). 'Which is louder? Behind?' (press fork against mastoid again) 'Or in front?' (fork next to ear).
- If in doubt, hold the fork against the mastoid until the child reports that they have just stopped being able to hear it and then check whether they can still hear it next to their ear (should be able to: air conduction should be better than bone conduction).
- The Weber tuning fork test (whether the tuning fork placed centrally on the forehead is louder in one or other ear) is less reliable in children.

## Cranial nerves IX and X

### *Palatal and bulbar function*

For an approach to the evaluation of poorly articulated speech, and swallowing difficulties, see  p. 192.

The gag reflex tests sensory and motor components of IX and X. In the conscious child, it is rarely necessary to elicit a gag reflex formally to assess palatal and bulbar function: this can be inferred from observation of feeding and swallowing behaviour. Symmetry of palatal movement can be assessed by observing whether the uvula is midline and moves vertically upward on saying 'aah'. Unilateral IX nerve injury causes the uvula to move to the side of the cerebral lesion. In practice, IX, X and XI are very closely related, and isolated injury to one nerve is rare. Hoarseness or stridor implicates X nerve involvement.

In the disabled child, demonstration of the presence of a detectable gag reflex is not an adequate demonstration of the safety of oral feeding and a formal feeding and swallowing assessment is required (see  p. 248).

**Cranial nerves XI and XII*****Neck and tongue movements***

Confusion sometimes arises as the action of the sternomastoid is to turn the head to the contralateral side (the distance from the mastoid process to the sternum is greater when the head is midline than when it is turned away). Assess power by asking the child to turn their head to the contralateral side and then prevent you pushing back. Also assess shoulder shrug power (spinal accessory nerve).

The integrity of 12th nerve function is assessed by observation of the tongue at rest in the open mouth (fasciculation?), the symmetry of tongue movement on attempted protrusion, and, if required, by palpating from outside, the pressure with which the tongue can be pressed against the inside of the cheek on each side (and its symmetry). Chronic 12th nerve lesions may result in ipsilateral tongue atrophy and wasting.

## Peripheral nervous system

Examination of the peripheral nervous system comprises both the formal static assessment of appearance, tone, power, coordination, reflexes, and sensation adapted from the adult approach, and the sensitive, dynamic, integrated evaluation that comes from consideration of posture and gait. The latter forms a very sensitive screening test that will detect all but perhaps the mildest of pyramidal weaknesses, although formal neurological evaluation may be very helpful in identifying the cause of a puzzling gait or postural abnormality.

### Formal peripheral neurological examination

#### Appearance

- Note the symmetry of muscle bulk and limb length.
- Inspection of shoes can be helpful: asymmetrical wear of the soles may reflect a tendency to weight-bear on one part of the foot. Mild pyramidal weakness (causing perhaps only a subtle tendency to walk on the toes) may be reflected in greater wear at the toe.
- Fasciculation is rare outside the context of neonatal type 1 spinal muscular atrophy (SMA), where it most prominently affects the tongue.

#### Tone

- Younger children can find it hard to 'just relax', which can cause misleading impressions of increased tone. Posture may be a more useful indicator of decreased tone.
- Increased tone may be pyramidal (spastic) or extra-pyramidal (dystonic) in nature. The two may co-exist, particularly in cerebral palsy and acquired brain injury where the failure to consider extrapyramidal stiffness can result in effective therapies being missed.
- Classically, pyramidal or spastic stiffness has a clasp-knife quality to it. Dystonia in a limb can sometimes be brought out by passively moving the arm whilst asking the child to perform repeated movements (e.g. clenching and opening the fist) in the contralateral limb.


#### Power

See Table 1.3.

- Younger children may be confused by requests to 'pull against me' in formal power testing.
- The most effective approach to a formal examination of power in a child above about 4 yrs of age is usually: 'Let me show you how I want you to hold your arms [move arm passively to desired test position, e.g. symmetrical 'chicken wing' posture] . . . OK, hold them there . . . Now don't let me move them [try to move it]'.
- Examine shoulder abduction on each side simultaneously, then elbow flexion on each side before elbow extension, etc. Formal examination of power in the legs is best performed in supine lying, although seated assessment is possible.

- A useful technique to screen for subtle hemiparesis is to ask a child to stand still for 20s with arms outstretched, palms upward and eyes closed. Mild pyramidal weakness results in *pronator drift*: a downward drift and pronation of the affected arm.

Dynamic assessment of power by examination of posture, gait, and movement may be more informative.

*Proximal* weakness of shoulder and hip girdle (associated with complaints of difficulty raising head from pillow, combing hair, raising arms above the head, getting up from chair, climbing stairs) usually implies muscle disease and *distal* weakness (difficulty opening bottles, turning keys, buttoning clothes, writing), generally neuropathic disease. There are, however, exceptions to these generalizations (see  p. 176).

Assessment of *fatiguability* is important if neuromuscular junction disease is suspected. This is most readily assessed in the limbs by assessing baseline shoulder abduction strength (using the 'let me move your arms, now hold them there and don't let me move them' approach), then fatiguing one arm (e.g. asking an older child repeatedly to lift a heavy book held in one hand above his head) and then reassessing shoulder abduction looking now for asymmetry. Fatiguability of eye movements is assessed by the ability to maintain up-gaze.

► Assessment of *fatiguability* is important if neuromuscular junction disease is suspected. This is most readily assessed in the limbs by assessing baseline shoulder abduction strength (using the 'let me move your arms, now hold them there and don't let me move them' approach), then fatiguing one arm (e.g. asking an older child repeatedly to lift a heavy book held in one hand above his head), and then reassessing shoulder abduction looking now for asymmetry. Fatiguability of eye movements is assessed by the ability to maintain an upward gaze.

**Table 1.3** Medical research Council (MRC) scale for muscle strength

**MRC scale**

0	Nil
1	Flicker of movement
2	Movement, gravity eliminated
3	Sustained antigravity power
3+	Momentarily against resistance
4/4+	Movement against resistance
5–	Unsure if weak
5	Normal

## Reflexes


See Table 1.4. The successful elicitation of a deep tendon reflex requires the muscle belly to be relaxed yet moderately extended. Attention to optimal limb position is thus helpful. Young children may also be disconcerted by the idea of being hit! For both these reasons, examination of reflexes in the upper limb can be helped by your holding the arm, placing a finger or thumb over the tendon and striking your own finger or thumb (while making jokes about what a strange thing that is to do!).

- With the child's hands on his/her lap, press firmly with your thumb over the biceps tendon just above the elbow and strike your thumb. Elicited jerks are often as much felt (through your thumb) as seen.
- Supinator reflexes can be elicited by striking your fingers placed just proximal to the wrist over the radial side of the partially supinated forearm as it rests in the child's lap.
- Triceps may require a slightly different approach: hold the arm abducted at the shoulder to 90°, with the forearm hanging down passively (you won't have a hand free, so strike the tendon directly).
- In younger children, adequate relaxation of quadriceps muscles for elicitation of knee jerks can be assured with both child and examiner being seated and facing each other. Put the child's feet either up on the front edge of your chair or (if clean!) on your knees.
- Plantar responses are elicited in the usual manner. Note the very first movement of the hallux. A positive Babinski comprises upward initial movement of the hallux and/or spreading (fanning) of the toes, but is normal below 18 months of age.
- Abdominal reflexes are elicited by scratching the skin along a dermatome towards the midline. They may be absent in 15% of the normal population and may be asymmetrical. They can help localize thoracic spinal cord lesions, although they are less reliable than a sensory level to pinprick. In children with scoliosis, their absence may indicate a syrinx.

**Table 1.4** Reflex root levels

Reflex	Root level
Biceps	C5,6
Brachioradialis	C5,6
Triceps	C6,7
Knee	L3,4
Ankle	1

## Sensation


See Figure 1.7. Examine the spinothalamic (pain and temperature) and dorsal column (light touch, proprioception, and two-point discrimination) separately in all areas pertinent to the clinical scenario. (Loss of spinothalamic with preserved dorsal column sensation is an important sign of syringomyelia; see  p. 217).



► Perception of the cold of a metallic object, such as a tuning fork is a more acceptable assessment of spinothalamic function than examining sensation to pinprick.

- Subjective reporting of altered sensation should not be over-interpreted. If a child can discriminate hot and cold, or sharp and blunt, and locate light touch accurately, then function is intact.
- In assessing light touch, hold cotton wool still against the skin without moving it. Tickling (which may be elicited by stroking) is a spinothalamic, not dorsal column, sensation.
- Joint position sense may be assessed at a single joint in the older child in the usual manner, but it is more useful to screen for impaired proprioception by performing the Romberg test (looking for increased body sway in standing with eyes closed).

### Coordination

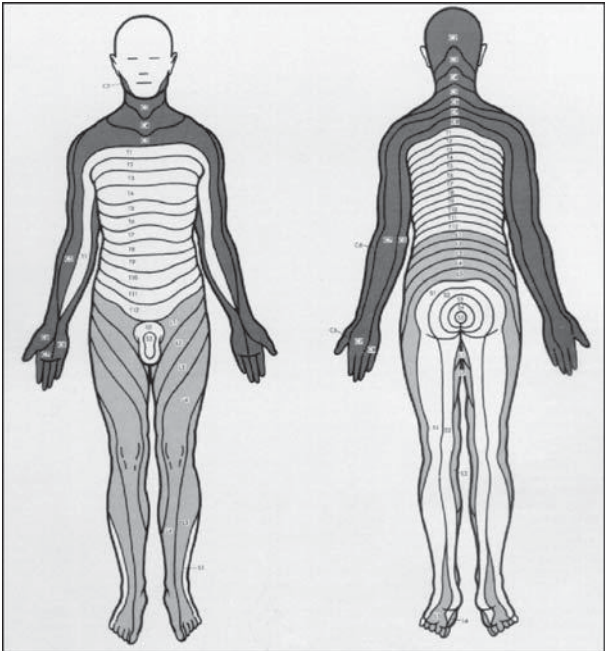
- Coordination of leg movements is assessed in walking (see  'Gait', p. 38). Ask the child to move his finger from tip of his nose to the tip of your finger; emphasize that accuracy, not speed, is what is wanted.
- Cerebellar or proprioceptive problems impair accuracy, e.g. in landing precisely on the tip of the nose (dysmetria). Other movement disorders (such as tics or myoclonus) will interfere with the intended trajectory, but a child will usually slow down just before reaching the target to ensure an accurate landing (with the help of intact cerebellar function).
- Cerebellar dysfunction gives rise to patterns of *ataxia* that can be distinguished (Table 1.5). Midline cerebellar (vermis) disease tends to affect midline (i.e. trunk) coordination, giving rise to problems with tandem gait. Hemispheric cerebellar disease tends to cause *limb ataxia* (seen on finger–nose testing), which in uni-hemispheric disease may be asymmetrical (ipsilateral to the affected cerebellar hemisphere).
- Developmental coordination disorder (dyspraxia) manifests as poor functional coordination in complex motor action sequences (e.g. shoe-tying; or the throw a ball—clap hands, whilst it is in the air—catch it again manoeuvre), but there is no formal deficit on cerebellar testing.

**Table 1.5** Patterns of cerebellar dysfunction

Cerebellar lesion	Signs
Posterior (flocculo-nodular lobe; archi-cerebellum)	<i>Eye movement disorders:</i> nystagmus; vestibulo-ocular reflex; postural and gait dysfunction
Midline (vermis; paleo-cerebellum)	Truncal and gait ataxia
Hemisphere (neo-cerebellum)	<i>Ipsilateral limb ataxia:</i> dysmetria, dysidiadochokinesis, 'intention' tremor; dysarthria Hypotonia

**Strength**

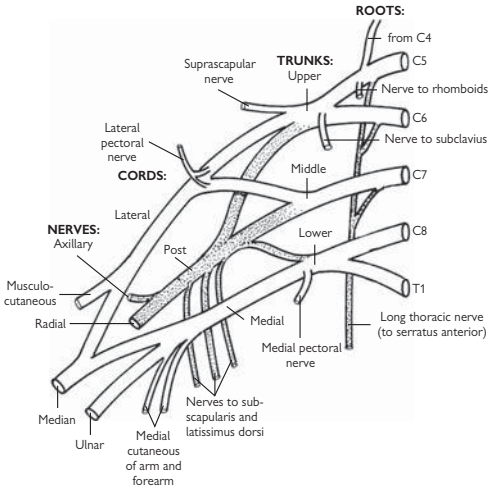
See Figure 1.7.



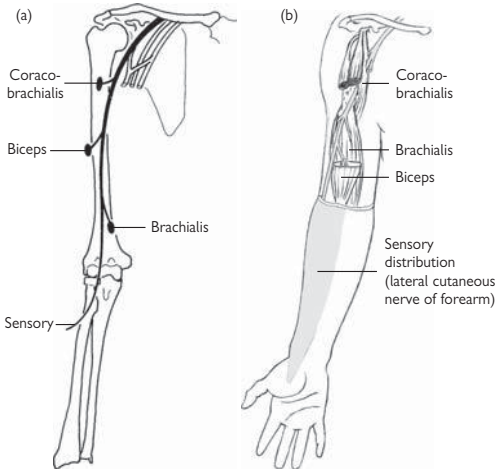
**Fig. 1.7** Dermatomes.

Innervation of the upper limbs

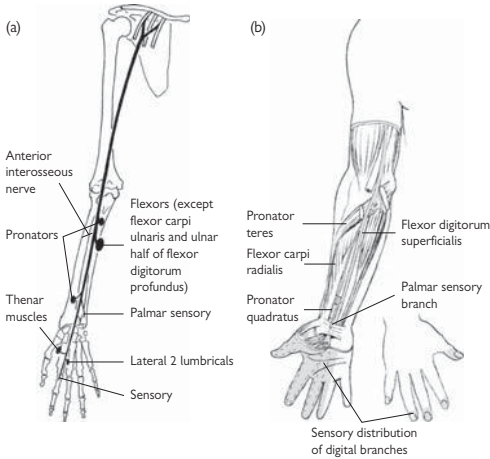
See Figures 1.8–1.12.



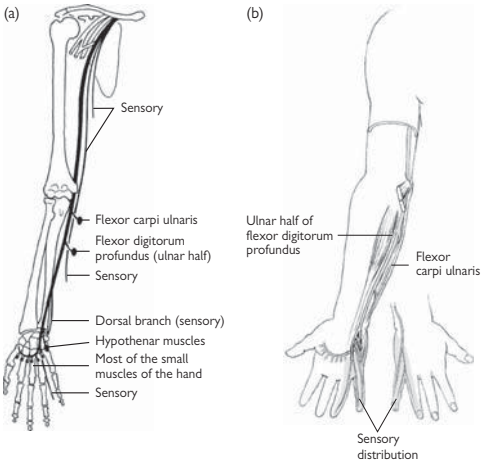
**Fig. 1.8** Brachial plexus. Reproduced with permission from MacKinnon P, Morris J (2005). *Oxford Textbook of Functional Anatomy*, Vol. 1, 2nd edn. Oxford University Press.



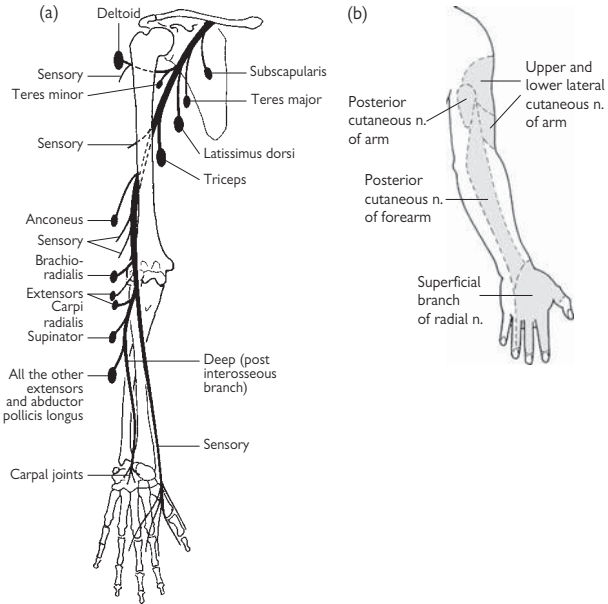
**Fig. 1.9** Course of musculocutaneous nerve supply to (a) muscles and (b) skin. Reproduced with permission from MacKinnon P, Morris J (2005). *Oxford Textbook of Functional Anatomy*, Vol. 1, 2nd edn. Oxford University Press.



**Fig. 1.10** Course of median nerve supply to (a) muscles and (b) skin. Reproduced with permission from MacKinnon P, Morris J (2005). *Oxford Textbook of Functional Anatomy*, Vol. 1, 2nd edn. Oxford University Press.



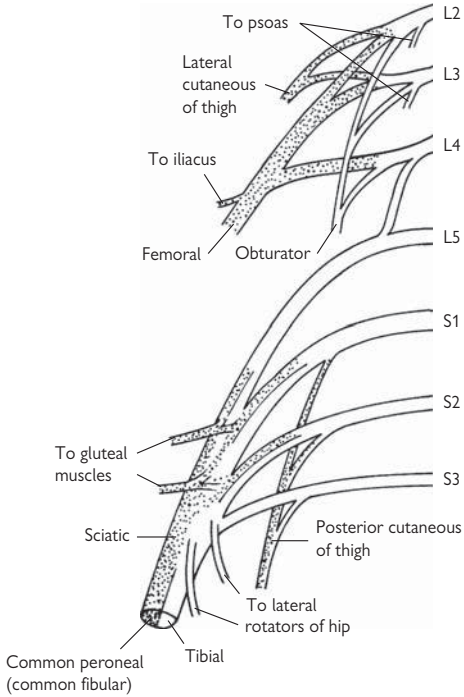
**Fig. 1.11** Course of ulnar nerve supply to (a) muscles and (b) skin. Reproduced with permission from MacKinnon P, Morris J (2005). *Oxford Textbook of Functional Anatomy*, Vol. 1, 2nd edn. Oxford University Press.



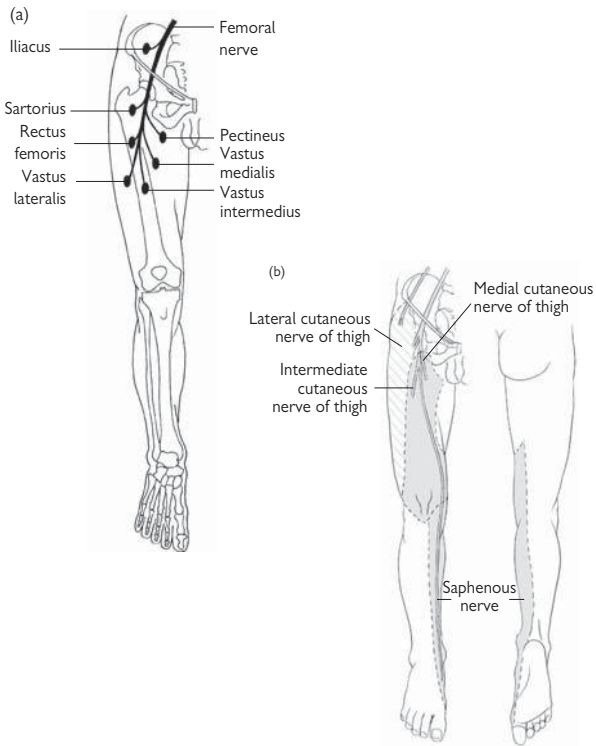
**Fig. 1.12** Course of radial nerve supply to (a) muscles and (b) skin. Reproduced with permission from MacKinnon P, Morris J (2005). *Oxford Textbook of Functional Anatomy*, Vol. 1, 2nd edn. Oxford University Press.

## Innervation of lower limb

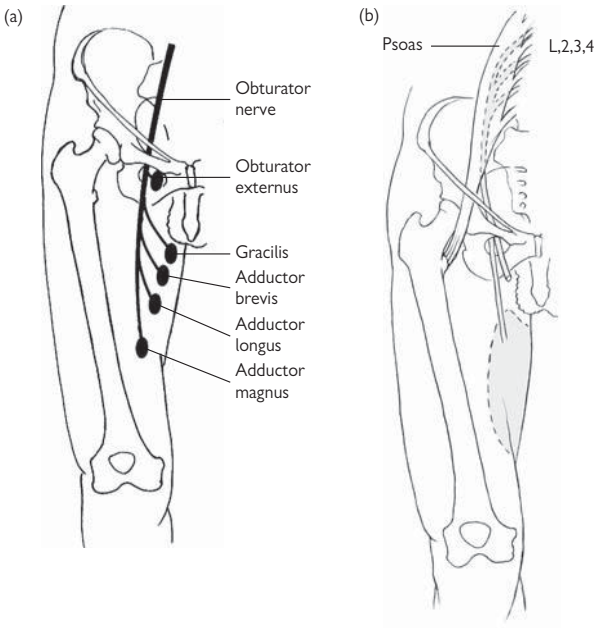
See Figures 1.13–1.17.



**Fig. 1.13** Lumbosacral plexus. Reproduced with permission from MacKinnon P, Morris J (2005). *Oxford Textbook of Functional Anatomy*, Vol. 1, 2nd edn. Oxford University Press.

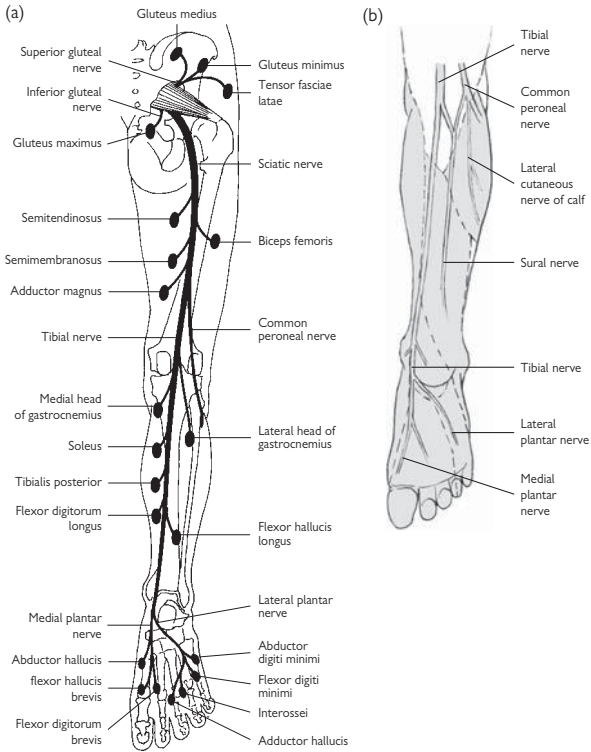


**Fig. 1.14** Course of femoral nerve supply to (a) muscles and (b) skin. Reproduced with permission from MacKinnon P, Morris J (2005). *Oxford Textbook of Functional Anatomy*, Vol. 1, 2nd edn. Oxford University Press.

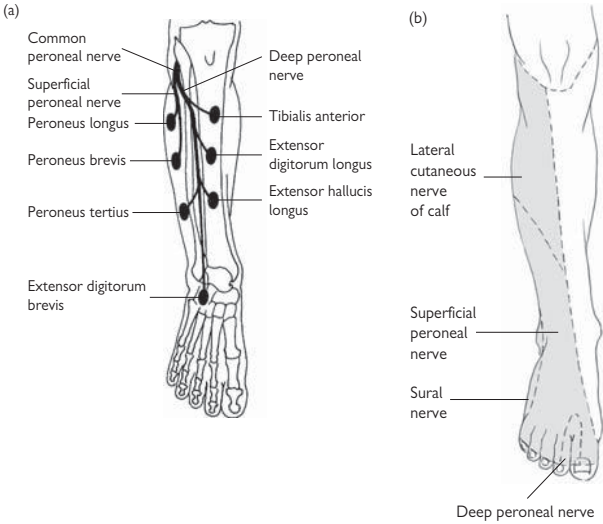


**Fig. 1.15** Course of obturator nerve supply to (a) muscles and (b) skin. Reproduced with permission from MacKinnon P, Morris J (2005). Oxford Textbook of Functional Anatomy, Vol. 1, 2nd edn. Oxford University Press.





**Fig. 1.16** Course of sciatic nerve supply to (a) muscles and (b) skin. Reproduced with permission from MacKinnon P, Morris J (2005). *Oxford Textbook of Functional Anatomy*, Vol. 1, 2nd edn. Oxford University Press.



**Fig. 1.17** Course of common peroneal nerve supply to (a) muscles and (b) skin. Reproduced with permission from MacKinnon P, Morris J (2005). *Oxford Textbook of Functional Anatomy*, Vol. 1, 2nd edn. Oxford University Press.

## Posture and gait


### Posture


- Note extraneous movements (tics, chorea, etc.).
- Note whether stance is broad based.
- Ask the child to stand with their feet together, arms outstretched, and still with their eyes open. Is this difficult? Is it harder with their eyes closed? (Romberg test implying poor proprioception). A downward drift and pronation of one arm in this procedure implies mild pyramidal weakness.
- Is the child able to stand straight? Hip or knee flexion contractures may result in a 'crouch' stance.

### Gait

- Whilst it is usually fairly straightforward to recognize a gait as normal, when the gait is clearly not normal it can be challenging to put your finger on what is wrong.
- Neurological disease typically gives one of several 'gestalt' gait appearances that allow pattern recognition.


### Neurological gait 'gestalts'

- *Spastic hemiparesis*: equinus posture of the foot. Tendency to catch a toe on the floor either resulting in leg swing laterally during swing phase or it is compensated by hip flexion. Swing of the ipsilateral arm is impaired and may be held in a flexed posture. Asymmetric toe wear on shoes can be seen.
- *Spastic paraparesis or diplegia*: legs are adducted across midline when viewed from in front ('scissor gait'). Knees scraping together. Bilateral toe walking, and/or crouched stance due to bilateral flexion contractures at hips is seen. There is arm involvement in spastic quadriplegia.
- *Cerebellar ataxia*: wide-based, staggering irregularly. Tandem gait is very difficult. Unilateral cerebellar disease gives ipsilateral ataxia (in tandem gait tends always to fall to same side; or compare the child's ability to walk round a chair clockwise and anticlockwise).
- *Sensory ataxia*: as cerebellar ataxia, but markedly worse with the eyes closed. The child watches his feet intently as he walks.
- *Proximal weakness* (e.g. *Duchenne dystrophy*): marked lumbar lordosis. A 'waddling' gait resulting from exaggerated rotation and 'throwing' of the hips to each side, accompanied by exaggerated alternating lateral flexion of the trunk (thus, moving the body's centre of gravity as near to the hip joint as possible—to lessen the work the gluteal muscles have to do when the contralateral leg is off the floor). The ability to climb stairs is very limited.
- *Flaccid foot drop*: weak foot dorsiflexion (tibialis anterior) results in the toe scraping the floor during the swing phase. 'Slapping' footfall sound. Tendency to step 'high' on the affected side flexing the hip to lift the foot clear of the floor.
- *Antalgic*: reluctance to weight-bear, restricted range of movements, painful.
- *Functional*: awkward posture, with tense, small, laboured shuffling steps, or exaggerated staggers or unsteadiness (astasia-abasia), which actually requires intact coordination to be able to reproduce (see  p. 311).

- Dystonic and athetotic gaits can be extremely variable and extremely bizarre.
  - They can be mistaken for non-organic gait disturbances (and vice versa).
  - Dystonic gaits are typically accompanied by sustained posturing of the arms, trunk, head and neck: involvement of one foot and ankle is a common presentation.
  - Dystonia will also be demonstrable at rest (see  p. 25).
  - Dystonic gaits may show apparently bizarre variability, e.g. much less evident when running than walking, or when walking backward than forward.

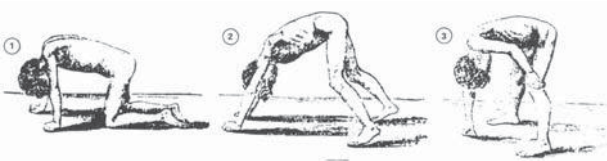
#### *When you do not recognize a pattern*

Children with cerebral palsy and other chronic neurodisability can have very idiosyncratic gaits due to the presence of additional biomechanical factors (contractures limiting the range of joint movement; limb length discrepancy, misalignment or other orthopaedic factors). These should, however, be identifiable during static examination on the couch.

Observe walking and running gaits over a significant distance and repeated requests. Do not try to take in all aspects of a child's gait simultaneously: there is too much to watch. In challenging situations it can be helpful to video the gait to permit unhurried evaluation. Complex situations (certainly if surgery is being considered) may require formal gait analysis (see  p. 246).

In order to limit information overload in the clinic situation consider:

- *Listening to the gait:* sounds bizarre, but with eyes closed listen to the footfalls. Is the cadence irregular (ataxia)? Is it asymmetric (unilateral weakness or pain)? Is the sound of the foot-fall normal (e.g. the split 'contact-slap' of a foot drop, or the single foot fall of a toe walker)?
- *Base:* wide- or narrow-based? Watch where the feet fall and their distance from an imaginary centre line. Symmetrical? Consistent?
- *Toe-heel or heel-toe?*
- *Hip internally rotated or externally rotated?*
- *Is it a weak gait?* Waddle? Difficulty stepping up? Gowers'?
- Starting at the feet and working up, consider the alignments of limb segments and the range of movement at each joint during the gait cycle and correlate with findings at rest on static examination.
- Gowers' manoeuvre and sign (Figure 1.18).



**Fig. 1.18** Gowers' manoeuvre and sign. Reprinted from Gowers WR. (1879). Clinical lecture on pseudohypertrophic muscular paralysis. *Lancet* ii: 73–5. Copyright (1879), with permission from Elsevier.

► Remember the key feature that defines a positive Gowers' sign is not so much the 'walking up legs', which may be absent if the proximal weakness is mild, as *the need to turn from supine lying to prone* as a prelude to getting up.

### Location of peripheral signs

Remember, the 'where' comes from *signs* (i.e. patterns of weakness and/or distribution of sensory disturbances) interpreted in the light of neuro-anatomical knowledge.

### Patterns of weakness

See Table 1.6. If the pattern suggests peripheral nerve involvement, this needs to be narrowed down further on the basis of Figures 1.7–1.17 as implying either a specified peripheral nerve or a nerve *root* (radiculopathy). In the latter case the pattern of weakness does not correspond to a particular peripheral nerve, but to a root level. It will normally be associated with a corresponding dermatomal sensory loss, although a very focal lesion can selectively involve the ventral or dorsal root only causing isolated weakness or dermatomal sensory loss, respectively.

For example, weak ankle dorsiflexion could represent a common peroneal nerve injury (Figure 1.16) or an L5 root injury, but in the latter case sensory loss additionally includes the sole of the foot, lateral side of the knee and the back of the thigh. Also, the L5 root pattern of motor weakness involves hip abductors and foot inverters.

**Table 1.6** Patterns of weakness

	Brain	Cord	Peripheral nerve	Neuro-muscular junction	Muscle
Pattern of weakness	Axial, truncal, or generalized hypotonia	Paraplegic or quadriplegic	Root or nerve distribution	Generalized	Variable distribution with individual conditions
Wasting	N	N	Y	N	Y
Fasciculation	N	N	Y	N	N
Tone	↑	↓	↓	Normal	Normal
Power	Normal or slight ↓	↓	↓	↓	↓
Reflexes	↑	↓ or absent*	↓	Normal	Normal
Plantar reflex	↑	δ*	↓	Normal	Normal

\* Note signs are initially of a lower motor neurone (LMN) pattern in the acute phase of spinal shock.


Autonomic instability is seen in both peripheral nerve lesions (Guillain-Barré (GBS)) and acute spinal shock.

# Neonatal neurological examination

## Gestational age

Interpretation of clinical and investigation findings will crucially depend on an accurate knowledge of gestational age. If there are doubts about timing of maternal last menstrual period (LMP), then various assessment scales based on physical characteristics (development of cartilage in pinna; breast bud; external genitalia) are available. Estimations of gestational age based on tone and posture (e.g. presence of 'scarf sign') are undesirable, particularly in the context of a neonate who has come to specialist neurological attention, whose tone is quite probably abnormal for age!

## External appearance

- Note head size and shape, and plot occipitofrontal circumference.
- Palpate fontanelles (anterior and posterior).
- Observe for stigmata of neurocutaneous syndromes. Cutaneous feature of neurofibromatosis are absent in neonates, and those of tuberous sclerosis (TS) subtle: only hypopigmented macules are present in the newborn. In Caucasian infants in whom TS is a consideration, Wood's ultraviolet (UV) light examination is mandatory. A number of inconsequential diffuse pigmentary changes may be seen under Wood's light. Pathognomonic lesions are 'ash leaf' (biconvex, 'lens-shaped') often with the long axis aligned along a dermatome.
- Note spontaneous limb posture (see  p. 42) and joint contractures.

## Alertness

Level of alertness is a sensitive 'summary' indicator of central nervous system (CNS) function. Nursing staff and/or parents' assessments over several hours will be very informative. Avoid examining immediately after a feed (sleepy) or when very hungry and distressed.

## Cranial nerves

### Acuity and eye movements

- Tracking of a bright red ball or similar target should be elicitable in >90% of infants of >34 weeks gestation.
- Dysconjugate eye movements are normal in the newborn if not visually attending, and roving eye movements are normal at <32 weeks.
- OKN (analogous to the repeated pursuit-refixation that occurs on looking at the passing scene from a train) simultaneously assesses acuity and eye movements. A rotating drum or tape with black and white stripes can be used. It can conveniently be examined by holding the child upright close to the examiner's face and then fairly rapidly turning on the spot for several rotations first one way then the other. The rotation induces repeated nystagmus comprising a brief tonic eye deviation to one side (confirming intactness of horizontal eye movements in that direction, as well as vestibular input) that is then overcome by the child's re-fixation on the examiner's face (i.e. demonstrating sufficient acuity to re-fixate).

- Note that visual tracking in its narrowest sense can probably be maintained by subcortical visual systems and may not exclude significant occipital cortex pathology. However, a responsive smile in a slightly older infant is necessarily cortical.

### ***Pupils and fundoscopy***

The physiological pupil reaction to light is consistently detectable at >32 weeks. More premature infants will blink to bright light.

Fundoscopy should include confirmation of a normal red reflex. Opacities in the cornea or media require a formal ophthalmological assessment to exclude cataract. A white retina is a potential sign of retinoblastoma and requires urgent referral.

### ***Facial movement (VII)***

- Any asymmetry of facial movement is typically very evident when crying. Lower motor neuron facial nerve injury can be seen after forceps delivery due to pressure over the zygoma. Bilateral facial palsy can be seen in Moebius syndrome.
- Asymmetric crying facies is an important benign differential of unilateral lower motor neuron facial nerve injury. This is caused by developmental hypoplasia of the depressor angularis oris muscle resulting in a failure of the lower lip on the affected side to grimace fully. The asymmetric crying facies may be mistaken for facial nerve injury but the face above the mouth (particularly the nasolabial folds) will be normal. An association with structural heart disease is reported, but uncommon.

### ***Hearing***

'Alerting' responses to perceived auditory stimuli may be very subtle, and clinical assessment can be difficult. Universal neonatal hearing screening programmes are increasingly widespread.

### ***Bulbar function***


In practice, a history of efficient sucking and swallowing is the most useful indicator of bulbar function.

### ***Sternocleidomastoid***

Most readily examined in the supine position, lying with the head over the edge of the bed and supported by the examiner's hand. As this is slowly lowered, the sternocleidomastoid will become more apparent and palpable.

## **Peripheral neurological examination**

### ***Tone and power***

- Distinguishing the hypotonic child from the child who is hypotonic and peripherally weak is key to the assessment of the 'floppy' neonate (see  p. 132).
- Interpretation of findings on assessment of tone must bear in mind gestational age: the pathological 'frog-leg' posture of a term infant with a neuromuscular disease would be normal at 26 weeks.

- Resting tone becomes increasingly flexor (i.e. limbs held spontaneously in a gently flexed position) with gestation, with flexor tone developing in the legs before the arms (hips and knees held flexed by 32 weeks; elbows held flexed after 36 weeks).
- Observation of spontaneous limb movement is the best indication of power. Particularly helpful is whether antigravity power is being seen, i.e. whether limbs are being lifted off the bed.
- Observation of the *quality* of spontaneous limb movement (its rhythmicity, jerkiness, amplitudes, etc.) is an extremely useful and sensitive indicator of neurological status and outlook, but again depends on gestation, and requires considerable experience and practice. See work of Heinz Prechtl. *Jitteriness* is usually a non-specific indicator of biochemical disturbances (e.g. hypoglycaemia), rather than intrinsic neurological disease.
- Before reporting asymmetry of tone, ensure the head is midline and that one is not simply detecting the physiological asymmetric tonic neck reflex.
- The Moro reflex is primarily useful as a means of inducing movements that can be assessed for symmetry and evidence of peripheral weakness (see Table 1.7). It should not persist beyond 6 months.

**Table 1.7** Normal age ranges for primitive reflexes

	Normal age at abolition
Babinski	12–18 months
Grasp	4–6 months; later in toes
Moro	3–4 months
Rooting	3–4 months
Stepping	3–4 months
Sucking	3–4 months
Asymmetric tonic neck reflex	3–4 months

The most common peripheral nerve injury in neonatal practice is a proximal cervical root injury at C5/6/7 (usually unilateral) due to shoulder dystocia and a difficult delivery. The classic Erb palsy comprises weakness of shoulder abduction, elbow flexion and finger extension (see [p. 398](#)). The arm is held extended, internally rotated with flexion at the wrist. No biceps reflex can be elicited, although one may be present in the triceps. Sensation is diminished in the lateral aspect of the arm.

### **Deep tendon reflexes**

Plantar reflexes are not informative in infancy. It can be hard to state confidently that deep tendon reflexes are pathologically exaggerated or depressed: alertness, sedative drugs, systemic illness and many other factors can lead to temporary symmetric changes in reflexes. Asymmetry of reflexes is, however, very informative. Neither crossed adductor responses nor a few beats of unsustained clonus are pathological in the neonate.



**Sensory examination**


In practice, the most common indication for sensory examination is in defining sensory levels in spina bifida. Although thankfully much rarer, be alert to trauma to the cervical spinal cord resulting in a flaccid tetraparesis with variable ventilatory function. To the novice, this picture may be mistaken for a globally suppressed, asphyxiated neonate. Pointers include the clinical context (breech extraction, no biochemical evidence of global hypoxic ischaemic insult) with a combination of preservation of facial alertness but lack of perception of painful stimuli. A limb may still withdraw from pain due to local spinal reflexes, but crying implies central perception of the stimulus.

## Real world examination sequences

### Real world neurological examination of the neonate

Care should be taken to avoid prolonged undressing that risks hypothermia, particularly in the sick neonate.

#### *In supine lying (in cot)*

- Note alertness.
- Note head shape, dysmorphic features, neurocutaneous stigmata.
- Palpate fontanelles.
- Examine range of doll's eye movements.
- Note visual interest in face. If there is particular concern/interest in visual acuity, consider OKN suppression assessment (see  p. 41).
- Note symmetry of cry/smile.
- Note spontaneous antigravity limb movements.
- Deep tendon reflexes.
- Assert gentle arm traction to observe head lag.

#### *In prone lying (in hand)*

Note tone (omit in sick neonate).

#### *Return to cot*

- *Ophthalmoscopy*: symmetry of light reflex; red reflex; fundoscopy.
- *Moro reflex*: primarily indicates integrity of the peripheral nervous system.
- *Head circumference*.

### Real world neurological examination of the infant

#### *Sitting on mother's knee*

- Note alertness; visual interest in faces; spontaneous vocalization.
- Observe range and symmetry of eye movements tracking an interesting object. Re-fixation on objects moved peripherally from central vision implies intactness of the visual field in that direction.
- Note the level at which the mother has to support the trunk, e.g. under arms, around waist, at pelvis, etc.
- Opportunistically, note upper limb and hand movements for symmetry and completeness; note hand regard, bringing of hands to the midline.
- Offer an object (e.g. a small ring) and note the symmetry of hand use, transfer of object between hands and/or to the mouth.

#### *On the couch*

- Lying supine, note attempts to sit up or roll over.
- From supine lying pull to sit and note head lag.
- In sitting, note the need for support. If not yet sitting unsupported, gently tip to each side to detect lateral righting reflexes and their symmetry.
- Lift an older infant (>6mths) onto their feet. Observe for scissoring. Optionally examine for forward and downward parachute reflexes.

**Lying on mother's shoulder, head turned to side (looking outward)**

Ophthalmoscopy: light reflex; red reflex; fundoscopy.

**Back on mother's knee**

- Biceps, quadriceps deep tendon reflexes.
- Head circumference.

**Real world neurological examination of the toddler**

This is the group *par excellence* where opportunistic observation forms the backbone of the examination. There is little to be gained from the attempted formal examination of a crying child.

**Sitting (on mother's knee)**

- Opportunistically note language, interaction with mother, family members, and strangers (i.e. you!)
- Opportunistically observe visual attention, range and symmetry of eye movements.

**Moving around the room**

A playroom-type setting with equipment to climb in and onto is the most informative.

- *Observe gait:* Is it wide-based? (allow for age). Is it symmetric?
- Observe climbing up step or stair. Observe picking an item off the floor from the standing position: squats down? Can rise from squat?
- *Observe upper limb function:* ideally in the sitting position (e.g. colouring, sat at desk) for handedness, dexterity, coordination in reaching.
- Encourage an independent walk or run (e.g. from one parent to other).

**Back on mother's knee**

- Biceps, quadriceps deep tendon reflexes.
- *Ophthalmoscopy:* light and red reflex (views of disks will require an assistant to secure the child's visual interest).
- Head circumference.

**Real world examination of a grossly normal older child****Higher mental function**

- Informal impressions of language, understanding of and participation in the consultation.
- Observation of 'restlessness' may indicate disorders of attention.

**Cranial nerve function**

- Pupil reactivity to light and accommodation.
- Fundoscopy.
- Pursuit eye movements.
- Binocular assessment of temporal visual fields to confrontation.
- Bite and waggle jaw from side to side (V); grimace and eye closure (VII).
- Symmetry of uvula movement on 'ahh' (IX); put out tongue (XII).
- Shrug shoulders (XI).

### Peripheral nerve function

Isolated sensory losses without accompanying motor signs are very uncommon in paediatrics; therefore, motor examination suffices except in situations of specific concern.

- Stand with feet together, arms outstretched, palms upward, and eyes closed. This is a sensitive screen for even mild pyramidal weakness of arms (causes slow pronation and downward drift of the affected arm), and combines a Romberg test.
- In the same position with eyes still closed, slowly bring one index finger up to touch the nose, and repeat on the other side. Screens for cerebellar and/or proprioceptive loss.
- Walking and running gaits.
- Deep tendon reflexes.


### Supplemental tasks if indicated

- Visual acuity/hearing when indicated by history.
- Gowers' sign.
- Assess for visceromegaly, heart murmurs, skeletal signs of storage disorders.





### Fog's test

Elicits associated movements in the upper limbs, when the child is asked to heel-walk, toe-walk, or walk on inverted or everted feet. In the 4-yr-old, the upper limbs normally mirror the pattern of movement in the lower limbs. This becomes much less marked or has disappeared entirely by 9–10 yrs of age. Asymmetries that are marked and reproducible point to a hemi-syndrome on the exaggerated side. The signs should not be over-read. The more demanding tasks, such as walking on the inner border of the feet, are more likely to reveal a mild, non-significant asymmetry with mildly excessive posturing in the non-dominant arm. Posturing that is bilaterally exaggerated for the child's age points to an underlying developmental dyspraxia or clumsiness, which is unlikely to be pathological.

### Real world examination of the unconscious child

For recognition of brainstem herniation syndromes and assessment of conscious level in emergency settings, see  p. 537.

- Document blood pressure, pulse and respiratory rate.
- The examination of a stable unconscious child comprises assessments of *brainstem* function as manifest by cranial nerve signs; and *hemispheric* function as reflected by spontaneous or induced limb movement, although the latter are particularly sensitive to the effects of sedation and anaesthesia (or, indeed, paralysis!) and may not be assessable.
  - as well as observing, enquire of nursing staff as to what limb movements have been noted in recent hours occurring either spontaneously or induced by cares and other procedures;
  - localizing movements (e.g. reaching for nasogastric tube (NGT) or endotracheal tube (ET)) implies largely intact cortical function;
  - abnormal flexion (decorticate posturing) implies loss of cortical function (but preserved subcortical function);
  - abnormal extension (decerebrate posturing) implies loss of hemispheric function on the contralateral side;
  - prognostically the best motor performance is most relevant although asymmetry of motor performance is very informative.

- Tendon reflexes, and the presence of clonus and plantar responses can be examined in the usual manner. Reflexes can be suppressed by sedative agents, but asymmetry of reflexes is informative.
- Pupil size can reflect severe brainstem dysfunction (see  p. 537) or the effects of opiate sedation. Pupillary size and responses to light should be examined for evidence of either herniation (see Figure 6.1) or afferent pupillary defect (see  p. 537) particularly in the context of orbital trauma.
- Demonstration of venous pulsation (see  p. 17) or papilloedema on fundoscopy is informative in relation to intracranial pressure (ICP) although the absence of papilloedema cannot be taken as reassurance of normal ICP.
- Resting eye position is not very informative. Oculocephalic reflex eye movements are useful and can be elicited even in the intubated child with assistance to ensure the tube is not dislodged. The head is turned sharply to one side with eyes held open, but the direction of gaze in space is preserved (i.e. the eyes move in the orbits to compensate for head turn, allowing evaluation of extra-ocular movement). These manoeuvres should not be performed in the context of traumatic injury unless and until the cervical spine has been 'cleared' as stable. As an alternative, consider the use of caloric testing (see  p. 511).
- Elicit corneal reflexes.
- Note symmetry of nasolabial folds, and any grimace or other induced facial expression.
- In an intubated child, assessment of gag is most usefully assessed by enquiring after the response nurses are noting to oropharyngeal suction (rather than suction of the endotracheal tube itself).

## Synthesis

Synthesizing historical and clinical findings into a differential diagnosis and investigation plan is the essence of the clinical process.

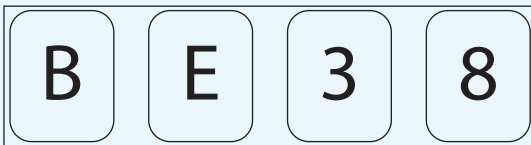
❗ Neurologists' diagnostic pronouncements are sometimes and unwisely regarded as infallible by other paediatricians. Be aware of some of the causes of downfall!

### Some general points

- Remember the examination findings locate the site of the problem, the history suggests its nature.
- Try to define the system(s) involved (i.e. the 'where?') in broad terms: central or peripheral nervous system? Cerebellum? Basal ganglia? Cerebral hemispheres? Bilaterally or unilaterally?
- Ultimately the history is the richer source of information and is more likely to lead you to the diagnosis.
- It is vitally important to be aware of the prior likelihood of particular conditions. Some conditions in paediatric neurology are orders of magnitude more likely than others. Familiarity with ethnic or other factors that cause local 'pockets' of particular conditions is important.
- Unusual presentations of common conditions are still probably more likely than common presentations of uncommon conditions.
- Humans have an inherent tendency to see the evidence that supports their working hypothesis, and not look for the evidence that might disprove it (so-called 'confirmation bias', see Box 1.2). Actively try to disprove your diagnostic hypotheses!

### Box 1.2 Card sorting

In a classic psychological experiment subjects were shown four playing cards:



Which two cards have to be turned over in order to check the validity of the hypothesis that 'every consonant has an even number on the other side of the card'? People tend to assume that the B and 8 cards must be turned over, whereas B and 3 are correct. Whatever is on the reverse of the 8 card remains consistent with the hypothesis; it would be finding a consonant on the back of the 3 card that would disprove it.

- When all you have is a hammer, everything looks like a nail. Just because the child has been referred to a neurologist does not mean this is a problem of neurological origin.
- Beware 'search bias', settling on the first plausible explanation you can think of for the picture: try to generate five! Consider each diagnosis in turn: what would the signs and symptoms be if the child had that diagnosis? This may prevent you dismissing uncommon, but treatable conditions at an early stage because of a cognitive error that there is insufficient information yet to act on.
- Beware 'availability bias'. People overestimate the likelihood of aeroplane crashes as a cause of death because, as newsworthy events, they can readily recall an example. Similarly just because you remember that disease X turned out to be the cause of sign last time, don't overestimate the likelihood of its being responsible again at the expense of other possibilities.
- Beware Kouska's fallacy. It can be hard to evaluate the significance of combinations of findings that you cannot immediately connect and would normally be individually thought of as uncommon. It is more likely that the events are causally linked, either directly or indirectly (even if you can't see the link) than that they are really occurring coincidentally completely by chance. The assumption that the findings are independent is sometimes called Kouska's fallacy, after a fictional character who used this technique to disprove the existence of life!


► Remember:

- What else could it be?
- Is there anything that doesn't fit?
- Is it possible there's more than one problem?
- What is the family most worried about?
- Ask them to retell the story from the beginning. Details that were omitted first time, different wordings, or emphases may be seen to have significance in light of other data

### Further reading

Groopman JE (2008). *How Doctors Think*. Mariner Books, New York.

# Neurodiagnostic tools

- Principles of investigation 52
  - Principles of neuroradiology 54
  - Neuroradiological anatomy 64
  - Brainstem anatomy 69
  - Principles of neurophysiology 70
  - Peripheral neurophysiological tests 76
  - Neurophysiological testing of central sensory pathways 82
  - Specialist investigations 85
  - Practical procedures 94
  - Neuropsychological testing 99
- 



## Principles of investigation

### Sensitivity, specificity and all that jazz . . .

This subject tends to bring some people out in a rash (Table 2.1). Unfortunately it is of fundamental importance to paediatric neurology, so bear with us!

**Table 2.1** Sensitivity and specificity

	Disease truly present	Disease truly absent
Test result positive (abnormal)	A (true positives)	B (false positives)
Test result negative (normal)	C (false negatives)	D (true negatives)

#### Sensitivity

The probability that the test will identify a case when the disease is present ( $=A/(A+C)$ ), i.e. if the test is administered to a group of people all of whom actually have the disease, in what proportion it will be (correctly) positive.

#### Specificity

The probability that the test will be negative when the disease is not present ( $=D/(D+B)$ ), i.e. if the test is administered to a group of people *none* of whom actually have the disease, how confident we can be that the test will *not* mistakenly give a positive result? Although this is slightly confusingly framed in the negative, this is so that both sensitivity and specificity are 'good things'.

#### Positive predictive value

The probability of the disease truly being present if the test is positive ( $=A/(A+B)$ ).

#### Negative predictive value

The probability of the disease being absent if the test is negative ( $=D/(D+C)$ ).

Positive (PPV) and negative predictive value (NPV) answer the questions 'just how useful/meaningful is a positive (or negative) test result?' Whilst PPV may sound like sensitivity it is not: it has been 'turned round'. The probability, given that an animal is a cat, of it having four legs (the sensitivity of the four-leg test in identifying cats) will generally be greater than the probability, given that an animal has four legs, of it being a cat (the positive predictive value of the four-leg test). PPV and NPV *depend on the prevalence of the condition in the population you are studying*, i.e. how likely it was that the disease was present *before* you applied the test. Relying on the four-leg test to identify cats in Battersea Dogs' Home is unwise *because the prior likelihood of finding cats in a dog pound is very low*. If you apply a test to look for a condition that under the circumstances is improbable, false positives are quite likely and could even outnumber true positives.

### Utility Indices

The positive and negative utility indices (UI) are numbers that quantify the ultimate value of a test in ruling in (positive UI) or ruling out (negative UI) a diagnosis. A test may have a high PPV but ultimately be of little use as it's rarely positive in the population you're testing. The positive UI is defined as sensitivity  $\times$  PPV, and the negative UI as specificity  $\times$  NPV.

#### An extreme example . . .

. . . of looking for a disease in a situation where it is unlikely.

- Suppose the prior probability is 1 in 100,000 (there are considerably rarer conditions in paediatric neurology). We use a test with 99% specificity and sensitivity (much better than some tests we use).
- We test 1 million people, and given the prevalence expect there are 10 true cases in this population. The test has 99% sensitivity, so should pick up all 10 (it only misses 1 case in 100).
- However, it also has 99% specificity, meaning that 1 time in 100 it will say the disease is present when it is not. Unfortunately, in testing the 999,990 people who don't have the disease, on just under 10,000 occasions (1%) it will *falsely state the condition is present*.
- So how useful is a positive test result? (i.e. what is the positive predictive value?) Unfortunately, not much use at all. We will get a total of 10 010 positive test results, of which only 10 are truly positive, a PPV of  $\sim$ 0.1%.
- What difference has applying the test made to the odds that the condition is present in a given individual? Beforehand, (the 'prior likelihood') it was 1 in 100,000. Now, having applied the test, and assuming the individual is among those with a positive test result, the so-called posterior likelihood is 1 in 10,010—only 9 times higher.
- Applying the test has done little to increase the certainty with which we can say the individual is affected by the disease. This is all because the disease was so improbable in the population to start with. In this example, the prior likelihood has to get above 1% (by careful clinical evaluation and selecting a population in which the condition is reasonably likely) before the true positive test results outnumber the false positives!

❗ This sort of situation is potentially common in paediatric neurology, where individually rare disorders are sought with imperfect tests, and is why it is dangerous blindly to apply batteries of tests to individuals looking on the off-chance for diseases that are improbable given the clinical context.

### The nose-picking principle of paediatric neurology

'Performing an investigation in paediatric neurology is like picking your nose: don't find a result and *then* wonder what to do with it!' In other words, perform investigations:

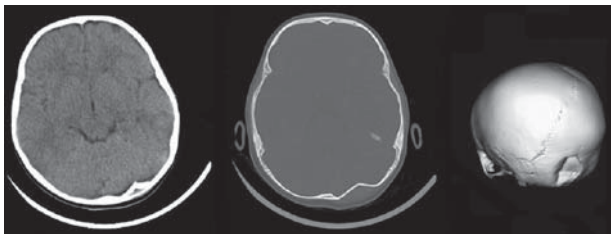
- Only when you have reasonable clinical grounds to suspect the condition being sought (to avoid generating potentially false-positive results whose significance you are uncertain of).
- Only when the test result will influence a management decision (this may include establishing a diagnosis for purposes of genetic counselling, prognostication or parental peace of mind even if no specific treatments exist).

## Principles of neuroradiology

See Table 2.2 for a comparison of the radiological characteristics of some neurological pathologies.

### Computed tomography

- X-ray-based technique delivering a radiation dose one or two orders of magnitude greater than a standard chest X-ray. This is a significant disadvantage in children, particularly if multiple studies are anticipated.
- Main advantages are speed (important if a child is critically ill) and its adequacy for many neurosurgical management decisions. CT thus retains a major role in the early management of neurotrauma.
- As an X-ray technique, it is better suited than magnetic resonance imaging (MRI) to study of the bony skull and to the detection of intracranial calcification:
  - In the assessment of fractures (e.g. of the orbital roof) and craniosynostosis, 'bone windows' will be used: adjusting the 'brightness' and 'contrast' of the image to increase sensitivity at the white end of the grey scale. This is at the expense of detail in the intracranial cavity that appears as an 'underexposed' void.
  - Spiral CT is particularly useful in these contexts but with an even higher radiation dose (Figure 2.1).



**Fig. 2.1** CT imaging of a left occipital depressed skull fracture using conventional windowing (left). The fracture is more obvious on the bone window image (centre). Spiral CT reconstructs a 3D image of the skull and the fracture is clearly visible (right). Note that axial CT (and MR) images are conventionally orientated 'as if looking up from the feet' and thus a left-sided fracture appears on the right side of the image.

White (or light grey) structures on CT are X-ray absorbing substances and in practice will be either:


- Blood.
- Bone (or calcification).
- *Contrast*: intravenously injected contrast media enhance highly vascular structures such as arteriovenous malformations, some tumours and abscesses.

Distinguishing these is generally straightforward—blood is not as white as calcium/bone (i.e. it appears light grey rather than white).

Areas of reduced X-ray absorption in brain tissue (appearing darker grey) are typically due to oedema.

Metallic implants (such as clips or intracranial pressure (ICP) monitoring devices) tend to cause 'sunburst'-like beam hardening artefacts although this does not affect their functioning.

### **Computed tomography angiography**

CT studies are performed following injection of intravenous contrast by a high-velocity injector to achieve temporarily high concentrations. As with magnetic resonance angiography (MRA) (see  p. 57), 3D reconstruction techniques are available. Superior to MRA for evaluation of some forms of large vessel (particularly carotid) disease, vasculitis, and can be useful in the early evaluation of cerebral haemorrhage.

### **Magnetic resonance imaging**

In a very strong magnetic field, protons (hydrogen atoms) emit a weak radio signal that can be detected in an overlying coil. The signal is modified by the physicochemical environment of the protons (e.g. water content, mobility) and it is this information that is represented in the scan image. MRI does not involve ionizing radiation and is theoretically superior to CT in all situations other than imaging bone or detection of calcification. Image acquisition is, however, prolonged (typically 20–30 min or more for a full study), and a claustrophobic and noisy experience for young children.

- Neonates and infants can typically be scanned in spontaneous sleep after a feed.
- Oral sedation is widely used in toddlers because of limited anaesthetic resources but is controversial. Increasingly unreliable over 5 yrs of age.
- General anaesthetic is safe and guarantees images unaffected by movement artefact, the child waking in the scanner, etc., but requires specialist (non-metallic) equipment.

Artefact due to metallic implants is a problem with MRI. The function of cardiac pacemakers, vagus nerve stimulators and other devices can be affected. Smaller objects, such as arterial clips, may move, and larger metal implants, such as spinal rods can create signal voids obscuring the normal anatomy. Metallic objects can also heat up and cause local tissue damage.

Gadolinium contrast medium (injected intravenously) highlights vascular structures and can be useful in the evaluation of inflammatory lesions, but its use is intentionally restricted. Hypersensitivity to gadolinium is well recognized (0.1% population). An extremely rare progressive systemic disease (nephrogenic systemic fibrosis) has been linked to gadolinium exposure in individuals with impaired renal function.

MRI scanners are defined by the field strength of their main magnet, measured in Tesla (T). 1–1.5T magnets are widespread and 3T machines are becoming more widely available. Stronger magnets allow greater spatial resolution (ability to see more detail) and/or shorter image acquisition times. Open scanners are becoming more widely available: they are less claustrophobic and may allow a child to cooperate without anaesthesia; however, the open design results in a lower magnet field strength.

### **Sequences**

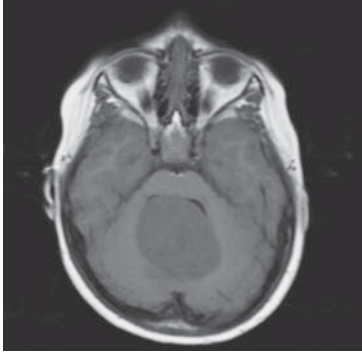
Many different MRI sequences are possible, each reflecting different physicochemical properties of brain tissue, and in turn suited to the detection of different brain pathologies.

**T1**

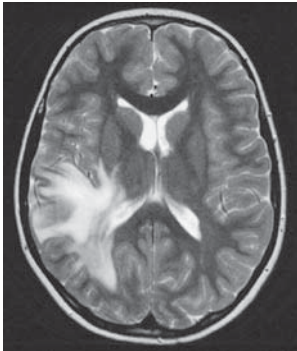
Tends to reflect visible appearances better than other sequences. Lesions visible on T1 are likely to be visually identifiable at surgery. Grey matter looks grey and white matter white (or lighter grey). Cerebrospinal fluid (CSF) looks black (Figure 2.2).

**T2**

T2 weighting is particularly sensitive to the presence of water. Pathologically, areas of high T2 signal intensity reflect oedema, e.g. due to inflammation or tumour. Not surprisingly CSF is bright white (Figure 2.3).



**Fig. 2.2** T1 MRI. Typical T1-weighted image showing a large posterior fossa tumour (medulloblastoma). T1 appearances tend to reflect macroscopic appearances at surgery and suggest this tumour will be identifiable and potentially resectable.



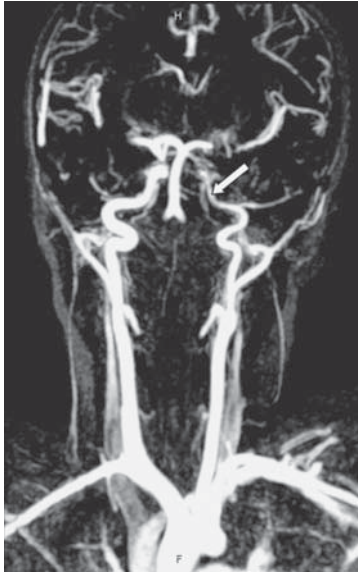**Fig. 2.3** T2 MRI. Typical T2-weighted image showing white CSF in lateral ventricles; grey matter is lighter grey than white matter. The large area of high T2 signal in the right parieto-occipital white matter reflects water, i.e. oedema, representing inflammation. This child presented almost asymptotically with a quadrantanopic visual field defect (c.f. lesion 'momentum', see [□□](#) p. 5), thus clinically a slow-growing tumour was suspected but, surprisingly, biopsy showed demyelination.

*Fluid-attenuated inversion recovery*

Can be thought of as T2 with the CSF signal specifically suppressed. This makes it particularly suitable for the detection of periventricular abnormalities that can otherwise be 'swamped' by the CSF signal (e.g. subependymal nodules in tuberous sclerosis and white matter changes in multiple sclerosis).

*Magnetic resonance angiography angiography/venography*

This is an important and widely utilized means of non-invasive imaging of large arteries and veins. Requires skilled interpretation, as artefactual flow voids giving the appearance of apparent vessel narrowing are quite common. It is significantly less reliable in evaluation of the posterior circulation. Useful for excluding venous sinus thrombosis (Figure 2.4).



**Fig. 2.4** MRA. Typical MRA image showing narrowing of left internal carotid proximal to the circle of Willis (white arrow) due to dissection.

*Diffusion-weighted imaging*

Quantifies the extent to which water is free to diffuse within tissues, which usually reflects cytotoxic oedema (increased intracellular space for diffusion). Its main clinical application is in the very early identification of ischaemia/infarction (before changes become visible in other sequences) enabling consideration of emergency treatments of stroke such as thrombolysis. Under certain circumstances, diffusion-weighted imaging (DWI) signal changes can reflect increased extracellular space for diffusion (e.g. tissue loss or vasogenic oedema).

Diffusion weighted imaging also forms the basis of tractography (or diffusion tensor imaging, DTI), a novel technique aimed at demonstrating white matter tract alignments (on the basis that water will diffuse more readily along a white matter tract than perpendicular to it; Figure 2.5).



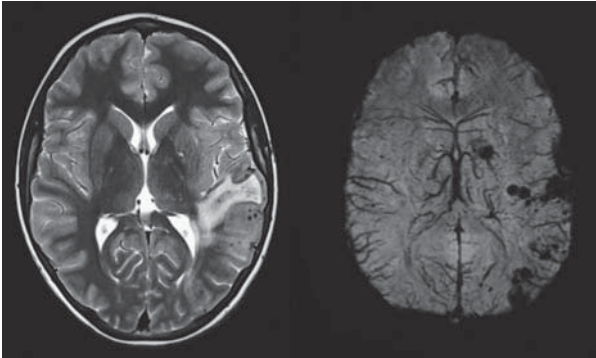
**Fig. 2.5** Sagittal (left) and coronal (right) diffusion tensor images (tractography) of white matter fibres passing through corpus callosum in a healthy adult. False colour is often used in these studies to aid visualization.

*Fat-saturation sequences*

A technique that selectively suppresses the signal from fat. Particularly useful for examination of the carotids in axial views of the neck in suspected carotid artery dissection (see [□](#) p. 447), and can be at least as sensitive as MRA in this context.

*'T2 star' (T2\*)*

A sequence sensitive to the presence of paramagnetic material, including calcification, but particularly iron. This includes iron deposition due to micro-haemorrhage and also conditions such as NBIA/PKAN (see [□](#) p. 430). These areas appear black. A particular variant of T2\* imaging known as susceptibility-weighting imaging (SWI) applies mathematical post-processing to enhance the "contrast" and visibility of these deposits (Figure 2.6). It is particularly useful in the quantification of micro-haemorrhage that occurs in diffuse axonal injury after traumatic brain injury (allowing prognostication) and confirmation of suspected cavernomas (see [□](#) p. 453).




**Fig. 2.6** Conventional T2w imaging (left) in this child with CNS scleroderma shows an area of left parietal oedema and hints at adjacent areas of micro-haemorrhage; these and many others are much more evident on the SWI imaging (right).

#### *Functional magnetic resonance imaging*

Primarily a research tool at present. Signals dependent on the levels of deoxyhaemoglobin in a region are used to infer local increases in blood flow, which in turn is taken as an indication of increased local neuronal activity. Together with carefully designed control tasks the approach can be used to localize sites of brain activation during the performance of specific tasks (such as a limb movement, or cognitive task) to infer localization of that function. It can also be used to localize a seizure focus and is likely to play an increasing role in the evaluation of epilepsy surgery candidates particularly if the seizure focus is near an area of potentially 'eloquent' cortex.

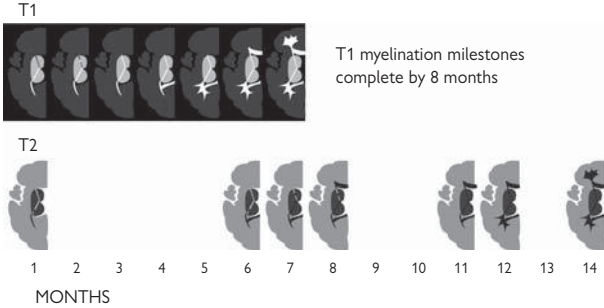
#### **Magnetic resonance spectroscopy**

Chemicals have specific magnetic resonance signatures, which can be used to quantify their levels in a user-defined "volume of interest", the minimum size of which is determined by scanner magnet strength but is typically  $\sim 1 \text{ cm}^3$ . Substances assayed by magnetic resonance spectroscopy (MRS) include lactate, choline, and creatine. Increased lactate levels may indicate failure of aerobic metabolism (e.g. mitochondrial disease, or in the centres of hypoxic tumours). Choline is found in cell membranes and levels are typically elevated in tumours. An absent creatine peak is the hallmark of the rare, but treatable creatine-synthesis disorder guanidinoacetate N-methyltransferase (GAMT) deficiency (see  p. 282).



**Magnetic resonance changes with development**

Normal MRI appearances of white and grey matter on T1 and T2 change markedly in the first 2 years of life, reflecting progression of myelination (see Figure 2.7).



**Fig. 2.7** Normal maturational changes in T1 and T2 imaging. Adapted from Staudt et al. (2000). Normal myelination in childhood brains using MRI—a meta-analysis. *RöFo* 172(10): 802–11, with permission of Georg Thieme Verlag.

**Other imaging modalities****Cranial ultrasound**

A non-invasive imaging particularly important in neonatal neurology. As in other forms of ultrasonography (e.g. echocardiography) ultra-high frequency sound waves are emitted from a probe that also detects returning echoes off underlying tissues. The distance of the reflecting structure from the probe can be inferred from the echo latency, and a real-time image of the structures underlying the probe constructed.

Its use in brain imaging is limited to the period before closure of the anterior fontanelle. It is particularly useful for assessment of ventricular size, and for the detection of intra- and peri-ventricular haemorrhage (blood is echogenic), and its non-invasive and portable nature makes it particularly suitable for use in sick neonates in intensive care settings. Since it cannot 'see around corners' it is poor at imaging the cerebral cortex, subcortical structures away from the midline, and the posterior fossa.

**Cerebral angiography (digital subtraction angiography)**

The 'gold standard' form of angiography for the evaluation and treatment of cerebrovascular disease. It requires invasive arterial (or venous) catheterization (typically percutaneously via femoral artery) and injection of radio-opaque contrast to visualize the arterial tree. In the newer digital subtraction angiography (DSA), the 'before' X-ray image is digitally subtracted from the image after injection, offering greater detail of fine-bore vessels.

Very importantly, angiography also permits endovascular treatment of suitable arteriovenous malformations, aneurysms, or other vascular malformations (through the placement of endovascular coils or the use of glue embolization).

***Positron emission tomography (PET)***

A functional imaging technique using gamma cameras to localize the uptake in different brain regions of positron-emitting isotopes (which indirectly cause gamma emission). In principle positron-emitting isotopes can be incorporated into a wide variety of molecules and used to reflect and map a wide variety of brain processes. These include mapping of blood flow (oxygen-15), glucose metabolism (fluoro-deoxyglucose), and the presence of particular neurotransmitter receptors (e.g. labelled flumazenil binding to benzodiazepine receptors). It is largely a research technique as an on-site cyclotron is required to manufacture the isotopes, but it has a role in identifying the location of seizure foci in evaluation of candidates for epilepsy surgery.

***Single photon emission computed tomography (SPECT)***

'Poor man's PET'. Directly gamma-emitting isotopes can be injected and conventional gamma camera imaging used to map cerebral blood flow semi-quantitatively at the time of injection. Used in the evaluation of candidates for epilepsy surgery (by comparing ictal and inter-ictal patterns of blood flow) and in planning cerebral revascularization surgery.

**Table 2.2** Radiological characteristics of neurological pathologies

Pathology	Ultra-sound	CT	MRI-T1	MRI-T2/FLIR	DWI	MRS	Other sequences
Oedema	Diffuse echogenicity	Hypodense. Reduced grey-white matter differentiation; sulcal pattern flattened	Hypointense	Hyperintense	Hyperintense. ‘Cytotoxic’: Decreased ADC (restricted diffusion) ‘Vasogenic’: Increased ADC (increased diffusion)		
Mitochondrial cytopathy		Focal hypo-densities	Hypointense	Hyperintense	Vasogenic pattern in MELAS	Lactate doublet peak in mitochondrial disorders; NAA/Cr reduced	Perfusion-imaging: increased perfusion indices
Infarction	Decreased echogenicity	Hypodense	Hypointense	Hyperintense in chronic lesions (lags DWI changes)	Hyperintense with decreased ADC (cytotoxic pattern) in recent lesions. Normal/ increased ADC in older lesions	Lactate increased, NAA/Cr reduced,	Perfusion-imaging: increased MTT, reduced CBF (reduced perfusion)
Haemorrhage	Increased echogenicity	Hyperdense	Hypointense, then hyperintense after a few days. Hypointense in chronic lesions	Hypointense early. Hyperintense cavity in later lesions			

Abscess		Hypodense. Contrast-enhancing	Hypointense	Hyperintense. Surrounding oedema hyperintensity typical	Hyper-intense/low ADC (restricted diffusion)		Perfusion-imaging: Decreased perfusion indices
Demyelination		Hypo-dense/normal	Hypointense. Contrast-enhancement in acute lesions	Hyperintense. Focal lesions with surrounding oedema (hypointense rim) in 'tumefactive' lesions	Variable ADC.	Increased choline/Cr; myo-inositol and lactate peak. Decreased NAA/Cr	
Tumour (glioma)	–	Hypodense. Perilesional oedema and contrast-enhancement in high-grade lesion	Hypointense. Contrast-enhancement in high-grade lesion	Hyperintense. High-grade lesions have oedema	Hypointense/high ADC (more restricted diffusion in high-grade)	Increased choline/Cr ratio; decreased NAA/Cr	Perfusion imaging: increased perfusion indices in high-grade lesion
Fat/lipoma	Increased echogenicity	Hypodense	Hyperintense. No contrast enhancement	Hyperintense			
Calcification	Increased echogenicity	Hyperdensities	Variable (subtle)	Hypointense (subtle)			

Differential of ring-enhancing lesions.

Infective: toxoplasmosis, cysticercosis; TB, miliary bacterial abscesses.

Haemorrhage.

Lymphoma, high-grade glioma.

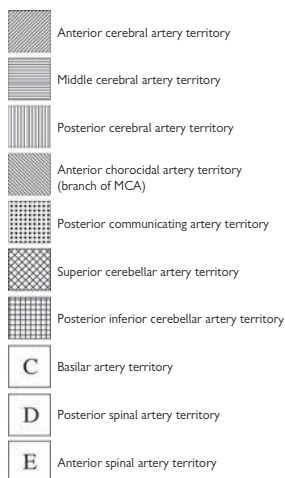
Demyelination.

Tumour.

## Neuroradiological anatomy

See Figures 2.8 and 2.9.

- 1 Amygdala
- 2 Anterior commissure
- 3 Aqueduct
- 4 Caudate nucleus (head)
- 5 Caudate nucleus (tail)
- 6 Central sulcus
- 7 Cerebellum
- 8 Cerebral peduncles
- 9 Corpus callosum
- 10 Fornix
- 11 Fourth cranial (trochlear) nerve nucleus
- 12 Globus pallidus
- 13 Hippocampus
- 14 Hypophysis
- 15 Inferior colliculus
- 16 Infundibulum
- 17 Insula
- 18 Internal capsule
- 19 Internal capsule (anterior limb)
- 20 Internal capsule (genu)
- 21 Internal capsule (posterior limb)
- 22 Lateral ventricle
- 23 Mammillary bodies
- 24 Medulla (oblongata)
- 25 Motor strip
- 26 Optic chiasm
- 27 Optic tract
- 28 Pineal gland
- 29 Pons
- 30 Putamen
- 31 Red nucleus
- 32 Sensory strip
- 33 Septum pellucidum
- 34 Splenium of corpus callosum
- 35 Substantia nigra
- 36 Subthalamic nucleus
- 37 Superior colliculus
- 38 Tectum
- 39 Thalamus
- 40 Third cranial nerve
- 41 Third ventricle
- 42 Trigone
- 43 Visual cortex



**Fig. 2.8** (a–f) Neuroanatomical sections. Adapted from Fix JD (1995). *High Yield Neuroanatomy*, Williams & Wilkins, New York, with permission of Wolters Kluwer.

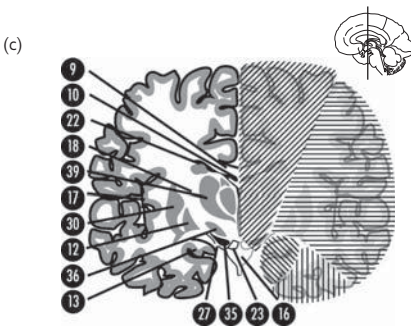
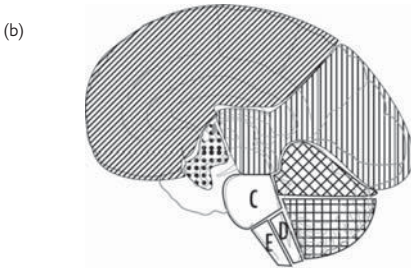
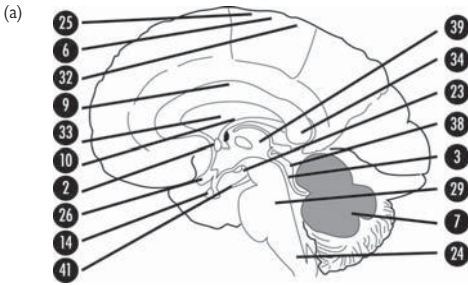
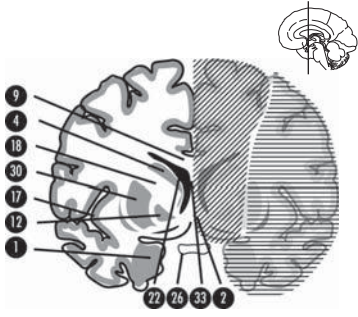
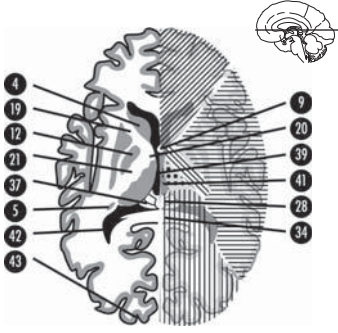


Fig. 2.8 (Continued).

(d)



(e)



(f)

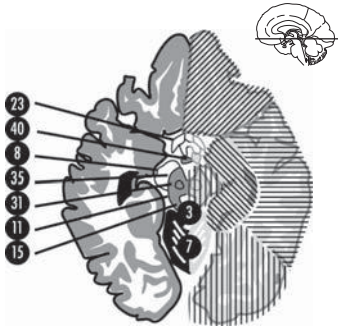
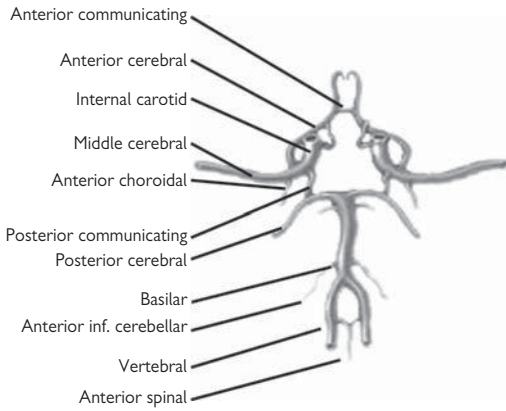


Fig. 2.8 (Continued).



**Fig. 2.9** Circle of Willis.



### Anatomical terms in radiology reports

A number of potentially unfamiliar descriptor phrases are commonly used in neuroradiology reports:

#### *Centrum semiovale*

Refers to the subcortical white matter of the frontal and parietal lobes. This is essentially all the white matter superior to the lateral ventricles, extending fully anteriorly and posteriorly (area A in Figure 2.10). The name comes from the approximately semi-circular outline (in each hemisphere) of this area in axial views.

#### *Corona radiata*

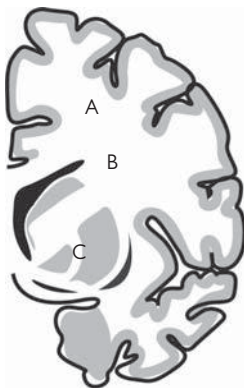
Effectively the 'transitional zone' of white matter (B in Figure 2.10) between the centrum semiovale and the internal capsule containing afferent and efferent fibres funnelling into the latter.

#### *Corpus striatum*

The internal capsule, basal ganglia and the intervening white matter (C in Figure 2.10).

#### *Trigone*

The triangular junction of the temporal and occipital horns of the lateral ventricle and the main body (see location 42 in Figure 2.8(e)).



**Fig. 2.10** Centrum semiovale and related structures.

# Brainstem anatomy

See Figure 2.11.

Note that some simplifications have been made: The CN III and IV nuclei are shown in the same cut although in fact they are at slightly different levels (with CN IV more caudal). Similarly the origins of CN IX, X, XII have been somewhat simplified.

Hatching patterns have been used to help "connect" tracts at different levels.



Corticospinal/corticobulbar tract (descending)



Pain and temperature (spinothalamic tract) (ascending)



Vibration/light touch (dorsal columns becoming medial lemniscus) (ascending)



Spinothalamic and dorsal column modalities combine in medial lemniscus at midbrain level

- 1 Descending corticospinal tract fibres in cerebral peduncles
- 2 Descending corticospinal tract fibres in pons
- 3 Descending corticospinal tract fibres in pyramids
- 4 Lateral corticospinal tract (crosses in pyramids)
- 5 Spinothalamic tract in spinal cord (fibres cross immediately from contralateral dorsal root)
- 6 Ascending spinothalamic tract in medulla
- 7 Ascending spinothalamic tract in pons
- 8 Spinothalamic fibres join with dorsal column fibres in medial lemniscus in midbrain (from here project to thalamus)
- 9 Ascending dorsal column fibres
- 10 Ascending dorsal column fibres in medial lemniscus
- 11 Medial longitudinal fasciculus running between midbrain and pons only, connecting CN III with IV and VI on each side to facilitate conjugate horizontal eye movement (see [p. 122](#))
- 12 Periaqueductal grey matter
- 13 Red nucleus
- 14 Substantia nigra
- 15 Cerebellar peduncle (middle)
- 16 Sensory fibres from CN VII (taste) entering trigeminal tract
- 17 Nucleus ambiguus (CN IX motor and X)
- 18 Sensory fibres from CN IX (oropharynx) entering trigeminal tract
- 19 Tractus and nucleus solitarius
- 20 Dorsal motor nucleus of CN X
- 21 Hypoglossal nucleus (CN XII)
- 22 Vestibular nuclei (CN VIII)

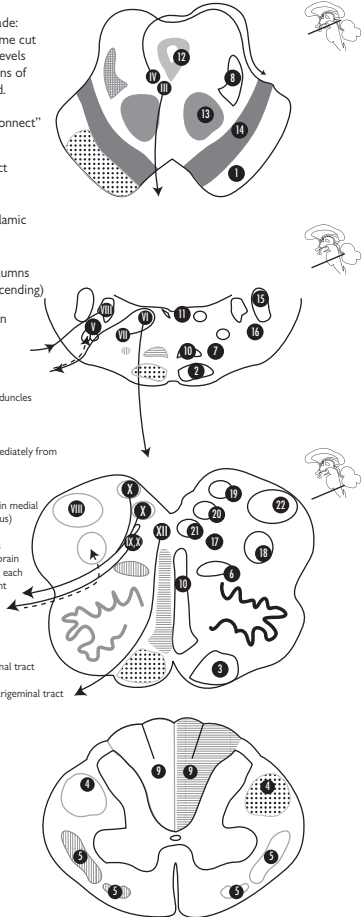


Fig. 2.11 Brainstem anatomy.

## Principles of neurophysiology

### Electroencephalography

#### What is electroencephalography?

- An aid to diagnosis, which has to be interpreted in the context of the clinical history.
- Electroencephalography (EEG) records the difference in electrical potentials generated by neurons in two locations against a time base.
- Potentials recorded are mainly postsynaptic membrane potentials generated from superficial cortical layers. They fluctuate over time.
- Electrical potentials generated are attenuated by up to 90% by the CSF, skull and scalp. They are of low amplitude (10–200  $\mu\text{V}$ ), and must be amplified and filtered before they can be interpreted.

#### Best quality recordings

Obtained by:

- Cleaning and preparing the scalp prior to electrode placement minimizing resistance and artefact.
- Twenty-minute recording, documenting relevant clinical events.
- Activation procedures including hyperventilation and photic stimulation.

#### Electrode placement

- Standard positions designated using the international '10–20 system'. Even numbers refer to right-sided electrodes, odd numbers to left-sided electrodes.
- F, frontal; Fp, fronto-polar; P, parietal; C, central; T, temporal; O, occipital; Z, midline; A, auricular.
- Typically up to 16 pairs of electrodes (or individual electrodes versus a reference) are displayed in a montage suitable for the particular clinical question at hand (Figure 2.12). Digital EEG machines allow on-the-fly reformatting of the display montage, something that was impossible in the paper era.

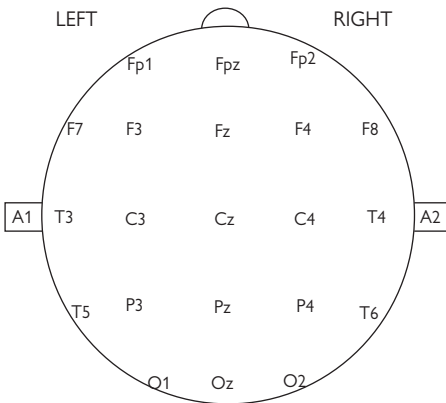



Fig. 2.12 EEG montage.


## Indications for electroencephalography

### *In the management of epilepsy*

Use the EEG to:

- Help determine seizure type and epilepsy syndrome in individuals in whom epilepsy is suspected (see  p. 262).
- To assess the risk of seizure recurrence in individuals presenting with a first unprovoked seizure.

Do not use the EEG:

- To 'exclude epilepsy' when the clinical assessment suggests another cause (because of the danger of a false-positive result: see Table 2.1).
- In isolation to make a diagnosis of epilepsy.
- Repeatedly if a clinical diagnosis has already been reached (consider sleep studies or other special procedures; see  p. 71).

An EEG should be performed only to support a diagnosis of epilepsy. Generally, an EEG would only be considered after more than one epileptic seizure, but may in certain circumstances (for example, at a 'one-stop' first seizure clinic) be ordered after a first seizure where the history is strongly suggestive of epilepsy.

### *In general acute neurology*

One often-overlooked role of the EEG in general acute neurology is as an 'ESR of the brain'—or more accurately, of the cerebral cortex. The presence of normal age-appropriate background rhythms is a strong indicator of intact cortical function suggesting cortical sparing in any process under evaluation.

Photic stimulation and hyperventilation should remain part of standard EEG assessment. The individual, and family and/or carer should be made aware that such activation procedures may induce a seizure and they have a right to refuse.

## Special procedures

- When a standard EEG has not contributed to diagnosis or classification, a sleep EEG should be performed. In children, a sleep EEG is best achieved through sleep deprivation or the use of melatonin.
- Long-term video or ambulatory EEG may be used in the assessment of individuals who present diagnostic difficulties after clinical assessment and standard EEG. This is usually only helpful when events are daily.
- Video EEG has an important place in the assessment of children for epilepsy surgery. Ictal records help define the site of seizure origin.

## Basic EEG characteristics and reading reports

Separate consideration is given to the background (a general indicator of cortical function) and paroxysmal activity (related to epilepsy).

### *Background rhythms*

Alter both with age (Figure 2.13) and the child's arousal level. Normal background rhythm frequencies increase and amplitudes decrease with age. An alpha rhythm on eye closure (Figure 2.14) should be present by age 8 ('8 Hz by 8 yrs'). During sleep the EEG slows.

The basic rhythms are:

- *Delta*: <4 Hz.
- *Theta*: 4 to <8 Hz.
- *Alpha*: 8–13 Hz.
- *Beta*: >13 Hz.

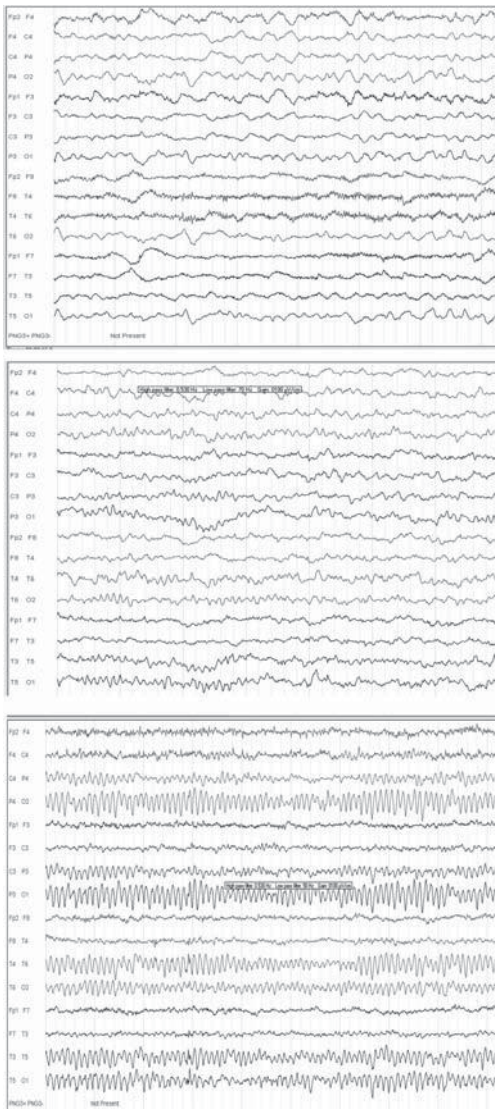
A technical report will follow each record along with an opinion on the relevance of the findings to the clinical situation. Comment should be made on whether the background rhythms are appropriate for the child's age and on any asymmetries.

### ***Paroxysmal activity***

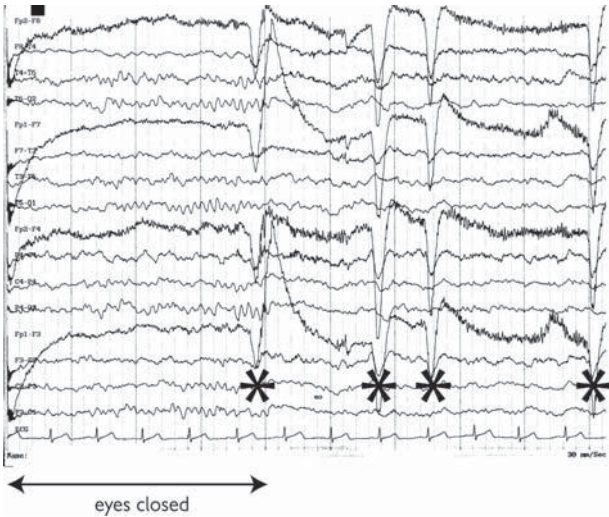
Many EEGs show non-specific abnormalities, such as an excess of dysrhythmic or slow wave activity in posterior areas. These findings are so common in the general population that they offer little or no support for a diagnosis of epilepsy: beware of over-interpreting them. More supportive of epilepsy would be persistent sharp, spike, or spike-wave complexes (Figures 2.15 and 2.16). An ictal record, capturing a seizure and demonstrating spike-wave discharge during the seizure is the only truly diagnostic finding. A persistent slow wave focus may indicate an underlying structural lesion.

### **Potential pitfalls of using an electroencephalogram**

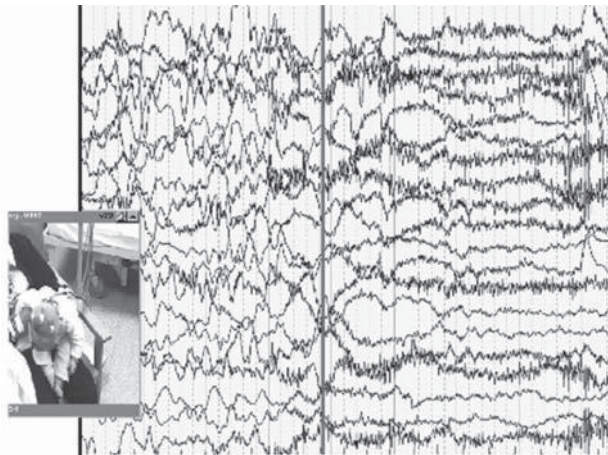
- Interictal EEGs are commonly normal in individuals with epilepsy.
  - Individuals who have never had any seizures (such as army recruits who have undergone routine EEG) may have epileptiform abnormalities on EEG.
  - Epileptiform spikes are common in conditions such as cerebral palsy even when there is no history of seizures.
  - Range of normal appearances very age dependent: in particular physicians without specific experience of neonatal EEG may report normal neonatal EEG appearances as pathological.
  - Some specific patterns, such as that seen in benign epilepsy of childhood with central-midtemporal spikes (BECTS), can also be seen in relatives without seizures and reflect a genetic tendency.
- ❗ If the EEG and the clinical impression are incongruent, be prepared to regard an EEG with epileptiform features as not adding extra support to a diagnosis of epilepsy.



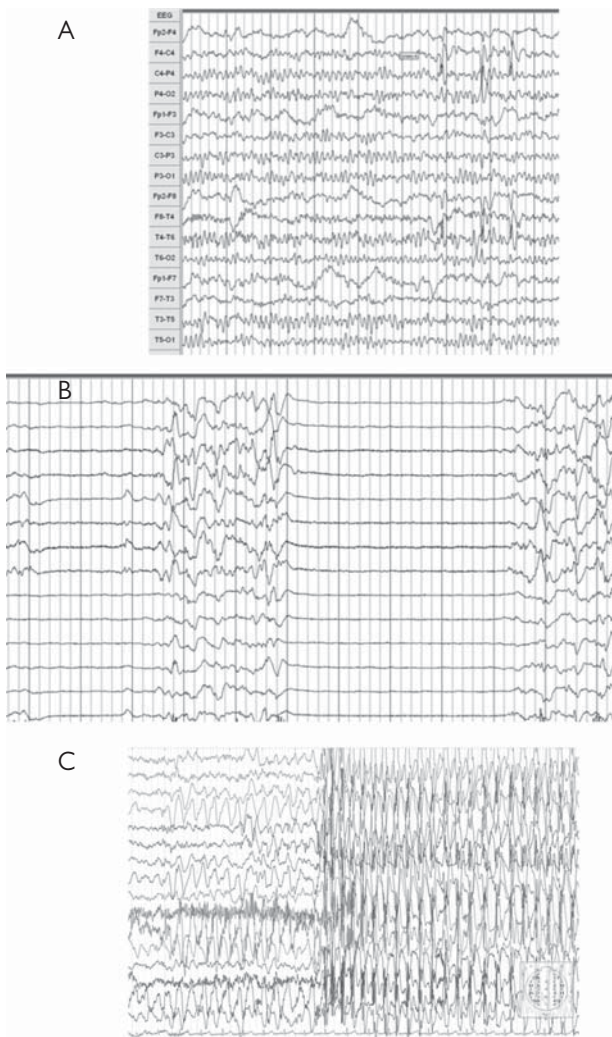
**Fig. 2.13** Changes in normal EEG with age. From top, normal (awake) 10-day-old infant. Centre, normal 5-year-old: theta rhythms posteriorly with emerging alpha. Bottom, normal 12-year-old with well-developed alpha rhythm.



**Fig. 2.14** Normal alpha rhythm appearing particularly in occipital leads during eye closure, abolished when eyes open (also implied by the appearance of eye-blink artefacts caused by movement of the eyeball, asterisks).



**Fig. 2.15** Hypsarrhythmia. The high voltage, chaotic EEG associated with infantile spasms. At the instant of the flexion spasm shown in the video window (left) marked by the vertical line, the EEG loses amplitude, a so-called electro-decremental event, and becomes contaminated by movement artefact.



**Fig. 2.16** Further EEG examples. (A) Repeated single spikes in centrotemporal leads in this example predominantly on right (even lead numbers). Appearance supports a diagnosis of benign childhood epilepsy with centrotemporal spikes (BECTS) in the appropriate clinical context (see [□](#) p. 268). Centre (B) Burst suppression EEG—periods of abnormal slow high voltage synchronous ‘burst’ activity separated by periods of relative electrical silence. A non-specific indicator of major suppression of cortical function seen (for example) in deep barbiturate anaesthesia, and profound encephalopathy of any cause. Bottom (C) generalized 3Hz spike wave activity typical of childhood absence epilepsy (see [□](#) p. 270). The slow activity prior to the onset of the 3Hz activity reflects hyperventilation-related changes.



## Peripheral neurophysiological tests

These are becoming less important in routine practice, with the advent of specific DNA tests for the hereditary sensory motor neuropathies, and the increased sophistication of muscle histopathology.

### Nerve conduction studies

See Tables 2.3 and 2.4.

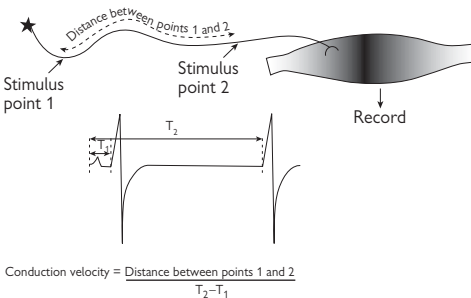
#### Procedure

Some children smile through the procedure, others scream. A low threshold for premedication (e.g. with oral morphine analgesia plus anxiolytic doses of diazepam) is advised. A pick up surface electrode is placed to record the compound muscle action potential (CMAP) over the appropriate muscle group. A stimulating electrode is placed at two defined points along a given nerve pathway a known distance apart. Supra-maximal stimulation is used to ensure the fastest fibres are being stimulated.

#### Nerve conduction studies

Measure amplitude, latency, configuration, and conduction velocities of motor, sensory, or mixed nerves (Figure 2.17).

Conduction velocity is dependent on the diameter and degree of myelination of the neuron. In the newborn infant the velocity is only about one half the adult levels and does not reach adult level until 3–5 yrs of age (at times later).



**Fig. 2.17** Measurement of nerve conduction velocity.

### *Repetitive nerve stimulation*

CMAPs are recorded following a volley of 6–10 supramaximal stimulations of a nerve, e.g. at 3 Hz. Changes in CMAP amplitude (e.g. sequential decrements) may indicate a disorder ('fatigue') of neuromuscular transmission. Some neuromuscular transmission disorders (Lambert–Eaton, botulism) can cause paradoxical sequential increments in CMAP amplitude.

- Demyelination is predominantly reflected in reduced conduction velocities (since fast conduction depends on myelin).
- Axonal neuropathies often show maintained conduction velocity, but the amplitude of the action potential is reduced.
- Conduction block is a feature of acute and chronic inflammatory demyelinating polyneuropathies (i.e. Guillain–Barré, CIDP) and is demonstrated in motor nerve studies only. Patchy demyelination causes attenuation of the compound muscle action stimulated proximally but stimulation nearer the muscle (distal to the patchy demyelination) gives normal results.
- In practice, overlapping forms of these pictures are often seen.

### **The late responses**

These studies may be abnormal even when distal motor responses are normal as they test proximal function—they are useful in assessing radiculopathies, plexopathies, polyneuropathies, and proximal mononeuropathies.

#### *H-reflex*

The H-reflex is a standardized, quantifiable 'electrical monosynaptic stretch reflex' and is typically studied in the posterior tibial nerve (soleus; assessing S1 integrity) or median nerve (flexor carpi radialis, C7; Figure 2.18). Stimulation (1, above) simultaneously initiates a direct motor 'M' response (2) and an afferent signal (3) that generates a second delayed motor 'H' response via the monosynaptic stretch reflex (4). Asymmetry of response is key to determining abnormalities: under normal circumstances, latencies should not differ between sides by >1 ms.

#### *F-wave*

F-wave studies are used to assess the proximal segments of the motor nerve function, and are performed in combination with the examination of motor nerves. It is a long latency 'echo' muscle action potential seen after supramaximal stimulation of a nerve: the stimulus travels antidromically along the motor fibre and reaches the anterior horn cell at a critical time to depolarize it (3, Figure 2.19). The response is then fired down along the axon and causes a minimal contraction of the muscle. Unlike the H-reflex, the F-wave is always preceded by a motor response and its amplitude is rather small, usually in the range of 0.2–0.5 mV. It is best obtained in the small foot and hand muscles.

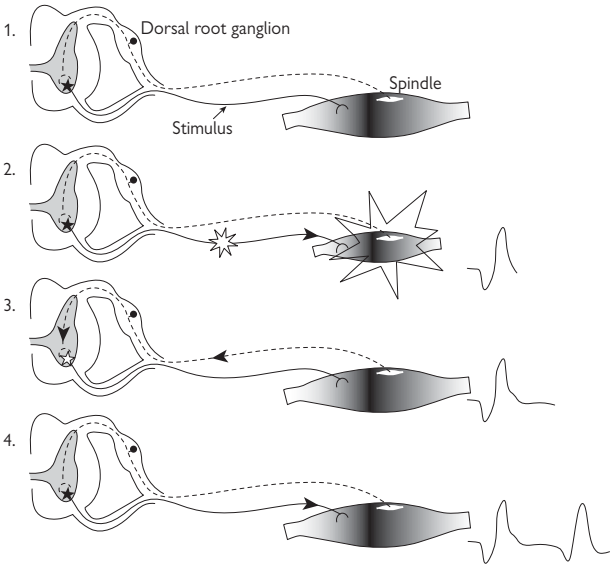
**Table 2.3** Indicative sensory conduction findings according to age

Age (n)	Median nerve		Sural nerve	
	Conduction velocity (m/s)	Amplitude ( $\mu$ V)	Conduction velocity (m/s)	Amplitude ( $\mu$ V)
7 dayl mth (20)	22.31 (2.16)*	6.22 (1.30)	20.26 (1.55)	9.12 (3.02)
1–6 mths (23)	35.52 (6.59)	15.86 (5.18)	34.63 (5.43)	11.66 (3.57)
6–12 mths (25)	40.31 (5.23)	16.00 (5.18)	38.18 (5.00)	15.10 (8.22)
1–2 yrs (24)	46.93 (5.03)	24.00 (7.36)	49.73 (5.53)	5. (9.98)
2–4 yrs (22)	49.51 (3.34)	24.28 (5.49)	52.63 (2.96)	23.27 (6.84)
4–6 yrs (20)	51.71 (5.16)	25.12 (5.22)	53.83 (4.34)	22.66 (5.42)
6–14 yrs (21)	53.84 (3.26)	26.72 (9.43)	53.85 (4.19)	26.75 (6.59)

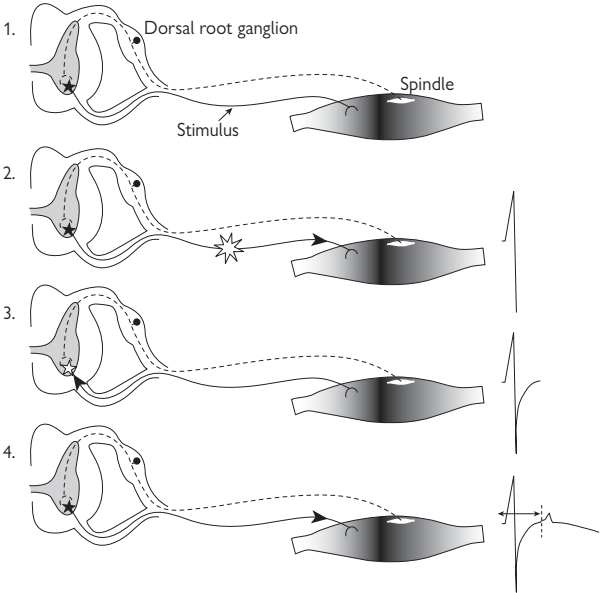
**Table 2.4** Indicative motor conduction findings according to age

Age (n)	Median nerve				Peroneal nerve			
	DML (ms)	CV (ms)	F (ms)	AMP (mV)	DML (ms)	CV (ms)	F (ms)	AMP (mV)
7 day–1 mth (20)	2.23 (0.29)*	25.43 (3.84)	16.12 (1.5)	3.00 (0.31)	2.43 (0.48)	22.43 (1.22)	22.07 (1.46)	3.06 (1.26)
1–6 mths (23)	2.21 (0.34)	34.35 (6.61)	16.89 (1.65)	7.37 (3.24)	2.25 (0.48)	35.18 (3.96)	23.11 (1.89)	5.23 (2.31)
6–12 mths (25)	2.13 (0.19)	43.57 (4.78)	17.31 (1.77)	7.67 (4.45)	2.31 (0.6)	43.55 (3.77)	25.86 (1.35)	5.41 (2.01)
1–2 yrs (24)	2.04 (0.18)	48.23 (4.58)	17.44 (1.29)	8.90 (3.61)	2.29 (0.43)	51.42 (3.02)	25.98 (1.95)	5.80 (2.48)
2–4 yrs (22)	2.18 (0.43)	53.59 (5.29)	17.91 (1.11)	9.55 (4.34)	2.62 (0.75)	55.73 (4.45)	29.52 (2.15)	6.10 (2.99)
4–6 yrs (20)	2.27 (0.45)	56.26 (6.61)	19.44 (1.51)	10.37 (3.66)	3.01 (0.43)	56.14 (4.96)	29.98 (2.68)	7.10 (4.76)
6–14 yrs (21)	2.73 (0.44)	57.32 (3.35)	23.23 (2.57)	12.37 (4.79)	3.25 (0.51)	57.05 (4.54)	34.27 (2.29)	8.15 (4.19)

\*Mean (SD) DML, distal motor latency; CV, conduction velocity; AMP, amplitude; F, F-wave latency; Adapted with permission from Parano E, Uncini A, De Vivo DC, Lovelace RE (1993). Electrophysiologic correlates of peripheral nervous system maturation in infancy and childhood. *J Child Neurol* 8(4): 336–8. Reprinted by permission of SAGE publications.



**Fig. 2.18** H-reflex.



**Fig. 2.19** F-wave.

**Procedure**

This is uncomfortable, but best done on someone able to cooperate by contracting individual muscle groups. Individual muscle groups are sampled with the insertion of a needle electrode. Sedation compromises the ability to cooperate, but give analgesia. Pragmatism needs to be used!

- Muscle tissue is normally electrically silent at rest. Action potentials appear with voluntary contraction. Each potential is produced by groups of fibres responding to a single motor neuron. As voluntary effort increases, individual action potentials summate and become confluent to form a 'complete interference pattern', and the baseline disappears.
- Occasional small potentials ('spikes') are seen if the needle is near the motor end plate.
- A loudspeaker system is used to allow electrical activity to be heard: aural impressions can be informative.

❗ The main role of EMG is to help differentiate neuropathies and myopathies. Appearances can be ambiguous, however, and it is important to interpret the findings in the light of other aspects of the clinical picture, the technical adequacy of the study and the experience of the neurophysiologist. As with any other ancillary medical test, clinical correlation is crucial.

**Neurogenic change (denervation)**

- The interference pattern is reduced so that the EMG baseline becomes partially visible.
- Spontaneous fibrillation potentials occur at rest (resting muscle normally silent). These are sharp, bi-phasic and of short duration with low amplitude potentials of about 100  $\mu$ V.
- High amplitude polyphasic fasciculation potentials of long duration also occurring at rest indicate anterior horn cell disease (notably spinal muscle atrophy).
- Individual motor unit potentials are either normal or of large amplitude, long duration and polyphasic. They indicate collateral re-innervation by surviving neurons with an increased territory.

**Myopathic changes**

Random loss of muscle fibres results in low amplitude EMG with poly-phasic short duration potentials. Sound like 'crackles' on a loudspeaker.

**Myotonia**

- Spontaneous bursts of potentials in rapid succession (up to 100/s or more) with waxing and gradually waning.
- The sound is characteristic, described as resembling a 'dive bomber' or accelerating motorcycle: tapping the muscle adjacent to the needle may provoke a burst.

**Myasthenia**

Decay of the interference pattern with sustained effort.

**Specialized electromyography****Single fibre electromyography**

Single fibre electromyography (SFEMG) selectively records muscle fibre action potential from a single motor unit: its main uses are in the deter-

mination of jitter (a measure of neuromuscular junction transmission) and fibre density (muscle spatial organization).

There are age-dependent normal values for jitter, measurement of which is expressed as mean consecutive difference or mean sorted difference between the trigger potential and an adjacent muscle fibre potential.

- Neuromuscular junction disease is associated with increased jitter.
- Fibre density is the mean number of muscle fibre potentials on 20 separate insertions and increases with age. It is significantly increased in neuropathy.

### **Macro-electromyography**

This is modified SFEMG using the distal 15 mm of the needle cannula. The large recording surface picks up electrical activity from all muscle fibres from a single motor unit. In general, macro-EMG motor unit potential amplitude and area correlate with motor unit muscle fibre number. They are therefore low in myopathy and high in neuropathy.

### **Quantitative electromyography**

Motor unit morphology can be quantified by analysing the duration, amplitude, phases, turns, area or area/amplitude ratio for 20 or more randomly selected simple motor units from a given muscle.

Results may be compared with age-matched normative data. The most sensitive parameters for myopathy seem to be motor unit potential (MUP) duration and MUP area/amplitude ratio.

### **Exercise testing: short and long exercise test**

Exercise may produce characteristic changes in CMAP amplitude in children with myotonic myopathies and periodic paralysis.

- In myotonic dystrophy and (particularly) myotonia congenita, exercise will produce an immediate fall in the amplitude of the CMAP followed by a prompt recovery within minutes.
- A long exercise test of 2–5 min with periodic breaks to prevent ischaemia is useful in the diagnosis of periodic paralysis. After an initial increment in amplitude, a progressive long-lasting fall in CMAP amplitude is seen (~50%, 20–40 min after exercise) with recovery in 1 h. This may also be seen in paramyotonia congenita.

## Neurophysiological testing of central sensory pathways

Many central sensory neurophysiological techniques use repeated averaging of EEG recordings time-locked to a repeating visual or auditory stimulus to extract EEG features that consistently appear following the stimulus. They are *passive* responses that can be elicited in the uncooperative (ill or young) child. Table 2.5 lists some sample requirements for specialist investigations.

### Visual-evoked potentials

- Uses a reversing checkerboard (or, if no response, strobe flash) typically 128 stimuli at 3 Hz with scalp electrodes placed 2 cm above theinion and 4 cm to the left and right of this point.
- The large volume of macular fibres means that this is essentially a test of retino-cortical conduction of the central retina.
- A five-component waveform is seen.
- The amplitude is typically variable and affected by visual acuity, the integrity of the visual pathway and stimulus type.
- The latency of the VEP (reflecting conduction velocity of fastest fibres) is much more constant and repeatable. As with peripheral nerves, slowed conduction reflects *demyelination*.

### Clinical application

- *Optic nerve lesions:*
  - Demyelination (e.g. optic neuritis). Abnormal and markedly delayed wave form. As visual acuity returns, amplitude will improve but delayed latency is typically permanent.
  - Compression (e.g. craniopharyngioma or optic nerve glioma in neurofibromatosis). Amplitude of the waveform decreases. Can also aid monitoring of condition in idiopathic intracranial hypertension.
- *Visual field abnormalities and acuity (specialist centres only):*
  - Partial-field stimulation can provide basic indication of visual field integrity in uncooperative children (e.g. monitoring use of vigabatrin).
  - Reducing checkerboard square size until visual evoked potential (VEP) is abolished gives an indication of visual acuity.
- *Macular disease:* ischaemic and toxic lesions result in disturbance of waveform and delayed conduction. Aids monitoring of progression.

### Limitations

- Relatively insensitive to partial disruption of visual pathways.
- Gives no indication of actual visual processing, just arrival of data to occipital cortex.

### Electroretinogram and electro-oculogram

- Recorded by measuring the potential difference between electrodes from a contact lens electrode or a skin electrode applied close to the eye and a reference electrode on the forehead. A strobe flash is the stimulus. As the rapidity of flashes increases, a flicker electroretinogram (ERG) is obtained.

- ERG is a combination of rod- and cone-system responses. In light-adapted retina, the response is dominated by the cone system. In the dark-adapted state, there will be a pure rod response.
- The electro-oculogram (EOG) detects the mass-change in ocular resting potential as the retina passes from the light-adapted to the dark-adapted state.
- Need sedation/anaesthesia for very young children.

#### **Clinical application**

- To determine the function of rods and cones, the function of the outer retinal layers and to determine the retinal level of a pathological insult.
- Rod function typically is lost early in retinitis pigmentosa.
- In early detection of retinopathy associated with neurodegenerative conditions.
- Ophthalmic artery occlusion.

#### **Brainstem auditory-evoked responses**

- The short-latency responses measured in routine clinical practice reflect the function of the auditory nerve and pathways in the brainstem.
- Longer latency responses are used in research contexts to evaluate early steps of auditory processing (e.g. pitch perception).
- Short-latency tests are unaffected by sedation or general anaesthetic.
- Stimulus is a loud click at 10 Hz with contralateral ear masking.
- Five waveforms are evoked. Currently it is thought they are related to the following anatomical structures:
  - wave I—action potential of cranial nerve VIII;
  - wave II—cochlear nucleus (with VIII cranial nerve);
  - wave III—ipsilateral superior olivary nucleus;
  - wave IV—nucleus or axons of lateral lemniscus;
  - wave V—inferior colliculus.
- Peak latencies influenced by age, sex, auditory acuity, stimulus repetition rate, intensity, and polarity.


#### **Clinical application**

- Determining hearing threshold in a uncooperative child (e.g. neonate).
- Identifying those who would benefit from a hearing aid.
- Defining the site of disruption of auditory pathways relative to the structures listed.
- Intra-operative monitoring during cerebello-pontine angle tumour surgery to help preserve auditory nerve function.
- Longitudinal monitoring of potential toxicity of chelating agents in thalassaemias.

#### **Somatosensory-evoked potentials**

- Typically elicited by stimulation of the median nerve at the wrist, the common peroneal nerve at the knee and/or the posterior tibial nerve at the ankle with recording from electrodes placed over the scalp, spine and peripheral nerves.




- Depend on the integrity of fast conducting large diameter fibres travelling in the posterior columns of the spinal cord.
- Integrity at the level of the peripheral nerve, plexus, spinal root, spinal cord, brainstem, thalamocortical projections or primary somatosensory cortex can be inferred.
- Less used clinically since the advent of MRI, but remains useful for intra-operative monitoring in scoliosis or other spinal cord surgery.
- Persistently absent cortical SSEPs in the context of acquired brain injury is a very poor prognostic sign (see  p. 512).

## Specialist investigations

Paediatric neurology does involve a number of potentially unfamiliar investigations on blood, CSF, urine, and skin. A basic understanding of these tests can aid their organization!

### Cerebrospinal fluid

#### Cerebrospinal fluid glucose

Low CSF glucose can result from infection. In the absence of infection, a CSF glucose  $<2.5$  mM raises the possibility of GLUT1 deficiency syndrome (GLUT1DS), a *treatable* cause of infantile seizures, acquired microcephaly, ataxia and developmental delay (see  p. 282). Diagnosis rests on *paired* measurement of blood (taken first to avoid spurious elevation of plasma glucose from stress of LP!) and CSF glucose after a 4–6 h fast and demonstration of a ratio  $<0.5$  (range 0.19–0.49).

#### Cerebrospinal fluid protein studies

High CSF protein reflects either entry of plasma proteins (albumin) into the CSF (i.e. breakdown of the blood–brain barrier) due to inflammation, or intracerebral demyelination or tissue destruction (e.g. in some neurodegenerative diseases). Further studies can help clarify this:

##### Albumin ratio (useful $\leq 10$ days of onset)

Albumin can cross the blood–brain barrier (BBB), but is not synthesized intrathecally; hence, a raised CSF to serum albumin ratio indicates BBB breakdown. Normal value  $<0.0043$  (CSF and serum albumin converted to same units).

##### IgG index (time independent)

Distinguishes local production of IgG (e.g. multiple sclerosis, viral encephalitis, subacute sclerosing panencephalitis (SSPE)) from leakage from serum. CSF and serum levels of IgG can be compared using albumin as a reference protein: a raised level indicates intrathecal IgG synthesis.


$$(\text{IgG}_{\text{CSF}} : \text{IgG}_{\text{serum}}) / (\text{albumin}_{\text{CSF}} : \text{albumin}_{\text{serum}}) \text{ normal } < 0.6$$

##### IgG oligoclonal bands (useful $\geq 10$ days of onset)

Indicated by the presence of two or more discrete bands in the G region on isoelectric focusing. Requires a paired serum sample: detection of oligoclonal bands in CSF absent in serum suggests the local production of IgG of restricted specificity, due to an intracerebral inflammatory response.

- Present in up to 95% of children with multiple sclerosis (tends to persist).
- Present transiently in Guillain–Barré, bacterial meningitis and viral encephalitis. Significant false positive rate in 74% of non-inflammatory conditions).
- New bands may appear in SSPE.



#### CSF neurotransmitters and folate metabolites

A number of rare disorders of neurotransmitter metabolism involving serotonin, catecholamines, tetrahydrobiopterin, and folate biochemistry, can result in movement disorders (see  p. 462). Measurement of CSF levels of their metabolites (usually 5 hydroxyindolacetic acid (5HIAA); homovanillic acid (HVA); neopterin and biopterins; and folate metabolites) is technically challenging. There is a rostrocaudal gradient of neurotransmitter

metabolites: hence tubes provided by the laboratory are numbered to collect specimens in a specific order. If the CSF is blood stained it will either need to be centrifuged immediately and the supernatant transferred to a fresh tube, or the procedure should be abandoned until a later date. Samples must be frozen immediately into liquid nitrogen.

CSF neopterin levels are also elevated non-specifically in CNS inflammatory states.

### **CSF lactate and pyruvate**


See also section on blood lactate (see  p. 89). Spurious elevation of lactate in CSF is less problematic than in blood and elevated CSF lactate is strong circumstantial evidence of a disorder of oxidative metabolism (including mitochondrial disorders). CSF lactate elevation also occurs in meningitis. Temporary elevations may occur immediately after seizures but these tend to be modest. Contamination of CSF with blood will falsely elevate CSF lactate (see CSF proline, see  'CSF amino acids', p. 86). CSF lactate tends to be low-normal or low in GLUT1 deficiency.

CSF lactate:pyruvate ratio is rarely more informative than CSF lactate alone: however in the context of elevated CSF lactate and a suspected disorder of oxidative metabolism a low L:P ratio (<20) would support a diagnosis of pyruvate dehydrogenase deficiency (PDH). The ratio tends to be high (>25) in other respiratory chain disorders.

### **CSF amino acids**

- Paired blood and CSF amino acid estimation is required for the diagnosis of non-ketotic hyperglycaemia (normal CSF: plasma glycine ratio <0.025; ratio >0.1 often found in non-ketotic hyperglycaemia (NKH)).
- CSF proline levels should be extremely low (<5  $\mu\text{M}$ ): higher levels indicate contamination of CSF with blood, and provide useful 'quality assurance' when interpreting CSF:plasma ratios of other compounds (e.g. preventing a false positive conclusion that CSF:plasma glycine ratio is elevated).
- Elevated CSF threonine may occur in pyridoxine-dependent seizures (threonine dehydratase is pyridoxine dependent); however, normal levels do not exclude this diagnosis.
- Low CSF serine may indicate a serine synthesis defect (may also have secondarily low 5MTHF levels): interpretation of CSF:plasma ratios requires fasting as plasma serine levels rise markedly after meals.

### **CSF pipercolate**

Elevated in pyridoxine dependent seizures (see  p. 462) and tends to remain high even when on B6 supplementation which can be helpful.

### **CSF interferon alpha**


Interferon alpha ( $\text{IFN}\alpha$ ) is a cytokine produced in the early stages of viral infections such as herpes simplex virus (HSV). It does not cross the BBB so elevated CSF levels indicate intrathecal synthesis. Normal <2 IU/mL; raised in neuro-lupus and Aicardi-Goutières syndrome. A paired blood sample may be helpful but CSF should be immediately frozen and sent to the appropriate laboratory.

## Urine

### *Urine microscopy*

Metachromatic granules in epithelial cells in early morning second sample of urine stained with toluidine blue are indicative of metachromatic leukodystrophy.

### *Urine catecholamine metabolites*

Catecholamines are dopamine, noradrenaline and adrenaline: their metabolites are the metadrenalines vanillmandelic acid (VMA) and HVA. Elevated levels are useful in the diagnosis of neuroblastoma. There is a high false-negative rate for this test, which may be supplemented with a meta-iodobenzyl guanidine (MIBG) test (see  p. 381).

### *Urine organic acids*

Abnormal profiles may be present all the time or only during metabolic decompensation. Many substances may create artefactual changes including concomitant valproate administration. Urine will keep in the fridge at 4°C overnight without the need for preservative, but then should be stored at -20°C. Capillary gas chromatography-mass spectrometry (GC-MS) is the preferred method of analysis.

There is a risk of false negatives if urine is too dilute or the child has recovered from metabolic decompensation. Results may be available within hours in emergency situations.

### *Urine amino acids*

Analysis may be used to diagnose a metabolic defect or to monitor treatment of aminoacidurias. Ensure paired plasma and CSF samples are obtained if you suspect NKH. Secondary abnormalities are very common.

### *Urinary mucopoly- and oligosaccharide screen*

Urine mucopolysaccharide screening tests uses 2-D electrophoresis to detect greatly elevated levels of glycosaminoglycans in mucopolysaccharidoses. There are three patterns of GAG excretion: increased dermatan sulphate and heparan sulphate (types I/II/VI and VII), increased heparan sulphate in type III, and increased keratan sulphate in type IV. Additionally, thin-layer chromatography is performed to identify the oligosaccharidoses (including mannosidosis and fucosidosis).

### *Urine sulphites*

The presence of sulphites in urine indicates molybdenum cofactor or sulphite oxidase deficiency. Some urinalysis test strips have an appropriate indicator square. There is a significant false negative risk if the sample is not tested within 20 min of voiding due to degradation of sulphites.

### *Urine alpha-aminoadipic semialdehyde*

$\alpha$ -aminoadipic semialdehyde dehydrogenase deficiency causes pyridoxine dependent seizures. A raised serum/CSF pipercolic acid level is a non-specific marker (raised in peroxisomal disorders, decreased with long term treatment) but urine alpha-aminoadipic semialdehyde (AASA) is specific for the condition.

### *Urine creatinine, creatine, and guanidinoacetate*

Disorders of creatine metabolism may be suspected from a low serum creatinine concentration. 24hr urinary creatinine, creatine and guanidinoacetate (GAA) levels will help to differentiate between the deficiencies.

**Urine uric acid**

Urinary uric acid/creatinine ratio is a simple, but useful method of screening for disorders of purine metabolism.

**Blood****pH and base excess**

This is usually assayed on arterial blood in the intensive care unit (ICU) setting, but a well-perfused capillary sample is adequate for routine testing. Acidosis may accompany many metabolic conditions, notably mitochondrial cytopathies, organic acidopathies, and catabolic states. Alkalosis may accompany hyperammonaemia.

**Free and acyl carnitine**


Carnitine is required for the transport of long chain fatty acids (FACs) as acyl coenzyme A esters across the mitochondrial membrane for FAC oxidation. Low levels occur with primary defects or secondary to other causes. Acyl carnitines are toxic esters of carnitine produced in the transport and metabolism of FAs: raised levels occur in FAC oxidation defects and organic acidaemias. The gold standard for analysis is now tandem mass spectrometry (MS/MS) because of small sample requirements, automation and processing speed. A dried blood spot on a filter paper ('Guthrie card') will suffice, and a result is typically possible within 24 h in emergency situations.

Note that plasma acylcarnitine analysis may give false negatives in screening for MCAD deficiency as individuals with secondary carnitine deficiency may not show a significant elevation of C6–C10 acylcarnitines. Either urine organic acids (in acute episodes) or acylglycines should be analysed.

**Ammonia**

Hyperammonaemia is an important indication of urea cycle disorders and/or liver dysfunction; however, artefactually raised ammonia levels due to improper sample collection are common. Blood obtained should be free flowing, and the laboratory forewarned to accept and promptly handle the sample, which should be transported on ice as red cells and glutamine in the serum can otherwise both also release ammonia.

**Lysosomal ('white cell') enzymes**

Measurement of enzyme activities in lysosomes can be used to identify children affected by lysosomal storage disease or heterozygote carriers, as well as to monitor the response to bone marrow transplant or enzyme replacement therapy. Many laboratories screen for a panel of enzymes; however, this may not include the enzyme you are specifically interested in! It is important that the laboratory has appropriate quality assurance procedures in place. See  p. 433.

**Buffy coat histology**

When blood is centrifuged, the 'buffy coat' is the enriched white cell fraction, visible as a white layer between the red cells (bottom) and the plasma (top). This sample can be fixed and prepared for electron microscopy for inclusion bodies, which can be useful in the diagnosis of lysosomal disease and neuronal ceroid lipofuscinosis.

**Peripheral blood film**

Examination of a peripheral blood film by an experienced haematologist can be useful in a number of situations:


### *Vacuolated lymphocytes*

Indicative of a lysosomal disorder (requiring further characterization).

### *Alder–Reilly granules*

Dense metachromatic granules resembling toxic granulations seen in leucocytes in mucopolysaccharidoses.

### *Acanthocytes*

Red blood cells with multiple, irregularly spaced thorn-like projections or spicules of variable size, associated with abetalipoproteinaemia, some cerebellar ataxias, some progressive neurodegenerative diseases such as NBIA/PKAN (see  p. 430) and dentate-rubral-pallido-luysian atrophy (DRPLA), end-stage liver disease and hepatorenal failure. A small number of acanthocytes may be seen in other forms of severe haemolytic anaemia, particularly after splenectomy.

### *Basophilic stippling*

Represents ribosomal RNA precipitated during staining: seen in heavy metal poisoning as well as thalassaemias, haemoglobinopathies, sideroblastic anaemias, and pyrimidine-5'-nucleotidase deficiency.

### **Lactate**

Free flowing blood is typically collected immediately into perchloric acid to deproteinize it. For the laboratory to interpret the levels of the volume of added blood must be accurately known: this is usually done by pre-weighing the tube. Check local arrangements. Spurious elevations of plasma lactate levels are common (e.g. systemic hypoperfusion; restriction of blood flow locally with a tourniquet).

### **Karyotype analysis**

Cells are cultured and stained. Metaphase spreads are selected, and the chromosomes are arranged in descending order by size and compared with a standard. Both size and staining pattern are included in the analysis. Techniques constantly improve in terms of the types of staining available, and the analysis is now often computerized. This often makes it worth repeating the test if it has not been done for some years.

### **Fluorescent in situ hybridization**



Fluorescently labelled DNA probes are used to detect the presence of sequence abnormalities (or absence of normal sequences) below the resolution of routine cytogenetics. The fluorescently labelled probe is added to a denatured sample and hybridizes at the target site as the DNA re-anneals into a double helix. The probe signal can be detected by fluorescence microscopy. Most commonly used to identify Prader–Willi/Angelman (chromosome 15), 22q-, Miller–Dieker and Smith–Magenis syndromes.

### **Comparative genome hybridization**

This technique is becoming increasingly available and may replace routine karyotyping in the near future. Effectively a 'high resolution karyotype' it detects copy number imbalances (due to deletion or duplication) relative to a control sample. The clinical significance of identified copy-number variations (i.e. whether they are relevant to the clinical presentation or coincidental) can be challenging: first step typically is to check whether they are shared by unaffected family members.

It is important to appreciate that comparative genome hybridization (CGH) only identifies excesses or deficiencies in the number of copies of a DNA sequence (so called copy number variants (CNVs)) due to duplication or deletion. Balanced rearrangements, inversions or other rearrangements that do not alter total copy number will not be detected. Likewise this technique will not identify sequence mutations.

### **DNA testing**

An increasing number of probes are available to aid clinical work (e.g. a probe detecting the presence of a triplet repeat mutation in the fragile-X gene, FMR-1 identifies affected males and females, as well as transmitting males and female carriers of the mutation). Probes are also available routinely to look for common mitochondrial DNA deletions (see  p. 369). Hundreds of tests are now available (at high cost!) to confirm diagnoses, with guidance available at  [www.genetests.org](http://www.genetests.org).

### **'Next generation' sequencing**

An area of rapid technical development, likely to greatly reduce the cost and time per base of DNA sequencing to a point where sequencing of much or all of an individual's exome at a single sitting is likely to become feasible in the near future. (The exome comprises the sum of the exons, the transcribed segments comprising ~1.5% of a person's whole genome). The accuracy of these techniques is not yet as high as conventional ('Sanger') sequencing and putative mutations will need to be confirmed conventionally. As with CGH, these techniques will create major new bioinformatics and clinical challenges in the evaluation of the relevance if any of identified mutations.

### **Ring chromosome 20 mosaicism**

This is a recognized syndrome of severe epilepsy and learning difficulties with severe behavioural features. A standard request for 'karyotyping' will typically examine a few cells only. Ring chromosome 20 mosaicism should be specified if this is a consideration so that more cells are examined: examination of 50 cells will identify 6% mosaicism with 95% confidence.

### **Ischaemic lactate test**

Not advocated by some because of potentially serious rhabdomyolysis, it can be used to exclude abnormalities of glycogen metabolism, particularly McArdle's disease (glycogen storage disease (GSD) V). Cannulate and draw baseline lactate and ammonia. Inflate the sphygmomanometer to above systolic BP, exercise the forearm by squeezing a ball at 1 Hz for 1 min. Stop and maintain the cuff for 1 min, then release the cuff, and take blood for lactate and ammonia at 2 and 12 min. A normal lactate response is a 3–5 × rise by 1 min with subsequent decline and excludes GSD V.

### **Transferrin isoforms**

These should be examined to diagnose congenital disorders of glycosylation (CDGs; previously known as carbohydrate-deficient glycoprotein syndromes) arising from defects in genes coding for enzymes involved in the glycosylation of proteins. Transferrin is a sensitive and convenient marker, secreted by the liver and normally present in different isoforms due to differences in glycosylation. These can be separated by isoelectric focusing (IEF) due to differences in their charge, immunofixed and visualized with anti-transferrin antibody. The presence of abnormal isoforms indicates the possibility of

a CDG. IEF only identifies abnormal glycosylation but not the cause of the abnormality: further analysis requires enzyme studies on fibroblasts.


- *False positives*: uncontrolled fructosaemia, galactosaemia, liver disease.
- *False negatives*: have been described with enzymatic confirmation of CDG despite normal transferrin IEF.

### Very long chain fatty acids

Most peroxisomal disorders can be detected by an accumulation of very long chain fatty acids (VLCFAs). Elevated VLCFAs, often with raised pipecolic and phytanic acid levels, imply either peroxisomal biogenesis or oxidation disorders. Decreased red blood cell (RBC) plasmalogens imply biogenesis defects; normal plasmalogens imply oxidation or mild biosynthesis defects.

Normal VLCFA with decreased RBC plasmalogens is seen in the peroxisomal form of rhizomelic chondrodysplasia punctata (RCDP); where the activity of DHAP-AT may also be reduced.

### Biotinidase

The phenotypic range of this treatable deficiency state is broad (see  p. 468). Consider testing especially where there is hypotonia, severe infantile epilepsy, alopecia, rashes, and hearing loss.

**Table 2.5** Sample requirements for specialist investigations

Test	Sample
Amino and organic acids	3 mL of urine
Free and acyl carnitine	1 mL of LiHep or a dry blood spot
Transferrin isoelectric focusing	1 mL of clotted blood
Lysosomal storage disorders:	
white cell enzymes	5 mL of EDTA
mucopoly- and oligosaccharide screen	3 mL of fresh urine
Carbohydrate disorders:	
sugar chromatography	5 mL of urine
Peroxisomal disorders:	
VLCFA	Together 5 mL of EDTA
pipecolic acid	
phytanic acid	
plasmalogens	
Biotinidase	2–3 mL of LiHep
DNA mutations	5 mL of EDTA

LiHep = heparinized blood; EDTA = EDTA blood.

Note: most specific enzyme assays can be carried out on cultured skin fibroblasts, cultured amniotic fluid cells or chorionic villus samples. Check with the laboratory.



**Bone marrow aspirate**

Bone marrow aspirate histology may be informative in Gaucher and Niemann–Pick disease type C or in diagnosing CNS lymphoma.

**Muscle biopsy****Histology***Dystrophic change*

- Necrosis of fibres with phagocytosis, etc.
- Regeneration: splitting of fibres, hyalinized fibres.
- Atrophic/hypertrophic fibres, random.
- Excess collagen and fat.

*Myopathic change*

- Increased fibrous septae.
- Muscle fibre variation in size.
- Increase in fat.
- Fibre type predominance.
- Increase in internal nuclei.

*Neuropathic*

Fibre type grouping.

**Histochemistry**

- Abnormal fat, glycogen or amyloid deposition.
- ‘Ragged-red fibres’ due to accumulation of abnormally proliferating mitochondria.

**Immunohistochemistry**

- Dystrophin (absent or deficient in Duchenne and Becker dystrophies).
- Sarcoglycans (deficient in limb girdle muscular dystrophy (LGMD) types 2C, D, E, F).
- Calpain (deficient in LGMD2A).
- Laminin A2 (deficient in some congenital muscular dystrophies).
- Merosin (deficient in merosin-deficient congenital muscular dystrophy).
- Emerin (deficient in Emery–Dreifuss dystrophy).
- *Oxidative enzyme staining*: Gomori, cytochrome oxidase (COX), subdural haemorrhage (SDH), NADH.

**Chemistry**

- Enzyme analysis (e.g. phosphorylase deficiency in McArdle disease, acid maltase deficiency in type II Pompe disease).
- Assay of enzymes of the respiratory chain (complexes I to IV) in mitochondrial disease.

**Electron microscopy**

Ultrastructural change, e.g. nemaline rods, inclusion bodies.

**Nerve biopsy**

- Segmental demyelination and remyelination cause layers of myelin giving an onion bulb appearance to the myelin sheath, indicative of demyelinating disease.
- Axonal degeneration, loss of axons.

## Skin biopsy

### *Electron microscopy*

- Presence of inclusion bodies in apocrine sweat gland are containing skin indicative of some neuronal ceroid lipofuscinoses.
- Abnormal glycogen-containing inclusions in Lafora-body disease.
- Chromosome abnormalities, particularly in mosaicism or some neurocutaneous syndromes.

### *Fibroblast culture*

Undertake biochemical studies when:

- Genetic testing is not available/cannot exclude a diagnosis e.g. cholesterol esterification studies and filipin staining for Niemann–Pick disease type C.
- When conventional tests are negative but there is still a strong clinical suspicion e.g. glutaric aciduria type 1.

## Practical procedures

### Skin biopsy

Skin is taken for histology and/or establishment of fibroblast cultures. Whilst not specific, the diagnosis of a number of neurological conditions may be assisted by the demonstration at electron microscopy of inclusion bodies in apocrine sweat gland-containing skin (i.e. axilla). Fibroblast cultures can be established from skin taken immediately post-mortem.

Take sample aseptically to include the full thickness of the dermis. Establishment of fibroblast culture may be indicated for enzyme analysis to investigate inborn errors of metabolism or chromosome analysis to look for tissue specific mosaicism (e.g. hypomelanosis of Ito). Skin for fibroblast culture must be scrupulously sterile or contaminants will prevent the culture establishing. Take a small sample (a few millimetres in diameter) to prevent necrosis of the centre of a larger sample.

### Equipment needed

- Punch biopsy needle size 3 or 4 mm.
- Fine forceps (not essential).
- Scalpel and dressing pack.
- 0.5% lidocaine.
- 2 mL syringe.

### Procedure

- Liaise with the laboratory for transport medium. Ideally, a technician should be present if fixation is required.
- If for histology, skin can be collected into 0.9% saline in a sterile universal container. For fibroblast culture collection into tissue culture medium is strongly preferred (use saline only exceptionally).
- Decide on the site. Liaise with the laboratory as this could depend on the reason for the biopsy, e.g. from pigmented and unpigmented skin in hypomelanosis of Ito looking for fibroblast mosaicism, axilla for apocrine sweat glands in Lafora body disease, or forearm for general eccrine glands.
- Prepare skin with alcohol, chlorhexidine or Hibitane. Avoid iodine-containing compounds such as betadine as these interfere with cell growth in culture.
- Infiltrate around site with 0.2–0.5 mL 0.5% lidocaine if necessary.
- Push the punch biopsy into the skin to the hilt.
- Lift up with fine forceps or an orange needle.
- Cut away the tethered portion with a scalpel.
- If a punch biopsy not available, then a tent of skin can be lifted with a green needle and cut across with a scalpel, but this leaves a ragged cut edge.
- Apply pressure to bleeding with a gauze swab.
- Divide into required portions according to the number of bottles.
- Apply Steristrips to oppose the skin.
- Cover with dressing and a bandage.
- Samples destined for fibroblast culture can be stored for 24 h at 4°C in sterile saline or 3–5 days at 4°C in culture medium.

## Muscle biopsy

The following applies to needle biopsies. Although the technique is relatively simple, success depends on obtaining several samples of adequate size from a single insertion site. Subsequent specimen processing should only be done by laboratory technicians familiar with the techniques.

### Equipment needed

- Scalpel.
- Dressing pack.
- Reusable biopsy needle—size 3–5 mm (Bergstrom or UCH).
- 1% lidocaine;
- Dressings.

### Procedure

- *Prepare the site:* usually the upper third of the rectus femoris/vastus lateralis.
- Infiltrate lidocaine around skin and down to the fascia but not into the muscle.
- Incise skin and cut through the deep fascia.
- Insert the biopsy needle minus the central cutting rod.
- Press muscle together so the tissue enters the side window of the needle, or the aspiration port (if present) can be used to suck up muscle.
- Cut off the sample by ramming the inner sharpened cylinder along the needle.
- Rotate and repeat at multiple sites, via the same incision, until adequate samples are obtained.
- Remove the needle and use the obturator to remove specimens.
- Apply pressure with gauze.
- Apply dressing.
- Ultrasound helps to identify affected muscles for biopsy.

## Lumbar puncture and manometry

### Equipment needed

- Assorted lumbar puncture (LP) needles sized according to the size of the child.
- Dressing pack or dedicated LP pack.
- Povidone iodine.
- Gloves.
- *Manometer:* have 2 available in case the pressure exceeds the upper limit of one.
- Universal bottles, a fluoride oxalate bottle for CSF glucose.
- Bottles for neurotransmitter studies (if relevant) should be provided by the laboratory along with instructions for order, volume to collect and transport (dry ice or liquid nitrogen).
- Topical anaesthetic cream over the site if desired.
- 1% lidocaine.
- 2-mL syringe.
- Orange needle.
- Collodion.
- Sticking plaster.
- ► Experienced nurse and or play therapist to hold the child.
- Assistant to hold the bottles.

**Procedure**

- Lateral decubitus position with the child held tightly curled: your assistant needs to be confident!
- Take time to ensure the pelvis and back are in the vertical plane and not tilting away from you.
- Identify the L3–4 intervertebral space, located along a line joining the iliac crests.
- Prep the area.
- In a larger child infiltrate lidocaine subcutaneously and infiltrate in the intended direction of the spinal needle.
- Insert the needle horizontally with bevel up and perpendicular to the skin, aiming towards the umbilicus.
- Little or no resistance should be felt except for a ‘pop’ as the dura is penetrated.
- Remove the stylet, attach the manometer, straighten the legs and measure the pressure when the CSF stops rising and swings with respiration.
- Turn the tap to drip the CSF into bottles.
- Remove the needle.
- Apply pressure, collodion, and sticking plaster.
- Beware the CSF pressure may be artificially elevated due to a general anaesthetic or PEEP from ventilation.
- Post-LP headaches *may* be avoided with 25 G pencil point (blunt) needles instead of the usual bevelled tip. However, the flow rate using this is very slow and may be a limiting factor.

**Intrathecal medicine**

Inadvertent intrathecal injection of cytotoxics intended for intravenous use in the treatment of acute lymphoblastic leukaemia has been a repeated cause of medical tragedy. **❗ CHECK, AND RECHECK, THAT THE DRUG IS FOR INTRATHECAL USE. ❗ CHECK THE DOSE. ❗ INADVERTENT INTRATHECAL INJECTION OF VINCRISTINE IS UNIFORMLY FATAL.**

Intrathecal cytotoxics should only be given by paediatric oncologists in a dedicated setting. In neurological practice, the only indication is intrathecal instillation of antibiotics (typically vancomycin) into, or sampling from, external ventricular drains (EVDs).

- Clean gloves, sterile field and syringes with alcohol.
- Remove the approximate volume in tubing, e.g. 5 mL.
- Send for samples if required.
- Replace with vancomycin and 0.9% saline flush to equal volume.
- Lock with the tap for 1 h then release.

**Shunt tap**

This should ideally only be performed by a neurosurgeon as different shunt designs have different access points and some are not suitable for tapping (Figure 2.20). However, if this is not possible, the following show access sites.

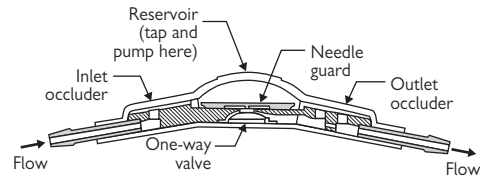
*Equipment needed*

- Povidone iodine.
- Dressing pack with gauze swabs, tweezers, gloves.
- Sticking plaster.

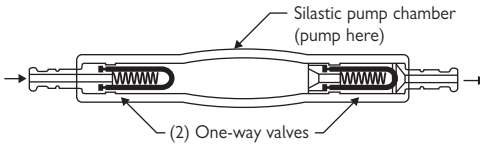
- 23 G butterfly needle.
- Manometer if needed to measure pressure.
- Sterile universal bottles.
- Glucose bottle (fluoride oxalate).
- Local anaesthetic cream may be applied before the procedure if desired.

### Procedure

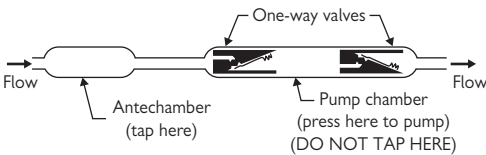
- Prepare the site.
- Insert the butterfly into the tapping chamber.
- Connect to the manometer if desired, while occluding the outlet valve.
- High opening pressure suggests distal obstruction.
- Absence of spontaneous flow or a poor drip rate suggest proximal obstruction.
- Obtain CSF for investigations.
- Remove the butterfly.
- Apply pressure then the sticking plaster.



(a) Heyer-Schulte valve

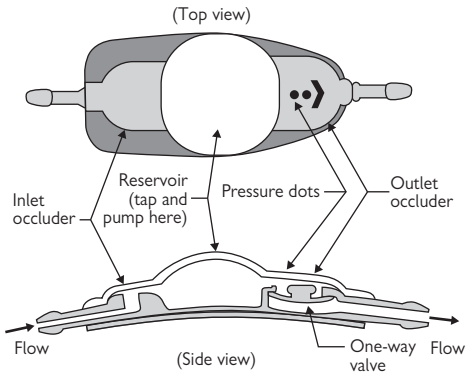


(b) Hakim valve

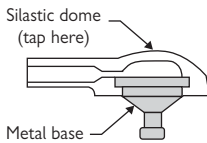


(c) Holter valve

**Fig. 2.20** (a–e) Ventriculo–peritoneal shunt valves in common use. Reproduced from Greenberg, MS. (2001). *Handbook of Neurosurgery*, 5th edition. Thieme International, New York, with permission.



(d) PS Medical valve



(e) Salmon-Rickham valve

**Fig. 2.20** (Continued).

## Neuropsychological testing

The use of standardized neuropsychological tests can support both diagnosis and rehabilitation planning. Neuropsychological testing complements and supplements assessment by an educational psychologist.

### Domains and modules

Development is considered to be 'domain specific'. A domain is a set of representations sustaining a particular area of knowledge (e.g. language). A module is a more specific term to describe an information-processing unit (e.g. phonological module within a language domain). Modules may be differentially vulnerable at different developmental stages.

### Indications for neuropsychological testing

- Evaluation of developmental disorders.
- Detection of conditions not demonstrated on standard neurodiagnostic testing (e.g. subtle sequelae of traumatic brain injury).
- Monitoring the neuropsychological status of children (e.g. monitoring changes following surgery for a brain tumour or epilepsy surgery).
- Characterization of cognitive capacities in planning rehabilitation programmes.
- Research.

### Assessment strategies

- Fixed test battery.
- Flexible—hypothesis driven—tests chosen on the basis of the referral question.
- Combination of fixed and flexible.

### Psychological capacities tested

#### Intelligence

- The Wechsler Intelligence Scale for Children (WISC), currently at version four (WISC-IV), provides a robust verbal/non-verbal assessment for children aged 6–16 yrs. Four domain scores and an overall IQ score are provided:
  - Verbal Comprehension Index (vocabulary, comprehension, general knowledge);
  - Perceptual Reasoning Index (block design, picture concepts, matrix reasoning);
  - Working Memory Index (digit span, letter-number sequences, mental arithmetic);
  - Processing Speed Index (*timed* tasks including coding, symbol search).
- An equivalent instrument for younger children (>30 mths) is the Wechsler Preschool and Primary Scale of Intelligence (WPPSI).
- In younger children, a diagnosis of learning disability may be withheld until the child is older, with a temporary label of developmental delay.
- Instruments designed for infants below 18 months test sensorimotor function primarily.
- There is limited correspondence between test results in infancy and those in school age children in longitudinal studies.



**Adaptive function**

- A more pragmatic assessment of social function including temperament, sociability, affective status, and motivation to cooperate.
- Typical measures include the Vineland Adaptive Behaviour Scales.

**Mental status evaluation**

- The WISC provides verbal and performance scores, which may indicate differential hemisphere dysfunction. The overall IQ score is a summary of several aspects of cognitive function.
- Scatter in the subtest scores may suggest more detailed testing.

Further testing may include:

- Attention/inhibition.
- Mood and motivation.
- Orientation and memory.
- Speech and linguistic function.

Specific instruments exist for all these domains.

**Visuospatial**

Visuospatial tests assess right hemisphere function predominantly, although a left hemisphere influence may be present if verbal mediation occurs.

**Visuomotor functioning**

Closely related to visual item perception and visuospatial processing, visuomotor functioning adds a manipulation or graphomotor component to the perceptual tasks.

**Social-emotional functions**

These are particularly important in children with non-verbal learning disabilities.

**Executive functions**

Capacities that include:

- Attending in a selective and focused manner.
- Inhibition of off-task responding.
- Self-monitoring.
- Flexible concept formation.
- Planning.
- Judgement.
- Decision making.

Observation of spontaneous behaviour is also necessary to assess executive function, as the 'structured' nature of formal assessment compensates for the deficits being sought. Qualitative data (the types of errors produced) may be useful in determining context-related processing difficulties from executive function problems. No single test of executive function can test all of the 'executive functions'.

**What do the results mean?**

This involves three stages:

- Assessing the age appropriateness of behavioural function.
- Evaluating the skills necessary to the function.
- Neuropsychological evaluation and interpretation of results in light of the function, and assessment as to whether the results constitute a distinct neuropsychological profile.

**Tests in common use**

- Bayley Scales of Infant Development.
- Griffiths.
- British Ability Scales (primarily used within education: essentially measures of progress in literacy and numeracy against National Curriculum standards).
- WISC versions.

Specialized tests exist for specific situations (e.g. development scales for children with visual impairment). Discuss with your clinical psychology service.



*This page intentionally left blank*

# Signs and symptoms

- Agitation and confusion 104
- Back pain 106
- Behaviour disorders 107
- Developmental impairment 109
- Exercise limitation and muscle pain 117
- Eye movement abnormalities 119
- Facial movement abnormalities 126
- Facial sensation abnormalities 130
- The floppy infant 132
- Foot deformities 135
- Funny turns: episodic events 136
- Funny turns: likely epilepsy? 141
- Gait abnormalities 144
- Head shape abnormalities 146
- Head size abnormalities 148
- Headache 151
- Hearing loss 155
- Incontinence 157
- Movement abnormalities 159
- Magnetic resonance imaging and brain development 163
- Unexpected findings on magnetic resonance imaging 167
- White matter abnormalities on magnetic resonance imaging 170
- Numbness, pain, tingling, and sensory disturbance 174
- Peripheral weakness 176
- Psychomotor regression 179
- School failure 186
- Sleep disturbance 188
- Speech difficulties 192
- Swallowing and feeding problems 194
- Toe walking 196
- Unsteadiness and falls 197
- Visual disturbances 200

## Agitation and confusion

### Differential diagnosis

- Straightforward—if extreme—emotional reactions (panic, anger) to stress (e.g. from prolonged hospitalization or chronic illness).
- Reactions to pain, particularly in children with severe learning disability who cannot report its location.
- Acute confusional state or delirium.
- Psychosis (schizophrenia, manic depression).
- *Dementia*: very rare in paediatric practice, but can occur in later-onset neurodegenerative diseases.

See Table 3.1 for details of prevalence, onset, etc.

**Table 3.1** Differential diagnosis of agitation and confusion

	Delirium (acute confusional state)	Emotional reactions	Psychosis	Dementia
Prevalence	Common	Common	Rare as a new presentation in an acute hospital setting	Extremely rare
Onset	Acute or subacute	Acute or acute-on-chronic		Insidious
Course	Fluctuating, usually resolves over days to weeks			Progressive
Conscious level	Often impaired, can fluctuate rapidly	Intact		Clear until later stages
Cognitive defects	Poor short-term memory, poor attention span	Absent	Absent	Poor short-term memory, attention less affected until severe
Hallucinations	Common, especially visual	None	Auditory; third person	Often absent
Delusions	Fleeting, non-systematized	None	Fixed and systematized	Often absent
Psychomotor activity	Increased, reduced or unpredictable	Typically increased		Can be normal

### Assessment

The key question is whether there is any confusion or impairment of consciousness: the hallmark of an acute confusional state. A spectrum is seen from mild impairment to near unconsciousness. Severity typically fluctuates, being worse at night. Abnormalities in all areas of cognition are present.

Subtle degrees of confusion are confirmed by specific testing of *orientation*. This has two components.

**Knowledge of time, place and identity of other people**

- What is your name?
- How old are you?
- When is your birthday?
- Where do you live?
- Names of family members
- Where are you now? (Are you at home?)
- Is it day time or night time? Morning or afternoon?
- What time, day, month, year is it?

**Registration of events**


- Who came to see you today?
- What was the score in favourite football team's match/what happened in favourite reality TV show last night?

Orientation cannot be assessed in very young children. Formal tests of orientation (e.g. Children's Orientation and Amnesia Test) exist, but are time-consuming; norms are age-dependent.

**Other features of acute confusional state**

- Overactive and agitated, underactive and drowsy, or mixed.
- Fluctuates: worse at night.
- Anxious/irritable/depressed/perplexed.
- Thought abnormalities:
  - reduced speed;
  - muddled content;
  - ideas of reference, delusions.
- Speech mumbling and incoherent.
- Visual illusions and misinterpretations. Visual hallucinations are a marker of confusion until proven otherwise:
  - typically of small, moving, fear inducing things such as insects or snakes;
  - may co-exist with visual misinterpretations as part of the clouded sensorium.

**Acute management**

One of many important reasons for correctly distinguishing an acute confusional state from emotional reaction is the very different approach to management. Emotional reactions will be managed by verbal de-escalation. However attempts to argue, persuade, or cajole a child with an acute confusional state will be counter-productive. The mainstay of management is environmental modification. For investigation and management of acute confusional state see  p. 534.

## Back pain

Always a cause of concern in childhood and adolescence. Consider:

### Infection

#### *Discitis in toddlers*

- The child will often refuse to stand or will walk with a very straight back, 'guarding' the spine (i.e. an antalgic gait).
- May be febrile.
- Check full blood count (FBC), erythrocyte sedimentation rate (ESR), blood cultures.
- Plain spine X-ray may show a narrow disc space.
- Consider a bone scan and magnetic resonance imaging (MRI).
- Treat for *Staphylococcus aureus* (usually for 6 weeks). If there is no response to intravenous (IV) antibiotics, consider needle aspiration.

#### *Osteomyelitis*

- Managed similarly. Always consider tuberculosis (TB).

### Skeletal causes

- *Disc herniation*: uncommon in childhood. The pain is worse on raising the leg.
- *Spondylolysis*: defect of the pars interarticularis; may have a fracture. Seen in gymnasts and rugby players.
- *Spondylolisthesis*: slippage of a vertebra anteriorly. The significant cause of back pain in adolescents. Increased with hyperextension activities such as gymnastics, ballet, skating. Treatment—symptomatic, but if there is no improvement, may need surgery.
- *Osteochondritis*: Scheuermann disease often seen with a kyphosis.
- *Rheumatic disease*: juvenile rheumatoid arthritis (JRA), ankylosing spondylitis.
- *Scoliosis*: usually not painful.

### Tumours

- *Malignant*: neuroblastoma, lymphoma, leukaemia.
- *Metastatic*: neuroblastoma, rhabdomyosarcoma, Wilm tumour, retinoblastoma, teratoma.
- Osteoma, osteoblastoma.

### Intra-abdominal causes

Pyelonephritis, retrocaecal appendix, pancreatitis.

### Others

- Back pain can be the initial presentation of Guillain-Barré syndrome in toddlers, causing initial confusion, although the fuller picture quickly develops.
- May be the presenting feature of transverse myelitis, particularly if associated with paraesthesiae in the lower trunk or legs.
- Functional disorder, illness behaviour.
- Plexiform neurofibromas can cause pain without being externally visible.
- (Extremely rarely) as part of a generalized pain syndrome in acute attacks of porphyria (see [p. 367](#)).
- Risk factors for benign causes: obesity, heavy back-packs, joint laxity.

## Behaviour disorders

A term describing a common situation where parents, teachers and/or other carers are experiencing (perceived) difficulty managing a child. A general approach is to decide whether behaviour is:

- A response to environment.
- Biologically mediated.
- (Often) a combination of both.

Then,

- Define the pattern.
- Identify the aetiology.
- Draw up a management plan, which should include counselling and/or medication; or where a metabolic disorder is identified, more complex condition-specific intervention.

### History

- What is the nature of the concern around behaviour?
- When was it first noticed? Recent onset after period of normality?
- Recent major life events?
- When is it noticed? Home and school?
- Are nursery/pre-school reports available?
- Are there concerns about developmental impairment?
- Are unrealistic parental expectations an issue?
- Is there any suggestion of poor parental child-management skills?
- Are there co-morbidities?

### Formulation

#### *A response to environment?*

Causes often difficult to define without detailed family therapy. Family factors include:

- Deprivation and neglect.
- Inconsistent or unskilled parenting.
- Unstable families.
- Violence in the home.
- Parents with anti-social personalities.

#### *A child under pressure?*

- Struggling at school with:
  - specific learning difficulties;
  - developmental coordination disorder;
  - associated poor self-esteem.
  - see 📖 'School failure', p. 186.
- Struggling with friendships:
  - Learnt (anti-) social behaviour
  - Problems with inter-personal skills (autism?)

#### *Biologically mediated?*

- Any cause of developmental impairment (is the behavioural pattern more appropriate for the child's developmental age than their chronological age?)( See 📖 p. 109).
- Autistic spectrum disorder (see 📖 p. 114).



- Specific learning difficulties (e.g. dyslexia): often reflecting in part poor self-esteem and a child under stress.
- Epilepsy (see 📖 p. 517).
- Late-onset metabolic disease particularly when deterioration follows period of normality (see 📖 p. 365).

#### ***A mixture of environment and biologically-mediated disorders?***

For example, the child with genetically-determined learning difficulties under pressure at school adopting strategies for task avoidance or attention seeking.

Each dimension needs assessment and appropriate intervention.

### **Specific patterns**

#### ***Oppositional defiant disorder***

The child is often negative and defiant, with a frequent loss of temper; arguing or non-compliant with adults. The child may be angry and resentful, irritable and easily annoyed, and deliberately annoying other people.

#### ***Conduct disorder***

The child shows a persistent tendency to transgress normally accepted rules or the rights of others. This is often seen as:

- Bullying or threatening
- Initiating fights and harming others.
- Cruelty to people or animals.
- Destroying property, fire-setting, theft, running away from home or truancy from school.

#### ***Attention deficit disorder***

A developmental disorder resulting in difficulty directing attention to tasks, listening to or following instructions, or organizing activities. Children exhibit distractibility, varying degrees of fidgetiness and impulsivity (e.g. interrupting and intruding on others).

Treatment with stimulant drugs (methylphenidate, atomoxetine) may be indicated; a behavioural approach with firm, consistent handling with the definition of boundaries of acceptable behaviour usually used first, particularly for the under 5s.

## Developmental impairment

The US equivalent is 'mental retardation'. A general approach is to decide whether delay is:

- Of recent onset or longstanding.
- Static or progressive (regressive).
- Global or specific:
  - Each area of development should be carefully assessed in turn. It is easy for one area of more obvious delay, such as gross motor, to 'mask' more subtle deficits in others, such as language
  - An attempt should be made to quantify the degree of delay for all areas. This gives a profile of skills that can be compared with in the future, to see if development is static, progressing or regressing.

### History

- What is the nature of the delay?
- When was it noticed?
- Are nursery/pre-school reports available?
- Are there concerns about other areas—motor, communication, social interaction, vision, hearing, general health?
- If further questioning is suggestive of developmental regression or an obvious inheritable cause, see 📖 'Psychomotor regression', p. 179.

### Global impairment

#### Causes

A genetic or syndromic cause is typically identified in ~20% of children investigated for global developmental impairment, in the absence of neurological (particularly motor) signs, regression, dysmorphism, family history, or other evidence of genetic causes. Metabolic testing contributes in ~1% of cases. Causes that are sometimes overlooked include:

- *'Mild' cerebral palsy (CP) and dyspraxia*: motor difficulty can disadvantage development in general; co-existent attention deficit hyperactivity disorder (ADHD) is common. Some authorities denote this combination disorders of attention, motor processing and perception (DAMP).
- *Less obvious genetic causes*: including fragile X, 22q11 deletion syndrome, Sotos (not always obvious), Angelman (not always obvious in early stages), Rett (before stereotypies and regression are evident), maternal phenylketonuria (associated with microcephaly), some of the less dysmorphic mucopolysaccharidoses (type III), Duchenne muscular dystrophy, myotonic dystrophy, tuberous sclerosis (TS), neurofibromatosis type 1. Cerebral malformations, especially subtle ones.
- *Infection including human immunodeficiency virus (HIV) and cytomegalovirus (CMV)*: note that HIV encephalopathy can be the sole presenting feature of acquired immunodeficiency syndrome (AIDS) in children and is treatable (see 📖 p. 341).
- Antenatal exposure to toxins including alcohol.
- Postnatal exposure to toxins, e.g. lead (still important in some areas of USA).

### History

- *Birth history*: maternal alcohol, medication, or recreational drugs; infection; movements *in utero*; oligo- or polyhydramnios; pre-, peri- or post-natal risk factors for CP.
- Evidence of general clumsiness in fine/gross motor skills? Early oromotor problems.
- Recurrent or persistent infections. Repeated hospital admissions.
- Risk factors for HIV infection.
- Family history of learning difficulties.
- Consanguinity.
- Is there a behavioural phenotype?

### Examination

Examination is to look for inheritable causes; see also 📖 'Psychomotor regression', p. 179. In order of diagnostic yield: face, then hands, then skin.

- 'Gestalts' include 22q11, Cornelia de Lange, Kabuki (everted outer third eyelid, 'thumb print' appearance to centre of bottom lip), 1p36 deletion (linear eyebrows, deaf, aggressive seizures).
- Skin abnormalities, including signs of neurocutaneous syndromes.
- Neurological abnormalities, particularly pyramidal or extrapyramidal motor signs.

### Investigations

If no specific clues are found in the history, then the chances of finding a diagnosis are small.


However, a general screen is often taken with variations on the following:

- *Blood*: karyotype, toxoplasmosis, rubella, cytomegalovirus, herpes virus (congenital infection syndrome (TORCH)), urea & electrolytes (U&E), liver function tests (LFT), FBC, amino acids, (venous) blood gas, thyroid function, creatinine kinase (CK).
- *Urine*: organic acids, amino acids, mucopolysaccharidosis (MPS)/ glycosaminoglycans (GAG), oligosaccharides.
- MRI of the head, particularly in the presence of motor signs. Otherwise, depending on severity of the delay, although subtle abnormalities are being increasingly found with high resolution scans.


The following may be considered if specific features in history or examination are suggestive:

- Maternal phenylketonuria (PKU) status.
- Electroencephalography (EEG).
- Fragile X.
- Specific polymerase chain reactions (PCRs) on stored Guthrie card blood spots (CMV, rubella) for suspected congenital infection.

### Genetics review

- An area undergoing rapid change. Routine karyotyping has a resolution of 4–8 mega base-pairs, with a yield of 1–5% in children with unexplained developmental delay.
- Studies using fluorescent *in situ* hybridization (FISH) and multiplex ligation dependent probe amplification (MLPA) have detected submicroscopic telomeric abnormalities in an additional 5% of patients.
- To date, array-based comparative genomic hybridization techniques (array CGH) have identified submicroscopic interstitial chromosomal imbalances known as copy number variations (CNVs) in an additional 5–20% of individuals.
- It is likely that array CGH will play an important role in identifying novel microdeletion/microduplication syndromes, with the disadvantages of cost, currently-limited access to this investigation, and the identification of abnormalities of unknown significance (see  p. 90).
- In the absence of identified single-gene disorder, empirical (average) recurrence risks are approximately 1 in 7.5 for a brother and 1 in 20 for a sister of an index male; 1 in 12 for a brother and 1 in 15 for a sister of an index female.
- X-linked learning difficulties are probably important in non-dysmorphic, but otherwise healthy boys (perhaps 10% all LD? At least 130 different genes).

### Specific motor delay/late walking

This often presents as a child with delayed sitting or walking. As the child will usually be young, the motor problem usually predominates and delay in other areas (language, etc.) may go unnoticed. For children who have achieved motor milestones, but remain awkward or clumsy, see  'Gait abnormalities', p. 144.

### Causes

'Physiological' causes include:

- Familial delay.
- Variations on normal developmental patterns, e.g. 'bottom shuffling'.
- Ligamentous laxity.
- Prematurity with development not corrected for gestational age.

Common pathological causes include:

- Undiagnosed 'mild' CP.
- Developmental coordination disorder (dyspraxia).
- Duchenne muscular dystrophy in boys (vital to diagnose early for genetic counselling and family planning purposes).

Less common causes include hypothyroidism, Prader–Willi, cord lesions and neuromuscular conditions, such as spinal muscular atrophy (SMA), congenital muscular dystrophy, and hereditary sensorimotor neuropathies.

**History**

- Take detailed developmental history to see if other skills are also delayed.
- Early hand preference?
- Early visual preference for one side?
- Floppiness?
- Weakness/stiffness (resistance when changing nappies, clothes).
- Disparity of skills of the upper limbs compared with the lower limbs.
- Oromotor difficulties.
- Bladder/bowel control problems (dribbling urine/constipation).
- Family history.

**Examination**

Observation of level of alertness, interest in the environment, and social interaction can give an idea of whether there is cognitive impairment and, hence, a more generalized 'central' cause.

Opportunistic observation of quality of movement in free play will often be more informative than attempted formal motor examination. Observe for asymmetry or stiffness, and identify the limbs affected.

- *Tone*: increased or decreased? Central or peripheral lesion pattern?
- Long tract signs, contractures, scoliosis, persistence of immature reflexes, reflex level (check abdominal reflexes).

**Investigation**

- Check CK in all boys not walking by 18 mths.
- Perform MRI of the brain if corticospinal, extrapyramidal, or cerebellar signs are present. If MRI of the brain is normal and signs are consistent consider MRI of the spine.
- Consider investigations for neuromuscular disease (see 📖 p. 176).

**Specific language delay**

The assessment of language delay is complex! Language is more than speech, and requires both verbal and non-verbal skills to permit social communication.


**Some definitions**

- *Language*: a system of learned symbols with socially shared meaning.
- *Speech*: the production and perception of the oral symbols used for language.
- *Voice*: the acoustic characteristics of speech and non-speech sound.
- *Phonology*: the production of individual speech sounds.
- *Syntax*: the grammar of a language.
- *Pragmatics*: the use of words.
- *Semantics*: the meaning of words.
- *Receptive function*: speech comprehension.
- *Expressive function*: speech generation.



Presentation of language delay can therefore be conceptualized as being due to a problem with:

- The form of the language (phonology, syntax).
- The content of the language (semantics).
- The function or appropriateness of the language (pragmatics).


### Causes

- Developmental dysphasia:
  - mixed receptive–expressive (e.g. verbal auditory agnosia);
  - expressive (e.g. developmental verbal dyspraxia);
  - higher order processing (e.g. semantic pragmatic disorder).
- Pervasive developmental disorders including autism (see  p. 114).
- Reading disorders (dyslexia):
  - selective comprehension deficit;
  - speech sound discrimination;
  - dysnomia (inability to retrieve word from memory when needed).
- Emotional reactions as seen after major trauma or abuse, and selective mutism.

A neurologist can seek associated neurological conditions. These include:

- *Epilepsy*: non-convulsive status and Landau–Kleffner spectrum (see  p. 272).
- Worster–Drought and bilateral perisylvian syndrome.
- Duchenne dystrophy.
- Cerebellar mutism after posterior fossa surgery (see  p. 461).
- Occasionally adrenoleukodystrophy can present with a receptive language problem.

### History

- Current problem as seen by carers. Supplemented by screening questionnaires or Speech and Language Therapist (SALT) reports to pinpoint areas of concern.
- How does the problem manifest in different situations: home, school, with adults, peers, older or younger children?
- How does the child communicate his needs?
- Dribbling/drooling, swallowing difficulties, aspiration, reflux?
- Deterioration over weeks or months after early normality?
- Epilepsy?
- Behavioural problems including ADHD and mood problems?
- Auditory agnosia?
- A detailed developmental history as in the section on PDD (see  p. 115).

► Parents should understand about half of a child's speech at 2 yrs and three-quarters at 3 yrs.

### Examination

- *Oral cavity inspection*: tongue, palate, dentition, tongue, and frenulum.
- Oral-motor examination to evaluate the strength of the muscles of the lips, jaw and tongue (e.g. move the tongue from side to side, smile, frown, puff out the cheeks, etc.).
- Drooling?
- Coordination and sequencing of speech musculature. Ask the child to repeat strings of sounds (e.g. puh–tuh–kuh) as quickly as possible and perform actions such as licking a lollipop.
- Associated dyspraxia?
- Reading ability.
- Oral-sensory perception (identifying an object in the mouth through the sense of touch).

*Assessment by other professionals*

Evaluation cannot be made by a neurologist alone and should include SALT, psychologist, occupational therapist (OT), and/or physiotherapist assessments.

- Cognitive ability. Irrespective of the nature of the problem, a cognitive assessment will inform prospects of a child communicating verbally or with an assistive device.
- Hearing assessment.
- Overall quality of verbal and non-verbal social communication skills (observation of the child in play: gesture, pointing, imitation).
- Quality of voice.
- Comprehension of language (evaluated using standardized tests).
- Expressive ability (word knowledge, use of grammar, ability to sequence a set of ideas, communication of needs).
- *Observation of articulation*: vowel and consonant sounds and combined sounds (syllables, etc.). Estimate of overall intelligibility of speech.

**Investigations**

- Limited role for formal neurological investigations.
- MRI in selected cases where there is strong evidence of a motor disorder.
- Sleep and waking EEG in suspected Landau–Kleffner and related disorders.

**Pervasive developmental disorder**

The *Diagnostic and Statistical Manual of Mental Disorders*, 4th edn (DSM-IV) concept includes autism, Asperger syndrome, and pervasive developmental disorder (PDD) ‘not otherwise specified’ (PDD-NOS, synonymous with *International Classification of Diseases V. 10* (ICD-10) term ‘atypical autism’), which may be best understood as being part of a continuum of ‘autistic spectrum disorders’. Additionally includes Rett syndrome and childhood disintegrative disorder (very rare).

A number of ‘screening’ tools (e.g. Checklist for Autism in Toddlers, (CHAT)) have been developed to help identify children with the disorders. They vary in quality and complexity, and should only be used by those familiar with their usage and limitations.

❗ Diagnosis of autism requires the assessment of more than one professional and observation of the child in more than one setting.

The condition is characterized by the triad of impairments in:

- Communication.
- Social interaction.
- Interests/imagination.

Assessment may be helped by the use of standardized assessment instruments, such as the Autism Diagnostic Inventory (ADI)/Autism Diagnostic Observation Schedule (ADOS) (formal training in their use is required).

**Early history***0–6 mths*

- Smiled back, responsive?
- Reciprocal vocalizations?
- Able to make him laugh, how?
- What sort of baby was he?

*6–12 mths*

- Motor milestones.
- Cuddles?
- Peep-bo?
- Pleased to see you in the morning?
- Raised arms to be picked up?
- Wave bye-bye, clap?
- Turn to name?
- Musical, communicative babble?
- Cause and effect play?

*12–18 mths*

- When did he walk?
- What was he like once on his feet? Did he explore?
- Did he bring toys for joint play?
- *First words*: when, what, to request, to name, or just copied and not for communication?
- *Pointing*: for need or to show?
- Referential eye contact?
- *Looking at books together*: joint attention?
- Is he imitative?
- *Play*: symbolic, repetitive, spontaneous, needed direction?
- *Other behaviours*: rigidity, routine?

*18–24 mths*

- Self-help skills?
- Response to parents arriving/leaving?
- Response to familiar adults?
- Interaction with other children?
- Copy housework?
- *Language development*: if poor then how does he communicate needs?
- Response to nursery rhymes?

**Current situation***Social interaction*

- How does he show affection?
- Does he make eye contact?
- Gesture/facial expression?
- *Peer relationships*: interested, inappropriate, passive?
- Sensitivity to feelings and expressions of others?
- Behaviour in public, appropriate social inhibitions?



*Verbal and non-verbal communication*

- How are needs communicated?
- *Speech*: echolalia, repetitive, stereotyped, idiosyncratic, appropriate?
- Does he ask questions appropriate to the occasion, listen and understand answers?
- Is it possible to have a two-way conversation or does he direct topics?
- Does he expect you to know things you don't? Go off on tangent?
- Literal interpretation?
- *Appreciation of subtleties of humour*: does he understand jokes or slapstick humour?
- What does he play with? Is it truly imaginative or role-play?

*Patterns of behaviour*

- Preferred activities: are they obsessions, stereotyped, restricted?
- *Range of things he plays with*: does he have a fascination with non-functional/toy parts?
- Is he flexible with day-to-day activities or resistant to change?
- *Motor mannerisms*: hand flapping, spinning, rocking.

*Other information*

- Evidence of regression?
- Sleep pattern?
- Epilepsy.


**Examination**

- Neurocutaneous stigmata.
- Hearing and vision.
- Specific phenotype for Rett syndrome, fragile X, and TS.

**Investigations**

The following should be considered: chromosomes, fragile X-locus (FRAX), methyl-CpG-binding protein 2 gene (MECP2), EEG, MRI.

## Exercise limitation and muscle pain

These are relatively common complaints, but actual pathology is uncommon. Distinguish tiring and wanting to stop after a short distance, common in many neuromuscular (and other) conditions, from true *fatigue*: the development of or increase in weakness with exercise. See  'Neuromuscular conditions', p. 390 for more details.

### Causes

Non-neuromuscular causes, such as post-viral illness are common. Also consider non-neurological causes, such as arthropathy. Neuromuscular causes in children include the following.

#### Exercise limitation

- Myaesthesia, fatigue.
- Any significant neuromuscular condition.

#### Stiffness

- Myotonic dystrophy.
- Myotonia congenital.
- Paramyotonia.
- Periodic paralyses.
- Hypothyroidism.

#### Pain or cramps

- *Poorly localized deep ache or discomfort*: dystrophies or inflammatory myopathy.
- *Localized, excruciating*: viral myositis, muscle abscess, trauma, compartment syndrome.
- *Cramps (painful contractions relieved by stretching)*: neuropathies, metabolic myopathy, e.g. McArdle disease (with second wind phenomenon) or carnitine palmitoyl transferase deficiency (fatigue with prolonged exercise, no second wind).

### History

#### Exercise limitation

Try and understand why this is happening. Are there non-specific reasons or is the child actually weak?

#### Weakness

- Is it static or progressive.
- Does it fluctuating (myasthenia) or intermittent (periodic paralysis, myotonia congenita).
- Is it exercise-related (metabolic myopathy, especially with 'second wind phenomenon').
- *Pattern of weakness*:
  - proximal (reaching up, brushing hair, getting out of chair or up off the ground);
  - distal (gripping things);
  - both (myotonic dystrophy).

**Stiffness***Myotonia*

- Difficulty with hand release.
- 'Freezing' after a period of rest or on standing from sitting, improves with gentle exercise (warming up phenomenon)—myotonia congenita.
- Freezing with on-going activity, exacerbated by cold—paramyotonia, periodic paralysis.

**Pain**

- Localized (infection, peripheral nerve lesion, metabolic myopathy) or generalized (dermatomyositis, viral, drugs, metabolic myopathy).
- At rest (as 'localized' pain) or during exercise (metabolic myopathy).

**Family history**

- Cataract (myotonic dystrophy).
- Diabetes, deafness (mitochondrial).

**Myoglobinuria**

- Urine like 'Coca-Cola'.
- 'Haematuria' on testing with strip, but no red cells on microscopy.
- Metabolic myopathies, but can also occur in dystrophies, including boys with Duchenne muscular dystrophy (DMD) on steroids following strenuous activity.

**Anaesthetic history**

- Adverse reactions to previous anaesthetics.
- Family history of such reactions.

**Involvement of other systems**

Cardiomyopathy.

**Drugs**

- Lipid lowering agents.
- Antipsychotics.

**Examination**

Look at the neuromuscular section for more detail (see  p. 390).

## Eye movement abnormalities

Disorders of ocular movement disturb conjugate eye movements that maintain binocular vision. The key question to ask is whether this is a paralytic or non-paralytic squint, which is the same as asking:

► Is each eye *considered separately* capable of a full range of movement?

If the answer to this question is yes, this is a non-paralytic squint—a failure of coordination of the movements of each eye and by far the most common cause of non-conjugate eye movements. If no, then this reflects a lesion somewhere in the eye movement pathways, i.e. a paralytic squint.


### Non-paralytic squint

This affects 5% of pre-school children in the Western world. Ocular alignment is poor in newborns. Constant alignment begins around 3 mths of age and a 'nasal-ward' gaze bias persists until 6 mths.

Predisposing factors include very low birth weight, intraventricular or occipital-parietal haemorrhage, hydrocephalus, and trisomy 21. In neurologically normal children, squint is caused by genetic factors, intra-ocular anatomy or extra-ocular muscle conditions. A common cause is a unilateral refractive error (commonly long-sightedness). Failure to correct such factors early, leading to dominance of the influence of the 'good' eye during a *critical window* between birth and about 2 yrs of age results in permanent and irreversible imbalance in the representation of inputs from each eye in the *ocular dominance columns* of the visual cortex, and permanent *amblyopia*, suppression of the visual input from the 'weak' eye (even if the ocular cause of the imbalance is subsequently corrected). Prevention is by correction of the primary ocular deficit, and *patching* of the good eye to 'force' use of the weak eye.

### Squint types and ophthalmological jargon!

#### **Latent (heterophoria)**

- Intermittent.
- Brought on by stress/fatigue.
- Cover/uncover test (see  p. 22).

#### **Manifest (heterotropia)**

Constant.

#### **Convergent (esotropia if manifest; esophoria if latent)**

- Inward deviation.
- Need to rule out long-sightedness, i.e. accommodative squint attempting to overcome hyperopia.

#### **Divergent (exotropia if manifest; exophoria if latent)**

- Outward deviation.
- Need to rule out intra-ocular disease.

**Concomitant**

- Latin: *concomito*, 'I accompany'.
- The misalignment, or relative angle, between the two eyes remains constant as the eyes look around.

**Incomitant**

The relative angle between the eyes (the extent to which misalignment is evident) varies as the eyes move.

**Pseudo-squint**

Pseudo-esotropia due to prominent epicanthic folds and a broad nasal bridge (apparent convergence) accounts for 50% of suspected squints. The cover test will be normal and light reflex central.

- ❗ Any new 'squint' (i.e. appearing after a period of normal binocular eye movement control) warrants urgent neurological consideration including MRI; it may represent a cranial nerve palsy.

**Paralytic squint**

Amongst acquired third, fourth, and sixth cranial nerve palsies, in isolation or combination, trauma is the most common cause, followed by tumour.

**Cranial nerve disorder**

Lesion of cranial nerves III, IV, and VI, alone or in combination.

**Ocular muscle disorders**

- Congenital shortening of the superior oblique muscle or tendon (Brown syndrome).
- *Congenital fibrosis of extra-ocular muscles (CFEOM)*: bilateral ptosis and restricted up-gaze, autosomal dominant.

**Duane syndrome**

- Rare congenital non-progressive disorder of horizontal eye movement.
- Congenital absence of VI nerve nucleus (cause uncertain), with associated aberrant innervation of lateral rectus by the III nerve.
- Clinically, results in limited horizontal eye movement, and often globe retraction and narrowing of palpebral fissure on attempted eye adduction.


**Neuromuscular transmission**

- Congenital myasthenia (see 📖 p. 413 and Table 3.2).
- Ocular autoimmune myasthenia (see 📖 p. 411).

**Cranial nerve palsies****Acute acquired ophthalmoplegia**

- Defined as maximum intensity within 1 week of onset.
- Unilateral or bilateral.
- Partial or complete.
- See also Table 3.2.

**Table 3.2** Causes of paralytic squint

Cranial nerve	Always consider raised intracranial pressure
	Idiopathic
	Trauma
	<i>Vascular:</i> cavernous sinus thrombosis* (usually spread of ear or sinus infection)
	<i>Infection:</i> meningitis, orbital cellulitis, diphtheria*, Gradenigo syndrome (middle ear infection)
	<i>Inflammation:</i> Miller–Fisher*
Ocular muscle	Mitochondrial myopathies (usually chronic and progressive external ophthalmoplegia: see  p. 370)
	Thyroid disease
Neuromuscular transmission	Myasthenia gravis
	Botulism
	Tick paralysis
Brainstem	Tumour
	<i>Vascular:</i> arteriovenous malformation (AVM), haemorrhage, infarct, migraine, vasculitis
	<i>Demyelination:</i> acute disseminated encephalomyopathy (ADEM), multiple sclerosis (MS)
	<i>Toxic:</i> tricyclics, anti-epileptic drugs (AEDs)
	<i>Infection:</i> basilar meningitis*

\* Often bilateral involvement.

## Other eye movement disorder patterns

### Vertical gaze palsy (supranuclear gaze palsy)

- Child cannot look up or down fully.
- *Failure of upward gaze:* dorsal midbrain damage (pineal region); Niemann–Pick; variant Creutzfeld–Jakob disease (vCJD).
- *Failure of downward gaze:* rare; bilateral tectal/midbrain reticular formation lesions.

### Horizontal gaze palsy

- Unable or unwilling to look to one side; however, horizontal movements to Doll's Eye manoeuvre are present (i.e. this is a 'failure to generate the command' to look to one side, although the mechanism to move the eyes is intact).
- Typically due to disease in cerebral hemispheres:
  - lesion in the frontal eye fields in contralateral frontal lobe (results in tonic deviation toward side of the lesion with contralateral hemiplegia);

- parieto-occipital lesions giving rise to a hemianopia or hemi-inattention (i.e. unaware of visual targets on one side);
- Gaucher disease.

### **Ocular motor apraxia (saccade initiation failure)**

- Impairment of saccadic eye movements (that redirect the eye to a new visual target).
- Child uses head thrusting with overshoot or blinking to move their eyes instead.
- Usually associated with neurological problems:
  - *congenital malformations*—agenesis of corpus callosum or cerebellar vermis;
  - *neurodegenerative conditions*—lysosomal storage diseases (Fabry, Gaucher), ataxia telangiectasia.


### **Internuclear ophthalmoplegia**

- Normal horizontal eye movement requires connection between cranial nerve VI abducting one eye, and cranial nerves III and IV adducting the opposite eye.
- Cranial nerves III and IV are higher in the brainstem (more rostral) than VI, so a longitudinal connection passing vertically through the pons is required: the medial longitudinal fasciculus (MLF) (see Figure 2.11).
- MLF may be affected by demyelination, inflammation, infarction, intoxication, or traumatic axonal injury.
- The child is asymptomatic at rest, but complains of diplopia on lateral gaze.
- Lesion of the right MLF would cause failure of adduction of the right eye on attempted left gaze; left eye abducts normally.
- Both eyes may show nystagmus (more marked in the abducting eye).
- A combination of a lesion to MLF plus the ipsilateral VI nucleus or parapontine reticular formation) results in 'one-and-a-half' syndrome—loss of all horizontal eye movement except abduction of the contralateral eye.
- Can be bilateral resulting in intact abduction, but impaired adduction of each eye.

### **Ptosis**

Drooping of one or both eyelids from birth is common. It is essential to distinguish congenital from acquired; *look at baby photographs*.

#### **Congenital**

- Horner syndrome (see  p. 124).
- Myasthenia gravis.
- III nerve palsy.
- Syndromes associated with ptosis, e.g. Noonan, Saethre–Chotzen.
- *Congenital idiopathic*:
  - most common 'cause';
  - 70% unilateral;
  - eye movements normal;
  - may have Marcus–Gunn 'jaw-winking' phenomenon (synkinesis between III and V).

If examination findings suggest Horner or III lesion, MRI is required to exclude structural causes.

**Acquired**

- Horner syndrome (see 📖 p. 124).
- Myasthenia gravis.
- III nerve palsy.
- Migraine.
- Trauma.
- Infection/inflammation of lid or orbit.
- Mitochondrial myopathies.

**Ice pack test of ptosis for evaluation of possible myasthenia**

If neuromuscular junction dysfunction is being considered in a child with ptosis, hold an ice pack firmly over one eye for 2 min. Improvement in the ptosis (i.e. better elevation of the eyelid) relative to the opposite (control) eye strongly suggests myasthenia as the cause of the ptosis (this is only reliable if baseline ptosis is bilateral and relatively symmetrical).

**Nystagmus**

Involuntary, rhythmic oscillation of the eyes, in which at least one phase is slow.

- **Pendular:** slow in each direction.
  - assess visual acuity—can reflect difficulty fixing on target ('sensory nystagmus');
  - optic atrophy (need to rule out optic glioma);
  - demyelinating disease.
- **Jerky:** slower in one direction; named for the direction of the fast jerk return component. Always consider toxicity.

**Horizontal**

- Drug-induced (AEDs, psychoactive drugs, alcohol).
- Ictal.
- Vestibular (labyrinthine disease; usually with vertigo, nausea, vomiting, deafness, or tinnitus).

**Vertical**

- Downbeat (phenytoin, carbamazepine; cerebellar degeneration; heat stroke).
- Distinguished from nystagmus occurring only on looking down—sign of cervico-medullary junction or cerebellar lesion.
- Upbeat (medullary lesions).

**Dissociated**

- Monocular (spasmus nutans; chiasmatic tumour, amblyopia).
- See-saw (sellar and para-sellar tumour, retinitis pigmentosa).

**Congenital onset nystagmus**

- Relatively common.
- Present from birth, but may not be identified until several months of age.
- Familial, idiopathic or associated with visual impairment (VI).
- Usually conjugate and horizontal.
- Increased by fixation, visual interest, and arousal.
- Decreased by convergence and eyelid closure.



- Idiopathic (benign) congenital nystagmus typically has a 'null' direction of gaze in which the amplitude of the nystagmus is minimized: this may be eccentric, resulting in a head turn.
- **!** A diagnosis of exclusion: all children with nystagmus require MRI.
- **!** Nystagmus (particularly rotatory) is a common presentation of pineal region tumours in infants, but delayed presentation due to inappropriate reassurance by professionals is frequent.

### Physiological

High frequency (1–3 Hz), low amplitude, at extremes of lateral gaze (i.e. emerging during clinical examination of eye movements), especially with fatigue.

### Horner syndrome

- The combination of ipsilateral mild ptosis, miosis (small pupil), variable anhidrosis, and enophthalmos.
- Pharmacological testing provides useful confirmation. Cocaine eye drops are no longer readily available. 0.5% apraclonidine ( $\alpha$  agonist) eye drops will reverse miosis. Demonstration of marked mydriasis (dilatation) with paredrine eye drops (an amphetamine) confirms normal function of the final, third-order neuron in the sympathetic pathway (i.e. if paredrine effect absent, this is the site of the lesion).
- The presence of iris heterochromia, where the ipsilateral iris is more blue or green, and less brown than the normal contralateral iris (due to the absence of melanin) indicates the Horner syndrome is of congenital origin (there are other causes of iris heterochromia).
- Otherwise family photographs can be very helpful in establishing whether the Horner syndrome is congenital or acquired.
- Horner syndrome reflects disruption of the ipsilateral sympathetic pathway anywhere along its course. Important causes of acquired lesions include the lateral medullary syndrome (occlusion of the posterior inferior cerebellar artery causing ipsilateral ataxia, XII lesion, and contralateral disruption of spinothalamic function, see Figure 2.11), syringomyelia, brachial plexus injuries (Klumpke), cervical ribs, abnormalities of the aorta or carotid artery (e.g. dissection, aneurysm), lesions in the upper thorax, goitre, middle ear disease, and cavernous sinus thrombosis.

All cases of Horner syndrome require MR imaging. This must include the entire course of the sympathetic tract from medulla to upper thorax. Normal findings (i.e. 'idiopathic') are common in congenital onset situations.

### Spasmus nutans

- Onset 6–12 mths.
- Otherwise healthy child.
- Idiopathic, rarely associated with optic glioma.
- Triad of binocular nystagmus, titubation, and head tilt.
- High frequency, low amplitude, dysconjugate.
- Resolves spontaneously after 1–2 yrs.
- Diagnosis of exclusion—all children should be imaged.

## Opsoclonus

Also known as the 'dancing eyes' phenomenon or saccadomania. A pattern of uncontrolled saccades, i.e. rapid, chaotic, multidirectional, but *conjugate* eye movements.

Associated with:

- *Neuroblastoma* (see 📖 p. 460): particularly as part of the 'dancing eyes, dancing feet', opsoclonus-myoclonus syndrome.
- *Drugs*: amitriptyline, diazepam, phenytoin.
- Probably, infections (Coxsackie B, para-influenza, Epstein-Barr), although some authorities suggest even supposed post-infectious cases are, in fact, due to occult neuroblastoma.

GLUT1 deficiency (see 📖 p. 282) can present with eye movement abnormalities in infancy that can resemble opsoclonus.


## Ocular flutter

Brief horizontal oscillatory eye movements occurring with fixation. A feature of eye-movement disorders of cerebellar origin.




## Facial movement abnormalities

### Unusual movements

#### Tics

- Very common, particularly in boys.
- Peak ages at 5 yrs and then again around 10 yrs; majority largely or fully remit in adolescence.
- Worse with tiredness, stress, or boredom. Often disappear in sleep. Usually have family history.
- If accompanied by vocal tics or behavioural problems consider Tourette syndrome (see  p. 382).

#### Seizures

- Simple (clonic) partial motor seizures typically unilateral and due to structural lesions in contralateral primary motor cortex.
- May be difficult to control. If continuous, represents a form of *epilepsia partialis continua* (a feature of Rasmussen encephalitis (see  p. 222) and Alpers disease (see  p. 373)).
- Peri-oral seizures are a cardinal feature of benign childhood epilepsy with centrotemporal spikes (benign epilepsy with centrotemporal spikes (BECTS), Rolandic epilepsy: see  p. 268), but are often nocturnal and thus may not be noted.

#### Myokymia

Involuntary rippling movements often in the cheeks due to intrinsic pontine lesions (usually demyelination) or paraneoplastic. Very rare.

#### Hemifacial spasm

Intermittent twitching of facial muscles. Exclude structural lesions of the cerebello-pontine angle. Also a feature of gelastic seizures due to hypothalamic hamartoma. Very rare in children.

#### Facial weakness (Table 3.3)

- Generalized facial weakness may reflect a myopathic or neuromuscular junction pathology (tent-shaped, open mouth  $\pm$  ptosis).
- Beware asymmetric crying facies that may be mistaken for facial nerve palsy in newborns. This condition is due to hypoplasia of the depressor angularis oris muscle and results in an inability to pull down one corner of the mouth (resulting in an asymmetric crying face) and is usually obvious within hours of birth. Facial nerve function (reflected in, for example, symmetry of the nasolabial folds) is, however, normal.
- Misdiagnosis as a facial nerve injury (e.g. due to forceps delivery) is relatively common. A small number are associated with cardiac abnormalities, but most commonly it is a benign incidental condition that is less obvious in older childhood (less time crying!).

#### Decide if the involvement is an upper or lower motor neuron pattern

- Classically UMN facial weakness results in preserved forehead power and eye closure (the mechanism is controversial), but be aware that injury to selected lower branches of the facial nerve as they cross the cheek (e.g. by a parotid lesion) could result in the same pattern!
- Upper motor neurone (UMN) facial nerve weakness is unlikely to be isolated (e.g. likely to be associated with hemiplegia).

*Supranuclear facial weakness*

Voluntary facial movement (e.g. smiling for a photograph) originates in the face area of the motor cortex. Spontaneous (involuntary) facial expression of emotion has different, subcortical origins, and can be selectively preserved.

► Assess for concurrent involvement of the fifth, sixth, eighth and lower cranial nerves: very helpful in localizing the lesion.

*Pontine lesion*

- *Pseudobulbar palsy* due to high pontine lesions is a combination of (bilateral) UMN facial weakness with other lower cranial nerve defects, a hyperactive gag reflex, and typical emotional lability (weeping, laughing).
- Lateral pontine lesions result in facial analgesia and Horner syndrome ipsilateral to facial weakness.
- Lesions of the facial nerve nucleus itself inevitably result in ipsilateral sixth nerve weakness (due to a very close relationship) and usually contralateral hemiparesis.

*Cerebellopontine angle lesion*

Facial nerve closely related to fifth, sixth, and eighth nerves.

*Intratemporal segment lesion*

- The facial nerve has a long course, during various stages of which it is closely related to other cranial nerves. Its long course through a very narrow canal in the temporal bone is also unique, and probably underlies the vulnerability to traumatic or inflammatory injury.
- In the proximal segment it lies alongside the nervus intermedius. Involvement of hearing (either loss or hyperacusis due to involvement of the nerve to stapedius) is unavoidable.
- At the geniculate ganglion, secretomotor fibres leave to travel forward in the greater petrosal nerve to the lacrimal gland. Loss of tearing from the ipsilateral eye implies lesion is proximal to this.
- In principle, examination of taste in the anterior tongue should also have localizing value (chorda tympani), but in practice this is difficult as saliva carries material to the other side of the tongue too.

***Unilateral weakness of facial movement including forehead muscles***

This is a relatively common presentation and requires a careful search for the following causes:

- Hypertension.
- *Infection*: Epstein–Barr virus (EBV), mumps, herpes zoster of the geniculate ganglion (Ramsay–Hunt syndrome), Lyme disease, otitis media, mastoiditis.
- *Trauma*: instrumental delivery, facial fractures.
- *Infiltrative*: brainstem tumour, TB, leukaemia (expect other cranial nerve signs).
- *Idiopathic*: Bell palsy.
- *If bilateral or recurrent, consider evolving Melkersson–Rosenthal syndrome*: recurrent paralysis with facial/lip swelling and fissured/furrowed tongue (rare).
- Unlike adults, sarcoid is a very rare cause.

*History*

- Ask about noise intolerance (lesion in the proximal portion of the facial canal).
- Dry eyes/loss of tears.
- Tick bites (neuroborreliosis is an important cause of Bell palsy in Lyme-endemic areas), infection.

*Examination*

- BP.
- Assess the degree of impairment of eyelid closure and risk to the cornea (Bell phenomenon of eyes rolling upward on attempted closure seen if lids are not fully closed).
- Parotid swelling.
- Otoscopy for otitis media, cholesteatoma, herpetic lesions.
- Mouth for herpetic lesion of hard palate.
- Testing taste in anterior 2/3 for chorda tympani involvement is difficult.
- Exclude involvement of other cranial nerves (especially V: corneal reflex), presence of cerebellar and long tract signs: cerebellopontine lesion.

**Management of Bell palsy**

Good eye care with artificial tears and taping of the eyelid at night. If presentation is less than 7 days since onset, give prednisolone 1 mg/kg/day for 7 days and taper over 7 days. Some authorities recommend empiric use of aciclovir (e.g. for 5 days), however, this is controversial. It is, of course, clearly indicated in situations where a herpetic aetiology seems probable.

**Table 3.3** Causes of facial weaknesses

Facial weakness	Causes
<b>Congenital</b>	
Developmental	Moebius syndrome (aplasia of facial nerve nuclei/muscles* often multiple cranial nerves)
	Goldenhaar syndrome, Poland anomaly, DiGeorge syndrome, osteopetrosis, trisomy 13/18
	Bilateral congenital perisylvian syndrome*
Trauma	Birth nerve compression against sacrum, forceps delivery
Muscle disorders	Congenital muscular dystrophy, congenital myasthenic syndromes, congenital myopathies, myotonic dystrophy
<b>Acquired</b>	
Idiopathic (fairly common)	Bell palsy (may also have pain or numbness around ear and impairment of taste)
Infective	<i>Viral</i> —herpes zoster oticus (Ramsay–Hunt syndrome, vesicles seen in ear canal), herpes simplex, mumps, EBV
	<i>Borrelia</i> (Lyme disease), TB, listeria, diphtheritic neuropathy*, botulism (with ophthalmoplegia and dry mouth)
Vascular (rare in childhood)	Hypertension, diabetes, vasculitis
Inflammatory/autoimmune (MS rare in childhood)	Guillain–Barré*/Miller–Fisher syndrome*, otitis media, MS, myasthenia gravis*
Tumour	Pontine glioma, cerebellopontine angle tumour, leukaemia, meningeal carcinoma, parotid tumour
Trauma	Temporal or basal skull fractures
Granuloma	Sarcoidosis* (very rare in childhood)
Metabolic	Hypothyroidism*, hyperparathyroidism*
Genetic	<i>Melkersson syndrome</i> —recurrent facial nerve weakness with fissured tongue and facial/lip oedema
	<i>Fazio–Londé disease</i> —progressive bulbar palsy, muscular disorders including FSH dystrophy, myopathies, muscular dystrophy

\*Often bilateral.

FSH = facioscapulohumeral.

## Facial sensation abnormalities

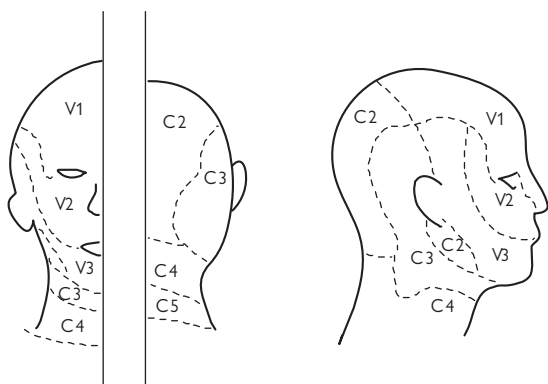
This can be divided into numbness or pain, or a combination of both (Table 3.4). All are very rare as isolated symptoms in children.

See Figure 3.1 for an overview of the dermatomal boundaries on the head and neck.

**Table 3.4** Facial sensation abnormalities

Sensation	Symptom
Pain in face	Referred from eye (iritis/glaucoma), sinuses, teeth, jaw
	Post-herpetic neuralgia
	Migraine
	Cluster headache (usually retro-orbital)
	Trigeminal neuralgia
	Functional*
Numbness in face	Simple partial sensory seizures
	Migraine
	Shingles
	MS
	Connective tissue diseases
	Sarcoidosis
	Dissociated sensory loss in syringobulbia (loss of pain sensation with preservation of light touch) tends to start peripherally on the face and spread to centre (sparing nose area until late)
	Non-organic*
Both pain and numbness	Preceding weakness in Bell palsy
	Tumour invading cranial nerve V—posterior fossa, base of skull, sinuses, salivary glands

\*In this context it is important to remember the trigeminal nerve territory in some detail: sensory disturbances that stop at the hairline (rather than the vertex), that extend down onto the neck, or that do not spare the angle of the jaw are not congruent with trigeminal nerve boundaries. National Institute for Health and Clinical Excellence (2012) Adapted from 'CG 137 The epilepsies: the diagnosis and management of the epilepsies in adults and children in primary and secondary care'. London: NICE. Available from (mouse symbol) [www.nice.org.uk](http://www.nice.org.uk). Reproduced with permission.



**Fig. 3.1** Dermatomal boundaries on the head and neck.



## The floppy infant

Floppy infants usually have poor head control, head lag, and truncal instability. When held in the air under the arms, infants will tend to 'slip through'. This section discusses chronic floppiness in infants, which may have been present in the prenatal period or developed later. *Acute* floppiness can occur with any severe acute systemic illness and is not discussed in this chapter.

► **Key question:** is the child 'just' floppy, or floppy *and weak* (e.g. in supine lying does the child have enough antigravity power to hold the limbs in the air?) Weakness implies a peripheral cause.

The approach to investigation depends on whether the floppiness is thought to be central (hypotonic, but preserved power) or peripheral in origin (hypotonic and weak).

In the majority of infants, the cause is central.

### History

- *Maternal history:* systemic diseases, drug history, unrecognized myotonic dystrophy?
- *Family history:* consanguinity, sudden infant deaths.
- *Pregnancy:* foetal movement, drug exposure (e.g. AEDs), polyhydramnios/oligohydramnios, abnormal presentation.
- *Delivery:* Apgar score (muscle tone?), resuscitation, cord gases.
- *Postnatal course:* feeding, alertness, response to stimuli, spontaneous activity, respiratory effort.
- *Course of floppiness:* deterioration over time?

### Examination

#### *Typical findings in hypotonia of central origin*

- Muscle strength usually normal.
- Reflexes normal or increased (may rarely be absent, especially in the first days of life).
- Axial tone often particularly affected with relatively good limb tone.

#### *Typical findings in floppiness of peripheral origin*

- Reduced axial and limb tone.
- *Anterior horn cell disease* (e.g. SMA): generalized weakness, decreased or absent reflexes, fasciculation, often described as alert.
- *Peripheral nerve disease:* weakness more distal than proximal, decreased or absent reflexes  $\pm$  fasciculation.
- *Neuromuscular junction disease:* weakness particularly affecting eyelids, eye movements, or bulbar function. Reflexes normal.
- *Muscle disease:* weakness more proximal than distal, reduced reflexes.
- **NB:** examination of the mother is also important to exclude myotonic dystrophy and myasthenia gravis.
- *Arthrogryposis:* often due to peripheral or systemic conditions, but remember that 50% ventilator-dependent children with arthrogryposis have a cerebral dysgenesis.

❗ Beware the mixed picture. Infants with peripheral hypotonia may be more at risk of hypoxic–ischaemic encephalopathy causing an additional, central problem.

## Causes of peripheral weakness

### Neonate

- Neonatal myotonic dystrophy (see 📖 p. 402).
- Neonatal myasthenia (see 📖 p. 412; affects around 12% of infants born to affected mothers via placental transfer of autoantibody, transient feeding problems, poor suck, respiratory distress).
- Neonatal severe forms of inherited myopathies, e.g. central core myopathy (see 📖 p. 406).
- Trauma, including birth-related spinal cord trauma (can be mistaken for birth asphyxia, but alert and no objective evidence of asphyxial insult, e.g. normal cord gases).

### Older infant

- *Spinal muscular atrophy type I* (Werdnig–Hoffman disease, see 📖 p. 410): visually alert infant. May have typical bell-shaped chest from paradoxical breathing (diaphragm relatively spared, weak intercostal muscles). May have visible tongue fasciculations.
- Hereditary sensorimotor neuropathies (see 📖 p. 392).
- *Infantile botulism*: absolute constipation typically for a few days prior to presentation; weakness descends (cf. Guillain–Barré) with loss of head control early.
- *Congenital myasthenic syndromes* (see 📖 p. 413): also an important cause of apnoea and apparent life-threatening events (ALTEs) in infants.
- *Congenital muscular dystrophies* (see 📖 p. 401): e.g. Fukuyama muscular dystrophy.
- Type II glycogen storage disease (Pompe disease).

## Central causes

### Neonate

- Down (trisomy 21).
- *Prader–Willi* (*deletion 15q11*): extreme floppiness with marked problems feeding and swallowing; mild dysmorphic features, hypopigmentation, undescended testes.
- *Zellweger syndrome*: peroxisomal disorder with dysmorphic features (high, prominent forehead), extreme floppiness, hepatosplenomegaly, seizures and renal cysts.

### Older infant

- Many infants with cerebral palsy are floppy for some months before the onset of spasticity. Consider hypoxic–ischaemic insult, intraventricular haemorrhage, periventricular leukomalacia, developmental brain malformations, congenital infection (check for hepatosplenomegaly).
- *Neurodegenerative diseases*:
  - Tay–Sachs disease (visual impairment, cherry red spot);
  - metachromatic leukodystrophy (upper and lower motor neuron signs, high CSF protein);
  - Canavan disease—macrocephaly, leukodystrophy.

- **Systemic disease:**
  - Hypothyroidism;
  - metabolic disorders, e.g. aminoaciduria;
  - electrolyte or glucose disturbance;
  - iatrogenic (drug toxicity, e.g. phenobarbital loading);
  - poisoning;
  - chronic disease of any nature.

### Investigation

#### **Suspected peripheral cause**

- Creatine kinase.
- Nerve conduction studies, electromyography (EMG).
- Muscle biopsy, molecular genetics (e.g. for spinal muscular atrophy deletion), as appropriate.

#### **Suspected central cause**

As appropriate:

- Electrolytes including magnesium, calcium. Check glucose.
- Thyroid function (treatable!).
- Neuroimaging (ultrasound may be appropriate in the first instance in neonates).
- EEG (may give prognostic information and help exclude seizures).
- Genetics review and karyotype if dysmorphic features.
- Toxoplasmosis, rubella, cytomegalovirus, herpes virus (TORCH) screen.
- Metabolic work-up.

# Foot deformities

## Causes

Numerous foot deformities are described: some have no neurological basis and can be idiopathic or familial.

- Metatarsus adductus.
- Idiopathic congenital talipes equinovarus (club foot).
- Idiopathic toe walking.

Some are more commonly associated with particular neurological or other disease.

- *Pes planus*: connective tissue disorders (Marfan); hereditary motor and sensory neuropathy (HMSN).
- *Pes cavus* (does not flatten on weight-bearing): cord lesion, HMSN, Friedreich ataxia, any neuromuscular condition.
- *Equinus deformity*: cerebral palsy, cord lesion, early Duchenne dystrophy, HMSN, dystonia.
- *Rocker bottom feet* (congenital vertical talus): chromosomal disorders (trisomy 18).

However, almost any neuromuscular condition can be associated with any foot deformity and a thorough neurological examination should be performed for all cases.

## History

- New onset.
- Progressive symptoms.
- Ataxia.
- Dysarthria.
- Bladder or bowel involvement.
- Family history.
- Sensory symptoms.
- Functional limitations.

## Examination

- Is it correctible?
- Does it fit into a particular type of foot deformity?
  - pes cavus;
  - pes planus;
  - metatarsus adductus;
  - varus deformity.
- Evidence of weakness.
- Reflexes.
- Spine.
- Wasting or (pseudo-) hypertrophy.
- Nerve hypertrophy.
- Reflexes.
- Weak dorsiflexion and eversion.
- Sensory impairment including saddle area.
- Joint position and vibration; pain and temperature sensation.

## Funny turns: episodic events

Paroxysmal events ('fits, faints, and funny turns') pose a diagnostic challenge as typically you will not witness the episodes, and diagnosis is dependent upon two descriptions: what the event felt like (from an older child, if awareness preserved) and what it looked like to an eyewitness observer. (Medical attention is often not sought until the episodes have been independently witnessed, typically by a parent or teacher).

Although epilepsy is often uppermost in the minds of parents and referring physicians, a wide variety of other causes of 'funny turns' are recognized: some are unique to children and infants.

❗ Never make a firm diagnosis on the nature of paroxysmal episodes (and specifically never make a diagnosis of epilepsy) before taking a detailed history from an eyewitness. Never rely on 'what the mother says the teacher saw'.

### Seizures

#### Epileptic

- An epileptic seizure is a clinical phenomenon associated with an abnormally excessive, synchronous discharge from a group of neurons. Its clinical manifestations may include paroxysmal changes in motor, sensory, or cognitive function. The clinical component depends on the seizure's:
  - Location.
  - Degree of anatomical spread over the cortex.
  - Duration.

In principle, there are very few phenomena that cannot be due to seizures, which complicates assessment. Seizures are, however, usually:

- *Stereotyped*: episodes resemble each other (although one child may have a repertoire of a small number of different seizure types, each will be stereotyped).
- Randomly distributed in time (i.e. not usually confined to particular situations or contexts).

Some **movements** are more likely to be seizures than others:

- Postures sustained for up to several seconds.
- Sustained head turns to one side, particularly if eyes are turned in the same direction.
- Subtle flickering of peri-oral and peri-orbital muscles.
- Shock-like jerks of the limbs, particularly if affecting both sides synchronously.

Conversely some movements are very atypical of seizures: this can be particularly relevant in the assessment of non-epileptic attack disorder:

- *Reciprocating* movements (e.g. violent side-to-side head movements; *alternating* thrashing movements of the limbs) except in the context of nocturnal frontal lobe epilepsy (see Box 4.11).
- Prolonged limp unresponsiveness.
- Pelvic thrusting.

The possibility of **sensory** or **perceptual** seizures poses particular problems in relation to 'soft' phenomena, such as episodic behaviour changes, outbursts of aggression, or reports of fluctuating awareness or concentration. Children with behavioural or developmental concerns are commonly referred—is any of it an epilepsy? Often the referrer of such children will have ignored the 'nose-picking principle' (see 📖 p. 53) and ordered an EEG showing non-specific abnormalities which have heightened anxiety.

Any of the following make a seizure disorder **less** likely:

- Context-specificity, e.g. arising at home but not at school, or in the presence of particular individuals.
- Significant variability between episodes (i.e. not stereotyped).
- The phenomena reflect or relate to the context, e.g. the aggressive language being used relates to what has immediately preceded it.
- The occurrence of the event at that time is understandable, e.g. an albeit disproportionate reaction to a preceding frustration or irritation.
- Event duration can be a helpful consideration. Seizures are typically brief—seconds to a minute. Phenomena lasting or developing over tens of minutes are less likely to be ictal: depending on the phenomenology, it may be worth considering a primary headache disorder (see 📖 p. 151).

## History

How many different types of events are being seen? Give each episode type a 'nickname' (e.g. 'the big shaking ones') and for each:

- *Clarify frequency:* 'How unusual would it be to go a day/week/month without one?'
- At what time of day/in what behavioural state does it happen? What is the relationship to sleep?
- *Triggers:* sleep deprivation, travel, excitement, photic stimuli, exercise.
- Is there any warning? How long?
  - warnings can be very brief and sometimes inferred, e.g. the child clings to a parent immediately prior to event onset;
  - 'Do you think your child knows one is coming?'
  - How long does it last?
  - How does it end, and how long does it take for the child to recover fully?
  - People's estimates of time are often inaccurate. Point out the second hand on the clinic clock to help them estimate.
- Is there any colour change? *Pallor at onset* suggests a primary cardiac mechanism due to structural or rhythm problems in an infant or, more commonly, neurocardiogenic syncope or reflex anoxic seizures (see 📖 p. 309). Cyanosis is non-specific as a late feature, but cyanosis early suggests a primarily apnoeic mechanism, such as occurs in cyanotic breath-holding episodes or gastro-oesophageal reflux.
- What motor phenomena occur? Explore what the words used mean to the witness:
  - 'Can you imitate for me now what he does?' (or replicate the movement using a doll);
  - determine any lateralization—which hand shows automatisms, which arm initially extends, which way do the head or eyes turn?

- Is the child's awareness affected by the episode? Older children can usually report whether they retain awareness (e.g. of what others are saying to them) during the episode.
- *Post-ictal symptoms, behaviour and impairment:* tiredness and sleep. Confusion, aphasia, or slurred speech. Lateralized or focal weakness. Headache may be associated with epilepsy, sometimes making it hard to distinguish migraine.
- Children are often referred with apparent 'lapses of awareness' for consideration of possible absence epilepsy. The typical scenario—'I have to call his name five times' before a child absorbed in his own thoughts (or computer game) responds—is distinguishable from a spell that actively interrupts a child mid-conversation or mid-mouthful. Video footage of phenomena can be immensely helpful.

### Assessment

Identifying a context in which events occur can be very helpful in the recognition of a wide range of non-epileptic childhood paroxysmal events, many of which are benign normal variants. See Tables 3.5 and 3.6 for detailed descriptions.

**Table 3.5** Situational clues to paroxysmal events at different ages





	<b>Infant</b>	<b>Toddler</b>	<b>Child</b>	<b>Adolescent</b>
In sleep	Benign neonatal sleep myoclonus	Night terrors	Parasomnias Confusional arousals	Parasomnias REM sleep disorders (e.g. sleep paralysis) Sleep walking
On feeding	GORD, Sandifer syndrome, shuddering spells	GORD, Sandifer syndrome		
Fever, intercurrent illness		Febrile seizures	Syncope	Syncope
Movement		(Kinesiogenic) paroxysmal dystonias, dyskinesias	(Kinesiogenic) paroxysmal dystonias, dyskinesias	(Kinesiogenic) paroxysmal dystonias, dyskinesias
Pain, shock	Structural cardiac or dysrhythmia Reflex anoxic seizure	Structural cardiac or dysrhythmia Cyanotic breath holding Reflex anoxic seizure	Structural cardiac or dysrhythmia Syncope	Structural cardiac or dysrhythmia Syncope
Hot weather, prolonged standing				Syncope
Tired, bored, meal-times, bed-time	Self-gratification events	Self-gratification events		
Tired, bored, stressed			Tics	Tics
Excitement, emotion	Shuddering spells			Cataplexy
Boredom		Self-gratification	Ritualistic behaviour*	Ritualistic behaviour*
Absorbed in TV, computer game			Distracted	Distracted

\* Particularly in children with learning difficulties.

GORD, gastro-oesophageal reflux. National Institute for Health and Clinical Excellence (2012). Adapted from 'CG 137 The epilepsies: the diagnosis and management of the epilepsies in adults and children in primary and secondary care'. London: NICE. Available from [www.nice.org.uk](http://www.nice.org.uk). Reproduced with permission.




**Table 3.6** Phenotypic clues to non-epileptic and epileptic attacks

	Infant	Toddler	Child	Adolescent
Rapidly repeating spasms	Infantile spasms Benign myoclonus of infancy Clonic seizure	Clonic seizure Focal seizure	Tics Behavioural stereotypy* Clonic seizure	Focal seizure Tics Behavioural stereotypy* Clonic seizure
Stiffness	Tonic seizure Coning (see  p. 537) Hyperekplexia	Tonic seizure <sup>¶</sup> Coning (see  p. 537)	Tonic seizure <sup>¶</sup> Coning (see  p. 537)	Tonic seizure <sup>¶</sup> Coning (see  p. 537)
Loss of tone	Cardiac dysrhythmia	Reflex anoxic seizure Atonic seizures <sup>§</sup>	Syncope Atonic seizures*	Syncope Cataplexy
Sustained distorted posture	Benign paroxysmal torticollis	(Kinesiogenic) paroxysmal dystonias, dyskinesias Drug reactions ICP elevations		(Kinesiogenic) paroxysmal dystonias, dyskinesias opisthotonus Drug reactions ICP elevations
Unsteadiness		Benign paroxysmal vertigo	Episodic ataxia Intoxication	Episodic ataxia Intoxication

\*Particularly in children with learning difficulties.

§ Would rarely occur in isolation, but typically as part of a polymorphic epilepsy.

¶ Tonic seizures can arise from acute cerebral hypoxia (e.g. reflex anoxic seizures, syncope: see  p. 141).

National Institute for Health and Clinical Excellence (2012). Adapted from 'CG 137 The epilepsies: the diagnosis and management of the epilepsies in adults and children in primary and secondary care'. London: NICE. Available from [www.nice.org.uk](http://www.nice.org.uk). Reproduced with permission.

## Funny turns: likely epilepsy?

- Consequences of both false positive (regarding a non-epileptic phenomenon as epilepsy) and false negative (failing to recognize epilepsy) diagnoses of epilepsy can be serious. However, the risks of false-positive diagnosis are almost certainly higher.
- In cases of genuine uncertainty it is important to be comfortable regarding a diagnosis of epilepsy as 'unestablished'. Families must be helped to understand the importance of avoiding premature conclusions.
- Diagnosing epilepsy is hard! Even in specialist centres false positive diagnosis rates have been estimated at 10–15%.
- It is a question that must be answered clinically, with recourse to EEG only for supportive evidence (see 📖 p. 72).
- ► Epilepsy is a tendency to recurrent, unprovoked (spontaneous) seizures, so even if you are sure the events are seizures, this may well still not be epilepsy.
- Deciding whether events are *recurrent* is usually fairly straightforward, although it is important to be sure that all 'recurrences' are of the same nature, i.e. the events are stereotyped.
- Deciding whether seizures are *unprovoked* is a vital consideration.

### Epilepsy vs. acute symptomatic seizures

- Acute symptomatic seizures arise as the immediate result of a variety of acute insults: hypoxia–ischaemia, hypoglycaemia, hypocalcaemia, metabolic derangements, infection, trauma, etc.
- Acute symptomatic seizures can be recurrent, the most common example being febrile convulsions. The diagnosis then is recurrent acute symptomatic seizures (of a cause to be identified), *not epilepsy*.
- *Common scenarios*:
  - the toddler experiencing reflex anoxic seizures (see 📖 p. 309) having caught a finger in a slamming door;
  - the adolescent girl brought in to the Emergency Room having passed out on a hot day at school.
- If there is a clear history of a trigger, do *not* be distracted into diagnosing epilepsy by the history of jerky limb movements and urinary incontinence at the *end* of the event.
- The details of the early stages of the episode—context, premonitory symptoms, presence of pallor, etc.—are likely to be more informative than late stages. It is more useful to know how the event started than how it ended. (Unfortunately the onset of the episode is also the least likely phase to have been observed.)

Although epilepsy is defined as a tendency to recurrent, unprovoked seizures, there *are* examples of true reflex epilepsies: photosensitivity to rapidly flickering light is the most common, but rare reading epilepsies, epilepsies on immersion in water, etc., are recognized. These are extremely uncommon and, in any case, practice poses little diagnostic difficulty as one can plan to perform EEG, whilst exposing the child to the stimulus. Photosensitivity is usually routinely sought in EEG studies.


- ▶ Of children with paroxysmal events in whom the initial diagnosis of epilepsy is tentative, fewer than 10% will ultimately prove to have epilepsy.
- ▶ The co-existence of multiple types of paroxysmal event (e.g. epilepsy and syncope; epilepsy and non-epileptic attacks) in one child is relatively common.


### There is no such thing as epilepsy . . .

. . . There are epilepsies.

Adopt a four-level approach to the diagnosis of epilepsy:

- Disease (is this epilepsy?)
- What seizure types are occurring?
- What is the epilepsy syndrome?
- What is the aetiology?

These levels correspond to the first four 'axes' of the currently proposed ILAE epilepsy classification scheme. 'Axis 5' comprises the consequent negative social and educational effects (see  p. 298).

This enables rational decisions about the need for further investigation (e.g. imaging), guides therapy choices and informs prognosis. Aetiology and syndrome are discussed further in Chapter 4 (see  p. 275), but both require the identification of the seizure types present.



### The role of EEG

Epilepsy novices overuse EEG in addressing the first question ('is this an epilepsy?'), and underuse it in the remaining challenges of identifying seizure type(s), aetiology, and syndrome. Routine EEGs are of limited value in deciding whether an individual has epilepsy, with significant false negative (sensitivity of first routine EEG ~60%) and more problematically false positive rates (paroxysmal activity seen in >30%, and frankly epileptiform in ~5% of normal children). False positive rates are even higher in children with a cerebral palsy, etc.

### What seizure types are occurring?

As with deciding if events are seizures, defining the seizure type(s) can be challenging. Family usage of terms such as 'jerk', 'shake', and 'fall' need to be unpacked, before they can be accurately 'mapped' onto conventional seizure descriptors (Table 3.7).

### The child with 'generalized tonic clonic seizures'

Generalized tonic clonic seizures (GTCs) tends to be used as a lazy shorthand by those who don't understand the importance of defining precisely what seizures are occurring. It is very rare for a child to have an epilepsy defined by true GTCs alone. *Either*, they have GTCs together with other (possibly unrecognized) seizures (e.g. in juvenile myoclonic epilepsy see  p. 271), *or* they have focal-onset seizures that are, in fact, secondarily generalizing (e.g. in benign childhood epilepsy with centrotemporal spikes see  p. 268).

**Table 3.7** Types of seizures

Jerk, shake	<p><i>Clonic</i> (rhythmic contractions followed by slightly slower relaxation) typically occurring immediately after a tonic phase as part of a tonic-clonic seizure, or confined to a body part as a focal seizure.</p> <p><i>Myoclonic</i> seizures are isolated lightning-fast, brief contractions occurring singly or in short runs, with full muscle relaxation between.</p> <p><i>Spasms</i> (sometimes referred to as tonic spasms) have a slightly longer phase of sustained contraction than a myoclonic jerk and typically occur in runs. They occur as infantile spasms but also in older children.</p> <p>Distinguishing these seizure types may be challenging clinically, and is a particularly important purpose of EEG.</p>
Stiff	<p>Usually a tonic seizure (sustained contraction for several seconds). There may be a low-amplitude 'vibratory' element to the contraction that is different from a clonic movement.</p>
Fall	<p>Beware the phrase 'drop attack': it is ambiguous</p> <p><i>Atonic</i> seizures result in a slump to the ground 'as if a puppet had its strings cut'.</p> <p>A <i>tonic</i> seizure resulting in rigidity can cause a child to fall 'like a felled tree'.</p> <p>Finally a child can be thrown to the ground by a large <i>myoclonic</i> seizure.</p> <p>In some seizures these are combined, as in myoclonic-atonic (also known as myoclonic-astatic) seizures.</p> <p>Many centres now use surface EMG alongside EEG in order to determine whether, and for how long, there is muscle contraction associated with a seizure. This helps to distinguish tonic, atonic and myoclonic events.</p>
Vacancy	<p>The word 'absence' creates a lot of confusion and diagnostic imprecision. An <i>absence</i> is a type of seizure (defined by its EEG features) that can cause loss of awareness, but loss of awareness also occurs with <i>focal seizures</i>.</p> <p>Most absence seizures are brief, lasting only a few seconds, but they may occur many times per day. They are often associated with subtle motor automatisms: lip smacking, chewing, or fiddling with the hands. Eyelid flickering may occur.</p> <p>Focal seizures (e.g. originating from the temporal lobe) may be associated with loss of awareness and responsiveness to surroundings. They would typically be longer (30s or more) and less frequent than absences and with more marked confusion or agitation. Again, EEG can make a valuable contribution to distinguishing these two seizure types.</p>


## Gait abnormalities

For acute presentations, see  p. 559.

### History

- Nature of the problem?
- Onset?
- Static or progressive?
- Isolated or associated with other symptoms of delay?
- Constant or intermittent?
- Degree of functional impairment—what does it stop him doing?
- Exercise intolerance, stiffness, or pain?
- Vestibular symptoms?
- Involvement of bladder or spine?
- Family history of any form of abnormal walk or use of assistive devices?
- *Symptoms suggestive of proximal weakness*: difficulties raising head from pillow, combing hair, brushing teeth, shaving, raising arms above head, getting up from chair, stairs and use of banisters, running, hopping, jumping.
- *Symptoms suggestive of peripheral weakness*: difficulties opening screw cap or door knob, turning key, buttoning clothes, writing, falling on uneven ground, tripping, hitting curb.

### Examination


- Give the child space to move.
- Observe posture and quality of movement of the upper limbs while the child is playing, as well as during formal examination of the lower limbs.
- Look for asymmetry—mild hemiplegia.
- Perform a detailed neurological examination with movements to bring out the abnormality. These include walking forwards and backwards, running, jumping, hopping, timed stand on one leg, tandem walking, Fog testing (walking on heels, outer and inner edges of feet, see  p. 47).
- Gowers' manoeuvre.
- Range of movement of hips, knees, and ankles.
- Tone, power, coordination, reflexes (including abdominal, sacral), sensory, joint position, touch, pain and temperature, Rombergism.
- Check the spine.
- If foot deformity is present, examine the parents' feet.
- See later sections for more specific testing in different conditions.

### Assessment

**Does the gait fit into a classic pattern?**

See  p. 38.

**Do the gait pattern and overall findings fit a diagnostic pattern?**

- *Long tract signs:* CP, X-linked leukodystrophy (X-ALD), metachromatic leucodystrophy (MLD), tethered cord, hereditary spastic paraparesis.
- *Long tract signs and a root level:* occult spinal dysraphism or other pathology, transverse myelitis.
- *Cerebellar signs:* posterior fossa tumour, ataxia telangiectasia (AT), Friedreich ataxia.
- *Vestibular symptoms:* vestibulitis, benign paroxysmal vertigo.
- *Clumsiness affecting other areas of motor coordination:* dyspraxia.
- *Intercurrent illness or acute onset:* Guillain–Barré, chronic inflammatory demyelinating neuropathy (CIDP).
- *Toe walking alone:* idiopathic toe walker (see  p. 196).
- *Toe walking and other symptoms and signs:* DMD, cord lesion.
- *Family history, delayed motor development, proximal weakness:* DMD, SMA.
- *Foot deformity:* club feet, CP, Friedreich.
- *Abnormal foot posture:* dystonia (e.g. primary torsion (DYT1) or DOPA-responsive).
- *Family history (variable severity), symmetrical distal involvement, weak dorsiflexion and eversion, pes cavus, absent reflexes, nerve hypertrophy:* HMSN.

A non-specific unusual gait is sometimes seen in children with a significant learning disability, but without a specific diagnosis.

Consider a non-organic gait disturbance when the features do not fit a recognized anatomical distribution, but beware that organic and non-organic disorders may co-exist.

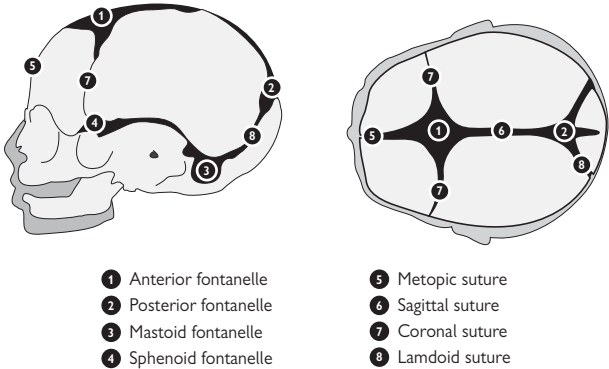
**Investigations**

According to differential diagnosis.

## Head shape abnormalities

This is a common clinical scenario. The vast majority can be reassured.

Head shape is determined by forces from within and outside the skull, and by the timing of closure of cranial sutures (Figure 3.2 and Table 3.8).



**Fig. 3.2** Sutures and fontanelles.

**Table 3.8** Description of head shape (sutures which may cause the shape with early fusion shown in parentheses)

Brachycephaly (both coronal)	Head abnormally wide and flat over occiput
Scaphocephaly/dolicocephaly (sagittal)	Abnormally long, narrow head
Plagiocephaly (one coronal or lambdoid)	Flattening on one side of head
Oxycephaly (all sutures)	Pointed head
Acrocephaly	High, tower-like head with vertical forehead
Trigonocephaly (metopic)	Triangular head with prominent vertical ridge in mid-forehead

### Intracranial forces affecting head shape

- Cerebellar agenesis causes a small posterior fossa.
- Large lateral ventricles cause bowing of the forehead.
- Dandy–Walker malformation causes bowing of the occiput.

### Extracranial forces affecting head shape

- Constriction due to multiple pregnancy or bicornuate uterus.
- Scaphocephaly in premature babies; brachy- or plagiocephaly in hypotonic infants (effect of relative immobility).

- ► Benign positional posterior plagiocephaly is much more common following widespread advocacy of supine sleeping for children (to avoid sudden infant death).

### Craniosynostosis

- Results from premature closure of one or more cranial sutures.
- Isolated, or associated with other disorders, e.g. ataxia telangiectasia, hyperthyroidism, mucopolysaccharidoses, rickets, sickle cell disease, thalassaemia major.
- Two-suture craniosynostosis is common (usually sagittal plus one other).

The hallmark clinically is *progressive* skull deformity. Plain skull X-ray (SXR) with Waters projection is a useful screening test, but is unreliable particularly for lambdoid sutures. Spiral 3D computed tomography (CT) is the definitive investigation, but involves a high radiation dose. If confirmed, refer to specialist neurosurgical unit.

#### **Specific syndromes with craniosynostosis as a feature**

- *Crouzon syndrome*: autosomal dominant. Premature closure of any or all sutures plus maldevelopment of facial bones. Characteristic facies. Beak nose, large tongue. May have mental retardation.
- *Apert syndrome*: autosomal dominant. Premature closure of coronal sutures, syndactyly and fusion of fingers and toes. Face deformity similar to Crouzon disease, but less severe. May have cerebral malformations and mental retardation.
- *Carpenter syndrome*: autosomal recessive. Similar to Apert syndrome plus polydactyly and hypogonadism. May have cerebral malformations and mental retardation.

#### **Syndromes with recognizable abnormal head shape**

- *Pear- or light bulb-shaped head*: Zellweger syndrome.
- *Narrow bifrontal diameter*: sulphite oxidase deficiency, molybdenum cofactor deficiency.
- *Brachycephaly*: Down syndrome.

### Large fontanelle

Closure of the anterior fontanelle is complete by 24 mths in 96% babies.

#### **More common causes of large fontanelle/delayed closure**

- Intrauterine growth retardation.
- Prematurity.
- Hydrocephalus.
- Achondroplasia.
- Down syndrome.

#### **Rarer causes**

- Hypothyroidism.
- Rickets.
- Osteogenesis imperfect.
- Congenital rubella.
- Apert syndrome.
- Cleidocranial dysostosis.
- Ring chromosome 20 syndrome.
- Zellweger syndrome.





## Head size abnormalities


A common clinical scenario. Consider the child's birth, past medical and family history, as well as development, and assess any features of regression. First and foremost measure both parents' heads if at all possible. Plot current and previous measurements on an appropriate chart (correct for age and sex). Many 'macrocephalic' and 'microcephalic' children are simply (familial) extreme outliers of the normal population.

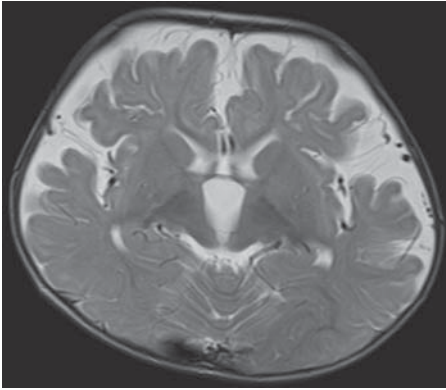
### Large head: >2 SDs above mean for age

A large head will be due to either a large brain, or a large volume of cerebrospinal fluid (CSF), most commonly the latter. Consider whether signs of raised intracranial pressure (ICP) present:

- History of headaches or irritability, particularly a steadily worsening picture over weeks (see  p. 153).
- Sunset eye sign.
- Full fontanelle, separation of the cranial sutures.
- Presence of venous pulsation on fundoscopy (see  p. 17) implies normal ICP; venous pulsation absent in 10% normal population, however!
- Papilloedema is a late and variable feature of raised ICP.
- Prominent scalp veins.

### If no signs of raised intracranial pressure

- *Familial*: very common. Measure both parents' occipitofrontal circumference (OFC). Note that the OFC of children with familial macrocephaly can rise across centiles during the early months of life. Often associated with benign enlargement of subarachnoid space (see  p. 149 and Figure 3.3).
- *Neurocutaneous disorders*: neurofibromatosis type 1, TS, incontinentia pigmenti.
- *Chromosomal*: fragile X.
- Cerebral gigantism (Soto syndrome).
- Achondroplasia.
- *Metabolic disorders* (a large head is usually acquired):
  - mucopolysaccharidoses;
  - glutaric aciduria type 1—characteristic symmetrical fronto-temporal atrophy with enlarged subarachnoid spaces that may radiologically give appearances confused with non-accidental injury;
  - galactosaemia;
  - leukodystrophies—metachromatic, canavan or Alexander disease;
  - maple syrup urine disease;
  - storage disorders—GM2 gangliosidosis: Tay–Sachs disease, Sandhoff disease.
- *Undiagnosed neurological disorder*: a large head in a child with developmental delay  $\pm$  seizures. Investigations are normal. This is a common clinical scenario.
- *Due to thickened skull*: thalassaemia, osteopetrosis, side effect of some AEDs.



**Fig. 3.3** MRI in familial macrocephaly showing prominent external subarachnoid spaces, particularly in frontotemporal regions. Note that this can be erroneously reported as 'frontal atrophy' (see □ p. 168), but OFC is *large* not small; or as showing benign external hydrocephalus but there is *no pressure*! The bridging veins clearly visible in the CSF spaces on this T2 image confirm that it is the subarachnoid space that is enlarged, and permits distinction from enlarged *subdural* spaces (see □ 'Chronic subdural effusion', p. 149).

#### **Benign enlargement of the subarachnoid space**

- Common and often familial.
- Large subarachnoid spaces especially frontally normalize by school age although macrocephaly persists.
- Mainstay of management is reassurance and non-intervention.
- In extreme cases there may be a danger of subdural haemorrhage from minor trauma due to 'instability' of the brain in the skull vault.

#### **Chronic subdural effusion**

Subdural haemorrhage following birth trauma invariably resolves by 4 weeks. Subdural haemorrhage detected at a later age raises the possibility of inflicted injury or central nervous system (CNS) infection.

#### **If raised intracranial pressure present consider hydrocephalus due to**

- Post-intraventricular haemorrhage.
- Posterior fossa tumour.
- Aqueduct stenosis (may be X-linked).
- Post-CNS infection.
- Dandy–Walker malformation.
- Klippel–Feil syndrome (dysmorphic with low hairline, short neck, limitation of neck movement).
- Vein of Galen malformation.
- Walker–Warburg syndrome (cerebro-ocular dysplasia).
- Chiari malformation (may be associated with spina bifida).

**Small head <2 SD below mean for age**

Indicates a small brain. Development is usually delayed

**Radiologically normal-but-small brain on magnetic resonance imaging**

- *Genetic*: primary microcephaly (autosomal recessive or dominant).
- *Chromosomal disorders*: aneuploidy of any chromosome, Miller–Dieker syndrome, ring chromosome 20.
- *Systemic disease*: chronic renal or cardiac disease, malnutrition.
- *Undiagnosed neurological disorder*: a small head in a child with developmental delay  $\pm$  seizures. Investigations are normal. This is a common clinical scenario.

**Radiologically abnormal brain**

- *Feature of anencephaly, encephalocele, agenesis of corpus callosum, holoprosencephaly, defective cellular migration*: lissencephaly, agyria, pachygyria, heterotopia.
- *Intrauterine infection*: toxoplasmosis, rubella, cytomegalovirus, herpes simplex (TORCH), HIV.
- *Perinatal brain injury*: hypoxic-ischaemic encephalopathy (HIE), intracranial haemorrhage, CNS infection.
- *Toxins*: foetal alcohol syndrome, maternal drug ingestion, maternal insulin-dependent diabetes mellitus (IDDM), maternal PKU.
- *Metabolic disorders*: infantile and late infantile neuronal ceroid lipofuscinosis, Smith–Lemli–Opitz syndrome, tetrahydrobiopterin deficiencies, congenital disorders of glycosylation.

**Declining occipitofrontal circumference**

In addition:

- Rett syndrome (girls).
- Angelman syndrome.
- Progressive encephalopathy with oedema, hypersarrhythmia and optic atrophy (PEHO) syndrome.
- GLUT-1 transporter deficiency.
- Sulphite oxidase deficiency; molybdenum cofactor deficiency.

## Headache

Headache is common in children and occurs at least annually in approximately 40% of children by 7yrs of age and 75% of children by 15yrs.

► Most parents who seek help for a child with headache are looking for reassurance that the headache is not due to a serious cause.

The brain itself, most of the meninges and the skull are not pain sensitive. Pain from supratentorial structures is referred to the front of the head. Pain from posterior fossa structures is referred to the back of head and neck in addition to the forehead. The glossopharyngeal and vagal nerves innervate part of the posterior fossa and pain is referred to the ear and throat. Pain referred to the head can arise from:

- Intracranial or extracranial arteries, large intracranial veins or venous sinuses.
- Cranial or spinal nerves.
- Basal meninges.
- Cranial and cervical muscles.
- Nasal cavity, sinuses, teeth, mucous membranes, skin, and subcutaneous tissues.

### Clinical evaluation

Attempt to characterize the headaches as one of:

- Isolated acute.
- Recurrent acute.
- Chronic non-progressive.
- Chronic progressive.

### First (isolated) acute headache

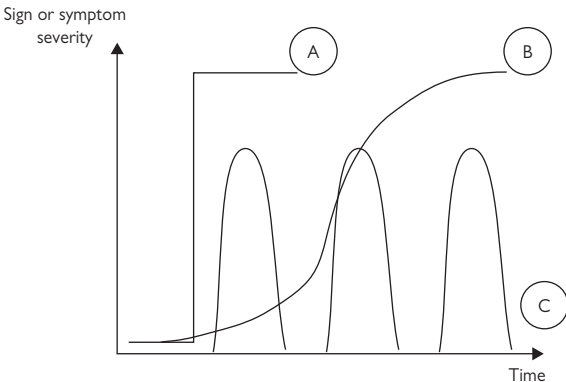
Although a first acute headache may be the initial presentation of a primary headache such as migraine, it is important to consider other possible causes.

- Spontaneous subarachnoid or intracerebral haemorrhage and acute onset hydrocephalus are rare, but require immediate management.
- Cranial trauma, meningitis, sinusitis, and dental abscess also require specific treatment, but are usually associated with clinical clues.
- ⚠ Headache may occasionally be the initial manifestation of hypertension and blood pressure must be measured.
- The acute onset of headache in the child who is otherwise well may occur following minor head trauma. In adolescents, a clear history of headache related to athletic or other exertion is common, and usually benign.
- The most common causes of isolated headaches in routine practice are viral illness, sinusitis, and the primary headaches (see ☞ p. 317), of which tension-type headache/migraine variants are by far the commonest.

## Recurrent or chronic headaches

### History

- More than one kind of headache? A mixed picture may imply mixed aetiology.
- Describe a typical episode:
  - Was there any warning?
  - Where does it hurt?
  - What is the pain like? (Children, like adults, will find it very hard to describe subtleties of pain type: you may have to ask leading questions: 'is it thumping/crushing/squeezing?').
  - Duration?
  - Frequency?
- See Figure 3.4.



**Fig. 3.4** Time courses.

- In this context, (A) might suggest an acute brain pathology, such as subarachnoid haemorrhage; (B) (inexorable progression) would raise important concerns about possible raised intracranial pressure; (C), with clear symptom-free periods is typical of migraine.
- Severity? Prevents activity? Causing school absenteeism?

❗ An occipital headache is unusual, and warrants prompt imaging.

### Pointers to migraine headache

- Generally, clear evidence of episodicity with clear, symptom-free periods.
- Associated autonomic features, particularly abdominal pain, nausea, or vomiting.
- Focal neurological signs or symptoms (e.g. visual disturbance, paraesthesia, weakness) before, during, or after the attack.
- Ask 'Can you tell your child has a headache just by the way they look? Does your child's appearance change during a headache?' Autonomic disturbance including facial pallor and/or 'dark rings under the eyes' are common in migraine.
- Aggravated by bright light or noise?

- Any relation to fatigue/stress (e.g. school week vs. weekend or vacation)? Particular foods, lack of sleep, menstrual cycle, exertion?
- Helped by sleep? Resting in the dark/quiet?
- Personal or family history of motion sickness?
- Is there a family history of headaches?
  - Many parents with migraine attribute their headache to other causes, e.g. sinus headaches. Ask parents to describe their headaches.
  - Many parents' tendency to migraine may have settled with time. Did they have headaches when they were younger?

#### *Pointers to raised intracranial pressure headache*


- Aggravated by activities that raise intracranial pressure? Coughing, straining at stool, bending?
- Woken from sleep by headache?

#### *Pointers to analgesia overuse headache*

'The headache is back before he's allowed to take another dose'. Can occur with any analgesic including paracetamol and, non-steroidal anti-inflammatory drugs (NSAIDs). It is a particular problem with compound analgesics, e.g. co-codamol.

#### **Examination**

Neurological examination can be confined to movement patterns and cranial nerves if there are no sensory symptoms.

- Growth parameters, head circumference, and blood pressure.
- Sinuses and teeth.
- Fundoscopy and retinal venous pulsation (see  p. 17). The presence of venous pulsation implies normal intracranial pressure but this is absent in 10% normal population. Absence of papilloedema does not exclude raised intracranial pressure!
- Visual fields (craniopharyngioma).
- Cranial bruits. Asymmetric 'machinery' bruit may indicate arteriovenous malformation. Innocent cranial bruits are heard in approximately 50% of 5-yr-old and 10% of 10-yr-old normal children. Asymmetry or elimination by compression of the ipsilateral carotid artery suggests an organic basis.
- Cognitive emotional status, particularly attitude of child (and family) toward the symptoms, and interaction between family members.

#### **Assessment**

The diagnosis of headache aetiology is *clinical*. The indications for investigation follow from a clinical assessment of the diagnosis.

Pragmatic criteria for a diagnosis of *migraine* are episodes characterized by at least three of the following:


- Hemicranial pain.
- Throbbing or pulsatile character to pain.
- Associated abdominal pain, nausea, or vomiting.
- Relieved by rest.
- Photophobia and/or phonophobia (rarely, osmophobia).
- Visual, sensory, or motor aura.
- Family history of migraine in first-degree relatives.

A key feature of straightforward migraine is the presence of symptom-free intervals of days at a time. The more constant the headache is, the less likely the diagnosis.


### **Tension-type headache**

Characteristically:

- Diffuse, symmetrical.
- 'Band-like' distribution around the head.
- Present most of the time, but there may be symptom-free periods.
- Characteristically a constant ache, although there may be a partially throbbing character to the pain.

Distinction between muscular contraction headache and migraine without aura is often difficult and it is important to recognize that a *mixed* migraine/tension headache is very common. The process may be complicated and perpetuated by inappropriate and excessive *analgesia use* (see  p. 320).

Worrying symptoms suggestive of raised intracranial pressure include:

- A chronic progressive picture worsening over days to weeks with or without vomiting.
- Worse when recumbent, bending, coughing, sneezing, straining to pass stools.
- Occipital headache.
- Recent deteriorations in behaviour or school performance.
- Physiological increases in intracranial pressure in sleep may result in a child being woken from sleep with a headache, a worrying symptom. When headaches occur at night, it is important to distinguish between those that wake the child out of sleep from those that are noticed after the child has woken normally.
- See 'Red Flag' features requiring further investigation in Chapter 4 (see  p. 318).

### **Investigations**

- If the history is typical for a primary headache (migraine or tension-type headache; or features of both making them 'unclassified'—which is common), and the neurological examination is normal, no imaging is required.
- If the differential diagnosis includes raised intracranial pressure headache, an urgent CT scan will demonstrate nearly all structural causes of headache. MRI may occasionally be necessary for the diagnosis of subtle vascular abnormalities or hypothalamo-pituitary lesions.
- **Check blood pressure.** A headache due to raised intracranial pressure may be the only symptom of systemic hypertension.

## Hearing loss

- **Conductive:** middle ear. Very common. Typically, a high frequency loss selectively affecting discrimination of consonants and intelligibility of speech.
- **Sensorineural:** cochlea, nerve, or brain (incidence—approximately 1/1000) Cochlear hearing loss pattern characterized by recruitment: a rapid increase in sensation of loudness once the hearing threshold is passed.
- **Hearing loss in the better ear:**
  - <20 dB: normal;
  - 20–40 dB: mild;
  - 40–70 dB: moderate;
  - 70–95 dB: severe;
  - >95 dB: profound.

### Causes

See Table 3.9.

**Table 3.9** Causes of hearing loss

Congenital	Genetic hearing loss (syndromic or isolated)
	Sporadic
	Malformations of the inner or middle ear
	Intrauterine infections (CMV, rubella)
Acquired	Prematurity, HIE, Kernicterus
	Meningitis
	Ototoxic drugs (gentamicin)
	Middle ear disease
	Trauma


### Consequences

- Unilateral hearing loss with poor sound localization, difficulties in noisy environments.
- Bilateral hearing loss:
  - up to 50 dB: delayed language development;
  - >70 dB: no spontaneous language development;
  - delay in reading and writing skills;
  - delayed psychosocial development;
  - otherwise normal cognition.

### History

- Pregnancy, delivery (illnesses, infections).
- *Neonatal intensive care:* including infections, antibiotics (gentamicin), significant jaundice.
- *Family history:* congenital deafness, consanguinity.
- *Development, especially language/communication:*
  - <2 mths—startles at sudden loud noise; shows interest in prolonged noises;



- 2–6 *mths*—listens and turns to voice; shows interest in noises (radio, food being prepared, parent entering room);
- 7–12 *mths*: looks to see where quiet sounds are coming from; talks/babbles to parent; says ‘ma’, ‘ba’, ‘da’; starts to understand name, ‘no’, ‘bye’.
- *Second year*: understand simple words and instructions without accompanying gestures; start to use some words.
- Past history of meningitis, head injury.
- *Epilepsy*: children with Landau–Kleffner syndrome (see  p. 272) present with a receptive auditory agnosia: they can no longer ‘make sense’ of sounds, particularly speech. Although not truly hearing impaired, they are often described as behaving ‘as if deaf’. By definition Landau–Kleffner syndrome includes concurrent seizures, although these can lag the onset of the auditory agnosia by a few weeks.

### Examination

- Dysmorphism.
- Ear abnormalities (Treacher–Collins, Goldenhaar syndrome).
- Eye disease (Usher, Alstrom, Refsum, Cockayne syndrome).
- Skeletal abnormality (Klippel–Feil, Crouzon, DIDMOAD syndromes).
- Skin nail or hair disorder (Waardenburg syndrome).
- Development and neurology.
- Ear, nose and throat (ENT).

### Primary investigations

- Audiogram.
- Audiogram of first-degree relatives.
- Electrocardiography (long QTc interval in Jervel–Lange–Nielsen).
- Ophthalmologist (diagnostic, correction of refractive errors to prevent double handicap).
- Urine (microscopic haematuria in Alport syndrome).
- Connexin 26 mutation (common cause of recessive, non-syndromic deafness).
- MRI cochlea/internal auditory meati (aetiology).

### Further investigations as indicated

- TORCH screen (CMV, rubella).
- FBC.
- U&E.
- Thyroid function test (TFT) (hypothyroidism in Pendred syndrome).
- Immunology.
- *Metabolic*: especially mitochondrial and peroxisomal disease.
- Renal ultrasound scan (USS).
- Chromosomes.
- Genetics referral.
- Vestibular investigations/electroretinogram (ERG; Usher syndrome).

### Refer for assessment if

- Child has failed a hearing screen.
- The parent is worried about the child’s hearing.
- Note whether the child is looking for visual clues.

# Incontinence

## History

- Note onset and progression.
- *Bladder*: retention, frequency, hesitancy, urgency, straining, urge incontinence.
- *Bowel*: constipation, stool incontinence.
- *Sexual*: erectile function.

## Examination

- *Lower limbs*: gait, deformities (talipes).
- *Perineum*: sensation particularly in S2–4 dermatomes (see Figure 1.7), anal tone, anocutaneous reflex, cremasteric reflex. S2–4 function (perianal sensation, anocutaneous reflex) will be absent in conus lesions.
- *Spine*: tuft of hair, subcutaneous lipoma, dermal sinus, scoliosis.
- *Abdomen*: palpable bladder, constipation, other abdominal masses (e.g. very rare anterior neural tube defects).
- *Micturition*: good stream? Leakage when crying?

## Investigations

- *X-ray spine*: spinal deformity (dysraphism, scoliosis).
- *MRI spine* (dysraphism, low-lying conus medullaris in tethered cord, cord compression, transverse myelitis).
- *Renal USS* (dilated ureters and pelvic system).
- *DMSA* (renal cortical scintigraphy; scarring).
- Renal function.
- *Video-urodynamic study* (pressure/volume study of bladder).
- *Cystourethrogram* (shape, size and capacity of bladder, residual urine volume, vesico-ureteric reflux).

See Table 3.10 for urinary signs and symptom.

## Bladder problems and management

- Avoid constipation.
- Prevent urinary tract infections (UTI; prophylactic antibiotics in reflux or recurrent infections).
- Treat *symptomatic* UTIs (no treatment for asymptomatic bacteraemia).
- *Catheterization*:
  - clean intermittent catheterization (parent or child >6 yrs, complications: infection, bleeding);
  - continuous catheterization in severe upper tract dilatation or in severely disabled children.

### Safe bladder

- <20 mL residue after voiding, normal upper tract, normal renal function, no pressure transmission.
- *Management*: toilet training, suprapubic pressure.

### Unsafe bladder

Large bladder residue after voiding, outlet obstruction, high pressure, hydronephrosis.

**Table 3.10** Urinary signs and symptoms

Neuropathic bladder	Constant severe daytime wetting, constipation, lower limb neurological signs Spinal dysraphism (spina bifida, tethered cord) Cord compression (discitis, spinal osteomyelitis, trauma, tumour, bleed, etc.) Transverse myelitis
Urinary tract infection	Secondary onset wetting, systemic features
Constipation	Secondary urinary problems
Detrusor instability	Daytime urinary frequency, urgency, and urge incontinence
Ectopic ureter	Constant dribble of urine between voidings
Posterior urethral valves	Poor urinary stream, daytime wetting, palpable bladder
Diabetes mellitus	Weight loss, polyuria, thirst and polydipsia
Diabetes insipidus	Polyuria, polydipsia, thirst

*Acontractile bladder (S2–4 or conus lesion, reflex interrupted)*

- Large weak bladder, does not contract.
- Weak sphincter, leakage with cough, cry.
- Patulous anus.
- *Management:* bladder expression, catheterization, continence with an artificial urinary sphincter.

*Contractile, reflex type bladder (S2–4 intact)*

- Detrusor sphincter dyssynergia: bladder contraction with sphincter contraction at the same time,
- Small volume, hyper-reflexic bladder.
- Intermittent reflex emptying usually incomplete.
- Brisk anal reflex.
- *Management:* anticholinergics (oxybutinin) and catheterization; sphincterotomy, pudendal neurectomy or urinary diversion to reduce outflow obstruction, cystoplasty to augment bladder capacity.

**Bowels**

The same spinal pathologies that cause bladder problems can cause bowel problems, and will need a similar approach. Usually, the bladder problems are more pronounced and bowel habits can often still be trained.

- *High spinal lesion:* intact reflex, absent sensation (continence can be gained). Stimulation with bisacodyl, finger, microenema.
- *Low lesion:* absent reflex, sensation present (incontinence more likely. Abdominal pressure, straining, manual evacuation, bulking agents.
- *Other:* high fibre diet, stool softeners and bowel stimulants for hard stools.

## Movement abnormalities

Abnormalities of posture and movement frequently associated with altered tone, usually hypotonia.


- Generally involuntary and not associated with depressed consciousness.
- Primary movement disorders due to abnormal levels of neurotransmitter and basal ganglia function.
- By convention, abnormal movements associated primarily with cerebellar dysfunction, the peripheral nervous system, or pyramidal tract lesions are excluded.
- Also usually excludes abnormal movements associated with epileptic discharges, but there can be considerable overlap between epilepsy and movement disorders.

### History and examination

- Family history (consanguinity, dominant conditions).
- Neonatal encephalopathy and neonatal jaundice.
- Age of onset and initial symptoms, temporal course.
- Precipitating and aggravating factors.
- Diurnal fluctuation.
- Photographs and family video can be very helpful.
- Observation of abnormal movements with limbs in different positions.
- Fine motor skill assessment tasks:
  - drawing and writing in older children;
  - pegboards and threading beads in younger children.
- Allowing the child to lightly rest their hands on the examiner's hands while distracted may be helpful in detecting subtle tremor, myoclonus, or chorea.
- Gait assessment including stressed gait (toe/heel walking), walking backwards, and tandem gait is essential, and may bring out or abolish dystonia.
- The 'striatal toe' or pseudo-Babinski sign may be present in some children falsely localizing the lesion to the pyramidal tract.

### Defining the phenotype

The first step in forming a differential diagnosis and planning investigations is to define exactly which movement abnormality is/are present. This can sometimes be helped by videoing and watching the movements off-line at leisure, or with colleagues.

For the differential diagnosis and investigation of movement disorders, see  p. 375.

Terminology can be confusing

- *Dyskinesia*: any form of excessive abnormal movement. Includes tics, stereotypies, akathisia, myoclonus, tremor, chorea, dystonia, athetosis
- *Hypokinesia*: any form of abnormally reduced movement. Includes bradykinesia (slowed movement) and the Parkinsonism triad of bradykinesia, rigidity, and tremor.

## Dyskinesias

### Tics

The most common movement disorder in childhood. They are stereotyped, involuntary and irresistible, purposeless repetitive movements of skeletal, or oropharyngeal muscles causing absurd motor or phonic phenomena.

- Can be suppressed voluntarily to some extent, but is often accompanied by a subjective sense of compulsion and prolonged suppression. May cause anxiety that is relieved only by 'release' of the tic.
- Situations that generate anxiety may exacerbate the tic.
- Vary in complexity and range from simple motor tics (e.g. eye closure, shoulder shrugs) to complex tics (such as scratching) to very elaborate or sustained movements. Phonic tics can also be simple (e.g. sniffing) to complex (partial words, animal sounds) to elaborate verbal outbursts (echolalia, palilalia, coprolalia).
- Sensory tics are a rare form of tic in which the child suffers episodes of inappropriate sensation (heat, pressure) only relieved by movement of the affected body part. Much more commonly tics are associated with a 'premonitory urge', as if there is an itch they need to scratch, although it can be difficult to separate a pure sensory phenomenon from compulsion in these situations.
- Tics can be difficult to differentiate from other movements, but are typified by the child being able to reproduce them, voluntarily having partial control over them and their not interfering with voluntary activity. ► Unlike most other forms of movement disorder they can occur in sleep. Tics typically tend to affect facial and proximal muscles.

### Stereotypies

- Complex motor tics may be confused with stereotypies—repetitive, rhythmic and purposeless movements, which may be bizarre, but are characterized by their *absolute voluntary nature*.
- Typical stereotypies include head rolling, arm waving, and head banging
- Frequent in children with pervasive developmental disorders.

### Akathisia

- A tic-like dyskinesia, characterized by constant restlessness and changes in posture associated with anxiety
- Like tics, may be under semi-voluntary control
- Differs from hyperkinesia, which probably reflects abnormalities in frontal attentional mechanisms and is characterized by high activity levels, rather than frequent changes in posture.

### Mirror movements

- Involuntary movements of one side of the body that mirror intentional movements on the other side of the body.
- Normal in infants and disappear by the age of 8 yrs as the corpus callosum becomes fully myelinated.
- Obligatory mirror movements are always abnormal at any age and suggest cervicomedullary junction pathology. Consider Klippel–Feil and Kallmann syndromes, also seen in some children with hemiplegia due to persistence of ipsilateral corticospinal tract projections.

### **Tremor**

This is a rhythmic oscillation of a body part (usually limb) resulting from synchronous contraction of reciprocally innervated muscles.

- *Postural tremor*: precipitated by maintenance of the body part position against gravity.
- *Action tremor* (intention tremor): precipitated by voluntary movement and worsens as the limb approaches its target. Usually a result of cerebellar dysfunction.
- *Rubral tremor*: relatively rare high amplitude slow (2–5 Hz) tremor that is present at rest, and worsens with posture and movement. Can be due to lesions anywhere in the cerebello-rubro-thalamic pathways including the red nuclei themselves (from which the tremor derives its name).

### **Chorea**

- Excessive, sudden, and irregularly-timed spontaneous movements usually affecting proximal limbs, trunk, and facial muscles.
- Purposeless. Exacerbated by action or mental concentration.
- Can be difficult to differentiate from motor tics and myoclonus. The 'milkmaid phenomenon' can be elicited by asking the child to grasp the examiner's fingers who can then feel the 'milking' movements of subtle chorea.
- Ballismus is a severe form of chorea characterized by violent, high amplitude involuntary movements of proximal limbs.

### **Dystonia and athetosis**

- Due to abnormal muscle contraction caused by sustained and simultaneous contraction of agonist and antagonist muscle pairs
- Frequently causes twisting and repetitive movements or abnormal postures.
- May also comprise overflow contraction where the muscle contractions spread to muscles not normally involved in maintenance of a given posture.
- *Athetosis* refers to abnormal movements associated with dystonia. Athetotic movements are complex, irregular, purposeless, 'wriggling', and tend to predominate over dystonia. It can co-exist with chorea (choreo-athetosis).
- *Action dystonia* is absent at rest and appears on voluntary movement that can be very specific (e.g. writing). *Postural dystonia* is abnormal posture that is sustained (from minutes to days). It is abolished in sleep. It may progress to fixed postures often with muscle hypertrophy and contractures.

A number of conditions can produce abnormal postures that may be mistaken for dystonia. They should be considered and if necessary electromyography used in uncertain cases:

- Muscular dystrophy.
- Rigidity.
- Spasticity.
- Myotonia.
- Hyperekplexia.
- Hysterical postures.

Non-drug-related focal dystonias are uncommon in children and most become generalized. If a focal dystonia is persistent, then other diagnoses such as tics should be considered.

Dystonia may be classified as:

- *Focal dystonia*: involvement of a single muscle group. Focal dystonias that can occur in children include:
  - blepharospasm;
  - orofacial dystonia (combination with blepharospasm known as Mieve syndrome);
  - writer's cramp;
  - spasmodic torticollis.
- *Segmental dystonia*: involvement of two or more adjacent body areas, e.g. face and neck, or neck and upper arm.
- *Hemidystonia*: involvement of half of the body.
- *Multifocal dystonia*: two or more non-contiguous segments involved.
- *Generalized dystonia*.

### **Myoclonus**

Myoclonus is the sudden involuntary 'lightning shock' muscular contractions of one or several muscle groups.

May be focal, multifocal, or generalized. Myoclonic jerks can be single or repetitive with varying rhythmicity. They may be spontaneous or reflexive, triggered by stimuli, such as noise and touch.

### **Hypokinetic-rigid syndrome (Parkinsonism)**

Rare in childhood compared with adults.

Often associated with *dystonia*.

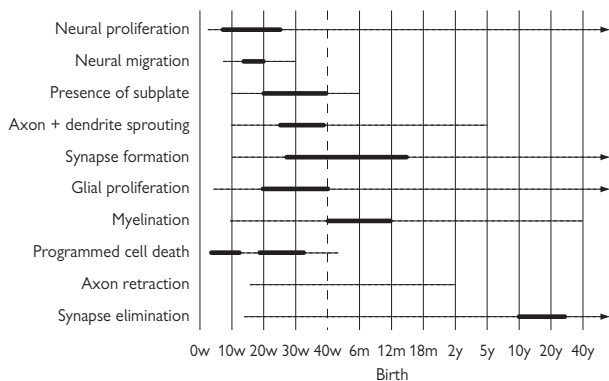
- *Hypokinesia/bradykinesia*: difficult slowed initiation and completion of movement, and paucity of voluntary and automatic movements.
- *Rigidity*: abnormal tone with increased resistance to passive movement that is constant regardless of the direction or velocity of movement—'lead pipe' rigidity.
- *Rest tremor*: 4–5 Hz tremor that occurs in the absence of voluntary movement and is diminished by intentional movement. Superimposed on rigidity, it causes the 'cog wheeling' phenomenon. For ataxia see 📖 p. 198.

## Magnetic resonance imaging and brain development

Radiological evidence of disordered brain development is a relatively common finding in MRI studies of children being investigated for developmental delay or 'cerebral palsy' particularly in association with seizures.

Brain development occurs in defined phases (Figure 3.5):

- Neurons arise from proliferating cells adjacent to the ventricular system.
- Primitive nerve cells (neuroblasts) migrate centrifugally from the centre to the periphery, using radial glial cells as a guiding scaffold, creating the multi-layered cortex.
- An 'inside-out' sequence of development occurs: deepest layers are formed first, each successive migration passing through earlier layers to form more superficial layers, so that the youngest neurons are closest to the surface.
- Once neurones have reached their final location further differentiation occurs, dendrites form, and synaptic connections are made when growth cones contact their post-synaptic targets.
- Some neurons act as temporary targets for incoming fibres and form transient connections before being eliminated by apoptosis when a more appropriate and permanent set of target cells are in place.
- Synaptic formation starts in the mid-trimester and continues during post-natal life.
- Oligodendrocytes begin to lay down myelin sheaths from 26 weeks gestation.



**Fig. 3.5** Stages of brain development. Reprinted from de Graaf-Peters (2006). de Graaf-Peters VB, Hadders-Algra M. (2006). Ontogeny of the human central nervous system: what is happening when? *Early Hum Dev* **82**(4): 257–66, with permission from Elsevier.



- Myelination occurs sequentially into the second decade.
- Fibres serving primary sensory and motor areas are myelinated shortly after birth while those associated with more complex cognitive functions are myelinated later (see Figure 2.7).

Radiological patterns of disordered development reflect the stage at which developmental progress was disrupted (Figure 3.6). This can either reflect a genetic (programming) error of brain development, or disruption by external injury or other noxious influences in what was an otherwise normally developing brain.

Evidence of bilateral, largely symmetrical changes indicate a likely genetic origin (with potential recurrence risk implications). Unilateral or strongly asymmetric patterns of involvement generally suggest acquired injury (with potentially lower recurrence risk implications); however, there are exceptions to this rule. Some radiological features may strongly implicate acquired pathogenesis (A5–8; B4, 5)

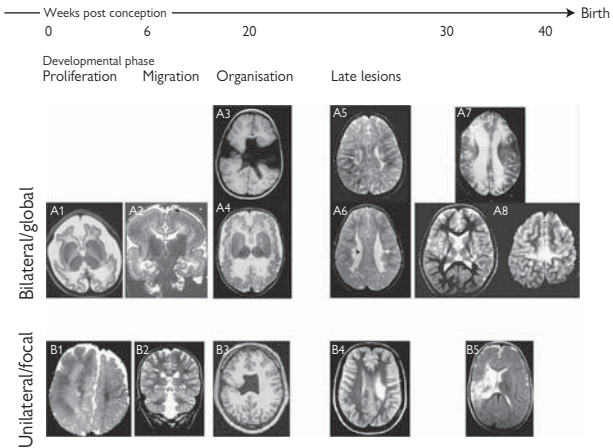
### Recognizable genetic brain malformation syndromes

Once a probable genetically-determined brain malformation syndrome has been identified it is important to try to define the radiological phenotype further to allow genetic confirmation, because of different recurrence risk implications (the mother or sister of a boy with a *DCX* mutation may be asymptomatic, but male offspring will be severely affected).

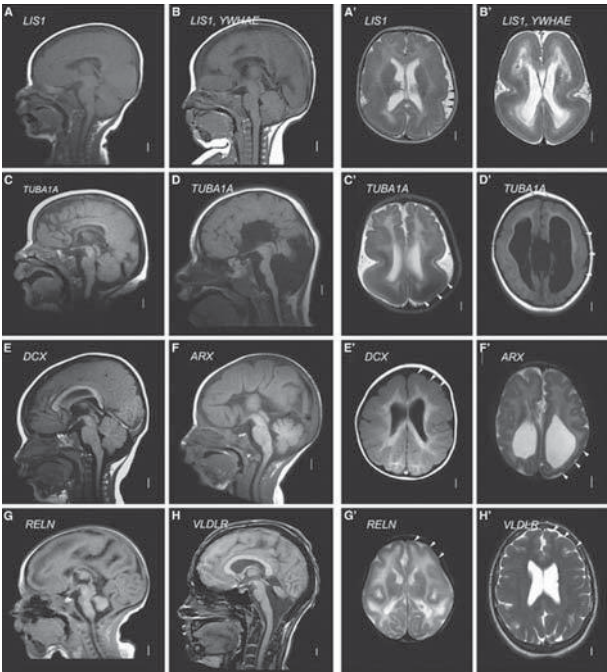
Several important genes have been identified in recent years causing brain malformation syndromes comprising lissencephaly (a combination of areas of smooth non-sulcated cortex, 'agyria', with abnormally thick gyri, 'pachygyria') and band heterotopia (thin 'ribbons' of grey matter in subcortical white matter underlying apparently relatively normal cortex, reflecting the failure of a 'wave' of neuronal migration from the ependymal zone to the cortex to complete).

These genes have relatively characteristic appearances in terms of the distribution of changes. (see Figure 3.7 for examples)

- *DCX*: X-linked recessive with severely affected boys. The lissencephaly and/or band heterotopia is predominantly frontal.
- *LIS1*: autosomal recessive. The lissencephaly and/or band heterotopia is predominantly posterior.
- *TUBA1A*: autosomal recessive. More widespread lissencephaly and/or band heterotopia (as *LIS1*) plus cerebellar hypoplasia  $\pm$  agenesis of the corpus callosum.
- *ARX*: X-linked recessive. Temporal and/or posterior lissencephaly.





**Fig. 3.6** Radiological appearances of developmental brain abnormalities. (1) Disorders of proliferation. A1 extreme microcephaly with simplified gyral pattern; B1 hemimegalencephaly. (2) Disorders of migration. A2 lissencephaly with thick cortex and typical cell sparse layer (arrow); B2 focal periventricular heterotopia (arrow). (3) Disorders of organization. A3 polymicrogyria-schizencephaly with polymicrogyric cortex lining the bilateral clefts; A4 generalized polymicrogyria; B3 unilateral schizencephaly. (4) Lesion pattern early third trimester. A5 mild periventricular leukomalacia (PVL) with periventricular gliosis (arrow) but no white matter reduction; A6 severe PVL with irregular ventricular enlargement due to white matter loss (arrow head) and periventricular gliosis (arrow); B4 unilateral periventricular lesion with white matter reduction and gliosis due to haemorrhagic infarction (arrow). (5) Lesion pattern late third trimester. A7 parasagittal hypoperfusion injury with cortical and subcortical damage in the parasagittal area (arrow); A8 acute severe term asphyxial insult of basal ganglia and thalamus lesions (left) with typical involvement of thalamus, globus pallidus and putamen (arrows), and lesions of the central region (arrows, right). B5 middle cerebral artery infarction with cortical, subcortical and thalamic involvement. Reprinted from Krägeloh-Mann (2004). *Imaging of early brain injury and cortical plasticity. Exp Neurol* **190**(Suppl 1): S84–90, with permission from Elsevier.



**Fig. 3.7** To help you decide which gene to request or what to suggest to your geneticist, here are typical appearances of defined monogenic brain malformation disorders. *RELN* and *VLDLR* are rarer causes of lissencephaly. *YWHAE* is a modifier gene. Reproduced from Dobyns WB (2010). The clinical patterns and molecular genetics of lissencephaly and subcortical band heterotopia. *Epilepsia* **51** (Suppl 1): 5–9, with permission of John Wiley & Sons, Inc.

## Unexpected findings on magnetic resonance imaging

With widespread availability of MRI it is common for radiological studies to identify unexpected findings of uncertain relevance, sometimes somewhat frivolously referred to as 'incidentalomas'. These can cause anxiety to inexperienced clinicians, radiologists, and of course, families. Assessing their significance can occasionally be challenging.

- Remember the 'nose-picking principle' (see  p. 53). Minimize the risk of unearthing incidentalomas by resisting the temptation to perform non-indicated examinations!
- Remember the 'what and where' approach (see  p. 4), and particularly the 'where'. If the site of the incidentaloma is distant from the likely site of pathology, given the examination findings, then it is easier to be reassuring about its non-significance.

### Recognized 'normal variants'

Refer to Figure 3.8 A–D.

#### *Cavum septum pellucidum (Figure 3.8 A and B)*

The septum pellucidum is the membrane separating the anterior horns of the two lateral ventricles. In foetuses the two layers of the septum are separated around a central cavity containing CSF. The large majority of these spontaneously close in early infancy, but may persist into adulthood. Note the MRI signal characteristics of the contents are those of CSF on all sequences.

#### *Prominent perivascular spaces (Figure 3.8 C)*

There is a potential, CSF-containing space around all cerebral arteries and arterioles as they enter the brain, formed by elongations along the vessel of the pia mater. Also known as Virchow–Robin spaces, they are associated with some neurological diseases (such as mucopolysaccharidoses), but are more commonly normal variants.

#### *Arachnoid cysts (Figure 3.8 D)*

Cysts can form in the arachnoid mater due to its filmy, self-adherent, nature (the name 'arachnoid', i.e. spider-like, is a reference to spiders' webs). Small cysts, such as that shown, are commonly asymptomatic (the location at the anterior pole of the temporal lobe is typical). They can spontaneously enlarge and very large cysts may rarely cause space-occupation symptoms, either directly or indirectly, via obstruction of CSF flow, and require neurosurgical treatment. Haemorrhage into very large cysts is also recognized; however, a cyst as small as that illustrated is very benign and should be ignored.

The evaluation of their relevance to some other situations can be more complex. They can give rise to seizures and, in children with epilepsy with congruent EEG data, consideration should be given to surgical treatment.

***Pineal cyst (Figure 3.8 E–G)***

Cysts arising from the pineal gland are generally benign, although larger cysts can cause obstruction of CSF flow and pressure effects, which may require neurosurgical intervention. Note that the signal characteristics of the contents of a pineal cyst match those of CSF on T1 and T2, but not fluid attenuated inversion recovery (FLAIR; Figure 3.8 F).

***Descent of cerebellar tonsils (Figure 3.8 H)***

Minor degrees of tonsillar descent are a common finding particularly in younger children with relatively small posterior fossae. If the degree of descent is <5 mm it is very probably benign and incidental. In situations of greater tonsillar descent, radiological evidence of foramen magnum crowding, and symptoms of headache, the findings may be significant. (see [□□](#) p. 333 for further discussion).

***Prominent central canal of spinal cord (Figure 3.8 I)***

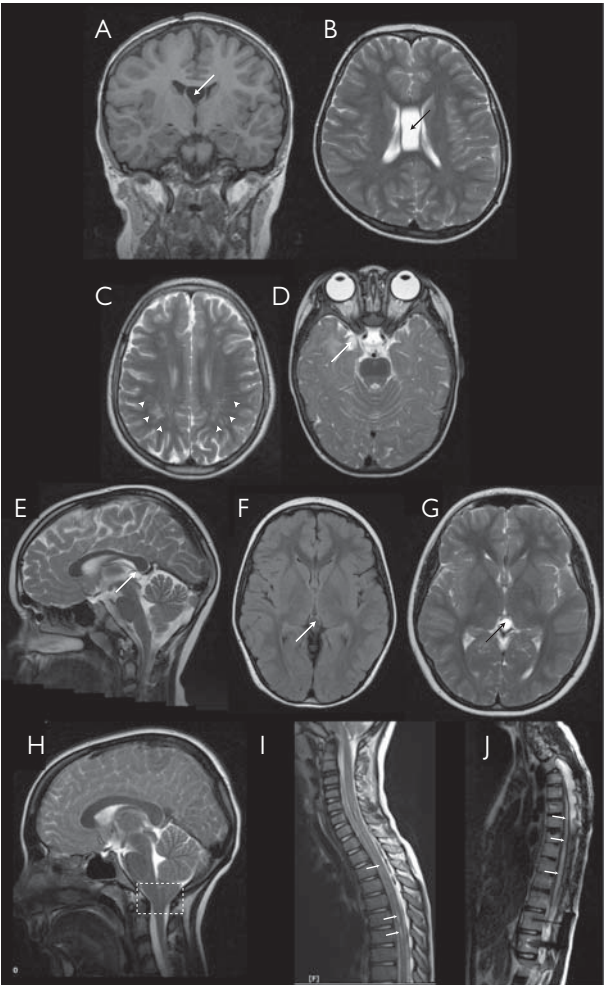
A prominent central canal of the spinal cord is a common finding and almost always incidental. The concern is usually that the appearance may represent a syrinx. In practice isolated syringes are very rare; nearly all are associated with other pathology affecting CSF flow, such as a Chiari II malformation (see also [□□](#) p. 333) or previous meningitis/arachnoiditis. In the example of a syrinx shown in Figure 3.8 J for comparison, the radiological evidence of associated scoliosis (reflected in the fact that the whole length of the spine cannot be imaged in a single plane) is further indication of the pathological nature of this case.

In unclear situations a follow-up study after an interval of 12 mths may clarify its non-progressive nature. Recall that testing spinothalamic sensation in relevant dermatomes is the most sensitive clinical indicator of a syrinx (see [□□](#) p. 217).

***'Mild cortical atrophy', 'prominent subarachnoid spaces'***

In comparison with adult brains, the subarachnoid space around the cerebral hemispheres in pre-adolescent children tends to be somewhat larger, particularly frontally (this relates to the fact that maturation of frontal lobe function—accompanied by demonstrable enlargement—is an adolescent phenomenon). This can lead to normal appearances being reported by adult neuroradiologists with less paediatric experience as 'mild cortical atrophy' or similar phrases.

If appearances are striking, and head circumference is large, consider benign external hydrocephalus (see Figure 3.3).



**Fig. 3.8** Common incidental findings on MRI.


## White matter abnormalities on magnetic resonance imaging

### Definitions

- *Leukoencephalopathy*: any disorder of white matter, whether genetic or acquired (includes leukodystrophies).
- *Leukodystrophy*: genetically determined white-matter diseases.

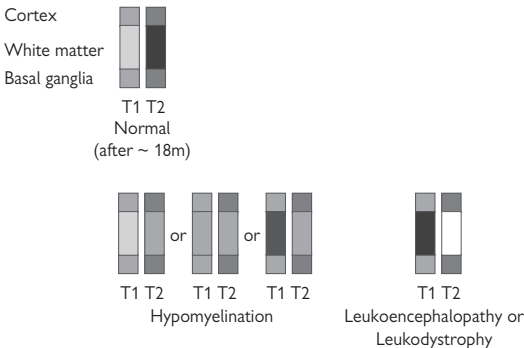
### Approach

The first step is to distinguish *hypomyelination* or delayed myelination from *dysmyelination* (i.e. a leukoencephalopathy). This is done by comparison of the T1 and T2 characteristics of the white matter in relation to the appearance of grey matter structures.

Because of physiological changes in white matter signal appearance in the first 2 yrs of life reflecting myelination (see  p. 60), this distinction can be difficult before the age of 18–24 mths. After this time, white matter should normally be dark (reflecting completed myelination) on T2 (Figure 3.9).

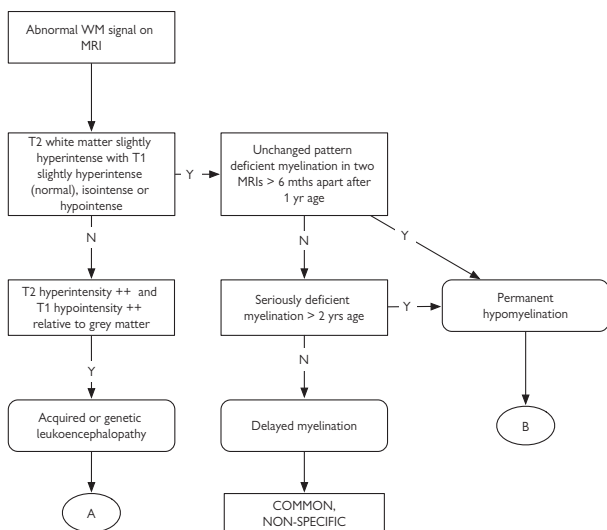
Further characterization is based on a combination of radiological features (particularly the anatomical location of abnormal white matter) and associated clinical features. Please note that variant and atypical forms make this a more complex process than the flowchart necessarily suggests (Schiffmann and van der Knaap, 2009<sup>1</sup>)!

The commonest leukodystrophies in UK practice are metachromatic leukodystrophy, x-lined adrenoleukodystrophy and Krabbe disease; followed by Canavan, Alexander, CACH/VWM (see Figures 3.10 and 3.11), and Pelizaeus-Merzbacher disease.



**Fig. 3.9.** Maturation changes of appearances of white and grey matter on T1 and T2.

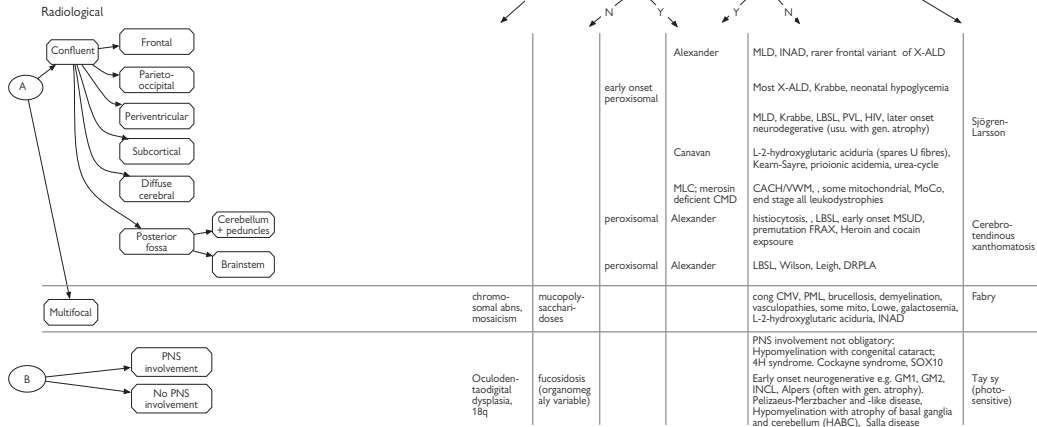
<sup>1</sup> Schiffmann R, van der Knaap MS (2009). Invited article: an MRI-based approach to the diagnosis of white matter disorders. *Neurology* **72**: 750–9.



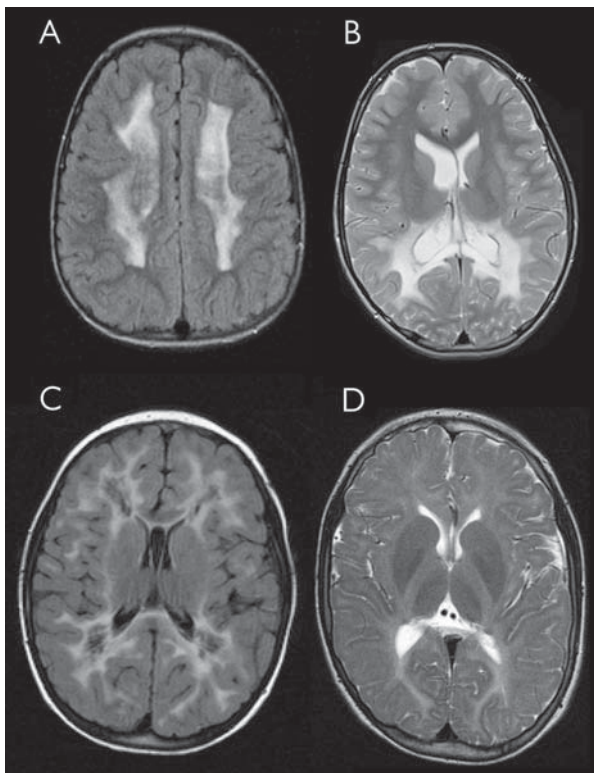
**Fig. 3.10** Approach to leukodystrophies. Work through the flow chart from the top left. Refer to (A) or (B) on the second flow chart to continue. Reproduced with permission from Naidu S, Bibat G, Lin D (2011). Clinical approach to identification of leukoencephalopathies. In: Raymond GV et al. (Eds), *Leukodystrophies*. London: published by MacKeith Press.



Abbreviations: MLD Metachromatic Leukodystrophy, X-ALD x-linked adrenoleukodystrophy, INAD infantile neuroaxonal dystrophy, LBSL leukoencephalopathy with brainstem and spinal cord involvement and lactate elevation PVL periventricular leukomalacia, CACH/VWM Childhood ataxia with central hypomyelination (=vanishing white matter disease), MoCo molybdenum cofactor deficiency/sulfite oxidase deficiency, CTX cerebrotendinous xanthomatosis, MSUD maple syrup urine disease, DRPLA dentatorubro-pallidoluysian atrophy, PML progressive multifocal leukoencephalopathy, MLC megalen-cephalic leukoencephalopathy with subcortical cysts, CMD congenital muscular dystrophy



**Fig. 3.10** (Continued) Approach to leukodystrophies. Figures reproduced with permission from Schiffmann R, van der Knaap MS (2009). Invited article: an MRI-based approach to the diagnosis of white matter disorders. *Neurology* 72: 750–9. Copyright (2009) Wolters Kluwer Health.

**Example images** (Figure 3.11)

**Fig. 3.11** Appearances of four leukoencephalopathies (A) Typical deep, periventricular distribution of clearly leukodystrophic change with sparing of U fibres in metachromatic leukodystrophy. (B) Posterior predominant confluent changes of X-linked adrenoleukodystrophy. (C) FLAIR image showing diffuse white matter involvement (involving U fibres) with emerging cavitation in CACH/VWM disease. (D) Global hypomyelination in Pelizaeus–Merzbacher disease.

## Numbness, pain, tingling, and sensory disturbance

Very rare in child neurology as an isolated phenomenon.

### Specific scenarios

- *Unilateral hemi-syndrome*: consider migraine or epilepsy (the duration of disturbed sensation will help differentiate). Dysaesthesia is contralateral to the dysfunctional hemisphere.
- *Distal legs or proximal arms*:
  - Extremely distressing paraesthesiae or allodynia (pain brought on by light touch) are often seen with the parainfective neuropathies (may be relieved by gabapentin or pregabalin). Distal leg symptoms may precede weakness in the Guillain–Barré syndrome. Proximal arm/shoulder pain or dysaesthesia often precedes the weakness of neuralgic amyotrophy.
  - Hereditary neuropathy with a tendency to pressure point palsies (median, or ulnar nerve symptoms, presents very rarely in childhood).
- Concern may be expressed about apparent insensitivity to pain. True anaesthesia raises possibility of hereditary sensory and autosomal neuropathy (HSAN) conditions, such as Riley–Day syndrome (see [p. 394](#)), although these are extremely rare. True anaesthesia will lead to injuries and tissue destruction. Much more commonly a child with developmental disability will show *indifference* to pain: he feels (and withdraws automatically from) painful stimuli but shows little emotional distress (i.e. doesn't cry). Histamine flare testing can be useful in ambiguous cases (see [p. 591](#)).
- Patchy sensory loss may accompany demyelinating conditions (ADEM), but rarely as an isolated feature. Multiple sclerosis may rarely present in childhood.
- Hemidysaesthesia may precede a TIA.
- Dissociated sensory loss (loss of pain sensation but preservation of light touch  $\pm$  dysaesthesia) particularly in the arms is very suggestive of a syrinx or other central cavity in the cervical cord.
- Acroparaesthesiae in a boy due to Fabry disease (X-linked; very rare).
- Severe abdominal pain with prominent autonomic features (tachycardia, diarrhoea)  $\pm$  neuropathic pain in limbs occurs in acute porphyrias (see [p. 367](#); essentially a post-pubertal disease only).
- Isolated numbness, tingling or other sensory disturbance is a relatively common non-organic, functional complaint (see [p. 311](#)). Such disturbances will typically be reported in patchy distributions that do not correspond to anatomical segmental or peripheral nerve territory distributions.

### Reflex sympathetic dystrophy

- Also known as causalgia, complex regional pain syndrome (CRPS).
- The precise mechanism is unknown, although it is presumed to involve disturbance of the sympathetic nervous system in the affected region. There may also be changes in central representations of sensory input from limbs.

- Almost exclusively presents in girls in adolescence or later.
- Typically involves the distal limb and follows minor trauma (e.g. ankle sprain).
- Over days to weeks after injury the affected area (usually the distal limb) becomes subjectively severely painful.
- Objective changes suggestive of sympathetic disturbance may occur, e.g. the affected area is flushed and warm, and shows increased sweating.
- Management is symptomatic:
  - gabapentin or pregabalin by mouth may be help neuropathic pain (amitriptyline or valproate are second line alternatives);
  - physiotherapy to maintain the range of movement and prevent secondary deformity;
  - in rare cases consider (in conjunction with specialist pain teams) regional anaesthesia, e.g. nerve blocks;
  - although, as with other medically unexplained syndromes, suggested involvement of child and adolescent mental health services (CAMHS) services is often met with hostility, secondary emotional morbidity is common and often a significant issue in its own right.
- Therapies such as desensitizing 'brushing' have some biological plausibility, but are unproven and risk unhelpful 'fixation' on symptoms.
- Other suggested therapies with some biological plausibility include 'mirror box' treatment (positioning the affected limb behind a mirror in such a way that it coincides in visual and proprioceptive space with the reflection of the unaffected limb in front of the mirror, and then brushing the normal limb so that the brain has the visual experience of 'seeing' the affected limb touched without experiencing pain).

### Paroxysmal extreme pain disorder

- The preferred name for what was previously known as familial rectal pain syndrome.
- Extremely rare.
- Autosomal dominant condition due to mutations in a voltage-gated sodium channel gene *SCN9A* resulting in inability to inactivate after nociceptive stimulus.
- Results in overwhelming severe burning pain typically beginning in eye, or jaw, or characteristically, rectum, usually triggered by normally-trivial stimuli such as eating, defecation, wiping perineum.
- Pain can become more generalized and has been described by adult women as much more severe than labour pains.
- There may be flushing skin changes in affected region.
- Episodes typically last seconds to a few minutes.
- Presents in infants with paroxysmal flushing and severe inconsolable distress. EEG is normal apart from tachycardia.
- Variable benefit from carbamazepine, gabapentin, topiramate. No benefit from opiates.

## Peripheral weakness

### Identify the pattern of weakness

#### Cranial involvement?

- *Facial weakness*: facioscapulohumeral (FSH) dystrophy, myasthenia, myotonic dystrophy, congenital myopathy, congenital muscular dystrophy.
- *Ptosis*: myasthenia, myotonic dystrophy, myotubular myopathy.
- *Ophthalmoplegia*: myasthenia, myotubular myopathy, merosin-deficient congenital muscular dystrophy, mitochondrial.
- *Tongue fasciculation*: spinal muscular atrophy, motor neuron disease.
- *Nasal voice*: myotonic dystrophy.

#### Proximal?

Difficulties raising head from pillow, combing hair, brushing teeth, shaving, raising arms above head, getting up from chair, stairs and use of banisters, running, hopping, jumping.

**Proximal weakness is usually due to muscle disease** (Duchenne, Becker, limb-girdle and congenital dystrophies, congenital myopathies), *but* also spinal muscular atrophies and some neuropathies (CIDP, and neuropathy due to porphyria).

#### Distal?

Difficulties opening screw cap or door knob, turning key, buttoning clothes, writing, falling on uneven ground, tripping, hitting curb, difficulty in heel walking, toe walking, foot drop.

**Distal weakness is usually due to neuropathy (any)**, *but* also some muscle diseases (Emery–Dreifuss, myotonic dystrophy, dysferlinopathy, Miyoshi myopathy).

#### Axial?

Difficulties bending forward, lifting head off the bed, respiratory involvement, nocturnal hypoventilation, and diaphragmatic weakness; seen in congenital myopathies and glycogen storage disorders.

### Identify the symptom time course

#### Variability?

Diurnal variability points towards *myasthenia* (e.g. wide eyes on waking, but ptosis towards end of day).

#### Neonatal presentation?

Antenatal onset suggested by polyhydramnios, reduced foetal movements, unusual foetal presentation in labour, contractures (arthrogryposis including foot deformity), congenital dysplasia of the hip.

❗ By contrast, infants with SMA type I usually have a period of normality after birth.



**Acute onset?**

Consider GBS, transverse myelitis, toxic, porphyria, critical illness polyneuropathy.

**Episodic or fluctuating? Progressive?**

See Figure 3.12.

**Associated features/system enquiry**

- *Toe walking*: Duchenne, Becker, Emery–Dreifuss, Charcot–Marie Tooth.
- *Falls*: unsteadiness in sensory neuropathy.
- *Myoglobinuria*: dystrophies, metabolic myopathies.
- *Numbness, tingling, pins and needles, burning, pain, walking on cotton wool*: sensory neuropathies.
- *Foot deformities* (see  p. 135).
- *Respiratory*: nocturnal hypoventilation, ineffective cough, diaphragmatic breathing pattern, recurrent infections.
- *Cardiac involvement*: Emery–Dreifuss, myotonic dystrophy, muscular dystrophies.
- *Feeding difficulties*.
- *Contractures* (see  'Examination', p. 177).
- *Vision*: muscle-eye-brain disease.
- *Hearing*.
- *Learning difficulties* (some dystrophies).
- *Medication and possible toxin exposure*.
- *Neonatal deaths, still births*.
- *Developmental delay* especially delayed walking.
- *Family history indicators*:
  - consanguinity—autosomal recessive;
  - parent to child—dominant;
  - mother-to-son, males only—X-linked recessive;
  - mother to child—mitochondrial.

**Examination**

- *Examine parents and siblings*: especially when considering neuropathies, myotonic dystrophy.
- Differentiate between a lesion of the brain, brainstem, cord, root, nerve, neuromuscular junction, muscle (see Table 1.6).
- *Syndromic features*.
- *Muscle bulk*.
- *Atrophy*, e.g. of peroneal and intrinsic hand muscles in HMSN.
- *(Pseudo-) hypertrophy*, e.g. of calves in Duchenne.
- *Tone, hypotonia, myotonia (percussion, grip, exercise)*:
  - *myotonia*—delayed muscle relaxation after sustained contraction; improvement with repeated contractions (warm-up);
  - *percussion myotonia*—prolonged contraction after hit with a tendon hammer (thenar eminence, forearm, tongue);
  - *paramyotonia*—paradoxical myotonia worsening with repeated contractions.
- *Reflexes absent in neuropathy, present in muscle disorders*.

- **Fasciculations:**
  - SMA;
  - neuropathies;
  - can be normal (caffeine consumption, fatigue).
- Tremor, pseudoathetosis in neuropathies.
- Poly-mini-myoclonus in SMA.
- **Contractures/skeletal:**
  - elbows—Emery–Dreifuss;
  - Achilles tendons—Duchenne, HMSN;
  - ileotibial band—Duchenne;
  - knee extension/flexion—sarcoglycanopathies;
  - fingers, elbows, ankles—Bethlem myopathy;
  - spine, neck—Ulrich, central core, minicore, lamin A/C (dominant Emery–Dreifuss);
  - foot deformity—neuropathy.
- **Cardiac:**
  - arrhythmias—Emery–Dreifuss, limb girdle muscular dystrophy (LGMD) 1B, myotonic dystrophy;
  - dilated cardiomyopathy—Duchenne, Becker, LGMD 2 C, D, E, F.
- **Nerve hypertrophy:** hypertrophic HMSN, leprosy, CIDP.
- **Functional assessment:**
  - compensatory lordosis;
  - hyperextension of knees;
  - consequences of proximal weakness: waddling gait, difficulties with steps, hopping and jumping, Gowers' sign;
  - timed 10 m (or other convenient standardized distance) walk;
  - speech;
  - fine motor function (e.g. pegboard).

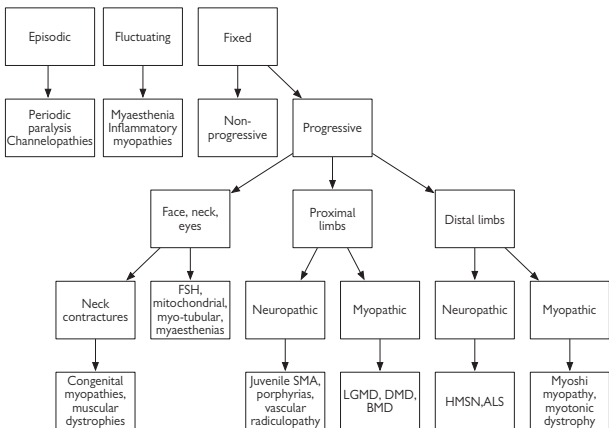


Fig. 3.12 Weakness flowchart.

## Psychomotor regression

Differentiate between true regression vs. evolution of signs in a static encephalopathy. There are a number of other conditions that may present with *apparent* regression.

### Non-neurodegenerative causes of apparent regression

#### 0–2 yrs

- Infantile spasms.
- Autistic regression.
- Evolution of signs in a static encephalopathy.

#### 2–5 yrs

- Lennox–Gastaut.
- Raised ICP (tumour, hydrocephalus).
- Spinal tumour.
- Para-neoplastic.
- DOPA-responsive dystonia.

#### School age

- Landau–Kleffner.
- Continuous spike-wave discharges during slow wave sleep (CSWS).
- Autoimmune, e.g. demyelinating disease.
- Widening gap between child and peers over time as demands of schooling increase.
- Idiopathic torsion dystonia.

#### Adolescents

- Autoimmune.
- Psychiatric disorders.
- Factitious illness.
- Chronic fatigue syndrome.
- Substance abuse.
- Thyroid disorder including Hashimoto encephalopathy.
- Vasculitis, e.g. systemic lupus erythematosus (SLE).

#### At any age


Consider:

- Epileptic regression (see 📖 p. 180).
- Psychosocial deprivation or abuse.
- Fabricated/induced illnesses.
- Cerebrovascular events.
- Raised ICP (space-occupying lesion, hydrocephalus, etc.).
- Toxic (lead, methotrexate, substance abuse, radiotherapy).
- Endocrine (hypothyroidism).

### Psychomotor regression and epilepsy

Regression is often a feature of severe epilepsies ('epileptic encephalopathy'). This can be an accompaniment of a severe primary seizure disorder (e.g. infantile spasms or Lennox–Gastaut syndrome), in association with potentially more reversible seizure disorders (CSWS and Landau–Kleffner spectrum; non-convulsive status epilepticus) or the seizures can be a



symptom of a progressive underlying neurological disease. This latter is particularly a consideration in the presence of myoclonic seizures (see  p. 283).

### Approach to diagnosis of neurodegenerative conditions


There is no such thing as a 'general neurometabolic screen'—narrow the differential diagnosis, and then focus investigations appropriately. Some of the conditions discussed are orders of magnitude more common than others. It is important to have this perspective, but equally to be aware of local ethnicity considerations creating local 'gene pools'.

A long-running UK surveillance programme for progressive intellectual and neurological decline in children identified a total of 147 diagnoses in 42% of reported cases. The six commonest diagnostic groups were leukoencephalopathies (7% combined), neuronal ceroid lipofuscinoses (5% combined), mitochondrial diseases (5%), mucopolysaccharidoses (4%), gangliosidoses (4%), and peroxisomal disorders (3%).<sup>2</sup>

#### Clues in the age at presentation

The typical ages at presentation for common neurodegenerative conditions are outlined in Table 3.11.

#### Clues from the history

- *Myoclonus*: gangliosidoses; neuronal ceroid lipofuscinosis (NCL); Gaucher type 3; Leigh; sub-acute sclerosing panencephalitis (SSPE); Lafora; vCJD; Unverricht–Lundborg.
- *Early visual impairment*: infantile or juvenile NCL; adrenoleukodystrophy (X-ALD); GM2 gangliosidosis.
- *Behavioural disturbance*: X-ALD; Sanfilippo; Wilson; juvenile Huntington; juvenile NCL.
- *Stroke-like episodes or episodic encephalopathy*: mitochondrial; Leigh; homocystinuria.
- *Gastrointestinal symptoms* (failure to thrive, vomiting, diarrhoea): abetalipoproteinaemia; Leigh; Gaucher type 2; Sanfilippo.
- *Rapidity of regression*: gangliosidoses, neurodegeneration with brain iron accumulation (NBIA, also known as pantothenate kinase-associated neurodegeneration (PKAN) and formerly Hallervorden–Spatz; see  p. 430), Krabbe, X-ALD, Alpers; Leigh.
- *Family history*: recessive inheritance or X-linked (Pelizaeus–Merzbacher, X-ALD, Hunter). Ask about history of sudden infant death, unexplained illness, or neurological presentations in family members. Ask about ethnicity and consanguinity.

#### Clues from the physical examination

See also Table 1.1.

- *Dysmorphism*: coarse facies of MPS (mild in Sanfilippo), GM1 gangliosidosis, mucopolidosis.
- *Macrocephaly*: in Canavan/Alexander, Krabbe, MLD.
- *Microcephaly*: in Rett, infantile NCL.
- *Skeletal abnormality*: in MPS, GM1 gangliosidosis, Gaucher.

<sup>2</sup> Verity C, Winstone AM, Stellitano L, Will R, Nicoll A. (2010). The epidemiology of progressive intellectual and neurological deterioration in childhood. *Arch Dis Child* **95**: 361–4.

- *Hepatosplenomegaly*: Gaucher, Niemann–Pick, MPS, gangliosidosis, Wilson.
- *Peripheral nerve involvement* (absent tendon jerks, abnormal EMG/NCV): MLD, multiple sulphatase deficiency, Krabbe, Refsum, X-ALD, Fabry, Leigh, Friedreich ataxia, infantile neuraxonal dystrophy (INAD).
- *Pyramidal signs*: leukoencephalopathies, e.g. MLD, Krabbe, X-ALD.
- *Extrapyramidal signs*: Leigh, juvenile Huntington, NBIA/PKAN, Wilson, vCJD.
- *Ataxia*: ataxia telangiectasia, Friedreich ataxia, Leigh, Niemann–Pick, cerebrotendinous xanthomatosis, mitochondrial, MLD, vCJD, Refsum.

### **Grey or white matter disorder?**

See Table 3.11

- *Grey matter disorders*: prominent seizures, personality change, and dementia  $\pm$  movement disorder. Motor features are late.
- *White matter disorders*: prominent spasticity, ataxia, hearing, and visual impairment. Seizures and dementia are late features.

**Table 3.11** Causes of grey and white matter disease

<b>Grey matter disorders</b>	<b>White matter disorders</b>
Alpers (PNDC)	Krabbe
Gangliosidosis GM1, GM2	MLD
Mucopolidoses	X-ALD
Fucosidosis	Pelizaeus–Merzbacher disease (PMD)
Wilson	Canavan
Lafora body disease	Alexander
Niemann–Pick A, C	Aicardi–Goutières
MPS	Sialidosis
Gaucher	Cockayne
Farber	Vanishing white matter disease
Leigh	Megalencephalic leukoencephalopathy, subcortical cysts
Menkes	Cerebrotendinous xanthomatosis
Huntington	Mitochondrial
Mitochondrial	Multiple sulphatase deficiency
	Sulphatide activator deficiency
	Cobalamin/folate metabolism disorders

**Age at onset: less than 2 years**

See Table 3.12.

**Table 3.12** Common degenerative disorders by age at presentation: diagnostic clues and investigations at age less than 2 yrs

Condition	Clues to diagnosis	Test
PMD	Boys, early eye movement abnormality, hypotonia, head bobbing, dystonia then spastic paraparesis slow cognitive decline	MRI electrophysiology, DNA testing (some cases)
MLD	Polyradiculopathy (delayed NCV, limb pains) with upper motor signs too, usually present as gait abnormality, high CSF protein	Lysosomal enzyme screen ('white cell enzymes'), MRI
Krabbe	Irritability, myoclonus, hypertonia, opisthotonus, hyperpyrexia, raised CSF protein, peripheral neuropathy	Lysosomal enzyme screen
Gangliosidoses	<i>GM1</i> : dysmorphic, skeletal abnormality, cherry red spot (50%), hepatosplenomegaly. <i>GM2</i> : early visual impairment, cherry red spot (100%), stimulus-sensitive myoclonus, hepatosplenomegaly	Lysosomal enzyme screen
Infantile NCL	Irritable infants with visual loss (early optic atrophy), chorea/dystonia, stimulus-induced myoclonus, microcephaly, EEG: flattened with loss of sleep spindles	Lysosomal enzyme screen, skin electron microscopy: neuronal granular inclusions
INAD	Presentation similar to MLD, but normal CSF protein, anterior horn cell type denervation on EMG, normal NCV. MRI shows cerebellar atrophy (sometimes with high T2 in cerebellar cortex) $\pm$ iron deposition in pallidus	PLAG26 mutations; <i>Skin biopsy</i> : spheroids in nerve axons
Rett	Acquired microcephaly, loss of speech and purposeful hand movements, seizures, bruxism	MECP2 mutation
Gaucher type 2	Failure to thrive, hepatosplenomegaly, hypertonia with neck extension, stridor, seizures, bone marrow suppression, strabismus, cherry red spot	Lysosomal enzyme screen, Gaucher cells in bone marrow, cytogenetics
Niemann-Pick A	Organomegaly, feeding problems, seizures, cherry red spot	Lysosomal enzyme screen, 'sea blue' histiocytes on bone marrow

**Age at onset: 2–5 years**

See Table 3.13.

**Table 3.13** Common degenerative disorders by age at presentation: diagnostic clues and investigations at age 2–5 yrs

Condition	Clues to diagnosis	Test
X-ALD	Behavioural/cognitive decline with early visual loss, then motor disorder	Very long chain fatty acids (VLCFA)
NCL—late infantile	Stimulus-induced myoclonus and other seizures, extrapyramidal motor disorder, visual loss later, visual-evoked potential (VEP): giant responses, electroretinogram (ERG): absent later  EEG: high amplitude slow, occipital spikes to slow (1 Hz) photic stimulation  Electron microscopy of skin: curvilinear inclusions in neurons	Tripeptidyl peptidase (TPP) assay
Mitochondrial	Varied presentations, eye movement abnormality, myopathy, seizures, strokes	Muscle biopsy, respiratory chain enzymes
Sanfilippo	Developmental delay then behavioural disturbance ++, then seizures and motor regression, hip dysplasia, diarrhoea	Urine GAG (heparin sulphate), lysosomal enzyme screen
Alpers	Intractable seizures (myoclonic, akinetic, generalized), liver function abnormality	Mitochondrial respiratory chain activity assay and polymerase gamma mutations
Leigh	Poor suck/swallow reflex, vomiting, irritability, seizures, rapid regression, abnormal eye movements and early optic atrophy	MRI, mitochondrial studies (skin/muscle), pyruvate dehydrogenase (PDH) studies
Gaucher type 3	Oculomotor apraxia, supranuclear palsy, myoclonus, ataxia, skeletal abnormality, hepatosplenomegaly, lung involvement	Lysosomal enzyme screen, Gaucher cells on bone marrow biopsy, cytogenetics

**Age at onset: 5–12 years**


See Table 3.14.

**Table 3.14** Common degenerative disorders by age at presentation: diagnostic clues and investigations at age 5–12 yrs

Condition	Clues to diagnosis	Test
NCL—juvenile	Visual loss (early optic atrophy) behavioural problems, dementia. Later in teens compulsive speech, seizures, motor disorder, ERG: attenuated early in the condition, vacuolated lymphocytes	Lysosomal enzyme screen Electron microscopy of skin: fingerprint inclusions in neurons
NBIA/PKAN	Extrapyramidal signs (lower than upper limbs), dystonic spasms, retinitis pigmentosa, rapid progression	MRI: 'tiger eyes', cytogenetics
Refsum	Ataxia, hepatomegaly, ichthyosis, retinitis pigmentosa, deafness, raised CSF protein	Phytanic acid
Niemann–Pick C	Vertical gaze palsy, seizures, ataxia, dystonia, hepatosplenomegaly, cherry red spot	'Sea blue' histiocytes on bone marrow, cholesterol transport/storage in cultured fibroblasts
Unverricht–Lunaborg disease	Generalized seizures then stimulus-sensitive myoclonus, ataxia/extrapyramidal signs, cognitive decline is slow, EEG: photosensitivity	EPM1 mutation
Friedreich ataxia	Ataxia, pyramidal signs with peripheral neuropathy (loss of reflexes, vibration and proprioception)	Fratxin mutation
HIV dementia	Vertical transmission, immunodeficiency	CD4 counts, viral titres

**Age at onset: adolescence**

See Table 3.15.

**Clues from imaging, electrophysiology and ophthalmology examination**For approach to white matter abnormalities see  p. 170.

MRI can support diagnosis of the following conditions:

- *Late infantile NCL*: cerebellar atrophy with periventricular white matter signal abnormality.
- *MLD*: symmetrical demyelination with rostro-caudal progression.
- *X-ALD*: signal abnormality in white matter posteriorly with anterior progression.

**Table 3.15** Common degenerative disorders by age at presentation: diagnostic clues and investigations at adolescence

Condition	Clues to diagnosis	Test
Wilson	Behaviour, psychiatric, and extrapyramidal movement disorders, hepatic involvement	Kaiser–Fleischer (KF) rings, penicillamine challenge
SSPE	Behaviour/cognitive decline, optic atrophy, extrapyramidal signs, myoclonus. EEG: synchronous periodic high voltage sharp/slow-wave complexes. History of measles <4 yrs. High CSF protein with oligoclonal bands (OGB)	Paired CSF and serum measles IgM; CSF measles PCR
vCJD	Psychiatric, sensory phenomena, then extrapyramidal and cerebellar signs and myoclonus	MRI, post-mortem
Lafora body disease	Rapid dementia, stimulus sensitive and resting myoclonus, visual seizures	Axillary skin biopsy with sweat glands (Lafora bodies)
SCA 7	Ataxia, dysarthria, dysphagia, progressive central visual loss	Cytogenetics
Cerebrotendinous xanthomatosis	Myoclonus, cataracts, xanthelasma, ataxia, slow progression	Cholestanol levels
Juvenile Huntington	Rigidity, seizures, dementia, family history (often paternal)	Cytogenetics



- *PMD*: signal abnormality in white matter on T2-weighted images, normal on T1.
- *Leigh*: symmetrical hypointense areas on T1-weighted image, hyperintense on T2, involving basal ganglia (mainly putamen) and brainstem with sparing of the mamillary body.
- *Vanishing white matter disease*: the signal in the periventricular white matter is similar to CSF; subcortical white matter appears streaky.
- *Multifocal leukoencephalopathy with subcortical cysts*: diffuse cerebral oedema with cystic changes especially in the parietal and temporal regions.
- *NBIA/PKAN*: 'tiger eyes' appearance with signal abnormality in the basal ganglia due to iron deposition.
- *vCJD*: bilateral pulvinar high signal.

Electrophysiology (EEG, VEP, ERG, EMG/NCV) and ophthalmology examination can also yield important clues to the diagnosis of specific neurodegenerative conditions.

## School failure

True, new-onset neurological regression in older children or adolescents is rare. It can be hard to tell whether the problem is, in fact, longstanding, but has recently come to light due to increasing academic expectations (e.g. at a move to a new school). Parental observations should be supplemented by reports from schoolteachers and/or educational psychologists.

### Causes

- *Non-neurological:*
  - previously unidentified learning difficulties, ADHD, autistic spectrum or pervasive developmental disorders, dyslexia;
  - bullying, stress;
  - chronic non-neurological illness (e.g. renal failure, diabetes) via school absence, emotional issues.
- *Drug side effects:*
  - prescribed (e.g. AEDs);
  - recreational drugs and alcohol abuse;
- *Sensory impairment:* evolving hearing or visual impairment.
- *Psychiatric:* depression, schizophrenia.
- *Epilepsy without obvious convulsive seizures:* absence epilepsy, non-convulsive status, Landau–Kleffner, and CSWS (see  p. 272).
- True neurodegenerative disorders presenting in later childhood will eventually manifest neurological signs, as well as cognitive deterioration. Conditions in which cognitive failure can be prominent initially include neuropsychiatric systemic lupus erythematosus, juvenile-onset neuronal ceroid lipofuscinosis, Wilson, juvenile Huntington, X-linked adrenoleukodystrophy, SSPE, and vCJD (see  p. 184).

### History

- Medication and drugs/alcohol?
- Mental state and mood?
- Seizures?
- Exposure to wild measles, tick bites?



### Examination

The child will be older and a formal (adult style) neurological examination with assessment of higher mental function (see Box 1.1) should be performed.

- Look at affect, mood, signs of distractibility, and slowness of cognitive processing.
- Cerebellar involvement?
- Pyramidal signs?
- *Extrapyramidal signs:* involuntary movements, abnormal posturing.
- *Handwriting:* micrographia (Wilson).
- *Eyes:* Kaiser–Fleischer rings, pigmentary retinopathy.
- Neuropsychological assessment can be very useful in defining the 'phenotype'.

### Assessment and investigation

Depending on impression.

- *Specific learning difficulty:*
  - relatively isolated weakness in one domain;
  - further investigation is not indicated; appropriate educational assessment and provision.
- *Mild global learning difficulties:* if clearly longstanding and non-progressive, further investigation is not indicated. Appropriate educational assessment and provision.
- *Moderate/severe learning difficulties:* As for global developmental delay, see  p. 109.
- *Psychiatric:* consider a neuropsychiatric review if a behavioural disturbance or mental illness prominent.
- *Neurological disease:* if there is concern of dementia, test more formally:
  - frontal lobe function—expressive dysphasia, primitive reflexes (palmar-mental, grasp, snout, glabellar), response-suppression (go versus no-go tasks);
  - temporal lobe function—long-term memory recall, receptive dysphasia (three-step command);
  - parietal lobe function—dressing apraxia, constructional apraxia, astereognosis, graphaesthesia, sensory inattention, dyscalculia (serial 7s, etc.).
- Unambiguous findings on formal neurological examination should lead to further investigation as for psychomotor regression (see  p. 179).
- Consider EEG (including deep sleep) if LKS or CSWS is suspected.



## Sleep disturbance

### Sleep

A reversible state of reduced awareness of and responsiveness to the environment, usually occurring when lying down quietly with little movement. There are two physiologically distinct sleep states: rapid eye movement (REM) sleep and non-REM sleep, which is further divided into four stages on the basis of EEG/electro-oculogram (EOG)/EMG features.

### Non-rapid eye movement sleep

#### Stage 1 (5–10% of sleep)

- Occurs at sleep onset or following arousal from another stage of sleep (see Figure 3.13).
- *Mixed EEG frequencies*: reduced  $\alpha$  activity, vertex sharp waves.
- Slow rolling eye movements.

#### Stage 2 (55–60% of sleep)

Slow EEG activity. Sleep spindles and 'K' complexes.

#### Stages 3 and 4 (25% of sleep)

Known as slow wave sleep; predominantly slow activity on EEG.

### Rapid eye movement sleep

Physiologically very different:

- Brain metabolism is high.
- Low voltage, non-alpha EEG.
- Spontaneous rapid eye movements.
- Skeletal muscle almost completely paralysed (EMG activity absent).

### The sleep cycle

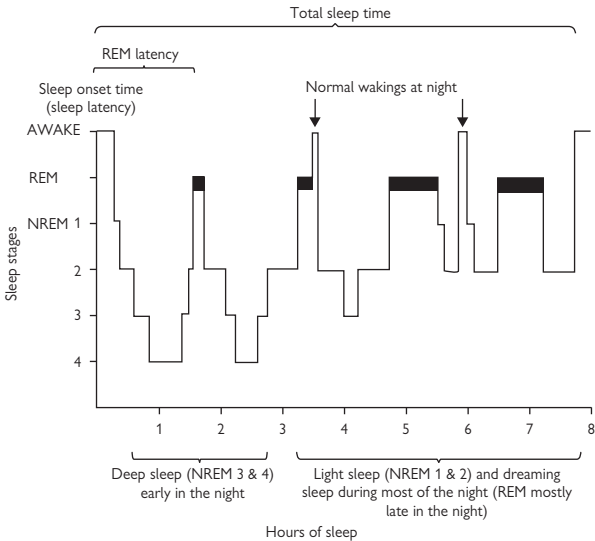
- Non-REM and REM sleep alternate cyclically throughout the night starting with non-REM for 80 min followed by REM for 10 min. The whole cycle repeats itself about 5–6 times.
- Each REM typically ends with a brief arousal or transition into light non-REM.

### History

- Is this a problem of getting to sleep or staying asleep?
- Is this a problem of being too sleepy during the day?
- Is this a problem of disturbed episodes at night?


#### Specific features in history

- 24 h sleep–wake schedule.
- Encourage the patient to keep a sleep log/diary.
- Undertake a systems review.
- Monitor caffeine intake.
- Does the patient have psychiatric/psychological/learning difficulties.
- Snoring or noisy breathing in sleep.



**Fig. 3.13** Sleep stages. Non-REM sleep predominates in the early part of the night, with REM sleep predominant in the later part of the night and particularly just before waking.

#### *In relation to parasomnias*

- Timing.
- Night terrors tend to occur at a fairly regular time.
- Events occurring in the early part of the night are probably non-REM sleep related and events occurring later in the night REM-sleep related (see  p. 439).
- Multiple events per night are very suggestive of frontal lobe epilepsy (see Box 4.11).

❗ Serious consideration should be given to the possibility that events occurring more than once per night, and/or clustering with several per night for a few nights at a time are nocturnal frontal lobe seizures. See Box 4.11.

#### Examination


Pay particular attention to physical factors that may disturb sleep (e.g. upper airway obstruction).

#### Video



Video recording of arousals can be very useful; however, 'half-hearted' attempts, where parents only start filming once woken will miss the most informative first part of the arousal. Continuous filming throughout the night is likely to be required (e.g. in a hospital videotelemetry unit).

### Assessment


#### *Difficulty getting to sleep or staying asleep*

Consider developmental issues (see  p. 439) and the effect of primary neurodevelopmental disorders on sleep.

#### *Excessive daytime sleepiness*

Likely to be due to poor nocturnal sleep hygiene but consider obstructive sleep apnoea and narcolepsy (under-recognized) (see  p. 443) and adolescent delayed sleep syndrome (see  p. 439).

#### *Disturbed episodes related to sleep (parasomnias)*

These are recurrent episodes of behaviour, experiences, or physiological changes that occur exclusively or predominantly during sleep. Decide whether these are primary, or secondary to neurodevelopmental or neuropsychiatric issues (see  p. 442).

If a primary parasomnia, the differential depends on whether it is occurring at sleep onset, out of non-REM sleep (i.e. particularly in the early hours of the night) or in REM sleep (later in the night). (Compare Figure 3.13.)

### Investigations

Formal investigation of sleep is resource intensive. Consider for:

- Investigation of excessive daytime sleepiness.
- Difficult parasomnias.
- Objective checks on diagnosis and treatment.

► Actigraphy (use of a wristwatch-like motion detector that records a diary of periods of movement and stillness (i.e. sleep) over several days) can be an extremely helpful, low cost initial evaluation in establishing sleep patterns.

#### *Polysomnography*

Information on the physiological changes of sleep including EEG, EMG, and EOG. This allows the stages of sleep to be categorized into a formal hypnogram. Analysis of the results is complex.


Some of the possible parameters are:

- Sleep continuity.
- Total time in bed.
- Time to go to sleep (sleep latency).
- Number of brief and longer awakenings.
- Time fully awake.
- Total time asleep and awake and sleep efficiency (total time in asleep/total time in bed × 100).
- *Non-REM measures:*
  - actual and percentage times in stages 1–4;
  - total slow wave sleep.
- *REM measures:*
  - time between first falling asleep and start of first REM period (REM latency);
  - actual and percentage time in REM;
  - total REM.


*Multiple sleep latency test*

This quantifies daytime sleepiness, particularly in the context of suspected narcolepsy. Measures the time taken to get to sleep during 5 opportunities at least 2 h apart during the day. Only feasible in children >8 yrs of age and normative data are age-dependent.

*CSF hypocretin*


Under evaluation as a diagnostic test for narcolepsy in younger children. Adult studies have suggested that CSF hypocretin levels very low in narcolepsy (see  p. 443).

## Speech difficulties

Neurological disorders that affect speech commonly also affect swallowing (see  p. 194) and vice versa, although they may occur in isolation and, as such, are discussed separately.

### Conceptual framework

#### Speech and language disorder

- Secondary to cognitive disability, hearing impairment or environmental adversity.
- For primary developmental language disorders see  p. 112.

#### Sound and speech production disorders (*dysphonia*)

- *Abnormal voice quality*: due to allergies, vocal abuse, chronic reflux, hypothyroidism, papilloma viruses (HPV6 and HPV11), trauma, recurrent laryngeal nerve palsy, Chiari malformation (recurrent laryngeal nerve palsy reported), psychological disorders.
- *Orofacial structural abnormalities*: nostril patency, enlarged adenoids, dental malocclusion, cleft lip/palate, macroglossia, significantly tongue-tied.
- Neuromotor disorders.

### Neuromotor speech disorders

#### Apraxia

Abnormal planning, sequencing, and coordination of articulation not due to muscle weakness.


#### Dysarthria

Weakness/paralysis of the musculature of speech (larynx, lips, tongue, palate, and jaw). Breathing and feeding/swallowing may also be affected. There are several different types of dysarthria.

##### *Spastic dysarthria*

- Due to hemispheric disease (cerebral palsy including Worster–Drought syndrome; acquired brain injury including stroke, tumour, neurosurgery; cytotoxic and other drugs, e.g. metoclopramide) or bilateral pontine injury ('pseudobulbar palsy').
- Slow slurred speech, drooling, reduced movement of muscles of lips and tongue, exaggerated jaw jerk and gag.

##### *Ataxic dysarthria*

- Cerebellar lesions.
- Slow articulation, soft monotonous voice. May be preceded by cerebellar mutism (see  'Posterior fossa syndrome', p. 461) at the time of the acquired insult.

##### *Hyperkinetic*

- Basal ganglia lesions.
- Slow laboured speech ± stuttering, extraneous tongue movements evident, grimacing.


*Lower motor neuron*

- Flaccid bulbar palsy due to lower motor neuron injury to cranial nerves V, VII, IX, and X, or their nuclei.
- Moebius syndrome, spinal muscular atrophy variants, bilateral VII palsy, brainstem pathology, Arnold–Chiari malformation.
- Voice is of low volume and monotonous.

*Mixed upper and lower motor neuron lesion patterns*

- Neuromuscular junction, e.g. myasthenia gravis.
- Primary myopathic (uncommon, e.g. FSH dystrophy).

*Secondary dysarthria*

Children with benign epilepsy with centro-temporal spikes (see  p. 268) may present with episodes of transient dysarthria. Dysarthria may also be the presentation of metabolic (e.g. Wilson disease) or neurodegenerative disorders (e.g. Huntington disease).

## Swallowing and feeding problems

### Mechanism of normal swallowing

- *First stage: oral (voluntary).* Tongue pushed against the palate, forcing food into the pharynx. Problems with this stage are usually due to impaired control of the tongue during swallowing causing difficulty keeping liquid in the mouth, difficulty chewing food, pocketing of food in the vestibule of the mouth, or aspiration of food during inhalation.
- *Second stage: pharyngeal (involuntary).* Receptors with afferents in V and IX trigger efferent signals via V, IX, X and XII to elevate the soft palate, seal the nasopharynx and close the glottis, and move the larynx under the base of tongue. Food is passed into the oesophagus. Problems with this phase may lead to retention of food in the pharynx and aspiration.
- *Third stage: oesophageal (involuntary).* Liquids usually fall by gravity; peristaltic waves push solids along (innervated by X). Problems with this phase can occur when there are motility disorders, mechanical obstruction or impaired opening of the lower oesophageal sphincter.

### Causes of swallowing disorders in children

- *Structural abnormality:* oesophagitis, gastro-oesophageal reflux, oesophageal strictures (e.g. secondary to ingested caustic material), tracheo-oesophageal fistula, impaction of a foreign body, cleft palate or velopharyngeal insufficiency (e.g. 22q11 deletion syndrome).
- *Neurological disorders:* see 📖 'Neuromotor speech disorders', p. 192.
- Motility disorders.
- Connective tissue diseases, e.g. dermatomyositis.
- Psychogenic.
- *iatrogenic:* large unpalatable tablets (calcium and iron supplements in particular); anticholinergic agents, calcium channel blockers, and drugs that increase fatigue or oral secretions.

### Assessment of disordered swallowing

A multidisciplinary team approach is beneficial in the assessment and management of children with swallowing problems. Speech pathologist, dietician, occupational therapist, physiotherapist, psychologist, ENT specialist, neurologist, gastroenterologist, and dentist.

#### History

- *Feeding history:* onset of problem (acute or chronic), severity (drooling, choking, coughing with feeds), voice change, nasal regurgitation, retention of food in the mouth, symptoms of gastro-oesophageal reflux.
- *Problems with particular textures/consistencies:* typically worst with thin liquid, e.g. water.
- Weight, nutritional status, caloric intake, centiles.
- *History of medical co-morbidities:* e.g. recurrent pneumonia, stridor.

**Examination**

- *Physical examination:* respiratory and neurological systems (including jaw jerk and gag reflex), ENT (macroglossia, tonsillar hypertrophy, para- or retro-pharyngeal masses, head and neck masses (e.g. goitre), nasal patency (e.g. choanal atresia)), cardiovascular system (atrial hypertrophy).
- A water swallow test may be used to check for abnormal drooling or coughing.
- *Observe feeding:* posture, self-feeding ability, pace of feeding, ability to handle oral secretions, tongue and jaw movements, coughing, the number of swallows required to clear a bolus of food, and noisy airway during swallowing.

**Investigation**

See  p. 249 for further details.


- Videofluorographic swallowing study.
- Cervical auscultation.
- Functional endoscopic evaluation of swallowing.
- Other tests may be indicated, e.g. oesophagogastroduodenoscopy (OGD), pH study, barium swallow, oesophageal motility studies.




## Toe walking

Toe walking may be associated with developmental delay of multiple aetiologies. The usual presentation, however, is in a child with normal IQ.

### Causes

- Primary idiopathic.
- Secondary to CP.
- Transient dystonia of infancy.
- Early DMD or other neuromuscular disease (*NB*: a normal CK only excludes dystrophies, and not other non-dystrophic myopathies).
- HMSN.
- Hereditary spastic paraplegia (see  p. 433).
- Spinal pathology—tethered cord, occult spinal dysraphism.
- Early leukodystrophy (X-ALD, MLD).


### History

- As for 'foot deformities', see  p. 135.
- Diurnal variation?
- Autistic behaviours.

### Examination

- Spine.
- Is it correctible? (Voluntarily, or passively correctible only?)
- Is there Achilles shortening?
- Intrinsic foot deformities?
- Range of movement of joints including upper limbs.
- Long tract signs?
- Diminished reflexes?
- Weakness and/or atrophy? Proximal—hip extension and abduction; distal - ankle dorsiflexion and eversion.

### Investigation

- Imaging of brain  $\pm$  cord if long tract signs are present.
-  Check CK in boys particularly if they are late walking.
- DNA tests for HMSN1 if the child and parent are areflexic. Nerve conduction studies if DNA screen negative.

### Empiric treatment (independent of cause)

- Conservative, e.g. accommodative footwear, stretches.
- Casting.
- Botulinum toxin injection to calves (not for lower motor neurone/neuromuscular disorders).
- Surgery, e.g. gastrocnemius recession, tendon lengthening/transfers, osteotomies.

## Unsteadiness and falls

Do not make the mistake of assuming a complaint of unsteadiness necessarily implies ataxia. Other causes include:

- Weakness: myopathic (generally proximal) or neuropathic (peripheral).
- Clumsiness (dyspraxia).
- Visual impairment.
- Syncope and other 'funny turns' (see Table 3.5) if any suggestion of associated altered awareness (may be difficult to distinguish).
- True vertigo (vestibular or labyrinthine disease): labyrinthitis is occasionally misdiagnosed as ataxia. Labyrinth or vestibular disease will not be associated with past pointing.
- Non-neurological causes: musculoskeletal factors including leg-length and alignment problems.

### History

#### *Time course of symptoms*

- Fixed or episodic?
- Duration of episodes?
- Progressive?

#### *Precise nature of symptoms experienced*

Complaints of 'dizziness' must be unpacked carefully. True vertigo is much more rare than pre-syncopal 'light-headed' feelings.

- *Pre-syncope*: older children and parents will be familiar with the sensation associated with suddenly standing up (e.g. after a hot bath).
- *True vertigo*:
  - much rarer;
  - explicit sensation of motion (usually as if the world is spinning).
- Very rare 'ship's deck' ataxia (as if the world is 'rolling'): associated with cerebellopontine angle disease.

#### *Associated features?*

- Fine motor skills (dressing, ball catching, writing).
- Worse in dark? (implies disordered proprioception).
- Speech (cerebellar dysarthria?).
- Headaches, travel sickness, family history of migraine? May suggest susceptibility to migrainous processes though such findings are common and may be misleading!
- Position-dependence (made worse by turning over in bed? Symptoms improved or worsened if head elevated on pillows etc.?)
- Epilepsy? Several seizure types can result in falls (see Table 3.7).

#### *Development*

Motor and speech milestones.

### Examination

- Skin (telangiectasiae).
- Eye movements (disordered smooth pursuit is a sensitive indicator of cerebellar disease).
- Speech articulation.

- **Cerebellar function:** assess truncal coordination (heel-toe walking) reflecting midline cerebellar (vermis) function and peripheral coordination (finger–nose) that reflects cerebellar hemisphere function (if asymmetrical implies ipsilateral disease).
- **Pyramidal tract signs:**
  - subtle pyramidal tract signs can result in falls if the child is catching the tip of their shoe on uneven ground. Examine shoes for evidence of scuffing and wear at the toe;
  - observe for pronator drift (see 📖 p. 25), fog testing (see 📖 p. 47).
- **Joint position sense (proprioception):**
  - Romberg sign (increased body sway in standing when eyes closed);
  - Difficulty touching own nose with finger with eyes closed.
- **Fine motor coordination:**
  - finger–thumb movement sequences;
  - throw ball and clap hands before catching;
  - handwriting (observe pencil grip).
- Examine for motion-sensitivity by rotating child slowly in chair, shaking head from side to side slowly, whilst looking ahead.

### Falls and unsteadiness due to phenomena other than ataxia

#### Dyspraxia

- Also known as developmental coordination disorder.
- Refers to the very common picture of relatively isolated fine motor sequencing problems resulting in clumsiness.
- Affects dressing (shoelaces), writing and drawing, and (typically) hand–eye coordination tasks such as ball catching.
- 🚫 Formal cerebellar signs (e.g. past pointing, or disordered pursuit eye movements) are incompatible with a diagnosis of dyspraxia
- a period of observation may be necessary to identify a progressive ataxic disorder—be particularly suspicious if the child is female (♂:♀ 4:1).

#### Vestibular disease

- Associated with true vertigo ± nystagmus.
- Seek ENT opinion.
- Consider opsoclonus–myoclonus syndrome in toddler/pre-school age group (rare: see 📖 p. 381).

#### Ataxia

- Cerebellar.
- **Sensory:**
  - due to large fibre neuropathy or dorsal column disease;
  - impaired joint position sense and vibration sense;
  - worse in the dark due to loss of compensatory visual information on body position. Romberg test will be positive.
- Mixed.
- Mixed ataxias (cerebellar and sensory) occur in Friedreich ataxia, and in children who have received vincristine (see 📖 p. 505) for posterior fossa tumours.

Consider whether ataxia is acute or chronic, progressive or non-progressive, or episodic.

**Acute ataxia**

- *Onset over hours*: consider intoxication as very probable.
- *Onset over hours to days*: consider para-infective processes including acute disseminated encephalomyelitis. A parainfective subacute onset ataxia is particularly characteristic 7–14 days post-Varicella. Conservative treatment only is required (see [📖](#) p. 344).
- *Onset over days to weeks*: consider expanding posterior fossa space-occupying lesion.
- *Causes of acute, subacute and acute recurrent ataxia*:
  - post-infectious cerebellitis (see [📖](#) p. 344);
  - Miller–Fisher syndrome (see [📖](#) p. 395);
  - episodic ataxias type 1 and 2 (see [📖](#) p. 304).

**Recurrent ataxias**

Good spells and bad spells, lasting days or weeks. Consider:

- *Paraneoplastic*: particularly opsoclonus–myoclonus (see [📖](#) p. 381) typically with nystagmus and involvement of the arms and hands  $\pm$  upper trunk (i.e. paleovermal and neocerebellar, see Table 1.5).
- NARP (neuropathy ataxia and retinitis pigmentosa with the 8993 mtDNA mutation). Recurrent ataxia without nystagmus. Retinal findings can be subtle.

**Slowly progressive ataxias (over months to years) with initial symptom-free period**

- Nearly all genetically determined progressive ataxias of older childhood are both extremely rare and dominantly inherited with high penetrance so that a family history will be informative (see [📖](#) p. 386).
- Friedreich ataxia (FA, see [📖](#) p. 385) is the most important recessively inherited progressive ataxia (i.e. where family history is negative).
- In toddlers consider ataxia telangiectasia (AT, see [📖](#) p. 422).

**Congenital, non- or slowly progressive ataxias with no initial symptom-free period**

- If imaging suggests unilateral or very asymmetric cerebellar involvement, the cause is probably acquired (e.g. vascular) insult.
- Identification of the anatomical pattern of cerebellar involvement can help narrow the differential (see [📖](#) p. 384 and Table 1.5).

**Suggested approach to initial investigation of chronic non-progressive or slowly progressive cerebellar disorders** (see [📖](#) p. 384)

- MRI.
- Fasting cholesterol/triglycerides and lipoprotein profile.
- Blood film (acanthocytes, vacuolated lymphocytes).
- LFT and CK.
- Transferrin isoforms.
- Amino and organic acids.
- Capillary pH, plasma lactate, mitochondrial DNA deletions.
- Alpha-foetoprotein.
- Vitamin E.
- Consider EMG/NCV for evidence of peripheral neuropathy.
- See also [🌐 www.ataxia.org.uk/data/files/ataxia\\_guidelines\\_web.pdf](http://www.ataxia.org.uk/data/files/ataxia_guidelines_web.pdf).

## Visual disturbances

Visual impairment (VI) may be:


- Congenital or acquired.
- Of sudden or progressive onset.
- Isolated, with a purely ocular basis, or associated with neurological or other systemic disease.
- In the setting of multiple impairments.

VI profoundly impacts a child's development, social, education, and employment opportunities. In developing countries, around 50% of children die within a few years of the onset of blindness. Even in the developed world, 10% of children die within 1 yr of diagnosis of severe VI.

### Normal visual development milestones

See Table 3.16.

**Table 3.16** Normal visual development milestones

Reliably present from 31 weeks gestation	Pupillary light reflex, blink response and dazzle response (eyelid remains closed in presence bright light) NB: these reflexes depend on brainstem structures: they do not indicate cortical vision
By 6 weeks post-term	Fixing and following (human face at 30 cm is best target)
From 3 mths post-term	Visually directed grasping (needs concurrent motor development)
By 5 mths post-term	Blink in response to threat
Any age	Persistent squint is abnormal (see  p. 119)

VEP: see response from 30 weeks gestational age, mature flash/pattern response by 3–4 mths post-term; response to orientation reversal later.

### Age of child and mode of presentation

See Table 3.17.

#### Key points on history taking

- First episode or recurrent?
- Unilateral or bilateral?
- Painless loss of vision in one eye like a 'wall developing' after trauma? (Retinal detachment)
- Photophobia?
- Headache, nausea (symptoms of raised intracranial pressure)?
- Tearing, painful eye, nausea and vomiting (symptoms of raised intra-ocular pressure/glaucoma)?
- Medical history: hypertension?
- *Drugs*: vigabatrin (field defects), phenytoin (blurred vision in toxicity), chemotherapy?
- Abnormal colour vision (optic neuritis)?

**Table 3.17** Age and mode of presentation

Infant	<p><b>Take parental concerns seriously</b></p> <p>Not fixing and following, poor eye contact</p> <p>Epiphora, photophobia (less apparent if born during winter months)</p>
Preschool	<p>Fails to imitate others</p> <p>Delayed development, distractible, immature</p> <p>Sits too close to TV; prefers toys with sounds</p> <p>New squint, scared in dim light, photophobia</p> <p>Clumsy, falling, 'ataxic', acute refusal to walk</p>
School-age	<p>Gradual onset may present as school failure</p> <p>Specific complaints of blurred or weak vision</p> <p>In acute onset 'grey-black curtain descending' or fogging</p>


❗ Remember to unpack descriptions of visual disturbance 'in one eye'. What children and families usually mean by this is 'to one side of what I can see'.

❗ Any visual sign or symptom truly confined to one eye (e.g. not evident when that eye is closed) is due to a cause anterior to the chiasm. In contrast a visual disturbance in one visual hemi-field (e.g. on the child's left) has a post-chiasmatic cause (see Figure 3.14)

Careful history and stepwise examination of the visual pathway from anterior to posterior will suggest specific ophthalmological, electro-diagnostic, laboratory and radiological investigations.

#### **Key points on examination from anterior to posterior**

- *External inspection*: microphthalmia, dysmorphism?
  - *Visual acuity*: light and movement perception, fixing and following?
  - Visual fields?
  - *Eye movements*: dysconjugate gaze, nystagmus, cranial nerve palsies, squint? (see 📖 p. 119).
  - *Pupils*: light and accommodation reflex; relative afferent pupillary defect (RAPD); leukocoria; fixed mid-position pupil in raised intra-ocular pressure (IOP)?
  - Roving eye movements? (strong indicator of pathology anterior to chiasm)
  - *Red and painful eye needs dilated slit lamp examination* with fluorescein by an ophthalmologist to exclude keratopathy, ulcer, infection, raised intraocular pressure (IOP) or an intra-ocular foreign body.
  - *Cornea and lens*: cloudy cornea, cataract.
  - *Fundoscopy*: swollen optic nerve disk (papillitis)? Central retinal artery occlusion (causing sudden painless and unilateral blindness)?
- ❗ Optic neuritis (papillitis) and papilloedema have very similar fundoscopic appearances but distinguishing them should not be difficult. Visual loss is prominent in papillitis and is the usual presenting complaint (only in the mildest cases is it confined to loss of colour vision). Visual impairment in

papilloedema occurs as a result of optic nerve ischaemia and as such usually only occurs in very longstanding situations (e.g. mis-managed idiopathic intracranial hypertension (see  p. 334) or fulminant situations with severe elevation of ICP (where prompt intervention may save vision).

### Visual impairment from birth

All babies with apparent VI should be seen by an ophthalmologist.

#### Clues from history

- *High-risk baby?* Prematurity, family history of squint, amblyopia or VI; perinatal infection; maternal medications.
- *Development?* VI interferes with all areas of development (social and fine motor more than language or gross motor). Forty per cent of children with VI have learning difficulties and/or CP.
- *Behaviour?* Blind babies eye-poke; VI babies may wave their hands in front of a light source.

#### Clues from examination

- *External eye:* microphthalmia, aniridia, albinism, buphthalmos, dysmorphism, colobomata.
- *Cornea:* clouding seen in mucopolysaccharidoses and Fabry disease; less commonly in GM1 gangliosidosis, Pelizaeus–Merzbacher, Zellweger and foetal alcohol syndrome.
- *Lens:* high myopia, cataract, dislocation (Ehlers–Danlos, Marfan, homocystinuria).
- *Fundoscopy:*
  - abnormal vitreous—haemorrhage, retinoblastoma, persistent primary hyperplastic vitreous, retinopathy of prematurity;
  - abnormal disc—optic nerve hypoplasia, optic atrophy;
  - abnormal retina—normal ERG (toxoplasmosis); abnormal ERG (Leber congenital amaurosis, retinal dystrophy).

#### If all examination findings are normal, consider

- *Cortical blindness:* occipital lobe injury; abnormalities on MRI.
- *Delayed visual maturation:* visually unresponsive in early months of life then develop normal vision; other developmental domains may be normal or abnormal.
- *Congenital idiopathic.*

### Leber congenital amaurosis

- Most common inherited cause of congenital VI, usually autosomal recessive.
- Rod-cone dystrophy and retinal degeneration.
- Presents at birth or in the first months of life with roving eyes or upbeat nystagmus, photophobia, day-blindness, and eye-poking.
- Sluggish pupillary light responses.
- The retina in infancy may appear normal; pigmentary retinopathy and disc pallor develop with age.
- ERG and VEP are usually undetectable from the outset.
- Associated features include cerebellar atrophy and learning difficulties.

### Cataracts in childhood

Less than half are idiopathic; all warrant a vigorous search for aetiology

- Congenital infections (rubella).
- Inborn errors of metabolism (galactosaemia, Morquio).
- Chromosomal abnormalities (trisomies 13, 18, 21, Turner syndrome).
- Maternal drugs and exposure (corticosteroids, chlorpromazine, radiation, malnutrition, diabetes).
- Biochemical derangement (hypocalcaemia, pseudohypoparathyroidism).
- Inherited conditions (hereditary spherocytosis, neurofibromatosis type 2, myotonic dystrophy).

### Cerebral visual impairment

VI due to visual pathway or occipital cortical injury or dysfunction is a common accompaniment of both developmental and acquired brain injury (see [📖](#) p. 252).

### Acquired visual impairment

For sudden onset monocular visual loss see [📖](#) p. 558.

Acquired VI in childhood is likely to have a primary ocular cause, in contrast to adults, in whom occipital cortical ischaemia and emboli are common.

Differentiating acute from progressive onset may not be straightforward. Slowly progressive loss may be perceived as of abrupt onset (e.g. progressive visual field restriction is usually only reported once it involves the macula, at which point a 'sudden deterioration' is reported). Progressive visual loss is usually noticed by a teacher or parent, rather than by the child. It is therefore best to consider both acute and progressive causes in every child (Tables 3.18 and 3.19). In addition, the causes of progressive loss overlap with the causes of congenital blindness.



## Anterior visual pathway (pre-chiasmatic and chiasmatic)

**Table 3.18** Causes of visual loss: site and mode of presentation

Acute		Progressive	
Cornea	Scarring	Vitamin A deficiency; harmful traditional medicines	Keratoconus (trisomy 21)
Lens			Cataract, dislocation
Macula		Photoc damage	Dystrophy
Retina	Trauma	Non-accidental injury (NAI), detached retina	Intraocular tumour
		Migraine, central retinal artery occlusion	Tapeto-retinal degeneration Metabolic disease, NCLs, Laurence–Moon–Biedl, Refsum, Usher, Cockayne
Optic nerve	Inflammation	Optic neuritis, papillitis	Optic atrophy LHON
	Compression	Raised ICP, raised IOP, trauma, orbital and extra-ocular tumour, bone disease (osteopetrosis), infection (abscess, sinusitis)	Compression Idiopathic ('benign') intracranial hypertension, raised ICP, raised IOP, tumour aneurysm, arteriovenous malformation
	Trauma		
	Tumour		
	Ischaemia	Hypotension, systemic vascular disease	Optic glioma
Chiasm			Tumour Craniopharyngioma, pituitary, hypothalamic tumour

*Posterior visual pathway (post-chiasmatic)***Table 3.19** Causes of visual loss: site and mode of presentation

	<b>Acute</b>		<b>Progressive</b>	
Optic radiation	Inflammation, trauma, tumour, radiation		Tumour	
Visual cortex	Inflammation	Acute disseminated encephalomyelitis	Inflammation	Rasmussen syndrome
	Compression	Trauma, tumour, hydrocephalus	Compression	Tumour, hydrocephalus
	Infection	Abscess, meningitis, cerebral malaria		
	Vascular	Migraine, cluster headaches, haemorrhage, infarct, anoxia		
	Benign occipital epilepsy			
	Post-traumatic transient cerebral blindness			
Systemic	Hypo-glycaemia	Glycogen storage disease, insulin therapy		
	Hypo-/hypertension			
	Toxicity/nutritional	Anti-TB drugs, sulphonamides, chloramphenicol, desferrioxamine, penicillamine, vincristine and BCNU, ciclosporin, heavy metals and solvents		
Other	Functional		Stimulus deprivation amblyopia	
			Chronic progressive external ophthalmoplegia (mitochondrial)	

❗ Children may report a visual symptom 'in one eye' but mean 'to one side of my visual world'. A visual field deficit (or indeed *any* visual sign or symptom) that is truly confined to one eye (i.e. it disappears when that eye is closed) is due to pathology anterior to the optic chiasm (A in Figure 3.14).

- Chiasmatic lesions (B) typically give bitemporal hemianopia.
- An homonymous hemianopia (C) arises from a lesion in the contralateral optic tract.
- Temporo-parietal lobe lesions result in partial deficits, rarely precisely quadrantanopic (D, E).
- A branch of the middle cerebral artery supplying the area of occipital cortex relating to the macula allows posterior cerebral artery lesions affecting the occipital cortex to result in 'macular sparing' (F).

### Progressive visual impairment

#### *Leber hereditary optic neuropathy (LHON)*

See 📖 p. 373.

#### *Compressive optic neuropathies*

See Table 3.20.

#### *Stimulus deprivation amblyopia*

- Reduced visual acuity in one eye.
- Adverse consequence of untreated cataract, squint, or refractive error.
- Age-dependent: highest risk up to 3 yrs, little risk after 6 yrs.

#### *Toxic, nutritional*

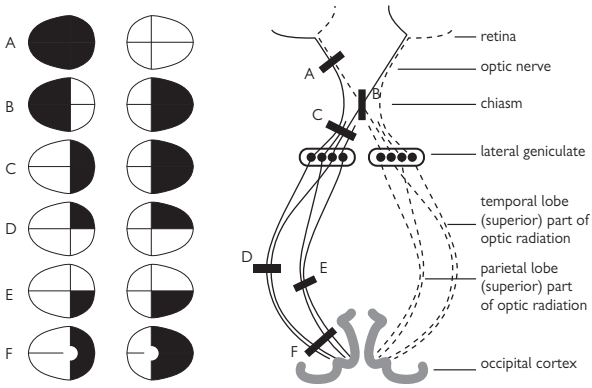
- Usually present with decreased acuity and colour vision, especially if there are central scotomata.
- Usually dose related. See Table 3.19. Reduce the dose or withdraw the drug. Consider B12/folate therapy.

#### *Idiopathic intracranial hypertension*

See 📖 p. 334

#### *Inborn errors of metabolism*

Juvenile NCL is an important cause of progressive visual loss in adolescence (see 📖 p. 430). Most other metabolic disorders do not usually present with visual disturbance, although eye features are common (see Table 1.2).



**Fig. 3.14** Localization of visual field defects.

**Table 3.20** Causes of compressive optic neuropathies

Region	Clinical features
Intraocular tumours	Always diminish visual acuity <i>New squint</i> : impaired acuity (sighted eye fixes, blind eye deviates) <i>Leukocoria</i> : recognition of retinoblastoma for prompt life-saving treatment
Retro-orbital tumours	Strabismus and proptosis Visual field defects occur late
Tumours around the chiasm	<i>Craniopharyngioma</i> : associated growth failure and endocrinopathies Bitemporal hemianopia in 50% I, III or VI nerve involvement if anterior extension <i>Pituitary adenomas</i> : only 1–2% of childhood intracranial tumours, 1/3 secrete ACTH, 1/3 secrete prolactin, 1/3 are silent

*This page intentionally left blank*

## Specific conditions

- Acquired brain injury 210
- Acquired spinal cord injury 215
- Autoimmune disease of the central nervous system 218
- 'Autoinflammatory' conditions 223
- Autoimmune encephalitides 224
- Cerebral palsies 227
  - Care of the disabled child 240
  - Feeding 248
  - Communication 251
  - Special senses 252
  - Respiratory disease in neurodisability 254
- Demyelinating disease 257
- Epilepsy 262
  - Investigating epilepsy 275
  - Am I missing an underlying cause? 280
  - Treatment of epilepsy 286
  - Epilepsy and daily life 298
  - Non-epileptic paroxysmal phenomena 304
- Functional illness 311
- Headache 317
- Hydrocephalus 324
  - Spina bifida and related disorders 329
- Idiopathic ('benign') intracranial hypertension 334
- Infection of the central nervous system 336
  - Congenital infection 355
- Late-onset metabolic disease 365
- Mitochondrial disease 369
- Movement disorders 375
- Neuromuscular conditions: introduction 390
  - Neuropathies 392
  - Disorders of muscle 399
  - Anterior horn cell disease 410
  - Myasthenic syndromes 411
  - Management of neuromuscular disease 416
- Neurocutaneous syndromes 418
- Neurodegenerative conditions 425
- Neurotransmitter disorders 435
- Sleep disorders 439
- Stroke 446
  - Cerebral haemorrhage 452
- Tumours of the central venous system 454
- Vitamin-responsive conditions 462

## Acquired brain injury

The term ‘acquired’ brain injury (ABI) encompasses both traumatically-acquired injury and non-traumatic injury such as stroke, meningitis, tumour: a very heterogeneous group of conditions pathophysiologically. The value of the ABI concept, as with ‘cerebral palsy’, is primarily operational. These children have in common:

- Focal or multifocal patterns of injury leading to idiosyncratic and unusual combinations of impairments.
- The difficulty of addressing new impairments and needs acquired ‘overnight’ in a system (particularly within education) built for children with slowly evolving, developmentally related needs.
- The ‘bereavement’ of losing the ‘child that was’ (both family and child remember things used not to be this way).
- A sudden need to learn how to ‘work the system’.
- In some cases (particularly traumatic injury acquired through ‘misadventure’) additional challenges created by pre-existing behavioural traits and family/social factors.

### Recognition of ‘low level’ states

Consciousness can simplistically be envisaged as having two components:



- *Arousal (i.e. not asleep)*: largely a function of brainstem structures (particularly the pontine reticular activating system).
- *Awareness of surroundings*: reflecting function of the cerebral cortex.

These can be dissociated. Arousal without awareness is the vegetative state.

Arousal can be readily assessed. The eye-opening scale of the Glasgow Coma Score (GCS) is essentially a measure of arousal (pontine integrity); however, awareness of surroundings can only be established by the observation of *movements that relate consistently in time to external events* (regarding eye movement and speech as specialized forms of movement).

- If a child has very limited reliable voluntary control of movement, he/she may not be able to demonstrate their awareness. This can occur in so-called ‘locked-in’ syndrome, although some preservation of eye movement is usual. Pure locked-in syndrome is extremely rare. Magnetic resonance imaging (MRI) data (pontine lesions with sparing of cortex) may alert the team to the possibility.
- Much more commonly, generally a child’s voluntary movements may be very delayed or inconsistent. These children are in the minimally conscious state. Demonstrating low levels of awareness requires careful and skilled multidisciplinary assessment—identifying movements (typically eye blinks, eye pointing or limb movements) that are under some voluntary control, but may follow many seconds after requests. Suitable ‘control’ requests are important to avoid false-positive situations (e.g. to avoid the danger of issuing a command—‘squeeze my hand’—repeatedly until the action occurs by chance).

## Acute medical management of acquired brain injury

- *Early fluid management:*
  - may have been fluid-restricted on PICU;
  - insensible losses may be high if agitated and/or pyrexial;
  - hyponatraemia can be iatrogenic (hypotonic fluids), due to SIADH or cerebral salt wasting (see  p. 509).
- Management of early agitation (see  p. 534):
  - common after severe injury;
  - environmental interventions: well lit, quiet setting (preferably cubicle); consider nursing on a floor mattress if at risk of coming out of bed;
  - paradoxically, stimulant therapy (methylphenidate, dexamfetamine) can be effective;
  - avoid benzodiazepines (chlorpromazine acceptable if no alternative).
- Aggressive prevention of contractures (splinting, botulinum toxin):

Oral antispasticity agents are relatively contraindicated because of sedative side effects complicating assessment of awareness, with the exception of dantrolene (monitor LFTs).

- In the context of traumatic injury, small extracranial fractures may occasionally be missed during the PICU phase. Unexplained distress on movement in children recovering from traumatic injury should prompt a careful evaluation for bony injury.
- Involvement of appropriate colleagues in assessment of bulbar function, early mobilization and evaluation of hearing and vision as a prelude to the re-establishment of communication.
- Nutrition and appropriate feeding strategies:
  - GORD and constipation common;
  - hyperalimentation has been shown to improve neurological outcome.
- Consider evaluation of pituitary function. The role of routine screening is questionable.<sup>1</sup>
- Treatment of seizures:
  - prophylactic AED therapy is unwarranted;
  - exclude hyponatraemia.
- Treat respiratory disease (e.g. aspiration due to impaired bulbar function). Liaise over closure of tracheostomy if performed during the PICU phase.
- Central dysautonomia syndrome (also known as hypothalamic–midbrain dysregulation or central hyperpyrexia) characterized by tachycardia, marked hyperpyrexia (often  $>40^{\circ}\text{C}$ ), hyperventilation and associated with severe (particularly brainstem) injury and poor outcome:
  - maintain fluid intake (high insensible fluid losses; risk of renal impairment from high plasma CK levels);
  - treat with opiates or clonidine.
- *Heterotopic/ectopic calcification in muscle bellies:* calcification of microhaemorrhages and tears resulting from severe spasticity and/or physiotherapy.

<sup>1</sup> Khadr SN, Crofton PM, Jones PA, et al. (2010). Evaluation of pituitary function after traumatic brain injury in childhood. *Clin Endocrinol* **73**: 637–44.



### Age at injury and time since injury

Manifestations of ABI result from a complex interaction between age at injury, time since injury, and the domain of outcome under consideration. Whilst a static concept of 'full recovery' of a previously fully established function after injury is meaningful in an adult (Figure 4.1, left), it is meaningless in the context of a young child in whom the function was not fully established at the time of injury. Returning to pre-injury levels of function (point A) is not 'full recovery': reaching point B as an adult is.

It follows that late outcome is generally better for functions that were nearly fully established at the time of injury. In crude terms, motor development completes before language development, which completes before cognitive development: hence the particular concern about late cognitive outcomes, and children injured at a young age.

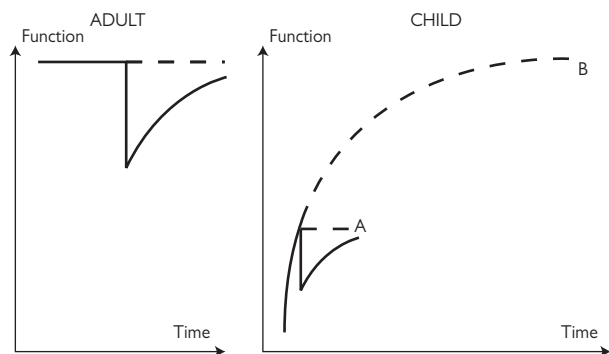


Fig. 4.1 Age at injury.

### Interdisciplinary working and goal setting


The distinguishing feature of rehabilitation is a process of working together. Multidisciplinary working can become problem based, and focused on impairments, with each professional seeing one part of the picture (dysphasia, contractures, seizures) and addressing it in isolation. In contrast, rehabilitation is characterized by a cross-disciplinary, forward-looking setting of specific, relevant and measurable goals, ideally involving child and family. This can result in interdisciplinary cooperation.

Typical goals might include:

- Prevent physical deformity.
- Achieve safe, effective means of nutrition.
- Establish a means of communication.
- Get to cousin's wedding next month.
- Identify suitable educational provision.

### Medium- and long-term medical management

In practice cognitive/behavioural issues and educational liaison/advocacy roles predominate.

- *Fatigue and timing of return to school:* arrange a graded return to school.
- *Behavioural change:*
  - disordered sleep;
  - post-traumatic stress disorder (PTSD)-like processes;
  - changed (e.g. over-lenient) parenting responses;
  - physical aggression due to combination of impulsiveness and inability to perceive sarcasm, teasing or irony in others' speech, leading to literal ('concrete') interpretation of others' remarks;
  - resulting social isolation.
- *Specific cognitive deficits:*
  - attentional difficulties;
  - executive (self-organization) difficulties;
  - struggling at times of transition (e.g. to secondary schooling) with sudden jump in expectations of self-direction and management;
  - arrange for formal neuropsychological assessment (see  p. 100).

Other issues include


- *Epilepsy:*
  - may not manifest for a decade or more post-injury;
  - do not assume a causal relationship—check that the EEG is consistent with partial onset at sites of known radiological change and not entirely unrelated primary generalized epilepsy!
  - usually fairly readily controlled with reasonable remission rates.
- *Headaches:*
  - post-traumatic migraine;
  - post-whiplash.
- *Dysgeusia* (food tastes 'metallic') usually due to anosmia because of fracture of the cribriform plate. Improves with time.

### **Psychiatric/emotional issues**

A major problem for both child and the rest of the family:

- Siblings often 'side-lined' in family's concern for injured child and can experience feelings of isolation.
- Family have a daily reminder of the child they lost and need support to grieve.
- Child may experience PTSD symptoms (intrusive flashbacks, etc.) particularly if recall of the event is preserved.
- Secondary behavioural morbidity may occur due to new experiences of educational failure and social isolation if not adequately addressed.


### Prognosis

- The outcome relates to both the *mechanism* and the *severity* of the insult.
- Outcome from traumatic brain injury (TBI) is notoriously variable and cognitive/behavioural outcome in particular late after injury is affected by many injury-independent variables.
- In general, younger children make better *motor* outcomes than adults do. Unfortunately, this has led to a misplaced optimism that 'plasticity' allows the young head-injured child greater scope for recovery in general. TBI tends to result in cognitive-only patterns of morbidity with relatively little residual motor disability (children who 'look OK'). The cognitive effects of injury (which are ultimately the main determinants of outcome) tend to compound over the period of development remaining, and deficits tend to become more apparent with time. Typical areas of difficulty include *new learning* (what the child knew at the time of injury is retained but learning efficiency for new material is reduced requiring more repetition) and *frontal lobe functions* including attention, impulse control and executive skills (see  p. 101). If a child has moved school in the interim the fact of the TBI may not have been communicated (because the child was thought to have 'recovered') resulting in mis-attribution of the late difficulties being seen.
- Crude estimates of injury severity can be made using the GCS motor score (see Table 6.1) and particularly duration of post-traumatic amnesia (PTA). This period ends with the restoration of orientation (awareness of time, place and person) and the ability to form new memories ('who came to visit you this morning?').
- Hypoxic-ischaemic injury has a worse prognosis than traumatic injury of similar apparent initial severity (Table 4.1).

**Table 4.1** Outcome in children still in a vegetative state 30 days after insult

		3 mths	6 mths	12 mths	18 mths
Traumatic	Recovered at least low-level consciousness	40%	65%	80%	84%
	Vegetative	60%	35%	20%	15%
	Dead	0%	0%	0%	1%
Hypoxic	Recovered at least low-level consciousness	20%	25%	50%	55%
	Vegetative	76%	70%	40%	27%
	Dead	4%	5%	10%	18%

## Acquired spinal cord injury


For emergency management of paraparesis, see  p. 559.

### Causes

#### Trauma

- Falls and road-traffic accidents with no, or poorly adjusted, seat belts (particularly cervical trauma in young children).
- Can be remarkably unapparent radiologically, an entity described as SCIWORA (spinal cord injury without radiological abnormalities).

#### Inflammatory

- Post-infectious processes (transverse myelitis, acute disseminated encephalomyelitis, see  p. 257).
- Abscesses, tuberculoma.

#### Vascular


- The anterior spinal artery supplies the ventral two-thirds of the cord.
- Originates from branches of the vertebral arteries and runs down the anterior of the medulla and then extends down the cord, fed variably by branches from segmental arteries at various levels including the artery of Adamkiewicz at around T10.
- Acute anterior spinal artery infarction can occur spontaneously, reflecting this variable and somewhat insecure blood supply. Onset is typically over several minutes. Sparing of the dorsal cord (different blood supply) leads to classic preservation of dorsal column (vibration, joint position) sensation (see Figure 2.11).
- Ischaemia due to spinal AVM.

#### Compression

- Tumours and other space-occupying lesions: may be *intrinsic* (arising from cord substance) or more commonly *extrinsic*. Compression due to expansion of a paraspinal neuroblastoma through a vertebral foramen is an important cause.
- Vertebral disc disease.
- *Syringomyelia*: expansion of the central canal causing a slowly evolving deficit. May arise as a secondary complication of other spinal disease.

### Acute management

See  p. 566 and Box 4.1.

- Neurosurgical evaluation and spinal stabilization by external fixation following traumatic cord injury.
- High-dose steroid therapy to minimize aggravation of cord compression by oedema.
- Ventilatory support for high lesions.
- Urinary catheterization and management of constipation.
- Spasticity management (particularly intrathecal baclofen, see  p. 245) and aggressive contracture prevention.

**Box 4.1 Autonomic dysreflexia**

- This is an important and characteristic problem of complete lesions above T6.
- Noxious stimuli below the level (as trivial as a full bladder or constipation, of which the child has no subjective awareness) leads to increased reflex sympathetic activity in the disconnected lower cord, vasoconstriction and sometimes dangerously severe hypertension.
- This is sensed by the central nervous system (CNS) above the lesion, resulting in increased vagal tone and (sometimes severe) bradycardia.
- Above the lesion, vasodilatation results in pounding headache, sweating and red blotches on the skin.
- Emergency treatment involves the relief of the cause (e.g. catheter blockage) and sitting upright. Extreme care must be taken in administering enemas and other potentially noxious stimuli below the level of the lesion.

**Prognosis**

- Depends on aetiology.
- Recovery from extrinsic compression is typically good, but dependent on prompt recognition and decompression.
- Inflammatory injury usually reasonable recovery but rarely complete.
- Vascular injuries (particularly anterior spinal artery syndrome) and severe trauma have the worst prognoses.

**Long-term management**

Many long-term management issues are shared with children with spina bifida, and these clinics (if available) may be best suited to meet the needs of a child with an acquired paraplegia.


**Motor**

- Weakness, spasticity, contractures.
- Spinal deformity and chest infection.
- Postural abnormalities.
- Pathological fractures.

**Sensory**

Skin breakdown due to lack of pain sensation from pressure (not being turned, ill-fitting shoes, etc.), scalds, cold weather.

**Sphincters**

- Constipation/faecal incontinence.
- Bladder dysfunction X.
- Renal failure if 'unsafe' bladder is not managed (see  p. 157).

**Emotional**

- Lack of independence.
- Depression in teenagers and adults.
- Sexual dysfunction is an important issue in adults.

### Syringomyelia

- Important, potentially reversible cause of further spinal cord injury.
- Expansion of central cavity of the cord due to abnormal cerebrospinal fluid (CSF) flow and pressure (symptoms can sometimes be related directly to a cough, sneeze or other Valsalva manoeuvre).
- Early signs can be subtle.
- Fibres of the *spinothalamic tracts* cross just anterior to the central canal cavity (Figure 2.11) and are most susceptible to disruption by central cavitation.
- Results in loss of pain (pinprick, temperature) but initially preserved sensation to light touch, and normal motor function.
- Early syringomyelia is only going to be detected if pain sensation is specifically examined.

## Autoimmune disease of the central nervous system

CNS manifestations and/or complications are recognized in a number of systemic diseases with an autoimmune basis. For discussion of CNS complications of known autoimmune disease including juvenile idiopathic (rheumatoid) arthritis (JIA), and Kawasaki disease (KD), see [p. 531](#) and following. For diseases with prominent renal involvement (Henoch Schönlein purpura, haemolytic–uraemic syndrome), see [p. 523](#) and following. This section addresses the situation of previously unidentified autoimmune disease presenting with CNS features.

This possibility should be particularly considered in the context of:

- New onset aggressive epilepsy of unidentified cause, particularly in school age children.
- New onset behavioural or cognitive symptoms, particularly frank delirium (see [p. 104](#)) or psychosis, particularly if associated with movement disorders and/or seizures.
- Focal deficits including cranial nerve signs or mononeuritis multiplex.

Remember the signs give the ‘where’ (see [p. 4](#)). Historical clues show that the ‘what’ is an autoimmune process including:

- Onset in second decade of life (or later) in previously well child.
- Females.
- Family history of autoimmune disease.
- Subacute onset over a few weeks.
- Fluctuating course.

Autoimmune diseases are often suspected for a period before being proven. Diagnosis is supported by demonstration of a systemic inflammatory response (particularly an elevated erythrocyte sedimentation rate (ESR); the C-reactive protein (CRP) may be relatively normal, which is a clue to a non-infectious basis for the inflammatory response) and supportive clinical findings. Confirmation is typically by detection of pathological auto-antibodies, which can take some weeks.

Primary neurological presentations are particularly seen in systemic lupus erythematosus (SLE) and polyarteritis nodosa. They are also well recognized in Hashimoto disease, sarcoidosis, and scleroderma. Other increasingly recognized and important conditions include autoimmune encephalitides due to anti-neuronal antibodies, and primary angiitis of the CNS in children (PACNS).

### Sydenham chorea (St Vitus dance)

Regarded as a major neurological manifestation of rheumatic fever (i.e. by definition preceded by group A B haemolytic streptococcal infection). As with other post-streptococcal disease, it had become relatively rare but has become more common again in the last few years.

► Chorea is often a late feature, so clear history and/or evidence of the preceding infection is often absent.

#### Clinical features

- Insidious onset over weeks.
- Emotional lability often very prominent.

- *Fidgety or clumsy involuntary movements*: mostly myoclonic or semi-purposeful proximally with more complex distal movements (e.g. chorea of outstretched hands).
- *Classically described features of motor impersistence include*:
  - 'Jack in the box tongue' (inability to maintain protrusion);
  - 'Milkmaid's grip' (inability to maintain a grasp of the examiner's fingers resulting in rhythmic gripping).
- *Also*:
  - 'Spoon hands' (wrist flexion, hyperextension of the metacarpophalangeal joints, finger straightening and thumb abduction);
  - 'Hung up' tendon reflexes (slow relaxation);
  - Hippus (slow rhythmic constriction and dilation of pupil).
- Prominent facial, tongue, and bulbar involvement.
- Speech is often dysarthric and/or 'explosive'.
- May be strikingly *asymmetrical* particularly at the outset.
- Writing, dressing and feeding difficulty due to poor coordination.

Typically spontaneous recovery is seen over 3 mths. Rarely a paralytic chorea develops with extreme hypotonia and immobility (chorea mollis).

### Investigations

- *MRI*: a transient increased T2 signal in the head of caudate and putamen but may be normal.
- Elevated ASOT and anti-DNAase B in supportive clinical context; thyroid function tests (TFTs), ANA and antiphospholipid antibodies (lupus anticoagulant, anticardiolipin) to exclude alternative diagnoses.
- Echocardiogram to look for evidence of cardiac involvement; it may show the characteristic pattern of mitral regurgitation.

### Treatment

May be left untreated. If debilitating, consider:

- Sodium valproate.
- Tetrabenazine or haloperidol.
- Rheumatic fever antibiotic prophylaxis.
- The role of immunomodulation (intravenous immunoglobulin (IVIG) or steroids) is still unproven although high dose methylprednisolone with prednisolone taper has been used.

### Cardiological aspects

- All children should be evaluated for rheumatic cardiac valve disease and if found should commence anti-streptococcal penicillin prophylaxis.
- Regimes and duration are controversial but should be at least until adulthood. Regimes include daily oral penicillin V (risk of poor long-term compliance) or particularly in developing countries monthly IM benzathine penicillin.

### PANDAS


(Paediatric auto-immune neuropsychiatric disorders associated with *Streptococcus*):

- *Catchy acronym essentially for a hypothesis*: that the spectrum of post-streptococcal neurological disease extends beyond Sydenham chorea to include other neuropsychiatric conditions, particularly tic disorders and obsessive-compulsive disorder (OCD) in the Tourette spectrum.



- Neuropsychiatric features in Sydenham chorea are certainly well recognized, and exacerbations of tic disorders with evidence of recent streptococcal infection are reported anecdotally.
- Anti-neuronal antibodies suggestive of cross-reactivity have been identified, but to date disease causation by passive transfer of antibody has not been demonstrated (i.e. causative role not as yet established).
- Potential clinical implication that immunomodulatory treatments (IVIg or steroids) should be tried in these conditions remains unestablished.

### ***Encephalitis lethargica/post-encephalitic Parkinsonism***

- A striking picture of extrapyramidal movement disorder (particularly akinesia) and oculogyric crisis with disturbed arousal (prolonged coma and/or disrupted sleep wake cycle) presenting weeks to years after a febrile illness with sore throat.
- Post-streptococcal mechanisms have been suggested but the first and only epidemic (1915–1926) appeared related to influenza.
- Possible risk of re-emergence with new influenza strains?
- Some cases may also represent autoimmune encephalitides particularly due to anti-NMDA receptor antibodies (see  p. 224).

### **Systemic lupus erythematosus**

Neurological complications occur in up to 75% of children with SLE and are often the presenting feature. Mechanisms include vasculitis, embolic phenomena due to endocarditis and thrombotic thrombocytopenic purpura (TTP). Lupus anticoagulant may predispose to thrombotic events.

#### **Diagnosis**

- Malar rash.
- Discoid rash.
- Skin photosensitivity.
- Oral or nasopharyngeal ulcers: painless.
- Arthritis >2 joints (non-erosive).
- Serositis (pleuritis; pericarditis).
- Renal disorder (proteinuria >0.5 g/day or 3+; cellular casts).
- Neurological disorder (seizures in the absence of identifiable cause; psychosis).
- Haematological disorder (haemolytic anaemia with reticulocytosis; thrombocytopenia, leukopenia; lymphopenia).
- Immunological disorder (positive LE cell preparation; anti-DNA antibody to native DNA in abnormal titre; antibody to Smith nuclear antigen (anti-Sm); antinuclear antibody in the absence of drugs that induce lupus syndrome (usually associated with histone antibodies); false-positive VDRL).

**Note:** anti-dsDNA is sensitive, but has low specificity (50–60%) for SLE.

#### **CNS syndromes**

May be primary or arise secondarily due to complications of SLE or its treatment such as:

- Infection in the immunocompromised.
- Hypertensive encephalopathy (due to renal disease or steroid use).
- Uraemia.

SLE is an important cause of cerebrovascular disease, both infarction (vasculitis, embolism, dissection, thrombophilia) and haemorrhage (thrombocytopaenia, hypertension).

### **CNS manifestations**

Headache, seizures, and psychiatric manifestations are most common.

- Any age: common in girls in 2nd decade.
- *Psychiatric disorders (40%):*
  - organic psychosis;
  - delirium, delusions, hallucinations;
  - depression (may be reactive);
  - cognitive disorder/dementia.
- Migrainous headaches (40%).
- *Stroke:*
  - intracerebral haemorrhage;
  - subarachnoid haemorrhage;
  - arterial dissection;
  - catastrophic stroke (in association with anti-phospholipid antibodies and lupus anticoagulant).
- Encephalopathy.
- Seizures.
- Idiopathic intracranial hypertension.
- Cerebral sinus thrombosis.
- Subdural haematoma.
- Aseptic meningitis.
- Focal neurological deficits.
- Stupor/coma.
- *Cranial nerve deficit:* III and VI.
- Optic neuritis.
- Acute myelopathy.
- Movement disorders (may precede systemic manifestations).

### **Investigations**

- CSF: pleocytosis/mild to moderate increase in protein.
- *CT scan/MRI:*
  - may be normal, or show infarction or haemorrhage;
  - later—cerebral atrophy and basal ganglia calcification.

### **Diagnosis**

- Clinical features.
- *Antibodies:*
  - antinuclear antibody—sensitive, but not specific;
  - anti-DNA—more specific;
  - anti-RNP and anti-Sm antigen.

### **Treatment**

- Steroids + immunosuppressant drugs (cyclophosphamide, mycophenolate mofetil, anti-B cell monoclonal antibodies).
- Plasmapheresis rarely.
- Anticoagulation.
- Aciclovir in the case of myelopathy in an individual with known SLE, as Varicella zoster virus (VZV) causing myelopathy is recognized.

**Polyarteritis nodosa and other vasculitides**

Necrosis and acute inflammation of medium- and small-sized arteries.

**Manifestations**

- Cerebral oedema.
- Seizures.
- Focal deficits including cranial nerve signs.
- Mononeuritis multiplex.

**Diagnosis**

- Check pANCA, cANCA (and antibodies to MPO/PR3), acute phase reactants and eosinophil count. pANCA positivity approximately 20% in PAN and 75% in Wegener granulomatosis. cANCA sensitivity and specificity much higher for latter.
- Renal biopsy/muscle biopsy.
- *Angiography*: peripheral aneurysms in liver, kidney, mesenterium.

**Treatment**

Steroids ± immunosuppression (cyclophosphamide).

**Rasmussen encephalitis**

- Rare condition presenting with new onset, increasingly continuous and aggressive epilepsy, often *epilepsia partialis continua*.
- Onset is typically between 5 and 15 years.
- Untreated, disease follows slow, but inexorably progressive course with development of increasingly fixed focal motor deficits (typically hemiplegia, but also focal cognitive deficits, e.g. aphasia) and intractable epilepsy.
- Clinical course mirrored by MRI evidence of slowly progressive, confluent and uni-hemispheric inflammatory process, progressing eventually to unilateral atrophy.
- Histology shows a T-cell mediated inflammatory process.
- Some cases appear to have been triggered by minor head trauma.
- An autoimmune mechanism is presumed, but the auto-antigen has not been identified. Initial reports of a role for antibodies to a subunit of the glutamate receptor (anti-GLUR3) have not been substantiated: why disease should remain uni-hemispheric and not multifocal is unclear.
- Immunomodulatory treatment (e.g. with intravenous immunoglobulin) has been reported although progression of neurological deficits is not prevented.
- Functional hemispherectomy may be required to provide adequate seizure control, but with inevitable morbidity of a dense hemiparesis, hemianopia, etc.

## 'Autoinflammatory' conditions

Growing recognition of conditions where although inflammatory processes have been activated there is little evidence of involvement of specific *immune* responses (humoral or cellular); hence, 'autoinflammatory', rather than 'autoimmune'. Many of these are presumed genetic mutations of inflammation regulation genes.

### Sarcoidosis

- Multisystem granulomatous inflammatory process previously considered to be of unknown cause; however, the early onset sarcoid (EOS) phenotype is due to mutations in *NOD2* (a gene involved in recognizing a common bacterial peptide).
- Recessive (loss of function) mutations in *NOD2* give rise to EOS. It is also a susceptibility gene in Crohn disease and Blau syndrome (a rare autosomal dominant (AD) granulomatous disease).
- Common sites of involvement outside the CNS include the chest, joints, uveitis, testes, and kidney.
- Neurological manifestations are protean:
  - sterile meningitis (visible on MRI with contrast) causing multiple cranial neuropathies and/or peripheral mononeuritis multiplex;
  - diffuse CNS infiltrative disease particularly of the hypothalamus and pituitary;
  - myelopathy;
  - peripheral neuropathy.
- Raised serum (and CSF) ACE levels supportive, but not specific.
- *Tissue diagnosis*: demonstration of non-caseating granulomatous process, with exclusion of mycobacterial infection. Kveim test discontinued because of infection risk.
- *NOD2* gene testing.
- Treatment is steroids  $\pm$  azathioprine, cyclophosphamide.

### Primary central nervous system vasculitis

- CNS vasculitis can occur secondary to bacterial and particularly viral infection, or as a presentation of multisystem rheumatological disease.
- Aseptic meningitis and/or diffuse inflammatory changes on MRI.
- Lesions tend to be predominantly proximal, unilateral and multifocal within the anterior circulation.
- Demonstration of vasculitis radiologically is unusual: even four-vessel angiography is insensitive to small-vessel disease. Sensitivity of MR arteriography is lower.
- CNS malignancy, infection, and demyelination are often serious alternative diagnostic considerations and most cases come to biopsy.
- Isolated primary CNS vasculitis (PACNS) is a rare, but well described entity. Management is by immunosuppression, typically with steroids initially (occasionally need for more aggressive cyclophosphamide), transitioning to steroid-sparing alternatives such as mycophenolate mofetil (MMF), azathioprine, methotrexate.

## Autoimmune encephalitides

Although recognized in adult neurology for some time the importance of these diseases in paediatric neurology is increasingly being recognized. It is possible that a large proportion of encephalitic illnesses that would previously have been 'presumed viral' are in fact autoimmune in origin.

Neuropsychiatric features are common. Symptoms reflect dysfunction of the hippocampus (short-term memory loss), the remainder of the limbic system (confusion, seizures, psychosis) and/or brainstem (central hypoventilation), producing a 'limbic encephalitis' syndrome.

Many adult neurological paraneoplastic syndromes are due to antibodies reacting with *intracellular* antigens (anti-Hu, Ma2, CV2/CRMP5, amphiphysin). These do not respond well to treatment.

By contrast in limbic encephalitis, the antibodies are directed to *cell surface* antigens in the CNS. They are thought to be directly pathogenic and consequently the various conditions respond more favourably to immunomodulatory therapy.

Not all the following antibodies have been described in children but this is a burgeoning field, they may be under-recognized and vigilance is required:


- **Voltage gated potassium channel (VGKC) antibodies:**
  - in adults associated with a syndrome of incessant widespread myokymia (with myotonia on electromyography (EMG)), cramps, sweating, insomnia, and delirium (Morvan syndrome);
  - paediatric cases associated with limbic encephalitis: prominent seizures with memory loss.
- **N-methyl-D-aspartate receptor (NMDA-R) antibodies:**
  - paediatric cases associated with a prominent dyskinetic movement disorder, prominent psychiatric features including mutism;
  - probably responsible for significant proportion of children with encephalitis lethargica.
- **$\alpha$ -amino-3-hydroxy-5-methyl-4-isoxazole propionic acid receptor (AMPA-R) antibodies.**
- **$\gamma$ -amino-butyric acid B (GABA<sub>B</sub>) receptor antibodies.**

### History and examination

The following features may present with an acute or subacute onset and not all need be present:

- **Behavioural change, agitation or neuropsychiatric symptoms:** often a fluctuating, encephalopathic course.
- **Short term memory loss:** may be severe.
- **Seizures:** complex partial or generalized semiology.
- **Movement disorder:** from bradykinesia to oromandibular dyskinesias with unusual dystonic/dyskinetic limb posturing.
- **Autonomic dysfunction:** central hypoventilation, sleep-wake cycle disturbance.

## Investigations

Consider other causes of psychosis and acute confusional state (see  p. 104). Important differentials include infectious encephalitis, glioma, lymphomatous infiltration, Hashimoto's encephalopathy.

### CSF

The following abnormalities may or may not be present:

- Pleocytosis.
- Raised protein.
- Oligoclonal bands.
- CSF can be frozen and stored for future research.

### Blood

Specific antibody assays should be requested after discussion with the relevant laboratory.

### Electroencephalography

Epileptiform activity to variable background slowing.

### MRI

FLAIR sequences may show increased signal in medial temporal lobes, non-specific changes in other parts of the brain or be normal. Follow-up MRI typically show temporal lobe atrophy.

### Other imaging modalities

In contrast with adult disease a paraneoplastic cause is very rare however occult tumours may be present and appropriate imaging should be considered, e.g. to exclude ovarian germ cell tumour in girls with NMDA-R encephalitis.

## Treatment

There are no established treatment regimes, but the following immunomodulatory therapies have been used:

- High dose intravenous methylprednisolone with a variable length of steroid taper.
- High (immunomodulatory) dose intravenous immunoglobulin (IVIG).
- Plasmapheresis.
- Rituximab, a monoclonal antibody to CD20 protein on B-cells.
- Other immunosuppression (cyclophosphamide, MMF, etc.).

The initial response may be dramatic with an arrest of symptoms and rapid acquisition of lost skills, but relapse can occur and long-term prognosis is not known.

## Hashimoto encephalopathy

Autoimmune thyroid disease associated with anti-thyroid peroxidase (anti-TPO), anti-thyroid microsomal, or antithyroglobulin antibodies. Neurological presentation can precede recognition of hypothyroidism, and indeed children can be euthyroid at presentation.

Neurological presentation is of diffuse cortical dysfunction:

- Seizures, sometimes prolonged, particularly with persisting coma.
- Confusion, disorientation and memory problems.

- Myoclonic jerks.
- Tremor.
- Disordered sleep.
- Psychosis.
- Transient aphasia.

Investigation findings typically non-specific:

- Electroencephalography (EEG) evidence of persisting encephalopathy  $\pm$  seizures.
- Variable elevation of CSF protein.
- Most will have disordered thyroid function: either frank hypothyroidism (rarely, hyperthyroidism), or isolated elevation of thyroid stimulating hormone (TSH).
- Non-specific elevations of ESR and liver function tests (LFTs).
- Demonstration of anti-thyroid peroxidase (anti-TPO), anti-thyroid microsomal or antithyroglobulin antibodies in a supportive clinical context is diagnostic.

Initial treatment with steroids often effective, but long-term steroid dependency is common and alternative steroid-sparing immunosuppression is required.


### Paraneoplastic syndromes of the nervous system

Rare in childhood (most commonly associated with small-cell lung cancer, gynaecological and breast tumours, or Hodgkin's lymphoma in adults), but developmental of antineuronal antibody tests in a clinical context has allowed prompt recognition and treatment.

#### CNS manifestations

- Commonly involve tumours expressing neuroendocrine proteins, e.g. neuroblastoma or containing neuronal tissue, e.g. teratoma.
- Probably immune-mediated, due to anti-neural antibodies reactive with neuronal proteins expressed on the tumour surface.

#### Examples

- Cerebellar degeneration syndromes with anti-Tr and -mGluR antibodies associated with Hodgkin lymphoma.
- *Opsoclonus-myoclonus*: sera of children with opsoclonus-myoclonus (see  p. 381) have antibodies (anti-Yo, Hu, Ri) that react with the cell surfaces of cerebellar granular neurons and neuroblastoma cells.
- Limbic and brainstem encephalitides due to anti-Ma antibodies associated with germ-cell tumour of testis.
- Myelitis with anti-Hu antibodies (also seen in limbic encephalitis).

#### Peripheral nervous system manifestations

Commonly involve tumours that derive from cells that produce immunoglobulins, e.g. thymoma.


#### Implications for practice

If imaging suggests inflammatory changes without an infective prodrome and a vasculitis screen is negative consider imaging to search for tumour and screen for antineuronal antibodies. However, not all antibodies detected are necessarily causal or tumour-related!

# Cerebral palsies

## Definition


This is a group of disorders of the development of movement and posture, causing activity limitation, attributed to non-progressive disturbances that occurred in the developing foetal or infant brain.

**Note:** the pattern and severity of the movement disorder may evolve during childhood mimicking a progressive neurological disorder—investigate further if in doubt (see  p. 229).

## Overall prevalence

- Approximately 2 per 1000 live-born infants.
  - The plural term 'cerebral palsies' highlights the heterogeneity of aetiologies, degrees of motor impairment, co-morbidity, functional ability, and prognosis.
- The usefulness of the CP concept is regularly questioned as increasing numbers of primary neurogenetic, neurodevelopmental, and neurometabolic causes are identified. The main justification for its retention is a pragmatic one relating to planning and provision of services, as these children tend to have similar needs whatever the cause.

## Classic descriptions of the cerebral palsies

Classic categories are based on the predominant movement disorder (spasticity, athetosis, etc.) and the pattern of limb involvement. This is a useful framework for epidemiological studies, but inadequate for clinical care of the individual child (see  'Classifications for clinical care', p. 227).

- *Spastic hemiplegia (upper limb involvement > lower limb):* 33–38%.
- *Spastic diplegia:* 35–43%.
- *Spastic quadriplegia/total body involvement:* 6%.
- *Dystonic and athetoid:* 7–15%.
- *Ataxic:* 6%.
- *Monoplegia:* lower limb spasticity typical, often presenting late. Poorly represented in epidemiological studies.
- *Worster–Drought phenotype:*
  - prominent orobuccopharyngeal palsy with marked feeding, speech, and cognitive problems and epilepsy, often due to bilateral perisylvian polymicrogyria;
  - relatively ignored in epidemiological studies.

## Classifications for clinical care

A *multi-axial* description of a child with a CP is important to facilitate inter-professional communication and therapies, guide investigations, and formulate a prognosis.

The following scheme is suggested for routine clinical care, e.g. to complement the problem list in clinic letters. Evaluate and record the findings along *each* of the following axes.

### Types of movement disorder

Presence not only of spasticity, but often under-recognized concurrent dystonia, dyskinesia/athetosis/hyperkinesia, ataxia, hypotonia.



**Pattern of anatomical involvement**

- Body parts involved; degree of symmetry.
- 'Classic' patterns are simple, but limited.

**Severity of motor impairment**

Distinguish and individually quantify spasticity, strength, presence of fixed contractures, and coordination.

**Co-morbidities**

Create a neurological and systemic problem list, e.g. learning disability, epilepsy, visual impairment, chest infections.

**Functional abilities of daily living**

Transfers; self-cares, etc. Standard measurement tools are available.

**Known aetiologies and risk factors**

*Nature and timing:* prenatal, perinatal, or postnatal/neonatal.

**Known neuroimaging findings**

- Periventricular leukomalacia, cerebral malformations, etc.
- Re-evaluate classification at regular intervals, e.g. at annual review.
- Classifying children below 2–3 yrs age may be inaccurate.
- Limb spasticity is more difficult to assess than early limb preference.
- Axial and limb hypotonia may evolve to dystonia, dyskinesia, and ataxia.
- Motor impairment scales are less reliable in infants.
- Cognitive development is difficult to ascertain in young infants—children may present with developmental delay.

**Aetiology and risk factors for a cerebral palsy**

Multiple risk factors and aetiologies often interact, hence the term 'causal pathway' to describe this complex process.

Ascertain risk factors using history, examination and investigations, particularly MRI.

**Prenatal factors**

- Prenatal factors account for >60% of term-born children and for >15% of pre-term.
- *Premature delivery:*
  - 20% of children with a CP were born at <32 weeks;
  - 4–8% of survivors of <32-week delivery develop a CP;
  - rates rise markedly in extreme prematurity (<25 weeks); higher in boys.
- Twin gestation and twin–twin transfusion.
- Small-for-gestational age.
- Placental insufficiency.
- Maternal infection or pyrexia.
- Intrauterine infections, e.g. TORCH, human immunodeficiency virus (HIV).
- Chromosomal and genetic disorders of neuronal proliferation, migration, and organization resulting in brain malformations.

**Perinatal/neonatal factors**

- Amnionitis.
- Antepartum placental haemorrhage.

- Neonatal meningitis.
- Kernicterus (rare at term in developed countries; consider in preterm born infants who develop dyskinetic cerebral palsy (CP)).
- Perinatal thrombophilia leading to intracranial arterial or venous stroke (consider in hemiplegic CP, especially if porencephaly is found on MRI).
- Perinatal cerebral haemorrhage (hemiplegic CP; consider COL4A1 mutations if there is a family history).
- *Neonatal encephalopathy*: 24% of term-born children with a CP had neonatal encephalopathy; development of a CP is crucially dependent on the severity of encephalopathy:
  - overall 13% of survivors develop a CP;
  - ~25% of those with Grade II and 75% with Grade III hypoxic-ischaemic encephalopathy.
- Ascribing a CP to 'perinatal asphyxia' or 'hypoxic-ischaemic encephalopathy' has medico-legal implications.

#### **Postnatal/post-neonatal factors**

- Meningo-encephalitis.
- Traumatic head injury (accidental and inflicted).
- Hypoxic-ischaemic events, e.g. near-drowning, prolonged hypotension.
- Arterial ischaemic/haemorrhagic stroke.

The prevalence of post-neonatal (28 days to 2 yrs age) onset of CP in developed countries is ~1 per 10,000 live births, accounting for only 5% of CP. It is more prevalent in developing countries.

#### **Investigations and differential diagnosis**


Investigations should be tailored to each child, To exclude a progressive or treatable disorder that mimics CP; to identify the specific aetiology of a CP, e.g. birth injury; identify co-morbidities; and for prognostication.

#### **When to consider an alternative diagnosis to cerebral palsy**


- No risk factors for CP in history.
- Family history of neurological disorders, especially 'cerebral palsy' or intellectual disabilities.
- Presentation late in infancy and early childhood, e.g. 'toe-walking' due to monoplegia/diplegia.
- Atypical clinical findings, e.g. microcephaly, cataracts, skin lesions.
- Ataxic CP. This is commonly genetic (see [Box 4.1](#) p. 384) and whilst not necessarily progressive, has implications for recurrence risk.
- Dyskinesia/dystonia without perinatal risk factors.
- Neonatal encephalopathy without perinatal risk factors.
- Imaging normal (see Box 4.2).

**Box 4.2 Identifying intrapartum hypoxic aetiology**

To provide strong evidence that the CP is due to an intra-partum hypoxic event in the term infant, look for a history of moderate or severe neonatal encephalopathy (Sarnat grade II and III) in association with:

- Near-term (34 weeks) delivery.
- CP with corticospinal involvement or dyskinetic type in keeping with MRI findings (see  p. 233).
- Typical late neuroimaging findings for perinatal timing of injury
  - After acute and profound hypoxia-ischaemia: injury to deep grey matter with bilateral basal ganglia lesions; then signal change in the pre- and post-central gyri, followed by more widespread hemisphere injury progressing to encephalomalacia.
  - After chronic partial injury hypoxia-ischaemia: signal change in parasagittal sub-cortical white matter, the watershed areas perfused by the terminal branches of the anterior/middle or middle and posterior cerebral arteries, again progressing to encephalomalacia.
- Umbilical arterial acidosis (pH <7.0 and base deficit >12 mM) or foetal scalp/early newborn acidosis of a similar degree.
- Any combination of the following indicators of an intrapartum event:
  - abnormal foetal heart rate on tocograph;
  - difficult delivery or other history suggestive of a hypoxic event around the time of labour;
  - low Apgar scores (<7 at 5 min);
  - need for resuscitative measures at delivery;
  - early multi-organ dysfunction;
  - early imaging suggestive of acute cerebral injury, e.g. cerebral oedema on cranial ultrasound and decreased resistance index in cerebral Doppler studies.

**Evidence against intrapartum hypoxia as the main cause**

- History of only mild neonatal encephalopathy (Sarnat grade I).
- Family history of CP (particularly a sibling).
- Predominantly ataxic movement disorder.
- Congenital microcephaly or other major anomalies.
- Intrauterine growth retardation.
- Reduced foetal heart rate variability from onset of labour.
- Presence of significant prenatal risk factors, amnionitis, major abruption.
- CNS or systemic infection.
- Significant postnatal risk factors, e.g. prolonged hypoxia and hypo-tension.
- Inherited coagulopathy.
- Early neuroimaging suggests long-standing injury, e.g. ventriculomegaly, cystic encephalomalacia.
- Neuroimaging findings for atypical for injury at term: schizencephaly; other neuronal migration disorders; periventricular leukomalacia (see  p. 232).
- Progression of motor signs (**Note:** ataxia and dyskinesia are usually preceded by a period of hypotonia in infancy).
- *Normal MRI brain:* consider trial of L-DOPA to identify DOPA-responsive dystonia.

## Conditions that can mimic a cerebral palsy

### All patterns

- Intracranial mass.
- DOPA-responsive dystonias.
- Mitochondrial disorders (very slow progression possible).
- Metabolic leukodystrophies.

### Lower-limb spastic weakness (*diplegia*)

- Spinal cord lesion (ask about continence, check sensation).
- Hereditary spastic paraplegias (see 📖 p. 433).
- Cerebral folate deficiency, arginase deficiency, biotinidase deficiency, Sjogren–Larsson, HIV.

### Ataxia

See also 📖 p. 384.

- *Genetic disorders*: ► treat any diagnosis of ‘ataxic CP’ with scepticism!
- Biotinidase deficiency, infantile neuroaxonal dystrophy, Pelizaeus–Merzbacher, ataxia telangiectasia (tend to be progressive).
- Other familial ataxia and cerebellar mass lesions (non-progressive).

### Dyskinesia/dystonia

- DOPA-responsive dystonia.
- GLUT1 deficiency.
- Glutaric aciduria 1.
- Lesch–Nyhan.
- Mitochondrial disorders.
- Rett syndrome.
- Neurodegeneration with brain iron accumulation (NBIA)/pantothenate kinase-associated neurodegeneration (PKAN).
- In older children consider:
  - Wilson disease (treatable);
  - idiopathic torsion dystonia (check *DYT1* mutation);
  - juvenile Huntington and Parkinsonism.

### Hypotonia

- May precede ataxic and dyskinetic CP, but also neuromuscular disorders.
- Common feature in global developmental delay.

## Specific diagnostic investigations

- *MRI brain*: single most useful investigation. Results will focus further investigations; recommended for all children, particularly term-born.
- *CT brain*: focal or diffuse calcifications can be missed on MRI (neurophakomatoses, TORCH, pseudo-TORCH, Aicardi–Goutières).
- *MRI spine*: thoracic and lumbar for lower-limb spastic weakness; cranio-cervical junction in quadripareisis.
- *Magnetic resonance spectroscopy (MRS)*: mitochondrial disorders, creatine synthesis defects.
- EEG where epilepsy suspected clinically (characteristic findings in Rett syndrome, infantile neuroaxonal dystrophy).
- *Karyotype*: more specific fluorescent *in-situ* hybridization (FISH) and microarray studies, e.g. Prader–Willi in hypotonia.

- **TORCH:** cytomegalovirus (CMV), Toxoplasma, HIV. Guthrie card blood spot PCR test.
- **Ammonia:** raised in arginase deficiency.
- Lactate.
- Urine organic acids, amino acids, muco/oligopolysaccharides, sulphite.
- Lysosomal enzymes.
- Very long chain fatty acids (adrenoleukodystrophy).
- **Biotinidase:** treatable disorder, can involve ataxia and spasticity.
- Coagulopathy screen in hemiplegia associated with unilateral MRI lesion.
- **Transferrin isoelectric focusing:** congenital disorders of glycosylation (CDG1a) can present with hypotonia and ataxia.
- Copper (low in Menkes) and caeruloplasmin (low in Menkes, Wilson.)
- **CSF studies:**
  - decreased CSF—blood glucose in GLUT1 deficiency;
  - CSF lactate for mitochondrial disorders;
  - CSF neurotransmitter studies for DOPA-responsive dystonias, cerebral folate deficiency;
  - CSF glycine and serine if neonatal seizures and progressive microcephaly (non-ketotic hyperglycinaemia and 3-phosphoglycerate dehydrogenase deficiency).
- **Nerve conduction studies:** hereditary neuropathy can present with toe-walking and tight Achilles tendons.
- Investigations for causes of developmental delay as indicated, e.g. creatinine kinase (CK), TFT, fragile X mutation (see [p. 110](#)).
- Ophthalmological, auditory, and speech and language evaluation.

### Magnetic resonance imaging brain findings: diagnostic and prognostic implications

#### No brain lesions

Approximately 10% of children in historical cohorts have no brain lesions; well-described in ataxia and dyskinesia-predominant CP.

**Consider:** progressive or genetic disorders; MRI spine if spasticity is present; repeating MRI brain if first MRI was done before 2–3 yrs of age or if a higher magnet-strength scanner is available. CT brain for calcifications. Trial of L-DOPA.

#### Periventricular leukomalacia (PVL)

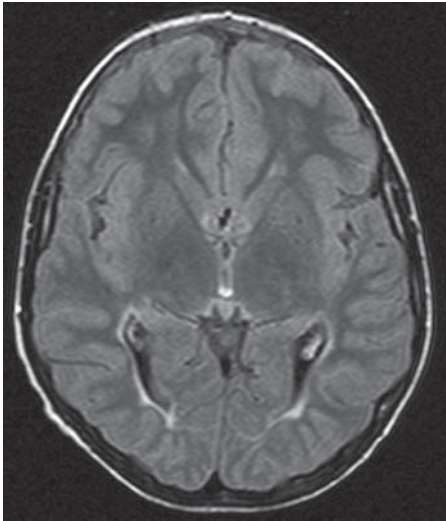
This is associated with lower limb predominant spasticity (diplegia; monoplegia if unilateral PVL; see Figure 4.2). There is predominant dystonia in some preterm infants. Epilepsy is less common than in cortical lesions. Assess for visual impairment and specific learning deficits. **Note:** PVL is occasionally reported after perinatal ischaemic injury at term.

A number of risk factors for PVL have been identified, although precise mechanism is not established.

- Results from injury to oligodendroglia between 26 and 34 weeks' gestation.
- CBF instability appears important (preterm infants have very poor CBF autoregulation). Risk factors include: mechanical ventilation; hypotension, hypoxaemia, acidosis, hypocarbia, patent ductus arteriosus. Predictive indices based on exposure to risk factors have been developed.

- Cytokine release due to chorioamnionitis or maternal infection is probably also important.
- Other risk factors include placental vascular anastomoses, twin pregnancy, antepartum haemorrhage, maternal cocaine abuse.
- Many infants have no identifiable risk factors.

**Consider:** leukodystrophies if there is an atypical distribution of white matter changes; or if marked cerebral or cerebellar atrophy/hypoplasia are present.



**Fig. 4.2** Typical FLAIR appearances of PVL: irregular lateral ventricle enlargement and reduced white matter thickness are seen particularly posteriorly; deep sulci nearly reach the ventricle; increased T2 signal in white matter reflecting gliosis. The latter typically implies third trimester injury. Fewer features are seen in mild PVL.

#### **Delayed myelination, hypomyelination** (see p. 170)

Appearances can range from local peri-trigonal changes to a widespread finding. It is associated with delayed developmental milestones, hypotonia and ataxia. It may also result from a perinatal ischaemic event. A thin juxtaventricular rim of normal myelination should be visible posteriorly—if not, suggests a leukodystrophy.

**Consider** Biotinidase deficiency, 3-phosphoglycerate dehydrogenase deficiency, Pelizaeus–Merzbacher, congenital disorders of glycosylation, Menkes, Sjogren–Larsson, other metabolic leukodystrophies. Repeat the MRI scan at 2–3 yrs age.

#### **Basal ganglia and thalamic lesions**

Bilateral infarctions in the putamen (posterior) and thalamus (ventrolateral nuclei) can result from perinatal acute, severe hypoxic–ischaemic injury at term. The typical association is with dystonia and dyskinesia. Spasticity

and total body involvement is present if the internal capsule and cortex are affected. Kernicterus is now more common in pre-term infants—look for globus pallidus lesions. A unilateral lesion suggests thrombo-embolic stroke.

► Term HIE characteristically causes an early high T2 signal and later atrophy in the putamen and thalamus. Involvement of the globus pallidus or caudate is suspicious for metabolic disease (especially mitochondrial disease and organic acidurias).

► Consider: mitochondrial disorders, post-encephalitis, or toxins if there were no prenatal risks or at late presentation; coagulopathy screen in a unilateral lesion.

### **Porencephaly**

This is a focal peri-ventricular cyst or irregular lateral ventricle enlargement, often a remnant of foetal/neonatal periventricular haemorrhagic venous infarction. No gliosis. Insult is typically second trimester, but extensive unilateral lesions are possible after arterial ischaemic or haemorrhagic stroke at term. Results in upper limb-predominant hemiplegia.

**Consider:** coagulopathy screen; *COL4A1* gene mutation in familial cases.


### **Cortical infarctions**

Symmetrical parasagittal and parieto-occipital/fronto-parietal watershed lesions can result in spastic quadripareisis. Suggests acute perinatal injury due to partial vascular ischaemia at term, e.g. hypotension. Focal symmetrical infarctions in perisylvian areas can lead to the Worster–Drought phenotype. Unilateral lesions suggest a thrombo-embolic cause; they result in spastic hemiplegia (usually upper limb-predominant). If there are non-vascular territory infarcts, consider mitochondrial disorders, e.g. mitochondrial encephalomyopathy, lactic acidosis, and stroke-like episodes (MELAS; deletions and point mutation test available).


### **Cystic encephalomalacia**

Multiple subcortical cysts and gliosis occur (↑T2 signal in remaining white matter); there is septation in the cysts. This suggests perinatal injury near term, or early postnatal injury. If diffuse consider neonatal/infantile meningitis; if there are watershed areas, consider severe perinatal ischaemic injury. Associated with spastic quadripareisis and multiple co-morbidities. If focal and cortical predominant, suggests thrombo-embolic stroke.


### **Schizencephaly**

This is a neuronal migration disorder; specific genes are implicated. Early gestation insult—distinguish from porencephaly. Type I (closed lip) and type II (open lip) with polymicrogyria. Type II is more commonly associated with early hemiplegia (balanced upper and lower limb severity) or quadripareisis and increased risk of learning disability and epilepsy (see  p. 276). Check for septo-optic dysplasia.

### **Other cerebral dysgenesis**

See Box 4.3. Disorders of neuronal proliferation, migration and organization including heterotopias, lissencephalies and hemimegalencephaly. Increased risk of epilepsy, and learning disability if extensive. Bilateral perisylvian poly-microgyria may result in Worster–Drought phenotype. Many specific genetic disorders: can also be caused by early to mid-gestational teratogens, e.g. CMV (see  p. 355).

**Box 4.3 Radiological signs of cerebral dysgenesis**

(See also  p. 163.)


In simple terms, brain development occurs in three phases:

- Massive neuronal proliferation from progenitor cells in the periventricular ependymal layer.
- Successive waves of centrifugal migration of neurons from this central periventricular zone out to the cortex (counter-intuitively, the latter waves migrate further, passing the earlier waves to reach the surface in an 'inside out' manner).
- Consolidation and organization of intracortical neuron-to-neuron connections.


Corresponding radiological indicators of dysgenesis include:

- *Ectopic grey matter*: subcortical 'islands' of grey matter that never made it all the way to the cortex.
- *Band heterotopias*: bands of grey matter representing arrested migration of a neuronal 'wave' (can result in 'double cortex' appearances with a layer of white matter sandwiched between two grey matter layers).
- Abnormally thick cortex due to failure of organization and 'pruning' (pachygyria).
- Abnormally simple cortex without sulcation (lissencephaly).

***Hypoplasia and agenesis of the corpus callosum***

A thin/hypoplastic corpus callosum may be secondary to PVL and extensive cortical lesions. Agenesis of corpus callosum suggests an early gestation insult, typically genetic cerebral dysgenesis. If septum pellucidum is absent, consider septo-optic dysplasia (check pituitary MRI scans, endocrine, and visual function). Consider pyruvate dehydrogenase deficiency (skin fibroblasts for enzyme studies). Consider Aicardi syndrome in girls (see  p. 276).

***Cerebellar hypoplasia and atrophy***

A non-progressive lesion (hypoplasia) may be indistinguishable from a progressive lesion (atrophy)—check antenatal ultrasound for clues. Hypotonia may precede ataxia. Inferior cerebellar hemisphere atrophy in extreme preterm survivors is associated with increased disability. Vermis atrophy may follow severe perinatal ischaemic injury—associated cortical, basal ganglia and brainstem lesions should be visible. Consider genetic and metabolic disorders e.g. mitochondrial disorders, congenital disorders of glycosylation, pontocerebellar hypoplasia type I, Joubert, infantile neuroaxonal dystrophy, Menkes (see  p. 384).

***Diffuse cortical atrophy***

A thin cortex/subcortex results in ventriculomegaly. It is the result of a severe neonatal encephalopathy due to an intrapartum hypoxic event. It is associated with spastic total body involvement CP and cognitive disability. It may also result from post-neonatal hypoxic events. If there is no clear history of risk factors consider a progressive disorder e.g. Alpers disease (check LFT, *POLG1* gene).



**Brainstem atrophy**


This is associated with severe, acute perinatal/postnatal ischaemic injury in term-born children. Corticospinal/bulbar injury leads to spastic total body involvement. It has a poor prognosis if there is bulbar weakness or a tendency to aspiration pneumonia.

**Consider** Pontocerebellar hypoplasia type 1, CDG1a if there are no historical risk factors.

**Prognosis in the cerebral palsies**

Estimating the prognosis (e.g. life expectancy, independent walking) in the individual child is an inexact art. Recent studies have utilized severity measures, e.g. gross motor function classification syndrome (GMFCS), rather than mere limb involvement and movement disorder (e.g. spastic hemiparesis, dystonic CP) to stratify cohorts (Figure 4.3). Multi-axial classification, e.g. including neuroimaging findings in stratification of cohorts, should improve accuracy in the future.

**Life expectancy**

- The majority of children with a CP (80–90%) survive into adulthood, including those with severe disability (60–70%). Paediatricians need to anticipate transfer to adult services!
- Current survival data by definition reflect medical care of 30 or more years ago. Survival of today's young children should be better.
- The severity of cognitive impairment, despite correlation with the severity of motor impairment, is an independent predictor of mortality.
- IQ <20 (50% survival to adulthood) vs. IQ >85 (>95% survival to adulthood).
- *Causes of death*: respiratory infections, aspiration, status epilepticus, other infections.
- For up to date reviews see  <http://www.lifeexpectancy.com>.

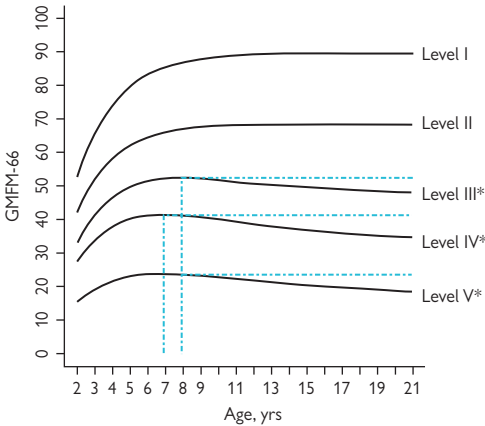
See Table 4.2.

**Walking and mobility**

Predictors include the pattern of limb involvement and movement disorders:

- *Spastic hemiplegia*: majority walk before 2 yrs.
- *Spastic quadriparesis/total body involvement*: majority unlikely to walk.
- *Other predictors for ability to walk by the age of 6 include development achieved at age 3 yrs*:
  - if unable to roll, only a minute percentage will walk with assistance;
  - if able to roll, but not sit (GMFCS level IV) then ~25% will walk with assistance;
  - if able to roll and sit, ~50% will walk, most with assistance;
  - if able to roll, sit, pull to stand (GMFCS level II), ~70% will walk, many unassisted;
  - these predictions assume normal vision.

► Be aware of the phenomenon of 'going-off feet' in adolescence. Increases in limb length, and body and limb weight have adverse biomechanical effects on children with precarious mobility. Gross motor skills are often best late in the first decade and a child who was just walking may cease to: recognizing this prevents unwarranted hunts for neurodegenerative disease.



**Fig. 4.3** Natural history of gross motor function in cerebral palsy as reflected by gross motor function measure (GMFM-66). Note that in more severely impaired children (Gross Motor Function Classification System (see Figure 4.4) levels III–V) it is normal for function to peak late in the first decade and then show a modest decline. Reproduced with permission from Hanna SE, Rosenbaum PL, Bartlett DJ, *et al.* (2009). Stability and decline in gross motor function among children and youth with cerebral palsy aged 2 to 21 years. *Dev Med Child Neurol* **51**: 295–302. Copyright (2009) MacKeith Press.

#### Prediction by aetiology

The ‘cause’ of a CP is a significant predictor of outcome.

Neonatal encephalopathy as a cause of a CP tends to result in a higher incidence of:

- Severe motor disability (47% vs. 25% for all other causes).
- Epilepsy (53% vs. 29%).
- Cognitive impairment (75% vs. 43%).
- Being non-verbal (47% vs. 22%).
- Early mortality (death by 6 yrs 19% vs. 5%).

CP due to cerebral dysgenesis, infection and cortical damage is associated with a higher incidence of epilepsy than that associated with periventricular leukomalacia.

#### Prediction by mode of presentation

Children presenting early in infancy, e.g. from follow-up in a high-risk neonate clinic, tend to have a more severe CP, e.g. total body involvement.

Children presenting in late infancy/early childhood, e.g. from health visitor concerns, have a milder CP. Children may already be walking, e.g. toe-walking in spastic diplegia. Mild cognitive impairment is more likely.

**Table 4.2** Typical profile of impairments and activity limitation across CP motor subtypes

	Hemiplegia	Diplegia	Quadriplegia
Typical GMFCS levels (see Figure 4.4)	I or II	III	IV or V
Epilepsy	~30% (50% after perinatal stroke). Focal. Epilepsy surgery consideration. Often late onset. Associated with lower IQ	~30%	90%; less frequent in dyskinetic. GTCs. Early onset
Other medical issues (age-dependent)	Minimal	Drooling, GORD, incontinence, enuresis	Hydrocephalus (15%), dysphagia, caries, chest infections, GORD, constipation, incontinence, malnutrition, drooling, osteopaenia, precocious puberty with delayed completion
Upper limb	Wrist flexion and pronator contractures; thumb adductor spasticity; fall-related fractures	Fine motor functions affected (handwriting, cutlery); proximal weakness may limit self-propelled wheelchair use	Shoulder, elbow flexion contractures; wrist flexion/extension contracture; thumb-in-palm and intrinsic hand muscle deformity; poor hand use
Lower limb orthopaedic of functional consequence	Calf/ankle contracture; leg length discrepancy; flexion at the knee	Foot deformity; hip and knee fixed flexion; hip subluxation; patella alta; torsional lower limb; spondylolysis	Scoliosis, pelvic obliquity, hip dislocation, long bone pathological fracture
Vision	Visual acuity usually normal; visual field/lateralized attention deficit	Strabismus, hypermetropia, astigmatism. Higher visual deficits.	Visual impairment and blindness frequent (ocular and cerebral causes)

Hearing	Normal range	No severe hearing loss	5% have severe hearing loss (higher after kernicterus)
Neuropsychology	Low normal range (20% have IQ < 70); 50% have IQ < 70; usually preterm. performance IQ most affected; worse with epilepsy. Focal deficits	Visual-perceptual deficits	80% have IQ < 70
Speech and language	Delayed speech; overall in line with IQ	Mild dysarthria	Majority non-verbal; severe dysarthria in dyskinetic
Behaviour and psychological	ADHD-like (20%), anxiety (25%), peer problems, autistic spectrum (3–15%)	Increased emotional and peer problems	Sleep disturbance; generalized pain/agitation
Academic/education	Mainstream school often without support. Dyslexia, dyspraxia, dysgraphia-like problems may become evident in later years	Mainstream school with support. Specific learning problems may become evident	Special school typical

## Care of the disabled child

### Models of disability

The current WHO model of disability (the International Classification of Functioning, ICF) envisages multilevel effects:

- *Impairments* are reductions of function at the level of a body organ such as weakness in a limb or poor vision in an eye.
- *Activities* are description of functioning at the level of the person in a standardized or idealized environment.
- *Participation* is involvement in 'real-life' situations, including the performance of social roles. It is seen as 'what matters' about disability.

Key to the International Classification of Functioning, Disability, and Health (ICF) model is the realization that whilst participation is affected by impairment, it is also determined by impairment-independent *contextual* factors. Change the child's environment (address discriminatory attitudes or legislation, lack of adapted facilities or appropriate services) and the same child's participation could dramatically improve without any change in impairment.

The ICF is a qualitative synthesis of two different concepts of disability. Extremes of the medical and social models of disability exaggerate, respectively, the importance of intrinsic impairment and environmental context on the disadvantage experienced by disabled people.

- The extreme medical model sees disability as arising from the biological nature of a disease, and emphasizes diagnosis; disability is something you 'have'.
- The extreme social model sees 'the process of disablement' as entirely arising from discriminatory attitudes and policies within society; disability is something 'done to you'. It regards medical diagnosis as largely irrelevant.
- This also drives a usage debate, with arguments that both 'disabled person' and 'person with disability' reflect enlightened attitudes.

The basic ICF conceptual framework is a useful guide to practice. Clinicians tend to focus on and treat impairments. Demonstrating an improved range of movement at a joint after botulinum toxin (i.e. reduced impairment) is not enough—has this improved participation?

In situations where we can do little to reduce impairment, devoting energy to improving the environment in which the impaired child lives may have much greater effects on participation.

### Management of spasticity and contractures

*Spasticity*: excessive and inappropriate involuntary muscle activity, causing a velocity-dependent increase in resistance to passive muscle stretch, i.e. a dynamic measure associated with exaggerated tendon reflexes.

- ▶ Velocity-independent resistance suggests dystonic rigidity, or long-standing CP with fixed changes in muscles, tendons and joints.

Spasticity can complicate CP, ABI and neuromuscular disorders. Consequences include:

- Pain and discomfort.
- Difficulty with care, e.g. in the groin area.
- Loss of function, e.g. mobility.
- Contractures.

Spasticity is treated to ameliorate one or more of these, not for its own sake. Realistic treatment goals should be agreed *prior* to treatment, and are the criteria against which treatment success is assessed.

### **Assessment**

#### *History*

Pain, discomfort and ease of care, and the impact of these on the life of child and family.

#### *Examination*

Tone, power and deep tendon reflexes. Reasonably objective rating scales can be used to monitor change over time.

### **Clinical measures of motor impairment and function**

Assessment of motor impairment and function should be inter-disciplinary, involving physiotherapists, occupational therapists and orthopaedic surgeons. Structured analysis of videotaped movements may aid decision making.

Identify and measure, if possible:

- Spasticity.
- Fixed tendon, bone, joint problems, e.g. Achilles contractures, scoliosis.
- Muscle weakness.
- Dystonia.
- Gross motor function (*do this at the very least*).
- Coordination and selective motor control (fine motor).
- Perceptual and cognitive problems, e.g. visual impairment.
- Abilities and disabilities in daily living, e.g. self-care.

Numerous structured observational scales and questionnaires exist for measuring motor impairments and functions of daily living. The focus here is on the cheap, rapid, and/or well-validated measures.

### **Spasticity scales**

#### *Modified Ashworth Scale*

A six-point ordinal scale. Simple and widely used, but not entirely reliable as speed of movement is not specified.

- 0 = no increase in muscle tone.
- 1 = slight increase in tone, with catch and release, or minimal resistance at end of range.
- 2 = minimal resistance through range following catch, but body part is easily moved.
- 3 = more marked increased tone throughout range.
- 4 = considerable increase in tone, passive movement difficult.
- 5 = affected part is rigid in flexion/extension.

**Dystonia**

Measurement scales for dystonia are not as well established as for spasticity. The Barry–Albright dystonia scale was developed for children with severe generalized dystonia (hypokinetic). Five-point ordinal scale, scored for the following body parts: eyes, mouth, neck, trunk, and each limb.

- 0 = normal.
- 1 = slight, body part affected less than 10% of the time.
- 2 = mild, body part affected less than 50% of the time; not interfering with function.
- 3 = moderate, body part affected more than 50% of the time and/or interferes with function.
- 4 = severe, body part affected more than 50% of the time; prevents or severely limits function.

**Gross motor function**

*Gross motor function classification system (GMFCS)*

This is a very simple and well-recognized classification of mobility in CP. Routine use in clinics is feasible. It is more reliable in children over 2 yrs old, but ignores quality of performance and upper limb functions. Part of its value is that the longitudinal ‘trajectory’ of children in each band has been defined. Thus, if you know the GMFCS score now, you can predict with some confidence levels of future function expected of young people in that ‘band’ (Figure 4.3).

Five-point ordinal scale described in levels I mild to V severe (see Figure 4.4).

**Gross motor function measure**

This is a more involved measure consisting of 66 motor tasks grouped into five dimensions, e.g. lying and rolling; sitting; standing; walking, running, and jumping tasks. It can detect change over time, thus it has been used for detecting response to therapy, and defining the prognosis for ambulation.

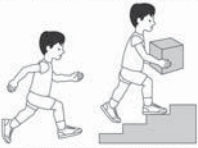




**Other measures**

A wide variety of specialist scales exist to assess specific constructs. Their use is generally restricted to research or formal evaluation exercises as they are time-consuming (typically 20–30 min).

- Fine motor coordination, e.g. movement assessment battery for children (MABC), gross motor performance measure (GMPM), quality of upper extremity skills test (QUEST).
- Visual perception and motor coordination, e.g. developmental test of visual–motor integration (VMI).

**Examples**

Limitations in daily living are not just due to motor impairments. Disability measures integrate the effects of co-morbidities (e.g. scoliosis), cognitive deficits, perceptual deficits (e.g. visual impairment) and behavioural disorders. Examples include the Pediatric Evaluation of Disability Inventory (PEDI) and WeeFIM (paediatric functional independence measure).

	<p><b>GMFCS Level I</b></p> <p>Children walk indoors and outdoors and climb stairs without limitation. Children perform gross motor skills including running and jumping, but speed, balance and coordination are impaired.</p>
	<p><b>GMFCS Level II</b></p> <p>Children walk indoors and outdoors and climb stairs holding onto a railing but experience limitations walking on uneven surfaces and inclines and walking in crowds or confined spaces and with long distances.</p>
	<p><b>GMFCS Level III</b></p> <p>Children walk indoors or outdoors on a level surface with an assistive mobility device and may climb stairs holding onto a railing. Children may use wheelchair mobility when traveling for long distances or outdoors on uneven terrain.</p>
	<p><b>GMFCS Level IV</b></p> <p>Children use methods of mobility that usually require adult assistance. They may continue to walk for short distances with physical assistance at home but rely more on wheeled mobility (pushed by an adult or operate a powered chair) outdoors, at school and in the community.</p>
	<p><b>GMFCS Level V</b></p> <p>Physical impairment restricts voluntary control of movement and the ability to maintain antigravity head and trunk postures. All areas of motor function are limited. Children have no means of independent mobility and are transported by an adult.</p>

**Fig. 4.4** Descriptors and illustrations of GMFCS levels at age 6–12 yrs. Illustrations © Kerr Graham, Bill Reid, and Adrienne Harvey, The Royal Children's Hospital, Melbourne. Used with permission.



### **Physical management**

Problems to be addressed encompass weakness, fatigue, and abnormal tone, abnormal posturing, reduced movement control, and muscle contractures. The aims of physiotherapy are to retain and improve function, and to preserve muscle length.

- Muscle strengthening exercises are controversial. They could potentially worsen spasticity although others emphasize the importance of maintaining muscle strength. Recent studies suggest training antagonists of shortened muscles may improve function.
- Muscle stretching exercises comprise slow manual stretching aimed at preventing shortening of the muscle and stiffness of the joint. Fast stretching may damage the muscle. Animal data suggest that several hours of stretch per day are probably necessary: only possible with splinting devices.

### **Positioning**

Frequent repositioning can prevent contractures. If this is not possible, prolonged periods of immobility should be in an optimal position (maintained by sleep systems, seating, and standing frames). Weight bearing enhances bone density and promotes joint remodelling in weight-bearing joints. This can help to prevent dislocation of the hips.


### **Splints**

Night splints provide prolonged stretching to prevent contractures. Day splints may prevent contractures, but are also intended to improve function by joint stabilization and support. Static splints limit the joint range of movement. Dynamic splints limit the joint range of movement in one plane only (e.g. an ankle foot orthosis preventing in- and eversion, while allowing plantar and dorsiflexion).

### **Serial casting**


Casting has a similar effect to splinting, but ensures compliance. Serial casting can help lengthen muscles, sometimes in combination with botulinum toxin injections; however, the duration of wearing a cast should be limited to prevent muscle atrophy during immobilization. During serial casting, 2–4 casts are applied in succession for 4–5 days each. The foot is positioned just past the point of resistance to passive movement, and the angle of correction is increased with every cast.

## **Medical management of spasticity**

Baclofen and diazepam are the most commonly used oral medications but their use is often limited by unwanted effects. Both can impair alertness, attention and, importantly, oromotor function. When used intrathecally, higher CSF levels of baclofen can be achieved without systemic side effects (see  'Surgical management', p. 245).

### **Botulinum toxin**

Derived from *Clostridium botulinum*. The toxin weakens the muscle by inhibiting the release of acetylcholine at the neuromuscular junction. The effect is reversible, probably through sprouting of new nerve terminals. There are several subtypes, of which botulinum toxin A is mostly used. This is commercially available in two forms: Botox<sup>®</sup> (Allergan) and Dysport<sup>®</sup> (Ipsen).

❗ It is vital to be aware that the dosage units of the commercial preparations are not equivalent and care must be taken to specify the brand intended when specifying doses (see  p. 579).

Botulinum toxin can reduce dynamic contractures, and regular injections may delay formation of fixed contractures and the need for surgery. It has little role in management of established contractures. It has also been used in dystonia, and as a test to predict the effect of future surgery. The effect of the toxin starts around 12–72 h after injection, and lasts between 3 and 6 mths. Injections have to be repeated every 6–12 mths to maintain the effect.

### **Injections**

Common sites of injection are calf muscles, hamstrings, and hip adductors. The injection site can be identified by vision and palpation, although ultrasound and EMG guidance have been suggested. Injection can be given after application of topical local anaesthetic cream, with oral sedation in younger children or nitrous oxide inhalation. In some children, and for injection of ileopsoas, general anaesthesia may be needed.

It is paramount that splints and physiotherapy are in place at the time of injections.

### **Adverse effects**

- Local pain at the injection site.
- Falls due to imbalance and fatigue.
- Loss of function if muscles have been weakened too much (e.g. ability to weight-bear for transfers, or walk).
- Incontinence especially after hip adductor injections.
- Swallowing problems and bulbar dysfunction have been reported after cervical injections for torticollis.
- The effect of the toxin, however, is temporary and all these problems resolve over time.

## **Surgical management**

### **Intrathecal baclofen**

Baclofen acts on the GABA-B receptors in the spinal cord. By intrathecal administration, higher CSF concentrations are possible without systemic effects. Intrathecal baclofen can be extremely effective in combatting severe total-body spasticity in children in GMFCS IV or V, improving seating and general care. Its role in less severely affected children (GMFCS I–III) is less clear (for example, reduction of leg spasticity providing anti-gravity strength may paradoxically worsen function).

A battery operated, remote controlled subcutaneous and fully enclosed pump (usually placed on the anterior abdominal wall) is connected to a tunnelled subcutaneous catheter delivering very slowly infusing baclofen directly into the intrathecal space. The pump is refilled every few weeks percutaneously, and its rate and other parameters can be defined using a remote control wireless programmer.

Assessment for pump implantation, and the management of implanted pumps, should only be performed in specialist centres.

A 25–50 microgram test dose may be given to assess sensitivity of muscle tone to baclofen (although this step may be omitted if there

is a clear history of responsiveness to oral baclofen). Maximal effect is seen ~4 h after injection with reversal by ~8 h. CSF pressure is measured. Pressures >20 mmHg are a relative contraindication to an intrathecal catheter because of the risk of a CSF leak. Subsequently, a pump can be implanted, and the dose titrated.

#### *Complications*

Infection, CSF leak, wound breakdown. Catheter disconnection, migration, or break can cause withdrawal symptoms with itching, extreme spasticity, fever, hallucinations, psychosis, and seizures.

❗ It is important that families are aware of the severe, potentially life-threatening dangers of acute total baclofen withdrawal due to catheter or pump failure and the need to seek emergency medical advice.

#### *Adverse effects*

Constipation. A mild overdose can cause hypotonia, listlessness, trouble concentrating, and urinary retention. These are easily reversible by reducing the dose. Severe overdose can cause hypotonia, respiratory depression and coma necessitating intensive care. Loss of trunk tone may accelerate progression of scoliosis if seating inadequate.

#### *Outcome*

Reduction of spasticity, with prevention of contractures and delay of surgery. There may be improved function.

#### **Selective dorsal rhizotomy**

Selected dorsal rootlets are transected, diminishing sensory input and feedback to anterior horn cells, and reducing spasticity. The procedure is performed in a few centres only, and is usually restricted to potential walkers aged 3–10 with severe spastic diplegia with no associated ataxia, dystonia or athetosis, or severe established contractures. Side effects may include paraesthesia and bladder problems.

#### **Orthopaedic surgery**

Orthopaedic soft tissues and bony surgery will be needed to address fixed deformities. Aims must be clearly defined and weighed against anaesthetic risk. Timing is of importance and problems often recur after surgery too early in life. Post-operative management with intensive physiotherapy and splinting is paramount.

#### *Surgery for gait abnormalities*

Past approaches of sequences of single operations (so-called 'birthday syndrome'—another year, another operation) have given way to single-stage multilevel surgery. Several deformities are corrected in one session, which might include any of: psoas, Achilles tendon or hamstring lengthening, hip adductor release, rectus femoris transfer or subtalar arthrodesis. Planning of these operations is complex and gait analysis can be important. Botulinum toxin injections can help predict the results of an operation. In general, it is preferred to postpone the surgery until at least 8 yrs of age, as prior to this the risk of recurrence of deformities is high. Vigorous conservative treatment is thus essential to maintain a child until surgery is appropriate.

### *Surgery to correct hip deformity/dislocation*

Problems with the hips can cause difficulty with seating, hygiene and/or pain.

It is important to have a surveillance system with regular reviews and 6–12 monthly X-rays to monitor for hip (sub-) luxation. Once the femoral head is 50% uncovered, hip dislocation is inevitable. When 25–40% uncovered, adductor and psoas release may prevent luxation. Adductor release may also be needed to ease hygiene. Once the femur head is more than 40% uncovered this often has to be combined with bony procedures (e.g. femoral osteotomy). When the hip is dislocated, more elaborate surgery may be needed (e.g. hip replacement, acetabular reconstruction, femoral head resection, hip arthrodesis).

### *Surgery for upper limbs*

Interventions for the upper extremity are limited, although there is a rising interest in this. As improvement in muscle control is usually not achievable, the aim of surgery is to obtain functional positions of joints. Release of a pronator contracture or tendon transfers can have a functional benefit in selected cases. Some families will opt for surgery to improve cosmetics.

### *Scoliosis surgery*

Scoliosis, like hip problems, can interfere with the seating position. Management of scoliosis can include spinal bracing and supportive seating. In general, the scoliosis will progress slowly despite these measures, and spinal fusion may still be needed.

## Feeding

Most experience has been gained in children with CP. However, children with other neuromuscular conditions experience similar problems. Problems of feeding tend to be in the following areas:

- *Time*: Feeds can be extremely time consuming, taking several hours.
  - *Poor intake*: Consequently caloric intake may be poor, resulting in poor growth, nutritional status, and general health.
- ▶ A report that ‘he’d eat all the time if I let him’ may not reflect excessive appetite and intake, but rather a permanently hungry child with slow feeding and inadequate intake!
- *Vomiting and gastro-oesophageal reflux*: this can again lead to poor intake, but can also cause discomfort.
  - *Aspiration*: problems with swallowing are related to bulbar or pseudobulbar involvement. It can occur both during swallowing, and after vomiting or reflux.

## Assessment


### Nutrition

Dietetic input is required to assess adequacy of intake both of calories and other nutrients. Weight and height (absolute, centile or Z-scores), upper arm length, lower leg length, and skin-fold thickness have been used to monitor progress, although there are few population standards for children with CP. General health, in particular the frequency of chest infections and admissions, is another important guide.

### Aspiration

An experienced speech and language therapist (SALT) can often assess whether aspiration is occurring. Assessment includes taking a history and a test feed. Apart from chewing, bolus formation, and swallowing, attention is also paid to aversive responses and persisting primitive reflexes, e.g. rooting and tongue thrust. Coughing during feeds is a strong indicator of aspiration. Usually, thin liquids cause greater problems than thickened fluids or puréed solids. Further supportive evidence can come from videofluoroscopy, cervical auscultation, salivogram, and/or milkscan and pernasal endoscopic observation of the oropharynx. Correlation between the methods is poor.

### Reflux

A history of recurrent vomiting or positing, especially if there is haematemesis, is very suspicious of gastro-oesophageal reflux disease (GORD). Regular spasms and arching after feeds suggests Sandifer syndrome (see  p. 304). Reflux is also an important cause of pain and distress, with secondary aggravation of spasticity or dystonia. Investigations include barium meal, endoscopy, and pH probe. Sometimes a treatment trial is warranted.

## Investigations for aspiration

### *Videofluoroscopy*

Ciné-radiographic observation of the preparatory oral and pharyngeal phases as well as the involuntary oesophageal phase of a swallow. Barium-containing contrast agent is mixed with food: the ability to compare different food consistencies and seating positions is very useful. Specific attention is paid to movement of the tongue and palate, bolus formation, nasal regurgitation, swallow, failure to clear from valleculae, laryngeal penetration and frank aspiration (passage of feed in the trachea beyond the larynx).

### *Salivogram*

Normal saline with radioactive technetium is inserted in the mouth of the supine child, after having been fasted. Scintigraphic evidence of radioactivity in the lungs after a few hours indicates aspiration.

### *Milkscan*

The child is given their usual milk or other drink, mixed with technetium, after fasting. Again, radioactivity in the lungs indicates aspiration.

### *Cervical auscultation*

Listening to airway sounds by auscultating neck with stethoscope. Simple and non-invasive, and can readily be repeated, but requires experienced assessor.

### *Functional endoscopic evaluation of swallowing (FEES)*

Real-time observation of the pharynx by endoscope passed through a (locally anaesthetized) nostril in an awake child. Allows observation over a prolonged period of the handling of secretions.

## Management

### *Treatment of swallowing problems*

- Maintain adequate nutrition, may require nasogastric tube (NGT) or percutaneous endoscopic gastrostomy (PEG).
- Modify diet (textures, thickening liquids, etc.) to optimize swallow.
- *Protect the airway*: balance the convenience of oral feeding versus the potential risks for aspiration, consider changes in posture/position (e.g. seating provision for feeding).
- Treat underlying or associated conditions that may affect swallow, e.g. gastro-oesophageal reflux.
- Ongoing monitoring of the child's respiratory status is essential.

An upright, well-supported posture is paramount during feeding, and an occupational therapist may help with this. The SALT can advise on avoidance or thickening of fluids and help with desensitization of overactive mouth reflexes. A dietician can advise on supplementary feeds. If oral intake is deemed dangerous, or inadequate, enteral feeding will be necessary via an NGT or gastrostomy. Long-term feeding via an NGT can be acceptable, especially with less irritant modern silk tubes; however, they can be uncomfortable, and cause increased salivation, bronchial hypersecretion, retching, heaving, and erosion of the nasal septum, as well as


being cosmetically unacceptable. Parents' perceptions can vary considerably, and should be taken into account.

The decision to insert a gastrostomy should be interdisciplinary, and made with the parents. Although safer than many surgical procedures, insertion of a PEG is not risk-free, especially in malnourished children with multiple disabilities. A period of NGT feeding is often initiated to improve nutrition and health before the procedure. There are benefits to physical health and quality of life. The gastrostomy 'takes the stress out of feeding', and drug administration becomes easier. Oral intake can still continue for pleasure, but there is no pressure to get calories in.

### **Reflux**

With an upright posture, gravity will help prevent reflux. Medical treatment includes reduction of acid production (ranitidine, omeprazole), prokinetics (domperidone, erythromycin, metoclopramide) and thickening agents (gaviscon, carobel). If gastrostomy is contemplated, and reflux is severe, the procedure can be combined with (laparoscopic) fundoplication.

### **Drooling**

Children with quadriplegic CP tend to drool. This is mainly due to poor bulbar function and is aggravated by problems with head control, lip closure, tongue control, dental malocclusion, chewing, sucking, swallowing, intraoral sensitivity and dysarthria. Reducing secretions by means of hyoscine patches or glycopyrrolate (see  p. 590) often helps this. Other options include a palatal plate, botulinum toxin injections in the parotid glands, and surgical transplantation of salivary ducts posteriorly.

### **Gastrostomy**

#### *Percutaneous endoscopic gastrostomy (PEG)*

An endoscope is passed into the stomach. The abdominal wall and stomach are perforated, and a gastrostomy is pulled through the resulting hole from the inside out. After about 6 mths, a skin flush button device replaces the tubing. Benefits include increased weight, length, and skin-fold thickness, less time spent feeding, improved health (reduced admissions for chest infections), and improvement in quality of life, improvement in social functioning, mental health, energy, vitality and general health perception.

### **Complications**

- Risk of anaesthesia.
- Laceration of the oesophagus.
- Pneumoperitoneum.
- Peritonitis.
- Colonic perforation.
- Local site infection.
- Vomiting, worsened GORD.
- Aspiration, pneumonia.
- Stoma leakage.
- Skin erosion, granulations.
- Tube blockage, tube migration.
- Tube pulled out.

## Communication

Communication requires the understanding of received messages, and the ability to conceive and convey a reply.

*Receptive* communication (understanding) therefore requires adequate hearing (for verbal communication) or vision (for gestural or symbolic communication), and the cognitive ability to interpret this information.

*Expressive* communication ultimately requires the ability to perform at least some movements voluntarily, with reasonable consistency. Speech production is, of course, a particular form of complex movement, but in some situations where speech is not possible, another voluntary movement can be recruited for purposes of communication.

- Children with neurological impairments may find hand and limb gestures easier to perform than speech production: hence, the existence of gesture-based communication systems, such as Makaton.
  - Many specialist communication systems exist, e.g. picture-exchange communication system (PECS) for children with autistic spectrum disorders.
  - For the non-verbal child cognitively capable of more complex forms of expressive communication, the key is to provide (through appropriate sound-, gesture- or eye movement-controlled switches) the ability to access an assistive (or augmentative) communication (AAC) device.
  - Benefiting from a sophisticated AAC system requires significant cognitive abilities (to form messages for communication and to learn the operation of the device); however, the greater danger is in underestimating a child's ability to use such devices.
- Dystonic CP and acquired dystonias are important causes of severe motor impairment with relatively preserved cognition, i.e. children who may particularly benefit from specialist AAC assessment.



## Special senses

### Hearing

- Neonatal screening in selected risk groups (e.g. neonatal intensive care unit graduates, positive family history, dysmorphism) or increasingly universally with oto-acoustic emissions (a sound stimulus produces an acoustic emission from the cochlea: but would miss an auditory nerve proximal to cochlea)  $\pm$  brainstem auditory evoked potentials.
- By history at 6 weeks; distraction testing at 10 mths or audiometry sweep test at school entry.

#### Investigation aims

- Identify associated conditions.
- Aid genetic counselling.
- Habilitation.
- Prognostication.

#### Total communication

Speech and language therapy; peripatetic specialist teacher of the deaf, partially hearing unit in mainstream schooling or specialist school.

#### Oral–aural strategy

- Spoken language.
- Hearing aids including consideration of a cochlear implant (after bacterial meningitis, progressive otosclerosis may occur within months: urgent assessment for a cochlear implant is required).
- Early amplification and auditory training may improve the outcome in language speech and development.

#### Manual–visual strategy

Training in sign language, lip-reading, reading facial expression, and social situation cues.

### Vision

Some processes that cause general neurological disease will also cause primary ocular (particularly retinal) disease or refractive errors.

More commonly, however, CNS damage affects vision via disruption of visual pathways or damage of cortical areas involved in visual processing perception. The term cerebral (or cortical) visual impairment (CVI) describes this common, under-recognized and underestimated problem.

Typical CVI behaviours include:

- Light gazing.
- Apparent eccentric gaze (i.e. looking to one side of the person speaking).
- Striking day-to-day variation in apparent visual abilities.

### ***Visuoperceptual problems***

As well as conventional visual field defects and visual inattention problems, other more or less discrete visuoperceptual disorders may occur in focal brain injury.

- Visual 'post-processing' (beyond the primary visual cortex) takes place in two streams:
  - the dorsal stream (occipital and parietal lobes) performs analysis of the position and the visuomotor planning of reaching ('where and how');
  - the ventral stream (occipital and temporal lobes) performs orientation and recognition ('what');
  - these streams may be differentially affected and result in a variety of relatively discrete visual-perceptual problems such as figure-ground discrimination (the recognition of an object against a complex background), perception of motion, size, etc.

Appropriate multidisciplinary assessment of these issues is likely to include specialist paediatric ophthalmology and neuropsychology or occupational therapy input.

## Respiratory disease in neurodisability

There are a number of reasons why a child with severe chronic neurodisability is at risk of respiratory complications. Consideration of which may be at work in an individual child is important in identifying potential interventions, realistic assessments of long-term respiratory prognosis and in informing the always difficult decisions about appropriateness of intensive care.

### Disturbed control of respiratory rate/rhythm

#### Central hypoventilation

Signs may be minimal when awake. Associated conditions:

- *Chiari malformation*: central, obstructive or mixed sleep apnoea.
- *Prader-Willi syndrome*: obstructive and central sleep apnoea.
- *Congenital central hypoventilation syndrome*: hypoventilation mainly in sleep. Developmental delay and seizures common. Other clues include absence of tears, Hirschprung disease. 90% have *de novo* PHOX2B mutation.
- *Brainstem damage* (acute disseminated encephalomyopathy (ADEM), syringobulbia, traumatic, tumour).
- *Leigh*: hypoventilation  $\pm$  apnoea awake and asleep.
- *Hypothalamic damage*: e.g. post-encephalitis. Other indicators may include temperature instability, or disturbance of the hypothalamopituitary axis.
- *Epileptic seizures*: temporal lobe focal seizures, migrating partial seizures of infancy (see [p. 266](#)).
- *Prolonged expiratory apnoea*: poorly understood, but probably an extreme form of toddler cyanotic breath holding (see [p. 310](#)). Appears more common in children with profound neurological disability.
- *Secondary to cardiac problems*: e.g. arrhythmias.
- *Medication side-effects*: e.g. benzodiazepines, chloral, phenobarbital, morphine.

#### Hyperventilation

May be interspersed with apnoeas:

- *Joubert*: hyperventilation alternating with apnoea typically more severe when awake.
- *Rett*: periodic breathing interspersed with profound hyperventilation and Valsalva. Associated with collapses. Respiration in sleep may be normal.
- Children with tumours in the floor of the third ventricle have been described presenting with a respiratory pattern similar to Rett.
- *Pitt-Hopkins*: hyperventilation and apnoea (see [p. 278](#)).

### Disturbed anatomy and control of upper airways

- Anatomical malformations (congenital or acquired).
- Neuromuscular control of the airway (both awake and during rapid eye movement (REM) sleep, i.e. obstructive sleep apnoea).

**Classic indicators**

- Snoring, stridor/stertor, apnoeas, open mouth breathing, drooling, feeding difficulties, recurrent chest infections, nocturnal arousals, recurrent otitis media.
- Poor sleep efficiency may worsen comorbid epilepsy.

**Associated conditions**

- Down syndrome.
- Mucopolysaccharidoses.
- Mid-face hypoplasia (e.g. Russell-Silver).
- Syndromic craniosynostosis (e.g. Apert, Pfeiffer, Crouzon).
- Choanal atresia (CHARGE).
- Laryngomalacia in generalized hypotonic disorders, CP, congenital myasthenic syndrome.
- Laryngospasm (acute, intermittent) due to GORD/aspiration-induced reflex.
- Velopharyngeal insufficiency e.g. Worster-Drought, brainstem lesions.
- Oromotor dyskinesia.
- Vocal cord paralysis e.g. dystonias, neuromuscular disorders (DOK7, CMT2C).
- Obesity-related syndromes.
- Medication side-effects e.g. baclofen, benzodiazepines, chloral.

**Lung and lower airways problems**

- Turbulent airflow through partially obstructed oro- and nasopharynx 'dislodges' bacteria which are carried to the lungs.
- Immobility can cause orthostatic pneumonia.
- Reduced forced vital capacity (FVC), reduced ability to generate inspiratory and expiratory pressure reduces cough flow velocity. This can increase tendency to infection through ineffective clearance of secretions and atelectasis.
- Aspiration may be primary oromotor-related or secondary to severe GORD/oesophageal motility and aggravated by poor clearance of secretions. May be exacerbated by seizures and medications.
- Aspiration may be 'silent'—lacking overt signs until presentation with chronic lung disease.
- *Classic indicators:* recurrent infections, wheeze, productive cough, oxygen requirement.

**Associated conditions**

- Tracheobronchomalacia, e.g. premature born infant, Hunter, Crouzon.
- Tracheoesophageal fistula, particularly h-type.
- Kyphoscoliosis leads to a restrictive lung defect.
- High spinal cord injury.
- Chronic lung disease of prematurity.
- Early diaphragm involvement in SMARD1, CMT variants, adult-variant Pompe. Reduced FVC lying compared with sitting. Reduced sniff nasal pressure. May occur in walking patients.
- Remember child may have asthma, cystic fibrosis, etc. Like any other child!
- *Medication side-effects:* glycopyrrolate (thickened secretions), morphine (cough suppressant).

### Syndrome specific considerations

- *Ataxia-telangiectasia*: interstitial lung disease, bronchiectasis.
- *Cockayne syndrome*: chest infections.
- *MECP2 duplication*: recurrent severe chest infections.
- *Benign hereditary chorea (TTF1 mutation)*: RDS in neonatal period, chronic interstitial disease, respiratory infections.
- Pulmonary AVMs in hereditary haemorrhagic telangiectasia. dyspnoea, lung haemorrhage, right-to-left shunting.
- Lymphangiomyomatosis (diffuse, small, thin-walled cysts) in young female adults with tuberous sclerosis. Progressive dyspnoea.

### Chronic nocturnal and diurnal hypoventilation

- Usually late complication of neuromuscular disease e.g. Duchenne muscular dystrophy (DMD), Ullrich congenital muscular dystrophy (CMD), progressive myaesthetic syndrome (CMS; e.g. slow channel syndrome).
- *Classic symptoms and signs*: morning headache, non-refreshing sleep, difficulty rousing (e.g. after elective general anaesthesia (GA)), excessive daytime sleepiness, nocturnal sweating, recurrent chest infections.
- Severe nocturnal hypoventilation causing overnight atelectasis, secondary infection.
- Daytime hypoventilation may follow due to decreased response to chronic hypercapnia.
- May result in raised ICP and cor pulmonale if left untreated.

### Interventions

- Medication review, e.g. glycopyrrolate, prophylactic antibiotics, anti-reflux, reduce sedatives.
- Preventative immunizations, e.g. influenza.
- Chest physiotherapy.
- Oxygen.
- Suction.
- Cough assist machine.
- Upper airways surgery, e.g. adenotonsillectomy.
- Non-invasive ventilation.
- Tracheostomy and invasive ventilation.
- Anti-reflux surgical procedures.
- Feeding strategies (occult aspiration).

## Demyelinating disease

- Affects 1–2/100,000 paediatric patients per year.
- Presentation varies from isolated unilateral visual disturbance (optic neuritis) to ADEM causing life-threatening raised intracranial pressure.
- The important question of the likelihood of the child experiencing further episodes of demyelination depends on accurate clinical classification of the presenting features, and the information obtained from relevant special investigations such as MRI and oligoclonal banding on CSF.

### Acute disseminated encephalomyelitis

- Typically, a disease of young children with peak incidence between 6 and 9 years of age.
- Frequently a clear history of recent viral illness (or less frequently a history of immunization with a live vaccine) in the preceding 2 weeks.
- The presence of a behavioural change or encephalopathy is essential for diagnosis.
- Bilateral (more frequently than unilateral) optic neuritis may occur.
- MRI shows single or multiple areas of 'fluffy' demyelinated plaques (high T2 signal) in any part of the hemispheres (neocortex, white matter and/or deep grey matter), brainstem and cerebellum. Lesions are often asymmetrical.
- Oligoclonal bands are frequently negative. Typically a monophasic illness.

### Relapsing/recurrent ADEM

- Although controversial, it appears that in <10% of cases, demyelination with encephalopathy can recur.
- Currently classified:
  - relapsing ADEM if it occurs within 3 mths of initial presentation;
  - recurrent ADEM if at the same anatomical site after 3 mths or;
  - multiphasic ADEM if at a different anatomical site after 3 mths.
- Recurrent and multiphasic courses represent an intermediate form with a higher ultimate risk of developing multiple sclerosis (MS);.
- It is particularly important to rule out macrophage-activation syndromes (see [p. 532](#)) and CNS vasculitides (see [p. 223](#)) in this group, although this is often difficult in practice. Biopsy may be required.

### Predicting relapse

The French KIDSEP study<sup>1</sup> followed 132 patients with a first presentation of ADEM (defined using arguably overly-restrictive criteria) for a median 7 yrs. 18% relapsed, over half within 6 mths. 8% had a third event, not always associated with encephalopathy (i.e. an MS-like episode).

<sup>1</sup> Mikaeloff Y, Caridade G, Husson B, et al. (2007). Acute disseminated encephalomyelitis cohort study: prognostic factors for relapse. *Eur J Paediatr Neurol* **11**: 90–5.

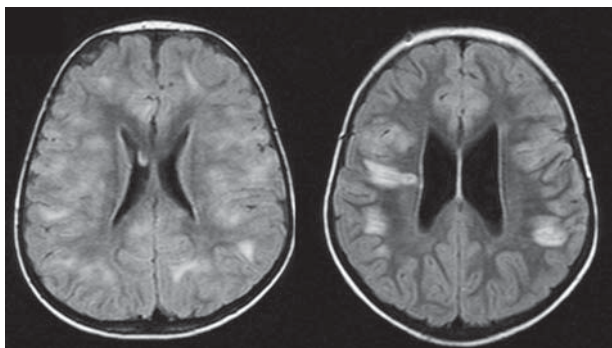
*Predictive risk factors*

- Family history (odds ratio 8).
- Optic neuritis (odds ratio 5, so need to specifically look for this).
- Radiological features suggesting high risk of converting to MS are specific but not sensitive. They include presence of lesions perpendicular to the corpus callosum or presence of well-defined lesions. Also so-called Barkhof criteria,<sup>2</sup> three amongst the following:
  - >1 gadolinium-enhancing T1 lesion or >8 T2 lesions;
  - >1 infratentorial T2 lesion;
  - >1 juxtacortical T2 lesion;
  - >2 periventricular lesions;

If present the odds ratio for relapse is 2.5, but 'typical ADEM' appearances are not protective (Figure 4.5).

- Complete recovery without neurological sequelae from first episode (OR 4).
- Passive smoking.

The first three of these are recognized risk factors for relapse in MS, emphasizing the biological overlap between recurrent ADEM and MS. Age, gender, and CSF findings (including presence/absence of oligoclonal bands) were not independently predictive in multivariate model.



**Fig. 4.5** Radiological appearances in two children presenting with first episode of ADEM at about 4 years of age. 'Typical' appearances on left. Child on right shows 'atypical' radiological features (well defined, periventricular, perpendicular to corpus callosum); had family history of MS and went on to develop relapsing-remitting MS.

<sup>2</sup> Barkhof F, Filippi M, Miller DH, et al. (1997). Comparison of MRI criteria at first presentation to predict conversion to clinically definite multiple sclerosis. *Brain* **120**: 2059–69.

### *Treatment of ADEM*

Steroids appear to hasten the rate, but not the ultimate extent of recovery. There is no evidence that steroid use affects the long-term prognosis or relapse risk. Pulsed methylprednisolone (typically 30 mg/kg maximum 1 g daily tds) and/or a few weeks of oral prednisolone are often used in the acute phase.

### **Paediatric multiple sclerosis**

- This is a disease predominantly of adolescence, but MS has been reported in children as young as 2 years. Presentation in the pre-pubertal age group is often atypical but responds similarly to disease modifying drugs (see Figure 4.6).
- Aetiology is a complex interplay between environment, genetics, and infection. Vitamin D levels may be important.
- Conventionally, an episode clinically consistent with a diagnosis of ADEM cannot be considered a first episode of MS. An episode of demyelination without encephalopathy is known as clinically isolated syndrome (CIS).
- Signs are often more discrete and isolated and include unilateral optic neuritis, weakness and spasticity, sensory symptoms (paraesthesias and abnormal vibration testing).
- MRI typically shows discrete periventricular (Dawson's fingers) areas of demyelination.
- Diagnosis is based on clinical or MRI evidence of two CIS disseminated in space and time (it is typically easier to demonstrate this radiologically than clinically).
- MS in children is usually relapsing–remitting, although primary progressive has been reported.
- Likely future outcome depends on a combination of age, sex, early relapse rate, with a worse outcome in the younger females with a high initial relapse rate.

### *Immunomodulatory drugs in MS*

As with ADEM, steroids are typically used in the acute phase and appear to shorten relapses with no evidence of an effect on longer term course.

Established disease-modifying treatment options include:

- *Interferon*  $\beta$ : reduces the relapse rate and accumulation of MRI lesion load and clinical disability in relapsing–remitting MS. Its role in secondary progressive MS is less clear. Some groups recommend use after second episode; others restrict to more severe cases.
- Glatiramer acetate.
- Azathioprine.
- Mitoxantrone.
- Campath and monoclonal antibody treatments (in severe cases with expert advice only).

Remember in very severe/persisting 'relapses' that it is particularly important to rule out macrophage-activation syndromes and CNS vasculitides.



### Other specific demyelinating syndromes

#### *Optic neuritis (ON)*

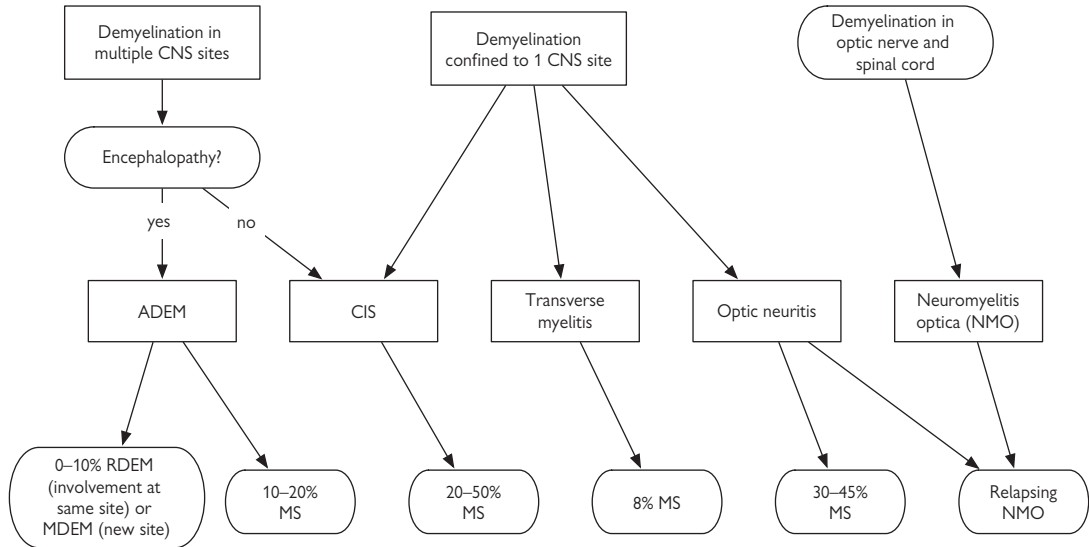
- Typically presents with sub-acute onset (over hours) of marked visual impairment.
- Frequently associated with headache, pain on eye movement and abnormal colour perception.
- Relative afferent pupillary defect (APD) common, and papillitis present. Visual acuity decreased on examination and colour charts abnormal.
- Visual-evoked potentials (VEPs) usually abnormal with evidence of delayed latency.
- Recovery of visual acuity to 20/40 or better; occurs in 75% of cases, but frequently there is residual colour deficit.
- Steroid therapy shortens the time to recovery with no effect on the final outcome.
- IV methylprednisolone followed by oral steroid taper is recommended.
- Abnormal brain MRI and recurrent optic neuritis increase probability of developing MS (40–50%).

#### *Neuromyelitis optica (NMO), formerly Devic' disease*

- Relapsing optic neuritis with longitudinally extensive acute transverse myelitis.
- A specific NMO IgG antibody (Aquaporin 4) can be identified in serum in ~80% cases. However, its presence is not essential for a diagnosis of NMO. Pick-up of aquaporin 4 may be higher in CSF.
- Poor long-term prognosis with 50% in wheelchair at 5 years.
- Treatment requires aggressive immunosuppression (azathioprine, steroids, mycophenolate mofetil, plasma exchange) to minimize relapse risk. Does not respond to interferon therapy.

#### *Acute transverse myelitis*


- Demyelination of one or more segments of the spinal cord resulting in acute or subacute onset of symptoms and signs of severe spinal cord dysfunction with motor, sensory and sphincter disturbance.
- All children will require MRI to exclude surgically remediable causes of cord compression.
- Treatment is typically with high-dose methylprednisolone.
- Plasma exchange needs to be considered if the response is poor.
- Approximately one-third make a full recovery, one third partial recovery (often residual urinary dysfunction) and one third with significant or severe impairments.
- Rehabilitative spinal care is crucial.



**Fig. 4.6** Risks of MS and other demyelinating syndromes after a first episode of CNS demyelination. Figure and data reprinted from Banwell B., Ghezzi A., Bar-Or A., et al. (2007). Multiple sclerosis in children: clinical diagnosis, therapeutic strategies, and future directions. *Lancet Neurol* 6: 887–902, with permission from Elsevier.

## Epilepsy


Remember the essential steps:

- Is it epilepsy? (See  p. 141.)
- What are the seizure types?
- What's the cause of the epilepsy?
- Do the features constitute an epilepsy syndrome?

### What is the cause of the epilepsy?

The ILAE system has three broad causal categories.

#### *Symptomatic*

The epilepsy is a consequence of an identifiable primary cause. Examples of symptomatic epilepsy include tuberous sclerosis or focal cortical dysplasia. Acute symptomatic seizures result from an immediately preceding precipitant such as hypoxia or fever. (Recurrent acute symptomatic seizures are not regarded as epilepsy: see  p. 141.) Remote symptomatic epilepsy results from a cause remote in time, e.g. previous stroke or meningoencephalitis.

#### *Idiopathic*

The term can cause some confusion as it is used in the etymologically correct sense of the cause being within the person (idios: Greek for 'pertaining to self', 'personal', or 'private'; pathos: 'disease'), rather than the usage in some areas of medicine of 'can't find a cause'. It is not the 'dustbin category'! It is the positive recognition of one of a number of specific epilepsy pictures where the cause is known to be polygenic and further investigation and imaging is generally not required. Important examples include juvenile myoclonic epilepsy, childhood absence epilepsy and other primary generalized epilepsies.

#### *Presumed symptomatic*

This term is now recommended in place of the older term 'cryptogenic' (Greek for 'hidden cause') as it conveys the intended meaning more clearly. A diagnosis of exclusion: no clear primary cause can be identified (e.g. neuroimaging normal) nor can a positive diagnosis of an idiopathic epilepsy syndrome be made. Many severe epilepsies presenting in infancy and early childhood fall into this group.

### Epilepsy syndromes

A syndrome (syn: Greek for 'together'; dromos: 'running') is a concurrence of features. The delineation of epilepsy syndromes has been one of the most important developments in epileptology in recent years; but it is important to appreciate that the approach has limitations.

Epilepsy syndromes are defined entirely phenotypically on features such as age at onset, seizure type(s), EEG features, natural history, family history, neurodevelopmental outcome, response to drugs, and so on. The syndromic diagnosis is important as it guides decisions relating to the need for investigation, AED selection and aspects of counselling (Boxes 4.4 and 4.5).

In recent years a number of genetic causes of epilepsy have been identified and it is clear that the genotype–phenotype relationship is complex: whether genotypic or phenotypic approaches will ultimately prove more clinically useful is still unclear.

In practice much is done in retrospect. With the passing of a few months, increased clarity in the history, and where appropriate repeat EEGs, the definition of the syndrome involved becomes possible in most cases.

► It is important to appreciate that some of these syndromes are very much more common than others. Some (e.g. particularly benign epilepsy with centrotemporal spikes (BECTS) and juvenile myoclonic epilepsy (JME) are sufficiently common to be important in general paediatric practice.

### **Examples of epilepsy syndromes**

#### *Neonatal*

- Benign familial neonatal seizures (BFNSs).
- Benign neonatal seizures (BNSs).
- Early infantile epileptic encephalopathy (EIEE) (Ohtahara syndrome).
- Early myoclonic encephalopathy (EME).

#### *Infant*

- Infantile spasms (ISs) (West syndrome).
- Benign myoclonic epilepsy of infancy (BMEI).
- Severe myoclonic epilepsy of infancy (SMEI) (Dravet syndrome).

#### *Pre-schooler*

- Severe myoclonic epilepsy of infancy (SMEI) (Dravet syndrome).
- Some progressive myoclonic epilepsies.
- Lennox–Gastaut syndrome (LGS).
- Epilepsy with myoclonic–astatic seizures (EMAS) (Doose syndrome).

#### *Child*

- Childhood absence epilepsy (CAE).
- Epilepsy with myoclonic absences (EMA).
- Benign epilepsy with central-midtemporal spikes (BECTS) ('Rolandic').
- Childhood epilepsy with occipital paroxysms (CEOP) (Panayiotopoulos type).
- Landau–Kleffner syndrome (LKS).

#### *Adolescent*

- CEOP (Gastaut type).
- Juvenile absence epilepsy (JAE).
- JME.
- Epilepsy with GTCS seizures on awakening.

The imperfect nature of current approaches to seizure and epilepsy classification is recognized and as of 2011 the International League against epilepsy (ILAE) is consulting on revised approaches. The basic concept of generalized and focal seizures is being tightened. Syndromes are no longer rigidly classified as generalized or focal. With increasing recognition of genetic causes of epilepsy it is intended that the 'presumed symptomatic' term will be replaced with groupings such as genetic, metabolic and unknown.

## Neonatal/infantile epilepsy syndromes

### **Benign familial neonatal seizures**

- Relatively rare syndrome with an age of onset range broader than that of BNSs (see [Box 4.4](#) 'Benign neonatal seizures', p. 264), but typically presenting at 2 or 3 days.
- Focal clonic seizures.
- Family history of similar neonatal seizures: autosomal dominant.
- Development is normal.
- Status epilepticus does not occur and seizures resolve spontaneously by 16 mths.
- Around 10–15% develop epilepsy in later life, and there is an increased risk of adult-onset seizures in family members.
- Need to exclude other causes. Family studies have shown mutations in voltage-gated potassium channel subunits on chromosomes 20q or 8q.

### **Benign neonatal seizures**

- Brief clonic seizures becoming progressively more severe, associated with apnoeic spells and sometimes status epilepticus. The infant is normal between seizures.
- As onset is typically at age 4–6 days, formerly referred to as *fifth day seizures* (although some earlier cases were probably linked to hexachlorophene exposure).
- At-risk infants born prematurely present 4–6 days post expected delivery date!
- Cases sporadic, diagnosis is by exclusion and underlying aetiology is not known.
- Seizures do not occur after the neonatal period, and prognosis for development is good. Later epilepsy risk is around 2%.

### **Early infantile epileptic encephalopathy (Ohtahara syndrome)**

- Onset is usually in the first 10 days of life, with no concerns prior to onset.
- The typical seizure is a tonic spasm-like movement, more sustained than an infantile spasm. These movements cluster, with the duration of each spasm around 10 s and the interval between spasms 10–15 s. Focal seizures occurring ~50%. Myoclonic seizures are rare.
- Mostly associated with severe structural abnormalities, but primary metabolic abnormalities are rarely seen (cf. EME, see [Box 4.4](#) p. 264).
- EEG shows a suppression-burst pattern awake and asleep, with the bursts accompanying the tonic spasms.
- Poor prognosis for development and increased mortality. Often later evolution into infantile spasms or LGS (see [Box 4.4](#)).
- Resistant to anti-epileptic drug (AED) treatment.

### **Early myoclonic encephalopathy**

- Onset within days of birth, again with suppression-burst pattern on EEG.
- Distinguished from EIEE by the presence of frequent, fragmented, migrating but massive myoclonus. Focal clonic and tonic seizures also occur.
- Tends to be associated with underlying metabolic disorders such as non-ketotic hyperglycaemia.

### **Severe myoclonic epilepsy of infancy; Dravet syndrome**

- ▶ Under recognized: probably 1–3% of all epilepsies beginning before 1 yr of life.
- Presents typically between 6 and 12 mths with recurrent episodes of febrile status epilepticus (often focal/lateralized).
- Prior development is normal.
- Multiple seizure types in the second year of life with prominent myoclonus emerging at >18 mths of age. Heat (febrile illness or even bathing in a hot bath) characteristically remains a precipitant.
- Interictal EEG shows generalized, focal, and multifocal abnormalities, and may show photosensitivity.
- Family history of epilepsy and/or febrile seizures in 15–25%.
- Up to 70% of cases associated with SCN1A sodium channel mutations:
  - other identified causative genes in some SCN1A-negative cases include SCN9A and PCDH19;
  - genotype–phenotype relationships are complex;
  - some children may have mutations in both SCN1A and SCN9A.
- Most effective treatments are sodium valproate and the combination of a benzodiazepine with stiripentol and/or topiramate. Carbamazepine and lamotrigine typically worsen the seizures.
- Loss of neurodevelopmental abilities, typically beginning 12 mths or more after onset of seizures, with emergence of an autistic picture.
- Increased risk of sudden unexpected death in epilepsy (SUDEP; see [□□](#) p. 302).
- A high proportion of children previously regarded as having suffered pertussis vaccine-related encephalopathy are now known to have SCN1A mutations and Dravet syndrome. The apparent relationship with vaccination reflects susceptibility to seizures with pyrexia.
- It is unclear currently whether early recognition and prompt aggressive AED therapy can improve the long-term developmental outcome.
- Similar pictures without myoclonic seizures can have the same mutations, so the term Dravet syndrome may be preferable.

### **Benign myoclonic epilepsy of infancy**

- Rare condition, accounting for only 1% of idiopathic generalized epilepsies. May be confused with infantile spasms until EEG available.
- Onset 4 mths to 3 yrs.
- Myoclonic seizures affecting trunk and upper limbs (e.g. brief nodding movements of the head), but only rarely the lower limbs, sometimes occurring in brief clusters of a few at a time.
- No drop attacks.
- Children are otherwise normal.
- ♂:♀ = 2:1.
- Interictal EEG is usually normal. Myoclonic jerks are associated with spike–wave or polyspike–wave discharges at frequencies >3 Hz.
- Treatment is with valproate or other broad-spectrum AEDs.

**Migrating partial seizures of infancy**

A recently-described, very rare picture that is still being delineated. Characterized by onset in the first weeks of life of a rapidly evolving epilepsy comprising very frequent (>hourly) partial seizures of multifocal origin (i.e. no single focus). The predominant foci move ('migrate') with time. Associated with extreme drug-resistance and a very poor neurodevelopmental outcome.

**Infantile spasms; West syndrome**

- Peak onset is between 4 and 7 mths, but can occur in the late neonatal period or after 12 mths.
- A history of several weeks, or even months, of subtler movements prior to presentation is common, so treatment is often delayed.
- Tonic spasms—sudden jerks with a sustained 'held' posture for a second or so occurring in clusters or runs especially on waking.
- Spasms may be either predominantly flexor or predominantly extensor. Focal brain pathology may cause *asymmetrical* spasms.
- Associated with variable encephalopathy: often loss of visual alertness and smile. The child may be irritable and distressed by the spasms.
- Cases are classified by underlying aetiology as symptomatic (about 90%), or presumed symptomatic (never, by definition, idiopathic), with prognosis strongly influenced by the underlying aetiology (see Box 4.4).
- Recently-described genetic causes include *CDKL5* (in females) and *ARX* (in affected males) gene mutations (see [p. 278](#)).

Note that hypsarrhythmia (see Figure 2.15) develops with time and evolves with age, and its presence is not necessary for the diagnosis of infantile spasms. The most common ictal EEG pattern is a broad slow-wave followed by voltage suppression (see Figure 2.15). West syndrome refers to the combination of spasms and EEG appearances of hypsarrhythmia.

See [p. 280](#) for the investigation of infantile spasms.

**Treatment**

The most effective treatments are adrenocorticotrophic hormone (ACTH) or tetracosactide depot (a synthetic ACTH preparation), high-dose oral corticosteroids and—particularly in tuberous sclerosis—vigabatrin.

- Relative merits of steroid and vigabatrin treatment are hotly debated! Data from the United Kingdom Infantile Spasms Study (UKISS) suggest higher overall spasm-cessation rates by day 14 with steroids (73%) than vigabatrin (54%). Proportion remaining seizure free at 14 mths identical in both groups (~40%) with borderline superior neurodevelopmental outcome at 14 mths in non-symptomatic cases treated with steroids (requires confirmation).
- Generally vigabatrin still regarded as superior in tuberous sclerosis (and possibly by extension in other lesional cases?).
- There is significant morbidity associated with both the use of steroids (hypertension, diabetes, immunosuppression, sometimes severe irritability) and vigabatrin (irreversible visual field deficits associated with prolonged use see [p. 616](#)).

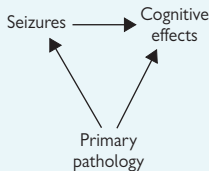
### Box 4.4 Epilepsy syndromes, development and aetiology

It is important to remember that epilepsy syndromes are defined phenotypically and can have multiple causes. Much confusion can arise from textbook statements that, for example, West syndrome can 'be a cause of' Lennox–Gastaut syndrome.

It is useful to recognize that there are a limited number of ways the brain can manifest dysfunction from an underlying pathology, and that this repertoire is age dependent (e.g. constrained by myelination status). In the same way that absence seizures are only a feature of epilepsies in a particular age band, infantile spasms are to an extent 'what seizures can look like' in a 6–12-mth-old. The manifestations of any given primary pathology may change with age and development, and a child can move through phenotypically described syndromes with time, e.g. from Ohtahara to West to Lennox–Gastaut syndrome all as manifestations of the same primary pathology.

### Box 4.5 Epileptic encephalopathy

The term 'epileptic encephalopathy' was introduced by Ohtahara and refers to situations in which the epileptiform activity itself is believed to be contributing to disturbed cerebral function (e.g. reduced awareness or cognitive deficits).



The implication is that such dysfunction might be at least partially reversible with AED therapy although this is often difficult in practice. The alternative possibility is always that the seizures and cognitive effects are each independent symptoms of the primary pathology and any direct causal link between them is weak.

Epileptic encephalopathies are a feature in ~40% children with epilepsy first presenting at between 1 month and 3 years of age.

The concern is that, left untreated, the cognitive effects of uncontrolled seizure activity may eventually result in a more severe, fixed, irreversible component to the cognitive disability. This concept is particularly applied to Ohtahara, West, Lennox–Gastaut and Landau–Kleffner syndromes, as well as to non-convulsive status epilepticus.



### Childhood onset epilepsy syndromes

#### *Benign epilepsy of childhood with central-temporal spikes (BECTS; Rolandic, or benign Rolandic epilepsy)*

- The most common focal onset epilepsy in childhood, yet often under-recognized. The value of making the diagnosis is that it allows you to convey a good prognosis.
  - More common in males. Onset between the ages of 3 and 13 yrs.
  - Key to recognition is that it is a secondarily generalizing seizure with a facial/perioral focal onset. Seizure onset is from sleep up to 80% of the time (so initial perioral features may not be experienced or witnessed) and these features will only be elicited by direct questioning.
  - The clues to a focal, perioral onset will be reflected either in the aura (the very earliest features of the seizure), although as seizures often arise from sleep this may not be available, or in the form of temporary post-ictal signs or symptoms.
  - Typical features include unilateral numbness or paraesthesia of the tongue, lips, gums or cheek; guttural sounds or speech arrest, hypersalivation, poor swallowing or drooling post-ictally; involuntary movements or tonic contractions of the tongue or jaw; or clonus affecting one side of the face.
  - The characteristic EEG finding is diphasic sharp-waves in the central-midtemporal area that have an orientation tangential to the cortex with a frontal positive dipole. These are often activated by sleep, though might appear only unilaterally in any given EEG recording.
- ▶ Incidental centrotemporal spikes in people who have never had seizures are well-recognized (e.g. in first-degree relatives of children with BECTS). Thus the presence of spikes is sensitive, but not specific, for a diagnosis of BECTS, and should only be regarded as supporting a diagnosis of BECTS in the context of an appropriate history.
- ▶ Similarly if history and/or EEG features are not entirely typical then consider MRI imaging to exclude a lesional epilepsy.
- Treatment is required only if the seizures are frequent or long, and they typically respond well to carbamazepine, gabapentin, levetiracetam, sulthiame or sodium valproate. (Carbamazepine is rarely associated in such cases with the complication of atonic and myoclonic seizures with a continuous spike and waves pattern in sleep.)
  - 90% achieve remission within several years, and most by the age of 16 yrs.
  - This syndrome was considered to have no adverse effects upon development but a proportion of cases have very frequent epileptiform discharges in sleep, sometimes approaching CSWS/ESES (see [□□](#) p. 272), and associated cognitive problems. Some authorities regard these children as being on a spectrum between straightforward BECTS and Landau-Kleffner syndrome (see [□□](#) p. 272).

### *Epilepsy with myoclonic absences*

- Age at onset is between 2 and 13 yrs and most cases are male.
- Half of cases have normal development at onset.
- Seizures typically have an abrupt onset of absences with severe, bilateral and synchronous rhythmic myoclonic jerks that affect the limbs. Tends to involve the mouth and chin, rather than the eyes or eyelids. Seizures typically last less than 1 min.
- Frequent prolonged generalized tonic-clonic seizures, pure absence seizures, and atonic seizures occur in one-third of cases, typically where the myoclonic absences persist. There is a family history of epilepsy in 25%. Associated with trisomy 12p and Angelman syndrome; most cases have no known aetiology. Poor prognosis for development and seizure control. It is typically treated with combined, high-dose sodium valproate and ethosuximide.


### *Childhood epilepsy with occipital paroxysms*

- The more common is the early-onset form (Panayiotopoulos syndrome). As with BECTS, there is commonly a family history of seizures and interictal EEG abnormalities in first-degree relatives.
- Peak age for the **early-onset variety** is 3–5 yr:
  - seizures typically occur with sleep onset;
  - lateral gaze deviation and vomiting, often with impaired consciousness;
  - can be prolonged and it is common for children to be admitted (often to HDU or PICU) and treated for suspected encephalitis;
  - most become seizure-free before 10 yrs of age, and most have only one or two seizures.
- The **late-onset form** of CEOP (Gastaut type) has onset peak at 7–9 yrs:
  - brief visual symptoms and retained consciousness, with a diffuse post-ictal headache, nausea and vomiting;
  - some seizures develop with versive movements, sensory abnormalities, dysphasia, automatisms, hemiclonic or generalized clonic movements;
  - the late-onset form has a slightly poorer prognosis for seizure cessation;
  - there is some phenotypic overlap with both migraine with aura and basilar-type migraine.
- EEG is typically similar in both forms and shows occipital epileptiform discharges suppressed by eye opening and activated by sleep, although a broader spectrum of interictal patterns has been described with Panayiotopoulos syndrome.
- Treatment with valproate: carbamazepine may aggravate.

**Childhood absence epilepsy**

- Also referred to as 'pyknolepsy' (refers to the clustering that tends to occur, with some children having hundreds of absence episodes a day).
- Use of the term 'petit mal' should be strongly discouraged, as it has come to be used indiscriminately for anything other than a generalized tonic-clonic seizure.
- Brief arrest of speech and activity (typically <5s). Subtle peri-oral or peri-ocular flickering may be seen.
- Events are usually reliably precipitated by 1–2 min of well-performed hyperventilation. Routinely tested in EEG but may also be useful in the outpatient setting.
- More common in girls. Onset typically at 4–8 yrs (onset before 3 yrs is rare).
- Strong genetic component, with a family history in one-third of cases and a risk of seizures in siblings of around 10%. In around 10% of cases, there will be a history of febrile seizures preceding onset of absences.
- GTC seizures do occur, if infrequently: families must be forewarned of this.
- EEG shows a 3 Hz generalized spike-and-wave pattern.
- Treatments: ethosuximide (may not prevent GTC seizures), valproate or lamotrigine. Carbamazepine will usually aggravate and is contraindicated. Prognosis for resolution of absences in early adulthood is very good, but GTC seizures may continue.

**Epilepsy with myoclonic-astatic (or myoclonic-atic) seizures (Doose syndrome)**

- A rare syndrome slightly more common in males. Family history in one-third of cases.
- Onset at 2–5 yrs, with frequent drop attacks. These can be due to the hallmark myoclonic-astatic seizures ('jerk and immediately drop'), and/or tonic seizures.
- Myoclonus sometimes involves ocular or oral muscles. One-third develops myoclonic status epilepticus, characterized by frequent facial twitching, drooling, and impaired consciousness; and three-quarters develop generalized tonic-clonic (GTC) seizures at some stage.
- EEG may be normal in the early stages, later developing biparietal slowing, generalized slow spike-and-wave discharges, and irregular spike-wave discharges accompanying the myoclonic-astatic attacks.
- Treatments are valproate, lamotrigine, and benzodiazepines. Prognosis is variable.
- Some authorities question the distinction between this and LGS (see  p. 271). The 'splitters' emphasize the family history and sometimes better prognosis of this syndrome.

**Absence epilepsy with eyelid myoclonia (Jeavons syndrome)**

- Onset between 2 and 14 yrs, with peak onset at 6–8 yrs.
- Commoner in females.
- Brief seizures (3–6 s duration) either spontaneously or precipitated by eye closure in light (but not in darkness).
- Upward gaze deviation and head retropulsion.
- Eyelids make repetitive clonic or fluttering movements.
- EEG shows brief, generalized 3 Hz spike waves and photosensitivity.

### **Lennox–Gastaut syndrome**

A term that can cause some confusion. In Europe it defines a relatively rare, tightly defined form of severe childhood epilepsy excluding many children with severe epilepsy who are otherwise unclassified or under the rubric of ‘severe polymorphic epilepsy’. In North America the term LGS tends to be used inclusively to include all the severe childhood epilepsies that cause a child to ‘stare, jerk and fall’.

- Tonic seizures are the hallmark; also atonic, and atypical absence seizures. If myoclonic seizures are prominent consider myoclonic–astatic epilepsy (see [□□](#) p. 270).
- Usually symptomatic, but up to 30% are ‘presumed symptomatic’.
- Widespread slow (2–2.5 Hz) spike-and-wave discharges interictally on EEG: commonly frontally dominant. Other background slowing is common. The most characteristic pattern in sleep is paroxysmal fast discharges with a frequency of 10–12 Hz.
- Initial treatment typically with sodium valproate and benzodiazepines, though lamotrigine, rufinamide, and topiramate can also be effective. Other treatments include felbamate, corticosteroids, ketogenic diet, and vagus nerve stimulation. The prognosis for cognitive development, behaviour and seizure control is generally poor.

### **Adolescent onset**

The most important epilepsies with onset in late childhood or early adolescence are the ‘idiopathic’ (see [□□](#) p. 262) or genetic generalized epilepsies. Although the JAE and JME phenotypes are particularly widely recognized, there is considerable overlap and it is probably better to regard these phenotypes as being points on a continuum.

### **Juvenile myoclonic epilepsy**

Onset is usually between the ages of 12 and 18 yrs. There are generalized tonic–clonic and myoclonic seizures that occur most commonly soon after waking. Often it is the first GTC seizure that prompts medical attention: the absences and myoclonus may have been happening unrecognized for some time although the child will have reputation for clumsiness and accidents first thing in the morning.


- Awareness is retained during the myoclonic jerks.
- GTC seizures are often preceded by a crescendo of myoclonic jerks, effectively a clonic–tonic–clonic seizure. Absence seizures occur in up to one-third.
- A history of dropping objects while preparing breakfast is common.
- Excessive tiredness, sleep deprivation, alcohol, and marijuana are potential triggering factors.
- EEG typically shows polyspike discharges followed by irregular slow waves with a frequency of between 1 and 3 Hz. Absences are associated with polyspike–wave complexes at 4–6 Hz that slow to 3 Hz. These epileptiform discharges are far less regular than those with CAE and JAE.
- Treatment is usually with valproate (but see [□□](#) p. 301), lamotrigine or levetiracetam. Carbamazepine is contraindicated. Prognosis for seizure control is generally good, but the consensus is that AED treatment should be maintained due to very high risk of relapse if treatment is withdrawn.

**Juvenile absence epilepsy**

- Peak age of onset is 12 yrs, typically near or soon after puberty.
- In contrast to CAE, there are typically only a few episodes per day, and consciousness seems to be less impaired even though the electrographic seizures tend to be longer.
- Around 80% will develop generalized tonic–clonic seizures, and 15% will also have myoclonic seizures (more subtle than those in JME, though there is some clinical overlap between these syndromes).
- EEG shows a 3-Hz generalized spike-and-wave pattern often induced by hyperventilation, but photosensitivity is unusual. Most respond to sodium valproate, though long-term seizure cessation is less likely than with CAE.

**Other rare syndromes****Acquired epileptic aphasia; synonym Landau–Kleffner syndrome**

This is a rare disorder with rapid onset (in a previously healthy child) of a child behaving ‘as if deaf’. There are fluctuating but rapidly progressive problems with comprehension of language, and failure to understand everyday noises (auditory agnosia, e.g. failing to recognize the significance of a ringing telephone) and an acquired expressive aphasia. Other cognitive and behavioural problems are common.

- Onset is usually at 3–8 yrs, ♂:♀ 2:1.
- There may be GTC seizures, atypical absences or partial motor seizures.
- EEG shows frequent epileptiform discharges, predominantly in sleep and over the temporal areas. The presumption is that this is an epileptic encephalopathy (see Box 4.5) in which cortical function is being disrupted by epileptic activity; however, a direct causal relationship is not always seen and it is typically easier to stop the overt seizures (usually cease before age 15) than restore language.
- The most common treatments for this are corticosteroids or benzodiazepines. Multiple subpial transaction (see  p. 294) has also been used.

**Epilepsy with continuous spike–waves in slow-wave sleep (CSWS, ESES)**

The term electrographic status epilepticus in sleep (ESES) is synonymous with continuous spike–waves in slow-wave sleep (CSWS). There is overlap between CSWS and Landau–Kleffner syndrome. One is a syndrome defined by EEG features, the other by clinical features. Many children with LKS will have CSWS or ‘near-CSWS’. LKS can be considered a subtype of CSWS with a temporal lobe focus and consequent regression primarily of language.

CSWS refers to a triad of continuous spike and wave activity occupying >80% of slow sleep, seizures and developmental regression.

- Onset is typically at 4–6 yrs (range 1–11).
- Associated with regression of memory and cognitive skills with hyperactivity.
- Males are affected more commonly than females.
- The most common initial event is a sleep onset generalized clonic seizure, but partial or complex partial seizures also occur and some cases clinically resemble BECTS (a variant sometimes referred to as atypical benign partial epilepsy).


- As CSWS develops, it is common to see atypical absences, myoclonus and atonic episodes.
- Treatment is often difficult and a variety of AEDs are often tried. The mainstays of treatment are:
  - benzodiazepines, often clobazam; clonazepam (rectal or IV bolus);
  - corticosteroids: high dose prednisolone (e.g. 2 mg/kg/day) for several weeks before tapering;
  - if there has been a response, prolonged steroid treatment can be achieved with minimized toxicity using a 4 mg/kg once weekly regime;
  - sodium valproate may be helpful for overt clinical seizures;
  - the addition of ethosuximide or levetiracetam to clobazam and/or valproate may be beneficial.
- Carbamazepine may exacerbate the condition.
- Some children may be suitable for surgical intervention (multiple subpial transaction), but results are variable.

### **Absence status epilepticus**

- Commonest form of non-convulsive status.
- Rarely seen before 10 yrs of age, but occurs in up to 20% of all children with juvenile absence epilepsy.
- AED drug treatment changes are the commonest precipitating factor:
  - introduction of tiagabine and levetiracetam in particular;
  - over-rapid withdrawal of AED medication.
- Associated impairment of consciousness variable.
- Presents as slow cognition, poor memory, confusion, inappropriate behaviour, experiencing strange sensations and feelings.
- May be associated with minor motor disturbances:
  - clonic jerks of eyelids or mouth;
  - atonic head or trunk drops;
  - lip-smacking, swallowing, fumbling or other automatisms;
  - *autonomic features*—pallor, pupil dilatation.
- *Characteristic EEG*: generalized discharges 1–4 Hz.
- In most cases oral or parenteral benzodiazepines will be effective:
  - buccal midazolam;
  - oral clonazepam especially if myoclonic jerks present;
  - IV lorazepam or midazolam infusion with continuous EEG monitoring.
- Recent reports suggest oral ketamine to be useful.

**Generalized epilepsy with febrile seizures plus**


Generalized epilepsy with febrile seizures plus (GEFS+) is an entity that sits awkwardly within the ILAE syndromic approach. Clinically, it can give rise to a wide variety of phenotypes (it's thus very difficult to make an individual diagnosis of GEFS+ without a family history): the distinguishing hallmark is a positive family history and a pedigree consistent with autosomal dominant inheritance with high penetrance (60% or more). Typically, children show a tendency to fever-associated seizures, although these can be of multiple types.

GEFS+ has been shown to be due to SCN1A mutations in many pedigrees. Other genes including SCN2A, SCN1B and a GABA receptor gene *GABRG2* have also been identified in other pedigrees. As such it is related to and on a spectrum with Dravet syndrome (see  p. 265), although typically much less severe. As with Dravet syndrome, valproate, benzodiazepines, topiramate, Levetiracetam and stiripentol may be effective. Carbamazepine, lamotrigine, and phenytoin typically worsen control.

# Investigating epilepsy


## Epilepsy as a symptom

To assess a child's epilepsy fully, correct assessments have to be made at least four levels.

- *Disease*: am I sure this is an epilepsy and not either a disease causing recurrent acute symptomatic seizures, or a disease causing events that are not seizures at all?
- *Seizure types*: what seizure type(s) am I seeing? Some seizure types increase the likelihood that there is an underlying cause for the epilepsy (e.g. myoclonic seizures in the appropriate clinical context).
- *Epilepsy syndrome*: see  p. 262 and following.
- *Aetiology*.

► If a child's epilepsy treatment is proving ineffective, review at each of these four levels: am I sure it is epilepsy? Have I misinterpreted seizure descriptions and selected the wrong drug? Have I missed a (possibly progressive) underlying cause?

The 2001 ILAE conceptual framework uses a similar multi-axial approach.

- Axis 1 ictal phenomenology (or 'semiology').
- Axis 2 seizure type(s).
- Axis 3 epilepsy syndrome (identifiable in many cases).
- Axis 4 aetiology, and finally.
- Axis 5 comorbidity—associated problems with cognition, behaviour and mood, and their resultant effects on life and schooling (see  p. 298).

## Role of EEG

EEG is *overused* at the level of disease (i.e. asking 'Is this epilepsy or not?' where its predictive value is poor) and *underused* as a means of defining epilepsy syndromes and aetiologies. Many epilepsy syndromes have, by definition, characteristic EEG features. A small number of primary causes of symptomatic epilepsy (e.g. infantile neuronal ceroid lipofuscinosis, subacute sclerosing panencephalitis (SSPE)) have EEG hallmarks. Other EEG findings are less specific.

## Role of imaging

Indications for imaging cause much confusion amongst novice epileptologists. The key to understanding the need for imaging is to make syndromic and/or aetiological diagnoses.

► Imaging is not normally required if a confident diagnosis of an idiopathic primary generalized epilepsy has been made. It is also not required if a diagnosis of childhood absence epilepsy or a benign focal epilepsy (BECTS or CEOP) is supported by clear clinical and EEG features.



In most other situations there is likely to be a role for imaging. Other than in an emergency situation where computed tomography (CT) imaging may be more practicable, MRI is the preferred imaging modality. Typical indications include:

- New onset focal epilepsy in a previously developmentally normal child, to rule out acquired lesions (infarction, neoplasia, inflammation).
- A past history implying a possible remote symptomatic cause for the epilepsy (e.g. previous asphyxia, meningitis).
- Children (typically pre-school age) with aggressive epilepsy with multiple seizure types (e.g. LGS), although the diagnostic yield is relatively low where there is no significant past medical history.
- Any new-onset seizure disorder in the neonatal period or infancy.
- Loss of previously established seizure control or change in seizure pattern.
- Any focal neurological signs on examination.

Current NICE guidelines recommend imaging within 4 weeks of first presentation of a seizure disorder.

### Symptomatic epilepsies with imaging abnormalities

#### *Cerebral dysgenesis syndromes*

Often present before 1-mth-old.

- Cerebral dysgenesis/focal cortical dysplasia (common):
  - schizencephaly, hemimegalencephaly, Miller–Dieker, linear sebaceous naevus syndrome;
  - some radiological phenotypes now recognized to be due to defined single-gene mutations (see Figure 3.7);
  - genetic counselling is advised.
- Aicardi syndrome:
  - relatively common (1–4% of infantile spasm series);
  - affects females only (isolated case reports in XXY males; presumed lethal in XY male foetus);
  - sporadic—no familial cases reported;
  - characteristic MRI features include agenesis of corpus callosum (with an elevated third ventricle), areas of dysplastic cortex, periventricular heterotopic grey matter, choroid plexus cysts, and papillomas and vermian agenesis;
  - characteristic chorioretinal ‘punched out’ lesions or ‘lacunae’ on dilated funduscopy;
  - may also see vertebral abnormalities and microphthalmia.

#### *CNS features of neurocutaneous disorders*

Tuberous sclerosis, neurofibromatosis, Sturge–Weber, etc.

#### *Acquired lesions*





##### *Tumours*

Dysembryoplastic neuroepithelial tumour (DNET).

##### *Vascular malformations*

- Cavernous angioma.
- Acquired ischaemic lesions, e.g. porencephalic cyst.

### *Inflammation*

- Seizures can occur as feature of autoimmune and autoinflammatory diseases of the CNS (see  p. 218) and MRI evidence of inflammation is often an important clue:
  - acute disseminated encephalomyelitis (see  p. 257);
  - CNS vasculitis (see  p. 223);
  - Rasmussen encephalitis (see  p. 222).


### *Metabolic disease*

It is important to recognize that some inborn errors of metabolism also give rise to anatomical/structural features on MRI. For example, agenesis of the corpus callosum can be seen in non-ketotic hyperglycinaemia), thus demonstration of structural brain abnormalities does not obviate the need for metabolic investigation.

## Symptomatic epilepsies with genetic abnormalities

### *Chromosomal abnormalities*

► Karyotyping is advised in intractable epilepsy or epilepsy with learning difficulties.

Chromosomal disorders associated with epilepsy generally include dysmorphic appearances and learning difficulties. If routine karyotyping is normal have a low threshold for proceeding to comparative genome hybridization (CGH; see  p. 89) after discussion with clinical geneticists.

### *Wolf–Hirschhorn syndrome*

- Deletion of the short arm of chromosome 4.
- Greek helmet facial appearance, cleft palate, cerebral abnormalities, developmental delay and seizures.
- *Investigation:* karyotype and FISH of 4p.

### *Miller–Dieker syndrome*

- Submicroscopic distal deletion of the short arm of chromosome 17 involves the *LIS1* gene.
- Facial features, seizures/infantile spasms, visceral abnormalities and type 1 lissencephaly (see Figure 3.7).
- *Investigations:* karyotype and FISH of 17p13.3.

### *Ring chromosomes*

Cytogenetic abnormalities resulting in ring-form chromosomes can cause epilepsy. Ring chromosome 20 can give severe epilepsy, learning, and behaviour problems (often bordering on the psychotic) without obvious dysmorphism, and the cytogenetic abnormality can be a mosaic so the laboratory should be asked to examine a larger number of mitotic figures (typically 50, but some sources suggest 200).

### *Single-gene disorders*

Seizures are a feature of a number of single-gene disorders associated with other features including developmental delay and other neurological signs (e.g. tuberous sclerosis, NF1, fragile X). Generally, these disorders will be diagnosed on the basis of their other features.

*'Pure' epilepsies*

Single-gene disorders showing conventional Mendelian inheritance are responsible for only 1% epilepsies without other clinical features. Genetic testing is not currently routinely available, and mutation confirmation rarely informs treatment at present. Examples to date have largely been channelopathies: mutations in genes coding for subunits of neuronal membrane ion channel proteins, some of which can have phenotypes with other neurological features.

- Benign familial neonatal convulsions. Mutations in *KCNQ2* or *KCNQ3* coding for specific potassium channel.
- Autosomal dominant nocturnal frontal lobe epilepsy. Mutation in *CHRNA4* and *CHRNB2* that code for proteins making up the neuronal nicotinic acetylcholine receptors.
- Mutations of *GABRG2* that codes for part of the GABA receptor.

One gene test that is increasingly available is *SCN1A* mutation testing in Dravet syndrome (SMEI, see [□](#) p. 265). Early confirmation can be helpful in counselling about the expected emergence of autistic spectrum problems etc. Mutations in *SCN1A*, *SCN2A*, and *SCN1B* resulting in dysfunction of the voltage-gated sodium channels can also cause a related phenotype: GEFS+.

*Angelman syndrome*

- In contrast to the traditional Mendelian model, it is now realized that genes may be labelled by methylation (known as imprinting) that distinguishes maternally and paternally derived copies.
- Arises from lack of maternally derived chromosome 15q11–13. 70% have deletion; 2–3% is due to paternal uni-parental disomy; imprinting centre mutations within 15q11–13 in 3% and mutation of the maternally derived *UBE3A* gene in 11%.
- The classic phenotype is of seizures, happy facial expression, and developmental delay.
- In 13% of cases with typical clinical features, there is no identified genetic cause.
- For girls with an Angelman phenotype, but apparently negative genetic studies, consider *MECP2* analysis.
- See also Pitt–Hopkins syndrome.
- *Investigations:* karyotype, 15q11–13 methylation studies, FISH, *UBE3A* (and possibly *MECP2*) mutation analysis.

*Rett syndrome, Rett-like syndromes and MECP2-associated phenotypes*

- Epilepsy is a common later feature of classic Rett syndrome (see [□](#) p. 426); however, an increasing range of *MECP2*-associated phenotypes is now recognized.
- *MECP2* point mutations are increasingly recognized as relatively common in males, typically giving rise to a severe neonatal onset epileptic encephalopathy with severe hypotonia, abnormal movements and breathing patterns.
- **Ⓢ** *MECP2* mutations should be considered in male infants with neonatal epileptic encephalopathy, severe hypotonia or in families with a pedigree consistent with X-linked learning disability.

- MECP2 duplications are causative in a small proportion (few percent) each of severe developmental delay in males and X-linked severe developmental delay. MECP2 duplications have to be specifically sought and are missed by the standard sequencing techniques used to identify MECP2 mutations.
- Some additional genes cause Rett-like pictures and should be considered particularly in girls where Rett syndrome was considered and excluded:
  - CDKL5 should be considered in girls with a Rett-like picture in whom aggressive early onset (<6 mths) seizures are prominent;
  - in 'congenital Rett' pictures with no clear early 'normal' phase consider FOXP1.
- Pitt-Hopkins syndrome (due to 18q deletions or microdeletions involving the *TCF4* gene) causes a picture with some Rett- and Angelman-like features (severe learning disability, Rett-like hyperventilation, Angelman-like distinctive wide-mouthed facies); however, seizures are not usually prominent.

## Am I missing an underlying cause?



### Neonatal seizures

See also  p. 480.

Almost all neonatal seizures are 'symptomatic' (that is, have an identifiable underlying cause) and as such must be fully investigated. The epilepsy syndrome approach has limited application in neonatal seizures.

#### Common causes

- Hypoxic–ischaemic encephalopathy.
- Infection.
- Structural. Note that structural brain abnormalities are seen in some metabolic disorders, e.g. glycine encephalopathy (non-ketotic hyperglycinaemia; NKH) and peroxisomal disorders, so further evaluation and investigation might be necessary.
- Maternal drug withdrawal.
- Metabolic.


If the initial evaluation has not identified a cause of neonatal seizures, consider a large number of—individually rare but collectively important—neurometabolic and neurodegenerative conditions. See  p. 483 for further details. EIEE and EME (see  p. 264) are epilepsy syndrome diagnoses (phenotypes) for which metabolic diagnoses should be sought and excluded.



Mutations in a particular gene (*STXBP1*, syntaxin-binding protein 1) have been associated with the EIEE phenotype.

### Infants

#### West syndrome






West syndrome sits rather awkwardly in the ILAE classification: it is a syndrome with many causes. Since optimal treatment and prognosis are strongly influenced by aetiology there is a case for seeing this as a heterogeneous group of conditions sharing a non-specific phenotype constrained by development (see Box 4.4). A cause will be identified in approximately 80% of the broad phenotype (i.e. epileptic spasms associated with typical or atypical ('modified') hypsarrhythmia). Typical causes include:

- Perinatal asphyxia and HIE.
- Cerebrovascular events.
- *Cerebral dysgenesis*: tuberous sclerosis and Aicardi syndrome (see Figure 3.6).
- Developmental cerebral malformations (lissencephaly, pachgyria, hemimegalencephaly, band heterotopias and cortical dysplasias (see Figure 3.7).
- Pre-, peri- or postnatal infection, particularly herpes encephalitis.
- Metabolic disorders.
- Degenerative disorders including progressive encephalopathy with oedema, hperarrhythmia, and optic atrophy (PEHO; see  p. 282).

- The UKISS study identified aetiology in 61%: HIE in 10%, chromosomal abnormalities, brain malformations and stroke in 8% each, tuberous sclerosis in 7%, periventricular leukomalacia or haemorrhage 5%. The remaining 32 aetiologies were all individually uncommon including SCN1A and CDLK5 mutations.
- It follows that the most useful investigations are MRI, careful neurocutaneous and neuro-ophthalmological examination, karyotype and targeted metabolic and genetic investigations. The latter may include consideration of some or all of.
- Pyridoxine/pyridoxal dependent seizures (see  p. 462). These usually present with seizures in the neonatal period but can occasionally present as de novo infantile spasms.
- Phenylketonuria (PKU).
- The phenotypic spectrum of glucose transporter deficiency (see  p. 282) is now recognized as being broader and often more subtle than with the cases described initially, and this diagnosis should be considered in any child with onset of seizures before the first birthday.
- Maple-syrup urine disease.
- Biotinidase deficiency.
- Menke disease.
- Hyperammonaemia.
- Non-ketotic hyperglycaemia.
- Leigh disease.
- Krabbe disease.
- ARX gene mutations in males.
- MECP2 deletions/duplications in males (commoner than point mutations as a cause of epileptic encephalopathies in males).
- CDKL5 gene mutations in females.

Children in whom a cause cannot be identified are categorized as presumed symptomatic. Those children making an ultimately good neurodevelopmental outlook are all in this group.

### ***Metabolic and neurodegenerative disorders associated with epilepsy in infants and children***

- ❗ Seizures accompany a vast number of neurodegenerative and neurometabolic diseases. There are, however, relatively few conditions in which seizures in isolation are likely to be the presenting sign, long pre-dating other features. The important neonatal/infant examples are NKH, sulphite oxidase/molybdenum cofactor deficiency and Menkes disease. In progressively older children, important considerations are Alpers disease/PNDC (see  p. 373), late infantile NCL, GLUT1 disease (see  p. 282) and the progressive myoclonic epilepsies (see  p. 283).
- Glucose transporter deficiency (see  p. 373).
- Post-neonatal vitamin B6/pyridoxal phosphate dependency, biotinidase deficiency or folinic acid dependency (see  p. 463).

*Conditions in which other features are more dominant than, or present before, seizure disorder*

- **Glutaric aciduria type 1:** typically presents between 6 and 18 mths with an acute encephalopathy and seizures precipitated by mild intercurrent illness.
- **Late-onset urea cycle disorders:** Predominantly present with recurrent encephalopathy associated with hyperammonaemia. Possible family history of unexplained death in male siblings.
- **Multiple carboxylase deficiency:** Classically has dermatological features as well as seizures, although these can be subtle—rash and alopecia appearing around 3 mths of age.
- **Neurotransmitter metabolism defects** (see 📖 p. 435).
- **Mitochondrial disorders** (see 📖 p. 369).
- **Lysosomal disorders** including neuronal ceroid lipofuscinoses (see 📖 p. 427).

*Rare causes of severe epilepsy and severe developmental delay*

- **3-Phosphoglycerate dehydrogenase deficiency:** microcephaly, severe delayed development. Intractable epilepsy and severely abnormal EEG. MRI: reduction in white matter.
- **Guanidinoacetate methyltransferase (GAMT) deficiency:** intractable epilepsy, developmental delay and extrapyramidal symptoms. Initial clue may be a low plasma creatinine (which is not normally regarded as abnormal!). However this is a non-specific finding common in small infants with reduced muscle mass. Further support comes from demonstration of low urine creatinine: calcium and creatinine: protein ratios. Confirm by brain MRS demonstration of absent creatine peak. Improves with creatine administration.
- **PEHO:** condition of unknown aetiology (recessive) with hypsarrhythmia and optic atrophy. MRI shows atrophy of the temporal lobes and folial atrophy of the cerebellum.

### **Glucose transporter-1 deficiency syndrome (GLUT1-DS)**

A disorder of brain energy metabolism caused by impaired GLUT1-mediated glucose transport into the brain. Expanding clinical spectrum:

- **Classical early-onset (84%):**
  - neonatal period *may* be normal;
  - seizures are main presentation: semiology includes cyanotic attacks and eye movement seizures (mistaken for opsoclonus-myoclonus);
  - mean age at seizure onset 26 weeks (neonates-77 mths) with 79% of all first seizures in first 6 mths;
  - then global developmental delay, especially affecting speech;
  - occipitofrontal circumference (OFC) decelerates after 3 mths;
  - complex movement disorder including ataxia, dystonia and pyramidal tract signs.
- **Classical late-onset (18%):**
  - seizure onset 2–10 yrs (seen in 40%);
  - movement disorder in 10%;
  - CSF—plasma glucose not as low as early-onset;
  - all have learning difficulties (mild in 70%);
  - microcephaly in 29%.

- Non-classical with mental retardation and movement disorder, but no epilepsy; mild mental retardation in 50%.
- Familial or sporadic paroxysmal, exercise-induced movement disorder, with or without seizures.
- Also minimal symptoms (adult clumsy on prolonged fasting).

#### Biochemistry

- CSF: plasma glucose ratio  $\leq 50\%$ .
- CSF glucose  $\leq 2.2$  mM.
- Decreased or normal CSF lactate (a low CSF glucose with high lactate has been reported in biotinidase deficiency: pyruvate carboxylase is a biotin-dependent enzyme).

#### Neurophysiology

EEG may show ictal focal slowing or discharges, 2.5–4 Hz spike and wave, aggravated by fasting and improved by food intake.

#### Genetics

- Autosomal dominant heterozygote mutations in *SLC2A1* gene encoding GLUT-1.
- Usually sporadic although familial transmission is reported.

#### Other investigations

- Erythrocyte studies (red blood cells (RBCs) share same GLUT1 transporter).
- MRI unremarkable.
- Fluorodeoxy-glucose positron emission tomography (FDG-PET) may have specific pattern.

#### Treatment

- Ketogenic diet, from infancy to at least adolescence.
- Seizures are controlled at lower blood levels of beta-hydroxybutyrate than needed to nourish the brain.
- Carnitine supplements.
- Avoid inhibitors of GLUT1 function (phenobarbitone, valproate, diazepam, general anaesthesia, chloral hydrate, methylxanthines, caffeine, green tea, ethanol).

#### **Neurodegenerative conditions that may present with symptomatic epilepsy in older children.**

- SSPE (see [p. 348](#)).
- HIV (see [p. 341](#)).
- Alpers/progressive neuronal degeneration of childhood with liver disease (PNDC; see [p. 373](#)).
- Wilson disease (see [p. 432](#)).
- Niemann–Pick type C (see [p. 431](#)).
- Huntington disease (see [p. 432](#)).

### **The progressive myoclonus epilepsies**

Of all indicators that epilepsy may be symptomatic of a progressive underlying neurological disease, the presence of *myoclonic seizures* is perhaps the most sensitive, although it is non-specific.



❗ Although myoclonic seizures may indicate a progressive underlying cause, most children experiencing myoclonic seizures—even as part of severe epilepsies—will have a syndrome such as SMEI or LGS, rather than a metabolic underlying primary cause.

Progressive myoclonus epilepsies (PMEs) are characterized by the triad of multiple seizure types (including myoclonic seizures), abnormal neurological signs and *progressive deterioration* (although the latter may be slow; Figure 4.7).

#### **PMEs presenting in infancy**

- Early infantile NCL (see 📖 p. 427).
- Tay–Sachs (see 📖 p. 427).
- Sandhoff.
- Tetrahydrobiopterin deficiencies (see 📖 p. 436).
- Alpers disease (see 📖 p. 373).

#### **PMEs presenting in early childhood**

- Juvenile myoclonic form of Huntington disease. (See 📖 p. 432):
  - onset >3 yrs—regression with cerebellar signs, rigidity and dystonic posturing; eventually seizures;
  - dominant transmission from the father (although the father may be undiagnosed at the time of the child's presentation).
- Late infantile NCL (see 📖 p. 428).

#### **PMEs presenting in childhood and adolescence**

- Juvenile NCL (see 📖 p. 430).
- Juvenile Gaucher (see 📖 p. 429):
  - hepatosplenomegaly precedes neurological deterioration and myoclonic epilepsy;
  - *lymphocytes*—low levels of glucocerebrosidase.
- Sialidosis (see Table 4.17).
- Galactosialidosis (see Table 4.17).
- Lafora body disease (see 📖 p. 433).
- Myoclonus epilepsy with ragged-red fibres (see 📖 p. 374).
- Unverricht-Lundborg disease (see 📖 p. 431).
- Dentato-rubral-pallido-luysian atrophy (DRPLA; very rare). (See Table 4.10.)

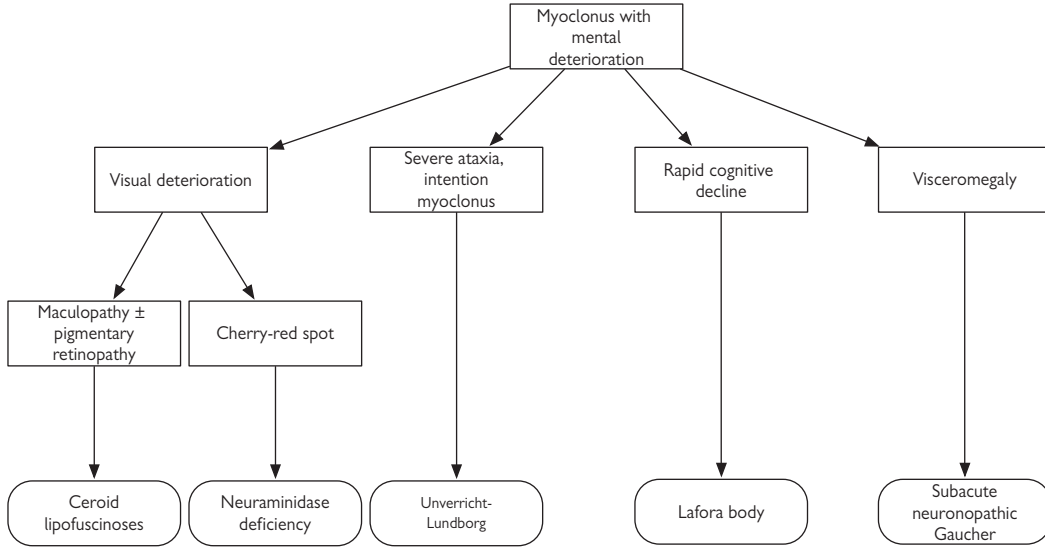


Fig. 4.7 Basic approach to PMEs.

## Treatment of epilepsy

### Principles of medical AED drug treatment

- Decide whether or not treatment is appropriate or necessary:
  - generally considered after two or more seizures; however, treatment may be unnecessary in self-limiting conditions such as BECTS, whereas it may be indicated for whole lifetime in JME;
  - there is no evidence that delaying treatment causes chronic epilepsy, reduced likelihood of seizure freedom at 2 yrs or reduced eventual prospects for successful drug withdrawal.
- The choice of AED drug must be tailored to the child's age, gender, co-morbidities and co-medication, as well as child and carer choice, on the basis of the risk–benefit ratio.
- Identification of seizure type and/or epilepsy syndrome is invaluable in choosing the most suitable AED.
- Aim for seizure control without unacceptable unwanted effects. Err on the side of living with seizures, rather than unwanted 24/7 drug effects that may be far more deleterious developmentally:
  - monotherapy should be used if possible;
  - start slow and go slow;
  - in general, combination therapy should only be used if monotherapy is ineffective since combinations tend to be associated with more side effects.
- If the first AED is unsuccessful the second AED should be started and built up to a therapeutic dose, and only then should the first AED be tapered off slowly.
- Consider AED withdrawal after two seizure-free years, but bear in mind the epilepsy syndrome (e.g. would not normally consider discontinuation in JME) and child and family psychosocial factors.
- AED withdrawal must take place gradually (see specific drug entries in Chapter 7). Withdraw one AED at a time.

### The anti-epileptic drugs

- The 'old' established AEDs include acetazolamide, benzodiazepines, carbamazepine, ethosuximide, barbiturates, phenytoin, and sodium valproate.
- The 'newer' AEDs include gabapentin, lacosamide, lamotrigine, levetiracetam, oxcarbazepine, rufinamide, tiagabine, topiramate, vigabatrin, and zonisamide.
- As prescriber you must be aware of the current licensed indications for the newer AEDs in children. A significant proportion of AED prescription in children with severe epilepsy remains 'off-licence': families must be made aware of this.
- Initial treatment should be with established AEDs, with the possible specific exception of vigabatrin in infantile spasms secondary to tuberous sclerosis. If these are relatively contraindicated (e.g. sodium valproate in young women of child-bearing age) or if the child has not improved, then the newer AEDs need to be considered.

- In the UK, there is guidance on drug choice, based on seizure type(s) and epilepsy syndrome, from the National Institute for Health and Clinical Excellence (NICE).

#### **Very general rule of thumb for first-line drugs**

- *Generalized epilepsies and syndromes*: valproate.
- *Focal seizures with or without generalization*: carbamazepine (although recent data suggest a higher probability of remission with lamotrigine particularly in adults, it takes longer to reach a therapeutic dose).
- *Infantile spasms*: ACTH/prednisolone as first-line (still debated by some) other than in context of tuberous sclerosis where vigabatrin is generally considered best first-line treatment.

See Tables 4.3 and 4.4.

#### **Role of AED blood monitoring**

The main problem with blood monitoring is slavish adherence to quoted laboratory 'therapeutic ranges'.

Drug monitoring gets you 'downstream' of pharmacokinetic sources of variation in therapeutic response (differences in drug concentration at the receptor for a given administered dose). Therapeutic ranges are only useful when pharmacokinetic variability outweighs pharmacodynamic variability (differences in the effect of a given drug concentration at the receptor which is largely genetically determined). The only drugs for which this applies (and thus lab-quoted 'therapeutic ranges' are useful in guiding dosing) are phenytoin, and to a lesser extent phenobarbital.

Other quoted 'therapeutic ranges' are population-derived statistical concepts generally of little relevance to the individual child. Children may have well-controlled epilepsy with lower levels or may tolerate and require higher levels for complete seizure control.

Other relative indications are:

- Detection of non-adherence (rough levels should be taken).
- When toxicity is suspected (level should be taken at around time of the maximum symptomatology).
- Adjustment of phenytoin dose.
- Management of pharmacokinetic interactions.
- Specific clinical conditions (pregnancy, organ failure).

**Table 4.3** Drug choice by seizure type

Seizure type	First-line drugs	Second-line drug	Other drugs that may be considered	Drugs to be avoided (may worsen seizures)
Generalized tonic–clonic	Carbamazepine*	Clobazam	Acetazolamide	Tiagabine
	Lamotrigine†	Levetiracetam	Clonazepam	Vigabatrin
	Valproate	Oxcarbazepine*	Phenobarbital*	
	Topiramate*		Phenytoin*	
Absence	Ethosuximide	Clobazam		Carbamazepine*
	Lamotrigine†	Clonazepam		Gabapentin
	Valproate	Topiramate*		Oxcarbazepine*
				Tiagabine
				Vigabatrin
Myoclonic	Valproate	Clobazam		Carbamazepine*
		Clonazepam		Gabapentin
		Lamotrigine†		Oxcarbazepine*
		Levetiracetam		Tiagabine
		Piracetam		Vigabatrin
		Topiramate*		

Tonic	Lamotrigine <sup>†</sup>	Clobazam	Acetazolamide	Carbamazepine*
	Valproate	Clonazepam	Phenobarbital*	Oxcarbazepine*
		Levetiracetam	Phenytoin*	
		Topiramate*		
Atonic	Lamotrigine <sup>†</sup>	Clobazam	Acetazolamide	Carbamazepine*
	Valproate	Clonazepam	Phenobarbital*	Oxcarbazepine*
		Levetiracetam		Phenytoin*
		Topiramate*		
Focal ± secondary generalization	Carbamazepine*	Clobazam	Acetazolamide	
	Lamotrigine <sup>†</sup>	Gabapentin	Clonazepam	
	Oxcarbazepine*	Lacosamide	Phenobarbital*	
	Valproate	Levetiracetam		
	Topiramate*	Phenytoin*		
	Tiagabine			

National Institute for Health and Clinical Excellence (2012) Adapted from 'CG 137 The epilepsies: the diagnosis and management of the epilepsies in adults and children in primary and secondary care'. London: NICE. Available from [www.nice.org.uk](http://www.nice.org.uk). Reproduced with permission.

**Table 4.4** Drug choice by epilepsy syndrome

Epilepsy syndrome	First-line drugs	Second-line drugs	Other drugs	Drugs to be avoided (may worsen seizures)
Childhood absence epilepsy	Ethosuximide Lamotrigine <sup>†</sup> Valproate	Levetiracetam Topiramate <sup>*</sup>	Acetazolamide	Carbamazepine <sup>*</sup> Oxcarbazepine <sup>*</sup> Phenytoin <sup>*</sup> Tiagabine Vigabatrin
Juvenile absence epilepsy	Lamotrigine <sup>†</sup> Valproate	Levetiracetam Topiramate <sup>*</sup>		Carbamazepine <sup>*</sup> Oxcarbazepine <sup>*</sup> Phenytoin <sup>*</sup> Tiagabine Vigabatrin
Juvenile myoclonic epilepsy	Lamotrigine <sup>†</sup> Valproate	Clobazam Clonazepam Levetiracetam Topiramate <sup>*</sup>	Acetazolamide	Carbamazepine <sup>*</sup> Oxcarbazepine <sup>*</sup> Phenytoin <sup>*</sup> Tiagabine Vigabatrin

Generalized tonic-clonic seizures only	Carbamazepine* Lamotrigine† Valproate Topiramate*	Levetiracetam	Acetazolamide Clobazam Clonazepam Oxcarbazepine* Phenobarbital* Phenytoin*	Tiagabine Vigabatrin
Focal epilepsies: cryptogenic, symptomatic	Carbamazepine* Lamotrigine† Oxcarbazepine* Valproate Topiramate*	Clobazam Gabapentin Lacosamide Levetiracetam Phenytoin* Tiagabine	Acetazolamide Clonazepam Phenobarbital*	
Infantile spasms	Steroids‡ Vigabatrin	Clobazam Clonazepam Valproate Topiramate*	Nitrazepam Zonisamide	Carbamazepine* Oxcarbazepine*
Benign epilepsy with centrotemporal spikes	Carbamazepine Lamotrigine† Oxcarbazepine* Valproate	Levetiracetam Topiramate*	Sulthiame¶	

(Continued)



**Table 4.4** (Continued)

Epilepsy syndrome	First-line drugs	Second-line drugs	Other drugs	Drugs to be avoided (may worsen seizures)
Benign epilepsy with occipital paroxysms	Carbamazepine*	Levetiracetam		
	Lamotrigine†	Topiramate*		
	Oxcarbazepine*			
	Valproate			
Severe myoclonic epilepsy of infancy	Clobazam	Levetiracetam	Phenobarbital*	Carbamazepine*
	Clonazepam	Stiripentol <sup>¶</sup>		Lamotrigine
	Valproate			Oxcarbazepine*
	Topiramate*			Vigabatrin
Continuous spike–wave of slow sleep	Clobazam	Levetiracetam		Carbamazepine*
	Clonazepam	Topiramate*		Oxcarbazepine*
	Ethosuximide			Vigabatrin
	Lamotrigine†			
	Valproate			
	Steroids‡			

Lennox–Gastaut syndrome	Lamotrigine <sup>†</sup>	Clobazam	Felbamate <sup>¶</sup>	Carbamazepine*
	Valproate	Clonazepam		Oxcarbazepine*
	Topiramate*	Ethosuximide		
		Levetiracetam		
		Rufinamide		
Landau–Kleffner syndrome	Lamotrigine <sup>†</sup>	Levetiracetam	Sulthiame <sup>¶</sup>	Carbamazepine*
	Valproate	Topiramate*		Oxcarbazepine*
	Steroids <sup>‡</sup>			
Myoclonic astatic epilepsy	Clobazam	Lamotrigine		Carbamazepine*
	Clonazepam	Levetiracetam		Oxcarbazepine*
	Valproate			
	Topiramate*			

\* Hepatic enzyme-inducing AED.

<sup>†</sup> Consider lamotrigine in preference to valproate in women of childbearing age (see [□](#) p. 301).

<sup>‡</sup> Steroids: prednisolone or ACTH.

<sup>¶</sup> Not licensed in the UK, but available by importation.

National Institute for Health and Clinical Excellence (2012) Adapted from 'CG 137 The epilepsies: the diagnosis and management of the epilepsies in adults and children in primary and secondary care'. London: NICE. Available from [www.nice.org.uk](http://www.nice.org.uk). Reproduced with permission.

► Correct attribution of cause and effect is a major challenge in the management of refractory epilepsy. Good and bad periods can seem to come and go without apparent reason: sometimes spontaneously without changes in medication, but more problematically sometimes when a change has recently been made.

Seizures do not necessarily follow simple random frequency distributions, but bear in mind the phenomenon of regression to the mean: there will usually be an average severity and frequency around which fluctuation occurs over time. Since treatment and management changes are generally made when things are worse than average, many such changes will be followed by improvement even if there is no truly causal relationship with the symptoms. It is worth reminding families that chance might be at play and that attribution of effects should not be automatic or assumed.

Complaints such as poor concentration might be due to undertreatment (incomplete seizure control), overtreatment (drug toxicity), unrelated to treatment (due to the primary cause of the epilepsy), or due to a combination of these factors.

In such situations it is all too easy to seek and find apparent patterns and 'reasons' for changes in a child's situation, only for families to become exasperated when a pattern they thought they had found ceases to hold.

The only practical solution to these dilemmas is to change one thing at a time; to make changes infrequently (resist the temptation to fiddle—a particular danger in an inpatient setting); and assess the effects of a change over a period of weeks (to allow random fluctuations in the condition to manifest themselves).

### Surgical treatment of epilepsy

Epilepsy surgery can take several forms. Resective surgery is removal of the brain parenchyma that is considered to be the source of seizures (the 'epileptogenic zone'). Other surgical approaches include:

- Corpus callosotomy.
- Hemispherotomy, also known as 'functional hemispherectomy' (the pathological cerebral hemisphere is disconnected by division of the corpus callosum and peduncles, but remains *in situ* to avoid complications of physical hemispherectomy).
- Multiple subpial transection (small vertical 'cross-hatching' cuts on the brain surface intended to limit horizontal seizure spread whilst preserving normal function of 'eloquent' cortex).
- Vagus nerve stimulation.
- Deep-brain stimulation (still experimental and of unproven benefit).

Resective surgical treatment of epilepsy is an option where:

- A child's epilepsy has focal (preferably unifocal) onset.
- There is a radiologically evident abnormality at the identified seizure origin (desirable but not essential).
- Seizures are not also originating from other foci (although under some circumstances a very dominant seizure focus might be removed in the knowledge that other foci remain).

- The predicted morbidity of resection is minimal, or at least acceptable, (if there is pre-existing significant morbidity or the epileptogenic focus is not in an eloquent area of the brain).
- Surgery must only be performed in specialized centres after an extensive evaluation.

### **Selection of surgical candidates**

Typically, surgery has been considered only when a child's epilepsy has been demonstrated to be medically intractable, but earlier consideration should be given to some candidates (e.g. hemimegalencephaly, Sturge-Weber syndrome), where the prospects of medical control are known to be poor and the neuro-developmental impact of continuing seizure activity is undesirable.

### **Common indications for epilepsy surgery**

- Mesial temporal sclerosis.
- Focal cortical dysplasias.
- Focal epilepsy associated with remote symptomatic causes, such as perinatal stroke.
- Low-grade developmental tumours such as DNETs.
- Diffuse unilateral hemispheric syndromes (Sturge-Weber, Rasmussen, hemimegalencephaly).

If a child is not suitable for resective surgery, palliative procedures (corpus callosotomy, multiple subpial transection) may still be considered.

### **Work-up**

There must be an acceptable risk-benefit ratio for the proposed surgery. There must be *concordant* data from a variety of sources, including:

- Clinical history.
- *Neuroradiology*: MRI, single photon emission computed tomography (SPECT), positron emission tomography (PET), functional MRI (fMRI).
- *Neurophysiology*: ictal and interictal videotelemetry.
- Neuropsychological assessment of cognition, behaviour, and mood.
- Assessment of likely effects of resection (e.g. of eloquent cortex). Wada testing (unilateral intracarotid injection of amytal to anaesthetize one hemisphere) can be used to assess if the remaining lobe can sustain memory and language function in older children, although fMRI is increasingly used instead.
- Intracranial electrode stimulation (electrocorticography) is a gold standard test for assessing cortical function.

### **Potential surgical candidates**

- Malformations of cortical development including hamartomas if localized and limited to one hemisphere.
- Some children with tuberous sclerosis.
- Arteriovenous malformations.
- Cavernomas.
- Sturge Weber.
- Cerebrovascular infarct.
- Tumours (Glial/PNET/DNET).
- Rasmussen.
- Mesial temporal sclerosis.

## Alternative epilepsy treatments

### Ketogenic diet

The mode of action is unclear—ketones are thought to cause neuronal inhibition indirectly but there are probably multiple mechanisms.

A trained dietician must create an individualized dietary plan. The child's weight, growth, pubertal status, and mobility must be taken into account. Two diets are generally available.

- The classic diet is based on high proportions of saturated dairy fat. Typically, fat-derived to non-fat (carbohydrate and protein) calories in a 3 or 4:1 ratio.
- The medium chain triglycerides (MCT) diet uses medium chain triglyceride oil (highly ketogenic). MCT-based diets are slightly less restrictive in terms of permitted carbohydrate.
- There is no evidence as yet for relative superiority of either form of diet.

### Clinical efficacy

Observational studies (level 4 evidence) show a very variable, but significant complete seizure-freedom rate.

### Candidate selection

- Treatment of choice in children with the rare glucose transporter (GLUT1) protein deficiency (see [□](#) p. 282).
- Contraindicated in pyruvate carboxylase and fatty acid oxidation disorders, and relatively contraindicated in respiratory chain and TCA cycle disorders. Check acylcarnitines before institution.
- A suitable option in children with treatment-resistant LGS, atonic seizures, myoclonic seizures and symptomatic focal epilepsy after failure of surgery.

### Problems

- Time consuming.
- Requires motivation of staff, family and child.
- Requires expert staff and education of family.
- Socially restrictive in terms of permitted foods.
- May require hospital admission to enable establishment.
- Requires regular blood and urine tests to ensure safety and efficacy.

### Adverse effects

- Hypoglycaemia especially at onset.
- Dehydration.
- Nausea and vomiting.
- Metabolic acidosis especially with infection and some AEDs such as topiramate.
- *Kidney stones*: again, more likely with topiramate.
- Constipation with the classical diet and diarrhoea with the MCT diet.
- Poor growth and weight gain.
- Lethargy and fatigue.
- Increased blood fat levels.
- Vitamin, calcium, trace element, and carnitine deficiencies; thus need regular monitoring and supplements.

### ***Vagus nerve stimulation (VNS)***

The VNS programmable generator resembles a cardiac pacemaker that is typically implanted beneath the left clavicle. The generator is connected to the left vagus nerve (mainly afferent fibres therefore fewer cardiac or gastrointestinal (GI) effects). Programmed with a computer-controlled wand. It can also be similarly activated acutely by swiping a special magnet.

Output current (0.5–1.5 mA), frequency, pulse duration, and duty cycle (typically 30 s per 5 min) can be adjusted.

#### *Mechanism of action*

Unclear, but alteration in blood flow to the thalamus and altered CSF levels of GABA, serotonin, and dopamine have been postulated. Benefits appear to increase over the first 18 mths of use.

Indicated for children with refractory focal and generalized epilepsies. Increased interest in use for LGS, hypothalamic hamartoma, and tuberous sclerosis (TS).

#### *Efficacy*

25–50% of children experience a 50% reduction of seizure frequency (i.e. the prospect of total seizure freedom is less than with a ketogenic diet).

#### *Unwanted effects*

Primarily a function of output current and to a lesser extent pulse duration and duty cycle. Side effects increase as output current and duty cycle increase. Side effects may respond to a reduction in pulse duration or output current.

#### *Adverse effects (implantation)*

- Vocal cord paralysis.
- Facial nerve palsy.
- Hemidiaphragm paralysis.
- Infection.
- Hyperaesthesia.

#### *Adverse effects (stimulation)*

- Hoarseness.
- Cervical paraesthesia.
- Dyspnoea (obstructive sleep apnoea is a contraindication).
- Cough.
- Throat pain.
- Dyspepsia.
- Swallowing difficulties.

## Epilepsy and daily life

For some children the psychosocial consequences of epilepsy can be more debilitating than the seizure disorder itself. Such difficulties may impact mental health and have indirect effects on seizure control. In the ILAE epilepsy classification scheme, such psychosocial consequences are described as 'axis 5' diagnoses.

Epilepsy is an individual condition, so informed choices about activities need to be made on an individual basis depending on the type and frequency of seizures, as well as the level of control with medication. The aim should be to maximize participation in all age-appropriate aspects of life, whilst taking a realistic approach to risk management; err on the side of inclusion.

### Schooling

Most children with epilepsy will attend mainstream school; however, there is evidence for underachievement.


- Poor progress is associated with early age of onset and long seizure history particularly if poor control is an issue.
- Intractable seizures are often associated with disorders of cognitive function, memory or attention. Neuropsychometry is recommended to define educational strengths and weaknesses and aid tailoring of educational support.
- Dominant hemisphere disturbances are likely to affect language-related skills.
- Other mechanisms of adverse impact on schooling include:
  - nocturnal seizures and poor sleep;
  - brief undetected epileptic discharges;
  - drug toxicity;
  - inappropriate teacher and parental expectations;
  - absence from school;
  - low self-esteem;
  - anxiety due to poor adjustment and stressors at home.

It is important that pupils with epilepsy participate fully in school life and achieve their full potential. The provisions of the Disability Discrimination Act cover children with epilepsy. Effective communication between the teacher, parents, doctor and child must exist. School staff may need training, often from an epilepsy specialist nurse.

For children with no additional physical or learning difficulties, or medical problems, the aim must be to enable full participation in school life with provisions made for their safety.

For some children, epilepsy is part of a wider spectrum of problems needing appropriate provision either in mainstream schooling with support or in a specialist educational setting.

### Education of school personnel involves

- Basic knowledge of epilepsy.
- Awareness of medical management including regular AEDs.
- First aid management including administration of rescue medication and when to call an ambulance.
- Special considerations including swimming and photosensitivity (see  p. 300).
- Awareness of potential for bullying and low self-esteem.
- Awareness of issues surrounding epilepsy and learning, and behaviour.

### Emotional adjustment


Adjusting to a diagnosis of epilepsy involves living with unpredictability. Some families also have to cope with additional 'hidden' deficits, such as language and memory problems or learning disability.

- The unpredictability of seizures erodes self-esteem and confidence. Families may prefer to live with a predictable pattern of seizures (e.g. occurring reliably first thing on waking, whilst child is still at home) than risk AED manipulations in an attempt to improve control.
- Ill-informed and prejudicial attitudes may be experienced.
- Unwanted effects of medication, e.g. weight gain or facial hair may be very detrimental to self-esteem.
- Highs and lows of successive treatment failures may be particularly hard to cope with, especially failure of epilepsy surgery.
- Anxiety, depression, agoraphobia, and suicide are over-represented in children with epilepsy.

### Responses

- Establish good communication between health, education, and the family. Consider a family-held child health care record.
- Education about epilepsy for teachers, school peers, family, and child.
- Encourage self-esteem. Avoid unnecessary restrictions.
- Minimize time off school for clinic appointments.
- Minimize disruptive responses to seizures (e.g. the school calling an ambulance followed by several hours in A&E).
- Ensure full education:
  - encourage tertiary education;
  - provide informed career advice: some careers (e.g. uniformed services) are unavailable or only available on restricted basis to people who have, or *who have ever had*, active epilepsy;
  - be aware of national policies on these issues to avoid young people experiencing refusal;
  - currently people who have had more than one seizure after the age of five are unable to enter the UK armed forces.
- Sensitive monitoring:
  - detect difficulties early;
  - detailed neuropsychological assessment.



- Avoid seizure triggers:
  - photic stimuli (flickering light sources, see  p. 300);
  - fatigue, late nights, excessive alcohol and recreational drug use are recognized triggers particularly in JME and other idiopathic generalized epilepsies.

### In and around water

- A child with poorly controlled seizures should be accompanied at all times in and around water. This includes bathing, as well as water sports.
- Showering is an alternative to bathing that will allow privacy.
- For a child with well-controlled seizures it is good practice for a designated person (with knowledge of how to manage a seizure and capable of effecting a rescue) to be in the vicinity.
- If no qualified life saver is present, then the child should not be allowed to swim any deeper than the supervisor's shoulder height.
- A 'buddy' system where all children swim with a partner makes the child less conspicuous.
- Although UK recreational underwater ('scuba') diving precautions are guidelines and do not have regulatory force they are likely to be applied by diving schools. They are currently very restrictive (arguably excessively so) and require an individual to have been seizure-free off medication for 5 yrs.

### Cycling

A child with poorly controlled seizures should cycle away from traffic under supervision. As for any cyclist, a helmet should be worn!

### Photosensitivity

Misinformation frequently leads to unwarranted restriction of information technology (IT) lessons and other computer-based activity.

- Photosensitivity is uncommon (5% of children and adolescents with epilepsy). Of these, about 40% only ever have photic-induced seizures.
- Identified by the advent of a triggered seizure or on photic stimulation during a standard EEG.
- Sources include natural (e.g. sunlight on water, travelling past sunlit trees) and artificial (e.g. TV, strobe) sources of flickering light.
- Typical provoking flicker rates are 10–50 Hz. Screen 'refresh rates' of older cathode ray tube type TVs (with prominent 'bulge' on back of set!) are in this range and pose a potential trigger source. ► However, nearly all computer monitors—even the cathode ray tube type—have much higher refresh rates that are safe. LCD (flat screen) and plasma TV screens are flicker free. Thus there is no need to limit access to IT lessons at school.
- Some seizures occurring during computer games may result from repetitive/geometric patterns in the image, or excitement, arousal, or fatigue, rather than display flicker.
- Nearly all patients with clinical pattern sensitivity show photo-paroxysmal responses on testing.
- Aim to reduce the intensity of the flickering light source relative to other steady illumination. Watch cathode ray tube type TV in

a well-lit room. Consider putting a small lamp on top of the set. Avoid getting too close to the screen: use the remote control. If it is necessary to approach the TV, cover one eye. Take regular breaks and avoid tiredness.

### Alcohol

- Excessive alcohol can cause seizures particularly in juvenile myoclonic and other primary generalized epilepsies.
- The frequency of seizures is increased in the 'hangover' period.
- However, abstinence not required!

### Driving

- Current UK legislation requires 12 mths' seizure freedom (with ongoing AED treatment if necessary) or 3 yrs' demonstration of a seizure disorder's restriction to sleep, before an ordinary driving licence can be given.
- Occurrence of a seizure resets the clock and driving must be suspended until event free for a further 12 mths.
- Some specialist vocational driving licences (bus, coach, heavy goods vehicle) require the driver to have been event free and off medication for 10 yrs.
- Legislation applies to any cause of paroxysmal events (e.g. recurrent syncope) not just epilepsy.
- Similar legislation applies in other countries.

### Contraception and reproductive health

- ► Enzyme-inducing AEDs (carbamazepine, topiramate, phenytoin, phenobarbital; see [p. 619](#)) enhance the clearance and reduce the effectiveness of the standard oral contraceptive pill (OCP) and a high-oestrogen OCP should be used.
- ► Consider using the high-oestrogen OCP semi-continuously (e.g. with a one week break only every third month).
- OCPs and contraceptive patches may increase clearance of lamotrigine: dosage increases may be advisable.
- Polycystic ovarian syndrome and menstrual irregularity appear to be a risk with valproate use; however, the mechanism involves weight gain and most young women ask to discontinue valproate anyhow if significant weight gain is occurring.
- Many AEDs have recognized teratogenicity profiles (e.g. foetal phenytoin and valproate syndromes; neural tube defects with valproate). The at-risk period for the foetus is early, quite possibly before pregnancy will have been recognized.
- Important recent data suggest significant adverse effects on verbal and performance IQ in children exposed to AEDs (particularly valproate) *in utero*. The effect may be dose dependent, so reducing dose, rather than discontinuing drug may be an option.
- There are therefore several separate grounds for questioning the use of valproate in young women of reproductive age, although the apparent 'safety' of alternatives, such as lamotrigine may simply reflect lack of accumulated experience.


- Lamotrigine appears less effective than valproate in JME, an important indication for continuing AED use in young women planning pregnancy.
  - The appropriate course of action for a young woman with epilepsy wishing to conceive depends on individual consideration of:
    - risks of discontinuing, reducing or changing AED in light of epilepsy syndrome;
    - risk to foetus of maternal seizures (especially convulsive status epilepticus);
    - options for mitigating risks of foetal exposure to AEDs (e.g. periconceptual high-dose folate use).
- ❗ Optimal management requires prospective planning: above all avoid unplanned pregnancy.

### Air travel

All regular and rescue medication is to be carried on the person, including a GP letter to explain to customs if necessary.

### Death in epilepsy

Epilepsy-related death in a child may be due to:

- Complication of seizure, e.g. aspiration, suffocation, injury or drowning.
- Convulsive status epilepticus.
- Related underlying condition, e.g. neurodegenerative disease or CP.
- SUDEP (see  'SUDEP', p. 302).

Risk factors for epilepsy related death:

- Epilepsy with onset in the first 12 mths of life.
- Symptomatic or secondary epilepsy, e.g. cerebral malformation.
- Severe myoclonic epilepsies of infancy and early childhood.
- Infantile spasms treated with steroids.
- Severe developmental delay present at the onset of epilepsy.

### SUDEP

Defined as a sudden, unexpected, non-traumatic and non-drowning death in children with epilepsy, with or without evidence for a seizure, excluding documented status epilepticus, in which a post-mortem examination does not reveal a toxicological or anatomical cause for death. Tentative explanations include primary or secondary cardiac arrhythmias and/or a primary respiratory dysfunction.

For bereaved relatives, the shock of SUDEP is often greater because they had not realized this could occur. They may also implicitly believe that the death could have been prevented. When and how to raise these matters with children and their families requires careful clinical judgement—the concern is for the potential negative effects on active participation in life of increased anxiety, more restrictive supervision and possible demands for more aggressive AED treatment. It is clear that the very large majority of paediatric epilepsy-related deaths are in children with significant associated neurodisability: in this group there is likely to be greater prior recognition of the presence of a life-limiting situation. The exact rate of SUDEP is still unknown but in children with idiopathic epilepsies with no additional neurological problems is likely to be of the order of 1 per 10,000 patient years.

Increasingly families bring up this subject themselves-sometimes at first consultation. Concise factual data to inform but not frighten families is a constructive approach. If appropriate comparative realistic rates of other causes of death in children and in the general population may bring things into perspective. For example, 29 children in the UK died from acute severe asthma in 2008.

*Risk factors for SUDEP*

- Young adult male.
- Early age of onset of seizures.
- GTC seizures.
- Increased frequency of seizures.
- Polytherapy and poor adherence to AED treatment.

## Non-epileptic paroxysmal phenomena

As emphasized in Chapter 3 (see Table 3.5), paroxysmal episodes in children have a wide differential diagnosis and misdiagnosis is an ever-present risk. Hazards of a false-positive diagnosis of epilepsy include exposure to unnecessary investigations, but more particularly treatment failure. It is important to be familiar with the wide range of non-epileptic processes that can give rise to paroxysmal or episodic signs or symptoms.

❗ The most important example of the reverse error (mistaking an epileptic condition for a non-epileptic one) arises in the context of frontal lobe epilepsy (often nocturnal) being mistaken for night terrors (see Box 4.11).

### Episodes without prominent alteration of awareness

The following conditions are arranged in approximate order by the age at which they are most commonly seen.

#### *Benign neonatal sleep myoclonus*

A healthy infant presents at a few weeks of age with quite dramatic myoclonic movements confined entirely to sleep. The jerks, which can be quite violent, typically occur in flurries and migrate, involving first one limb and then another in clusters of a few per second. The child is not woken or distressed by the episodes and the abnormal movements do not involve the face. They may be precipitated by gently rocking the sleeping infant.

Whilst the diagnosis can usually be made from history, it is important to ensure that ictal EEG is normal. No treatment is required: the phenomenon stops automatically, usually within a few months and there are no long-term neurodevelopmental implications.

#### *Gastro-oesophageal reflux*

Gastro-oesophageal reflux disease (GORD) enters the differential diagnosis of paroxysmal disorders in two ways. Occult GORD in an infant is an important cause of apnoea, a phenomenon for which epileptic aetiologies are also sometimes considered.

In older children, particularly children with significant neurological disability (but not confined to this group), GORD can precipitate episodic dystonic movements resulting in bizarre posturing particularly of the head and neck, a condition sometimes described as Sandifer syndrome.

#### *Shuddering spells*

This is a common, under-recognized variant of normal infant behaviour. Presenting the child with an interesting or novel object such as a toy (or dinner!) typically precipitates episodes. The child typically holds his or her arms out and shows an involuntary shiver or shudder sometimes involving most of the body.

The condition is entirely benign and requires no intervention.

#### *Hyperekplexia*

This is a rare differential of neonatal seizures in its severe form. Typically due to mutations in glycine receptor genes, with failure of inhibitory neurotransmission, it causes a marked susceptibility to startle. Sudden sounds, and particularly being touched or handled, precipitate episodes of severe total body stiffening. In the severe neonatal forms, these can result in life-threatening apnoea.

Tapping the nose is a particularly sensitive stimulant for this phenomenon and is a useful bedside test. The spells (and apnoea) can be terminated by forcibly flexing the neck: a manoeuvre family and carers should be taught. Event severity tends to lessen with time and so long as hypoxic complications are prevented, prognosis is good. Treatment is with valproate and clonazepam. Recessive and dominant forms are known.

#### ***Paroxysmal tonic upgaze of infancy***

This involves prolonged episodes lasting hours at a time of sustained or intermittent upward tonic gaze deviation, with down-beating nystagmus on down gaze. Horizontal eye movements are normal and the phenomenon disappears in sleep. The onset is usually before 10 mths of age. The episodes may worsen with fatigue or intercurrent illness. The diagnosis is one of exclusion, and demonstration of normal MRI is required. The condition tends to resolve by approximately 3 yrs of age. L-DOPA may be effective if indicated.

#### ***Benign myoclonus of early infancy***

This is a rare disorder of early infancy with spasms closely resembling those of West syndrome. Onset is between 1 and 12 mths, and movements settle by the end of the second year. A presumptive diagnosis of West syndrome is commonly made before it becomes apparent that the EEG is normal between and during the episodes.

Long-term neurological development is normal.

#### ***Benign paroxysmal torticollis***

This condition is rare. Recurrent episodes of cervical dystonia occur resulting in a head tilt or apparent torticollis. Events typically last several hours to a few days in duration and are accompanied by marked autonomic features (pallor and vomiting). The condition typically starts in infancy, resolving within the pre-school years, but such children often go on to develop hemiplegic migraine in later life. There is usually a family history of (hemiplegic) migraine and many cases are associated with calcium channel mutations.

#### ***Benign paroxysmal vertigo***

This resembles benign paroxysmal torticollis. Children present with sudden onset signs consistent with vertigo (poor coordination and nystagmus). The picture, however, is dominated by an impression of fear and distress. Children are often strikingly pale and may be nauseated and distressed but not encephalopathic. It may be a migraine variant (ion channel disorder).


The condition should not be confused with the similarly named benign paroxysmal *positional* vertigo, a condition of adults caused by debris in the utricle of the inner ear.

#### ***Self-comforting phenomena (self-gratification, masturbation)***

Witnessed self-comforting phenomena are common in normal toddlers, and in older children with neurological disability. A common setting is in high chairs or car travel seats fitted with a strap between the legs and with a tired or bored child. Older children often lie on the floor, prone or supine, with tightly adducted or crossed legs.

The child will typically extend the legs at the hips and press the thighs together. This may continue for prolonged periods, the child often becoming flushed and quite unresponsive to attempted interruption. The behaviour is self-limiting and no treatment is required. Parents sometimes require considerable reassurance that such behaviour is commonplace, normal and simply a source of comfort, not a sign of sexual deviancy.

### **Tics**

These are isolated 'fragments' of gestures or movements repeated compulsively, sometimes in conjunction with vocal tics as part of Tourette syndrome (see  p. 382). Older children can by definition at least briefly suppress the desire to tic, although they will often report a sense of rising tension, which only resolves by 'releasing' the movements.

### **Ritualistic movements and behavioural stereotypies**

These are relatively common in young children and older children with neurological disability particularly autistic spectrum disorders.

### **Hyperventilation and anxiety attacks**

The respiratory alkalosis resulting from hyperventilation is a potent cause of sensory phenomena (particularly peri-orally) and tetanic contraction of the muscles of the forearm and hand resulting in carpopedal spasm. Severe hyperventilation can sometimes result in syncopal collapse.


### **Episodic ataxia type 1**

This is caused by a potassium channel gene (*KCNA1*) mutation. Onset of paroxysmal attacks is from 5 yrs of age; sudden weakness, unsteady, and blurred vision, lasting minutes to hours. The child will eventually develop myokymia.

### **Episodic ataxia type 2**

Onset is in later childhood and the cause is calcium channel gene (*CACNA1A*) mutation. Unsteadiness and ataxia are associated with nausea and vomiting. Attacks become milder and less frequent with age, but cerebellar signs may persist (cerebellar vermis atrophy on imaging); usually acetazolamide responsive.

### **Paroxysmal dyskinesias**

A range of individually rare paroxysmal movement disorders is recognized including paroxysmal dystonias and choreoathetosis. They are generally grouped into kinesiogenic (movement induced) and non-kinesiogenic forms. The former are generally considerably shorter in duration and respond to AEDs (see Table 4.5). Dyskinesias occurring before meals or after fasting should raise suspicion of glucose transporter deficiency (see  p. 282).

### **Secondary paroxysmal movement disorders**

Paroxysmal dyskinesias can arise as a result of drugs (phenytoin, gabapentin), ABI (trauma, stroke, infections, perinatal hypoxic-ischaemic injury), metabolic disease (hypoparathyroidism, thyrotoxicosis, maple syrup urine disease, non-ketotic hyperglycaemia) and infections (HIV-AIDS, SSPE).

They generally respond to AEDs.

**Table 4.5** Paroxysmal dyskinesias: phenotypes and treatment

	<b>Paroxysmal non-kinesiogenic dyskinesia</b>	<b>Paroxysmal kinesiogenic dyskinesia</b>	<b>Paroxysmal exercise-induced dyskinesia</b>	<b>Paroxysmal hypnogenic dyskinesia</b>
Movement	Dystonia or choreoathetosis. May be unable to communicate during episode. Episodic ataxia	Dystonia often with prodromal sensation. May have chorea or ballismus.	Dystonia or chorea	Dystonia, chorea or ballism
Localization	Face, limbs, either unilateral or bilateral.	Legs, unilateral	Leg, unilateral, or arm if being exercised	Any, generalized, REM sleep
Duration	Minutes–hours	Seconds to <5 min	Minutes	Minutes
Frequency	3/day to 2/yr	100 s/day	2/day to 1/month	5/night to 5/yr
Age of onset	Infancy	Infancy to 30 s	Childhood	Childhood
Inheritance	Autosomal dominant	Autosomal dominant? Autosomal recessive	AD, sporadic	Heterogeneous
Male:female ratio	2:1	4:1	1:4	Variable

(Continued)



**Table 4.5** (Continued)

	<b>Paroxysmal non-kinesiogenic dyskinesia</b>	<b>Paroxysmal kinesiogenic dyskinesia</b>	<b>Paroxysmal exercise-induced dyskinesia</b>	<b>Paroxysmal hypnogenic dyskinesia</b>
Treatment	Clonazepam Valproate May be refractory	Carbamazepine (sensitive to very low doses) Phenytoin	Clonazepam, but may be refractory L-DOPA Acetazolamide	Short attacks usually responsive to CBZ, VPA or LEV. Longer attacks may respond to L-DOPA or acetazolamide
Precipitants	Fatigue, alcohol, caffeine, vibration	Sudden initiation of movement	Prolonged exercise, cold, stress	REM sleep

CBZ: carbamazepine; VPA: valproate; LEV: levetiracetam.


## Episodes with altered awareness

### *Syncopal mechanisms*

Involves loss of awareness due to a temporary inadequacy of cerebral blood flow. There is prominent early pallor. As stressed in Chapter 3, 'seizure-like' jerking limb movements and even incontinence of urine can result in the late phases of a syncopal episode, raising the risks of a misdiagnosis of epilepsy. The context in which the episode occurred and its earliest features are the most telling.

### *Cardiac disease*

The importance of correctly identifying an intermittent cardiac dysrhythmia or structural cardiac disease as the cause of episodic loss of awareness is self-evident. Historic clues will include the relationship to exercise and, as stressed, prominent early pallor.

- ▶ Any apparent syncope coming on in a lying position must be presumed to be cardiac in origin until proven otherwise.
- ▶ A history of exertional syncope should prompt search for prolonged QT syndromes (see  p. 309) but also (hypertrophic obstructive cardiomyopathy (HOCUM)), particularly if there is a family history (dominantly inherited). Note that ECG is insensitive to the presence of cardiomyopathy and echocardiography is required if this is suspected.

### *Reflex anoxic seizures/reflex asystolic syncope*

The term reflex asystolic syncope (RAS) has replaced 'reflex anoxic seizure' as it better conveys the fundamental mechanism. The phenomenon has also been referred to as pallid syncope and in the old paediatric literature extremely confusingly as a pallid breath-holding spell (a complete misnomer for reasons that should be apparent).

In understanding the process, it is helpful to realize that children with RAS grow into adults who faint at the sight of needles and blood. A sudden unexpected shock or pain results in a vagally mediated severe bradycardia or even asystole with consequent hypotension, pallor and loss of consciousness that may then lead to episodes of limb stiffening or clonic jerks. An accurate history identifies the triggers that consistently precede these episodes.


Episodes are self-limiting and generally require no specific treatment. Children should be evaluated by 12-lead ECG to exclude prolonged QT syndrome. Occasionally, severely affected children have come to cardiac pacemaker implantation.

- ▶ Long QT syndromes are estimated to have prevalence in the UK of between 1 in 2000 and 1 in 3000.
- *Long QT1*: associated with exercise, particularly swimming, with fairly frequent events, but a relatively low risk of sudden death.
- *Long QT2*: events occurring in response to emotional stress or auditory stimuli such as alarm clocks.
- *Long QT3*: events occur at rest and have a higher mortality.

*Vaso-vagal syncope*

In older children, this is probably the condition most frequently misdiagnosed as epilepsy. Common triggers include intercurrent illness, hot weather, missed meals, inadequate fluid intake, and prolonged standing. It is typically a disease of adolescents who will be able to report a prodromal awareness of feeling cold, clammy, and unwell. They may be able to report sounds becoming distant or their vision 'greying out'. If the event is not terminated by lying down in the prodromal phase, the child goes on to fall stiffly to the ground or slump, and may exhibit brief tonic or clonic movements, or urinary incontinence.


*Blue (cyanotic) breath-holding attacks*

There has in the past been a lot of confusion between this and RAS (see  p. 309). They are quite distinct processes. RAS is a cardiac phenomenon. Blue breath-holding spells are primarily hypoxic in origin due to disordered respiration. Typically, a toddler who has become angry or frustrated begins to cry and becomes 'stuck' at the end of a period of prolonged sobs (i.e. the condition is more accurately described as a prolonged end expiratory apnoea). As a result, the child becomes predominantly *blue*, limp, and may briefly lose consciousness; again, this may result in subsequent jerking limb movements.


*Daydreaming*

Daydreaming enters the differential of absence seizures as a cause of 'vacant spells'. The history often differentiates the two. Daydreaming typically occurs when bored, tired, or absorbed in watching a TV, and is characterized by reports from a parent or teacher of 'having to call his name three times before he responds'. The flavour is very different from absence or other seizure that actively interrupts and cuts across normal activity.

*Non-epileptic attacks*

Non-epileptic attack disorder (NEAD) (formally known as pseudo seizure; US usage: non-epileptic paroxysmal event) is a common and important differential of generalized seizures occurring usually in girls. It is common for the onset of NEAD to be quite explosive with urgent requests to see an adolescent with a sudden and dramatic onset of tens of episodes per day. They are typically briefer and less stereotyped than true epileptic seizures. Movements may include pelvic thrusting, rolling or reciprocating kicking or flailing movements. None of these occur as part of the repertoire of a generalized tonic-clonic seizure. Typically there is a lack of postictal drowsiness or confusion. Confirmation of the diagnosis may require videotelemetry particularly as it is not uncommon for NEAD to co-exist with genuine epileptic seizures in the same child. Pseudo syncope ('swooning') is a similar condition. Sexual abuse has been seen in association with this condition, so stay alert! See  p. 311.

*Narcolepsy and cataplexy*


Narcolepsy is an under-recognized cause of excessive daytime sleepiness (see  p. 443). Cataplexy is a sudden loss of muscle tone typically precipitated by laughter or startle that is a common feature of narcolepsy particularly by early adulthood (although there are other causes).

## Functional illness

Children presenting with symptoms or signs that are not of a conventional pathophysiological origin are well recognized in many paediatric subspecialties, and paediatric neurology is no exception. Recognition and appropriate management of functional symptoms is an important skill for the child neurologist. There are some adult data suggesting that pre-existing brain disease increases the risk of functional symptoms, but little evidence that neurological presentations are more common than other presentations of functional disease.

### Terminology

- This is a sensitive and important issue if a successful outcome is to be achieved. It is important to be aware that families may be accessing professional or patient support group material on the internet, and they need to understand that, although a variety of terms are in widespread use they are referring to essentially the same clinical problem.
- Terms include 'conversion disorder', 'psychogenic', 'dissociative', 'pseudoseizure', 'medically unexplained symptom', 'non-epileptic attack disorder', and 'hysteria'.
- Individual perceptions of the acceptability or offensiveness of particular terms will vary ('hysterical' is generally unhelpful but for families with no interest in classical Greek the term 'pseudoseizure' may not be as offensive as might be anticipated).
- In the particular context of seizures the terms non-epileptic seizure and non-epileptic attack disorder are in widespread use. 'Conversion disorder' is used in the *Diagnostic and Statistical Manual of Mental Disorders*, 4<sup>th</sup> edn (DSM-IV), and both 'conversion' and 'dissociation' in the International Classification of Disease, V. 10 (ICD10).
- The phrase 'medically unexplained' whilst accurate may engender lack of confidence in the physician and therapeutic process.
- It is important to convey to both child and family that ultimately the events are being driven by psychological stress (of which they may not be consciously aware). It may be helpful to refer to the understanding implied in the term 'conversion' that anxiety can be converted into physical symptoms.
- The concept of 'illness behaviour' can sometimes help: there are few people who have not had an extra day off school following an illness who are 'behaving ill' but actually have the choice to behave well—in that it would be physically possible to do so.

Although psychiatric diagnostic schemes emphasize distinctions between deliberate and subconscious intent, and possible motivations (e.g. 'secondary gain') as theoretically important, these are difficult distinctions to make in individual situations. Generally, such distinctions are not relevant to successful resolution (see  p. 313) although legal issues may occasionally arise in the context of clear-cut malingering.

► Functional symptoms frequently co-exist with organic brain disease, e.g. functional seizures in children with organic epilepsy.

► Onset of symptoms can often be linked to an initial organic event, e.g. a severe syncope or migraine, particularly if the index event occurred in an unusual setting or manner, or provoked a dramatic response from others.

### Presentations and diagnosis

Functional symptoms in neurology may include weakness or paralysis, numbness or pain, disturbed gait or balance, and seizures. Diagnostic pointers to functional basis include the following:

#### Paralysis

- Variable loss of function.
- *Hoover sign*: the examiner places his hand under the heel of one foot as the child lies supine and is asked to raise the other leg off the bed. Even if the movement is not performed there is usually an involuntary postural adjustment anticipating the lifting of the leg, felt as increased downward pressure of the held heel into the couch, which would not occur if legs were truly paralysed.
- Collapsing weakness, ipsilateral sternocleidomastoid weakness, lack of ipsilateral facial weakness, weakness with normal tone and reflexes.

#### Gait and stance

- Variability.
- Dragging an everted or inverted foot.
- Excessively slow movement.
- Romberg test 'positive' with the child always falling toward examiner irrespective of position.
- Unsteadiness of stance may be no worse with eyes closed compared to eyes open (i.e. not true Romberg's).
- Uneconomical gait.
- Walking 'as if on ice'.

#### Sensory

Whole limb anaesthesia, hemisensory loss for all modalities to the midline.

#### Seizures

- Contextuality (e.g. happening predominantly at school), precipitated by an immediate stressor.
- Long duration (e.g. >5 min), waxing and waning activity during the event.
- Presentation as seizure status, or prolonged limp unresponsiveness.
- Reciprocating movements (including side to side movements of the head and alternating rather than synchronous movements of the limbs).
- Pelvic thrusting.
- Ictal or postictal crying.
- Partial responsiveness during events.
- Closed eyes/resistance to eye opening, unexpectedly rapid recovery.

(Adapted with permission from Reuber M, Mitchell AJ, Howlett SJ, Crimlisk HL, Grünwald RA. (2005). Functional symptoms in neurology: questions and answers. *J Neurol Neurosurg Psychiatr* **76**: 307–14.)

#### Suggested language

'This is a temporary problem that occurs in children who are under stress/are badly upset/etc'. Emphasize that we see this commonly in paediatric neurology practice ('I know what I'm talking about') and the outcome is generally excellent. To children it may be appropriate to talk about being able to 'learn to control' these symptoms and offering to help teach this.

## Therapeutic principles

- Establishing that symptoms or signs are functional is the beginning, not the end, of the child neurologist's role.
- With experience, recognition that symptoms are functional is often relatively straightforward and can be made with some confidence. It is rare for a functional diagnosis to be subsequently revised to a somatic condition. Probably the most problematic areas relate to unwitnessed seizures (video footage or direct observation are often extremely helpful), and bizarre postures that may turn out to be dystonia.
- Pursuit of diagnostic 'certainty' through over-elaborate investigation may create further iatrogenic anxiety and delay or even prevent the family's engagement with psychosocial issues.
- Explicitly address the feelings of irritation or anger that these children can evoke in all members of the team as 'time wasters'. Such feelings are rapidly sensed by families and tend to exacerbate and perpetuate symptoms.
- Functional symptoms are well recognized in victims of child sexual abuse: such experiences should not be deliberately asked after through leading questions (certainly not by trainees); however, all staff should be prepared for the possibility a young person might disclose such experiences (perhaps to a relatively junior member of the team) and be ready to respond.
- Look forward, not backwards: it is more constructive, and often easier to achieve consensus between child, family and professionals, if discussion focuses on where one wants to be in x months time, rather than how the present situation arose.
- Establish any specific fears the child or family may have as to what the symptoms may represent and explain how these can be discounted.
- Earn acknowledgement by the child and family that you have 'heard' and understand any psychological, emotional or other current pressures.
- Acknowledge the possibility of an organic 'kernel' to symptoms (e.g. migraine, syncope) whilst stressing if appropriate that it is not responsible for the majority of symptoms. In the case of functional seizures, keep open the possibility that a (small) proportion of events may be due to epilepsy.
- Consider the appropriateness of continuing to see them in neurology outpatients. Potential advantages include acknowledgement of the 'legitimacy' of the symptoms, the frequent co-occurrence of organic disease (requiring ongoing specific management) and reassures that the functional diagnosis and possibility of organic alternatives will be regularly reviewed. In some situations however it may be more appropriate to hand over ongoing management to other services.
- Acute presentations promptly and appropriately managed may not require child psychiatry involvement; however, skilled child psychiatry input is invaluable in severe or prolonged cases.
- If possible copy all correspondence to the family to avoid perception (and reality) of agencies 'talking behind the family's back'. Be particularly careful to respect confidentiality in discussions with the school.

- Prolonged school absence creates specific considerations. There is a statutory legal requirement in UK for children under 16 yrs to receive schooling and educational agencies may be seeking to apply legal sanctions for truancy.
- Identify if absence/exclusion from school is being instituted by family or school.
- Identify perceived reasons for absence/exclusion from school. Perceptions of the illness by other professionals involved with the child need to be addressed, e.g. legal, health, and safety concerns of school staff to allow school re-integration; local therapy teams; local child and family mental health team; social services.

A multidisciplinary physical-psychosocial-schooling rehabilitation approach as used in children with acquired brain injuries may be useful for complex situations.

### Chronic fatigue syndrome

Many of the principles described apply to chronic fatigue syndrome or myalgic encephalomyelitis (CFS/ME). Although the nosological validity of the term 'myalgic encephalomyelitis' has been questioned (i.e. lack of good evidence of an inflammatory basis), the term is in common usage.

Many activists and patient groups resent any suggestion of psychological contributions to causation or prolongation of symptoms for whom an organic (e.g. post-viral) basis is seen as a *sine qua non* of the validity of the disease. It is, however, genuinely a medically unexplained condition where it is generally easier to agree on 'where we want to be' than 'how we got here', and in which medical investigation should be kept to a reasonable minimum whilst the situation remains under regular clinical review to ensure diagnostic confidence.

Ironically, controversy is greatest over some treatment approaches with the strongest evidence base (in adults) such as graded exercise and cognitive/behavioural therapy (CBT). In practice, CBT is less relevant to children. The controversy amongst some support groups about graded exercise relates to understandable fear of over-exhaustion and setback. In practice these fears can be explicitly addressed and review arrangements agreed.

More detailed guidance is available from the Royal College of Paediatrics and Child Health (RCPCH).

### Factitious or induced illness

The term factitious or induced illness (FI) refers to the range of ways in which the healthcare system can be manipulated to harm children, with healthcare workers unwitting instruments of the harm. FI is preferable to previous terms including 'Munchausen syndrome by proxy'. The phenomenon cannot be regarded as a 'syndrome' in the sense of a characteristic clinical picture that of itself implies a causative mechanism. There are pointers that are suggestive, but none are intrinsically diagnostic and there is always a differential diagnosis. The clinical aspects can vary widely, and the conclusion that they are due to FI can only be reached after careful multidisciplinary assessment.

A spectrum of problems exists from fictitious (reporting something that is not occurring), through fabrication of documentation and charts, to direct induction of symptoms or signs in a child.

FII can present to most if not all paediatric subspecialties. Common neurological symptoms include reported seizures, collapse, drowsiness, and developmental delay.

Verbal fabrications are much more common than induced physical signs of illness: this poses particular problems in the context of reported seizures, which by their nature are typically unobserved. Lack of independently observed seizures (e.g. at school), demonstrated non-adherence to drug treatment (e.g. prescription refill records, undetectable blood levels) and repeatedly normal EEGs despite descriptions of aggressive epilepsy may all raise concerns. However, as with non-epileptic attack disorder (see [□□](#) p. 310) FII and genuine epilepsy can co-exist, perhaps in up to 5% of cases.

The long-term effects on children (e.g. as future parents) of distorting understandings of themselves and health and illness (even if the situation is not likely to lead to serious immediate harm such as surgery) are unclear.

### **Thinking the unthinkable**

The possibility of FII has first to be entertained, if only to be discounted. FII often implies a *folie à trois* between child, parent, and misled professional, and it can be uncomfortable to acknowledge that one has been deceived. Any senior professional will, however, acknowledge that it has happened to them. The key is a story that does not hang together: symptoms not congruent with known diseases; symptoms, signs, and investigation results that do not correlate treatments that do not produce the expected results. Repeated presentations to multiple specialties, the reporting of new symptoms following resolution of the previous ones and particular reported symptoms (stopping breathing, loss of consciousness, seizures, choking, or collapse) are concerning.

If you have concerns as a trainee under supervision, these must be discussed with the child's named paediatrician at the earliest opportunity.

### **Initial concerns: questions to ask yourself**

- Are there child welfare concerns that might explain discrepancies in the child's symptoms or response to treatment?
- Is it clear that factors other than natural disorders may be operating?
- What are the needs of the child?<sup>1</sup>
- Is the child coming to quantifiable harm?
- Are the parents able to respond appropriately to the child's needs?  
Is the child being adequately safeguarded from significant harm, and are the parents able to promote the child's health and development?<sup>1</sup>
- Is action required to safeguard and promote the child's welfare?<sup>1</sup>

The 2009 RCPCH document *Fabricated or Induced Illness by Carers (FII): A Practical Guide for Paediatricians* suggests additional 'warning signs':

- A carer reporting symptoms and observed signs that are not explained by any known medical condition.
- Physical examination and results of investigations that do not explain symptoms or signs reported by the carer.

<sup>1</sup> DCSF (2010). Working together to safeguard children: a guide to inter-agency working to safeguard and promote the welfare of children. HMSO London. Available at: <https://www.education.gov.uk/publications/eOrderingDownload/00305-2010DOM-EN.pdf>



- The child having an inexplicably poor response to prescribed medication or other treatment, or intolerance of treatment.
- Acute symptoms that are exclusively observed by/in the presence of the carer.
- The carer reporting new symptoms on resolution of the child's presenting problems.
- The carer reporting symptoms in different children in sequence.
- The child's daily life and activities being limited beyond what is expected due to any disorder from which the child is known to suffer, for example, partial or no school attendance and the use of seemingly unnecessary special aids.
- Objective evidence of fabrication.
- The carer expressing concern that they are under suspicion of FII, or relatives raising concerns about FII.
- The carer seeking multiple opinions inappropriately.

### **Persisting concerns**

If concerns cannot be allayed, further assessment is mandatory. Procedures will vary by jurisdiction, and local policies should be followed, but it is clear that adequate assessment must involve other agencies able to evaluate concerns in the context of familiarity with the wider family background.

### **Specific investigations**

#### *Suspected hypoglycaemia*

- If hypoglycaemia is suspected or documented, measure true blood glucose (fluoride oxalate) and draw 2 mL of blood (in lithium heparin or serum) for C peptide and insulin. High insulin/low C peptide implies administration of exogenous insulin.
- Insulin/C-peptide samples have to be handled urgently: speak to on-call biochemist.
- 'Rebound' hyperglycaemia may occur after hypoglycaemia.


#### *Suspected intoxication*

- 'Blind' toxicology screens are unhelpful. The preferred sample (blood, urine) and handling requirements depend on the substance of interest.
- Collect all urine samples voided within 6 h of any collapse, and any vomitus or other samples available in plain containers. Arrange for their accurate labelling and careful freezing and storage to enable retrospective analysis if concerns regarding a particular intoxicant arise.

#### *Seizures*

- Prolactin levels typically rise after significant tonic-clonic seizures but may not, so that the value of normal levels is limited. Sample needs to be collected within 15 min (which severely limits their usefulness) and compared with a control sample taken exactly 24 h later (to allow for the normal circadian rhythm in the levels).
- Repeated prolonged/video EEGs may be required.

# Headache

Classified by the International Headache Society according to whether the headache is Primary or Secondary (to a defined disease process), by far the most common of headache types in childhood are migraine, tension-type headache or a difficult to classify hybrid of the two (see  p. 321).

## Migraine

### Epidemiology

Getting at least one migraine per year:

- 3% of all children 7–10 yrs.
- 3.5% of boys 11–15 yrs.
- 6% of girls 11–15 yrs.

Migraine is the most common cause of intermittent headaches in children. A female excess occurs after puberty.

### Pathophysiology

The pathophysiology of migraine remains very poorly understood. Previous vascular hypotheses of vasoconstriction and dilation have been discredited.

### Genetic factors

50–80% of children will have a parent with a migraine variant (which may have waned by the time a parent is interviewed, so a lack of a current headache history may be misleading). A family history of motion and travel sickness is also more common. A minor allele of *rs1835740* on chromosome 8q22.1 has been associated with migraine in a genome-wide association study. Migraine without aura probably multifactorial with genetic and environmental factors.

Single gene aetiologies have been identified in some rarer migraine subtypes. About 50% cases of familial hemiplegic migraine are associated with mutations of *CACNA1A* and 20% with *ATP1A2*. These and other findings suggest a channelopathy may compromise neurotransmitter homeostasis causing aura and other neurological manifestations of childhood headache.

### The trigeminal innervation

Large cerebral vessels, pial vessels, venous sinuses and dura mater are innervated by small diameter myelinated and unmyelinated neurons serving nociception. Cortical spreading depression may activate trigeminal neurons (especially ophthalmic division) to release substance P and calcitonin gene-related peptide, leading to sterile neurogenic inflammation, and plasma extravasation with mast cell degranulation and platelet aggregation. This causes trigeminal area allodynia (perceived pain from a normally non-painful stimulus), sensitization of thalamic neurons and a disordered central nervous system response.

Involvement of the trigeminal nucleus with the dorsal horns of C1 and C2 (remember how long the nucleus is!) means upper cervical neuronal activation may activate intracranial blood vessel neurones and vice versa. Thus, pain may be bilateral and frequently in the back of the head.

**Diagnosis**

- ❗ 'Red Flag' features that must trigger urgent imaging to rule out raised ICP.
- ❗ Headache worse lying down, bending over, or with coughing or straining.
- ❗ Visual symptoms on bending over, coughing, straining etc.
- ❗ Persistent, or morning, nausea or vomiting
- ❗ Symptoms that are progressively worsening over days to weeks with no, or increasingly rare, symptom-free intervals.
- ❗ Being woken at night by headache (note the difference between this and headache present on or soon after awakening which is not uncommon in migraine).
- ❗ Any change in personality, behaviour or educational performance.
- ❗ Any abnormality on physical examination to include field defect, short stature or cranial bruit; cerebellar signs or fundoscopic signs of raised intracranial pressure.



Usually, there are no red-flag features, and no physical signs. The episodes have a distinct start and finish and the child is well in between. At this point consider a primary headache syndrome.

The current IHS Classification recognizes 100 headache types in 14 groups! In practice the common primary headache types are:

- *Tension-type headache*: despite its name (and previous variations such as tension, and tension-like) there is no evidence of a primary psychological cause or any role for scalp muscle contraction, and it is now regarded as a type of primary headache. Episodes lasting minutes to days; the pain typically bilateral and mild/moderate intensity; no nausea but photo-/phonophobia may be present.
- *Migraine without aura* (previously known as common migraine): seen in approximately 80%. In children episodes may last 1–72 h, the headache is commonly bilateral. Occipital headache is unusual.
- *Migraine with aura* (previously known as classical migraine; and now encompassing the various recognized forms of migraine with focal neurological features such as ophthalmic, hemi-paraesthetic, hemiplegic or aphasic migraine and other 'complicated' migraines):
  - The aura lasts 5–20 min before headache onset and can be the sole manifestation of the episode. Aura is usually visual, flashing, sparkling or shimmering lights; fortification spectra (zigzags); black dots, and/or scotomata (field defects). Rarely there is distortion of size (micropsia/macropsia).
  - The absence of interictal signs and the frequent presence of a prodrome (tiredness, difficulty concentrating, autonomic features, etc.) is emphasized.

Migraine with aura includes complicated migraine. Clinically, these syndromes resemble transient ischaemic attacks: creating reversible focal neurological deficits lasting tens of minutes to a few hours. As such, migraine enters into the differential diagnosis of a wide range of episodic neurological symptoms and signs. In unusual situations, a diagnosis of migraine should only be entertained after adequate investigation of alternative diagnoses,

specifically exclusion of established infarction. MRI is typically entirely normal, although scattered punctate T2 hyperintensities in white matter are described particularly in adults. Prominent *autonomic* signs (nausea, vomiting, sweating, vasomotor changes in skin) are also suggestive.

- Migraine is the most common cause of third cranial nerve palsy in children (*ophthalmoplegic* migraine). Somewhat atypically these episodes may be longer (several days' duration). There is some evidence from acute MRI studies of inflammatory changes in the oculomotor nerve supporting the established use of short courses of oral steroids to shorten these attacks and reduce risk of permanent paresis.
- 'Basilar-type' migraine is characterized by symptoms referable to the posterior circulation—vertigo, ataxia, tinnitus and visual disturbance and is more often seen in the adolescent or young adult female.
- Confusional migraine is characterized by confusion and agitation, which may occur up to 15 min after minor head trauma. It may be associated with prominent expressive or receptive aphasia. A history of headache may be difficult to obtain.
- Individuals may establish a particular pattern of complicated migraine with a characteristic neurological deficit that may also be familial, in which case no further investigation of an otherwise typical episode is required. Otherwise migraine becomes a diagnosis of exclusion of alternative, more serious pathologies: see sections concerning investigation of children with arterial ischaemic stroke (see  p. 447) and confusional states (see  p. 534).

### Triggers

Migraine episodes may be triggered by a variety of factors including stress, relaxing after stress (e.g. exams), lack of sleep, excitement and menstruation. Food triggers (chocolate, hot dogs, smoked and spiced meats, Chinese food containing monosodium glutamate, cheese, cola drinks, bananas, yeast and beef extract, and wine) are less common in children than adults. Remember triggers may not consistently trigger; the child's threshold for the migraine bouts will anyway show periodicity.


### The childhood periodic syndromes

Recurrent disorders regarded as migrainous in that they commonly precede the establishment of a more conventional migraine picture. Symptom complexes may overlap. The child is well in between episodes:

- Cyclical vomiting describes recurrent stereotyped episodes of vomiting and intense nausea associated with pallor and lethargy.
- Abdominal migraine describes episodic midline abdominal pain of moderate to severe intensity lasting 1–72 h, associated with vaso-motor symptoms, nausea, and vomiting.
- Benign paroxysmal vertigo of childhood, a heterogeneous disorder describing recurrent brief episodes of vertigo occurring without warning and resolving spontaneously (see Figure 1.1). Between episodes, normal neurological examination, audiometric, and vestibular function tests.

### Chronic daily headache

Reported in 0.9% of UK children and up to 4% in the USA with a girl: boy ratio of 3:1. Where symptoms were being experienced at least 15 days a month averaging two hours per day for more than three mths. Almost 75% had chronic tension type headache and nearly 7% had chronic migraine. These families present a diagnostic and management challenge.

- Consider space-occupying lesions and idiopathic intracranial hypertension (further investigation may be required).
- With shorter histories consider chronic lymphocytic meningitis.
- One common formulation is that a physical symptom is being experienced as a result of mental health issues, particularly anxiety or depression, or illness behaviour. To help the latter explore whether the child is in a predicament of some sort, either at home or school. Once identified a way out of illness behaviour can usually be found (see  p. 311).
- Migraine prophylaxis and/or amitriptyline may be a useful adjunct alongside psychological approaches.

Chronic analgesia over-use headache may be an important factor contributing to and perpetuating headache symptoms in these situations. Under-recognized in children, it is a paradoxical consequence of regular, frequent analgesic use and results from long-term use of NSAIDs and paracetamol, as well as opiates. Compound analgesics (e.g. co-codamol) are particular culprits. Suspect in situations where the family are watching the clock and 'the headache is back before four hours have passed and he can have another dose'.

Explain the nature of the problem and the need to change the pattern of analgesia use. Children should be encouraged to reserve use for severe incapacitating attacks only. Migraine prophylaxis may be helpful. Clinical psychology involvement can also be very beneficial.

### Cluster headache and chronic paroxysmal hemicrania

Both uncommon in childhood.


Cluster headache describes:

- Distressing episodes of severe unilateral pain.
- Orbital, supra-orbital, temporal (or any combination of these).
- Lasting up to 3 h and occurring up to eight times a day.
- With at least one of the following all of which must be ipsilateral. Conjunctival injection, lacrimation, nasal congestion, rhinorrhoea, forehead and facial sweating, myosis, ptosis, or eyelid oedema.
- Rare under 10 yrs of age.
- 90% are male.
- Methysergide, lithium, and corticosteroids are effective prophylaxis. Methysergide should only be used for periods of up to 6 mths because of the risk of retroperitoneal fibrosis.
- Acute attacks can be treated with sumatriptan or by inhalation of 100% oxygen at a rate of 8:10 L/min.

Chronic paroxysmal hemicrania describes:

- Episodes of excruciating pain.
- Similar characteristics to cluster headache but tend to be shorter and more frequent.
- Bouts may occur at the same time each day.
- Striking therapeutic response to indomethacin.

### Chronic headache due to raised intracranial pressure

Expanding space-occupying lesions within the skull may cause progressively worsening headache, either due to their direct expansion or by secondary obstruction of CSF flow (as happens in the 50% of childhood tumours that are infratentorial). Hydrocephalus, with or without a tumour, is the most common cause. Idiopathic intracranial hypertension is relatively common (see  p. 334).

### Other causes of recurrent headache

- Refractive errors are an uncommon cause of headaches, but visual acuity should be checked. Refraction should be performed if there is a clear history of reading-related headache, relieved by rest.
- Headache can be both an ictal and a post-ictal phenomenon, but it is usually very clear that the child has had a seizure.

### Headache management and therapy

- One child may have multiple headache types.
- Different headache types may predominate at different times.
- Features of tension-type headache and migraine may co-exist in the same episode: headaches may be difficult to classify!
- Ask which questions the child and family would like answered (provide a question sheet to fill in beforehand). This helps fears to be addressed.

### *Migraine, tension-type and combination headache*

- Education is extremely important in the management of headache. The more the child and family understand, the less they worry.
- Most parents have an underlying fear that the headache is due to a brain tumour. The underlying cause of the headache should be explained to the child in addition to the parents.
- Unnecessary investigation may undermine reassurance: occasionally a family requires a normal scan result before being able to proceed.

### *Reassurance*

- Explain the benign nature of the problem and the natural history.
- Explain the periodicity (good spells and bad spells).
- Allow the child to gain some control over the problem.

### *Education*

- Learn to identify their own precipitating and exacerbating factors.
- Triggers are probably only relevant during a bad spell.
- Do not condemn children to lives free of chocolate and cheese unnecessarily; they can return to these after a period of remission.
- Good sleep hygiene and limitation of caffeine intake can be helpful.
- Understand the different roles of prophylactic and acute medication (cf. preventative and rescue inhalers in asthma).
- The term migraine or migraine variant with a biological explanation is enough to give most families the understanding and reassurance they need.


**Acute headache management**

- Simple analgesia, and rest, if possible.
- Sleep is effective in curing most migraine episodes.
- Simple analgesics, such as paracetamol, ibuprofen, or naproxen, are often effective if given in generous doses at the onset of the episode.
- There is no role for codeine or other opiate analgesics.
- Gastric motility and absorption may be impaired later in an episode.
- Anti-emetics (e.g. metoclopramide), used alone or in combination with simple analgesia, can also be effective.
- There is a limited role for triptans.

**Migraine prophylaxis**

- Use when headaches are intrusive e.g. missing significant time from school, sports activities, etc.
- Few children experiencing headache less than fortnightly consider it worthwhile to take regular prophylaxis.

No good evidence base; options include:

- Propranolol. Contra-indicated in asthma. May cause postural hypotension.
- Pizotifen. Common unwanted effects: increased appetite and weight gain, drowsiness dry mouth, constipation.
- Topiramate (considerably smaller doses than as AED). Warn about appetite suppression and nausea. Teenage girls need advice about concurrent use of oral contraceptive pill (see  p. 301).
- Cyproheptadine, calcium channel blockers, amitriptyline, flunarizine, riboflavin, valproate, feverfew (unlicensed).

**Behavioural and cognitive approaches**

Once a more chronic pattern has established, non-pharmacological approaches are more likely to be effective.

- Assessment should be directed towards identifying the predisposing, precipitating and perpetuating factors operating in the child's home and school environment.
- Academic difficulties, difficulties with peers, and home-related stress are the most common causes.
- 'Perfectionist' traits in high-achievers may respond well to cognitive-behavioural approaches.
- Depression may also be a contributing factor to daily headaches in some children and may require appropriate treatment.
- Chronic analgesic headache may be complicating the picture. Amitriptyline may be helpful.
- Advice (e.g. to avoid stress) needs to be practicable. It may be more realistic to suggest avoiding triggers during a known vulnerable period (e.g. peri-menstrually).

**Migraine and patent foramen ovale (PFO)**

- Some evidence of increased migraine risk in association with patent foramen ovale (PFO).
- Relative risk (RR) ~5 for migraine without, and RR ~3 for migraine with aura.
- Although it has been reported that PFO closure can improve migraine current evidence is very low grade.

**Prognosis**

Migraine/tension-type headache may be periodic with bad spells lasting weeks to months separated by good spells lasting months or years. In long-term follow-up of 9000 Swedish school children with migraine:

- One-third had been migraine-free for >1 yr at 6-yr follow-up.
- Two-thirds had been migraine-free for >2 yrs at 16-yr follow-up.
- At 40-yr follow-up, 30% were experiencing at least one migraine a year; half were migraine-free.



## Hydrocephalus


### Physiology

- CSF produced by modified ependymal cells in the choroid plexus within the lateral ventricles.
- Having exited via foramina of Luschka and the midline foramen of Magendie, bulk flow continues through the cerebromedullary cistern down the spinal cord and over the cerebral hemispheres.
- CSF returns to the vascular system passing through arachnoid granulations into dural venous sinuses.
- CSF production ~30 mL/h.
- Total CSF volume above 2 years approximately 150 mL, of which the ventricular system comprises ~35 mL.

### Blood–brain barrier

- Cerebral blood capillaries unique in having endothelial cells joined by tight junctions which are the physical basis of the blood–brain barrier (BBB).
- BBB excludes all water soluble molecules with molecular weight >500 Daltons. Lipid soluble molecules (oxygen, carbon dioxide, ethanol, steroid hormones) penetrate BBB readily.
- Specific transporters exist to allow and regulate entry of important hydrophilic molecules including glucose and amino acids.
- At certain sites, e.g. circumventricular organs, capillaries are fenestrated normally and neurons can ‘sample’ circulating blood.
- Inflammation of meninges disrupts the BBB and may enhance antibiotic penetration into the brain.
- Blood–CSF barrier anatomically distinct and composed of choroid plexus and arachnoid membrane.
- No major barrier between CSF and brain extracellular space so drugs introduced intrathecally bypass the BBB.

### Definitions and variants

- *Hydrocephalus*: increase in volume of CSF spaces in the brain particularly the ventricles (ventriculomegaly) associated with increased intracranial pressure and associated signs and symptoms.
- *Ventriculomegaly*: radiological appearance of increased ventricular volume not necessarily implying increased pressure (e.g. could be due to parenchymal atrophy).
- *Obstructive (non-communicating)*: obstruction to CSF flow in the ventricular system before reaching the subarachnoid space.
- *Communicating*: decreased absorption of CSF from arachnoid villi and subarachnoid spaces; or increased CSF production (choroid plexus papillomas).
- *External hydrocephalus*: enlarged subarachnoid spaces, e.g. around the frontal lobes, without ventricular dilation, normal in early infancy. In ambiguous cases may need ICP monitoring to clarify whether pressure truly raised. (See  p. 149.)

- *Normal pressure hydrocephalus*: ventricular dilatation, no parenchymal atrophy and normal CSF pressure with chronic symptoms (classically gait disturbance, cognitive deterioration and incontinence in the elderly). Not known to occur in children.

## Aetiology and associated conditions

### ***Congenital causes of obstructive hydrocephalus***

- *Aqueduct stenosis*: level of obstruction confirmed by enlarged lateral and third ventricles in presence small fourth ventricle  $\pm$  MRI CSF flow studies. X-linked aqueduct stenosis due to mutations in L1CAM accounts for 5% hydrocephalus in males (features adducted thumbs).
- *4th ventricle foramina stenosis*: genetic lesions at the foramina of Luschka and Magendie.
- *Dandy–Walker syndrome*: developmental cystic dilatation of the 4th ventricle with vermis hypoplasia.
- *Combined incidence of congenital variants*: 5–8 per 10 000 births.
- Congenital aetiologies may still cause adult presentations when the hydrocephalus decompensates.

### ***Developmental disorders featuring ventriculomegaly/hydrocephalus***

- *Neural tube defects*: particularly myelomeningocele and encephalocele.
- Achondroplasia.
- *Syndromic craniosynostosis*: 40% of Crouzon, Pfeiffer, Apert.
- Myotonic dystrophy.
- Neurofibromatosis type 1, Hurler, Down syndrome.
- Hemimegalencephaly (ventriculomegaly may mimic obstructive hydrocephalus).
- Macrocephaly and ventriculomegaly may be seen in idiopathic autism.
- There may be associated brain (agenesis of corpus callosum, septo-optic dysplasia) or non-neurological lesions (cardiac lesions in Down syndrome).

### ***Acquired causes of obstructive hydrocephalus***

- *Intraventricular haemorrhage*: 80% of premature babies with grade 3 and grade 4 haemorrhages develop progressive ventricular dilatation. Can also cause communicating hydrocephalus.
- *Tumours and cysts*: e.g. subependymal giant cell astrocytomas in tuberous sclerosis, colloid cyst of the 3rd ventricle; arachnoid cysts; ependymomas (including spinal ependymomas).
- *Vascular malformations*: e.g. AVM, vein of Galen aneurysm.
- *Other*: parenchymal oedema, ventricular scarring after toxoplasmosis, tuberculoma, and trauma.

### ***Communicating hydrocephalus***

- *Post-meningitis*: e.g. pneumococcus, tuberculosis, fungi.
- *Intracranial haemorrhage*: subarachnoid, subdural, neonatal intraventricular haemorrhage, trauma.
- *Foramen magnum and skull base lesions*: Chiari malformations (type II more than type I), myelomeningocele, craniosynostosis.
- Cerebral venous sinus thrombosis.
- Leptomeningeal tumour.

### Antenatal detected hydrocephalus

- There has been a reduction in the incidence of congenital hydrocephalus due to termination after foetal detection of gross ventriculomegaly and/or myelomeningocele at routine antenatal screening.
- Severity of foetal ventriculomegaly defined by lateral ventricle width at 20 weeks gestation:
  - 10–15 mm = mild;
  - >15 mm = severe;
  - ventricular size independent of gestational age >20 weeks;
  - the 10-yr mortality in non-tumour-related hydrocephalus is 71%.

#### Actions

- Detailed scan to identify further anomalies (spine, heart, urological).
- Foetal MRI to assess cerebral architecture increasingly available.
- Amniocentesis offered for foetal karyotype (e.g. trisomy 21).
- TORCH screen (e.g. toxoplasmosis).
- Parental counselling by specialist foetal management group including a neurosurgeon.
- Neonatal team notified if pregnancy continues.
- Monitoring for progression or resolution of ventriculomegaly *in utero*.
- After birth: neonatal examination, neurosurgical follow-up as required.

► The majority of children with isolated mild ventriculomegaly in the absence of associated lesions, with a normal karyotype and negative TORCH screen, do not have overt problems in early childhood.

### Symptoms and signs of hydrocephalus

Hydrocephalus may present with acute or chronic symptoms of raised intracranial pressure if it ‘decompensates’; or asymptotically, e.g. as macrocephaly picked up on routine surveillance (arrested hydrocephalus).

#### Early infancy

- Accelerated head growth; OFC crossing the centiles (may also be seen with benign external hydrocephalus); >1 cm per week in neonates.
- Bulging fontanelle (even when upright and settled).
- Cranial sutures widened.
- Prominent scalp veins.
- Sun-setting eyes.
- Parinaud syndrome.
- Irritability, poor feeding.
- Delayed development including abnormal visual behaviour.

#### Later childhood

- Macrocephaly, may be an isolated finding in arrested hydrocephalus.
- Headache.
- Vomiting.
- Lethargy and somnolence.
- Visual disturbance (check visual acuity and fields).
- Papilloedema is not reliable: often absent in acute decompensation.

❗ Check for bradycardia and elevated blood pressure—if present, urgent management of raised ICP required.

## Investigations

- **Cranial ultrasound:** in neonates, for monitoring progressive ventricular dilation after IVH and response to treatment.
- **CT scan:** for evidence of raised pressure:
  - hypodensity of periventricular brain tissue suggests trans-ependymal CSF flow;
  - temporal horn enlargement;
  - barrel-shaped third ventricle;
  - obliteration of basal cisterns and cortical sulci effaced.
- **MRI:** increased periventricular T2 signal suggests increased pressure (trans-ependymal CSF flow). Information additional to CT includes identifying aqueduct stenosis (CSF flow studies) and parenchymal lesions.

## Treatments

**Progressive ventricular dilatation in neonates** (see  p. 497)

- Diuretics (furosemide, acetazolamide).
- Repeated ventricular taps and lumbar puncture.
- *Other methods:* intraventricular fibrinolysis.
- 20–30% of those with grade 3 or 4 IVH needing repeated CSF removal eventually require a shunt.

## Shunts

- **Ventriculo-peritoneal shunts:** a proximal catheter in the lateral or 4th ventricle, a distal catheter in the peritoneal cavity. A long length of tube can be placed in the hope of avoiding re-operation between infancy and adulthood, although shunts placed in the neonatal period often fail (typically at about 5–6 yrs age) due to displacement of either the proximal or more commonly the distal catheter tip with growth.
- A selection of valve types is available including fixed and programmable resistance variants. The reservoir may be separate from the shunt-valve system.
- Ventriculo-atrial shunts are now out of favour due to need for re-operation with child's growth, higher morbidity and mortality (renal failure, infection).

## Endoscopic 3rd ventriculostomy

- For obstructive hydrocephalus particularly due to aqueductal stenosis.
- Typically not possible in the presence of Chiari malformation due to distortion of the third ventricle, and not effective in post-haemorrhagic hydrocephalus.
- Main advantage is avoidance of over-drainage symptoms and reduced risk of infection.
- A hole in the base of the 3rd ventricle creates a connection to the subarachnoid space of the basal cisterns.
- 70% success rate: any failures usually occur in the first 2–3 mths. Less successful in youngest infants. Infective complications occur in 2%.
- Ventricular size reduces less after ventriculostomy than after shunt placement: imaging less useful in evaluating possible failure.
- Very rarely, there is late (fatal) rupture of the basilar artery traumatized at ventriculostomy.

## Monitoring for sequelae

### Shunt complications

See  p. 500.

### Epilepsy


- Incidence 1 in 3 by 10 yrs post-shunt.
- *Underlying aetiology is a significant predictor:* TORCH, post-meningitis, parenchymal injury in neonates all cause epilepsy independent of ventriculomegaly.
- *Subacute/chronic shunt dysfunction can occasionally present with worsening seizures:* urgent neurosurgical referral is required if there is status epilepticus.

### Headaches


#### Causes

- Over-drainage (exacerbation by upright posture not an entirely sensitive or specific finding).
- Under-drainage.
- Decompensating hydrocephalus in unshunted children.
- Chiari malformation (consider if occipital headache; CT may miss the lesion).
- Slit-ventricle syndrome:
  - post-shunt episodic headaches, vomiting;
  - investigation confirms collapsed ventricles in the presence of raised, or fluctuating high and low ICP;
  - diagnosis—ambulatory ICP monitoring. Baseline intracranial ICP in the upright position is usually negative.
- ‘*Shunt migraine*’: may be very resistant to pharmacological therapy; consider referral to the pain management team and psychological interventions.

### Other chronic problems

- General cognition and specific deficits (see  ‘Cognitive disability’, p. 328).
- Fine motor and coordination: tremor, clumsiness.
- *Gross motor:* CP, spasticity (evolving upper motor neuron signs may suggest decompensating hydrocephalus).
- *Endocrine disorders:* precocious puberty.
- *Vision:* colour vision deficits, visual scotoma and field defects, strabismus.

### Cognitive disability

The typical profile includes good expressive language but weaker comprehension and impaired frontal lobe skills. The former leads to overestimation of cognitive abilities and under-recognition of the latter resulting in ‘cocktail party syndrome’ of ability to ‘small-talk’ but with limited intuitive and empathetic understanding of what is being said. Specific deficits: attention, short-term memory, reasoning, sequencing actions, mathematics (subcortical information processing deficits). Personal insight into difficulties often limited: some parallels with the cognitive issues after ABl (see  p. 213).

### Prognosis

5% mortality overall; shunt blockage remains a significant cause.

## Spina bifida and related disorders

Developmental spinal disorders in which contents of the vertebral canal protrude through defects in the vertebrae. The classic variants are:

- *Meningocele* (meninges and CSF in the lesion).
- *Myelomeningocele* (cord elements within lesion).
- *Lipomyelomeningocele* (myelomeningocele with intra/extra-dural lipoma in continuity with subcutaneous fat).


The spinal level of the lesion is a major determinant of morbidity.


The lesion may be covered with skin or open to the environment. The opening may be subtle (dermal sinus tract) or large (rachischisis), the latter associated with significant morbidity and mortality.

*Spina bifida occulta*: implies a developmental vertebral anomaly without overt spinal cord lesion. Generally not included in epidemiological studies of spina bifida, but may share latter's aetiology.

### Associated conditions

#### **Abnormal development of the spinal cord and ectopic elements**

- *Lipoma*: dorsal spinal cord only, or more extensive *transitional* lesion as in lipomyelomeningocele.
- *Fatty filum terminale*: lipoma restricted to filum. Common—may be thickened and associated with other dysraphism.
- *Dermoid cysts*: may grow in size, or rupture. Often associated with sinus tract.
- *Neurenteric cysts*: may emerge ventrally (intra-abdominal or thoracic). Often associated with vertebral abnormalities.
- *Diastematomyelia*: 'splitting' of the cord within the canal usually by a bony or fibrocartilaginous spur.
- *Diplomyelia*: duplicated spinal cord, each with its own dural sheath.
- *Syringomyelia*: often associated with Chiari II malformations (see  p. 333).
- *Low spinal cord termination*: the cord may terminate at L4/5.

► These malformations may be associated with progressive neurological deficit presenting later in childhood (see  'Monitoring for later sequelae', p. 331).

#### **Other malformations outside the spinal cord**

- 80% of children with myelomeningocele have hydrocephalus.
- Chiari malformation (mainly type II).
- Vertebral anomalies (e.g. Klippel-Feil, sacral dysgenesis).
- Anorectal anomalies.
- Urogenital and renal anomalies.
- Cardiac anomalies.
- Associated malformations may form a recognized syndrome e.g. VATER, Currarino triad (sacral, anal and urological anomalies).

### Aetiology and risk factors

CNS development from the embryonic neural tube involves co-ordinated activation of gene networks in nascent CNS cells and neighbouring tissue. Environmental insults interact with maternal and embryonic gene mutations and polymorphisms to cause neural tube defects.

**Environmental factors**

- Folic acid deficiency in diet.
- AEDs (sodium valproate, phenytoin, carbamazepine, polytherapy).
- Retinoids.
- Maternal diabetes.

**Genetic factors**

- Folate-dependent metabolic pathway gene polymorphisms (e.g. PCMT1, MTHFR, methionine synthase and methionine synthase reductase).
- Folate-independent pathways (lipomyelomeningocele are folate resistant).
- *Syndromes*: e.g. 22q11 microdeletion, X-linked and autosomal dominant Mendelian disorders (e.g. Currarino triad due to HLXB9; VANG1).
- May show intrafamilial variation in severity. Sporadic cases described.
- *Recurrence risk in non-syndromic NTD*: 5% risk for sibling of proband, 0.7% with pre-conceptual folate supplementation.

**Incidence**

- Marked geographical variation in incidence. The dramatic reduction in incidence over recent decades has now stabilized.
- Foetal incidence of NTD 17 per 10,000 pregnancies; live birth incidence 5.7–6.7 per 10,000 live births. The disparity is due to termination of pregnancy and *in utero* deaths, particularly of severe lesions.

**Antenatal detection**

- Raised maternal serum AFP and acetylcholinesterase.
- Anomaly scan at 20 weeks may show ventriculomegaly, posterior vertebral arch defects or talipes.
- ~15% of spina bifida not detected antenatally (poor visualization due to foetal position).

**Assessment of the child with spina bifida**

As with other complex neurodisability, a multi-disciplinary approach to assessment and management is essential. Early involvement of neurosurgeon, renal, or urological specialist and spinal orthopaedic surgeon required.

**Neonatal period and early infancy**

The child may present antenatally or with an unexpected lesion after birth:

- Open lesion.
- Large mid-line lipoma, preventing supine positioning and cares.
- Asymmetrical natal cleft.
- Dermal sinus above the natal cleft:
  - distinguish from benign sacral dimple in coccygeal region (benign dimples typically midline, just above natal cleft, without associated hair or haemangioma);
  - if in doubt U/S valuable to six mths of age; MRI thereafter.
- Midline nevus, e.g. hair patch (a subtle dermal sinus may also be present).
- Kyphosis or scoliosis.
- Talipes (may be asymmetrical).



Identify the following on examination:

- Anatomical level of the lesion (MRI spine).
- *Neurological level*: this is often higher than the anatomical level, and is a significant predictor of future disability. Assess muscle bulk, spontaneous anti-gravity movements, spinal reflexes, abnormal spread of reflexes, and sacral sensation.
- Associated CNS malformations.
- *Bone or joint deformities*: e.g. congenital hip dislocation (20%), kyphosis, and talipes. Refer to specialist orthopaedic teams.
- *Dermal sinus tract*: leads to risk of CNS infection. Often associated with underlying spinal malformation. Referral to neurosurgeon.
- Non-neurological anomalies (e.g. check anus, heart).
- *Bowel dysfunction*: assess anal tone. Neurogenic constipation often present (also effects of concurrent anorectal anomalies).
- *Bladder dysfunction*: often-incomplete bladder emptying against outflow resistance, leading to secondary reflux nephropathy. Check for a good urinary stream—urgent urological referral if not seen.


❗ Refer all children for urodynamic studies.

### Monitoring for later sequelae

Reassess the child for sequelae that may evolve over time:

- *Hydrocephalus requiring VP shunt*: 80% of myelomeningocele. Uncommon in other variants.
- *Chiari malformation and syringomyelia* (see  p. 333 (Chiari malformation) and  p. 217 (syringomyelia)): Progressive occipital headaches, squint, bulbar signs, upper limb dysaesthesia. Neurosurgical referral for posterior fossa decompression if present.
- *Cord tethering syndrome*: back pain, mixed upper motor neurone (spasticity) and lower motor neurone signs (clawing of feet, going 'off feet'), enlarging area of sensory disturbance, incontinence. *Urgent MRI spine if suspected and referral to neurosurgeon*. May recur many years after apparently successful surgery.
- *Urinary dysfunction*: overflow and urge incontinence, bladder dysynergia, UTI, risk of silent renal damage. Ensure regular renal/urology team follow-up. Management with continence advice, regular catheterizations, medication (pro- or anti-cholinergics) and surgical procedures (intravesical botulinum toxin and resineferatoxin injections; vesicostomy; bladder augmentation and bladder neck procedures).
- *Bowel dysfunction*: constipation with overflow soiling; faecal impaction may worsen urinary dysfunction. Managed with continence advice, diet, laxatives and enemas. Refer to paediatric surgeons. Conduit procedures for anterograde colonic washouts may be required.
- *Progressive bone and joint deformities*: kyphoscoliosis (20–40%), pathological fractures, hip dislocation, foot problems. Secondary cardio-respiratory, seating and ambulation issues. Treatments include bracing, rigid orthoses, spasticity management, physiotherapy and surgery.
- *Bone health*: multifactorial reductions in bone strength with tendency to distal femur fracture (25%) and pain.
- *Upper limb manipulation problems and truncal imbalance*: occupational therapist will assist with assessment and management.



- *Muscular symptoms*: e.g. fatigue and pain. Often seen in ambulant children. Not necessarily related to anatomical defect.
- *Cognition, vision and hearing deficits*: particularly in context of shunted hydrocephalus, see  p. 328.
- *Nutrition*: inadequate nutrition or obesity.
- *Trophic skin lesions*: poor healing, pressure ulcers on pelvic ischia and feet.
- *Psychosocial issues*: puberty and sex education, self-image problems, educational and occupational exclusion.
- *Latex allergy*: 15% sensitized. Potentially life-threatening anaphylaxis. Manage by latex avoidance during hospitalizations. Refer to allergy expert.
- *Tumours*: teratoma and benign dermoid cysts may present late with paraparesis.

## Prognosis

### Ambulation

Neurological level of lesion is main predictor of future need for mobility aids and ambulatory ability. Cognitive ability, perceptual disturbance, coordination, spasticity and bone deformities may impose further limits.

- *L5 strength (ankle dorsiflexion) predicts community ambulation*: outdoors walking and independent transfers. Ankle orthoses and foot care only.
- *L3–4 strength (knee extension) predicts household ambulation*: standing for transfers, walking short distances with hip-knee-ankle-foot orthoses, rigid gait orthoses and wheelchair for longer distances.
- *T6–L2 (trunk stability and hip flexion) predicts non-functional ambulation*: therapeutic weight bearing with orthoses. Wheelchair indoors for mobility.

Ambulation may deteriorate in later childhood.

### Cognition

The majority of children with myelomeningocele do not have overt learning disability. Mean IQ shows downward shift (~90). Performance IQ typically < verbal IQ. Recurrent VP shunt infections predict lower IQ.

### Mortality and morbidity

Increased risk of death in infancy with high spinal lesions, open lesions and multiple malformations.

Causes of increased mortality:

- Decompensated hydrocephalus.
- VP shunt infection.
- Renal failure.
- Peri-operative (particularly scoliosis surgery).

The majority of children can expect to survive well into adulthood. 30% of adults continue to require daily additional help.

Quality of life affected by sequelae and functional limitations rather than level of lesion *per se*.

### Chiari malformations

- *Chiari I*: the result of a small posterior fossa: contents may be displaced downward with cerebellar tonsils descending below foramen magnum. Fourth ventricle is in normal position; odontoid retroverted. If CSF flow at skull base affected can result in secondary syrinx.
- *Large displacement (tonsils >10mm below foramen magnum) nearly always symptomatic*: occipital headache with ICP features (worsened by cough, straining); cerebellar symptoms; downbeat nystagmus; tongue wasting, dysphagia; stridor; limb paraesthesiae and loss of pain secondary to syrinx but preserved joint position sense. May present with paroxysmal, acute persistent or chronic progressive pictures. Requires surgical posterior fossa decompression.
- *Incidental asymptomatic Chiari I malformations are a relatively common finding on MRI*: minor degrees of descent (<5 mm) should be managed conservatively if asymptomatic. Tonsillar descent in young children may resolve spontaneously with posterior fossa growth.
- *Possibly symptomatic*: not always clear if symptoms e.g. headache that led to detection of Chiari are related. Typically, tonsillar descent 5–10 mm. Potential iatrogenic harm from inappropriate operative correction of Chiari. MRI studies of CSF flow may help clarify whether descent is likely to be significant. If a child is experiencing headaches ICP monitoring may be indicated, ophthalmology, watchful waiting.
- *Similar appearances*: sometimes associated with low pressure headache; can be seen due to CSF overdrainage after lumbar puncture (LP).
- *Chiari II (= 'Arnold-Chiari malformation')*: in addition to tonsillar descent the pons is 'undersegmented' and the pons and fourth ventricle are abnormally low. The association with spina bifida is directly causative: the higher the spinal lesion the more severe the Chiari malformation. Isolated posterior fossa decompression is rarely indicated.
- *Chiari III*: rare, with additional feature of herniation of posterior fossa contents through posterior meningocele.

## Idiopathic ('benign') intracranial hypertension

► The label 'benign' is misleading and should be outlawed! An important, preventable cause of visual loss.

Also known as pseudotumour cerebri. A clinical syndrome of symptoms and signs of raised ICP in the absence of any space-occupying pathology on imaging. The clinical picture is indistinguishable from raised ICP due to tumour or hydrocephalus.

- Persisting, worsening headaches worsened by straining, coughing, sleep.
- Persistent vomiting.
- Papilloedema.
- Sixth cranial nerve palsy as a 'false localizing' sign.

### Diagnosis

- Normal CT sufficient to proceed with LP.
- Subtle MRI findings include prominent sleeves on optic nerve sheaths and 'reverse cupping' (outward) of optic nerve heads, downward displacement of the pituitary and floor of the third ventricle, and slim lateral ventricles.
- Documented elevation of ICP at lumbar puncture ( $>30$  cmH<sub>2</sub>O). Beware of making the diagnosis on ambiguous history and borderline ICP elevation. (Upper limit of normal ICP in children under GA conditions probably  $\sim 28$  cm H<sub>2</sub>O.<sup>1</sup>)
- In a largely-asymptomatic child referred with isolated 'papilloedema' consider the possibility of pseudo-papilloedema due to optic nerve Drusen (can be distinguished by careful ophthalmological evaluation).
- Beware false-positive elevation of ICP:
  - struggling/distress during lumbar puncture;
  - use of inappropriate anaesthetic agents if LP is done under GA;
  - ensure end-tidal CO<sub>2</sub> is normal (hypercarbia will elevate ICP).
- Exclusion of venous sinus thrombosis (if history suggestive) may require MRI/MRV (very similar clinical picture but by convention would not be regarded as idiopathic intracranial hypertension (IIH)).

### Associations

Cause uncertain (impaired CSF resorption?). Association with:

- Adolescent and older females.
- Obesity.
- Tetracycline use.
- Steroid use.
- Oral contraception.
- Excessive vitamin A consumption.

<sup>1</sup> Avery RA, Shah SS, Licht DJ, et al. (2010). Reference range for cerebrospinal fluid opening pressure in children. *N Engl J Med* **363**: 891–3.

### Management

❗ The risk of inadequately managed IIH is permanent visual loss due to chronic optic nerve ischaemia. Unfortunately lack of headache or other symptoms cannot be taken as reassurance. Long-term, regular (at least annual) ophthalmological review (particularly of visual fields) is required to detect early signs.

The volume of CSF removed at a single lumbar puncture (irrespective of 'closing pressures') will be replaced within several hours. The symptomatic benefit gained results from the CSF leak left after the LP. Beware *low pressure* headache after LP and don't confuse it with persisting symptoms! In contrast to high pressure headache symptoms are relieved by lying down and worsened by sitting up.

- Short-term symptomatic treatment with acetazolamide.
- In chronic symptomatic cases consider lumbo- or ventriculo-peritoneal shunting. (VP shunting technically harder than in hydrocephalus as ventricles not enlarged; however, LP shunts have a high failure rate over time).
- Role of optic nerve fenestration (to protect optic nerves against ischaemia) unclear.
- Unambiguous counselling regarding need for long-term regular monitoring (perimetry by high-street optician sufficient).

## Infection of the central nervous system

### Meningitis

This is caused by inflammation of the meninges, particularly the arachnoid and pia mater. Bacterial infection is usually associated with a polymorpho-nuclear response in the subarachnoid space; viral, tuberculous and fungal infection causes a lymphocytic response.

All meningitis is notifiable in the UK.

Meningitis is divided into acute (develops over hours to days) and chronic (days to weeks) forms.

#### Acute bacterial meningitis

##### Incidence and aetiology

- The epidemiology is changing as a result of immunization patterns.
- Host factors are important (e.g. immunocompromised individuals).
- *Neisseria meningitidis* (meningococcus). Gram-negative diplococcus; most common form of bacterial meningitis in the UK; mostly group B, shifting to group C. Vaccine available for A and C. Winter epidemics. Characterized by purpuric rash, septicaemia (mortality 5–20%).
- *Streptococcus pneumoniae* (pneumococcus). Mortality 20%. Gram-positive diplococcus; seven serotype vaccine given to all in UK as part of immunization programme.
- Group B streptococcus, *E.coli*, *Listeria*, *Klebsiella* in neonates.
- *Haemophilus influenzae* type b. Gram-negative pleomorphic coccus; affects neonates and young children. Mortality <5%. Vaccine available, and rare now in countries where vaccine has been introduced. Rarely encapsulated non-type b haemophilus can cause meningitis.
- Rarely *Streptococcus pyogenes* and *Staphylococcus aureus*.

##### Pathogenesis

- 95% of bacterial meningitides originate from blood-borne dissemination, 5% from local spread (e.g. mastoiditis, skull trauma) particularly pneumococcus.
- Bacteria from the circulation enter the CSF, probably across the choroid plexus and capillaries. Once in the CSF, an area of impaired host defence, the bacteria multiply. This generates an immune response and an inflammatory cascade killing the bacteria, but also causing brain injury (Table 4.6).

**Table 4.6** CSF finding in meningitis

	Appearance	Cells	Cell count	Protein	Glucose
Bacterial	Turbid	Polymorphs	100–1000+	<1.5 g/dL	<1/2 plasma
Viral	Clear	Mononuclear	50–1000	<1 g/dL	>1/2 plasma
TB	Fibrinous	Mononuclear	100–500	1–5 g/dL	<1/2 plasma
Fungal	Clea	Mononuclear	100+	<1 g/dL	>1/2 plasma


- **Additional mechanisms:**
  - direct toxic effect of agents released by bacteria or the immune system;
  - hypotension or vasculitis resulting in thrombosis and infarction;
  - development of vasogenic and cytotoxic oedema resulting in raised ICP, and diminished perfusion.

### **Clinical features**

- **Symptoms:**
  - triad of fever, headache and neck stiffness;
  - may be associated photophobia and myalgia.
- **Signs:**
  - meningism (Brudzinski and Kernig signs);
  - decreased consciousness;
  - petechial/purpuric rash in meningococcus;
  - seizures (30%), cranial nerve signs (15%), other focal neurology (10%);
  - septicæmic shock (particularly with meningococcus).
- In the very young and in the immunocompromised, symptoms, and signs may be less specific and more subtle, and a high index of suspicion is needed.

### **Investigations**

❗ If meningitis is suspected, LP is essential to make definitive diagnosis; failure to LP can result in unnecessary prolonged treatment, particularly with anti-viral therapy. If meningococcal infection is suspected, or the child is extremely ill and meningitis is suspected, start treatment prior to investigation.

- **Blood:**
  - FBC and differential;
  - blood culture;
  - CRP, urea and electrolytes (U&E); consider ESR, rapid antigen screen (RANS);
  - interferon gamma test (with Mantoux) if TBM suspected.
- **CSF:**
  - LP unless focal neurological signs including signs of herniation, or reduced level of consciousness (see  p. 537). However, LP is unnecessary in unequivocal systemic meningococcaemia (purpuric rash, shock, etc.);
  - Measure pressure and send for MC&S, protein, glucose;
  - Consider viral culture, RAS, PCR for meningococcus, herpes simplex and *M. tuberculosis*. Ziehl–Neelsen for acid-fast bacilli and TB culture if tuberculosis meningitis (TBM) is suspected, although yield low as large quantities CSF required.
- **Urine:** RANS.
  - Sputum (induced if necessary), or failing that gastric washings if TB suspected.
  - **Radiology.** If consciousness is reduced and/or there are focal neurological signs, CT/MRI to exclude abscess. Contrast studies may show meningeal enhancement in any meningitis.
  - Chest X-ray (CXR)/sinus X-ray if clinically indicated (particularly if TB suspected).

**Treatment***Antibiotics*

Choice depends on the age of the child, local epidemiology and resistance patterns and local microbiological advice.

- Typical regime based on a third generation cephalosporin (cefotaxime or ceftriaxone).
- In neonates, consider adding ampicillin (*Listeria*) ± aminoglycoside for Gram negative cover.
- Once the pathogen is identified from initial blood cultures or CSF, treatment can be tailored to known sensitivities.
- The prevalence of penicillin-resistant pneumococci (PRP) is rising; these PRP can also be resistant to cephalosporins and carbapenems as they all act on penicillin-binding proteins. The drug of choice then is combination therapy with vancomycin (high dose).
- Duration of treatment is 7–10 days. Pneumococcus and HiB can continue to spike temperatures for 7–10 days: consider imaging of the head for effusion/empyema or local abscess formation. Consider repeat LP.

*Steroids*

Controversial Steroids have been shown to decrease the CSF inflammatory response, decrease ICP, and reduce mortality and the severity of both acute and long-term neurological and auditory complications. However, the effect seems to be pathogen-specific, with most benefit seen with HiB (now rare because of vaccination). Adverse effects of high dose steroids have been reported and the anti-inflammatory effect in theory may decrease CSF penetration of certain antibiotics and delay sterilization of the CSF.

If given, they should:

- Ideally be administered before the first antibiotic dose at a dose of 0.6 mg/kg/day dexamethasone in four divided doses for 2–4 days.
- Not be used in neonatal meningitis.
- Preferably used for meningitis caused by HiB and *S. pneumoniae* (acknowledging one almost never knows the organism at the time, steroids should be given!!).

*Contacts*

For HiB and meningococcus, with rifampicin at 10 mg/kg for 4 or 2 days, respectively.

*Fluid management*

Do not assume hyponatraemia indicates syndrome of inappropriate anti-diuretic hormone (SIADH; see [p. 509](#)). Fluid restriction may further compromise cerebral circulation, so before restricting fluids check plasma and urinary sodium and osmolality, and urine output.

**Complications**

- *Acute*: effusions and empyema; seizures, hydrocephalus, abscess.
- *Chronic*: hearing, learning difficulties, seizures, spasticity, as well as more subtle cognitive and behavioural changes.

**Chronic bacterial meningitis**

- *Bacteria*: *M. tuberculosis*, *Borrelia burgdorferii*, syphilis.
- *Fungal* cryptococcus, histoplasmosis, coccidiomycosis and nocardia.
- Also consider non-infectious collagen vascular disease (see [p. 220](#) and [p. 223](#)).

## ***Tuberculous meningitis***

### *Incidence and aetiology*

- Caused by *M. tuberculosis* or occasionally *M. bovis*.
- Incidence in the UK is low, but increasing, in high incidence countries, TBM is often the most common form of bacterial meningitis.
- Extrapulmonary tuberculaosis (TB) is more common in children, particularly in the under-5 yrs age group.
- BCG is of contentious efficacy but studies seem to imply protection against the severer forms of TB in the developed world.

### *Pathogenesis*

- Primary infection occurs when the tubercle bacillus is inhaled into the lungs and taken up by alveolar macrophages. In the majority of cases, this primary infection passes unnoticed, with only the development of a positive tuberculin skin test to indicate that infection has taken place.
- In other individuals the mycobacteria continue to replicate after primary infection, overcome host immunity and disease develops, either as localized pulmonary disease or as a disseminated form of TB, such as miliary TB or TBM.
- Very young children and HIV-infected people are particularly prone to progressive primary TB and dissemination, suggesting that the competence of the host immune system plays an important role in containment of infection.

### *Clinical features*

Non-specific prodromal features develop over days to weeks.

Staging is useful in predicting prognosis. MRC grading:

- *Grade 1*: non-specific fever, malaise, loss of weight, headaches.
- *Grade 2*: confusion, focal neurological signs, e.g. cranial nerve palsies, seizures.
- *Grade 3*: coma, hemiplegia or paraplegia.

### *Investigations*

- *Blood*: full blood count (FBC), U&E, blood culture, CRP and ESR, interferon-gamma test.
- *Mantoux*: may be non-reactive, although up to 60% positive.
- *Sputum* (post induced cough if necessary) or gastric washings x 3 for acid-fast bacilli.
- *CSF* protein elevated, low glucose with predominant lymphocytosis; can be completely acellular in stage 1. Sensitivity of PCR for acid-fast bacilli (AFB) is low: 20–40% in adults. Sensitivity of CSF culture is also low in children (<10%) because of small numbers of organisms in a small volume of CSF (higher in adults where HIV-related TB is more typical). Rapid antigen test available.
- *Radiology*: CXR—50–90% has a primary focus on CXR.
- *CT/MRI with contrast*: triad of meningeal enhancement (particularly in basal cisterns), hydrocephalus, and infarction (secondary to vasculitis).

Diagnosis is often difficult to confirm initially, and needs to be based on clinical suspicion. Even if LP is negative, in view of the progressive disease course, do not delay treatment.



### Treatment

- **Controversial:** no consensus on the number of drugs or duration.
- **Typical UK regime:** four drugs (isoniazid, rifampicin, pyrazinamide, ethambutol) for 2 mths and then two drugs (isoniazid, rifampicin) for a further 10 mths.
- Ethionamide causes fewer ocular problems and crosses the BBB better, but is not easily available in the UK.
- **Steroids:** again controversial, are added in high doses for the first month (2–4 mg/kg), and then tailed off. Acetazolamide or ventriculoperitoneal shunting may be used for hydrocephalus (usually communicating).


### Mortality

Mortality is 10–50% depending on stage of presentation; 30% have residual neurological sequelae.

### Contacts

- Screening and chemoprophylaxis for contacts is essential.
- Notifiable disease.


## Viral ('aseptic') meningitis

Common. Clinical features include headache, fever and neck stiffness following a prodromal flu-like illness. Children do not look 'toxic' and drowsiness is uncommon. Look for other features that may give a clue to the aetiology (see  p. 340).

### CSF findings

White cell count is 10–1000, but usually  $<300 \times 10^6/L$ . Usually lymphocytes, but may have neutrophils in the first 48 h of illness. Protein is normal or mildly raised to 0.5–1 g/L. Glucose is normal, but may be low in mumps.

### Differential diagnosis

- **Other infections:** partially treated bacterial meningitis, brucellosis, *Listeria monocytogenes*, *Mycoplasma pneumoniae*, leptospirosis, Lyme disease, syphilis, rickettsial infections, TBM, fungal meningitis, parasitic infections.
- Non-infectious causes of CSF inflammation including collagen vascular and autoimmune disease, lymphoma and some drugs: see  'Recurrent aseptic meningitis', p. 354.

### Treatment: supportive

Prognosis usually full recovery within 2 weeks. May have fatigue and malaise for longer.

### Causative agents

**Enteroviruses (responsible for 85% of cases)** Include echovirus, Coxsackie, poliovirus. All cause diffuse rashes with or without more specific features:

- **Echovirus:** conjunctivitis, myopathy.
- **Coxsackie:** hand, foot, and mouth disease, myocarditis, pericarditis, pleurisy.
- **Polio:** isolated meningitis or meningitis before onset of typical paralysis.

**Mumps** Parotitis, orchitis, pancreatitis with elevated amylase and lipase (extraneural manifestations occur in 50% cases).

**Other herpes viruses** Herpes simplex virus (HSV) type 1 and 2, usually no cold sores or genital herpes present. Either a primary infection or reactivation of the virus:

- *Varicella zoster (VZV)*: may have typical chicken pox rash with fluid-filled blisters.
- *Epstein–Barr (EBV)*: pharyngitis, lymphadenopathy, splenomegaly, atypical peripheral lymphocytes, may have abnormal LFTs.
- *CMV*: may have abnormal LFTs and retinitis.
- *Herpes hominis virus (HHV) 6*: the cause of roseola infantum—rarely associated with meningoencephalitis.

**Measles** Confluent rash, lymphadenopathy, conjunctivitis, pneumonia.

**Arboviruses** Follows an infected mosquito bite—Japanese encephalitis virus (S or SE Asia), West Nile virus (most continents except N Europe).

**Adenovirus** Conjunctivitis, respiratory infection, vomiting and diarrhoea.

**Lymphocytic choriomeningitis** Orchitis, myocarditis, parotitis, alopecia. May have had contact with rodents.

#### ***HIV and HIV-associated progressive encephalopathy***

Encephalitis may be part of the seroconversion illness. HIV-associated progressive encephalopathy (HPE) is a child-specific AIDS-defining illness affecting about half of untreated children. HPE is much less common (a few percent) in children on highly active antiretroviral therapy (HAART). HAART can arrest HPE progression.

Features are of developmental stagnation, and later neurological and general cognitive regression with pyramidal signs, hypokinesia and evolving dysphagia and feeding difficulties. In older children, deteriorating school performance, social withdrawal, and emotional lability are seen.

#### **Viral (meningo-) encephalitis**

Uncommon. Clinical features include fever, headache, and encephalopathy. May have focal neurological signs and seizures. May have insidious onset with abnormal behaviour/memory problems that can be mistaken for psychiatric illness. A viral cause attributed in approximately 50% cases, with unknown aetiology most common, but HSV, enterovirus and varicella the most frequently diagnosed. LP prior to treatment important as HSV PCR can revert to negative after 48–72 h, resulting in unnecessary prolonged treatment with aciclovir.

#### **Causes**

HSV-1 and -2 are the most commonly diagnosed causes in Western countries, but globally Japanese encephalitis virus and rabies are more important.

#### ***HSV-1 and -2***

- Most common cause of viral meningoencephalitis in the UK.
- Beyond the neonatal period, majority of cases are due to HSV1.
- One-third primary infection, two-thirds reactivation.
- In neonates, HSV-2 infection can be blood borne causing multi-organ infection and diffuse encephalitis, and subsequent diffuse encephalomalacia.

*Herpes zoster encephalitis*

- Can occur during acute infection or due to later reactivation.
- The presence of a rash is unreliable: prognosis is poorer in those without a rash.
- After chicken pox, virus lies dormant in ganglia along entire neuraxis. Encephalitis is due to large or small vessel vasculitis. The former is usually found in the immunocompetent and typically leads to arterial stroke (see [p. 450](#)): mean onset is 7 weeks after the initial illness (up to 6 mths). Small vessel encephalitis usually occurs in the immunosuppressed: zoster infection occurred weeks to months earlier, followed by chronic progressive encephalitis. MRI reveals large and small ischaemic haemorrhagic infarcts of grey and white matter.
- For treatment, see [p. 343](#).

*Enteroviruses*

Epidemics are common in the Asia-Pacific region.

**CSF findings**

Similar to that of viral meningitis, although the protein count may be up to 6 g/l. May be normal if LP is performed in the first 48 h of illness. PCR for viral DNA/RNA is possible for many viral infections but may be negative if LP <48 h or >14 days after onset of illness. Viral isolation is sometimes possible. Measure IgM for specific viruses in the CSF. Discuss with the clinical virologist.

**MRI findings**

- *HSV-1 and -2*: most commonly give an abnormal signal (often with haemorrhage) in temporal lobes, insular cortex, frontal lobes and thalami. In neonates there are widespread signal abnormality—hypointense on T1, and hyperintense on T2. Cerebellum may also be involved. May have meningeal enhancement after gadolinium. Midline shift may be present if significant cerebral oedema is present.
  - ▶ Appearances may be atypical.
- *VZV*: multiple abnormal signals in grey and white matter representing vasculitis and infarction.
- *Enteroviruses*: may have abnormal signal isolated to brainstem or thalami.
- *Arboviruses*: may have abnormal signal in the basal ganglia and thalami.

**EEG abnormalities**

Diffuse slowing of the background, focal abnormalities and later periodic lateralizing epileptic discharges (PLEDS) may be present.

**Brain biopsy**

Not used routinely. Consider if findings will change management, e.g. if considering micro-abscesses from an embolic source, TB, or fungal/parasitic infection.

### Treatment

- Proven HSV-1 and -2: IV aciclovir for 21 days. Monitor renal function. If relapse occurs, re-treat and consider prophylaxis with oral aciclovir or valaciclovir for 90 days.
- CMV: ganciclovir and foscarnet combination therapy. Discuss with clinical virologist.
- Treat seizures, raised intracranial pressure (ICP) and other complications with supportive measures. Use of steroids is controversial. Consider using 3–5-day pulse of methylprednisolone or dexamethasone in severe cases with raised ICP. Consider surgical decompression in cases where raised ICP is refractory to medical treatment.

### Prognosis

Depends on the cause and severity of the illness at presentation. Mortality is improved by 40% in HSV-1 and -2 encephalitis if aciclovir is given promptly.

### Non-viral causes of infectious encephalitis

Viral causes are found in approximately 50% cases of encephalitis. Increasingly suspected that some 'presumed viral' encephalitides may be autoimmune (see [□□](#) p. 224). Consider the following if no viral cause is found especially if there is an appropriate travel history or if the child is immunocompromised. (Adapted with permission from Chaudhuri and Kennedy P (2002). Diagnosis and treatment of viral encephalitis. *Postgrad Med J* **78**: 575–83.)

#### Bacterial

- TB.
- *Mycoplasma pneumoniae*.
- *Listeria monocytogenes* (common in transplant patients).
- *Borrelia burgdorferii*.
- Leptospirosis.
- Brucellosis.
- Legionella.
- *Tropheryma Whippelii* (Whipple disease).
- *Nocardia actinomyces*.
- *Treponema pallidum*.
- *Salmonella typhi*.

Other causes of pyogenic meningitis/abscess: especially if septicaemia and micro-abscesses are possible.

#### Rickettsial (rash usually present)

- *Rickettsia rickettsii* Rocky Mountain spotted fever).
- *Rickettsia typhi* (endemic typhus).
- *Rickettsia prowazekii* (epidemic typhus).
- *Coxiella burnetti* (Q fever).
- Ehrlichiosis (*Ehrlichia chaffeensis*—human monocytic ehrlichiosis).

#### Fungal

- Cryptococcus (common in transplant recipients).
- Aspergillosis (common in transplant recipients).
- Candidiasis.
- Histoplasmosis.
- North American blastomycosis.

*Parasitic*

- Human African trypanosomiasis (sleeping sickness).
- Cerebral malaria.
- *Toxoplasma gondii*.
- *Echinococcus granulosus*.
- *Schistosomiasis*.

**Acute post-infectious cerebellitis**

- Most commonly described after varicella infection: also enterovirus, EBV, mumps and measles.
- More common in younger children (2–7 yrs of age).
- Abrupt onset ataxia and behavioural disturbance within 5–14 days of the chicken-pox rash (occasionally can be pre-eruptive).
- Symptoms are worst at onset or within 1–2 weeks then improve over 4–8 weeks, with full recovery for the majority.
- Management is supportive. Antivirals are not routinely given.
- Neuroimaging is only recommended in an atypical presentation or course (progressive deterioration, waxing and waning, altered sensorium, diminished reflexes).
- Differential includes Miller–Fisher syndrome (see 📖 p. 395).

**Anterior horn cell infection****Polio**

Polio virus is an enterovirus causing biphasic febrile illness with initial prodrome then further fever with acute-onset asymmetrical progressive flaccid paralysis of one or more limbs. Signs of aseptic meningitis with severe neck and back pain are common. No sensory involvement. Paralysis may also be bulbar and may also have autonomic involvement.

Peak incidence was in the 1950s. Since introduction of WHO global eradication programme cases have declined by 99%, but outbreaks have occurred in India in recent years.

**Investigations:** isolate poliovirus from stool.

**Treatment:** supportive.

**Prognosis:** mortality 10%. Weakness continues to improve up to a year from onset of illness. Children may develop later onset of weakness >30 yrs after initial illness—post-polio syndrome.

**Enterovirus 71**

Causes outbreaks of hand, foot and mouth disease in the Asia-Pacific region. Young children present with fever, rash on the soles and palms, and oral ulcers. May develop shock and pulmonary oedema. May develop polio-like neurological manifestations.

**Japanese encephalitis virus (JEV) and West Nile virus**

These are arboviruses requiring a bite from an infected mosquito. Children are more likely to be symptomatic with JEV. May develop polio-like neurological manifestations with or without meningitis or encephalitis.

**Paralytic rabies**

Differential diagnosis: Guillain–Barré syndrome (classical AIDP, or AMAN), tick paralysis, diphtheritic polyneuropathy, botulism.

## Focal CNS infection

See Table 4.7 for causes of focal CNS infection.

**Table 4.7** Causes of focal CNS infection

	Bacterial	Parasitic	Fungal
Immunocompetent	<i>Mycobacterium</i>	Neurocysticercosis	Histoplasmosis
	<i>Staphylococcus</i>	Echinococcus	Blastomycosis
	<i>Streptococcus</i>	Amoebiasis	Coccidiomycosis
	<i>Fusobacterium</i>	Paragonimiasis	Aspergillosis
		Sparganosis	
		Schistosomiasis	
		Malaria	
Immunocompromised	<i>Pseudomonas</i>	Toxoplasmosis	Candidiasis
	<i>Nocardia</i>		<i>Cryptococcus</i>
			<i>Rhizopus</i>

### Cerebral abscess

Brain abscesses can be caused by bacteria, fungi or parasites, with the most common causal organisms being *Staphylococcus*, *Streptococcus* and *Haemophilus*. Anaerobes such as bacteroides, *Streptococcus milleri* and *Fusobacterium* are also commonly found. Infection commonly follows haematogenous spread from a distant focus; these abscesses frequently form at the grey–white matter junction. Direct extension can occur from the ears or sinuses, or abscesses can develop following trauma or meningitis. Congenital cyanotic heart disease is a major predisposing factor.

#### Clinical features

The symptoms depend on the size and location, but generally present with fever, signs and symptoms of raised ICP and focal neurology.

#### Investigations

- Imaging—MRI or CT with contrast shows ring-enhancing lesions with surrounding oedema (may be multiple).
- LP is contra-indicated.
- *Bloods*: blood culture (frequently negative); CRP, ESR, white blood cells (WBC; to monitor treatment).
- EEG may show focal slowing.

#### Treatment

5–6 weeks of broad-spectrum IV antibiotics such as a 3rd generation cephalosporin with anaerobic cover (metronidazole) is recommended. Antibiotic treatment alone is often insufficient, and surgical drainage needs to be considered. Aspiration and/or excision relieve pressure and enable a microbiological diagnosis. Steroid use is controversial, and is mainly used for mass effect. Radiological resolution is frequently slow, with a ring lesion persisting for weeks to months.

*Complications*

40% of children have neurological sequelae, with 25–30% developing seizures.

**Protozoan and parasitic infections****Cerebral malaria**

- Responsible for over a million deaths annually, the majority in children.
- Mechanism of coma unknown. Reduced cerebral perfusion (secondary to raised ICP, sludging and systemic hypotension), severe anaemia, hypoglycaemia, seizures and the local release of cytokines may all be contributory factors.
- *Strict case definition*: unrousable coma which persists >60 min after a seizure; asexual *Plasmodium falciparum* forms on blood film and exclusion of other causes of encephalopathy.
- In practice, any child with a history of travel to an endemic area, presenting with fever, seizures, or a diminished level of consciousness, needs to have malaria excluded. In children, the time from onset of fever to coma is typically around 48 h.

*Investigations*

- Thick and thin smear for diagnosis and parasite count.
- Send multiple samples to avoid false negative results.
- Blood glucose, venous pH, electrolytes (renal failure), FBC (anaemia).
- LP once consciousness is improving to exclude bacterial meningitis.
- EEG if there is concern re subclinical status.
- CT or MRI if there is concern re diagnosis.
- Magnetic resonance venogram (MRV) to exclude venous sinus thrombosis if focal neurological signs.

*Treatment*

- Supportive treatment with oxygen, fluids for shock, blood for anaemia, and benzodiazepines for seizures.
- Parenteral quinine is usually the drug of choice, as chloroquine resistance is high (converting to oral quinine when improved: total 1 week treatment). Other possible treatments include quinidine, artemisan derivatives, or sulphadoxine/pyrimethamine.
- Combination treatments are available, and will probably soon be the recommended therapeutic option.

*Complications*

Mortality is high at around 20%, but in those that survive, the majority (~80%) have a normal outcome unless venous infarction occurs.

**Neurocysticercosis**

- Results from ingestion of infected pork and the encysted form of *Taenia solium* comes to rest in the brain parenchyma.
- The most common parasitic infection of CNS.
- The leading cause of late-onset epilepsy in developing countries.

*Clinical presentation*

- The majority of infections are asymptomatic, with symptoms starting when the cysticerci start to die:

- 90% of children present with seizures, focal or general, with 20% in status. 10% present with symptoms and signs of raised ICP;
- Occasionally cysticercotic encephalitis can occur when numerous degenerating lesions invoke an acute inflammatory reaction.

#### Diagnosis

- FBC (occasional eosinophilia), NCC ELISA (frequently positive in at risk individuals as this is an endemic disease, thus not specific).
- CSF: normal or occasionally mild pleocytosis and protein elevation. ELISA for NCC on CSF more specific.
- CT: ring-enhancing lesion with oedema, frequently multiple. A single lesion may pose diagnostic dilemma as it is difficult radiologically to exclude tuberculoma. MRI may show scolex.

#### Treatment

- Need for drug treatment is controversial but recent trials seem to indicate better outcome with treatment.
- Albendazole at 15 mg/kg/day 8-hourly for 8 days.
- Steroids only if there are multiple lesions or cysticercotic encephalitis.
- Re-image at 6 weeks to 3 mths to confirm resolution.


#### Echinococcosis

- Caused by *E. granulosus* or *multilocularis*.
- Prevalent in temperate areas/sheep-grazing areas.
- *Hepatic and pulmonary infection is common*: CNS involvement in only 1–2% (mainly children 5–10 yrs old).
- Symptoms and signs are of a space-occupying lesion with raised ICP.
- Treatment with albendazole ± steroids. Surgical resection is occasionally required after drug treatment for large lesions.

#### Amoebiasis

- Amoebic infections of the CNS produce either meningo-encephalitis (*Enteramoeba naegleria* and *acanthamoeba*) or cerebral abscess (*E. histolytica*).
- Transmission following either ingestion of contaminated water, or nasal inhalation. Cases present with fever, and signs of either raised ICP or meningo-encephalitis.
- Treatment with amphotericin B, miconazole or rifampicin.

#### Mycotic infections of the CNS

- Produces either meningitis or abscesses, mainly in the immunocompromised host (see  p. 351).
- The main organisms are *Candida albicans* and *Cryptococcus*.

#### CNS candidiasis

- Occurs mainly in susceptible neonates and infants.
- The course can be subacute, and detection can be difficult. CSF findings are variable.
- *Radiology*: micro-abscesses, thrombi or haemorrhages.
- Treatment is with amphotericin B (ideally liposomal).



*Cryptococcosis*

- Causes a granulomatous arachnoiditis presenting with headache, disturbance of consciousness or focal neurology.
- CSF is abnormal (see Table 4.6) and Indian ink staining is positive in 60% of cases. Cryptococcal antigen is positive in 98%.
- Treatment is with amphotericin B and 5-fluorocytosine.

**Slow viral and prion infections****SSPE**

- A late neurological presentation of previous measles caused by the host response to persistent measles virus in the brain.
- Very rare, although an increase is anticipated with the recent dip in MMR uptake.
- Age at presentation 5 and 15 yrs. Primary infection is usually at <4 yrs.
- ♂:♀ 2:1.
- Neurological regression with insidious onset over weeks to months:
  - behavioural changes and decline in school performance;
  - later tremors, myoclonus, seizures (often drop attacks), visual loss secondary to chorioretinitis or cortical blindness, chorea, pyramidal signs, cerebellar ataxia;
  - rapid motor deterioration, develop abnormal posturing, autonomic dysfunction and become comatose;
  - neuropathological features follow an occipitofrontal and cephalocaudal progression which accounts for symptom progression.

*Diagnosis*

- *CSF is usually acellular:* may have elevated protein. Glucose is normal. Anti-measles IgG in CSF and plasma and oligoclonal bands.
- *EEG is very characteristic:* bilateral, synchronous, symmetrical periodic delta ( $\delta$ ) wave complexes present from early stages with electrodecremental periods following the complexes. The background becomes increasingly slower with disease progression.
- *MRI abnormalities:* changes present early in disease progression. Hyperdensities on T2-weighted images are seen in the periventricular frontal, temporal and occipital white matter. Approximately 50% of children will have increased signals on T2-weighted images in the basal ganglia and thalamus. Generalized cerebral atrophy and ventricular dilatation occur with disease progression.

*Treatment*

No established treatment. There are reports from open trials that combinations of antiviral drugs (ribavirin, inosiplex and interferon  $\alpha$ ) may be worth considering.

*Prognosis*

Most children die within 3 yrs of diagnosis usually from pneumonia, urinary tract infection (UTI), bed sores, etc. Approximately 10% will live longer, rarely up to 10 yrs.

### **Variant Creutzfeldt–Jakob disease**

- A prion disease.
- The infectious agent is the converted form of a normally occurring, host-produced protein encoded on chromosome 20.
- Modified protein polymerises into pathogenic *plaques* resistant to host proteases and may also act as a template for the continuing conversion through re-folding of normal-form protein into the pathological form.
- There is a broad spectrum of manifestations.

Three types of Creutzfeldt-Jakob disease (CJD) are seen in humans:

- *Familial*: due to mutation in the prion protein gene *PrP* that predisposes to conversion to the pathological form. Very rare, adult-onset disease.
- *Sporadic CJD* (sCJD) is responsible for 80% of adult cases.
- *Acquired* due to cannibalism (Kuru) or iatrogenic transfer, e.g. of extracted human pituitary hormones. Variant CJD (vCJD) is the only form of CJD presenting in the paediatric age range and is thought to be due to transmission from cattle by eating infected meat or between humans via blood transfusion.

vCJD was first reported in 1996 in the UK. Both sCJD and vCJD are extremely rare in children. To date, there have been six definite or probable paediatric cases of vCJD identified in the UK. The incidence may have now peaked although this is not certain: concern remains that all cases to date have had a minority polymorphism in prion protein which may have a short incubation period. Active surveillance is being maintained in case a second wave develops in the majority population with longer incubation period.

#### *Clinical features*

Early symptoms are psychiatric: withdrawal, depression and anxiety. Then there is a decline in school performance and painful paraesthesias in the limbs. After approximately 6 mths, ataxia and involuntary movements (dystonic, choreiform, and myoclonic) develop. There is progressive neurological decline with dysphasia, dementia, dysphoria, rigidity, hyperreflexia, and primitive reflexes. Death occurs less than 3 yrs from the onset of symptoms (mean 14 mths).

#### *Investigations*

Changes on diffusion weighted image (DWI) and increased T2 signal in the posterior thalamus (pulvinar) is characteristic in established cases. EEG is non-specific (unlike adult sporadic CJD). CSF: neuronal protein 14-3-3 positive in 50% of cases of vCJD.

❗ EEG and LP require specific infection control precautions if vCJD is strongly suspected.

#### **Treatment**

Supportive only at present.

Discuss suspected cases with National CJD surveillance unit in Edinburgh. Useful website:  [www.cjd.ed.ac.uk](http://www.cjd.ed.ac.uk).

**Lyme disease**

- Multisystem disease caused by the spirochete *Borrelia burgdorferi*.
- Vectors are infected deer Ixodes ticks.
- Common in North America and parts of Europe (including UK).
- The incubation period is 7–30 days.

**Clinical features**

- Most commonly affected organ systems are the skin, nervous system, and heart.
- Expanding ‘bull’s eye’ erythematous rash: erythema chronicum migrans.
- Flu-like symptoms, myositis, hepatitis, arthralgias and rare cardiac conduction abnormalities.
- Approximately 15% develop nervous system involvement that typically consists of all or part of the triad of lymphocytic meningitis, cranial neuritis and painful radiculitis. Cranial nerves most typically involved are the 7th nerves bilaterally.

**Described neurological presentations***Peripheral*

- *Mononeuropathy multiplex*:
  - cranial neuropathy (usually bilateral 7th nerve);
  - radiculopathy;
  - brachial plexopathy;
  - lumbosacral plexopathy;
  - diffuse polyneuropathy;
  - motor neuropathy;
  - Guillain–Barré-like (not demyelinating).

*Central nervous system*

- *Infection in subarachnoid space*:
  - radiculitis;
  - cranial neuropathy;
  - meningitis.
- *Parenchymal infection*:
  - encephalitis (‘MS-like’ very rare);
  - myelopathy.

**Diagnosis**

- Exposure plus serology testing of serum and CSF.
- Confirm with Western blot test of the child’s serum against *B burgdorferi* antigens.
- May get a false-positive result with syphilis infection. Culture is difficult. PCR is not routine yet.

**Treatment**

Cefotaxime or ceftriaxone (14 days) for CNS involvement. Meningitis often resolves spontaneously. No evidence for use of steroids.

**Prognosis**

Usually very good.

### Central nervous system infection of the immunocompromised host

- This presents diagnostic challenges due to unusual pathogens, atypical insidious, and non-specific presentations.
- There are management challenges due to difficulty in eradicating some organisms and severe long-term consequences.

Typical 'teaching hospital' contexts include:

- Prematurity (naïve immune system).
- Congenital immunodeficiency (DiGeorge, Bruton, common variable immunodeficiency, severe combined immunodeficiency, etc.).
- Iatrogenic acquired immunocompromise through steroid treatment of chronic inflammatory conditions, treatment of malignancy or use of immunosuppression in oncology, immunology, or bone marrow transplant settings.
- Infective immunodeficiency due to HIV/AIDS (the CNS is second most commonly affected site, see 📖 p. 341).

The types of organisms that pose a risk depend on the cause and precise nature of the immunodeficiency:

#### Deficient B cell function

Meningitis caused by encapsulated bacterial pathogens.

#### Deficient T cell or macrophage function

CNS infections caused by intracellular organisms:

- Fungi (*Aspergillus*).
- Bacteria (*Nocardia*).
- Viruses (HSV, JC, CMV, HHV-6).
- Protozoa (*Toxoplasma gondii*).
- Unusual causes of bacterial meningitis presentation: *Listeria* or *Cryptococcus*.

#### Organisms

##### Bacterial

- Encapsulated organisms.
- Gram positive and negative.
- *Mycobacterium*.

##### Viral

- Herpes.
- HSV1/CMV/Varicella/HHV-6.
- Enteroviruses.

##### Fungal

- *Candida*.
- *Cryptococcus neoformans*.
- *Aspergillus*.

##### Parasitic

- *Toxoplasma gondii*.

**Clinical approach**

Often there is a non-specific neurological presentation (encephalopathy, seizures, focal neurological signs). The question is often whether this is this infection or a complication of treatment?

**'Radiological' presentation**

Incidental finding of intracerebral mass lesion particularly in the context of T cell deficiency: consider TB, lymphoma, toxoplasmosis.

**Toxoplasmosis****Reactivation of *Toxoplasma gondii***

- Subacute or acute presentation with confusion and headache, with or without fever and malaise.
- Meningeal signs are rare.
- Focal neurological signs are present in 60%:
  - seizures;
  - focal motor deficits and cranial nerve palsies;
  - sensory abnormalities;
  - cerebellar signs;
  - movement disorders;
  - neuropsychiatric symptoms.
- Antibody is detectable in serum, but is not useful in following the course of the illness.
- *MRI brain*: multiple ring-enhancing lesions  $\pm$  oedema reflecting multifocal necrotizing encephalitis. Frontal, parietal, basal ganglia, cerebellum; grey and white matter.

**Treatment**

- Combination therapy with sulphadiazine, pyrimethamine with folinic acid (clindamycin can be substituted for sulphadiazine).
- Ineffective against the tissue cyst form.
- Must continue as maintenance therapy.
- Prophylaxis in HIV-1 positive children with CD4 <100.

***Aspergillus fumigatus* infection**

- Mass lesions or cerebral infarcts; meningitis is rare.
- MRI brain.
- CSF PCR, antibody, antigen (galactomannan) or culture.
- Biopsy.

**Treatment**

- Itraconazole.
- Amphotericin B (IV or IT).

***Cryptococcal* infection**

- Inhalation of encapsulated fungus; avoids phagocytosis.
- Basilar chronic meningitis.
- Micro-abscesses in the basal ganglia (cryptococcomas).
- Focal neurology or seizures in 10%; increased ICP in 50% (mechanism unknown).

### Diagnosis

- CSF protein elevated, glucose low; WCC < 20. Indian ink stain (sensitivity 75–85%).
- Cryptococcal capsular antigen in the blood (99%) or CSF.

### Treatment

- **Induction:** 2 weeks. Intravenous amphotericin B and 5-flucytosine.
- **Consolidation:** 8 weeks/CSF culture negative:
  - fluconazole;
  - relapse occurs in 25–60% of HIV-1 children.
- Maintenance therapy. Fluconazole ± GM-CSF granulocyte–macrophage colony–stimulating factor.

### JC virus

JC virus is common. 70–90% of adults are infected. Primary infection is asymptomatic. The virus remains latent in the kidney, CNS lymphocytes. Immunosuppression permits reactivation and mutation to pathogenic virus which causes progressive multifocal leukoencephalopathy (PML).

- PML has been reported in connection with use of natalizumab (humanized monoclonal against  $\alpha$ 4-integrin used in treatment of multiple sclerosis and Crohn disease).
- Focal neurological deficits.
- Progressive dementia.
- Coma and death are common over a period of 4–6 mths.
- Fever and headache are *absent*.
- MRI shows multifocal white matter lesions without MRI mass effect or enhancement.
- CSF PCR for JC virus DNA has high sensitivity and specificity. Quantitation is useful prognostically.
- Brain biopsy with immunocytochemistry (definitive).

### Treatment

- Cidofovir?
  - some trials are supportive in children with HIV-1;
  - poor response in non-HIV-1 children.
- Mefloquine.
- Reversing immunosuppression. HAART in HIV-1.

## Other herpes virus central nervous system infections

### CMV encephalitis

Children with T cell counts < 50

- SCID/HIV-1/bone marrow transplant/solid organ transplant.
- Extra-CNS sites (retina, adrenals, gastrointestinal tract (GIT)).

### Features

- Subacute dementia and focal neurology.
- Microglial nodules found diffusely in the grey matter.
- Ventriculoencephalitis.
- Delirium.
- Ventriculomegaly.
- Cranial nerve deficits.

*Diagnosis*

- CSF:
  - pleocytosis;
  - hypoglycorrhachia;
  - elevated protein;
  - PCR DNA (PPV 92%, NPV 95%);
  - quantitative PCR is useful prognostically;
  - areas of increased signal on T2 MRI.

*Treatment*

- *Induction*: ganciclovir ± foscarnet; cidofovir
- *Maintenance*: ganciclovir.

**HHV-6 encephalitis**

- *There are two variants A and B*: type A is more neurotropic. Seen in solid organ and BM transplant recipients due to reactivation or reinfection. Causes encephalitis. There may be interactions between herpes viruses—HHV-6 may exacerbate CMV encephalitis. Possible cofactor in HIV disease?
- *Treatment*: ganciclovir, foscarnet, cidofovir.

**Varicella zoster infection**

Seen in T cell deficiency, primary immunodeficiency, HIV-1 infection and in the context of high dose steroid use.

- *Myelitis, ventriculitis, meningitis and large and small vessel encephalitis*:
  - stroke (large vessel);
  - chronic progressive encephalitis (small vessel).
- PCR VZV DNA.
- Treat with high dose IV aciclovir for 21 days. If vasculitis thought to be significant, consider prednisolone 2 mg/kg/day for 3–5 days.<sup>1</sup>

**Recurrent aseptic meningitis****Mollaret disease**

Recurrent self-limiting episodes of aseptic meningitis lasting 2–4 days. Rare in children. Assumed to have an infectious cause: may be associated with HSV type 1 and 2. Monocyte cells with characteristic ‘footprint nuclei’ are present in CSF. They also have an elevated CSF IgG level.

Differential diagnosis: collagen vascular diseases, sarcoidosis, lymphoma, complement factor 1 deficiency, meningeal carcinomatosis, structural causes, e.g. CNS tumours, mid-line fistula between skin and dura, or epidermoid cyst, toxic drug reactions: NSAIDs, IVIG, some chemotherapy agents, some antibiotics, e.g. penicillin, cephalosporins, trimethoprim.

<sup>1</sup> Gilden DH, Kleinschmidt-DeMasters BK, LaGuardia JJ, Mahalingam R, and Cohrs RJ. (2000). Neurologic complications of the reactivation of varicella-zoster virus. *N Engl J Med* **342**: 635.

## Congenital infection

The CNS of the neonate can be infected antenatally, during delivery or in the early postnatal weeks. The most important agents are those in the TORCH group:

T	toxoplasmosis
O	others i.e. syphilis and HIV
R	rubella
C	CMV
H	herpes simplex

However, other agents are important including VZV, LCMV, and enteroviruses. Damage results from:

- Direct teratogenic effects (disruption of CNS development).
- Tissue destruction due to inflammation.
- Or a combination of the two.

❗ Infection before 20 weeks' gestation may be suspected but difficult to prove as the foetus cannot produce specific antibodies in early pregnancy. Testing saved antenatal and postnatal maternal blood may be helpful. All the agents can cause an asymptomatic infection.

### Cytomegalovirus infection

The most common and potentially serious congenital infection. Primary maternal infection in the first or second trimester (which is often asymptomatic) will result in foetal infection in 60% of pregnancies. 10% of these are symptomatic at birth.

#### Clinical features

CNS abnormalities include:

- Meningoencephalitis, with parenchymal damage in the germinal matrix, periventricular white matter and cortex. Atrophy occurs later.
- *Calcifications*: periventricular, cortical or both.
- Microcephaly.
- Ventriculomegaly.
- *Neuronal migration disturbances*: all types seen.
- Cerebellar hypoplasia.
- Hearing loss.

Systemic features include:

- Intrauterine growth retardation; premature delivery.
- Chorioretinitis.
- Hepatosplenomegaly, jaundice, anaemia, thrombocytopenia, petechiae, ecchymoses.
- Inguinal hernias.
- Pneumonitis.

Infection is usually persistent (50% still have virus in the urine aged 5 years) and may cause progressive damage, particularly sensorineural hearing loss and retinitis.



**Investigations**

- CSF demonstrates pleocytosis (typically <100, mainly lymphocytes) and raised protein (usually <1.5 g/dL).
- CT is abnormal in 80%, demonstrating calcification, and major cortical and white matter abnormalities.
- MRI is more sensitive and may indicate neuronal migration abnormalities.
- 60% have abnormal brainstem auditory-evoked responses at birth (may manifest later so follow-up studies are important).

**Diagnosis**

- Discuss with infectious diseases (ID) colleagues.
- Demonstration of CMV seropositivity (or CMV excretion in urine) in an older child with neurological impairments does not establish a causal role for CMV. Infection in later postnatal life is commonly asymptomatic and seropositivity is very likely to be coincidental.
- The retained Guthrie (neonatal screening blood spot) sample is invaluable in retrospectively establishing timing of infection.
- Virus culture from urine.
- PCR for CMV DNA in urine, serum, CSF, cord blood, Guthrie card.
- Presence of IgM in foetal serum or persistence of foetal IgG in an older infant. Compare titres with maternal results.

**Outcome**

Depends on severity of CNS involvement, but 95% with symptomatic CNS infection at birth will have major neurological sequelae.

**Treatment**

- Symptomatic: treatment of seizures, tone abnormalities, etc.
- *Specific*: ganciclovir reduces progression of hearing deficits. Discuss with virologist.

**Toxoplasmosis**

Acquired transplacentally after primary infection in the mother. Risk factors include contact with cat litter or faeces, and eating undercooked meat.

- Maternal infection in first or second trimester results in foetal infection in 25% of whom 50% will be symptomatic.
- Maternal infection in third trimester results in foetal infection in 65% however large majority will be asymptomatic.
- Treatment of the mother reduces transmission risk and improves outcome, but maternal infection is often asymptomatic.

**Clinical features**

Similar systemic features to CMV infection although IUGR and prematurity are less common. May have these features without any neurological syndrome at birth, but develop neurological abnormalities later.

CNS abnormalities are seen in two-thirds of cases and include:

- *Meningoencephalitis*: multifocal, diffuse, necrotizing, and granulomatous.
- Hydranencephaly or porencephaly.
- Hydrocephalus secondary to obstruction of aqueduct.

- Intracranial calcification.
- *Microcephaly*: secondary to loss of brain tissue.
- Hearing loss.

### **Investigations**

- CSF demonstrates pleocytosis (typically <100) and protein (usually >2 g/dL).
- Ultrasound scan (USS) and CT may reveal basal ganglia and periventricular calcification.
- MRI helps define abnormalities.

### **Diagnosis (discuss with ID)**

- Presence of foetal IgM is most useful test. Compare IgG titres with maternal results.
- Confirm with PCR for Toxoplasma DNA in blood and or CSF.

### **Treatment**

- *Symptomatic*: treatment of seizures, tone abnormalities etc.
- *Specific*: pyrimethamine and sulfadiazine (with folinic acid supplementation) for 1 yr. Consider steroids if CSF protein >1 g/dL. Discuss with ID team.

### **Outcome**

Even those with asymptomatic infection may have problems identified later including learning difficulties, hearing impairment, and retinitis. For those with symptomatic infection, the neurological outcome depends on the severity and location of brain damage. If treated, approximately 25% will have motor deficits and an IQ of <70. 90% will have a retinopathy.

## **Rubella**

Incidence is low in UK due to high levels of vaccination. Foetal infection is acquired transplacentally after primary (usually asymptomatic) infection in the mother. The frequency and severity of infection are greater the earlier in gestation it occurs. Ocular and cardiac defects only occur in the 1st trimester. Infection later than 4 mths gestation is usually asymptomatic.

### **Clinical features**

Similar systemic features to CMV and toxoplasmosis infections. In addition, cardiac (peripheral pulmonary stenosis, PDA and myocardial necrosis) occur in up to 20%. Ocular abnormalities include 'salt and pepper' retinopathy, cataracts (pearly and central) and microphthalmia. Dermal erythropoiesis causes 'blueberry muffin' syndrome. Bony radiolucencies may be seen on X-rays of long bones.

CNS abnormalities include:

- *Meningoencephalitis*: multifocal necrotizing, diffuse, perivascular infiltrates.
- Full anterior fontanelle.
- Lethargy, hypotonia, and irritability.
- Opisthotonus and retrocollis.
- Progressive microcephaly due to impaired cell replication.
- Impaired myelination.
- *Hearing loss*: inflammation of cochlea (may be difficult to detect at birth).

**Investigations**

- CSF: pleocytosis (typically <100 mainly monocytes) and protein (usually <1.5 g/dL).
- USS and CT may show focal calcification in basal ganglia.
- MRI helps define focal lesions (usually in white matter) and demonstrate impaired myelination.

**Diagnosis (discuss with ID team)**

- Isolate virus from urine, throat or rectal swab or CSF.
- Presence of foetal IgM. Persistence of IgG in older infant. Compare titres to maternal results.

**Treatment**

Symptomatic only. No specific treatments are available.

**Outcome**

90% symptomatic infants will have sequelae including motor deficits, microcephaly, cognitive impairment, behavioural problems, and hearing loss.

**Herpes simplex**

Foetus usually infected during delivery: rarely postnatal infection from close contacts (usually HSV1). 50–75% type 2 and remainder type 1. Asymptomatic infection common in the mother but unusual in the infant. Premature infants more frequently affected. Foetal scalp electrodes are a risk factor.

**Clinical features**

Damage caused by inflammation and destruction. Many features similar to TORCH infections. Severe cases have multi-organ involvement: predilection for reticulo-endothelial system (anaemic, jaundice, bleeding). Specific features include vesicular mucocutaneous lesions (often over the site of viral entry), conjunctivitis, and keratitis. If infection is localized (without visceral involvement), symptom onset is later (2nd or 3rd week of life).

**CNS abnormalities**

Include:

- *Meningoencephalitis*: multifocal, severe and diffuse.
- Seizures/coma.
- Bulging fontanelle.

**Investigations**

- CSF pleocytosis (<100 usually lymphocytes), RBCs and protein (<1.5 g/dL). Glucose may be low.
- CT and USS may identify parenchymal abnormalities.
- MRI helps define focal lesions with DWI useful for identifying early changes.
- EEG: periodic lateralized epileptiform activity may be seen; associated with a poor prognosis.

**Diagnosis (discuss with ID team)**

- Examination of vesicular fluid/skin scrapings:
  - *histology*—multinucleated giant cells or intranuclear inclusions;
  - *electron microscopy*—viral particles identified.

- Viral isolation from throat, stool, urine, CSF (viral culture media swabs needed).
- PCR of CSF, early samples may be negative. Consider repeat LP.
- Serology less useful as IgM response may be delayed.
- Refer mother to sexually transmitted diseases (STD) clinic for testing.

### **Treatment**

- Aciclovir 20 mg/kg tds for 21 days.
- Supportive treatment.

### **Outcome**

Mortality highest for those with disseminated infection (30–60%). Lower in those with isolated CNS disease (15%). High levels of morbidity in survivors from both groups.

### **Syphilis**

- Incidence is low in the UK, but consider if risk factors exist, such as intravenous drug abuse or maternal HIV infection.
- Trans-placental infection usually occurs in the 2nd or 3rd trimester (due to a protective effect in the early placenta).
- Maternal spirochetaemia can occur in the primary, secondary or early latency stages of her disease. Outcome is worse if infection occurs in the primary or secondary stages
- The spirochetes infect many organs.

### **Systemic features**

Features not usually present until the infant is at least 2 weeks old. Similar systemic features to other TORCH infections, but skin and mucocutaneous lesions are common with a predilection for the face, oral, and anogenital regions. Liver enzymes are raised.

Neurological signs are usually absent, but signs of a subacute meningitis maybe present with a CSF pleocytosis (usually less than 50) and a mildly elevated protein (<1 g/dL). Cranial nerve palsies (VII, III, IV, and VI), a bulging fontanelle or hydrocephalus may be present.

### **Investigations**

Combination of tests usually needed including:

- Dark field microscopic examinations of skin, mucocutaneous lesions, nasal discharge, umbilical cord.
- Serology, VDRL test in serum or CSF (can get false positives).
- IgM fluorescence *Treponema* antibody-absorbed (FTA-ABS) assay (more specific).
- PCR for *Pallidum* DNA in serum or CSF.

### **Treatment**

Penicillin G for 14 days. If the mother has been treated in pregnancy, treatment of the infant may not be necessary.

### **Outcome**

Prognosis depends on severity of damage before treatment is started. Neurological sequelae are rare if treated promptly.

### Enteroviruses

Maternal infection with coxsackie viruses A or B or echovirus just prior or during delivery can cause an aseptic meningitis or meningoencephalitis. Abnormal signal may be seen in the cerebral white matter on MRI. Infections are more common in summer or autumn.

#### Diagnosis

- PCR for enterovirus RNA in CSF.
- Viral isolation from urine, throat, rectal swabs, and CSF.

#### Outcome

Generally good.

### Varicella

Two syndromes exist. Both are rare.

#### *Congenital varicella syndrome*

- Infection in first 20 weeks of pregnancy.
- CNS features include meningoencephalitis, myelitis, dorsal root ganglionopathies, denervation and hypoplasia of muscle, cutaneous scars in a dermatome distribution, chorioretinitis, microphthalmia, cataracts, optic atrophy, Horner syndrome.

#### *Perinatal varicella*

- Infection near delivery, onset within first 10 postnatal days.
- Multi-organ infection similar to herpes simplex with necrosis of the brain parenchyma.
- Diagnosis is from viral isolation from lesions or IgM in serum.

#### Diagnosis

- CSF analysis at birth is usually normal.
- IgM in serum.
- PCR for varicella DNA in serum and CSF.

#### Outcome

- Depends on degree of damage to CNS/PNS.
- It is unclear if immune globulin or aciclovir administered to the mother gives any protection to the fetus however.
- Outcome of the perinatal form can be improved by giving the infant immune globulin if born <5 days since the onset of maternal varicella or if she develops it within 2 days of giving birth.


### Lymphocytic choriomeningitis virus (LCMV)

- Uncommon, but possibly under diagnosed.
- Exposure to rodents needed (virus stable in murine urine and faeces).
- Foetal infection requires maternal infection in 1st or 2nd trimester.
- CNS features similar to other TORCH infections including neuronal migration defects, microcephaly and periventricular calcifications. All cases have chorioretinitis.
- Higher rate of spontaneous abortion.
- *Diagnosis serological*: PCR not available.
- No specific treatment is available.

### 'Pseudo-TORCH' syndromes

A rare group of disorders in which infants show features suggestive of TORCH infection (including microcephaly and intracerebral calcification), but direct infection cannot be demonstrated. Some have haematological or immunological abnormalities.

Genetic understanding of conditions causing this picture has improved considerably in recent years. Despite this, however, a diagnosis is still not always possible. Conditions to consider include:

- Aicardi–Goutières syndrome (see  'Aicardi–Goutières syndrome (AGS)', p. 361).
- Cerebro-retinal microangiopathy with calcification and cysts (CRMCC). A condition resembling Aicardi-Goutières, but without CSF pleocytosis or elevated levels of CSF interferon- $\alpha$ . two eponymous syndromes though overlapping forms exist:
  - *Coats plus disease*—retinal telangiectasia, retinal exudates, facial dysmorphism, abnormalities of hair and nails, skeletal defects, movement disorder, leukodystrophy;
  - *Labrune syndrome*—leukoencephalopathy, progressive intracerebral cysts;
  - Calcifications are extensive with predilection for thalamus, basal ganglia and the sub-cortical white matter;
  - Progressive disorder with onset usually the neonatal period. May develop GI bleeding.
- RNASET2-deficient cystic leukoencephalopathy. Autosomal recessive. Anterior temporal lobe cysts, calcifications in periventricular WM and parietal lobes.
- *COL4A1 mutation*: autosomal dominant, porencephalic cysts, abnormal retinal vessels, cataracts. Wide clinical phenotype.
- Cockayne syndrome.
- Band-like intracranial calcification, microcephaly and malformation of brain development (probably autosomal recessive (AR), no genes identified yet).
- Hoyeraal–Hreidarsson syndrome (dyskeratosis with progressive pancytopenia and diverse immune abnormalities). May have mutations in *DCK1* gene on X chromosome. Other brain abnormalities reported including hypoplasia of the corpus callosum and cerebellum, small brain stem, and abnormal pituitary.
- Mitochondrial cytopathies.

#### **Aicardi–Goutières syndrome (AGS)**

The genes responsible for AGS are nucleases involved in removing endogenous nucleic acid species. Failure of this removal leads to inappropriate activation of the innate immune system (which can also be activated by congenital infection); hence, the close resemblance with TORCH syndromes clinically.

#### *Neonatal form*

The originally described neonatal onset form (AGS1 commonly due to mutations in *TREX1*) gives a picture extremely reminiscent of congenital infection with encephalopathy, hepatosplenomegaly, abnormal LFTs, cerebral calcification on CT and CSF pleocytosis. Epilepsy, acquired microcephaly, and severe neurodisability develop with time.

*Infant-onset forms*

Later onset variants are most frequently due to *RNASEH2B* (*AGS2*) gene mutations. After a period of weeks to months of normal development the child develops encephalopathy with regression, declining OFC, and recurrent sterile pyrexias. Progression usually stops after a period of several months.

There are other AGS subtypes that show SLE-like features including chilblains, autoantibodies, and polygammaglobulinaemia. They can also develop a large vessel cerebral arteriopathy and are at risk of cerebral haemorrhage.

*Investigations*

- CSF is initially abnormal, but becomes normal with time (risking false negatives if performed late). Findings include pleocytosis (typically ~20, but always <100) and elevated CSF interferon- $\alpha$  and neopterin.
- *Radiological features comprise:*
  - intracerebral calcification of variable extent and distribution but most commonly affecting basal ganglia and deep white matter; can develop after several months (i.e. false negatives if done too early) and may be missed on MRI;
  - *white matter changes*—periventricular distribution;
  - *atrophy*—global with time including brainstem and cerebellum.

Management is currently symptomatic with no benefit demonstrated as yet for immunomodulatory treatment.

**Consequences of congenital HIV infection**

Children with congenital HIV are increasingly surviving into adulthood due to antiretroviral treatments (ART). HIV is a neurotropic virus and neurological manifestations are common. Presentations depend on:

- Age of the child.
- Level of immunosuppression as reflected in CD4 count. Opportunistic infection more likely if <200 cells/mL.
- Viral load and access, adherence and resistance to ART medication.

**HIV-related syndromes of CNS**

- *Meningitis:*
  - *Acute*—all bacterial causes more likely including listeria;
  - *Chronic*—fungal, e.g. *Candida*, TB, *Cryptococcus*, *Nocardia*.
- *Encephalitis:*
  - HSV, VZV, CMV;
  - JC virus causing progressive multifocal leukoencephalopathy (PML) (see [p. 353](#)).
- *Space occupying lesions:*
  - *infection related*—all bacterial abscesses more common (see [Table 4.7](#)); infective granulomas due to TB, *Toxoplasma*, *Aspergillus*; JC virus (PML);
  - *Neoplasia*—primary CNS lymphoma (may be associated with EBV), glioma.

**HIV-related syndromes of PNS**

- Polyradiculitis due to CMV or VZV. Neuropathic pain localized to one or more dermatomes.
- Myelitis due to HIV.
- *Peripheral neuropathies*:
  - HIV sensory neuropathy;
  - shingles (VZV);
  - Guillain–Barré syndrome (more common in adults as part of seroconversion illness);
  - ART complications.
- *Myositis*: HIV, CMV, ART complications.

**Stroke-like syndromes or dementia**

- *Vascular*: embolic or secondary to venous thrombosis, VZV vasculitis, cerebral aneurysms, Moya–Moya syndrome.
- *Infection*: HIV dementia, JC (PML).

**Static encephalopathy**

- Developmental delay (occasionally regression) with microcephaly.
- CP syndromes particularly spastic diplegia.

**History and examination**

HIV infection may already be diagnosed, but should be considered if no diagnosis or cause has been identified for children with neurological disorders as listed, particularly if the course is unusual, if the child has other illnesses suggestive of HIV (lymphadenopathy, weight loss, oral ulcers, parotid gland swelling, haematological abnormalities, elevated immunoglobulin levels, etc.) or if parental risk factors exist.

Antenatal screening is routine in the UK, but patients can opt out or have inadequate antenatal care. Occasionally asymptomatic abnormalities are detected on neonatal USS, e.g. basal ganglia calcification or an infarct.

**Investigations**

Establish HIV status with parental consent. If positive consider the following investigations depending on the neurological syndrome.

**CNS infections and space-occupying lesions**

- Liaise with ID colleagues before taking samples. Consider CSF PCR for TB, toxoplasma, CMV, JC, HSV, VZV, EBV.
- Send blood for cultures, cryptococcal antigen.
- Store serum sample for serology.
- Check HIV viral load in plasma and CSF.
- Fundoscopy for retinitis in CMV.
- Consider brain biopsy if diagnosis still unclear or no improvement after specific treatment(s).
- Cranial imaging findings depend on neurological syndrome but may reveal basal ganglia calcification or cerebral atrophy, as well as other abnormalities.

**PNS syndromes**

- Send CSF for PCR for CMV, VZV, HSV. Check HIV viral load in plasma and CSF.
- Nerve conduction studies/EMG.






*Stroke-like syndromes or dementia*

- Send CSF for PCR for VZV.
- Liaise with neurosurgical colleagues if an aneurysm or Moya–Moya is suspected (formal angiography may be needed).

*Static encephalopathy*

Cranial imaging.

**Treatment**

- Liaise closely with ID colleagues:
  - TB (see  p. 339);
  - *Toxoplasma*—pyrimethamine (with folinic acid) and sulphadiazine;
  - CMV—ganciclovir ± foscarnet;
  - *Cryptococcus*—manage raised ICP, amphotericin B and fluconazole (see  p. 348);
  - *Aspergillus*—amphotericin;
  - PML (see  p. 353).
- Neurosurgical referral as required for treatable vascular disorders, brain abscesses, complications of CNS infections causing raised ICP, consideration of brain biopsy.
- Child development team referral.

## Late-onset metabolic disease

Rare presentations of rare diseases: late-onset inborn errors of metabolism (IEMs) are there to catch us out! The key is to remember to ask the question, if only to exclude it: if you do not think of it the diagnosis will be missed!

Diagnosis permits

- Specific treatment.
- Prevention of metabolic decompensation.
- Accurate counselling.
- Early recognition may prevent irreversible neurological impairment.

► Consider a late-onset IEM particularly where there is:

- An informative family history (of course!); remember mild forms in those with partial deficiencies, e.g. PKU variants.
- Atypical psychiatric symptoms, particularly a striking change in behaviour or onset of psychosis.
- Subtle physical signs as part of a recognizable picture.
- A late-onset cerebellar ataxia.

### *A particular comment on late presentations of urea-cycle disorders*

Presentations may be acute or chronic, and vary with age.

- Early presentations (around 12–24 mths) tend to be ‘hepatogastric’ (i.e. GI symptoms in association with deranged liver function).
- In the next age band (average onset 4 yrs) encephalopathy and acute confusion predominate.
- Predominantly psychiatric presentations at a slightly later age (average onset 8 yrs).
- Deterioration with sodium valproate.
- Note that a **combination** should alert clinician.

### Psychiatric presentations

#### *Acute psychosis*

- Later onset urea cycle defects (average age at onset 8 yrs).
- Homocysteine remethylation defects.
- Porphyrrias.

#### *Chronic psychiatric symptoms in childhood or adolescence*

##### *Catatonia, visual hallucinations (aggravated by treatment)*

- Homocystinurias.
- Wilson disease.
- Adrenoleukodystrophy.
- Some lysosomal storage disorders.

##### *Mild learning difficulties, with late-onset behavioural or personality changes*

- Homocystinurias.
- Cerebrotendinous xanthomatosis.

- Non-ketotic hyperglycaemia.
- Monoamine oxidase A deficiency.
- Succinic semialdehyde dehydrogenase deficiency.
- Creatine transporter deficiency.
- $\alpha$  and  $\beta$  mannosidosis.

Early onset dementias are usually genetic, rather than metabolic, e.g. Huntington where seizures predominate.

### Some suggestive physical signs

#### *Episodes of confusion, coma or strokes*

- Cobalamin C disease.
- Methylene tetrahydrofolate reductase (MTHFR) deficiency.
- Mitochondrial disorders including MELAS.
- 3-HMG CoA lyase deficiency.
- Fabry disease.
- Urea cycle defects (average age at presentation 4 yrs).
- Some leukoencephalopathies including childhood ataxia with CNS hypomyelination (aka vanishing white matter disease (see [□](#) p. 431)).
- CADASIL (cerebral autosomal dominant arteriopathy with subcortical infarcts and leukoencephalopathy).

#### *Tremor*

- Tay–Sachs disease.
- Abetalipoproteinaemia.

#### *Polyneuropathy*

- Cerebrotendinous xanthomatosis.
- MTHFR deficiency.
- Cobalamin C disease.
- Krabbe disease.
- Megalencephalic leukodystrophy with cysts.
- Respiratory chain disorders (see [□](#) p. 430).
- Adrenomyeloneuropathy/adrenoleukodystrophy.
- Peroxisomal biogenesis disorders.
- Polyglucosan body disease.

#### *Proximal weakness with respiratory insufficiency*

Pompe disease.

#### *Skin features* (see also Table 1.1)

- *Xanthomata*: cerebrotendinous xanthomatosis.
- *Ichthyosis*: Sjogren–Larsson.
- *Melanoma*: adrenomyeloneuropathy/adrenoleukodystrophy.
- *Angiokeratoma*: Fabry disease.

#### *Visceral features*

- *Hepatogastric syndrome* (i.e. upper GI symptoms with deranged liver function tests): early onset urea cycle defects (average age at presentation 14 mths).
- *Chronic diarrhoea*: cerebrotendinous xanthomatosis.
- *Adrenal insufficiency*: adrenoleukodystrophy.

- *Chronic diarrhoea, cachexia, intestinal pseudo-obstructions*: MNGIE.
- *Diabetes/other endocrine features*: mitochondrial disorders.
- *Amenorrhoea*: childhood ataxia with CNS hypomyelination (CACH/vanishing white matter).

### Visual features

- *Retinitis pigmentosa*: cobalamin C, mitochondrial, and peroxisomal disorders.
- *Optic nerve atrophy*: cobalamin C, adrenoleukodystrophy, mitochondrial disease, megalencephalic leukodystrophy with cysts, Krabbe, organic acidurias, PKU, mucopolidosis type IV.
- *Cataract*: cerebrotendinous xanthomatosis, mitochondrial and peroxisomal disorders.
- *Macular dystrophy*: Sjogren–Larsson, mucopolidosis type IV.
- *Supra-nuclear gaze palsy*: Niemann–Pick C (seizures, visceral involvement), Gaucher.

### Auditory features

Mitochondrial and peroxisomal disorders.

### Macrocephaly

- Glutaric aciduria type 1.
- L-2-hydroxyglutaric aciduria.

### Polyneuropathy

- Cerebrotendinous xanthomatosis.
- MTHFR deficiency.
- Cobalamin C.
- Krabbe.
- Metachromatic leukodystrophy.
- Mitochondrial and peroxisomal disorders.
- Adrenomyeloneuropathy/adrenoleukodystrophy.
- Polyglucosan body disease.

### Acute porphyrias

Hereditary porphyrias are a heterogeneous group of eight disorders of haeme biosynthesis. Four of these (the 'acute hepatic porphyrias') give rise to acute attacks with neurological features including:

- *Prodrome*: minor behavioural change (anxiety, insomnia, restlessness).
- *Severe pain*: primarily abdominal but can involve back or thighs.
- *Prominent autonomic features*: nausea and vomiting; tachycardia and hypertension; diarrhoea or constipation.
- Variable neurological features including acute confusional state (sometimes severe), depression or seizures.
- Less commonly, peripheral weakness resembling Guillain–Barré syndrome.
- Attacks typically last several days to a week or more, before slowly resolving. Peripheral weakness can take longer to resolve. Pre-pubertal presentation is very rare.

**Investigation in association with specialist porphyria centre**

- *First line:* urine porphobilinogen and 5-aminolaevulinic acid; faeces total porphyrin and plasma fluorescence emission spectroscopy (peak at 624–628 nm) to delineate the type of acute porphyria (all collected in a light-proof containers e.g. wrap standard universals in aluminium foil). Samples are likely to be false-negative between attacks and repeated testing even during attacks may be necessary if suspicion is high.
- DNA analysis and enzyme activity can subsequently be used to detect presymptomatic carriers.

**Treatment**

- *Preventive:* avoid precipitants (list of safe and unsafe drugs; avoid alcohol, smoking, cannabis, fasting).
- *Acute specific:* repress haeme synthesis with haemin, treat hyponatraemia (precipitates seizures) and maintain normoglycaemia.
- *Acute symptoms:* opiates for pain; chlorpromazine for vomiting and hallucinations; lorazepam for insomnia and anxiety.

## Mitochondrial disease

This is a heterogeneous group of diseases caused by a failure of mitochondrial oxidative metabolism, with symptoms and biochemical defects often evident in muscle, heart and brain (because of large numbers of mitochondria and dependence on oxidative metabolism). Specific histochemical changes such as cytochrome c oxidase (COX) deficient fibres and ragged-red fibres are often evident in muscle biopsies, but normal histochemical appearance does not exclude mitochondrial disease, as many patients will have deficiencies of complexes I (and to a lesser extent III or V), which are not evident on routine histochemistry. Mitochondrial dysfunction in children is best identified by a combination of biochemical analysis of the individual respiratory chain components in muscle and molecular genetic studies on blood and muscle derived DNA.

As with many genetic conditions the observed clinical phenotype may be caused by different mutations in either the nuclear or mitochondrial genomes and, conversely, a single genotype can give rise to several distinct phenotypes.

### Mitochondrial genetics

The sometimes marked genotypic/phenotypic variation has several causes.

#### Two inheritance systems

- Mitochondrial DNA (mtDNA) is inherited maternally (the zygote is thought to recognize 'paternal' mitochondria from sperm shortly after fertilization and to destroy them by ubiquitination), but the *majority* of mitochondrial proteins are coded for by genes in the cell nucleus (with normal Mendelian, not maternal inheritance).
- mtDNA codes for 13 polypeptides and 24 structural RNA molecules, and contributes to each of the complexes except complex II. At least a further 60 proteins coded for by nuclear DNA are imported into mitochondria and show autosomal inheritance.
- Thus, for example, a single phenotype (chronic progressive external ophthalmoplegia, CPEO) may be sporadic, autosomal dominant, autosomal recessive, or maternally inherited.
- It is suggested that mtDNA encoded defects give milder disease than nuclear-encoded DNA defects: they tend to present later and be associated with better life-expectancy.

#### Heteroplasmy and mosaicism

- There are many hundreds of mitochondria present in a single myocyte and each mitochondrion contains approximately 10–15 copies of mtDNA. However, not all the mitochondria in one cell are genetically homogeneous, and a dual population of wild-type and mutated mtDNA may co-exist (heteroplasmy) while remaining clinically silent.
- If the proportion of mutated mtDNA exceeds a tissue-dependent 'threshold', then disease will ensue.

- Disease manifestations typically relate to tissues highly dependent on oxidative metabolism including brain, muscle (skeletal and cardiac), kidney (tubules), liver, gut, and pancreas (endocrine and exocrine).
- Mitochondria are randomly segregated to daughter cells during meiosis and this may result in a skewed distribution of mutated mtDNA among a cell population. When this process occurs during foetal organogenesis, some tissues inherit high levels of mutant mtDNA, while in others it may be undetectable. Some mtDNA mutations are also 'lost' from rapidly dividing tissues (possibly due to 'fitness' selection); this can be problematic when testing blood DNA from older children for large-scale single deletions and specific point mutations.

#### **Greater frequency of point mutations and poorer repair mechanisms**

Recent prevalence estimates suggest that the carrier frequency for pathogenic mtDNA mutations is 1 in 200 of the UK population, with approximately 1 in 10000 adults developing clinical disease as a consequence. Disease prevalence due to nuclear genetic mutations has not been subject to the same epidemiological study, but mutations in genes, such as *POLG* are thought to account for a substantial proportion of mitochondrial disease in adults.

### **Clinical presentations**

Mitochondrial disease can present at all ages, but are increasingly recognized in childhood. Multiple, apparently unrelated organs can be affected typically including combinations among: muscle, heart, eyes, brain (including hearing, seizures, extrapyramidal syndromes), liver, blood, and pancreas. Some combinations have been defined as 'syndromes', although even these can be incomplete or overlap.

#### **Myopathy**

The single most common feature. It is typically proximal and may include the face. It may include exercise-related features including myalgia and rhabdomyolysis.

#### **Eye movements**

Ptosis and/or external ophthalmoplegia (i.e. failure of each eye to be able to abduct) are very characteristic changes in adults but less often observed in children. Typically, these are slowly progressive: the main differential in practice is myasthenia.

#### **Eye involvement**

Retinal pigmentation, or optic atrophy are seen. See also 📖 'Leber hereditary optic neuropathy (LHON)', p. 373.

#### **CNS involvement**

CNS manifestations can be protean, and relatively non-specific, including pyramidal and extrapyramidal syndromes (dystonia), seizures (epilepsia partialis continua), migraine, and stroke-like episodes.

### *MRI*

MRI can be correspondingly non-specific, but highly symmetrical changes can be an indicator of metabolic processes (rather than injury by extrinsic processes). Symmetric high T2 signal of the basal ganglia and brainstem is effectively the radiological counterpart of Leigh syndrome (historically defined pathologically) and is particularly suggestive of mitochondrial disease (although there are alternative causes). Calcification of the basal ganglia (CT imaging) is seen in MELAS (see [□□](#) p. 374), as well as a number of other 'metabolic' disorders. Areas of infarction associated with mitochondrial stroke-like episodes tend to occur in the parieto-occipital regions and often do not conform to a single vascular territory.

MR spectroscopy allows estimation of lactate contents of a 'region of interest' but in most circumstances probably adds little to CSF lactate estimation.

### **Sensorineural deafness**

Particularly if acquired and symmetrical. A combination of deafness and diabetes (or family history of such combinations) is very suggestive.

### **Cardiac involvement**

Unexplained hypertrophic or dilated cardiomyopathy may require transplantation, but this option should be carefully considered in the context of multisystem disease. Right bundle branch block and Wolff–Parkinson–White (WPW) syndrome may be symptomatic, and require drug treatment or implanted pacemaker.

### **Renal disease**

Particularly tubular dysfunction (Fanconi syndrome).

### **Pancreatic disease**

Exocrine pancreas dysfunction (resulting in fat malabsorption and steatorrhoea) or endocrine dysfunction causing diabetes.

### **Liver disease**

Hepatocerebral mtDNA depletion syndromes cause profound encephalopathy and liver failure; when associated with seizures suspect Alpers–Huttenlocher Syndrome (see [□□](#) p. 373) and investigate for mutations in polymerase gamma. Neonatal liver failure with lactic acidemia may be due to mutations in TRMU and associated with a good prognosis if the patient can be supported through the liver failure.


### **Haematological disease**

Sideroblastic anaemia or pancytopenia have been associated with Pearson's Syndrome, resulting from large-scale deletions or rearrangements of mtDNA, and MLASA (Myopathy, Lactic Acidosis and Sideroblastic Anaemia) as a consequence of mutations in *PUS1*.



### Suspecting mitochondrial disease

#### Clues

- A recognized syndrome (see  p. 373) including partial and overlap forms.
- Multi-organ involvement of combinations of the systems described.
- Short stature.
- A history of stepwise neurological or neurodevelopmental deteriorations with variable, often incomplete, recovery between deteriorations.
- Any suggestion of disturbed respiratory drive (e.g. unexplained hypoventilation).
- High CSF protein (in the absence of CNS inflammation) suggests CNS necrosis and Kearns–Sayre Syndrome should be considered.
- High blood lactate, but more specifically high CSF lactate. A mitochondrial cause of a clinical picture with prominent CNS involvement is unlikely if CSF lactate is normal (although CSF lactate may be normal in, for example, a predominantly myopathic mitochondrial disease). Recent status epilepticus, severe shock, or asphyxia and meningitis are the main non-mitochondrial causes of high CSF lactate.

#### Investigation

This should be directed by specialist advice guided by phenotype. It will often include CSF lactate, neuroimaging (MRI), and muscle biopsy (to include histochemistry, biochemical analysis of respiratory chain complexes and molecular biology assays). The level of mutated mtDNA may be low or absent in blood and the mutation missed on routine sequencing. In contrast, nuclear gene mutations are readily identified on DNA extracted from blood.

#### Histochemistry

*Characteristically ragged-red fibres:* irregular reddish patches around the circumference of fibres visible on Gomori trichrome stain, representing accumulations or proliferations of abnormal mitochondria. Several important mitochondrial diseases including Leber hereditary optic neuropathy (LHON) and neuropathy, ataxia and retinitis pigmentosa (NARP) are not associated with ragged-red fibres; and some other non-mitochondrial primary myopathies, and even normal ageing, can also cause ragged-red fibres.

Other histochemical techniques include staining for succinate dehydrogenase (SDH) or NADH-tetrazolium reductase (NADH-TR) as markers for mitochondrial proliferation, and cytochrome c oxidase (COX), absence of which is indicative of a disease affecting complex IV of the mitochondrial respiratory chain. Sequential COX-SDH assay provides the best opportunity to identify COX-negative fibres (blue). Association of COX negativity with ragged-red appearance is characteristic of some conditions.

## Recognized syndromes


Leigh and Alpers-Huttenlocher syndromes are probably the most common in paediatric neurological practice. The 'archetypal' mitochondrial syndromes such as MELAS and MERRF are rare in children.

### *Leigh syndrome*

Involvement of the brainstem and basal ganglia structures: originally defined pathologically but now essentially a radiological diagnosis. Clinically heterogeneous: often an early-onset, aggressive picture of brainstem involvement (including eye movement and respiratory abnormalities, 'sighing respiration') plus a motor disorder (pyramidal  $\pm$  extrapyramidal). Stepwise deterioration is characteristic—occasionally a long period of stability can cause a child to be misdiagnosed as having 'cerebral palsy' before the ultimately progressive nature of the process declares itself.

A much rarer, dominantly inherited condition (autosomal dominant acute necrotizing encephalopathy, ADANE) has similar clinical features of acute deteriorations with intercurrent illness and superficially similar radiology. Its importance lies in identifying pre-symptomatic first-degree relatives who can benefit from immunization and prophylactic antibiotics to reduce risk of acute deterioration. The radiological discriminators include involvement of external capsule and brainstem in ADANE, which is relatively atypical for Leigh.

### *Alpers-Huttenlocher Syndrome/progressive neuronal degeneration of childhood (PNDC)*

See also  p. 429. A clinical picture of onset is seen in the toddler age group of refractory status epilepticus (often epilepsia partialis continua) sometimes progressing after weeks or months to include deranged liver function. In those children in whom a metabolic basis has been confirmed, nearly all have been mitochondrial and due to mutations in *POLG*.

### *Leber hereditary optic neuropathy (LHON)*

Relatively painless (c.f. optic neuritis) onset of permanent visual failure occurs in late adolescence/early adulthood. This progresses over several weeks typically sequentially (one eye then the other) associated with swelling of the optic nerve head in the acute phase. Family history is found in >50% of cases. Associated dystonia, ataxia, and spasticity are rare and late developments.

### *Kearns–Sayre syndrome and chronic progressive external ophthalmoplegia*


Chronic progressive external ophthalmoplegia (CPEO) is rare in children. Slowly progressive weakness of ocular muscles occurring over months or years sometimes with proximal limb weakness is very suggestive.


Kearns–Sayre syndrome (KSS) is a more severe picture characterized by the onset of CPEO and pigmentary retinopathy before the age of 20 yrs. Frequent additional features include ataxia, heart block (may be asymptomatic at presentation but important to detect), deafness, endocrinopathy (adrenal, thyroid, pancreas), renal tubular dysfunction, and myopathy.

***Mitochondrial myopathy, encephalopathy, lactic acidosis and stroke-like episodes (MELAS)***

Stroke-like episodes occur (acute onset of any focal neurological syndrome) with focal acute inflammatory ischaemic changes on MRI that are not confined to a single vascular territory. Associated short stature, sensorineural hearing loss and GI dysmotility. Screen for cardiomyopathy and arrhythmias.

***Myoclonic epilepsy with ragged-red fibres (MERRF)***

This is a progressive myoclonic epilepsy (see  p. 283) with typical onset in later childhood comprising seizures (multiple seizure types but including by definition myoclonic seizures), ataxia, myopathy (with ragged-red fibres), optic atrophy, headache, deafness, and progressive neurological deterioration with cognitive decline.

A useful resource for parents and professionals for advice on case management is to be found at  [www.mitochondrialncg.nhs.uk](http://www.mitochondrialncg.nhs.uk) the website of the UK National Commissioning Group (NCG) for Rare Mitochondrial Diseases of Adults and Children.

## Movement disorders

These produce defective speed or accuracy in movement, often accompanied by involuntary movements. The basal ganglia store movement patterns. Abnormal function can lead to underactivity—hypo- or bradykinesia, often with rigidity; or more often a dyskinesia—tremor, chorea, dystonia tics, or myoclonus.

### Diseases associated with dystonia and athetosis

#### *Transient idiopathic dystonia of infants*

Onset is usually before 5 mths and affects a single upper limb and trunk and to lesser degree the lower limb, causing a hemidystonia. It is persistent and present in sleep but attenuated. The dystonia is abolished when the infant moves purposefully. The dystonias resolve with no sequelae at around 12 mths.

#### *ABI post-HIE ('athetoid cerebral palsy')*

Results from acute and profound hypoxia-ischaemia (>10 minutes) in term infants resulting in injury to deep grey matter. Following a period of fluctuating axial and limb tone more obvious choreo-athetosis may emerge in the second 6 mths of life. May also be caused by bilirubin induced neurologic dysfunction (BIND) due to haemolytic disease of the newborn secondary to rhesus iso-incompatibility (in developing countries), ABO incompatibility (in developed countries, particularly with early discharge of babies) or G6PD deficiency; or hyperbilirubinaemia in sick preterm babies. Often associated with deafness.

#### *Pontocerebellar hypoplasia type 2 (PCH2)*

Severe infantile-onset movement disorder characterized by chorea and dystonia associated with microcephaly and severe developmental delay. Unlike the confusingly-similarly named PCH1 (see [□□](#) p. 384) there is no anterior horn pathology, but MRI appearances are very similar with hypoplasia of the cerebellum and ventral pons. The genetic basis is not currently identified (presumed autosomal recessive). Life expectancy limited.

#### *Torticollis*

Torticollis and head tilt may result from a number of conditions (see Box 4.6). Look for associated signs such as orofacial dystonia, long tract signs, neck injury or signs of raised intracranial pressure.

Episodic torticollis that is not fixed may be due to tics, paroxysmal dyskinesia (see [□□](#) p. 306), spasmus nutans (see [□□](#) p. 379) or benign paroxysmal torticollis (see [□□](#) p. 305).

#### *Idiopathic torsion dystonia*

- An autosomal dominant (AD) trait with reduced penetrance associated with mutations in the torsin A gene *DYT1*.
- Age of onset is before 15 yrs and starts as dystonia in one limb and often only in specific postures, frequently leading to misdiagnosis of a psychogenic disorder.
- Typically signs initially appear at the ankle resulting in abnormal foot posture and gait.

- Disappears in sleep; progresses over 5–10 yrs to become generalized involving the trunk and contralateral limbs. Then usually plateaus but results in significant deformity and contractures.
- Diagnosis is by exclusion of causes of secondary dystonia and DNA analysis.

### *DOPA-responsive dystonia*

See  p. 436.

### *Hereditary myoclonic dystonia*

An autosomal dominant (AD) disorder with onset before the age of 10. Mild dystonia usually affects proximal arm muscles and neck associated with stimulus-sensitive myoclonic jerks of proximal muscles (phenotypes vary and may include obsessive-compulsive disorder). It is responsive to sodium valproate and characteristically to alcohol (older members of the pedigree may have identified this!). The course is static but often intrusive.

### *Mohr–Tranebjaerg syndrome*

A rare X-linked primary dystonia with profound sensorineural hearing loss. The deafness is early with development of dystonia in later childhood. Developmental delay and long tract signs are also present.

### *Secondary dystonia*

See Table 4.8 for causes of secondary dystonia.

**Table 4.8** Causes of secondary dystonia

Metabolic	Neurodegenerative	Drugs/toxins	Other causes
Glutaric aciduria type 1	Ataxia	Phenothiazines	Hypoxia- ischaemia, or viral encephalitis leading to: Striatal necrosis/ basal ganglia infarction or porencephaly (often hemidystonia)  Alternating hemiplegia of childhood  HIV infection  Basal ganglia neoplasm  Vascular malformations  Sandifer syndrome
Methylmalonic acidemia	Juvenile Huntington disease	Haloperidol	
Propionic acidemia	Metachromatic leukodystrophy	telangiectasia	
Lesch–Nyhan	Wilson disease	Mitochondrial disease	
GM1 and GM2 gangliosidosis	Krabbe	Metoclopramide	
Homocystinuria	NBIA		
Galactosaemia	Neuronal ceroid lipofuscinosis		
Niemann–Pick type C	Neuroaxonal dystrophy		
Mucopolysaccharidoses	Rett syndrome		
Sulphite oxidase deficiency	Olivocerebellar atrophy		
Biotinidase deficiency	Spinocerebellar ataxias		
Creatine deficiency	Infantile bilateral striatal necrosis		
HypoPTH	Pelizaeus–Merzbacher		
Hartnup disease	Neuroacanthocytosis		
Tyrosinosis			
Vitamin E deficiency			

**Treatment of dystonia**

- All children with idiopathic dystonia should have a trial of L-DOPA given in conjunction with a peripheral DOPA decarboxylase inhibitor (see 📖 p. 594).
- Trihexyphenidyl (dose increased slowly to minimize unwanted effects), pimozide, benzodiazepines (clonazepam or diazepam) or oral baclofen may help.
- Botulinum toxin A injections are increasingly used in the treatment of focal dystonias. There is an important role for physiotherapy to prevent contractures in prolonged or fixed dystonias.
- Episodes of severe generalized dystonia ('*status dystonicus*') can be difficult to treat (see 📖 p. 551).

**Box 4.6 Causes of torticollis**

- Cervical cord tumours, syrinx and cervicomedullary junction malformations
- Posterior fossa tumours
- Diplopia
- Sandifer syndrome
- Spasmus nutans
- Sternocleidomastoid injury and 'tumour'
- Juvenile idiopathic arthritis
- Dystonia
- Tics
- Benign paroxysmal torticollis of infancy
- Paroxysmal dyskinesia

**Diseases associated with hypokinetic-rigid syndrome**

These frequently co-exist with dystonia. Some conditions causing a hypokinetic rigid syndrome in adults may present with dystonia in children.

**Juvenile Huntington disease**

See 📖 p. 432.

**Wilson disease**

See 📖 p. 432.

**NBIA/PKAN**

See 📖 p. 430.

**Neuronal intranuclear inclusion disease**

Rare slowly progressive disorder with Parkinsonism, behavioural and cognitive regression, progressive ophthalmoplegia, and ataxia, intestinal pseudo-obstruction and frequent oculogyric crises.

Diagnosis is by the finding of eosinophilic neuronal nuclear inclusions on rectal biopsy.

**Primary dystonia–parkinsonism syndromes**

Extremely rare conditions that include X-linked parkinsonism and autosomal dominant rapid-onset dystonia–parkinsonism that may appear within 24 h. Treatment with L-DOPA and anti-Parkinsonian drugs is of limited use.

*Niemann–Pick type C* (see  p. 431)

*Mitochondrial cytopathies* (see  p. 369)


*Juvenile GM2 gangliosidosis* (see Table 4.17)

*Phenylketonuria*

*Subacute sclerosing panencephalitis* (see  p. 348)

### Primary Parkinsonism and Parkinson disease

#### *Juvenile idiopathic parkinsonism and early-onset Parkinson's disease*

- Development of Parkinsonism before the age of 20 usually with preserved intellect.
- Heterogeneous group with different patterns of inheritance.
- *Dystonia of the feet is an early feature in early-onset Parkinson's disease:* tremor and depression are less common than in the adult form.
- Main differentials are juvenile Huntington disease, Wilson disease, DOPA-responsive dystonia and secondary causes of Parkinsonism.
- All share good initial response to L-DOPA followed by fluctuating response and hyperkinetic movements. Many cases are variants of DOPA-responsive dystonia (see  p. 436).

#### *Secondary Parkinsonism*

- *Hydrocephalus (especially aqueduct stenosis):* improved by shunting.
- Central pontine myelinolysis.
- Drugs and poisons (mercury, manganese, carbon monoxide, methanol, amphotericin B, cytosine-araboside).
- Infections (post-encephalitis, mycoplasma, influenza, PML).
- Basal ganglia neoplasm.
- Any cause of basal ganglia calcifications (see Box 4.7).

### Box 4.7 Causes of basal ganglia calcification

#### *Genetic/metabolic*

Mitochondrial cytopathies; NBIA; Cockayne; NF1; Down; microcephaly–intracranial calcification syndrome; Aicardi–Goutières; familial idiopathic basal ganglia calcification (Fahr disease); bilateral striatal calcinosis; tuberous sclerosis; Krabbe; PKU; McCune–Albright.

#### *Endocrine*

Primary hypoparathyroidism (PTH); pseudohypoPTH; pseudopseudo-hypoPTH; hyperPTH; hypothyroidism.

#### *Infections*

CMV; toxoplasmosis; neurocystercosis; viral encephalitis; HIV.

#### *Toxins*

Carbon monoxide; lead; chromium.

#### *Structural*

Radiation; methotrexate; excess vitamin D; basal ganglia tumours; metastases; hypoxic–ischaemic injury (status marmoratus).

### **Symptomatic treatment of hypokinetic-rigid syndrome**

- Bradykinesia and rigidity respond better than tremor to dopamine agonists. Initially a trial of L-DOPA should be given in association with a peripheral decarboxylase inhibitor (benserazide or carbidopa). Entacapone may increase the bioavailability and duration of action.
- Common side effects include nausea, vomiting, orthostasis and chorea.
- Experience of D2 agonists, such as bromocriptine, pergolide, apomorphine, pramipexole, ropinirole, and cabergoline in children is limited.
- Anticholinergic agents may also be used when L-DOPA is ineffective. Trihexyphenidyl is probably the most widely used paediatric anticholinergic agent.

### **Diseases associated with tremor**

#### **Physiological**

Often enhanced to clinically detectable levels by anxiety, excitement, caffeine, fatigue, or stress.

#### **Essential**

AD in many families, but tremor in first-degree relatives is often not present. Usually appears after school entry. Diagnosis is clinical and based on the finding of persistent fine (8–10 Hz) postural and action tremor of over 1 yr duration in the absence of other neurodevelopmental abnormalities, systemic disease, or drugs. It may interfere with writing, is usually limited to the hands, but the jaw and neck may be affected. It is exacerbated by stress and fatigue and relieved by alcohol. Treatment is not usually required, but first line is low dose propranolol or primidone.

#### **Jittering**

A high frequency, low amplitude tremor affecting limbs and the chin seen in nearly 50% of all newborn infants during excitement and crying. Essentially a stimulus-sensitive clonus, it usually disappears in the neonatal period. It may also be a manifestation of hypoglycaemia, hypocalcaemia, and drug withdrawal or hypoxic–ischaemic injury.

**Shuddering spells** (see 📖 p. 304)

#### **Spasmus nutans**

A slow head tremor (2–4 Hz) seen in infants often with monocular horizontal nystagmus. It is rarely seen after age 3 yrs. It has a benign course but needs to be differentiated from congenital nystagmus and MRI is recommended to rule out optic gliomas.

#### **Secondary tremor**

##### *Endocrine*

Hyperthyroidism; hypocalcaemia; hypoglycaemia; uraemia; vitamin B12 deficiency; Kwashiorkor.

##### *Drugs and toxins*

Salbutamol; sodium valproate; carbamazepine; L-DOPA; iron; neuroleptics; tricyclics; lithium; thyroid hormone; theophylline, caffeine; corticosteroids; calcium channel blockers; antihelminthics ('worm wobbles').



**Metabolic**

Hepatic and renal encephalopathy; Wilson disease; PKU; Lesch–Nyhan; NCL.


**Neuromuscular**

Spinal muscular atrophy; chronic polyneuropathy (Roussy–Levy syndrome); AIDP.

**Structural**

Hydrocephalus ('bobble head doll' syndrome); subdural haematoma.

**Other**

Opsoclonus–myoclonus (see  p. 381); ataxia telangiectasia; Pelizaeus–Merzbacher; foetal alcohol syndrome; psychogenic.

**Diseases associated with myoclonus****Physiological**

A significant number of children have myoclonus without evidence of other neurological impairment especially in sleep. This may comprise single myoclonic jerks at the onset of sleep or subtle erratic jerking of the hands, face, or legs in REM sleep. Rarely physiological myoclonus can occur in wakefulness particularly after exertion, when fatigued or after a sudden sensory stimulus. Investigate to exclude epilepsy.

**Benign neonatal sleep myoclonus; benign myoclonus of early infancy**

See  p. 304.



**Essential**

A sporadic or AD condition causing chronic focal, segmental, or generalized myoclonus. It begins in the teenage or young adult years and predominantly affects proximal and facial muscles. It tends to co-exist with essential tremor in families. The remainder of the neurological exam is normal and the course is static. Treatment with clonazepam if required.

**Hyperekplexia**

See  p. 304.

**Myoclonic epilepsies**

- Early myoclonic epileptic encephalopathy (see  p. 264).
- Juvenile myoclonic epilepsy.
- Benign myoclonic epilepsy of infancy.
- Severe myoclonic epilepsy of infancy (Dravet syndrome).
- Myoclonic–astatic epilepsy (Doose syndrome).
- Lennox–Gastaut.
- (Angelman syndrome).
- Progressive myoclonic epilepsy syndromes (see  p. 283).

**Infectious**

- Subacute sclerosing panencephalitis.
- HSV.
- vCJD.

### **Drugs and toxins**

- Bismuth.
- Heavy metals.
- L-DOPA.
- Carbamazepine.
- Tricyclics.

### **Others**

- Renal failure.
- Hepatic failure.
- Dialysis syndrome.
- Spinal trauma.
- Spinal tumour.

### **Autoimmune/paraneoplastic**

Progressive encephalomyelitis with rigidity and myoclonus (PERM) in adults.

*Opsoclonus–myoclonus (Kinsbourne syndrome; ‘dancing eyes and dancing feet’ syndrome)*

- Affects infants and young children.
- Characterized by complex eye and limb movement disorder. Opsoclonus (sometimes known as ‘saccadomania’) is a condition of uncontrolled, frequent, conjugate, saccadic eye movements often occurring in flurries. Although the syndrome is named for this feature, it is often fleeting and subtle—the most striking feature is often extreme irritability. Small amplitude limb myoclonus and true ataxia are also present to varying extents.
- Strongly associated with neuroblastoma and appears to be a paraneoplastic autoimmune phenomenon. Although post-infectious opsoclonus–myoclonus (OMS) is described, some suggest that in apparent neuroblastoma negative cases the tumour has simply regressed.
- Although the oncological prognosis is usually good, the neurodevelopmental outlook can be poor unless aggressive immunosuppression is instituted.
- Mainstay of treatment is immunomodulation with corticosteroids (e.g. monthly dexamethasone pulses) and/or cyclophosphamide. IVIG and plasmapheresis are also reported as being effective.
- *Investigation:* spot and 24 h urine collection for catecholamines (may be negative); MIBG (iodine-131-meta-iodobenzylguanidine) scintigraphy can help localize a neuroblastoma; MRI ± surgical biopsy confirm tumour presence. Thyroid uptake blocked by potassium iodide beforehand and for some days after intravenous injection of radiolabelled MIBG.

### *Lance–Adams syndrome*

Action myoclonus following hypoxic injury, usually occurring during the recovery phase. May be associated with pseudobulbar palsy and cerebellar findings. Myoclonus may be unremitting and interfere with rehabilitation. Treatment is difficult—valproate, primidone, propranolol, benzodiazepines, baclofen and piracetam have been used.

**Diseases associated with chorea****Primary***Benign hereditary chorea*

- An AD condition linked to 14q and possibly to mutations in the gene *TITF1*.
- Onset before 5 often with a delay in walking, clumsiness, and frequent falling. Chorea affects mainly the trunk and proximal limbs. The disorder is static and not paroxysmal, and not associated with impairment of cognition or intelligence. It may remit spontaneously.
- The chorea rarely impairs functioning and may respond to AEDs such as phenytoin, carbamazepine, as well as haloperidol or clonazepam.

**Secondary***Sydenham chorea*

See  p. 218.

*Cardiopulmonary bypass ('post-pump' chorea)*

Chorea develops in 1–5% of children with cyanotic heart disease usually with systemic pulmonary collateral circulations after cardiopulmonary bypass especially if accompanied by circulatory arrest or deep hypothermia. The chorea onset is 2 weeks after surgery. It may be mild and resolve (see Table 4.9 for causes). In a number of children, it can be profound and unremitting, accompanied by hypotonia, orofacial dyskinesias and pseudobulbar palsy. The chorea is refractory to drug treatment but sedatives are used to provide comfort. MRI and EEG are usually normal. In persistent chorea, the MRI after some months may show diffuse cerebral atrophy.

**Tic disorders and Tourette syndrome****DSM-IVR criteria**

- Occur many times a day nearly daily.
- Cause distress or impairment in social or other areas of functioning.
- Age of onset before 18 yrs.
- Not due to an effect of a substance or a general medical condition.

**Gilles de la Tourette syndrome**

Multiple motor and at least one vocal tic present at some point during the illness (not necessarily concurrently) for >1 yr and never a tic-free period of more than 3 consecutive months.

- Average age of onset 5–10 yrs, nearly always before 15 yrs.
- Common psychiatric co-morbidities:
  - obsessive–compulsive disorder (OCD);
  - attention-deficit hyperactivity disorder;
  - trichotillomania;
  - increased rates of learning difficulties and conduct disorder, though most will have neither;
  - increased frequency of sleep disturbance especially somnambulism, night terrors and enuresis.

**Table 4.9** Causes of chorea

Metabolic	Genetic	Infectious	Drugs/toxins
Glutaric aciduria type 1	Ataxia telangiectasia	Sdenham	Oestrogen and OCPs
PKU	Canavan disease	Echovirus	L-DOPA
Galactosaemia	Huntington disease	HIV	Phenytoin
Lesch–Nyhan	NBIA	EBV	Lithium
Wilson disease	NCL	HSV	Ritalin
B12 deficiency	Pelizaeus–Merzbacher	Borreliosis	CO
Hypocalcaemia	Fahr disease	Systemic	Methanol
HypoPTH	Neuroacanthocytosis	SLE	Manganese
Hyponatraemia	Friedreich ataxia	Behcet	Toluene
Hypoglycaemia	DRPLA	Pregnancy (chorea gravidarum)	Phenothiazines
Hypo-magnesaemia	Pontocerebellar hypoplasia type 2	Antiphospholipid antibody syndrome	Ethosuximide
Addison	Machado–Joseph	<b>Vascular</b>	Amphetamines
Porphyria	Incontinentia pigmenti	Cyanotic heart disease	Neuroleptic withdrawal syndrome
Hyperthyroidism	Abetalipoproteinaemia	Cardiopulmonary bypass	<b>Others</b>
		Moya–Moya	Congenital malformations
		Polycythaemia vera	HIE
		Post-strangulation	
		Stroke	




*Diagnosis*

- Clinical history and careful observation.
- No role for laboratory investigations or imaging other than to exclude conditions that may mimic tics.
- EEG is discouraged due to the high incidence of non-specific abnormalities.
- A number of medications may induce tics especially stimulants such as methylphenidate and dexamfetamine.

*Treatment*

- The majority of children with tics do not require medication (do not 'treat the parent').
- CBT is used with success in older children.
- Medical options:
  - pimozide (obtain baseline ECG);
  - clonidine particularly in children with attention deficit hyperactivity disorder (ADHD) symptoms as well;
  - risperidone, quetiapine, mirtazapine (anecdotal evidence of effectiveness only);
  - haloperidol is second line due to unwanted effects (the risk of tardive dyskinesia is less than in adults).
- Treatment of co-morbidities is as important:
  - clomipramine for OCD symptoms;
  - selective serotonin reuptake inhibitor (SSRIs; e.g. fluoxetine) if anxiety is predominant, but caution should be used in prescribing to adolescents;
  - tricyclics especially nortryptiline are useful in management of tics associated with anxiety or ADHD symptoms;
  - although they are known to induce tics, stimulants can be used to treat ADHD in children with tics safely; non-stimulant medication choices such as atomoxetine are increasingly used.

**Ataxias**

For acute ataxias, see acute post-infectious cerebellitis (see  p. 344) and Miller–Fisher syndrome (see  p. 395). For episodic ataxias, see  p. 306.

***Congenital, non-progressive ataxias with no initial symptom-free period***

If imaging suggests unilateral or very asymmetric cerebellar involvement, it is probably an acquired (e.g. vascular) insult.

Otherwise, identify the pattern of cerebellar involvement:

- Pontocerebellar hypoplasia or hypoplasia of cerebellar hemispheres.
- Vermian agenesis/dysgenesis.
- Cerebellar atrophy due to cerebellar cortical or white matter degeneration.

*Syndromes with pontocerebellar hypoplasia*

- Pontocerebellar hypoplasia type 1 (PCH1). Autosomal recessive. Resembles severe type 1 SMA (Werdnig–Hoffman) with pontocerebellar hypoplasia on MRI. (This and PCH2 are sometimes referred to as olivopontocerebellar hypoplasia but there is an unrelated adult neurological disorder with this name and the term is best avoided to prevent confusion).
- Pontocerebellar hypoplasia type 2 (PCH2). Autosomal recessive. Failure of cerebellar growth in late prenatal life. Severe feeding difficulties in the neonatal period evolving into a picture of severe generalized delay with prominent movement disorder (chorea and dyskinesia). Again, pontocerebellar hypoplasia is seen on MRI.

- Congenital disorders of glycosylation (also known as carbohydrate-deficient glycoprotein) syndromes: congenital disorder of glycosylation (CDG) I and III.
- Progressive encephalopathy with oedema (PEHO) syndrome (progressive encephalopathy with peripheral oedema, hypersarrhythmia, and optic atrophy).

*Syndromes with vermian agenesis/dysgenesis*

- *Joubert syndrome*: characteristic large face, prominent early breathing pattern irregularities worse when awake than asleep  $\pm$  retinal and renal and hepatic involvements. MRI shows the pathognomonic 'molar tooth' sign due to absent cerebellar vermis. Genetically heterogeneous.
- *COACH syndrome*: cerebellar vermis hypo- or aplasia, oligophrenia, congenital ataxia, ocular coloboma, and hepatic fibrosis).

*Non-progressive pan-cerebellar atrophy*

Chromosomal (trisomy 18, 21); extreme prematurity, congenital CMV.


*Progressive pan-cerebellar atrophy*

- *Metabolic causes (isolated congenital ataxia is a rare presentation)*: pyruvate decarboxylase, mitochondrial, glutaric aciduria type 1, L-2-hydroxy glutaric aciduria (specific MRI appearances with white matter signal change in the U-fibres at the base of the sulci); succinic semi-aldehyde dehydrogenase (SSADH) deficiency.
- Phenytoin, radiation, other drugs.
- Others (see Ramaekers: 1997).<sup>1</sup>


***Slowly progressive ataxia (over months to years) with initial symptom-free period***

Friedreich ataxia (FA) is an important and relatively common cause of progressive ataxia. It is by far the most common recessively inherited ataxia (i.e. where family history is negative).

- Typical presentation is between 5 and 20 yrs of age with increasing ataxia affecting gait, and prominent early dysarthria.
- Combination of spinocerebellar degeneration and peripheral neuropathy resulting in the characteristic combination of upgoing plantar responses (positive Babinski) with very depressed or absent ankle and knee reflexes.
- Cardiac involvement, pes cavus and scoliosis occasionally pre-date onset of the full neurological picture.
- There are rare forms with preserved reflexes, and other conditions (ataxia with oculomotor apraxia, several types) that give the cerebellar picture but without the Babinski response.

In practice the most common alternative diagnostic consideration of pes cavus and areflexia is HMSN1, but in this condition a parent should be at least mildly affected (sometimes just an asymptomatic areflexia) and there will be no Babinski response (see  p. 392).

<sup>1</sup> Ramaekers VT, Heimann G, Reul J, Thron A, Jaeken J. (1997). Genetic disorders and cerebellar structural abnormalities in childhood. *Brain* **120**: 1739–51.

In toddlers consider DNA repair disorders of which *ataxia telangectasia* is the commonest (see  p. 422).

- Oculomotor apraxia is a characteristic early feature: children cannot initiate saccades to switch gaze to another target and instead initiate eye movement with a head turn in a characteristic manner.
- Dystonia/choreoathetosis is often as prominent as cerebellar signs.
- Telangectasiae are first seen behind the pinnae and on the conjunctivae.
- Occasionally, ataxia is very early onset and appears quasi-congenital.

Also consider Cockayne syndrome (usually with peripheral neuropathy), xeroderma pigmentosum (with photosensitivity) and ataxia with oculomotor apraxia (AOA1).

#### *Spinocerebellar ataxias*

Of the many remaining genetically determined causes of progressive ataxias nearly all are (i) extraordinarily rare and (ii) dominantly inherited with high penetrance so that a family history will be informative. These are the spinocerebellar ataxias (SCAs).

- 28 types of SCA described to date: most are triplet-repeat expansion diseases.
- As triplet-repeat diseases are technically very easy to identify, genetic testing for types 1, 2, 3, 6, 7, 8, 10, 12, 14, 17, and DRPLA is widely available.
- They are all slowly progressive and are associated with cerebellar atrophy but have varying associated features (see Table 4.10).
- Symptom overlap makes genetic testing essential. Identifiable SCA mutations account for only 60% of all dominant hereditary ataxias. When the gene is test normal consider a neurological examination for family members who are concerned they may have symptoms of ataxia.

#### **Late-onset cerebellar ataxias**

A heterogeneous group of neurodegenerative disorders that may be hereditary or sporadic, the latter symptomatic or idiopathic. Diagnosis is important for prognosis, genetic counseling, and possible therapeutic implications. See Figure 4.8 and Table 4.11 for approach to late onset ataxias.

#### *Non-genetic causes of progressive ataxia*

At any age consider systemic disorders:

- Autoimmune conditions.
- Endocrine (hypoparathyroidism, hypothyroidism).
- GI disorders causing hypovitaminosis E.

Also consider aminoacidurias (Hartnup, maple syrup urine disease (MSUD)), a- and hypo-betalipoproteinaemia, biotinidase deficiency, carnitine acetyltransferase deficiency, cerebrotendinous xanthomatosis, hyperammonaemia, L-2 hydroxyglutaric acidaemia, Niemann-Pick Type C, Refsum, Wilson.

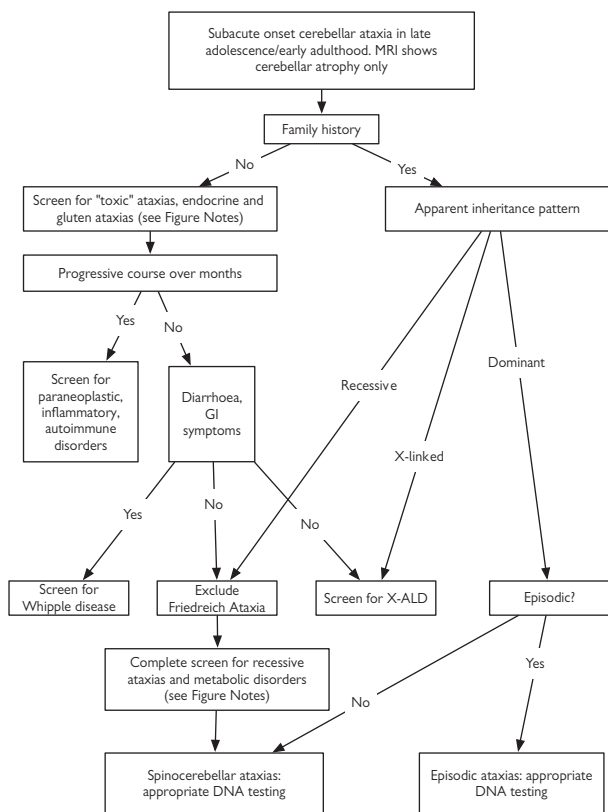
Symptom onset in tumours and metabolic disorders may be acute or slow; metabolic ataxia may also be recurrent. In adolescents, consider MS and vCJD if accompanied by academic failure.

**Table 4.10** Spinocerebellar ataxias capable of paediatric presentation

Type	Percentage of all dominant ataxias	Average decade of onset (range)	Average duration before death (yrs)	Additional features
SCA1	10%	4th (2nd–7th)	15 (10–28)	Retained reflexes
SCA2	15–20%	3rd–4th (2nd–8th)	10 (1–30)	Slow eye movements, sometimes dementia
SCA3	20–50%	4th (2nd–8th)	10 (1–20)	Muscle weakness and atrophy Machado–Joseph disease)
SCA5	Rare	3rd–4th	Decades	Sensory loss
DRPLA	3%	4th (1st–7th)		Ataxia, choreoathetosis, myoclonic epilepsy, learning difficulties and dementia, mental illness

Note: DRPLA shows anticipation. If Huntington crosses your mind, think also of DRPLA.





**Fig. 4.8** Approach to late onset ataxias. Reproduced from Brusse E *et al.* (2007). *Diagnosis and Management of early- and late-onset cerebellar ataxia. Clinical Genetics* 71: 12–24, with permission of John Wiley & Sons, Inc.

Notes to Figure 4.8:

Six types of episodic ataxia.

Toxic causes. Alcohol, drugs, AEDs, benzodiazepines, antineoplastics, heavy metals (mercury, lead), chemicals (solvents, pesticides).

Endocrine: hypothyroidism.

Malabsorption: coeliac disease (gluten ataxia), vitamin deficiency.

Miscellaneous: paraneoplastic syndromes (see [p. 226](#)), demyelinating disorders.

Inflammatory: Whipple disease, parainfectious/immune-mediated ataxia.

Investigations to consider (with the condition in mind): see Table 4.11.

**Table 4.11** Possible investigations in progressive ataxia

Vitamin E	Ataxia with vitamin E deficiency
Acanthocytes	Chorea-acanthocytosis, abetalipoproteinaemia
Cholesterol, triglycerides, LDLs, VLDLs	Abetalipoproteinaemia
Lactate, pyruvate, mtDNA deletions, muscle biopsy	Mitochondrial disease
Immunoglobulins, alpha-foetoprotein, leukocyte irradiation	Ataxia telangiectasia
Direct gene test	Ataxia-oculomotor apraxia (AOA 1 and 2)
Bile alcohols	Cerebrotendinous xanthomatosis
Plasma: phytanic acid; copper, caeruloplasmin	Refsum; Wilson, acaeruloplasminaemia
Beta-hexosaminidase;	GM2 gangliosidosis (hexosaminidase deficiency)
Beta-galactosidase;	GM1 gangliosidosis
Arylsulfatase-a	Metachromatic leukodystrophy
Beta-galactocerebrosidase;	Krabbe
Neuraminidase	Sialidosis
Skin biopsy	Niemann-pick type c

## Neuromuscular conditions: introduction

Neuromuscular conditions are disorders of the 'motor unit' which comprises of the anterior horn cell, peripheral nerve, neuromuscular junction and muscle. In the past two decades vast progress has been made in the elucidation of the underlying genetic and cellular protein basis of many neuromuscular disorders. Many clinically defined entities are genetically heterogeneous and mutations in some genes can result in various clinical phenotypes.

### Common presentations of neuromuscular disease

- *Floppy infant*: hypotonic and weak.
- Ventilator dependent neonate requiring minimal ventilation, but failing extubation.
- Arthrogryposis.
- Delayed motor development in the face of normal cognitive development, *but* note that many boys with Duchenne muscular dystrophy have associated learning difficulties and indeed may present with speech and language delay with achievement of early motor milestones.
- *Poor gait*: slow or unable to run, falls, difficulty with steps.
- Toe walking.
- Foot deformity.
- Episodic weakness.
- Recurrent apnoea.
- Pain on or after exercise.
- *Abnormal biochemistry*: raised CK, raised ALT.

▶ ALT is not liver specific, but is also present in muscle. If other parameters of liver function normal check CK. We have seen Duchenne dystrophy diagnosed after (normal) liver biopsy for investigation of 'abnormal LFTs'!

### Investigation of neuromuscular disease

#### *Creatine (phospho)kinase*

- Normal in congenital myopathies, myasthenic syndromes, spinal muscular atrophy (SMA). Although may be up to 7 times upper limit of normal (ULN) in SMA type III.
- Muscular dystrophy usually >7 times ULN.
- May be mildly raised up to 3 times ULN in neuropathies.
- Also increased in:
  - metabolic myopathy;
  - inflammatory myopathy;
  - female Duchenne/Becker carrier;
  - hypothyroidism;
  - malignant hyperthermia;
  - status dystonicus;
  - excessive exercise;
  - after EMG, IM injection, or other muscle trauma.

**Electrophysiology**

See  p. 70.


**Muscle biopsy***Genetic studies*

There are a few conditions in which DNA analysis is the initial investigation of choice, these include:

- SMA.
- Myotonic dystrophy.
- Facioscapulohumeral dystrophy.
- Duchenne/Becker muscular dystrophy.
- Spinal muscular atrophy with respiratory distress (SMARD).

In other conditions the clinical phenotype, and results of muscle biopsy and/or neurophysiology guide genetic testing.

**Metabolic tests**

- *Lactate*: mitochondrial disease.
- *Carnitine/acyl carnitine profile*: fatty acid oxidation defects.
- *Forearm ischaemic lactate test*: glycogen storage disease (see  p. 90).

**Imaging**

- *Muscle ultrasound, MRI*: pattern of muscle involvement may help diagnosis.
- Brain MRI.

## Neuropathies

### Inherited neuropathies

All typically present in the first or second decade with slowly progressive distal wasting, weakness, and hypo- or areflexia, variable distal sensory loss and pes cavus.

There are two different classification schemes for the inherited neuropathies, which causes a lot of confusion! Until recently a *phenotypic* approach (particularly whether neurophysiological data indicated an axonal or demyelinating neuropathy, see Table 4.12) was used to classify various *hereditary motor and sensory neuropathies* (HMSNs). As causative genes have been identified, a *genotypic* classification has emerged naming the conditions as different forms of *Charcot–Marie–Tooth* disease (e.g. CMT1, CMT2). Since, however, different genotypes can result in indistinguishable clinical pictures; the phenotypic approach is still useful in practice and is adopted here. Pragmatically classified as type 1 (demyelination on neurophysiology) or type 2 (axonal) together with a statement of the inheritance pattern.

**Table 4.12** Causes of neuropathy

70% hereditary	65% Hereditary sensory motor neuropathy (HMSN)
	15% metabolic (metachromatic, Krabbe leukodystrophies; Refsum; mitochondrial)
	10% Friedreich ataxia
	2% Hereditary neuropathy with liability to pressure palsies (HNPP)
20–30% acquired	Guillain–Barré (acute)
	CIDP (chronic)
20% uncertain	Drug/toxin; inflammatory/infective; nutritional; systemic; neoplastic

### HMSN I (*Charcot–Marie–Tooth* disease)

This is very common. Suspect if the child is totally areflexic at knees and ankles. Diagnosis of the most common form, dominant HMSN 1A, is very probable if areflexia can be demonstrated in a parent (who is often otherwise asymptomatic). In practice, typical clinical cases can be confirmed by DNA analysis without resorting to neurophysiology.

- Autosomal dominant.
- Onset 2–40 yrs, most school-age; slowly progressive.
- Delayed motor development in early onset form.
- Toe walking, clumsiness, falls, later foot drop.
- Distal weakness and wasting, affecting feet first.
- Inability to walk on heels is an early sign.
- Later weakness of intrinsic hand muscles.
- Peroneal muscular atrophy, later calves.

- Hypotonia.
- *Foot deformity*: pes cavus, ankle inversion, high arch, hammer toes.
- Areflexia.
- Mild distal sensory loss.
- Enlargement of peripheral nerves in 25%.
- Postural tremor in 25%.
- Spinal deformities.
- *Neurophysiology*: slow nerve conduction velocity (10–30 m/s); no conduction block; absent sensory action potentials.
- DNA testing for duplications in *PMP22* identifies 70–80% cases. Other genes (e.g. *MFN2*) may be tested if the phenotype is confirmed and *PMP22* testing negative.

### **HMSN II axonal degeneration**

- *Autosomal dominant form*:
  - similar to HMSN I but later onset and slower course. No enlargement of nerves, less marked weakness; mild reduction in NCV;
  - consider in weakness and wasting of distal limbs in a school-age child.
- *Autosomal recessive form*:
  - severe form of peroneal muscular atrophy and weakness;
  - rapid progression of weakness, onset <5 yrs;
  - complete paralysis below elbows and knees by teens;
  - moderate sensory changes;
  - axonal degenerative polyneuropathy.

### **Hereditary neuropathy with liability to pressure palsies (HNPP)**

- *Allelic with HMSN I*: due to *PMP22* deletion. Autosomal dominant.
- Onset <20 yrs.
- Recurrent mononeuropathy simplex or multiplex related to trauma or prolonged compression (especially peroneal nerve at fibular head, ulnar at elbow, radial in humeral groove, median in carpal tunnel due to pressure).
- Recovery over days to weeks can be incomplete.
- *Neurophysiology*: slowing of motor and sensory nerve conduction in affected and unaffected nerves.
- *Sural biopsy*: tomaculous (= sausage-like) swelling of myelin sheets, transnodal myelination, and segmental demyelination.


### **HMSN III (Dejerine–Sottas disease)**

- Early onset <2 yrs.
- More marked clinical manifestations than type I.
- Slow motor development, delay in walking >2 yrs.
- Distal wasting and weakness, proximal weakness in 2nd decade.
- Pes cavus, absent reflexes.
- Enlarged peripheral nerves.
- Hypotonia, ataxia, scoliosis.
- Involvement of cranial nerves later.
- *Neurophysiology*: severe slowing of both motor and sensory nerves.
- Rise in CSF protein.
- *Nerve biopsy*: poor myelination.

Other types of HMSNs with additional clinical features

- HMSN IV: Refsum disease (now classified as a peroxisomal disease).
- HMSN V: with spastic paraparesis.
- HMSN VI: with optic atrophy.
- HMSN VII: with retinitis pigmentosa.
- HMSN X: with X-linked inheritance.

#### **Hereditary sensory and autonomic neuropathies**

- Pain sensation conveyed by small myelinated and unmyelinated fibres.
- Insensitivity to pain; silent foot ulceration, burns and other injuries; destructive arthropathy with Charcot joints.
- C.f. *indifference* to pain (see  p. 174).
- Some associated with sensorineural hearing loss.
- *Type 1*: AD inheritance. Presents in 2nd or 3rd decade with distal sensory loss and later muscle wasting and weakness. Sensory involvement is prominent and can lead to complications such as ulceration and amputation. High incidence of distal lancinating pains. Mutations in serine palmitoyltransferase gene on 9q in some (but not all) pedigrees.
- *Type 2*: AR. Early onset sensory neuropathy affecting all modalities of sensation. Gene defect currently unknown.
- *Type 3 (Riley–Day syndrome)*: AR. Ashkenazi Jews. Autonomic symptoms predominate, but sensory and motor signs are present.
- *Type 4*: AR. Congenital insensitivity to pain and anhidrosis. May be allelic with type 5.

#### **Hereditary motor neuropathies (distal SMAs)**

- Variable inheritance.
- *Early onset*: most <10 yrs.
- Purely motor involvement mainly of the legs.
- Very slow progression.
- Foot deformity; difficulty walking.
- Lower leg wasting.
- Normal nerve conduction studies.
- *EMG*: denervation.

#### **Giant axonal neuropathy**

- Very rare.
- Severe early onset generalized sensory and motor neuropathy. Moderate reductions in nerve conduction velocity (NCV); severely reduced or absent compound muscle action potential (CMAPs) and sensory nerve action potentials (SNAPs).
- Accompanied by severe developmental delay, seizures, pyramidal, and cerebellar signs. MRI may show signal change in periventricular and cerebellar white matter.
- Characteristic tightly curled hair.
- Recessively inherited.
- Nerve biopsy shows distorted 'giant axons' swollen by the accumulation of neurofilaments (also in brain).
- Mutations in *GAN* gene, though probably genetically heterogeneous.

## Acquired neuropathies


### *Guillain–Barré syndrome (GBS)*

This has an incidence of 1–2/100 000.

The most common cause of the picture is an acute inflammatory demyelinating polyneuropathy (AIDP), and the term AIDP is often used synonymously with GBS (Box 4.8). Variants giving a similar/related clinical picture include acute motor axonal neuropathy (AMAN), acute motor and sensory axonal neuropathy with prominent sensory features (AMSAN, poor prognosis) and Miller–Fisher syndrome (ophthalmoplegia, ataxia, areflexia).

The mechanism is an immunological cross-reactivity secondary to a prodromal illness within the previous 4 weeks, typically URTI or gastroenteritis. Implicated organisms include mycoplasma, CMV, EBV, vaccinia, variola, campylobacter, VZV, measles, mumps, hepatitis A and B, rubella, influenza A and B, coxsackie and echovirus.

*Campylobacter jejuni* is particularly associated with the AMAN variant and a more severe course.

For diagnosis and management (see  p. 564).

### Box 4.8 GBS diagnostic criteria

#### *Required for diagnosis*

- Progressive motor weakness
- More than one limb
- Minimal weakness to total paralysis
- Areflexia

#### *Supportive*

- Progression of weakness stops <4 weeks into illness
- Relative symmetry
- Mild sensory involvement
- Cranial nerve involvement
- Recovery
- Autonomic dysfunction
- Absence of fever at onset
- CSF: elevated protein after first week; <10 lymphocytes
- Nerve conduction abnormalities during the illness
- Absence of other cause, e.g. porphyria, diphtheria, toxins

### *Miller–Fisher syndrome*

- Probably a variant of GBS.
- Triad of ataxia, ophthalmoplegia, and areflexia.
- Altered sensorium or abnormal EEG suggests brainstem encephalitis.

#### *Other rare subtypes of GBS*

- Generalized selective sensory involvement giving peripheral ataxic syndrome without weakness. NCVs axonal or demyelinating.
- Pharyngeal–cervical variant with intact eye movements (cf. Miller–Fisher). NCVs axonal or demyelinating.
- Acute idiopathic autonomic involvement (NCVs normal).



**Chronic inflammatory demyelinating polyneuropathy (CIDP)**

Subacute onset variant of AIDP. In practice HMSN is often an important differential: useful pointers to CIDP (vs. HMSN) in bold:

- Any age.
- Lack of family history.
- Insidious or subacute onset.
- Very young may present with developmental delay.
- Weakness especially lower limb, often more proximal.
- Can be fluctuating and asymmetric.
- Cranial nerves may be involved.
- Mild sensory symptoms.
- Depressed or absent tendon reflexes.
- Autonomic dysfunction is rare.
- Most mixed motor and sensory signs.
- CSF protein raised in 80%.
- Electrophysiology: variable conducting velocity and patchy conduction block. In contrast to HMSN, F-responses delayed or absent. Abnormalities should be present in at least three nerves to make diagnosis.

See Box 4.9 for diagnostic criteria.


**Box 4.9 Diagnostic criteria for CIDP****Clinical course**

Subacute (progression for more than 2 mths), chronic progressive or relapsing and remitting course.


**Evidence of demyelination**

- *Electrophysiology*: slow nerve conduction and conduction block.
- *Pathology*: nerve biopsy findings.


**Absence of systemic disease**

See  p. 397 for acquired neuropathies.

**Differential diagnosis**

- AIDP (see  p. 395).
- Inherited neuropathies.

**Much more rarely**

MNGIE (mitochondrial neurogastrointestinal encephalomyopathy); toxic/metabolic; paraneoplastic; neuropathy with monoclonal gammopathy of unknown significance (MGUS); infection (HIV, Lyme, leprosy, diphtheria); rheumatological/vasculitic (see  p. 397); porphyria.

**Treatment**

- **Steroids**: e.g. 1.5 mg/kg alternate days. Short-term improvement in 65–95%. Begins usually after 1–4 weeks and plateaus at 6 mths.
- **Plasma exchange**: efficacious, but needs to be repeated as often as every 4 weeks. Limited by inconvenience (and complications) of venous access and hospitalization.
- **IVIg**: proven to be effective in several trials and meta-analyses. However, benefit lasts only 2–12 weeks, and very expensive.

- *Other drugs:* some evidence of benefit from azathioprine, cyclophosphamide, ciclosporin A.

#### *Prognosis*

- Time course may be relapsing–remitting, chronic progressive, monophasic, or have a GBS-like onset.
- Some children have a monophasic course, peak disability by 3 mths, recovering by a year.
- Long-term morbidity.

## Secondary neuropathies

### **Metabolic**

- Diabetes.
- Hypoglycaemia.
- Uraemia.
- Porphyria.
- Hypothyroidism.
- Acromegaly.

### **Toxic**

- Arsenic.
- Lead.
- Mercury.
- Thallium.
- Vincristine.
- Isoniazid.

### **Deficiencies**

- Vitamin B1.
- Vitamin B6.
- Vitamin B12.
- Vitamin E.

### **Paraproteinaemia**

- Multiple myeloma.
- Waldenstrom.
- Cryoglobulinaemia.

### **Connective tissue disorders**

- Polyarteritis nodosa.
- Wegener granulomatosis.
- Sjögren syndrome.
- SLE.
- Rheumatoid arthritis.
- Scleroderma.

### **Infectious**

- HIV.
- Lyme.
- Leprosy.

### **Hereditary neuropathies**

- Amyloid neuropathy.
- Metachromatic leukodystrophy.

- Krabbe disease.
- Abetalipoproteinaemia.
- Refsum disease.

### Entrapment neuropathies

#### **More common entrapment neuropathies and their scenarios**

Paucity of arm movement in a baby, following a difficult delivery involving traction of the head and/or shoulder:

- *Erb palsy*:
  - arm (commonest) adducted, internally rotated, elbow extended, forearm pronated: 'waiter's tip';
  - C5,6 upper trunk.
- *Klumpke paralysis*:
  - elbow flexed, forearm supinated, wrist extended, claw hand;
  - may get an associated Horner syndrome;
  - C8, T1 lower trunk.
- *Complete brachial plexus injury*:
  - whole arm is limp;
  - look for an associated fractured clavicle.

A child with a mucopolysaccharidosis/mucopolipidosis having difficulty with fine motor tasks or with loss of grip strength:

- Median nerve compression.
- Young children do not usually complain but have difficulty with pencil grip or other fine motor tasks.
- In older children, symptoms include pain, tingling or numbness in the hands, often in the early hours of the morning, waking them from sleep, with shaking of the hands to relieve the symptoms.
- Flexion of wrist for 60s may reproduce the symptoms—Phalen test.
- Tapping over the median nerve at the wrist may induce tingling—Tinel sign.

A child with a fractured humerus, or a teenager after sleeping awkwardly on an arm (especially whilst intoxicated) presenting with wrist drop:

- Radial nerve compression (in the spiral groove of the humerus).
- Wrist drop with sensory loss over the lateral aspect of the dorsum of the hand between the thumb and index finger: 'Saturday night palsy'.

*Foot drop following trauma to the side of the lower leg*

- Common peroneal/lateral popliteal nerve injury (around the neck of the fibula).
- Foot drop with sensory loss over the lateral aspect of the leg.

*Other sites*

- *Suprascapular nerve*: spinoglenoid notch.
- *Medial nerve*: carpal tunnel.
- *Ulnar nerve*: cubital tunnel at elbow; palmar fascia and pisiform bone in hand.
- *Lateral cutaneous nerve of thigh*: inguinal ligament.
- *Obturator nerve*: obturator canal.
- *Posterior tibial*: tarsal tunnel, medial malleolus.

## Disorders of muscle

### Muscular dystrophies

#### *Dystrophinopathies*

A number of clinical phenotypes result from mutations in the dystrophin gene (at Xp21): Duchenne/Becker muscular dystrophy, X-linked cardiomyopathy and a cramps/myalgia syndrome.

#### *Duchenne/Becker muscular dystrophy*

DMD is defined by loss of independent ambulation by 13 years, Becker muscular dystrophy (BMD) by independent ambulation beyond 16 years, those losing ambulation between 13 and 16 years are considered outliers or intermediate. The severity of the clinical phenotype depends on the amount of residual functional dystrophin.

#### *DMD*

- Is single most common neuromuscular condition in paediatric practice
- incidence—1:3500 ♂ infants.
- 1/3 are new mutations.
- 10–20% of new mutations gonadal mosaicism.
- Onset <5 yrs.
- Usually, but not always delayed gross motor milestones, global developmental delay common.
- Symmetrical proximal weakness.
- Muscle hypertrophy especially calf, but temporalis, masseter, and forearm muscles may be involved.
- Intellectual impairment, normal IQ distribution displaced to left, affects verbal > performance IQ.
- Cardiomyopathy, screening important <10 yrs, every 2 yrs and prior to surgery, >10 yrs annually.
- Respiratory involvement during teens.
- Wheelchair for mobility by 8–12 yrs.
- Life span increased decade on decade from 1960s, currently 50% survival to 25 yrs.
- *Diagnosis*: CK as a screen. Gene test, muscle biopsy (little or no dystrophin staining).

#### *BMD*

- 1:300–1:600 males.
- Presentation similar, but variable severity/onset (5–15 yrs).
- Slow progression, life expectancy 40 yrs to normal.
- *Diagnosis*: gene test and biopsy: patchy dystrophin staining.

Atypical presentations include:

- Myalgia.
- Myoglobinuria.
- Malignant hyperthermia like reaction.
- Achilles tendon contractures.
- Cardiomyopathy.
- Abnormal 'liver function tests' (muscle isoenzymes).

Manifesting female carriers:

- May present with global developmental delay/learning difficulty.
- Weakness onset usually >16 yrs, may be asymmetric.
- Cardiomyopathy 8% DMD carriers.
- Severe DMD like phenotype rare and usually associated with chromosomal translocation.

### **Emery–Dreifuss muscular dystrophy (EMD)**

*Clinical features*

- Presentation at any age, most commonly in late childhood/early adult life.
- Early contractures before significant weakness: elbows, Achilles tendons and spine with rigidity (limited trunk and neck flexion).
- Muscle wasting and weakness in a scapulohumeroperoneal distribution:
  - scapular winging;
  - weakness biceps and triceps;
  - weakness of anterior tibial and peroneal muscles.
- Cardiomyopathy with conduction defects (sino-atrial (SA), arterio-ventricular (AV)), arrhythmias. Important clinically; can be life-threatening. Most require pacing/implantable defibrillator.
- CK mildly raised.

### **Genetics**

- EDMD 1, X-linked, mutations in emerin gene, atrial arrhythmias and A-V conduction defects.
- EDMD 2 and 3, AD, AR respectively, mutations in lamin A/C gene, ventricular fibrillation and dilated cardiomyopathy more common than in EDMD 1.

### **Limb girdle muscular dystrophy (LGMD)**

Genetically heterogeneous group with combined prevalence 1/10,000–20,000.

*LGMD1 (10%)*

- AD inheritance.
- Currently 3 known genes, *LGMD1 A* – myotilin mutations, *LGMD 1B* – Lamin A/C mutations (also causes EDMD), *LGMD 1 C* – Caveolin mutations (also cause rippling muscle disease).

*LGMD 2 (90%)*

- AR inheritance.
- Currently 15 known genes (*LGMD2A-O*).
- All have spectrum of severity with onset in childhood or adult life.
- Childhood onset similar phenotype to DMD/BMD with waddling gait, toe walking, exercise intolerance, increased lumbar lordosis, tight tendoachilles, scapular winging, calf hypertrophy.
- Myalgia, myoglobinuria.
- *Most common childhood onset: sarcoglycanopathies LGMD2C* ( $\gamma$  sarcoglycan), *LGMD2D* ( $\alpha$  sarcoglycan), *LGMD2E* ( $\beta$  sarcoglycan), *LGMD2F* ( $\delta$  sarcoglycan); *LGMD2I FKR*P mutations (also cause congenital muscular dystrophy).

**Facioscapulohumeral dystrophy (FSHD)**

- Autosomal dominant, 1/20,000.
- Onset varies, usually mild, but early onset can be more progressive, males more frequently symptomatic than females, intra-familial variation.
- Initial facial weakness (eyes and mouth) followed by a descending involvement of shoulder weakness (due to poor scapular fixation) with scapular winging, proximal arm and ankle dorsiflexion weakness, weakness may be asymmetric.
- Later pelvic and tibial weakness.
- Later biceps, triceps and truncal weakness.
- Severe infantile onset: 2–5% of all FSHD, facial weakness, and lumbar lordosis, associated with sensorineural deafness and Coat's disease (retinal vasculopathy).

**Distal myopathy**

- Uncommon in childhood, mostly adult onset.
- Majorities are dominantly inherited, a few are recessive and a few may be either dominant or recessive.
- Distal weakness may involve legs only or arms and legs.
- Genetically heterogeneous.
- Cardiac involvement in some.

**Congenital muscular dystrophies**

This is a group of conditions, presenting at birth or in early childhood with hypotonia, weakness, and contractures. The conditions are static or show only slight progression. CK is normal or mildly raised, while muscle biopsy shows dystrophic changes. Some are associated with disorders of myelin or neuronal migration and/or congenital eye abnormalities.

**CMD 1A**

- Primary laminin A2 (merosin) deficiency.
- Severe muscle weakness of face, trunk and limbs from birth.
- Feeding and respiratory difficulties.
- CK elevated.
- *Progress*: some improvement in muscle strength, may sit independently.
- *MRI brain*: white matter changes. Epilepsy in 30%. Usually normal cognition.

**CMD due to glycosylation disorders**

Disorders of glycosylation of  $\alpha$ -dystroglycan cause abnormal basal lamina formation in muscle and brain (Table 4.13). There is varying severity of disorganization of cortical lamination, muscular dystrophy, and eye problems, depending on the genetic defect. The manifestation of the brain disorder may be so severe that muscle involvement is overlooked.

**Table 4.13** Congenital muscular dystrophies due to glycosylation disorders

Abbreviation	Type	Glycosyl-transferases
CMD 1C	Congenital muscular dystrophy type 1C	FKRP
LGMD 2I	Limb girdle muscular dystrophy 2I	FKRP
CMD 1D	Congenital muscular dystrophy type 1D	LARGE
MEB	Muscle eye brain disease	POMGnT1
FCMD	Fukuyama congenital muscular dystrophy	Fukutin
WWS	Walker Warburg syndrome	POMT1

### Collagen VI-related myopathies

Mutations in COL6A1, COL6A2, COL6A3.

#### Bethlem myopathy

- Autosomal dominant.
- Slow progressive limb girdle weakness from childhood onward, mild.
- Flexion contractures: fingers, elbows, ankles.
- No cardiomyopathy.
- CK normal or slightly elevated.
- *Muscle biopsy*: non-specific myopathy.

#### Ulrich myopathy

- Contractures, proximal>distal, torticollis, kyphoscoliosis/spinal rigidity.
- Distal joint laxity.
- Skin, hyperkeratosis pilaris, keloid, atrophic scars.
- May be dominant or recessive mutations.

### Myotonic dystrophy (DM)

#### Genetics

- ► genes, both 'triplet-repeat' expansion disorders: severity depends on length of expansion.
- DM1 (Steinert) CTG expansion in DMPK gene.
- DM2 (Proximal myotonic myopathy PROMM) CTG expansion in intron1 of ZNF9 gene.
- *Anticipation*: repeat length expands in next generation, DM1>DM2.

#### DM1

Severity and age at onset depends on length of CTG expansion (greater number of repeats leads to earlier onset and more severe phenotype).

- >50 repeats: affected.
- >2000 repeats: congenital onset.

Potentially a multisystem disorder with cataracts, balding, gonadal failure, cardiac dysrhythmia, hyperglycaemia, hypersomnia, and learning disability but late onset forms (e.g. after middle age) have minimal features (cataracts, asymptomatic myotonia).

- **Congenital onset:**
  - 25% of affected mothers' offspring;
  - Polyhydramnios, reduced foetal movements;
  - Hypotonia, respiratory and feeding difficulty in neonatal period usually improves;
  - Facial weakness;
  - Talipes, arthrogryposis;
  - Learning difficulties;
  - 50% ventricular dilatation;
  - ► Myotonia is absent at birth;
  - Later respiratory involvement (diaphragm and intercostal muscles) and cardiac features (hypotension, syncope, palpitations, mitral valve prolapse, conduction defects, arrhythmias).
- **Adolescent and young adult:**
  - Myotonia;
  - Moderately severe facial weakness and ptosis;
  - Limb weakness and wasting (forearms, foot dorsiflexors);
  - Weak neck flexion;
  - Learning difficulties.

### **DM2 (PROMM)**

- Autosomal dominant.
- Onset late childhood-adult.
- Proximal muscle weakness but hands may be involved early with weakness of finger flexors.
- Myotonia may be asymmetric and intermittent.
- Muscle pain, variable, proximal, legs>arms, worse in cold.
- Calf muscle hypertrophy.
- Cataracts.

### **Ion channel disorders**

#### **Chloride channel *CLCN1* Myotonia congenita**

##### *Autosomal dominant form (Thomson)*

- Onset: infancy–adult.
- Mild myotonia, worse in cold or stress.
- Improvement with 'warming up' and repeated exercise.
- Proximal weakness or normal.
- *Treatment:* quinine, mexiletine, carbamazepine, acetazolamide.

##### *Autosomal recessive form (Becker)*

- Onset: 4–12 yrs.
- Myotonia more severe than in the dominant form.
- *Warm up:* improvement with repeated exercise.
- Muscle hypertrophy of legs and gluteals.
- Rapid decrease in power with exercise, subsequent improvement.
- *Treatment:* mexiletine.

##### *Paramyotonia congenita*

- Mutations in *SCN4A* sodium channel or *CLCN1* chloride channel.
- Myotonia, worse with exercise and cold, predominantly affects face, neck and arms, onset in infancy.



- Weakness, onset in adolescence or never, provoked by cold or after exercise or may occur spontaneously, lasts minutes to days.
- *Treatment:* keep warm, acetazolamide, mexiletine.

### Periodic paralyses

#### **Hyperkalaemic periodic paralysis**

*Sodium channel SCN4A*

- Autosomal dominant, incomplete penetration.
- Presents at the end of the first decade.
- Paroxysmal paralysis, daily to only a few times a year, frequency increases with age.
- Episodes are usually brief (<60 min), but may be longer.
- Weakness is usually proximal and symmetrical but may be distal and asymmetrical particularly following exercise of a muscle may be associated with paraesthesiae. Falls may result from sudden-onset attack.
- *Trigger:* 20–30 min into rest period after exercise; cold, hunger may occur on waking.
- May be associated with myotonia/paramyotonia.
- *Treatment:* mild exercise, salbutamol spray, Ca gluconate injection.
- *Prevention:* acetazolamide, frequent meals, dihydrochlorothiazide.
- ► Increased risk of malignant hyperthermia with general anaesthesia.

*Potassium channel KCNJ2 (Andersen's syndrome)*

- ► Potassium may be increased or decreased.
- Dysmorphic features; hypertelorism, mandibular and malar hypoplasia, clinodactyly, syndactyly.
- Episodic weakness, no myotonia.
- Cardiac arrhythmias and risk of sudden death.

#### **Hypokalaemic periodic paralysis**

- Calcium (CACNA1S), sodium (SCN4A) or potassium channel (KCNJ2 and KCNE3) mutations.
- Autosomal dominant.
- Presents in the first or second decade.
- Attacks of generalized paralysis, sometimes moderate weakness.
- In late night or early morning.
- Rare to frequent attacks.
- Lasts hours to days.
- *Trigger:* muscle exercises with subsequent rest (hours later) stress, cold, carbohydrate-rich foods.
- *Treatment:* potassium supplements.
- *Prevention:* acetazolamide, dihydrochlorophenamide, spironolactone, low sodium diet.
- ► Increased risk of malignant hyperthermia with general anaesthesia.

### Metabolic myopathies

Can present early in life:

- Floppy.
- Multisystem disorder.

Or later in life:

- Progressive muscle weakness.
- Exercise intolerance.
- Reversible weakness.
- Cramp/myalgia with exercise.
- Myoglobinuria/rhabdomyolysis.

### Glycogenoses

*GSD type 2 Pompe disease (acid maltase deficiency)*

Deficiency of  $\alpha$ 1, 4 glucosidase, disease severity correlates with level of residual enzyme activity.

- *Infantile form (Pompe disease):*
  - profound hypotonia and weakness;
  - macroglossia;
  - cardiomegaly;
  - hepatomegaly;
  - respiratory and feeding difficulty;
  - death <2 yrs.
- *Childhood/adolescent onset:*
  - progressive proximal weakness, onset <15 yrs more rapid progression;
  - respiratory insufficiency (presenting symptom in 30%);
  - adult onset;
  - slowly progressive muscle weakness, muscle cramps;
  - enzyme replacement therapy now available stabilizes disease.

*GSD type 5 McArdle, myophosphorylase deficiency*

- Cramps and contractures with exercise.
- *Second wind:* improvement after continued exercise.
- Myoglobinuria, raised CK.

### **Mitochondrial defects in fatty acid oxidation** (see also p. 369)

These present typically with intolerance of *prolonged* exercise (in contrast to glycogenoses where pain and weakness occur early during exercise) characterized by rhabdomyolysis and myalgia. Examples include CPT-2 deficiency, very long and short chain 3-hydroxy acyl CoA dehydrogenase, trifunctional protein and co-enzyme Q10 deficiencies. Other disorders (medium and short chain acyl CoA dehydrogenase, carnitine transporter deficiencies) cause fixed weakness.

Other features include:

- Cardiomyopathy.
- Pigmentary retinopathy.
- Peripheral neuropathy.
- Hypoketotic hypoglycaemia.

### **Mitochondrial defects of oxidative phosphorylation** (see also p. 369)

- Unusual to have isolated muscle involvement.
- High lactate.
- COX-deficient fibres on biopsy.
- Abnormal mitochondria on electron microscopy.

### Congenital myopathies

Myopathies characterized by:

- Hypotonia and motor delay.
- Static or slowly progressive.
- CK normal.
- Muscle biopsy:
  - myopathic without dystrophic changes;
  - defined by morphology on muscle biopsy;
  - specific changes on histology, immunocytochemistry, electron microscopy (EM).

#### Central core disease

- Mutations in *RYR1* gene (ryanodine receptor), may be autosomal dominant or recessive.
- *Muscle biopsy*: central areas of derangement of sarcomeres with absence of oxidative enzyme activity, fibre type 1 predominance.
- Hypotonic from birth/infancy, delayed motor development.
- Facial and proximal limb weakness.
- *Skeletal deformities*: congenital hip dislocation, scoliosis, foot deformity.
- Association with malignant hyperthermia.
- Cardiomyopathy and respiratory insufficiency are rare.

#### Minicore disease

- Genetically heterogeneous, *SEPN1* mutations recessive or sporadic (new mutation), *RYR1* mutations recessive or dominant.
- *Muscle biopsy*: multiple small areas devoid of oxidative enzyme activity, fibre type 1 predominance.
- Hypotonia delayed motor development.
- Variable weakness, mainly proximal and axial.
- Ophthalmoplegia in some.
- Contractures of paraspinal muscles with scoliosis.
- Early diaphragmatic involvement with respiratory insufficiency.

#### Nemaline rod myopathy

- *Histologically*: multiple rod-like particles derived from Z band material.
- Clinically and genetically heterogeneous.
- Onset may be congenital (severe), childhood, or adult.
- Inheritance recessive, dominant, or sporadic.
- Congenital forms mostly  $\alpha$ -actin, nebulin, troponin T1 mutations. Severe with respiratory insufficiency, marked hypotonia, feeding difficulties, majority require respiratory support, may have arthrogryposis.
- Childhood onset forms mainly  $\alpha$ -actin, nebulin,  $\alpha$ -trophomyosin,  $\beta$ -trophomyosin mutations:
  - often remain ambulant;
  - may develop respiratory failure.

#### Myotubular myopathy (centronuclear myopathy)

- *Muscle biopsy*: central nucleus surrounded by clear zone (resembles foetal myotubes), fibre type 1 predominance.
- Variable presentation.

- Neonatal form, X-linked, *MTN1* mutations:
  - polyhydramnios and reduced foetal movements;
  - diffuse hypotonia and weakness;
  - respiratory failure;
  - poor suck;
  - ptosis and ophthalmoplegia;
  - association with coagulopathy and undescended testes.
- Milder forms have autosomal recessive or dominant inheritance.

### **Malignant hyperthermia**


#### *Presents as*

- Generalized muscle rigidity, or localized to jaw.
- Tachycardia, tachypnoea.
- Rhabdomyolysis, acidosis, hyperkalaemia, myoglobinuria, raised CK.
- Hyperthermia occurs late.

#### *Triggers*

- Inhalational anaesthetics (isoflurane, desflurane, enflurane, sevoflurane).
- Depolarizing muscle relaxants (succinylcholine).
- Less severe episodes may be triggered by exercise in hot conditions.

#### *Treatment*

PICU management of fluid balance, rhabdomyolysis and possible renal involvement. Dantrolene (see  p. 552).

#### *Associated with*

*RYR1* (ryanodine receptor) mutations in 50% malignant hyperthermia (MH) families, 20% MH patients; calcium (*CACNL2A* and *CACNA1S*) and sodium (*SCN4A*) channel gene mutations.

Anaesthetic reactions may also occur in:

- Dystrophin-deficient muscular dystrophies.
- Myotonic dystrophy.

**!** It is therefore very important to warn patients with neuromuscular disorders of the increased risk of anaesthetic reactions and emphasize the need for them to inform an anaesthetist of their condition prior to any procedure requiring GA so appropriate anaesthetic agents can be used.

## **Inflammatory myopathies**

### **Juvenile dermatomyositis**

#### *Demographics*

- 2–3 cases per million per year.
- Median age of onset 7.
- ♀:♂ 5:1.
- Adult association with malignancies not seen in children.
- Systemic vasculopathy with inflammation of skin and muscle.

#### *Presentation*

- Slowly increasing proximal weakness.
- Muscles are stiff, tender; child is *miserable*.
- Can have dysphagia.

- Heliotrope rash.
- Extensor surfaces of joints can be red, atrophic and scaly.
- Nail bed capillary loops.
- Calcification of subcutaneous tissues.
- Can have gastrointestinal involvement, arthropathy, fever, pulmonary disease, iritis, and seizures.

#### *Diagnostic criteria*

- Typical 'heliotrope' purple rash on face and upper eyelids.
- Periorbital oedema.
- Gottron papules (metacarpophalangeal and proximal interphalangeal joints, extensor surfaces).
- Plus three of:
  - progressive symmetrical muscle weakness affecting proximal limb girdle and neck muscles;<sup>1</sup>
  - raised muscle enzymes (CK, LDH, AST, aldolase);
  - muscle biopsy with perivascular atrophy, inflammatory infiltrates, muscle fibre necrosis;
  - EMG indicative of myopathy and denervation.

#### *Treatment*

- Prednisolone 1 mg/kg/24 h tapering over a year.
- *Other:* IVIG, methotrexate, azathioprine, ciclosporin.
- 30–70% develop subcutaneous calcinosis later in disease.

#### *Prognosis*

- 80% will remit without impairment.
- Others may be left with impairments and continuing disease.
- *Poor prognostic signs:*
  - skin ulceration;
  - severe gastrointestinal involvement;
  - lung involvement;
  - CNS involvement.
- Rare death from infection or cardiac involvement.

#### **Polymyositis**

- Generally >20 yrs.
- Neck flexor and proximal weakness.
- Myalgia and tenderness.
- CK raised 50-fold.
- Dysphagia.
- No rash.
- Overlap with collagen vascular diseases.

<sup>1</sup> Neck extensor weakness (resulting in a 'dropped head' in extreme cases) is a rare but 'hard' sign typically due (in children) to myasthenia gravis, polymyositis, dermatomyositis, inclusion body myositis, chronic inflammatory demyelinating polyneuropathy, facioscapulohumeral dystrophy, myotonic dystrophy, or congenital myopathy.

***Infective myositis****Viral myositis*

- Common. Causes tender, aching calves or thighs.
- Elevated CK.
- Due to coxsackie, echo, influenza.
- Self-limiting.

*Bacterial myositis*

- Localized pain, swelling, and weakness.
- Usually due to penetrating injury.
- *Treatment:* antibiotics and drainage.

*Parasitic myositis*

- *Cestodes:* cysticercosis (myalgia, fever, headache, seizures).
- *Nematodes:* trichinosis.
- *Protozoa:* toxoplasmosis.

***Endocrine and toxic myopathies***

- A number of toxins and drugs can cause myalgia or myopathy. History should always include a drug history and possible exposure to toxins.
- Hypothyroidism (Semelaigne syndrome: hypothyroidism with muscle hypertrophy and short stature).

## Anterior horn cell disease

### Spinal muscular atrophy

- Majority have homozygous deletions of exons 7 and 8 of SMN1 gene.
- Number of copies of SMN2, among other factors, modifies presentation.
- Classification is clinical but there is a continuum of severity (see Table 4.14).

**Table 4.14** Spinal muscular atrophies


Type	Onset age	Development
0	Before birth	Ventilator dependent at birth
1 Werdnig–Hoffman	<6/12	Never sit unsupported
2 Intermediate	6–18/12	Sit but never walk unsupported
3 Kugelberg–Welander	>18/12	Walk unsupported at some stage

- Alert, normal facial expression (normal cognition, no facial weakness).
- Pattern of weakness: proximal > distal, legs > arms.
- Absent reflexes.
- Tongue fasciculations.
- Intercostal muscles weak with diaphragmatic sparing.
- Contractures (forearm pronation).
- Survival depends on respiratory function and bulbar function (aspiration risk).
- Most children with SMA1 die within the first year of life.

### SMA with respiratory distress

- Autosomal recessive, mutations in *IGHMBP2* gene.
- Presents with respiratory distress due to diaphragmatic weakness: elevated hemi diaphragm on CXR; paradoxical breathing.
- Weakness more marked in the arms and distally.

### Pontocerebellar hypoplasia type 1 (PCH1)

- Not to be confused with similarly named, but clinically unrelated PCH2 (see  p. 375).
- Neonatal presentation with Werdnig–Hoffman like picture characterized by respiratory insufficiency and congenital contractures.
- MRI confirms hypoplasia of cerebellum and ventral pons.
- Autosomal recessive, but genetic basis unidentified.
- Cerebellar growth failure is late and antenatal monitoring of growth of posterior fossa is unreliable.

### Distal SMA

Now regarded as a distal hereditary motor neuropathy (HMN) (see  p. 394).

## Myasthenic syndromes

These are disorders in neuromuscular transmission characterized by muscle weakness and fatigability on exercise (Table 4.15).

### Autoimmune myasthenia gravis

#### Juvenile myasthenia gravis


- Onset 1–17 yrs.
- 5>4 (4:1).
- 0.25–2.0 per 100,000.
- Antibody-mediated post-synaptic disorder:
  - 80% acetylcholine receptor (AChR) antibody positive;
  - 14% muscle-specific kinase (MuSK) antibody positive;
  - standard AChR assays have limited sensitivity and some apparent seronegative cases may have detectable AChR antibodies using more sensitive cell-based assays (i.e. may still be autoimmune even if apparently AChR/MuSK ab negative).

#### Presentation

- Insidious or sudden onset (with febrile illness).
- Diurnal variation.
- Fatigable weakness on examination:
  - 1 min sustained upgaze;
  - sustained shoulder abduction with arms outstretched.
- Ptosis, ophthalmoplegia, bulbar, respiratory, dysphonia, dysphagia, dyspnoea.
- Proximal weakness.
- Tendon jerks normal or brisk.
- Myasthenic crisis.

#### Investigations

See Box 4.10.

- Ice pack test for evaluation of ptosis (see  p. 123).
- Antibodies (anti-AChR, MuSK).
- Thyroid function and antibodies.
- Neurophysiology. Repetitive nerve stimulation: decrement in compound muscle action potential.
- Single fibre EMG: increased jitter.
- Trial of anticholinesterases.

#### Treatment

- *Mild (ocular only, no bulbar weakness):*
  - *anticholinesterases*—Neostigmine has a short duration of action and significant parasympathetic side effects. Preferred for short-term management of transient neonatal myasthenia, but otherwise pyridostigmine is preferred because of less frequent dosing (3–4-hourly) and fewer side effects.
  - *Unwanted parasympathetic effects* (salivation, abdominal cramps, bradycardia) may require careful concomitant antimuscarinic use, e.g. propantheline, but there is a risk of cholinergic crisis.



- **Moderate:**
  - Admission, supportive management (feeding, respiratory).
  - Start or increase pyridostigmine.
  - Subcutaneous neostigmine in those unable to swallow.
  - **Steroids:** care needed because they can cause an initial deterioration. Start 5 mg alternate days and increase by 5mg weekly until on 1–1.5 mg/kg alternate days. Slow weaning is recommended. Steroid-sparing agents: the benefit of azathioprine is proven in trials. Methotrexate is also used. Introduce at outset with steroids as benefit is commonly delayed.
- **Severe (myasthenic crisis):** see 📖 'Emergencies' section, p. 569.
- **Thymectomy:**
  - Best results in AChR-positive with generalized symptoms <2 yrs from onset.
  - Pre-operative IVIG or plasmapheresis.
  - 60% remission, 20% improved.
- **Other immunotherapy:** prednisolone, azathioprine, IVIG, plasma exchange.
- 30% spontaneous remission at 15 yrs.

#### Box 4.10 Tensilon® test

- Give a rapid-onset short-acting anticholinesterase, e.g. edrophonium (Tensilon®).
- Perform with a placebo test (0.9% saline) and video to reduce the risk of bias. A double blind trial is recommended but in practice it is often unrealistic due to obvious muscarinic side effects of edrophonium.
- **NB:** because of the small but definite risk of severe side effects (bradycardia, hypotension, asystole), monitor BP and heart rate, and have available atropine 0.02 mg/kg/dose IV (minimum 0.1 mg, max. 2 mg).
- Nil by mouth 4 h before test.
- Edrophonium 20 microgram/kg 'test' dose.
- If there is no adverse effect within 30s, give a second edrophonium 80 microgram/kg dose (max. total dose 10 mg).
- Assess over next minute.
- A positive test is an immediate response, e.g. resolution of ptosis, increased FVC, increased muscle strength (lasts about 5 min).
- A positive test is not 100% specific for myasthenia: can also be seen in motor neuron disease and botulism. A negative test does not exclude diagnosis.
- Tensilon test is not without risk. Usually a trial of oral pyridostigmine is preferable.

#### Transient neonatal myasthenia

- Transplacental transfer of AChR subunit antibodies.
- 10–15% of myasthenic mothers.
- Hypotonia, weakness, bulbar and respiratory insufficiency within 4 days of birth.

- *Diagnosis*: antibodies, response to cholinesterase inhibitors.
- Antibodies against foetal AChR only: mothers are unaffected, presents as arthrogryposis multiplex congenital which may be recurrent.

#### **Lambert–Eaton myasthenic syndrome**

- Autoimmune, often paraneoplastic.
- Rare in children.
- Antibodies to voltage-gated calcium channels on presynaptic nerve terminal.

### **Congenital myasthenic syndromes**

These are genetic disorders of the neuromuscular junction in which the safety margin of neuromuscular transmission is compromised.

AChR antibodies are negative and there is no response to immunomodulation. Rare (less than 1 per 200,000).

#### **Presentation**

- *Birth*: hypotonia, weakness (including ocular, bulbar and respiratory weakness). Talipes often a feature from birth even if generalized weakness is not evident.
- *Infancy/childhood*: hypotonia, fatigability, weak cry, feeding difficulties, delayed motor milestones, recurrent chest infections, episodic apnoea.

► Consider congenital myasthenic syndromes in differential of apparent acute life-threatening events and severe episodic apnoea. Children may be essentially symptom free between episodes.

#### **Characterization by**

- Clinical features and family history.
- Response to anticholinesterases (AChEs).
- Negative antibodies.
- Electrophysiology (see 📖 p. 81).
- Molecular studies.
- Less commonly, histology and *in vitro* electrophysiology.

See Table 4.15.

### **Medications contraindicated in myasthenic syndromes**

- Drugs directly affecting neuromuscular junction function are, of course, absolutely contraindicated—primarily botulinum toxin.
- Penicillamine and interferon treatment can trigger autoimmune myasthenia.
- Aminoglycoside, macrolide, and fluoroquinolone antibiotics are relatively contraindicated.
- Quinine derivatives, magnesium supplements, calcium channel and 'beta blockers' can exacerbate weakness.

**Table 4.15** Congenital myaesthetic syndromes

	Defect	Inheritance	Onset	Presentation	Response to AChE inhibitor	Treatment
<b>Presynaptic</b> CMS with episodic apnoea	ChAT reduced expression, reduced ACh production	AR	Neonate or infant	Hypotonia. Weakness, especially bulbar, respiratory. Episodic apnoea. Gradual improvement	Improvement	AChE inhibitor
<b>Synaptic</b> AChE deficiency	ColQ mutation affects synaptic AChE	AR	<2 yrs	Generalized and respiratory weakness. Scoliosis	None or worse	Ephedrine
Postsynaptic AChR deficiency	Mutation of AChR (mostly $\epsilon$ unit, survival through foetal $\gamma$ unit)	AR	<2 yrs	Weakness: ptosis, ocular, bulbar and limbs	Improvement	AChE inhibitor, 3,4-DAP
AChR localization	Rapsyn deficiency, abnormal clustering of AChR at NMJ	AR	Variable	<b>Severe (birth, infancy):</b> Reduced foetal movements, arthrogryposis, hypotonia, ptosis, feeding difficulties, No ophthalmoplegia <b>Mild (child, adult):</b> Delayed motor milestones, mild proximal/diffuse weakness. Improves with age	Improvement	AChE inhibitor 3,4-DAP

Slow channel syndrome	Mutation AChR subunits: prolonged opening	AD or sporadic	Variable	Selective wasting/weakness: cervical, scapular, finger extension, ptosis. No ophthalmoplegia	Worse	Quinidine Fluoxetine
Fast channel syndrome	Shortened opening	AR	<2 yrs	Reduced foetal movement. Weakness: ptosis, oculomotor, bulbar, diffuse limb weakness	Variable. Can cause apnoeas	AChE inhibitor 3,4-DA

Abbreviations: AChR, acetyl choline receptor; AChE, acetyl cholinesterase; ChAT, choline acetyl transferase; 3, 4-DAP, 3, 4 diaminopyridine.

## Management of neuromuscular disease

### Practical and psychological support

- *Family support*: care co-ordinator.
- Genetic counselling.
- Education.
- *Social worker*: advise on benefits, housing adaptations funding, etc.
- *Occupational therapy*: arrange wheelchair, equipment and adaptations for independence.
- Palliative care.

### Musculoskeletal (see also p. 240)

#### Prevention of contractures



- Physiotherapy and stretching, splints.
- *Encourage mobilization*: splints and standing frames.
- *Prevention of scoliosis*: prolongation of ambulation, standing.
- Spinal surgery and other orthopaedic surgery in selected cases.

#### Nutrition and feeding

- *Bone status, especially if on steroids*: calcium, vitamin D. Bisphosphonates if vertebral fractures present.
- *Dietician*: avoid obesity, especially if on steroids.
- *Speech and language therapy*: NGT or gastrostomy if swallowing is unsafe.

#### Respiratory

- *Patterns*:
  - restrictive lung disease in muscular dystrophy (weak intercostals and diaphragm, scoliosis);
  - poor cough in SMA (weak intercostals and abdominals; poor glottis closure);
  - aspiration in SMA (bulbar weakness, gastro-oesophageal reflux.)
- *History*:
  - recurrent chest infections;
  - nocturnal hypoventilation (restless sleep, morning headache, lethargy, reduced appetite, weight loss);
  - coughing or choking during eating or drinking indicates aspiration.
- *Examination*: note that children with neuromuscular disease cannot generate respiratory distress.
- *Investigations*:
  - FVC (sitting or standing and lying, worse when lying indicates a weak diaphragm);
  - overnight O<sub>2</sub> saturations (if FVC < 25% of predicted or symptomatic);
  - early morning CO<sub>2</sub>;
  - polysomnography.

- **Prevention:**
  - vaccinations—*Pneumococcus*, influenza;
  - feeding assessment and advice (SALT) (see also  p. 248);
  - treatment of gastro-oesophageal reflux;
  - assisted cough (manual or mechanical).
- **Treatment:**
  - early antibiotic treatment of chest infections, antibiotic available at home, IV antibiotic if not improving;
  - assisted cough, physiotherapy;
  - non-invasive positive pressure ventilation (NIPPV) for palliation, prolongation of life, better quality of life (see  p. 526);
  - severe intercurrent chest infections may require increased and/or invasive ventilation; extubation should be performed carefully under optimized circumstances (clear chest, in air, no secretions) to maximize chances of success;
  - the appropriateness of such interventions should have been agreed prospectively with the family and young person concerned.

### **Cardiac**

- Cardiac failure (ventricular dysfunction seen in muscular dystrophies including female carriers, metabolic myopathies and congenital myopathies).
- Cardiac assessment, DMD - at diagnosis, pre-surgery, every 2 yrs to 10yrs, annually thereafter, BMD – every 5 yrs. Angiotensin-converting enzyme (ACE) inhibitor  $\pm$   $\beta$ -blocker if function abnormal.
- Annual 24 h ECG to screen for arrhythmias from 10 yrs of age in Emery–Dreifuss, from diagnosis in myotonic dystrophy.

### **Disease modifying treatments**

- **Steroids in Duchenne dystrophy:**
  - prolongation of walking, possible benefits to respiratory and cardiac function;
  - serious side effects: weight gain, osteoporosis and fractures, cataract, slowing of height gain, immunosuppression, hypertension, behaviour;
  - typical regime 0.75 mg prednisolone or 0.9 mg deflazacort daily (or 10 d on, 10 d off);
  - check varicella status and vaccinate prior to starting if not immune;
  - dual-energy X-ray absorptiometry (DEXA) scan at baseline and annually;
  - monitor blood pressure, weight gain, behaviour.
- Trials of genetic therapies ongoing, e.g. exon skipping in DMD aiming to 'convert Duchenne to Becker' by modifying the splicing of the dystrophin gene.

## Neurocutaneous syndromes

There are a number of conditions in which skin abnormality is associated with neurological disorders, since both skin and central nervous system originate from ectoderm.

### Neurofibromatosis type I (von Recklinghausen disease)

#### Epidemiology

1:4000, autosomal dominant, 50% are new mutations, chromosome 17q11.2.

#### Diagnostic criteria

Progressive condition with onset in infancy. Cutaneous features become increasingly evident through the first decade (axillary freckling appears early) but diagnosis may be missed in early years. NIH criteria sensitive by age 10.

#### NIH criteria

Presence of at least 2 of the following:

- 6 or more *café au lait* spots (>5 mm pre-pubertal/>15 mm post-pubertal).
- More than 2 neurofibroma or 1 plexiform neurofibroma.
- Axillary or inguinal freckling (Crowe sign).
- Optic glioma.
- >2 iris hamartomas (Lisch nodules).
- Distinctive osseous lesion such as sphenoid wing dysplasia or thinning of long bone cortex with or without pseudoarthrosis.
- First-degree relative (parent, sibling, or offspring) with NF1 by the NIH criteria.

#### Minor features

Macrocephaly, short stature (growth hormone deficiency), epilepsy including infantile spasms, learning difficulties (in 60%), hypertension (aortic coarctation, renal artery stenosis or phaeochromocytoma). Scoliosis may also be present (10–40%).

#### Risk of neoplasm

- *Optic glioma (pilocytic astrocytoma)*: mostly chiasmic, found in up to 20% though symptomatic in <5% (decreased visual acuity, visual field defect, proptosis, precocious puberty due to hypothalamus compression).
- Gliomas are usually astrocytomas of the brainstem (more common in females, may cause obstructive hydrocephalus), cerebral peduncles, globus pallidus and midbrain.
- Ependymoma, meningioma, medulloblastoma.
- The risk of malignant transformation of neurofibroma to neurofibrosarcoma is <5% in children (higher in adults). Presentation is with rapid growth of lesion and pain.
- Increased risk of Wilm tumour, rhabdomyosarcoma, leukaemia, melanoma, medullary thyroid carcinoma and phaeochromocytoma.

**Management**

- Physical examination (palpation of skin lesions, neurological examination including visual acuity and fields, measurement of growth, blood pressure (BP)).
- Regular MRI is not indicated as treatment focuses on symptomatic lesions. Optic gliomas are usually indolent lesions but some may cause local compression and require debulking and/or chemotherapy. May be monitored by serial VEPs.
- Hydrocephalus is managed with ventriculoperitoneal shunting.
- Surgery is often indicated for plexiform neurofibromas that are disfiguring or painful. Neurofibromas may be paraspinal, presenting with myelopathy from cord compression and may require debulking.
- Genetic counselling for family members.
- Prognosis varies with the phenotype in the individual.

**Neurofibromatosis type 2****Epidemiology**

1:40 000, autosomal dominant; chromosome 22.

**Diagnostic criteria**

A progressive condition with presentation (usually with acute hearing loss, tinnitus, vertigo) after puberty. Younger children present with visual deficits (juvenile posterior subcapsular lenticular opacity) or skin tumours.

For diagnosis **either** one of the following must be present:

- Bilateral vestibular nerve schwannomas (found in 90%).
- A first-degree relative with NF2 and either of the following in the index case:
  - unilateral vestibular nerve schwannomas; or
  - two of the following—neurofibroma, meningioma, glioma, schwannoma (often of facial, trigeminal or spinal nerves) or juvenile posterior subcapsular cataract (found in 60% of children with neurofibromatosis type 2 (NF2)).

**Or** two of the following must be present

- Multiple meningiomas.
- Unilateral vestibular nerve schwannomas.
- Neurofibroma, glioma, schwannoma, cerebral calcification or juvenile posterior subcapsular cataract.

**Management**

- Schwannomas are slowly progressive and if symptomatic may be resected or managed with stereotactic radiosurgery. Treatment may also be indicated if schwannomas are pre-symptomatic to preserve hearing.
- Genetic counselling for family members.

**Tuberous sclerosis****Epidemiology**

- 1:9 000, autosomal dominant, mutations in either TSC1 on chromosome 9q34 (hamartin) or TSC2 on chromosome 16p13 (tuberin).



- Two-thirds of cases are new mutations (usually TSC2 mutations), one third are inherited (usually TSC1 mutations), with implications for other children and family members.
- TSC2 mutation associated with more severe phenotype, although exceptions with some TSC2 mutations, and overlap of phenotype with TSC1.
- Hamartin and Tuberin form a complex that inhibits mTOR ('mammalian target of rapamycin') in early life which results in controlled cell proliferation, mutations in this complex result in tumour formation in most major organs.
- The potential of mTOR inhibitors such as everolimus to control tuber formation (particularly growth of SEGAs) is under evaluation.

#### **Diagnostic criteria**

- Usually presents with seizures (60–90%, usually infantile spasms, usual onset <1 yr, 50% will be intractable), developmental delay—especially with autistic features (25–50%).
- Learning difficulties in 45%, others have normal intellect (IQ >70, but often have specific deficits e.g. attention or memory).
- Table 4.16 outlines testing of asymptomatic patients with TS.
- Two major or one major and two minor features must be present for the diagnosis of this condition.

#### **Major features**

- Adenoma sebaceum (facial angiofibroma, seen in 80%).
- Periungual fibroma (seen after adolescence in 20%, especially girls).
- Three or more hypomelanotic patches (seen in 90%; best seen with a Wood light).
- Shagreen patch (connective tissue nevus).
- Multiple retinal nodular hamartomas (seen in >50%).
- Cortical tuber.
- Subependymal nodule.
- Subependymal giant cell astrocytoma (SEGA), often at the foramen of Munro causing hydrocephalus typically from the second decade of life onward.
- Cardiac rhabdomyoma.
- Lymphangiomyomatosis (occurs in females, present with dyspnoea, haemoptysis or spontaneous pneumothorax).
- Renal angiomyolipoma (if it exists with lymphangiomyomatosis both count as one major feature).

#### **Minor features**

- Dental enamel pits.
- Bone cysts.
- Gingival fibromas.
- Non-renal hamartoma.
- Hamartomatous rectal polyp.
- Retinal achromatic patch.
- Confetti skin lesions.
- Multiple renal cysts.
- Cerebral white matter radial migration lines.

**Management**

- AED therapy for seizures.
- Multidisciplinary approach for developmental problems.
- Resection of sub-ependymal giant cell astrocytoma (SEGA) if symptomatic ( $\pm$  ventriculoperitoneal (VP) shunt), everolimus now has FDA approval for treatment of inoperable lesions.
- Epilepsy surgery evaluation if intractable seizures.
- Monitoring of renal function and blood pressure, monitoring of vision.
- Sudden regression in skills may be related to uncontrolled seizures or be the consequence of hydrocephalus.
- Genetic counselling for family members.

**Table 4.16** Testing of asymptomatic patients with TS

	Initial testing	Repeat testing
Neurodevelopmental assessment	At diagnosis, on school entry	As clinically indicated
Ophthalmology	At diagnosis	As clinically indicated
EEG	At diagnosis	As clinically indicated
ECG	At diagnosis	As clinically indicated
Echo	If cardiac symptoms	If cardiac dysfunction
Renal USS	At diagnosis	Every 1–3 years
MRI	At diagnosis	Every 1–3 years
Chest CT	In adulthood (women only)	If respiratory dysfunction

**Prognosis**

- Varies with the phenotype in a particular individual.
- *Major causes of death:* renal disease, primary brain tumours, pulmonary lymphangioliomyomatosis, status epilepticus, and pneumonia.

**Sturge–Weber syndrome**

A congenital disorder with angiomas of the face, eye, and meninges.

**Clinical features***Essential*

- An ipsilateral facial port wine stain (in the distribution of the first branch of the trigeminal nerve) is present at birth.
  - Ipsilateral leptomeningeal angioma (causing contralateral seizures  $\pm$  hemiplegia, hemiatrophy, and homonymous hemianopia).
- Only 15% of all children with facial port wine stain will have Sturge–Weber syndrome (SWS).
- Progressive venous infarction of the brain underlying the leptomeningeal angioma leads to atrophy and calcification.

- Ocular vascular malformations may cause glaucoma (30%), buphthalmos, iris heterochromia or optic atrophy.
- Learning difficulties (90%), developmental delay, dental abnormalities and skeletal lesions.
- MRI with gadolinium demonstrates leptomeningeal enhancement, white matter abnormalities and often unilateral hypertrophy of the choroid plexus; the vascular malformation itself may be impossible to see.
- Hydrocephalus may result from increased venous pressure or from extensive A–V anastomosis. Headache is common.

### **Management**

Laser therapy for the port wine stain, AEDs for seizures, aspirin may reduce stroke-like episodes, regular ophthalmology review to monitor and manage glaucoma (both medical and surgical therapy may be required). Lobectomy or hemispherectomy may improve quality of life when intractable seizures are a problem—refer early as may preserve cognition.

### **Prognosis**

Children with more extensive leptomeningeal involvement or bilateral disease have a worse prognosis. Early onset of intractable seizures is also associated with worse outcome and greater risk of learning disabilities.

## **Ataxia telangiectasia**

### **Epidemiology**

1:40,000, autosomal recessive or sporadic mutation in chromosome 11q23.3. ATM protein is absent in 85% of cases of AT and present, but malfunctioning in the remaining 15%. Heterozygotes have an increased risk of malignancy, especially breast cancer.

### **Clinical features**

- Slowly progressive cerebellar ataxia, dystonia, and dysarthria with onset in the second year of life (precedes skin manifestations).
- Later choreoathetosis, oculomotor apraxia, nystagmus.
- Telangiectasia of the skin (ears, eyelids, cheeks, neck, antecubital, and popliteal fossae) and bulbar conjunctiva.
- Increased susceptibility to bronchopulmonary infections (in ~70% due to IgA and/or IgE deficiency).
- Intelligence is preserved until late.
- Children have short stature (70%) and progeric changes (90%).
- Lymphoid tissue (tonsils, adenoids, and thymus) may be absent.
- Alpha-fetoprotein is raised in 95% of cases, carcinoembryonic antigen is raised, and IgA and IgE are low/absent.
- Chromosome fragility is manifest as frequent chromosome abnormalities (in 80%), especially 14:14 translocations.
- Glucose intolerance in 50% and adolescent diabetes is characterized by hyperglycaemia with infrequent glycosuria and no ketosis.
- MRI demonstrates atrophy of the cerebellum and later atrophy of the posterior columns of the spinal cord.
- If investigations for AT are negative, consider testing for the AOA1 (ataxia with oculomotor apraxia) gene.

**Risk of neoplasm**

Lymphoreticular (leukaemia, lymphoma, lymphosarcoma, Hodgkin disease) and other malignancies especially of the skin.

**Management**

- Control of infections with antibiotics and IVIG.
- Protection from sunlight and radiation.
- Multidisciplinary support for a progressive neurological disorder.

**Prognosis**

Death can occur in late childhood or early teens but many with appropriate supportive care will live well into adult life.

**Von Hippel–Lindau disease****Epidemiology**

1:40,000, autosomal dominant mutation in chromosome 3p25–26. The mutation leads to angiogenic neoplasms. Cysts form around these tumours and the cyst is often far greater in size than the tumour. The mass effect from the cyst is often responsible for symptoms.

**Clinical features**

- Usually presents in adolescence with visual symptoms or later with signs of posterior fossa mass effect.
- Although classically regarded as a neurocutaneous syndrome there is usually no skin involvement!

**Diagnostic features**

- Retinal haemangioma/haemangioblastoma (may lead to retinal detachment if multiple).
- CNS haemangioblastoma (especially of the cerebellum and spinal cord).
- Renal carcinoma.
- Multiple congenital cysts of the pancreas.
- Polycythaemia (from excessive erythropoietin).

**Risk of neoplasm**

Cerebellar haemangioblastomas are seen in around 75% of children and ultimately multiple CNS haemangioblastomas develop. Spinal cord haemangioblastomas are associated with syringomyelia in around 80%. Pheochromocytoma, angiomas of the liver and kidney, papillary cystadenomas, and endolymphatic sac tumours all occur with greater frequency.

**Management**

Early detection and early surgical excision is the goal of management of symptomatic CNS haemangioblastomas. The recurrence rate is 8–15%. Radiotherapy may be used for multiple or inaccessible lesions. Regular ophthalmological examination to follow small retinal haemangioblastoma is appropriate, but if visual loss or retinal detachment occurs then this may be treated with laser photocoagulation or cryocoagulation. Screening for pheochromocytoma may include blood pressure monitoring and HVA and VMA assay.

**Prognosis**

CNS haemangioblastomas are a major cause of morbidity and are the cause of death in >50% of children with von Hippel–Lindau. 30% of deaths are due to renal cell carcinoma.

**Other neurocutaneous syndromes*****Hypomelanosis of Ito***

An autosomal dominant condition presenting with congenital hypopigmented skin lesions (linear streaks following dermatomes or irregular whorls) in association with learning disability, seizures, motor disorder, and abnormalities of the eye (strabismus, myopia, optic nerve hypoplasia), hair, teeth, and bone.

***Incontinentia pigmenti***

An X-linked dominant condition affecting females in >90% of cases (lethal in males). Bullous skin lesions (contain eosinophilic fluid) are found in a linear pattern on the trunk and limbs. Then verrucous lesions appear over the dorsum of the fingers from the 6th week of life. These heal, resulting in atrophic cutaneous areas. Hyperpigmented areas then appear and later gradually fade. It is associated with seizures, learning disability and motor disorder and with abnormalities of the eye (retinal detachment, optic atrophy, papillitis, nystagmus, cataracts and strabismus), hair (alopecia), teeth (delayed dentition, pegged teeth, and abnormal crown formation), and bone (spina bifida, hemivertebrae).

***Neurocutaneous melanosis***

Leptomeningeal melanosis is associated with cutaneous nevi, e.g. multiple giant hairy pigmented nevi and congenital melanocytic nevi. Cutaneous giant hairy nevi usually have a 'bathing suit' or 'cape' distribution. Leptomeningeal involvement is usually brainstem, cerebral peduncles and basilar cerebrum and cerebellum. Hydrocephalus and learning disabilities with behaviour problems are common. CSF protein is elevated and cytology reveals abnormal melanin-containing cells. Prognosis is poor.


***Linear sebaceous nevus/epidermal nevus syndrome***

A midline or near midline yellow-brown hairless plaque occurs on the face or scalp at birth or in early childhood which may become malignant. This condition is associated with CNS abnormality (unilateral lissencephaly, heterotopic grey matter and hemimegalencephaly) causing learning disability, motor disorder and seizures, as well as eye abnormalities.

## Neurodegenerative conditions


Neurodegeneration (progressive neurological and/or cognitive decline) is caused by a heterogeneous group of conditions. Individually rare (over 600 causes described), the overall prevalence is 0.6/1000 live births.

### Features

- Progressive intellectual and neurological degeneration, although either neurological or cognitive elements may predominate initially.
- Typically evolve over years after a period of normal development (this can be difficult to demonstrate if very early onset).
- Loss of already attained developmental skills (in children under 4 yrs, this may initially manifest as developmental stagnation).
- Duration greater than 3 mths.
- Evidence of generalized brain dysfunction.
- Development of abnormal neurological signs (eye signs are easily missed if not specifically looked for).
- Due to CNS dysfunction (consider non-neurological causes of apparent regression, so-called pseudo-regression, see  p. 179).

The most common conditions include mucopolysaccharidoses (especially type III), adrenoleukodystrophy, neuronal ceroid lipofuscinoses, mitochondrial cytopathies, Rett syndrome, metachromatic leukodystrophy, Alpers' syndrome, and G<sub>M2</sub> gangliosidoses.

### Focused investigation

- A diagnosis will be made in about 75% of cases. Average time to diagnosis is 3–6 mths.
- There is no general 'screen'; however, MRI and neurophysiology (EEG, ERG, VEP) will be valuable for all. This will guide focused biochemistry, histopathology and genetic testing.
- The clinical picture will focus differential diagnoses (see  p. 180).

### Importance of diagnosis

- These diseases are severe, debilitating and continue inexorably to death, and diagnosis will have enormous medical, educational, and psycho-social implications for the child and family.
- Specific diagnosis allows multidisciplinary planning, contact with condition-specific support groups and accurate and sensitive counselling with regard to prognosis, inheritance and prenatal testing.
- Until recently, diagnosis has not particularly informed therapy although recently enzyme replacement and substrate reduction therapy and bone marrow transplantation have been developed for the treatment of some lysosomal diseases.

### Most common diagnoses by age at presentation

Age at onset is one of the most useful 'handles' diagnostically. These conditions are listed by most typical age at onset, and are all discussed in more detail on subsequent pages. It is, however, important to appreciate that many have variants that present at other ages: typically less rapidly progressing forms presenting at later ages. In these situations, the main implications of diagnosis may be for family members other than the index case.

On-line and computer-aided systems exist to help focus investigations and differential diagnoses in what can be a very confusing area ([www.simulconsult.com](http://www.simulconsult.com)).

#### 0–2 yrs

- Infantile NCL.
- Krabbe leukodystrophy.
- Metachromatic leukodystrophy.
- Pelizaeus–Merzbacher disease.
- Rett syndrome.
- Tay–Sachs: infantile.
- Infantile neuraxonal dystrophy.
- Gaucher type 2.

#### 2–5 yrs



- Mucopolysaccharidoses (Sanfilippo).
- NCL: late infantile.
- Mitochondrial diseases.
- Alpers syndrome.
- Gaucher type 3.

#### 5–12 yrs

- NCL: juvenile.
- Adrenoleukodystrophy.
- Rasmussen syndrome.
- Hallervorden–Spatz syndrome.
- Refsum disease.
- Unverricht–Lundborg disease.
- Niemann–Pick C.
- Friedrich ataxia (FA).
- HIV dementia.

### First 2 yrs of life

#### Rett syndrome

- *Presentation*: initially a normal girl who between 6 and 18 mths shows regression of speech and functional hand movements, sleep disturbance and agitation, and acquired microcephaly.
- *Clinical course*: severe cognitive impairment, stereotypical hand movements, spasticity, scoliosis, GTC seizures in the majority, non-epileptic ‘vacant spells’. Respiratory rhythm disturbances including hyperventilation (see  p. 254).
- *Neurophysiology*: EEG non-specific.
- *Genetics*: X-linked, predominantly females; *MECP2* gene (85%), A number of other genes causing Rett-like pictures have been identified (e.g. *CDLK5*), and *MECP2* mutations are associated with other phenotypes (see  p. 278 for more details).
- *Management*:
  - symptomatic treatment of seizures, hyperventilation;
  - monitoring for scoliosis, osteoporosis;
  - periodic ECG monitoring (associated with prolongation of QT interval);
  - avoid drugs associated with prolongation of QT interval including macrolide antibiotics, haloperidol, pimozide, SSRIs.

**Early infantile neuronal ceroid lipofuscinosis (CLN1, Santavouri–Haltia)**

NCLs (Batten diseases) are autosomal recessive lysosomal storage diseases, characterized by the accumulation of autofluorescent lipopigment in tissues (inclusion bodies). They are classified by age of presentation.

► Remember: the infantile form presents with delay, late infantile with aggressive seizures and juvenile form with visual loss.

- *Presentation*: at end of the first year, developmental arrest; infrequent seizures; blindness; movement disorder; microcephaly.
- *Clinical course*: irritability, hypotonia, dystonic spasms.
- *Neurophysiology*: attenuation then loss of electroretinogram (ERG) and VEPs.
- *Histopathology*: granular inclusions in neurons on electron microscopy of skin biopsy.
- *Biochemistry*: palmitoyl-protein thioesterase (PPT) assay: may not be routinely included as part of your laboratory's standard white cell enzyme (WCE) panel.

**Krabbe leukodystrophy (common infantile form)**

- *Presentation*: first months of life: severe irritability, spasticity, and delay.
- *Clinical course*: regression with febrile illnesses; decerebrate by 1 yr, areflexic, decreased visual awareness.
- *Neurophysiology*: decreased nerve conduction.
- *Histopathology*: needle-like inclusion bodies in macrophages and brain; demyelination on nerve biopsy; foamy histiocytes.
- *Biochemistry*: raised CSF protein; WCE.

**Tay–Sachs disease (classic infantile  $G_{M2}$  gangliosidosis)**

Gangliosidoses are lysosomal storage disorders characterized by accumulation of gangliosides in neurons. Like NCLs, gangliosidoses are classified by age of presentation.

**Infantile Tay–Sachs disease**

- *Presentation*: 4–6 mths, motor weakness.
- *Clinical course*: rapidly progressive hypotonia, seizures by 6 mths (massive myoclonus), blind by 1 yr, death in 4 yrs.
- *Particular features*: macular degeneration; cherry red spot; macrocephaly from year 2.
- *Neurophysiology*: EEG initially unremarkable, becomes very abnormal; VEP abolished by 18 mths; ERG normal.
- *Neuroimaging*: white matter abnormalities.
- *Biochemistry*: WCE.

**Pelizaeus–Merzbacher disease**

- Demyelinating disorder of the white matter. Traditionally the classical and more severe congenital forms are distinguished by rate of progression, though there is considerable overlap.
- *Presentation*: onset in first year of life: nystagmus, spastic paraparesis and movement disorder (usually dystonia).
- *Neuroimaging*: characteristic hypomyelination of cerebral white matter.
- *Genetics*: males affected (X-linked); mutation in the *PLP* gene (75%).



**Metachromatic leukodystrophy (late infantile; sulphatide lipodosis)**

- **Presentation:** 18 mths; regression, flaccid limb paresis and absent reflexes (peripheral neuropathy).
- **Clinical course:** within 3–6 mths hypertonia, optic atrophy, decerebrate and decorticate posture; death by 8–10 yrs.
- **Neuroimaging:** MRI shows symmetrical demyelination (typically frontal and occipital horns).
- **Histopathology:** metachromatic sulphatides in nerves.
- **Neurophysiology:** slow nerve conduction; abnormal VEPs and somatosensory evoked potentials (SSEPs).
- **Biochemistry:** WCE; raised CSF protein.

**Infantile neuroaxonal dystrophy (INAD; Seitelberger disease)**

- Progressive degeneration of central and peripheral nervous systems.
- Inheritance is autosomal recessive: PLA2G6 testing available.
- **Presentation:** hypotonic infant with decreased limb reflexes.
- **Clinical course:** becomes spastic; opisthotonic posturing; optic atrophy; death by 5 yrs.
- **Histopathology:** axonal spheroids on axillary skin biopsy.
- **Neuroimaging:** MRI shows diffuse cerebellar hyperintensity and atrophy ± iron deposition in basal ganglia: INAD now sometimes referred to as PLAN (phospholipase associated neurodegeneration) and regarded as a form of NBIA (see [p. 430](#)).
- **Neurophysiology:** EMG shows anterior horn cell disease and denervation (nerve conduction studies normal). Brainstem auditory-evoked response (BAERs), somatosensory-evoked potentials (SSEPs) and VEPs progressively worsen (ERG is unremarkable).

**HIV-associated progressive encephalopathy**

See [p. 341](#).

**Pre-school years (2–5 yrs)****Late infantile neuronal ceroid lipofuscinosis (CLN2, Jansky–Bielschovsky)**

- **Presentation:** 2–4 yrs, seizures (myoclonic and tonic–clonic).
- **Clinical course:** myoclonus is a prominent feature; motor difficulties, ataxia; blindness occurs late; death within 3–10 yrs.
- **Neurophysiology:** slow (1 Hz) flash on routine EEG produces large posterior spikes (useful clinical screen); VEPs and SSEPs abnormally enlarged, ERG low amplitude, eventually extinguished.
- **Histopathology:** curvilinear inclusions in white cells or neurons on electron microscopy of skin biopsy.
- **Biochemistry:** tripeptidyl amino peptidase (TPP) for the most common variety (may not be part of standard WCE panel).

**Mucopolysaccharidosis type III (Sanfilippo)**

Mucopolysaccharidoses (MPS) are a group of lysosomal enzyme disorders characterized by the accumulation of glycosaminoglycans (GAG).

MPS III (Sanfilippo) is the most common neurodegenerative disease in childhood in the UK.

- **Clinical course:** triphasic; 1–5 yrs developmental delay, 3–12 yrs behaviour disturbance (daytime aggression, hyperactive and mood swings; night insomnia and non-epileptic paroxysms), 10–15 yrs degenerative then vegetative. Death by 15–25 yrs.

- *Mild somatic MPS features*: mixed deafness; hip dysplasia; diarrhoea (autonomic neuropathy due to gut deposits).
- School failure may not have been recognized at presentation, although it will be identifiable on specific questioning.
- Hyperactivity is usually not helped by stimulants: nocturnal sedation can be effective.
- *Biochemistry*: excess urine GAG excretion (heparan sulphate), confirm by WCE.

### **Mitochondrial disorders**

See  p. 369.

#### ***Progressive neuronal degeneration of childhood (PNDC, Alpers disease, PNDC with liver disease; Huttenlocher disease; infantile poliodystrophy)***

This name encompasses a group of diseases characterized by presentation in infancy or early childhood with neuronal degeneration with or without liver failure.

- *Presentation*: hypotonia, fail to thrive, developmental delay, seizures, hepatic derangement.
- *Clinical course*: epilepsy partialis continua (EPC); episodes of major status epilepticus; usually develop late hepatic failure ('Huttenlocher variant') with rapid progression to death. Valproate can precipitate hepatic failure and some cases of significant 'valproate hepatotoxicity' in young children may have been PNDC.
- *Genetics*: familial or sporadic inheritance. Most cases appear to be due to mitochondrial defects: various mutations have been described, particularly polymerase G (POLG1) involved in mitochondrial replication.
- *Histopathology*: brain spongiosis, neuronal loss and astrocytosis.
- *Neurophysiology*: characteristic EEG changes; abnormal flash VEPs; ERG normal.

#### ***Juvenile Gaucher type 3 (neuronopathic)***

- *Presentation*: variable onset (infancy to adolescence); ocular motor apraxia and supranuclear gaze palsy (i.e. saccadic eye movement abnormalities, but intact dolls' eye movements).
- *Clinical course*: myoclonus, ataxia, dementia. Variable prognosis. Treatment now includes enzyme replacement and substrate inhibition therapies, though these do not seem to halt neurological deterioration.
- *Systemic problems*: bone lesions, hepatosplenomegaly and lung involvement.
- *Biochemistry*: WCE.
- *Histopathology*: lipid-engorged Gaucher cells (deposition and storage of glucocerebroside (glucosylceramide) in tissues).
- *Neurophysiology*: changes in evoked potentials reflect disease progression; SSEPs enlarge, BAEPs deteriorate.

#### ***HIV-associated progressive encephalopathy***

See  p. 341.

**School age (5–12 yrs)**

Consider also aggressive variants of typically adolescent-onset disease.

**Juvenile NCL (CLN3; Batten–Spielmeier–Vogt–Sjögren)**

- *Presentation:* 4–14 yrs (peak 6–10 yrs of age); subtle behaviour change; markedly decreased visual acuity (macular and retinal degeneration).
- *Clinical course:* cognitive decline, extra-pyramidal and pyramidal signs; blind by 2–6 yrs; seizures occur late (absence, myoclonus of face); death in early twenties.
- *Genetics:* DNA diagnosis, homozygous deletion in the CLN3 gene.
- *Histopathology:* light microscopy shows vacuolated lymphocytes; EM shows ‘fingerprint’ bodies.
- *Neurophysiology:* EEG no change with photic; ERG absent early on; VEPs disappear; SSEPs increase in amplitude.

**Adrenoleukodystrophy (X-ALD)**

- Peroxisomal disorder; X-linked recessive (10% of female carriers are symptomatic); defective ALD protein leads to demyelination.
- *Presentation:* 4–10 yrs; significant behavioural problems (withdrawal, irritability, hyperactivity).
- *Clinical course:* rapid cognitive deterioration; optic atrophy; seizures and clinical adrenal impairment are late features. Decerebrate in 2–4 yrs. ‘Lorenzo’s oil’ improves biochemical abnormalities and may stabilize pre-clinical disease (e.g. siblings of probands with no MRI changes), but has no effect on long-term outcome in symptomatic individuals. Bone marrow transplantation is an option in selected cases (MRI changes but no neurological signs).
- *Neuroimaging:* white matter abnormality, posterior to anterior progression.
- *Biochemistry:* elevated plasma very long-chain fatty acids; adrenal insufficiency.

**Rasmussen syndrome**

Chronic progressive unihemispheric inflammation of the brain, of uncertain but probable immune aetiology (see [□](#) p. 222).

- *Clinical course:* age of onset and rapidity of course are variable. Characterized by intractable focal seizures, progressive hemiplegia and increasing cognitive impairment; multiple seizure types, EPC in many; diagnosis made on unilateral clinical, EEG (unihemispheric slowing and seizure onset) and MRI brain features (progressive cerebral hemi-atrophy).
- *Treatment:* AEDs, steroids, immune-modulation (tacrolimus, azathioprine). IVIG of benefit in some; eventually hemispherectomy.

**Neurodegeneration with brain iron accumulation (NBIA)**

An umbrella term to cover a number of disorders characterized by pallidal iron deposition, axonal spheroids, and gliosis. Previously known by the eponym Hallervorden–Spatz syndrome. A subset due to defects in pantothenate kinase (PANK2) is also referred to as Pantothenate kinase-associated neurodegeneration (PKAN). INAD (see [□](#) p. 428) also a form of NBIA, sometimes referred to as PLAN (phospholipase associated neurodegeneration).

- *Presentation:* in the first two decades of life, progressive dystonia, rigidity and choreoathetosis with cognitive decline.
- *Supportive clinical features:* retinitis pigmentosa, optic atrophy (seizures are not prominent).
- *Clinical course:* variable rate of progression; iron chelation has not proven useful.
- *Neuroimaging:* characteristic MRI shows basal ganglia 'eye-of-the-tiger' sign.
- *Genetics:* PANK2, PLAG2 gene mutations.
- *Neurophysiology:* VER and ERG are abnormal in 25% of cases.

#### **Friedreich ataxia** (see also 📖 p. 385)

- *Presentation:* onset in childhood or adolescence; slowly progressive ataxia; pyramidal tract signs; peripheral neuropathy; absent reflexes, upgoing plantars, pes cavus.
- *Systemic problems:* scoliosis; cardiomyopathy.
- *Genetics:* DNA testing for Frataxin mutations (autosomal recessive).
- *Neurophysiology:* EMG shows sensory axonal neuropathy.

#### **Niemann–Pick C**

- *Presentation:* mid–late childhood; seizures and emerging school failure; vertical gaze palsy (particular feature: cf. horizontal eye movement disorder of Gaucher).
- *Clinical course:* heterogeneous; organomegaly, cherry red spot (50%), ataxia, dystonia. Narcolepsy and cataplexy are common features. Narcolepsy may be helped by Modafinil; cataplexy by tricyclics, SSRIs or sodium oxybate.
- *Histopathology:* foamy sea-blue histiocytes on bone marrow.
- *Biochemistry:* abnormal cholesterol studies on cultured fibroblasts (diagnosis).
- *Genetics:* NPC1 gene (not for diagnosis as majority have private mutations).

#### **Unverricht–Lundborg disease (ULD)**

Occurs worldwide, but is increased in Scandinavia and southern Europe:

- *Presentation:* 7–16 yrs (peak 10–13), seizures (clonic, tonic–clonic, often nocturnal).
- *Clinical course:* generalized epilepsy with increasingly prominent debilitating action myoclonus (i.e. progressive myoclonic epilepsy: see 📖 p. 283) and ataxia; normal cognition or subtle deficits; slowly progressive over decades, not life-limiting.
- *Genetics:* autosomal recessive; CSTB gene; deficient cystatin B, a protease inhibitor.
- *Neurophysiology:* EEG photosensitivity (90%), high amplitude SSEPs.
- *Treatment:* valproate for seizures; N-acetyl cysteine may be beneficial.

#### **Leukoencephalopathy with vanishing white matter (VWM) disease**

- *Presentation:* Episodes of deterioration, including coma, following infections and minor head traumas, resulting in increasing spasticity and/or ataxia. Variable age at onset with aggressive forms presenting in childhood and less aggressive forms later in adolescence or even early adulthood.

- **Genetics:** autosomal recessive; mutations in any of the 5 subunits coding a transcription initiation factor eIF2B.
- **Radiology:** pathognomonic MRI changes initially showing diffusely abnormal white matter then progressing to striking cystic degeneration and disappearance of white matter and replacement with CSF.

### Adolescence

Consider also late presentations of typically childhood-onset disease.

#### Juvenile Huntington disease

- Dominantly inherited triplet repeat disorder showing anticipation. The longer the repeat length, the earlier the presentation. Juvenile presentations are usually paternally inherited and occasionally a big expansion will result in the child presenting before the father's diagnosis has been made although a family history of progressive psychiatric or neurological symptoms is often present.
- **Presentation:** the juvenile form features rigidity, dystonia, and myoclonic and generalized seizures. This contrasts with the presentation more typical of adult-onset disease of progressive dementia with prominent psychiatric symptoms, tremor, chorea and late seizures.
- Diagnosis is by DNA mutation analysis, but **only after specialist counselling**. MRI may be normal early, but will show progressive ventriculomegaly and caudate atrophy.

#### Wilson disease (*hepato-lenticular degeneration*)

Consider this in all unexplained neurological regression and personality change as the neurological deterioration is preventable. It is a recessively inherited defect of copper transport resulting in deposition in the brain, liver, and cornea.

- **Presentation:** extrapyramidal features predominate from adolescence, with early dysarthria in particular (hepatic presentation in younger child). Slit lamp examination of the eyes reveals Kayser–Fleischer rings (almost pathognomonic).
- **Clinical course:** penicillamine or trientine zinc chelation effectively retards disease and reverses changes.
- **Biochemistry:** low plasma caeruloplasmin, low serum copper, high 24 h urinary copper. If there is any doubt, proceed to penicillamine challenge, increased copper on liver biopsy.
- **Radiology:** low T1 and high T2 signals in lentiform nuclei, brainstem, and white matter.
- **Treatment options:** penicillamine and trientine; zinc acetate, which blocks copper absorption; and tetrathiomolybdate. Penicillamine has high toxicity and may worsen the neurological symptoms initially. Fulminant hepatic disease may require liver transplantation.

#### Subacute sclerosing panencephalitis (SSPE)

See 📖 p. 348.

**Lafora disease**

- **Presentation:** mid-adolescence generalized tonic–clonic seizures.
- **Clinical course:** rapid course; severe myoclonus, resting and action (c.f. action only in Unverricht–Lundborg disease (ULD)); seizures with visual features; cortical blindness; early depression; profound cognitive impairment; death in 7–10 yrs.
- **Histopathology:** Lafora inclusion bodies on axillary skin biopsy (investigation of choice for diagnosis).
- **Neurophysiology:** changes pre-date symptoms; EEG photosensitivity; giant SSEPs.
- **Genetics:** autosomal recessive, mutations in the *EPM2A* and *B* genes.

**Variant Creutzfeld–Jacob disease (vCJD)**

See  p. 349.

**HIV-associated progressive encephalopathy**

See  p. 341.

**Hereditary spastic paraparesis**

A heterogeneous group of conditions characterized by spastic paraparesis progressing slowly over years typically with onset in teens or twenties (but can be much earlier). X-linked, autosomal dominant, and recessive inheritance is all common.


- **Diagnosis of ‘pure’ forms is by exclusion:** evidence of slowly progressive spastic paraparesis with normal brain and spine imaging.
- Various ‘complicated’ forms (10% of all cases) with additional features such as optic atrophy, retinopathy, ataxia or ichthyosis.
- Many genes have been identified, although only genetic testing is only readily available for a proportion of subtypes (particularly the dominant forms).
- Clinical features (other than inheritance pattern) generally do not permit distinction between various genetic subtypes.
- Management is supportive.


**White cell enzymes**

Deficient enzyme activity in white cells can be diagnostic of lysosomal storage diseases (Table 4.17).

**Supportive care for neurodegenerative conditions**

Even if cure is not possible there is much we can do to help:

See  p 3, general advice.

- Manage and talk about the parents’ grief reaction as an important separate issue from the child’s disease. This will help the family make some sense of their feelings and help them support each other through the grieving process and as it resolves. This process may take 3 or 4 mths though the child’s life may be very much longer than this.
- Agree goals rather than define impairments (see  p. 212, interdisciplinary working):
  - How can mobility be maintained as long as possible?
  - How will feeding difficulties be overcome?
  - How will medical problems, particularly seizures, be managed?

In the medium term as the child or young person becomes more dependent consider:

- Involvement of a children's hospice, remembering that many hospices have outreach staff to support care in the child's home.
- Pay attention to nutrition to maintain health, wellbeing and mood.
- Treating mood disturbance, dysphoria or agitation. Consider SSRIs, sedation and ultimately a morphine infusion if distress is clear.

Always offer to meet with the family again after the child eventually dies to address unresolved issues they may have.

**Table 4.17** White cell enzymes

Group	Disease	Deficient/abnormal enzyme
Mucopolysaccharidoses	MPS I (Hurler,Scheie)	$\alpha$ -L-Iduronidase
	MPS II (Hunter)	Iduronate-2-sulphatase
	MPS III A (Sanfilippo)	Heparan N-sulphatase
	MPS III B (Sanfilippo)	N-Acetyl $\alpha$ -glucosaminidase
	MPS III C (Sanfilippo)	Acetyl-CoA: $\alpha$ -glucosaminide N-Acetyl-transferase
	MPS III D (Sanfilippo)	N-Acetylglucosamine 6-sulphatase
	MPS VII (Sly)	$\beta$ -Glucuronidase
Neuronal ceroid lipofuscinosis	NCL 1 (infantile)	Palmitoyl-protein thioesterase
	NCL 2 (classic late Infantile form)	Tripeptidyl amino peptidase I
GM2 gangliosidoses	Tay-Sachs	Hexosaminidase A
	Sandhoff	Hexosaminidase A and B
Oligosaccharidoses	Fucosidois	$\alpha$ -Fucosidase
	$\alpha$ -Mannosidosis	$\alpha$ -Mannosidase
	Sialidosis type I	Neuraminidase
Mucopolipidoses	Mucopolipidoses II (I-cell disease)	Mannose-6-phosphate phosphotransferase
Sphingolipidoses	Metachromatic leukodystrophy	Arylsulphatase A (sulphatidase)
	Krabbe leukodystrophy	Galactocerebrosidase $\beta$ -galactosidase
	Niemann-Pick type A	Sphingomyelinase
	Gaucher disease	Glucocerebrosidase
	GM1 gangliosidosis	$\beta$ -Galactosidase
	Galactosialidosis	$\beta$ -Galactosidase and sialidase

## Neurotransmitter disorders

This is a group of IEMs affecting synthesis, metabolism, and catabolism of neurotransmitters, their co-factors or receptors.

Neurotransmitters have wide-ranging effects, regulating neurons involved in memory and cognition, motor function, temperature, balance and pain. Disorders of neurotransmission are potentially treatable causes of epileptic encephalopathies and movement disorders (complete symptom control for some disorders, improved quality of life for others); untreated they can result in severe neurological dysfunction and death.

Diagnosis is difficult and often delayed: presenting features are non-specific. Mild, moderate and severe forms are seen, and accurate diagnosis relies upon specialized biochemical tests of CSF, urine, and plasma.

Neurotransmitters include:

- *Biogenic monoamines*:
  - *catecholamines*—dopamine (DA), norepinephrine (NE), epinephrine (EPI);
  - *indoleamines*—serotonin (5-HT) and melatonin;
  - histamine.
- *Amino acids*: glutamate, aspartate, glycine, D-serine, GABA.
- Acetylcholine.
- Purines (AMP, ADP, ATP).
- Neuropeptides.

In the brain, glutamate is the most prevalent excitatory neurotransmitter and GABA the major inhibitory neurotransmitter.

### Cofactors

- Tetrahydrobiopterin (BH4) is a critical cofactor in the synthesis of the neurotransmitter precursors L-DOPA and 5-HTP (see [📖](#) p. 436).
- Pyridoxal phosphate is also a critical cofactor (see [📖](#) p. 462).

There are three main categories of paediatric neurotransmitter disorders.

- Disorders of biogenic amine metabolism.
- Disorders of GABA metabolism.
- Disorders of glycine metabolism.

### Disorders of biogenic amines

These are caused by the failure of synthesis of dopamine, serotonin, norepinephrine, epinephrine, or the cofactor tetrahydrobiopterin. They have characteristic CSF neurotransmitter profiles.

#### General characteristic features

- Epileptic encephalopathy, myoclonic epilepsy.
- Intestinal motility dysfunction, feeding difficulties.
- Developmental delay, especially expressive speech delay.
- Microcephaly, central hypotonia, peripheral hypertonia.

#### Additional features

##### *Dopamine deficiency*

- Movement disorder (hypokinesia or dyskinesia) with diurnal variation.
- Oculogyric crises.
- Hypersalivation.



*Norepinephrine deficiency*

- Ptosis, miosis.
- Increased oculopharyngeal secretions.
- Postural hypotension.

*Serotonin deficiency*

- Disturbed temperature regulation.

**Aromatic L-amino acid decarboxylase deficiency**

- *Clinical features:* hypotonia; paroxysms ('spells') of limb dystonia, orofacial dystonia, oculogyric crises, flexor spasms; myoclonic jerks; sleep disturbance; autonomic disturbance.
- *Treatment:* dopaminergic receptor agonists, monoamine oxidase (MAO) inhibitors, anticholinergics, pyridoxine (enzyme cofactor).

**Tyrosine hydroxylase deficiency**

- *Clinical features:* causes a severe infantile form of DOPA-responsive dystonia including infantile parkinsonism–dystonia, oculogyric crises, Parkinsonism, tremor, ptosis, miosis, increased oropharyngeal secretions, autonomic instability, hypotonia, toe-walking.
- *Treatment:* L-DOPA responsive, MAO inhibitors; caution: particularly sensitive to drug side effects.

**Dopamine  $\beta$ -hydroxylase deficiency****Monoamine oxidase deficiency****Tetrahydrobiopterin synthesis defects**

BH4 synthesis and reclamation disorders have features of both dopamine and serotonin deficiency—hypotonia, dystonia and oculogyric crises. Diagnosis is by CSF biogenic amine and pterin profile, plus phenylalanine challenge. In addition to L-DOPA, consider BH4 replacement and phenylalanine dietary restriction ('atypical phenylketonuria').

**Dopamine transporter deficiency syndrome**

- *Clinical features:* infantile parkinsonism, hyperkinesia or mixed hypo/hyperkinesic pattern; severe childhood parkinsonism, cognitive impairment and pyramidal tract signs.
- *Biochemistry and genetics:* elevated ratio of homovanillic acid to 5-hydroxyindole acetic acid (5HIAA); mutations in *SLC6A3*, gene encoding DA transporter.

**GTPCH I deficiency**

- *Clinical features:* the most common cause of DOPA-responsive dystonia (Segawa disease) in the UK. Age of onset is usually 4–8 yrs, but infant and neonatal presentations are described. Initial presentation is of insidious gait abnormality secondary to leg dystonia (L > R and usually equinovarus foot) often misdiagnosed as CP. The dystonia worsens through the day and decreases significantly following sleep. Upper limb dystonia then appears followed by development of Parkinsonism. Torticollis and truncal dystonia are uncommon. The disease plateaus in teenage years.

- Brisk tendon reflexes, striatal toe and ankle clonus may confuse the diagnosis. Diagnosis is by DNA analysis but a trial of L-DOPA is warranted in all suspected cases.
- Phenotypic variations with focal dystonias (e.g. writer's cramp), paroxysmal and action dystonia.
- *Treatment:* L-DOPA. The response to low doses of L-DOPA is typically quick (within 72 h) and dramatic. Lifelong L-DOPA treatment is required, but resistance to L-DOPA and on/off phenomena are extremely rare.

### 6-PTS deficiency

#### *Sepiapterin reductase deficiency*

#### *Tetrahydrobiopterin reclamation defects*

Dihydropteridine reductase deficiency.

## Disorders of GABA metabolism

### *Characteristic features*

- Developmental delay, hypotonia.
- Ataxia.
- Seizures.

#### *Succinic semialdehyde dehydrogenase deficiency*

- *Clinical features:* developmental delay, hypotonia, decreased reflexes, epilepsy, non-progressive ataxia, behavioural problems, hyperactivity; rarely psychosis, myopathy, autism. Abnormal basal ganglia signal on MRI brain.
- *Diagnosis:* urine organic acids (massive increase in G hydroxybutyrate, (GHB) in infancy, lessens with age), plasma enzymes, CSF raised GHB and modest elevation in GABA.
- *Treatment:* no established treatment. Reports of usefulness of vigabatrin (irreversible inhibitor of GABA-transaminase); lamotrigine (inhibits release of the major GABA precursor glutamate); SSRIs and methylphenidate for behavioural problems.

#### *GABA transaminase deficiency*

*Clinical features:* progressive epileptic encephalopathy, developmental delay, hypotonia, macrosomia. No known treatment.

## Disorders of glycine metabolism

Non-ketotic hyperglycinaemia (see [□](#) p. 482).

### Investigation

While the clinical features can be protean, the usual presentations of infantile parkinsonism–dystonia and early childhood dystonia are clinically recognizable. Disorders of biogenic amines should also be considered in the child with a diagnosis of ‘cerebral palsy’ without apparent cause. Because most disorders of biogenic amines are treatable, they warrant careful investigation and a trial of L-DOPA (see [□](#) p. 594).

**Key investigations**

- CSF amine neurotransmitter metabolites.
- CSF individual pterin species.
- **NB:** very specific guidelines for collection of specimens must be followed, discuss with specialist laboratory in advance.
- Remember when interpreting, the child is likely to have been resting before the lumbar puncture. Exercise depletes dopamine; rest replenishes; if it cannot be replenished, the movement disorder will be kinesogenic, i.e. worse when tired.

**When indicated***Phenylalanine challenge*

Both enzyme (phenylalanine hydroxylase) and cofactor (BH4) are needed to convert phenylalanine to tyrosine.

- Fast for at least 6 h before test.
- Baseline plasma phenylalanine and tyrosine.
- Oral L-phenylalanine load—100 mg/kg in orange juice or via NGT.
- Measure plasma phenylalanine and tyrosine at 0, 2, 4, and 6 h.
- An abnormal test is a slow drop in phenylalanine and a slow rise in tyrosine.
- Phenylalanine can be combined with a BH4 test.


*BH4 challenge*

- Give BH4 (20 mg/kg diluted in water) 2 h post-phenylalanine load and 30 min before a normal meal. Then measure plasma phenylalanine and tyrosine at 0, 1, 2, 4, and 8 h.
- If enzyme, rather than cofactor is deficient, phenylalanine and tyrosine remain high.

**Genetic tests for specific mutations**

- Plasma or fibroblast enzymes (aromatic amine decarboxylase, dopamine  $\beta$ -hydroxylase, monoamine oxidase and dihydropteridine reductase deficiencies) on Guthrie card.
- Quantitative urine and plasma catecholamines.

**Principles of treatment****Replace amine neurotransmitters***L-DOPA*

- DOPA with a peripheral DOPA decarboxylase inhibitor, e.g. co-careldopa (see  p. 594).
- 5-Hydroxytryptophan (up to 8 mg/kg/day).

**Other treatments to increase DOPA**

- *MAO B inhibitors:* selegiline.
- *COMT inhibitors:* entacapone.
- *DA receptor agonists:* bromocriptine, pergolide, pramipexole, ropinirole.

**Replace cofactors and precursors**

- BH4 (up to 20 mg/kg/day).
- Pyridoxine (vitamin B6).

## Sleep disorders

### Development and sleep disorders

The amount of sleep and its architecture changes during life.

- Newborns sleep for most of the day in evenly-spaced periods of 1–4 h. REM makes up 50% of total.
- With development the length of individual sleep periods increases and proportion of REM decreases.
- Normal stages of sleep have developed by 6 mths. During early childhood the sleep pattern approaches that seen in adults.
- The proportion of time in deep sleep continually declines with age.

20–30% of all children experience some sleep disturbance. The pattern of reported problems varies between countries. Most do not come to any medical attention.

REM sleep is prominent in early infancy thus sleep is naturally more fragmented. The toddler years are particularly sensitive to parenting: 25% of children have problems in settling and sleeping. Deep non-REM sleep is prominent in early childhood and arousal disorders are common in this age group. Sleep-related problems present at two ages.

#### Toddlers

25% have problems of getting to sleep and/or night waking.

#### Adolescence

- Erratic sleep–wake patterns.
- *Delayed sleep phase syndrome*: inability to get off to sleep and great difficulty getting up in the morning:
  - slow-wave sleep declines in adolescence but sleep requirements do not;
  - natural delay in getting off to sleep is related to puberty and melatonin;
  - social reasons for sleeping late;
  - sleep deprivation leading to excessive daytime sleepiness, mood swings and poor behaviour.

### International classification of sleep disorders

American Academy of Sleep Medicine.

- Insomnias.
- Sleep-related breathing disorders.
- Hypersomnia (excessive daytime sleepiness not due to disturbed nocturnal sleep; includes narcolepsy).
- Circadian sleep disorders.
- Parasomnias.
- Sleep-related movement disorders.
- Isolated symptoms probably normal variants.
- Other sleep disorders.

#### Parasomnias

Recurrent episodes of behaviour, experiences or physiological changes that occur exclusively or predominantly during sleep.

Primary parasomnias are classified according to the stage of sleep in which they occur:

- Episodes that occur in the transition between wakefulness and sleep.
- Arousal disorders (from deep non-REM sleep).
- Parasomnias associated with REM sleep.
- Others.

Secondary parasomnias occur secondary to a physical or psychiatric disorder.

#### **Primary parasomnias at sleep onset**

- Sleep starts/hypnic jerks/'exploding head syndrome'.
- Hypnagogic hallucinations.
- Sleep paralysis.
- *Rhythmic movement disorder*: head banging, humming or rocking to aid getting to sleep.
- Restless legs syndrome (difficulty getting to sleep because of unpleasant cramping sensations in the legs).

#### **Primary parasomnias during light non-REM sleep**

- Bruxism.
- Periodic limb movement in sleep (brief contractions lasting about 2 s in the toes, hips, and knees at intervals of about 20 s).

#### **Primary parasomnias in deep non-REM sleep (arousal disorders)**

These include confusional arousals and sleep-walking. Susceptibility often runs in families with children moving from one arousal disorder to another as they develop. Some households have different members exhibiting different arousal disorders. Shared features include:

- One episode per night, usually in the first half of the night.
- Genetic with a family history in up to 60%.
- Young age when slow-wave sleep is deep and long lasting.
- Associated with:
  - fever/intercurrent illness;
  - CNS depressant medication;
  - external or internal sleep-interrupting stimuli;
  - obstructive sleep apnoea.
- Curious combination of seeming asleep and awake at the same time:
  - confused and disorientated;
  - remaining asleep during the episode though as the child grows older they tend to wake up at the end;
  - unresponsive to external stimuli including the parents' attempts to wake the child up;
  - little recall.
- A child may go from one arousal to another.

#### **Confusional arousal**

- Very common.
- Child does not wake up, but partially arouses from deep non-REM, slow-wave sleep to a lighter stage of non-REM or REM sleep.
- The child is asleep during the episode itself, but may wake immediately after.
- Usually occurs in infants and toddlers.
- Movements with moaning and groaning; progress to agitated, confused behaviour with intense crying, calling out, and thrashing around.
- The child may appear awake, but is not, and attempts to wake them increase agitation and prolong the episode.

- If carers manage to wake him/her, the child is often very confused and frightened.
- Lasts 5–15 min.
- If left alone the child will simply return to sleep.

#### *Sleep walking*

- Occur at 4–8 yrs of age; 17% children sporadically.
- Less dramatic than confusional arousal.
- The child walks about calmly, to their parent's bedroom, toilet, etc.
- Eyes wide open with a glassy stare.
- Automatisms, urinating in inappropriate places.
- Accidental injury is very possible.
- At later age may take the agitated form which is worsened by attempts to intervene, with an even greater risk of injury.

#### *Night (or sleep) terrors (Box 4.11)*

- This occurs in 3% children mainly in later childhood.
- Later onset cases tend to persist longer.
- Parents are woken by the child's piercing scream.
- The child is terrified, with eyes wide open, sweaty, vocalizing.
- May run into something, or injure himself or others.
- Lasts a few minutes and then settles back to sleep.
- If the child wakes up then a feeling of fear is reported, but does not have the extended narrative of a nightmare.

### **Box 4.11 Night terrors and frontal lobe epilepsy**

Whilst the error of a false positive diagnosis of epilepsy is probably much more common, the characteristic example of a false negative is to label nocturnal frontal lobe seizures as night terrors (or confusional arousals). The error is understandable: frontal lobe seizures often comprise loud cries or shrieks and violent pedalling or thrashing movements of the limbs that do not conform to conventional notions of seizure phenomenology. If video is available careful observation of the onset will show tell-tale tonic posturing of the arms  $\pm$  head turn. In clinic settings the main clues are:

- *Event frequency:* frontal lobe seizures are often multiple per night. Night terrors very rarely if ever occur more than once per night.
- *Clustering:* frontal lobe seizures will often occur multiply per night for several nights and then remit.

An overnight video is crucial in cases of uncertainty but the onset of the attack must be captured to be informative. Frontal lobe seizures often have very little accompanying change on surface EEG, but the events are stereotyped and very characteristic.

#### *Management of non-REM sleep disorders*

- Reassurance and explanation to the parents.
- Regular and adequate sleep routines.
- Secure environment.
- Refrain from trying to waken the child.
- Refrain from recounting episode in front of the child.

- Scheduled awakening with sleep walking/night terrors. These events often occur at a fairly consistent time each evening. Fully waking the child 30 min ahead of the anticipated time is often effective at preventing them.
- Rarely, short-term use of benzodiazepine, e.g. diazepam.

### **Primary parasomnias of REM sleep**

#### *Nightmares*

- Very common.
- Occur in the latter part of the night when REM sleep is most abundant.
- The child wakes up, very frightened and will describe the nightmare in great detail. Involves the child or a loved one.
- Anxious and afraid to sleep again.

#### *REM sleep behaviour disorder*

- Initially thought to be a rare disorder of elderly men but now also recognized in adults with neurodegenerative disease (e.g. Parkinson) and narcolepsy.
- Seen in juvenile Parkinson disease and following withdrawal from antidepressant drugs and alcohol.
- Under normal conditions, pontine centres generate a physiological paralysis (atonia) in the limbs during REM sleep to prevent the 'acting out' of dreamed movement.
- Loss of this mechanism results in sometimes violent dream reenactment.

### **Primary parasomnias on waking**

- Hypnopompic hallucinations.
- Sleep paralysis.

### **Primary parasomnia with inconsistent relationship to sleep**


Sleep talking.

### **Secondary parasomnias**

- Very high parasomnia rates are described in children with learning difficulties.
- Sleep disturbance is part of the 'behavioural phenotype' of some syndromes including William, Rett, Smith–Magenis, Angelman.
- Upper airway obstruction may contribute to sleep disturbance (a feature of many neurological conditions).
- High prevalence in autism, ADHD, and depression.
- Chiari malformations can present with sleep disorders.

### **Excessive daytime sleepiness (hypersomnia)**

Most commonly reflect insufficiently restful, poor quality night-time sleep. Consider in particular.


- Lifestyle-related (i.e. inadequate nocturnal sleep due to nocturnal TV watching, computer gaming).
- Delayed sleep phase syndrome (see  p. 439).
- Restless leg syndrome.
- Factitious illness and over-reporting of symptoms.
- Chronic fatigue syndrome (i.e. confusing fatigue with actual sleepiness).

## Narcolepsy

Can be conceptualized as a loss of stability of the normal sleep on/off 'switch' resulting in rapid cycling between the two states, and experience of sleep-boundary problems (hypnogogic hallucinations, sleep paralysis).

- Misunderstood, under-recognized, and poorly managed particularly in paediatric age-range.
- Adult prevalence is comparable with multiple sclerosis and Parkinson disease.
- Adults retrospectively report symptoms back to early childhood.
- 50% start in childhood (3/10 000) with average age of onset of 14 yrs, but may be as young as 2 yrs.

### Five main features

- *Excessive daytime sleepiness is the defining symptom of narcolepsy:* irresistible **sleep attacks**. Last minutes to 1 h. Refreshing and occur anywhere.
- *Cataplexy:* a sudden, temporary loss of muscle tone triggered by strong emotion.
- *Hypnagogic* (on going to sleep) or *hypnopompic* (just after awakening) hallucinations. May be vivid and distressing. Usually not volunteered as so bizarre/embarrassing.
- *Sleep paralysis:* waking from REM sleep without reversal of the physiological REM atonia (see  p. 442) resulting in inability to breath and fear of death.
- Disturbed night time sleep.
- Note isolated daytime sleepiness (without other features) is most commonly due to lifestyle issues and inadequate nocturnal sleep.

### Clinical features

There is a highly individual patient symptom profile creating potential diagnostic difficulties. Studies have shown that the diagnosis is only correctly made in 38% of patients with narcolepsy prior to evaluation by a sleep specialist.

- Sleep attacks or irresistible urges to sleep most prominent during sedentary activities. They are brief fugue like lapses in consciousness with indistinct boundaries. Automatic behaviours may occur during these periods.
- Sleep attacks, atonia, and hallucinations are parts of REM sleep that intrude on wakefulness.
- Cataplexy is considered to be the most specific symptom of the condition. Prevalence rates reported to be 60–100%. Absence of cataplexy should prompt review of diagnosis.
- Hallucinations occur in 50% and sleep paralysis 60% in adults.
- Poor memory and concentration.
- Overnight sleep is disrupted with resultant tiredness during the day.
- Blurred vision/double vision, although the extraocular muscles are not supposed to be involved.



*Special features in childhood*

- Sleepiness is difficult to assess and quantify.
  - May actually manifest as poor behaviour and overactivity.
  - Cataplexy may only develop later or may be subtle buckling at the knees.
  - The child may conceal frightening or embarrassing aspects, e.g. hallucination/sleep paralysis.
  - Distinguish from delayed sleep maturation, especially in primary school children. The need for a daytime nap continues after the toddler age group; night-time sleep is not restless or disturbed, behaviour disturbance not expected.
- In young children, even if cataplexy is absent, some evidence of abnormal REM sleep should be present, e.g. abnormally vivid nightmares (even during daytime naps), hallucinatory experiences and sleep paralysis.

*Aetiology*

- Narcolepsy is associated with decreased or absent levels of hypocretin in CSF. This is thought to be the result of degeneration of hypocretin-secreting neurons, likely to be the consequence of an autoimmune process. Narcolepsy has been associated with expression of HLA-DQB1\*0602 and the much less common HLA-DQB1\*0102. 90% of patients with narcolepsy/cataplexy are positive for HLA-DQB1\*0602 which is therefore a sensitive, but not specific association (seen in 20% normal population).
- Think of Niemann–Pick type C.

*Evaluation*

- *Direct observation*: facial expression, posture, yawning.
- History from rest of family.
- HLA type DQB1\*0602 is sensitive (present in >90% of narcolepsy sufferers) but *not specific* (present in 20% of the normal population)
- *Epworth Sleepiness Scale*: self-administered questionnaire. Range 0–24 with a range of more than 10 suggestive of a sleeping disorder (narcolepsy scores 13–23).
- The Multiple Sleep Latency Test (MLST) is the classic investigation in adults. The test establishes that the sufferer repeatedly enters REM sleep (confirmed by simultaneous EEG) within a short time of being allowed to sleep. Impractical in young children (under 10) and there are no normative paediatric data.
- *Maintenance of wakefulness test (MWT)*: again an adult tool. Assesses how long a patient can stay awake in a comfy chair sat in a quiet dark room. The test lasts for 20 min and a mean test result of fewer than twenty minutes indicates pathological sleepiness.
- Polysomnography used mainly to eliminate other causes of excessive daytime sleepiness such as obstructive sleep apnoea (OSA).
- Levels of CSF hypocretin are significantly reduced or absent in cases of narcolepsy with cataplexy with CSF hypocretin-1 concentrations of <110 pg/mL in adults or less than one third of mean normal control values. In the absence of cataplexy the value of measuring CSF hypocretin is debateable.

- Studies have shown that the tests are not interchangeable as they reflect different aspects of narcolepsy. It is essential not to base the diagnosis of narcolepsy on the result of a single test. Positive results from more than one test are required for a positive diagnosis.

#### *Treatment*

- Establish accurate diagnosis.
- Manage excessive day time sleepiness with planned day time naps with or without drug treatment.
- Address poor nocturnal sleep hygiene.
- Modafinil generally used (sodium oxybate—unlicensed—may be indicated for selected patients with combination narcolepsy and cataplexy). Stimulants such as dexamphetamine, methylphenidate used as a second line.
- Avoid known cataplexy triggers. Consider symptomatic treatment with clomipramine in severe cases.
- Clomipramine for cataplexy.

#### ***Kleine–Levin syndrome***


Excessive sleepiness occurring intermittently, with normal sleeping patterns between episodes.

- Rare.
- Usually presents in adolescent males but may also occur in females.
- Usually follows a stressful period or a viral infection.
- Periods of hypersomnia (20 h/day) lasting for hours or weeks occur at intervals of weeks/months.
- *During the awake periods:*
  - overeating sometimes causing obesity;
  - hypersexual behaviour;
  - restlessness;
  - mood disorder;
  - mild organic confusional state;
  - short periods of elation/depression and sleeplessness may occur at the end of the phase before returning back to normal.
- Tends to improve with time.
- May respond to lithium, fluoxetine, carbamazepine.

## Stroke

The incidence is 2.6/100,000.

### Definitions

- *Stroke*: focal neurological deficit lasting more than 24 h with a vascular basis.
- *Transient ischaemic attack*: focal neurological deficit lasting less than 24 h. In children migraine is the commonest cause.
- *Stroke-like episode*: focal neurological deficit lasting more than 24 h (i.e. stroke), but not of a vascular basis. The main example is MELAS (see  p. 374) where 'stroke' happens due to energy failure. Imaging will show radiological changes typical of infarction but this is typically multifocal and not confined to single vascular anatomical territories.

### Presentations

- Acute onset focal neurological deficit (typically hemiparesis  $\pm$  visual field defect).
- Seizures (particularly in the neonate).
- Headache.
- Neck pain.

### Elements to consider in history

- Febrile?
- Otitis media/mastoiditis/tonsillitis.
- Recent varicella infection.
- Pre-existing cardiac disease.
- Recent trauma particularly to the neck (including 'awkward' falls).
- Sickle cell disease.
- History/family history of stroke.
- Abrupt onset (favours haemorrhage or embolus) versus 'stuttering' onset (favours thrombosis).

### Acute management

- ABC.
- Measure BP.
- If GCS  $<8$  needs PICU input, consider neurosurgical referral as they may need decompression (e.g. evacuation of haematoma) to manage raised ICP.
- Treat seizures.

### Thrombolysis

The role of emergency thrombolysis, infusing fibrinolytic agents either intravenously (e.g. streptokinase) or via endovascular intra-arterial infusion (e.g. tissue plasminogen activator, rtPA) in arterial ischaemic stroke is the subject of active research in adults and is still not fully established. The potential benefit of arterial recanalization has to be balanced against the risks of adverse effects (particularly major cerebral haemorrhage, occurring in 5–10%) and this balance is more favourable the earlier the intervention can be delivered. Adult trials suggest a window of up to four hours from the stroke but even in this group the routine use of thrombolysis remains unestablished.

In practice, paediatric thrombolysis will only be a consideration when a stroke occurs to a child who is already an inpatient in a centre with interventional neuroradiological expertise, where the likely mechanism is clear (e.g. post-cardiac surgery), primary cerebral haemorrhage can be quickly excluded by CT and transfer delays to the angiography suite can be avoided.

## Investigation

### Initial investigations (within hours)

- CT head (to exclude haemorrhage) if there will be any delay in access to MRI.
- Baseline biochemistry, haematology including coagulation (HbS if appropriate), ESR and CRP.
- Discuss need for urgent MRI and MRA with neurologist or neuroradiologist: may affect acute management:
  - if dissection is suspected (history of trauma, neck pain, headache, posterior circulation stroke, Horner syndrome implying carotid artery injury) ask for fine basal cuts and fat saturation sequences;
  - if CT is suggestive of sino-venous thrombosis.
- All children require MRI/MRA at least within a few days of an acute presentation.

### Relative indications for conventional angiography

Conventional four-vessel angiography is associated with ~1% risk of stroke from the procedure. However, it remains indicated in certain situations.

- *Haemorrhagic stroke*: to identify AVM, aneurysm. Definitive endovascular treatment of a vascular abnormality may be possible.
- *Posterior circulation stroke*: MRA visualizes posterior circulation relatively poorly.
- *Clinical suspicion of vasculitis*: MRA insensitive to the detection of radiologic appearances of vasculitis, particularly small-vessel disease.
- Possibly in situation of suspected dissection, although fat-saturation axial views are generally very sensitive to the presence of dissection of the large vessels of the neck.

### Other investigations

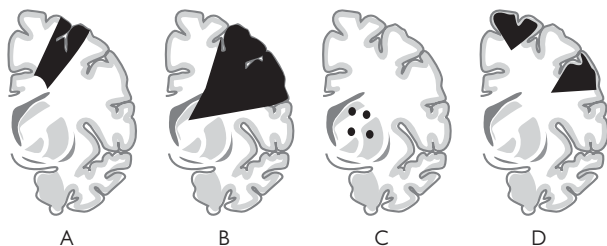
Should be tailored to suspected mechanism(s), see Figure 4.9.

## Radiology

Identifying the primary cause of a stroke in childhood guides management, including steps to prevent the occurrence of possible further strokes (Figure 4.9). The primary investigation is neuroimaging. CT is useful acutely to exclude haemorrhage if any delay in availability of MRI is likely. Note that CT evidence of infarction develops over several hours and CT less than ~4 h post-ictus may appear normal.

► MRI is essential to the adequate evaluation of all strokes.

Imaging is crucial in distinguishing haemorrhage, arterial ischaemia and venous ischaemia/infarction. Within the arterial ischaemic group, consideration of lesion location in relation to vascular territories (see [p. 64](#), and following) is very helpful in distinguishing embolic and thrombotic causes. Non-invasive MR angiography (MRA) in experienced centres will also give



**Fig. 4.9** Schematic representation of how patterns of neuroradiological involvement suggest mechanism in arterial ischaemic stroke. (A) wedge shape infarction straddling the boundary between anterior and middle cerebral artery circulation (usually bilateral and fairly symmetrical) typical of watershed infarction due to hypoperfusion (e.g. period of hypotension). (B) Wedge shaped infarction in single arterial territory (here, middle cerebral artery) implies local thromboembolic cause. (C) One or more small infarctions in subcortical structures implies involvement of small perforator arteries: consider small vessel vasculitides as well as thrombotic conditions. (D) Multiple wedge-shaped infarctions in >1 arterial territory implies emboli from a distant source.

useful information about large vessels in the anterior circulation although its sensitivity for posterior circulation (vertebral or basilar artery) disease is poorer.

The evidence base for secondary prevention measures in paediatric ischaemic stroke is limited; see, for example: <http://www.rcpch.ac.uk/Research/ce/Guidelines-frontpage/Guideline-Appraisals-by-Specialty-Subspecialty/Neurology#Stroke>.

Recommendations based on these guidelines are indicated later with an asterisk (\*).

### Embolic arterial ischaemic stroke

- Radiological patterns include Figure 4.9B and D.
- *From a distant source:*
  - left side of the heart;
  - paradoxical embolism from any source in a child with congenital heart disease permitting right-to-left shunting and the normal neonate (due to foetal circulation) where emboli of placental origin are common;
  - dissection of the intracerebral artery. Occurs after even apparently trivial trauma to the head or neck creating an 'intimal tear' in the carotid artery.

### Investigations

- *Trans-thoracic echocardiogram:* discuss need for trans-oesophageal echo with cardiologists.
- If carotid dissection being considered (history of recent 'minor' neck trauma) axial fat-saturation MR sequences (or CT angiography) are very useful in detecting this (better than MRA; formal angiography rarely required).
- In practice children showing the pattern in Figure 4.9B will also need investigation for thrombotic causes.

### **Treatment and secondary prevention**

If embolic mechanism proven or strongly suspected, medium term anti-coagulation with low molecular weight heparin (LMWH)  $\pm$  conversion to warfarin should be considered, e.g. for 3 mths in dissection or until source of emboli removed.

### **Thrombotic arterial ischaemic stroke**

- Loosely, stroke due to 'sticky blood'.
- Radiological patterns include Figure 4.9B, C, and D.

#### **Investigations**

- *Thrombophilia screen*: factor V Leiden (activated protein C resistance), protein C, protein S, prothrombin 20210 mutation, antithrombin III, antiphospholipid antibodies (anticardiolipin and lupus anticoagulant). Consider vWF antigen, factors VIII and XII (discuss with haematology).
- Lactate, pyruvate, amino acids, cholesterol, triglycerides, lipoprotein A,  $\text{NH}_3$  autoantibodies and ANCA.
- Total homocysteine (fasted, within 5 days), B12, folate.
- MELAS/MERRF mutations.
- Viral serology + Lyme.
- Consider CSF protein, glucose, culture, lactate, pyruvate, zoster titres.
- Urine organic acids.
- The importance of primary thrombophilia is probably over-estimated. Transient abnormalities in 'thrombophilia screen' results are common and may be important in post-infectious and other mechanisms of stroke.

### **Treatment and secondary prevention**

- All children with radiologically proven ischaemic stroke should be commenced on low-dose aspirin pending further investigation *unless* the child has sickle cell disease, or radiological evidence of haemorrhage(\*).
- If a pro-thrombotic state is confirmed and deemed significant (isolated and heterozygote states for some prothrombotic conditions such as factor V Leiden are of doubtful relevance—discuss with haematologist) then prolonged treatment with antiplatelet agents (low dose aspirin and/or dipyridamole) should be considered.
- Children with sickle cell disease should receive an intensive blood transfusion regime (every 3–6 weeks) to maintain Hb between 10 and 12.5 g/dL and HbS <30% (\*). This may be relaxed after 3 yrs to maintain HbS < 50% and stopped after 2 yrs in patients who experienced stroke in the context of a precipitating illness (e.g. aplastic crisis) and whose repeat vascular imaging is normal at this time.

### **Vasculopathic arterial ischaemic stroke**

- Stroke due to 'funny blood vessels'.
- Radiological patterns include Figure 4.9B and D. Pattern C particularly suggestive of small vessel disease.

**Large vessel disease**

- Moya-moya 'disease' is better thought of as a radiological *syndrome*, arising from large vessel cerebrovascular disease of any cause. The term is Japanese for 'wisp of smoke' and relates to the angiographic appearances of the many tiny collaterals that open in response to large vessel narrowing. Important causes include sickle cell disease, neurofibromatosis, Down, Noonan, and William syndromes.
- Look for evidence of extracranial arterial disease including evaluation for renal artery stenosis by angiography or renal artery Doppler (fibromuscular dysplasia).

**Small vessel disease**

- Primary vasculitis.
- Post-varicella arteritis; also post-*mycoplasma*, Lyme disease, etc.
- Varicella vasculitis in immunocompromised individuals.
- Systemic vasculitis may be suggested by elevated ESR in the presence of normal CRP. Primary cerebral vasculitis has protean manifestations and biopsy is often required to establish diagnosis.

**Treatment and secondary prevention**

- *Treatment of underlying cause:*
  - surgical vascular procedures to correct large vessel stenoses if amenable;
  - surgical bypass and revascularization procedures to ameliorate the effects of Moya-Moya syndrome;
  - aggressive transfusion programmes in sickle cell disease (see [ ] p. 449);
  - treatment of primary vasculitides.
- Consider anti-platelet treatment with aspirin particularly in small vessel disease including proven/suspected post-varicella stroke.

**Venous infarction**

- Radiological appearances of ischaemia in non-arterial distributions.
- CT usually suggestive of venous sinus thrombosis (VST), confirmed by MR venography (or Doppler cranial ultrasound in neonates).

**Causes**

Usually clear from clinical context:

- Sigmoid sinus thrombosis commonest form of VST, usually associated with ipsilateral middle ear/mastoid bacterial sepsis.
- Hypercoagulable states (dehydration or polycythaemia in neonate, polycythaemia in congenital heart disease, sickle disease, and other haemoglobinopathies, asparaginase treatment for leukaemia), oral contraceptive pill, exchange transfusion in sickle cell.

**Treatment**

- Correct underlying cause.
- Systematic reviews confirm an overall benefit to formal anticoagulation (\*). Optimal duration of anticoagulation is unclear, but repeat MRV to confirm re-canalization may be helpful.

### Specialist and further investigations

- Flexion and extension views of the cervical spine in vertebrobasilar stroke.
- *Further conventional angiograms:*
  - to monitor progression of vascular disease;
  - in preoperative assessment of Moya–Moya.



## Cerebral haemorrhage

For cerebral haemorrhage in the perinatal period see  p. 495.

### Cerebral aneurysms

- Typically occur in the arteries of the Circle of Willis (see Figure 2.9). Haemorrhage risk increases with size. Because of association with Circle of Willis, aneurysms typically associated with haemorrhage into subarachnoid space (subarachnoid haemorrhage, SAH).
- SAH typically presents with very sudden onset, very severe ('ice pick') headache. CT usually readily confirms blood in subarachnoid space: in rare cases, where CT does not confirm clinical suspicions lumbar puncture should be performed.
- Aneurysms particularly likely in SAH in older adolescent.
- Syndromic associations of cerebral aneurysms with other conditions:
  - coarctation of the aorta;
  - autosomal dominant polycystic kidney disease (esp. anterior communicating artery aneurysms).
- Some aneurysms are familial (about 10% patients report a first degree relative with SAH). However, the role of screening for aneurysms in an asymptomatic first-degree relative of an index patient with SAH remains uncertain due to the risk-benefit ratio of surgery for an asymptomatic aneurysm. It is currently suggested that screening be confined to individuals with two or more first-degree relatives with aneurysmal SAH. MRA is adequate to detect aneurysms of sufficient size (>7 mm) to warrant prophylactic surgery although the optimal timing(s) of MRA studies is uncertain.
- The presence of any symptoms or signs suggestive of SAH, or of a posterior circulation aneurysm (cranial nerve palsies or brainstem signs) clearly indicates increased risk of haemorrhage.

### Treatment

- The aim of acute treatment of SAH is to minimize risks of massive cerebral ischaemia/infarction due to *delayed spasm* of cerebral arteries provoked by presence of subarachnoid blood.
- So called 3-H regime comprises induction of mild hypertensive, hypervolaemic and haemodiluted state, though no class I evidence. Nimodipine appears to reduce morbidity.
- Given the associations with coarctation, renal artery and kidney disease, hypertension is an important co-morbidity. Treatment should be delayed and very cautious until vasospasm risk period is passed.
- Treatment options include surgical clipping at open surgery, and endovascular occlusion with coils or glues. The post-operative mortality in *adults* who have sustained SAH is lower for coiling than clipping, although there is some suggestion that rates of recurrence of the aneurysm may be higher.

### Arteriovenous malformations

- Developmental (congenital) abnormalities of angiogenesis resulting in persistent direct large calibre connections between arterial and venous side of circulation. Haemorrhage risk related to high flow.
- A feature of several multi-organ vascular malformation syndromes, e.g. Osler–Weber–Rendu, von Hippel Lindau.
- Treatment needs to be individualized in discussion with specialist centres. Approaches are often multi-stage (e.g. sequential endovascular interventions before a definite surgical excision).
- Some arteriovenous malformations (AVMs) will be deemed inoperable by virtue of their size and location, and the potential morbidity to surrounding brain tissue, which may derive its blood supply from the abnormal vessels.

### Cavernous haemangiomas ('cavernomas').

- Common developmental abnormality of capillary structure.
- Characteristic MRI and (usually) CT appearances due to surrounding blood-breakdown products.
- Usually not apparent on conventional or MR angiography as they are not high-flow structures.
- Catastrophic haemorrhage is rare. Tend to present with focal seizures presumed due to slow leakage of blood products into surrounding area.
- Often multiple and dominantly inherited, therefore, screening of first-degree relatives warranted.
- Consideration should be given to primary surgical resection of large cavernomas because of haemorrhage risk.
- May be associated with retinal vascular malformations.

## Tumours of the central venous system

### Epidemiology

CNS tumours (incidence 3.5/100,000) are the most common solid tumours in childhood, and collectively the third largest group of childhood neoplasias (after leukaemias and lymphomas). The male to female ratio is equal except for a male predominance in medulloblastoma and germ cell tumours. The most common CNS tumours are gliomas (60%), medulloblastoma (20%), and ependymomas (10%).

### Supratentorial tumours

- Supratentorial tumours predominate in infants (especially chiasmatic-hypothalamic gliomas, primitive neuroepithelial tumours (PNETs) and choroid plexus tumours).
- May be hemispheric (70%, mainly gliomas, rarely ependymomas, choroid plexus tumours, PNETs, ganglioglioma) or midline (low grade glioma, craniopharyngioma, germ cell or pineal cell tumour).
- *Suprasellar tumours*: craniopharyngioma, germinoma.

### Infratentorial tumours

- In contrast to adults (where supratentorial tumours predominate), infratentorial tumours at least as common in children.
- Medulloblastomas (20%), cerebellar astrocytomas (15%), ependymomas (5%), malignant gliomas (3%), brainstem gliomas (8%), other rare tumours.
- Intramedullary spinal cord tumours are rare and are usually astrocytomas (60%) or ependymomas.
- Solid metastatic tumours are rare in childhood, leukaemia being the most common metastatic CNS malignancy. Other CNS tumours (medulloblastoma, ependymoma) can metastasize to elsewhere in CNS.

### Common presentations

Presentation depends on the age of the child and the location of the tumour.


#### Presentations by age

- Presentations become increasingly specific and localizing with age.
- Presentations in infants typically non-specific (irritability, lethargy, vomiting and failure to thrive, developmental regression and increasing head size).
- *Young child*: more likely to have focal signs; may also have symptoms/signs of raised ICP.
- *Adolescent*: localizing symptoms/signs more common.

#### Presentations by location

##### Supratentorial tumour presentations

- *Hemispheric gliomas*: seizures, focal neurological deficit, personality change.
- *Optic nerve gliomas, craniopharyngiomas*:
  - progressive visual field defects;
  - endocrine dysfunction (short stature, hypothyroidism and diabetes insipidus);

- behaviour and appetite changes;
- ► diencephalic syndrome in infants and toddlers (see  p. 478);
- symptoms/signs of raised ICP (retrochiasmatic tumours may cause hydrocephalus);
- symptoms in younger children are often solely of raised ICP.
- *Suprasellar germ cell tumours*: Endocrine dysfunction (diabetes insipidus and/or precocious puberty).
- *Pineal tumours*:
  - eye movement abnormalities (Parinaud syndrome—impaired upward gaze, dilated pupils reacting only to accommodation);
  - nystagmus (particularly rotatory);
  - symptoms/signs of raised ICP.

#### *Infratentorial tumour presentations*


- *Medulloblastomas*: cerebellar signs (ataxia, dysmetria), symptoms/signs of raised ICP, neck pain  $\pm$  intermittent abnormal head postures (tonsillar herniation).
- *Cerebellar astrocytomas*: similar presentation to medulloblastoma, slower progression.
- *Ependymomas*: nausea and vomiting are key features due to compression of areas associated with vomiting in the brainstem, symptoms/signs of raised ICP.
- *Diffuse intrinsic pontine glioma*: rapidly progressive cranial nerve defects, pyramidal tract signs.

#### *Intramedullary spinal tumour presentations*

Insidious onset of symptoms (pain, paraesthesia, paresis, sensory level, sphincter disturbance, spinal deformity). Torticollis and hydrocephalus may be features, especially for ependymomas. Usually spinal tumours are seen in older child, astrocytomas usually occur in upper thoracic cord and ependymomas in the cervical cord.

### **Low-grade gliomas (astrocytoma, oligodendroglioma)**

30–40% all childhood CNS tumours. Despite their ‘benign’ reputation, morbidity is significant and death not unknown.

Presentation is determined by site (see  p. 454). Posterior fossa presentation commonest.


#### **Aetiology**


*Inherited genetic conditions are responsible for 5%*

- NF1 (gene *neurofibromin*) thought to be a tumour suppressor.
- Tuberous sclerosis.
- von Hippel–Lindau.
- Li-Fraumeni (mutation in *p53* tumour suppressor gene: more typically get medulloblastomas).
- Gorlin syndromes.


Exposure to ionizing radiation is a known risk factor

#### **WHO grading system**


- *Grade 1*
  - pilocytic astrocytoma;
  - subependymal giant cell astrocytoma (SEGA) of tuberous sclerosis; see  p. 420.

- *Grade 2:*
  - fibrillary astrocytoma;
  - protoplasmic;
  - gemistocytic;
  - mixed.
- *Other:*
  - pilomyxoid glioma;
  - ganglioglioma;
  - gangliocytoma;
  - dysembryoplastic neuroepithelial tumour (DNET; see  p. 460).

#### *Chiasmatic–hypothalamic gliomas*

- 30% are associated with neurofibromatosis type 1 (NF1) when they tend to be more indolent. Prognosis is worse in infants and when the tumour extends into the hypothalamus.
- Clinical presentation may include visual field defects, strabismus, proptosis, endocrinopathies and diencephalic syndrome (see  p. 478).
- In NF, the tumour is observed with serial imaging, and surgical intervention is reserved for progressive or symptomatic tumours (usually only if vision is significantly impaired).
- In other children, chemotherapy and/or radiotherapy are used (radiotherapy deferred in younger children if possible). Surgery is deferred for tumours causing mass effect or hydrocephalus.

#### *Cerebellar astrocytomas*

- *Usually pilocytic astrocytomas:* brightly enhancing, well demarcated partly cystic tumours with minimal surrounding oedema.
- Optimally managed by resection (achieved in >70%).
- Residual tumour may be observed as some will spontaneously regress. Recurrence is treated with re-operation if possible.
- A long-term perspective on disease control is required, with different strategies at different times.
- Operative complications are usually transient and related to cerebellar swelling: cerebellar signs, cerebellar mutism (see  p. 461), 6th and 7th nerve palsies, pseudobulbar symptoms and hemiparesis. Impaired initiation of voiding, chewing, and eye opening may also occur.
- Treatment is complete surgical resection. Radical resection is associated with >75% 5-yr survival. Adjuvant chemotherapy or radiotherapy is reserved for evidence of disease recurrence or progression. 5-yr survival in incomplete resection >60% (>80% with radiotherapy).
- Adjuvant treatment if needed is chemotherapy in younger children and radiotherapy over 8 yrs (because of demonstrated severe late cognitive effects of radiotherapy to immature CNS).
- Malignant transformation of non-irradiated low-grade gliomas is rare, but surveillance for tumour progression or recurrence is necessary.
- Chemotherapy may have a role in the management of children with optic pathway glioma, for children with inaccessible disease and in recurrent or progressive tumours (after repeat resection).
- Late cognitive morbidity probably relates to prolonged hydrocephalus.

## High-grade gliomas (anaplastic astrocytomas and glioblastoma multiforme)

Poorly circumscribed with ring-like enhancement and significant surrounding oedema with mass effect.

### WHO grading system

- **Grade 3:**
  - anaplastic astrocytoma;
  - anaplastic oligodendroglioma;
  - malignant oligoastrocytoma;
  - gliomatosis cerebri.
- **Grade 4:**
  - glioblastoma multiforme;
  - giant-cell glioblastoma;
  - gliosarcoma;
  - glioblastoma with sarcomatous elements.
- Treatment is by gross total resection, radiotherapy to the tumour bed and a margin of surrounding brain and adjuvant chemotherapy. The extent of resection possible predicts long-term survival. Over-expression of p53 and glioblastoma multiforme are associated with poor prognosis.
- Five-year survival following gross resection and adjuvant therapy is 20–40%.
- Further intensification of chemotherapeutic regimens with autologous bone marrow or peripheral stem cell reconstitution under evaluation in children with glioblastoma multiforme.

### Brainstem gliomas

- Tectal tumours are usually slow growing and resection is indicated; however, shunting may be required for hydrocephalus.
- Other focal brainstem gliomas are less indolent, but have a good prognosis with resection.
- In contrast, diffuse intrinsic brainstem gliomas (DIPG, 80% of all brainstem gliomas) are inoperable with a very poor prognosis. These are usually diffuse and fibrillary in type with characteristic appearance on MRI.
- Median survival after diagnosis is 9 mths despite aggressive radiotherapy.

### Medulloblastoma

- This is the most common malignant CNS tumour.
- Usually in the midline posterior fossa. MRI shows a brightly enhancing mass with some necrotic/cystic areas, usually arising from the vermis, invading into the fourth ventricle and brainstem. Less commonly found in cerebellar hemispheres or cerebellopontine angle.
- More commonly seen in males; peak incidence is at 4 yrs of age.
- Prognosis depends on age (infants <3 mths have a worse prognosis), extent of resection, presence of metastases and the presence of certain biological characteristics such as amplification of *c-myc* oncogene.

- Management comprises complete surgical resection. Proximity to the CSF makes seeding frequent (20 %) and staging is required with preoperative craniospinal MRI and CSF cytology.
- Craniospinal irradiation (over 3 yrs of age) is required to reduce the risk of metastases, followed by chemotherapy. Use of focal radiotherapy in under threes being evaluated.
- 5-yr survival for medulloblastoma is 80% for standard risk and 50% for high risk.

#### **Supratentorial primitive neuroectodermal tumour (PNET)**

- These tumours are similar histologically to medulloblastomas but are biologically different with a worse prognosis. Neuroaxis staging is followed by gross total resection, CSI and chemotherapy.
- Radiotherapy is deferred in younger children in favour of chemotherapy.
- Younger children (<3 yrs) have a worse prognosis. Further intensification of chemotherapeutic regimens with autologous bone marrow or peripheral stem cell reconstitution is being evaluated in children.

#### **Ependymoma**

- These can arise anywhere in the CNS from ependymal or subependymal cells; 60% occur in the posterior fossa.
- Incidence peaks at ~4 yrs of age.
- Radiologically usually contrast-enhancing, and *heterogeneous* with areas of haemorrhage, necrosis, and calcification.
- Typically midline and intraventricular.
- Initial management guided by staging MRI of brain and spine:
  - if no evidence of metastasis then aiming for 100% resection particularly important, even at risk of neurological morbidity;
  - consider repeat surgery if 48 h post-operative imaging shows residual disease;
  - if imaging shows metastases at presentation then resection is more conservative and targeted at maintaining CSF flow and debulking.
- Around  $\frac{1}{3}$  of tumours are infiltrative and not fully resectable.

Ependymomas not typically very chemosensitive. Mainstay of adjuvant treatment is focal radiotherapy to tumour bed, certainly in over-3s. The role of radiotherapy in under-3s is under evaluation—chemotherapy may have a role if there is residual or disseminated disease, but has failed to reduce the need for radiotherapy in very young children. Overall 5-yr survival 50–60%.

#### **Less common central nervous system tumours**

##### **Craniopharyngioma**

- This is a benign tumour but is locally aggressive and recurs.
- Proximity to optic pathways and pituitary make management difficult.
- Most tumours in childhood are calcified. On T2 MRI the tumour is hyperintense, lobulated, heterogeneous and cystic with ring enhancement.

- Preoperatively children require documentation of visual fields and assessment for electrolyte abnormality and endocrinopathy. Children should have supplemental steroids before surgery and prior to treating hypothyroidism. Hydrocephalus should be controlled.
- Surgery may be required urgently in situations of acute visual deterioration or hydrocephalus, but otherwise endocrine and electrolyte abnormality should be corrected first.
- Surgery allows gross total resection of the tumour in 70–80% of cases and decompression in others.
- Radiotherapy is of benefit if the resection is subtotal or for recurrent disease.
- Most children have panhypopituitarism, appetite, and behavioural disturbance and memory dysfunction as a consequence of the tumour or treatment.

### ***Intracranial germ cell tumours (GCT)***

- Heterogeneous, rare group of tumours comprising benign and malignant forms which can co-exist in a single tumour!
- Should be suspected in any case of midline tumour particularly at suprasellar or pineal location.
- Embryonal carcinoma and yolk sac tumours may secrete alpha-fetoprotein (AFP) and can infrequently spread to the lung or bone. Embryonal carcinoma and choriocarcinoma may secrete  $\beta$ -human chorionic gonadotrophin ( $\beta$ HCG).
- AFP and  $\beta$ HCG should be measured in the CSF, as well as in serum and can be used to aid diagnosis (may obviate need for biopsy). Secreting tumours generally have a worse prognosis.
- Management comprises urgent CSF diversion (if required). If done by third ventriculostomy then endoscopic biopsy may be required (in AFP/ $\beta$ HCG negative cases).
- Teratomas managed by resection.
- Germinomas very radio- and chemotherapy sensitive.
- High risk of endocrine disturbance due to disruption of hypothalamo-pituitary axis: assess pre- and again post-operatively.


### ***Choroid plexus tumours***

- Papilloma or carcinoma, typically presenting as raised ICP (overproduction of CSF and ventricular obstruction) in the first few years of life. Lumbar puncture should be avoided.
- MRI demonstrates a large enhancing, highly vascular intraventricular mass. Benign papillomas have a 'cauliflower' like appearance with a distinct stalk.
- Management is gross total resection ( $\pm$  shunt insertion), which may be difficult due to tumour size, vascularity and proximity to important structures. Endovascular procedures (intra-arterial embolization) may aid subsequent resection.
- Papillomas have a good prognosis if completely resected.
- Carcinomas are invasive and vascular (<50% achieve gross total resection at operation) and are prone to CSF dissemination, and chemotherapy and/or radiotherapy (if >3 yrs) may be required as adjuncts. Five-year survival rates are around 25%, with the extent of surgical resection being important for prognosis.



**Neuroblastoma**

Not a primary CNS tumour but included here because of important neurological presentations and complications.

- Malignant tumour of neural crest origin.
- May arise in the olfactory pathway, adrenal gland or sympathetic nervous system.
- Most present with an abdominal mass and/or bone pain.
- Neurological presentations include Horner syndrome, spinal cord compression, ataxia and opsoclonus–myoclonus (see  p. 381; 2% of presentations).
- Metastases to the retrobulbar area may present with proptosis or periorbital echymoses (raccoon eyes).
- Prognosis is related to age at diagnosis, clinical stage of disease and (in children older than 1 yr) regional lymph node involvement.
- Unfavourable outcomes have been associated with elevated serum ferritin, neuron-specific enolase levels and lactate dehydrogenase.
- Amplification of the N-Myc proto-oncogene and low TrkA expression are also associated with unfavourable prognosis.
- Low risk children are managed with gross surgical resection. Chemotherapy is used in addition to surgery in intermediate risk children. Myeloablative chemotherapy or chemoradiotherapy followed by autologous bone marrow transplantation is under investigation for the high risk group.

**Dysembryoplastic neuroepithelial tumour (DNET)**

- Rare cortically based tumour.
- Important cause of intractable focal epilepsy.
- Well circumscribed, usually supratentorial, more common in the temporal lobes and more common in males.
- Amenable to complete resection, no recurrence is expected and prognosis is good.

**Peripheral nerve tumours**

Schwannoma, neurofibroma, perineuroma, malignant peripheral nerve sheath tumour.

**Meningeal tumours**

Meningioma, mesenchymal tumours (e.g. lipoma, fibrosarcoma, leiomyosarcoma, rhabdomyosarcoma), melanocytic tumours (e.g. malignant melanoma, melanomatosis).

**Staging evaluation**

This is required for posterior fossa medulloblastoma, ependymoma and for pineal lesions (e.g. PNET, germ cell tumour, etc.):


- Craniospinal MRI.
- CSF cytology.
- For malignant germ cell tumour: AFP and  $\beta$ HCG may be raised.

### Complications of cranial irradiation

Radiation therapy should be deferred in very young children if at all possible, and chemotherapy is the adjuvant of choice in this group.

- *Acute/subacute complications*: drowsiness, nausea and headache, lethargy and fatigue.
- *Chronic complications*: alopecia, dental problems, hearing loss (also a complication of platinum chemotherapy), endocrine dysfunction (hypothalamus, pituitary and/or thyroid hormones), growth retardation (especially with CSI), radionecrosis, vasculopathy (e.g. Moya–Moya syndrome), neurocognitive and behaviour problems, secondary tumours (incidence of secondary tumours is around 2%, usually gliomas or meningiomas).

### Additional management issues

- AEDs may be required to control seizures (e.g. phenytoin).
- Hydrocephalus may require shunting or placement of an external ventricular drain (EVD).
- Peritumoural oedema: treat with dexamethasone (see  p. 585).
- *Endocrinopathy*: hydrocortisone should be administered peri-operatively to children who have tumours in the vicinity of the hypothalamus. Injury to the pituitary stalk during surgery can mean that levels of vasopressin fluctuate postoperatively (typically a period of diabetes insipidus (DI) then SIADH, then DI returns).

### Cerebellar mutism (posterior fossa syndrome)

This is a complication of posterior fossa surgery, particularly resection of midline posterior fossa tumours, such as medulloblastoma (therefore more common in children than adults). It can be seen after other insults involving the cerebellum or brainstem. The syndrome onset is typically *delayed* by 24–48 h after insult.

- Features include persistent eye closure, sphincter incontinence, decreased oral intake and oromotor apraxia, truncal ataxia, emotional lability and irritability and occasionally hypersomnolence.
- Language is particularly affected: the child typically is mute, but may scream or whine. Comprehension of language is relatively preserved.
- Recovery is associated with a speech pattern described as ataxic dysarthria.
- Thought to be due to disruption of dentato-rubro-thalamo-cortical fibres.
- No known effective preventative measures.
- Diagnosis is clinical. Characteristic picture in the appropriate context and absence of other causes.
- Changes on MRI have been reported but no characteristic pattern.
- Management is supportive, including active interdisciplinary rehabilitation.

## Vitamin-responsive conditions

Worldwide the most common vitamin responsive conditions are due to nutritional deficiency (childhood malnutrition or malabsorption). This section, however, deals mainly with inborn errors of metabolism that may be thought of as treatable early epileptic encephalopathies. Most present with seizures, often within days of birth. Structural brain abnormalities may be present. Treatment is life-long. Although rare, these disorders are potentially treatable, and prompt diagnosis and treatment may have marked impact on outcome.

### Vitamin B6


This is the cofactor for over 100 enzymes, including enzymes involved in the metabolism of neurotransmitters (GABA, glutamate), glycogenolysis, porphyrin synthesis and transamination of amino acids.

There are three dietary forms:

- Pyridoxine (vegetables).
- Pyridoxamine (red meat).
- Pyridoxal 5'-phosphate (PLP, the active cofactor to which all are converted).

#### *Pyridoxine-dependent epilepsy (PDE)*

*Typical early-onset group*

- *Prenatal seizures*: mother may report abnormal foetal movements.
- *Present in the first days of life in about 1/3 of cases*: neonatal encephalopathy with irritability, hyper-alertness and stimulus-sensitive startle; accompanied by systemic features that add to diagnostic dilemma: respiratory distress, abdominal distension, vomiting and metabolic acidosis.
- Multiple seizure types emerge in days, AED resistant.
- May have associated structural brain abnormalities.
- Prompt response to IV pyridoxine (see  p. 609).

*Atypical later onset group*

- No encephalopathy or structural brain abnormality.
- Seizures begin any time up to 3 yrs of age.
- First seizures may be febrile and develop into status.
- May show initial but unsustained response to conventional anti-epileptic drugs.
- Respond to oral pyridoxine.

**Outcome** Life-long treatment; likely learning difficulties, particularly language delay; more severe motor disorder and developmental delay if treatment is delayed.

**Biochemical markers** Urine L-alpha-amino adipic semialdehyde (AASA) and CSF pipercolic acid levels remain high even on treatment.

**Genetics** Mutations in the *ALDH7A1* gene for antiquitin, a lysine catabolism enzyme, lead to inactivation of PLP.

#### *Pyridoxal 5'-phosphate-dependent epilepsy*

**Clinical features** Similar to early-onset pyridoxine-responsive seizures, commonly a history of foetal distress, intractable neonatal-onset seizures, EEG burst-suppression pattern, but no response to pyridoxine.

**Genetics** Pyridoxine 5'-phosphate oxidase (PNPO) mutation.

**Treatment** Pyridoxal phosphate 10–50 mg/kg/day (prompt response).

***Pyridoxine and pyridoxal-responsive seizures***

There is a group of children with severe symptomatic epilepsy, often infantile spasms, who respond to vitamin B<sub>6</sub>, but in whom subsequent withdrawal is possible.

***Diagnosis and treatment***

See Box 4.12.

**Box 4.12 Diagnosis and treatment**

Step 1. Response to vitamin

- Full resuscitation available because of risk of collapse.
- Preferably with EEG monitoring.
- Pyridoxine 100 mg IV/pyridoxal phosphate 100 mg orally.
- Prompt response with cessation of seizures (within minutes).
- Side effect of cerebral depression in up to 20%: hypotonia, sedation, apnoea, akinesia, isoelectric EEG (support until recovery).

Step 2. Biochemical and genetic confirmation

- Urine AASA levels remain high even when supplemented with pyridoxine/pyridoxal. Proceed to genetic testing (PNPO) if AASA levels supportive. In such cases withdrawal of pyridoxine to confirm dependency is no longer recommended.
- Children with normal AASA levels may be non-specific pyridoxine responders, even if not strictly pyridoxine-dependent.
- In children with questionable responses to pyridoxine then withdrawal should taken place with careful observation for possible deterioration.

In confirmed cases of dependency or responsiveness treatment is life-long. Pyridoxine 15 mg/kg/day, decrease if peripheral neuropathy; PLP 30–40 mg/kg/day in at least 4 doses, may need up to 100 mg/kg/day in 8 doses, monitor LFTs.

**Vitamin B12 (cobalamin)**

This is an essential water-soluble vitamin from meat and dairy products. Deficiency may be seen in vegans and their breast-fed infants.

***Inborn errors of B12 metabolism***

See Figure 4.10. Most other neurological disorders responsive to cobalamin are inborn errors of metabolism, inherited in an autosomal recessive manner and presenting with:

- *Neurology*: developmental delay; peripheral neuropathy.
- *Haematology*: pallor; megaloblastic anaemia.
- *Gastroenterology*: anorexia, diarrhoea, and vomiting; failure to thrive (FTT); stomatitis, atrophic glossitis.

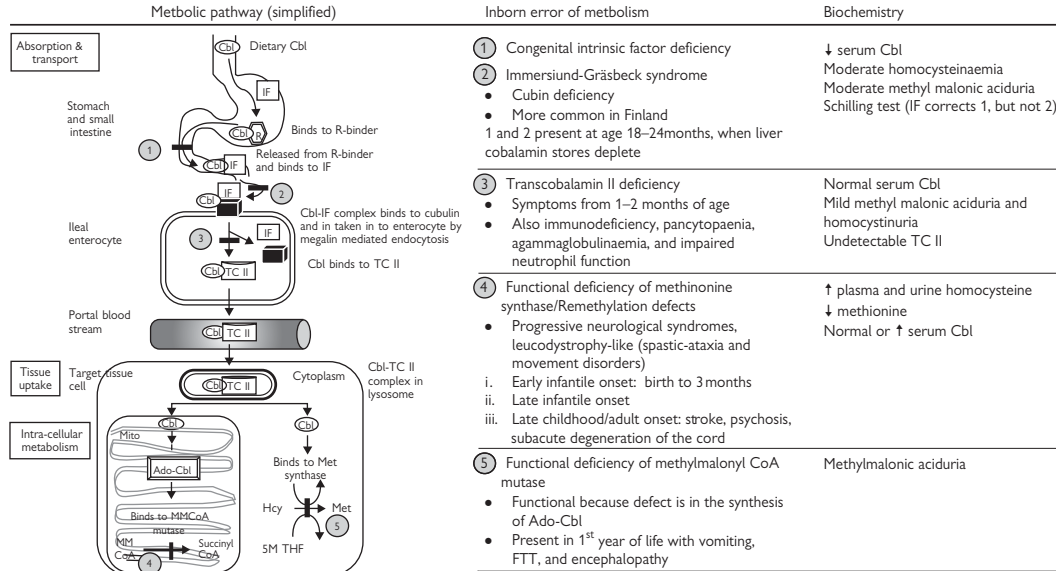


Fig. 4.10 Vitamin B12 dependent disorders.


**Treatment**

- Hydroxycobalamin 1 mg/day IM until a response is seen. Expect to see improvement in haematological and biochemical indices, mood and well-being within 1 week; in contrast, neurological improvement takes months to years, and indeed in the remethylation defects, progression continues.
- Then monthly to maintain hepatic stores.
- May also need betaine 500 mg/kg/day (an alternative methyl donor) or L-methionine.
- Monitor treatment by plasma total homocysteine and methionine.

**Acquired B12 deficiency and subacute combined degeneration of the cord**

Acquired B12 deficiency occurs in pernicious anaemia, an autoimmune condition resulting in destruction of the gastric parietal cells responsible for secretion of *intrinsic factor*. This is a glycoprotein essential for B12 absorption in the distal ileum. Pre-symptomatic diagnosis of B12 deficiency following identification of a megaloblastic anaemia is typical, however late diagnosis can result in neurological damage. Many effects of B12 deficiency are secondary to folate deficiency (as folate regeneration is B12 dependent) and will be ameliorated by folate supplementation. There are, however, some specifically B12 dependent processes including myelination that are not folate-responsive. This has led to debate about the wisdom of introduction of folate fortification of flour as a public-health measure to prevent neural tube defects (by ensuring adequate folate levels in women in the early days of pregnancy during neural tube formation); as folate supplementation will treat megaloblastic anaemia.

The syndrome of late neurological damage due to B12 deficiency comprises non-specific psychiatric features with a characteristic pattern of spinal cord involvement known as *subacute combined degeneration of the cord*. This resembles the findings in FA (which also involves dorsal column function):

- Loss of dorsal column functions (joint position and vibration sense).
- Sensory ataxia with positive Romberg sign (unsteadiness in standing worse on eye closure).
- Distressing paraesthesias.
- The very characteristic combination of depressed or absent deep tendon reflexes particularly at knees and ankles with upgoing plantars (positive Babinski sign), c.f. Friedreich ataxia (see  p. 385).

**Treatment**

- As inborn disorders of B12 metabolism.

**Folate**

Folates are water-soluble vitamins, essential from dietary sources (leafy vegetables, nuts, beans). The active metabolite is 5-methyltetra-hydrofolate (5-MTHF). Transport across the blood-brain barrier is mediated by high affinity membrane-associated folate receptors. As folate metabolism is closely linked to B12 metabolism, not surprisingly clinical features are similar.

**Hereditary folate malabsorption**


- *Biochemistry*: deficient intestinal folate absorption and deficient transport of folate into the CNS.
- *Inheritance*: autosomal recessive, but occurs mostly in girls.
- *Clinical features*: severe anaemia, GI symptoms and variable neurological involvement (learning difficulties, seizures, ataxia, peripheral neuropathy).
- *Diagnosis*: megaloblastic anaemia, low serum and red cell folate, raised plasma homocysteine, reduced CSF 5-MTHF even after temporary correction of serum folate with 5-formylTHF injection. Mutations in SLC46A1 identified in all cases to date.
- *Treatment*: folinic (not folic) acid (latter blocks receptor-mediated transport of 5-MTHF) initially 10–15 mg/kg od orally (much higher doses may be needed. Dose titrated against CSF folate concentrations). Systemic features (anaemia, etc.) normalize rapidly: neurological prognosis depends on early recognition.

**Cerebral folate deficiency syndrome**

Two forms—an inherited genetic syndrome due to mutations in the cerebral folate receptor gene *FOLR1* (autosomal recessive); also an described infantile-onset autoimmune disorder with autoantibodies to the folate receptor blocking folate uptake into CSF.

- *Clinical features*: onset at 4–6 mths of age, marked irritability, developmental delay or regression, acquired microcephaly, cerebellar ataxia, lower limb pyramidal tract signs, dyskinesias; later epilepsy and autism.
- *Diagnosis*: low CSF 5-MTHF but normal folate metabolism outside the central nervous system (i.e. normal serum and red cell folate, normal homocysteine levels, normal haematological indices).
- *Treatment*: folinic acid (mechanism of action uncertain).

**Folinic acid-responsive seizures**

Neonates with intractable seizure picture resembling pyridoxine-dependent epilepsy (see  p. 462) found serendipitously to respond to folinic acid (and not pyridoxine or pyridoxal). In two cases mutations in *ALDH7A1* were identified (the same gene responsible for pyridoxine-dependent epilepsy), i.e. the conditions appear genetically identical. The reasons for the differential treatment responses is unclear.

- *Genetics*: mutations in *ALDH7A1* gene allelic with PDE.
- *Treatment*: folinic acid 2–5 mg/kg/day IV results in immediate cessation of seizures, then long term 5 mg twice a day orally (increase dose with weight).

**Vitamin E**

This is a generic term for a group of related compounds (tocopherols and tocotrienols). It is fat-soluble; absorption in the gut requires bile salts. An antioxidant, particularly protecting membrane phospholipids from radical oxygen species. The CNS and retina are particularly vulnerable in vitamin E deficiency (high concentrations of susceptible fatty acids, disproportionately high oxygen supply and iron concentrations from which to generate free radicals, relative deficiency of other antioxidant systems).

► Particular neurological features of vitamin E-responsive conditions: spinocerebellar degeneration (pyramidal tract, ataxia, polyneuropathy) and retinopathy.

Neurological conditions responsive to vitamin E can be considered as two groups: conditions of vitamin E deficiency and conditions of increased stress on antioxidant protection.

### **Conditions of vitamin E deficiency**

- *Newborn and pre-term infants*: have reduced serum vitamin E and are at increased risk of oxidative stress (sudden increase in oxygen to the lung at birth). Studies have indicated that vitamin E supplementation decreases the incidence of intraventricular haemorrhage and of retinopathy of prematurity in pre-terms, but may increase the risk of sepsis and necrotizing enterocolitis by impairing normal oxygen-dependent antimicrobial defences. Prophylactic vitamin E is not currently recommended, while the risk/benefit ratio remains unclear.
- *Malabsorptive conditions*: any chronic fat malabsorptive state would be expected to reduce the absorption of vitamin E.
  - *Abetalipoproteinaemia*—all children have undetectable serum vitamin E. Untreated they develop ataxia, peripheral neuropathy and retinal degeneration leading to blindness; high dose supplementation prevents, delays progression or reverses these neurological features (A-tocopheryl acetate 100 mg/kg/day).
  - *Acquired deficiency in cholestatic liver disease: without bile salts, vitamin E is not absorbed from the gut*—associated ataxia and peripheral neuropathy are now rare, as all children should receive prophylaxis with the water-soluble form of vitamin E (A-tocopheryl polyethylene glycol-1000 succinate).
- *Ataxia with vitamin E deficiency (AVED)*: a familial disorder mutations in gene for an hepatic  $\alpha$ -tocopherol transfer protein; severe vitamin E deficiency, but without fat malabsorption; usually presents in adolescence or adulthood with spinocerebellar degeneration and retinopathy. It is crucial to differentiate AVED from Friedreich ataxia, because AVED responds to vitamin E (800 mg/day).

### **Conditions of increased stress on antioxidant protection**

There is evidence for increased oxidative stress in Down syndrome, Friedreich ataxia, ischaemia/reperfusion injury and the NCLs. Vitamin E, folic acid and antioxidant supplementation in Down syndrome has not shown benefit in terms of psychomotor development.

### **Biotin metabolism**

Biotin is a B-group vitamin, essential for covalently binding to carboxylase enzymes (enzymes that have a central role in gluconeogenesis, in amino acid metabolism and in fatty acid biosynthesis for the Krebs cycle).

Dietary deficiency is extremely rare as dietary biotin is endogenously recycled. It may occur as a complication of long-term parenteral nutrition if not supplemented. Inborn errors involve the enzymes needed for biotin recycling—biotinidase deficiency (which responds to biotin treatment); and *holo*-carboxylase synthase deficiency (attaches biotin to the carboxylase enzymes and does not respond to biotin treatment).



**Biotinidase deficiency**

- *Clinical features:* variable age of onset but most commonly with neurological symptoms, epilepsy (often infantile spasms) and hypotonia at 3–4 mths of age (can be up to 10 yrs); ataxia in older children. Dermatitis, alopecia or conjunctivitis should raise suspicion. Later lactic acidosis, hearing and visual loss.
- *Diagnosis:* plasma biotinidase level (usually <10% activity), organic aciduria (because of the effect on carboxylases). May show low CSF glucose with raised lactate (c.f. GLUT1 deficiency; see □ p. 282).
- *Treatment:* biotin 5–20 mg/day orally; prompt resolution of abnormal biochemistry, skin, seizures and ataxia; hearing and visual loss are irreversible.

**Holocarboxylase synthase deficiency**

Symptoms begin as a neonate. Seizures are less common (25–50%). May need higher doses: of biotin: 10–40 mg/day.

# Consultation with other services

- General principles 470
- Cardiology consultations 471
- Endocrinology consultations 474
- Gastroenterology consultations 476
- Neonatal neurology 480
- Neonatal encephalopathy 487
- Neurosurgical consultations 500
- Oncology consultations 502
- PICU consultations 507
- Psychiatry consultations 517
- Neuropsychiatric liaison work 520
- Renal consultations 523
- Respiratory consultations 526
- Rheumatology consultations 531

## General principles

Consultation requests should be met with:


- A request for a clear statement of the question to be addressed or function to be performed if you feel this has not been provided by the referrer. Serial involvement of subspecialty teams without clearly understood roles and responsibilities can lead to 'teaching hospital syndrome'.
- Deference and sensitivity to the relationship already built between the referring consultant and the child and family.
- Good liaison and clear agreement with the referring team on how to deliver new information to the family involved and how to draw up a new management plan.
- Focused discussion over specific interventions.

Independent note-keeping, particularly of the contents of telephone consultations, is important as you cannot check how your advice has been recorded in the child's clinical records.

Common referral themes will be related to specific specialist services.

Remember non-neurological colleagues may have adopted a less skilled clinical approach; it is always best to repeat the detail of the history and carry out your own neurological examination.

### **'When all you have is a hammer, everything looks like a nail'**

As a neurologist you have a responsibility to be aware of your own susceptibility to this tendency (see  p. 49), as well as that of others you may consult in turn. Ensure the referrer appreciates the importance of considering other, non-neurological perspectives on the problem on which you were consulted.

# Cardiology consultations

## Aetiologies

### The heart

- Congenital heart disease (e.g. transposition of the great arteries; other cyanotic conditions; hypoplastic left heart syndrome); valvular disease; cardiomyopathy; arrhythmias.
- Resulting in hypoperfusion, embolus (right to left shunting, arrhythmia).

### Procedures

- Balloon atrial septostomy, cardiac catheterization.
- Extracorporeal membrane oxygenation (ECMO).
- Cardiopulmonary bypass and deep hypothermic circulatory arrest.


### Clinical context

- Underlying conditions (e.g. genetic syndromes).
- Drugs (e.g. warfarin, ciclosporin).
- Sepsis, etc.



## Stroke/cerebrovascular accident

- May present as cardiorespiratory instability, seizures, abnormal posturing, limb weakness, headaches.
- Early assessment of neurological impairment and prognostication may not be possible due to systemic instability, sedation, paralysis for ventilation. Re-assess the child over time:
  - there is a high prior probability that an ischaemic stroke occurring in a cardiothoracic setting will be embolic;
  - one of the few settings where in-hospital thromboembolic stroke may occur: this may make emergency thrombolysis a consideration (see [p. 446](#)).
  - consider cerebral abscess—cyanotic heart disease and endocarditis are risk factors; acute presentation and computed tomography (CT) scan mimics vascular cause.
- *In congenital heart disease:*
  - focal infarcts may be noted on pre-operative neuroimaging (40% of TGA) due to prior atrial septostomy, cardiorespiratory depression at presentation, perinatal events;
  - post-operative infarcts and haemorrhages seen in 15% (micro-emboli as bypass clamps are released or from device closures; haemorrhages after ECMO and anticoagulation);
  - low-flow cardiac conditions, e.g. hypoplastic left heart syndrome predispose to thrombus and embolic stroke; requires anticoagulation and/or antiplatelet treatment;
  - paradoxical emboli from the right side of the circulation in children with cyanotic heart disease (right-to-left shunting).
- Infarcts, haemorrhages, and mycotic aneurysms in infective endocarditis.
- Central venous hypertension may predispose to cerebral vein thrombosis leading to multi-focal infarcts and haemorrhages.
- Focal vascular lesions may exist on background of diffuse ischaemic brain injury which has wider neurocognitive sequelae (see [p. 472](#)).



### Seizures

- *Multiple aetiologies:* stroke, diffuse hypoxic-ischaemic injury, abscess, drugs (e.g. posterior reversible encephalopathy syndrome (PRES) see  p. 524).
- May be related to underlying genetic syndrome, e.g. hypoplastic heart syndrome, 22q11 deletion, infantile spasms in Down syndrome (DS) and tuberous sclerosis (TS).
- Distinguish from non-epileptic myoclonus, chorea, jitteriness.



### Movement disorder

- 'Post-pump' chorea after bypass or ECMO (see  p. 382).
- Myoclonus following cardiac arrest, typically interfering with voluntary movements—Lance–Adams syndrome (see  p. 381).
- Sydenham's chorea in context of acute rheumatic fever.
- Underlying genetic syndrome, e.g. Friedreich.

### Neuropathy

- Critical illness neuropathy after prolonged ventilation and intensive care (see  p. 514).
- Compression mono-neuropathies (pressure palsies: see  p. 398) secondary to prolonged immobility.

### Hypoxic-ischaemic insult

- May present with seizures, prolonged coma or ventilation requirements.
- Assessment and prognostication following cardiac arrest: see  p. 512.
- Hypothermia routinely provided for preoperative circulatory arrest is protective (c.f. cold water drowning, see  p. 512).
- Ischaemia is associated with ligation of the carotid artery in ECMO.
- Magnetic resonance imaging (MRI) may demonstrate diffuse injury affecting combination of white matter, basal ganglia, and cortex. Periventricular white matter injury in young infants associated with late neurocognitive deficits.

### Neurodevelopmental prognosis in congenital heart disease

- Developmental scores relate more to underlying genetic syndromes (relevant in 12% of infants, e.g. DS, 22q11 deletion), ApoE2 allele and perinatal condition more than intraoperative factors.
- Neurocognitive scores in later childhood are low end of normal across multiple domains.
- May have additional focal deficits, e.g. stroke-related hemiplegia. Consider referral of infants with complicated in-patient course to community or developmental paediatrician.
- Hypoplastic left heart syndrome commonly associated with agenesis of corpus callosum or holoprosencephaly (10%), cortical malformations, congenital microcephaly. 60% have major disabilities.

### Cardiological aspects of neurological and neurodevelopmental conditions

#### Down syndrome

Atrial, ventricular, or atrioventricular septal defects.

### **Tuberous sclerosis**

- Cardiac rhabdomyomas may be the presenting feature of TS, often detected on routine antenatal scan (50% turn out to have TS).
- Rhabdomyomas may cause outflow obstruction, cardiac failure or arrhythmias in infancy, but regress spontaneously by 6 years.

### **Williams syndrome**

- Classically, supravalvular aortic stenosis.
- Also pulmonary stenosis, mitral valve regurgitation.
- A more generalized large-vessel arteriopathy (e.g. cranial arteries) and arterial hypertension with risk of stroke is recognized.

### **Noonan's syndrome**

- Classically, pulmonary valve stenosis.
- Also ASD and peripheral pulmonary artery stenosis.
- Wider arteriopathy includes Moyamoya disease with risk of stroke.

### **Cardiomyopathies**

- Barth syndrome (X-linked developmental delay, myopathy, neutropaenia, low carnitine and cardiolipins).
- Danon disease (developmental delay, myopathy).
- Congenital disorder of glycosylation (CDG1a).
- Muscular dystrophies.
- Metabolic myopathies, e.g. mitochondria, fatty acid oxidation, glycogenoses (Pompe).
- Friedreich.

### **Paroxysmal events**

Discussed further elsewhere (see  p. 136).

❗ Any paroxysmal event characterized by early pallor, particularly if brought on by exertion or occurring at rest, should be carefully evaluated for a primary cardiac cause.

### **The heart and epilepsy**

- Abnormal cardiac repolarization reported in chronic epilepsy.
- Ictal and peri-ictal tachycardia common in temporal lobe seizures.
- Ictal asystole is rare but described in chronic focal epilepsy in adults, necessitating cardiac pacemaker.

## Endocrinology consultations

### Coma

- ► Think thyroid function. Hashimoto's thyroiditis (see 📖 p. 225) can present with reduced conscious levels—usually in girls with normal T4 but abnormal anti thyroid peroxidase antibodies.
- ► Think hypopituitarism.
- ► Think syndrome of inappropriate anti-diuretic hormone secretion (SIADH).

### Tremor

Not usually thyrotoxic, but check. May also exacerbate tics.

### Addison disease/adrenoleukodystrophy

A proportion of children with Addison's disease will have X-ALD (see 📖 p. 430) due to a mutation in the *ALD* gene. Screening is by measurement of VLCFAs.

The concern is to identify young people with X-ALD prior to onset of neurological symptoms when a bone marrow transplant (BMT) may be indicated. BMT may still be considered even with MRI changes: the presence of neurological/neuropsychological deficits would increase the risk of progression following BMT. Loes' score is used to grade the condition, and a score <10 is compatible with BMT.

### Growth hormone treatment and seizures

- Consider genetic disorders with growth failure including the holoprosencephaly spectrum; signs may be subtle, such as a single central incisor:
  - correlation between the severity of the MRI, facial, endocrine, and ophthalmological features is poor;
  - MRI may fail to reveal pituitary abnormalities, but full anterior and posterior pituitary function is required as endocrine dysfunction may be life-threatening, and of late onset.
- *Septo-optic dysplasia*: remember this has quite a broad phenotype some with just isolated optic hypoplasia.

### Hypothalamic hamartoma

- Typically associated with refractory epilepsy, including gelastic seizures and precocious puberty.
- Cognitive and behavioural effects of poor seizure control tend to be cumulative, and surgical remediation of epilepsy should be actively considered.
- Options include gamma knife and transcallosal disconnection.
- Both the immediate and late postoperative course can be complicated by anterior and posterior pituitary dysfunction.

### **Congenital hyperinsulinism (Nesidioblastosis)**




- May result in acute symptomatic seizures due to hypoglycaemia (both in the neonatal period and later) and also later primary epilepsy (mechanism uncertain).
- Progress of the disorder involves pancreatic  $\beta$ -cell destruction by influx of calcium and eventually secondary diabetes mellitus.
- MRI may show features of hypoglycaemic damage with posterior grey and white matter damage.
- Nesidioblastosis should be considered in resistant epilepsy even with electroencephalogram (EEG) features suggestive of idiopathic generalized epilepsy.



## Gastroenterology consultations

### Feeding difficulties in infancy (see p. 248)

Feeding difficulty can be a feature of any neurological disorder and may be the presenting feature of treatable disorders without other neurological signs. Children may be referred urgently following unexpected severity of videofluoroscopy findings, e.g. silent aspiration of thickened fluids and purees. Assisted feeding via a nasogastric tube (NGT) or gastrostomy tube can be necessary.


- Identify if oropharyngeal motor problems present, e.g. evolving cerebral palsy. Drooling, early respiratory problems are common comorbidities. Worster–Drought/congenital perisylvian syndrome (see  p. 227) may show minimal generalized motor signs. May co-exist with gastro-oesophageal reflux disease GORD (see  p. 477).
- Check oropharyngeal and oesophageal structural/anatomical problems have been excluded, e.g. submucous cleft palate.
- Conditioned feeding/oral-sensory aversion with minimal motor signs is a feature of numerous neurodevelopmental disorders, e.g. extremely premature born infant, Russell–Silver, Noonan. GORD often present.
- Profound hypotonia and marked feeding problems are characteristic of the early phase of Prader–Willi syndrome. Also consider peroxisomal disorders and congenital muscular dystrophies. Tongue fasciculation of SMA type 1 and congenital neuropathies. Early cerebral palsy typically shows milder hypotonia and antigravity muscle weakness.
- Congenital myasthenic syndromes can present with episodic dysphagia with minimal signs (ptosis, limb weakness) between episodes (see  p. 413).

Irritability interfering with feeds can have a primary, neurological cause including:

- Krabbe.
- GM1 gangliosidosis.
- Leigh's.
- Non-accidental injury (NAI), cerebral injury, e.g. meningoencephalitis.

Irritability can also be secondary to malnutrition (in which case it will be eased by supplemental nasogastric feeding) due to dysphagia, which in turn may have a primary neurological basis due to an evolving motor disorder, such as dyskinetic cerebral palsy.

Other problems to consider:


- Any tone-reducing medications (e.g. benzodiazepines).
- Chiari malformation causing bulbar weakness (*Note*: CT will miss this).
- Infantile botulism (see  p. 133). Bulbar, head, and neck involvement are *early* with weakness *descending* (c.f. Guillain–Barré syndrome (GBS)). Absolute constipation is a prominent feature.
- Neonatal acquired myasthenia.
- Infantile GBS (particularly pharyngeal variant).

### Investigations to consider



- MRI brain.
- Karyotype and other genetic tests as indicated (e.g. 22q11 deletion, congenital myasthenia genes).

- Lumbar puncture (LP; e.g. raised cerebrospinal fluid (CSF) protein of immune disorders).
- Electromyography (EMG)/nerve conduction velocity (NCV) and specialized studies (e.g. stimulated single fibre EMG).
- Acetylcholine receptor antibodies (MuSK antibodies typically in older children).
- Trial of pyridostigmine (may not improve and, indeed, worsen congenital myaesthetic syndrome (CMS) subtypes).


### Gastro-oesophageal reflux disease and vomiting

- For management of chronic GORD in children with neurodisability, see  p. 440.
- In new-onset vomiting, consider posterior fossa imaging to exclude a space-occupying lesion; and hyperammonaemia secondary to urea cycle disorder.

#### Cyclical vomiting


Repeated bouts of vomiting lasting hours to days usually occurring at a characteristic time of day for the child: can result in severe electrolyte imbalance. Family history of migraine often: classified as a primary headache disorder (see  p. 319). Benign paroxysmal torticollis of infancy (see  p. 319) is similar with earlier onset plus torticollis and eye deviation. Both are diagnoses of exclusion (easier to be confident of diagnosis in recurrent episodes).

In initial presentations or where diagnosis uncertain, consider checking:

- Abdominal imaging (to exclude volvulus and other causes intestinal obstruction).
- Amylase.
- Renal function.
- Ammonia (late presenting urea cycle disorders (see  p. 365).
- Acid-base status.
- Plasma amino acids.
- Urine organic acids.
- Urine porphyrin screen.
- Acyl carnitine profile (fatty acid oxidation disorders).
- Liver function tests.
- Urine toxicology (particularly cannabis exposure).

Acute episodes are managed symptomatically with fluid and electrolyte correction, and anti-emetics (lorazepam, ondansetron). There is some evidence for benefit from migraine prophylactic agents (propranolol, pizotifen).

#### Sandifer syndrome

- Dyskinetic movement disorder related to severe GORD (see  p. 304).
- More common in children with neurodisability, but can also occur in neurologically intact children.
- Responds to treatment of GORD.

#### Lysinuric protein intolerance


Disturbed transport of dibasic amino acids resulting in anorexia, growth failure, lethargy, vomiting, and diarrhoea.


### Diencephalic syndrome

A child <3 yrs of age with hyperkinesia and euphoria, and striking emaciation without early gastrointestinal symptoms. Typically caused by gliomas of the 3rd ventricle.

### Neurological associations of hepatocellular failure

Commonly seen following an episode of status epilepticus. Causes include:

- Hypoxic hepatic injury (commonest, with good prognosis).
- Idiopathic drug response: particularly valproate toxicity. Consider changing the anti-epileptic drug (AED) regime.
- Alpers disease (see  p. 373). Rare, but probably accounting for many cases of apparent valproate-induced liver disease.

❗ Disturbed liver function is an important early presentation of Wilson disease (see  p. 432). Hepatocellular dysfunction (typically late in the first decade of life) may pre-date development of neurological symptoms, and early chelating therapy may prevent neurological morbidity. ► Perform copper studies in all unexplained hepatocellular failure.



### Neurological complications of prolonged total parenteral nutrition

Prolonged total parenteral nutrition (TPN) may result in trace metal deficiencies that can have neurological manifestations including myelopathy due to copper deficiency and an extrapyramidal movement disorder (with basal ganglia changes on MRI) due to excess manganese.

### Neurological associations of coeliac disease, malabsorption, and inflammatory bowel disease

- Can be associated with movement disorder thought to be caused, at least in part, by vitamin E malabsorption (also seen in other malabsorption states such as Crohn disease).
- An autoimmune mechanism may also be implicated in coeliac disease with demonstration of antigliadin antibodies in the CSF of some adults with ataxias and myoclonus.
- Neuropathy associated with coeliac disease (no single mechanism).
- Inflammatory bowel disease (IBD)-associated neuropathy often subclinical, sensory. Acute presentation: unilateral foot drop due to sacral nerve compression during colonoscopy.
- TNF-alpha antagonists may induce a chronic demyelinating neuropathy. Sulphasalazine-induced neuropathy.

### Encephalopathy in gastrointestinal/liver conditions

- Encephalopathy and seizures are common after liver transplantation e.g. posterior reversible encephalopathy due to ciclosporin (see  p. 524).
- Consider opportunistic infections in children on immunomodulatory treatments for IBD (e.g. natalizumab-related PML; infliximab-related TB. See  p. 351).
- Cerebral venous sinus thrombosis in acute IBD due to prothrombotic state. May present without focal neurological signs.
- Sulphasalazine-related encephalopathy.

- D-lactic acidosis is a rare cause of recurrent encephalopathic episodes in children with short-gut syndrome (e.g. after neonatal NEC).
  - short small intestine results in carbohydrate delivery to D-lactate producing bacteria in colon;
  - recurrent encephalopathy with acidosis: L-lactate levels (the 'normal' lactate) are normal, but D-lactate are elevated;
  - treatment by antibiotics (to clear D-lactate producers), probiotic yoghourts.
- Familial Mediterranean fever may be associated with encephalopathy, demyelination, and seizures.

### Parenteral maintenance of antiepileptic therapy

A common request for advice, e.g. in the context of abdominal surgery, or intestinal malabsorption syndromes, is for alternative maintenance regimes for children with epilepsy taking regular AEDs.

- For routine operations (where a nil-by-mouth period is unlikely to exceed a few hours) the risks of a single delayed dose are small and no special precautions are required.
- For periods of 24–48 h consider a single loading dose of IV phenytoin (particularly for children with epilepsy due to known structural brain abnormalities) or lorazepam.

For longer periods of interruption to enteral feeding:

- Consider conversion of the existing AED regime to the parenteral route:
  - valproate, phenytoin, or phenobarbital can be given parenterally at the same dose (although phenytoin levels should be monitored and the dose adjusted if required, see Box 7.1).
  - carbamazepine and topiramate can be given rectally with dose adjustment (see [p. 580](#) and [p. 614](#)).
- If the existing regime is not readily adapted, consider temporary supplemental cover with IV phenytoin.

## Neonatal neurology

### Neonatal seizures

This is the most common and specific form of overt neurological dysfunction in the newborn. The incidence is 1–5/1000 live births rising to 20–60/1000 in the very low birth weight (VLBW).

### Neonatal seizures are usually symptomatic


#### Causes (in order of importance)

- Hypoxic-ischaemic encephalopathy (HIE) and stroke very much commoner than (in decreasing order):
  - Intracranial haemorrhage.
  - Cerebral infarction.
  - CNS infection.
  - Metabolic abnormalities.
  - Cerebral dysgenesis.
  - Inborn errors of metabolism.
  - Neonatal epilepsies.

Approximately 10% are idiopathic (see Table 5.1 for neonatal seizure types).

► Note that some inborn errors of metabolism (e.g. non-ketotic hyperglycinaemia) are associated with structural brain abnormality (typically symmetrical absence or hypoplasia of brain structures): demonstration of a structural abnormality may not be the complete explanation for the occurrence of seizures.


The seizures are almost certainly *not* 'generalized tonic-clonic seizures', which are virtually unknown in the neonatal period. Look carefully at the semiology.

Differential diagnosis is of non-epileptic behaviours including jittering, tremor, dyskinesias, dystonia, startle responses (e.g. hyperekplexia) and sleep myoclonus (see  p. 304).

**Table 5.1** Neonatal seizure types

Myoclonic	Focal, multifocal, generalized
Tonic	Focal, generalized
Clonic	Focal, multifocal
Subtle	Ocular phenomena
	Oral–buccal–lingual movements
	Periodic/rhythmic limb movements (e.g. 'bicycling')
	Autonomic phenomena
	Apnoea

### History

- Family history (consanguinity, dominant conditions such as benign familial neonatal convulsions, see  p. 264).
- Pregnancy (infections, drugs) including quality of foetal movements, e.g. rhythmic kicking or hiccupping suggesting *in utero* seizures.
- Peripartum events (presentation, duration of labour, fever, or other signs of infection, mode of delivery, meconium staining of the liquor, cord pH, Apgar scores, resuscitation).
- Timing of onset of seizures.
- Description of seizure.

### Examination

- Head size.
- Dysmorphic features, rashes, neurocutaneous findings.
- Signs of metabolic abnormalities including odour, jaundice, failure to thrive, visceral organomegaly, diarrhoea, vomiting, cataracts.
- Other signs of neurological dysfunction (including abnormalities and/or asymmetries of state, awareness, sucking and feeding, tone, eye movements, facial symmetry, movement including extraneous movements).
- Try to suppress any rhythmic movements with gentle restraint (will not be able to suppress epileptic events) and attempt to stimulate/wake the baby (will terminate benign neonatal sleep myoclonus).
- It is often possible to diagnose non-epileptic events from the clinical examination alone.

### Investigations

#### Imaging

- Primary cerebral dysgenesis disorders.
- Neonatal stroke.

#### Neurophysiology

The gold standard for diagnosis is ictal EEG with video demonstrating electrographic seizures with a clinical correlate; however:

- The normal term and pre-term newborn EEG can have 'epileptic' findings that are normal for maturity and are not indicative of an active seizure disorder. These include sharp waves, occasional spikes, slowing,  $\delta$  brushes,  $\alpha$  bursts, and *tracé discontinué* and *tracé alternant* patterns. Ensure your neurophysiologist is familiar with normal variants in neonatal EEG!
- Some newborn seizures may not have an EEG signature because the seizure focus is too deep to be captured by scalp electrodes.

Inter-ictal EEG may be helpful in diagnosis when it shows electrographic seizures, epileptiform features, or abnormalities of background, such as low amplitude or burst-suppression patterns.

#### Other investigations

Initially, these should be used to diagnose correctable metabolic conditions and include glucose, electrolytes,  $\text{Ca}^{2+}$ ,  $\text{Mg}^{2+}$ ,  $\text{K}^+$ ,  $\text{HCO}_3^-$ , and  $\text{NH}_3$ .

Further investigations should be guided by the history and examination.

- Sepsis work-up including LP is usually necessary. Start broad antibiotic coverage as well as treatment with aciclovir until CSF cultures and HSV PCR studies are negative.
- HIE causing significant cerebral oedema, intracranial haemorrhage and structural anomalies can be seen on cranial ultrasound, CT or MRI.
- In case of neonatal abstinence/withdrawal, urine toxicology is helpful.
- If an inborn error of metabolism (IEM) is suspected, initial investigations should include glucose, pH, lactate, and  $\text{NH}_3$ , and then be directed by the examination and EEG (Boxes 5.1 and 5.2).

### Treatment

- Correct metabolic abnormalities (glucose, calcium, Na). Give antibiotic and antiviral treatment if sepsis is suspected
- IV phenobarbital 20 mg/kg loading dose (may also given orally). If no response, a further 20 mg/kg may be given in 10 mg/kg increments. There is limited value in pushing levels beyond 40–60 mg/L. The half-life varies from 100 to 300 h in the newborn (400 h in the pre-term) falling to 60 h after 4 weeks. Maintenance dosing usually starts at 3–4 mg/kg/day as a daily dose
- If no response give phenytoin (PHT) 18 mg/kg loading dose. Achieving adequate plasma levels with oral PHT may be very difficult in the newborn: maintenance doses may be as high as 10 mg/kg/day
- Lorazepam as third line option 0.05–0.15 mg/kg administered in increments of 0.05 mg/kg over 2–5 min until seizures are controlled. Adverse events include sedation, hypotension, and respiratory depression.

### Further management

If seizures continue despite triple therapy in adequate doses consider the following in particular.

### Non-ketotic hyperglycinaemia

An autosomal recessive condition caused by deficiency in the glycine cleavage system leading to high levels of glycine in the brain and CSF with cerebral excitation but brainstem and spinal cord inhibition.

- Causes stupor, respiratory abnormalities and hypotonia, absent sucking, characteristic hiccoughs, and refractory myoclonic seizures.
- Commonly initially mistaken for HIE, but the child does not improve and there is no clear evidence of perinatal asphyxial insult.
- Diagnosis is by demonstration elevated CSF glycine and a CSF: plasma glycine ratio over 8% (normal ratio <4%).
- CSF proline <5  $\mu\text{M}$  (reported as part of same CSF amino acid profile) confirms the CSF sample is free of blood contamination.
- EEG usually shows a burst-suppression pattern. Frequently lethal by the age of 1 yr.
- May be associated with structural brain abnormalities (e.g. posterior fossa) on MRI.
- Controversial role for supplementation with benzoate and dextromethorphan.

### Protocol for further investigation of refractory neonatal seizures of unknown cause

The importance of the individually very rare, but collectively significant metabolic diseases that can present with refractory neonatal seizures lies in the ready treatability of some and the neurodevelopmental consequences of delayed treatment. Their reliable identification requires a thorough approach systematically applied.

#### Box 5.1 Inborn errors of metabolism (IEMs) causing neonatal seizures

- Nesidioblastosis
- Urea cycle disorders
- Non-ketotic hyperglycinaemia
- Pyridoxine/pyridoxal-dependent epilepsy
- Folinic acid responsive seizures
- Biotinidase deficiency
- Perinatal hypophosphatasia
- Adenylsuccinate lyase deficiency
- Methylene tetrahydrofolate (MTHFR) deficiency
- D-2-hydroxyglutaric aciduria
- Congenital disorders of glycosylation
- 3-Phosphoglycerate dehydrogenase deficiency
- GABA-T deficiency
- Congenital glutamine deficiency
- Glutamate transporter deficiency
- Neonatal ceroid lipofuscinosis with cathepsin deficiency
- Smith–Lemli–Opitz syndrome
- Creatine deficiency disorders


Conditions are ranked by (very approximate) prevalence. Conditions whose potential treatability makes them particularly important to rule out are identified in blue.

#### Day 1

If not already performed, perform a 'metabolic' lumbar puncture to collect the following:

- Paired blood and CSF glucose.
- Paired blood and CSF amino acids.
- CSF neurotransmitters including HVA, 5-HIAA, MTHF.
- Blood homocysteine.
- Urine purine and pyrimidines.
- Transferrin isoelectric focusing.

#### Exclude glucose transporter deficiency (*GLUT1DS*; *DeVivo syndrome*)

- Diagnosed by demonstration of CSF:plasma glucose ratio <40% in the absence of other causes of hypoglycorrachia (such as systemic hypoglycaemia, meningitis).
- Confirmed by genetic testing (SLC2A1 mutations).
- For further details see  p. 282.



**Box 5.2 Available investigations for IEMs causing neonatal seizures****Serum**

- Creatine kinase
- Lactate and pyruvate
- Ammonia
- Biotinidase
- Amino acids
- Carnitine, acylcarnitines
- Transferrin isoelectric focusing
- Copper and caeruloplasmin
- Cholesterol
- Fatty acids
- Pimelic and phytanic acid
- Uric acid

**Urine**

- Organic acids
- Amino acids
- Acylglycines
- Sulphites
- Xanthine, hypoxanthine
- Pimelic acid
- Guanidinoacetate

**CSF**

- Glucose with paired blood glucose
- Cell count
- Lactate
- Amino acids (paired with blood for CSF: plasma glycine ratio)
- Neurotransmitters and folate metabolites


**Others**

- MRI and MRS (look for lactate peak, absence of creatine)
- Skin biopsy for inclusions
- Fibroblast culture
- Muscle biopsy for light and electron microscopy, electron transport chain studies

**Exclude pyridoxine-dependent seizures**

- Very rare, but should be considered in all refractory neonatal seizures. Diagnose and treat by administering 100 mg B6 IV every 10 min for 200–500 mg total dose.
- Continuous EEG monitoring is desirable, but not essential.
- There is a risk of apnoea during administration. EEG should normalize within 6–8 h of administration if pyridoxine dependent.


### Days 2–7

Children who are pyridoxine-responsive (rather than dependent) may show a delayed response, and some conditions respond to pyridoxal phosphate, but not pyridoxine (see  p. 462). Therefore, it is more efficient to treat with pyridoxal phosphate if available, and define the biochemical defect subsequently in more detail if a response is seen.

Pyridoxal phosphate should be given at 10 mg/kg/day. If not available, pyridoxine is continued 100 mg per day for 1 week.

### Week 2

Having obtained remaining specimens (see Box 5.2) treat with a cocktail of creatine (300 mg/kg/day), folinic acid (2.5 mg twice a day), and biotin (10 mg/day) pending the remaining results.

- *Biotinidase deficiency*: assay biotinidase activity in blood.
- *Folinic acid-responsive seizures*: diagnosed by clinical response to folinic acid: recent reports suggest in fact allelic to pyridoxine dependent epilepsy.<sup>1</sup> (See also  p. 466.)

If seizures are refractory, the decision about more intensive therapy is dependent on the individual child. The options are of intravenous high-dose suppressive therapy, usually requiring continuous cardiorespiratory support and EEG monitoring; or oral AEDs (Table 5.2).

### Discontinuation of therapy

- Neonatal seizures are usually symptomatic and do not necessarily persist after the acute insult.
- If seizures are easy to control, the underlying aetiology resolves and the neurological examination normalizes, it is reasonable to stop AEDs early (e.g. after 6 weeks to 3 months).
- Seizures due to cortical malformations or malignant early epilepsy syndromes such as neonatal myoclonic epilepsy and Ohtahara syndrome imply long-term treatment.

### Outcome

This is strongly determined by aetiology. Overall 10–30% subsequently develop epilepsy, but as high as 80% for cerebral dysgenesis and 30% for severe HIE or meningitis.

1 Gallagher RC, Van Hove JL, Scharer G, et al. (2009). Folinic acid-responsive seizures are identical to pyridoxine-dependent epilepsy. *Ann Neurol* **65**: 550–6.

**Table 5.2** AEDs in refractory neonatal seizures**High dose suppressive IV therapy**

Phenobarbital	>30 mg/kg
Thiopental	10 mg/kg then 2–5 mg/kg/h
Pentobarbital	10 mg/kg then 0.5–1 mg/kg/h
Midazolam	0.2 mg/kg then 0.1–0.4 mg/kg/h
Lignocaine	2 mg/kg then 6 mg/kg/h
Valproate	20 mg/kg then 20 mg/kg/day in 2–3 doses

**Oral AEDs**

Clonazepam	0.1 mg/kg/day in 2–3 doses
Carbamazepine	15–20 mg/kg/day in 2–3 doses
Valproate	20 mg/kg/day in 3 doses
Topiramate	3–15 mg/kg/day in 2 doses
Levetiracetam	10 mg/kg/day in 2 doses
Zonisamide	2.5 mg/kg/day
Vigabatrin	50 mg/kg/day increasing to 200 mg/kg/day

## Neonatal encephalopathy

This has an incidence of 6 per 1000 live births. It is associated with significant mortality (15–20%) and permanent neurodevelopmental disability (25%). There are many different causes including HIE, stroke, traumatic brain injury, hypoglycaemia, maternal medications, and IEMs.

### Hypoxic–ischaemic encephalopathy

This is the neurological consequence of perinatal asphyxia due to lack of oxygen or perfusion to the foetus. It is often accompanied by tissue lactic acidosis. The terms HIE and birth asphyxia should be reserved for circumstances where there is sufficient perinatal data to support the diagnosis. The term ‘neonatal depression’ is preferred to describe the baby who emerges limp, cyanosed, with poor heart rate or respiratory effort.

The incidence is 1–1.5% of live births. Risk factors include low gestational age and birth weight, IUGR, post-maturity, abruption, cord prolapse, shoulder dystocia, and breech presentation. In term infants, maternal diabetes and hypertension/toxaemia are also risk factors.

Factors suggesting HIE as the cause for neonatal encephalopathy are a history of abnormal foetal heart rate (especially after a normal heart rate), metabolic acidosis at birth ( $\text{pH} \leq 7$ ,  $\text{BE} -12 \text{ mM}$ ), Apgar score 0–6 for  $\geq 5$  min and multiple organ dysfunction (renal, cardiac, hepatic, haematological, pulmonary, persistent pulmonary hypertension of the newborn (PPHN)).

### Differential diagnosis

- Acute blood loss.
- Infection.
- Inborn errors of metabolism (especially non-ketotic hyperglycinaemia).
- Intracranial haemorrhage.
- Central nervous system (CNS) malformation.
- Impediments to ventilation (e.g pneumothorax, ascites, tracheal web).
- Cervical spinal cord injury (otherwise alert, non-encephalopathic child who cannot self-ventilate).
- Neuromuscular disease, maternal drugs, including anaesthetics, and cardiopulmonary disease.

### Investigations

- Full blood count (FBC), glucose,  $\text{Ca}^{2+}$ ,  $\text{Mg}^{2+}$ ,  $\text{PO}_4^{2-}$ , pH, ammonia, lactate, urea and electrolytes (U&E), clotting, liver function tests (LFTs), creatinine kinase (CK), CKMB/troponin, and sepsis screen (consider herpes virus) for correctable metabolic disturbances, evidence of end-organ damage and other causes.
- Consider toxicology screen for opiates, cocaine, tricyclics, selective serotonin reuptake inhibitors (SSRIs), amphetamines, barbiturates, and alcohol.
- Examination of placenta for evidence of chorioamnionitis, infarction, haemorrhage, and thrombi.
- Head ultrasound (US) or CT to rule out haemorrhage and look for evidence of oedema or infarct (may be missed on early CT).

- EEG to look at background, voltage, seizures, and for evidence of burst-suppression.
- The imaging modality of choice is MRI with diffusion-weighted imaging (DWI), although this is frequently difficult in an unstable child and may need to be delayed.
- Areas of restricted diffusion correspond to ischaemic brain tissue and appear early (within an hour of insult). There is potential for pseudo-normalization of diffusion between 24 and 48 h after the insult, so MRI imaging should be immediate or deferred until the 3rd day of life. MRI will give information as to the extent of hypoxic injury, mechanism, and prognosis. Common patterns are:
  - Focal or multifocal cortical necrosis due to loss of perfusion in one or more vascular territories, e.g. middle cerebral artery (MCA). Usually due to a thrombotic or embolic event. Results in cystic encephalomalacia, ulegyria (loss of sulcal depth), or porencephaly depending on the territory, and a pyramidal pattern cerebral palsy.
  - Watershed infarction usually due to hypotension causing loss of perfusion of border zones. Results particularly in parasagittal and parietoccipital white matter loss and auditory, visuospatial and language deficits. In pre-term infants causes spastic diplegia.
  - Selective neuronal necrosis is an injury confined to specific cell types, e.g. hippocampi, brainstem nuclei, thalami, and basal ganglia. Prolonged partial asphyxia causes diffuse cortical necrosis, epilepsy, and learning disability. Acute total asphyxia may spare cortex but cause thalamic, basal ganglia and brainstem injury, and dyskinetic cerebral palsy.

See  p. 232.

### **Management of HIE**

- ABCs: protection of airway, maintenance of adequate respiration, and cardiopulmonary circulation.
- *Aim for normoxia and normocapnia*: avoid hypercapnia, which may cause cerebral acidosis, and cerebral 'steal phenomenon' and hyperperfusion. Hypocapnia may lead to decreased cerebral blood flow (CBF).
- Maintain cerebral perfusion pressure (CPP) in normal range. Aim for mean arterial pressure (MAP) of at least 45–50 mmHg in term infants, 35–40 mmHg in infants 1000–2000 g, and 30–35 mmHg in infants <1000 g. Continuously monitor MAP and if possible central venous pressure (CVP).
- Prevent hyperperfusion injury by minimizing rapid boluses of colloid or crystalloid.
- Use pressors as necessary to minimize need for volume expansion in maintenance of CPP.
- Avoid hyperviscosity by keeping haematocrit <65%.
- Keep glucose ~4.5–5 mM.
- Aim for normal serum Ca.

**Therapeutic cooling for neonatal encephalopathy<sup>1</sup>**

72 h of cooling to a core temperature of 33–34°C started within 6 h of birth reduces death and disability at 18 months of age in:

- Infants with moderate to severe neonatal encephalopathy.
- >36 weeks' gestation.
- <6 h old.

Therapeutic hypothermia is achieved by either selective head, or total body cooling. Effective cooling is only achieved with good communication between regional neonatal intensive care and subsidiary units, supported by a multidisciplinary team experienced in neonatal intensive care, neonatal electrophysiology (such as cerebral function analyzing monitor (CFAM) and EEG), and neuroimaging (MRI), supervised by experienced clinicians.

**Practical considerations**

- Avoid external heat sources.
- Use cooling apparatus.
- Monitor rectal temperature.
- Notify to UK Total Body Cooling Trial (TOBY).

**Other measures**

- Control seizures.
- If possible, measure ICP and treat cerebral oedema. Cerebral oedema can be minimized by avoiding fluid overload (consider fluid restriction) and watching for signs of SIADH and acute tubular necrosis.
- At least take daily measurements of serum and urine Na, and osmolarity to look for signs of SIADH or acute tubular necrosis.

**Outcome**

Overall mortality is 10%; there are neurological sequelae in 20–40%. Indicators of poor outcome are Sarnat stage 3 encephalopathy, severe prolonged asphyxia, elevated ICP, early seizures, abnormal neurological signs at discharge and markedly abnormal EEG (burst-suppression, isoelectric; see Table 5.3).

**Neonatal brain death**

The notion that irreversible brain death can be reliably ascertained in the neonate remains controversial and in UK practice determination of brain death is currently deemed not possible in children <2 months corrected age.

**Metabolic encephalopathies**

A large number of metabolic, toxic, infectious, and genetic abnormalities may cause a neonatal encephalopathy. Acute metabolic encephalopathies have very similar clinical features due to accumulation of toxic metabolites in the CNS. The placenta usually clears toxic metabolites so the presentation may be delayed from hours to weeks post-partum (cf. HIE).

<sup>1</sup> Position Statement of the British Association of Perinatal Medicine, July 2010.

**Table 5.3** Sarnat scoring system

	Stage 1 (mild)	Stage 2 (moderate)	Stage 3 (severe)
Consciousness	Hyper alert, irritable	Lethargic ≠ obtunded	Comatose
Motor control	Over-reactive	Diminished spontaneous movement	Absent or diminished movements
Tone	Normal	Low	Flaccid
Posture	Distal flexion	Strong distal flexion	Intermittent decerebrate
Deep tendon reflexes	Brisk	Brisk with spread	Decreased or absent
Myoclonus	+/-	++	-
Suck	Normal	Suppressed	Absent
Moro	Weak	Weak/absent	Absent
Autonomic	Generalized sympathetic	Generalized parasympathetic	Both depressed
Pupils	Mydriasis	Miosis	Mid-position, anisocoria, poorly reactive
GI motility	Normal/decreased	Diarrhoea	Variable
Heart rate	Tachycardia	Bradycardia	Variable
Respirations	Spontaneous	Occasional apnoea	Periodic breathing or apnoea
Seizures	None	Common focal/multifocal	Uncommon
EEG	Normal	Low voltage, slow, seizures	Periodic, burst-suppression pattern, isoelectric
Symptoms	<24 h	2–14 days	Hours–weeks
Outcome	100% normal	80% normal unless symptoms persist more than 7 days	50% mortality 50% severe neuro-developmental disability

### Features of metabolic neonatal encephalopathies

- Alteration in mental state: irritability, lethargy, stupor, coma.
- Seizures.
- Feeding abnormalities: poor feeding, vomiting, failure to thrive.
- Respiratory abnormalities: tachypnoea, apnoea.
- Alteration in tone: hypotonia, hypertonia.

The presentation may mimic neonatal sepsis.

**Two patterns of presentation**

- Apparently well newborn with a period without symptoms, who goes on to develop lethargy, poor feeding, vomiting that progresses to stupor or coma, hyper- or hypotonia, seizures, respiratory alkalosis, metabolic acidosis, and hyperammonaemia (see Figures 5.1 and 5.2).
  - organic acidaemias, such as propionic, methylmalonic acidaemia (MMA) and isovaleric acidaemia (IVA);
  - urea cycle defects;
  - Maple syrup urine disease (MSUD).
- Frank and early neurological syndrome with profound hypotonia, coma, seizures, and apnoea without significant acid-base disturbances or hyperammonaemia:
  - non-ketotic hyperglycinaemia;
  - molybdenum cofactor deficiency;
  - pyridoxine-dependent seizures;
  - primary lactic acidosis;
  - mitochondrial disease;
  - peroxisomal disorders.

**Suggestive features in peripartum history**

- Absence of risk factors or clinical findings consistent with HIE.
- Consanguinity.
- Maternal acute fatty liver of pregnancy or haemolysis, elevated liver enzyme levels and low platelets (HELLP) syndrome. These complications of pregnancy are of unknown (probably heterogeneous) aetiology; however, some of the involved children later manifest fatty acid oxidation disorders.
- Oligohydramnios.
- Prolonged labour (steroid sulphatase deficiency).
- Abnormalities of foetal movement (*in utero* seizures, recurrent hiccoughs, non-ketotic hyperglycinaemia (NKH)).
- Hydrops foetalis (lysosomal disorders).
- Neonatal hypoglycaemia (fatty acid oxidation disorders, glycogen storage disorders).
- Neonatal hepatic dysfunction (galactosaemia, tyrosinaemia).
- Neutropaenia, thrombocytopenia.

**Suggestive examination findings**

- *Dysmorphism*: pyruvate dehydrogenase (PDH) deficiency, glutaric aciduria II, CDG, Zellweger, Smith–Lemli–Opitz.
- Cardiac dysfunction (mitochondrial disease, Pompe, CDG).
- Abnormal body odour (maple syrup urine, isovaleric aciduria, glutaric aciduria type II).
- Jaundice and hepato/splenomegaly.

**Initial investigations of suspected IEM**

- FBC and differential.
- Urea and electrolytes, creatine.
- Blood gas with base excess.
- Anion gap.
- Glucose.
- Lactate.



- Ammonia.
- Liver function tests.
- Plasma amino acids.\*
- Uric acid.\*
- Plasma carnitine and acylcarnitine.\*
- Biotinidase.\*
- Urine ketones.
- Urine reducing substances.
- Urine ferric chloride reaction
- Urine organic acids with orotic acid.\*
- Urine amino acids.\*
- CSF glucose, protein, cell count.
- CSF lactate.
- CSF amino acids.\*
- CSF neurotransmitter and folate metabolites.\*
- CT or MRI.
- Urinary sulphite.
- EEG.

\* Tests that may be deferred to second line.

### **Management of the newborn with a suspected metabolic encephalopathy**

- Manage cardiorespiratory depression (ventilate).
- Stop milk/protein feeds.
- Start 10% dextrose with electrolytes (initially 3 mL/kg/h).
- Correct hypoglycaemia if present.
- Avoid over hydration if renal function is impaired.
- Monitor for cerebral oedema (fullness of anterior fontanelle); avoid hypercarbia.
- Frequent monitoring (4–6 hourly) of acid–base state and electrolytes.
- Correct metabolic acidosis with intravenous bicarbonate (may require large amounts, up to 20–40 mmol/kg of  $\text{HCO}_3$ ).

Treat hyperammonaemia if a urea cycle defect suspected with Na benzoate (250 mg/kg load followed by 250 mg/kg/24 h infusion) or arginine 0.6 g/kg (6 mL/kg 10% arginine) over 90 min.

▶▶ Discuss urgently with a metabolic physician if hyperammonaemia present. Urea cycle defects, MSUD, and organic acidaemias will almost certainly require haemofiltration or haemodialysis support.

- B12 1 mg IM if organic acidaemias are suspected.
- Biotin 10 mg orally daily.
- Thiamine 50 mg orally daily.
- Carnitine 25 mg/kg 6 hourly for suspected organic acidaemias or fatty acid oxidation disorders.
- *Treat seizures per protocol*: if seizures are prominent, consider trial of pyridoxine/pyridoxal, biotin and folinic acid, see [p. 483](#).
- Once a diagnosis has been determined, therapy should be tailored to the underlying IEM, e.g. Na benzoate and dextrometorphan for NKH, dietary manipulation, etc.

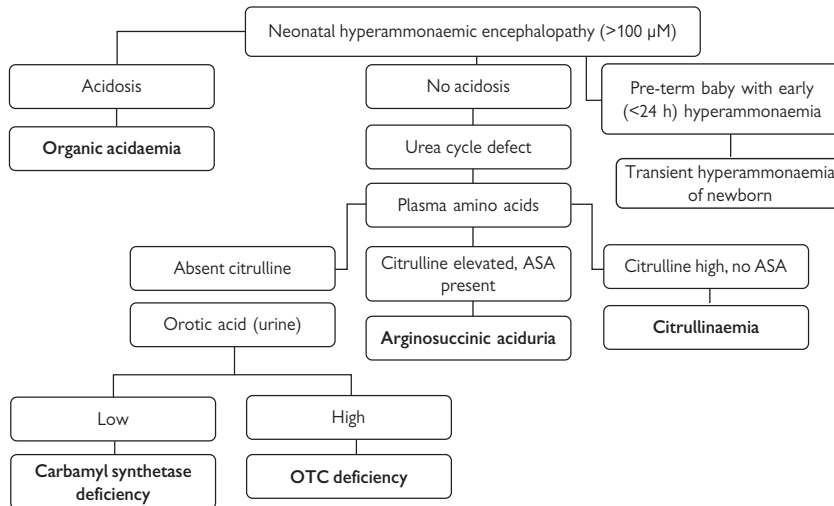


Fig. 5.1 Hyperammonaemia flow chart.

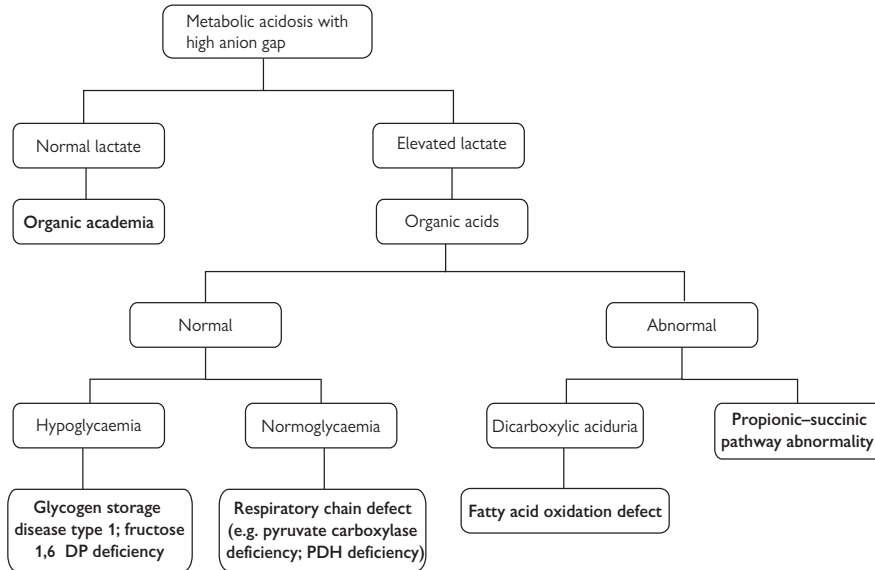


Fig. 5.2 Metabolic acidosis flow chart.

## Cerebral haemorrhage in the neonate

Occurs in 2–30% of newborns depending on the location of the haemorrhage and gestational age.

### *Extra-axial bleeding*

- Term or pre-term.
- Extradural, subdural, and subarachnoid.

### *Intra-axial bleeding*

- Pre-term or term.
- *Intraparenchymal haemorrhage*: cerebral and cerebellar.
- Germinal matrix haemorrhage/intraventricular haemorrhage.

### *Extradural haemorrhage*

Extradural haemorrhage/haematoma (EDH) is very rare in the newborn and is usually related to trauma, such as skull fracture.

### *Subdural haemorrhage*

Subdural haemorrhage (SDH) is relatively common secondary to rupture of draining veins and sinuses due to cranial deformation and torsional forces. Risk factors include non-vertex presentation, large foetal head size, primiparous, or older multiparous mother, instrumental delivery or rapid/prolonged labour. Small, clinically inconsequential SDH are common in vaginal deliveries.

If SDH is large, then presentation is soon after birth.

- Infratentorial haemorrhage causes brainstem compression with obtundation, respiratory abnormalities, abnormal extraocular movements, pupillary abnormalities, and nuchal rigidity.
- Supratentorial haemorrhage causes raised ICP, a bulging fontanelle, split sutures and downward herniation signs. SDH over the cerebral convexities causes seizures in 50% probably due to co-existent subarachnoid haemorrhage (SAH).
- A large SDH may cause systemic hypovolaemia.

Diagnosis is by CT or cranial ultrasound scan (USS). LP should be deferred if large SDH suspected. Investigate for sepsis and bleeding diathesis.

### *Management*

- Supportive with treatment of seizures.
- Correct hypovolaemia and anaemia.
- Urgent neurosurgical consultation if progressive brainstem compression, opisthotonus, or tense bulging fontanelle. Surgical evacuation of the clot is warranted in the minority with a large SDH.
- Ongoing for late development of hydrocephalus and chronic subdural effusions.

► The occurrence of small, clinically silent SDHs in otherwise well neonates is pertinent to investigation of SDH in later infancy in the context of NAI. They were noted in 8% children in one study: all had fully resolved by 4 weeks.

### *Subarachnoid haemorrhage*

- Primary SAH is frequent in term infants and usually clinically silent: usually due to parturitional rupture of small leptomeningeal or bridging veins.
- Secondary SAH occurs in pre-term infants due to subarachnoid extension of an IVH or posterior fossa SDH.
- Rarely causes significant hypovolaemia.
- Usually mild alteration in mental status, irritability and seizures. If the infant has a profoundly abnormal neurological exam, suspect either rare catastrophic large SAH (e.g. in the setting of bleeding diathesis) or HIE (in which SAH is frequently present).
- Diagnosis by CT supplemented by LP to diagnose small SAH (xanthochromic or haemorrhagic CSF).
- Treatment is supportive. Monitor occipitofrontal circumference (OFC) for development of late hydrocephalus secondary to chemical arachnoiditis.

### *Intraparenchymal haemorrhage*

- Cerebral IPH is uncommon in term newborns, but present in up to 10% of autopsied pre-term infants. Rare as a primary event: usually secondary to ruptured aneurysm or arteriovenous malformation (AVM), or secondary to coagulation disturbance.
- More common in a region of focal hypoxic injury (haemorrhagic transformation of arterial or venous infarction in term infants; watershed/periventricular in pre-term). Also seen in infants on ECMO. Cerebellar intraparenchymal haemorrhage (IPH) is more common in pre-term infants. May be primary, secondary to venous infarction or from extension of germinal matrix haemorrhage (GMH)/intraventricular haemorrhage (IVH).
- Cerebral IPH usually causes seizures, focal neurological signs, irritability or obtundation. Large cerebellar IPH may be similar to posterior fossa SDH.
- CT for urgent diagnosis, but should be followed with MRI with susceptibility and diffusion sequences to look for evidence of infarction, as well as MR angiography (MRA)/venography (MRV).
- Management is supportive with treatment of any underlying cause (e.g. venous sinus thrombosis). A large IPH may cause obstructive hydrocephalus.
- Prognosis depends on location, size, and aetiology of IPH. A large cerebral IPH may lead to epilepsy, hemiparesis, visual, or cognitive impairment. Cerebellar IPH in term infants has a relatively good prognosis, but residual cerebellar abnormalities, such as tremor and ataxia may exist, as well as mild cognitive and speech/language deficits. Large cerebellar IPH in the pre-term infant may lead to severe motor and cognitive deficits.

**Germinal matrix/intraventricular haemorrhage**

Diagnosis is almost always made by cranial ultrasound as part of a routine NICU screening programme.

- Present in up to 20% pre-term infants <32 weeks. Germinal matrix fragility is secondary to ischaemia reperfusion (e.g. after volume infusion resulting in fluctuating CBF).
- Term IVH is usually a haemorrhage from the choroid plexus or secondary to deep venous sinus thrombosis and thalamic infarction (Table 5.4).

It is usually clinically silent, but may present with a catastrophic syndrome of rapid neurological deterioration with coma, flaccid tone, tonic posturing, absence of spontaneous movements or a subacute deterioration in alertness and spontaneous movement over hours to days.

**Table 5.4** Neonatal intraventricular haemorrhage

Grade	Description	Risk of ventricular dilation and hydrocephalus	Risk of major neurological disability
I	GMH with no or minimal IVH (<10% ventricular volume)	5%	<2%
II	IVH occupying 10–50% of ventricle on parasagittal view	12%	<2%
III	IVH occupying 50% ventricular volume	75%	50%
Periventricular haemorrhagic infarction	Periventricular echo density	N/A	>90%

**Prevention**

- Antenatal glucocorticoids.
- Slow infusion of colloid and hypo-osmolar infusions.
- Prevent CBF fluctuations by sedation, treatment of seizures and gradual changes in mechanical ventilation.

**Management of established ventricular dilation**

- Assess speed of progression by daily OFC and clinical assessment, and weekly ultrasound.
- *Determination of obstructive vs. communicating hydrocephalus:*
  - perform LP aiming to remove 1–1.5 mL of CSF/kg; if little or no CSF is obtained, obstructive hydrocephalus is likely;
  - liaise with neurosurgery for consideration of ventricular tap or placement of ventricular reservoir.
- *Temporizing measures:*
  - 40% of infants will show spontaneous resolution;
  - options include serial LP, ventricular or reservoir tap, and adjunctive treatment with furosemide or acetazolamide;

- *Indications for neurosurgical intervention:*
  - rapid progression with deterioration in clinical status;
  - slow progression refractory to temporizing measures beyond 4 weeks.

### Neonatal stroke

Usually presents as seizure (see  p. 480).


#### Causes

- Global hypoxic-ischaemic encephalopathy (in association with other signs of HIE, see Box 4.2).
- Focal cerebral infarction due to embolus or thrombosis: it may be possible to distinguish on the basis of involved areas radiologically (e.g. > one territory? See Figure 4.9).

#### Embolic stroke

- Placental via persistent foetal circulation allowing right to left shunting (note placental condition).
- Cardiac.

#### Thrombotic stroke

- Polycythaemia (4% newborns are polycythaemic).
- Venous thrombosis (suggestive radiological appearances: typically secondary to infection, dehydration, prothrombotic state, venous congestion due to heart disease).
- Primary thrombophilia (see  p. 449).

#### Haemorrhagic stroke

- Subdural.
- Subarachnoid.
- Primary due to leptomeningeal vessel damage.
- Secondary due to extension of parenchymal or ventricular haemorrhage).
- Intraventricular/intraparenchymal.


### The floppy or weak newborn

See clinical presentations section,  p. 517 .

#### Arthrogryposis

Typically affecting multiple joints relatively symmetrically (arthrogryposis multiplex congenita, AMC). Relatively common (3 per 1000).

Indicates limited *in utero* movement, which in turn may reflect:

- Primary neurological cause of weakness, either central or neuromuscular in origin (for further assessment, see  p. 517).
- *Limited room for foetal movement:* clear antenatal history of oligohydramnios or uterine abnormality (tends to improve in first few months postnatally).
- Orthopaedic abnormalities of joint anatomy.
- *Primary muscle aplasia (amyotrophy):* this is the most common cause, accounting for ~40% of AMC, but a diagnosis of exclusion after assessment for primary neuromuscular disease. Scoliosis and pooling of secretions with aspiration makes a myopathy (particularly nemaline rod) likely.
- Half of those who are ventilator dependent have a developmental brain abnormality.

### Aneurysmal malformation of the vein of Galen

A persistent embryonic prosencephalic vein of Markowski normally present at 6–11 weeks of foetal life, which drains into vein of Galen; so a misnomer! Associated rarely with dominantly inherited capillary malformation-arteriovenous malformation and *RASA1* gene mutations.

Presentations:


- Cranial bruit: heard by parents!
- Developmental impairment with macrocephaly.
- High-output heart failure in the newborn from decreased resistance and high blood flow in the lesion.
- *Associated cerebral ischemic changes*: stroke, or steal phenomena with motor deficit.
- Mass effects leading to neurological impairment.
- CSF outflow obstruction and hydrocephalus.
- Haemorrhage—rare.

Management is usually by sequential endovascular embolizations. however morbidity is high and treatment should be managed by supra-regional centres with appropriate expertise.



## Neurosurgical consultations


### Headache

This often occurs in a child with hydrocephalus who has had normal ICP monitoring. Once raised pressure has been excluded the assessment is as for other children: primary headaches, especially migraine and tension-type headache are the most common (see  p. 151).

### Shunt complications

In evaluation of possible shunt malfunction a good history is at least as valuable as neuroimaging data.


#### Suspected blockage/fracture/other loss of function

- Up to 40% in the first year; 5–10% per year afterwards. 60–80% of shunts placed in infancy need revision within 10 yrs. Subsequent shunts have similar longevity.
- *Symptoms are typically subacute or chronic:* lethargy, headache, visual disturbance, behaviour alteration, non-specific symptoms, and occasionally seizures.
- Ultimately a good history is the most useful investigation. Relationship of headaches to posture particularly helpful (raised pressure headache due to shunt blockage typically worse after period of lying down, e.g. first thing in morning, also aggravated by cough, sneeze or straining at stool). Relationship of symptoms to recent shunt revisions also informative.
- If shunt complication is suspected, discuss this early with the child's usual neurosurgical team. ►► Refer urgently to a neurosurgeon if there is reduced Glasgow Coma Score (GCS).
- CT scan and X-ray series of the shunt at a local centre if the GCS is normal; otherwise stabilize and arrange rapid transfer to a neurosurgical centre. ⚠ Normal ventricles on CT do not exclude raised ICP!
- Consider neuroimaging data (including flow studies), ICP pressure monitoring and sampling of CSF from the shunt device (see  p. 97).
- A pragmatic approach is sometimes required (e.g. therapeutic trial of acetazolamide to reduce CSF production if raised ICP is suspected).

#### Over-drainage

- *Lethargy:* in contrast to raised pressure headache, headache due to over-drainage ('low pressure headache') is initially worse on *sitting or standing up*, improved by lying down.
- May occur immediately after lumbar puncture due to CSF leak.
- CT may show slit ventricles. MRI may show tonsillar descent. Ambulatory ICP monitoring may be needed for diagnosis.
- If occurring immediately after lumbar puncture then can be managed conservatively with bed rest for a few days until the leak has closed. If related to recent shunt revision then the shunt valve needs to be changed (to one with an increased opening pressure). A shunt with a programmable valve (whose opening pressure can be adjusted remotely) is particularly valuable.




### Infection

- Typically due to colonization of shunt with skin flora during insertion.
- Overall incidence ~10%: 90% occur within 9 months of placement.
- Risk much higher with post-operative CSF leak.
- Role of antibiotic-impregnated shunts in preventing infection being actively investigated
- Drowsiness, irritability, raised temperature. May be difficult to differentiate from urinary tract infection (UTI). Infection screen (FBC, C-reactive protein (CRP), urgent urine microscopy).
- Discuss with the neurosurgical team *before* tapping the shunt reservoir (see  p. 97; many neurosurgical teams insist on performing their own shunt taps).
- Treatment requires a period of shunt externalization (allowing the distal end of the shunt to drain into an external reservoir, rather than the peritoneum), prolonged intravenous and intrathecal antibiotics, and shunt replacement once CSF indices indicate eradication of the infection.


### Other shunt complications

Haemorrhage, abdominal pseudo-cysts, viscus penetration, shunt migration.

### Complications of intracerebral haemorrhage

- E.g. a subarachnoid haemorrhage from an aneurysm or arteriovenous malformation.
- Typical contributions of the neurologist include:
  - completing evaluation of aetiology (see  p. 218);
  - consideration of screening for family members (see  p. 452);
  - seizure control;
  - rehabilitation for acquired disability (see  p. 210).



### Sequelae of acquired brain injury

Arrangements for the post-acute early rehabilitation phase of children's recovery from acquired brain injury (ABI) vary between centres, but clear lines of medical responsibility are important (see  p. 210).


### Intracerebral sepsis

Liaison in management of cerebral abscesses (see  p. 345).

### Seizures in the context of neurosurgical disease

- *Disordered sodium homeostasis is common:*
  - dilutional hyponatraemia (see  p. 509);
  - cranial diabetes insipidus after craniopharyngioma and pituitary surgery.
- Interruption to regular intake of AED in children with known epilepsy, e.g. due to periods of nil-by-mouth. Convert to parenteral equivalents (see  p. 479) or consider temporary cover with phenytoin or phenobarbital.

## Oncology consultations


Common reasons for consultation are management of seizures (see  p. 504) and intrathecal methotrexate neurotoxicity. A wide range of neurological symptoms and signs can occur in the context of paediatric oncology. It is always tempting to blame the chemotherapy, but consider also:

- Metabolic derangements.
- Hypertension.
- Infection.
- Disease progression with meningeal seeding of tumour.

### Encephalopathy

Apply the usual clinical approach, with an open mind.

#### Metabolic


- Hypo- or hyperglycaemia.
- Hyperammonaemia and deranged liver function.
- *Electrolyte derangements, e.g.*
  - chemotherapy-related diarrhoea (severe mucositis);
  - attempted correction (hypocalcaemic seizures in a child overcorrected for diarrhoeal bicarbonate loss);
  - vincristine causing SIADH;
  - silent gastrointestinal tract (GIT) perforation (on steroids) and third space losses.
- Check that infection treatments have been instituted.
- Consider moving the child to the intensive care unit (ICU); see  p. 536.

#### Drug-induced encephalopathy


##### Methotrexate neurotoxicity

- Relatively common complication of intrathecal *or* systemic methotrexate treatment.
- *Very variable presentation:*
  - mood disturbance;
  - headaches;
  - drowsiness;
  - seizures;
  - focal neurological signs.
- Cytotoxic (intracellular) oedema detectable by diffusion-weighted MRI an early feature (T2 imaging may be initially normal, but becomes abnormal over days).
- Dextromethorphan suggested as symptomatic treatment.

##### Cyclosporin neurotoxicity

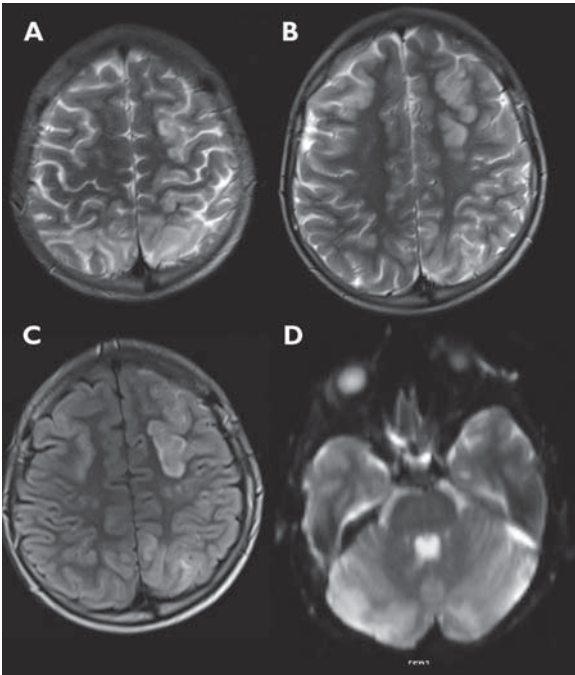
A relatively common cause of encephalopathy with seizures and motor signs closely resembling (both radiologically and clinically) PRES seen in hypertension (see  p. 524).


*Other drug encephalopathies with white matter changes on MRI*

- Amphotericin B, cytosine arabinoside, cisplatin, 5-fluorouracil (5-FU), fludarabine, ifosfamide, methotrexate, vincristine, ciclosporin (Figure 5.3), tacrolimus (FK506)
- Hypertensive encephalopathy (see  p. 523).

*Other drug encephalopathies with normal/uninformative MRI*


- Aciclovir (particularly if renal function impaired).
- Cephalosporins.
- Granulocyte colony-stimulating factor.
- *Ifosfamide is both directly and indirectly neurotoxic:*
  - causes electrolyte derangements including nephrogenic diabetes insipidus (DI);
  - non-convulsive status has been described;
  - treatment of direct encephalopathy with methylene blue.
- Steroids cause mood changes and irritability, as well as hypertension and idiopathic intracranial hypertension.



**Fig. 5.3** Typical appearances of ciclosporin neurotoxicity. Note that in this case changes are relatively asymmetric and not confined to occipital cortex (c.f. PRES, see  p. 524). T2 sequences top (A and B); FLAIR sequence (C), and DWI (D).


## Seizures

### Causes


- Any cause of encephalopathy (see  p. 502) including antibiotics, busulfan, chlorambucil, high-dose methotrexate, vincristine (hyponatraemia).
- Non-convulsive status epilepticus particularly with cisplatin, ifosfamide.

### Treatment



See  p. 286.

- Phenytoin is useful in acute presentation, particularly if cause of seizures likely to be temporary.
- Conventional first line approaches (carbamazepine and valproate) appropriate in many cases.
- If hepatotoxicity present (due to chemotherapy) consider benzodiazepines.
- Clomethiazole (see  p. 582) can be useful in palliative situations.

## Gait disturbance

- Often disease progression is a (well founded) concern.
- Assess (see  p. 144) to define more precisely the mechanism of the problem:
  - peripheral weakness (mono- or polyneuropathy e.g. due to vincristine);
  - loss of muscle bulk secondary to immobility or illness?
  - steroid myopathy?
  - ataxia?

## Paraesthesia

- Pressure palsy mononeuropathy causing immobility in a debilitated child. The characteristic distribution of the sensory disturbance and (if relevant) the motor deficit corresponding to the involved nerve should be sought (see  p. 30).
- Peripheral neuropathy occurs with vincristine and other chemotherapy agents (see  p. 505).

## Stroke

- Arterial infarction is reported with certain combinations:
  - vinblastine, bleomycin; and cisplatin;
  - cisplatin and 5-FU;
  - carboplatin and cyclophosphamide.
- CT will rule out acute haemorrhage due to thrombocytopenia.
- Asparaginase (used in acute lymphoblastic anaemia induction) associated with dural sinus thrombosis. Anticoagulate with low molecular weight heparin once a secondary haemorrhage into a venous infarct has been excluded.

## Headache

- Particularly related to intravenous immunoglobulin (IVIG) use (prevented by propranolol); also ondansetron, amphotericin B.
- Idiopathic ('benign') intracranial hypertension with steroid use.

### Cranial nerve signs

#### *Ophthalmoplegia, ptosis*

Vincristine.

#### *Facial palsy*

Cytosine arabinoside, ciclosporin after BMT, vincristine.

#### *Oto-toxicity*

Carboplatin, cisplatin; cytosine arabinoside (with vestibular involvement).

#### *Vocal cord palsy*

Vincristine (but diagnosis of exclusion: image!).

### Ataxia

Cytosine arabinoside, 5-FU.

### Aseptic meningitis

Intrathecal methotrexate.

### Autonomic dysfunction

Ileus, constipation, and bladder atony with vincristine.

### Myelopathy

- Intrathecal methotrexate, cytosine arabinoside or corticosteroids.
- Lhermitte's sign ('electric shock'-like sensations in the spine on neck flexion) may occur after cisplatin, BMT, or spinal irradiation.

### Peripheral neuropathy

- Vincristine, cisplatin, cytosine arabinoside
- Neurotoxicity with vincristine is dose-related and cumulative. A poor nutritional state may exacerbate the severity:
  - numbness and tingling are a common early sign;
  - muscle cramps;
  - mild symptoms (loss of ankle reflexes, slapping gait) are common even at conventional dosages;
  - reduction in dose of vincristine may be necessary if symptoms are severe, symptoms and signs are slowly reversible on discontinuation of the drug.

Treatment in all cases is supportive, with consideration of reduction or discontinuation of the responsible agent in conjunction with the oncology team.

### Cerebellar mutism

See  p. 461.

### Opportunistic central nervous system infections

See  p. 351.

Unusual infections arise due to impaired host defence as a result of:

- Aggressive anti-cancer therapy.
- Immunosuppression for organ transplantation or autoimmune disease.
- Acquired immunodeficiency syndrome (HIV/AIDS).

Diagnosis can be difficult, with a wide range of possible agents including many organisms normally of low pathogenicity. Concurrent infection with more than one agent is frequent.

Manifestations of CNS infection such as headache, meningism, or fever may be mild or absent.

Survival without deficit depends on rapid diagnosis and effective therapy.

### Diagnostic pointers

#### Clinical setting

- Children receiving chemotherapy causing marked lymphopaenia (e.g. acute lymphoblastic leukaemia (ALL), Hodgkin) and prednisolone develop a typical spectrum of CNS disease:
  - bacterial meningitis (*Haemophilus influenzae*, *Streptococcus pneumoniae* or *Listeria monocytogenes*);
  - fungal meningitis (*Cryptococcus neoformans*, *Aspergillus fumigatus*);
  - viral infections (herpes viruses and progressive multifocal leucoencephalopathy (PML)).
- In the context of HIV/AIDS, there is a strong association between Epstein–Barr virus (EBV) infection and the development of primary CNS lymphoma.

#### Time course of symptom progression

May help define the pathogen.

- *Acute onset*: bacterial meningitis with ‘conventional’ organisms.
- *Subacute presentation with fever and headache*: *C. neoformans*, *M. tuberculosis*, *L. monocytogenes* or herpes virus.
- *Chronic progressive focal neurological picture*: PML.

#### Pattern of clinical signs and symptoms

- *Focal deficits*: space-occupying lesion (toxoplasmosis, aspergillosis, PML, *Cryptococcus*, bacterial brain abscess, metastatic malignancy) or stroke (Varicella zoster virus (VZV) vasculitis; haemorrhage secondary to thrombocytopenia).
- *Spinal cord*: extradural abscess or tumour; transverse myelitis due to CMV, Herpes simplex virus (HSV), VZV, or parasitic infection; intrinsic infiltrative tumour.
- *Radicular mononeuropathy or polyradiculopathy*: HSV or CMV.

Consider data from peripheral blood count and differential, acute phase reactants, CSF cellular response (although this may be misleading), MRI and culture of blood, CSF, nose, throat, sputum, and urine (bacteria, fungi, and viruses). Specific management requires close liaison with oncologists, microbiologists, and virologists.

## PICU consultations

For issues specific to cardiac ICU, see  p. 471.

### Coma

For acute (emergency) management of coma, see  p. 536.

Coma is a common medical emergency with many causes. The prevalence of each cause differs with age. A significant number of children will have an unexplained or cryptogenic encephalopathy despite extensive investigations.

#### Causes of coma

##### Traumatic

Accidental traumatic brain injury (TBI) or inflicted non-accidental injury (NAI).


##### Non-traumatic

- *Hypoxia-ischaemia*: cardiac/respiratory arrest, acute life-threatening event, suffocation, drowning, severe hypotension, birth related (NICU).
- *Infection/inflammation*: meningo-encephalitis, abscess, shunt infection, post-infectious acute disseminated encephalopathy (ADEM), cerebellitis.
- *Epilepsy*: post-ictal, subtle motor status epilepticus, non-convulsive status epilepticus (NCSE).
- *Vascular*: intracerebral haemorrhage/embolism, hypertensive encephalopathy, venous sinus disease with venous infarct.
- *Metabolic*: hypoglycaemia, diabetic ketoacidosis (DKA), renal failure, adrenal failure, liver failure/hyperammonaemia, hyper-/hyponatraemia.
- *Toxic*: accidental or deliberate drug ingestion, heavy metal poisoning, e.g. lead or iron.
- *Hydrocephalus*: first episode (post IVH or CNS infection, tumour), blocked shunt.

#### Identification of the cause

Cause may be obvious from history. If not, consider the following:

##### Infective and para-infective

- *Uncommon infections*: malaria, TB, meningitis, or Japanese encephalitis if they have travelled previously to an endemic area or are in high risk group (see  p. 336).
- *ADEM*: onset 1–2 weeks after viral or other infection or vaccination resulting in coma  $\pm$  focal neurological signs.
- Rarely, coma can result from acute onset primary peripheral neuromuscular disease causing hypoventilation and hypoxia (e.g. rapidly progressing, unidentified GBS).

##### Trauma

- Particularly with bilateral periorbital haemorrhage, otorrhoea or rhinorrhoea (positive BM stick with CSF) indicating basal skull fracture.
- *Non-accidental injury*: retinal haemorrhages  $\pm$  bulging fontanelle  $\pm$  shock or pallor. The story may not be consistent with the severity of the illness.



*Metabolic/toxic*

- Pear drops smell of ketones and tachypnoea in diabetic ketoacidosis.
- Unusual smell, decompensation after intercurrent illness (causing a catabolic state), unexplained hypoglycaemia, family history of unexplained deaths in siblings suggestive of an inherited metabolic defect.
- History of pica ± learning disability in lead encephalopathy.

*Raised intracranial pressure*

- History of perinatal IVH or prematurity, previous meningitis or recent symptoms suggestive of raised intracranial pressure in hydrocephalus.
- Recent dehydration or family history of thrombophilia in venous sinus thrombosis.
- Child with a ventriculo-peritoneal (VP) shunt.

*Vasculitic*

Recent gastroenteritis in haemolytic–uraemic syndrome (HUS) with CNS involvement.

**Immediate investigations**

See  p. 539. Ensure these are complete.

**Further/subsequent investigations to consider**

It is not intended that this list be slavishly followed in all cases. Tailor the investigation to the clinical picture.

*Blood*

- Plasma amino acids, carnitine, and acylcarnitine.
- Haemoglobin electrophoresis.
- Serology ± PCR for other infectious causes.
- DNA for mitochondrial mutations and storage.
- Autoantibodies including ANA and dsDNA, erythrocyte sedimentation rate (ESR).
- Serum angiotensin-converting enzyme.
- Thyroid autoantibodies and function.
- Blood film for malaria.


*Urine*

- Na level.
- Porphyrin screen.

*Lumbar puncture if not contraindicated* (see  p. 537)

- CSF amino acids.
- Cytospin for malignant cells.

*MRI*

Especially if ADEM, posterior fossa pathology or stroke is a possibility. Additional sequences such as inversion recovery, diffusion-weighted imaging, MRA or MRV may be indicated (see  p. 57).

*EEG*

- Rarely provides direct clues to aetiology, but may be useful (e.g. demonstration of marked asymmetry suggesting a focal pathology).
- Periodic complexes in herpes encephalitis.
- Exclude non-convulsive status epilepticus.

### Others

- Sputum or stool for culture and viral studies.
- Muscle or skin biopsy (fibroblast culture) for investigation of mitochondrial disorders.
- *Brain biopsy*: consider if the result will make a difference to management.

### Hyponatraemia in a neuro-intensive care setting

Hyponatraemia commonly occurs following neurological disease (e.g. TBI, tumours, meningoencephalitis, and stroke) and may indicate poor prognosis. It is particularly common after subarachnoid haemorrhage (30%).

It is an important preventable cause of secondary neurological insult, aggravating cerebral oedema, precipitating seizures, and sometimes causing irreversible white matter change.

Causes include:

- Syndrome of inappropriate ADH secretion (SIADH): can occur after CNS injury, but is over diagnosed and often assumed when the true cause is either:
    - *dilutional hyponatraemia*—inappropriate use of large volumes of hypotonic fluid; or
    - *cerebral salt-wasting (CSW) syndrome*—the cause is unknown, but appears to be primarily a natriuretic effect on the kidneys.
- Key to distinguishing CSW from SIADH or dilutional hyponatraemia is that CSW is associated with hypovolaemia (due to salt and water loss).

### Evaluation of hyponatraemia

- If measured plasma osmolality is  $2 \times [\text{Na}]_{\text{plasma}}$  in the absence of uraemia, consider hyperglycaemia or mannitol as the cause of hyponatraemia.
- Blood urea is often low in SIADH (dilutional), but normal/high in CSW.
- Low output of concentrated urine in SIADH; high output of dilute urine in CSW.

In CSW there is

- Clinical evidence of hypovolaemia: poor skin turgor, shrunken eyes, dry mucous membranes, absence of perspiration, tachycardia. Low central venous pressure (CVP  $<6$  mmHg) and low pulmonary capillary wedge pressure (PCWP) if measured ( $<8$  mmHg).
- Loss of weight on serial testing since admission (weight increased in SIADH).
- Negative water balance on input/output chart.
- Negative 24 h Na balance (output input over 24 h):
  - calculate input from infused fluids;
  - output (mmol per 24 h) =  $[\text{Na}]_{\text{urine}} \times \text{urine output in 24 h}$ ;
  - Na balance neutral in SIADH.
- Marked elevation of  $[\text{Na}]_{\text{urine}}$  (variable in SIADH).
- Biochemical evidence of haemoconcentration with elevation of high urea, haematocrit, urate (low in SIADH), potassium (not usually seen in SIADH).
- In complex/ambiguous cases, seek specialist (e.g. nephrology) advice.
- Some children may have SIADH first then evolve to CSW after a few days.

**Management**

- In dilutional hyponatraemia, correct fluid prescription.
- In SIADH, consider further fluid restriction (discuss with intensivist).

**Management of CSW**

- Treat the underlying neurological process especially intracranial pressure or hydrocephalus.
- **Volume replacement:**
  - maintain hydration with intravenous isotonic saline (0.9% NaCl);
  - blood products are useful if the child is anaemic;
  - colloids may help by expanding the volume and absorbing interstitial third-space fluid;
  - match urine loss and keep a positive fluid balance.
- **Positive sodium balance:**
  - calculate Na deficit =  $(140 - [\text{Na}]_{\text{plasma}}) \times \text{total body water}$  (estimate as 50–60% of ideal body weight);
  - aim to correct at no more than 1 mM per hour with oral salt or hypertonic saline to ensure positive Na balance;
  - there is a risk of precipitating central pontine myelinolysis with over-rapid correction;
  - consider preventing further salt loss with volume expansion using fludrocortisone (risk of hypokalaemia, fluid overload and hypertension).
- **Monitor:**
  - serum Na, volume status (including overload with pulmonary oedema); monitor CVP or even PCWP;
  - Na and water balance.

**Brainstem death examination**

Brainstem death (BSD) should be suspected in any deeply comatose and apnoeic child with a profound or diffuse brain insult. Causes of BSD in children are TBI, CNS infection, and cerebral hypoxia secondary to cardiac/respiratory arrest; smoke inhalation/carbon monoxide poisoning, intracerebral haemorrhage, tumour, and drug ingestion.

❗ The validity of BSD testing in neonates has not been established and should not be performed in children of less than 2 months corrected age.

**Diagnostic criteria for brainstem death**

- Profound coma of *known cause* with total unresponsiveness to noxious stimuli.
- A structural brain lesion sufficient to explain the clinical findings.
- Apnoea despite induced hypercapnia (see 📖 'Apnoea test', p. 511).
- Absence of all reflexes subserved by the brainstem and cranial nerves (pupillary light, vestibuloocular, corneal, gag and cough reflexes). Spinal reflexes, including deep tendon reflexes; and spinal myoclonus may (rarely) be preserved.
- Irreversibility.

**Pre-conditions**

- Body temperature 35°C.
- Metabolic and endocrine causes or contributors to coma and/or neuromuscular blockade—particularly drugs—must be excluded.

**Serial testing**

- Two senior doctors, preferably the consultant in charge of care and another independent doctor, should perform testing.
- Wait 6 h from onset of the coma before initial testing. Wait 24 h if the coma follows a cardiac arrest or general anaesthetic.
- Tests should be repeated in all cases. Timing is at the discretion of medical staff (typically 24 h apart), but should take the family's needs into account.

**Cranial nerve reflex testing***Pupillary light reflexes*

Test in a dark room with a bright source. Pupils will be mid-position in BSD. May dilate further after cardiac arrest. Pupils should not respond to light.

*Corneal reflex*

Test with a cotton bud; no blink response seen.

*Gag/cough reflex*

No response to pharyngeal or tracheal suction to carina via an endotracheal (ET) tube.

*Vestibulo-ocular reflexes*

Equivalent to oculocephalic reflex testing.

- Make sure no eardrum perforation is present.
- Elevate the head to 30° above horizontal.
- Infuse 20 mL of ice-cold water into each external auditory meatus with an assistant holding the child's eyes open.
- There should be no eye movement, limb movement, or grimace.

**Apnoea test**

Hypercapnia is the stimulus to breathe. The technique of apnoeic oxygenation used is:

- Adjust ventilator settings to achieve a PaCO<sub>2</sub> of 6 kPa (45 mmHg).
- Use 100% FiO<sub>2</sub> for 10 min. Pre-oxygenation will reduce the risks of the test, e.g. hypotension, cardiac arrhythmias, acidosis.
- Take baseline arterial blood gas.
- Take child off the ventilator and place a catheter at the carina with 100% O<sub>2</sub> at 8 L/min.
- Observe for 10 min ensuring oxygenation is maintained by a saturation monitor.
- PaCO<sub>2</sub> must rise to 8 kPa (>60 mmHg; i.e. rising at a rate of 3 mmHg or 0.4 kPa/min), whilst PaO<sub>2</sub> should remain at 26 kPa (>200 mmHg).

Failure of test—any respiratory effort including sighing.

**EEG**

EEG data may be very suggestive of BSD if no electrical activity is recorded, but you may get a false positive from metabolic/toxic suppression. It is useful in excluding epilepsy. Occasional false negatives may occur as some BSD children may retain rudimentary EEG activity (an isoelectric EEG is not necessary for diagnosis of BSD in the UK).

The legal time of death is when the first set of tests is completed, not when intensive care is withdrawn.

**Further reading**

Department of Health (1998). *Code of practice for brain stem death*, Available at: [www.dh.gov.uk](http://www.dh.gov.uk).

**Prognostication after acquired brain injury**

Neurologists are often requested to assist in assessing prognosis for recovery for a child in a coma.

**Traumatic injury***Predictors of mortality*

- Age (mortality is high in infants and young children, lowest in mid-adolescence then rising again), but this is confounded by injury mechanisms and severity (e.g. NAI in infants).
- Pupillary response (dilated non-reactive pupils persisting after initial resuscitation).
- Extracranial trauma (pelvic, chest injury).

*Predictors of morbidity*

- GCS motor score at 72 h:
  - M1, M2 or M3—almost invariably associated with severe disability;
  - M4, M5 or M6—good recovery or moderate disability in 75%.
- Hypoxia on admission.
- Hyperglycaemia may be an independent predictor of poor outcome.

**Non-traumatic coma***Cardiopulmonary arrest*

- Rare, usually in-hospital
- Outcome is poor. ~10–30% survive to discharge from the PICU
- Best predictor of mortality is whether consciousness was normal prior to arrest
- Out-of-hospital arrest has extremely poor outcome. Only 5% survival in better than vegetative state in one series.

*Respiratory arrest (without cardiac arrest)*

75% survival.

*Near-drowning*

- Outcomes after cold water immersion can be remarkably good:
  - thought to be protective effect of hypothermia;
  - intact survival reported after 60 min pulse-less immersion under ice.
- Warm water drowning (e.g. a swimming pool) is very different:
  - tends to a bimodal outcome—either vegetative or intact;
  - Arterial pH, ICP, and plasma glucose predict.

**Clinical assessment**

- Motor response to pain is the best clinical predictor of morbidity.
- Sedation/paralysis may cause false pessimism.
- Reliably absent motor response (e.g. repeated several days apart) has 100% positive predictive value for poor outcome.
- Radiological data may also be very informative.

## Electrophysiological indicators of outcome

### EEG

- Isoelectric, low-amplitude, suppression-burst, and markedly asymmetrical appearances are recognized as poor prognostic signs in all age groups, but positive and negative predictive values are uncertain.
- Normal sleep and reactive patterns suggest good outcome.
- 'Alpha coma' (coma associated with abnormally invariant and widespread A rhythms on EEG) has a poor outlook.
- The prognostic value of more sophisticated measures (quantitative EEG in neonates, compressed spectral array (CFAM) in older children) is under research.

### Evoked potentials

- Probably more useful than EEG. Relatively unaffected by anaesthesia.
- Easily repeated and (lack of) change over time is particularly informative.

#### Brainstem auditory-evoked potentials

- Largely reflect brainstem integrity. Hence, give similar data to clinical assessment of brainstem function.
- Reflect mortality, but not morbidity.

#### Visual-evoked potentials

Of limited value. May even be normal in vegetative state.

#### Cortical somatosensory-evoked potentials

- Positive predictive value (PPV) of preserved somatosensory-evoked potentials (SSEP) for good outcome is 90%.
- PPV of bilaterally absent SSEPs for poor outcome is 90%:
  - occasional false pessimism due to subdurals (can also suppress EEG amplitude);
  - selective brainstem injury (usually radiologically evident) can interrupt SSEP transmission to an intact cortex and also cause false pessimism—therefore, interpret with care in severe traumatic injury;
  - accuracy in neonates is less certain—false pessimism may be a risk.
- Multimodality-evoked potentials (combining several data sources) may be most accurate.

## Withdrawal of care decisions

Your job as consulting neurologist is to try objectively to describe future levels of neurodisability, as well as the (often considerable) width of the 'confidence interval' on that forecast.

Decisions as to whether such outcomes are 'acceptable' are highly value-laden, and family and professional views on these issues will be influenced by many factors. In addition to the brainstem death and persisting ('permanent') vegetative state situations, UK guidance (Royal College of Paediatrics and Child Health (RCPCH)) endorses *consideration* of withholding/withdrawal of intensive care on the grounds of:

- 'No chance' (delaying death with no significant alleviation of suffering).
- 'Intolerability' (excessive treatment is burdensome).
- 'No purpose' (a judgement of quality of future life).

The only general principles that can be given here are that discussion must:

- Remain centred on the perceived interests of the child.
- Solicit the views of all involved parties (including family, carers, and nursing staff).

### Difficulty weaning from the ventilator

This is an infrequent, but recurrent requests for a consultation from PICU, usually in the context of a child ventilated for an apparently non-neurological problem.

► Investigation is guided by asking whether this is a child who is not waking up, or a child who is waking, but not breathing adequately. EEG may be helpful in this context. Causes of both:

Do not assume non-neurological causes have been excluded. Consider:

- Biochemical?
  - $\text{PO}_4^{2-}$ ;
  - $\text{K}^+$  (particularly in a child with neuromuscular disease);
  - $\text{Na}^+$ ;
  - malnutrition.
- Drugs?
  - causing a neuropathy—vincristine;
  - causing a myopathy—steroids;
  - causing a neuromuscular blocking effect—aminoglycosides;
  - prolonged effect—thiopentone (zero order kinetics and accumulation in adipose tissue).
- Cardiac or respiratory causes?
  - Ensure an opinion has been sought.
- Secondary effect of the primary non-neurological illness/PICU setting?
  - missed high cervical cord injury;
  - missed phrenic nerve injury;
  - hypoxic-ischaemic encephalopathy—evidence for this in history, charts, imaging?
  - critical illness polyneuropathy, usually in the context of multi-organ system failure. variable sensory-motor axonal neuropathy, myopathic changes;
  - ‘junior ICU syndrome’—dyskinesias (particularly choreoathetosis) associated with prolonged sedative use.
- Known primary neurological illness more severe than appreciated?
  - any cerebral insult;
  - botulism—ventilatory support may be required for months;
  - —particularly the acute motor axonal neuropathy (AMAN) form;
  - ongoing non-convulsive seizure activity.

### Undiagnosed neurological illness revealed in the acute presentation?

#### Central origin

- Neurodegenerative disease.
- Inborn error of metabolism.
- Mitochondrial disease.
- Posterior fossa abnormality, e.g. Arnold Chiari.
- Brainstem pathology.
- Central hypoventilation syndrome—hypoventilation during sleep, autonomic dysfunction, pupillary abnormalities, PHOX2B mutation analysis.

### *Neuromuscular origin*

- Myotonic dystrophy.
- Spinal muscular atrophy with respiratory distress type 1 (SMARD1).
- Autoimmune myasthenia gravis and congenital myasthenic syndromes.



### **Specific investigations to consider**

As well as specific tests for the conditions already listed:

- Tensilon<sup>®</sup> test.
- Diaphragm fluoroscopy.
- Peripheral neurophysiological studies with repetitive nerve stimulation and single-fibre electromyography (EMG).
- Muscle biopsy.

## **Abnormal movements on the ventilator**

### **Are they seizures?**


- Abnormal mouthing or chewing movements, or isolated limb jerks are relatively common in ventilated children and the possibility of seizures may be queried.
- Review history:
  - evidence of significant cerebral insult?
  - medication, particularly recent changes;
  - electrolyte and biochemical status (esp. Na, Ca, Mg, glucose).
- Evidence in favour of seizures may include
  - Synchronous changes in pulse rate, blood pressure or saturation
- Evidence against seizure disorder includes:
  - movements relate to handling, cares or change of position;
  - movements can be 'stilled' with gentle restraint or change of limb position (particularly in neonates).
- Differentials include:
  - post-pump and post-anoxic movement disorders (see  'Abnormal movements on extubation', p. 515);
  - decerebrate posturing and status dystonicus;
  - cerebral dysautonomia in severe (usually traumatic) midbrain injury (see  p. 211).

## **Abnormal movements on extubation**

### **Post-pump chorea**

See  p. 382.

### **Post-hypoxic movement disorders**


Lance–Adam syndrome (intention myoclonus) particularly after CO poisoning and other severe global hypoxia (e.g. strangulation); see  p. 381.

### **Drug/sedation withdrawal**


- Jittery tremors.
- Seen following withdrawal of opiates, benzodiazepines, and phenytoin.
- Treated with slow benzodiazepine taper ± clonidine.



### Acute life-threatening events

- Acute life-threatening events (ALTEs, which may be recurrent) are a rare, but dramatic PICU picture with a wide differential, of which direct neurological causes are relatively uncommon although ALTEs are often seen in children with neurodisability.
- Common causes include:
  - gastro-oesophageal reflux;
  - aspiration;
  - congenital myaesthetic syndromes, particularly choline acetyl transferase deficiency (CHAT), rapsyn deficiency (see Table 4.15);
  - central or obstructive apnoea (respiratory rhythm abnormalities noted in Rett syndrome and some mitochondrial disease);
  - primary cardiac dysrhythmias.
- Neurological causes include:
  - congenital myasthenia;
  - subtle (particularly frontal) seizures.
- Involvement of multiple specialities (respiratory, gastroenterology, cardiology) often occurs and good cross-disciplinary communication is vital.
- Polygraphic recording (ECG, saturation, chest excursions, nasal air flow, oesophageal pH) with video recording is extremely valuable. Understanding the pathophysiology of the event, particularly in relation to its onset, is invaluable. Is it heralded by a cardiac rhythm disturbance, or hypoxia? If the latter, is this caused by hypoventilation, obstruction or right-to-left shunting?
- Be prepared to consider carer-induced illness (see  p. 314).

### Refractory status epilepticus

- See  p. 545 for treatment regimes.
- EEG may be used to titrate therapy, e.g. to suppression-burst for 12 h before attempted withdrawal.
- Secondary complications of aggressive antiepileptic therapy are common (e.g. pneumonia and intestinal ileus with thiopentone infusion).
- The aggressiveness of anti-epileptic treatment needs to be tailored to individual circumstances including the aetiology (if known) of the status epilepticus, response to therapy in previous episodes and prior levels of neurodisability.

## Psychiatry consultations

### Conduct/behaviour disorder: is it epilepsy?

This question is often centred on displays of temper or other erratic/inappropriate behaviour.

- A detailed history defines the nature of the events (see [p. 136](#)). Video footage may be very useful and is certainly a higher priority than EEG.
- Is it truly paroxysmal?
- Is it truly stereotyped (i.e. features repeated between episodes), or is its occurrence situational or contextual?
- Does it occur in certain settings? Were there well-defined triggers? An ABC analysis is often undertaken in children with behavioural problems, using diaries or other methods to assess the Antecedents (what was happening in the run-up to the episode of concern), the features of the Behaviour itself (a detailed account) and the Consequences (what happened next: how others responded to the behaviour). The more an ABC analysis makes sense (i.e. the behaviour is explicable on the grounds of antecedents or consequences) the less likely it is to be epilepsy (see [p. 136](#)).

Recourse to EEG for supportive evidence should only be considered after careful reflection if genuine diagnostic doubt persists (because of the risk of over-interpreting non-specific findings of uncertain significance, which are more likely in the population being referred to psychiatry services particularly if they have any learning difficulties).

Psychiatrists occasionally use antiepileptic drugs for 'episodic dyscontrol'. They are effective mood stabilizers: their efficacy is not evidence of epilepsy.

Previously unidentified attendant developmental co-ordination disorder (DCD), and/or specific learning difficulties leading to educational and other failure are a far more common cause of conduct/behaviour disturbance. Liaise with the local neurodevelopmental paediatrician and educational services.

- Define the child's educational strengths and weaknesses.
- Examination will reveal significant coordination difficulties.
- Educational liaison/remedial therapy as appropriate.


Also consider mannerisms, stereotypies and tics.

### Psychosis: is it organic?

#### History

The typical story is of gradual emergence of unusual behaviour and/or social withdrawal together with falling school performance.



Main differentials of primary psychiatric psychosis are behavioural problems (particularly at school) due to unrecognized learning difficulties (see [p. 186](#)), acute confusional states (see [p. 104](#)) and, much more rarely, primary neurodegenerative disease (see [p. 179](#)).

- Is there hard evidence of true cognitive decline (i.e. actual loss of clearly previously established ability)? Compare 'developmental ceiling' effects (see  p. 186).
- Any history of an active seizure disorder?
- Family history particularly of schizophrenia and psychosis.
- Hallucinations? Visual or auditory? The former is more common in acute confusional state (see Table 3.1).
- Fluctuating higher mental function.

### Examination

The presence of motor signs (pyramidal, extrapyramidal, or cerebellar) is incompatible with a diagnosis of primary psychosis.

### Assessment

- In a young child with visual and cognitive regression mistaken for 'autism' consider late infantile neuronal ceroid lipofuscinosis (NCL; see  p. 428).
- In older children consider neurodegenerative disorders particularly:
  - Wilson;
  - juvenile X-linked adrenoleukodystrophy;
  - systemic lupus erythematosus and CNS vasculitides;
  - late onset vitamin B12 deficiency;
  - Huntington disease (see  p. 432);
  - Variant Creutzfeld-Jakob disease (vCJD), SSPE.

### Acute behavioural disturbance

See  p. 104.

### Unwanted drug effects

#### Tardive dyskinesia

This is most often associated with neuroleptics (phenothiazine, haloperidol), atypical antipsychotics (olanzapine) and, more rarely, with anti-emetics (metaclopramide or prochlorperazine), but it can also occur with theophylline. Estimated to occur in 71% of those taking these drugs?

- Late complication (hence, tardive).
- Usually affects mouth and face with stereotyped chewing, tongue protrusion, or lip smacking, may involve rocking or finger flexion and extension.
- May be associated with oculogyric crises. Consider treatment with procyclidine or benztropine.
- Associated with akathisia: sense of restlessness.
- Management: discontinue the drug if possible or substitute a drug less likely to give problem (e.g. aripiprazole for olanzapine or clozapine [but beware agranulocytosis]). Consider diazepam, clonazepam, or promethazine.






**Neuroleptic malignant syndrome**

This complicates the use of the neuroleptics. It may present with an altered level of consciousness or behaviour, progressing to muscle rigidity, hyperthermia rhabdomyolysis, and autonomic dysfunction.

- *Laboratory tests:* high CK, myoglobinuria, leucocytosis.
- Withdraw the drug.
- Aggressive correction of hyperpyrexia, dehydration, and hypovolaemia in the PICU.
- Bromocriptine may reverse the syndrome; dantrolene is helpful in achieving peripheral muscle relaxation.
- 20% mortality from respiratory failure.
- If clinically indicated, a low potency neuroleptic can be reintroduced very slowly when the individual recovers, although there is a risk that the syndrome might recur.

## Neuropsychiatric liaison work


Effective liaison between neurology and psychiatry is important for children with a number of conditions. Examples include:

- The adolescent with dyskinetic cerebral palsy who presents with loss of weight, food refusal, and a fluctuating affect (due to increasing insight into the disability).
- The child with an autistic spectrum disorder and seizures, who presents with new episodes of altered awareness, odd affect, and possible auditory hallucinations (role of epilepsy and/or its treatment).
- Rage and aggression in the context of temporal lobe epilepsy.
- Epilepsy and pseudo-seizures.
- 'Non-organic' disorders; illness behaviour. As stressed on  p. 311, a significant proportion of individuals may have an underlying neurological disorder (e.g. sensory neuropathy accompanying a gait disturbance), but symptoms may well exceed the difficulties expected for that diagnosis.
- Factitious or induced illness (see  p. 314).
- Medically unexplained symptoms including chronic fatigue syndrome (see  p. 314) and reflex sympathetic dystrophy (see  p. 174).
- Acquired brain injury (see  p. 213).

### Areas of joint management

#### Tics and Tourette syndrome

##### Neurologist

- Establishing diagnosis of tics after consideration of differentials, such as myoclonus or seizure disorder.
- Diagnosis of Tourette syndrome if appropriate ( p. 382).
- Arrangement of 12-lead ECG prior to consideration of treatment with agents that may prolong the QT interval. Check QT<sub>c</sub>.

##### Psychiatrist

- Assessment and treatment of co-morbidities (obsessive compulsive disorder (OCD), attention deficit hyperactivity disorder (ADHD)).
- Advice on monitoring of medication used and its escalation.
- Advice on psychological strategies for managing tics (e.g. massed practice).


#### Behavioural management in difficult to control epilepsy

Children with poorly-controlled seizures may have difficulties with behaviour and attention interictally. Episodic behavioural episodes may be mistaken for seizures and (for example) lead to excessive and inappropriate use of emergency seizure medication (e.g. buccal midazolam).

The role of the neurologist is to:

- Define seizure events where possible (reviewing video telemetry data).
- Define the extent of subclinical seizure activity and its impact on cognitive function.
- Define a protocol for seizure management for psychiatry staff.

Psychotropic medications (e.g. stimulants) have the theoretical potential to lower the seizure threshold, although this risk is often small in practice.

Psychiatrists may play a role in addressing some of the emotional and social ('axis 5') effects of severe epilepsy (see  p. 298).

### Aggression, conduct disorder, and oppositional defiant disorder

Precise diagnostic criteria for these conditions are established, but their practical value is debated. Difficulties may occur only in the family context or in a wider social context. The main concern with conduct disorder is that the younger the onset of difficulties, the worse the outcome in terms of risk of serious offending in later life.

Described as occurring in two age groups—middle childhood/early adolescence, and adolescence. In the latter, a distinction between socialized (with preservation of peer relationships) and unsocialized (offending alone with little guilt or concern) is useful. Physical aggression is less common in adolescence—truancy becomes more common; drug taking, sexual offences and prostitution can occur and gang fighting occurs in large cities.

#### Management

- Parenting skill training (e.g. Webster–Stratton for parents and children).
- Cognitive problem-solving skill training and family therapy (may be limited by learning difficulties).
- Social measures including support for housing and benefit applications.
- Very limited role for psycho-pharmaceutical intervention.



Consider assessment for occult learning difficulties, sensory and perceptual difficulties, and autism.

### Autism and epilepsy

Epilepsy is common in children with autism (one of the strongest pieces of evidence for a neurobiological, rather than psychosocial basis for autism), and many general epilepsy management principles apply.

#### Autistic regression

'Setback autism'—the onset of social and communicative withdrawal *after* apparently normal acquisition of the first few words—is relatively common.

- There has been debate about the extent to which non-convulsive status epilepticus, particularly continuous spike-wave discharges during slow wave sleep (CSWS)-like processes (see  p. 272), might contribute to autistic regression (by analogy with Landau–Kleffner syndrome, see  p. 272).
- This hypothesis would suggest that some children might be potentially helped by AEDs, such as steroids, but this is controversial:
  - the incidence of epilepsy in autistic children is comparable in those with and without a clear history of regression;
  - regression ('setback') rates are comparable in those with and without epilepsy;
  - sleep EEG 'epileptiform' abnormalities are seen in 10% even in the absence of regression and epilepsy (19% in those with regression).

- IQ is related to the presence of regression, not the presence of the EEG abnormality.
- In practice, achieving a sleep EEG is often very challenging in children with autism and yield is low. Epileptic exacerbation of autistic symptoms appears rare; nevertheless, sleep EEG is worth considering particularly if the severity of the autistic picture appears to fluctuate.
- Autistic symptoms *do* appear to be particularly common in children with seizures of right temporal lobe onset.

For most children with autism and epilepsy, antiepileptic therapy should be long term even if seizure freedom has been achieved. Long-term remission (seizure freedom off medication) is probably about 15%.

## Renal consultations

### Henoch–Schönlein purpura (anaphylactoid purpura)

This is an IgA-mediated autoimmune disorder affecting the joints, kidney, GIT and skin. A wide range of neurological manifestations occur in 2–7%.

- Headaches, changes in consciousness or behaviour, seizures, hemiplegia, paraplegia, cortical blindness.
- *Peripheral nervous system effects*: polyneuropathy, mononeuropathy and brachial plexopathy.
- Management is supportive.

### Systemic lupus erythematosus

See  p. 220.

### Haemolytic–uraemic syndrome

This is closely related to the pathologically indistinguishable entity of thrombotic thrombocytopenic purpura (TTP). Both cause thrombotic microangiopathy: the kidney is the major target in HUS and the brain in TTP but there is some overlap. HUS is broadly broken down into those with (D+) and without (D–) a diarrhoeal prodrome.

#### D+ HUS

A triad of thrombocytopenia, bloody stools, and renal failure. Associated with *E. coli* O157:H7 and *Shigella dysenteriae* infection. Typically food-borne, initially though person-to-person spread, a risk as it may be shed in the stool for several weeks after resolution of symptoms. Organisms produce verocytotoxins that bind to endothelial cells in the kidney.

#### D–HUS

- *Heterogeneous aetiology*:
  - drugs (including ciclosporin, tacrolimus, quinine);
  - autoimmune disease including SLE;
  - neuraminidase-producing organisms including *Pneumococcus*;
  - familial and neonatal forms.



Children with a recurrent, familial, or neonatal course have worse outcomes. Better in those who do not require dialysis. Late mortality is as high as 25%.

#### Neurological features

- Neurological complications occur in 30–50%.
- Seizures, stupor, coma, hallucinations, focal deficits including extrapyramidal signs. A cerebellar syndrome with truncal ataxia and mutism has been described.
- May occur in the absence of significant renal failure or hypertension.
- Management is symptomatic. Neurological sequelae occur in 10–20%.

### Hypertensive encephalopathy

#### Presentations

- Raised ICP syndrome with characteristic headache (see  p. 318) and papilloedema.
- Focal seizures.
- New onset focal motor signs (due to haemorrhage).
- Posterior Reversible Encephalopathy Syndrome (PRES) (see  'Posterior reversible encephalopathy syndrome', p. 524).



**Management**


Liaise early with PICU/renal consultant

- Control of seizures must be guided by blood pressure. AEDs may lower blood pressure and have an impact on cerebral perfusion.
- Both cerebral and renal autoregulation are affected by hypertension and sudden drops in blood pressure are to be avoided. Sudden drops in blood pressure risk focal infarction particularly of the optic nerve.
- A gradual reduction in blood pressure titrated with a labetalol infusion is a recommended approach with volume boluses given as required.

**Posterior reversible encephalopathy syndrome**


- A relatively common cause of encephalopathy with seizures and motor signs.
- Non-specific: despite the name may not be strictly posterior (occipital) or, indeed, fully reversible!
- Classically presents with seizures whose occipital onset are indicated by post-ictal visual loss (in otherwise alert—if terrified—child). Any focal neurological syndrome possible.
- Classically causes a symmetrical posterior white matter signal change on MRI:
  - distribution of signal change however highly variable;
  - early DWI, will demonstrate cytotoxic oedema and intracellular swelling;
  - T2 changes may be delayed;
  - ischaemia/infarction may enter radiological differential diagnosis—consideration of whether changes conform to an arterial territory or watershed distribution may be helpful.
- Prognosis depends on prompt recognition: usually there is near complete recovery on treatment of cause. Delay in treatment may result in permanent ischaemic change.
- Treatment otherwise is supportive.
- Very similar appearances and features can be seen in ciclosporin toxicity (see Figure 5.3 for typical appearances).
- Child may, of course, be both hypertensive and on ciclosporin!

**Idiopathic (“benign”) intracranial hypertension**

- Secondary to prolonged steroid use for renal disease (e.g. nephritic syndrome).
- For investigation and management, see  p. 334.

**Rhabdomyolysis/myoglobinuria**

Rarely presents primarily to the renal team, although nephrological input may be required for fluid management and/or acute secondary renal failure.

See  p. 404 for investigation.

**Neurological effects of uraemia**


These are now rare because of early dialysis.

- Encephalopathy.
- Seizures.
- Myoclonus.

- *Peripheral neuropathy:*
  - affecting two-thirds of children in chronic renal failure;
  - distal symmetrical mixed sensory-motor polyneuropathy;
  - restless legs, burning feet sensations;
  - rarely a fulminant course with flaccid quadriplegia;
  - improves with dialysis and transplantation.
- Myopathy.


### Neurological complications of renal transplantation

Essentially the risks of chronic immunosuppression.

- Infection in an immunocompromised host (see  p. 351).
- Ciclosporin neurotoxicity (see Figure 5.3).
- The reason for transplantation (e.g. renal dysplasia) may be associated with a risk of seizures as occurs in Bardet–Biedl syndrome. Poorly controlled seizures may warrant investigation for other causes (Laurence–Moon–Biedl syndrome has been associated with hypothalamic hamartoma).

## Respiratory consultations

### Long-term ventilation

CNS or neuromuscular disease may lead to respiratory insufficiency. Decisions on the use of long-term ventilation must be preceded by clear discussions with the child and family, on the aims of treatment and a frank exchange of views on end of life issues (see  p. 513). It will support respiration, and probably improve quality of life and survival.

### Functional factors predisposing to ventilatory failure

- Inspiratory failure due to: poor central drive, poor co-ordination, or weakness of diaphragm, external intercostals, or accessory muscles.
- Expiratory failure and poor cough due to poor co-ordination or weakness of abdominal muscles and internal intercostals.
- Bulbar paresis leading to poor swallow and secretion retention.

See  p. 254.

### Nocturnal respiratory failure and support

Poor tone during rapid eye movement (REM) sleep exposes diaphragmatic weakness; bulbar weakness leads to obstructive sleep apnoea. Strongly suggested by daytime hypercarbia, an indication for further assessment.

### Indications for nocturnal non-invasive ventilation (NIPPV)

- Night-time restlessness or sleep-disordered breathing.
- Headaches.
- Daytime fatigue or hypersomnolence.
- Deterioration in school work.

### Assessment

- Review sleep quality at clinic visits.
- Annual assessment to include where possible overnight CO<sub>2</sub> monitoring (or pulse oximetry), polysomnography, and respiratory function tests in neuromuscular disease.

### Indications

- PaCO<sub>2</sub> >6 kPa (45 mmHg).
- Nocturnal oxygen saturation <88% for 5 consecutive minutes.
- Maximal inspiratory pressure <60 cm H<sub>2</sub>O.
- Forced vital capacity <50% predicted.

### Difficulties/contraindications for NIPPV

- Poor mask tolerance.
- Bulbar involvement with secretion retention despite assisted cough.

The respiratory/long-term ventilation team will advise on mask fitting and ventilator type.

Ventilators are usually pressure-support, bi-level type devices (BIPAP). The set expiratory positive airway pressure prevents airway obstruction. An inspiratory positive airway pressure is set together with a back-up rate for when the child does not trigger a breath. Volume-type ventilators may be used to supply higher pressures when needed but cannot compensate for leaks like pressure-support devices.

**Diurnal respiratory failure and support**

More common in CNS disorders, but use in neuromuscular disease is increasing. Often preceded by tracheostomy.

*Indications*

- Diurnal hypercarbia despite adequate nocturnal ventilation.
- Dyspnoea.
- Increasing infections despite adequate cough therapy.

Mask or mouthpiece used with a portable volume ventilator, set in the assist-control mode. An open circuit is used with the circuit pressure to prevent alarming the child. The respiratory rate is set on the lowest possible to allow the child to take breaths as needed. A breath is activated by drawing air through the mouthpiece, thus creating a small negative pressure in the circuit by 'sipping' or inhaling.

**Disordered breathing patterns****Central apnoea**

Central hypoventilation syndrome is defined as persistent alveolar hypoventilation and/or apnoea during sleep, and impaired ventilatory responses to hypercapnia. Cessation of breathing occurs for >20 seconds, at times accompanied by bradycardia and cyanosis.



Generally, a problem of infancy, but may be seen later in childhood due to acquired brain injury, e.g. post-irradiation of posterior fossa tumours.

*Physiological causes*

- Inefficient central control of respiration seen in preterm babies (periods of regular, irregular or periodic breathing predominate), diminishing as term approaches; worse if ill.
- Drugs.
- Sepsis.
- Metabolic:
  - hypoglycaemia;
  - hypocalcaemia;
  - hypo- or hyper- magesaemia,
- Intracranial haemorrhage.
- Polycythaemia with hyperviscosity.
- Necrotizing enterocolitis.
- Patent ductus arteriosus.
- Temperature control (incubators).

*Pathological causes*

- Gastro-oesophageal reflux.
- Seizures.
- Neuromuscular disease.
- Encephalitis.
- Cardio-pulmonary disease.
- Metabolic disease.

- Anatomical abnormalities of brainstem, including Chiari malformation:
  - usually an incidental finding but take note if posterior fossa contents 'tight' (see  p. 333);
  - achondroplasia.
- Genetic disease:
  - Prader–Willi syndrome;
  - Riley–Day syndrome (familial dysautonomia, see  p. 394).

### **Idiopathic congenital central hypoventilation syndrome**

Unexplained by any of the listed possible causes. Polysomnography shows hypoventilation predominates in non-REM sleep with absent ventilatory and arousal response to hypercapnia and hypoxia.

Seen with autonomic dysfunction—very low heart rate and respiratory rate variability, abrupt asystole, abnormal pupillary reactivity, temperature dysregulation, profuse sweating, swallowing difficulties, and/or oesophageal dysmotility.

#### *Associations*

- Hirschsprung disease (seen in 20% cases).
- Neural tumours e.g., neuroblastoma, ganglioneuroblastoma or ganglioneuroma (seen in 5–10%).
- Test for *PHOX2B* gene mutation (encodes a key transcription factor in the development of the autonomic nervous system).

### **Late-onset central hypoventilation syndrome**

Presents following respiratory infection or anaesthesia, which may trigger the need for nocturnal ventilator support. Often preceded by chronic pulmonary hypertension, right heart failure, or respiratory infections with seizures or need for mechanical ventilation.

#### *Test for PHOX2B*

Mutations show variable penetrance and environmental cofactors may provoke presentation.

### **Management of central hypoventilation syndromes**





- Detailed history.
- Oesophageal pH monitoring.
- EEG.
- Polysomnography, as available/required:
  - When not available assemble as much data as possible from ECG/EEG/video, nursing observations.
  - In particular, what is the sequence? Bradycardia before apnoea? Reflux before apnoea? Breathing strongly against closed glottis?

#### *Counsel parents*

Consider acetazolamide, non-invasive/long-term ventilation as appropriate.

## Hyperpnoea

### Causes

- Raised ICP.
- Impending coning.
- *Behavioural phenotype in a number of syndromes, including:*
  - Rett (see  p. 278);
  - Joubert (see  p. 385);
  - Angelman (see  p. 278);
  - Leigh syndrome (a number of patterns may be observed, including sighing or apnoea);
  - Pitt-Hopkins (see  p. 278);
  - learnt behaviour, often for pleasure, in children with global impairment (may enjoy inducing seizures).

## Stridor

Occurs most often in neonates or infancy. History and examination give diagnostic clues, but endoscopy is usually, and imaging may be required.

### History

- Age at onset.
- Acute or chronic.
- Character, variation, triggers, relieving, or exacerbating factors.

### Examination

- Severity.
- Phase (inspiratory, expiratory, biphasic).
- General tone and posture.
- Handling secretions?
- Character of cough, cry, and voice?

### Imaging

- Lateral neck X-ray for soft tissues.
- *Barium swallow:* tracheo-oesophageal fistula?
- MRI.
- Possibly pH monitoring.

Stridor may be inspiratory, expiratory, or biphasic. Inspiratory stridor suggests a laryngeal obstruction, expiratory stridor implies tracheobronchial obstruction, and a biphasic stridor suggests a subglottic or glottic abnormality.

Acute stridor is infective. Most neurological stridor is chronic; other causes include congenital or acquired stenosis or other compressive abnormalities, including webs, rings aberrant vessels, etc.


## Laryngomalacia

- Accounts for 75% of childhood stridor.
- Inspiratory: worse with crying or feeding.
- Better when prone.
- Consider central hypotonia or a neuromuscular disorder.
- *Gastro-oesophageal reflux:* remediable with treatment.

***Vocal cord dysfunction***

- If unilateral may give weak cry and/or biphasic stridor, improving when lying on affected side.
- Bilateral paresis may give severe respiratory distress.
- Consider:
  - syringobulbia or other ponto-medullary abnormality;
  - Chiari II abnormality;
  - recent intrathoracic surgery.

***Dystonia/dyskinesia of vocal cords/larynx***

- Occasionally seen in older children as a focal dystonia or as part of a more generalized dystonia.
- Leads to paroxysmal dysphonia or pervasive strangulated sound to utterance.
- Liaison is centred on respiratory support, chronic lung disease as a co-morbidity (see  p. 254), and disordered breathing patterns.

## Rheumatology consultations

### Central nervous system features of autoimmune and autoinflammatory disease

What used to be referred to as 'rheumatic' diseases are increasingly understood in terms of disorders of the regulation of either the inflammatory or immune response. Whereas 'autoimmune' disorders typically involve cross-reactivity between a host and a target antigen, 'autoinflammatory' disorders are genetically-determined disorders of regulation of inflammation.


These conditions are characterized by diffuse inflammatory changes in the connective tissue, which may involve the CNS or peripheral nervous system in isolation or as part of a systemic vasculitis. In this section we deal primarily with CNS complications of known disease.

For discussion of CNS presentations of previously unrecognized autoimmune disease including:


- Sydenham chorea.
- Systemic lupus erythematosus.
- Sarcoidosis.
- Polyarteritis nodosa and other vasculitides.
- Hashimoto encephalopathy.
- Primary angiitis of the CNS.
- Autoimmune encephalitides.
- Rasmussen encephalitis.
- Paraneoplastic syndromes.

See  p. 218.

### Henoch-Schönlein purpura

See  p. 523, renal section.

### Haemolytic uraemic syndrome

See  p. 523, renal section.

### Kawasaki's disease

#### Diagnosis

Unexplained fever for 5 days and four of the following:

- Non-purulent conjunctivitis.
- Papulosquamous peripheral lesions.
- Erythematous trunk lesions.
- Cervical lymphadenitis.
- Inflamed mucous membranes in oropharynx and respiratory tract.

25% have aseptic meningitis (mononuclear CSF pleocytosis). Hemiplegia, seizures and subdural effusions have been reported. Do mention here the marked irritability as a non-specific, but significant feature (particularly in the 'small ones'/atypical Kawasaki disease (KD).

#### Treatment

IVIg; aspirin.



### **Chronic infantile neurological cutaneous and articular syndrome**

- Severe chronic inflammatory disease of neonatal onset.
- Also known as neonatal onset multisystem inflammatory disease (NOMID).
- Triad of:
  - persisting, migratory skin rash (starting in first few days of life);
  - sterile meningitis resulting in progressive neurological impairment (particularly vision and hearing);
  - recurrent arthritis—overgrowth of the patella and distal femur gives the characteristic knee appearance.
- Sometimes dysmorphic.
- Sometimes dominant family history.


#### **Treatment**

Interleukin-1 blocking agents (anakinra, canakinumab).

### **Haemophagocytic lymphohistiocytosis**

- A rare syndrome of multi-system involvement with widespread activity of inflammatory mechanisms, particularly activation of macrophages.
- Results in a pro-inflammatory clinical picture of fever, coagulopathy, CNS vasculitis, and hallmark evidence of phagocytosis of erythrocytes by macrophages.
- May be primary/familial (autosomal recessive) or secondary to infective triggers (particularly EBV).
- A clinically identical macrophage activation syndrome (of unknown cause) can be seen as a rare complication of rheumatological disease such as juvenile idiopathic arthritis, SLE, or CINCA).

### **Dermatomyositis**

Although primarily a disease of muscle and skin, CNS vasculitis can occur (see  p. 223).

See also infection in the immunocompromised host (see  p. 351).

# Emergencies

Acute agitation 534

Emergency management of coma 536

Traumatic coma 541

Status epilepticus 544

Status dystonicus 551

Sudden onset visual loss 558

The child who suddenly stops walking 559

Acute ataxia 572

## Acute agitation

In nearly all situations, environmental, rather than pharmacological, management of acute agitation or psychosis is to be preferred.

### Environmental changes

- Reduce environmental noise (e.g. TV).
- Ensure the room is well lit.
- Preferably use a familiar setting.
- Allow the child to mobilize to an extent consistent with safety—avoid restraint. Consider removing the bed and hazardous items (e.g. potential missiles) from the room and allowing sleeping on a mattress on the floor.
- Reduce numbers of unfamiliar bystanders to the minimum consistent with safety of personnel.
- Have familiar (e.g. family) members present.
- Ensure any sensory impairments are minimized (find misplaced hearing aids, glasses, etc.).
- Establish a rapport and attempt to reassure verbally and calm down: preferably consistently by the same member of staff.
- If medication is necessary, oral medication (haloperidol or risperidone) is preferable to parenteral administration.
- If parenteral administration is considered necessary, intramuscular administration is usually safer and more practicable than intravenous administration in an acute situation. Parenteral haloperidol can cause acute oculogyric crisis or dystonia (treat with procyclidine).

### Identify and treat the cause

Delirium has a large number of possible causes many of which are life threatening. It is therefore a medical emergency.

#### Causes of delirium

#### Morbid mnemonic! I WATCH DEATH

- *Infection*: extracerebral (pneumonia, urinary tract infections (UTI), sepsis, malaria) or intracerebral (meningitis or encephalitis, cerebral abscess); parainfectious including acute disseminated encephalomyopathy (ADEM).
- *Withdrawal*: alcohol, benzodiazepines, opiates, and other sedatives.
- *Acute metabolic*: hypoxia, hypoglycaemia, hepatic, renal, or pulmonary insufficiency. Electrolyte imbalance. Very rarely, porphyria.
- *Trauma*: head injury, burns, heatstroke.
- *Central nervous system (CNS) pathology*: space-occupying lesion/ infection, epilepsy (status and post-ictal states), other encephalopathies.
- Hypoxia.
- *Deficiency*: thiamine B1; folate; pyridoxine B6; B12.

- *Endocrine*: thyroid, adrenal, hypopituitarism, or parathyroid dysfunction.
- *Acute vascular*: transient ischaemic attack (TIA), stroke. Hypertensive encephalopathy, post-cardiac surgery. Cardiac failure or ischaemia. Subdural haemorrhage. Sub-arachnoid haemorrhage. Vasculitis, e.g. systemic lupus erythematosus (SLE). Cerebral venous thrombosis and migraines.
- *Toxins or drugs*: prescribed (steroids, sedatives, anti-epileptic drugs (AEDs) and narcotic analgesics) or recreational. CO poisoning.
- *Heavy metals*: lead, mercury.

### Drug treatment

Drug treatment of delirium should only be used when essential and then with care, especially in children. Antipsychotics and benzodiazepines can aggravate delirium, exacerbate underlying causes (for example, benzodiazepines worsening respiratory failure) and cause significant unwanted effects, e.g. acute dystonic reactions.


#### **Benzodiazepines**

- Usually preferred when delirium is associated with withdrawal from alcohol or sedatives.
- They may also be used as an alternative or adjuvant to antipsychotics when these are ineffective or cause unacceptable side effects.
- Intravenous/oral or buccal lorazepam doses may be given up to every 4 h.
- In children with delirium due to hepatic insufficiency, lorazepam is preferred to haloperidol.
- Excessive sedation or respiratory depression from benzodiazepines is reversible with flumazenil.

#### **Antipsychotic drugs**

- Antipsychotics are the most commonly used drugs in adults, but are less popular in children because of extrapyramidal effects.
- Onset of action is usually rapid, with improvement seen in hours to days.
- Haloperidol is often used because it has few anticholinergic side effects, minimal cardiovascular side effects, and no active metabolites.
- As it is a high potency drug, it is less sedating than phenothiazines and therefore less likely to exacerbate delirium. Low dose haloperidol is adequate for most children. In severe behavioural disturbance, haloperidol may be given intramuscularly or intravenously.
- It is preferable to use a fixed dosing regimen from the time of diagnosis, rather than giving the drug 'as required' in response to a recurrence of the disturbed behaviour.
- However, this mandates **at least daily review of the prescription** (dose and frequency) in light of wanted and unwanted effects.

## Emergency management of coma

For subsequent approach to investigation after immediate stabilization of child in coma see  p. 507.

- Remember initial resuscitation measures: **A**irway, **B**reathing, **C**irculation (ABC).
- Treat hypoglycaemia (if no explanation take plasma sample before treating).

### Assess Glasgow Coma Score

Coma level should be rapidly assessed using the modified Glasgow Coma Scale (GCS; see Table 6.1).

**Table 6.1** Modified Glasgow Coma Scale

	>5 yrs	<5 yrs
<i>Eye opening</i>		
4	Spontaneous	Same as >5 yrs
3	To voice	
2	To pain	
1	None	
<i>Verbal</i>		
5	Orientated	Alert, babbles, coos, words or sentences normal
4	Confused	Less than usual ability, irritable cry
3	Inappropriate words	Cries to pain
2	Incomprehensible sounds	Moans to pain
1	No response to pain	No response to pain
<i>Motor</i>		
6	Obeys commands	Normal spontaneous movements
5	Localizes to supra-ocular pain	Localizes to supra-ocular pain or withdraws to touch in infant <9 mths
4	Withdraws from nail bed pressure	Withdraws from nail bed pressure
3	Flexion from nail bed pressure	Flexion from nail bed pressure
2	Extension to supra-ocular pain	Extension to supra-ocular pain
1	No response to supra-ocular pain	No response to supra-ocular pain

If the coma score is deteriorating or  $<12$ , look for signs of raised intracranial pressure (RICP) and examine the brainstem reflexes for signs of herniation syndromes (see Figure 6.1) as rapid recognition and treatment of RICP can save lives.

### Examine for signs of herniation

Recognition and management of RICP is potentially life-saving. However, RICP is also dangerous.

- It reduces cerebral perfusion pressure (= mean arterial pressure – intracranial pressure), which causes cerebral ischaemia.
- Differences in pressure between different brain compartments cause herniation syndromes that cause direct mechanical damage and ischaemia and haemorrhage secondary to vascular distortion. Recognition requires examination of the brainstem reflexes.

❗ Don't mistake tonic posturing due to coning for a tonic seizure: treatment with benzodiazepines is likely to cause aggravating respiratory depression.

### Examination of brainstem reflexes

#### *Pupil response to light*

Use a bright torch. Note resting pupil size and symmetry, and briskness and symmetry of the response to light.

Do not mistake a dilated non-reactive pupil due to an afferent pupillary defect (optic nerve involvement in fracture of the bony orbit) for a fixed dilated pupil due to third cranial nerve involvement in a herniation syndrome (the consensual response is present in the former, absent in the latter. See [p. 18](#)).

#### *Oculocephalic ('doll's eye') reflex*

Exclude cord injury then turn the head from side to side, watch the eyes. The normal response is to maintain eye orientation in space (eyes move relative to the head and orbits). The abnormal response is to maintain position relative to the head (Figure 6.1).

#### *Oculovestibular ('caloric') reflex*

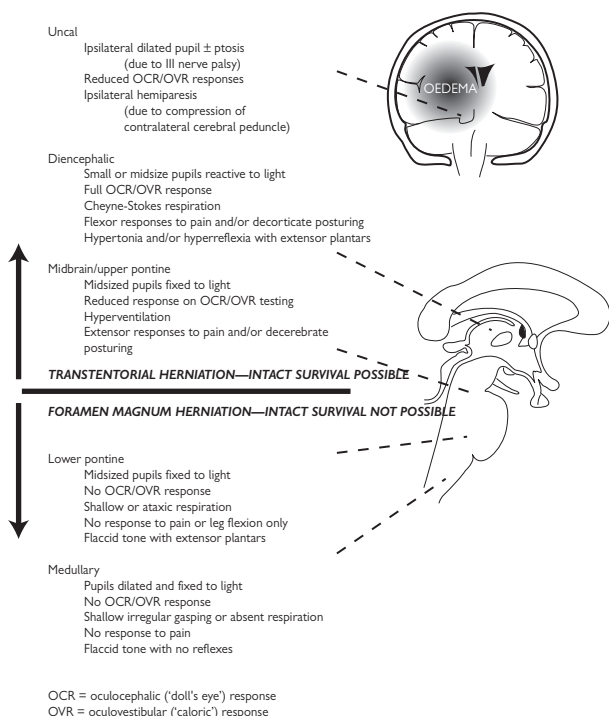
Equivalent to the oculocephalic reflex. Exclude a perforated eardrum then put the head in the midline and  $30^\circ$  back. Inject 20 mL of ice-cold water into the ear canal. Normally induces nystagmus with fast phase away from the tested ear (Figure 6.1).

#### *Examine fundi*

- Papilloedema in raised intracranial pressure (ICP; may not be present if ICP has increased rapidly).
- Presence of venous pulsation implies normal ICP (see [p. 17](#)).
- Macular star in hypertensive encephalopathy.
- Retinal haemorrhages in non-accidental injury (NAI).

### Stabilize

- If GCS is  $<8$  or there is evidence of herniation, intubate and ventilate.
- If GCS is 8–10 and there is evidence of herniation, give mannitol 0.25 g/kg bolus, or intubate and ventilate.




**Fig. 6.1** Herniation syndromes. OCR: oculocephalic ('doll's eye') response; OVR: oculovestibular ('caloric') response.


Intubation and ventilation of the unconscious child will be either for the purpose of securing a safe airway due to an inadequate cough and gag reflex, or for the management of raised intracranial pressure. Borderline cases should be discussed urgently with an intensivist or anaesthetist.

- If tonic eye deviation or nystagmus, assume subtle motor status epilepticus (see [p. 544](#)).
- If cause not obvious, and the child is either <12 mths old or GCS is >12 then perform lumbar puncture (LP). Then start IV 3rd generation cephalosporin.
- If GCS <12 or deteriorating, delay LP and start IV 3rd generation cephalosporin and IV acyclovir.
- Consider emergency cranial imaging (see [p. 541](#)).
- Liaise with local ICU and/or neurosurgeon, and arrange transfer if necessary.
- May need urinary catheterization and arterial line.


### Immediate investigations

- **Blood:** BM stick and plasma glucose, urea & electrolytes (U&E) and creatinine, plasma osmolality, full blood count (FBC) and film, C-reactive protein (CRP,  $\text{Ca}^{2+}$ ,  $\text{Mg}^{2+}$ , blood gas, ammonia, liver function test (LFT), lactate, viral studies, blood cultures (if febrile), coagulation if signs of bleeding or non-blanching rash, group and save if trauma. If deliberate/accidental poisoning is a possibility, save plasma sample.
- **Urine:** dipstick test for glucose and ketones, toxicology, microbiology, osmolality. Take samples for amino and organic acids. Freeze an acute sample if any suspicion of inborn errors of metabolism.
- **LP if not contraindicated** (see  p. 537): measure opening pressure; send for cell count, Gram stain, glucose (with matching plasma sample), lactate and protein, PCR/viral antibodies for herpes simplex encephalitis  $\pm$  other infectious agents. Send oligoclonal bands (with matching serum sample) if ADEM is suspected. Save a sample if possible. Consider a cytospin sample.
- **Computed tomography (CT):** with contrast if an abscess is suspected.
- **Other radiology:** skull, cervical, chest and pelvic X-rays if multiple trauma.

### If an inborn error of metabolism is suspected

- Usually occurs in a neonate, but occasionally a urea cycle disorder can present in later childhood with coma and hyperammonaemia.
- In any situation where a previously unidentified inborn error of metabolism (IEM) seems possible, stop feeds (source of protein that may further destabilize) and administer 10% dextrose to prevent tissue catabolism.
- For management of hyperammonaemia and metabolic acidosis, see NICU consults (see  p. 492). Hyperammonaemia will almost certainly require haemodialysis or haemofiltration.

### Further/subsequent investigations to consider

See  'PICU consultations', p. 507.

### Management of raised intracranial pressure

#### Basic measures


- Nurse head in midline and tilted up 30°. Keep head still. Minimal handling/suction.
- Ventilate to normocapnia. Hyperventilate/bag for raised ICP spikes.
- **Fluid:** maintain good circulating volume. Observe for syndrome of inappropriate antidiuretic hormone secretion (SIADH) or cranial diabetes insipidus. Careful fluid balance. 6-hourly U&E/osmolality.
- **Mannitol bolus:** use for spikes of raised ICP. Pay careful attention to fluid balance following the bolus (avoid hypovolaemia) as it acts as an osmotic diuretic.
- **Hydrocephalus:** consider ventriculo-peritoneal (VP) shunt/3rd ventriculostomy. Discuss with a neurosurgeon.
- **Seizures:** treat obvious seizures as they may cause RICP spike.
- **Electroencephalography (EEG):** will be useful if subtle motor status or non-convulsive status epilepticus (NCSE) is suspected. May be helpful in prognosis.



- *Consider use of cerebral function analysing monitor (CFAM):* 1–4 channels EEG shown as power spectrum (proportion of EEG activity in each frequency band). Requires close support from neurophysiologists including regular routine EEGs to interpret CFAM changes and ensure focal discharges not being missed.
- *Prophylactic barbiturates:* use is controversial and not standard in the UK.
- *Reducing body temperature:* mild hypothermia may be useful in head injury, stroke, neonatal hypoxic-ischaemic encephalopathy (HIE). Avoid rapid rewarming.
- *ICP monitoring:* consider in severe head trauma or if the child remains unconscious with signs of raised ICP and stable blood pressure (BP) more than 6 h after initial investigations and management. ICP can be measured with a direct pressure-sensing probe or via a ventricular drain and manometer. The latter allows cerebrospinal fluid (CSF) sampling and drainage as an additional management approach. Contraindicated in children with low platelet count ( $<50 \times 10^9/L$ ) and with caution in other bleeding diatheses.
- *CSF drainage or surgical decompression:* may be useful if RICP persists.

## Traumatic coma

Severe TBI has a mortality of between 8 and 15% in the UK.

- Initial management should be the same as for coma (see  p. 536).
- Avoid sedative (strong opiate) analgesia until assessment has been made.
- A cervical immobilization collar should be used when any of the following risk factors are present:
  - GCS <15 at any time since injury;
  - neck pain or tenderness;
  - focal neurological deficit;
  - paraesthesia in the extremities;
  - any other clinical suspicion of neck injury;
  - these children should have AP and lateral neck X-rays taken (including peg view if child is >10 yrs). Preferable to avoid neck CT in young children (high radiation doses to thyroid). Removal of cervical collar only after neuroradiological/neurosurgical review.
- Intubate and ventilate if indicated.
- Immediately if:
  - GCS  $\leq$ 8;
  - gag reflex lost;
  - respiratory difficulties (hypoxia, hypercarbia, respiratory arrhythmia) present.
- Consider if:
  - GCS deteriorating;
  - bilateral fractured mandible or other facio-oral injury present;
  - history of or witnessed seizures.

Arrange CT if:

- GCS <13 at any time since injury or <15 at 2 h after injury.
- Skull fracture present.
- Any sign of basal skull fracture (haemotympanum, 'panda eyes', CSF otorrhoea, Battles sign—blood over mastoid process).
- History of or witnessed seizures.
- Focal neurological deficit.
- Persistent vomiting.
- Dangerous mechanism of injury, including fall from >1 m (5 steps).
- Child has known coagulopathy/increased risk of fractures.

### Abnormal computed tomography findings

You may be the first person to look at the CT scan. Look for signs of:

- Skull fracture.
- *Cerebral oedema*: compression of CSF spaces, effacement of sulci, midline shift. May get reversal sign in severe cases—white matter is hyperintense compared with grey matter.
- *Haemorrhage (blood is white/hyperintense)*:
  - *epidural*—hyperintense extraparenchymal collection, blood does not cross sutures;

- *subdural*—hyperintense crescentic extraparenchymal collections over frontoparietal convexities; often compresses the ipsilateral ventricle; often bilateral; common in infants; consider non-accidental head injury in infants.
- *subarachnoid haemorrhage (SAH)*—hyperintense blood anywhere in the subarachnoid space, but most common in the posterior interhemispheric fissure or along tentorium cerebelli; often accompanied by intraparenchymal damage.
- *intraparenchymal*—homogenous hyperintense lesions within the parenchyma; may also get haemorrhagic contusions that are a mixture of oedema and haemorrhage; contusions are often a contra-coup injury.
- *punctate haemorrhages in cerebral white matter*—indicates diffuse axonal injury; seen after rotational head injury that causes shearing at the grey/white matter border; often associated with intraventricular haemorrhage and signs of oedema.
- *intraventricular haemorrhage*—hyperintense blood seen in the ventricles.

#### **When to get a magnetic resonance imaging scan**

Acutely if the neurological deficit cannot be explained by the CT findings. MRI is more sensitive for abnormalities caused by shearing injuries. Following the acute phase, MRI is the image modality of choice. Timing depends on the individual child.

#### **When to discuss with a neurosurgeon**



- If any CT scan abnormality present.
- There is persisting coma or confusion despite resuscitation.
- There is a deterioration in GCS (especially the motor component).
- Progressive focal neurological signs.
- Seizure without full recovery.
- Definite or suspected penetrative injury.
- CSF leak.

#### **Early neurosurgical intervention**

- *Evacuation of haematoma*: usually necessary if a midline shift >5 mm or if signs of herniation syndrome are present.
- *ICP monitoring*: often indicated if abnormalities on CT scan are present, or if the CT is normal and either systemic hypotension or abnormal posturing is present. The catheter is inserted into the subarachnoid space, brain parenchyma, or ventricles.
- *Surgical decompression with bone flap*: indicated for intracranial hypertension when medical measures have failed. Bone is refrigerated and autoclaved before reattaching.
- *External ventricular drain (EVD)*: indicated if hydrocephalus is present following SAH or intraventricular haemorrhage (IVH).

### Subsequent management

Liaise with ICU, neurosurgical colleagues, and therapists involved in neurorehabilitation.

- See section for management of RICP. See  p. 539.
- *General supportive measures*: prevention of pressure sores.
- Observe for paroxysms of sympathetic over activity with hypertension, fever and hyperhidrosis as well as other brainstem signs in children with diffuse axonal injury (see  p. 211).
- Monitor for signs of diabetes insipidus (DI) and treat with DDAVP if necessary.
- A VP shunt may be required if ventriculomegaly forms after clamping the EVD or if hydrocephalus develops after SAH or IVH.
- Observe for complications of direct vascular trauma including:
  - *Traumatic dissection*—usually follows neck trauma, e.g. whiplash injury. Presents with neck/head pain, stroke symptoms and signs  $\pm$  Horner's syndrome and lower cranial neuropathies. Need MRA for diagnosis.
  - *Carotid-cavernous fistula*—presents with visual problems, may have proptosis or chemosis of the eye and orbital bruits. Need CT angiogram or MRA for diagnosis.
- Tracheotomy may be necessary if prolonged ventilation is required.

See section on neurorehabilitation (see  p. 212) for more details.

### **Non-accidental (inflicted) traumatic brain injury**

The forensic evaluation of suspected non-accidental head injury is beyond the scope of this book. Your hospital should have protocols in place for the notification of concerns regarding possible inflicted (NAI) and its investigation.

From a clinical management perspective, the mechanism of injury in NAI head trauma in infants is often repeated shaking and/or impact against a hard surface. Secondary hypoxic injury is common. The repetitive nature of the inflicted acceleration/deceleration, the severity of the forces and the additional hypoxia can cause very aggressive cerebral oedema. Acute management of seizures can also be challenging, although this typically abates after a few days. Mortality and late morbidity rates are high.

## Status epilepticus

### Introduction

Generalized convulsive status epilepticus (CSE) is defined as a continuous generalized convulsion or repeated seizures without full recovery of consciousness between, lasting for 30 min or longer. A precise definition of non-convulsive status epilepticus (NCSE) is lacking.

Outcome is aetiology- and age-dependent. Overall mortality is significant, 3–9% die within 30 days of an episode of CSE or NCSE. Neurological sequelae are more frequent in infants: 30% vs. 6% over 1 yr of age.

Causes of CSE include fever (febrile convulsions comprise  $\frac{1}{3}$  of all CSE in childhood), epilepsy, withdrawal or change of AEDs, CNS infections, cerebral hypoxia, and metabolic disturbance.

### The first steps

These steps take minutes only and can be done concomitantly with preparing to start the CSE treatment algorithm (Table 6.2 and Figure 6.2).

**Table 6.2** The first steps

	Action	Consider
Airway	Open and maintain airway	Hypoxia causes seizures
	Give high flow oxygen	Hypoxia contributes to damage
Breathing	Support breathing	Grunting and increased respiratory rate are common
		Beware the exhausted child, the child with neuromuscular disease and respiratory depression, either central or secondary to administered drugs
Circulation	Support circulation Check blood glucose: if hypoglycaemic, draw blood for later investigation and give 5 mL/kg of dextrose 10%	Inappropriate bradycardia may be due to raised intracranial pressure
		Shocked child, treat for sepsis
		Hypertension may be the cause of seizures
Disability	Assess conscious level, pupils, posture Check for neck-stiffness	Decorticate and decerebrate posturing can be mistaken for a tonic seizure
		Consider acute dystonia
		Consider non-epileptic attacks
Exposure	Check for rash Measure temperature	Fever (infection, ecstasy)
		Hypothermia (ethanol, barbiturates)

- ▶ Conditions that can be mistaken for status epilepticus:
  - Extensor posturing due to raised intracranial pressure.
    - In this setting, sedative drugs, e.g. diazepam, suppress respiration, and aggravate the situation by causing hypercarbia;
  - Status dystonicus;
  - Non-epileptic 'pseudostatus'.

### Treatment algorithm

A seizure that has not stopped spontaneously within 5 min is less likely to do so; therefore, start drug treatment.

This algorithm is useful for most children, over 4 weeks of age, presenting in accident and emergency or children's wards. Children with epilepsy and recurrent episodes of CSE may have their own individualized CSE treatment algorithm.

Thiopental is now the approved name for thiopentone (likewise phenobarbital for phenobarbitone).

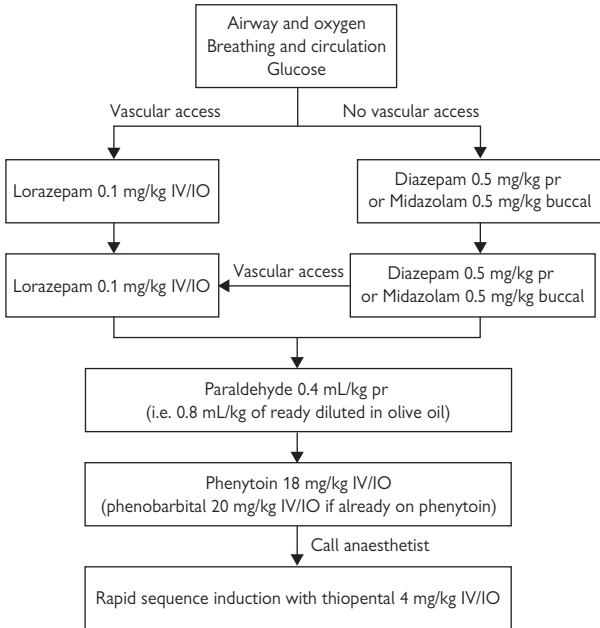



Fig. 6.2 Status epilepticus flow chart.

- ▶ NB: do not forget supportive medical management.
- Continue to monitor airway, breathing, and circulation.
- Maintain normoglycaemia.
- Monitor electrolytes and fluid input–output.
- Treat pyrexia.
- Use nasogastric tube (NGT) to empty stomach contents.
- Management of raised ICP (see  p. 539).

## Practical aspects of drugs used in the convulsive status epilepticus algorithm

### Choice of first drug

- Rectal diazepam is a safe and effective AED. If respiratory depression occurs, breathing may be supported until this effect wears off.
- Buccal midazolam is equally effective (perhaps, more so) and may be more acceptable in some circumstances.
- Once IV access is established, lorazepam is the drug of choice. It is effective, has a longer duration of action (12–24 h) than diazepam (1–4 h) and has reportedly fewer respiratory depressant effects. A lorazepam dose of 0.05 mg/kg may be effective for many children.

### Paraldehyde

- Paraldehyde must be diluted in an equal volume of olive oil or saline (not arachis oil because of the risk of nut allergy), take particular care in correct prescribing.
- Side effects include rectal irritation and sedation.
- Paraldehyde reacts with plastic and so must be given immediately if drawn up in a plastic syringe.
- It should not be given intramuscularly (IM; risk of sterile abscess formation).

### Phenytoin

- Phenytoin, 18 mg/kg, must be made up in 0.9% saline solution and infused slowly (over 20–30 min, max. 1 mg/kg/min) with cardiac monitoring (risk of cardiac arrhythmias).
- If the child stops having seizures during the infusion, continue to infuse the full dose.
- Phenytoin is particularly irritative to veins; watch for injection site extravasation.
- Fosphenytoin, a pro-drug of phenytoin, is less cardiotoxic and may be given over 10 min; it can also be given IM. Fosphenytoin is prescribed in 'phenytoin equivalents' (fosphenytoin 75 mg is equivalent to phenytoin 50 mg); take care as mistakes can easily be made. (Limited availability.)
- If a child is already on phenytoin, there is a small risk of toxicity.

### Thiopental


- A general anaesthetic agent with some antiepileptic effects, it is given by trained persons only to facilitate stabilization and transfer to an intensive care setting for further management. **Beware:** it accumulates and can be cardiotoxic.

### Refractory convulsive status epilepticus

❗ It is very important to remember that the evidence base for the use of the following drugs and their doses in refractory status epilepticus is that of opinion, experience, and case report. Use of these drugs in status epilepticus is unlicensed. Careful attention must be paid to pharmacopoeia and administration advice.

❗ Management of these children will always be individualized in the light of underlying diagnoses, precipitants, and triggers. Seek specialist advice.

Refractory or resistant CSE may be defined as being present when 2 or 3 AEDs have failed after following the algorithm.

Manage in an intensive care setting; airway and breathing support and close monitoring of other parameters allow the use of very high doses of AEDs. See also  p. 516. For possible treatment options see Table 6.3.

**Table 6.3** Possible treatment options

	Route	Dose	Note
Phenobarbital	IV	20 mg/kg/ dose	Repeated doses until child stops seizing; or plasma levels >40 mg/L
Phenytoin	IV	9–18 mg/kg/ dose	Repeated doses until child stops having seizures, or plasma levels >20 mg/L
Midazolam	IV	0.2 mg/kg IV or buccal loading dose	Loading dose followed by IV infusion start at 2 microgram/kg/min, increase in 4 microgram/kg/min increments every 30 min to initial max. of 20 microgram/kg/min (use of higher doses reported)
Clonazepam	IV	50 microgram/ kg/ dose (max 1 mg)	Can follow with infusion of 10–60 microgram/kg/min. Troublesome secretions may limit use
Sodium valproate	IV	25 mg/kg loading dose	25 mg/kg loading dose if not already on drug 10 mg/kg loading dose if already on drug Then infusion of 2–3 mg/kg/min (higher infusion rates reported)
Levetiracetam	IV	20 mg/kg loading dose	If no initial clinical or electrographic response proceed to other treatments. If response, ±load again, follow with maintenance 12-hourly. Accumulates if impaired renal function
Anaesthetic agents	IV and inhaled		Liaise with intensivist/anaesthetist

(Continued)



**Table 6.3** (Continued)

	Route	Dose	Note
Thiopentone	IV	5 mg/kg bolus	Infusion rate 3–5 mg/kg/h. Maintain seizure-free for 12 h (or titrate to suppression-burst on EEG) and then wean over 2–3 days  Caution: hypotension, atelectasis, paralytic ileus
Lignocaine (lidocaine)	IV	4 mg/kg/h Increase if needed to 10–12 mg/kg/h	Beware, narrow therapeutic window and drug accumulation limit use to 48 h  Must then be weaned slowly, by no greater than 1–2 mg/kg/h decrements every 24–48 h. Rebound seizures may occur on weaning; if this occurs, increase dose again and resume wean more gradually
Isoflurane and desflurane	Inhaled		Onset of action in minutes, see burst-suppression on EEG  Caution: hypotension, apnoea, atelectasis, infection, paralytic ileus
Propofol			No longer recommended, increased mortality compared with midazolam

There are many other reports in the literature of drugs used with effect. For some children, acute resective surgery may be considered.

### Clustering

After an episode of CSE or independently frequent seizures may continue without being in actual status. The child should be managed in a high-dependency setting with the facility to support airway and breathing rapidly if needed.

The intravenous drugs discussed for refractory CSE (see Table 6.3) may be considered, with awareness of the risk of respiratory depression and hypotension. Other possible treatment options are shown in Table 6.4.

**Table 6.4** Other treatment options for seizure clusters


	Route	Dose	Note
Chloral hydrate	Oral	10–40 mg/kg/dose po qid for 24 h	Expect sedation
Clomethiazole	Oral	1–3 mg/kg 4-hourly increased to 2-hourly if unresponsive	Can be very sedating. Watch for respiratory depression. Cardiac arrhythmias have been reported with IV preparation which has been phased out in UK. May aggravate Lennox–Gastaut-type epilepsy

**Table 6.4** (Continued)

Clobazam	Oral	1–2 mg/kg/day po divided into two or three doses	Oral secretions may be limiting (as with clonazepam)
Paraldehyde	Rectal	1–3 mL/kg per dose 3–6 hourly	Sedation and rectal irritation may be limiting
Phenobarbital	Oral /IV	10–20 mg/kg loading dose	Further doses to maintain plasma levels in upper reference range
Phenytoin	IV	9–18 mg/kg per dose	See Table 6.3
Thiopental	IV	5 mg/kg bolus	See Table 6.3
Valproate	IV	10–25 mg/kg per dose	See Table 6.3
Topiramate	NG	2 mg/kg/day	Rapid titration over days to 10–15 mg/kg total daily dose
Vigabatrin	Oral	50 mg/kg total daily dose	Titrate up in 10–50 mg/kg /day steps up to 150 mg/k total daily dose  May precipitate abnormal movements

### Neonatal status epilepticus

The incidence of seizures is higher in the neonatal period than at any other time of life; they have a prevalence of 2–3 per 1000 term live births rising to 10–15 per 1000 pre-terms. Most neonatal seizures are subtle, manifesting with combinations of motor, behavioural, and autonomic symptoms, making them difficult to recognize clinically. General tonic–clonic seizures are exceptional.

► Neonatal seizures are more likely to be symptomatic, thus it is vital to look for the cause and if possible, treat it. Prognosis depends largely on this underlying cause (see  p. 480).


**Drug treatment**

There is a lack of good clinical evidence for AED efficacy. How aggressive treatment should be is a point of debate, as is the possible adverse effect of AEDs on the developing brain, in particular phenobarbital, which is the mainstay of treatment. More recent evidence indicates an adverse effect of neonatal seizures themselves on long-term neurodevelopmental outcome and increased epilepsy in later life. Keep the number of AEDs used to the minimum possible (neonates quickly develop tolerance; see Table 6.5).

Remember the vitamin responsive conditions (see  p. 329).

**Table 6.5** Drugs in neonatal status epilepticus

Phenobarbital	<p>First line</p> <p>Effective in about a third of babies</p> <p>20–40 mg/kg IV loading dose to achieve therapeutic levels</p> <p>NB: loading doses can cause apnoea in an unventilated baby</p> <p>Followed by 5 mg/kg/day in two divided doses</p>
Phenytoin	<p>Some studies report equal efficacy to phenobarbital</p> <p>Probably more effective second line agent than benzodiazepines</p> <p>15 mg/kg IV loading dose</p>
Benzodiazepines	<p>Most benzodiazepines have been tried with some reported effect</p> <p><b>NB: longer drug half-life in babies</b></p> <p><i>Diazepam</i>: single doses (0.3–1 mg/kg IV) are used, but avoid infusions as half-life is very long in babies (30–75 h)</p> <p><i>Lorazepam</i>: limited published experience in neonates, 0.05–0.15 mg/kg/dose</p> <p><i>Clonazepam</i>: once daily dose (100 microgram/kg) is probably as effective as infusion due to very long half-life (24–48 h); increased secretions can be problematic</p> <p><i>Midazolam</i>: limited published experience. Loading dose of 150 µ/kg followed by infusion of up to 300 µ/kg/h</p> <p>Myoclonic jerks and dystonic posturing reported as side effects</p>

For further details of treatment regimes, see  p. 482.

# Status dystonicus

## Definition

Increasingly frequent and severe episodes of generalized dystonia that require urgent hospital admission. Status dystonicus can occur in the context of an acute illness affecting the CNS or in children with known chronic dystonia (either primary or secondary). The latter group may be particularly difficult to treat and may require prolonged periods of hospitalization. **!** These guidelines are for use in those children who have severe and unremitting dystonic spasms that requires inpatient management of associated medical complications and pain. Clear treatment goals should be established for these children before pursuing approaches that may include heavy sedation and/or muscle paralysis. Goals of treatment are usually those of achieving comfort and medical stability, rather than improving function.

## Medical complications of status dystonicus

- Elevated body temperature.
- Pain.
- Exhaustion from sleep deprivation and exertion.
- Rhabdomyolysis leading to myoglobinuria and raised creatinine kinase (CK).
- Dehydration with electrolyte disturbance from excess sweating.
- Acute renal failure as a consequence of myoglobinuria/dehydration.
- Bulbar dysfunction with risk of pulmonary aspiration.
- Respiratory insufficiency.
- Death.

## Initial management

### Airway/breathing

Respiratory muscle spasm, vocal cord adductor spasm, and aspiration may compromise the airway and breathing. Perform chest examination, check oxygen saturation and arterial blood gases (ABG). Consider whether oral feeding is safe.

Indications for paralysis and intubation include:


- Airway compromise/respiratory failure.
- Exhaustion/severe discomfort despite maximal sedation and muscle relaxants.
- Metabolic compromise, e.g. renal failure requiring haemodialysis (relative indication).

### Circulation

Increased insensible losses through sweating can rapidly lead to dehydration and maintenance fluids may need to be increased by an additional 5–20% each day to compensate for increased insensible losses: monitor vital signs, peripheral perfusion, signs of dehydration, and renal function.

### Identify triggers and manage pain/distress

Pain may be a significant trigger of dystonia (e.g. gastro-oesophageal reflux, constipation, dental caries, mouth ulcers, hip dislocation). Other recognized triggers include intercurrent illness/infections, stress from surgery/anaesthetics, and the addition or withdrawal of certain drugs.

❗ For a child with an implanted intrathecal baclofen pump (see  p. 245) status dystonicus must be presumed to be due to pump or (more probably) catheter failure and acute baclofen withdrawal until proven otherwise.

Removal of triggers may alleviate dystonia. Pain and distress are also consequences of severe dystonia, and adequate analgesia should be given.

### Rhabdomyolysis and myoglobinaemia with risk of acute renal failure

Measure myoglobin levels (urine dipstick positive for blood in the absence of red blood cells on urine microscopy, confirmed with plasma CK and myoglobin levels. Note that the rise in CK is slow and levels may not peak until 24–48 h after muscle damage, whereas myoglobinaemia is usually cleared within 6 h).

- Manage the child on the basis of electrolyte abnormality (usually increased  $K^+$ ,  $PO_4^{2-}$ ,  $Ca^{2+}$ , urate) and not on the basis of CK.
- Seek advice from the renal team if acute renal failure is present.
- If urine output is reasonable ( $>0.5$  mL/kg/h):
  - high fluid input = 3 L/m<sup>2</sup>/day (0.45% saline/2.5% dextrose);
  - add sodium bicarbonate to fluids, aim for urine pH  $>7$  (start with 10 mmol sodium bicarbonate/500 mL).
- If oligo- or anuric:
  - consider a fluid challenge (5–10 mL/kg), possibly with furosemide to establish urine output;
  - if unsuccessful, dialyse for severe electrolyte disturbance (continuous veno-venous haemofiltration (CVVH) should clear myoglobin reasonably well, but no real data in children).
- Monitor BM: hypoglycaemia can result from pancreatic dysfunction associated with myoglobinaemia.
- Administer dantrolene 2.5 mg/kg IV and repeat as required at 10 min intervals to a max. cumulative dose of 10 mg/kg.

### Acute control of dystonia

#### Non-pharmacological interventions

Many children with dystonia may be quite physically disabled, but with intact cognition. In some of these children, psychological/emotional factors can further aggravate their underlying dystonia. This should be considered and appropriate support provided. In addition, positioning can be very helpful in aborting the spasms in some children. In particular, using seating, pillows, etc., to maintain hip flexion, and to keep the neck flexed and head in the midline position is important. Physiotherapy assessment may provide additional strategies to improve spasm-free periods and sleep. In some children, handling may exacerbate dystonia and this should be minimized to necessary cares.

**Pharmacological control**

This is difficult and largely centred on sedation, muscle relaxation, and supportive care. New onset dystonia with acute CNS illness usually improves over time and may be managed expectantly. Status dystonicus in the context of a chronic neurological disorder may be more difficult to manage. The risks of complications from severe dystonia need to be measured against the risk of unwanted effects from the high doses of specific anti-dystonia drugs often required (Table 6.6). Specialist advice is required! Consider use of objective dystonia scales and serial video to assess response to treatment.

**Light sedation and muscle relaxation**

A number of sedatives (triclofos or chloral and trimeprazine) and/or muscle relaxants (oral/rectal diazepam, buccal/IV midazolam, IV lorazepam) may be useful alone or in combination to provide relief from painful and exhausting spasms and allow periods of sleep. Extreme care should be taken to monitor children when using combinations of drugs with sedating properties.

**Heavy sedation/muscle relaxation**

IV midazolam may be used. Chlormethiazole has the advantage that it is less of a respiratory depressant than midazolam and can be weaned to titrated oral doses, although the IV form has been withdrawn in the UK. Midazolam has a long half-life, allowing slow weaning. It also has a spinal interneuron blocking action, of benefit to children with dystonia. Levels of sedation achieved with these drugs require close monitoring of cardiovascular and respiratory function, and this may necessitate PICU admission.

**Identifying the cause****New onset, severe acute dystonia***Drugs*

- Neuroleptic malignant syndrome due to antidopaminergics (including tetrabenazine, haloperidol, sulpiride), anticholinergics, and also reported with sudden levodopa withdrawal.
- Acute intrathecal baclofen withdrawal (a severe medical emergency; treatment is with high dose parenteral benzodiazepines  $\pm$  respiratory support until baclofen delivery can be restored).
- Reported with the use of carbamazepine and metoclopramide.
- See Table 6.6.

*Acute brain injury*

After severe acquired brain injury particularly involving basal ganglia, both traumatic and non-traumatic.

**Table 6.6** Acute treatment options for dystonia

Drug	Doses	Side effects to look for
Chloral hydrate	30–50 mg/kg (max. 1 g/dose) tds (can be given rectally)	Gastric irritant, rash, headache Ketonuria Eosinophilia, low white cell count (WCC)
Triclofos	Dose depends on age/weight <b>Do not use with chloral</b> as both are derivatives of the same drug	Derivative of chloral hydrate. Same side effects, but less gastric irritation
Alimemazine (Trimeprazine, Vallergran)	2 mg/kg/dose (max. 60 mg) max. bd (caution with use <6 months)	Antimuscarinic effects (urinary retention, dry mouth, GI disturbance) Extrapyramidal effects Mood change, irritability Liver dysfunction Arrhythmias
Diazepam oral and rectal	Rectal (PRN: can repeat dose ×1) <1 yr 2.5 mg pr 1–3 yrs 5 mg pr >3 yrs 10 mg pr Oral <1 yr 250 microgram/kg bd 1–4 yrs 2.5 mg bd 5–12 yrs 5 mg bd >12 yrs 10 mg bd	Long half-life Doses may be cumulative Drowsiness, irritability Respiratory depression Tolerance may occur
Dantrolene (particularly if rhabdomyolysis)	2.5 mg/kg IV and repeat as required at 10 min intervals to a max. cumulative dose of 10 mg/kg. Maintenance 0.5–3 mg/kg bd/qid prn; not to exceed 100 mg qid	Derangement of LFTs
Midazolam buccal (use IV preparation)	500 microgram/kg (max 10 mg) sublingual	See Midazolam IV, this table
Lorazepam IV	Used prn 50 microgram/kg/dose (max 4 mg) Can repeat ×1 if required Max dose of 0.1 mg/kg or 8 mg in 12 h	Respiratory depression Hypotension Use with caution in liver disease

**Table 6.6** (Continued)

Midazolam IV	Slow IV injection of 100–200 microgram/ kg then infusion of 30 microgram/kg/h increasing according to response	Respiratory depression Cardiovascular depression (severe hypotension) Potentiated by erythromycin and other drugs
Levodopa (All doses quoted are for the levodopa component of <i>Sinemet</i> )	<i>Sinemet-62.5</i> (carbidopa 12.5 mg, levodopa 50 mg): start 1 mg/kg/day (unless <1 yr: 0.25 mg/kg/day) increasing to max dose 10 mg/kg/day Once total dose of levodopa is >100 mg/day switch to <i>Sinemet-110</i> (10 mg carbidopa, 100 mg levodopa) as less carbidopa is preferable	GI upset Sleep disturbance Hypotension, arrhythmias Red urine Psychiatric manifestations Peripheral neuropathy
Trihexyphenidyl (Benzhexol)	Start 1 mg tds (<8 yrs) or 2 mg tds (>8 yrs). Increase total dose by 1 mg (<8 yrs) or 2 mg (>8 yrs) every 7 days until clinical effect or side effects intervene or max dose 10 mg tds	Anticholinergic effects (urinary retention, dry mouth, dry eyes, blurred vision, gastro-intestinal disturbance, etc.)
Tetrabenazine	<4 yrs start 6.25 mg od >4 yrs start 12.5 mg od, increasing to 12.5 mg tds Adolescent start 25 mg od increasing to 25 mg tds	Onset of action can be delayed for months Depression, which may be severe with suicidal ideation
Sulpiride	If >8 yrs 50 mg bd, increment total dose by 50 mg to max 100 mg bd If <8 yrs (use haloperidol in preference as doses better described) 25 mg bd, increment total dose by 25 mg to max 50 mg bd	Drowsiness at higher doses Extrapyramidal signs Tardive dyskinesia
Haloperidol	12.5–25 microgram/kg bd (max 10 mg/day) further increase under guidance from paediatric neurologist	Extrapyramidal signs Tardive dyskinesia




**Chronic dystonia**

- Primary (dystonia is the sole clinical sign  $\pm$  tremor): an unlikely cause of acute status dystonicus.
- Secondary dystonia as part of a heredo-degenerative disease (e.g. pantothenate kinase-associated neurodegeneration (PKAN), Wilson disease) and 'dystonia plus' syndromes (with other features, e.g. dystonia–myoclonus syndrome, DOPA-responsive dystonia with Parkinsonism).

**Targeted investigations**

- MRI.
- *Blood*: FBC, vacuolated white cells, reticulocytes, wet blood film for acanthocytes, U&Es, LFTs, Ca, Mg, phosphate, uric acid, Cu and caeruloplasmin, autoantibodies screen, amino acids, lactate, purines and pyrimidines, lysosomal enzymes (hexosaminidase, arylsulphatase, fucosidase,  $\beta$ -galactosidase), acylcarnitine species, cholesterol, triglycerides, lipoprotein strip, and transferrin isoelectric focusing (IEF).
- HIV serology (depending on clinical history).
- Molecular genetics (depending on clinical/family history):
  - *DYT1* (*DYT1* gene mutation in idiopathic torsion dystonia);
  - *DYT5* mutation in DOPA-responsive dystonia;
  - *SCA6*;
  - *DRPLA* (relevant if of Japanese origin, or family history);
  - Huntington (formal consent and counselling required: discuss with clinical geneticist).
- Urine amino and organic acids, homo-vanilic acid (HVA), uric acid, Cu, sulphite, oligosaccharide, and mucopolysaccharidoses screen.
- CSF microscopy, biochemistry, lactate, amino acids, amine neurotransmitter metabolites, and pterin species.
- Muscle biopsy for histopathology, histochemistry, and respiratory chain enzymes.
- Rectal biopsy (full thickness not suction) for intraneuronal storage material seen in the gangliosidoses, neuronal intranuclear inclusion disease and neuronal ceroid lipofuscinosis (NCL).
- Skin biopsy for fibroblast culture and electron microscopy (EM) of nerves.
- Bone marrow biopsy.
- Slit-lamp examination (for Kaiser–Fleischer rings).
- Visual-evoked potential (VEP)/electroretinogram (ERG), electromyography (EMG)/nerve conduction velocity (NCV), EEG.

### Longer-term treatment options

- Levodopa for idiopathic primary dystonia and considered in other cases. Use for 3 months in maximal doses before discontinuing.
- In severe and disabling dystonia, the next option is a slow escalation of trihexyphenidyl (benhexol) to high dose or until unwanted effects (anticholinergic, e.g. urinary retention, blurred vision, gastrointestinal (GI) upset) intervene. In which case, reduce the dose and maintain at a reduced level for 1 month before increasing again. This may allow greater toleration of higher doses.
- The next step is difficult. Consider adding tetrabenazine (used at low doses because of unwanted effect of significant depression) in combination with either sulpiride or haloperidol to trihexyphenidyl (benhexol). If extrapyramidal unwanted effects (Parkinsonism, akathisia) emerge using sulpiride/haloperidol then increasing the dose of trihexyphenidyl (benhexol) may alleviate these and allow for further increases in sulpiride/haloperidol. Sulpiride/haloperidol have the long-term potentially irreversible side effect of tardive dyskinesia.
- Intrathecal baclofen (see  p. 245) may give sedation-free symptom relief. Doses required for dystonia are often very much higher than for spasticity. Should only be offered in centres familiar with implantation and the management of complications.
- Consider deep brain stimulation (specialist centres only).

## Sudden onset visual loss

Truly *monocular* visual loss implies a cause anterior to the chiasm.

Duration is a clue to cause:

- *Seconds*: disc swelling.
- *Minutes*: emboli, occipital epilepsy.
- *Hours*: retinal migraine.
- *Days*: optic neuritis.

### Optic neuritis

- Typical age at presentation ~7 yrs; ♀ > ♂.
- Preceding viral illness.
- Usually bilateral.
- Presents with severe loss of acuity, field defects, and central scotomata.
- Disc swelling of optic neuritis may be mistaken for papilloedema. However, in papilloedema, visual loss is late and relative afferent pupillary defect (RAPD) rare.
- VEP, usually abnormal (helpful in retrobulbar neuritis where no other signs may be found). VEP is normal in functional blindness.
- See 📖 p. 260.

### Functional visual loss

- Very difficult problem; often occurs in teenage girls.
- Visual fields usually reported as markedly constricted and tunnel vision on confrontation, easier diagnosis when visual loss is total, rather than partial.
- *Helpful observations*:
  - visual behaviour: orientated in space and able to manoeuvre without injury;
  - pupillary responses normal;
  - electro-diagnostic tests normal (VEP and ERG);
  - normal nystagmus with an optokinetic drum;
  - moving a mirror close to the face will cause the eyes to move if vision is present (refixation reflex).

### Retinal migraine

- A major cause of transitory monocular blindness.
- Scintillating, shimmering scotomata, abnormal perception of colour and movement, can be binocular, usually lasts less than 30 min.
- Recurrences are in the same eye.

### Binocular visual loss

Progressive visual field restriction (e.g. due to a slowly expanding lesion at the optic chiasm or in an optic radiation, see Figure 3.14, or retinal dystrophy) can be surprisingly asymptomatic until it extends to involve the macula, at which point it may present acutely.

## The child who suddenly stops walking

In the absence of symptoms of encephalopathy, there are many reasons for a child suddenly to stop or to refuse to walk. This child warrants immediate attention. Until the cause is determined, the child who has lost the ability to walk should be considered a potential neurological/neurosurgical emergency and urgent imaging may be required.

► A seemingly unrelated and more immediate presenting complaint may mask the fact that the child has also lost the ability to walk or mobilize. Avoid this pitfall by performing a thorough neurological assessment in any sick child.

### History

The list of causes is enormous, but the history will provide a starting point. Specific questions should include:

- What can the child not do?
- What is the temporal sequence of events?
- Was there a precipitating factor?
- Are there any sensory disturbances (loss or gain)?
- Is there pain, where is the location and quality?
- Is there or has there been intercurrent illness?
- Is the child well or is there systemic illness?
- Is the child on any medication?
- Has there been foreign travel?
- Have there been insect bites?
- Is there a family history?
- What is the child's mood/affect?
- What does the child/family think is the cause?

### ***Always specifically ask about bladder and bowel function to identify spinal pathology***

Historical clues to aetiology may include:

- *Post-ictal*: Todd paresis.
- *Post-migraine*: hemiplegic migraine.
- *Preceding trauma*: cord pathology causing compression, infarction, transection; stroke due to arterial dissection.
- *Recent intercurrent illness*: Guillain–Barré, transverse myelitis.
- *Viral encephalitis*: echo, entero, Coxsackie virus.
- *Tic bite*: Lyme disease.
- *Semi-acute onset with bladder and or bowel involvement*: spinal tumour.
- *Chemotherapy*: vincristine, cisplatin.
- *Infant with progressive constipation, poor suck and descending pattern of involvement*: infant botulism (history of exposure to sources such as honey may not be present).
- *Adolescent with history of intravenous drug abuse*: wound botulism.

### Examination

As ever, the purpose of examination is to locate the site(s) of pathology. Acute weakness will be due to either cord, nerve root, peripheral nerve, neuromuscular junction or muscle weakness.

- *Identify the pattern of weakness:*
  - proximal (myopathy?);
  - peripheral (neuropathy?);
  - symmetrical or asymmetrical?
- Are peripheral tendon reflexes present? Plantar responses?
- What is the anatomical distribution of any sensory disturbances. Is it consistent with a spinal dermatomal level, or a peripheral nerve pattern? (see Table 1.6).
- *What modalities of sensation are involved:* selective loss of spinothalamic (pain and temperature) sensation with preservation of vibration and joint position sense seen in anterior spinal artery syndrome.
- Is there involvement of the sphincters?
  - Is anal sphincter closed tight or lax?
  - Is perianal sensation intact?
  - Is the anal reflex (sphincter contraction in response to drawing point across perianal skin) preserved.

### Investigation

The main urgent decision is whether this child needs emergency MRI of the spine at appropriate level(s). This is required in any situation where examination locates the lesion to the spinal cord, as extrinsic spinal cord compression is a neurosurgical emergency with outcome depending on prompt relief of compression. Organize urgent MRI when:

- Back pain present (in contrast, *limb* pain is common in, and consistent with, Guillain Barré).
  - Weakness is in all muscle groups below a particular spinal root level.
  - A dermatomal pattern of sensory involvement is present (but not always seen).
  - Sphincter involvement typically implies intrinsic cord involvement and **sphincter function may be preserved** in situations of external cord compression.
  - If in doubt discuss with regional neurosurgical service urgently.
- ▶ Establish whether this is a child who *can't* move because of weakness; from a child who *doesn't want* to walk because of pain, or fear (e.g. due to unsteadiness and fear of falling).
- ▶ Be persistent in cajoling and assisting the child to walk as much as possible in order to try to make this distinction.

### The child who is unable to walk and has peripheral weakness

See Table 6.7 for causes.

**Table 6.7** Causes of inability to walk and peripheral weakness

Affected region	Cause		Useful early investigations
Muscle	Myositis	Transient acute myositis/myalgia with viral illnesses Dermatomyositis	Elevated CK; viral titres
	Rhabdomyolysis	Disorders of carbohydrate metabolism Disorders of fatty acid metabolism	Elevated CK; acyl carnitine profile when symptomatic
	Periodic paralysis (autosomal dominant channelopathies)	Familial hypokalaemic periodic paralysis Familial hyperkalaemic periodic paralysis Familial normokalaemic periodic paralysis	
Neuromuscular junction	Autoimmune	Myasthenia gravis	Tensilon test; peripheral neurophysiology
	Acquired	Botulism Tick paralysis (North America, Dermacentor species) ICU weakness (combination of neuromuscular blockade drugs, corticosteroid myopathy and depletion of myosin; usually presenting as failure to wean from ventilator)	Peripheral neurophysiology

*(Continued)*


**Table 6.7** (Continued)

Affected region	Cause	Useful early investigations	
Peripheral nerve	Guillain–Barré syndrome	Peripheral neurophysiology; CSF protein (late)	
	Metabolic		Acute intermittent porphyria
	Toxic		Vincristine, lead, mercury, arsenic
Anterior horn cell	Poliomyelitis	Peripheral neurophysiology	
Spinal cord	Spinal cord compression	MRI	
	Epidural		Metastases (leukaemia, lymphoma, neuroblastoma) Abscess Haematoma (haemophilia, trauma) Bony compression (Morquio syndrome, Down syndrome; fracture/ dislocation of vertebrae)
	Intradural		Neurofibroma

Intramedullary	Glioma Ependymoma Hydromyelia	
Spinal cord transection	Trauma	MRI
Transverse myelitis		MRI
Vascular	Anterior spinal artery occlusion (infarction of anterior portion of cord resulting in loss of spinothalamic pain and temperature sensation, with preservation of dorsal column light touch, proprioception and vibration due to different blood supply)  Vascular malformations (may present with acute bleed or infarct in first two decades of life)	MRI
Discitis	(Rare before adulthood)	MRI



### Guillain–Barré syndrome

GBS is an acute immune-mediated demyelinating polyradiculoneuritis, frequently preceded by a non-specific infection, and presenting with a classic triad of weakness, areflexia and elevated CSF protein without pleocytosis (the latter may not be present early). See also  p. 395 and Box 6.1.

#### Presentation

- Progressive ascending motor weakness with areflexia/hyporeflexia.
- Almost half will become non-ambulant.
- Usually symmetrical.
- Not uncommon:
  - sensory impairment, often with distressing paraesthesiae;
  - cranial nerve involvement;
  - autonomic dysfunction.
- Rarely and transiently sphincter dysfunction.

#### Clinical features

- Symmetrical ascending weakness starting in legs.
- Absent deep tendon reflexes.
- Can have bulbar and ocular involvement.
- Respiratory involvement in 50%: monitor respiratory function (no single parameter is reliable in children).
- Pain, paraesthesia. Toddlers in particular may present with predominant early symptoms of back pain, rather than weakness.
- Autonomic dysfunction (constipation, urinary retention, incontinence, excessive sweating, hypertension, arrhythmias).
- Raised protein in the CSF (from the second week) with absence of lymphocytes (<10).
- *Neurophysiology*: slow nerve conduction with conduction block.
- Enhancement of nerve roots on MRI.
- Rarely diagnostic confusion can occur if encephalopathy due to hypoxia has already occurred, masking the peripheral site of the pathology.

#### Investigations

##### CSF

- Raised protein (after first week).
- Less than 10 white cells/mm<sup>3</sup>.

##### Nerve conduction studies

- 80% show slowing or block.
- Distal latencies increased (may not be abnormal for several weeks).

##### Others

- Serology for mycoplasma, Epstein–Barr virus (EBV), cytomegalovirus (CMV), Varicella zoster virus (VZV), Borrelia.
- Stool for campylobacter, Coxsackie.
- Antianglioside antibodies (may be helpful where there is diagnostic doubt):
  - anti-GQ1b in Miller–Fisher variant;
  - anti-GM1 in acute motor axonal neuropathy (AMAN) variant.

- Consider MRI brainstem and cord if doubtful features:
  - clear sensory level;
  - predominant bladder or bowel dysfunction;
  - explosive/rapid onset.

### Box 6.1 Practice points

- A focal asymmetric weakness may be the initial presenting feature.
- Uncommon conditions, but with clinically similar presentations, are neurotropic viral infections—poliomyelitis, West Nile virus, Japanese encephalitis.

Examination should correlate with neuroanatomy or else suspect a non-organic cause.

### Management

► Careful monitoring of bulbar, respiratory, cardiovascular, and autonomic status is vital.

There are a number of complications of GBS (Table 6.8).

**Table 6.8** Complications of Guillain–Barré syndrome

Bulbar dysfunction	Dysphagia, weak cough, unable to clear secretions
Respiratory compromise	Vital capacity below 15–20 mL/kg, breathlessness on exertion; deteriorating blood gases (rising CO <sub>2</sub> )
<b>Do not wait until the child becomes hypoxic or exhausted. Most deaths in childhood are due to preventable respiratory complications</b>	
Autonomic instability	Sweating, sinus tachycardia, hypertension, labile blood pressure, bradycardia, arrhythmias
Monitor temperature, heart rate, BP, respiratory rate, vital capacity, pupils, GCS, cough, swallow, urine output	

### Treatment

#### IV immunoglobulin

Give 2 g/kg in a single dose or divided over 5 days.

Indicated if there is:

- Progressive deterioration at the time of presentation.
- Patient is non-ambulant.
- Bulbar dysfunction.
- Respiratory compromise.

Points to note:

- Accelerates the rate of recovery.
- Re-treat with half dose IVIG if relapse.
- Late treatment (3 weeks after symptom onset) is not of proven benefit.

Plasmapheresis is as effective as IVIG, but there are practical difficulties. Long-term outcome is *worsened* by steroids.


#### Admit to PICU

- If there is rapidly progressive tetraparesis.
- If there is respiratory compromise;
- If bulbar dysfunction occurs.
- If there is autonomic cardiovascular instability (autonomic instability is a predictor of fatal cardiac arrhythmias).

#### General care

- Thrombosis prophylaxis in older, larger children (stockings and low-molecular weight heparin).
- Nutrition, skin care.
- Gabapentin useful for painful dysaesthesiae (common in recovery phase).
- Psychology.
- Rehabilitation.
- Monitor for occasional late complication of communicating hydrocephalus due to high CSF protein.

#### Typical clinical course

- Deterioration over 2–4 weeks (>4 weeks implies chronic inflammatory demyelinating neuropathy (CIDP), see  p. 396).
- May be severe with respiratory compromise requiring ventilation (15–20%).
- Plateau phase.
- Recovery phase:
  - good recovery for most with significant improvement evident within about 2 weeks;
  - morbidity, about 10% left with significant residual disability;
  - mortality, from respiratory and autonomic dysfunction, is lower than in adults (1–8%);
  - positive prognostic factors include milder course, early start of recovery, younger age, no evidence of denervation.

### Spinal cord compression

See Box 6.2.

#### Box 6.2 Key features of spinal cord dysfunction

- Sensory level.
- Level of motor weakness.
- No cranial nerve involvement.
- Urinary symptoms (frequency, dribbling, retention, priapism).
- *Breathing may be affected in high lesions.*

#### Symptoms

- Paraesthesiae in the legs.
- Weakness (difficulty climbing stairs).
- Bladder and bowel (constipation).
- Back pain.

**Early signs**

- Tender over the affected area of the spine.
- Loss of pin-prick sensation in the legs.
- Loss of proprioception and vibration sense in the feet.
- Deep tendon reflexes in the legs are brisker than in the arms (or may be paradoxically reduced, particularly in thoracic lesions).
- Sweat level (decreased sweating below the lesion).
- Sensory level (more reliably examined over the back, not the abdomen).


**Late signs**

- Definite weakness.
- Definite hyperreflexia and extensor plantars.
- Loss of abdominal reflexes.
- Loss of anal tone.

**Investigations**

- All children with suspected spinal cord compression need urgent spinal imaging (MRI).
- Investigations for malignancy as appropriate.

**Management**

- High dose steroids in all, dexamethasone 0.25 mg/kg IV (max. 10 mg).
- Neurosurgical referral.
- Specific treatment depends on cause:
  - surgical decompression;
  - radiotherapy;
  - spinal shock in traumatic spinal cord injury (loss of sympathetic tone to blood vessels resulting in delayed capillary refill time, hypotension, bradycardia), IV methyl prednisolone 30 mg/kg load, then continuous infusion of 5 mg/kg/h for 15 h.
- *Supportive care:*
  - respiratory support;
  - careful attention to bladder and bowel;
  - GI stress ulcer prophylaxis;
  - prevention of pressure sores;
  - nutrition.
- Rehabilitation by a multidisciplinary team (see  p. 215).

**Transverse myelitis**

Transverse myelitis is an acute focal inflammation of the spinal cord with demyelination and swelling, most often thoracic (80%) or cervical (10%). Affected children are usually aged 5 yrs or older.

Post-infectious, autoimmune, and primary inflammatory mechanisms have been suggested. A preceding infection is noted in 60% (EBV, mumps, mycoplasma, rubella, rubeola, varicella).

**Clinical course**

Abrupt or rapid onset, over 1–2 days, of the features of spinal cord dysfunction.

### Early symptoms

- Paraesthesia of the legs.
- Back pain at affected segmental level.
- Fever, lethargy, malaise, myalgia.
- Later motor loss (initial spinal shock—weak and flaccid—becoming spastic and paraplegic).
- Loss of bowel and bladder function.
- Improvement usually begins after 1 week (although may not be for a number of weeks).
- Most will make a good recovery (poor prognostic indicator—catastrophic onset).


### Examination

- Identify the segmental level.
- Transitional zone (between affected and unaffected spine) dysaesthesia and hyperalgesia.
- Loss of sweating below the level.
- Flaccid paralysis initially (may become spastic with upper motor neurone (UMN) signs as recovery proceeds).

### Investigations

- MRI to exclude spinal cord compression and to confirm the lesion—moderate cord swelling, increased signal on T2, enhanced with gadolinium.
- CSF pleocytosis (lymphocytosis), normal or slightly raised protein, normal glucose.
- EMG normal (may be some anterior horn cell dysfunction in involved segments).
- Serology for likely infections.

### Treatment

- High dose IV steroids.
- IV immunoglobulin.
- NB: supportive care (as for spinal cord compression).
- Rehabilitation (see  p. 215).

## Myasthenia gravis

Disorder of neuromuscular transmission caused by absence or abnormal function of acetylcholine receptors (AChRs) at both voluntary and involuntary muscle end plates.

Can present at any age.

- **Neonatal:**
  - *transient neonatal*—transplacental transfer of maternal AChR antibodies; symptoms occur within hours of birth; if there are none by 3 days of age, then they are unlikely to develop;
  - *Neonatal*—antibody negative, inherited genetic defect, remission rare, mostly unresponsive to anticholinesterase, but usually a mild course.
- **Juvenile:** autoimmune, usually >8 yrs of age, similar to the adult form, may be associated with thymomas, autoimmune thyroid disease, and seizures. Remits and relapses.

**Myasthenic crisis**

- Life-threatening complication of myasthenia.
- Defined as weakness severe enough to require intubation and ventilation:
  - unable to clear secretions;
  - ineffective cough;
  - nasal voice;
  - dysphagia;
  - pneumonia with hypoxia;
  - vital capacity below 15 mL/kg.
- May be precipitated by infection, surgery, stress, menses, being under-medication.
- Occurs in 15–20% of children, most within 2 yrs of the disease.

**Management**

- Supportive.
- Pharyngeal suction.
- Ventilation.
- Consider plasma exchange or, in neonates, exchange transfusion.
- IV immunoglobulin.

**Cholinergic crisis**

- Due to overmedication with anticholinesterases.
- Diarrhoea, cramps, sweating, muscle weakness, meiosis, bradycardia, salivation, fasciculation (presence often allows differentiation from a myasthenic crisis—but it can be difficult).

**Treatment**

- Withhold anticholinesterases.
- Consider atropine.

See Box 4.10 for Tensilon<sup>®</sup> test.

### The child who is unwilling to walk because of pain or balance problems, without peripheral weakness?

See Table 6.9 for causes of unwillingness to walk due to factors other than weakness.

**Table 6.9** Causes of unwillingness to walk due to factors other than weakness

<b>Skin and nails</b>	<b>Infections, injuries</b>		
Bones and Joints	Irritable hip		
	Perthe disease		
	Septic arthritis		
	Inflammatory arthritides	Henoch–Schönlein purpura	
Brainstem and cerebellum	Acute cerebellar ataxia		
	Infectious and post-infectious	Varicella, measles, mumps, herpes simplex, EBV	
		Mycoplasma	
		Meningitis	
		Cerebellar abscess	
	Paraneoplastic	Dancing eye/opsoclonus myoclonus syndrome ( $\pm$ neuroblastoma)	
	Posterior fossa space-occupying lesion	Tumour	
		Bleed	
	Toxic	Alcohol, AEDs, sedatives, methotrexate, piperazine, lead	
	Metabolic	Maple syrup urine disease	
Urea cycle defects (arginosuccinic aciduria)			
Organic acidurias			
Mitochondrial disorders			
Hartnup disease			
	Pyruvate dehydrogenase deficiency (may be precipitated by fever or excitement)		
	Thyroid disease		
Genetic	Episodic ataxia types 1 and 2		
Demyelination	Multiple sclerosis		

**Table 6.9** (Continued)

	Head injury	Haematoma Vertebro-basilar occlusion
	Hydrocephalus	
	Vascular	Basilar migraine Basilar artery thrombosis/embolism Kawasaki disease
Basal ganglia and cortex	Movement disorder	(new onset dystonia)
	Stroke	
	Epilepsy	Todd's paresis (post-ictal) Non-convulsive status epilepticus Alternating hemiplegia
	Vascular	Hemiplegic migraine
Eyes and ears	Vertigo	
	Labyrinthitis	
	Visual loss	
Other	Functional, i.e. illness behaviour (take complaints of back pain seriously as it is rarely a functional symptom in childhood)	



## Acute ataxia

Ataxia describes incoordination of voluntary movement and posture.


**Causes of acute ataxia** (see  p. 199)

In children, ataxia usually indicates nervous system disease, especially involving the cerebellum. The diagnosis of cerebellar ataxia is made by the presence of clinical signs of cerebellar dysfunction (see Table 1.5).

**In the child who was previously healthy, the most common causes are:**

- Drug ingestion (especially aged 1–4 yrs; ask about medications at home).
- Acute post-infectious cerebellitis.

**Non-cerebellar causes of acute ataxia include:**

- *Sensory ataxia*: GBS, Miller–Fisher variant.
- Epileptic pseudoataxia.
- Primary brain tumours usually cause progressive ataxia, but acute ataxia may signify a bleed or acute hydrocephalus. Alternatively, the ataxia may seem of acute onset because it has only just been noticed.
- Opsoclonus–myoclonus syndrome (Kinsbourne syndrome, ‘dancing eyes, dancing feet’; see  p. 381) may present (typically in the preschool child) initially with striking ataxia, sometimes of relatively acute onset, with the eye and limb movement disorder arising later.


For causes of congenital, chronic and progressive ataxia see  p. 384.

### Investigations

Expect to find a diagnosis for most:

- CT or MRI for posterior fossa space-occupying lesion and structural lesions.
- Acute and convalescent sera for viral titres (including varicella, EBV, measles, mumps, echovirus, Coxsackie B).

Where clinical picture suggests appropriate:

- CSF for protein, cytology, and infection (if scan is normal and no cause is apparent).
- Toxicology screen.
- Amino acids, organic acids.
- Relevant investigations (see  p. 381) in suspected neuroblastoma-related opsoclonus–myoclonus.
- EEG for minor status.

# Pharmacopoeia

Pharmacopoeia: A–Z 574

Acute sedation protocols 619

Interactions of anti-epileptic drugs 619

**!** This section is not intended to override advice contained in national or hospital formularies. It is intended as general guidance. The doses quoted have been obtained from a variety of sources and/or used over a number of years by experienced neurologists. At times they may appear to exceed recommended dosages in formularies.

The unwanted effect and contraindication data are not intended to be exhaustive. Consult more detailed sources of information before using drugs with which you are unfamiliar.

If in doubt, consult your pharmacist and other colleagues.

Young children typically require higher doses per kilogram body weight than adults. Doses are given on a per kilogram basis together with typical maximum adult doses. Per kilogram dosing may be excessive in adolescents, and doses in adolescents calculated on a per kilogram basis should be reviewed (and possibly reduced) in line with typical adult doses.

## Acetazolamide

**Neurological indications** Reduction of cerebrospinal fluid (CSF) production in treatment of raised intracranial pressure (ICP) including neonatal post-haemorrhagic ventriculomegaly and idiopathic intracranial hypertension. Third line treatment of focal, generalized, and absence seizures.

### Dosing

#### Starting doses and escalation regimen

- **Raised ICP:** 25 mg/kg/24 h po/IV divided three times daily, increased by increments of 25 mg/kg/24 h po/IV as necessary to max. 100 mg/kg/24 h (adult max. 1000 mg/24 h).
- **Epilepsy:** <12 years: 7.5 mg/kg/24 h po divided 2–3 times daily, increased at weekly intervals to 15 mg/kg/24 h, then 22.5 mg/kg/24 h divided 2–3 times daily. 12–18 years: 250 mg 2–4 times daily (adult max. 1000 mg/24 h).

**Preparations** 250 mg tablet, 250 mg modified-release capsule, liquid 250 mg/5 mL; 500 mg IV injection. Tablets can be crushed and dispersed in water.

**Contraindications** Hypokalaemia, hyponatraemia, hyperchloraemic acidosis, sulphonamide hypersensitivity.

**Important interactions and unwanted effects** Rash and (rarely) Stevens–Johnson syndrome. Paraesthesiae. Nephrotoxicity with concomitant non-steroidal anti-inflammatory drug (NSAID) use. Elevates carbamazepine concentrations.

**Comments** Not recommended for prolonged use. Monitor electrolytes: alkalosis causes hypokalaemia that may need bicarbonate or potassium supplementation. Maintain bicarbonate level >18 mmol/L.

## Aciclovir

**Neurological indications** Treatment of proven or possible herpes simplex virus (HSV) or Varicella zoster encephalitis.

### Dosing

#### Suspected or possible herpes encephalitis IV—neonate

3 months: 20 mg/kg 8-hourly

- 3 months–12 years: 250 mg/m<sup>2</sup> 8-hourly.
- >12 years: 5 mg/kg 8-hourly (doubled if central nervous system (CNS) involvement).

#### Comments

Give as IV infusion over 1 h (at all ages). If diagnosis of HSV encephalitis is established, or child is immunocompromised, **double dose** and treat for at least 14 days (21 days in neonates).

**Preparations** 250 and 500 mg IV injection. Tablets, dispersible tablets, and liquid are available for other indications.

**Important interactions and unwanted effects** Dose must be decreased in renal impairment: risk of toxic encephalopathy.

## ACTH (tetracosactide)

**Neurological indications** Treatment of infantile spasms and epileptic encephalopathies.

### Dosing

500 µg of Synacthen Depot<sup>®</sup> IM in the buttock on alternate days increasing to 750 microgram IM on alternate days if no response after 1 week.

### Discontinuation regimen

Dose typically maintained until seizure free for 1–2 weeks then decreased to 50% dose for 2 weeks, then 25% dose for 2 weeks before stopping.

**Preparations** The biological preparation of ACTH is not available in the UK. Tetracosactide (tetracosactrin) is a 1 mg/mL synthetic analogue. 500 microgram Synacthen Depot<sup>®</sup> IM on alternate days has approximately the bioactivity of 40 IU of ACTH IM daily.

**Contraindications** Acute systemic infection. Do not use in neonates (depot contains benzyl alcohol).

**Important interactions and unwanted effects** Risk of anaphylaxis (see product literature). Hypertension and hyperglycaemia are common (monitor blood pressure and for glycosuria at least weekly). Irritability may be marked. Increased appetite and weight gain. Increased susceptibility to infection: sepsis can be overwhelming, and prompt medical attention should be sought at any sign of intercurrent illness. Gastrointestinal (GI) haemorrhage.

**Comments** Some authorities regard ACTH as superior to oral prednisolone, although the evidence base is weak and is less well tolerated.

## Amitriptyline

**Neurological indications** Chronic headache and other chronic pain syndromes particularly with sleep disruption; second-line treatment of peripheral neurogenic pain (gabapentin, pregabalin preferred).

### Dosing

#### Starting doses

- 2–12 yrs: 200–500 microgram/kg (max. 25 mg) nocte (from *British National Formulary for Children* (BNF-C)).
- Over 12 yrs: 25–50 mg po at night.

**Maintenance doses**

- 2–12 yrs: max 1 mg/kg bd (under specialist advice).
- over 12 yrs: usual dose 75 mg nocte, max. 100 mg/24 h po in divided doses.

**Discontinuation regimen**

50% of the dose for 4 weeks; 25% of the dose for 2 weeks, then stop. Avoid abrupt discontinuation.

**Preparations** 10 mg, 25 mg, 50 mg tablets, oral solution 25 mg/5 mL, 50 mg/5 mL.

**Contraindications** Cardiac arrhythmias, heart block, and acute porphyria. Electrocardiogram (ECG) is advisable before use.

**Important interactions and unwanted effects** Many interactions: check current information. Unwanted effects include confusion, fatigue, sedation, postural hypotension, syncope, and ‘anticholinergic’ effects (dry mouth, blurred vision, urinary retention, constipation). In the event of overdose, do not treat arrhythmias with anti-arrhythmic drugs—IV sodium bicarbonate may be used.

**Comments** Limit treatment duration to a total of 3 mths. Licensed for treatment of depression over 16 in UK.

## Aspirin

**Neurological indications** Stroke prophylaxis (antiplatelet agent) in specific contexts, e.g. stenotic cerebrovascular disease.

**Dosing**

- 1–5 mg/kg/24 h (max. 75 mg/24 h) po od.
- Dose can be titrated using an *in vitro* platelet thromboelastograph (‘Platelet TEG<sup>®</sup>’) assay of inhibition of platelet function.

**Preparations** 75 mg dispersible and enteric-coated tablets. For doses <75 mg, disperse the tablet in 15 mL of water and give the appropriate volume, discarding the remainder. Give with food or milk.

**Contraindications** Severe hepatic or renal impairment, haemophilia and bleeding disorders.

**Important interactions and unwanted effects** Not common in a low-dose regimen, however hypersensitivity may occur.

**Comments** May increase risk of Reye syndrome and should be temporarily suspended during acute febrile illnesses particularly varicella and influenza.

## Atomoxetine

**Neurological indications** Treatment of attention-deficit hyperactivity disorder (ADHD).

## Dosing

### Starting doses and escalation regimen

- Child over 6 (weight <70 kg) 500 microgram/kg/24 h po once daily for 7 days. Increase at weekly intervals.
- Child over 6 (weight >70 kg) dose 40 mg/24 h po once daily for 7 days. Increase at weekly intervals.

### Maintenance doses

1.2–1.8 mg/kg/24 h po (max. 120 mg daily BNF-C) divided into 1 or 2 doses (bd dosing may reduce unwanted effects).

**Preparations** 10, 18, 25, 40, and 60, 80-mg capsules: may be opened into water, milk, or fruit juice.

**Important interactions and unwanted effects** Anorexia, dry mouth, nausea, drowsiness.

**Comments** Use with caution in cardiovascular or hepatic disease. Many children with ADHD may have co-existing epilepsy. It has been reported that stimulants may exacerbate pre-existing seizure tendencies: in our opinion, this risk is not high and epilepsy is not a contraindication to stimulant therapy if otherwise clinically indicated. May take 4–6 weeks to see an effect.

Monitor pulse and blood pressure. Carers should be taught to seek medical attention in the case of unexplained nausea, vomiting, darkened urine or jaundice.

## Baclofen

**Neurological indications** Treatment of spasticity and dystonia.

## Dosing

### Starting doses and escalation regimen

- <10 years: 0.75 mg/kg/24 h orally divided in three doses.
- Child over 10: 5 mg tds. Increase by this amount at weekly intervals.

### Maintenance doses

0.75–2 mg/kg/24 h (max. 2 mg/kg/24 h up to 100 mg/24 h).

### Discontinuation regimen

Avoid abrupt withdrawal (seizure risk). Reduce to 50% for 1 week, then 25% for 1 week, then stop.

**Preparations** 10 mg tablets, 5 mg/5 mL liquid. Tablets may be crushed and dispersed in water.

**Contraindications** Peptic ulceration.

**Important interactions and unwanted effects** Lethargy, sedation, and bulbar compromise; often limit usefulness. Liquid contains 2 g sorbitol per 5 mL—may cause diarrhoea.

**Comments** Avoid abrupt withdrawal.

Baclofen also may be delivered as a continuous intrathecal infusion by an implanted programmable pump for treatment of spasticity of cerebral origin. Requires a specialist team to monitor, maintain and titrate. Doses are typically 100–1200 microgram/24 h.

## Benzatropine (bentropine)

**Neurological indications** Emergency treatment of dystonia.

### Dosing

#### Starting doses and escalation regimen

*Child* >3 yrs: 20–100 microgram/kg (max. 2 mg) IV or IM followed by oral treatment if required (20 microgram/kg max. 1 mg) repeated as necessary (max. 6 mg/24 h, or until pupillary dilatation is seen).

**Preparations** 2 mg/2 mL injection for IV, IM, or oral use.

**Important interactions and unwanted effects** See  'Trihexyphenidyl', p. 615.

**Comments** Parenteral route makes benztropine useful in severe dystonia and status dystonicus.

## Benzhexol

See  'Trihexyphenidyl', p. 615.

## Biotin (vitamin H)

**Neurological indications** Inborn errors of metabolism—defects of biotin metabolism including biotinidase deficiency; isolated carboxylase defects.

### Dosing

#### Starting doses and escalation regime

- *Neonates*: 5–10 mg daily, then increase according to response (e.g. 5 mg every 2 days).
- *1 month to 18 years*: 10 mg once a day, then increase according to response (e.g. 5 mg every 2 days).

#### Maintenance doses

- *Neonate*: 10–50 mg daily.
- *1 month to 18 years*: 20–50 mg daily (up to 100 mg daily in isolated carboxylase defects).

**Preparations** Tablets 5 mg; injection 5 mg/mL. Tablets may be crushed and mixed with food or drink.

**Contraindications** None known

**Important interactions and unwanted effects** None.

**Comments** May be used pragmatically initially if a problem of biotin metabolism suspected. Close contact with tertiary specialists in metabolic disease advised.

## Botulinum toxin A

**Neurological indications** Treatment of focal dystonia or localized spasticity attributable to specific muscle groups.

### Dosing

❗ It is essential to be aware that the dosing units of the two commonly available commercial preparations are not equivalent and to specify the preparation intended on the prescription.

#### Maximum total dose per administration

- *Dysport*<sup>®</sup>: 20–30 *Dysport*<sup>®</sup> units/kg IM.
- *Botox*<sup>®</sup>: 8–12 *Botox*<sup>®</sup> units/kg IM (max 600 U).
- Typically, 30–50% of the maximum permitted dose used at first administration (Table 7.1).

**Table 7.1** Typical target adult doses (*Dysport*<sup>®</sup> units<sup>\*</sup>)

Adductors	300–500
Biceps	250–500
Brachioradialis	150–350
Gastrocnemius	300–500
Tibialis posterior	100–250
Forearm flexors	300–500
Hamstrings	Up to 500
Quadriceps	Up to 250
Sternomastoid	100–150
Thenar group	50–100

\*1 *Botox*<sup>®</sup> unit = approximately 2.5–4 *Dysport*<sup>®</sup> units. Precise conversion rates are not possible. Doses should be reduced proportionately in view of body weight and muscle bulk.

**Preparations** Powder is reconstituted immediately before use in 0.9% saline typically at a dilution of 100 *Dysport*<sup>®</sup> U/mL or 200 *Botox*<sup>®</sup> U/mL (higher concentration, smaller-volume injections may be useful in some contexts).

**Contraindications** Myaesthesia. Concurrent aminoglycoside use.



**Important interactions and unwanted effects** Some diffusion from injection sites typically occurs; cervical injection (typically for dystonia) may cause dysphagia. Effects may be potentiated by aminoglycosides. Sometimes flu-like symptoms.

**Comments** Specialist use only. Target muscles are identified by clinical examination. Needle placement is guided by surface anatomy and/or ultrasound (US) guidance. Confirmation of placement prior to administration can be achieved by observing the needle pivoting about the insertion point in the skin as the target muscle is passively extended.

Clinical effects last 8–12 weeks. All targeted muscles should be treated at a single session. Frequent administration probably increases the risk of antibody formation that limits effectiveness.

Additional unlicensed indications include treatment of drooling by injection into salivary glands (in specialist centres).

## Calcium and vitamin D supplements

**Neurological indications** Prophylaxis of osteomalacia in the context of long-term steroid or phenytoin use.

### Dosing

Typical regimes provide ~500 mg of calcium (12 mmol  $\text{Ca}^{2+}$ ) and 400 units (10 mg) of cholecalciferol daily (e.g. Calcichew D3 Forte® once daily). Higher doses may be used under specialist advice.

**Preparations** Various calcium/vitamin D preparations are available: individual preference and palatability may be important.

**Comments** Monitor bone mineral density in long-term steroid use (e.g. >3 months).

## Carbamazepine

**Neurological indications** Treatment of focal seizures; some paroxysmal movement disorders; neurogenic pain; empiric mood-stabilizer in psychiatric practice (including bipolar disorder). May worsen primary generalized epilepsies (especially juvenile myoclonic epilepsy (JME), tonic, atonic, and absence seizures).

### Dosing

#### Starting doses and escalation regimen

Oral

5 mg/kg/24 h oral (divided in 2 doses) increasing by 5 mg/kg/24 h every 3–7 days.

#### Maintenance doses

Maximum doses guided by clinical assessment of tolerance: typically 20 mg/kg/24 h, but occasionally fast metabolizers tolerate (and need)

higher doses. Maximum adult dose is typically 1.2 g/24 h, occasionally higher (1.6–2 g/day).

*Discontinuation regimen*

75% of the dose for 2–4 weeks; 50% of the dose for 2–4 weeks; 25% of the dose for 2–4 weeks, then stop.

*Missed dose regimen*


Give next dose when due; no additional doses.

**Preparations** Tablets (100, 200, 400 mg), liquid (100 mg/5 mL), chew-able tablets (100, 200 mg), controlled-release tablet (200, 400 mg), suppository (125, 250 mg). Controlled release tablets can be halved if scored, but cannot be crushed (thought to limit post-dose drug level peaks).

**Contraindications** Atrio-ventricular conduction abnormalities (unless paced). History of bone marrow depression, porphyria. Consider testing children Han-Chinese or Thai origin for HLA-B\*1502 allele prior to treatment commencing as ↑ risk of Stevens Johnson Syndrome.

**Important interactions and unwanted effects** Drowsiness or unsteadiness may occur transiently on introduction or dose escalation (reduce rate of escalation) or as a dose-limiting unwanted effect at higher doses. May also occur transiently 1–2 h after dosing as blood levels peak: either fractionate dose further (e.g. into three divided doses) or use controlled-release preparation.

- Occasional rash.
- Rare lupus-like syndrome.
- Rare blood dyscrasias, and osteomalacia.
- Hyponatraemia (SIADH).


Plasma carbamazepine levels are increased by concomitant oral use of macrolide antibiotics (erythromycin, azithromycin). For interactions between anti-epileptic drugs (AEDs), see  p. 619. Many other important interactions: see other sources.

**Comments** Rectal administration (suppository or liquid) is possible for periods of up to 1 week: dose should be increased by 25% (max. 250 mg qds). Enzyme induction will reduce effectiveness of standard oral contraception.

## Chloral hydrate

**Neurological indications** Refractory status dystonicus, agitation, and non-convulsive status epilepticus. Sedation for painless procedures and night sedation.

### Dosing

- *Epilepsy*: 80–240 mg/kg/24 h divided in 4–6 doses.
- *Sedation for procedures*: see  p. 619.

**Discontinuation regimen**

*Epilepsy*: 50% of the dose for 3–5 days; 25% dose for 3–5 days, then stop.

**Preparations** Elixir 200 mg/5 mL, 500 mg /5 mL (mix with milk, water, or fruit juice to reduce unwanted effects and disguise the taste!)

**Contraindications** Use with care in respiratory disease. Avoid in severe hepatic or renal impairment, cardiac disease, gastritis, or porphyria.

**Important interactions and unwanted effects** Gastric irritation; nausea; vomiting; sleepiness; rash.

**Comments** Do not use concomitantly with triclofos (which is a derivative of chloral). Not licensed in children for sedation. Dilute liquid with water or juice if necessary to disguise the taste.

## Clobazam

**Neurological indications** Anti-epileptic.

### Dosing

#### *Starting doses and escalation regimen*

500 microgram/kg/24 h po divided in two doses. Increased according to response after 5–7 days.

#### *Maintenance doses*

1 mg/kg/24 h po (max. < 12 yrs: 30 mg/24 h, 12–18 yrs: 60 mg/24 h) divided in two doses.


#### *Discontinuation regimen*

75% of the dose for 2 months; 50% of the dose for 2 months; 25% of the dose for 2 months, then stop (faster withdrawal is possible if treatment duration is short).

**Preparations** 10-mg tablet (can be crushed and dispersed in water), liquid can be formulated.

**Contraindications** Ventilatory insufficiency, sleep apnoea syndrome; severe hepatic impairment; depression.

**Important interactions and unwanted effects** Sedating, particularly in combination (e.g. with phenobarbital).

**Comments** Risk of withdrawal seizures if discontinued abruptly. Liquid has a very short shelf life necessitating frequent re-supply. For interactions between AEDs, see  p. 619.

## Clomethiazole (chlormethiazole)

**Neurological indications** Treatment of convulsive status epilepticus.

### Dosing

#### *Maintenance doses*

1–3 mg/kg (0.03–0.06 mL/kg of syrup) po 4-hourly increasing to 2-hourly if unresponsive. (max 0.4 mL/kg/day to 20 mg/day).

**Preparations** Syrup (discontinued commercially) (as edisylate) 250 mg/5 mL and capsules (192 mg as base): one 250 mg capsule equivalent to 5 mL syrup.

**Contraindications** Respiratory depression (may require ICU support).

**Important interactions and unwanted effects** Respiratory suppression, tachyphylaxis may occur rapidly, sedation, increased secretions. May worsen seizures in Lennox Gastaut Syndrome.

**Comments** Intravenous preparation now withdrawn in the UK (reacts with PVC giving sets. Risk of thrombophlebitis and cardiac toxicity).

## Clonazepam

**Neurological indications** Anti-epileptic.

### Dosing

#### Starting doses and escalation regimen

- Under 5 yrs, 250 microgram po at night increased at weekly intervals.
- 5–12 yrs, 500 microgram po at night increased at weekly intervals.
- 12–18 yrs, 1 mg po at night increased at weekly intervals.

#### Maintenance doses

- Less than 1 yr, 0.5–1 mg/24 h po divided in 2–4 doses.
- 1–5 yrs, 1–3 mg/24 h po divided in 2–4 doses.
- 5–12 yrs, 3–6 mg/24 h po divided in 2–4 doses.
- 12–18 yrs, 4–8 mg/24 h po divided in 2–4 doses.

#### Discontinuation regimen

75% of the dose for 1 month; 50% of the dose for 1 month; 25% of the dose for 1 month, then stop.

**Preparations** Tablet (500 microgram, 2 mg), intravenous injection, liquid 250 microgram/5 mL (not commercially available), 500 microgram/5 mL, 2 mg/5 mL.

**Contraindications** See 📖 'Clobazam', p. 582.

**Important interactions and unwanted effects** Increased salivation and bronchorrhoea (may be temporary, increased with IV administration); sedation; irritability; behaviour disturbance.

**Comments** Individual sensitivity for both wanted and unwanted effects is very variable. Intravenous preparation can be used rectally. For interactions between anti-epileptic drugs, see 📖 p. 619.

## Clonidine

**Neurological indications** Treatment of agitation (particularly post-traumatic brain injury and opiate withdrawal); tic disorders.

## Dosing

### Starting doses and escalation regimen

Test dose 1 microgram should be given prior to treatment and monitor blood pressure (BP)

1.5–3 microgram/kg/24 h po divided in three doses, increased if necessary every 5–7 days.

### Maintenance doses

- Sedation: 5–25 microgram/kg/24 h po (max. 1.2 mg/24 h).
- Tic disorders: 3–10 microgram/kg/24 h po (max. 300 microgram/24 h).

### Discontinuation regimen

75% of the dose for 2 days; 50% of the dose for 2 days; 25% of the dose for 2 days, then stop.

**Preparations** Tablet (25, 100, 300 microgram), liquid. 100-microgram tablet can be crushed and dispersed in water.

**Contraindications** Porphyria.

**Important interactions and unwanted effects** Antihypertensive—monitor BP (particularly on induction and withdrawal). Avoid sudden withdrawal to prevent hypertensive crisis withdrawal syndrome. Drowsiness.

**Comments** Unlicensed.

## Dantrolene

**Neurological indications** Treatment of spasticity, malignant hyperthermia.

## Dosing

### Starting doses and escalation regimen

- Spasticity:
  - under 12: 0.5 mg/kg po as single daily dose increasing to 0.5 mg/kg 3 times a day after 7 days. Further increase by 0.5 mg/kg/dose until satisfactory response.
- Over 12: 25 mg po once daily increasing to 25 mg after 7 days. Further increase by 0.5 mg/kg/dose until satisfactory response.
- Malignant hyperpyrexia/severe rhabdomyolysis (1 mth–18 yrs): 2–3 mg/kg IV bolus, then 1 mg/kg repeated as required at 10 min intervals to maximum cumulative dose of 10 mg/kg.

### Maintenance doses

Spasticity

1 month–18 yrs: 8 mg/kg/24 h divided in 3–4 doses (max. 400 mg/24 h).


**Preparations** Capsule (25, 100 mg). Liquid for injection (20 mg).

**Contraindications** Liver disease.

**Important interactions and unwanted effects** Drowsiness, fatigue, weakness, vomiting, diarrhoea. May cause liver disease: monitor liver function periodically.


**Comments** Typically used in inpatient setting (e.g. in early rehabilitation after acquired brain injury): useful as it is less sedating than oral baclofen at effective antispasticity doses.

## Dexamethasone

**Neurological indications** Emergency and perioperative management of cerebral oedema associated with cerebral tumour. Treatment of bacterial meningitis (see  p. 338).

### Dosing

#### Cerebral tumour

- *Child under 35 kg*: 20 mg slow IV stat; then 4 mg IV po every 2 h for 3 days; then 4 mg IV po every 6 h for 1 day; then 2 mg IV po every 6 h for 4 days, then decrease by 1 mg/24 h daily.
- *Child over 35 kg*: 25 mg slow IV stat; then 4 mg IV po every 2 h for 3 days, then 4 mg IV po every 4 h for 1 day, then 4 mg IV po divided in every 6 h for 4 days, then decrease by 2 mg/24 h daily.
- *Pneumococcal meningitis*: 150 microgram/kg every 6 h for 4 days starting before or with first dose of antibiotic (see  p. 338).

**Preparations** Injection 10 mg/2 mL, tabs 0.5, 2 mg, liquid 2 mg/5mL.

**Important interactions and unwanted effects** As for ACTH.

**Comments** Well absorbed orally. Note that dosing may differ, based on specific oncology protocols.

## Dexamfetamine

**Neurological indications** Treatment of attention-deficit hyperactivity disorder.

### Dosing

#### Starting doses and escalation regimen

- *3–5 yrs*: 2.5 mg/24 h increasing by 2.5 mg/24 h increments at weekly intervals typically given in an 08.00 and 12.00 hours regimen.
- *Over 6 yrs*: 5 mg/24 h increasing by 5 mg/24 h increments at weekly intervals typically given in an 08.00 and 12.00 hours regimen.

#### Maintenance doses

*Max 3–5 yrs*

- *20 mg daily, 6 years and over*: 40 mg daily. Doses may be given in 3–4 divided doses if necessary. Discontinuation regimen.
- 50% for 1 week then stop.

**Preparations** 5 mg tablet (can be halved).

**Contraindications** Cardiac disease, hypertension; agitation or psychosis.

**Important interactions and unwanted effects** Anorexia. May aggravate tic disorders, agitation, or psychosis.

**Comments** Very short-acting: doses typically given in morning and at lunchtime with food to limit rebound effects late in evening. Monitor weight. Many children with attention-deficit hyperactive disorder may have co-existing epilepsy. It has been reported that stimulants may exacerbate pre-existing seizure tendencies: in our opinion, this risk is not high and epilepsy is not a contraindication to stimulant therapy if otherwise clinically indicated. **Note:** Controlled Drug (CD) regulations apply in the UK.

## Diazepam

**Neurological indications** Status epilepticus (rectal route particularly useful in out-of-hospital settings, but buccal midazolam is preferable), muscle spasm (e.g. after orthopaedic procedures in children with dystonic cerebral palsy), severe/dangerous sleep walking.

### Dosing

- *Status epilepticus* (as IV injection over 3–5 min):
  - under 12—300–400 microgram/kg, repeated after 10 min if necessary;
  - over 12—10–20 mg repeated after 10 min if necessary;
  - rectally 0.5 mg/kg repeated after 5 min if necessary (or 5 mg pr under 2 yrs; 5–10 mg pr between 2 and 12 yrs; 10 mg pr over 12 yrs).
- *Muscle spasm (orally)*:
  - 1–5 yrs—5 mg/24 h divided in two doses;
  - 5–12 yrs—10 mg/24 h divided in two doses;
  - 12–18 yrs—20 mg/24 h divided in two doses; max. 40 mg/24 h.
- *Sleep walking*: 1–5 mg at night.

### Discontinuation regimen

Avoid prolonged use if possible. After short-term use (e.g. <2 weeks) reduce to 75% for 1 week; 50% for 1 week; then stop. After prolonged use, taper more gradually, e.g. 75% of the dose for 1 month; 50% of the dose for 1 month; 25% of the dose for 1 month; then stop.

**Preparations** Tablets (2, 5 mg), oral solution (2 mg/5 mL, 5 mg/5 mL), emulsion for intravenous injection (5 mg/mL: avoid in neonates as contains benzyl alcohol), tubes of rectal solution (2.5, 5, 10 mg).

**Contraindications** Respiratory depression.

**Important interactions and unwanted effects** Respiratory depression particularly in the context of IV treatment for status epilepticus. Can be late, occurring 20–30 min after injection: keep child monitored.

Risks are greater (and likelihood of seizure termination poorer) with multiple, smaller doses, rather than a single larger dose. Dependence/tolerance may develop.

## Edrophonium

**Neurological indications** Diagnosis of myaesthetic syndromes.

**Comments** For protocol, see Box 4.10.

## Enoxaparin (low molecular weight heparin)

**Neurological indications** Treatment of established venous thrombosis. Prophylaxis of thrombosis.

### Dosing

- *Prophylaxis of thrombosis:*
  - under 2 months—0.75 mg/kg/dose enoxaparin subcutaneously (SC) 12-hourly;
  - over 2 months—0.5 mg/kg/dose enoxaparin SC 12-hourly (max 40mg daily).
- *Treatment of established venous thrombosis:*
  - under 2 months: 1.5–2 mg/kg/dose enoxaparin SC 12-hourly;
  - over 2 months: 1 mg/kg/dose enoxaparin SC 12-hourly adjusted as necessary (see Table 7.2).

**Dose adjustment for treatment of established thrombosis** (Table 7.2)

**Table 7.2** Target anti-Xa level (4 h post-dose) 0.5–1.0 U/mL

Anti-Xa level	Action
<0.35 U/mL	Increase dose by 25% and recheck 4 h after next dose
0.35–0.49 U/mL	Increase dose by 10% and recheck 4 h after next dose
0.5–1.0 U/mL	No change to dose. When dose steady, a weekly level check (4 h post-dose) is adequate
1.1–1.5 U/mL	Decrease dose by 20%. Check trough level before next dose
1.6–2 U/mL	Delay next dose 3 h and decrease by 30%. Check trough level before and peak level 4 h post-dose
>2 U/mL	Withhold dose. Check trough level when next dose due and 12-hourly, withholding until level <0.5 U/mL then decrease dose by 40%.



**Discontinuation regimen**

**Treatment of established venous thrombosis** If long-term anticoagulation is planned, heparin is discontinued once warfarin dose is established.

**Preparations** Subcutaneous injection (20 mg/0.2 mL, 40 mg/0.4 mL, 60 mg/0.6 mL).

**Contraindications** Reduce dose in severe renal and hepatic involvement; standard heparin may be preferable.

**Comments** Low molecular weight heparin (LMWH) has a longer duration of action than standard (unfractionated) heparin: the latter may therefore be preferable in certain situations. For general prophylaxis of thrombosis however subcutaneous administration and the reduced need for monitoring of coagulation profiles in routine use are major advantages of LMWH.

Other LMWHs include dalteparin and tinzaparin. Treatment regimens are comparable (tinzaparin once daily dosing), although dosage units are not interchangeable.

In the context of thromboembolic cerebrovascular disease where a decision has been made to anticoagulate, LMWH would typically be used for a few days, while warfarin is introduced until International normalization ratio (INR) stably within reference range.

## Ethosuximide

**Neurological indications** Treatment of absence and myoclonic seizures.

### Dosing

#### Starting doses and escalation regimen


- Under 6 yrs: 125 mg/24 h increasing by 125 mg/24 h increments divided in 2 doses at 7–14-day intervals.
- Over 6 yrs: 250 mg/24 h increasing by 250 mg/24 h increments divided in 2 doses at 7–14-day intervals.

#### Maintenance doses

20 mg/kg/24 h divided in 2 doses, increased if tolerated and effective to max. 50 mg/kg/24 h (max. 1.5 g/24 h).

**Preparations** Capsule (250 mg), liquid (250 mg/5 mL).

**Contraindications** Porphyria.

**Important interactions and unwanted effects** Liquid has an unpleasant taste. Dose-limiting effects are usually gastrointestinal (nausea, diarrhoea). Also weight loss, dizziness. Rarely blood dyscrasias. For interactions between anti-epileptic drugs, see  p. 619.

**Comments** Counsel to seek prompt medical advice if fever, sore throat, ulcers, bruising, or bleeding.

## Folinic acid

**Neurological indications** Pragmatic treatment for neonatal onset seizures.

### Dosing

**Starting dose and escalation regime**

15 mg daily (po IV). This is likely to be the maintenance dose, although with advice of a neurometabolic paediatrician larger doses may be tried.

**Preparations** Tablets of folinic acid (as calcium salt) 15 mg. Tablets may be crushed and dispersed in water. Can be given IV as calcium folinate.

**Contraindications** None known.

**Important interactions, unwanted effects** None.

## Flunarizine

**Neurological indications** Migraine prophylaxis, particularly familial hemiplegic migraine.

### Dosing

Under 40 kg: 5 mg at night; >40 kg, 10 mg at night.

**Preparations** Capsule.

**Important interactions and unwanted effects** Weight gain, increased appetite, drowsiness, headache.

**Comments** Effects on headache frequency may be delayed for several weeks.

## Fosphenytoin

See  p. 604.

## Gabapentin

**Neurological indications** Neurogenic pain and dysaesthesiae; adjunctive treatment of focal seizures.

### Dosing

**Starting doses and escalation regimen**

10 mg/kg/24 h (max. 300 mg) od on day 1, then bd on day 2 then tds thereafter.

**Maintenance doses**


30–40 mg/kg/24 h. Higher doses (e.g. up to 60 mg/kg/24 h; adult max. 3.6 g/24 h) have been used with benefit.

**Discontinuation regimen**

50% of the dose for 1 week then stop.

**Preparations** Capsules (100, 300, 400 mg) (can be opened, but bitter taste), tablet (600, 800 mg) liquid manufacturer.

**Important interactions and unwanted effects** Sedation at high doses. Occasional insomnia.

**Comments** Generally well tolerated even at high dose. For interactions between anti-epileptic drugs, see  p. 619. Capsules can be opened and dispersed in water. Bitter taste can be masked with blackcurrant juice.

## Glycopyrronium bromide (glycopyrrolate)


**Neurological indications** Reduction of oral and upper airway secretions particularly in severely disabled child (unlicensed).

**Dosing**

120–400 microgram/kg/24 h divided in 3–4 doses.

**Preparations** Tablet (1, 2 mg). Liquid for injection (200 microgram/mL) can be given orally. Tablets can be crushed and dispersed in water.

**Contraindications** Urinary retention. Chest infection.

**Important interactions and unwanted effects** See  'Trihexyphenidyl', p. 615. Thicker, more viscous airway secretions may be harder to clear, aggravate atelectasis, and precipitate chest infections. Profound antimuscarinic effects may be seen.

## Haloperidol

**Neurological indications** Treatment of severe chorea and tic disorder; emergency treatment of severe aggression or violent behaviour.

**Dosing**

Starting doses and escalation regimen.

**Tics and chorea**

- Under 12 yrs: 25–50 microgram/kg/24 h po divided in two doses.
- Over 12 yrs: 0.5mg 2–3 times daily.

**Acute agitation**

- Under 12 yrs: 10–30 microgram/kg po repeated after 60 min if necessary.
- Over 12 yrs:
  - 2.5–5 mg IM;
  - 1–5 mg po repeated after 60 min if necessary.

**Maintenance doses***Tics and chorea*


- Under 12 yrs: 50–75 microgram/kg/24 h (max. 10 mg/24 h) divided in 2–3 doses.
- Over 12 yrs: 6–15 mg/24 h (occasionally more) divided in 2–3 doses.

**Discontinuation regimen***Movement disorder*

- 75% for 2 weeks.
- 50% for 2 weeks.
- 25% for 2 weeks.
- Then stop.

**Preparations** Capsule (500 microgram, 1.5, 5, 10 mg), liquid (5 mg/mL) IM injection (5 mg/mL).

**Contraindications** Significant liver or renal disease.

**Important interactions and unwanted effects** Early dyskinesia after a few doses (reversible); tardive dyskinesia (may be incompletely reversible; see  p. 518); other extrapyramidal unwanted effects. Neuroleptic malignant syndrome (very rare).

## Histamine

**Neurological indications** Identification of autonomic neuropathy in consideration of neuropathic causes of apparent indifference to pain.

**Dosing**

0.2–0.5 mL of 1:10 000 histamine solution injected intradermally (usually supplied as 1:1000 solution so needs ×10 dilution).

**Comment** Lack of wheal response suggests autonomic neuropathy (i.e. significant result).

## Intravenous immunoglobulin

**Neurological indications** Treatment of acute inflammatory demyelinating neuropathy (AIDP; Guillain-Barré) and chronic inflammatory demyelinating neuropathy (CIDP). Use reported in Rasmussen syndrome. Considered in treatment of transverse myelitis and ADEM, and under specialist advice in myaesthesia gravis.

**Dosing**

- All indications: Total dose 2 g/kg either as a single dose or fractionated over 3–5 consecutive days. Standard infusion protocols start at very

low dose to minimize risk of anaphylaxis and escalate over several hours: consult product leaflet.


- Monitor temperature, pulse, and respiration frequently during administration.

**Preparations** Various. No evidence of differential efficacy.

**Contraindications** Known anti-IgA antibodies. **IgA deficiency must be excluded prior to first use.**

**Important interactions and unwanted effects** Fever, rash (consider continuing with antihistamine/steroid cover). More rarely anaphylaxis. As a pooled-blood product, risk in principle of transmission of infectious agents though all known pathogens screened.

## Ketamine

**Neurological indications** Third line treatment of non-convulsive status epilepticus (see  p. 273).

### Dosing

#### Child 1–18 yrs

- *Oral protocol:* 1.5 mg/kg/24 h divided in two doses for up to 5 days.
- *PICU protocol:* continuous infusion initially 0.5–2 mg/kg as slow IV injection over 1 min, followed by continuous intravenous infusion of 0.6–2.7 mg/kg/h adjusted according to response.

#### Discontinuation regimen

Oral treatment is typically maintained alongside conventional AEDs for 5 days then discontinued without weaning.

**Preparations** Parenteral preparation can be given orally in fruit juice. Oral solution available.

**Important interactions and unwanted effects** Respiratory suppression.

**Comments** For intravenous infusion, dilute to 1 mg/mL with 0.9% saline or glucose 5%.

## Lacosamide

**Neurological indications** Adjunctive treatment of focal seizures.

### Dosing

#### Starting doses and escalation regimen

- Not currently licensed below 16 years of age in UK.
- *16–18-yr-olds:* 50 mg bd increasing at weekly intervals by increments of 50 mg bd.


**Maintenance doses**

- >16 years: 200 mg bd.

**Preparations** Tablets (50, 100, 150, 200 mg); 15 mg/mL syrup; intravenous infusion (10 mg/mL).

**Important interactions and unwanted effects** Risk of PR-interval prolongation. Do not use in presence 2nd or 3rd degree heart block.

**Comments** Intravenous formulation available: no dosing adjustment required.

For interactions between anti-epileptic drugs see  p. 619. Off-license use in children under 16 years of age must be under specialist supervision.

## Lamotrigine

**Neurological indications** Treatment of focal, generalized, and absence seizures.

### Dosing

**Starting doses and escalation regimen**

*Without valproate.*

- Under 6 yrs: 5 mg on alternate days for 2 weeks.
- Over 6 yrs: 5 mg daily for 2 weeks.
- Over 12 yrs: 25 mg on alternate days for 2 weeks.
- Then increase by 300–600 microgram/kg/24 h (under 12) or 25–50 mg/24 h (over 12) every 1–2 weeks

*With valproate*

Halve the doses without valproate.

**Maintenance doses**

*Without valproate*

- <12 yrs: initial target dose 5 mg/kg/24 h to max. 15 mg/kg/24 h divided in 2 doses (max single dose 200 mg).
- >12 yrs: 100–200 mg bd (max. 700 mg/24 h).

*With valproate*

(Inhibits lamotrigine degradation) halve doses.

**Preparations** Tablets (25, 50, 100, 200 mg) and dispersible (chewable) tablets (2, 5, 25, 100 mg).

**Important interactions and unwanted effects** Rash that is occasionally serious including Steven–Johnson syndrome. Mood disturbance. Rarely hepatic dysfunction, lymphadenopathy, leukopenia, thrombocytopenia.

**Comments** Initial desensitizing dose and slow escalation are used to reduce the otherwise high incidence of rash. Warn families to report any rash urgently and to discontinue treatment. Not licensed for use as

monotherapy in children under 12 yrs, or as adjunctive treatment in children under 2 yrs. Lamotrigine can sometimes be cautiously reintroduced despite previous rash formation if indicated, using the increments given here increasing at intervals of 2–3 months.

For interactions between AEDs see  p. 619.

## Levetiracetam

**Neurological indications** Generalized, absence and focal seizures.

### Dosing

#### Starting doses and escalation regimen


- <50 kg: 10 mg/kg/24 h in 1–2 divided doses, incrementing by 10 mg/kg/24 h every 7 days.
- 12–18 yrs: 250 mg bd, increasing by 500 mg bd every 7–14 days.

#### Maintenance doses

- <50kg: 40mg/kg/24 h occasionally up to 60 mg/kg/24 h.
- >50kg/12 yrs: Max 1.5g bd.

**Preparations** Tablet (250, 500 mg, 1 g), oral solution (500 mg/5 mL). Concentrate for IV infusion.

**Important interactions and unwanted effects** Drowsiness, weakness, behavioural disturbance. Rarely precipitates non-convulsive status epilepticus. Reduce dose if eGFR <80 mL/min/1.73m<sup>2</sup>.

**Comments** Generally well tolerated. For interactions between anti-epileptic drugs, see  p. 619. IV dose same as PO maintenance.

## Levodopa (L-DOPA)

**Neurological indications** Treatment of DOPA-responsive conditions including DOPA-responsive dystonia and tetrahydrobiopterin synthesis disorders.

### Dosing

#### Starting doses and escalation regimen

1–2 mg/kg/24 h in 4–6 divided doses increasing by 1 mg/kg/24 h every 3–5 days.

#### Maintenance doses

Increase progressively until clinical effect or unwanted effects (particularly vomiting) supervene. Typical doses for DOPA-responsive dystonias (DRD) are around 10–12 mg/kg/24 h. Lack of response after 3 months at maximum clinically tolerated dose is sufficient to exclude L-DOPA responsive dystonia (DRD; response can be delayed).

**Preparations** 1 part carbidopa:4 parts levodopa preparation is recommended; at higher doses consider preparation containing 1:10 carbidopa:levodopa.

Tablets may be crushed and dispersed in water immediately prior to administration.

- Sinemet<sup>®</sup> 62.5 mg scored tablet containing carbidopa 12.5:levodopa 50. Also available: Sinemet<sup>®</sup> 110 (carbidopa 10:levodopa 100 mg); Sinemet<sup>®</sup> Plus (carbidopa 25:levodopa 100 mg); and Sinemet<sup>®</sup> 275 (carbidopa 25 mg:levodopa 250 mg).
- Madopar<sup>®</sup> soluble tablet containing 50 mg levodopa:12.5 mg benserazide.

**Contraindications** Closed angle glaucoma.

**Important interactions and unwanted effects** Sudden onset of sleep, excessive sedation. Nausea and vomiting, autonomic disturbance (e.g. postural hypotension and syncope).

**Comments** Amino acid precursor of dopamine, which replenishes striatal dopamine. Usually administered with a DOPA decarboxylase inhibitor to reduce unwanted systemic effects. Prescribed doses are expressed as levodopa.

## Lorazepam

**Neurological indications** Emergency treatment of status epilepticus.

### Dosing

100 microgram/kg IV (max. 4 mg IV over 60 seconds) repeated once if initial dose is ineffective. Can also be given sublingually or rectally.

**Preparations** Intravenous injection (4 mg/mL).

**Contraindications** See  'Diazepam', p. 586.

**Important interactions and unwanted effects** See  'Diazepam', p. 586.

**Comments** Superior to parenteral diazepam as the latter tends to enter adipose tissue lowering acute circulating levels, and where repeated doses can accumulate before re-entering the bloodstream, causing late respiratory effects. One larger dose is typically more effective than repeated partial doses.

Dilute with equal volume 0.9% saline or water for injection and inject slowly through a large vein. In neonates, dilute to 100 microgram/mL (i.e. 1 mL/kg total volume).

## Mannitol

**Neurological indications** Emergency treatment of known or suspected cerebral oedema.



**Dosing**

0.25–1.5 g/kg (2.5–7.5 mL/kg of 20% solution) IV infused over 30–60 min. Repeated if necessary after 4–8 h, max. twice.

**Preparations** 10 and 20% solutions. May crystallize out of solution. Warm, allow to cool, and administer via an in-line filter.

**Contraindications** Cardiac failure or pulmonary oedema. Pre-existing hypernatraemia or hypovolaemia. Intracranial bleeding. Anuria.

**Important interactions and unwanted effects** Hypovolaemia due to obligatory diuresis. Extravasation may occur.

**Comments** A transient artefactual hypertonic hyponatraemia typically occurs on initial use (the mannitol causes water shift from the intracellular to the extracellular compartment and a dilutional hyponatraemia with normal total body Na). Prolonged or frequent use will result in hypernatraemia, limiting further use.

## Melatonin

**Neurological indications** Sleep induction for EEG; treatment of sleep–wake cycle disorders particularly in children with neurodisability (most studied in children with visual impairment).

**Dosing****Maintenance doses**

*For sleep EEG*

- Under 2 yrs: 2.5–5 mg.
- Over 2 yrs: 2.5–10 mg as single dose 30 min prior to procedure.

*For sleep–wake cycle disorders*

- Under 2 yrs: 2.5–5 mg.
- Over 2 yrs: 2.5–10 mg at night.

**Preparations** Standard capsule (1, 2, 3, 5 mg) and 2 mg controlled-release tablet (3 mg). Standard capsule can be opened into water, milk, or fruit juice. Liquid available.

**Comments** Standard formulation is effective for ~5 h. Treatment with a combination of standard and controlled-release preparation has been described. Use in visual impairment argued on the basis of loss of physiological light/dark sleep cues. Does not affect EEG. Safety of long-term use is not established.

Doses >10mg show no additional efficacy.

## Methylphenidate

**Neurological indications** Treatment of attention-deficit hyperactivity disorder.

## Dosing

### Starting doses and escalation regimen (based on standard release tablets).

For controlled-release dosing refer to relevant product literature.

- 4–6 yrs: 2.5 mg bd, increased at weekly intervals by 2.5 mg/24 h.
- Over 6 yrs of age: 5 mg po once or bd; 5–10 mg/24 h increments every 5–7 days.

### Maintenance doses

- 4–6 yrs: max 1.4 mg/kg/24 h in 2–3 divided doses.
- >6 yrs: 1–2 mg/kg/24 h up to 60 mg/24 h), typically at 08.00 and 13.00 hours. Max 2.1 mg/kg/24 h or 90 mg/24 h. Avoid giving last dose later than 16.00 hours.

**Preparations** Tablets and controlled-release tablets.

**Contraindications** See  'Dexamfetamine', p. 586.

**Important interactions and unwanted effects** See  'Dexamfetamine', p. 586.

**Comments** Short duration of action permits tailored use, e.g. omitting doses at weekends and during school holidays. Consider initial and subsequent blinded trials omitting doses: ideally with a semi-objective symptom severity measure (e.g. Connor questionnaire for parents and teachers). Many children with attention-deficit hyperactive disorder may have a co-existing epilepsy. It has been reported that stimulants may exacerbate pre-existing seizure tendencies: in our opinion, this risk is not high and epilepsy is not a contraindication to stimulant therapy if otherwise clinically indicated.

Typically given morning and midday, or controlled-release preparation once daily in the morning. Discontinue if no effect after 1 mth. Not recommended under 4 yrs old. **Note:** CD regulations apply in the UK.

## Methylprednisolone


**Neurological indications** 'Pulse' remission-initiating treatment of non-infectious CNS inflammation including demyelination and vasculitis.

## Dosing

30 mg/kg (max. 1 g) IV infusion once daily for 3 days. Diluted in 0.9% saline or glucose 5% and administered over at least 30 min.

**Preparations** Powder for reconstitution.

**Contraindications** Active systemic infection.

**Important interactions and unwanted effects** Rapid infusion may be associated with severe hypertension and cardiovascular collapse. May cause insomnia; if possible avoid giving in the evening. See typical unwanted steroid effects under ACTH  p. 575. High dose methylprednisolone may increase blood ciclosporin levels.

**Comments** Usually followed by a maintenance course of oral prednisolone.

## Midazolam

**Neurological indications** Rescue for prolonged seizures; status epilepticus (Accident & Emergency Department (A&E) and Intensive Care Unit (ICU)); sedation for minor procedures.

### Dosing

#### **Buccal use as rescue treatment**

*Buccal administration*

- Neonate: 300 microgram/kg as a single dose.
- Child, 1–6 mths: 300 microgram/kg up to 2.5 mg, repeated once if necessary.
- Child 6 mths to 1 year: 2.5 mg repeated once if necessary.
- Child 1–5 yrs: 5 mg repeated once if necessary.
- Child 5–10 yrs: 7.5 mg repeated once if necessary.
- Child 10–18 yrs: 10 mg repeated once if necessary.

#### **Intravenous use for status epilepticus (A&E and ICU settings)**

- All ages. Rapid intravenous injection 150–200 microgram/kg followed by continuous infusion of 1 microgram/kg/min (increase by 1 microgram/kg/min every 15 min until seizure control).
- Usual maximum 300 microgram/kg/h, occasionally higher when ventilated.

#### **Sedation for procedures**

By intravenous injection over 2–3 min, 5–10 min before procedure.

- Child 1 mth to 12 yrs: initially 25–50 microgram/kg increased if necessary in small steps:
  - <6 yrs: max. total dose 300 microgram/kg or 6 mg;
  - 6–12 yrs: max. total dose 10 mg).
- Child 12–18 yrs: initially 2–2.5 mg increased in steps of 0.5–1 mg if necessary, usual range 3.5–5 mg (maximum total dose 7.5 mg). Pharmacokinetic data suggest the rate of metabolism and clearance in children is higher than in young adults.

**Preparations** Injection 2 mg/2 mL, 5 mg/5 mL, 10 mg/2 mL, oral liquid 2.5 mg/mL, prefilled oral syringes of 2.5 mg, 5 mg, 7.5 mg, and 10 mg, buccal liquid 10 mg/mL.

Dilute intravenous solution with glucose 5% or NaCl 0.9%. IV injection over 2–3 min.

**Important interactions and unwanted effects** Rapid intravenous injection (<2 min) may cause seizure-like myoclonus in preterm neonates. Monitor closely, watch for respiratory depression, laryngospasm, bronchospasm, respiratory arrest, hypotension, heart rate changes, cardiac arrest, anaphylaxis. Rarely involuntary movement on withdrawal, paradoxical excitement and aggression, urinary retention, and incontinence.

Not licensed for children under 6 months.

## Neostigmine

**Neurological indications** Short-term treatment of myaesthesia and disorders of neuromuscular transmission.

### Dosing

#### IM/SC

A test dose of 0.05 mg/kg should be given then:

- <12 years: 10–40 microgram/kg/dose IM or SC every 3–4 h as required.
- >12 years: 1–2.5 mg every 3–4 h as required.

#### Oral

- 1 mth–6 yrs: 7.5 mg repeated every 3–4 h as required, max 90 mg/day.
- 6–2 years: 15 mg repeated every 3–4 h as required, max 90 mg/day.
- >12 years: 15–30 mg repeated every 3–4 h as required, max 300 mg/day.

**Preparations** Injection (2.5 mg/mL) tablets 15mg (scored).

**Contraindications** Intestinal obstruction, urinary retention.

**Important interactions and unwanted effects** Has strong muscarinic action, and concomitant atropine or propantheline treatment may be required to treat abdominal cramps, excess salivation or diarrhoea. If bronchoconstriction develops consider overdose.

## Nitrazepam

**Neurological indications** Treatment of myoclonic seizures in infants and third-line treatment of infantile spasms.

### Dosing

#### Starting doses and escalation regimen

125 microgram/kg po at night increasing by 125 microgram/kg/24 h increments divided in 3 doses every 3–4 days.

#### Maintenance doses

0.3–1 mg/kg/24 h po divided into 3 doses.

#### Discontinuation regimen

75% of the dose for 2 months; 50% of the dose for 2 months; 25% of the dose for 2 months: then stop.

**Preparations** Tablets (5 mg), liquid (2.5 mg/5 mL).

**Contraindications** See  'Diazepam', p. 586.

**Important interactions and unwanted effects** See  'Diazepam', p.586.

## Orphenadrine

**Neurological indications** Treatment of dystonia.

### Dosing

#### *Starting doses and escalation regimen*

25 mg po once daily increasing by 25 mg/24 h increments every 7 days.

#### *Maintenance doses*

Typical maximum daily doses:


- <6 yrs: up to 150 mg/24 h po.
- <12 yrs: up to 250 mg/24 h po.
- >12 yrs: up to 400 mg/24 h po all divided in two doses.

**Preparations** Liquid (50 mg/5 mL), tablet (50 mg).

**Contraindications** Porphyria.

**Important interactions and unwanted effects** See  'Trihexyphenidyl', p. 615.

## Oxcarbazepine

**Neurological indications** See  'Carbamazepine', p. 580: particularly in case of partial response to carbamazepine limited by dose-dependent toxicity. May worsen primary generalized epilepsies (especially JME), tonic atonic and absence seizures.

### Dosing

#### *Starting doses and escalation regimen*

5 mg/kg/24 h (max. 300 mg/24 h) divided in two doses, increasing in 5–10 mg/kg/24 h (max. 300 mg/24 h) increments at weekly intervals.


#### *Maintenance doses*

20–40 mg/kg/24 h (max. 2.4 g/24 h) divided in 2–3 doses.

#### *Discontinuation regimen*


75% for 2 weeks; 50% for 2 weeks; 25% for 2 weeks; then stop.

**Preparations** Tablets 150, 300, and 600 mg, oral suspension 300 mg/5 mL.

**Important interactions and unwanted effects** See  'Carbamazepine', p. 581. Hyponatraemia due to SIADH is considerably more common than with carbamazepine. A past history of rash formation with carbamazepine is a relative, but not absolute contraindication to oxcarbazepine use, although extra caution is required.

**Comments** Oxcarbazepine is a drug very closely-related to carbamazepine, modified so as to prevent conversion to a particular metabolite responsible for many of the dose-related unwanted effects of

the latter. In theory, therefore, it should be similarly efficacious and better tolerated. Can be directly substituted (without a transition period) for carbamazepine: typical starting dose of oxcarbazepine = 150% of the prior carbamazepine dose.

For interactions between anti-epileptic drugs, see  p. 619.

## Oxybate sodium

**Neurological indications** Cataplexy, severe narcolepsy.

### Dosing

- Age 12–16 years (few data on its use <12 yrs): initially 1.5 g twice at night; first dose just prior to sleep; second dose 2–4 h later (needs alarm!).
- >16 yrs: 1.5–2.25 g twice at night; first dose just prior to sleep; second dose 2–4 h later (needs alarm!)

Titrate slowly in 750 mg steps every 1–2 weeks based on subjective and objective sleep investigation criteria.

Doses 3–4.5 g twice at night (4.5 g twice at night in the adult-sized teenager).

**Preparations** Liquid 500 mg/mL. Needs further dilution and preparation by family before ingesting. Dilute to 60 mL with water.

**Contraindications** Situations where poor adherence likely; unsuitable family and social situations (controlled drug); alcohol-dependency; sleep apnoea.

**Important interactions and unwanted effects** Nausea, salty taste, headache, enuresis, bowel habit alterations. Interacts with alcohol to cause sedation. Doses should only be taken in bed. Death reported in adults with multiple comorbidities and polypharmacy.

**Comments** Has also been used in adult movement disorders e.g. myoclonus. Very expensive. If therapy has been stopped for more than 14 consecutive days it should be recommenced at the initial starting dose and re-titrated.

## Paraldehyde

**Neurological indications** Status epilepticus.

### Dosing

- **Given rectally.**
- **All ages:** 0.4 mL/kg to a max. of 10 mL.
- Dilute in 9 vols of 0.9% saline, or 1 vol. of olive or sunflower oil (avoid peanut/arachis oil because of anaphylaxis risk). Some centres keep a pre-mixed preparation for immediate use. Dose is expressed in mL of paraldehyde.

**Preparations** Sterile liquid for rectal or IM administration.

**Contraindications** Gastric disorders; colitis (with rectal administration).

**Important interactions and unwanted effects** Frequent rectal administration can result in proctitis. Do not leave undiluted in a plastic syringe for any longer than necessary as it will dissolve the syringe: dilute and administer promptly!

**Comments** Intramuscular administration is possible, but not recommended. Risk of sterile abscess.

## Phenobarbital (phenobarbitone)

**Neurological indications** Status epilepticus; maintenance AED.

### Dosing

#### Starting doses and escalation regimen

**Status epilepticus:** 20 mg/kg (max. 1 g) slow IV injection (dilute to at least 20 mg/mL with water for injections and infuse at max. 1 mg/kg/min); additional 5 mg/kg doses may be considered. In frequent recurrent seizures, oral loading may be adequate (dose unchanged).

#### Maintenance doses

- **Maintenance AED.**
- **Neonate:** 2.5–5 mg/kg/24 h once daily; 1 mth–12 yrs 4–10 mg/kg/24 h divided in 1–2 doses.
- **Over 12 yrs:** 60–180 mg once daily.
- Due to auto-induction of metabolism, higher doses may be required (under specialist advice).


#### Missed dose regimen

If one or more doses have been missed and breakthrough seizures have occurred, consider giving a single *additional* partial loading dose (e.g. 5 mg/kg single dose).

**Preparations** Tablets (15, 30, and 60 mg; may be crushed), elixir (unpleasant taste; some preparations contain alcohol), intravenous injection (60 mg/mL, 200 mg/mL).

**Contraindications** Porphyria.

**Important interactions and unwanted effects** Drowsiness, respiratory depression. Skin reactions. Megaloblastic anaemia with prolonged use (treat with folate).

**Comments** Aim for trough levels of 15–40 mg/L, although higher levels may be acceptable if there are no signs of toxicity. Injection may be given rectally (same as oral dose). Induces liver enzymes—many important interactions (see other sources). For interactions between anti-epileptic drugs, see  p. 619.

Avoid alcohol containing solutions in children.

# Phenytoin

**Neurological indications** Status epilepticus. Acute seizure management particularly in ICU setting (e.g. post-neurosurgery). Maintenance AED for all seizure types except absence epilepsy and absence status (may aggravate).

## Dosing

**Starting doses and escalation regimen** (see Box 7.1)

**Status epilepticus and urgent initiation of maintenance AED. Neonates (specialist advice only) to 18 yrs:** 18 mg/kg slow IV infusion (over 30 min with cardiac monitoring; max rate 1 mg/kg/min to max 50 mg/min). In less urgent situations, oral loading (same dose) may be appropriate. Commence maintenance at 5 mg/kg/24 h divided in 2 doses.

## Maintenance doses

- *Under 12 yrs:* typically 5–10 mg/kg/24 h oral or IV (max. 300–600 mg daily). Dose requirements are toward the top end of this range (sometimes higher) in neonates and infants.
- *12–18 yrs:* 150–200 mg bd (max. 300 mg bd).
- Due to near zero-order elimination kinetics particularly at higher blood levels, dose increments should be small to prevent inadvertent overdosing (ideally <10% increases at >fortnightly intervals).

## Missed dose regimen

If one or more doses have been missed and breakthrough seizures have occurred, consider giving an *additional* partial loading dose (e.g. 5 mg/kg single dose).

## Preparations

- As *phenytoin sodium*: capsules (25, 50, 100, and 300 mg); tablets 100 mg;
- As *phenytoin*: chewable Infatabs<sup>®</sup> (50 mg); suspension (various strengths) injection 50 mg/mL.

**Contraindications** Porphyruria.

**Important interactions and unwanted effects** Nausea, headache, tremor, ataxia (dose-dependent). Dyskinesias after intravenous use particularly in children with underlying neurodisability (not uncommon on ICU). Rarely blood dyscrasias, rash including Stevens–Johnson syndrome. Osteomalacia (consider calcium/vitamin D supplementation if prolonged treatment is anticipated).


Hirsutism and gum hyperplasia are common fully reversible unwanted effects. Gum hyperplasia may be limited by scrupulous attention to teeth-cleaning (it is accelerated by the presence of plaque). Dental surgeons can offer cosmetic gum resection in established cases where continuing phenytoin use is required.

**Comments** Aim for trough level 10–20 mg/L (6–15 mg/L in neonates). Phenytoin is highly protein bound and levels may need to be adjusted for serum albumin. Phenytoin liquid is a suspension (i.e. particles floating in liquid) not a solution. Left standing, the drug will settle in the bottle



resulting in under-dosing at the top of the bottle and toxicity as the bottle empties unless it is vigorously shaken (consider use of Infatabs® as an alternative).

Nasogastric feeds should be suspended for 1–2 h before and after oral/enteral phenytoin to improve absorption.

Licensed for use in children. For interactions between anti-epileptic drugs, see  p. 619.

Intravenous phenytoin infusion is strongly alkaline and must be infused slowly into a large vein to avoid phlebitis and/or tissue injury due to extravasation. Use in-line filter (0.22–0.5 µm), flush with saline before and after infusion, and dilute to 10 mg/mL.

**Fosphenytoin** is a less alkaline pro-drug that reduces this risk and may be given more rapidly IV and also IM. Due to its need for conversion to phenytoin it is not clear that the faster infusions of fosphenytoin possible necessarily lead to earlier establishment of therapeutic brain phenytoin levels. Intravenous infusions of both fosphenytoin and phenytoin have been associated with severe cardiac arrhythmias.

Fosphenytoin doses should be expressed as phenytoin equivalents (PE): 1.5 mg fosphenytoin sodium = 1 mg phenytoin sodium, i.e. 1 mg PE.

### Box 7.1 Levels and loading doses

Phenytoin, and to a lesser extent phenobarbital, have reputations as difficult drugs to titrate. It is common to see inexperienced prescribers struggling with over- and undershooting levels. The main reason for this is failure to appreciate how long it takes to establish a new steady-state drug level after a dose change, ► which is often several days and for phenytoin can be up to 2 weeks.

This time can be shortened by the use of a single loading dose (or a 'negative loading dose', i.e. one or more missed doses if trying to reduce the level). The loading dose does not influence the steady-state level ultimately achieved, which is determined solely by the maintenance dose.

Thus, if a blood level is still low and seizures are occurring a few days after starting phenytoin, give a further partial load (e.g. 5 or 10 mg/kg), but do not increase the maintenance dose (to avoid risk of overshoot) unless further levels clearly show the effect of this loading dose to be temporary with levels falling again.

In general, if a child is seizure free and alert on phenobarbital or phenytoin, do not adjust the dose even if the level is outside the 'reference range'.

Adjustments of maintenance doses in light of steady-state blood levels should be in small increments (<10% previous dose).

## Pimozide

**Neurological indications** Tourette's syndrome

### Dosing

**Starting doses and escalation regime:**

- Child 2 to 12 years—1 to 4 mg daily.
- Child 12 to 18 years—2 to 10 mg daily.

**Preparation** Tablets 4 mg, scored.

**Contraindications** History of arrhythmias or congenital QT prolongation. It is recommended to carry out an ECG before use looking for prolonged QT syndrome and annual ECG during treatment.

**Important interactions and unwanted effects** Some sedation, serious arrhythmias; glycosuria and rarely hyponatraemia. Antimuscarinic effects.

**Discontinuation regime** Slowly over 3 weeks.

## Piracetam

**Neurological indications** Cortical or segmental myoclonus.

### Dosing

- Initially 150 mg/kg/24h in 2–3 divided doses to a maximum of 300 mg/kg/24 h in 2–3 divided doses.
- Stop escalation if wanted or unwanted effects appear.
- *Reduce dose in renal impairment:*
  - two-thirds of normal dose if eGFR 50–80 mL/min/1.73 m<sup>2</sup>;
  - one-third of normal dose in 2 divided doses if eGFR 30–50 mL/min/1.73 m<sup>2</sup>;
  - one-sixth normal dose as a single dose if eGFR 20–30 mL/min/1.73 m<sup>2</sup>;
  - avoid if eGFR less than 20 mL/min/1.73 m<sup>2</sup>.

**Preparations** Scored 800 mg tablets; oral solution 333 mg/mL (33%).

**Contraindications** Cerebral haemorrhage. Hepatic impairment.

**Important interactions and unwanted effects** Weight gain, nervousness, hyperkinesia, and less commonly drowsiness, and depression.

**Comments** Oral solution has a bitter taste. Should be administered undiluted followed by a glass of water or soft drink.

## Pizotifen

**Neurological indications** Prophylaxis of migraine.

### Dosing

#### Starting doses and escalation regimen

- 5–12 yrs: 500 microgram po at night initially.
- Over 12 yrs: 1.5 mg po initially at night.

#### Maintenance doses

- <12 yrs: max 1.5 mg/24 h, max single dose 1 mg.
- >12 yrs: max 4.5 mg/24 h, max single dose 3 mg (majority of the dose should be given in the evening).

**Preparations** Tablets (500 microgram, 1.5 mg), elixir (250 microgram/5 mL).

**Important interactions and unwanted effects** Dry mouth, constipation, increased appetite and weight gain, drowsiness.

## Prednisolone (prednisone)

**Neurological indications** Treatment of infantile spasms and epileptic encephalopathies. Treatment of non-infectious CNS inflammation (e.g. demyelination, vasculitis).

### Dosing

#### Starting doses and escalation regimen

- *Infantile spasms*: 10 mg qds for 14 days; increasing to 20 mg tds after 7 days if no response.
- *Epileptic encephalopathies*: 2–4 mg/kg/24 h (max. 60 mg) in 2–4 divided doses.
- *CNS inflammation*: 2 mg/kg/24 h (max. 60 mg) od.

#### Maintenance doses

- *Infantile spasms*: if not controlled after 7 days increase to 20 mg tds for 7 days.
- *Epileptic encephalopathies*: 2–4 mg/kg/24 h (max. 60 mg) In 2–4 divided doses; regimen of 4 mg/kg as a single weekly dose permits prolonged use over several months with minimization of Cushingoid effects.
- *CNS inflammation*: 2 mg/kg/24 h (max. 60 mg) once daily.

#### Discontinuation regimen

- *Infantile spasms*: if taking 10 mg qds for 14 days, reduce by 10 mg every 5 days then stop. If dose increased to 20 mg tds for 7 days, reduce to 40 mg/24 h for 5 days then 20 mg/24 h for 5 days then 10 mg/24 h for 5 days then stop.
- *Epileptic encephalopathies*: typically maintained at full dose for up to 4 weeks before reducing to alternate day regimen for up to 2 weeks and then withdrawal over a further 2 weeks.

- **CNS inflammation:** typically maintained at full dose for up to 4 weeks before reducing to alternate day regimen. For ADEM and acute demyelination, would then typically withdraw over 2 weeks. For CNS vasculitides and steroid-dependent conditions, long-term treatment over many months may be required.

**Preparations** Crushable (1, 5, and 25 mg), enteric-coated (2.5 and 5 mg) and soluble (5 mg) tablets.

**Contraindications** Active infection.

**Important interactions and unwanted effects** Steroid effects (see  'ACTH', p. 575).

**Comments** Prolonged steroid treatment over months requires monitoring of bone mineral density and calcium/vitamin D supplementation. Provide steroid card. Take with food. Gastric protection with a proton-pump inhibitor or H<sub>2</sub>-antagonist may be required at high doses or prolonged courses.

## Pregabalin

**Neurological indications** Neuropathic pain and paraesthesiae; also adjunctive treatment of focal seizures).

### Dosing


#### **Starting doses and escalation regimen**

Over 12 yrs: 75 mg/24 h divided in 3 doses; 75 mg/24 h increments at weekly intervals.

#### **Maintenance doses**

300 mg/24 h divided in 3 doses (adult max. 600 mg/24 h).

**Preparations** Capsule (25, 50, 75, 100, 150, 200, and 300 mg).

**Comments** Generally well tolerated and free of interactions. For interactions between anti-epileptic drugs, see  p. 619.

## Procyclidine

**Neurological indications** Emergency treatment of acute dystonia and oculogyric crises.

### Dosing

Single intravenous dose:

- Under 2 yrs: 0.5–2 mg;
- 2–10 yrs: 2–5 mg;
- 10–18 yrs: 5–10 mg.
- Repeat after 30 min if necessary. Can also be given IM or po.

**Preparations** Tablets (5 mg), syrup (2.5 mg/mL, 5 mg/5 mL), injection (10 mg/2 mL).

**Contraindications** See  'Trihexyphenidyl', p. 615.

**Important interactions and unwanted effects** See  'Trihexyphenidyl', p. 615.

**Comments** Onset of effect in 5–10 min: may take 30 min for full effect.

## Propranolol

**Neurological indications** Migraine prophylaxis.

### Dosing

#### Maintenance doses

- 2–12 yrs: up to 60 mg/24 h divided in 2–3 doses (max 4 mg/kg/24 h).
- >12 yrs: up to 120 mg/24 h divided in 2–3 doses (max 160 mg/24 h).

#### Discontinuation regimen

Trial of withdrawal after 2–3 months' symptom freedom.

**Preparations** Tablets (10, 40, 80, and 160 mg), oral solution (5 mg/5 mL, 10 mg/5 mL, 50 mg/5 mL).

**Contraindications** Significant asthma, uncontrolled heart failure, sick-sinus syndrome, 2nd/3rd degree arterioventricular (AV) block, metabolic acidosis.

**Important interactions and unwanted effects** Postural hypotension at excessive doses. Bronchospasm in susceptible individuals.

## Pyridostigmine

**Neurological indications** Treatment of myasthenia gravis.

### Dosing

#### Starting doses and escalation regimen

- Neonate: 5–10 mg/dose (give 1 h before feeds) repeated as required up to 4–6-hourly.
- <6 yrs: 30 mg/dose repeated as required up to 4–6-hourly.
- >6 yrs: 60 mg/dose repeated as required up to 4–6 times daily
- Increase by increments of 25–50% daily until max. improvement is seen.

#### Maintenance doses

- <12 yrs: 30–360 mg/24 h divided in 4–6 doses.
- >12 yrs: 30–1200 mg/24 h divided in 4–6 doses.

**Preparations** Tablets (60 mg).

**Contraindications** Intestinal or urinary obstruction. Care in asthma, bradycardia, hypotension, epilepsy.

**Important interactions and unwanted effects** Nausea, vomiting, increased salivation, abdominal cramps.

**Comments** Weaker muscarinic action than neostigmine, but longer acting and fewer GI side effects. Avoid doses >450 mg/24 h because of risk of AChR down-regulation. Immunosuppressant therapy is usually considered if the dose is >360 mg/24 h.

## Pyridoxal phosphate

**Neurological indication** Refractory epilepsy in infants (may be superior to pyridoxine). Consider if trial of pyridoxine fails especially in infantile spasms.


### Dosing

10 mg/kg/24 h and increase weekly to 50 mg/kg/24 h.

**Preparation** Tablets 15 mg (can be crushed and mixed with water).

**Important interactions and unwanted effects** Anorexia, GI disturbances, sedation.

## Pyridoxine (vitamin B6)


**Neurological indications** Treatment of refractory epilepsy in infants (see  p. 484).

### Dosing

- Test dose 50–100 mg oral or IV, ideally with EEG monitoring.
- Maintenance (if responsive) po/IV.
- Long-term use of doses greater than 200 mg daily is associated with neuropathy.
- *Neonates and infants*: typically 100–200 mg/24 h divided in two doses.
- *Older children*: 400 mg/24 h (max. 30 mg/kg/24 h or 1 g/24 h).

**Preparation** Tablets (10, 20, and 50 mg; can be halved, quartered, or crushed and dissolved in water), injection (50 mg/2 mL), liquid.

**Important interactions and unwanted effects** Severe apnoea, hypotension and bradycardia have been reported with first doses (usually when given IV, give as a slow IV injection over 5 min). Otherwise well tolerated.

**Comments** Use for a minimum of 3 weeks. Try not to make any other changes in anti-epileptics during this period to aid interpretation (see  p. 484, for further details). The dose for optimal neurodevelopmental outcome may be greater than the dose that controls seizures.

## Risperidone

**Neurological indications** Treatment of severe chorea and tic disorders. Treatment of acutely disturbed behaviour (see 'Comments').

### Dosing

#### Starting doses and escalation regimen


- *Movement disorder*: over 12 yrs, 1 mg/24 h divided in 2 doses increasing at weekly intervals by 1 mg/24 h if required.
- *Acutely disturbed behaviour*: over 12 yrs, 2 mg/24 h divided in 2 doses with rapid titration according to response.

#### Maintenance doses

- *Movement disorder*: over 12 yrs, up to 4 mg/24 h divided in 2 doses.
- *Acutely disturbed behaviour*: over 12 yrs, usual maintenance dose 4–8 mg/24 h, but doses up to 10 mg/24 h may be used for brief periods.

**Preparations** Tablet (0.5, 1, and 2 mg), dispersible tablet (0.5, 1 or 2 mg), liquid (5 mg/5 mL; can be diluted in water or juice for immediate use).

**Contraindications** See  'Haloperidol', p. 591.

**Important interactions and unwanted effects** See  'Haloperidol' p. 590. Risk of neuroleptic malignant syndrome particularly at high doses.

**Comments** Use of antipsychotics to manage acutely disturbed behaviour should only be considered in extreme situations (e.g. a large adolescent with severe learning difficulties and/or autism with a risk of injury to themselves or others) and in consultation with liaison psychiatry service. Reduce dose in hepatic and renal impairment.

## Rufinamide

**Neurological indications** Epilepsy, particularly Lennox-Gastaut syndrome.

### Dosing

- *Child 4–18 years less than 30 kg*: 100 mg bd increasing if required by 100 mg bd at 7–14-day intervals; max. 500 mg bd (lf on valproate max. 300 mg bd).
- *Child 4–18 years over 30 kg*: 200 mg bd increasing if required by 200 mg bd at 7–14-day intervals.
- *Maximum doses*: 900 mg bd for body weight 30–50 kg; 1.2 g bd for body-weight 50–70 kg; 1.6 g bd for body-weight over 70 kg.
- Doses may be escalated more rapidly at 2-day intervals under specialist supervision.

**Preparations** 100, 200, and 400 mg tablets, which may be crushed and mixed with water.

**Contraindications** Severe liver impairment; breast feeding.

**Important interactions and unwanted effects** May raise phenytoin levels; metabolism inhibited by valproate.

**Comments** A serious hypersensitivity syndrome has been reported in children after initiating therapy; consider withdrawal if rash or signs or symptoms of hypersensitivity syndrome develop.

## Stiripentol

**Neurological indications** Anti-epileptic drug particularly for severe myoclonic epilepsy of infancy (Dravet Syndrome).


### Dosing

#### *Starting doses and escalation regimen*

*Child 3–18 years:* initially 10 mg/kg in 2–3 divided doses; titrate dose over minimum of 3 days to max. 50 mg/kg/day in 2–3 divided doses.

**Preparations** Capsule, powder for suspension (250 mg, 500 mg).

**Important interactions and unwanted effects** Stiripentol reduces clearance of other AEDs (particularly benzodiazepines) and unwanted effects relate largely to such accumulation. Nausea may occur when used with valproate.

**Comments** Most commonly used in conjunction with valproate and/or clobazam in treatment of severe myoclonic epilepsy of infancy (see  p. 265). Valproate and clobazam doses may need to be halved. Other AEDs metabolized by the cytochrome P450 system (phenobarbital, phenytoin, carbamazepine) will also accumulate. Avoid giving with milk/dairy products, carbonated drinks, or fruit juice. Avoid caffeine.

## Sulpiride

**Neurological indications** Tourette's syndrome.

### Dosing

#### *Starting doses and escalation regime*

- *Child 2–12 yrs:* 50–400 mg bd.
- *Child 12–18 yrs:* 100–400 mg bd.

**Preparations** Tablets 200 mg; 400 mg. Oral solution 200 mg per 5 mL.

**Contraindications** Porphyria.

**Important interactions and unwanted effects** Antimuscarinic effects; may cause agitation in low dose, hepatitis.

**Discontinuation regime** Slowly over 3 weeks.



## Sultiame (sulthiame)

**Neurological indications** Focal epilepsies, particularly used in atypical Rolandic or perisylvian epilepsy syndromes.

### Dosing

- Initially 3 mg/kg/day divided into 2–3 doses.
- Maintenance dose 5–10 mg/kg/day divided into 3 doses.

**Preparations** Tablets 50 and 200mg. Tablets can be divided.

**Contraindications** Hypersensitivity to sulphonamides; porphyria; hyperthyroidism.

**Important interactions and unwanted effects** Gastric irritation in 10%. Dose-dependent adverse effects similar to ethosuximide and acetazolamide. Hypersalivation. Stevens-Johnson. Can increase phenytoin and lamotrigine levels.

**Comments** Marketed since the 1960s. Widespread use and experience in German-speaking countries; not currently in UK. Needs to be imported.

## Sumatriptan

**Neurological indications** Acute symptom relief in migraine attack.

### Dosing

- 6–10 yrs: 25 mg po as single dose. Repeat after 2 h if needed.
- 10–12 yrs: 50 mg po as single dose. Repeat after 2 h if needed.
- Over 12 yrs: 50–100 mg po or 10 mg as nasal spray as single dose, Repeat after 2 h if needed. No more than two doses (20 mg) in 24 h.

**Preparations** Tablets 50 and 100 mg, Nasal spray 10 mg/spray, 20 mg/spray.

**Contraindications** Vasospasm, previous cerebrovascular accident or transient ischaemic attack, peripheral vascular disease, hypertension.

**Important interactions and unwanted effects** Taste disturbance, mild irritation or burning sensation in the nose or throat, heat, heaviness, pressure or tightness, flushing in any part of the body, dizziness, weakness, fatigue, drowsiness and transient increases in blood pressure.

**Comments** Licensed for over 12s in the UK. Other triptans are not direct equivalents: rizatriptan has a short half-life, and frovatriptan has a much longer half-life than sumatriptan. Zolmitriptan and rizatriptan available as dissolvable wafers.

## Tetrabenazine

**Neurological indications** Involuntary movement; choreoathetosis.

### Dosing

- *Under 5s*: Start 3.125 mg bd; increasing by this dose at weekly intervals according to response; likely maximum 12.5 mg bd.
- *5–10-yr-olds*: Start 6.25 mg bd, increasing by this dose at weekly intervals according to response; likely maximum 37.5 mg bd.
- *10–18-yr-olds*: Start 12.5 mg bd, increasing by this dose at weekly intervals according to response; likely maximum 62.5 mg bd.

**Preparations** 25mg tablets, which may be crushed and mixed with water.

**Contraindications** Severe hepatic or renal impairment.

**Important interactions and unwanted effects** Interacts with metoclopramide: increased risk of dystonia. Drowsiness, GI disturbances, depression, extrapyramidal dysfunction, hypotension; rarely Parkinsonism; neuroleptic malignant syndrome reported. Daily doses greater than 50 mg should not be given without *CYP2D6* genotyping.

## Tetracosactide (tetracosactrin)

See  'ACTH', p. 575.

## Tiagabine

**Neurological indications** Adjunctive treatment of focal seizures. May worsen generalized tonic-clonic, atonic and myoclonic seizures.

### Dosing


#### *Starting doses and escalation regimen*

*Over 12 yrs*: 5 mg bd for 1 week po increased by 5–10 mg/24 h divided in 2 doses every 5–7 days.

#### *Maintenance doses*

30–45 mg/24 h po divided in 2–3 doses as tolerated and according to response. Doses >30 mg/24 h may be given as 3 divided doses. Higher doses in conjunction with enzyme-inducing drugs.

**Preparations** Tablet (5, 10, and 15 mg).

**Important interactions and unwanted effects** Nausea, diarrhoea, sleepiness, tremor, rarely non-convulsive status epilepticus. For interactions between anti-epileptic drugs, see  p. 619.

## Tizanidine

**Neurological indications** Increased tone due to cortico-spinal tract involvement.

### Dosing

Start with 0.03 mg/kg/24 h, increasing by 0.03–0.05 mg/kg/24h at three daily intervals up to 0.75 mg/kg/24h in 3 divided doses; to stop escalation if wanted or unwanted effects appear.

**Preparations** 2 and 4 mg tablets, which may be crushed and mixed with water.

**Contraindications** Severe hepatic or renal impairment.

**Important interactions and unwanted effects** Interacts with ciprofloxacin and phenytoin. Dry mouth, sleepiness or light-headedness, GI haemorrhage.

## Topiramate

**Neurological indications** Broad-spectrum AED. Migraine prophylaxis.

### Dosing

#### Starting doses and escalation regimen

- <16 yrs: 0.5–1 mg/kg/24 h increasing by 1 mg/kg/24 h divided in two doses every 1–2 weeks.
- >16 yrs: 25 mg nocte increasing by 25–50 mg/24 h divided in two doses every 1–2 weeks.


#### Maintenance doses

- AED: 5–10 mg/kg/24 h (occasionally up to 15 mg/kg/24 h) in two divided doses. Adult max. 400 mg/24 h.
- Migraine prophylaxis: typically 50–100 mg/24 h.

**Preparations** Tablet (25, 50, 100, and 200 mg), sprinkle capsule (15, 25, and 50 mg). Tablets can be crushed and dispersed in water.

**Contraindications** Narrow or closed angle glaucoma.

**Important interactions and unwanted effects** Nausea, anorexia with weight loss, paraesthesiae. Somnolence and cognitive impairment.

**Comments** Adverse effects are less probable with slower introduction. For interactions between AEDs, see  p. 619.

## Trihexyphenidyl (benzhexol)

**Neurological indications** Dystonia and extrapyramidal movement disorders.

### Dosing

#### Starting doses and escalation regimen

3 months–18 yrs: 1–2 mg/24 h po in 1 or 2 divided doses incrementing by 1 mg/24 h every 3–7 days, divided in 3–4 doses according to response.

#### Maintenance doses

5–10 mg/24 h, max 2mg/kg/day (adult max. 20 mg/24 h) in 3 or 4 divided doses.

**Preparations** Tablet (2 and 5 mg), liquid (5 mg/5 mL).

**Contraindications** Intestinal obstruction, urinary retention, closed angle glaucoma, myasthenia gravis.

**Important interactions and unwanted effects** Urinary retention, constipation, tachycardia, anhidrosis (and hyperpyrexia), dry mouth, blurred vision, confusion, agitation, hallucination.

**Comments** New approved name for benzhexol. Gradual dose escalation can result in children tolerating comparatively high doses.

## Valproate

**Neurological indications** Broad spectrum AED. Migraine prophylaxis, mood stabilizer (e.g. in bipolar disorder). Treatment of (particularly non-convulsive) status epilepticus.

### Dosing

#### Starting doses and escalation regimen

- *Epilepsy and migraine*: 10 mg/kg/24 h (>12 yrs 600 mg/24 h) divided in 2 doses increasing by 10 mg/kg/24 h (>12 yrs 200 mg/24 h) every 5–7 days.
- *Non-convulsive status epilepticus*: 20 mg/kg IV loading dose over 30 min then 30–40 mg/kg/24 h continuous IV infusion for 24–48 h (max 2.5 g/24 h).

#### Maintenance doses


20–40 mg/kg/24 h divided in 2 doses, max 60 mg/24 h (adult 1–2 g/24 h, occasionally 2.5 g/24 h).


**Preparations** Crushable tablet (100 mg) enteric-coated tablets (200 and 500 mg) controlled-release tablet (200, 300, and 500 mg), oral liquid (200 mg/5 mL), intravenous injection (100 mg/mL) modified-release granules (50, 100, 250, 500, and 750 mg, and 1 g).

**Contraindications** Active liver disease or family history of severe liver disease. Known or suspected Alpers syndrome. Porphyria. Pregnancy.

**Important interactions and unwanted effects** Transient thinning of the hair; hair invariably re-grows and this is rarely a reason to stop the drug. Weight gain. Gastric irritation (usually helped by enteric-coated preparation). Thrombocytopenia (tends to be dose-related).

Impaired hepatic function leading rarely to fatal hepatic failure (some cases likely to be due to unidentified beta-oxidation or mitochondrial depletion (Alper) syndromes: avoid use if mitochondrial disease suspected).

Teratogen causing distinct foetal valproate syndrome and/or neural tube defects, and possible adverse developmental outcomes in babies exposed *in utero* (see  p. 301).

**Comments** Routine monitoring of liver function in an asymptomatic child is not indicated. Carers should be taught to seek medical attention in case of unexplained nausea, vomiting, darkened urine or jaundice. For interactions between anti-epileptic drugs, see  p. 619.

## Vigabatrin

**Neurological indications** Treatment of infantile spasms particularly in tuberous sclerosis. Adjunctive treatment of severe epilepsies. May worsen generalized tonic-clonic, absence and myoclonic seizures.

### Dosing

#### Starting doses and escalation regimen

*Infantile spasms*: 50 mg/kg/24 h increasing if required every 48 h to 100 mg/kg/24 h and then 150 mg/kg/24 h divided in 2 doses.

#### Maintenance doses

*Infantile spasms*: up to 150 mg/kg/24 h (max 3 g/day).

#### Discontinuation regimen

*Infantile spasms*: withdraw slowly, e.g. by 20% per mth.

**Preparations** Tablet (500 mg), powder (500 mg sachet). Powder can be dispersed in 10 mL of water and the appropriate volume used to give small doses. Tablets can be crushed and dispersed in water or squash. Sachets can be administered rectally.

**Contraindications** Pre-existing or potential for visual impairment (particularly visual field impairments).

**Important interactions and unwanted effects** Visual field defects. Occur in 30–50% of adults on drug for more than 1–2 yrs. Often small and asymptomatic; however, they are irreversible. Unable to monitor in children with developmental age <8 yrs.

# Warfarin

**Neurological indications** Anticoagulation in the context of embolic or dissecting arterial cerebrovascular disease.

## Dosing

Give doses at 18.00 hours and check INR at 09.00 hours daily.

### Starting doses and escalation regimen

- Day 1: 0.2 mg/kg (max. 10 mg) single dose.
- Day 2: 0.1 mg/kg (max. 5 mg) single dose.
- Day 3: 0.1 mg/kg (max. 5 mg) single dose.

### Maintenance doses

- Adjust the maintenance dose in light of the INR (Table 7.3), recalling that the **INR primarily reflects the dose given the night before last**.
- Round doses to nearest 0.25 mg.

**Table 7.3** INR

<1.5	Increase dose by 20%
1.5–1.9	Increase dose by 10%
2–3	No change
3.1–4	Decrease dose by 10%
4.1–4.5	Decrease dose by 20%
4.6–5	Omit one dose then restart at 20% lower dose
>5	Omit until INR <4.5 then restart at 20% lower dose

### Reversal regimen

- **Elective:** e.g. prior to invasive procedure in absence of active bleeding. Give SC vitamin K1: 0.5–2 mg if warfarin needs to be restarted, otherwise 2–5 mg.
- **Urgent:** 0.5–2 mg SC vitamin K1 20 mL/kg failure to thrive (FFP). **Only if life-threatening** give 5–10 mg of vitamin K by slow IV infusion over 10–20 min (significant anaphylaxis risk) and 20 mL/kg FFP factor IX concentrate.

**Preparations** Tablet (0.5, 1, 3, and 5 mg; smallest practical increment 0.25 mg).

**Contraindications** Severe gastritis or ulcer, severe hypertension, bacterial endocarditis. Adjust dose (e.g. omit initial loading) in severe hepatic or renal disease.

**Comments** Typically aim for INR 2.5 (range 2–3). Wide range of interactions with other drugs. Check before prescribing.

## Zonisamide

**Neurological indications** Broad-spectrum AED.

### Dosing

**Starting doses and escalation regimen**

2 mg/kg/24 h increasing by 2 mg/kg/24 h divided in two doses every 1–2 weeks.

**Maintenance doses**

8–18 mg/kg/24 h (very occasionally up to 30 mg/kg/24 h) divided in two doses. Adult max. 500 mg/24 h.

**Preparations** Capsules (25, 50, 100, and 200 mg).

**Important interactions and unwanted effects** Somnolence, poor concentration. More rarely nephrolithiasis, (encourage reporting of back/abdominal pain or urinary symptoms), Stevens–Johnson syndrome, agranulocytosis, oligohydrosis and hyperthermia (beware in small children). Teratogenesis (risk in teenage pregnancy).

## Acute sedation protocols

### Magnetic resonance imaging scan

- Chloral hydrate 100 mg/kg (max. 2 g).
- *Top up (if needed)*: paraldehyde 0.3 mL/kg + equal volume of olive oil.

#### *Alternatively (if >20 kg)*

Secobarbital (quinalbarbitone) 7.5–10 mg/kg (max. 200 mg).

### Computed tomography scan

- Chloral hydrate 75 mg/kg (max. 2 g).
- *Top up (if needed)*: paraldehyde 0.3 mL/kg + equal volume of olive oil.

#### *Alternatively (if >20 kg)*

Secobarbital (quinalbarbitone) 7.5–10 mg/kg (max. 200 mg).

## Interactions of anti-epileptic drugs

- Enzyme-inducing drugs, such as carbamazepine, phenobarbital, phenytoin may lower plasma concentrations of clobazam, clonazepam, lamotrigine and active metabolites of oxcarbazepine, phenytoin, tiagabine, topiramate and valproate, and at times ethosuximide and zonisamide.
- Protein binding is often competitive so ethosuximide, oxcarbazepine and topiramate may raise the plasma concentration of phenytoin.
- Lamotrigine is reported sometimes to raise the plasma concentration of carbamazepine, making unwanted effects more likely.
- Valproate raises the plasma concentration of the active metabolite of carbamazepine, lamotrigine, phenobarbital, and phenytoin.
- Vigabatrin lowers the concentration of phenytoin and at times phenobarbital.
- Gabapentin and levetiracetam are not reported to have interactions.
- Oral contraceptives may lower the concentrations of enzyme-inducing drugs, which may, in turn, lower the concentration of the oral contraceptive.



*This page intentionally left blank*

# Index

## A

- abdominal migraine 319
- abdominal reflexes 27
- abducens nerve (VI) 19–20
- abetalipoproteinaemia 467
- absence epilepsy with eyelid myoclonia 270
- absence seizures 143, 288
- absence status
  - epilepticus 273
- acanthocytes 89
- accessory nerve (XI) 24
- acetazolamide 574
- aciclovir 574
- acid maltase deficiency 405
- acquired brain injury 210, 212, 214, 501, 512–13
- acquired epileptic aphasia 272
- acrocephaly 146
- ACTH 575
- actigraphy 190
- action dystonia 161
- action tremor 161
- activities 240
- acuity 16, 41
- acute acquired
  - ophthalmoplegia 120
- acute agitation 534
- acute ataxia 199, 572
- acute bacterial meningitis 336–8
- acute confusional state 104
- acute disseminated encephalomyelitis (ADEM) 257–8
- acute inflammatory demyelinating polyneuropathy (AIDP) 395
- acute life threatening events (ALTEs) 516
- acute motor and sensory axonal neuropathy with prominent sensory features (AMSAN) 395
- acute motor axonal neuropathy (AMAN) 395
- acute porphyrias 367
- acute post-infectious cerebellitis 344
- acute sedation protocols 619
- acute transverse myelitis 260
- acyl carnitine 88
- adaptive function 100
- Addison's disease 474
- adenovirus 340
- adrenoleukodystrophy 173, 183, 430, 474
- afferent pupillary defect 18
- aggression 521
- agitation 104, 534
- Aicardi–Goutières syndrome (AGS) 361
- Aicardi syndrome 276
- akathisia 160
- albumin ratio 85
- Alder–Reilly granules 89
- alertness 41
- Alpers disease 183, 429
- Alpers–Huttenlocher syndrome 373
- alpha-aminoadipic semialdehyde 87
- alpha coma 513
- amblyopia 119, 206
- amino acids
  - CSF 86
  - urine 87
- amitriptyline 575
- ammonia 88
- amoebiasis 347
- amyotrophy 498
- analgesia overuse
  - headache 153, 320
- anaphylactoid purpura 523
- anaplastic astrocytomas 457
- Andersen syndrome 404
- aneurysmal malformation of vein of Galen 499
- Angelman syndrome 278
- anisocoria 18
- anosmia 16
- antalgic gait 38
- anterior horn cell disease 410
- anterior horn cell infection 344
- anterior spinal artery infarction 215
- anti-epileptic drugs 288, 290, 286–7, 294
- interactions 619
- anxiety attacks 306
- Apert syndrome 147
- apnoea test 511
- apraxia 192
- aqueduct stenosis 325
- arachnoid cysts 167, 169
- arboviruses 340
- Arnold–Chiari malformations 333
- aromatic L-amino acid decarboxylase deficiency 436
- arousal 210, 440
- arteriovenous malformations 453
- arthrogryposis 498
- ARX 164
- aseptic meningitis 340, 354, 505
- Aspergillus fumigatus* 352
- aspiration 248–9
- aspirin 576
- assistive (or augmentative) communication 251
- astrocytoma 455
- asymmetric crying facies 42, 126
- ataxia 198, 384, 387–9, 505
- acute 199, 572
- chronic non-progressive 199
- chronic-progressive 199
- episodic 140, 306
- patterns in cerebellar disease 28
- 'ship's deck' 197
- ataxia telangiectasia 422
- ataxia with vitamin E deficiency (AVED) 467
- ataxic dysarthria 192
- athetoid cerebral palsy 375
- athetosis 39, 161, 375
- atomoxetine 576
- atonic seizure 143, 289
- attention 13
- attention deficit disorder 108
- autism 114, 521
- autistic regression 521
- autoimmune disease 218, 531
- autoimmune
  - encephalitides 224
- autoimmune myasthenia gravis 411–12
- autoinflammatory conditions 223, 531
- autonomic dysfunction 505
- autonomic dysreflexia 216
- availability bias 50
- awareness 210, 309
- axonal neuropathies 77, 393

## B

- Babinski reflex 27, 43
- back pain 106
- baclofen 244–6, 577

- bacterial meningitis  
 acute 336–8  
 chronic 338  
 bacterial myositis 409  
 bad news 3  
 ballismus 161  
 band heterotopias 164, 235  
 Barry–Albright dystonia  
 scale 242  
 Barth syndrome 473  
 basal ganglia 233, 378  
 base excess 88  
 basophilic stippling 89  
 Batten diseases 427  
 Batten–Spielmeier–Vogt–  
 Sjögren syndrome 430  
 Becker muscular  
 dystrophy 399  
 behavioural stereotypy 306  
 behaviour disorders 107, 517  
 Bell palsy 128  
 Bell phenomenon 128  
 benign enlargement of the  
 subarachnoid space 149  
 benign epilepsy of childhood  
 with central-temporal  
 spikes 268, 291  
 benign epilepsy with  
 occipital paroxysms 292  
 benign familial neonatal  
 seizures 264  
 benign hereditary  
 chorea 382  
 benign myoclonic epilepsy  
 of infancy 265  
 benign myoclonus of early  
 infancy 305  
 benign neonatal  
 seizures 264  
 benign neonatal sleep  
 myoclonus 304  
 benign paroxysmal postural  
 vertigo 306  
 benign paroxysmal  
 torticollis 305  
 benign paroxysmal  
 vertigo 305, 320  
 benign positional posterior  
 plagiocephaly 146  
 benign Rolandic  
 epilepsy 268  
 benzatropine (bentropine)  
 578  
 benzhexol 615  
 Bethlem myopathy 402  
 BH4 challenge 438  
 bilirubin induced neurologic  
 dysfunction (BIND) 375  
 biogenic amines 435  
 biotin 467, 578  
 biotinidase 91, 468  
 birth asphyxia 487  
 ‘birthday syndrome’ 246  
 bladder 157  
 Blau syndrome 223  
 blood–brain barrier 324  
 blood pressure 154  
 blood tests 88  
 blueberry muffin  
 syndrome 357  
 blue (cyanotic) breath  
 holding attacks 310  
 body part naming 7  
 bone abnormalities 9  
 bone marrow aspirate 92  
 botulinum toxin 244, 579  
 botulism 133  
 bowels 158  
 brachial plexus 30  
 brachial plexus injury 398  
 brachycephaly 146  
 brain abscess 345  
 brain death, neonatal 489  
 brain development 60, 163,  
 165–6  
 brainstem anatomy 69  
 brainstem atrophy 236  
 brainstem auditory evoked  
 responses 83, 513  
 brainstem death 510  
 brainstem gliomas 457  
 brainstem reflexes 537  
 Brown syndrome 120  
 brushing therapy 175  
 buffy coat histology 88  
 bulbar function 23, 42
- C**
- CACH/WWM disease 173  
 CACNA1A 306, 317  
 calcium supplements 580  
 caloric reflex 537  
*Campylobacter jejuni* 395  
 Canavan disease 133  
 candidiasis 347  
 carbamazepine 580  
 carbohydrate-deficient  
 glycoprotein  
 syndromes 90, 384  
 carboxylase deficiency 282  
 cardiac disease 309  
 cardiology consultations 471  
 cardiomyopathies 473  
 cardiopulmonary bypass,  
 chorea 382  
 card sorting 49  
 carnitine 88  
 carotid-cavernous  
 fistula 543  
 Carpenter syndrome 147  
 cataplexy 310, 443  
 cataracts 203  
 catatonia 365  
 catecholamine  
 metabolites 87  
 causalgia 174  
 cavernous haemangiomas  
 (cavernomas) 453  
 cavum septum  
 pellucidum 167, 169  
 CDLK5 426  
 central apnoea 527  
 central core disease 406  
 central dysautonomia  
 syndrome 211  
 central hyperpyrexia 211  
 central hypoventilation 254,  
 528  
 central nervous system  
 autoimmune disease 218,  
 531  
 congenital infection 355  
 infection 336, 345, 505  
 tumours 454  
 vasculitis 223  
 centronuclear  
 myopathy 406  
 centrum semiovale 68  
 cerebellar astrocytomas 456  
 cerebellar ataxia 38  
 late-onset 386, 388  
 cerebellar atrophy 235  
 cerebellar dysfunction 28  
 cerebellar hypoplasia 235  
 cerebellar mutism 461  
 cerebellar tonsils 168–9  
 cerebral abscess 345  
 cerebral aneurysms 452  
 cerebral angiography 60  
 cerebral dysgenesis  
 syndromes 276  
 cerebral folate deficiency  
 syndrome 466  
 cerebral haemorrhage 452,  
 495, 497, 501  
 cerebral malaria 346  
 cerebral palsies 227  
 aetiology 228  
 classic descriptions 227  
 classifications for clinical  
 care 227  
 definition 227  
 differential diagnosis 229  
 intrapartum hypoxia 230  
 investigations 229, 231  
 life expectancy 236  
 mild 109  
 mimics of 231  
 mobility 236  
 MRI 232–3, 235  
 neonatal encephalopathy  
 228, 237  
 prevalence 227  
 prognosis 236–8  
 risk factors 228  
 walking 236  
 cerebral salt-wasting  
 syndrome 509–10

- cerebral visual impairment syndrome 203, 252
- cerebro-retinal microangiopathy with calcification and cysts (CRMCC) 361
- cerebrospinal fluid (CSF) 85
- cerebrotendinous xanthomatosis 104
- cerebrovascular accident 471
- cervical auscultation 249
- channelopathies 278
- Charcot–Marie–Tooth disease 392
- cherry red spot 19
- Chiari malformations 331, 333
- chiasm 204, 207
- chiasmatic–hypothalamic gliomas 456
- childhood absence epilepsy 270, 290
- childhood epilepsy with occipital paroxysms 269
- childhood periodic syndromes 319
- child sexual abuse 313
- chloral hydrate 581
- chlormethiazole 583
- cholestatic liver disease 467
- cholinergic crisis 569
- chorea 161, 382–3
- chorea mollis 219
- choreo-athetosis 161
- choroid plexus tumours 459
- chronic bacterial meningitis 338
- chronic daily headache 320
- chronic fatigue syndrome 314
- chronic infantile neurological cutaneous and articular (CINCA) syndrome 532
- chronic inflammatory demyelinating polyneuropathy 396
- chronic nocturnal and diurnal hypoventilation 256
- chronic paroxysmal hemicrania 320
- chronic progressive external ophthalmoplegia 373
- ciclosporin neurotoxicity 502–3
- circle of Willis 67
- clobazam 582
- clomethiazole 583
- clonazepam 583
- clonic seizure 143
- clonidine 583
- cluster headache 320
- COACH syndrome 385
- Coats plus disease 361
- cobalamin 463–4
- cocktail part syndrome 328
- coeliac disease 478
- cognitive development 7
- cognitive estimates 13
- cognitive syndromes 14
- COL4A1 mutation 361
- collagen VI-related myopathies 402
- coma 366, 474, 507, 536, 538
- traumatic 541
- common peroneal nerve 37
- communication 14, 251
- comparative genome hybridization 89
- complex partial seizures 143
- compressive optic neuropathies 207
- computed tomography 54, 62, 619
- angiography 55
- concentration 13
- concomitant squint 120
- conduct disorder 108, 517, 521
- conduction block 77
- confusion 104, 366
- confusional arousal 440
- congenital central hypoventilation syndrome 254
- congenital disorders of glycosylation 90, 384, 401–2
- congenital fibrosis of extra-ocular muscles 120
- congenital heart disease 471–2
- congenital hyperinsulinism 475
- congenital infection 355
- congenital muscular dystrophies 401–2
- congenital myasthenic syndromes 413–14
- congenital myopathies 406
- congenital varicella syndrome 360
- congenital vertical talus 135
- consciousness 13, 210
- consultation 2, 470
- continuous spike–waves in slow-wave sleep 272, 292
- contractures 240
- coordination 28
- cord tethering syndrome 331
- cornea 204
- corneal opacity 19
- corneal reflex 22, 511
- corona radiata 68
- corpus callosum 235
- corpus striatum 68
- cortical atrophy diffuse 235 mild 168
- cortical blindness 202
- cortical infarctions 234
- cortical visual impairment 252
- cough reflex 511
- cover test 22
- cramps 117
- cranial bruits 153
- cranial irradiation 461
- cranial nerves 22, 16–17, 19–20, 41
- oncology 505
- palsies 120
- reflexes 511
- cranial ultrasound 60, 62
- craniopharyngioma 458
- cranosynostosis 147
- creatine 87
- creatine (phospho) kinase 390
- creatinine 87
- Creutzfeldt–Jakob disease 349
- Crouzon syndrome 147
- cryptococcal infection 352
- cryptococcosis 348
- CSF 85
- CSWS see continuous spike–waves in slow-wave sleep
- CT angiography 55
- cyanotic breath holding attacks 310
- cyclical vomiting 319, 477
- cystic encephalomalacia 234
- cytomegalovirus 340, 353, 355

## D

- dancing eyes and dancing feet 125, 381
- Dandy–Walker syndrome 325
- dantrolene 584
- daydreaming 310
- daytime sleepiness 442
- DCX 164
- death 3
- Dejerine–Sottas disease 393
- delayed sleep phase syndrome 439

- delayed visual  
   maturation 202  
 delirium 104, 534  
 dementia 14, 104  
 demyelination 77, 261, 257–8  
 dermatomes 29, 131  
 dermatomyositis 407  
 dermoid cyst 329  
 developmental coordination  
   disorder 198  
 developmental history 7  
 developmental  
   impairment 109  
 Devic disease 260  
 DeVivo syndrome 483  
 dexamethasone 585  
 dexamfetamine 585  
 diastematomyelia 329  
 diazepam 244, 586  
 diencephalic syndrome 478  
 diffuse cortical atrophy 235  
 diffusion tensor imaging 58  
 diffusion-weighted  
   imaging 58, 62  
 digital subtraction  
   angiography 60  
 dihydropteridine reductase  
   deficiency 437  
 diplomyelia 329  
 diplopia 21  
 disability  
   care 240, 243  
   giving news of 3  
   models of 240  
 disc herniation 106  
 discitis 106  
 disorders of attention,  
   motor processing and  
   perception (DAMP) 109  
 distal myopathy 401  
 distal SMAs 394, 410  
 distal weakness 26  
 dizziness 197  
 DM1 and DM2 402  
 DNA testing 90  
 dolicocephaly 146  
 doll's eye reflex 537  
 domains 99  
 Doose syndrome 270  
 dopamine  $\beta$ -hydroxylase  
   deficiency 436  
 dopamine transporter  
   deficiency syndrome 436  
 dorsal stream 253  
 Down syndrome 147, 472  
 Dravet syndrome 265, 278  
 drooling 250  
 drowning 512  
 DRPLA 387  
 drugs  
   inducing  
     encephalopathy 502  
     unwanted effects 518  
   Duane syndrome 20, 120  
   Duchenne muscular  
     dystrophy 399, 417  
   dying 3  
   dysarthria 192  
   dysautonomia 8  
     see also central  
       dysautonomia syndrome  
   dysembryoplastic  
     neuroepithelial  
     tumour 460  
   dysgeusia 213  
   dyskinesia 159–60  
   dysmorphology 10  
   dysphonia 192  
   dyspraxia 28, 109, 198  
   dystonia 161  
     classification 162  
     diseases associated  
       with 375–6  
     measurement 242  
     treatment 377  
   dystonic gait 39  
   dystrophinopathies 399
- E**
- early infantile epileptic  
   encephalopathy 264  
 early infantile neuronal  
   ceroid lipofuscinosis 427  
 early myoclonic  
   encephalopathy 264  
 early-onset Parkinson's  
   disease 378  
 echinococcosis 347  
 edrophonium 587  
 electroencephalography  
   (EEG) 70, 73–4  
   acquired brain injury 513  
   brainstem death 511  
   epilepsy 71–2, 74–5,  
     142, 275  
   neonatal seizures 481  
 electrographic status  
   epilepticus in sleep 272  
 electromyography  
   (EMG) 80–1  
 electro-oculogram  
   (EOG) 82  
 electroretinogram  
   (ERG) 82  
 embolic arterial ischaemic  
   stroke 448  
 Emery–Dreifuss muscular  
   dystrophy 400  
 emotional reactions 104  
 encephalitis 341  
 encephalitis lethargica 220  
 endocrine myopathies 409  
 endocrinology 9, 474  
 endoscopic third  
   ventriculostomy 327  
 enoxaparin 587  
 enteral feeding 249  
 enterovirus 71 344  
 enteroviruses 340, 342, 360  
 entrapment  
   neuropathies 398  
 ependymoma 458  
 epidermal nevus  
   syndrome 424  
 epilepsy partialis  
   continua 126  
 epilepsy 141, 262  
   air travel 302  
   alcohol 301  
   anti-epileptic drugs 288,  
     290, 286–7, 294  
   autism 521  
   behavioural  
     management 520  
   cause 262  
   chromosomal  
     abnormalities 277  
   conduct/behaviour  
     disorder 517  
   contraception 301  
   cycling 300  
   daily life 298  
   death 302  
   driving 301  
   EEG 71–2, 74–5, 142, 275  
   emotional adjustment 299  
   four level approach to  
     diagnosis 142  
   genetic abnormalities 277  
   heart 473  
   hydrocephalus 328  
   idiopathic 262  
   ILAE conceptual  
     framework 275  
   imaging 275–6  
   inflammation 277  
   investigations 275  
   ketogenic diet 296  
   metabolic disorders 277,  
     281  
   neurodegenerative  
     disorders 281  
   parenteral maintenance  
     of antiepileptic  
     therapy 479  
   phenotypic cues 140  
   photosensitivity 300  
   pregnancy 301  
   presumed  
     symptomatic 262  
   psychomotor  
     regression 179  
   reproductive health 301  
   responses 299  
   schooling 298  
   SUDEP 302  
   surgical treatment 294  
   symptomatic 262

treatment 286, 288, 290, 294  
 vagus nerve  
 stimulation 297  
 water 300  
 epilepsy syndromes 262–3, 269–72, 267–268  
 epilepsy with myoclonic absences 269  
 epilepsy with myoclonic-astatic (atonic) seizures 270  
 epileptic encephalopathy 179, 267  
 epileptic seizures 136  
 episodic ataxia type 1 306  
 episodic ataxia type 2 306  
 Epstein–Barr virus 340  
 equinus deformity 135  
 Erb palsy 43, 398  
 erythema chronicum migrans 350  
 ESES see continuous spike-waves in slow-wave sleep  
 esophoria 119  
 esotropia 119  
 essential tremor 379  
 ethosuximide 588  
 evoked potentials 82–3, 513  
 examination 8, 41, 43, 45  
 excessive daytime sleepiness 442  
 executive function 100  
 exercise limitation 117  
 exercise test 81  
 exome 90  
 exophoria 119  
 exotropia 119  
 expressive  
 communication 251  
 external appearance 8, 41  
 external hydrocephalus 324  
 extra-axial bleeding 495  
 extradural  
 haemorrhage 495  
 extraocular muscles 20  
 extubation 515  
 eye examination 19, 16, 42  
 eye movements 21, 41, 119, 121

## F

facial movements 23, 42, 126  
 facial nerve (VII) 23  
 facial sensation 130–1  
 facial weakness 126, 130  
 facioscapulohumeral dystrophy 401  
 factitious or induced illness 314  
 falls 197

familial rectal pain syndrome 175  
 fatiguability 26  
 fatty acid oxidation defects 405  
 fatty filum terminale 329  
 febrile convulsions 141  
 feeding 194, 248, 476  
 femoral nerve 34  
 fifth day seizures 264  
 fist-edge-hand 13  
 flaccid foot drop 38  
 floppy infant/  
 floppiness 132, 498  
 flunarizine 589  
 fluorescent in situ hybridization 89  
 focal CNS infection 345  
 focal cortical necrosis 488  
 focal epilepsies 291  
 focal seizure 289  
 Fog's test 47  
 folate 465  
 folate metabolites 85  
 folic acid 589  
 folic acid-responsive seizures 466  
 fontanelle 8, 146–7  
 foot deformities 135  
 Friedreich ataxia 184, 385, 431  
 frontal lobe epilepsy 441  
 frontal lobe function 13–14  
 fucosidosis 434  
 Fukuyama congenital muscular dystrophy 402  
 functional endoscopic evaluation of swallowing (FEES) 249  
 functional gait 38  
 functional  
 hemispherectomy 294  
 functional illness 311  
 functional MRI 59  
 functional visual loss 558  
 fundoscopy 16, 42, 537  
 fungal encephalitis 343  
 funny turns 136–8, 142–3, 139–41  
 F-wave 77, 79

## G

GABA metabolism 437  
 gabapentin 589  
 GABA transaminase deficiency 437  
 gag reflex 23, 511  
 gait 38, 144  
 functional illness 312  
 oncology 504  
 surgery 246  
 galactosialidosis 434  
 gangliosidoses 182, 434  
 gastroenterology  
 consults 476  
 gastrointestinal problems 9  
 gastro-oesophageal reflux disease (GORD) 248, 477  
 management 250  
 paroxysmal events 304  
 gastrostomy 250  
 Gaucher disease 434  
 type 2 182  
 type 3 183, 429  
 gaze palsies 121  
 generalized epilepsy with febrile seizures plus 274  
 generalized tonic-clonic seizures 142, 288, 291  
 germ cell tumours 458  
 germinal matrix haemorrhage 497  
 gestational age 41  
 giant axonal neuropathy 394  
 Glasgow Coma Scale 536  
 glaucoma 19  
 glioblastoma  
 multiforme 457  
 gliomas 455–7  
 global dementia 14  
 global developmental impairment 109  
 globus pallidus 233  
 glossopharyngeal nerve (IX) 23  
 glucose, CSF 85  
 glucose transporter–1 deficiency syndrome 282, 483  
 glue ear 23  
 GLUT-1DS 282, 483  
 glutaric aciduria type 1 148, 282  
 glycine metabolism 437  
 glycogenoses 405  
 glycopyrrolate 590  
 glycopyrronium bromide 590  
 GM1 gangliosidosis 182, 434  
 GM2 gangliosidosis 182, 434  
 'going-off feet' 237  
 Gower sign 39  
 grasp 43  
 grey matter disorders 181, 235  
 Gross Motor Function Classification System 236, 242–3  
 Gross Motor Function Measure 237, 242  
 growth hormone treatment 474  
 GTPCH I deficiency 436

- guanidinoacetate 87  
 guanidinoacetate methyltransferase (GAMT) deficiency 282  
 Guillain-Barré syndrome 395, 564–5
- H**
- haemolytic-uraemic syndrome 523  
 haemophagocytosis  
   lymphohistiocytosis 532  
 hair 8  
 Hallervorden-Spatz syndrome 430  
 haloperidol 590  
 hand, foot and mouth disease 344  
 hand regard 7  
 Hashimoto encephalopathy 225  
 headache 151–2, 317, 500  
   analgesia overuse 153, 320  
   chronic daily 320  
   cluster 320  
   hydrocephalus 328  
   management and therapy 321  
   oncology 504  
   raised intracranial pressure 153–4, 321  
   refractive errors 321  
   tension-type 154, 318, 321  
 head shape 146–7  
 head size 8, 11, 148–9  
 hearing 23, 252, 321  
   loss 9, 155  
   neonates 42  
   tuning fork tests 23  
 heart abnormalities 9  
 hemifacial spasm 126  
 hemispherotomy 294  
 Henoch-Schönlein purpura 523  
 heparin, low molecular weight 587  
 hepatocellular failure 478  
 hepatogastric syndrome 366  
 hepato-lenticular degeneration 432  
 hereditary motor and sensory neuropathies (HMSNs) 394  
 hereditary motor neuropathies 394  
 hereditary myoclonic dystonia 376  
 hereditary neuropathy with liability to pressure palsies 393  
 hereditary sensory and autonomic neuropathies 394  
 hereditary spastic paraparesis 433  
 herniation 537–8  
 herpes hominis virus (HHV-6) 340, 354  
 herpes simplex (HSV-1/HSV-2) 340–1, 358  
 herpes viruses 340, 353  
 herpes zoster encephalitis 342  
 heterophoria 119  
 heteroplasmy 369  
 heterotropia 119  
 HHV-6 340, 354  
 higher cognitive function 13, 15  
 hip deformity/dislocation 247  
 histamine 591  
 history taking 6  
 HIV  
   congenital infection 362  
   meningitis 341  
 HIV-associated progressive encephalopathy 340  
 HIV dementia 184  
 hoarseness 8  
 holocarboxylase synthase deficiency 468  
 Hoover sign 312  
 horizontal gaze palsy 121  
 Horner syndrome 124  
 Hoyeraal-Hreidarsson syndrome 361  
 H-reflex 77, 79  
 Hunter syndrome 434  
 Huntington disease 104, 432  
 Hurler syndrome 434  
 Huttenlocher disease 429  
 hydrocephalus 324  
   aetiology 325  
   antenatal detection 326  
   communicating 324–5  
   endoscopic third ventriculostomy 327  
   external 324  
   investigations 327  
   large head 149  
   monitoring for sequelae 328  
   normal pressure 325  
   obstructive (non-communicating) 324–5  
   prognosis 328  
   progressive ventricular dilatation 327  
   shunts 98, 327, 500  
   spina bifida 331  
   symptoms and signs 326  
   treatments 327  
 hyperammonaemia 493  
 hyperekplexia 304  
 hyperkalaemic periodic paralysis 404  
 hyperkinetic dysarthria 192  
 hyperpnoea 529  
 hypersomnia 442  
 hypertension 151, 154  
 hypertensive encephalopathy 523  
 hyperventilation 254, 306  
 hypnagogic hallucinations 443  
 hypnopompic hallucinations 443  
 hypocretin 191  
 hypoglossal nerve (XII) 24  
 hypoglycaemia 316  
 hypokalaemic periodic paralysis 404  
 hypokinesia 159  
 hypokinetic-rigid syndrome 162, 378, 377–8  
 hypomelanosis of Ito 424  
 hypomyelination 233  
 hyponatraemia 509  
 hypothalamic hamartoma 474  
 hypothalamic-midbrain dysregulation 211  
 hypoxic-ischaemic encephalopathy 487  
 hypoxic-ischaemic insult 472
- I**
- I-cell disease 434  
 ice pack test 123  
 idiopathic (benign) intracranial hypertension 334, 524  
 idiopathic torsion dystonia 375  
 ifosfamide neurotoxicity 503  
 IgG index 85  
 IgG oligoclonal bands 85  
 illness behaviour 311  
 immunocompromised, CNS infection 351  
 impairment 240  
 inborn errors of metabolism 206, 365, 483–4  
 incidentalomas 167, 169  
 incomitant squint 120  
 incontinence 157–8  
 incontinentia pigmenti 424  
 infantile neuroaxonal dystrophy (INAD) 182, 428  
 infantile neuronal ceroid lipofuscinosis 182, 434

infantile poliodystrophy 429  
 infantile spasms 266, 291  
 infection of CNS 336,  
 345, 505  
 congenital 355  
 infective myositis 409  
 inflammatory bowel  
 disease 478  
 inflammatory  
 myopathies 407  
 intelligence 99  
 intention tremor 161  
 interferon alpha 86  
 International Classification  
 of Functioning 240  
 internuclear  
 ophthalmoplegia 122  
 intoxication 316  
 intra-axial bleeding 495  
 intracerebral  
 haemorrhage 452, 495,  
 497, 501  
 intracerebral sepsis 501  
 intracranial pressure,  
 raised 149  
 headache 153–4, 321  
 management 539  
 intraocular tumours 207  
 intraparenchymal  
 haemorrhage 496  
 intrapartum hypoxia 230  
 intrathecal baclofen 246  
 intrathecal medicine 96  
 intravenous  
 immunoglobulin 591  
 intraventricular  
 haemorrhage 497  
 investigation 52  
 ion channel disorders 403  
 ischaemic lactate test 90

**J**

Jack-in-the box tongue 219  
 Jansky–Bielschovsky  
 syndrome 428  
 Japanese encephalitis  
 virus 344  
 jaw jerk 22  
 JC virus 353  
 Jeavons syndrome 270  
 jitter 81  
 jitteriness 43  
 jittering 379  
 joint abnormalities 9  
 Joubert syndrome 254, 385  
 juvenile absence  
 epilepsy 272, 290  
 juvenile  
 dermatomyositis 407  
 juvenile Gaucher type 3 429  
 juvenile Huntington  
 disease 104, 432

juvenile idiopathic  
 parkinsonism 378  
 juvenile myasthenia  
 gravis 411–12, 568  
 juvenile myoclonic  
 epilepsy 271, 290  
 juvenile neuronal ceroid  
 lipofuscinosis 184, 430

**K**

karyotype analysis 89  
 Kawasaki's disease 531  
 Kearns–Sayre  
 syndrome 373  
 kernicterus 228, 233  
 ketamine 592  
 ketogenic diet 296  
 kidney problems 9  
 Kinsbourne syndrome 381  
 Kleine–Levin syndrome 445  
 Klippel–Feil syndrome 149  
 Klumpke paralysis 398  
 knee jerks 27  
 Kouska's fallacy 50  
 Krabbe leukodystrophy  
 182, 427, 434  
 Kugelberg–Welander  
 disease 410  
 kuru 349

**L**

Labrune syndrome 361  
 labyrinthitis 197  
 lacosamide 592  
 lactate  
 blood 89  
 CSF 86  
 lactate:pyruvate ratio 86  
 Lafora body disease 104, 433  
 Lambert–Eaton myasthenic  
 syndrome 413  
 lamotrigine 593  
 Lance–Adams  
 syndrome 381, 515  
 Landau–Kleffner  
 syndrome 156, 272, 293  
 language delay 112  
 laryngeal dystonia/  
 dyskinesia 530  
 laryngomalacia 529  
 late infantile neuronal ceroid  
 lipofuscinosis 183,  
 428, 434  
 late-onset cerebellar  
 ataxias 386, 388  
 late-onset metabolic  
 disease 365  
 latex allergy 332  
 L-DOPA 594  
 Leber congenital  
 amaurosis 203

Leber hereditary optic  
 neuropathy 373  
 Leigh syndrome 183, 373  
 Lennox–Gastaut  
 syndrome 271, 293  
 lens 19, 204  
 lesion  
 age of insult 5  
 location 4  
 momentum 5  
 leukodystrophy 170–1, 173  
 leukoencephalopathy 170  
 leukoencephalopathy with  
 vanishing white matter  
 disease 431  
 levetiracetam 594  
 levodopa 594  
 Lhermitte's sign 505  
 limb ataxia 28  
 limb girdle muscular  
 dystrophy 400, 402  
 linear sebaceous nevus 424  
 lipoma 329  
 lipomyelo-  
 meningocele 329  
 LIS1 164  
 lissencephaly 164  
 liver disease 478  
 locked-in syndrome 210  
 long QT syndromes 309  
 lorazepam 595  
 lower airway problems 255  
 low level states 210  
 low molecular weight  
 heparin 587  
 lumbar puncture 95  
 lumbosacral plexus 33  
 lung problems 255  
 Lyme disease 350  
 lymphocytes, vacuolated 89  
 lymphocytic choriomeningitis  
 340, 360  
 lysinuric protein  
 intolerance 477  
 lysosomal (white cell)  
 enzymes 88, 433–4

**M**

macrocephaly 148–9  
 macro-  
 electromyography 81  
 macula 19, 204  
 magnetic resonance  
 angiography 57  
 magnetic resonance imaging  
 (MRI) 55  
 brain development 60,  
 163, 165–6  
 cerebral palsy 232–3, 235  
 diffusion-weighted  
 imaging 58, 62  
 epilepsy 276



- magnetic resonance imaging (MRI) (*cont.*)  
 fat saturation  
   sequences 58  
 fluid-attenuated inversion  
   recovery 57, 62  
 functional MRI 59  
 gadolinium contrast 55  
 sedation protocol 619  
 susceptibility-weighting  
   imaging 58–9  
 T1-weighted imaging 56, 62  
 T2-weighted imaging 56, 62  
 T2\* imaging 58–9  
 unexpected findings  
   (incidentalomas) 167,  
   169  
 white matter abnormalities  
   170–1, 173
- magnetic resonance  
 spectroscopy 59, 62
- malabsorption 478
- malignant hyperthermia 407
- mannitol 595
- mannosidosis 434
- manometry 95
- Marcus–Gunn jaw-  
 winking 122
- masturbation 305
- McArdle disease 405
- measles 340
- MECP2-associated  
 phenotypes 278
- median nerve 31
- medical model of  
 disability 240
- medulloblastoma 457
- MELAS 374
- melatonin 596
- Melkersson–Rosenthal  
 syndrome 128
- memory 13
- meningeal tumours 460
- meningitis 336  
 acute bacterial 336–8  
 chronic bacterial 338  
 CSF findings 336  
 recurrent aseptic 354  
 viral (aseptic) 340
- meningocoele 329
- mental retardation 109
- mental status 100
- metabolic acidosis 494
- metabolic disorders 277,  
 281, 365
- metabolic encephalopathies  
 489, 493–4, 502
- metabolic myopathies 404
- metachromatic  
 leukodystrophy  
 (MLD) 173, 182, 428, 434
- methotrexate  
 neurotoxicity 502
- methylphenidate 596
- methylprednisolone 597
- microcephaly 150
- midazolam 598
- migraine 317  
 abdominal 319  
 aura 318  
 basilar-type 319  
 complicated 319  
 confusional 319  
 diagnosis 153, 318  
 management and  
   therapy 321  
 ophthalmoplegic 319  
 patent foramen ovale 322  
 pointers 152  
 prophylaxis 322  
 shunt migraine 328  
 triggers 319  
 visual disturbances 558
- migrating partial seizures of  
 infancy 266
- mild cortical atrophy 168
- milkmaid phenomenon 161,  
 219
- milkscan 249
- Miller–Dieker  
 syndrome 277
- Miller–Fisher syndrome 395
- minicore disease 406
- minimally conscious  
 state 210
- Mini-Mental State  
 Examination 14–15
- mirror box treatment 175
- mirror movements 160
- mitochondrial disease 183,  
 369
- mitochondrial myopathy,  
 encephalopathy, lactic  
 acidosis and stroke-like  
 episodes (MELAS) 374
- Möbius syndrome 20
- Modified Ashworth  
 Scale 241
- modules 99
- Mohr–Tranebjaerg  
 syndrome 376
- Mollaret disease 354
- molybdenum cofactor  
 deficiency 147
- momentum of lesion 5
- monoamine oxidase  
 deficiency 436
- Moro reflex 43
- mosaicism 369
- motor impairment 241, 243
- movement  
 abnormalities 159,  
 375–8, 383, 387–9
- moya-moya disease 450
- MRI, *see* magnetic  
 resonance imaging
- mucopolipidoses 434
- mucopolysaccharide  
 screen 87
- mucopoly-  
 saccharidoses 428, 434
- multifocal cortical  
 necrosis 488
- multiple carboxylase  
 deficiency 282
- multiple sclerosis 259, 261
- multiple sleep latency  
 test 191
- multiple subpial  
 transection 294
- mumps 340
- muscle biopsy 92, 95, 391
- muscle disorders 399, 402
- muscle eye brain  
 disease 402
- muscle pain 117
- muscle strengthening and  
 stretching exercises 244
- muscular dystrophies 402,  
 399–401
- musculocutaneous  
 nerve 30
- myalgic encephalomyelitis  
 314
- myasthenia gravis 568  
 ice pack test 123  
 juvenile 411–12, 568  
 transient neonatal 412, 568
- myasthenic crisis 569
- myasthenic syndromes 414,  
 411–12
- mycotic infections 347
- myelination, delayed 233
- myelomeningocoele 329
- myelopathy 505
- myoclonic astatic  
 epilepsy 293
- myoclonic-astatic  
 seizures 143, 270
- myoclonic-atic  
 seizures 143, 270
- myoclonic epilepsies 380
- myoclonic epilepsy with  
 ragged-fibres 374
- myoclonic seizures 143,  
 283, 285, 288
- myoclonus 162, 380
- myoglobinaemia 552
- myoglobinuria 524
- myokimia 126
- myophosphorylase  
 deficiency 405
- myositis  
 bacterial 409  
 viral 409
- myotonia 177
- myotonia congenita 403
- myotonic dystrophy 402
- myotubular myopathy 406

## N

- narcolepsy 310, 443  
 NARP 199  
 nasogastric tubes 249  
 near-drowning 512  
 neck  
   asymmetric tonic reflex 43  
   movements 24  
 negative predictive value 52  
 nemaline rod myopathy 406  
 neonatal depression 487  
 neonatal onset multisystem  
   inflammatory disease  
   (NOMID) 532  
 neonates  
   brain death 489  
   cerebral haemorrhage  
     495, 497  
   encephalopathy 228, 237,  
     487, 490, 493–4, 497  
   epilepsy syndromes 264  
   examination 41, 43, 45  
   floppiness 133, 498  
   myasthenia 412, 568  
   neurology 480, 486, 483–4  
   seizures 280, 480, 486,  
     483–4  
   status epilepticus 549–50  
   stroke 498  
   visual impairment 202  
 neoplasms 9  
 neostigmine 599  
 nephrogenic systemic  
   fibrosis 55  
 nerve biopsy 92  
 nerve conduction  
   studies 78–9, 76–7  
 nesidioblastosis 475  
 neuroblastoma 460  
 neurocutaneous melanosis  
   424  
 neurocutaneous  
   syndrome 41, 418, 421  
 neurocysticercosis 346  
 neurodegeneration 104,  
   180–2, 184, 281, 425, 434  
 neurodegeneration with  
   brain iron accumulation  
   (NBIA) 184, 430  
 neuroenteric cyst 329  
 neurofibromatosis  
   type 1 418  
 neurofibromatosis  
   type 2 419  
 neuroleptic malignant  
   syndrome 519  
 neuromuscular  
   conditions 390  
   management 416  
 neuromyelitis optica 260  
 neuronal ceroid  
   lipofuscinoses (NCL)  
     early infantile 427  
     infantile 182, 434  
     juvenile 184, 430  
     late infantile 183, 428, 434  
 neuronal intranuclear  
   inclusion disease 377  
 neuropathies 392, 395–6  
 neurophysiology 70, 73–4, 84  
 neuropsychiatric liaison  
   work 520  
 neuropsychological testing 99  
 neuroradiological  
   anatomy 64, 67–8  
 neuroradiology 54, 62, 56–60  
 neurosurgical consultation  
   500  
 neurotransmitter disorders  
   435  
 neurotransmitter  
   metabolites 85  
 'next generation'  
   sequencing 90  
 Niemann-Pick disease  
   A 182, 434  
   C 184, 431  
 nightmares 442  
 night terrors 441  
 nitrazepam 599  
 N-methyl-D-aspartate  
   (NMDA-R)  
   antibodies 224  
 nodes, enlarged 8  
 NOMID 532  
 non-accidental traumatic  
   brain injury 543  
 non-epileptic attack  
   disorder (NEAD) 310  
 non-ketotic hyperglycaemia  
   86, 482  
 non-paralytic squint 119  
 non-progressive pan-  
   cerebellar atrophy 385  
 non-rapid eye movement  
   sleep 188  
 non-verbal  
   communication 14  
 Noonan's syndrome 473  
 nose-picking principle 53  
 numbness 174  
 nutrition 248  
 nutritional amblyopia 206  
 nystagmus 19, 123
- O**  
 object permanence 7  
 obturator nerve 35  
 ocular flutter 125  
 ocular motor apraxia 122  
 oculocephalic reflex 48, 537  
 oculomotor apraxia 386  
 oculomotor nerve (III)  
   19–20, 319  
 oculovestibular  
   reflexes 511, 537  
 Ohtahara syndrome 264  
 olfactory nerve (I) 16  
 oligodendroglioma 455  
 oligosaccharide screen 87  
 oligosaccharidoses 434  
 oncology  
   consultations 502–3  
 one-and-a-half  
   syndrome 122  
 onset of symptoms and  
   signs 4–5  
 ophthalmoplegia 19, 120  
 opportunistic infection,  
   CNS 505  
 oppositional defiant  
   disorder 108, 521  
 opsochonus 125  
 opsochonus-myoclonus  
   syndrome 226, 381  
 optic atrophy 19  
 optic nerve (II) 16, 204  
 optic neuritis 17, 202, 260,  
   558  
 optic radiation 205  
 optokinetic nystagmus  
   (OKN) 21, 41  
 organic acids 87  
 organomegaly 9  
 orientation 13, 105  
 orphenadrine 600  
 orthopaedic surgery 246  
 osteochondritis 106  
 osteomyelitis 106  
 otitis media 23  
 overflow contraction 161  
 oxcarbazepine 600  
 oxidative phosphorylation  
   defects 405  
 oxybate sodium 601  
 oxycephaly 146
- P**  
 paediatric ICU 507  
 pain 174  
 palatal function 23  
 pallid breath-holding  
   spell 309  
 pallid syncope 309  
 Panayiotopoulos  
   syndrome 269  
 PANDAS 219  
 pantothenate kinase-  
   associated  
   neurodegeneration 430  
 papillitis 17, 202  
 papilloedema 17, 202  
 paraesthesia 504  
 paraldehyde 601  
 paralysis 312  
 paralytic rabies 344

- paralytic squint 119–21  
 paramyotonia 177  
 paramyotonia congenita 403  
 paraneoplastic syndromes 226  
 parasitic encephalitis 344  
 parasitic infection 346  
 parasitic myositis 409  
 parasomnias 189–90, 439  
 parietal lobe dysfunction 14  
 Parkinson disease 378  
 parkinsonism 162, 220, 378  
 paroxysmal dyskinesias 306–7  
 paroxysmal events 72, 136, 139, 304, 307, 309, 473  
 paroxysmal exercise-induced dyskinesia 307  
 paroxysmal extreme pain disorder 175  
 paroxysmal hypnogenic dyskinesia 307  
 paroxysmal kinesigenic dyskinesia 307  
 paroxysmal non-kinesigenic dyskinesia 307  
 paroxysmal tonic upgaze of infancy 305  
 participation 240  
 patent foramen ovale 322  
 PEHO 282, 384  
 Pelizaeus–Merzbacher disease (PMD) 173, 182, 427  
 percussion myotonia 177  
 percutaneous endoscopic gastrostomy (PEG) 250  
 perinatal varicella 360  
 periodic paralyses 404  
 peri-oral seizure 126  
 peripheral blood film 88  
 peripheral nerve tumours 460  
 peripheral nervous system 30, 25–9, 31–7, 42–3, 39–40  
 peripheral neuropathy 505  
 peripheral neurophysiology 78–9, 76–7  
 peripheral weakness 133, 176, 178, 561  
 perivascular spaces 167, 169  
 periventricular haemorrhagic infarction 234  
 periventricular leukomalacia 232–3  
 pervasive developmental disorder 114  
 pes cavus 135  
 pes planus 135  
 PET 61  
 pH 88  
 phenobarbital (phenobarbitone) 602  
 phenylalanine challenge 438  
 phenytoin 603–4  
 3-phosphoglycerate dehydrogenase deficiency 282  
 photosensitivity 300  
 physiotherapy 244  
 Piaget's model 7  
 pimozide 605  
 pineal tumours 455  
 pineal cyst 168–9  
 pipecolate 86  
 piracetam 605  
 Pitt-Hopkin syndrome 254, 279  
 pizotifen 606  
 PKAN 184  
 plagiocephaly 146  
 plantar reflex 27, 43  
 play 7  
 pointing 7  
 polio 344  
 polyarteritis nodosa 222  
 polymyositis 408  
 polyneuropathy 366–7  
 polysomnography 190  
 Pompe disease 405  
 pontocerebellar hypoplasia type 1 (PCH1) 384, 410  
 pontocerebellar hypoplasia type 2 (PCH2) 375, 384  
 porencephaly 234  
 porphyrias 367  
 port wine stain 421  
 positioning 244  
 positive predictive value 52  
 positron emission tomography (PET) 61  
 post-encephalitic parkinsonism 220  
 posterior fossa syndrome 461  
 posterior reversible encephalopathy syndrome 524  
 'post-pump' chorea 382  
 post-traumatic amnesia 13  
 postural dystonia 161  
 postural tremor 161  
 posture 38  
 power 25–6, 42  
 Prader–Willi syndrome 133  
 praxis 13  
 prednisolone (prednisone) 606  
 pregabalin 607  
 presenting complaint 6  
 pre-syncope 197  
 primary dystonia–parkinsonism syndromes 377  
 primary muscle aplasia 498  
 primary parkinsonism 378  
 primitive neuroectodermal tumour 458  
 prion infections 348  
 procyclidine 607  
 progressive encephalopathy with oedema (PEHO) 282, 384  
 progressive myoclonus epilepsy 283, 285  
 progressive neuronal degeneration of childhood 373, 429  
 progressive pan-cerebellar atrophy 385  
 progressive ventricular dilatation 327  
 proline 86  
 PROMM 403  
 pronator drift 26  
 propranolol 608  
 protein studies, CSF 85  
 proto-linguistic pointing 7  
 protozoan infection 346  
 proverb understanding 13  
 proximal myotonic myopathy 403  
 proximal weakness 26, 38  
 pseudobulbar palsy 127  
 pseudo seizure 310  
 pseudo-squint 120  
 pseudo syncope 310  
 pseudo-TORCH syndromes 361  
 pseudotumour cerebri 334  
 psychiatry consultations 517  
 psychomotor regression 104, 179, 181–4  
 psychosis 104, 365, 517  
 ptosis 122  
 6-PTS deficiency 437  
 pupils 18, 42, 511, 537  
 putamen 233  
 pyridoxepsy 270  
 pyridostigmine 608  
 pyridoxal phosphate 609  
 pyridoxal 5'-phosphate-dependent epilepsy 462  
 pyridoxine 609  
 pyridoxine and pyridoxal-responsive seizures 463, 484–5  
 pyridoxine-dependent epilepsy 462  
 pyruvate 86

## R

- radial nerve 32
  - ragged-red fibres 372
  - raised intracranial
    - pressure 149
    - headache 153–4, 321
    - management 539
  - rapid eye movement
    - sleep 188
  - Rasmussen syndrome 222, 430
  - receptive
    - communication 251
  - recurrent aseptic meningitis 354
  - red blood cell
    - plasmalogens 91
  - red reflex 17
  - reflex anoxic seizure 309
  - reflex astylosic
    - syncope 309
  - reflexes 27, 43
  - reflex sympathetic dystrophy 174
  - reflux, see gastro-oesophageal reflux disease
  - refractive errors 119, 321
  - refractory status
    - epilepticus 516, 547
  - Refsum disease 184
  - REM sleep 188
  - REM sleep behaviour disorder 442
  - renal consultations 523
  - renal transplantation 525
  - respiratory
    - consultations 526
  - respiratory disease 254
  - retina 19, 204
  - retro-orbital tumours 207
  - Rett-like syndromes 278
  - Rett syndrome 182, 254, 278, 426
  - review appointment 2
  - rhabdomyolysis 524, 552
  - rheumatic disease 106, 531
  - rhizomelic chondrodysplasia punctata 91
  - rickettsial encephalitis 343
  - Riley–Day syndrome 394
  - ring chromosome 20 277
    - mosaicism 90
  - Rinne tuning fork test 23
  - risperidone 610
  - ritualistic movements 306
  - RNASET2-deficient
    - cystic leuko-encephalopathy 361
  - rocker bottom feet 135
  - Rolandic epilepsy 268
  - Romberg test 28, 38
  - rooting reflex 43
  - rubella 357
  - rubral tremor 161
  - rufinamide 610
- S**
- saccade initiation
    - failure 122
  - saccadomania 125, 381
  - St Vitus dance 218
  - salivogram 249
  - Sandifer syndrome 477
  - Sandoff syndrome 434
  - Sanfilippo syndrome 183, 428, 434
  - Santavouri–Haltia syndrome 427
  - sarcoidosis 223
  - Sarnat scoring system 490
  - scaphocephaly 146
  - Scheie syndrome 434
  - schizencephaly 234
  - school
    - epilepsy 298
    - failing at 186
  - sciatic nerve 36
  - scissor gait 38
  - SCIWORA 215
  - SCN1A 265, 278
  - scoliosis 106, 247
  - search bias 50
  - sedation 619
  - Seitelberger disease 428
  - seizures
    - acute symptomatic 275
    - cardiology 472
    - epileptic 136
    - facial movements 126
    - factitious or induced illness 316
    - functional illness 312
    - neonates 280, 480, 486, 483–4
    - neurosurgical disease 501
    - oncology 504
    - types 142–3
  - selective dorsal rhizotomy 246
  - selective neuronal necrosis 488
  - self-comforting phenomenon 305
  - self-gratification 305
  - Semelaigne syndrome 409
  - sensitivity 52
  - sensory ataxia 38
  - sensory disturbances 174, 312
  - sensory examination 27, 29, 44
  - sepiapterin reductase deficiency 437
  - septo-optic dysplasia 474
  - septum pellucidum 167, 169
  - serial casting 244
  - serine 86
  - setback autism 521
  - severe myoclonic epilepsy of infancy 265, 292
  - sexual abuse 313
  - shared attention 7
  - ship's deck ataxia 197
  - shoes, wear patterns 25
  - shuddering attacks 304
  - shunt 98, 327, 500
  - shunt migraine 328
  - shunt tap 96
  - SIADH 509
  - sialidosis type I 434
  - signs 4–5
  - simple (clonic) partial
    - motor seizure 126
  - single fibre EMG 81
  - single-gene disorders 277
  - single photon emission
    - computed tomography (SPECT) 61
  - skin abnormalities 8
  - skin biopsy 93–4
  - sleep attacks 443
  - sleep cycle 188
  - sleep disorders 188–9, 439, 441
  - sleep paralysis 443
  - sleep terrors 441
  - sleep walking 441
  - slit-ventricle syndrome 328
  - slow viral infections 348
  - Sly syndrome 434
  - social-emotional
    - functions 100
  - social model of disability 240
  - somatosensory evoked potentials 83, 513
  - sound and speech
    - production disorders 192
  - spasms 143
  - spasmus nutans 124, 379
  - spastic diplegia 38
  - spastic dysarthria 192
  - spastic hemiparesis 38
  - spasticity 240
    - medical management 244
    - surgical management 245
  - spasticity scales 241
  - spastic paraparesis 38
  - specificity 52
  - specific language delay 112
  - specific motor delay 111
  - SPECT 61
  - speech and language
    - disorder 192
  - speech difficulties 192

- sphingolipidoses 434  
 spina bifida 329  
 spina bifida occulta 329  
 spinal cord  
   acquired injury 215–16  
   compression 215, 566  
   low termination 329  
   prominent central canal 168–9  
 spinal muscular atrophy 410  
   distal C4.S33.1.6, 410  
   type I 133, 410  
 spinal muscular atrophy with respiratory distress 410  
 spinocerebellar ataxias (SCA) 386–7  
   SCA7 104  
 splints 244  
 spondylolisthesis 106  
 spondylolysis 106  
 spoon hands 219  
 squint 22, 120–1  
 SSPE 104, 348  
 status dystonicus 551, 554  
 status epilepticus 544–6  
   absence status  
     epilepticus 273  
     clustering 548  
   electrographic status  
     epilepticus in sleep 272  
     neonates 549–50  
     refractory 516, 547  
     treatment algorithm 545  
 stepping reflex 43  
 stereotypies 160, 306  
 sternocleidomastoid 42  
 stiffness 117–18  
 stigmata 41  
 stimulus deprivation  
   amblyopia 206  
 stiripentol 611  
 stridor 8, 529  
 stroke 9, 366, 446, 448, 471  
   neonatal 498  
   oncology 504  
 stroke-like episode 446  
 Sturge–Weber syndrome 421  
 subacute combined degeneration of the cord 465  
 subacute sclerosing panencephalitis (SSPE) 104, 348  
 subarachnoid  
   haemorrhage 452, 496  
 subarachnoid space  
   benign enlargement 149  
   prominent 168  
 subdural haemorrhage 149, 495  
 succinic semialdehyde dehydrogenase deficiency 437  
 sucking reflex 43  
 SUDEP 302  
 sulphatide lipidosis 428  
 sulphite oxidase deficiency 147  
 sulphites 87  
 sulphiride 611  
 sulthiame (sultiame) 612  
 sumatriptan 612  
 supinator reflexes 27  
 supranuclear gaze palsy 121  
 supratentorial primitive neuroectodermal tumour 458  
 surgical sieve 4  
 sutures 146  
 swallowing 8, 194, 249  
 swinging penlight test 18  
 swooning 310  
 Sydenham chorea 218  
 symbolic play 7  
 symptoms 4–5  
 syncope 309  
 syndrome of inappropriate ADH secretion (SIADH) 509  
 synthesis 49–50  
 syphilis 359  
 syringomyelia 217, 329, 331  
 syrinx 168–9  
 systemic lupus erythematosus 220
- T**  
 tardive dyskinesia 518  
 Tay–Sachs disease 133, 427, 434  
 ‘teaching hospital syndrome’ 470  
 temperature perception 22, 27  
 temporal lobe dysfunction 14  
 tendon reflexes 27, 43  
 Tensilon® test 412  
 tension-type headache 154, 318, 321  
 tetrabenazine 613  
 tetracosactide 575  
 tetrahydrobiopterin  
   reclamation defects 437  
 tetrahydrobiopterin  
   synthesis defects 436  
 thalamus 233  
 theory of mind 7  
 therapeutic cooling 489  
 threonine 86  
 thrombolysis 446  
 thrombotic arterial ischaemic stroke 449  
 thrombotic  
   thrombocytopenic purpura 523  
 tiagabine 613  
 tickle 28  
 tics 126, 160, 306, 382, 520  
 time-course 4–5  
 tingling 174  
 tizanidine 614  
 toe walking 196  
 tone 25, 42  
 tongue movements 24  
 tonic seizures 143, 289  
 tonic spasms 143  
 tonsils, enlarged orange 8  
 topiramate 614  
 TORCH group 355  
 torticollis 375, 377  
 total parenteral nutrition 478  
 touch perception 22, 27  
 Tourette syndrome 382, 520  
 toxic amblyopia 206  
 toxic myopathies 409  
 toxoplasmosis 352, 356  
 tractography 58  
 transferrin isoforms 90  
 transient idiopathic dystonia of infants 375  
 transient ischaemic attack 446  
 transient neonatal myasthenia 412, 568  
 transverse myelitis 260, 567  
 traumatic coma 541  
 traumatic dissection 543  
 tremor 161, 366, 379, 474  
 triceps reflexes 27  
 trigeminal nerve (V) 22  
 trigone 68  
 trigonocephaly 146  
 trihexyphenidyl 615  
 trochlear nerve (IV) 19–20  
 TUB1A 164  
 tuberculous meningitis 339  
 tuberous sclerosis 41, 421, 419–21, 473  
 tumours, CNS 454  
 tuning fork tests 23  
 tyrosine hydroxylase deficiency 436
- U**  
 ulnar nerve 31  
 Ulrich myopathy 402  
 unconscious child 47  
 unsteadiness 197  
 Unverricht–Lundborg disease 184, 431  
 uraemia 524  
 urea-cycle disorders 282, 365

uric acid 88  
 urinary signs and symptoms 158  
 urine tests 87  
 utility indices 53

## V

vagus nerve (X) 23  
 vagus nerve stimulation 297  
 valproate 615  
 vanishing white matter disease 431  
 variant Creutzfeld–Jakob disease (vCJD) 104, 349  
 varicella zoster 340, 354, 360  
 vasculitides 222–3  
 vasculopathic arterial ischaemic stroke 449  
 vaso-vagal syncope 310  
 vegetative state 210  
 vein of Galen, aneurysmal malformation 499  
 venous infarction 450  
 venous pulsation 17  
 ventilation  
 abnormal movements on ventilator 515  
 long-term 526  
 weaning 514  
 ventral stream 253  
 ventriculo-atrial shunt 327  
 ventriculomegaly 324–5  
 ventriculo-peritoneal shunt 327  
 verbal communication 14  
 vertical gaze palsy 121  
 vertigo 197  
 very long chain fatty acids 91  
 vestibular disease 198  
 vestibulo-ocular reflexes 511, 537  
 videofluoroscopy 249  
 vigabatrin 616  
 viral encephalitis 341  
 viral meningitis 340  
 viral meningo-encephalitis 341  
 viral myositis 409  
 Virchow–Robin spaces 167, 169  
 visual acuity 16, 41  
 visual cortex 205  
 visual development milestones 200  
 visual disturbances 200–1, 207, 204–5, 252, 558  
 visual evoked potentials 82, 513  
 visual fields 16, 207  
 visual hallucinations 105, 365  
 visual tracking 41  
 visuomotor function 100  
 visuoperception 253  
 visuospatial tests 100  
 vitamin B6 462–3, 609  
 vitamin B12 463–4  
 vitamin D supplements 580  
 vitamin E 466  
 vitamin H (biotin) 467, 578  
 vitamin-responsive conditions 462–4  
 vocal cord dysfunction/dystonia/dyskinesia 530  
 voice disorders 192  
 voltage gated potassium channel (VGKC) antibodies 224  
 vomiting 248, 477  
 Von Hippel–Lindau disease 423  
 von Recklinghausen disease 418

## W

waddling gait 38  
 Walker Warburg syndrome 402

walking  
 delayed 111  
 suddenly stopping 559, 561, 565, 570  
 warfarin 617  
 watershed infarction 448, 488  
 water swallow test 195  
 Wechsler Intelligence Scale for Children (WISC) 99  
 weakness  
 emergencies 560–1  
 neonates 498  
 patterns 40  
 Weber tuning fork test 23  
 Werdnig–Hoffman disease 133, 410  
 West Nile virus 344  
 West syndrome 266, 280  
 what, when and where 4–5  
 white cell enzymes 88, 433–4  
 white matter  
 disorders 170–1, 173, 181  
 Williams syndrome 473  
 Wilson disease 104, 432, 478  
 withdrawal of care 513  
 Wolf–Hirschhorn syndrome 277  
 Wood's light 41  
 Worcester–Drought phenotype 227

## X

X-linked  
 adrenoleukodystrophy (X-ALD) 173, 183, 430

## Z

Zellweger syndrome 133  
 zonisamide 618