

ELSEVIER SAUNDERS

The Curtis Center
170 S Independence Mall W 300E
Philadelphia, Pennsylvania 19106

CLINICAL PEDIATRIC NEUROLOGY

A Signs and Symptoms Approach, Fifth Edition

1-4160-0169-7

Copyright © 2005, 2001, 1997, 1993, 1988 by Elsevier, Inc.

All rights reserved. No part of this publication may be reproduced or transmitted in any form or by any means, electronic or mechanical, including photocopying, recording, or any information storage and retrieval system, without permission in writing from the publisher.

Permissions may be sought directly from Elsevier's Health Sciences Rights Department in Philadelphia, PA, USA: phone: (+1) 215-238-7869; fax: (+1) 215-238-2239; e-mail: healthpermissions@elsevier.com. You may also complete your request online via the Elsevier homepage (<http://www.elsevier.com>) by selecting "Customer Support," then "Obtaining Permissions."

NOTICE

Neurology is an ever-changing field. Standard safety precautions must be followed, but as new research and clinical experience broaden our knowledge, changes in treatment and drug therapy may become necessary or appropriate. Readers are advised to check the most current product information provided by the manufacturer of each drug to be administered to verify the recommended dose, the method and duration of administration, and contraindications. It is the responsibility of the licensed prescriber, relying on experience and knowledge of the patient, to determine dosages and the best treatment for each individual patient. Neither the publisher nor the author assumes any liability for any injury and/or damage to persons or property arising from this publication.

Library of Congress Cataloging-in-Publication Data

Fenichel, Gerald M.

Clinical pediatric neurology: a signs and symptoms approach / Gerald M. Fenichel.—5th ed.
p. ; cm.

Includes bibliographical references and index.

ISBN 1-4160-0169-7

1. Pediatric neurology. 2. Nervous system—Diseases—Diagnosis. I. Title.

[DNLM: 1. Nervous System Diseases—diagnosis—Child. 2. Nervous System

Diseases—diagnosis—Infant. WS 340 F333c 2005]

RJ486.F46 2005

618.92'8—dc22

2004061427

Publishing Director: Susan Pioli

Editorial Assistant: Joan Ryan

Senior Project Manager: Robin E. Davis

Marketing Manager: Michael Passanante

Design Manager: Steven Stave

Printed in the United States of America.

Last digit is the print number: 9 8 7 6 5 4 3 2 1

Working together to grow
libraries in developing countries

www.elsevier.com | www.bookaid.org | www.sabre.org

ELSEVIER

BOOK AID
International

Sabre Foundation

*To my wife Barbara, with love,
on the occasion of 47 years together.*

Preface

It is now almost 20 years since I began work on the first edition. Several people have asked how I came to use the format of a *signs and symptoms approach*. The idea was not mine. The suggestion came from Dana Dreibelbis, then an editor for W. B. Saunders publishing company. It was probably the third edition before I finally got the organization correct.

With each new edition, the text evolved into a personal statement reflecting my approach to the practice of pediatric neurology. If I were not actively engaged in practice, I could not continue writing the text. The text is a practical approach to diagnosis and management, and it expresses my own biases in situations in which a single standard of practice is not established.

Modern neuroimaging, which has greatly improved diagnosis, has also dampened the neurologist's skill in clinical diagnosis. A well-taken history and directed examination remain the starting points for diagnosis. More often than not, they are the only requirements for diagnosis. Invest most of your time in listening to the history. If you have no idea what is wrong after hearing the history, it is unlikely that diagnostic tests will enlighten you. A differential diagnosis is a list that contains one correct answer and several wrong answers.

There is little to commend a list of wrong answers. Their exclusion is both time consuming and expensive. Better to think through the possibilities at the onset and zero in on the right answer.

In prior editions, I have recommended two web-based resources for genetic disorders: Online Mendelian Inheritance in Man (<http://www.ncbi.nih.gov/omim>) and GeneClinics (<http://www.geneclinics.org>). GeneReviews, now part of GeneClinics, contains a wealth of up-to-date information on neurological disorders. I have referenced it throughout the text and rarely go to the clinic without logging on.

The intent of this book is to provide a sensible approach to the common presenting problems of children with disorders of the nervous system. The general organization remains the same because the presenting clinical features are unchanged. Some chapters have required more revision than others, but the reader will find new information in all.

I wish to express my gratitude to Susan F. Pioli, Publishing Director, Elsevier Health Sciences, for her friendship and assistance in developing several textbooks.

GERALD M. FENICHEL, MD

Chapter 1

Paroxysmal Disorders

THE SUDDEN ONSET of neurological dysfunction characterizes paroxysmal disorders. In children, such events often clear completely. Disturbance of ion channels (channelopathies) is often the underlying cause. Examples of channelopathies are genetic epilepsies, migraine, periodic paralysis, and paroxysmal movement disorders.

Approach to Paroxysmal Disorders

The diagnosing physician almost never witnesses the paroxysmal event. The nature of the event requires surmising what transpired by listening to the eyewitness description offered by a family member or, worse, to the secondhand description that the parent heard from a teacher. Never accept a secondhand description. Most “spells” are not seizures, and epilepsy is not a diagnosis of exclusion. The most common confusion is between seizures and syncope. Most people stiffen and tremble at the end of a faint.

Spells seldom remain unexplained when viewed. Because observation of the spell is crucial to diagnosis, ask the family to videotape the spell. Most families either own or can borrow a video camera. Even when a purchase is required, it is more cost-effective than brain imaging studies, and the family has something useful to show for the expenditure. Always ask the following two questions: Has this ever happened before? Does anyone else in the family have similar episodes? Often, no one offers this important information until requested. Episodic symptoms that last only seconds and cause no abnormal signs usually remain unexplained and do not warrant laboratory investigation. The differential diagnosis of paroxysmal disorders is

different in neonates, infants, children, and adolescents and presented best by age groups.

Paroxysmal Disorders of Newborns

Seizures are the main paroxysmal disorder of newborns. The challenge for the clinician is to differentiate seizure activity from normal neonatal movements and from pathological movements caused by other mechanisms (Table 1-1).

Seizure Patterns

Seizures in newborns, especially premature newborns, are poorly organized and difficult to distinguish from normal activity. Newborns with hydranencephaly or atelencephalia are capable of generating the full variety of neonatal seizure patterns. This capability supports the notion that seizures may arise from the brainstem and the hemispheres. The absence of myelinated pathways for seizure propagation may confine seizures arising in the brainstem. For the same reason, seizures originating in one hemisphere are unlikely to spread beyond the contiguous cortex or to produce secondary bilateral synchrony.

Table 1-2 lists clinical patterns that have been associated with epileptiform discharges in newborns. This classification is useful but does not do justice to the rich variety of patterns observed or take into account that 50% of prolonged epileptiform discharges on the electroencephalogram (EEG) are not associated with visible clinical changes. Generalized tonic-clonic seizures do not occur. Many newborns suspected of having generalized tonic-clonic seizures are actually *jittery* (see the section on

TABLE 1-1
Movements That Resemble Neonatal Seizures

Benign nocturnal myoclonus
Jitteriness
Nonconvulsive apnea
Normal movement
Opisthotonos
Pathological myoclonus

TABLE 1-2
Seizure Patterns in Newborns

Apnea with tonic stiffening of body
Focal clonic movements of one limb or both limbs on one side
Multifocal clonic limb movements
Myoclonic jerking
Paroxysmal laughing
Tonic deviation of the eyes upward or to one side
Tonic stiffening of the body

Jitteriness later in this chapter). Newborns paralyzed with pancuronium to assist mechanical ventilation pose a special problem in seizure identification. In this situation, the presence of rhythmic increases in systolic arterial blood pressure, heart rate, and oxygenation should alert physicians to the possibility of seizures.

The term *subtle seizures* encompasses several different patterns in which tonic or clonic movements of the limbs are lacking. EEG monitoring has consistently failed to show that such movements are associated with epileptiform activity. One exception is tonic deviation of the eyes, which is usually a seizure manifestation.

The definitive diagnosis of neonatal seizures often requires EEG monitoring. A split-screen, 16-channel video-EEG is the ideal means for monitoring, but an ambulatory EEG cassette capable of marking the time of events is serviceable. Epileptiform activity in a newborn is usually widespread and detectable even when the newborn is clinically asymptomatic.

Focal Clonic Seizures

CLINICAL FEATURES. Repeated, irregular jerking movements affecting one limb or both limbs on one side are characteristic of focal clonic seizures. Rarely are such movements sustained for long periods, and they do not “march” as though spreading along the motor cortex. *In an otherwise alert and responsive full-term new-*

born, focal clonic seizures always indicate a cerebral infarction or hemorrhage. In newborns with states of decreased consciousness, focal clonic seizures may indicate a focal infarction superimposed on a generalized encephalopathy.

DIAGNOSIS. During the seizure, the EEG may show a unilateral focus of high-amplitude sharp waves adjacent to the rolandic fissure. The discharge can spread to involve contiguous areas in the same hemisphere and can be associated with unilateral seizures of the limbs and adverse movements of the head and eyes. The interictal EEG usually shows focal slowing or amplitude attenuation.

Newborns with focal clonic seizures should be evaluated immediately using non-contrast-enhanced computed tomography (CT) or ultrasound to look for intracerebral hemorrhage. If the CT scan is normal, contrast-enhanced CT or magnetic resonance imaging (MRI) 3 days later is performed to look for cerebral infarction. Ultrasound is not useful in detecting small cerebral infarctions.

Multifocal Clonic Seizures

CLINICAL FEATURES. In multifocal clonic seizures, migratory jerking movements are noted in first one limb and then another. Facial muscles also may be involved. The migration appears random and does not follow expected patterns of epileptic spread. Sometimes, prolonged movements occur in one limb, suggesting a focal rather than a multifocal seizure. Detection of the multifocal nature comes later, when nursing notes appear contradictory concerning the side or the limb affected. Multifocal clonic seizures are a neonatal equivalent of generalized tonic-clonic seizures. They are ordinarily associated with severe, generalized cerebral disturbances, such as hypoxic-ischemic encephalopathy (HIE).

DIAGNOSIS. Standard EEG usually detects multifocal epileptiform activity. If not, a 24-hour EEG monitor is appropriate.

Myoclonic Seizures

CLINICAL FEATURES. Brief, repeated extension and flexion movements of the arms, the legs, or all limbs characterize myoclonic seizures. They constitute an uncommon seizure pattern in a newborn, but their presence suggests severe, diffuse brain damage.

DIAGNOSIS. No specific EEG pattern is associated with myoclonic seizures in a newborn. Myoclonic jerks often occur in infants born to drug-addicted mothers. Whether these movements are seizures,

jitteriness, or myoclonus (discussed later) is uncertain.

Tonic Seizures

CLINICAL FEATURES. The characteristic features of tonic seizures are extension and stiffening of the body, usually associated with apnea and upward deviation of the eyes. Tonic posturing without the other features is rarely a seizure manifestation. Tonic seizures are more common in premature than in full-term newborns and usually indicate structural brain damage rather than a metabolic disturbance.

DIAGNOSIS. Tonic seizures in premature newborns are often a symptom of intraventricular hemorrhage and an indication for ultrasound study. Tonic posturing also occurs in newborns with forebrain damage, not as a seizure manifestation but as a disinhibition of brainstem reflexes. Prolonged disinhibition results in *decerebrate posturing*, an extension of the body and limbs associated with internal rotation of the arms, dilation of the pupils, and downward deviation of the eyes. Decerebrate posturing is often a terminal sign in premature infants with intraventricular hemorrhage caused by pressure on the upper brainstem (see Chapter 4).

Tonic seizures and decerebrate posturing look similar to *opisthotonos*, a prolonged arching of the back not associated with eye movements. The cause of *opisthotonos* is probably meningeal irritation. It occurs in kernicterus, infantile Gaucher disease, and some aminoacidurias.

Seizure-like Events

Apnea

CLINICAL FEATURES. An irregular respiratory pattern with intermittent pauses of 3 to 6 seconds, often followed by 10 to 15 seconds of hyperpnea, is a common occurrence in premature infants. The pauses are not associated with significant alterations in heart rate, blood pressure, body temperature, or skin color. Immaturity of the brainstem respiratory centers causes this respiratory pattern, termed *periodic breathing*. The incidence of periodic breathing correlates directly with the degree of prematurity. Apneic spells are more common during active than quiet sleep.

Apneic spells of 10 to 15 seconds are detectable at some time in almost all premature and some full-term newborns. Apneic spells of 10 to 20 seconds are usually associated with a 20% reduction in heart rate. Longer episodes of

apnea are almost invariably associated with a 40% or greater reduction in heart rate. The frequency of these apneic spells correlates with brainstem myelination. Even at 40 weeks of conceptional age, premature newborns continue to have a higher incidence of apnea than do full-term newborns. The incidence of apnea sharply decreases in all infants at 52 weeks' conceptional age.

DIAGNOSIS. Apneic spells in an otherwise normal-appearing newborn are a sign of brainstem immaturity and not a pathological condition. The sudden onset of apnea and states of decreased consciousness, especially in premature newborns, suggests an intracranial hemorrhage with brainstem compression. Immediate ultrasound examination is in order.

Apneic spells are almost never a seizure manifestation, unless they are associated with tonic deviation of the eyes, tonic stiffening of the body, or characteristic limb movements. *Prolonged apnea without bradycardia, and especially with tachycardia, is a seizure until proved otherwise.*

MANAGEMENT. Short episodes of apnea do not require intervention.

Benign Nocturnal Myoclonus

CLINICAL FEATURES. Sudden jerking movements of the limbs during sleep occur in normal people of all ages (see Chapter 14). They appear primarily during the early stages of sleep as repeated flexion movements of the fingers, wrists, and elbows. The jerks do not localize consistently, stop with gentle restraint, and end abruptly with arousal. When prolonged, the usual misdiagnosis is focal clonic or myoclonic seizures.

DIAGNOSIS. The distinction between nocturnal myoclonus and seizures or jitteriness is that it occurs solely during sleep, it is not activated by a stimulus, and the EEG is normal.

MANAGEMENT. Treatment is not required. Anticonvulsant drugs may increase the frequency of benign nocturnal myoclonus by causing sedation.

Jitteriness

CLINICAL FEATURES. Jitteriness or tremulousness is an excessive response to stimulation. Touch, noise, or motion provokes a low-frequency, high-amplitude shaking of the limbs and jaw. Jitteriness is commonly associated with a low threshold for the Moro reflex, but it can occur in the absence of any apparent stimulation and be confused with myoclonic seizures.

DIAGNOSIS. Jitteriness usually occurs in newborns with perinatal asphyxia, who may have seizures as well. EEG monitoring, the absence of eye movements or alteration in respiratory pattern, and the presence of stimulus activation distinguishes jitteriness from seizures. Newborns of addicted mothers and newborns with metabolic disorders are also jittery.

MANAGEMENT. Reduced stimulation decreases jitteriness. Newborns of addicted mothers require sedation to facilitate feeding and to decrease energy expenditure.

Differential Diagnosis of Seizures

Seizures are a feature of almost all brain disorders in newborns. The time of onset of the first seizure is helpful in determining the cause (Table 1-3). Seizures occurring during the first 24 hours, and especially in the first 12 hours, are usually due to HIE. Sepsis, meningitis, and subarachnoid hemorrhage are next in frequency, followed by intrauterine infection and trauma. Direct drug effects, intraventricular hemorrhage at term, and pyridoxine dependency are relatively rare causes of seizures.

The more common causes of seizures 24 to 72 hours after birth are intraventricular hemorrhage in premature newborns, subarachnoid

hemorrhage, cerebral contusion in large full-term newborns, and sepsis and meningitis at all gestational ages. The usual causes of focal clonic seizures in full-term newborns are cerebral infarction, intracerebral hemorrhage, and venous thrombosis. Cerebral dysgenesis causes seizures at this time and remains an important cause of seizures throughout infancy. All other conditions are relatively rare. Newborns with metabolic disorders are usually lethargic and feed poorly before the onset of seizures.

After 72 hours, the initiation of protein and glucose feedings makes inborn errors of metabolism, especially aminoacidurias, a more important consideration. Table 1-4 outlines a battery of screening tests for metabolic disorders. Transmission of herpes simplex infection occurs during delivery, and symptoms begin during the second half of the first week of life. Conditions that cause early and late seizures include cerebral dysgenesis, cerebral infarction, intracerebral hemorrhage, and familial neonatal seizures.

Aminoacidopathies

Maple Syrup Urine Disease

An almost complete absence (<2% of normal) of branched-chain ketoacid dehydrogenase causes the neonatal form of maple syrup urine disease

TABLE 1-3
Differential Diagnosis of Neonatal Seizures by Peak Time of Onset

24 Hours

Bacterial meningitis and sepsis (see Chapter 4)
Direct drug effect
Hypoxic-ischemic encephalopathy
Intrauterine infection (see Chapter 5)
Intraventricular hemorrhage at term (see Chapter 4)
Laceration of tentorium or falx
Pyridoxine dependency
Subarachnoid hemorrhage

24 to 72 Hours

Bacterial meningitis and sepsis (see Chapter 4)
Cerebral contusion with subdural hemorrhage
Cerebral dysgenesis (see Chapter 18)
Cerebral infarction (see Chapter 11)
Drug withdrawal
Glycine encephalopathy
Glycogen synthase deficiency
Hypoparathyroidism-hypocalcemia
Idiopathic cerebral venous thrombosis
Incontinentia pigmenti
Intracerebral hemorrhage (see Chapter 11)
Intraventricular hemorrhage in premature newborns (see Chapter 4)
Pyridoxine dependency
Subarachnoid hemorrhage
Tuberous sclerosis
Urea cycle disturbances

72 Hours to 1 Week

Familial neonatal seizures
Cerebral dysgenesis (see Chapter 18)
Cerebral infarction (see Chapter 11)
Hypoparathyroidism
Idiopathic cerebral venous thrombosis
Intracerebral hemorrhage (see Chapter 11)
Kernicterus
Methylmalonic acidemia
Nutritional hypocalcemia
Propionic acidemia
Tuberous sclerosis
Urea cycle disturbances

1 to 4 Weeks

Adrenoleukodystrophy, neonatal (see Chapter 6)
Cerebral dysgenesis (see Chapter 18)
Fructose dysmetabolism
Gaucher disease type 2 (see Chapter 5)
GM₁ gangliosidosis type 1 (see Chapter 5)
Herpes simplex encephalitis
Idiopathic cerebral venous thrombosis
Ketotic hyperglycemic
Maple syrup urine disease, neonatal
Tuberous sclerosis
Urea cycle disturbances

TABLE 1-4
Screening for Inborn Errors of
Metabolism That Cause Neonatal
Seizures

Blood Glucose Low

Fructose 1,6-diphosphatase deficiency
 Glycogen storage disease, type 1
 Maple syrup urine disease

Blood Calcium Low

Hypoparathyroidism
 Maternal hyperparathyroidism

Blood Ammonia High

Argininosuccinic acidemia
 Carbamoylphosphate synthetase deficiency
 Citrullinemia
 Methylmalonic acidemia (may be normal)
 Multiple carboxylase deficiency
 Ornithine transcarbamoylase deficiency
 Propionic acidemia (may be normal)

Blood Lactate High

Fructose 1,6-diphosphatase deficiency
 Glycogen storage disease, type 1
 Mitochondrial disorders
 Multiple carboxylase deficiency

Metabolic Acidosis

Fructose 1,6-diphosphatase deficiency
 Glycogen storage disease, type 1
 Maple syrup urine disease
 Methylmalonic acidemia
 Multiple carboxylase deficiency
 Propionic acidemia

(MSUD). Branched-chain ketoacid dehydrogenase is composed of six subunits, but the main abnormality in MSUD is deficiency of the E1 subunit on chromosome 19q13.1-q13.2. Leucine, isoleucine, and valine cannot be decarboxylated and accumulate in blood, urine, and tissues (Figure 1-1). Later onset forms of MSUD are described in Chapters 5 and 10. Transmission of the defect is by autosomal recessive inheritance.

CLINICAL FEATURES. Affected newborns appear healthy at birth, but lethargy, feeding difficulty, and hypotonia develop after ingestion of protein. Seizures begin in the second week and are associated with the development of cerebral edema. When seizures begin, they continue with increasing frequency and severity. Without therapy, cerebral edema becomes progressively worse and results in coma and death within 1 month.

DIAGNOSIS. Plasma amino acid concentrations show increased plasma concentrations of the three branch-chained amino acids. Measures of enzyme in lymphocytes or cultured fibroblasts serve as a confirmatory test. Heterozygotes have diminished levels of enzyme activity.

MANAGEMENT. Hemodialysis may be necessary to correct the life-threatening metabolic acidosis. A trial of thiamine (10 to 20 mg/kg/day) improves the condition in a thiamine-responsive MSUD variant. Stop the intake of all natural protein, and correct dehydration, electrolyte imbalance, and metabolic acidosis. A special diet low in branched-chain amino acids started immediately by nasogastric tube may prevent further encephalopathy. Newborns diagnosed in the first 2 weeks and treated rigorously have the best prognosis.

Glycine Encephalopathy

A defect in the glycine cleaving system causes glycine encephalopathy (nonketotic hyperglycinemia). Inheritance is autosomal recessive (Applethorpe et al, 2003).

CLINICAL FEATURES. Affected newborns are normal at birth but become irritable and refuse feeding 6 hours to 8 days after delivery. The onset of symptoms is usually within 48 hours, but delays by a few weeks occur in milder allelic forms. Hiccups are an early and continuous feature; some mothers relate that the infant hiccupped in utero. Progressive lethargy, hypotonia, respiratory disturbances, and myoclonic seizures follow. Some newborns survive the acute illness, but mental retardation, epilepsy, and spasticity characterize the subsequent course.

In the milder forms, the onset of seizures is after the neonatal period. The developmental outcome is better, but moderate mental retardation is present.

DIAGNOSIS. During the acute encephalopathy, the EEG shows a burst-suppression pattern, which evolves during infancy into hypsarrhythmia. MRI shows partial agenesis of the corpus callosum. Hyperglycinemia and especially elevated concentrations of glycine in the cerebrospinal fluid (CSF), in the absence of hyperammonemia or organic acidemia, establishes the diagnosis.

MANAGEMENT. No therapy has proved to be effective. Hemodialysis provides only temporary relief of the encephalopathy, and diet therapy has not proved successful in modifying the course. Diazepam, a competitor for glycine receptors, in combination with choline, folic acid, and sodium benzoate, may stop the seizures. Oral administration of sodium benzoate at doses of 250 to 750 mg/kg/day can reduce the plasma glycine concentration into the normal range. This substantially reduces but does not normalize CSF glycine concentration. Carnitine, 100 mg/kg/day, may increase the glycine conjugation with benzoate.

6 Chapter 1: Paroxysmal Disorders

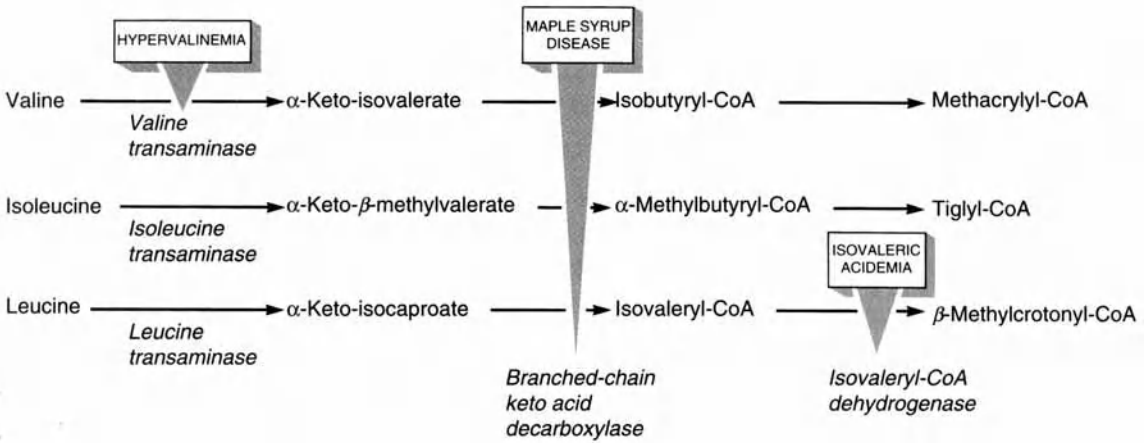


Figure 1-1. Metabolic blocks in branched-chain amino acid metabolism. (Reprinted with permission from Swaiman KF. Aminoacidopathies and organic acidemias resulting from deficiency of enzyme activity and transport abnormalities. In: Swaiman FK, Ashwal S, eds. *Pediatric Neurology*, Third Edition, Volume One. Mosby: St. Louis; 1999; 386.)

Urea Cycle Disturbances

Carbamyl phosphate synthetase deficiency, ornithine transcarbamoylase deficiency, citrullinemia, argininosuccinic acidemia, and argininemia (arginase deficiency) are the disorders caused by defects in the enzyme systems responsible for urea synthesis (Figure 1-2). A similar syndrome results from deficiency of the cofactor producer *N*-acetyl glutamate synthetase. Arginase deficiency does not cause symptoms in newborns. Ornithine transcarbamoylase deficiency is an X-linked trait; transmission of all others

is by autosomal recessive inheritance (Summar and Tuchman, 2004). The estimated prevalence of all urea cycle disturbances is 1:30,000 live births.

CLINICAL FEATURES. The clinical features of urea cycle disorders are due to ammonia intoxication (Table 1-5). Progressive lethargy, vomiting, and hypotonia develop the first day after delivery, even before the initiation of protein feeding. Progressive loss of consciousness and seizures follow on subsequent days. Vomiting and lethargy correlate well with plasma ammonia

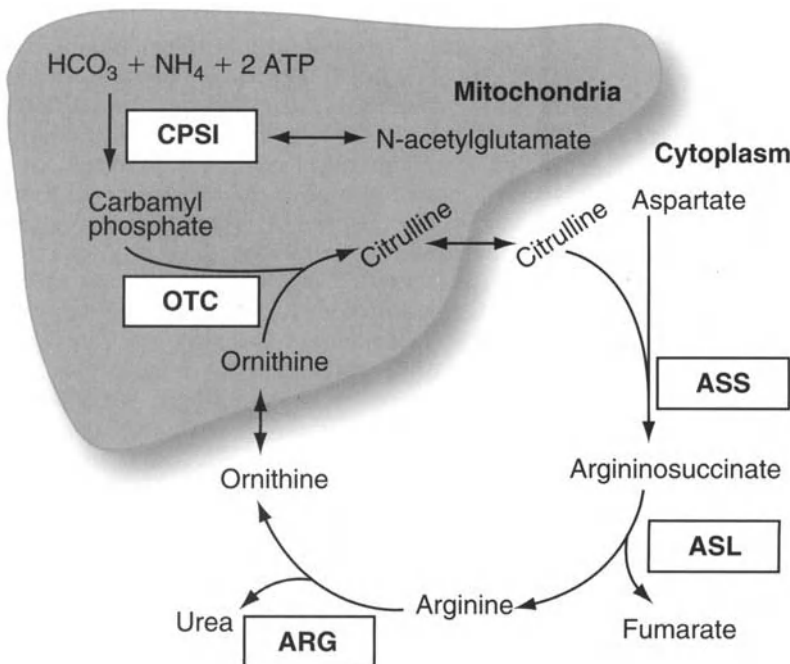


Figure 1-2. Ammonia metabolism and the urea cycle. ARG, arginase; ASL, argininosuccinate lyase; ASS, argininosuccinate synthetase; CPSI, carbamoyl phosphate synthetase I; OTC, ornithine transcarbamoylase. (Reprinted with permission from Summar ML, Tuchman M. [21 June 2004] Urea cycle disorders overview. In: *GeneClinics: Medical Genetics Knowledge Base*. [database online] University of Washington, Seattle. Available at <http://www.geneclinics.org>.)

TABLE 1-5
Causes of Neonatal Hyperammonemia

Liver failure
Primary enzyme defects in urea synthesis
Argininosuccinic acidemia
Carbamoyl phosphate synthetase deficiency
Citrullinemia
Ornithine transcarbamoylase deficiency
Other disorders of amino acid metabolism
Glycine encephalopathy
Isovaleric acidemia
Methylmalonic acidemia
Multiple carboxylase deficiency
Propionic acidemia
Transitory hyperammonemia of prematurity

concentrations greater than 200 $\mu\text{g/dL}$ (>120 $\mu\text{mol/L}$), coma correlates with concentrations greater than 300 $\mu\text{g/dL}$ (>180 $\mu\text{mol/L}$), and seizures correlate with concentrations greater than 500 $\mu\text{g/dL}$ (>300 $\mu\text{mol/L}$). Death follows quickly in untreated newborns. Newborns with partial deficiency of carbamoyl phosphate synthetase and female carriers of ornithine transcarbamoylase deficiency may become symptomatic after ingesting a large protein load.

DIAGNOSIS. Suspect the diagnosis of a urea cycle disturbance in every newborn with a compatible clinical syndrome and hyperammonemia without organic acidemia. Hyperammonemia can be life-threatening, and diagnosis within 24 hours is essential. Determine the blood ammonia concentration and the plasma acid-base status. A plasma ammonia concentration of 150 mmol/L or higher, associated with a normal anion gap and a normal serum glucose concentration, strongly suggests a urea cycle disorder. Plasma quantitative amino acid analysis differentiates the specific urea cycle disorder. A definitive diagnosis of carbamoyl phosphate synthetase I deficiency, ornithine transcarbamoylase deficiency, or *N*-acetyl glutamate synthetase deficiency depends on determination of enzyme activity from a liver biopsy specimen.

MANAGEMENT. Treatment cannot await specific diagnosis in newborns with symptomatic hyperammonemia due to inborn errors of urea synthesis. The essentials of treatment are (1) reducing plasma ammonia concentration by limiting nitrogen intake to 1.2 to 2 g/kg/day and using essential amino acids for protein, (2) allowing alternative pathway excretion of excess nitrogen with sodium benzoate and phenylacetic acid, (3) reducing the amount of nitrogen in the diet, (4) reducing catabolism through the introduction of calories supplied

by carbohydrates and fat, and (5) reducing the risk of neurological complications. Arginine concentrations are low in all inborn errors of urea synthesis except for arginase deficiency and require supplementation.

Even with optimal supervision, episodes of hyperammonemia may occur and may lead to coma and death. In such cases, intravenous administration of sodium benzoate, sodium phenylacetate, and arginine and nitrogen-free alimentation are appropriate. A poor response to drug therapy is an indication for peritoneal dialysis or hemodialysis.

Benign Familial Neonatal Seizures

In some families, several members have seizures in the first weeks of life but do not have epilepsy or other neurological abnormalities later on. Transmission of the trait is autosomal dominant, and abnormal gene loci map to chromosomes 20q and 8q. The mutations are in the voltage-gated potassium genes (Lerche et al, 2001).

CLINICAL FEATURES. Brief multifocal clonic seizures develop during the first week, sometimes associated with apnea. Onset may be delayed until 4 weeks. With or without treatment, the seizures usually stop spontaneously within 6 weeks. Febrile seizures occur in one third of affected children; some have febrile seizures without first having neonatal seizures. Epilepsy develops later in life in 10% to 15% of affected newborns.

DIAGNOSIS. Suspect the syndrome when seizures develop without apparent cause in a healthy newborn. Laboratory tests, including the interictal EEG, are normal. During a seizure, the initial apnea and tonic activity are associated with flattening of the EEG; generalized spike-wave discharges occur during the clonic activity. A family history of neonatal seizures is crucial to diagnosis but may not be discovered until interviewing the grandparents; parents are frequently unaware that they had neonatal seizures.

MANAGEMENT. Phenobarbital usually stops seizures. After 4 weeks of complete seizure control, taper and discontinue the drug. Initiate a longer trial if seizures recur.

Benign Familial Neonatal-Infantile Seizures

The onset of a second benign genetic epilepsy syndrome is anytime from 6 days to 3 months. The genetic defect is missense mutations in the sodium channel (Berkovic et al, 2004). Febrile seizures are uncommon. The seizures are partial

in onset, then become generalized. Seizures stop by age 12 months.

Bilirubin Encephalopathy

Unconjugated bilirubin is bound to albumin in the blood. *Kernicterus*, a yellow discoloration of the brain that is especially severe in the basal ganglia and hippocampus, occurs when the serum unbound or free fraction becomes excessive. An excessive level of the free fraction in an otherwise healthy newborn is approximately 20 mg/dL (340 $\mu\text{mol/L}$). Kernicterus was an important complication of hemolytic disease from maternal-fetal blood group incompatibility, but this condition is now uncommon. The management of other causes of hyperbilirubinemia in full-term newborns is not difficult. Critically ill premature infants with respiratory distress syndrome, acidosis, and sepsis are the group at greatest risk. In such newborns, an unbound serum concentration of 10 mg/dL (170 $\mu\text{mol/L}$) may be sufficient to cause bilirubin encephalopathy, and even the albumin-bound fraction may pass the blood-brain barrier.

CLINICAL FEATURES. Three distinct clinical phases of bilirubin encephalopathy occur in full-term newborns with untreated hemolytic disease. Hypotonia, lethargy, and a poor sucking reflex occur within 24 hours of delivery. Bilirubin staining of the brain is already evident in newborns who die during this first clinical phase. On the second or third day, the newborn becomes febrile and shows increasing tone and opisthotonic posturing. Seizures are not a constant feature but may occur at this time. Characteristic of the third phase is apparent improvement with normalization of tone. This apparent improvement may cause second thoughts about the accuracy of the diagnosis, but the improvement is short-lived. Evidence of neurological dysfunction begins to appear toward the end of the second month, and the symptoms become progressively worse throughout infancy.

In premature newborns, the clinical features are subtle, and the phases of increased tone and opisthotonos may be absent. The typical clinical syndrome after the first year includes extrapyramidal dysfunction, usually athetosis, which occurs in virtually every case (see Chapter 14); disturbances of vertical gaze, upward more often than downward, in 90%; high-frequency hearing loss in 60%; and mental retardation in 25%.

DIAGNOSIS. In newborns with hemolytic disease, the basis for a presumed clinical diagnosis

is significant hyperbilirubinemia and a compatible evolution of symptoms. The diagnosis is difficult to establish, however, in critically ill premature newborns, in whom the cause of brain damage is more often asphyxia than kernicterus.

The brainstem auditory evoked response may be useful in assessing the severity of bilirubin encephalopathy and its response to treatment. The auditory nerve and pathways are especially susceptible to bilirubin encephalopathy. The generators of wave I and wave V of the brainstem auditory evoked response are the auditory nerve and the inferior colliculus. The latency of both waves increases in proportion to the concentration of free albumin and decreases after exchange transfusion.

MANAGEMENT. Maintaining serum bilirubin concentrations below the toxic range, either by phototherapy or exchange transfusion, prevents kernicterus. When kernicterus has occurred, further damage can be limited, but not reversed, by lowering serum bilirubin concentrations.

Drug Withdrawal

Marijuana, alcohol, narcotic-analgesics, and hypnotic-sedatives are the drugs most commonly used during pregnancy. Marijuana and alcohol do not cause drug dependence in the fetus and are not associated with withdrawal symptoms. Hypnotic-sedatives, such as barbiturates, do not ordinarily produce withdrawal symptoms, unless the ingested doses are large. Phenobarbital has a sufficiently long half-life in newborns that sudden withdrawal does not occur. The prototype of narcotic withdrawal in the newborn is with heroin or methadone, but a similar syndrome occurs with codeine and propoxyphene.

CLINICAL FEATURES. Symptoms of opiate withdrawal are more severe and tend to occur earlier in full-term (first 24 hours) than in premature (24 to 48 hours) newborns. The initial feature is a coarse tremor, present only during the waking state, which can shake an entire limb. Irritability; a shrill, high-pitched cry; and hyperactivity follow. The newborn seems hungry but has difficulty feeding and vomits afterward. Diarrhea and other symptoms of autonomic instability are common.

Myoclonic jerking is present in 10% to 25% of newborns experiencing withdrawal. Whether these movements are seizures or jitteriness is not clear. Definite seizures occur in fewer than 5%. Maternal use of cocaine during pregnancy is associated with premature delivery, growth retarda-

tion, and microcephaly. Newborns exposed to cocaine, in utero or after delivery through breast milk, often show features of cocaine intoxication, including tachycardia, tachypnea, hypertension, irritability, and tremulousness.

DIAGNOSIS. Suspect and anticipate drug withdrawal in every newborn whose mother has a history of substance abuse. Even when such a history is not available, the combination of irritability, hyperactivity, and autonomic instability should provide a clue to the diagnosis. Careful questioning of the mother concerning her use of prescription and nonprescription drugs is imperative. Blood and urine analyses identify specific drugs.

MANAGEMENT. Symptoms remit spontaneously in 3 to 5 days, but appreciable mortality occurs among untreated newborns. Phenobarbital, 8 mg/kg/day, or chlorpromazine, 3 mg/kg/day, relieves symptoms and reduces mortality. Secretion of morphine, meperidine, opium, and methadone in breast milk is insufficient to cause or relieve addiction in newborns.

The occurrence of seizures in itself does not indicate a poor prognosis. The long-term outcome relates more closely to the other risk factors associated with substance abuse in the mother.

Hypocalcemia

The definition of hypocalcemia is a blood calcium concentration less than 7 mg/dL (<1.75 mmol/L). The onset of hypocalcemia in the first 72 hours after delivery is associated with low birth weight, asphyxia, maternal diabetes, transitory neonatal hypoparathyroidism, maternal hyperparathyroidism, and DiGeorge syndrome. Later onset hypocalcemia occurs in infants fed evaporated cow's milk and other improper formulas, in maternal hyperparathyroidism, and in DiGeorge syndrome.

Hypoparathyroidism in a newborn may result from maternal hyperparathyroidism or may be a transitory phenomenon of unknown cause. Hypocalcemia occurs in less than 10% of stressed newborns and enhances their vulnerability to seizures, but it is rarely the primary cause.

DiGeorge Syndrome (22q11.2 Microdeletion Syndrome)

DiGeorge syndrome is associated with microdeletions of chromosome 22q11.2 (McDonald-McGinn et al, 2004). Disturbance of cervical neural crest migration into the derivatives of the pharyngeal arches and pouches explains the

phenotype. Organs derived from the third and fourth pharyngeal pouches (thymus, parathyroid gland, and great vessels) are hypoplastic.

CLINICAL FEATURES. The 22q11.2 *deletion* syndrome encompasses two *phenotypes*: DiGeorge syndrome and *velocardiofacial syndrome* (Shprintzen syndrome). The acronym *CATCH* is used to describe the phenotype of cardiac abnormality, T-cell deficit, clefting (multiple minor facial anomalies), and hypocalcemia. Most children with DiGeorge syndrome are identified in the neonatal period with a major *congenital* heart defect, hypocalcemia, and immunodeficiency. Diagnosis of children with velocardiofacial syndrome comes later because of cleft palate or craniofacial deformities.

The initial symptoms of DiGeorge syndrome may be due to congenital heart disease, hypocalcemia, or both. Jitteriness and tetany usually begin in the first 48 hours after delivery. The peak onset of seizures is on the third day, but a 2-week delay may occur. Many affected newborns die of cardiac causes during the first month; survivors fail to thrive and have frequent infections because of the failure of cell-mediated immunity.

DIAGNOSIS. Newborns with DiGeorge syndrome come to medical attention because of seizures and heart disease. Seizures or a prolonged Q-T interval brings attention to hypocalcemia. Molecular genetic testing confirms the diagnosis.

MANAGEMENT. Management requires a multi-specialty team, including cardiology, immunology, medical genetics, and neurology specialists. Plastic surgery, dentistry, and child development specialists contribute later on. Hypocalcemia generally responds to parathyroid hormone or to oral calcium and vitamin D.

Hypoglycemia

A transitory, asymptomatic hypoglycemia is detectable in 11% of newborns during the first hours after delivery and before initiating feeding. Hypoglycemia is not associated with neurological impairment later in life. Symptomatic hypoglycemia may result from cerebral stress or inborn errors of metabolism (Table 1-6).

CLINICAL FEATURES. The time of onset of symptoms depends on the underlying disorder. Early onset is generally associated with perinatal asphyxia or intracranial hemorrhage, and late onset is associated with inborn errors of metabolism. Hypoglycemia is rare and mild among newborns with classic MSUD, ethylmalonic aciduria, and isovaleric acidemia and is invari-

TABLE 1-6
Causes of Neonatal Hypoglycemia

Primary Transitional Hypoglycemia

Complicated labor and delivery
 Intrauterine malnutrition
 Maternal diabetes
 Prematurity

Secondary Transitional Hypoglycemia

Asphyxia
 Central nervous system disorders
 Cold injuries
 Sepsis

Persistent Hypoglycemia

Aminoacidurias
 Maple syrup urine disease
 Methylmalonic acidemia
 Propionic acidemia
 Tyrosinosis
 Congenital hypopituitarism
 Defects in carbohydrate metabolism
 Fructose 1,6-diphosphatase deficiency
 Fructose intolerance
 Galactosemia
 Glycogen storage disease, type 1
 Glycogen synthase deficiency
 Hyperinsulinism
 Organic acidurias
 Glutaric aciduria type 2
 3-Methylglutaryl-CoA deficiency

ably severe in newborns with 3-methylglutamic aciduria, glutaric aciduria type 2, and disorders of fructose metabolism.

The syndrome includes any of the following symptoms: apnea, cyanosis, tachypnea, jitteriness, high-pitched cry, poor feeding, vomiting, apathy, hypotonia, seizures, and coma. Symptomatic hypoglycemia is often associated with later neurological impairment.

DIAGNOSIS. Neonatal hypoglycemia is defined as a whole blood glucose concentration of less than 20 mg/dL (<1 mmol/L) in premature and low-birth-weight newborns, less than 30 mg/dL (<1.5 mmol/L) in term newborns during the first 72 hours, and less than 40 mg/dL (<2 mmol/L) in full-term newborns after 72 hours. Finding a low glucose concentration in a newborn with seizures prompts investigation into the cause of the hypoglycemia.

MANAGEMENT. Intravenous administration of glucose normalizes blood glucose concentrations, but the underlying cause must be determined before providing definitive treatment.

Hypoxic-Ischemic Encephalopathy

Asphyxia at term is usually an intrauterine event, and hypoxia and ischemia occur together; the

result is HIE. *Acute total asphyxia* often leads to death from circulatory collapse. Survivors are born comatose. Lower cranial nerve dysfunction and severe neurological handicaps are the rule (Roland et al, 1998).

Partial, prolonged asphyxia is the usual mechanism of HIE in surviving full-term newborns. The fetal circulation accommodates to reductions in arterial oxygen by maximizing blood flow to the brain, and to a lesser extent the heart, at the expense of other organs.

Clinical experience indicates that fetuses may be subject to considerable hypoxia without the development of brain damage. The incidence of cerebral palsy among full-term newborns with a 5-minute Apgar score of 0 to 3 is only 1% if the 10-minute score is 4 or higher. Any episode of hypoxia sufficiently severe to cause brain damage also causes derangements in other organs. Newborns with mild HIE always have a history of irregular heart rate and usually pass meconium. Newborns with severe HIE may have lactic acidosis, elevated serum concentrations of hepatic enzymes, enterocolitis, renal failure, and fatal myocardial damage.

CLINICAL FEATURES. *Mild HIE* is relatively common. The newborn is lethargic but conscious immediately after birth. Other characteristic features are jitteriness and sympathetic overactivity (tachycardia, dilation of pupils, and decreased bronchial and salivary secretions). Muscle tone is normal at rest, tendon reflexes are normoreactive or hyperactive, and ankle clonus is usually elicited. The Moro reflex is complete, and a single stimulus generates repetitive extension and flexion movements. Seizures are not an expected feature, and their occurrence suggests concurrent hypoglycemia or the presence of a second condition.

Symptoms diminish and disappear during the first few days, although some degree of overresponsiveness may persist. Newborns with mild HIE are believed to recover normal brain function completely. They are not at greater risk for later epilepsy or learning disabilities.

Newborns with *severe HIE* are stuporous or comatose immediately after birth, and respiratory effort is usually periodic and insufficient to sustain life. Seizures begin within the first 12 hours. Hypotonia is severe, and tendon reflexes, the Moro reflex, and the tonic neck reflex are absent. Sucking and swallowing are depressed or absent, but the pupillary and oculovestibular reflexes are present. Most of these newborns have frequent seizures, which may appear on EEG without clinical manifestations. They may progress to status epilepticus.

The response to anticonvulsant drugs is usually incomplete. Generalized increased intracranial pressure characterized by coma, bulging of the fontanelles, loss of pupillary and oculovestibular reflexes, and respiratory arrest develops between 24 and 72 hours of age.

The newborn may die at this time or may remain stuporous for several weeks. The encephalopathy begins to subside after the third day, and seizures decrease in frequency and eventually stop. Jitteriness is common as the infant becomes arousable. Tone increases in the limbs during the succeeding weeks. Neurological sequelae are expected in newborns with severe HIE who remain comatose for more than 1 week.

DIAGNOSIS. EEG and CT are helpful in determining the severity and prognosis of HIE. In mild HIE, the EEG background rhythms are normal or lacking in variability. In severe HIE, the background is always abnormal and shows suppression of background amplitude. The degree of suppression correlates well with the severity of HIE. The worst case is a flat EEG or one with a burst-suppression pattern. A bad outcome is invariable if the amplitude remains suppressed for 2 weeks or a burst-suppression pattern is present at any time. Epileptiform activity also may be present but is less predictive of the outcome than is background suppression.

CT shows the cerebral edema as decreased tissue attenuation of the hemispheres 2 to 4 days after severe prolonged partial asphyxia. Repeat CT or MRI after 1 month shows the full extent of injury. Survivors of near-total asphyxia have decreased tissue attenuation in the basal ganglia and thalamus.

MANAGEMENT. The management of HIE in newborns requires immediate attention to derangements in several organs and correction of acidosis. Clinical experience indicates that control of seizures, maintenance of adequate ventilation and perfusion, and prevention of fluid overload increase the chance of a favorable outcome. The simple procedure of elevating the head to 30 degrees and reducing fluids by 10% may reduce intracranial pressure.

A separate section describes the use of phenobarbital to treat seizures in newborns. If high dosages of phenobarbital prove ineffective, other drugs are unlikely to be successful. Seizures usually cease spontaneously during the second week, and stopping anticonvulsants after a further 2 weeks of control is reasonable.

The incidence of later epilepsy among infants who had neonatal seizures caused by HIE is 30% to 40%. Continuing anticonvulsant therapy after the initial seizures have stopped does not influence the outcome.

Organic Acid Disorders

Characteristic of organic acid disorders is the accumulation of compounds, usually ketones, or lactic acid that causes acidosis in biological fluids (Seashore, 2004). Among the more than 50 organic acid disorders are abnormalities in vitamin metabolism, lipid metabolism, glycolysis, the citric acid cycle, oxidative metabolism, glutathione metabolism, and 4-aminobutyric acid metabolism. The clinical presentations vary considerably, and several chapters contain descriptions. The organic acid disorders that most often cause neonatal seizures are defects in the further metabolism of branched-chain amino acids.

Isovaleric Acidemia

Isovaleric acid is a fatty acid derived from leucine. The enzyme isovaleryl-CoA dehydrogenase converts isovaleric acid to propionyl-coenzyme A (CoA) (see Figure 1-1). Genetic transmission is autosomal recessive inheritance. The heterozygote state is detectable in cultured fibroblasts.

CLINICAL FEATURES. Two phenotypes are associated with the same enzyme defect. One is an acute, overwhelming disorder of the newborn; the other is a chronic infantile form. Newborns are normal at birth but within a few days become lethargic, refuse to feed, and vomit. The clinical syndrome is similar to MSUD except that the urine smells like “sweaty feet” instead of maple syrup. Sixty percent of affected newborns die within 3 weeks. The survivors have a clinical syndrome identical to the chronic infantile phenotype.

DIAGNOSIS. The excretion of isovaleryl-lysine in the urine detects isovaleric acidosis. Assays of isovaleryl-CoA dehydrogenase activity use cultured fibroblasts. The clinical phenotype correlates not with the percentage of residual enzyme activity, but with the ability to detoxify isovaleryl-CoA with glycine.

MANAGEMENT. Dietary restriction of protein, especially leucine, decreases the occurrence of later psychomotor retardation. Levocarnitine, 50 mg/kg/day, is a beneficial supplement to the diet of some children with isovaleric acidemia.

In acutely ill newborns, oral glycine, 250 to 500 mg/day, in addition to protein restriction and levocarnitine, lowers mortality.

Methylmalonic Acidemia

D-Methylmalonyl-CoA is racemized to L-methylmalonyl-CoA by the enzyme D-methylmalonyl racemase and then isomerized to succinyl-CoA, which enters the tricarboxylic cycle. The enzyme D-methylmalonyl-CoA mutase catalyzes the isomerization. The cobalamin (vitamin B₁₂) coenzyme adenosylcobalamin is a required cofactor. Genetic transmission of the several defects in this pathway is by autosomal recessive inheritance. *Mutase deficiency* is the most common abnormality. Propionyl-CoA, propionic acid, and methylmalonic acid accumulate and cause hyperglycinemia and hyperammonemia.

CLINICAL FEATURES. Affected infants appear normal at birth. In 80% of infants with complete mutase deficiency, the symptoms appear during the first week after delivery; infants with defects in the synthesis of adenosylcobalamin generally show symptoms after 1 month. Symptoms include lethargy, failure to thrive, recurrent vomiting, dehydration, respiratory distress, and hypotonia after the initiation of protein feeding. Leukopenia, thrombocytopenia, and anemia are present in more than half of patients. Intracranial hemorrhage may result from a bleeding diathesis. The outcome for newborns with complete mutase deficiency is usually poor. Most die within 2 months of diagnosis; survivors have recurrent acidosis, growth retardation, and mental retardation.

DIAGNOSIS. Suspect the diagnosis in any newborn with metabolic acidosis, especially if associated with ketosis, hyperammonemia, and hyperglycinemia. An increased concentration of methylmalonate in the plasma and urine confirms the diagnosis. The specific enzyme defect can be determined in fibroblasts. Techniques for prenatal detection are available.

MANAGEMENT. Some affected newborns are cobalamin responsive and others are not (Nicolaidis et al, 1998). Management of newborns with mutase deficiency is similar to management of propionic acidemia. The long-term results are poor. Vitamin B₁₂ supplementation is useful in some defects of adenosylcobalamin synthesis, and hydroxocobalamin administration is reasonable while awaiting the definitive diagnosis. Maintain treatment with protein restriction (0.5 to 1.5 g/kg/day) and hydroxocobalamin, 1 mg weekly. As in propionic acidemia, oral sup-

plementation of levocarnitine reduces ketogenesis in response to fasting.

Propionic Acidemia

Propionyl-CoA forms as a catabolite of methionine, threonine, and the branched-chain amino acids. Its further carboxylation to D-methylmalonyl-CoA requires the enzyme propionyl-CoA carboxylase and the coenzyme biotin (see Figure 1-1). Isolated deficiency of propionyl-CoA carboxylase causes propionic acidemia (Hamilton et al, 1995). Transmission of the defect is autosomal recessive.

CLINICAL FEATURES. Most affected children appear normal at birth; symptoms may begin the first day after delivery or be delayed for months or years. In newborns, the symptoms are nonspecific, such as feeding difficulty, lethargy, hypotonia, and dehydration. Recurrent attacks of profound metabolic acidosis, often associated with hyperammonemia, which respond poorly to buffering, are characteristic. Untreated newborns rapidly become dehydrated, have generalized or myoclonic seizures, and become comatose.

Hepatomegaly caused by fatty infiltration occurs in 28% of patients. Neutropenia, thrombocytopenia, and occasionally pancytopenia may be present. A bleeding diathesis accounts for massive intracranial hemorrhage in some newborns. Children who survive beyond infancy develop infarctions in the basal ganglia.

DIAGNOSIS. Consider propionic acidemia in any newborn with ketoacidosis or with hyperammonemia without ketoacidosis. Propionic acidemia is the probable diagnosis when the plasma concentrations of glycine and propionate and the urinary concentrations of glycine, methylcitrate, and beta-hydroxypropionate are increased. Although the urinary concentration of propionate may be normal, the plasma concentration is always elevated, without a concurrent increase in the concentration of methylmalonate.

Deficiency of enzyme activity in peripheral blood leukocytes or in skin fibroblasts establishes the diagnosis. Molecular genetic testing is available. Prenatal diagnosis is provided by detecting methylcitrate, a unique metabolite of propionate, in the amniotic fluid and showing deficient enzyme activity in amniotic fluid cells.

MANAGEMENT. A newborn in ketoacidosis requires dialysis to remove toxic metabolites, parenteral fluids to prevent dehydration, and protein-free nutrition. Restricting protein intake to 0.5 to 1.5 g/kg/day decreases the frequency

and severity of subsequent attacks. Oral administration of levocarnitine reduces the ketogenic response to fasting and may be useful as a daily supplement. Intermittent administration of non-absorbed antibiotics reduces the production of propionate by gut bacteria.

Herpes Simplex Encephalitis

Herpes genitalis (herpes simplex virus type 2) accounts for most herpetic infections of newborns. Infection commonly occurs during the second stage of labor by contact with maternal genital herpes, which is asymptomatic or unrecognized in 60% to 80% of women. Symptomatic infections occur in 8% of newborns whose mothers have a history of recurrent genital herpes simplex virus infection. The risk of contamination at birth is greatest when the mother has primary genital herpes involving the cervix at delivery and the newborn is premature and delivered with instrumentation, including scalp electrodes.

CLINICAL FEATURES. The clinical spectrum of perinatal herpes simplex virus infection is considerable. Among symptomatic newborns, one third have disseminated disease; one third have localized involvement of the brain; and one third have localized involvement of the eyes, skin, or mouth. Whether infection is disseminated or localized, approximately half of infections involve the central nervous system. The overall mortality rate is 62%, and 50% of survivors have permanent neurological impairment.

The onset of symptoms may be the fifth day but is usually in the second week. A vesicular rash is present in 30%, usually on the scalp after vertex presentation and on the buttocks after breech presentation. Conjunctivitis, jaundice, and a bleeding diathesis may be present. The first symptoms of encephalitis are irritability and seizures. Seizures may be focal or generalized and are frequently refractory to therapy. Neurological deterioration is progressive and characterized by coma and quadriparesis.

DIAGNOSIS. Culture specimens are collected from cutaneous vesicles, mouth, nasopharynx, rectum, or CSF. Polymerase chain reaction is the standard for diagnosing herpes encephalitis. The EEG is always abnormal and shows a periodic pattern of slow waves or spike discharges. The CSF examination shows a lymphocytic leukocytosis, red blood cells, and an elevated protein concentration.

MANAGEMENT. The best treatment is prevention. Acyclovir, 800 mg, as a single oral dose suppresses recurrent genital herpes in adults.

Deliver all women with genital herpes at term whose membranes are intact or ruptured for less than 4 hours by cesarean section. Give acyclovir, 10 mg/kg every 8 hours for 10 to 14 days, to the newborn. Of infants with disseminated disease, 10% relapse within 2 weeks after completion of the course. Mortality remains 50% or greater in newborns with disseminated disease.

Trauma and Intracranial Hemorrhage

Neonatal head trauma occurs most often in large term newborns of primiparous mothers. Prolonged labor and difficult extraction are usual because of fetal malposition or a precipitous delivery before sufficient dilation of the maternal cervix. Intracranial hemorrhage may be subarachnoid, subdural, or intraventricular. Intraventricular hemorrhage is discussed in Chapter 4.

Idiopathic Cerebral Venous Thrombosis

The causes of cerebral venous thrombosis in newborns are coagulopathies, polycythemia, sepsis, and asphyxia. Cerebral venous thrombosis, especially involving the superior sagittal sinus, also occurs without known predisposing factors.

CLINICAL FEATURES. The initial symptom is focal seizures or lethargy beginning anytime during the first month. Intracranial pressure remains normal, lethargy slowly resolves, and seizures respond to phenobarbital. The long-term outcome is uncertain and probably depends on the extent of hemorrhagic infarction of the hemisphere.

DIAGNOSIS. CT is satisfactory for diagnosis, but MRI provides a more comprehensive assessment of the involved vessels and the extent of brain damage.

MANAGEMENT. Anticoagulation does not influence outcome.

Primary Subarachnoid Hemorrhage

CLINICAL FEATURES. Blood in the subarachnoid space probably originates from tearing of the superficial veins by shearing forces during a prolonged delivery with the head engaged. Mild HIE is often associated with subarachnoid hemorrhage, but the newborn is usually well when an unexpected seizure occurs on the first or second day of life. Lumbar puncture, performed because of suspected sepsis, reveals

blood in the CSF. Most newborns with subarachnoid hemorrhages are neurologically normal later.

DIAGNOSIS. CT is useful to document the extent of hemorrhage. Blood is present in the interhemispheric fissure and the supratentorial and infratentorial recesses. EEG may reveal epileptiform activity without background suppression. This finding indicates that seizures are not caused by HIE and that the prognosis is more favorable. Clotting studies exclude the possibility of a coagulopathy.

MANAGEMENT. Seizures usually respond to phenobarbital. Specific therapy is not available for the hemorrhage, and posthemorrhagic hydrocephalus is uncommon.

Subdural Hemorrhage

CLINICAL FEATURES. Subdural hemorrhage is usually the consequence of a tear in the tentorium near its junction with the falx. Causes of tear include excessive vertical molding of the head in vertex presentation, anteroposterior elongation of the head in face and brow presentations, or prolonged delivery of the aftercoming head in breech presentation. Blood collects in the posterior fossa and may produce brainstem compression. The initial features are those of mild-to-moderate HIE. Clinical evidence of brainstem compression begins 12 hours or longer after delivery. Characteristic features include irregular respiration, an abnormal cry, declining consciousness, hypotonia, seizures, and a tense fontanelle. Intracerebellar hemorrhage is sometimes present. Mortality is high, and neurological impairment among survivors is common.

DIAGNOSIS. CT or ultrasound visualizes subdural hemorrhages.

MANAGEMENT. Small hemorrhages do not require treatment, but surgical evacuation of large collections relieves brainstem compression.

Pyridoxine Dependency

Pyridoxine dependency is a rare disorder transmitted as an autosomal recessive trait (Gospe, 2002). The genetic locus is unknown, but the presumed cause is impaired glutamic decarboxylase activity.

CLINICAL FEATURES. Newborns experience seizures soon after birth. The seizures are usually multifocal clonic at onset and progress rapidly to status epilepticus. Although presentations consisting of prolonged seizures and recurrent episodes of status epilepticus are typical, recur-

rent self-limited events, including partial seizures, generalized seizures, atonic seizures, myoclonic events, and infantile spasms, also occur. The seizures respond only to pyridoxine. A seizure-free interval of 3 weeks may occur after pyridoxine discontinuation. Intellectual disability is common.

An atypical form includes seizure-onset up to 2 years of age. The seizures initially respond to anticonvulsants, but then become intractable.

DIAGNOSIS. In most cases, the diagnosis is suspected because of an affected older sibling. In the absence of a family history, suspect the diagnosis in newborns with continuous seizures. Characteristic of the infantile-onset variety is intermittent myoclonic seizures, focal clonic seizures, or generalized tonic-clonic seizures. The EEG is continuously abnormal because of generalized or multifocal spike discharges. An intravenous injection of pyridoxine, 100 mg, stops the clinical seizure activity and often converts the EEG to normal in less than 10 minutes; sometimes 500 mg is required.

MANAGEMENT. A lifelong dietary supplement of pyridoxine, which varies from 10 to 50 mg/kg/day, prevents further seizures. Subsequent psychomotor development is best with early treatment, but this does not ensure a normal outcome. The dose needed to prevent mental retardation may be higher than that needed to stop seizures.

Incontinentia Pigmenti (Bloch-Sulzberger Syndrome)

Incontinentia pigmenti is a rare neurocutaneous syndrome involving the skin, teeth, eyes, and central nervous system. Genetic transmission is X-linked (Xq28) with lethality in the hemizygous male (Scheuerle, 2003).

CLINICAL FEATURES. The female-to-male ratio is 20:1. An erythematous and vesicular rash resembling epidermolysis bullosa is present on the flexor surfaces of the limbs and lateral aspect of the trunk at birth or soon thereafter. The rash persists for the first few months, then a verrucous eruption that lasts for weeks or months replaces the original rash. Between 6 and 12 months of age, deposits of pigment appear in the previous area of rash in bizarre polymorphic arrangements. The pigmentation later regresses and leaves a linear hypopigmentation. Alopecia, hypodontia, abnormal tooth shape, and dystrophic nails may be associated. Some infants have retinal vascular abnormalities that predispose to retinal detachment in early childhood.

Neurological disturbances occur in fewer than half of the cases. In newborns, the prominent feature is the onset of seizures on the second or third day, often confined to one side of the body. Residual neurological handicaps may include mental retardation, epilepsy, hemiparesis, and hydrocephalus.

DIAGNOSIS. The clinical findings and biopsy of the skin rash are diagnostic. *Molecular genetic testing* of the *IKBK* gene reveals mutations in about 80% of probands.

MANAGEMENT. Neonatal seizures caused by incontinentia pigmenti usually respond to standard anticonvulsant drugs. The blistering rash requires topical medication and oatmeal baths. Regular ophthalmological examinations manage retinal detachment.

Treatment of Neonatal Seizures

Animal studies suggest that continuous seizure activity, even in the normoxemic brain, may cause brain damage by inhibiting protein synthesis and breaking down polyribosomes. In premature newborns, an additional concern is that the increased cerebral blood flow associated with seizures increases the risk of intraventricular hemorrhage. Protein binding of anticonvulsant drugs may be impaired in premature newborns, and the free fraction concentration may be toxic, whereas the measured protein-bound fraction seems to be therapeutic.

The initial steps in managing newborns with seizures are to maintain vital function, identify and correct the underlying cause (i.e., hypocalcemia) when possible, and provide rapidly a therapeutic blood concentration of an anticonvulsant drug when needed.

Phenobarbital

Intravenous phenobarbital is the treatment of choice for newborns with seizures. A unitary relationship usually exists between the intravenous dose of phenobarbital in milligrams per kilogram of body weight and the blood concentration in micrograms per milliliter measured 24 hours after the load. A blood concentration of 20 $\mu\text{g/mL}$ is safely achievable with a single intravenous loading dose of 20 mg/kg injected at a rate of 5 mg/min. The usual maintenance dose is 4 mg/kg/day. Use additional boluses of 10 mg/kg, to a total of 40 mg/kg, for infants who fail to respond to the initial load. Phenobarbital monotherapy is effective in 70% to 85% of newborns with seizures after achieving a blood concentration of 40 $\mu\text{g/mL}$. In term

newborns with intractable seizures from HIE, in whom mechanical ventilation is invariable, use additional boluses of phenobarbital to achieve a blood concentration of 70 $\mu\text{g/mL}$. If such concentrations of phenobarbital are ineffective, the addition of other drugs is unlikely to be helpful.

The half-life of phenobarbital in newborns varies from 50 to 200 hours. The basis for administering additional doses is assessment of current blood concentration information. After the 10th day, the half-life shortens as a result of enzyme induction, and a steady state is easier to achieve.

Phenytoin

Fosphenytoin sodium is safer than phenytoin for intravenous administration. Oral doses of phenytoin are poorly absorbed in newborns. A single intravenous injection of 20 mg/kg at a rate of 0.5 mg/kg/min safely achieves a therapeutic blood concentration of 15 to 20 $\mu\text{g/mL}$ (40 to 80 $\mu\text{mol/L}$). The half-life is long during the first week, and the basis for further administration is assessment of the current blood concentration. Most newborns require a maintenance dosage of 5 to 10 mg/kg/day (Painter et al, 1999).

Duration of Therapy

Seizures caused by an acute, self-limited encephalopathy, such as HIE, do not ordinarily require prolonged maintenance therapy. In most newborns, seizures stop when the acute encephalopathy is resolved. Discontinue therapy after 2 weeks of complete seizure control. If seizures recur, reinstitute anticonvulsant therapy. In contrast to newborns with seizures caused by acute encephalopathy, newborns with seizures caused by cerebral dysgenesis are treated continuously; 80% become epileptic in childhood.

Paroxysmal Disorders in Children Younger than 2 Years of Age

The pathophysiology of paroxysmal disorders in infants is more variable than in newborns (Table 1-7). Seizures, especially febrile seizures, are the main cause of paroxysmal disorders, but apnea and syncope (breath-holding spells) also are relatively common. Often the basis for requested neurological consultation in infants with paroxysmal disorders is the suspicion of seizures. The

TABLE 1-7
Paroxysmal Disorders in Children
Younger than 2 Years

Apnea and Breath-holding

Cyanotic
 Pallid

Dystonia

Glutaric aciduria (see Chapter 14)
 Transient paroxysmal dystonia of infancy

Migraine

Benign paroxysmal vertigo (see Chapter 10)
 Cyclic vomiting
 Paroxysmal torticollis (see Chapter 14)

Seizures

Febrile seizures
 Epilepsy triggered by fever
 Infection of the nervous system
 Simple febrile seizure
 Nonfebrile seizures
 Generalized tonic-clonic seizures
 Partial seizures
 Benign familial infantile seizures
 Ictal laughter
 Myoclonic seizures
 Infantile spasms
 Benign myoclonic epilepsy
 Severe myoclonic epilepsy
 Myoclonic status
 Lennox-Gastaut syndrome

Stereotypies (see Chapter 14)

determination of which “spells” are seizures is often difficult and relies more on obtaining a complete description of the spell than on laboratory test results. Ask the parents to provide a sequential history. If more than one spell occurred, they should first describe the one that was best observed or most recent. The following questions should be included: What was the child doing before the spell? Did anything provoke the spell? Did the child’s color change? If so, when and to what color? Did the eyes move in any direction? Did the spell affect one body part more than other parts?

In addition to obtaining a home video of the spell, ambulatory or prolonged split-screen video-EEG monitoring is the only way to identify the nature of unusual spells. Seizures characterized by decreased motor activity with indeterminate changes in the level of consciousness arise from the temporal, temporoparietal, or parieto-occipital regions, whereas seizures with motor activity usually arise from the frontal, central, or frontoparietal areas (Acharya et al, 1997).

Apnea and Syncope

The definition of infant apnea is cessation of breathing for 15 seconds or longer or for less than 15 seconds if accompanied by bradycardia. Premature newborns with respiratory distress syndrome may continue to have apneic spells as infants, especially if they are neurologically abnormal.

Apneic Seizures

Apnea alone is rarely a seizure manifestation (Freed and Martinez, 2001). The frequency of apneic seizures relates inversely to age, occurring more often in newborns than infants and rarely in children. Isolated apnea occurs as a seizure manifestation in infants and young children, but when reviewed on video, identification of other features becomes possible. Overall, reflux accounts for much more apnea than seizures in most infants and young children. Among infants with apneic seizures, EEG abnormalities appear only at the time of apnea. Monitoring is required for diagnosis.

Breath-Holding Spells

Breath-holding spells with loss of consciousness occur in almost 5% of infants. The cause is a disturbance in central autonomic regulation probably transmitted by autosomal dominant inheritance with incomplete penetrance. Approximately 20% to 30% of parents of affected children have a history of the condition. The term *breath-holding* is a misnomer because breathing always stops in expiration. Cyanotic and pallid breath-holding occurs; cyanotic spells are three times more common than pallid spells. Most children experience only one or the other, but 20% have both.

The spells are involuntary responses to adverse stimuli. In approximately 80% of affected children, the spells begin before 18 months of age, and in all cases, they start before 3 years of age. The last episode usually occurs by age 4 and no later than age 8.

Cyanotic Syncope

CLINICAL FEATURES. The usual provoking stimulus for cyanotic spells is anger, frustration, or fear. The infant’s sibling takes away a toy, the infant cries, then stops breathing in expiration. Cyanosis develops rapidly, followed quickly by limpness and loss of consciousness. Crying may not precede cyanotic episodes provoked by pain.

If the attack lasts for only seconds, the infant may resume crying on awakening. Most spells, especially the ones referred for neurological evaluation, are longer and are associated with tonic posturing of the body and trembling movements of the hands or arms. The eyes may roll upward. These movements are mistaken for seizures by even experienced observers, but they are probably a brainstem release phenomenon. Concurrent EEG shows flattening of the record, not epileptiform activity.

After a short spell, the infant recovers rapidly and seems normal immediately; after a prolonged spell, the infant first arouses, then goes to sleep. When an infant begins having breath-holding spells, the frequency increases for several months, then declines, then the spells finally cease.

DIAGNOSIS. The typical sequence of cyanosis, apnea, and loss of consciousness is crucial for diagnosis. Cyanotic syncope and epilepsy are confused because of lack of attention to the precipitating event. It is not sufficient to ask, "Did the child hold his breath?" The question conjures up the image of breath-holding during inspiration. Instead, questioning should be focused on precipitating events, absence of breathing, facial color, and family history. The family often has a history of breath-holding spells.

Between attacks, the EEG is normal. During an episode, the EEG first shows diffuse slowing, then rhythmic slowing during the tonic-clonic activity.

MANAGEMENT. Piracetam, 40 mg/kg/day, showed a 92% reduction in spells compared with 30% for placebo (Donma, 1998). The drug is not available in the United States, but levetiracetam is similar and equally effective. I believe that picking up the child, which is the natural act of the mother or other observer, prolongs the spell. Placing a child who has lost consciousness because of decreased cerebral perfusion in an upright position seems wrong. I always caution parents to hold the child with the head in a dependent position.

Most important is to identify the nature of the spell and explain that it is harmless. Children do not die during breath-holding spells, and the episodes always cease spontaneously. Does anyone know an adult who has breath-holding spells?

Pallid Syncope

CLINICAL FEATURES. The provocation of pallid syncope is usually a sudden, unexpected, painful event, such as a bump on the head. The child

rarely cries but instead becomes white and limp and loses consciousness. These episodes are truly terrifying to behold. Parents invariably believe the child is dead and begin mouth-to-mouth resuscitation. After the initial limpness, the body may stiffen, and clonic movements of the arms may occur. As in cyanotic syncope, these movements represent a brainstem release phenomenon, not seizure activity. The duration of the spell is difficult to determine because the observer is so frightened that seconds seem like hours. Afterward the child often falls asleep and is normal on awakening.

DIAGNOSIS. Pallid syncope is the result of reflex asystole. Pressure on the eyeballs to initiate a vagal reflex provokes an attack. I do not recommend provoking an attack as an office procedure. The history alone is diagnostic.

MANAGEMENT. As with cyanotic spells, the major goal is to reassure the family that the child will not die during an attack. The physician must be extremely convincing.

Febrile Seizures

An infant's first seizure often occurs at the time of fever. Three explanations are possible: (1) an infection of the nervous system; (2) an underlying seizure disorder in which the stress of fever triggers the seizure, although subsequent seizures may be afebrile; or (3) a *simple febrile seizure*, a genetic age-limited epilepsy in which seizures occur only with fever. Nervous system infection is discussed in Chapters 2 and 4. *Children who have seizures from encephalitis or meningitis do not wake up afterward; they are usually comatose.* The distinction between epilepsy and simple febrile seizures is sometimes difficult and may require time rather than laboratory tests.

Epilepsy specialists who manage monitoring units have noted that a large proportion of adults with intractable seizures secondary to mesial temporal sclerosis have prior histories of febrile seizures as children. The reverse is not true. Among children with febrile seizures, mesial temporal sclerosis is rare (Tarkka et al, 2003).

CLINICAL FEATURES. Febrile seizures not caused by infection or another definable cause occur in approximately 4% of children. Only 2% of children whose first seizure is associated with fever have nonfebrile seizures (epilepsy) by age 7. The most important predictor of subsequent epilepsy is an abnormal neurological or developmental state. Complex seizures, defined as prolonged, focal, or multiple, and a family history of epilepsy slightly increase the probability of subsequent epilepsy.

A single, brief, generalized seizure occurring in association with fever is likely to be a simple febrile seizure. The seizure need not occur during the time when fever is rising. "Brief" and "fever" are difficult to define. Parents do not time seizures. When a child has a seizure, seconds seem like minutes. A prolonged seizure is one that is still in progress after the family has contacted the physician or has left the house for the emergency department. Postictal sleep is not seizure time.

Simple febrile seizures are familial and probably transmitted by autosomal dominant inheritance with incomplete penetrance. One third of infants who have a first simple febrile seizure have a second one at the time of a subsequent febrile illness, and half of these have a third febrile seizure. The risk of recurrence increases if the first febrile seizure occurs before 18 months of age or at a body temperature less than 40°C (Berg et al, 1997). More than three episodes of simple febrile seizures are unusual and suggest that the child may have nonfebrile seizures later.

DIAGNOSIS. Any child thought to have an infection of the nervous system should undergo a lumbar puncture for examination of the CSF. Approximately one quarter of children with bacterial or viral meningitis have seizures. After the seizure, obtundation is expected.

In contrast, infants who have simple febrile seizures usually look normal after the seizure. Lumbar puncture is unnecessary after a brief, generalized seizure from which the infant recovers rapidly and completely, especially if the fever subsides spontaneously or is otherwise explained.

Blood cell counts; measurements of glucose, calcium, and electrolytes; urinalysis; and EEG on a routine basis are not cost-effective and are discouraged. Individual decisions for laboratory testing depend on the clinical circumstance. Obtain an EEG on every infant who is not neurologically normal or who has a family history of epilepsy. Infants with prolonged focal febrile seizures require brain MRI; many show a preexisting hippocampal abnormality (VanLandingham et al, 1998).

MANAGEMENT. Because only one third of infants with an initial febrile seizure have a second seizure, treating every affected infant is unreasonable. Treatment is unnecessary in the low-risk group with a single, brief, generalized seizure. No evidence has shown that a second or third simple febrile seizure, even if prolonged, causes epilepsy or brain damage (Verity et al, 1998).

As a rule, I recommend anticonvulsant prophylaxis only if I believe the infant has a condition other than simple febrile seizures and follow these guidelines:

1. Infants with an abnormal neurological examination or developmental delay are candidates for prophylactic anticonvulsant therapy.
2. When the initial febrile seizure is complex (multiple, prolonged, or focal) but the infant recovers rapidly and completely, do not treat unless the family has a history of nonfebrile seizures.
3. A family history of simple febrile seizures is a relative contraindication to therapy.
4. Treat children who have frequent and prolonged febrile seizures with prophylactic phenobarbital.

Nonfebrile Seizures

Disorders that produce nonfebrile tonic-clonic or partial seizures in infancy are not substantially different from disorders that cause nonfebrile seizures in childhood (see the following section). Major risk factors for the development of epilepsy in infancy and childhood are congenital malformations, neonatal seizures, and a family history of epilepsy.

A complex partial seizure syndrome with onset during infancy, sometimes in the newborn period, is *ictal laughter* associated with hypothalamic hamartoma. The attacks are brief, occur several times each day, and may be characterized by pleasant laughter or giggling. The first thought is that the laughter appears normal, but then facial flushing and pupillary dilation are noted. With time, the child develops drop attacks and generalized seizures. Personality change occurs, and precocious puberty may be an associated condition.

A first partial motor seizure before age 2 years is associated with a recurrence rate of 87%, whereas with a first seizure at a later age the rate is 51%. The recurrence rate after a first nonfebrile, asymptomatic, generalized seizure is 60% to 70% at all ages. The younger the age at onset of nonfebrile seizures of any type, the higher the incidence of symptomatic rather than idiopathic epilepsy.

Approximately 25% of children who have recurrent seizures during the first year, excluding neonatal seizures and infantile spasms, are developmentally or neurologically abnormal at the time of the first seizure. The initial EEG has

prognostic significance; normal EEG results are associated with a favorable neurological outcome.

Intractable seizures in children younger than 2 years old are often associated with later mental retardation. The seizure types with the greatest probability of mental retardation in descending order are myoclonic, tonic-clonic, complex partial, and simple partial.

Transmission of *benign familial infantile epilepsy* is by autosomal dominant inheritance. Onset is 3 months. The gene locus, on chromosome 19, is different from the locus for benign familial neonatal seizures. Motion arrest, decreased responsiveness, staring or blank eyes, and mild convulsive movements of the limbs characterize the seizures. Anticonvulsant drugs provide easy control, and seizures stop spontaneously within 2 to 4 years.

Myoclonus and Myoclonic Seizures

Infantile Spasms

Infantile spasms are age-dependent myoclonic seizures that occur with an incidence of 25:100,000 live births in the United States and Western Europe. An underlying cause can be determined in approximately 75% of patients; congenital malformations and perinatal asphyxia are common causes, and tuberous sclerosis accounts for 20% of cases in some series (Table 1-8). Despite considerable concern in the past, immunization is not a cause of infantile spasms.

The combination of infantile spasms, agenesis of the corpus callosum (and other midline cerebral malformations), and retinal malformations is referred to as *Aicardi syndrome*. All affected children are females, and genetic transmission of the disorder is as an X-linked dominant trait with hemizygous lethality in males.

CLINICAL FEATURES. The peak age at onset is 4 to 7 months, and onset always occurs before 1 year of age. The spasm can be a flexor or an extensor movement; some children have both. Spasms generally occur in clusters, shortly after the infant awakens from sleep and not activated by stimulation. A rapid flexor spasm involving the neck, trunk, and limbs followed by a tonic contraction sustained for 2 to 10 seconds is characteristic. Less severe flexor spasms consist of dropping of the head and abduction of the arms or flexion at the waist resembling colic. Extensor spasms resemble the second component of the Moro reflex: The head moves backward, and the arms suddenly spread.

TABLE 1-8
Neurocutaneous Disorders Causing Seizures in Infancy

Incontinentia Pigmenti

Seizure type
Neonatal seizures
Generalized tonic-clonic
Cutaneous manifestations
Erythematous bullae (newborn)
Pigmentary whorls (infancy)
Depigmented areas (childhood)

Linear Nevus Sebaceous Syndrome

Seizure type
Infantile spasms
Lennox-Gastaut syndrome
Generalized tonic-clonic
Cutaneous manifestation
Linear facial sebaceous nevus

Neurofibromatosis

Seizure type
Generalized tonic-clonic
Partial complex
Partial simple motor
Cutaneous manifestations
Café au lait spots
Axillary freckles
Neural tumors

Sturge-Weber Syndrome

Seizure type
Epilepsia partialis continua
Partial simple motor
Status epilepticus
Cutaneous manifestation
Hemifacial hemangioma

Tuberous Sclerosis

Seizure type
Neonatal seizures
Infantile spasms
Lennox-Gastaut syndrome
Generalized tonic-clonic
Partial simple motor
Partial complex
Cutaneous manifestations
Abnormal hair pigmentation
Adenoma sebaceum
Café au lait spots
Depigmented areas
Shagreen patch

Whether flexor or extensor, the movement is usually symmetrical and brief.

When the spasms are secondary to an identifiable cause (symptomatic), the infant is usually abnormal neurologically or developmentally at spasm onset. Microcephaly is common in this group. Prognosis depends on the cause, but as a rule, symptomatic patients do poorly.

Idiopathic spasms characteristically occur in infants who had been developing normally at

the onset of spasms and have no history of prenatal or perinatal disorders. Neurological findings, including head circumference, are normal. Approximately 40% of children with idiopathic spasms are neurologically normal or only mildly retarded subsequently. With improvement in diagnostic testing, idiopathic infantile spasms are less frequent.

DIAGNOSIS. The delay from spasm onset to diagnosis is often considerable. Infantile spasms are so unlike the usual perception of seizures that even experienced pediatricians may be slow to realize the significance of the movements. Often, colic is the first diagnosis because of the sudden flexor movements and is treated several weeks before suspecting seizures.

EEG differentiates infantile spasms from benign myoclonus of early infancy (Table 1-9). The EEG is the most important test for diagnosis. EEG findings vary, however, with the duration of recording, sleep state, and underlying disorder. *Hypsarrhythmia* is the usual pattern recorded during the early stages of infantile spasms. A chaotic and continuously abnormal background of high voltage and random slow waves and spike discharges is characteristic. The spikes vary in location from moment to moment and are generalized but never repetitive. Typical hypsarrhythmia usually appears during wakefulness or active sleep. During quiet sleep, greater interhemispheric synchrony occurs, and the background may have a burst-suppression appearance.

The EEG may normalize briefly on arousal, but when spasms recur, an abrupt attenuation of the background or high-voltage slow waves appear. Within a few weeks, greater interhemispheric synchrony replaces the original chaotic

pattern of hypsarrhythmia. The distribution of epileptiform discharges changes from multifocal to generalized, and background attenuation follows the generalized discharges.

MANAGEMENT. Corticosteroids, in the form of adrenocorticotropic hormone (ACTH), prednisone, or prednisolone, are the traditional treatment for infantile spasms (Mikati et al, 2002). Several alternative treatments avoid the adverse effects of corticosteroids and have a longer lasting effect. Clonazepam and levetiracetam are probably the safest alternatives. Valproate monotherapy controls spasms in 70% of infants with doses of 100 to 300 mg/kg/day. It is not a drug of first choice because of an unacceptable rate of fatal hepatotoxicity in this age group. Because fatal hepatotoxicity occurs mainly in infants with certain inborn errors of metabolism, however, valproate is a reasonable choice when infantile spasms are secondary to HIE or tuberous sclerosis.

Vigabatrin is especially useful when tuberous sclerosis is the underlying cause of spasms (Hancock and Osborne, 1999), but it is not commercially available in the United States. Zonisamide has shown efficacy in preliminary studies (Suzuki et al, 2002).

Initiate hormonal therapy when pharmacological therapy fails. Continue clonazepam in neurologically abnormal infants, however; ACTH or prednisone usually provides only temporary respite from seizures, and long-term anticonvulsant therapy is essential. ACTH may be more beneficial than prednisone (Baram et al, 1996). The ideal dosages and treatment duration of either ACTH or prednisone are not established. ACTH gel is usually given twice daily as an intramuscular injection of 75 U/m² for 2 to 6 weeks, then tapered to zero during a 1-week period. Use oral prednisone, 2 mg/kg/day, for 2 weeks, then taper over 2 weeks.

The response to hormonal therapy is never graded; control is either complete or not at all. Even when the response is favorable, one third of patients have relapses during or after the course of treatment. Failure to respond and relapses occur more often in symptomatic than idiopathic cases. A second course of treatment is effective in 75% of cases in which the first course was successful, albeit at the price of increased adverse reactions.

Consider high-dose pyridoxine in the treatment of infantile spasms when ACTH fails initially or relapses occur. Some cases of infantile spasms or other seizures of infancy may be atypical presentations of pyridoxine-dependent seizures. In most cases, the anticonvulsant

TABLE 1-9
Electroencephalographic (EEG)
Appearance in Myoclonic Seizures of
Infancy

Seizure Type	EEG Appearance
Infantile spasms	Hypsarrhythmia Slow spike and wave Burst-suppression
Benign myoclonus	Normal
Benign myoclonic epilepsy	Spike and wave (3 cps) Polyspike and wave (3 cps)
Severe myoclonic epilepsy	Polyspike and wave (>3 cps)
Lennox-Gastaut syndrome	Spike and wave (2-2.5 cps) Polyspike and wave (2-2.5 cps)

properties of pyridoxine and ACTH are unrelated to their physiological functions, however. The recommended dosage of pyridoxine is 30 to 40 mg/kg/day.

Some children with idiopathic infantile spasms who are refractory to medical therapy have an area of cortical abnormality demonstrable by some combination of positron emission tomography (PET), closed-circuit television EEG, and MRI. Surgical removal of the area, which usually proves to contain dysplastic tissue, often provides seizure control.

Benign Myoclonus of Infancy

CLINICAL FEATURES. Many series of patients with infantile spasms include a few with normal EEG results. These infants cannot be distinguished from others with infantile spasms by clinical features because the age at onset and the appearance of the movements are the same. The spasms occur in clusters, frequently at mealtime. Clusters increase in intensity and severity over weeks or months, then abate spontaneously. After 3 months, the spasms usually stop altogether, and although they may recur occasionally, no spasms occur after 2 years of age. Affected infants are normal neurologically and developmentally and remain so afterward. The term *benign myoclonus* suggests that the spasms are an involuntary movement rather than a seizure.

DIAGNOSIS. A normal EEG result distinguishes this condition from other types of myoclonus in infancy. No other tests are required.

MANAGEMENT. Treatment is not required.

Benign Myoclonic Epilepsy

CLINICAL FEATURES. Benign myoclonic epilepsy is a rare disorder of uncertain cause. One third of patients have family members with epilepsy, suggesting a genetic etiology. Onset is between 4 months and 2 years of age. Affected infants are neurologically normal at the onset of seizures and remain so afterward. Brief myoclonic attacks characterize the seizures. These may be restricted to head nodding or may be so severe as to throw the child to the floor. The head drops to the chest, eyes roll upward, the arms move upward and outward, and legs flex. Myoclonic seizures may be single or repetitive, but consciousness is not lost. No other seizure types occur in infancy, but generalized tonic-clonic seizures may occur in adolescence.

DIAGNOSIS. EEG during a seizure shows generalized 3 cycles per second (cps) spike-wave or polyspike-wave discharges. Sensory stimuli do

not activate seizures. The pattern is consistent with primary, generalized epilepsy.

MANAGEMENT. Valproate produces complete seizure control. If left untreated, seizures may persist for years. The use of valproate is potentially dangerous in infants because of hepatotoxicity. Levetiracetem may be useful.

Early Epileptic Encephalopathy with Suppression Bursts

The onset of two syndromes, early infantile epileptic encephalopathy (*Ohtahara syndrome*) and early myoclonic encephalopathy (Dulac, 2001), which may be the same disorder, is in the first 3 months of age. In one patient from my practice, the seizures began immediately after birth. Tonic spasms and myoclonic seizures occur in each. Both syndromes are associated with serious underlying metabolic or structural abnormalities. Some cases are familial, indicating an underlying genetic disorder. Progression to infantile spasms and the Lennox-Gastaut syndrome is common. On EEG, a suppression pattern alternating with bursts of diffuse, high-amplitude, spike-wave complexes is recorded. These seizures are refractory to most anticonvulsant drugs. The drugs recommended for infantile spasms are used for these infants.

Severe Myoclonic Epilepsy

Severe myoclonic epilepsy is an important but poorly understood syndrome. A seemingly healthy infant has a seizure, then undergoes progressive neurological deterioration that ends in a chronic brain damage syndrome. Because its cause is unknown, any preceding event is thought to be causative, often, but improperly, immunization.

CLINICAL FEATURES. A family history of epilepsy is present in 25% of cases. The first seizures are frequently febrile, are usually prolonged, and can be generalized or focal clonic in type. Febrile and nonfebrile seizures recur, sometimes as status epilepticus. Generalized myoclonic seizures appear after 1 year of age. At first mild and difficult to recognize as a seizure manifestation, they later become frequent and repetitive and disturb function. Partial complex seizures with secondary generalization also may occur. Coincident with the onset of myoclonic seizures are the slowing of development and the gradual appearance of ataxia and hyperreflexia.

DIAGNOSIS. The initial differential diagnosis is febrile seizures. The prolonged and sometimes focal nature of the febrile seizures raises

suspicion of symptomatic epilepsy. A specific diagnosis is not possible until the appearance of myoclonic seizures in the second year. Interictal EEG findings are normal at first. Paroxysmal abnormalities appear in the second year. These are characteristically generalized spike-wave and polyspike-wave complexes with a frequency greater than 3 cps. Photic stimulation, drowsiness, and quiet sleep activate the discharges.

MANAGEMENT. The seizures are resistant to therapy with anticonvulsant drugs. Valproate and benzodiazepines should be tried first. If these fail, try levetiracetem or zonisamide. Carbamazepine may increase seizure frequency.

Biotinidase Deficiency

Genetic transmission of this relatively rare disorder is as an autosomal recessive trait (Wolf, 2003). The cause is defective biotin absorption or transport and was previously called *late-onset multiple (holo) carboxylase deficiency*.

CLINICAL FEATURES. Age at onset is usually around 3 months. Seizures and hypotonia are the initial features. The seizures may be generalized tonic-clonic, myoclonic, or infantile spasms. Other features that may be seen initially or develop later are ataxia, respiratory disturbances, dermatitis, and alopecia.

DIAGNOSIS. Ketoacidosis, hyperammonemia, and organic aciduria are present. Showing biotinidase deficiency in serum establishes the diagnosis. In profound biotinidase deficiency, mean serum biotinidase activity is less than 10% of normal. In partial biotinidase deficiency, serum biotinidase activity is 10% to 30% of normal. Identification of profound or partial deficiency is usually by newborn screening.

MANAGEMENT. Early treatment with biotin, 5 to 20 mg/day, successfully reverses most of the symptoms and may prevent mental retardation.

Lennox-Gastaut Syndrome

The triad of seizures (atypical absence, atonic, and myoclonic), 1.5- to 2-Hz spike-wave complexes on EEG, and mental retardation characterizes Lennox-Gastaut syndrome. In most children, the seizures are secondary to underlying brain damage, but some are primary epilepsies.

CLINICAL FEATURES. The peak age at onset is 3 to 5 years; less than half of the cases begin before age 2. Approximately 60% have an identifiable underlying cause. Neurocutaneous disorders such as tuberous sclerosis, perinatal disturbances, and postnatal brain injuries are most common. Of

children with Lennox-Gastaut syndrome, 20% have a history of infantile spasms, sometimes with a seizure-free interval before development of the syndrome.

Although the syndrome occurs in normal children, most are neurologically abnormal before its onset. The first seizures are usually tonic, but may be generalized tonic-clonic or focal clonic. Stiffening of the body, upward deviation of the eyes, dilation of the pupils, and alteration in the respiratory pattern are the characteristic features of tonic seizures. The seizures frequently occur during sleep, and enuresis may be an associated condition.

Atypical absence seizures occur in almost every patient. In addition to the stare, trembling of the eyelids and mouth occurs, followed by loss of facial tone so that the head leans forward and the mouth hangs open. Characteristic of atonic seizures is a sudden dropping of the head or body, at times throwing the child to the ground. Most children with Lennox-Gastaut syndrome function in the mentally retarded range by 5 years of age.

DIAGNOSIS. An EEG is essential for diagnosis. A generalized burst of 2- to 2.5-cps spike-wave complexes is the characteristic feature during atypical absence or atonic seizures. Tonic seizures are associated with 1-cps slow waves followed by generalized rapid discharges without postictal depression.

In addition to EEG, looking for the underlying cause requires a thorough evaluation with special attention to skin manifestations that suggest a neurocutaneous syndrome (see Table 1-8). MRI is useful for the diagnosis of congenital malformations, postnatal disorders, and neurocutaneous syndromes.

MANAGEMENT. Seizures are difficult to control with drugs. Consider the ketogenic diet when drugs fail. Valproate and clonazepam are usually the most effective drugs. Lamotrigine, felbamate, and topiramate have shown promise as add-on drugs. Vigabatrin, not available in the United States, may be the most effective (Delanty and French, 1998).

Migraine

CLINICAL FEATURES. Migraine attacks are uncommon in infancy, but when they occur, the clinical features are often paroxysmal and suggest the possibility of seizures. Cyclic vomiting is probably the most common manifestation. Attacks of vertigo (see Chapter 10) or torticollis (see Chapter 14) may be especially perplexing, and some infants have attacks in which

they rock back and forth and appear uncomfortable.

DIAGNOSIS. The stereotypical presentation of *benign paroxysmal vertigo* is recognizable as a migraine variant. Other syndromes often remain undiagnosed until the episodes evolve into a typical migraine pattern. A history of migraine in one parent, usually the mother, is essential for diagnosis.

MANAGEMENT. As a rule, antimigraine drugs are not an option for infants.

Paroxysmal Disorders of Childhood

Similar to infants, in children, seizures are the usual first consideration for any paroxysmal disorder. Seizures are the most common paroxysmal disorder requiring medical consultation. Syncope, especially presyncope, is considerably more common, but diagnosis and management occur at home unless associated symptoms suggest a seizure.

Migraine is probably the most common cause of paroxysmal neurological disorders in childhood; its incidence is 10 times greater than that of epilepsy. Chapters 2, 3, 10, 11, 14, and 15 describe migraine syndromes that may suggest epilepsy. Several links exist between migraine and epilepsy: (1) Ion channel disorders cause both; (2) both are familial, paroxysmal, and associated with transitory neurological disturbances; and (3) migraine sufferers have an increased incidence of epilepsy, and epileptics have an increased incidence of migraine. In children who have epilepsy and migraine, both disorders may have a common aura, and one may provoke the other. Basilar migraine (see Chapter 10) and benign occipital epilepsy best exemplify the fine line between epilepsy and migraine. Characteristic of both are seizures, headache, and epileptiform activity. Children who have epilepsy and migraine require treatment for each condition, but some drugs (valproate and topiramate) serve as prophylactic agents for both.

Paroxysmal Dyskinesias

Paroxysmal dyskinesia occurs in several different syndromes. The best delineated are familial paroxysmal (kinesiogenic) choreoathetosis, paroxysmal nonkinesiogenic dyskinesia (PNKD), supplementary sensorimotor seizures, and paroxysmal nocturnal dystonia. The clinical distinction

between the first two depends on whether or not movement provokes the dyskinesia. The second two are more clearly epilepsies and are discussed elsewhere in this chapter. A familial syndrome of *exercise-induced dystonia and migraine* does not show linkage to any of the known genes for paroxysmal dyskinesias (Munchau et al, 2000). Channelopathies probably account for all paroxysmal dyskinesias.

Familial Paroxysmal Choreoathetosis

Genetic transmission is as an autosomal dominant trait, and the gene maps to chromosome 16p11.2. The disorder shares some clinical features with benign familial infantile convulsions and paroxysmal choreoathetosis. All three disorders map to the same region on chromosome 16, suggesting that they may be allelic disorders.

CLINICAL FEATURES. Familial paroxysmal choreoathetosis usually begins in childhood. Most cases are sporadic. Sudden movement, startle, or change in position precipitates an attack, which lasts less than a minute. Several attacks occur each day. Each attack may include dystonia, choreoathetosis, or ballismus (see Chapter 14) and may affect one or both sides of the body. Some patients have an "aura," described as tightness or tingling of the face or limbs.

DIAGNOSIS. The clinical features distinguish the diagnosis.

TREATMENT. Low dosages of carbamazepine or phenytoin are effective in stopping attacks.

Familial Nonkinesiogenic Dystonia

Genetic transmission of PNKD is as an autosomal dominant trait. The gene maps to chromosome 2q33-35.

CLINICAL FEATURES. PNKD usually begins in childhood or adolescence. Attacks of dystonia, chorea, and athetosis last 5 minutes to several hours. Precipitants are alcohol, caffeine, hunger, fatigue, nicotine, and emotional stress. Preservation of consciousness is a constant during attacks, and life expectancy is normal.

DIAGNOSIS. Ictal and interictal EEGs are normal. Consider children with EEG evidence of epileptiform activity to have a seizure disorder and not a paroxysmal dyskinesia.

MANAGEMENT. PNKD is difficult to treat, but clonazepam taken daily or at the first sign of an attack may reduce the frequency or severity of attacks. Gabapentin is effective in some children.

Hyperventilation Syndrome

Hyperventilation induces alkalosis by altering the proportion of blood gases. This is easier to accomplish in children than in adults.

CLINICAL FEATURES. During times of emotional upset, the respiratory rate and depth may increase insidiously, first appearing like sighing, then as obvious hyperventilation. The occurrence of tingling of the fingers disturbs the patient further and may induce greater hyperventilation. Headache is an associated symptom. Allowing hyperventilation to continue may result in loss of consciousness.

DIAGNOSIS. The observation of hyperventilation as a precipitating factor of syncope is essential to diagnosis. Often patients are unaware that they were hyperventilating, but probing questions elicit the history in the absence of a witness.

MANAGEMENT. Breathing into a paper bag aborts an attack in progress.

Sleep Disorders

Narcolepsy-Cataplexy

Narcolepsy-cataplexy is a sleep disorder characterized by an abnormally short latency from sleep onset to rapid eye movement (REM) sleep. A person with narcolepsy attains REM sleep in less than 20 minutes instead of the usual 90 minutes. Characteristic of normal REM sleep are dreaming and severe hypotonia. In narcolepsy-cataplexy, these phenomena occur during wakefulness.

Human narcolepsy, in contrast to animal narcolepsy, is not a simple genetic trait (Scammell, 2003). Evidence suggests an immunologically mediated destruction of hypocretin-containing cells in human narcolepsy. An alternate name for hypocretin is *orexin*. Human narcoleptics have an 85% to 95% reduction in the number of orexin/hypocretin-containing neurons.

CLINICAL FEATURES. Onset may occur at any time from early childhood to middle adulthood, usually in the teens or 20s and rarely before age 5. The syndrome has four components:

1. *Narcolepsy* refers to short sleep attacks. Three or four attacks occur each day, most often during monotonous activity, and are difficult to resist. Half of patients are easy to arouse from a sleep attack, and 60% feel refreshed afterward. Narcolepsy is usually a lifelong condition.
2. *Cataplexy* is a sudden loss of muscle tone induced by laughter, excitement, or startle.

Almost all patients who have narcolepsy have cataplexy as well. The patient may collapse to the floor, then arise immediately. Partial paralysis, affecting just the face or hands, is more common than total paralysis. Two to four attacks occur daily, usually in the afternoon. They are embarrassing but do not cause physical harm.

3. *Sleep paralysis* occurs in the transition between sleep and wakefulness. The patient is mentally awake but unable to move because of generalized hypotonia. Partial paralysis is less common. The attack may end spontaneously or when the patient is touched. Two thirds of patients with narcolepsy-cataplexy also experience sleep paralysis once or twice each week. Occasional episodes of sleep paralysis may occur in people who do not have narcolepsy-cataplexy.
4. *Hypnagogic hallucinations* are vivid, usually frightening, visual and auditory perceptions occurring at the transition between sleep and wakefulness: a sensation of dreaming while awake. These are an associated event in half of the patients with narcolepsy-cataplexy. Episodes occur less than once a week.

DIAGNOSIS. Syndrome recognition is by the clinical history. The symptoms are embarrassing or sound “crazy,” however, and considerable prompting is required before patients divulge a full history. Narcolepsy can be difficult to distinguish from other causes of excessive daytime sleepiness. The multiple sleep latency test is the standard for diagnosis. Patients with narcolepsy enter REM sleep within a few minutes of falling asleep.

MANAGEMENT. Symptoms of narcolepsy tend to worsen during the first years, then stabilize, whereas cataplexy tends to improve with time. Two scheduled 15-minute naps each day can reduce excessive sleepiness. Most patients also require pharmacological therapy.

Methylphenidate or pemoline is usually prescribed for narcolepsy but should be given with some caution because of potential abuse. Use small dosages on schooldays or workdays and no medicine, if possible, on weekends and holidays. When not taking medicine, patients should be encouraged to schedule short naps.

Modafinil, a wake-promoting agent distinct from stimulants, has proven efficacy for narcolepsy. The adult dose is 200 mg every morning, and although not approved for children, reduced dosages, depending on the child's weight, are in common usage. Treatments for

cataplexy include selective serotonin reuptake inhibitors, clomipramine, and protriptyline.

Sleep (Night) Terrors and Sleepwalking

Sleep terrors and sleepwalking are a partial arousal from non-REM sleep.

CLINICAL FEATURES. The onset usually occurs by 4 years of age and always by age 6. Two hours after falling asleep the child awakens in a terrified state, does not recognize people, and is inconsolable. An episode usually lasts 5 to 15 minutes but can last for 1 hour. During this time the child screams incoherently, may run if not restrained, then goes back to sleep. Afterward, the child has no memory of the event.

Most children with sleep terrors experience an average of one or more episodes each week. Night terrors stop by 8 years of age in half of affected children but continue into adolescence in one third.

DIAGNOSIS. Half of children with night terrors are also sleepwalkers, and many have a family history of either sleepwalking or sleep terrors. The history alone is the basis for diagnosis. A sleep laboratory evaluation often shows that children with sleep terrors experience sleep-disordered breathing (Guilleminault et al, 2003).

MANAGEMENT. Correction of the breathing disturbance ends sleep terrors and sleepwalking.

Stiff Infant Syndrome

Stiff infant syndrome, also called *hyperexplexia* or *startle disease*, is a rare disorder transmitted as an autosomal dominant trait (Tijssen et al, 1997). The abnormal gene is a subunit of the glycine receptor on chromosome 5q32.

CLINICAL FEATURES. The onset is at birth or early infancy. When the onset is at birth, a newborn may appear hypotonic during sleep and develop generalized stiffening on awakening. Apnea and an exaggerated startle response may be associated signs. Hypertonia in a newborn is unusual. Rigidity diminishes but does not disappear during sleep. Tendon reflexes are brisk, and the response spreads to other muscles.

The stiffness resolves spontaneously during infancy, and by 3 years of age most children are normal; however, episodes of stiffness may recur during adolescence or early adult life in response to startle, cold exposure, or pregnancy. Throughout life, affected individuals show a pathologically exaggerated startle response to visual, auditory, or tactile stimuli that would

not startle normal individuals. In some, the startle is associated with a transitory, generalized stiffness of the body that causes falling without protective reflexes, often leading to injury. The stiffening response is often confused with the stiff-man syndrome (see Chapter 8).

DIAGNOSIS. A family history of startle disease helps the diagnosis, but often is lacking. In startle disease, in contrast to startle-provoked epilepsy, the EEG is always normal.

MANAGEMENT. Clonazepam is the most useful agent to reduce the attack frequency. Valproate and levetiracetam also are useful. Affected infants improve with time.

Syncope

Syncope is loss of consciousness because of a transitory decline in cerebral blood flow. The causes include an irregular cardiac rate or rhythm and alterations of blood volume or distribution.

CLINICAL FEATURES. Syncope is a common event in otherwise healthy children, especially in adolescence. The mechanism is a vasovagal reflex by which an emotional experience produces peripheral pooling of blood. Other stimuli that provoke the reflex are overextension or sudden decompression of viscera, the Valsalva maneuver, and stretching with the neck hyperextended. Fainting in a hot, crowded church is especially common. Usually the faint occurs as the worshiper rises after prolonged kneeling.

Healthy children do not faint while lying down and rarely while seated. Fainting from anything but standing or arising suggests a cardiac arrhythmia and requires further investigation. The child may first feel faint (described as "faint," "dizzy," or "lightheaded") or may lose consciousness without warning. The face drains of color, and the skin is cold and clammy. With loss of consciousness, the child falls to the floor. The body stiffens, and the limbs *tremble*. The latter is not a seizure, and the trembling movements never appear tonic-clonic. The stiffening and trembling are especially common when keeping the child upright prolongs the reduced cerebral blood flow. This is common in a crowded church where the child has no room to fall and bystanders attempt to bring the child outside. A short period of confusion may follow, but recovery is complete within minutes.

DIAGNOSIS. The criteria for differentiating syncope from seizures are the precipitating factors and the child's appearance. Seizures do not produce pallor and cold, clammy skin. Always

inquire about the child's facial color in all initial evaluations of seizures. Laboratory investigations are not cost-effective when syncope occurs in expected circumstances and the results of the clinical examination are normal. Recurrent orthostatic syncope requires investigation of autonomic function, and any suspicion of cardiac abnormality warrants ECG monitoring. Always ask the child if irregular heart rate or beats occurred at the time of syncope or at other times.

MANAGEMENT. Infrequent syncopal episodes of obvious cause do not require treatment.

Staring Spells

Daydreaming is a pleasant escape for people of all ages. Children feel the need for escape most acutely when in school and may stare vacantly out the window to the place where they would rather be. Daydreams can be hard to break, and a child may not respond to verbal commands. Neurologists and pediatricians often recommend EEG studies for daydreamers. Sometimes the EEG shows sleep-activated central spikes or another abnormality not related to staring, which may lead the physician to prescribe inappropriate anticonvulsant drug therapy.

Staring spells are characteristic of absence epilepsies and complex partial seizures. They are usually distinguishable because absence is brief (5 to 15 seconds) and the child feels normal immediately afterward, whereas complex partial seizures usually last for more than 1 minute and are followed by fatigue. The associated EEG patterns and the response to treatment are quite different, and the basis for appropriate treatment is precise diagnosis before initiating treatment.

Absence seizures occur in four epileptic syndromes: childhood absence epilepsy, juvenile absence epilepsy, juvenile myoclonic epilepsy (JME), and epilepsy with grand mal on awakening (Janz, 1997). All four syndromes are genetic disorders transmitted as autosomal dominant traits. The phenotypes have considerable overlap. The most significant difference is the age at onset.

Childhood and Juvenile Absence Epilepsy

Childhood absence epilepsy begins between ages 6 and 8 years, and juvenile absence epilepsy begins between ages 10 and 16 years. One may be a continuum of the other. As a rule, adolescent onset is associated with a higher frequency of

generalized tonic-clonic seizures and is more likely to persist into adult life. Development of generalized tonic-clonic seizures or myoclonic seizures during treatment of absence predicts lack of remission and progression to JME.

CLINICAL FEATURES. The reported incidence of epilepsy in families of children with absence varies from 15% to 40%. Concurrence in monozygotic twins is 75% for seizures and 85% for the characteristic EEG abnormality.

Affected children are otherwise healthy. Typical attacks last 5 to 10 seconds and occur up to 100 times each day. The child stops ongoing activity, stares vacantly, sometimes with rhythmic movements of the eyelids, then resumes activity. Aura and postictal confusion never occur. Longer seizures may last for 1 minute and are indistinguishable by observation alone from complex partial seizures. Associated features may include myoclonus, increased or decreased postural tone, picking at clothes, turning of the head, and conjugate movements of the eyes. Occasionally, prolonged absence status causes confusional states in children and adults. These often require emergency department visits (see Chapter 2).

Approximately 50% of children with absence have at least one generalized tonic-clonic seizure. Many first come to medical care because of a generalized tonic-clonic seizure, even though absence attacks have occurred undiagnosed for months or years. The occurrence of a generalized tonic-clonic seizure in an untreated child does not change the diagnosis, prognosis, or treatment plan.

DIAGNOSIS. The EEG is pathognomonic. Bilaterally synchronous and symmetrical paroxysms of 3-cps spike-wave complexes appear concurrently with the clinical seizure (Figure 1-3). The amplitude of discharge is greatest in the frontocentral regions. Although the discharge begins with a frequency of 3 cps, it may slow to 2 cps as it ends. Hyperventilation usually activates the discharge. The interictal EEG is usually normal, but when abnormal, the typical features are focal or multifocal spike discharges or diffuse slowing. Children with interictal abnormalities are more likely to have mental retardation or developmental delay.

Although the EEG pattern of discharge is stereotyped, variations on the theme in the form of multiple spike and wave discharges are also acceptable. During sleep, the discharges often lose their stereotypy and become polymorphic in form and frequency but remain generalized. When a correlation between clinical and EEG findings is made, looking for an underlying

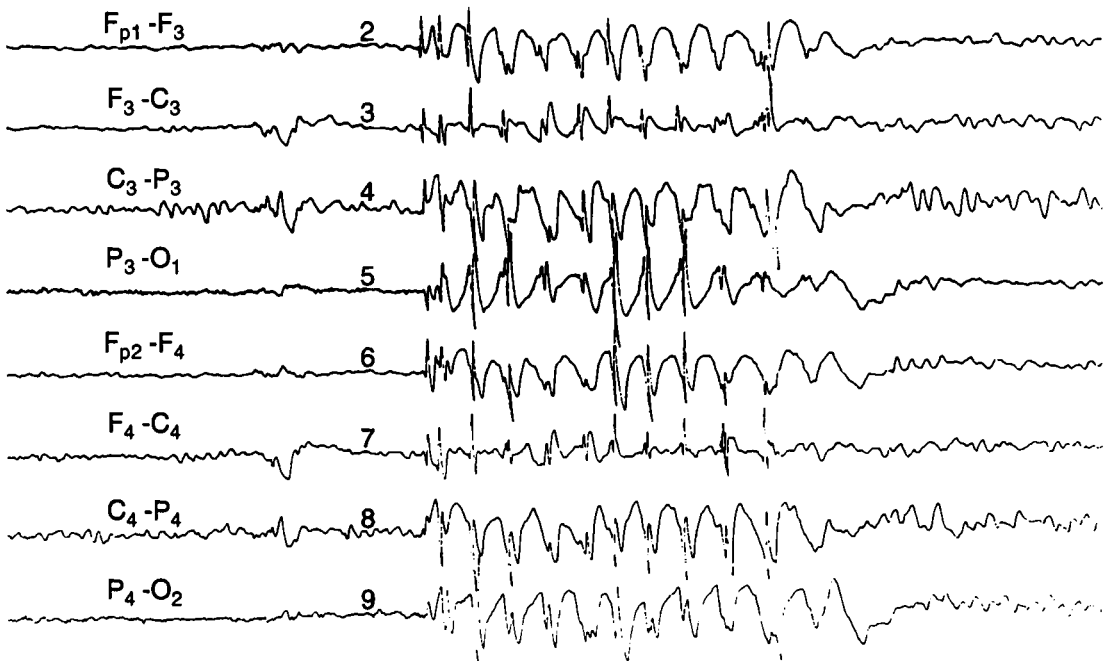


Figure 1-3. Absence epilepsy. A generalized burst of 3-cps spike-wave complexes appears during hyperventilation.

disease is unnecessary. The distinction between absence epilepsy and JME (see later section on Myoclonic Seizures) is the age at onset and absence of myoclonic seizures.

MANAGEMENT. Ethosuximide and valproate are equally effective in the treatment of absence, with each providing complete relief of seizures in 80% of children. Ethosuximide is preferred because of its lower incidence of serious side effects. If neither drug alone provides seizure control, use them in combination at reduced dosages or substitute another drug. Lamotrigine and levetiracetam are effective (see under Lamotrigine later for precautions concerning the combination of valproate and lamotrigine). The EEG becomes normal if treatment is successful, and repeating the EEG is useful to confirm the seizure-free state.

Ethosuximide alone is the first treatment for children with only a 3-cps spike-wave on EEG, even if a tonic-clonic seizure occurred before initiation of therapy. Substitute valproate for ethosuximide when ethosuximide fails. Clonazepam is sometimes useful in the treatment of refractory absence. Carbamazepine may accentuate the seizures and cause absence status.

Complex Partial Seizures

Complex partial seizures arise in the cortex, most often the temporal lobe, but also can orig-

inate from the frontal or parietal lobes. Complex partial seizures (discussed more fully later) may be symptomatic of an underlying focal disorder.

CLINICAL FEATURES. Complex partial seizures either occur spontaneously or are sleep-activated. Most last 1 to 2 minutes and rarely less than 30 seconds. Less than 30% of children report an aura. It is usually a nondescript unpleasant feeling, but also may be a stereotyped auditory hallucination or abdominal discomfort. The first feature of the seizure can be staring, automatic behavior, tonic extension of one or both arms, or loss of body tone. Staring is associated with a change in facial expression and followed by automatic behavior. Automatism vary from facial grimacing and fumbling movements of the fingers to walking, running, and resisting restraint. Automatic behavior in a given patient tends to be similar from seizure to seizure.

The seizure usually terminates with a period of postictal confusion, disorientation, or lethargy. Transitory aphasia is sometimes present. Secondary generalization is likely if the child is not treated or if treatment is abruptly withdrawn.

Partial complex status epilepticus is a rare event characterized by impaired consciousness, staring alternating with wandering eye movements, and automatisms of the face and hands. Such children may arrive at the emergency

department in a confused or delirious state (see Chapter 2).

DIAGNOSIS. The etiology of complex partial seizures is heterogeneous, and a cause is often not determined. Contrast-enhanced MRI is an indicated study in all cases. It may reveal a low-grade glioma or dysplastic tissue, especially migrational defects.

Record an EEG in the waking and sleeping states. Hyperventilation and photic stimulation are not useful as provocative measures. Results of a single EEG may be normal in the interictal period, but repeated EEGs usually reveal either a spike or a slow-wave focus in the frontal or temporal lobe or multifocal abnormalities. During the seizure, repetitive focal spike discharges occur in the involved area of cortex, which change to spike-slow wave complexes, then slow waves with amplitude attenuation as the seizure ends.

MANAGEMENT. Carbamazepine, oxcarbazepine, phenytoin, and valproate are effective for seizure control. Cost, side effects, and dosage schedule are the basis for choosing one or another. Topiramate and levetiracetam are useful as add-on therapy in children whose seizures are hard to control. Consider temporal lobe surgery when seizures are refractory to drugs (see section on Surgical Approaches to Childhood Epilepsy).

Myoclonic Seizures

Myoclonus is a brief, involuntary muscle contraction (jerk) that may represent (1) a seizure manifestation, as in infantile spasms; (2) a physiological response to startle or to falling asleep; or (3) an involuntary movement either alone or in combination with tonic-clonic seizures (see Table 14-8). Myoclonic seizures are often difficult to distinguish from myoclonus (the movement disorder) on clinical grounds alone. Chapter 14 discusses *essential myoclonus* and other nonseizure causes of myoclonus.

Juvenile Myoclonic Epilepsy

JME is a hereditary disorder, probably inherited as an autosomal dominant trait (Wheless and Kim, 2002). Known genetic loci for the syndrome include *5q34-q35*, *3q26-qter*, and *2q22-q23*. The critical region for JME susceptibility is 6p21.

CLINICAL FEATURES. JME occurs in both genders with equal frequency. Seizures in affected children and their affected relatives may be tonic-clonic, myoclonic, or absence. The usual age at onset of absence seizures is 7 to 13 years;

of myoclonic jerks, 12 to 18 years; and of generalized tonic-clonic seizures, 13 to 20 years.

The myoclonic seizures are brief and bilateral, but not always symmetrical, flexor jerks of the arms, which may be repetitive. The jerk sometimes affects the legs, causing the patient to fall. The highest frequency of myoclonic jerks is in the morning. Consciousness is not impaired, so the patient is aware of the jerking movement. Seizures are precipitated by sleep deprivation, alcohol ingestion, and awakening from sleep.

Most patients also have generalized tonic-clonic seizures, and a third experience absence. All are otherwise normal neurologically. The potential for seizures of one type or another continues throughout adult life.

DIAGNOSIS. Delays in diagnosis are common, often until a generalized tonic-clonic seizure brings the child to medical attention. Ignoring the myoclonic jerks is commonplace. The interictal EEG in JME consists of bilateral, symmetrical spike and polyspike-and-wave discharges of 3.5 to 6 Hz, usually maximal in the fronto-central regions (Figure 1-4). Photic stimulation often provokes a discharge. Focal EEG abnormalities may occur.

Management. Levetiracetam is excellent therapy, stopping seizures in almost all cases. Other effective drugs include valproate, lamotrigine, and topiramate (Prasad et al, 2003). Treatment is lifelong.

Progressive Myoclonus Epilepsies

The term *progressive myoclonus epilepsies* is used to cover several progressive disorders of the nervous system characterized by (1) myoclonus; (2) seizures that may be tonic-clonic, tonic, or myoclonic; (3) progressive mental deterioration; and (4) cerebellar ataxia, involuntary movements, or both. Some of these disorders are due to specific lysosomal enzyme deficiencies, whereas others are probably mitochondrial disorders (Table 1-10).

Lafora Disease

Lafora disease is a rare hereditary disease probably transmitted by autosomal recessive inheritance. Mutations in the laforin or the malin genes (*6q24*, *6p22.3*) cause the disease.

CLINICAL FEATURES. Onset is between 11 and 18 years old, with the mean at age 14. Tonic-clonic or myoclonic seizures are the initial feature in 80% of cases. Myoclonus becomes progressively worse, may be segmental or massive, and increases with movement. Mental retardation

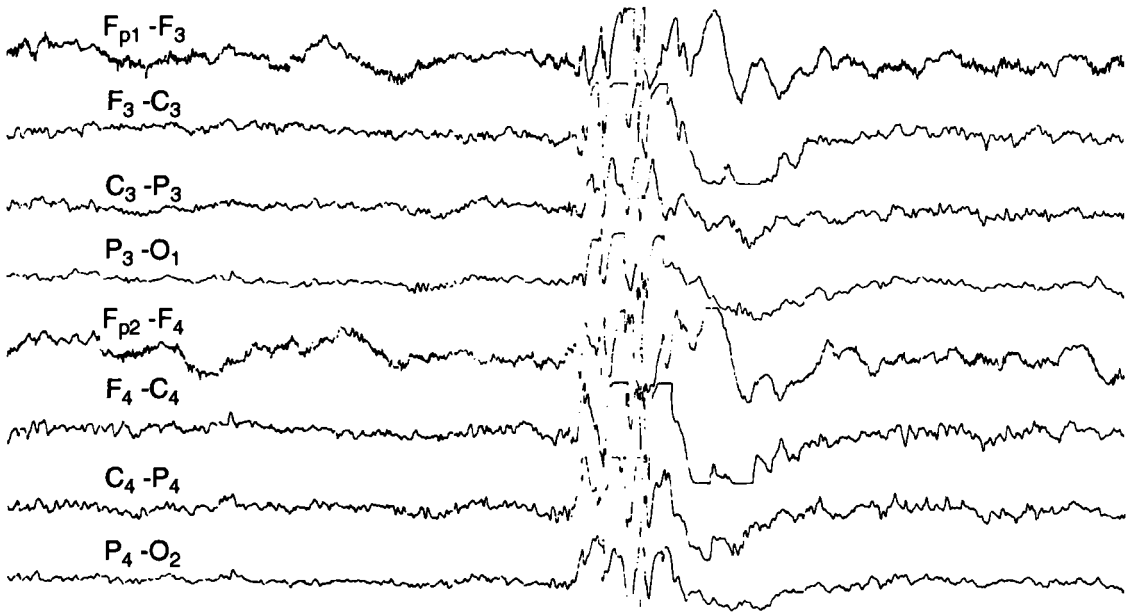


Figure 1-4. Juvenile myoclonic epilepsy. The interictal discharge is a 3.5- to 6-cps multispikes-wave complex.

begins early and is relentlessly progressive. Ataxia, spasticity, and involuntary movements occur late in the course. Death occurs 5 to 6 years after the onset of symptoms.

DIAGNOSIS. The EEG is normal at first and later develops nonspecific generalized polyspike discharges during the waking state. The background becomes progressively disorganized, and epileptiform activity becomes more constant. Photosensitive discharges are a regular feature late in the course.

Antemortem diagnosis is by showing periodic acid-Schiff-positive inclusion bodies consisting of aggregates of filaments composed of polyglucosans in biopsy specimens of liver or sweat gland (Andrade et al, 2003).

MANAGEMENT. The seizures become refractory to most anticonvulsant drugs. Some combination of valproate, clonazepam, and phenobarbi-

tal is often tried. Treatment of the underlying disease is not available.

Unverricht-Lundborg Syndrome

Unverricht-Lundborg syndrome is clinically similar to Lafora disease except that inclusion bodies are not present. Genetic transmission is by autosomal recessive inheritance. Most reports of the syndrome are from Finland and other Baltic countries, but distribution is worldwide. Mutations in the cystatin B gene cause defective function of a cysteine protease inhibitor (Lehesjoki and Koskiniemi, 2004).

CLINICAL FEATURES. Onset is usually between 6 and 15 years of age. The main features are stimulus-sensitive myoclonus and tonic-clonic epileptic seizures. As the disease progresses, other neurological symptoms appear.

DIAGNOSIS. EEG shows marked photosensitivity. Genetic molecular diagnosis is available.

MANAGEMENT. Valproate has been the drug of choice. Levetiracetam may be of equal value (Crest et al, 2004). Treatment often stops the tonic-clonic seizures and stabilizes the myoclonus.

Partial Seizures

This section discusses several different seizure types of focal cortical origin other than complex partial seizures. Such seizures may be purely motor or purely sensory or may affect

TABLE 1-10 Progressive Myoclonus Epilepsies

Ceroid lipofuscinosis, juvenile form (see Chapter 5)
Glucosylceramide lipidosis (Gaucher type 3) (see Chapter 5)
Lafora disease
Myoclonus epilepsy and ragged-red fibers (see Chapter 5)
Ramsay Hunt syndrome (see Chapter 10)
Sialidoses (see Chapter 5)
Unverricht-Lundborg syndrome

higher cortical function. The benign childhood partial epilepsies are the most common cause of partial seizures in children. Benign centrotemporal (rolandic) epilepsy and benign occipital epilepsy are the most common forms. The various benign partial epilepsy syndromes begin and cease at similar ages, have a similar course, and occur in the members of the same family. It seems likely that they are different phenotypic expressions of the same genetic defect.

Partial seizures are also secondary to underlying diseases, which can be focal, multifocal, or generalized. Neuronal migrational disorders and gliomas often cause intractable partial seizures (Porter et al, 2003). Cerebral cysticercosis is an important cause in Mexico and Central America and is becoming more common in the Southwestern United States (Carpio and Hauser, 2002). MRI is a recommended study for all children with intractable focal seizures or a new or progressing neurological deficit. Many may be candidates for surgical therapy.

Any seizure that originates in the cortex may discharge into the brainstem, causing a generalized tonic-clonic seizure (secondary generalization). If the discharge remains localized for a few seconds, the patient experiences a focal seizure or an aura before losing consciousness. Often the secondary generalization occurs so rapidly that a tonic-clonic seizure is the initial symptom. In such cases, cortical origin of the seizure may be detectable on EEG. Normal EEG findings are common, however, during a simple partial seizure and do not exclude the diagnosis.

Acquired Epileptiform Aphasia

Acquired aphasia in children associated with epileptiform activity on EEG is called the *Landau-Kleffner syndrome*. The syndrome seems to be a disorder of auditory processing. The cause is unknown except for occasional cases associated with temporal lobe tumors.

CLINICAL FEATURES. Age at onset ranges from 2 to 11 years, with 75% beginning between age 3 and 10 years. The first symptom may be aphasia or epilepsy. Auditory verbal agnosia is the initial characteristic of aphasia. The child has difficulty understanding speech and stops talking. "Deafness" or "autism" develops. Several seizure types occur, including generalized tonic-clonic, partial, and myoclonic seizures (Camfield and Camfield, 2002). Atypical absence is sometimes the initial feature and may be associated with continuous spike and slow waves during slow-

wave sleep. Hyperactivity and personality change occur in half of affected children, probably caused by aphasia. Intelligence is not affected, and the neurological examination is otherwise normal. Recovery of language is more likely to occur if the syndrome begins before 7 years of age. Seizures cease generally by age 10 and always by age 15.

DIAGNOSIS. Acquired epileptiform aphasia, as the name implies, is different from autism and hearing loss because the diagnosis requires that the child have normal language and cognitive development before onset of symptoms and normal hearing. The EEG shows multifocal cortical spike discharges with a predilection for the temporal and parietal lobes. Involvement is bilateral in 88% of cases. An intravenous injection of diazepam may normalize the EEG and improve speech transiently, but this should not suggest that epileptiform activity causes the aphasia. Instead, both features reflect an underlying cerebral disorder. Every child with the disorder requires cranial MRI to exclude the rare possibility of a temporal lobe tumor.

MANAGEMENT. Standard anticonvulsant drugs, such as carbamazepine and phenytoin, usually control the seizures but do not improve speech. Corticosteroid therapy, especially early in the course, may normalize the EEG and provide long-lasting remission of aphasia and seizures.

Acquired Epileptiform Opercula Syndrome

This syndrome and *autosomal dominant rolandic epilepsy and speech apraxia* are probably the same entity (Scheffer et al, 1995). They are probably different from acquired epileptiform aphasia but may represent a spectrum of the same underlying disease process.

CLINICAL FEATURES. Onset is before age 10 years. Brief nocturnal seizures occur that mainly affect the face and mouth but may become secondarily generalized. Oral dysphasia, inability to initiate complex facial movements (blowing out a candle), speech dysphasia, and drooling develop concurrently with seizure onset. Cognitive dysfunction is associated. Genetic transmission is by autosomal dominant inheritance with anticipation.

DIAGNOSIS. The EEG shows centrotemporal discharges or status epilepticus during slow-wave sleep.

MANAGEMENT. The dysphasia does not respond to anticonvulsant drugs.

Autosomal Dominant Nocturnal Frontal Lobe Epilepsy

Bizarre behavior and motor features during sleep are the characteristics of this epilepsy syndrome, often misdiagnosed as a sleep or psychiatric disorder (Hayman et al, 1997). The abnormal gene is located at *20q13.2-q13.3* and may be allelic with one of the genes for benign neonatal familial epilepsy. Genetic transmission is as an autosomal dominant trait with a penetrance rate of approximately 70%.

CLINICAL FEATURES. Seizures begin in childhood and usually persist into adulthood. Most attacks occur when dozing or first falling off to sleep. Clusters of 4 to 11 seizures, each lasting less than a minute, occur in one night. A vocalization, usually a gasp or grunt that awakens the individual, is common. Other auras include special sensory sensations, psychic phenomena (e.g., fear, malaise), shivering, and difficulty breathing. Thrashing or tonic stiffening with superimposed clonic jerks follows. The eyes are open, and the individual is aware of what is happening; many sit up and try to grab on to a bed part.

DIAGNOSIS. The family history is important to the diagnosis, but many family members may not realize that their own attacks are seizures or want others to know that they experience such bizarre symptoms. The interictal EEG is usually normal, and concurrent video-EEG is often required to capture the event, which reveals generalized discharges with diffuse distribution. Often, movement artifact obscures the initial ictal EEG. Children who have seizures when awake and no family history of epilepsy may have supplementary sensorimotor seizures (see later section on Supplementary Sensorimotor Seizures).

MANAGEMENT. Carbamazepine is usually effective in preventing seizures.

Benign Occipital Epilepsy of Childhood

Genetic transmission is by autosomal dominant inheritance. It may be a phenotypic variation of benign rolandic epilepsy. Both epilepsies are commonly associated with migraine (Andermann and Zifkin, 1998).

CLINICAL FEATURES. Age at onset is usually between 4 and 8 years. One third of patients have a family history of epilepsy, frequently benign rolandic epilepsy. The initial seizure manifestation can consist of (1) visual hallucinations, usually flashing lights or spots; (2) blindness, hemianopia, or complete amaurosis; (3) visual

illusions, such as micropsia, macropsia, or metamorphopsia; or (4) loss of consciousness lasting for 12 hours. More than one feature may occur simultaneously. Unilateral clonic seizures, complex partial seizures, or generalized tonic-clonic seizures follow the visual aura. Afterward the child may have migraine-like headaches and nausea. Attacks occur when the child is awake or asleep, but the greatest frequency is at the transition from wakefulness to sleep. Photic stimulation or playing video games may induce seizures.

DIAGNOSIS. Results of the neurological examination, CT, and MRI are normal. The interictal EEG shows unilateral or bilateral high-amplitude, occipital spike-wave discharges with a frequency of 1.5 to 2.5 cps. Eye opening enhances the discharges; light sleep inhibits them. A similar interictal pattern occurs in some children with absence epilepsy, suggesting a common genetic disorder among different benign genetic epilepsies. During a seizure, rapid firing of spike discharges occurs in one or both occipital lobes.

Epilepsy associated with ictal vomiting is a variant of benign occipital epilepsy (Panayiotopoulos, 1999). Seizures occur during sleep, and vomiting, eye deviation, speech arrest, and hemiconvulsions are characteristic.

MANAGEMENT. Complete seizure control is usually accomplished with standard anticonvulsant drugs. Typical seizures never persist beyond 12 years of age. Not all children with occipital discharges have benign genetic epilepsy, however. Persistent or hard-to-control seizures raise the question of a structural abnormality in the occipital lobe and require an MRI examination.

Benign Childhood Epilepsy with Centrotemporal Spikes

Benign rolandic epilepsy is an alternate name for benign childhood epilepsy with centrotemporal spikes (Camfield and Camfield, 2002). Transmission is as an autosomal dominant trait. In 40% of close relatives, there is a history of febrile seizures or epilepsy.

CLINICAL FEATURES. The age at onset is between 3 and 13 years, with a peak at 7 to 8 years. Seizures usually stop spontaneously by age 14. Even without drug therapy, 10% of patients have only one seizure, 70% have infrequent seizures, and only 20% have frequent seizures. With drug therapy, 20% have isolated seizures, and 6% have frequent seizures. Of children, 70% have seizures only while asleep; 15%, only when awake; and 15%, awake and asleep.

The typical seizure wakes the child from sleep. Paresthesias occur on one side of the mouth, followed by ipsilateral twitching of the face, mouth, and pharynx, resulting in speech arrest and drooling. Consciousness is preserved. The seizure lasts for 1 or 2 minutes. Daytime seizures do not generalize, but nocturnal seizures in children younger than 5 years old often spread to the arm or evolve into a generalized tonic-clonic seizure.

DIAGNOSIS. When evaluating a child for a first nocturnal, generalized tonic-clonic seizure, ask the parents if the child's mouth was "twisted." If they answer affirmatively, the child probably has benign childhood epilepsy with centrotemporal spikes. Parents never report this observation spontaneously.

Results of neurological examination and brain imaging studies are normal. Interictal EEG shows unilateral or bilateral spike discharges in the central or centrotemporal region. The spikes are typically of high voltage and activated by drowsiness and sleep. The frequency of spike discharge does not correlate with the subsequent course. Children with typical clinical seizures and EEG abnormalities do not require neuroimaging. Children with atypical features or hard-to-control seizures should have MRI to exclude a low-grade glioma.

MANAGEMENT. Infrequent, nocturnal seizures do not require treatment. A single bedtime dose of phenobarbital is usually satisfactory for seizure control. When medication is withdrawn after 2 years of treatment, 80% remain seizure-free. Treat children who resume having seizures until age 14. All children eventually stop having seizures whether they are treated or not.

Epilepsia Partialis Continua

Focal motor seizures that do not stop spontaneously are termed *epilepsia partialis continua*. This is an ominous symptom and usually indicates an underlying cerebral disorder. Possible causes include infarction, hemorrhage, tumor, and inflammation. Make every effort to stop the seizures with intravenous anticonvulsant drugs (see later section on Treatment of Status Epilepticus). The response to anticonvulsant drugs and the outcome depend on the underlying cause.

Hemiconvulsions-Hemiplegia Syndrome (Rasmussen Syndrome)

Rasmussen syndrome is a poorly understood disorder. Although originally described as a form of

focal, viral encephalitis, an infectious etiology is not established.

CLINICAL FEATURES. Focal jerking frequently begins in one body part, usually one side of the face or one hand, then spreads to contiguous parts. Trunk muscles are rarely affected. The rate and intensity of the seizures vary at first, but then become more regular and persist during sleep. By 4 months from first symptom, all patients have refractory motor seizures (Granata et al, 2003b). The seizures defy treatment and progress to affect first both limbs on one side of the body, then the limbs on the other side. Progressive hemiplegia develops and remains after seizures have stopped.

DIAGNOSIS. EEG shows continuous spike discharges originating in one portion of the cortex, with spread to contiguous areas of the cortex and to a mirror focus on the other side. Secondary generalization may occur. MRI is a required study in every case. The initial imaging studies are usually normal, but repeat studies after 6 months show atrophy of the hemisphere with dilation of the ipsilateral ventricle. PET shows widespread hypometabolism of the affected hemisphere at a time when the spike discharges remain localized. The CSF is usually normal, although a few monocytes may be present.

MANAGEMENT. The treatment of Rasmussen syndrome is especially difficult. Standard anticonvulsant therapy is not effective in stopping seizures, and progressive hemiplegia is the rule. The use of immunosuppressive therapy is recommended by some authors (Granata et al, 2003a), and antiviral therapy is recommended by others. These medical approaches are rarely successful. Early hemispherectomy is the treatment of choice (Kossoff et al, 2003).

Reading Epilepsy

The belief was that reading epilepsy and JME were variants because many children with reading epilepsy experience myoclonic jerks of the limbs shortly after arising in the morning. More recent studies indicate, however, that reading epilepsy is an idiopathic, localization-related epilepsy originating from the left temporal lobe (Archer et al, 2002).

CLINICAL FEATURES. Onset is usually in adolescence. Myoclonic jerks involving orofacial and jaw muscles develop while reading. Reading time before seizure onset is variable. The initial seizure is usually in the jaw and described as "jaws locking or clicking." Other initial features are quivering of the lips, choking in the

throat, or difficulty speaking. Myoclonic jerks of the limbs may follow, and some children experience a generalized tonic-clonic seizure if they continue reading. Generalized tonic-clonic seizures also may occur at other times.

DIAGNOSIS. The history of myoclonic jerks during reading and during other processes requiring higher cognitive function is crucial to the diagnosis. The interictal EEG usually shows generalized discharges, and brief spike-wave complexes can be provoked by reading that are simultaneous with jaw jerks.

MANAGEMENT. Some patients can control their seizures without the use of anticonvulsant drugs by quitting reading at the first sign of orofacial or jaw jerks. Most require anticonvulsant therapy. Valproate is effective.

Temporal Lobe Epilepsy

Temporal lobe epilepsy in children may be primary or secondary. Inheritance of primary temporal lobe epilepsy is often as an autosomal dominant trait. Among children with secondary temporal lobe epilepsy, 30% give a history of an antecedent illness or event, and 40% show MRI evidence of a structural abnormality.

CLINICAL FEATURES. Seizure onset in primary temporal lobe epilepsy occurs in adolescence or later. The seizures consist of simple psychic (déjà, cognitive disturbances, illusions, and hallucinations) or autonomic (nausea, tachycardia, sweating) symptoms. Secondary generalization is unusual. Seizure onset in secondary temporal lobe epilepsy is during the first decade and often occurs during an acute illness. The seizures are usually complex partial in type, and secondary generalization is more common.

DIAGNOSIS. A single EEG in children with primary temporal lobe epilepsy is likely to be normal. The frequency of interictal temporal lobe spikes is low, and diagnosis requires prolonged video-EEG monitoring. The incidence of focal interictal temporal lobe spikes is 78% in children with secondary temporal lobe epilepsy, but detection may require several EEG studies.

MANAGEMENT. Monotherapy with phenytoin, carbamazepine, or oxcarbazepine is usually satisfactory for seizure control in both types.

Generalized Seizures

Generalized tonic-clonic seizures are the most common seizures of childhood. They are dramatic and frightening events that invariably

demand medical attention. Seizures that are prolonged or repeated without recovery are termed *status epilepticus*. Many children with generalized tonic-clonic seizures have a history of febrile seizures during infancy (Scheffer and Berkovic, 1997). Some of these represent a distinct autosomal dominant disorder. Table 1-11 summarizes the diagnostic considerations in a child who has had a generalized tonic-clonic seizure.

CLINICAL FEATURES. The onset may occur anytime after the neonatal period, but the onset of primary generalized epilepsy without absence is usually during adolescence. With absence, the age at onset shifts to the first decade.

Sudden loss of consciousness is the initial feature. The child falls to the floor, and the body stiffens (tonic phase). Repetitive jerking movements of the limbs follow (clonic phase); these movements at first are rapid and rhythmic, then become slower and more irregular as the seizure ends. The eyes roll backward in the orbits; breathing is rapid and deep, causing saliva to froth at the lips; and urinary and fecal incontinence may occur. A postictal sleep follows the seizure from which arousal is difficult. Afterward the child appears normal but may have sore limb muscles and a painful tongue, bitten during the seizure.

DIAGNOSIS. A first generalized tonic-clonic seizure requires laboratory evaluation. Individualize the evaluation. Important determining factors include neurological findings, family history, and known precipitating factors. An eyewitness report of focal features at the onset of the seizure or the recollection of an aura indicates a partial seizure with secondary generalization.

During the seizure, the EEG shows generalized repetitive spikes in the tonic phase, then periodic bursts of spikes in the clonic phase. Movement artifact usually obscures the clonic portion. As the seizure ends, the background rhythms are slow, and the amplitude attenuates.

TABLE 1-11
Diagnostic Considerations for a First Nonfebrile Tonic-Clonic Seizure After 2 Years of Age

Acute encephalopathy or encephalitis (see Chapter 2)
Isolated unexplained seizure
Partial seizure of any cause with secondary generalization
Primary generalized epilepsy
Progressive disorder of the nervous system (see Chapter 5)

Between seizures, brief generalized spike or spike-wave discharges that are polymorphic in appearance may occur. Discharge frequency sometimes increases with drowsiness and light sleep. The presence of focal discharges indicates secondary generalization of the tonic-clonic seizure.

The CSF is normal after a brief tonic-clonic seizure due to primary epilepsy. Prolonged or repeated seizures may cause a leukocytosis, however, 80 cells/mm^3 with a polymorphonuclear predominance. The protein concentration can be mildly elevated, but the glucose concentration is normal.

MANAGEMENT. Do not start prophylactic anticonvulsant therapy in an otherwise normal child who has had a single unexplained seizure. The recurrence rate is probably less than 50% after 1 year. Several drugs are equally effective in children with recurrent seizures that require treatment.

Epilepsy with Generalized Tonic-Clonic Seizures on Awakening

Epilepsy with generalized tonic-clonic seizures on awakening is a familial syndrome distinct from JME. Onset occurs in adolescence, and 90% of seizures occur on awakening, regardless of the time of day. Seizures also occur with relaxation in the evening. Absence and myoclonic seizures may occur. The mode of inheritance is unknown.

CLINICAL FEATURES. Onset occurs in adolescence, and 90% of seizures occur on awakening, regardless of the time of day. Seizures also occur with relaxation in the evening. Absence and myoclonic seizures may occur.

DIAGNOSIS. The EEG shows a pattern of idiopathic generalized epilepsies.

MANAGEMENT. Treatment is similar to that of JME (Wheless and Kim, 2002).

Pseudoseizures

“Hysterical” seizures are an effective method of seeking attention and secondary gain. They occur more often in adolescence than childhood and more often in girls than boys (3:1). A history of sexual abuse is common in women who experience pseudoseizures. People with pseudoseizures also may have true seizures; often the pseudoseizures begin when true seizures come under control, and the secondary gain of epilepsy is lost.

CLINICAL FEATURES. Pseudoseizures rarely simulate true seizures but are sometimes difficult to

distinguish by observation alone. The clinical features include a rich variety of motor and behavioral phenomena, but often one observes three broad patterns:

1. Unilateral or bilateral motor activity characterized by tonic posturing and tremulousness in which the patient’s movements are thrashing or jerking rather than tonic-clonic; different movements may occur simultaneously.
2. Behavioral or emotional changes in which distress or discomfort is expressed, followed by semipurposeless, but not stereotyped, behaviors, such as fumbling with objects or walking.
3. Periods of unresponsiveness during which attacks may be precipitated and ended by suggestion. Patients usually do not hurt themselves or experience incontinence.

DIAGNOSIS. Pseudoseizures usually occur at home and are thought to be real seizures. If the child has epilepsy, calls to the physician result in needless revisions of drug schedules, often to the patient’s detriment. Consider the possibility of pseudoseizures when frequent seizures develop in children whose epilepsy was recently controlled. Children who develop pseudoseizures in the absence of an epilepsy history often present to emergency departments and are given anticonvulsant drugs before initiating investigations. It is difficult to stop the medications and obtain a baseline EEG. The diagnosis of most pseudoseizures is by observation alone. When doubt remains, video-EEG monitoring is the best method of diagnosis.

MANAGEMENT. Present the diagnosis of pseudoseizures in a positive and supportive manner. The diagnosis does not imply that the person is crazy or faking. The spells can be stopped, but not with anticonvulsant drugs. Psychiatric referral is not always necessary, but the need for psychological counseling is common. Determining the secondary gain provided by seizures and offering alternative methods of satisfaction is the best approach to treatment. Most children with pseudoseizures stop having attacks when the diagnosis is established.

Video Game–Induced Seizures

Children who experience seizures while playing video games have a photosensitive seizure disorder demonstrable on EEG during intermittent photic stimulation. Two thirds have primary generalized epilepsy (generalized tonic-clonic,

absence, and JME), and the rest have partial epilepsies, usually benign occipital epilepsy.

Managing Seizures

Anticonvulsant Drug Therapy

The goal of anticonvulsant therapy is to achieve maximal normal function by balancing seizure control against drug toxicity (Hirtz et al, 2003). A balance is required between seizure risk and potential drug toxicity, while considering the sensibilities of the patient and the family.

Indications for Starting Therapy

Initiate prophylactic therapy whenever there is a reasonable expectation that seizures will recur and impair the child's quality of life. Always treat JME and absence epilepsy, not only because more seizures will occur, but also because uncontrolled absence impairs education. After a first unexplained and untreated seizure, less than half of otherwise normal children have a second seizure. The risk of recurrence in a neurologically abnormal child is considerably higher. The risk of recurrence after a second untreated generalized tonic-clonic seizure is 90%, but the recurrence risk with some specific epilepsies is considerably lower because of the benign cortical epilepsies of childhood. Delaying therapy and allowing more seizures to occur does not reduce the chance of ultimately providing seizure control. *In an otherwise normal child who is not driving a car, it is reasonable to withhold therapy after a first unexplained seizure until a second seizure occurs.*

Discontinuing Therapy

Anticonvulsant drug therapy is required in children who experience seizures during an acute encephalopathy (e.g., anoxia, head trauma, encephalitis). Stop therapy when the acute encephalopathy is over and seizures have stopped. Only children with chronic brain damage have epilepsy later on, and treatment is restarted when seizures recur. Later epilepsy is not preventable by the continuous use of anticonvulsant drugs after an acute encephalopathy.

Pooled data on epilepsy in children suggest that discontinuing anticonvulsant therapy is successful after 2 years of complete control. Pooled data are worthless when applied to the individual child. *I suspect that many otherwise normal children started on anticonvulsant medication after a first seizure who then remain*

seizure-free for 2 years should not have received medication in the first place. The decision to stop therapy, similar to the decision to start therapy, requires an individualized approach to the child and the cause of the epilepsy. Children who are neurologically abnormal (remote symptomatic epilepsy) and children with specific epileptic syndromes that are known to persist into adult life are likely to have recurrences, whereas children with benign epilepsies of childhood are likely to remain seizure-free. Three fourths of relapses occur during the withdrawal phase and in the 2 years thereafter. Contrary to popular belief, the rapid withdrawal of anticonvulsant drugs in a person who does not need therapy does not provoke seizures. Seizures occur in people with epilepsy when the blood concentration is no longer therapeutic, without regard to the rate of decline. As a rule, I try to stop anticonvulsant therapy 1 year before driving age in children who are seizure-free and neurologically normal.

Principles of Therapy

Start therapy with a single drug. Most children with epilepsy achieve complete seizure control with monotherapy when using the correct drug for the seizure type. Even patients whose seizures are never controlled are likely to do better on the smallest number of drugs. Polytherapy poses several problems: (1) Drugs compete with each other for protein binding sites, (2) one drug can increase the rate and pathway of catabolism of a second drug, (3) drugs have cumulative toxicity, and (4) compliance is more difficult.

When using more than one drug, choose drugs that have different spectra of activity or mechanisms of action. Change only one drug at a time. When making several changes simultaneously, it is impossible to determine which drug is responsible for a beneficial or an adverse effect.

Administer anticonvulsant drugs once or twice a day and never more often than three times each day. Compliance and number of doses are inversely related. With many drugs, an acceptable steady state can be attained using a twice-a-day regimen, and some can be administered once a day. *It is difficult to remember to take medicine to prevent something from happening when you are not in pain.*

Blood Concentrations

The development of techniques to measure blood concentrations of anticonvulsant drugs

was an important advance in the treatment of epilepsy. Measuring total drug concentrations, protein-bound and free fractions, is customary even though the free fraction is responsible for efficacy and toxicity. Although the ratio of free to bound fractions is relatively constant, some drugs have a greater affinity for binding protein than other drugs and displace them when used together. The free fraction of the displaced drug increases and causes toxicity even though the measured total drug concentration is "therapeutic."

Reference values of drug concentrations are guidelines. Some patients are seizure-free with concentrations that are below the reference value, and others are unaffected by apparently toxic concentrations.

Most anticonvulsants follow first-order kinetics; that is, blood levels increase proportionately with increases in the oral dose. The main exception is phenytoin, whose metabolism changes from first-order to zero-order kinetics when the enzyme system responsible for its catabolism saturates. Then a small increment in oral dose produces large increments in blood concentration.

The half-lives of the anticonvulsants listed in Table 1-12 are at steady state. Half-lives are generally longer when therapy with a new drug begins. Achieving a steady state usually requires five half-lives. Similarly, five half-lives are required to eliminate a drug after discon-

tinuing administration. Drug half-lives vary from individual to individual and may be shortened or increased by the concurrent use of other anticonvulsants, antibiotics, and antipyretics. This is one reason that children with epilepsy may have a toxic response to a drug or increased seizures at the time of a febrile illness.

Some anticonvulsants have active metabolites with anticonvulsant and toxic properties. With the exception of phenobarbital derived from primidone, these metabolites are not usually measured. Active metabolites may provide seizure control or have toxic effects when the blood concentration of the parent compound is low.

Adverse Reactions

Many anticonvulsant drugs irritate the gastric mucosa and cause nausea and vomiting. When this occurs, taking smaller doses at shorter intervals, using enteric-coated preparations, and administering the drug after meals may relieve symptoms.

Toxic adverse reactions are dose related. Almost all anticonvulsant drugs cause sedation when blood concentrations are excessive. Subtle cognitive and behavioral disturbances, recognizable only by the patient or family, often occur at low blood concentrations. Never discount the patient's observation of a toxic effect

TABLE 1-12
Anticonvulsant Drugs for Children

Drug	Initial Dose (mg/kg/day)	Target Dose (mg/kg/day)	Blood Concentration ($\mu\text{g}/\text{mL}$)	Half-Life (hr)
Carbamazepine	10	20-30	4-12	14-27
Clonazepam	0.02 mg/day	0.5-1 mg/day	*	20-40
Ethosuximide	10	15-40	*	30-40
Felbamate	15	15-45	40-80	20-23
Lamotrigine (nonvalproate)	0.5	5-15	*	25 (monotherapy)
Levetiracetam	15	50 mg/kg	†	5
Oxcarbazepine	10	20-40	†	9
Phenobarbital	3-5	5-10	15-40	35-73
Phenytoin	5-10	5-10	10-25	24
Primidone	5	10-25	8-12	8-22
Topiramate	1-3	5-9	†	18-30
Valproate	20	30-60	50-100	6-15
Vigabatrin	40-60	60-80	†	Days
Zonisamide	1.5	6	†	24

*Not clinically useful.

†Not established.

Note: Concomitant therapy with other drugs often influences dosages.

because the blood concentration is within the therapeutic range. As doses are increased, attention span, memory, and interpersonal relations may become seriously impaired. This is especially common with barbiturates but can occur with any drug.

Idiosyncratic reactions are not entirely dose related. They may occur as hypersensitivity reactions (usually manifest as rash, fever, and lymphadenopathy) or because of toxic metabolites. Idiosyncratic reactions are not always predictable, and respecting the patient's observation is essential. *Notwithstanding package inserts and threats of litigation, routine laboratory studies of blood counts and organ function in a healthy child are neither cost-effective nor helpful.* I prefer to do studies based on clinical features.

Selection of an Anticonvulsant Drug

The use of generic drugs is difficult to avoid in managed care health programs. Several different manufacturers provide generic versions of each drug; the bioavailability and half-life of these products vary considerably, and maintaining a predictable blood concentration may be difficult. Common reasons for loss of seizure control in children who were previously seizure-free are noncompliance and changing from the brand name to a generic drug or from one generic to another. Patients should ask their pharmacist to tell them when their source of generic drug is going to change.

Carbamazepine (Tegretol, Tegretol-XR [Novartis]; Carbatrol [Shire Pharmaceuticals])

INDICATIONS. Carbamazepine is indicated for partial seizures and primary or secondary generalized tonic-clonic seizures. It increases the frequency of absence and myoclonic seizures and so is contraindicated.

ADMINISTRATION. Approximately 85% of the drug is protein bound. Carbamazepine induces its own metabolism, and the initial dose should be 25% of the maintenance dose to prevent toxicity. The usual maintenance dosage is 15 to 20 mg/kg/day to provide a blood concentration of 4 to 12 µg/mL. Infants often require 30 mg/kg/day. The half-life at steady state is 5 to 27 hours, and children usually require doses three times a day. Two long-acting preparations are available. Concurrent use of cimetidine, erythromycin, fluoxetine, and propoxyphene interferes

with carbamazepine metabolism and causes toxicity.

ADVERSE EFFECTS. A depression of peripheral leukocytes is expected but is rarely sufficient (absolute neutrophil count <1000) to warrant discontinuation of therapy. Routine white blood cell counts each time the patient returns for a follow-up visit are not cost-effective and do not allow the prediction of life-threatening events. The most informative time to repeat the white blood cell count is concurrently with a febrile illness.

Cognitive disturbances occur within the therapeutic range. Sedation, ataxia, and nystagmus occur at toxic blood concentrations. Nonepileptic myoclonus is an allergic reaction.

Clonazepam (Klonopin [Roche])

INDICATIONS. Clonazepam treats infantile spasms, myoclonic seizures, absence, and partial seizures.

ADMINISTRATION. The initial dosage is 0.025 mg/kg/day in two divided doses. Recommended increments are 0.025 mg/kg every 3 to 5 days as needed and tolerated. The usual maintenance dosage is 0.1 mg/kg/day in three divided doses. Most children cannot tolerate dosages of more than 0.15 mg/kg/day. The therapeutic blood concentration is 0.02 to 0.07 µg/mL, 47% of the drug is protein bound, and the half-life is 20 to 40 hours. Rectal administration is suitable for maintenance if needed.

ADVERSE EFFECTS. Toxic effects with dosages within the therapeutic range include sedation, cognitive impairment, hyperactivity, and excessive salivation. Idiosyncratic reactions are unusual.

Ethosuximide (Zarontin [Pfizer US Pharmaceuticals])

INDICATIONS. Ethosuximide is the drug of choice for treating absence epilepsy. It is also useful for myoclonic absence.

ADMINISTRATION. The drug is absorbed rapidly, and peak blood concentrations appear within 4 hours. The half-life is 30 hours in children and 60 hours in adults. The initial dosage is 10 to 15 mg/kg/day in three divided doses after meals to avoid gastric irritation. Dose increments of 10 mg/kg/day can be prescribed as needed and tolerated to provide seizure control without adverse effects. Blood concentration measurements are not useful.

ADVERSE EFFECTS. The common adverse reactions are nausea and abdominal pain. These

symptoms occur from gastric irritation within the therapeutic range and limit the drug's usefulness. The liquid preparation causes more irritation than the capsule. The medication should always be taken after eating.

Felbamate (MedPointe Pharmaceuticals)

INDICATIONS. Felbamate has a wide spectrum of anticonvulsant activity. Its primary use is for refractory partial and generalized seizures, Lennox-Gastaut syndrome, atypical absence, and atonic seizures.

ADMINISTRATION. Felbamate is rapidly absorbed after oral intake. Maximal plasma concentrations occur in 2 to 6 hours. The initial dosage is 15 mg/kg/day in three divided doses. Avoid nighttime doses if the drug causes insomnia. To attain seizure control, use weekly dosage increments of 15 mg/kg, as needed, to a total dose of approximately 45 mg/kg/day. Toxicity limits the total dosage, and blood concentration measurements are not useful.

ADVERSE EFFECTS. Initial evidence suggested that adverse effects of felbamate were mild and dose related (nausea, anorexia, insomnia, weight loss) except when in combination with other anticonvulsants. The addition of felbamate increases the plasma concentrations of phenytoin and valproate 30%. The carbamazepine serum concentration falls, but the concentration of its active epoxide metabolite increases almost 50%.

Postmarketing experience showed that felbamate causes fatal liver damage and aplastic anemia. Regular monitoring of blood counts and liver function is required. This is a valuable drug in refractory epilepsy, however, and has a place when used with caution and informed consent.

Lamotrigine (Lamictal [GlaxoSmithKline])

INDICATIONS. Lamotrigine is useful in absence epilepsy, atonic seizures, JME, Lennox-Gastaut syndrome, and partial seizures. The spectrum of activity is similar to that of valproate.

ADMINISTRATION. The initial dosage is 0.5 mg/kg/day. Small incremental increases are required to achieve a maintenance dosage of 5 to 15 mg/kg/day. This is a slow process, and the main disadvantage of using lamotrigine as a primary drug is the long interval required to achieve seizure control. Plasma concentrations are not measured. The concomitant use of lamotrigine and other anticonvulsants shortens the half-life of lamotrigine but does not lower

the blood concentration of the other drugs. In contrast, the concomitant use of valproate markedly extends the half-life of lamotrigine. A 50% reduction in the initial dose and the dosage increments is required when used in combination with valproate.

ADVERSE EFFECTS. The main allergic reaction is rash, which is more likely with rapid dosing increments. Other adverse effects are dizziness, ataxia, diplopia, and headache.

Levetiracetam (Keppra [UCB Pharma])

INDICATIONS. Levetiracetam has a broad spectrum of activity and is useful for most seizure types. It is especially effective in the treatment of JME.

ADMINISTRATION. Levetiracetam is available as a tablet and suspension. The half-life is short, but the duration of efficacy is longer. Twice-daily dosing is required. The initial dose in children is 10 to 20 mg/kg, and the target dose is 40 to 60 mg/kg.

ADVERSE EFFECTS. Levetiracetam is not metabolized in the liver. Metabolism occurs in the blood, and excretion is in the urine. It does not interfere with the metabolism of other drugs and has no life-threatening side effects. It makes some children nasty. The addition of pyridoxine (100 mg/day) may reverse this effect. When starting the drug, warn parents of possible personality change and add pyridoxine when reported. Stopping the drug may be necessary.

Oxcarbazepine (Trileptal [Novartis])

INDICATIONS. Oxcarbazepine is the active breakdown product of carbamazepine. It has the same therapeutic profile as carbamazepine.

ADMINISTRATION. Oxcarbazepine is available as a tablet and as a suspension. Twice-daily dosing is required. The initial dose is 5 to 10 mg/kg, which is incrementally increased, as needed, to a total dose of 600 to 1800 mg/day in two divided doses.

ADVERSE EFFECTS. The main adverse effect is drowsiness, but this is not as severe as with carbamazepine. Hyponatremia is a potential problem, especially in combination with other medications that decrease serum sodium levels.

Phenobarbital

INDICATIONS. Phenobarbital treats tonic-clonic and simple partial seizures in newborns and infants. It is especially useful to manage epilepsy in people who cannot remember to take medica-

tion more than once a day or have only nocturnal seizures.

ADMINISTRATION. Oral absorption is slow, and once-daily dosing is best when given with the evening meal than at bedtime if seizures are hypnagogic. Because intramuscular absorption requires 1 to 2 hours, the intramuscular route is useless for rapid loading (see Treatment of Status Epilepticus); 50% of the drug is protein bound, and 50% is free.

Initial and maintenance dosages are 3 to 5 mg/kg/day. The half-life is 50 to 140 hours in adults, 35 to 70 hours in children, and 50 to 200 hours in term newborns. Because of the long half-life at all ages, once-a-day doses are usually satisfactory, achieving steady-state blood concentrations after 2 weeks of therapy. Therapeutic blood concentrations are 15 to 40 µg/mL.

ADVERSE EFFECTS. Hyperactivity is the most common and limiting side effect in children. Adverse behavioral changes occur in half of children between ages 2 and 10. Warn parents of this possibility at the onset of therapy. Behavioral changes are dose related.

Phenobarbital has no life-threatening side effects. Drowsiness and cognitive dysfunction, rather than hyperactivity, are the usual adverse effects after 10 years of age. Infants tolerate phenobarbital well, and it remains the drug of choice for oral use in newborns and infants. Allergic rash is the main idiosyncratic reaction.

Phenytoin (Dilantin [Pfizer US Pharmaceuticals])

INDICATIONS. Phenytoin treats tonic-clonic and partial seizures. Never use generic preparations. Blood concentrations are erratic.

ADMINISTRATION. Never use generic preparations. Blood concentration are erratic. Oral absorption is slow and unpredictable in newborns, erratic in infants, and probably not reliable until 3 to 5 years of age. Even in adults, considerable individual variability exists. When absorbed, phenytoin is 70% to 95% protein bound. A typical maintenance dosage is 7 mg/kg/day in children. The half-life is 60 hours in term newborns, 140 hours in premature infants, 5 to 14 hours in children, and 10 to 34 hours in adults. Capsules usually require two divided doses, but tablets are more rapidly absorbed and may require three divided doses a day. Administration of three times the maintenance dose achieves rapid oral loading. Fosphenytoin sodium has replaced parenteral phenytoin (see discussion of Status Epilepticus).

ADVERSE EFFECTS. The major adverse reactions are hypersensitivity, gum hypertrophy, and hirsutism. Hypersensitivity reactions usually occur within 6 weeks of the initiation of therapy. Rash, fever, and lymphadenopathy are characteristic. When such a reaction has occurred, discontinue the drug. Concurrent use of antihistamines is not appropriate management. Continued use of the drug may produce Stevens-Johnson syndrome or a lupus-like disorder.

The cause of gum hypertrophy is a combination of phenytoin metabolites and plaque on the teeth. Persons with good oral hygiene are unlikely to have gum hypertrophy. Discuss the importance of good oral hygiene at the onset of therapy. Hirsutism is rarely a problem and then only for girls. Discontinue the drug when it occurs. Memory impairment, decreased attention span, and personality change may occur at therapeutic concentrations, but they occur less often and are less severe than with phenobarbital.

Primidone (Mysoline [Athena Neurosciences Inc])

INDICATIONS. Primidone treats tonic-clonic and partial seizures.

ADMINISTRATION. Primidone metabolizes to at least two active metabolites, phenobarbital and phenylethylmalonamide. The half-life of primidone is 6 to 12 hours and of phenylethylmalonamide is 20 hours. The usual maintenance dosage is 10 to 25 mg/kg/day, but the initial dosage should be 25% of the maintenance dosage or intolerable sedation occurs. A therapeutic blood concentration of primidone is 8 to 12 µg/mL. The blood concentration of phenobarbital derived from primidone is generally four times greater, but this ratio alters with concurrent administration of other anticonvulsant drugs.

ADVERSE EFFECTS. The adverse effects are the same as for phenobarbital except that the risk of intolerable sedation from the first tablet is greater.

Tiagabine (Gabitril [Cephalon Inc])

INDICATIONS. Tiagabine is adjunctive therapy for partial-onset and generalized seizures.

ADMINISTRATION. The initial single-day dose is 0.2 mg/kg/day. Increase every 2 weeks by 0.2 mg/kg until achieving optimal benefit or adverse reactions occur. Most children tolerate doses of 4 to 6 mg/day.

ADVERSE EFFECTS. The most common adverse effects are somnolence and difficulty concentrating.

Topiramate (Topamax [Ortho Biotech])

INDICATIONS. Use for partial-onset and generalized epilepsies, especially Lennox-Gastaut syndrome.

ADMINISTRATION. The initial dose is 1 to 2 mg/kg/day, increased incrementally to 10 mg/kg/day twice daily.

ADVERSE EFFECTS. Fatigue and altered mental status occur at toxic dosages. Glaucoma is a rare idiosyncratic reaction. Appetite is often diminished.

Valproate (Depakene, Depakote, and Depacon [Abbott Pharmaceutical])

INDICATIONS. Use valproate mainly for generalized seizures. It is especially useful for mixed seizure disorders, including myoclonic seizures, simple absence, myoclonic absence, myoclonus, and tonic-clonic seizures.

ADMINISTRATION. Oral absorption is rapid, and the half-life is 6 to 15 hours. Three-times-daily dosing of the liquid achieves constant blood concentrations. An enteric-coated capsule (Depakote and Depakote sprinkles) slows absorption and allows twice-a-day dosing in children.

The initial dosage is 10 to 15 mg/kg/day. Increments of 10 mg/kg/day to a dose of 60 mg/kg/day provide a blood concentration of 50 to 100 µg/mL. Blood concentrations of 80 to 120 µg/mL are often required to achieve seizure control. Protein binding is 95% at blood concentrations of 50 µg/mL and 80% at 100 µg/mL. Doubling the blood concentration increases the free fraction eightfold. Valproate has a strong affinity for plasma proteins and displaces other anticonvulsant drugs.

Valproate is absorbed rectally, and rectal administration provides therapeutic blood concentrations when oral administration is not possible. Peak concentrations occur 3 hours after rectal administration, and the serum concentration is approximately 75% of the oral dose. Intravenous administration with Depacon is the better substitute for oral therapy, however.

ADVERSE EFFECTS. Valproate has dose-related and idiosyncratic hepatotoxicity. Dose-related hepatotoxicity is harmless and characterized by increased serum concentrations of transaminases. Important dose-related effects are increased appetite and weight gain, a reduction in the platelet count, pancreatitis, and hyperammonemia. Thrombocytopenia may result in serious bleeding after trivial injury, whereas pancreatitis and hepatitis are associated with nausea

and vomiting. Hyperammonemia causes cognitive disturbances and nausea. These adverse reactions are reversible by reducing the daily dose. Reduced plasma carnitine concentrations occur in children taking valproate, and some believe that carnitine supplementation helps relieve cognitive impairment.

The major idiosyncratic reaction is fatal liver necrosis attributed to the production of an aberrant and toxic metabolite. The major risk (1:800) is in children younger than 2 years old who are receiving polytherapy. Many such cases may result from the combination of valproate on an underlying inborn error of metabolism. Fatal hepatotoxicity does not occur in children older than 10 years of age treated with valproate alone.

The clinical manifestations of idiosyncratic hepatotoxicity are similar to those of Reye syndrome (see Chapter 2). They may begin after 1 day of therapy or may not appear for 6 months. No reliable way exists to monitor patients for idiosyncratic hepatotoxicity or to predict its occurrence.

Vigabatrin

INDICATIONS. Vigabatrin is unavailable in the United States despite proven efficacy in treating infantile spasms and partial seizures.

ADMINISTRATION. Vigabatrin is a very-long-acting drug and needs only single-day dosing, but twice-daily dosing is preferable to reduce adverse effects. The initial dose is 10 mg/kg/day, which increases incrementally, as needed, to 100 mg/kg/day.

ADVERSE EFFECTS. Visual field defects are the adverse reaction that prevented approval for the use of this drug in the United States. The defect is rare and consists of circumferential field constriction with nasal sparing. Behavioral problems, fatigue, confusion, and gastrointestinal upset are usually mild and dose related.

Zonisamide (Zonegran [Elan Pharmaceuticals])

INDICATIONS. Similar to levetiracetam, zonisamide has a broad spectrum of activity. It is effective against primary generalized and partial onset epilepsies.

ADMINISTRATION. Zonisamide is a long-acting drug and is administered twice daily. The initial dose in children is 2 mg/kg/day. The maximal dose is 12 mg/kg/day.

ADVERSE EFFECTS. Common adverse effects are drowsiness and anorexia. Of greater concern is

the possibility of oligohydrosis and hyperthermia. Monitoring for decreased sweating and hyperthermia is required.

Management of Status Epilepticus

The definition of status epilepticus is a prolonged single seizure (>20 minutes) or repeated seizures without interictal recovery. Generalized tonic-clonic status is life-threatening and the most common emergency in pediatric neurology. The causes of status epilepticus are (1) a new acute illness, such as encephalitis; (2) a progressive neurological disease; (3) loss of seizure control in a known epileptic; or (4) a febrile seizure in an otherwise normal child. The cause is the main determinant of outcome. Recurrence of status epilepticus is most likely in children who are neurologically abnormal and is rare in children with febrile seizures.

Absence status and complex partial status are often difficult to identify as status epilepticus. The child may appear to be in a confusional state.

Immediate Management

Home management of prolonged seizures or clusters of seizures in children with known epilepsy is possible using rectal diazepam to prevent or abort status epilepticus. A rectal diazepam gel is commercially available, or the intravenous preparation can be given rectally (0.4 mg/kg) through a lubricated syringe. If the rectal dose fails to stop the seizures, hospital emergency services are required. Status epilepticus is a medical emergency requiring prompt attention. Initial assessment should be rapid and includes cardiorespiratory function, a history leading up to the seizure, and a neurological examination. Establish a controlled airway immediately and ventilate. Next, establish venous access. Request blood measurements of glucose, electrolytes, and anticonvulsant concentrations. Perform other tests (i.e., a toxic screen) as indicated. After blood is withdrawn, start an intravenous infusion of saline solution for the administration of anticonvulsant drugs and the administration of an intravenous bolus of a 50% glucose solution, 1 mg/kg.

Drug Treatment

The ideal drug for treating status epilepticus is one that acts rapidly, has a long duration of action, and does not produce sedation. The use of benzodiazepines (diazepam and lorazepam) for this purpose is common. They are inadequate

by themselves, however, because their duration of action is brief. In addition, children given intravenous benzodiazepines after a prior load of barbiturate often have respiratory depression. The dose of diazepam is 0.2 mg/kg, not to exceed 10 mg at a rate of 1 mg/min. Lorazepam may be preferable to diazepam because of its longer duration of action. The usual dosage in children 12 years old or younger is 0.1 mg/kg. After age 12, it is 0.07 mg/kg.

My preference is intravenous fosphenytoin because it has a long duration of action, does not produce respiratory depression, and does not impair consciousness. The initial dose is 20 mg/kg (calculated as phenytoin equivalents). Administration can be intravenous or intramuscular, but the intravenous route is preferred. In contrast to phenytoin, which required slow infusions (0.5 mg/kg/min) to avoid cardiac toxicity, fosphenytoin infusions are rapid and often obviate the need for prior benzodiazepine therapy. Infants generally require 30 mg/kg.

Fosphenytoin is usually effective, unless a severe, acute encephalopathy is the cause of status. Children who fail to wake up at an expected time after the clinical signs of status have stopped require an EEG to exclude the possibility of electrical status epilepticus.

When fosphenytoin fails, several alternatives are available; I prefer pentobarbital coma. Transfer the patient from the emergency department to an intensive care unit. Intubation and mechanical ventilation must be in place. After placing an arterial line, monitor the patient's blood pressure, cardiac rhythm, body temperature, and blood oxygen saturation.

With an EEG monitor recording continuously, infuse 10-mg/kg boluses of pentobarbital until a burst-suppression pattern appears on the EEG (Figure 1-5); a minimum of 30 mg/kg is generally required. Hypotension is the most serious complication and requires treatment with vasopressors. It generally does not occur until after the administration of 40 to 60 mg/kg. Barbiturates tend to accumulate, and the usual dosage needed to maintain pentobarbital coma is 3 mg/kg/hr. Maintaining coma for several days is safe. Continuous EEG recording indicates a burst-suppression pattern. Slow or stop the barbiturate infusion every 24 to 48 hours to see if coma is still required to prevent seizure discharges.

Ketogenic Diet

The Bible mentions fasting as a treatment for epilepsy. The introduction of diet-induced keto-




Figure 1-5. Burst-suppression pattern in pentobarbital coma. Long intervals of amplitude suppression are interrupted by bursts of mixed frequencies.

sis to mimic fasting dates to 1921, when barbiturates and bromides were the only available anticonvulsant drugs. This method became less popular with the introduction of effective pharmacotherapy. It remains an effective method, however, to treat children with seizures refractory to anticonvulsant drugs at nontoxic levels. The diet is most effective in infants and young children. A diet that consists of 60% medium-chain triglycerides, 11% long-chain saturated fat, 10% protein, and 19% carbohydrate is commonly used. The main side effects are abdominal pain and diarrhea (Nordli, 2002).

The ketogenic diet causes a prompt elevation in plasma ketone bodies that the brain uses as an energy source. The mechanism of action is not established. The ketogenic diet is most effective for control of myoclonic seizures, infantile spasms, atonic/akinetic seizures, and mixed seizures of Lennox-Gastaut syndrome.

Vagal Nerve Stimulation

Vagal nerve stimulation is a treatment for refractory seizures that uses a programmed stimulus from a chest-implanted generator via coiled electrodes tunneled to the left cervical vagus nerve. The main adverse effects are voice changes or hoarseness. The ketogenic diet is preferable to vagal nerve stimulation in children younger than 12 years old (Wheless and Maggio, 2002). Vagal nerve stimulation is a

consideration, however, in children and adolescents before progressing to a surgical option.

Surgical Approaches to Childhood Epilepsy

Epilepsy surgery is an excellent option for selected children with intractable epilepsy. Surgery is never a substitute for good medical therapy, and anticonvulsant drug therapy often continues after surgery. Three procedures—hemispherectomy, interhemispheric commissurotomy, and temporal lobectomy—are appropriate for different situations. None of these procedures is new, and all have gone through phases of greater or lesser popularity since their introduction.

Hemispherectomy

The use of hemispherectomy or, more correctly, hemidecortication is exclusively for children with intractable epilepsy and hemiplegia. The original procedure consisted of removing the cortex of one hemisphere along with a variable portion of the underlying basal ganglia. The extent of surgery depended partly on the underlying disease. The resulting cavity communicated with the third ventricle and developed a subdural membrane lining. The immediate results were good. Seizures were relieved in about 80% of children, and behavior and

spasticity improved without deterioration of intellectual function or motor function in the hemiparetic limbs.

Late complications of hemorrhage, hydrocephalus, and hemosiderosis occurred in 35% of children and were sometimes fatal. The subdural membrane repeatedly tore, bleeding into the ventricular system and staining the ependymal lining and the pia arachnoid with iron. Because of these complications, less radical alternatives are generally preferred. These alternatives are the Montreal-type hemispherectomy and interhemispheric commissurotomy. The Montreal-type hemispherectomy is a modified procedure with removal of most of the damaged hemisphere, but with portions of the frontal and occipital lobes left in place but disconnected from the other hemisphere and brainstem. The best results are in children with diseases affecting only one hemisphere, Sturge-Weber syndrome (Kossoff et al, 2002) and Rasmussen encephalitis (Kossoff et al, 2003).

Interhemispheric Commissurotomy

Disconnecting the hemispheres from each other and from the brainstem is an alternative to hemispherectomy in children with intractable epilepsy and hemiplegia. Another use of this procedure is to decrease the occurrence of secondary generalized tonic-clonic seizures from partial or minor generalized seizures. The efficacy of commissurotomy and hemispherectomy in children with infantile hemiplegia is probably comparable, but efficacy of commissurotomy in other forms of epilepsy is unknown.

Complete and partial commissurotomies are in use. Complete commissurotomy entails division of the entire corpus callosum, anterior commissure, one fornix, and the hippocampal commissure. Complete commissurotomies may be one-stage or two-stage procedures. Partial commissurotomies vary from division of the corpus callosum and hippocampal commissure to division of only the anterior portion of the corpus callosum.

Two immediate, but transitory, postoperative complications may follow interhemispheric commissurotomy: (1) a syndrome of mutism, left arm and leg apraxia, and urinary incontinence and (2) hemiparesis. These complications are more common after one-stage, complete commissurotomy than after two-stage procedures or partial commissurotomy and probably are caused by prolonged retraction of one hemisphere during surgery. Long-term complications

may include stuttering and poorly coordinated movements of the hands.

Temporal Lobectomy

The results of temporal lobectomy depend on the selection criteria and the skill of the epileptology team. Complete seizure relief should be attainable in more than half of children with intractable partial complex seizures of temporal lobe origin (Gilliam et al, 1997). Of children who were free of seizures at 5 years, 40% had recurrences by 15 years (Jarrar et al, 2002).

Only children who have a unilateral temporal focus are candidates for surgery. PET is proving valuable for identifying the epileptic focus. The surgical procedure is a subpial resection of the superior temporal gyrus, hippocampus, and amygdala. Intraoperative EEG determines the extent of resection. Twelve percent of specimens contain benign tumors, gliomas, and gangliogliomas. The most common complication is superior quadrantanopsia (40%), and the most serious complication is aphasia (10%), which is usually transitory.

References

- Acharya JN, Wyllie E, Lüders HO, et al. Seizure symptomatology in infants with localization-related epilepsy. *Neurology* 1997;48:189-196.
- Andermann F, Zifkin B. The benign occipital epilepsies of childhood. An overview of the idiopathic syndrome and of the relationship to migraine. *Epilepsia* 1998; 4:S9-S23.
- Andrade DM, Ackerley CA, Minett TSC, et al. Skin biopsy in Lafora disease. Genotype-phenotype correlations and diagnostic pitfalls. *Neurology* 2003;61:1611-1614.
- Applegarth DA, Toone J, Hamosh A. (16 May 2003) Glycine encephalopathy. In: *GeneClinics: Medical Genetics Knowledge Base*. [database online] University of Washington, Seattle. Available at <http://www.geneclinics.org>.
- Archer JS, Briellmann RS, Syngieniotis A, et al. Spike-triggered fMRI in reading epilepsy. Involvement of left frontal cortex working memory area. *Neurology* 2002;60:415-421.
- Baram TZ, Mitchell WG, Tournay A, et al. High-dose corticotropin (ACTH) versus prednisone for infantile spasms. A prospective, randomized, blinded study. *Pediatrics* 1996;97:375-379.
- Berg AT, Shinnar S, Darefsky AS, et al. Predictors of recurrent febrile seizures. A prospective cohort study. *Arch Pediatr Adolesc Med* 1997;151:371-378.
- Berkovic S, Heron SE, Giordano L, et al. Benign familial neonatal-infantile seizures. Characterization of a new sodium channelopathy. *Ann Neurol* 2004;55:550-557.
- Camfield P, Camfield C. Epileptic syndromes in childhood. Clinical features, outcomes, and treatment. *Epilepsia* 2002;43:27-32.

- Carpio A, Hauser WA. Prognosis for seizure recurrence in patients with newly diagnosed neurocysticercosis. *Neurology* 2002;59:1730-1734.
- Crest C, Dupont S, Leguern E, et al. Levetiracetam in progressive myoclonic epilepsy. An exploratory study in 9 patients. *Neurology* 2004;62:640-643.
- Delanty N, French J. Treatment of Lennox-Gastaut syndrome. Current recommendations. *CNS Drugs* 1998; 10:181-188.
- Donma MM. Clinical efficacy of piracetam in treatment of breath-holding spells. *Pediatr Neurol* 1998;18:41-45.
- Dulac O. Epileptic encephalopathy. *Epilepsia* 2001; 92(Suppl13):23-26.
- Freed GE, Martinez F. Atypical seizures as the cause of apnea in a six-month old child. *Clin Pediatr* 2001;40: 283-285.
- Gilliam F, Wyllie EW, Kashden J, et al. Epilepsy surgery outcome. Comprehensive assessment in children. *Neurology* 1997;48:1368-1374.
- Gospe SM. Pyridoxine-dependent seizures. Findings from recent studies pose new questions. *Pediatr Neurol* 2002;26:181-185.
- Granata T, Fusco L, Gobbi G, et al. Experience with immunomodulating treatments in Rasmussen's encephalitis. *Neurology* 2003a;61:1807-1810.
- Granata T, Gobbi G, Spreafico R, et al. Rasmussen's encephalitis. Early characteristics allows diagnosis. *Neurology* 2003b;60:422-425.
- Guilleminault C, Palombini L, Pelayo R, et al. Sleepwalking and sleep terrors in prepubertal children. What triggers them? *Pediatrics* 2003;111:e17-e25.
- Hamilton RL, Haas RH, Nyhan WL, et al. Neuro-pathology of propionic academia. A report of two patients with basal ganglia lesions. *J Child Neurol* 1995;10:25-30.
- Hancock E, Osborne JP. Vigabatrin in the treatment of infantile spasms in tuberous sclerosis. Literature review. *J Child Neurol* 1999;14:71-74.
- Hayman M, Scheffer LE, Chinvarun Y, et al. Autosomal dominant nocturnal frontal lobe epilepsy. Demonstration of frontal focal onset and intrafamilial variation. *Neurology* 1997;49:969-975.
- Hirtz D, Berg A, Bettis D, et al. Practice parameter. Treatment of the child with a first unprovoked seizure. Report of the Quality Standards Subcommittee of the American Academy of Neurology and the Practice Committee of the Child Neurology Society. *Neurology* 2003;60:166-175.
- Janz D. The idiopathic generalized epilepsies of adolescence childhood and juvenile age of onset. *Epilepsia* 1997;38:4-11.
- Jarrar RG, Buchhalter JR, Meyer FB, et al. Long-term follow-up of temporal lobectomy in children. *Neurology* 2002;59:1635-1637.
- Kossoff EH, Buck C, Freeman JM. Outcomes of 32 hemispherectomies for Sturge-Weber syndrome worldwide. *Neurology* 2002;59:1735-1738.
- Kossoff EH, Vining EPG, Pillas DJ, et al. Hemispherectomy for intractable unihemispheric epilepsy. Etiology vs outcome. *Neurology* 2003;61:887-890.
- Lehesjoki A-E, Koskineniemi M-L. (24 June 2004) Unverricht-Lundborg disease. In: *GeneClinics: Medical Genetics Knowledge Base*. [database online] University of Washington, Seattle. Available at <http://www.geneclinics.org>.
- Lerche H, Jukak-Rott K, Lehmann-Horn F. Ions channels and epilepsy. *Am J Med Genet* 2001;106:146-159.
- McDonald-McGinn DM, Emanuel MS, Zackai EH. (23 July 2004) 22q11.2 deletion syndrome. In: *GeneClinics: Medical Genetics Knowledge Base*. [database online] University of Washington, Seattle. Available at <http://www.geneclinics.org>.
- Mikati MA, Lepejian GA, Holmes GL. Medical treatment of patients with infantile spasms. *Clin Neuropharmacol* 2002;25:61-70.
- Munchau A, Shahidi GA, Eunson LH, et al. A new family with paroxysmal exercise induced dystonia and migraine. A clinical and genetic study. *J Neurol Neurosurg Psychiatry* 2000;68:609-614.
- Nicolaides P, Leonard J, Surtees R. Neurological complications of methylmalonic acidemia. *Arch Dis Child* 1998;78:508-512.
- Nordli D. The ketogenic diet. Uses and abuses. *Neurology* 2002;58(Suppl 7):S21-S23.
- Painter MJ, Sher MS, Sten AD, et al. Phenobarbital compared with phenytoin for the treatment of neonatal seizures. *N Engl J Med* 1999;341:485-489.
- Panayiotopoulos CP. Extraoccipital benign childhood partial seizures with ictal vomiting and excellent prognosis. *J Neurol Neurosurg Psychiatry* 1999;66:82-85.
- Porter BE, Judkins AR, Clancy RR, et al. Dysplasia. A common finding in intractable pediatric temporal lobe epilepsy. *Neurology* 2003;61:365-368.
- Prasad A, Kuzniecky RL, Knowlton RC, et al. Evolving antiepileptic drug treatment in juvenile myoclonic epilepsy. *Arch Neurol* 2003;60:1100-1105.
- Roland EH, Poskitt K, Rodriguez E, et al. Perinatal hypoxic-ischemic thalamic injury. Clinical features and neuroimaging. *Ann Neurol* 1998;44:161-166.
- Scammell TE. The neurobiology, diagnosis, and treatment of narcolepsy. *Ann Neurol* 2003;53:154-160.
- Scheffer IE, Berkovic SF. Generalized epilepsy with febrile seizures plus a genetic disorder with heterogeneous clinical phenotypes. *Brain* 1997;120:479-490.
- Scheffer IE, Jones L, Pozzebon M, et al. Autosomal dominant Rolandic epilepsy and speech dyspraxia. A new syndrome with anticipation. *Ann Neurol* 1995;38: 633-642.
- Scheuerle AE. (27 March 2003) Incontinentia pigmenti. In: *GeneClinics: Medical Genetics Knowledge Base*. [database online] University of Washington, Seattle. Available at <http://www.geneclinics.org>.
- Seashore M. (28 June 2004) Organic acidemias. An overview. In: *GeneClinics: Medical Genetics Knowledge Base*. [database online] University of Washington, Seattle. Available at <http://www.geneclinics.org>.
- Summar ML, Tuchman M. (21 June 2004) Urea cycle disorders overview. In: *GeneClinics: Medical Genetics Knowledge Base*. [database online] University of Washington, Seattle. Available at <http://www.geneclinics.org>.
- Suzuki Y, Imai K, Toribe Y, et al. Long-term response to zonisamide in patients with West syndrome. *Neurology* 2002;58:1556-1559.
- Tarkka R, Paakko E, Pyhtinen J, et al. Febrile seizures and mesial temporal sclerosis. No association in a long-term follow-up study. *Neurology* 2003;60:215-218.
- Tijssen MAJ, Padberg GW, van Dijk JG. The startle pattern in the minor form of hyperekplexia. *Arch Neurol* 1997;54:388-393.

- VanLandingham KE, Heinz ER, Cavazos JE, et al. Magnetic resonance imaging evidence of hippocampal injury after prolonged focal febrile convulsions. *Ann Neurol* 1998;43:413-426.
- Verity C, Greenwood R, Golding J. Long-term intellectual and behavioral outcomes of children with febrile convulsions. *N Engl J Med* 1998;338:1723-1728.
- Wheless JW, Kim HL. Adolescent seizures and epilepsy syndromes. *Epilepsia* 2002;43:33-52.
- Wheless JW, Maggio V. Vagus nerve stimulation therapy in patients younger than 18 years. *Neurology* 2002; 59;(Suppl 4):S21-S25.
- Wolf, B. (24 March 2003) Biotinidase deficiency. In: *GeneClinics: Medical Genetics Knowledge Base*. [database online] University of Washington, Seattle. Available at <http://www.geneclinics.org>.

Chapter 2

Altered States of Consciousness

THE TERMS USED in the text to describe states of decreased consciousness are provided in Table 2-1. With the exception of *coma*, these definitions are not standard. They are more precise, however, and more useful than such terms as *semicomatose* and *semistuporous*. The term *encephalopathy* describes a diffuse disorder of the brain in which at least two of the following symptoms are present: (1) altered states of consciousness, (2) altered cognition or personality, and (3) seizures. *Encephalitis* is an encephalopathy accompanied by cerebrospinal fluid (CSF) pleocytosis.

Lack of responsiveness is not always lack of consciousness. Infants with botulism (see Chapter 6) may have such severe hypotonia and ptosis that they cannot move their limbs or eyelids in response to stimulation. They appear to be in a coma or stupor but are actually alert. The *locked-in syndrome* (a brainstem disorder in which the individual can process information but cannot respond) and catatonia are other examples of diminished responsiveness in the alert state.

Either increased or decreased neuronal excitability may characterize the progression from consciousness to coma. Patients with increased neuronal excitability (the *high road*) become restless and then confused; next, tremor, hallucinations, and delirium (an agitated confusional state) develop. Myoclonic jerks may occur. Seizures herald the end of delirium, and stupor or coma follow. Table 2-2 summarizes the differential diagnosis of the high road to coma. Tumors and other mass lesions are not expected causes. Instead, metabolic, toxic, and inflammatory disorders are likely.

Decreased neuronal excitability (the *low road*) lacks an agitated stage. Instead, awareness progressively deteriorates from lethargy to obtunda-

tion, stupor, and coma. The differential diagnosis is considerably larger than that with the high road and includes mass lesions and other causes of increased intracranial pressure (Table 2-3). Table 2-4 lists conditions that cause recurrent encephalopathies. A comparison of Tables 2-2 and 2-3 shows considerable overlap between conditions whose initial features are agitation and confusion and conditions that begin with lethargy and coma; the disorders responsible for each are described together to prevent repetition.

Diagnostic Approach to Delirium

Assume that any child with the acute behavioral changes of delirium (agitation, confusion, delusions, or hallucinations) has an organic encephalopathy until proved otherwise. The usual causes of delirium are toxic or metabolic disorders diffusely affecting both cerebral hemispheres. Schizophrenia should not be a consideration in a prepubertal child with acute delirium. Fixed beliefs, unalterable by reason, are *delusions*. The paranoid delusions of schizophrenia are logical to the patient and frequently part of an elaborate system of irrational thinking in which the patient feels menaced. Delusions associated with organic encephalopathy are less logical, are not systematized, and tend to be stereotyped.

A *hallucination* is the perception of sensory stimuli that are not present. Organic encephalopathies usually cause visual hallucinations, whereas psychiatric illness usually causes auditory hallucinations, especially if the voices are accusatory. Stereotyped auditory hallucinations that represent a recurring memory are an exception and suggest temporal lobe seizures.

TABLE 2-1
States of Decreased Consciousness

Term	Definition
Lethargy	Difficult to maintain the aroused state
Obtundation	Responsive to stimulation other than pain*
Stupor	Responsive only to pain*
Coma	Unresponsive to pain

*Responsive indicates cerebral alerting, not just reflex withdrawal.

History and Physical Examination

Delirious children, even with stable vital function, require rapid assessment because the potential for deterioration to a state of diminished consciousness is real. Obtain a careful history of the following: (1) the events leading to the behavioral change; (2) drug or toxic exposure (prescription drugs are more often at fault than substances of abuse, and a medicine cabinet inspection should be ordered in every home the child has visited); (3) a personal or family history of migraine or epilepsy; (4) recent or concurrent fever, infectious disease, or systemic illness; and (5) a previous personal or family history of encephalopathy.

Examination of the eyes, in addition to determining the presence or absence of papilledema, provides other etiological clues. Small or large pupils that respond poorly to light, nystagmus, or impaired eye movements suggest a drug or toxic exposure. Fixed deviation of the eyes in one lateral direction may indicate that (1) the encephalopathy has focal features, (2) seizures are a cause of the confusional state, or (3) seizures are part of the encephalopathy. The general and neurological examinations should specifically include a search for evidence of trauma, needle marks on the limbs, meningismus, and cardiac disease.

Laboratory Investigations

Individualize laboratory evaluation; not every test is essential for each clinical situation. The first step is to obtain blood and urine tests. Studies of potential interest include culture; complete blood count; sedimentation rate; toxicity screen; blood concentrations of glucose, electrolytes, calcium and phosphorus, urea nitrogen, ammonia, and thyroid-stimulating hormone; and liver enzymes. If possible, obtain a computed tomography (CT) scan of the head while the results of these tests are pending. If sedation is required to perform the

TABLE 2-2
Causes of Agitation and Confusion

Epileptic

Absence status (see Chapter 1)
Complex partial seizure (see Chapter 1)

Infectious Disorders

Bacterial infections
Cat-scratch disease
Meningitis (see Chapter 4)
Rickettsial infections
Lyme disease
Rocky Mountain spotted fever
Viral infections
Aseptic meningitis
Arboviruses
Herpes simplex encephalitis
Measles encephalitis
Postinfectious encephalomyelitis
Reye syndrome

Metabolic and Systemic Disorders

Disorders of osmolality
Hypoglycemia
Hyponatremia
Endocrine disorders
Adrenal insufficiency
Hypoparathyroidism
Thyroid disorders
Hepatic encephalopathy
Inborn errors of metabolism

Disorders of pyruvate metabolism (see Chapter 5)
Medium-chain acyl-CoA dehydrogenase deficiency
Respiratory chain disorders (see Chapters 5, 6, 8, 10)
Urea cycle disorder, heterozygote (see Chapter 1)
Renal disease
Hypertensive encephalopathy
Uremic encephalopathy

Migraine

Acute confusional
Aphasic
Transient global amnesia

Psychological

Panic disorder
Schizophrenia

Toxic

Immunosuppressive drugs
Prescription drugs
Substance abuse
Toxins

Vascular

Congestive heart failure
Embolism
Hypertensive encephalopathy
Lupus erythematosus
Subarachnoid hemorrhage
Vasculitis

TABLE 2-3
Causes of Lethargy and Coma

Epilepsy

Postictal state (see Chapter 1)
 Status epilepticus (see Chapter 1)

Hypoxia-Ischemia

Cardiac arrest
 Cardiac arrhythmia
 Congestive heart failure
 Hypotension
 Autonomic dysfunction
 Dehydration
 Hemorrhage
 Pulmonary embolism
 Near-drowning
 Neonatal (see Chapter 1)

Increased Intracranial Pressure

Cerebral abscess (see Chapter 4)
 Cerebral edema (see Chapter 4)
 Cerebral tumor (see Chapters 4 and 10)
 Herniation syndromes (see Chapter 4)
 Hydrocephalus (see Chapters 4 and 18)
 Intracranial hemorrhage
 Spontaneous (see Chapter 4)
 Traumatic

Infectious Disorders

Bacterial infections
 Cat-scratch disease
 Gram-negative sepsis
 Hemorrhagic shock and encephalopathy syndrome
 Meningitis (see Chapter 4)
 Toxic shock syndrome
 Rickettsial infections
 Lyme disease
 Rocky Mountain spotted fever
 Viral infections
 Aseptic meningitis
 Arboviruses
 Herpes simplex encephalitis
 Measles encephalitis
 Postinfectious encephalomyelitis
 Reye syndrome
 Postimmunization encephalopathy

Metabolic and Systemic Disorders

Disorders of osmolality
 Diabetic ketoacidosis (hyperglycemia)
 Hypoglycemia

Hypernatremia
 Hyponatremia
 Endocrine disorders
 Adrenal insufficiency
 Hypoparathyroidism
 Thyroid disorders
 Hepatic encephalopathy
 Inborn errors of metabolism
 Disorders of pyruvate metabolism (see Chapter 5)
 Glycogen storage disorders (see Chapter 1)
 Medium-chain acyl-CoA dehydrogenase (MCAD) deficiency
 Respiratory chain disorders (see Chapter 5, 6, 8, 10)
 Urea cycle disorder, heterozygote (see Chapter 1)
 Renal disorders
 Acute uremic encephalopathy
 Chronic uremic encephalopathy
 Dialysis encephalopathy
 Hypertensive encephalopathy
 Other metabolic disorders
 Burn encephalopathy
 Hypomagnesemia
 Parenteral hyperalimentation
 Vitamin B complex deficiency

Migraine Coma

Toxic
 Immunosuppressive drugs
 Prescription drugs
 Substance abuse
 Toxins
Trauma
 Concussion
 Contusion
 Intracranial hemorrhage
 Epidural hematoma
 Subdural hematoma
 Intracerebral hemorrhage
 Neonatal (see Chapter 1)
Vascular
 Hypertensive encephalopathy
 Intracranial hemorrhage, nontraumatic (see Chapter 4)
 Lupus erythematosus (see Chapter 11)
 Neonatal idiopathic cerebral venous thrombosis (see Chapter 1)
 Vasculitis (see Chapter 11)

study, a short-acting benzodiazepine is preferred. Nondiagnostic blood studies and normal CT results are an indication for lumbar puncture to look for infection or increased intracranial pressure. A manometer should always be available to measure CSF pressure.

An electroencephalogram (EEG) can be useful in the evaluation of delirious patients and should be obtained at an opportune time. Findings are usually abnormal in acute organic encephalopathies and normal in psychiatric

illnesses. The minimal EEG finding in encephalopathy is slowing of the posterior rhythm. Diffuse theta and delta activity, absence of faster frequencies, and intermittent rhythmic delta activity are characteristic of severe encephalopathies. Specific abnormalities may include epileptiform activity consistent with absence or complex partial status; triphasic waves indicating hepatic or uremic encephalopathy; and periodic lateralizing epileptiform discharges in one temporal lobe, suggesting herpes encephalitis.

TABLE 2-4
Causes of Recurrent Encephalopathy

Burn encephalopathy
Epilepsy
Hashimoto's thyroiditis
Hypoglycemia
Increased intracranial pressure (recurrent)
Medium-chain acyl-CoA dehydrogenase deficiency
Mental disorders
Migraine
Mitochondrial disorders
Pyruvate metabolism disorders
Substance abuse
Urea cycle disorder

Diagnostic Approach to Lethargy and Coma

The diagnostic approach to states of diminished consciousness in children is similar to the approach suggested for delirium except for greater urgency. The causes of progressive decline in the state of consciousness are diffuse or multifocal disturbances of the cerebral hemispheres or focal injury to the brainstem. Physical examination reveals the anatomical site of abnormality in the brain.

History and Physical Examination

Obtain the same historical data as for delirium except that mass lesions are an important consideration. Inquire further concerning trauma or preceding symptoms of increasing intracranial pressure. Direct the physical examination at determining the anatomical site of disturbed cerebral function and its cause. The important variables in locating the site of abnormality are state of consciousness, pattern of breathing, pupillary size and reactivity, eye movements, and motor responses. The cause of lethargy and obtundation is usually mild depression of hemispheric function. Stupor and coma are characteristic of much more extensive disturbance of hemispheric function or involvement of the diencephalon and upper brainstem. Derangements of the dominant hemisphere may have a greater effect on consciousness than derangements of the nondominant hemisphere.

Cheyne-Stokes respiration, in which periods of hyperpnea alternate with periods of apnea, is usually caused by bilateral hemispheric or diencephalic injuries, but can result from bilateral damage anywhere along the descending pathway between the forebrain and upper pons.

Alertness, pupillary size, and heart rhythm may vary during Cheyne-Stokes respiration. Alertness is greater during the waxing portion of breathing. Lesions just ventral to the aqueduct or fourth ventricle cause a sustained, rapid, deep hyperventilation (central neurogenic hyperventilation). Abnormalities within the medulla and pons affect the respiratory centers and cause three different patterns of respiratory control: (1) *apneustic breathing*, a pause at full inspiration; (2) *ataxic breathing*, haphazard breaths and pauses without a predictable pattern; and (3) *Ondine's curse*, failure of automatic breathing when asleep.

In metabolic encephalopathies, retention of the pupillary light reflex is usual. Absence of the pupillary reflex in a comatose patient indicates a structural abnormality. The major exception is drugs: The cause of fixed dilation of pupils in an alert patient is topical administration of mydriatics. In comatose patients, hypothalamic damage causes unilateral pupillary constriction and a Horner syndrome; midbrain lesions cause mid-position fixed pupils; pontine lesions cause small but reactive pupils; and lateral medullary lesions cause a Horner syndrome.

Tonic lateral deviation of both eyes indicates a seizure originating in the hemisphere opposite to the direction of gaze or a destructive lesion in the hemisphere in the direction of gaze. The assessment of ocular motility in comatose patients is the instillation of ice water sequentially 15 minutes apart in each ear to chill the tympanic membrane. Ice water in the right ear causes both eyes to deviate rapidly to the right, then slowly return to the midline. The rapid movement to the right is a brainstem reflex, and its presence indicates that much of the brainstem is intact. Abduction of the right eye with failure of left eye adduction indicates a lesion in the medial longitudinal fasciculus (see Chapter 15). The slow movement that returns the eyes to the left requires a corticopontine pathway originating in the right hemisphere and terminating in the left pontine lateral gaze center. Its presence indicates unilateral hemispheric function. Skew deviation, the deviation of one eye above the other (hypertropia), usually indicates a lesion of the brainstem or cerebellum (Leigh and Zee, 1999).

Carefully observe trunk and limb position at rest, spontaneous movements, and response to noxious stimuli. Spontaneous movement of all limbs generally indicates a mild depression of hemispheric function without structural disturbance. Monoplegia or hemiplegia except when in the postictal state suggests a structural

disturbance of the contralateral hemisphere. An extensor response of the trunk and limbs to a noxious stimulus is termed *decerebrate rigidity*. The most severe form is *opisthotonos*: The neck is hyperextended and the teeth clenched; the arms adducted, hyperextended, and hyperpronated; and the legs extended with the feet plantar flexed. Decerebrate rigidity indicates brainstem compression and is considered an ominous sign whether present at rest or in response to noxious stimuli. Flexion of the arms and extension of the legs is termed *decorticate rigidity*. It is uncommon in children except after head injury and indicates hemispheric dysfunction with brainstem integrity.

Laboratory Investigations

Laboratory investigations are similar to those described for the evaluation of delirium. Perform head CT with contrast enhancement promptly to exclude the possibility of a mass lesion and herniation. It is a great error to send a child whose condition is uncertain for CT without someone in attendance who knows how to monitor deterioration and intervene appropriately.

Hypoxia and Ischemia

Hypoxia and ischemia usually occur together. Prolonged hypoxia causes personality change first, then loss of consciousness; acute anoxia results in immediate loss of consciousness.

Prolonged Hypoxia

CLINICAL FEATURES. Prolonged hypoxia can result from severe anemia (oxygen-carrying capacity reduced by at least half), congestive heart failure, chronic lung disease, and neuromuscular disorders. The best-studied model of prolonged, mild hypoxia involves ascent to high altitudes. Mild hypoxia causes impaired memory and judgment, confusion, and decreased motor performance. Greater degrees of hypoxia result in obtundation, multifocal myoclonus, and sometimes focal neurological signs such as monoplegia and hemiplegia. Children with chronic cardiopulmonary disease may have an insidious alteration in behavioral state as the arterial oxygen concentration slowly declines.

Neuromuscular disorders that weaken respiratory muscles, such as muscular dystrophy, often produce nocturnal hypoventilation as a first symptom of respiratory insufficiency.

Frequent awakenings and fear of sleeping are characteristic (see Chapter 7).

DIAGNOSIS. Consider chronic hypoxia in children with chronic cardiopulmonary disorders who become depressed or undergo personality change. Arterial oxygen pressure (P_{aO_2}) values less than 40 mm Hg are regularly associated with obvious neurological disturbances, but minor mental disturbances may occur at P_{aO_2} concentrations of 60 mm Hg, especially when hypoxia is chronic.

MANAGEMENT. Encephalopathy usually reverses when P_{aO_2} is increased, but persistent cerebral dysfunction may occur in mountain climbers after returning to sea level, and permanent cerebral dysfunction may develop in children with chronic hypoxia. As a group, children with chronic hypoxia from congenital heart disease have a lower IQ than nonhypoxic children. The severity of mental decline relates to the duration of hypoxia. Treat children with neuromuscular disorders who develop symptoms during sleep with overnight, intermittent positive-pressure ventilation (see Chapter 7).

Acute Anoxia and Ischemia

The usual circumstance in which acute anoxia and ischemia occur is cardiac arrest or sudden hypotension. Anoxia without ischemia occurs with suffocation (near-drowning, choking). Prolonged anoxia leads to bradycardia and cardiac arrest. In adults, hippocampal and Purkinje cells begin to die after 4 minutes of total anoxia and ischemia. Exact timing may be difficult in clinical situations when ill-defined intervals of anoxia and hypoxia occur. Remarkable survivals are sometimes associated with near-drowning in water cold enough to lower cerebral temperature and metabolism. The pattern of hypoxic-ischemic brain injury in newborns is different and depends largely on brain maturity (see Chapter 1).

CLINICAL FEATURES. Consciousness is lost within 8 seconds of cerebral circulatory failure, but the loss may take longer when anoxia occurs without ischemia. Presyncopal symptoms of lightheadedness and visual disturbances sometimes precede loss of consciousness. Seizures and extensor rigidity follow.

Prediction of outcome after hypoxic-ischemic events depends on age and circumstances. Only 13% of adults who have had a cardiac arrest regain independent function in the first year after arrest. The outcome in children is better because the incidence of preexisting cardiopulmonary disease is lower. Absence of pupillary

responses on initial examination is an ominous sign; such patients do not recover independent function. Twenty-four hours after arrest, lack of motor responses in the limbs and eyes identifies patients with a poor prognosis. Persistent early-onset myoclonus is a negative prognostic sign (Krumholz and Berg, 2002). In contrast, a favorable outcome is predictable for patients who rapidly recover roving or conjugate eye movements and limb withdrawal from pain. Children who are unconscious for longer than 60 days do not regain language skills or the ability to walk.

Two delayed syndromes of neurological deterioration follow anoxia. The first is *delayed postanoxic encephalopathy*, the appearance of apathy or confusion 1 to 2 weeks after apparent recovery. Motor symptoms follow, usually rigidity or spasticity, and may progress to coma or death. Demyelination is the suggested mechanism. The other syndrome is *postanoxic action myoclonus*. This syndrome usually follows a severe episode of anoxia and ischemia caused by cardiac arrest. All voluntary activity initiates disabling myoclonus (see Chapter 14). Symptoms of cerebellar dysfunction are also present.

DIAGNOSIS. Cerebral edema is prominent during the first 72 hours after severe hypoxia. CT during that time shows decreased density with loss of the differentiation between gray and white matter. Severe, generalized loss of density on the CT scan correlates with a poor outcome. An EEG that shows a burst-suppression pattern or absence of activity is associated with a poor neurological outcome or death; lesser abnormalities are not useful in predicting the prognosis.

MANAGEMENT. The principles of treating patients who have sustained hypoxic-ischemic encephalopathy do not differ substantially from the principles of caring for other comatose patients. Maintaining oxygenation, circulation, and blood glucose concentration is essential. Regulate intracranial pressure to levels that allow satisfactory cerebral perfusion (see Chapter 4). Anticonvulsant drugs manage seizures (see Chapter 1). Anoxia is invariably associated with lactic acidosis. Restoration of acid-base balance is essential.

The use of barbiturate coma to slow cerebral metabolism is common practice, but neither clinical nor experimental evidence indicates a beneficial effect after cardiac arrest or near-drowning. Hypothermia prevents brain damage during the time of hypoxia and ischemia but has questionable value after the event. Cortico-

steroids do not improve neurological recovery in patients with global ischemia after cardiac arrest. Postanoxic action myoclonus sometimes responds to valproate.

Persistent Vegetative State

The term *persistent vegetative state* (PVS) describes patients who, after recovery from coma, return to a state of wakefulness without cognition. PVS is a form of eyes-open permanent unconsciousness with loss of cognitive function and awareness of the environment but preservation of sleep-wake cycles and vegetative function. Survival is indefinite with good nursing care. The usual causes, in order of frequency, are anoxia and ischemia, metabolic or encephalitic coma, and head trauma. Anoxia-ischemia has the worst prognosis. Children who remain in a PVS for 3 months do not regain functional skills.

The American Academy of Neurology has adopted the policy that all medical treatment, including the provision of nutrition and hydration, may be ethically discontinued when a patient's condition has been diagnosed as PVS, it is clear that the patient would not want to be maintained in this state, and the family agrees to discontinue therapy.

Brain Death

The guidelines for brain death suggested by the American Academy of Neurology (1995) are generally accepted. Table 2-5 summarizes the important features of the report. The Academy urged caution in applying the criteria to children younger than 5 years old, but subsequent experience supports the validity of the standards in newborns and through childhood. Absence of cerebral blood flow is the earliest and most definitive proof of brain death.

Infectious Disorders

Bacterial Infections

Cat-Scratch Disease

The causative agent of cat-scratch disease is *Bartonella (Rochalimaea) henselae*, a gram-negative bacillus transmitted by a cat scratch and perhaps by cat fleas (Marra, 1995). It is the most common cause of chronic benign lymphadenopathy in children and young adults. The estimated incidence in the United States is

TABLE 2-5
Diagnostic Criteria for Clinical Diagnosis
of Brain Death

Prerequisites

Cessation of all brain function
 Proximate cause of brain death known
 Condition irreversible

Cardinal Features

Coma
 Absent brainstem reflexes
 Pupillary light reflex
 Corneal reflex
 Oculocephalic reflex
 Oculovestibular reflex
 Oropharyngeal reflex
 Apnea (established by formal apnea test)

Confirmatory Tests (Optional)

Cerebral angiography
 Electroencephalography
 Radioisotope cerebral blood flow study
 Transcranial Doppler ultrasonography

22,000 per year, and 80% of cases occur in children younger than 12 years old.

CLINICAL FEATURES. The major feature is lymphadenopathy proximal to the site of the scratch. Fever is present in only 60% of cases. The disease is usually benign and self-limited. Unusual systemic manifestations are oculoglandular disease, erythema nodosum, osteolytic lesions, and thrombocytopenic purpura. The most common neurological manifestation is encephalopathy. Transverse myelitis, radiculitis, cerebellar ataxia, and neuroretinitis are rare manifestations.

Encephalitis occurs in less than 1% of patients with cat-scratch disease. The mechanism is unknown, but the cause may be either a direct infection or a vasculitis. The male-to-female ratio is 2:1. Only 17% of cases occur in children younger than 12 years old and 15% in children 12 to 18 years old. The frequency of fever and the site of the scratch are the same in patients with encephalitis compared with patients without encephalitis. The initial and most prominent feature is a decreased state of consciousness ranging from lethargy to coma. Seizures occur in 46% of cases and combative behavior in 40%. Focal findings are rare.

DIAGNOSIS. The diagnosis requires local lymphadenopathy, contact with a cat, and an identifiable site of inoculation. Enzyme-linked immunosorbent assay tests and polymerase chain reaction (PCR) amplification from infected tissues are available for diagnosis. The CSF is

normal in 70% of cases. Lymphocytosis in the CSF, when present, does not exceed 30 cells/mm³. The EEG is diffusely slow, and cranial magnetic resonance imaging (MRI) or CT is normal.

MANAGEMENT. All affected children recover completely, 50% within 4 weeks. Intravenous gentamicin (5 to 7 mg/kg/day) or oral trimethoprim (10 mg/kg twice daily) and sulfamethoxazole (100 mg/kg twice daily) may speed recovery in children with severe encephalopathy.

Gram-Negative Sepsis

CLINICAL FEATURES. The onset of symptoms in gram-negative sepsis may be explosive and characterized by fever or hypothermia, chills, hyperventilation, hemodynamic instability, and mental changes (irritability, delirium, or coma). Neurological features may include asterixis, tremor, and multifocal myoclonus. Multiple organ failure follows (1) renal shutdown caused by hypotension, (2) hypoprothrombinemia caused by vitamin K deficiency, (3) thrombocytopenia caused by nonspecific binding of immunoglobulin, (4) disseminated intravascular coagulation with infarction or hemorrhage in several organs, and (5) progressive respiratory failure.

DIAGNOSIS. Always consider sepsis in the differential diagnosis of shock, and obtain blood cultures. When shock is the initial feature, gram-negative sepsis is the likely diagnosis. In *Staphylococcus aureus* infections, shock is more likely to occur during the course of the infection and not as an initial feature. The CSF is usually normal or may have an elevated concentration of protein. MRI or CT of the brain is normal early in the course and shows edema later on.

MANAGEMENT. Septic shock is a medical emergency. Promptly initiate antibiotic therapy at maximal doses (see Chapter 4). Treat hypotension by restoration of intravascular volume, and address each factor contributing to coagulopathy. Mortality is high even with optimal treatment.

Hemorrhagic Shock
Encephalopathy Syndrome

Bacterial sepsis is the presumed cause of the hemorrhagic shock encephalopathy syndrome.

CLINICAL FEATURES. Most affected children are younger than 1 year of age, but cases occur in children 26 months old. Half of children have mild prodromal symptoms of a viral gastroenteritis

or respiratory illness. In the rest, the onset is explosive; a previously well child is found unresponsive and having seizures. Fever of 38°C or higher is a constant feature. Marked hypotension with poor peripheral perfusion is the initial event. Profuse watery or bloody diarrhea with metabolic acidosis and compensatory respiratory alkalosis follows. Disseminated intravascular coagulopathy develops, and bleeding occurs from every venipuncture site. The mortality rate is 50%; the survivors have mental and motor impairment.

DIAGNOSIS. The syndrome resembles toxic shock syndrome, gram-negative sepsis, heatstroke, and Reye syndrome. Abnormal renal function occurs in every case, but serum ammonia concentrations remain normal, hypoglycemia is unusual, and blood cultures yield no growth.

CSF is normal except for increased pressure. CT shows small ventricles and loss of sulcal marking caused by cerebral edema. The initial EEG background is diffusely slow or may be isoelectric. A striking pattern called *electric storm* evolves over the first hours or days. Runs of spikes, sharp waves, or rhythmic slow waves that fluctuate in frequency, amplitude, and location characterize the pattern.

MANAGEMENT. Affected children require intensive care with ventilatory support, volume replacement, correction of acid-base and coagulation disturbances, anticonvulsant therapy, and control of cerebral edema.

Rickettsial Infections

Lyme Disease

A spirochete (*Borrelia burgdorferi*) causes Lyme disease. The vector is the hard-shelled deer ticks: *Ixodes dammini* in the eastern United States, *I. pacificus* in the western United States, and *I. ricinus* in Europe. Lyme disease is now the most common vector-borne infection in the United States. Six northeastern states account for 80% of cases.

CLINICAL FEATURES. The neurological consequences of disease are variable, and some are uncertain. Consequences associated with the early stages of disease have the greatest acceptance. The first symptom (stage 1) in 60% to 80% of patients is a skin lesion of the thigh, groin, or axillae (erythema chronicum migrans), which may be associated with fever, regional lymphadenopathy, and arthralgia. The rash begins as a red macule at the site of the tick bite, then spreads to form a red annular lesion with partial clearing, sometimes appearing as alternating rings of rash and clearing.

Neurological involvement (neuroborreliosis) develops weeks or months later when the infection disseminates (stage 2). Most children have only headache, which clears completely within 6 weeks; the cause may be mild aseptic meningitis or encephalitis. Fever may not occur. Facial palsy, sleep disturbances, and papilledema are rare. Polyneuropathies are uncommon in children. Transitory cardiac involvement (myopericarditis and atrioventricular block) may occur in stage 2.

A year or more of continual migratory arthritis begins weeks to years after the onset of neurological features (stage 3). Only one joint, often the knee, or a few large joints are affected. During stage 3, the patient feels ill. Encephalopathy with memory or cognitive abnormalities and confusional states, with normal CSF results, may occur. Other psychiatric or fatigue syndromes appear less likely to be causally related (Halperin et al, 1996).

DIAGNOSIS. The spirochete grows on cultures from the skin rash during stage 1 of the disease. At the time of meningitis, the CSF may be normal at first, but then shows a lymphocytic pleocytosis (about 100 cells/mm³), an elevated protein concentration, and a normal glucose concentration. *B. burgdorferi* grows on culture from the CSF during the meningitis (Halperin et al, 1996). A two-test approach establishes the diagnosis of neuroborreliosis (Garcia-Monco and Benach, 1995). The first step is to show the production of specific IgG and IgM antibodies in CSF. Antibody production begins 2 weeks after infection, and IgG is always detectable at 6 weeks. The second step, used when the first is inconclusive, is PCR to detect the organism.

MANAGEMENT. Either ceftriaxone (2 g once daily intravenously) or penicillin (3 to 4 million U intravenously every 3 to 4 hours) for 2 to 4 weeks treats encephalitis. Examine the CSF toward the end of the 2- to 4-week treatment course to assess the need for continuing treatment and again 6 months after the conclusion of therapy. Intrathecal antibody production may persist for years after successful treatment, and in isolation, it does not indicate active disease. Patients in whom CSF pleocytosis fails to resolve within 6 months should be retreated.

The treatment of peripheral or cranial nerve involvement without CSF abnormalities is with oral agents, either doxycycline, 100 mg twice daily for 14 to 21 days, or amoxicillin, 500 mg every 8 hours for 10 to 21 days. An effective vaccine against Lyme disease is available and used for children who live in endemic areas (Sigal et al, 1998; Steere et al, 1998).

Rocky Mountain Spotted Fever

Rocky Mountain spotted fever is an acute tick-borne disorder caused by *Rickettsia rickettsii*. Its geographic name is a misnomer; the disease occurs in much of the United States, with a special predilection for southwestern and southeastern states.

CLINICAL FEATURES. Fever, myalgia, and rash are constant symptoms and begin 2 to 14 days after tick bite. The rash first appears around the wrist and ankles 3 to 5 days after onset of illness and spreads to the soles of the feet and forearms. It may be maculopapular, petechial, or both. Headache is present in 66% of affected individuals, meningitis or meningoencephalitis is present in 33%, focal neurological signs are present in 14%, and seizures are present in 6%. The focal abnormalities result from microinfarcts.

DIAGNOSIS. *R. rickettsii* are demonstrable by direct immunofluorescence or immunoperoxidase staining of a skin biopsy specimen of the rash. Other laboratory tests may indicate anemia, thrombocytopenia, coagulopathy, hyponatremia, and muscle tissue breakdown. Serology retrospectively confirms the diagnosis. The CSF shows a mild pleocytosis.

MANAGEMENT. Initiate treatment when the diagnosis is first suspected. Delayed treatment results in 20% mortality. Oral or intravenous tetracycline (25 to 50 mg/kg/day) or chloramphenicol (50 to 75 mg/kg/day) in four divided doses or oral doxycycline (100 mg twice a day for 7 days) is effective. Continue treatment for 2 days after the patient is afebrile.

Toxic Shock Syndrome

Toxic shock syndrome is a potentially lethal illness caused by infection or colonization with some strains of *S. aureus*.

CLINICAL FEATURES. The onset is abrupt. High fever, hypotension, vomiting, diarrhea, myalgia, headache, and a desquamating rash characterize the onset. Multiple organ failure may occur during desquamation. Serious complications include cardiac arrhythmia, pulmonary edema, and oliguric renal failure. Initial encephalopathic features are agitation and confusion. These may be followed by lethargy, obtundation, and generalized tonic-clonic seizures.

Most pediatric cases have occurred in menstruating girls who use tampons, but this syndrome also may occur in children with occlusive dressings after burns or surgery and as a complication of influenza and influenza-like illness in

children with staphylococcal colonization of the respiratory tract.

DIAGNOSIS. No diagnostic laboratory test is available. The basis for diagnosis is the typical clinical and laboratory findings. More than half of patients have sterile pyuria; immature granulocytic leukocytes; coagulation abnormalities; hypocalcemia; low serum albumin and total protein concentrations; and elevated concentrations of blood urea nitrogen, transaminase, bilirubin, and creatine kinase. Cultures of specimens from infected areas yield *S. aureus*.

MANAGEMENT. Hypotension usually responds to volume restoration with physiological saline solutions. Some patients require vasopressors or fresh-frozen plasma. Initiate antibiotic therapy promptly with an agent effective against *S. aureus*.

Viral Infections

Because encephalitis usually affects the meninges and the brain, the term *meningoencephalitis* may be more accurate. Distinguishing encephalitis from aseptic meningitis is useful, however, for viral diagnosis because most viruses cause primarily one or the other, but not both. An annual incidence of 7.4:100,000 for encephalitis and 10.9:100,000 for aseptic meningitis remained relatively constant in one Minnesota County over a 32-year period. Both conditions are more common in the summer, in childhood, and in males.

Routine childhood immunization has reduced the number of pathogenic viruses circulating in the community. Enteroviruses and herpes simplex virus (HSV) are now the most common viral causes of meningitis and encephalitis in children. Specific viral identification is possible, however, in only 15% to 20% of cases.

The classification of viruses undergoes frequent change, but a constant first step is the separation of viruses with a DNA core from those with an RNA core. The only DNA viruses that cause acute postnatal encephalitis in immunocompetent hosts are herpesviruses. RNA viruses that cause encephalitis are myxoviruses (influenza and measles encephalitis), arboviruses (St. Louis encephalitis, eastern equine encephalitis, western equine encephalitis, and California-La Crosse encephalitis), retroviruses (acquired immunodeficiency syndrome encephalitis), and rhabdoviruses (rabies). RNA viruses (especially enteroviruses and mumps) are responsible for aseptic meningitis.

Some viruses, such as HSV, are highly neurotropic (usually infect the nervous system) but

rarely neurovirulent (rarely cause encephalitis), whereas others, such as measles, are rarely neurotropic but are highly neurovirulent. In addition to viruses that directly infect the brain and meninges, encephalopathies may follow systemic viral infections. These probably result from demyelination caused by immune-mediated responses of the brain to infection.

Aseptic Meningitis

The term *aseptic meningitis* defines a syndrome of meningismus and CSF leukocytosis without bacterial or fungal infection. Drugs or viral infections are the usual cause. Viral meningitis is a benign, self-limited disease from which 95% of children recover completely.

CLINICAL FEATURES. The onset of symptoms is abrupt and characterized by fever, headache, and stiff neck except in infants who do not have meningismus. Irritability, lethargy, and vomiting are common. "Encephalitic" symptoms are not part of the syndrome. Systemic illness is uncommon, but its presence may suggest specific viral disorders. The acute illness usually lasts less than 1 week, but malaise and headache may continue for several weeks.

DIAGNOSIS. In most cases of aseptic meningitis, the CSF contains 10 to 200 leukocytes/mm³, but cell counts of 1000 cells/mm³ or greater may occur with lymphocytic choriomeningitis. The response is primarily lymphocytic, but polymorphonuclear leukocytes may predominate early in the course. The protein concentration is generally 50 to 100 mg/dL (0.5 to 1 g/L), and the glucose concentration is normal, although it may be slightly reduced in children with mumps and lymphocytic choriomeningitis.

Aseptic meningitis usually occurs in the spring or summer, and enteroviruses are responsible for most cases in children. Nonviral causes of aseptic meningitis are rare, but Lyme disease, Kawasaki disease, leukemia, systemic lupus erythematosus (SLE), and migraine should be considered.

Individuals with a personal or family history of migraine may have attacks of severe headache associated with stiff neck and focal neurological disturbances, such as hemiparesis and aphasia. CSF examination shows a pleocytosis of 5 to 300 cells/mm³ that is mainly lymphocytes and a protein concentration of 50 to 100 mg/dL (0.5 to 1 g/L). Whether the attacks are migraine provoked by intercurrent aseptic meningitis or represent a "meningitic" form of migraine is unresolved. The recurrence of attacks in some people suggests that the mechanism is wholly migrainous.

Bacterial meningitis is the major concern when a child has meningismus. Although CSF examination provides several clues that differentiate bacterial from viral meningitis, initiate antibiotic therapy for every child with a clinical syndrome of aseptic meningitis until CSF culture is negative for bacteria (see Chapter 4). This is especially true for children who received antibiotic therapy before examination of the CSF.

MANAGEMENT. Treatment for herpes encephalitis with acyclovir is routine in children with viral meningitis or encephalitis until excluding that diagnosis. Treatment of viral aseptic meningitis is symptomatic. Bed rest in a quiet environment and mild analgesics provide satisfactory relief of symptoms in most children.

Arboviral (Arthropod-Borne) Encephalitis

The basis of arboviruses classification is ecology rather than structure. Ticks and mosquitoes are the usual vectors, and epidemics occur in the spring and summer. Each type of encephalitis has a defined geographic area. Arboviruses account for 10% of encephalitis cases reported in the United States.

California-La Crosse Encephalitis

The California serogroup viruses, principally La Crosse encephalitis, are the most common cause of arboviral encephalitis in the United States (Rust et al, 1999). The endemic areas are the Midwest and western New York State. Most cases occur between July and September. Small woodland mammals serve as a reservoir and mosquitoes as the vector.

CLINICAL FEATURES. Most cases of encephalitis occur in children, and asymptomatic infection is common in adults. The initial feature is a flulike syndrome that lasts 2 or 3 days. Headache heralds the encephalitis. Seizures and rapid progression to coma follow. Focal neurological disturbances are present in 20% of cases. Symptoms begin to resolve 3 to 5 days after onset, and most children recover without neurological sequelae. Death is uncommon and occurs mainly in infants.

DIAGNOSIS. Examination of CSF shows a mixed pleocytosis with lymphocytes predominating. The count is usually 50 to 200 cells/mm³ (range 0 to 600 cells/mm³). The virus is difficult to culture, and diagnosis depends on showing a fourfold or greater increase in hemagglutination inhibition and neutralizing

antibody titers between acute and convalescent sera.

MANAGEMENT. Treatment is supportive. No effective antiviral agent is available.

Eastern Equine Encephalitis

Eastern equine encephalitis is the most severe type of arboviral encephalitis.

CLINICAL FEATURES. Eastern equine encephalitis is a perennial infection of horses from New York to Florida. Human cases do not exceed five each year, and they follow epidemics in horses. The mortality rate is high. Wild birds serve as a reservoir and mosquitoes as a vector. Consequently, almost all cases occur during the summer.

Onset is usually abrupt and characterized by high fever, headache, and vomiting, followed by drowsiness, coma, and seizures. A long duration of non-neurological prodromal symptoms predicts a better outcome. In infants, seizures and coma are often the first clinical features. Signs of meningismus are often present in older children. Children usually survive the acute encephalitis, but expected sequelae include mental impairment, seizures, and disturbed motor function.

DIAGNOSIS. The CSF pressure is usually elevated, and examination reveals 200 to 2000 leukocytes/mm³, of which half are polymorphonuclear leukocytes. MRI shows focal lesions in the basal ganglia and thalamus (Deresiewicz et al, 1997). Diagnosis relies on showing a fourfold or greater rise in complement fixation and neutralizing antibody titers between acute and convalescent sera.

MANAGEMENT. Treatment is supportive. No effective antiviral agent is available.

Japanese B Encephalitis

Japanese B encephalitis is a major form of encephalitis in Asia and is an important health hazard to nonimmunized travelers during the summer. The virus cycle includes mosquitoes, pigs, and birds.

CLINICAL FEATURES. The initial features are malaise, fever, and headache or irritability lasting 2 to 3 days. Meningismus, confusion, and delirium follow. During the second or third week, photophobia and generalized hypotonia develop. Seizures may occur at any time. Finally, rigidity, a masklike facies, and brainstem dysfunction ensue. Mortality rates are high among indigenous populations and lower among Western travelers, probably because of a difference in the age of the exposed populations.

DIAGNOSIS. Examination of the CSF shows pleocytosis (20 to 500 cells/mm³). The cells are initially mixed, but later lymphocytes predominate. The protein concentration is usually 50 to 100 mg/dL (0.5 to 1 mg/L), and the glucose concentration is normal. Diagnosis depends on showing a fourfold or greater elevation in the level of complement-fixing antibodies between acute and convalescent sera.

MANAGEMENT. Treatment is supportive. No effective antiviral agent is available, but immunization with an inactivated vaccine protects against encephalitis in more than 90% of individuals.

St. Louis Encephalitis

St. Louis encephalitis is endemic in the western United States and epidemic in the Mississippi valley and the Atlantic states. It is the most common cause of epidemic viral encephalitis in the United States. The vector is a mosquito, and birds are the major reservoir.

CLINICAL FEATURES. Most infections are asymptomatic. The spectrum of neurological illness varies from aseptic meningitis to severe encephalitis leading to death. The mortality rate is low. Headache, vomiting, and states of decreased consciousness are the typical features. A slow evolution of neurological symptoms, the presence of generalized weakness and tremor, and the absence of focal findings and seizures favor a diagnosis of St. Louis encephalitis over herpes simplex encephalitis. The usual duration of illness is 1 to 2 weeks. Children usually recover completely, but adults may have residual mental or motor impairment.

DIAGNOSIS. CSF examination reveals a lymphocytic pleocytosis (50 to 500 cells/mm³) and a protein concentration of 50 to 100 mg/dL (0.5 to 1 g/L). The glucose concentration is normal. The virus is difficult to grow on culture, and diagnosis requires a fourfold or greater increase in complement fixation and hemagglutination inhibition antibody titers between acute and convalescent sera.

MANAGEMENT. Treatment is supportive. No effective antiviral agent is available.

West Nile Virus Encephalitis

West Nile virus is one of the world's most widely distributed viruses. It emerged in eastern North America in 1999 (Nash et al, 2001). Its distribution is now continental. *Culex* mosquitoes are the vector.

CLINICAL FEATURES. Most infections are asymptomatic. A nonspecific febrile illness characterizes the onset. Encephalitis occurs in less than 1% of infected individuals. Flaccid weakness and areflexia, suggesting polyneuropathy, are common features (Tyler, 2001). Case fatality is 12% to 14%.

DIAGNOSIS. Detection of IgM antibodies in CSF or IgM and IgG antibodies in serum is diagnostic.

Western Equine Encephalitis

CLINICAL FEATURES. Western equine encephalitis is a rare disorder. Wild birds serve as the reservoir and mosquitoes as the vector. More recent cases all have been from North Dakota, South Dakota, and Canada. Infants account for 20% to 30% of cases. Irritability, fever, meningismus, bulging of the fontanelles, seizures, and coma characterize the infection in infants. Older children may have a flulike syndrome before symptoms of meningoencephalitis develop. The initial symptom is usually behavioral change, including delirium, followed by drowsiness and coma. The EEG shows focal abnormalities that lateralize to one temporal lobe and suggest herpes encephalitis. Symptoms last for 1 to 2 weeks, and although the overall mortality rate is 10%, most fatalities are infants. Of surviving infants, 50% have permanent mental impairment and seizures.

DIAGNOSIS. CSF pleocytosis is first a mixture of polymorphonuclear leukocytes and lymphocytes and then lymphocytes alone. The protein concentration is 50 to 100 mg/dL (0.5 to 1 g/L). Diagnosis relies on showing a fourfold or greater rise in complement fixing or neutralizing antibodies between acute and convalescent sera.

MANAGEMENT. Treatment is supportive. No effective antiviral agent is available for western equine encephalitis.

Herpes Simplex Encephalitis

Two similar strains of HSV are pathogenic to humans. HSV-1 is associated with orofacial infections, and HSV-2 is associated with genital infections. Both are worldwide in distribution. Forty percent of children have antibodies to HSV-1, but routine detection of antibodies to HSV-2 occurs at puberty. HSV-1 is the causative agent of acute herpes simplex encephalitis after the newborn period, and HSV-2 is the causative agent of encephalitis in the newborn (see Chapter 1).

Initial orofacial infection with HSV-1 may be asymptomatic. The virus replicates in the skin, infecting nerve fiber endings and then the trigeminal ganglia. Further replication occurs within the ganglia before the virus enters a latent stage, during which it is not recoverable from the ganglia. Reactivation occurs during times of stress, especially intercurrent febrile illness. The reactivated virus ordinarily retraces its neural migration to the facial skin, but occasionally spreads proximally to the brain, causing encephalitis. The host's immunocompetence maintains the virus in a latent state. An immunocompromised state results in frequent reactivation and severe, widespread infection.

HSV is the most common cause of nonepidemic encephalitis and accounts for 10% to 20% of cases. The estimated annual incidence is 2.3 cases per 1 million population; 31% of cases occur in children.

CLINICAL FEATURES. Primary infection is often the cause of encephalitis in children. Only 22% of children with encephalitis have a history of recurrent labial herpes infection. Typically the onset is acute and characterized by fever, headache, lethargy, nausea, and vomiting. Of children, 80% show focal neurological disturbances (hemiparesis, cranial nerve deficits, visual field loss, aphasia, and focal seizures), and 20% show behavioral changes or generalized seizures without clinical evidence of focal neurological deficits. Both groups have focal abnormalities on neuroimaging studies or EEG. When a seizure occurs, the child is comatose. The acute stage of encephalitis lasts approximately 1 week. Recovery takes several weeks and is often incomplete.

Herpes meningitis is usually associated with genital lesions. The causative agent is HSV-2. The clinical features are similar to those of aseptic meningitis caused by other viruses.

DIAGNOSIS. Prompt consideration of herpes simplex encephalitis is important because treatment is available. CSF pleocytosis is present in 97% of cases. The median count is 130 leukocytes/mm³ (range 0 to 1000 leukocytes/mm³); 500 red blood cells/mm³ may be present as well. The median protein concentration is 80 mg/dL (0.8 g/L), but 20% of affected patients have normal protein concentrations, and 40% have concentrations greater than 100 mg/dL (>1 g/L). The glucose concentration in the CSF is usually normal, but in 7% of cases, it is less than half of the blood glucose concentration.

In the past, the demonstration of periodic lateralizing epileptiform discharges on EEG was presumptive evidence of herpes encephalitis.

MRI has proved to be a more sensitive early indicator of herpes encephalitis, however. T₂-weighted studies show increased signal intensity involving the cortex and white matter in the temporal and inferior frontal lobes (Figure 2-1). The areas of involvement then enlarge and coalesce. The identification of the organism in the CSF by PCR has obviated the need for brain biopsy to establish the diagnosis (Redington and Tyler, 2002).

MANAGEMENT. Most physicians begin acyclovir treatment in every child with a compatible clinical history. Treatment of HSV encephalitis with intravenous acyclovir (10 mg/kg every 8 hours for 14 days) reduces mortality from 70% in untreated patients to 25% to 30% (Whitley and Kimberlin, 1998). The highest mortality rate is in patients already in coma at treatment onset. Function returns to normal in 38%. New neurological disturbances may occur in some children after cessation of therapy (De Tiege et al, 2003). These syndromes are more likely when the original treatment course is short. A syndrome of choreoathetosis occurs within 1 month of the original encephalitis. Brain MRI does not show new necrotic areas, and the mechanism may be immune mediated. A second syndrome, which may occur early or years later, lacks choreoathetosis but resembles the initial infection more. The cause is probably renewed viral replication.

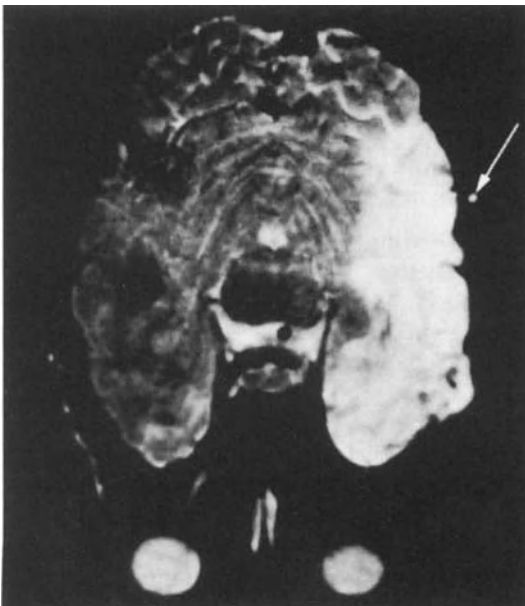


Figure 2-1. MRI of herpes encephalitis. T₂-weighted image shows increased signal intensity in both temporal lobes (arrow).

Measles (Rubeola) Encephalitis

Compulsory immunization had almost eliminated natural measles infection in the United States, but the incidence began increasing again in 1990 because of reduced immunization rates. The risk of encephalitis from natural disease is 1:1000. The mechanism of measles encephalitis may be direct viral infection, an allergic demyelination, or both. Chapter 5 describes a chronic form of measles encephalitis (see section on Subacute Sclerosing Panencephalitis).

CLINICAL FEATURES. Measles is a neurotropic virus, and EEG abnormalities are often present even without clinical symptoms of encephalopathy. Symptoms of encephalitis usually begin 1 to 8 days after the appearance of rash or are delayed for 3 weeks. The onset is usually abrupt and characterized by lethargy or obtundation that rapidly progresses to coma. Generalized seizures occur in half of children. The spectrum of neurological disturbances includes hemiplegia, ataxia, and involuntary movement disorders. Acute transverse myelitis also may occur (see Chapter 12). The incidence of neurological morbidity (mental retardation, epilepsy, and paralysis) is high but does not correlate with the severity of acute encephalitis.

Measles immunization does not cause an acute encephalopathy or any chronic brain damage syndrome. Generalized seizures may occur during the second week after immunization. These are mainly febrile seizures, and recovery is complete.

DIAGNOSIS. Examination of CSF shows a lymphocytic pleocytosis. The number of lymphocytes is usually highest in the first few days but rarely exceeds 100 cells/mm³. Protein concentrations are generally 50 to 100 mg/dL (0.5 to 1 g/L), and the glucose concentration is normal.

MANAGEMENT. Treatment is supportive. Anticonvulsant drugs usually provide satisfactory seizure control.

Postinfectious Encephalomyelitis

Acute disseminated encephalomyelitis is a central demyelinating disorder that occurs during or after a systemic viral illness. An immune-mediated mechanism is the presumed pathophysiology. Examples of postinfectious disorders are discussed in other chapters, including Guillain-Barré syndrome (see Chapter 7), acute cerebellar ataxia (see Chapter 10), transverse myelitis (see Chapter 12), brachial neuritis (see Chapter 13), optic neuritis (see Chapter 16), and Bell's palsy (see Chapter 17). The incidence of some

postinfectious disorders increases in immunocompromised populations, providing further support for the immune hypothesis.

The cause-and-effect relationship between viral infection and many of these syndromes is virtually impossible to establish, especially when 30 days is the accepted latency period between viral infection and onset of neurological dysfunction. The average school-age child has four to six “viral illnesses” each year so that 33% to 50% of children report a viral illness 30 days before the onset of any life event. No reports list a greater than 50% incidence of viral illness 30 days before onset for any syndrome listed previously.

CLINICAL FEATURES. MRI has expanded the spectrum of clinical features associated with postinfectious encephalopathy by allowing the demonstration of small demyelinating lesions. The encephalopathy is often preceded by lethargy, headache, and vomiting. Whether these “systemic features” are symptoms of a viral illness or of early encephalopathy is not clear. The onset of neurological symptoms is abrupt and characterized by focal motor signs, altered states of consciousness, or both (Murthy et al, 2002). Optic neuritis, transverse myelitis, or both may precede encephalopathy (see Chapter 12). Some children never have focal neurological signs, whereas in others the initial feature suggests a focal mass lesion. Mortality is highest in the first week. Although recovery among survivors is variable, most do well (Tenenbaum et al, 2002).

DIAGNOSIS. T₂-weighted MRI reveals a marked increase in signal intensity throughout the white matter (Figure 2-2). The corpus callosum and periventricular region are commonly affected (Hynson et al, 2001). The lesions resolve in the weeks that follow, and no new lesions are expected. In boys, exclude the diagnosis of adrenoleukodystrophy (see Chapter 5). The CSF is frequently normal. Occasional abnormalities are a mild lymphocytic pleocytosis and elevation of the protein concentration.

MANAGEMENT. Intravenous high-dose methylprednisolone is the accepted treatment and believed to lead to rapid recovery. This treatment protocol is empirical.

Reye Syndrome

Reye syndrome is a systemic disorder of mitochondrial function that occurs during or after viral infection. The occurrence is higher with salicylate use for symptomatic relief during viral illness. Recognition of this relationship has led to decreased use of salicylates in children and a

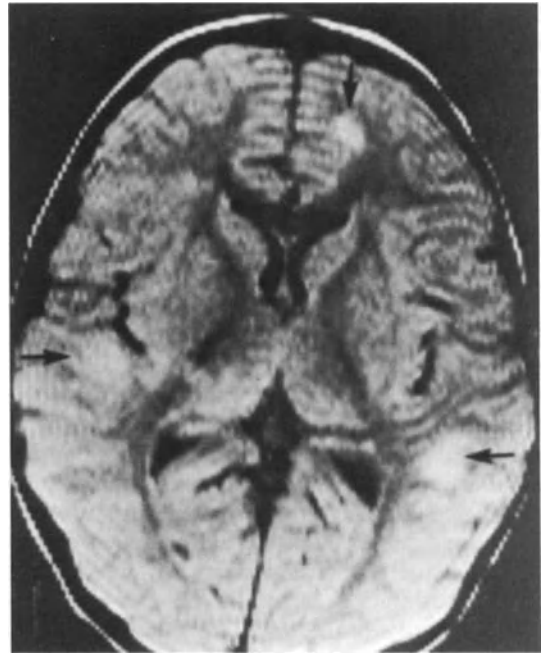


Figure 2-2. Postinfectious demyelination of the cerebral hemispheres. Areas of increased signal intensity are seen in both hemispheres (arrows).

marked decline in the incidence of Reye syndrome (Belay et al, 1999).

CLINICAL FEATURES. In the United States, sporadic cases generally are associated with varicella (chickenpox) or nonspecific respiratory infections; small epidemics are associated with influenza B infection. When varicella is the precipitating infection, the initial stage of Reye syndrome occurs 3 to 6 days after the appearance of rash.

The clinical course is relatively predictable and classified into five stages:

- Stage 0—vomiting, but no symptoms of brain dysfunction
- Stage I—vomiting, confusion, and lethargy
- Stage II—agitation, delirium, decorticate posturing, and hyperventilation
- Stage III—coma and decerebrate posturing
- Stage IV—flaccidity, apnea, and dilated, fixed pupils

The progression from stage I to stage IV may be explosive, evolving in less than 24 hours. More commonly, the period of recurrent vomiting and lethargy lasts for 1 day or longer. In most children with vomiting and laboratory evidence of hepatic dysfunction after varicella or respiratory infection, a liver biopsy specimen shows

the features of Reye syndrome, despite normal cerebral function. The designation of this stage is Reye stage 0. Stages I and II represent metabolic dysfunction and cerebral edema. Stages III and IV indicate generalized increased intracranial pressure and herniation.

Focal neurological disturbances and menin- gismus are not part of the syndrome. Fever is not a prominent feature, and hepatomegaly occurs in half of patients late in the course. The outcome is variable, but as a rule, infants do worse than older children do. Progression to stages III and IV at all ages is associated with a high death rate and with impaired neurological function in survivors.

DIAGNOSIS. Typical blood abnormalities are hypoglycemia, hyperammonemia, and increased concentrations of hepatic enzymes. Serum bilirubin concentrations are normal, and jaundice does not occur. Acute pancreatitis sometimes develops and is identified by increased concentrations of serum amylase. The CSF is normal except for increased pressure. The EEG shows abnormalities consistent with a diffuse encephalopathy.

Liver biopsy is definitive. Light microscopy shows panlobular accumulation of small intracellular lipid droplets and depletion of succinic acid dehydrogenase in the absence of other abnormalities. Electron microscopic changes include characteristic mitochondrial abnormalities, peroxisomal proliferation and swelling, proliferation of smooth endoplasmic reticulum, and glycogen depletion.

Conditions that mimic Reye syndrome are disorders of fatty acid oxidation, ornithine transcarbamoylase deficiency, and valproate hepatotoxicity. Assume an inborn error of metabolism in any child with recurrent Reye syndrome (see Table 2-4) or a family history of similar illness. Metabolic products of valproate are mitochondrial poisons that produce an experimental model of Reye syndrome.

MANAGEMENT. Admit all children to a pediatric intensive care unit. Children with stages I and II disease are treated with intravenous hypertonic (10% to 15%) glucose solution at normal maintenance volumes. Stages III and IV require treatment of increased intracranial pressure (see Chapter 4) by elevation of the head, controlled mechanical ventilation, and mannitol. Corticosteroids are of limited benefit and not used routinely. Some authorities continue to advocate intracranial pressure monitors and pentobarbital coma, despite failure to affect outcome. This once common and deadly disease has almost disappeared with discontinuation of salicylate therapy for children.

Postimmunization Encephalopathy

Three types of vaccine are in general use in the United States: live-attenuated viruses, whole or fractionated-killed organisms, and toxoids. Live-attenuated virus vaccines (measles, mumps, rubella, varicella, and oral poliomyelitis) produce a mild and harmless infection with subsequent immunity. Even under ideal circumstances of vaccine preparation and host resistance, however, symptoms of the natural disease and its known neurological complications may develop in vaccine recipients.

Whole-killed organisms (pertussis, influenza, rabies, and inactivated poliomyelitis) do not reproduce their natural disease, but alleged injury to the nervous system is a toxic or allergic mechanism. Whole-cell pertussis vaccine causes seizures, and although causation of chronic brain damage is not established, the Institute of Medicine has conceded the possibility based on the National Childhood Encephalopathy Study. A safe acellular vaccine replaced whole-cell vaccine. Semple rabies vaccine had been an important cause of encephalitis, but the newer vaccine, prepared from virus grown on human diploid cells, is safe and only rarely implicated as a cause of polyneuropathy. Semple vaccine, still in use in some parts of the world, contains myelin-basic protein known to cause encephalomyelitis. None of the other whole-killed organism vaccines causes encephalopathy.

Toxoid production is by the inactivation of toxins produced by bacteria. Diphtheria and tetanus toxoids are the only such vaccines now in use. Tetanus toxoid is associated with Guillain-Barré syndrome and brachial plexitis; neither is associated with encephalopathy.

Metabolic and Systemic Disorders

Disorders of Osmolality

The number of particles in a solution determines the osmolality of a solution. Sodium salts, glucose, and urea are the primary osmoles of the extracellular space; potassium salts, of the intracellular space; and plasma proteins, of the intravascular space. Because cell membranes are permeable to water and osmotic equilibrium is constant, the osmolality of the extracellular space determines the volume of intracellular fluid. Hypernatremia and hyperglycemia are the

major causes of serum hyperosmolality, and hyponatremia is the main cause of serum hypo-osmolality.

Diabetic Ketoacidosis

The major cause of symptomatic hyperglycemia in children is diabetic ketoacidosis. Nonketotic hyperglycemic coma, associated with mild or non-insulin-requiring diabetes, is unusual in children.

CLINICAL FEATURES. Diabetic ketoacidosis develops rapidly in children who have neglected to take prescribed doses of insulin or who have a superimposed infection. Initial features are polydipsia, polyuria, and fatigue. The child hyperventilates to compensate for metabolic acidosis. Lethargy rapidly progresses to coma. Ketoacidosis is the leading cause of death in children with diabetes; mortality rates are 10%.

Cerebral edema is an early and almost constant feature of diabetic ketoacidosis. The mechanism is not established. The severity of cerebral edema correlates with changes in level of consciousness. Edema may contribute to death in some cases. Other, less common neurological complications of diabetic ketoacidosis are venous sinus thrombosis and intracerebral hemorrhage. Both are associated with focal or generalized seizures.

DIAGNOSIS. The basis for diagnosis is the combination of a blood glucose level greater than 400 mg/dL (>22 mmol/L), the presence of serum and urinary ketones, an arterial pH less than 7.25, and a serum bicarbonate concentration less than 15 mmol/L.

MANAGEMENT. In children with moderate-to-severe diabetic ketoacidosis, avoid the rapid administration of hypotonic fluids at a time of high serum osmolality. Replace fluid deficits evenly over 48 hours. Reduce the sodium deficit by half in the first 12 hours, and eliminate the remainder over the next 36 hours. Provide bicarbonate ion in physiological proportions.

Hypoglycemia

Symptomatic hypoglycemia after the neonatal period is usually associated with insulin use in the treatment of diabetes mellitus. Only a few cases are caused by sepsis and inborn errors of metabolism.

CLINICAL FEATURES. Clinical features are not precisely predictable from the blood glucose concentration. Hypoglycemia does not usually become symptomatic until blood concentrations are less than 50 mg/dL (<2.8 mmol/L). The rate

of decline may be important in determining the clinical features. Dizziness and tremor may occur at blood concentrations less than 60 mg/dL (<3.1 mmol/L) and serve as a warning of insulin overdose. Greater declines in blood glucose concentration result in confusion, delirium, and loss of consciousness. Sudden hemiplegia, usually transitory and sometimes shifting between the two sides, is a rare feature of hypoglycemia. The mechanism is unknown, and CT shows no evidence of infarction.

DIAGNOSIS. Always suspect hypoglycemia in diabetic children with altered mental status or decreased consciousness. Measure the blood glucose concentration promptly.

MANAGEMENT. Diabetic children should be encouraged to carry a source of sugar for use at the first symptom of hypoglycemia. Children who are comatose from hypoglycemia should receive immediate intravenous glucose replacement. Complete recovery is the rule.

Hypernatremia

The usual causes of hypernatremia are (1) dehydration in which water loss exceeds sodium loss and (2) overhydration with hypertonic saline solutions. Hypernatremia is a medical emergency and, if not corrected promptly, may lead to permanent brain damage and death.

CLINICAL FEATURES. Hypernatremic dehydration may be a consequence of vomiting or diarrhea, especially if water intake is restricted. Overzealous correction of hyponatremia causes iatrogenic hypernatremia. Rapid alterations in sodium concentration are much more likely to cause encephalopathy than are equivalent concentrations attained slowly. The symptoms of hypernatremia are referable to the nervous system and include irritability, lethargy progressing to coma, and seizures. The presence of focal neurological deficits suggests cerebral venous sinus thrombosis.

DIAGNOSIS. Symptomatic hypernatremia develops at sodium concentrations greater than 160 mEq/L (>160 mmol/L). EEG shows the non-specific slowing associated with metabolic encephalopathies. Focal slowing on the EEG or focal abnormalities on examination warrant neuroimaging to look for venous sinus thrombosis.

Chronic or recurrent episodes of hypernatremia may result from hypodipsia (lack of thirst), a rare condition encountered in children with congenital or acquired brain disorders. The syndrome is usually associated with a defect in secretion of antidiuretic hormone.

MANAGEMENT. Rapid water replacement can lead to cerebral edema. The recommended approach is to correct abnormalities of intravascular volume before correcting the water deficit.

Hyponatremia

Hyponatremia may result from water retention, sodium loss, or both. The syndrome of inappropriate antidiuretic hormone secretion (SIADH) is an important cause of water retention. Sodium loss results from renal disease, vomiting, and diarrhea. Permanent brain damage from hyponatremia is uncommon but may occur in otherwise healthy children if the serum sodium concentration remains less than 115 mEq/L for several hours.

Syndrome of Inappropriate Antidiuretic Hormone Secretion

SIADH occurs in association with several neurological disorders, including head trauma, infections, and intracranial hemorrhage.

CLINICAL FEATURES. Most patients with SIADH have a preexisting loss of consciousness from their underlying neurological disorder. In these patients, hyponatremia is the only feature of SIADH. In patients who are alert, lethargy develops from the hyponatremia but rarely progresses to coma or seizures.

DIAGNOSIS. The care of children with acute intracranial disorders requires vigilance for SIADH. Repeated determinations of the serum sodium concentration are required. Measure the urinary sodium concentration once documenting hyponatremia and low serum osmolality. The urine osmolality in SIADH does not always exceed the serum osmolality, but the urine is less than maximally dilute, which excludes the dilutional hyponatremia of water intoxication.

MANAGEMENT. All signs of SIADH respond to fluid restriction. An intake of 50% to 75% of daily water maintenance is generally satisfactory.

Sodium Loss

CLINICAL FEATURES. Movement of water into the brain causes *hyponatremic encephalopathy*. Serum sodium concentrations less than 125 mEq/L (<125 mmol/L) are associated with nausea, vomiting, muscular twitching, and lethargy. Seizures and coma are associated with a further decline to less than 115 mEq/L (<115 mmol/L).

DIAGNOSIS. Hyponatremia is a potential problem in children with vomiting or diarrhea or with renal disease. Serum and urinary sodium concentrations are low.

MANAGEMENT. Infuse hypertonic sodium chloride (514 mEq/L) with the goal of increasing the serum sodium concentration to 125 to 130 mEq/L (125 to 130 mmol/L) but by no more than 25 mEq/L (25 mmol/L) in the first 48 hours. More rapid corrections are associated with seizures, hypernatremic encephalopathy, and the possibility of central pontine myelinolysis.

Endocrine Disorders

Adrenal Disorders

Adrenal hypersecretion causes agitation or depression but does not produce coma. Adrenal failure may result from sepsis, abrupt withdrawal of corticosteroid therapy, or adrenal hemorrhage. Initial symptoms are nausea, vomiting, abdominal pain, and fever. Lethargy progresses to coma and is associated with hypovolemic shock. Prompt intravenous infusion of fluids, glucose, and corticosteroids is lifesaving.

Parathyroid Disorders

All of the neurological features of hyperparathyroidism relate to hypercalcemia. Weakness and myopathy are relatively common. Alterations in mental status occur in 50% of patients and include apathy, delirium, paranoia, and dementia. Apathy and delirium occur at serum calcium concentrations greater than 11 mg/dL (>2.75 mmol/L), and psychosis and dementia develop at concentrations of 16 mg/dL or greater (≥4 mmol/L).

Seizures are the main feature of hypoparathyroidism and hypocalcemia. They may be generalized or focal and often are preceded by tetany. Hypocalcemic seizures do not respond to anti-convulsant drugs; calcium replacement is the only treatment.

Thyroid Disorders

Hyperthyroidism causes exhilaration bordering on mania and may be associated with seizures and chorea (see Chapter 14). Thyroid storm (crisis) is a life-threatening event characterized by restlessness, cardiac arrhythmia, vomiting, and diarrhea. Delirium is an early feature and may progress to coma.

Acquired hypothyroidism affects the central and the peripheral nervous systems. Peripheral

effects include neuropathy and myopathy. Central effects are cranial nerve abnormalities, ataxia, psychoses, dementia, seizures, and coma. Delusions and hallucinations occur in more than half of patients with long-standing disease. Myxedema coma, a rare manifestation of long-standing hypothyroidism in adults, is even less common in children. A characteristic feature is profound hypothermia without shivering.

Hashimoto's Encephalopathy

Hashimoto's thyroiditis is an immune-mediated disease associated with high titers of antithyroid antibodies. It often occurs in association with other immune-mediated disorders.

CLINICAL FEATURES. The progression of symptoms is variable but usually begins with headache and confusion that progress to stupor. Focal or generalized seizures and transitory neurological deficits (strokelike episodes) may be an initial or a late feature. Tremulousness and myoclonus commonly occur during some stage in the illness. The encephalopathy lasts several days, then gradually disappears. Recurrent episodes are the rule and may coincide with the menstrual cycle (Sellal et al, 2002).

DIAGNOSIS. Suspect Hashimoto's thyroiditis in every case of recurrent encephalopathy. The CSF protein concentration is elevated, sometimes to greater than 100 mg/dL (>1 g/L), but the pressure and cell count are normal. Affected individuals are usually euthyroid. The diagnosis depends on the presence of antithyroid antibodies. Antibodies against thyroglobulin and the microsomal fraction are most common, but antibodies against other thyroid elements and other organs also may be present. Antithyroid antibodies and circulating immune complexes are detectable in the CSF but do not correlate with clinical symptoms (Ferracci et al, 2003).

MANAGEMENT. Corticosteroids are beneficial in ending an attack and preventing further episodes. The long-term prognosis is good.

Hepatic Encephalopathy

Children with acute hepatic failure often develop severe cerebral edema. Viral hepatitis, drugs, toxins, and Reye syndrome are the main causes of acute hepatic failure. The cause of encephalopathy is hepatic cellular failure and the diversion of toxins from the hepatic portal vein into the systemic circulation. Severe viral hepatitis with marked elevation of the unconjugated bilirubin concentration may lead to kernicterus in older children.

In children with chronic cholestatic liver disease, demyelination of the posterior columns and peripheral nerves may result from vitamin E deficiency. The major features are ataxia, areflexia, and gaze paresis, without evidence of encephalopathy (see Chapter 10).

CLINICAL FEATURES. The onset of encephalopathy can be acute or slowly evolving (Tessier et al, 2002). Malaise and fatigue are early symptoms that accompany the features of hepatic failure: jaundice, dark urine, and abnormal results of liver function tests. Nausea and vomiting occur with fulminating hepatic failure. The onset of coma may be spontaneous or induced by gastrointestinal bleeding, infection, high protein intake, and excessive use of tranquilizers or diuretics. The first features are disturbed sleep and a change in affect. Drowsiness, hyperventilation, and asterixis, a flapping tremor at the wrist with arms extended and wrists flexed, follow. Hallucinations sometimes occur during early stages, but a continuous progression to coma is more common. Seizures and decerebrate rigidity develop as the patient becomes comatose.

DIAGNOSIS. In hepatic coma, the EEG pattern is not specific but is always abnormal and suggests a metabolic encephalopathy: loss of posterior rhythm, generalized slowing of background, and frontal triphasic waves. Biochemical markers of liver failure include a sharp increase in serum transaminase, increased prothrombin time, mixed hyperbilirubinemia, hyperammonemia, and a decline in serum albumin concentration.

MANAGEMENT. The goal of treatment is to maintain cerebral, renal, and cardiopulmonary function until liver regeneration or transplantation can occur. Cerebral function is impaired not only by abnormal concentrations of metabolites, but also by cerebral edema.

Inborn Errors of Metabolism

The inborn errors of metabolism that cause states of decreased consciousness are usually associated with hyperammonemia, hypoglycemia, or organic aciduria. Neonatal seizures are an early feature in most of these conditions (see Chapter 1), but some may not cause symptoms until infancy or childhood. Inborn errors with a delayed onset of encephalopathy include disorders of pyruvate metabolism and respiratory chain disorders (see Chapters 5, 6, 8, and 10); hemizygotes for ornithine carbamoylase deficiency and heterozygotes for carbamoyl phosphate synthetase deficiency (see Chapter 1); glycogen storage diseases (see Chapter 1); and primary carnitine deficiency.

Medium-Chain Acyl-CoA Dehydrogenase Deficiency

Medium-chain acyl-CoA dehydrogenase (MCAD) deficiency is a disorder of β -oxidation of fatty acids (Zschocke et al, 2001). Transmission of the trait is by autosomal recessive inheritance. It is the main cause of the disorder previously called *primary carnitine deficiency* (Table 2-6). Carnitine has two main functions: (1) the transfer of long-chain fatty acids into the inner mitochondrial membrane to undergo β -oxidation and generate energy and (2) the modulation of the acyl-CoA/CoA ratio and the esterification of potentially toxic acyl-CoA metabolites. The transfer of fatty acids across the mitochondrial membrane requires the conversion of acyl-CoA to acylcarnitine and the enzyme carnitine palmitoyltransferase. If the carnitine concentration is deficient, toxic levels of acyl-CoA accumulate and impair the citric acid cycle, gluconeogenesis, the urea cycle, and fatty acid oxidation.

CLINICAL FEATURES. The characteristic features of the disorder are intolerance to prolonged fasting, recurrent episodes of hypoglycemia, and coma. Affected children are normal at birth. Recurrent attacks of nonketotic hypoglycemia, vomiting, confusion, lethargy, and coma are provoked by intercurrent illness or fasting during infancy and early childhood. Cardiorespiratory arrest and sudden infant

death may occur, but MCAD is not an important cause of sudden infant death syndrome. Between attacks, the child may appear normal. In some families, the deficiency causes cardiomyopathy, whereas in others it causes only mild-to-moderate proximal weakness (see Chapters 6 and 7). Deficiencies of long-chain and short-chain acyl-CoA dehydrogenase cause a similar clinical phenotype.

DIAGNOSIS. All affected children have low or absent urinary ketones during episodes of hypoglycemia and elevated serum concentrations of aspartate aminotransferase and lactate dehydrogenase. Blood carnitine concentrations are less than 20 $\mu\text{mol/mg}$ noncollagen protein. Showing the enzyme deficiency or the genetic mutation establishes the diagnosis.

MANAGEMENT. All affected children must avoid fasting and supplement their diet with levocarnitine. The initial dosage is 50 mg/kg/day, which is increased as tolerated (up to 800 mg/kg/day) until the desired blood concentration is attained. Adverse effects of carnitine include nausea, vomiting, diarrhea, and abdominal cramps. Other recommended supplements include riboflavin and glycine, but their efficacy is less well established.

During an acute attack, provide a diet rich in medium-chain triglycerides and low in long-chain triglycerides in addition to carnitine. General supportive care is required for hypoglycemia and hypoprothrombinemia.

Renal Disorders

Children with chronic renal failure are at risk for acute or chronic uremic encephalopathy, dialysis encephalopathy, hypertensive encephalopathy, and neurological complications of the immunocompromised state.

Acute Uremic Encephalopathy

CLINICAL FEATURES. In children with acute renal failure, symptoms of cerebral dysfunction develop over several days. Asterixis is often the initial feature. Periods of confusion and headache, sometimes progressing to delirium and to lethargy follow. Weakness, tremulousness, and muscle cramps develop. Myoclonic jerks and tetany may be present. If uremia continues, decreasing consciousness and seizures follow.

The *hemolytic-uremic syndrome* is a leading cause of acute renal failure in children younger than 5 years old. The combination of thrombocytopenia, uremia, and Coombs-negative

TABLE 2-6
Differential Diagnosis of Carnitine Deficiency

Inborn Errors of Metabolism

- Aminoacidurias
 - Glutaric aciduria
 - Isovaleric acidemia
 - Methylmalonic acidemia
 - Propionic acidemia
- Disorders of pyruvate metabolism
 - Multiple carboxylase deficiency
 - Pyruvate carboxylase deficiency
 - Pyruvate dehydrogenase deficiency
- Disorders of the respiratory chain
 - Medium-chain acyl-CoA dehydrogenase deficiency
 - Phosphoglucomutase deficiency

Acquired Conditions

- Hemodialysis
 - Malnutrition
 - Pregnancy
 - Reye syndrome
 - Total parenteral nutrition
 - Valproate hepatotoxicity
-

hemolytic anemia is characteristic. Encephalopathy is the usual initial feature, but hemiparesis and aphasia caused by thrombotic stroke can occur in the absence of seizures or altered states of consciousness. Most children recover, but they may have chronic hypertension. Survivors usually have normal cognitive function, but may have hyperactivity and inattentiveness.

DIAGNOSIS. The mechanism of uremic encephalopathy is multifactorial and does not correlate with concentrations of blood urea nitrogen alone. Hyperammonemia and disturbed equilibrium of ions between the intracellular and extracellular spaces are probably important factors. Late in the course, acute uremic encephalopathy may be confused with hypertensive encephalopathy. A distinguishing feature is that increased intracranial pressure is an early feature of hypertensive encephalopathy but not of acute uremic encephalopathy. Early in the course, the EEG shows slowing of the background rhythms and periodic triphasic waves (Palmer, 2002).

MANAGEMENT. Hemodialysis reverses the encephalopathy and should be initiated as quickly as possible after diagnosis.

Chronic Uremic Encephalopathy

CLINICAL FEATURES. Congenital renal hypoplasia is the usual cause of chronic uremic encephalopathy. Renal failure begins during the first year, and encephalopathy occurs between 1 and 9 years of age. Growth failure precedes the onset of encephalopathy. Three stages of disease occur sequentially:

Stage 1 consists of delayed motor development, dysmetria and tremor, or ataxia. Examination during this stage shows hyperreflexia, mild hypotonia, and extensor plantar responses. Within 6 to 12 months, the disease progresses to stage 2.

Stage 2 includes myoclonus of the face and limbs, partial motor seizures, dementia, and generalized seizures. Facial myoclonus and lingual apraxia make speech and feeding difficult, and limb myoclonus interferes with ambulation. The duration of stage 2 is variable and may be months to years.

Stage 3 consists of progressive bulbar failure, a vegetative state, and death.

DIAGNOSIS. The basis for diagnosis is the clinical findings. Serial EEG shows progressive slowing, then superimposed epileptiform activ-

ity, and serial CT shows progressive cerebral atrophy. Hyperparathyroidism with hypercalcemia occurs in some children with chronic uremic encephalopathy, but parathyroidectomy does not reverse the process.

MANAGEMENT. Hemodialysis and renal transplantation have not altered the course in most patients.

Dialysis Encephalopathy

Long-term dialysis may be associated with acute, transitory neurological disturbances attributed to the rapid shift of fluids and electrolytes between intracellular and extracellular spaces (*dialysis disequilibrium syndrome*). Most common are headaches, irritability, muscle cramps, and seizures. Seizures usually occur toward the end of dialysis or 24 hours later. Lethargy or delirium may precede the seizures.

Progressive encephalopathies associated with dialysis are often fatal. Two important causes exist: (1) opportunistic infections in the immunodeficient host, usually caused by cytomegalovirus and mycoses in children, and (2) the dialysis dementia syndrome.

Dialysis Dementia Syndrome

CLINICAL FEATURES. The mean interval between the start of dialysis and onset of symptoms is 4 years (range 1 to 7 years), and subsequent progression of symptoms varies from weeks to years. A characteristic speech disturbance develops either as an initial feature or later in the course. It begins as intermittent hesitancy of speech (stuttering and slurring) and may progress to aphasia. Agraphia and apraxia may be present as well. Subtle personality changes suggesting depression occur early in the course. A phase of hallucinations and agitation may occur, and progressive dementia develops.

Myoclonic jerking of the limbs is often present before the onset of dementia. First noted during dialysis, it soon becomes continuous and interferes with normal activity. Generalized tonic-clonic seizures often develop and become more frequent and severe as the encephalopathy progresses. Complex partial seizures may occur, but focal motor seizures are unusual.

Neurological examination reveals the triad of speech arrest, myoclonus, and dementia. In addition, symmetric proximal weakness (myopathy) or distal weakness and sensory loss (neuropathy) with loss of tendon reflexes may occur.

DIAGNOSIS. EEG changes correlate with disease progress. A characteristic early feature is the

appearance of paroxysmal high-amplitude delta activity in the frontal areas, despite a normal posterior rhythm. Eventually the background becomes generally slow, and frontal triphasic waves are noted. Epileptiform activity develops in all patients with dialysis dementia and is the EEG feature that differentiates dialysis dementia from uremic encephalopathy. The activity consists of sharp, spike, or polyspike discharges that may have a periodic quality.

MANAGEMENT. Aluminum toxicity derived from the dialysate fluid is the probable cause in most cases. Removal of aluminum from dialysate prevents the appearance of new cases and progression in some established cases.

Hypertensive Encephalopathy

Hypertensive encephalopathy occurs when increases in systemic blood pressure exceed the limits of cerebral autoregulation. The result is damage to small arterioles, which leads to patchy areas of ischemia and edema. Focal neurological deficits are relatively common.

CLINICAL FEATURES. The initial features are transitory attacks of cerebral ischemia and headache. Misinterpretation of such symptoms as part of uremic encephalopathy is common, despite the warning signs of focal neurological deficits. Headache persists and is accompanied by visual disturbances and vomiting. Seizures and diminished consciousness follow. The seizures are frequently focal at onset and then generalized. Examination reveals papilledema and retinal hemorrhages.

DIAGNOSIS. Because the syndrome occurs in children receiving long-term renal dialysis while awaiting transplantation, the differential diagnosis includes disorders of osmolality, uremic encephalopathy, and dialysis encephalopathy. A posterior cerebral edema syndrome associated with hypertensive encephalopathy is evident on MRI (Figure 2-3). Hypertensive encephalopathy is distinguishable from other encephalopathies associated with renal disease by the greater elevation of blood pressure and the presence of focal neurological disturbances.

MANAGEMENT. Hypertensive encephalopathy is a medical emergency. Treatment consists of anticonvulsant therapy and aggressive efforts to reduce hypertension. Measures to reduce cerebral edema are required in some patients.

Other Metabolic Encephalopathies

Table 2-3 lists several less common causes of metabolic encephalopathy. Some are attributa-

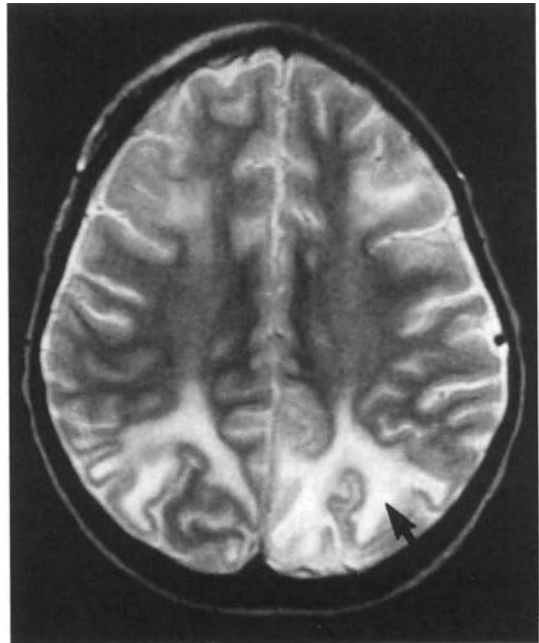


Figure 2-3. MRI of hypertensive encephalopathy. Arrow points to increased signal intensity in both occipital lobes.

ble to derangements of a single substance, but most are multifactorial.

In 5% of children with burns covering 30% of the body surface, an encephalopathy that may have an intermittent course develops (*burn encephalopathy*). The onset is days to weeks after the burn. Altered mental states (delirium or coma) and seizures (generalized or focal) are the major features. The encephalopathy is not attributable to a single factor.

Encephalopathies that occur during total parenteral hyperalimentation are generally due to hyperammonemia caused by excessive loads of amino acids. The causes of hypomagnesemia in infancy include prematurity, maternal deficiency, maternal or infant hypoparathyroidism, a high phosphorus diet, exchange transfusion, intestinal disorders, and specific defects in magnesium absorption. These conditions are often associated with hypocalcemia. Excessive use of diuretics causes hypomagnesemia in older children. Symptoms develop when plasma magnesium concentrations are less than 1.2 mg/dL (<0.5 mmol/L) and include jitteriness, hyperirritability, and seizures. Further decline in serum magnesium concentrations leads to obtundation and coma.

Deficiency of one or more B vitamins may be associated with lethargy or delirium, but only thiamine deficiency causes coma. Thiamine

deficiency is relatively common in alcoholic adults and produces Wernicke encephalopathy but is uncommon in children. Subacute necrotizing encephalopathy (Leigh's disease) is a thiamine deficiency-like state in children (see Chapters 5 and 10).

Systemic Lupus Erythematosus

The pathophysiology of the neurological dysfunction associated with SLE is immune complex deposition in the brain rather than vasculitis. The clinical and imaging features are consistent with diffuse encephalopathy rather than stroke.

CLINICAL FEATURES. The female-to-male ratio is 8:1. Central nervous system manifestations are the initial feature of SLE in 20% of cases (Steinlin et al, 1995). Most common are neuropsychiatric disturbances (50%), seizures (20%), and headache (20%). Some degree of cognitive dysfunction is measurable in most patients, but dementia is uncommon. Depression and anxiety are relatively common. It is uncertain whether depression is symptomatic of the disease or a reaction to chronic illness. Corticosteroids, which are a mainstay of treatment, also may contribute to the anxiety. Frank psychosis, as defined by impaired reality testing and hallucinations, occurs in less than 15% of patients.

DIAGNOSIS. Other criteria establish the diagnosis of SLE before the development of encephalopathy. Patients with encephalopathy usually have high serum titers of anti-DNA and lymphocytotoxic antibodies and high CSF titers of antineural antibodies. These findings further support the concept that the encephalopathy is immune mediated.

MANAGEMENT. Treatment of some encephalopathic features is symptomatic, but immunosuppressive therapy directed at the underlying disorder is the main therapeutic modality.

Migraine

Migraine causes several neurological syndromes and is discussed in many chapters. Among its less common syndromes are a confusional state, an amnestic state, and coma.

Acute Confusional Migraine

CLINICAL FEATURES. A confused and agitated state resembling toxic-metabolic psychosis occurs as a migraine variant in children between

the ages of 5 and 16 (Sheth et al, 1995). Most affected children are 10 years old or older. The symptoms develop rapidly. The child becomes delirious and appears to be in pain but does not complain of headache. Impaired awareness of the environment, retarded responses to painful stimuli, hyperactivity, restlessness, and combative behavior are evident. The duration of an attack is usually 3 to 5 hours but may be 20 hours. The child eventually falls into a deep sleep, appears normal on awakening, and has no memory of the episode. Confusional attacks tend to recur over days or months, then evolve into typical migraine episodes.

DIAGNOSIS. Migraine is always a clinical diagnosis, and other possibilities require exclusion. The diagnosis relies heavily on a family history of migraine, but not of confusional migraine. During or shortly after a confusional attack, the EEG shows unilateral temporal or occipital slowing.

MANAGEMENT. Most individuals experiencing a first attack come for emergency services. Intramuscular chlorpromazine, 1 mg/kg, treats the acute attack. After ending the attack, suggest a prophylactic agent to prevent further episodes (see Chapter 3).

Migraine Coma

Migraine coma is a rare, extreme form of migraine.

CLINICAL FEATURES. The major features of migraine coma are (1) recurrent episodes of coma precipitated by trivial head injury and (2) apparent meningitis associated with life-threatening cerebral edema. Migraine coma occurs in kindred with familial hemiplegic migraine (see Chapter 11), but a similar syndrome may occur in sporadic cases as well. Coma develops after trivial head injury and is associated with fever. Cerebral edema causes increased intracranial pressure. States of decreased consciousness may last for several days. Recovery is then complete.

DIAGNOSIS. Coma following even trivial head injury causes concern for intracranial hemorrhage. The initial CT scan may be normal, especially if obtained early in the course. CT scans obtained between 24 and 72 hours show either generalized or focal edema. Examination of the CSF reveals increased pressure and pleocytosis (≤ 100 cells/mm³). The combination of fever, coma, and CSF pleocytosis suggests viral encephalitis, and herpes is a possibility if edema localizes to one temporal lobe.

MANAGEMENT. Treat children who have experienced migraine coma with a prophylactic agent

to prevent further attacks (see Chapter 3). The major treatment goal during the acute attack is to decrease intracranial pressure by reducing cerebral edema (see Chapter 4).

Transient Global Amnesia

Sudden inability to form new memories and repetitive questioning about events, without other neurological symptoms or signs, characterizes transient global amnesia. It usually occurs in adults and is not a migraine symptom. Migraine is the probable cause, however, when such attacks occur in children or in more than one family member (Sheth et al, 1995).

CLINICAL FEATURES. Attacks range in duration from 20 minutes to several hours, and retrograde amnesia is present on recovery. Many adults with transient global amnesia have a history of migraine, and a similar syndrome occurs in children with migraine after trivial head injury. The attacks are similar to acute confusional migraine except that the patient has less delirium and greater isolated memory deficiency.

DIAGNOSIS. A personal or family history of migraine is essential for diagnosis. The CT scan shows no abnormalities, but the EEG may show slowing of the background rhythm in one temporal lobe.

MANAGEMENT. Management is the same as for migraine with aura (see Chapter 3).

Psychological Disorders

Panic disorders and schizophrenia may have an acute onset of symptoms suggesting delirium or confusion and must be distinguished from acute organic encephalopathies.

Panic Disorder

CLINICAL FEATURES. Recognition of panic attack as a disorder of adolescents and school-age children is relatively recent. A panic attack is an agitated state caused by anxiety. Principal features are paroxysmal dizziness, headache, and dyspnea. Hyperventilation often occurs and results in further dizziness, paresthesias, and lightheadedness. Usual factors provoking attacks are phobias, such as fear of going to school and fear of crowds. Attacks can last minutes to hours and recur daily.

DIAGNOSIS. Panic attacks simulate cardiac or neurological disease, and many children undergo extensive and unnecessary medical eval-

uation before reaching a correct diagnosis. Suspect panic disorder in children with recurrent attacks of hyperventilation, dizziness, or dyspnea.

MANAGEMENT. Antidepressant drugs have varying degrees of efficacy. Alprazolam has the best success rate. Initial dosages are small (0.25 mg/kg/day), and recurrent dosing may be needed.

Schizophrenia

CLINICAL FEATURES. Schizophrenia is a disorder of adolescence or early adult life and is never seen in prepubertal children. Schizophrenic individuals do not have an antecedent history of an affective disorder. An initial feature is often declining work performance simulating dementia. Intermittent depersonalization (not knowing where or who one is) may occur early in the course and suggests complex partial seizures.

Thoughts move with loose association from one idea to another until they become incoherent. Delusions and hallucinations are common and usually have paranoid features. Motor activity is either lacking or excessive and purposeless. This combination of symptoms in an adolescent may be difficult to distinguish clinically from drug encephalopathy.

DIAGNOSIS. The diagnosis is established by careful evaluation of mental status. The family may have a history of schizophrenia. Neurological and laboratory findings are normal. A normal EEG in an alert child with the clinical symptoms of an acute encephalopathy points to a psychological disturbance, including schizophrenia.

MANAGEMENT. Schizophrenia is incurable, but antipsychotic drugs alleviate many of the symptoms.

Toxic Encephalopathies

Accidental poisoning with drugs and chemicals left carelessly within reach is relatively common in children ages 1 to 4. Between ages 4 and 10, a trough occurs in the frequency of poisoning, followed by increasing frequency of intentional poisoning with substances of abuse and prescription drugs.

Immunosuppressive Drugs

Immunosuppressive drugs are used extensively in children undergoing organ transplantation. The drugs themselves, secondary metabolic

disturbances, and cerebral infection may cause encephalopathy at times of immunosuppression. Children given amphotericin B to treat aspergillosis after bone marrow transplantation for leukemia have developed a severe encephalopathy with parkinsonian features (Mott et al, 1995).

Corticosteroid Psychosis

Daily use of corticosteroids at doses less than 1 mg/kg may cause hyperactivity, insomnia, and anxiety. The higher dosages used for immunosuppression (generally >2 mg/kg/day) may precipitate a psychosis similar to schizophrenia or delirium. Stopping the drug reverses the symptoms.

Cyclosporine Encephalopathy

Cyclosporine, the drug most commonly used to prevent organ rejection, causes encephalopathy in 5% of recipients. The blood concentration of the drug does not correlate simply with any neurological complication. The more common syndrome consists of lethargy, confusion, cortical blindness, and visual hallucinations without any motor disturbances. A similar syndrome also occurs in children with hypertension from other causes who are not taking cyclosporine. A second syndrome is a combination of motor symptoms (ataxia, tremor, paralysis) and altered states of consciousness and cognition.

MRI shows widespread edema and leukoencephalopathy. In children with the syndrome of visual disturbances and encephalopathy, the most intense disturbances are in the occipital lobes (see Figure 2-3). The encephalopathy clears completely after stopping the drug. Sometimes restarting the drug at a lower dose does not cause encephalopathy.

OKT3 Meningoencephalitis

OKT3 is an anti-T cell monoclonal antibody used to initiate immunosuppression and to treat transplant rejection. Of patients, 14% develop fever and sterile meningitis 24 to 72 hours after the first injection, and 10% develop encephalopathy within 4 days. The encephalopathy slowly resolves over the next 2 weeks, even when the drug is continued.

Prescription Drug Overdoses

Most intentional overdoses are with prescription drugs because they are readily available.

The drugs usually found in homes are benzodiazepines, salicylates, acetaminophen, barbiturates, and tricyclic antidepressants. Delirium or coma may be due to toxic effects of psychoactive drugs (anticonvulsants, antidepressants, antipsychotics, and tranquilizers).

CLINICAL FEATURES. As a rule, toxic doses of psychoactive drugs produce lethargy, nystagmus or ophthalmoplegia, and loss of coordination. Higher concentrations cause coma and seizures. Involuntary movements may occur as an idiosyncratic or dose-related effect. Diazepam is remarkably safe, and an overdose does not cause coma or death when taken alone. Other benzodiazepines also are reasonably safe.

Tricyclic antidepressants are among the most widely prescribed drugs in the United States and account for 25% of serious overdoses. The major features of overdose are coma, hypotension, and anticholinergic effects (flushing, dry skin, dilated pupils, tachycardia, decreased gastrointestinal motility, and urinary retention). Seizures and myocardial depression also may be present.

After phenothiazine or haloperidol ingestion, symptom onset may be delayed 6 to 24 hours, then occur intermittently. Extrapyramidal disturbances (see Chapter 14) and symptoms of anticholinergic poisoning are prominent features. Fatalities are uncommon and probably caused by cardiac arrhythmia.

DIAGNOSIS. Most drugs can be identified by the laboratory within 2 hours. Perform a urine drug screen in all cases of unidentified coma or delirium. If an unidentifiable product is in the urine, identification may be possible in the plasma. The blood drug concentration should be determined.

MANAGEMENT. The specificities and degree of supportive care needed depend on the drug and the severity of the poisoning. Most children need an intravenous line and careful monitoring of cardiorespiratory status. A continuous electrocardiogram is often required because of concern for arrhythmia. Remove unabsorbed drug from the stomach by lavage and repeated doses of activated charcoal (30 mg every 6 hours), administered to prevent absorption and increase drug clearance. Treat extrapyramidal symptoms with intravenous diphenhydramine, 2 mg/kg.

Poisoning

Most accidental poisonings occur in small children ingesting common household products. Usually the ingestion quickly comes to attention

because the child is sick and vomits. Insecticides, herbicides, and products containing hydrocarbons or alcohol are commonly ingested. Clinical features vary depending on the agent ingested. Optimal management requires identification of constituent poisons, estimation of the amount ingested, interval since exposure, cleansing of the gastrointestinal tract, specific antidotes when available, and supportive measures.

Substance Abuse

Alcohol is the most common substance of abuse in the United States. More than 90% of high school seniors have used alcohol one or more times, and 6% are daily drinkers. Approximately 6% of high school seniors use marijuana daily; less than 0.1% use hallucinogens or opiates regularly. The use of cocaine, stimulants, and sedatives has been increasing in recent years. Daily use of stimulants occurs in 1% of high school seniors.

CLINICAL FEATURES. The American Psychiatric Association defines the diagnostic criteria for substance abuse as (1) a pattern of pathological use with inability to stop or reduce use; (2) impairment of social or occupational functioning, which includes school performance in children; and (3) persistence of the problem for 1 month or longer.

The clinical features of acute intoxication vary with the substance used. Almost all substances disturb judgment, intellectual function, and coordination. Alcohol and sedatives lead to drowsiness, sleep, and obtundation. In contrast, hallucinogens cause bizarre behavior, which includes hallucinations, delusions, and muscle rigidity. Drugs such as phencyclidine (angel dust) and lysergic acid diethylamide (LSD) produce a clinical picture that simulates schizophrenia.

The usual symptoms of marijuana intoxication are euphoria and a sense of relaxation at low doses and a dreamlike state with slow response time at higher doses. Very high blood concentrations produce depersonalization, disorientation, and sensory disturbances. Hallucinations and delusions are unusual with marijuana and suggest mixed-drug use.

Consider amphetamine abuse when an agitated state is coupled with peripheral evidence of adrenergic toxicity: mydriasis, flushing, diaphoresis, and reflex bradycardia caused by peripheral vasoconstriction. Cocaine affects the brain and heart. Early symptoms include euphoria, mydriasis, headache, and tachycardia. Higher doses produce emotional lability, nausea

and vomiting, flushing, and a syndrome that simulates paranoid schizophrenia. Life-threatening complications are hyperthermia, seizures, cardiac arrhythmia, and stroke. Associated stroke syndromes include transient ischemic attacks in the distribution of the middle cerebral artery, lateral medullary infarction, and anterior spinal artery infarction.

DIAGNOSIS. The major challenge is to differentiate acute substance intoxication from schizophrenia. Important clues are a history of substance abuse obtained from family or friends, associated autonomic and cardiac disturbances, and alterations in vital signs. Urinary and plasma screening generally detects the substance or its metabolites.

MANAGEMENT. Management of acute substance abuse depends on the substance used and the amount ingested. Physicians must be alert to the possibility of multiple drug or substance exposure. An attempt should be made to empty the gastrointestinal tract of substances taken orally. Support of cardiorespiratory function and correction of metabolic disturbances are generally required. Intravenous diazepam reduces the hallucinations and seizures produced by stimulants and hallucinogens. Standard cardiac drugs are useful to combat arrhythmias.

Toxicity correlates poorly with drug blood concentrations with regard to the following substances: amphetamines, benzodiazepines, cocaine, hallucinogens, and phencyclidine. The basis for management decisions is the patient's condition.

The most vexing problem with substance abuse is generally not the acute management of intoxication, but rather breaking the habit. This requires the patient's motivation and long-term inpatient and outpatient treatment.

Trauma

Pediatric neurologists are rarely involved in the acute care of severe head trauma. More often, request for consultation comes later when some symptoms persist. Trivial head injuries, without loss of consciousness, are commonplace in children and an almost constant occurrence in toddlers. Suspect migraine whenever transitory neurological disturbances (e.g., amnesia, ataxia, blindness, coma, confusion, and hemiplegia) follow trivial head injuries. Important causes of significant head injuries are child abuse in infants, sports and play injuries in children, and motor vehicle accidents in adolescents. *Suspect juvenile myoclonic epilepsy in an*

adolescent involved in a single motor vehicle accident who has no memory of the event but never sustained a head injury. It is likely that an absence seizure caused loss of control of the vehicle.

Concussion

Concussion is an alteration in mental status after a blow to the head (American Academy of Neurology, 1997). Loss of consciousness may or may not occur. Guidelines are available from the American Academy of Neurology and the American Academy of Pediatrics pertaining to the management of concussions in sports.

CLINICAL FEATURES. Confusion and amnesia are the main features. The confusion and amnesia may occur immediately after the blow to the head or several minutes later. Frequently observed features of concussion include a befuddled facial expression, slowness in answering questions or following instructions, easy distractibility, disorientation, slurred or incoherent speech, incoordination, emotionality, and memory deficits.

In the following days to weeks, the child may have any of these symptoms: low-grade headache, lightheadedness, poor attention and concentration, memory dysfunction, easy fatigability, irritability, difficulty with focusing vision, noise intolerance, anxiety, and sleep disturbances.

Among children who have lost consciousness, the child is invariably tired and sleeps long and soundly if left undisturbed after regaining consciousness. Many children complain of headache and dizziness for several days or weeks after concussion (see Posttraumatic Headache in Chapter 3). They may be irritable and have memory disturbances. The severity and duration of these symptoms usually correlate with the severity of injury but sometimes seem disproportionate.

Focal or generalized seizures and sometimes status epilepticus may occur 1 or 2 hours after head injury. Seizures may occur in children who did not lose consciousness. Such seizures rarely portend later epilepsy.

DIAGNOSIS. Obtain a cranial CT scan, without contrast and with windows adjusted for bone and soft tissue, whenever loss of consciousness, no matter how brief, follows a head injury. CT scan is probably cost-effective because it reduces the number of hospital admissions. MRI in children with moderate head injury may show foci of hypointensity in the white matter, which indicates axonal injury as the mechanism

of lost consciousness (Adelson and Kochanek, 1998). Order an EEG for any suspicion that the head injury occurred during a seizure or if neurological disturbances are disproportionate to the severity of injury.

MANAGEMENT. Mild head injuries do not require immediate treatment, and a child whose neurological examination and CT scan findings are normal does not require hospitalization. Tell the parents to allow the child to sleep.

Severe Head Injuries

The outcome after severe head injuries is usually better for children than for adults, but children younger than 1 year old have double the mortality of children 1 to 6 years old and three times the mortality of children 6 to 12 years old. CT evidence of diffuse brain swelling on the day of injury is associated with a 53% mortality rate.

Shaking Injuries

CLINICAL FEATURES. Shaking is a common method of child abuse in infants (Duhaime et al, 1998). An unconscious infant arrives at the emergency department with bulging fontanelles. Seizures may have precipitated the hospital visit. The history is fragmentary and inconsistent among informants. Typically the infant was in the care of a babysitter or the mother's boyfriend.

The infant shows no external evidence of head injury, but ophthalmoscopic examination shows retinal and optic nerve sheath hemorrhages. Retinal hemorrhages are more common after inflicted injuries than after accidental injuries and may be due to rotational forces. Many of the hemorrhages may be old, suggesting repeated shaking injuries. On the thorax or back, the examiner notes bruises that conform to the shape of a hand that held the infant during the shaking. Healing fractures of the posterior rib cage indicate prior child abuse. Death may result from uncontrollable increased intracranial pressure or contusion of the cervicomedullary junction.

DIAGNOSIS. CT shows a swollen brain but may not show subdural collections of blood if bleeding is recent. A subdural tap is diagnostic and therapeutic.

MANAGEMENT. Bilateral subdural taps remove large collections of blood. The intention is to remove as much blood as possible. The amount available for drainage through a subdural tap is only a small percentage of the total volume in the subdural space. The goal of the subdural

tap is not to remove all subdural blood, but rather to remove a sufficient quantity to relieve increased intracranial pressure and to aid reabsorptive mechanisms. Repeat taps daily until the removable volume begins to decline, then every other day to reduce the accumulated fluid. A subdural-peritoneal shunt may be required, and some neurosurgeons prefer to place a shunt immediately. A low peripheral hematocrit value that continues to decrease is an indication for transfusion.

Seek protective services to prevent further injuries. Overall the neurological and visual outcomes among victims of shaking are poor. Most have considerable residual handicap.

Closed Head Injuries

Supratentorial subdural hematomas are venous in origin, are frequently bilateral, and usually occur without associated skull fracture. Supratentorial epidural hematomas are usually associated with skull fracture. Epidural and subdural hematomas are almost impossible to distinguish on clinical grounds alone. Progressive loss of consciousness is a feature of both types, and both may be associated with a lucid interval between the time of injury and neurological deterioration. Posterior fossa epidural and subdural hemorrhages occur most often in newborns (see Chapter 1) and older children with posterior skull fractures.

CLINICAL FEATURES. Loss of consciousness is not always immediate; a lucid period of several minutes may intervene between injury and onset of neurological deterioration. The Glasgow Coma Scale quantifies the degree of responsiveness after head injuries (Table 2-7). Scores of 8 or less correlate well with severe injury.

Acute brain swelling and intracranial hemorrhage cause the clinical features. Increased intracranial pressure is always present and may lead to herniation if uncontrolled. Focal neurological deficits suggest intracerebral hemorrhage.

Mortality rates in children with severe head injury are usually 10% to 15% and have not changed substantially since the 1990s. Low mortality rates are sometimes associated with higher percentages of survivors in chronic vegetative states. Duration of coma is the best guide to long-term morbidity. Permanent neurological impairment is an expected outcome when coma persists for 1 month or longer.

DIAGNOSIS. Perform cranial CT as rapidly as possible after closed head injuries. Typical findings are brain swelling and subarachnoid hemor-

TABLE 2-7
Glasgow Coma Scale*

Eye Opening (E)	
Spontaneously	4
To speech	3
To pain	2
None	1
Best Motor Response (M)	
Obeys	6
Localizes	5
Withdraws	4
Abnormal flexion	3
Abnormal extension	2
None	1
Verbal Response (V)	
Oriented	5
Confused conversation	4
Inappropriate words	3
Incomprehensible sounds	2
None	1

*Coma score = E + M + V.

rhage with blood collecting along the falx. Intracranial hemorrhage also may be detectable. Immediately after injury, some subdural hematomas are briefly isodense and not observed. Later the hematoma appears as a region of increased density, convex toward the skull and concave toward the brain. With time, the density decreases.

Intracerebral hemorrhage is usually superficial but may extend deep into the brain. Frontal or temporal lobe contusion is common. Discrete deep hemorrhages without a superficial extension are not usually the result of trauma. Keep the neck immobilized in children with head injuries until radiographic examination excludes fracture-dislocation of the cervical spine. The force of a blow to the skull frequently propagates to the neck. Examine the child for limb and organ injury when head injury occurs in a motor vehicle accident.

MANAGEMENT. Manage all severe head injuries in an intensive care unit. Essential support includes controlled ventilation, prevention of hypotension, and sufficient reduction in brain swelling to maintain cerebral perfusion. Chapter 4 contains a review of methods to reduce cerebral edema. Barbiturate coma does not affect the outcome.

Acute expanding intracranial hematomas warrant immediate surgery. Small subdural collections, not producing a mass effect, can remain in place until the patient's condition stabilizes and options are considered.

Open Head Injuries

The clinical features, diagnosis, and management of open head injuries are similar as described for closed injuries. The major differences are the greater risk of epidural hematoma and infection and the possibility of damage to the brain surface from depression of the bone. Supratentorial epidural hematomas are usually temporal or temporoparietal in location. The origin of the blood may be arterial (tearing of the middle meningeal artery), venous, or both. Skull fracture is present in 80% of cases. Increased intracranial pressure accounts for the clinical features of vomiting and decreased states of consciousness. Epidural hematoma has a characteristic lens-shaped appearance (Figure 2-4).

Infratentorial epidural hematoma is venous in origin and associated with occipital fracture. The clinical features are headache, vomiting, and ataxia. Skull fractures, other than linear fractures, are associated with an increased risk of infection. A depressed fracture is one in which the inner table fragment is displaced by at least the thickness of the skull. A *penetrating* fracture is one in which the dura is torn. Most skull fractures heal spontaneously. Skull fractures that do not heal are usually associated with a dural tear and feel pulsatile (Johnson and Helman, 1995). In infants, serial radiographs of

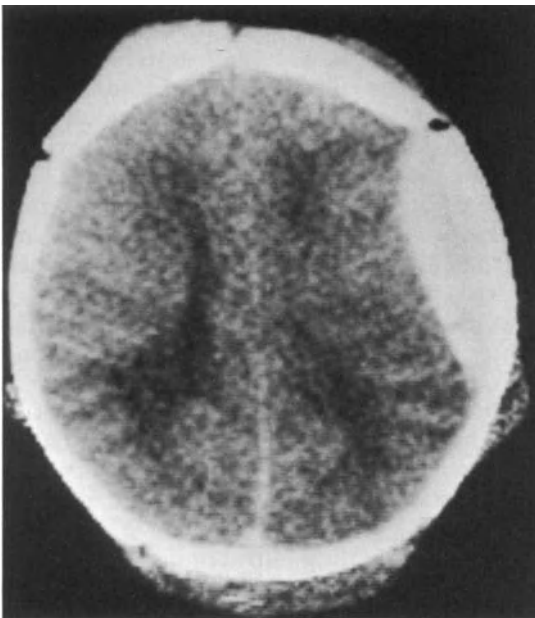


Figure 2-4. Epidural hematoma. The hematoma appears as a lens-shaped density just below the skull.

the skull may suggest that the fracture is enlarging because the rapid growth of the brain causes the fracture line to spread further to accommodate the increasing intracranial volume.

Depressed fractures of the skull vault may injure the underlying brain and tear venous sinuses. The result is hemorrhage into the brain and subdural space. Management includes elevation of depressed fragments, debridement and closure of the scalp laceration, and systemic penicillin.

Basilar skull fractures with dural tear may result in leakage of CSF from the nose or ear and meningitis. Such leaks usually develop within 3 days of injury. The timing and need for dural repair are controversial, but the need for intravenous antibiotic coverage is established.

Posttraumatic Epilepsy

The rates of late posttraumatic epilepsy from the military (28% to 53%), which include missile injuries, are higher than the civilian rates (3% to 14%). Posttraumatic epilepsy follows 34% of missile injuries but only 7.5% of nonmissile injuries. Late seizures after closed head injury are more likely to occur in association with intracranial hematoma or depressed skull fracture. The prophylactic use of anticonvulsant therapy after a head injury to prevent posttraumatic seizures had been customary. Phenytoin prophylaxis decreases the risk of early posttraumatic seizures but not late posttraumatic seizures (Chang and Lowenstein, 2003).

References

- Adelson PD, Kochanek PM. Head injury in children. *J Child Neurol* 1998;13:2-15.
- American Academy of Neurology. Practice parameters for determining brain death in adults (summary statement). *Neurology* 1995;45:1012-1014.
- American Academy of Neurology. Practice parameters for concussion in sports. *Neurology* 1997;48:581-585.
- Belay ED, Bresee JS, Holman RC, et al. Reye's syndrome in the United States from 1981 through 1987. *N Engl J Med* 1999;340:1377-1382.
- Chang BS, Lowenstein DH. Practice parameter. Antiepileptic drug prophylaxis in severe traumatic brain injury. Report of the Quality Standards Subcommittee of the American Academy of Neurology. *Neurology* 2003;60:10-16.
- Deresiewicz RL, Thaler SJ, Hsu L, et al. Clinical and neuro-radiologic manifestations of eastern equine encephalitis. *N Engl J Med* 1997;336:1867-1874.
- De Tiege X, Rozenberg F, Des Portes V, et al. Herpes encephalitis relapses in children. Differentiation of two neurologic entities. *Neurology* 2003;61:241-243.
- Duhaime A-C, Christian CW, Rorke LB, et al. Nonaccidental head injury in infants—the “shaken baby syndrome.” *N Engl J Med* 1998;338:1822-1829.

- Ferracci F, Moretto G, Candeago RM, et al. Antithyroid antibodies in the CSF. Their role in the pathogenesis of Hashimoto's encephalopathy. *Neurology* 2003;60:712-714.
- Garcia-Monco JC, Benach JL. Lyme neuroborreliosis. *Ann Neurol* 1995;37:691-702.
- Halperin JJ, Logigian EL, Finkel MF, et al. Practice parameters for the diagnosis of patients with nervous system Lyme borreliosis (Lyme disease). *Neurology* 1996;46:619-627.
- Hynson JL, Kornberg AJ, Coleman LT, et al. Clinical and radiological features of acute disseminated encephalomyelitis in children. *Neurology* 2001;56:1308-1312.
- Johnson DL, Helman T. Enlarging skull fractures in children. *Child Nerv Syst* 1995;11:265-268.
- Krumholz A, Berg AT. Further evidence that for status epilepticus 'one size fits all' does not fit. *Neurology* 2002;58:515-516.
- Leigh RJ, Zee DS. *The Neurology of Eye Movements*, Third Edition. Oxford University Press: New York; 1999.
- Marra CM. Neurological complications of *Bartonella henselae* infection. *Curr Opin Neurol* 1995;8:164-169.
- Mott SH, Packer RJ, Vezina LG, et al. Encephalopathy with Parkinsonian features in children following bone marrow transplantations and high-dose amphotericin B. *Ann Neurol* 1995;37:810-814.
- Murthy SNK, Faden HS, Cohen ME, et al. Acute disseminated encephalomyelitis in children. *Pediatrics* 2002;110:e21.
- Nash D, Mostashari F, Fine A, et al. The outbreak of West Nile virus in the New York City area in 1999. *N Engl J Med* 2001;344:1807-1814.
- Palmer CA. Neurological manifestations of renal disease. *Neurol Clin* 2002;20:23-40.
- Redington JJ, Tyler KL. Viral infections of the nervous system, 2002. *Arch Neurol* 2002;59:712-718.
- Rust RS, Thompson WH, Matthews CG, et al. La Crosse and other forms of California encephalitis. *J Child Neurol* 1999;14:1-14.
- Sellal F, Berton C, Andriantseho M, et al. Hashimoto's encephalopathy. Exacerbations associated with menstrual cycle. *Neurology* 2002;59:1633-1635.
- Sheth RD, Riggs JE, Bodensteiner JB. Acute confusional migraine. A variant of transient global amnesia. *Pediatr Neurol* 1995;12:129-131.
- Sigal LH, Zahradnik JM, Lavin P, et al. A vaccine consisting of recombinant *Borrelia burgdorferi* outer surface protein A to prevent Lyme disease. *N Engl J Med* 1998;339:216-222.
- Steere AC, Sikand VK, Meurice F, et al. Vaccination against Lyme disease with recombinant *Borrelia burgdorferi* outer-surface lipoprotein with adjuvant. *N Engl J Med* 1998;339:209-215.
- Steinlin MI, Blaser SI, Gilday DL, et al. Neurological manifestations of pediatric systemic lupus erythematosus. *Pediatr Neurol* 1995;13:191-197.
- Tenembaum S, Chamoles N, Fejerman N. Acute disseminated encephalomyelitis. A long-term follow-up study of 84 pediatric patients. *Neurology* 2002;59:1224-1231.
- Tessier G, Villeneuve E, Villeneuve JP. Etiology and outcome of acute liver failure. Experience from a liver transplantation centre in Montreal. *Can J Gastroenterol* 2002;16:672-676.
- Tyler KI. West Nile virus encephalitis in America. *N Engl J Med* 2001;344:1858-1859.
- Whitley R, Kimberlin DW. Herpes simplex viruses. *Clin Infect Dis* 1998;26:541-555.
- Zschocke J, Schulze A, Lindner M, et al. Molecular and functional characterization of mild MCAD deficiency. *Hum Genet* 2001;108:404-408.

Chapter 3

Headache

Approach to Headache

Most children referred to a neurologist for “headache” have already had a normal brain imaging study. The distinction between painful and harmful headaches occurs before consultation. Nevertheless, families seek medical attention for a child with headache not only hoping to relieve pain, but also seeking assurance that the child does not have a serious intracranial disease. Not every headache is explicable, and the term *psychogenic* is not a synonym for idiopathic.

In my practice, I see two headache patterns among most children. One is chronic low-grade headache, and the other is an intermittent disabling headache. The cause of the former is either caffeine or analgesic abuse, and the latter is migraine. Ten percent of children 5 to 15 years old have migraine. Children with migraine average twice as many days lost from school as children without migraine.

An initial headache classification proposed by the International Headache Society in 1988 has undergone several revisions with the newest published in 2004 (International Headache Society, 2004). As a rule, only poorly understood disorders require classification by a committee.

Sources of Pain

Table 3-1 lists pain-sensitive structures of the head and neck. The main pain-sensitive structures inside the skull are blood vessels. Mechanisms that stimulate pain from blood vessels are vasodilation, inflammation, and traction-displacement. Increased intracranial pressure causes pain mainly by the traction and displace-

ment of intracranial arteries (see Chapter 4). The brain parenchyma, its ependymal lining, and the meninges, other than the basal dura, are insensitive to pain.

Pain transmission from supratentorial intracranial vessels is by the trigeminal nerve, whereas pain transmission from infratentorial vessels is by the first three cervical nerves. The ophthalmic division of the trigeminal nerve innervates the arteries in the superficial portion of the dura and refers pain to the eye and forehead. The second and third divisions of the trigeminal nerve innervate the middle meningeal artery and refer pain to the temple. All three divisions of the trigeminal nerve innervate the cerebral arteries and refer pain to the eye, forehead, and temple. In contrast, referred pain from all structures in the posterior fossa is to the occiput and neck.

Several extracranial structures are pain sensitive. Major scalp arteries are present around the eye, forehead, and temple and produce pain when dilating or stretched. Cranial bones are insensitive, but periosteum, especially in the sinuses and near the teeth, is painful when inflamed. The inflamed periosteum is usually tender to palpation or other forms of physical stimulation. Muscles attached to the skull are a possible source of pain. The largest muscle groups are the neck extensors, which attach to the occipital ridge; the masseter muscles; and the frontalis muscle. The mechanism of muscle pain is incompletely understood but probably involves prolonged contraction. The extraocular muscles are a source of muscle contraction pain in patients with heterophoria. When an imbalance exists, especially in convergence, long periods of close work cause difficulty in maintaining conjugate gaze, and pain localizes to the orbit and forehead.

TABLE 3-1
Sources of Headache Pain

Intracranial
Cerebral and dural arteries
Dura mater at base of brain
Large veins and venous sinuses
Extracranial
Cervical roots
Cranial nerves
Extracranial arteries
Muscles attached to skull
Periosteum/sinuses

Pain from the cervical roots and cranial nerves is generally due to mechanical traction from injury or malformation. Pain follows this nerve distribution: the neck and back of the head up to the vertex for the cervical roots and the face for the cranial nerves.

Taking the History

History is everything when attempting to diagnose the cause of headache. The first step is to identify the headache pattern. Is the headache chronic but nondisabling, in which the child does not miss any or many days of school or social events? Or is the headache periodic and disabling, in which the child looks sick and goes to bed? Many children have both.

Most children, especially young children, are incapable of describing the quality of their pain, and such descriptions are rarely informative even when provided by older children. The use of terms such as “throbbing” and “splitting” more often describe the intensity than the character of the pain. The more important questions have to do with the frequency, duration, and location of headache and its associated symptoms. Time of onset may indicate a stressful period for a child, such as attending school or visitation by a separated parent.

Asking how often or how long headaches occur in a child younger than age 10 is rarely productive. Young children have no sense of time (“Are we almost there?”), but parents are usually quite helpful in this regard. The following four questions are useful in determining the headache pattern:

1. “Is the headache chronic but not disabling, or does it occur occasionally and prevent normal activity?” The number of school days missed because of headache is a good indication of frequency, severity, and disability.

2. “What is the longest period of time that you have been headache-free?” This identifies a common headache pattern in which the child has a flurry of headaches over a week or two, then after a prolonged headache-free interval experiences another flurry of daily headaches.
3. “How many different kinds of headache do you have?” A common response is that the child has two kinds of headache: one headache is severe and causes the child to look sick (migraine), and the other is a mild headache that is almost constant but not disabling (analgesic rebound headache).
4. “What analgesics have you used and how often?” This helps establish what has worked and what has failed and may establish the diagnosis of analgesic rebound headache as a contributing factor.

Helpful responses to traditional questions concerning the history of headache can be obtained from children 10 years old or older. Several typical headache patterns, when present, allow recognition of either the source or the mechanism of pain:

1. A continuous, low-intensity, chronic headache, in the absence of associated symptoms or signs, is unlikely to indicate a serious intracranial disease.
2. Intermittent headaches, especially those that make the child look and feel sick, from which the child recovers completely and is normal between attacks, are likely to be migraine.
3. A severe headache of recent onset, different from anything previously experienced, from which the child never returns to a normal baseline, is probably due to significant intracranial disease.
4. Explaining brief, intense pain lasting for seconds, in an otherwise normal child, is rare.
5. Periosteal pain, especially inflammation of the sinuses, localizes and the area is tender to palpation. Sinusitis as a cause of headache is overstated. Evidence of “sinusitis” is a common feature of computed tomography (CT) scans in children evaluated for other reasons.
6. Cervical root and cranial nerve pain has a radiating or shooting quality.

Evaluation

Children referred to a pediatric neurologist for headache commonly arrive with a cranial CT scan or at least a report of a normal study. The

only question asked by the primary physician was “Does this child have a brain tumor?” This may be the only question asked by the parent. The normal CT scan neither explained nor cured the headache. A routine brain imaging study on every child with chronic headache is not cost-effective and is not a substitute for an adequate history and physical examination. A joint committee of the American Academy of Neurology and the Child Neurology Society published a practice parameter for the evaluation of children and adolescents with recurrent headache. Children with normal neurological examinations require neither electroencephalogram (EEG) nor neuroimaging (Lewis et al, 2002).

Migraine

Ten percent of children 5 to 15 years old have migraine, and migraine accounts for 75% of headaches in young children referred for neurological consultation. Children with migraine average twice as many days lost from school as children without migraine. Migraine is a hereditary disorder with a multifactorial inheritance pattern. When interviewing both parents, at least one parent gives a history of migraine in 90% of cases. The figure decreases to 80% if only one is present, usually the mother. The prevalence of migraine is 2.5% in children younger than age 7 (both genders equally affected), 5% in children age 7 to puberty (female-to-male ratio of 3:2), 5% in postpubertal boys, and 10% in postpubertal girls. The higher incidence of migraine in pubertal girls than in boys probably relates to the triggering effect of the menstrual cycle on migraine attacks. Approximately one quarter of children are migraine-free by age 25 years, boys significantly more often than girls, and more than half still have headaches at age 50. Of those who become parents, 50% have at least one child who has migraine (Bille, 1997).

Genetics of Migraine

Familial hemiplegic migraine, a channelopathy, is the only known monogenic migraine syndrome. Other migraine types are more complex, seeming to result from the interaction of genetic susceptibility and environmental factors. Genetic factors are more evident in migraine with aura than in migraine without aura. Migraine and migraine-like headaches are part of several known genetic disorders.

Triggering Factors

Among persons with a predisposition to migraine, the provocation of individual attacks is usually an idiosyncratic triggering factor. Common triggering factors are stress, exercise, head trauma, and the premenstrual decline in circulating estrogen. An allergic basis for migraine is not established. I accept without comment parental statements implicating specific foods and food additives.

Stress and Exercise

Migraine symptoms may first occur during stress or exercise or, more often, during a time of relaxation after a period of stress. When stress is the triggering factor, attacks are most likely to occur in school or just after returning home. Attacks rarely occur on awakening. Children with migraine do not have a specific personality type. Migraine is just as likely in a “slug” as in an overachiever.

Head Trauma

The mechanism by which blows to the head and whiplash head movements provoke migraine attacks is unknown. Trivial blows to the head during competitive sports are significant triggering factors because they occur against a background of vigorous exercise and stress. A severe migraine attack—headache, vomiting, and transitory neurological deficits—after a head injury suggests the possibility of intracranial hemorrhage. A reduction in the number of diagnostic tests is achievable by appreciating the cause-and-effect relationship between head trauma and migraine. Transitory cerebral blindness and other transitory neurological deficits sometimes occur after head trauma in children with migraine (see Chapter 16).

Menstrual Cycle

The higher rate of migraine among postpubertal girls compared with prepubertal children of both sexes or with postpubertal boys supports the observation that hormonal changes in the normal female cycle trigger attacks of migraine. The widespread use of oral contraceptives has provided some insight into the relationship between the female hormonal cycle and migraine. Some oral contraceptives increase the frequency and intensity of migraine attacks in many women with a history of migraine and may precipitate the initial attack in genetically

predisposed women who previously have been migraine-free. Among women taking oral contraceptives, the greatest increase in frequency of migraine occurs at midcycle. The decline in the concentration of circulating estrogens is probably the critical factor in precipitating an attack.

Clinical Syndromes

Migraine in children can be divided into three groups: migraine with aura (classic migraine), migraine without aura (common migraine), and migraine equivalent syndromes. Migraine without aura is more than twice as common as migraine with aura in school-age children. Migraine with and without aura are variable expressions of the same genetic defect; both kinds of attacks may occur in the same individual at different times. The main feature of migraine equivalent syndromes is a transitory disturbance in neurological function. Headache is a minor feature or is not present. These syndromes are discussed in several other chapters (Table 3-2).

Ice-pick headache, called *primary stabbing headache* by the International Headache Society, is a peculiar migraine equivalent that occurs mainly during adolescence or later. A severe pain on top of the head drives the patient to the floor. It ends as quickly as it comes. Bouts may repeat over days or months, then remit spontaneously. Ice-pick headache ends so quickly that treatment is not required, only reassurance.

Migraine with Aura

Migraine with aura is a biphasic event. In the initial phase, a wave of excitation followed by depression of cortical function spreads over both hemispheres from back to front associated with decreased regional cerebral blood flow and transitory neurological disturbances. The cause of these disturbances is primarily neuronal

depression rather than ischemia. The second phase is usually, but not always, associated with increased blood flow in the internal and the external carotid circulations. Headache, nausea, and sometimes vomiting occur in the second phase. The explanation of the mechanism of headache and nausea is uncertain, but increased blood flow is not an explanation.

During an attack, the main clinical features may reflect only the first phase (aura), only the second phase, or both. The usual features of the aura are visual aberrations: the perception of sparkling lights or colored lines, blind spots, blurred vision, hemianopia, transitory blindness, micropsia, and visual hallucinations. Only one third of children describe visual symptoms and then only when asked specific questions. The visual aura tends to be stereotyped and unique to the child. The perception of the imagery may be limited to one eye, may be limited to one visual field, or may be without localization.

Visual hallucinations and other visual distortions may disturb time sense and body image. This symptom complex in migraine is called the *Alice-in-Wonderland syndrome*. More extreme disturbances in mental state—amnesia, confusion, and psychosis—are discussed in the sections on confusional migraine and transient global amnesia (see Chapter 2).

Dysesthesias of the limbs and perioral region are the next most common sensory features. Other possible features of the aura are focal motor deficits, usually hemiplegia (see Hemiplegic Migraine) or ophthalmoplegia (see Ophthalmoplegic Migraine), and aphasia. These deficits, although alarming, are transitory; normal function usually returns within 24 hours and always within 72 hours.

A migraine attack may terminate at the end of the initial phase without headache. Alternatively the initial phase may be brief or asymptomatic, and headache may be the major symptom (see Migraine Without Aura). The pain is usually dull at first, then becomes throbbing, pulsating, or pounding. Severe headache that is maximal at onset is not migraine. Pain is unilateral in approximately two thirds of patients and bilateral in the rest. It is most intense in the region of the eye, forehead, and temple. Eventually the pain becomes constant and diffuse. Most headaches last 2 to 6 hours and are associated with nausea and sometimes vomiting. Anorexia and photophobia are concomitant symptoms. The child looks sick and wants to lie down. Always ask the parent, "Does the child look sick?" With migraine, the

TABLE 3-2
Migraine Equivalents

Acute confusional migraine (see Chapter 2)
Basilar migraine (see Chapter 10)
Benign paroxysmal vertigo (see Chapter 10)
Cyclic vomiting
Hemiplegic migraine (see Chapter 11)
Ophthalmoplegic migraine (see Chapter 15)
Paroxysmal torticollis (see Chapter 14)
Transient global amnesia (see Chapter 2)

answer is always “yes.” Vomiting frequently heralds the end of the attack, and the fatigued child falls into a deep sleep. Normal function resumes when the child awakens. Most children average one attack per month but may have long intervals without attacks and other intervals when attacks occur weekly. The intervals with frequent headaches are probably times of stress.

Migraine Without Aura

The attacks of migraine without aura are monophasic. Headache and vomiting are the only features, and attacks are more difficult to identify as migrainous. The typical initial symptoms are personality change, malaise, and nausea. Recurrent vomiting may be the only feature of the attack in preschool children.

The headache may be unilateral and pounding, but more often the child has difficulty localizing the pain and describing its quality. When the headache is prolonged, the pain is not of uniform intensity; instead, intermittent severe headaches superimpose on a background of chronic discomfort in the neck and other pericranial muscles. Physical activity aggravates the pain. Migraine without aura may be difficult to separate from other headache syndromes or from intercurrent illness. The important clues are that the child appears sick, wants to lie down, and is sensitive to light and sound. Nausea and vomiting may occur repeatedly, need not herald the termination of the attack, and can be more prominent than the headache.

Diagnosis

The clinical features are the basis for migraine diagnosis; migraine is one of the few remaining neurological disorders in which the physician cannot stumble on the diagnosis by imaging the brain. Salient features are a family history of migraine and some combination of recurrent headache, nausea, or neurological disturbances, especially if sleep relieves symptoms. The physician should be reluctant to make the diagnosis if questioning of both biological parents does not elicit a family history of migraine. When obtaining the history, be certain that you are speaking with the biological parents. Almost half of children with migraine also have a history of motion sickness. The significance of this association is uncertain; the incidence of motion sickness in the pediatric population approaches 100%, depending on the amount of motion.

Diagnostic tests are unnecessary when the family history and clinical features clearly establish a migraine diagnosis. Brain imaging is indicated only when uncertainty exists. The main reason is abnormalities on examination. Lesser reasons are a negative family history or atypical features of the attack. The only reason to request an EEG in children with migraine-like headaches is to exclude the possibility of benign occipital epilepsy (see Chapter 1).

Management

The essential caveat for the treatment of migraine is that regardless of treatment, about half of affected children have more than a 50% reduction in headache frequency in the 6 months after the initial visit to a neurologist. This is consistent with the experience of most blinded, controlled trials of drug therapy, in which the placebo success rate is usually 50%. When the child's parents are convinced that the headache is due to migraine and not brain tumor, they are less anxious, the child is more relaxed, and headaches either decrease in frequency or become less a topic of discussion and concern. The therapeutic efficacy of neurological consultation has the dual effect of making drug evaluation difficult and reinforcing the neurologist's belief that the drug regimen selected is useful.

The two approaches to migraine therapy are treatment of the acute attack and prophylaxis. Many children need both. Whichever the approach, tell the patient and family that migraine will not soon go away and that they need to learn how to live with it. After all, migraine is not a temporary condition; it is often a lifelong condition.

1. Instruct the patient and the parents to avoid, when possible, activities that are known to trigger attacks.
2. When an attack occurs, give in to it. Take medication and go to bed; do not try to maintain activity.
3. Never use narcotics or other addictive drugs to treat severe attacks.
4. Sleep ends the attack. Any medication that puts the child to sleep will end the attack.

Treating the Acute Attack

Migraine that starts in the school is difficult to manage unless the school allows the prompt use of abortive medication and has a quiet room. Often, this is not the case. The two main

symptoms of a migraine attack are headache and nausea. Nonprescription analgesics and nonsteroidal anti-inflammatory drugs, especially ibuprofen, are more effective than placebo in controlling pain (Mather, 2003). Many people find relief with Exedrin Migraine, a relatively inexpensive nonprescription medication. Sleep is an ideal treatment. I often prescribe oral promethazine, generally 25 mg in school-age children. It relieves nausea and causes drowsiness. When the child awakens, the attack is usually over. Its use is limited to the home, however.

The triptans, 3,5 substituted indoles, selective serotonin agonists, were an important development to abort acute migraine attacks. They are considerably more expensive than nonsteroidals or promethazine but do not cause sedation when maintained performance is required. The first member of this group was sumatriptan. After administering 0.06 mg/kg subcutaneously, the severity of an attack decreased within 60 minutes in 78% of children aged 6 to 18 years (Linder, 1996). Boys respond more frequently than girls do. Adverse effects include fatigue; tingling of the head and arms; and a sensation of pressure or stiffness in the neck, throat, and chest. Availability of the oral compound (sumatriptan succinate) followed the study, and although a dosing schedule for children is not established, 25 mg of the oral preparation is safe and effective in most school-age children. Seven oral triptans are approved by the Food and Drug Administration for use in adults. The sublingual forms have more rapid onset of action, are well tolerated, and are readily administered in circumstances in which water is not available.

Triptan nasal sprays are available and may be the most effective mode of administration but are impractical to carry around (Silberstein and McCorry, 2003). They take effect 15 minutes after administration at a dose of 10 to 20 mg in adults. A dosing schedule for children is not established, but the adolescent dose is the same as for an adult. Dihydroergotamine is available as an intranasal preparation and is useful when nausea and vomiting limit the use of oral medications or when other medications are ineffective. The triptans and dihydroergotamine are not approved by the Food and Drug Administration for children, but off-label use is common among headache specialists.

Migraine Prophylaxis

A large number of agents with diverse pharmacological properties are available for daily use to prevent migraine attacks. I suggest prophylactic

agents only for children who miss school more than once each month. The drugs with proven efficacy are amitriptyline, propranolol, and valproate (Silberstein and Freitag, 2003). All three drugs require a trial of at least 3 months with the frequency of attacks compared each month with prior attacks. Children and parents should be urged to use a migraine diary. Cyproheptadine, commonly used by pediatricians, is no better than placebo in controlled clinical trials.

Amitriptyline

Amitriptyline is inexpensive and has an acceptable side-effect profile at low dosages (10 to 25 mg at bedtime). This is my first choice. The mechanism of action is unknown.

Propranolol

Propranolol is a beta-adrenergic blocking agent. It decreases headache frequency by at least half in 80% of patients. The mechanism of action is probably central and not by beta-adrenergic blockade. Propranolol must have central action because it causes depression. Other beta-blockers have efficacy as well.

The dosage in children is 2 mg/kg in three divided doses. Because depression is a dose-related adverse reaction and because lower doses may be effective, start treatment at 1 mg/kg/day. Depression is the most common reason to discontinue therapy. Forewarn parents that depression is possible when starting the drug. Propranolol may provoke an asthmatic attack in predisposed children. Hypotension and pulse rate reduction do not occur in children with normal cardiovascular systems. The maintenance dose of the sustained-release tablet is one third greater than that of the short-acting preparation. Plasma levels of propranolol are not useful in determining the effective dose for migraine.

People who respond to propranolol do not develop tolerance. When abruptly stopping the drug after 6 to 12 months of therapy, however, some individuals have rebound headaches of increased frequency. Others continue to show the benefits achieved during therapy.

Valproate

Valproate is widely used for epilepsy prophylaxis. A once-daily dose of 250 to 500 mg in sustained-release preparation is effective for migraine prophylaxis. Side effects include easy bruising from low platelets, increased appetite,

and tremor. Several other seizure medications are currently in use for migraine prophylaxis.

Cluster Headache

Cluster headache is uncommon in children. It occurs mainly in boys and rarely affects other family members (Russell et al, 1995). Cluster headache is distinct from chronic paroxysmal hemicrania and hemicrania continua (see following section on Indomethacin-Responsive Headache).

CLINICAL FEATURES. The onset is almost exclusively after age 10. Clusters of headaches recur over periods of weeks or months separated by intervals of 1 to 2 years. A cluster of daily attacks lasting 4 to 8 weeks may occur once or twice a year, often in the autumn or spring. Headaches do not occur in the interim.

Headache is the initial feature, often beginning during sleep. The pain occurs in bursts lasting 30 to 90 minutes and repeats two to six times each day. It is always unilateral and affects the same side of the head in each attack. Pain begins behind and around one eye before spreading to the entire hemicrania. During an attack, the affected individual cannot lie still but typically walks the floor in anguish. This feature distinguishes cluster headache from migraine, in which the child wants to go to bed. Pain is intense and described either as throbbing or constant. The scalp may seem edematous and tender. One third of individuals with cluster headache experience sudden intense jabs of pain suggesting tic douloureux. Nausea and vomiting do not occur, but symptoms of hemicranial autonomic dysfunction—injection of the conjunctiva, tearing of the eye, Horner syndrome, sweating, flushing of the face, and stuffiness of the nose—develops ipsilateral to the headache.

DIAGNOSIS. The clinical features alone establish the diagnosis of cluster headache. Laboratory studies have no value.

MANAGEMENT. The management of cluster headache consists of suppressing recurrences of a bout in progress and relieving acute pain. Prednisone suppresses bouts of cluster headache. An initial dose is 1 mg/kg/day for the first 5 days, followed by a tapering dose over 2 weeks. If headaches reappear during the tapering process, the dose is increased and maintained at a level sufficient to keep the patient headache-free. If the bout of cluster headache is prolonged, taper the prednisone dose before the appearance of adverse side effects.

Sumatriptan or oxygen inhalation or both treat the acute attack. The dose of sumatriptan in adults is a 6-mg injection. Most adolescents would require the same. Inhalation of 100% oxygen at a rate of 8 to 10 L/min relieves an acute attack in most patients. Lithium is useful for patients with a chronic form of cluster headache in which the headache never ceases. Provide increasing doses to achieve a blood concentration of 1.2 mEq/L (1.2 mmol/L). Most patients have at least a partial response to lithium, but only 50% are relieved completely. The addition of daily oral ergotamine enhances the beneficial effect of lithium.

Indomethacin-Responsive Headache

Indomethacin-responsive headache syndromes are a group of seemingly unrelated headache disorders that respond to indomethacin and to nothing else. The syndromes include chronic paroxysmal hemicrania, hemicrania continua, and benign exertional headache.

Chronic Paroxysmal Hemicrania

CLINICAL FEATURES. As with cluster headache, the main features of chronic paroxysmal hemicrania are unilateral throbbing pain associated with ipsilateral autonomic features. The attack duration is briefer but more frequent than in cluster headache (Goadsby and Lipton, 1997). Attacks last weeks to months followed by remissions that last months to years. The pain is located in the frontal and retro-orbital regions and is accompanied by conjunctival injection and tearing.

DIAGNOSIS. The clinical features are the basis for diagnosis; laboratory studies are normal.

MANAGEMENT. Chronic paroxysmal hemicrania responds to indomethacin. The typical adult dosage is 75 mg/day. Successive attacks often require larger dosages. Acetazolamide may prove successful when indomethacin fails.

Hemicrania Continua

CLINICAL FEATURES. Hemicrania continua is a continuous unilateral headache of moderate severity. Autonomic symptoms may be associated but are not prominent. Some patients have continuous headaches lasting weeks to months separated by pain-free intervals; others never experience remissions. The episodic form may later become continuous.

DIAGNOSIS. The clinical features establish the diagnosis after excluding other causes of chronic headache, such as increased intracranial pressure and chronic use of analgesics.

MANAGEMENT. The headaches usually respond to indomethacin at dosages of 25 to 75 mg/day.

Benign Exertional Headache

Exertion, especially during competitive sports, is a known trigger for migraine in predisposed individuals (see Migraine earlier in this chapter). Persons who do not have migraine also may experience headaches during exercise. Headache during sexual intercourse may be a form of exertional headache or is at least a comorbid condition (Frese et al, 2003).

CLINICAL FEATURES. Exertional headaches tend to be acute and severe, starting early in the course of exercise, whereas headaches with sexual activity increase with sexual excitement and may have a dull or throbbing quality. Headache may occur during prolonged sexual arousal and during sexual intercourse.

DIAGNOSIS. The association between exertion and headache is easily recognized. Requests for medical consultation are unusual, unless the patient is a competitive athlete whose performance is impaired.

MANAGEMENT. Indomethacin use before exertion may prevent headache. The prophylactic use of indomethacin, 25 mg three times a day, or propranolol, 1 to 2 mg/kg/day, also reduces the incidence of attacks.

Chronic Low-Grade Headaches

Chronic low-grade headaches are constant or intermittent daily headaches. The child is not sick and usually continues normal activity but is constantly complaining of headache. The two most common causes of chronic low-grade headache are excessive use of analgesics and caffeine (Warner et al, 1998).

Analgesic Rebound Headache

CLINICAL FEATURES. Analgesic rebound is a common cause of chronic headache in people of all ages. Individuals with migraine are especially predisposed to analgesic rebound headaches (*extended migraine*). The term refers to a vicious cycle of headache–analgesic use–headache when the analgesic effect wears off—more analgesic use. The pain is generalized, of low intensity, and dull.

It interferes with but does not prevent routine activities, and activity is not an aggravating factor (Zwart et al, 2003).

DIAGNOSIS. Any child using nonprescription analgesics every day, or even most days, is likely to suffer from analgesic rebound headache.

MANAGEMENT. Stop all analgesic use, and avoid caffeine. Amitriptyline (10 mg) given at bedtime often helps the transition to the analgesic-free state. Gabapentin, 2400 mg/day, has proven efficacy in the treatment of chronic daily headache and may be useful for analgesic rebound headache (Spira et al, 2003). The first few days may be difficult, but a positive effect within weeks reinforces the recommended management. During the first months, the patient should keep a headache calendar to document the decline in headache frequency.

Caffeine Headache

CLINICAL FEATURES. Many children, especially adolescents, drink large volumes of carbonated beverages containing caffeine each day. The amount of caffeine in many popular beverages is equivalent to that in a cup of brewed coffee. The exact mechanism of the caffeine headache is not established; it could be a withdrawal effect or a direct effect of caffeine. Individuals who regularly drink large amounts of caffeine-containing beverages often notice a dull frontotemporal headache an hour or more after the last use. More caffeine relieves the headache, initiating a caffeine addiction. Withdrawal symptoms may become severe and include throbbing headache, anxiety, and malaise.

DIAGNOSIS. Most people associate caffeine with coffee and are unaware of the caffeine content of soft drinks. In addition to coffee, tea, and colas, other popular drinks with high caffeine content are deceptive because they do not have a cola color. Adolescent girls frequently use diet colas as a substitute for food and become caffeine dependent.

MANAGEMENT. Caffeine addiction, similar to other addictions, is often hard to break. Most patients require abrupt cessation. As in analgesic rebound headache, 10 mg of amitriptyline at bedtime for the first month may be useful in breaking the cycle.

Posttraumatic Headache

Several different kinds of headache are associated with head trauma. Forty percent of people experience a vascular headache the first day or

two after head injury. It is a diffuse, pounding headache made worse by movement of the head or by coughing and straining. Dizziness may be associated. Posttraumatic vascular headaches subside spontaneously. Prolonged posttraumatic headaches are analgesic rebound headaches.

CLINICAL FEATURES. The child sustains a head injury, with or without loss of consciousness, or a whiplash injury. CT scans of the head or neck do not reveal intracranial or vertebral injury. Shortly afterward, the child experiences head or neck pain or both requiring analgesic treatment—first a narcotic and then a nonprescription analgesic. A dull daily headache develops, for which a variety of analgesic medications provide no permanent relief.

DIAGNOSIS. In the absence of imaging evidence of intracranial or vertebral injury, consider all chronic low-grade head or neck pain after trauma an analgesic rebound headache.

MANAGEMENT. See previous discussion of Analgesic Rebound Headache.

Tension Headache

The term *tension headache* is time honored. The name suggests that the cause of headache is stress. This is usually true with regard to episodic tension headaches (see section on Pain from Other Cranial Structures that follows), but the mechanism of chronic tension headache is less well established and is probably multifactorial. One often obtains a family history of chronic tension headache, and about half of adults with chronic tension headache date the onset to childhood.

CLINICAL FEATURES. Individuals with chronic headache of any cause may be depressed and anxious. Pain is usually bilateral and diffuse, and the site of most intense pain may shift during the course of the day. Much of the time, the headache is dull and aching; sometimes it is more intense. Headache is generally present on awakening and may continue all day but is not aggravated by routine physical activity. Most children describe an undulating course characterized by long periods in which headache occurs almost every day and shorter intervals when they are headache-free.

Nausea, vomiting, photophobia, phonophobia, and transitory neurological disturbances are not associated with chronic tension headache. When these features are present, they usually occur only a few times a month and suggest intermittent migraine against a background of chronic tension headache. The neurological examination is normal.

DIAGNOSIS. The diagnosis of chronic tension headache is to some extent a diagnosis of exclusion. Common causes of chronic headache in children that require distinction are migraine and analgesic rebound headache. Both may coexist with chronic tension headache. Brain imaging is sometimes required to exclude the specter of brain tumor. The management of chronic tension headache is often easier after a normal head CT scan.

MANAGEMENT. Chronic tension headache is by definition difficult to treat, or it would not be a chronic headache. Most children have tried and received no benefit from several nonprescription analgesics before coming to a physician, and analgesic rebound headache often complicates management. The use of more powerful analgesics or analgesic-muscle relaxant combinations has limited value and generally adds upset stomach to the child's distress.

It is not always clear that a child with chronic tension headache is experiencing stress. When a stressful situation is identified (e.g., divorce of the parents, custody battle, unsuitable school placement, physical or sexual abuse), the headache cannot be managed without resolution of the stress.

Headaches Associated with Drugs and Foods

Many psychotropic drugs, analgesics, and cardiovascular agents cause headache. Cocaine use produces a migraine-like headache in individuals who do not have migraine at other times. Drug-induced headache is suspect in a child who has headache following the administration of any drug. These headaches tend to be intermittent rather than daily.

Food Additives

CLINICAL FEATURES. The addition of chemicals to foods preserves shelf life and enhances appearance. Ordinarily concentrations are low, and adverse effects occur only in genetically sensitive individuals. Nitrites are powerful vasodilators used to enhance the appearance of cured meats, such as hot dogs, salami, bacon, and ham. Diffuse, throbbing headaches may occur just after ingestion.

Monosodium glutamate (MSG), primarily used in Chinese cooking, may cause generalized vasodilation. Sensitive individuals develop a throbbing bitemporal headache and a band headache, sometimes associated with pressure

and tightness of the face and a burning sensation over the body. Symptom onset is 20 minutes after MSG ingestion.

DIAGNOSIS. The association between ingestion of a specific food and headache is quickly evident to the patient.

MANAGEMENT. Avoiding the offending chemical prevents headache. This is not easy; prepared foods often do not contain a list of all additives.

Marijuana

Marijuana is a peripheral vasodilator and causes a sensation of warmth, injection of the conjunctivae, and sometimes frontal headache. The headache is mild and ordinarily is experienced only during marijuana use. Marijuana metabolites remain in the blood for several days, however, and chronic headaches occur in children who are regular users.

Headache and Systemic Disease

Vasculitis

Headaches caused by vasculitis, especially temporal arteritis, are important in the differential diagnosis of vascular headaches in adults. Cerebral vasculitis is uncommon in children and usually occurs as part of a collagen vascular disease, as a result of hypersensitivity, or as part of an infection of the nervous system.

Connective Tissue Disorders

Headache is a feature of systemic lupus erythematosus (SLE) and mixed connective tissue disease. In patients with connective tissue disease, it is not clear that the cause of neurological symptoms, including headache, is vasculitis of the cerebral arteries.

CLINICAL FEATURES. Severe headache occurs in 10% of children with SLE. It may occur in the absence of other neurological manifestation and can be the initial feature of SLE.

Mixed connective tissue disease is a syndrome with features of SLE, scleroderma, and polymyositis. Its course is usually less severe than that of SLE. Of people with mixed connective tissue disease, 35% report vascular headaches. The headaches are moderate and generally do not interfere with activities of daily living. They may be unilateral or bilateral but are generally throbbing. More than half of patients report a visual aura, and some have

nausea and vomiting. Some of these children may be experiencing migraine aggravated by the underlying vasculitis; in others, the cause of headache is the vasculitis itself.

DIAGNOSIS. The diagnosis of connective tissue disease depends on the combination of a compatible clinical syndrome and the demonstration of antinuclear antibodies in the blood. The presence of antinuclear antibodies in a child with headache who has no systemic symptoms of connective tissue disease should suggest the possibility of a hypersensitivity reaction.

MANAGEMENT. The ordinary treatment of children with connective tissue disease is corticosteroids. In many cases, headaches develop while the child is already taking corticosteroids; this is not an indication to increase the dose. Headache is not a disabling symptom, it does not indicate a generalized encephalopathy, and treatment with analgesics is unnecessary.

Hypersensitivity Vasculitis

The important causes of hypersensitivity vasculitis in children are serum sickness, Henoch-Schönlein purpura (see Chapter 11), amphetamine abuse, and cocaine abuse. Children with serum sickness or Henoch-Schönlein purpura have systemic symptoms that precede the headache. Persistent headache and behavioral changes are often the only neurological consequences of Henoch-Schönlein purpura. In contrast, substance abuse can cause a cerebral vasculitis in the absence of systemic symptoms. The features are headache, encephalopathy, focal neurological deficits, and subarachnoid hemorrhage.

Hypertension

A sudden increase in systemic blood pressure causes the explosive, throbbing headache associated with orgasm and pheochromocytoma. Children with chronic hypertension may have low-grade occipital headache on awakening that diminishes as they get up and begin activity or frontal throbbing headache during the day. Most children with chronic hypertension are asymptomatic, however. When a child with renal disease develops headache, hypertension is probably not the cause (see Chapter 2). Instead, pursue alternative causes. Headaches are common in patients undergoing dialysis and may be due to psychological tension, the precipitation of migraine attacks, and dialysis itself. Dialysis headache begins a few hours after terminating the procedure and is characterized by mild

bifrontal throbbing headache, sometimes associated with nausea and vomiting.

Pain from Other Cranial Structures

Eyestrain

CLINICAL FEATURES. Prolonged ocular near-fixation in a child with a latent disturbance in convergence may cause dull, aching pain behind the eyes that is quickly relieved when the eyes are closed. The pain is of muscular origin and caused by the continuous effort to maintain conjugate gaze. If work continues despite ocular pain, episodic tension headache may develop.

DIAGNOSIS. Refractive errors are often a first consideration in children with eyestrain. Eyeglasses do not correct the headache. Refractive errors do not cause eyestrain in children, as presbyopia does in adults.

MANAGEMENT. Resting the eyes relieves eyestrain.

Episodic Tension Headache

CLINICAL FEATURES. Episodic tension headache is common in people of all ages and both genders. Fatigue, exertion, and temporary life stress cause the headache. The mechanism is probably prolonged contraction of muscles attached to the skull. The pain is constant, aching, and tight. Localization is mainly to the back of the head and neck, sometimes becomes diffuse, and then is described as a constricting band around the head. Nausea, vomiting, photophobia, and phonophobia are not present. Headaches usually last from 30 minutes to all day. One episode may last for several days, with some waxing and waning, but not for a week.

DIAGNOSIS. Episodic tension headache differs from chronic tension, which has similar clinical features but persists for weeks, months, or years. Most episodic tension headaches are self-diagnosed, and the individual rarely seeks medical attention.

MANAGEMENT. Rest, relaxation, warm compresses to the neck, and nonprescription analgesics relieve pain.

Sinusitis

When questioned about migraine symptoms, most parents identify their own episodic headache, preceded by scintillating scotomata and followed by nausea and vomiting, as

sinusitis. This diagnosis, favored by physicians and patients to describe chronic or episodic headaches, is usually wrong.

CLINICAL FEATURES. Children with sinusitis are usually sick. They are febrile, feel stuffy, and have difficulty maintaining a clear airway. Localized tenderness is present over the infected frontal or maxillary sinuses, and inflammation of the ethmoidal or sphenoidal sinuses causes deep midline pain behind the nose. Blowing the nose or quick movements of the head, especially bending forward, exaggerate the pain. Concurrent vascular headache caused by fever is common.

DIAGNOSIS. Radiographs reveal clouding of the sinuses and sometimes a fluid level. CT of the skull is exceptionally accurate in identifying sinusitis but usually an unnecessary expense. It is impressive how often CT of the head, performed for reasons other than headache, shows radiographic evidence of asymptomatic sinusitis. Radiographic evidence of sinusitis does not explain a patient's headache.

MANAGEMENT. The primary objective of treatment is to allow the sinus to drain. Decongestants usually accomplish drainage, but sometimes surgery is required. Antibiotics have limited usefulness if drainage is not established.

Temporomandibular Joint Syndrome

The temporomandibular joint (TMJ) syndrome does not cause chronic generalized daily headache. The pain is unilateral and centered over and below the TMJ (Rothner, 1995).

CLINICAL FEATURES. TMJ syndrome is a rare disease in children, occurring as young as 8 years of age. The duration of symptoms before diagnosis may be 5 years and averages 2 years. The primary disturbance is arthritis of the TMJ causing localized pain in the lower face and crepitus in the joint. Because of pain on one side, chewing occurs on the other, with overuse of the affected side. The overused masseter muscle becomes tender; a muscle contraction headache ensues. Localization of pain is on the side of the face and the vertex. Bruxism or dental malocclusion is the usual cause of arthritis, but a prior injury of the jaw accounts for one third of TMJ syndromes in children.

DIAGNOSIS. Radiographs of the TMJ usually show some internal derangement of the joint and may show degenerative arthritis. Magnetic resonance imaging (MRI) using surface coils is the most effective technique to show the disturbed joint architecture.

MANAGEMENT. TMJ treatment based on controlled experiments is not established. Placebos provide considerable benefit, and TMJ is not an indication for extensive oral surgery. Non-steroidal anti-inflammatory drugs, application of heat to the tense muscles, and dental splints may prove useful.

Whiplash and Other Neck Injuries

Whiplash and other neck injuries cause pain by rupturing cervical disks, damaging soft tissue, injuring occipital nerves, and causing excessive muscle contraction. The muscles contract in an effort to splint the area of injury and reduce further tissue damage.

CLINICAL FEATURES. Constant contraction of the neck extensors causes a dull, aching pain not only in the neck, but also in the shoulders and upper arms. This may persist for 3 months after the injury. Holding the head in a fixed position is common. Nausea and vomiting are not associated symptoms.

DIAGNOSIS. Cervical spine radiographs are required after any neck or head injury to determine the presence of fracture or dislocation. Shooting pains, radiating either to the occiput or down the arm and into the fingers, suggest the possibility of disk herniation and require further study with MRI.

MANAGEMENT. Warn the patient and family at the onset that prolonged head and neck pain is an expected outcome after injury and does not indicate a serious condition. Several different interventions achieve pain relief. Lying or sitting with the head supported, superficial application of heat to the painful muscles, muscle relaxants, and non-narcotic analgesics are potentially effective. When pain persists after 3 months and affects the head as well, the possibility of analgesic rebound headache is more likely.

Seizure Headache

Diffuse headache caused by vasodilation of cerebral arteries is a frequent occurrence after a generalized tonic-clonic convulsion. In patients who have epilepsy and migraine, one can trigger the other; frequently, headache and seizure occur concurrently. Approximately 1% of epileptic patients report headache as a seizure manifestation (seizure headache). Most patients with seizure headaches have epilepsy before the development of headache. In rare children, headache is the only feature of their seizure disorder.

CLINICAL FEATURES. Headache is part of several epilepsy syndromes. The most common syndrome in children is *benign occipital epilepsy* (see Chapter 1). The sequence of events suggests migraine. I have evaluated one eloquent adolescent who complained of paroxysmal “head pain unlike other headaches” that was associated with EEG evidence of generalized epileptiform activity. Anticonvulsants relieved head pain.

Headache also may occur as a seizure manifestation in patients known to have a seizure disorder. These individuals usually have a long history of partial or generalized seizures before headache becomes part of the syndrome. Associated ictal events depend on the site of the cortical focus and may include auditory hallucinations, visual disturbances, vertigo, *deja vu*, and focal motor seizures. Headache may be the initial feature of the seizure or can follow other partial seizure manifestations, such as *deja vu* and vertigo. Headache description may be throbbing, sharp, or without an identified quality. Complex partial seizures, simple partial seizures, or generalized tonic-clonic seizures follow the headache phase. Spike foci in patients with seizure headaches are usually temporal in location.

DIAGNOSIS. Chronic headache in children is not an indication for EEG. Interictal discharges, especially rolandic spikes, do not indicate that the headaches are a seizure manifestation, only that the child has a genetic marker for epilepsy. Children with paroxysmal headaches, clearly not migraine, may require an EEG study. If interictal spike discharges are seen, an effort should be made to record a seizure headache with an EEG monitor. The observation of continuous epileptiform activity during a headache provides reassurance that headache is a seizure manifestation and anticonvulsant drugs would prove effective.

MANAGEMENT. The response to anticonvulsant therapy is diagnostic and therapeutic. Because the seizure focus is usually cortical and most often in the temporal lobe, either carbamazepine or phenytoin is recommended.

References

- Bille B. A 40-year follow-up of school children with migraine. *Cephalgia* 1997;17:488-491.
- Frese A, Eikermann A, Frese K, et al. Headache associated with sexual activity. Demography, clinical features, and comorbidity. *Neurology* 2003;61:796-800.
- Goadsby PJ, Lipton RB. A review of paroxysmal hemicranias, SUNCT syndrome and other short lasting headaches with

- autonomic features, including new cases. *Brain* 1997;120:193-209.
- International Headache Society. The International Classification of Headache Disorders. Second Edition. *Cephalalgia* 2004;24(Suppl 1).
- Lewis DW, Ashwal S, Dahl G, et al. Practice parameter. Evaluation of children and adolescents with recurrent headaches. Report of the Quality Standards Committee of the American Academy of Neurology and the Practice Committee of the Child Neurology Society. *Neurology* 2002;59:490-498.
- Linder SL. Subcutaneous sumatriptan in the clinical setting. The first 50 consecutive patients with acute migraine in a pediatric neurology office practice. *Headache* 1996;36:419-422.
- Mather DB. Acute management of migraine. Highlights of the US Headache Consortium. *Neurology* 2003;60(Suppl 2):S21-S23.
- Rothner AD. Miscellaneous headache syndromes in children and adolescents. *Semin Pediatr Neurol* 1995;2:159-164.
- Russell MB, Andersson PG, Thomsen LL. Familial occurrence of cluster headache. *J Neurol Neurosurg Psychiatry* 1995;58:341-343.
- Silberstein SD, Freitag FG. Preventive treatment of migraine. *Neurology* 2003;60(Suppl 2):S34-S38.
- Silberstein SD, McCory DC. Ergotamine and dihydroergotamine. History, pharmacology, and efficacy. *Headache* 2003;43:144-166.
- Spira PJ, Beran RG, The Australian Gabapentin Chronic Daily Headache Group. Gabapentin in the prophylaxis of chronic daily headache. A randomized placebo-controlled study. *Neurology* 2003;61:1753-1759.
- Warner JS, Vasconcellos E, Pina-Garza JE, et al. Daily headaches in adolescents and children. *J Child Neurol* 1998;38:636 (abstract).
- Zwart JA, Dyb G, Hagen K, et al. Analgesic use. A predictor of chronic pain and medication overuse headache. The Head-HUNT study. *Neurology* 2003;61:160-164.

Chapter 4

Increased Intracranial Pressure

INCREASED INTRACRANIAL PRESSURE is not a presenting complaint (Table 4-1). Most often, headache, vomiting, personality change, and alterations in states of consciousness bring it to medical attention. Less frequently, diplopia or the observation that one or both eyes are turning in is the initial complaint. The basis of referral for some children is the diagnosis of papilledema by another physician. Some conditions causing increased intracranial pressure are discussed elsewhere in this book (see Chapters 2, 3, 10, and 15). This chapter is restricted to conditions in which symptoms of increased intracranial pressure are initial and prominent features.

Pathophysiology

Normal intracranial pressure in the resting state is approximately 10 mm Hg (136 mm H₂O). Pressures greater than 20 mm Hg are abnormal. When the cranial bones fuse during childhood, the skull is a rigid box enveloping its content. Intracranial pressure is then the sum of the individual pressures exerted by the brain, blood, and cerebrospinal fluid (CSF). An increase in the volume of any one component requires an equivalent decrease in the size of one or both of the other compartments if intracranial pressure is to remain constant. Because the provision of oxygen and nutrients to the brain requires relatively constant cerebral blood flow, the major adaptive mechanisms available to relieve pressure are the compressibility of the brain and the rapid reabsorption of CSF by arachnoid villi. Infants and young children, in whom the cranial bones are still unfused, have the additional adaptive mechanism of spreading the cranial bones apart to increase cranial volume.

Cerebrospinal Fluid

The choroid plexus accounts for at least 70% of CSF production, and the transependymal movement of fluid from the brain to the ventricular system accounts for the remainder. The average volumes of CSF are 90 mL in children 4 to 13 years old and 150 mL in adults. The rate of formation is approximately 0.35 mL/min or 500 mL/day. Approximately 14% of total volume turns over every hour. The rate at which CSF forms remains relatively constant and declines only slightly as CSF pressure increases. In contrast, the rate of absorption increases linearly as CSF pressure exceeds 7 mm Hg. At a pressure of 20 mm Hg, the rate of absorption is three times the rate of formation.

Impaired absorption, not increased formation, is the usual mechanism of progressive hydrocephalus. Choroid plexus papilloma is the only pathological process in which formation sometimes can overwhelm absorption. When absorption is impaired, efforts to decrease the formation of CSF are not likely to have a significant effect on volume.

Cerebral Blood Flow

Systemic arterial pressure is the primary determinant of cerebral blood flow. Normal cerebral blood flow remains remarkably constant from birth to adult life and is generally 50 to 60 mL/min/100 g brain weight. The autonomic innervation of blood vessels on the surface and at the base of the brain is richer than vessels of any other organ. These nerve fibers allow the autoregulation of cerebral blood flow. *Autoregulation* refers to a buffering effect by which cerebral blood flow remains constant despite changes in systemic arterial perfusion

TABLE 4-1
Features of Increased Intracranial Pressure

In Infants

Bulging fontanelle
 Failure to thrive
 Impaired upward gaze (setting sun sign)
 Large head (see Chapter 18)
 Shriill cry

In Children

Diplopia (see Chapter 15)
 Headache (see Chapter 3)
 Mental changes
 Nausea and vomiting
 Papilledema

pressure. Alterations in the arterial blood concentration of carbon dioxide have an important effect on total cerebral blood flow. Hypercarbia dilates cerebral blood vessels and increases blood flow, whereas hypocarbia constricts cerebral blood vessels and decreases flow. Alterations in blood oxygen content have the reverse effect, but are less potent stimuli for vasoconstriction or vasodilation than are alterations in the blood carbon dioxide concentration.

Cerebral perfusion pressure is the difference between mean systemic arterial pressure and intracranial pressure. Reducing systemic arterial pressure or increasing intracranial pressure reduces perfusion pressure to dangerous levels. The autoregulation of the cerebral vessels is lost when cerebral perfusion pressure decreases to less than 50 cm H₂O or in the presence of severe acidosis. Arterial vasodilation or obstruction of cerebral veins and venous sinuses increases intracranial blood volume. Increased intracranial blood volume, similar to increased CSF volume, results in increased intracranial pressure.

Cerebral Edema

Cerebral edema is an increase in the brain's volume caused by an increase in its water and sodium content. Increased intracranial pressure results from either localized or generalized cerebral edema. The categories of cerebral edema are *vasogenic*, *cytotoxic*, or *interstitial*.

Increased capillary permeability causes vasogenic edema; this occurs with brain tumor, abscess, trauma, and hemorrhage. The fluid is located primarily in the white matter and responds to treatment with corticosteroids. Osmotic agents have no effect on vasogenic edema, but they reduce total intracranial pres-

sure by decreasing normal brain volume. *Cytotoxic edema*, characterized by swelling of neurons, glia, and endothelial cells, constricts the extracellular space. The usual causes are hypoxia, ischemia, or infection of the nervous system. Corticosteroids do not decrease edema, but osmotic agents may relieve intracranial pressure by reducing brain volume.

Transepndymal movement of fluid causes interstitial edema from the ventricular system to the brain; this occurs when CSF absorption is blocked and the ventricles enlarge. The fluid collects chiefly in the periventricular white matter. Agents intended to reduce CSF production, such as acetazolamide and furosemide, may be useful. Corticosteroids and osmotic agents are not effective.

Mass Lesions

Mass lesions (e.g., tumor, abscess, hematoma, arteriovenous malformation) increase intracranial pressure by occupying space at the expense of other intracranial compartments, provoking cerebral edema, blocking the circulation and absorption of CSF, increasing blood flow, and obstructing venous return.

Symptoms and Signs

The clinical features of increased intracranial pressure depend on the child's age and the rate at which pressure increases. Newborns and infants present a special case because expansion of skull volume allows partial venting of increased pressure. The rate of intracranial pressure increase is important at all ages. Intracranial structures accommodate slowly increasing pressure remarkably well, but sudden changes are intolerable and result in some combination of headache, personality change, and states of decreasing consciousness.

Increased Intracranial Pressure in Infancy

Measurement of head circumference and palpation of the anterior fontanelle are readily available methods of assessing intracranial volume and pressure rapidly. The measure of head circumference is the greatest anteroposterior circumference. Normal standards are different for premature and full-term newborns. Normal head growth in a term newborn is 2 cm/mo for the first 3 months, 1 cm/mo for the second 3 months, and 0.5 cm/mo for the next 6 months.

Excessive head growth is a major feature of increased intracranial pressure throughout the first year up to 3 years of age. Normal head growth does not preclude the presence of increased intracranial pressure, however. In post-hemorrhagic hydrocephalus, considerable ventricular dilation precedes any measurable change in head circumference by compressing the brain parenchyma.

The palpable tension of the anterior fontanelle is an excellent measure of intracranial pressure. In a quiet infant, a fontanelle that bulges above the level of the bone edges and is sufficiently tense to cause difficulty in determining where bone ends and fontanelle begins is abnormal and indicates increased intracranial pressure. A full fontanelle, which is clearly distinguishable from the surrounding bone edges, may indicate increased intracranial pressure, but alternate causes are crying, edema of the scalp, subgaleal hemorrhage, and extravasation of intravenous fluids. The normal fontanelle clearly demarcates from bone edges, falls below the surface, and pulsates under the examining finger. Although the size of the anterior fontanelle and its rate of closure are variable, increased intracranial pressure should be suspected when separation of the metopic and coronal sutures is sufficient to admit a fingertip.

The infant experiences lethargy, vomiting, and failure to thrive when cranial suture separation becomes insufficient to decompress increased intracranial pressure. Sixth cranial nerve palsies, impaired upward gaze (setting sun sign), and disturbances of blood pressure and pulse may ensue. Papilledema is uncommon.

Increased Intracranial Pressure in Children

Headache

Headache is a common symptom of increased intracranial pressure at all ages. Traction and displacement of intracranial arteries are the major causes of headache from increased intracranial pressure (see Chapter 3). As a rule, the trigeminal nerve innervates pain from supratentorial intracranial vessels, and referral of pain is to the eye, forehead, and temple. In contrast, cervical nerves innervate infratentorial intracranial vessels, and referral of pain is to the occiput and neck.

With generalized increased intracranial pressure, as occurs from cerebral edema or obstruction of the ventricular system, headache is generalized and more prominent on awakening

and when rising to a standing position. Pain is constant but may vary in intensity. Coughing, sneezing, straining, and other maneuvers that transiently increase intracranial pressure exaggerate headache. The quality of the pain is often difficult to describe. Vomiting in the absence of nausea, especially on arising in the morning, is often a concurrent feature. In the absence of generalized increased intracranial pressure, localized, or at least unilateral, headache can occur if a mass causes traction on contiguous vessels.

In children younger than 10 years old, separation of sutures may relieve symptoms of increased intracranial pressure temporarily. Such children may have a symptom-free interval of several weeks after weeks or months of chronic headache and vomiting. The relief of pressure is temporary, and symptoms eventually return with their prior intensity. An intermittent course of symptoms should not direct attention away from the possibility of increased intracranial pressure.

An individual who was previously well and then experienced an acute, intense headache described as "the worst headache I ever had in my life" probably has suffered a subarachnoid hemorrhage. A small hemorrhage may not cause loss of consciousness but still produces sufficient meningeal irritation to cause intense headache and some stiffness of the neck. Fever may be present.

Diplopia and Strabismus

Paralysis of one or both abducens nerves is a common feature of generalized increased intracranial pressure and may be a more prominent feature than headache in children with idiopathic intracranial hypertension (*pseudotumor cerebri*).

Papilledema

Papilledema is passive swelling of the optic disk caused by increased intracranial pressure (Table 4-2). *Extension of the arachnoid sheath of the optic nerve to the retina is essential for the production of papilledema. This extension does not occur in a small percentage of people, and they can have severe increased intracranial pressure without papilledema.* The edema is usually bilateral and when unilateral suggests a mass lesion behind the affected eye. Early papilledema is asymptomatic. Only with advanced papilledema does transitory obscuration of vision occur. Preservation of visual acuity

TABLE 4-2
Differential Diagnosis of a Swollen Disk

Congenital disk elevation
Increased intracranial pressure
Ischemic neuropathy
Juvenile diabetes
Optic glioma
Papillitis
Retinitis
Retrolbulbar mass
Uveitis

differentiates papilledema from primary optic nerve disturbances, such as optic neuritis, in which visual acuity is always profoundly impaired early in the course (see Chapter 16).

The observation of papilledema in a child with headache or diplopia confirms the diagnosis of increased intracranial pressure. The diagnosis of papilledema is not always easy, however, and congenital variations of disk appearance may confuse the issue. The earliest sign of papilledema is loss of spontaneous venous pulsations in the vessels around the disk margin. Spontaneous venous pulsations occur in approximately 80% of normal adults, but the rate is closer to 100% in children. Spontaneous venous pulsations cease when intracranial pressure exceeds 200 mm H₂O. Papilledema is not present if spontaneous venous pulsations are present, no matter how obscure the disk margin may appear to be. Conversely, when spontaneous venous pulsations are lacking in children, one should suspect papilledema even though the disk margin is flat and well visualized.

As edema progresses, the disk swells and is raised above the plane of the retina, causing obscuration of the disk margin and tortuosity of the veins (Figure 4-1). Associated features include small flame-shaped hemorrhages and nerve fiber infarcts known as *cotton wool*. If the process continues, the retina surrounding the disk becomes edematous so that the disk appears greatly enlarged (Figure 4-2), and retinal exudates radiate from the fovea. Eventually the hemorrhages and exudates clear, but optic atrophy ensues, and blindness may be permanent. Even if increased intracranial pressure is relieved during the early stages of disk edema, 4 to 6 weeks is required before the retina appears normal again.

Congenitally elevated disks, usually caused by hyaline bodies (drusen) within the nerve head, give the false impression of papilledema. The

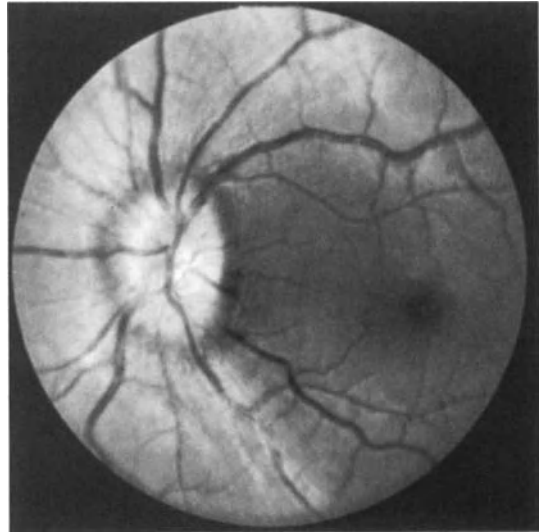


Figure 4-1. Acute papilledema. The optic disk is swollen, and peripapillary nerve fiber layer hemorrhages are evident.

actual drusen are not observable before age 10, and only the elevated nerve head is apparent. Drusen continue to grow and can be seen in older children and in their parents (Figure 4-3). Drusen are an autosomal dominant trait and occur more often in Europeans than other ethnic groups. Spontaneous venous pulsations differentiate papilledema from anomalous nerve head elevations. Their presence excludes papilledema.

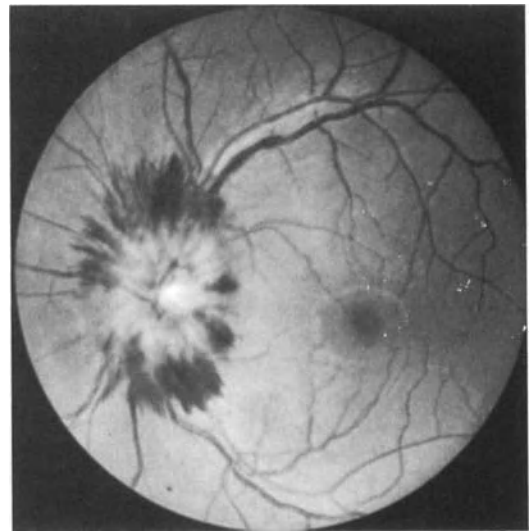


Figure 4-2. Established papilledema. The optic disk is elevated, and opacification of the nerve fiber layer shows around the disk margin and retinal folds (Paton lines) temporarily.

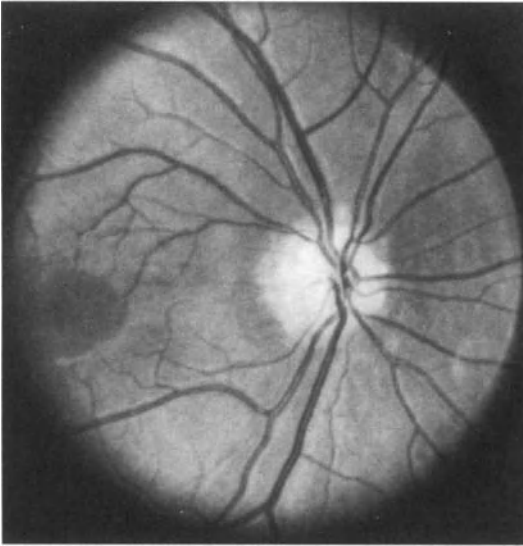


Figure 4-3. Drusen. The disk margin is indistinct, the physiological cup is absent, and yellowish globular bodies are present on the surface.

Herniation Syndromes

Increased intracranial pressure may cause portions of the brain to shift from their normal location into other compartments, compressing structures already occupying that space. These shifts may occur under the falx cerebri, through the tentorial notch, and through the foramen magnum (Table 4-3).

Increased intracranial pressure is a relative contraindication for lumbar puncture. The

TABLE 4-3
Herniation Syndromes

Unilateral (Uncal) Transtentorial Herniation

Decerebrate rigidity
Declining consciousness
Dilated and fixed pupil
Homonymous hemianopia
Increased blood pressure, slow pulse
Respiratory irregularity

Bilateral (Central) Transtentorial Herniation

Decerebrate or decorticate rigidity
Declining consciousness
Impaired upward gaze
Irregular respiration
Pupillary constriction or dilation

Cerebellar (Downward) Herniation

Declining consciousness
Impaired upward gaze
Irregular respirations
Lower cranial nerve palsies
Neck stiffness or head tilt

change in fluid dynamics causes herniation in certain circumstances. The hazard is greatest when pressure between cranial compartments is unequal. This prohibition is relative, and early lumbar puncture is the rule in infants and children with suspected infections of the nervous system despite the presence of increased intracranial pressure. In other situations, lumbar puncture is rarely essential for diagnosis, but usually accomplished safely in the absence of papilledema. The following computed tomography (CT) criteria define people at increased risk of herniation after lumbar puncture:

- Lateral shift of midline structures
- Loss of the suprachiasmatic and basilar cisterns
- Obliteration of the fourth ventricle
- Obliteration of the superior cerebellar and quadrigeminal plate cisterns

Falx Herniation

Herniation of one cingulate gyrus under the falx cerebri is more common in the presence of one enlarged hemisphere. The major feature is compression of the internal cerebral vein and the anterior cerebral artery, resulting in still greater increased intracranial pressure because of reduced venous outflow and arterial infarction.

Unilateral (Uncal) Transtentorial Herniation

The tentorial notch allows structures to pass from the posterior to the middle fossa. The brainstem, the posterior cerebral artery, and the third cranial nerve are its normal components. Unilateral transtentorial herniation characteristically occurs when enlargement of one temporal lobe causes the uncus or hippocampus to bulge into the tentorial notch. Falx herniation is usually an associated feature. Because considerable intracranial pressure is required to cause such a shift, consciousness decreases even before the actual herniation. It declines continuously as the brainstem compresses. Direct pressure on the oculomotor nerve causes ipsilateral dilation of the pupil; sometimes dilation of the contralateral pupil occurs because the displaced brainstem compresses the opposite oculomotor nerve against the incisura of the tentorium. Contralateral homonymous hemianopia occurs (but is impossible to test in an unconscious patient) because of compression of the ipsilateral posterior cerebral artery. With further

pressure on the midbrain, both pupils dilate and fix, respirations become irregular, decerebrate posturing is noted, and death results from cardiorespiratory collapse.

Bilateral (Central) Transtentorial Herniation

Central herniation usually is associated with generalized cerebral edema. Both hemispheres displace downward pushing the diencephalon and midbrain caudad through the tentorial notch. The diencephalon becomes edematous, and the pituitary stalk is avulsed. The clinical features are states of decreasing consciousness, pupillary constriction followed by dilation, impaired upward gaze, irregular respiration, disturbed control of body temperature, decerebrate or decorticate posturing, and death.

Cerebellar Herniation

Increased pressure in the posterior fossa may cause upward herniation of the cerebellum through the tentorial notch or downward displacement of one or both cerebellar tonsils through the foramen magnum. Upward displacement causes compression of the midbrain, resulting in impairment of upward gaze, dilated or fixed pupils, and respiratory irregularity. Downward cerebellar herniation causes compression of the medulla, resulting in states of decreasing consciousness, impaired upward gaze, and lower cranial nerve palsies. One of the earliest features of cerebellar herniation into the foramen magnum is neck stiffness or head tilt in an effort to relieve the pressure by enlarging the surface area of the foramen magnum.

Medical Treatment

Several measures to lower increased intracranial pressure are available, even in circumstances in which surgical intervention is required (Table 4-4).

Monitoring Intracranial Pressure

Severe head trauma is the usual reason for continuous monitoring of intracranial pressure in children. Despite advances in technology, the effect of pressure monitoring on the outcome in medical diseases associated with increased intracranial pressure is questionable. It has no value in children with hypoxic-ischemic en-

TABLE 4-4
Medical Measures to Decrease Intracranial Pressure

Corticosteroids
Elevation of head
Glycerol
Hyperventilation
Hypothermia
Mannitol
Osmotic diuretics
Pentobarbital coma

cephalopathies and has marginal value in children with other kinds of encephalopathies.

Head Elevation

Elevating the head of the bed 30 to 45 degrees above horizontal improves jugular venous drainage and decreases intracranial pressure. Systemic blood pressure remains unchanged, resulting in increased cerebral perfusion.

Hyperventilation

Intracranial pressure decreases within seconds of the initiation of hyperventilation. The mechanism is vasoconstriction resulting from hypercarbia. The goal is to lower the arterial pressure of carbon dioxide to 25 to 30 mm Hg. Ischemia may result from further reductions. Avoid hyperventilation in patients with head trauma.

Osmotic Diuretics

Mannitol is the osmotic diuretic most widely used in the United States. A 20% solution of mannitol, 0.25 g/kg, infused intravenously exerts its beneficial effects as a plasma expander and as an osmotic diuretic. Excretion is by the kidneys, and large doses may cause renal failure, especially when using nephrotoxic drugs concurrently. Maintain serum osmolarity at less than 320 mOsm and adequate intravascular volume.

Corticosteroids

Corticosteroids, such as dexamethasone, are effective in the treatment of vasogenic edema. The intravenous dosage is 0.1 to 0.2 mg/kg every 6 hours. Onset of action is 12 to 24 hours; peak action may be longer. The mechanism

is uncertain. Cerebral blood flow is not affected. Corticosteroids are most useful for reducing edema surrounding mass lesions and are not useful in the treatment of severe head injury.

Hypothermia

Hypothermia decreases cerebral blood flow and frequently is used concurrently with pentobarbital coma. Body temperature maintained between 27°C and 31°C is ideal. The gain of using hypothermia in addition to other measures that decrease cerebral blood flow is uncertain.

Pentobarbital Coma

Barbiturates reduce cerebral blood flow, decrease edema formation, and lower the brain's metabolic rate. These effects do not occur at anticonvulsant plasma concentrations but require brain concentrations sufficient to produce a burst-suppression pattern on the electroencephalogram. Barbiturate coma is particularly useful in patients with increased intracranial pressure resulting from disorders of mitochondrial function, such as Reye syndrome. Pentobarbital is preferred to phenobarbital (see Chapter 1).

Hydrocephalus

Hydrocephalus is a condition marked by an excessive volume of intracranial CSF. It is termed *communicating* or *noncommunicating*, depending on whether or not the CSF communicates between the ventricular system and the subarachnoid space. Congenital hydrocephalus occurs in approximately 1:1000 births. It generally is associated with other congenital malformations, and the causes are genetic disturbances or intrauterine disorders, such as infection and hemorrhage. Often, no cause is determined. Congenital hydrocephalus is discussed in Chapter 18 because its initial feature is usually macrocephaly.

The causes of acquired hydrocephalus are brain tumor, intracranial hemorrhage, or infection. Solid brain tumors generally produce hydrocephalus by obstructing the ventricular system, whereas nonsolid tumors, such as leukemia, impair the reabsorptive mechanism in the subarachnoid space.

Intracranial hemorrhage and infection may produce communicating and noncommuni-

cating hydrocephalus and may increase intracranial pressure through the mechanisms of cerebral edema and impaired venous return. Because several factors contribute to increased intracranial pressure, acquired hydrocephalus is discussed by cause in the sections that follow.

Brain Tumors

Primary tumors of the posterior fossa and middle fossa are discussed in Chapters 10, 15, and 16 (Table 4-5). This section discusses tumors of the cerebral hemispheres. Supratentorial tumors comprise approximately half of brain tumors in children. They occur more commonly in children younger than 2 years old and adolescents.

Choroid Plexus Tumors

Choroid plexus papilloma is an unusual tumor, representing less than 2% of childhood brain

TABLE 4-5
Brain Tumors in Children

Hemispheric Tumors

Choroid plexus papilloma

Glial tumors

Astrocytoma

Ependymoma

Oligodendroglioma

Primitive neuroectodermal tumors

Pineal region tumors

Pineal-parenchymal tumors

Pineoblastoma

Pineocytoma

Germ cell tumors

Embryonal cell carcinoma

Germinoma

Teratoma

Glial tumors

Astrocytoma

Ganglioglioma

Other tumors

Angiomas

Dysplasia

Meningioma

Metastatic tumors

Middle Fossa Tumors

Optic glioma (see Chapter 16)

Sellar and parasellar tumors (see Chapter 16)

Posterior Fossa Tumors

Astrocytoma (see Chapter 10)

Brainstem glioma (see Chapter 15)

Ependymoma (see Chapter 10)

Hemangioblastoma (see Chapter 10)

Medulloblastoma (see Chapter 10)

tumors (Costa et al, 1997). Onset is usually during infancy, and the tumor may be present at birth. Two histological types of tumors exist: choroid plexus papilloma, a low-grade variant, and choroid plexus carcinoma, a malignant variant (Pencalet et al, 1998).

CLINICAL FEATURES. Choroid plexus tumors usually are located in one lateral ventricle, but also may arise in the third ventricle. The main features are those of increased intracranial pressure from hydrocephalus. Communicating hydrocephalus may result from excessive production of CSF by the tumor, but noncommunicating hydrocephalus caused by obstruction of the ventricular foramen is the rule. If the tumor is pedunculated, its movement may cause intermittent ventricular obstruction by a ball-valve mechanism. The usual course is one of rapid progression, with only a few weeks from first symptoms to diagnosis.

Infants with choroid plexus tumors usually have macrocephaly and are thought to have congenital hydrocephalus. Older children have nausea, vomiting, diplopia, headaches, and weakness. Papilledema is the rule.

DIAGNOSIS. Intraventricular enhancing masses with a peculiar “cauliflower” shape on magnetic resonance imaging (MRI) are characteristic of choroid plexus tumors. Because affected children show clear evidence of increased intracranial pressure, CT is usually the first test performed. The tumor is located within one ventricle as a mass of increased density with marked contrast enhancement. Hydrocephalus of one or both lateral ventricles is present. Because choroid plexus papillomas are vascular, angiography is a consideration before surgery. Many tumors bleed spontaneously, and the spinal fluid may be xanthochromic or grossly bloody. The protein concentration in the CSF is usually elevated.

MANAGEMENT. The extent of surgical resection is the most important factor that determines prognosis. Gross total resection is curative for papilloma. For choroid plexus carcinoma, adjuvant therapy is often necessary. Because most children diagnosed with choroid plexus carcinoma are younger than age 3 years, chemotherapy is the treatment of choice. The indications for radiation are children older than 3 years who have had a subtotal resection, histological features of malignancy, or dissemination of the tumor along the neuraxis. The 5-year survival rate is 50%, with most deaths occurring within 7 months of surgery. Complete tumor removal completely relieves hydrocephalus without the need of a shunt.

Glial Tumors

Tumors of glial origin constitute approximately 40% of supratentorial tumors in infants and children. The common glial tumors of childhood in order of frequency are astrocytoma, ependymoma, and oligodendroglioma. A mixture of two or more cell types is the rule. Oligodendroglioma occurs exclusively in the cerebral hemispheres, whereas astrocytoma and ependymoma have either a supratentorial or an infratentorial location.

Oligodendroglioma is mainly a tumor of adolescence. These tumors grow slowly and tend to calcify. The initial symptom is usually a seizure rather than increased intracranial pressure.

Astrocytoma

The grading of hemispheric astrocytomas is by histological appearance: low-grade, anaplastic, and glioblastoma multiforme. Low-grade astrocytomas confined to the posterior fossa constitute 12% to 18% of all pediatric intracranial tumors and 20% to 40% of all brainstem tumors. No gender predilection exists; the peak age at diagnosis is 6 to 10 years. Low-grade astrocytomas are more common than high-grade astrocytomas in children.

Anaplastic tumors and glioblastoma multiforme are *high-grade tumors*. Glioblastoma multiforme accounts for fewer than 10% of childhood supratentorial astrocytomas and is more likely to occur in adolescence than in infancy. High-grade tumors may evolve from low-grade tumors.

CLINICAL FEATURES. The initial features of glial tumors in children depend on location and may include seizures, hemiparesis, and movement disorders affecting one side of the body. Seizures are the most common initial feature of low-grade gliomas. Tumors infiltrating the basal ganglia and internal capsule are less likely to cause seizures than tumors closer to cortical structures. A slow-growing tumor may not cause a mass effect because surrounding neural structures accommodate infiltrating tumors. Such tumors may cause only seizures for several years before causing weakness of the contralateral limbs.

Headache is a relatively common complaint. Pain localizes if the tumor produces focal displacement of vessels without increasing intracranial pressure. A persistent focal headache usually correlates well with tumor location.

The initial features in children with medullary tumors may be progressive dysphagia, hoarseness, ataxia, and hemiparesis. Cervicomedullary

tumors cause neck discomfort, weakness or numbness of the hands, and an asymmetric quadriparesis. Midbrain tumors cause features of increased intracranial pressure, diplopia, and hemiparesis.

Symptoms of increased intracranial pressure, generalized headache, nausea, and vomiting are initial features of hemispheric astrocytoma in only one third of children but are common at the time of diagnosis. Intracranial pressure is likely to increase when rapidly growing tumors provoke edema of the hemisphere. A mass effect collapses one ventricle, shifts midline structures, and puts pressure on the aqueduct. When herniation occurs or when the lateral ventricles are dilated because of pressure on the aqueduct, the early features of headache, nausea, vomiting, and diplopia are followed by generalized weakness or fatigability, lethargy, and declining consciousness.

Papilledema occurs in children with generalized increased intracranial pressure, but macrocephaly occurs in infants. When papilledema is present, abducens palsy is usually an associated symptom. Other neurological findings depend on the site of the tumor and may include hemiparesis, hemisensory loss, or homonymous hemianopia.

DIAGNOSIS. MRI is always preferable to CT when a tumor is suspected. Low-grade gliomas appear as low-density or cystic areas that enhance with contrast material (Figure 4-4). A low-density area surrounding the tumor that does not show contrast enhancement indicates edema.

High-grade gliomas have patchy areas of low and high density, sometimes evidence of hemorrhage, and cystic degeneration. Marked contrast enhancement, often in a ring pattern, is

noted. When a mass effect is present, MRI shows a shift of midline structures, deformity of the ipsilateral ventricle, and swelling of the affected hemisphere with obliteration of sulcal markings (Figure 4-5). A mass effect occurs in half of low-grade astrocytomas and almost all high-grade tumors.

MANAGEMENT. Treat all children with increased intracranial pressure caused by hemispheric astrocytoma with dexamethasone to reduce vasogenic cerebral edema. Headache and nausea frequently are relieved within 24 hours; neurological deficits improve as well. Surgical resection of the tumor is the next step in treatment. Complete removal is rarely possible except with cystic cerebral astrocytoma, which resembles cerebellar astrocytomas in having a mural nodule within the cyst. In these tumors, the 5-year survival rate after surgery alone is 90%.

Children with low-grade astrocytomas of the cerebral hemisphere have a 20-year survival rate of 85% after surgical resection alone (Pollack et al, 1995). Postoperative radiotherapy impairs cognition without increasing survival. Postoperative radiation should be recommended for anaplastic astrocytomas. Children with anaplastic astrocytomas have less than a 30% 5-year survival rate even with radiotherapy, and children with glioblastoma multiforme have less than a 3% 5-year survival. Because the 5-year survival rate of children with high-grade astrocytomas is poor, several chemotherapy protocols are being tried (Packer, 1999).

Ependymoma

Ependymomas are tumors derived from cells that line the ventricular system and may be either supratentorial or infratentorial in location.

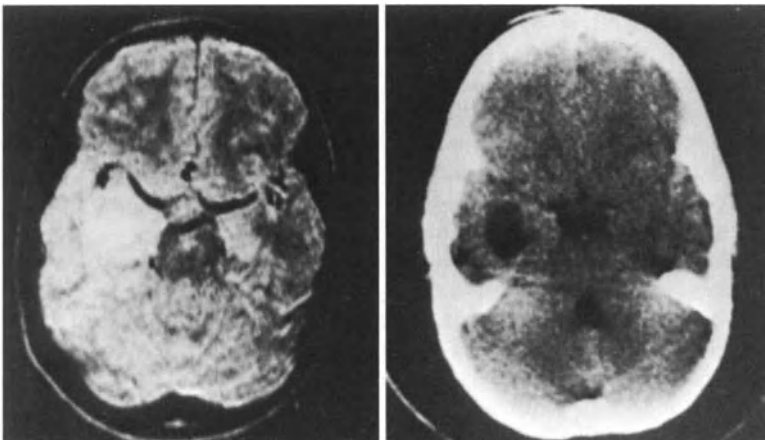


Figure 4-4. Low-grade glioma. MRI (left) reveals an area of increased signal intensity in the right temporal lobe, which appears as a cystic lesion on CT (right).

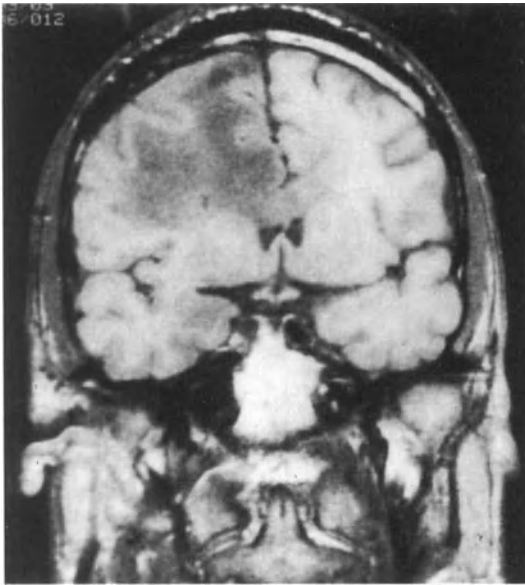


Figure 4-5. Malignant glioma. MRI shows a malignant astrocytoma invading the corpus callosum.

Infratentorial ependymoma is discussed in Chapter 10 because the initial symptom is often ataxia. Symptoms of increased intracranial pressure are the first feature in 90% of children with posterior fossa ependymoma, and papilledema is present in 75% at the time of initial examination. Approximately 60% of children with ependymoma are younger than 5 years old at the time of diagnosis, and only 4% are older than 15 years. As a rule, infratentorial ependymoma occurs at a younger age than supratentorial ependymoma.

The expected location of supratentorial ependymoma is in relation to the third and lateral ventricles. Ependymal tumors may arise within the hemispheres, however, at a site distant from the ventricular system. Such tumors probably derive from ependymal cell rests.

CLINICAL FEATURES. Symptoms of increased intracranial pressure are less prominent with supratentorial tumors than with infratentorial tumors. Common manifestations are focal weakness, seizures, and visual disturbances. Papilledema is a common feature in all patients with ependymoma. Hemiparesis, hyperreflexia, and hemianopia are typical features, but some children show only ataxia. The duration of symptoms before diagnosis averages only 7 months but can be 1 month for malignant tumors and several years for low-grade tumors.

DIAGNOSIS. Tumor density on CT is usually greater than brain density, and contrast enhancement is present. Small cysts within the tumor are

relatively common. Approximately one third of supratentorial ependymomas contain calcium.

Tumors within the third ventricle cause marked dilation of the lateral ventricles, with edema of the hemispheres and obliteration of sulcal markings. High-grade tumors are likely to seed the subarachnoid space, producing metastases in the spinal cord and throughout the ventricular system. In such cases, tumor cells may line the lateral ventricles and produce a “cast” of contrast enhancement around the ventricles.

MANAGEMENT. Complete surgical resection is possible in only 30% of cases. Even after complete resection, the 5-year rate of progression-free survival is 60% to 80%. Survival relates directly to the effectiveness of surgical removal followed by either radiation therapy or chemotherapy (Pollack et al, 1995). The role of radiation therapy is uncertain, and radiation therapy is reserved for children in whom a gross total resection is not possible (McLaughlin et al, 1998). The usual dose of radiation is 5400 cGy to the posterior fossa. The only indication for neuraxis radiation therapy is the presence of leptomeningeal disease at the time of diagnosis. No chemotherapy protocol has proved useful.

Primitive Neuroectodermal Tumors

Primitive neuroectodermal tumors (PNET) are tumors of childhood consisting of small, undifferentiated, darkly staining cells that have neuronal, glial, and mesenchymal elements. Medulloblastoma is an infratentorial PNET. Supratentorial PNET are discussed here; medulloblastoma is discussed in Chapter 10.

CLINICAL FEATURES. Age at onset may be anytime during childhood but is usually before age 10. Both genders are equally affected. Because PNET are highly malignant, the progression of symptoms is rapid, and the time to diagnosis is usually less than 3 months. Approximately half of children show features of increased intracranial pressure. The tumor site determines other manifestations. Two thirds of tumors are located in the frontal or parietal lobe. Seizures, monoparesis, hemiplegia, and ophthalmoplegia are initial features in approximately 10% of patients. Hydrocephalus or head enlargement is unusual early in the course.

DIAGNOSIS. On CT, PNET are high-density lesions that enhance and produce hydrocephalus. The tumor mass is surrounded by cerebral edema, and midline structures frequently are shifted under the falx. MRI shows homogenous to mixed signal intensity in the tumor. On T₂-weighted images, the lesions are

nearly isointense to brain parenchyma, but they enhance intensely after contrast administration.

MANAGEMENT. Dexamethasone often relieves cerebral edema. Complete tumor resection is attempted but rarely accomplished. PNET are radiosensitive and may respond transiently to chemotherapy. Radiation of the entire craniospinal axis is required. Survival is usually less than 1 year. Several chemotherapeutic trials are ongoing.

Pineal Region Tumors

The derivation of tumors in the pineal region is from several histological types. Germ cell tumors are the most common, followed by tumors of the pineal parenchyma. The incidence of pineal region tumors is 10 times higher in Japan than in the United States or Western Europe. Pineal region tumors are more common in boys than in girls and generally become symptomatic during adolescence.

CLINICAL FEATURES. Because pineal region tumors are in a midline location, where they can invade or compress the third ventricle or aqueduct, symptoms of increased intracranial pressure are common. The first symptoms may be acute and accompanied by midbrain dysfunction. Midbrain dysfunction resulting from pressure by pineal region tumors on the periaqueductal gray is *Parinaud syndrome*: loss of pupillary light reflex, supranuclear palsy of upward gaze with preservation of downward gaze, and retraction-convergence nystagmus when upward gaze is attempted. Eventually, paralysis of upward and downward gaze and loss of accommodation may occur.

Tumors growing into or compressing the anterior hypothalamus produce loss of vision, diabetes insipidus, precocious puberty, and emaciation. Precocious puberty occurs almost exclusively in boys. Extension of tumor into the posterior fossa produces multiple cranial neuropathies and ataxia, and lateral extension causes hemiparesis.

DIAGNOSIS. Pineal germinomas are well circumscribed and relatively homogeneous. The MRI appearance is low signal intensity on T₂-weighted images and marked enhancement with intravenous contrast. Teratomas appear lobulated and have hyperdense and multicystic areas. Calcification may be present, and contrast enhancement is not uniform. Tumors that spread into the ventricular system and have intense contrast enhancement are likely to be malignant. Tumors that contain abundant amounts of calcium are likely to be benign.

CT or MRI sometimes identifies asymptomatic non-neoplastic pineal cysts in children undergoing imaging for other reasons. These are developmental variants of the pineal gland, which may contain calcium. They only rarely grow to sufficient size to obstruct the aqueduct or cause Parinaud syndrome.

MANAGEMENT. Stereotactic biopsy is essential to establish the histological type and to plan therapy. Ventricular drainage relieves hydrocephalus when needed. Germinomas are highly radiosensitive, and 5-year survival rates of 50% to 80% occur. Other tumors of the pineal region are less radiosensitive. Complete surgical removal of pineal region tumors was discouraged in the past because mortality and morbidity rates were prohibitively high. Improved surgical techniques now allow successful removal in many cases.

Other Tumors

Cerebral metastatic disease is unusual in childhood. Tumors that produce cerebral metastases most frequently are osteogenic sarcoma and rhabdomyosarcoma in patients younger than 15 years old and testicular germ cell tumors after age 15. The cerebral hemispheres, more often than posterior fossa structures, are affected. Pulmonary involvement always precedes cerebral metastasis. Brain metastasis is rarely present at the time of initial cancer diagnosis.

Meningioma is uncommon in children. The initial features may be focal neurological signs, seizures, or increased intracranial pressure (Mallucci et al, 1996).

Intracranial Arachnoid Cysts

Primary arachnoid cysts are CSF-filled cavities within the arachnoid. The cause of cyst formation is uncertain. They represent a minor disturbance in arachnoid formation and not a pathological process. Arachnoid cysts are found in 0.5% of postmortem examinations; two thirds are supratentorial and one third are infratentorial.

CLINICAL FEATURES. Most cysts are asymptomatic structures identified by CT or MRI. Deciding whether the cyst caused the symptom for which the imaging study was required is often problematic. Subarachnoid cysts are usually present from infancy, but may develop, or at least enlarge enough to detect, during adolescence.

Large cysts can produce symptoms by compressing adjacent structures or by increasing

intracranial pressure. Focal neurological disturbances vary with the location but are most often hemiparesis or seizures when the cyst is supratentorial and ataxia when the cyst is infratentorial. Compression of the parietal lobe from early infancy may result in undergrowth of contralateral limbs.

Increased intracranial pressure can result from mass effect or from hydrocephalus and is associated with cysts in all locations. Clinical features include macrocephaly, headache, and behavioral change.

DIAGNOSIS. It has become common for children with headache, learning or behavioral disorders, and suspected seizure disorders to undergo imaging studies of the brain. Many of these studies show incidental arachnoid cysts. A cause-and-effect relationship is a consideration only if the cyst is large and clearly explains the symptoms. Positron emission tomography may be useful in deciding whether an arachnoid cyst is having a pressure effect on the brain. Hypometabolism in the surrounding brain indicates brain compression.

MANAGEMENT. Simple drainage of the cyst often results in reaccumulation of fluid and recurrence of symptoms. Superficial cysts require excision, and deeply located cysts require a shunt into the peritoneal space.

Intracranial Hemorrhage

Head Trauma

Head trauma is a major cause of intracranial hemorrhage from the newborn period through childhood and adolescence. It is associated with intracerebral hemorrhage, subarachnoid hemorrhage, subdural hematoma, and epidural hematoma. Increased intracranial pressure is a constant feature of intracranial hemorrhage and occurs from cerebral edema after concussion without hemorrhage. Intracranial hemorrhage from head trauma is discussed in Chapter 2.

Intraventricular Hemorrhage in the Newborn

Intraventricular hemorrhage is primarily a disorder of live-born premature neonates with respiratory distress syndrome. The autoregulation of cerebral blood flow, which meets local tissue needs by altering cerebrovascular resistance, is impaired in premature newborns with respiratory distress syndrome. During episodes of systemic hypotension, decreased cerebral blood

flow increases the potential for cerebral infarction. Such infarctions usually occur symmetrically in the white matter adjacent to the lateral ventricles. These are termed *periventricular leukomalacia*.

During episodes of systemic hypertension, cerebral blood flow increases. Hemorrhage occurs first in the subependymal germinal matrix, then bursts through the ependymal lining into the lateral ventricle. The term for such hemorrhages is *periventricular-intraventricular hemorrhages*. The predilection of the germinal matrix for hemorrhage during episodes of increased cerebral blood flow is unknown. The likely explanation is prior ischemic injury that weakens the capillary walls and their supporting structures, making them vulnerable to rupture during episodes of increased cerebral blood flow. Intraventricular hemorrhage also occurs in full-term newborns, but the mechanism of hemorrhage at term is different from that before term.

Periventricular-Intraventricular Hemorrhage in Premature Newborns

The incidence of periventricular-intraventricular hemorrhage (PIVH) in premature newborns with birth weight less than 2000 g has been declining. The reason for the decline is probably attributable to advances in ventilatory care. PIVH occurs in approximately 20% of premature newborns of birth weight less than 1500 g (Roland and Hill, 1997). It occurs on the first day in 50% of and before the fourth day in 90% of affected newborns. PIVH originates from rupture of small vessels in the subependymal germinal matrix. Approximately 80% of germinal matrix hemorrhages extend into the ventricular system. Hemorrhagic lesions into the cerebral parenchyma accompany severe hemorrhages. Parenchymal hemorrhages are usually unilateral and result from hemorrhagic venous infarction in the periventricular region (Volpe, 2000).

The following is a grading system for PIVH:

- I—isolated subependymal hemorrhage
- II—intraventricular hemorrhage without ventricular dilation
- III—intraventricular hemorrhage with ventricular dilation
- IV—intraventricular hemorrhage with ventricular dilation and hemorrhage into the parenchyma of the brain

Hemorrhage into the parenchyma of the brain (grade IV) is a coexistent process caused by

hemorrhagic infarction (*periventricular hemorrhagic infarction*) and is not an extension of the first three grades of intraventricular hemorrhage.

CLINICAL FEATURES. Routine ultrasound examinations are standard in the care for all newborns whose birth weight is 1800 g or less and often reveal PIVH in newborns in whom no clinical suspicion existed. Among this group, some have blood in the CSF, and others have clear CSF. Only newborns with grade III or IV hemorrhage have predictable clinical features.

In some premature newborns, PIVH produces rapid neurological deterioration characterized by decreasing states of consciousness, severe hypotonia, and respiratory insufficiency. Within minutes to hours, the infant shows obvious evidence of increased intracranial pressure: bulging fontanelle, decerebrate posturing, loss of pupillary reflexes, and respiratory arrest. Hypothermia, bradycardia, hypotension, and hematocrit may decrease by 10%.

Often the hemorrhage manifests by stepwise progression of symptoms over hours or days. The initial symptoms are subtle and include change in behavior, diminished spontaneous movement, and either an increase or a decrease in appendicular tone. The fontanelles remain soft, and vital signs are stable. These first symptoms may correspond to grade I hemorrhage. Some newborns become stable and have no further difficulty. Others undergo clinical deterioration characterized by hypotonia and declining consciousness. This deterioration probably corresponds to the presence of blood in the ventricles. The child becomes lethargic or obtunded, then may stabilize. If continued bleeding causes acute ventricular dilation, apnea and coma follow. Seizures occur when blood dissects into the cerebral parenchyma.

Newborns with PIVH are at risk for progressive hydrocephalus. The likelihood is much greater among children with grade III or IV hemorrhage. Initial ventricular dilation is probably due to plugging of the arachnoid villi and impaired reabsorption of CSF. The ventricles can enlarge by compressing the brain without causing a measurable change in head circumference. Weekly ultrasound studies are imperative to follow the progression of hydrocephalus.

DIAGNOSIS. Ultrasound is the standard for the diagnosis of intraventricular hemorrhage in the newborn. Ultrasound is preferred over other brain imaging techniques because it is accurate and easily performed in the intensive care nurs-

ery. MRI during infancy or childhood is useful to show the extent of brain damage from the combination of periventricular leukomalacia and PIVH.

PREVENTION. Table 4-6 lists some methods to prevent PIVH. A premature newborn transported to an intensive care nursery has a far greater chance of hemorrhage than a fetus transported to the delivery room in utero. Muscle paralysis with pancuronium bromide in ventilated premature newborns reduces the incidence and severity of PIVH by stabilizing fluctuations of cerebral blood flow velocity. Phenobarbital may dampen fluctuations of systemic blood pressure and cerebral blood flow, and indomethacin inhibits prostaglandin synthesis, regulating cerebral blood flow. The efficacy of both agents is inconclusive.

Extension of hemorrhage occurs in 20% to 40% of cases. Serial ultrasound scans provide early diagnosis of posthemorrhagic hydrocephalus, which develops in 10% to 15% of premature newborns with PIVH. Factors that influence the management of posthemorrhagic hydrocephalus are the rate of progression, ventricular size, and intracranial pressure. The hydrocephalus ultimately arrests or regresses in 50% of children and progresses to severe hydrocephalus in the remainder. Rapid ventricular enlargement requires intervention in less than 4 weeks.

MANAGEMENT. When intraventricular hemorrhage has occurred, treatment is directed toward the prevention or stabilization of progressive posthemorrhagic hydrocephalus. The efficacy of treatment for posthemorrhagic hydrocephalus is difficult to assess because the role of ventricular dilation in causing chronic neurological impairment is not established. Newborns with progressive posthemorrhagic hydrocephalus also have

TABLE 4-6
Prevention of Periventricular-
Intraventricular Hemorrhage

Antenatal

Delivery in specialized center
Prevention of prematurity

Postnatal

Avoidance of rapid volume expansion
Correction of coagulation abnormalities
Maintenance of stable systemic blood pressure
Muscle paralysis of ventilated premature newborns
Potential pharmacological agents
 Indomethacin
 Phenobarbital

experienced asphyxial encephalopathy, germinal matrix hemorrhage, and periventricular leukomalacia. Neurological morbidity correlates better with the degree of parenchymal damage than with ventricular size.

The definitive treatment is placement of a ventriculoperitoneal shunt. Early shunt placement, while the ventricles still contain blood, has a high incidence of shunt failure and infection, so temporizing measures are required. These measures include CSF drainage by serial lumbar punctures, external ventriculostomy, and drugs that reduce CSF production (carbonic anhydrase inhibitors and diuretics [acetazolamide and furosemide]).

Intraventricular Hemorrhage at Term

In contrast to intraventricular hemorrhage in a premature newborn, which originates almost exclusively from the germinal matrix, intraventricular hemorrhage at term may originate from the veins of the choroid plexus, from the germinal matrix, or both.

CLINICAL FEATURES. Full-term newborns with intraventricular hemorrhage form two groups. In more than half, delivery was difficult, frequently from breech position, and some degree of intrauterine asphyxia sustained. Usually, these newborns show bruising and require resuscitation. At first, they appear to be improving, then multifocal seizures occur on the second day postpartum. The fontanelle is tense, and the CSF is bloody.

The other half of affected infants have experienced neither trauma nor asphyxia and appear normal at birth. During the first hours postpartum, apnea, cyanosis, and a tense fontanelle develop. The mechanism of hemorrhage is unknown. Posthemorrhagic hydrocephalus is common in both groups, and 35% require shunt placement.

DIAGNOSIS. Ultrasound is as useful for diagnosis of intraventricular hemorrhage in full-term newborns as in premature newborns.

MANAGEMENT. The treatment of full-term newborns with intraventricular hemorrhage is the same as for premature newborns with intraventricular hemorrhage.

Arterial Aneurysms

Arterial aneurysms are vestiges of the embryonic circulation and are present in a rudimentary form before birth. Only rarely do they rupture during childhood. Symptomatic arterial

aneurysms in childhood may be associated with coarctation of the aorta or polycystic kidney disease. Aneurysms tend to be located at the bifurcation of major arteries at the base of the brain.

CLINICAL FEATURES. Subarachnoid hemorrhage is usually the first feature of a ruptured aneurysm. The initial symptoms may be catastrophic: sudden loss of consciousness, tachycardia, hypotension, and evidence of increased intracranial pressure, but in most patients the first bleeding is a “warning leak” that may go unrecognized. Severe headache, stiff neck, and low-grade fever characterize the warning leak. Occasionally, aneurysms produce neurological signs by exerting pressure on adjacent cranial nerves. The oculomotor nerve is most frequently affected, resulting in disturbances of gaze and pupillary function.

Physical activity does not relate to the time of rupture. Aneurysmal size is the main predictor of rupture; aneurysms smaller than 1 cm in diameter have a low probability of rupture.

The patient’s state of consciousness is the most important predictor of survival. Approximately 50% of patients die during the first hospitalization, some from the initial hemorrhage during the first 14 days. Untreated, another 30% die from recurrent hemorrhage in the next 10 years. Unruptured aneurysms may cause acute severe headache without nuchal rigidity. The mechanism of headache may be aneurysmal thrombosis or localized meningeal inflammation.

DIAGNOSIS. On the day of aneurysmal rupture, CT shows intracranial hemorrhage in all patients, but the blood rapidly reabsorbs, and only two thirds have visible hemorrhage on the fifth day using standard MRI or magnetic resonance angiography (MRA). Lumbar puncture is common because the stiff neck, headache, and fever suggest bacterial meningitis. The fluid is grossly bloody and thought traumatic, unless centrifugation reveals xanthochromic fluid. When a diagnosis of subarachnoid hemorrhage is established, all vessels need to be visualized to determine the aneurysmal site and the presence of multiple aneurysms. Four-vessel cerebral arteriography had been the standard imaging study, but improved MRA technology may replace angiography.

MANAGEMENT. The definitive treatment is surgical clipping and excision of the aneurysm. Early surgery prevents rebleeding in conscious patients (Olafsson et al, 1997). Cerebral vasospasm and ischemia are the leading causes of death and disability among survivors of an initial aneurysm

rupture. Pharmacological means to prevent rebleeding are becoming less important with the increasing frequency of early operative intervention. Medical therapy for the prevention and treatment of vasospasm includes a regimen of volume expansion and induced systemic hypertension. Nimodipine is effective for the prevention of delayed ischemia.

The 6-month survival rate in patients who are conscious at the time of admission is approximately 86%. In contrast, only 20% of patients comatose on admission live 6 months.

Arteriovenous Malformations

Approximately 0.1% of children have an arteriovenous malformation, of which 12% to 18% become symptomatic in childhood (Menovsky and van Overbeeke, 1997). These are not on a genetic basis. Two types of malformations occur. One type arises early in gestation from an abnormal communication between primitive choroidal arteries and veins. Such malformations are in the midline and give rise to the vein of Galen malformation, malformations involving the choroid plexus, and shunts between cerebellar arteries and the straight sinus. The other type arises later in gestation or even after birth between superficial arteries and veins. The result is an arteriovenous malformation within the parenchyma of the cerebral hemisphere. Interconnections exist between the vessels of the scalp, skull, and dura, causing anastomotic channels between the extracranial and intracranial circulations to remain patent. Approximately 90% of arteriovenous malformations are supratentorial, and 10% are infratentorial.

Deep Midline Malformations

Hydrocephalus and cardiac failure during infancy are the presenting features of large deep midline malformations, especially malformations involving the great vein of Galen. They rarely bleed (Meyers et al, 2000). These malformations are discussed in Chapter 18.

CLINICAL FEATURES. Small, deep midline malformations are rarely symptomatic in childhood. Bleeding into the parenchyma of the brain or into the subarachnoid space brings the problem to attention. Secondary venous changes reroute the drainage to the pial veins, which then bleed. Because the bleeding is from the venous rather than the arterial side of the malformation, the initial symptoms are not as catastrophic as with arterial aneurysms. Symptoms may evolve over

several hours, and no characteristic clinical syndrome is associated. Most patients describe sudden severe headache, neck stiffness, and vomiting. Fever is frequently an associated symptom. The presence of focal neurological deficits depends on the location of the malformation and may include hemiparesis, sensory disturbances, and oculomotor palsies. Many patients recover completely from the first hemorrhage; the risk of recurrent hemorrhage is small.

DIAGNOSIS. Contrast-enhanced MRI or CT easily reveals most arteriovenous malformations and shows the degree of ventricular enlargement. Four-vessel arteriography or MRA defines all arterial and venous channels.

MANAGEMENT. Microsurgical excision, when feasible, is the treatment modality of choice. Management of deep midline malformations is by venous embolization. The results vary with the size and location of the malformation.

Supratentorial Malformations

CLINICAL FEATURES. Among children with arteriovenous malformations in and around the cerebral hemispheres, the initial feature is intracranial hemorrhage in half and seizures in half. Recurrent vascular headache may precede the onset of hemorrhage and seizures or may develop concurrently. Headaches are usually unilateral but may not occur consistently on the same side. In some patients, the headaches have a migraine quality: scintillating scotomata and unilateral throbbing pain. The incidence of these migraine-like headaches in patients with arteriovenous malformations does not seem to be greater than in the general population. The malformation probably provokes a migraine attack in people who are genetically predisposed.

Most patients who have seizures have at least one focal seizure, but among the seizures associated with arteriovenous malformations, half are focal seizures and half are generalized seizures. No specific location of the malformation is associated with a higher incidence of seizures. Small superficial malformations, especially in the centroparietal region, are associated with the highest incidence of hemorrhage. Hemorrhage may be subarachnoid only or may dissect into the brain parenchyma.

DIAGNOSIS. MRI and contrast-enhanced CT provide excellent visualization of the malformation in most children. Four-vessel arteriography is required to define all arterial and venous channels, but MRA may serve the same function as the technology improves.

MANAGEMENT. The photon knife is becoming the standard of treatment for small malformations. Other options for management include microsurgical excision and embolization. Superficial malformations are more accessible for direct surgical excision than malformations deep in the midline. In considering treatment modes, the physician must balance the decision to do something against the decision to do nothing based on the likelihood of further bleeding and the morbidity due to intervention.

Cocaine Abuse

Intracranial hemorrhage is associated with cocaine abuse, especially crack, in young adults. The hemorrhages may be subarachnoid or intracerebral in location. Sudden transitory increases in systemic blood pressure are the cause.

Infectious Disorders

Infections of the brain and meninges produce increased intracranial pressure by causing cerebral edema, by obstructing the flow and reabsorption of CSF, and by impairing venous outflow. Symptoms of increased intracranial pressure are frequently the initial features of bacterial and fungal infections and, occasionally, viral encephalitis. Viral infections are more likely to cause seizures, personality change, or decreased consciousness and are discussed in Chapter 2.

Bacterial Meningitis

The offending organism and the clinical features of bacterial meningitis vary with age (Table 4-7). It is useful to discuss the syndromes of bacterial meningitis by age group: newborn, infants and young children (28 days to 5 years), and school-age children.

Meningitis in the Newborn

Meningitis occurs in approximately 1:2000 term newborns and 3:1000 premature newborns and accounts for 4% of all neonatal deaths. It is a consequence of septicemia, and organs other than the brain are infected. Maternal infection is the main risk factor for sepsis and meningitis.

An early-onset (first 5 days) and a late-onset (after 5 days) pattern of meningitis have been identified in newborns. In early-onset meningitis, acquisition of infection is at the time of deliv-

TABLE 4-7
Most Common Organisms Responsible for Bacterial Meningitis

Newborn

Escherichia coli
Group B *Streptococcus*
Listeria monocytogenes
Other Enterobacteriaceae

Infancy and Preschool

Haemophilus influenzae
Mycobacterium tuberculosis
Neisseria meningitidis
Streptococcus pneumoniae

School Age

M. tuberculosis
N. meningitidis
S. pneumoniae

ery, and the responsible organisms are usually *Escherichia coli* or group B *Streptococcus*. The newborn becomes symptomatic during the first week, and the mortality rate is 20% to 50%. In late-onset meningitis, acquisition of infection is postnatal, and symptoms may begin the fourth day postpartum but usually begin after the first week. Newborns requiring intensive care are specifically at risk for late-onset meningitis because of excessive instrumentation. The responsible organisms are *E. coli*, group B *Streptococcus*, enterococci, gram-negative enteric bacilli (*Pseudomonas* and *Klebsiella*), and *Listeria monocytogenes*. The mortality rate is 10% to 20%.

CLINICAL FEATURES. Newborns infected in utero or during delivery may experience respiratory distress and shock within 24 hours of birth. Other features that may be associated with septicemia include hyperthermia, hypothermia, jaundice, hepatomegaly, lethargy, anorexia, and vomiting.

In late-onset meningitis, the clinical manifestations are variable. Initial symptoms are usually nonspecific and include lethargy, disturbed feeding, and irritability. As the meningitis worsens, hyperthermia, respiratory distress or apnea, and seizures are present in about half of newborns, but bulging of the fontanelle occurs in only a quarter, and nuchal rigidity is unusual. Shock is the usual cause of death.

DIAGNOSIS. The diagnosis of septicemia and meningitis in the newborn is often difficult to establish based on symptoms. The first suspicion of septicemia should prompt lumbar puncture. Even in the absence of infection, the CSF of febrile newborns averages 11 leukocytes/mm³ (range 0

to 20 leukocytes/mm³). Less than 6% are polymorphonuclear leukocytes. The protein concentration has a mean value of 84 mg/dL (0.84 g/L), with a range from 40 to 130 mg/dL (0.4 to 1.3 g/L), and the glucose concentration has a mean value of 46 mg/dL (0.46 g/L), with a range from 36 to 56 mg/dL (0.36 to 0.56 g/L).

In newborns with meningitis, the leukocyte count is usually in the thousands, and the protein concentration may vary from less than 30 mg/dL (<0.3 g/L) to greater than 1000 mg/dL (>10 g/L). A Gram-stained smear of CSF permits identification of an organism in less than half of cases. Even when the smear is positive, identification may be inaccurate. Rapid detection of bacterial antigens by immunoelectrophoresis, latex agglutination, and radioimmunoassays is helpful in the diagnosis of several bacterial species.

MANAGEMENT. Start treatment with the first suspicion of sepsis. Laboratory confirmation is not required. The choice of initial antibiotic coverage varies, but usually includes ampicillin and an aminoglycoside. An alternative regimen is ampicillin and cefotaxime, but cefotaxime-resistant strains are emerging rapidly. Administration of intravenous antibiotics is in divided doses (Table 4-8). Identification of an organism leads to specific therapy.

Ampicillin and cefotaxime treat *E. coli*, penicillin or ampicillin treats group B *Streptococcus*, and cefotaxime and an aminoglycoside treat *Klebsiella pneumoniae*. *Pseudomonas* is difficult to eradicate, and combined intravenous and intrathecal therapy may be required. Carbenicillin and gentamicin are preferred for intravenous use.

TABLE 4-8
Intravenous Antibiotic Dosages for Newborns

Drug	0-7 Days	8-28 Days
Ampicillin	100-150 mg/kg/day (q12h)	150-200 mg/kg/day (q8h)
Cefotaxime	100 mg/kg/day (q8h)	150-200 mg/kg/day (q8h)
Ceftazidime	60 mg/kg/day (q12h)	90 mg/kg/day (q8h)
Gentamicin	5 mg/kg/day (q12h)	7.5 mg/kg/day (q8h)
Methacillin	100-150 mg/kg/day (q8h)	150-200 mg/kg/day (q6h)
Penicillin G	100,000-150,000 U/kg (q12h)	150,000-400,000 U/kg/day (q8h)
Vancomycin	20 mg/kg/day (q12h)	40-60 mg/kg/day (q6h)

The duration of treatment for neonatal meningitis is at least 2 weeks beyond the time the CSF becomes sterile. Two days after discontinuing antibiotic therapy, reculture the CSF. A positive culture indicates the need for a second course of therapy. *Citrobacter diversus* infections often cause a hemorrhagic necrosis of the brain, with liquefaction of the cerebral white matter and abscess formation. CT readily identifies the abscesses. Surgical drainage further damages the overlying preserved cortex and is not recommended.

Mortality is 20% to 30% and is highest for gram-negative infections. The type of infecting organism and the gestational age of the infant are the main variables that determine mortality. Permanent neurological sequelae occur in 30% to 50% of survivors, including hydrocephalus, cerebral palsy, epilepsy, mental retardation, and deafness. Even when the head circumference is normal, exclusion of hydrocephalus requires CT evaluation.

Meningitis in Infants and Young Children

For children 6 weeks to 3 months old, group B *Streptococcus* remains a leading cause of meningitis, and *E. coli* is less common. The other important organism is *Neisseria meningitidis* (Riordan et al, 1995). *Haemophilus influenzae*, which had been an important pathogen after 3 months of age, has almost disappeared because of routine immunization. *S. pneumoniae* and *N. meningitidis* are now the principal causes of meningitis in children older than 1 month (Quagliarello and Scheld, 1997).

CLINICAL FEATURES. The onset of meningitis may be insidious or fulminating. The typical clinical findings include fever, irritability, and neck stiffness. A bulging fontanelle is a feature in young infants. After the fontanelle closes, headache, vomiting, and lethargy are initial features. Seizures occur in about a third of children with meningitis. They usually occur during the first 24 hours of illness and often bring the child to medical attention. When seizures occur, state of consciousness declines. Seizures can be focal or generalized and often difficult to control.

Examination reveals a sick and irritable child who resists being touched or moved. Ophthalmoscopic findings are usually normal or show only minimal papilledema. Focal neurological signs are unusual except in tuberculous meningitis or in cases in which abscess formation has occurred.

The rapidity with which neurological function declines depends on the severity of cerebral edema and cerebral vasculitis. Death may ensue from brainstem compression caused by transtentorial herniation. Peripheral vascular collapse can result from brainstem herniation, endotoxic shock, or adrenal failure. Of children with meningococemia, 60% have a characteristic petechial or hemorrhagic rash. The rash, although generalized, is most prominent below the waist.

Meningeal irritation causes neck stiffness, characterized by limited mobility and pain on attempted flexion of the head. With the child supine, meningeal irritation is tested. Pain and resistance to extending the knee with the leg flexed at the hip is the *Kernig sign*. Spontaneous flexion at the hips when passively flexing the neck is the *Brudzinski sign*. These signs of meningeal irritation also occur with subarachnoid hemorrhage and infectious meningitis.

DIAGNOSIS. Lumbar puncture and examination of the CSF are essential for the diagnosis of bacterial meningitis. Because bacterial meningitis is often associated with septicemia, however, the blood, urine, and nasopharynx are cultured. The peripheral white blood cell count, especially immature granulocytes, is usually increased. Peripheral leukocytosis is much more common in bacterial than in viral infections but does not rule out viral meningitis. The platelet count is important because some infections are associated with thrombocytopenia. Proper evaluation of the CSF concentration of glucose requires a concurrent measure of the blood glucose concentration. The diagnosis of syndrome of inappropriate antidiuretic hormone secretion (SIADH) requires measurement of serum electrolytes, especially sodium. SIADH occurs in most patients with acute bacterial meningitis. Every child at risk for tuberculous meningitis requires a tuberculin skin test.

Perform lumbar puncture as quickly as possible when bacterial meningitis is suspected. Cranial CT before lumbar puncture has become routine, but has questionable value and adds considerably to the cost of care. When the need for CT scanning significantly delays lumbar puncture, obtain blood cultures and initiate antimicrobial therapy. Generalized increased intracranial pressure is always part of acute bacterial meningitis and is not a contraindication to lumbar puncture.

Information derived from lumbar puncture includes opening and closing pressures, appearance, white blood cell count with differential count, red blood cell count, concentrations of glu-

ucose and protein, and identification of microorganisms as shown by Gram stain and culture. The characteristic findings are increased pressure, a cloudy appearance, a cellular response of several thousand polymorphonuclear leukocytes, a reduction in the concentration of glucose to less than half of that in the plasma, and an elevated protein concentration. The expected findings of bacterial meningitis may vary, however, with the organism, the timing of the lumbar puncture, the prior use of antibiotics, and the immunocompetence of the host.

MANAGEMENT. Administer antimicrobials and dexamethasone immediately. Do not delay treatment until after obtaining the results of lumbar puncture. The rate of dexamethasone administration is 15 mg/kg every 6 hours for 2 days (McIntyre et al, 1997). Children treated with dexamethasone become afebrile more quickly and have an improved neurological outcome and a lower incidence of postmeningitic deafness.

Ampicillin and an aminoglycoside are the initial treatment of meningitis. Gram stain identification is useful but can be misleading, and the final choice of antibiotic therapy should await the results of culture and antibiotic sensitivity. Several special cases exist in the choice of initial antimicrobials to treat bacterial meningitis. Staphylococcal species usually cause meningitis in children with a ventricular shunt in place. The presence of gram-positive cocci on smear indicates the addition of nafcillin to the preceding choices. Anaerobic and aerobic organisms frequently cause meningitis secondary to chronic sinusitis or dental infection. Penicillin G and chloramphenicol are reasonable choices for initial therapy, although the addition of cefotaxime covers some gram-negative organisms not sensitive to chloramphenicol. The usual cause of meningitis after trauma is *S. pneumoniae*, whereas meningitis after neurosurgical procedures may be due to either streptococcal or staphylococcal organisms. Gram-negative organisms also may be responsible, indicating a need for the combination of penicillin G and cefotaxime. The appropriate choice of antimicrobial, alone or in combination, follows identification of a specific organism (Table 4-9).

The outcome for infants and children with bacterial meningitis depends on the infecting organism and the speed of initiating appropriate antibiotic therapy. Ten percent of children have persistent bilateral or unilateral hearing loss after bacterial meningitis, and 4% have neurological deficits. The incidence of hearing loss is 31%

TABLE 4-9
Intravenous Antibiotic Dosages for Children

Drug	Dosage
Amikacin	20-30 mg/kg/day (q8h)
Ampicillin	200-300 mg/kg/day (q6h)
Cefotaxime	200 mg/kg/day (q6h)
Ceftriaxone	80-100 mg/kg/day (q12h)
Ceftazidime	125-150 mg/kg/day (q8h)
Chloramphenicol	75-100 mg/kg/day (q6h)
Gentamicin	7.5 mg/kg/day (q8h)
Penicillin G	250,000 U/kg/day (q6h)
Tobramycin	6 mg/kg/day (q8h)
Vancomycin	40-60 mg/kg/day (q6h)

after infection with *S. pneumoniae* and 6% after infection with *H. influenzae*. Hearing loss occurs early and probably is not related to the choice of antibiotic. Children with neurological deficits are at risk for epilepsy.

Meningitis in School-Age Children

S. pneumoniae and *N. meningitidis* account for most cases of bacterial meningitis in previously healthy school-age children in the United States, whereas *Mycobacterium tuberculosis* is a leading cause of meningitis in economically deprived populations. The symptoms of bacterial meningitis in school-age children do not differ substantially from the symptoms encountered in preschool children (see previous section on clinical features and treatment). In one retrospective study of children treated for bacterial meningitis in the 1980s, 8.5% had major neurological deficits (mental retardation, seizures, hydrocephalus, cerebral palsy, blindness, or hearing loss), and 18.5% had learning disabilities (Grimwood et al, 1995).

Special Circumstances

Pneumococcus

Conditions associated with pneumococcal meningitis are otitis media, skull fractures, and sickle cell disease. Children with asplenia and chronic illnesses require immunization with Pneumovax. Penicillin G and ampicillin are equally effective in treating meningitis caused by penicillin-sensitive strains of *S. pneumoniae*. The treatment of organisms resistant to penicillin and ceftriaxone is a combination of ceftriaxone and vancomycin.

Meningococcus

Children with complement deficiency or asplenia require immunization for meningococcus. All household members who may have had saliva-exchange contact also require prophylaxis for meningococcal meningitis. A 2-day course of oral rifampin is prescribed, 10 mg/kg every 12 hours for children 1 month to 12 years old and 5 mg/kg every 12 hours for infants younger than 1 month old.

Tuberculous Meningitis

Worldwide, tuberculosis remains a leading cause of morbidity and death in children. In the United States, tuberculosis accounts for less than 5% of bacterial meningitis cases in children, but it occurs with higher frequency where sanitation is poor. Infection of children follows inhalation of the organism from adults. Tuberculosis occurs first in the lungs, then disseminates to other organs within 6 months.

CLINICAL FEATURES. The peak incidence of tuberculous meningitis is between 6 months and 2 years of age. The first symptoms tend to be more insidious than with other bacterial meningitides, but they sometimes progress in a fulminating fashion. Tuberculous meningitis, in contrast to fungal meningitis, is not a cause of chronic meningitis. If not treated, a child with tuberculous meningitis dies within 3 to 5 weeks.

Most often, fever develops first, and the child becomes listless and irritable. Headache may cause the irritability. Vomiting and abdominal pain are sometimes associated symptoms. Headache and vomiting become increasingly frequent and severe. Signs of meningismus develop during the second week after onset of fever. Cerebral infarction occurs in 30% to 40% of affected children. Seizures may occur early, but more often, they occur after meningismus is established. Consciousness declines progressively, and focal neurological deficits are noted. Most common are cranial neuropathies and hemipareses. Papilledema occurs relatively early in the course.

DIAGNOSIS. Consider the diagnosis of tuberculosis in any child with a household contact. General use of tuberculin skin testing in children is crucial to early detection. In the early stages, children with tuberculous meningitis may have only fever. The peripheral white blood cell count generally is elevated (10,000 to 20,000 cells/mm³). Hyponatremia and hypochloremia are frequently present because of inappropriate secretion of antidiuretic hormone. The CSF is

usually cloudy and increased in pressure. The leukocyte count in the CSF may range from 10 to 250 cells/mm³ and rarely exceeds 500 cells/mm³. Lymphocytes predominate. The glucose concentration declines throughout the course of the illness and is generally less than 35 mg/dL (<1.8 mmol/L). Conversely, the protein concentration increases steadily and is usually greater than 100 mg/dL (>1 g/L).

Smears of CSF stained by the acid-fast technique generally show the bacillus. Recovery of the organism from the CSF is not always successful even when guinea pig inoculation is used. Newer diagnostic tests include a polymerase chain reaction technique with reported sensitivities of 70% to 75% and enzyme-linked immunosorbent assay and radioimmunoassay tests for antimycobacterial antigens in the CSF.

MANAGEMENT. Early treatment enhances the prognosis for survival and for neurological recovery. A positive skin test is reason to initiate isoniazid therapy in an asymptomatic child. Complete neurological recovery is unlikely when the child becomes comatose. Mortality rates of 20% are recorded even when treatment is initiated early.

The recommended initial drug regimen for treatment of tuberculous meningitis in the first 2 months is isoniazid, 20 mg/kg/day orally up to 500 mg/day; streptomycin, 20 mg/kg/day intramuscularly up to 1 g/day until establishing drug susceptibility; rifampin, 15 mg/kg/day orally up to 600 mg/day; and pyrazinamide, 30 mg/kg/day. Continue isoniazid and rifampin therapy for an additional 10 months. The use of corticosteroids to reduce inflammation is appropriate to reduce inflammation and cerebral edema.

Communicating hydrocephalus is a common complication of tuberculous meningitis because of impaired reabsorption of CSF. Periodic CT assessment of ventricular size is routine and specifically indicated when mental function deteriorates. Before the infection is controlled, treatment of communicating hydrocephalus is by repeated lumbar punctures and acetazolamide. In many cases, obstructive hydrocephalus develops later; in these cases, a surgical shunt is required.

Brain Abscess

The factors commonly predisposing to pyogenic brain abscess in children are meningitis, chronic otitis media, sinusitis, and congenital heart disease. Brain abscesses in the newborn are usually the result of meningitis caused by *C. diversus*

and other species of Enterobacteriaceae. Pyogenic abscesses in children younger than 5 months but older than the neonatal period are uncommon and usually occur in children with hydrocephalus and shunt infection. The organisms most often responsible are *Staphylococcus* species. After 5 months of age, the infecting organisms are diverse, and many abscesses contain a mixed flora. Coagulase-positive *S. aureus* and anaerobic *Streptococcus* are the organisms most frequently recovered.

CLINICAL FEATURES. The clinical features of brain abscess, similar to those of any other space-occupying lesion, depend on the age of the child and the location of the mass. A period of cerebritis, characterized by fever, headache, and lethargy, precedes encapsulation of the abscess. Seizures also may occur, but in the absence of seizures, the initial symptoms may not be severe enough to arouse suspicion of cerebral infection. If the period of cerebritis is not recognized, the initial clinical manifestations are the same as those of other mass lesions. Infants have abnormal head growth, a bulging fontanelle, failure to thrive, and sometimes seizures. Older children show signs of increased intracranial pressure and focal neurological dysfunction. Fever is present in only 60% of cases, and meningeal irritation is relatively uncommon. Based on clinical features alone, pyogenic brain abscess is difficult to separate from other mass lesions, such as brain tumor. About 80% of abscesses are in the cerebral hemispheres. Hemiparesis, hemianopia, and seizures are the usual clinical features. Cerebellar abscess most often results from chronic otitis and is manifest as nystagmus and ataxia.

DIAGNOSIS. The combination of headache and papilledema, with or without focal neurological dysfunction, suggests the possibility of a mass lesion and calls for neuroimaging. Most abscesses appear on CT as an area of decreased density surrounded by a rim of intense enhancement referred to as a *ring lesion*. This lesion, although characteristic, is not diagnostic. Malignant brain tumors may have a similar appearance. Ring enhancement occurs during the late stages of cerebritis, just before capsule formation. After the capsule forms, the diameter of the ring decreases and the center becomes more hypodense. Multiple abscesses may be present.

MANAGEMENT. The development of neuroimaging has altered the management of cerebral abscess. Previously, surgical drainage was immediate on diagnosis of abscess formation.

Antimicrobials are the initial therapy now even for encapsulated abscesses, and progress is followed with serial scans.

The initial step in treatment is to reduce brain swelling by the use of corticosteroids. Follow the steroids with an intravenous antimicrobial regimen that generally includes a penicillinase-resistant penicillin, such as methicillin, 300 mg/kg/day, and chloramphenicol, 100 mg/kg/day. This combination is effective against *Staphylococcus* and mixed gram-negative organisms. Identification of a specific organism by culture of CSF or blood allows specific antimicrobial therapy. In general, penicillin G is preferable to ampicillin for penicillin-sensitive organisms. If medical therapy does not resolve the abscess, surgical drainage is necessary. Even in such cases, prolonged medical therapy before surgery increases the success of total excision.

Subdural and Epidural Empyema

Meningitis in infants and sinusitis in older children are the most common factors causing infection in the subdural space. The subdural space is sterile in children with bacterial meningitis, but contamination may occur when a subdural tap occurs before sterilizing the subarachnoid space with antibiotics. In older children, the usual cause of subdural and epidural abscesses is by penetrating head injuries or chronic mastoiditis. Infections of the subdural space are difficult to contain and may extend over an entire hemisphere.

CLINICAL FEATURES. Subdural empyema produces increased intracranial pressure because of mass effect, cerebral edema, and vasculitis. Vasculitis leads to thrombosis of cortical veins, resulting in focal neurological dysfunction and increased intracranial pressure. Children with subdural infections have headache, fever, vomiting, seizures, and states of decreasing consciousness. Unilateral and alternating hemipareses are common.

DIAGNOSIS. Suspect subdural empyema in children with meningitis whose condition declines after an initial period of recovery or in children who continue to have increased intracranial pressure of uncertain cause. Examination of the CSF may not be helpful, but the usual abnormality is a mixed cellular response, generally less than 100 cells/mm³ and with a lymphocytic predominance. The glucose concentration is normal, and the protein concentration is only mildly elevated.

CT is particularly helpful in showing a subdural or epidural abscess. The infected collection

appears as a lens-shaped mass of increased lucency just beneath the skull. A shift of midline structures is generally present. In infants, subdural puncture provides an abscess specimen for identification of the organism. Subdural puncture also drains much of the abscess.

MANAGEMENT. The treatment of subdural or epidural empyema requires corticosteroids to decrease intracranial pressure, antimicrobials to eradicate the organisms, and anticonvulsants for seizures. Medical therapy and CT to monitor progress may replace surgical drainage of subdural empyema, when considered an absolute necessity.

Fungal Infections

Fungi exist in two forms: molds and yeasts. Molds are filamentous and divided into segments by hyphae. Yeasts are unicellular organisms surrounded by a thick cell wall and sometimes a capsule. Several fungi exist as yeast in tissue but are filamentous when grown in culture. Such fungi are *dimorphic*. Table 4-10 lists common fungal pathogens. Fungal infections of the central nervous system may cause an acute, subacute, or chronic meningitis; solitary or multiple abscesses; and granulomas. Fungal infections of the nervous system are most common in children who are immunosuppressed, especially children with leukemia or acidosis. Fungal infections also occur in immunocompetent children. *Cryptococcus neoformans* and *Coccidioides immitis* are the leading causes of fungal meningitis in immunocompetent children.

Candidal Meningoencephalitis

Candida is a common inhabitant of the mouth, vagina, and intestinal tract. Ordinarily it causes no symptoms; however, *Candida* can multiply and become an important pathogen in

TABLE 4-10
Common Fungal Pathogens

Yeast Forms

Candida
Cryptococcus neoformans

Dimorphic Forms

Blastomyces dermatitidis
Coccidioides immitis
Histoplasma capsulatum

Mold Forms

Aspergillus

immunosuppressed children taking multiple antibiotics, children with debilitating diseases, transplant recipients, and critically ill neonates undergoing treatment with long-term vascular catheters. The most common sites of infection are the mouth (thrush), skin, and vagina. Candidal meningitis is almost unheard of in healthy, nonhospitalized children.

CLINICAL FEATURES. *Candida* reaches the brain and other organs by vascular dissemination. The brain is involved less often than other organs, and fever, lethargy, and vomiting are the prominent features. Hepatosplenomegaly and arthritis may be present.

Cerebral involvement can be in the form of meningitis, abscess formation, or both. The clinical features of meningoencephalitis are fever, vomiting, meningismus, papilledema, and seizures leading to states of decreased consciousness. In some individuals, a single large cerebral abscess forms that causes focal neurological dysfunction and papilledema.

DIAGNOSIS. Suspect cerebral *Candida* infection when unexplained fever develops in children with risk factors for disseminated disease. The organism can be isolated from blood, joint effusion fluid, or CSF. When meningitis is present, a predominantly neutrophilic response is present in the CSF associated with a protein concentration that is generally 100 mg/dL (1 g/L). Reduction of the glucose concentration is small. Children who have a candidal abscess rather than meningitis are likely to have normal or near-normal CSF. CT reveals a mass lesion resembling a pyogenic abscess or tumor.

MANAGEMENT. When candidal infection develops in a child because of an indwelling vascular catheter, remove the catheter. Treat with amphotericin B and flucytosine, which have a synergistic effect. Dosages are the same as for other fungal infections; the drugs are administered for 6 to 12 weeks, depending on the efficacy of therapy and the presence of adverse reactions.

Coccidioidomycosis

C. immitis is endemic in the San Joaquin Valley of California and all southwestern states. Inhalation is the route of infection, and almost 90% of individuals become infected within 10 years of moving into an endemic area. Only 40% of patients become symptomatic; the other 60% are positive only by skin test.

CLINICAL FEATURES. Malaise, fever, cough, myalgia, and chest pain follow respiratory infection. The pulmonary infection is self-limited. The incidence of fungal dissemination from the lung

to other organs is 1:400. The dissemination rate is considerably higher in infants than in older children and adults.

The usual cause of coccidioidal meningitis is hematogenous spread from lung to meninges, but sometimes meningitis occurs by direct extension after infection of the skull. Symptoms of meningitis develop 2 to 4 weeks after respiratory symptoms begin. The main features are headache, apathy, and confusion. These symptoms may persist for weeks or months without concurrent seizures, meningismus, or focal neurological disturbances. If the meningitis becomes chronic, hydrocephalus eventually develops because the basilar meningitis prevents reabsorption of CSF.

DIAGNOSIS. Suspect coccidioidal meningitis in patients living in endemic areas when headache develops after an acute respiratory infection. Skin hypersensitivity among individuals living in an endemic area is not helpful because a large percentage of the population is exposed and has a skin test positive for the organism. The CSF generally shows increased pressure, and the lymphocytic cellular response is 50 to 500 cells/mm³. Often, eosinophils also are present. The protein concentration ranges from 100 to 500 mg/dL (1 to 5 g/L), and the glucose concentration is less than 35 mg/dL (<1.8 mmol/L). Isolation of the fungus confirms the diagnosis, but this is often difficult to accomplish. Complement-fixing antibodies are detected in the CSF in 70% of cases, and positive culture results occur in less than half.

MANAGEMENT. Amphotericin B is the drug of choice for coccidioidal meningitis. It must be administered intravenously (Table 4-11) and intrathecally. The initial intrathecal dose is 0.1 mg for the first three injections. An increased dose of 0.25 to 0.5 mg three or four times each week completes the course. Prolonged treatment is required, and some clinicians recommend weekly intrathecal injections indefinitely. Adverse reactions to intrathecal administration include aseptic meningitis and pain in the back and legs. Miconazole may be administered intravenously and intrathecally to patients unable to tolerate high doses of amphotericin B.

Cryptococcal Meningitis

Birds, especially pigeons, carry *C. neoformans* and disseminate it widely in soil. Acquisition of human infection is by inhalation. Dissemination is blood-borne, but the central nervous system is a favorite target, causing subacute and chronic meningoencephalitis.

TABLE 4-11
Dosage Schedule for Amphotericin B

Administer amphotericin B first intravenously in a single test dose of 0.1 mg/kg (not to exceed 1 mg) over at least 20 minutes to assess the child's temperature and blood pressure responses

If the response is acceptable, administer the first therapeutic dose of 0.25 mg/kg over 2 hours the same day as the test dose

Increase the dose in daily increments of 0.1-0.25 mg/kg, depending on the severity of infection, until achieving the daily maintenance dose of 1 mg/kg

In life-threatening situations, use daily dosages of 1.25-1.5 mg/kg

CLINICAL FEATURES. Cryptococcal meningitis is uncommon before age 10, and perhaps only 10% of cases occur before age 20. Male infection rates are greater than female rates. Most children with cryptococcal meningitis are immunocompetent.

The first symptoms are usually insidious; chronic headache is the major feature. The headache waxes and wanes, but eventually becomes continuous and associated with nausea, vomiting, and lethargy. Body temperature may remain normal, especially in older children and adults, but younger children often have low-grade fever. Personality and behavioral changes are relatively common. The child becomes moody, listless, and sometimes frankly psychotic. Characteristic features of increased intracranial pressure are blurred vision, diplopia, and papilledema. Seizures and focal neurological dysfunction are not early features but are signs of vasculitis, hydrocephalus, and granuloma formation.

DIAGNOSIS. Even when suspected, the diagnosis of cryptococcal meningitis fails to be established. The CSF may be normal but more often shows an increased opening pressure and less than 100 cells/mm³ lymphocytes. The protein concentration is elevated, generally greater than 100 mg/dL (>1 g/L), and the glucose concentration is less than 40 mg/dL (<2 mmol/L).

The diagnosis of cryptococcal meningitis relies on detection of cryptococcal polysaccharide antigen by latex agglutination, demonstration of the organism in India ink preparations of CSF, or CSF culture. Approximately 50% of India ink preparations and 75% of culture results are positive. The latex agglutination test for cryptococcal polysaccharide antigen is sensitive and specific for cryptococcal infection.

MANAGEMENT. The treatment of choice is intravenous amphotericin B (0.3 to 0.5 mg/kg/day)

combined with oral flucytosine (150 mg/kg/day) in four divided doses (Sanchez and Noskin, 1996). Amphotericin B, diluted with 5% dextrose and water in a drug concentration no greater than 1 mg/10 mL of fluid, constitutes the intravenous solution. Nephrotoxicity is the limiting factor in achieving desirable blood levels. Table 4-11 summarizes the intravenous regimen, which is generally the same for all fungal infections of the nervous system. The total dose varies with the response and the side effects, but is usually 1500 to 2000 mg/1.7 m² of body surface. Continuous therapy for 4 to 6 weeks is required.

The toxic effects include chills, fever, nausea, and vomiting. Frequent blood counts and urinalyses monitor for anemia and nephrotoxicity. Manifestations of renal impairment are the appearance of cells or casts in the urine, an elevated blood concentration of urea nitrogen, and decreased creatinine clearance. When renal impairment occurs, discontinue the drug and restart at a lower dose.

Cytopenia limits the use of flucytosine. Seriously ill patients, treated late in the course of the disease, also should be given intrathecally administered amphotericin B and miconazole. A decline of the agglutination titer in the CSF indicates therapeutic efficacy. Periodic cranial CT monitors for the development of hydrocephalus.

Other Fungal Infections

Histoplasmosis is endemic in the central United States and causes pulmonary infection. Miliary spread is unusual. Neurological histoplasmosis may take the form of leptomeningitis, focal abscess, or multiple granulomas. Blastomycosis is primarily a disease of North America. Hematogenous spread from the lungs infects the brain. Multiple abscesses form, which give the CT appearance of metastatic disease. The cellular response in the CSF is markedly increased when fungi produce meningitis and may be normal or only mildly increased with abscess formation. Amphotericin B is the mainstay of therapy for fungal infections; the combination of itraconazole and amphotericin B treats *Histoplasma capsulatum*.

Idiopathic Intracranial Hypertension (Pseudotumor Cerebri)

The term *idiopathic intracranial hypertension* (IIH) characterizes a syndrome of increased

intracranial pressure, normal CSF content, and a normal brain with normal or small ventricles on brain imaging studies. IIH may have an identifiable underlying cause or may be idiopathic. Identification of a specific cause is usual in children younger than 6 years old, whereas most idiopathic cases occur after age 11. Table 4-12 lists some causes of IIH. An established cause-and-effect relationship is uncertain in many of these conditions. The most frequent causes are otitis media, head trauma, the use of certain drugs and vitamins, and feeding after malnutrition.

CLINICAL FEATURES. Patients with IIH have headaches that are diffuse, are worse at night, and often wake them from sleep in the early hours of the morning. Sudden movements, such as coughing, aggravate headache. Headaches may be present for several months before establishing a diagnosis. Some patients complain of dizziness. Transitory loss of vision may occur with change of position. Prolonged papilledema may lead to visual loss (Friedman and Jacobson, 2002).

Young children may have only irritability, somnolence, or apathy. Less common symp-

toms are transitory visual obscurations, neck stiffness, tinnitus, paresthesias, and ataxia. Most children are not acutely ill, and mental ability is normal.

Neurological examination is normal except for papilledema and abducens nerve palsy. Features of focal neurological dysfunction are lacking. Loss of vision is the main concern. Untreated IIH may lead to progressive papilledema and optic atrophy. Loss of vision may be rapid and severe. Early diagnosis and treatment are essential to preserve vision.

DIAGNOSIS. Pseudotumor cerebri is a diagnosis of exclusion. Brain imaging is required in every child with headache and papilledema to exclude a mass lesion or hydrocephalus. The results of imaging studies are usually normal in children with pseudotumor cerebri. In some, the ventricles are small, and normal sulcal markings are obliterated. Assess visual fields, with special attention to the size of the blind spot, at baseline and after treatment is initiated. Exclude known underlying causes of pseudotumor cerebri by careful history and physical examination. Ordinarily, identification of an underlying cause is easily established.

MANAGEMENT. The goals of therapy are to relieve headache and preserve vision. A single lumbar puncture, with the closing pressure reduced to half of the opening pressure, is sufficient to reverse the process in many cases. The mechanism by which lumbar puncture is effective is unknown, but a transitory change in CSF dynamics seems sufficient to readjust the pressure.

The usual treatment of children with pseudotumor cerebri is acetazolamide, 10 mg/kg/day, after the initial lumbar puncture. Whether the acetazolamide is an important addition to lumbar puncture is not clear. If symptoms return, the lumbar puncture is repeated on subsequent days. Some children require serial lumbar punctures.

Occasionally, children continue to have increased intracranial pressure and evidence of progressive optic neuropathy despite the use of lumbar puncture and acetazolamide. In such patients, studies should be repeated to look for a cause other than idiopathic pseudotumor cerebri. If studies are negative, lumboperitoneal shunt is the usual option to reduce pressure. Optic nerve fenestration relieves papilledema but does not relieve increased intracranial pressure. A newly proposed technique is stenting the venous sinus to reduce pressure (Higgins et al, 2003). Usefulness of this technique is not yet established.

TABLE 4-12
Causes of Idiopathic Intracranial Hypertension

Drugs
Corticosteroid withdrawal
Nalidixic acid
Oral contraceptives
Tetracycline
Thyroid replacement
Vitamin A
Systemic disorders
Guillain-Barré syndrome
Iron deficiency anemia
Leukemia
Polycythemia vera
Protein malnutrition
Systemic lupus erythematosus
Vitamin A deficiency
Vitamin D deficiency
Head trauma
Infections
Otitis media
Sinusitis
Metabolic disorders
Adrenal insufficiency
Diabetic ketoacidosis (treatment)
Galactosemia
Hyperadrenalism
Hyperthyroidism
Hypoparathyroidism
Pregnancy

References

- Costa JM, Ley L, Claramunt E, et al. Choroid plexus papillomas of the III ventricle in infants. Report of three cases. *Child Nerv Syst* 1997;13:244-249.
- Friedman DI, Jacobson DM. Diagnostic criteria for idiopathic intracranial hypertension. *Neurology* 2002;59:1492-1495.
- Grimwood K, Anderson VA, Bond L, et al. Adverse outcome of bacterial meningitis in school-age survivors. *Pediatrics* 1995;95:646-656.
- Higgins JN, Cousins C, Owler BK, et al. Idiopathic intracranial hypertension. 12 cases treated by venous sinus stenting. *J Neurol Neurosurg Psychiatry* 2003;12:1662-1666.
- Mallucci CL, Parkes SE, Barber P, et al. Paediatric meningeal tumors. *Child Nerv Syst* 1996;12:582-589.
- McIntyre PB, Berkey CS, King SM, et al. Dexamethasone as adjunctive therapy in bacterial meningitis. A meta-analysis of randomized clinical trials since 1988. *JAMA* 1997;278:925-931.
- McLaughlin MP, Marcus RB, Buatti JM, et al. Ependymoma. Results, prognostic factors and treatment recommendations. *Int J Radiat Oncol Biol Phys* 1998;40:845-850.
- Menovsky T, van Overbeeke JJ. Cerebral arteriovenous malformations in childhood. State of the art with special reference to treatment. *Eur J Pediatr* 1997;56:741-746.
- Meyers PM, Halbach VV, Phatouros CP, et al. Hemorrhagic complications in vein of Galen malformations. *Ann Neurol* 2000;47:748-755.
- Olafsson E, Hauser A, Gudmundsson G. A population-based study of prognosis of ruptured cerebral aneurysm. Mortality and recurrence of subarachnoid hemorrhage. *Neurology* 1997;48:1191-1195.
- Packer RJ. Brain tumors in children. *Neurology* 1999;56:421-425.
- Pencalet P, Sainte-Rose C, Lellouch-Tubiana A, et al. Papillomas and carcinomas of the choroid plexus in children. *J Neurosurg* 1998;88:521-528.
- Pollack IF, Gerszten PC, Martinez AJ, et al. Intracranial ependymomas of childhood. Long-term outcome and prognostic factors. *Neurosurgery* 1995;37:655-667.
- Quagliarello VJ, Scheld WM. Treatment of bacterial meningitis. *N Engl J Med* 1997;336:708-716.
- Riordan FAI, Thomson APJ, Sills JA, et al. Bacterial meningitis in the first three months of life. *Postgrad Med J* 1995;71:36-38.
- Roland EH, Hill A. Intraventricular hemorrhage and posthemorrhagic hydrocephalus. *Clin Perinatol* 1997;24: 589-605.
- Sanchez JL, Noskin GA. Recent advances in the management of opportunistic fungal infections. *Compr Ther* 1996;22:703-712.
- Volpe JJ: *Neurology of the Newborn*, Fourth Edition. WB Saunders: Philadelphia; 2000.

Chapter 5

Psychomotor Retardation and Regression

THE DIFFERENTIAL DIAGNOSIS of psychomotor retardation (developmental delay) is quite different from that of psychomotor regression. Slow progress in the attainment of developmental milestones may be caused by either static (Table 5-1) or progressive (Table 5-2) encephalopathies. In contrast, the loss of developmental milestones previously attained usually indicates a progressive disease of the nervous system, but also may result from parental misperception of attained milestones or by the development of new clinical features from an established static disorder as the brain matures (Table 5-3).

Developmental Delay

Delayed achievement of developmental milestones is a common problem evaluated by child neurologists. Two important questions require answers: (1) Is developmental delay restricted to specific areas, or is it global? (2) Is development delayed or regressing?

In infants, the second question is often difficult to answer. Even in static encephalopathies, new symptoms, such as involuntary movements and seizures, may occur as the child gets older, and delayed acquisition of milestones without other neurological deficits is sometimes the initial feature of progressive disorders. When it is clear that milestones previously achieved are lost or that focal neurological deficits are evolving, however, a progressive disease of the nervous system is a consideration.

The *Denver Developmental Screening Test* is an efficient and reliable method for assessing development in the physician's office. It rapidly assesses four different components of development: personal-social, fine motor adaptive, language, and gross motor. Several psycho-

metric tests amplify the results, but the *Denver Developmental Screening Test* in combination with neurological assessment provides sufficient information to initiate further diagnostic studies.

Language Delay

Normal infants and children have a remarkable facility for acquiring language during the first decade of life. Children exposed to two languages concurrently learn both. Vocalization of vowels occurs in the first month, and by 5 months, laughing and squealing are established. At 6 months, infants begin articulating consonants, usually *M*, *D*, and *B*. Parents translate these to mean "mama," "dada," and "bottle" or "baby," although this is not the infant's intention. These first attempts at vowels and consonants are automatic and sometimes occur even in deaf children. In the months that follow, the infant imitates many speech sounds, babbles and coos, and finally learns the specific use of "mama" and "dada" by 1 year of age. Receptive skills are always more highly developed than expressive skills because language must be decoded before it is encoded. By 2 years of age, children have learned to combine at least 2 words, understand more than 250 words, and follow many simple verbal directions.

Developmental disturbances in the language cortex of the left hemisphere that occur before 5 years of age displace language to the right hemisphere. This displacement does not occur in older children.

Autistic Spectrum Disorders

Infantile autism is a developmental disorder of brain function defined by behavioral characteristics. The terms *autistic spectrum disorders*

TABLE 5-1
Diagnosis of Developmental Delay:
No Regression

Predominant Speech Delay

Bilateral hippocampal sclerosis
 Congenital bilateral perisylvian syndrome
 (see Chapter 17)
 Hearing impairment (see Chapter 17)
 Infantile autism

Predominant Motor Delay

Ataxia (see Chapter 10)
 Hemiplegia (see Chapter 11)
 Hypotonia (see Chapter 6)
 Neuromuscular disorders (see Chapter 7)
 Paraplegia (see Chapter 12)

Global Developmental Delay

Cerebral malformations
 Chromosomal disturbances
 Intrauterine infection
 Perinatal disorders
 Progressive encephalopathies (see Table 5-2)

(ASD) and *pervasive developmental disorders* classify the spectrum of behavioral consequences. *Asperger disorder* represents the high-functioning end of autistic spectrum disorders. The high concordance in monozygotic twins, a 4.5% increased risk for recurrence in siblings, and autistic behav-

TABLE 5-3
Causes of Apparent Regression in Static
Encephalopathy

Increasing spasticity (usually during the first year)
 New-onset movement disorders (usually during the second year)
 New-onset seizures
 Parental misperception of attained milestones
 Progressive hydrocephalus

iors in children with several genetic disorders support a hereditary basis.

Autism has become an increasingly popular diagnosis. An apparent increasing incidence of diagnosis suggests to some investigators an environmental factor. Data do not confirm the notion, however, of an autism epidemic or causation by any environmental factor. Most biological studies suggest prenatal factors.

CLINICAL FEATURES. Major diagnostic criteria are impaired sociability, impaired verbal and non-verbal communication skills, and restricted activities and interests (Rapin, 2002). Failure of language development is the feature most likely to bring autistic infants to medical attention and correlates best with the outcome; children who fail to develop language before age 5 have the

TABLE 5-2
Progressive Encephalopathy: Onset Before Age 2

Acquired immunodeficiency syndrome encephalopathy
 Disorders of amino acid metabolism
 Homocystinuria (21q22)
 Maple syrup urine disease
 Intermediate form
 Thiamine-responsive form
 Phenylketonuria
 Disorders of lysosomal enzymes
 Ganglioside storage disorders
 GM₁ gangliosidosis
 GM₂ gangliosidosis (Tay-Sachs disease, Sandhoff disease)
 Gaucher disease type II (glucosylceramide lipidosis)
 Globoid cell leukodystrophy (Krabbe disease)
 Glycoprotein degradation disorders
 I-cell disease
 Mucopolysaccharidoses
 Type I (Hurler syndrome)
 Type III (Sanfilippo disease)
 Niemann Pick disease type A (sphingomyelin lipidosis)
 Sulfatase deficiency disorders
 Metachromatic leukodystrophy (sulfatide lipidoses)
 Multiple sulfatase deficiency
 Carbohydrate-deficient glycoprotein syndromes
 Hypothyroidism

Mitochondrial disorders
 Alexander disease
 Mitochondrial myopathy, encephalopathy, lactic acidosis, and stroke (see Chapter 11)
 Progressive infantile poliodystrophy (Alpers disease)
 Subacute necrotizing encephalomyelopathy (Leigh disease)
 Trichopolydystrophy (Menkes syndrome)
 Neurocutaneous syndromes
 Chédiak-Higashi syndrome
 Neurofibromatosis
 Tuberous sclerosis
 Other disorders of gray matter
 Infantile ceroid lipofuscinosis (Santavuori-Haltia disease)
 Infantile neuroaxonal dystrophy
 Lesch-Nyhan disease
 Progressive neuronal degeneration with liver disease
 Rett syndrome
 Other disorders of white matter
 Aspartoacylase deficiency (Canavan disease)
 Galactosemia: transferase deficiency
 Neonatal adrenoleukodystrophy (see Chapter 6)
 Pelizaeus-Merzbacher disease
 Progressive hydrocephalus

worst outcome. The IQ is less than 70 in most children with autism. Some autistic children show no affection to their parents or other care providers, whereas others are affectionate on their own terms. Autistic children do not show normal play activity; some display a morbid preoccupation with spinning objects, stereotyped behaviors such as rocking and spinning, and relative insensitivity to pain. An increased incidence of epilepsy in autistic children is probable.

DIAGNOSIS. Infantile autism is a clinical diagnosis and not confirmable by laboratory tests. Infants with profound hearing impairment may display autistic behavior, and tests of hearing are diagnostic. An electroencephalogram (EEG) is indicated when seizures are suspected.

MANAGEMENT. Autism is not curable, but several drugs may be useful to control specific behavioral disturbances. Behavior modification techniques improve some aspects of the severely aberrant behavior. Despite the best program of treatment, however, these children function in a moderately to severely retarded range, although some individuals have islands of normal or extraordinary ability (*idiot savant*).

Bilateral Hippocampal Sclerosis

Bilateral hippocampal sclerosis and the *congenital bilateral perisylvian syndrome* cause a profound impairment of language development. The former also causes failure of cognitive capacity that mimics infantile autism, whereas the latter causes a pseudobulbar palsy (see Chapter 17). Infants with medial bilateral hippocampal sclerosis generally come to medical attention for refractory seizures. The syndrome emphasizes, however, that the integrity of one medial hippocampal gyrus is imperative for language development.

Hearing Impairment

The major cause of isolated delay in speech development is hearing impairment (see Chapter 17). Hearing loss may occur concomitantly with global developmental retardation, as in rubella embryopathy, cytomegalic inclusion disease, neonatal meningitis, kernicterus, and several genetic disorders. Hearing loss need not be profound; it can be insidious, yet delay speech development. The loss of high-frequency tones, inherent in telephone conversation, prevents the clear distinction of many consonants that humans learn to fill in through experience; infants do not have experience in supplying missing sounds.

The hearing of any infant with isolated delay in speech development requires audiometric testing. Crude testing in the office by slamming objects and ringing bells is inadequate. Hearing loss is suspected in children with global retardation caused by disorders ordinarily associated with hearing loss or in retarded children who fail to imitate sounds. Other clues to hearing loss in children are excessive gesturing and staring at the lips of people who are talking.

Delayed Motor Development

Infants with delayed gross motor development but normal language and social skills are often hypotonic and may have a neuromuscular disease (see Chapter 6). Isolated delay in motor function also is caused by ataxia (see Chapter 10), mild hemiplegia (see Chapter 11), and mild paraplegia (see Chapter 12). Many such children have a mild form of cerebral palsy, sufficient to delay the achievement of motor milestones but not severe enough to cause a recognizable disturbance in cognitive function during infancy. Mild disturbances in cognitive function are detected more often when a child enters school.

Global Developmental Delay

Most infants with global developmental delay have a static encephalopathy caused by an antenatal or perinatal disturbance. One percent of infants with developmental delay and no evidence of regression have an inborn error of metabolism, however, and 3.5% to 10% have a chromosomal disorder (Shevell et al, 2003). An exhaustive search for an underlying cause in every infant whose development is slow but not regressing is not cost-effective. Factors that increase the likelihood of finding a progressive disease are an affected family member, parental consanguinity, organomegaly, and absent tendon reflexes. Unenhanced cranial magnetic resonance imaging (MRI) and chromosome analysis are reasonable screening tests in all infants with global developmental delay. MRI often detects a malformation or other evidence of prenatal disease and provides a diagnosis that ends the uncertainty.

Chromosomal Disturbances

Abnormalities in chromosome structure or number are the most common cause of severe mental retardation, but they still constitute only one third of the total. Abnormalities of autosomal

chromosomes are always associated with infantile hypotonia (see Chapter 6). In addition, multiple minor face and limb abnormalities usually are associated features. These abnormalities in themselves are common, but they assume diagnostic significance in combination. Table 5-4 summarizes the clinical features that suggest chromosomal aberrations, and Table 5-5 lists some common chromosome syndromes.

Fragile X Syndrome

The fragile X syndrome is the most common chromosomal cause of mental retardation. Its prevalence in males is approximately 20:100,000. The name derives from a fragile site (constriction) detectable in folate-free culture medium at the Xq 27 location. The unstable fragment contains a trinucleotide repeat in the *FMR1* gene that becomes larger in successive generations (*DNA amplification*), causing more severe phenotypic expression. A decrease in the repeat size to normal also may occur.

CLINICAL FEATURES. The *phenotypic* features of males with full *mutations* vary in relation to puberty. Prepubertal boys grow normally but have an occipitofrontal head circumference larger than the 50th percentile. Achievement of motor and speech milestones is late, and temperament is abnormal, sometimes suggesting autism. Other physical features that become

more obvious after puberty include a long face, prominent forehead, large ears, prominent jaw, and large genitalia.

The phenotype of females depends on the nature of the *FMR1* mutation and random X-chromosome inactivation. About 50% of females who inherit a full fragile X mutation are mentally retarded; however, they usually are less severely affected than males with a full mutation. Approximately 20% of males with a fragile X chromosome are normal, whereas 30% of carrier females are mildly affected. An asymptomatic man can pass the abnormal chromosome to his daughters, who are usually asymptomatic as well. The daughter's male and female children may be symptomatic.

DIAGNOSIS. DNA-based testing has replaced the use of *chromosome* analysis using modified culture techniques to induce fragile sites (Saul and Tarleton, 2004). Molecular genetic testing is now the standard of diagnosis.

MANAGEMENT. Treatment consists of pharmacological management of behavior problems and educational intervention.

Cerebral Malformations

Approximately 3% of all children have at least one major malformation, but the responsible etiological factors are identifiable in only 20%

TABLE 5-4
Clinical Indications for Chromosome Analysis

Genitourinary

Ambiguous genitalia
Polycystic kidney

Head and Neck

High nasal bridge
Hypertelorism or hypotelorism
Microphthalmia
Mongoloid slant (in non-Asians)
Occipital scalp defect
Small mandible
Small or fish mouth (hard to open)
Small or low-set ears
Upward slant of eyes
Webbed neck

Limbs

Abnormal dermatoglyphics
Low-set thumb
Overlapping fingers
Polydactyly
Radial hypoplasia
Rocker-bottom feet

TABLE 5-5
Selected Autosomal Syndromes*

Defect	Features
5p monosomy	Characteristic "cri du chat" cry Moonlike face Hypertelorism Microcephaly
10p trisomy	Dolichocephaly "Turtle's beak" Osteoarticular anomalies
Partial 12p monosomy	Microcephaly Narrow forehead Pointed nose Micrognathia
18 trisomy	Pointed ears Micrognathia Occipital protuberance Narrow pelvis
21 trisomy	Rocker-bottom feet Hypotonia Round flat (mongoloid) facies Brushfield spots Flat nape of neck

*Growth retardation and mental retardation are features of all autosomal chromosome disorders.

of cases. Many intrauterine diseases cause destructive changes that cause malformation of the developing brain. The exposure of an embryo to infectious or toxic agents during the first weeks after conception can disorganize the delicate sequencing of neural development at a time when the brain is incapable of generating a cellular response. Alcohol, lead, prescription drugs, and substances of abuse are factors in the production of cerebral malformations. Although a cause-and-effect relationship is difficult to establish in any individual, maternal cocaine use is probably responsible for vascular insufficiency and infarction of many organs, including the brain.

Suspect a cerebral malformation in any retarded child who is dysmorphic, has malformations of other organs, or has an abnormality of head size and shape (see Chapter 18). Non-contrast-enhanced computed tomography (CT) is satisfactory to show major malformations, but MRI is the better method to show migrational defects and is more cost-effective for diagnosis of malformations.

Intrauterine Infections

The most common intrauterine infections are human immunodeficiency virus (HIV) and cytomegalovirus (CMV). The acquired immunodeficiency syndrome (AIDS) epidemic in adults is responsible for the re-emergence of congenital syphilis, but it has not been associated with a concomitant increase in the incidence of intrauterine toxoplasmosis. HIV infection can occur in utero, but acquisition of most infections occurs perinatally. Infected infants are asymptomatic in the newborn period and later develop progressive disease of the brain (see the section on progressive encephalopathies later). Rubella embryopathy has almost disappeared because of mass immunization, but it reappears when immunization rates decline.

Congenital Syphilis

Reported cases of congenital syphilis have increased since 1988, partly because of an actual increase in case number, but also because the case definition has broadened. By the current definition, all stillborn infants and live infants born to a woman with a history of untreated or inadequately treated syphilis have congenital syphilis.

CLINICAL FEATURES. Infection of the fetus is transplacental. Two thirds of infected newborns are asymptomatic and are identified only on

screening tests. The more common features in symptomatic newborns and infants are hepatosplenomegaly, periostitis or osteochondritis, pneumonia (pneumonia alba), persistent rhinorrhea (snuffles), and a maculopapular rash that can involve the palms and soles. If left untreated, the classic stigmata of Hutchinson's teeth, saddle nose, interstitial keratitis, saber shins, mental retardation, hearing loss, and hydrocephalus develop. The onset of neurological disturbances is usually after age 2 years and includes eighth nerve deafness and mental retardation. The combination of nerve deafness, interstitial keratitis, and peg-shaped upper incisors is the *Hutchinson triad*.

DIAGNOSIS. Every newborn infant's mother should have serologic testing to exclude syphilis infection before discharge from the nursery. Nontreponemal antibody tests (Venereal Disease Research Laboratory and rapid plasma reagin card tests) are screening tests, and the fluorescent treponemal antibody test absorbed with nonpallidum treponemas is confirmatory. Suspect concomitant HIV infection in every infant with congenital syphilis.

MANAGEMENT. Consultation with an infectious disease specialist is beneficial in all children suspected of having congenital syphilis. Treatment typically consists of intravenous aqueous penicillin G at a dose of 50,000 U/kg/dose every 12 hours for the first 7 days of life, then every 8 hours thereafter, for a total of 10 days. Alternatively, administer procaine penicillin G intramuscularly at a dose of 50,000 U/kg/day for 10 days.

Cytomegalic Inclusion Disease

CMV is a member of the herpesvirus group and produces a chronic infection characterized by long periods of latency punctuated by intervals of reactivation. CMV is the most common congenital viral infection (1% to 2% of all live births) and results either from primary maternal infection or from reactivation of the virus in the mother. Adults also can transmit CMV sexually causing an unapparent cervical infection. Pregnancy may cause reactivation of maternal infection. Less than 0.05% of newborns with viruria have symptoms of cytomegalic inclusion disease.

CLINICAL FEATURES. Less than 10% of infected newborns are symptomatic. The typical clinical features are skin rash, hepatosplenomegaly, jaundice, chorioretinitis, and microcephaly with cerebral calcification. Migrational defects (lissencephaly, polymicrogyria, and cerebellar

agenesis) are the main consequence of fetal infection during the first trimester. Some infants have microcephaly secondary to intrauterine infection without evidence of systemic infection at birth.

DIAGNOSIS. In symptomatic cases, virus can be cultured from throat swabs or urine, and CMV-specific IgM is present in serum, although the latter has poor sensitivity in the newborn period. Newer techniques, such as the shell-vial method of culture or polymerase chain reaction (PCR) for CMV DNA, establish a virological diagnosis. Isolation of CMV from the urine or cerebrospinal fluid (CSF) during the first 3 weeks postpartum indicates active infection in the newborn. These newborns should be isolated from women of childbearing age. In infants with developmental delay and microcephaly, establishing the diagnosis of cytomegalic inclusion disease is by serological demonstration of prior infection and a consistent pattern of intracranial calcification.

MANAGEMENT. Much of the brain damage from congenital CMV occurs in utero and is not influenced by postnatal treatment. Ganciclovir, 4 to 6 mg/kg every 12 hours for 6 weeks, has been successful in preventing sensorineural hearing loss; however, adverse reactions (particularly neutropenia) are common. Treatment requires consultation with an infectious disease specialist.

Rubella Embryopathy

CLINICAL FEATURES. Rubella embryopathy is a multisystem disease characterized by intrauterine growth retardation, cataracts, chorioretinitis, congenital heart disease, sensorineural deafness, hepatosplenomegaly, jaundice, anemia, thrombocytopenia, and rash. Of children with a congenital rubella syndrome, 80% have nervous system involvement. The neurological features are bulging fontanelle, lethargy, hypotonia, and seizures. Seizure onset is from birth to 3 months of age.

DIAGNOSIS. Rubella embryopathy is not a cause of psychomotor retardation, unless the newborn has other symptoms of rubella infection.

MANAGEMENT. No treatment is available for active infection.

Toxoplasmosis

Toxoplasma gondii is a protozoan estimated to infect 1:1000 live births in the United States each year. The symptoms of toxoplasmosis in the mother usually go unnoticed. Transplacental

transmission of toxoplasmosis is possible in situations of primary maternal infection during pregnancy or in immunocompromised mothers who have chronic or recurrent infection. The rate of placental transmission is highest during the last trimester, but fetuses infected at that time are least likely to have symptoms later on. The transmission rate is lowest during the first trimester, but fetuses infected at that time have the most serious sequelae.

CLINICAL FEATURES. A quarter of infected newborns have multisystem involvement (fever, rash, hepatosplenomegaly, jaundice, and thrombocytopenia) at birth. Neurological dysfunction is manifest as seizures, altered states of consciousness, and increased intracranial pressure. The triad of hydrocephalus, chorioretinitis, and intracranial calcification is the hallmark of congenital toxoplasmosis in older children. About 8% of infected newborns who are asymptomatic at birth later show neurological sequelae, especially psychomotor retardation.

DIAGNOSIS. The Sabin-Feldman dye test has been the standard for diagnosis, but another useful serological test to diagnose congenital toxoplasmosis in newborns is an enzyme-linked immunosorbent assay that shows IgM-specific antibody to *Toxoplasma* in umbilical cord blood. The demonstration of IgM-specific antibody is essential to prove active infection in the newborn. IgG-specific antibody appears in the newborn's serum by passive transfer from the mother and does not indicate active infection. Persistence of IgG-specific antibody correlates with active infection. In older children, the diagnosis requires not only serological evidence of prior infection, but also compatible clinical features.

MANAGEMENT. A combined prenatal and postnatal treatment program for congenital toxoplasmosis can reduce the neurological morbidity. When seroconversion indicates acute maternal infection, fetal blood and amniotic fluid are cultured and fetal blood tested for *Toxoplasma*-specific IgM. The mother requires only spiramycin treatment, unless proven fetal infection exists, then pyrimethamine (Daraprim) and sulfadoxine are required. In newborns with clinical evidence of toxoplasmosis, administer pyrimethamine and sulfadiazine for 1 year. Because pyrimethamine is a folic acid antagonist, administer leucovorin during therapy and for 1 week after discontinuation of treatment. Routine monitoring of the peripheral platelet count is required. Newborns with a high protein concentration in the CSF or chorioretinitis also require prednisone, 1 to 2 mg/kg/day.

Perinatal Disorders

Perinatal infection, asphyxia, maternal drug use, and trauma are the main perinatal events that cause psychomotor retardation (see Chapter 1). The important infectious diseases are bacterial meningitis (see Chapter 4) and herpes encephalitis (see Chapter 1). Although the overall mortality rate for bacterial meningitis is now less than 50%, half of survivors show significant neurological disturbances almost immediately. Mental and motor disabilities, hydrocephalus, epilepsy, deafness, and visual loss are the most common sequelae. Psychomotor retardation may be the only or the most prominent sequelae. Progressive mental deterioration can occur if meningitis causes a secondary hydrocephalus.

Telling Parents Bad News

It is not possible to make bad news sound good. The goal of telling parents that their child will have a neurological impairment or mental retardation is that they hear and understand what you are saying. The mind must be prepared to hear bad news. It is a mistake to tell people more than they are ready to accept. Too often, parents bring their child for a second or third opinion because previous physicians "didn't tell us anything." The physicians most likely said too much too fast and were tuned out.

My goal for the first visit is to establish that the child's development is not normal (not a normal variation), that something is wrong with the brain, and that I share the parents' concern. Mothers often come alone for this crucial visit and must restate your comments later to doubting fathers and grandparents. Most parents cannot handle more information than "the child is not normal" at the first consultation, and further discussion awaits a later visit. Always answer probing questions fully, however. Parents must never lose confidence in your willingness to be forthright. The timing of the next visit depends on the age of the child and the severity of the retardation. The more the child falls behind in reaching developmental milestones, the more ready parents will be to accept the diagnosis of mental retardation.

When the time comes to tell a mother that her child is retarded, she will cry. If she does not cry, she has not heard what you were saying or understood its implications and you have failed

to communicate effectively. It is not helpful to describe mental retardation as mild, moderate, or severe. Parents want to know what the child will do. Will he walk, need special schools, and live alone? The next question is "What can I do to help my child?" Parents must do something. Direct them to programs that provide developmental specialists and other parents who can help them learn how to live with a chronic handicapping disorder and gain access to community resources.

Progressive Encephalopathies with Onset Before Age 2

The differential diagnosis of progressive diseases of the nervous system that start before age 2 years is different from nervous system diseases that begin during childhood (Table 5-6). The history and physical examination must answer

TABLE 5-6 Progressive Encephalopathy: Onset After Age 2

Disorders of Lysosomal Enzymes

Gaucher disease type III (glucosylceramide lipidosis)
Globoid cell leukodystrophy (late-onset Krabbe disease)
Glycoprotein degradation disorders
Aspartylglycosaminuria
Mannosidosis type II
GM₂ gangliosidosis (juvenile Tay-Sachs disease)
Metachromatic leukodystrophy (late-onset sulfatide lipidoses)
Mucopolysaccharidoses types II and VII
Niemann-Pick type C (sphingomyelin lipidosis)

Infectious Disease

Acquired immunodeficiency syndrome encephalopathy
Congenital syphilis
Subacute sclerosing panencephalitis

Other Disorders of Gray Matter

Ceroid lipofuscinosis
Juvenile
Late infantile (Bielschowsky-Jansky disease)
Heller syndrome
Huntington disease
Mitochondrial disorders
Late-onset poliodystrophy
Myoclonic epilepsy and ragged-red fibers (MERRF)
Progressive neuronal degeneration with liver disease
Xeroderma pigmentosum

Other Disorders of White Matter

Adrenoleukodystrophy
Alexander disease
Cerebrotendinous xanthomatosis

three questions before initiating laboratory diagnosis:

1. Is only the central nervous system involved, or are other organs involved? Other organ involvement suggests lysosomal, peroxisomal, and mitochondrial disorders.
2. Are the clinical features referable only to the central nervous system or to the central and the peripheral nervous systems? Nerve or muscle involvement suggests mainly lysosomal and mitochondrial disorders.
3. Does the disease affect primarily the gray matter or the white matter?

Early features of gray matter disease are personality change, seizures, and dementia. Focal neurological deficits, spasticity, and blindness are characteristic of white matter disease. Whether the process begins in the gray matter or the white matter, eventually clinical features of dysfunction develop in both. The EEG is usually abnormal early in the course of gray matter disease and late in the course of white matter disease. MRI shows cortical atrophy in gray matter disease and cerebral demyelination in white matter disease (Figure 5-1). Visual evoked responses and motor conduction velocities are useful in documenting demyelination, even sub-clinical, in the optic and peripheral nerves.

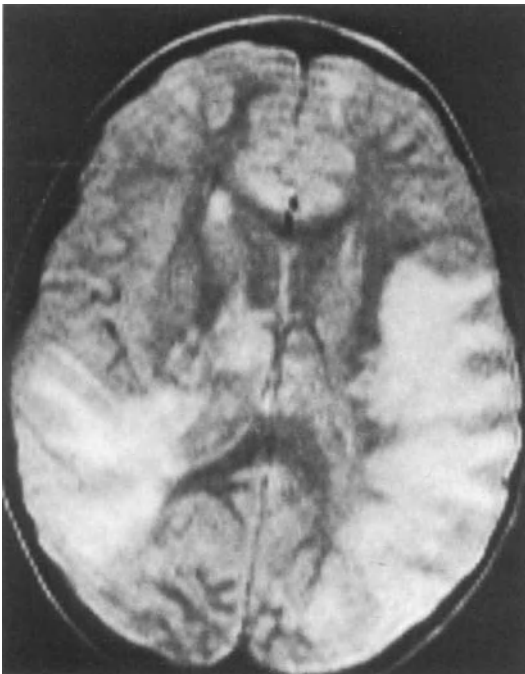

Figure 5-1. Krabbe disease. MRI shows extensive demyelination of cerebral hemispheres.

Acquired Immunodeficiency Syndrome Encephalopathy

AIDS is a human retroviral disease caused by the lentivirus subfamily now designated as HIV. Adults spread HIV by sexual contact, intravenous drug abuse, and blood transfusion. Pediatric AIDS cases result from transplacental or perinatal transmission of HIV from mothers who are intravenous drug users and prostitutes. Transmission may occur by breast-feeding. The mother may be asymptomatic when the child becomes infected.

CLINICAL FEATURES. Evidence of infection is apparent during the first year in 30% of children born to AIDS-infected mothers. As a rule, the outcome is worse when the onset of symptoms is early, and the rate of progression in the child relates directly to the severity of disease in the mother.

Of children with HIV, 20% present with severe symptoms or die in infancy (Galli et al, 2000). The cause of their poor prognosis is unknown. The spectrum of neurological and non-neurological manifestations in HIV-infected children is different from adults. Hepatosplenomegaly and bone marrow failure, lymphocytic interstitial pneumonia, chronic diarrhea and failure to thrive, acquired microcephaly, cerebral vasculopathy, and basal ganglia calcification occur more frequently in children. Opportunistic infections that represent recrudescence of previously acquired infections in adults (e.g., cerebral toxoplasmosis, progressive multifocal leukoencephalopathy) are rare in infants.

AIDS encephalopathy may be subacute or indolent and is not associated with failure to thrive or opportunistic infections. The onset of encephalopathy may occur 2 months to 5 years after exposure to the virus. By 18 months of age, 90% of affected infants show symptoms. Progressive loss of developmental milestones, microcephaly, dementia, and spasticity characterize the encephalopathy. Other features in less than 50% of children are ataxia, pseudobulbar palsy, involuntary movement disorders, myoclonus, and seizures. Death usually occurs a few months after the onset of AIDS encephalopathy.

DIAGNOSIS. The standard test for HIV infection in infancy is HIV-DNA PCR on peripheral blood lymphocytes. A positive HIV-DNA PCR result within 48 hours of birth is evidence of intrauterine transmission.

MANAGEMENT. The introduction of routine maternal treatment with highly active antiretroviral therapy in 1996 has decreased greatly the incidence of pediatric AIDS. Combined treat-

ment with zidovudine, didanosine, and nevirapine is well tolerated and may have sustained efficacy against HIV-1. Bone marrow suppression is the only important evidence of toxicity.

Disorders of Amino Acid Metabolism

Disorders of amino acid metabolism impair neuronal function by causing excessive production of toxic intermediary metabolites and reducing the production of neurotransmitters. The clinical syndromes are either an acute neonatal encephalopathy with seizures and cerebral edema (see Chapter 1) or mental retardation and dementia. Some disorders of amino acid metabolism cause cerebral malformations, such as agenesis of the corpus callosum. Although the main clinical features of aminoaciduria are referable to gray matter dysfunction (mental retardation, seizures), myelination is often profoundly delayed or defective.

Homocystinuria

The main defect responsible for the syndrome is almost complete deficiency of the enzyme cystathionine- β -synthase (Picker and Levy, 2004). Two *phenotypic* variants are recognized, *B6-responsive homocystinuria* and *B6-nonresponsive homocystinuria*. B6-responsive homocystinuria is usually milder than the non-responsive variant. Transmission of all forms is by autosomal recessive inheritance. Heterozygotes have partial deficiencies. Cystathionine synthase catalyzes the condensation of serine and homocysteine to form cystathionine (Figure 5-2). When the enzyme is deficient, the blood and urine concentrations of homocysteine, homocystine, and methionine are increased. Newborn screening programs detect hypermethioninemia.

CLINICAL FEATURES. Affected infants appear normal at birth. Neurological features include mild-to-moderate mental retardation, ectopia lentis, and cerebral thromboembolism. Developmental delay occurs in half of cases, and intelligence declines progressively with age in untreated children. Most eventually function in the mildly retarded range. Intelligence is generally higher in B6-responsive than B6-nonresponsive homocystinuria.

High plasma homocysteine concentrations adversely affect collagen metabolism and are responsible for intimal thickening of blood vessel walls, leading to arterial and venous thromboembolic disease. Cerebral thromboembolism

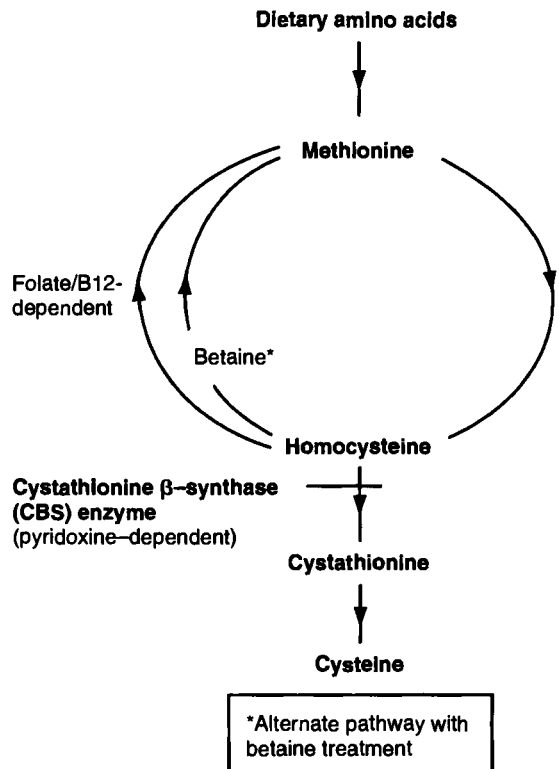


Figure 5-2. Metabolic disturbance in homocystinuria. Absence of cystathionine β -synthase (cystathionine synthetase) blocks the metabolism of homocysteine, causing the accumulation of homocysteine and methionine. (From Picker JD, Levy HL. [15 January 2004] Homocystinuria caused by cystathionine beta-synthase deficiency. In: *GeneClinics: Medical Genetics Knowledge Base*. [database online] University of Washington, Seattle. Available at <http://www.geneclinics.org>.)

is a life-threatening complication. Emboli may occur in infancy, but they usually occur in adulthood. Young adult heterozygotes are also at risk. Occlusion of the coronary or carotid arteries can lead to sudden death or severe neurological handicap. Thromboembolism is the first clue to the diagnosis in 15% of cases.

Dislocation of the lens, an almost constant feature of homocystinuria, typically occurs between 2 and 10 years of age. Almost all patients have lens dislocation by age 40. Older children have osteoporosis, often first affecting the spine resulting in scoliosis. Many children are tall and thin, with blond, sparse, brittle hair and a Marfan syndrome habitus. This habitus does not develop until middle or late childhood and serves as a clue to the diagnosis in fewer than 40% of cases.

The diagnosis is suspected in any infant with isolated and unexplained developmental delay because disease-specific features may not appear until later childhood. The presence of

either thromboembolism or lens dislocation strongly suggests homocystinuria.

DIAGNOSIS. The biochemical features of homocystinuria are increased concentrations of plasma homocystine, total homocysteine, and methionine; increased concentration of urine homocystine; and reduced cystathionine β -synthase enzyme activity. Molecular genetic diagnosis is available.

MANAGEMENT. Challenge all patients with pyridoxine (vitamin B_6) before starting treatment. Treat patients who are responsive with pyridoxine, approximately 200 mg/day. Patients who are not responsive still receive doses of 100 to 200 mg daily. All patients also require a protein-restricted diet, but vitamin B_6 -nonresponsive neonates also require frequent metabolic monitoring. The diet is continued indefinitely. Identification of disease in newborn screening yields the best results. Treatment with betaine, 5 to 10 g/day in two divided doses, provides an alternate remethylation pathway to convert excess homocysteine to methionine and may help prevent thrombosis. Folate and vitamin B_{12} optimize the conversion of homocysteine to methionine and help to decrease homocysteine levels.

Maple Syrup Urine Disease (Intermediate)

The three major branched-chain amino acids (BCAA) are leucine, isoleucine, and valine. In the course of their metabolism, they are first transaminated to α -ketoacids, then further catabolized by oxidative decarboxylation (see Figure 1-1). Branched-chain ketoacid (BCKA) dehydrogenase is the enzyme responsible for oxidative decarboxylation. Mutations in at least four genes cause maple syrup urine disease. These genes encode the catalytic components of the branched-chain α -ketoacid dehydrogenase complex (BCKD), which catalyzes the catabolism of the branched-chain amino acids, leucine, isoleucine, and valine.

Deficiency is associated with several different phenotypes. Three clinical phenotypes are the more common forms: *classic*, *intermittent*, and *intermediate*. An acute encephalopathy with ketoacidosis characterizes the classic and intermittent forms (see Chapters 1 and 10). The ketoacidosis is usually milder as well. The levels of dehydrogenase enzyme activity in the intermediate and intermittent forms are approximately the same (5% to 40%), whereas activity in the classic form is 0 to 2% of normal. Phenotypic differences between the intermedi-

ate and intermittent forms may relate to protein intake.

CLINICAL FEATURES. The onset of the intermediate form is late in infancy, often in association with a febrile illness or a large protein intake. In the absence of vigorous early therapeutic intervention, moderate mental retardation results. Ataxia and failure to thrive are common. Infants with intermediate maple syrup urine disease are slow in achieving milestones and are hyperactive. As children, they generally function in the moderately retarded range of intelligence. Physical development is normal except for coarse, brittle hair. The urine may have the odor of maple syrup. Acute mental changes, seizures, and focal neurological deficits do not occur. Some infants with the intermediate form are thiamine responsive. In these children, mental retardation is moderate.

DIAGNOSIS. BCAA and BCKA concentrations are elevated, although not as high as in the classic disease. A presumptive diagnosis requires the demonstration of BCAA in the urine by a ferric chloride test or the 2,4-dinitrophenylhydrazine test. Quantitative measurement of blood and urine BCAA and BCKA is diagnostic.

TREATMENT. A protein-restricted diet is the main treatment of infants with intermediate maple syrup urine disease. In addition, a trial of thiamine, 100 mg/day, tests whether the biochemical error is thiamine responsive. If 100 mg is not effective, try daily doses up to 1 g of thiamine before designating the condition as thiamine refractory.

Phenylketonuria

Phenylketonuria (PKU) is a disorder of phenylalanine metabolism caused by partial or total deficiency of the hepatic enzyme phenylalanine hydroxylase, for which the gene is located on chromosome 12q.24.1. Genetic transmission is autosomal recessive, and occurrence is approximately 1:16,000 live births. Failure to hydroxylate phenylalanine to tyrosine leads to further metabolism by transamination to phenylpyruvic acid (Figure 5-3). Oxidation of phenylpyruvic acid to phenylacetic acid causes a musty odor in the urine.

The four categories of phenylalanine hydroxylase deficiency are classic PKU, moderate PKU, mild PKU, and mild hyperphenylalaninemia (HPA). In classic PKU, phenylalanine hydroxylase deficiency is complete or near-complete. Patients tolerate less than 250 to 350 mg of dietary phenylalanine per day to keep plasma phenylalanine concentration below a safe level

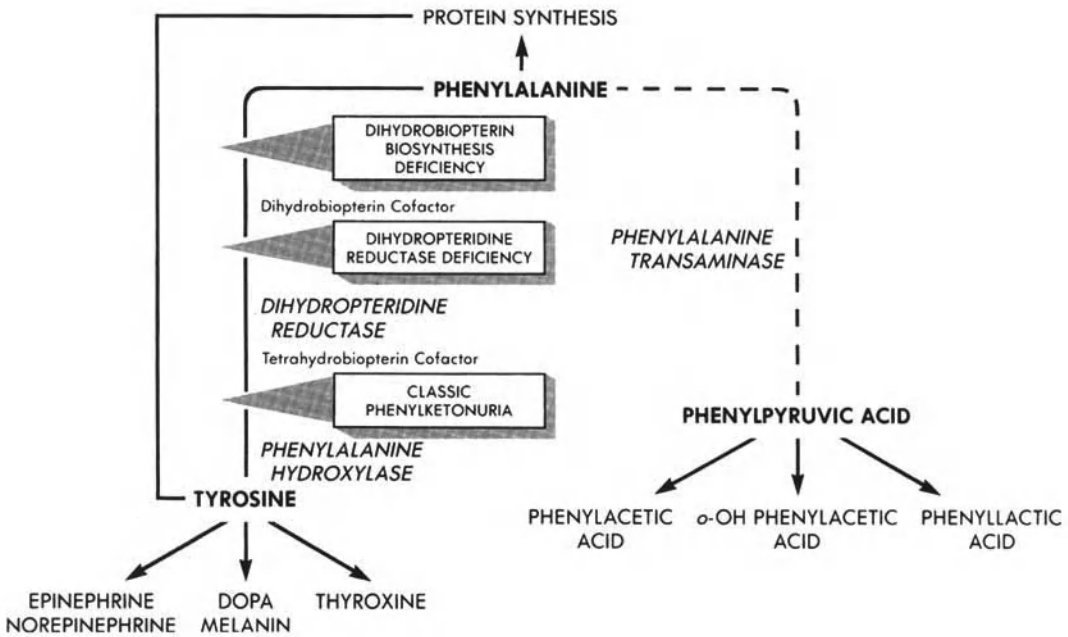


Figure 5-3. Metabolic blocks in phenylalanine metabolism leading to phenylketonuria. (From Swaiman KF. Aminoacidopathies and organic acidemias resulting from deficiency of enzyme activity and transport abnormalities. In: Swaiman FK, Ashwal S, eds. *Pediatric Neurology*, Third Edition, Volume One. Mosby: St. Louis; 1999.)

of 300 $\mu\text{mol/L}$ (5 mg/dL). Individuals with moderate PKU tolerate 350 to 400 mg of dietary phenylalanine per day, individuals with mild PKU tolerate 400 to 600 mg of dietary phenylalanine per day, and individuals with mild HPA have plasma phenylalanine concentrations less than 600 $\mu\text{mol/L}$ (10 mg/dL) on a normal diet (Weglage et al, 2001).

HPA also may result from the impaired synthesis or recycling of tetrahydrobiopterin. Tetrahydrobiopterin is the cofactor in the phenylalanine, tyrosine, and tryptophan hydroxylation reactions. Inheritance of HPA caused by tetrahydrobiopterin deficiency is as an autosomal recessive trait and accounts for 2% of patients with HPA.

CLINICAL FEATURES. Affected children are normal at birth. Early diagnosis requires compulsory mass screening. The screening test detects hyperphenylalaninemia, which is not synonymous with PKU (Table 5-7). Blood phenylalanine and tyrosine concentrations must be precisely determined in every newborn detected by the screening test to differentiate classic PKU from other conditions. In newborns with classic PKU, hyperphenylalaninemia develops 48 to 72 hours after initiation of milk feeding. Blood phenylalanine concentrations are 20 mg/dL or greater, and serum tyrosine levels are less than 5 mg/dL. When blood phenylalanine concentrations reach 15 mg/dL, phenylalanine spills over into the urine, and the addition of ferric chlo-

ride solution (5 to 10 drops of ferric chloride to 1 mL of urine) produces a green color.

Untreated infants appear normal during the first months, but the skin may have a musty odor because of phenylacetic acid in the sweat. Developmental delay is sometimes obvious by the third month and always before the end of the first year. By the beginning of the second year, developmental regression is evident. Behavioral disturbances characterized by hyperactivity and aggressiveness are common; focal neurological deficits are unusual. Approximately 25% of affected infants have seizures. Some have infan-

TABLE 5-7
Differential Diagnosis of Hyperphenylalaninemia

Classic phenylketonuria
Complete hydroxylase deficiency (0-6%)
Benign variants
Other
Partial hydroxylase deficiency (6-30%)
Phenylalanine transaminase deficiency
Transient hydroxylase deficiency
Malignant variants
Dihydropteridine reductase deficiency
Tetrahydrobiopterin synthesis deficiency
Tyrosinemia
Transient tyrosinemia
Tyrosinosis
Liver disease
Galactose 1-phosphate uridylyl transferase deficiency

tile spasms and hypsarrhythmia; others have tonic-clonic seizures. Infants with PKU frequently have blond hair, pale skin, and blue eyes owing to diminished pigment production. Eczema is common. These skin changes are the only non-neurological features of PKU.

DIAGNOSIS. Newborn screening detects all cases of PKU. The screening test detects the presence of hyperphenylalaninemia. Plasma phenylalanine concentrations greater than 1000 $\mu\text{mol/L}$ in the untreated state are diagnostic. The use of molecular genetic testing is primarily for genetic counseling and prenatal testing. Blood phenylalanine levels less than 25 mg/dL and a normal concentration of tyrosine characterize benign variants of PKU. Disturbances in tetrahydrobiopterin underlie the malignant forms of PKU. Seizures are the initial symptom, and mental retardation and motor deficits occur later. Progressive calcification of the basal ganglia occurs in untreated children.

Transitory tyrosinemia occurs in 2% of full-term newborns and in 25% of premature newborns. The cause is a transitory deficiency of the enzyme *p*-hydroxyphenylpyruvic acid. It is a benign condition and can be distinguished from PKU because the blood concentrations of tyrosine and phenylalanine are elevated.

MANAGEMENT. A National Institutes of Health consensus conference (2001) formulated guidelines for management. A phenylalanine-restricted diet should be started immediately in newborns with a blood phenylalanine concentration of 20 mg/dL or greater. Dietary therapy is complex and is best undertaken and administered by physicians and nutritionists with experience in treating patients with hyperphenylalaninemia. The goal of therapy is to maintain blood phenylalanine concentrations between 4 and 6 mg/dL. Diet therapy is required throughout life to prevent intellectual deterioration.

Tetrahydrobiopterin is a cofactor for phenylalanine hydroxylase, tyrosine hydroxylase, and tryptophan hydroxylase. Defective recycling or synthesis causes deficiency. In infants with cofactor deficiency, a phenylalanine-restricted diet reduces the blood phenylalanine concentration but does not prevent neurological deterioration. For these children, tetrahydrobiopterin administration is the therapy of choice.

Disorders of Lysosomal Enzymes

Lysosomes are cytoplasmic vesicles containing hydrolytic enzymes that degrade the products of cellular catabolism. The causes of lysosomal enzyme disorders are impaired enzyme synthe-

sis, abnormal enzyme targeting, or a defective accessory factor needed for enzymatic processing. When lysosomal enzymes are impaired, abnormal storage of materials occurs, causing cell injury and death. One or several organs may be affected, and the clinical features depend on the organs involved. Mental retardation and regression are features of many lysosomal enzyme storage diseases. In some diseases, such as acid lipase deficiency (Wolman disease) and ceramide deficiency (Farber lipogranulomatosis), mental retardation occurs, but is neither a prominent nor an initial feature. These disorders are not included for discussion.

Gaucher Disease Type II (Glucosylceramine Lipidosis)

Transmission of Gaucher disease is by autosomal recessive inheritance. The abnormal gene is located on chromosome 1q21. Deficiency of the enzyme glucocerebrosidase (glucosylceramide β -glucosidase) causes the lysosomal storage of glucocerebrosides. Deficiency of saposin C, an enzymatic cofactor, is a rare cause.

Although Gaucher disease encompasses a continuum of clinical findings, the identification of five clinical subtypes is useful in determining prognosis and management (Pastores, 2004). Type I does not affect the brain. Age at onset distinguishes types II and III. Neurovisceral storage characterizes both types. Type II has onset before age 2 years, limited psychomotor development, and a rapidly progressive course with death by age 2 to 4 years. Type III begins after age 2 years and has a more slowly progressive course with longer survival. The other two types include a perinatal-lethal form and a cardiovascular form.

CLINICAL FEATURES. Symptom onset in infants with Gaucher disease type II is usually before 6 months of age and frequently before 3 months of age. The initial features are motor regression and cranial nerve dysfunction. Children are first hypotonic and then spastic. Head retraction is an early and characteristic sign that probably is due to meningeal irritation. Difficulties in sucking and swallowing, trismus, and oculomotor palsies are typical. Mental deterioration is rapid, but seizures are uncommon. Splenomegaly is more prominent than hepatomegaly, and jaundice is not expected. Hypersplenism results in anemia, thrombocytopenia, and leukopenia. Death usually occurs during the first year and always by the second.

DIAGNOSIS. Assay of acid β -glucosylceramidase enzyme activity in peripheral blood leukocytes

or other nucleated cells is reliable for diagnosis. Glucosylceramidase enzyme activity in peripheral blood leukocytes is 0 to 15% of normal. Carrier detection and prenatal diagnosis are available.

MANAGEMENT. Patients with chronic neurological involvement benefit from bone marrow transplant. Transplantation corrects the metabolic defect, improves blood counts, and reduces increased liver volume. The associated morbidity and mortality limit its usefulness, however. Enzyme replacement therapy uses imiglucerase (Cerezyme), a recombinant glucosylceramidase enzyme preparation. Regular intravenous infusions of imiglucerase are safe and effective in reversing hematological and visceral involvement, but not neurological disease.

Globoid Cell Leukodystrophy (Krabbe Disease)

Krabbe disease (galactosylceramide lipidosis) is a rapidly progressive demyelinating disorder of infants caused by deficient activity of the enzyme galactosylceramide β -galactosidase (Wenger and Coppola, 2002). A juvenile and an adult form of the disease also occur. Transmission is by autosomal recessive inheritance, and the gene maps to chromosome 14. Galactosylceramide is stored within multinucleated macrophages of the white matter of the central nervous system, forming globoid cells.

CLINICAL FEATURES. The median age of onset is 4 months (range 1 to 7 months). Initial symptoms are irritability and hyperreactivity to stimuli. Progressive hypertonicity in the skeletal muscles follows. Unexplained low-grade fever is common. Psychomotor development arrests, then regresses. Within 2 to 4 months, the infant is in a permanent position of opisthotonos, and all previously achieved milestones are lost. Tendon reflexes become hypoactive and disappear. Startle myoclonus and seizures develop. Blindness occurs, and before 1 year, 90% of these infants are either dead or in a chronic vegetative state. Several variant forms of globoid leukodystrophy with different clinical features exist: infantile spasm syndrome (see Chapter 1), focal neurological deficits (see Chapters 10 and 11), and polyneuropathy (see Chapter 7). The juvenile form is discussed later in this chapter.

DIAGNOSIS. MRI shows diffuse demyelination of the cerebral hemispheres (see Figure 5-3). Motor nerve conduction velocity of peripheral nerves is usually prolonged, and the protein content of CSF is elevated. Deficient activity of galactosylceramide β -galactosidase in leuko-

cytes or cultured fibroblasts establishes the diagnosis. The use of molecular genetic testing is for carrier detection only.

MANAGEMENT. Hematopoietic stem cell transplantation slows the course of disease in children with infantile-onset Krabbe disease diagnosed before symptom onset. Neurological manifestations may reverse.

Glycoprotein Degradation Disorders

Glycoproteins are complex molecules composed of oligosaccharides attached to protein. Disorders of glycoprotein degradation are uncommon and resemble mild forms of mucopolysaccharidoses (MPS). Genetic transmission is autosomal recessive. The main forms are deficiency of the enzyme α -mannosidase coded on chromosome 19cen-q12 and deficiency of the lysosomal enzyme α -fucosidase coded on chromosome 1q34.

CLINICAL FEATURES. The clinical features are either a Hurler phenotype (Table 5-8) or a myoclonus-dementia complex. Some patients have macular degeneration (cherry-red spot). Angiokeratoma may be present. These disorders are indistinguishable from other lysosomal storage diseases by clinical features alone.

DIAGNOSIS. The urine shows excessive excretion of oligosaccharides or glycoasparagines but not mucopolysaccharides. Biopsy of the skin and other tissues shows membrane-bound vacuoles containing amorphous material. Tissue concentrations of glycoproteins and often glycolipids are increased.

MANAGEMENT. Treatment is supportive.

GM₁ Gangliosidosis

Deficiency of the lysosomal enzyme β -galactosidase causes GM₁ gangliosidosis. The amount and type of residual activity determine whether the phenotype is a generalized gangliosidosis, as in GM₁ gangliosidosis, or visceral storage of mucopolysaccharides with little brain disease,

TABLE 5-8
Hurler Phenotype

Abdominal hernia
Coarse facial features
Corneal opacity
Deafness
Dysostosis multiplex
Mental retardation
Stiff joints
Visceromegaly

as in Morquio B disease. The β -galactosidase gene is located on chromosome 3p21, and disease transmission is autosomal.

CLINICAL FEATURES. The onset is between 6 and 18 months. Weakness and incoordination are early features. Spasticity, mental retardation, and seizures follow. Psychomotor development is first slow, then regresses. Affected newborns are poorly responsive, hypotonic, and hypoactive. The Hurler phenotype is present (see Table 5-8) except that the cornea is clear and a cherry-red spot of the macula is present in 50% of patients (Table 5-9). Death occurs between the ages of 3 and 7 years.

DIAGNOSIS. The absence of mucopolysacchariduria and the presence of a cherry-red spot distinguish infantile GM₁ gangliosidosis from Hurler syndrome. Showing enzyme deficiency in leukocytes, cultured fibroblasts, or serum establishes the diagnosis.

MANAGEMENT. Treatment is supportive.

GM₂ Gangliosidosis

The GM₂ gangliosidoses are a group of related disorders in which GM₂ gangliosides are stored because of deficiency of hexosaminidase A, hexosaminidase B, or the GM₂ activator of hexosaminidase A or B. The abnormal gene, transmitted by autosomal recessive inheritance, may be a mutation in the gene for the α -subunit on chromosome 15, the β -subunit on chromosome 5, or the glycoprotein activator for hexosaminidase (AB variant) on chromosome 5.

Sandhoff Disease

In Sandhoff disease, hexosaminidase A and B are severely deficient. Disease transmission is by autosomal recessive inheritance. Globosides and GM₂ gangliosides accumulate in brain and viscera.

CLINICAL FEATURES. The clinical features and course of Sandhoff disease are identical to the

features and course of Tay-Sachs disease. The only difference is that organs other than the central nervous system are sometimes involved. Moderate hepatosplenomegaly may be present, and occasionally patients have bony deformities similar to those of infantile GM₁ gangliosidosis.

DIAGNOSIS. Suspect the disease in every non-Jewish infant with a Tay-Sachs phenotype. Peripheral lymphocytes are not vacuolated, but foamy histiocytes may be present in the bone marrow. Hexosaminidase deficiency in leukocytes, cultured fibroblasts, or serum establishes the diagnosis in patients and carriers. Prenatal diagnosis is available by the detection of *N*-acetylglucosaminyl oligosaccharides in amniotic fluid.

MANAGEMENT. Treatment is supportive.

Tay-Sachs Disease

Deficiency of hexosaminidase A due to mutation at 15q23-24 causes Tay-Sachs disease (*infantile GM₂ gangliosidosis*). The gene frequency is 1:30 in Ashkenazi Jews and 1:300 in gentiles. The central nervous system is the only affected organ. Partial deficiencies of hexosaminidase A cause the juvenile and adult forms of GM₂ gangliosidosis (Kaback, 2004).

CLINICAL FEATURES. The typical initial symptom, between 3 and 6 months of age, is an abnormal startle reaction (Moro reflex) to noise or light. Motor regression begins between 4 and 6 months of age. The infant comes to medical attention because of either delayed achievement of motor milestones or loss of milestones previously attained. A cherry-red spot of the macula is present in almost every patient but is not specific for Tay-Sachs disease because it also is present in several storage diseases and in central retinal artery occlusion (see Table 5-9). The cherry-red spot develops as retinal ganglion cells in the parafoveal region accumulate stored material, swell, and burst. The red color of the normal fundus is then observable. Optic atrophy and blindness follow.

By 1 year of age, the infant is severely retarded, unresponsive, and spastic. During the second year, the head enlarges, and seizures develop. Most children die by 5 years of age.

DIAGNOSIS. Suspect the diagnosis in any Jewish child with psychomotor retardation and a cherry-red spot of the macula. Deficient activity of hexosaminidase A in white blood cells or serum establishes the diagnosis. The same assay detects heterozygotes. Mutation analysis identifies the carrier state.

MANAGEMENT. Treatment is supportive.

TABLE 5-9
Lysosomal Enzyme Disorders with a Cherry-Red Spot

Cherry-red spot myoclonus (see Chapter 1)
Farber lipogranulomatosis
GM₁ gangliosidosis
GM₂ gangliosidosis
Metachromatic leukodystrophy
Niemann-Pick disease
Sialidosis type III

I-Cell Disease

Deficiency or dysfunction of the enzyme *N*-acetylglucosamine phosphotransferase causes I-cell disease (mucopolipidosis II). Lysosomal storage of several mucolipids occurs. Transmission is by autosomal recessive inheritance. The gene maps to chromosome 4q21-23.

CLINICAL FEATURES. I-cell disease resembles Hurler syndrome except that symptoms appear earlier, the neurological deterioration is more rapid, and mucopolysacchariduria is not present. Affected newborns are small for gestational age and may have hyperplastic gums. Coarsening of facial features and limitation of joint movements occur within the first months. The complete Hurler phenotype is present within the first year except that corneal opacification is not always present. Gingival hypertrophy is striking. Death from congestive heart failure usually occurs before age 5.

DIAGNOSIS. Consider I-cell disease in infants with the Hurler phenotype and negative screening for mucopolysacchariduria. Showing a specific pattern of lysosomal enzyme deficiency in fibroblasts establishes the diagnosis.

MANAGEMENT. Treatment is supportive.

Mucopolysaccharidoses

Deficiency of the lysosomal enzymes responsible for catalyzing the degradation of glycosaminoglycans (mucopolysaccharides) causes the MPS. Mucopolysaccharides are a normal component of cornea, cartilage, bone, connective tissue, and the reticuloendothelial system. Excessive storage may occur in all these tissues. Transmission of all MPS except type II is by autosomal recessive inheritance. Type II is an X-linked trait.

MPS I (Hurler Syndrome)

Absence of the lysosomal hydrolase α -L-iduronidase causes the Hurler syndrome. The gene maps to chromosome 4p16.3. Dermatan sulfate and heparan sulfate cannot be fully degraded and appear in the urine. Mucopolysaccharides are stored in the cornea, collagen, and leptomeninges, and gangliosides are stored in cortical neurons (Portigal and Clarke, 2003).

CLINICAL FEATURES. The clinical features of MPS I range from mild to intermediate to severe (see Table 5-8). Infants with severe MPS I appear normal at birth. Coarsening of the facial features occurs during the first 2 years. Corneal clouding and cardiac involvement occur in all patients. Progressive skeletal dysplasia (*dysostosis multi-*

plex) involves all bones in severe MPS I. By 3 years, linear growth ceases. Hearing loss and progressive mental retardation is the rule. Cardiorespiratory failure and death occur by age 10 years. Symptoms of intermediate MPS I begin between 3 and 8 years of age, and survival to adulthood is common. *Dysostosis multiplex*, arthropathy, corneal clouding, joint stiffness, deafness, and valvular heart disease occur. Diagnosis of mild MPS I occurs after 15 years of age; intellect, stature, and life span are normal.

DIAGNOSIS. The physical and radiographic appearance suggests the diagnosis. Deficiency of the enzyme α -L-iduronidase in peripheral blood leukocytes or cultured fibroblasts establishes the diagnosis. Mutation analysis is available for prenatal diagnosis.

MANAGEMENT. Bone marrow transplantation and enzyme replacement therapy are promising treatment modalities. Efficacy is not yet established.

MPS III (Sanfilippo Disease)

Type III MPS is distinct from other MPS because only heparan sulfate is stored in viscera and appears in the urine. Gangliosides are stored in neurons. Four different, but related, enzyme deficiencies cause similar phenotypes. All are transmitted by autosomal recessive inheritance.

CLINICAL FEATURES. The Hurler phenotype is not prominent, but hepatomegaly is present in two thirds of cases. Dwarfism does not occur. The major feature is neurological deterioration characterized by delayed motor development beginning toward the end of the second year, followed by an interval of arrested mental development and progressive dementia. Hyperactivity and sleep disorders are relatively common between the ages of 2 and 4. Retardation in most affected children is severe by age 11, and death occurs before age 20. Considerable variability exists, however, and type MPS III is a consideration even when the onset of mental regression occurs after age 5.

DIAGNOSIS. Suspect the diagnosis in infants and children with progressive psychomotor regression and a screening test positive for mucopolysacchariduria. The presence of heparan sulfate, but not dermatan sulfate, in the urine is presumptive evidence of the disease. Definitive diagnosis requires the demonstration of enzyme deficiency in cultured fibroblasts.

MANAGEMENT. Bone marrow transplantation is an experimental therapy.

Niemann-Pick Disease Type A (Sphingomyelin Lipidosis)

Deficiency of the enzyme sphingomyelinase causes Niemann-Pick disease type A. Transmission is by autosomal recessive inheritance. Type A is the acute infantile form of Niemann-Pick disease.

CLINICAL FEATURES. The onset of the acute infantile form occurs in the first months of life. The features are feeding difficulty, failure to thrive, and hepatomegaly. Splenomegaly occurs later and is not prominent. A cherry-red spot is present in half of cases (see Table 5-9). Psychomotor regression, characterized by postural hypotonia and loss of reactivity to the environment, occurs during the first year but often is overlooked because of the child's failure to thrive. With time, emaciation, a tendency toward opisthotonos, exaggerated tendon reflexes, and blindness develop. Seizures are uncommon.

DIAGNOSIS. The clinical course suggests the diagnosis. Vacuolated histiocytes are present in the bone marrow, and vacuolated lymphocytes are present in the peripheral blood. A deficiency of sphingomyelinase in leukocytes or cultured fibroblasts establishes the diagnosis.

MANAGEMENT. Treatment is supportive.

Sulfatase Deficiency Disorders

Metachromatic Leukodystrophy (Sulfatide Lipidoses)

Metachromatic leukodystrophy is a disorder of central and peripheral myelin metabolism. Deficiency of either aryl-sulfatase A (chromosome 22) or its sphingolipid activator protein B (saposin B) causes the disease; together they form cerebrosidase sulfatase. Transmission is by autosomal recessive inheritance. Infantile, juvenile, and adult forms exist. Because peripheral neuropathy is a prominent feature of the infantile form, it is discussed in Chapter 7. The juvenile form affects primarily the brain and is discussed later in this chapter.

Multiple Sulfatase Deficiency

Multiple sulfatase deficiency is a rare disorder characterized by deficiency of several sulfatases (arylsulfatase A, arylsulfatase B, iduronate sulfatase, *N*-acetylgalactosamine-6-sulfate sulfatase, and heparan-*N*-sulfatase) and the accumulation of sulfatides (glycosaminoglycans, sphingolipids, and steroid sulfates) in tissue and body fluids. Mutations in the sulfatase-modifying factor-1 gene (3p26) are the cause.

CLINICAL FEATURES. Development during the first year is normal, but in the second year, developmental arrest and regression occur. Ataxia and speech disturbances also occur during the second year. Neurological deterioration is progressive. The appearance suggests an MPS: short stature, microcephaly, and facial dysmorphism. Retinal degeneration can occur as well and suggests a neuronal ceroid lipofuscinosis.

DIAGNOSIS. Sulfatase activity is deficient, but not absent, in cultured skin fibroblasts and leukocytes. If only arylsulfatase A is measured, an improper diagnosis of juvenile sulfatide lipidosis is a consideration because peripheral neuropathy is not present. The facial dysmorphism is not consistent, however, with either the infantile or the juvenile form of sulfatide lipidosis.

MANAGEMENT. Treatment is supportive.

Carbohydrate-Deficient Glycoprotein Syndromes

The carbohydrate-deficient glycoprotein (CDG) syndromes are a group of genetic, multisystem diseases with major nervous system involvement (Stibler et al, 1995). Deficiency of the carbohydrate moiety of secretory glycoproteins, lysosomal enzymes, and membrane glycoproteins is characteristic of the group. CDG syndromes occur mainly in northern Europeans, and transmission is by autosomal recessive inheritance. The affected organelles are not lysosomes, but may be the Golgi apparatus or the endoplasmic reticulum.

CLINICAL FEATURES. Affected newborns with CDG syndrome type I seem normal except for the appearance of dysmaturity. Failure to thrive, developmental delay, hypotonia, and multisystem failure occur early in infancy. Neurological deterioration follows. The main features are mental deficiency, ataxia, retinitis pigmentosa, hypotonia, and weakness. Characteristic features in childhood and adolescence are short stature, failure of sexual maturation, skeletal abnormalities, liver dysfunction, and polyneuropathy. Children with CDG syndrome type II have a more profound mental retardation but no cerebellar ataxia or peripheral neuropathy, and children with CDG syndrome types III and IV have severe neurological impairment and seizures from birth.

DIAGNOSIS. The most constant abnormality in all CDG syndromes is an abnormal serum transferrin isoform pattern. This is the basis for diagnosis. Each type has a distinctive pattern of abnormal serum transferrin patterns.

MANAGEMENT. Treatment is supportive.

Hypothyroidism

Congenital hypothyroidism secondary to thyroid dysgenesis occurs in 1:4000 live births. Mutations in the genes encoding thyrotropin, thyrotropin-releasing hormone, thyroid transcription factor 2, and other factors are causative (Clifton-Bligh et al, 1998). Early diagnosis and treatment are imperative to ensure a favorable outcome. Newborn screening is universal in the United States and detects virtually all cases.

CLINICAL FEATURES. Affected infants are usually asymptomatic at birth. Clinical features evolve insidiously during the first weeks postpartum, and their significance is not always appreciated. Frequently, gestation lasts for more than 42 weeks, and birth weight is greater than 4 kg. Early clinical features include a wide-open posterior fontanelle, constipation, jaundice, poor temperature control, and umbilical hernia. The tongue is sometimes large, which makes feeding difficult. Edema of the eyes, hands, and feet may be present at birth but is often unrecognized in early infancy.

DIAGNOSIS. Radiographs of the long bones show delayed maturation, and radiographs of the skull show excessive numbers of wormian bones. A low serum concentration of thyroxine and a high serum concentration of thyroid-stimulating hormone establish the diagnosis.

MANAGEMENT. Initiate treatment with levothyroxine, 24 to 50 g/day, as soon as possible. Early treatment prevents most, if not all, of the sequelae of congenital hypothyroidism. Each month of delay reduces the ultimate intelligence of the infant.

Mitochondrial Disorders

Mitochondrial disorders involve pyruvate metabolism, the Krebs cycle, and respiratory complexes. Figure 8-2 depicts the five respiratory complexes, and Table 8-6 lists the disorders assigned to abnormalities in each of these complexes.

Alexander Disease

Alexander disease is a rare disorder caused by a mutation in the gene encoding reduced nicotinamide adenine dinucleotide (NADH)-ubiquinone oxidoreductase flavoprotein-1 (Gorospe, 2003). Disease transmission is autosomal dominant. Most affected newborns represent new mutations. The abnormal gene maps to chromosome 17q21 and encodes glial fibrillary acidic protein. Rosenthal fibers, the pathological hallmark of disease, are rod-shaped or

round bodies that stain red with hematoxylin and eosin and black with myelin stains. They appear as small granules within the cytoplasm of astrocytes. Rosenthal fibers are scattered diffusely in the cerebral cortex and the white matter but have a predilection for the subpial, subependymal, and perivascular regions.

CLINICAL FEATURES. In the past, diagnosis depended on autopsy. Expansion of the clinical features expanded with accuracy of antemortem diagnosis. Infantile, juvenile, and adult forms are recognized. The infantile form is the most common. It accounts for 70% of cases with an identifiable glial fibrillary acidic protein *mutation*. The onset is anytime from birth to early childhood. Affected infants show arrest and regression of psychomotor development, enlargement of the head secondary to megalencephaly, spasticity, and seizures. Megalencephaly may be the initial feature. Optic atrophy does not occur. Death by the second or third year is the rule.

DIAGNOSIS. Four of the five following criteria establish an MRI-based diagnosis of Alexander disease:

1. Extensive cerebral white matter abnormalities with a frontal preponderance
2. A periventricular rim of decreased signal intensity on T₂-weighted images and elevated signal intensity on T₁-weighted images
3. Abnormalities of the basal ganglia and thalamus
4. Brainstem abnormalities, particularly involving the medulla and midbrain
5. Contrast enhancement of one or more of the following: ventricular lining, periventricular rim, frontal white matter, optic chiasm, fornix, basal ganglia, thalamus, dentate nucleus, brainstem (van der Knaap et al, 1995)

Molecular genetic testing confirms the diagnosis.

MANAGEMENT. Treatment is supportive.

Progressive Infantile Poliiodystrophy (Alpers Disease)

The original description of Alpers disease was a progressive degeneration of cerebral gray matter associated with cirrhosis of the liver. It probably encompassed several disease processes. Known causes include pyruvate carboxylase deficiency, disturbed pyruvate metabolism and NADH oxidation, and mitochondrial respiratory chain abnormalities. One patient had a complex I deficiency, another had a complex IV

deficiency, and two others had a combined deficiency of complexes I and IV (Gauthier-Villars et al, 2001).

CLINICAL FEATURES. The onset of symptoms is during either infancy or childhood. The disorder with infantile onset tends to be sporadic and is characterized first by delay in the achievement of developmental milestones, then by either myoclonic or tonic-clonic seizures. The first seizure may be status epilepticus. Transitory hemiplegia sometimes follows prolonged seizures. Psychomotor regression becomes evident, and blindness may occur. Although clinical signs of liver disease often appear later in the course, biochemical evidence of liver disease may predate the onset of seizures. Most patients die before age 3 years.

DIAGNOSIS. Postmortem examination establishes the definitive diagnosis. An elevated blood lactate concentration should suggest disturbed pyruvate usage and prompt investigation of mitochondrial enzymes in liver and skeletal muscle.

MANAGEMENT. Treatment is supportive.

Subacute Necrotizing Encephalomyelopathy (Leigh's Disease)

Subacute necrotizing encephalomyelopathy (SNE) is a syndrome of progressive poliodystrophy primarily affecting neurons of the brainstem, thalamus, basal ganglia, and cerebellum. Several different abnormalities in mitochondrial DNA (mtDNA) cause SNE. Transmission is usually by autosomal recessive inheritance, but X-linked inheritance also occurs (Thorburn and Rahman, 2003).

CLINICAL FEATURES. Progressive neurological disease, with motor and intellectual developmental delay, is characteristic. Signs and symptoms of brainstem or basal ganglia disease predominate. Onset of symptoms is between 3 and 12 months of age and often follows a viral infection. Decompensation (often with lactic acidosis) during an intercurrent illness typically is associated with psychomotor retardation or regression. Neurological features include hypotonia, spasticity, movement disorders (including chorea), cerebellar ataxia, and peripheral neuropathy. Extraneurological manifestations may include hypertrophic cardiomyopathy. Most affected individuals have a progressive course with episodic deterioration interspersed with variable periods of stability during which development may be stable or even show some progress. Death typically occurs by 2 to 3 years of age, most often due to respiratory or cardiac failure. In undiagnosed cases, death may appear

to be sudden and unexpected. Later onset of SNE (i.e., after 1 year of age, including presentation in adulthood) and slower progression occur in 25% of individuals.

DIAGNOSIS. Lactate concentrations are increased in blood and CSF. Lactic acidemia is usually more common in postprandial samples. An oral glucose load causes blood lactate concentrations to double after 60 minutes and is more consistent in CSF samples than blood samples. Blood concentrations of lactate and pyruvate usually are elevated and increase further at the time of clinical exacerbation. MRI greatly increases diagnostic accuracy. MRI features include bilateral symmetrical hyperintense signal abnormality in the brainstem or basal ganglia or both on T₂-weighted images. Approximately 10% to 20% of individuals with SNE have detectable mutations on molecular genetic testing.

MANAGEMENT. Affected children are less likely to have acute exacerbations of illness on a carbohydrate-restricted diet. Provide calories primarily as lipids. Large doses of thiamine are helpful in some patients. Sodium bicarbonate is useful for acute exacerbations.

Neurocutaneous Syndromes

Neurofibromatosis Type 1

The neurofibromatoses (NF) are divisible into a peripheral type (type 1) and a central type (type 2). Transmission of both is by autosomal dominant inheritance with considerable variation in expression. The abnormal gene for neurofibromatosis type 1 (NF1) is located on chromosome 17q, and its abnormal protein product is neurofibromin. Approximately 100 mutations of NF1 have been identified in various regions of the gene. NF1 is the most common of the neurocutaneous syndromes, occurring in approximately 1:3000 individuals. Almost 50% of patients with NF1 are new mutations. New mutations are associated with increased paternal age. Neurofibromatosis type 2 (NF2) is characterized by bilateral acoustic neuromas and other intracranial and intraspinal tumors (see Chapter 17).

CLINICAL FEATURES. The clinical manifestations are highly variable (Friedman and Birch, 1997). In mild cases, café au lait spots and subcutaneous neurofibromas are the only features. Axillary freckles are common.

Severely affected individuals have developmental and neoplastic disorders of the nervous system. The main central nervous system abnormalities are optic pathway glioma, intraspinal neurofibroma, dural ectasia, and aqueductal

stenosis. Acoustic neuromas are not part of NF1. The usual cognitive defect is a learning disability, not mental retardation.

DIAGNOSIS. Two or more of the following features are considered diagnostic:

1. Six café au lait spots greater than 5 mm in diameter in prepubertal individuals or greater than 15 mm in postpubertal individuals
2. Two or more neurofibromas or one plexiform neurofibroma
3. Freckling in the axillary or inguinal region
4. Optic glioma
5. Two or more iris hamartomas (Lisch nodules)
6. A distinctive osseous lesion, such as sphenoid dysplasia or thinning of long bones
7. A first-degree relative with NF1.

MRI may provide additional diagnostic information. Areas of increased T₂ signal intensity are often present in the basal ganglia, cerebellum, brainstem, and subcortical white matter. The histology of these areas is not established, and they tend to disappear with age. The total burden of such areas correlates with intellectual impairment (Feldmann et al, 2003). DNA-based testing is available but rarely needed.

MANAGEMENT. Management is primarily supportive: anticonvulsant drugs for seizures, surgery for accessible tumors, and orthopedic procedures for bony deformities. Routine MRI studies to screen for optic gliomas in nonsymptomatic children are unnecessary.

Tuberous Sclerosis

Transmission of the tuberous sclerosis complex (TSC) is by autosomal dominant inheritance and has variable phenotypic expression (Weiner et al, 1998). Two genes are responsible for TSC. One gene (*TSC1*) is located at chromosome 9q34, and the other (*TSC2*) is near the gene for adult polycystic kidney disease at chromosome 16p13.3. *TSC1* is more likely than *TSC2* to account for familial cases and is generally a less severe phenotype.

CLINICAL FEATURES. The most common initial symptom of neurological dysfunction during infancy is seizures, especially infantile spasms (see Chapter 1). Some infants have evidence of developmental delay before the onset of seizures. The delay is often insufficient to prompt medical consultation. Most children with tuberous sclerosis who have mental retardation eventually have seizures, and all infants

with intractable seizures later function in the retarded range. Seizures and mental retardation are due to disturbed histogenesis of the brain, which contains decreased numbers of neurons and bizarrely shaped astrocytes. Glial tumors are common in the subependymal region and may cause obstructive hydrocephalus.

In late infancy and early childhood, café au lait spots develop, and an isolated raised plaque in the skin over the lower back or buttocks (*shagreen patch*) is present by 15 years in 50% of affected children. During childhood, adenomata sebaceum (actually angiokeratomas) appear on the face, usually in a butterfly distribution. Other organ involvement includes retinal tumors; rhabdomyoma of the heart; renal tumors; and cysts of the kidney, bone, and lung. A shortened life expectancy results from renal disease, cardiovascular disorders, brain tumors, and status epilepticus.

DIAGNOSIS. A National Institutes of Health consensus conference revised the diagnostic criteria for TSC (Table 5-10) (Hyman and Whittemore, 2000). *Molecular genetic testing* of the *TSC1* and *TSC2* genes is complicated by the large size of the two genes, the large number of *disease-causing mutations*, and a 10% to 25% rate of *somatic mosaicism*. Molecular testing for both genes is available, however.

MANAGEMENT. The recommended evaluations in children with TSC are renal ultrasonography every 1 to 3 years followed by renal CT/MRI if large or numerous renal tumors are detected, cranial CT/MRI every 1 to 3 years, echocardiography if cardiac symptoms indicate the need, and chest CT if pulmonary symptoms indicate the need. Anticonvulsants are helpful in reducing seizure frequency but rarely provide complete control. Mental retardation is not reversible.

Genetic counseling is an important aspect of patient management. Although disease transmission is autosomal dominant, gene expression is so variable that neither parent may appear affected. One quarter of parents without a personal or family history of tuberous sclerosis are shown to be affected by a careful history and physical examination, including funduscopic examination, renal ultrasound, and cranial MRI.

Other Disorders of Gray Matter

Early-Infantile Neuronal Ceroid-Lipofuscinosis (Santavuori-Haltia Disease)

The neuronal ceroid-lipofuscinoses (NCLs) are a group of inherited, lysosomal storage

TABLE 5-10
Diagnostic Criteria for Tuberous Sclerosis Complex (TSC)

Definite TSC: 2 major features or 1 major feature plus 2 minor features
Probable TSC: 1 major feature plus 1 minor feature
Possible TSC: 1 major feature or ≥ 2 minor features

Major Features

Cardiac rhabdomyoma, single or multiple
 Cortical tuber*
 Facial angiofibromas or forehead plaque
 Hypomelanotic macules (≥ 3)
 Lymphangiomyomatosis†
 Multiple retinal nodular hamartomas
 Nontraumatic ungual or periungual fibromas
 Renal angiomyolipoma†
 Shagreen patch (connective tissue nevus)
 Subependymal giant cell astrocytoma
 Subependymal nodule

Minor Features

Bone cysts
 Cerebral white matter radial migration lines*
 "Confetti" skin lesions
 Gingival fibromas
 Hamartomatous rectal polyps
 Multiple randomly distributed pits in dental enamel
 Multiple renal cysts
 Nonrenal hamartoma
 Retinal achromic patch

*When cerebral cortical dysplasia and cerebral white matter migration tracts occur together, they are counted as one rather than two features of TSC.

†When lymphangiomyomatosis and renal angiomyolipomas are present, other features of tuberous sclerosis must be present before TSC is diagnosed.

disorders characterized by progressive mental and motor deterioration, seizures, and early death. Visual loss is a feature of most forms. Classification of these disorders had been by age at onset and rapidity of progression, but now is by mutation analysis (Wisniewski, 2004). The two infantile forms are infant neuronal ceroid-lipofuscinosis (INCL) and late-infantile neuronal ceroid-lipofuscinosis (LINCL). INCL occurs primarily in Finnish people. The responsible mutation occurs in the palmitoyl protein thioesterase gene on chromosome 1. This site has been designated *NCL1*. The more common *NCL* types occur after age 2 years (see section on Progressive Encephalopathies with Onset after Age 2 later) and are caused by mutations at other sites.

CLINICAL FEATURES. Children with INCL are normal at birth; they develop retinal blindness and seizures by 2 years of age, followed by progressive mental deterioration. The macula degener-

ates and has a brownish color, the optic disk is atrophic, and the peripheral retina is hypopigmented. Death generally occurs between 8 and 11 years of age.

DIAGNOSIS. Palmitoyl protein thioesterase activity is deficient in fibroblasts, leukocytes, lymphoblasts, amniotic fluid cells, and chorionic villi.

MANAGEMENT. Treatment of seizures and myoclonus is with a combination of anticonvulsant drugs (see Chapter 1). No treatment for the underlying metabolic error is available.

Infantile Neuroaxonal Dystrophy

Infantile neuroaxonal dystrophy (*Seitelberger disease*) is a disorder of axon terminals transmitted by autosomal recessive inheritance. It shares many pathological features with Hallervorden-Spatz disease (see Chapter 14) and may be an infantile form.

CLINICAL FEATURES. Affected children usually develop normally during the first year, but most children never walk. Facial dysmorphism includes prominent forehead, strabismus, small nose, wide mouth, micrognathia, and large, low-set ears (Seven et al, 2002). Motor regression occurs at the end of the first year, manifesting as clumsiness and frequent falling. The infant is first hypotonic and hyporeflexic. Muscle atrophy may be present as well. At this stage, a peripheral neuropathy may be suspected, but motor nerve conduction velocity and the protein content of the CSF are normal.

After the initial phase of hypotonia, symptoms of cerebral degeneration become prominent. Increasing spastic quadriplegia, optic atrophy, involuntary movements, and mental regression are evident. By 2 years of age, most children are severely handicapped. Deterioration to a vegetative state follows, and death usually occurs by age 10 years.

DIAGNOSIS. The CSF is usually normal. Electromyography shows a denervation pattern consistent with anterior horn cell disease. Motor nerve conduction velocities are normal. T₂-weighted MRI shows marked cerebellar atrophy with diffuse hyperintensity of the cerebellar cortex. The hyperintensity is probably due to extensive gliosis.

A definitive diagnosis requires evidence of neuroaxonal spheroids in peripheral nerve endings, conjunctiva, or brain. Neuroaxonal spheroids are large eosinophilic spheroids, caused by axonal swelling, throughout the gray matter. They are not unique to neuroaxonal dystrophy and are seen in Hallervorden-Spatz disease,

infantile GM₂ gangliosidosis, Niemann-Pick disease type C, and several other neurodegenerative conditions.

MANAGEMENT. Treatment is supportive.

Lesch-Nyhan Disease

Lesch-Nyhan disease results from deficiency of the enzyme hypoxanthine guanine phosphoribosyltransferase. The gene map locus is chromosome Xq26-q27.2.

CLINICAL FEATURES. Affected newborns appear normal at birth except for mild hypotonia. Delayed motor development and poor head control are present during the first 3 months. Progressive limb rigidity and torticollis or retrocollis follow. The progression of neurological disturbance is insidious, and cerebral palsy is often misdiagnosed. During the second year, facial grimacing, corticospinal tract dysfunction, and involuntary movements (usually chorea but sometimes athetosis) develop.

It is not until after age 2, and sometimes considerably later, that affected children begin biting their fingers, lips, and cheeks. Compulsive self-mutilation is characteristic, but not constant, and causes severe disfigurement. Often wrapping the hands or removing teeth is necessary to prevent further harm. In addition to self-directed aggressive behavior, aggressive behavior toward caretakers may be present. Mental retardation is constant but of variable severity. Intelligence is difficult to evaluate because of behavioral and motor disturbances.

DIAGNOSIS. Uric acid concentrations in the blood and urine are elevated. Some parents note a reddish discoloration of diapers caused by uric acid. The demonstration that hypoxanthine guanine phosphoribosyltransferase activity is less than 1.5% in erythrocytes or cultured fibroblasts establishes the diagnosis. *Molecular genetic testing* of the *HPRT1* gene (chromosomal locus Xq26-q27.2) is used for determination of carrier status in at-risk females (Nicklas et al, 2003).

MANAGEMENT. Allopurinol decreases the urinary concentration of uric acid and prevents the development of nephropathy. Levodopa or tetra-benzazine may abate the self-mutilatory behavior. No treatment is available, however, to prevent progressive degeneration of the nervous system.

Rett Syndrome

Rett syndrome occurs only in girls. Males may have such a severe phenotype that they do not survive (Zoghbi, 2004). The estimated preva-

lence is 1:10,000 to 1:20,000. Mutations in the gene encoding methyl-CpG-binding protein-2, chromosome Xq28, cause the disease.

CLINICAL FEATURES. Affected girls are normal during the first year. Developmental arrest usually begins at 12 months (range, 5 to 18 months). The initial features are deceleration of head growth leading to microcephaly, lack of interest in the environment, and hypotonia. Within a few months, rapid developmental regression occurs characterized by loss of language skills, gait ataxia, seizures, and autistic behavior. A characteristic feature of the syndrome is loss of purposeful hand movements before age 3. Stereotyped activity develops that looks like hand wringing or washing. Repetitive blows to the face are another form of stereotyped hand movement.

After the initial rapid progression is a continued slower progression of neurological deterioration. Spastic paraparesis and quadriparesis are frequent end points. Dementia is usually severe. Stimulation produces an exaggerated, stereotyped reaction consisting of jerking movements of the trunk and limbs with episodes of disorganized breathing and apnea, followed by hyperpnea. Seizures occur in most children before age 3 years. After the period of rapid deterioration, the disease becomes relatively stable, but dystonia may develop later. Girls with Rett syndrome usually survive into adulthood, but have an increased incidence of sudden, unexplained death.

DIAGNOSIS. The clinical features are the initial basis for diagnosis. Confirmation by molecular genetic testing is available.

MANAGEMENT. Seizures often respond to standard anticonvulsant drugs. Treatment is otherwise supportive.

Trichopolydystrophy (Menkes Syndrome)

Menkes syndrome is a primary defect in the intestinal transport of copper (Kaler, 2003). The gene defect maps to chromosome Xq13. The symptoms are secondary to deficiency of copper-dependent enzymes, especially dopamine β-hydroxylase (DBH) and lysyl oxidase.

CLINICAL FEATURES. Autonomic dysfunction, including temperature instability and hypoglycemia, may be present in the neonatal period. Death occurs between 7 months and 3.5 years of age. The initial symptoms usually develop in the first 3 months. Development arrests, then regresses. The infant becomes lethargic and less reactive. Myoclonic seizures, provoked

by stimulation, are an early and almost constant feature. By the end of the first year, the infant is in a chronic vegetative state, and most die before 18 months.

The appearance of the scalp hair and eyebrows is almost pathognomonic. The hair is sparse, poorly pigmented, and wiry. The shafts break easily, forming short stubble (kinky hair). Radiographs of the long bones suggest osteogenesis imperfecta. Other facial abnormalities include abnormal fullness of the cheeks, a high-arched palate, and micrognathia.

DIAGNOSIS. Low plasma concentrations of ceruloplasmin and copper suggest the diagnosis. A protocol of mutation analysis, mutation scanning, and sequence analysis detects mutations in more than 95% of patients. Such testing is clinically available. Prenatal diagnosis is possible.

MANAGEMENT. Subcutaneous injections of copper histidine or copper chloride before 10 days of age normalizes developmental outcome in some but not in others.

Other Disorders of White Matter

Aspartoacylase Deficiency (Canavan Disease)

The inheritance of Canavan disease (also called *spongy degeneration of infancy*) is autosomal recessive. Deficiency of aspartoacylase underlies the disease. Different mutations account for Jewish and non-Jewish cases, but the variability of the clinical course cannot be explained by genetic heterogeneity alone (Matalon, 2003).

CLINICAL FEATURES. Psychomotor arrest and regression occur during the first 6 months postpartum. Clinical features include decreased awareness of the environment, difficulty in feeding, irritability, and hypotonia. Eventually, spasticity replaces the initial flaccidity. A characteristic posture, with leg extension, arm flexion, and head retraction, occurs, especially when the infant is stimulated. Macrocephaly is evident by 6 months of age. The head continues to enlarge throughout infancy, and this growth reaches a plateau by the third year. Optic atrophy leading to blindness evolves between 6 and 10 months. Life expectancy is the second decade.

DIAGNOSIS. Abnormal excretion of *N*-acetylaspartic acid is detectable in the urine, and aspartoacylase activity in cultured fibroblasts is less than 40% of normal. MRI shows diffuse symmetrical leukoencephalopathy even before neurological symptoms are evident. Demyelination of peripheral nerves does not occur, and the CSF

is normal. Molecular diagnosis is available for the mutation in Ashkenazi Jews.

MANAGEMENT. Treatment is supportive.

Galactosemia: Transferase Deficiency

Three separate inborn errors of galactose metabolism produce galactosemia in the newborn, but only galactose-1-phosphate uridylyltransferase deficiency produces mental retardation. Transmission of the defect is by autosomal recessive inheritance, and the gene map locus is 9p13 (Elsas, 2003).

CLINICAL FEATURES. Affected newborns appear normal, but cataracts are already developing. The first milk feeding provokes the initial symptoms, including failure to thrive, vomiting, diarrhea, jaundice, and hepatomegaly. During this time, some newborns have clinical features of increased intracranial pressure, probably resulting from cerebral edema. The combination of a tense fontanelle and vomiting suggests a primary intracranial disturbance and can delay the diagnosis and treatment of the metabolic error.

DIAGNOSIS. Newborn screening detects galactosemia. It is a consideration in any newborn, however, with vomiting and hepatomegaly, especially when cataracts are present. The best time to test the urine for reducing substances is after feeding. Measurement of erythrocyte galactose-1-phosphate uridylyltransferase activity and *isoelectric focusing* of galactose-1-phosphate uridylyltransferase establish the diagnosis. Molecular genetic testing is available for carrier detection and genetic counseling.

MANAGEMENT. Immediate dietary intervention requires replacement of all milk and milk products with a formula that is free of bioavailable lactose. Long-term results of treatment have been disappointing, however; IQ is low in many cases despite early and seemingly adequate therapy. Delayed achievement of developmental milestones occurs during the first year. Intellectual function is in the moderately retarded range by age 5. After age 5, truncal ataxia develops and progresses in severity. Associated with ataxia is a coarse resting tremor of the limbs. Because of the restricted diet, cataracts and hepatomegaly are not present.

Pelizaeus-Merzbacher Disease

Pelizaeus-Merzbacher disease is a rare demyelinating disorder transmitted by X-linked

recessive inheritance. The gene maps to chromosome Xq22. Defective biosynthesis of a proteolipid protein (PLP1) that composes half of the myelin sheath protein causes the disorder (Garbern et al, 2004). Mutations in the *PLP1* gene also are responsible for one form of hereditary spastic paraplegia (see Chapter 12). Infantile, neonatal, and transitional phenotypes of Pelizaeus-Merzbacher disease exist.

CLINICAL FEATURES. The first symptoms of the neonatal form suggest spasmus nutans (see Chapter 15). The neonate has an intermittent nodding movement of the head and pendular nystagmus. Chorea or athetosis develops, psychomotor development arrests by the third month, and regression follows. Limb movements become ataxic, and tone becomes spastic, first in the legs and then in the arms. Optic atrophy and seizures are late occurrences. Death occurs by 5 to 7 years of age. When the onset of disease is at the end of the first month or later, the symptoms are the same as in the neonatal form, but the course is more prolonged and survival to adult life is relatively common.

DIAGNOSIS. MRI shows diffuse demyelination of the hemispheres with sparing of scattered small areas. Molecular genetic testing is available for diagnosis and carrier detection.

MANAGEMENT. Treatment is supportive.

Progressive Hydrocephalus

CLINICAL FEATURES. Progressive dilation of the ventricular system may be a consequence of congenital malformations, infectious diseases, intracranial hemorrhage, or connatal tumors. Whatever the cause, the clinical features of increasing intracranial pressure are similar. Head circumference enlarges; the anterior fontanelle feels full; and the infant becomes lethargic, has difficulty feeding, and vomits. Ataxia and a spastic gait are common.

DIAGNOSIS. Progressive hydrocephalus is often insidious in premature newborns with intraventricular hemorrhage, especially when delayed progression follows initial arrest. Hydrocephalus is always suspected in newborns and infants with excessive head growth. Head CT confirms the diagnosis.

MANAGEMENT. Ventriculoperitoneal shunt is the usual procedure to relieve hydrocephalus in newborns and small infants with primary dilation of the lateral ventricles (see Chapter 18).

Progressive Encephalopathies with Onset After Age 2

Disorders of Lysosomal Enzymes

GM₂ Gangliosidosis (Juvenile Tay-Sachs Disease)

Deficiency of *N*-acetyl- β -hexosaminidase (Hex A) underlies the infantile and the juvenile forms of Tay-Sachs disease. Different mutations underlie the acute and chronic forms. There is no ethnic predilection.

CLINICAL FEATURES. Hex A deficiency often begins with ataxia and incoordination between 2 and 10 years of age. Speech, life skills, and cognition decline. Spasticity and seizures are present by the end of the first decade of life. Loss of vision occurs much later than in the acute infantile form of the disease, and a cherry-red spot is not a consistent finding. Instead, optic atrophy and *retinitis pigmentosa* may occur late in the course. A vegetative state with decerebrate rigidity develops by 10 to 15 years of age, followed within a few years by death, usually due to infection. In some cases, the disease pursues a particularly aggressive course, culminating in death in 2 to 4 years.

DIAGNOSIS. Serum, leukocytes, and fibroblasts are deficient in Hex A activity.

MANAGEMENT. Treatment is supportive.

Gaucher Disease Type III (Glucosylceramide Lipidosis)

As in other types, the cause of late-onset Gaucher disease is deficiency of the enzyme glucocerebrosidase. Transmission is by autosomal recessive inheritance.

CLINICAL FEATURES. The range of age at onset is from early childhood to adult life. Hepatosplenomegaly usually precedes neurological deterioration. The most common neurological manifestations are seizures and mental regression. Mental regression varies from mild memory loss to severe dementia. Myoclonus and myoclonic seizures develop in many patients. Some combination of spasticity, ataxia, and cranial nerve dysfunction may be present as well. Vertical oculomotor apraxia, as described in Niemann-Pick disease, may occur.

DIAGNOSIS. Gaucher cells are present in the bone marrow and are virtually diagnostic. Confirmation requires the demonstration of deficient glucocerebrosidase activity in hepatocytes or leukocytes.

MANAGEMENT. Patients with chronic neurological involvement benefit from bone marrow transplant. Transplantation corrects the metabolic defect, improves blood counts, and reduces increased liver volume. The associated morbidity and mortality limit its usefulness, however. Enzyme replacement therapy uses imiglucerase, a recombinant glucosylceramidase enzyme preparation. Regular intravenous infusions of imiglucerase are safe and effective in reversing hematological and visceral involvement, but not neurological disease.

Globoid Cell Leukodystrophy (Late-Onset Krabbe Disease)

Deficiency of the enzyme galactosylceramide β -galactosidase causes globoid cell leukodystrophy. Transmission is by autosomal recessive inheritance. The onset of symptoms in late infancy and in adolescence can occur in the same family. The severity of the enzyme deficiency is similar in all phenotypes from early infancy to adolescence.

CLINICAL FEATURES. Neurological deterioration usually begins between the ages of 2 and 6 (range 1 year to adolescence). The major features are mental regression, cortical blindness, and generalized or unilateral spasticity. The initial feature may be progressive spasticity rather than dementia. In contrast to the infantile form, peripheral neuropathy is not a feature of the juvenile form, and the protein content of the CSF is normal. Progressive neurological deterioration results in a vegetative state.

DIAGNOSIS. MRI shows diffuse demyelination of the cerebral hemispheres. Showing the enzyme deficiency in leukocytes or cultured fibroblasts establishes the diagnosis.

MANAGEMENT. Hematopoietic stem cell transplantation slows the course of disease in children with infantile-onset Krabbe disease diagnosed before symptom onset. Neurological manifestations may reverse. Treatment is supportive.

Metachromatic Leukodystrophy (Late-Onset Lipidosis)

Deficiency of the enzyme arylsulfatase A causes the juvenile and infantile forms of sulfatide lipidosis. Genetic transmission of both is autosomal recessive inheritance. Two groups of mutations in the gene encoding arylsulfatase A are identified as *I* and *A*. Patients with *I* mutations generate no active enzyme, and patients with *A* mutations generate small amounts. Late-

onset disease is associated with *I-A* genotype, and the adult form with an *A-A* genotype correlates with the clinical phenotype.

CLINICAL FEATURES. The onset of symptoms is generally between 5 and 10 years (range, infancy to adolescence). The early-onset juvenile form is clinically different from the infantile form despite the age overlap. No clinical symptoms of peripheral neuropathy occur, progression is slow, and the protein content of the CSF is normal.

Mental regression, speech disturbances, and clumsiness of gait are the prominent initial features. The dementia usually progresses slowly over 3 to 5 years but sometimes progresses rapidly to a vegetative state. A delay of several years may separate the onset of dementia from the appearance of other neurological disturbances. Ataxia may be an early and prominent manifestation. A spastic quadriplegia eventually develops in all affected children, and most have seizures. Death usually occurs before age 20.

DIAGNOSIS. The juvenile form can overlap in age with a late-onset form, which usually manifests as psychosis or dementia. MRI shows demyelination in the cerebral hemispheres. Motor nerve conduction velocities may be normal early in the course. Showing deficiency of arylsulfatase A in leukocytes or cultured fibroblasts establishes the diagnosis.

MANAGEMENT. Treatment is supportive.

Mucopolysaccharidoses

MPS result from deficiencies of enzymes involved in the catabolism of dermatan sulfate, heparan sulfate, or keratan sulfate. At least seven major types of MPS are recognized. Four of these—types I, II, III, and VII—affect the nervous system and cause mental retardation. The onset of types I and III is in infancy (see earlier section). Types II and VII ordinarily have their onset in childhood after 2 or more years of normal development.

Type II MPS (Hunter Syndrome)

Hunter syndrome is the only MPS transmitted by X-linked inheritance. The gene maps to chromosome Xq28.

CLINICAL FEATURES. Patients with Hunter syndrome have a Hurler phenotype (see Table 5-8), but lack corneal clouding. Iduronate sulfatase is the deficient enzyme; dermatan sulfate and heparan sulfate are stored in the viscera and appear in the urine.

The Hurler phenotype may develop rapidly or evolve slowly during childhood and not be

recognized until the second decade or later. A prominent feature is the appearance of a nodular, ivory-colored lesion on the back, usually around the shoulders and upper arms. Mental regression caused by neuronal storage of gangliosides is slowly progressive, but many patients come to medical attention because of chronic hydrocephalus. Affected children survive into adult life. The accumulation of storage materials in collagen causes the entrapment of peripheral nerves, especially the median and ulnar nerves.

DIAGNOSIS. The presence of mucopolysacchariduria with equal excretion of dermatan sulfate and heparan sulfate suggests the diagnosis. Establishing the diagnosis requires showing enzyme deficiency in cultured fibroblasts or serum. The detection of iduronate sulfatase activity in amniotic fluid is useful for prenatal diagnosis.

MANAGEMENT. Treatment is supportive.

Type VII MPS (Sly Disease)

Sly disease is a rare disorder caused by deficiency of the enzyme β -glucuronidase. Transmission is by autosomal recessive inheritance.

CLINICAL FEATURES. The patient has an incomplete Hurler phenotype, with hepatosplenomegaly, inguinal hernias, and dysostosis multiplex as the major features. Corneal clouding does not occur, and the face, although unusual, is not typical of the Hurler phenotype. Psychomotor retardation develops after age 2, but not in all cases.

DIAGNOSIS. Dermatan sulfate and heparan sulfate are present in the urine, causing a screening test to be positive for mucopolysacchariduria. Specific diagnosis requires the demonstration of β -glucuronidase deficiency in leukocytes or cultured fibroblasts.

MANAGEMENT. Treatment is supportive.

Niemann-Pick Disease Type C (Sphingomyelin Lipidosis)

The chronic neuronopathic form of Niemann-Pick disease type C (NPC) is similar to the acute infantile form except that onset is usually after age 2, progression is slower, and there is no specific racial predilection. The biochemical defect is deficient esterification of cholesterol. Transmission of the defect is autosomal recessive inheritance, and the gene maps to chromosome 18q11-12 (Patterson, 2004).

CLINICAL FEATURES. Age at onset and predominant symptoms distinguish three phenotypes.

Characteristic of the early-onset form is organomegaly and rapidly progressive hepatic dysfunction during the first year, often in the first 6 months. Developmental delay occurs during the first year, and neurological deterioration (ataxia, vertical gaze apraxia, and dementia) occurs between 1 and 3 years of age.

The delayed-onset form is more common than the other two and has the most stereotyped clinical features. Early development is normal. Cerebellar ataxia or dystonia is the initial feature (mean age 3 years), and apraxia of vertical gaze and cognitive difficulties follow (mean age 6 years). Oculomotor apraxia, in which the eyes move reflexively but not voluntarily, is unusual in children (see Chapter 15). Vertical gaze apraxia is particularly uncommon and always suggests NPC. Progressive neurological degeneration is relentless. Dementia, seizures, and spasticity cause severe disability during the second decade. Organomegaly is seldom prominent early in the course. The late-onset form begins in adolescence or adult life and is similar to the delayed-onset form except that the progression is considerably slower.

DIAGNOSIS. Biochemical testing that shows impaired cholesterol esterification and positive filipin staining in cultured fibroblasts confirms the diagnosis. Biochemical testing for carrier status is unreliable. Most patients with NPC have NPC1, caused by a *mutation* in the *NPC1* gene, and fewer than 20 patients have been diagnosed with NPC2, caused by *mutations* in the *NPC2* gene. *Molecular genetic testing* of the *NPC1* and *NPC2* genes detects *disease-causing mutations* in more than 90% of individuals with NPC. Such testing is available clinically.

MANAGEMENT. Treatment is supportive. Bone marrow transplantation, combined bone marrow and liver transplantation, and cholesterol-lowering therapy are not effective.

Infectious Diseases

Infectious diseases are an uncommon cause of progressive dementia in childhood. Several fungal species may cause chronic meningitis characterized by personality change and some decline in higher intellectual function. *Cryptococcus* infection is especially notorious for its indolent course. The major features of these infections are fever and headache. Chronic meningitis is not a serious consideration in the differential diagnosis of isolated psychomotor regression. In contrast, chronic viral infections, especially HIV (see the previous discussion of AIDS encephalopathy), may produce a clinical picture similar to that of

many genetic disorders in which dementia is a prominent feature.

Subacute Sclerosing Panencephalitis

Subacute sclerosing panencephalitis (SSPE) is a form of chronic measles encephalitis that previously was endemic in several parts of the world but has almost disappeared in countries that require routine measles immunization. In a non-immunized population, the average age at onset is 8 years. As a rule, children with SSPE have experienced natural infection with the rubeola virus at an early age, half before age 2 years. A concomitant infection with a second virus at the time of initial exposure to measles and immunosuppression are additional risk factors for SSPE. In the United States, incidence rates were highest in rural areas, especially in the southeastern states and the Ohio River Valley.

CLINICAL FEATURES. The first symptoms of SSPE are personality change and declining school performance. Personality change may consist of aggressive behavior or withdrawal, and parents may seek psychological rather than medical services. Retinal examination during this early stage shows pigmentary changes in the macula. Generalized seizures, usually myoclonic, develop next. An EEG at this time shows the characteristic pattern of periodic bursts of spike-wave complexes (approximately every 5 to 7 seconds) occurring synchronously with the myoclonic jerk. After the onset of seizures, the child shows rapid neurological deterioration characterized by spasticity, dementia, and involuntary movements. Within 1 to 6 years from the onset of symptoms, the child is in a chronic vegetative state.

DIAGNOSIS. The diagnosis is suspected based on the clinical course and the characteristic EEG. Confirmation requires demonstration of an elevated antibody titer against rubeola, usually associated with elevated gamma globulin con-

centrations, in the CSF. The CSF is otherwise normal. The rubeola antibody titer in blood also is markedly elevated. A similar progressive disorder of the nervous system may occur in children who were born with rubella embryopathy (chronic rubella panencephalitis).

MANAGEMENT. Some patients have improved or stabilized after several 6-week treatments of intraventricular α -interferon, starting at 105 U/m² body surface area/day combined with oral inosine pranobex (Isoprinosine), 100 mg/kg/day. Courses can be repeated six times at 2- to 6-month intervals.

Other Disorders of Gray Matter

Ceroid Lipofuscinosis

Several neurodegenerative disorders characterized by dementia and blindness are forms of ceroid lipofuscinosis (Wisniewski, 2004). When first described, the classification relied on eponyms depending on the age at onset (Table 5-11). The common pathological feature is the accumulation of autofluorescent lipopigments, ceroid and lipofuscin, within the brain, retina, and some visceral tissues. Genetic transmission of all neuronal lipofuscinoses is by autosomal recessive inheritance except for one adult form (Table 5-12). See the previous section for the description of the early-infantile form. The early and late juvenile disorders are allelic. The early-infantile, late-infantile, and juvenile forms map to different chromosomes.

Late Infantile Neuronal-Ceroid Lipofuscinosis (Jansky-Bielschowsky Disease)

CLINICAL FEATURES. Visual failure begins between 2 and 3 years of age and progresses slowly. The onset of seizures and dementia is at 2 to 4 years. The seizures are myoclonic, akinetic, and tonic-clonic and are usually refractory to anticonvul-

TABLE 5-11
Neuronal Ceroid Lipofuscinoses

	Infantile	Late-Infantile	Early-Juvenile	Late-Juvenile
Other Names	Santavuori-Haltia disease	Jansky-Bielschowsky disease	Batten or Spielmeier-Vogt disease	Batten or Spielmeier-Vogt disease
Age of Onset	6-12 mo	2-3 yr	4-10 yr	8-12 yr
Chromosome Location	1p (CLN1)	11p15.5 (CLN2)	16p12.1 (CLN3)	16p12.1 (CLN3)

TABLE 5-12
Distinguishing Clinical Features of Neuronal Ceroid-Lipofuscinosis Phenotypes and Their Associated Genes

Clinical Forms	Percent of Patients by Genotype			Presenting Symptoms
	Percent of Patients	Gene	Age of Onset	
Infantile (INCL) (Santavuori-Haltia)	50%	<i>PPT1</i>	6-24 mo	Cognitive/motor decline, visual loss, seizures ¹ Chronic course: all of above and behavior abnormalities ¹
	50%		3-38 yr	
Late infantile (LINCL) Classic (cLINCL) (Jansky-Bielschowsky) and others	8%	<i>PPT1</i>	2-8 yr	Motor/cognitive decline, visual loss, seizures ²
	80% ³	<i>CLN2</i>		
	12% ⁴	<i>TPP1</i> Other		
Finnish variant (fLINCL)	100%	<i>CLN5</i>	4-7 yr	Cognitive/motor decline, visual loss, seizures ²
Gypsy/Indian, early-juvenile variant (vLINCL)	8-15%	<i>CLN6</i>	18 mo-8 yr ^{5,6}	Motor/cognitive decline, visual loss, seizures ²
Turkish variant (tLINCL)	?	<i>CLN8</i>	3-7.5 yr	Motor decline, visual loss, seizures ²
Juvenile (JNCL) (Batten disease, Spielmeier-Vogt disease)	21%	<i>PPT1</i>	4-10 yr	Visual loss, cognitive/motor decline, seizures ²
	7%	<i>CLN2</i>		
	72%	<i>CLN3</i>		
Northern epilepsy (NE) (progressive epilepsy with mental retardation [PEMR])	100%	<i>CLN8</i>	5-10 yr	Cognitive decline, seizures
Adult (ANCL) (Kufs' disease)		<i>PPT1</i> ⁷	15-50 yr	Type A: Motor/cognitive decline, seizures Type B: Behavior abnormalities, motor/cognitive decline
		<i>CLN3</i> ⁸		
		<i>CLN4</i> ⁹		

¹Wisniewski and Zhong, 2001: rapid progression.

²Wisniewski and Zhong, 2001: subacute or chronic course.

³Zhong et al, 1998.

⁴Zhong et al, 2000.

⁵Gao et al, 2002.

⁶Teixeira et al, 2003.

⁷van Diggelen et al, 2001.

⁸Wisniewski and Zhong, 2001.

⁹Berkovic et al, 1988.

From Wisniewski KE. (27 January 2004) Neuronal ceroid-lipofuscinoses. In: *GeneClinics: Medical Genetics Knowledge Base*. [database online] University of Washington, Seattle. Available at <http://www.geneclinics.org>.

sant drugs. Severe ataxia develops, owing in part to seizures and in part to motor system deterioration. Myoclonus, involuntary movements, and dementia follow. Dementia sometimes precedes the first seizure.

Ophthalmoscopic findings are abnormal before visual symptoms occur. They include attenuation of vessels, early optic atrophy, and pigmentary degeneration of the macula. The loss of motor, mental, and visual function is relentlessly progressive, and within months, the

child is in a chronic vegetative state. Death is usually between 10 and 15 years.

DIAGNOSIS. The finding of diminished *CLN2* protease activity in blood leads to molecular genetic testing, which accomplishes antemortem and prenatal diagnosis.

MANAGEMENT. Seizures are difficult to control but may respond in part to a combination of anticonvulsant drugs (see Chapter 1). No treatment is available for the underlying metabolic error.

Early-Juvenile Ceroid-Lipofuscinosis (Batten)

CLINICAL FEATURES. Onset of visual failure is between 4 and 5 years, and the onset of seizures and dementia is between 5 and 9 years. Macular degeneration and pigmentary aggregation are present on ophthalmoscopic examination. Loss of ambulation occurs after age 10. Myoclonus is prominent. Death occurs between 10 and 20 years.

DIAGNOSIS. Molecular genetic testing is available.

MANAGEMENT. Treatment is the same as for the late-infantile form.

Late Juvenile Ceroid-Lipofuscinosis (Spielmeyer-Vogt Disease)

CLINICAL FEATURES. The mean age at onset of the juvenile disease is 5 years (range 4 to 10 years). Decreasing visual acuity is the most prominent feature. Time to blindness is shorter than in the early-juvenile form. Ophthalmoscopic examination shows attenuation of retinal vessels, a patchy retinal atrophy that resembles retinitis pigmentosa, mild optic atrophy, and a granular discoloration of the macula that may have a bull's-eye appearance with a dull red spot in the center.

Declining school performance and behavioral disturbances are characteristic. Delusions and hallucinations are common. Blindness and dementia are the only symptoms for many years. Late in the course, speech becomes slurred, and Parkinson-like rigidity develops. Myoclonic jerks and tonic-clonic seizures begin years after onset but are not usually severe. Death usually occurs within 15 years of onset.

DIAGNOSIS. Antemortem diagnosis is reasonably certain because of the characteristic retinal changes and confirmed by skin and conjunctival biopsy or by molecular genetic testing. Fingerprint bodies are present in the cytoplasm of several cell types. The electroretinogram shows depression or absence of retinal potentials early in the course. Leukocytes in the peripheral blood are frequently abnormal. Translucent vacuoles are present in lymphocytes, and azurophilic granules occur in neutrophils.

MANAGEMENT. Treatment is not available for the underlying metabolic defect. Seizures usually respond to standard anticonvulsant drugs.

Heller Syndrome

The original description of Heller syndrome was a progressive dementia of childhood affect-

ing boys and girls between the ages of 1 and 4 years. The term *childhood disintegrative disorder* is replacing the term *Heller syndrome*. Many of the early-onset cases in girls were actually Rett syndrome.

CLINICAL FEATURES. Heller syndrome probably has a male predominance. Affected children develop normally up to at least 30 months of age, which differentiates Heller syndrome from infantile autism. The dementia progresses for 1 to 3 years. The result is profound mental retardation with marked autistic features but no effect on motor skills.

DIAGNOSIS. The clinical syndrome is the basis for diagnosis. The syndrome is differentiated from Rett syndrome by the age at onset, male predominance, and lack of motor disturbances and from infantile autism by the age at onset. Exclusion of all other causes of progressive dementia of childhood is required (see Table 5-4).

MANAGEMENT. Treatment is supportive.

Huntington Disease

Huntington disease is a chronic degenerative disease of the nervous system transmitted by autosomal dominant inheritance. The Huntington disease gene maps to chromosome 4p16.3 and codes a protein known as *huntingtin*. The function of huntingtin is unknown. The gene contains an expanded trinucleotide (CAG) repeat sequence. The normal number of repeats is less than 29. Adult-onset Huntington disease patients usually have more than 35 repeats, whereas juvenile-onset patients often have 50 or more (Haig et al, 2004).

CLINICAL FEATURES. The age of onset is usually between 35 and 55 but may be as early as 2 years. Approximately 10% of affected children show symptoms before 20 years of age and 5% before 14 years of age. When Huntington disease begins in childhood, the father is the affected parent in 83% of cases and may be asymptomatic when the child is born.

The initial features are usually progressive dementia and behavioral disturbances. Declining school performance often brings the child to medical attention. Rigidity, with loss of facial expression and associative movements, is more common than choreoathetosis and hyperkinesia in early-onset cases. Cerebellar dysfunction occurs in approximately 20% of cases and can be a major cause of disability. Ocular motor apraxia also may be present (see Chapter 15). Seizures, which are rare in adult-onset cases, are present in 50% of affected children. The course in childhood is relentlessly

progressive, and the average duration from onset to death is 8 years.

DIAGNOSIS. Reliable molecular testing is available to determine the size of the expanded CAG repeat.

MANAGEMENT. Rigidity may be temporarily relieved with levodopa, bromocriptine, and amantadine. Neuroleptics are useful for behavioral control, but treatment is not available for the dementia.

Mitochondrial Encephalomyopathies

The mitochondrial encephalomyopathies are a diverse group of disorders with defects of oxidative metabolism. Three such disorders were described earlier in the section on progressive encephalopathies of infancy. Progressive external ophthalmoplegia or myopathy is characteristic of the later onset mitochondrial disorders. Childhood dementia occurs in a syndrome of myoclonic epilepsy associated with ragged-red fibers in skeletal muscle. Genetic transmission is by maternal inheritance.

Myoclonic Epilepsy and Ragged-Red Fibers

Point mutations in mtDNA cause the syndrome of myoclonic epilepsy and ragged-red fibers. Mutation in more than one mitochondrial gene produces the phenotype. The severity of the clinical phenotype is proportional to the amount of mutant mtDNA (DiMauro and Hirano, 2003).

CLINICAL FEATURES. Clinical heterogeneity is common even among members of the same family and ranges from severe central nervous system dysfunction to myopathy. The four cardinal features are myoclonus, myoclonic epilepsy, ataxia, and ragged-red fiber in muscle biopsy. Onset ranges from childhood to the 30s. An insidious decline in school performance is often the initial feature, but generalized tonic-clonic seizures or myoclonus may be the symptoms that first prompt medical consultation. Flickering light or watching television may induce seizures. Brief myoclonic twitching develops, often induced by action (action myoclonus), which may interfere with hand movement and posture. Ataxia is a constant feature as the disease progresses, and this may be due to action myoclonus rather than cerebellar dysfunction. Some patients have hearing loss, short stature, and exercise intolerance.

Neurological deterioration is progressive and may include spasticity, sensory loss, and central

hypoventilation. Clinical evidence of myopathy is not always present.

DIAGNOSIS. Molecular genetic testing is available. Serum concentrations of pyruvate and lactate may be elevated. The EEG shows slowing of the background rhythms and a photoconvulsive response. Ragged-red fibers are present in muscle specimens of weak muscles (see Figure 8-3). Unaffected muscles do not contain ragged-red fibers.

MANAGEMENT. Anticonvulsant therapy may provide seizure control early in the course but often fails as the disease progresses. Avoid glucose loads. Treatment is not available for the underlying defect.

Xeroderma Pigmentosum

Xeroderma pigmentosum is a group of uncommon neurocutaneous disorders characterized by susceptibility to sun-induced skin disorders and progressive neurological deterioration (Wattendorf and Kraemer, 2004). Genetic transmission is autosomal recessive. Several different gene mutations have been associated with these disorders. In the United States, the most common form is termed XPA C, and the gene maps to chromosome 9q34.

CLINICAL FEATURES. A photosensitive dermatitis develops during the first year, and skin cancer may develop. After age 3, progressive psychomotor retardation and poor head growth leads to microcephaly. Sensorineural hearing loss and spinocerebellar degeneration may develop after age 7. Approximately one third of patients are short in stature, and some have a phenotype suggesting Cockayne syndrome, which is a separate genetic error (see Chapter 7) but also involves defective DNA repair.

DIAGNOSIS. The typical skin rash and neurological deterioration in the central and peripheral nervous systems suggest the diagnosis. Molecular genetic testing is available on a research basis, but abnormal DNA repair is demonstrable in cultured fibroblasts.

MANAGEMENT. Treatment is supportive. Radiation is contraindicated.

Other Diseases of White Matter

Adrenoleukodystrophy

Adrenoleukodystrophy is a progressive demyelination of the central nervous system associated with adrenal cortical failure (Moser et al, 2004). Genetic transmission is X-linked. Affected children have an impaired ability to oxidize

very-long-chain fatty acids, especially hexacosanoic acid, because of deficiency of a peroxisomal acyl coenzyme A synthetase. Very-long-chain fatty acids accumulate in tissues and plasma. Many cases previously designated as *Schilder disease* were probably the juvenile form of adrenoleukodystrophy.

Four phenotypes may coexist in the same family. The cerebral form accounts for approximately 56% of cases and is discussed in this section; a slowly progressive adrenomyeloneuropathy accounts for 25% of cases (see Chapter 12). The remaining patients have only Addison's disease or are asymptomatic.

CLINICAL FEATURES. The onset of the cerebral form is usually between 4 and 8 years of age. The first symptoms are usually an alteration in behavior ranging from a withdrawn state to aggressive outbursts. Poor school performance follows invariably and may lead parents to seek psychological services. Neurological deterioration is relentlessly progressive and includes disturbances of gait and coordination, loss of vision and hearing, and ultimate deterioration to a vegetative state. Seizures are a late manifestation. The average interval from onset to a vegetative state or death is 3 years.

DIAGNOSIS. The level of very-long-chain fatty acids in plasma is elevated in males of all ages, even in males who are asymptomatic, and in 85% of female carriers. Molecular-based diagnosis is available but used primarily for genetic counseling. T₂-weighted MRI shows high signal intensity in the periventricular white matter even in asymptomatic individuals. Adrenal insufficiency, as evidenced by a subnormal response to stimulation by adrenocorticotrophic hormone, may be demonstrable even in asymptomatic children.

MANAGEMENT. Assessment of adrenal function and corticosteroid replacement therapy can be lifesaving but have no effect on nervous system involvement. Bone marrow transplantation is an option for boys and adolescents who are in the early clinical stages and have MRI evidence of brain involvement. Dietary therapy has no established benefit.

Cerebrotendinous Xanthomatosis

Cerebrotendinous xanthomatosis is a rare disorder of bile acid synthesis transmitted as an autosomal recessive trait (Moghadasian et al, 2002). Mutations in the sterol 27-hydroxylase gene on the distal portion of chromosome 2q cause an absence of chenodeoxycholic acid in the bile and a marked increase of cholestanol in

plasma. Sterols are stored in all tissues, but especially the central nervous system.

CLINICAL FEATURES. Dementia begins in early childhood but is insidious in its progression so that affected children seem mildly retarded rather than actively deteriorating. By age 15, cataracts are present, and tendinous xanthomas begin to form. They are small at first and may go unnoticed until adult life. Progressive spasticity and ataxia develop during adolescence, and the patient becomes incapacitated in early adult life. A demyelinating neuropathy also may be present. Speech and swallowing are impaired, and death occurs from brainstem dysfunction or myocardial infarction.

DIAGNOSIS. The symptom complex of diarrhea, cataracts, tendon xanthomas, and progressive neurological deterioration establishes the diagnosis, but complete expression of all features occurs late in the course. The presence of cataracts or Achilles tendon xanthoma is an indication for biochemical screening. Elevated plasma concentrations of cholestanol or xanthomas establish the diagnosis. MRI shows progressive cerebral atrophy and demyelination.

MANAGEMENT. Daily administration of 750 mg of chenodeoxycholic acid lowers blood cholestanol and improves nerve conduction velocities. Tendon xanthomas also resolve.

References

- Clifton-Bligh RJ, Wentworth JM, Heinz P, et al. Mutation of the gene encoding human TTF-2 associated with thyroid agenesis, cleft palate and choanal atresia. *Nat Genet* 1998;19:399-401.
- DiMauro S, Hirano M. (2 June 2003) MERRF. In: *GeneClinics: Medical Genetics Knowledge Base*. [database online] University of Washington, Seattle. Available at <http://www.geneclinics.org>.
- Elsas LJ. (27 March 2003) Galactosemia. In: *GeneClinics: Medical Genetics Knowledge Base*. [database online] University of Washington, Seattle. Available at <http://www.geneclinics.org>.
- Feldmann R, Denecke J, Grenzebach M, et al. Neurofibromatosis type 1. Motor and cognitive function and T2-weighted MRI hyperintensities. *Neurology* 2003;61:1728.
- Friedman JM, Birch PH. Type 1 neurofibromatosis. A descriptive analysis of the disorder in 1,728 patients. *Am J Med Genet* 1997;70:138-143.
- Galli L, de Martino M, Tovo PA, et al. Predictive value of the HIV paediatric classification system for the long-term course of perinatally infected children. *Int J Epidemiol* 2000;29:573-578.
- Garbern J, Krajewski K, Hobson G. (11 June 2004) Pelizaeus-Merzbacher disease. In: *GeneClinics: Medical Genetics Knowledge Base*. [database online] University of Washington, Seattle. Available at <http://www.geneclinics.org>.

- Gauthier-Villars M, Landrieu P, Cormier-Daire V, et al. Respiratory chain deficiency in Alpers syndrome. *Neuropediatrics* 2001;32:150-152.
- Gorospe JR. (11 December 2003) Alexander disease. In: *GeneClinics: Medical Genetics Knowledge Base*. [database online] University of Washington, Seattle. Available at <http://www.geneclinics.org>.
- Haig B, Huq M, Hayden MR. (25 May 2004) Huntington disease. In: *GeneClinics: Medical Genetics Knowledge Base*. [database online] University of Washington, Seattle. Available at <http://www.geneclinics.org>.
- Hyman MH, Whittemore H. National Institute of Health Consensus Conference. Tuberous sclerosis. *Arch Neurol* 2000;57:662-665.
- Kaback MM. (9 January 2004) Hexosaminidase A deficiency. In: *GeneClinics: Medical Genetics Knowledge Base*. [database online] University of Washington, Seattle. Available at <http://www.geneclinics.org>.
- Kaler SG. (9 May 2003) ATP7A-related copper transport disorders. In: *GeneClinics: Medical Genetics Knowledge Base*. [database online] University of Washington, Seattle. Available at <http://www.geneclinics.org>.
- Matalon R. (7 November 2003) Canavan disease. In: *GeneClinics: Medical Genetics Knowledge Base*. [database online] University of Washington, Seattle. Available at <http://www.geneclinics.org>.
- Moghadasian MH, Salen G, Frohlich JJ, et al. Cerebrotendinous xanthomatosis. A rare disease with diverse manifestations. *Arch Neurol* 2002;59:527-529.
- Moser HW, Moser AB, Steinberg SJ. (15 April 2004) X-linked adrenoleukodystrophy. In: *GeneClinics: Medical Genetics Knowledge Base*. [database online] University of Washington, Seattle. Available at <http://www.geneclinics.org>.
- National Institutes of Health. NIH Consensus Development Conference Statement. Phenylketonuria. Screening and management. *Pediatrics* 2001;108:972-982.
- Nicklas JA, O'Neill JP, Jinnah HA, et al. (6 February 2003) Lesch-Nyhan syndrome. In: *GeneClinics: Medical Genetics Knowledge Base*. [database online] University of Washington, Seattle. Available at <http://www.geneclinics.org>.
- Pastores GM. (18 February 2004) Gaucher disease. In: *GeneClinics: Medical Genetics Knowledge Base*. [database online] University of Washington, Seattle. Available at <http://www.geneclinics.org>.
- Patterson MC. (4 February 2004) Niemann-Pick disease, type C. In: *GeneClinics: Medical Genetics Knowledge Base*. [database online] University of Washington, Seattle. Available at <http://www.geneclinics.org>.
- Picker JD, Levy HL. (15 January 2004) Homocystinuria caused by cystathionine beta-synthase deficiency. In: *GeneClinics: Medical Genetics Knowledge Base*. [database online] University of Washington, Seattle. Available at <http://www.geneclinics.org>.
- Portugal CL, Clarke LA. (13 June 2003) Muco-polysaccharidoses type I. In: *GeneClinics: Medical Genetics Knowledge Base*. [database online] University of Washington, Seattle. Available at <http://www.geneclinics.org>.
- Rapin I. The autistic-spectrum disorders. *N Engl J Med* 2002;347:302-303.
- Saul RA, Tarleton JC. (20 April 2004) Fragile X syndrome. In: *GeneClinics: Medical Genetics Knowledge Base*. [database online] University of Washington, Seattle. Available at <http://www.geneclinics.org>.
- Seven M, Ozkiloglu A, Yuksel A. Dysmorphic face in two siblings with infantile neuroaxonal dystrophy. *Genet Counsel* 2002;13:465-473.
- Shevell M, Ashwal S, Donley D, et al. Practice parameter. Evaluation of the child with global developmental delay. Report of the Quality Standards Committee of the American Academy of Neurology and the Practice Committee of the Child Neurology Society. *Neurology* 2003;60:367-380.
- Stibler H, Stephani U, Kutsch U. Carbohydrate-deficient glycoprotein syndrome—a fourth subtype. *Neuropediatrics* 1995;26:235-237.
- Thorburn DR, Rahman S. (30 October 2003) Mitochondrial DNA-associated Leigh syndrome and NARP. In: *GeneClinics: Medical Genetics Knowledge Base*. [database online] University of Washington, Seattle. Available at <http://www.geneclinics.org>.
- van der Knaap MS, Valk J, Barth PG, et al. Leukoencephalopathy with swelling in children and adolescents. MRI patterns and differential diagnosis. *Neuroradiology* 1995;37:679-686.
- Wattendorf DJ, Kraemer KH. (24 February 2004) Xeroderma pigmentosa. In: *GeneClinics: Medical Genetics Knowledge Base*. [database online] University of Washington, Seattle. Available at <http://www.geneclinics.org>.
- Weiner DM, Ewalt DE, Roach ES, Hensle TW. The tuberous sclerosis complex. A comprehensive review. *J Am Coll Surg* 1998;187:548-561.
- Weglage J, Pietsch M, Feldmann R, et al. Normal clinical outcome in untreated subjects with mild hyperphenylalaninemia. *Pediatr Res* 2001;49:532-536.
- Wenger DA, Coppola BS. (25 November 2002) Krabbe disease. In: *GeneClinics: Medical Genetics Knowledge Base*. [database online] University of Washington, Seattle. Available at <http://www.geneclinics.org>.
- Wisniewski KE. (27 January 2004) Neuronal ceroid-lipofuscinoses. In: *GeneClinics: Medical Genetics Knowledge Base*. [database online] University of Washington, Seattle. Available at <http://www.geneclinics.org>.
- Zoghbi HY. (11 February 2004) Rett syndrome. In: *GeneClinics: Medical Genetics Knowledge Base*. [database online] University of Washington, Seattle. Available at <http://www.geneclinics.org>.

Chapter 6

The Hypotonic Infant

TONE IS THE resistance of muscle to stretch. Clinicians test two kinds of tone: phasic and postural. *Phasic tone* is a rapid contraction in response to a high-intensity stretch. The tendon reflex response tests phasic tone. Striking the patellar tendon briefly stretches the quadriceps muscle. The spindle apparatus, sensing the stretch, sends an impulse through the sensory nerve to the spinal cord. This information is transmitted to the alpha motor neuron, and the quadriceps muscle contracts (*monosynaptic reflex*). *Postural tone* is the prolonged contraction of antigravity muscles in response to the low-intensity stretch of gravity. When postural tone is depressed, the trunk and limbs cannot maintain themselves against gravity, and the infant appears hypotonic.

The maintenance of normal tone requires intact central and peripheral nervous systems. Hypotonia is a common symptom of neurological dysfunction and occurs in diseases of the brain, spinal cord, nerves, and muscles (Table 6-1). One anterior horn cell and all the muscle fibers that it innervates compose a *motor unit*. The motor unit is the unit of force. Weakness is a symptom of all motor unit disorders. A primary disorder of the anterior horn cell body is a *neuronopathy*, a primary disorder of the axon or its myelin covering is a *neuropathy*, and a primary disorder of the muscle fiber is a *myopathy*. In infancy and childhood, cerebral disorders far outnumber motor unit disorders. The term *cerebral hypotonia* encompasses all causes of postural hypotonia caused by a cerebral disease or defect.

Appearance of Hypotonia

When lying supine, all hypotonic infants look similar, regardless of the underlying cause or

location of the abnormality within the nervous system. Spontaneous movement is lacking, full abduction of the legs places the lateral surface of the thighs against the examining table, and the arms lie either extended at the sides of the body or flexed at the elbow with the hands beside the head. Pectus excavatum is present when the infant has long-standing weakness in the chest wall muscles. Infants who lie motionless eventually develop flattening of the occiput and loss of hair on the portion of the scalp that is in constant contact with the crib sheet. When placed in a sitting posture, the head falls forward, the shoulders droop, and the limbs hang limply.

Newborns who are hypotonic in utero may be born with hip dislocation, multiple joint contractures (*arthrogryposis*), or both. Hip dislocation is a common feature of intrauterine hypotonia. The forceful contraction of muscles pulling the femoral head into the acetabulum is a requirement of normal hip joint formation. Arthrogryposis varies in severity from clubfoot, the most common manifestation, to symmetrical flexion deformities of all limb joints. Joint contractures are a nonspecific consequence of intrauterine immobilization. Among the several disorders that equally decrease fetal movement, however, some commonly produce arthrogryposis and others never do. Table 6-2 summarizes the differential diagnosis of arthrogryposis. As a rule, newborns with arthrogryposis who require respiratory assistance do not survive extubation unless the underlying disorder is myasthenia. The traction response, vertical suspension, and horizontal suspension further evaluate tone in infants who appear hypotonic at rest.

TABLE 6-1
Differential Diagnosis of Infantile Hypotonia

Cerebral hypotonia	Infantile neuronal degeneration
Benign congenital hypotonia	Neurogenic arthrogryposis
Chromosome disorders	Polyneuropathies
Prader-Willi syndrome	Congenital hypomyelinating neuropathy
Trisomy	Giant axonal neuropathy (see Chapter 7)
Chronic nonprogressive encephalopathy	Hereditary motor-sensory neuropathies (see Chapter 7)
Cerebral malformation	Disorders of neuromuscular transmission
Perinatal distress	Familial infantile myasthenia
Postnatal disorders	Infantile botulism
Peroxisomal disorders	Transitory myasthenia gravis
Cerebrohepatorenal syndrome (Zellweger syndrome)	Fiber-type disproportion myopathies
Neonatal adrenoleukodystrophy	Central core disease
Other genetic defects	Congenital fiber-type disproportion myopathy
Familial dysautonomia	Myotubular (centronuclear) myopathy
Oculocerebrorenal syndrome (Lowe syndrome)	Acute
Other metabolic defects	Chronic
Acid maltase deficiency (see "Metabolic Myopathies")	Nemaline (rod) myopathy
Infantile GM ₁ gangliosidosis (see Chapter 5)	Autosomal dominant
Spinal cord disorders	Autosomal recessive
Spinal muscular atrophies	Metabolic myopathies
Acute infantile	Acid maltase deficiency
Autosomal dominant	Cytochrome-c oxidase deficiency
Autosomal recessive	Muscular dystrophies
Cytochrome-c oxidase deficiency	Bethlem myopathy (see Chapter 7)
X-linked	Congenital dystrophinopathy (see Chapter 7)
Chronic infantile	Congenital muscular dystrophy
Autosomal dominant	Merosin deficiency primary
Autosomal recessive	Merosin deficiency secondary
Congenital cervical spinal muscular atrophy	Merosin positive
	Congenital myotonic dystrophy

Traction Response

The traction response is the most sensitive measure of postural tone and is testable in premature newborns within an isolette. Grasping the hands and pulling the infant toward a sitting

position initiates the response. A normal term infant lifts the head from the surface immediately with the body. When attaining the sitting position, the head is erect in the midline for a few seconds. During traction, the examiner should feel the infant pulling back against traction and observe flexion at the elbow, knee, and ankle. The traction response is not present in premature newborns of less than 33 weeks' gestation. After 33 weeks, the neck flexors show increasing success in lifting the head. At term, only minimal head lag is present; after attaining the sitting posture, the head may continue to lag or may be erect briefly, then fall forward. The presence of more than minimal head lag and of failure to counter traction by flexion of the limbs in the term newborn is abnormal and indicates hypotonia.

TABLE 6-2
Differential Diagnosis of Arthrogryposis

Cerebral malformations
Cerebrohepatorenal syndrome
Chromosomal disorders
Fetal, non-nervous system causes
Motor unit disorders
Congenital benign spinal muscular atrophy
Congenital cervical spinal muscular atrophy
Congenital fiber-type disproportion myopathy
Congenital hypomyelinating neuropathy
Congenital muscular dystrophy
Genetic myasthenic syndromes
Infantile neuronal degeneration
Myotonic dystrophy
Neurogenic arthrogryposis
Phosphofructokinase deficiency
Transitory neonatal myasthenia
Nonfetal causes

Vertical Suspension

To perform vertical suspension, the examiner places both hands in the infant's axillae and, without grasping the thorax, lifts straight up. The muscles of the shoulders should have sufficient strength to press down against the exam-

iner's hands and allow the infant to suspend vertically without falling through. While in vertical suspension, the head is erect in the midline with flexion at the knee, hip, and ankle joints. When suspending a hypotonic infant vertically, the head falls forward, the legs dangle, and the infant may slip through the examiner's hands because of weakness in the shoulder muscles.

Horizontal Suspension

When suspended horizontally, a normal infant keeps the head erect; maintains the back straight; and flexes the elbow, hip, knee, and ankle joints. A healthy full-term newborn makes intermittent efforts to maintain the head erect, the back straight, and the limbs flexed against gravity. Hypotonic newborns and infants drape over the examiner's hands, with the head and legs hanging limply.

Approach to Diagnosis

The first step in diagnosis is to determine whether the disease location is in the brain, spine, or motor unit. More than one site may be involved (Table 6-3). The brain and the peripheral nerves are concomitantly involved in some lysosomal and mitochondrial disorders. Brain and skeletal muscles are abnormal in infants with acid maltase deficiency and neonatal myotonic dystrophy. Newborns with severe hypoxic-ischemic encephalopathy may have hypoxic injury to the spinal cord and the brain. Several motor unit disorders produce sufficient hypotonia at birth to impair respiration and cause perinatal asphyxia (Table 6-4). Such infants may have cerebral hypotonia as well. Newborns with spinal cord injuries are frequently the product of long, difficult deliveries in which brachial plexus

TABLE 6-3
Combined Cerebral and Motor Unit Hypotonia

Acid maltase deficiency
Familial dysautonomia
Giant axonal neuropathy
Hypoxic-ischemic encephalomyopathy
Infantile neuronal degeneration
Lipid storage diseases
Mitochondrial (respiratory chain) disorders
Neonatal myotonic dystrophy
Perinatal asphyxia secondary to motor unit disease

TABLE 6-4
Motor Unit Disorders with Perinatal Respiratory Distress

Acute infantile spinal muscular atrophy
Congenital hypomyelinating neuropathy
Congenital myotonic dystrophy
Familial infantile myasthenia
Neurogenic arthrogyrosis
X-linked myotubular myopathy

injuries and hypoxic-ischemic encephalopathy are concomitant problems.

Clues to the Diagnosis of Cerebral Hypotonia

Cerebral hypotonia in newborns usually does not pose diagnostic difficulty. The history and physical examination identify the problem. Many clues to the diagnosis of cerebral hypotonia exist (Table 6-5). Most important is the presence of other abnormal brain functions, including decreased consciousness and seizures. Cerebral malformation is the likely explanation for hypotonia in an infant with dysmorphic features or with malformations in other organs.

A tightly fistled hand in which the thumb is constantly enclosed by the other fingers and does not open spontaneously (*fisting*) and adduction of the thigh so that the legs are crossed when the infant is suspended vertically (*scissoring*) are precursors of spasticity and indicate cerebral dysfunction. Eliciting postural reflexes in newborns and infants when spontaneous movement is lacking indicates cerebral hypotonia. In some acute encephalopathies, and especially in metabolic disorders, the Moro reflex may be exaggerated. The tonic neck reflex is an important indicator of cerebral abnormality if the responses are excessive, are obligatory, or persist beyond 6 months of age.

TABLE 6-5
Clues to Cerebral Hypotonia

Abnormalities of other brain functions
Dysmorphic features
Fisting of the hands
Malformations of other organs
Movement through postural reflexes
Normal or brisk tendon reflexes
Scissoring on vertical suspension

When hemispheric damage is severe but the brainstem is intact, turning the head produces full extension of both ipsilateral limbs and tight flexion on the contralateral side. An obligatory reflex is one in which these postures are maintained as long as the head is kept rotated. Tendon reflexes are generally normal or brisk, and clonus may be present.

Clues to Motor Unit Disorders

Disorders of the motor unit are not associated with malformations of other organs except for joint deformities and the maldevelopment of bone structures. The face sometimes looks dysmorphic when facial muscles are weak or when the jaw is underdeveloped.

Tendon reflexes are absent or depressed. Loss of tendon reflexes that is out of proportion to weakness more likely is caused by neuropathy than myopathy, whereas diminished reflexes that are consistent with the degree of weakness more often are caused by myopathy than neuropathy (Table 6-6). Muscle atrophy suggests motor unit disease but does not exclude the possibility of cerebral hypotonia. Failure of growth and atrophy can be considerable in brain-damaged infants. The combination of atrophy and fasciculations is strong evidence of denervation. The observation of fasciculations in newborns and infants is often restricted to the tongue, however, and distinguishing fasciculations from normal random movements of an infant's tongue is difficult unless atrophy is present.

Postural reflexes, such as the tonic neck and Moro reflex, are not impossible on weak muscles. The motor unit is the final common pathway of tone; limbs that do not move voluntarily cannot move reflexively.

Cerebral Hypotonia

Hypotonia is a feature of almost every cerebral disorder in newborns and infants. This section does not discuss conditions in which the major

symptoms are states of decreased consciousness, seizures, and progressive psychomotor retardation. The discussion instead focuses on conditions in which hypotonia is sufficiently prominent that the examining physician may consider the possibility of motor unit disease.

Benign Congenital Hypotonia

The term *benign congenital hypotonia* is retrospective and refers to infants who are hypotonic at birth or shortly thereafter and later have normal tone. It encompasses many different pathological processes that affect the brain, the motor unit, or both. Most affected children have cerebral hypotonia. An increased incidence of mental retardation, learning disabilities, and other sequelae of cerebral abnormality are evident later in life, despite the recovery of normal muscle tone.

Chromosome Disorders

Despite considerable syndrome diversity, common characteristics of autosomal chromosome aberrations in newborns are dysmorphic features of the hands and face and profound hypotonia. For this reason, any hypotonic newborn with dysmorphic features of the hands and face, with or without other organ malformation, requires chromosome studies.

Prader-Willi Syndrome

Hypotonia, hypogonadism, mental retardation, short stature, and obesity characterize Prader-Willi syndrome. Approximately 70% of children with this syndrome have an interstitial deletion of the paternally contributed proximal long arm of chromosome 15(q11-13). The basis for the syndrome in most patients who do not have a deletion is *maternal disomy* (both chromosomes 15 are from the mother). Paternal disomy of chromosome 15 causes *Angelman syndrome*.

CLINICAL FEATURES. Decreased fetal movement occurs in 75% of pregnancies, hip dislocation in 10%, and clubfoot in 6%. Hypotonia is profound at birth, and tendon reflexes are absent or greatly depressed. Feeding problems are invariable, and prolonged nasogastric tube feeding is common (Table 6-7). Cryptorchidism is present in 84% and hypogonadism in 100%. Some newborns lack the associated features, however, and show only hypotonia (Miller et al, 1999).

Hypotonia and feeding difficulty persist until 8 to 11 months of age, then are replaced by rela-

TABLE 6-6
Clues to Motor Unit Disorders

Absent or depressed tendon reflexes
Failure of movement on postural reflexes
Fasciculations
Muscle atrophy
No abnormalities of other organs

TABLE 6-7
Difficulty of Feeding in the Alert Newborn

Congenital myotonic dystrophy
Familial dysautonomia
Genetic myasthenic syndromes
Hypoplasia of bulbar motor nuclei (see Chapter 17)
Infantile neuronal degeneration
Myophosphorylase deficiency
Neurogenic arthrogryposis
Prader-Willi syndrome
Transitory neonatal myasthenia

tively normal muscle tone and insatiable hunger. Delayed developmental milestones and later mental retardation are constant features. Minor abnormalities that become more obvious during infancy include a narrow bifrontal diameter of the skull, strabismus, almond-shaped eyes, enamel hypoplasia, and small hands and feet. Obesity is the rule during childhood. The combination of obesity and minor abnormalities of the face and limbs produces a resemblance among children with this syndrome.

Major and minor clinical criteria are established (Table 6-8). Weighting of major criteria is 1 point each; minor criteria are ½ point each.

For children younger than 3 years old, 5 points are required for diagnosis, 4 of which must be major criteria. For children 3 years old and older, 8 points are required for diagnosis, at least 5 of which must be major criteria. Supportive findings increase or decrease the level of suspicion of the diagnosis.

DIAGNOSIS. DNA-based *methylation* testing detects the absence of the paternally contributed region on *chromosome* 15q11.2-q13 associated with Prader-Willi syndrome.

MANAGEMENT. Dietary supervision helps control obesity. Specific treatment is not available.

Chronic Nonprogressive Encephalopathy

Cerebral dysgenesis may be due to known or unknown noxious environmental agents, chromosomal disorders, or genetic defects. In the absence of an acute encephalopathy, hypotonia may be the only symptom at birth or during early infancy. Hypotonia is usually worse at birth and improves with time. Cerebral dysgenesis is suspected when hypotonia is associated with malformations in other organs or abnormalities in head size and shape. Magnetic resonance imaging (MRI) of the head is advisable when cerebral malformation is suspected. The

TABLE 6-8
Criteria for Clinical Diagnosis of Prader-Willi Syndrome

Major Criteria

Neonatal and infantile central hypotonia with poor suck and improvement with age
Feeding problems or failure to thrive in infancy, with need for gavage or other special feeding techniques
Onset of rapid weight gain between 12 months and 6 years of age, causing central obesity
Hyperphagia
Characteristic facial features: narrow bifrontal diameter, almond-shaped palpebral fissures, down-turned mouth
Hypogonadism
Genital hypoplasia: small labia minora and clitoris in girls; hypoplastic scrotum and cryptorchidism in boys
Incomplete and delayed puberty
Infertility
Developmental delay/mild-to-moderate mental retardation/multiple learning disabilities

Minor Criteria

Decreased fetal movement and infantile lethargy, improving with age

Typical behavior problems, including temper tantrums, obsessive-compulsive behavior, stubbornness, rigidity, stealing, and lying
Sleep disturbance/sleep apnea
Short stature for the family by 15 years of age
Hypopigmentation
Small hands and feet for height age
Narrow hands with straight ulnar border
Esotropia, myopia
Thick, viscous saliva
Speech articulation defects
Skin picking

Supportive Findings

High pain threshold
Decreased vomiting
Scoliosis or kyphosis or both
Early adrenarche
Osteoporosis
Unusual skill with jigsaw puzzles
Normal neuromuscular studies (e.g., muscle biopsy, EMG, NCV)

EMG, electromyogram; NCV, nerve conduction velocity.

From Gunay-Aygun M, Schwartz S, Heeger S, et al. The changing purpose of Prader-Willi syndrome clinical diagnostic criteria and proposed revised criteria. *Pediatrics* 2001;108:E92.

identification of a cerebral malformation provides useful information not only for prognosis, but also on the feasibility of aggressive therapy to correct malformations in other organs.

Brain injuries occur in the perinatal period and, less commonly, throughout infancy secondary to anoxia, hemorrhage, infection, and trauma. The sudden onset of hypotonia in a previously well newborn or infant, with or without signs of encephalopathy, always suggests a cerebral cause. A premature newborn showing a decline in spontaneous movement and tone may have an intraventricular hemorrhage. Hypotonia is an early feature of meningitis in full-term and premature newborns. Tendon reflexes may be diminished or absent during the acute phase.

Genetic Disorders

Familial Dysautonomia

Familial dysautonomia, or *Riley-Day syndrome*, is a genetic disorder transmitted by autosomal recessive inheritance in Ashkenazi Jews. The abnormal gene maps to chromosome 9q31-q33. Similar clinical syndromes, which are often sporadic and with an unknown pattern of inheritance, occur in non-Jewish infants.

CLINICAL FEATURES. In the newborn, the important clinical features are meconium aspiration, poor or no sucking reflex, and hypotonia. The causes of hypotonia are disturbances in the brain, dorsal root ganglia, and peripheral nerves. Tendon reflexes are hypoactive or absent. The feeding difficulty is unusual and provides a diagnostic clue. Sucking and swallowing are normal separately but cannot be coordinated for effective feeding. Other noticeable clinical features of the newborn or infant are pallor, temperature instability, absence of fungiform papillae of the tongue, diarrhea, and abdominal distention. Poor weight gain and lethargy, episodic irritability, absent corneal reflexes, labile blood pressure, and failure to produce overflow tears completes the clinical picture.

DIAGNOSIS. Ophthalmological examination is useful to detect the signs of postganglionic parasympathetic denervation: supersensitivity of the pupil, shown by a positive miotic response to 0.1% pilocarpine or 2.5% methacholine; corneal insensitivity; and absence of tears.

MANAGEMENT. Treatment is symptomatic. Bethanechol (*Urecholine*), 1 to 2 mg/kg/day orally, provides limited help. The basis for use is the observation that injections of acetylcholine provide transitory relief of some symptoms.

Longevity has increased because of improved treatment of symptoms.

Oculocerebrorenal Syndrome (Lowe Syndrome)

Transmission of the oculocerebrorenal syndrome is by X-linked recessive inheritance (Xq26.1). Female carriers show partial expression in the form of minor lenticular opacities (Lin et al, 1999).

CLINICAL FEATURES. The important features at birth are hypotonia and hyporeflexia, sometimes associated with congenital cataracts and glaucoma. Table 16-2 lists the differential diagnosis of cataracts in newborns and infants. Features that appear later in infancy are mental retardation and a progressive disorder of the renal tubules resulting in metabolic acidosis, proteinuria, aminoaciduria, and defective acidification of the urine. Many infants die after failing to thrive. Others have mild symptoms, including growth retardation, borderline intellectual function, mild renal disturbances, and late-onset cataract formation. Life expectancy is normal in milder cases.

DIAGNOSIS. Diagnosis depends on recognition of the clinical constellation. MRI shows diffuse and irregular foci of increased signal consistent with demyelination.

MANAGEMENT. Most patients require alkalization therapy, and many benefit from supplements of potassium, phosphate, calcium, and carnitine.

Peroxisomal Disorders

Peroxisomes are subcellular organelles that participate in the biosynthesis of ether phospholipids and bile acids; the oxidation of very-long-chain fatty acids, prostaglandins, and unsaturated long-chain fatty acids; and the catabolism of phytanate, pipercolate, and glycolate. Hydrogen peroxide is a product of several oxidation reactions and is catabolized by the enzyme catalase. Mutations in 11 different *PEX* genes cause this spectrum of disorders. *PEX* genes encode the proteins required for peroxisomal assembly.

The infantile syndromes of peroxisomal dysfunction all are disorders of peroxisomal biogenesis; the intrinsic protein membrane is identifiable, but all matrix enzymes are missing. The prototype, cerebrohepatorenal (Zellweger) syndrome, is a continuum of phenotypes that include neonatal adrenoleukodystrophy (and infantile Refsum disease [see Chapter 16]). The latter are milder variants. Infantile hypotonia is

a prominent feature of peroxisomal biogenesis disorders (Steinberg et al, 2003).

CLINICAL FEATURES. Affected newborns are poorly responsive and have severe hypotonia, arthrogryposis, and dysmorphic features. Sucking and crying are weak. Tendon reflexes are hypoactive or absent. Characteristic craniofacial abnormalities include a pear-shaped head owing to a high forehead and an unusual fullness of the cheeks, widened sutures, micrognathia, a high-arched palate, flattening of the bridge of the nose, and hypertelorism. Organ abnormalities include biliary cirrhosis, polycystic kidneys, retinal degeneration, and cerebral malformations secondary to abnormalities of neuronal migration.

Limited extension of the fingers (camptodactyly) and flexion deformities of the knee and ankle characterize the arthrogryposis. Neonatal seizures are common. Bony stippling (chondrodysplasia punctata) of the patella and other long bones may occur. Older children have retinal dystrophy, sensorineural hearing loss, developmental delay with hypotonia, and liver dysfunction. Infants with Zellweger syndrome are significantly impaired and usually die during the first year of life, usually having made no developmental progress. The clinical course of neonatal adrenoleukodystrophy and infantile Refsum disease is variable; some children can be hypotonic, whereas others learn to walk and talk. The condition is often slowly progressive.

Difficult-to-control seizures often begin shortly after birth but may begin anytime during infancy. Death from aspiration, gastrointestinal bleeding, or liver failure usually occurs within 6 months to 1 year.

DIAGNOSIS. Very-long-chain fatty acids plasma concentrations are increased, levels of plasmalogens in red blood cell membranes are reduced, and cultured skin fibroblasts show a reduced rate of plasmalogen synthesis. Plasma and urine show increased concentrations of pipercolic acid, and the urine contains excessive amounts of bile acid intermediates.

MANAGEMENT. Treatment is symptomatic. Anticonvulsants are given for seizures, and vitamin K is given for bleeding disorders.

Other Metabolic Defects

Infantile hypotonia is rarely the only manifestation of inborn errors of metabolism. Acid maltase deficiency causes a severe myopathy and is discussed with other metabolic myopathies. Hypotonia may be the only initial feature of generalized GM₁ gangliosidosis (see Chapter 5).

Spinal Cord Disorders

Hypoxic-Ischemic Myelopathy

Hypoxic-ischemic encephalopathy is an expected outcome in severe perinatal asphyxia (see Chapter 1). Affected newborns are hypotonic and areflexic. The main cause of hypotonia is the cerebral injury, but spinal cord dysfunction also contributes. Concurrent ischemic necrosis of gray matter occurs in the spinal cord and in the brain. The spinal cord component is evident on postmortem examination and by electromyogram (EMG) in survivors.

Spinal Cord Injury

Only in the newborn does spinal cord injury enter the differential diagnosis of hypotonia. Injuries to the cervical spinal cord occur almost exclusively during vaginal delivery; approximately 75% are associated with breech presentation and 25% with cephalic presentation. Because the injuries are always associated with a difficult and prolonged delivery, decreased consciousness is common, and hypotonia is falsely attributed to asphyxia or cerebral trauma. The presence of impaired sphincter function and loss of sensation below the midchest should suggest myelopathy, however.

Injuries in Breech Presentation

Traction injuries to the lower cervical and upper thoracic regions of the cord occur almost exclusively when the angle of extension of the fetal head exceeds 90°. The risk of spinal cord injury to a fetus in breech position whose head is hyperextended is greater than 70%. In such cases, delivery always should be by cesarean section. The tractional forces applied to the extended head are sufficient not only to stretch the cord, but also to herniate the brainstem through the foramen magnum. In addition, the hyperextended position compromises the vertebral arteries as they enter the skull.

The spectrum of pathological findings varies from edema of the cord without loss of anatomical continuity to massive hemorrhage (epidural, subdural, and intramedullary). Hemorrhage is greatest in the lower cervical and upper thoracic segments but may extend the length of the cord. Concurrent hemorrhage in the posterior fossa and laceration of the cerebellum also may be present.

CLINICAL FEATURES. Mild tractional injuries, which cause cord edema but not intraparenchymal

hemorrhage or loss of anatomical continuity, produce few clinical features. The main feature is hypotonia, often falsely attributed to asphyxia.

Hemorrhage into the posterior fossa accompanies severe tractional injuries. Affected newborns are unconscious and atonic at birth with flaccid quadriplegia and diaphragmatic breathing. Few survive the neonatal period. Injuries restricted to the low cervical and high thoracic segments produce near-normal strength in the biceps muscles and weakness of the triceps muscles. The result is flexion of the arms at the elbows and flaccid paraplegia. Spontaneous movement and tendon reflexes in the legs are absent, but foot withdrawal from pinprick may occur as a spinal reflex. The infant has a distended bladder and dribbling of urine. Absence of sweating below the injury marks the sensory level, which is difficult to measure directly.

DIAGNOSIS. Radiographs of the vertebrae show no abnormalities because bone displacement does not occur. MRI of the spine shows intraspinal edema and hemorrhage. Unconscious newborns generally are thought to have intracerebral hemorrhage or asphyxia (see Chapter 2), and the diagnosis of spinal cord injury may not be considered until consciousness is regained and the typical motor deficits are observed. Even then, the suspicion of a neuromuscular disorder may exist until disturbed bladder function and the development of progressive spastic paraplegia alert the physician to the correct diagnosis.

MANAGEMENT. The treatment of spinal cord traction injuries of the newborn is similar to the management of cord injuries in older children (see Chapter 12).

Injuries in Cephalic Presentation

Twisting of the neck during midforceps rotation causes high cervical cord injuries in cephalic presentation. The trunk fails to rotate with the head. The risk is greatest when amniotic fluid is absent because of delay from the time of membrane rupture to the application of forceps. The spectrum of injury varies from intraparenchymal hemorrhage to complete transection. Transection usually occurs at the level of a fractured odontoid process, with atlantoaxial dislocation.

CLINICAL FEATURES. Newborns are flaccid and fail to breathe spontaneously. Infants with milder injuries may have shallow, labored respirations, but all require assisted ventilation at birth. Most are unconscious at birth owing to edema in the brainstem. When infants are conscious, eye movements, sucking, and the withdrawal reflex are the only movements observed.

Tendon reflexes are at first absent but later become exaggerated if the infant survives. Bladder distention and overflow incontinence occur. Priapism may be present. Sensation is difficult to assess because the withdrawal reflex is present. Death from sepsis or respiratory complications generally occurs in the first week. Occasionally, children have survived for several years.

DIAGNOSIS. The appearance of children with high cervical cord injuries suggests a neuromuscular disorder, especially infantile spinal muscular atrophy (SMA), because the limbs are flaccid, but the eye movements are normal. EMG of the limbs should exclude that possibility. Radiographs of the cervical vertebrae usually do not show abnormalities, but MRI shows marked thinning or disruption of the cord at the site of injury.

MANAGEMENT. Intubation and respiratory assistance should begin before diagnosis. Chapter 12 discusses management of spinal cord transection.

Motor Unit Disorders

Evaluation of Motor Unit Disorders

In the diagnosis of cerebral hypotonia in infants, the choice of laboratory tests varies considerably, depending on the disease entity (Table 6-9). This is not the case with motor unit hypotonia. The available battery of tests readily defines the anatomy and cause of pathological processes affecting the motor unit. DNA-based testing is now commercially available for many disorders and preferable to muscle or nerve biopsy.

Serum Creatine Kinase

Increased serum concentrations of creatine kinase (CK) reflect skeletal or cardiac muscle

TABLE 6-9
Evaluation of Motor Unit Disorders

DNA-based testing
Edrophonium chloride (Tensilon test)
Electrodiagnosis
Electromyography
Nerve conduction studies
Repetitive stimulation
Muscle biopsy
Nerve biopsy
Serum creatine kinase

necrosis. Obtain blood for CK determination before the performance of EMG or muscle biopsy. Both transiently elevate the serum concentration of CK. The basis for laboratory reference values for normal serum concentration is nonambulatory adults. Normal values tend to be higher in an ambulatory population, especially after exercise. The serum concentration of CK in severely asphyxiated newborns can be 1000 IU/L secondary to acidosis. Even normal newborns have a higher than normal concentration during the first 24 hours postpartum. A normal CK level in a hypotonic infant is strong evidence against a rapidly progressive myopathy, but it does not exclude fiber-type disproportion myopathies and some metabolic myopathies. Conversely, expect mild elevations in CK concentration in rapidly progressive SMA.

Electrodiagnosis

EMG is extremely useful in the diagnosis of infantile hypotonia when an experienced physician performs the study. It enables the prediction of the final diagnosis in most infants younger than 3 months old with hypotonia of motor unit origin. Hypotonic infants with normal EMG findings rarely show abnormalities on muscle biopsy. The needle portion of the study helps to distinguish myopathic from neuropathic processes. The appearance of brief, small-amplitude, polyphasic potentials characterizes myopathies, whereas the presence of denervation potentials at rest (fibrillations, fasciculations, sharp waves) and motor unit potentials that are large, prolonged, and polyphasic characterizes denervation. Studies of nerve conduction velocity are useful in distinguishing axonal from demyelinating neuropathies; demyelinating neuropathies cause greater slowing of conduction velocity. Repetitive nerve stimulation studies show disturbances in neuromuscular transmission.

Muscle Biopsy

The muscle selected for biopsy should be weak but still able to contract. Histochemical analysis is essential for the complete evaluation of muscle histology. The demonstration of fiber types, muscle proteins, and storage materials is required. The intensity of the reaction to myosin adenosine triphosphatase (ATPase) at pH 9.4 arbitrarily divides skeletal muscle into two fiber types. Type I fibers react weakly to ATPase, are characterized by oxidative metabolism, and

serve a tonic function. Type II fibers react intensely to ATPase, use glycolytic metabolism, and serve a phasic function. Type I and II fibers are generally equal in number and randomly distributed in each fascicle. Abnormalities in fiber type number, fiber type size, or both characterize some disorders.

Chapter 7 describes and illustrates the structural proteins of muscle. Merosin is the main protein associated with congenital muscular dystrophy (CMD). The important storage materials identified in skeletal muscle are glycogen and lipid. In most storage disorders, vacuoles are present in the fibers that contain the abnormal material. Light microscopy reveals the vacuoles, and histochemical reactions identify the specific material.

Nerve Biopsy

Sural nerve biopsy is useless in the diagnosis of infantile hypotonia and is never performed at any age unless electrodiagnosis discloses sural neuropathy. Its main use is in the diagnosis of vasculitis.

Tensilon Test

Edrophonium chloride (*Tensilon*) is a rapidly acting anticholinesterase that temporarily reverses weakness in patients with myasthenia. Ptosis and oculomotor paresis are the only functions that are reliably tested. Rare patients are supersensitive to edrophonium chloride and may stop breathing because of depolarization of end plates or an abnormal vagal response. Equipment for mechanical ventilation should always be available when performing the test. In newborns, a subcutaneous injection of 0.15 mg/kg produces a response within 10 minutes. In infants, the drug is administered intravenously at a dose of 0.2 mg/kg and reverses weakness within 1 minute.

Spinal Muscular Atrophies

The SMA are genetic disorders in which anterior horn cells in the spinal cord and motor nuclei of the brainstem are progressively lost. The mechanism is probably a defect in programmed cell death, wherein the deletion of cells, a normal process during gestation, continues after birth. The onset of weakness may be any age from birth to adult life. Some disorders show a generalized distribution of weakness, and others affect specific muscle groups. Disorders with onset in infancy usually cause

generalized weakness and hypotonia. Infantile SMA is a common motor unit disorder causing infantile hypotonia.

Infantile Spinal Muscular Atrophy (SMA I)

The clinical subtypes of autosomal recessive SMA are a continuum of disease. The severe type (SMA I), which always begins before age 6 months, is discussed in this section. The intermediate (SMA II) and juvenile (SMA III) types are discussed in Chapter 7. The *SMN1* (*survival motor neuron*) gene on chromosome 5q12.2-q13.3 is the primary SMA disease-causing gene (Prior and Russman, 2003). Normal individuals have the *SMN1* gene and the *SMN2* gene, an almost identical copy of the *SMN1* gene, on the same chromosome. The overlap in clinical features between the three types is considerable, and two different clinical phenotypes can occur in a single family. The course among siblings is usually the same, but SMA I and II sometimes occur among siblings and are then attributed to the number of copies of the *SMN2* gene.

CLINICAL FEATURES. The age at onset is birth to 6 months. Reduced fetal movement may occur when neuronal degeneration begins in utero. Affected newborns have generalized weakness involving proximal more than distal muscles, hypotonia, and areflexia. Newborns who are hypotonic in utero and weak at birth may have difficulty adapting to extrauterine life and experience postnatal asphyxia and encephalopathy. Most breathe adequately at first and appear alert despite the generalized weakness because facial expression is relatively well preserved, and extraocular movement is normal. Some newborns have paradoxical respiration because intercostal paralysis and thoracic collapse occur before diaphragmatic movement is impaired, whereas others have diaphragmatic paralysis as an initial feature. Despite intrauterine hypotonia, arthrogryposis is not present. Neurogenic arthrogryposis may be a distinct entity and is described separately in this chapter.

When weakness begins in infancy, the decline in strength can be sudden or decremental. At times, the infant seems to improve because of normal cerebral development, but the progression of weakness is relentless. The tongue may show atrophy and fasciculations, but these are difficult to see in newborns. After the gag reflex is lost, feeding becomes difficult, and death results from aspiration and pneumonia. When weakness is present at birth, death usually occurs by 6 months of age, but the course is vari-

able when symptoms develop after 3 months of age. Some infants attain sitting balance but do not walk. Survival time is not predictable.

DIAGNOSIS. Molecular genetic testing of the *SMN1* gene is available. About 95% of individuals with SMA are *homozygous* for the absence of exon 7 and 8 of *SMN1*, and about 5% are *compound heterozygotes* for absence of exons 7 and 8 of *SMN1* and a *point* mutation in *SMN1* (Prior and Russman, 2003). The serum concentration of CK is usually normal, but may be mildly elevated in infants with rapidly progressive weakness. EMG studies show fibrillations and fasciculations at rest, and the mean amplitude of motor unit potentials is increased. Motor nerve conduction velocities are usually normal.

Muscle biopsy is unnecessary because of the commercial availability of DNA-based testing. The pathological findings in skeletal muscle are characteristic. Routine histological stains show groups of small fibers adjacent to groups of normal-sized or hypertrophied fibers. When the myosin ATPase reaction is applied, all hypertrophied fibers are type I, whereas medium-sized and small fibers are a mixture of types I and II (Figure 6-1). Type grouping, a sign of reinnervation in which large numbers of fibers of the same type are contiguous, replaces the normal random arrangement of fiber types. Some biopsy specimens show uniform small fibers of both types.

MANAGEMENT. Treatment is supportive. DNA analysis of chorionic villus biopsy specimens provides prenatal diagnosis.

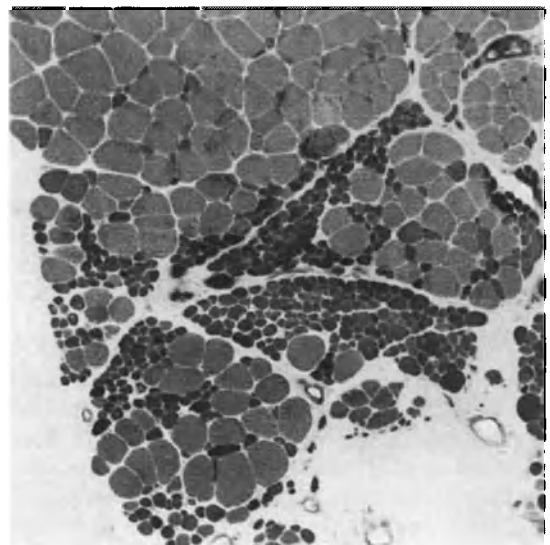


Figure 6-1. Infantile spinal muscular atrophy (ATPase reaction). The normal random distribution pattern of fiber types is lost. Groups of large type I fibers (light shade) are adjacent to groups of small type II fibers (dark shade).

Infantile Spinal Muscular Atrophy with Respiratory Distress Type 1

Originally classified as a variant of SMA I, infantile SMA with respiratory distress type 1 is a distinct genetic disorder resulting from mutations in the gene encoding the immunoglobulin μ -binding protein 2 on chromosome 11q13 (Grohmann et al, 2003).

CLINICAL FEATURES. Intrauterine growth retardation, weak cry, and foot deformities are the initial features. Most infants come to attention between 1 and 6 months of age because of respiratory distress secondary to diaphragmatic weakness, weak cry, and progressive distal weakness of the legs. Sensory and autonomic nerve dysfunction accompanies the motor weakness. Sudden infant death occurs without respiratory support.

DIAGNOSIS. Consider the diagnosis in infants with a SMA I phenotype lacking the 5q gene abnormality and infants with distal weakness and respiratory failure.

MANAGEMENT. Treatment is supportive.

Congenital Cervical Spinal Muscular Atrophy

Congenital cervical SMA is a rare sporadic disorder characterized by severe weakness and wasting confined to the arms. Contractures of the shoulder, elbow, and wrist joints are present at birth. The legs are normal. Postnatal progression of weakness does not occur. Central nervous system function is normal. This cervical distribution of weakness usually occurs as a progressive disorder with onset in adolescence (see Chapter 7).

Neurogenic Arthrogryposis

The original use of the term *neurogenic arthrogryposis* was to denote the association of arthrogryposis with infantile SMA. Transmission occurs by autosomal recessive inheritance in some families and by X-linked inheritance in others. Some individuals with autosomal recessive inheritance have deletions in the SMN gene. I am aware of two sets of identical twins in which one twin was born with neurogenic arthrogryposis and the other remained normal. This suggests that some sporadic cases may have nongenetic causes.

Families with X-linked neurogenic arthrogryposis tend to have clinical or pathological features that distinguish them from others. Arthrogryposis may not occur in every affected

family member, weakness or joint deformity may be limited to the legs or arms, and progression is minimal.

CLINICAL FEATURES. In neurogenic arthrogryposis, the most active phase of disease occurs in utero. Severely affected newborns have respiratory and feeding difficulties, and some die of aspiration. The less severely affected ones survive and have little or no progression of their weakness. The respiratory and feeding difficulties lessen with time. Contractures are present in proximal and distal joints. Micrognathia and a high-arched palate may be associated features, and a pattern of facial anomalies suggesting trisomy 18 is present in some newborns. Newborns with respiratory distress at birth may not have a fatal course. Limb weakness may be minimal, and long intervals of stability occur.

DIAGNOSIS. The diagnosis is suspected in newborns with arthrogryposis, normal serum concentrations of CK, and EMG findings compatible with a neuropathic process. Muscle histological examination reveals the typical pattern of denervation and reinnervation. Cranial MRI investigates cerebral malformations in children with microcephaly.

MANAGEMENT. Initiate an intensive program of rehabilitation immediately after birth. Surgical release of contractures is often required.

Cytochrome-*c* Oxidase Deficiency

Cytochrome-*c* oxidase deficiency is clinically heterogeneous. Phenotypes range from isolated myopathy to severe multisystem disease, with onset from infancy to adulthood. A boy with a marked SMA presented with hypotonia, severe axial and limb weakness, and normal bulbar muscle strength (Rubio-Gozalbo et al, 1999). He died at age 5 months from respiratory failure. Electrodiagnosis revealed positive sharp waves and fibrillation potentials with normal motor nerve conduction velocities. Muscle biopsy showed a preponderance of type I fibers, with atrophy of both fiber types. Cytochrome-*c* oxidase activity was absent from all but intrafusal muscle fibers, and the activity was reduced in cultured skin fibroblasts. Western blot analysis showed decreased levels of all cytochrome-*c* oxidase subunits. Analysis of mitochondrial DNA and the SMN gene was unrevealing.

Polyneuropathies

Polyneuropathies are uncommon in childhood and are less common during infancy. Table 6-10 lists the polyneuropathies with onset in infancy.

TABLE 6-10
Polyneuropathies with Possible Onset
in Infancy

Axonal

Familial dysautonomia
 Hereditary motor-sensory neuropathy type II
 (see Chapter 7)
 Idiopathic with encephalopathy (see Chapter 7)
 Infantile neuronal degeneration
 Subacute necrotizing encephalopathy (see Chapters 5
 and 10)

Demyelinating

Acute inflammatory demyelinating polyneuropathy
 (Guillain-Barré syndrome) (see Chapter 7)
 Chronic inflammatory demyelinating polyneuropathy
 (see Chapter 7)
 Congenital hypomyelinating neuropathy
 Globoid cell leukodystrophy (see Chapter 5)
 Hereditary motor-sensory neuropathy type I (see Chapter 7)
 Hereditary motor-sensory neuropathy type III
 (see Chapter 7)
 Metachromatic leukodystrophy (see Chapter 5)

They divide into disorders that primarily affect the myelin (demyelinating) or the axon (axonal). In newborns and infants, the term *demyelinating* also refers to disorders in which myelin has failed to form (hypomyelinating). Only with congenital hypomyelinating neuropathy is infantile hypotonia the initial feature. The others are more likely to start as progressive gait disturbance or psychomotor retardation. Chapter 7 discusses the clinical approach to neuropathy.

**Congenital Hypomyelinating
 Neuropathy**

The term *congenital hypomyelinating neuropathy* encompasses several disorders with similar clinical and pathological features. Sporadic occurrence is the rule, but autosomal recessive inheritance occurs in some families. Congenital hypomyelinating neuropathy results from a congenital impairment in myelin formation. Mutations in the early growth response 2 gene (Warner et al, 1998) or the myelin protein 0 gene (Szigeti et al, 2003) are causative.

CLINICAL FEATURES. The clinical features are indistinguishable from the features of acute infantile SMA. Arthrogryposis may be present. Newborns have progressive flaccid weakness and atrophy of the skeletal muscles, a bulbar palsy that spares extraocular motility, and areflexia. Respiratory insufficiency causes death during infancy.

In some children, failure to meet motor milestones is the initial manifestation. Examination shows diffuse weakness, distal atrophy, and areflexia. Weakness progresses slowly and is not life threatening during childhood. Sensation remains intact.

DIAGNOSIS. The serum concentration of CK is normal, EMG findings are consistent with denervation, and motor nerve conduction velocities are usually less than 10 m/sec. The protein concentration of the cerebrospinal fluid is markedly elevated in almost every case. Screening for mutations in the peripheral myelin protein and P zero myelin genes is essential to separate the genetic causes of this syndrome from those of chronic demyelinating inflammatory demyelinating polyneuropathies.

MANAGEMENT. Some infants with hypomyelinating neuropathies respond to treatment with oral prednisone. One prednisone-treated newborn in my practice became normal clinically and electrophysiologically by 1 year of age. He relapsed several times later in childhood, then responded to prednisone and to intravenous immunoglobulin. Such children may have a congenital form of chronic inflammatory demyelinating neuropathy (see Chapter 7). Whatever the mechanism, treat every affected child with a course of oral prednisone, 2 mg/kg/day. Children who respond become stronger within 4 weeks of starting therapy. Following the initial response, maintain alternate-day therapy, 0.5 mg/kg, for at least 1 year.

**Disorders of Neuromuscular
 Transmission**

Infantile Botulism

Human botulism ordinarily results from eating food contaminated by preformed exotoxin of the organism *Clostridium botulinum*. The exotoxin prevents the release of acetylcholine, causing a cholinergic blockade of skeletal muscle and end organs innervated by autonomic nerves. Infantile botulism is an age-limited disorder in which ingested *C. botulinum* colonizes the intestinal tract and produces toxin in situ. Dietary contamination with honey or corn syrup accounts for almost 20% of cases, but in most the source is not defined (Cherington, 1998).

CLINICAL FEATURES. The clinical spectrum of infantile botulism includes asymptomatic carriers of organisms; mild hypotonia and failure to thrive; severe, progressive, life-threatening paralysis; and sudden infant death. Infected infants are between 2 and 26 weeks of age and

usually live in a dusty environment adjacent to construction or agricultural soil disruption. The highest incidence is between March and October. A prodromal syndrome of constipation and poor feeding is common. Progressive bulbar and skeletal muscle weakness and loss of tendon reflexes develop 4 to 5 days later. Typical features on examination include diffuse hypotonia, ptosis, dysphagia, weak cry, and dilated pupils that react sluggishly to light. Infantile botulism is a self-limited disease generally lasting 2 to 6 weeks. Recovery is complete, but relapse occurs in 5% of infants.

DIAGNOSIS. The syndrome suggests postinfectious polyradiculoneuropathy (Guillain-Barré syndrome), infantile SMA, or generalized myasthenia gravis. Clinical differentiation of infantile botulism from Guillain-Barré syndrome is difficult, and some reported cases of Guillain-Barré syndrome during infancy might have been infantile botulism. Infantile botulism differs from infantile SMA by the early appearance of facial and pharyngeal weakness, the presence of ptosis and dilated pupils, and the occurrence of severe constipation. Infants with generalized myasthenia do not have dilated pupils, absent reflexes, or severe constipation.

Electrophysiologic studies provide the first clue to the diagnosis. Repetitive stimulation between 20 and 50 Hz reverses the presynaptic block and produces an incremental increase in the size of the motor unit potentials in 90% of cases. The EMG shows short-duration, low-amplitude motor unit potentials. The isolation of organisms from the stool is diagnostic.

MANAGEMENT. The use of antitoxin and antibiotics does not influence the course of the disease. Gentamicin, an agent that produces presynaptic neuromuscular blockade, may worsen the condition. Intensive care is necessary throughout the period of profound hypotonia, and many infants require ventilator support. Sudden apnea and death are a constant danger.

Familial Infantile Myasthenia

Several genetic defects causing myasthenic syndromes have been identified (Table 6-11). All are autosomal recessive traits except for the slow channel syndrome, which is an autosomal dominant trait (see Chapter 7). Among the autosomal recessive forms, the causative mutation in one is in the choline acetyltransferase gene on chromosome 10q, and another maps to chromosome 17. All genetic myasthenic syndromes are seronegative for antibodies that bind the acetylcholine receptor (AChR). The

TABLE 6-11
Genetic Myasthenic Syndromes

Presynaptic defects
Defect in acetylcholine resynthesis or mobilization
Paucity of synaptic vesicles and reduced quantal release
Postsynaptic defects
End plate acetylcholinesterase deficiency
Kinetic abnormalities of the receptor without primary AChR deficiency
Abnormal interaction of acetylcholine and receptor
High conductance and fast closure of the AChR channel
Slow channel syndrome
Primary AChR deficiency

AChR, acetylcholine receptor.

genetic and clinical features are the basis for classifying congenital myasthenic syndromes.

Few laboratories are able to determine the site of abnormality or the responsible gene. Clinicians recognize two clinical syndromes: familial infantile myasthenia with prominent respiratory and feeding difficulty at birth and congenital myasthenia with predominantly ocular findings (see Chapter 15). The causes of familial infantile myasthenia include a presynaptic defect in acetylcholine resynthesis and packaging and several postsynaptic defects involving the kinetics of the AChR or congenital end plate acetylcholinesterase deficiency.

CLINICAL FEATURES. Respiratory insufficiency and feeding difficulty may be present at birth. Many affected newborns require mechanical ventilation. Ptosis and generalized weakness either are present at birth or develop during infancy (Mullaney et al, 2000). Arthrogryposis also may be present. Although facial and skeletal muscles are weak, extraocular motility is usually normal. Within weeks, infants become stronger and no longer need mechanical ventilation. Episodes of weakness and life-threatening apnea occur repeatedly throughout infancy and childhood, however, sometimes even into adult life.

DIAGNOSIS. The intravenous or subcutaneous injection of edrophonium chloride, 0.15 mg/kg, establishes the diagnosis. The weakness and the respiratory distress reverse almost immediately after intravenous injection and within 10 minutes of subcutaneous injection. A decrement in the amplitude of successive motor unit potentials with low-frequency repetitive nerve stimulation confirms the diagnosis. Identification of the precise defect requires special laboratory techniques.

MANAGEMENT. Long-term treatment with neostigmine or pyridostigmine prevents sudden

episodes of apnea at the time of intercurrent illness. The weakness in some children responds to a combination of pyridostigmine and diaminopyridine. Diaminopyridine is not commercially available in the United States but can be obtained on a compassionate use basis from *Jacobus Pharmaceutical Company, Inc.* (Princeton, NJ; fax no. 609-799-1176). Thymectomy and immunosuppressive therapy are not beneficial.

Transitory Neonatal Myasthenia

A transitory myasthenic syndrome occurs in approximately 15% of newborns of myasthenic mothers (Hoff et al, 2003). The passive transfer of antibody directed against fetal AChR from a myasthenic mother to her normal fetus is the presumed cause. Fetal AChR is structurally different from adult AChR. The severity of symptoms in the newborn correlates with the ratio of fetal to adult AChR antibodies in the mother but does not correlate with the severity or duration of weakness in the mother.

CLINICAL FEATURES. Women with myasthenia have a higher rate of complications of delivery (Hoff et al, 2003). Difficulty feeding and generalized hypotonia are the major clinical features in the infant. Affected infants are eager to feed, but fatigue quickly, and nutrition is inadequate. Symptoms usually arise within hours of birth, but delay until the third day occurs. Some newborns were hypotonic in utero and born with arthrogryposis. Weakness of cry and lack of facial expression are present in 50%, but only 15% have limitation of extraocular movement and ptosis. Respiratory insufficiency is uncommon. Weakness becomes progressively worse in the first few days, then improves. The mean duration of symptoms is 18 days (range 5 days to 2 months). Recovery is complete, and transitory neonatal myasthenia does not develop into myasthenia gravis later in life.

DIAGNOSIS. High serum concentrations of AChR binding antibody in the newborn and temporary reversal of weakness by the subcutaneous or intravenous injection of edrophonium chloride, 0.15 mg/kg, establishes the diagnosis.

MANAGEMENT. Treat newborns with severe generalized weakness and respiratory distress with plasma exchange. For less impaired newborns, 0.1% neostigmine methylsulfate by intramuscular injection before feeding sufficiently improves sucking and swallowing to allow adequate nutrition. Progressively reduce the dose as symptoms remit. An alternative route for neostigmine is by

nasogastric tube at a dose 10 times the parenteral level.

Congenital Myopathies

Congenital myopathies are developmental disorders of skeletal muscle. The main clinical feature is infantile hypotonia. Muscle biopsy is usual for diagnosis. The common histological feature is that type I fibers are greater in number, but smaller in size, than type II fibers (Figure 6-2). Many infants with hypotonia and type I fiber predominance later are shown to have a cerebral abnormality; cerebellar aplasia is particularly common.

The term *congenital fiber-type disproportion myopathy* describes newborns with hypotonia, and sometimes arthrogryposis, whose muscle biopsy specimens show type I predominance as the only histological abnormality. The biopsy specimens in some infants have not only a type I fiber predominance, but also a unique histological feature that names the condition (*central core disease, multiminicore disease, myotubular myopathy, and nemaline myopathy*). Several other congenital myopathies have been reported in one child or one family; these are not discussed here.

Central Core Disease

Central core disease is a rare but distinct genetic entity transmitted by autosomal dominant inheritance. Mutations in the ryanodine receptor-1 gene on chromosome 19q13 are responsible for central core disease and malignant hyperthermia (Monnier et al, 2000).

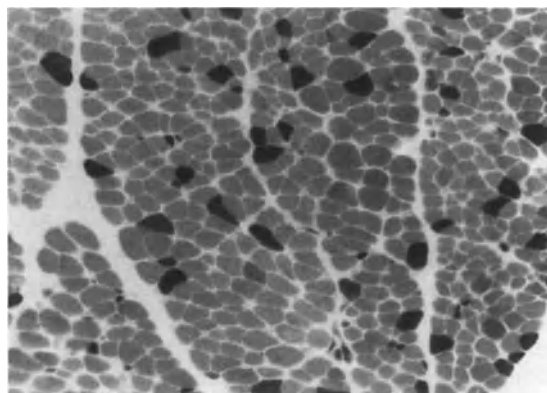


Figure 6-2. Fiber-type disproportion myopathy (ATPase reaction). Type I fibers (*light shade*) are more numerous than type II fibers (*dark shade*). Type II fibers are generally larger in diameter than type I fibers.

CLINICAL FEATURES. Mild hypotonia is present immediately after birth or during infancy. Congenital dislocation of the hips is relatively common. Slowly progressive weakness begins after age 5 years. Weakness is greater in proximal than in distal limb muscles and is greater in the arms than in the legs. Tendon reflexes of weak muscles are depressed or absent. Extraocular motility, facial expression, and swallowing are normal. Some children become progressively weaker, have motor impairment, and develop kyphoscoliosis. In others, weakness remains mild and never causes disability. Most children with central core disease are at risk of malignant hyperthermia and should not be administered anesthetics without appropriate caution (see Chapter 8).

DIAGNOSIS. The serum concentration of CK is normal, and the EMG findings may be normal. More frequently, the EMG suggests a myopathic process. Diagnosis depends on muscle biopsy. Sharply demarcated cores of closely packed myofibrils undergoing varying degrees of degeneration are present in the center of all type I fibers (Figure 6-3). Because of the tight packing of myofibrils, the cores are deficient in sarcoplasmic reticulum, glycogen, and mitochondria.

MANAGEMENT. Treatment is supportive.

Congenital Fiber-Type Disproportion Myopathy

The congenital fiber-type disproportion myopathies are a heterogeneous group of diseases that have a similar pattern of muscle histology. The initial feature of all these diseases is infantile

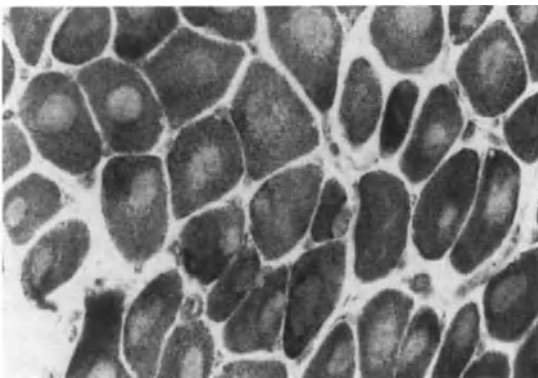


Figure 6-3. Central core disease (reduced diphosphopyridine nucleotide reaction). The center of every fiber has a central core that appears clear when oxidative enzyme reactions are applied.

hypotonia. Both genders are involved equally. Most cases are sporadic; genetic transmission in some is autosomal dominant inheritance and in others is autosomal recessive inheritance. Despite the label “congenital,” an identical pattern of fiber-type disproportion may be present in patients who are asymptomatic at birth and first have weakness during childhood.

CLINICAL FEATURES. The severity of weakness in the newborn varies from mild hypotonia to respiratory insufficiency. Many had intrauterine hypotonia and show congenital hip dislocation, dysmorphic features, and joint contractures. Proximal muscles are weaker than distal muscles. Facial weakness, high-arched palate, ptosis, and disturbances of ocular motility may be present. When axial weakness is present in infancy, kyphoscoliosis often develops during childhood. Tendon reflexes are depressed or absent. Intellectual function is normal. Weakness is most severe during the first 2 years, then becomes relatively stable or progresses slowly.

DIAGNOSIS. Type I fiber predominance and hypotrophy are the essential histological features. Type I fibers are 15% smaller than type II fibers. Other laboratory studies are not helpful. The serum concentration of CK may be slightly elevated or normal, and the EMG may be consistent with a neuropathic process, a myopathic process, or both. Nerve conduction velocities are normal.

MANAGEMENT. Physical therapy should be initiated immediately, not only to relieve existing contractures, but also to prevent new contractures from developing.

Multiminicore Disease

The presence of multiple small zones of sarcomeric disorganization with lack of oxidative activity defines multiminicore disease (Ferreiro et al, 2000). The clinical features associated with the defining pathology are variable. Inheritance is probably autosomal recessive.

CLINICAL FEATURES. Both genders are equally affected. Onset is at birth or during infancy. Affected newborns are hypotonic. Delayed achievement of motor milestones characterizes infantile onset. Axial weakness is typical, as evidenced by scoliosis and neck flexor weakness. Proximal limb muscle weakness is common, and distal weakness is rare. Limb contractures are uncommon.

DIAGNOSIS. Muscle biopsy specimens show zones of sarcomeric disorganization in both muscle fiber types that do not run the entire

length of the fiber. Not every fiber contains a minicore. Type I fibers predominate in number.

MANAGEMENT. Treatment is supportive.

Myotubular (Centronuclear) Myopathy

Several clinical syndromes are included in the category of myotubular (centronuclear) myopathy. Transmission of some is by X-linked inheritance, others by autosomal dominant inheritance, and others by autosomal recessive inheritance. The autosomal dominant form has a later onset and a milder course. The common histological feature on muscle biopsy specimen is an apparent arrest in the morphogenesis of the muscle fiber at the myotube stage.

Acute Myotubular Myopathy

The abnormal gene that causes acute myotubular myopathy maps to the long arm of the X chromosome (Xq28) and is designated *MTM1*. *Myotubularin* is the protein encoded by the *MTM1* gene (Das and Herman, 2004).

CLINICAL FEATURES. Newborns with severe myotubular myopathy are hypotonic and require respiratory assistance. The face is myopathic, motor milestones are delayed, and most fail to walk. Death in infancy is common. Infants with forms that are more moderate achieve motor milestones more quickly, and about 40% require no ventilator support. In the mildest forms, ventilatory support is required only in the newborn period; delay of motor milestones is mild, walking is achieved, and facial strength is normal. Weakness is not progressive and may improve slowly over time. Female *carriers* are generally asymptomatic.

DIAGNOSIS. The serum concentration of CK is normal. The EMG may suggest a neuropathic process, a myopathic process, or both. Muscle biopsy specimen shows type I fiber predominance and hypotrophy, the presence of many internal nuclei, and a central area of increased oxidative enzyme and decreased myosin ATPase activity. Molecular genetic testing is available.

MANAGEMENT. Treatment is supportive.

Chronic Myotubular Myopathy

Inheritance of chronic myotubular myopathy may be either autosomal dominant or recessive. Some forms are associated with mutations in the myogenic factor-6 gene (12q21).

CLINICAL FEATURES. In general, age at onset of the recessive form is later than the X-linked

form and earlier than the dominant form. Some children with the disease have hypotonia at birth; others come to attention because of delayed motor development. The pattern of limb weakness may be proximal or distal. The axial and neck flexor muscles also are weak. Ptosis, but not ophthalmoplegia, is sometimes present at birth. The course is usually slowly progressive. Possible features include ophthalmoplegia, loss of facial expression, and continuing weakness of limb muscles. Some have seizures and mental deficiency.

DIAGNOSIS. The serum concentration of CK is normal, and EMG findings are abnormal but do not establish the diagnosis. Muscle biopsy is essential for diagnosis, and the histological features are identical to those of the acute form.

MANAGEMENT. Treatment is supportive.

Nemaline (Rod) Myopathy

Transmission of nemaline myopathy is either as an autosomal dominant or as a recessive trait. Approximately 20% of cases are recessive, 30% are dominant, and 50% are *sporadic* (North, 2002). Several different genetic abnormalities cause the same histological features that define the disorder.

CLINICAL FEATURES. Nemaline myopathy is characterized by weakness and hypotonia with depressed or absent deep tendon reflexes. Muscle weakness is usually most severe in the face, neck flexors, and proximal limb muscles. Significant differences exist in survival between patients classified as having severe, intermediate, and typical *congenital* nemaline myopathy. The severity of neonatal respiratory disease and the presence of arthrogryposis multiplex congenita are associated with death in the first year of life. Independent ambulation before 18 months of age is predictive of survival. Most children with typical *congenital* nemaline myopathy eventually are able to walk.

At least three different phenotypes occur in children. Transmission of two congenital types is by autosomal recessive inheritance: (1) a severe neonatal form that causes immediate respiratory insufficiency and neonatal death and (2) a milder form in which affected newborns often appear normal or are mildly hypotonic and not brought to medical attention until motor milestones are delayed. This form tends to be slowly progressive, with greater weakness in proximal than distal muscles. Weakness of facial muscles causes a dysmorphic appearance in which the face appears long and narrow, and the palate is high and arched. Axial weakness leads to scoliosis.

Transmission of the childhood-onset form is by autosomal dominant inheritance. Onset of ankle weakness occurs late in the first or early in the second decade. The weakness is slowly progressive, and affected individuals may be wheelchair bound as adults.

DIAGNOSIS. The serum concentration of CK is either normal or only mildly elevated. EMG findings may be normal, and when abnormal they are not the basis for diagnosis. Muscle biopsy is essential for diagnosis. Within most fibers are multiple small rodlike particles, which are thought to be derived from lateral expansion of the Z disk. The greatest concentration of particles is under the sarcolemma (Figure 6-4). Type I fiber predominance is a prominent feature. Molecular diagnosis is available for the *alpha actin* (*ACT1*) gene responsible for congenital and childhood forms

MANAGEMENT. Treatment is supportive. Parents who have the abnormal gene but are not weak may have rod bodies and fiber-type predominance in their muscles.

Muscular Dystrophies

Congenital Dystrophinopathy

Dystrophinopathies occasionally cause weakness at birth. In such cases, dystrophin is completely absent. Immunofluorescence reactions for all three domains of dystrophin are essential for diagnosis. See Chapter 7 for a complete discussion of dystrophinopathies.

Congenital Muscular Dystrophy

The CMD are a group of myopathies characterized by hypotonia at birth or shortly thereafter,

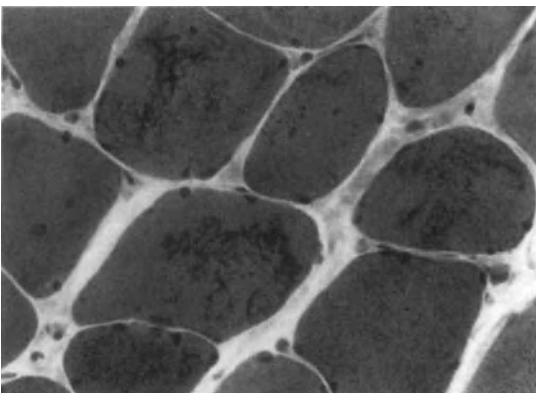


Figure 6-4. Nemaline (rod) myopathy (trichrome). A spectrum of fiber sizes is present. The small fibers are all type I and contain rodlike bodies in a subsarcolemmal position.

the early formation of multiple joint contractures, and diffuse muscle weakness and atrophy (Gordon et al, 2004). Inheritance of all CMD is autosomal recessive. CMD are divisible into syndromic and nonsyndromic forms. In syndromic CMD, muscle and brain are abnormal. In nonsyndromic forms, muscular disease occurs without cerebral involvement.

An alternative classification of CMD is by the absence or presence of *merosin* (laminin $\alpha 2$) in muscle. Merosin, located in the extracellular matrix, is the linking protein for the dystroglycan complex (see Figure 7-3). Merosin deficiency may be primary or secondary. Primary merosin deficiency affects only muscle, whereas secondary merosin deficiencies occur in the syndromic CMD.

Merosin-Positive Nonsyndromic Congenital Muscular Dystrophy

The phenotype associated with merosin-positive CMD is not homogeneous. Transmission is by autosomal recessive inheritance with considerable genetic heterogeneity. One form, mapped to chromosome 1p36-p35, consistently shows early rigidity of the spine, scoliosis, and reduced vital capacity, as are found in the *rigid spine syndrome* (Flanigan et al, 2000). *Ullrich disease*, caused by mutations in the collagen VI gene, is a form of CMD in which muscle fiber necrosis is secondary to loss of collagen links (Ishikawa et al, 2002).

CLINICAL FEATURES. Approximately half of affected individuals are abnormal at birth because of some combination of hypotonia, poor ability to suck, and respiratory distress. Delayed achievement of motor milestones is usual. Limb-girdle weakness is the rule, generalized weakness may be present, and about half of the individuals have facial weakness. Joint deformities may be present at birth or develop during infancy.

DIAGNOSIS. The serum concentration of CK is mildly elevated, and muscle biopsy specimen shows fiber necrosis and regeneration. Brain MRI is normal.

MANAGEMENT. Physical therapy is important to prevent and reduce contractures.

Primary Merosin-Deficient Congenital Muscular Dystrophy

The abnormal gene site for primary merosin-deficient CMD is chromosome 6q22-23. The abnormal protein is laminin. The phenotypes associated with merosin deficiency are generally more severe than the phenotypes with merosin

present. Merosin deficiency also is associated with later onset muscular dystrophies (Jones et al, 2001).

CLINICAL FEATURES. Hypotonia, arthrogryposis, and respiratory insufficiency are severe at birth. Infants have generalized limb weakness, with proximal muscles affected earlier and more severely than distal muscles. Facial and neck weakness is common, but extraocular motility is normal. Tendon reflexes may be present or absent and are often difficult to test because of joint contractures. Contractures at birth may involve any joint, but torticollis and clubfoot are particularly common, and congenital dislocation of the hips is often an associated feature.

Muscle hypertrophy is not present. Weakness and contractures delay motor development. The best motor achievement is the ability to sit unsupported. Intelligence is either normal or borderline subnormal. Chronic hypoventilation leading to respiratory failure is the usual cause of death.

DIAGNOSIS. The serum concentration of CK is high in newborns and tends to decline with age. Asymptomatic siblings and parents may have elevated serum concentrations of CK. EMG findings are consistent with a myopathic process. The muscle histological appearance is characteristic. Features include a variation in fiber size with occasional central nucleation, extensive fibrosis, and proliferation of adipose tissue; fibers undergoing regeneration and degeneration; and thickening of the muscle spindle capsule. A mononuclear infiltrate surrounding muscle fibers is often present early in the course. Cases of "neonatal polymyositis" are actually merosin-deficient CMD. Molecular genetic diagnosis is available.

Infants who are merosin deficient have an abnormal T₂ MRI signal in the cerebral white matter indicating hypomyelination mainly in the occipital horns. Structural disturbances of the occipital cortex may be associated (Philpot et al, 1999).

MANAGEMENT. Physical therapy is important to prevent further contractures.

Syndromic Congenital Muscular Dystrophy

In at least three disorders, CMD coexists with involvement of the central nervous system. These are *Fukuyama CMD*, *muscle-eye-brain disease*, and the *Walker-Warburg syndrome*. *Fukuyama CMD* occurs almost exclusively in Japan, *muscle-eye-brain disease* occurs mainly in Finland, and *Walker-Warburg syndrome* has

wide geographical distribution. Each has a different gene abnormality.

The major feature is a disturbance of cellular migration to the cortex between the fourth and fifth gestational months, resulting in polymicrogyria, lissencephaly, and heterotopia. Other abnormalities may include fusion of the frontal lobes, hydrocephalus, periventricular cysts, optic nerve atrophy, hypoplasia of the pyramidal tracts, reduction in the number of anterior horn cells, and inflammation of the leptomeninges.

Walker-Warburg syndrome and *Fukuyama CMD* show reduced but not absent merosin expression. *Muscle-eye-brain disease* has normal merosin expression. An abnormal MRI T₂ signal in the centrum semiovale that resembles hypomyelination is a marker of abnormal merosin expression.

CLINICAL FEATURES. *Fukuyama CMD* is the most common form of muscular dystrophy in Japan. One quarter of mothers with an affected child have a history of spontaneous abortion. Affected newborns are normal at birth but soon develop hypotonia, an expressionless face, a weak cry, and an ineffective suck. Weakness affects proximal more than distal limb muscles. Mild contractures of the elbow and knee joints may be present at birth or develop later. Tendon reflexes are usually absent. Pseudohypertrophy of the calves develops in half of cases. Affected children may achieve sitting balance, but never stand.

Symptoms of cerebral involvement are present early in infancy. Febrile or nonfebrile generalized seizures are usually the first manifestation. Delayed development is always global, and microcephaly is the rule. Mental retardation is severe. Weakness and atrophy are progressive and result in severe disability, cachexia, and death before 10 years of age.

Neonatal hypotonia, developmental delay, and ocular abnormalities characterize *muscle-eye-brain disease*. Most affected children walk by age 4 years, then decline in all psychomotor skills. Specific eye abnormalities include glaucoma, progressive myopia, progressive retinal atrophy, and juvenile cataracts. The cerebral and muscle abnormalities of *Walker-Warburg syndrome* are similar to those in *muscle-eye-brain disease*. Ocular abnormalities include corneal clouding, cataracts, retinal dysplasia or detachment, and optic nerve hypoplasia.

DIAGNOSIS. Molecular genetic testing is available for all three syndromes. The serum concentration of CK is generally elevated, and the EMG indicates a myopathy. Muscle biopsy specimens show excessive proliferation of adipose tissue and collagen out of proportion to

the degree of fiber degeneration. Typical MRI abnormalities are dilation of the cerebral ventricles and subarachnoid space and lucency of cortical white matter.

MANAGEMENT. Treatment is supportive.

Congenital Myotonic Dystrophy

Myotonic dystrophy is a multisystem disorder transmitted by autosomal dominant inheritance (Adams, 2001). Symptoms usually begin after age 10 (see Chapter 7). An unstable DNA triplet in the *DMPK* gene (chromosome 19q13.2-13.3) causes the disease. Repeats may increase 50 to several thousand times in successive generations. The number of repeats correlates with the severity of disease, but repeat size alone does not predict phenotype. Repeat size changes from mother to child are greater than from father to child, and for this reason, the mother is usually the affected parent when a child has CMD. A mother with repeats of 100 units has a 90% chance that her child will have repeats of 400 units or more.

The main features during pregnancy are reduced fetal movement and polyhydramnios. Fifty percent of infants are born prematurely. Inadequate uterine contraction may prolong labor, and forceps assistance is common. Severely affected newborns have inadequate diaphragmatic and intercostal muscle function and are incapable of spontaneous respiration. In the absence of prompt intubation and mechanical ventilation, many die immediately after birth.

Prominent clinical features in the newborn include facial diplegia, in which the mouth is oddly shaped so that the upper lip forms an inverted V; generalized muscular hypotonia; joint deformities ranging from bilateral clubfoot to generalized arthrogryposis; and gastrointestinal dysfunction, including choking, regurgitation, aspiration, swallowing difficulties, and gastroparesis. Limb weakness in the newborn is more often proximal than distal. Tendon reflexes are usually absent in weak muscles. Percussion does not elicit myotonia in newborns, and EMG is not a reliable test.

Neonatal mortality is 16%, a frequent cause of death being cardiomyopathy. Survivors usually gain strength and are able to walk; however, a progressive myopathy similar to the late-onset form occurs eventually. Severe mental retardation is the rule and may result from a combination of early respiratory failure and a direct effect of the mutation on the brain.

DIAGNOSIS. The diagnosis of congenital myotonic dystrophy in the newborn requires exami-

nation of the mother. She is likely to have many clinical features of the disease and show myotonia on EMG. Showing DNA amplification on chromosome 19 in the mother and the child confirms the diagnosis. Test nonsymptomatic family members at risk for the carrier state.

MANAGEMENT. The immediate treatment is intubation and mechanical ventilation. Fixed joints respond to physical therapy and casting. Metoclopramide alleviates gastroparesis.

Metabolic Myopathies

Acid Maltase Deficiency (Pompe Disease)

Acid maltase is a lysosomal enzyme, present in all tissues, that hydrolyzes maltose and other branches of glycogen to yield glucose. It has no function in maintaining blood glucose concentrations. Three distinct clinical forms of deficiency are recognized: infantile, childhood (see Chapter 7), and adult. Transmission of all forms is by autosomal recessive inheritance. The defective gene site is chromosome 17q25.2-25.3.

CLINICAL FEATURES. The infantile form may begin immediately after birth but usually appears during the second month. Profound generalized hypotonia without atrophy and congestive heart failure are the initial symptoms. Hypotonia is the result of glycogen storage in the brain, spinal cord, and skeletal muscles, causing mixed signs of cerebral and motor unit dysfunction, including decreased awareness and depressed tendon reflexes. The mixed signs may be confusing, but the presence of cardiomegaly is almost diagnostic. The electrocardiogram shows abnormalities, including short P-R intervals and high QRS complexes on all leads. Most patients die of cardiac failure by 1 year of age.

Characteristic of a second, milder subtype of the infantile form is less severe cardiomyopathy, absence of left ventricular outflow obstruction, and less than 5% of residual acid maltase activity. Longer survival is possible with assisted ventilation and intubation (Slonim et al, 2000).

DIAGNOSIS. Muscle biopsy establishes the diagnosis. Muscle fibers contain large vacuoles packed with glycogen. Acid maltase activity is deficient in fibroblasts and other tissues.

MANAGEMENT. A phase I/II open-label, single-dose study of recombinant human α -glucosidase infused intravenously twice weekly in three infants with infantile glycogen storage disease type II showed a steady decrease in heart size and maintenance of normal cardiac function for

more than 1 year in all three infants (Amalfitano et al 2001). Improvements of skeletal muscle functions also occurred.

Cytochrome-c Oxidase Deficiency

The electron transfer chain and oxidative phosphorylation are the principal sources of ATP synthesis (see Chapter 8). Deficiencies of mitochondrial enzymes that comprise the electron transfer chain in skeletal muscle may cause hypotonia in newborns or infants and exercise intolerance in older children. Deficiency of cytochrome-*c* oxidase causes several different neuromuscular and cerebral disorders in childhood. Deficiency can result from mutations in either nuclear or mitochondrial DNA. Inheritance of most isolated cytochrome-*c* oxidase deficiencies is autosomal recessive and caused by mutations in nuclear-encoded genes (Shoubridge, 2001). Most cases are sporadic.

CLINICAL FEATURES. Clinical features vary with the number of enzyme deficiencies, the percentage reduction in enzyme activity, and the presence of mitochondrial enzyme deficiencies in organs other than muscle. Profound generalized weakness, causing difficulty in feeding, early respiratory failure, and death; severe lactic acidosis; and the de Toni-Fanconi-Debré syndrome (glycosuria, proteinuria, phosphaturia, and generalized aminoaciduria) characterize the complete syndrome. Onset is anytime within the first 6 months. Ptosis, ophthalmoplegia, and macroglossia may be present. Newborns with multiple enzyme deficiencies in multiple organs die within 6 months.

DIAGNOSIS. Suspect a deficiency in respiratory chain enzymes in any hypotonic infant with lactic acidosis. The serum concentration of CK is elevated, but EMG findings may be normal. Muscle biopsy reveals vacuoles, mainly in type I fibers, with abnormal glycogen and lipid accumulations. Mitochondria are large, increased in number, and abnormal in structure (ragged-red fibers).

MANAGEMENT. No effective treatment is available for infants with overwhelming disease caused by multiorgan enzyme deficiency.

References

- Adams C. (14 August 2001) Myotonic dystrophy. In: *GeneClinics: Medical Genetic Knowledge Base*. [database online] University of Washington, Seattle. Available at <http://www.geneclinics.org>.
- Amalfitano A, Bengur AR, Morse RP, et al. Recombinant human acid alpha-glucosidase enzyme therapy for infantile glycogen storage disease type II. Results of a phase III clinical trial. *Genet Med* 2001;3:132-138.
- Cherington M. Clinical spectrum of botulism. *Muscle Nerve* 1998;21:701-710.
- Das S, Herman GD. (3 May 2004) X linked myotubular myopathy. In: *GeneClinics: Medical Genetic Knowledge Base*. [database online] University of Washington, Seattle. Available at <http://www.geneclinics.org>.
- Ferreiro A, Estounet B, Chareau D, et al. Multi-minicore disease—searching for boundaries. Phenotype analysis of 38 cases. *Ann Neurol* 2000;48:745-757.
- Flanigan KM, Kerr L, Bromberg MB. Congenital muscular dystrophy with rigid spine syndrome. A clinical, pathological, radiological, and genetic study. *Ann Neurol* 2000;47:152-161.
- Gordon E, Hoffman EP, Pegoraro E. (2 January 2004) Congenital muscular dystrophy overview. In: *GeneClinics: Medical Genetic Knowledge Base*. [database online] University of Washington, Seattle. Available at <http://www.geneclinics.org>.
- Grohmann K, Varon R, Stolz P, et al. Infantile spinal muscular atrophy with respiratory distress type 1 (SMARD). *Ann Neurol* 2003;54:719-724.
- Gunay-Aygun M, Schwartz S, Heeger S, et al. The changing purpose of Prader-Willi syndrome clinical diagnostic criteria and proposed revised criteria. *Pediatrics* 2001;108:E92.
- Hoff JM, Daltveit AK, Gilhus NE. Myasthenia gravis. Consequences for pregnancy, delivery, and the newborn. *Neurology* 2003;61:1362-1366.
- Ishikawa H, Sugie K, Murayama K, et al. Ullrich disease. Collagen VI deficiency. EM suggests a new basis for molecular weakness. *Neurology* 2002;59:920-923.
- Jones KJ, Morgan G, Johnston H, et al. The expanding phenotype of laminin $\alpha 2$ chain (merosin) abnormalities. Case series and review. *J Med Genet* 2001;38:649-657.
- Lin T, Lewis RA, Nussbaum RL. Molecular confirmation of carriers for Lowe syndrome. *Ophthalmology* 1999;106:119-122.
- Miller SP, Riley P, Shevell MI. The neonatal presentation of Prader-Willi syndrome revisited. *J Pediatr* 1999;134:226-228.
- Monnier N, Romero NB, Leral J, et al. An autosomal dominant congenital myopathy with cores and rods is associated with a neomutation in the RYR1 gene encoding the skeletal muscle ryanodine receptor. *Hum Mol Genet* 2000;9:2599-2608.
- Mullaney P, Vajsar J, Smith R, et al. The natural history and ophthalmic involvement in childhood myasthenia gravis at The Hospital for Sick Children. *Ophthalmology* 2000;107:504-510.
- North N. (25 November, 2002) Nemaline myopathy. In: *GeneClinics: Medical Genetic Knowledge Base*. [database online] University of Washington, Seattle. Available at <http://www.geneclinics.org>.
- Philpot J, Cowan F, Pennock J, et al. Merosin-deficient muscular dystrophy. The spectrum of brain involvement on magnetic resonance imaging. *Neuromuscul Disord* 1999;9:81-85.
- Prior TW, Russman BS. (17 October 2003) Spinal muscular atrophy. In: *GeneClinics: Medical Genetic Knowledge Base*. [database online] University of Washington, Seattle. Available at <http://www.geneclinics.org>.
- Rubio-Gozalbo ME, Smeitink JAM, Ruitenbeek W, et al. Spinal muscular atrophy-like picture, cardiomyopathy, and cytochrome-c-oxidase deficiency. *Neurology* 1999;52:383-386.
- Shoubridge EA. Cytochrome c oxidase deficiency. *Am J Med Genet* 2001;106:46-52.

- Slonim AE, Bulone L, Ritz S, et al. Identification of two subtypes of infantile acid maltase deficiency. *J Pediatr* 2000;137:283-285.
- Steinberg SJ, Raymond GV, Braverman NE, et al. (12 December 2003) Peroxisome biogenesis disorders, Zellweger syndrome spectrum. In: *GeneClinics: Medical Genetic Knowledge Base*. [database online] University of Washington, Seattle. Available at <http://www.geneclinics.org>.
- Szigeti K, Saifi GM, Armstrong D, et al. Disturbance of muscle fiber differentiation in congenital hypomyelinating neuropathy caused by a novel myelin protein zero mutation. *Ann Neurol* 2003;54:398-402.
- Warner LE, Mancias P, Butler IJ, et al. Mutations in the early growth response 2 (EGR2) gene are associated with hereditary myelinopathies. *Nat Genet* 1998;18:382-384.

Chapter 7

Flaccid Limb Weakness in Childhood

MOST CHILDREN WITH acute or chronic flaccid limb weakness have a disorder of the motor unit. Flaccid leg weakness may be the initial feature of disturbances in the lumbosacral region, but other symptoms of spinal cord dysfunction are usually present. Also, consult Table 12-1 when considering the differential diagnosis of flaccid leg weakness without arm impairment. Cerebral disorders may cause flaccid weakness, but dementia (see Chapter 5) or seizures (see Chapter 1) are usually a concomitant feature.

Clinical Features of Neuromuscular Disease

Weakness is decreased strength, as measured by the force of a maximal contraction. *Fatigue* is inability to maintain a less than maximal contraction, as measured by exercise tolerance. Weak muscles are always fatigued more easily than normal muscles, but fatigue may occur in the absence of weakness. Conditions in which strength is normal at rest, but fatigue or cramps occur with exercise are discussed in Chapter 8.

Initial Complaint

Limb weakness in children usually is noted first in the legs and then in the arms (Table 7-1). This is because many neuromuscular disorders affect the legs before the arms, and walking is impaired. Delayed development of motor skills is often an initial or prominent feature in the history of children with neuromuscular disorders. Marginal motor delay in children with otherwise normal development rarely raises concern and often is considered part of the spectrum of normal development. Prompts for neurological consultation in older children with

neuromuscular disorders are failure to keep up with peers or easy fatigability.

An abnormal gait can be the initial symptom of either proximal or distal leg weakness. With proximal weakness, the pelvis fails to stabilize and waddles from side to side as the child walks. Running is especially difficult and accentuates the hip waddle. Descending stairs is particularly difficult in children with quadriceps weakness; the knee cannot lock and stiffen. Difficulty with ascending stairs suggests hip extensor weakness. Rising from the floor or a deep chair is difficult, and the hands help to push off.

Stumbling is an early complaint when there is distal leg weakness, especially weakness of the evictors and dorsiflexors of the foot. Falling is first noted when the child walks on uneven surfaces. The child is thought to be clumsy, but after a while parents realize that the child is "tripping on nothing at all." Repeated ankle spraining occurs because of lateral instability. Children with footdrop tend to lift the knee high in the air so that the foot clears the ground. The weak foot then comes down with a slapping motion (*steppage gait*).

Toe walking is commonplace in Duchenne muscular dystrophy (DMD) because the pelvis thrusts forward to shift the center of gravity, and the gastrocnemius muscle is stronger than the peroneal muscles. Toe walking also occurs in upper motor neuron disorders that cause spasticity and in children who have tight heel cords but no identifiable neurological disease. Muscular dystrophy usually is associated with hyporeflexia, and spasticity is associated with hyperreflexia. The ankle tendon reflex may be difficult to elicit, however, when the tendon is tight for any reason.

Adolescents, but usually not children, with weakness complain of specific disabilities.

TABLE 7-1
Symptoms of Neuromuscular Disease

Abnormal gait
Steppage
Toe walking
Waddling
Easy fatigability
Frequent falls
Slow motor development
Specific disability
Arm elevation
Climbing stairs
Hand grip
Rising from floor

A young woman with proximal weakness may have difficulty keeping her arms elevated to groom her hair or rotating the shoulder to get into and out of garments that have a zipper or hook in the back. Weakness of hand muscles often comes to attention because of difficulty with handwriting. Adolescents may notice difficulty in unscrewing jar tops or working with tools. Teachers report to parents when children are slower than classmates in climbing stairs, getting up from the floor, and skipping and jumping. Parents may report a specific complaint to the physician, but more often, they define the problem as inability to keep up with peers.

A child whose limbs are weak also may have weakness in the muscles of the head and neck. Specific questions should be asked about double vision, drooping eyelids, difficulty chewing and swallowing, change of facial expression and strength (whistling, sucking, chewing, blowing), and clarity and tone of speech. Weakness of neck muscles frequently is noticed when the child is a passenger in a car that suddenly accelerates or decelerates. The neck muscles are unable to stabilize the head, which snaps backward or forward.

Physical Findings

The examination begins by watching the child sit, stand, and walk. A normal child sitting cross-legged on the floor can rise to a standing position in a single movement without using the hands. This feat is lost sometime after age 15 in most children; then rising from a low stool tests proximal leg strength. A child with weak pelvic muscles uses the hands for assistance, and with progressive weakness the hands are used to climb up the legs (Gower sign) (Figure 7-1).

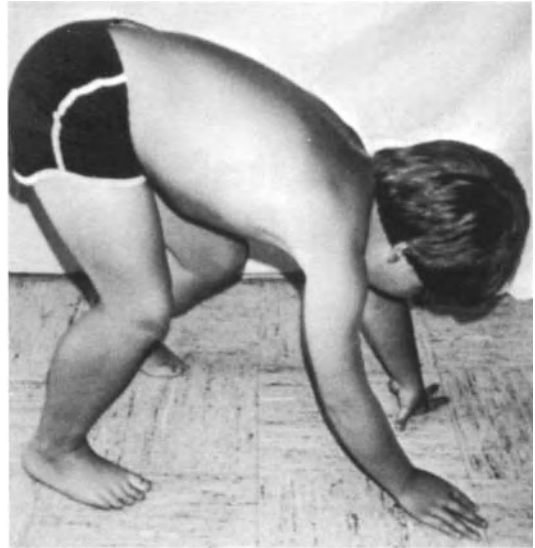

Figure 7-1. Gower sign. The child rises from the floor by pushing off with the hands to overcome proximal pelvic weakness.

After normal gait is observed, the child is asked to walk first on the toes and then on the heels (Table 7-2). Inability to walk on the toes indicates gastrocnemius muscle weakness, and inability to walk on the heels indicates weakness of the anterior compartment muscles. Push-ups are a quick test of strength in almost all arm muscles. Most normal children can do at least one push-up. Then ask the child to touch the tip of the shoulder blade with the ipsilateral thumb. This is an impossible task when the rhomboids are weak.

Finally, face and eye movements are tested. The best test of facial strength is to blow out the cheeks and hold air against compression. Normally the lips are smooth. Wrinkling of the

TABLE 7-2
Signs of Neuromuscular Disease

Observation
Atrophy and hypertrophy
Fasciculations
Functional ability
Palpation
Muscle texture
Tenderness
Examination
Joint contractures
Myotonia
Strength
Tendon reflexes

perioral tissues and failure to hold air indicate facial weakness. During this period of observation and during muscle strength testing, the physician should look for atrophy or hypertrophy. Wasting of muscles in the shoulder causes bony prominences to stand out even further. Wasting of hand muscles flattens the thenar and hypothenar eminences. Wasting of the quadriceps muscles causes a tapering appearance of the thigh that exaggerates when the patient tenses the thigh by straightening the knee. Atrophy of the anterior tibial and peroneal muscles gives the anterior border of the tibia a sharp appearance, and atrophy of the gastrocnemius muscle diminishes the normal contour of the calf.

Loss of tendon reflexes occurs early in denervation, especially when sensory nerves are involved, but parallels the degree of weakness in myopathy. Tendon reflexes are usually normal even during times of weakness in patients with myasthenia gravis and may be normal between episodes of recurrent weakness in patients with metabolic myopathies. *Myotonia*, a disturbance in muscle relaxation after contraction, is described in the section on myotonic dystrophy.

Progressive Proximal Weakness

Progressive proximal weakness in childhood is most often due to myopathy, usually a muscular dystrophy (Table 7-3). Juvenile spinal muscular atrophy (SMA) is the only chronic denervating disease in which weakness is more proximal than distal. Electromyogram (EMG) and muscle biopsy readily distinguish this condition from myopathic disorders. Limb-girdle myasthenia is rare but is an important consideration because specific treatment is available (Table 7-4).

**TABLE 7-3
Progressive Proximal Weakness**

- Spinal cord disorders (see Chapter 12)
- Juvenile spinal muscular atrophies
 - Autosomal dominant
 - Autosomal recessive
 - GM₂ gangliosidosis (hexosaminidase A deficiency)
- Myasthenic syndromes
 - Acquired limb-girdle myasthenia
 - Slow-channel syndrome
- Muscular dystrophies
 - Bethlem myopathy
 - Dystrophinopathies
 - Facioscapulohumeral syndrome
 - Severe childhood autosomal recessive muscular dystrophy
- Inflammatory myopathies
 - Dermatomyositis
 - Polymyositis
- Metabolic myopathies
 - Acid maltase deficiency
 - Carnitine deficiency
 - Debrancher enzyme deficiency (see Chapter 8)
 - Lipid storage myopathies
 - Mitochondrial myopathies (see Chapter 8)
 - Myophosphorylase deficiency (see Chapter 8)
- Endocrine myopathies
 - Adrenal cortex
 - Parathyroid
 - Thyroid

Spinal Muscular Atrophies

Autosomal Recessive Type

Although age at onset distinguishes three subtypes of SMA, the subtypes are actually a continuum. The severe type (SMA I) always begins before 6 months of age (see Chapter 6), the intermediate type (SMA II) begins between 6 and 18 months, and the juvenile type (SMA III) begins after 18 months. The *SMN1* (survival

**TABLE 7-4
Distinguishing Features in Proximal Weakness**

	Neuronopathy	Myopathy	Myasthenia
Tendon reflexes	Absent	Depressed or absent	Normal
Electromyogram	Fasciculations; denervation potentials; high-amplitude polyphasic motor potentials	Brief, small-amplitude polyphasic motor units	Normal
Nerve conduction	Normal or mildly slow	Normal	Abnormal repetitive stimulation
Creatine kinase concentration	Normal or mildly elevated	Elevated	Normal
Muscle biopsy	Group atrophy, group typing	Fiber necrosis, fatty replacement, excessive collagen	Normal

motor neuron) gene on chromosome 5q12.2-q13.3 is believed to be the primary SMA disease-causing gene (Prior and Russman, 2003). Normal individuals have the *SMN1* gene and the *SMN2* gene, an almost identical copy of the *SMN1* gene, on each chromosome.

CLINICAL FEATURES. In SMA II, fetal movements are normal, and the infant is normal at birth. The initial feature of SMA II is delayed motor development. As a rule, affected children achieve sitting balance, but are unable to stand unsupported and are wheelchair confined. A fine hand tremor is often present. Contractures of the hips and knees and scoliosis eventually develop. Some affected children die in childhood because of respiratory failure, but most survive into adulthood. An unusual form of SMA II is one that begins with head drop followed by generalized weakness and respiratory insufficiency. This variant causes death by 3 years of age.

The initial feature of SMA III is gait instability caused by proximal weakness. Similar to SMA II, a fine action tremor is common. Disease progression is slow, sometimes in a stepwise fashion, and often seems arrested. Weakness may progress either to the distal muscles of the legs or to the proximal muscles of the arms. The hands are the last parts affected. Facial muscles may be weak, but extraocular motility is always normal. Tendon reflexes are hypoactive or absent. The sensory examination is normal. Cases with ophthalmoplegia are probably genetically distinct.

Some children have more profound weakness of the arms than of the legs and are likely to have facial weakness as well. Within a family, some children may have predominant leg weakness, whereas siblings may have predominant arm weakness.

DIAGNOSIS. Showing the gene abnormality on chromosome 5 establishes the diagnosis. EMG and muscle biopsy are unnecessary if genetic analysis shows the appropriate mutation. The findings on both tests are similar to findings described for SMA I in Chapter 6. The serum concentration of creatine kinase (CK) may be two to four times the upper limit of normal, and the increase in concentration correlates directly with the duration of illness.

MANAGEMENT. Proper management of SMA in children increases longevity and decreases disability. The goals are to maintain function and prevent contractures. Children who quickly take to a wheelchair develop disuse atrophy. Dietary counseling prevents obesity, which only increases the strain on weak muscles. The prevention of contractures usually requires range-of-motion

exercise and the early use of splints, especially at night. Families need genetic counseling.

Autosomal Dominant Type

The existence of a childhood autosomal dominant type of SMA is controversial. A genetic linkage is not established but is not on chromosome 5. The onset of weakness is before age 10 years in most children, but some have mild joint contractures at birth. A new dominant mutation would be difficult to distinguish from the autosomal recessive form.

CLINICAL FEATURES. A more generalized pattern of weakness is more prominent in the autosomal dominant type than in the autosomal recessive type, but proximal muscles are weaker than distal muscles. The weakness is slowly progressive and may stabilize after adolescence. Most patients walk and function well into middle and late adult life. Bulbar weakness is unusual and mild when present. Extraocular muscles are not affected. Tendon reflexes are depressed or absent in weak muscles. Joint contractures are uncommon.

DIAGNOSIS. The serum concentration of CK is normal or only mildly elevated. The EMG is the basis for diagnosis.

MANAGEMENT. Treatment for the dominant type is the same as for the recessive type. Genetic counseling should stress the complete penetrance of the phenotype. Antenatal diagnosis is not available. When the family has no history of SMA, genetic counseling is difficult, but autosomal dominant inheritance is a consideration if the onset is after 3 years of age.

GM₂ Gangliosidosis

The typical clinical expression of hexosaminidase-A deficiency is *Tay-Sachs disease* (see Chapter 5). Several phenotypic variants of the enzyme deficiency with onset throughout childhood and adulthood exist. Transmission of all variants is by autosomal recessive inheritance. The initial features of the juvenile-onset type mimic those of juvenile SMA (Navon et al, 1997).

CLINICAL FEATURES. Weakness, wasting, and cramps of the proximal leg muscles begin after infancy and frequently not until adolescence. Distal leg weakness, proximal and distal arm weakness, and tremor follow. Symptoms of cerebral degeneration (personality change, intermittent psychosis, and dementia) become evident after motor neuron dysfunction is established.

Examination shows a mixture of upper and lower motor neuron signs. The macula is usually normal, and the cranial nerves are intact, with the exception of atrophy and fasciculations in the tongue. Fasciculations also may be present in the limbs. Tendon reflexes are absent or exaggerated, depending on the relative severity of upper and lower motor neuron dysfunction. Plantar responses are sometimes extensor and sometimes flexor. Tremor, but not dysmetria, is present in the outstretched arms, and sensation is intact.

Some children never develop cerebral symptoms and have only motor neuron disease; some adults have only dementia and psychosis. The course is variable and compatible with prolonged survival.

DIAGNOSIS. The serum concentration of CK is normal or only mildly elevated. Motor and sensory nerve conduction velocities are normal, but needle EMG shows neuropathic motor units. Showing a severe deficiency or absence of hexosaminidase-A activity in leukocytes or cultured fibroblasts establishes the diagnosis.

MANAGEMENT. No treatment is available. Heterozygote detection is possible because enzyme activity is partially deficient. Prenatal diagnosis is available.

Myasthenic Syndromes

Proximal weakness and sometimes wasting may occur in acquired immune-mediated myasthenia and in a genetic myasthenic syndrome.

Limb-Girdle Myasthenia

Limb-girdle myasthenia is immune-mediated myasthenia gravis that begins as progressive proximal weakness of the limbs and spares ocular motility.

CLINICAL FEATURES. Onset is after 10 years of age, and girls are affected more often than boys. Weakness does not fluctuate with exercise. Muscles of facial expression may be affected, but other bulbar function is not. Tendon reflexes are usually present but may be hypoactive. The clinical features suggest limb-girdle dystrophy or polymyositis.

DIAGNOSIS. The diagnosis of limb-girdle myasthenia is possible in every child with proximal weakness and preserved tendon reflexes. Repetitive nerve stimulation shows a decremental response, and the serum concentration of antibodies that bind the acetylcholine receptor is increased. No reports of families with limb-girdle myasthenia affecting two or more siblings

have appeared in recent years. Some of these families may have had the slow-channel syndrome or another genetic myasthenia.

MANAGEMENT. The treatment is the same as for other forms of antibody-positive myasthenia (see Chapter 15).

Slow-Channel Syndrome

The slow-channel syndrome is a genetic disorder of the skeletal muscle acetylcholine receptor (Croxen et al, 2002). Genetic transmission is by autosomal dominant inheritance.

CLINICAL FEATURES. No symptoms are present at birth. Onset is usually during infancy, but delay until adult life occurs. Weakness of the cervical and scapular muscles is often the initial feature. Other common features are exercise intolerance, ophthalmoparesis, and muscle atrophy. Ptosis, bulbar dysfunction, and leg weakness are unusual. The syndrome progresses slowly, and many patients do not come to medical attention until after age 10 years.

DIAGNOSIS. Weakness does not respond either to injection or to oral administration of anticholinesterase medication. Two patients were hypersensitive to edrophonium (Tensilon) and responded with muscarinic side effects. Repetitive nerve stimulation at a rate of three stimuli per second causes an abnormal decremental response, and single-nerve stimulation causes a repetitive muscle potential. Muscle biopsy specimens show type I fiber predominance. Group atrophy, tubular aggregates, and an abnormal end plate configuration are present in some specimens.

MANAGEMENT. Cholinesterase inhibitors, thymectomy, and immunosuppression are not effective. Quinidine sulfate improves strength, and fluoxetine is equally beneficial in patients who do not tolerate quinidine (Harper et al, 2003).

Muscular Dystrophies

The dystrophies are a group of genetic myopathies. The usual cause is a defect in a structural protein (Figure 7-2). Enzyme deficiencies, such as acid maltase deficiency, are not dystrophies, but rather *metabolic myopathies*. For most dystrophies, the abnormal gene and gene product are established.

The term *limb-girdle muscular dystrophy* (LGMD) encompasses several muscular dystrophies characterized by progressive proximal muscle weakness (Gordon et al, 2004). LGMD transmitted by X-linked inheritance is discussed in the section on DMD and Becker muscular dystrophy (BMD). *Danon disease*, an X-linked

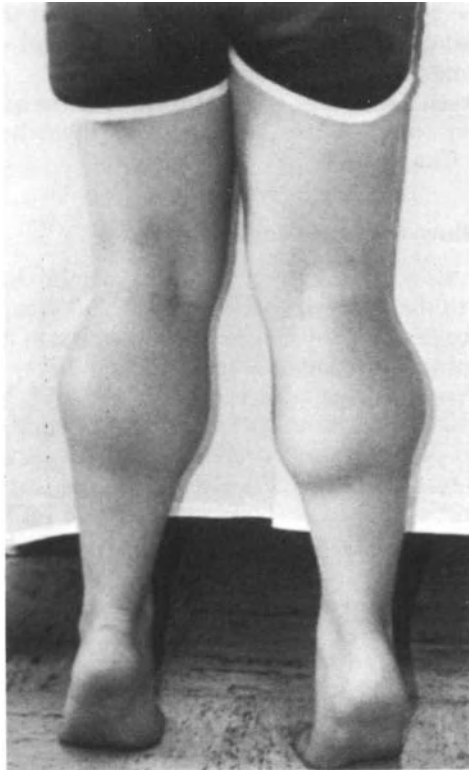

Figure 7-2. Enlarged calf muscles in Duchenne muscular dystrophy. Enlarged calves also occur in other neuromuscular disorders.

cardiomyopathy and skeletal myopathy with onset in late adolescence, is not discussed (Sugie et al, 2002).

The more common forms of LGMD transmitted by autosomal dominant inheritance are facioscapulohumeral (FSH) dystrophy (see Chapter 17), the dominant form of Emery-Dreifuss dystrophy, Bethlem myopathy, and the myopathies associated with caveolinopathies.

The caveolinopathies are uncommon and are not discussed.

Autosomal recessive types may begin in childhood or adulthood. These are distinguishable by the location of the abnormal gene and in some cases by the abnormal gene product (Table 7-5). Deficiencies in the dystrophin-associated glycoprotein complex called the *sarcoglycan* cause many of these conditions (Duggan et al, 1997). Some of the phenotypes are similar to DMD and explain most cases of affected females with a DMD phenotype (see the later section on Severe Childhood Autosomal Recessive Muscular Dystrophy).

Bethlem Myopathy

Bethlem myopathy is a slowly progressive LGMD transmitted by autosomal dominant inheritance. The abnormal gene links to the collagen type VI gene located on chromosome 21 (Jöbsis et al, 1999).

CLINICAL FEATURES. The onset of contractures or weakness always occurs in the first 2 years. Diminished fetal movements and congenital hypotonia may be present. The usual initial features are congenital flexion contractures of the elbows, ankles, and interphalangeal joints of the last four fingers, but sparing the spine. The contractures are at first mild and unrecognized by parents. Mild proximal weakness and delayed motor development are common. The contractures and the weakness progress slowly and produce disability in middle life but do not shorten the life span. Tendon reflexes are normal or depressed. Cardiomyopathy does not occur.

DIAGNOSIS. The serum concentration of CK is normal or slightly elevated. EMG usually shows myopathy, and muscle biopsy specimens show a nonspecific myopathy.

TABLE 7-5
Autosomal Recessive Limb-Girdle Muscular Dystrophies

LGMD	Location	Gene Product	Clinical Features
LGMD-2A	15q	Calpain 3	Onset at 8-15 years, progression variable
LGMD-2B	2p13-16	Dysferlin	Onset at adolescence, mild weakness; gene site is the same as for Miyoshi myopathy
LGMD-2C	13q12	Sarcoglycan	Duchenne-like, severe childhood autosomal recessive muscular dystrophy (SCARM1)
LGMD-2D	17q21	α -Sarcoglycan (adhalin)	Duchenne-like, severe childhood autosomal recessive muscular dystrophy (SCARM2)
LGMD-2E	4q12	β -Sarcoglycan	Phenotype between Duchenne and Becker muscular dystrophies
LGMD-2F	5q33-34	Sarcoglycan	Slowly progressive, growth retardation

MANAGEMENT. Physical therapy for contractures is the main treatment.

Dystrophinopathies: Duchenne and Becker Muscular Dystrophy

DMD and BMD are variable phenotypic expressions of a gene defect at the Xp21 site (Korf et al, 2004). Several different phenotypes are associated with abnormalities at the Xp21 site (Table 7-6). The abnormal gene product in DMD and BMD is a reduced muscle content of the structural protein dystrophin. In DMD, the dystrophin content is less than 3% of normal, and in BMD, the dystrophin content is 3% to 20% of normal. DMD has a worldwide distribution, with a mean incidence of 1:3500 male births. The traditional phenotypic difference between the two dystrophies is that BMD has a later age of onset (>5 years old), unassisted ambulation after age 15, and survival into adult life. A spectrum of intermediate phenotypes exists, however.

Among the spectrum of dystrophinopathy phenotypes are *quadriiceps myopathy* and *cramps on exercise*. The characteristic features of quadriiceps myopathy are slowly progressive weakness of the quadriiceps muscle, calf enlargement, and an elevated serum concentration of CK. Another syndrome of dystrophin deficiency comprises mental retardation and an elevated concentration of serum CK without muscle weakness.

CLINICAL FEATURES. The initial feature in most boys with DMD is a gait disturbance; onset is always before age 5 and is often before age 3. Toe walking and frequent falling are typical complaints. Often, one obtains a retrospective history of delayed achievement of motor milestones. Early symptoms are insidious and likely dismissed by parents and physicians. Only when proximal weakness causes difficulty in rising from the floor and an obvious waddling gait is

medical attention sought. At this stage, mild proximal weakness is present in the pelvic muscles, and the Gower sign is present. The calf muscles are often large (Figure 7-3). The ankle tendon is tight, and the heels do not quite touch the floor. Tendon reflexes still may be present at the ankle and knee but are difficult to obtain.

The decline in motor strength is linear throughout childhood. Motor function usually appears static between the ages of 3 and 6 years because of cerebral maturation. Most children maintain their ability to walk and climb stairs until 8 years of age. Between ages 3 and 8, the child shows progressive contractures of the ankle tendons and the iliotibial bands, increased lordosis, a more pronounced waddling gait, and increased toe walking. Gait is more precarious, and the child falls more often. Tendon reflexes at the knees and ankles are lost, and proximal weakness develops in the arms.

The range of intelligence scores in boys with DMD shifts downward. Although most affected boys function in the normal range, the percentage of boys with learning disabilities and mental retardation is increased.

Considerable variability of expression occurs even within the DMD phenotype. On average, functional ability declines rapidly after 8 years of age because of increasing muscle weakness and contractures. By 9 years old, some children require a wheelchair, but most can remain ambulatory until age 12 and may continue to stand in braces until age 16.

Scoliosis occurs in some boys; early use of a wheelchair is not the cause. Deterioration of vital capacity to less than 20% of normal leads to symptoms of nocturnal hypoventilation. The child awakens frequently and is afraid to sleep. The immediate cause of death is usually a combination of respiratory insufficiency and cardiomyopathy. In some patients with chronic hypoxia, intercurrent infection or aspiration causes respiratory arrest.

DIAGNOSIS. Before 5 years of age, the serum concentration of CK is 10 times the upper limit of normal. CK concentration then declines with age at an approximate rate of 20% per year.

Mutation analysis is the standard for diagnosis, carrier detection, and fetal diagnosis. Intragenic deletions occur in 60% of affected boys, and duplications occur in another 6%. Dystrophin analysis of muscle is useful to distinguish DMD from BMD. Muscle biopsy is not essential, however, when molecular diagnosis is positive.

MANAGEMENT. Although DMD is not curable, it is treatable. Prednisone, 0.75 mg/kg/day, increases

TABLE 7-6
Phenotypes Associated with the Xp21 Gene Site

Becker muscular dystrophy
Dilated cardiomyopathy without skeletal muscle weakness
Duchenne muscular dystrophy
Familial X-linked myalgia and cramps (see Chapter 8)
McLeod syndrome (elevated serum creatine kinase concentration, acanthocytosis, and absence of Kell antigen)
Mental retardation and elevated serum creatine kinase
Quadriiceps myopathy

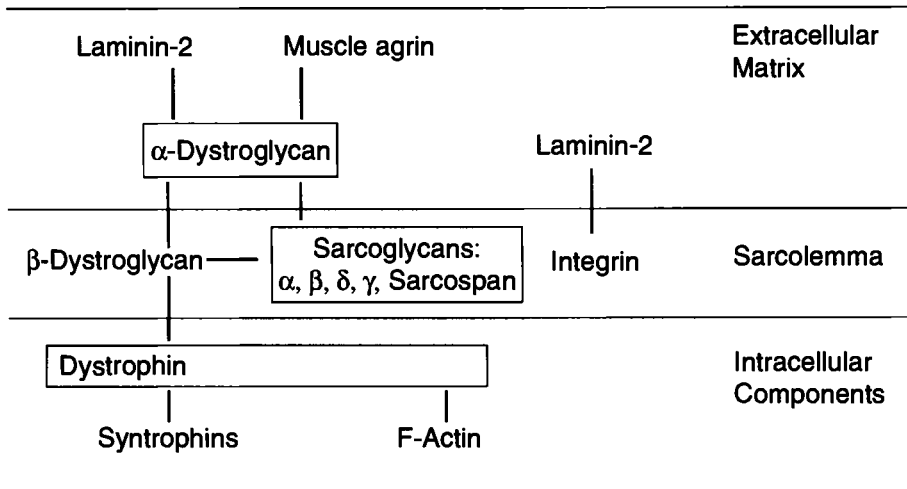


Figure 7-3. The structural proteins of muscle fibers.

strength and function. Treatment goals are to maintain function, prevent contractures, and provide psychological support not only for the child, but also for the family. The child must be kept standing and walking as long as possible. Passive stretching exercises prevent contractures, lightweight plastic ankle-foot orthoses maintain the foot in a neutral position during sleep, and long-leg braces maintain walking. Scoliosis is neither preventable nor reversible by external appliances; only surgery is effective to straighten the spine.

Facioscapulohumeral Dystrophy

Although the classification of progressive FSH weakness is as a muscular dystrophy, patients with genetic FSH weakness may have histological evidence of myopathy, neuropathy, and inflammation. The FSH syndrome is associated with a deletion within a DNA repeat motif named *D4Z4* at chromosome 4q35 (Figlewicz and Tawil, 2003). The size of the deletion correlates with the severity of disease. Considerable interfamilial and intrafamilial heterogeneity exists. There may be a negative family history because affected family members are unaware they have a problem.

CLINICAL FEATURES. Weakness usually begins after age 10. Initial involvement is often in the shoulder girdle, with subsequent spread to the humeral muscles. The deltoid is never affected. Facial weakness is present but often overlooked until late in the course. The progression of weakness is insidious and delays the diagnosis. Late in the course, leg muscles may be involved.

Anterior tibial weakness is most prominent, but proximal weakness also may occur.

The course of FSH syndrome is variable. Many patients do not become disabled, and their life expectancy is normal. Others are wheelchair confined in adult life. In the infantile form, progression is always rapid, and disability is always severe (see Chapter 17). Deafness and retinal vascular abnormalities are part of the phenotype. The most severe manifestations are retinal telangiectasia, exudation, and detachment (*Coates disease*).

DIAGNOSIS. Molecular genetic testing is the standard for diagnosis. The serum concentration of CK can be normal or increased to five times normal. EMG may show denervation potentials, myopathic motor units, or both. Histological changes are minimal in many limb muscles and are never diagnostic. Occasional fibers are myopathic, some appear denervated, and inflammatory cells may be present.

MANAGEMENT. No treatment for the weakness is available. Retinal examination for Coates disease is required. Coagulation of retinal telangiectasia prevents blindness.

Proximal Myotonic Dystrophy

Myotonic dystrophy 2, or proximal myotonic dystrophy, is genetically distinct from the more common distal form. A CCTG repeat expansion is present at locus 3q21. In contrast to distal myotonic dystrophy, a congenital form does not exist (Day et al, 2003). Onset of symptoms is between 20 and 30. Molecular genetic testing is available for children at risk.

Severe Childhood Autosomal Recessive Muscular Dystrophy

A deficiency of any of the subunits of the sarcoglycan complex of proteins associated with dystrophin causes severe childhood autosomal recessive muscular dystrophy (SCARMD) (see Table 7-5). Sarcoglycan complex defects account for 11% of children with Duchenne phenotypes.

CLINICAL FEATURES. SCARMD affects both genders equally. The clinical features are identical to features described for the dystrophinopathies.

DIAGNOSIS. SCARMD is a likely diagnosis in all girls with a Duchenne phenotype and in boys who appear to have DMD but show normal dystrophin content in muscle. Immunohistochemical reagents applied to muscle sections show the absence or presence of the sarcoglycan components. Mutation analysis is available for diagnosis.

MANAGEMENT. Management is the same as for DMD.

Inflammatory Myopathies

The inflammatory myopathies are a heterogeneous group of disorders the causes of which are infectious, immune mediated, or both. A progressive proximal myopathy occurs in adults, but not in children, with acquired immunodeficiency syndrome (AIDS). The serum CK concentration is elevated, however, in children with AIDS treated with zidovudine. *Acute infectious myositis* is described in the section on acute generalized weakness. The conditions discussed in this section are immune mediated.

Dermatomyositis

Dermatomyositis is a systemic angiopathy in which vascular occlusion and infarction account for all pathological changes observed in muscle, connective tissue, skin, gastrointestinal tract, and small nerves. More than 30% of adults with dermatomyositis have an underlying malignancy, but cancer is not a factor before age 16. The childhood form of dermatomyositis is a relatively homogeneous disease.

CLINICAL FEATURES. Peak incidence is generally between ages 5 and 10 years, but onset may be 4 months of age. The initial features may be insidious or fulminating. Insidious onset is characterized by fever, fatigue, and anorexia in the absence of rash or weakness. These symptoms may persist for weeks or months and suggest an underlying infection. Dermatitis precedes myositis in

most children. An erythematous discoloration and edema of the upper eyelids that spread to involve the entire periorbital and malar regions are characteristic. Erythema and edema of the extensor surfaces overlying the joints of the knuckles, elbows, and knees develop later. With time, the skin appears atrophic and scaly.

Proximal weakness, stiffness, and pain characterize the myopathy. Weakness generalizes, and flexion contractures develop rapidly and cause joint deformities. Tendon reflexes become increasingly difficult to obtain and finally disappear.

Calcinosis of subcutaneous tissue, especially under discolored areas of skin, occurs in 60% of children. When severe, it produces an armor-like appearance, termed *calcinosis universalis*, on radiographs. In some children, stiffness is the main initial feature, and skin and muscle symptoms are only minor. In the past, gastrointestinal tract infarction was a leading cause of death. The mortality rate is less than 5% with modern treatment.

DIAGNOSIS. The combination of fever, rash, myalgia, and weakness is compelling evidence for the diagnosis of dermatomyositis. The serum CK concentration usually is elevated early in the course. During the time of active myositis, resting EMG shows increased insertional activity, fibrillations, and positive sharp waves; muscle contraction produces brief, small-amplitude polyphasic potentials. The diagnostic feature on the muscle biopsy specimen is perifascicular atrophy (Figure 7-4). Capillary necrosis usually starts at the periphery of the muscle fascicle and causes ischemia in the adjacent muscle fibers. The most profound atrophy occurs in fascicular borders that face large connective tissue septae.

MANAGEMENT. The inflammatory process is active for approximately 2 years. Corticosteroids may suppress the inflammatory response and provide symptomatic relief, but they do not cure the underlying disease. The best results are obtained when corticosteroids are started early in high doses and are maintained for long periods.

Initiate prednisone at 2 mg/kg/day, not to exceed 100 mg/day. The response follows a predictable pattern. Temperature returns to normal within 48 hours. The serum CK concentration returns to normal by the second week, and muscle strength increases simultaneously. When these events occur, reduce the prednisone dosage to alternate-day therapy to reduce the frequency and severity of corticosteroid-induced side effects. Alternate-day or daily therapy is equally effective if the doses are large and the treatment

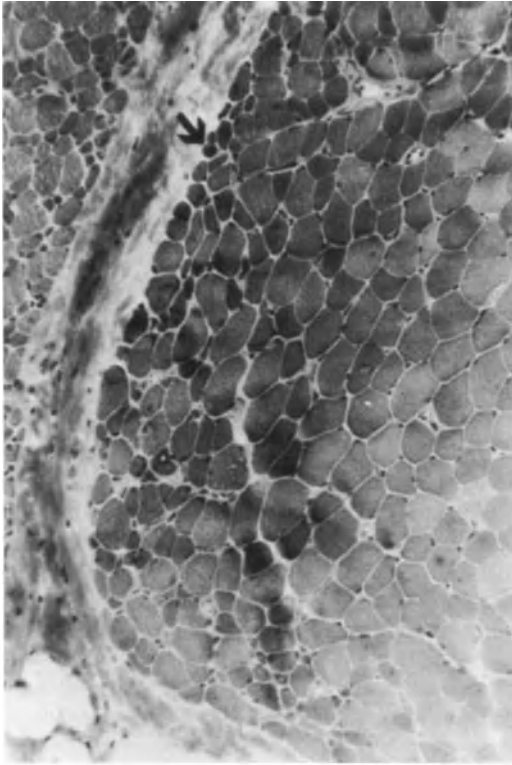


Figure 7-4. Perifascicular atrophy in childhood dermatomyositis (trichrome stain). The muscle fibers at the edge of each fascicle are atrophied (arrow).

is maintained. As muscle strength increases, taper the original dosage of alternate-day prednisone by 10% per month for 5 months. Further reductions are at a rate of 5% per month. For most children, the alternate-day maintenance dosage needed for normal muscle strength and a normal serum CK concentration is 25% of the starting dosage. When the response is inadequate, add methotrexate. The response of the skin rash to prednisone is variable; in some children, the rash heals completely, but most have some permanent scarring from the disease.

Although most children show a dramatic improvement and seem normal within 3 months, prednisone should be continued for a full 2 years. Relapse invariably follows premature discontinuation of treatment. Calcinosis and contractures are more likely to develop in children treated intermittently. Corticosteroids also are useful in the treatment of calcinosis universalis. In addition to prednisone, a well-structured program of physical therapy prevents contractures.

Of children with dermatomyositis, 80% have a favorable outcome after initiating high-dose prednisone within 4 months of the onset of symptoms. Start oral methotrexate, 10 to 20

mg/m² twice weekly, in children who do not respond to high-dose prednisone. Regular monitoring of liver function and white blood cell count is required.

Plasmapheresis or courses of intravenous immunoglobulin are a valuable adjunct in children whose condition is refractory to corticosteroids. When the disease becomes inactive, reactivation is unlikely. Late progression or recurrence may occur, however, and require treatment with an additional 1-year course of corticosteroids.

Polymyositis

Polymyositis without evidence of other target organ involvement is uncommon before puberty. Children with systemic lupus erythematosus may have myalgia and arthralgia as early symptoms, but rarely have muscle weakness at onset. Skin, joint, and systemic manifestations usually precede the onset of myopathy. Polymyositis in children is similar to the disorder in adults except that malignancy is not a causative factor.

CLINICAL FEATURES. Polymyositis begins as a symmetrical proximal weakness that develops insidiously and progresses to a moderate handicap within weeks to months. The patient may have prolonged periods of stability or remission that suggest the diagnosis of LGMD because of the slow progress. Tendon reflexes are present early in the course but are less active as muscle bulk is lost. Cardiorespiratory complications are less common in childhood than in adult polymyositis.

DIAGNOSIS. The serum CK concentration is not always increased, but EMG usually shows myopathic and neuropathic features. Muscle biopsy specimens may show several different patterns of abnormality, and perivascular inflammation may not be present. Instead, one observes features of myopathy, denervation, or both.

MANAGEMENT. The same treatment schedule suggested for childhood dermatomyositis is useful for children with polymyositis. The response to corticosteroids is far less predictable in polymyositis than in dermatomyositis. Treat children who fail to respond to corticosteroids with methotrexate. Plasmapheresis and intravenous immunoglobulins are reasonable alternatives when other remedies fail.

Metabolic Myopathies

Acid Maltase Deficiency

The initial features of acid maltase deficiency may occur in infancy, childhood, or adulthood.

The enzyme defect is the same regardless of age of onset, and different ages of onset may occur within the same family. The speed of progression is variable, but the severity of cardiorespiratory involvement correlates with the amount of residual enzyme activity. The abnormal gene location is 17q25.2-q25.3, and transmission is by autosomal recessive inheritance.

CLINICAL FEATURES. Infants with acid maltase deficiency have glycogen storage in skeletal and cardiac muscles. Death occurs from cardiac failure during infancy (see Chapter 6). In the childhood form, only skeletal muscle is involved, and the main clinical feature is slowly progressive proximal limb weakness. Tendon reflexes are hypoactive or unobtainable. Some children have mild hypertrophy of the calves simulating DMD. The weakness is steadily progressive and leads to disability and respiratory insufficiency by age 20. A late age at onset predicts a more benign course.

DIAGNOSIS. Showing glycogen storage in muscle fibers and the absence of acid maltase in muscle or fibroblasts establishes the diagnosis of acid maltase deficiency.

MANAGEMENT. Recombinant human α -glucosidase infused intravenously twice weekly in three infants with infantile acid maltase deficiency improved cardiac function (Amalfitano et al, 2001). The treated infants lived well past the critical age of 1 year and continued to have normal cardiac function. Ongoing clinical trials in adults with late-onset skeletal muscle disease indicate improved skeletal muscle function (Winkel et al, 2004).

Other Carbohydrate Myopathies

Slowly progressive proximal weakness is sometimes the initial feature of McArdle disease and debrancher enzyme deficiency. Both disorders are considerations in the differential diagnosis. The initial symptom of these disorders is usually exercise intolerance (see Chapter 8).

Carnitine Deficiency

Carnitine is an essential cofactor in the transfer of long-chain fatty acids across the inner mitochondrial membrane and modulates the acyl-to-acyl coenzyme A ratio. Its deficiency causes a failure in the production of energy for metabolism and the storage of triglycerides. It occurs (1) in newborns receiving total parenteral alimentation, (2) in several systemic disorders, (3) as the result of several genetic disorders of organic acid metabolism, (4) in children treated

with valproate, (5) and as a primary genetic defect that causes deficiency of the cellular carnitine transporter.

Transmission of the primary genetic defect, on chromosome 5q33.1, is by autosomal recessive inheritance (Shoji et al, 1998). The clinical features may be restricted to skeletal muscle or may include systemic symptoms resembling those of Reye syndrome (see Chapter 2).

CLINICAL FEATURES. The main clinical feature of muscle carnitine deficiency is the childhood onset of slowly progressive proximal weakness, affecting the legs before and more severely than the arms. Sudden exacerbations or fluctuations are superimposed. Occasionally, patients have recurrent attacks of myoglobinuria and cardiomyopathy. The cardiomyopathy is usually asymptomatic but is demonstrable on electrocardiogram (ECG) and echocardiogram.

DIAGNOSIS. The serum concentration of CK is elevated. EMG findings are nonspecific. Muscle biopsy specimens show a vacuolar myopathy with lipid storage mainly in type I fibers. The biochemical measurement of free and total carnitine establishes the diagnosis.

MANAGEMENT. Dietary therapy with levocarnitine is usually effective. Diarrhea is the major side effect. The usual dosage is 100 mg/kg/day in three or four divided doses.

Other Lipid Myopathies

Children with progressive proximal weakness associated with lipid storage in muscle and normal carnitine content usually have a disturbance of mitochondrial fatty acid oxidation. These disorders are genetically heterogeneous and difficult to distinguish from other mitochondrial myopathies.

CLINICAL FEATURES. Progressive proximal weakness begins anytime from early childhood to adolescence. The legs are affected first followed by the arms. Exercise intolerance is noted, and in some cases, the ingestion of fatty foods leads to nausea and vomiting. The pattern and progression of weakness may resemble DMD, including the presence of calf hypertrophy. Limb weakness is steadily progressive, and cardiomyopathy may develop.

DIAGNOSIS. The serum CK concentration is markedly elevated. EMG findings are abnormal and are consistent with a myopathic process. Muscle biopsy is crucial to diagnosis. Type I muscle fibers contain fatty droplets. Carnitine and carnitine O-palmitoyltransferase concentrations are normal.

MANAGEMENT. Patients with fat intolerance may show improvement on a diet free of long-chain fatty acids.

Endocrine Myopathies

Progressive proximal limb weakness may occur in children with hyperthyroidism, hypothyroidism, hyperparathyroidism, hypoparathyroidism, hyperadrenalism, and hypoadrenalism.

CLINICAL FEATURES. Systemic features of endocrine disease usually predate the onset of weakness. Weakness may be the initial feature, however, in primary or secondary hypoparathyroidism and in thyroid disorders. Weakness is much more prominent in the legs than in the arms. Tendon reflexes, even in weak muscles, are normal or diminished but generally are not absent.

DIAGNOSIS. The serum CK concentration is typically normal. EMG is not useful for diagnosis. Many endocrinopathies produce neuropathy and myopathy. In Cushing disease and in hyperparathyroidism, muscle histological studies show type II fiber atrophy. Other endocrinopathies show nonspecific myopathic changes that vary with the severity of disease.

MANAGEMENT. Treating the underlying endocrinopathy corrects the weakness.

Progressive Distal Weakness

Neuropathy is the most common cause of progressive distal weakness (Table 7-7). Among the slowly progressive neuropathies of childhood,

hereditary disorders are more common than acquired disorders. The only common acquired neuropathy is acute inflammatory demyelinating polyradiculoneuropathy (AIDP), or more commonly, *Guillain-Barré syndrome* (GBS), in which weakness evolves rapidly.

Diagnosis in Neuropathy and Neuronopathy

The initial feature of neuropathy in children is progressive symmetrical distal weakness affecting the legs and then the arms. When sensation is disturbed, dysesthesias are experienced. These consist of tingling, "pins and needles," or a burning sensation in the feet. Dysesthesias usually occur in acquired but not in hereditary neuropathies. The progression of weakness and sensory loss are in a distal-to-proximal direction (glove-and-stocking distribution). Tendon reflexes are lost early, especially when sensory fibers are affected.

An important first step in diagnosis is to determine the primary site of the disorder: cell body (anterior horn cell), nerve axon, or myelin. Electrodiagnosis accomplishes localization (Table 7-8). In primary disorders of the cell body (neuronopathy), resting muscle shows fibrillations and fasciculations. Voluntary contraction activates reduced numbers of motor unit potentials whose amplitude is normal or increased because of collateral reinnervation. Motor conduction nerve velocity is normal or only slightly diminished, and the amplitude of sensory action potentials is normal. In axonopathies, the EMG

TABLE 7-7
Progressive Distal Weakness

Spinal cord disorders (see Chapter 12)	Drug-induced (see Table 7-10)
Motor neuron diseases	Systemic vasculitis
Juvenile amyotrophic lateral sclerosis	Toxins
Monomelic (see Chapter 13)	Uremia
Spinal muscular atrophies	Idiopathic neuropathy
Autosomal dominant forms	Chronic axonal neuropathy
Autosomal recessive forms	Chronic demyelinating neuropathy
Neuropathies	Myopathies
Hereditary motor sensory neuropathies	Autosomal dominant childhood myopathy
Charcot-Marie-Tooth disease (see Table 7-9)	Autosomal dominant infantile myopathy
Familial amyloid neuropathy (see Chapter 9)	Autosomal recessive distal (Miyoshi) myopathy
Giant axonal neuropathy (16q24)	Inclusion body myopathies
Other genetic neuropathies	Myotonic dystrophy
Other lipid neuropathies	Scapulo (humeral) peroneal syndrome
Pyruvate dehydrogenase deficiency (see Chapter 10)	Emery-Dreifuss muscular dystrophy type 1
Refsum disease	Emery-Dreifuss muscular dystrophy type 2
Sulfatide lipidoses: metachromatic leukodystrophy	Scapuloperoneal myopathy
Neuropathies with systemic diseases	Scapuloperoneal neuronopathy

TABLE 7-8
Electrodiagnosis in Neuropathy

	Neuronopathy	Axonal	Demyelinating
Fasciculations	+++	+++	+
Denervation potentials	+++	+++	+
Reduced number of motor units	+++	+++	0
High-amplitude potentials	+++	+++	0
Slow motor velocity	0	+	+++
Reduced sensory potentials	0	+	+++

0, absent; +, rare; +++, common.

shows fibrillations at rest and a reduced number of motor unit potentials that are normal or increased in amplitude. High-amplitude potentials may be polyphasic. Motor nerve conduction velocity slows, and sensory action potentials have reduced amplitude. Marked slowing of motor conduction velocity and reduced amplitude of sensory evoked potentials characterize demyelinating neuropathies. EMG findings may be normal early in the course.

Neuronopathy

Juvenile Amyotrophic Lateral Sclerosis

Autosomal recessive forms map to chromosomes 2q33 and 15q12. The gene for an autosomal dominant form localizes to chromosome 9q34 (Rabin et al, 1999).

CLINICAL FEATURES. Age at onset is after 12 years, and progression is slow. The clinical features are some combination of spastic paraplegia and wasting of the hands or peroneal atrophy. Bulbar palsy and pseudobulbar palsy are present in the recessive forms but not in the dominant form.

DIAGNOSIS. Diagnosis depends on the family history and the clinical features.

MANAGEMENT. Only supportive therapy is available.

Spinal Muscular Atrophy

The distal forms of SMA are genetically heterogeneous. Sometimes the disease is segmental (juvenile progressive segmental SMA), affecting only the hands or the feet. Transmission of the trait is by autosomal dominant, autosomal recessive, or X-linked inheritance. The dominant form maps to chromosome 7p and may be allelic to the axonal form of Charcot-Marie-Tooth (CMT) disease (Ellsworth et al, 1999).

CLINICAL FEATURES. These disorders usually begin with weakness and wasting in the anterior compartment of the legs associated with pes cavus deformities of the feet. Preservation of tendon reflexes may occur. In some families with dominantly inherited disease, the weakness begins in the plantar flexors, causing inability to stand on the toes. In other families, weakness and wasting are more prominent in the hands, especially the thenar muscles and first dorsal interossei.

In the severe autosomal recessive form, weakness progressively involves the proximal muscles of the legs and sometimes the hands. Weakness in the arms varies among families but shows concordance within an individual family. Approximately 25% of patients have scoliosis. Calf atrophy or hypertrophy may be present, even among members of the same family.

Juvenile segmental SMA is primarily a disorder of teenage boys, probably transmitted by autosomal recessive inheritance. Atrophy of the hands, often asymmetrical, progresses for 2 to 4 years and sometimes involves the forearms. Fasciculations and cramps are common. The atrophy usually arrests, but may progress to involve the legs and can be associated with hyperreflexia. Progressive atrophy with hyperreflexia in the legs suggests a link between juvenile segmental SMA and familial amyotrophic lateral sclerosis.

DIAGNOSIS. Electrodiagnosis is crucial to distinguish these disorders from peripheral neuropathies. Motor nerve conduction velocity is normal despite total denervation of the small muscles of the foot. Sensory evoked potentials also are normal. The serum CK concentration is usually normal but may be mildly elevated. Muscle biopsy specimens show nonspecific changes of denervation, and the sural nerve is normal.

MANAGEMENT. Hand and foot braces may help to prolong function.

Neuropathy

Charcot-Marie-Tooth Disease

The terms *Charcot-Marie-Tooth disease* and *hereditary motor and sensory neuropathy* are interchangeable (Bird, 2004). Each encompasses several genetic neuropathies that are further divisible based on molecular and linkage findings (Table 7-9). The typical patient has progressive distal weakness, mild-to-moderate sensory loss, depressed or absent tendon reflexes, and high-arched feet.

Charcot-Marie-Tooth 1 (CMT1):
Demyelinating Type

CMT1 (hereditary motor and sensory neuropathy type I) is an autosomal dominant form of demyelinating neuropathy. It accounts for 50% of all CMT cases (Bird, 2004). The genetic abnormality may consist of cases with DNA duplications of the peripheral myelin protein gene (*PMP2*) on chromosome 17p (CMT1A) or an abnormality of the *MPZ* gene on chromosome 1q22 (CMT1B). The 17p11 duplication causes trisomic expression of the peripheral myelin protein, PMP-22 (Bird, 2004). Deletion in the 17p11 region with monosomic expression of PMP-22 is the cause of *hereditary polyneuropathy with liability to pressure palsies* (see Chapter 13).

CLINICAL FEATURES. The subtypes are clinically indistinguishable, and the molecular findings

are the sole basis of designation. CMT1 is not usually a severe disorder in childhood. The main early features are pes cavus, weakness of the peroneal muscles, and diminished reactivity of the ankle tendon reflex. With time, the anterior tibial and the peroneal muscles become weak, producing footdrop. The calf muscles become weak in some families but may hypertrophy in some families with the 17p duplication. Eventually, usually after age 20, weakness spreads to the proximal muscles of the legs and hands. Scoliosis is unusual. Cramps with exercise are present in weak muscles. Position sense becomes impaired in the fingers and toes. Dyesthesias are never a problem. Hip dysplasia may be an associated feature.

Peripheral nerve enlargement occurs in adults but not in children. Repeated episodes of demyelination and remyelination are the cause of enlargement.

DIAGNOSIS. Diagnosis relies on characteristic clinical findings and a family history of the disease. Motor nerve conduction velocities are less than 50% of normal in affected individuals. The cerebrospinal fluid (CSF) protein content is usually normal in children but may be elevated in adults. A DNA-based test is available for CMT1A that detects more than 95% of cases. Persons with CMT1A have three copies of the *PMP-22* gene.

MANAGEMENT. No specific treatment is available, but proper foot care may minimize discomfort and maximize function. Shoes should be roomy

TABLE 7-9
Charcot-Marie-Tooth (CMT) Disease

Disease	Inheritance	Locus	Product
CMT1A	AD	17p11	Peripheral myelin protein
CMT1B	AD	1q22	Myelin P0 protein
CMT1C	AD	16p13.1.1-p12.3	
CMT1D	AD	10q21.1-22.1	Early growth response protein 2
CMT2A	AD	1p36	Kinosin-like protein, mitofusin 2
CMT2B	AD	3q21	Ras-related protein
CMT2C	AD	12q23-24	Unknown
CMT2D	AD	7p15	Glycyl-tRNA synthetase
CMT2E	AD	8p21	Neurofilament triplet L protein
CMT2G	AD	2q12-13	Unknown
CMT2L	AD	12q24	Unknown
CMT4A	AR	8q13-q21	Ganglioside-induced differentiation
CMT4B1	AR	11q22	Myotubularin-related protein 2
CMT4B2	AR	11q15	Myotubularin-related protein 13
CMT4C	AR	5q32	Unknown
CMT4D	AR	8q24.3	NDRG1 protein
CMT4E	AR	10q21	Early growth response protein 2
CMTX	XLD	Xq13.1	Connexin 32

Modified from Bird TD. (4 May 2004) Charcot-Marie-Tooth hereditary neuropathy overview. In: *GeneClinics: Medical Genetic Knowledge Base*. [database online] University of Washington, Seattle. Available at <http://www.geneclinics.org>.

and soft to prevent rubbing against bony prominences. Footwear molded to the shape of the foot is especially useful. When footdrop is present, a lightweight plastic ankle-foot orthosis that fits into the patient's own shoe not only lifts the foot, but also prevents turning and injury of the ankle.

Charcot-Marie-Tooth 2 (CMT2): Neuronal Type

Genetic transmission of CMT2 is by autosomal dominant inheritance. The phenotype clinically resembles CMT1 except that the nerve conduction velocity is either normal or mildly abnormal. Several subtypes are recognized (see Table 7-9). Seven different genetic abnormalities are associated with a similar phenotype (Bird, 2004).

CLINICAL FEATURES. The clinical features of CMT2 overlap with the features of CMT1. In general, patients with CMT2 are less disabled and have less sensory loss than do patients with CMT1. The gene locus for CMT2A is 1p36 and for CMT2B is 3q21. Distal weakness begins in the legs and can be asymmetrical. Later the hands are affected. Tendon reflexes are obtainable to a later age in CMT2 compared with CMT1. Progression of symptoms is slow, and disability does not occur until middle adult life.

Prominent vocal cord and respiratory (intercostal and diaphragmatic) muscle paralysis occurs in CMT2C. The onset is insidious and difficult to date precisely. The initial symptom may be hoarseness or frequent tripping, but neonatal respiratory disturbance also occurs. The course is one of progressive peroneal atrophy with minimal sensory deficit. CMT2D includes prominent weakness and atrophy of the hands.

DIAGNOSIS. The CSF protein content is normal, as is the serum CK concentration. Because the pathological process is primarily axonal rather than demyelinating, motor nerve conduction velocities are either normal or only mildly slowed ($\geq 60\%$ of normal). The EMG shows a denervation pattern in affected muscles. DNA-based testing is available on a research basis.

MANAGEMENT. Management is the same as for CMT1.

Charcot-Marie-Tooth 3 (CMT3): Dejerine-Sottas Syndrome

CMT3 originally was described as a severe demyelinating neuropathy of infancy and childhood associated with slow nerve conduction velocity, elevated CSF protein, marked clinical weakness, and hypertrophic nerves with onion

bulb formation. Patients with CMT3 are heterozygous for point mutations in the *PMP-22* gene, which causes CMT1A; the *Po* myelin gene, which causes CMT1B or various types of CMT4; or the *EGR2* gene, which causes CMT4E. The new classification of CMT3 is CMT1A, CMT1B, or CMT4.

Charcot-Marie-Tooth 4 (CMT4)

CMT4 comprises seven different disorders characterized by progressive motor and sensory neuropathy and autosomal recessive inheritance. Genetic identification of all loci and most gene products is complete.

CLINICAL FEATURES. Affected people have the typical CMT phenotype. Distal muscle weakness develops in the second year, and proximal muscles are involved by age 10. Associated findings may include mild sensory loss, absent tendon reflexes, skeletal deformities, and scoliosis.

DIAGNOSIS. All members of the CMT4 group are demyelinating neuropathies with normal protein concentrations in the CSF. Nerve conduction velocities are slow (15 to 17 m/sec). Molecular genetic diagnosis is available on a research basis.

MANAGEMENT. The treatment plan is similar to that for other CMT types.

Charcot-Marie-Tooth X (CMTX)

Inheritance of CMTX is as an X-linked dominant trait. Mutations in the connexin 32 genes are associated.

CLINICAL FEATURES. Affected males have a moderate-to-severe peripheral neuropathy that tends to be more severe than that seen in CMT1A. Females have a mild neuropathy or are asymptomatic. Symptoms develop in males during the first decade. The initial physical findings are depressed or absent tendon reflexes and footdrop. Mild-to-moderate sensory loss in the feet and hearing loss may be associated.

DIAGNOSIS. Detection of CMTX is by a DNA-based test of the connexin 32 gene. The test detects 100% of cases and is commercially available.

MANAGEMENT. The treatment plan is similar to that for other CMT types.

Other Genetic Neuropathies

Giant Axonal Neuropathy

Giant axonal neuropathy (GAN) is a rare disorder transmitted by autosomal recessive inheritance (Timmerman and Kühlenbäumer, 2003).

The cause is *mutations* in the *GAN* gene (chromosome 16q24.1) encoding the *protein* gigaxonin. The gene maps to chromosome 16q24. The underlying defect is one of generalized intermediate filament organization, with neurofilaments predominantly affected. Central and peripheral axons are affected.

CLINICAL FEATURES. Patients with giant axonal neuropathy have a severe early-onset peripheral motor and sensory neuropathy and characteristic tightly curled hair that differs markedly from that of the parents. Patients often show signs of central nervous system involvement, including mental retardation, cerebellar signs (ataxia, nystagmus, dysarthria), and pyramidal tract signs.

Both genders are at equal risk. Many patients are from consanguineous marriages. Affected children are pale and thin and have a chronic polyneuropathy accompanied by kinky pale hair. Gait impairment usually begins by 3 years of age but can appear later. Symmetrical distal atrophy of leg muscles is a constant early feature. Impairment of vibratory and proprioceptive sensations in the legs is profound, and diminished or absent tendon reflex response is the rule. Central involvement may result in cerebellar dysfunction, dementia, optic atrophy, and cranial neuropathies.

DIAGNOSIS. Genetic diagnosis is only on a research basis. A sural nerve biopsy specimen shows enlarged axons filled with disrupted neurofilaments surrounded by thin or fragmented myelin sheaths. Large myelinated nerve fibers are mainly affected. Magnetic resonance imaging (MRI) of the brain may show increased signal intensity of the white matter.

MANAGEMENT. Treatment is symptomatic.

Sulfatide Lipidosis: Metachromatic Leukodystrophy

Metachromatic leukodystrophy is an inherited disorder of myelin metabolism caused by deficient activity of the enzyme arylsulfatase A. Transmission of the genetic defect on *chromosome 22q* is by autosomal recessive inheritance. Infantile, juvenile, and adult forms are recognized. This section discusses the late infantile form only.

CLINICAL FEATURES. After a period of normal development, gait disturbances develop, usually before 2 years of age but sometimes not until age 4. Initial features may be spasticity, ataxia, or distal weakness of the feet with loss of the ankle tendon reflex. Progressive weakness of all limbs results in generalized hypotonia and hyporeflexia. Weakness, dementia, and optic

atrophy are progressive. Death occurs within several years of onset.

DIAGNOSIS. At the time of initial leg weakness, the protein content of the CSF is elevated, and motor nerve conduction velocities are reduced. Head MRI shows subcortical demyelination with a posterior predominance of white matter abnormalities. The absence of arylsulfatase A in white blood cells establishes the diagnosis. Prenatal diagnosis is possible by analysis of arylsulfatase A in amniocytes.

MANAGEMENT. Bone marrow transplantation early in the course of disease may slow its progress.

Other Lipid Disorders

Peripheral neuropathy occurs in globoid cell leukodystrophy (Krabbe disease), but is not as prominent a feature as in metachromatic leukodystrophy. The usual initial features are psychomotor retardation and irritability rather than flaccid weakness (see Chapter 5). Tendon reflexes may be absent or hyperactive, and half of cases show slowing of motor nerve conduction velocity. The CSF protein concentration is always elevated.

Progeria, small stature, ataxia, retinitis pigmentosa, deafness, and mental retardation are characteristic of *Cockayne syndrome* (see Chapter 16). A primary segmental demyelinating neuropathy is present in 10% to 20% of cases but is not an initial symptom. The main features are hyporeflexia and reduced motor nerve conduction velocity. Other disorders of lipid metabolism in which demyelinating neuropathy is present, but not an important feature, include Niemann-Pick disease, Gaucher disease, and Farber disease.

Idiopathic Axonal Neuropathy

CLINICAL FEATURES. Most axonal neuropathies are either hereditary or toxic. Glue sniffing is an example of a toxic cause. Some children have a progressive axonal neuropathy for which no cause can be determined. Progressive weakness of the feet, with or without sensory impairment, is often the initial feature. Electrodiagnostic studies in parents and siblings sometimes establish a hereditary basis.

DIAGNOSIS. The EMG shows fibrillations and fasciculations, but motor nerve conduction velocity is normal or only mildly delayed. The protein content of the CSF is normal.

MANAGEMENT. Children with idiopathic axonal neuropathies usually have a slowly progressive

weakness unresponsive to corticosteroids. Occasional patients do respond, however, and patients with a subacute progression merit a 2-month trial of prednisone. These responsive cases may be variants of chronic inflammatory demyelinating neuropathy, in which axonal involvement and demyelination are present.

Neuropathies with Systemic Disease

Drug-Induced Neuropathy

Several pharmaceutical drugs can cause neuropathy (Table 7-10). These neuropathies are often subclinical and detected only by electrodiagnosis

or because of loss of the ankle tendon reflex. Drugs that commonly produce clinical evidence of motor and sensory neuropathy are isoniazid, nitrofurantoin, vincristine, and zidovudine.

Isoniazid

CLINICAL FEATURES. The initial symptoms are numbness and paresthesias of the fingers and toes. If treatment is continued, superficial sensation diminishes in a glove-and-stocking pattern. Distal limb weakness follows and is associated with tenderness of the muscles and burning dysesthesias. Reduced or absent ankle tendon reflexes are expected.

TABLE 7-10
Neuropathies Caused by Pharmaceuticals

Drugs	Clinical and Pathological Features	Comment
Antineoplastic		
Cisplatin	S, DA, N	Binds to DNA; disrupts axonal transport (?)
Suramin	SM, DA, SD	DA: inhibits binding of growth factors; SD: immunomodulating effects (?)
Taxanes (paclitaxel, docetaxel)	S, DA	Promote microtubule assembly; disrupt axonal transport
Vincristine	S > M, M, DA	Interferes with microtubule assembly; disrupts axonal transport
Antimicrobial		
Chloroquine	SM, DA	Myopathy
Dapsone	M, DA	Optic atrophy
Isoniazid	SM, DA	Pyridoxine antagonist
Metronidazole	S, DA	
Nitrofurantoin	SM, DA	
Antiviral (NRTIs)		
Didanosine (ddI)	SM, DA	Reversible neuropathy
Fialuridine (FIAU)	S, DA	Irreversible neuropathy; also myopathy
Lamivudine (3TC)	S, DA	Least common NRTI neuropathy
Stavudine (d4T)	SM, DA	More associated with lipodystrophy syndrome
Zalcitabine (ddC)	SM, DA	Most neurotoxic NRTI
Zidovudine (AZT)	—	Myopathy only
Cardiovascular		
Amiodarone	SM, SD	Lysosomal lamellar inclusions, myopathy
Hydralazine	SM, DA	Pyridoxine antagonist
Perhexiline	SM, SD	Lipid inclusions
Other		
Colchicine	SM, DA	Neuromyopathy, increased creatine kinase levels
Disulfiram	SM, DA	
Gold	SM, DA	Myokymia
Lipid-lowering agents (statins)	SM, DA	May also cause rhabdomyolysis
Nitrous oxide	S, DA	Inhibits vitamin B ₁₂ -dependent methionine synthase; myelopathy
Phenytoin	SM, DA	Asymptomatic in most
Pyridoxine	S, N, DA	Doses >250 mg/day
Thalidomide	S, N	
Tryptophan (tainted)	SM, DA	Eosinophilia-myalgia syndrome

DA, distal axonopathy; M, motor; N, neuronopathy; NRTI, nucleoside analogue reverse transcriptase inhibitor; S, sensory; SD, segmental demyelination; SM, sensorimotor neuropathy.

From Bosch EP, Smith BE. Disorders of peripheral nerves. In: Bradley WG, Daroff RB, Fenichel GM, Jankovic J, eds. *Neurology in Clinical Practice*, Fourth Edition. Butterworth-Heinemann: Boston; 2004.

DIAGNOSIS. Suspect isoniazid neuropathy whenever neuropathy develops in a child taking the drug.

MANAGEMENT. Isoniazid interferes with pyridoxine metabolism and produces neuropathy by causing a pyridoxine deficiency state. The administration of pyridoxine along with isoniazid prevents neuropathy without interfering with antituberculous activity. The longer the symptoms progress, the longer the time until recovery. Although pyridoxine can prevent the development of neuropathy, it has little effect on the speed of recovery when neuropathy is established.

Nitrofurantoin

CLINICAL FEATURES. Nitrofurantoin neuropathy most often occurs in patients with impaired renal function. A high blood concentration of nitrofurantoin causes an axonal neuropathy. The initial features are usually paresthesias, followed within a few days or weeks by sensory loss in a glove-and-stocking pattern and weakness of distal muscles. Pure motor neuropathy is present occasionally.

DIAGNOSIS. Suspect nitrofurantoin neuropathy in any child with neuropathy taking the drug. It may be difficult to distinguish from uremic neuropathy.

MANAGEMENT. Complete recovery usually follows complete cessation of the drug. Occasional patients have developed complete paralysis and death despite discontinuation of nitrofurantoin.

Vincristine

CLINICAL FEATURES. Neuropathy is an expected complication of vincristine therapy. The ankle tendon reflex is lost first; later, other tendon reflexes become less reactive and may be lost. The first symptoms are paresthesias, often starting in the fingers rather than the feet and progressing to mild loss of superficial sensation but not position sense. Weakness follows sensory loss as evidenced by clumsiness in the hands and cramps in the feet. Distal muscles are affected more than proximal muscles and extensors more than flexors. Weakness may progress rapidly, with loss of ambulation in a few weeks. The initial weakness may be asymmetrical and suggests mononeuropathy multiplex.

DIAGNOSIS. Electrodiagnostic features are consistent with axonal neuropathy, fibrillations and fasciculations on needle EMG, but normal motor nerve conduction velocity.

MANAGEMENT. The neuropathy is dose related, and usually the patient recovers 1 to 3 months after discontinuing the drug.

Toxins

Several heavy metals, inorganic chemicals, and insecticides produce polyneuropathies in children. In adults, industrial exposure, agricultural exposure, and attempted homicide are the usual causes of heavy metal poisoning. Small children who have a single accidental ingestion are more likely to have acute symptoms of systemic disease or central nervous system dysfunction than a slowly progressive neuropathy. Sometimes, progressive distal weakness is an early sign in older children addicted to sniffing glue or gasoline. Even in these cases, symptoms of central nervous system dysfunction are usually present.

Uremia

Some degree of neuropathy occurs at some time in many children undergoing long-term periodic hemodialysis. Uremic neuropathy is more common in boys than in girls, but the reason for the gender bias is unknown.

CLINICAL FEATURES. The earliest symptoms may be muscle cramps in the hands and feet, burning feet or restless legs, and loss of the ankle tendon reflex. After the initial sensory symptoms, the disorder progresses to a severe distal, symmetrical, mixed motor and sensory polyneuropathy affecting the legs more than the arms. The rate of progression is variable and may be fulminating or may evolve over several months.

A pure motor neuropathy develops in some children with uremia. Symptoms begin after starting hemodialysis. The rapid progression of distal weakness in all limbs does not respond to dialysis but may reverse after renal transplantation.

DIAGNOSIS. Uremia causes an axonal neuropathy, but chronic renal failure causes segmental demyelination that is out of proportion to axonal changes. Repeated measures of motor nerve conduction velocity are a useful way to monitor neuropathy progression. Slow conduction velocities are present even before clinical symptoms occur. Reduced creatinine clearance correlates with slowing of the conduction velocity.

MANAGEMENT. Dialysis reverses early neuropathy. Patients with severe neuropathy rarely recover fully despite adequate treatment.

Vasculitis and Vasculopathy

Polyneuropathy and mononeuropathy multiplex are relatively common neurological complications of vasculitis in adults but not in children. Children with lupus erythematosus are generally sicker than are adults, but peripheral neuropathy is neither an initial nor a prominent feature of the disease. Motor and sensory neuropathies occur in children with chronic juvenile rheumatoid arthritis.

Myopathies

Hereditary Distal Myopathies

The hereditary distal myopathies, as a group, are uncommon except for myotonic dystrophy (Saperstein et al, 2001). Forms that usually have an adult onset are not discussed here.

Autosomal Dominant Childhood-Onset Distal Myopathy

This clinical phenotype most resembles the syndromes described by Gower and later by Laing and colleagues (1995). The gene site is on chromosome 14q11 and may be allelic to Welander distal myopathy.

CLINICAL FEATURES. Age at onset is after 4 years; onset may be delayed to after age 20. The initial weakness is in the toe and ankle extensors and neck flexors. Weakness of the finger extensors develops years later, with relative sparing of the finger flexors and intrinsic hand muscles. Some proximal limb muscles become weak late in life without impairing walking.

DIAGNOSIS. EMG findings are consistent with a myopathic process. Muscle biopsy specimens show variation in fiber size, nuclear clumps, moth-eaten type I fibers, and small angulated type II fibers. The serum CK concentration is one to three times the upper limit of normal.

MANAGEMENT. Treatment is symptomatic.

Autosomal Recessive Distal (Dysferlin) Myopathy

Two main phenotypes characterize the dysferlinopathies—one with limb-girdle weakness and the other with distal weakness. *Miyoshi myopathy* is the distal weakness phenotype, and LGMD type 2B (LGMD2B) is the proximal weakness phenotype (Matsuda et al, 1999). The two disorders are allelic, and both phenotypes occur in members of the same family.

CLINICAL FEATURES. The initial weakness of Miyoshi myopathy is in the distal parts of the legs, especially the gastrocnemius and soleus muscles. Over a period of years, the weakness and atrophy spread to the thighs and gluteal muscles. The forearms may become mildly atrophic with decrease in grip strength, but sparing the small muscles of the hands. The abnormal gene site is on chromosome 2p13.3-p13.1. Ambulation usually is preserved.

DIAGNOSIS. The peculiar pattern of calf atrophy is almost diagnostic. The serum CK concentration is at least five times the upper limit of normal; this distinguishes Miyoshi myopathy from the other distal myopathies. EMG findings are consistent with a myopathy, and a muscle biopsy specimen shows a chronic active myopathy without vacuoles.

MANAGEMENT. Most patients are not greatly impaired and do not require assistive devices.

Inclusion Body Myopathy 2

The presence of vacuolar degeneration of muscle fibers, accompanied by intrafiber clusters of paired helical filaments (*inclusion bodies*), defines inclusion body myopathies. When inflammation is an associated feature, the term *inclusion body myositis* is applied. In general, inclusion body myositis is a sporadic disorder with onset after age 30 years, whereas inclusion body myopathy is hereditary, is transmitted by autosomal recessive inheritance, and may begin in childhood. *Nonaka myopathy* is the term applied in hereditary inclusion body myopathy in Japan. The terms *Welander myopathy* and *Markesbery-Griggs-Udd myopathy* apply to genetic inclusion body myopathies in other populations. Inclusion body myopathy 2 is a specific disorder associated with mutations in the gene *GNE*.

CLINICAL FEATURES. The onset of weakness is in the second or third decade. The initial symptom is difficulty with gait resulting from footdrop. The weakness progresses to involve the thigh and hand muscles within several years. Neck flexor and shoulder girdle weakness, with relative sparing of the triceps, is a late feature. Quadriceps sparing, even at advanced stages, is common but not constant (Argov et al, 2003).

DIAGNOSIS. The serum CK concentration is normal or only mildly elevated. Light microscopy characteristically shows muscle fibers with single or multiple vacuoles rimmed with basophilic material. Electron microscopy shows the filamentous inclusions, usually adjacent to vacuoles.

Molecular genetic testing for GNE mutations is available.

MANAGEMENT. The weakness does not respond to corticosteroid or immunosuppressive therapy. Treatment is symptomatic.

Myotonic Dystrophy

Myotonic dystrophy 1 is a multisystem disorder transmitted by autosomal dominant inheritance with variable penetrance. An unstable DNA region on chromosome 19 that can amplify 50 to several thousand times causes the disease (Adams, 2001). Amplification increases in successive generations and correlates with more severe disease. A neonatal form occurs in children born to mothers with myotonic dystrophy (see Chapter 6). A proximal form of myotonic dystrophy is a distinct genetic disorder and considered in the section on distal weakness.

CLINICAL FEATURES. The onset of symptoms is usually during adolescence or later. The major features are myotonia (a disturbance in muscle relaxation after contraction), weakness in the face and distal portion of the limbs, cataracts, frontal baldness, and multiple endocrinopathies. The pattern of muscle atrophy in the face is so stereotypical that all patients with the disease have a similar facies. The face is long and thin because of wasting of the temporal and masseter muscles, and the neck is thin because of atrophy of the sternocleidomastoid muscles. The eyelids and corners of the mouth droop, and the lower part of the face sags, producing the appearance of sadness.

Although seeking medical treatment is rare before adolescence, myotonia is usually present in childhood and is detectable by EMG, if not by clinical examination. Percussion of muscle exhibits myotonia. When percussed, the thenar eminence dimples and remains dimpled at the site of percussion. In addition, the thumb abducts and remains in that position for several seconds. The physician also can detect myotonia by shaking hands with the patient, who has difficulty letting go and releases the grip in part by flexing the wrist to force the finger flexors to open.

Some patients have little or no evidence of muscle weakness, only cataracts, frontal baldness, or endocrine disturbances. The presence of muscle weakness before age 20 is likely to be relentlessly progressive, however, causing severe distal weakness in the hands and feet by adult life. Smooth and cardiac muscle involvement may be present. Disturbed gastrointestinal motility is characteristic. Endocrine disturbances include testicular atrophy, infertility in women,

hyperinsulinism, adrenal atrophy, and disturbances in growth hormone secretion.

DIAGNOSIS. The basis for the diagnosis of myotonic dystrophy is usually the clinical features, family history, and molecular genetic studies. EMG and muscle biopsy are unnecessary. Studies to show the presence and number of trinucleotide repeats are commercially available and are the best method to detect asymptomatic individuals and for prenatal diagnosis.

MANAGEMENT. Myotonia frequently responds to drugs that stabilize membranes: Mexiletine is probably the most effective; procainamide, phenytoin, and carbamazepine also are useful. Weakness and not myotonia disable the patient, however. Braces for footdrop are usually required as the disease progresses.

Scapulo (Humeral) Peroneal Syndromes

Progressive weakness and atrophy affecting the proximal muscles of the arms and the distal muscles of the legs may result from neuronopathy or myopathy. Some patients with dominantly inherited scapulo (humeral) peroneal syndromes are a variant phenotype of FSH syndrome, whereas others do not show linkage to the FSH locus on chromosome 4q35.

Emery-Dreifuss Muscular Dystrophy Type 1

Genetic transmission of Emery-Dreifuss muscular dystrophy type 1 is by X-linked recessive inheritance. The abnormal gene product is emerin.

CLINICAL FEATURES. The onset of symptoms is between 5 and 15 years old. The earliest feature of the disease is the development of contractures in the flexors of the elbows, the ankle tendon, and the extensors of the hand. Contractures are followed by muscle weakness and wasting first in the biceps and triceps muscles, then in the deltoid and other shoulder muscles. The peroneal muscles are severely affected. Calf hypertrophy does not occur. The progression of symptoms is slow, and the condition usually stabilizes by age 20. In some patients, weakness progresses into adult life, however, and ambulation is eventually lost.

All patients develop a cardiomyopathy that leads to permanent atrial paralysis. Bradycardia and syncope may precede muscle weakness or be delayed until age 20. The earliest symptom is pathological fatigue after minor activity. A permanent pacemaker is required at the first sign of cardiac involvement. Sudden death is common. Female heterozygotes develop a cardiomyopathy

late in life and require a pacemaker. These individuals do not develop skeletal muscle weakness.

DIAGNOSIS. Neither EMG nor muscle biopsy is diagnostic. Molecular genetic testing establishes the diagnosis.

MANAGEMENT. Treatment for the skeletal muscle weakness is symptomatic. Early implantation of a permanent pacemaker is lifesaving.

Emery-Dreifuss Muscular Dystrophy Type 2

Transmission of Emery-Dreifuss muscular dystrophy type 2 is by autosomal dominant inheritance. The gene locus is 1q21.2, which encodes the gene for lamin A/C (Bonne et al, 1999). The phenotype is the same as for Emery-Dreifuss muscular dystrophy type 1.

Scapuloperoneal Myopathy

Scapuloperoneal myopathy is a dominantly inherited disorder with usual onset in adult life. The phenotype is similar to that of FSH dystrophy except that the face is not usually involved. The abnormal gene is on chromosome 12 and different from that of FSH dystrophy.

Acute Generalized Weakness

The sudden onset or rapid evolution of generalized flaccid weakness, in the absence of symptoms of encephalopathy, is always due to disorders of the motor unit. Among the disorders listed in Table 7-11, AIDP (GBS) is the most common. The combination of acute weakness and rhabdomyolysis, as evidenced by myoglobinuria, indicates that muscle is degenerating rapidly. This may occur in some disorders of carbohydrate and fatty acid metabolism (see Chapter 8), after intense and unusual exercise, in some cases of infectious and idiopathic polymyositis, and in intoxication with alcohol and cocaine. Death from renal failure is a possible outcome in patients with rhabdomyolysis.

Infectious Disease

Acute Infectious Myositis

Acute myositis in children most often follows influenza or other respiratory infections (Mackay et al, 1999). Boys are affected more often than girls.

CLINICAL FEATURES. Ordinarily, prodromal respiratory symptoms persist for 3 to 8 days before the onset of severe symmetrical muscle pain and

TABLE 7-11
Acute Generalized Weakness [Gene Location]

Infectious Disorders

Acute infectious myositis
Acute inflammatory polyradiculoneuropathy (Guillain-Barré syndrome)
Acute axonal neuropathies
Chronic inflammatory polyradiculoneuropathy
Enterovirus infections

Metabolic Disorders

Acute intermittent porphyria (see Chapter 9)
Hereditary tyrosinemia (see Chapter 9)

Neuromuscular Blockade

Botulism
Corticosteroid-induced quadriplegia
Intensive care unit weakness
Tick paralysis

Periodic Paralysis

Andersen syndrome
Familial hypokalemic (FPPI) [1q31-32]
Familial hyperkalemic (FPPII) [17q23-25]
Familial normokalemic (FPPIII)

weakness, which may cause severe disability within 24 hours. Pain and tenderness are most severe in the calf muscles. Tendon reflexes are present.

DIAGNOSIS. The serum concentration of CK is elevated, usually more than 10 times the upper limit of normal.

MANAGEMENT. Spontaneous resolution of the myositis occurs almost immediately. Bed rest is required for 2 to 7 days until pain subsides, after which the patient recovers completely.

Acute Inflammatory Demyelinating Polyradiculoneuropathy

AIDP (more commonly GBS) is an acute monophasic demyelinating neuropathy. Peripheral nerves are the target of an abnormal immune response. More than half of patients describe an antecedent viral infection. Respiratory tract infections are more common than gastrointestinal infections (Paradiso et al, 1999). Enteritis caused by specific strains of *Campylobacter jejuni* is more often the inciting disease in the acute axonal form of GBS than in the demyelinating form.

CLINICAL FEATURES. The natural history of AIDP in children is similar to the history in adults. The clinical features are sufficiently stereotypical that establishing the diagnosis usually does not require laboratory confirmation. This is

especially important because the characteristic laboratory features may not be present at the onset of clinical symptoms. The two essential features are progressive motor weakness involving more than one limb and areflexia. Frequently, insidious sensory symptoms, usually ignored, precede the onset of weakness. These symptoms consist of fleeting dysesthesias and muscle tenderness in limbs that are soon to become paralytic. Weakness progresses rapidly, and approximately 50% of patients reach a nadir by 2 weeks, 80% by 3 weeks, and the rest by 4 weeks. The weakness may be ascending or descending but is relatively symmetrical qualitatively, if not quantitatively. Tendon reflexes are absent in all weak muscles and are absent even before the muscle is weak. Bilateral facial weakness occurs in half of patients. Autonomic dysfunction (arrhythmia, labile blood pressure, and gastrointestinal dysfunction) is commonly associated, and a syndrome of acute autonomic dysfunction without paralysis may be a variant.

Recovery of function usually begins 2 to 4 weeks after progression stops. In children, recovery is usually complete. The prognosis is best when recovery begins early. Respiratory paralysis is unusual, but with support of respiratory function during the critical time of profound paralysis, complete recovery is expected.

DIAGNOSIS. Examination of the CSF previously was crucial in distinguishing GBS from acute poliomyelitis. In the absence of poliomyelitis, CSF examination is less important. A physician first sees most children during the second week of symptoms. At that time, the concentration of protein may be normal or elevated, and the number of mononuclear leukocytes per cubic millimeter may be 10 or fewer. Electrophysiological studies are more important than CSF analysis for diagnosis, especially to distinguish AIDP from acute axonal neuropathy. AIDP has a better prognosis than acute axonal neuropathy.

MANAGEMENT. Careful monitoring of respiratory function is crucial. Intubation is essential if vital capacity declines rapidly to less than 50% of normal. Adequate control of respiration prevents death from the disorder. Corticosteroids are not helpful because, although they may produce some initial improvement, they tend to prolong the course. Plasma exchange or the use of intravenous immune globulin hastens recovery from GBS (Hughes et al, 2003).

Acute Motor Axonal Neuropathy

The axonal form of GBS occurs more often in rural and economically deprived populations

than does AIDP and often follows enteritis (Paradiso et al, 1999).

CLINICAL FEATURES. The clinical features are indistinguishable from the features of AIDP except that sensation usually is not affected. Maximal weakness, symmetrical quadriparesis, and respiratory failure usually occur in 1 week. Tendon reflexes are absent early in the course. Distal atrophy occurs. Recovery is slow, and the mean time to ambulation is 5 months.

DIAGNOSIS. The CSF cell count is normal, but the protein concentration increases after 1 or 2 weeks. Electrophysiological studies are consistent with an axonopathy rather than a demyelinating neuropathy, and sensory nerve action potentials are normal.

MANAGEMENT. Respiratory support is often required. Specific treatment is not available, but most children recover spontaneously.

Chronic Inflammatory Demyelinating Polyradiculoneuropathy

Acquired demyelinating neuropathies occur in an acute and a chronic form. The acute form is GBS (described in the previous section) (see Table 7-11). The chronic form is *chronic inflammatory demyelinating polyradiculoneuropathy* (CIDP). The acute and chronic forms may be difficult to distinguish from each other at the onset of symptoms, but their distinguishing feature is the subsequent course (Ryan et al, 2000). CIDP, similar to GBS, is immune mediated. The preceding infection is more often a respiratory illness than a gastrointestinal illness. Both are so common in all school-age children, however, that the cause-and-effect relationship is difficult to establish.

CLINICAL FEATURES. CIDP is more common in adults than in children. The usual initial features are weakness and paresthesias in the distal portions of the limbs causing a gait disturbance. Cranial neuropathies are unusual. Mandatory criteria for diagnosis are (1) progressive or relapsing motor and sensory dysfunction of more than one limb, of a peripheral nerve nature, developing over at least 2 months, and (2) areflexia or hyporeflexia, usually affecting all four limbs. The course is monophasic in a quarter of children and has a relapsing course in the remainder. Three quarters have residual weakness.

DIAGNOSIS. Exclusionary criteria in establishing the diagnosis of CIDP are a family history of a similar disorder, a pure sensory neuropathy, other organ involvement, or abnormal storage

of material in nerves. The protein content of the CSF is always greater than 0.45 g/L, and a few mononuclear cells may be present. Motor nerve conduction velocity is less than 70% of the lower limit of normal in at least two nerves. Sural nerve biopsy is not mandatory, but specimens show features of demyelination, cellular infiltration of the nerve, and no evidence of vasculitis.

Electrodiagnosis differentiates acquired demyelinating neuropathies from familial demyelinating neuropathies. Acquired neuropathies show a multifocal disturbance of conduction velocity, whereas slowing of conduction velocity is uniform throughout the length of the nerve in hereditary disorders.

MANAGEMENT. An ideal treatment protocol is not established (Ropper, 2003). Immediate and long-term use of prednisone and intravenous immune globulin or plasma exchange is effective in most children. As a rule, long-term therapy is essential, and relapse may follow discontinuation of therapy. The outcome is more favorable in children than in adults.

Viral Infections

Enterovirus Infections

Poliovirus, coxsackievirus, and the echovirus group are RNA viruses that inhabit the intestinal tract of humans. They are neurotropic and produce paralytic disease by destroying the motor neurons of the brainstem and spinal cord. Of this group, poliovirus causes the most severe and devastating disease. Coxsackievirus and echoviruses are more likely to cause aseptic meningitis, although they can cause an acute paralytic syndrome similar to that of poliomyelitis.

CLINICAL FEATURES. Enterovirus infections occur in epidemics during the spring and summer. The most common syndrome associated with poliovirus infection is a brief illness characterized by fever, malaise, and gastrointestinal symptoms. Aseptic meningitis occurs in more severe cases. The extreme situation is paralytic poliomyelitis. Initial symptoms are fever, sore throat, and malaise lasting 1 to 2 days. After a brief period of apparent well-being, fever recurs in association with headache, vomiting, and signs of meningeal irritation. Pain in the limbs or over the spine is an antecedent symptom of limb paralysis. Flaccid muscle weakness develops rapidly thereafter. The pattern of muscle weakness varies, but is generally asymmetrical. One arm or leg is often weaker than the other limbs.

Bulbar polio occurs with or without spinal cord disease. It is often life-threatening. Affected

children have prolonged episodes of apnea and require respiratory assistance. Several motor cranial nerves may be involved as well, but sparing the extraocular muscle.

The introduction of inactivated poliomyelitis vaccine in 1954, followed by the use of live-attenuated vaccine in 1960, has abolished the disease in the Western hemisphere and Europe. Vaccine-associated poliomyelitis is rare since inactivated polio vaccine replaced the live-attenuated vaccine.

DIAGNOSIS. The diagnosis is suspected from the clinical findings. Isolation and viral typing from stool and nasopharyngeal specimens provide confirmation. The CSF initially shows a polymorphonuclear reaction, with the cell count ranging from 50 to 200/mm³. After 1 week, lymphocytes predominate; after 2 to 3 weeks, the total cell count decreases. The protein content is elevated early and remains elevated for several months.

MANAGEMENT. Treatment is supportive.

West Nile Virus

West Nile virus has spread across the United States since arriving in New York in 1999 (Li et al, 2003).

CLINICAL FEATURES. After a flulike illness, an acute, severe, asymmetrical paralysis occurs, which may affect only one limb and may involve the face. Sensory features are minimal, and encephalopathy does not occur.

DIAGNOSIS. The EMG indicates severe denervation in affected muscles. EMG and MRI localize the abnormality to the motor neuron or ventral horn.

MANAGEMENT. Treatment is supportive.

Neuromuscular Blockade

Children treated for prolonged periods with neuromuscular blocking agents for assisted ventilation may remain in a flaccid state for days or weeks after discontinuing the drug. This is especially true in newborns receiving several drugs that block the neuromuscular junction.

Botulism

Clostridium botulinum produces a toxin that interferes with the release of acetylcholine at the neuromuscular junction. Chapter 6 describes the infantile form, but most cases occur after infancy in individuals who eat food, usually preserved at home, contaminated with the organism.

CLINICAL FEATURES. The first symptoms are blurred vision, diplopia, dizziness, dysarthria, and dysphagia, which have their onset 12 to 36 hours after the ingestion of toxin. Some patients have bulbar signs only; in others, flaccid paralysis develops in all limbs. Patients with generalized weakness always have ophthalmoplegia with sparing of the pupillary response. Tendon reflexes may be present or absent.

DIAGNOSIS. Repetitive supermaximal nerve stimulation at a rate of 20 to 50 stimuli per second produces an incremental response characteristic of a presynaptic defect. The electrical abnormality evolves with time and may not be demonstrable in all limbs on any given day.

MANAGEMENT. Botulism can be fatal because of respiratory depression. Treatment relies primarily on supportive care, which is similar to the management of GBS. Antitoxin does not influence the course of the disease.

Corticosteroid-Induced Quadriplegia

The administration of high-dose intravenous corticosteroids, especially in combination with a neuromuscular blocking agent, may cause acute generalized weakness.

CLINICAL FEATURES. Most patients with this syndrome receive corticosteroids to treat asthma. The onset of weakness is 4 to 14 days after starting treatment. The weakness is usually diffuse at onset but may be limited to proximal or distal muscles. Tendon reflexes usually are preserved. Complete recovery is the rule.

DIAGNOSIS. The serum CK concentration may be normal or elevated. EMG shows brief, small-amplitude polyphasic potentials, and the muscle is electrically inexcitable to direct stimulation.

MANAGEMENT. Respiratory assistance may be required. Cessation of the offending drugs usually ends the disorder and allows the patient to recover spontaneously.

Tick Paralysis

In North America, the female tick of the species *Dermacentor andersoni* and *Dermacentor variabilis* elaborates a salivary gland toxin that induces paralysis. The mechanism of paralysis is unknown (Vednarayanan et al, 2002).

CLINICAL FEATURES. Affected children are usually younger than 5 years old. The clinical syndrome is similar to GBS except that ocular motor palsies and pupillary abnormalities are more common. A severe generalized flaccid weakness, usually first affecting the legs, develops rapidly and sometimes is associated with bifacial palsy.

Respiratory paralysis requiring assisted ventilation is common. Tendon reflexes are usually absent or greatly depressed. Dysesthesias may be present at the onset of weakness, but examination fails to show loss of sensation.

DIAGNOSIS. The CSF protein concentration is normal. Nerve conduction studies may be normal or may show mild slowing of motor nerve conduction velocities. Decreased amplitude of the compound muscle action potentials is common. High rates of repetitive stimulation may show a normal result or an abnormal incremental response.

MANAGEMENT. In North America, strength returns quickly after removing the causative tick. The tick may be hard to find, however, because it hides in body hair. In contrast, paralysis is more severe in Australia and may worsen over 1 to 2 days after removal before improvement begins.

Intensive Care Unit Weakness

Almost 2% of children admitted to intensive care units develop muscle weakness (Banwell et al, 2003). Most are organ transplant recipients treated with neuromuscular blocking agents, corticosteroids, and aminoglycoside antibiotics. The usual clinical feature is failure to wean from a respirator. Some of these children exemplify "corticosteroid-induced quadriplegia" (described earlier). Corticosteroid myopathy accounts for some cases. These children show increased blood concentrations of CK and histological evidence of myofiber necrosis. A third possible cause is the depletion of myosin from muscle. Muscle biopsy distinguishes the several types of prolonged weakness that may occur in patients with severe illness requiring intensive care.

Periodic Paralysis

The usual classification of periodic paralysis is in relation to serum potassium: hyperkalemic, hypokalemic, or normokalemic. In addition, periodic paralysis may be primary (genetic) or secondary. The cause of secondary hypokalemic periodic paralysis is urinary or gastrointestinal loss of potassium. Urinary loss accompanies primary hyperaldosteronism, licorice intoxication, amphotericin B therapy, and several renal tubular defects. Gastrointestinal loss most often occurs with severe chronic diarrhea, prolonged gastrointestinal intubation and vomiting, and a draining gastrointestinal fistula. Urinary loss or

gastrointestinal loss or both may occur in children with anorexia nervosa who overuse diuretics or induce vomiting. Thyrotoxicosis is an important cause of hypokalemic periodic paralysis, especially in Asians. Secondary hyperkalemic periodic paralysis is associated with renal or adrenal insufficiency.

Familial Hypokalemic Periodic Paralysis

Genetic transmission of familial hypokalemic periodic paralysis is by autosomal dominant inheritance with decreased penetrance in women. The underlying defect in 70% of cases is mutations in the gene encoding the muscle dihydropyridine-sensitive calcium channel α_1 subunit (CACNA1S) that maps to chromosome 1q31-32. Twelve percent have mutations in *SCN4A* (chromosomal locus 17q23.1-q25.3).

CLINICAL FEATURES. The onset of symptoms occurs before 16 years of age in 60% of cases and by 20 years of age in the remainder. Attacks of paralysis are infrequent at first, but then may occur several times a week. Factors that trigger an attack include rest after exercise (many attacks occur early in the morning), a large meal with high carbohydrate content (pizza is the trigger of choice in adolescents), emotional or physical stress, alcohol ingestion, and exposure to cold. Before and during the attack, the patient may have excessive thirst and oliguria. The weakness begins with a sensation of aching in the proximal muscles. Sometimes, only the proximal muscles are affected; at other times, there is complete paralysis so that the patient cannot even raise the head. Facial muscles are rarely affected, and extraocular motility is always normal. Respiratory distress does not occur. When the weakness becomes extreme, the muscles feel swollen, and the tendon reflexes are absent. Most attacks last 6 to 12 hours and some for the whole day. Strength recovers rapidly, but after several attacks residual weakness may be present.

DIAGNOSIS. Molecular genetic testing is available, but the clinical features usually establish the diagnosis. During the attack, the serum concentration of potassium ranges from 0.9 to 3 mL (normal range 3.5 to 5 mL), and ECG changes occur, including bradycardia, flattening of T waves, and prolongation of the P-R and Q-T intervals. The muscle is electrically silent and not excitable. The oral administration of glucose, 2 g/kg, with 10 to 20 U of crystalline insulin given subcutaneously provokes attacks. The serum potassium concentration decreases, and paralysis ensues within 2 to 3 hours.

MANAGEMENT. Treatment of attacks in patients with good renal function is with repeated oral doses of potassium. Intravenous infusions cannot increase the serum potassium concentration. In adolescents, 5 to 10 g is used. Consider smaller amounts for younger children. Daily use of carbonic anhydrase inhibitors is beneficial in many families to prevent attacks (Tawil et al, 2000).

Familial Hyperkalemic Periodic Paralysis Type 1

Genetic transmission of familial hyperkalemic periodic paralysis type 1 is by autosomal dominant inheritance. The frequency is the same in both genders. The cause is a defect of the gene encoding the sodium channel on chromosome 17q23-25 (Jurkat-Rott and Lehmann-Horn, 2003).

CLINICAL FEATURES. The onset of weakness is in early childhood and sometimes in infancy. As in hypokalemic periodic paralysis, resting after exercise may provoke attacks. Only moderate exercise is required. Weakness begins with a sensation of heaviness in the back and leg muscles. Sometimes the patient can delay the paralysis by walking or moving about. In infants and small children, characteristic attacks are episodes of floppiness in which the child lies around and cannot move. In older children and adults, mild and severe attacks may occur. Factors causing attacks are potassium-rich foods, rest after exercise, a cold environment, emotional stress, glucocorticoids, and pregnancy. Mild attacks last for less than 1 hour and do not produce complete paralysis. More than one mild attack may occur in a day. Severe attacks are similar to the complete flaccid paralysis seen in hypokalemic periodic paralysis and may last several hours. Residual weakness may persist after several severe attacks. Mild myotonia of the eyelids, face, and hands may be present between attacks. Older patients may develop a progressive myopathy.

DIAGNOSIS. Molecular genetic testing is commercially available for several of the mutations that cause disease. Between attacks, the serum concentration of potassium is normal but increases at least 1.5 mM/L during attacks. When the potassium concentration is high, ECG changes are consistent with hyperkalemia. The oral administration of potassium chloride just after exercise in the fasting state provokes an attack. During the attack, the muscles are electrically silent. Myotonia in patients with hyperkalemic periodic paralysis is mild and may occur only on exposure to cold.

MANAGEMENT. Acute attacks seldom require treatment because they are brief. Prophylactic measures include avoidance of meals rich in potassium (grapefruit juice) and cold exposure. Daily low doses (25 to 50 mg) of hydrochlorothiazide may prevent attacks by decreasing serum potassium concentrations.

Familial Normokalemic Periodic Paralysis

Several families have experienced an autosomal dominant inherited periodic paralysis in which no alteration in the serum concentration of potassium could be detected. These cases may represent a variant of hyperkalemic periodic paralysis resulting from a mutation in the muscle-specific sodium gene (Chinnery et al, 2002).

Andersen Potassium-Sensitive Cardiodysrhythmic Periodic Paralysis (Andersen Syndrome)

Andersen syndrome is a distinct channelopathy affecting skeletal and cardiac muscles (Canun et al, 1999). The genetic defect at 17q23.1-q24.2 involves the α -subunit of the skeletal muscle's sodium channel and the cardiac muscle potassium channel responsible for most long Q-T intervals.

CLINICAL FEATURES. The main features are short stature, dysmorphic features, periodic paralysis, and a prolonged Q-T interval. The dysmorphic features include broad nose, low-set ears, small mandible, and syndactyly. The periodic paralysis may be associated with hyperkalemia, hypokalemia, or normokalemia. The prolonged Q-T interval may be the only feature in some individuals. The initial feature may be an arrhythmia, especially ventricular tachycardia, or attacks of paralysis.

DIAGNOSIS. The diagnosis is suspected in any dysmorphic child with a prolonged Q-T interval or a periodic paralysis.

MANAGEMENT. The arrhythmias associated with prolonged Q-T interval are life-threatening and must be treated. Affected family members with periodic paralysis are responsive to oral potassium.

References

- Adams C. (14 August 2001) Myotonic dystrophy. In: *GeneClinics: Medical Genetic Knowledge Base*. [database online] University of Washington, Seattle. Available at <http://www.geneclinics.org>.
- Amalfitano A, Bengur AR, Morse RP, et al. Recombinant human acid alpha-glucosidase enzyme therapy for infantile glycogen storage disease type II. Results of a phase III clinical trial. *Genet Med* 2001;3:132-138.
- Argov Z, Eisenberg I, Grabov-Nardini G, et al. Hereditary inclusion body myopathy. The Middle Eastern genetic cluster. *Neurology* 2003;60:1519-1523.
- Banwell BL, Mildner RJ, Hassall AC, et al. Muscle weakness in critically ill children. *Neurology* 2003;61:1779-1782.
- Bird TD. (4 May 2004) Charcot-Marie-Tooth hereditary neuropathy overview. In: *GeneClinics: Medical Genetic Knowledge Base*. [database online] University of Washington, Seattle. Available at <http://www.geneclinics.org>.
- Bonne G, Di Barletta MR, Varnous S, et al. Mutations in the gene encoding lamin A/C cause autosomal dominant Emery-Dreifuss muscular dystrophy. *Nat Genet* 1999;21:285-288.
- Canun S, Perez N, Beirana LG. Andersen syndrome autosomal dominant in three generations. *Am J Med Genet* 1999;85:147-156.
- Chinnery PF, Walls TJ, Hanna MG, et al. Normokalemic periodic paralysis revisited. Does it really exist? *Ann Neurol* 2002;52:251-252.
- Croxen R, Hatton C, Shelley C, et al. Recessive inheritance and variable penetrance of slow-channel congenital myasthenic syndromes. *Neurology* 2002;59:162-168.
- Day JW, Ricker K, Jacobson JF, et al. Myotonic dystrophy type 2. Molecular, diagnostic and clinical spectrum. *Neurology* 2003;60:657-664.
- Duggan DJ, Gorospe JR, Fanin M, et al. Mutations in the sarcoglycan genes in patients with myopathy. *N Engl J Med* 1997;336:618-624.
- Ellsworth RE, Ionasescu V, Searby C, et al. The CMT2D locus. Refined genetic position and construction of a bacterial clone-based physical map. *Genome Res* 1999;9:568-574.
- Figlewicz DA, Tawil R. (18 March 2003) Facioscapulo-humeral dystrophy. In: *GeneClinics: Medical Genetic Knowledge Base*. [database online] University of Washington, Seattle. Available at <http://www.geneclinics.org>.
- Gordon E, Pegoraro E, Hoffman EP. (11 February 2004) Limb-girdle muscular dystrophy. In: *GeneClinics: Medical Genetic Knowledge Base*. [database online] University of Washington, Seattle. Available at <http://www.geneclinics.org>.
- Harper CM, Fukudome T, Engel AG. Treatment of slow-channel congenital myasthenic syndrome with fluoxetine. *Neurology* 2003;61:1710-1713.
- Hughes RAC, Wijdicks EFM, Barohn R, et al. Practice parameter. Immunotherapy for Guillain-Barré syndrome. Report of the Quality Standards Subcommittee of the American Academy of Neurology. *Neurology* 2003;61:736-740.
- Jöbsis GJ, Boers JM, Barth PG, et al. Bethlem myopathy. A slowly progressive congenital muscular dystrophy. *Brain* 1999;122:649-655.
- Jurkat-Rott K, Lehmann-Horn F. (18 July 2003) Hyperkalemic periodic paralysis type 1. Hyperkalemic periodic paralysis type 1. In: *GeneClinics: Medical Genetic Knowledge Base*. [database online] University of Washington, Seattle. Available at <http://www.geneclinics.org>.
- Korf BR, Darras BT, Urion DK. (24 March, 2004) Dystrophinopathies. In: *GeneClinics: Medical Genetic Knowledge Base*. [database online] University of Washington, Seattle. Available at <http://www.geneclinics.org>.

- Laing NG, Laing BA, Meredith C, et al. Autosomal dominant distal myopathy. Linkage to chromosome 14. *Am J Hum Genet* 1995;56:422-427.
- Li J, Loeb JA, Shy ME, et al. Asymmetric flaccid paralysis. A neuromuscular presentation of West Nile Virus infection. *Ann Neurol* 2003;53:703-710.
- Mackay MT, Kornberg AJ, Shield LK, et al. Benign acute childhood myositis. Laboratory and clinical features. *Neurology* 1999;53:2127-2131.
- Matsuda C, Aoki M, Hayashi YK, et al. Dysferlin is a surface-associated protein that is absent in Miyoshi myopathy. *Neurology* 1999;53:1119-1122.
- Navon R, Khosravi R, Melki J, et al. Juvenile-onset spinal muscular atrophy caused by compound heterozygosity for mutations in the HEXA gene. *Ann Neurol* 1997;41:631-638.
- Paradiso G, Tripoli J, Galicchio S, et al. Epidemiological, clinical, and electrodiagnostic findings in childhood Guillain-Barré syndrome. A reappraisal. *Ann Neurol* 1999;46:701-707.
- Prior TW, Russman BS. (17 October 2003) Spinal muscular atrophy. In: *GeneClinics: Medical Genetic Knowledge Base*. [database online] University of Washington, Seattle. Available at <http://www.geneclinics.org>.
- Rabin BA, Griffin JW, Crain BJ, et al. Autosomal dominant juvenile amyotrophic lateral sclerosis. *Brain* 1999;122:1539-1550.
- Ropper AH. Current treatments for CIDP. *Neurology* 2003;60(Suppl 3):S16-S22.
- Ryan MM, Grattan-Smith PJ, Procopis PG, et al. Childhood chronic inflammatory demyelinating polyneuropathy. Clinical course and long-term outcome. *Neuromusc Disord* 2000;10:398-406.
- Saperstein DS, Amato AA, Barohn RJ. Clinical and genetic aspects of distal myopathies. *Muscle Nerve* 2001;24:1440-1450.
- Shoji Y, Koizumi A, Kayo T, et al. Evidence for linkage of human primary systemic carnitine deficiency with D5S436. A novel gene locus on chromosome 5q. *Am J Hum Genet* 1998;63:101-108.
- Sugie K, Yamamoto A, Murayama K, et al. Clinicopathological features of genetically confirmed Danon disease. *Neurology* 2002;58:1773-1778.
- Tawil R, McDermott MP, Brown R Jr, et al. Randomized trials of dichlorphenamide in the periodic paralyses. *Ann Neurol* 2000;47:46-53.
- Timmerman V, Kuhlensäumer G. (9 January 2003) Giant axonal neuropathy. In: *GeneClinics: Medical Genetic Knowledge Base*. [database online] University of Washington, Seattle. Available at <http://www.geneclinics.org>.
- Vednarayanan VV, Evans OB, Subramony SH. Tick paralysis in children. Electrophysiology and possibility of misdiagnosis. *Neurology* 2002;59:1088-1090.
- Winkel LPF, Van den Hout JMP, Kamphoven JHJ, et al. Enzyme replacement therapy in late-onset Pompe's disease. A three year follow-up. *Ann Neurol* 2004;55:495-502.

Chapter 8

Cramps, Muscle Stiffness, and Exercise Intolerance

A CRAMP IS an involuntary painful contraction of a muscle or part of a muscle. Cramps can occur in normal children during and after vigorous exercise and after excessive loss of fluid or electrolytes. The characteristic electromyogram (EMG) finding for such cramps is the repetitive firing of normal motor unit potentials. Stretching the muscle relieves the cramp. Partially denervated muscle is particularly susceptible to cramping not only during exercise, but also during sleep. Night cramps may awaken patients with neuronopathies, neuropathies, or root compression. Cramps during exercise occur also in patients with several different disorders of muscle energy metabolism. The EMG characteristic of these cramps is electrical silence.

Muscle stiffness and spasms are not cramps, but are prolonged contractions of several muscles that are able to impose postures. Such contractions may or may not be painful. When painful, they lack the explosive character of cramps. Prolonged contractions occur when muscles fail to relax (myotonia) or when motor unit activity is continuous (Table 8-1). Prolonged, painless muscle contractions occur also in dystonia and in other movement disorders (see Chapter 14).

Many normal children, especially preadolescent boys, complain of pain in their legs at night and sometimes during the day, especially after a period of increased activity. These pains are not true cramps. The muscle is not in spasm, the pain is diffuse and aching in quality, and the discomfort lasts for an hour or longer. Stretching the muscle does not relieve the pain. These pains are not a symptom of neuromuscular disease and are called *growing pains*, for want of better understanding. Mild analgesics or heat relieves symptoms.

Exercise intolerance is a relative term for an inability to maintain exercise at an expected

level. The causes of exercise intolerance considered in this chapter are fatigue and muscle pain. Fatigue is a normal consequence of exercise and occurs in everyone at some level of activity. In general, weak children become fatigued more quickly than children who have normal strength. Many children with exercise intolerance and cramps, but no permanent weakness, have a defect in an enzyme needed to produce energy for muscular contraction (Table 8-2). A known mechanism underlies several such inborn errors of metabolism. Even when the full spectrum of biochemical tests is available, however, identification of a metabolic defect is not possible in some children with cramps during exercise.

Myasthenia gravis is a disorder characterized by exercise intolerance, but it is not covered in this chapter because the usual initial symptoms are either isolated cranial nerve disturbances (see Chapter 15) or limb weakness (see Chapters 6 and 7). Conditions that produce some combination of cramps and exercise intolerance are divisible into three groups: (1) diseases with abnormal muscle activity, (2) diseases with decreased energy for muscle contraction, and (3) myopathies. As a rule, the first and third groups are symptomatic at all times, whereas the second group is symptomatic only with exercise. The first group usually requires an EMG for diagnosis. EMG is the initial diagnostic test in children with muscle stiffness that is not due to spasticity or rigidity. It usually leads to the correct diagnosis (Table 8-3).

Abnormal Muscle Activity

Continuous Motor Unit Activity

The cause of continuous motor unit activity (CMUA) is the uncontrolled release of acetylcholine packets at the neuromuscular junction.

TABLE 8-1
Diseases with Abnormal Muscle Activity

Continuous motor unit activity
Neuromyotonia
Paroxysmal ataxia and myokymia (see Chapter 10)
Schwartz-Jampel syndrome
Stiff-man syndrome
Thyrotoxicosis
Cramps-fasciculation syndrome
Myotonia
Myotonia congenita
Myotonia fluctuans
Systemic disorders
Hypoadrenalism
Hypocalcemia (tetany)
Strychnine poisoning
Hypothyroidism
Uremia

TABLE 8-2
Diseases with Decreased Muscle Energy

Defects of carbohydrate utilization
Lactate dehydrogenase deficiency
Myophosphorylase deficiency
Phosphofructokinase deficiency
Phosphoglycerate kinase deficiency
Phosphoglycerate mutase deficiency
Defects of fatty acid oxidation
Carnitine O-palmitoyltransferase 2 deficiency
Very-long-chain acyl coenzyme A dehydrogenase deficiency
Mitochondrial (respiratory chain) myopathies
Myoadenylate deaminase deficiency

The EMG features of CMUA are repetitive muscle action potentials in response to a single nerve stimulus; high-frequency bursts of motor unit potentials of normal morphology abruptly start and stop. Rhythmic firing of doublets, triplets, and multiplets occur. During long bursts, the potentials decline in amplitude. This activity is difficult to distinguish from normal voluntary activity. CMUA occurs in a heterogeneous group of disorders characterized clinically by some combination of muscle pain, fasciculations, myokymia, contractures, and cramps (Table 8-4).

The primary defect in CMUA disorder may reside within the spinal cord (*stiff-man syndrome*) or the peripheral nerve (*neuromyotonia*). The original name for neuromyotonia is *Isaac syndrome*. These disorders may be sporadic or familial in occurrence. When familial, the usual mode of transmission is autosomal dominant inheritance.

TABLE 8-3
Electromyography in Muscle Stiffness

Normal Between Cramps*
Brody myopathy
Defects of carbohydrate metabolism
Defects of lipid metabolism
Mitochondrial myopathies
Myoadenylate deaminase deficiency
Rippling muscle disease
Tubular aggregates
Silent Cramps
Brody disease
Defects of carbohydrate metabolism
Rippling muscle disease
Tubular aggregates
Continuous Motor Activity
Neuromyotonia
Schwartz-Jampel syndrome
Stiff-man syndrome
Myotonia
Myotonia congenita
Myotonic dystrophy
Schwartz-Jampel syndrome
Myopathy
Emery-Dreifuss muscular dystrophy
Rigid spine syndrome
X-linked myalgia

*Or may be myopathic.

TABLE 8-4
Abnormal Muscle Activity

<i>Fasciculations</i> —Spontaneous, random twitching of a group of muscle fibers
<i>Fibrillation</i> —Spontaneous contraction of a single muscle fiber, not visible through the skin
<i>Myotonia</i> —Disturbance in muscle relaxation after voluntary contraction or percussion
<i>Myokymia</i> —Repetitive fasciculations causing a quivering or undulating twitch
<i>Neuromyotonia</i> —Continuous muscle activity characterized by muscle rippling, muscle stiffness, and myotonia

Neuromyotonia

The primary abnormality in neuromyotonia is in the nerve or the nerve terminal. Most childhood cases are sporadic in occurrence, but some show a pattern of autosomal dominant inheritance. An autoimmune process directed against the potassium channel may account for some sporadic cases (Shillito et al, 1995).

CLINICAL FEATURES. The clinical triad includes involuntary muscle twitching (fasciculations or myokymia), muscle cramps or stiffness, and myotonia. Excessive sweating frequently is asso-

ciated with the muscle stiffness. The age at onset is anytime from birth to adult life.

The initial features are muscle twitching and cramps brought on by exercise. Later these symptoms also occur at rest and during sleep. The cramps may affect only distal muscles, causing painful posturing of the hands and feet. As a rule, leg weakness is greater than arm weakness. These disorders are not progressive and do not lead to permanent disability. Attacks of cramping are less frequent and severe with age.

In some children, cramps and fasciculations are not as prominent as stiffness, which causes abnormal limb posturing associated frequently with excessive sweating. Leg involvement is more common than arm involvement, and the symptoms suggest dystonia (see Chapter 14). Limb posturing may begin in one foot and remain asymmetrical for months. Most cases are sporadic. Muscle mass, muscle strength, and tendon reflexes are normal. Fasciculations are sporadic and seen only after prolonged observation.

DIAGNOSIS. Some adult-onset cases are associated with malignancy, but this is never the case in children. Muscle fibers fire repetitively at a rate of 100 to 300 Hz, either continuously or in recurring bursts, producing a pinging sound. The discharge continues during sleep and persists after procaine block of the nerve.

MANAGEMENT. Carbamazepine and phenytoin, at usual anticonvulsant doses, are effective in reducing or abolishing symptoms.

Schwartz-Jampel Syndrome

The Schwartz-Jampel syndrome (SJS) is a hereditary disorder, transmitted by autosomal recessive inheritance. The gene locus maps to *1p36.1*. Characteristic features include short stature, skeletal abnormalities, and persistent muscular contraction and hypertrophy. Giedion and colleagues (1997) found that some children had mild skeletal changes that may be secondary to CMUA (SJS-1), whereas others had primary bone dysplasia with CMUA (SJS-2). The first group shows linkage to chromosome *1p36.1-p34*, whereas the second group does not.

CLINICAL FEATURES. SJS-1 corresponds to the original description of Schwartz and Jampel. Bone deformities are not prominent at birth. CMUA of the face is the main feature producing a characteristic triad that includes narrowing of the palpebral fissures (blepharophimosis), pursing of the mouth, and puckering of the chin. Striking or even blowing on the eyelids induces blepharospasm. CMUA in the limbs produces

stiffness of gait and exercise intolerance. Motor development during the first year is slow, but intelligence is normal. SJS-2 has prominent bone deformities at birth that suggest the Morquio syndrome (osteochondrodystrophy). Neonatal mortality is high.

DIAGNOSIS. The EMG shows CMUA. Initial reports suggested incorrectly that the abnormal activity seen on the EMG and expressed clinically was myotonia. Myotonia may be present, but CMUA is responsible for the facial and limb symptoms. The serum concentration of creatine kinase (CK) can be mildly elevated. The histological appearance of the muscle is usually normal but may show variation in fiber size and an increased number of central nuclei.

MANAGEMENT. Phenytoin or carbamazepine diminishes the muscle stiffness. Early treatment with relief of muscle stiffness reduces the severity of subsequent muscle deformity.

Myotonic Disorders

Myotonia Congenita

Myotonia congenita is a genetic disorder characterized by muscle stiffness and hypertrophy. Weakness is not prominent, but stiffness may impair muscle function. The disease can be transmitted as either an autosomal dominant (*Thomsen disease*) or autosomal recessive (*Becker disease*) trait. Recessive inheritance may underlie all myotonia congenita, however, with some modifying factors responsible for differences (Sun et al, 2001). The overlap of clinical features is considerable, and clinical features alone cannot determine the pattern of genetic transmission. Abnormalities in the chloride channel on chromosome *7q35* underlie all cases.

CLINICAL FEATURES. Clinical features are stereotyped. After rest, muscles are stiff and difficult to move. With activity, the stiffness disappears, and movement may be normal. One of my patients played Little League baseball and could not sit while he was waiting to bat for fear that he would be unable to get up. The onset usually dates to infancy. The myotonia may cause generalized muscle hypertrophy, giving the infant a Herculean appearance. The tongue, face, and jaw muscles are sometimes involved. Cold exposure exacerbates stiffness, which is painless. Percussion myotonia is present. Muscle mass, strength, and tendon reflexes are normal.

DIAGNOSIS. EMG establishes the diagnosis. Repetitive discharges at rates of 20 to 80 cycles/sec are recorded when the needle first is inserted into the muscle and again on voluntary

contraction. Two types of discharges occur: a biphasic spike potential of less than 5 msec and a positive wave of less than 50 msec. The waxing and waning of the amplitude and frequency of potentials produces a characteristic sound. Dystrophy is not present. The serum CK concentration is normal, and muscle biopsy specimens do not contain necrotic fibers.

MANAGEMENT. Myotonia does not always require treatment, but sometimes phenytoin or carbamazepine at ordinary anticonvulsant doses can provide relief. Mexiletine is probably the more effective drug and is my first choice.

Myotonia Fluctuans

Myotonia fluctuans is a disorder of the muscle sodium channel on chromosome 17q23-25. Transmission is by autosomal dominant inheritance. Allelic disorders with overlapping clinical phenotypes include hyperkalemic periodic paralysis and paramyotonia congenita.

CLINICAL FEATURES. The onset of stiffness is usually after age 10 years and worsens with exercise or potassium ingestion. Cramps in the toes, fingers, and eyelids, especially when tired or cold, begin in childhood (Orrell et al, 1998). Physical examination reveals mild myotonia but normal strength. Symptoms vary from day to day. Myotonia affects the extraocular muscles and the trunk and limbs. The severity of myotonia fluctuates on a day-by-day basis. "Warming up" usually relieves symptoms, but exercise also may worsen symptoms. A bad day may follow a day of exercise or potassium ingestion, but neither exercise nor potassium ingestion causes immediate worsening of myotonia. Cooling does not trigger or worsen myotonia.

DIAGNOSIS. The EMG shows myotonia and a mild reduction in the amplitude of compound muscle action potential on cooling and administration of potassium. DNA analysis shows a mutation in the gene for the sodium channel subunit.

MANAGEMENT. Daily use of mexiletine or acetazolamide may relieve the stiffness.

Systemic Disorders

Hypoadrenalism

A small percentage of patients with Addison's disease complain of cramps and pain in truncal muscles. At times, paroxysmal cramps occur in the lower torso and legs and cause the patient to double up in pain. Hormone replacement relieves the symptoms.

Hypocalcemia and Hypomagnesemia

Tetany caused by dietary deficiency of calcium is rare in modern times except in newborns fed cows' milk. Hypocalcemic tetany is more likely to result from hypothyroidism or hyperventilation-induced alkalosis.

The initial symptom of tetany is tingling around the mouth and in the hands and feet. With time, the tingling increases in intensity and becomes generalized. Spasms in the muscles of the face, hands, and feet follow. The hands assume a typical posture in which the fingers extend, the wrists flex, and the thumbs abduct. Fasciculations and laryngeal spasm may be present. Percussion of the facial nerve, either just anterior to the ear or over the cheek, produces contraction of the muscles innervated by that branch of the nerve.

A similar syndrome occurs with magnesium deficiency. In addition to the tetany, encephalopathy occurs. Restoring the proper concentration of serum electrolytes relieves the cramps associated with hypocalcemia and hypomagnesemia.

Thyroid Disease

Myalgia, cramps, and stiffness are the initial features in half of patients with hypothyroidism. Stiffness is worse in the morning, especially on cold days, and the probable cause is the slowing of muscular contraction and relaxation; this is different from myotonia, in which only relaxation is affected. Activity worsens the stiffness of hypothyroidism, which may be painful, whereas activity relieves myotonia and is painless. The slowing of muscular contraction and relaxation is sometimes shown when tendon reflexes are tested. The response tends to "hang up."

Percussion of a muscle produces a localized knot of contraction called *myoedema*. This localized contraction lasts for 1 minute before slowly relaxing.

Myokymia; CMUA of the face, tongue, and limbs; and muscle cramps develop occasionally in patients with thyrotoxicosis. Restoring the euthyroid state reverses all of the neuromuscular symptoms of hypothyroidism and hyperthyroidism.

Uremia

Uremia is a known cause of polyneuropathy (see Chapter 7). Even before clinical evidence of polyneuropathy is present, however, 50% of

patients complain of nocturnal leg cramps and flexion cramps of the hands. Excessive use of diuretics may be the triggering factor. Muscle cramps occur also in approximately one third of patients undergoing hemodialysis. Monitoring with EMG during dialysis documents a buildup of spontaneous discharges. After several hours, usually toward the end of dialysis treatment, repetitive high-voltage discharges occur associated with clinical cramps. Because standard dialysis fluid is slightly hypotonic, many nephrologists have attempted to treat the cramps by administering hypertonic solutions. Either sodium chloride or glucose solutions relieve cramps in most patients. The cramps apparently result from either extracellular volume contraction or hypo-osmolarity. Similar cramps occur in children with severe diarrhea or vomiting.

Decreased Muscle Energy

Three sources for replenishing adenosine triphosphate (ATP) during exercise are available: (1) the phosphorylation of adenosine diphosphate (ADP) to ATP by phosphocreatine within the exercising muscles, (2) glycogen and lipids within the exercising muscles, and (3) glucose and triglycerides brought to the exercising muscles by the blood. A fourth and less efficient source for ATP derives from ADP via an alternate pathway using adenylate kinase and deaminase. Phosphocreatine stores are the main source that replenishes ATP during intense activity of short duration. During the first 30 seconds of intense endurance exercise, phosphocreatine decreases 35%, and muscle glycogen stores decrease 25%. Exercise lasting longer than 30 seconds is associated with the mobilization of substantial amounts of carbohydrate and lipid.

The breakdown of muscle glycogen (glycogenolysis) and the anaerobic metabolism of glucose to pyruvate (glycolysis) provide the energy to sustain a prolonged contraction (Figure 8-1). Anaerobic glycolysis is an inefficient mechanism for producing energy and is not satisfactory for endurance exercise. Endurance requires the further aerobic metabolism in mitochondria of pyruvate generated in muscle by glycolysis. Oxidative metabolism provides high levels of energy for every molecule of glucose metabolized (see Figure 8-1).

The central compound of oxidative metabolism in mitochondria is acetyl coenzyme A (acetyl CoA). Acetyl CoA derives from pyruvate, from

fatty acids, and from amino acids. When exercise is prolonged, fatty acids become an important substrate to maintain muscular contraction. Oxidation of acetyl CoA is through the Krebs cycle. Hydrogen ion release reduces nicotinamide adenine dinucleotide (NAD). These reduced compounds enter a sequence of oxidation-reduction steps in the respiratory chain that liberate energy. Energy is stored as ATP. This process of liberating and storing energy is *oxidation-phosphorylation coupling*. Disorders that prevent the delivery of glucose or fatty acids, the oxidation process in the mitochondria, or the creation of ATP impair the production of energy for muscular contraction.

Clinical Features of Decreased Muscle Energy

Exercise intolerance is the invariable result of any disturbance in the biochemical pathways that support muscle contraction. The common symptom is fatigue. Other symptoms are myalgia and cramps. Muscle pain is the expected outcome from unaccustomed exercise. Muscle pain develops during exercise when the mechanisms to supply energy for contraction are impaired. The ischemic exercise test had been the first step in the diagnosis of muscle energy disorders, but it has become less important with the ease of tissue diagnosis by muscle biopsy and the commercial availability of methods for measuring enzyme activity in fibroblasts. Ischemia is unnecessary to perform the test. I have stopped using the test. It is almost impossible to get a child to cooperate sufficiently to do the test properly.

Defects of Carbohydrate Utilization

Myophosphorylase Deficiency (McArdle Disease)

A gene on chromosome 11q13 encodes myophosphorylase. Myophosphorylase exists in two forms: Phosphorylase *a* is the active form, and phosphorylase *b* is the inactive form. Phosphorylase *b* kinase is the enzyme that converts the inactive form to the active form and is itself activated by a protein kinase. Deficiencies of either enzyme result in exercise intolerance.

Genetic transmission of myophosphorylase deficiency is by autosomal recessive inheritance. The gene encodes on chromosome 11q13. Reports of autosomal dominant inheritance may represent manifesting heterozygotes.

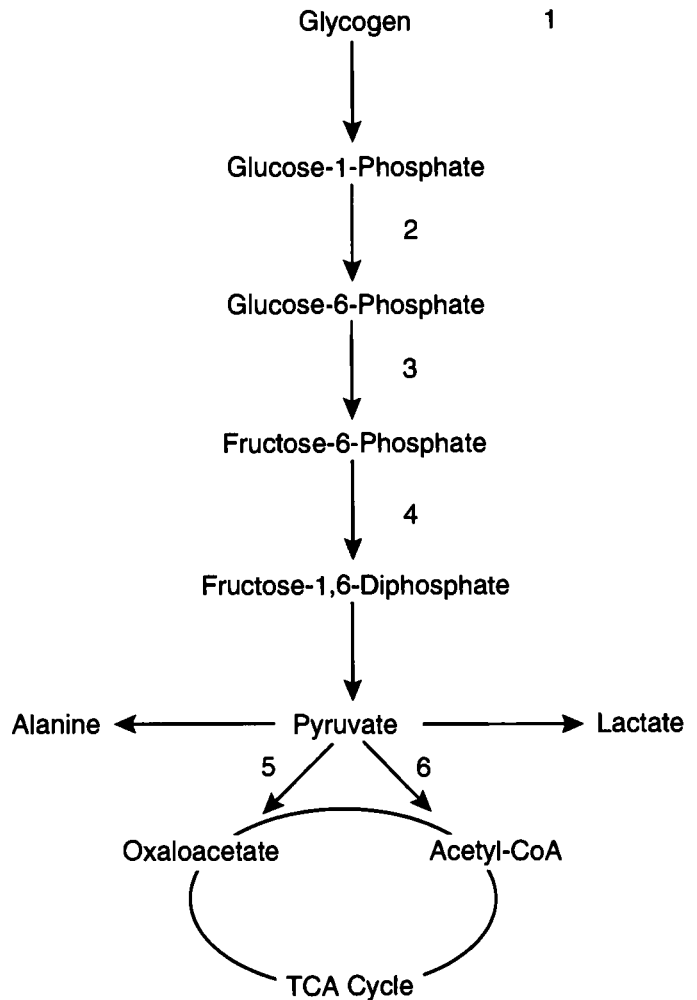


Figure 8-1. Glycogen metabolism. 1, Myophosphorylase, initiates glycogen breakdown; 2, phosphoglucomutase; 3, phosphoglucose isomerase; 4, phosphofructokinase; 5, pyruvate carboxylase; 6, pyruvate dehydrogenase complex.

Phosphorylase activity is deficient only in muscle. The deficiency blocks the first step of glycogenolysis, and muscle glycogen is unavailable to produce glucose for energy. Liver phosphorylase concentrations are normal, and hypoglycemia does not occur.

CLINICAL FEATURES. The severity of symptoms varies with the percentage of enzyme activity. Children with only mild deficiency states have few or no symptoms until adolescence. Aching becomes increasingly prominent, then, after an episode of vigorous exercise, severe cramps occur in exercised muscles. Myoglobinuria is sometimes present. The pain can last hours. Thereafter, exercise leads to repeated bouts of cramps that cause a decline in the overall level of activity. Pain begins soon after initiating vigorous exercise, and myoglobinuria occurs several hours later. Some patients exercise through the pain by slowing down just before the time of fatigue. Once passing that point, exercise may

continue unimpeded. This phenomenon is probably due to an increase in cardiac output, the use of blood glucose and free fatty acids as a substrate for muscle metabolism, and the recruitment of more motor units.

Examination is generally unrevealing. Usually, muscle mass, muscle strength, and tendon reflexes are normal. Only adult patients develop weakness, and even then, the tendon reflexes are normal. An alternate presentation of myophosphorylase deficiency is a slowly progressive proximal weakness beginning during childhood or adulthood. Affected individuals may never complain of cramps on exercise or of myoglobinuria. Tendon reflexes are present until late in the course of disease.

DIAGNOSIS. The EMG is usually normal. The serum CK concentration is elevated, and myoglobin may appear in the urine coincidentally with the cramps. Salient features of muscle biopsy specimens are histochemical evidence of

subsarcolemmal blebs containing glycogen and the absence of phosphorylase. Muscle fiber degeneration and regeneration are present immediately after an episode of cramps and myoglobinuria. Definitive diagnosis requires the biochemical demonstration of decreased myophosphorylase activity.

MANAGEMENT. Creatine supplementation may increase muscle function (Vorgerd et al, 2000). Patients usually learn to live with their disorder by controlling their level of exercise.

Other Disorders of Glucose Utilization

Four other enzyme deficiencies associated with the anaerobic glycolysis of carbohydrates produce a syndrome identical to myophosphorylase deficiency—cramps on exercise and myoglobinuria (see Figure 8-1). They are muscle phosphofructokinase deficiency, muscle phosphoglycerate kinase deficiency, muscle phosphoglycerate mutase deficiency, and lactate dehydrogenase deficiency. All are autosomal recessive traits except phosphoglycerate kinase deficiency, which is an X-linked trait. Phosphofructokinase deficiency is the most common member of this group and causes infantile hypotonia as well (see Chapter 6). Attacks may be associated with nausea, vomiting, and muscle pain. The mutase deficiency occurs mainly in African-Americans.

Muscle biopsy specimens show subsarcolemmal collections of glycogen, but the histochemical reaction for phosphorylase is normal. Biochemical analysis correctly identifies the disorders.

Defects of Long-Chain Fatty Acid Metabolism

Long-chain fatty acids are the principal lipid oxidized to produce acetyl CoA.

Carnitine O-Palmitoyltransferase 2 Deficiency

The mitochondrial oxidation of fatty acids is the main source of energy for muscles during prolonged exercise and during fasting. The carnitine O-palmitoyltransferase (CPT) enzyme system is essential for the transfer of fatty acids across the mitochondrial membrane. This system includes CPT-1 in the outer mitochondrial membrane and CPT-2 and carnitine-acylcarnitine translocase in the inner mitochondrial membrane.

CPT-2 deficiency is an autosomal recessive trait (gene locus 1p32) with three main pheno-

types. The most severe phenotype is a fatal nonketotic-hypoglycemic encephalopathy of infants, and exercise intolerance with myoglobinuria characterizes the less severe phenotypes in adults. CPT-2 deficiency is the most common metabolic disorder of skeletal muscle. The phenotypic variations in the muscle diseases caused by CPT-2 deficiency probably relate to the type of molecular defect and to superimposed environmental factors, such as prolonged fasting, exercise, cold exposure, and intercurrent illness.

CLINICAL FEATURES. The features of CPT-2 deficiency usually begin between the ages of 15 and 25. Performing heavy exercise of short duration poses no difficulty. Pain, tenderness, and swelling of muscles develop, however, after sustained aerobic exercise. Severe muscle cramps, as in myophosphorylase deficiency, do not occur. Associated with the pain may be actual muscle injury characterized by an increased serum concentration of CK and myoglobinuria. Muscle injury also may accompany periods of prolonged fasting, especially in patients on low-carbohydrate, high-fat diets. In the interval between attacks, results of muscle examination, serum CK concentration, and EMG are usually normal. People with CPT-2 deficiency are at risk for malignant hyperthermia.

DIAGNOSIS. The clinical features suggest the diagnosis, and measuring the concentration of CPT-2 in muscle provides confirmation. Muscle histology is usually normal between attacks.

MANAGEMENT. Frequent carbohydrate feedings and the avoidance of prolonged aerobic activity minimize muscle destruction.

Very-Long-Chain Acyl Coenzyme A Dehydrogenase Deficiency

The chain length of their preferred substrates describes four mitochondrial acyl CoA dehydrogenases: short-chain acyl CoA dehydrogenase, medium-chain acyl CoA dehydrogenase, long-chain acyl CoA dehydrogenase, and very-long-chain acyl CoA dehydrogenase. The first three are located in the mitochondrial matrix, and deficiency causes recurrent coma (see Chapter 2). Very-long-chain acyl CoA dehydrogenase is bound to the inner mitochondrial membrane, and deficiency causes exercise-induced myoglobinuria (Gegersen, 2001).

CLINICAL FEATURES. Onset is usually after age 10, but can occur by age 4. Pain and myoglobinuria occur during or after prolonged exercise or fasting. Weakness may be profound. Carbohydrate ingestion before or during exercise reduces the

intensity of pain. Examination between attacks is normal.

DIAGNOSIS. The serum CK concentration is slightly elevated between attacks and increased further at the time of myoglobinuria. EMG is consistent with myopathy, and muscle biopsy specimen shows lipid storage in type I fibers. Plasma free fatty acids, but not ketones, increase during a 24-hour fast, suggesting impaired ketogenesis.

MANAGEMENT. Frequent small carbohydrate feeds, dietary fat restriction, and carnitine supplementation reduce the frequency of attacks.

Mitochondrial (Respiratory Chain) Myopathies

The respiratory chain, located in the inner mitochondrial membrane, consists of five protein complexes: complex I (NADH-coenzyme Q reductase); complex II (succinate-coenzyme Q reductase); complex III (reduced coenzyme Q-cytochrome *c* reductase); complex IV (cytochrome *c* oxidase); and complex V (ATP synthase) (Figure 8-2).

Coenzyme Q is a shuttle between complexes I and II and complex III. One newborn with a defect of coenzyme Q had a clinical syndrome of seizures, abnormal ocular movements, and lactic acidosis. The clinical syndromes associated with mitochondrial disorders are continually expanding and revised. The organs affected are organs highly dependent on aerobic metabolism, including nervous system, skeletal muscle, heart, and kidney (Table 8-5). Exercise intolerance, either alone or in combination with symptoms of other organ failure, is a common feature of mitochondrial disorders. The several clinical syndromes defined do not correspond exactly with any one of the respiratory complexes (Table 8-6).

CLINICAL FEATURES. The age at which mitochondrial myopathies begin ranges from birth to adulthood but is before 20 in most patients.

Half of patients have ptosis or ophthalmoplegia, one fourth have exertional complaints in the limbs, and one fourth have cerebral dysfunction. With time, considerable overlap occurs among the three groups. Eventually, 75% have ophthalmoplegia, and 50% have exertional complaints. Pigmentary retinopathy occurs in 33% and neuropathy in 25%.

Exercise intolerance usually develops by age 10. With ordinary activity, active muscles become tight, weak, and painful. Cramps and myoglobinuria are unusual but may occur. Nausea, headache, and breathlessness sometimes are associated features. During these episodes, the serum lactate and CK concentrations may increase. Generalized weakness with ptosis and ophthalmoplegia may follow prolonged periods of activity or fasting. These symptoms may last several days, but recovery is usually complete.

DIAGNOSIS. A mitochondrial myopathy is a consideration in all children with exercise intolerance and ptosis or ophthalmoplegia. This combination of symptoms also may suggest myasthenia gravis. In myasthenia, the ocular motor features fluctuate, however, whereas in mitochondrial myopathies they are constant.

Some children with mitochondrial myopathies have an increased concentration of serum lactate after exercise. An easy-to-perform test is the glucose-lactate tolerance test. During an ordinary oral glucose tolerance test, measure lactate and glucose concentrations simultaneously. In some children with mitochondrial disorders, lactic acidosis develops, and glucose is slow to clear.

Muscle biopsy specimens show a clumping of the mitochondria, which become red when the Gomori trichrome stain is applied (Figure 8-3). These muscle cells are *ragged-red fibers*. Commercial laboratories can identify several specific respiratory complex disturbances.

MANAGEMENT. Treatment with cocktails that include riboflavin, ubiquinone, vitamin C, mena-

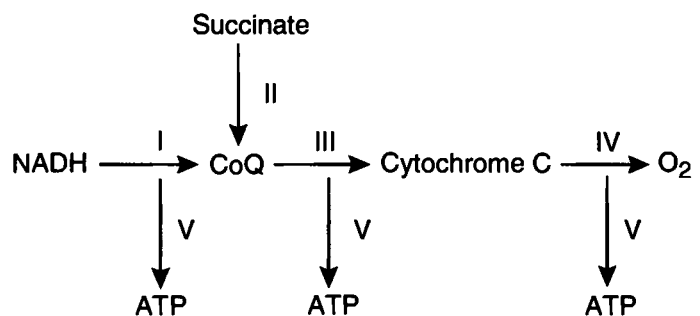


Figure 8-2. Respiratory complexes. Complex I (NADH-coenzyme Q reductase); complex II (succinate-coenzyme Q reductase); complex III (reduced coenzyme Q-cytochrome *c* reductase); complex IV (cytochrome *c* oxidase); complex V (ATP synthase).

TABLE 8-5
Clinical Features of Mitochondrial Disease

Nervous System

Ataxia
Central apnea
Deafness
Dementia
Hypotonia
Mental retardation
Neuropathy
Ophthalmoplegia
Optic atrophy
Retinitis pigmentosa

Heart

Cardiomyopathy
Conduction defects

Kidney

Aminoaciduria
Hyperphosphaturia

Skeletal Muscle

Exercise intolerance
Myopathy

TABLE 8-6
Mitochondrial Disorders

Complex I (NADH-Coenzyme Q Reductase)

Congenital lactic acidosis, hypotonia, seizures, and apnea
Exercise intolerance and myalgia
Kearns-Sayre syndrome (see Chapter 15)
Metabolic encephalopathy, lactic acidosis, and stroke (see Chapter 11)
Progressive infantile poliomyelopathy (see Chapter 5)
Subacute necrotizing encephalomyelopathy (see Chapter 5)

Complex II (Succinate-Coenzyme Q Reductase)

Encephalomyopathy (?)

Complex III (Coenzyme QH₂-Cytochrome c Reductase)

Cardiomyopathy
Kearns-Sayre syndrome (see Chapter 15)
Myopathy and exercise intolerance with or without progressive external ophthalmoplegia

Complex IV (Cytochrome c Oxidase)

Fatal neonatal hypotonia (see Chapter 6)
Menkes syndrome (see Chapter 5)
Myoclonus epilepsy and ragged-red fibers
Progressive infantile poliomyelopathy (see Chapter 5)
Subacute necrotizing encephalomyelopathy (see Chapter 5)
Transitory neonatal hypotonia (see Chapter 6)

Complex V (Adenosine Triphosphate Synthase)

Congenital myopathy
Neuropathy, retinopathy, ataxia, and dementia
Retinitis pigmentosa, ataxia, neuropathy, and dementia

dione, and niacin is popular but has no established benefit.

Myoadenylate Deaminase Deficiency

The muscle form of adenosine monophosphate deaminase encodes on chromosome 1p. Deficiency of myoadenylate deaminase is a familial trait, and the mode of inheritance is autosomal recessive. The deficiency state occurs in infants with hypotonia, in children with progressive myopathies and recurrent rhabdomyolysis, in children and adults with exercise intolerance, and in asymptomatic individuals. Establishing a cause-and-effect relationship between myoadenylate deaminase deficiency and exercise intolerance in any one individual is often difficult because most people with the deficiency state are asymptomatic.

CLINICAL FEATURES. The typical history is one of intermittent muscle pain and weakness with exercise. The pain varies from a diffuse aching to a severe cramping type of pain associated with muscle tenderness and swelling. Between attacks, children are normal. Symptoms last for 1 to 20 years, with a mean duration of less than 9 years.

DIAGNOSIS. During attacks, the serum CK concentration may be normal or markedly elevated. EMG and muscle histological studies are usually normal. The forearm ischemic exercise test suggests the diagnosis. Patients with myoadenylate deaminase deficiency fail to generate ammonia but show normal elevations of lactate. Ammonia levels may fail to rise even in normal individuals, however, and enzyme analysis of muscle is required for diagnosis. Obligate heterozygotes have a reduced concentration of myoadenylate deaminase in muscle but are capable of normal ammonia production and are asymptomatic.

MANAGEMENT. Treatment is not available.

Myopathic Stiffness and Cramps

This section addresses several conditions that cause muscle stiffness or cramps or both in which the primary abnormality is thought to be in skeletal muscle.

Brody Myopathy

The autosomal recessive, but not the autosomal dominant, form of Brody myopathy is caused by

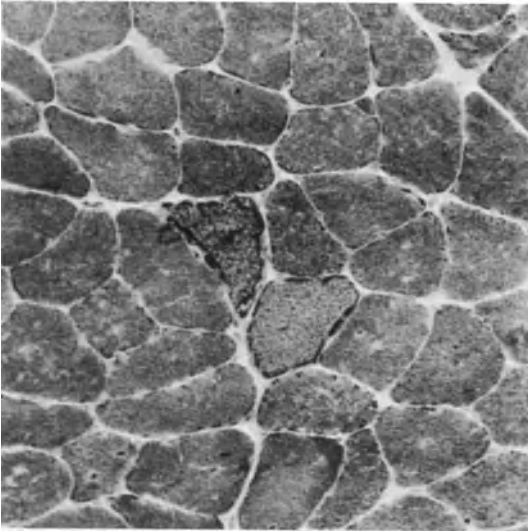


Figure 8-3. Ragged-red fibers (trichrome stain). The mitochondria are enlarged and stain intensely with hematoxylin.

a mutation in the gene (16p12) that encodes the fast-twitch skeletal muscle, calcium-activated ATPase in sarcoplasmic reticulum (Odermatt et al, 1997).

CLINICAL FEATURES. The main clinical feature is difficulty of relaxation after contraction. The EMG supports the diagnosis. Symptoms of exercise-induced stiffness and cramping begin before age 10 and become progressively worse with age. In contrast to myotonia, stiffness becomes worse rather than better with continued exercise. Exercise resumes after a period of rest. Muscle strength and tendon reflexes are normal.

DIAGNOSIS. Muscle histology reveals type II atrophy. Establishing the diagnosis requires showing the biochemical defect.

MANAGEMENT. Dantrolene, which reduces the myofibrillar Ca^{2+} concentration by blocking Ca^{2+} release from the sarcoplasmic reticulum, provides symptomatic relief. Verapamil also may be useful.

Cramps and Tubular Aggregates

Tubular aggregates are abnormal double-walled structures that originate from the sarcoplasmic reticulum and are located in a subsarcolemmal position (Figure 8-4). Aggregates appear in muscle biopsy specimens from patients with several neuromuscular disorders. In some families, patients have a progressive myopathy, whereas others experience only cramps or myalgia.

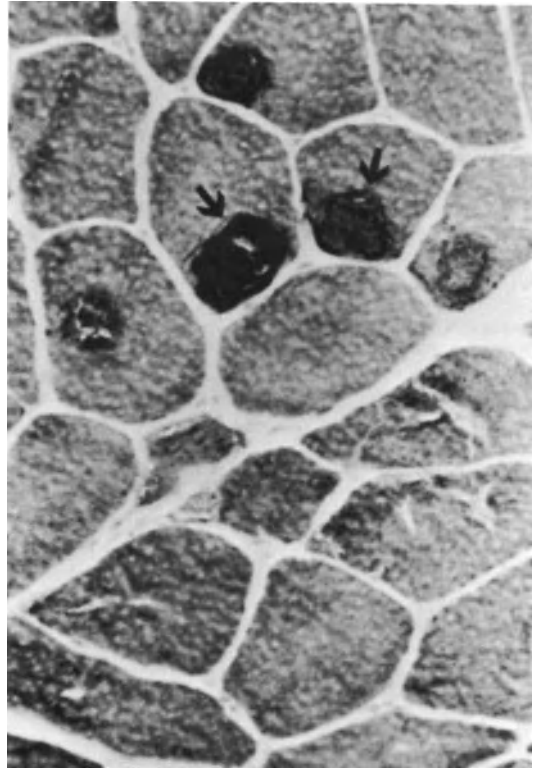


Figure 8-4. Tubular aggregates (ATPase reaction). Dark material is present beneath the sarcolemma in type I and type II fibers (arrows).

Sporadic Cases

CLINICAL FEATURES. Onset is usually in the teens or 20s. Cramps may occur at rest or be induced by exercise. The thigh and calf muscles become swollen, stiff, and tender. Cramping occurs more often in cold weather and at night, interfering with sleep. Myalgia is present between cramps. Episodic stiffness of the mouth and tongue interferes with speech. Cramps are not associated with myoglobinuria. Muscle mass, strength, and tendon reflexes are normal.

DIAGNOSIS. The serum CK concentration is normal. EMG results are normal except that in some patients the cramps are electrically silent. Muscle histology results are the basis for a diagnosis. Light and electron microscopic examinations show tubular aggregates in type II fibers. Evidence of glycogen or lipid storage is not present.

MANAGEMENT. The cramps do not respond to medication.

Autosomal Dominant Cases

CLINICAL FEATURES. Muscle aches, cramps, and proximal weakness begin after age 10. The

cramps are exercise induced, but also may occur at rest and during sleep. Usually the legs cramp more than the arms, but the pattern varies from family to family. Weakness, when it occurs, is mild and progresses slowly.

DIAGNOSIS. The serum CK concentration is moderately elevated. EMG results suggest a myopathic process in some families and a neuropathic process in others. Muscle biopsy specimens may show tubular aggregates in type I and type II fibers. Type I fiber predominance and type II hypotrophy are present in some patients.

TREATMENT. No treatment is available for either the myopathy or the cramps.

Familial X-Linked Myalgia and Cramps

Familial X-linked myalgia and cramps is another phenotype associated with a decreased amount of skeletal muscle dystrophin, which usually is associated with Becker muscular dystrophy (see Chapter 7). Almost all cases occur in boys (Samaha and Quinlan, 1996) except for one girl who also had hypertrophy of the calves (Malapart et al, 1995). Half of the boys and the one girl showed a deletion in the dystrophin gene.

CLINICAL FEATURES. Symptoms begin in early childhood, frequently between 4 and 6 years of age. Boys first have cramps with exercise, then cramps at rest. Usually the limb muscles are affected, but chest pain also may occur. The cramping continues throughout life but is not associated with atrophy or weakness. Tendon reflexes are normal.

DIAGNOSIS. Affected family members have elevated concentrations of serum CK, especially after exercise. The EMG and muscle biopsy specimen are usually normal or show only mild, nonspecific changes. This disorder and the McLeod phenotype (acanthocytosis, elevated serum concentration of CK, and absence of the Kell antigen) are allelic conditions. EMG and muscle specimens show nonspecific myopathic changes. DNA analysis may be normal or may show a deletion in the first third of the dystrophin gene or in exons 45 through 52.

MANAGEMENT. Pharmaceutical agents do not relieve the cramps. Exercise avoidance is the only way to avoid cramping.

Malignant Hyperthermia

Malignant hyperthermia is a disorder of calcium regulation in skeletal muscle (Rosenberg and Sambuughin, 2003). Transmission is as an auto-

somal dominant trait. Genetic localization was first to chromosome 19q13.1 and the skeletal muscle ryanodine receptor. Malignant hyperthermia proved to be genetically heterogeneous, however, with additional loci on chromosomes 17q, 7q, and 3q. Several neuromuscular disorders, such as carnitine *O*-palmitoyltransferase deficiency 2, muscular dystrophy, and central core disease, predispose to the syndrome. The administration of several inhalation anesthetics or succinylcholine triggers attacks of muscular rigidity and necrosis associated with a rapid increase in body temperature. Nonanesthetic triggers of rhabdomyolysis in susceptible persons include severe exercise in hot conditions, neuroleptic drugs, alcohol, and infections.

CLINICAL FEATURES. The first symptoms are tachycardia, tachypnea, muscle fasciculations, and increasing muscle tone. Body temperature increases dramatically (2°C per hour). All muscles become rigid, and a progressive and severe metabolic acidosis develops. Seizures and death may occur without prompt treatment.

DIAGNOSIS. The basis for diagnosis is the response to anesthesia or succinylcholine. The serum CK concentration increases to 10 times the upper limit of normal. Molecular diagnosis is available in Europe for detection of two responsible genes. No reliable test for identifying all susceptible individuals is available.

MANAGEMENT. Treatment includes termination of anesthesia, body cooling, treatment of metabolic acidosis, and intravenous injection of dantrolene, 1 to 2 mg/kg, repeated every 5 to 10 minutes to a total dose of 10 mg/kg. Individuals with known or suspected malignant hyperthermia should be pretreated with dantrolene before using an anesthetic.

Neuroleptic Malignant Syndrome

Neuroleptic malignant syndrome, similar to malignant hyperthermia, is a disorder of the skeletal muscle calcium channels.

CLINICAL FEATURES. Several neuroleptic agents may induce an idiosyncratic response characterized by muscle rigidity, hyperthermia, altered states of consciousness, and autonomic dysfunction in susceptible individuals. Implicated agents include phenothiazines, butyrophenones, and thioxanthenes. Persons of all ages are affected, but young men predominate. Symptoms develop over 1 to 3 days. The first symptoms are rigidity and akinesia, followed by fever, excessive sweating, urinary incontinence, and hypertension. Consciousness fluctuates, and the 20% mortality rate is due to respiratory failure.

DIAGNOSIS. The clinical findings are the basis of diagnosis. The only helpful laboratory test results are an increased serum concentration of CK and a leukocytosis.

MANAGEMENT. The offending neuroleptic agent must be withdrawn promptly and general supportive care provided. Bromocriptine reverses the syndrome completely.

Rigid Spine Syndrome

Rigid spine syndrome and severe classic multi-minicore myopathy are the same entity. Mutations in the Selenoprotein N 1 (SEPN1) gene at 1p36-p35 underlie both conditions.

CLINICAL FEATURES. Marked limitation in flexion of the dorsolumbar and cervical spine begin in infancy or early childhood secondary to contractures in the spinal extensors. Movement of the spine and the thoracic cage is lost. Extension of the elbow and ankles may be limited. The condition is not progressive, but scoliosis often leads to respiratory failure (Ferreiro et al, 2002).

DIAGNOSIS. The basis for diagnosis is the clinical features.

MANAGEMENT. Management is symptomatic.

Rippling Muscle Disease

Mechanical stimulation of muscle produces electrically silent contractions in several families. Transmission of the disorder is by autosomal dominant inheritance. Two forms of the disease exist. The cause of one form (RMD2) is a mutation in the gene encoding caveolin-3, which maps to 3p25 (Kubisch et al, 2003). Another locus (RMD1) maps to chromosome 1q41. It is a disorder of skeletal muscle calcium channels, different from the defects causing malignant hyperthermia and neuroleptic malignant syndrome (Stephan and Hoffman, 1999).

CLINICAL FEATURES. The initial feature in children with the caveolin-3 gene mutation is frequent falls (Schara et al, 2002). Other features include muscle pain and cramps after exercise that persist for several hours. Stiffness occurs during rest after the child exercises or maintains posture for long periods. Percussion of muscles causes local swelling and a peculiar rippling movement that lasts 10 to 20 seconds. Muscle hypertrophy develops. Muscle strength, tone, and coordination and tendon reflexes are normal.

DIAGNOSIS. The serum CK concentration is mildly elevated, and muscle biopsy findings are normal. EMG of the muscle swelling after per-

cussion does not show any electrical activity. Molecular genetic diagnosis confirms the diagnosis.

MANAGEMENT. Management is symptomatic.

References

- Barker RA, Revesz T, Thom M, et al. Review of 23 patients affected by the stiff man syndrome. Clinical subdivision into stiff trunk (man) syndrome, stiff limb syndrome, and progressive encephalomyelitis with rigidity. *J Neurol Neurosurg Psychiatry* 1998;65:633-640.
- Ferreiro A, Quijano-Roy S, Pichereau C, et al. Mutations of the selenoprotein N gene, which is implicated in rigid spine muscular dystrophy, cause the classical phenotype of multi-minicore disease. Reassessing the nosology of early-onset myopathies. *Am J Hum Genet* 2002;71:739-749.
- Giedion A, Boltshauser E, Briner J, et al. Heterogeneity in Schwartz-Jampel chondrodystrophic myotonia. *Eur J Pediatr* 1997;156:214-223.
- Gregersen N, Andresen BS, Corydon MJ, et al. Mutation analysis in mitochondrial fatty acid oxidation defects. Exemplified by acyl-CoA dehydrogenase deficiencies, with special focus on genotype-phenotype relationship. *Hum Mutat* 2001;18:169-189.
- Kubisch C, Schoser BGH, During M, et al. Homozygous mutations in caveolin-3 cause a severe form of rippling muscle disease. *Ann Neurol* 2003;53:512-520.
- Malapert D, Recan D, Leturcq F, et al. Sporadic lower limb hypertrophy and exercise induced myalgia in a woman with dystrophin gene deletion. *J Neurol Neurosurg Psychiatry* 1995;59:552-554.
- Odermatt A, Taschner PEM, Scherer SW, et al. Characterization of the gene encoding human sarcolipin (SLN), a proteolipid associated with SERCA1. Absence of structural mutations in five patients with Brody disease. *Genomics* 1997;45:541-553.
- Orrell RW, Jurkat-Rott K, Lehmann-Horn F, et al. Familial cramp due to potassium-aggravated myotonia. *J Neurol Neurosurg Psychiatry* 1998;65:569-572.
- Rosenberg H, Sambuughin N. (19 December 2003) Malignant hyperthermia susceptibility. In: *GeneClinics: Medical Genetics Knowledge Base*. [database online] University of Washington, Seattle. Available at <http://www.geneclinics.org>.
- Samaha FJ, Quinlan JG. Myalgia and cramps. Dystrophinopathy with wide-ranging laboratory findings. *J Child Neurol* 1996;11:21-24.
- Schara U, Vorgerd M, Popovic N, et al. Rippling muscle disease in children. *J Child Neurol* 2002;17:483-490.
- Shillito P, Molenaar PC, Vincent A, et al. Acquired neuromyotonia. Evidence for autoantibodies directed against K⁺ channels of peripheral nerves. *Ann Neurol* 1995;38:714-722.
- Stephan DA, Hoffman EP. Physical mapping of the rippling muscle disease locus. *Genomics* 1999;55:268-274.
- Sun C, Tranebjaerg L, Torbergson T, et al. Spectrum of CLCN1 mutations in patients with myotonia congenita in Northern Scandinavia. *Eur J Hum Genet* 2001;9:903-909.
- Vorgerd M, Grehl T, Jäger M, et al. Creatine therapy in myophosphorylase deficiency (McArdle disease). A placebo-controlled crossover trial. *Arch Neurol* 2000;57:956-963.

Chapter 9

Sensory and Autonomic Disturbances

THIS CHAPTER DEALS primarily with sensory disturbances of the limbs and trunk. Autonomic dysfunction often is associated with sensory loss but sometimes occurs alone. Chapter 17 discusses sensory disturbances of the face.

Sensory Symptoms

Pain, dysesthesias, and loss of sensibility are the important symptoms of disturbed sensation. Peripheral neuropathy is the most common cause of disturbed sensation at any age. As a rule, hereditary neuropathies are more likely to cause loss of sensibility without discomfort, whereas acquired neuropathies are more likely to be painful. Discomfort is more likely than numbness to bring a patient to medical attention.

Nerve root pain generally follows a dermatomal distribution. Ordinarily, it is described as deep and aching. The pain is more proximal than distal and may be constant or intermittent. When intermittent, the pain may radiate in a dermatomal distribution. The most common cause of root pain in adults is sciatica associated with lumbar disk disease. Disk disease also occurs in adolescents, usually because of trauma. In children, radiculitis is a more common cause of root pain. Examples of radiculitis are the migratory aching of a limb preceding paralysis in Guillain-Barré syndrome (see Chapter 7) and the radiating pain in a C5 distribution that heralds an idiopathic brachial neuritis (see Chapter 13).

Polyneuropathy involving small nerve fibers causes dysesthetic pain. This pain differs from previously experienced discomfort and is described as “pins and needles,” tingling, or burning. It compares with the abnormal sensation felt when dental anesthesia is wearing off. The discomfort is superficial, distal, and usually

symmetrical. Dysesthetic pain is never a feature of hereditary neuropathies in children.

Loss of sensibility is the sole initial feature in children with sensory neuropathy. Because clumsiness is the initial feature, delay in establishing a correct diagnosis is common. Strength is normal, as are tests of cerebellar function. Tendon reflexes are absent. The combination of areflexia and clumsiness should suggest a sensory neuropathy. Table 9-1 summarizes the pattern of sensory loss as a guide to the anatomical site of abnormality.

Painful Arm Syndromes

Three painful arm syndromes are acute idiopathic brachial neuritis (also called *neuralgic amyotrophy* or *brachial plexitis*), familial recurrent brachial neuritis, and complex regional pain syndrome (CRPS) (reflex sympathetic dystrophy). In the first two syndromes, muscle atrophy follows a transitory pain in the shoulder or arm. Monoplegia is the prominent feature (see Chapter 13). Although muscle atrophy also occurs in CRPS, pain is the prominent feature.

Complex Regional Pain Syndrome I

The presence of regional pain and sensory changes following a noxious event defines *complex regional pain syndrome*. A working group of the International Association for the Study of Pain developed a new terminology (Rowbotham, 1998) that separates reflex sympathetic dystrophy from causalgia. *CRPS I* replaces the term *reflex sympathetic dystrophy*. *CRPS I* is defined as “a pain syndrome that develops after an injury, is not limited to the distribution of a single peripheral nerve, and is disproportional to the

TABLE 9-1
Patterns of Sensory Loss

Pattern	Site
All limbs	Spinal cord or peripheral nerve
Both legs	Spinal cord or peripheral nerve
Glove-and-stocking	Peripheral nerve
Legs and trunk	Spinal cord
One arm	Plexus
One leg	Plexus or spinal cord
Unilateral arm and leg	Brain or spinal cord

inciting event.” CRPS II requires demonstrable peripheral nerve injury and replaces the term *causalgia*.

CLINICAL FEATURES. The essential feature of CRPS I is sustained burning pain in a limb combined with vasomotor and pseudomotor dysfunction, leading to atrophic changes in skin, muscle, and bone after trauma. The pain is of greater severity than that expected from the inciting injury. The mechanism remains a debated issue. Catecholamine hypersensitivity may account for the decreased sympathetic outflow and autonomic features in the affected limb (Wasner et al, 2001).

The mean age at onset in children is 11 years, and girls are affected more often than boys. CRPS I frequently follows trauma to one limb, with or without fracture. The trauma may be relatively minor, and the clinical syndrome is so unusual that a diagnosis of “hysterical” or “malingering” is common. Time until onset after injury is usually within 1 or 2 months, but the average interval from injury to diagnosis is 1 year.

The first symptom is pain at the site of injury, which progresses either proximally or distally without regard for dermatomal distribution or anatomical landmarks. Generalized swelling and vasomotor disturbances of the limb occur in 80% of children. Pain is intense, described as burning or aching, and is out of proportion to the injury. It may be maximally severe at onset or may become progressively worse over 3 to 6 months. Movement or dependence exacerbates the pain, causing the patient to hold the arm in a position of abduction and internal rotation, as if swaddled to the body. The hand becomes swollen and hyperesthetic and feels warmer than normal.

Children with CRPS I do better than adults. Reported outcomes vary widely, probably based on the standard of diagnosis. In my own experience, most children begin recovering within 6 to

12 months. Long-term pain is unusual, as are the trophic changes of the skin and bones that often occur in adults. Recovery is usually complete, and recurrence is unusual.

DIAGNOSIS. The basis for diagnosis is the clinical features; laboratory tests are not confirmatory. Because the syndrome follows accidental or surgical trauma, litigation is commonplace and requires careful documentation of the clinical features examination. In recent years, CRPS I has become popular on the Internet and often is self-diagnosed incorrectly. Websites caution that physicians misdiagnose the condition as hysterical. The result is increasing numbers of hysterical patients seeking consultation for an incorrect, self-diagnosis of CRPS I.

One simple test is to immerse the affected limb in warm water. Wrinkling of the skin of the fingers or toes requires intact sympathetic innervation. The absence of wrinkling is evidence of a lesion in either the central or the peripheral sympathetic pathway. The other unaffected limb serves as a control.

MANAGEMENT. Management for most children is range-of-motion exercise and over-the-counter analgesics. Treatment of more severe syndromes, as occur in adults, includes the oral administration of guanethidine, anticonvulsants, gabapentin (Wheeler et al, 2000), prednisone with or without stellate ganglion blockade, and sympathectomy. No specific treatment modality has proven efficacy (Hooshmand and Hashmi, 1999).

Central Congenital Insensitivity (Indifference) to Pain

Most children with congenital insensitivity to pain have a hereditary sensory neuropathy. In many early reports, sensory neuropathy was not a consideration, and appropriate tests were not performed. This section is restricted to children and families with a central defect. Sensory neuropathy testing is normal, and mild mental retardation often is associated. Several affected children are siblings with consanguineous parents. Autosomal recessive inheritance is suspected. The Lesch-Nyhan syndrome is a specific metabolic disorder characterized by self-mutilation (presumably because of indifference to pain) and mental retardation without evidence of sensory neuropathy (see Chapter 5).

CLINICAL FEATURES. Children with congenital insensitivity to pain come to medical attention when they begin to crawl or walk. Their parents recognize that injuries do not cause crying and

that the children fail to learn the potential of injury from experience. The result is repeated bruising, fractures, ulcerations of the fingers and toes, and mutilation of the tongue. Sunburn and frostbite are common. Examination shows absence of the corneal reflex and insensitivity to pain and temperature but relative preservation of touch and vibration sensations. Tendon reflexes are present, an important differential point from sensory neuropathy.

DIAGNOSIS. Electromyogram, nerve conduction studies, and examination of the cerebrospinal fluid are normal.

MANAGEMENT. No treatment is available for the underlying insensitivity, but the repeated injuries require supportive care. Injuries and recurrent infections reduce longevity.

Foramen Magnum Tumors

Extramedullary tumors in and around the foramen magnum are known for false localizing signs and for mimicking other disorders, especially syringomyelia and multiple sclerosis. In children, neurofibroma caused by neurofibromatosis is the only tumor found in this location.

CLINICAL FEATURES. The most common initial symptom is unilateral or bilateral dysesthesias of the fingers. Suboccipital or neck pain also occurs. Ignoring such symptoms is common early in the course. Numbness and tingling usually begin in one hand, then migrate to the other. Dysesthesias in the feet are a late occurrence. Gait disturbances, incoordination of the hands, and bladder disturbances generally follow the sensory symptoms and are so alarming that they prompt medical consultation.

Many patients have café au lait spots, but few have evidence of subcutaneous neuromas. The distribution of weakness may be one arm, one side, or both legs; 25% of patients have weakness in all limbs. Atrophy of the hands is uncommon. Sensory loss may involve only one segment or may have a “cape” distribution. Diminished pain and temperature sensations are usual, and other sensory disturbances may be present. Tendon reflexes are brisk in the arms and legs. Patients with neurofibromatosis may have multiple neurofibromas causing segmental abnormalities in several levels of the spinal cord.

DIAGNOSIS. Magnetic resonance imaging (MRI) is the best method for showing abnormalities at the foramen magnum.

MANAGEMENT. Surgical excision of a C2 root neurofibroma relieves symptoms completely.

Hereditary Neuropathies

Hereditary Sensory and Autonomic Neuropathies

The classification of hereditary sensory and autonomic neuropathy (HSAN) attempts to synthesize information based on natural history, mode of inheritance, and electrophysiological characteristics. Table 9-2 provides the HSAN classification.

Hereditary Sensory and Autonomic Neuropathy Type I

HSAN I is the only HSAN transmitted as an autosomal dominant inheritance. As with other dominantly inherited neuropathies, variable expression is the rule (Dyck et al, 2000). The history alone is insufficient to determine whether the parents are affected; physical examination and electrophysiological studies are required. HSAN I maps to chromosome 9q22.1-22.3.

CLINICAL FEATURES. Symptoms begin during adolescence or later. The major clinical features are lancinating pains in the legs and ulcerations of the feet. Initial symptoms are usually insidious, however, and the precise onset is often difficult to date. A callus develops on the sole of the foot, usually in the skin overlying a weight-bearing bony prominence. The callus blackens, becomes

TABLE 9-2
Disturbances of Sensation

Brachial neuritis
Neuralgic amyotrophy (see Chapter 13)
Recurrent familial brachial neuropathy (see Chapter 13)
Complex regional pain syndrome I (reflex sympathetic dystrophy)
Congenital insensitivity (indifference) to pain
Lesch-Nyhan syndrome
Mental retardation
With normal nervous system
Foramen magnum tumors
Hereditary metabolic neuropathies
Acute intermittent porphyria
Hereditary tyrosinemia
Hereditary sensory and autonomic neuropathy (HSAN)
HSAN I (autosomal dominant)
HSAN II (autosomal recessive)
HSAN III (familial dysautonomia)
HSAN IV (with anhidrosis)
Lumbar disk herniation
Syringomyelia
Thalamic syndromes

necrotic, and breaks down into an ulcer that is difficult to heal. Sensory loss precedes the ulcer, but often it is the ulcer, not the sensory loss, that first brings the patient to medical attention. Although plantar ulcers are an important feature, they are not essential for diagnosis. When the proband has typical features of plantar ulcers and lancinating pain, other family members may have sensory loss in the feet, mild pes cavus, or peroneal atrophy and loss of the ankle tendon reflex.

Sensory loss in the hands is variable and never as severe as in the feet. Finger ulcers do not occur. Distal muscle weakness and wasting are present in all advanced cases.

DIAGNOSIS. Autosomal dominant inheritance and sensory loss in the feet are essential for the diagnosis. The presence of plantar ulcers and lancinating pain is helpful but not crucial. Clinical grounds differentiate HSAN I from familial amyloid polyneuropathy. Urinary incontinence, impotence, and postural hypotension are frequent features of amyloidosis but do not occur in HSAN I. Molecular genetic testing is available.

Electrophysiological studies show slowing of sensory nerve conduction velocity and the absence of sensory nerve action potentials. A sural nerve biopsy specimen reveals a marked decrease or absence of myelinated fibers and a mild-to-moderate reduction of small myelinated fibers.

MANAGEMENT. No treatment is available for the neuropathy, but good foot care prevents plantar ulcers. Patients must avoid tight-fitting shoes and activities that traumatize the feet. Weight bearing is discontinued at the first sign of a plantar ulcer. Much of the foot mutilation reported in previous years was due to secondary infection of the ulcers. Warm soaks, elevation, and antibiotics prevent infection from mutilating the foot.

Hereditary Sensory and Autonomic Neuropathy Type II

HSAN II probably includes several disorders transmitted by autosomal recessive inheritance. The genetic abnormalities are unknown. Some cases are relatively static, and others have a progressive course. Many cases are sporadic; instances of parental consanguinity and affected sibs occur in some families.

CLINICAL FEATURES. Symptoms probably begin during infancy and possibly at the time of birth. Infantile hypotonia is common (see Chapter 6). In contrast to HSAN I, which affects primarily

the feet, HSAN II involves all limbs equally and the trunk and forehead. The result is a diffuse loss of all sensation; diminished touch and pressure is probably earlier and greater in extent than are temperature and pain. Affected infants and children are constantly hurting themselves without a painful response. The absence of the protection that pain provides against injury results in ulcerations and infections of the fingers and toes, stress fractures, and injuries to long bones. Loss of deep sensibility causes injury and swelling of joints, and loss of touch makes simple tasks, such as tying shoes, manipulating small objects, and buttoning buttons, difficult if not impossible. Tendon reflexes are absent throughout. Sweating diminishes in all areas of decreased sensibility, but no other features of autonomic dysfunction are present.

HSAN II may be associated with impaired hearing, taste, and smell; with retinitis pigmentosa; or with the early onset of cataracts. It is not clear whether such cases represent separate genetic disorders or are part of the phenotypic spectrum of a single genetic disorder.

DIAGNOSIS. The diagnosis relies primarily on the history and examination. Absence of sensory nerve action potentials confirms that the congenital absence of pain is due to peripheral neuropathy and not to a cerebral abnormality. Motor nerve conduction velocities are normal, as are the morphological characteristics of motor unit potentials. Fibrillations are sometimes present. Sural nerve biopsy reveals an almost complete absence of myelinated fibers.

The boundary between HSAN II and HSAN IV (discussed later) is difficult to delineate clinically. Mental retardation and anhidrosis are more prominent in HSAN IV than in HSAN II.

MANAGEMENT. No treatment is available for the neuropathy. Parents must be vigilant for painless injuries. Discoloration of the skin and swelling of joints or limbs should raise the possibility of fracture. Children must learn to avoid activities that might cause injury and to examine themselves for signs of superficial infection.

Hereditary Sensory and Autonomic Neuropathy Type III

The usual name for HSAN III is *familial dysautonomia* or *Riley-Day syndrome*. This disorder is present at birth. Cardinal features are hypotonia, feeding difficulties, and poor control of autonomic function. Because neonatal hypotonia is prominent, this condition is discussed in Chapter 6.

Hereditary Sensory and Autonomic Neuropathy Type IV (Familial Dysautonomia Type II)

Genetic transmission of HSAN IV is by autosomal recessive inheritance. The abnormal gene site is 1q21-22 (Bonkowski et al, 2003). The major features are congenital insensitivity to pain, anhidrosis, and mental retardation. All the clinical abnormalities are present at birth. Although complications of the pain-free state are a continuous problem, the underlying disease may not be progressive.

CLINICAL FEATURES. Anhidrosis, rather than insensitivity to pain, causes the initial symptoms. Affected infants have repeated episodes of fever, sometimes associated with seizures. These episodes usually occur during the summer, and the cause is an inability to sweat in response to exogenous heat. Sweat glands are present in the skin, but lack sympathetic innervation. Most infants are hypotonic and areflexic. Attainment of developmental milestones is slow, and by 2 or 3 years of age, the child has had several self-inflicted injuries caused by pain insensitivity. Injuries may include ulcers of the fingers and toes, stress fractures, self-mutilation of the tongue, and Charcot joints.

Sensory examination shows widespread absence of pain and temperature sensation. Touch, vibration, and stereognosis are intact in some patients. Tendon reflexes are absent or hypoactive. The cranial nerves are intact, and the corneal reflex and lacrimation are normal. Mild-to-moderate retardation is present in almost every case. Other features, present in some children, are blond hair and fair skin, Horner syndrome, and aplasia of dental enamel.

DIAGNOSIS. Familial dysautonomia (HSAN III) and HSAN IV have many features in common and are easily confused. Insensitivity to pain is not prominent in HSAN III, however, and fungiform papillae of the tongue are present in HSAN IV. Anhydrotic ectodermal dysplasia is another hereditary disorder that shares many features with HSAN IV. Affected children also have unexplained fevers and abnormalities of tooth formation. Children with ectodermal dysplasia are anhydrotic, however, because sweat glands are absent. The nervous system is intact, and sensation to pain is present. Diagnosis of HSAN IV depends primarily on the clinical features, but the absence of sensory evoked potentials, the absence of an axon reflex after histamine injection into the skin, and the presence of sweat glands on skin biopsy specimens are confirmatory.

MANAGEMENT. No treatment is available for the underlying disease. Constant vigilance is required to prevent injuries to the skin and bones with secondary infection.

Metabolic Neuropathies

Acute Intermittent Porphyria

Acute intermittent porphyria is an autosomal dominant disorder that results from an error in pyrrole metabolism due to deficiency of porphobilinogen (PBG) deaminase. The gene location is 11q23.3. Individuals with similar degrees of enzyme deficiency may have considerable variation in phenotypic expression (Puy et al, 1997).

CLINICAL FEATURES. Approximately 90% of individuals with acute intermittent porphyria never have clinical symptoms. Onset is rarely before puberty. Symptoms are periodic and occur at irregular intervals. Alterations in hormonal levels during a normal menstrual cycle or pregnancy and exposure to certain drugs, especially barbiturates, trigger attacks. The most common clinical feature of acute intermittent porphyria is an attack of severe abdominal pain, often associated with vomiting, constipation, or diarrhea. Tachycardia, hypertension, and fever may be associated. Limb pain is common, and muscle weakness often develops. The weakness is a result of a motor neuropathy that causes greater weakness in proximal than distal muscles and in the arms more than the legs. Tendon reflexes are usually decreased and may be absent in weak muscles. Approximately half of patients have cerebral dysfunction; mental changes are particularly common, and seizures sometimes occur. Chronic mental symptoms, such as depression and anxiety, sometimes continue between attacks.

DIAGNOSIS. Suspect acute intermittent porphyria in people with acute or episodic neurological or psychiatric disturbances. Increased excretion of aminolevulinic acid and PBG occurs during attacks, but levels may be normal between attacks. Definitive diagnosis requires measurement of PBG deaminase activity in erythrocytes. The risk of attacks correlates with the excretion of PBG in the urine when the patient is free of symptoms.

MANAGEMENT. The most important aspect of managing symptomatic disease is to prevent acute attacks by avoiding known precipitating factors. During an attack, patients frequently require hospitalization because of severe pain. Carbohydrates are believed to reduce porphyrin synthesis and should be administered

intravenously daily at a dose of 300 to 500 g as a 10% dextrose solution. Reports of benefit from hematin infusions, a specific feedback inhibitor of heme synthesis, are in the literature. Hematin is neither readily available nor very soluble, however, and may carry a risk of renal damage.

Hereditary Tyrosinemia

Hereditary tyrosinemia type I is caused by deficiency of the enzyme fumarylacetoacetate hydrolase. Transmission of the genetic trait is by autosomal recessive inheritance, and the gene map locus is *15q23-q25*.

CLINICAL FEATURES. The major features are acute and chronic liver failure and a renal Fanconi syndrome. Recurrent attacks of painful dysesthesias or paralysis are a prominent feature of the disease in half of children. The attacks usually begin at 1 year of age, and infection precedes the attack in half of the cases. Perhaps because of the child's age, pain localization is poor and referred to the legs and lower abdomen. Associated with the pain is axial hypertonicity, which ranges in severity from mild neck stiffness to opisthotonos. Generalized weakness occurs in 30% of attacks and may necessitate respiratory support. Less common features of attacks are seizures and self-mutilation. Between attacks, the child appears normal.

DIAGNOSIS. The basis for diagnosis is an increased blood concentration of tyrosine and a deficiency of fumarylacetoacetate hydrolase. Crises are caused in part by an acute axonal neuropathy. The neuropathy is demonstrable by electromyogram studies. Succinylacetone, a metabolite of tyrosine, accumulates and inhibits porphyrin metabolism. Increased urinary excretion of γ -aminolevulinic acid is present in acute intermittent porphyria and hereditary tyrosinemia.

MANAGEMENT. Of patients treated with the drug 2-(2-nitro-4-trifluoromethylbenzoyl)-1,3-cyclohexanedione (NTBC), 90% have shown a favorable response (Holme and Lindstedt, 1998). Liver transplantation is the definitive treatment.

Spinal Disorders

Lumbar Disk Herniation

Trauma is the usual cause of lumbar disk herniation in children. Almost all cases occur after age 10. Cases are more common in boys than in girls and frequently are sports related. Delays in

diagnosis are commonplace because lumbar disk herniation is so unusual in children.

CLINICAL FEATURES. The initial features are pain and inability to function normally because of pain and inability to move the back. Straight leg raising and bending forward from the waist are impaired. Frequently the pain has been present for a long time because most children accommodate to their disability. Examination reveals diminished sensation to pinprick in the distribution of the L5 and S1 dermatome and diminished or absent ankle tendon reflexes in more than half of patients.

DIAGNOSIS. Radiographs of the lumbosacral spine reveal minor congenital anomalies (hemivertebrae, sacralization of the lumbar spine) in an unusually large number of cases. MRI of the spine or myelography confirms the diagnosis.

MANAGEMENT. Bed rest provides immediate relief in most patients. The indication for surgical treatment is pain that persists and limits function despite adequate medical measures.

Syringomyelia

Syringomyelia is a generic term for a fluid-filled cavity within the substance of the spinal cord. The cavity varies in length and may extend into the brainstem. A cephalic extension is termed *syringobulbia*. The cavity, or syrinx, is central in the gray matter and may enlarge in all directions. The cervicothoracic region is a favorite site, but thoracolumbar syrinx also occurs, and occasionally a syrinx extends from the brainstem to the conus medullaris.

The mechanism of syrinx formation is uncertain. Cavitation of the spinal cord sometimes follows trauma and infarction, but these are not important mechanisms of syringomyelia in children. In childhood, the cause of primary syringomyelia is either a congenital malformation or a cystic astrocytoma. In the past, the two were distinguishable only by postmortem examination. Astrocytomas of the spinal cord, similar to those of the cerebellum, may have large cysts with only a nubbin of solid tumor. MRI has greatly enhanced antemortem diagnosis of cystic astrocytoma by showing small areas of increased signal intensity in one or more portions of the cyst. Cystic astrocytoma is more likely to produce symptoms during the first decade, whereas congenital syringomyelia becomes symptomatic in the second decade or later and is usually associated with the Chiari anomaly. Chapters 12 and 13 consider cystic astrocytoma of the spinal cord;

this section deals primarily with congenital syringomyelia.

CLINICAL FEATURES. The initial symptoms of syringomyelia depend on the cyst's location. Because the cavity is near the central canal, it first affects crossing fibers subserving pain and temperature. When the syrinx is in the cervical area, pain and temperature typically are lost in a "cape" or "vest" distribution. Early involvement is often unilateral or at least asymmetrical and sometimes involves the fingers before the shoulders. Preservation of touch and pressure persists until the cyst enlarges into the posterior columns or the dorsal root entry zone. Loss of pain sensibility in the hands often leads to injury, ulceration, and infection, as seen in HSAN. Pain is prominent. Complaints include neck ache, headache, back pain, and radicular pain.

Scoliosis is common, and torticollis may be an initial sign in children with cervical cavities. As the cavity enlarges into the ventral horn, weakness and atrophy develop in the hands and may be associated with fasciculations; pressure on the lateral columns causes hyperreflexia and spasticity in the legs. Long cavities may produce lower motor neuron signs in all limbs. Sphincter control sometimes is impaired. The posterior columns are generally the last to be affected so that vibration sense and touch are preserved until relatively late in the course. The progress of symptoms is extremely slow and insidious. The spinal cord accommodates well to the slowly developing pressure within. At the time of consultation, a long history of minor neurological handicaps, such as clumsiness or difficulty running, is common.

Bulbar signs are relatively uncommon and usually asymmetrical. They include hemiatrophy of the tongue with deviation on protrusion, facial weakness, dysphasia, and dysarthria. Disturbances of the descending pathway of the trigeminal nerve cause loss of pain and temperature sensations on the same side of the face as the facial weakness and tongue hemiatrophy.

DIAGNOSIS. MRI is the diagnostic test of choice. It not only shows the cavity (Figure 9-1) and the Chiari malformation, but also the presence of small foci of glioma.

MANAGEMENT. Syrinxes occurring with hydrocephalus and communicating with the fourth ventricle do well after ventriculoperitoneal shunt. Syrinxes associated with Chiari I malformations collapse after shunting from the syrinx to the cerebellopontine angle, and noncommunicating syrinxes often collapse after excision of an extramedullary obstruction.

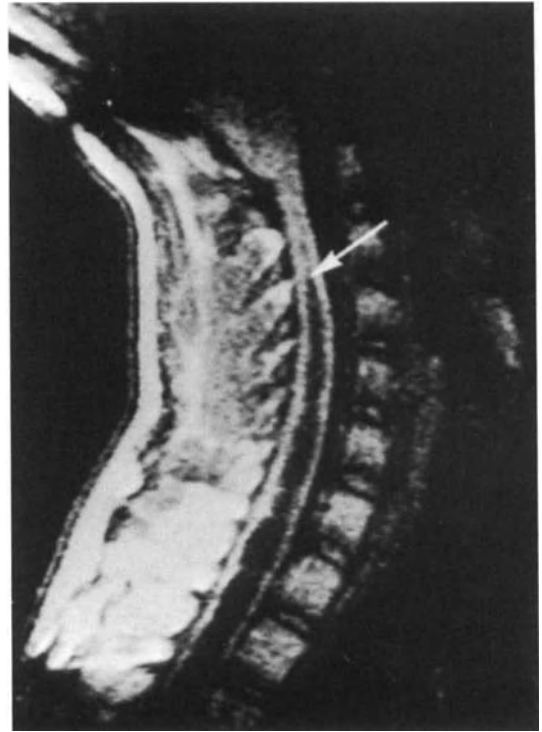

Figure 9-1. Cervical syringomyelia. MRI shows a long cavity (arrow) beginning just below the foramen magnum.

Thalamic Pain

The thalamic pain syndrome occurs almost exclusively in adults after infarction of the thalamus. Similar symptoms sometimes occur in patients with thalamic glioma. The location of the lesion is usually the ventroposterolateral nucleus of the thalamus. Thalamic-type pain also occurs with lesions of the parietal lobe, medial lemniscus, and dorsolateral medulla (MacGowan et al, 1997).

CLINICAL FEATURES. Touching the affected limb or part of the body produces intense discomfort described as sharp, crushing, or burning. Suffering is considerable, and the quality of the pain is unfamiliar to the patient. Several different modes of stimulation, such as changes in ambient temperature, auditory stimulation, and changes in emotional state, can accentuate the pain. Despite the severity of these dysesthesias, the affected limb is otherwise anesthetic to ordinary sensory testing.

DIAGNOSIS. The presence of thalamic pain should prompt imaging studies to determine the presence of tumor, infarction, or demyelinating disease.

MANAGEMENT. The combination of levodopa and a peripheral decarboxylase inhibitor may be helpful for relieving pain. If this does not prove satisfactory, administer some combination of analgesic and tranquilizing medication.

References

- Bonkowski JL, Johnson J, Carey JC, et al. An infant with primary tooth loss and palmar hyperkeratosis. A novel mutation in the NTRK1 gene causing congenital insensitivity to pain with anhidrosis. *Pediatrics* 2003;112:e237-e241.
- Dyck PJ, Dyck PJB, Schaid DJ. Genetic heterogeneity in hereditary sensory and autonomic neuropathies. The need for improved ascertainment. *Muscle Nerve* 2000; 23:1453-1455.
- Holme E, Lindstedt S. Tyrosinaemia type I and NTBC (2(2-nitro-4-trifluoromethylbenzoyl)-1,3-cyclohexanedione). *J Inherit Metab Dis* 1998;21:507-517.
- Hooshmand H, Hashmi M. Complex regional pain syndrome (reflex sympathetic dystrophy syndrome). Diagnosis and therapy—a review of 824 patients. *Pain Digest* 1999;9:1-24.
- MacGowan DJ, Janal MN, Clark WC, et al. Central post-stroke pain and Wallenberg's lateral medullary infarction. Frequency, character, and determinants in 63 patients. *Neurology* 1997;49:120-125.
- Puy H, Deybach JC, Lamoril J, et al. Molecular epidemiology and diagnosis of PBG deaminase gene defects in acute intermittent porphyria. *Am J Hum Genet* 1997;60:1373-1383.
- Rowbotham MC. Complex regional pain syndrome type I (reflex sympathetic dystrophy). More than a myth. *Neurology* 1998;51:4-5.
- Wasner G, Schattschneider J, Heckmann K, et al. Vascular abnormalities in reflex sympathetic dystrophy (CRPS I). Mechanisms and diagnostic value. *Brain* 2001;124:587.
- Wheeler DS, Vaux KK, Tam DA. Use of gabapentine in the treatment of childhood reflex sympathetic dystrophy. *Pediatr Neurol* 2000;22:220-231.

Chapter 10

Ataxia

THE TERM ATAXIA denotes disturbances in the fine control of posture and movement. The cerebellum and its major input systems from the frontal lobes and the posterior columns of the spinal cord provide this control. The initial and most prominent feature is usually an abnormal gait. The ataxic gait is wide-based, lurching, and staggering, and it provokes disquiet in an observer for fear that the patient is in danger of falling. One observes a similar gait in people who are attempting to walk in a vehicle that has several directions of motion at once, such as a railroad train.

When an abnormality occurs in the vermis of the cerebellum, the child cannot sit still but constantly moves the body to-and-fro and bobs the head (*titubation*). In contrast, disturbances of the cerebellar hemispheres cause a tendency to veer in the direction of the affected hemisphere, with dysmetria and hypotonia in the ipsilateral limbs. Bifrontal lobe disease may produce symptoms and signs that are indistinguishable from the symptoms and signs of cerebellar disease.

Loss of sensory input to the cerebellum, because of peripheral nerve or posterior column disease, necessitates constant looking at the feet to know their location in space. The gait also is wide-based, but is not so much lurching as careful. The foot raises high with each step and slaps down heavily on the ground. Station and gait are considerably worse with the eyes closed, and the patient may fall to the floor (*Romberg sign*). Sensory ataxia is more likely to cause difficulty with fine finger movements than with reaching for objects. Other features of cerebellar disease are a characteristic speech that varies in volume and has an increased separation of syllables

(*scanning speech*), hypotonia, limb and ocular dysmetria, and tremor.

The differential diagnosis of a child with acute ataxia or recurrent attacks of ataxia (Table 10-1) is quite different from that of a child with chronic static or progressive ataxia (Table 10-2). These two presentations are discussed separately. One “suddenly” may become aware of what had been a slowly progressive ataxia, however, and children with recurrent ataxia may never recover to baseline function after each attack. Progressive ataxia superimposes on the acute attacks.

Acute or Recurrent Ataxia

The two most common causes of ataxia among children who were previously healthy then suddenly have an ataxic gait are drug ingestion and acute postinfectious cerebellitis. Migraine, brainstem encephalitis, and an underlying neuroblastoma are the next considerations. Recurrent ataxia is uncommon and usually is caused by hereditary disorders; migraine is the most common cause, and disorders of pyruvate metabolism are second.

Brain Tumor

Primary brain tumors ordinarily cause chronic progressive ataxia (see discussion later). Ataxia may be acute, however, if the brain tumor bleeds or causes hydrocephalus. In addition, early clumsiness may not become apparent until it becomes severe enough to cause an obvious gait disturbance. Brain imaging is a recommendation for most children with acute cerebellar ataxia.

TABLE 10-1
Acute or Recurrent Ataxia

Brain tumor
Conversion reaction
Drug ingestion
Encephalitis (brainstem)
Genetic disorders
Dominant recurrent ataxia
Episodic ataxia type 1
Episodic ataxia type 2
Hartnup disease
Maple syrup urine disease
Pyruvate dehydrogenase deficiency
Migraine
Basilar
Benign paroxysmal vertigo
Postinfectious/immune
Acute postinfectious cerebellitis
Miller Fisher syndrome
Multiple sclerosis
Myoclonic encephalopathy/neuroblastoma
Pseudoataxia (epileptic)
Trauma
Hematoma (see Chapter 2)
Postconcussion
Vertebrobasilar occlusion
Vascular disorders
Cerebellar hemorrhage
Kawasaki disease

Conversion Reaction

CLINICAL FEATURES. Hysterical gait disturbances are relatively common in children, especially girls between 10 and 15 years old. Hysteria is involuntary and usually provides a secondary gain. In contrast, malingering is a voluntary act.

Hysterical gait disturbances are often extreme. The child appears to sit without difficulty, but when brought to standing immediately begins to sway from the waist. Stance is not wide to improve stability. Instead the child lurches, staggers, and otherwise travels across the room from object to object. The lurching maneuvers are often complex and require extraordinary balance. Strength, tone, sensation, and tendon reflexes are normal.

DIAGNOSIS. The diagnosis of hysterical gait disturbances is by observation; laboratory tests are not ordinarily required to exclude other possibilities.

MANAGEMENT. Determination of the precipitating stress is important. Conversion may represent a true call for help in a desperate situation, such as sexual abuse. Such cases require referral to a multispecialty team able to deal with the whole family. Most children with hysterical gait disturbances are responding to an immediate and less serious life stress. Usually, symptoms are treatable by the use of suggestion and do not require psychiatric referral except when conversion is used repeatedly to handle stress.

Drug Ingestion

The incidence of accidental drug ingestion is highest between ages 1 and 4 years.

CLINICAL FEATURES. An overdose of most psychoactive drugs causes ataxia, disturbances in personality or sensorium, and sometimes seizures. Toxic doses of anticonvulsant drugs, especially phenytoin, may cause marked nystag-

TABLE 10-2
Chronic or Progressive Ataxia

Brain tumors	Ataxia without oculomotor apraxia
Cerebellar astrocytoma	Ataxia with episodic dystonia
Cerebellar hemangioblastoma (von Hippel-Lindau disease)	Friedreich ataxia
Ependymoma	Hartnup disease
Medulloblastoma	Juvenile GM ₂ gangliosidosis
Supratentorial tumors (see Chapter 4)	Juvenile sulfatide lipidosis
Congenital malformations	Maple syrup urine disease
Basilar impression	Marinesco-Sjögren syndrome
Cerebellar aplasias	Pyruvate dehydrogenase deficiency
Cerebellar hemisphere aplasia	Ramsay Hunt syndrome
Dandy-Walker malformation (see Chapter 18)	Refsum disease (HSMN IV) (see Chapter 7)
Vermal aplasia	Respiratory chain disorders (see Chapter 8)
Chiari malformation	X-linked inheritance
Hereditary ataxias	Adrenoleukodystrophy (see Chapter 5)
Autosomal dominant inheritance (see Table 10-3)	Leber optic neuropathy (see Chapter 16)
Autosomal recessive inheritance	With adult-onset dementia
Abetalipoproteinemia	With deafness
Ataxia-telangiectasia	With deafness and loss of vision

mus and ataxia without an equivalent alteration in sensorium. Excessive use of antihistamines in the treatment of an infant or young child with allergy or an upper respiratory tract infection may cause ataxia. This is especially true in children with otitis media, who may have underlying unsteadiness because of middle ear infection.

DIAGNOSIS. Carefully question the parents or care providers of every child with acute ataxia concerning drugs intentionally administered to the child and other drugs accessible in the home. Specific inquiry concerning the use of anticonvulsant or psychoactive drugs by family members is mandatory. Screen urine for drug metabolites, and send blood for analysis when a specific drug is suspected.

MANAGEMENT. Treatment depends on the specific drug ingested and its blood concentration. In most cases of ataxia caused by drug ingestion, the drug can be safely eliminated spontaneously if vital function is not compromised, if acid-base balance is not disturbed, and if liver and kidney function is normal. In life-threatening situations, dialysis may be necessary while supporting vital function in an intensive care unit.

Encephalitis (Brainstem)

Ataxia may be the initial feature of viral encephalitis affecting primarily the structures of the posterior fossa. Potential etiological agents include echoviruses, coxsackieviruses, adenoviruses, and *Coxiella burnetii* (Sawaishi et al, 1999).

CLINICAL FEATURES. Cranial nerve dysfunction often is associated with the ataxia. Generalized encephalitis characterized by declining consciousness and seizures may develop later. Meningismus is sometimes present. The course is variable, and although most children recover completely, some have considerable neurological impairment. Children who have only ataxia and cranial nerve palsies, with no disturbance of neocortical function, tend to recover best. These cases are indistinguishable from Miller Fisher syndrome on clinical grounds alone.

DIAGNOSIS. Diagnosis requires showing a cellular response, primarily mononuclear leukocytes, in the cerebrospinal fluid (CSF), with or without some elevation of the protein content. Prolonged interpeak latencies of the brainstem auditory evoked response are evidence of an abnormality within the brainstem parenchyma and not the peripheral sensory input system. The electroencephalogram (EEG) is usually normal in children with brainstem encephalitis who have a normal sensorium.

MANAGEMENT. No specific treatment is available for the viral infection.

Genetic Disorders

Dominant Recurrent Ataxias

At least two distinct genetic defects are recognized that cause episodic ataxia (EA)—EA-1 and EA-2. Both are the result of ion channel mutations. Mutations in a potassium channel gene underlie EA-1, and mutations in a voltage-dependent calcium channel underlie EA-2 (Subramony et al, 2003).

Episodic Ataxia Type 1 (Paroxysmal Ataxia and Myokymia)

EA-1 results from a mutation of the potassium channel gene *KCNA1* on chromosome 12p. The additional feature of continuous motor unit activity (see Chapter 8) suggests a defect in membrane stability affecting the central and peripheral nervous systems.

CLINICAL FEATURES. The onset of attacks is usually between 5 and 7 years old. Abrupt postural change, startle, and anxiety may provoke an attack. The child becomes aware of attack onset by the sensation of spreading limpness or stiffness lasting for a few seconds. Incoordination, trembling of the head or limbs, and blurry vision often follow. Some children feel warm and perspire. Some can continue standing or walking, but most sit down. Attacks usually last less than 10 minutes but can last 6 hours. Myokymia of the face and limbs begins at about age 12 years. Physical findings include large calves; normal muscle strength; and widespread myokymia of face, hands, arms, and legs, with a hand posture resembling carpopedal spasm. Electromyogram at rest shows continuous spontaneous activity.

DIAGNOSIS. The basis for clinical diagnosis is the history of typical attacks and the family history. Electromyogram confirms the diagnosis by showing continuous motor unit activity, most often in the hands, but also in the proximal arm muscles and sometimes in the face.

MANAGEMENT. Some patients respond to daily phenytoin or carbamazepine. When these agents fail, a trial of daily acetazolamide is reasonable.

Episodic Ataxia Type 2 (Acetazolamide-Responsive Ataxia)

EA-2, one form of spinocerebellar ataxia (SCA6), and one type of familial hemiplegic migraine all represent allelic mutations in the

same calcium channel gene on chromosome 19p. About half of patients have migraine headaches; some episodes may be typical of basilar migraine (Spacey, 2003).

CLINICAL FEATURES. Clinical heterogeneity is considerable despite genetic localization to the 19p site. The onset is generally during school age or adolescence. The child first becomes unsteady, then is unable to maintain posture because of vertigo and ataxia. Vomiting is frequent and severe. Jerk nystagmus, sometimes with a rotary component, occurs during attacks. One to three attacks may occur each month, with symptoms lasting 1 hour to 1 day. Attacks become milder and less frequent with age. Slowly progressive truncal ataxia and nystagmus may persist between attacks. In some patients, ataxia is the only symptom; others have only vertigo; and still others have only nystagmus. Most affected individuals are normal between attacks, but some are phenotypically indistinguishable from individuals with SCA6 (see discussion on progressive hereditary ataxias later).

DIAGNOSIS. The clinical features and the family history are the basis for diagnosis. Molecular diagnosis is available on a research basis. Magnetic resonance imaging (MRI) may show selective atrophy of the cerebellar vermis. Basilar artery migraine and benign paroxysmal vertigo can be distinguished from dominant recurrent ataxia because in these conditions, older family members have migraine but do not have recurrent ataxia. Attacks of benign paroxysmal vertigo rarely last more than a few minutes.

MANAGEMENT. Daily oral acetazolamide prevents recurrence of attacks in almost every case. The mechanism of action is unknown. The dose is generally 125 mg twice a day in young children and 250 mg twice a day in older children. Flunarizine, 5 to 10 mg/day, may serve as an alternative therapy for children with acetazolamide intolerance. Anticonvulsant and antimigraine medications have no value.

Hartnup Disease

Hartnup disease is a rare disorder transmitted by autosomal recessive inheritance. The abnormal gene localizes to chromosome 5p15 (Nozaki et al, 2001). The basic error is a defect of amino acid transport in kidney and small intestine. The result is aminoaciduria and the retention of amino acids in the small intestine. Tryptophan conversion is to nonessential indole products instead of nicotinamide.

CLINICAL FEATURES. Affected children are normal at birth but may be slow in attaining develop-

mental milestones. Most achieve only borderline intelligence; others are normal. Affected individuals are photosensitive and have a severe pellagra-like skin rash after exposure to sunlight. Nicotinamide deficiency causes the rash. Many patients have episodes of limb ataxia, sometimes associated with nystagmus. Mental changes, ranging from emotional instability to delirium or states of decreased consciousness, may occur. Examination reveals hypotonia and normal or exaggerated tendon reflexes. Stress or intercurrent infection triggers the neurological disturbances, which may be due to the intestinal absorption of toxic amino acid breakdown products. Most patients have rash and neurological disturbances, but each can occur without the other. Symptoms progress over several days and last for a week to a month before recovery occurs.

DIAGNOSIS. The constant feature of Hartnup disease is aminoaciduria involving neutral monoaminomonocarboxylic amino acids. These include alanine, serine, threonine, asparagine, glutamine, valine, leucine, isoleucine, phenylalanine, tyrosine, tryptophan, histidine, and citrulline.

MANAGEMENT. Daily oral administration of nicotinamide, 50 to 300 mg, may reverse the skin and neurological complications. A high-protein diet helps make up for the amino acid loss.

Maple Syrup Urine Disease (Intermittent)

Maple syrup urine disease is a disorder of branched-chain amino acid metabolism caused by deficiency of the enzyme branched-chain keto acid dehydrogenase. The result of the deficiency is a neonatal organic acidemia. Transmission of the defect is by autosomal recessive inheritance. Three phenotypes are associated, depending on the percentage of enzyme deficiency. The *classic* form begins as seizures in the newborn (see Chapter 1), the *intermediate* form causes progressive mental retardation (see Chapter 5), and the *intermittent* form causes recurrent attacks of ataxia and encephalopathy.

CLINICAL FEATURES. Affected individuals are normal at birth. Between 5 months and 2 years, minor infections, surgery, or a diet rich in protein provokes episodes of ataxia, irritability, and progressive lethargy. The length of an attack varies. Most children recover spontaneously, but some die of severe metabolic acidosis. Psychomotor development is normal in survivors.

DIAGNOSIS. The urine has a maple syrup odor during the attack, and the blood and urine have

elevated concentrations of branched-chain amino acids and keto acids. Between attacks, the concentrations of branched-chain amino acids and keto acids are normal in blood and urine. Establishing the diagnosis requires showing the enzyme deficiency in cultured fibroblasts.

MANAGEMENT. Children with intermittent maple syrup disease need a protein-restricted diet. Some have a thiamine-responsive enzyme defect, and 1 g of thiamine a day treats the acute attacks. If this is successful, a recommended maintenance dose is 100 mg/day. The main objective during an acute attack is to reverse ketoacidosis. Protein should not be given. Peritoneal dialysis may be helpful in life-threatening situations.

Pyruvate Dehydrogenase Deficiency

The pyruvate dehydrogenase (PDH) complex is responsible for the oxidative decarboxylation of pyruvate to carbon dioxide and acetyl coenzyme A. Disorders of the complex are associated with several neurological conditions, including subacute necrotizing encephalomyelopathy (*Leigh syndrome*), mitochondrial myopathies, and lactic acidosis. The complex contains three main components that are termed *E1*, *E2*, and *E3*. *E1* consists of two α subunits encoded on the X chromosome and two β subunits. Episodes of intermittent ataxia and lactic acidosis characterize the X-linked form of PDH-E1 deficiency. *E1* deficiency is the most common form of PDH deficiency.

CLINICAL FEATURES. The clinical features range from severe neonatal lactic acidosis and death to episodic ataxia with lactic and pyruvic acidosis and spinocerebellar degeneration. Most patients show mild developmental delay during early childhood. Episodes of ataxia, dysarthria, and sometimes lethargy usually begin after age 3 years. In more severely affected patients, episodes may begin during infancy and are associated with generalized weakness and states of decreased consciousness. Some attacks are spontaneous, but intercurrent infection, stress, or a meal high in carbohydrate provokes others. Attacks recur at irregular intervals and may last 1 day to several weeks.

The severity of neurological dysfunction in any individual probably reflects the level of residual enzyme activity. Individuals with generalized weakness also are areflexic and have nystagmus or other disturbances in ocular motility. Ataxia is the predominant symptom. Intention tremor and dysarthria may be present. Hyperventilation is common, and metabolic

acidosis may be the cause. Patients with almost complete PDH deficiency die of lactic acidosis and central hypoventilation during infancy.

DIAGNOSIS. PDH deficiency should be suspected in children with lactic acidosis, hypotonia, progressive or episodic ataxia, the Leigh disease phenotype, and recurrent polyneuropathy. The pyruvic acid concentration is elevated, and the lactate-to-pyruvate ratio is low. The blood concentration of lactate may be elevated between attacks; lactate and pyruvate concentrations are always elevated during attacks. Some children also have hyperalaninemia. Analysis of enzyme activity in cultured fibroblasts, leukocytes, or muscle establishes the diagnosis.

MANAGEMENT. The ketogenic diet is a rational treatment for PDH complex deficiency (Klepper et al, 2002). Patients usually are treated with thiamine (100 to 600 mg/day) and a high-fat (>55%), low-carbohydrate diet. Current treatments do not prevent disease progression in most patients. In addition, daily oral acetazolamide, 125 mg twice a day in small children and 250 mg twice a day in older children, may significantly abort the attacks. The treatment of several patients with biotin, carnitine, coenzyme Q10, and thiamine supplements has not established efficacy.

Migraine

Basilar Migraine

The term *basilar (artery) migraine* characterizes recurrent attacks of brainstem or cerebellar dysfunction that occur as symptoms of a migraine attack. Girls are affected more often than boys. The peak incidence is during adolescence, but attacks may occur at any age. Infant-onset cases are more likely to present as benign paroxysmal vertigo.

CLINICAL FEATURES. Gait ataxia occurs in approximately 50% of patients. Other symptoms include visual loss; vertigo; tinnitus; alternating hemiparesis; and paresthesias of the fingers, toes, and corners of the mouth. An abrupt loss of consciousness may occur, usually lasting for only a few minutes. Cardiac arrhythmia and brainstem stroke are rare life-threatening complications. A severe, throbbing, occipital headache usually follows the neurological disturbances. Nausea and vomiting occur in less than one third of cases. Children may have repeated basilar migraine attacks, but with time, the episodes evolve into a pattern of classic migraine. Even during attacks of classic migraine, the patient

may continue to complain of vertigo and even ataxia.

DIAGNOSIS. EEG distinguishes basilar migraine from benign occipital epilepsy. The EEG shows occipital intermittent delta activity during and just after an attack in basilar migraine and occipital discharges in epilepsy.

MANAGEMENT. Treatment of basilar artery migraine is the same as for other forms of migraine (see Chapter 3). Frequent attacks require a prophylactic agent.

Benign Paroxysmal Vertigo

Benign paroxysmal vertigo is primarily a disorder of infants and preschool children but may occur in older children.

CLINICAL FEATURES. Recurrent attacks of vertigo are characteristic. Vertigo is maximal at onset. True cerebellar ataxia is not present, but vertigo is so profound that standing is impossible. The child either lies motionless on the floor or wants holding. Consciousness is maintained throughout the event, and headache is not associated. The predominant symptoms are pallor, nystagmus, and fright. Episodes last only minutes and may recur at irregular intervals. With time, attacks decrease in frequency and stop completely. Migraine develops in 21% (Lindskog et al, 1999).

DIAGNOSIS. The diagnosis is primarily clinical, and laboratory tests are useful only to exclude other possibilities. A family history of migraine, although not paroxysmal vertigo, is present in 40% of cases. Some parents indicate that they experience vertigo with their attacks of migraine. Only in rare cases does a parent have a history of benign paroxysmal vertigo.

MANAGEMENT. The attacks are so brief and harmless that treatment is not required.

Postinfectious/Immune Disorders

In many conditions discussed in this section, the underlying cause of cerebellar dysfunction and some other neurological deficits is an altered immune state. Preceding viral infections are usually incriminating, but documentation is limited to only half of cases. Natural varicella infections and the varicella vaccine are definite preceding causes. No other vaccine links to acute cerebellar ataxia.

Acute Cerebellar Ataxia

Acute cerebellar ataxia usually affects children between 2 and 7 years old, but it may occur in

16-year-olds. The disorder affects both genders equally, and the incidence among family members is not increased.

CLINICAL FEATURES. The onset is explosive. A previously healthy child awakens from a nap and cannot stand. *Ataxia is maximal at onset.* Some worsening may occur during the first hours, but a longer progression, or a waxing and waning course, negates the diagnosis. Ataxia varies from mild unsteadiness while walking to complete inability to stand or walk. Even when ataxia is severe, sensorium is clear, and the child is otherwise normal. Tendon reflexes may be present or absent; their absence suggests Miller Fisher syndrome. Nystagmus, when present, is usually mild. Chaotic movements of the eyes (opsoclonus) should suggest the myoclonic encephalopathy/neuroblastoma syndrome.

Symptoms begin to remit after a few days, but recovery of normal gait takes 3 weeks to 5 months. Patients with pure ataxia of the trunk or limbs and only mild nystagmus are likely to recover completely. Marked nystagmus or opsoclonus (see the section on myoclonic encephalopathy/neuroblastoma syndrome later), tremors of the head and trunk, and moderate irritability usually are followed by persistent neurological sequelae.

DIAGNOSIS. The diagnosis of acute postinfectious cerebellitis is one of exclusion. Every child should have drug screening, and most have a brain imaging study. The necessity of imaging the brain in typical cases, especially children with varicella infection, is debatable. Lumbar puncture is indicated when encephalitis is suspected.

MANAGEMENT. Acute postinfectious cerebellitis is a self-limited disease. Treatment is not required.

Miller Fisher Syndrome

Ataxia, ophthalmoplegia, and areflexia characterize Miller Fisher syndrome. A similar disorder with ataxia and areflexia but without ophthalmoplegia is *acute ataxic neuropathy*. Some authors believe that Miller Fisher syndrome is a variant of Guillain-Barré syndrome; others believe that it is a form of brainstem encephalitis. In support of the hypothesis of a Guillain-Barré–like, immune-mediated hypothesis is the finding that *Campylobacter jejuni* is a causative agent in Miller Fisher syndrome and Guillain-Barré syndromes (Jacobs et al, 1995).

CLINICAL FEATURES. A viral illness precedes the neurological symptoms by 5 to 10 days in 50% of cases. Either ophthalmoparesis or ataxia may be the initial feature. Both are present early in

the course. The initial ocular motor disturbance is paralysis of upgaze, followed by loss of lateral gaze, then downgaze. Recovery takes place in the reverse order. Preservation of the Bell phenomenon sometimes occurs despite paralysis of voluntary upward gaze, suggesting the possibility of supranuclear palsy. Ptosis occurs but is less severe than vertical gaze palsy.

Decreased peripheral sensory input probably causes areflexia and more prominent limb than trunk ataxia. Weakness of the limbs may be noted. Unilateral or bilateral facial weakness occurs in a significant minority of children. Recovery generally begins within 2 to 4 weeks after symptoms become maximal and is complete within 6 months.

DIAGNOSIS. The clinical distinction between Miller Fisher syndrome and brainstem encephalitis can be difficult. Disturbances of sensorium, multiple cranial nerve palsies, an abnormal EEG, or prolongation of the interpeak latencies of the brainstem auditory evoked response should suggest brainstem encephalitis. The CSF profile in Miller Fisher syndrome parallels that of Guillain-Barré syndrome. A cellular response occurs early in the course, and protein elevation occurs later.

MANAGEMENT. Corticosteroids, adrenocorticotropic hormone, and plasmapheresis are not beneficial. The outcome in untreated children is excellent.

Multiple Sclerosis

Multiple sclerosis is usually a disease of young adults, but 3% to 5% of cases occur in children younger than 6 years old (Ruggieri et al, 1999). Whether the childhood forms of multiple sclerosis are etiologically distinct from the adult types is unknown.

CLINICAL FEATURES. The female-to-male ratio is 1.5:3. Ataxia, concurrent with a febrile episode, is the most common initial feature in children, followed by encephalopathy, hemiparesis, or seizures. Intranuclear ophthalmoplegia, unilateral or bilateral, develops in one third of patients (see Chapter 15).

The clinical features that occur in multiple sclerosis are sufficiently variable that no single prototype is valid. The essential feature is repeated episodes of demyelination in noncontiguous areas of the central nervous system. Focal neurological deficits that develop rapidly and persist for weeks or months characterize an episode. Afterward the child has partial or complete recovery. Months or years separate recurrences, which are often concurrent with a febrile illness. Lethargy, nausea, and vomiting

sometimes accompany the attacks in children but rarely in adults. The child is usually irritable and shows truncal and limb ataxia. Tendon reflexes are generally brisk throughout. The long-term outcome is unpredictable.

DIAGNOSIS. Multiple sclerosis may be the suspected diagnosis at the time of the first attack, but definitive diagnosis requires recurrence to establish a polyphasic course. Examination of the CSF at the time of exacerbation shows fewer than 25 lymphocytes/mm³, a normal or mildly elevated protein content, and sometimes the presence of oligoclonal bands.

MRI is the technique of choice for the diagnosis of multiple sclerosis and shows occult disease in 80% of affected individuals at the time of first presentation (Figure 10-1). The finding of three or more white matter lesions on T₂-weighted MRI, especially if one of these lesions is in the periventricular region, is a sensitive predictor of definite multiple sclerosis (Frohman et al, 2003). The extent and severity of lesions may not correlate, however, with the clinical syndrome. Visual evoked responses are useful to document prior or concurrent optic neuritis, and peroneal somatosensory evoked responses document myelitis.

MANAGEMENT. Acute exacerbations require a short course of corticosteroids. After an initial administration of methylprednisolone, 500 to 1000 mg, depending on the age, a tapering dose schedule is used. Experience is not available in

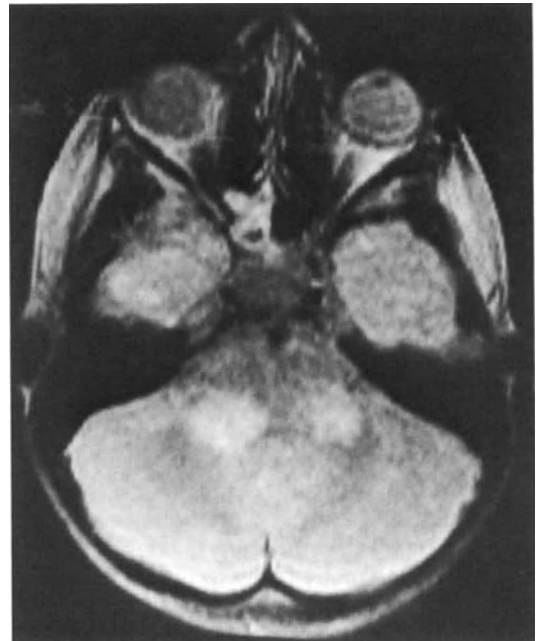

Figure 10-1. MRI in multiple sclerosis. Two areas of increased signal intensity are present in the cerebellum.

children with the drugs used to prevent relapses in adults.

Myoclonic Encephalopathy/Neuroblastoma Syndrome

Myoclonic encephalopathy is a syndrome characterized by chaotic eye movements (dancing eyes, opsoclonus), myoclonic ataxia, and encephalopathy. The pathophysiological mechanism is an altered immune state. Initially the syndrome was attributed either to the presence of occult neuroblastoma or to an unknown cause. With improved imaging techniques, all cases appear to be neuroblastoma related. Of children with neuroblastoma, 2% to 3% develop a myoclonic encephalopathy. A specific causal antibody is not established (Bataller et al, 2003).

CLINICAL FEATURES. The mean age at onset is 18 months (range 1 month to 4 years) (Russo et al, 1997). In contrast to acute postinfectious cerebellitis and Miller Fisher syndrome, in which neurological symptoms are fully expressed within 1 to 2 days, the evolution of symptoms in myoclonic encephalopathy may take 1 week or longer. Either ataxia or chaotic eye movements may bring the child to medical attention. Almost half of affected children show personality change or irritability, suggesting the presence of a more diffuse encephalopathy. Some children look ataxic, but the imbalance is actually myoclonus, constant rapid muscular contractions that have an irregular occurrence and a widespread distribution (see Chapter 14). Opsoclonus is a disorder of ocular muscles that is similar to myoclonus. Spontaneous, conjugate, irregular jerking of the eyes in all directions is characteristic. The movements are most prominent with attempts to change fixation and are associated with blinking or eyelid flutter. Opsoclonus persists even in sleep and becomes more severe with agitation.

DIAGNOSIS. The clinical features are the basis for diagnosis of myoclonic encephalopathy. Laboratory investigation is required to determine the underlying cause. An occult neuroblastoma is the expected cause in all children with recurrent ataxia or the myoclonic encephalopathy syndrome. Neuroblastoma is also the likely cause when an acute ataxia progresses over several days or waxes and wanes. The occult neuroblastoma is equally likely to be in the chest or the abdomen. In contrast, only 10% to 15% of neuroblastomas are in the chest when myoclonic encephalopathy is absent. The usual studies to detect neuroblastoma are MRI of the

chest and abdomen (Figure 10-2) and measurement of the urinary excretion of homovanillic acid and vanillylmandelic acid.

MANAGEMENT. Long-term neurological outcome does not depend on finding and removing the tumor. Partial or complete remission of the neurological symptoms may occur regardless of whether neuroblastoma is present. In most children, a prolonged course follows, with waxing and waning of neurological dysfunction. Either adrenocorticotropic hormone or oral corticosteroids provide partial or complete relief of symptoms in 80% of patients. Marked improvement usually occurs 1 to 4 weeks after initiation of therapy. Relapses occur after discontinuing therapy, but also may occur while treatment is in progress. On long-term follow-up, two thirds of patients showed mild neurological deficits, and the remainder showed little or none (Hayward et al, 2001).

Pseudoataxia (Epileptic Ataxia)

CLINICAL FEATURES. Ataxia and other gait disturbances can be the only clinical features of seizure activity. Limb and gait ataxia may be present, and the child's epilepsy may be undiagnosed. If the child already is taking anticonvulsant drugs, a toxic drug effect is often the initial diagnosis. During the ataxic episode, the child may appear inattentive or confused. Similar to other seizure manifestations, ataxia is sudden in onset and episodic.

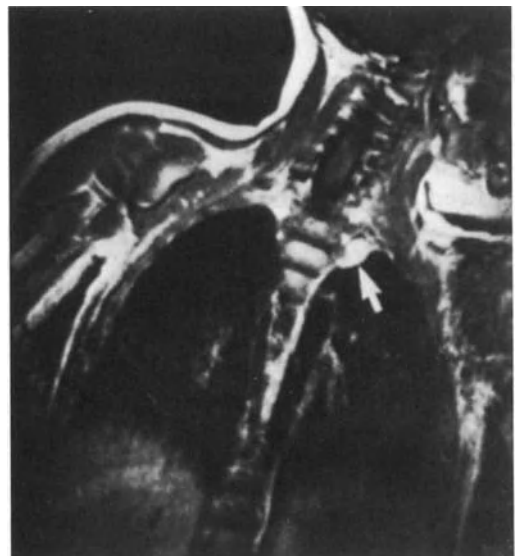

Figure 10-2. MRI shows an apical neuroblastoma (arrow) in a child with normal radiographs and CT scan of the chest.

DIAGNOSIS. The absence of nystagmus suggests that ataxia is a seizure manifestation and not caused by drug toxicity. The usual EEG findings concurrent with ataxia are prolonged, generalized, 2- to 3-Hz spike-wave complexes that have a frontal predominance. This is the typical EEG finding in Lennox-Gastaut syndrome (see Chapter 1). Such discharges ordinarily are associated with myoclonic jerks or akinetic seizures. Either one occurring briefly, but repeatedly, could interrupt smooth movement and produce ataxia.

MANAGEMENT. Pseudoataxia usually responds to anticonvulsant drugs. Select drugs with efficacy for slow spike-wave discharges (see Chapter 1).

Trauma

Mild head injuries are common in children and are an almost daily occurrence in toddlers. Recovery is always complete despite considerable parental concern. More serious head injuries, associated with loss of consciousness, seizures, and cerebral contusion, are less common but account for several thousand deaths in children annually. Ataxia may follow even mild head injuries. In most cases, ataxia is part of the so-called postconcussion syndrome, in which imaging studies do not show any structural derangement of the nervous system. In others, a cerebellar contusion or posterior fossa hematoma may be present (see Chapter 2). Ataxia also may follow cervical injuries, especially during sports. Trauma to the vertebrobasilar artery is causal.

Postconcussion Syndrome

CLINICAL FEATURES. Many adults complain of headache, dizziness, and mental changes after even a mild head injury. Some of these symptoms also occur after head injury in children and probably represent a transitory derangement of cerebral function caused by the trauma. Even mild head trauma can cause a cerebral axonopathy, which may explain the persistence of symptoms.

In infants and small children, the most prominent postconcussive symptom is ataxia. This is not a typical cerebellar ataxia and may be only an unsteady gait. No limb dysmetria is present, and other neurological functions are normal.

In older children with postconcussive syndromes, headache and dizziness are as common as ataxia. The headache description is usually low grade and constant. It is often an analgesic-

rebound headache (see Chapter 3). Gait is less disturbed, possibly because an older child compensates better for dizziness, but the sensation of unsteadiness is still present.

DIAGNOSIS. The clinical syndrome is the basis for diagnosis. Cranial computed tomography (CT) at the time of injury to exclude intracranial hemorrhage is normal, but MRI may show foci of high signal intensity on T₂-weighted images, indicating axonal injury.

MANAGEMENT. Ataxia usually clears completely within 1 month and always within 6 months. Decreased activity during the time of ataxia is the only treatment needed.

Vertebrobasilar Occlusion

Trauma to the vertebrobasilar arteries may occur with chiropractic manipulation and sports injuries. Bony canals encase the vertebral arteries from C2 to the foramen magnum. Sudden stretching of the arteries by hyperextension or hyperflexion of the neck causes endothelial injury and thrombosis.

CLINICAL FEATURES. The onset of symptoms is within minutes or hours of injury. Vertigo, nausea, and vomiting are the initial symptoms of brainstem ischemia. Occipital headache also may be present. Ataxia is due to incoordination of the limbs on one side. It may be maximal at onset or progress over several days. Examination shows some combination of unilateral brainstem disturbances (diplopia, facial weakness) and ipsilateral cerebellar dysfunction.

DIAGNOSIS. CT or MRI shows a unilateral infarction in the cerebellar hemisphere. Infarction of the lateral medulla also may occur. Arteriography localizes the arterial thrombosis.

MANAGEMENT. Many children recover completely in the months that follow injury. The value of anticoagulation is not established.

Vascular Disorders

Cerebellar Hemorrhage

Spontaneous cerebellar hemorrhage in children, in the absence of a coagulopathy, is due to arteriovenous malformation, although less than 10% of intracranial arteriovenous malformations in children are in the cerebellum. The two major features of cerebellar hemorrhage are ataxia and headache.

Kawasaki Disease

Kawasaki disease is a systemic vasculitis that occurs predominantly in infants and children.

CLINICAL FEATURES. Five of the following six criteria are required for diagnosis: fever, conjunctival congestion, reddening of the oropharynx and lips, indurative edema of the limbs, polymorphic exanthems, and lymphadenopathy. Arthralgia, carditis, and aseptic meningitis may be associated features. Kawasaki disease is identical to childhood polyarteritis nodosa.

Multiple infarcts may occur in the brain. Acute ataxia, facial palsy, ocular motor palsies, and hemiplegia may occur. The neurological and coronary artery complications make Kawasaki disease a serious illness with guarded prognosis.

DIAGNOSIS. Clinical features of multisystem disease are essential for diagnosis. Abnormal laboratory findings include an increased sedimentation rate, a positive test for C-reactive protein, and increased serum complement and globulin levels. Skin biopsy specimen shows the typical histopathological changes of arteritis.

MANAGEMENT. Intravenous high-dose gamma globulin is an effective method of treatment.

Chronic or Progressive Ataxia

Brain tumor is always an initial concern when progressive ataxia develops in previously normal children, especially if headache is present as well (see Table 10-2). Congenital abnormalities that cause ataxia often are associated with some degree of mental deficiency. The onset of symptoms may occur during infancy or be delayed until adult life. Friedreich ataxia is the most common hereditary form of progressive ataxia. The causes of chronic or progressive ataxia are usually easy to diagnose, and many are treatable. Failure to establish a diagnosis can have unfortunate consequences for the child.

Brain Tumors

Approximately 85% of primary brain tumors in children 2 to 12 years old are located in the posterior fossa. Supratentorial tumors predominate in children younger than 2 and older than 12. Among tumors, 70% of primary brain tumors are gliomas, and only 5% of central nervous system tumors arise from the spinal cord. Neuroectodermal tumors are the second most common malignancy of childhood and the most common solid tumors. The four major tumors of the posterior fossa are cerebellar astrocytoma, brainstem glioma, ependymoma, and primitive neuroectodermal tumors (medulloblastoma). The initial feature of brainstem

glioma is cranial nerve dysfunction, not ataxia (see Chapter 15). Although this discussion is limited to tumors of the posterior fossa, supratentorial brain tumors also may cause ataxia. Approximately one quarter of children with supratentorial brain tumors have gait disturbances at the time of their first hospitalization, and many show signs of cerebellar dysfunction. Gait disturbances occur with equal frequency whether supratentorial tumors are in the midline or the hemispheres, whereas cerebellar signs are more common with midline tumors.

Cerebellar Astrocytoma

Cerebellar astrocytomas comprise 12% of brain tumors in children. The tumor usually grows slowly in the cerebellar hemisphere and consists of a large cyst with a mural nodule. It may be in the hemisphere, in the vermis, or in the hemisphere and the vermis, or it may occupy the fourth ventricle. Midline tumors are likely to be solid.

CLINICAL FEATURES. Occurrence is equal in both genders. The peak incidence is 5 to 9 years old, but the tumor may occur in infancy. Headache is the most common initial complaint in school-age children; unsteadiness of gait and vomiting are the initial symptoms in preschool children. Headache can be insidious and intermittent; typical morning headache and vomiting are rare. The first complaints of headache and nausea are nonspecific and often attributed to a flu-like illness. Only when symptoms persist is the possibility of increased intracranial pressure considered. In infants and small children, separation of cranial sutures often relieves the symptoms of increased intracranial pressure. For this reason, gait disturbances without headache or vomiting are the common initial sign of cerebellar astrocytoma in infants.

Papilledema is present in most affected children at initial examination but is often absent in infants with separation of cranial sutures. Ataxia is present in three quarters, dysmetria in half, and nystagmus in only a quarter. Ataxia varies in severity from a wide-based, lurching gait to a subtle alteration of gait observed only with tandem walking or quick turning. Its cause is partly the cerebellar location of the tumor and partly hydrocephalus. When the tumor is in the cerebellar hemisphere, ipsilateral or bilateral dysmetria may be present. Other neurological signs sometimes present in children with cerebellar astrocytoma are abducens palsy, multiple cranial nerve palsies, stiff neck, and head tilt.

DIAGNOSIS. MRI is the best imaging study for diagnosis.

MANAGEMENT. Children with life-threatening hydrocephalus should undergo a shunting procedure as the first step in treatment. The shunt relieves many of the symptoms and signs, including ataxia. Corticosteroids are sufficient to relieve pressure in many children with less severe hydrocephalus.

The 5-year survival rate after surgical removal approaches 95%. The mural nodule must be located and removed at surgery, or the tumor may recur. The amount of tumor resected is difficult to determine at the time of resection, and postoperative imaging studies improve on the surgeon's estimate. The need for adjuvant radiotherapy is not established.

The total removal of deeper tumors that involve the floor of the fourth ventricle is rare. Local recurrence is common after partial resection. Repeat surgery may be curative in some cases, but postoperative radiation therapy seems to offer a better prognosis after partial resection. The overall disease-free survival rates after either surgery alone or surgery and radiotherapy are 92% at 5 years and 88% at 25 years. Low-grade cerebellar astrocytomas never require chemotherapy, regardless of the degree of surgical resection.

High-grade cerebellar astrocytoma (glioblastoma) is rare in children. More than 30% of pediatric patients have dissemination of tumor through the neuraxis (spinal cord drop metastases). Examination of CSF for cytological features and complete myelography always follow surgical resection in patients with glioblastoma. An abnormal result in either indicates whole-axis radiation therapy.

Cerebellar Hemangioblastoma (von Hippel–Lindau Disease)

Von Hippel–Lindau (VHL) disease is a multisystem disorder transmitted by autosomal dominant inheritance (Schimke et al, 2002). The most prominent features are hemangioblastomas of the cerebellum and retina and pancreatic cysts. All children with cerebellar hemangioblastomas have VHL disease. Among adults, 60% have isolated tumors and do not have the genetic defect. The expression of VHL disease is variable even within the same kindred. The most common features are cerebellar and retinal hemangioblastoma (59%), renal carcinoma (28%), and pheochromocytoma (7%).

CLINICAL FEATURES. Mean age at onset of cerebellar hemangioblastoma in VHL disease is 32

years; onset before age 15 is unusual. The initial features are headache and ataxia. Retinal hemangioblastomas occur at a younger age and may cause visual impairment from hemorrhage before age 10. They may be multiple and bilateral and appear on ophthalmoscopic examination as a dilated artery leading from the disk to a peripheral tumor with an engorged vein. Spinal hemangioblastomas are intramedullary in location and lead to syringomyelia. Pheochromocytomas occur in 7% to 19% of patients and may be the only clinical manifestation.

DIAGNOSIS. Suspect the diagnosis in individuals with any of the following: more than one hemangioblastoma of the central nervous system, an isolated hemangioblastoma associated with a visceral cyst or renal carcinoma, or any known manifestation with a family history of disease. *Molecular genetic testing* of the VHL gene detects mutations in nearly 100% of patients. The gene for VHL disease is a tumor-suppressor gene that maps to chromosome 3p25. Clinical testing allows the identification of asymptomatic, affected family members who need annual examinations to look for treatable abnormalities. Such examinations should include indirect ophthalmoscopy, renal ultrasound, and gadolinium-enhanced MRI of the brain every 3 years.

MANAGEMENT. Cryotherapy or photocoagulation of smaller retinal lesions can lead to complete tumor regression without visual loss. The treatment of cerebellar hemangioblastoma is surgical, and total extirpation is the rule.

Ependymoma

The derivation of posterior fossa ependymoma is the cells that line the roof and floor of the fourth ventricle. These tumors can extend into both lateral recesses and grow out to the cerebellopontine angle. They account for 10% of primary brain tumors in children.

CLINICAL FEATURES. Of all childhood brain tumors, 8% are ependymomas. The peak incidence in children is birth to 4 years. The incidence in both genders is equal. The clinical features evolve slowly and are often present for several months before initial consultation. Symptoms of increased intracranial pressure are the first feature in 90% of children. Disturbances of gait and coordination, neck pain, or cranial nerve dysfunction are the initial features in the remainder. Half of affected children have ataxia, usually of the vermal type, and one third have nystagmus. Head tilt or neck stiffness is present in one third of children and

indicates extension of tumor into the cervical canal.

Although steady deterioration is expected, some children have an intermittent course. Episodes of headache and vomiting, ataxia, and even nuchal rigidity last for days or weeks and are then followed by periods of well-being. The cause of the intermittent symptoms is transitory obstruction of the fourth ventricle or aqueduct by the tumor acting in a ball-valve fashion.

DIAGNOSIS. MRI is better than CT at showing the tumor's location in the fourth ventricle and its extraventricular extensions. Marked dilation of the ventricular system is usual.

MANAGEMENT. The goals of surgical therapy are to relieve hydrocephalus and remove as much tumor as possible without damaging the fourth ventricle. Irradiation to the posterior fossa usually follows surgery, but not neuraxis radiation, unless the diagnosis of leptomeningeal spread is established. Poor prognostic features include age younger than 2 to 5 years at diagnosis, brainstem invasion, and a radiation dose of less than 4500 cGy (Paulino et al, 2002).

Medulloblastoma

Medulloblastoma is a primitive neuroectodermal tumor of the posterior fossa with the capacity to differentiate into neuronal and glial tissue. Most tumors are in the vermis or fourth ventricle, with or without extension into the cerebellar hemispheres. Approximately 10% are in the hemisphere alone.

CLINICAL FEATURES. Most series indicate a male-to-female ratio of 3:2. Ninety percent of cases have their onset during the first decade and the remainder during the second decade. Medulloblastoma is the most common primary brain tumor with onset during infancy.

The tumor grows rapidly, and the interval between onset of symptoms and medical consultation is generally brief, 2 weeks in 25% of cases and less than 1 month in 50%. Vomiting is an initial symptom in 58% of children, headache in 40%, an unsteady gait in 20%, and torticollis or stiff neck in 10%. The probable cause of prominent vomiting, with or without headache, as an early symptom is tumor irritation of the floor of the fourth ventricle. Gait disturbances are more common in young children and refusal to stand or walk is characteristic rather than by ataxia.

Two thirds of children have papilledema at the time of initial examination. Truncal ataxia and limb ataxia are equally common, and both may be present. Only 22% of children have nystagmus. Tendon reflexes are hyperactive when

hydrocephalus is present and hypoactive when the tumor is causing primarily cerebellar dysfunction.

DIAGNOSIS. CT or MRI easily identifies medulloblastoma (Figure 10-3). The tumors are vascular and become enhanced when contrast medium is used.

MANAGEMENT. The combination of surgical extirpation, radiation therapy, and chemotherapy greatly improves the prognosis for children with medulloblastoma. Surgery provides histological identification, debulks the tumor, and relieves obstruction of the fourth ventricle. Ventriculoperitoneal shunting reduces intracranial pressure even before decompressive resection. Treatment of children younger than 3 years old at diagnosis is with chemotherapy alone or chemotherapy with field radiotherapy.

The overall 5-year survival rate is approximately 40%. Survival is better (60% to 70%) in children who have gross total tumor resection compared with partial resection or biopsy. Craniospinal radiation increases survival better than local field radiation. The use of adjuvant chemotherapy significantly improves survival. Most initial recurrences occur at the primary site. One histological variant, *anaplastic large cell medulloblastoma*, carries a poorer prognosis because of a higher risk for early metastatic involvement and recurrence (Eberhart et al, 2002). The presence of dissemination is the most important factor that correlates with outcome (Helton et al, 2002).

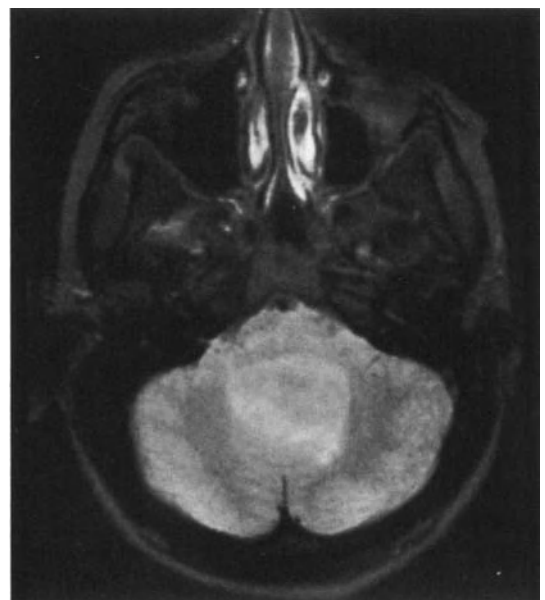


Figure 10-3. MRI of medulloblastoma. The tumor is seen as an enhancing mass in the vermis of the cerebellum.

Congenital Malformations

Basilar Impression

Basilar impression is a disorder of the craniovertebral junction. Posterior displacement of the odontoid process compresses the spinal cord or brainstem.

CLINICAL FEATURES. The first symptoms are often head tilt, neck stiffness, and headache. Minor trauma to the head or neck frequently precipitates the onset of symptoms. Examination shows ataxia, nystagmus, and hyperreflexia.

DIAGNOSIS. MRI is the best method to visualize the cervicomedullary junction and an associated Chiari malformation or syringobulbia (Figure 10-4).

MANAGEMENT. Surgical decompression of the foramen magnum usually relieves symptoms.

Cerebellar Malformations

Congenital Hemisphere Hypoplasia

Congenital hypoplasia of the cerebellum can be unilateral or bilateral. Unilateral cerebellar hypoplasia is not associated with genetic disorders (Ramaekers et al, 1997). More than half of patients with bilateral disease have an identifiable genetic disorder transmitted by autosomal recessive inheritance. The common histological feature is the absence of granular cells, with relative preservation of Purkinje cells. In some hereditary forms, granular cell degeneration may continue postnatally and cause progressive cerebellar dysfunction during infancy.

CLINICAL FEATURES. Developmental delay and hypotonia are the first features suggesting a cerebral abnormality in an infant. Titubation of

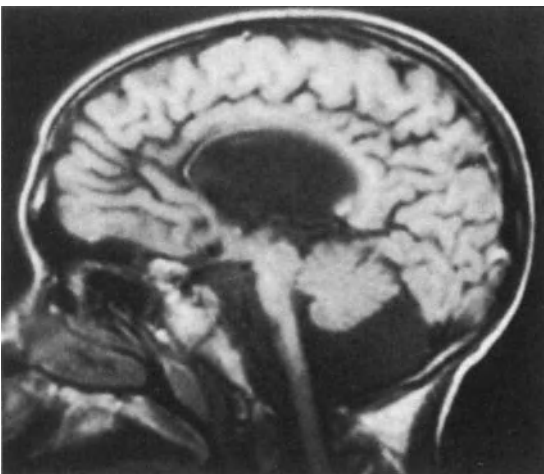


Figure 10-4. Aplasia of the cerebellum associated with thinning of the corpus callosum.

the head is a constant feature, and some combination of ataxia, dysmetria, and intention tremor is noted. A jerky, coarse nystagmus is usually present. Tendon reflexes may be increased or diminished. Infants with hyperactive reflexes probably have congenital abnormalities of the corticospinal tract in addition to cerebellar hypoplasia. Seizures occur in some hereditary and some sporadic cases. Other neurological signs and symptoms may be present, depending on associated malformations. Mental retardation is a constant feature but varies from mild to severe.

DIAGNOSIS. MRI is the study of choice (see Figure 10-4). It shows not only the extent of cerebellar hypoplasia, but also associated anomalies. The folial pattern of the cerebellum is prominent, and there is compensatory enlargement of the fourth ventricle, cisterna magna, and vallicula.

MANAGEMENT. No treatment is available.

Vermal Aplasia

Aplasia of the vermis is relatively common and often associated with other cerebral malformations. All or part of the vermis may be missing, and when the vermis is incomplete, the caudal portion is usually lacking. Dominantly inherited aplasia of the anterior vermis is a rare condition.

CLINICAL FEATURES. Partial agenesis of the cerebellar vermis may be asymptomatic. Symptoms are nonprogressive and vary from only mild gait ataxia and upbeating nystagmus to severe ataxia. Complete agenesis causes titubation of the head and truncal ataxia. Vermal agenesis frequently is associated with other cerebral malformations, producing a constellation of symptoms and signs referable to neurological dysfunction. Two examples are the Dandy-Walker malformation (see Chapter 18) and *Joubert syndrome*.

The clinical features of Joubert syndrome include a characteristic facies, oculomotor apraxia, and hyperpnea intermixed with central apnea in the neonatal period (Maria et al, 1999). Cerebellar vermal agenesis is a constant feature of Joubert syndrome, but several other cerebral malformations are usually present as well. More than one sibling in a family may be involved, but the parents are normal. All patients are mentally retarded, and some are microcephalic. Several affected children have died unexpectedly, possibly from respiratory failure.

DIAGNOSIS. MRI shows agenesis of the vermis of the cerebellum with enlargement of the cisterna magna. Other cerebral malformations,

such as agenesis of the corpus callosum, also are associated.

MANAGEMENT. No treatment is available.

X-Linked Cerebellar Hypoplasia

Some families with cerebellar hemispheric and vermal hypoplasia have a genetic defect that maps to the short arm of the X chromosome (Bertorini et al, 2000).

CLINICAL FEATURES. Hypotonia, mild dysphagia, and delayed motor development are present from birth. By age 4 years, action tremor of the upper limbs and slow eye movements are noted. In adults, neurological symptoms include moderate dysarthria, unsteady gait with truncal and locomotor ataxia, intention tremor, and limitation of vertical gaze with slow conjugate eye movements. Male family members show delayed developmental milestones and show some combination of nonprogressive ataxia, dysarthria, and external ophthalmoplegia. Intelligence is normal.

DIAGNOSIS. Brain MRI shows severe global atrophy of the cerebellar vermis and hemispheres.

MANAGEMENT. No treatment is available.

Chiari Malformation Type I

The type I Chiari malformation is a displacement of the cerebellar tonsils and posterior vermis of the cerebellum through the foramen magnum, compressing the spinomedullary junction. The type II Chiari malformation has an additional downward displacement of a dysplastic lower medulla and a lumbosacral meningocele (see Chapter 12). A molecular genetic hypothesis of ectopic expression of a segmentation gene in the rhombomeres explains the several cerebellar and brainstem anomalies and the defective basioccipital and supraoccipital bone formation (Sarnat et al, 2002).

CLINICAL FEATURES. The onset of symptoms is frequently during adolescence or adulthood. Major clinical features are headache, head tilt, pain in the neck and shoulders, ataxia, and lower cranial nerve dysfunction. Physical signs vary among patients and may include weakness of the arms, hyperactive tendon reflexes in the legs, nystagmus, and ataxia. The Chiari I malformation is often an incidental finding on neuroimaging studies in children with headache.

DIAGNOSIS. MRI provides the best visualization of posterior fossa structures. The distortion of the cerebellum and the hindbrain is precisely identified (Figure 10-5).

MANAGEMENT. Recommended treatment is surgical decompression of the foramen magnum to

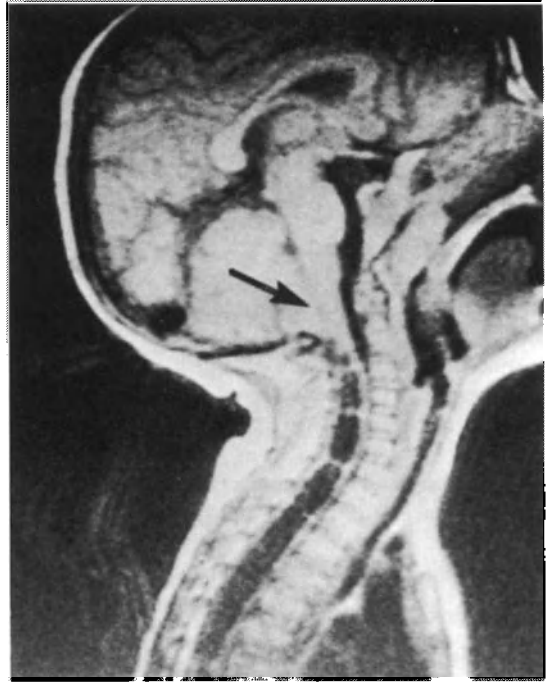

Figure 10-5. Chiari malformation. MRI shows displacement of the cerebellar tonsils (arrow) into the foramen magnum.

at least the C3 vertebra. Significant improvement occurs in more than half of patients.

Progressive Hereditary Ataxias

Autosomal Dominant Inheritance

Spinocerebellar Degenerations

A genotypic classification of the dominantly inherited ataxias has replaced the phenotypic classification that included Marie's ataxia, olivopontocerebellar atrophy, and spinocerebellar atrophies (SCA) (Bird, 2004). Table 10-3 lists the progressive autosomal dominant ataxias with onset in childhood. The genetic abnormality is usually a trinucleotide repeat. The original description of SCA3 was in Portuguese families from the Azores and was named *Machado-Joseph disease*.

CLINICAL FEATURES. The clinical features overlap, and genetic testing is the best method for diagnosis. Table 10-3 lists distinguishing clinical features.

DIAGNOSIS. DNA-based genetic tests are available for the diagnosis of SCA1, SCA2, SCA3, SCA6, SCA7, and dentarubral-pallidolusyan atrophy.

MANAGEMENT. Treatment is symptomatic and, depending on the disease, may include anticonvulsants, muscle relaxants, and assistive devices.

TABLE 10-3
Autosomal Dominant Cerebellar Ataxias: Clinical Characteristics

Disease	Average Onset (Range in Years)	Clinical Features (All Include Ataxia)
SCA1	4th decade (<10 to >60)	Pyramidal signs, peripheral neuropathy
SCA2	3rd-4th decade (<10 to >60)	Slow saccadic eye movement, peripheral neuropathy, decreased DTR, dementia
SCA3	4th decade (10-70)	Pyramidal and extrapyramidal signs; lid retraction, nystagmus, decreased saccade velocity; amyotrophic fasciculations, sensory loss
SCA4	4th-5th decade (19-59)	Sensory axonal neuropathy
SCA5	3rd-4th decade (10-68)	Early onset, slow course
SCA7	3rd-4th decade (6 mo to 60)	Visual loss with retinopathy
SCA12	3rd (8-55)	Early tremor, late dementia
DRPLA	U.S.: rare (8-20); Japan: 20% (40-60s)	Early onset correlates with shorter duration; chorea, seizures, dementia, myoclonus

DRPLA, dentatorubral-pallidoluysian atrophy; DTR, deep tendon reflexes; SCA, spinocerebellar ataxia.

Adapted from Bird TD. (23 January 2004) Ataxia overview. In: *GeneClinics: Medical Genetics Knowledge Base*. [database online] University of Washington, Seattle. Available at <http://www.geneclinics.org>.

Hypobetalipoproteinemia

CLINICAL FEATURES. Several different disorders are associated with hypocholesterolemia and reduced, but not absent, concentrations of apolipoprotein B and apolipoprotein A. Some patients with this lipid profile have no neurological symptoms; others have severe ataxia beginning in infancy. Malabsorption does not occur, but the infant fails to thrive and has progressive fatty cirrhosis of the liver. Severe hypotonia and absence of tendon reflexes are present in the first months.

DIAGNOSIS. The diagnosis is considered in children with unexplained progressive ataxia. The total serum lipid content is normal, but the concentration of triglycerides is increased. Reduced concentrations of total high-density lipoprotein and low-density lipoprotein cholesterol concentrations and apolipoproteins are characteristic.

MANAGEMENT. Administering 1000 to 10,000 mg/day of α -tocopherol prevents many of the complications of hypobetalipoproteinemia. Vitamin A and K supplements also are required.

Autosomal Recessive Inheritance

Ataxia is a feature of many degenerative disorders but is a presenting or cardinal feature in the disorders discussed in this section.

Abetalipoproteinemia

Molecular defect in the gene for the microsomal triglyceride transfer protein at chromosome 4q22-q24 causes abetalipoproteinemia. Trans-

mission is by autosomal recessive inheritance. Other terms for the disorder are *acanthocytosis* and *Bassen-Kornzweig syndrome*. Microsomal triglyceride transfer protein catalyzes the transport of triglyceride, cholesteryl ester, and phospholipid from phospholipid surfaces. The results are fat malabsorption and a progressive deficiency of vitamins A, E, and K.

CLINICAL FEATURES. Fat malabsorption is present from birth, and most newborns come to medical attention because of failure to thrive, vomiting, and large volumes of loose stool. A correct diagnosis is possible at that time. Delayed psychomotor development occurs during infancy. A cerebellar ataxia develops in one third of children during the first decade and in almost every child by the end of the second decade. Tendon reflexes are usually lost by age 5. Progressive gait disturbances, dysmetria, and difficulty performing rapid alternating movements characterize the limb ataxia, which progresses until age 20, then becomes stationary. Proprioceptive sensation in the hands and feet is lost, whereas pinprick and temperature sensations are less severely affected. Sensory loss results from demyelination in the posterior columns of the spinal cord and the peripheral nerves.

Retinitis pigmentosa is an almost constant feature. The age at onset is variable but is usually before age 10. The initial symptom is night blindness. Nystagmus is common. Its cause may be either the cerebellar disturbance or the loss of central vision.

DIAGNOSIS. Severe anemia, with hemoglobin levels less than 8 g/dL (<5 mmol/L), is common in young children but not in adults. The anemia,

which may result from malabsorption, corrects with parenteral supplementation of iron or folate. Plasma cholesterol levels are less than 100 mg/dL (<2.5 mmol/L), and triglyceride levels are less than 30 mg/dL (<0.3 mmol/L). The absence of apolipoprotein B in plasma confirms the diagnosis. Measure the child's and the parents' plasma apolipoprotein B concentrations. In abetalipoproteinemia, the heterozygote is normal; if partial deficiency of apolipoprotein B is present, the diagnosis of familial hypobetalipoproteinemia is more likely.

MANAGEMENT. The cause of the neurological complications of abetalipoproteinemia is chronic vitamin E deficiency. Dietary fat restriction and large oral doses of vitamin E (100 mg/kg/day) prevent the onset of symptoms or arrest their progression.

Ataxia-Telangiectasia

Ataxia-telangiectasia primarily affects the nervous and immune systems (Gatti, 2003). The gene associated with ataxia-telangiectasia is a large gene located at chromosome 11q22-23, and more than 100 mutations have been discovered. The gene product is involved in cell-cycle progression and the checkpoint response to DNA damage. Transmission is by autosomal recessive inheritance.

CLINICAL FEATURES. The principal feature is a progressive truncal ataxia that begins during the first year. In infants, choreoathetosis develops instead of, or in addition to, ataxia. The ataxia begins as clumsiness and progresses so slowly that cerebral palsy is often the erroneous diagnosis. Oculomotor apraxia is present in 90% of patients but may be mild at first and overlooked (see Chapter 15). Many children have a dull or expressionless face. Intellectual development is normal at first but often lags with time. One third of children ultimately function in the mildly retarded range.

Telangiectasia usually develops after 2 years of age and sometimes not until age 10. It first appears on the bulbar conjunctivae, giving the eyes a bloodshot appearance. Similar telangiectasia appears on the upper half of the ears, on the flexor surfaces of the limbs, and in a butterfly distribution on the face. Sun exposure or irritation exacerbates the telangiectasia.

Recurrent sinopulmonary infection is a serious feature of the disease and reflects an underlying immunodeficiency. The synthesis of antibodies and certain immunoglobulin subclasses is disturbed because of disorders of B-cell and helper T-cell function. Serum and salivary IgA is absent

in 70% to 80% of children, and IgE is absent or diminished in 80% to 90%. The IgM concentration may be elevated in compensation for the IgA deficiency. The thymus has an embryonic appearance, and the α -fetoprotein concentration is elevated in most patients.

Taken together, the many features of this disease suggest a generalized disorder of tissue differentiation and cellular repair. The result is a 38% risk of malignancy; most are lymphoma and lymphocytic leukemia. Two thirds of patients are dead by age 20. Infection is the most common cause of death, and neoplasia is second.

DIAGNOSIS. Suspect the diagnosis in infants with some combination of ataxia, chronic sinopulmonary infections, and oculomotor apraxia. As the child gets older, the addition of telangiectasia to the other clinical features makes the diagnosis a certainty. Complete studies of immunocompetence are required. Ninety percent of patients with ataxia-telangiectasia have an elevated α -fetoprotein concentration, and approximately 80% have decreased serum IgA, IgE, or IgG. Especially characteristic is a selective deficiency of the IgG2 subclass. Molecular genetic testing is available in children with a compatible clinical syndrome and normal serum concentrations of α -fetoprotein and immunoglobulin.

The acanthocyte is an abnormal erythrocyte characterized by thorny projections from the cell surface that prevent normal rouleau formation and cause a low erythrocyte sedimentation rate. Between 50% and 70% of peripheral erythrocytes undergo transformation to acanthocytes. Acanthocytes also occur in association with other neurological disorders in which lipoproteins are normal (see the discussions of McLeod syndrome and neuroacanthocytosis).

MANAGEMENT. Treat all infections vigorously. Intravenous antibiotics sometimes are required for what would otherwise be a trivial sinusitis in a healthy child. Patients with ataxia-telangiectasia are exquisitely sensitive to radiation, which produces cellular and chromosomal damage. Radiation may be a precipitant in the development of neoplasia. Despite the frequency of sinopulmonary infections, minimize radiological studies.

Ataxia with Oculomotor Apraxia

Ataxia with oculomotor apraxia may be mistaken for ataxia-telangiectasia but is a different gene disorder with a locus in 9p14 (Le Ber et al, 2003).

CLINICAL FEATURES. Development is normal during the first year, but a slowly progressive ataxia

develops during childhood. Oculomotor apraxia is not present at birth but follows the ataxia. Eventually a severe motor neuropathy develops resulting in quadriplegia. Intellect remains normal in some ethnic groups but not in others.

DIAGNOSIS. The clinical features are the basis for diagnosis.

MANAGEMENT. Treatment is supportive.

Friedreich Ataxia

Friedreich ataxia is the most common recessively inherited ataxia. The cause is an unstable triplet repeat of the *frataxin* gene on chromosome 9q13 (Bidichandani and Ashizawa, 2002). The size of the triplet expansion correlates with an earlier age at onset and a more rapid progression.

CLINICAL FEATURES. The onset is usually between 2 and 16 years of age, but symptoms may begin later. The initial feature is ataxia or clumsiness of gait in 95% of cases and scoliosis in 5%. The ataxia is slowly progressive and associated with dysarthria, depressed tendon reflexes, extensor plantar responses, and loss of position and vibration senses. Two thirds of patients have a hypertrophic cardiomyopathy, and 10% have diabetes mellitus. An atypical presentation occurs in 25%. Onset is after age 25 years, tendon reflexes are present, and progression is slow.

DIAGNOSIS. The clinical features suggest the diagnosis, and genetic molecular testing provides confirmation. Motor nerve conduction velocities in the arms and legs are slightly slower than normal. In contrast, sensory action potentials are absent or markedly reduced in amplitude. Spinal somatosensory evoked responses are usually absent. Common changes on the electrocardiogram are reduced amplitude of T waves and left or right ventricular hypertrophy. Arrhythmias and conduction defects are uncommon.

MANAGEMENT. The underlying disturbance is not curable, but symptomatic treatment is available. Surgical stabilization prevents severe scoliosis. Regular electrocardiograms and chest radiographs to determine heart size are useful to monitor the development of cardiomyopathy. Chest pain on exertion responds to propranolol, and congestive heart failure responds to digitalis. Patients with diabetes require insulin treatment.

Juvenile GM₂ Gangliosidosis

Transmission of all juvenile forms of α -hexosaminidase-A and β -hexosaminidase-A deficiency is by autosomal recessive inheritance.

Some, such as Tay-Sachs disease, are restricted to Ashkenazi Jews, whereas others occur in individuals of non-Jewish descent (see Chapter 5). In all of these conditions, GM₂ gangliosides are stored within the central nervous system.

CLINICAL FEATURES. A progressive ataxic syndrome occurs in patients with late-onset hexosaminidase-A deficiency. Age at onset is usually younger than 15 years old. Before neurological deterioration becomes evident, family members may believe that affected children are only clumsy. Intention tremor, dysarthria, and limb and gait ataxia are prominent.

DIAGNOSIS. Any child with an apparent "spinocerebellar degeneration" may have juvenile GM₂ gangliosidosis. Diagnosis requires the measurement of α -hexosaminidase-A and β -hexosaminidase-A activity in fibroblasts.

MANAGEMENT. Specific treatment is not available.

Juvenile Sulfatide Lipidosis

Sulfatide lipidosis (metachromatic leukodystrophy) is a disorder of central and peripheral myelin metabolism usually caused by deficient activity of the enzyme arylsulfatase A. The defective gene is on chromosome 22q. The late infantile form is discussed in Chapters 5 and 7. The usual cause of the juvenile form is arylsulfatase deficiency, but a secondary cause is saposin B deficiency.

CLINICAL FEATURES. Juvenile sulfatide lipidosis begins later and has a slower course than the late infantile disease. Onset is usually between 4 and 12 years. Initial symptoms are poor school performance, behavioral change, and a gait disturbance. Spasticity, progressive ataxia of the trunk and limbs, generalized tonic-clonic convulsions, and mental deterioration follow. Peripheral neuropathy is not a prominent clinical feature, but prolonged motor conduction velocities are usual late in the course. Protein concentration in the cerebrospinal fluid may be normal or only slightly elevated.

Progression is relatively rapid. Most children deteriorate into a vegetative state and die within 10 years. The time from onset to death ranges from 3 to 17 years; the age at onset does not predict the course.

DIAGNOSIS. MRI shows widespread demyelination of the cerebral hemispheres. Late-onset disease may resemble multiple sclerosis. Diagnosis requires the demonstration of reduced or absent arylsulfatase A in peripheral leukocytes. Individuals with reduced amounts require testing for saposin B deficiency.

MANAGEMENT. Allogeneic bone marrow transplantation is an experimental treatment.

Marinesco-Sjögren Syndrome

Cerebellar ataxia, congenital cataracts, and mental retardation are the characteristic features of Marinesco-Sjögren syndrome. This complex has many causes. Some families have a mitochondrial disorder. Other families have congenital cataracts, delayed motor development, ataxia, demyelinating peripheral neuropathy, and dysmorphic facial features (Merlini et al, 2002).

CLINICAL FEATURES. A constant feature is cataracts, which may be congenital or develop during infancy. The type of cataract varies and is not specific. Dysarthria, nystagmus, and ataxia of the trunk and limbs characterize the cerebellar dysfunction during infancy. Strabismus and hypotonia frequently are present in childhood. Developmental delay is a constant feature but varies from mild to severe. Other features include short stature, delayed sexual development, pes valgus, and scoliosis. Although the onset of symptoms is in infancy, progression is slow or stationary. Ataxia leads to wheelchair confinement by the 20s or 30s, and shortening of life span is significant.

DIAGNOSIS. Diagnosis of Marinesco-Sjögren syndrome relies primarily on the triad of bilateral cataracts, progressive cerebellar ataxia, and mental retardation. The underlying biochemical defect is unknown, and laboratory tests are not helpful.

MANAGEMENT. Treatment is supportive.

Other Metabolic Disorders

Descriptions of Hartnup disease and maple syrup urine disease are in the section on acute or recurrent ataxia. After an acute attack of these diseases, some patients never return to baseline, but instead have chronic progressive ataxia. Such patients require screening for metabolic disorders (Table 10-4). Refsum disease is an inborn error of phytanic acid metabolism, and transmission is by autosomal recessive inheritance. The cardinal features are retinitis pigmentosa, chronic or recurrent polyneuropathy, and cerebellar ataxia. Affected individuals usually have either night blindness or neuropathy (see Chapter 7).

Disorders of pyruvate metabolism and of the respiratory chain enzymes cause widespread disturbances in the nervous system and are described in Chapters 5, 7, and 8. The common features among the several disorders of mitochondrial metabolism include lactic acidosis,

TABLE 10-4
Metabolic Screening in Progressive Ataxias

Disease	Abnormality
Blood	
Abetalipoproteinemia	Lipoproteins, cholesterol
Adrenoleukodystrophy	Very-long-chain fatty acids
Ataxia-telangiectasia	IgA, IgE, α -fetoprotein
Hypobetalipoproteinemia	Lipoproteins, cholesterol
Mitochondrial disorders	Lactate, glucose-lactate tolerance
Sulfatide lipidoses	Arylsulfatase A
Urine	
Hartnup disease	Amino acids
Maple syrup urine disease	Amino acids
Fibroblasts	
Carnitine acetyltransferase deficiency	Carnitine acetyltransferase
GM ₂ gangliosidosis	Hexosaminidase
Refsum disease	Phytanic acid
Bone Marrow	
Neurovisceral storage	Sea-blue histiocytes

ataxia, hypotonia, ophthalmoplegia, mental retardation, and peripheral neuropathy. An increased concentration of blood lactate or the production of lactic acidosis by administration of a standard glucose tolerance test suggests a mitochondrial disorder. Deficiency of PDH may produce acute, recurrent, or chronic ataxias and is discussed in the section on acute or recurrent ataxia. Respiratory chain disorders produce a combination of ataxia, dementia, myoclonus, and seizures.

X-Linked Inheritance

Ataxia may be the initial feature of the infantile form of adrenoleukodystrophy (see Chapter 5). The clinical features of adrenoleukodystrophy can mimic spinocerebellar degeneration, and adrenoleukodystrophy requires consideration in any family with only males affected. An X-linked ataxia associated with hypotonia, deafness, and loss of vision in early childhood occurs in some families. Other families have only ataxia and deafness. The abnormal gene site and gene product are not established, and it is not possible to know if these are allelic or different disorders.

References

- Bataller L, Rosenfeld MR, Graus F, et al. Autoantigen diversity in the opsoclonus-myoclonus syndrome. *Ann Neurol* 2003;53:347-353.

- Bertini E, des Portes V, Zanni G, et al. X-linked congenital ataxia. A clinical and genetic study. *Am J Med Genet* 2000;92:53-56.
- Bidichandani SI, Ashizawa T. (9 December 2002) Freidreich ataxia. In: *GeneClinics: Medical Genetics Knowledge Base*. [database online] University of Washington, Seattle. Available at <http://www.geneclinics.org>.
- Bird TD. (23 January 2004) Ataxia overview. In: *GeneClinics: Medical Genetics Knowledge Base*. [database online] University of Washington, Seattle. Available at <http://www.geneclinics.org>.
- Connolly AM, Dodson WE, Prensky AL, et al. Course and outcome of acute cerebellar ataxia. *Ann Neurol* 1994; 35:673-679.
- Eberhart CG, Kepner JL, Goldthwaite PT, et al. Histopathologic grading of medulloblastomas. A Pediatric Oncology Group study. *Cancer* 2002;94:552-560.
- Frohman EM, Goodin DS, Calabresi PA, et al. The utility of MRI in suspected MS. Report of the Therapeutics and Technology Assessment Subcommittee of the American Academy of Neurology. *Neurology* 2003;61:602-611.
- Gatti RA. Ataxia-telangiectasia. (10 April 2003) Ataxia-telangiectasia. In: *GeneClinics: Medical Genetics Knowledge Base*. [database online] University of Washington, Seattle. Available at <http://www.geneclinics.org>.
- Hayward K, Jeremy RJ, Jenkins S, et al. Long-term neurobehavioral outcomes in children with neuroblastoma and opsoclonus-myoclonus-ataxia syndrome. Relationship to MRI findings and anti-neuronal antibodies. *J Pediatr* 2001;139:552-559.
- Helton KJ, Gajjar A, Hill DA, et al. Medulloblastoma metastatic to the suprasellar region at diagnosis: A report of six cases with clinicopathologic correlation. *Pediatr Neurosurg* 2002;37:111-117.
- Jacobs BC, Endtz H, van der Meche FG, et al. Serum anti-GQ1b IgG antibodies recognize surface epitopes on *Campylobacter jejuni* from patients with Miller Fisher syndrome. *Ann Neurol* 1995;37:260-264.
- Klepper J, Leiendecker B, Bredahl R, et al. Introduction of a ketogenic diet in young infants. *J Inherit Metab Dis* 2002;25:449-460.
- Le Ber I, Moreira MC, Rivaud-Pechoux S, et al. Cerebellar ataxia with oculomotor apraxia type 1. Clinical and genetic studies. *Brain* 2003;126:2761-2762.
- Lindskog U, Ödkvist L, Noaksson L, et al. Benign paroxysmal vertigo in childhood. A long-term follow-up. *Headache* 1999;39:33-37.
- Maria BL, Boltshauser E, Palmer SC, et al. Clinical features and revised diagnostic criteria in Joubert syndrome. *J Child Neurol* 1999;14:583-591.
- Merlini L, Gooding R, Lochmuller H, et al. Genetic identity of Marinesco-Sjogren/myoglobinuria and CCFDN syndromes. *Neurology* 2002;58:231-236.
- Nozaki J, Dakeishi M, Ohura T, et al. Homozygosity mapping to chromosome 5p15 of a gene responsible for Hartnup disorder. *Biochem Biophys Res Commun* 2001;284: 255-260.
- Paulino AC, Wen BC, Buatti JM, et al. Intracranial ependymomas. An analysis of prognostic factors and patterns of failure. *Am J Clin Oncol* 2002;25:117-122.
- Ramaekers VTh, Heimann G, Reul J, et al. Genetic disorders and cerebellar structural abnormalities in childhood. *Brain* 1997;120:1739-1751.
- Ruggieri M, Polizzi A, Pavone L, et al. Multiple sclerosis in children less under 6 years of age. *Neurology* 1999; 53:478-484.
- Russo C, Cohen SL, Petruzzi J, et al. Long-term neurological outcome in children with opsoclonus-myoclonus associated with neuroblastoma. A report of the pediatric oncology group. *Med Pediatr Oncol* 1997;29: 284-288.
- Sarnat HB, Benjamin DR, Siebert JR, et al. Agenesis of the mesencephalon and metencephalon with cerebellar hypoplasia. Putative mutation in the EN2 gene. Report of 2 cases in early infancy. *Pediatr Dev Pathol* 2002; 5:54-68.
- Sawaishi Y, Takahashi I, Hirayama Y, et al. Acute cerebellitis caused by *Coxiella burnetti*. *Ann Neurol* 1999; 45:124-127.
- Schimke RN, Collins DL, Stolle CA. (14 November 2002) Von Hippel-Lindau syndrome. In: *GeneClinics: Medical Genetics Knowledge Base*. [database online] University of Washington, Seattle. Available at <http://www.geneclinics.org>.
- Spacey S. (29 December 2003) Episodic ataxia type 2. In: *GeneClinics: Medical Genetics Knowledge Base*. [database online] University of Washington, Seattle. Available at <http://www.geneclinics.org>.
- Subramony SH, Schott K, Raikie RS, et al. Novel CACNA1A mutation causes febrile episodic ataxia with interictal cerebellar deficits. *Ann Neurol* 2003;54:725-731.

Chapter 11

Hemiplegia

THE APPROACH TO children with hemiplegia must distinguish between acute hemiplegia, in which weakness develops within a few hours, and chronic progressive hemiplegia, in which weakness evolves over days, weeks, or months. The distinction between an acute and an insidious onset should be easy but can be problematic. In children with a slowly evolving hemiplegia, missing early weakness is possible until an obvious level of functional disability is attained; at this point, the hemiplegia seems new and acute.

An additional presentation of hemiplegia in infants who come to medical attention because of developmental delay is slowness in meeting motor milestones and early establishment of hand preference. Children should not establish a hand preference until the second year. They have a static structural problem from birth (hemiplegic cerebral palsy), but the clinical features are not apparent until the child is old enough to use the affected limbs.

Magnetic resonance imaging (MRI) is the diagnostic modality of choice for investigating all forms of hemiplegia. MRI is especially informative in showing migrational defects in hemiplegic cerebral palsy associated with seizures. Magnetic resonance angiography is sufficiently informative to obviate the need for arteriography in most children.

Hemiplegic Cerebral Palsy

The term *hemiplegic cerebral palsy* comprises several pathological entities that result in limb weakness on one side of the body. In premature infants, the most common cause is periventricular hemorrhagic infarction (see Chapter 4). In term infants, the underlying causes are often cerebral malformations, cerebral infarction, and

intracerebral hemorrhage. Imaging studies of the brain are useful to provide the family with a definitive diagnosis; this often relieves guilt and prevents litigation against the obstetrician.

The usual concern that brings infants with hemiplegia from birth for a neurological evaluation is delayed crawling or walking. Abnormalities of the legs are the focus of attention. *An associated but seldom recognized feature is that hand dominance was established during the first year; this is never normal.* Unilateral facial weakness is never associated, probably because bilateral corticobulbar innervation of the lower face persists until birth. Epilepsy occurs in half of children with hemiplegic cerebral palsy. Infants with injury to the dominant hemisphere can develop normal speech in the nondominant hemisphere, but it is at the expense of visuoperceptual and spatial skills. Infants with hemiplegia and early-onset seizures are an exception; they show cognitive disturbances of verbal and nonverbal skills.

Congenital Malformations

Migrational defects constitute most congenital malformations causing infantile hemiplegia (Figure 11-1). The affected hemisphere is often small and may show a unilateral perisylvian syndrome in which the sylvian fossa is widened (Sébire et al, 1996). Chapter 17 describes a bilateral perisylvian syndrome with speech disturbances. Seizures and mental retardation are often associated. As a rule, epilepsy is more common when congenital malformations cause infantile hemiplegia than when the cause is stroke.

Neonatal Infarction

Cerebral infarction from arterial occlusion occurs more often in full-term newborns than in

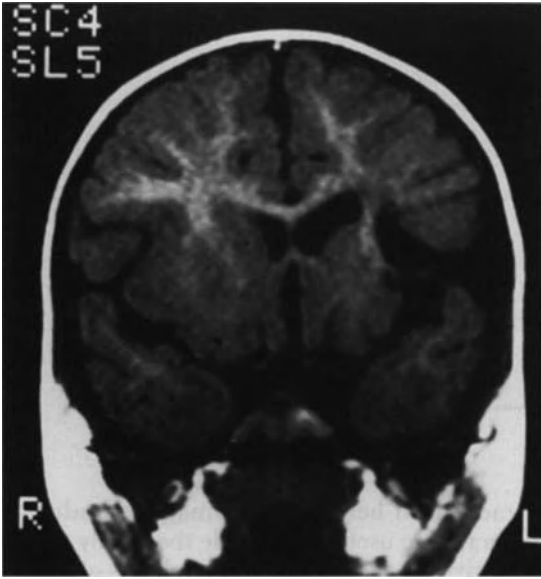


Figure 11-1. Schizencephaly. The rim of gray matter around the defect in the left hemisphere indicates that the abnormality is a schizencephaly rather than an infarction. The child's main abnormality was hemiplegia.

premature newborns. MRI shows three patterns of infarction: (1) *arterial border zone infarction* is associated with resuscitation and is caused by hypotension; (2) *multiartery infarction* is not often associated with perinatal distress and may be caused by congenital heart disease, disseminated intravascular coagulation, and polycythemia; and (3) *single-artery infarction* can result from injury to the cervical portion of the carotid artery during a difficult delivery owing to either misapplication of obstetric forceps or hyperextension and rotation of the neck with stretching of the artery over the lateral portion of the upper cervical vertebrae. Trauma is a rare associated event, however, and the cause of most single-artery infarctions, especially large infarctions in the frontal or parietal lobes, is unexplained.

CLINICAL FEATURES. Newborns with large single-artery infarcts appear normal at birth but develop repetitive focal seizures during the first 4 days postpartum. Some recover fully, but most show a hemiparesis that spares the face later on.

DIAGNOSIS. MRI is necessary to show small infarcts, but ultrasound is satisfactory to detect large infarcts in the complete distribution of the middle cerebral artery. The size of the defect on MRI correlates directly with the probability of later hemiplegia (Mercuri et al, 1999). Follow-up imaging studies may show either unilateral

enlargement of the lateral ventricle or porencephaly in the distribution of the middle cerebral artery contralateral to the hemiparesis. Hemiatrophy of the pons contralateral to the abnormal hemisphere may be an associated feature.

Maternal use of cocaine during pregnancy can cause cerebral infarction and hemorrhage in the fetus. Cocaine is detectable in the newborn's urine during the first week postpartum.

MANAGEMENT. Anticonvulsant drugs are usually effective for seizure control (see Chapter 1). Rehabilitative measures are the mainstay of therapy.

Neonatal Hemorrhage

Small unilateral parietal or temporal hemorrhages occur almost exclusively in term newborns and are not associated with either trauma or asphyxia. Larger hemorrhages into the temporal lobe sometimes result when obstetric forceps apply excessive force to the lateral skull, but more often, they are idiopathic. Intraventricular hemorrhage may be an associated feature.

CLINICAL FEATURES. Newborns with small hemorrhages are normal at birth and seem well until seizures begin, anytime during the first week. The symptoms of larger hemorrhages may be apneic spells, seizures, or both. Seizures may be focal or generalized, and hemiplegia or hypotonia is present on examination. Some infants recover completely, whereas others show residual hemiplegia and mental retardation.

DIAGNOSIS. Seizures and apneic spells usually prompt lumbar puncture to exclude the possibility of sepsis. The cerebrospinal fluid is grossly bloody. Computed tomography (CT) shows hemorrhage, and follow-up studies show focal encephalomalacia.

MANAGEMENT. Treatment is available for seizures but not for hemorrhage.

Acute Hemiplegia

The sudden onset of an acute, focal neurological deficit suggests either a vascular or an epileptic mechanism (Table 11-1). Infants and children who have acute hemiplegia are divisible almost equally into two groups according to whether or not *epilepsia partialis continua* precedes the hemiplegia. Both groups may have seizures on the paretic side after hemiplegia is established. Cerebral infarction, usually in the distribution of the middle cerebral artery, accounts for one quarter of cases in which

TABLE 11-1
Differential Diagnosis of Acute Hemiplegia

Alternating hemiplegia
Asthmatic amyotrophy (see Chapter 13)
Cerebrovascular disease
Diabetes mellitus
Epilepsy
Hypoglycemia (see Chapter 2)
Kawasaki disease (see Chapter 10)
Migraine
Trauma
Tumor

seizures precede the hemiplegia and more than half of cases in which hemiplegia is the initial feature. Whatever the cause, the probability of a permanent motor deficit is almost 100% when the initial feature is epilepsia partialis continua and about 50% when it is not.

Alternating Hemiplegia

Alternating hemiplegia is a rare and poorly understood clinical syndrome with hemiplegia as a cardinal feature (Swoboda et al, 2004). Considerations of its nosological identity include migraine, epilepsy, and familial paroxysmal choreoathetosis. Most cases are sporadic, but some families show mutations in a sodium potassium adenosine triphosphatase (ATPase) gene also implicated in familial hemiplegic migraine type 2 (FHM2). The clinical spectrum of both disorders, expanded by mutation analysis, now overlaps.

CLINICAL FEATURES. Onset is from birth to 18 months (mean 8 months). The initial features are mild developmental delay and abnormal eye movements. Motor attacks may be hemiplegia, dystonia, or both. As a rule, young infants have more dystonic features, and older children are more likely to have flaccid hemiplegia. Brief episodes of monocular or binocular nystagmus, lasting 1 to 3 minutes, often are associated with dystonic and hemiplegic attacks. Because the attack onset is abrupt, dystonia is often mistaken for a seizure, and hemiplegia is mistaken for a stroke. Most reports of epileptic seizures in infants with this syndrome are probably dystonic attacks.

The duration of hemiplegia varies from minutes to days, and intensity waxes and wanes during a single episode. During long attacks, hemiplegia may shift from side to side, or both sides may be affected. The arm is usually

weaker than the leg, and walking may not be impaired. Hemiplegia disappears during sleep and reappears on awakening, but not immediately.

Dystonic episodes may affect primarily the limbs on one side, causing hemidystonia, or affect the trunk, causing opisthotonic posturing. Some children scream during attacks as if in pain. Headache may occur at the onset of an attack but not afterward. Writhing movements that suggest choreoathetosis may be associated. Mental slowing occurs early in the course, and mental regression follows later. Stepwise neurological impairment occurs as well, as if recovery from individual attacks is incomplete.

DIAGNOSIS. Results of electroencephalogram (EEG), cerebral arteriography, and MRI are normal. The diagnosis relies entirely on the clinical features.

MANAGEMENT. Anticonvulsant and antimigraine medications have consistently failed to prevent attacks or prevent progression. Flunarizine, a calcium channel-blocking agent, reduces the frequency of attacks, but its efficacy is not established. Other calcium channel-blocking agents and anticonvulsant drugs have not been useful. Alternating hemiplegia and dopa-responsive dystonia (see Chapter 14) share the feature of episodic dystonia with diurnal variation, and infants with attacks of dystonia should receive a trial of levodopa-carbidopa.

Cerebrovascular Disease

The annual incidence of stroke in children after the newborn period is approximately 2.3:100,000 (Fullerton et al, 2003). This represents a significant decline since the 1980s (Fullerton et al, 2002). Half are ischemic, and half are nontraumatic intracerebral and subarachnoid hemorrhages (Lanthier et al, 2000). The incidence rate is slightly higher in black than in white children and lowest in Hispanic children. Girls have a lower incidence than boys, but the gender and racial differences are not attributable to head injuries or sickle cell disease. Approximately 25% of ischemic strokes in children are associated with a known risk factor (Table 11-2). The coexistence of multiple risk factors predicts a poor outcome.

Stroke is always a consideration when a previously healthy child suddenly becomes hemiparetic or develops any focal neurological disturbance. Cranial computed tomography (CT) or MRI confirms the diagnosis. Clinical features vary with the age of the child and the location of the stroke. Hemiplegia, either

TABLE 11-2
Causes of Stroke**Cerebrovascular Malformations**

Arteriovenous malformation
 Fibromuscular dysplasia
 Hereditary hemorrhagic telangiectasia
 Sturge-Weber syndrome

Coagulopathies/Hemoglobinopathies

Antiphospholipid antibodies/lupus anticoagulant
 Congenital coagulation defects
 Disseminated intravascular coagulation
 Drug-induced thrombosis
 Malignancy
 Sickle cell anemia/disease
 Thrombocytopenic purpura

Heart Disease

Arrhythmia
 Atrial myxoma
 Bacterial endocarditis
 Cardiac catheterization
 Cardiomyopathy
 Cyanotic congenital defects
 Mitral valve prolapse
 Prosthetic heart valve
 Rhabdomyoma
 Rheumatic heart disease

Trauma

Arterial dissection
 Blunt trauma to neck
 Intraoral trauma
 Vertebral manipulation

Vasculitis

Carotid infection
 Drug abuse (amphetamines and cocaine)
 Hemolytic-uremic syndrome (see Chapter 2)
 Hypersensitivity vasculitis
 Isolated angitis
 Kawasaki disease (see Chapter 10)
 Meningitis (see Chapter 4)
 Mixed connective tissue disease
 Systemic lupus erythematosus
 Takayasu arteritis
 Varicella infection

Vasculopathies

Fabry disease
 Homocystinuria (see Chapter 5)
 Mitochondrial encephalopathy, lactic acidosis, and stroke (MELAS)
 Moyamoya disease

immediately or as a late sequela, is a common feature.

CT identifies infarction as an area of increased lucency that enhances with contrast material. As a rule, visualization of the lucent area is not possible in the first 24 hours after stroke. Cerebral infarction is often superficial, affecting gray and white matter, and is in the distribution of a single artery. Multiple infarcts suggest either embolism or vasculitis. Small, deep lesions of the internal capsule are rare but can occur in infants.

Table 11-3 summarizes the evaluation of a child with cerebral infarction. The usual line of investigation includes tests for coagulopathies, vaculitis, and vasculopathies; a search for cardiac sources of emboli; and cerebral arteriography. An area of increased density on a non-contrast-enhanced CT scan identifies intracerebral hemorrhage. Edema frequently surrounds the area of increased density and may produce a mass effect with shift of midline structures.

Arteriovenous Malformations

Supratentorial malformations may cause acute or chronic, progressive hemiplegia. Intraparenchymal hemorrhage causes acute hemiplegia. The major clinical features of hemorrhage into a hemisphere are loss of consciousness, seizures,

and hemiplegia. Large hematomas cause midline structures to shift and increase intracranial pressure. Chapter 4 discusses arteriovenous malformations.

Brain Tumors

The usual cause of acute hemiplegia from brain tumor is hemorrhage into or around the tumor. Hemorrhage may hide the underlying tumor on CT, and MRI is more informative (see Chapter 4).

Carotid and Vertebral Artery Disorders**Cervical Infections**

Unilateral and bilateral occlusions of the cervical portion of the internal carotid arteries may occur in children with a history of chronic tonsillitis and cervical lymphadenopathy. Whether this occurrence is cause and effect or coincidence is uncertain. Tonsillitis may cause carotid arteritis.

Unilateral cerebral infarction may occur in the course of cat-scratch disease (see Chapter 2) and mycoplasma pneumoniae. In both diseases, the presence of submandibular lymph node involvement is associated with arteritis of the

TABLE 11-3
Evaluation of Cerebral Infarction

Blood

Activated protein C resistance, antiphospholipid antibodies, apolipoproteins, cholesterol (high density and low density), complete blood count, culture, erythrocyte sedimentation rate, factor V, free protein S, lactic acid, Leiden mutation, lupus anticoagulant, plasminogen, protein C, serum homocystine, and triglycerides

Bacterial endocarditis
 Homocystinuria
 Hypercoagulable state
 Hyperlipidemia
 Leukemia
 Lupus erythematosus
 MELAS
 Polycythemia
 Sickle cell anemia
 Vasculitis

Urine

Cocaine, urinalysis

Cocaine abuse
 Homocystinuria
 Nephritis
 Nephrosis

Heart

Echocardiogram, electrocardiogram

Bacterial endocarditis
 Congenital heart disease
 Mitral valve prolapse
 Rheumatic heart disease

Brain

Arteriography, magnetic resonance imaging

Arterial dissection
 Arterial thrombosis
 Arteriovenous malformation
 Fibromuscular hypoplasia
 Moyamoya disease
 Vasculitis

MELAS, mitochondrial encephalopathy, lactic acidosis, and stroke.

adjacent carotid artery. Necrotizing fasciitis is a serious cause of inflammatory arteritis with subsequent occlusion of one or both carotid arteries. The source of parapharyngeal space infection is usually chronic dental infection. Mixed aerobic and anaerobic organisms are isolated on culture.

CLINICAL FEATURES. The usual sequence in cervical arteritis is fever and neck tenderness followed by sudden hemiplegia. Bilateral hemiplegia may occur when both sides are infected.

DIAGNOSIS. Culture of the throat or lymph node specimens is required to identify the offending organism or organisms. Arteriography identifies the site and extent of carotid occlusion.

MANAGEMENT. An aggressive course of antibiotic therapy, especially for necrotizing fasciitis, is mandatory. The outcome is variable, and recovery may be partial or complete.

Fibromuscular Dysplasia

Fibromuscular dysplasia is an idiopathic segmental nonatheromatous disorder of the inter-

nal carotid artery. The cervical portion of the artery is most often affected.

CLINICAL FEATURES. Transitory ischemic attacks and stroke are the only clinical features of fibromuscular dysplasia. Fibromuscular dysplasia is primarily a disease of women older than age 50, but it can occur in children.

DIAGNOSIS. Arteriography shows an irregular contour of the internal carotid artery in the neck resembling a string of beads. Suspect concomitant fibromuscular dysplasia of the renal arteries if hypertension is present.

MANAGEMENT. Operative transluminal balloon angioplasty and carotid endarterectomy are options to treat the stenosis. The long-term prognosis in children is unknown.

Trauma to the Carotid Artery

Children may experience carotid thrombosis and dissection from seemingly trivial injuries sustained in child abuse (grabbing and shaking the neck) or during exercise and sports. Injuries to the carotid artery also may occur in the tonsillar

fossa during a tonsillectomy or during a fall, when the child has a blunt object (e.g., pencil, lollipop) in the mouth.

CLINICAL FEATURES. Usually a delay of several hours, sometimes days, separates the injury from the onset of symptoms. The delay probably represents the time needed for thrombus to form within the artery. Clinical features usually include hemiparesis, hemianesthesia, hemianopia, and aphasia when the dominant hemisphere is affected. Deficits may be transitory or permanent, but some recovery always occurs. Seizures are uncommon.

DIAGNOSIS. Magnetic resonance angiography safely visualizes carotid dissection and occlusion.

MANAGEMENT. Heparin followed by oral anticoagulation therapy is the recommended therapy. Neither anticoagulation nor surgical repair has proven efficacy, however.

Trauma to the Vertebral Artery

Vertebral artery thrombosis or dissection may follow minor neck trauma, especially rapid neck rotation. The site of occlusion is usually at the C1-2 level. Boys are affected more often than girls (Ganesan et al, 2002)

CLINICAL FEATURES. The usual features of vertebral artery injury are headache and brainstem dysfunction. Repeated episodes of hemiparesis associated with bitemporal throbbing headache and vomiting may occur and are readily misdiagnosed as basilar artery migraine. The outcome is relatively good, survival is the rule, and chronic neurological disability is unusual.

DIAGNOSIS. The clue to diagnosis is the presence of one or more areas of infarction on CT or MRI. The possibility of stroke leads to an arteriographic study, which reveals the basilar artery occlusion.

MANAGEMENT. Long-term aspirin prophylaxis is a common recommendation, although it is not proven effective.

Cocaine Use

Cocaine is a potent vasoconstrictor that causes infarction in several organs. Stroke occurs mainly in young adults and may follow any route of administration but occurs more often when *crack cocaine* is smoked. The interval from administration to stroke is usually unknown but may be minutes to hours. Intracerebral hemorrhage and subarachnoid hemorrhage are more common than cerebral infarction and often occur in people with underlying aneurysms or arteri-

ovenous malformations. Vasospasm or vasculitis is the probable cause of infarction.

Diabetes Mellitus

Acute but transitory attacks of hemiparesis occur in children with insulin-dependent diabetes mellitus. Complicated migraine is a suggested mechanism, but the pathophysiology is unknown.

CLINICAL FEATURES. Attacks frequently occur during sleep in a child with a respiratory illness. Hemiparesis is present on awakening; weakness is greater in the face and arm than in the leg. Sensation is intact, but aphasia is present if the dominant hemisphere is affected. Tendon reflexes may be depressed or brisk in the affected arm, and an extensor plantar response is usually present. Headache is a constant feature and may be unilateral or generalized. Some patients are nauseated. The family does not have a history of migraine. Attacks last 3 to 24 hours, and recovery is complete. Recurrences are common.

DIAGNOSIS. Stroke is not a complication of juvenile insulin-dependent diabetes except during episodes of ketoacidosis (see Chapter 2). Head CT in children with transitory hemiplegia does not show infarction.

MANAGEMENT. Although some children have further attacks, a method for prevention of recurrences is not established. Prophylactic phenobarbital was useful in one child.

Epilepsy

Hemiparetic Seizures

Todd paralysis refers to hemiparesis that lasts for minutes or hours and follows a focal or generalized seizure. It occurs most often after prolonged seizures, especially seizures caused by an underlying structural abnormality. The mechanism may be ischemic.

Hemiparesis may be a seizure manifestation and a postictal event. Such seizures are *hemiparetic* or *focal inhibitory* seizures. Todd paralysis may be difficult to distinguish from hemiparetic seizures because it is not always clear whether a seizure preceded the hemiparesis or whether the hemiparesis is ictal or postictal.

CLINICAL FEATURES. The initial feature may be a brief focal seizure followed by flaccid hemiparesis or the abrupt onset of flaccid monoparesis or hemiparesis. Consciousness is not impaired, and the child seems well otherwise. The severity and distribution of weakness fluctuate, affecting one limb more than the other and sometimes the face.

Tendon reflexes are normal in the hemiparetic limbs, but the plantar response may be extensor.

DIAGNOSIS. EEG shows recurrent spike-and-slow-wave discharges in the contralateral hemisphere. A radioisotope scan shows increased focal uptake in the affected hemisphere. Results of MRI, CT, and cerebral arteriography are normal.

MANAGEMENT. Seizures respond to standard anticonvulsant drugs (see Chapter 1).

Heart Disease

Congenital Heart Disease

Cerebrovascular complications of congenital heart disease are most likely in children with cyanotic disorders. The usual complications are venous sinus thrombosis in infants and embolic arterial occlusion in children. The risk of embolization is greatest at the time of cardiac surgery or catheterization (Roach, 2000). Emboli may occur from valvular vegetations or bacterial endocarditis. In either case, the development of cerebral abscess is a major concern. Cerebral abscess of embolic origin is exceedingly rare in children younger than 2 years old with congenital heart disease and occurs only as a complication of meningitis or surgery.

CLINICAL FEATURES. Venous thrombosis occurs most often in infants with cyanotic heart disease who are dehydrated and polycythemic. One or more sinuses may occlude. Failure of venous drainage always increases intracranial pressure. Hemiparesis is a major clinical feature and may occur first on one side and then on the other with sagittal sinus obstruction. Seizures and decreased consciousness are associated features. The mortality rate is high in infants with thrombosis of major venous sinuses, and most survivors have neurological morbidity.

Children with cyanotic heart disease are at risk for arterial embolism when vegetations are present within the heart or if a right-to-left shunt allows peripheral emboli to bypass the lungs and reach the brain; this can occur spontaneously or at the time of cardiac surgery. The potential for cerebral abscess formation increases in children with right-to-left shunt because decreased arterial oxygen saturation lowers cerebral resistance to infection.

The initial feature is sudden onset of hemiparesis associated with headache, seizures, and loss of consciousness. Seizures are at first focal and recurrent but later become generalized.

DIAGNOSIS. MRI is the preferred procedure to detect venous thrombosis and emboli. A pattern

of hemorrhagic infarction occurs adjacent to the site of venous thrombosis, and multiple areas of infarction are associated with embolization.

The CT appearance may be normal during the first 12 to 24 hours after embolization. By the next day, contrast enhancement shows a low-intensity lesion. Although the sequence is consistent with a sterile embolus, the possibility of subsequent abscess formation is a consideration. Repeat enhanced CT or MRI within 1 week reveals ring enhancement as a sign of abscess development.

MANAGEMENT. Treatment for venous thrombosis is primarily supportive and directed toward correcting dehydration and controlling increased intracranial pressure. Dexamethasone is useful to decrease cerebral volume, but osmotic diuretics may cause further thrombosis. The infarction is usually hemorrhagic, and anticoagulants are contraindicated. Distinguishing a septic from a sterile thrombosis is impossible, and all infants receive antibiotic treatment.

Children with arterial emboli, but without evidence of hemorrhagic infarction, should undergo anticoagulation to prevent further embolization. Add dexamethasone if cerebral edema and mass effect is associated with the infarction. All children should begin antibiotic therapy to prevent cerebral abscess formation. Stop antibiotics after 1 week if abscess formation fails to occur, and continue for 6 to 8 weeks if an abscess forms.

Mitral Valve Prolapse

Mitral valve prolapse is a familial disorder present in 5% of children. It is usually asymptomatic but is estimated to cause recurrent attacks of cerebral ischemia in 1:6000 cases each year. Sterile emboli from thrombus originating either from the prolapsing leaflet or at its junction with the atrial wall cause the recurrent attacks.

CLINICAL FEATURES. The initial feature is usually a transitory ischemic attack in the distribution of the carotid circulation producing partial or complete hemiparesis. Weakness usually clears within 24 hours, but recurrent episodes, not in the same arterial distribution, are the rule. Basilar insufficiency is less common and usually results in visual field defects. The interval between recurrences varies from weeks to years. Permanent neurological deficits occur in less than 20% of individuals.

DIAGNOSIS. Only 25% of patients have late systolic murmurs or a midsystolic click. In the

remainder, a cardiac examination is normal. Two-dimensional echocardiography is required to establish the diagnosis.

MANAGEMENT. No treatment is needed for asymptomatic children with auscultatory or electrocardiogram abnormalities. No specific treatment is available for a transient ischemic attack. After a child has had a transient ischemic attack, however, administer daily aspirin to reduce the likelihood of further thrombus formation in the heart.

Rheumatic Heart Disease

The frequency and severity of rheumatic fever and rheumatic heart disease in North America have been decreasing for several decades. A mini-epidemic of acute rheumatic fever recurs every 5 to 10 years. Rheumatic heart disease involves the mitral valve in 85% of patients, the aortic valve in 54%, and the tricuspid and pulmonary valves in less than 5%.

CLINICAL FEATURES. The main features of mitral valve disease are cardiac failure and arrhythmia. Aortic valve disease is often asymptomatic. Neurological complications are always due to bacterial endocarditis except in the immediate postoperative period, when embolization is the likely explanation. Symptoms are similar to congenital heart disease except that cerebral abscess is less common.

DIAGNOSIS. Rheumatic heart disease is an established diagnosis long before the first stroke. Multiple blood cultures identify the organism and select the best drug for intravenous antibiotic therapy.

MANAGEMENT. Bacterial endocarditis requires vigorous intravenous antibiotic therapy.

Hypercoagulable States

A prethrombotic condition is present in 30% to 40% of children who experience an arterial ischemic stroke or sinovenous thrombosis (Bonduel et al, 1999; DeVeber et al, 1998). Abnormalities of blood cells or blood cell concentration may place the child at risk for hemorrhagic or ischemic stroke. Low platelet count secondary to autoimmune thrombocytopenia or bone marrow suppression may lead to hemorrhage. Anything that increases blood viscosity, such as sickled cells, polycythemia, or chronic hypoxia, may predispose to arterial or venous infarct. Dehydration is associated with arterial strokes and central venous thrombosis, possibly because it increases viscosity. Anemia is a risk factor for arterial ischemic infarction and cen-

tral venous thrombosis, possibly because of alterations in hemodynamics or imbalances in thrombotic pathways.

CLINICAL FEATURES. The typical features of venous thrombosis are headache and obtundation caused by increased intracranial pressure, seizures, and successive hemiplegia on either side. An inherited hypercoagulable state should be suspected in children with recurrent venous thromboses, a family history of venous thrombosis, or thrombosis at an unusual site (Table 11-4). Arterial thromboses usually cause ischemic stroke in the distribution of a single cerebral artery.

DIAGNOSIS. Suspect venous thrombosis when hemiplegia and increased intracranial pressure develop suddenly. The diagnosis of sagittal sinus thrombosis is suggested when parasagittal hemorrhage or infarction is associated with a flow void in the sagittal sinus on MRI. Cerebral arteriography is the more definitive procedure. Table 11-3 summarizes laboratory studies.

MANAGEMENT. Symptomatic treatment includes decreasing intracranial pressure and rehydrating the patient without increasing cerebral edema. Anticoagulant therapy is often required.

Ischemic Arterial Infarction

Capsular Stroke

Small, deep infarcts involving the internal capsule occur in adults with hypertensive angiopathy. They also occur, although rarely, in infants and young children. The onset of weakness is sudden and may occur during sleep or wakefulness.

CLINICAL FEATURES. The face and limbs are involved, and a typical hemiplegic posture and

TABLE 11-4
Inherited Hypercoagulable States

Activated protein C resistance
Factor V Leiden mutation
Deficiencies
Protein C
Protein S
Antithrombin III
Other genetic factors
Prothrombin gene 20210 mutation
Methylene tetrahydrofolate reductase gene defect
Elevated lipoprotein (a)
Plasminogen activator inhibitor promoter polymorphism
Elevated antiphospholipid antibodies and lupus anticoagulant
Elevated factor VIII levels and low plasminogen or high fibrinogen

gait develop. Hypalgesia and decreased position sense are difficult to show in infants but are demonstrable in older children. Larger infarcts affecting the striatum and the internal capsule of the dominant hemisphere cause speech disturbances. At the onset of hemiplegia, the child is mute and lethargic. As speech returns, evidence of dysarthria and aphasia develops. Eventually, speech becomes normal. Hemiplegia may clear completely in the following year, but some children have residual weakness of the hand.

DIAGNOSIS. MRI shows capsular infarcts. A cause is rarely determined despite extensive study.

MANAGEMENT. Initiate a rehabilitative treatment program when the child's condition is stable.

Cerebral Artery Infarction

Acute infantile hemiplegia may result from infarction in the distribution of the middle cerebral artery or one of its branches, the posterior cerebral artery, or the anterior cerebral artery.

CLINICAL FEATURES. Sudden hemiplegia is the typical initial feature. Hemianesthesia, hemianopia, and aphasia (with dominant hemisphere infarction) also are present. Some children are lethargic at the onset of symptoms, but consciousness is seldom lost completely. Epilepsia partialis continua precedes hemiplegia in approximately one third of cases. When this is the case, permanent hemiplegia is a constant feature, and epilepsy is common. When hemiplegia occurs without seizures, half of patients recover completely, and the remainder are left with partial paralysis.

DIAGNOSIS. Complete occlusion of the middle cerebral artery produces a large area of lucency on CT involving the cortex, underlying white matter, basal ganglia, and internal capsule. Occlusion of superficial branches of the middle cerebral artery produces a wedge-shaped area of lucency extending from the cortex into the subjacent white matter. Table 11-3 lists studies for hypercoagulable states.

MANAGEMENT. Treat seizures with anticonvulsant drugs (see Chapter 1). Consider hemispherectomy or commissurotomy for intractable seizures (see Chapter 1).

Lipoprotein Disorders

Familial lipid and lipoprotein abnormalities may cause premature cerebrovascular disease in infants and children. Genetic transmission of these disorders is by autosomal dominant inheritance.

CLINICAL FEATURES. Ischemic episodes cause transitory or permanent hemiplegia, sometimes associated with hemianopia, hemianesthesia, and aphasia. Affected families have a history of cerebrovascular and coronary artery disease developing at an early age.

DIAGNOSIS. Most children have low plasma concentrations of high-density lipoprotein cholesterol, others have high plasma concentrations of triglycerides, and some have both. The mechanism of arteriosclerosis is lipoprotein-mediated endothelial damage with secondary thrombus formation.

MANAGEMENT. The management program comprises dietary treatment, lipid-lowering medications, and daily aspirin administration.

Mitochondrial Encephalopathy, Lactic Acidosis, and Stroke

The most common *mutation* in mitochondrial encephalopathy, lactic acidosis, and stroke (MELAS) is in the mitochondrial *gene* *MTTL1* encoding tRNA (Leu-UUR) (DiMauro, 2003).

CLINICAL FEATURES. MELAS is a multisystem disorder. Early psychomotor development is usually normal, but short stature is common. First onset of symptoms is frequently between the ages of 2 and 10 years. The most common initial symptoms are generalized tonic-clonic seizures, recurrent headaches, anorexia, and recurrent vomiting. Exercise intolerance or proximal limb weakness can be the initial feature. Seizures often are associated with strokelike episodes of transient hemiparesis or cortical blindness. These strokelike episodes may be associated with altered consciousness and may be recurrent. The cumulative residual effects of the strokelike episodes gradually impair motor abilities, vision, and mentation, often by adolescence or young adulthood. Sensorineural hearing loss is common.

Affected children are usually normal at birth. Failure to thrive, growth retardation, and progressive deafness are characteristic of onset during infancy. In later onset cases, the main neurological features are recurrent attacks of prolonged migraine-like headaches and vomiting, seizures (myoclonic, focal, generalized) that often progress to status epilepticus, sudden onset of focal neurological defects (hemiplegia, hemianopia, aphasia), and encephalopathy. Mental deterioration, when present, occurs anytime during childhood. Neurological abnormalities are initially intermittent, then become progressive, leading to coma and death.

DIAGNOSIS. MRI shows multifocal infarctions that do not conform to definite vascular

territories. The initial infarctions are often in the occipital lobes; progressive disease affects the cerebral and cerebellar cortices, basal ganglia, and thalamus. The concentration of lactate in the blood and cerebrospinal fluid is elevated. Muscle biopsy specimens show *ragged-red fibers* (see Chapter 7). Genetic diagnosis is commercially available.

MANAGEMENT. Specific treatment is not available, but a cocktail of vitamins is often used. The administration of coenzyme Q10 (50 to 100 mg three times a day) and levocarnitine (1000 mg three times a day) has benefited some patients. Idebenone, a form of coenzyme Q10 that crosses the blood-brain barrier more efficiently, also may be beneficial. Anecdotal reports indicate that dichloroacetate, which reduces blood lactate by activating the pyruvate dehydrogenase complex, is useful.

Moyamoya Disease

Moyamoya disease is a chronic, progressive, noninflammatory vasculopathy that results in a slowly progressive, bilateral occlusion of the internal carotid arteries starting at the carotid siphon. Occlusion of the basilar artery also may occur. Because the occlusion is slowly progressive, multiple anastomoses form between the internal and external carotid arteries. The result is a new vascular network at the base of the brain composed of collaterals from the anterior or posterior choroidal arteries, the basilar artery, and the meningeal arteries. On angiography, these telangiectasias produce a hazy appearance, similar to a puff of smoke, from which is derived the Japanese word *moyamoya* (Figure 11-2). The disorder is worldwide in distribution, with a female-to-male ratio of 3:2.

CLINICAL FEATURES. The initial symptoms vary from recurrent headache to abrupt hemiparesis. Infants and young children tend to have an explosive onset characterized by the sudden development of complete hemiplegia affecting the face and limbs. The child is at least lethargic and sometimes comatose. When the child is sufficiently alert, examination may reveal hemianopia, hemianesthesia, and aphasia. Some children have chorea of the face and all limbs, which is worse on one side. Recovery follows, but before it is complete, new episodes of focal neurological dysfunction occur on either the same or the opposite side. These episodes include hemiparesis, hemianesthesia, or aphasia, alone or in combination. The outcome is generally poor. Most children have chronic

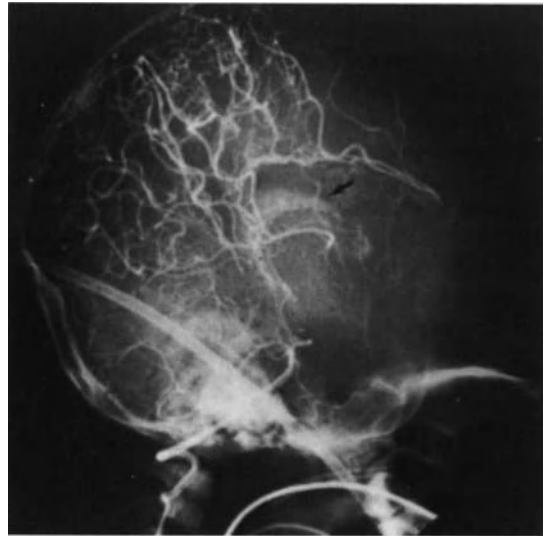

Figure 11-2. Moyamoya disease. Arteriography shows occlusion of the carotid artery at the siphon and new anastomotic vessel formation (arrow).

weakness on one or both sides, epilepsy, and mental retardation. Some have died.

Recurrent transient ischemic attacks are an alternative manifestation. Episodic hemiparesis and dysesthesias lasting minutes or hours, not associated with loss of consciousness, characterize the attacks. Frequently, hyperpnea or excitement triggers attacks, which may recur daily. After 4 or 5 years, the attacks cease, but residual deficits persist.

Repeated episodes of monoparesis or symptoms of subarachnoid hemorrhage are other possible features of moyamoya disease. Monoparesis generally occurs after infancy and subarachnoid hemorrhage after 16 years of age.

DIAGNOSIS. CT or MRI usually shows a large cerebral infarction caused by stenosis in the internal carotid artery. Definitive diagnosis requires arteriographic demonstration of bilateral stenosis in the distal internal carotid arteries and the development of collaterals in the basal ganglia and meninges. Studies should include a search for an underlying vasculopathy or coagulopathy.

MANAGEMENT. Treatment options depend on finding the underlying cause.

Sickle Cell Disease

Sickle cell disease is a genetic disorder of African-American children transmitted by autosomal recessive inheritance. The term *sickle cell disease* encompasses a group of disorders associated with *mutations* in the *HBB* gene and

defined by the presence of hemoglobin S (Hb S). Sickle cell anemia (Hb SS) accounts for 60% to 70% of sickle cell disease in the United States. The other forms of sickle cell disease result from coinheritance of Hb S with other abnormal globin β chain variants (Vichinski and Schlis, 2003). Neurological complications occur in 25% of homozygotes and may occur at times of stress, such as surgery, in heterozygotes. The abnormal erythrocytes clog large and small vessels, decreasing total, hemispheric, or regional blood flow. Cerebral infarction usually occurs in the region of arterial border zones.

CLINICAL FEATURES. The major systemic features are jaundice, pallor, weakness, and fatigability from chronic hemolytic anemia. Half of homozygotes show symptoms by 1 year, and all have symptoms by 5 years of age. The incidence of cerebral infarction varies among studies but may be 46% (Steen et al, 2003). Strokes occur at the time of a thrombotic, vaso-occlusive crisis. Dehydration or anoxia is often the cause of a crisis. Fever and pain in the abdomen and chest are characteristic. Focal or generalized seizures are the initial neurological feature in 70% of patients. After the seizures have ended, hemiplegia and other focal neurological deficits are noted. Some recovery follows, but there is a tendency for recurrent strokes, epilepsy, and mental retardation. Strokes affecting both hemispheres produce a pseudobulbar palsy with brainstem dysfunction.

The worst case is a child who is in a coma and has meningismus. Diffuse decrease in cerebral blood flow associated with subarachnoid or intracerebral hemorrhage is the usual cause. The mortality rate is high.

DIAGNOSIS. The presence of significant quantities of Hb S establish the diagnosis. High-performance liquid chromatography, *isoelectric focusing*, and hemoglobin electrophoresis are used to quantify Hb S. *Mutation analysis* is available. Most affected children have an established diagnosis long before their first stroke. CT or MRI documents the extent of cerebral infarction and hemorrhage. After several such crises, cortical atrophy may be present. Cerebral arteriography offers little additional information and carries the risk of increasing ischemia.

MANAGEMENT. Treatment for children with acute stroke includes monitoring of neurological status and treatment of increased intracranial pressure and seizures if present. An exchange transfusion protocol is initiated with the goal of decreasing Hb S percentage to less than 30% of the total hemoglobin. A preventive long-term transfusion protocol follows. Without regular preventive

therapy, 60% to 90% of patients who have had a stroke have a second stroke within 3 years. Routine *screening* of children with transcranial Doppler identifies children with abnormal velocity of arterial blood flow. These children have a high occurrence of stroke, which transfusion therapy prevents.

Vasculopathies

Hypersensitivity Vasculitis

The term *hypersensitivity vasculitis* covers several disorders that have a known underlying cause (drugs, infection), a characteristic purpura of the legs, and a venulitis. Neurological complications occur only in Henoch-Schönlein purpura, for which an antecedent infection is the probable cause.

CLINICAL FEATURES. The systemic features of Henoch-Schönlein purpura are fever, a purpuric rash on the extensor surfaces of the limbs, and abdominal pain with nausea and vomiting. Joint and renal disturbances may be present. Almost half of affected children have headache and abnormalities on EEG. Focal neurological deficits occur in one third of patients, with hemiplegia accounting for half of these cases. A seizure may precede hemiplegia. Associated with hemiplegia are hemianesthesia, hemianopia, and aphasia. These deficits may be permanent.

DIAGNOSIS. CT or MRI shows infarction, hemorrhage, or both.

MANAGEMENT. Corticosteroids treat the underlying disease.

Isolated Angiitis of the Central Nervous System

Isolated angiitis of the central nervous system is an inflammation of small cerebral vessels. It is rare in children. The clinical features are recurrent headache, sometimes of a migrainous type, encephalopathy, and stroke. Arteriography shows multiple areas of irregular narrowing of the cerebral vessels. Corticosteroid therapy may be beneficial, but additional treatment with pulse cyclophosphamide is often required.

Systemic Lupus Erythematosus

Several collagen vascular disorders can cause neurological disturbances in adults, but systemic lupus erythematosus is the main cause in children. Mixed connective tissue disease is a rare cause of either large vessel occlusion or hemorrhage secondary to fibrinoid necrosis.

CLINICAL FEATURES. The clinical features of lupus in children are similar to the features in adults except for a higher incidence of hepatosplenomegaly, chorea (see Chapter 14), nephritis, and avascular necrosis. Most children have fever, arthralgia, and skin rash at the time of diagnosis. Neurological features are present in one quarter of children at the time of diagnosis. In contrast to systemic complaints, neurological disturbances are likely to progress or develop anew even after initiating treatment. Neurological dysfunction develops in about one third of children sometime during the course of disease. Headache, seizures, cranial neuropathies, and mental disorders are common features. Hemiplegia usually follows a seizure, and the cause may be either cerebral infarction or hemorrhage. Neurological episodes during treatment are often complications of immunosuppression, such as fungal meningitis, rather than primary complications of the underlying disease.

DIAGNOSIS. The diagnosis of lupus requires a compatible clinical syndrome and the detection of an abnormal titer of antinuclear antibody or anti-DNA antibody to native DNA. The presence of anticardiolipin antibodies is associated with hemolytic anemia and thrombotic events. CT or MRI of the head is useful to determine the presence of hemorrhage or infarction. Results of cerebral arteriography may be normal.

MANAGEMENT. Large doses of corticosteroids are the mainstay of therapy, but mortality is higher in children than in adults.

Takayasu Arteritis

Takayasu arteritis, a disorder of unknown cause, involves the aorta and its major branches.

CLINICAL FEATURES. Onset usually occurs between 15 and 20 years of age but may occur in infancy. Ninety percent of patients are female. The most common features are fever, weight loss, myalgias, arthralgia, hypertension, absent pulses, and vascular bruits. Stroke occurs in only 5% to 10% of patients. Focal seizures and sudden hemiplegia characterize stroke.

DIAGNOSIS. CT reveals a focal hypodense area, indicating infarction. Arteriography shows involvement of the ascending aorta and its major branches. Cardiac catheterization is necessary to define the full extent of arteritis. Some vessels have a beaded appearance; others terminate abruptly and have prestenotic dilation.

MANAGEMENT. Corticosteroids are the treatment of choice. Left untreated, the mortality rate is 75%. Early diagnosis and treatment can lead to full recovery.

Infections

Hemiplegia occurs during the course of bacterial meningitis, resulting from vasculitis or venous thromboses, and during the course of viral encephalitis, especially herpes simplex, resulting from parenchymal necrosis. In bacterial and viral infections, prolonged or repetitive focal seizures precede the hemiplegia. Brain abscess may cause hemiplegia, but its evolution is usually slowly progressive rather than acute.

Varicella

Arterial ischemic strokes may occur during the course of varicella infection and probably after varicella immunization, 1 week to several months after the appearance of rash (Sébire et al, 1999). The infarcts are small and located in the basal ganglia and internal capsule.

Migraine

Migraine is a hereditary disorder associated with, but not caused by, paroxysmal alterations in cerebral blood flow. Transitory neurological abnormalities may accompany the attack. The cause is a primary neuronal disturbance rather than cerebral ischemia. Cerebral infarction may occur in adolescents, however, during a prolonged attack of classic migraine. Such instances may represent something more than ordinary migraine. Mitochondrial disorders and channelopathies are possible mechanisms. The occurrence of focal motor deficits, usually hemiplegia or ophthalmoplegia (see Chapter 15), during an occasional migraine attack is called *complicated migraine*. In some families, hemiplegic migraine is a familial trait.

Complicated Migraine

CLINICAL FEATURES. The family has a history of migraine, but other family members have not experienced hemiplegia during an attack. The evolution of symptoms is variable but usually includes scintillating or simple scotomas, unilateral dysesthesias of the hand and mouth, and unilateral weakness of the arm and face usually sparing the leg. Occurring concurrently with hemiparesis is a throbbing frontotemporal headache contralateral to the affected hemisphere. Nausea and vomiting follow. The patient falls asleep and usually recovers function on awakening. Hemiparesis lasts for less than 24 hours.

DIAGNOSIS. Migraine is a clinical diagnosis that relies on a positive family history of the disorder. During an attack of hemiplegic migraine, an EEG focus of polymorphic delta activity is present in the hemisphere contralateral to the weakness. Neuroimaging studies are unnecessary.

MANAGEMENT. Chapter 3 provides a summary of migraine management.

Familial Hemiplegic Migraine

FHM differs from complicated migraine because other family members with migraine have had at least one hemiplegic attack. Transmission of the trait is by autosomal dominant inheritance. Two genetic loci exist. *FHM1* on chromosome 19p is allelic with the gene for hereditary paroxysmal cerebellar ataxia and encodes a calcium channel (Gardner, 2004). *FHM2* is allelic for alternating hemiplegia and encodes a sodium-potassium ATPase pump.

CLINICAL FEATURES. Hemiplegia is an essential feature. Associated features may include visual disturbance; sensory loss, such as numbness or paresthesias of the face or a limb; and difficulty with speech. Attacks are stereotyped, occur primarily in childhood or adolescence, may be precipitated by trivial head trauma, and rarely occur more often than once a year. The hemiplegia, although more severe in the face and arm, also affects the leg and always outlasts the headache. Hemianesthesia of the hemiplegic side is a prominent feature. Aphasia occurs when the dominant hemisphere is affected. Confusion, stupor, or psychosis may be present during an attack. The psychosis includes auditory and visual hallucinations and delusions. Occasionally, patients have fever and a stiff neck.

Symptoms last 2 or 3 days. When the attack is over, the neurological deficits usually resolve completely, but permanent sequelae are possible. A gaze-evoked nystagmus may persist between attacks. Recurrent hemiplegic attacks may occur on either the same or the opposite side. Families with linkage to chromosome 1 may experience seizures during severe attacks.

DIAGNOSIS. Diagnosis is based on the clinical findings and *family history*. The diagnostic criteria are as follows: (1) Attack fulfills criteria for migraine with aura; (2) aura includes some degree of hemiparesis, and hemiparesis may be prolonged; (3) at least one *first-degree relative* (i.e., parent, sib, offspring) has identical attacks. Approximately 50% of families with FHM, including all families with FHM/ataxia, have *FHM1* (i.e., *linkage* to 19p13 or *mutations* in the *CACNA1A* gene. *Molecular testing* for muta-

tions in *CACNA1A* is available on a research basis only. The CAG *trinucleotide repeat* expansion typical of individuals with spinal cerebellar ataxia type 6 (also caused by *mutations* in *CACNA1A*) has not been observed in families with *FHM1*. *Mutations* in *ATP1A2* cause *FHM2*. *Molecular genetic testing* of *ATP1A2* is available on a research basis only. *Linkage* studies have identified two additional loci: 1q25-q31 and 6p12.2-p21.1. A family history of hemiplegic migraine is essential for diagnosis.

MANAGEMENT. Acetazolamide is a useful prophylactic agent in several channelopathies and may be useful in children with FHM.

Trauma

Trauma accounts for half of all deaths in children. Approximately 10% of traumatic injuries in children are not accidental. Head injury is the leading cause of death from child abuse, and half of survivors have permanent neurological handicaps. Epidural hematoma, subdural hematoma, cerebral laceration, and intracerebral hemorrhage can produce focal signs such as hemiplegia. Brain swelling is such a prominent feature of even trivial head injury in children, however, that diminished consciousness and seizures are the typical clinical features (see Chapter 2).

Tumors

The initial clinical feature of primary tumors of the cerebral hemispheres is more likely to be chronic progressive hemiplegia than acute hemiplegia. Tumors may cause acute hemiplegia, however, when they bleed or provoke seizures and are a consideration in the evaluation of acute hemiplegia.

Chronic Progressive Hemiplegia

The important causes of chronic progressive hemiplegia are brain tumor, brain abscess, and arteriovenous malformations. Increased intracranial pressure is the initial feature of all three. These conditions are discussed in Chapter 4. Progressive hemiplegia is sometimes an initial feature of demyelinating diseases (see Chapters 5 and 10) (Table 11-5).

Sturge-Weber Syndrome

The Sturge-Weber syndrome (SWS) is a sporadic neurocutaneous disorder characterized by

TABLE 11-5
Progressive Hemiplegia

Arteriovenous malformation (see Chapter 4)
Brain abscess (see Chapter 4)
Cerebral hemisphere tumor (see Chapter 4)
Demyelinating diseases
Adrenoleukodystrophy (see Chapter 5)
Late-onset globoid leukodystrophy (see Chapter 5)
Multiple sclerosis (see Chapter 10)
Sturge-Weber syndrome

the association of a venous angioma of the pia mater with a port-wine stain of the face. Other findings include mental retardation, contralateral hemiparesis and hemiatrophy, and homonymous hemianopia. The syndrome occurs sporadically and in all races.

CLINICAL FEATURES. The clinical features are highly variable; individuals with cutaneous lesions and seizures, but with normal intelligence and no focal neurological deficit, are common. The cutaneous angioma is usually present at birth. It is flat and variable in size but usually involves the upper lid. The size of the cutaneous angioma does not predict the size of the intracranial angioma. It is unilateral in 70% of children and ipsilateral to the venous angioma of the pia. Even when the facial nevus is bilateral, the pial angioma is usually unilateral. The characteristic neurological and radiographic features of SWS may be present without the cutaneous angioma. Only 10% to 20% of children with a port-wine nevus of the forehead have a leptomeningeal angioma. Bilateral brain lesions occur in at least 15% of children.

Seizures occur in 80% of children with SWS. Onset is generally within the first year, and the seizure type is usually focal motor, sometimes leading to partial or generalized status epilepticus (see Chapter 1). Among children with SWS who have seizures in the first year, 80% show developmental delay and mental retardation.

Hemiplegia, contralateral to facial angioma, occurs in 50% of children. Hemiplegia often appears after a focal-onset seizure and progresses in severity after subsequent seizures. Transitory episodes of hemiplegia, not related to clinical or EEG evidence of seizure activity, may occur. Some episodes are associated with migraine-like headache; others occur in the absence of other symptoms and cerebral ischemia may be the

cause. Glaucoma occurs in 71% of children with SWS, usually developing before age 10.

DIAGNOSIS. The association of neurological abnormalities and a port-wine stain of the face should suggest SWS. The pial angioma is best visualized by contrast-enhanced MRI and only rarely by angiography.

MANAGEMENT. Seizures are often difficult to control with anticonvulsant medications. Hemispherectomy sometimes improves seizure control and promotes normal intellectual development. Early hemispherectomy is the recommended therapy when focal seizure onset is in infancy. Corpus callosum section may be useful for patients with extensive disease.

References

- Bonduel M, Sciuccata G, Hepner M, et al. Prethrombotic disorders in children with arterial ischemic stroke and sinovenous thrombosis. *Arch Neurol* 1999;56:967-971.
- DeVeber G, Monagle P, Chan A, et al. Prothrombotic disorders in infants and children with cerebral thromboembolism. *Arch Neurol* 1998;55:1539-1543.
- DiMauro S. (18 June 2003) MELAS. In: *GeneClinics: Medical Genetics Knowledge Base*. [database online] University of Washington, Seattle. Available at <http://www.geneclinics.org>.
- Fullerton HJ, Chetkovitch DM, Wu YW, et al. Deaths from stroke in US children, 1979 to 1998. *Neurology* 2002; 59:34-39.
- Fullerton HJ, Wu YW, Zhao S, et al. Risk of stroke in children. Ethnic and gender disparities. *Neurology* 2003; 61:189-194.
- Ganesan V, Chong WK, Cox TC, et al. Posterior circulation stroke in childhood. Risk factors and recurrence. *Neurology* 2002;59:1552-1556.
- Gardner KL. (15 March 2004) Familial hemiplegic migraine. In: *GeneClinics: Medical Genetics Knowledge Base*. [database online] University of Washington, Seattle. Available at <http://www.geneclinics.org>.
- Lanthier S, Carmant L, David M, et al. Stroke in children. The coexistence of multiple risk factors predicts poor outcome. *Neurology* 2000;54:371-378.
- Mercuri E, Rutherford M, Cowan F, et al. Early prognostic indicators of outcome in infants with neonatal cerebral infarction. A clinical, electroencephalogram, and magnetic resonance imaging study. *Pediatrics* 1999;103: 39-46.
- Roach ES. Etiology of stroke in children. *Semin Pediatr Neurol* 2000;7:244-260.
- Sébire G, Husson B, Dusser A, et al. Congenital unilateral perisylvian syndrome. Radiological basis and clinical correlations. *J Neurol Neurosurg Psychiatry* 1996; 61:52-56.
- Sébire G, Meyer L, Chabrier S. Varicella as a risk factor for cerebral infarction in childhood. A case-control study. *Ann Neurol* 1999;45:679-680.
- Steen RG, Xiong X, Langston JW, et al. Brain injury in children with sickle cell disease. Prevalence and etiology. *Ann Neurol* 2003;54:564-572.

Swoboda KJ, Kanavakis E, Xaidara A, et al. Alternating hemiplegia of childhood or familial hemiplegic migraine? A novel ATP1A2 mutation. *Ann Neurol* 2004;55:884-887.

Vichinski E, Schlis K. (15 December 2003) Sickle cell disease. In: *GeneClinics: Medical Genetics Knowledge Base*. [database online] University of Washington, Seattle. Available at <http://www.geneclinics.org>.

Chapter 12

Paraplegia and Quadriplegia

IN THIS TEXT, the term *paraplegia* denotes partial or complete weakness of both legs, and the term *quadriplegia* denotes partial or complete weakness of all limbs, obviating need for the terms *paraparesis* and *quadriparesis*. Many conditions described fully in this chapter are abnormalities of the spinal cord. The same spinal abnormality can cause paraplegia or quadriplegia, depending on the location of the injury, so these conditions are discussed together in this chapter.

Approach to Paraplegia

Weakness of both legs, without any involvement of the arms, suggests an abnormality of either the spinal cord or the peripheral nerves. Ordinarily a pattern of distal weakness and sensory loss, muscle atrophy, and absent tendon reflexes provides recognition of peripheral neuropathies (see Chapters 7 and 9). In contrast, spinal paraplegia causes spasticity, exaggerated tendon reflexes, and a dermatomal level of sensory loss. Disturbances in the conus medullaris and cauda equina, especially congenital malformation, may produce a complex of signs in which spinal cord or peripheral nerve localization is difficult; both may be involved. Spinal paraplegia may be asymmetrical at first, then the initial feature is monoplegia (see Chapter 13). When anatomical localization between the spinal cord and peripheral nerves is difficult, electromyogram and nerve conduction studies are useful in making the distinction.

Cerebral abnormalities sometimes cause paraplegia. In such a case, the child's arms and legs are usually weak. Leg weakness is so much greater than arm weakness, however, that paraplegia is the chief complaint. The brain and the

spinal cord may be abnormal, and the abnormalities can be in continuity (syringomyelia) or separated (Chiari malformation and myelomeningocele).

Spinal Paraplegia and Quadriplegia

Table 12-1 lists conditions that cause acute, chronic, or progressive spinal paraplegia. In the absence of trauma, spinal cord compression and myelitis are the main causes of an acute onset or rapidly progressive paraplegia. Spinal cord compression from any cause is a medical emergency requiring rapid diagnosis and therapy to avoid permanent paraplegia. Corticosteroids have the same dehydrating effect on the spinal cord as on the brain and provide transitory decompression before surgery.

Several techniques are available to visualize the spinal cord. Each has its place, and sometimes the use of more than one technique achieves a comprehensive picture of the disease process. Magnetic resonance imaging (MRI) is the procedure of choice, however, to visualize the spine and is used first. Computed tomography (CT) and radioisotope bone scanning are useful for visualizing the vertebral column, especially when osteomyelitis is a consideration. Isotope bone scans localize the process but rarely provide an etiology.

Symptoms and Signs

Clumsiness of gait, refusal to stand or walk, and loss of bladder or bowel control are the common complaints of spinal paraplegia. Clumsiness of gait is the usual feature of slowly progressive disorders. When functional decline is sufficiently

TABLE 12-1
Spinal Paraplegia

Congenital malformations	Lupus myelopathy
Arachnoid cyst	Metabolic disorders
Arteriovenous malformations	Adrenomyeloneuropathy (adrenoleukodystrophy)
Atlantoaxial dislocation	Argininemia
Caudal regression syndrome	Krabbe disease
Dysraphic states	Neonatal cord infarction
Chiari malformation	Transverse myelitis
Myelomeningocele	Devic disease
Tethered spinal cord	Encephalomyelitis
Syringomyelia (see Chapter 9)	Idiopathic
Familial spastic paraplegia	Trauma
Autosomal dominant	Concussion
Autosomal recessive	Epidural hematoma
X-linked recessive	Fracture-dislocation
Infections	Neonatal cord trauma (see Chapter 6)
Asthmatic amyotrophy (see Chapter 13)	Tumors
Diskitis	Astrocytoma
Epidural abscess	Ependymoma
Herpes zoster myelitis	Ewing's sarcoma
Polyradiculoneuropathy (see Chapter 7)	Neuroblastoma
Tuberculous osteomyelitis	

insidious, the disturbance may go on for years without raising concern. Refusal to stand or walk is a symptom of an acute process. When a young child refuses to support weight, the underlying cause may be weakness, pain, or both.

Scoliosis is a feature of many spinal cord disorders. It occurs with neural tube defects, spinal cord tumors, and several degenerative disorders. It also occurs when the paraspinal muscles are weaker on one side of the spine than on the other side. The presence of scoliosis, in females before puberty and in males of all ages, should strongly suggest either a spinal cord disorder or a neuromuscular disease (see Chapters 6 and 7).

Abnormalities in the skin overlying the spine, such as an abnormal tuft of hair, pigmentation, a sinus opening, or a mass may indicate an underlying dysraphic state. Spina bifida is usually an associated feature.

Foot deformities and especially stunted growth of a limb are malevolent signs of lower spinal cord dysfunction. The usual deformity is foreshortening of the foot, called *pes cavus*. In such cases, disturbances of bladder control are often an associated feature.

Brief, irregular contractions of small groups of muscles that persist during sleep characterize *spinal myoclonus*. The myoclonic contractions are often mistaken for seizure activity or fasciculations. The cause of myoclonus is irritation

of pools of motor neurons and interneurons, usually by an intramedullary tumor or syrinx. The dermatomal distribution of the myoclonus localizes the site of irritation within the spinal cord.

Congenital Malformations

Some congenital malformations, such as caudal regression syndrome and myelomeningocele, are obvious at birth. Many others do not cause symptoms until adolescence or later. Congenital malformations are always a consideration when progressive paraplegia appears in childhood.

Arachnoid Cysts

Arachnoid cysts of the spinal cord, similar to those of the brain (see Chapter 4), are usually asymptomatic and discovered incidentally on imaging studies. Familial cases should suggest neurofibromatosis type 2 (see Chapter 5).

CLINICAL FEATURES. Arachnoid cysts may be single or multiple and are usually thoracic. Symptomatic arachnoid cysts are unusual in childhood and encountered more often in adolescents and young adults. The features are back or radicular pain and paraplegia. Standing intensifies symptoms, and changes in position may relieve or exacerbate symptoms. The pain tends to increase in severity with time.

DIAGNOSIS. MRI is the diagnostic modality of choice. The cyst has the same MRI characteristics as cerebrospinal fluid (CSF).

MANAGEMENT. Shunting of a symptomatic cyst is curative. It is common to blame a subarachnoid cyst, however, for symptoms that have another cause.

Arteriovenous Malformations

Arteriovenous malformations of the spinal cord are uncommon in childhood. No cases reported show infantile onset, and only 14% begin before age 5.

CLINICAL FEATURES. The progression of symptoms is usually insidious, and the time from onset to diagnosis may be several years. Subacute or chronic pain is the initial feature in one third of patients, and subarachnoid hemorrhage is the initial feature in one quarter. Paraplegia is an early feature in only one third, but monoplegia or paraplegia is present in almost all children at the time of diagnosis. Most children have a slowly progressive spastic paraplegia and loss of bladder control.

When subarachnoid hemorrhage is the initial feature, the malformation is more likely to be in the cervical portion of the spinal cord. Blunt trauma to the spine may be a precipitating factor. The onset of paraplegia or quadriplegia is acute and associated with back pain. Back pain and episodic weakness that improve completely or in part may be initial features in some children, but impairment is progressive. This type of presentation is misleading, and the diagnosis is delayed for several years.

DIAGNOSIS. MRI is the first step in diagnosis. It distinguishes intramedullary locations from dural and extramedullary locations of the malformation and allows recognition of thrombus formation. Arteriography is still necessary to show the intramedullary extent of the malformation and all of the feeding vessels.

MANAGEMENT. The potential approaches to therapy for intraspinal and intracranial malformations are similar (see Chapter 4).

Atlantoaxial Dislocation

The odontoid process is the major factor preventing dislocation of C1 onto C2. Aplasia of the odontoid process can occur alone or as part of Morquio syndrome, other mucopolysaccharidoses, Klippel-Feil syndrome, several types of genetic chondrodysplasia, and some chromosomal abnormalities (Crockard and Stevens, 1995). Asymptomatic atlantoaxial subluxation

may occur in 20% of children with Down syndrome secondary to congenital hypoplasia of the articulation of C1 and C2; symptomatic dislocation is much less common.

CLINICAL FEATURES. Congenital atlantoaxial dislocation produces an acute or slowly progressive quadriplegia that may begin anytime from the neonatal period to adulthood. When the onset is in a newborn, the clinical features resemble an acute infantile spinal muscular atrophy (see Chapter 6). The infant has generalized hypotonia with preservation of facial expression and extraocular movement. The tendon reflexes are absent at first, but then become hyperactive.

Dislocations during childhood frequently follow a fall or head injury. In such cases, symptoms may begin suddenly and include not only those of myelopathy, but also symptoms related to vertebral artery occlusion.

Morquio syndrome is primarily a disease of the skeleton, with only secondary abnormalities of the spinal cord. Beginning in the second year or thereafter, the following features develop in affected children: prominent ribs and sternum, knock-knees, progressive shortening of the neck, and dwarfism. The odontoid process is aplastic or absent. Acute, subacute, or chronic cervical myelopathy develops, sometimes precipitated by a fall. Loss of endurance, fainting attacks, and a "pins and needles" sensation in the arms characterize an insidious onset of symptoms.

The essential feature of *Klippel-Feil syndrome* is a reduced number and abnormal fusion of cervical vertebrae. As in Morquio syndrome, the head seems to rest directly on the shoulders, the posterior hairline is low, and movement in all directions is limited. Elevation of the scapulae and deformity of the ribs (*Sprengel deformity*) are often present. Weakness and atrophy of the arm muscles and mirror movements of the hands are features of evolving paraplegia. Associated abnormalities may be present in several different organ systems.

Symptomatic atlantoaxial dislocation in children with Down syndrome may occur anytime from infancy to the 20s. Females are affected more often than males. Symptoms include neck pain, torticollis, and an abnormal gait. Spinal cord compression is progressive and leads to quadriplegia and urinary incontinence.

DIAGNOSIS. C1 usually moves anteriorly to C2. Flexion radiographs assess the separation between the dens and the anterior arch of C1. MRI is best to view the relationship between the cord and the subluxing bones. Lateral

radiographs of the cervical portion of the spine in extension and flexion may show atlantoaxial instability, but CT provides better documentation of instability.

MANAGEMENT. Surgical stabilization of the atlantoaxial junction is a consideration in any child with evidence of spinal cord compression. The choice of surgical procedure depends on the mechanism of compression.

Caudal Regression Syndrome

The term *caudal regression syndrome* comprises several malformations of the caudal spine that range from sacral agenesis to sirenomelia, in which only one leg is present. Understanding of the mechanism of caudal regression is incomplete, but some cases are clearly genetic in origin (Lynch et al, 2000). Although the name implies regression of a normally formed cord, defects in neural tube closure and prosencephalization are often associated features. The risk of caudal regression is greater among infants of diabetic mothers. The clinical spectrum varies from absence of the lumbosacral spinal cord, resulting in small, paralyzed legs, to a single malformed leg associated with malformations of the rectum and genitourinary tract.

Chiari Malformation

The type I Chiari malformation is elongation of the cerebellar vermis with herniation of its caudal end through the foramen magnum. The type II malformation combines cerebellar herniation with distortion and dysplasia of the medulla and occurs in more than 50% of children with lumbar myelomeningocele. The herniated portion may become ischemic and necrotic and can cause compression of the brainstem and upper cervical spinal cord. Ectopic expression of a segmentation gene in the rhombomeres may explain the Chiari malformation and the brainstem anomalies, myelodysplasia, and defective bone formation that results in a small posterior fossa.

CLINICAL FEATURES. Most Chiari I malformations are discovered as an incidental finding on MRI ordered because of headache. The malformation is rarely the cause of the headache. The initial features of a symptomatic Chiari malformation are usually insidious. Oropharyngeal dysfunction is a presenting feature in 35% of children younger than 6 years old, followed by scoliosis (23%) and head and neck pain (23%) (Greenlee et al, 2002). Among older children, headache and neck pain are the first features in 38%, and

weakness is the first feature in 56%. Eighty percent show motor deficits on examination, usually atrophy and hyporeflexia in the arms and spasticity and hyperreflexia in the legs. Sensory loss and scoliosis are each present in half of cases.

Type II malformations are suspected in every child with myelomeningocele. In most cases, the cerebellar displacement is asymptomatic. The cause of hydrocephalus may be aqueductal stenosis or an obstruction of the outflow of CSF from the fourth ventricle secondary to herniation. Respiratory distress is the most important feature of the Chiari malformation and the usual cause of death. Rapid respirations, episodes of apnea, and Cheyne-Stokes respirations may occur. Other evidence of brainstem compression includes poor feeding, vomiting, dysphagia, and paralysis of the tongue. Sudden cardiorespiratory failure is the usual cause of death.

DIAGNOSIS. MRI is the best method to visualize the posterior fossa and cervical cord. CT is useful to delineate bony abnormalities further.

MANAGEMENT. Posterior fossa decompression is the usual technique to manage newborns with myelomeningocele and respiratory distress caused by the Chiari malformation. The results are not encouraging. Posterior fossa decompression is usually successful in relieving symptoms of cord compression in older children without myelomeningocele. Ventriculoperitoneal shunt also may be required.

Myelomeningocele

Dysraphia comprises all defects in the closure of the neural tube and its coverings. Closure occurs during the third and fourth weeks of gestation. The mesoderm surrounding the neural tube gives rise to the dura, skull, and vertebrae, but not to the skin. Defects in the final closure of the neural tube and its mesodermal case do not preclude the presence of a dermal covering.

Despite extensive epidemiological studies, the causes of myelomeningocele remain unknown. Causes are likely to be multifactorial, including genetic and environmental factors. Because women who previously have had a child with dysraphia have an approximate 2% risk of recurrence, prenatal diagnosis is available to prevent repetition.

α -Fetoprotein, the principal plasma protein of the fetus, is present in amniotic fluid. The concentration of α -fetoprotein in the amniotic fluid increases when plasma proteins exude through a skin defect. Prenatal diagnosis is possible in every case by the combination of

measuring the maternal serum concentration of α -fetoprotein and ultrasound examination of the fetus.

The incidence of dysraphic defects has been declining in the United States and the United Kingdom. Antenatal screening alone does not explain the decline; changes in crucial environmental factors may be important. Because the ingestion of folic acid supplements during early pregnancy reduces the incidence of neural tube defects, the consumption of 0.4 mg of folic acid daily is advisable for all women of childbearing age. Women with a prior history of delivering an infant with a neural tube defect should take 4 mg/day of folic acid from at least 4 weeks before the conception through the first 3 months of pregnancy.

CLINICAL FEATURES. Spina bifida cystica, the protrusion of a cystic mass through the defect, is an obvious deformity of the newborn's spine. More than 90% are thoracolumbar. Among newborns with spina bifida cystica, the protruding sac is a meningocele without neural elements in 10% to 20% and is a myelomeningocele in the rest. Meningoceles tend to have a partial dermal covering and are often pedunculated, with a narrow base connecting the sac to the underlying spinal cord. Myelomeningoceles usually have a broad base, lack epithelial covering, and ooze a combination of CSF and serum. Portions of the dome contain exposed remnants of the spinal cord.

In newborns with spina bifida cystica, it is important to determine the extent of neurological dysfunction caused by the myelopathy, the potential for the development of hydrocephalus, and the presence of other malformations in the nervous system and in other organs. When myelomeningocele is the only deformity, the newborn is alert and responsive and has no difficulty in feeding. Diminished consciousness or responsiveness and difficulty in feeding should suggest perinatal asphyxia or cerebral malformations, such as hydrocephalus. Cyanosis, pallor, or dyspnea suggests associated malformations in the cardiovascular system. Multiple major defects are present in 27% of cases.

The spinal segments involved can be determined by locating the myelomeningocele with reference to the ribs and iliac crest. Several patterns of motor dysfunction are observable depending on the cyst's location. Motor dysfunction results from interruption of the corticospinal tracts and from dysgenesis of the segmental innervation. At birth, the legs are flaccid, and the hips are dislocated. Spastic paraplegia, a spastic bladder, and a level of sen-

sory loss develop in infants with a thoracic lesion. Segmental withdrawal reflexes below the level of the lesion, which indicate the presence of an intact but isolated spinal cord segment below the cyst, are present in half of patients. Infants with deformities of the conus medullaris maintain a flaccid paraplegia, have lumbosacral sensory loss, lack a withdrawal response in the legs, and have a distended bladder with overflow incontinence.

Only 15% of newborns with myelomeningocele have clinical evidence of hydrocephalus at birth, but ultrasound detects hydrocephalus in 60% of affected newborns. Hydrocephalus eventually develops in 80%. The first clinical features of hydrocephalus often follow the repair of the myelomeningocele, but the two are not related. Aqueductal stenosis is the cause of hydrocephalus in three quarters of infants with myelomeningocele.

DIAGNOSIS. Examination alone establishes the diagnosis of spina bifida cystica. Electromyogram may be useful to clarify the distribution of segmental dysfunction. Cranial ultrasound to look for hydrocephalus is required for every newborn. MRI is useful to define malformations of the brain, especially the Chiari malformation (see Figure 10-5). Therapeutic decisions may require such information. Even in the absence of hydrocephalus at birth, repeat ultrasound examinations in 2 to 4 weeks are required to evaluate ventricular size.

MANAGEMENT. Intrauterine surgery to close the back is an experimental procedure based on the hypotheses that exposure of the cord to amniotic fluid increases injury and increases hindbrain herniation (Tulipan et al, 1998). The usefulness of the procedure is not established. The chance of surviving the first year is poor without back closure shortly postpartum. Closure is not a surgical emergency, however, and delay for a week or longer does not influence the survival rate. Other factors associated with increased mortality are a high spinal location of the defect and clinical hydrocephalus at birth. The long-term outcome depends on the degree of mental retardation and the neurological deficit from the spinal defect.

Tethered Spinal Cord

A thickened filum terminale, a lipoma, a dermal sinus, or diastematomyelia may anchor the conus medullaris to the base of the vertebrae. Spina bifida occulta is usually an associated feature. As the child grows, the tether causes the spinal cord to stretch and the lumbosacral segments to

become ischemic. The mitochondrial oxidative metabolism of neurons is impaired, and neurological dysfunction follows.

Dermal sinus is a midline opening of the skin usually marked by a tuft of hair or port-wine stain. An abnormal invagination of ectoderm into the posterior closure site of the neural tube causes the problem. Most sinuses terminate subcutaneously as a blind pouch or dermoid cyst. Others extend through a spina bifida to the developing neuraxis, at which point they attach to the dura or the spinal cord as a fibrous band or dermoid cyst. Such sinuses tether the spinal cord and serve as a route for bacteria from the skin to reach the subarachnoid space and cause meningitis.

Diastematomyelia consists of a bifid spinal cord (also called *diplomyleia*) that is normal in the cervical and upper thoracic regions, then divides into lateral halves (Figure 12-1). Two types of diastematomyelia occur with equal frequency. In one type, a dural sheath surrounds each half of the cord, and a fibrous or bony septum separates the two halves. When the cord separates, it never rejoins. In the other type, a single dural sheath surrounds both halves, and a septum is not present. The two halves rejoin after one or two segments. The cause of spinal cord splitting is not the presence of a septum, but rather a primary disturbance in the formation of luminal borders caused by faulty closure of the neural tube. It is usually associated with other dysraphic disturbances, such as spina bifida occulta or cystica.

CLINICAL FEATURES. The initial features of a tethered spinal cord occur at any age from infancy to young adulthood. The clinical features vary with age. External signs of spinal dysraphism (tuft of hair, subcutaneous lipoma, and dermal sinus) are present in more than half of patients, and spina bifida occulta or sacral deformity is present in almost 90%.

Infants and young children are most likely to show clumsiness of gait, stunted growth, defor-

mity of one foot or leg, and disturbances in bladder function. These may occur alone or in combination. Consequently the first specialist consulted may be an orthopedic surgeon, urologist, neurologist, or neurosurgeon. The progression of symptoms and signs is insidious, and a static problem is the first diagnosis in most children. Children with only a clumsy gait or disturbances in urinary control tend to have normal or exaggerated tendon reflexes and an extensor plantar response. In some children, diminished or absent ankle tendon reflexes are noted on one or both sides. Children with foot deformity usually have pes cavus and stunted growth of the entire leg. The other leg may appear normal or have a milder deformity without a growth disturbance. Diminished tendon reflexes in the deformed foot are more likely than increased reflexes.

The initial feature of tethered spinal cord in older children and adolescents is either clumsiness of gait or scoliosis. Bilateral, but mild, foot deformities are sometimes present, and urinary incontinence and constipation are reported. Exaggerated knee and ankle tendon reflexes are usual, and the plantar response is usually extensor.

DIAGNOSIS. The electromyogram is not a useful screening procedure because the results are usually abnormal. Radiographs of the spine may show spina bifida, but MRI is the appropriate diagnostic test and is particularly useful in the detection of lumbosacral lipoma. The essential feature of a tethered spinal cord is a low-lying conus medullaris. At 28 weeks' gestation, the tip of the conus is at the L3 vertebral level. It generally increases one level by 40 weeks' gestation. A conus that extends below the L2-3 interspace in children 5 years old and older is always abnormal.

MANAGEMENT. Surgical relief of the tethering prevents further deterioration of neurological function and improves preexisting deficits in 50% of children (Cornette et al, 1998).

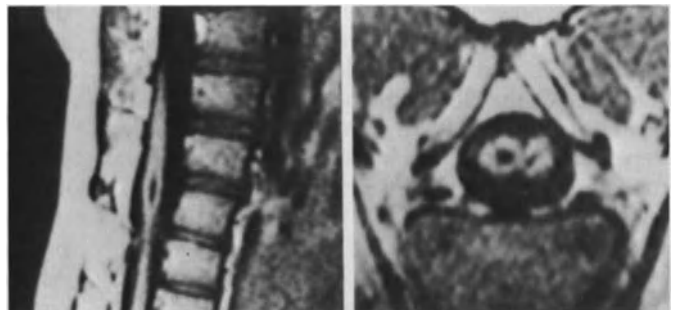


Figure 12-1. Diplomyelia. MRI shows two cords with two central canals. Longitudinal section shows an enlarged segment with a cystic center.

Hereditary Spastic Paraplegia

Hereditary spastic paraplegia (HSP) is a heterogeneous group of genetic disorders in which the prominent clinical feature is progressive spastic paraplegia. Some families have *pure* or *uncomplicated* HSP, which may be associated with a hypertonic urinary bladder disturbance and a mild decrease in vibration and joint position sensation. Others have *complicated* or *complex* HSP, in which the spastic paraplegia is associated with other neurological findings, such as seizures, dementia, amyotrophy, extrapyramidal disturbance, or peripheral neuropathy (Fink, 2004). Genetic transmission of HSP is by autosomal dominant inheritance in 70% of cases and by autosomal recessive inheritance in 25%. Genetic heterogeneity exists even within the dominant and recessive forms. The X-linked form is uncommon, reported in fewer than 20 families. Linkage studies have mapped the abnormal gene to the long arm of the X chromosome.

Autosomal Dominant Inheritance

Children with autosomal dominant spastic paraplegia (ADSP) usually have pure spastic paraplegia without prominent disturbances of other neurological systems. Even among these “pure” ADSP, genetic heterogeneity exists. Uncomplicated HSP has seven identified loci, and the complicated form has two other loci (Fink, 2003). Families with “complicated” ADSP (mental retardation, ataxia, and extraocular abnormalities) do not show linkage to any of these loci.

CLINICAL FEATURES. The age at onset ranges from infancy to 68 years (mean 29 years). Early-onset and late-onset cases may occur among members of the same family. Motor milestones are normal in affected infants except for toe walking. Frequently the diagnosis in such children is cerebral palsy (CP), especially if the affected parent is asymptomatic or has only a mildly stiff gait. Increased tone is more prominent than weakness. Tone increases slowly for 10 years, then stabilizes. At this point, the child may have minimal stiffness of gait or be unable to stand or walk.

Usually, tendon reflexes are brisk in the legs and arms, and ankle clonus may be present. Occasional children with absent or diminished ankle tendon reflex have an associated axonal neuropathy. Increased reflexes are usually the only sign of involvement of the arms. Vibratory and position sense are diminished in half of patients. Urinary symptoms, usually in the form

of frequency and urgency, and pes cavus deformities each occur in one third of affected children.

DIAGNOSIS. Familial spastic paraplegia is difficult to diagnose in the absence of a family history of the defect and becomes a diagnosis of exclusion; this is especially true in children, in whom dominant transmission is usual. MRI of the brain and spinal cord is usually normal. The differential diagnosis includes multiple sclerosis, structural abnormalities involving the spinal cord, vitamin B₁₂ deficiency, adrenomyeloneuropathy and other leukodystrophies, and dopa-responsive dystonia. The diagnosis of HSP is suspect in any child with slowly progressive spastic paraplegia. Laboratory studies are not helpful except to exclude other conditions, such as spinal cord compression, adrenoleukodystrophy, and argininemia. DNA-based diagnosis is available on a clinical or a research basis for many of the subtypes.

MANAGEMENT. Many centers use botulinum toxin A (Botox) injections to relieve spasticity. My own experience with Botox is less than enthusiastic. Many patients require ankle-foot orthoses to improve gait. Treatment is not available for the underlying condition.

Autosomal Recessive Inheritance

Autosomal recessive inheritance of HSP may be pure or complicated. Both forms are genetically heterogeneous. Autosomal recessive cases account for 25% of the total.

CLINICAL FEATURES. Spastic paraplegia may begin during infancy or be delayed until adolescence. Involvement of other neurological systems follows. The common associated features, alone or in combination, include cerebellar dysfunction, pseudobulbar palsy, sensory neuropathy, and pes cavus. Children with sensory neuropathy lose the once hyperactive tendon reflexes in the legs. Some children show developmental delay and never achieve bladder control. When sensory loss is progressive, the symptoms resemble those of familial sensory neuropathies described in Chapter 9. The outcome varies from mild disability to wheelchair confinement.

DIAGNOSIS. In the absence of a family history, the course of disease may suggest CP until the progressive nature of the spasticity is recognized. Sensory neuropathy with mutilation of digits may lead to the erroneous diagnosis of syringomyelia. Laboratory tests are useful only to exclude other diagnoses. Argininemia, a treatable cause of autosomal recessive progressive spastic paraplegia, is a consideration (Prasad et al, 1997).

MANAGEMENT. No treatment is available for the underlying defect, but the sensory neuropathy requires supportive care (see Chapter 9).

Infections

Primary myelitis from acquired immunodeficiency syndrome (AIDS) is uncommon in children and not discussed in this section.

Diskitis (Disk Space Infection)

Disk space infection is a relatively uncommon disorder of childhood in which one disk space is infected secondary to subacute osteomyelitis of the adjacent vertebral bodies. The cause is bacterial infection. *Staphylococcus aureus* is the organism most often grown on culture of disk material removed by needle biopsy and is probably the major cause. The same organism rarely is isolated from cultures of the blood, however, because the infection is subacute, cultures are rarely positive, and biopsy is unnecessary.

CLINICAL FEATURES. The initial feature is either difficulty walking or back pain. Difficulty walking occurs almost exclusively in children younger than 3 years old. The typical child has a low-grade or no fever, is observed to be limping, and may refuse to stand or walk. This symptom complex evolves over 24 to 48 hours. Affected children prefer to lie on their sides rather than to rest supine, resist standing, and seem uncomfortable and walk with a shuffling gait. Examination shows loss of lumbar lordosis and absolute resistance to flexion of the spine. The hips or back are sometimes tender.

Pain as an initial feature occurs more often after 3 years of age. The pain may be abdominal or vertebral. When abdominal, the pain gradually increases in intensity and may radiate from the epigastrium to the umbilicus or pelvis. Abdominal pain in association with low-grade fever and an elevated peripheral white blood cell count invariably suggests the possibility of appendicitis or other intra-abdominal disease. Abdominal pain is the least common presenting feature.

Back pain is the most common complaint. Older children may indicate a specific area of pain and tenderness. Younger children may have only an abnormal posture intended to splint the painful area. Back pain usually leads to prompt diagnosis because attention is immediately directed to the spine. Examination reveals loss of lumbar lordosis and decreased movement of the spine, especially flexion.

DIAGNOSIS. Disk space infection is a consideration in all children who have sudden back pain

or refuse to walk and in whom neurological findings are normal. Strength, tone, and tendon reflexes in the legs are normal. Radiographs of the spine reveal narrowing of the affected intervertebral space, most often in the lumbar region but sometimes the C5-6 positions. MRI is the best imaging modality to show inflammation within the disk. It shows osteomyelitis of the surrounding vertebrae and of the disk space (Figure 12-2).

MANAGEMENT. Antibiotics are effective in treating the infection. Initiate intravenous anti-staphylococcal antibiotics as soon as diagnostic confirmation is complete. After 2 to 5 days, use the oral route, then continue antibiotics on an outpatient basis. Immobilization is not necessary because children are nearly asymptomatic when discharged from hospital.

Herpes Zoster Myelitis

Immunosuppressed individuals may experience reactivation of the varicella-zoster virus that had been latent in sensory ganglia after primary chickenpox infection.

CLINICAL FEATURES. The spinal cord becomes involved within 3 weeks after a truncal rash appears. The myelopathy usually progresses for 3 weeks, but progression may last 6 months in people with AIDS. Cord involvement is bilateral in 80% of cases.

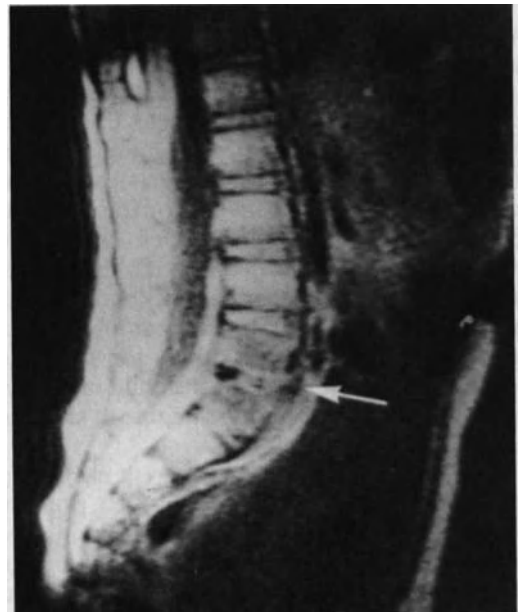

Figure 12-2. Diskitis. MRI reveals collapse of the disk space (arrow) and demineralization of the adjoining vertebral bodies.

DIAGNOSIS. Diagnosis depends on recognition of the characteristic herpetic rash at the dermatomal level of the myelitis. The myelitis sometimes precedes the onset of rash. Images of the spine are required to exclude other causes. The CSF shows a pleocytosis and protein elevation that is greatest at the time of maximal neurological deficit.

MANAGEMENT. Treatment with corticosteroids and acyclovir is a standard practice, although their benefit is uncertain.

Tuberculous Osteomyelitis

Tuberculosis causes vertebral infection by hematogenous dissemination. Any level of the vertebral column may be affected. The infection usually begins in one vertebral body, then spreads to adjacent vertebrae and the surrounding soft tissue. Fewer than 20% of patients with tuberculous osteomyelitis have symptoms of spinal cord dysfunction. The pathophysiological mechanisms include epidural abscess, arteritis, and vertebral collapse. In addition, tuberculous granuloma of the spine may occur in the absence of vertebral disease.

CLINICAL FEATURES. Tuberculosis of the vertebrae and spine is primarily a disease of children and young adults. Young children with vertebral osteomyelitis not extending to the spinal cord may refuse to walk because of pain, and their symptoms may mimic paraplegia. The prominent features are fever, anorexia, and back pain. In children younger than 10 years old, infection is generally diffuse, affecting several vertebrae and adjacent tissues. Older children tend to have localized infection, but with a higher incidence of spinal cord compression. The symptoms and signs of spinal cord compression from tuberculosis are similar to those described for epidural abscess except that progression is slower.

DIAGNOSIS. The CSF is usually under pressure and shows a pleocytosis with polymorphonuclear leukocytes predominating early in the course and lymphocytes predominating in later stages. The total cell count rarely exceeds 500 cells/mm³. Protein concentrations are elevated, and glucose concentrations are depressed. Stained smears show acid-fast organisms, and the organism can be isolated on cultures of the CSF.

Early stages of vertebral osteomyelitis can be shown by a technetium bone scan or plain radiographs. The search for contiguous abscess requires MRI. As the disease progresses, radiographs reveal collapse of adjacent vertebrae and gibbus formation.

MANAGEMENT. Treatment of tuberculous osteomyelitis and meningitis are similar. The recommended drug combinations are oral isoniazid, intramuscular streptomycin, and oral rifampin. Continue streptomycin and rifampin therapy for 8 weeks after clinical improvement, and continue isoniazid for 2 years (Dutt and Stead, 1997).

Lupus Myelopathy

Transverse myelopathy is a rare complication of systemic lupus erythematosus. The usual features are back pain, rapidly progressive paraplegia, and bowel and bladder dysfunction. Sensory loss is not a constant feature. The protein concentration of the CSF is elevated. Recovery is poor, and mortality is high.

Metabolic Disorders

Adrenomyeloneuropathy

Adrenomyeloneuropathy is the most common phenotype of adrenoleukodystrophy, accounting for 40% to 50% of cases (Moser et al, 2002). The etiology is impaired ability to oxidize very-long-chain fatty acids (see Chapter 5). Genetic transmission is by X-linked inheritance.

CLINICAL FEATURES. Paraparesis begins after age 20 and is slowly progressive throughout adult life. Intellectual impairment is usual, and prolonged survival is the rule (van Geel et al, 1997). Most patients develop Addison's disease, which predates the paraparesis almost half of the time. A sensory neuropathy may be associated. Approximately 20% of female heterozygotes develop adrenomyeloneuropathy.

DIAGNOSIS. Multiple sclerosis is a common misdiagnosis among female heterozygotes. The demonstration of increased plasma concentrations of very-long-chain fatty acids is essential for diagnosis.

MANAGEMENT. Symptomatic males require regular assessment of adrenal function and corticosteroid replacement therapy for adrenal insufficiency. Corticosteroid replacement therapy has no effect on nervous system involvement. Bone marrow transplantation is an option for boys and adolescents who are in early stages of symptom with evidence of brain involvement on MRI. Bone marrow transplantation carries a 20% risk of morbidity and mortality and is not recommended for patients without MRI evidence of brain involvement (Shapiro et al, 2000). Dietary therapy and other pharmacological agents have not proved to be useful.

Arginase Deficiency

Argininase catalyzes the metabolism of arginine to ornithine and urea in the urea cycle. Genetic transmission of arginase deficiency is as an autosomal recessive trait. The assigned gene locus is on chromosome 6q23.

CLINICAL FEATURES. Motor and cognitive development slows in early childhood, then regresses. Most children develop a progressive spastic paraplegia or quadriplegia. Other features may include recurrent vomiting and seizures (Prasad et al, 1997).

DIAGNOSIS. The serum concentration of arginine is always elevated, and 90% of children have elevated blood concentrations of ammonia. Arginase is absent from red blood cells.

MANAGEMENT. Dietary protein restriction may slow the progression of the disorder and sometimes cause improvement.

Krabbe Disease

The early infantile form of Krabbe disease (globoid leukodystrophy) causes psychomotor regression (see Chapter 5) and a peripheral neuropathy (see Chapter 7). The disorder is due to mutations of the gene encoding glycosylceramidase (*GALC*) at chromosome site 14q31 (Wenger and Coppola, 2002).

A late-onset form of the disease, with onset from childhood to adolescence, may show only a pure spastic paraplegia or more often spastic paraplegia and visual loss. Many patients with late-onset disease are *compound heterozygotes*, having one copy of two different mutations associated with enzyme deficiency. Allogeneic hematopoietic stem cell transplantation slows the progress of late-onset disease (Krivit et al, 1998).

Neonatal Cord Infarction

Infarction of the spinal cord is a hazard in newborns undergoing umbilical artery catheterization. The artery of Adamkiewicz arises from the aorta at the level of T10-12 and is the major segmental artery to the thoracolumbar spinal cord. Placing the catheter tip between levels T8 and T11 may cause embolization of the artery resulting in acute and sometimes irreversible paraplegia. A similar syndrome occurs among premature or small-for-date newborns in the absence of catheterization. The mechanism in such cases is unknown, but hypotension may be causal.

Transverse Myelitis

Transverse myelitis is an acute demyelinating disorder of the spinal cord that evolves in hours or days. The incidence is 1 to 4 new cases/1 million people/year (Transverse Myelitis Consortium Working Group, 2002). The age distribution shows peaks in the teens and 30s. It may occur alone or in combination with demyelination in other portions of the nervous system. The association of transverse myelitis and optic neuritis is *Devic disease*; acute demyelination throughout the neuraxis is *diffuse encephalomyelitis*. These terms are descriptive and do not suggest an underlying cause.

Multiple sclerosis is usually suspected in adults with transverse myelitis, although only 20% eventually have other demyelinating lesions. Multiple sclerosis is uncommon in childhood, and the initial feature is more likely to be cerebellar or extraocular dysfunction than myelitis (see Chapter 10).

The belief is widely held by many specialists that a prior infectious illness or immunization causes transverse myelitis, especially encephalomyelitis, in children. No evidence supports this belief. School-age children average four to six "viral" episodes annually. Half of children with any illness report a history of a viral infection within the preceding 30 days. Similarly, despite several case reports, no established cause-and-effect relationship exists between any licensed vaccines and demyelinating disorders of the central nervous system.

CLINICAL FEATURES. Mean age at onset is 9 years. Symptoms progress rapidly, attaining maximal deficit within 2 days. The level of myelitis is usually thoracic and demarcated by the sensory loss. Asymmetrical leg weakness is common. The bladder fills and does not empty voluntarily. Tendon reflexes may be increased or reduced. Recovery begins after 6 days but may be incomplete. Visual acuity is checked daily because of the possibility of Devic disease. Of patients, 50% make a full recovery, 10% have no recovery, and 40% recover incompletely. Most resume walking, but many continue to have sensory disturbances.

Several children have a relapsing myelitis in which attacks of acute myelitis recur over months or years. None develop multiple sclerosis or more disseminated disease. Recovery after each attack may be complete.

DIAGNOSIS. MRI of the spine excludes acute cord compression and sometimes shows swelling at the level of myelitis. Cranial MRI excludes

disease that is more widespread. CSF pleocytosis, elevated IgG index, or gadolinium enhancement verifies spinal cord inflammation.

MANAGEMENT. Corticosteroid use is the recommended treatment despite the absence of controlled studies. The recommended protocol is high-dose intravenous therapy followed by tapering doses of prednisone.

Devic Disease (Neuromyelitis Optica)

Devic disease is a distinct disorder that occurs mainly in children and is not part of the spectrum of multiple sclerosis. No cause is determined in most children with Devic disease. A temporal association between pulmonary tuberculosis and Devic disease occurs in adolescents and adults. In these cases, the neurological disease seems to be an immune reaction to tuberculosis and not caused by antituberculous therapy.

CLINICAL FEATURES. A history of anorexia or a flulike syndrome a few days or a week before the first neurological symptoms is common. The anorexia and fever may be part of the acute demyelinating illness rather than a viral infection. Myelitis precedes optic neuritis in 13% of patients and follows it in 76%; myelitis and neuritis occur simultaneously in 10%. Optic neuritis and transverse myelitis generally occur within 1 week of each other. The child remains irritable while the neurological symptoms are evolving.

Bilateral optic neuritis occurs in 80% of patients (see Chapter 16). Diminished visual acuity in both eyes may be present at onset, or one eye may become affected before the other. Loss of vision is acute and accompanied by pain. Blindness is often complete within hours. The initial ophthalmoscopic examination may have normal results but more often shows swelling of the disk. The pupils dilate, and the light response is sluggish.

Back pain and leg discomfort herald myelitis. The legs become weak, and the patient has difficulty standing and walking. Paraplegia becomes complete; it is first flaccid, then becomes spastic. Tendon reflexes first diminish, then later become brisk and are associated with extensor plantar responses. The bladder is spastic, and the patient has overflow incontinence. In some patients, one detects a sensory level, but more often, the sensory deficit is patchy and difficult to delineate in an irritable child. The course is variable. Some patients develop an encephalomyelitis (see following section on diffuse en-

cephalomyelitis), some have permanent paraplegia, and some have a relapsing course with repeated episodes of myelitis (Wingerchuk and Weinshenker, 2003). Most children recover but not always completely.

DIAGNOSIS. MRI of the spine excludes spinal cord compression syndrome, and MRI of the head excludes other demyelinating lesions (Figure 12-3). The CSF in children with Devic disease is usually abnormal. The protein content is mildly to moderately increased, and a mixed pleocytosis of neutrophils and mononuclear cells is present.

MANAGEMENT. A course of corticosteroids is usual for children with Devic disease. Although the value of corticosteroids is not established, most physicians believe they are beneficial. The regimen is the same as for diffuse encephalomyelitis. Bladder care with intermittent catheterization is imperative, as are measures to prevent bedsores and infection. The family and the child often need psychological counseling.

Diffuse Encephalomyelitis

Diffuse encephalomyelitis also is discussed in the section on Devic disease and in Chapter 2. The major clinical difference from Devic disease is that the cerebral hemispheres and the spinal cord are affected. Cerebral demyelination may

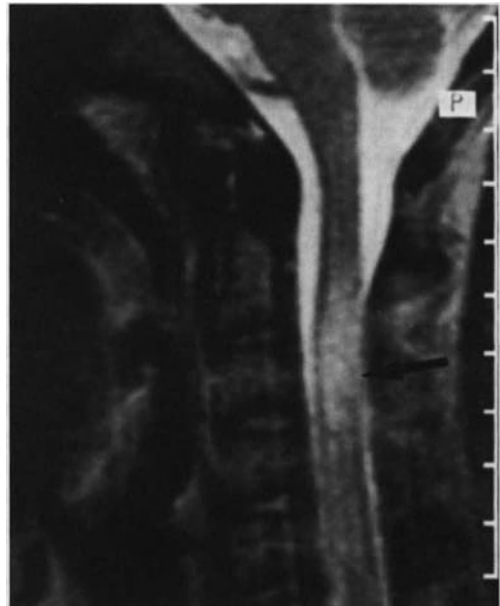

Figure 12-3. Demyelination of the spinal cord in an adolescent girl with multiple sclerosis.

precede, follow, or occur concurrently with the myelitis.

CLINICAL FEATURES. In addition to the myelitis, an encephalopathy characterized by decreased consciousness, irritability, and spastic quadriplegia occurs. If the brainstem is affected, dysphagia, fever, cranial nerve palsies, and irregular respiration are present.

DIAGNOSIS. MRI is required to appreciate the full extent of demyelination. The cerebral hemispheres, cerebellum, and brainstem contain multiple white matter lesions that become confluent (see Figure 2-2). Measures of very-long-chain fatty acids exclude adrenoleukodystrophy.

MANAGEMENT. Most authorities agree with the use of corticosteroids. Prednisone, 2 mg/kg/day (not to exceed 100 mg), or its equivalent in a parenteral form is the initial dose, which is tapered over a 4-week period, depending on the response. The benefit of such a course of therapy is not established, and some patients become corticosteroid dependent and relapse after stopping prednisone. Such children require long-term alternate-day therapy.

Trauma

Spinal cord injuries are relatively rare, especially before adolescence. The major cause is motor vehicle accidents, followed by sports-related injuries. The injuries affect the cervical spinal cord in 65% of cases before 15 years of age and in 71% of cases before 9 years of age. Fifteen percent of patients have injuries at multiple levels. Neurological function that is intact immediately after the injury remains intact afterward. Even patients with incomplete function are likely to recover completely. Evidence of complete transection on initial examination indicates that paralysis is permanent.

Compressed Vertebral Body Fractures

CLINICAL FEATURES. Compression fractures of the thoracolumbar region occur when a child jumps or falls from a height greater than 10 feet and lands in a standing or sitting position. Transection of the spinal cord has not occurred, but spinal cord concussion may cause paraplegia. Back pain at the fracture site is immediate and intense. Nerve root compression causes pain that radiates into the groin and legs.

DIAGNOSIS. Thoracolumbar radiographs reveal the fracture. MRI of the spinal cord is normal.

MANAGEMENT. Immobilization relieves the back pain and promotes healing of the fracture.

Fracture-Dislocation and Spinal Cord Transection

Motor vehicle accidents are the usual cause of spinal cord transection from fracture-dislocation of the vertebral column injury. A forceful flexion of the spine fractures the articular facets and allows the vertebral body to move forward or laterally, with consequent contusion or transection of the spinal cord. The common sites of traumatic transection are C1-2, C5-7, and T12-L2.

CLINICAL FEATURES. Neurological deficits at and below the level of spinal cord contusion or transection are immediate and profound. Many children with fracture-dislocations sustained head injuries at the time of trauma and are unconscious. Immediately after the injury, the child has flaccid weakness of the limbs below the level of the lesion associated with loss of tendon and cutaneous reflexes (spinal shock). In high cervical spinal cord lesions, eliciting the knee and ankle tendon reflexes, anal reflex, and plantar response may be possible during the initial period of spinal shock. Spinal shock lasts for approximately 1 week in infants and young children and 6 weeks in adolescents.

First, the superficial reflexes return, then the plantar response becomes one of extension, and finally massive withdrawal reflexes (mass reflex) appear. Trivial stimulation of the foot or leg triggers the mass reflex, usually in a specific zone unique to the patient. The response at first is dorsiflexion of the foot, flexion at the knees, and flexion and adduction at the thighs. Later, contractions of the abdomen, sweating, piloerection, and emptying of the bladder and bowel occur. During this time of heightened reflex activity, the tendon reflexes return and become exaggerated.

Below the level of injury, sensation is lost to a variable degree, depending on the completeness of the transection. When the injury is incomplete, sensation begins to return within weeks and may continue to improve for 2 years. Patients with partial or complete transections may complain of pain and tingling below the level of injury. In addition to the development of a small, spastic bladder, autonomic dysfunction includes constipation, lack of sweating, orthostatic hypotension, and disturbed temperature regulation.

DIAGNOSIS. Radiographs of the vertebrae readily identify fracture-dislocations. Imaging of the spinal cord provides further information on the presence of compressive hematomas and the structural integrity of the spinal cord (Figure 12-4). The presence of a complete block on mye-

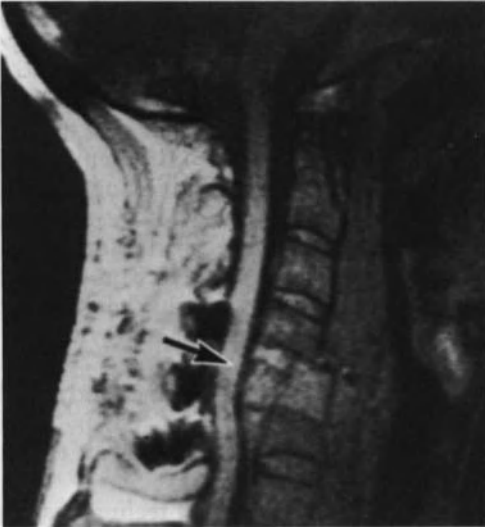

Figure 12-4. Fracture-dislocation. C4 is dislocated on C5, causing compression (arrow) of the cord.

lography indicates a poor prognosis for return of function.

MANAGEMENT. The immediate treatment of fracture-dislocation is to reduce the dislocation and prevent further damage to the cord by the use of corticosteroids, surgery, and immobilization. An intravenous infusion of methylprednisolone, 30 mg/kg within the first 8 hours after injury followed by 4 mg/kg/hr for 23 hours, significantly reduces neurological morbidity. Discussion of the long-term management of spinal cord injuries is beyond the scope of this text. Specialized centers provide the best results.

Spinal Cord Concussion

A direct blow on the back may produce a transitory disturbance in spinal cord function. The cause of dysfunction is edema (spinal shock); the spinal cord is intact.

CLINICAL FEATURES. Most injuries occur at the level of the cervical cord or the thoracolumbar juncture. The major clinical features are flaccid paraplegia or quadriplegia, a sensory level at the site of injury, loss of tendon reflexes, and urinary retention. Recovery begins within a few hours and is complete within 1 week.

DIAGNOSIS. At the onset of weakness, a spinal cord compression syndrome, such as epidural hematoma, is a consideration, and an imaging study of the spine is necessary.

MANAGEMENT. See the section on fracture-dislocation and spinal cord transection for the indications for methylprednisolone treatment.

Spinal Epidural Hematoma

Spinal epidural hematoma usually results from direct vertebral trauma and is especially common in children with an underlying bleeding tendency. The hematoma causes symptoms by progressive compression of the cord, and the clinical features are similar to any other extradural mass lesion. MRI is usually the basis for diagnosis. Treatment is surgical evacuation.

Tumors of the Spinal Cord

Ewing's sarcoma accounts for nearly 20% of cases of spinal cord compression in children older than 5 years old, whereas neuroblastoma is the most common cause in younger children. Astrocytoma and ependymoma are the main primary tumors. Motor deficits, usually paraplegia, are an early feature in 86% of spinal cord tumors and back pain occurs in 63%.

Astrocytoma

Chapter 9 discusses the problems of differentiating cystic astrocytoma of the spinal cord from syringomyelia (see section on syringomyelia).

CLINICAL FEATURES. Astrocytomas are usually long and may extend from the lower brainstem to the conus medullaris. The initial features of multiple-segment spinal astrocytomas may occur in the arms or legs. Weakness of one arm is characteristic of one syndrome. Pain in the neck may be associated, but bowel and bladder function are normal. Examination shows mild spastic weakness of the legs. The solid portion of the tumor is in the neck, and its caudal extension is cystic.

Progressive spastic paraplegia, sometimes associated with thoracic pain, characterizes a second syndrome. Scoliosis may be associated. In these patients, the solid portion of the tumor is in the thoracic or lumbar region. When solid tumor extends into the conus medullaris, tendon reflexes in the legs may be diminished or absent, and bowel and bladder function are impaired.

Intra-axial tumors of the cervicomedullary junction are often low grade and have an indolent course. They may cause cranial nerve dysfunction or spinal cord compression. Difficulty swallowing and nasal speech are the main features of cranial nerve dysfunction (see Chapter 17).

DIAGNOSIS. MRI is the definitive diagnostic procedure. It allows visualization of the solid and the cystic portions of the tumor (Figure 12-5).

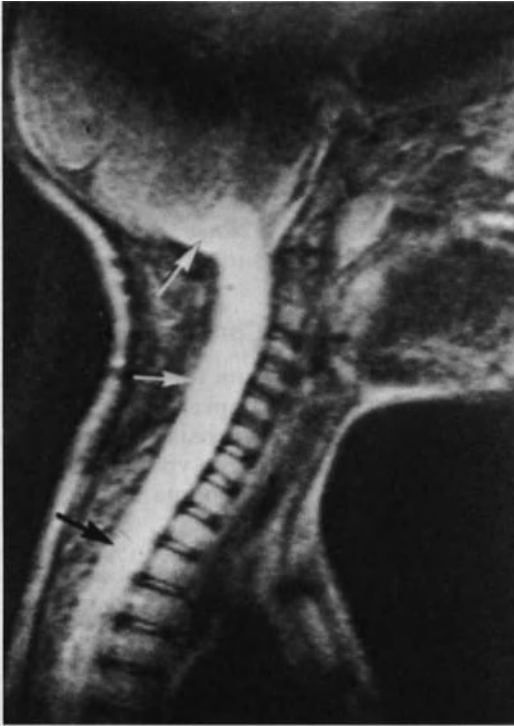

Figure 12-5. Astrocytoma of the cervical cord. The tumor shows an intense signal (arrows) on T_2 -weighted images.

MANAGEMENT. Evaluating proposed treatment options is difficult because the natural history of the tumor is one of slow progression. The 5-year survival rate with low-grade astrocytoma is greater than 90%. Complete resection should be attempted using microsurgical technique. Remove the solid portion, and aspirate the cystic portion. MRI is repeated 1, 6, and 12 months after surgery. The benefits of radiation therapy, either after resection or at the time of recurrence, are not established.

Ependymoma

Ependymomas are composed primarily of ependymal cells and arise from the lining of the ventricular system or central canal. They are more often intracranial than intraspinal in children. When intraspinal, they tend to be located in the lumbar region or in the cauda equina, but may occur anywhere along the neuraxis.

CLINICAL FEATURES. Clinical features vary with the location of the tumor. The initial feature may be scoliosis, pain in the legs or back, paresthesia, or weakness in one or both legs. Delay in diagnosis is frequent when scoliosis is the only sign. Eventually, all children have difficulty

walking, and this feature usually leads to appropriate diagnostic testing.

Stiff neck and cervical pain that is worse at night are the early features of cervical ependymomas. Tumors of the cauda equina may rupture sometimes and produce meningismus, fever, and pleocytosis, mimicking bacterial meningitis. Spastic paraplegia is the usual finding on examination. Cervical tumors cause weakness of one arm as well. Tumors of the cauda equina produce flaccid weakness and atrophy of leg muscles associated with loss of tendon reflexes.

DIAGNOSIS. MRI is the primary modality for imaging tumors of the spinal cord. Lumbar puncture, when indicated, shows an elevated protein content in the CSF.

MANAGEMENT. Microsurgical techniques make possible the complete removal of intramedullary ependymomas. The role of postoperative local radiation therapy in treating benign tumors is uncertain. Malignant ependymomas of the spinal cord are unusual in children but require total neuraxis irradiation when present.

Neuroblastoma

Neuroblastoma is the most common extracranial solid tumor of infancy and childhood. Neurological dysfunction results from direct invasion, metastasis, and distant “humoral” effects (see Chapter 10). Half of cases occur before 2 years of age, and 60% occur before 1 year. The derivation of neuroblastoma is cells of the sympathetic chain and cranial ganglia. Tumors in a paraspinal location may extend through a neural foramen and compress the spinal cord.

CLINICAL FEATURES. Paraplegia is the initial manifestation of neuroblastoma extending into the epidural space from a paravertebral origin. Because most affected children are infants, the first symptom is usually refusal to stand or walk. Mild weakness may progress to complete paraplegia within hours or days. Examination generally reveals a flaccid paraplegia, a distended bladder, and exaggerated tendon reflexes in the legs. Sensation may be difficult to test.

DIAGNOSIS. Chest radiographs usually show the extravertebral portion of the tumor. MRI delineates the extent of spinal compression.

MANAGEMENT. In children with acute spinal cord compression, high-dose corticosteroids, before surgical extirpation and radiation therapy, provides some symptomatic relief. The survival rate in infants with neuroblastoma confined to a single organ is greater than 60%.

Cerebral Paraplegia and Quadriplegia

Almost all progressive disorders of the brain that result in quadriplegia also have dementia as an initial or prominent feature (see Chapter 5). Pure paraplegia of cerebral origin is unusual. The patient at least has impairment of fine finger movements and increased tendon reflex activity in the arms. Pure paraplegia always should direct attention to the spinal cord.

Cerebral Palsy

CP is a nonprogressive disorder of posture or movement caused by a lesion of the developing brain (Ashwal et al, 2004). The prevalence of moderately severe cases is approximately 2:1000 live births; the prevalence of CP has increased among small premature infants as more have survived. Reduced life expectancy is the norm in children with CP who are immobile, profoundly retarded, or require special feeding (Strauss et al, 1998). Otherwise, children with CP may live well into adulthood. CP is often a misdiagnosis for several slowly progressive disorders (Table 12-2). Perinatal asphyxia is a known cause of CP but accounts for only a few cases. Prenatal factors are a more important cause but are difficult to identify with precision in an individual patient. In general, head MRI is appropriate in every child with CP to identify the brain abnormality. In contrast,

only selected patients require metabolic and genetic evaluations.

CP is not always a permanent condition. Many infants with only mild motor impairments improve and achieve normal motor function in childhood; 25% of such children are retarded or have some behavioral or cognitive disturbance. Traditionally the classification of CP is by the pattern of motor impairment. The spastic types are paraplegia or diplegia, quadriplegia, and hemiplegia (see Chapter 11). The hypotonic types are ataxic (see Chapter 10) and athetoid (see Chapter 14).

Spastic Diplegia (Paraplegia)

Diplegia means weakness of all four limbs, but that the legs are weaker than the arms. The motor impairment in the arms may be limited to increased responses of tendon reflexes; the classification of such children is *paraplegia*. Periventricular leukomalacia is the usual cause of spastic diplegia in children born prematurely. Cystic lesions in the white matter are often unilateral or at least asymmetrical, causing a hemiplegia superimposed on spastic diplegia.

CLINICAL FEATURES. Many children with spastic diplegia have normal tone, or even hypotonia, during the first 4 months. The onset of spasticity in the legs is insidious and slowly progressive during the first year. Four-point creeping is impossible because of leg extension. Infants achieve movement either by rolling or by crawling on the floor with the belly on the ground. The milestone of sitting up alone is achieved late or never achieved. From the supine position, the infant pulls to a standing rather than a sitting position. Later, bending forward at the waist, to compensate for the lack of flexion at the hip and knee, and placing one hand on the floor for balance accomplishes sitting posture. Most children with spastic diplegia stand on their toes, with flexion at the knees and an increased lumbar lordosis. Leg spasticity makes walking difficult but is achievable by throwing the body forward or from side to side to transfer weight.

Examination shows spasticity of the legs and less spasticity of the arms. All limbs show exaggerated tendon reflexes. Reflex sensitivity and responsiveness are increased; percussion at the knee causes a crossed adductor response. Ankle clonus and an extensor plantar response are usually present. When the infant is vertically suspended, the legs cross at the thigh because of strong adductor muscles contractions (*scissoring*). Subluxation or dislocation of the hips is relatively common in children with severe

TABLE 12-2
Slowly Progressive Disorders Sometimes Misdiagnosed as Cerebral Palsy

Condition	Chapter
Polyneuropathy	
GM ₁ gangliosidosis type II	5
Hereditary motor and sensory neuropathies	7
Infantile neuroaxonal dystrophy	5
Metachromatic leukodystrophy	5
Ataxia	
Abetalipoproteinemia	10
Ataxia-telangiectasia	10
Friedreich ataxia	10
Spasticity-Chorea	
Familial spastic paraplegia	12
Glutaric aciduria type I	14
Lesch-Nyhan syndrome	5
Niemann-Pick disease type C	5
Pelizaeus-Merzbacher disease	5
Rett syndrome	5

spasticity; the cause in part is from the constant adduction of the thighs and by insufficient development of the hip joint resulting from delayed standing or inability to stand.

DIAGNOSIS. Spastic diplegia is a clinical diagnosis. MRI easily identifies abnormalities in the deep white matter secondary to periventricular leukomalacia, but children with a known history of perinatal distress secondary to prematurity do not require follow-up imaging studies. It is important not to mistake CP for a progressive disease of the brain or cervical portion of the spine. Features that suggest a progressive disease are a family history of CP, deterioration of mental function, loss of motor skills previously obtained, atrophy of muscles, and sensory loss.

MANAGEMENT. There are probably as many methods to manage spastic diplegia and quadriplegia as there are children with CP. In general, a multidisciplinary approach, including infant stimulation, physical therapy, and occupational therapy, helps the child achieve an adequate functional status. Controlled clinical trials are rarely accomplished, and one such trial concluded that physical therapy offered no short-term advantage. Most drugs to relieve spasticity have marginal benefit and often cause unacceptable sedation. Levodopa improves motor function without sedation (Brunstrom et al, 2000).

Injections of botulinum toxin and selective posterior rhizotomy are useful procedures for the treatment of spasticity. Try botulinum toxin first. Children younger than 8 years show the best results of selective posterior rhizotomy. Surgery also is useful to relieve contractures, but requires thoughtful planning so that only one procedure is required. Initiate a program of physical therapy that maintains the desired range of motion postoperatively.

Spastic Quadriplegia

In spastic quadriplegia, all limbs are affected, the legs often more severely than the arms. The term *double hemiplegia* is applied if the arms are worse than the legs. Intrauterine disease, usually malformations, is the cause of most spastic quadriplegia. Hypoxic-ischemic encephalopathy of the term newborn accounts for a few cases.

CLINICAL FEATURES. Developmental delay is profound, and identification of the infant as neurologically abnormal occurs early. Failure to meet motor milestones, abnormal posturing of the head and limbs, and seizures are the common reasons for neurological evaluation. In severely affected children, the characteristic supine pos-

ture is retraction of the head and neck, flexion of the arms at the elbows with the hands clenched, and extension of the legs. Infantile reflexes (Moro and tonic-neck) are obligatory and stereotyped and persist after 6 months of age. Microcephaly is frequently an associated feature.

Because of damage to both hemispheres, supranuclear bulbar palsy (dysphagia and dysarthria) is common. Disturbances in vision and ocular motility are frequently associated features. Seizures occur in 50% of affected children.

DIAGNOSIS. The clinical findings are the basis for diagnosis. Laboratory studies are useful when the underlying cause is not obvious or the possibility of a genetically transmitted defect exists. MRI of the brain is especially useful to show malformations.

MANAGEMENT. Treatment is the same as described in the section on spastic diplegia (paraplegia).

References

- Ashwal S, Russman BS, Blasco PA, et al. Practice parameter. Diagnostic assessment of the child with cerebral palsy. Report of the Quality Standards Subcommittee of the American Academy of Neurology and the Practice Subcommittee of the Child Neurology Society. *Neurology* 2004;62:851-863.
- Brunstrom JE, Bastian AJ, Wong M, et al. Motor benefit from levodopa in spastic quadriplegic cerebral palsy. *Ann Neurol* 2000;47:662-665.
- Cornette L, Verpoorten C, Lagae L, et al. Tethered cord syndrome in occult spinal dysraphism. Timing and outcome of surgical release. *Neurology* 1998;50:1761-1765.
- Crockard HA, Stevens JM. Craniovertebral junction anomalies in inherited disorders. Part of the syndrome or caused by the disorder? *Eur J Pediatr* 1995;154:504-512.
- Dutt AK, Stead W. Tuberculosis. *Dis Mon* 1997;43:247-276.
- Fink JK. Hereditary spastic paraplegia. Nine genes and counting. *Arch Neurol* 2003;60:1045-1049.
- Fink JK. (26 February 2004) Hereditary spastic paraplegia overview. In: *GeneClinics: Medical Genetics Knowledge Base*. [database online] University of Washington, Seattle. Available at <http://www.geneclinics.org>.
- Greenlee JDW, Donovan, KA, Hasan DM, et al: Chiari I malformation in the very young child. The spectrum of presentations and experience in 31 children under age 6 years. *Pediatrics* 2002;110:1212-1219.
- Krivit W, Shapiro EG, Peters C, et al. Hematopoietic stem-cell transplantation in globoid-cell leukodystrophy. *N Engl J Med* 1998;338:1119-1126.
- Lynch SA, Wang Y, Strachan T, et al. Autosomal dominant sacral agenesis. Currarino syndrome. *J Med Genet* 2000;37:561-566.
- Moser HW, Moser AB, Steinberg SJ. (26 August 2002) X-Linked Adrenoleukodystrophy. In: *GeneClinics: Medical Genetics Knowledge Base*. [database online] University of Washington, Seattle. Available at <http://www.geneclinics.org>.

- Prasad AN, Breen JC, Ampola MG, et al. Argininemia. A treatable genetic cause of progressive spastic diplegia simulating cerebral palsy. Reports and literature review. *J Child Neurol* 1997;12:301-309.
- Shapiro E, Krivit W, Lockman L, et al. Long-term effect of bone-marrow transplantation for childhood-onset cerebral X-linked adrenoleukodystrophy. *Lancet* 2000;356:713-718.
- Strauss DJ, Shavelle RM, Anderson TW. Life expectancy of children with cerebral palsy. *Pediatr Neurol* 1998;18:143-149.
- Transverse Myelitis Consortium Working Group. Proposed diagnostic criteria and nosology of acute transverse myelitis. *Neurology* 2002;59:499-505.
- Tulipan N, Hernanz-Schulman M, Bruner JP. Reduced hind-brain herniation after intrauterine myelomeningocele repair. A report of four cases. *Pediatr Neurosurg* 1998;29:274-278.
- van Geel BM, Assies J, Wanders RJA, et al. X linked adrenoleukodystrophy. Clinical presentation, diagnosis, and therapy. *J Neurol Neurosurg Psychiatry* 1997;63:4-14.
- Wenger DA, Coppola S. (25 November 2002) Krabbe disease. In: *GeneClinics: Medical Genetics Knowledge Base*. [database online] University of Washington, Seattle. Available at <http://www.geneclinics.org>.
- Wingerchuk DM, Weinschenker BG. Neuromyelitis optica. Clinical predictors of a relapsing course and survival. *Neurology* 2003;60:848-853.

Chapter 13

Monoplegia

THE SPINE AND the proximal portion of nerves are the usual abnormal sites underlying flaccid weakness of one limb. Many conditions that cause paraplegia or quadriplegia begin as monoplegia. One also must consult the differential diagnosis of spinal paraplegia provided in Table 12-1 when considering monoplegia. In addition, several cerebral disorders that cause hemiplegia may begin as a monoplegia so that tables in Chapter 11 also are applicable.

Approach to Monoplegia

Either pain or weakness may cause refusal to use a limb. The cause of most painful limbs is injuries. Other causes are arthritis, infection, and tumor. A trivial pull on an infant's arm may dislocate the radial head and cause an apparent monoplegia. Pain and weakness together is a feature of plexitis.

Table 13-1 summarizes the differential diagnosis of acute monoplegia. Plexopathies and neuropathies are the leading causes of pure monoplegia. Stroke often affects one limb more than others, usually the arm more than the leg. The presentation may suggest monoplegia, but careful examination often reveals increased tendon reflexes and an extensor plantar response in the seemingly unaffected leg. Any suggestion of hemiplegia rather than monoplegia or increased tendon reflexes in the paretic limb should focus attention on the brain and cervical cord as the pathological site.

Chronic progressive brachial monoplegia is uncommon. When it occurs, one should suspect syringomyelia and tumors of the cervical cord or brachial plexus. Chronic progressive weakness of one leg suggests a tumor of the spinal cord or a neurofibroma of the lumbar plexus.

A monomelic form of spinal muscular atrophy, affecting only one leg or one arm, should be considered when progressive weakness is unaccompanied by sensory loss.

Spinal Muscular Atrophies

The first report of a monomelic form of spinal muscular atrophy was from Asia, but the condition is probably equally common among Europeans. The terms used to describe the entity are *benign focal amyotrophy* and *monomelic amyotrophy*. Although trauma and immobilization of the limb may precede the onset of atrophy by several months, a cause-and-effect relationship is not established.

The transmission of the familial form is by autosomal recessive inheritance. Two affected brothers had a mutation in the superoxide dismutase 1 gene. In one set of male identical twins, both developed atrophy of first one hand and then the other.

CLINICAL FEATURES. Onset is usually in the teens or 20s and has a male preponderance. The initial features are usually weakness and atrophy in one limb—the arm in 75% and the leg in 25%. Tendon reflexes in the involved limb are hypoactive or absent. Sensation is normal. The weakness and atrophy affect only one limb in half of cases and spread to the contralateral limb in the remainder. Tremor of one or both hands often is associated with the wasting. The appearance of fasciculations heralds weakness and wasting. Progression is slow, and spontaneous arrest within 5 years is the rule. Another limb may become weak, however, after a gap of 15 years.

DIAGNOSIS. Needle electromyogram (EMG) studies of all limbs are essential to show the

TABLE 13-1
Differential Diagnosis of Acute Monoplegia

Complicated migraine (see Chapter 11)
Dislocation of the radial head
Hemiparetic seizures (see Chapter 11)
Monomelic spinal muscular atrophy
Plexopathy and neuropathy
Acute neuritis
Asthmatic plexitis
Idiopathic plexitis
Osteomyelitis plexitis
Poliomyelitis (see Chapter 7)
Tetanus toxoid plexitis
Hereditary
Hereditary brachial neuritis
Hereditary neuropathy with liability to pressure palsy
Injury
Lacerations
Pressure injuries
Traction injuries
Stroke (see Table 11-2)

extent of involvement. Motor conduction is normal. Magnetic resonance imaging (MRI) of the spine and plexus is required to exclude a tumor.

MANAGEMENT. Physical therapy, occupational therapy, splinting, and bracing are the main treatment options.

Plexopathies

Acute Idiopathic Plexitis

Acute plexitis is a demyelinating disorder of the brachial or lumbar plexus thought to be immune mediated. Brachial plexitis is far more common than lumbar plexitis.

Brachial Plexitis

Brachial plexitis (brachial neuritis, neuralgic amyotrophy) occurs from infancy to adult life. Prior tetanus toxoid immunization has occurred in 10% to 20% of childhood and adult cases and in almost all infants. The site of immunization does not correlate with the limb involved.

CLINICAL FEATURES. The onset of symptoms is usually explosive. Pain is the initial feature in 95% of patients. Pain localization is to the shoulder but may be more diffuse or limited to the lower arm. Pain is severe. It may awaken the patient, and the description is "sharp, stabbing, throbbing, or aching." The duration of pain, which is frequently constant, varies from sev-

eral hours to 3 weeks. As the pain subsides, weakness appears. Weakness is in the distribution of the upper plexus alone in half of patients and the entire plexus in most of the rest. Lower plexitis alone is unusual. Although the initial pain abates, paresthesias may accompany the weakness. Two thirds of people report improved strength during the month after onset. Upper plexus palsies improve faster than do lower plexus palsies. Among all patients, approximately 30% recover within 1 year, 75% by 2 years, and 90% by 3 years. After 3 years, further improvement may occur, but permanent residua are expected. Recurrences are unusual and less severe than the initial episode.

DIAGNOSIS. Pain and weakness in one arm are also symptoms of spinal cord compression, indicating the need for spinal cord imaging studies. When the onset is characteristic of brachial plexus neuritis, however, the clinical features alone establish the diagnosis. Diagnostic tests are not essential. The cerebrospinal fluid (CSF) is usually normal. A slight lymphocytosis and mild elevation in protein content are sometimes noted. EMG and nerve conduction studies are helpful in showing the extent of plexopathy. Electrical evidence of bilateral involvement may be present in patients with unilateral symptoms.

MANAGEMENT. Corticosteroids do not affect the outcome. Range-of-motion exercises are recommended until strength recovers.

Lumbar Plexitis

Lumbar plexitis occurs at all ages and is similar to brachial plexitis except that it affects the leg instead of the arm. The mechanism is probably the same as in brachial plexitis.

CLINICAL FEATURES. Fever is often the first symptom, followed by pain in one or both legs. The pain has an abrupt onset and may occur in a femoral or sciatic distribution. Sciatica, when present, suggests disk disease. Young children refuse to stand or walk, and older children limp. Weakness may develop concurrently with pain or be delayed for 3 weeks. The onset of weakness is insidious and often difficult to date, but usually it begins 8 days after the onset of pain. Weakness progresses for 1 week, then stabilizes. Tendon reflexes are absent in the affected leg but are present in other limbs.

Recovery is characterized first by abatement of pain, then by increasing strength. The average time from onset of pain to maximal recovery is 18 weeks (range 8 weeks to several years). Functional recovery is almost universal, but mild weakness may persist.

DIAGNOSIS. The sudden onset of pain and weakness in one leg suggests spinal cord or disk disease. MRI of the spine is a means of excluding other disorders; the results are invariably normal in lumbar plexitis. The CSF is normal except for a mild elevation of the protein concentration. EMG performed 3 weeks after onset shows patchy denervation.

MANAGEMENT. Corticosteroids do not affect the outcome. Range-of-motion exercises are required to ensure the best recovery.

Acute Symptomatic Plexitis

Asthmatic Amyotrophy (Hopkins Syndrome)

Sudden flaccid paralysis of one or more limbs, resembling poliomyelitis, may occur during recovery from an asthmatic attack. All affected children had received poliomyelitis vaccine previously. The probable cause of the syndrome is an infection by a neurotropic virus other than poliovirus. Adenovirus, echovirus, and coxsackievirus have been isolated from stool, throat, or CSF in some cases.

CLINICAL FEATURES. Age at onset is 1 to 11 years, and the male-to-female ratio is 7:4. The interval between the asthmatic attack and the paralysis is 1 to 11 days, with an average of 5 days. Monoplegia occurs in 90%, with the arm involved twice as often as the leg. The other 10% have hemiplegia or diplegia. Meningeal irritation is not present. Sensation is intact, but the paralyzed limb is painful in half of cases. Recovery is incomplete, and all affected children have some degree of permanent paralysis.

DIAGNOSIS. Asthmatic amyotrophy is primarily a clinical diagnosis based on the sequence of events. The diagnosis requires distinction from paralytic poliomyelitis and idiopathic brachial neuritis. The basis for excluding paralytic poliomyelitis is normal CSF in asthmatic amyotrophy. A few white blood cells may be present in the CSF but never to the extent encountered in poliomyelitis, and the protein concentration is normal. EMG during the acute phase shows active denervation of the paralyzed limb, but the pattern of denervation does not follow the radicular distribution expected in a brachial neuritis.

MANAGEMENT. Treatment is symptomatic and includes analgesics for pain and physical therapy.

Hereditary Brachial Plexopathy

The two major phenotypes of *focal familial recurrent neuropathy* are hereditary brachial

plexopathy (also called *hereditary neuralgic amyotrophy*) and hereditary neuropathy with liability to pressure palsies (see section on mononeuropathies later). The phenotypes can be confused because isolated nerve palsies may occur in hereditary brachial plexopathy, and brachial plexopathy occurs in patients with hereditary neuropathy with a liability to pressure palsies. Transmission of both disorders is by autosomal dominant inheritance, but the underlying mutations are at different sites on chromosome 17. The location of the responsible gene for hereditary brachial plexopathy is chromosome 17q25 (Stögbauer et al, 2000).

CLINICAL FEATURES. Hereditary brachial plexopathy may be difficult to distinguish from idiopathic brachial plexitis in the absence of a family history or a patient's history of similar episodes. Events that may trigger an attack in genetically predisposed individuals include infection, emotional stress, strenuous use of the affected limb, and childbirth. Immunization, which may precipitate sporadic brachial plexopathies, is not a factor in the genetic form.

Two different courses exist with only one type per family suggesting the possibility of genetic heterogeneity (van Alfen et al, 2000). Characteristic of the *classic course* is severe attacks with relatively symptom-free intervals. Patients with the *chronic course* experience interictal persistence of pain and weakness. The initial attack usually occurs during the teens or 20s but may appear at birth. Attributing palsies at birth to trauma is common despite the positive family history. Weakness resolves completely, only to recur later.

Severe arm pain exacerbated by movement characterizes the attack. Weakness follows in days to weeks, which is usually maximal within a few days and always by 1 month. The entire plexus may be involved, but more often, only the upper trunk alone is affected. Even with total plexus involvement, the upper plexus is weaker than other parts. Examination shows proximal arm weakness. Distal weakness also may be present. Tendon reflexes are absent from affected muscles. Weakness persists for weeks to months and is associated with atrophy and fasciculations. Pain, which is frequently the only sensory finding, subsides after the first week.

Recovery begins weeks to months after attaining maximal weakness. Return of function is usually complete, although some residual weakness may persist after repeated attacks. The frequency of attacks is variable; several attacks may occur within a single year, but the usual pattern is two or three attacks per decade.

Occasional children have an episode of lumbar plexopathy. Pain in the thigh and proximal weakness are characteristic. Brachial and lumbar plexopathies are never concurrent, although bilateral brachial plexopathy is a relatively common event. Isolated cranial nerve palsies may occur in families with hereditary brachial plexopathy. The vagus nerve is the one most often affected and causes hoarseness and dysphagia. Other cranial neuropathies result in transitory facial palsy and unilateral hearing loss.

DIAGNOSIS. The family history, early age at onset, unique triggering events, recurrences, and involvement of other nerves differentiate hereditary brachial plexopathy from idiopathic brachial neuritis. EMG shows a diffuse axonopathy in the affected arm and some evidence of denervation in the asymptomatic arm. Asymptomatic legs are electrically normal.

MANAGEMENT. Corticosteroid use is not beneficial. Analgesics are useful at the onset of an attack. Range-of-motion exercises prevent contractures.

Neonatal Traumatic Brachial Neuropathy

The incidence of neonatal brachial plexus birth injuries is estimated at 1:1000 live births. It seems likely that the incidence has increased in recent years because of the societal and financial pressures to avoid cesarean section. The cause of obstetrical brachial plexus palsies is excessive traction on the plexus. Upper plexus injuries occur when pulling the head and arm away from each other; this occurs in the vertex position when the head is pulling forcefully to deliver the aftercoming shoulder or when normal contractions force the head and neck downward with the shoulder trapped by the pelvis. Injuries in the breech position occur when pulling the arm downward to free the aftercoming head or when rotating the head to occipitoanterior when the shoulder is fixed. Complete (upper and lower) plexus injuries occur during vertex deliveries when traction is exerted on a prolapsed arm and in breech deliveries when the trunk is pulled downward, but an aftercoming arm is fixed.

CLINICAL FEATURES. Most neonatal brachial plexus injuries occur in large full-term newborns of primiparous mothers, especially when the fetus is malpositioned and the delivery is long and difficult. The traditional division of brachial plexus injuries is into injuries involving the upper roots (named for *Erb* and *Duchenne*)

and injuries involving the lower roots (named for *Klumpke*). Solitary lower root injuries are unusual, however. In 88%, the palsy affects only the C5-7 cervical roots, and 12% have a complete plexus palsy. Bilateral, but not symmetrical, involvement occurs in 8% of cases.

Because the upper plexus (C5-7) is always involved, the posture of the arm is typical and reflects weakness of the proximal muscles. The arm is abducted and internally rotated at the shoulder and is extended and pronated at the elbow so that the partially flexed fingers face backward. Extension of the wrist is lost, and the fingers are fisted. The biceps and triceps reflexes are absent. Injuries that extend higher than the C4 segment result in ipsilateral diaphragmatic paralysis.

Newborns with complete brachial plexus palsies have flaccid, dry limbs with neither proximal nor distal movement. A Horner syndrome is sometimes associated. Sensory loss to pinprick is present with partial or complete palsies but may not conform to the segmental pattern of weakness.

DIAGNOSIS. Recognition of brachial plexus palsy is by the typical posture of the arm and by failure of movement when the Moro reflex is tested. Because the injury often takes place during a long and difficult delivery, asphyxia also may be present. In such cases, generalized hypotonia may mask the focal arm weakness. Approximately 10% of newborns with brachial plexus injuries have facial nerve palsy and fractures of the clavicle or humerus.

MANAGEMENT. The spontaneous recovery rate is approximately 70%. One goal of therapy is to prevent the development of contractures. Range-of-motion exercises prevent contractures, whereas splinting or other forms of immobilization cause them. Significant recovery occurs throughout the first year, but infants who show no improvement in strength at the end of 6 months are unlikely to show functional improvement later. Surgical reconstruction of the plexus (e.g., nerve grafts, neuroma excision) is a consideration in infants with no evidence of spontaneous recovery at 6 months. The benefit of reconstructive surgery is not established, however.

Osteomyelitis-Neuritis

Apparent limb weakness caused by pain is a well-recognized phenomenon. A true brachial neuritis may occur, however, in response to osteomyelitis of the shoulder. Ischemic nerve damage caused by vasculitis is the assumed mechanism.

CLINICAL FEATURES. Osteomyelitis-neuritis occurs predominantly during infancy. The initial feature is a flaccid arm without pain or tenderness. Body temperature may be normal at first but soon becomes elevated. Pain develops on movement of the shoulder, and tenderness to palpation follows. No swelling is present. The biceps and triceps reflexes may be depressed or absent.

DIAGNOSIS. Osteomyelitis of the proximal humerus is suspected when brachial plexitis develops during infancy. Radiographs of the humerus become abnormal at the end of the first week, when they show destruction of the lateral margin of the humerus, but radioisotope bone scan shows a focal area of uptake in the proximal humerus, the scapula, or both shortly after onset. After 3 weeks, EMG shows patchy denervation in the muscles innervated by the upper plexus. These results support the idea that this is a true plexitis and not just a painful limb.

Aspirates from the shoulder joint or blood culture identify the organism. Group B streptococci are often isolated in specimens from young infants. Older children have other bacterial species.

MANAGEMENT. Intravenous antibiotics are given for 3 to 4 weeks. Usually penicillin is the recommended antibiotic for treatment. Recovery of arm strength may be incomplete.

Postnatal Injuries

Brachial Plexus

Traction and pressure injuries of the brachial plexus are relatively common because of its superficial position. Motor vehicle and sports accidents account for most severe injuries. Mild injuries also occur in the following situations: (1) when an adult suddenly yanks a child's arm, either protectively or to force movement; (2) by a blow to the shoulder, such as in a football scrimmage or from the recoil of a rifle; (3) because of prolonged wearing of a heavy backpack; (4) when the arm is kept hyperextended during surgery; and (5) by pressure in the axilla from poorly positioned crutches.

CLINICAL FEATURES. Mild injuries do not affect all portions of the plexus equally. Diffuse weakness is uncommon. Pain may be an important initial feature, and sensory loss is uncommon. Recovery begins within days or weeks and is complete. Atrophy does not occur.

More severe injuries usually are associated with fractures of the clavicle and scapula and dislocation of the humerus. The upper plexus generally is affected more severely than is the lower plexus, but complete paralysis may be

present at the onset. Sensory loss is less marked than weakness, and the two may not correspond in distribution. Pain is common, not only from the plexopathy, but also from the bone and soft tissue injuries. The most painful injuries are injuries associated with root avulsion.

Tendon reflexes are absent, and atrophy develops in denervated muscle. Recovery progresses from proximal to distal, and the Tinel sign plots the recovery: tingling in the distal part of a limb caused by tapping over the regenerating segment of a nerve. Complete reinnervation, when it occurs, may take several months or years. The completeness of recovery depends on the severity and nature of the injury. Pressure and traction injuries in which anatomical integrity is not disturbed recover best, whereas injuries that tear the nerve or avulse the root do not recover at all.

DIAGNOSIS. EMG is useful in identifying the pattern of nerve injury and in providing information on the prognosis. Even with mild traction injuries, the amplitude of motor and sensory action potentials attenuates, and motor and sensory conduction slows.

MANAGEMENT. Mild injuries do not require treatment other than range-of-motion exercises. For more severe traction injuries, resting the limb for the first month is usually necessary. During that time, provide analgesia as needed for pain, and electrically stimulate muscles away from the site of injury, to maintain tone. Initiate range-of-motion exercises when pain subsides. Prompt correction is required of fractures and dislocations that cause pressure on the brachial plexus. Lacerated nerves require surgical restoration of anatomical integrity.

Lumbar Plexus

Injuries of the lumbar plexus are much less common than are injuries of the brachial plexus. The pelvis and the heavy muscles of the hip provide considerable protection from direct trauma.

CLINICAL FEATURES. Lumbar plexus injuries usually are associated with fracture-dislocation of the pelvis. Motor vehicle accidents or falls from a considerable height are required to produce sufficient force to fracture the pelvis. The patient usually has multiple injuries, and the lumbar plexus injury may be the last identified. Lumbar plexus injuries produce a patchy weakness that is difficult to differentiate from mononeuritis multiplex.

DIAGNOSIS. EMG helps distinguish plexus injuries and nerve injuries.

MANAGEMENT. Fracture-dislocations require treatment to relieve pressure on the plexus. As with brachial plexus injuries, the completeness of recovery depends on the anatomical integrity of the nerves.

Plexus Tumors

Plexus tumors in childhood are rare. The most common primary tumor is the plexiform neurofibroma (Figure 13-1). These can affect either the brachial or the lumbar plexus. They grow slowly and cause progressive but selected weakness over several years. Secondary tumors of the brachial plexus are the neuroblastoma and primitive neuroectodermal tumors arising in the chest. MRI visualizes plexus tumors when fat subtraction techniques are used.

Mononeuropathies

Radial Neuropathy

Radial nerve injuries usually occur in the spinal groove of the humerus, just below the takeoff of the motor branch to the triceps muscle. Injury may occur with fractures of the humerus or by external pressure. Such pressure usually results when a sleeping or sedated patient is in a position that compresses the nerve between the humerus and a hard surface, such as an operating room table or chair. Isolated radial nerve injuries may occur in newborns with a history of failure of progression of labor. These may

result from prolonged radial nerve compression (Hayman et al, 1999).

CLINICAL FEATURES. Wristdrop and drop finger are characteristic of injuries to the radial nerve within the spiral groove. The brachioradialis muscle may be weak, and its tendon reflex may be lost. Sensory disturbances are restricted to the back of the hand near the base of the thumb. With the wrist dropped, a fist is mechanically difficult to make, but the finger flexors are not weak.

DIAGNOSIS. Electrophysiological studies are useful for locating the site of injury and assessing the anatomical integrity of the nerve and the prognosis for recovery.

MANAGEMENT. Pressure injuries recover completely in 6 to 8 weeks. During that time, a splint is useful for placing the wrist in extension so that the patient can flex the fingers.

Ulnar Neuropathy

The most common site of ulnar injury is the elbow. This injury may result from external pressure, recurrent dislocation of the nerve from its groove, and fracture of the distal humerus.

CLINICAL FEATURES. Paresthesias on the ulnar side of the hand, the little finger, and the ring finger are experienced. Tapping the ulnar groove increases the discomfort. Hand strength is lost, and the intrinsic muscles become wasted. The little finger and the adjacent side of the ring finger have diminished or absent sensation.

DIAGNOSIS. Electrophysiological techniques localize the injury along the course of the nerve.

MANAGEMENT. Minor pressure injuries do not require treatment, and recovery is complete within a few weeks. Injuries to the elbow that cause fracture or nerve dislocation require surgical repair.

Median Neuropathy

The cause of nontraumatic median neuropathies is compression of the nerve in the carpal tunnel and traumatic injuries at the elbow. In children, a storage disease, such as mucopolysaccharidosis, may cause nerve compression in the carpal tunnel, but idiopathic cases occur as well. Fracture at the elbow is the usual cause of traumatic median neuropathy.

CLINICAL FEATURES. The most common features are numbness and pain in the hand. Nontraumatic median neuropathy is often bilateral. Weakness and atrophy are more likely to occur in traumatic injuries of the nerve than in carpal tunnel entrapment.

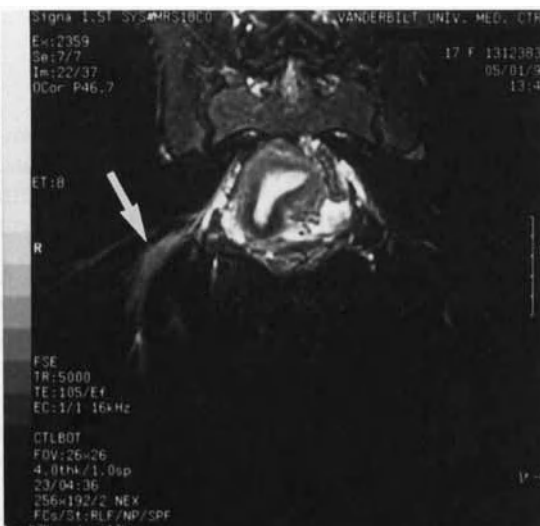


Figure 13-1. Neurofibroma of the lumbar plexus. MRI of the plexus using a subtraction technique shows enlargement of the sciatic nerve (arrow).

DIAGNOSIS. EMG is useful to localize the lesion, especially when surgical decompression is an option.

MANAGEMENT. Surgical decompression may be beneficial for nontraumatic and traumatic injuries.

Peroneal Neuropathy

The peroneal nerve lies in a superficial position adjacent to the fibula. External pressure readily compresses the nerve against the bone. This compression most often occurs in children who have undergone significant weight loss or trauma to the nerve. EMG documented a prenatal peroneal palsy, presumably caused by pressure, in one newborn (Jones et al, 1996).

CLINICAL FEATURES. The prominent feature is an acute, painless footdrop. Dorsiflexion and eversion of the foot are weak. Sensation is usually intact, but sometimes there is numbness over the lower lateral leg and dorsum of the foot. When only the deep branch of the peroneal nerve is involved, sensory loss is restricted to a small triangle between the first two toes. Complete or significant spontaneous recovery is the rule except after considerable trauma.

DIAGNOSIS. Electrodiagnosis is useful to discriminate peroneal nerve lesions from disturbances of the fifth lumbar root.

MANAGEMENT. A footdrop brace is a useful aid to walking until recovery is complete.

Hereditary Neuropathy with Liability to Pressure Palsy

The characteristic feature of hereditary neuropathy with liability to pressure palsy (also called *tomaculous neuropathy*) is the development of a mononeuropathy after trivial trauma. In some cases, the brachial plexus is affected. Transmission of the disorder is as an autosomal dominant trait, caused by deletion of the gene encoding peripheral myelin protein-22 caused by a deletion in chromosome 17p11.2 (Li et al, 2002).

CLINICAL FEATURES. The first episode usually occurs during the teens or 20s. Typical precipi-

tating factors include sleeping on a limb, body contact in sports, constrictive clothing, or positioning during surgery. Individuals quickly learn to avoid activities that provoke episodes. Superficial nerves (radial, ulnar, median, peroneal) are the ones most commonly affected. The resulting mononeuropathy is painless and affects motor and sensory fibers. Tendon reflexes are lost. Recovery is complete within days to weeks.

DIAGNOSIS. Except for the family history, the first episode might suggest ordinary pressure palsy, although the trivial nature of the trauma should alert the physician to the underlying neuropathy. Consider the diagnosis in children with repeated neuropathies or multifocal neuropathies even in the absence of a family history.

Molecular genetic testing establishes the diagnosis. Electrophysiological studies show slow conduction time, not only in the affected limb, but also in all limbs. Other family members may show generalized slowing of conduction between attacks.

MANAGEMENT. No treatment is available for the underlying neuropathy. Alterations in lifestyle may be needed to avoid pressure palsies. Treat acute episodes with physical therapy. Some patients eventually develop a generalized motor and sensory neuropathy.

References

- Hayman M, Roland EH, Hill A. Newborn radial nerve palsy. Report of four cases and review of published reports. *Pediatr Neurol* 1999;21:648-651.
- Jones HR Jr, Herbison GJ, Jacobs SR, et al. Intrauterine onset of a mononeuropathy. Peroneal neuropathy in a newborn with electromyographic findings at age one day compatible with prenatal onset. *Muscle Nerve* 1996;19:88-91.
- Li J, Krajewski K, Shy ME, et al. Hereditary neuropathy with liability to pressure palsy. The electrophysiology fits the name. *Neurology* 2002;58:1769-1773.
- Stögbauer F, Young P, Kühlenbaumer G, et al. Hereditary recurrent focal neuropathies. Clinical and molecular features. *Neurology* 2000;54:546-551.
- van Alfen N, van Engelen BGM, Reinders JWC, et al. The natural history of hereditary neuralgic amyotrophy in the Dutch population. Two distinct types? *Brain* 2000; 123:718-723.

Chapter 14

Movement Disorders

INVOLUNTARY MOVEMENTS ARE usually associated with abnormalities of the basal ganglia and their connections, and they occur in several different neurological disorders. Abnormal movements can be the main or initial features of disease, or they can occur as a late manifestation. This chapter discusses the former type.

Approach to the Patient

Movement disorders are not describable; they require visualization. If abnormal movements are not present at the time of examination, instruct the parents to videotape the movements at home. Some relatively common movements are recognizable by description, but the rich variety of abnormal movements and postures that may occur defies classification. The most experienced observer, at times, mistakes one movement for another or has difficulty conceptualizing the nature of an abnormal movement.

Many abnormal movements are paroxysmal or at least intermittent. Movement, startle, emotional upset, or sleep induces some movements. The physician should ask what makes the movement worse and if it is action induced. Ask children to perform the action during the examination. Paroxysmal movements raise the question of epilepsy. The concurrent presence of seizures and involuntary movements characterizes many neurological disorders of childhood. *Nocturnal paroxysmal dystonia*, previously thought to be a movement disorder, is actually a frontal lobe seizure (see Chapter 1). The clinical and conceptual distinction between spinal myoclonus and spinal seizures remains a gray area. The following guidelines are useful to distinguish involuntary movements from seizures:

1. Involuntary movements, with the exception of spinal myoclonus and periodic movements of sleep, abate or disappear during sleep; seizures persist or may worsen.
2. Involuntary movements usually have a more stereotyped appearance and, with the exception of acute drug reactions, are more persistent than seizures.
3. Seizures are often characterized by loss of consciousness or awareness; involuntary movements are not.
4. Seizures are usually accompanied by epileptiform activity on electroencephalogram (EEG); involuntary movements are not.

Involuntary contractions of a muscle that do not move a joint may be fasciculations, focal seizures, or myoclonus. Low-amplitude jerking movements that move a joint or muscles may be focal seizures, chorea, myoclonus, tics, or hemifacial spasm. High-amplitude jerking movements that move a limb or limbs may be seizures, ballismus, or myoclonus. Slow, writhing movements and abnormal posturing may be due to athetosis, dystonia, continuous motor unit activity (see Chapter 8), or seizures. The possible causes of rhythmic movements may be tremor, seizures, or myoclonus.

Chorea and Athetosis

Chorea is a rapid movement affecting any part of the body that often incorporates into a voluntary movement to hide it. The movements are random, but neither rhythmic nor stereotyped, and they migrate from side to side and limb to limb. Because the involuntary movement flows into a voluntary movement, it gives the appearance of

constant movement (restlessness). *Akathisia*, an inward compulsion to move (discussed later) also causes the appearance of restlessness. Depending on the condition, chorea may be unilateral or bilateral and may affect the face, trunk, and limbs. An observer cannot describe chorea precisely because it has no fixed form.

Chorea is more readily observed when separated from the superimposed voluntary movement that follows. Ask the child to raise both hands upward beside the head with the palms facing each other. Low-amplitude jerking movements occur that turn the arm into pronation. When the child lightly grips the examiner's fingers, the grip alternately tightens and loosens, as if the patient is "milking" the examiner's hands. Hypotonia is common in many conditions causing chorea. Tendon reflexes may be normoreactive, but at times, a choreic movement occurs during the patellar response, producing an extra kick.

Athetosis is a slow, writhing movement of the limbs that may occur alone but is often associated with chorea (*choreoathetosis*). The usual cause of athetosis without chorea is perinatal brain injury. Kernicterus previously was a major cause of chorea but is now a rare event. Perinatal asphyxia is now the predominant etiology. Many children with athetosis have atonic cerebral palsy, and others have spastic diplegia.

Ballismus is a high-amplitude, violent flinging of a limb from the shoulder or pelvis. It is an extreme form of chorea. In adults, it may occur in limbs contralateral to a vascular lesion in the subthalamic nucleus; in children, it is usually associated with chorea and seen in Sydenham chorea and lupus erythematosus.

Tardive dyskinesia is a complex syndrome usually characterized by buccolingual masticatory movements that include tongue protrusion, lip smacking, puckering, and chewing. It is rare in children. Dopamine antagonist drugs (neuroleptics and typical antiemetics) are the usual cause of tardive dyskinesia. It may be a subtype of chorea, or at least a related disorder, and sometimes is associated with choreic movements of the limbs. Most children thought to have developed tardive dyskinesia usually have motor tics.

Tables 14-1 and 14-2 summarize the differential diagnosis of chorea and choreoathetosis. Chorea is a cardinal feature of the conditions listed in Table 14-1. The details of many of these conditions are discussed in other chapters because concurrent features are more prominent. Although abnormal movements are the only manifestation, familial paroxysmal choreoathe-

TABLE 14-1
Differential Diagnosis of Chorea as an Initial or Prominent Symptom

Cardiopulmonary bypass surgery
Genetic disorders
Abetalipoproteinemia (see Chapter 10)
Ataxia-telangiectasia (see Chapter 10)
Benign familial chorea
Fahr disease
Familial paroxysmal choreoathetosis (see Chapter 1)
Glutaric aciduria
Hepatolenticular degeneration (Wilson disease)
Huntington disease (see Chapter 5)
Lesch-Nyhan syndrome (see Chapter 5)
Machado-Joseph disease (see Chapter 5)
Neuroacanthocytosis
Drug-induced movement disorders
Anticonvulsants
Antiemetics
Oral contraceptives
Psychotropic agents
Stimulants
Theophylline
Systemic conditions
Hyperthyroidism
Lupus erythematosus
Pregnancy (chorea gravidarum)
Sydenham (rheumatic) chorea
Tumors of cerebral hemisphere (see Chapter 4)

TABLE 14-2
Conditions That May Include Chorea

Alternating hemiplegia (see Chapter 11)
Bilateral striatal necrosis (see Dystonia)
Cerebral palsy
Congenital malformations (see Chapters 5 and 18)
Intrauterine disease (see Chapter 1)
Perinatal asphyxia (see Chapter 1)
Unknown causes
Genetic disorders
Ceroid-lipofuscinosis (see Chapter 5)
Idiopathic torsion dystonia
Incontinentia pigmenti (see Chapter 1)
Pantothenate kinase-associated neurodegeneration
Pelizaeus-Merzbacher disease (see Chapter 5)
Phenylketonuria (see Chapter 5)
Porphyria (see Chapter 7)
Infectious diseases
Bacterial meningoencephalitis (see Chapter 4)
Viral encephalitis (see Chapter 2)
Metabolic encephalopathies (see Chapter 2)
Addison disease
Burn encephalopathy
Hypernatremia
Hypocalcemia
Hypoparathyroidism
Vitamin B ₁₂ deficiency
Rett syndrome (see Chapter 5)
Vascular conditions
Moyamoya disease (see Chapter 11)
Poststroke (see Chapter 11)

tosis is described in Chapter 1 because it is more likely to be confused with epilepsy than with other causes of chorea.

Table 14-2 contains a partial list of conditions in which chorea and choreoathetosis may occur, but in which they are either late features or at least not prominent early in the course. Movement disorders are a relatively common feature of several cerebral degenerative disorders. In contrast, chorea and seizures may be confused when chorea develops during an acute illness, such as bacterial meningitis, metabolic encephalopathies, or encephalitis. At times, the movement disorder is due to the underlying brain disorder and at times to drugs used in treatment.

Cardiopulmonary Bypass Surgery

Severe choreoathetosis is a complication in 10% of children with congenital heart disease after cardiopulmonary bypass surgery and profound hypothermia. Deep hypothermia and circulatory arrest are not essential factors in the pathophysiology but are often associated. The mechanism of basal ganglia injury is unknown.

CLINICAL FEATURES. Most affected children are older than 1 year and have cyanotic heart disease with systemic-to-pulmonary collaterals. Choreoathetosis begins within 2 weeks postoperatively and may be associated with orofacial dyskinesias, hypotonia, affective changes, and pseudobulbar signs. Some children have only mild chorea that resolves spontaneously within 2 months. Others may have severe exhausting chorea, unresponsive to treatment, which results in either death or severe neurological morbidity. Cognitive disturbance is likely in half of survivors (du Plessis et al, 2002).

DIAGNOSIS. The clinical features are the only basis for diagnosis. Magnetic resonance imaging (MRI) results are normal during the acute illness.

MANAGEMENT. Sedation prevents exhaustion in severely affected children. The choreoathetosis is often refractory to drug therapy. Clonazepam and levetiracetam may reduce the movement.

Drug-Induced Chorea

Choreiform movements and akathisia or dystonic posturing may occur as effects of drugs, especially dopamine antagonists. Chorea is more often a consequence of the abrupt discontinuation of dopamine antagonist. Akathisia is more likely to be a dose-related effect, whereas dystonia is usually an idiosyncratic reaction (see section on dystonia later). Phenytoin and ethosuximide may

induce chorea as a toxic or idiosyncratic manifestation. Oral contraceptives are associated with chorea. The mechanism is unknown. Neuroleptics are associated with idiosyncratic dystonic reactions and tardive dyskinesia, and stimulant drugs (dextroamphetamine and methylphenidate) are associated with chorea, akathisia, and tic (see section on tic and Tourette syndrome later).

Tardive Dyskinesia

The term *tardive dyskinesia* denotes drug-induced choreiform movements that occur late in the course of drug therapy. These movements are often limited to the lingual facial and buccal muscles. Drug-induced buccolingual dyskinesia is unusual in children.

Tardive dyskinesias are most often associated with drugs used to modify behavior (neuroleptics), such as phenothiazines or haloperidol, and antiemetics, such as metoclopramide and prochlorperazine; they also occur in children with asthma treated with theophylline. The estimated incidence of tardive dyskinesia in children taking neuroleptic drugs is 1%. I suspect that such children were taking large dosages to treat major behavioral disorders.

CLINICAL FEATURES. Tardive dyskinesia is a complex of stereotyped movements. It usually affects the mouth and face, resembles chewing, and includes tongue protrusion and lip smacking. The trunk may be involved in rocking movements and the fingers in alternating flexion and extension resembling piano playing. Limb chorea, dystonia, myoclonus, tics, and facial grimacing may be associated features. Stress exacerbates the movements, and sleep relieves them. Symptoms appear months to years after the start of therapy and are not related to changes in dosage. In children, discontinuing the drug usually stops the movement, but the movements may remain unchanged in adults.

DIAGNOSIS. Drug-induced dyskinesia is suspected in any child who shows abnormal movements of the face or limbs while taking neuroleptic drugs. The distinction of tardive dyskinesia from facial tics is important in children with Tourette syndrome, and the distinction of facial mannerisms from tics is important in children with schizophrenia.

MANAGEMENT. Discontinue all neuroleptic drugs as quickly as possible when symptoms of dyskinesia develop. When psychosis requires drug therapy, discontinuation may not be practical. In such circumstances, the movements sometimes respond to diazepam.

Emergent Withdrawal Syndrome

Chorea and myoclonus may appear for the first time after abruptly discontinuing or reducing the dosage of neuroleptic drugs. Lingual-facial-buccal dyskinesia also may be present. The symptoms are self-limited and cease in weeks to months.

Genetic Disorders

Cerebellar ataxia is often the initial feature of abetalipoproteinemia and ataxia-telangiectasia. Chorea may occur in both conditions, but only in ataxia-telangiectasia does chorea occur without ataxia. Huntington disease is an important cause of chorea and dystonia, but in children, the initial feature is declining school performance. Huntington disease in children is discussed in Chapter 5.

Benign Familial (Hereditary) Chorea

Benign familial chorea is a rare disorder transmitted by autosomal dominant inheritance (Kleiner-Fisman et al, 2003). The gene locus is on chromosome 14q. Benign familial chorea and familial paroxysmal choreoathetosis (see Chapter 1) may be genetically related disorders.

CLINICAL FEATURES. The onset of chorea is usually in early childhood, often when the child is beginning to walk. Delayed motor development may be associated. Other possible features are intention tremor, dysarthria, hypotonia, and athetosis. Intelligence is normal. Most children have only chorea, which declines in intensity by adolescence. Adults may be asymptomatic or may have mild hypotonia and ataxia.

DIAGNOSIS. Benign familial chorea may be difficult to distinguish from other causes of chorea in children, especially familial paroxysmal chorea. A family history of the disorder is crucial to diagnosis, but difficult to obtain when parents show incomplete expression. Chorea is continuous and not episodic or paroxysmal. Neuroimaging studies and EEG results are normal.

MANAGEMENT. Chlorpromazine or haloperidol is beneficial in some individuals.

Fahr Disease

Fahr disease is the combination of encephalopathy and progressive calcification of the basal ganglia. *Idiopathic basal ganglia calcification* (IBGC) is another term applied to the same condition. Calcification of the basal ganglia occurs with infectious, metabolic, and genetic disorders.

Inheritance of IBGC disease is as an autosomal dominant trait (14q). Most affected people are asymptomatic (Bodaty et al, 2002). It is uncertain whether the central nervous system calcification is a metastatic deposition or a primary disorder of neuronal calcium metabolism.

CLINICAL FEATURES. Onset may be in childhood, but the usual age is in the 20s to 40s. The core clinical features of IBGC are neuropsychiatric and movement disorders. The expression of IBGC varies within a family.

DIAGNOSIS. Diagnosis requires bilateral calcification of the basal ganglia associated with neurological deterioration and the absence of an underlying metabolic disorder. The most common area of calcification is the globus pallidus. Additional areas of involvement include the putamen, caudate, dentate, thalamus, and cerebral white matter. Every child with basal ganglia calcification requires assessment of parathyroid function to exclude the possibility of either hyperparathyroidism or pseudohypoparathyroidism.

MANAGEMENT. Specific treatment for IBGC is not available. Symptoms may respond to drug therapy.

Neuroacanthocytosis (Choreoacanthocytosis)

Familial and nonfamilial cases of a progressive neurological disorder exist in which the main features are chorea and acanthocytosis with normal lipoprotein levels (Rampoldi et al, 2003). The acanthocyte is an abnormal erythrocyte that has thorny projections from the cell surface. Acanthocytosis occurs in at least three neurological syndromes: McLeod syndrome (see Chapter 8), neuroacanthocytosis, and abetalipoproteinemia (see Chapter 10). The clinical features in severe cases of McLeod syndrome may be similar to the features of neuroacanthocytosis.

CLINICAL FEATURES. Onset is usually in adulthood, but may occur before age 10. The most consistent neurological findings are impairment of frontal lobe function and psychiatric symptoms. Tics, oromandibular dyskinesia and dystonia, and self-mutilation of the lips may be associated features. Phenotypic variability is considerable and may include axonal neuropathy, loss of tendon reflexes, dementia, seizures, and neurosis.

DIAGNOSIS. The association of acanthocytes or echinocytes (cells with rounded projections) and neurological disease in the absence of lipoprotein abnormality is required for diagnosis.

Exclusion of McLeod syndrome is by testing for the Kell antigen.

MANAGEMENT. Only symptomatic treatment is available. Death occurs 10 to 20 years after onset.

Paroxysmal Choreoathetosis

Paroxysmal choreoathetosis occurs in children who are otherwise normal and in children with an obvious underlying static encephalopathy. Children who are otherwise normal have a genetic disease, familial paroxysmal choreoathetosis (see Chapter 1), and children with an underlying static encephalopathy may have one of several nongenetic disorders. Acquired paroxysmal choreoathetosis occurs most often in children with cerebral palsy. Either hemiplegia or diplegia may be present, and the involuntary movements affect only the paretic limbs. The onset of the movement disorder often begins 10 or more years after the acute encephalopathy.

Systemic Disorders

Hyperthyroidism

The ocular manifestations of thyrotoxicosis are discussed in Chapter 15. Tremor is the most common associated movement disorder. Chorea is unusual, but when present, it may affect the face, limbs, and trunk. The movements cease when the child becomes euthyroid.

Lupus Erythematosus

CLINICAL FEATURES. Lupus-associated chorea is uncommon, but may be the initial feature of the disease. Onset of symptoms is 7 years before to 3 years after the appearance of systemic features. It is indistinguishable from Sydenham chorea in appearance. Average duration is 12 weeks, but one fourth of patients have recurrences. Additional neurological features of lupus (ataxia, psychosis, and seizures) are common in children who have chorea but occur only after the appearance of systemic symptoms. Chorea may be a solitary manifestation of disease.

DIAGNOSIS. The diagnosis is clear in children with known lupus erythematosus. When chorea is the initial feature of lupus, the diagnosis is more problematic. The erythrocyte sedimentation rate may be elevated in lupus and Sydenham chorea and is not a distinguishing feature. The presence of elevated concentrations of antinuclear antibodies is crucial to diagnosis.

MANAGEMENT. The treatment of children with neurological manifestations of lupus erythematosus requires high doses of corticosteroids. The overall outcome is poor.

Pregnancy (Chorea Gravidarum)

Chorea of any cause beginning in pregnancy is chorea gravidarum. Rheumatic fever was previously the most frequent cause, but it is now the antiphospholipid antibody syndrome, with or without systemic lupus erythematosus.

CLINICAL FEATURES. The onset of chorea is usually during the second to fifth month of pregnancy but may begin postpartum. Cognitive change may accompany the chorea. Symptoms usually resolve spontaneously within weeks to months.

DIAGNOSIS. Women who develop chorea during pregnancy require studies for rheumatic fever, antiphospholipid antibody syndrome, and systemic lupus erythematosus.

MANAGEMENT. Chorea gravidarum is a self-limited condition, and drugs should be used cautiously so as not to harm the fetus. Pimozide is useful.

Sydenham (Rheumatic) Chorea

Sydenham chorea is the most common cause of acquired chorea in children. It is a cardinal feature of rheumatic fever and is sufficient alone to make the diagnosis. Rheumatic chorea occurs primarily in populations with untreated streptococcal infections. One hypothesis is that a mistaken antibody attack against cells in the basal ganglia occurs after exposure of genetically predisposed children to group A β -hemolytic streptococcal infection.

CLINICAL FEATURES. The onset is frequently insidious, and diagnosis is often delayed. Chorea, hypotonia, dysarthria, and emotional lability are cardinal features. Difficulty in school may bring the child to medical attention. Chorea causes the child to be restless, and discipline by the teacher results in emotional excess. Obsessive-compulsive behavior may be present, and the behavioral change may be considered a sign of mental illness.

Examination reveals a fidgeting child with migratory chorea of limbs and face. Initially the chorea may be unilateral, but eventually it becomes generalized in most patients. Efforts to conceal chorea with voluntary movement only add to the appearance of restlessness. Gradual improvement occurs over several months. Most children recover completely. Rheumatic valvular

heart disease develops in one third of untreated patients.

DIAGNOSIS. The clinical features establish the diagnosis. Laboratory tests are not confirmatory. The differential diagnosis includes lupus-associated chorea and drug-induced chorea. Examine the blood for lupus antinuclear antibodies and thyroid function. The onset of Sydenham chorea is usually 4 months after the provocative streptococcal infection, and the antistreptolysin O titer is then back to normal or only slightly increased. During the time of illness, T₂-weighted MRI may show increased signal intensity in the putamen and globus pallidus that resolves when the child has recovered.

MANAGEMENT. Pimozide usually controls the acute neurological symptoms without producing sedation. If pimozide does not relieve the symptoms, benzodiazepines, phenothiazines, and haloperidol are therapeutic options. The treatment of all children with Sydenham chorea is the same as for acute rheumatic fever: penicillin in high doses for 10 days to eradicate active streptococcal infection and prophylactic penicillin therapy until age 21.

Dystonia

Dystonia is characterized by repetitive muscle contractions that are often sustained at the peak. The appearance is one of an abnormal posture rather than an involuntary movement. The muscle contractions can affect the limbs, trunk, or face (*grimacing*). Involvement may be of a single body part (*focal dystonia*), two or more contiguous body parts (*segmental dystonia*), the arm and leg on one side of the body (*hemidystonia*), or one or both legs and the contiguous trunk and any other body part (*generalized dystonia*).

Table 14-3 summarizes the differential diagnosis of abnormal posturing. Continuous motor

TABLE 14-3
Differential Diagnosis of Abnormal Posturing

Dystonia
Hysteria
Muscular dystrophy
Myotonia
Neuromyotonia
Rigidity
Spasticity
Stiff-man syndrome

unit activity (see Chapter 8) may be difficult to distinguish from dystonia by clinical inspection alone, especially when only one or two limbs are affected. Electromyogram distinguishes the two disorders in many cases.

Persistent focal dystonias are relatively common in adults but are unusual in children except when drug induced. Most dystonias in children begin focally and eventually become generalized. Children with focal, stereotyped movements of the eyelids, face, or neck are much more likely to have a tic than focal dystonia. Table 14-4 lists childhood forms of focal dystonia. Generalized dystonia usually begins in one limb. The patient has difficulty performing an act rather than a movement so that the foot becomes dystonic when walking forward but may not be dystonic when sitting, standing, or running.

Table 14-4
Differential Diagnosis of Dystonia in Childhood

Focal dystonia
Blepharospasm
Drug-induced dystonia
Generalized dystonia beginning as focal dystonia
Torticollis
Writer's cramp
Generalized genetic dystonias
Ataxia with episodic dystonia (see Chapter 10)
Ceroid-lipofuscinosis (see Chapter 5)
Dopa-responsive dystonia
Familial paroxysmal choreoathetosis (see Chapter 1)
Glutaric acidemia type I
Hallervorden-Spatz disease
Hepatolenticular degeneration (Wilson disease)
Huntington disease (see Chapter 5)
Idiopathic torsion dystonia
Infantile bilateral striatal necrosis
Leber disease (see Chapter 16)
Machado-Joseph disease (see Chapter 10)
Mitochondrial disorders (see Chapters 5, 8, and 11)
Transient paroxysmal dystonia of infancy (see Chapter 1)
Generalized symptomatic dystonias
Perinatal cerebral injury (see Chapter 1)
Postinfectious
Poststroke
Posttraumatic
Toxin-induced
Tumor-induced
Hemidystonia
Alternating hemiplegia (see Chapter 11)
Antiphospholipid syndrome (see Chapter 11)
Basal ganglia tumors
Neuronal storage disorders

Drug-Induced Dystonia

Acute Reactions

Focal or generalized dystonia may occur as an acute idiosyncratic reaction after a first dose of dopamine antagonist (antiemetics and antipsychotics). Possible reactions include trismus, opisthotonos, torticollis, and oculogyric crisis. Difficulty with swallowing and speaking may occur. Metoclopramide, a nonphenothiazine antiemetic that blocks postsynaptic dopamine receptors, may produce acute and delayed (tardive) dystonia. The acute reactions are usually self-limited or respond to treatment with anticholinergics, such as benztropine, but they may be prolonged and resistant to therapy.

Tardive Dystonia

Usually, tardive dystonia has a generalized distribution in children, but occurs as a focal disturbance in adults. Tetrabenazine is helpful in most patients, and anticholinergic drugs offer relief in others.

Focal Dystonias

Blepharospasm

Blepharospasm is an involuntary spasmodic closure of the eyes. Table 14-5 summarizes the differential diagnosis for children. Essential blepharospasm, an incapacitating condition, is a disorder of middle or late adulthood and never begins in childhood. Tics account for almost all cases of involuntary eye closure in children. Eye fluttering occurs during absence seizures (see Chapter 1) but is not confused with dystonia. Focal dystonia involving eye closure in children is usually drug induced. Baclofen, clonazepam,

trihexyphenidyl, and injections of botulinum A toxin are often successful in treating blepharospasm and orofacial dystonia in adults.

Torticollis

Table 14-6 summarizes the differential diagnoses of torticollis and head tilt. The first step in diagnosis is to distinguish fixed from nonfixed torticollis. In fixed torticollis, the neck is not movable to the neutral position. The cause may be a structural disturbance of the cervical vertebrae or pain that prevents movement.

Evidence of concurrent dystonia in the face or limbs indicates the need for further evaluation directed at underlying causes of dystonia. When torticollis and corticospinal tract signs (hyperactive tendon reflexes, ankle clonus, or extensor plantar responses) are associated, suspect a cervical spinal cord disturbance, and order a cervical MRI study. Symptoms of increased intracranial pressure indicate a posterior fossa tumor with early herniation. When torticollis is the only abnormal feature, the underlying causes are focal dystonia, injury to the neck muscles, and juvenile rheumatoid arthritis.

Nonfixed torticollis that occurs in attacks suggests benign paroxysmal torticollis or familial paroxysmal choreoathetosis. The combination of head tilt and nystagmus in infants is termed *spasmus nutans* (see Chapter 15). Tic can cause head turning, but the movement is spasmodic so that torticollis is not a consideration.

Benign Paroxysmal Torticollis

The underlying cause of benign paroxysmal torticollis is unknown. A migraine variant, closely related to benign paroxysmal vertigo

TABLE 14-5
Differential Diagnosis of Blepharospasm in Childhood

Continuous motor unit activity
Drug-induced
Encephalitis
Hemifacial spasm
Hepatolenticular degeneration (Wilson disease)
Huntington disease
Hysteria
Myokymia
Myotonia
Schwartz-Jampel syndrome
Seizures

TABLE 14-6
Differential Diagnosis of Torticollis and Head Tilt

Benign paroxysmal torticollis
Cervical cord syringomyelia (see Chapter 12)
Cervical cord tumors (see Chapter 12)
Cervicomedullary malformations (see Chapters 10 and 18)
Diplopia (see Chapter 15)
Dystonia
Familial paroxysmal choreoathetosis (see Chapter 1)
Juvenile rheumatoid arthritis
Posterior fossa tumors (see Chapter 10)
Sandifer syndrome
Spasmus nutans (see Chapter 15)
Sternocleidomastoid injuries
Tic and Tourette syndrome

(see Chapter 10), is the apparent cause in some infants but not in others.

CLINICAL FEATURES. Onset is always in the first year. Head tilting to one side (not always the same side) and slight head rotation characterize the episodes. The child may resist efforts to return the head to a neutral position, but overcoming the resistance is possible. Some children have no other symptoms, whereas others have pallor, irritability, malaise, and vomiting. Most attacks last 1 to 3 days, end spontaneously, and tend to recur three to six times a year. Children who are old enough to stand and walk become ataxic during attacks.

With time, the attacks may evolve into episodes characteristic of benign paroxysmal vertigo or classic migraine or may simply cease without further symptoms. The disorder may occur in siblings, indicating a genetic factor, but usually the family history reveals only migraine.

DIAGNOSIS. The disorder is suspected in any infant with attacks of torticollis that remit spontaneously; a family history of migraine should be pursued. Familial paroxysmal choreoathetosis and familial paroxysmal dystonia do not begin during early infancy. Sandifer syndrome, intermittent torticollis associated with hiatal hernia, is an alternative consideration.

MANAGEMENT. No treatment is available or needed for the acute attacks.

Writer's Cramp

Writer's cramp is a focal, task-specific dystonia. It may occur only when writing or when performing other specific manual tasks, such as typing or playing the piano (occupational cramp). The cramp is more often isolated but may be associated with other focal dystonias, such as torticollis, or with generalized dystonia.

CLINICAL FEATURES. Onset is usually after 20 years of age but may be in the teens. In writer's cramp or other task-specific dystonias, the dystonic postures occur when the patient attempts to write or perform the task. The initial features are any of the following: aching in the hand when writing, loss of handwriting neatness or speed, and difficulty in holding writing implements. All three symptoms are eventually present. Dystonic postures occur when the patient attempts to write. During writing, the hand and arm lift from the paper, and the fingers may flex or extend. Writing with the affected hand becomes impossible and the patient learns to write with the nondominant hand, which also may become dystonic.

Symptoms are at first intermittent and are especially severe when others observe the writing. Later the movement occurs with each attempt at writing. Some patients have lifelong difficulty with using the dominant hand for writing and may have difficulty with other manual tasks as well. Others experience remissions and exacerbations. Progression to generalized dystonia is rare.

DIAGNOSIS. People often attribute the cause of writer's cramp or other task-specific dystonias to psychological factors despite the lack of associated psychopathological features. Early diagnosis can save considerable expense and concern. Distinguish isolated focal dystonia and generalized dystonia with focal onset. Thoroughly explore the family history, and repeat the examination to determine the presence of dystonia in other body parts.

MANAGEMENT. Botulinum toxin type A is used to treat focal dystonias. The same oral medications used to treat generalized dystonia should be used in patients with focal dystonia (see section on idiopathic torsion dystonia later).

Generalized Genetic Dystonias

The classification of autosomal dominant dystonias (DYT) uses a numeric system. Three autosomal dominant dystonias are important entities in childhood.

Dopa-Responsive Dystonia

Other names for dopa-responsive dystonia (DYT5) include *dystonia-parkinsonism syndrome*, *dystonia with diurnal variation*, and *Segawa disease*. The cause of the syndrome is either of two different genetic abnormalities. The inheritance of one type is as an autosomal dominant trait and the other is as an autosomal recessive trait. The dominant type is due to mutations in the gene for guanosine triphosphate cyclohydrolase 1, the cofactor for tyrosine hydroxylase, and the recessive form is due to mutations in the tyrosine hydroxylase gene (Furukawa, 2004). Most reported cases of "juvenile parkinsonism" are probably variants of dopa-responsive dystonia.

CLINICAL FEATURES. Marked variation in expressivity occurs between affected members of the same kindred and even between monozygotic twins (Gröttsch et al, 2004). Age at onset is usually between 4 and 8 years but ranges from infancy to 12 years. Incorrect diagnosis of early-onset cases is common; cerebral palsy is the common misdiagnosis. The initial feature is

nearly always a gait disturbance caused by leg dystonia. Flexion at the hip and knee and plantar flexion of the foot cause toe walking. Flexor and extensor posturing of the arms develop. Finally, parkinsonian features, such as cogwheel rigidity, masklike facies, and bradykinesia, appear. The disease reaches a plateau in adolescence. Postural or intention tremor occurs in almost half of patients, but typical parkinsonian tremor is unusual.

Diurnal fluctuation in symptoms occurs in more than half of patients. Symptoms improve considerably on awakening and worsen later in the day. Movement and exercise exacerbate dystonia in some patients. Other disorders with exercise-induced dystonia as the main or only clinical feature may be expressions of the same genetic error.

DIAGNOSIS. Dopa-responsive dystonia may be difficult to differentiate from other genetic disorders with dystonia because of phenotypic variation among family members (see also section on rapid-onset dystonia-parkinsonism later). Diagnosis by mutation analysis is available. Important clues to diagnosis are features of parkinsonism without other neurological signs, diurnal variation in severity of symptoms, exacerbation of symptoms with exercise, and response to levodopa.

MANAGEMENT. A small dose of levodopa usually provides immediate and complete relief in most patients, even when initiating treatment long after symptoms begin. No other dystonia responds so well. Initiate carbidopa-levodopa therapy at the lowest possible dose, and slowly increase the dose until a response is established. Long-term therapy is beneficial and required; symptoms return after discontinuing the drug. Trihexyphenidyl, in doses lower than ordinarily needed to treat idiopathic torsion dystonia, and bromocriptine also are partially effective.

Glutaric Acidemia Type I

Glutaric acidemia type I is a rare inborn error in the catabolism of lysine, hydroxylysine, and tryptophan. Genetic transmission is by autosomal recessive inheritance. Deficiency of glutaryl-coenzyme A dehydrogenase causes the disorder.

CLINICAL FEATURES. Megalencephaly is usually present at birth. Neurological findings may be otherwise normal. Two patterns of illness occur in affected infants (Bjugstad et al, 2000). In two thirds of infants, the initial feature is an acute encephalopathy characterized by somnolence, irritability, and excessive sweating. Seizures

sometimes occur. The prognosis in such cases is poor. Afterward, development regresses, and progressive choreoathetosis and dystonia occur.

The other pattern is more insidious, and the prognosis is better. Affected infants are at first hypotonic and later have mild developmental delay and dyskinesias. Cerebral palsy is a common misdiagnosis (see Chapter 12).

DIAGNOSIS. Metabolic acidosis may be present. Abnormal urinary concentrations of glutaric, 3-hydroxyglutaric, 3-hydroxybutyric, and acetoacetic acids are detectable. Showing the enzyme deficiency in cultured fibroblasts establishes the diagnosis. Prenatal diagnosis is available. Computed tomography often shows diffuse attenuation of cerebral white matter and cerebral atrophy, most marked in the frontal and temporal lobes.

MANAGEMENT. Disease progression slows in patients with little or no neurological disease by oral carnitine supplementation together with the immediate administration of fluids, glucose, electrolytes, and antipyretics during febrile illnesses.

Hepatolenticular Degeneration (Wilson Disease)

Genetic transmission of hepatolenticular degeneration is by autosomal recessive inheritance. The defective gene site is chromosome 13q14-q21, and the abnormal gene product is the main copper transporter moving copper from the hepatocyte into the bile. Mutations that completely prevent function of the *gene* produce a more severe *phenotype* than certain types of *missense mutations*. Symptom onset is younger than 12 years old, and liver manifestations are expected. Tissue damage occurs after excessive copper accumulation in the liver, brain, and cornea.

CLINICAL FEATURES. Wilson disease can present with hepatic, neurological, or psychiatric disturbances, alone or in combination. The age at onset ranges from 3 to older than 50 years (Cox and Roberts, 2003). Hepatic failure is the prominent clinical feature in children younger than 10 years old, usually without neurological symptoms or signs. Neurological manifestations with only minimal symptoms of liver disease are more likely when the onset of symptoms is after age 10. A single symptom, such as a disturbance of gait or speech, is often the initial feature and may remain unchanged for years. Eventually the initial symptoms worsen, and new features develop (dysarthria, dystonia, dysdiadochokinesia, rigidity, gait and postural abnormalities, tremor, and drooling). Dystonia of bulbar

muscles is responsible for three prominent features of the disease: dysarthria, a fixed pseudosmile (risus sardonicus), and a high-pitched whining noise on inspiration. Psychiatric disturbances precede the neurological abnormalities in 20% of cases and range from behavioral disturbances to paranoid psychoses. Dementia is not an early feature of the disease.

The Kayser-Fleischer ring, a yellow-brown granular deposit at the limbus of the cornea, is a certain indicator of the disease. The cause is copper deposition in the Descemet membrane. It is present in almost all patients with neurological manifestations, although it may be absent in children with liver disease alone.

DIAGNOSIS. Hepatolenticular degeneration is a consideration in any child with dysarthria and dystonia. The further association of chronic liver disease increases the probability of hepatolenticular degeneration. The detection of low serum copper and ceruloplasmin concentrations and increased urinary copper excretion or the demonstration of a Kayser-Fleischer ring by slit-lamp examination establishes the diagnosis. Of patients, 96% have a serum ceruloplasmin concentration of less than 20 mg/dL, corresponding to less than 56 g/dL of ceruloplasmin copper. *Molecular genetic testing of the ATP7B gene* (chromosomal locus 13q14.3-q21.1) is clinically available.

MANAGEMENT. Treatment is lifelong. Copper chelating agents (e.g., penicillamine or trientine) that increase urinary excretion of copper are the primary treatment for Wilson disease. The dose of penicillamine is 250 mg four times a day for children older than 10 and half as much for younger children. Ingestion of penicillamine is always on an empty stomach together with a daily dose of 25 mg of pyridoxine. Measures of 24-hour urine copper excretion confirm chelation. Urinary copper values should be 5 to 10 times normal. Improvement is slow; neurological improvement frequently takes several months. Worsening may occur during the first months of therapy, but this should not be a cause for alarm. Early treatment provides satisfactory results, without excess morbidity and mortality.

Oral administration of zinc interferes with absorption of copper and is useful after initial decoppering with a chelating agent. Antioxidants, such as vitamin E, help to prevent tissue damage, particularly to the liver. Liver transplantation is required for patients who fail to respond or cannot tolerate medical therapy. All siblings of patients with Wilson disease require careful screening for disease and early treatment.

Idiopathic Torsion Dystonia

Early-onset idiopathic torsion dystonia (DYT1) (dystonia musculorum deformans) is transmitted by autosomal dominant inheritance with reduced penetrance (30% to 40%) and variable expression. The gene locus is chromosome 9q34 (de Leon and Bressman, 2004). The frequency of idiopathic torsion dystonia in Ashkenazi Jews is 5 to 10 times greater than in other groups. Nonfamilial cases probably represent autosomal dominant inheritance with incomplete penetrance.

CLINICAL FEATURES. Age at onset has a bimodal distribution. For early onset, the mode is 9 years, and for late onset, the mode is 45 years. The early-onset cases are more genetically homogeneous.

The limbs usually become dystonic before the trunk. The initial features may be in the arms, legs, or larynx. Early leg involvement is more common in children than in adults. Despite the focal features at onset, dystonia always generalizes in children, affecting the limbs and trunk. Spontaneous stabilization is the rule, but remission is unusual. The eventual outcome varies from complete disability to functional independence. Other clinical features include dysarthria, orofacial movements, dysphagia, postural tremor, and blepharospasm. Mental deterioration does not occur, but as a group, patients with familial disease have a lower IQ than patients with sporadic cases.

DIAGNOSIS. The clinical features of dystonic movements and postures and the family history suggest the diagnosis. Normal perinatal history, no exposure to drugs, no evidence of intellectual or corticospinal deterioration, and no demonstrable biochemical disorder exclude other possibilities. Molecular genetic testing confirms the diagnosis.

MANAGEMENT. Medical management is often ineffective. Deep brain stimulation of the bilateral globus pallidum is useful in many patients (Volkman and Benecke, 2002). High-dose anticholinergic therapy (trihexyphenidyl, 30 mg/day) provides the best medical results. Although children tend to tolerate higher doses than adults do, confusion and memory impairment may limit usefulness. Other drugs that may be of value include baclofen, carbamazepine, and benzodiazepines. All juvenile-onset dystonic patients should have a trial of levodopa to exclude dopa-responsive dystonia. Botulinum toxin is useful for selected focal problems.

Infantile Bilateral Striatal Necrosis

Bilateral striatal necrosis occurs in several genetic disorders that share pathological features of bilateral, symmetrical, spongy degeneration of the corpus striatum with variable degeneration of the globus pallidus (Straussberg et al, 2002). Onset is in infancy or early childhood.

CLINICAL FEATURES. Three clinical syndromes are associated with infantile bilateral striatal necrosis. One type has an insidious onset during infancy or childhood and a long clinical course that includes dystonia, cognitive impairment, seizures, and death. Most of these cases are probably mitochondrial disorders; one affected child had a point mutation in the mitochondrial *ATPase 6* gene. A clinical and pathological overlap exists between progressive infantile bilateral striatal necrosis, subacute necrotizing encephalomyelopathy (see Chapter 5), and Leber hereditary optic neuropathy (see Chapter 16).

A second syndrome begins as an acute encephalopathy, usually following a febrile illness with nausea and vomiting. The major features are dystonia and tremor. The severity of symptoms may fluctuate at the time of intercurrent illness. Some children recover spontaneously, whereas others are permanently impaired.

The third syndrome occurs in Arab kinships but may have a wider distribution. The etiology may be defective transport of biotin across the blood-brain barrier. Transmission is probably by autosomal recessive inheritance. Onset is usually between age 3 and 5 years. The first symptoms are nerve palsy, dysarthria, and dysphagia. Cranial nerve palsies, cogwheel rigidity, dystonia, and quadriparesis follow the initial features.

DIAGNOSIS. The observation of static or progressive striatal necrosis on serial MRI studies suggests the diagnosis.

MANAGEMENT. All features of biotin-responsive striatal necrosis respond to administration of biotin, 5 to 10 mg/kg/day, but reappear within 1 month after biotin is discontinued. All children with evidence of bilateral striatal necrosis should have a trial of biotin.

Pantothenate Kinase–Associated Neurodegeneration

Pantothenate kinase–associated neurodegeneration, previously called *Hallervorden-Spatz syndrome*, is a neurodegeneration with brain iron

accumulation (Coryell and Hayflick, 2003). It is a genetic disorder transmitted as an autosomal recessive trait. The abnormality is in the *pank2* gene (chromosome locus 20p13).

CLINICAL FEATURES. The characteristic features are progressive dystonia and basal ganglia iron deposition. The disorder becomes symptomatic between 2 and 10 years of age in more than half of patients but may not appear until the 20s. The initial feature is progressive rigidity, first in the foot, causing an equinovarus deformity, and then in the hand. Other features are choreoathetosis, rigidity, and dysarthria. Two thirds of patients have a pigmentary retinopathy (Hayflick et al, 2003). Mental deterioration and spasticity follow, with progression to spastic immobility and death within 5 to 10 years.

DIAGNOSIS. The MRI features and molecular genetic testing are the basis for antemortem diagnosis. T₂-weighted MRI shows low-intensity signal images from the globus pallidus with a central area of increased signal intensity, the *eye-of-the-tiger sign*. Postmortem examination shows degeneration of the pallidum and substantia nigra with deposition of iron-containing material.

MANAGEMENT. Agents that chelate iron have not proved effective. Only symptomatic treatment is available.

Rapid-Onset Dystonia-Parkinsonism

Rapid-onset dystonia-parkinsonism (DYT12) is a separate autosomal dominant form of dystonia characterized by an unusually rapid evolution of signs and symptoms (Pittcock et al, 2000). The abnormal gene maps to chromosome 9q13.

CLINICAL FEATURES. The disorder is characterized by the acute (hours) or subacute (days to weeks) development of generalized dystonia and parkinsonism that responds poorly to treatment with levodopa. Age at onset is 14 to 45 years. Severe bulbar symptoms, such as dysarthria, drooling, and orofacial dystonia, are associated. Some patients show hypertonicity and hyperreflexia. The onset may be associated with stress or anxiety.

DIAGNOSIS. Diagnosis depends on the clinical features. The phenotypic variability is sufficient to hide the disease in family members.

MANAGEMENT. A trial of levodopa is reasonable in any child with new-onset dystonia even though it is not effective in idiopathic torsion dystonia. If dopa fails, trihexyphenidyl is the

drug of choice and is usually effective. High dosages are required, usually 30 mg/day in three divided doses. Children tolerate such high dosages when the dose is increased slowly; adults rarely tolerate such high dosages. The response is not predictable from measurement of plasma concentrations.

If trihexyphenidyl is not effective, add baclofen. The initial dosage is 5 to 10 mg/day, increased 10 mg weekly until a benefit is attained or adverse reactions occur. Diazepam is an alternative to baclofen and is added at low dosages and increased slowly as tolerated. If a patient does not respond to this combination, try tetrabenazine, or some combination of carbamazepine, benzotropine, pimozide, or bromocriptine.

Symptomatic Generalized Dystonia

An underlying tumor, an active encephalopathy, or prior brain damage can cause dystonia.

CLINICAL FEATURES. The onset of dystonia may be at the time of an acute encephalopathy, after the acute phase is over, or several years later, when the encephalopathy is static. Delayed-onset chorea and dystonia in children with perinatal disturbances, such as asphyxia or kernicterus, usually begin by 2 to 3 years of age but may not begin until adolescence. After involuntary movements appear, they tend to become progressively more severe, but intellectual decline is not an associated feature. Delayed-onset dystonia may have a generalized distribution.

Hemidystonia most often occurs after stroke or head injury but may be a symptom of neuronal storage diseases or tumors of the basal ganglia, alternating hemiplegia, and antiphospholipid antibody syndrome (see Chapter 11). The dystonic limbs are contralateral to the damaged basal ganglia.

DIAGNOSIS. Children with a known cause for the development of dystonia or chorea do not require extensive studies. The new symptoms are discouraging for patients and families, who have adjusted to a fixed neurological deficit. Provide assurance that the new symptoms are not evidence of new brain degeneration, but only the appearance of new symptoms from old lesions. This sequence is most likely when injury is perinatal and brain maturation is required to manifest involuntary movements.

The appearance of hemidystonia, even with a known predisposing event, necessitates MRI to look for localized changes that may require treatment, such as an expanding cyst. Consider

the possibility of tumor in children who had been neurologically intact before hemidystonia appeared.

MANAGEMENT. The drugs used to treat symptomatic dystonia are the same drugs that are used to treat genetic dystonia, but the results may not be as favorable. Botulinum toxin may be useful when specific muscle contractions are causing severe disability.

Hemifacial Spasm

Involuntary, irregular contractions of the muscles innervated by one facial nerve characterize hemifacial spasm. This is a rare condition in children. The spasms may develop because of aberrant regeneration after facial nerve injury, secondary to posterior fossa tumor, or without apparent cause.

CLINICAL FEATURES. Spasms are embarrassing and disturbing but not painful. The orbicularis oculi muscles are the muscles affected first and most commonly, causing forced closure of the eye. As facial muscles on one side become affected, they pull the mouth to one side. Spasms may occur several times a minute, especially during times of stress. The subsequent course depends on the underlying cause.

DIAGNOSIS. Hemifacial spasm in children may be mistaken for a focal seizure. The stereotyped appearance of the spasm and a concurrent normal EEG are distinguishing features. Posterior fossa tumor should be suspected in every child with hemifacial spasm. Brain MRI is required in every instance, unless symptoms are explained by a history of prior facial nerve injury.

MANAGEMENT. Some patients respond to treatment with carbamazepine at anticonvulsant doses (see Chapter 1), but most do not respond to medical therapy. Injection of botulinum toxin into the muscles in spasm is the treatment of choice. Surgical procedures to relieve pressure on the facial nerve from adjacent vessels are of questionable value.

Mirror Movements

Mirror movements are involuntary movements of one side of the body, usually the hands, which occur as mirror reversals of an intended movement on the other side of the body. They are normal during infancy and tend to disappear before 10 years of age, coincident with myelination of the corpus callosum. Persistence of mirror movements may be a familial trait caused by ipsilateral and contralateral organization of

the corticospinal pathways. Obligatory mirror movements are abnormal even in infants and suggest a congenital abnormality at the cervicomedullary junction.

Myoclonus

The term *myoclonus* encompasses several involuntary movements characterized by rapid muscle jerks. They are less frequent and severe during sleep but may not disappear. Myoclonus may be rhythmic or nonrhythmic; focal, multifocal, or generalized; or spontaneous or activated by movement (action myoclonus) or sensory stimulation (reflex myoclonus).

Nonepileptic myoclonus is distinguished from tic, chorea, tremor, and seizures easily. Tics are usually more complex and stereotyped movements than myoclonus and are briefly suppressed by voluntary effort; myoclonus is not voluntarily suppressible. Chorea is more random than myoclonus and often incorporated into voluntary movement; myoclonus is never part of a larger movement. Rhythmic myoclonus and tremor look alike and are difficult to distinguish clinically. Tremor is a continuous to-and-fro movement, whereas rhythmic myoclonus has a pause between movements.

Table 14-7 summarizes the etiological classification of myoclonus. Physiological myoclonus occurs in normal people when falling asleep, during sleep (nocturnal myoclonus), when waking up, and during times of anxiety. Nocturnal myoclonus is a rhythmic jerking of the legs during sleep that is common in children. It requires distinction from the restless legs syndrome, a

genetic disorder transmitted by autosomal dominant inheritance (Earley, 2003). Leg discomfort at rest, relieved by movement, characterizes the syndrome. Misdiagnosis of such symptoms as “growing pains” is common. Periodic limb movements mainly occur during sleep, but also during wakefulness. Epileptic myoclonus is associated with epileptiform activity on the EEG (see Chapter 1). The causes of symptomatic myoclonus include drugs, electrolyte abnormalities, cerebral injury, or part of a generalized progressive encephalopathy.

Essential Myoclonus

Essential myoclonus is a chronic condition of focal, segmental, or generalized jerking aggravated by action or stress. Affected people are otherwise normal. Occurrence is usually sporadic, but when familial, transmission is by autosomal dominant inheritance.

CLINICAL FEATURES. Onset is before age 20. Both genders are equally affected. The movements are predominantly in the face, trunk, and proximal muscles. Although usually generalized, movements may be restricted to one side of the body. No other neurological disturbances develop, and life expectancy is not affected. Essential tremor may be present in the same family.

DIAGNOSIS. The clinical features and family history establish the diagnosis. Careful neurological examination, EEG, and brain imaging exclude symptomatic and epileptic myoclonus. A period of observation and repeat laboratory investigations may be necessary to eliminate other causes.

Table 14-7
Etiological Classification of Myoclonus

Physiological	Drug-induced
Anxiety-induced	Carbamazepine
Exercise-induced	Levodopa
Sleep jerks and nocturnal myoclonus	Tricyclic antidepressants
Essential	Lysosomal storage diseases (see Chapter 5)
Epileptic (see Chapter 1)	Metabolic encephalopathies (see Chapter 2)
Symptomatic	Dialysis syndromes
Post-central nervous system injury	Disorders of osmolality
Hypoxia (see Chapter 2)	Hepatic failure
Trauma (see Chapter 2)	Renal failure
Stroke (see Chapter 11)	Myoclonic encephalopathy (see Chapter 10)
Basal ganglia degenerations	Idiopathic
Idiopathic torsion dystonia	Neuroblastoma
Hallerorden-Spatz disease	Spinal cord tumor (see Chapter 12)
Hepatolenticular degeneration	Spinocerebellar degenerations (see Chapter 10)
(Wilson disease)	Toxic encephalopathies (see Chapter 2)
Huntington disease (see Chapter 5)	Viral encephalitis

MANAGEMENT. Mild essential myoclonus does not require treatment. Botulinum toxin type A injection into the affected muscles often reduces the movement. Clonazepam is the drug of choice in children requiring therapeutic intervention. Carbamazepine, tetraabenazine, and valproate are useful in symptomatic myoclonus and may be beneficial in generalized myoclonus.

Symptomatic Myoclonus

Myoclonus is often a symptom of an underlying neurological disease. Generalized myoclonus is the rule when the cause is a diffuse, progressive encephalopathy (e.g., lysosomal storage diseases) and segmental when the lesion is focal in the brainstem or spinal cord. Multifocal myoclonus may occur as a non-dose-dependent side effect of carbamazepine therapy in children.

Posthypoxic Myoclonus (Lance-Adams Syndrome)

Posthypoxic myoclonus is a form of action myoclonus in patients who have had an episode of hypoxia. It does not follow hypoxic-ischemic encephalopathy of the newborn. Single or repetitive myoclonic jerks occur when voluntary movement is attempted. Facial and pharyngeal muscle myoclonus interferes with speech and swallowing. Cerebellar disturbances are usually associated findings. Myoclonus usually begins during recovery from anoxic encephalopathy and once started never remits. It may respond to valproate, 5-hydroxytryptophan, or clonazepam.

Segmental (Focal) Myoclonus

Segmental myoclonus is an involuntary contraction of contiguous muscles innervated by the brainstem or spinal cord. It may be rhythmic or nonrhythmic. Rhythmic segmental myoclonus looks like a focal seizure. The underlying causes in children are limited mainly to demyelinating diseases and intrinsic tumors. Cystic astrocytoma of the spinal cord is the major cause of spinal myoclonus and may be the initial feature (see Chapter 12).

Palatal myoclonus is the most common segmental myoclonus of brainstem origin. Unilateral or bilateral rhythmic contractions of the palate (80 to 180/min), which usually persist during sleep, are characteristic. It may be associated with rhythmic contractions of the eyes, larynx, neck, diaphragm, trunk, and limbs. Lesions in the central tegmental tract or the dentato-olivary pathways cause palatal myoclonus. The

median interval between the precipitating cause and the onset of palatal myoclonus is 10 to 11 months. Clonazepam and tetraabenazine are the most useful drugs in the treatment of segmental myoclonus.

Stereotypies

Stereotypies are repeated, purposeless movements that may be simple or complex. Simple stereotypies are foot or finger tapping and hair curling. Complex stereotypies range from shuddering attacks to sequential movements of the head, arms, and body. They appear intentional. Occasionally a history of similar movements is present in other family members. The shaking of crossed legs in infants and young children, often attributed to “masturbation,” is a stereotypy. The difference is that stereotypies are outgrown, and masturbation is not.

The main differential diagnosis is with seizures and complex tics. Seizures are never stereotyped. Complex tics are more difficult to differentiate. Stereotypies differ from tics in that suppression of the movement does not cause tension, and other features of Tourette syndrome are not present. Stereotypies tend to disappear as the child ages. Treatment is neither needed nor effective. The best management is to ignore the movements.

Tic and Tourette Syndrome

Tics or habit spasms are complex, stereotyped movements (motor tic) or utterances (verbal tic) that are sudden, brief, and purposeless movements. They may be confused with chorea, but their stereotyped appearance distinguishes them. A tic can be described accurately and reproduced by an observer (e.g., “he blinks his eyes”); chorea cannot. Tics are suppressible for short periods, with some discomfort, and never incorporated into a voluntary movement. Chorea is harder to suppress and usually elaborated into a voluntary movement. Stress exacerbates tics and chorea, and both disappear during sleep.

Tourette syndrome is any combination of verbal and motor tics. It is not a separate disease, but rather part of a phenotypic spectrum that includes simple motor tic, attention deficit disorder, and obsessive-compulsive behavior (Jankovic, 2001). Transmission of the syndrome is as a highly penetrant, autosomal dominant trait in which males more commonly express tics and attention deficit disorder and

females express obsessive-compulsive behavior. Bilineal transmission is common and may correlate with the severity of disease. The abnormal gene locus is unknown.

In addition to the strong evidence for a genetic basis for Tourette syndrome, environmental factors also play a role. Stimulants provoke tics in predisposed children, and streptococcal infection may cause the sudden onset of severe tic or obsessive-compulsive disorder. The term *PANDAS* (*pediatric autoimmune neuropsychiatric disorders associated with streptococcal infection*) acknowledges the association between streptococcal infection and the acute exacerbation of chorea or tic (Dale et al, 2001).

CLINICAL FEATURES. Affected children are not mentally disturbed before symptoms begin. Although the frequency of behavioral disturbances increases in children with Tourette syndrome, the movement disorder and the behavioral disturbances each should be considered an expression of the same underlying genetic defect; one does not cause the other.

Onset is anytime from 2 to 15 years of age (mean 6 to 7 years). The most severe period of tic severity is between 8 and 12 years of age, and half of children are tic-free by age 18 years. Often, neck muscles are the first affected, causing a head movement in which the child appears to be tossing hair back from the face. New motor tics develop either in place of, or in addition to, existing tics. They usually affect the head, eyes, or face. Common tics include eye blinking, grimacing, lip smacking, and shrugging of one or both shoulders.

The initial verbal tics are usually a clearing of the throat, a snorting or sniffing noise, and a coughlike noise. Many children who make sniffing or coughing noises undergo an extensive evaluation for allergy and are found to be allergic to something. Desensitization is the next unsuccessful intervention. Grunting and hissing are other verbal tics. Uttering profanities (coprolalia) is rare in children. The patient is able to suppress profane language, when it occurs, and replace profanities with barking or coughing noises.

Symptoms wax and wane spontaneously and in response to stress and excitement. Tics usually become less frequent when children are out of school. Although some children outgrow their tics, some have lifelong difficulty, and others have prolonged remissions with recurrence in middle age or later. Half of children with tics have an attention deficit disorder, and a third have an obsessive-compulsive disorder. The characteristics of attention deficit disorder are

hyperactivity (attention deficit hyperactivity disorder), short attention span, restlessness, poor concentration, and impaired impulse control. Stimulants treat attention deficit hyperactivity disorder, but all stimulants, including caffeine, have the potential to accentuate tics in genetically predisposed children.

Characteristic of obsessive-compulsive behavior are ritualistic actions and thoughts, which may include touching things repeatedly, placing objects in a certain place, washing and rewashing hands, obsessive thoughts about sex or violence, and counting objects. The following questions elicit a history of obsessive-compulsive behavior in family members, especially mothers: (1) Do you routinely go back and check the door and lights after you leave the house? (2) Do you have routines in the way that you clean the house or fold clothes? The diagnosis of obsessive-compulsive behavior is assured if the mother responds that these habits are driving her family crazy.

DIAGNOSIS. The clinical features establish the diagnosis. Laboratory tests are not helpful and are unnecessary in obvious cases. EEG, MRI, and psychological test results are normal. Tics do not ordinarily occur in degenerative diseases of the nervous system or as an adverse reaction to drugs. Drug-induced tics are the potentiation of Tourette syndrome in a genetically predisposed child. Carbamazepine, lamotrigine, amphetamine, and methylphenidate may trigger the symptoms. Withdrawal of the potentiating drug does not always stop the tics.

MANAGEMENT. Most children with tics and Tourette syndrome do not require drug treatment. The decision to prescribe medication depends on whether the tics bother the child. Drug therapy is not required if the tics bother the parents but do not disturb the child's life. Tell the parents that the tics are not a sign of progressive neurological or mental illness, tics worsen with stress, and tics diminish in frequency if ignored. Caffeine ingestion may exacerbate tics and should be reduced or removed from the diet.

Drug treatment is difficult to evaluate because the disorder's natural history is one of exacerbation and remission. The most useful drugs to control tic are pimozide, fluphenazine, ziprasidone, and haloperidol. Pimozide is my personal preference. The incidence of adverse effects is low when small doses are used. The dosage of pimozide is initially 1 mg/day and is increased 1 mg each week as needed. The maintenance dosage is usually 2 to 4 mg/day and never exceeds 10 mg/day. The initial dose of

fluphenazine is 1 mg/day and is increased 1 mg each week. The usual maintenance dosage is 2 to 6 mg/day and never exceeds 10 mg/day. Start haloperidol as a single dose of 0.5 mg at night, and slowly increase by 0.5 mg each week until tics are reasonably controlled or adverse reactions are noted. The usual maintenance dosage is 1 to 3 mg/day in two divided doses.

The major toxic effects of all three drugs are sedation, irritability, and depression of appetite. Dystonia and akathisia are idiosyncratic reactions. Many physicians recommend clonidine because it is also useful for attention deficit disorder. I have not found it as effective for tics. One randomized, placebo-controlled trial found pergolide, 0.15 to 0.45 mg/day, safe and efficacious in treating tics (Gilbert et al, 2003).

Any of these drugs may lose their efficacy after prolonged use, but effectiveness may return after an interval of withholding the drug. Interrupted therapy with one drug or alternating between two drugs is reasonable. Treat obsessive-compulsive disorder, when it occurs as part of the Tourette phenotype, with serotonin reuptake inhibitors, such as fluoxetine, escitalopram, or sertraline. A modest dose of either drug may be effective not only for the obsessive-compulsive disorder, but also for the tics, either alone or in conjunction with pimozide.

The long-term outcome for children with tics is difficult to ascertain. Many reports indicate that tics improve and may cease in adulthood, but a more recent report indicated that tics were still present in 90% of adults with childhood-onset tics (Pappert et al, 2003).

Tremor

Tremor is an involuntary oscillating movement with a fixed frequency. The product of tremor frequency and amplitude is constant; because frequency decreases with age, amplitude increases. Shuddering, cerebellar ataxia or dysmetria, and asterixis are not tremors because they lack rhythm. Myoclonus may be rhythmic, but the movement interrupts between oscillations.

All normal people have a low-amplitude physiological tremor, inherent in movement, which is not ordinarily observable without a measuring device. Physiological tremor enhances to a clinically detectable level in some situations (anxiety, excitement, exercise, fatigue, stress) and by drugs (adrenergic agonists, nicotine, prednisone, thyroid hormone, and xanthines). Hyperthyroidism

is routinely associated with enhanced physiological tremor.

Parkinsonism is a common cause of pathological tremors in adults, but it does not occur in children except when drug induced or as part of a complex degenerative disorder. Typical parkinsonian tremor is seldom present in these situations. Essential (familial) tremor is the major cause of tremor in children.

Essential (Familial) Tremor

Essential (familial) tremor is a monosymptomatic condition transmitted as an autosomal dominant trait. Two different gene loci are responsible. One maps to chromosome 3q13 (Louis, 2001) and the other to chromosome 2p25-p22 (Higgins et al, 2003).

CLINICAL FEATURES. Onset is usually in adulthood. Childhood and adult-onset cases are similar. The tremor usually appears after age 10 but can begin by 2 years of age. Only limbs in use show the tremor. The head, face, and neck are affected sometimes. The head tremor is usually mild and has a “no-no” appearance. The tremor frequency in the limbs is typically between 4 and 8 Hz. Essential tremor may impair function, especially schoolwork, and disturbs the patient. Thirty percent of children also have dystonia. In young children, the tremor has the appearance of restlessness or clumsiness. Only later does the tremor display an *action tremor* quality.

Greater precision of movement enhances the tremor. Tremor appears first and most prominently in the hands. It is further enhanced by anxiety, concentrated effort to stop the tremor, and fatigue. Essential tremor is generally lifelong.

DIAGNOSIS. Essential tremor in children is often mistaken for cerebellar dysfunction because it occurs with action (intention). The two are easily differentiated because essential tremor is rhythmic and not dysmetric (does not become worse at the end point) and because it is not associated with other signs of cerebellar dysfunction.

MANAGEMENT. Not all people with essential tremor require treatment. Medication should be reserved for situations in which tremor impairs function. Propranolol, 1 to 2 mg/kg/day, or primidone, 2 to 10 mg/kg/day, is effective to control tremor in 70% of cases. Other options include topiramate (Connor, 2002) and gabapentin. A surgical option for individuals with incapacitating essential tremor is deep brain stimulation of the ventral intermediate nucleus of the thalamus (Vaillencourt et al, 2003). Alcohol ingestion

relieves essential tremor, but this treatment should be discouraged.

Paroxysmal Dystonic Head Tremor

CLINICAL FEATURES. Paroxysmal dystonic head tremor is an uncommon nonfamilial syndrome of unknown cause. The major feature is attacks of horizontal head tremor (frequency 5 to 8 Hz), as if the person were saying "no." Onset occurs in adolescence, and all patients in the literature and three adolescents in my own practice were boys. The attacks vary from 1 to 30 minutes, are not provoked by any single stimulus, and cannot be suppressed. A head tilt precedes the onset of tremor by 5 to 10 years. The attacks are lifelong but do not progress to other neurological symptoms. Results of the examination are otherwise normal.

DIAGNOSIS. Imaging studies of the brain show no abnormalities. In an infant, the combination of head nodding and head tilt would be diagnosed as spasmus nutans even in the absence of nystagmus (see Chapter 15), and perhaps the underlying mechanism is similar.

MANAGEMENT. Daily use of clonazepam reduces the frequency and severity of attacks, but the head tilt may persist.

References

- Brodsky H, Mitchell P, Luscombe G, et al. Familial idiopathic basal ganglia calcification (Fahr's disease) without neurological, cognitive and psychiatric symptoms is not linked to the IBGC1 locus on chromosome 14. *Hum Genet* 2002;110:8-14.
- Bjugstad KB, Goodman SI, Freed CR. Age at symptom onset predicts severity of motor impairment and clinical outcome of glutaric acidemia type 1. *J Pediatr* 2000;137:681-686.
- Connor GS. A double-blind placebo-controlled trial of topiramate treatment for essential tremor. *Neurology* 2002;59:132-134.
- Coryell J, Hayflick S. (8 March 2003) Pantothenate kinase associated neurodegeneration. In: *GeneClinics: Medical Genetics Knowledge Base*. [database online] University of Washington, Seattle. Available at <http://www.geneclinics.org>.
- Cox DW, Roberts EA. (24 April 2003) Wilson disease. In: *GeneClinics: Medical Genetics Knowledge Base*. [database online] University of Washington, Seattle. Available at <http://www.geneclinics.org>.
- Dale RC, Church AJ, Cardoso F, et al. Poststreptococcal acute disseminated encephalomyelitis with basal ganglia involvement and auto-reactive antibasal ganglia antibodies. *Ann Neurol* 2001;50:588-595.
- de Leon DMS, Bressman SB. (5 February 2004) Early-onset primary dystonia (DYT1). In: *GeneClinics: Medical Genetics Knowledge Base*. [database online] University of Washington, Seattle. Available at <http://www.geneclinics.org>.
- du Plessis AJ, Bellinger DC, Gauvreau K, et al. Neurologic outcome of choreoathetoid encephalopathy after cardiac surgery. *Pediatr Neurol* 2002;27:9-17.
- Earley CJ. Restless legs syndrome. *N Engl J Med* 2003;348:2103-2109.
- Furukawa Y. (5 March 13, 2004) Dopa-responsive dystonia. In: *GeneClinics: Medical Genetics Knowledge Base*. [database online] University of Washington, Seattle. Available at <http://www.geneclinics.org>.
- Gilbert DL, Dure L, Sethuraman G, et al. Tic reduction with pergolide in a randomized controlled trial in children. *Neurology* 2003;60:606-611.
- Grötzsch H, Schnorf H, Morris MA, et al. Phenotypic heterogeneity of dopa-responsive dystonia in monozygotic twins. *Neurology* 2004;62:637-639.
- Hayflick SJ, Westaway SK, Levinson B, et al. Genetic, clinical, and radiographic delineation of Hallervorden-Spatz syndrome. *N Engl J Med* 2003;348:33-40.
- Higgins JJ, Jankovic J, Lombardi RQ, et al. Haplotype analysis of the ETM2 locus in essential tremor. *Neurogenetics* 2003;4:185-189.
- Jankovic J. Tourette's syndrome. *N Engl J Med* 2001;345:1184-1192.
- Kleiner-Fisman G, Rogaeva W, Houle S, et al. Benign hereditary chorea. Clinical, genetic, and pathological findings. *Ann Neurol* 2003;54:244-247.
- Louis ED. Essential tremor. *N Engl J Med* 2001;345:887-891.
- Pappert EJ, Goetz CG, Louis ED, et al. Objective assessments of longitudinal outcome in Gilles de la Tourette syndrome. *Neurology* 2003;61:936-940.
- Pittcock SJ, Joyce C, O'Keane V, et al. Rapid-onset dystonia-parkinsonism: A clinical and genetic analysis of a new kindred. *Neurology* 2000;55:991-995.
- Rampoldi L, Dobson-Stone C, Daneck A, et al. (12 March 2003) Chorea-acanthocytosis. In: *GeneClinics: Medical Genetics Knowledge Base*. [database online] University of Washington, Seattle. Available at <http://www.geneclinics.org>.
- Straussberg R, Shorer Z, Weitz R, et al. Familial infantile bilateral striatal necrosis. Clinical features and response to biotin treatment. *Neurology* 2002;59:983-989.
- Vaillencourt DE, Sturman MM, Metmann LV, et al. Deep brain stimulation of the VIM thalamic nucleus modifies several features of essential tremor. *Neurology* 2003;61:919.
- Volkman J, Benecke R. Deep brain stimulation for dystonia. Patient selection and evaluation. *Move Disord* 2002;17(Suppl 3):S112-S115.

Chapter 15

Disorders of Ocular Motility

THE MAINTENANCE OF binocular vision by conjugate movement of the eyes is perhaps the most delicate feat of muscular coordination achieved by the nervous system. Disorders of the visual sensory system, ocular muscles, ocular motor nerves, neuromuscular transmission, or gaze centers of the central nervous system may disturb ocular motility. This chapter discusses nonparalytic strabismus, paralytic strabismus (ophthalmoplegia), gaze palsies, ptosis, and nystagmus. Visual and pupillary disorders are discussed in Chapter 16.

Nonparalytic Strabismus

Strabismus (squint), or abnormal ocular alignment, affects 3% to 4% of preschool children. Many individuals have a latent tendency for ocular misalignment, *heterophoria*, which becomes apparent only under stress or fatigue. During periods of misalignment, a child may have diplopia or headache. Constant ocular misalignment is *heterotropia*. Children with heterotropia suppress the image from one eye to avoid diplopia. If only one eye fixates continuously, visual acuity may be lost permanently in the other (developmental amblyopia).

In nonparalytic strabismus, the amount of deviation in different directions of gaze is relatively constant (comitant). Each eye moves through a normal range when tested separately (*ductions*), but the eyes are disconjugate when used together (*versions*). Many children with chronic brain damage syndromes, such as malformations or perinatal asphyxia, have faulty fusion or faulty control of conjugate gaze mechanisms (nonparalytic strabismus). In neurologically normal children, the most common cause

of nonparalytic strabismus is either a genetic influence or an intraocular disorder. Ocular alignment in the newborn is usually poor, with transitory shifts of alignment from convergence to divergence. Constant ocular alignment usually begins after 3 months of age. Approximately 2% of newborns exhibit tonic downward deviation of the eyes during the waking state. The eyes assume a normal position during sleep and are able to move upward reflexively.

Esotropia

Esotropia is an inward deviation (convergence) of the eyes. Early-onset or infantile esotropia is present before 1 year of age. The observation of accommodative esotropia is usually between 2 and 3 years of age and may be undetected until adolescence.

CLINICAL FEATURES. Children with infantile esotropia often alternate fixation between eyes and may cross-fixate, that is, look to the left with the right eye and to the right with the left eye. The misalignment is sufficient that family members see that a problem exists. Some children fixate almost entirely with one eye and are at risk for permanent loss of visual acuity (*developmental amblyopia*) in the other eye.

Accommodative esotropia occurs when accommodation compensates for hyperopia. Accommodation more sharply focuses the blurred image. Because convergence accompanies accommodation, one eye turns inward. Some children with accommodative esotropia cross-fixate and use each eye alternatively, while the other maintains fixation. If one eye is more hyperopic than the other eye, however, only the better eye fixates, and the unused eye has a considerable potential for amblyopia.

DIAGNOSIS. An ophthalmologist should examine the eyes to determine whether hyperopia is present.

MANAGEMENT. Eyeglasses correct hyperopic errors. The treatment of early-onset esotropia, in which only one eye fixates, consists of alternate eye patching. Early corrective surgery is required for persistent esotropia.

Exotropia

Exotropia is an outward divergence of the eyes. It may be intermittent or constant.

CLINICAL FEATURES. Intermittent exotropia is a relatively common condition that begins before 4 years of age. It is most often evident when the child is fatigued and fixating on a far object or in bright sunlight. The natural history of the condition is unknown. Constant exotropia may be congenital, but poor vision in the outward-turning eye is also a cause.

DIAGNOSIS. Exotropia is an indication to examine the eye for intraocular disease.

MANAGEMENT. In children with intermittent exotropia, the decision to perform corrective surgery depends on the frequency and degree of the abnormality. When exotropia is constant, treatment depends on the underlying cause of visual loss.

Ophthalmoplegia

The causes of paralytic strabismus include disorders of the ocular motor nerves, the ocular muscles, or neuromuscular transmission. Table 15-1 summarizes the muscles and nerves and their functions. The eye appears to deviate in a direction opposite to the field of action of the paralyzed ocular muscle, and diplopia is experienced. Strabismus and separation of images

worsen when the child gazes in the direction of action of the paralyzed muscle.

Congenital Ophthalmoplegia

Testing of eye movements is uncommon in newborns, and ophthalmoplegia is often missed. It is common for strabismus to remain unnoticed for several months, then discounted as transitory esotropia. Congenital ophthalmoplegia should be considered even when a history of ophthalmoplegia at birth is lacking.

Oculomotor Nerve Palsy

CLINICAL FEATURES. Congenital oculomotor nerve palsy usually is unilateral and complete. Pupillary reflex paralysis is variable. Other cranial nerve palsies, especially abducens, may be associated. The palsy is often unrecognized at birth. Most oculomotor nerve palsies are idiopathic, but some are genetic or caused by orbital trauma. The affected eye is exotropic and usually amblyopic. Lid retraction on attempted adduction or downward gaze may be evidence of aberrant regeneration.

DIAGNOSIS. Magnetic resonance imaging (MRI) excludes the possibility of an intracranial mass compressing the nerve. Exophthalmos suggests an orbital tumor. An unreactive, dilated pupil excludes the diagnosis of myasthenia gravis, but a normal pupil requires testing for myasthenia.

MANAGEMENT. Extraocular muscle surgery may improve the cosmetic appearance but rarely improves ocular motility or visual function.

Trochlear Nerve Palsy

CLINICAL FEATURES. Congenital superior oblique palsy is usually unilateral. Birth trauma is usually the suspected cause, but the actual cause is rarely established. Most congenital cases are idiopathic. The head tilts away from the paralyzed side to keep the eyes in alignment and to avoid diplopia. The major ocular features are noncomitant hypertropia, greatest in the field of action of the involved superior oblique muscle; underaction of the paretic superior oblique muscle and overaction of the inferior oblique muscle; and increased hypertropia when the head tilts to the paralyzed side (positive *Bielschowsky test*).

DIAGNOSIS. Head tilt, or *torticollis* (see Chapter 14), is not a constant feature. When examination confirms a superior oblique palsy, important etiological considerations other than congenital include trauma, myasthenia gravis, and brainstem glioma.

TABLE 15-1
Extraocular Muscles

Ocular Muscles	Innervation	Functions
Lateral rectus	Abducens	Abduction
Medial rectus	Oculomotor	Adduction
Superior rectus	Oculomotor	Elevation, intorsion, adduction
Inferior rectus	Oculomotor	Depression, extorsion, adduction
Inferior oblique	Oculomotor	Extorsion, elevation, abduction
Superior oblique	Trochlear	Intorsion, depression, abduction

MANAGEMENT. Prisms are not effective; patients require surgery. Several procedures are available to restore the balance between the superior and inferior oblique muscles.

Abducens Nerve Palsy

CLINICAL FEATURES. Congenital abducens nerve palsy may be unilateral or bilateral and sometimes is associated with other cranial nerve palsies. Lateral movement of the affected eye is limited partially or completely. Most infants use cross-fixation and retain vision in both eyes. In the few reported cases of congenital palsy with pathological correlation, the abducens nerve is absent, and its nucleus is hypoplastic.

Möbius syndrome is the association of congenital facial diplegia and bilateral abducens nerve palsies (see Chapter 17). *Duane syndrome* is aplasia of one or both nuclei of the abducens nerve with innervation of the atrophic lateral rectus by fibers of the oculomotor nerve (Chung et al, 2000). Ten percent of cases are genetic; the gene locus is on chromosome 8. The characteristic features are lateral rectus palsy, some limitation of adduction, and narrowing of the palpebral fissure because of globe retraction on attempted adduction. Other ocular, ear, and systemic malformations may be associated.

DIAGNOSIS. MRI excludes the possibility of an intracranial mass lesion, and hearing testing is required.

MANAGEMENT. Surgical procedures may be useful to correct head turn and to provide binocular vision, but they do not restore ocular motility.

Brown Syndrome

Brown syndrome results from congenital shortening of the superior oblique muscle or tendon. The result is mechanical limitation of elevation in adduction. Usually, only one eye is involved.

CLINICAL FEATURES. Elevation is limited in adduction but is relatively normal in abduction. Passive elevation (forced duction) also is restricted. Other features include widening of the palpebral fissure on adduction and backward head tilt.

DIAGNOSIS. The diagnosis of Brown syndrome requires the exclusion of acquired shortening of the superior oblique muscle. The causes of acquired shortening of the superior oblique muscle include juvenile rheumatoid arthritis, trauma, and inflammatory processes affecting the top of the orbit (see section on orbital inflammatory disease later).

MANAGEMENT. Surgical procedures that extend the superior oblique muscle can be useful in congenital cases.

Congenital Fibrosis of the Extraocular Muscles

Inheritance of congenital fibrosis of the extraocular muscles (CFEOM) is by autosomal dominant inheritance, and the abnormal gene maps to chromosome 12p (OMIM, 2003). If all affected members of a family have typical CFEOM, the phenotypic classification is *FEOM1*. *FEOM2* is associated with bilateral ptosis with the eyes fixed in an exotropic position. Genetic transmission is as an autosomal recessive trait.

CLINICAL FEATURES. Affected children have congenital bilateral ptosis and restrictive ophthalmoplegia, with their eyes partially or completely fixed in a downward position. CFEOM is a relatively static disorder that is phenotypically homogeneous when completely penetrant. Some children have mild delay in achieving milestones during infancy, and some have a mild facial diplegia. The head is tilted back to allow vision, and diplopia is not associated despite the severe misalignment of the eyes.

DIAGNOSIS. The clinical findings and the family history are the basis for diagnosis. Laboratory studies are useful only to exclude other possibilities.

MANAGEMENT. The goal of treatment is improvement of vision by correcting ptosis.

Congenital Myasthenia Gravis

Several clinical syndromes of myasthenia gravis occur in the newborn (see Chapter 6). Congenital myasthenia gravis has ophthalmoplegia as the primary clinical feature. Genetic transmission is by autosomal recessive inheritance, and the most common cause is a deficiency of muscle acetylcholine receptors (AChRs) at the end plate. Other underlying defects include abnormal acetylcholine resynthesis or immobilization, reduced end plate acetylcholinesterase, and impaired function of the AChR (Engel et al, 2002). In 25% of patients with AChR deficiency, AChR mutations are undetectable. Among these patients, *rapsyn* (*receptor-associated protein at the synapse*) deficiency is an important causative factor (Burke et al, 2003).

CLINICAL FEATURES. Although transmission of these disorders is by autosomal recessive inheritance, a male-to-female bias of 2:1 exists. Symmetrical ptosis and ophthalmoplegia are present at birth or shortly thereafter. Mild facial

weakness may be present but is not severe enough to impair feeding. If partial at birth, the ophthalmoplegia becomes complete during infancy or childhood. Generalized weakness sometimes develops.

DIAGNOSIS. The diagnosis is suspected in any newborn with bilateral ptosis or limitation of eye movement. Intramuscular injection of edrophonium chloride produces a transitory improvement in ocular motility. Repetitive nerve stimulation of the limbs at a frequency of 3 Hz may evoke a decremental response that is reversible with edrophonium chloride; this suggests that the underlying defect, although producing symptoms only in the eyes, causes generalized weakness at birth. Commercial testing is available for rapsyn mutations.

MANAGEMENT. No evidence of an immunopathy exists, and immunosuppressive therapy is not a recommendation. Thymectomy and corticosteroids are ineffective. Anticholinesterases may decrease facial paralysis but have little or no effect on ophthalmoplegia. In some children, the weakness responds to 3,4-diaminopyridine (DAP), an agent that releases acetylcholine (Harper and Engel, 2000) combined with anticholinesterases. DAP is not commercially available in the United States but can be obtained on a compassionate use basis for individual patients from Jacobus Pharmaceutical Company, Princeton, New Jersey.

Congenital Ptosis

Congenital drooping of one or both lids is relatively common, and the drooping is unilateral in 70%. The cause is unknown, but the condition rarely occurs in other family members. The three forms of hereditary congenital ptosis are simple ptosis, ptosis with external ophthalmoplegia, and ptosis with blepharophimosis. Genetic transmission of the simple form is by X-linked inheritance.

CLINICAL FEATURES. Congenital ptosis is often unnoticed until early childhood or even adulthood and then is diagnosed as an “acquired” ptosis. Miosis is sometimes an associated feature and suggests the possibility of Horner syndrome except that the pupil responds normally to pharmacological agents. Some patients have a synkinesis between the oculomotor and trigeminal nerves; jaw movements produce opening of the eye (*Marcus-Gunn phenomenon*).

DIAGNOSIS. Table 15-2 lists the differential diagnosis of ptosis. Distinguishing congenital ptosis from acquired ptosis is essential. The examination of baby pictures is more cost-effective than MRI to make the distinction. If miosis is present,

TABLE 15-2
Causes of Ptosis

Congenital

Congenital fibrosis of extraocular muscles
Horner syndrome
Myasthenia
Oculomotor nerve palsy

Acquired

Horner syndrome
Lid inflammation
Mitochondrial myopathies (see Chapter 8)
Myasthenia gravis
Oculomotor nerve palsy
Oculopharyngeal dystrophy (see Chapter 17)
Ophthalmoplegic migraine
Orbital cellulitis
Trauma

test the eye with pharmacological agents to determine whether sympathetic hypersensitivity is present indicating Horner syndrome. Concurrent paralysis of extraocular motility is evidence against congenital ptosis.

MANAGEMENT. Early corrective surgery to elevate the lid improves appearance and vision.

Acute Unilateral Ophthalmoplegia

Table 15-3 summarizes the causes of acquired ophthalmoplegia. Many of these conditions are discussed in other chapters. The definition of *acute ophthalmoplegia* is reaching maximum intensity within 1 week of onset. It may be partial or complete (Table 15-4). Generalized increased intracranial pressure is always an important consideration in patients with unilateral or bilateral abducens palsy (see Chapter 4).

Aneurysm

Arterial aneurysms are discussed fully in Chapter 4 because the important clinical feature in children is hemorrhage rather than nerve compression. This section addresses possible ophthalmoplegic features.

CLINICAL FEATURES. Aneurysms at the junction of the internal carotid and posterior communicating arteries are an important cause of unilateral oculomotor palsy in adults but are a rare cause in children. Compression of the nerve by expansion of the aneurysm causes the palsy. Intense pain in and around the eye is frequently experienced at the time of hemorrhage. Because the parasympathetic fibers are at the periphery of the nerve, mydriasis is an almost constant feature of ophthalmoplegia caused by aneurysms of

TABLE 15-3
Causes of Acquired Ophthalmoplegia

Brainstem	Postinfectious
Brainstem encephalitis (see Chapter 10)	Idiopathic (postviral)
Intoxication	Miller Fisher syndrome (see Chapter 10)
Multiple sclerosis (see Chapter 10)	Polyradiculoneuropathy (see Chapter 7)
Subacute necrotizing encephalopathy (see Chapter 10)	Trauma
Tumor	Head
Brainstem glioma	Orbital
Craniopharyngioma (see Chapter 16)	Tumor
Leukemia	Cavernous sinus hemangioma
Lymphoma	Orbital tumors
Metastases	Sellar and parasellar tumors (see Chapter 16)
Pineal region tumors	Sphenoid sinus tumors
Vascular	Vascular
Arteriovenous malformation	Aneurysm
Hemorrhage	Carotid-cavernous fistula
Infarction	Cavernous sinus thrombosis
Migraine	Migraine
Vasculitis	Neuromuscular Transmission
Nerve	Botulism (see Chapter 7)
Familial recurrent cranial neuropathies (see Chapter 17)	Myasthenia gravis
Increased intracranial pressure (see Chapter 4)	Tic paralysis
Infectious	Myopathies
Diphtheria	Fiber-type disproportion myopathies (see Chapter 6)
Gradenigo syndrome	Kearns-Sayres syndrome
Meningitis (see Chapter 4)	Mitochondrial myopathies (see Chapter 8)
Orbital cellulitis	Oculopharyngeal dystrophy (see Chapter 17)
Inflammatory	Orbital inflammatory disease
Sarcoid	Thyroid disease
Tolosa-Hunt syndrome	Vitamin E deficiency

TABLE 15-4
Causes of Acute Unilateral Ophthalmoplegia

Aneurysm*†
Brain tumors
Brainstem glioma
Parasellar tumors (see Chapter 16)
Tumors of pineal region (see Chapter 4)
Brainstem stroke*
Cavernous sinus fistula
Cavernous sinus thrombosis
Gradenigo syndrome
Idiopathic ocular motor nerve palsy*
Increased intracranial pressure (see Chapter 4)
Multiple sclerosis* (see Chapter 10)
Myasthenia gravis*
Ophthalmoplegic migraine*†
Orbital inflammatory disease**
Orbital tumor*
Recurrent familial* (see Chapter 17)
Tolosa-Hunt syndrome**†
Trauma
Head
Orbital

*May be recurrent.

†May be associated with pain.

the posterior communicating artery. Pupillary involvement may develop, however, several days after onset of an incomplete external ophthalmoplegia. A normal pupil with complete external ophthalmoplegia effectively excludes the possibility of aneurysm.

Sometimes, aneurysms affect the superior branch of the oculomotor nerve earlier and more severely than the inferior branch. Ptosis may precede the development of other signs by hours or days.

DIAGNOSIS. Contrast-enhanced MRI and magnetic resonance angiography identify most aneurysms.

MANAGEMENT. Surgical clipping is the treatment of choice whenever technically feasible. Oculomotor function often returns to normal after the procedure.

Brainstem Glioma

CLINICAL FEATURES. Symptoms begin between 2 and 13 years of age, with a peak between ages 5 and 8 years. The time from onset of symptoms to diagnosis is less than 6 months. Cranial nerve

palsies, usually abducens and facial, are the initial features in most cases. Later, contralateral hemiplegia and ataxia, dysphagia, and hoarseness develop. Hemiplegia at onset is associated with a more rapid course. With time, cranial nerve and corticospinal tract involvement may become bilateral. Increased intracranial pressure is not an early feature, but direct irritation of the brainstem emetic center may cause vomiting rather than increased pressure. Intractable hiccough, facial spasm, personality change, and headache are early symptoms in occasional patients.

Brainstem gliomas carry the worst prognosis of any childhood tumor. The course is one of steady progression, with median survival times of 9 to 12 months.

DIAGNOSIS. MRI delineates the tumor well and differentiates tumor from inflammatory and vascular disorders (Figure 15-1).

MANAGEMENT. Radiation therapy is the treatment of choice. Several chemotherapeutic programs are undergoing experimental trials, but none has established benefit.

Brainstem Stroke

Table 11-2 summarizes the causes of stroke in children. Small brainstem hemorrhages resulting from emboli, leukemia, or blood dyscrasias have the potential to cause isolated ocular motor palsies, but this is not the rule. Other cra-

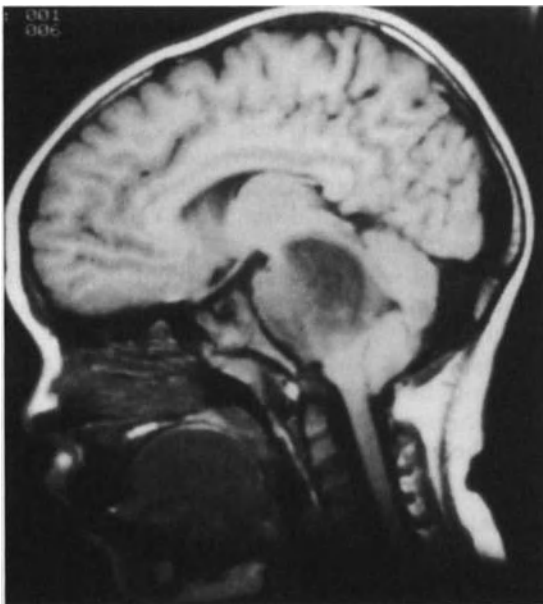


Figure 15-1. Brainstem glioma. MRI shows a large lesion infiltrating the brainstem.

nial nerves also are involved, and hemiparesis, ataxia, and decreased consciousness are often associated features.

Carotid-Cavernous Sinus Fistula

CLINICAL FEATURES. Arteriovenous communications between the carotid artery and the cavernous sinus may be congenital, but trauma is the usual cause. The injury may be closed or penetrating. The carotid artery or one of its branches ruptures into the cavernous sinus, increasing pressure in the venous system. The results are a pulsating proptosis, redness and swelling of the conjunctiva, increased intraocular pressure, and ophthalmoplegia. If a bruit is present over the eye, compression of the ipsilateral carotid artery reduces the volume.

DIAGNOSIS. Carotid arteriography reveals rapid cavernous sinus filling, poor filling of the distal intracranial branches, and engorgement of and retrograde flow within venous drainage pathways.

MANAGEMENT. Transarterial balloon embolization or coiling of the affected cavernous sinus is the mainstay of treatment.

Cavernous Sinus Thrombosis

Cavernous sinus thrombosis may produce either unilateral or bilateral ophthalmoplegia. The cause is usually the anterograde spread of infection from the mouth, face, nose, or paranasal sinuses.

CLINICAL FEATURES. The development of fever, malaise, and frontal headache after dental infection is the typical history. Proptosis, orbital congestion, ptosis, external ophthalmoplegia, pupillary paralysis, and blindness may follow the initial symptoms. The infection begins in one cavernous sinus and spreads to the other. If untreated, it may extend to the meninges. Even with vigorous antibiotic treatment, the mortality rate is 15%.

DIAGNOSIS. The ocular signs may suggest orbital cellulitis or orbital pseudotumor. The cerebrospinal fluid is normal early in the course. A mixed leukocytosis develops, and the protein concentration is moderately elevated even in the absence of meningitis. When the meninges are involved, the pressure becomes elevated, the leukocytosis increases, and the glucose concentration decreases. Cranial computed tomography (CT) may show clouding of infected paranasal sinuses. Magnetic resonance angiography shows decreased or absent flow in the cavernous portion of the carotid artery.

MANAGEMENT. Intravenous antibiotic therapy is similar to the course used to treat meningitis. Surgical drainage of infected paranasal sinuses is sometimes necessary.

Gradenigo Syndrome

CLINICAL FEATURES. The abducens nerve lies adjacent to the medial aspect of the petrous bone before entering the cavernous sinus. Infections of the middle ear sometimes extend to the petrous bone and cause thrombophlebitis of the inferior petrosal sinus. The infection involves not only the abducens nerve, but also the facial nerve and the trigeminal ganglion. The resulting syndrome consists of ipsilateral paralysis of abduction, facial palsy, and facial pain.

DIAGNOSIS. The combination of unilateral abduction and facial palsy also occurs after closed head injuries. The diagnosis of Gradenigo syndrome requires the demonstration of middle ear infection. CT of the mastoid bone shows the infection. Lumbar puncture reveals a cellular response and an elevation of protein content.

MANAGEMENT. Prompt antibiotic therapy prevents permanent nerve damage.

Idiopathic Cranial Nerve Palsy

The sudden onset of a single, otherwise unexplained, cranial neuropathy usually is attributed to an immune-mediated reaction to a prior viral infection. A cause-and-effect relationship between viral infection and ocular motor palsies is not established, however. Abducens nerve palsy is more common than either oculomotor or trochlear nerve palsies. Bilateral involvement is unusual.

CLINICAL FEATURES. The chief complaint is a painless diplopia. Examination reveals a paralytic strabismus. Girls are affected more often than boys, and the left eye is affected more often than the right. Restoration of full motility is within 6 months, but shorter duration recurrences occur in half of children.

DIAGNOSIS. Examination of the cerebrospinal fluid and MRI of the head and orbit exclude tumor and infection. Tumors in and around the orbit are sometimes difficult to show, and if ophthalmoplegia persists, a repeat MRI may be necessary. Myasthenia gravis is a diagnostic consideration. An edrophonium chloride test may be useful, but myasthenia gravis is unlikely when there is a fixed single nerve deficit.

MANAGEMENT. Isolated cranial nerve palsies are not an indication for corticosteroid therapy. In children younger than 9 years old, intermittent

patching of the normal eye may be necessary if the affected eye never fixates.

Myasthenia Gravis

Some neonatal forms of myasthenia are discussed in Chapter 6; congenital myasthenia is included in the section on congenital ophthalmoplegia earlier in this chapter, and limb-girdle myasthenia is discussed in Chapter 7. This section describes the immune-mediated form of myasthenia encountered from late infancy through adulthood. The two clinical forms are *ocular myasthenia*, which primarily or exclusively affects the eye muscles, but facial and limb muscles may be mildly involved, and *generalized myasthenia*, in which weakness of bulbar and limb muscles is moderate to severe. The term *juvenile myasthenia* to denote immune-mediated myasthenia gravis in children has no special meaning. The disease is similar in children and adults.

CLINICAL FEATURES. The initial symptoms do not appear until after 6 months of age; 75% of children first have symptoms after age 10. Prepubertal onset is associated with a male bias, ocular symptoms only, and seronegativity for AChR antibodies, whereas postpubertal onset is associated with a strong female bias, generalized myasthenia, and seropositivity. In general, the disease is less severe in boys than in girls.

The initial features of the ocular and the generalized form are usually ptosis, diplopia, or both. Myasthenia is the most common cause of acquired unilateral or bilateral ptosis. Pupillary function is normal. At the onset of ocular symptoms, 40% to 50% of patients have weakness of other bulbar or limb muscles. Ocular motor weakness is generally not constant initially, and the specific muscles affected may change from examination to examination. Usually both eyes are affected, but one is more affected than the other.

Children with ocular myasthenia may have mild facial weakness and easy fatigability of the limbs. They do not have respiratory distress or difficulty speaking or swallowing, however. The subsequent course of ocular myasthenia may be one of steady progression to complete ophthalmoplegia or one of relapses and remissions. The relapses are of varying severity and last weeks to years. At least 20% of patients have permanent remissions. Prepubertal onset is more commonly associated with spontaneous remission than postpubertal onset.

Children with generalized myasthenia have generalized weakness within 1 year of the initial

ocular symptoms. The symptoms include dysarthria, dysphagia, difficulty chewing, and limb muscle fatigability. Spontaneous remissions are unusual. Respiratory insufficiency (*myasthenic crisis*) occurs in one third of untreated children.

Children with generalized myasthenia, but not children with ocular myasthenia, have a higher than expected incidence of other autoimmune disorders, especially thyroiditis and collagen vascular diseases. Thymoma is present in 15% of adults with generalized myasthenia but occurs in less than 5% of children. When thymoma occurs in children, it is likely to be malignant.

DIAGNOSIS. The edrophonium chloride test is often set as a standard of diagnosis for the ocular and the generalized forms of myasthenia gravis, but it has limitations. Edrophonium chloride is a short-acting anticholinesterase administered intravenously at a dose of 0.15 mg/kg. Before initiating the test, an end point for the study must be determined. The best end point is the resolution of ptosis or the restoration of ocular motility, and test results are difficult to evaluate in their absence. Ptosis generally responds better than ocular motor paralysis to edrophonium chloride.

Some patients with myasthenia are supersensitive to edrophonium chloride. Fasciculations and respiratory arrest may develop after administration of a full dose. For this reason, first inject a test dose of one tenth the full dose. Respiratory embarrassment sometimes develops in response to the test dose, and a hand ventilator should be readily available before any drug is given. Atropine is an effective antidote to the muscarinic side effects of edrophonium chloride but does not counteract the nicotinic effects on the motor end plate that result in paralysis of the skeletal muscles.

After the test dose is given, the remainder should be injected one third at a time (approximately 0.05 mg/kg), allowing 1 minute after each injection to test the response. Interpretation may be difficult. The judgment of improved strength is always subjective and influenced by examiner bias. The test becomes more objective when combined with electrophysiological studies. *I rarely use the edrophonium test for diagnosis and rely more on the clinical features, the serum antibody concentrations, and electrophysiological studies.*

Some physicians now use the *ice-pack test* instead. Place a very cold compress on the ptotic lid for 5 minutes. Partial opening of the lid suggests myasthenia. Five minutes of resting with the eye closed may accomplish the same result without the ice pack.

Results of repetitive nerve stimulation studies are abnormal in 66% of children when proximal nerves are stimulated, but in only 33% when distal nerves are studied. Abnormal repetitive nerve study findings are unusual in children with ocular myasthenia but are the rule in children with generalized myasthenia. Patients with mild myasthenia show a decremental response at low rates of stimulation (2 to 5/sec) but not at high rates (50/sec). In severe myasthenia, low and high rates of stimulation produce a decremental response.

Of patients with generalized immune-mediated myasthenia, 85% have elevated serum concentrations of antibodies against the AChR (>10 nmol/L). Patients with ocular myasthenia may be seronegative or have low antibody concentrations. Among children who are seronegative, many have a genetic disorder secondary to rapsyn mutations, and others have antibodies directed against muscle-specific tyrosine kinase (*MuSK*). The distinction between early-onset, seronegative immune-mediated and genetic myasthenia is important; one responds to immunotherapy, and the other does not. MuSK antibodies concentration testing is commercially available; rapsyn mutation analysis is not.

MANAGEMENT. The basis for managing non-genetic myasthenia in children is experience and retrospective studies, primarily done in adults (Richman and Agius, 2003). Children with ocular myasthenia, but not children with generalized myasthenia, have a reasonable hope of spontaneous remission. Anticholinesterase therapy is the treatment of choice for ocular myasthenia. The initial dose of neostigmine is 0.5 mg/kg every 4 hours in children younger than 5 years old and 0.25 mg/kg in older children, not to exceed 15 mg in any child. The equivalent dose of pyridostigmine is four times greater. After initiating treatment, the dose is slowly increased as needed and tolerated. Diarrhea and gastrointestinal cramps are the usual limiting factors. Do not administer edrophonium chloride to determine whether the child would benefit from higher oral doses of anticholinesterases. It is not an accurate guide and may cause cholinergic crisis in children with generalized myasthenia.

Several retrospective studies in adults suggest that early immunotherapy (Kuppersmith, 2003; Mee et al, 2003) and thymectomy reduce the conversion of ocular myasthenia to generalized myasthenia. *The evidence is not convincing and not applicable to children.*

Ocular myasthenia can be difficult to treat, and evaluating the efficacy of treatment is

especially difficult. The response to anticholinesterase is often transitory, and the addition of corticosteroids is usually without benefit. The efficacy of any drug regimen in ocular myasthenia is difficult to assess because of the fluctuating course of the disease.

The place of thymectomy in the management of myasthenia is not established. Experience indicates that most children who undergo thymectomy early in the course are in remission within 3 years. Corticosteroids accomplish the same result, however, and prior thymectomy does not reduce the need for long-term corticosteroid treatment. The starting dose of prednisone is 1.5 mg/kg/day, not to exceed 100 mg/day. High-dose corticosteroids may make the patient weaker at first. After 5 days of daily treatment, switch to alternate-day therapy for the remainder of the month. Taper the prednisone dose by 10% each month until reaching a dose that keeps the patient symptom-free. The usual maintenance dose is 10 to 20 mg every other day. I have been unsuccessful in eventually stopping prednisone. Concurrent anticholinesterase medication is unnecessary with corticosteroids but is useful if the patient weakens on the alternate days when corticosteroids are not used.

The clinical characteristics and response to treatment of individuals with nongenetic, generalized myasthenia who are seronegative do not differ from the characteristics and response of individuals who are seropositive except that seronegative patients are unlikely to show thymic abnormalities and are unlikely to benefit from thymectomy. Plasmapheresis, intravenous immunoglobulin, and high-dose intravenous corticosteroids are useful for acute intervention in patients who have respiratory insufficiency.

Ophthalmoplegic Migraine

The mechanism of ophthalmoplegia in migraine is not established. Although migraine is hereditary, the tendency for ophthalmoplegia is not.

CLINICAL FEATURES. Transitory ocular motor palsy (lasting ≤ 4 weeks) may occur as part of a migraine attack in children and adults. The palsy affects the oculomotor nerve alone in 83% of cases and affects all three nerves in the remainder. Ptosis usually precedes ophthalmoplegia. Partial or complete pupillary involvement is present in 60%. The average age at onset is 15 years, but the onset may be in infancy. In infants, recurrent painless ophthalmoplegia or ptosis may be the only feature of the migraine attack. In older children, ophthalmoplegia usually occurs during the headache phase and is ipsilateral to the headache.

DIAGNOSIS. The diagnosis is obvious when ophthalmoplegia occurs during a typical migraine attack in a child previously known to have migraine. Diagnostic uncertainty is greatest when an infant has transitory strabismus or ptosis as an isolated sign. In such cases, a family history of migraine is essential for diagnosis. Even so, MRI studies of the head and orbit are appropriate in most infants with a first episode of ophthalmoplegia. Contrast-enhanced MRI may reveal a reversible enhancement and thickening of the cisternal segment of the oculomotor nerve during an attack (Mark et al, 1998).

MANAGEMENT. The management of ophthalmoplegic migraine is the same as other forms of migraine (see Chapter 3).

Orbital Inflammatory Disease

The term *orbital inflammatory disease* encompasses a group of nonspecific inflammatory conditions involving the orbit. Some experts include the Tolosa-Hunt syndrome as part of the spectrum. Inflammation may be diffuse or localized to specific tissues within the orbit (*orbital myositis*).

CLINICAL FEATURES. The disorder is unusual before age 20 years but may occur at 3 months of age. Males and females are equally affected. Acute and chronic forms exist. The main features are pain, ophthalmoplegia, proptosis, and lid edema evolving over several days or weeks. One or both eyes may be involved. Ocular motility is disturbed in part by the proptosis but mainly by myositis. Some patients have only myositis, whereas others have inflammation in other orbital structures. Vision is initially preserved, but vision is threatened if the condition remains untreated.

DIAGNOSIS. The development of unilateral pain and proptosis in a child suggests an orbital tumor. Bilateral proptosis suggests thyroid myopathy. MRI shows a soft tissue mass without sinus involvement or bone erosion. Orbital involvement by lymphoma or leukemia produces a similar radiographic appearance. The extraocular muscles may appear enlarged.

MANAGEMENT. Orbital inflammatory disease has a self-limited course, but treatment is required to prevent vision loss or permanent ophthalmoplegia. Administer prednisone, 1 mg/kg/day, for at least 1 month before tapering. Reinitiate the full dose if the disorder recurs during the taper.

Orbital Tumors

CLINICAL FEATURES. The initial feature of *intraorbital* tumors is proptosis, ophthalmoplegia, or

ptosis. When the globe displaces forward, the palpebral fissure widens, and closing the eye fully may not be possible. The exposed portion of the eye becomes dry and erythematous, and exposure keratitis may occur. The direction of displacement of the globe is the best clue to the tumor's position. Ophthalmoplegia may occur because of forward displacement of the globe, causing direct pressure on one or more ocular muscles.

DIAGNOSIS. The differential diagnosis of proptosis in children includes infection and inflammation, hemorrhage and other vascular disorders, orbital tumors, hyperthyroidism and other metabolic disorders, developmental anomalies, and Hand-Schüller-Christian disease and related disorders; some are idiopathic. The most common orbital tumors are dermoid cyst, hemangioma, metastatic neuroblastoma, optic glioma, and rhabdomyosarcoma.

MANAGEMENT. Treatment varies with the tumor type. Many require surgical resection.

Tolosa-Hunt Syndrome

Tolosa-Hunt syndrome is a painful ophthalmoplegia attributed to an idiopathic granulomatous disease of the cavernous sinus or superior orbital fissure. No other structures are involved.

CLINICAL FEATURES. The description of pain is steady and penetrating, involving the entire hemicranium but centered around or behind the eye. It may precede the ophthalmoplegia by several days, may occur concurrently, or may appear later. The oculomotor nerve ordinarily is involved first and more severely than the two others, but all three ocular motor nerves and the first and second divisions of the trigeminal nerve and the ocular sympathetic system may be affected. Vision diminishes, and the pupil is usually small and may be reactive or nonreactive. Symptoms last days or months. Spontaneous remissions occur, but partial neurological deficits may persist.

DIAGNOSIS. Tolosa-Hunt syndrome is easily confused with ophthalmoplegic migraine. The main features that distinguish the two entities are that patients with ophthalmoplegic migraine also have migraine without ophthalmoplegia, have family histories of migraine, and do not have trigeminal nerve involvement. Tolosa-Hunt syndrome differs from orbital inflammatory disease by the absence of proptosis and the presence of trigeminal nerve involvement. Other diseases of the cavernous sinus, such as tumor or thrombosis, may resemble Tolosa-Hunt syndrome. The erythrocyte sedimentation

rate is elevated in most patients. MRI shows alterations in the shape and signal of the cavernous sinus that are almost diagnostic.

MANAGEMENT. Prednisone, 1 mg/kg/day, is diagnostic and therapeutic. If pain subsides within 2 days of initial administration, the diagnosis is likely but not certain. Other lesions in the cavernous sinus or orbit also may respond to corticosteroids. Ophthalmoplegia may subside but can take several days or weeks to clear completely. Failure of prednisone to relieve pain excludes the diagnosis of Tolosa-Hunt syndrome and indicates the need to seek another cause.

Trauma

Trauma accounts for 40% of isolated acquired ocular motor nerve palsies and 55% of multiple nerve palsies in children. Hemorrhage and edema into the nerves or muscles may occur from closed head injuries even in the absence of direct orbital injury. In the presence of orbital fractures, the nerves and muscles are vulnerable to laceration, avulsion, or entrapment by bone fragments.

CLINICAL FEATURES. Superior oblique palsy, caused by trochlear nerve damage, is a relatively common consequence of closed head injuries. Usually the trauma is severe, often causing loss of consciousness, but it may be mild. The palsy is more often unilateral than bilateral. Patients with unilateral superior oblique palsy have a marked hypertropia in the primary position and a compensatory head tilt to preserve fusion; 65% of cases resolve spontaneously. When bilateral involvement is present, the hypertropia is milder and alternates between the two eyes; spontaneous recovery occurs in only 25% of cases. Transitory lateral rectus palsy is rare in newborns; the cause is attributed to birth trauma. The palsy is unilateral and clears completely within 6 weeks.

DIAGNOSIS. Direct injuries to the orbit with associated hemorrhage and swelling do not pose a diagnostic dilemma. CT of the head with orbital views shows the extent of fracture so that the need for surgical intervention can be determined. CT also may show a lateral mid-brain hemorrhage as the cause of trochlear nerve palsy.

A delay between the time of injury and the onset of ophthalmoplegia makes diagnosis more problematic. The possible mechanisms of delayed ophthalmoplegia after trauma to the head include progressive local edema in the orbit; progressive brainstem edema; progressive

increased intracranial pressure; development of meningitis, mastoiditis, or petrous osteomyelitis; venous sinus or carotid artery thrombosis; and carotid cavernous fistula.

MANAGEMENT. Local trauma and fracture of the orbit may require surgical repair. Surgery directed at rebalancing the extraocular muscles sometimes improves vision after permanent paralysis of ocular motor nerves following head injury. Botulinum toxin is another treatment option for bilateral sixth nerve palsies.

Acute Bilateral Ophthalmoplegia

Many of the conditions that cause acute unilateral ophthalmoplegia (see Table 15-4) also may cause acute bilateral ophthalmoplegia. The conditions listed in Table 15-5 often have a high incidence of bilateral involvement. Thyrotoxicosis is discussed with the chronic conditions because progression of ophthalmoplegia usually occurs over a period greater than 1 week.

Botulism

Several strains of the bacterium *Clostridium botulinum* elaborate a toxin that disturbs neuromuscular transmission. The infantile form of botulism, which causes ptosis but not ophthalmoplegia, is discussed in Chapter 6. This section addresses late-onset cases.

CLINICAL FEATURES. The cause of botulism is most often the ingestion of toxin in home-canned food. This situation is most likely when canning at high altitudes, where the boiling temperature is too low to destroy spores. Because *C. botulinum* spores are ubiquitous in soil, infection also may follow burns, wounds, and the sharing of needles among drug addicts. Blurred vision, diplopia, dizziness, dysarthria, and dysphagia begin 12 to 36 hours after ingestion of toxin.

TABLE 15-5
Causes of Acute Bilateral Ophthalmoplegia

Basilar meningitis (see Chapter 4)
Brainstem encephalitis (see Chapter 10)
Carotid-cavernous fistula
Cavernous sinus thrombosis
Diphtheria
Intoxication
Miller Fisher syndrome (see Chapter 10)
Myasthenia gravis
Polyradiculoneuropathy (see Chapter 7)
Subacute necrotizing encephalomyelopathy (see Chapter 5)
Tick paralysis (see Chapter 7)

The pupillary response is usually normal. An ascending paralysis similar to Guillain-Barré syndrome follows the early symptoms and may lead to death from respiratory paralysis. Patients remain conscious and alert throughout. Most patients make a complete recovery within 2 to 3 months, but patients with severe involvement may not return to normal for a year.

DIAGNOSIS. The presence of ophthalmoplegia and the electromyogram findings distinguish botulism from Guillain-Barré syndrome. The motor and sensory nerve conduction velocities are normal, the amplitude of evoked muscle action potentials is reduced, and a decremental response is not ordinarily present at low rates of stimulation, although facilitation may be present at high rates of stimulation. Showing the organism or the toxin in food, stool, or a wound establishes the diagnosis.

MANAGEMENT. Antitoxin administration, 20,000 to 40,000 U two or three times a day, is the recommended treatment. Empty the stomach and intestines of their contents. DAP is effective in some patients and should be used for patients with potential respiratory failure. Ensure the availability of mechanical respiratory support when the diagnosis is suspected.

Intoxications

CLINICAL FEATURES. Anticonvulsants, tricyclic antidepressants, and many other psychoactive drugs selectively impair ocular motility at toxic blood concentrations. Overdose may be accidental or intentional. A child, found unconscious, arrives at the emergency department. The state of consciousness varies from obtundation to stupor, but the eyes do not move, either by rapidly rotating the head laterally or with ice water irrigation of the ears. Complete ophthalmoplegia is expected in a comatose child if brainstem function is otherwise impaired (see Chapter 2), but in a noncomatose child with otherwise intact brainstem function, ingestion of a drug that selectively impairs ocular motility should be suspected.

DIAGNOSIS. Question the family about drugs available in the household, and screen the blood and urine for toxic substances.

MANAGEMENT. Specific treatment depends on the drug ingested; in most cases, supportive care is sufficient.

Chronic Bilateral Ophthalmoplegia

Table 15-6 lists the conditions responsible for bilateral ophthalmoplegia developing over a

TABLE 15-6
Causes of Chronic Bilateral Ophthalmoplegia

Brainstem glioma
Chronic meningitis (see Chapter 4)
Chronic orbital inflammation
Graves ophthalmopathy
Kearns-Sayre syndrome
Myasthenia gravis
Congenital
Juvenile
Myopathies
Fiber-type disproportion myopathy (see Chapter 6)
Mitochondrial myopathies (see Chapter 8)
Myotubular myopathy (see Chapter 6)
Oculopharyngeal muscular dystrophy (see Chapter 17)
Subacute necrotizing encephalomyelopathy (see Chapter 5)
Thyroid disease
Vitamin E deficiency

period longer than 1 week. Most conditions have been discussed in previous sections of this chapter or are addressed in other chapters.

Graves Ophthalmopathy

The association of ophthalmopathy with hyperthyroidism is not causal. The two conditions are associated autoimmune diseases. One hypothesis suggests the presence of a cross-reacting antigen in thyroid and orbital tissues. Myasthenia gravis also may be associated.

CLINICAL FEATURES. Disorders of ocular motility are sometimes present in most patients with hyperthyroidism and may precede systemic features of nervousness, heat intolerance, diaphoresis, weight loss, tachycardia, tremulousness, and weakness. The main orbital pathology is a myopathy of the extraocular muscles. The muscles become inflamed, swollen with interstitial edema, and finally fibrotic. If the two eyes are equally affected, the patient may not complain of diplopia despite considerable limitation of ocular motility. Staring or lid retraction (*Dalrymple sign*) occurs in more than 50% of cases, lid lag on downward gaze (*von Graefe sign*) occurs in 30% to 50%, and proptosis (exophthalmos) occurs in almost 90%. Severe exophthalmos is due to edema and infiltration of all orbital structures.

DIAGNOSIS. Thyroid disease is a consideration in any child with evolving ophthalmoplegia. CT of the orbit shows enlargement of the extraocular muscles. Thyroid function tests are often normal, but a thyroid-releasing hormone stimu-

lation test and a measure of the concentration of thyroid-stimulating immunoglobulin may confirm the diagnosis.

MANAGEMENT. Meticulous control of hyperthyroidism does not cure the ophthalmopathy. While treating hyperthyroidism, avoid overtreatment causing hypothyroidism. If the exophthalmos progresses, even after the patient is euthyroid, corticosteroids may prevent further proptosis, but persistent optic nerve compression requires surgical decompression.

Kearns-Sayre Syndrome

Deletions of mitochondrial DNA cause Kearns-Sayre syndrome (DiMauro and Hirano, 2003). Variability in the clinical syndrome reflects variability in the size of the deletion and the specific respiratory complex affected (see Chapter 8). Most cases are sporadic.

CLINICAL FEATURES. The invariable features of the disease are onset before 20 years of age, progressive external ophthalmoplegia, ptosis, and pigmentary degeneration of the retina. At least one of three other features also must be present for diagnosis: heart block, cerebrospinal fluid protein level greater than 100 mg/dL, or cerebellar dysfunction.

DIAGNOSIS. Diagnosis is based on the major clinical criteria. Electrocardiogram monitoring for cardiac arrhythmia and cerebrospinal fluid examination are essential.

MANAGEMENT. Treatment with vitamins or coenzyme Q, depending on the specific respiratory complex defect, may be beneficial in some patients. A cardiac pacemaker may be life-saving.

Gaze Palsies

This section discusses supranuclear palsies. The examiner must show that the eyes move normally in response to brainstem gaze center reflexes (doll's head maneuver, caloric testing, and Bell's phenomenon) to verify supranuclear palsy. Table 15-7 lists the differential diagnosis of gaze palsies.

Apraxia of Horizontal Gaze

Ocular motor apraxia is a deficiency in voluntary, horizontal, lateral, fast eye movements (saccades) with retention of slow pursuit movements. Bringing the eyes to a desired position requires jerking movements of the head. The rapid phase of optokinetic nystagmus is absent.

TABLE 15-7
Gaze Palsies**Apraxia of Horizontal Gaze**

Ataxia-telangiectasia (see Chapter 10)
 Ataxia-ocular motor apraxia (see Chapter 10)
 Brainstem glioma
 Congenital ocular motor apraxia
 Huntington disease (see Chapter 5)

Internuclear Ophthalmoplegia

Brainstem stroke
 Brainstem tumor
 Exotropia (pseudo-INO)
 Multiple sclerosis
 Myasthenia gravis (pseudo-INO)
 Toxic-metabolic

Vertical Gaze Palsy

Aqueductal stenosis (see Chapter 18)
 Congenital vertical ocular motor apraxia
 Gaucher disease (see Chapter 5)
 Hydrocephalus (see Chapters 4 and 18)

Miller Fisher syndrome (see Chapter 10)
 Niemann-Pick disease, type C (see Chapter 5)
 Tumor (see Chapter 4)
 Midbrain
 Pineal region
 Third ventricle

Horizontal Gaze Palsy

Adversive seizures (see Chapter 1)
 Brainstem tumors
 Destructive lesions of the frontal lobe (see Chapter 11)
 Familial horizontal gaze palsy

Convergence Paralysis

Head trauma
 Idiopathic
 Multiple sclerosis (see Chapter 10)
 Pineal region tumors (see Chapter 4)
 INO, internuclear ophthalmoplegia.

Congenital Ocular Motor Apraxia

CLINICAL FEATURES. Although ocular motor apraxia is present at birth, detection is not until late infancy. Failure of fixation raises questions concerning visual impairment. Refixation requires overshooting head thrusts, often accompanied by blinking of the eyes. With the head held immobile, the child makes no effort to initiate horizontal eye movements.

Many children with ocular motor apraxia have other signs of cerebral abnormality, such as psychomotor retardation, learning disabilities, and clumsiness. When hypotonia is present, the child may have difficulty making the head movements needed for refixation. Agenesis of the corpus callosum and agenesis of the cerebellar vermis are concurrent conditions in some children. The association does not indicate that the malformations are responsible for ocular motor apraxia.

DIAGNOSIS. Consider the possibility of ocular motor apraxia in any infant referred for evaluation of visual impairment. Children with ocular motor apraxia require brain MRI to search for other cerebral malformations and tests for ataxia-telangiectasia (see Chapter 10) and lysosomal storage diseases (see Chapter 5).

MANAGEMENT. Management depends on the underlying condition.

Internuclear Ophthalmoplegia

The medial longitudinal fasciculus (MLF) contains fibers that connect the abducens nucleus

to the contralateral oculomotor nucleus to perform horizontal conjugate lateral gaze. Unilateral lesions in the MLF disconnect the two nuclei so that when the patient attempts lateral gaze, the adducting eye ipsilateral to the abnormal MLF is unable to move medially, but the abducting eye is able to move laterally. Nystagmus (actually *overshoot dysmetria*) is often present in the abducting eye. This symptom complex, which may be unilateral or bilateral, is *internuclear ophthalmoplegia* (INO). The usual cause of unilateral INO is vascular occlusive disease and of bilateral INO is either demyelinating disease or rarely toxic-metabolic conditions.

Patients with myasthenia gravis sometimes have ocular motility dysfunction that resembles an INO except that nystagmus is usually lacking. The disorder is a *pseudo-INO* because the MLF is intact. Exotropia is another cause of pseudo-INO. When the normal eye is fixating in full abduction, there is no visual stimulus to bring the paretic eye into full adduction. Nystagmus is not present in the abducting eye.

The combination of an INO in one direction of lateral gaze and complete gaze palsy in the other is a *one-and-a-half syndrome*. The underlying pathology is a unilateral lesion in the dorsal pontine tegmentum that affects the pontine lateral gaze center and the adjacent MLF. Multiple sclerosis is the usual cause. Other causes include brainstem glioma, infarction, or myasthenia gravis.

Toxic-Metabolic Disorders

CLINICAL FEATURES. Toxic doses of several drugs may produce the clinical syndrome of INO. Usually the patient is comatose and may have complete ophthalmoplegia that evolves into a bilateral INO. The drugs reported to produce INO include amitriptyline, barbiturates, carbamazepine, doxepin, phenothiazine, and phenytoin. INO also may occur during hepatic coma.

DIAGNOSIS. Drug intoxications are always a consideration in children with decreased consciousness who were previously well. The presence of INO after drug ingestion suggests the possibility of anticonvulsant or psychotropic drug ingestion.

MANAGEMENT. The INO resolves as the blood concentration of the drug decreases.

Vertical Gaze Palsy

Children with supranuclear vertical gaze palsies are unable to look upward or downward fully, but they retain reflex eye movements, such as Bell's phenomenon. Disorders of upward gaze in children are generally due to damage to the dorsal midbrain, and the usual cause is a tumor in the pineal region. The features are impaired upward and downward gaze; eyelid retraction; and occasional disturbances in horizontal movement, convergence, and skew deviation. Mydriasis with light-near dissociation is an early feature of extrinsic compression of the dorsal midbrain. Isolated paralysis of upward gaze may be the initial feature of the Miller Fisher syndrome and of vitamin B₁ deficiency. Bilateral lesions in the midbrain reticular formation cause isolated disturbances of downward gaze. They are rare in children but may occur in neurovisceral lipid storage disease.

Congenital Vertical Ocular Motor Apraxia

CLINICAL FEATURES. Congenital vertical ocular motor apraxia is a rare syndrome similar to congenital horizontal ocular motor apraxia except for the direction of gaze palsy. At rest, the eyes are fixated in either an upward or a downward position, with little random movement. Initially the child uses head flexion or extension to fixate in the vertical plane; later the child learns to use head thrusts. Bell's phenomenon is present.

DIAGNOSIS. Vertical gaze palsy suggests intracranial tumor, and head MRI is required. Gaze

palsies present from birth without the later development of other neurological signs usually indicate a nonprogressive process, however. Bilateral restriction of upward eye movement resulting from muscle fibrosis is a consideration. In children with ocular motor apraxia, the eyes can move upward reflexively or by forced ductions; in children with muscle fibrosis, the eyes do not move upward by any means.

MANAGEMENT. Specific treatment is not available.

Horizontal Gaze Palsy

The usual cause of inability to look to one side is a lesion in the contralateral frontal or ipsilateral pontine gaze center. Immediately after developing a frontal lobe lesion, the eyes are tonically deviated toward the side of the lesion, and contralateral hemiplegia is often present. The eyes move horizontally reflexively by stimulation of the brainstem gaze center with ice water caloric techniques. In contrast, an irritative frontal lobe lesion, such as one causing an epileptic seizure, generally causes the eyes to deviate in a direction opposite to the side with the seizure focus. Movements of the head and eyes during a seizure are *adversive seizures* (see Chapter 1). The initial direction of eye deviation reliably predicts a contralateral focus, especially if the movement is forced and sustained in a unilateral direction. Later movements that are mild and unsustained are not predictive.

Convergence Paralysis

Convergence paralysis, inability to adduct the eyes to focus on a near object in the absence of medial rectus palsies, can be caused by a pineal region tumor; in such cases, however, other signs of midbrain compression are usually present. Convergence paralysis is sometimes factitious or due to lack of motivation or attention. The absence of pupillary constriction when convergence is attempted identifies factitious convergence paralysis.

Convergence insufficiency is common after closed head injuries. The head injury need not be severe. Patient complaints may include diplopia, headache, or eyestrain while reading or doing other close work. Convergence insufficiency also occurs in the absence of prior head injury. The onset often follows a change in study time or intensity, poor lighting in the workplace, or the use of new contact lenses or eyeglasses. Treatment consists of convergence exercises.

Nystagmus

Nystagmus is an involuntary, rhythmic oscillation of the eyes in which at least one phase is slow. With *pendular nystagmus*, the movements in each direction are slow. The oscillations of congenital pendular nystagmus are in the horizontal plane even on vertical gaze. On lateral gaze, the oscillations may change to jerk nystagmus.

Movements of unequal speed characterize *jerk nystagmus*. Following an initial slow component in one direction is a fast component with saccadic velocity in the other direction. Oscillation may be horizontal or vertical. The direction of jerk nystagmus is named for the fast (saccadic) component. Nystagmus intensity increases in the horizontal plane when gaze is in the direction of the fast phase.

Table 15-8 describes other eye movements that cannot be classified as nystagmus but that have diagnostic significance. *Opsoclonus* consists of conjugate, rapid, chaotic movements in all directions of gaze, often referred to as “dancing eyes.” It occurs in infants with neuroblastoma (see Chapter 10). *Ocular flutter* is a brief burst of conjugate horizontal saccadic eye movements that interrupt fixation. It occurs in the recovery phase of opsoclonus or in association with cerebellar disease. *Ocular dysmetria* is overshooting or undershooting of the eyes during refixation or an oscillation before the

eyes come to rest on a new fixation target. *Ocular bobbing* is not downbeat nystagmus, but is a sudden downward movement of both eyes with a slow drift back to midposition. It most often occurs in comatose patients with pontine dysfunction. Congenital nystagmus and acquired nystagmus are discussed separately because their differential diagnoses are different (Table 15-9).

Physiological Nystagmus

A high-frequency (1 to 3 Hz), low-amplitude oscillation of the eyes occurs normally when sustaining lateral gaze to the point of fatigue. A jerk nystagmus, present at the end point of lateral gaze, is also normal. A few beats are usual, but even sustained nystagmus occurring at the end point is normal, unless associated with other signs of neurological dysfunction, or is distinctly asymmetrical.

Congenital Nystagmus

Although congenital nystagmus is present at birth, it may be unnoticed until infancy or childhood, then misdiagnosed as acquired nystagmus.

TABLE 15-8
Abnormal Eye Movements

Movement	Appearance	Pathology
Nystagmus	Rhythmic oscillation	Variable
Opsoclonus	Nonrhythmic, chaotic conjugate movements	Neuroblastoma
Ocular flutter	Intermittent bursts of rapid horizontal oscillations during fixation	Cerebellar/brainstem disease
Ocular dysmetria	Overshooting, undershooting, or oscillation on refixation	Cerebellar disease
Ocular bobbing	Intermittent, rapid downward movement	Pontine lesions
Periodic alternating gaze	Cyclic conjugate lateral eye deviations, alternating from side to side	Posterior fossa

TABLE 15-9
Differential Diagnosis of Nystagmus

Physiological
Congenital
Albinism
Associated with blindness
Familial
Idiopathic
Spasmus nutans
Idiopathic
Tumors of optic nerve and chiasm (see Chapter 16)
Acquired nystagmus
Pendular
Brainstem infarction
Multiple sclerosis (see Chapter 10)
Oculopalatal syndrome
Brainstem infarction
Spinocerebellar degeneration
Jerk
Horizontal
Drug induced
Ictal nystagmus
Vestibular nystagmus
Vertical
Downbeat
Upbeat
Dissociated
Divergence
Monocular
Seesaw

One reason that congenital nystagmus may remain unnoticed is that the *null point*, the angle of ocular movement at which the nystagmus is minimal, may be wide. Often, nystagmus is mistaken for normal movement.

A defect in the gaze-holding mechanism, secondary to loss of visual acuity before 2 years of age, was once the accepted mechanism of congenital nystagmus. The present belief is that the visual defect is not causal, but associated. When congenital nystagmus is genetic, transmission may occur as an autosomal recessive, autosomal dominant, or X linked trait.

CLINICAL FEATURES. Congenital nystagmus is usually in a horizontal plane but may be either pendular or jerk in character. Convergence generally diminishes, and fixation increases the intensity of nystagmus. Because a null zone exists where nystagmus is minimal, the head may be held to one side, or tilted, or both to improve vision. Periodic head turning may accompany periodic alternating nystagmus.

Two forms of head oscillation are associated with congenital nystagmus. One is involuntary and does not improve vision. The other, also seen in spasmus nutans, is opposite in direction to the nystagmus but not phase locked and improves vision. Many children have impaired vision from the nystagmus in the absence of a primary disturbance in visual acuity.

DIAGNOSIS. Determination that the nystagmus was present at birth is important but not always possible. Carefully examine the eyes for abnormalities in the sensory system that may accentuate nystagmus. If the neurological findings are otherwise normal, MRI is unnecessary.

MANAGEMENT. Nystagmus may reduce after correcting a visual defect, particularly with contact lenses rather than eyeglasses, and by the use of prisms or surgery to move the eyes into the null zone without the head's turning.

Spasmus Nutans

Spasmus nutans is difficult to classify as either a congenital or an acquired nystagmus. It is probably never present at birth; the onset is early in infancy. Nystagmus, head nodding, and abnormal head positioning are the clinical features of spasmus nutans.

CLINICAL FEATURES. Onset typically occurs between 6 and 12 months of age. Nystagmus is characteristically binocular (but may be monocular); has high frequency and low amplitude; is often dysconjugate; and can be horizontal, vertical, or torsional in direction. The titubation of the head, held in a tilted position, resembles

nodding. Head tilt and movement may be more prominent than nystagmus, and torticollis is often the first complaint (see Chapter 14). The syndrome usually lasts 1 to 2 years, sometimes 5 years, then resolves spontaneously.

DIAGNOSIS. Spasmus nutans is ordinarily a transitory, benign disorder of unknown cause. Rarely a glioma of the anterior visual pathways or subacute necrotizing encephalopathy (see Chapter 10) mimics the syndrome. Tumor is a consideration if the nystagmus is monocular, the optic nerve is pale, or the onset is after 1 year of age. Typical cases do not require imaging studies of the head and orbit.

MANAGEMENT. Treatment is not required.

Acquired Nystagmus

Pendular Nystagmus

Pendular nystagmus may be either congenital or acquired. In adults, the usual causes of acquired pendular nystagmus are brainstem infarction and multiple sclerosis. In children, pendular nystagmus in the absence of other neurological signs is either congenital or the first sign of spasmus nutans. The development of optic atrophy in a child with pendular nystagmus indicates a glioma of the anterior visual pathway. Vertical pendular nystagmus is unusual and sometimes occurs in association with rhythmic vertical oscillations of the palate (*palatal myoclonus* or *tremor*). One encounters the syndrome of oculopalatal oscillation in some cases of spinocerebellar degeneration and in ischemic disorders of the deep cerebellar nuclei and central tegmental tract.

Jerk Nystagmus

Drug-Induced Nystagmus

CLINICAL FEATURES. Many psychoactive drugs, including tranquilizers, antidepressants, anti-convulsants, and alcohol, produce nystagmus at high therapeutic or toxic blood concentrations. The nystagmus evoked by lateral gaze is either horizontal or horizontal-rotary. Vertical nystagmus may be present on upward but rarely on downward gaze. Several antiepileptic drugs and lithium also may produce primary-position downbeat nystagmus.

DIAGNOSIS. Suspect drug overdose in patients with nystagmus and decreased consciousness. Request a drug screen, and measure drug blood concentrations.

MANAGEMENT. Nystagmus resolves when the blood concentration of the drug decreases.

Ictal Nystagmus

CLINICAL FEATURES. Nystagmus as a seizure manifestation is binocular. It can be jerk, pendular, or rotary, and it may occur alone or in association with other ictal manifestations. Sometimes, pupillary oscillations synchronous with nystagmus are present. As a rule, concurrent epileptiform discharges are focal, contralateral to the fast phase of nystagmus, and frontal, parieto-occipital, or occipital. Individual cases exist, however, of nystagmus accompanying generalized 3-Hz spike-wave discharges, ipsilateral focal discharges, and periodic lateralized epileptiform discharges.

DIAGNOSIS. Other seizure manifestations that identify the nature of the nystagmus are usually present. The electroencephalogram confirms the diagnosis by the presence of epileptiform activity concurrent with nystagmus.

MANAGEMENT. Ictal nystagmus responds to anticonvulsant drug therapy (see Chapter 1).

Vestibular Nystagmus

Vestibular nystagmus occurs with disorders of the labyrinth, vestibular nerve, vestibular nuclei of the brainstem, or vestibulocerebellum.

CLINICAL FEATURES. Labyrinthine disease (especially labyrinthitis) usually is associated with severe vertigo, nausea, and vomiting (see Chapter 17). Deafness, or tinnitus, or both may be present as well. Movement of the head enhances the nystagmus and is more critical to the mechanism of nystagmus than the position obtained. Nystagmus is usually horizontal and torsional, with an initial slow phase followed by a rapid return. It is worse when gaze is in the direction of the fast phase. Fixation reduces nystagmus and vertigo.

Vertigo and nausea are mild when nystagmus is of central origin. Nystagmus is constantly present and not affected by head position. It may be horizontal or vertical and not affected by fixation. Other neurological disturbances referable to the brainstem or cerebellum are frequently associated features.

DIAGNOSIS. Observation alone readily identifies vestibular nystagmus. It is identical to the nystagmus provoked by caloric stimulation or rotation. Labyrinthine disorders in children are usually infectious, sometimes viral, and sometimes a result of otitis media. Central causes of vestibular nystagmus include spinocerebellar degeneration, brainstem glioma or infarction, subacute necrotizing encephalomyelitis, periodic ataxias, and demyelinating disorders.

MANAGEMENT. Several different classes of drugs appreciably reduce the vertigo and nausea associated with labyrinthine disease. Diazepam is especially effective. Other useful drugs include scopolamine, antihistamines, and tranquilizers.

Downbeat Nystagmus

CLINICAL FEATURES. In primary position, the eyes drift slowly upward, then reflexly beat downward. The intensity of the nystagmus is usually greatest when directing the eyes slightly downward and laterally. Downbeat nystagmus is distinguishable from *downward-beating nystagmus*, in which the nystagmus is present only on downward gaze. The cause of downward-beating nystagmus is toxic doses of anticonvulsant and sedative drugs, whereas downbeat nystagmus indicates a structural abnormality of the brainstem, especially the cervicomedullary junction or cerebellum. Patient complaints include dizziness, oscillopsia, blurred vision, and difficulty reading. Approximately one third of patients are asymptomatic. Cerebellar ataxia is present in about half of patients and usually is the only associated neurological sign.

DIAGNOSIS. Congenital and acquired cerebellar degenerations are the most common identifiable cause. The Chiari malformation is another consideration. Metabolic disturbances include phenytoin toxicity and hypomagnesemia resulting from either dietary depletion or the use of lithium salts.

A mother and her son had a congenital hereditary downbeat nystagmus. The condition was present in the boy at birth. By infancy, he needed to keep his chin down to look at people. He had no other neurological abnormalities, but the nystagmus caused difficulty in learning to read. His mother had a subclinical downbeat nystagmus evident only in oblique downward gaze.

MANAGEMENT. Clonazepam improves oscillopsia and acuity in some individuals. First try a single test dose of 1 mg to determine whether long-term therapy would be useful. Trihexyphenidyl may prove effective when clonazepam fails. Prisms that increase convergence are rarely useful.

Upbeat Nystagmus

CLINICAL FEATURES. In primary position, the eyes drift slowly downward, then spontaneously beat upward. Upward gaze accentuates the nystagmus. A large-amplitude and a small-amplitude type occur. Large-amplitude nystagmus increases

in intensity during upward gaze and indicates a lesion in the anterior vermis of the cerebellum or an abnormality in the anterior visual pathway. Anterior visual pathway abnormalities include Leber congenital amaurosis, bilateral optic nerve hypoplasia, and congenital cataract (see Chapter 16). Small-amplitude nystagmus decreases in intensity during upward gaze and, when present, suggests an intrinsic lesion of the medulla.

DIAGNOSIS. Upbeat nystagmus is usually an acquired disorder caused by vascular lesions or tumors of the brainstem or cerebellar vermis. Every child with a normal anterior visual pathway requires a head MRI study. Upbeat nystagmus also occurs with impairment of smooth pursuit movements in dominantly inherited cerebellar vermian atrophy.

MANAGEMENT. Specific treatment is not available.

Dissociated Nystagmus

Divergence Nystagmus

Divergence nystagmus is a rare condition in which both eyes beat outward simultaneously. The mechanism, although poorly understood, suggests a posterior fossa abnormality and occurs with spinocerebellar degenerations.

Monocular Nystagmus

Monocular nystagmus may be congenital or acquired. The most important diagnostic considerations in children are spasmus nutans and chiasmal tumors. Although no clinical feature consistently differentiates the two groups, optic nerve abnormalities, especially optic hypoplasia, sometimes occur in children with tumors but not in children with spasmus nutans.

A coarse pendular vertical nystagmus may develop in an amblyopic eye years after the visual loss. The nystagmus occurs in the blind eye when attempting distance fixation with the sighted eye and inhibited by convergence.

Seesaw Nystagmus

Seesaw nystagmus is the result of two different oscillations. One is a pendular vertical oscillation. The other is a torsional movement in which one eye rises and intorts, while the other falls and extorts. It may be congenital or acquired. The congenital form is sometimes associated with absence of the chiasm and a horizontal pendular nystagmus. Acquired cases are usually due to tumors of the sellar and parasellar regions and are associated with bitemporal hemianopia.

References

- Burke G, Cossins J, Maxwell S, et al. Rapsyn mutations in hereditary myasthenia. Distinct early- and late-onset phenotypes. *Neurology* 2003;61:826-828.
- Chung M, Stout JT, Borchert MS. Clinical diversity of hereditary Duane's retraction syndrome. *Ophthalmology* 2000; 107:500-503.
- DiMauro S, Hirano H. (2003) Mitochondrial deletion syndromes. In: *GeneReviews at GeneTests: Medical Genetics Information Resource*. [database online] University of Washington, Seattle. Available at <http://www.genetests.org>.
- Engel AG, Kaminski HJ, Preston DC. Congenital myasthenic syndromes. In: Katirji B, et al, eds. *Neuromuscular Disorders in Clinical Practice*. Butterworth-Heinemann: Boston; 2002;953-963.
- Harper CM, Engel AG. Treatment of 31 congenital myasthenic syndrome patients with 3,4-diaminopyridine. *Neurology* 2000;54(Suppl 3):A395.
- Kuppersmith MJ. Does early immunotherapy reduce the conversion of ocular myasthenia gravis to generalized myasthenia gravis. *J Neuro-Ophthalmol* 2003;23:249-250.
- Mark AS, Casselman J, Brown D, et al. Ophthalmoplegic migraine. Reversible enhancement and thickening of the cisternal segment of the oculomotor nerve on contrast-enhanced MR images. *AJNR Am J Neuroradiol* 1998; 19:1887-1891.
- Mee J, Paine M, Byrne, E, et al. Immunotherapy of ocular myasthenia gravis reduces conversion to generalized myasthenia gravis. *J Neuro-Ophthalmol* 2003;23: 251-255.
- Online Mendelian Inheritance in Man, OMIM*. (15 December 2003) MIM Number: 135700. [database online] Johns Hopkins University, Baltimore. Available at <http://www.ncbi.nlm.nih.gov/omim/>.
- Richman DP, Agius MA. Treatment of autoimmune myasthenia gravis. *Neurology* 2003;61:1652-1661.

Chapter 16

Disorders of the Visual System

CONGENITAL AND ACQUIRED visual impairments in children are often associated with neurological disorders. The most common visual disorders are uncorrected refractive errors, amblyopia, strabismus, cataracts, and genetic disorders. Two conditions that are increasing in frequency are retinopathy of prematurity and retinal hemorrhage caused by child abuse.

Assessment of Visual Acuity

The assessment of visual acuity in preverbal children relies mainly on assessing fixation and following and on observing the way an infant or young child interacts with the environment.

Clinical Assessment

The pupillary light reflex is an excellent test of the functional integrity of the subcortical afferent and efferent pathways and is reliably present after 31 weeks' gestation. A blink response to light develops at about the same time, and the lid may remain closed for as long as light is present (the dazzle reflex). The blink response to threat may not be present until 5 months of age. These responses are integrated in the brainstem and do not provide information on the cognitive (cortical) aspects of vision.

Observing fixation and following behavior is the principal means to assess visual function in newborns and infants. The human face, at a distance of approximately 30 cm, is the best target for fixation. By 9 weeks of age, 90% of infants fixate on faces. After obtaining fixation, the examiner slowly moves from side to side to test the *following response*. Visually directed grasping is present in normal children by 3 months of age but is difficult to test before 6 months.

Absence of visually directed grasping may indicate a motor rather than a visual disturbance.

The *refixation reflex* evaluates the visual fields in infants and young children by moving an interesting stimulus in the peripheral field. Clues to visual impairment are structural abnormalities (e.g., microphthalmia, cloudy cornea), an absent or asymmetrical pupillary response to light, dysconjugate gaze, nystagmus, and failure to fixate or follow. Staring at a bright light source and oculodigital stimulation indicate severe visual impairment.

Visual Evoked Response

The visual evoked response to strobe light shows the anatomical integrity of visual pathways without patient cooperation. At 30 weeks' gestation, a positive "cortical" wave with a peak latency of 300 msec is first demonstrable. The latency linearly declines at a rate of 10 msec each week throughout the last 10 weeks of gestation. In the newborn, the morphology of the visual evoked response is variable during wakefulness and active sleep and easiest to obtain just after the child goes to sleep. By 3 months of age, the morphology and latency of the visual evoked response are mature.

Congenital Blindness

Cortical blindness is the most common cause of congenital visual impairment among children referred to a neurologist. Ophthalmologists are more likely to see ocular abnormalities. The causes of congenital visual impairment are numerous and include prenatal and perinatal disturbances. Optic nerve hypoplasia, with or without other ocular malformations, is the most

common ocular abnormality, followed by congenital cataracts and corneal opacities. Corneal abnormalities usually do not cause visual loss unless clouding is extensive. Such extensive clouding may develop in the mucopolysaccharidoses and Fabry disease. Table 16-1 lists conditions with corneal clouding present during childhood.

Congenital Cataract

For the purpose of this discussion, *congenital cataract* includes cataracts discovered within the first 3 months. Table 16-2 lists the differential diagnosis. Approximately one third are hereditary, one third are syndromic, and one third are idiopathic.

In previous studies, intrauterine infection accounted for one third of congenital cataracts. That percentage has declined with prevention of rubella embryopathy by immunization. Genetic and chromosomal disorders account for at least one third, and the cause cannot be determined in half of the cases. Nonsyndromic, solitary, congenital cataracts usually are transmitted by autosomal dominant inheritance. The mode of transmission of syndromic congenital cataracts varies. In many hereditary syndromes, cataracts can be either congenital or delayed in appearance until infancy, childhood, or adulthood. Several of these syndromes are associated with dermatoses, including incontinentia pigmenti (irregular skin pigmentation), *Marshall syndrome* (anhidrotic ectodermal dysplasia), *Schäfer syndrome* (follicular hyperkeratosis), congenital ichthyosis, and *Siemens syndrome* (cutaneous atrophy).

Congenital cataracts occur in approximately 10% of children with trisomy 13 and trisomy 18 and in many children with trisomy 21. The

association of congenital cataract and lactic acidosis or cardiomyopathy indicates a mitochondrial disorder.

CLINICAL FEATURES. Small cataracts may impair vision and may be difficult to detect by direct ophthalmoscopy. Large cataracts appear as a white mass in the pupil and, if left in place, quickly cause deprivation amblyopia. The initial size of a cataract does not predict its course; congenital cataracts may remain stationary or increase in density but never improve spontaneously. Other congenital ocular abnormalities, aniridia, coloboma, and microphthalmos occur in 40% to 50% of newborns with congenital cataracts.

DIAGNOSIS. Large cataracts are obvious on inspection. Smaller cataracts distort the normal red reflex when the direct ophthalmoscope is at arm's length distance from the eye and a +12 to +20 lens is used. Genetic disorders and maternal drug exposure are important considerations when cataracts are the only abnormality. Intrauterine disturbances, such as maternal illness and fetal infection, are usually associated with growth retardation and other malformations. Dysmorphic features are always an indication for ordering chromosome analysis. Galactosemia is suspected in children with hepatomegaly and milk intolerance (see Chapter 5), but cataracts may be present even before the development of systemic features.

MANAGEMENT. Developmental amblyopia is preventable by recognizing and removing cataracts before age 3 months. Urgent referral to a pediatric ophthalmologist is the standard of care.

Congenital Optic Nerve Hypoplasia

Optic nerve hypoplasia is a developmental defect in the number of optic nerve fibers and may result from excessive regression of retinal ganglion cell axons. Hypoplasia may be bilateral or unilateral and varies in severity. It may occur as an isolated defect or be associated with intracranial anomalies. The most common association is with midline defects of the septum pellucidum and hypothalamus (septo-optic dysplasia). Septo-optic dysplasia (*de Morsier syndrome*) is familial in some cases and transmitted as an autosomal recessive trait. The abnormal gene location is chromosome 3p21.

CLINICAL FEATURES. The spectrum of congenital pituitary defects ranges in severity from isolated growth hormone deficiency to septo-optic dysplasia with panhypopituitarism (Thomas et al, 2001). When hypoplasia is severe, the child is

TABLE 16-1
Corneal Clouding in Childhood

Cerebrohepato-renal syndrome (Zellweger syndrome)
Congenital syphilis
Fabry disease (ceramide trihexosidosis)
Familial high-density lipoprotein deficiency (Tangier disease)
Fetal alcohol syndrome
Glaucoma
Infantile GM ₁ gangliosidosis
Juvenile metachromatic dystrophy
Marinesco-Sjögren disease
Mucopolipidosis
Mucopolysaccharidoses
Multiple sulfatase deficiency
Pelizaeus-Merzbacher disease
Trauma (forceps at birth)

TABLE 16-2
Cataract Etiology**Congenital Cataract**

Chromosomal aberrations

- Trisomy 13
- Trisomy 18
- Trisomy 21*
- Turner syndrome*

Drug exposure during pregnancy

- Chlorpromazine
- Corticosteroids
- Sulfonamides

Galactokinase deficiency

Galactose-1-phosphate uridylyltransferase deficiency

Galactosemia

Genetic

Autosomal dominant inheritance

- Hereditary spherocytosis*
 - Incontinentia pigmenti*
 - Marshall syndrome*
 - Myotonic dystrophy*
 - Schäfer syndrome*
 - Without other anomalies
- Autosomal recessive inheritance
- Congenital ichthyosis*
 - Congenital stippled epiphyses (Conradi disease)
 - Marinesco-Sjögren syndrome*
 - Siemens syndrome*
 - Smith-Lemli-Opitz syndrome
- X-linked inheritance (oculocerebrorenal syndrome)*

Idiopathic

Intrauterine infection*

- Mumps
- Rubella
- Syphilis

Maternal factors

- Diabetes
- Malnutrition
- Radiation
- Prematurity

Syndromes of uncertain etiology

- Hallermann-Streiff syndrome
- Pseudo-Turner syndrome*
- With oxycephaly
- With polydactyly

Acquired Cataract

Drug induced

- Corticosteroids
- Long-acting mitotics

Genetic

- Autosomal dominant inheritance
 - Alport syndrome
- Autosomal recessive inheritance
 - Cockayne disease
 - Hepatolenticular degeneration (Wilson disease)
 - Rothmund-Thomson syndrome
 - Werner syndrome
- X-linked inheritance
 - Pseudo-pseudohypoparathyroidism

Chromosomal

- Prader-Willi syndrome

Metabolic

- Cretinism
- Hypocalcemia
- Hypoparathyroidism
- Juvenile diabetes
- Pseudohypoparathyroidism

Trauma

- Varicella (postnatal)

Dislocated Lens

- Crouzon syndrome
- Ehlers-Danlos syndrome
- Homocystinuria
- Hyperlysinemia
- Marfan syndrome
- Sturge-Weber syndrome
- Sulfite oxidase deficiency

*Cataracts may not be noted until infancy or childhood.

severely visually impaired, and the eyes draw attention because of strabismus and nystagmus. Ophthalmoscopic examination reveals a small, pale nerve head (Figure 16-1). A pigmented area surrounded by a yellowish mottled halo sometimes is present at the edge of the disk margin, giving the appearance of a double ring. The degree of hypothalamic-pituitary involvement varies. Possible symptoms include neonatal hypoglycemia and seizures, recurrent hypoglycemia in childhood, growth retardation, diabetes insipidus, and sexual infantilism. Some combination of mental retardation, cerebral palsy, and epilepsy is often present and indicates malformations in other portions of the brain.

DIAGNOSIS. All infants with ophthalmoscopic evidence of optic nerve hypoplasia require cranial magnetic resonance imaging (MRI) and an

assessment of endocrine status. The common findings on MRI are cavum septum pellucidum, hypoplasia of the cerebellum, aplasia of the corpus callosum, aplasia of the fornix, and an empty sella. Absence of the pituitary infundibulum with posterior pituitary ectopia indicates congenital hypopituitarism. Endocrine studies should include assays of growth hormone; anti-diuretic hormone; and the integrity of hypothalamic-pituitary control of the thyroid, adrenal, and gonadal systems. Infants with hypoglycemia usually have growth hormone deficiency. Superior segmental optic nerve hypoplasia is associated with congenital inferior visual field defects and occurs in children born to mothers with insulin-dependent diabetes.

MANAGEMENT. No treatment is available for optic nerve hypoplasia, but endocrine abnormalities

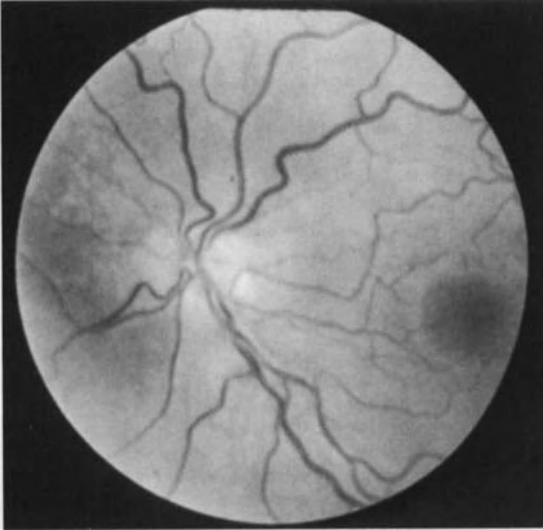


Figure 16-1. Optic nerve hypoplasia. The optic nerve is small and pale, but the vessels are of normal size.

respond to replacement therapy. Children with corticotropin deficiency may experience sudden death. Children with visual impairment may benefit from visual aids.

Coloboma

Coloboma is a defect in embryogenesis that may affect only the disk or may include the retina, iris, ciliary body, and choroid. Colobomas isolated to the nerve head appear as deep excavations, deeper inferiorly. They may be unilateral or bilateral. The causes of congenital coloboma are genetic (monogenic and chromosomal) and intrauterine disease (toxic and infectious). Retinochoroidal colobomas are glistening white or yellow defects inferior or inferior nasal to the disk. The margins are distinct and surrounded by pigment. *Morning glory disk* is not a form of coloboma; it is an enlarged dysplastic disk with a white excavated center surrounded by an elevated annulus of pigmentary change. Retinal vessels enter and leave at the margin of the disk, giving the appearance of a morning glory flower. The morning glory syndrome is associated with transsphenoidal encephaloceles. Affected children are dysmorphic with midline facial anomalies.

Leber Congenital Amaurosis

Leber congenital amaurosis, a group of autosomal recessive retinal dystrophies, is the most common genetic cause of congenital visual impairment. Mutations on chromosomes 1, 6,

14, 17, and 19 cause a similar clinical syndrome. The common feature is disturbance of the retinal pigmentary epithelium.

CLINICAL FEATURES. The clinical characteristics of Leber congenital amaurosis are moderate-to-severe visual impairment at or within a few months of birth, nystagmus, and sluggish pupillary responses. Additional features include symmetrical midfacial hypoplasia with enophthalmos and hypermetropic refractive errors. Although substantial variation among families exists, the phenotype is relatively constant within families. Ophthalmoscopy of the retina shows no abnormality in infancy and early childhood, but with time, progressive retinal stippling and pallor of the disk appear. Mental retardation and other neurological disturbances may be associated.

DIAGNOSIS. The retinal appearance and abnormal electroretinogram establish the diagnosis in infants. Neuroimaging shows cerebellar atrophy in children with mental slowing. Other disorders that may be mistaken for Leber congenital amaurosis are peroxisomal disorders and several varieties of infantile-onset progressive retinal degeneration.

MANAGEMENT. The retinopathy is not reversible.

Acute Monocular or Binocular Blindness

The differential diagnoses of acute and progressive blindness show considerable overlap. Although older children recognize sudden visual loss, slowly progressive ocular disturbances may produce an asymptomatic decline until vision is severely disturbed, especially if unilateral. When finally noticed, the child's loss of visual acuity seems acute. Teachers or parents are often the first to recognize a slowly progressive visual disturbance. Table 16-3 lists conditions in which visual acuity is normal and then suddenly lost. Table 16-4 lists disorders in which the underlying pathological process is progressive. The patient first perceives the condition. Consult both tables in the differential diagnosis of acute blindness. The duration of a transitory monocular visual loss suggests the underlying cause: Seconds indicate optic disk disorders, such as papilledema or drusen; minutes indicate emboli; hours indicate migraine; and days indicate optic neuropathy, most commonly optic neuritis.

Cortical Blindness

Cortical blindness in children may be permanent or transitory, depending on the cause. The

TABLE 16-3
Causes of Acute Loss of Vision

Carotid dissection (see Chapter 11)
Cortical blindness
Anoxic encephalopathy (see Chapter 2)
Benign occipital epilepsy (see Chapter 1)
Hydrocephalus
Hypoglycemia
Hypertension (malignant or accelerated)
Hyperviscosity
Hypotension
Migraine (see Chapter 3)
Occipital metastatic disease
Posttraumatic transient cerebral blindness
Systemic lupus erythematosus
Toxic (e.g., cyclosporine)
Trauma
Hysteria
Optic neuropathy
Demyelinating
Idiopathic optic neuritis
Multiple sclerosis (see Chapter 10)
Neuromyelitis optica (see Chapter 12)
Ischemic
Toxic
Traumatic
Pituitary apoplexy
Pseudotumor cerebri (see Chapter 4)
Retinal disease
Central retinal artery occlusion
Migraine
Trauma

causes of transitory cortical blindness in childhood include migraine (see Chapter 3), mild head trauma, brief episodes of hypoglycemia or hypotension, and benign occipital epilepsy (see Chapter 1). Acute and sometimes permanent blindness may occur after anoxia; secondary to massive infarction of, or hemorrhage into, the visual cortex; and when multifocal metastatic tumors or abscesses are located in the occipital lobes. The main feature of cortical blindness is loss of vision with preservation of the pupillary light reflex. Funduscopic examination is normal.

Hypoglycemia

Repeated episodes of acute cortical blindness may occur at the time of mild hypoglycemia in children with glycogen storage diseases and after insulin overdose in diabetic children.

CLINICAL FEATURES. Sudden blindness is associated with clinical evidence of hypoglycemia (sweating and confusion). Ophthalmoscopic and neurological findings are normal. Recovery is complete in 2 to 3 hours.

DIAGNOSIS. During an episode of cortical blindness caused by hypoglycemia, electroencephalo-

TABLE 16-4
Causes of Progressive Loss of Vision

Compressive optic neuropathies
Aneurysm (see Chapters 4 and 15)
Arteriovenous malformations (see Chapters 4, 10, and 11)
Craniopharyngioma
Hypothalamic and optic tumors
Pituitary adenoma
Pseudotumor cerebri (see Chapter 4)
Disorders of the lens (see Table 16-3)
Cataract
Dislocation of the lens
Hereditary optic atrophy
Leber hereditary optic neuropathy
Wolfram syndrome
Intraocular tumors
Tapetoretinal degenerations
Abnormal carbohydrate metabolism
Mucopolysaccharidosis (see Chapter 5)
Primary hyperoxaluria
Abnormal lipid metabolism
Abetalipoproteinemia (see Chapter 10)
Hypobetalipoproteinemia (see Chapter 10)
Multiple sulfatase deficiency (see Chapter 5)
Neuronal ceroid-lipofuscinosis (see Chapter 5)
Niemann-Pick disease (see Chapter 5)
Refsum disease (see Chapter 7)
Other syndromes of unknown etiology
Bardet-Biedl syndrome
Cockayne syndrome
Laurence-Moon syndrome
Refsum disease (see Chapter 7)
Usher syndrome (see Chapter 17)

gram (EEG) shows high-voltage slowing over both occipital lobes. Afterward the EEG returns to normal. Brain MRI shows diffuse edema in the occipital lobes.

MANAGEMENT. Recovery occurs when blood glucose concentration normalizes.

Transitory Posttraumatic Cerebral Blindness

CLINICAL FEATURES. Transitory posttraumatic cerebral blindness is a benign syndrome that most often occurs in children with a history of migraine or epilepsy. The spectrum of visual disturbance is broad; a juvenile and an adolescent pattern exist. In children younger than 8 years old, the precipitating trauma usually is associated with either a brief loss of consciousness or a report that the child was “stunned.” The child claims blindness almost immediately on regaining consciousness, which lasts for an hour or less. During the episode, the child may be lethargic and irritable but is usually coherent. Recovery is complete, and the child may not recall the event.

In older children, a syndrome of blindness, confusion, and agitation begins several minutes or hours after trivial head trauma. Consciousness is not lost. All symptoms resolve after several hours, and the child has complete amnesia for the event. These episodes share many features with acute confusional migraine and are probably a variant of that disorder (see Chapter 2).

DIAGNOSIS. Head computed tomography is invariable in children with any neurological abnormality after head trauma, but is probably unnecessary if the blindness has cleared. Children with persistent blindness require MRI to exclude injury to the occipital lobes. Occipital intermittent rhythmic delta activity on EEG suggests migraine as the underlying cause. Recognition of the syndrome can avoid the trouble and expense of other studies. Scrutinize the family history for the possibility of migraine or epilepsy. The rapid and complete resolution of all symptoms confirms the diagnosis.

MANAGEMENT. Treatment is unnecessary if the symptoms resolve spontaneously.

Hysterical Blindness

A spurious claim of complete binocular blindness is easy to identify. A pupillary response to light indicates that the anterior pathway is intact, and only cortical blindness is a possibility. Simply observing the child's visual behavior, such as making eye contact, avoiding obstructions in the waiting room, and following nonverbal instructions, confirms effective visual capability. Otherwise, assess visual function by using a full-field optokinetic stimulus tape or by moving a large mirror in front of the patient to stimulate matching eye movements. In the case of hysterical monocular blindness, perform the same tests with a patch covering the normal eye.

Spurious claims of partial visual impairment are more difficult to challenge. Helpful tests include observing visual behavior, noting failure of acuity to improve linearly with increasing test size, noting inappropriate ability to detect small test objects on a tangent screen, and noting constricted (tunnel) visual fields to confrontation.

Optic Neuropathies

Demyelinating Optic Neuropathy

Demyelination of the optic nerve (optic neuritis) may occur as an isolated finding affecting one or both eyes, or it may be associated with demyelination in other portions of the nervous system. Neuromyelitis optica (*Devic syndrome*), the syn-

drome combining optic neuritis and transverse myelitis, is discussed in Chapter 12, and multiple sclerosis is discussed in Chapter 10. MRI is useful for surveying the central nervous system for demyelinating lesions (see Figure 10-3). The incidence of later multiple sclerosis among children with optic neuritis is 15% or less if the child has no evidence of more diffuse involvement when brought to medical attention. The incidence is almost 100% when diffuse involvement is present or when optic neuritis recurs within 1 year. Unilateral optic neuritis and retrobulbar neuritis as opposed to papillitis has a higher incidence of later multiple sclerosis than bilateral optic neuritis.

CLINICAL FEATURES. Monocular involvement is characteristic of optic neuritis in adults, but binocular involvement occurs in more than half of children. Binocular involvement may be concurrent or sequential, sometimes occurring over weeks. The initial feature in some children is pain in the eye, but for most, it is blurred vision, progressing within hours or days to partial or complete blindness. Visual acuity reduces to less than 20/200 in almost all affected children within 1 week. A history of a preceding "viral" infection or immunization is common, but a cause-and-effect relationship between optic neuritis and these events is not established.

Results of ophthalmoscopic examination may be normal at the onset of symptoms if neuritis is primarily retrobulbar. Visual loss readily distinguishes papillitis from papilledema. In optic neuritis, visual loss occurs early, and in papilledema, visual loss is a late feature. *Neuroretinitis* is the association of swelling of the optic nerve head with macular edema or a macular star. Ophthalmoscopic examination shows disk swelling, peripapillary retinal detachment, and a macular star (Figure 16-2). Neuroretinitis suggests the possibility of conditions other than idiopathic optic neuritis.

In the absence of myelitis, the prognosis in children with bilateral optic neuritis is good. Complete recovery occurs in 90% of children affected.

DIAGNOSIS. Optic neuritis is a consideration whenever monocular or binocular blindness develops suddenly in a child. Ophthalmoscopic or slit-lamp examination confirms the diagnosis. Visual evoked response testing further confirms the diagnosis. MRI of the orbit rarely reveals swelling and demyelination of the optic nerve. Examination of the cerebrospinal fluid is unnecessary; examination sometimes shows a leukocytosis and an increased concentration of protein but provides no information concerning

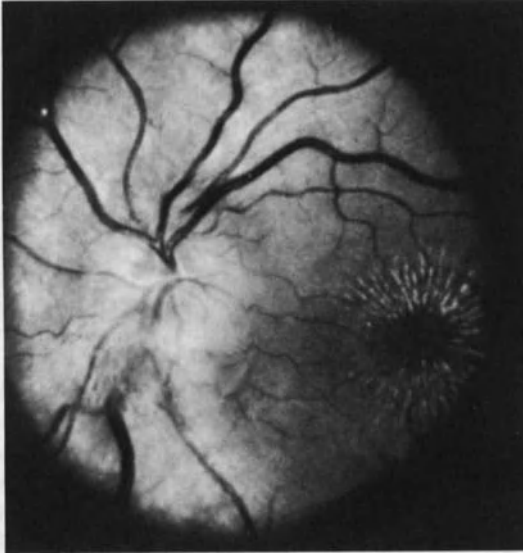

Figure 16-2. Neuroretinitis. The optic disk is swollen, and the peripapillary nerve fiber layer is opacified. Exudates surround the macula in a star pattern. (Courtesy of Patrick Lavin, MD.)

the etiology or prognosis. Accelerated hypertension causes bilateral swelling of the optic nerves; recording blood pressure is an essential part of the evaluation.

MANAGEMENT. Intravenous methylprednisolone, 250 mg every 6 hours for 3 days, followed by oral prednisone, 1 mg/kg/day for 14 days, speeds the recovery of visual loss and, in adults, may reduce the rate of development of multiple sclerosis over a 2-year period. Oral corticosteroids alone are not a recommended therapy.

Ischemic Optic Neuropathy

Infarction of the anterior portion of the optic nerve is rare in children and is usually associated with systemic vascular disease or hypotension.

CLINICAL FEATURES. Ischemic optic neuropathy usually occurs as a sudden segmental loss of vision in one eye, but slow or stepwise progression over several days is possible. Recurrent episodes are unusual except with migraine and some idiopathic cases.

DIAGNOSIS. Altitudinal visual field defects are present in 70% to 80% of patients. Color vision loss is roughly equivalent in severity to visual acuity loss, whereas in demyelinating optic neuritis, the disturbance of color vision is greater than that of visual acuity. Ophthalmoscopic examination reveals diffuse or partial swelling of the optic disk. When swelling is diffuse, it gives the appearance of papilledema, and flame-

shaped hemorrhages appear adjacent to the disk margin. After acute swelling subsides, optic atrophy follows.

MANAGEMENT. Treatment depends on the underlying cause of ischemia.

Toxic-Nutritional Optic Neuropathies

Drugs, toxins, and nutritional deficiencies alone or in combination may cause an acute or progressive optic neuropathy. These factors may cause optic neuropathy by inducing mitochondrial changes, perhaps in susceptible populations with mitochondrial DNA (mtDNA) mutations.

CLINICAL FEATURES. Implicated drugs include barbiturates, antibiotics (chloramphenicol, isoniazid, streptomycin, sulfonamides), chemotherapeutic agents, chlorpropamide, digitalis, ergot, halogenated hydroxyquinolines, penicillamine, and quinine. Nutritional deficiencies that may cause optic neuropathies include folic acid, vitamins B₁, B₂, B₆, and B₁₂. Symptoms vary with the specific drug, but progressive loss of central vision is typical. In some cases, visual loss is rapid and develops as acute binocular blindness that may be asymmetrical at onset, suggesting monocular involvement. Many of the drugs produce optic neuropathy by interfering with the action of folic acid or vitamin B₁₂ and causing a nutritional deficiency.

DIAGNOSIS. Drug toxicity is suspected whenever central and paracentral scotomas develop during the course of drug treatment. Optic nerve hyperemia with small paracentral hemorrhages may be an early feature. Later the disk becomes pale.

MANAGEMENT. Drug-induced optic neuropathy is dose related. Dosage reduction may be satisfactory in some cases, especially if concurrent treatment with folic acid or vitamin B₁₂ reverses the process. Some drugs require complete cessation of therapy.

Traumatic Optic Neuropathies

Trauma to the head may cause an indirect optic neuropathy in one or both eyes. The optic nerve, tethered along its course, is subject to shearing forces when the skull suddenly accelerates or decelerates. Possible consequences include acute swelling, hemorrhage, or tear. Optic neuropathy is particularly common in children who sustain bicycle injuries when not wearing a helmet.

CLINICAL FEATURES. Loss of vision is usually immediate. Delayed visual loss caused by a

hematoma or edema may respond to corticosteroids and has a better prognosis. The distinction between traumatic optic neuropathy and cortical blindness is easy because the pupillary response in optic neuropathy diminishes. The prognosis for recovery is best if there is a brief delay between the time of injury and the onset of blindness.

DIAGNOSIS. The loss of vision and pupillary light response immediately after a head injury should suggest the diagnosis. Ophthalmological examination may reveal peripapillary hemorrhages.

MANAGEMENT. Suggested treatments consist of corticosteroids and surgical decompression of the nerve.

Pituitary Apoplexy

Pituitary apoplexy is a rare, life-threatening condition caused by hemorrhagic infarction of the pituitary gland.

CLINICAL FEATURES. Pituitary infarction occurs most often when there is a preexisting pituitary tumor, but also may occur in the absence of tumor. Several different clinical features are possible, depending on the structures affected by the swollen gland. These include any of the following, alone or in combination: monocular or binocular blindness, visual field defects, ophthalmoplegia, chemical meningitis, cerebrospinal fluid rhinorrhea, and shock from hypopituitarism. Leakage of blood and necrotic material into the subarachnoid space causes chemical meningitis associated with headache, meningismus, and loss of consciousness.

DIAGNOSIS. MRI of the head with views of the pituitary gland establishes the diagnosis. Endocrine testing may show a deficiency of all pituitary hormones.

MANAGEMENT. Patients deteriorate rapidly and may die within a few days without prompt administration of corticosteroids. Replacement of other hormones is required but not lifesaving. In patients who continue to do poorly, as evidenced by loss of consciousness, hypothalamic instability, or loss of vision, urgent surgical decompression of the expanding pituitary mass is required.

Retinal Disease

Central Retinal Artery Occlusion

Migraine and coagulopathies are the main predisposing disorders among children with retinal artery obstruction. Others are sickle cell dis-

ease, cardiac disorders, vasculitis, and pregnancy. Congenital heart disease is the usual pre-existing condition causing emboli to the central retinal artery in young people. Mitral valve prolapse is a potential cause but is more likely to produce transitory cerebral ischemia than monocular blindness.

CLINICAL FEATURES. Most affected children have an abrupt loss of monocular vision of variable intensity without premonitory symptoms. Some describe spots, a shadow, or a descending veil before the loss of vision. Bilateral retinal artery occlusion is uncommon in children.

DIAGNOSIS. The clinical history and ophthalmoscopic examination are the basis for the diagnosis of retinal artery obstruction. The posterior pole of the retina becomes opacified except in the foveal region, which contains a cherry-red spot. The peripheral retina appears normal. Visual field examination and fluorescein angiography help confirm the diagnosis in some cases. When the diagnosis is established, the underlying cause must be sought. Evaluation should include auscultation of the heart, radiographs of the chest, echocardiography in selected cases, complete blood cell count with sedimentation rate, cholesterol and triglyceride screening, coagulation studies, hemoglobin electrophoresis, and lupus anticoagulant and antiphospholipid antibodies.

MANAGEMENT. Acute treatment requires immediate ophthalmological consultation. The management of idiopathic occlusion of the retinal artery in adults is controversial, with some authorities recommending the use of corticosteroids. In children, giant cell arteritis is not a consideration, and corticosteroids are unnecessary. Visual acuity is more likely to improve when the obstruction is in a branch artery rather than in the central retinal artery.

Retinal Migraine

CLINICAL FEATURES. Visual symptoms are relatively common during an attack of classic migraine (see Chapter 3). The typical scintillating scotomas, or "fortification spectra," are field defects caused by altered neuronal function in the occipital cortex. The affected field is contralateral to the headache.

Transitory monocular blindness is an unusual feature of migraine. Careful questioning differentiates a field defect from a monocular defect. Migraine is the main cause of transitory monocular blindness in children. The visual loss is sudden in most cases, may be partial or complete, and often precedes and is ipsilateral to the

headache. Recurrences are usually in the same eye, and attacks may occur without headache. One parent, usually the mother, has a history of migraine.

Typical patients have a long personal history of migraine with aura in which field defects and monocular blindness occur separately or together. A mosaic or jigsaw pattern of scotomas that clears within minutes is experienced. Permanent monocular blindness is unusual and occurs mainly in adolescent girls and women. Many patients with persistent blindness have other risk factors for vascular disease, such as the use of oral contraceptives or vasculitis.

DIAGNOSIS. Consider the diagnosis in children with a history of migraine with aura. Ophthalmoscopic findings may be normal initially, then include retinal edema with scattered hemorrhages. Fluorescein angiography reveals several patterns of retinal vaso-occlusive disease involving the branch retinal artery, the central retinal artery, the central retinal vein, and the cilioretinal artery.

MANAGEMENT. Children who have retinal ischemia during migraine attacks require prophylaxis with pharmaceutical agents that prevent further episodes.

Retinal Trauma

Direct blunt injury to the orbit causes visual impairment by retinal contusion, tear, or detachment. A diminished pupillary response characterizes all three. Contusion is associated with retinal edema. Although visual loss is immediate, the retina appears normal for the first few hours and only later becomes white and opaque. The severity of visual loss varies, but complete recovery is the rule.

Retinal tear often is associated with vitreous hemorrhage. Visual loss is usually immediate and easily diagnosed by its ophthalmoscopic appearance. Recovery is spontaneous, unless there is detachment, for which cryotherapy is required.

Progressive Loss of Vision

Compressive Optic Neuropathy

Compression of one or both optic nerves often occurs in the region of the chiasm. The visual loss may involve one eye or one visual field. In children with tumors in and around the diencephalon, the most constant feature is growth failure, which may be unrecognized until other symptoms develop.

Craniopharyngioma

CLINICAL FEATURES. Craniopharyngiomas are the most common nonglial tumors in children. The peak age range for diagnosis of this tumor is 6 to 14 years. The initial features of craniopharyngioma in children are growth retardation, visual disturbances, endocrinopathies, and failure of sexual maturation. Field defects are frequently asymmetrical or unilateral. Bitemporal hemianopia is present in 50% of children, with craniopharyngioma and homonymous hemianopia in 10% to 20%. Diminished visual acuity in one or both eyes and optic atrophy are constant features.

Approximately 25% of children have hydrocephalus that causes headache and papilledema. Hypothalamic involvement may produce diabetes insipidus or the hypodipsia-hyponatremia syndrome, characterized by lethargy, confusion, and hypotension. Other features depend on the direction of tumor growth. Anterior extension may compress the olfactory tract, causing anosmia, whereas lateral extension may compress the third and fifth nerves.

DIAGNOSIS. MRI is diagnostic. The important feature is a multicystic and solid enhancing suprasellar mass, which causes hydrocephalus and stretches the optic nerves and chiasm (Brunel et al, 2002).

MANAGEMENT. Surgical removal of the tumor is the most effective treatment. Complete microsurgical resection is the treatment of choice for newly diagnosed craniopharyngiomas. Recurrences occur in 30% after complete resection, 57% after incomplete resection, and 30% when radiation follows subtotal resection. The 5- and 10-year survival rates after postoperative radiotherapy are 84% and 72% for children. Most long-term survivors experience panhypopituitarism, cognitive impairment, and obesity.

Optic Pathway and Diencephalic Gliomas

Of optic pathway gliomas, 60% are pilocytic astrocytomas, and the remaining 40% are fibrillary astrocytomas. Optic gliomas represent 3% to 5% of childhood brain tumors. They may involve any part of the optic pathway from the optic nerves to the optic radiations. They also infiltrate the adjacent hypothalamus and temporal lobes. More than 50% of children with optic gliomas have neurofibromatosis type 1 (NF1). Precocious puberty is a common initial feature in children with NF1. The rate of tumor growth is slower in children with NF1 than when NF1 is not present.

CLINICAL FEATURES. Initial symptoms depend on the location, but hypothalamic tumors eventually affect the optic chiasm, and optic chiasm tumors affect the hypothalamus. In children younger than 3 years old, tumors of the hypothalamus may produce *diencephalic syndrome*, characterized by marked loss of subcutaneous fat and total body weight with maintenance or acceleration of long bone growth. Despite the appearance of cachexia, the infant is mentally alert and does not seem as sick as the appearance suggests. Pendular or seesaw nystagmus may be associated. The precise endocrine mechanism that leads to diencephalic syndrome is unknown. Hamartomas of the tuber cinereum, optic pathway gliomas that compress the hypothalamus, and craniopharyngiomas also are associated with diencephalic syndrome. Precocious puberty, rather than diencephalic syndrome, can be the initial feature of hypothalamic tumors in infants and children.

Age is an important prognostic factor for optic gliomas. Children younger than 5 years old have a more aggressive course. The presenting features of unilateral optic nerve gliomas are visual loss, proptosis, and optic atrophy. Chiasmatic tumors in infants present as large suprasellar masses, which also may extend into the hypothalamus and third ventricle, producing hydrocephalus and endocrine abnormalities. Binocular involvement suggests involvement of the optic chiasm or tract. Visual field deficits vary. Increased intracranial pressure suggests extension of tumor from the chiasm to the hypothalamus.

DIAGNOSIS. MRI of the hypothalamus identifies gliomas as high-density signals on T₂-weighted studies. MRI permits visualization of the hypothalamus in several different planes and identification of brainstem extension of tumor (Figure 16-3). MRI with enhancement identifies optic pathway gliomas as an enlarged tubular appearance of the nerve and chiasm. Examine the entire visual pathway in all children with optic nerve gliomas because many tumors involve the chiasm and retrochiasmatic pathways. Routine MRI screening for optic pathway gliomas in asymptomatic children with NF1 does not affect the outcome (Listernick et al, 1997). Regular ophthalmological examinations are the preferred method for surveillance.

MANAGEMENT. Several factors influence management decisions. The indications for early intervention are younger age, progressive symptoms, and extensive central nervous system involvement. Chemotherapy, the initial treatment, may provide stabilization or regression

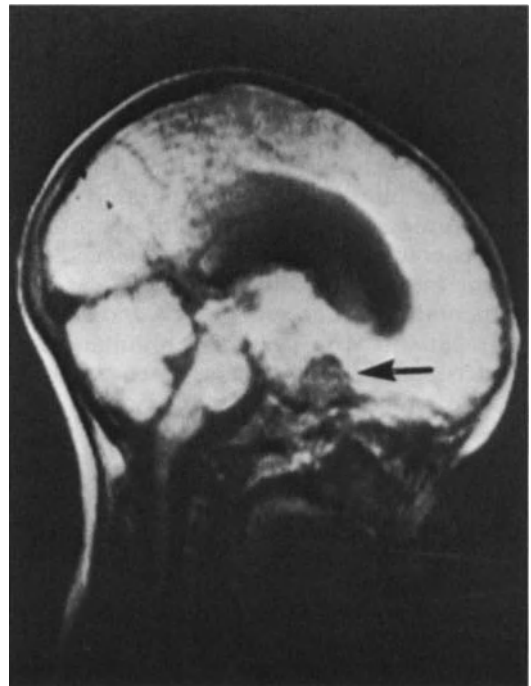

Figure 16-3. Optic nerve glioma identified by MRI (arrow).

(Silva et al, 2000). Older children and children who fail chemotherapy receive radiation therapy, which provides 5-year survival rates of 30%. Stereotaxic-guided biopsy of hypothalamic tumors is often dangerous and provides no greater diagnostic information than imaging. Tumors located in the floor of the fourth ventricle, lateral recesses, cerebellar pontine angle, or cervical medullary junction may be surgically accessible and have a more benign course. Never resect intrinsic optic nerve or chiasmatic gliomas unless the child is already blind, and the tumor is impinging on adjacent structures.

Optic pathway gliomas associated with NF1 rarely progress significantly after diagnosis. Biopsy or removal of tumor from a sighted eye is considered only when the tumor is malignant, progressively enlarging or causing severe proptosis, and likely to cause blindness or death. Tumor regression and improved vision may occur spontaneously.

Pituitary Adenoma

Pituitary adenomas represent only 1% to 2% of intracranial tumors of childhood. Visual field defects may be unilateral temporal, bitemporal, or occasionally homonymous. Optic atrophy is present in 10% to 20% of cases.

CLINICAL FEATURES. The onset of symptoms is usually during adolescence. The presenting features relate to the hormone secreted by the tumor. Approximately one third of adenomas secrete prolactin, one third are nonfunctioning, and many of the rest secrete growth hormone or adrenocorticotrophic hormone (Thapar et al, 1995). Amenorrhea is usually the first symptom in girls with prolactin-secreting tumors. Galactorrhea also may be present. In boys, the initial features are growth retardation, delayed puberty, and headache.

Gigantism results when increased concentrations of growth hormone circulate before the epiphyses close. After closure, growth hormone causes acromegaly. Increased concentrations of adrenocorticotrophic hormone cause Cushing syndrome.

DIAGNOSIS. MRI provides excellent visualization of the tumor and identification of its extrasellar extent. Measurement of hormone production is useful in distinguishing the tumor type.

MANAGEMENT. Surgical resection is the preferred treatment for tumors that compress the optic pathways. Medical treatment may suffice for small tumors.

Hereditary Optic Neuropathy

Hereditary optic neuropathies may affect only the visual system, the visual system and central nervous system, or multiple systems. The underlying abnormality may lie in the nuclear DNA or the mtDNA. These disorders can cause acute, subacute, or chronic decline in visual acuity.

Leber Hereditary Optic Neuropathy

Leber hereditary optic neuropathy is a multisystem mitochondrial disease caused by one or more mutations of the mtDNA (Chinnery, 2003). All mutations are missense mutations in complexes I, III, and IV of the respiratory chain. The cause of intrafamily phenotypic variability may be the ratio of mutant to normal mtDNA within an individual. Alternative mutations probably cause interfamilial variability.

CLINICAL FEATURES. The characteristic early symptom is painless, rapid loss of central vision. Onset is usually between 10 and 30 years, but children younger than 10 years old may be affected. Age at onset may vary by several decades within kindreds. The disease occurs earlier in males but is more severe in females. The acute phase begins with blurring of central vision and color desaturation in both eyes.

Central vision deteriorates to finger counting. Minor neurological abnormalities, such as a postural tremor or the loss of ankle reflexes, are common. Less than half of patients have a family history of similar disease. The characteristic changes in the ocular fundus include circum-papillary telangiectatic microangiopathy, swelling of the nerve fiber layer around the disk, and absence of peripapillary staining on fluorescein angiography. Some patients never have these characteristic features, however, even at the time of acute visual loss.

DIAGNOSIS. Leber hereditary optic neuropathy is a consideration in every kindred with optic neuropathy or with progressive neurological impairment in which transmission is restricted to the maternal line. The optic fundus changes, especially microangiopathy, are the basis for diagnosis in the context of a compatible family history. Molecular genetic testing is available.

MANAGEMENT. Treatment is rehabilitative.

Wolfram Syndrome

Wolfram syndrome is the combination of diabetes insipidus and diabetes mellitus with optic atrophy and bilateral neurosensory hearing loss. A mutation in a gene in the 4p16 region predisposes to multiple mtDNA deletions in families with Wolfram syndrome (OMIM, 2004).

CLINICAL FEATURES. The onset of diabetes is usually before age 10. Insulin therapy is required soon after diagnosis. Visual loss progresses rapidly in the teens but does not lead to complete blindness. Diabetes does not cause optic atrophy; rather, all clinical features result from a progressive neurodegenerative process. The sensorineural hearing loss affects high frequencies first. The hearing loss is progressive but rarely leads to severe hearing loss. Features reported in some patients include anosmia, autonomic dysfunction, ptosis, external ophthalmoplegia, tremor, ataxia, nystagmus, seizures, central diabetes insipidus, and endocrinopathies. Psychiatric illness occurs in most cases of Wolfram syndrome, and heterozygous carriers have a predisposition for psychiatric disorders.

DIAGNOSIS. Diagnosis depends on the combination of the preceding list of clinical features. mtDNA analysis confirms the clinical suspicion.

MANAGEMENT. Symptomatic treatment is required for each of the clinical features.

Retinoblastoma

Although retro-orbital tumors generally cause strabismus and proptosis, intraocular tumors

always diminish vision. Retinoblastoma is the only malignant intraocular tumor of childhood. Prompt recognition of retinoblastoma can be lifesaving.

The typical features of retinoblastoma in a young child are an abnormal appearance of the eye, loss of vision, and strabismus. Monocular blindness is usually unrecognized by parents. Older children may complain of visual blurring and floaters. Ocular pain is uncommon. Leukokoria, a white pupillary reflex, is the initial feature in most children with retinoblastoma. In bright sunlight or in a flash photograph, the pupil does not constrict and has a white color. Strabismus occurs when visual acuity is impaired. The sighted eye fixates, and the other remains deviated outward in all directions of gaze.

Referral of all children with intraocular tumors is to an ophthalmologist. A neurologist may be the primary consulting physician when the tumor is part of a larger syndrome that includes mental retardation. Such syndromes include retinoblastoma associated with deletion of the long arm of chromosome 13, retinal astrocytoma associated with tuberous sclerosis, choroidal hemangioma associated with Sturge-Weber disease, and optic nerve glioma in children with neurofibromatosis.

Tapetoretinal Degenerations

Most tapetoretinal degenerations are hereditary and due to inborn errors of lipid or carbohydrate metabolism. These disorders cause dementia, peripheral neuropathy, and ataxia as initial features and are discussed in several chapters. The conditions discussed here are less common, but other neurological features are not prominent initial complaints.

Bardet-Biedl Syndrome

Bardet-Biedl syndrome is a genetically heterogeneous disorder with linkage to eight loci on eight different chromosomes (Katsanis et al, 2001). The common features of all types are mental retardation, pigmentary retinopathy, polydactyly, obesity, and hypogonadism.

CLINICAL FEATURES. Pigmentary retinopathy is usually manifest in the teens. Its characteristic features may be salt-and-pepper retinopathy, macular pigmentation, or macular degeneration. In some patients, the retina appears normal, but the electroretinogram always shows abnormalities. Heterozygotes have an increased frequency of obesity, hypertension, diabetes mellitus, and renal disease.

DIAGNOSIS. Diagnosis depends on recognition of the clinical constellation of symptoms and signs.

MANAGEMENT. Treatment is symptomatic.

Cockayne Syndrome

Cockayne syndrome (CS), similar to xeroderma pigmentosum (see Chapter 5), is a disorder of DNA repair (Nance, 2003). It has several types: CS types I, II, III, and xeroderma pigmentosum–Cockayne syndrome. Inheritance is autosomal recessive.

CLINICAL FEATURES. In CS type I, prenatal growth is normal. Growth and developmental failure begins in the first 2 years. Height, weight, and head circumference are below the fifth percentile. Progressive impairment of vision, hearing, and central and peripheral nervous system function leads to severe disability. Death typically occurs in the first or second decade.

The characteristic features of CS type II are growth failure at birth, with little or no postnatal neurological development. Congenital cataracts or other structural anomalies of the eye may be present. Contractures develop in the spine and joints. Patients typically die by age 7 years. CS type III is rare and has late onset. Xeroderma pigmentosum–Cockayne syndrome includes facial freckling and early skin cancers typical of xeroderma pigmentosum and some features typical of CS, such as mental retardation, spasticity, short stature, and hypogonadism. Approximately 55% of affected children develop a pigmentary retinopathy, and 60% develop a sensorineural hearing loss.

DIAGNOSIS. The diagnosis is by the clinical features and by assay of DNA repair in skin fibroblasts or lymphoblasts. Molecular genetic testing is available on a research basis.

MANAGEMENT. Treatment is symptomatic.

Laurence-Moon Syndrome

The Laurence-Moon syndrome is a distinct disorder with mental retardation, pigmentary retinopathy, hypogonadism, and spastic paraplegia without polydactyly and obesity. The highest prevalence is in the Arab population of Kuwait.

Disorders of the Pupil

When a person is awake, the size of the pupil is constantly changing in response to light and autonomic input. This pupillary unrest is called

hippus. An isolated disturbance of pupillary size is not evidence of intracranial disease.

Aniridia

Hypoplasia of the iris may occur as a solitary abnormality or may be associated with mental retardation, genitourinary abnormalities, and Wilms tumor. About two thirds of cases are genetic and transmitted as an autosomal dominant trait. One third of sporadic cases are associated with Wilms tumor. In some cases, the short arm of chromosome 11 is abnormal.

Benign Essential Anisocoria

Twenty percent to 30% of healthy people have an observable difference in pupillary size. Similar to congenital ptosis, it may go unnoticed until late childhood or adulthood and then is thought to be a new finding. The size difference is constant at all levels of illumination but may be greater in darkness. The absence of other pupillary dysfunction or disturbed ocular motility suggests essential anisocoria, but old photographs are invaluable to confirm the diagnosis.

Fixed, Dilated Pupil

CLINICAL FEATURES. A fixed, dilated pupil is an ominous sign in unconscious patients because it suggests transtentorial herniation (see Chapter 4). A dilated pupil that does not respond to light or accommodation in a child who is otherwise well and has no evidence of ocular motor dysfunction or ptosis can result only from the application of a pharmacological agent or from a damaged iris sphincter. The application may be accidental, as when inadvertently wiping a drug or chemical from the hand to the eye. Many cosmetics, particularly hair sprays, contain chemicals that can induce mydriasis. A careful history is essential to diagnosis. Factitious application of mydriatics is a relatively common attention-seeking device, and convincing parents that the problem is self-inflicted may be difficult. Occasionally a parent is the responsible party.

DIAGNOSIS. Instill 1% pilocarpine in both eyes using the normal eye as a control. Parasympathetic denervation produces prompt constriction. A slow or incomplete response indicates pharmacological dilation.

MANAGEMENT. Pharmacologically induced mydriasis is often long lasting, but eventually resolves.

Horner Syndrome

Horner syndrome results from sympathetic denervation; it may be congenital or acquired. When acquired, it may occur at birth as part of a brachial plexus injury, during infancy from neuroblastoma, or in childhood from tumors or injuries affecting the superior cervical ganglion or the carotid artery.

CLINICAL FEATURES. Unilateral Horner syndrome consists of the following ipsilateral features: mild-to-moderate ptosis (ptosis of the lower lid in one third); miosis, which is best appreciated in dim light so that the normal pupil dilates; and anhidrosis of the face, heterochromia, and apparent enophthalmos when the syndrome is congenital.

DIAGNOSIS. Disruption of the sympathetic system, anywhere from the hypothalamus to the eye, causes a Horner syndrome. Brainstem disturbances from stroke are common in adults, but peripheral lesions are more common in children. Topical instillation of 1% hydroxyamphetamine usually produces pupillary dilation after 30 minutes when postganglionic denervation is present. False-negative results can occur, however, during the first week after injury (Donahue et al, 1996). A 10% cocaine solution produces little or no dilation, regardless of the site of abnormality.

MANAGEMENT. Treatment depends on the underlying cause.

Tonic Pupil Syndrome (Adie Syndrome)

CLINICAL FEATURES. The cause of tonic pupil syndrome is a defect in the orbital ciliary ganglion. The onset usually occurs after childhood but may occur by age 5 years. Women are affected more often than men. The defect is usually monocular and manifests as anisocoria or photophobia. The abnormal pupil is slightly larger in bright light, but changes little, if at all, with alteration in illumination. In a dark room, the normal pupil dilates and is larger than the tonic pupil. With attempted accommodation, which also may be affected, the pupil constricts slowly and incompletely and redilates slowly afterward. Binocular tonic pupils occur in children with dysautonomia and in association with diminished tendon reflexes (Holmes-Adie syndrome).

DIAGNOSIS. The tonic pupil is supersensitive to parasympathomimetic agents; 0.125% pilocarpine achieves constriction.

MANAGEMENT. The condition is benign and seldom needs treatment.

References

- Brunel H, Raybaud C, Peretti-Viton P, et al. Craniopharyngioma in children. MRI study of 43 cases. *Neurochirurgie* 2002;48:309-318.
- Chinnery PC. (7 March 2003) Leber hereditary optic neuropathy. In: *GeneReviews at GeneTests: Medical Genetics Information Resource*. [database online] University of Washington, Seattle. Available at <http://www.genetests.org>.
- Donahue SP, Lavin PJM, Digre K. False-negative hydroxylamphetamine (Paredrine) test in acute Horner's syndrome. *Am J Ophthalmol* 1996;122:900-901.
- Katsanis N, Ansley SJ, Badano JL, et al. Triallelic inheritance in Bardet-Biedl syndrome, a mendelian recessive disorder. *Science* 2001;293:2256-2259.
- Listernick R, Louis DN, Packer RJ, et al. Optic pathway gliomas in children with neurofibromatosis 1. Consensus statement from the NF1 optic pathway glioma task force. *Ann Neurol* 1997;41:143-149.
- Nance MA. (23 September 2003) Cockayne syndrome. In: *GeneReviews at GeneTests: Medical Genetics Information Resource*. [database online] University of Washington, Seattle. Available at <http://www.genetests.org>.
- Online Mendelian Inheritance in Man, OMIM*. (2004) Wolfram syndrome. MIM Number 222300. [online database] Johns Hopkins University, Baltimore. Available at <http://www.ncbi.nlm.nih.gov/omim/>.
- Silva MM, Goldman S, Keating G, et al. Optic pathway hypothalamic gliomas in children under three years of age. The role of chemotherapy. *Pediatr Neurosurg* 2000;33:151-158.
- Thapar K, Kovacs K, Muller PJ. Clinical-pathological correlations of pituitary tumors. *Clin Endocrinol Metab* 1995;9:243-270.
- Thomas PQ, Dattani MT, Brickman JM, et al. Heterozygous HESX1 mutations associated with isolated congenital pituitary hypoplasia and septo-optic dysplasia. *Hum Mol Genet* 2001;10:39-45.

Chapter 17

Lower Brainstem and Cranial Nerve Dysfunction

THIS CHAPTER ADDRESSES disorders causing dysfunction of cranial nerves VII through XII. Many such disorders also disturb ocular motility (see Chapter 15). The basis for chapter assignment of a disorder is by the most usual initial clinical feature. For example, the discussion of myasthenia gravis is in Chapter 15 because diplopia is a more common initial complaint than dysphagia.

An acute isolated cranial neuropathy, such as facial palsy, is usually a less ominous sign than multiple cranial neuropathies and is likely to have a self-limited course. An isolated cranial neuropathy may be the first sign of progressive cranial nerve dysfunction, however. Conditions causing isolated and multiple cranial neuropathies are discussed together because they may not be separable at onset.

Facial Weakness and Dysphagia

Anatomical Considerations

Facial Movement

The motor nucleus of the facial nerve is a column of cells in the ventrolateral tegmentum of the pons. Nerve fibers leaving the nucleus take a circuitous path in the brainstem before emerging close to the pontomedullary junction. The fibers then enter the internal auditory meatus with the acoustic nerve. Fibers for voluntary and reflexive facial movements separate rostral to the lower pons. After bending forward and downward around the inner ear, the facial nerve traverses the temporal bone in the facial canal and exits the skull at the stylomastoid foramen. Extracranially the facial nerve passes into the parotid gland, where it divides into several branches, which

innervate all muscles of facial expression except the levator palpebrae superioris.

Sucking and Swallowing

The sucking reflex requires the integrity of the trigeminal, facial, and hypoglossal nerves. Stimulation of the lips produces coordinated movements of the face, jaw, and tongue. The automatic aspect of the reflex disappears after infancy but returns in bilateral disease of the cerebral hemispheres.

Fibers of the trigeminal and glossopharyngeal nerves ending in the nucleus solitarius form the afferent arc of the swallowing reflex. The motor roots of the trigeminal nerve, the glossopharyngeal and vagus fibers from the nucleus ambiguus, and the hypoglossal nerves form the efferent arc. A swallowing center that coordinates the reflex is located in the lower pons and upper medulla. A bolus of food stimulates the pharyngeal wall or back of the tongue, and the combined actions of the tongue, palatine arches, soft palate, and pharynx move the food into the esophagus.

Approach to Diagnosis

The causes of facial muscle weakness may be supranuclear palsy (pseudobulbar palsy); intrinsic brainstem disease; or disorders of the motor unit, including facial nerve, neuromuscular junction, and facial muscles (Tables 17-1 and 17-2). The differential diagnosis of dysphagia is similar (Table 17-3) except that isolated dysfunction of the nerves that enable swallowing is rare.

Pseudobulbar Palsy

Because the corticobulbar innervation of most cranial nerves is bilateral, pseudobulbar palsy

TABLE 17-1
Causes of Congenital Facial Weakness

Aplasia of facial muscles
Birth injury
Congenital myotonic dystrophy (see Chapter 6)
Congenital bilateral perisylvian syndrome
Fiber-type disproportion myopathies (see Chapter 6)
Myasthenic syndromes
Congenital myasthenia (see Chapter 15)
Familial infantile myasthenia (see Chapter 6)
Transitory neonatal myasthenia (see Chapter 6)

occurs only when hemispheric disease is bilateral. Many children with pseudobulbar palsy have a progressive degenerative disorder of gray or white matter. Most of these disorders are discussed in Chapter 5 because dementia is usually the initial feature. Bilateral strokes, simultaneous or in sequence, cause pseudobulbar palsy in children; the usual causes are coagulation defects, leukemia, and trauma (see Chapter 11). Pseudobulbar palsy is the main feature of the congenital bilateral perisylvian syndrome, which is discussed in this chapter. Episodic pseudobulbar palsy (oral apraxia, dysarthria, and drooling) may indicate acquired epileptiform opercular syndrome (see Chapter 1).

The characteristic feature of pseudobulbar palsy is an inability to use bulbar muscles in vol-

untary effort, whereas reflex movements, initiated at a brainstem level, are normal. Extraocular motility is unaffected. The child can suck, chew, and swallow but cannot coordinate these reflexes for eating; movement of a food bolus from the front of the mouth to the back has a volitional component. Emotionally derived facial expression occurs, but voluntary facial movements do not. Severe dysarthria is often present. Affected muscles do not show atrophy or fasciculations. The gag reflex and jaw jerk are usually exaggerated, and emotional volatility is often an associated feature.

Newborns with familial dysautonomia have difficulty feeding, despite normal sucking and swallowing, because they fail to coordinate the two reflexes (see Chapter 6). Table 6-8 summarizes the differential diagnosis of feeding difficulty in an alert newborn. Children with cerebral palsy often have a similar disturbance in the coordination of chewing and swallowing that impairs feeding.

Motor Unit Disorders

Disorders of the facial nuclei and nerves always cause ipsilateral facial weakness and atrophy, but associated features vary with the site of abnormality, as follows:

1. *Motor nucleus*: Hyperacusis is present, but taste, lacrimation, and salivation are normal.

TABLE 17-2
Causes of Postnatal Facial Weakness

Autoimmune and postinfectious	Infectious mononucleosis
Bell's palsy	Lyme disease (see Chapter 2)
Idiopathic cranial polyneuropathy	Otitis media
Miller Fisher syndrome (see Chapter 10)	Sarcoidosis
Myasthenia gravis (see Chapter 15)	Tuberculosis
Genetic	Metabolic disorders
Juvenile progressive bulbar palsy (Fazio-Londe disease)	Hyperparathyroidism
Muscular disorders	Hypothyroidism
Facioscapulohumeral syndrome (see Chapter 7)	Multiple sclerosis (see Chapter 10)
Facioscapulohumeral syndrome, infantile form	Syringobulbia
Fiber-type disproportion myopathies (see Chapter 6)	Toxins
Myotonic dystrophy (see Chapter 7)	Trauma
Oculopharyngeal dystrophy	Delayed
Myasthenic syndromes	Immediate
Congenital myasthenia (see Chapter 15)	Tumor
Familial infantile myasthenia (see Chapter 6)	Glioma of brainstem (see Chapter 15)
Osteopetrosis (Albers-Schönberg disease)	Histiocytosis X
Recurrent facial palsy	Leukemia
Melkersson syndrome	Meningeal carcinoma
Hypertension	Neurofibromatosis
Infectious	
Diphtheria	
Herpes zoster oticus	

TABLE 17-3
Neurological Causes of Dysphagia

Autoimmune/postinfectious
Dermatomyositis (see Chapter 7)
Guillain-Barré syndrome (see Chapter 7)
Idiopathic cranial polyneuropathy
Myasthenia gravis (see Chapter 15)
Transient neonatal myasthenia gravis (see Chapter 6)
Congenital or perinatal
Aplasia of brainstem nuclei
Cerebral palsy (see Chapter 5)
Chiari malformation (see Chapter 10)
Congenital bilateral perisylvian syndrome
Syngobulbia
Genetic
Degenerative disorders (see Chapter 5)
Familial dysautonomia (see Chapter 6)
Familial infantile myasthenia (see Chapter 6)
Fiber-type disproportion myopathies (see Chapter 6)
Myotonic dystrophy (see Chapters 6 and 7)
Oculopharyngeal dystrophy
Glioma of brainstem
Infectious
Botulism (see Chapters 6 and 7)
Diphtheria
Poliomyelitis (see Chapter 7)
Juvenile progressive bulbar palsy

2. *Facial nerve between the pons and the internal auditory meatus:* Taste sensation is spared, but lacrimation and salivation are impaired, and hyperacusis is present.
3. *Geniculate ganglion:* Taste, lacrimation, and salivation are impaired, and hyperacusis is present.
4. *Facial nerve from the geniculate ganglion to the stapedius nerve:* Taste and salivation are impaired, and hyperacusis is present, but lacrimation is normal.
5. *Facial nerve from the stapedius nerve to the chorda tympani:* Taste and salivation are impaired, hyperacusis is not present, and lacrimation is normal.
6. *Facial nerve below the exit of the chorda tympani nerve:* Only facial weakness is present.

Disturbances of cranial nerve nuclei seldom occur in isolation; they are often associated with other features of brainstem dysfunction (bulbar palsy). Usually some combination of dysarthria, dysphagia, and diplopia is present. Examination may show strabismus, facial diplegia, loss of the gag reflex, atrophy of bulbar muscles, and fasciculations of the tongue.

The facial weakness associated with myasthenia gravis and facial myopathies is usually bilateral. In contrast, brainstem disorders usually begin on one side and eventually progress to

bilateral impairment. Facial nerve palsies are usually unilateral. The differential diagnosis of recurrent facial palsy or dysphagia is limited to disorders of the facial nerve and neuromuscular junction (Table 17-4).

Congenital Syndromes

Congenital Bilateral Perisylvian Syndrome

Congenital bilateral perisylvian syndrome results from a disturbance in neuronal migration that results in pachygyria of the sylvian and rolandic regions. Most cases are sporadic. The transmission of familial cases is by X-linked inheritance (Xq28); such cases are more severe in males than in females (Villard et al, 2002).

CLINICAL FEATURES. All affected children have a pseudobulbar palsy that causes failure of speech development and dysphagia. Mental retardation and seizures are present in approximately 85% of cases. The retardation varies from mild to severe, and the seizures, which begin between ages 4 and 12, may be atypical absence, atonic/tonic, partial, or generalized tonic-clonic.

DIAGNOSIS. Magnetic resonance imaging (MRI) shows bilateral perisylvian gyral malformations, pachygyria, and polymicrogyria (Figure 17-1). Postmortem studies have confirmed the MRI impression.

MANAGEMENT. The seizures are usually difficult to control, and corpus callosotomy has been useful in some cases with intractable drop attacks. Speech therapy does not overcome the speech disorder, and instruction in sign language is the better alternative for children of near-normal intelligence.

Congenital Dysphagia

Congenital dysphagia usually is associated with infantile hypotonia and is discussed in Chapter 6.

TABLE 17-4
Causes of Recurrent Cranial Neuropathies and Palsies

Familial
Isolated facial palsy
Melkersson syndrome
Hypertensive facial palsy
Myasthenia gravis
Sporadic multiple cranial neuropathies
Toxins

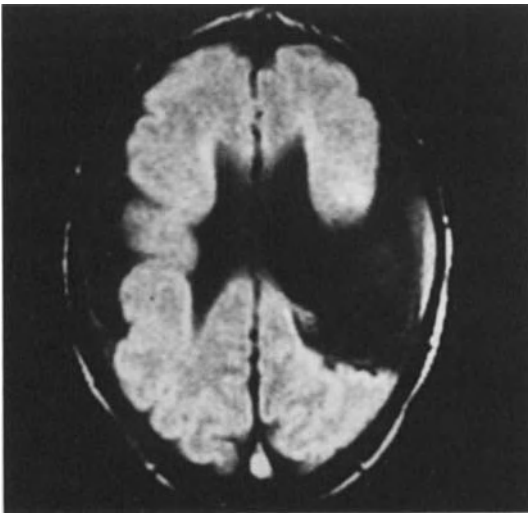


Figure 17-1. MRI of congenital bilateral perisylvian syndrome. This child has lissencephaly and schizencephaly. Bilateral disturbances in the perisylvian region caused a pseudobulbar palsy.

Because the neuroanatomical substrates of swallowing and breathing are contiguous, congenital dysphagia and dyspnea are often concurrent. Isolated aplasia of the cranial nerve nuclei subserving swallowing is not established.

Congenital Facial Asymmetry

The cause of most facial asymmetries at birth is congenital aplasia of muscle and not trauma to the facial nerve. Facial diplegia, whether complete or incomplete, suggests Möbius syndrome or other congenital muscle aplasia. Complete unilateral palsies are likely to be traumatic in origin, whereas partial unilateral palsies may be either traumatic or aplastic. The term *neonatal facial asymmetry* is probably more accurate than facial nerve palsy to denote partial or complete unilateral facial weakness in the newborn and emphasizes the difficulty in differentiating traumatic nerve palsies from congenital aplasias.

Aplasia of Facial Muscles

CLINICAL FEATURES. Möbius syndrome is the best-known congenital aplasia of facial nerve nuclei and facial muscles. The site of pathology is usually the facial nerve nuclei and their internuclear connections. Facial diplegia may occur alone, with bilateral abducens palsies, or with involvement of several cranial nerves (Verzijl et al, 2003). Congenital malformations elsewhere in the body—dextrocardia, talipes equinovarus, absent pectoral muscle, and limb deformities—

are sometimes associated features. Most cases are sporadic, but familial recurrence occurs. Autosomal dominant, autosomal recessive, and X-linked recessive modes of inheritance are proposed. Identified loci are on chromosomes 13, 3, and 10. Other developmental causes of unilateral facial palsy are *Goldenhar syndrome*, *Poland anomaly*, *DiGeorge syndrome*, osteopetrosis, and trisomies 13 and 18.

DIAGNOSIS. Congenital facial diplegia is by definition a Möbius syndrome. All cases require MRI of the brain to determine if other cerebral malformations are present. Causes other than primary malformations include intrauterine toxins (e.g., thalidomide), vascular malformations, or infarction.

Electromyogram (EMG) can help determine the timing of injury. Denervation potentials are present only if injury to the facial nuclei or nerve occurred 2 to 6 weeks before the study. Facial muscles that are aplastic, as in Möbius syndrome or nerve injury occurring early in gestation, do not show active denervation.

MANAGEMENT. Surgical procedures may provide partial facial movement.

Depressor Anguli Oris Muscle Aplasia

CLINICAL FEATURES. Isolated unilateral weakness of the depressor anguli oris muscle (DAOM) is the most common cause of facial asymmetry at birth. One corner of the mouth fails to move downward when the child cries. All other facial movements are symmetrical. The lower lip on the paralyzed side feels thinner to palpation, even at birth, suggesting antepartum hypoplasia.

DIAGNOSIS. Traumatic lesions of the facial nerve would not selectively injure nerve fibers to the DAOM and spare all other facial muscles. Electrodiagnostic studies aid in differentiating aplasia of the DAOM from traumatic injury. In aplasia, the conduction velocity and latency of the facial nerve are normal. Fibrillations are not present at the site of the DAOM. Instead, motor unit potentials are absent or decreased in number.

MANAGEMENT. No treatment is available or needed. The DAOM is not a significant component of facial expression in older children and adults, and absence of the muscle is difficult to notice.

Birth Injury

Perinatal traumatic facial palsy is a disorder of large term newborns delivered vaginally after a prolonged labor. Nerve compression against the

sacrum during labor is more often the cause than is the misapplication of forceps. Children with forceps injuries, an unusual event, have forceps marks on the cheeks.

CLINICAL FEATURES. The clinical expression of complete unilateral facial palsy in the newborn can be subtle and may not be apparent immediately after birth. Failure of eye closure on the affected side is the first noticeable evidence of weakness. Only when the child cries does flaccid paralysis of all facial muscles become obvious. The eyeball rolls up behind the open lid, the nasolabial fold remains flat, and the corner of the mouth droops during crying. The normal side appears paralyzed because it pulls and distorts the face; the paralyzed side appears to be normal. When paralysis of the facial nerve is partial, the orbicularis oculi is the muscle most frequently spared. In these injuries, the compression site is usually over the parotid gland, with sparing of nerve fibers that course upward just after leaving the stylomastoid foramen.

DIAGNOSIS. The diagnosis of facial asymmetry is made by observing the face of the crying newborn. Carefully examine the facial skin for laceration. Otosopic examination is useful to establish the presence of hemotympanum. EMG does not alter the management of the palsy.

MANAGEMENT. Prospective studies regarding the natural outcome of perinatal facial nerve injuries are not available. Most authors are optimistic and indicate a high rate of spontaneous recovery. Such optimism may be appropriate, but its basis is only anecdotal experience. In the absence of data on long-term outcome, the efficacy of any suggested therapeutic intervention cannot be evaluated. Most newborns are not candidates for surgical intervention unless the nerve laceration occurs at delivery. In that event, the best response is to reconstitute the nerve if possible or at least to allow the proximal stump a clear pathway toward regeneration by debridement of the wound.

Immune-Mediated and Infectious Disorders

Postinfectious demyelination of the cranial nerve VII is the cause of most cases of acute unilateral facial neuritis (Bell's palsy) or bilateral facial neuritis. The basis for distinguishing a bilateral Bell's palsy from Guillain-Barré syndrome (acute inflammatory demyelinating polyneuropathy) is the preservation of limb tendon reflexes in Bell's palsy. Guillain-Barré syndrome is discussed in Chapter 7.

Bell's Palsy

Bell's palsy is an acute idiopathic paralysis of the face caused by dysfunction of the facial nerve. The pathogenesis is believed to be viral (most often herpes simplex), but also may be postviral immune-mediated demyelination. The annual incidence is approximately 3:100,000 in the first decade, 10:100,000 in the second decade, and 25:100,000 in adulthood. Only 1% of cases have clinical evidence of bilateral involvement, but many have electrophysiological abnormalities on the unaffected side.

CLINICAL FEATURES. A history of viral infection, usually upper respiratory, is recorded in many cases, but the frequency is not significantly greater than expected by chance. The initial feature of neuritis is often pain or tingling in the ear canal ipsilateral to the subsequent facial palsy. Sensory symptoms, when present, are usually mild and do not demand medical attention. The palsy has an explosive onset and becomes maximal within hours. Either the child or the parents may notice the palsy first, which affects all muscles on one side of the face. Half of the face sags, enlarging the palpebral fissure. Weakness of the levator palpebrae muscle prevents closure of the lid. Efforts to use muscles of expression cause the face to pull to the normal side. Eating and drinking become difficult, and the dribbling of liquids from the weak corner of the mouth causes embarrassment.

The most commonly affected portion of the nerve is within the temporal bone; taste, lacrimation, and salivation are impaired; and hyperacusis is present. Examination of all facial nerve functions in small children is difficult, however, and precise localization is not crucial to diagnosis or prognosis. The muscles remain weak for 2 to 4 weeks, then strength returns spontaneously. The natural history of Bell's palsy in children is not established, but experience indicates that almost all patients recover completely.

DIAGNOSIS. Complete neurological examination is required in every child with acute unilateral facial weakness to determine whether the palsy is an isolated abnormality. Mild facial weakness on the other side or the absence of tendon reflexes in the limbs suggests the possibility of Guillain-Barré syndrome. These children require observation for the development of progressive limb weakness.

Exclude possible underlying causes (e.g., hypertension, infection, and trauma) of facial nerve palsy before considering the diagnosis of Bell's palsy. Examine the ear ipsilateral to the

facial palsy for herpetic lesions (see later discussion of herpes zoster ophthalmicus). MRI shows contrast enhancement of the involved nerve, but acute, isolated facial palsy is not an indication for MRI in every child. A more reasonable approach is to watch the child and recommend an imaging study if other neurological disturbances develop or if the palsy does not begin to resolve within 1 month.

MANAGEMENT. Always protect the cornea if the blink reflex is absent. Patch the eye when the child is outside the home or at play, and apply artificial tears several times a day to keep the cornea moist. The use of corticosteroids, advocated in adults, has no scientific basis in children because their prognosis for complete spontaneous recovery is excellent. The clinician who elects to use corticosteroid therapy first must exclude hypertension or infection as an underlying cause.

Idiopathic Cranial Polyneuropathy

As the name implies, idiopathic cranial neuropathy is of uncertain nosology. The presumed mechanism is postinfectious, and many consider the syndrome an abortive form of Guillain-Barré syndrome.

CLINICAL FEATURES. Onset is usually in adulthood, and most childhood cases occur in adolescence. In similar cases described in infants, the infants subsequently developed limb weakness, and infantile botulism was the more likely diagnosis (see Chapter 6). Constant, aching facial pain usually precedes weakness by hours or days. The pain is often localized to the temple or frontal region but can be anywhere in the face. Weakness may develop within 1 day or may evolve over several weeks. Extraocular motility is usually affected. Facial and trigeminal nerve disturbances occur in half of cases, but lower cranial nerve involvement is uncommon. Occasional patients have transitory visual disturbances, ptosis, pupillary abnormalities, and tinnitus. Tendon reflexes in the limbs remain active. Recurrent idiopathic cranial neuropathies occur as sporadic cases in adults, but usually occur on a familial basis in children.

DIAGNOSIS. The differential diagnosis includes Guillain-Barré syndrome, infant and childhood forms of botulism, brainstem glioma, juvenile progressive bulbar palsy, pontobulbar palsy with deafness, and Tolosa-Hunt syndrome. Preservation of tendon reflexes in idiopathic cranial polyneuropathy is the main feature distinguishing it from Guillain-Barré syndrome. Prominent autonomic dysfunction and limb

weakness distinguish botulism from idiopathic cranial polyneuropathy (see Chapters 6 and 7). Cranial nerve dysfunction in patients with brainstem glioma, juvenile progressive bulbar palsy, and pontobulbar palsy with deafness usually evolves over a longer period. Tolosa-Hunt syndrome, comprising painful ophthalmoplegia and idiopathic cranial polyneuropathy, shares many features and may be a variant of the same disease process (see Chapter 15).

All laboratory findings are normal. The possibility of a brainstem glioma requires MRI of the brainstem in all cases. Examination of the cerebrospinal fluid occasionally reveals a mild elevation of protein concentration and a lymphocyte count of 5 to 6/mm³.

MANAGEMENT. The disease is self-limited, and full recovery is the expected outcome 2 to 4 months after onset. The use of corticosteroids is routine and believed to ease facial pain and shorten the course. The pain relief may be dramatic, but evidence documenting a shortened course is lacking.

Genetic Disorders

Facioscapulohumeral Syndrome

Facioscapulohumeral syndrome (see Chapter 7) sometimes begins during infancy as facial diplegia. Transmission of all forms of the disease is by autosomal dominant inheritance. The responsible gene maps to chromosome 4q35 in many, but not all, families.

CLINICAL FEATURES. The onset of infantile facioscapulohumeral syndrome is usually during infancy and no later than age 5. Facial diplegia is the initial feature. When onset is early in infancy, a common misdiagnosis is congenital aplasia of facial muscles. Later, nasal speech and sometimes ptosis develop. Progressive proximal weakness begins 1 to 2 years after onset, first affecting the shoulders and then the pelvis. Pseudohypertrophy of the calves may be present. Tendon reflexes are depressed, then absent in weak muscle. Progression of weakness is often rapid and unrelenting, leading to disability and death from respiratory insufficiency before age 20. Typical features are a striking asymmetry of muscle involvement from side to side and sparing of bulbar extraocular and respiratory muscles (Tawil et al, 1998). The weakness also may stabilize for long intervals and not cause severe disability until adulthood. Retinal telangiectasia and high-frequency hearing loss occur in about half of affected families (Padberg et al, 1995). Both conditions are progressive

and may not be symptomatic in early childhood.

DIAGNOSIS. The diagnosis of facioscapulohumeral syndrome is suspected in every child with progressive facial diplegia. A family history of facioscapulohumeral syndrome is not always obtainable because the affected parent may show only minimal expression of the phenotype. Molecular-based testing is reliable for diagnosis.

Myasthenia gravis and brainstem glioma are a consideration in infants with progressive facial diplegia. The serum concentration of creatine kinase is helpful in differentiating these disorders. It is usually elevated in infantile facioscapulohumeral syndrome and is normal in myasthenia gravis and brainstem glioma. Electrophysiological studies show brief, small-amplitude polyphasic potentials in weak muscles and a normal response to repetitive nerve stimulation.

MANAGEMENT. Treatment is supportive.

Juvenile Progressive Bulbar Palsy

Juvenile progressive bulbar palsy, also known as *Fazio-Londe disease*, is a motor neuron disease limited to bulbar muscles. Most cases are sporadic; autosomal recessive inheritance is the suspected means of transmission, but a rare autosomal dominant subtype may occur.

CLINICAL FEATURES. Age at onset distinguishes two clinical patterns. Stridor is the initial feature in early-onset cases (ages 1 to 5 years). Progressive bulbar palsy follows, and respiratory compromise causes death within 2 years of onset. Respiratory symptoms are less common in later onset cases (ages 6 to 20 years). The initial feature may be facial weakness, dysphagia, or dysarthria. Eventually the disorder affects all lower motor cranial nerve nuclei except the ocular motor nerve nuclei. Some children show fasciculations and atrophy of the arms, but limb strength and tendon reflexes usually remain strong despite severe bulbar palsy.

DIAGNOSIS. The major diagnostic considerations are myasthenia gravis and brainstem glioma. MRI of the brainstem excludes brainstem tumors. EMG is useful to show active denervation of facial muscles, with sparing of the limbs and normal repetitive stimulation of nerves. A rapidly progressive motor neuron disease affecting the face and limbs in children may represent a childhood form of amyotrophic lateral sclerosis.

MANAGEMENT. The disorder is often devastating. A previously normal child is no longer able to

speak intelligibly or swallow. Feeding gastrostomy and a communication device are soon required. The child needs considerable psychological support. Treatment is not available for the underlying disease.

Oculopharyngeal Muscular Dystrophy

Autosomal dominant inheritance is the usual means of genetic transmission. The incidence is highest in families of French-Canadian descent, but the disorder is not restricted to any ethnic group. Mitochondrial myopathies account for cases with similar features not transmitted by autosomal dominant inheritance.

CLINICAL FEATURES. Onset is usually in the 30s, but may be as early as adolescence. The initial features are ptosis and dysphagia, followed by proximal weakness in the legs and external ophthalmoplegia. Eventually the disease affects all skeletal muscle, but spares smooth and cardiac muscle. Many patients with oculopharyngeal muscular dystrophy also have EMG or biopsy evidence of denervation in the limbs. The neurogenic features may be attributable to neuronopathy rather than neuropathy, suggesting that this disorder is actually a spinal (bulbar) muscular atrophy.

DIAGNOSIS. Definitive diagnosis relies on DNA testing. Muscle biopsy specimens reveal a random variation in the size of the fibers, necrotic fibers, some fibrosis, and occasional internal nuclei. Autophagic vacuoles (rimmed vacuoles) and intranuclear fibrillary inclusion bodies are features common to oculopharyngeal muscular dystrophy, inclusion body myositis, and several hereditary distal myopathies/dystrophies. The presence of ragged-red fibers on histological examination of muscle indicates an underlying mitochondrial myopathy.

MANAGEMENT. The goal of therapy is symptom relief. Dietary changes help early dysphagia, but gastrostomy is eventually required. Levator palpebral shortening may correct ptosis.

Osteopetrosis (Albers-Schönberg Disease)

The term *osteopetrosis* encompasses at least three hereditary skeletal disorders of increased bone density. Transmission of the most common form is by autosomal recessive inheritance (chromosome 11q). The features are macrocephaly, progressive deafness and blindness, hepatosplenomegaly, and severe anemia beginning in fetal life or early infancy. The calvaria

thickens, and cranial nerves are compressed and compromised as they pass through the bone. The thickened calvaria also may impair venous return and cause increased intracranial pressure.

The main clinical features of the dominant form (1p) are fractures and osteomyelitis, especially of the mandible. Treatment with high-dose calcitriol reduces the sclerosis and prevents many neurological complications.

Melkersson Syndrome

Seven percent of facial palsies are recurrent. Autosomal dominant inheritance with variable expression is the suspected means of transmission in many cases. Some kindred members may have only recurrent facial nerve palsy, whereas others have recurrent neuropathies of the facial and ocular motor nerves. Melkersson syndrome may be genetically distinct from other recurrent facial palsies with a gene locus at chromosome 9p11.

CLINICAL FEATURES. Melkersson syndrome is a rare disorder characterized by the triad of recurrent facial palsy, lingua plicata, and facial edema. Attacks of facial palsy usually begin after age 10, but the deeply furrowed tongue is present from birth. The first attack of facial weakness is indistinguishable from Bell's palsy except that a migraine-like headache may precede the attack. Subsequent attacks are associated with eyelid edema, which is soft, painless, nonerythematous, and nonpruritic. The edema is most often asymmetrical, involving only the upper lip on the paralyzed side, but it may affect the cheek and eyelid of one or both sides. Cold weather or emotional stress may precipitate an attack of facial swelling. Lingua plicata is present in 30% to 50% of cases. Furrowing and deep grooving on the dorsal surface of the tongue are permanent from birth. The transmission of this feature is by autosomal dominant inheritance, but it occurs as an isolated finding in some families.

DIAGNOSIS. The diagnosis of Melkersson syndrome is established when two features of the triad are present. It is a consideration in any child with a personal or family history of recurrent facial palsy or recurrent facial edema. The presence of lingua plicata in any member of the kindred confirms the diagnosis. Histopathology of the affected eyelid reveals a granulomatous lymphangitis unique to the disease (Cockerham et al, 2000).

MANAGEMENT. This disease has no established treatment.

Hypertension

Unilateral facial palsy may be a feature of malignant hypertension in children. The cause of the palsy is swelling and hemorrhage into the facial canal.

CLINICAL FEATURES. The course of the facial paralysis is indistinguishable from that in Bell's palsy. Nerve compression occurs in the proximal segment, impairing lacrimation, salivation, and taste. The onset coincides with an increase in blood pressure to greater than 120 mm Hg, and recovery begins when the pressure reduces. The duration of palsy varies from days to weeks. Recurrences are associated with repeated episodes of hypertension.

DIAGNOSIS. The occurrence of facial palsy in a child with known hypertension suggests that the hypertension is out of control.

MANAGEMENT. Control of hypertension is the only effective treatment.

Infection

The facial nerve sometimes is involved when bacterial infection spreads from the middle ear to the mastoid. External otitis may lead to facial nerve involvement by spread of infection from the tympanic membrane to the chorda tympani. Diphtheria may cause single or multiple cranial neuropathies from a direct effect of its toxin. Facial palsy, dysarthria, and dysphagia are potential complications. Basilar meningitis, from tuberculosis or other bacterial infections, causes inflammation of cranial nerves as they leave the brain and enter the skull. Multiple and bilateral cranial nerve involvement is usually progressive.

Herpes Zoster Oticus (Ramsay Hunt Syndrome)

Herpes zoster infection of the geniculate ganglion causes herpes zoster oticus.

CLINICAL FEATURES. The initial feature is pain in and behind the ear. This pain is often more severe and persistent than that expected with other causes of Bell's palsy. Unilateral facial palsy, indistinguishable from Bell's palsy by appearance, follows. Examination of the ipsilateral ear, especially in the fossa of the helix and behind the lobule, shows a vesicular eruption characteristic of herpes zoster. Hearing loss is associated in 25% of cases.

DIAGNOSIS. The only historical feature distinguishing herpes zoster oticus from Bell's palsy is the severity of ear pain. Examination of the ear for vesicles is crucial to the diagnosis.

MANAGEMENT. Herpes zoster infections are usually self-limited but painful. A combination of oral acyclovir, 800 mg five times a day for 7 days, and oral prednisone, 1 mg/kg for 5 days and then tapered, improves the outcome for facial nerve function in patients 15 years old and older (Murakami et al, 1997). Complete recovery occurs in 75% of patients treated within 7 days of onset and in 30% treated after 7 days. The varicella vaccine may reduce the incidence of new cases and decrease the severity of symptoms (Hato et al, 2000).

Sarcoidosis

Cranial nerve dysfunction is the most common neurological complication of sarcoidosis. Basilar granulomatous meningitis is the usual cause, but the facial nerve also may be involved when parotitis is present.

CLINICAL FEATURES. Onset is usually in the 20s but may occur in adolescence. Neurological complications occur in only 5% of patients with sarcoidosis, but, when present, they are often an early feature of the disease. Unilateral or bilateral facial nerve palsy is the most common feature. Visual impairment or deafness is next in frequency. Single cranial neuropathies are present in 73%, and multiple cranial neuropathies are present in 58%. Any cranial nerve except the accessory nerve may be involved. Systemic features of sarcoidosis occur in almost every case: Intrathoracic involvement is present in 81% and ocular involvement in 50%. Uveoparotitis is an uncommon manifestation of sarcoidosis. The patient ordinarily comes to medical attention because of visual impairment and a painful eye. The mouth is dry, and the parotid gland is swollen. Facial nerve compression and palsy are present in 40% of cases.

DIAGNOSIS. Sarcoidosis is a consideration in any patient with single or multiple cranial neuropathies. Documentation of multisystem disease confirms the diagnosis. Radiographs of the chest either establish or are compatible with the diagnosis in almost all patients with neurological manifestations.

Increased serum concentrations of serum angiotensin-converting enzyme are detectable in 75% of patients with active pulmonary disease, and patients with neurosarcoidosis may have elevated cerebrospinal fluid concentrations of angiotensin-converting enzyme. Biopsy specimens of lymph nodes or other affected tissues provide histological confirmation.

MANAGEMENT. Prednisone therapy, 0.5 to 1 mg/kg/day, is maintained until a clinical response

is evident, then slowly tapered at a rate that prevents relapse. The prognosis for neurological complications of sarcoidosis is good without treatment, but corticosteroids seem to hasten recovery.

Metabolic Disorders

Hyperparathyroidism

The most common neurological features of primary hyperparathyroidism are headache and confusion (see Chapter 2). Occasionally, hyperparathyroidism is associated with a syndrome that is similar to amyotrophic lateral sclerosis and includes ataxia and internuclear ophthalmoplegia. Dysarthria and dysphagia are prominent features.

Hypothyroidism

Cranial nerve abnormalities are unusual in hypothyroidism. Deafness is the most common feature, but acute facial nerve palsy resembling Bell's palsy also occurs.

Syringobulbia

Syringobulbia is usually the medullary extension of a cervical syrinx (see Chapter 12), but also may originate in the medulla. The syrinx usually involves the nucleus ambiguus and the spinal tract and motor nucleus of the trigeminal nerve. Symptoms in order of frequency are headache, vertigo, dysarthria, facial paresthesias, dysphagia, diplopia, tinnitus, and palatal palsy.

Toxins

Most neurotoxins produce either diffuse encephalopathy or peripheral neuropathy. Only ethylene glycol, trichloroethylene, and chlorocresol exposure cause selective cranial nerve toxicity. Ethylene glycol is antifreeze. Ingestion causes facial diplegia, hearing impairment, and dysphagia. Trichloroethylene intoxication can cause multiple cranial neuropathies but has a predilection for the trigeminal nerve. It was previously a treatment for tic douloureux. Chlorocresol, a compound used in the industrial production of heparin, caused recurrent unilateral facial palsy in one exposed worker. Inhalation of the compound caused tingling of one side of the face followed by weakness of the muscles. The neurological disturbance was brief, was relieved by exposure to fresh air, and could be reproduced experimentally.

Trauma

Facial palsy after closed head injury usually is associated with bleeding from the ear and fracture of the petrous bone.

CLINICAL FEATURES. The onset of palsy may be immediate or delayed for 3 weeks after injury. In most cases, the interval is 2 to 7 days. The mechanism of delay is unknown.

DIAGNOSIS. Electrophysiological studies are helpful in prognosis. If the nerve is intact but shows a conduction block, recovery usually begins within 5 days and is complete. Most patients with partial denervation recover full facial movement but have evidence of aberrant reinnervation. Full recovery is not an expected outcome when denervation is complete.

MANAGEMENT. The management of traumatic facial palsy is controversial. Some authors have recommended surgical decompression and corticosteroids, but no evidence supporting either mode of therapy is available.

Tumors

Tumors of the facial nerve are rare in children. The major neoplastic cause of facial palsy is brainstem glioma (see Chapter 15), followed by tumors that infiltrate the meninges, such as leukemia, meningeal carcinoma, and histiocytosis X. Acoustic neuromas are unusual in childhood and are limited to children with neurofibromatosis type 2. These neuromas cause hearing impairment before facial palsy and are discussed in the next section.

Hearing Impairment and Deafness

Anatomical Considerations

Sound, mechanically funneled through the external auditory canal, causes the tympanic membrane to vibrate. Ossicles transmit the vibrations to the oval window of the cochlea, the sensory organ of hearing. The air-filled space extending from the tympanic membrane to the cochlea comprises the *middle ear*. The membranous labyrinth within the osseous labyrinth is the principal structure of the *inner ear*. It contains the cochlea, the semicircular canals, and the vestibule. The semicircular canals and vestibule are the sensory organs of vestibular function. The cochlea consists of three fluid-filled canals wound into a snail-like configuration.

The organ of Corti is the transducer within the cochlea that converts mechanical to electrical energy. The auditory portion of the eighth nerve transmits impulses to the ipsilateral cochlear nuclei of the medulla. The transmission of information from the cochlear nuclei on each side is to both superior olivary nuclei, causing bilateral representation of hearing throughout the remainder of the central pathways. From the superior olivary nuclei, transmission is by the lateral lemniscus to the inferior colliculus. Further cross-connections occur in collicular synapses. Rostrally directed fibers from the inferior colliculi ascend to the medial geniculate and auditory cortex of the temporal lobe.

Symptoms of Auditory Dysfunction

The major symptoms of disturbance in the auditory pathways are hearing impairment, tinnitus, and hyperacusis. The characteristic feature of hearing impairment in infants is failure to develop speech (see Chapter 5) and in older children inattentiveness and poor school performance. Fifty percent of infants use words with meaning by 12 months and join words into sentences by 24 months. Failure to accomplish these tasks by 21 months and 3 years is always abnormal. A hearing loss of 25 to 30 dB is sufficient to interfere with normal acquisition of speech.

Hearing Impairment

Hearing impairment is classified as conductive, sensorineural (perceptive), or central. The cause of conductive hearing impairment is a disturbance in the external or middle ear. Faithful delivery of the mechanical vibrations that make up the sensory input of hearing to the inner ear does not occur because the external canal is blocked or the tympanic membrane or ossicles are abnormal. The major defect in conductive hearing loss is sound amplification. Patients with conductive hearing impairment are better able to hear loud speech in a noisy background than soft speech in a quiet background. Tinnitus may be associated.

Sensorineural hearing impairment may be congenital or acquired; a disturbance of the cochlea or auditory nerve is the cause. The frequency content of sound is improperly analyzed and transduced. High frequencies may be selectively lost. Individuals with sensorineural hearing impairment have difficulty discriminating speech when there is background noise. Central hearing impairment results from disturbance of

the cochlear nuclei or their projections to the cortex. Brainstem lesions usually cause bilateral hearing impairment. Cortical lesions lead to difficulty in processing information. Pure-tone audiometry is normal, but background noise or competing messages impair speech discrimination. The cause of approximately one third of childhood deafness is genetic; one third, acquired; and one third, idiopathic. Many idiopathic cases are probably genetic as well.

Tinnitus

Tinnitus is the illusion of noise in the ear. The noise is usually high-pitched and constant. In most cases, the cause of tinnitus is a disturbance of the auditory nerve, but it also may occur as a simple partial seizure originating from the primary auditory cortex. Sounds generated by the cardiovascular system (heartbeat and bruit) are sometimes audible, especially while a person is lying down, but should not be confused with tinnitus.

Hyperacusis

The cause of hyperacusis is failure of the stapedius muscle to dampen sound by its effect on the ossicles. This failure occurs with damage to the chorda tympani branch of the facial nerve (see the discussion of Bell's palsy earlier).

Tests of Hearing

Office Testing

Hearing assessment in the office is satisfactory for severe hearing impairment but is unsatisfactory for detecting loss of specific frequency bands. The speech and hearing handicap generated by a high-frequency hearing impairment should not be underestimated. Dropping a large object and watching the infant and parents startle from the noise is not a test of hearing. When testing an infant, the physician should stand behind the patient and provide interesting sounds to each ear; bells, chimes, rattles, or a tuning fork are useful. When the infant sees the source of the interesting sound or hears it several times, interest is lost. The use of different high-frequency and low-frequency sounds is required for each ear. The normal responses of the infant are to become alert and to attempt to localize the source of the sound.

In older children, observing their response to spoken words at different intensities and with tuning forks that provide pure tones of

different frequencies tests hearing. The *Rinne test* compares air conduction (conductive plus sensorineural hearing) with bone conduction (sensorineural hearing). A tuning fork is held against the mastoid process until the sound fades, then is held 1 inch from the ear. Normal children hear the vibration produced by air conduction twice as long as that produced by bone conduction. Impaired air conduction with normal bone conduction indicates a conductive hearing loss.

The *Weber test* compares bone conduction in the two ears. Localization of the signals transmitted by bone conduction is to the better hearing ear or the ear with the greater conductive deficit. With a tuning fork placed at the center of the forehead, inquire whether the perception of sound is equal in both ears. A normal response is to hear the sound in the center of the head. If bone conduction is normal in both ears, sound localization is to the ear with impaired air conduction because the normal blocking response of air conduction is lacking. If a sensorineural hearing impairment is present in one ear, the perception of bone conduction is in the good ear. Ooscopic examination is imperative in every child with hearing problems or tinnitus. The cause seen through the speculum may be impacted wax, otitis media, perforated tympanic membrane, or cholesteatoma.

Specialized Testing

The usual battery of auditory tests includes pure-tone air and bone conduction testing and measures of speech threshold and word discrimination.

Pure-Tone Audiometry

With selected frequencies presented by earphones (air conduction) or by a vibrator applied to the mastoid (bone conduction), the minimal level perceived for each frequency is determined. International standards define the normal hearing levels. The test can be performed adequately only in children old enough to cooperate. With conductive hearing impairment, air conduction is abnormal, and bone conduction is normal; with sensorineural hearing impairment, both are abnormal; and with central hearing impairment, both are normal.

Speech Tests

The speech reception threshold measures the intensity at which a subject can repeat 50% of

presented words. The speech discrimination test measures the subject's ability to understand speech at normal conversational levels. Both tests are abnormal out of proportion to pure-tone loss with auditory nerve disease, abnormal in proportion to pure-tone loss with cochlear disease, and normal with conductive and central hearing loss.

Special Tests

Cochlear lesions may cause diplacusis and recruitment. Auditory nerve lesions produce tone decay. Diplacusis is a distortion of pure tones so that the subject perceives a mixture of tones. With recruitment, the sensation of loudness increases at an abnormally rapid rate as the intensity of sound is increased. Tone decay is diminished perception of a suprathreshold tone with time.

Brainstem Auditory Evoked Response

The brainstem auditory evoked response (BAER) is a useful test of hearing and the integrity of the brainstem auditory pathways in infants and small children. No cooperation is required, and sedation improves the accuracy of results. When each ear is stimulated with repetitive clicks, an electrode over the ipsilateral mastoid referenced to the forehead records five waves. Wave I is generated by the acoustic nerve, wave II by the cochlear nerve, wave III by the superior olivary complex, wave IV by the lateral lemniscus, and wave V by the inferior colliculus. The BAER first appears at a conceptional age of 26 to 27 weeks. The absolute latencies of waves I and V and the V-I interpeak interval decline progressively with advancing conceptional age. The latency of wave V bears an inverse relationship to the intensity of the stimulus and tests hearing.

An initial test uses a stimulus intensity of 70 dB. Failure to produce wave V indicates a hearing impairment. Repeated tests at higher intensities find the response threshold. If wave V is present, the repeated tests at sequential reductions of 10 dB establish the lowest intensity capable of producing wave V, the *hearing threshold*. Because the latency of wave V is proportional to the intensity of the stimulus, a latency-intensity curve is drawn. In normal newborns, the latency of wave V decreases by 0.24 to 0.44 msec for each 10 dB in sound intensity between 70 and 110 dB.

In children with conductive hearing impairment, prolonged time is required to transmit sound across the middle ear and activate the

cochlea. This prolonged time reduces the total amount of sound energy, prolongs the latency of wave I, and shifts the latency-intensity curve of wave V to the right. The amount of shift is equivalent to the hearing impairment, without altering the slope of the curve. In children with sensorineural hearing impairment, the latency-intensity curve of wave V shifts to the right because of the hearing impairment. In addition, the slope of the curve becomes steeper, exceeding 0.55 msec/dB.

Congenital Deafness

The diagnosis of congenital deafness in newborns is rarely considered in the absence of an external ear deformity or a family history of genetic hearing loss. Congenital ear malformations are present in approximately 2% of newborns with congenital deafness. Genetic factors account for one third of all congenital deafness and half of profound deafness. Between 1:2000 (0.05%) and 1:1000 (0.1%) children are born with profound hearing loss; half of prelingual deafness is genetic, most often autosomal recessive and nonsyndromic. Mutations in the genes that encode the protein connexin 26 and 30 account for half of autosomal recessive nonsyndromic hearing loss. The carrier rate is 3:100. Only a small percentage of prelingual deafness is syndromic or autosomal dominant nonsyndromic (Smith et al, 2003).

Aplasia of Inner Ear

Inner ear aplasia always is associated with auditory nerve abnormalities. The three main types are the *Michel defect*, which is complete absence of the otic capsule and eighth cranial nerve; the *Mondini defect*, which is incomplete development of the bony and membranous labyrinths and dysgenesis of the spiral ganglion; and the *Scheibe defect*, which is dysplasia of the membranous labyrinth and atrophy of the eighth nerve.

Chromosome Disorders

Hearing impairment is relatively uncommon in children with chromosomal disorders. Abnormalities of chromosome 18 are often associated with profound sensorineural hearing loss and malformations of the external ear.

Genetic Disorders

Several hundred gene abnormalities are associated with hereditary hearing loss and deafness.

The hearing loss may be conductive, sensorineural, or mixed. Some disorders are congenital, and some develop later in childhood.

Infantile Refsum Disease

Infantile Refsum disease is part of the Zellweger syndrome spectrum of disorders of peroxisome biogenesis. It differs from later onset Refsum disease (see Chapter 7), a single-enzyme peroxisomal disorder. The gene locus is on chromosome 7q21-q22, and transmission of the disorder is by autosomal recessive inheritance (Steinberg et al, 2003).

CLINICAL FEATURES. Features include early onset, mental retardation, minor facial dysmorphism, retinitis pigmentosa, sensorineural hearing deficit, hepatomegaly, osteoporosis, failure to thrive, and hypocholesterolemia.

DIAGNOSIS. The concentration of protein in the spinal fluid is elevated, and EEG may show epileptiform activity. Liver transaminase levels are elevated, as is the serum concentration of bile acids. An elevated plasma concentration of very-long-chain fatty acids is essential to the diagnosis.

MANAGEMENT. No curative therapy is presently available for Zellweger syndrome spectrum. Symptomatic therapy includes evaluation of feeding, hearing, vision, liver function, and neurological function. All affected children benefit from appropriate educational placement and the use of hearing aids.

Isolated Deafness

Isolated deafness in newborns and infants is usually genetic, and transmission may be by autosomal dominant, autosomal recessive, or X-linked inheritance. In many sporadic cases, transmission is by autosomal recessive inheritance. Genetic disorders transmitted by autosomal dominant inheritance are often causative of congenital deafness associated with external ear deformities, but chromosomal disorders and fetal exposure to drugs and toxins are considerations. Maternal use of heparin during pregnancy produces an embryopathy characterized by skeletal deformities, flattening of the nose, cerebral dysgenesis, and deafness.

In the absence of an external malformation or family history, deafness often goes unnoticed until the infant fails to develop speech. Intrauterine infection with cytomegalovirus is an important cause of congenital deafness (see Chapter 5); 10% of newborns infected in utero with cytomegalovirus develop a sensorineural

hearing loss. Mass immunization has almost eliminated rubella embryopathy, previously a significant cause of childhood deafness in the United States.

Pendred Syndrome

Pendred syndrome, the second most common type of autosomal recessive syndromic hearing loss, is a genetic defect in thyroxine synthesis. Transmission is by autosomal recessive inheritance. Goiter and sensorineural hearing impairment are the characteristic features. The hearing impairment is profound. Goiter is not present at birth; it develops in early puberty (40%) or adulthood (60%).

CLINICAL FEATURES. Sensorineural hearing impairment is present at birth and is severe in 50% of cases. Milder hearing impairment may not be detectable until the child is 2 years old. Vestibular function also may be impaired. A diffuse, non-nodular goiter becomes apparent during the first decade, often in infancy. No clinical signs of hypothyroidism are present. Growth and intelligence are usually normal.

DIAGNOSIS. A perchlorate discharge test documents delayed organification of iodine by the thyroid. The deafness is associated with an abnormality of the bony labyrinth (Mondini dysplasia, or dilated vestibular aqueduct) diagnosed by computed tomography (CT) of the temporal bones. Vestibular function is abnormal in most affected persons. Molecular genetic testing of the *SLC26A4* gene (chromosomal locus 7q22-q31) is available clinically; 75% of cases show recognized mutations in the chromosomal locus 7q22-q31. Thin-section, high-resolution MRI in the axial and sagittal planes shows enlargement of the endolymphatic sac and duct in association with a large vestibular aqueduct (Phelps et al, 1998).

MANAGEMENT. Medical rather than surgical treatment is better for managing goiter. Exogenous hormone decreases production of thyroid-stimulating hormone, with subsequent reduction in goiter size. The hearing loss is irreversible.

Usher Syndrome

Usher syndrome is the most common type of autosomal syndromic hearing loss. Affected infants are born with sensorineural hearing loss. Later, they develop retinitis pigmentosa. Usher syndrome affects more than 50% of deaf-blind persons in the United States. The visual impairment, caused by retinitis pigmentosa, is usually not apparent before age 10. During

the teens, night blindness and loss of peripheral vision become evident and inexorably progress.

CLINICAL FEATURES. Three types of Usher syndrome are recognized. Severe-to-profound sensorineural hearing loss and abnormal vestibular dysfunction characterize type 1. The vestibular deficit delays developmental motor milestones for sitting and walking. Mild-to-severe sensorineural hearing loss and normal vestibular function characterize type 2. Hearing aids provide effective amplification, and oral communication is possible. Characteristic features of type 3 are progressive hearing loss and progressive deterioration of vestibular function. Vestibular responses to caloric testing are absent, and mild ataxia may be present. Mental retardation is present in 25% of cases.

DIAGNOSIS. Molecular genetic testing is available for some subtypes of Usher syndrome types 2 and 3. The combination of retinitis pigmentosa and hearing impairment is also present in other syndromes. Usher syndrome is the only one in which profound deafness is present at birth.

MANAGEMENT. Deafness in type 1 Usher syndrome is not correctable with hearing aids.

Waardenburg Syndrome

Waardenburg syndrome is the most common type of autosomal dominant syndromic hearing loss. It consists of sensorineural hearing loss and pigmentary abnormalities of the skin, hair (white forelock), and eyes (heterochromia iridis). Several clinical forms exist (Smith et al, 2003). The gene map locus is chromosome 2q35.

CLINICAL FEATURES. Waardenburg syndrome is relatively easy to recognize because of its cutaneous features: a white forelock, eyes of different colors (usually different shades of blue), hypertelorism, and depigmented dermal patches. Hearing loss is not a constant feature. An additional feature is a wide bridge of the nose owing to lateral displacement of the inner canthus of each eye. The presence of other abnormalities differentiates four subtypes. Lateral displacement of the inner canthus of the eye, a characteristic feature of Waardenburg syndrome type I, is not present in type II. In type III, arm abnormalities are present, and Hirschsprung disease is part of type IV.

DIAGNOSIS. The family history and the cutaneous features establish the diagnosis. Molecular genetic testing is available for Waardenburg syndrome types I and III.

MANAGEMENT. Treatment is symptomatic.

Later Onset Genetic Disorders

Several of the disorders listed in Table 17-5 are discussed in other chapters. Sensorineural hearing impairment occurs as part of several spinocerebellar degenerations, hereditary motor sensory neuropathies, and sensory autonomic neuropathies. It is a major feature of Refsum disease (hereditary motor sensory neuropathy type IV), and dietary measures reduce the serum concentrations of phytanic acid.

Deafness–Dystonia–Optic Neuronopathy Syndrome

Inheritance of the disorder is as an X-linked trait. Carrier females are unaffected (Tranebjaerg, 2004).

CLINICAL FEATURES. Progressive deafness begins before age 2 years and progresses to profound hearing loss by age 10. Dystonia or ataxia or both develop in the teens followed by decreased vision from optic neuropathy in the 20s and dementia at age 40.

DIAGNOSIS. The clinical features are diagnostic. The serum IgG is less than 200 mg/dL and IgM and IgA are less than 20 mg/dL. Molecular genetic testing is available.

MANAGEMENT. Treatment is symptomatic.

Pontobulbar Palsy with Deafness

Pontobulbar palsy (Brown–Vialeto–van Laere syndrome) with deafness is a rare hereditary motor neuron disorder. The mode of transmission is autosomal recessive (Megarbane et al, 2000).

CLINICAL FEATURES. Bilateral nerve deafness and a variety of cranial nerve disorders, usually involving the motor components of cranial nerves VII and IX to XII (more rarely cranial nerves III, V, and VI) characterize the disorder. Spinal motor nerves and, less commonly, upper motor neurons are sometimes affected. Onset most often occurs during the teens. Progressive sensorineural hearing loss is the initial symptom and may affect first one ear and then the other. Facial weakness and dysphagia accompany or quickly follow deafness. Tongue atrophy occurs in most cases, but masseter and ocular motor palsies are uncommon.

Approximately half of patients have evidence of pyramidal tract dysfunction, such as extensor plantar responses, and half have atrophy and fasciculations of limb muscle. Loss of tendon reflexes is an early feature of most cases. Respiratory insufficiency is a common feature and a frequent cause of death.

TABLE 17-5
Hearing Impairment and Deafness

Congenital	Pontobulbar palsy with deafness
Aplasia of inner ear	Mitochondrial disorders (see Chapter 8)
Michel defect	Spinocerebellar degenerations (see Chapter 10)
Mondini defect	Wolfram syndrome (see Chapter 16)
Scheibe defect	Xeroderma pigmentosum (see Chapter 5)
Chromosome disorders	Infectious diseases
Trisomy 13	Bacterial meningitis
Trisomy 18	Otitis media (see Vertigo)
18q-syndrome	Sarcoidosis (see Facial Weakness)
Genetic disorders	Viral encephalitis (see Chapter 2)
Isolated deafness	Viral exanthems
Pendred syndrome	Metabolic disorders
Usher syndrome	Hypothyroidism
Waardenburg syndrome	Mènière disease (see Vertigo)
Intrauterine viral infection (see Chapter 5)	Skeletal disorders
Maternal drug use	Apert acrocephalosyndactyly
Drugs	Cleidocranial dysostosis
Antibiotics	Craniofacial dysostosis (Crouzon disease)
β -blockers	Craniofacial dysostosis (Crouzon disease)
Chemotherapy	Craniofacial dysostosis (Crouzon disease)
Genetic neurological disorders	Klippel-Feil syndrome
Familial spastic paraplegia (see Chapter 12)	Mandibulofacial dysostosis (Treacher Collins syndrome)
Hereditary motor sensory neuropathies (see Chapter 7)	Osteogenesis imperfecta
Hereditary sensory autonomic neuropathies (see Chapter 9)	Osteopetrosis (Albers-Schönberg disease)
Infantile Refsum disease	Susac syndrome (see Chapter 2)
Neurofibromatosis type 2 (see Acoustic Neuroma)	Trauma (see Vertigo)
	Tumor
	Acoustic neuroma
	Cholesteatoma (see Vertigo)

DIAGNOSIS. The presence of deafness and areflexia distinguishes pontobulbar palsy from juvenile progressive bulbar palsy, but also can suggest a hereditary motor sensory neuropathy if symptoms of bulbar palsy are delayed. The diagnosis depends on the clinical features. MRI of the brainstem excludes the possibility of tumor.

MANAGEMENT. Most patients require a feeding gastrostomy. Treatment is not available for the underlying disease.

Acquired Hearing Impairment

Drug-Induced Impairment

Antibiotics are the most commonly used class of drugs with potential ototoxicity in children. The incidence of toxic reactions is greatest with amikacin, furosemide, and vancomycin and only a little less with kanamycin and neomycin. Permanent damage is unusual with any of these drugs. The characteristic syndrome consists of tinnitus and high-frequency hearing impairment. Vancomycin produces hearing loss only when blood concentrations exceed 45 $\mu\text{g/mL}$.

By contrast, aminoglycosides may cause irreversible cochlear toxicity, which begins as tinnitus, progresses to vertigo and high-frequency hearing impairment, and finally impairs all frequencies. This possibility is of special concern in sick preterm newborns given aminoglycosides for periods of 15 days or longer.

β -Adrenoceptor blocking drugs are a rare cause of hearing impairment and tinnitus. Cessation of therapy reverses symptoms. Cisplatin, an anticancer drug, has ototoxic effects in 30% of recipients. Tinnitus is the major feature. The hearing impairment is at frequencies above those used for speech. Salicylates tend to concentrate in the perilymph of the labyrinth and are ototoxic. Tinnitus and high-frequency hearing impairment result from long-term exposure to high doses.

Infectious Diseases

Otitis media is a common cause of reversible conductive hearing impairment in children, but only rarely does infection spread to the inner ear (see section on vertigo later). Hearing impairment is a relatively common symptom of

viral encephalitis (see Chapter 2) and may be an early feature. Sudden hearing loss also may accompany childhood exanthems (chickenpox, mumps, and measles), and in such cases virus can be isolated from the cochlear and auditory nerves.

The overall incidence of persistent unilateral or bilateral hearing loss in children with acute bacterial meningitis is 10%. Early treatment with dexamethasone reduces the risk (see Chapter 4). *Streptococcus pneumoniae* meningitis also is associated with a 20% incidence of persistent dizziness, gait ataxia, and other neurological deficits.

The site of disease is probably the inner ear or auditory nerve. Organisms may gain access to the inner ear from the subarachnoid space. Otitis media is the source of meningitis in many children and produces a transitory conductive hearing loss but does not cause a permanent sensorineural hearing loss. It is common in many centers to screen all children hospitalized for treatment of acute bacterial meningitis with BAER audiometry before discharge.

Metabolic Disorders

Mènière disease is characterized by vertigo, tinnitus, and hearing impairment. Vertigo is often the presenting feature (see later). Tinnitus and decreased hearing are common features of hypothyroidism and are reversible by thyroid replacement therapy.

Skeletal Disorders

The combination of hearing impairment and skeletal deformities almost always indicates a genetic disease. Skeletal disorders may be limited, usually to the face and digits, or generalized. The partial list in Table 17-6 highlights common syndromes. Genetic transmission for almost all is autosomal dominant inheritance with variable expression. The exceptions are osteopetrosis, which has autosomal recessive inheritance; craniometaphyseal dysplasia, which has a dominant and a recessive form; and the Klippel-Feil anomaly, for which the pattern of transmission is uncertain.

Trauma

Acute auditory and vestibular injuries occur with fractures of the petrous portion of the temporal bone. Vestibular function is more likely to be impaired than auditory function (see section on vertigo later).

TABLE 17-6
Causes of Vertigo

Drugs and toxins
Epilepsy
Complex partial seizures
Simple partial seizures
Infections
Otitis media
Vestibular neuronitis
Mènière disease
Migraine
Basilar migraine (see Chapter 10)
Benign paroxysmal vertigo (see Chapter 10)
Motion sickness
Multiple sclerosis (see Chapter 10)
Psychogenic
Hyperventilation syndrome (see Chapter 1)
Panic attacks
Trauma
Migraine
Posttraumatic neurosis
Temporal bone fracture
Vestibular concussion
Whiplash injury

Tumor

Acoustic neuroma and cholesteatoma are the tumors most likely to impair hearing in children. Other cerebellopontine angle tumors are extremely rare before the 20s or 30s. Cholesteatoma is discussed in the section on vertigo.

Acoustic Neuroma

Acoustic neuromas are actually schwannomas of the eighth nerve. Only 6% of acoustic neuromas come to medical attention in the second decade and even fewer in the first decade. Children with acoustic neuroma usually have neurofibromatosis type 2 (NF2), a genetic disease distinct from neurofibromatosis type 1 (see Chapter 5). Genetic transmission of NF2 is by autosomal dominant inheritance, with the gene locus on chromosome 22. Acoustic neuromas are the most constant feature of the phenotype. Later, other cerebral tumors, such as meningioma, glioma, schwannoma, and juvenile posterior subcapsular lenticular opacity, may develop. Café au lait spots may be present on the skin but are fewer than five in number.

CLINICAL FEATURES. Deafness or tinnitus is the usual initial complaint. Approximately one third of patients have nonaudiological symptoms, such as facial numbness or paresthesia, vertigo, headache, and ataxia. Hearing impairment is present in almost every patient; ipsilateral diminished corneal reflex occurs in 50%;

and ataxia, facial hypesthesia or weakness, and nystagmus occur in 30% to 40%. Large tumors cause obstructive hydrocephalus with symptoms of increased intracranial pressure and brainstem compression.

DIAGNOSIS. Molecular-based testing is available. Several schemes for the clinical diagnosis of NF2 are available (Baser et al, 2002). One commonly used scheme includes bilateral vestibular schwannomas or a family history of NF2 in one or more first-degree relatives plus (1) unilateral vestibular schwannomas at age younger than 30 years or (2) any two of the following: meningioma, glioma, schwannoma, or juvenile posterior subcapsular lenticular opacities/juvenile cortical cataract. Every child with progressive hearing impairment or tinnitus requires careful examination for café au lait spots. Exploration of the family history for acoustic neuroma or other neurological disturbance also is required.

Abnormalities in pure-tone audiometry and in the BAER are present in almost every patient, but are not necessary for diagnosis. Gadolinium-enhanced MRI is the test of choice to visualize tumors in the cerebellopontine angle (Figure 17-2).

MANAGEMENT. Surgery and the photon (gamma ray) knife are useful for tumor resection. Surgery often sacrifices residual hearing and sometimes causes a facial palsy. The superiority

of the photon knife to standard surgery is not yet established.

Vertigo

Vertigo is the sensation of rotation or spinning. It terrifies small children. Balance is lost, and posture is difficult to maintain, giving the appearance of ataxia (see Chapter 10). Nausea and nystagmus are often associated features. When nystagmus is present, the fast phase is in the same direction as the perceived rotation. Movement of the head exacerbates all symptoms.

Anatomical Considerations

The semicircular canals and the vestibule, within the labyrinth, are the sensory organs of the vestibular system. The stimulus for excitation of the semicircular canals is rotary motion of the head; for the vestibule, it is gravity. The vestibular portion of the eighth cranial nerve transmits information from the sensory organs to the vestibular nuclei in the brainstem and the cerebellum. The vestibular nuclei have extensive connections with the cerebellum and medial longitudinal fasciculus. Cortical projections terminate in the superior temporal gyrus and frontal lobe.

Approach to Vertigo

History and Physical Examination

Children often complain of dizziness or lightheadedness but rarely complain of vertigo. Carefully question children who complain of dizziness or lightheadedness about the sensation of rotation. Whether the subject or the environment rotates is irrelevant. The illusion of rotation distinguishes vertigo from presyncope, ataxia, and other disturbances of balance and localizes the disturbance to the vestibular system. Vertigo implies dysfunction of the labyrinth or vestibular nerve (peripheral vertigo) or the brainstem or temporal lobe (central vertigo).

Important historical points to document include the course of vertigo (acute, recurrent, or chronic), precipitating events (trauma, infection, or position change), association of hearing impairment and tinnitus, drug exposure, cardiovascular disease, and family history of migraine. Migraine and epilepsy are the usual causes of acute, episodic attacks of vertigo, not induced by motion, with migraine as the more common of the two. The usual cause of a single, prolonged

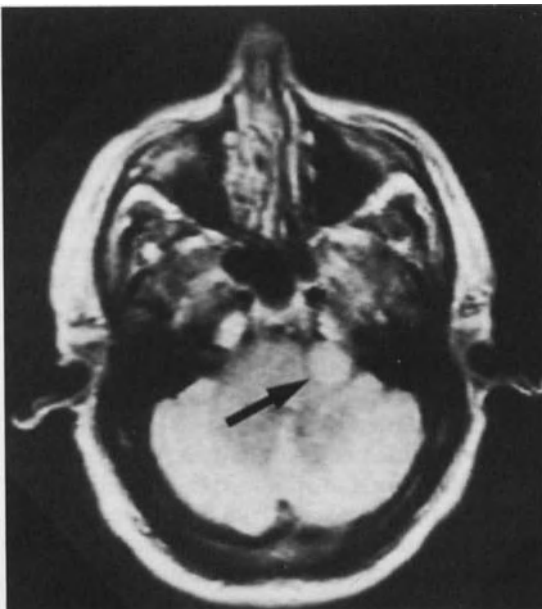


Figure 17-2. CT of acoustic neuroma. A large tumor (arrow) is pressing on and displacing the brainstem.

attack of vertigo, especially in combination with nausea and vomiting, is infection of the labyrinth or vestibular nerve. Chronic vertigo often waxes and wanes and may seem intermittent rather than chronic. Central and peripheral causes of vertigo are considerations (see Table 17-6), but the clinical and laboratory features readily distinguish central from peripheral vertigo (Table 17-7).

Special Tests

Not every child who complains of dizziness requires caloric and audiometric testing (Fife et al, 2000). Caloric testing is described in this section, and audiometric testing is described in the section on hearing impairment. The Nylan-Hallpike test is useful to define position-induced vertigo.

Caloric Testing

The simplest method of caloric testing is to instill small quantities of cool water into the external auditory canal with a rubber-tipped syringe.

Before instilling the water, inspect the canal to determine whether there is clear passage to an intact tympanic membrane. Use a sufficient quantity of water, depending on the child's size, to keep the tympanic membrane cooled for 20 seconds. A normal response is slow deviation of the eyes to the side stimulated, followed by a fast component to the opposite side. If stimulation with cool water fails to produce a response, repeat the procedure with ice water. Absence of nystagmus indicates absence of peripheral vestibular function. Partial dysfunction of one vestibular apparatus results in asymmetry of response (directional preponderance).

Nylan-Hallpike Test

The Nylan-Hallpike test requires tilting the patient backward from the sitting position to the supine position so that the head hangs down below the level of the examining table. Observe the eyes for position-induced nystagmus after turning the head 45 degrees to the right and then to the left.

Causes of Vertigo

Drugs

Many drugs that disturb vestibular function also disturb auditory function. This section addresses only drugs affecting vestibular function more than auditory function. Toxic doses of anticonvulsants and neuroleptics produce ataxia, incoordination, and measurable disturbances of vestibular function, but patients do not ordinarily complain of vertigo.

Antibiotics are the main class of drugs with vestibular toxicity. Streptomycin, minocycline, and aminoglycosides have a high incidence of toxic reactions, and sulfonamides have a low incidence. Streptomycin disturbs vestibular function but has little effect on hearing. Variation in individual susceptibility prevents the establishment of a toxic milligram-per-kilogram dose. The vestibular toxicity of streptomycin is so predictable, however, that high dosages of the drug are used therapeutically to destroy vestibular function in patients with severe Ménière disease.

Minocycline produces nausea, vomiting, dizziness, and ataxia at standard therapeutic doses. Onset of symptoms is 2 to 3 days after starting treatment, and symptoms cease 2 days after cessation. Gentamicin and other aminoglycosides have an adverse effect on vestibular and auditory function. Some disturbance occurs in 2% of patients treated with gentamicin. Vestibular

TABLE 17-7
Distinguishing Peripheral and Central Vertigo

Peripheral Vertigo

Clinical Features

Hearing loss, tinnitus, and otalgia may be associated features

Past pointing and falling in the direction of unilateral disease occur

Ataxia occurs with the eyes closed in bilateral disease

Vestibular and positional nystagmus is present

Laboratory Features

Caloric testing reveals vestibular paresis, directional preponderance, or both

Pure-tone audiometry reveals sensorineural hearing loss

Recruitment is present with end-organ disease and tone decay with nerve disease

Central Vertigo

Clinical Features

Cerebellar and cranial nerve dysfunction are frequently associated

Hearing is intact

Loss of consciousness may be associated

Laboratory Features

Pure-tone audiometry and speech discrimination are normal

Comprehension of competing messages is impaired

Caloric testing may reveal directional preponderance but not vestibular paresis

Brainstem evoked response, EEG, CT, or MRI may be abnormal

CT, computed tomography; EEG, electroencephalogram; MRI, magnetic resonance imaging.

dysfunction, either alone or in combination with auditory dysfunction, occurs in 84% of cases, whereas auditory dysfunction alone occurs in only 16%. Ototoxic effects develop when the total dose exceeds 17.5 mg/kg.

Epilepsy

Vertigo can be the only feature of a simple partial seizure or the initial feature of a complex partial seizure. The experience of vertigo is an aura in 10% to 20% of patients with complex partial seizures.

CLINICAL FEATURES. The recognition of vertigo as an aura is simple when a complex partial seizure follows. Diagnosis is more problematic when vertigo is the only feature of a simple partial seizure. The child ceases activity, becomes pale, appears frightened, then recovers. Unsteadiness and nausea may be associated features.

DIAGNOSIS. All children with unexplained brief attacks of vertigo, especially when vestibular and auditory function is normal between attacks, require an EEG. Ambulatory EEG or 24-hour video monitoring is required to capture an attack if an interictal EEG is normal.

MANAGEMENT. The management of simple and complex partial seizures is discussed in Chapter 2.

Infections

Bacterial Infection

Otitis media and meningitis are leading causes of vestibular and auditory impairment in children. Acute suppurative labyrinthitis resulting from extension of bacterial infection from the middle ear has become uncommon since the introduction of antibiotics. Even without direct bacterial invasion, however, bacterial toxins may cause serous labyrinthitis.

Chronic otitic infections cause labyrinthine damage by the development of cholesteatoma. A cholesteatoma is a sac containing keratin, silvery white debris shed by squamous epithelial cells. Such cells are not normal constituents of the middle ear but gain access from the external canal after infection repeatedly perforates the eardrum. Cholesteatomas erode surrounding tissues, including bone, and produce a fistula between the perilymph and the middle ear.

CLINICAL FEATURES. The characteristics of acute suppurative or serous labyrinthitis are the sudden onset of severe vertigo, nausea, vomiting, and unilateral hearing loss. Meningismus also may be present. Chronic otitis causes similar symptoms. Severe vertigo that is provoked by

sneezing, coughing, or merely applying pressure on the external canal indicates fistula formation. Otoloscopic examination reveals evidence of otitis media and tympanic membrane perforation and allows visualization of cholesteatoma.

DIAGNOSIS. When vestibular dysfunction develops in children with otitis media, order radiographs or CT of the skull to visualize erosion of bone or mastoiditis. The presence of meningismus or increased intracranial pressure (see Chapter 4) necessitates CT to exclude the possibility of abscess and examination of cerebrospinal fluid to exclude meningitis.

MANAGEMENT. Vigorous antibiotic therapy and drainage of the infected area are required in every case. Myringotomy and mastoidectomy provide drainage when needed. Cholesteatomas are progressive and require surgical excision.

Viral Infections

Viral infections may affect the labyrinth or vestibular nerve. The two are difficult to differentiate by clinical features, and the terms *vestibular neuritis* and *neuronitis* describe acute peripheral vestibulopathies. Vestibular neuritis may be part of a systemic viral infection, such as mumps, measles, and infectious mononucleosis, or it may occur in epidemics without an identifiable viral agent or as part of a postinfectious cranial polyneuritis. The incidence in children is low, accounting for less than 7% of all cases.

CLINICAL FEATURES. The main feature is the acute onset of vertigo. Any attempt to move the head results in a severe exacerbation of vertigo, nausea, and vomiting. Nystagmus is present on fixation and increased by head movement. The patient is unable to maintain posture and lies motionless in bed. Recovery begins during the first 48 hours. Spontaneous nausea diminishes, and nystagmus on fixation ceases. With each day, vertigo decreases in severity, but positional nystagmus is still present. Recovery is usually complete within 3 weeks.

DIAGNOSIS. The clinical features are the basis for establishing the diagnosis. Brain imaging is unnecessary when acute-onset vertigo is an isolated symptom and begins improving within 48 hours (Hotson and Baloh, 1998).

MANAGEMENT. During the acute phase, keep the child in bed and provide vestibular sedation. Diazepam is effective in dampening the labyrinth and relieving the symptoms. Children should not use transdermal scopolamine. As recovery progresses, activity is increased gradually and sedation is reduced.

Mènière Disease

Mènière disease is uncommon in children. The mechanism of disease is an overaccumulation of endolymph that results in rupture of the labyrinth.

CLINICAL FEATURES. Rupture of the labyrinth causes the clinical features, hearing impairment, tinnitus, and vertigo. Hearing impairment fluctuates and may temporarily return to normal when the rupture heals. Tinnitus may be ignored, but vertigo demands attention and is often the complaint that brings the disorder to attention. A typical attack consists of disabling vertigo and tinnitus lasting for 1 to 3 hours. Tinnitus, fullness in the ear, or increased loss of hearing may precede the vertigo. Tinnitus becomes worse during the attack. Pallor, sweating, nausea, and vomiting are often associated features. Afterward the patient is tired and sleeps. Attacks occur at unpredictable intervals for years, then subside, leaving the patient with permanent hearing loss. Bilateral involvement is present in 20% of cases. Nystagmus is present during an attack. At first, the fast component is toward the abnormal ear (irritative); later, as the attack subsides, the fast component is away (paralytic). Between attacks, the results of examination are normal, with the exception of unilateral hearing impairment.

DIAGNOSIS. Pure-tone audiometry shows threshold fluctuation. Speech discrimination is preserved, and recruitment is present on the abnormal side. Caloric stimulation shows unilateral vestibular paresis or directional preponderance.

MANAGEMENT. The underlying disease is not reversible. Managing the acute attack and increasing the interval between attacks are the goals of therapy. Acute attacks are managed with bed rest, sedation, and antiemetics. Maintenance therapy usually consists of a low-salt diet and diuretics; neither provides substantial benefit.

Migraine

Of migraineurs, 17% report vertigo at the time of an attack. These individuals have no difficulty in recognizing vertigo as a symptom of migraine. Another 10% experience vertigo in the interval between attacks and may have difficulty relating vertigo to migraine. Brief (minutes), recurrent episodes of vertigo in infants and small children are usually a migraine equivalent, despite the absence of headache. The attacks later evolve into classic migraine. Affected children appear

ataxic (see section on benign paroxysmal vertigo in Chapter 10).

Motion Sickness

Unfamiliar body accelerations or a mismatch in information provided to the brain by the visual and vestibular systems during acceleration of the body induces motion sickness. Motion in the visual field opposed to actual body movement induces motion sickness. Allowing a child to look out the window while riding in a car reduces the incidence of motion sickness. Small children in the back seat, where the only visual input is the car interior, are at the greatest risk for motion sickness. A minivan may reduce the incidence of motion sickness by allowing children access to a window.

The prevalence of motion sickness depends on how violent the movement is and approaches 100% in the worst case. Twenty-five percent of a ship's passengers become sick during a 2- to 3-day Atlantic crossing, and 0.5% of commercial airline passengers are affected. The first symptom is pallor, which is followed by nausea and vomiting. Because nausea usually precedes vomiting, there is time to prevent vomiting in some situations. Stopping the motion is the best way to abort an attack. Watching the environment move opposite the direction of body movement may inhibit early attacks. Individuals with known susceptibility to motion sickness should take an antihistamine, diazepam, or scopolamine before travel.

Trauma

Fifty percent of children complain of dizziness and headache during the first 3 days after a closed head injury, with or without loss of consciousness. One third have persistent vertigo without hearing loss. This group can be separated into patients with direct trauma to the labyrinth (vestibular concussion) and patients in whom the vestibular apparatus is not injured. Children with posttraumatic neurosis complain of dizziness or giddiness but do not experience the illusion of rotation.

Vestibular Concussion

CLINICAL FEATURES. Vestibular concussion follows blows to the parieto-occipital or temporoparietal region of the skull. Severe vertigo is present immediately after injury. The child is unsteady and sways toward the affected side. Symptoms persist for several days, then resolve completely,

but specific movements of the head (paroxysmal positional vertigo) precipitate recurrent episodes of vertigo and nausea lasting for 5 to 10 seconds.

DIAGNOSIS. All children with vertigo after a head injury require head CT. Fractures through the petrous pyramid require special attention. Bleeding from the ear or a facial palsy should raise suspicion of such a skull fracture. Moving the injured ear downward induces positional nystagmus by the Nylan-Hallpike technique. Caloric testing or electronystagmography shows a reduced response from the injured ear.

MANAGEMENT. Immediately after injury, treat with an antihistamine and diazepam until the acute phase is over. Fatigue therapy treats individuals with paroxysmal positional vertigo. Tilt the patient to a position that reproduces symptoms and maintain the position until the vertigo subsides for at least 30 seconds. The patient then sits up for 30 seconds. Repeat the procedure four times. Repeat this exercise several times each day until the patient is no longer sensitive to positional change.

Whiplash Injury

Whiplash injuries frequently are associated with vestibular and auditory dysfunction. Basilar artery spasm probably causes the symptoms.

CLINICAL FEATURES. Vertigo may be present immediately after injury and subsides within a few days. Brief attacks of vertigo and tinnitus, sometimes associated with headache or nausea, may develop months later in children who appear fully recovered from the injury. Many features of the attacks suggest basilar artery migraine (see Chapter 10) and probably represent a posttraumatic migraine.

DIAGNOSIS. During the acute phase, the Nylan-Hallpike technique induces vertigo, and caloric testing documents unilateral dysfunction. Vestibular function also may be abnormal in children who are experiencing basilar artery migraine, especially at the time of an attack. EEG often shows occipital intermittent rhythmic delta activity (see Figure 10-2).

MANAGEMENT. Treatment is symptomatic.

References

- Baser ME, Friedman JM, Wallace AJ, et al. Evaluation of clinical diagnostic criteria for neurofibromatosis 2. *Neurology* 2002;59:1759-1765.
- Cockerham KP, Hidayat AA, Cockerham GC, et al. Melkersson-Rosenthal syndrome. New clinicopathologic findings in 4 cases. *Arch Ophthalmol* 2000;118:227-232.
- Fife TD, Tusa RJ, Furman JM, et al. Assessment. Vestibular testing techniques in adults and children. Report of the therapeutics and technology assessment subcommittee of the American Academy of Neurology. *Neurology* 2000;55:1431-1441.
- Hato N, Kasaki H, Honda N, et al. Ramsay-Hunt syndrome in children. *Arch Neurol* 2000;48:254-256.
- Hotson JR, Baloh RW. Acute vestibular syndrome. *N Engl J Med* 1998;333:680-686.
- Megarbane A, Desgueres I, Rizkallah E, et al. Brown-Vialetto-Van Laere syndrome in a large inbred Lebanese family. Confirmation of autosomal recessive inheritance? *Am J Med Genet* 2000;92:117-121.
- Murakami S, Hato N, Horiuchi J, et al. Treatment of Ramsay Hunt syndrome with acyclovir-prednisone. Significance of early diagnosis and treatment. *Ann Neurol* 1997;41:353-357.
- Padberg GW, Brouwer OF, de Keizer RJW, et al. On the significance of retinal vascular disease and hearing loss in facioscapulohumeral muscular dystrophy. *Muscle Nerve* 1995;2(Suppl):S73-S80.
- Phelps PD, Coffey RA, Trembath RC, et al. Radiological malformations of the ear in Pendred syndrome. *Clin Radiol* 1998;53:268-273.
- Smith RJH, Green GE, Van Camp G. (December 2003) Hereditary hearing loss and deafness overview. In: *Online Mendelian Inheritance in Man, OMIM*. [database online] The Johns Hopkins University, Baltimore. Available at <http://www.ncbi.nih.gov/omim>.
- Steinberg SJ, Raymond GV, Braverman NE. (December 2003) Peroxisome biogenesis disorders, Zellweger syndrome spectrum. In: *Online Mendelian Inheritance in Man, OMIM*. [database online] The Johns Hopkins University, Baltimore. Available at <http://www.ncbi.nih.gov/omim>.
- Tawil R, Figlewicz DA, Griggs RC, et al. Facioscapulohumeral dystrophy. A distinct regional myopathy with a novel molecular pathogenesis. *Ann Neurol* 1998;43:279-282.
- Tranebjaerg L. (February 5, 2004) Deafness-dystonia-optic neuropathy syndrome. In: *GeneClinics: Medical Genetics Knowledge Base* [database online]. University of Washington, Seattle. Available at <http://www.geneclinics.org>.
- Verzijl HT, van der Zwaag B, Cruysberg JRM, et al. Mobius syndrome redefined. A syndrome of rhombencephalic maldevelopment. *Neurology* 2003;61:327-333.
- Villard L, Nguyen K, Cardoso C, et al. A locus for bilateral perisylvian polymicrogyria maps to Xq28. *Am J Hum Genet* 2002;70:1003-1008.

Chapter 18

Disorders of Cranial Volume and Shape

THE VOLUMES OF the three compartments that fill the skull (brain, cerebrospinal fluid, and blood) determine the size of the skull during infancy. Expansion of one compartment comes at the expense of another. In this way, intracranial volume and pressure remain constant (see Chapter 4). The extracerebral spaces (epidural, subdural, and subarachnoid) may expand with blood and significantly affect cranial volume. Less important factors contributing to head size are the thickness of the skull bones and the rate of their fusion.

The skull's content determines its shape, as do external forces acting on the skull. Even more important is the rate at which individual skull bones fuse. The more recent move to have infants sleep supine instead of prone is leading to a generation of children with flat occiputs.

Measuring Head Size

Head circumference is determined by measuring the greatest occipitofrontal circumference. Influencing the accuracy of the measurement is fluid in and beneath the scalp and head shape. After a prolonged and difficult delivery, edema or blood may thicken the scalp and a cephalohematoma may be present as well. Fluid that infiltrates from a scalp infusion can increase head circumference markedly.

A round head has a larger intracranial volume than an oval head of equal circumference. A head with a relatively large occipitofrontal diameter has a larger volume than a head with a relatively large biparietal diameter. Head circumference measurements are most informative when plotted over time. The head sizes of male and female infants are different, and one should not rely on head growth charts that provide

median values for both sexes. The rate of head growth in premature infants is considerably faster than in full-term newborns (Figure 18-1). For this reason, the charting of head circumference is always by conceptional age and not by postnatal age.

Macrocephaly

Macrocephaly means a large head—greater than 2 standard deviations from the normal distribution; 2% of the “normal” population has macrocephaly. Investigation of such individuals may show an abnormality causing macrocephaly, but many are normal, often with a familial tendency for a large head. When asked to evaluate a large head in an otherwise normal child, first ask the parents for their hat sizes.

The causes of a large head include hydrocephalus (an excessive volume of CSF in the skull), megalencephaly (enlargement of the brain), thickening of the skull, and hemorrhage into the subdural or epidural spaces. Hydrocephalus is traditionally communicating (nonobstructive) or noncommunicating (obstructive), depending on whether CSF communicates between the ventricles and subarachnoid space (Table 18-1). Hydrocephalus is the main cause of macrocephaly at birth in which intracranial pressure is increased.

The causes of megalencephaly are anatomical and metabolic. The anatomical disorders are primary megalencephaly and neurocutaneous disorders (Table 18-2). Children with anatomical megalencephaly are often macrocephalic at birth but have normal intracranial pressure. Children with metabolic megalencephaly are usually normocephalic at birth and develop megalencephaly from cerebral edema during the neonatal period.

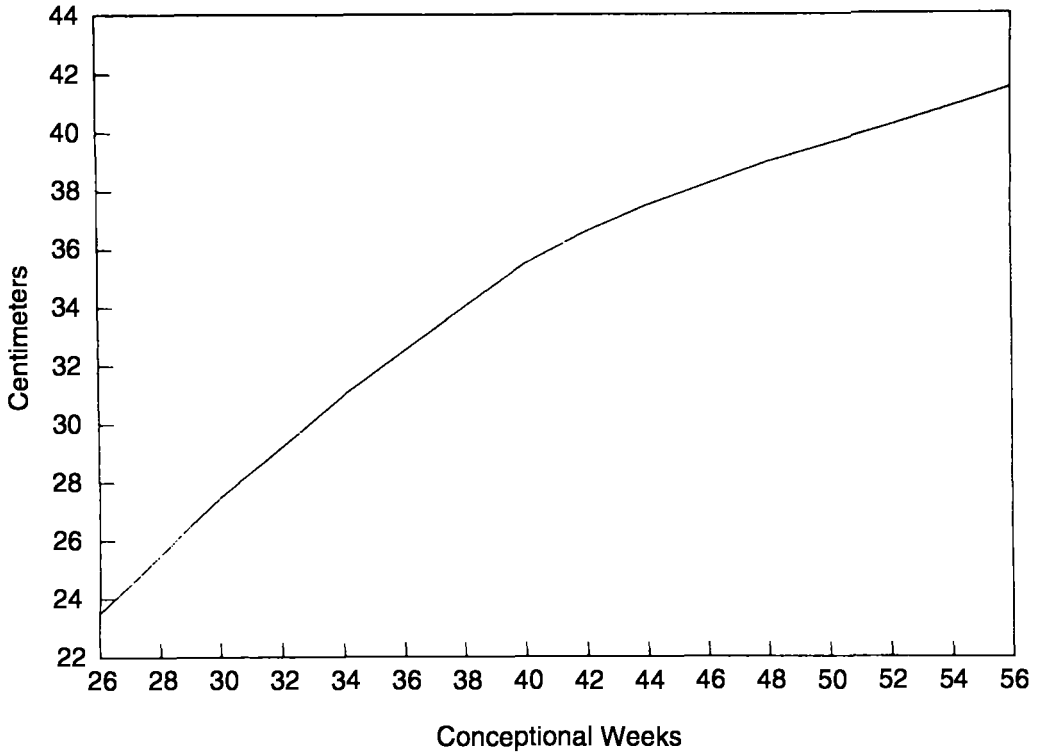


Figure 18-1. Normal growth of head circumference in boys. The rate of growth in premature infants is greater than in full-term infants.

TABLE 18-1
Causes of Hydrocephalus

Communicating
Achondroplasia
Basilar impression (see Chapter 10)
Benign enlargement of subarachnoid space
Choroid plexus papilloma (see Chapter 4)
Meningeal malignancy
Meningitis (see Chapter 4)
Posthemorrhagic (see Chapter 4)
Noncommunicating
Aqueductal stenosis
Infectious
X-linked
Chiari malformation (see Chapter 10)
Dandy-Walker malformation
Klippel-Feil syndrome
Mass lesions
Abscess (see Chapter 4)
Hematoma (see Chapters 1 and 2)
Tumors and neurocutaneous disorders
Vein of Galen malformation
Walker-Warburg syndrome
Hydranencephaly
Holoprosencephaly
Massive hydrocephalus
Porencephaly

TABLE 18-2
Causes of Megalencephaly

Anatomical Megalencephaly
Genetic megalencephaly
Megalencephaly with achondroplasia
Megalencephaly with gigantism (Sotos syndrome)
Megalencephaly with a neurological abnormality
Neurocutaneous disorders
Epidermal nevus syndrome
Hypomelanosis of Ito
Incontinentia pigmenti (see Chapter 1)
Neurofibromatosis (see Chapter 5)
Tuberous sclerosis (see Chapter 5)
Metabolic Megalencephaly
Alexander disease (see Chapter 5)
Canavan disease (see Chapter 5)
Galactosemia: transferase deficiency (see Chapter 5)
Gangliosidosis (see Chapter 5)
Globoid leukodystrophy (see Chapter 5)
Glutaric aciduria type I (see Chapter 14)
Leukoencephalopathy with swelling and cysts
Maple syrup urine disease (see Chapter 1)
Metachromatic leukodystrophy (see Chapter 5)
Mucopolysaccharidoses (see Chapter 5)

Increased thickness of the skull bones does not cause macrocephaly at birth or in the newborn period. Macrocephaly develops during infancy. Table 18-3 lists the conditions associated with increased skull growth. The text does not contain a separate discussion. Intracranial hemorrhage in the newborn is discussed in Chapter 1, and intracranial hemorrhage in older children is discussed in Chapter 2.

Communicating Hydrocephalus

The usual cause of communicating hydrocephalus is impaired absorption of CSF secondary to meningitis or subarachnoid hemorrhage. Meningeal malignancy, usually leukemia or primary brain tumor, is a less common cause. The excessive production of CSF by a choroid plexus papilloma rarely causes communicating hydrocephalus because the potential rate of CSF reabsorption far exceeds the productive capacity of the choroid plexus (see Chapter 4). Such tumors more commonly cause hydrocephalus by obstructing one or more ventricles.

Benign Enlargement of Subarachnoid Space

The terms used to describe benign enlargement of the subarachnoid space include *external hydrocephalus*, *extraventricular hydrocephalus*, *benign subdural effusions*, and *benign extracerebral fluid collections*. It is a relatively common cause of macrocephaly in infants, a fact not fully appreciated before the widespread use of computed tomography (CT) to investigate large head size. A genetic cause is likely in some cases, with the infant's father often having a large head.

CLINICAL FEATURES. The condition occurs more commonly in boys than girls. A large head cir-

cumference is the only feature. An otherwise normal infant is brought to medical attention because serial head circumference measurements show an enlarging head size. The circumference is usually above the 90th percentile at birth, grows to exceed the 98th percentile, then parallels the normal curve (Figure 18-2). The anterior fontanelle is large but soft. Neurological findings and developmental status are normal.

DIAGNOSIS. Cranial CT shows an enlarged frontal subarachnoid space, widening of the sylvian fissures and other sulci, and normal or minimally enlarged ventricular size (Figure 18-3). Normal ventricular size distinguishes this condition from cerebral atrophy. In infants, the upper limit of normal size for the frontal subarachnoid space is 5.7 mm and for the sylvian fissure is 7.6 mm.

MANAGEMENT. Most affected infants develop normally and do not require ventricular shunts. Plot head circumference measurements monthly for 6 months after diagnosis to be certain that growth is paralleling the normal curve. Repeat CT is unnecessary, unless head growth deviates from the normal curve, neurological examination is abnormal, or development is delayed.

Meningeal Malignancy

Tumors that infiltrate the meninges and subarachnoid space impair the reabsorption of CSF and cause communicating hydrocephalus. Meningeal spread usually occurs from a known primary tumor site. Diffuse meningeal gliomatosis is the exception where the initial feature may be hydrocephalus.

CLINICAL FEATURES. Tumors that infiltrate the meninges are usually aggressive and cause rapid progression of symptoms. Headache and vomiting are the initial features, and lethargy and personality change follow. Meningismus and papilledema are common features and may suggest bacterial meningitis. Multifocal neurological disturbances may be present.

DIAGNOSIS. Magnetic resonance imaging (MRI) shows dilation of the entire ventricular system but not of the subarachnoid space, which may appear obliterated except for a layer of enhancement. The pressure of the CSF and its protein concentration are increased. The glucose concentration may be depressed or normal. Tumor cell identification in the CSF is rarely successful, and meningeal biopsy is usually required for tissue diagnosis.

MANAGEMENT. Ventricular shunt relieves symptoms of increased intracranial pressure. Radiation therapy and chemotherapy provide palliation

TABLE 18-3
Conditions with a Thickened Skull
Causing Macrocephaly

Anemia
Cleidocranial dysostosis
Craniometaphyseal dysplasia of Pyle
Epiphyseal dysplasia
Hyperphosphatemia
Leontiasis ossea
Orodigitofacial dysostosis
Osteogenesis imperfecta
Osteopetrosis
Pyknodysostosis
Rickets
Russell dwarf

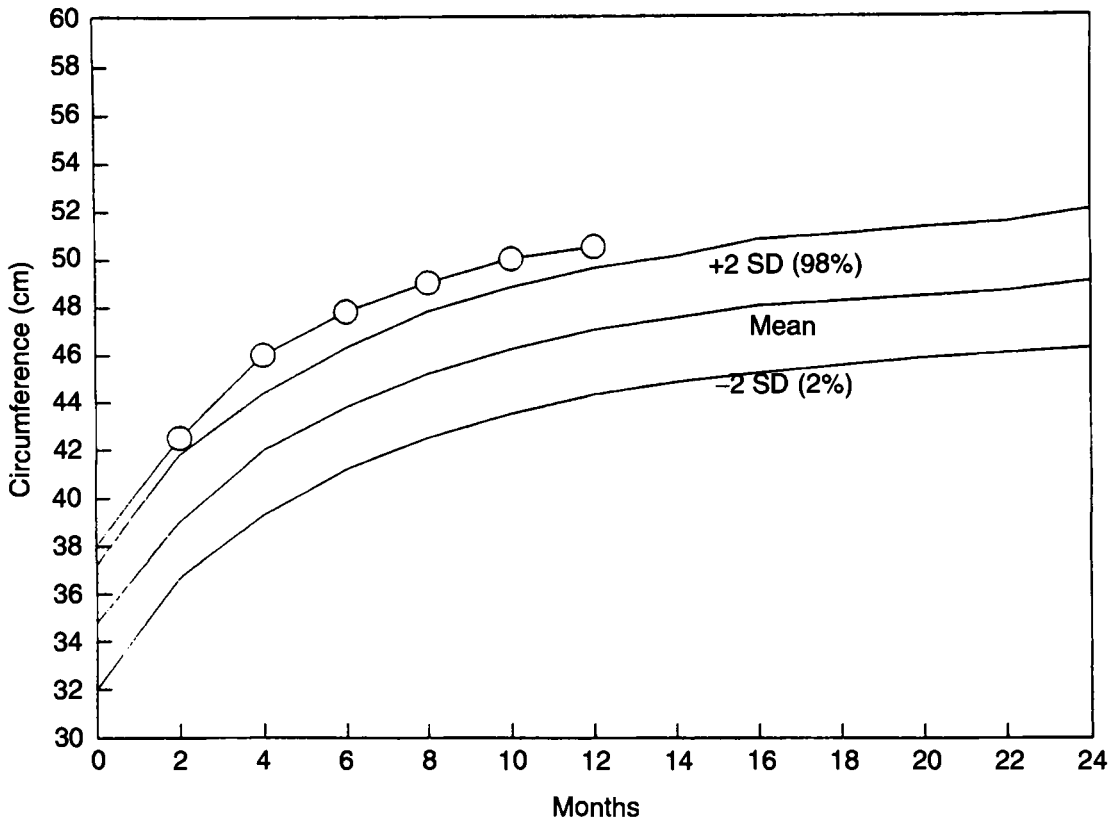


Figure 18-2. Benign enlargement of the subarachnoid space. Head circumference is already large at birth, grows to exceed the 98th percentile, then parallels the curve.

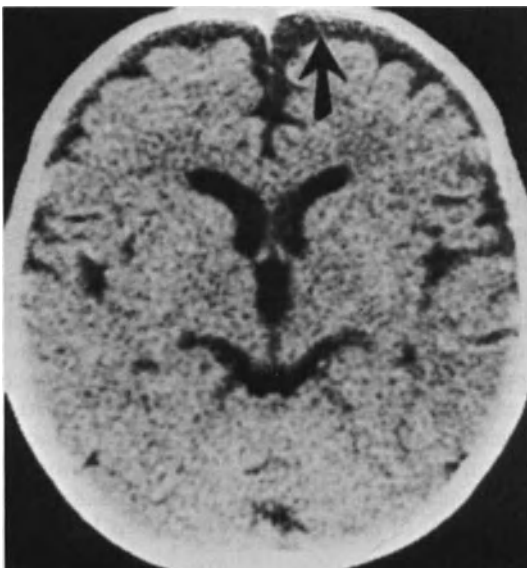


Figure 18-3. Benign enlargement of the subarachnoid space. CT reveals an enlarged frontal subarachnoid space (arrow), prominent sulci, and normal ventricular size.

and extend life in some cases, but the outcome is generally poor.

Noncommunicating Hydrocephalus

Complete obstruction of the egress of CSF from the ventricles to the subarachnoid space causes increased pressure and dilation of all ventricles proximal to the obstruction. The incidence of congenital hydrocephalus is 0.4:1000 to 0.8:1000 live births and stillbirths. X-linked hydrocephalus accounts for 4% of all cases (Schrandt-Stumple and Fryns, 1998).

Noncommunicating hydrocephalus is the most common form of hydrocephalus in fetuses. Aqueductal stenosis is the usual cause of congenital hydrocephalus in the absence of other associated cerebral malformations. Aqueductal stenosis is less common during infancy, but its frequency increases during childhood. Mass lesions are the most common cause of aqueductal obstruction during childhood. Children with congenital hydrocephalus who have seizures

usually have other cerebral malformations. Such children have a higher incidence of mental retardation.

Congenital Aqueductal Stenosis

At birth, the mean length of the cerebral aqueduct is 12.8 mm, and its smallest cross-sectional diameter is usually 0.5 mm. The small lumen of the cerebral aqueduct, in relation to its length, makes it especially vulnerable to internal compromise from infection and hemorrhage and to external compression by tumors and venous malformations. Congenital atresia or stenosis of the cerebral aqueduct can occur as a solitary malformation or can occur in families as an X-linked trait (Haverkamp et al, 1999).

CLINICAL FEATURES. Hydrocephalus is present at birth. Head circumference ranges from 40 to 50 cm and may cause cephalopelvic disproportion and poor progress of labor. The forehead is bowed, the scalp veins are dilated, the skull sutures are widely separated, and the fontanelles are large and tense. These signs exaggerate when the infant cries, but also are present in the quiet state. The eyes are deviated downward so that the sclera shows above the iris (*setting sun sign*), and abducens palsies may be present. Adduction and flexion of the thumbs occurs in approximately 20% of newborns with X-linked aqueductal stenosis. The thumb position, previously considered an associated malformation, is actually a nonspecific sign of corticospinal tract compression by the dilated lateral ventricles.

DIAGNOSIS. Intrauterine sonography is diagnostic after 20 weeks when the ventricles expand. Sonograms performed earlier are misleading. When macrocephaly is present in the fetus, amniotic fluid assays of α -fetoprotein is useful for the detection of neural tube defects (see Chapter 12). Chromosomal analysis provides further information concerning the integrity of the fetal nervous system to develop a management plan.

CT readily provides the postpartum diagnosis of aqueductal stenosis. Easily visualized are marked enlargement of the lateral ventricle, the third ventricle, and the cephalic end of the cerebral aqueduct. The remainder of the cerebral aqueduct and the fourth ventricle cannot be seen (Figure 18-4).

MANAGEMENT. Congenital hydrocephalus caused by aqueductal stenosis is severe, does not respond to medical therapy directed at decreasing the volume of CSF, and progresses to a stage that harms the brain. Diversion of the CSF from

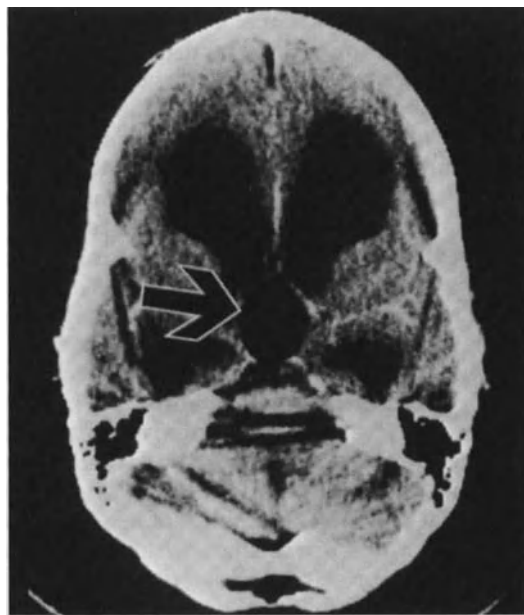

Figure 18-4. Aqueductal stenosis. CT shows marked enlargement of the third ventricle (arrow) and the lateral ventricles.

the ventricular system to an extracranial site is the only effective method of management. The management of fetal hydrocephalus depends on the presence of other malformations. Three quarters of affected fetuses have other abnormalities, usually spina bifida. Voluntary termination of such pregnancies is common.

Ventriculoperitoneal shunt is the procedure of choice for newborns and small infants with aqueductal stenosis. It is easier to revise and better tolerated than ventriculoatrial shunt. Mechanical obstruction and infection are the most common complications of shunt placement in infancy (see Chapter 4).

The relief of hydrocephalus increases the potential for normal development, even when the cerebral mantle appears thin preoperatively, but does not always result in a normal child. The growth of intelligence is often uneven, with better development of verbal skills than of non-verbal skills. Associated anomalies may cause motor deficits and seizures.

Dandy-Walker Malformation

The Dandy-Walker malformation consists of a ballooning of the posterior half of the fourth ventricle, often associated with failure of the foramen of Magendie to open, aplasia of the posterior cerebellar vermis, heterotopia of the inferior olivary nuclei, pachygyria of the

cerebral cortex, and other cerebral and sometimes visceral anomalies. Hydrocephalus may not be present at birth, but develops during childhood or later. The size of the lateral ventricles does not correlate with the size of the cyst in the fourth ventricle. Other malformations are present in two thirds of children. The most common associated malformation is agenesis of the corpus callosum. Other malformations are heterotopia, abnormal gyrus formation, dysraphic states, aqueductal stenosis, and congenital tumors (Cavalcanti and Salomao, 1999).

CLINICAL FEATURES. Diagnosis at birth occurs in only a quarter of affected newborns and in three quarters by 1 year. Macrocephaly is the usual initial feature. Bulging of the skull, when present, is more prominent in the occipital than in the frontal region. The rapidity of head growth is considerably slower than with aqueductal stenosis. Compression of posterior fossa structures leads to neurological dysfunction, including apneic spells, nystagmus, truncal ataxia, cranial nerve palsies, and hyperreflexia in the legs.

DIAGNOSIS. Macrocephaly or ataxia is the indication for CT or MRI. Both studies show cystic dilation of the posterior fossa and partial or complete agenesis of the cerebellar vermis (Figure 18-5). MRI is more useful because it also identifies other cerebral abnormalities, such as heterotopia. Incomplete vermian agenesis may be difficult to differentiate from an

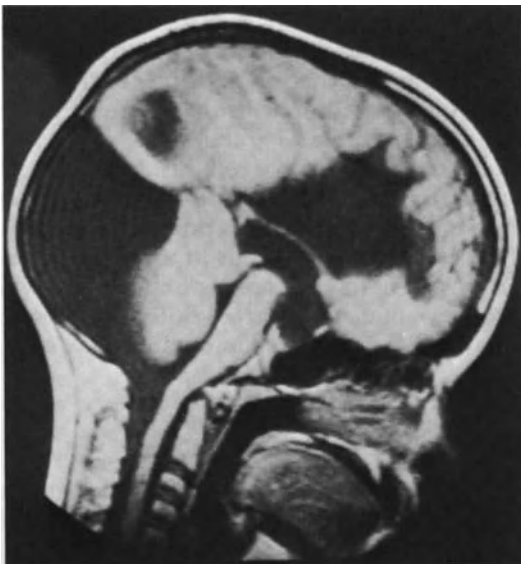

Figure 18-5. Dandy-Walker malformation. CT shows cystic dilation of the fourth ventricle and partial agenesis of the cerebellar vermis.

enlarged cisterna magna. The Dandy-Walker malformation is part of the spectrum of anomalies associated with trisomy 9 and with mutations on the X chromosome.

MANAGEMENT. Decompression of the cyst alone provides immediate relief of symptoms; however, hydrocephalus recurs, and ventricular shunting is required in two thirds of affected children. Shunting of the lateral ventricle alone provides immediate relief of hydrocephalus but fails to relieve brainstem compression. The procedure of choice is a dural shunt of the lateral ventricle and the posterior fossa cyst.

Even after successful shunt placement, many children have transitory episodes of lethargy, personality change, and vomiting that falsely suggest shunt failure. The mechanism of such episodes, which may prove fatal, is unknown.

Klippel-Feil Syndrome

Klippel-Feil syndrome is a malformation of the craniocervical skeleton that may be associated with the Chiari malformation and with basilar impression. Obstruction of the egress of CSF from the fourth ventricle to the subarachnoid space causes hydrocephalus. Several different entities comprise the syndrome. One or more are recessive, one is dominant, and some may have no genetic basis. The three types of malformation are type I, extensive fusion of thoracic and upper cervical vertebrae; type II, one or two interspace fusions with hemivertebrae and occipitoatlantal fusion; and type III, cervical and lower thoracic or lumbar fusion. Type II is the most common form.

CLINICAL FEATURES. The essential features of the Klippel-Feil syndrome are a low posterior hairline, a short neck, and limitation of neck movement. Head asymmetry, facial asymmetry, scoliosis, and mirror movements of the hands are common. Unilateral or bilateral failure of downward migration of the scapula (*Sprengel deformity*) is present in 25% to 35% of patients. Malformations of the genitourinary system and deafness are associated features. The deafness may be of the sensorineural, conductive, or mixed type (McGaughan et al, 1998). Hydrocephalus affects the fourth ventricle first and then the lateral ventricles. The resulting symptoms are those of posterior fossa compression: ataxia, apnea, and cranial nerve dysfunction.

DIAGNOSIS. Radiographs of the spine reveal the characteristic fusion and malformations of vertebrae. MRI may show an associated Chiari malformation and dilation of the ventricles.

MANAGEMENT. Children with unstable cervical vertebrae require cervical fusion to prevent myelopathy. Children with symptoms of obstructive hydrocephalus require a ventriculoperitoneal shunt to relieve pressure in the posterior fossa.

Congenital Brain Tumors

Congenital brain tumors and congenital brain malformations are disorders of cellular proliferation. A noxious agent active during early embryogenesis might stimulate either or both abnormalities. The relative oncogenicity or teratogenicity depends on the virulence of the agent, the timing of the insult, the duration of exposure, and the genetic background and health of the fetus. The most common tumors of infancy are astrocytoma, medulloblastoma, teratoma, and choroid plexus papilloma.

CLINICAL FEATURES. Congenital tumors are more often supratentorial than infratentorial and more often in the midline than situated laterally. Newborns with hemispheric gliomas and teratomas may develop hydrocephalus in utero or in the first days or weeks postpartum. The point of obstruction is usually at the cerebral aqueduct (see Chapter 4). Choroid plexus papillomas usually are located in one lateral ventricle and become symptomatic during infancy rather than in the perinatal period. They produce hydrocephalus either by obstruction of the foramen of Monro or by excessive production of CSF (see Chapter 4). Medulloblastomas are located in the posterior fossa and obstruct the fourth ventricle and cerebral aqueduct (see Chapter 10).

The clinical features of all congenital tumors are those of increasing intracranial pressure: enlarging head size, separation of the sutures, lethargy and irritability, difficulty feeding, and vomiting. Seizures are unusual. Because of its posterior fossa location, medulloblastoma also produces nystagmus, downward deviation of the eyes, opisthotonos, and apnea.

DIAGNOSIS. CT or MRI, performed to investigate hydrocephalus, readily visualizes all congenital tumors. Intrauterine sonography identifies some tumors.

MANAGEMENT. Complete resection of congenital brain tumors is unusual, with the exception of choroid plexus papilloma. Management of individual tumors is discussed in Chapters 4 and 10.

Vein of Galen Malformation

Arteriovenous malformations of the cerebral circulation may become symptomatic during

infancy and childhood (see Chapters 4 and 10); the malformation associated with congenital hydrocephalus is the vein of Galen malformation. Vein of Galen vascular malformations are not aneurysms and do not involve the vein of Galen. Instead the normal vein of Galen does not develop, and the median prosencephalic vein of Markowsky persists, dilates, and drains to the superior sagittal sinus. Multiple arteriovenous fistulas are associated.

CLINICAL FEATURES. Of newborns with vein of Galen malformations, 80% are male. The usual initial feature is either high-output cardiac failure or an enlarging head size. Hemorrhage almost never occurs early in the course. A cranial bruit is invariably present. Some affected children experience an unexplained, persistent hypoglycemia.

Large midline arteriovenous malformations produce a hemodynamic stress in the newborn because of the large quantities of blood shunted from the arterial to the venous system. The heart enlarges in an effort to keep up with the demands of the shunt, but high-output cardiac failure ensues. Affected newborns often come first to the attention of a pediatric cardiologist because of the suspicion of congenital heart disease, and the initial diagnosis of an intracranial malformation is during cardiac catheterization.

When the hemodynamic stress is not severe and cardiac compensation is possible, the initial symptoms are in infancy or early childhood. In such a case, obstructive hydrocephalus results from compression of the tegmentum and aqueduct. Symptoms usually begin before age 5 and always before age 10. The lateral ventricles enlarge, causing headache, lethargy, and vomiting. In infants, the head enlarges, and the fontanelle feels full.

DIAGNOSIS. Contrast-enhanced CT (Figure 18-6) or MRI readily visualizes the vein of Galen malformation. The lateral and third ventricles dilate behind the compressed cerebral aqueduct. Radiographs of the chest in newborns with high-output cardiac failure show an enlarged heart with a normal shape.

MANAGEMENT. The overall results of direct surgical approaches are poor; the mortality rate is high, as is neurological morbidity in survivors. Embolization has become the treatment of choice, but the long-term results are not established.

Walker-Warburg Syndrome

Cerebral and ocular abnormalities characterize Walker-Warburg syndrome. Hydrocephalus is a

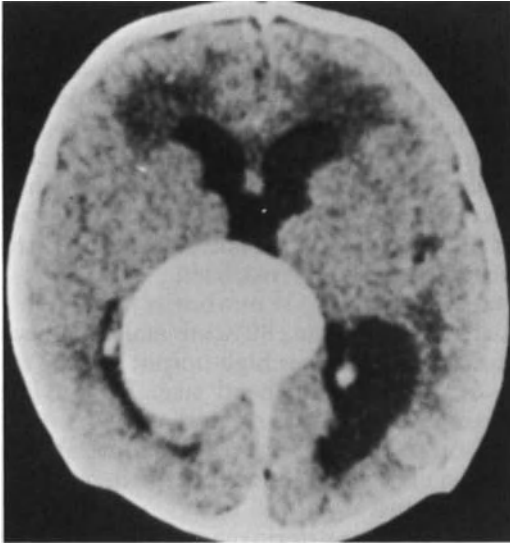


Figure 18-6. Vein of Galen malformation. The malformation is visible on contrast-enhanced CT as a large aneurysmal sac compressing the midbrain and producing obstructive hydrocephalus.

constant feature. The syndrome, also known as the *HARD ± E syndrome*, is a congenital condition characterized by hydrocephalus (*H*), agyria (*A*), and retinal dysplasia (*RD*), with or without encephalocele (*±E*). The disorder is often associated with congenital muscular dystrophies (see Chapter 6). The condition is usually lethal within the first few months of life. The abnormal gene locus maps to chromosome 9q34. The risk of recurrence among siblings exceeds 50%, but generation-to-generation transmission does not occur, suggesting autosomal recessive inheritance.

CLINICAL FEATURES. Hydrocephalus is usually present at birth. The cause may be aqueductal stenosis or the Dandy-Walker malformation. Most children with a Dandy-Walker malformation and ocular abnormalities have Walker-Warburg syndrome. Some children are born with microcephaly, yet have enlarged ventricles. Severe neurological abnormalities are caused by partial or total agyria (lissencephaly) resulting from failure of neuronal migration. The pattern of architectural abnormalities throughout the neuraxis suggests a disruption of cerebral maturation in the fourth month of gestation.

Several ocular abnormalities may be present, usually in combination: hypoplasia of the iris, abnormal anterior chamber, microphthalmos, cataracts, persistence of primary vitreous, optic disk coloboma, retinal detachment, retinal dysplasia, and hypoplasia of the optic nerve. In

addition to having hydrocephalus and blindness, affected infants are hypotonic and have difficulty feeding. Seizures are uncommon. Most affected children die during the neonatal period or early infancy.

DIAGNOSIS. The basis for diagnosis is the characteristic combination of cerebral and ocular abnormalities. Congenital infections may produce similar disturbances, but multisystem disease (visceromegaly and disturbed hematopoiesis), an expected feature of most intrauterine infections, is lacking in Walker-Warburg syndrome. Cerebro-ocular abnormalities at birth also are encountered in septo-optic dysplasia (see Chapter 16) and oculocerebrorenal syndrome (see Chapter 6), but hydrocephalus is not a component of either syndrome.

MANAGEMENT. The management of hydrocephalus is by ventricular shunt, but the outcome is poor because of the concomitant severe cerebral malformations.

Hydranencephaly

The term *hydranencephaly* encompasses several conditions that result in the extensive replacement of brain by CSF. The cause of hydranencephaly may be failure of normal brain development or an intrauterine disorder that destroys the brain parenchyma. Progressive obstructive hydrocephalus may cause hydranencephaly if left untreated. Excessive pressure within the lateral ventricles destroys the midline structures and reduces the cerebral mantle to a thin membrane. Head circumference at birth is large when hydranencephaly is caused by obstructive hydrocephalus, is small when the condition is caused by intrauterine diseases, and may be large or small with primary malformations.

Porencephaly

Porencephaly is a term used loosely in the literature. Originally the term described hemispheric cysts that communicated with the subarachnoid space and the lateral ventricle secondary to defects in the final stages of prosencephalization. The present use of the term is broader and includes any hemispheric cyst; the usual causes are intrauterine or perinatal infarction or trauma. The injured immature brain loses neurons, glia, and supporting structures. A fluid-filled cyst is formed in the injured area and may not communicate with either the ventricular system or the subarachnoid space. Pressure within the cyst often becomes

excessive, causing compression of adjacent structures and macrocrania.

Congenital Midline Porencephaly

Congenital midline porencephaly is a distinct malformation characterized by congenital hydrocephalus, alopecia, or encephalocele in the parietal midline and a midline defect in the posterior cerebral mantle. Midline porencephaly differs from holoprosencephaly because the forebrain divides into two separate hemispheres. The cause may be early hydrocephalus with upward out-pouching and destruction of adjacent structures, including the corpus callosum, cerebral mantle, skull, and scalp. The syndromes of giant inter-hemispheric cyst and dygenesis of the corpus callosum are probably the same (Griebel et al, 1995).

CLINICAL FEATURES. The head is large in utero and may cause cephalopelvic disproportion at delivery. Possible defects in the parietal midline range from a small, round area of alopecia to an encephalocele. Affected children are severely retarded and blind. Most die during infancy or early childhood.

DIAGNOSIS. CT or MRI shows a large dorsal cyst that has destroyed the septum pellucidum and corpus callosum. The cyst communicates with enlarged lateral ventricles and extends through a skull defect to produce an encephalocele.

MANAGEMENT. Shunting the cyst may ease care by reducing the size of the head or encephalocele, but it does not prevent severe neurological impairment from the underlying cerebral malformation.

Anatomical Megalencephaly

Anatomical megalencephaly includes conditions in which the brain enlarges because the number or size of cells increases in the absence of a metabolic disease or an acute encephalopathy.

Achondroplasia

Achondroplasia is a genetic disorder, transmitted as an autosomal dominant trait (4p16.3). New mutations account for more than 80% of cases. It is the most frequent form of short-limbed dwarfism (Francomano, 2003).

CLINICAL FEATURES. The main features are short stature caused by rhizomelic shortening of the limbs (the proximal portion of the limbs is shorter than the distal portion), large head with frontal bossing and midface hypoplasia, lumbar lordosis, and limitation of elbow extension.

Stunted formation of enchondral bone causes the typical recessed facial appearance.

Affected newborns have true megalencephaly. Increased intracranial pressure occurs at times secondary to stenosis of the sigmoid sinus at the level of the jugular foramina. Despite considerable, and sometimes alarming, enlargement of head circumference, achondroplastic dwarfs seldom show clinical evidence of increased intracranial pressure or progressive dementia. Respiratory disturbances are common. Dyspnea may result from cervicomedullary compression. Other features of cervicomedullary compression are hyperreflexia, spasticity, and sensory disturbances of the limbs.

DIAGNOSIS. Clinical examination and radiological features establish the diagnosis. Accurate molecular diagnosis is available. CT shows a small posterior fossa and enlargement of the sphenoid sinuses. Basilar impression is sometimes present. Ventricular size varies from normal in newborns and young infants to moderate or severe dilation in older children and adults.

MANAGEMENT. Ventricular size, after initial dilation, usually remains stable, and surgical diversion of CSF is rarely needed. Decompressive surgery is required in children with evidence of progressive cervicomedullary compromise.

Benign Familial Macrocephaly

CLINICAL FEATURES. The term *benign familial macrocephaly* describes a familial condition in which neurological and mental function is normal, but head circumference is larger than the 98th percentile. The suspected mechanism of transmission is autosomal dominant inheritance, but the genetic basis for nonsyndromic macrocephaly is probably multifactorial, with a polymorphic genetic basis. Head circumference may not be large at birth but increases during infancy, usually to 2 to 4 cm above the 98th percentile. Body size is normal, and no physical deformities are present.

DIAGNOSIS. The enlargement is indistinguishable by physical examination from benign enlargement of the subarachnoid space, but CT distinguishes the two. CT is normal in benign familial macrocephaly.

MANAGEMENT. Treatment is not required.

Megalencephaly with a Neurological Disorder

The term *megalencephaly with a neurological disorder* encompasses all disorders, other than

neurocutaneous syndromes, in which the head is large and the child is neurologically abnormal.

CLINICAL FEATURES. Head circumference may be large at birth or may become large during infancy. It is generally 2 to 4 cm greater than the 98th percentile. Results of neurological tests are normal, but the children have learning disabilities, mental deficiency, or seizures. Neurological status remains stable.

DIAGNOSIS. Excluding the possibility of a neurocutaneous disorder requires careful examination of the skin and retina of other family members. Results of CT or MRI may be normal or may show mild dilation of the ventricular system. Agenesis of the corpus callosum is the only abnormality found in some families with macrocrania and borderline intelligence.

MANAGEMENT. Seizures often respond to anti-convulsant drugs. Special education is usually required. Treatment is not available for the underlying disorder.

Megalencephaly with Gigantism

Megalencephaly with gigantism is also called *cerebral gigantism* or *Sotos syndrome* (Cole and Hughes, 1990). It probably encompasses several disorders; most are sporadic and some clearly genetic, transmitted by autosomal dominant inheritance (5q35). Chromosome studies are usually normal. Some show a translocation.

CLINICAL FEATURES. Affected children are in the 75th to 90th percentile at birth and grow at an excessive rate in height, weight, head circumference, and bone age up to age 3. Afterward the rate of growth is normal. A prominent forehead, high-arched palate, and hypertelorism are present in almost every case. Small numbers of other patients may have other dysmorphic features. Many have mild learning problems that are less apparent as they become adults. All children with the syndrome are large as adults, but not gigantic; many appear normal as adults.

DIAGNOSIS. Cranial CT is usually normal except for mild ventricular widening. Extensive studies of endocrine function have failed to show a consistent abnormality other than glucose intolerance. Plasma somatomedin levels are elevated during the first year in some infants and fall below normal during early childhood.

MANAGEMENT. Treatment is not available, and it is not required.

Neurocutaneous Disorders

Seizures (see Table 1-8) and mental retardation (see Chapter 5) are common to most neurocu-

taneous disorders. The cutaneous features may be present at birth (incontinentia pigmenti) or during infancy (neurofibromatosis, tuberous sclerosis). The cause of macrocrania is either hydrocephalus or megalencephaly. Hemimegalencephaly, hemihypertrophy of the body, or hypertrophy of a single limb should always suggest the possibility of a neurocutaneous disorder.

Hypomelanosis of Ito

Hypomelanosis of Ito, also called *incontinentia pigmenti achromians*, does not represent a distinct entity, but rather is a symptom of many different states of mosaicism (Kuster et al, 1998). Most cases are sporadic, and several different chromosomal anomalies are associated. The X chromosome often is involved.

CLINICAL FEATURES. The cutaneous feature is a large, hypopigmented area that has a whorled or streaked appearance. It appears in the first year and is a negative image of the hyperpigmented lesions of incontinentia pigmenti (see Chapter 1). Other cutaneous features are café au lait spots, angiomatous nevi, heterochromia of the iris or hair, and other nevi. Seizures and mental retardation are the most common neurological abnormalities. IQ scores are below 70 in more than half of patients, but approximately 20% have IQ scores above 90. Approximately half of patients have seizures, usually with onset in the first year. Focal seizures are most common, although occasional patients have infantile spasms and Lennox-Gastaut syndrome. Spastic diplegia also may be present. Disturbances of neuronal migration cause these symptoms. Megalencephaly occurs in approximately 25% of cases. One third of patients have skeletal and eye anomalies, including limb hypertrophy or atrophy, facial hemiatrophy, poorly formed ears, dysplastic teeth, hypertelorism, strabismus, and corneal opacities.

DIAGNOSIS. The characteristic cutaneous lesions are crucial to the diagnosis, and all family members as well as the child require careful examination. Chromosome studies may be useful in the child and parents. MRI usually shows generalized cerebral or cerebellar hypoplasia, severe cortical neuronal migration anomalies, and hemimegalencephaly and lissencephaly. Hemimegalencephaly may be ipsilateral or contralateral to the cutaneous hypopigmentation.

MANAGEMENT. Treatment is symptom directed.

Epidermal Nevus Syndrome

Epidermal nevus syndrome, also called *linear nevus sebaceous syndrome*, refers to several

disorders that have in common an epidermal nevus and neurological manifestations, such as seizures or hemimeganencephaly (Dodge and Dobyns, 1995).

CLINICAL FEATURES. A unilateral linear nevus is present on the skin of the face or scalp. It may not be visible at birth, but the nevus darkens during infancy and becomes verrucous. Hemihypertrophy of the face, head, and limbs ipsilateral to the nevus may be present at birth or may develop during infancy.

The spectrum of neurological disability is considerable. Developmental delay and seizures are expected. Head enlargement may be generalized or unilateral. Focal neurological deficits, such as hemiplegia and hemianopia, contralateral to the nevus are relatively common. Eye abnormalities, such as microphthalmia and coloboma, occur in one third of children.

DIAGNOSIS. Diagnosis relies on recognition of the linear nevus. Electroencephalogram usually shows unilateral slowing and epileptiform discharges ipsilateral to the nevus. Electroencephalogram shows hypsarrhythmia when infantile spasms are the initial feature (see Chapter 1). Hemihypsarrhythmia also may occur. Megalencephaly ipsilateral to the epidermal nevus is the most frequent finding on MRI. Several types of cerebral dysplasia may be associated, usually ipsilateral to the epidermal nevus. Focal pachygyria is the most common.

MANAGEMENT. Seizures may respond to standard anticonvulsant therapy (see Chapter 1), but treatment is not available for the underlying cerebral malformation.

Metabolic Megalencephaly

Several inborn errors of metabolism produce megalencephaly by storage of abnormal substances or by producing cerebral edema (see Table 18-2). These are discussed elsewhere because the initial features are usually developmental regression (see Chapter 5) or seizures (see Chapter 1). Two exceptions are glutaric aciduria type I (see Chapter 14) and leukoencephalopathy with swelling and cysts. Infants with glutaric aciduria type I are normal until age 3 years except for macrocephaly and then develop an acute encephalitic illness that resembles encephalitis. Most infants with metabolic megalencephaly have a normal head circumference at birth. Head enlargement parallels neurological regression and clinical evidence of increased intracranial pressure. The ventricles are often small.

Leukoencephalopathy with Swelling and Cysts

The metabolic defect is not established, but an affected sibling pair and instances of parental consanguinity suggest autosomal recessive inheritance (van der Knaap et al, 1995).

CLINICAL FEATURES. The initial feature is abnormal head enlargement in a child whose development is either normal or only mildly delayed. A slowly progressive ataxia and spasticity develop, with intellectual functioning preserved for years after onset. Seizures and mild mental deterioration may occur late in the course.

DIAGNOSIS. MRI shows a severe leukoencephalopathy that suggests a demyelinating white matter disorder. The hemispheres appear swollen, with cystlike spaces in the frontoparietal and anterior temporal areas, but with relative sparing of the occipital white matter.

MANAGEMENT. Treatment is symptomatic.

Microcephaly

Microcephaly means a head circumference that is smaller than 2 standard deviations below the normal distribution. The standard for head circumference varies among different ethnic groups. A small head circumference indicates a small brain. Most full-term newborns whose head circumferences are smaller than 2 standard deviations, but who are neurologically normal, have normal intelligence at age 7, but a head circumference smaller than 3 standard deviations usually indicates later mental retardation.

A small head circumference at birth establishes the antepartum timing of brain damage but does not distinguish primary from secondary microcephaly (Table 18-4). Primary microcephaly encompasses conditions in which the brain is small and never formed properly because of genetic or chromosomal abnormalities. Secondary microcephaly implies that the brain was forming normally, but a disease process impaired further growth. Normal head circumference at birth, followed by failure of normal head growth, usually indicates a secondary microcephaly. Chromosomal disorders are an exception to that rule unless they cause defective prosencephalization or cellular migration.

Perinatal brain damage does not cause a recognizable decrease of head circumference until 3 to 6 months postpartum. Failure of normal brain growth removes the force keeping the cranial bones separated, and they fuse prematurely. A primary disorder of the skull (craniosynostosis) may cause premature closure of

TABLE 18-4
Conditions Causing Microcephaly

Primary Microcephaly

Microcephaly vera (genetic)
 Chromosomal disorders
 Defective neurulation
 Anencephaly
 Encephalocele
 Defective prosencephalization
 Agenesis of the corpus callosum
 Holoprosencephaly (arrhinencephalia)
 Defective cellular migration

Secondary Microcephaly

Intrauterine disorders
 Infection
 Toxins
 Vascular
 Perinatal brain injuries
 Hypoxic-ischemic encephalopathy
 Intracranial hemorrhage
 Meningitis and encephalitis
 Stroke
 Postnatal systemic diseases
 Chronic cardiopulmonary disease
 Chronic renal disease
 Malnutrition

the cranial sutures even though the brain is attempting to grow normally (Chumas et al, 1997). The distinction between the two is relatively simple: Craniostenosis is always associated with an abnormal skull shape and heaping up of bone along the cranial sutures; failure of brain growth produces a relatively normal-shaped skull with some overlapping of skull bones.

Cranial MRI may be informative in distinguishing primary from secondary microcephaly. In most children with primary microcephaly, either MRI results are normal or a recognizable pattern of cerebral malformation is present. In children with secondary microcephaly, the brain image is usually abnormal, characterized by one or more of the following features: ventricular enlargement, cerebral atrophy, and porencephaly.

Primary Microcephaly

Many cerebral malformations are of uncertain cause, and classification as primary or secondary is not possible. Morphogenetic errors, although lacking in the traditional stigmata of tissue injury, could result from exposure of the embryo to a noxious agent during the first weeks after conception. At this early stage, disorganization of the delicate sequencing

of neuronal development could occur when the brain is incapable of generating a cellular response.

Microcephaly Vera (Genetic)

The term *microcephaly vera* encompasses genetic defects that decrease bulk growth of the brain. Transmission of the defect is as an autosomal recessive trait. Jackson and colleagues (1998) identified a genetic locus, which they named *MCPH1*, for primary microcephaly, at chromosome 8pter-p22.

CLINICAL FEATURES. Children with the autosomal recessive form of microcephaly vera are usually short and have a characteristic disproportion in size between the face and the skull. The forehead slants backward, and the reduced size of the skull causes the scalp to wrinkle in the occipital region. The chin is small, and the ears and nose are prominent. Mental retardation is moderate to severe, and other neurological abnormalities, such as spastic diplegia and seizures, may be present.

DIAGNOSIS. Results of brain imaging are normal.

MANAGEMENT. Treatment is symptomatic.

Chromosomal Disorders

Chromosomal disorders are not usually a cause of microcephaly at birth, unless cerebral aplasia, such as holoprosencephaly, is part of the syndrome. Hypotonia and dysmorphism are the prominent features of chromosomal disorders in newborns (see Chapter 5), and microcephaly becomes evident during infancy.

Defective Neurulation

At the end of the first week of gestation, a rostrocaudal axis appears on the dorsal aspect of the embryo. This axis is responsible for the subsequent induction of a neural plate, the anlage of the nervous system. The neural plate changes into a closed neural tube during the third and fourth weeks. Defects in closure are *dysraphic states*. The most rostral portion of the neural tube, the anterior neuropore, closes at about the 24th day.

Anencephaly

Anencephaly is the result of defective closure of the anterior neuropore, just as myelomeningocele is the result of defective closure of the posterior neuropore (see Chapter 12). The rate of each is declining. The cause of the malformations and

the reason for their decline in prevalence are unknown.

CLINICAL FEATURES. Less than half of anencephalic children are born alive, and those who are rarely survive the first month. The scalp is absent, and the skull is open from the vertex to the foramen magnum. The exposed brain appears hemorrhagic and fibrotic. It consists mainly of the hindbrain and parts of the diencephalon; the forebrain is completely lacking. The orbits are shallow, and the eyes protrude. The neck is in retroflexion, and the proximal portions of the arms seem overgrown compared with the legs. The overall appearance of the anencephalic newborn is grotesque and described as “toad-like.”

DIAGNOSIS. After the birth of an infant with a neural tube defect, the chance of anencephaly or myelomeningocele in subsequent pregnancies increases twofold to fivefold. After two affected infants have been born, the chance of having another affected infant doubles again. Prenatal diagnosis of dysraphic states is discussed in the section on myelomeningocele in Chapter 12.

MANAGEMENT. Do not recommend interventions that prolong life.

Encephalocele

An encephalocele is a protrusion of cortex and meninges, covered by skin, through a defect in the skull. An encephalocele may occur in any location; however, most are midline-occipital except in Asians, in whom the defects are usually midline-frontal.

CLINICAL FEATURES. The size of the encephalocele may range from a small protrusion to a cyst as big as the skull. When the protrusion is large, the skull is likely to be microcephalic. The size of the mass does not predict its contents, but an encephalocele with a sessile base is more likely to contain cerebral tissue than one with a pedunculated base. Encephaloceles rarely occur as a solitary cerebral malformation and usually are associated with abnormalities of the cerebral hemispheres, cerebellum, and midbrain.

DIAGNOSIS. Cranial MRI is reasonably accurate in defining the contents of the encephalocele. Despite its midline location, the derivation of the protruded material is usually from the one hemisphere that is smaller than the other and displaced across the midline by the larger hemisphere.

MANAGEMENT. The contents of the encephalocele and the extent of other malformations should influence any decision to remove the encephalo-

cele surgically. The outcome of surgical removal of an occipital meningocele, in which the sac contains no neural tissue, is often excellent. Children with protruded brain material and associated malformations usually die during infancy.

Defective Prosencephalization

The forebrain develops between 25 and 30 days' gestation from a midline vesicle generated from the closed anterior neuropore. Between 30 and 40 days' gestation, bilateral cerebral vesicles are formed by the cleavage and outpouching of the midline vesicle. The midline vesicle is the primordium of the third ventricle, and the bilateral cerebral vesicles are the primordia of the lateral ventricles.

Holoprosencephaly

Defective cleavage of the embryonic forebrain leads to a spectrum of malformations. Use of the term *arrhinencephalia* to refer to the full spectrum of abnormalities is common, but holoprosencephaly is a more accurate term.

Total failure of cleavage produces a small brain with a midline vesicle covered by a horseshoe of limbic cortex. With less severe defects, the third ventricle and diencephalon differentiate, and partial cleavage of the occipital hemispheres occurs. The corpus callosum is hypoplastic or absent. The minimal defect (arrhinencephalia) is the unilateral or bilateral absence of the olfactory bulbs and tracts associated with some degree of rhinic lobe aplasia. Hemispheric cleavage is complete, the ventricles are normal, and the corpus callosum is present in part or in total.

Almost half of patients with holoprosencephaly have an abnormal numerical or structural chromosomal abnormality. Less than a quarter of children with monogenic holoprosencephaly have a recognizable syndrome, and the remaining children have nonsyndromic holoprosencephaly (Muenke and Gropman, 2003). An autosomal dominant form maps to the chromosome 7p36.2 locus, and a defect at the same locus results in sacral agenesis. Abnormalities of chromosome 13 account for most chromosomal abnormalities that cause holoprosencephaly.

CLINICAL FEATURES. Craniofacial dysplasia is usually associated, and malformations in other organs are common. The facial deformities are primarily in the midline (cyclopia or ocular hypotelorism, flat nose, cleft lip, and cleft palate), and their severity is often predictive of the severity of the brain malformation.

Associated malformations include congenital heart defects, clubbing of the hands or feet, polydactyly and syndactyly, hypoplasia of the genitourinary system, an accessory spleen and liver, and malrotation of the intestine.

Most children with severe defects in cleavage of the forebrain are stillborn or die in the neonatal period. Microcephaly, hypotonia, apnea, and seizures are prominent features. Hypotonia is especially severe when the defect is associated with a chromosomal abnormality. Infants who survive have severe intellectual, motor, and sensory impairment. Children with only arhinencephalia may appear physically normal and may display minor disturbances in neurological function, such as learning disabilities and seizures.

DIAGNOSIS. Suspect holoprosencephaly in every infant with midline facial deformities, especially when malformations are present in other organs. MRI provides excellent visualization of the malformation. Molecular genetic testing is available for many forms.

MANAGEMENT. Considering the multiplicity of malformations, measures to extend life are inappropriate.

Agenesis of the Corpus Callosum

Anomalous development of the three telencephalic commissures (the corpus callosum and the anterior and hippocampal commissures) is an almost constant feature of defective prosencephalization. The prevalence of agenesis of the corpus callosum on CT is 2% to 3% in North America and 7% to 9% in Japan. Most cases are isolated malformations. Agenesis also occurs in association with other prosencephalic dysplasias and with some metabolic defects (see section on glycine encephalopathy in Chapter 1) and as a solitary genetic defect. When only the corpus callosum is absent, the anterior and hippocampal commissures may be normal or enlarged. Callosal agenesis is part of Aicardi syndrome (see Chapter 1); Andermann syndrome (autosomal recessive callosal agenesis, mental deficiency, and peripheral neuropathy); and trisomies 8, 11, and 13.

CLINICAL FEATURES. Solitary agenesis of the corpus callosum is clinically unapparent except for subtle disturbances in the interhemispheric transfer of information, for which special testing is needed. Mental retardation or learning disabilities occur in most cases, and epilepsy usually indicates concurrent focal heterotopia.

DIAGNOSIS. Neuroimaging shows lateral displacement of the lateral ventricles and upward dis-

placement of the third ventricle. Intraventricular pressure is normal.

MANAGEMENT. Treatment is symptomatic.

Defective Cellular Migration

When neurons that should form the superficial layers of the cerebral cortex are unable to pass through the already established deeper layers of neurons, the results are a simplification of the cortical convolution pattern (agryria) and an abnormal accumulation of neurons in the white matter (heterotopia). Complete absence of gyri causes a smooth cerebral surface (lissencephaly), whereas incomplete gyral formation reduces the number and enlarges the size of the existing convolutions (pachygyria).

Several types of lissencephaly exist. Some affect only the cerebral cortex; some affect the cortex, cerebellum, and brainstem; and others are combined with facial dysmorphism. Microcephaly and a peculiar facies that includes micrognathia, high forehead, thin upper lip, short nose with anteverted nares, and low-set ears characterize Miller-Dieker syndrome. A microdeletion at the 17p13.3 locus occurs in most patients with Miller-Dieker syndrome, and deletions on chromosome 17 occur in other lissencephaly syndromes (Dobyns, 1999). Transmission of lissencephaly also occurs as an X-linked dominant trait with two different phenotypes; classic lissencephaly occurs in males, and bilateral periventricular nodular heterotopia occurs in females (Dobyns et al, 1996).

CLINICAL FEATURES. Referral of most children with lissencephaly is for evaluation of developmental delay or intractable myoclonic seizures. Many initially exhibit muscular hypotonia that later evolves into spasticity and opisthotonos. Microcephaly is not always present, but all children have mental retardation, epilepsy, and cerebral palsy. Bilateral periventricular nodular heterotopia usually presents with sporadic or familial epilepsy and normal intelligence. Isolated heterotopia is an important cause of intractable epilepsy in an otherwise normal child (see Chapter 1).

DIAGNOSIS. MRI abnormalities establish the diagnosis. A smooth cortical surface except for rudimentary sulci (agryria) may be limited to the parietal or frontal regions or encompass the whole brain. The sylvian fissure is broad and triangular, the interhemispheric fissure is widened, and nests of gray matter are present within the white matter. The ventricles may be enlarged and the corpus callosum absent. Genetic tests are

available that detect the mutations on chromosomes 17 and X.

MANAGEMENT. Seizures are usually intractable, but standard drugs for the management of infantile spasms or myoclonic seizures may provide partial relief (see Chapter 1). Death often occurs during infancy, but long survival is possible.

Secondary Microcephaly

Intrauterine Disorders

Intrauterine infection is an established cause of microcephaly. Cytomegalovirus infection (see Chapter 5) can be manifest as microcephaly, without any features of systemic disease. Because maternal infection is asymptomatic, such cases are difficult to identify as caused by cytomegalovirus disease. Surveys of cytomegalovirus antibody show a higher rate of seropositive individuals among microcephalic than normocephalic children, however; this suggests that such cases do exist.

Efforts to identify environmental toxins that produce cerebral malformation have had only limited success. Drugs of abuse and several pharmaceutical agents are suspect, but the evidence is rarely compelling. The only absolute conclusion derived from an abundance of studies is that a negative impact occurs on fetuses of women whose lifestyle includes some combination of heavy alcohol or drug use, poor nutrition, and inadequate health care. The expression of the negative impact includes intrauterine growth retardation, dysmorphic features, and microcephaly.

Aplasia of major cerebral vessels is a rare malformation of unknown cause. Brain tissue that the aplastic vessels should have supplied with blood either never forms or is infarcted and replaced by calcified cystic cavities. The cavities are present at birth, and the CT appearance suggests an intrauterine infection except that the cysts conform to a vascular distribution.

Perinatal Brain Injuries

Perinatal brain injuries are an important cause of failure of brain growth during infancy when head circumference is normal at birth. The initial features of this group of disorders are neonatal encephalopathy and seizures (see Chapter 1). Children with microcephaly and mental retardation from perinatal brain injuries always have cerebral palsy and often have epilepsy. Microcephaly and mental retardation

in the absence of motor impairment are always of prenatal origin.

Postnatal Systemic Disease

Infants who are chronically ill and malnourished fail to thrive. All growth is retarded, but usually head growth is maintained better than length and weight. If body size is below the 3rd percentile, head circumference might be at the 5th or 10th percentile. Failure to correct the systemic disturbance usually causes brain injury, brain growth slows, and head circumference falls into the microcephalic range.

Abnormal Head Shape

Although skull content almost exclusively determines skull size, skull shape results from forces acting from within and without and from the time of closure of the cranial sutures.

Intracranial Forces

The shape of the brain contributes to the shape of the skull by influencing the time of closure of cranial sutures. Temporal lobe agenesis results in a more narrow calvaria, and cerebellar agenesis results in a small posterior fossa. Hydrocephalus produces characteristic changes in skull shape. Large lateral ventricles cause bowing of the forehead, and the Dandy-Walker malformation causes bowing of the occiput. In infants with subdural hematomas, separation of the sagittal suture may cause bitemporal widening.

Extracranial Forces

Constricting forces in utero, such as a bicornuate uterus or multiple fetuses, may influence head shape. Physical constraint of the skull in utero may contribute to premature closure of a cranial suture, but perinatal and postnatal constraints do not. Molding of the skull is common during a prolonged vaginal delivery, but the closure of cranial sutures is unaffected. Molding does not influence eventual head shape.

In premature infants, *scaphocephaly* (Table 18-5) often develops because the poorly mineralized skull flattens on one side and then the other with turning of the child from side to side. The shape of the skull becomes normal with maturity.

Plagiocephaly or occipital flattening is a frequent finding in hypotonic infants. The cause is constant lying in the same position. The hair

TABLE 18-5
Terms That Describe Head Shapes

Term	Definition
Acrocephaly	High, tower-like head with vertical forehead
Brachycephaly	Broad head with recessed lower forehead
Oxycephaly	Pointed head
Plagiocephaly	Flattening of one side of head
Scaphocephaly (dolicocephaly)	Abnormally long, narrow head
Trigonocephaly	Triangular head with prominent vertical ridge in the midforehead

over the flattened portion of skull is usually sparse from rubbing against the bed surface. A normal head shape resumes by changing the infant's laying position.

Craniosostenosis

Craniosostenosis and *craniosynostosis* are terms for premature closure of one or more cranial sutures; the result is always an abnormal skull shape. These terms are applicable only to infants in whom the sutures close while the brain is growing. Early closure of sutures in infants with microcephaly is not premature because the intracranial pressure required to keep sutures apart is lacking.

Most cases of craniosostenosis are sporadic and of uncertain etiology. Autosomal dominant and recessive forms of single-suture closure occur. Autosomal dominant inheritance is more common than autosomal recessive inheritance, but also is more easily identifiable as hereditary. Many sporadic cases could represent autosomal recessive inheritance.

Craniosostenosis may be one feature of a larger recognized syndrome of chromosomal or genetic abnormality. Genetic disorders often are associated with syndactyly or polydactyly (see the section on *acrocephalosyndactyly* later), whereas chromosomal disorders are usually characterized by other limb malformations and growth retardation. Craniosostenosis also is associated with other disorders (Table 18-6). Some of these associations are coincidental, but a cause-and-effect relationship probably does exist with metabolic disorders of bone.

CLINICAL FEATURES. In nonsyndromic craniosostenosis, the only clinical feature is an abnormal head shape. Normal bone growth is impaired in a plane perpendicular to the fused sutures but is

TABLE 18-6
Disorders Associated with Craniosostenosis

Ataxia-telangiectasia
Familial hypophosphatemia
Hyperthyroidism
Idiopathic hypercalcemia
Mucopolysaccharidoses
Polycythemia vera
Rickets
Renal rickets
Vitamin D deficient
Vitamin D resistant
Sickle cell disease
Thalassemia major

able to occur in a parallel plane. The cause of scaphocephaly is premature fusion of the sagittal suture; brachycephaly, premature fusion of both coronal sutures; plagiocephaly, premature fusion of one coronal or one lambdoid suture; trigonocephaly, premature fusion of the metopic suture; and oxycephaly, premature fusion of all sutures. When several sutures close prematurely, the growing brain is constricted, and symptoms of increased intracranial pressure develop. Communicating and noncommunicating hydrocephalus occur more frequently in infants with craniosostenosis than in normal infants. It is more likely that a common underlying factor causes both rather than one causing the other. Two-suture craniosostenosis is common. The sagittal suture is usually involved, in combination with either the metopic or the coronal suture (Chumas et al, 1997).

DIAGNOSIS. Visual inspection of the skull and palpation of the sutures are sufficient for diagnosis in most cases of one-suture or two-suture craniosostenosis. Radiography of the skull shows a band of increased density at the site of the prematurely closed sutures. All children with craniosostenosis of multiple sutures and children with craniosostenosis of a single suture and suspected hydrocephalus require a head CT scan.

MANAGEMENT. The two indications for surgery to correct craniosostenosis are to improve the appearance of the head and to relieve increased intracranial pressure. The cosmetic indication should be used sparingly and only to make severe deformities less noticeable.

Acrocephalosyndactyly

The combination of craniosostenosis and fusion of fingers and toes characterizes acrocephalosyn-

dactly. Some degree of mental retardation is often present.

Apert syndrome is syndactyly and premature closure of the coronal suture resulting in brachycephaly. The gene abnormality, inherited as a dominant trait, is a mutation in the gene encoding fibroblast growth factor receptor-2 (10q26). The forehead is high and prominent, and the face is similar to but less severely deformed than the face in Crouzon disease. Agenesis of the corpus callosum and limbic structures may be an associated feature. The IQ is higher than 70 in 50% of the children who have a skull decompression before 1 year of age versus only 7% of children operated on later in life (Reiner et al, 1996).

Carpenter syndrome differs from Apert syndrome because transmission is by autosomal recessive inheritance, and polydactyly and syndactyly are associated with premature closure of all sutures, obesity, and hypogonadism. Approximately 75% of patients are retarded secondary to cerebral malformations that are demonstrable on MRI.

Crouzon Disease (Craniofacial Dysostosis)

Crouzon disease is the combination of premature closure of any or all cranial sutures and maldevelopment of facial bones. Mutations in the gene for fibroblast growth factor receptor-2 cause the disorder. Transmission is by autosomal dominant inheritance.

CLINICAL FEATURES. The facial deformity is present at birth and becomes worse during infancy. The skull is usually widened anteriorly secondary to premature closure of the coronal suture. The eyes are widely separated and prominent, but the lower face appears recessed because of maxillary hypoplasia and prognathism. Adding to the deformity are a beaklike nose and a large, protuberant tongue. Intracranial pressure often increases because several cranial sutures are usually involved.

DIAGNOSIS. The typical facies and genetic pattern of inheritance are diagnostic. Head CT or MRI is useful to follow the progression of cerebral compression.

MANAGEMENT. A sequential neurosurgical and plastic surgical approach has been successful in opening the sutures to relieve intracranial pressure and in advancing the facial bones forward to improve the cosmetic appearance.

References

- Cavalcanti DP, Salomao MA. Dandy-Walker malformation with postaxial polydactyly. Further evidence for autosomal recessive inheritance. *Am J Med Genet* 1999; 85:183-184.
- Chumas PD, Cinalli G, Arnaud E, et al. Classification of previously unclassified cases of craniosynostosis. *J Neurosurg* 1997;86:177-181.
- Cole TRP, Hughes HE. Sotos syndrome. *J Med Genet* 1990;27:571-576.
- Dobyns WB. (4 October 1999) Lissencephaly and subcortical band heterotopia (agyria-pachygyria-band spectrum). Overview. In: *GeneClinics: Medical Genetic Knowledge Base*. [database online] University of Washington, Seattle. Available at <http://www.geneclinics.org>.
- Dobyns WB, Andermann E, Andermann F, et al. X-linked malformations of neuronal migration. *Neurology* 1996; 47:331-339.
- Dodge NN, Dobyns WB. Agenesis of the corpus callosum and Dandy-Walker malformation associated with hemimegalencephaly in the sebaceous nevus syndrome. *Am J Med Genet* 1995;56:147-150.
- Francomano CA. (19 December 2003) Achondroplasia. In: *GeneClinics: Medical Genetic Knowledge Base*. [database online] University of Washington, Seattle. Available at <http://www.geneclinics.org>.
- Griebel ML, Williams JP, Russell SS, et al. Clinical and developmental findings in children with giant interhemispheric cysts and dysgenesis of the corpus callosum. *Pediatr Neurol* 1995;13:119-124.
- Haverkamp F, Wolffe J, Aretz M, et al. Congenital hydrocephalus internus and aqueduct stenosis. Aetiology and implications for genetic counseling. *Eur J Pediatr* 1999; 158:474-478.
- Jackson AP, McHale DP, Campbell DA, et al. Primary autosomal recessive microcephaly (MCPH1) maps to chromosome 8p22-pter. *Am J Hum Genet* 1998;63: 541-546.
- Kuster W, Ehrig T, Happel R. Hypomelanosis of Ito. No entity, but a cutaneous sign of mosaicism. In: Nordlund JJ, Boissy R, Hearing V, et al, eds. *The Pigmentary System and Its Disorders*. Oxford University Press: New York; 1998;594-601.
- McGaughran JM, Kuna P, Das V. Audiological abnormalities in the Klippel-Feil syndrome. *Arch Dis Child* 1998;79:352-355.
- Muenke M, Gropman A. (27 January 2003) In: *GeneClinics: Medical Genetic Knowledge Base*. [database online] University of Washington, Seattle. Available at <http://www.geneclinics.org>.
- Reiner D, Arnaud E, Cinalli G, et al. Prognosis for mental function in Apert's syndrome. *J Neurosurg* 1996;85: 66-72.
- Schrander-Stumple C, Fryns J-P. Congenital hydrocephalus. Nosology and guidelines for clinical approach and genetic counseling. *Eur J Pediatr* 1998;157: 355-362.
- van der Knaap MS, Barth PG, Stroink H, et al. Leukoencephalopathy with swelling and a discrepantly mild clinical course in eight children. *Ann Neurol* 1995;37: 324-334.

Index

Note: Page numbers followed by f and t refer to figures and tables, respectively.

- Abducens nerve palsy
 congenital, 301
 idiopathic, 305
 in Gradenigo syndrome, 305
 increased intracranial pressure and, 302
- Abetalipoproteinemia
 acanthocytosis in, 284–285
 ataxia in, 233–234
- Abscess, brain, 110–111, 245
- Absence epilepsy, childhood or juvenile, 26–27, 27f
- Acanthocytosis
 in ataxia-telangiectasia, 234
 neurological syndromes associated with, 284–285
- Accommodative esotropia, 299
- Acetazolamide
 in ataxia, 221–222
 in hemiplegic migraine, 251
 in idiopathic intracranial hypertension, 114
 in myotonia fluctuans, 202
 in pyruvate dehydrogenase deficiency, 223
- N*-Acetyl glutamate synthetase deficiency, 7
- Acetyl choline receptor antibodies, in myasthenia, 306
- Acetyl coenzyme A, oxidation of, 203
- Achondroplasia, anatomical megalencephaly and, 361
- Acid lipase deficiency, 128
- Acid maltase deficiency
 hypotonia in, 155, 167–168
 proximal weakness in, 180–181
- Acidemia
 glutaric, type I
 dystonia in, 289
 megalencephaly in, 363
 in neonates, 11–13
 isovaleric, 11–12
 methylmalonic, 12
 propionic, 12–13
- Acidosis. *See also* Ketoacidosis.
 lactic, 223
 metabolic, in methylmalonic acidemia, 12
- Acoustic neuroma, 340, 346–347, 347f
- Acquired immunodeficiency syndrome (AIDS)
 encephalopathy in, 124–125, 141–142
 proximal myopathy in, 179
- Acrocephalosyndactyly, 368–369
- Acrocephaly, 368t
- Acromegaly, pituitary adenoma and, 327
- Action myoclonus, postanoxic, 52, 294
- Acyclovir
 in herpes encephalitis, 13, 59
 in herpes zoster myelitis, 263
 in herpes zoster oticus, 339
- Acyl-CoA dehydrogenase deficiency
 medium-chain, 65
 very-long-chain, 205–206
- Addison's disease, 182, 202
- Adenoma, pituitary, 326–327
- Adenomata sebaceum, 135
- Adenosine triphosphate (ATP), sources for, 203
- Adenosylcobalamin deficiency, 12
- Adenoviruses, ataxia from, 225
- Adie syndrome, 329
- Adolescents, limb weakness in, 171–172
- Adrenal disorders, altered states of consciousness in, 63
- β-Adrenergic blocking agents, ototoxicity of, 345
- Adrenocorticotrophic hormone
 in myoclonic encephalopathy/neuroblastoma syndrome, 226
 pituitary adenoma and, 327
- Adrenoleukodystrophy
 cerebral form of, 145–146
 infantile, ataxia in, 236
 neonatal, cerebral hypotonia in, 154–155
- Adrenomyeloneuropathy, 263
- Adversive seizures, 312

- Agitation, 47, 48t
- Aicardi syndrome, 19, 366
- AIDS. *See* Acquired immunodeficiency syndrome (AIDS).
- Akathisia, 282, 283
- Alberts-Schönberg disease, 337–338
- Alcohol
- embryo exposure to, cerebral malformations from, 121
 - in essential tremor, 296
- Alexander disease, 133
- Alice-in-Wonderland syndrome, 80
- Alpers disease, 133–134
- Alprazolam, in panic attack, 69
- Aluminum, dialysis dementia syndrome and, 67
- Amblyopia, developmental, 299, 318
- Amenorrhea, in prolactin-secreting tumors, 327
- Amikacin
- in bacterial meningitis, 109t
 - ototoxicity of, 345
- Amino acid(s)
- branched-chain
 - in maple syrup urine disease, 4–5
 - metabolism of, disorders of, 6f
 - metabolism of, disorders of
 - developmental delay in, 125–128
 - in neonates, 4–7, 5t
- Aminoaciduria, in Hartnup disease, 222
- Aminoglycosides
- in bacterial meningitis, 107, 107t
 - ototoxicity of, 345
 - vestibular toxicity of, 348–349
- Amitriptyline
- in analgesic rebound headache, 84
 - in caffeine headache, 84
 - in migraine prophylaxis, 82
- Ammonia
- excess of. *See* Hyperammonemia.
 - metabolism of, urea cycle and, 6f
- Amnesia
- global, transient, 69
 - in concussion, 72
- Amoxicillin, in Lyme disease, 54
- Amphetamine
- abuse of, altered states of consciousness in, 71
 - tics from, 295
- Amphotericin B
- dosage schedule for, 113t
 - encephalopathy and, 70
 - in coccidioidal meningitis, 112
 - in cryptococcal meningitis, 113
- Ampicillin
- in bacterial meningitis, 107, 107t, 108, 109t
 - in pneumococcal meningitis, 109
- Amyotrophic lateral sclerosis, juvenile, distal weakness in, 183
- Amyotrophy
- asthmatic, 275
 - monomelic (benign focal), 273–274
 - neuralgic, 274
 - hereditary, 275–276
- Analgesics
- in migraine, 82
 - rebound headache from, 84, 85
- Anaplastic astrocytoma, 98, 99
- Anaplastic large cell medulloblastoma, 230
- Andermann syndrome, corpus callosum agenesis in, 366
- Andersen syndrome, 196
- Anemia
- in abetalipoproteinemia, 233–234
 - sickle cell, 248–249
 - retinal artery occlusion and, 324
- Anencephaly, 364–365
- Aneurysms, arterial
- ophthalmoplegic features of, 302–303
 - ruptured, 104–105
- Angelman syndrome, 152
- Angiitis, isolated, of central nervous system, 249
- Angioma, facial, in Sturge-Weber syndrome, 252
- Angiotensin-converting enzyme, serum, in sarcoidosis, 339
- Anhidrosis, in hereditary sensory and autonomic neuropathy IV, 215
- Anhidrotic ectodermal dysplasia, congenital cataract and, 318
- Aniridia, 318, 329
- Anisocoria
- benign essential, 329
 - tonic pupil syndrome and, 329
- Anoxia. *See also* Hypoxia.
- acute, 51–52
 - encephalopathy after, 52
 - myoclonus after, 52, 294
- Anterior fontanelle, size of, increased intracranial pressure and, 93
- Anterior horn cell body, disorders of. *See* Neuronopathy.
- Antibiotics
- in bacterial meningitis, 107, 107t, 108, 109t
 - in brain abscess, 111
 - in diskitis, 262
 - in tuberculous meningitis, 110
 - ototoxicity of, 345
 - prophylactic, in congenital heart disease, 245
 - vestibular toxicity of, 348
- Anticholinergic therapy, in idiopathic torsion dystonia, 290
- Anticholinesterase therapy, in ocular myasthenia, 306

- Anticonvulsants, 35–41
 adverse effects of, 36–37
 ataxia from, 220–221
 blood concentrations of, 35–36, 36t
 discontinuation of, 35
 dosages of, 36t
 half-lives of, 36, 36t
 in hypoxic-ischemic encephalopathy, 11
 in neonates, 14, 15
 initiation of, indications for, 35
 ophthalmoplegia from, 309
 principles of, 35–37, 36t
 prophylactic, in febrile seizures, 18
 selection of, 37–41
 vertigo from, 348
- Antidepressants, tricyclic
 ophthalmoplegia from, 309
 overdose of, encephalopathy from, 70
- Antidiuretic hormone, secretion of
 in bacterial meningitis, 108
 in hyponatremic encephalopathy, 63
- Antiemetics, tardive dyskinesia from, 283
- Antihistamines, ataxia from, 221
- Antiretroviral therapy, 124–125
- Antitoxin, in botulism, 309
- Anxiety, chronic headache in, 85
- Aorta, coarctation of, arterial aneurysms and,
 104
- Apert syndrome, 369
- Apgar score, after hypoxia, 10
- Aphasia, epileptiform, acquired, 30
- Apnea
 in cyanotic syncope, 16–17
 in infants, 16–17
 in neonates, 3
- Apneustic breathing, 50
- Apolipoprotein, 237
- Apoplexy, pituitary, blindness in, 324
- Apraxia
 oculomotor. *See* Oculomotor apraxia.
 speech, autosomal dominant rolandic epilepsy
 and, 30
- Aqueductal stenosis, congenital,
 noncommunicating hydrocephalus and,
 357, 357f
- Arachnoid cysts
 intracranial, 101–102
 spinal paraplegia in, 256–257
- Arboviral encephalitis, 56–58
- Arginase deficiency, 264
 hereditary spastic paraplegia and, 261
- Arginine, in neonatal urea cycle disorders, 7
- Arm
 in neonatal brachial neuropathy, 276
 pain in, syndromes associated with, 211–212
 weakness in, 172–173. *See also* Quadriplegia.
- Arhinencephaly, 365
- Arterial aneurysms
 ophthalmoplegic features of, 302–303
 ruptured, 104–105
- Arterial embolism, in cyanotic heart disease, 245
- Arterial pressure, in cerebral blood flow, 91–92
- Arteriovenous malformations
 deep midline, 105
 hemiplegia in, 242
 noncommunicating hydrocephalus in, 359, 360f
 of spinal cord, 257
 supratentorial, 105–106
- Arteritis
 cervical, 242–243
 Takayasu, hemiplegia in, 250
- Arthritis
 in Lyme disease, 54
 rheumatoid, juvenile, neuropathy in, 189
- Arthrogyrosis
 differential diagnosis of, 150t
 hypotonia and, 149, 159
 in familial infantile myasthenia, 161
 neurogenic, 159
- Arthropods, encephalitis from, 56–58
- Aspartoacylase deficiency, 138
- Asperger disorder, 118
- Asphyxia, perinatal
 acute total, 10
 dystonia and, 292
 jitteriness and, 4
 partial prolonged, hypoxic-ischemic
 encephalopathy from, 10–11
- Asthmatic amyotrophy, 275
- Astrocytoma, 98–99, 99f–100f
 cerebellar, 228–229
 cystic, 98, 216
 noncommunicating hydrocephalus in, 359
 optic pathway, 325
 spinal, 267–268, 267f
 vs. syringomyelia, 216
- Asystole, reflex, in pallid syncope, 17
- Ataxia, 219–236
 acetazolamide-responsive, 221–222
 acute cerebellar, 224
 acute or recurrent, 219–228, 220t
 drug-induced, 220–221
 in basilar migraine, 223–224
 in benign positional vertigo, 224
 in brain tumors, 219
 in cerebellar hemorrhage, 227
 in conversion reaction, 220
 in encephalitis, 221
 in genetic disorders, 221–223
 in Hartnup disease, 222
 in Kawasaki disease, 227–228
 in maple syrup urine disease, 222–223
 in Miller Fisher syndrome, 224–225
 in multiple sclerosis, 225–226, 225f

Ataxia (*Continued*)

- in myoclonic encephalopathy/neuroblastoma syndrome, 226, 226f
- in postconcussion syndrome, 227
- in postinfectious/immune disorders, 224–226
- in pyruvate dehydrogenase deficiency, 223
- in trauma, 227
- in vascular disorders, 227–228
- in vertebrobasilar occlusion, 227
- chronic or progressive, 219, 220t, 228–236
 - in basilar impression, 231
 - in brain tumors, 228–230
 - in cerebellar astrocytoma, 228–229
 - in cerebellar hemangioblastoma, 229
 - in cerebellar malformations, 231–232, 231f, 232f
 - in Chiari I malformation, 232, 232f
 - in congenital malformations, 231–232, 232f
 - in ependymoma, 229–230
 - in medulloblastoma, 230, 230f
- differential diagnosis of, 219, 220t
- dominant recurrent, 221–223
- epileptic, 226–227
- episodic
 - type 1, 221
 - type 2, 221–222
- Friedreich, 235
- paroxysmal, 221
- progressive hereditary, 232–236
 - autosomal dominant, 232–233, 233t
 - autosomal recessive, 233–236
 - in abetalipoproteinemia, 233–234
 - in hypobetalipoproteinemia, 233
 - in infantile adrenoleukodystrophy, 236
 - in juvenile GM₂ gangliosidosis, 235
 - in juvenile sulfatide lipidosis, 235–236
 - in Marinesco-Sjögren syndrome, 236
 - in metabolic disorders, 236, 236t
 - in spinocerebellar degenerations, 232
 - with oculomotor apraxia, 234–235
- X-linked, 236
- Ataxia-telangiectasia, 234, 284
- Ataxic breathing, 50
- Atelencephaly, seizures and, 1
- Athetosis, 281–286
 - causes of, 282
 - with chorea. *See* Choreoathetosis.
- Atlantoaxial dislocation, 257–258
- Attention deficit disorder, in Tourette syndrome, 294–296
- Audiometry, pure-tone, 341
- Auditory dysfunction. *See also* Deafness; Hearing loss.
 - assessment of, 341–342
 - symptoms of, 340–341
- Auditory evoked responses, brainstem, 342
- Auditory nerve, lesions of, tone decay in, 342

Aura

- migraine with, 80–81
- vertigo as, 349
- Autistic spectrum disorders, developmental delay in, 117–119
- Autoimmune disorders. *See* Immune disorders.
- Automatisms, in complex partial seizures, 27
- Autonomic and sensory neuropathy, hereditary, 213–215. *See also* Hereditary sensory and autonomic neuropathy.
- Autonomic disorders. *See* Dysautonomia.
- Autoregulation, of cerebral blood flow, 91–92
- Axonopathy. *See also* Neuropathy.
 - diagnosis of, 182–183, 183t
 - giant, distal, 185–186
 - idiopathic, distal, 186–187
 - in hereditary tyrosinemia type I, 216
 - motor, acute, 192
- Back pain, in diskitis, 262
- Baclofen, in rapid-onset dystonia-parkinsonism, 292
- Ballismus, 282
- Barbiturate coma
 - in anoxia/ischemia, 52
 - in increased intracranial pressure, 97
 - in status epilepticus, 41, 42f
- Bardet-Biedl syndrome, 328
- Basal ganglia
 - idiopathic calcification of, 284
 - iron deposition in, in pantothenate kinase-associated neurodegeneration, 291
- Basilar artery
 - occlusion of, 244
 - spasm of, vertigo and, 351
- Basilar impression, ataxia in, 231
- Basilar migraine, ataxia in, 223–224
- Bassen-Kornzweig syndrome. *See* Abetalipoproteinemia.
- Batten disease, 142t, 143t, 144
- Becker muscular dystrophy
 - familial X-linked myalgia and, 209
 - proximal weakness in, 177
- Behavioral disturbances
 - in phenylketonuria, 127
 - in Tourette syndrome, 294–295
- Bell's palsy, 335–336, 338
- Benzodiazepines, in status epilepticus, 41
- Beta blockers, ototoxicity of, 345
- Betaine, in homocystinuria, 126
- Bethanechol, in familial dysautonomia, 154
- Bethlem myopathy, proximal weakness in, 176–177
- Bielschowsky test, in trochlear nerve palsy, 300
- Bilateral (central) transtentorial herniation, increased intracranial pressure and, 96
- Bilirubin encephalopathy, 8

- Biopsy**
 in motor unit hypotonia, 157
 liver, in Reye syndrome, 61
 muscle
 in central core disease, 163, 163f
 in motor unit hypotonia, 157
 in proximal weakness, 173t
- Biotin**, in infantile bilateral striatal necrosis, 291
- Biotinidase deficiency**, 22
- Birth**. *See* Perinatal *entries*.
- Blastomycosis**, 113
- Blepharospasm**, differential diagnosis of, 287, 287t
- Blindness**. *See also* Visual loss.
 acute, 320–325, 321t
 in optic neuropathies, 322–324, 323f
 in pituitary apoplexy, 324
 in retinal disease, 324–325
 cerebral, transitory posttraumatic, 321–322
 congenital, 317–320
 in cataract, 318, 319t
 in coloboma, 320
 in Leber congenital amaurosis, 320
 in optic nerve hypoplasia, 318–320, 320f
 cortical, 320–322
 in head injury, 321–322
 in hypoglycemia, 321
 vs. traumatic optic neuropathy, 324
 hysterical, 322
 in Devic disease, 265
 in neuronal ceroid lipofuscinoses, 142, 144
 transitory monocular, migraine and, 324–325
- Blink response**, 317
- Bloch-Sulzberger syndrome**. *See* Incontinentia pigmenti.
- Bone marrow transplantation**
 in adrenomyeloneuropathy, 263
 in Gaucher disease type II, 128–129, 140
- Borrelia burgdorferi***, 54. *See also* Lyme disease.
- Botulinum toxin A**
 in essential myoclonus, 294
 in hemifacial spasm, 292
 in hereditary spastic paraplegia, 261
 in spastic diplegia, 270
 in symptomatic generalized dystonia, 292
 in writer's cramp, 288
- Botulism**
 infantile, motor unit hypotonia in, 160–161
 late-onset, ophthalmoplegia in, 309
 neuromuscular blockade in, 193–194
 vs. idiopathic cranial polyneuropathy, 336
- Brachial plexitis/neuritis**, 274
 in osteomyelitis-neuritis, 276–277
- Brachial plexopathy**
 hereditary, 275–276
 neonatal traumatic, 276
- Brachial plexus**
 injuries of
 obstetrical, 276
 traction and pressure, 277
 palsy of, in neonates, 276
 tumors of, 278
- Brachycephaly**, 368t
- Brain**. *See also* Cerebral *entries*.
 chronic damage to, nonparalytic strabismus in, 299
 compression of, arachnoid cysts and, 101–102
 hemorrhage into. *See under* Hemorrhage.
 herniation syndromes of, increased intracranial pressure and, 95–96, 95t
 infection of, increased intracranial pressure and, 106–113
 inflammation of. *See* Encephalitis.
 injury to. *See* Encephalopathy; Head injury.
- Brain abscess**, 110–111, 245
- Brain death**, 52, 53t
- Brain tumors**, 97–101, 97t
 ataxia in
 acute, 219
 chronic, 228–230
 congenital, noncommunicating hydrocephalus in, 359
 hemiplegia in, 242, 251
 hemispheric, 97–101
 hydrocephalus in, 97
- Brainstem**
 disorders of, ophthalmoplegia from, 303t
 glioma of
 facial palsy and, 340
 ophthalmoplegia in, 303–304, 304f
 vs. facioscapulohumeral syndrome, 337
 vs. idiopathic cranial polyneuropathy, 336
 lesions of, upbeat nystagmus in, 316
 lower, disorders of, 331–351
- Brainstem auditory evoked responses**, 342
- Brainstem stroke**, 304
- Branched-chain amino acids**
 in maple syrup urine disease, 4–5
 metabolism of, disorders of, 6f
- Breath-holding spells**, in infants, 16
- Breathing**
 apneustic, 50
 ataxic, 50
 cessation of. *See* Apnea.
 periodic, 3
 sleep-disordered, sleep terrors and, 25
- Breech presentation**, injuries in, 155–156
- Brody myopathy**, 207–208
- Brown syndrome**, 301
- Brown-Vialetto-van Laere syndrome**. *See* Pontobulbar palsy with deafness.
- Brudzinski sign**, in bacterial meningitis, 108
- Bulbar palsy**, juvenile progressive, 336, 337

- Bulbar polio, 193
 Burns, encephalopathy in, 67
- Café au lait spots
 in neurofibromatosis, 135
 in tuberous sclerosis, 135
- Caffeine
 headache from, 84
 tics and, 295
- Calcification
 intracranial, in congenital toxoplasmosis, 122
 of basal ganglia, 284
- Calcinosis universalis, 179, 180
- Calcium channel blockers
 in alternating hemiplegia, 241
 in episodic ataxia, 222
- Calcium channels, skeletal muscle, neuroleptic malignant syndrome and, 209–210
- Calf muscles, in Duchenne muscular dystrophy, 176f, 177
- California encephalitis, 56–57
- Caloric testing, in vertigo, 348
- Campylobacter jejuni*, 224
- Canavan disease, 138
- Candidal meningoencephalitis, 111–112
- Capsular stroke, 246–247
- Carbamazepine, 37
 dosage of, 36t
 in continuous motor unit activity, 201, 202
 in episodic ataxia type 1, 221
 in hemifacial spasm, 292
 tics from, 295
- Carbamyl phosphate synthetase deficiency, 7
- Carbidopa, in dystonia, 241, 289
- Carbohydrate(s), administration of, in acute intermittent porphyria, 215–216
- Carbohydrate-deficient glycoprotein syndrome, developmental delay in, 132
- Carbohydrate myopathies, proximal weakness in, 181
- Carbohydrate utilization defects, exercise intolerance in, 203–205
- Carbon dioxide, arterial, cerebral blood flow and, 92
- Carcinoma, choroid plexus, 98
- Cardiac arrest
 anoxia and ischemia after, 51–52
 deep midline arteriovenous malformation and, 105
- Cardiopulmonary bypass surgery, choreoathetosis in, 283
- Carnitine
 deficiency of, 65, 65t, 181
 in glycine encephalopathy, 5
 supplementation of
 in glutaric acidemia type 1, 289
 in very-long-chain acyl-CoA dehydrogenase deficiency, 206
- Carnitine O-palmitoyltransferase-2 deficiency, 205
- Carotid artery
 aneurysm of, oculomotor palsy from, 105
 disorders of, hemiplegia in, 242
 occlusion of
 cervical infection and, 242–243
 fibromuscular dysplasia and, 243
 trauma to, 243–244
- Carotid-cavernous sinus fistula, 304
- Carpal tunnel, median nerve compression in, 278–279
- Carpenter syndrome, 369
- Cat-scratch disease, 52–53, 242–243
- Cataplexy, 24–25
- Cataract
 congenital, 318, 319t
 differential diagnosis of, 319t
 in Marinesco-Sjögren syndrome, 236
- CATCH syndrome, in neonates, 9
- Caudal regression syndrome, 258
- Causalgia, 212
- Caveolinopathies, 176
- Cavernous sinus
 disorders of, vs. Tolosa-Hunt syndrome, 308
 fistula of, 304
 thrombosis of, 304–305
- Cefotaxime, 107, 107t, 108, 109t
- Ceftazidime, 107, 107t, 108, 109t
- Ceftriaxone
 in bacterial meningitis, 108, 109t
 in Lyme disease, 54
- Cellular migration, defective, 366–367
- Central core disease, motor unit hypotonia in, 162–163, 163f
- Central nervous system. *See also* Brain; Spinal cord.
 fungal infections of, 111–113, 111t
 in systemic lupus erythematosus, 68
 isolated angiitis of, 249
- Centronuclear myopathy, motor unit hypotonia in, 164
- Cephalic presentation, injuries in, 156
- Ceramide deficiency, 128
- Cerebellar artery, arteriovenous malformations of, 105
- Cerebellar ataxia, 219, 224, 227, 236
- Cerebellar degenerations, downbeat nystagmus in, 315
- Cerebellar malformations, ataxia in, 231–232, 231f, 232f
- Cerebellar vermis
 agenesis of, in Dandy-Walker malformation, 358, 358f
 aplasia of, 231–232
 lesions of, upbeat nystagmus in, 316
- Cerebellitis, acute postinfectious, 224

- Cerebellum**
 astrocytoma of, 228–229
 congenital hypoplasia of, 231, 231f
 disorders of
 ataxia in, 219. *See also* Ataxia.
 clinical features of, 219
 vs. essential tremor, 296
 hemangioblastoma of, 229
 hemorrhage into, ataxia in, 227
 herniation of, increased intracranial pressure and, 96
 tumors of, 228–230
 X-linked hypoplasia of, 232
- Cerebral abscess**, 110–111, 245
- Cerebral artery infarction**, 247
- Cerebral blindness**, transitory posttraumatic, 321–322
- Cerebral blood flow**, autoregulation of, 91–92
- Cerebral cysticercosis**, partial seizures in, 30
- Cerebral edema**
 bilateral transtentorial herniation and, 96
 cytotoxic, 92
 in diabetic ketoacidosis, 62
 in hypertensive encephalopathy, 67, 67f
 in hypoxic-ischemic encephalopathy, 11
 in maple syrup urine disease, 5
 in severe hypoxia, 52
 increased intracranial pressure from, 92
 interstitial, 92
 vasogenic, 92, 96–97
- Cerebral gigantism**, 362
- Cerebral hemispheres**
 cysts of, 360–361
 demyelination of, in Krabbe disease, 124f, 129
 glioma of, noncommunicating hydrocephalus in, 359
 laceration of, hemiplegia in, 251
 metastasis to, 101
 thromboembolism of, in homocystinuria, 125
 tumors of, 97–101, 97t
 vasculitis of, headache and, 86
- Cerebral hypotonia**. *See* Hypotonia, cerebral.
- Cerebral infarction**, 102–103. *See also* Stroke.
 carotid artery occlusion and, 242–244
 causes of, 242t
 evaluation of, 242, 243t
 focal clonic seizures in, 2
 from cocaine abuse, 244
 in congenital heart disease, 245
 in hypercoagulable states, 246, 246t
 in hypersensitivity vasculitis, 249
 in MELAS syndrome, 247–248
 in mitral valve prolapse, 245–246
 in Moyamoya disease, 248
 in sickle cell disease, 249
 incidence of, 241
 infections and, 250
 internal capsule, 246–247
- Cerebral infarction (Continued)**
 neonatal, 239–240
 vertebral artery trauma and, 244
- Cerebral malformations**
 amino acid metabolic disorders and, 125
 developmental delay in, 120–121
- Cerebral palsy**
 differential diagnosis of, 269t
 feeding problems in, 332
 hemiplegic, 239–240, 240f
 paraplegia in, 269–270, 269t
- Cerebral paraplegia**, 269–270
- Cerebral perfusion pressure**, 92
- Cerebral venous thrombosis**, idiopathic, in neonates, 13
- Cerebral vessels**, aplasia of, microcephaly and, 367
- Cerebrohepatorenal syndrome**
 cerebral hypotonia in, 154–155
 hearing loss in, 343
- Cerebrospinal fluid**
 absorption of, 92
 formation of, 91
 in bacterial meningitis, 108
 in hydrocephalus, 91
 in tuberculous meningitis, 109–110
 intracranial, in hydrocephalus, 97
 intracranial pressure and, 91
 leakage of, skull fracture and, 74
 leukocytosis of, 56, 57
 replacement of brain by. *See* Hydranencephaly.
- Cerebrotendinous xanthomatosis**, 146
- Cerebrovascular disease**. *See also specific disorders*, e.g., Arteriovenous malformations.
 causes of, 242t
 evaluation of, 242, 243t
 hemiplegia in, 241–250
- Cerebrum**. *See* Cerebral hemispheres.
- Ceroid lipofuscinoses**. *See* Neuronal ceroid lipofuscinoses.
- Cervical arteritis**, 242–243
- Cervical roots**, pain from, 78
- Cervical spinal cord**
 traction injury to, 155–156
 twisting injury to, 156
- Cervical spinal muscle atrophy**, congenital, 159
- Cervicomedullary compression**, in achondroplasia, 361
- Cervicomedullary tumors**, 98–99
- Channelopathies**, paroxysmal disorders in, 1
- Charcot-Marie-Tooth disease**. *See also* Hereditary sensory and autonomic neuropathy.
 distal weakness in, 184–185, 184t
 type 1 (demyelinating), 184–185
 type 2 (neuronal), 185
 type 3, 185
 type 4, 185
 type X, 185

- Chelating agents, in Wilson disease, 290
- Chenodeoxycholic acid, in cerebrotendinous xanthomatosis, 146
- Cherry-red spot of macula
in Niemann-Pick disease, 132
lysosomal enzyme disorders with, 130, 130t
- Cheyne-Stokes respiration, 50
- Chiara malformation, 232, 232f, 258, 315
- Child abuse, shaking injuries and, 72–73
- Childhood disintegrative disorder, 144
- Chloramphenicol
in bacterial meningitis, 108, 109t
in brain abscess, 111
in Rocky Mountain spotted fever, 55
- Chlorocresol, cranial nerve toxicity of, 339
- Chlorpromazine, in neonatal drug withdrawal, 8–9
- Choking, anoxia after, 51–52
- Cholestatic liver disease, demyelination in, 378
- Cholesteatoma
hearing loss in, 346
vertigo in, 349
- Chorea, 281–286
benign familial (hereditary), 284
conditions that may include, 282t, 283
differential diagnosis of, 282–283, 282t
drug-induced, 283
in emergent withdrawal syndrome, 284
in Fahr disease, 284
in hyperthyroidism, 285
in systemic lupus erythematosus, 285
Sydenham (rheumatic), 285–286
vs. myoclonus, 293
vs. tics, 294
- Chorea gravidarum, 285
- Choreoacanthocytosis, 284–285
- Choreoathetosis
conditions that may include, 282t, 283
differential diagnosis of, 282–283, 282t
in cardiopulmonary bypass surgery, 283
in herpes encephalitis, 59
paroxysmal, 23, 285
- Choriomeningitis, lymphocytic, 56
- Chorioretinitis, in congenital toxoplasmosis, 122
- Choroid plexus
arteriovenous malformations of, 105
carcinoma of, 98
papilloma of, 97–98
cerebrospinal fluid formation in, 91, 355
noncommunicating hydrocephalus in, 359
- Chromosome(s)
analysis of, clinical indications for, 120, 120t
disorders of
autosomal, 120t
cerebral hypotonia in, 152–153
- Chromosome(s) (*Continued*)
congenital cataract in, 318
developmental delay in, 119–120, 120t
hearing loss in, 342
microcephaly in, 364
- Chromosome 22q11.2 microdeletion syndrome, in neonates, 9
- Cingulate gyrus, herniation of, 95
- Cisplatin, ototoxicity of, 345
- Clavicle, fracture of, 277
- Clonazepam, 37
dosage of, 36t
in downbeat nystagmus, 315
in essential myoclonus, 294
in infantile spasms, 20
in paroxysmal dystonic head tremor, 297
in segmental myoclonus, 294
- Clonidine, in tics, 296
- Clostridium botulinum*, 160. *See also* Botulism.
- Clumsiness of gait
in sensory neuropathy, 211
in spinal paraplegia, 255–256
- Cluster headache, 83
- Coagulopathy, 246t
cerebral infarction in, 242t, 246
retinal artery occlusion and, 324
- Coarctation of the aorta, arterial aneurysms and, 104
- Coates disease, 178
- Cocaine abuse
altered states of consciousness in, 71
cerebral infarction from, 244
headache from, 85
intracranial hemorrhage from, 106
- Coccidioidal meningitis, 112, 113t
- Cochlea
anatomy of, 340
lesions of, 342
- Cockayne syndrome
distal weakness in, 186
pigmentary retinopathy in, 328
- Coenzyme Q, 206
- Coenzyme Q10, in MELAS syndrome, 248
- Collagen vascular disease, 249, 306
- Coloboma, 318, 320
- Coma
barbiturate
in anoxia/ischemia, 52
in increased intracranial pressure, 97
in status epilepticus, 41, 42f
causes of, 49t
definition of, 48t
diagnostic approach to, 50–51
hepatic, 64
high road to, 47, 48t
history in, 50
hypoglycemic, 62

- Coma (*Continued*)
 laboratory investigations in, 51
 low road to, 47, 48t
 migraine, 68–69
 myxedema, 64
 physical examination in, 50–51
 quantification of responsiveness in, 73, 73t
- Commissurotomy, interhemispheric,
 in epilepsy, 43
- Complex regional pain syndrome
 type I, 211–212
 type II, 212
- Computed tomography
 in congenital aqueductal stenosis, 357, 357f
 in Dandy-Walker malformation, 358, 358f
 in hypoxic-ischemic encephalopathy, 11
 of subarachnoid space enlargement, 355, 356f
- Concussion
 ataxia after, 227
 in head injury, 72
 spinal cord, 267
 vestibular, 350–351
- Confusion, 47
 causes of, 48t
 in concussion, 72
- Congenital malformations. *See* Malformation(s),
 congenital.
- Conjugate gaze, abnormalities of, 299–300
- Connective tissue disorders
 headache in, 86
 mixed, 249
- Consciousness
 altered states of, 47–74, 48t. *See also specific disorders, e.g., Coma.*
 decreased, states of, 47, 48t
 loss of
 in cyanotic syncope, 16–17
 in generalized tonic-clonic seizures, 33
- Conus medullaris, deformities of, in
 myelomeningocele, 259
- Convergence insufficiency, after head injury, 312
- Convergence paralysis, 311t, 312
- Conversion reaction, ataxia in, 220
- Copper
 accumulation of, in Wilson disease, 289–290
 deficiency of, in Menkes syndrome, 137–138
- Corneal clouding, differential diagnosis of, 318,
 318t
- Corpus callosum
 agenesis of, 366
 dysgenesis of, 361
 thinning of, 231f
- Cortical atrophy, in gray matter disorders, 124
- Cortical blindness, 320–322
 in head injury, 321–322
 in hypoglycemia, 321
 vs. traumatic optic neuropathy, 324
- Corticosteroids. *See also specific agents, e.g., Prednisone.*
 in adrenomyeloneuropathy, 263
 in dermatomyositis, 179–180
 in diffuse encephalomyelitis, 265
 in herpes zoster myelitis, 263
 in idiopathic axonal neuropathy, 186–187
 in idiopathic cranial polyneuropathy, 336
 in increased intracranial pressure, 96–97
 in infantile spasms, 20
 in multiple sclerosis, 225
 in myasthenia, 307
 in myoclonic encephalopathy/neuroblastoma
 syndrome, 226
 in pituitary apoplexy, 324
 in polymyositis, 180
 in transverse myelitis, 265
 psychosis from, 70
 quadriplegia from, 194
- Counseling, in pseudoseizures, 34
- Coxiella burnetii*, ataxia from, 225
- Coxsackievirus infections
 ataxia from, 225
 distal weakness in, 193
- Cramp(s), 199, 200t
 in carbohydrate utilization defects, 203
 in familial X-linked myalgia, 209
 in hypoadrenalism, 202
 in hypothyroidism, 202
 in myophosphorylase deficiency, 204
 in myotonia fluctuans, 202
 in neuromyotonia, 201
 in uremia, 203
 myopathic, 207–210
 on exercise, 177, 196, 199, 203. *See also Exercise intolerance.*
 silent, 200t
 tubular aggregates and, 208–209, 208f
 writer's, 288
- Cranial nerves
 compression of, in osteopetrosis,
 337–338
 dysfunction of, 331–351
 in sucking reflex, 331
 pain from, 78
 palsy of
 ataxia with, 221
 idiopathic, 305
 in brainstem glioma, 303–304
 in hereditary brachial plexopathy, 276
 recurrent, 333t
 toxin-induced, 339
- Cranial polyneuropathy, idiopathic, 336
- Cranial sutures, premature closure of. *See*
 Craniostenosis.
- Cranio cervical skeleton, malformation of, in
 Klippel-Feil syndrome, 358–359

- Craniofacial abnormalities, in peroxisomal disorders, 155
- Craniofacial dysostosis, 369
- Craniofacial dysplasia, in holoprosencephaly, 365
- Craniopharyngioma, 325
- Craniostenosis, 368–369
 - disorders associated with, 368t
 - vs. failure of brain growth, 363–364
 - with fusion of fingers and toes, 368–369
- Craniovertebral junction, disorders of, 231
- Creatine, supplementation of, in
 - myophosphorylase deficiency, 205
- Creatine kinase, serum
 - in motor unit hypotonia, 156–157
 - in proximal weakness, 173t
- Crouzon disease, 369
- Cryotherapy, in retinal hemangioblastoma, 229
- Cryptococcal meningitis, 112–113, 113t, 141
- Cushing syndrome, 327
- Cyanosis, in infantile syncope, 16–17
- Cyanotic heart disease
 - arterial embolism in, 245
 - cerebral abscess in, 245
 - venous thrombosis in, 245
- Cyclosporine encephalopathy, 70
- Cyst(s)
 - arachnoid
 - intracranial, 101–102
 - spinal paraplegia in, 256–257
 - hemispheric, 360–361
 - in leukoencephalopathy, 363
 - pineal, 101
- Cystathionine- β -synthase deficiency, in
 - homocystinuria, 125, 125f
- Cystic astrocytoma, 98, 216
- Cysticercosis, cerebral, partial seizures in, 30
- Cytochrome-c-oxidase deficiency, motor unit hypotonia in, 159, 168
- Cytomegalic inclusion disease, developmental delay in, 121–122
- Cytomegalovirus infection, intrauterine
 - congenital deafness and, 343
 - microcephaly and, 367
- Cytotoxic cerebral edema, 92
- Dalrymple sign, in Graves ophthalmopathy, 310
- Dandy-Walker malformation
 - noncommunicating hydrocephalus in, 357–358, 358f
 - Walker-Warburg syndrome and, 360
- Dandy-Walker syndrome, 231
- Danon disease, 175–176
- Dantrolene
 - in Brody myopathy, 208
 - in malignant hyperthermia, 209
- de Morsier syndrome. *See* Septo-optic dysplasia.
- Deafness, 340–347. *See also* Hearing loss.
 - congenital, 342–344
 - differential diagnosis of, 344, 345t
 - isolated, 343
 - pontobulbar palsy with, 336, 344–345
- Deafness–dystonia–optic neuronopathy syndrome, 344
- Death, brain, 52, 53t
- Debrancher enzyme deficiency, proximal weakness in, 181
- Decarboxylase inhibitor, in thalamic pain, 218
- Decerebrate posturing
 - in comatose patients, 51
 - in premature infants, 3
- Decorticate rigidity, 51
- Deep brain stimulation
 - in essential tremor, 296
 - in idiopathic torsion dystonia, 290
- Dehydration, in hypernatremia, 62
- Dejerine-Sottas syndrome, 185
- Delirium
 - diagnostic approach to, 47–49
 - history in, 48
 - laboratory investigations in, 48–49
 - physical examination in, 48
- Delivery. *See* Perinatal *entries*.
- Delusions, 47
- Dementia. *See also* Developmental delay.
 - dialysis, 66–67
 - progressive, 123t, 139–146
- Demyelinating polyradiculoneuropathy
 - acute inflammatory, 191–192
 - chronic inflammatory, 192–193
- Demyelination
 - diagnosis of, 183, 183t
 - in Charcot-Marie-Tooth disease, 184–185
 - in cholestatic liver disease, 378
 - of cerebral hemispheres, in Krabbe disease, 124f, 129
 - of facial nerve, postinfectious, 335–336
 - of optic nerve, 322–323, 323f
 - of spinal cord, in transverse myelitis, 264–266, 265f
 - postinfectious, 59–60, 60f
- Denver Developmental Screening Test, 117
- Depression, chronic headache in, 85
- Depressor anguli oris muscle, aplasia of, 334
- Dermacentor andersoni*, paralysis from, 194
- Dermacentor variabilis*, paralysis from, 194
- Dermal sinus, in tethered spinal cord, 260
- Dermatomes, nerve root pain from, 211
- Dermatomyositis
 - perifascicular atrophy in, 179, 180f
 - proximal weakness in, 179–180
- Dermatosis, congenital cataract and, 318

- Developmental delay, 117–123. *See also*
 Encephalopathy, progressive.
 assessment of, 117
 differential diagnosis of, 117, 118t
 global, 118t, 119–123
 hearing loss in, 119
 in acquired immunodeficiency syndrome,
 124–125
 in amino acid metabolism disorders, 125–128
 in autistic spectrum disorders, 117–119
 in bilateral hippocampal sclerosis, 119
 in carbohydrate-deficient glycoprotein syndrome,
 132
 in cerebral malformations, 120–121
 in chromosome disorders, 119–120, 120t
 in congenital syphilis, 121
 in cytomegalic inclusion disease, 121–122
 in fragile X syndrome, 120
 in globoid cell leukodystrophy, 129, 140
 in glycoprotein degradation disorders, 129
 in GM₁ gangliosidosis, 129–130
 in GM₂ gangliosidosis, 130, 139
 in homocystinuria, 125–126, 125f
 in hypothyroidism, 133
 in I-cell disease, 131
 in intrauterine infections, 121–122
 in lysosomal enzyme disorders, 128–132,
 139–141
 in maple syrup urine disease, 126
 in metachromatic leukodystrophy, 132, 140
 in mitochondrial disorders, 133–134, 145
 in mucopolysaccharidoses, 131, 140–141
 in neurocutaneous syndromes, 134–135
 in Niemann-Pick disease, 132, 141
 in perinatal disorders, 123
 in phenylketonuria, 126–128, 127f
 in progressive encephalopathies
 after age 2, 139–146
 before age 2, 123–139
 in rubella embryopathy, 122
 in speech, 117–119, 118t
 in sulfatase deficiency disorders, 132
 in toxoplasmosis, 122
 informing parents about, 123
 of language, 117–119, 118t
 of motor skills, 118t, 119
 in neuromuscular disease, 171
 in spinal muscle atrophy, 174
 pervasive, 118
 seizures and, 18
 vs. regression, 117
- Devic syndrome, 265, 322
- Dexamethasone
 in astrocytoma, 99
 in bacterial meningitis, 108
 in increased intracranial pressure, 96–97
- Dextroamphetamine, chorea from, 283
- Diabetes insipidus
 in craniopharyngioma, 325
 in Wolfram syndrome, 327
- Diabetes mellitus
 hemiplegia in, 244
 hypoglycemic encephalopathy in, 62
 in craniopharyngioma, 325
 in Wolfram syndrome, 327
 ketoacidosis in, encephalopathy and, 62
- Dialysis
 cramps in, 203
 encephalopathy in, 66
 headache and, 86–87
 in maple syrup urine disease, 5
 neuropathy in, 188
- Dialysis dementia syndrome, 66–67
- 3,4-Diaminopyridine (DAP)
 in botulism, 309
 in congenital myasthenia gravis, 302
 in familial infantile myasthenia, 162
- Diastematomyelia, in tethered spinal cord, 260,
 261f
- Diazepam
 in glycine encephalopathy, 5
 in rapid-onset dystonia-parkinsonism, 292
 in status epilepticus, 41
 in vestibular neuritis, 349
 in vestibular nystagmus, 315
- Dichloroacetate, in MELAS syndrome, 248
- Diencephalic syndrome, 326
- Diencephalon, glioma of, 325–326
- Diet
 in abetalipoproteinemia, 234
 in carnitine *O*-palmitoyltransferase-2 deficiency,
 205
 in galactosemia, 138
 in homocystinuria, 126
 in isovaleric acidemia, 11–12
 in maple syrup urine disease, 5, 126, 223
 in medium-chain acyl-CoA dehydrogenase
 deficiency, 65
 in methylmalonic acidemia, 12
 in phenylketonuria, 128
 in very-long-chain acyl-CoA dehydrogenase
 deficiency, 206
 ketogenic
 in epilepsy, 41–42
 in pyruvate dehydrogenase deficiency, 223
 low-protein
 in arginase deficiency, 264
 in maple syrup urine disease, 5, 126, 223
 in methylmalonic acidemia, 12
 in neonatal urea cycle disorders, 7
 in propionic acidemia, 12–13
- DiGeorge syndrome
 facial palsy in, 334
 in neonates, 9

- Dihydroergotamine, in migraine, 82
 Dimorphic fungal pathogens, 111, 111t
 Diphtheria, facial palsy and, 339
 Diplacuisis, 342
 Diplegia
 facial, 334, 336
 spastic, 269–270
 Diplomyelia, in tethered spinal cord, 260, 261f
 Diplopia
 in increased intracranial pressure, 93
 in myasthenia, 305, 306
 papilledema and, 94
 Disk herniation, lumbar, 216
 Diskitis (disk space infection), 262, 262f
 Dislocation
 atlantoaxial, 257–258
 of hip, in intrauterine hypotonia, 149
 of humerus, 277
 of lens, in homocystinuria, 125
 of pelvis, 277–278
 of vertebral column, 266–267, 267f
 Dissociated nystagmus, 316
 Diuretics, osmotic, in increased intracranial pressure, 96
 Diurnal variation, dystonia with, 288–289
 Dizziness. *See* Vertigo.
 DNA viruses, encephalitis from, 55
 Dopa-responsive dystonia, 288–289
 Dopamine antagonists, dystonia from, 287
 Dorsal midbrain, lesions of, vertical gaze palsy in, 312
 Double hemiplegia, 270
 Down syndrome, atlantoaxial dislocation in, 257
 Downbeat nystagmus, 315
 Downward-beating nystagmus, 315
 Doxycycline
 in Lyme disease, 54
 in Rocky Mountain spotted fever, 55
 Drug(s)
 abuse of. *See* Substance abuse.
 ataxia from, 220–221
 chorea from, 283
 dystonia from, 283, 287
 embryo exposure to, cerebral malformations from, 121
 headache from, 85–86
 internuclear ophthalmoplegia from, 312
 maternal abuse of
 cerebral malformations from, 121
 microcephaly and, 367
 neuropathy from, 187–188, 187t
 nystagmus from, 314
 optic neuropathy from, 323
 ototoxic, 345
 overdose of
 encephalopathy from, 70
 ophthalmoplegia from, 309
 Drug(s) (*Continued*)
 tardive dyskinesia from, 283
 tics from, 295
 vestibular toxicity of, 348–349
 withdrawal from, in neonates, 8–9
 Drusen, in congenitally elevated disks, 94, 95f
 Duane syndrome, abducens nerve palsy in, 301
 Duchenne muscular dystrophy
 calf muscles in, 176f, 177
 proximal weakness in, 177–178
 Dysarthria
 in pantothenate kinase–associated neurodegeneration, 291
 in pseudobulbar palsy, 332
 in Wilson disease, 290
 Dysautonomia
 familial
 feeding problems in, 154, 332
 type I, 154, 214
 type II, 215
 tonic pupil syndrome and, 329
 Dysesthesia, 211
 in foramen magnum tumors, 213
 in hereditary tyrosinemia type I, 216
 in migraine with aura, 80
 in neuropathy, 182
 Dysferlin myopathy, 189
 Dyskinesia
 lingual-facial-buccal, in emergent withdrawal syndrome, 284
 paroxysmal, 23
 tardive, 282, 283
 Dysmetria
 ocular, 313, 313t
 overshoot, in internuclear ophthalmoplegia, 311
 Dysmorphic features, in hypotonia, 151, 152
 Dysostosis multiplex, in Hurler syndrome, 131
 Dysphagia, 331–340
 congenital, 333–334
 differential diagnosis of, 331, 332t
 in congenital bilateral perisylvian syndrome, 333
 in juvenile progressive bulbar palsy, 337
 in oculopharyngeal muscular dystrophy, 337
 neurological causes of, 333t
 Dysplasia
 anhidrotic ectodermal, congenital cataract and, 318
 craniofacial, in holoprosencephaly, 365
 fibromuscular, 243
 septo-optic
 optic nerve hypoplasia and, 318
 vs. Walker-Warburg syndrome, 360
 skeletal, in Hurler syndrome, 131
 Dysraphic states
 microcephaly and, 364, 365
 spinal paraplegia and, 256, 258–261

- Dystonia, 286–292**
 alternating hemiplegia and, 241
 differential diagnosis of, 286, 286t
 dopa-responsive, 288–289
 drug-induced, 283, 287
 familial nonkinesiogenic, 23
 focal, 287–288, 287t
 generalized
 genetic, 288–292
 symptomatic, 292
 idiopathic torsion, 290
 in deafness–dystonia–optic neuronopathy syndrome, 344
 in hemifacial spasm, 292
 in infantile bilateral striatal necrosis, 291
 in pantothenate kinase–associated neurodegeneration, 291
 in paroxysmal dystonic head tremor, 297
 in Wilson disease, 289–290
 tardive, 287
 with diurnal variation, 288–289
 with parkinsonism, 288–289
 rapid-onset, 291–292
- Dystrophin, deficiency of**
 in familial X-linked myalgia and cramps, 209
 in muscular dystrophy, 177–178, 177t
- Dystrophy. *See also* Adrenoleukodystrophy; Leukodystrophy.**
 facioscapulohumeral, proximal weakness in, 178
 muscular. *See* Muscular dystrophy.
 myotonic
 congenital, motor unit hypotonia in, 167
 distal, 190
 proximal, 178
 neuroaxonal, infantile, 136–137
 reflex sympathetic, 211–212
- Ear**
 anatomy of, 340
 congenital malformations of, 342
 hearing disorders of. *See* Deafness; Hearing loss.
- Eastern equine encephalitis, 57**
- Echoviruses**
 ataxia from, 225
 distal weakness in, 193
- Ectodermal dysplasia, anhidrotic, congenital**
 cataract and, 318
- Eczema, in phenylketonuria, 127**
- Edema**
 cerebral. *See* Cerebral edema.
 in leukoencephalopathy, 363
 of face, in Melkersson syndrome, 338
 of optic disk. *See* Papilledema.
- Edrophonium chloride test**
 in familial infantile myasthenia, 161
 in motor unit hypotonia, 157
 in myasthenia, 306
- Elbow**
 in median neuropathy, 278–279
 in ulnar neuropathy, 278
- Electric storm, in hemorrhagic shock**
 encephalopathy syndrome, 54
- Electrodiagnosis, in neuropathy, 182–183, 183t**
- Electroencephalography**
 in absence epilepsy, 26–27, 27f
 in delirium, 49
 in dialysis dementia syndrome, 66–67
 in hemorrhagic shock encephalopathy syndrome, 54
 in hypoxic-ischemic encephalopathy, 10–11
 in juvenile myoclonic epilepsy, 28, 29f
 in myoclonic seizures of infancy, 20–21, 20t
 in pentobarbital coma, 41, 42f
- Electromyography**
 in motor unit hypotonia, 157
 in proximal weakness, 173t
- Embolism**
 arterial, in cyanotic heart disease, 245
 thrombotic, cerebral, in homocystinuria, 125
- Embryopathy, rubella**
 chronic panencephalitis and, 142
 developmental delay in, 122
- Emergent withdrawal syndrome, 284**
- Emery-Dreifuss muscular dystrophy**
 type 1, 190–191
 type 2, 191
- Empyema, subdural and epidural, 111**
- Encephalitis. *See also* Meningoencephalitis.**
 arboviral (arthropod-borne), 56–58
 brainstem
 ataxia in, 221
 vs. Miller Fisher syndrome, 225
 California–La Crosse, 56–57
 definition of, 47
 Eastern equine, 57
 herpes, 13, 58–59, 59f
 in cat-scratch disease, 53
 incidence of, 55
 Japanese B, 57
 measles (rubeola), 59, 142
 postinfectious, 59–60, 60f
 seizures from, 17
 St. Louis, 57
 viral causes of, 55
 hearing loss from, 345–346
 West Nile virus, 57–58
 Western equine, 58
- Encephalocele**
 in congenital midline porencephaly, 361
 microcephaly and, 365
 transsphenoidal, morning glory disk and, 320
- Encephalomyelitis**
 diffuse, 265–266
 disseminated, acute, 59–60, 60f

- Encephalomyelopathy, necrotizing, subacute, 134, 223, 291
- Encephalomyopathy, mitochondrial
in MELAS syndrome, 247–248
progressive, 133–134, 145
- Encephalopathy. *See also* Leukoencephalopathy.
AIDS, 124–125, 141–142
bilirubin, 8
burn, 67
cyclosporine, 70
definition of, 47
dialysis, 66
drug overdose and, 70
dystonia and, 292
epileptic, infantile, early, 21
glycine, 5
Hashimoto's, 64
hemorrhagic shock, 53–54
hepatic, 64
hypernatremic, 62–63
hypertensive, 67, 67f
hyponatremic, 63
hypoxic-ischemic, 51–52
in neonates, 10–11
immunosuppressive drugs and, 69–70
in diabetic ketoacidosis, 62
in Lyme disease, 54
in systemic lupus erythematosus, 68
in total parenteral nutrition, 67
metabolic, 64–65, 65t, 67–68
myoclonic
early, 21
with neuroblastoma, 226, 226f
necrotizing, subacute, 68
postanoxic, delayed, 52
postimmunization, 61
progressive, 117. *See also* Developmental delay.
differential diagnosis of, 118t, 123–124, 123t
infantile (before age 2), 117, 118t, 123–139
juvenile (after age 2), 123t, 139–146
recurrent, causes of, 50t
static
cerebral hypotonia in, 153–154
regression in, 118t
toxic, 69–71
uremic
acute, 65–66
chronic, 66
Wernicke, 67–68
- Endocrine disorders
altered states of consciousness in, 63–64
myopathy in, 182
- Enterococcal infection, meningitis in, 106
- Enterovirus infection, weakness in, 193
- Ependymoma, 99–100
ataxia in, 229–230
of spinal cord, 268
- Epidermal nevus syndrome, 19t, 362–363
- Epidural empyema, 111
- Epidural hematoma, 73, 74, 74f
spinal, 267
- Epilepsia partialis continua, 32
- Epilepsy. *See also* Seizures; Status epilepticus.
absence, childhood or juvenile, 26–27, 27f
after neonatal hypoxic-ischemic encephalopathy, 11
altered states of consciousness in, 48t, 49t
ataxia in, 226–227
benign childhood, with centrotemporal spikes, 31–32
frontal lobe, nocturnal, autosomal dominant, 31
hemiplegia in, 244–245
ictal vomiting associated with, 31
in infants
benign familial, 19
myoclonic
benign, 21
severe, 21–22
ketogenic diet for, 41–42
migraine and, 22–23
myoclonic
and ragged red fibers, 145
benign, 21
juvenile, 28, 29f, 71–72
progressive, 28–29, 29t
severe, 21–22
occipital, benign, 31, 88
posttraumatic, 74
reading, 32–33
rolandic
autosomal dominant, and speech apraxia, 30
benign, 31
surgical treatment of, 42–43
temporal lobe, 33
transitory posttraumatic cerebral blindness and, 321
vagal nerve stimulation for, 42
vertigo in, 349
with generalized tonic-clonic seizures on awakening, 34
- Epileptic encephalopathy, infantile, early, 21
- Epileptiform aphasia, acquired, 30
- Epileptiform opercula syndrome, acquired, 30
pseudobulbar palsy in, 332
- Episodic ataxia
type 1, 221
type 2, 221–222
- Escherichia coli* infection, meningitis in, 106, 107
- Esotropia, 299–300
- Ethosuximide, 37–38
chorea from, 283
dosage of, 36t
in absence epilepsy, 27
- Ethylene glycol, cranial nerve toxicity of, 339

- Ewing's sarcoma, spinal cord compression in, 267
- Exanthems, childhood, hearing loss in, 346
- Exedrin Migraine, 82
- Exercise
- ATP replenishment in, 203
 - exertional headache in, 84
 - migraine from, 79
- Exercise intolerance, 199, 200t, 203–207
- in Brody myopathy, 208
 - in carbohydrate (glucose) utilization defects, 203–205
 - in long-chain fatty acid metabolism defects, 205–206
 - in mitochondrial myopathy, 206–207, 206f, 207t
 - in myoadenylate deaminase deficiency, 207
 - in rippling muscle disease, 210
- Exophthalmos. *See* Proptosis.
- Exotropia, 300, 311
- Extensor spasm, in infants, 19–20
- External auditory canal, 340
- Extracerebral fluid collections, benign, 355, 356f
- Extraocular muscles, 300t
- as pain source, 77
 - congenital fibrosis of, 301
 - myopathy of, in Graves ophthalmopathy, 310
- Eye(s)
- alignment of, 77
 - convergence paralysis/insufficiency of, 311t, 312
- Eye movements. *See* Ocular motility.
- Eye-of-the-tiger sign, in pantothenate kinase-associated neurodegeneration, 291
- Eyelid, edema of, in Melkersson syndrome, 338
- Eyestrain, 87
- Face
- congenital asymmetry of, 334–335
 - diplegia of, 334, 336
 - edema of, in Melkersson syndrome, 338
 - midline deformities of, in holoprosencephaly, 365, 366
- Facial bones, maldevelopment of, craniostenosis with, 369
- Facial muscles
- aplasia of, 334
 - assessment of, 172–173
 - innervation of, 331
 - spasm of, 292
 - weakness of, 331–340. *See also* Facial nerve, palsy of.
 - anatomical considerations in, 331
 - approach to, 331–333, 332t
 - congenital, 332t, 333–335
 - in congenital bilateral perisylvian syndrome, 333, 334f
 - in genetic disorders, 336–338
 - in idiopathic cranial polyneuropathy, 336
- Facial muscles (*Continued*)
- in juvenile progressive bulbar palsy, 337
 - in metabolic disorders, 339
 - in motor unit disorders, 332–333
 - in nemaline (rod) myopathy, 164
 - in pseudobulbar palsy, 331–332
 - in syringobulbia, 339
 - isolated, 334
 - postnatal, 332t, 335–340
 - toxin-induced, 339
- Facial nerve
- anatomy of, 331
 - demyelination of, postinfectious, 335–336
 - in motor unit disorders, 333
 - motor nucleus of, 332
 - palsy of. *See also* Facial muscles, weakness of.
 - head injury and, 340
 - hypertension and, 338
 - immune-mediated, 335–336
 - in Bell's palsy, 335–336
 - in Gradenigo syndrome, 305
 - in herpes zoster oticus, 338–339
 - in Melkersson syndrome, 338
 - in sarcoidosis, 339
 - infection and, 335–336, 338–339
 - perinatal traumatic, 334–335
 - recurrent, 333t, 338
 - tumors of, 340
- Facioscapulohumeral syndrome, 178, 336–337
- Fahr disease, 284
- Fainting. *See* Syncope.
- Falling
- in rippling muscle disease, 210
 - leg weakness and, 171
- Falx herniation, increased intracranial pressure and, 95
- Farber lipogranulomatosis, 128
- Fasciculations, 200t
- in hypocalcemia, 202
 - in neuromyotonia, 201
- Fasciitis, necrotizing, carotid artery occlusion in, 243
- Fatigue
- in carbohydrate utilization defects, 203
 - in neuromuscular disease, 171
- Fatigue therapy, in vestibular concussion, 351
- Fatty acid metabolism defects
- long-chain, 205–206
 - medium-chain, 65
- Fazio-Londe disease, 337
- Febrile seizures
- in infants, 17–18
 - neonatal seizures and, 7
 - vs. epilepsy, 17
- Feeding problems
- in alert newborn, 153t
 - in familial dysautonomia, 154, 332
 - in familial infantile myasthenia, 161

- Felbamate, 36t, 38
- Fetus, hydrocephalus in, congenital aqueductal stenosis and, 357, 357f
- Fiber-type disproportion myopathy, congenital, hypotonia in, 162, 162f, 163
- Fibrillation, 200t
- Fibromuscular dysplasia, 243
- Finger drop, in radial neuropathy, 279
- Fisting, in cerebral hypotonia, 151
- Fistula, carotid-cavernous sinus, 304
- Flaccid limb weakness, 171–196. *See also* Weakness.
- Flexion, in traction response, 150
- Flexion deformity, 149
- Flexor spasm, in infants, 19
- Fluid restriction, in syndrome of inappropriate antidiuretic hormone, 63
- Fluid therapy
in diabetic ketoacidosis, 62
in hyponatremic encephalopathy, 63
- Flunarizine
in alternating hemiplegia, 241
in episodic ataxia, 222
- Fluoxetine, in slow-channel syndrome, 175
- Fluphenazine, in tics, 295–296
- Folic acid
in toxic-nutritional optic neuropathy, 323
supplementation of, 259
- Follicular hyperkeratosis, congenital cataract and, 318
- Following response, visual, 317
- Fontanelle, anterior, size of, increased intracranial pressure and, 93
- Food additives, headache and, 85–86
- Foot care
in Charcot-Marie-Tooth disease, 184–185
in hereditary sensory and autonomic neuropathy I, 214
- Foot deformities, in spinal paraplegia, 256
- Footdrop, in peroneal neuropathy, 279
- Foramen magnum tumors, 213
- Fosphenytoin, in status epilepticus, 41
- Fracture, skull, 73, 74
- Fracture-dislocation
of pelvis, 277–278
of vertebral column, 266–267, 267f
- Fragile X syndrome, developmental delay in, 120
- Friedreich ataxia, 235
- Frontal lobe epilepsy, nocturnal, autosomal dominant, 31
- Frontalis muscle, as pain source, 77
- Fukuyama congenital muscular dystrophy, 166–167
- Fungal infections, of central nervous system, 111–113, 111t, 141
- Furosemide, ototoxicity of, 345
- Gabapentin
in analgesic rebound headache, 84
in essential tremor, 296
- Gait
assessment of, 172
ataxic. *See* Ataxia.
disturbances of
in Duchenne muscular dystrophy, 177
in leg weakness, 171
in spinal muscle atrophy, 174
in spinal paraplegia, 255–256
heel walking and, 172
toe walking and, 171, 172
- Galactorrhea, in prolactin-secreting tumors, 327
- Galactosemia, 138
- β -Galactosidase deficiency, 129
- Galactosylceramide lipidosis, 129
- Galactosylceramide β -galactosidase, deficiency of, 140
- Ganciclovir, in cytomegalic inclusion disease, 122
- Gangliosidoses
GM₁, 129–130, 155
GM₂
infantile, 130
juvenile, 139, 235
proximal weakness in, 173–174
- Gaucher disease, type II, 128–129, 139–140
- Gaze
conjugate, abnormalities of, 299–300
horizontal
apraxia of, 310–312, 311t
palsy of, 311t, 312
palsies of, 310–313, 311t
periodic alternating, 313t
vertical, palsy of, 311t, 312
- Genetic disorders
ataxia in, 221–223
cerebral hypotonia in, 154–155
chorea in, 284–285
congenital cataract in, 318
dystonia in, 288–292
facial weakness in, 336–338
hearing loss in, 342–344
- Geniculate ganglion
herpes zoster infection of, 338–339
in motor unit disorders, 333
- Genital herpes, in neonates, 13
- Gentamicin
in bacterial meningitis, 107, 107t, 108, 109t
in cat-scratch disease, 53
vestibular toxicity of, 348–349
- Germinoma, pineal, 101
- Giant axonal neuropathy, distal weakness in, 185–186
- Gigantism
cerebral, 362
megalencephaly with, 362
pituitary adenoma and, 327

- Glasgow Coma Scale, 73, 73t
 Glial tumors, 98–100, 99f–100f
 Glioblastoma multiforme, 98, 99
 Glioma
 astrocytic. *See* Astrocytoma.
 brainstem
 facial palsy and, 340
 ophthalmoplegia in, 303–304, 304f
 vs. facioscapulohumeral syndrome, 337
 vs. idiopathic cranial polyneuropathy, 336
 diencephalic, 325–326
 hemispheric, noncommunicating hydrocephalus
 in, 359
 high-grade, 99, 100f
 low-grade, 99, 99f
 optic nerve, 325–326, 326f
 partial seizures in, 30
 Globoid cell leukodystrophy. *See* Krabbe disease.
 Glucose
 blood concentration of, in neonatal
 hypoglycemia, 9–10
 hypertonic, in Reye syndrome, 61
 metabolism of, disorders of, 203–205
 Glucose-lactate tolerance test, in mitochondrial
 myopathy, 206
 α -Glucosidase, in acid maltase deficiency,
 167–168, 181
 Glucosylceramine lipidosis, 128–129,
 139–140
 Glutaric acidemia, type I
 dystonia in, 289
 megalencephaly in, 363
 Glycine
 encephalopathy from, in neonates, 5
 oral, in isovaleric acidemia, 11
 Glycogen
 in skeletal muscle, 157
 metabolism of, 203, 204f
 Glycogenolysis, 203, 204f
 Glycolysis, 203, 204f
 Glycoprotein degradation disorders,
 developmental delay in, 129
 Glycoprotein syndrome, carbohydrate-deficient,
 developmental delay in, 132
 Goldenhar syndrome, facial palsy in, 334
 Gower sign, 172, 172f
 Gradenigo syndrome, 305
 Gram-negative sepsis, 53
 Graves ophthalmopathy, 310
 Gray matter disorders, 123t
 characteristics of, 124
 infantile, 135–138
 late infantile or juvenile, 142–145
 Growing pains, 199
 Growth hormone
 deficiency of, in neonatal hypoglycemia, 319
 pituitary adenoma and, 327
 Growth retardation, in prolactin-secreting
 tumors, 327
 Guillain-Barré syndrome
 axonal form of, 192
 demyelinating form of, 191–192
 vs. Bell's palsy, 335
 vs. botulism, 309
 vs. idiopathic cranial polyneuropathy, 336
 vs. Miller Fisher syndrome, 224
 Gum hypertrophy, from phenytoin, 39
 Gyri, defective, 366–367
 Hallervorden-Spatz disease, 136
 Hallucinations, 47
 hypnagogic, 24
 in migraine with aura, 80
 Haloperidol
 in tics, 296
 overdose of, encephalopathy from, 70
 tardive dyskinesia from, 283
 Hand dominance, in hemiplegic cerebral
 palsy, 239
 Hand muscles, weakness of, 172
 HARD \pm syndrome. *See* Walker-Warburg
 syndrome.
 Hartnup disease, ataxia in, 222, 236, 236t
 Hashimoto's encephalopathy, 64
 Head
 circumference of. *See also* Macrocephaly;
 Microcephaly.
 charting of, 353, 354f
 increased intracranial pressure and,
 92–93
 measurement of, 353
 elevation of, in increased intracranial
 pressure, 96
 growth rates of, 353, 354f
 muscular weakness in, 172
 oscillation of, in congenital nystagmus,
 314
 pain sensitive structures of, 77–78, 78t
 paroxysmal dystonic tremor of, 297
 shape of, abnormal, 367–369
 extracranial forces in, 367–368
 in craniostenosis, 368–369, 368t
 intracranial forces in, 367
 terminology for, 368t
 trauma to. *See* Head injury.
 Head injury
 altered states of consciousness in, 71–74
 closed, 73
 coma and, 50
 concussion in, 72
 convergence insufficiency after, 312
 cortical blindness after, 321–322
 facial palsy after, 340
 Glasgow Coma Scale in, 73, 73t

Head injury (Continued)

- headache after, 84–85
- hemiplegia in, 251
- in neonates, 13–14
- increased intracranial pressure in, 102
- migraine after, 79
- mild, 72
- open, 74, 74f
- ophthalmoplegia after, 308–309
- optic neuropathy after, 323–324
- perinatal, microcephaly and, 367
- seizures in, 3, 14
- severe, 72–74
- shaking and, 72–73
- vertigo and, 350–351

Head tilt

- differential diagnosis of, 287, 287t
- in benign paroxysmal torticollis, 288
- in spasmus mutans, 314
- in superior oblique palsy, 300

Headache, 77–88

- analgesic rebound, 84, 85
- approach to, 77–79, 78t
- caffeine, 84
- chronic low-grade, 84–85
- cluster, 83
- cranial structures in, 87–88
- drug-induced, 85–86
- evaluation of, 78–79
- exertional, benign, 84
- food additives and, 85–86
- history in, 78
- hypertension and, 86–87
- ice-pick, 80, 80t
- in astrocytoma, 98
- in chronic paroxysmal hemicrania, 83
- in hemicrania continua, 83–84
- in hypertensive encephalopathy, 67
- in idiopathic intracranial hypertension, 114
- in increased intracranial pressure, 93
- in mixed connective tissue disorders, 86
- in prolactin-secreting tumors, 327
- in subarachnoid hemorrhage, 93
- in supratentorial malformations, 105
- in systemic lupus erythematosus, 86
- indomethacin-responsive, 83–84
- migraine. *See* Migraine.
- pain sources in, 77–78, 78t
- papilledema and, 94
- posttraumatic, 84–85
- primary stabbing, 80, 80t
- seizure, 88
- tension
 - chronic, 85
 - episodic, 87
- vasculitis and, 86

Hearing loss, 340–347

- acquired, 345–347
- assessment of, 341–342
- central, 340–341
- conductive, 340
- congenital, 342–344
- differential diagnosis of, 344, 345t
- drug-induced, 345
- in chromosome disorders, 342
- in genetic disorders, 342–345
- in infantile Refsum disease, 343
- in infectious diseases, 345–346
- in metabolic disorders, 346
- in Pendred syndrome, 343
- in skeletal disorders, 345t, 346
- in trauma, 346
- in tumors, 346–347, 347f
- in Usher syndrome, 343–344
- in Waardenburg syndrome, 344
- in Wolfram syndrome, 327
- sensorineural, 340

Hearing tests, 341–342**Hearing threshold, 342****Heart disease**

- cerebral infarction in, 242t, 245–246
- congenital
 - cerebral infarction in, 245
 - retinal artery occlusion and, 324
- cyanotic, 245
- hemiplegia in, 245–246
- retinal artery occlusion and, 324
- rheumatic, 246

Heavy metal poisoning, neuropathy in, 188**Heel walking, 172****Heller syndrome, 144****Hemangioblastoma, cerebellar, 229****Hematin, in acute intermittent porphyria, 216****Hematoma**

- epidural, 73, 74, 74f
- hemiplegia in, 251
- spinal, 267
- subdural, 73, 251

Hematopoietic stem cell transplantation, in Krabbe disease, 129**Hemianopia, homonymous, contralateral, 95****Hemiconvulsions-hemiplegia syndrome, 32****Hemicrania, chronic paroxysmal, headache in, 83****Hemicrania continua, headache in, 83–84****Hemidystonia, 292****Hemifacial spasm, 292****Hemihypertrophy of body, in neurocutaneous disorders, 362****Hemimegalencephaly, in neurocutaneous disorders, 362**

Hemiplegia, 239–252

- acute
 - differential diagnosis of, 240–241, 241t
 - in arteriovenous malformations, 242
 - in brain tumors, 242, 251
 - in capsular stroke, 246–247
 - in carotid artery disorders, 242
 - in cerebral artery infarction, 247
 - in cerebrovascular disease, 241–250, 242t, 243t
 - in cocaine abuse, 244
 - in diabetes mellitus, 244
 - in epilepsy, 244–245
 - in heart disease, 245–246
 - in hypercoagulable states, 246, 246t
 - in ischemic arterial infarction, 246–251
 - in lipoprotein disorders, 247
 - in MELAS syndrome, 247–248
 - in migraine, 250–251
 - in mitral valve prolapse, 245–246
 - in Moyamoya disease, 248
 - in sickle cell disease, 248–249
 - in systemic lupus erythematosus, 249–250
 - in Takayasu arteritis, 250
 - in trauma, 251
 - in vasculopathy, 249–250
- infections and, 250
- alternating, 241
- chronic progressive, 251–252, 252t
- diagnostic approach to, 239
- double, 270
- hemiconvulsions and, 32
- infantile, 239–240, 240f
- Hemiplegic cerebral palsy, 239–240, 240f
- Hemiplegic migraine, 251
 - familial, 79
- Hemispherectomy, for epilepsy, 42–43
- Hemodialysis. *See* Dialysis.
- Hemoglobinopathy, cerebral infarction from, 242t
- Hemolytic disease, in neonates, bilirubin encephalopathy in, 8
- Hemolytic-uremic syndrome, 65–66
- Hemorrhage
 - hydrocephalus after
 - increased intracranial pressure and, 92–93
 - management of, 103–104
 - intracerebellar, ataxia in, 227
 - intracerebral
 - focal clonic seizures in, 2
 - in closed head injury, 73
 - intracranial
 - apnea in, 3
 - hydrocephalus in, 97
 - in closed head injury, 73
 - in cocaine abuse, 106
 - in neonates, 13–14

Hemorrhage (*Continued*)

- in supratentorial malformations, 105
- increased intracranial pressure in, 102–104
- intraparenchymal, hemiplegia in, 242
- intraventricular
 - at term, 104
 - cerebral hypotonia in, 154
 - in premature neonates, 102–104
 - tonic seizures in, 3
- neonatal, 13–14, 102–104, 240
- periventricular-intraventricular
 - clinical features of, 103
 - diagnosis of, 103
 - grading system for, 102
 - in premature neonates, 102–104
 - management of, 103–104
 - prevention of, 103, 103t
- retinal, in shaking injuries, 72
- subarachnoid
 - headache in, 93
 - in neonates, 13–14
 - in ruptured aneurysms, 104–105
- subdural, in neonates, 14
- subependymal, 102
- Hemorrhagic shock encephalopathy syndrome, 53–54
- Henoch-Schönlein purpura, 86, 249
- Heparin, maternal use of, congenital deafness and, 343
- Hepatitis, valproate and, 40
- Hepatolenticular degeneration, 289–290
- Hepatotoxicity, valproate, 40
- Hereditary motor and sensory neuropathy. *See* Charcot-Marie-Tooth disease.
- Hereditary sensory and autonomic neuropathy
 - type I, 184–185, 213–214
 - type II, 214
 - type III, 154, 214
 - type IV, 215
- Herniation syndromes, of brain, increased intracranial pressure and, 95–96, 95t
- Herpes encephalitis, 58–59, 59f
 - type 2 (genital), in neonates, 13
- Herpes zoster myelitis, spinal paraplegia in, 262–263, 263f
- Herpes zoster oticus, facial palsy and, 338–339
- Heterophoria, 299
- Heterotropia, 299
- Hexosaminidase deficiency, in GM₂ gangliosidoses, 130, 139, 235
- Hip dislocation, in intrauterine hypotonia, 149
- Hippocampal sclerosis, bilateral, developmental delay in, 119
- Hippus, 329
- Hirsutism, from phenytoin, 39
- Histoplasmosis, 113

- HIV. *See* Human immunodeficiency virus (HIV) infection.
- Holmes-Adie syndrome, 329
- Holoprosencephaly, 365–366
- Homocystinuria, developmental delay in, 125–126, 125f
- Homonymous hemianopia, contralateral, 95
- Hopkins syndrome, 275
- Horizontal gaze
apraxia of, 310–312, 311t
palsy of, 311t, 312
- Horizontal suspension, in infantile hypotonia, 151
- Horner syndrome, 302, 329
- Human immunodeficiency virus (HIV) infection
encephalopathy in, 124–125, 141–142
proximal myopathy in, 179
- Humeral peroneal syndromes, distal weakness in, 190–191
- Humerus
dislocation of, 277
proximal, osteomyelitis of, 277
- Hunter syndrome, 140–141
- Huntington disease, 144–145, 284
- Hurler phenotype, 129, 129t, 130, 131, 140–141
- Hurler syndrome, 131
- Hutchinson triad, 121
- Hyaline bodies, in congenitally elevated disks, 94, 95f
- Hydranencephaly, 1, 354t, 360
- Hydrocephalus
acquired, causes of, 97
causes of, 353, 354t
communicating, 97, 353, 354t, 355–356
causes of, 355
meningeal tumors and, 355–356
subarachnoid space enlargement and, 355, 356f
congenital, 97, 356–357
external (extraventricular), 355, 356f
in arteriovenous malformations, 105
in congenital midline porencephaly, 361
in craniopharyngioma, 325
in craniostenosis, 369
in myelomeningocele, 259
in tuberculous meningitis, 110
increased intracranial pressure in, 97
noncommunicating, 97, 353, 354t, 356–360
congenital aqueductal stenosis and, 357, 357f
in congenital brain tumors, 359
in Dandy-Walker malformation, 357–358, 358f
in Klippel-Feil syndrome, 358–359
in vein of Galen malformation, 359, 360f
in Walker-Warburg syndrome, 359–360
posthemorrhagic
increased intracranial pressure and, 92–93
management of, 103–104
progressive
cerebrospinal fluid absorption in, 91
- Hydrocephalus (*Continued*)
developmental delay in, 139
in periventricular-intraventricular hemorrhage, 103
- Hydrochlorothiazide, in familial hyperkalemic periodic paralysis, 196
- Hydroxocobalamin, in methylmalonic acidemia, 12
- Hyperactivity, phenobarbital-induced, 39
- Hyperacusis, 341
- Hyperadrenalism, proximal weakness in, 182
- Hyperammonemia
encephalopathy in, 67
in neonates
causes of, 7t
in propionic acidemia, 12
in urea cycle disorders, 6–7
with metabolic acidosis, 12
valproate and, 40
- Hyperbilirubinemia, neonatal, in encephalopathy, 8
- Hypercalcemia, altered states of consciousness in, 63
- Hypercarbia, in cerebral blood flow, 92
- Hypercoagulable states, cerebral infarction in, 246, 246t
- Hyperexplexia, 25
- Hyperglycemia, diabetic ketoacidosis and, 62
- Hyperglycinemia, in neonates
nonketotic, 5
with metabolic acidosis, 12
- Hyperkeratosis, follicular, congenital cataract and, 318
- Hypertremia, encephalopathy in, 62–63
- Hyperopia, 299–300
- Hyperparathyroidism
altered states of consciousness in, 63
facial weakness in, 339
proximal weakness in, 182
- Hyperphenylalaninemia, 126–128, 127f, 127t
- Hypersensitivity, to phenytoin, 39
- Hypersensitivity vasculitis
cerebral infarction in, 249
headache in, 86
- Hypertension
encephalopathy and, 67, 67f
headache and, 86–87
intracranial. *See* Intracranial pressure, increased.
malignant, facial nerve palsy in, 338
- Hyperthermia, malignant, 163, 209
- Hyperthyroidism
altered states of consciousness in, 63
movement disorders in, 285
ophthalmopathy in, 310
proximal weakness in, 182
- Hypertropia, in superior oblique palsy, 308
- Hyperventilation, initiation of, in increased intracranial pressure, 96

- Hyperventilation syndrome, 24
- Hypnagogic hallucinations, 24
- Hypoadrenalism, 182, 202
- Hypobetalipoproteinemia, ataxia in, 233
- Hypocalcemia
 - altered states of consciousness in, 63
 - in neonates, 9
 - tetany in, 202
- Hypocarbica, in cerebral blood flow, 92
- Hypodipsia, hypernatremia from, 62
- Hypodipsia-hyponatremia syndrome, in craniopharyngioma, 325
- Hypoglossal nerve, 331
- Hypoglycemia
 - cortical blindness in, 321
 - encephalopathy in, 62
 - in neonates, 9–10, 10t
- Hypomagnesemia
 - downbeat nystagmus in, 315
 - encephalopathy in, 67
 - tetany in, 202
- Hypomelanosis of Ito, 362
- Hypomyelinating neuropathy, congenital, motor unit hypotonia in, 160
- Hyponatremia
 - encephalopathy in, 63
 - in craniopharyngioma, 325
- Hypoparathyroidism
 - altered states of consciousness in, 63
 - in neonates, 9
 - proximal weakness in, 182
- Hypopituitarism, congenital, 319
- Hypotension, sudden, anoxia and ischemia after, 51–52
- Hypothalamus
 - anterior, pineal tumors in, 101
 - midline defects of. *See* Septo-optic dysplasia.
 - tumors of, 326, 326f
- Hypothermia
 - in anoxia/ischemia, 52
 - in increased intracranial pressure, 97
- Hypothyroidism
 - altered states of consciousness in, 63–64
 - developmental delay in, 133
 - facial weakness in, 339
 - hearing loss in, 346
 - muscle stiffness in, 202
 - proximal weakness in, 182
- Hypotonia, 156
 - benign congenital, 152
 - cerebral, 152–155
 - definition of, 149
 - diagnosis of, 151–152, 151t
 - in chromosome disorders, 152–153
 - in chronic nonprogressive encephalopathy, 153–154
 - in familial dysautonomia, 154
 - Hypotonia (*Continued*)
 - in genetic disorders, 154–155
 - in metabolic disorders, 155
 - in oculocerebrorenal syndrome, 154
 - in peroxisomal disorders, 154–155
 - in Prader-Willi syndrome, 152–153
 - in spinal cord disorders, 155–156
 - in hypoxic-ischemic myelopathy, 155
 - in spinal cord injury, 155–156
 - infantile, 149–168
 - appearance of, 149–151
 - diagnosis of, 151–152, 151t–152t
 - differential diagnosis of, 150t
 - horizontal suspension in, 151
 - traction response in, 150
 - vertical suspension in, 150–151
 - intrauterine, 149
 - motor unit, 156–168
 - diagnosis of, 151t, 152, 152t
 - electromyography in, 157
 - evaluation of, 156–157, 156t
 - in acid maltase deficiency, 167–168
 - in central core disease, 162–163, 163f
 - in congenital fiber-type disproportion myopathy, 162, 162f, 163
 - in congenital hypomyelinating neuropathy, 160
 - in congenital myopathies, 162–165
 - in congenital myotonic dystrophy, 167
 - in cytochrome-c-oxidase deficiency, 159, 168
 - in familial infantile myasthenia, 161–162, 161t
 - in infantile botulism, 160–161
 - in metabolic myopathies, 167–168
 - in multimincore disease, 163–164
 - in muscular dystrophies, 165–167
 - in myotubular (centronuclear) myopathy, 164
 - in nemaline (rod) myopathy, 164–165, 165f
 - in neurogenic arthrogyrosis, 159
 - in neuromuscular transmission disorders, 160–162
 - in polyneuropathies, 159–160, 160t
 - in spinal muscle atrophy, 157–159, 158f
 - in transitory neonatal myasthenia, 162
 - muscle biopsy in, 157
 - nerve biopsy in, 157
 - serum creatine kinase in, 156–157
 - Tensilon test in, 157
 - with perinatal respiratory distress, 151, 151t
- Hypoxia
 - ischemia and
 - altered states of consciousness in, 49t
 - encephalopathy from, 51–52
 - in neonates, 2, 10–11
 - myelopathy from, 155
 - myoclonus after, 52, 294
 - prolonged, 51
 - Hypsarrhythmia, in infantile spasms, 20
 - Hysterical blindness, 322

- I-cell disease, 131
- Ice-pack test, in myasthenia, 306
- Ice-pick headache, 80, 80t
- Ichthyosis, congenital, cataract and, 318
- Ictal laughter, 18
- Ictal nystagmus, 315
- Ictal vomiting, epilepsy and, 31
- Idebenone, in MELAS syndrome, 248
- Imiglucerase, in Gaucher disease type II, 140
- Immune disorders
 - ataxia in, 224–226
 - facial nerve palsy in, 335–336
 - myasthenia in, ophthalmoplegia and, 305–307
- Immunization, encephalopathy after, 61
- Immunosuppressive drugs, encephalopathy and, 69–70
- Inclusion body myopathy, 189–190
- Inclusion body myositis, 189
- Incontinentia pigmenti
 - congenital cataract and, 318
 - in infants, 19t
 - in neonates, 14–15
- Incontinentia pigmenti achromians, 362
- Indomethacin-responsive headache, 83–84
- Infants. *See also* Neonates.
 - adrenoleukodystrophy in, 236
 - apnea in, 16–17
 - bacterial meningitis in, 107–109, 109t
 - bilateral striatal necrosis in, 291
 - biotinidase deficiency in, 22
 - botulism in, motor unit hypotonia and, 160–161
 - breath-holding spells in, 16
 - epilepsy in
 - benign familial, 19
 - myoclonic
 - benign, 21
 - severe, 21–22
 - epileptic encephalopathy with suppression bursts in, 21
 - esotropia in, 299
 - familial myasthenia in, 161–162, 161t
 - GM₂ gangliosidosis in, 130
 - gray matter disorders in, 135–138, 142–145
 - hemiplegia in, 239–240, 240f
 - hypotonic, 149–168. *See also* Hypotonia, infantile.
 - increased intracranial pressure in, 92–93
 - Krabbe disease in, 124f, 129
 - Lennox-Gastaut syndrome in, 22
 - migraine in, 22–23
 - myoclonus in, benign, 21
 - neuroaxonal dystrophy in, 136–137
 - neurofibromatosis in, 19t
 - neuronal ceroid lipofuscinoses in, 135–136, 142–143
- Infants (*Continued*)
 - paroxysmal disorders in, 15–23, 16t
 - premature
 - apnea in, 3
 - decerebrate posturing in, 3
 - periventricular-intraventricular hemorrhage in, 102–104
 - tonic seizures in, 3
 - progressive encephalopathy in, 117, 118t, 123–139
 - progressive poliodystrophy in, 133–134
 - Refsum disease in
 - cerebral hypotonia and, 154–155
 - hearing loss and, 343
 - seizures in
 - apneic, 16
 - benign familial, 7
 - differential diagnosis of, 15–23, 16t
 - febrile, 17–18
 - myoclonic, 19–21, 20t
 - neurocutaneous disorders causing, 19t
 - nonfebrile, 19–23
 - spasms in, 19–21, 19t
 - spinal muscle atrophy in, 158, 158f
 - with arthrogryposis, 159
 - with respiratory distress, 159
 - stiff, 25
 - syncope in
 - cyanotic, 16–17
 - pallid, 17
 - white matter disorders in, 138–139
- Infarction
 - anterior optic nerve, 323
 - cerebral. *See* Cerebral infarction.
 - cerebral artery, 247
 - internal capsular, 246–247
 - ischemic arterial, 246–251
 - periventricular hemorrhagic, 102–103
 - spinal cord, 264
- Infection
 - altered states of consciousness in, 48t, 49t, 52–61
 - ataxia in, 224–226
 - bacterial, 52–55
 - disk space, 262, 262f
 - facial palsy and, 335–336, 338–339
 - fungal, of central nervous system, 111–113, 111t, 141
 - hearing loss in, 345–346
 - hemiplegia and, 250
 - increased intracranial pressure and, 106–113
 - intracranial, hydrocephalus in, 97
 - intrauterine
 - congenital cataract in, 318
 - congenital deafness in, 343
 - developmental delay in, 121–122
 - microcephaly in, 367

Infection (Continued)

- perinatal, developmental delay in, 123
- progressive encephalopathy in, 141–142
- respiratory, Reye syndrome and, 60
- rickettsial, 54–55
- sinopulmonary, in ataxia-telangiectasia, 234
- spinal paraplegia in, 262–263, 262f, 263f
- vertigo in, 349
- viral, 55–61
 - encephalomyelitis after, 59–60, 60f
 - Reye syndrome and, 60–61
 - vertigo in, 349
 - weakness in, 193
 - weakness in, 191–193
- Inferior oblique, 300t
- Inferior rectus, 300t
- Inflammatory myopathies, proximal weakness in, 179–180, 180f
- Influenza B infection, Reye syndrome and, 60
- Inner ear
 - anatomy of, 340
 - aplasia of, 342
- Inosine pranobex, in subacute sclerosing panencephalitis, 142
- Insulin
 - administration of, in Wolfram syndrome, 327
 - overdose of, hypoglycemic encephalopathy in, 62
- Intensive care unit patients, weakness in, 194
- α-Interferon, in subacute sclerosing panencephalitis, 142
- Interhemispheric commissurotomy, for epilepsy, 43
- Internuclear ophthalmoplegia, 311–312, 311t
- Interstitial cerebral edema, 92
- Intervertebral disk, lumbar, herniation of, 216
- Intoxications. *See* Toxins.
- Intracerebellar hemorrhage, ataxia in, 227
- Intracerebral hemorrhage
 - focal clonic seizures in, 2
 - hemiplegia in, 251
 - in closed head injury, 73
- Intracranial arachnoid cysts, 101–102
- Intracranial hemorrhage
 - apnea in, 3
 - hydrocephalus in, 97
 - in closed head injury, 73
 - in cocaine abuse, 106
 - in neonates, 13–14
 - in supratentorial malformations, 105
 - increased intracranial pressure in, 102–104
- Intracranial infection, hydrocephalus in, 97
- Intracranial pressure
 - cerebral blood flow and, 91–92
 - cerebral edema and, 92
 - cerebrospinal fluid and, 91
 - increased, 91–114

Intracranial pressure (Continued)

- abducens palsy and, 302
- altered states of consciousness in, 49t
- arterial aneurysms and, 104–105
- arteriovenous malformations and, 105–106
- as pain source, 77
- astrocytoma and, 98–99, 99f–100f
- bacterial meningitis and, 106–110
- brain abscess and, 110–111
- choroid plexus tumors and, 97–98
- cocaine abuse and, 106
- diplopia and, 93
- ependymoma and, 99–100
- fungal infections and, 111–113
- glial tumors and, 98–100, 99f–100f
- headache in, 93
- herniation syndromes and, 95–96, 95t
- hydrocephalus and, 97
- idiopathic, 113–114, 114t
- idiopathic intracranial hypertension and, 113–114, 114t
- in children, 93–94, 94f, 94t
- in hypoxic-ischemic encephalopathy, 11
- in infants, 92–93
- infection and, 106–113
- intracranial arachnoid cysts and, 101–102
- intracranial hemorrhage and, 102–104
- medical treatment of, 96–97, 96t
- papilledema and, 93–94, 94f, 94t
- pathophysiology of, 91–92
- pineal region tumors and, 101
- primitive neuroectodermal tumors and, 100–101
- signs and symptoms of, 92–96, 92t
- strabismus and, 93
- subdural and epidural empyema and, 111
- mass lesions and, 92
- monitoring, 96
- Intraocular tumors, 327–328
- Intraparenchymal hemorrhage, hemiplegia in, 242
- Intrauterine hypotonia, 149
- Intrauterine infection
 - congenital cataract and, 318
 - congenital deafness and, 343
 - developmental delay and, 121–122
 - microcephaly and, 367
- Intravenous immune globulin, in Kawasaki disease, 228
- Intraventricular hemorrhage. *See also* Periventricular-intraventricular hemorrhage.
 - at term, 104
 - cerebral hypotonia in, 154
 - in premature neonates, 102–104
 - tonic seizures in, 3
- Ion channel disorders, paroxysmal disorders in, 1
- Iris, hypoplasia of, 329

- Iron deposition, in basal ganglia, in pantothenate kinase-associated neurodegeneration, 291
- Isaac syndrome. *See* Neuromyotonia.
- Ischemia
 hypoxia and
 altered states of consciousness in, 49t
 encephalopathy from, 51–52
 in neonates, 2, 10–11
 myelopathy from, 155
 in optic neuropathy, 323
 transient
 in fibromuscular dysplasia, 243
 in mitral valve prolapse, 245–246
 in Moyamoya disease, 248
- Ischemic arterial infarction, 246–251
- Isoniazid
 in tuberculous meningitis, 110
 in tuberculous osteomyelitis, 263
 neuropathy from, 187–188
- Isovaleric acidemia, in neonates, 11–12
- Ixodes* spp., 54
- Jansky-Bielschowsky disease, 142–143, 142t, 143t
- Japanese B encephalitis, 57
- Jerk nystagmus, 313
- Jerks, myoclonic. *See* Myoclonus.
- Jitteriness
 in drug withdrawal, 8–9
 in neonates, 3–4
- Joint contractures, 149
- Joubert syndrome, 231
- Juvenile amyotrophic lateral sclerosis, distal weakness in, 183
- Juvenile epilepsy
 absence, 26–27, 27f
 myoclonic, 28, 29f
- Juvenile GM₂ gangliosidosis, 139, 235
- Juvenile gray matter disorders, 142–145
- Juvenile myasthenia, 305
- Juvenile neuronal ceroid lipofuscinoses, 144
- Juvenile progressive bulbar palsy, 336, 337
- Juvenile progressive encephalopathy, 123t, 139–146
- Juvenile rheumatoid arthritis, neuropathy in, 189
- Juvenile spinal muscle atrophy, 173–174, 183
- Juvenile white matter disorders, 145–146
- Kanamycin, ototoxicity of, 345
- Kawasaki disease, ataxia in, 227–228
- Kayser-Fleischer ring, in Wilson disease, 290
- Kearns-Sayre syndrome, 310
- Kernicterus, 3, 8, 292
- Kernig sign, in bacterial meningitis, 108
- Ketoacid dehydrogenase, branched-chain, deficiency, in maple syrup urine disease, 5, 126
- Ketoacidosis
 diabetic, 62
 in neonates, in propionic acidemia, 12–13
- Ketogenic diet
 in epilepsy, 41–42
 in pyruvate dehydrogenase deficiency, 223
- Ketosis, in neonates, with metabolic acidosis, 12
- Kidney(s)
 congenital hypoplasia of, chronic uremic encephalopathy in, 66
 disorders of
 altered states of consciousness in, 65–67
 headache in, 86–87
- Klebsiella* infection, meningitis in, 106, 107
- Klippel-Feil syndrome
 atlantoaxial dislocation in, 257
 noncommunicating hydrocephalus in, 358–359
- Krabbe disease
 distal weakness in, 186
 infantile, 124f, 129
 late-onset, 140
 spinal paraplegia in, 264
 variants of, 129
- Krebs cycle, 203
- La Crosse encephalitis, 56–57
- Labyrinth, 340, 347
 disorders of
 vertigo in, 349
 vestibular nystagmus in, 315
 rupture of, in Mènière disease, 350
- Lactate dehydrogenase deficiency, 205
- Lactic acidosis, 223
- Lafora disease, 28–29
- Lamotrigine, 37–38
 dosage of, 36t
 tics from, 295
- Lance-Adams syndrome, 52, 294
- Landau-Kleffner syndrome, 30
- Language. *See* Speech.
- Lateral rectus, 300t
 palsy of, traumatic, 308
- Laughter, ictal, 18
- Laurence-Moon syndrome, 328
- Lead, embryo exposure to, cerebral malformations from, 121
- Leber congenital retinal amaurosis, 320
- Leber hereditary optic neuropathy, 291, 327
- Leg
 nocturnal pain in, 199
 weakness in. *See also* Paraplegia; Quadriplegia.
 in neuromuscular disease, 171
- Leigh's disease, 68, 134
- Lennox-Gastaut syndrome, 22, 227
- Lens dislocation, in homocystinuria, 125
- Lesch-Nyhan disease, 137, 212

- Lethargy
 causes of, 49t
 definition of, 48t
 diagnostic approach to, 50–51
- Leucovorin, in toxoplasmosis, 122
- Leukocytosis
 in bacterial meningitis, 106–107, 108
 of cerebrospinal fluid, 56, 57
- Leukodystrophy
 globoid. *See* Krabbe disease.
 metachromatic, 132, 140
 ataxia in, 235–236
 distal weakness in, 186
- Leukoencephalopathy, with swelling and cysts, megalencephaly in, 363
- Leukokoria, in retinoblastoma, 328
- Leukomalacia, periventricular, 102, 269
- Levetiracetam, 38
 dosage of, 36t
 in cyanotic syncope, 17
 in infantile spasms, 20
- Levocarnitine
 in carnitine deficiency, 181
 in medium-chain acyl-CoA dehydrogenase deficiency, 65
 in MELAS syndrome, 248
 in organic acid disorders, 11, 12
 in propionic acidemia, 12
- Levodopa
 in dopa-responsive dystonia, 289
 in dystonia, 241
 in rapid-onset dystonia-parkinsonism, 291
 in thalamic pain, 218
- Levothyroxine, in hypothyroidism, 133
- Lightheadedness. *See* Vertigo.
- Limb-girdle muscular dystrophy, 175–176
- Limb-girdle myasthenia, proximal weakness in, 175
- Limb posturing, in neuromyotonia, 201
- Limbs, weakness of, 171–196. *See also* Weakness.
- Linear nevus sebaceous syndrome, 19t, 362–363
- Lingua plicata, in Melkersson syndrome, 338
- Lingual-facial-buccal dyskinesias, in emergent withdrawal syndrome, 284
- Lipid
 disorders of
 myopathy in, 181–182
 neuropathy in, 186
 in skeletal muscle, 157
 within exercising muscle, 203
- Lipidosis
 galactosylceramide, 129
 glucosylceramine, 128–129, 139–140
 sphingomyelin, 132, 141
 sulfatide. *See* Metachromatic leukodystrophy.
- Lipofuscinoses, ceroid. *See* Neuronal ceroid lipofuscinoses.
- Lipogranulomatosis, Farber, 128
- Lipoprotein disorders, hemiplegia in, 247
- Lissencephaly, 362, 366–367
- Listeria monocytogenes* infection, meningitis in, 106
- Lithium, in cluster headache, 83
- Liver
 biopsy of, in Reye syndrome, 61
 disease of
 cholestatic, 378
 encephalopathy in, 64
 necrosis of, valproate and, 40
- Lobectomy, temporal, for epilepsy, 43
- Locked-in syndrome, 47
- Lorazepam, in status epilepticus, 41
- Lowe syndrome. *See* Oculocerebrorenal syndrome.
- Lumbar disk herniation, 216
- Lumbar lordosis, loss of, in diskitis, 262
- Lumbar plexopathy, 276
- Lumbar plexus
 injuries of, 277–278
 tumors of, 278, 278f
- Lumbar puncture
 in bacterial meningitis, 106–107, 108
 in idiopathic intracranial hypertension, 114
 in increased intracranial pressure, contraindication to, 95
- Lupus erythematosus, systemic
 chorea in, 285
 encephalopathy in, 68
 headache in, 86
 hemiplegia in, 249–250
 myelopathy in, 263
 neuropathy in, 189
- Lyme disease, 54
- Lymphadenopathy
 cervical, carotid artery occlusion and, 242–243
 in cat-scratch disease, 53
- Lymphocytic choriomeningitis, 56
- Lysosomal enzymes, disorders of
 progressive encephalopathy in, 123t, 128–132, 139–141
 with cherry-red spot of macula, 130t
- Macrocephaly, 353, 354f, 355–363. *See also* specific type.
 benign familial, 361
 causes of, 353, 354t, 355, 355t
 choroid plexus tumors and, 98
 hydrocephalus and, 353, 354t
 megalencephaly and, 353, 354t
 thickened skull and, 355, 355t
- Macrocrania, in neurocutaneous disorders, 362
- Macula, cherry-red spot of
 in Niemann-Pick disease, 132
 lysosomal enzyme disorders with, 130, 130t

- Magnetic resonance imaging
 in astrocytoma, 99, 99f, 100f
 in brainstem glioma, 304, 304f
 in congenital bilateral perisylvian syndrome, 333, 334f
 in diskitis, 262, 262f
 in herpes encephalitis, 59, 59f
 in hypertensive encephalopathy, 67, 67f
 in hypothalamic tumors, 326, 326f
 in Krabbe disease, 124, 124f
 in medulloblastoma, 230, 230f
 in multiple sclerosis, 225, 225f
 in myoclonic encephalopathy/neuroblastoma syndrome, 226, 226f
 in optic nerve hypoplasia, 319
 in postinfectious encephalomyelitis, 60, 60f
 in syringomyelia, 217, 217f
 in transverse myelitis, 265, 265f
- Malformation(s)
 arteriovenous. *See* Arteriovenous malformations.
 cerebellar, 231–232, 231f, 232f
 cerebral
 amino acid metabolic disorders and, 125
 developmental delay in, 120–121
 cerebrovascular, cerebral infarction from, 242t
 Chiari, 232, 232f, 258, 315
 congenital
 ataxia in, 231–232, 231f
 hemiplegia in, 239, 240f
 of ear, 342
 spinal paraplegia in, 256–260
 craniocervical, in Klippel-Feil syndrome, 358–359
 Dandy-Walker
 noncommunicating hydrocephalus in, 357–358, 358f
 Walker-Warburg syndrome and, 360
 vein of Galen, 105, 359, 360f
- Malignant hypertension, facial nerve palsy in, 338
 Malignant hyperthermia, 163, 209
 Mannitol, in increased intracranial pressure, 96
 Maple syrup urine disease
 ataxia in, 236, 236t
 developmental delay in, 126
 in neonates, 4–5, 6f
 intermittent, ataxia in, 222–223
 seizures in, 5
- Marfan syndrome habitus, in homocystinuria, 125
- Marijuana, headache from, 86
 Marinesco-Sjögren syndrome, ataxia in, 236
 Markesbery-Griggs-Udd myopathy, 189
 Marshall syndrome, congenital cataract and, 318
 Mass lesions, intracranial pressure and, 92
 Masseter muscles, as pain source, 77
 McArdle disease. *See* Myophosphorylase deficiency.
- McLeod syndrome, acanthocytosis in, 284–285
 Measles (rubeola) encephalitis, 59, 142
 Medial rectus, 300t
 Median neuropathy, 278–279
 Medications. *See* Drug(s).
 Medium-chain acyl-CoA dehydrogenase deficiency, 65
- Medullary tumors, 98–99
 Medulloblastoma
 ataxia in, 230, 230f
 noncommunicating hydrocephalus in, 359
- Megalencephaly
 anatomical, 353, 354t, 361–363
 in achondroplasia, 361
 in neurocutaneous disorders, 362–363
 causes of, 353, 354t
 macrocephaly from, 353
 metabolic, 353, 354t, 363
 with a neurological disorder, 361–362
 with gigantism, 362
- MELAS syndrome, 247–248
 Melkersson syndrome, 338
 Mènière disease
 hearing loss in, 346
 vertigo in, 350
- Meningeal tumors, communicating hydrocephalus from, 355–356
- Meningioma, 101
 Meningismus, 56
 Meningitis
 aseptic (viral), 55, 56
 bacterial, 106–110
 antibiotics in, 107, 107t, 108, 109t
 developmental delay in, 123
 hearing loss in, 346
 in infants and young children, 107–109, 109t
 in neonates, 106–107, 107t
 in school-age children, 109
 organisms in, 106, 106t
 vertigo in, 349
 basilar, facial palsy and, 339
 cerebral hypotonia in, 154
 coccidioidal, 112, 113t
 cryptococcal, 112–113, 113t
 fungal, 111
 herpes, 58
 meningococcal, 109
 pneumococcal, 109
 seizures from, 17
 subdural and epidural empyema and, 111
 tuberculous, 109–110
- Meningocele, 259
 Meningococcal meningitis, 109
 Meningoencephalitis, 55
 candidal, 111–112
 OKT3, 70
- Menkes syndrome, 137–138

- Menstrual cycle, migraine and, 79–80
- Mental retardation. *See also* Developmental delay;
 Encephalopathy, progressive.
 in Marinesco-Sjögren syndrome, 236
 in retinoblastoma, 328
 seizures and, 18
- Merosin, in congenital muscular dystrophy, 157,
 165–166
- Metabolic acidosis, in methylmalonic acidemia, 12
- Metabolic disorders
 altered states of consciousness in, 48t, 49t,
 64–65
 ataxia in, 236, 236t
 carnitine deficiency in, 65, 65t
 cerebral hypotonia in, 155
 encephalopathy in, 64–65, 67–68
 facial weakness in, 339
 hearing loss in, 346
 megalencephaly in, 353, 354t, 363
 myopathy in
 motor unit hypotonia in, 167–168
 proximal weakness in, 180–182
 neonatal jitteriness in, 4
 neonatal seizures in, 4–8, 5t
 neuropathy in, 215–216
 Reye syndrome and, 61
 spinal paraplegia in, 263–264
- Metachromatic leukodystrophy, 132, 140
 ataxia in, 235–236
 distal weakness in, 186
- Metastasis, cerebral, 101
- Methicillin
 in bacterial meningitis, 107t
 in brain abscess, 111
- Methotrexate, in dermatomyositis, 180
- Methylmalonic acidemia, in neonates, 12
- Methylphenidate
 chorea from, 283
 in narcolepsy, 24
 tics from, 295
- Methylprednisolone
 in fracture-dislocation and spinal cord
 transection, 267
 in multiple sclerosis, 225
 in optic neuritis, 323
- Metoclopramide
 tardive dyskinesia from, 283
 tardive dystonia from, 287
- Mexiletine, in myotonic disorders, 201, 202
- Michel defect, 342
- Microangiopathy, telangiectatic, in Leber
 hereditary optic neuropathy, 327
- Microcephaly, 363–367
 anencephaly and, 364–365
 causes of, 363–364, 364t
 corpus callosum agenesis and, 366
 defective cellular migration and, 366–367
- Microcephaly (*Continued*)
 defective neurulation and, 364
 defective prosencephalization, 365–367
 encephalocele and, 365
 holoprosencephaly and, 365–366
 in chromosome disorders, 364
 in cytomegalic inclusion disease, 122
 intrauterine disorders and, 367
 perinatal brain injury and, 367
 postnatal systemic disease and, 367
 primary, 364–367, 364t
 secondary, 364t, 367
- Microcephaly vera, 364
- Microdeletion syndrome, chromosome 22q11.2,
 in neonates, 9
- Microphthalmos, congenital cataract and, 318
- Midbrain
 lesions of, vertical gaze palsy in, 312
 tumors of, 99
- Middle cerebral artery, infarction of, 247
- Middle ear, 340
- Middle fossa, tumors of, 97t
- Midline facial deformities, in holoprosencephaly,
 365, 366
- Midline porencephaly, congenital, 361
- Migraine, 79–83
 altered states of consciousness in, 48t, 49t,
 68–69
 basilar, ataxia in, 223–224
 clinical syndromes of, 80–81
 coma in, 68–69
 complicated, 250–251
 confusional, acute, 68
 diagnosis of, 81
 epilepsy and, linkage between, 22–23
 equivalents of, 80, 80t
 extended, 84
 familial hemiplegic, 79
 genetics of, 79
 hemiplegic, 251
 in infants, 22–23
 incidence of, 79
 management of, 81–83
 ophthalmoplegic, 307, 308
 prophylaxis in, 82–83
 retinal, 324–325
 retinal artery occlusion and, 324
 seizures in, 22–23
 transitory posttraumatic cerebral blindness
 and, 321
 triggering factors in, 79–80
 vertigo in, 350
 with aura, 80–81
 without aura, 81
- Miller-Dieker syndrome, lissencephaly in, 366
- Miller Fisher syndrome, 221
 ataxia in, 224–225

- Minocycline, vestibular toxicity of, 348
- Miosis
 in Horner syndrome, 329
 ptosis with, 302
- Mirror movements, 292–293
- Mitochondrial disorders
 ataxia in, 236, 236t
 clinical features of, 207t
 congenital cataract in, 318
 encephalomyopathy in, in MELAS syndrome, 247–248
 encephalopathy in, progressive, 133–134, 145
 myopathy in, 206–207, 206f, 207t, 223
- Mitochondrial DNA mutations
 Kearns-Sayre syndrome from, 310
 optic neuropathy and, 323
- Mitral valve prolapse, retinal artery occlusion and, 324
- Mixed connective tissue disorders, headache in, 86
- Möbius' syndrome
 abducens nerve palsy in, 301
 facial palsy in, 334
- Modafinil, in narcolepsy, 24
- Molds, 111, 111t
- Mondini defect, 342
- Monocular nystagmus, 316
- Mononeuropathy, monoplegia in, 278–279
- Monoplegia, 273–279
 approach to, 273
 differential diagnosis of, 273, 274t
 in mononeuropathy, 278–279
 in plexitis
 acute idiopathic, 274–275
 acute symptomatic, 275–278
 in plexus tumors, 278, 278f
 in spinal muscle atrophy, 273–274
- Monosodium glutamate, headache from, 85–86
- Monosomy, developmental delay and, 120t
- Montreal-type hemispherectomy, for epilepsy, 43
- Morning glory disk, 320
- Morquio B disease, 129
- Morquio syndrome, atlantoaxial dislocation in, 257
- Motion sickness, 350
- Motor and sensory neuropathy, hereditary. *See* Charcot-Marie-Tooth disease.
- Motor axonopathy, acute, 192
- Motor development, delayed, 118t, 119
 in neuromuscular disease, 171
 in spinal muscle atrophy, 174
- Motor unit
 continuous activity of, disorders with, 199–201, 200t
 definition of, 149
 disorders of
 facial weakness in, 332–333
 hypotonia in. *See* Hypotonia, motor unit.
- Movement disorders, 281–297. *See also specific disorders, e.g.,* Chorea.
 approach to, 281
 paroxysmal, 281
 vs. seizures, 281
- Moyamoya disease, 248
- Mucopolidosis II, 130–131
- Mucopolysaccharidoses
 type I, 131
 type II, 140–141
 type III, 131
 type VII, 141
- Multiminicore disease
 motor unit hypotonia in, 163–164
 severe classic myopathy in, 165, 210
- Multiple sclerosis, 225–226, 225f
 ataxia in, 225
 one-and-a-half syndrome in, 311
 optic neuritis and, 322
 transverse myelitis in, 264, 265f
- Muscle
 abnormal activity in, 199–203, 200t
 biopsy of
 in central core disease, 163, 163f
 in motor unit hypotonia, 157
 in proximal weakness, 173t
 carnitine deficiency in, 181, 205
 decreased energy in, 200t, 203–207. *See also* Exercise intolerance.
 pain in. *See* Myalgia.
 rippling, 210
 skeletal, calcium regulation in, malignant hyperthermia and, 209
 strength assessment of, 172–173
 weakness of, 171–196. *See also* Weakness.
- Muscle-eye-brain disease, 166–167
- Muscle fibers
 disorders of. *See* Myopathy.
 structural proteins of, 178f
 types of, 157
- Muscle spasm, 199
 hemifacial, 292
 in hypocalcemia, 202
 in stiff man syndrome, 200
 infantile, 19–21, 19t
- Muscle stiffness, 199
 electromyography in, 199, 200t
 in hypothyroidism, 202
 in myotonic disorders, 201, 202
 myopathic, 207–210
- Muscular dystrophy
 autosomal recessive, severe childhood, 179
 Becker
 familial X-linked myalgia and, 209
 proximal weakness in, 177
 congenital
 Fukuyama, 166–167

- Muscular dystrophy (*Continued*)
 hypotonia in, 165–167
 merosin-deficient, 165–166
 merosin-positive, 165
 syndromic, 166–167
- Duchenne
 calf muscles in, 176f, 177
 proximal weakness in, 177–178
- Emery-Dreifuss
 type 1, 190–191
 type 2, 191
- limb-girdle, 175–176
 autosomal dominant, 176
 autosomal recessive, 176, 176t
- oculopharyngeal, 337
 proximal weakness in, 175–179
- Mutase deficiency, 12
- Myalgia, 199
 familial X-linked, and cramps, 209
 in carbohydrate utilization defects, 203
 in carnitine O-palmitoyltransferase-2 deficiency, 205
 in hypothyroidism, 202
 in myophosphorylase deficiency, 204
 in very-long-chain acyl-CoA dehydrogenase deficiency, 205
- Myasthenia, 199
 congenital, ophthalmoplegia in, 301–302
 familial infantile, motor unit hypotonia in, 161–162, 161t
 generalized, 305–306, 307
 immune-mediated, ophthalmoplegia in, 305–307
 juvenile, 305
 limb-girdle, 175
 ocular, 305, 306–307
 proximal weakness in, 173t, 175
 pseudo-internuclear ophthalmoplegia in, 311
 respiratory insufficiency in, 306
 transitory neonatal, motor unit hypotonia in, 162
 vs. facioscapulohumeral syndrome, 337
- Myasthenic crisis, 306
- Mycobacterium tuberculosis* infection, meningitis in, 109
- Mycoplasma pneumoniae, carotid artery occlusion in, 242–243
- Mydriasis, 329
- Myelin
 disorders of. *See* Neuropathy.
 impaired formation of, 160
- Myelitis. *See also* Encephalomyelitis.
 herpes zoster, spinal paraplegia in, 262–263, 263f
 transverse, 256t, 264–266, 265f
- Myelomeningocele
 Chiari malformation in, 258
 spinal paraplegia in, 258–259
- Myelopathy, lupus, 263
- Myoadenylate deaminase deficiency, 207
- Myoclonic encephalopathy
 early, 21
 with neuroblastoma, 226, 226f
- Myoclonic epilepsy
 and ragged red fibers, 145
 benign, 21
 juvenile, 28, 29f, 71–72
 progressive, 28–29, 29t
 severe, 21–22
- Myoclonic seizures, 28–29
 in infants, 19–21, 20t
 in neonates, 2–3
- Myoclonus
 differential diagnosis of, 293
 essential, 293–294
 etiologic classification of, 293, 293t
 generalized, 294
 in chronic uremic encephalopathy, 66
 in dialysis dementia syndrome, 66
 in emergent withdrawal syndrome, 284
 in infants, benign, 21
 multifocal, 294
 nocturnal, 3, 293
 palatal, 294, 314
 physiological, 293
 postanoxic, 52, 294
 segmental (focal), 294
 spinal, 256, 294
 symptomatic, 294
- Myoedema, in hypothyroidism, 202
- Myoglobinuria
 in myophosphorylase deficiency, 204
 in very-long-chain acyl-CoA dehydrogenase deficiency, 205
- Myokymia, 200t
 in thyrotoxicosis, 202
 paroxysmal ataxia and, 221
- Myopathy. *See also* Encephalomyopathy.
 Bethlem, 176–177
 Brody, 207–208
 carbohydrate, 181
 congenital, motor unit hypotonia in, 162–165
 cramps and, 207–210
 definition of, 149
 distal weakness in, 189–191
 dysferlin, 189
 endocrine, 182
 fiber-type disproportion, congenital, 162, 162f, 163
 hereditary distal, 189–190
 autosomal dominant, 189
 autosomal recessive, 189
 inclusion body, 189–190
 inflammatory, 179–180, 180f
 lipid, 181–182

Myopathy (Continued)

- Markesbery-Griggs-Udd, 189
 - metabolic
 - motor unit hypotonia in, 167–168
 - proximal weakness in, 180–182
 - mitochondrial, 206–207, 206f, 207t, 223
 - Miyoshi, 189
 - myotubular (centronuclear), 164
 - nemaline (rod), 164–165, 165f
 - Nonaka, 189
 - ophthalmoplegia from, 303t
 - proximal weakness in, 173t
 - quadriceps, 177
 - scapuloperoneal, 191
 - severe classic, in multiminicore disease, 165, 210
 - Welander, 189
- Myophosphorylase deficiency*, 181, 203–205
- Myositis*
- acute infectious, 191
 - inclusion body, 189
 - orbital, 307
- Myotonia*, 200t. *See also* *Neuromyotonia*.
- Myotonia congenita*, 201–202
- Myotonia fluctuans*, 201–202
- Myotonic dystrophy*
- congenital, motor unit hypotonia in, 167
 - distal, 190
 - proximal, 178
- Myotubular (centronuclear) myopathy, motor unit hypotonia in*, 164
- Myxedema coma*, 64
- Narcolepsy*, 24–25
- Narcotics, withdrawal from, in neonates*, 8–9
- Nausea, in vestibular nystagmus*, 315
- Near-drowning, anoxia after*, 51–52
- Neck extensors, as pain source*, 77
- Neck injury, pain in*, 88
- Neck muscles, weakness of*, 172
- Necrosis*
- liver, valproate and, 40
 - striatal, infantile bilateral, 291
- Necrotizing encephalomyelopathy, subacute*, 134, 223, 291
- Necrotizing encephalopathy, subacute*, 68
- Necrotizing fasciitis, carotid artery occlusion in*, 243
- Neisseria meningitidis, meningitis in*, 107, 109
- Nemaline (rod) myopathy, motor unit hypotonia in*, 164–165, 165f
- Neomycin, ototoxicity of*, 345
- Neonates. See also* *Infants*.
- adrenoleukodystrophy in, cerebral hypotonia and, 154–155
 - aminoacidopathies in, 4–8
 - apnea in, 3
 - bacterial meningitis in, 106–107, 107t
 - benign nocturnal myoclonus in, 3

Neonates (Continued)

- bilirubin encephalopathy in, 8
 - brachial plexus palsy in, 276
 - CATCH syndrome in, 9
 - cerebral infarction in, 239–240
 - cerebral venous thrombosis in, 13
 - DiGeorge syndrome in, 9
 - drug withdrawal in, 8–9
 - feeding problems of, differential diagnosis of, 153t
 - glycine encephalopathy in, 5
 - head trauma in, 13–14
 - hemorrhage in, 240
 - intracranial, 13–14
 - intraventricular, 102–104
 - subarachnoid, 13–14
 - subdural, 14
 - herpes simplex encephalitis in, 13
 - hyperammonemia in, 6–8, 6f, 7t, 11, 12
 - hyperglycinemia in
 - nonketotic, 5
 - with metabolic acidosis, 12
 - hypocalcemia in, 9
 - hypoglycemia in, 9–10, 10t
 - hypoparathyroidism in, 9
 - hypoxic-ischemic encephalopathy in, 10–11
 - incontinentia pigmenti in, 14–15
 - isovaleric acidemia in, 11–12
 - jitteriness in, 3–4
 - maple syrup urine disease in, 4–5, 6f
 - methylmalonic acidemia in, 12
 - myasthenia in
 - congenital, 301–303
 - transitory, 162
 - organic acid disorders in, 11–13
 - paroxysmal disorders in, 1–15, 2t
 - propionic acidemia in, 12–13
 - pyridoxine dependency in, 14
 - seizures in, 1–15, 2t
 - benign familial, 7
 - differential diagnosis of, 4–15, 4t
 - focal clonic, 2
 - from metabolic disorders, 1–8, 5t
 - movements that resemble, 2t
 - multifocal clonic, 2
 - myoclonic, 2–3
 - patterns of, 1–2, 2t
 - tonic, 3
 - treatment of, 15
 - spinal cord infarction in, 264
 - trauma in, 13–14
 - urea cycle disturbances in, 6–8, 6f, 7t
- Neostigmine*
- in familial infantile myasthenia, 161–162
 - in ocular myasthenia, 306
 - in transitory neonatal myasthenia, 162
- Nerve biopsy, in motor unit hypotonia*, 157

- Nerve conduction, in proximal weakness, 173t
- Nerve root pain, 211
- Nerve stimulation studies, in myasthenia, 306
- Neural tube defects, 258–259
- Neuralgic amyotrophy, 274
hereditary, 275–276
- Neuritis
brachial, 274, 276–277
facial, 335–336
optic, 322–323, 323f
in Devic disease, 265
multiple sclerosis and, 322
vestibular, 349
- Neuroacanthocytosis, 284–285
- Neuroaxonal dystrophy, infantile, 136–137
- Neuroblastoma
in myoclonic encephalopathy/neuroblastoma syndrome, 226, 226f
of spinal cord, 268
- Neuroborreliosis, 54
- Neurocutaneous disorders
anatomical megalencephaly in, 362–363
developmental delay in, 134–135
infantile seizures in, 19t
- Neurodegeneration, pantothenate kinase–associated, 291
- Neurofibroma, of lumbar plexus, 278, 278f
- Neurofibromatosis
in infants, 19t
type 1
developmental delay in, 134–135
optic glioma in, 325–326
type 2, acoustic neuroma in, 346–347, 347f
- Neuroleptic malignant syndrome, 209–210
- Neuroleptics
chorea from, 283
tardive dyskinesia from, 283
vertigo from, 348
withdrawal reactions to, 284
- Neurological disorders
acanthocytosis in, 284–285
dysphagia in, 333t
hearing loss in, 345t
megalencephaly in, 361–362
- Neuroma, acoustic, 340, 346–347, 347f
- Neuromuscular blockade, weakness in, 193–194
- Neuromuscular disease. *See also* Weakness.
clinical features of, 171–173, 172f, 172t
- Neuromuscular transmission disorders
motor unit hypotonia in, 160–162
ophthalmoplegia from, 303t
- Neuromyelitis optica, 265, 322
- Neuromyotonia, 200–201, 200t
- Neuronal ceroid lipofuscinoses, 142–144, 142t, 143t
early infantile, 135–136
juvenile, 144
late infantile, 142–143
- Neuronal migration disorders, partial seizures in, 30
- Neuronopathy
definition of, 149
diagnosis of, 182, 183t
distal weakness in, 182, 183, 183t
proximal weakness in, 173t
- Neuropathy. *See also* Axonopathy; Neuronopathy; Polyneuropathy.
acute ataxic, 224
definition of, 149
demyelinating. *See* Demyelination.
diagnosis of, 182–183, 183t
distal weakness in, 184–189
drug-induced, 187–188, 187t
focal familial recurrent, 275
hereditary, with liability to pressure palsy, 279
hereditary motor and sensory. *See* Charcot-Marie-Tooth disease.
hereditary sensory and autonomic.
See Hereditary sensory and autonomic neuropathy.
hypomyelinating, congenital, motor unit hypotonia in, 160
in juvenile rheumatoid arthritis, 189
in uremia, 188
in vascular disorders, 189
lipid disorders in, 186
median, 278–279
metabolic, hereditary, 215–216
monoplegia in, 278–279
ophthalmoplegia in, 303t
optic. *See* Optic neuropathy.
peripheral
in hereditary sensory and autonomic neuropathy II, 214
paraplegia in, 255
sensory loss in, 211
peroneal, 279
radial, 278
sensory, 211, 212t
tomaculous, 279
toxin-induced, 188
ulnar, 278
- Neuroretinitis, 322, 323f
- Neurosarcoidosis, 339
- Neurulation, defective, microcephaly and, 364
- Newborns. *See* Neonates.
- Nicotinamide, in Hartnup disease, 222
- Niemann-Pick disease
type A, 132
type C, 141
- Night terrors, 25
- Nitrites, headache from, 85
- Nitrofurantoin, neuropathy from, 188
- Nitrogen, dietary restriction of, in urea cycle disturbances, 7

- Nocturnal frontal lobe epilepsy, autosomal dominant, 31
- Nocturnal myoclonus, 293
benign, in neonates, 3
- Nonsteroidal anti-inflammatory drugs, in migraine, 82
- NTBC, in hereditary tyrosinemia type I, 216
- Null point, in nystagmus, 314
- Nutrition. *See also* Diet.
parenteral, encephalopathy in, 67
- Nutritional deficiency, optic neuropathy and, 323
- Nylan-Hallpike test, 348
- Nystagmus, 313–316
acquired, 314–316
congenital, 313–314
differential diagnosis of, 313, 313t
dissociated, 316
divergence, 316
downbeat, 315
downward-beating, 315
drug-induced, 314
ictal, 315
in internuclear ophthalmoplegia, 311
in spasmus mutans, 314
in vestibular neuritis, 349
jerk, 313, 314–315
monocular, 316
pendular, 313, 314
physiological, 313
seesaw, 316
upbeat, 315–316
vestibular, 315
- Obsessive-compulsive behavior, in Tourette syndrome, 294–295
- Obtundation, definition of, 48t
- Occipital epilepsy, benign, 31, 88
- Ocular abnormalities, in Walker-Warburg syndrome, 360
- Ocular bobbing, 313, 313t
- Ocular dysmetria, 313, 313t
- Ocular flutter, 313, 313t
- Ocular motility
assessment of, in comatose patients, 50
disorders of, 299–316. *See also specific disorders, e.g., Ophthalmoplegia.*
differential diagnosis of, 313, 313t
- Ocular myasthenia, 305, 306–307
- Ocular pain, 87
- Oculocerebrorenal syndrome
cerebral hypotonia in, 154
vs. Walker-Warburg syndrome, 360
- Oculomotor apraxia, 310–312, 311t
ataxia with, 234–235
congenital, 311, 312
in ataxia-telangiectasia, 234
vertical, 312
- Oculomotor nerve palsy
aneurysm and, 302–303
congenital, 300
from trauma, 308–309
- Oculopharyngeal muscular dystrophy, 337
- Odontoid process, aplasia of, 257
- Ohtahara syndrome, 21
- Oligodendroglioma, 98
- Ondine's curse, 50
- One-and-a-half syndrome, 311
- Opercula syndrome, epileptiform, acquired, 30
- Ophthalmopathy, Graves, 310
- Ophthalmoplegia, 300–312
acquired, causes of, 303t
bilateral
acute, 309, 309t
chronic, 309–310, 310t
congenital, 300–302
in brainstem glioma, 303–304, 304f
internuclear, 311–312, 311t
unilateral, acute, 302–309, 303t
- Ophthalmoplegic migraine, 307, 308
- Opiates. *See* Narcotics.
- Opisthotonos, 3, 51
- Opsoclonus, 226, 313, 313t
- Optic chiasm, tumors of, 326
- Optic disk
congenitally elevated, 94, 95f
morning glory anomaly of, 320
swelling of. *See* Papilledema.
- Optic nerve
anterior, infarction of, 323
congenital hypoplasia of, 318–320, 320f
glioma of, 325–326, 326f
- Optic neuritis, 322–323, 323f
in Devic disease, 265, 322
multiple sclerosis and, 322
- Optic neuropathy, 322–324
compressive, 325–327, 326f
demyelinating. *See* Optic neuritis.
drug-induced, 323
hereditary, 327
in deafness–dystonia–optic neuronopathy syndrome, 344
in idiopathic intracranial hypertension, 114
ischemic, 323
Leber hereditary, 291, 327
nutritional, 323
toxic, 323
traumatic, 323–324
- Oral contraceptives
chorea from, 283
migraine and, 79–80
- Orbit
trauma to, 308–309, 325
tumors of, 307–308
- Orbital inflammatory disease, 307

- Organ of Corti, 340
- Organic acid disorders, in neonates, 11–13
- Ornithine transcarbamoylase deficiency, 7
- Osmolality, disorders of, altered states of consciousness in, 61–63
- Osteomyelitis
neuritis with, 276–277
tuberculous, 263
- Osteopetrosis, 334, 337–338
- Otitis externa, facial palsy and, 339
- Otitis media
hearing loss in, 345, 346
vertigo in, 349
- Otoscope examination, 341
- Overshoot dysmetria, in internuclear ophthalmoplegia, 311
- Oxcarbazepine, 36t, 38
- Oxidative phosphorylation coupling, 203
- Oxycephaly, 368t
- Oxygen inhalation, in cluster headache, 83
- Pachygyria, 366–367
- Pain
central congenital insensitivity to, 212–213
dysesthetic. *See* Dysesthesia.
in complex regional pain syndrome I, 211–212
in headache, sources of, 77–78, 78t
in increased intracranial pressure, 93
in lumbar disk herniation, 216
in migraine with aura, 80
in neck injury, 88
in sinusitis, 87
in temporomandibular joint syndrome, 87–88
in whiplash, 88
leg, nocturnal, 199
muscle. *See* Myalgia.
ocular, 87
thalamic, 217–218
- Painful arm syndromes, 211–212
- Palatal myoclonus, 294, 314
- Palsy. *See also specific nerves, e.g.,* Facial nerve, palsy of.
Bell's, 335–336, 338
brachial plexus, in neonates, 276
bulbar, juvenile progressive, 336, 337
cerebral. *See* Cerebral palsy.
gaze, 310–313, 311t
pontobulbar, with deafness, 336, 344–345
pressure, hereditary neuropathy with liability to, 279
pseudobulbar, 310–313, 311t
facial weakness in, 331–332
- Pancreatitis, valproate and, 40
- Pancuronium paralysis, in neonates, seizure identification and, 2
- PANDAS, 295
- Panic attack, 69
- Pantothenate kinase–associated neurodegeneration, 291
- Papilledema
in astrocytoma, 99, 238
in brain abscess, 110
in ependymoma, 100
in idiopathic intracranial hypertension, 114
in increased intracranial pressure, 93–94, 94f, 94t
in medulloblastoma, 230
vs. papillitis, 322
- Papilloma, choroid plexus, 97–98
cerebrospinal fluid formation in, 91, 355
noncommunicating hydrocephalus in, 359
- Paralysis. *See also* Hemiplegia; Monoplegia; Palsy; Paraplegia; Quadriplegia.
convergence, 311t, 312
pancuronium, in neonates, seizure identification and, 2
periodic, 194–196
sleep, 24
tick, 194
Todd, 244–245
- Paraplegia, 255–270
approach to, 255
cerebral, 269–270, 269t
spastic, 269–270
hereditary, 261–262
spinal, 255–260
causes of, 255, 256t
hereditary spastic, 261–262
in adrenomyeloneuropathy, 263
in arachnoid cysts, 256–257
in arginase deficiency, 264
in arteriovenous malformations, 257
in astrocytoma, 267–268, 267f
in atlantoaxial dislocation, 257–258
in caudal regression syndrome, 258
in Chiari malformation, 258
in congenital malformations, 256–260
in Devic disease, 265
in diffuse encephalomyelitis, 265–266
in diskitis, 262, 262f
in ependymoma, 268
in herpes zoster myelitis, 262–263, 263f
in infections, 262–263, 262f, 263f
in Krabbe disease, 264
in lupus myelopathy, 263
in metabolic disorders, 263–264
in myelomeningocele, 258–259
in neuroblastoma, 268
in spinal cord concussion, 267
in spinal cord infarction, 264
in spinal cord injuries, 266–267, 267f
in spinal epidural hematoma, 267
in tethered spinal cord, 259–260, 261f

- Paraplegia (*Continued*)
 in tuberculous osteomyelitis, 263
 in tumors, 267–268, 267f
 signs and symptoms of, 255–256
- Parathyroid hormone, abnormalities of.
See Hyperparathyroidism;
 Hypoparathyroidism.
- Parenteral nutrition, encephalopathy in, 67
- Parinaud syndrome, 101
- Parkinsonism
 dystonia with, 288–289
 rapid-onset, 291–292
 tremor in, 296
- Paroxysmal choreoathetosis, 23, 285
- Paroxysmal disorders, 1–44. *See also specific type, e.g.,* Seizures.
 approach to, 1
 childhood, 23–35
 in children less than 2 years old, 15–23, 16t
 neonatal, 1–15, 2t
- Paroxysmal dyskinesia, 23
- Paroxysmal dystonic head tremor, 297
- Paroxysmal movement disorders, 281
- Paroxysmal torticollis, benign, 287–288
- Pectus excavatum, in hypotonia, 149
- Pelizaeus-Merzbacher disease, 138–139
- Pelvis, fracture-dislocation of, 277–278
- Pemoline, in narcolepsy, 24
- Pendred syndrome, hearing loss in, 343
- Pendular nystagmus, 314
- Penicillamine, in Wilson disease, 290
- Penicillin
 in bacterial meningitis, 107, 107t, 108, 109t
 in congenital syphilis, 121
 in Lyme disease, 54
 in pneumococcal meningitis, 109
- Pentobarbital coma
 in anoxia/ischemia, 52
 in increased intracranial pressure, 97
 in status epilepticus, 41, 42f
- Pergolide, in tics, 296
- Perifascicular atrophy, in dermatomyositis, 179, 180f
- Perinatal disorders
 developmental delay and, 123
 dystonia and, 292
 hypoxic-ischemic encephalopathy and, 10–11
 jitteriness and, 4
 microcephaly and, 367
- Perinatal injury
 facial palsy from, 334–335
 in breech presentation, 155–156
 in cephalic presentation, 156
 to brachial plexus, 276
 to spinal cord, hypotonia and, 155–156
- Periodic alternating gaze, 313t
- Periodic breathing, 3
- Periodic paralysis, 194–196
 Anderson potassium-sensitive
 cardiodyrhythmic, 196
 familial hyperkalemic, type 1, 195–196
 familial hypokalemic, 195
 familial normokalemic, 196
- Periosteal pain, 77, 78
- Peripheral neuropathy
 in hereditary sensory and autonomic
 neuropathy II, 214
 paraplegia in, 255
 sensory loss in, 211
- Perisylvian syndrome
 congenital bilateral, 119, 333, 334f
 unilateral, 239
- Periventricular hemorrhagic infarction, 102–103
- Periventricular-intraventricular hemorrhage.
See also Intraventricular hemorrhage.
 clinical features of, 103
 diagnosis of, 103
 grading system for, 102
 in premature neonates, 102–104
 management of, 103–104
 prevention of, 103, 103t
- Periventricular leukomalacia, 102, 269
- Peroneal neuropathy, 279
- Peroxisomal disorders, cerebral hypotonia in, 154–155
- Persistent vegetative state, 52
- Personality change, in subacute sclerosing
 panencephalitis, 142
- Pertussis vaccine, whole-cell, seizures from, 61
- Pervasive developmental disorders, 118
- Pes cavus, 256
- Phasic tone, 149
- Phenobarbital, 38–39
 dosage of, 36t
 in hypoxic-ischemic encephalopathy, 11
 in neonatal drug withdrawal, 8–9
 in neonatal seizures, 15
 prophylactic, in febrile seizures, 18
- Phenothiazine
 overdose of, encephalopathy from, 70
 tardive dyskinesia from, 283
- Phenylketonuria, developmental delay in, 126–128, 127f
- Phenytoin, 39
 ataxia from, 220–221
 chorea from, 283
 dosage of, 36t
 downbeat nystagmus from, 315
 in continuous motor unit activity, 201, 202
 in episodic ataxia type 1, 221
 in neonatal seizures, 15
 metabolism of, 36
- Phosphofructokinase deficiency, 205

- Phosphoglycerate kinase deficiency, 205
 Phosphoglycerate mutase deficiency, 205
 Phosphorylase deficiency, 181, 203–205
 Photocoagulation, in retinal hemangioblastoma, 229
 Photophobia, tonic pupil syndrome and, 329
 Photosensitive seizure disorder, 34
 Physical therapy, in spastic diplegia, 270
 Pigmentary retinopathy, 328
 Pimozide
 in Sydenham chorea, 286
 in tics, 295–296
 Pineal region tumors, 101, 312
 Piracetam, for cyanotic syncope, in infants, 17
 Pituitary adenoma, 326–327
 Pituitary apoplexy, blindness in, 324
 Pituitary disorders, optic nerve hypoplasia and, 318–319
 Plagiocephaly, 367–368, 368t
 Plantar ulcers, in hereditary sensory and autonomic neuropathy I, 214
 Plexitis
 brachial, 274
 lumbar, 274–275
 monoplegia in
 acute idiopathic, 274–275
 acute symptomatic, 275–278
 Plexopathy
 brachial
 hereditary, 275–276
 neonatal traumatic, 276
 lumbar, 276
 monoplegia in, 275–278
 Plexus tumors, monoplegia in, 278, 278f
 Pneumococcal meningitis, 109
 Pneumonia, mycoplasmal, carotid artery occlusion in, 242–243
 Poisoning, accidental, 70–71
 Poland anomaly, facial palsy in, 334
 Poliiodystrophy, progressive infantile, 133–134
 Poliomyelitis, paralytic, vs. asthmatic amyotrophy, 275
 Poliovirus infection, 193
 Polycystic kidney disease, arterial aneurysms and, 104
 Polymyositis, proximal weakness in, 180
 Polyneuropathy. *See also* Neuropathy.
 cranial, idiopathic, 336
 motor unit hypotonia in, 159–160, 160t
 sensory loss in, 211
 with possible onset in infancy, 160t
 Polyradiculoneuropathy, demyelinating
 acute inflammatory, 191–192
 chronic inflammatory, 192–193
 Pompe disease
 hypotonia in, 155
 proximal weakness in, 180–181
 Pontine gaze center, lesions of, horizontal gaze palsy in, 312
 Pontobulbar palsy with deafness, 336, 344–345
 Porencephaly, 360–361
 Porphyria, acute intermittent, 215–216
 Port-wine stain, facial, in Sturge-Weber syndrome, 252
 Postconcussion syndrome, ataxia in, 227
 Posterior communicating artery, aneurysm of, 105–106, 302–303
 Posterior fossa
 decompression of, in Chiari malformation, 258
 ependymoma of, 100
 medulloblastoma of
 ataxia in, 230, 230f
 noncommunicating hydrocephalus in, 359
 tumors of, 97t
 ataxia in, 228–230
 hemifacial spasm and, 292
 Postinfectious encephalitis, 60f
 Posttraumatic epilepsy, 74
 Postural tone, 149
 Posture
 abnormal, differential diagnosis of, 286, 286t
 decerebrate
 in comatose patients, 51
 in premature infants, 3
 dystonic, drug-induced, 283, 287
 muscle spasm and, 199
 Potassium, serum, in periodic paralysis, 194–196
 Prader-Willi syndrome
 cerebral hypotonia in, 152–153
 diagnostic criteria for, 153t
 Precocious puberty, in hypothalamic tumors, 326
 Prednisone
 in cluster headache, 83
 in congenital hypomyelinating neuropathy, 160
 in dermatomyositis, 179–180
 in diffuse encephalomyelitis, 265
 in Duchenne muscular dystrophy, 177–178
 in herpes zoster oticus, 339
 in myasthenia, 307
 in optic neuritis, 323
 in orbital inflammatory disease, 307
 in sarcoidosis, 339
 in Tolosa-Hunt syndrome, 308
 in toxoplasmosis, 122
 Pregnancy
 chorea in, 285
 retinal artery occlusion and, 324
 Premature infants
 apnea in, 3
 decerebrate posturing in, 3
 periventricular-intraventricular hemorrhage in, 102–104
 tonic seizures in, 3

- Prescription medications. *See* Drug(s).
- Pressure palsy, hereditary neuropathy with liability to, 279
- Primidone, 39
dosage of, 36t
in essential tremor, 296
- Primitive neuroectodermal tumor (PNET), 100–101
- Prochlorperazine, tardive dyskinesia from, 283
- Prolactin, pituitary adenoma and, 327
- Propionic acidemia, in neonates, 12–13
- Propranolol
in essential tremor, 296
in migraine prophylaxis, 82
- Proptosis
in Graves ophthalmopathy, 310
in orbital inflammatory disease, 307
in orbital tumors, 307–308
- Prosencephalization, defective, microcephaly and, 365–367
- Protein, dietary restriction of
in maple syrup urine disease, 5, 126, 223
in methylmalonic acidemia, 12
in neonatal urea cycle disorders, 7
in propionic acidemia, 12–13
- Protein complexes, of respiratory chain, 206, 206f
disorders associated with, 206–207, 207t.
See also Mitochondrial disorders.
- Pseudoataxia, 226–227
- Pseudobulbar palsy, 310–313, 311t, 331–332
- Pseudo-internuclear ophthalmoplegia, in myasthenia, 311
- Pseudomonas* infection, meningitis in, 106, 107
- Pseudoseizures, 34
- Pseudotumor cerebri, 113–114, 114t
- Psychiatric disorders, in Wolfram syndrome, 327
- Psychoactive drugs
ataxia from, 220
ophthalmoplegia from, 309
overdose of, encephalopathy from, 70
- Psychological counseling, in pseudoseizures, 34
- Psychological disorders, altered states of consciousness in, 48t, 69
- Psychomotor retardation and regression, 117–146, 118t. *See also* Developmental delay; Encephalopathy, progressive.
- Psychosis, corticosteroid, 70
- Ptosis
congenital, 302
differential diagnosis of, 302, 302t
in congenital fibrosis of extraocular muscles, 301
in congenital myasthenia gravis, 302
in familial infantile myasthenia, 161
in migraine, 307
in myasthenia, 305, 306
in orbital tumors, 307–308
- Puberty
delayed, in prolactin-secreting tumors, 327
precocious, in hypothalamic tumors, 326
- Pupil(s)
dilated fixed, 329
disorders of, 328–329
size difference in, 329
tonic, 329
- Pupillary light reflex
absence of, in comatose patients, 50
assessment of, 317
- Pure-tone audiometry, 341
- Pyrazinamide, in tuberculous meningitis, 110
- Pyridostigmine
in familial infantile myasthenia, 161–162
in ocular myasthenia, 306
- Pyridoxine
in homocystinuria, 126
in infantile spasms, 20–21
in isoniazid neuropathy, 188
in Wilson disease, 290
neonatal dependency on, 14
- Pyrimethamine, in toxoplasmosis, 122
- Pyruvate dehydrogenase deficiency, ataxia in, 223, 236, 236t
- Q-T interval, prolongation of, in Andersen syndrome, 196
- Quadriceps myopathy, 177
- Quadriplegia, 255–270. *See also* Paraplegia.
cerebral, 269–270
corticosteroid-induced, 194
spastic, 270
- Quinidine, in slow-channel syndrome, 175
- Rabies vaccine, Semple, encephalitis from, 61
- Radial neuropathy, 278
- Ragged-red fibers
in MELAS syndrome, 248
in mitochondrial myopathy, 206, 208f
- Ramsay Hunt syndrome, facial palsy and, 338–339
- Rash
in incontinentia pigmenti, 14–15
in Lyme disease, 54
in Rocky Mountain spotted fever, 55
in xeroderma pigmentosum, 145
- Rasmussen syndrome, 32
- Reading epilepsy, 32–33
- Recruitment, auditory, 342
- Refixation reflex, 317
- Reflex(es)
pupillary light, 50, 317
sucking, 331
swallowing, 331

- Reflex(es) (*Continued*)
- tendon
 - in motor unit hypotonia, 152
 - in proximal weakness, 173t
 - weakness and, 173
 - Reflex sympathetic dystrophy, 211–212
 - Refsum disease
 - ataxia in, 236, 236t
 - infantile
 - cerebral hypotonia in, 154–155
 - hearing loss in, 343
 - Respiration, Cheyne-Stokes, 50
 - Respiratory chain, protein complexes of, 206, 206f
 - disorders associated with, 206–207, 207t.
 - See also* Mitochondrial disorders.
 - Respiratory distress
 - intraventricular hemorrhage and, 102
 - perinatal, motor unit hypotonia with, 151, 151t
 - Respiratory infection, Reye syndrome and, 60
 - Respiratory insufficiency
 - in familial infantile myasthenia, 161
 - in myasthenia, 306
 - Restless leg syndrome, 293
 - Restlessness, appearance of, in movement disorders, 281–282
 - Reticular formation, lesions of, vertical gaze palsy in, 312
 - Retina
 - disease of
 - acute blindness in, 324–325
 - in Leber congenital amaurosis, 320
 - pigmentary, 328
 - hemangioblastoma of, 229
 - hemorrhage of, in shaking injuries, 72
 - in papilledema, 94, 94f
 - trauma to, 325
 - Retinal artery, central, occlusion of, 324
 - Retinal migraine, 324–325
 - Retinitis pigmentosa
 - in abetalipoproteinemia, 233
 - in Usher syndrome, 343–344
 - Retinoblastoma, 327–328
 - Retinochoroidal coloboma, 320
 - Rett syndrome, 137, 144
 - Reye syndrome, 60–61
 - Rheumatic fever, chorea in, 285–286
 - Rheumatic heart disease, 246
 - Rheumatoid arthritis, juvenile, neuropathy in, 189
 - Rhizotomy, selective posterior, in spastic diplegia, 270
 - Rickettsia rickettsii*, 55
 - Rifampin
 - in meningococcal meningitis, 109
 - in tuberculous meningitis, 110
 - in tuberculous osteomyelitis, 263
 - Rigid spine syndrome, 165, 210
 - Rigidity
 - decerebrate, 3, 51
 - decorticate, 51
 - Riley-Day syndrome, 154, 214
 - Rinne test, 341
 - Rippling muscle disease, 210
 - RNA viruses, encephalitis from, 55
 - Rocky Mountain spotted fever, 55
 - Rod myopathy, motor unit hypotonia in, 164–165, 165f
 - Rolandic epilepsy
 - autosomal dominant, and speech apraxia, 30
 - benign, 31
 - Romberg sign, 219
 - Rosenthal fibers, in Alexander disease, 133
 - Rotation, illusion of, in vertigo, 347
 - Rubella embryopathy
 - chronic panencephalitis and, 142
 - developmental delay in, 122
 - Rubeola encephalitis, 59, 142
 - St. Louis encephalitis, 57
 - Salicylates
 - ototoxicity of, 345
 - Reye syndrome and, 60–61
 - Sandhoff disease, 130
 - Sanfilippo disease, 131
 - Santavuori-Haltia disease, 135–136, 142t, 143t
 - Sarcoidosis, 339
 - Sarcoma, Ewing's, spinal cord compression in, 267
 - Scalp arteries, as pain source, 77
 - Scaphocephaly, 367, 368t
 - Scapula, fracture of, 277
 - Scapulo (humeral) peroneal syndromes, distal weakness in, 190–191
 - Schafer syndrome, congenital cataract and, 318
 - Scheibe defect, 342
 - Schizencephaly, 239, 240f
 - Schizophrenia, 69
 - School-age children, bacterial meningitis in, 109
 - Schwartz-Jampel syndrome, 201
 - Scissoring
 - in cerebral hypotonia, 151
 - in spastic diplegia, 269
 - Sclerosing panencephalitis, subacute, progressive encephalopathy from, 142
 - Sclerosis
 - hippocampal, bilateral, developmental delay in, 119
 - juvenile amyotrophic lateral, distal weakness in, 183
 - multiple. *See* Multiple sclerosis.
 - tuberous
 - developmental delay in, 135
 - diagnosis of, 135, 136t
 - in infants, 19t

Scoliosis

- in Duchenne muscular dystrophy, 177
- in Friedreich ataxia, 235
- in spinal paraplegia, 256

Screening tests

- for congenital syphilis, 121
- for hyperphenylalaninemia, 127–128
- for metabolic disorders causing neonatal seizures, 4, 5t

Seesaw nystagmus, 316

Segawa disease, 288–289

Seitelberger disease, 136–137

Seizures

- adversive, 312
- anticonvulsants for, 35–41. *See also* Anticonvulsants.
- apneic, 16
- epileptic. *See* Epilepsy.
- false (hysterical), 34
- febrile
 - in infants, 17–18
 - neonatal seizures and, 7
 - vs. epilepsy, 17
- focal clonic, in neonates, 2
- generalized tonic-clonic, 33–34, 33t
- headache and, 88
- hemiparetic, 244–245
- in astrocytoma, 98
- in bacterial meningitis, 107
- in bilirubin encephalopathy, 8
- in concussion, 72
- in congenital bilateral perisylvian syndrome, 333
- in dialysis dementia syndrome, 66
- in drug withdrawal, 8–9
- in glycine encephalopathy, 5
- in head injury, 3, 14
- in herpes simplex encephalitis, 13
- in hypertensive encephalopathy, 67
- in hypocalcemia, 9
- in hypoglycemia, 9–10
- in hypoxic-ischemic encephalopathy, 10, 11
- in incontinentia pigmenti, 14–15
- in infants
 - apneic, 16
 - benign familial, 7
 - differential diagnosis of, 15–23, 16t
 - febrile, 17–18
 - myoclonic, 19–21, 20t
 - neurocutaneous disorders causing, 19t
 - nonfebrile, 18–23
- in intracranial hemorrhage, 13–14
- in juvenile myoclonic epilepsy, 28
- in Lennox-Gastaut syndrome, 22
- in maple syrup urine disease, 5
- in mesial temporal sclerosis, febrile seizures as children and, 17

Seizures (*Continued*)

- in migraine, 223
 - in neonates, 1–15, 2t
 - benign familial, 7
 - differential diagnosis of, 4–15, 4t
 - focal clonic, 2
 - from metabolic disorders, 4–8, 5t
 - movements that resemble, 2t
 - multifocal clonic, 2
 - myoclonic, 2–3
 - patterns of, 1–2, 2t
 - tonic, 3
 - treatment of, 15
 - in organic acid disorders, 11–13
 - in phenylketonuria, 127
 - in pyridoxine dependency, 15
 - in supratentorial malformations, 105
 - in tuberous sclerosis, 135
 - in urea cycle disturbances, 6–7
 - management of, 35–43
 - multifocal clonic, in neonates, 2
 - myoclonic, 28–29
 - in infants, 19–21, 19t
 - in neonates, 2–3
 - nystagmus in, 315
 - partial, 29–33
 - complex, 27–28
 - posttraumatic, 74
 - prolonged. *See* Status epilepticus.
 - subtle, 2
 - tonic, in neonates, 3
 - video game-induced, 34–35
 - vs. jitteriness, 4
 - vs. movement disorders, 281
 - vs. stereotypies, 294
 - vs. syncope, 25–26
- Semicircular canal, 340, 347
- Sensory loss, 211–218, 213t
- in brachial neuritis, 211
 - in central congenital insensitivity to pain, 212–213
 - in complex regional pain syndrome I, 211–212
 - in foramen magnum tumors, 213
 - in fracture-dislocation and spinal cord transection, 266
 - in hereditary metabolic neuropathies, 215–216
 - in hereditary sensory and autonomic neuropathies, 213–215. *See also* Hereditary sensory and autonomic neuropathy.
 - in lumbar disk herniation, 216
 - in syringomyelia, 216–217, 217f
 - in thalamic syndromes, 217–218
 - patterns of, 211, 212t
- Sepsis, gram-negative, 53
- Septicemia, in neonates, 106–107, 107t
- Septo-optic dysplasia
- optic nerve hypoplasia and, 318
 - vs. Walker-Warburg syndrome, 360

- Septum pellucidum, midline defects of. *See*
Septo-optic dysplasia.
- Serum sickness, headache in, 86
- Setting sun sign, 357
- Shagreen patch, 135
- Shaking injuries, 72–73
- Shock
hemorrhagic, 53–54
septic, 53
spinal
in fracture-dislocation and spinal cord
transection, 266
in spinal cord concussion, 267
- Shrintzen syndrome, in neonates, 9
- Sickle cell disease, 248–249, 324
- Siemens syndrome, congenital cataract and, 318
- Sinopulmonary infection, in ataxia-telangiectasia,
234
- Sinus
cavernous
disorders of, vs. Tolosa-Hunt syndrome, 308
fistula of, 304
thrombosis of, 304–305
dermal, in tethered spinal cord, 260
- Sinusitis, pain in, 87
- Skeletal disorders, hearing loss in, 345t, 346
- Skeletal dysplasia, in Hurler syndrome, 131
- Skew deviation, in comatose patients, 50
- Skull
blood vessels in, pain sensitivity of, 77
fracture of, 73, 74
fusion of, intracranial pressure and, 91
shape of
determinants of, 353
disorders of, 353–369
structures of, pain from, 87–88
thickened, macrocephaly and, 355, 355t
volume of
disorders of, 353–369
skull size and, 353
- Sleep. *See also* Nocturnal *entries*.
in migraine, treatment of, 81
- Sleep disorders, 24–25
- Slow-channel syndrome, proximal weakness in,
175
- Sly disease, 141
- Sodium, loss of, hyponatremic encephalopathy
from, 63
- Sodium benzoate, in glycine encephalopathy, 5
- Sotos syndrome, 362
- Spasm(s)
basilar artery, vertigo and, 351
infantile, 19t
muscle. *See* Muscle spasm.
- Spasmus mutans, 287
- nystagmus in, 314
- Spastic diplegia, 269–270
- Spastic paraplegia, 269–270
hereditary, 261–262
- Spastic quadriplegia, 270
- Speech
developmental delay in, 117–119, 118t
disturbances of
in congenital bilateral perisylvian syndrome,
333
in dialysis dementia syndrome, 66
- Speech apraxia, autosomal dominant rolandic
epilepsy and, 30
- Speech tests, 341–342
- Sphingomyelin lipidosis, 132, 141
- Spielmeyer-Vogt disease, 142t, 143t, 144
- Spina bifida cystica, 258–259
- Spina bifida occulta, 259–260
- Spinal cord
arachnoid cysts of, 256–257
arteriovenous malformations of, 257
astrocytoma of, 267–268, 267f
cervical
traction injury to, 155–156
twisting injury to, 156
compression of, 255
concussion of, 267
demyelination of, in transverse myelitis,
264–266, 265f
disorders of
cerebral hypotonia in, 155–156
sensory loss in, 216–217
ependymoma of, 268
epidural hematoma of, 267
imaging of, 255
infarction of, 264
injury to, hypotonia in, 155–156
lumbar. *See* Lumbar *entries*.
neuroblastoma of, 268
rigid, 165, 210
tethered, 259–260, 261f
thoracic, traction injury to, 155–156
transection of, fracture-dislocation and,
266–267, 267f
trauma to, 266–267, 267f
tuberculosis of, 263
tumors of, 267–268, 267f
- Spinal muscle atrophy
autosomal dominant, 174
autosomal recessive, 173–174
cervical, congenital, 159
distal weakness in, 183
hypotonia in, 157–159, 158f
infantile, 158, 158f
with arthrogryposis, 159
with respiratory distress, 159
juvenile, 173–174, 183
monomelic, 273–274
proximal weakness in, 173–174

- Spinal myoclonus, 256, 294
 Spinal paraplegia. *See* Paraplegia, spinal.
 Spinal shock
 in fracture-dislocation and spinal cord transection, 266
 in spinal cord concussion, 267
 Spinning, illusion of, in vertigo, 347
 Spinocerebellar degenerations, ataxia in, 232
 Spiramycin, in toxoplasmosis, 122
 Spongy degeneration of infancy, 138
 Sprengel deformity, in Klippel-Feil syndrome, 358
Staphylococcus aureus
 in diskitis, 262
 in gram-negative sepsis, 53
 in toxic shock syndrome, 55
 Staring spells, 26–28
 in absence epilepsy, 26–27, 27f
 in complex partial seizures, 27–28
 Startle disease, 25
 Status epilepticus, 33
 causes of, 41
 complex partial, 27–28
 in pyridoxine dependency, 14
 management of, 41, 42f
 Steppage gait, 171
 Stereotypies, 294
 Stiff infant syndrome, 25
 Stiff-man syndrome, 200
 Stimulants, chorea from, 283
 Strabismus
 in increased intracranial pressure, 93
 nonparalytic, 299–300
 paralytic. *See* Ophthalmoplegia.
 Streptococcal infection
 hearing loss in, 346
 in Sydenham chorea, 285–286
 meningitis in, 106, 107, 346
 tics and, 295
Streptococcus pneumoniae, meningitis in, 109
 Streptomycin
 in tuberculous meningitis, 110
 in tuberculous osteomyelitis, 263
 vestibular toxicity of, 348
 Stress
 migraine from, 79
 tension headache from, 85
 Striatal necrosis, infantile bilateral, 291
 Stroke. *See also* Cerebral infarction.
 bilateral, pseudobulbar palsy in, 332
 brainstem, 304
 capsular, 246–247
 causes of, 242t
 evaluation of, 242, 243t
 monoplegia and, 273
 Stumbling, leg weakness and, 171
 Stupor, 47
 definition of, 48t
 Sturge-Weber syndrome
 hemiplegia in, 251–252
 in infants, 19t
 Subarachnoid hemorrhage
 headache in, 93
 in neonates, 13–14
 in ruptured aneurysms, 104–105
 Subarachnoid space, benign enlargement of,
 communicating hydrocephalus from, 355, 356f
 Subdural effusions, benign, 355, 356f
 Subdural empyema, 111
 Subdural hematoma, 73
 Subdural hemorrhage, in neonates, 14
 Subdural taps, in shaking injuries, 72–73
 Subependymal hemorrhage, 102
 Substance abuse
 altered states of consciousness in, 71
 headache in, 86
 maternal
 cerebral malformations and, 121
 microcephaly and, 367
 neonatal jitteriness and, 4
 neonatal seizures and, 8–9
 Sucking reflex, 331
 Suffocation, anoxia after, 51–52
 Sulfadiazine, in toxoplasmosis, 122
 Sulfamethoxazole, in cat-scratch disease, 53
 Sulfatase deficiency
 developmental delay in, 132
 multiple, 132
 Sulfatide lipidoses. *See* Metachromatic leukodystrophy.
 Sumatriptan
 in cluster headache, 83
 in migraine, 82
 Superior oblique, 300t
 congenital shortening of, in Brown syndrome, 301
 palsy of, 300–301, 308
 Superior rectus, 300t
 Supranuclear palsy, 310–313, 311t
 facial weakness in, 331–332
 Supratentorial malformations, 105–106
 Sural nerve biopsy, in motor unit hypotonia, 157
 Surgery, epilepsy, 42–43
 Swallowing, difficulty in. *See* Dysphagia.
 Swallowing reflex, 331
 Sydenham (rheumatic) chorea, 285–286
 Syncope, 26
 in infants
 cyanotic, 16–17
 pallid, 17
 vs. seizures, 25–26
 Syndactyly, craniostenosis with, 368–369
 Syndrome of inappropriate antidiuretic hormone (SIADH)
 hyponatremic encephalopathy in, 63
 in bacterial meningitis, 108

- Syphilis, congenital, developmental delay in, 121
- Syringobulbia, 216, 339
- Syringomyelia, 216–217, 217f
- Systemic disorders
 altered states of consciousness in, 49t, 61–68
 microcephaly from, 367
- Takayasu arteritis, hemiplegia in, 250
- Tapetoretinal degenerations, 328
- Tardive dyskinesia, 282, 283
- Tardive dystonia, 287
- Tay-Sachs disease. *See* Gangliosidoses, GM₂.
- Telangiectasia, 234, 284
- Telangiectatic microangiopathy, in Leber hereditary optic neuropathy, 327
- Temporal bone, fractures of, hearing loss in, 346
- Temporal lobe epilepsy, 33
- Temporal lobectomy, for epilepsy, 43
- Temporomandibular joint syndrome, pain in, 87–88
- Tendon reflexes
 in motor unit hypotonia, 152
 in proximal weakness, 173t
 weakness and, 173
- Tensilon test. *See* Edrophonium chloride test.
- Tension headache
 chronic, 85
 episodic, 87
- Tentorial notch
 arteriovenous malformations above, 105–106
 bilateral herniation through, 96
 unilateral herniation through, 95–96
- Teratoma
 hemispheric, noncommunicating hydrocephalus in, 359
 pineal, 101
- Tetanus toxoid, 61
- Tetany
 in hypocalcemia, 202
 in hypomagnesemia, 202
- Tethered spinal cord, 259–260, 261f
- Tetrabenazine, in segmental myoclonus, 294
- Tetracycline, in Rocky Mountain spotted fever, 55
- Tetrahydrobiopterin deficiency, in hyperphenylalaninemia, 127
- Thalamic pain, 217–218
- Theophylline, tardive dyskinesia from, 283
- Thiamine
 deficiency of, encephalopathy in, 67–68
 in maple syrup urine disease, 5, 126, 223
 in pyruvate dehydrogenase deficiency, 223
- Thoracic spinal cord, traction injury to, 155–156
- Thrombocytopenia, valproate and, 40
- Thromboembolism, cerebral, in homocystinuria, 125
- Thrombosis
 carotid artery, 243–244
 cavernous sinus, 304–305
 venous
 cerebral, in neonates, 13
 in cyanotic heart disease, 245
 in hypercoagulable states, 246
 vertebral artery, 244
- Thymectomy, in myasthenia, 307
- Thymoma, myasthenia and, 306
- Thyroid hormones, abnormal levels of.
See Hyperthyroidism; Hypothyroidism.
- Thyroid storm, 63
- Thyroiditis, myasthenia and, 306
- Tiagabine, 39
- Tick paralysis, 194
- Tics, 294–296
 drug-induced, 295
 management of, 295–296
 streptococcal infection and, 295
 vs. myoclonus, 293
 vs. stereotypies, 294
- Tinnitus, 341
- Titubation, 219
- Tobramycin, in bacterial meningitis, 109t
- α -Tocopherol, in hypobetalipoproteinemia, 233
- Todd paralysis, 244–245
- Toe walking, 171, 172
- Tolosa-Hunt syndrome, 307, 308, 336
- Tomaculous neuropathy, 279
- Tone
 loss of. *See* Hypotonia.
 phasic, 149
 postural, 149
- Tone decay, 342
- Tonic pupil syndrome, 329
- Topiramate
 dosage of, 36t
 in essential tremor, 296
- Torsion dystonia, idiopathic, 290
- Torticollis
 benign paroxysmal, 287–288
 differential diagnosis of, 287, 287t
 in spasmus mutans, 314
 in superior oblique palsy, 300
- Total parenteral nutrition, encephalopathy in, 67
- Tourette syndrome, 294–296
- Toxic-metabolic disorders, internuclear ophthalmoplegia in, 312
- Toxic shock syndrome, 55
- Toxins
 altered states of consciousness from, 48t, 49t
 cranial nerve toxicity of, 339
 encephalopathy from, 69–71
 neuropathy from, 188
 ophthalmoplegia from, 309

- Toxoid, tetanus, 61
 Toxoplasmosis, developmental delay in, 122
 Traction response, in infantile hypotonia, 150
 Transferase deficiency, 138
 Transient ischemic attacks
 in fibromuscular dysplasia, 243
 in mitral valve prolapse, 245–246
 in Moyamoya disease, 248
 Transverse myelitis, 256t, 264–266, 265f
 Trauma
 ataxia in, 227
 brachial plexopathy from, 276
 carotid artery, 243–244
 cerebral infarction from, 242t
 epilepsy from, 74
 facial nerve palsy from, 334–335
 head. *See* Head injury.
 headache from, 84–85
 hearing loss from, 346
 hemiplegia in, 251
 in neonates, 13–14
 lateral rectus palsy from, 308
 oculomotor nerve palsy from, 308–309
 optic neuropathy from, 323–324
 orbital, 308–309, 325
 retinal, 325
 spinal paraplegia from, 256t
 superior oblique palsy from, 308
 to spinal cord, 266–267, 267f
 transitory cerebral blindness from, 321–322
 vertebral artery, 244
 vertigo from, 350–351
 Tremor, 296–297
 essential (familial), 296–297
 head, paroxysmal dystonic, 297
 in hyperthyroidism, 285
 palatal, 314
 parkinsonian, 296
 physiological, 296
 vs. myoclonus, 293
 Tremulousness, in neonates, 3–4
 Trichloroethylene, cranial nerve toxicity of, 339
 Trichopoliodystrophy, 137–138
 Tricyclic antidepressants
 ophthalmoplegia from, 309
 overdose of, encephalopathy from, 70
 Trigeminal nerve
 in pain transmission, 77
 in sucking reflex, 331
 in swallowing reflex, 331
 Trigenocephaly, 368t
 Trihexyphenidyl
 in downbeat nystagmus, 315
 in idiopathic torsion dystonia, 290
 in rapid-onset dystonia-parkinsonism, 291–292
 Trimethoprim, in cat-scratch disease, 53
 Triptans, in migraine, 82
 Trisomy
 congenital cataract and, 318
 corpus callosum agenesis in, 366
 developmental delay and, 120t
 facial palsy in, 334
 Trochlear nerve palsy, congenital, 300–301
 Tuberculous meningitis, 109–110
 Tuberculous osteomyelitis, 263
 Tuberos sclerosis
 developmental delay in, 135
 diagnosis of, 135, 136t
 in infants, 19t
 Tubular aggregates, cramps and, 208–209, 208f
 Tumors. *See also specific site and type, e.g., Brain tumors.*
 hearing loss in, 346–347, 347f
 hemiplegia in, 251
 spinal paraplegia in, 267–268, 267f
 Tuning fork, 341
 Tympanic membrane, 340
 Tyrosinemia
 hereditary, type I, 216
 transitory, 128
 Ulcers, plantar, in hereditary sensory and autonomic neuropathy I, 214
 Ullrich disease, 165
 Ulnar neuropathy, 278
 Unilateral (uncal) transtentorial herniation, increased intracranial pressure and, 95–96
 Unverricht-Lundborg syndrome, 29
 Upbeat nystagmus, 315–316
 Urea cycle
 ammonia metabolism and, 6f
 disturbances of, in neonates, 6–7, 7t
 Uremia
 cramps in, 203
 neuropathy in, 188
 Uremic encephalopathy
 acute, 65–66
 chronic, 66
 Usher syndrome, hearing loss in, 343–344
 Uterus
 hypotonia of, 149
 infection of
 congenital cataract and, 318
 congenital deafness and, 343
 developmental delay and, 121–122
 microcephaly and, 367
 Vaccine
 encephalopathy associated with, 61
 for Lyme disease, 54

- Vagal nerve stimulation, for epilepsy, 42
- Valproate, 40
dosage of, 36t
for migraine prophylaxis, 82–83
hepatotoxicity of, 40
in absence epilepsy, 27
in infantile spasms, 20
Reye syndrome and, 61
- Vancomycin
in bacterial meningitis, 107, 107t, 108, 109t
ototoxicity of, 345
- Varicella
cerebral infarction in, 250
Reye syndrome and, 60
- Vascular disorders
altered states of consciousness in, 48t, 49t
ataxia in, 227–228
cerebral infarction in, 242t, 249–250
neuropathy in, 189
- Vasculitis
cerebral infarction from, 242t, 249
headache from, 86
hypersensitivity, 86, 249
neuropathy from, 189
retinal artery occlusion and, 324
- Vasogenic cerebral edema, 92, 96–97
- Vegetative state, persistent, 52
- Vein of Galen malformation, 105
noncommunicating hydrocephalus in, 359, 360f
- Velocardiofacial syndrome, in neonates, 9
- Venous angioma, facial, in Sturge-Weber syndrome, 252
- Venous thrombosis
cerebral, in neonates, 13
in cyanotic heart disease, 245
in hypercoagulable states, 246
- Ventricle(s), hemorrhage into.
See Intraventricular hemorrhage;
Periventricular-intraventricular hemorrhage.
- Ventricular shunt, in Dandy-Walker malformation, 358
- Ventriculoperitoneal shunt
in congenital aqueductal stenosis, 357, 357f
in periventricular-intraventricular hemorrhage, 104
- Verapamil, in Brody myopathy, 208
- Vertebrae, tuberculosis of, 263
- Vertebral artery, trauma to, 244
- Vertebral column, fracture-dislocation of, 266–267, 267f
- Vertebrobasilar occlusion, ataxia acute or recurrent in, 227
- Vertical gaze, palsy of, 311t, 312
- Vertical suspension, in infantile hypotonia, 150–151
- Vertigo, 347–351
anatomical considerations in, 347
approach to, 347–348
benign paroxysmal, 23
benign positional, 224
causes of, 346t, 348–351
central vs. peripheral, 348, 348t
drug-induced, 348–349
head injury and, 350–351
in epilepsy, 349
in infectious diseases, 349
in Ménière disease, 350
in migraine, 350
in trauma, 350–351
in vestibular nystagmus, 315
motion sickness and, 350
tests for, 348
whiplash injury and, 351
- Very-long-chain acyl-CoA dehydrogenase deficiency, 205–206
- Vestibular concussion, 350–351
- Vestibular dysfunction. *See also* Vertigo.
in Usher syndrome, 344
- Vestibular neuritis, 349
- Vestibular nystagmus, 315
- Vestibular system, anatomy of, 347
- Vestibule, 340, 347
- Video game–induced seizures, 34–35
- Video monitoring, in paroxysmal disorders, 1, 16
- Vigabatrin, 40
dosage of, 36t
in infantile spasms, 20
- Vincristine, neuropathy from, 188
- Viral infection, 55–61
Reye syndrome and, 60–61
vertigo in, 349
weakness in, 193
- Vision
color, in ischemic optic neuropathy, 323
disorders of. *See* Blindness; Visual loss.
- Visual acuity, assessment of, 317
- Visual aura, migraine with, 80–81
- Visual evoked response, 317
- Visual field defect, from vigabatrin, 40
- Visual loss
acute, differential diagnosis of, 320, 321t
in Devic disease, 265
in idiopathic intracranial hypertension, 114
progressive, 325–328
differential diagnosis of, 320, 321t
in compressive optic neuropathy, 325–327, 326f
in craniopharyngioma, 325
in diencephalic syndrome, 326
in optic nerve glioma, 325–326, 326f
in pituitary adenoma, 326–327

Visual loss (*Continued*)

- in retinoblastoma, 327–328
- in tapetoretinal degenerations, 328
- in Wolfram syndrome, 327

Visual system, disorders of, 317–329

Vitamin A, supplementation of, in hypobetalipoproteinemia, 233

Vitamin B₆-dependent homocystinuria, 125Vitamin B₁₂, in toxic-nutritional optic neuropathy, 323

Vitamin E, in abetalipoproteinemia, 234

Vitamin K, supplementation of, in hypobetalipoproteinemia, 233

Vomiting

- ictal, epilepsy and, 31
- in migraine, 81

von Graefe sign, in Graves ophthalmopathy, 310

Von Hippel-Lindau disease, 229
brain tumors in, 229

Waardenburg syndrome, hearing loss in, 344

Walker-Warburg syndrome

- merosin-deficient myopathy in, 166–167
- noncommunicating hydrocephalus in, 359–360

Weakness

- acute generalized, 191–194, 191t
 - in infectious disorders, 191–193
 - in neuromuscular blockade, 193–194
- progressive distal, 182–191, 182t
 - in Charcot-Marie-Tooth disease, 184–185, 184t
 - in juvenile amyotrophic lateral sclerosis, 183
 - in myopathies, 189–191
 - in neuropathy, 182, 183, 183t
 - in neuropathy, 184–189
 - in scapulo (humeral) peroneal syndromes, 190–191
 - in spinal muscle atrophy, 183
- progressive proximal, 173–182, 173t
 - in Bethlem myopathy, 176–177

Weakness (*Continued*)

- in endocrine myopathies, 182
- in GM₂ gangliosidosis, 174–175
- in inflammatory myopathies, 179–180, 180f
- in metabolic myopathies, 180–182
- in muscular dystrophy, 175–179
- in myasthenic syndromes, 175
- in spinal muscle atrophy, 173–174

Weber test, 341

Welder myopathy, 189

Wernicke encephalopathy, 67–68

West Nile virus infection

- encephalitis from, 57–58
- weakness in, 193

Western equine encephalitis, 58

Whiplash injury

- pain in, 88
- vertigo from, 351

White matter disorders, 123t

- characteristics of, 124, 124f
- infantile, 138–139
- juvenile, 145–146

Wilms tumor, aniridia and, 329

Wilson disease, 289–290

Wolfram syndrome, 327

Wolman disease, 128

Wristdrop, in radial neuropathy, 279

Writer's cramp, 288

X-linked ataxia, 236

X-linked hypoplasia of cerebellum, 232

Xeroderma pigmentosum, 145

- with Cockayne syndrome, 328

Xp21 gene defects, phenotypes associated with, 177t

Yeast pathogens, 111, 111t

Zellweger syndrome

- cerebral hypotonia in, 154–155
- hearing loss in, 343

Zonisamide, 36t, 40–41