

Oncoplastic and Reconstructive Surgery of the Breast

Guidubaldo Querci della Rovere MD FRCS Comm OMRI
The Royal Marsden Hospital, Sutton, Surrey, UK

John R Benson MA DM FRCS
Cambridge Breast Unit, Addenbrooke's Hospital, Cambridge, UK

Nicholas Breach FRCS
The Royal Marsden Hospital, Sutton, Surrey, UK

Maurizio Nava MD
Istituto Nazionale Tumori, Milan, Italy



Taylor & Francis
Taylor & Francis Group

LONDON AND NEW YORK

A MARTIN DUNITZ BOOK

**Also available as a printed book
see title verso for ISBN details**

Oncoplastic and Reconstructive Surgery of the Breast

Guidubaldo Querci della Rovere MD FRCS Comm OMRI
The Royal Marsden Hospital, Sutton, Surrey, UK

John R Benson MA DM FRCS
Cambridge Breast Unit, Addenbrooke's Hospital, Cambridge, UK

Nicholas Breach FRCS
The Royal Marsden Hospital, Sutton, Surrey, UK

Maurizio Nava MD
Istituto Nazionale Tumori, Milan, Italy



Taylor & Francis
Taylor & Francis Group

LONDON AND NEW YORK

A MARTIN DUNITZ BOOK

© 2004 Taylor & Francis, a member of the Taylor & Francis Group plc

First published in the United Kingdom in 2004

by Taylor & Francis, a member of the Taylor & Francis Group plc,
11 New Fetter Lane, London EC4P 4EE

Tel.: +44 (0) 20 7583 9855

Fax.: +44 (0) 20 7842 2298

E-mail: info@dunitz.co.uk

Website: <http://www.dunitz.co.uk>

This edition published in the Taylor & Francis e-Library, 2004.

All rights reserved. No part of this publication may be reproduced, stored in a retrieval system, or transmitted, in any form or by any means, electronic, mechanical, photocopying, recording, or otherwise, without the prior permission of the publisher or in accordance with the provisions of the Copyright, Designs and Patents Act 1988 or under the terms of any licence permitting limited copying issued by the Copyright Licensing Agency, 90 Tottenham Court Road, London W1P 0LP.

Although every effort has been made to ensure that all owners of copyright material have been acknowledged in this publication, we would be glad to acknowledge in subsequent reprints or editions any omissions brought to our attention.

Although every effort has been made to ensure that drug doses and other information are presented accurately in this publication, the ultimate responsibility rests with the prescribing physician. Neither the publishers nor the authors can be held responsible for errors or for any consequences arising from the use of information contained herein. For detailed prescribing information or instructions on the use of any product or procedure discussed herein, please consult the prescribing information or instructional material issued by the manufacturer.

A CIP record for this book is available from the British Library.

ISBN 0-203-30010-6 Master e-book ISBN

ISBN 0-203-34026-4 (Adobe eReader Format)

ISBN 1 84184 351 2 (Print Edition)

Distributed in the USA by

Fulfilment Center

Taylor & Francis

10650 Toebben Drive

Independence, KY 41051, USA

Toll Free Tel.: +1 800 634 7064

E-mail: taylorandfrancis@thomsonlearning.com

Distributed in Canada by

Taylor & Francis

74 Rolark Drive

Scarborough, Ontario M1R 4G2, Canada

Toll Free Tel.: +1 877 226 2237

E-mail: tal_fran@istar.ca

Distributed in the rest of the world by

Thomson Publishing Services

Cheriton House

North Way

Andover, Hampshire SP10 5BE, UK

Tel.: +44 (0)1264 332424

E-mail: salesorder.tandf@thomsonpublishingservices.co.uk

Composition by Scribe Design, Gillingham, Kent

Contents

<i>Acknowledgements</i>	iv
<i>List of Contributors</i>	v
<i>Foreword</i>	vii
<i>Preface</i>	viii
1 Breast reconstruction and the specialist breast surgeon <i>Guidubaldo Querci della Rovere, John R Benson</i>	1

Section I Materials, mastectomy and tissue expansion

2 The history and development of breast prostheses and the silicone problem <i>Nicholas Collis, David T Sharpe</i>	7
3 Skin sparing and skin-reducing mastectomy <i>Guidubaldo Querci della Rovere, Marco Greco, Maurizio Nava, Efstrados P Kouskos, John R Benson</i>	21
4 Breast reconstruction with subpectoral prosthesis or tissue expanders <i>Maurizio Nava, Marcello Bonavita, Nazzareno Arioli, Anna Colombetti, Roberto Grillo, Egidio Riggio</i>	33
5 Commentary: materials, mastectomy and tissue expansion <i>Martin I Newman, Lloyd B Gayle</i>	55

Section II Flaps

6 Breast reconstruction with the latissimus dorsi myocutaneous flap <i>Stefano Modena, Giuseppe Mangiante, Guidubaldo Querci della Rovere</i>	63
7 Pedicled TRAM flap reconstruction <i>Jean-Yves Petit, Mario Rietjens, Omar Youssef, Francesca De Lorenzi</i>	77
8 Autologous breast reconstruction using abdominal free flaps <i>Adam Searle</i>	83
9 Commentary: flaps <i>Paul Roberto Leal, Jose Kogut</i>	89

Section III Subcutaneous mastectomy and oncoplastic surgery of the breast

10 Breast reconstruction after conservative surgery <i>Jean-Yves Petit, Omar Youssef, Cristina Garusi</i>	95
11 Subcutaneous mastectomy and reconstruction <i>Nicholas Breach</i>	105
12 Contralateral breast adjustment and nipple reconstruction <i>Alessandro Nannelli, Claudio Calabrese, Luigi Cataliotti, Guidubaldo Querci della Rovere</i>	109
13 Commentary: subcutaneous mastectomy and oncoplastic surgery of the breast <i>Scott L Spear</i>	123

Section IV The patient

14 Psychological issues in breast reconstruction <i>Margaret Watson</i>	131
15 Breast reconstruction with myocutaneous flaps: biomechanical aspects <i>Gemma Martino, Hubert Godard, Maurizio Nava, John R Benson</i>	135
16 Chronic pain after reconstructive surgery for breast cancer <i>Jackie Filshie, John Williams</i>	145
17 Contraindications to breast reconstruction <i>John R Benson</i>	157
18 Breast reconstruction from a woman's point of view: the experience of a male breast surgeon <i>Alfonso M Pluchinotta</i>	167
19 Breast reconstruction from a woman's point of view: the experience of a female Clinical Nurse Specialist – Breast Care <i>Lisa Wolf</i>	175
20 Breast reconstruction following mastectomy: patients' expectations <i>Guidubaldo Querci della Rovere</i>	181

Appendix

Types of prosthesis <i>Arikoge J Ogedegbe, Delilah Hassanally</i>	185
--	-----

Index	197
-------	-----

Acknowledgements

The editors are very grateful to the following people for their assistance:

For their secretarial support:

Mrs June New, Royal Marsden Hospital, Sutton, Surrey

Ms Yvonne Glendenning, Breast Unit Addenbrooke's Hospital, Cambridge

Alessandra Calestani, Istituto Nazionale Tumori, Milan

For carrying out the per-operative photography:

Mr Dennis Underwood, Medical Photographer, Royal Marsden Hospital, Sutton, Surrey

Contributors

Nazzareno Arioli
Istituto Nazionale Tumori
Via Venezian
Milan, Italy

John R Benson
Cambridge Breast Unit
Addenbrooke's Hospital
Cambridge, UK

Marcello Bonavita
Istituto Nazionale Tumori
Via Venezian
Milan, Italy

Nicholas Breach
The Royal Marsden Hospital
Sutton, Surrey, UK

Claudio Calabrese
Clinical Chirurgica
Univerita' di Firenze
Careggi, Florence, Italy

Luigi Cataliotti
Clinical Chirurgica
Univerita' di Firenze
Careggi, Florence, Italy

Nicholas Collis
Consultant Plastic Surgeon
Royal Victoria Infirmary
Newcastle upon Tyne, UK

Anna Colombetti
Istituto Nazionale Tumori
Via Venezian
Milan, Italy

Francesca De Lorenzi
European Institute of Oncology
Via Ripamonti
Milan, Italy

Jacqueline Filshie
The Royal Marsden Hospital
Sutton, Surrey, UK

Cristina Garusi
European Institute of Oncology
Via Ripamonti
Milan, Italy

Lloyd B Gayle
Department of Plastic Surgery
New York Presbyterian Hospital
New York, NY, USA

Hubert Godard
Maitre de Conférences
Université de Paris 8
Saint Denis
France

Marco Greco
Istituto Nazionale Tumori
Via Venezian
Milan, Italy

Roberto Grillo
Istituto Nazionale Tumori
Via Venezian
Milan, Italy

Delilah Hassanally
Royal Marsden Hospital
Sutton, Surrey, UK

Jose Kogut
Cirurgia Plastica
Istituto Nacional de Cancer-INCA
Rio de Janeiro
Brazil

Efstratos P Kouskos

Breast Unit,
Second Department of Propedeutic Surgery
Athens University Medical School and
'Laiko' General Hospital
Athens, Greece

Paul Roberto Leal

Cirurgia plastica
Instituto Nacional de Cancer-INCA
Rio de Janeiro
Brazil

Giuseppe Mangiante

Department of Surgery
Policlinico Universitario, Borgo Roma
Verona, Italy

Gemma Martino

METIS-Centro Studi in Oncologia-Formazione e
Terapia
Milan, Italy

Stefano Modena

Department of Surgery
Policlinico Universitario, Borgo Roma
Verona, Italy

Alessandro Nannelli

Clinical Chirurgica
Univerita' di Firenze
Careggi, Florence, Italy

Maurizio Nava

Istituto Nazionale Tumori
Via Venezian
Milan, Italy

Martin I Newman

Department of Plastic Surgery
New York Presbyterian Hospital
New York, NY, USA

Arikoge J Ogedegbe

The Royal Marsden Hospital
Sutton, Surrey, UK

Jean-Yves Petit

European Institute of Oncology
Milan, Italy

Alfonso M Pluchinotta

Department of Surgery
Policlinico Universitario
Padua, Italy

Edigio Riggio

Istituto Nazionale Tumori
Via Venezian
Milan, Italy

Mario Rietjens

European Institute of Oncology
Via Ripamonti
Milan, Italy

Guidubaldo Querci della Rovere

The Royal Marsden Hospital
Sutton, Surrey, UK

Adam Searle

The Royal Marsden Hospital
London, UK

David T Sharpe

The Yorkshire Clinic
Bingley, UK

Scott L Spear

Georgetown Medical Center
Washington DC, USA

Margaret Watson

The Royal Marsden Hospital
Sutton, Surrey, UK

John Williams

The Royal Marsden Hospital
Sutton, Surrey, UK

Lisa Wolf

The Royal Marsden Hospital,
Sutton, Surrey, UK

Omar Youssef

European Institute of Oncology
Milan, Italy

Foreword

Techniques of formal breast reconstruction following mastectomy for breast cancer were introduced more than four decades ago. Initial methods involved simple placement of a silicone implant at the site of mastectomy and echoed early techniques for augmentation mammoplasty, which were first reported at the beginning of the 1960s. These implant-only based reconstructions yielded poor cosmetic results, which would be deemed unacceptable when judged by contemporary standards.

The 1970s and 1980s witnessed significant advances in breast reconstruction with the development of myocutaneous flaps, which were either pedicled (latissimus dorsi and TRAM) or free flaps. A variety of tissue expanders with a range of shapes and sizes also became available during this period, which could be employed alone or in conjunction with autologous tissue transfer to achieve not only symmetry of volume but also a degree of ptosis. Nonetheless, cosmetic results from breast reconstruction remained modest and this was attributable to innate limitations of prosthetic material coupled with a shortage of appropriately trained surgical personnel who could undertake these more complex techniques involving myocutaneous flaps. Indeed, such methods were offered and regularly carried out in only a few specialised centres. Capsular contracture was a particular problem with implant-based reconstructions and invariably caused distortion and displacement of silicone implants, which precluded satisfactory longer term results. Throughout the 1990s, surgical techniques were refined and standardized, thus permitting some degree of consensus on the optimum choice of reconstruction after various types of oncological surgery. The latter had generally become more conservative with less mutilating excisions.

This progressive evolution and improvement in breast reconstruction has been greatly aided in recent years by advances in implant design and technology which have focussed on reduction of capsule formation with textured-coating and tailoring of prostheses to individual patients with the advent of anatomically shaped implants.

This book takes the reader by the hand and guides them through all aspects of modern breast recon-

struction (be they a novice or experienced 'breast' surgeon). It is opportune that the title includes the term 'oncoplastic' which has only recently seeped into common usage and encompasses the principle that extirpative and reconstructive components are planned jointly and carried out simultaneously whenever feasible.

The book benefits from a rather didactic style with step-by-step discussion of individual types of reconstruction. Many of these methods demand careful and precise surgical execution and implant selection for successful outcomes and the finer details of technique have often been lacking from allied texts in the past.

The commentaries at the end of each section are particularly valuable; they offer a critical opinion on the subject and content of corresponding chapters and help the reader to form a balanced viewpoint on individual techniques (indications for and variants thereof).

The section addressing the patient should be highlighted – for it is the woman herself who is the recipient of breast reconstruction. It is rare to find issues such as patient expectations together with the psychological impact and side-effects of breast reconstruction described so well and in such depth.

The book is edited by four specialists who collectively have much experience and knowledge within the field of breast and reconstructive surgery. This is evident throughout the excellent and erudite text, which provides a global perspective of the subject with appropriate modulation of extent, depth and analysis of each topic. The book constitutes a complete, detailed and reliable source of reference for any breast specialist with an interest in breast reconstruction.

Andrea Grisotti
Head, Plastic Surgery Department
Clinica San Pio X
Milan, Italy

Formerly
Head of Plastic and Reconstructive Department
Istituto Nazionale Tumori
Milan, Italy

Preface

Breast cancer is the commonest malignancy amongst women in Western countries and an estimated 400,000 women die annually from this disease worldwide. Though mortality rates have fallen modestly in the past two decades, the incidence of breast cancer continues to rise with an average lifetime risk of approximately 10%. This poses an enormous burden upon healthcare systems in terms of both service delivery and financial resources. Despite more widespread adoption of breast conserving surgery, a significant proportion of women either require or are recommended mastectomy and an increasing number of these patients are undergoing immediate breast reconstruction. Furthermore, poor results from breast conservation have led some women to seek partial breast reconstruction and techniques have evolved to refashion the breast at the time of wide local excision by transposition of residual breast tissue and use of dermoglandular flaps. The demand for reconstructive procedures of various types has accelerated in recent years, which, coupled with enhanced patient expectations, has fostered development of oncoplastic and reconstructive techniques in breast surgery. This has occurred *pari-passu* with the continued development of dedicated breast units. The United Kingdom was amongst the earliest countries to establish multi-disciplinary breast teams and the first breast unit was set up by Hedley Atkins at Guy's Hospital in London almost 40 years ago. This was soon followed by a similar unit at the Royal Marsden Hospital and further units were subsequently created in Cardiff and Edinburgh under the auspices of Sir Patrick Forrest. No breast units existed in the United States until 1973, when Mel Silverstein founded the University of California Breast Unit in Los Angeles (UCLA).

The universal establishment of breast units with a multidisciplinary ethos has contributed to improved outcomes for women with breast cancer. Not only have these units facilitated cooperation and pooling of expertise from health professionals in different specialties but have permitted interaction between clinicians and basic scientists to promote translational research.

With the advent of breast cancer screening, there has been further consolidation of breast units and better quality control for symptomatic breast cancer patients. In parallel with improvements in the diagnostic field of breast diseases, surgeons with a declared interest in breast surgery have learnt and developed specific skills in the field of oncoplastic and reconstructive surgery with the help of plastic surgery colleagues. This has enabled increased numbers of women to be offered immediate breast reconstruction at the time of mastectomy. The issue of whether reconstruction should be undertaken by two separate teams of breast/plastic surgeons or a single 'oncoplastic' surgeon remains an area of debate, which is further discussed in the editorial section of this book.

This book provides a comprehensive and contemporary account of techniques in oncoplastic and reconstructive surgery of the breast. The text incorporates a detailed description of current implant design and technology, together with stepwise accounts of implant-only-based and autologous tissue reconstruction. Much emphasis is placed throughout individual chapters on patient selection, which is critical for optimum cosmetic and functional results. There are separate sections on psychological issues, including patient expectation and breast reconstruction from the perspective of a breast care nurse. The text also addresses specific contra-indications to reconstruction and problems relating to chronic pain following reconstructive surgery.

This book is aimed at the breast surgical specialist involved with oncoplastic and reconstructive aspects of breast cancer surgery. It is hoped that the text will be a source of guidance and assistance to trainees in this field (general surgical and/or plastic surgical background) who will form the next generation of 'breast' surgeons. The volume should also appeal to non-surgical colleagues engaged in the management and support of women with breast cancer.

*Guidubaldo Querci della Rovere
John R Benson*

1 Breast reconstruction and the specialist breast surgeon

G Querci della Rovere, John R Benson

Introduction

Over the past 20 years there has been a progressive decrease in the proportion of mastectomies in favour of more conservative breast surgery. This has coincided with an increase in demand for either immediate or delayed breast reconstruction by those patients requiring mastectomy.

There are several reasons for this shift in management of early operable breast cancer:

- biological considerations based on results of clinical trials
- influence of culture and media
- specialization and surgical training.

Biological considerations based on results of clinical trials

Over a period spanning more than 30 years, Bernard Fisher¹ undertook extensive clinical and laboratory studies leading to the synthesis of concepts on the clinical behaviour and pathobiology of breast cancer which can be summarized as follows:

1. As far as survival is concerned there is no difference between local excision, local excision plus radiotherapy and modified radical mastectomy; there is, however, a progressive decrease in local recurrence with the more aggressive treatments.
2. Local recurrence is associated with worse survival, but survival is the same with the various types of treatment, local recurrence is not the cause of, but simply an indicator of poor prognosis.

The clinical trials conducted by Fisher and others²⁻⁴ demonstrated that mastectomy and breast conserva-

tion surgery were equivalent in terms of survival, but it is the significance attributed to local recurrence which is perhaps of greater interest and has hitherto been underestimated. Local recurrence is not the instigator of distant metastases and hence poor prognosis, but an indicator of a tumour-host relationship which favours distant relapse. This concept conflicts with the surgical principles of clear excision margins. Surgeons strive to obtain microscopically negative margins at the time of primary surgery in order to minimize the chance of local recurrence. Some would advocate that surgical extirpation and reconstruction should not be carried out by the same surgeon, lest the former be compromised in extent by cosmetic considerations. However, if Fisher's concept of biological pre-determinism pertains to most breast cancers and local recurrence per se does not influence survival, is there a danger of overtreating patients in efforts to prevent local recurrence? Acceptable local recurrence rates are subjective and a matter of judgement. Higher rates of local recurrence might provide improved cosmesis without reducing overall survival.

Influence of culture and media

Were the breasts to serve a purely physiological function, then once breast feeding was complete, breasts would become redundant and dispensable. Indeed, it is believed that the women of Amazonia removed one breast so as to facilitate use of a bow and arrow for hunting and defence. However, with cultural evolution, the breast as an organ is celebrated in many fields of human endeavour and emotion – religious, political, erotic, literary or commercial. Ease of access to information technology has resulted in greater awareness and knowledge of breast cancer and its treatment. Consequently, patients are no longer passive

recipients of medical experience and wisdom. Instead, there is a clamour for accurate and clear information although information requirements of individual patients may be difficult to assess. There is now a trend towards shared decision making with patients often being forearmed with information at the time of consultation. The demands and expectations of patients are higher now than in the past, and these encompass the cosmetic outcome of any reconstructive surgery.

Specialization and surgical training

The NHS Breast Screening Programme (NHSBSP) was initiated in the United Kingdom (UK) in 1988 and is now well established with over 100 screening units around the country which are regularly monitored for quality assurance targets. The success of the NHSBSP is ultimately measured by the proportional reduction in mortality from breast cancer amongst screened women. An indirect benefit of the screening programme has been an improvement in management of patients with symptomatic breast disease. Prior to the advent of screening, procedures such as excisional biopsy of the breast (and even mastectomy) were often placed at the end of general operating lists and delegated to junior surgical staff. The multidisciplinary approach for screen-detected lesions has now been embraced for management of symptomatic cases of breast cancer with surgeons, radiologists, pathologists, clinical/medical oncologists and breast care nurses collectively (and consensually) determining treatment of individual patients.

This more focused management of symptomatic breast disease spurned the breast surgical specialist; breast surgery is now a recognized subspecialty of general surgery with a structured training programme for designated 'breast surgeons'. In parallel with this development of breast surgery as a subspecialty, increasing numbers of women are demanding reconstruction and cosmetic expectations are high. With a general shortage of plastic surgeons available to undertake breast reconstruction (and much geographical variation in service provision), many breast surgeons have extended their surgical repertoire to include immediate reconstruction. There are several advantages of immediate, over delayed, reconstruction including superior cosmetic results with the use of skin-sparing techniques which are restricted to immediate reconstructive procedures. Patients benefit psychologically from not having to adjust to the disfigurement of mastectomy and further hospitalization and general anaesthesia are avoided.

Are oncological and plastic surgery compatible?

There is an innate conflict between the basic aims of oncological and plastic surgery – the intention of the former is to eradicate all locoregional disease whilst the latter is reliant on preservation of as much breast tissue as possible for optimal cosmesis. Notwithstanding the aims of surgical excision, attainment of low rates of local recurrence does not necessarily translate into improved survival rates. It is implicit with breast conservation surgery that higher rates of local recurrence are accepted, although it must be understood that there are no detrimental effects on survival. For any given size of tumour, a smaller volume of resected tissue yields a better cosmetic result but the risk of local recurrence is correspondingly higher. The oncological surgeon must judge not only when breast reconstructive surgery is feasible and appropriate, but also the extent of local resection when breast conservation is offered in lieu of mastectomy. Both radiotherapy and chemo-endocrine therapy contribute to local control in the adjuvant setting, but cannot compensate for 'dirty' margins. Invasive tumours should be excised with a minimal margin of clearance of 1 mm which is considered acceptable in the context of combined modality treatment. Greater margins of clearance (e.g. 5 mm) have been advocated but are likely to mandate excision of larger volumes of tissue with worse cosmetic results. Indeed, sometimes foci of ductal carcinoma in situ at the excision margins are accepted provided there is microscopic clearance of all invasive tumour. Radiotherapy is administered on the presumption of residual foci of tumour within the breast.

Holland's seminal studies on mastectomy specimens revealed residual tumour in 43% of cases even with a margin of clearance of 2 cm around the index lesion. Although clinical data suggest that higher rates of local recurrence are associated with smaller margins of clearance, absolute differences in recurrence rates are modest; it is conceivable that some patients and clinicians would accept a slightly increased risk of local recurrence for cosmetic gain provided survival was not compromised. If this were not the case and local recurrence resulted in distant disease and impaired survival, then radical mastectomy and chest wall radiotherapy should be offered to all patients with early invasive breast cancer. Thus both oncological and plastic surgery share the aim of providing the best cosmetic results without imposing any unintentional risk to long-term survival.

Post-mastectomy radiotherapy is increasingly being employed for premenopausal patients with node

positive breast cancer (four or more nodes) following publication of two randomized trials demonstrating a survival benefit from selective adjuvant radiotherapy in this subgroup of patients. Surgeons must take account of the possibility of postoperative radiotherapy when planning breast reconstruction. When radiotherapy is anticipated, reconstruction with autologous tissue is the preferred option. This either completely avoids the need for an implant, or (e.g. latissimus dorsi (LD) flap) ensures that any prosthetic material is well covered with muscle tissue. In those patients requiring radiotherapy on the basis of tumour size, preoperative radiotherapy can be used and the tissues subsequently assessed prior to mastectomy and reconstruction.

Who should perform breast reconstruction?

There is some controversy over the issue of whether the oncological or plastic surgeon should perform reconstruction. In the UK there are three potential arrangements for breast reconstruction:

1. A specialist breast surgeon performs all reconstructions, including both implant and autologous tissue reconstructions. Liaison with a plastic surgeon would be required only for difficult cases.
2. A specialist breast surgeon chooses to perform straightforward cases of implant and LD flap reconstructions, but defers more complex procedures such as TRAM (transverse rectus abdominis myocutaneous) flaps to plastic surgery colleagues.
3. The oncological and plastic surgeons collaborate at the outset for all cases of reconstruction. Decisions on the optimal form of reconstruction are made jointly for each patient and the reconstructive stage of surgery is carried out predominantly by the plastic surgeon. Clearly the plastic surgeon must be available in theatre at the time of immediate reconstruction and coordination of work schedules is crucial. Patients should not be denied immediate reconstruction and obliged to accept a delayed procedure for logistical reasons.

These scenarios apply not only to reconstruction following mastectomy, but also reconstruction of the breast when there is a significant glandular defect after conservation surgery. Arrangements for breast reconstruction within any institution will depend to some extent on historical factors and territoriality together with experience and interests of individual surgeons. There are innate advantages of a single 'oncoplastic' surgeon carrying out both the excisional

and reconstructive components of surgery. However, this requires special training and it is likely that not all breast surgeons will possess the necessary skills and inclination to undertake such procedures. Moreover, in an increasingly litigious environment, it is essential that breast (oncological) surgeons obtain cosmetic results comparable to their plastic surgeon colleagues. With an ever increasing demand for breast reconstruction, there are advantages of both approaches. Service needs could be met and reconstructive capacity maximized by increasing numbers of either plastic surgeons or the number of breast surgeons with plastic surgical training. However, patients must be appropriately selected and surgery performed to the highest standard. Breast specialists trained in breast oncological and plastic surgery need not necessarily be recruited exclusively from the ranks of general surgical trainees. Plastic surgeons could be trained in breast diseases and become competent in excisional procedures of the breast including mastectomy, axillary dissection and breast conservation surgery.

Conclusions

Techniques of breast reconstruction have advanced greatly over the past two decades and breast cancer surgery must now be carried out with due consideration of cosmetic outcome without oncological compromise. Disfiguring and mutilating excisions can no longer be justified and are not acceptable. Surgeons must balance the oncological and cosmetic needs of individual patients and understand the principles thereof. Breast resection and reconstructive surgery can be undertaken either by an appropriately trained breast surgeon alone or in collaboration with a plastic surgical colleague. It is essential that one or both (as the case may be) surgeons discuss management options with each patient and reach a balanced judgement which takes account of age, medical and psychosocial background together with the desires and expectations of individual women.

Women aware of breast cancer issues and who participate in early detection programs should be rewarded with gentle and appropriate care and not punished with heavy and often unjustified treatments.

Umberto Veronesi

References

1. Fisher B. The evolution of paradigms for the management of breast cancer. *Perspect Cancer Res* 1992; 52: 2371–83.

2. Fisher B, Anderson S, Bryant J et al. Twenty-year follow-up of a randomized trial comparing total mastectomy, lumpectomy, and lumpectomy plus irradiation for the treatment of invasive breast cancer. *N Engl J Med* 2002; 347: 1233–41.
3. Veronesi U, Cascinelli N, Mariani L et al. Twenty-year follow-up of a randomized study comparing breast-conserving surgery with radical mastectomy for early breast cancer. *N Engl J Med* 2002; 347: 1227–32.
4. Sarazin D, Dewar JA, Arrigada R et al. Conservative management of breast cancer. *Br J Surg* 1986; 73: 604–6.

Materials, mastectomy and tissue expansion

2 The history and development of breast prostheses and the silicone problem

Nicholas Collis, David T Sharpe

Introduction

The female breast has long been a dominant symbol of perceived femininity and sexual attractiveness in Western society, a role increasingly reinforced by the media and modern advertising. It is hardly surprising that women have desired changes to their breasts purely for cosmetic purposes. Feelings of inadequacy, doubts about essential femininity and desirability, low self-esteem, lack of confidence and sexual inhibition have been well documented, as have the great psychological benefits of breast augmentation.¹ Enhancing the appearance and shape of the female breast has been a goal sought by fashionable women, designers and dressmakers down the centuries. The use of surgical techniques to enhance the female breast, however, have largely been limited to the past 100 years.

This period has seen the rapid evolution of surgical techniques for reconstructive and aesthetic surgery. More importantly for the development of breast augmentation surgery, has been the equally rapid development in the use of synthetic materials for a diverse range of clinical problems. However, for this technology to be successful, it has required a development in the understanding of the interaction between the body and an implanted foreign material, that is, 'biocompatibility'.

A foreign material implanted into body tissues incites an inflammatory response. If possible this response will attempt to destroy the foreign material by enzymatic dissolution and phagocytosis by macrophages. However, if this is not possible and the foreign body is 'well behaved' in that it does not exert a noxious stimulus then the body surrounds

and imprisons the implant in a fibrous capsule and a 'tissue truce' is declared. Alternatively, if the noxious stimulus continues, the body's response intensifies with the aim of extruding the implant, especially if there is little soft tissue coverage. The latter may also occur if a previously quiescent implant becomes infected or starts to become more of a stimulus because of chemical changes in the material's structure with time – degradation. Similarly, a rigidly fixed implant is much more likely to be tolerated than a mobile one. Thus there is a spectrum of tissue tolerance, which is under constant immunological review. No foreign material can be truly 'acceptable' to the body.

In 1958, JT Scales² reviewed the criteria for tissue compatibility for a material's suitability for implantation. The material should:

- be chemically inert
- not be physically modified by tissue fluids
- not excite an inflammatory or foreign body cell response in the tissues
- be non-carcinogenic
- be capable of standing up to the mechanical strains imposed upon it
- be capable of being fabricated in the form required with reasonable ease and relatively low cost
- be capable of being sterilized.

The materials and methods used during the evolution of breast augmentation surgery can be discussed in three groups (Box 2.1), culminating in the introduction of the silicone breast implant in the early 1960s. These implants have evolved over the past 40 years and latterly been the subject of controversy, which will be discussed later.

Box 2.1 History of materials used for breast augmentation with dates of introduction

1. Autologous tissue

Subcutaneous fat grafts (1917)
 Derma-fat-fascia grafts (1945)
 Local pedicled fat flaps (1959)
 Omentum (1963)³

2. Alloplastic injections

Paraffin injections (1900)
 Silicone injections (1950)

3. Alloplastic implants

Glass balls (1930)
 Ivalon sponge (polyvinyl alcohol) (1949)
 Polystan sponge (polyethylene) (1951)
 Etheron sponge (di-isocyanate polyether) (1960)
 Polyurethane/polyester (1962)
 Teflon-coated silicone sponge (1963)
 Silicone elastomer gel implant (1963)

Transplantation of autologous tissue

In the early part of the last century free autologous tissue transfer was limited to grafts. Neuber first described free fat grafts in 1893.⁴ Czerny is generally accredited with performing the first breast augmentation/reconstruction in 1895 by successfully transplanting as a free graft, a large lumbar lipoma to replace an excised area of breast tissue.⁵ However, the inevitable consequences of transferring all but small volumes of fat tissue lead to an unpredictable volume of graft loss, infection, fibrosis and late calcification.⁶ This obviously made the results of breast augmentation unpredictable in terms of size, symmetry and consistency. It was recommended that grafts should be 25–50% larger than required to account for subsequent loss.^{7,8} The results of fat transfer alone were later improved by including fascia and/or dermis in the fat grafts, with the buttocks as favoured donor sites. Reports using these techniques, including their complications, were still appearing in the literature in the 1970s.^{9–12} The use of local pedicled flaps reduced the problems of tissue loss still further.¹³ However, they were limited in volume by local availability and the additional donor site scarring.

Injections of alloplastic materials

Gersuny introduced subcutaneous paraffin injections to fill out soft tissue deformities in 1899, although contrary to later reports, he never extended the indications to the breast. Lagarde in 1903 is credited with this suggestion. The results of subcutaneous liquid paraffin injections were disappointing because of the many complications. These varied from local breast ulceration and fistula formation to retinal, pulmonary and cerebral embolism.¹⁴ Although this method was used around 100 years ago, the resulting complications were still being dealt with many decades later.

Subglandular silicone injections were used in the 1950s and 1960s. Unfortunately clinical use took the lead over controlled experiments in animals, which only started to be reported in 1965.¹⁵ Liquid silicone was injected with a catalyst to promote room temperature vulcanization (RTV) to form a gel consistency over 24 hours. Sometimes an inflammatory agent (to encourage encapsulation) was also added. Similar complications were encountered, with capsule formation, dependent migration, silicone fistulas, granuloma formation and calcification.^{16–18} This method of breast augmentation was particularly favoured in the Far Eastern countries such as Japan and China. The procedure was often not carried out by physicians or indeed ‘medical grade silicone’ used. In fact, it was the complications of liquid silicone injections in Japan, mistakenly reported as arising from silicone breast implants on an American chat show in 1990 that overnight sparked the silicone breast implant controversy. (The development of silicone, silicone breast implants and their controversy will be considered in subsequent sections.)

Preformed alloplastic sponge implants

Developments in the chemical industry in the first half of the last century marked the beginning of the era of the alloplastic implants. Box 2.1 shows that several different synthetic sponge materials were evaluated as potential subcutaneous prostheses. Initially, the open cell nature of the sponge (Ivalon, Polystan and Etheron) allowed tissue ingrowth, supposedly acting as a framework for living tissue ‘and what was inert becomes living’.¹⁹ Despite a small number of experiments in dogs, rats and mice which highlighted the encapsulation, fibrotic ingrowth, shrinkage, degradation, late calcification and occasional implant extrusion (less likely in

animals due to the presence of the panniculus carnosus), the materials were declared 'inert, non-toxic and non-carcinogenic', and 'suitable as subcutaneous prostheses'.^{19–23} There were several reports of using these plastics in other areas of surgery: general, vascular, orthopaedic and neurosurgery.^{21,24–32} The first reported use of Ivalon as a breast implant was in 1952. The implants were initially hand carved and then sterilized prior to surgery. Over the next decade these and several other plastic materials/combinations (such as Ivalon in polyethylene bags³³ and Teflon-coated silicone sponge^{34,35}) were also evaluated and used as breast implants.^{33,36–40} In 1967, it was estimated that 40 000 breast implant procedures had been performed using these alloplastic sponge materials.⁴¹ Implantation procedures evolved to try to reduce the complications. However, all of these materials suffered from varying degrees of the same problems encountered in the animal models, although least with silicone foam materials.⁴² The risks of infection, extrusion and stimulating a chronic inflammatory response, resulting in fibrous invasion, degradation, encapsulation and late calcification are not the attributes of a naturally feeling breast tissue substitute.⁶ Subsequently, many surgeons cautioned against the use of these materials, particularly in the circumstances where they were being used for cosmetic purposes.^{9,43} A survey in 1961 reported that 110 of 283 plastic surgeons did not perform breast augmentations.⁴⁴ Nevertheless, many patients had very satisfying results, receiving both physical and psychological benefits from their surgery, in the absence, at the time, of a better alternative.^{12,33,39,45}

The implant materials remained under suspicion at the time for a possible role in promoting carcinogenicity. Oppenheimer and co-workers in 1949 and 1951 observed a carcinogenic effect when implanting many different plastics, including Polystan (polyethylene) and Ivalon (polyvinyl) in rodents.^{32,46,47} Other investigators similarly reported sarcomatous reactions to various materials in the rat model.^{19,20,48–55} This was later thought by others to be a species-specific reaction^{2,56} ('Oppenheimer effect' or solid state tumorigenesis), and was never substantiated by other animal research or many years of clinical use.^{12,15,21,23,34,37,38,40,44,57}

There is no epidemiological evidence to suggest that the presence of a breast implant increases the risk,^{1,58–61} or delays the presentation of carcinoma of the breast. In fact some of the evidence suggests that the risk is lower, and presentation is at an earlier stage. Augmented women tend to have a lower volume of breast tissue and as a group tend to be more breast aware, picking up and presenting with abnormalities earlier.

Silicone breast implants

The history of silicone

Silicone is a family of synthetic materials whose development was largely due to the enthusiasm of Professor FS Kipping, an academic chemist, from Nottingham University who published 54 papers on the subject of silicon-carbon chemistry between 1899 and 1944. Many of his experiments resulted in various consistencies of 'uninviting glues'. He termed the polymeric compounds containing Si-O-Si linkages 'silicones'. The successful commercial development of silicones required knowledge concerning the principles of polymerization and the properties of macromolecules. These were developed by Staudinger, Emil, Fischer and Carothers in the period 1914–1940. Some of the polymers were transparent and aroused interest as possible glass substitutes. Dr JF Hyde of the Corning Glass Works investigated the potential industrial applications of this work in the 1930s. Because of the great thermal heat stability (–54 to +540°F or –47.8 to +282.2°C), one of the first uses was as insulation for electric motors so that they could run at higher temperatures without burning out. World War II interceded and Corning approached the Dow Chemical Company for engineering and research assistance for the war effort. Thus the Dow Corning Corporation was formed. Silicone was used for insulating the spark plugs of military aircraft, as a damping fluid in sensitive instruments, and for its anti-foaming properties in the engine oil of aircraft. Silicone rubber was invented in 1943. After the war, silicone found many diverse civilian applications in furniture polish, high temperature paints, high temperature rubber insulation, waterproofing and for mould release compounds.

Silicone had its first medical application towards the end of World War II when its hydrophobic properties ensured the complete drainage of penicillin bottles. In 1946 siliconized glass was used in blood handling after it was reported to prolong the clotting time. In 1948 Rowe et al published the first toxicology studies, which were primarily on the effect of silicone fluids given both orally and by subcutaneous injection.⁶² In 1950 DeNicola successfully reconstructed a urethra with a silicone rubber tube.⁶³ By 1952 almost 30 papers had been published on the use of silicones (mostly fluids) in the biological world. However, no further toxicology studies had been performed. In 1953 Dow Corning Sialastic® S9711 and Sialastic® S2000 were the first silicone rubbers developed specifically for medical use (experimental artificial bile duct). In the same year the first silicone-related plastic surgery literature was published by Brown et al.⁶⁴ Although the

main uses were in wound dressings, where studies showed that silicone did not affect wound healing.⁶⁵ Brown realized the potential of silicone as a possible permanent subcutaneous prosthesis. In 1955 the first successful Sialastic® S2000 hydrocephalus shunt was used. This seemingly simple application was important because of the prolonged contact of silicone with a variety of tissues with no apparent untoward effect. It was not until 1959 that the effects of various grades of silicone rubber as prostheses in dogs over a 1-year period was reported.⁶⁶ There was a delicate fibrous capsule, little inflammatory reaction and no tissue invasion (unlike the sponge materials already discussed). There was also no effect on wound healing, infection or extrusion of the implant. Dow Corning were totally unprepared for the demand for both information and materials, and the Dow Corning Centre for Aid to Medical Research was established in 1959. Outside contractors failed to supply the consistent quality of silicone required for medical use and in 1962 Dow Corning established its Medical Products Division and with it 'medical grade silicone'.

What is silicone?

Silicon (without the final 'e') is a ubiquitous element, the second most abundant element on earth, and accounts for 27.6% of the earth's crust by weight. In its natural form silicon is bonded to oxygen and occurs in various forms as *silica* and *silicates*. It is the main constituent of sand. Silica may exist in a crystalline or amorphous form. The former, unlike the latter, is a strong immunological stimulant⁶⁷⁻⁶⁹ and adjuvant,⁷⁰ causing, for instance, pulmonary fibrosis by inhalation (iron foundry lung).⁷¹ It may also cause scleroderma.^{72,73} Crystalline silica is not a component of silicone⁷⁴⁻⁷⁶ and its conversion from amorphous silica, which is present in silicone breast implants (see below), requires non-physiological conditions with both very high temperatures and catalysts. Physiological degradation of silicone and its metabolic conversion to silica is not thought to occur. There is currently no valid assay method for *silicone* itself,⁷⁷ being measured indirectly via conversion to silicon.

Silicone (with the final 'e') is the generic name for a family of synthetic silicon-carbon based polymers, or chains of molecules, of alternating silicon and oxygen atoms (a bond not found in nature). When these chains are short, the resultant silicone is a low viscosity fluid; and if the chains are long, the fluid has a corresponding high viscosity. The Si-O polymer chain has, attached to each silicon atom, two organic groups, usually methyl (CH₃) and sometimes phenyl groups (C₆H₅). Silicones are sometimes therefore referred to as polydimethylsiloxanes (PDMS).

Silicone rubber is made from high viscosity silicone polymers. Fillers and vulcanizing agents are compounded with the base polymer. These chemicals act as fugitives in that they are not chemically incorporated into the elastomer. Hence heat vulcanized medical grade silicone rubber only contains silicone polymer and reinforcing silica filler. This process of vulcanization crosslinks the polymer chains so that they cannot slip away from each other as in a fluid. There are two categories: heat-vulcanizing and RTV types. The most commonly used agents in the heat-vulcanized type of medical grade silicone are dichlorobenzoylperoxide and platinum. They also act as fugitives in that they do not actually become part of the rubber molecule. Hence, medical grade silicone of this type only contains silicone polymer and reinforcing silica filler. The RTV silicone rubbers can be subdivided into one and two component types. The former, containing the necessary ingredients, vulcanizes by absorbing water vapour, proceeding from the outside towards the interior. The latter uses an organo-metallic catalyst that causes vulcanization in a few minutes (and continues for 24 hours) when stirred into the rubber base. The only acceptable (non-toxic) medical catalyst is stannous octoate. Industrial grade silicones contain various additives to enhance certain properties for specific applications. They are often very toxic and are usually not tested for use in medicine, emphasizing the importance of using only medical grade silicone.⁷⁸ This term requires three criteria to be met:

1. Careful quality control of monomers, catalysts and any additives.
2. A history of successful implantation in animals and humans.
3. Manufacture is under pharmaceutically clean conditions.

Medical grade silicones are available in a wide range of forms, pre-shaped devices, block, sheet, rod, tube, sponge and a variety of fluids and adhesives. Thermal stability means that they are easily sterilized. Silicones have several useful properties (Box 2.2), which vary depending on chain length and

Box 2.2 Some useful properties of silicones

Chemically inert including acids and alkalis
Heat stable (-54 to 540°F)
Specific gravity 0.98 (fat is 0.90)
Hydrophobic
Lowers surface tension (anti-foaming)
Flexible elastomers
Non-stick
Permeability

Table 2.1 Exposure to silicone

Non-medical	Medical
Infant bottle teats	Drugs
Baby milk formulas	Intravenous tubing
Deodorants	Hypodermic needles
Hair sprays	Syringes
Cosmetics	Cerebrospinal fluid shunt tubing
Food additives	Slow release drug release systems
Food processing	Testicular prostheses
Polishes	Penile implants
Lubricants	Cardiac valves
	Digital joint prostheses
	Intraocular lens implants
	Breast, calf, chin, pectoral, lip implants
	1st stage hand tendon reconstructions
	Feeding tubes, urinary catheters
	Wound dressings

crosslinking. This has resulted in a diverse range of applications, for both non-medical and medical purposes (Table 2.1). Consequently, everyday exposure to silicone is common. Silicone has improved the quality of the majority of our lives, in addition to saving or prolonging many more who may otherwise have died through illnesses.

Development of the silicone breast implant

Work began on the first implant, the Sialastic® mammary prosthesis, in 1961 after Dr Cronin and his resident Dr Gerow approached Dow Corning with their ideas, having become disenchanted with sponge mammary implants. After testing several designs and consistencies in dogs, the first prosthesis was implanted in 1962 and reported in 1963.⁷⁹ The first implants consisted of a thick Sialastic® rubber (elastomer) shell containing silicone gel and had Dacron cloth patches on the back for fixation. After several designs, the Dacron patches were eventually discontinued as unnecessary. Some initially felt that they were the cause of capsular contracture.⁸⁰ At first, the implants had anterior and posterior seams in order to make silicone sheets into a bag. In 1969 a seamless design was developed. In addition, a stronger Sialastic® silicone rubber was developed so that the implants could be made with thinner shells, giving a more natural feel. As further developments ensued these first implants were later termed first generation breast implants. Other subsequent developments are chronicled in Table 2.2.

Table 2.2 Development of the silicone breast implant

Innovation (date)	Problems
Sialastic® gel filled implant (G1) (1962)	Capsular contracture
Dacron fixation patches stopped (1965)	Removal, ?cause of contracture
Simaplast inflatable implant (1965)	Saline leakage/deflation
Seamless implant (1969)	
Double lumen implants (1976)	Leakage/deflation
Silicone gel implant (G2), 'low bleed' (1975)	Capsular contracture, rupture
Polyurethane coated natural Y implant (1970)	Withdrawn 1991, ?cancer risk
Closed capsulotomy (1975)	Implant rupture
Anatomical shaped implants (1976)	
Silicone gel filled implant (G3) (1980)	Capsular contracture
Même (Aesthetech Corporation) polyurethane implants (1986)	Withdrawn 1991
Surface texturing (1988)	
Hydrogel filled implants (1990)	Osmotic swelling
Gel implant moratorium (1992)	USA, Canada, Australia, France
Trilucent lipid filled implants (1993)	Withdrawn 1999
Anatomical cohesive gel implants (1995)	
G1-3, the three 'generations' of smooth walled silicone gel implants.	

The body's natural response to a foreign material is to encapsulate it in a thin fibrous capsule. Silicone elastomer induces a much less marked response than previously used materials.⁸¹⁻⁸⁴ However, contracture of the capsule (via myofibroblasts) converts the normal soft disc shape into a firm sphere, the smallest surface area for its volume, occasionally distorting the breast and causing pain and discomfort. Capsular contracture was reported to affect between 30 and 70% of patients, the majority occurring in the first 3 years. It is usually graded clinically using the Baker classification (Box 2.3).⁸⁵

The exact cause of capsular contracture remains a mystery. Capsule formation is a normal response to the introduction of a foreign material and like most physiological responses is probably a spectrum, in terms of both degree and timing. There are general patient factors and local breast factors. Early severe

Box 2.3 Baker classification of capsular contracture

Grade 1	Soft capsule, normal breast appearance, no evidence of implant
Grade 2	Minimal capsule, palpable implant but not visible
Grade 3	Moderate, firm breast, visible implant
Grade 4	Severe, breast hard, breast distortion and discomfort/tenderness

From Baker JL Jr. Presented at the Aesthetic Breast Symposium, 1975 and in: *Symposium of Aesthetic Surgery of the Breast*, St Louis: Mosby, 1978: 256–63.⁸⁵

contracture represents one end of the spectrum, rather like the development of hypertrophic scars. The capsule response could be altered by other factors of which infection (clinical and subclinical) is the most plausible.^{86–92} Intraoperative implant contamination from the nipple is the most obvious source, which is easily remedied by the use of non-permeable adherent nipple dressings.⁹³ Silicone gel bleed also has some support in the literature.^{94,95} Other proposed causes include haematoma, and foreign bodies such as glove powder, dust and cotton wool from swabs.⁹⁶ However, only silicone and infection have any kind of literature support, the others being suppositions quoted in successive publications on the subject.

The persistent problem of capsular contracture led to the production of implants with thinner walls and less gel. These second generation implants were softer with a more natural feel, but the problem of capsular contracture remained. Other attempts to reduce this problem included inflatable dextran or saline filled (Simaplast), and double lumen (saline inner, silicone gel outer) implants. They were prone to deflation due to leaks from the valves and seams at first (up to 75% at 3 years^{80,97}) and later due to ‘fold flaw’ creases in underfilled implants. There were several modifications by different manufacturers to address these problems, some eventually withdrawing them from market (Simaplast, Klein, McGhan). By 1976 only the Heyer-Schulte thick RTV elastomer type inflatable implant was left on the market.

In 1975, the concept of closed capsulotomy was introduced where vigorous external manipulation of the breast was used to try to disrupt the fibrous capsule. Unfortunately, the ability of these implants to rupture then began to become apparent. Studies also demonstrated silicone in the capsules surrounding the implants. It was recognized that a small

amount of silicone ‘bleed’ occurs from intact implants. It was thought that this could be the cause of capsular contracture. These problems were partly addressed by the third generation ‘low bleed’ implants which have a strong shell (high performance (HP) elastomer) and an inner surface which was coated with a ‘barrier layer’ to reduce the diffusion of silicone. These became available in the mid 1980s. Capsular contracture remained a problem.

The first polyurethane coated silicone implants were introduced in 1970, the Natural Y implant.⁹⁸ This was followed by the Mème (Aesthetech Corporation) implant in 1986.⁹⁹ The polyurethane resulted in varied collagen orientations in the capsule, compared to the single orientation in smooth implant capsules. After initial scepticism, it was evident that they successfully reduced the incidence of capsular contracture. It has since been shown that the polyurethane coating fragmented with time¹⁰⁰ and reduced their ability to prevent the capsule problem.¹⁰¹ However, they were withdrawn from use in 1991 because of a possible cancer risk from chemical breakdown of the polyurethane foam to 2-toluene diamine (TDA), a known carcinogen. The American Food and Drug Administration (FDA) admitted in 1995 that after further study the risk was only about one in a million, which is small when compared to the risk of developing breast cancer.

The most recent, major step in silicone breast implant technology, following on from the success of the polyurethane coated implants, was the introduction of surface texturing in the late 1980s. An outer textured silicone elastomer is added to the implant during the manufacturing process. Manufacturers use different texture patterns (fingers, caves and waves), the textured elastomer being added as a separate and final process during implant production. Textured surfaced implants have been shown to reduce the capsular contracture rate from 58 to 8%.¹⁰² This was one of the few well designed intra-patient randomized controlled studies using smooth and textured implants. A recent 10-year review has shown the effect is maintained in the long term.¹⁰¹ The effect of texturing in reducing capsular contracture remains a mystery. Texturing alters the capsule response. The magnitude of the texturing is important.¹⁰³ Texturing may produce a more disorganized collagen pattern in the capsule.^{103–105} A reduced proportion of type III collagen compared to the smooth implant was reported in the rabbit model.¹⁰⁶ Increased type III collagen is a feature of Dupuytren’s disease. The role of synovial metaplasia^{107–110} is uncertain, although texturing may induce a more persistent and villous hypertrophy, compared to smooth implants. Synovial cells secrete lubricating factors, notably proteoglycans that have been shown to inhibit

collagen lattice contracture.¹¹¹ Proteoglycan filled implants have been shown to produce thinner capsules.¹¹² A recent study examining capsules of different ages histologically found that textured implants were associated with significantly more foreign material and foreign body granulomatous reaction, regardless of age, than smooth implants.¹⁰⁴ Perhaps this represents loss of texturing with time, which may be a problem of all or just some textured implant types.

Submuscular as opposed to subglandular placement also results in a lower incidence of capsular contracture,^{1,96} regardless of texturing. Speculative explanations for the latter effect include a mechanical massaging action of the overlying pectoralis major muscle and antibacterial effect of an interposed muscle between the breast and implant. However, submuscular placement can result in a less favourable cosmetic result because of the effect of a functioning muscle on implant position. There is no literature on histological comparison of the capsules of subpectoral and subglandular implants.

Saline filled implants have been reported as causing less contracture.^{113,114} However, a high rate of spontaneous deflation (more than 15% in some reported series)^{115,116} and a high incidence of being able to feel folds in the implant have thrown them into disfavour. Consequently the vast majority of implants used today in the UK are textured, silicone gel filled and placed in a subglandular position. In contrast, in the USA because of implant restrictions since 1992, many are saline filled and placed in a submuscular position.

Trilucent™ (LipoMatrix) implants were introduced in 1995 as an alternative to silicone gel. The proposed benefits over silicone filled implants were safety of the triglyceride filler and relative radiolucency for mammography. Regardless of the lack of long-term animal and clinical studies, demand was high because of the controversy over the safety of silicone gel. The physiological triglyceride, which does bleed through the silicone capsule, was envisaged to be absorbed, metabolized and stored in normal fat storage sites, if not required for energy.¹¹⁷ However, further studies have since shown that the results of metabolism are potentially toxic and even genotoxic. These implants have been the subject of a voluntary recall (March 1999) pending the results of further clinical and toxicological studies.

Lifespan of the silicone breast implant

Silicone gel breast implants were originally envisaged as being able to last a lifetime. This is obviously not the case. As already mentioned,

implants have evolved through three generations over the past four decades. Changes in implant specifications determine their ability to withstand years of repetitive minor trauma and any deterioration in physical properties that may occur with time.^{118,119} One of the most important concerns over their use is the long-term integrity of silicone gel implants. Reports suggesting that the risk of implant rupture increases simply with duration in vivo (with up to 95% of implants having ruptured by 20 years) have been used to suggest that implants should simply be removed because of their age. They fail to account for the evolution of these devices through three generations over the past 35 years.^{118,120–123} The majority of implants in these studies are second generation from the late 1970s and early 1980s. These implants proved to be weaker, and in consequence led to the development of the thicker walled smooth and then textured third generation implants. Peters et al did account for implant generation.¹²⁴ They showed that the first and third generation implants had very low failure rates, but those of the second generation started to fail at 4 years with 80% or more failed by 12 years.¹²⁴ Our research, based on 478 consecutively explanted silicone gel breast implants, confirmed the differences between the three generations.¹²⁵ There is also as yet no evidence that current textured silicone gel filled implants, in use in our practice since 1989, are subject to the same loss of integrity as the preceding second generation smooth implants. However true failure rates are unknown as the majority are probably asymptomatic. Implant failure is usually intracapsular, where the elastomer envelope breaks with subsequent leakage of silicone gel, which is contained within the fibrous capsule. Occasionally the silicone escapes into the surrounding breast parenchyma (extracapsular rupture). Our studies suggest that this may occur with prolonged intracapsular rupture. Implant and synchronous capsular rupture may also follow trauma such as a road traffic accident or perhaps closed capsulotomy. The resulting foreign body reaction results in the formation of granulomas.

Clinical diagnosis of rupture is difficult and imaging is usually required. Ultrasound is able to image the whole implant and its interior unlike mammography, and does not involve radiation. However, it is highly operator dependent. The 'stepladder' sign of multiple linear echoes represents a collapsed implant shell and is the ultrasound correlate of the magnetic resonance imaging (MRI) 'linguine' sign, denoting intracapsular rupture. MRI is the best imaging modality, allowing the entire implant to be seen in a variety of planes and it is not as operator dependent. It can distinguish between silicone and normal tissues within the breast. However, it is much more costly than mammography or ultra-

sound. Ultrasound has often been considered the investigation of choice in evaluating implant-related complications.¹²⁶ With the increasing availability of and experience with MRI this should now be considered the investigation of choice. However, the only true test of implant integrity is that of removal, explantation.

The silicone controversy

It is estimated that one to two million women in the USA have received silicone breast implants in the past three decades. There have been more than 2000 studies on silicone and silicone implantable devices in the past half-century, reaching a peak in the 1990s with epidemiological studies on human populations.

The silicone controversy relates to the accusation that silicone was linked to autoimmune diseases (rheumatoid arthritis, scleroderma, lupus erythematosus and atypical connective tissue disease) and later various neurological disorders. Human adjuvant disease is a term that has previously been used to describe clinical syndromes in patients with silicone implants.¹²⁷ An adjuvant is a substance that enhances an immune response to another substance, either by acting as a depot for antigens (as in human immunization) and itself acting as an antigen or containing components of microbial origin that have superantigens or mitogens which can activate T or B lymphocytes.

The first case report in 1964 concerned liquid silicone injections in the Japanese medical literature. Between 1982 and 1988 there were only a dozen isolated case reports about breast implants. Silicone gel bleed¹²⁸ and implant rupture was the source of immunological exposure. Cadaveric tissue silicon assays have shown elevated levels within the implant capsule only, with levels at distant sites, including the spleen and liver (reticuloendothelial system) equivalent to baseline levels in non-augmented cadavers.¹²⁹ Capsular levels have been shown to be greater in silicone gel when compared to saline filled implants.¹³⁰ The FDA did not believe there was cause for alarm in 1989, but were asking manufacturers for more information in 1990. However, when in 1990, the CBS television *Face to face with Connie Chung* show suggested that silicone implants were 'poisoning' women, it unleashed an avalanche of worldwide negative media attention, and nowhere was this worse than in the USA. Feminists and pressure groups added their views. At the time many women were probably disenchanted with their implant surgery because of the high rate of capsular contracture (textured implants were still being evaluated), and the relative weakness of second

generation implants. Revision surgery was not without its problems. Several hundred articles appeared in the medical literature relating illness to silicone gel implants, further supporting the controversy, despite most being anecdotal, single case reports, or small case series. The controversy caused considerable anxiety to the extent that some women even removed their own implants! The implants appeared to be guilty until proven innocent.

In the USA, the FDA banned the use of silicone breast implants in 1992¹³¹ (except for use in reconstruction and cosmetic augmentation as part of scientific trials), not because they were thought to be unsafe, but probably as a result of public and political pressure. Australia, France and Canada followed suit. Curiously, saline filled silicone breast implants and other silicone containing medical devices were still allowed, as was silicone in food, cosmetics and drugs.

The large sums of money initially involved (\$7.3 million in one case in 1991) unleashed a flood of litigation against the implant manufacturers, a process in which the lawyers were only too willing to participate. Some law firms even solicited patients by advertising, sending them to be seen by their 'medical experts'. Expensive tests were developed and marketed by some of these professional anti-implant witnesses, claiming to be able to detect antibodies to silicone. All were later proved to be invalid (at best). Given the number of women in the USA with breast implants, it would be expected that a proportion would suffer from connective tissue diseases just by mere coincidence. A whole host of non-specific symptoms were put forward as evidence of these diseases. In the courtroom non-medical or non-scientifically educated jurors had to interpret the evidence laid before them and make a decision as to where the 'guilt' lay. The media may already have influenced their decision. The fact that much of the evidence against silicone breast implants in the literature was anecdotal or of poor epidemiological quality meant little, sometimes with authors not declaring their interest as expert witnesses for the plaintiff. The normal scientific process had been hijacked by the legal system. In a letter to the Lord Chancellor (DTS personal communication, January 1998), four professors (including the chairman of the FDA panel which examined silicone breast implants in 1992, and the chairman of the Canadian government investigation into silicone breast implants in 1992) express their dismay that the UK legal process may fall prey to 'the threat junk science imposes on society'. They reminded him that the UK Medical Devices Agency Review Panel on breast implants has already completed two careful and thoughtful reviews, and on both occasions reached the conclusion that there

was no evidence of a connection between breast implants and systemic disease.^{132,133} They warned of the 'price paid in North America as a direct result of such frivolous and groundless litigation'. The financial pressure was such that in April 1994 the silicone implant manufacturers agreed to a class action settlement, establishing a fund of \$4.2 billion to compensate women with implants who later developed one or more of eight specified disorders. After it became clear that this was a gross underestimate on the basis of then current awards, Dow Corning (also facing 20 000 lawsuits outside the settlement), filed for Chapter 11 bankruptcy protection in May 1995. This potentially had a knock-on effect on the manufacturers of other silicone containing medical devices, some of which are lifesaving. Interestingly, there have been no substantiated reports of connective tissue diseases occurring in patients exposed to silicone used in other areas of medical practice, such as Sialastic finger joints, arterio-venous shunts, heart valves, pacemakers and patients requiring regular injections such as those with diabetes who are estimated to receive several cubic centimetres of silicone over a lifetime.

As the results of more rigorous, scientifically controlled, trials become available, the balance of favour is swinging back towards the medicine and the science. A report for the American Academy of Neurology,¹³⁴ reviewing the literature, concluded that to date there is no clear relationship of silicone breast implants and connective tissue disease, and certainly no association or causal relationship between silicone breast implants and neurological disorders. Further research, preferably in the form of prospective cohort studies is needed. The largest case-control study of patients with systemic sclerosis to date failed to support any association between systemic sclerosis and silicone breast implants.¹³⁵ The results are consistent with other large epidemiological case-control studies looking at connective tissue diseases in general.¹³⁶⁻¹⁴⁰ An analytical review of silicone immunology suggested there was no basis for silicone causing human adjuvant disease or convincing evidence that silicone gel is either immunogenic or mitogenic.⁷⁸ It suggested that papers claiming immune responses to silicone had fundamental defects in methodology and interpretation, none being published in primary immunology journals. These papers are often not balanced accounts of controversial material, containing no disclosure of the authors' activities as expert witnesses for plaintiffs in implant litigation. In view of the amount of controversy (and money) surrounding this issue, further research should be conducted according to rigorous standards and reviewed by qualified immunologists. The report by the UK Independent Review Group (July 1998)¹⁴¹ also found no evidence to support a ban on the use of silicone

gel filled breast implants. Recent developments have shown that American courts are no longer prepared to entertain anecdotal evidence. The assertion that silicone breast implants cause disease has been challenged by the 'independent science panels' set up to objectively examine the evidence in courts in the USA, notably the Oregon County judgment of Judge Robert Jones.¹⁴² The panels hear and cross-examine the various expert witnesses from both sides. A recent ruling by the Senate in 1999 supported the use of silicone breast implants. Perhaps the FDA will now consider re-licensing silicone breast implants, although it may be difficult to persuade the manufacturers to follow suit.

References

1. McGrath MH, Burkhardt BR. The safety and efficacy of breast implants for augmentation mammoplasty. *Plast Reconstr Surg* 1984; 74: 550-60.
2. Scales JT. Biological and mechanical factors in prosthetic surgery. In: Gilles L, ed. *Modern Trends in Surgical Materials*. London: Butterworth, 1961.
3. Zavaleta D, Marino E. Hipoplasia mamaria unilateral: relleno mamario con epiplon mayor transplantado. *Prensa Med Argent* 1963; 50: 639.
4. Neuber TGA. Fett transplantation. *Chir Kong Verhandl* 1893; 1: 66.
5. Czerny V. Plastischer Ersatz der Brustdrüse durch ein Lipom. *Zentralbl Chir* 1895; 27: 72.
6. Lewis JR. The augmentation mammoplasty. *Plast Reconstr Surg* 1965; 35: 51-9.
7. Gurney CE. Experimental study of the behaviour of free fat transplants. *Surgery* 1938; 3: 680.
8. Peer LA. Loss of weight and volume in human fat grafts, with postulation of a 'cell survival theory'. *Plast Reconstr Surg* 1950; 5: 217-30.
9. Chohnoky T. Late adverse results following breast reconstructions. *Plast Reconstr Surg* 1963; 31: 445-52.
10. Murray DS. Breast augmentation with gluteal dermofat grafts: a 5-10 year follow up. *Br J Plast Surg* 1976; 29: 1-4.
11. Milward TM. Calcification in dermofat grafts. *Br J Plast Surg* 1973; 26: 179-80.
12. Conway H, Smith JW. Breast plastic surgery: reduction mammoplasty, mastopexy, augmentation mammoplasty and mammary reconstruction. *Plast Reconstr Surg* 1958; 21: 8-19.
13. Longacre JJ. Reconstruction of the breast utilizing local pedicled flaps. *Plast Reconstr Surg* 1954; 14: 431.
14. Beekman WH, Hage JJ, Jorna LB, Mulder JW. Augmentation mammoplasty: the story before the silicone bag prosthesis. *Ann Plast Surg* 1999; 43: 446-51.
15. Rees TD, Ballantyne DL, Hawthorne DL. Silicone fluid research: a follow up summary. *Plast Reconstr Surg* 1970; 46: 50-5.

16. Ellenbogen R, Rubin L. Injectable fluid silicone therapy. *JAMA* 1975; 234: 308.
17. Boo Chai K. The complications of augmentation mammoplasty by silicone injection. *Br J Plast Surg* 1969; 22: 281–5.
18. Ortiz-Monaterio F, Trigos I. Management of patients with complications from injections of foreign materials into the breast. *Plast Reconstr Surg* 1972; 50: 42–7.
19. Grindley JH, Waugh JM. Plastic sponge which acts as a framework for living tissue. *Arch Surg* 1951; 63: 288.
20. Harrison JH, Swanson DS, Lincoln AF. A comparison of the tissue reactions to plastic materials. *Arch Surg* 1957; 74: 139.
21. Moore AM, Brown JB. Investigation of polyvinyl compounds for use as subcutaneous prosthesis. *Plast Reconstr Surg* 1952; 10: 453–9.
22. Bing J. The tissue reaction to implanted plastics. *Acta Pathol Microbiol Scand* 1955; Suppl 105: 16.
23. LeVeen HH, Barberio JR. Tissue reaction to plastics used in surgery with special reference to Teflon. *Ann Surg* 1949; 129: 74.
24. Grindley JH, Claggett OR. A plastic sponge prosthesis for use after pneumonectomy: a preliminary report of an experimental study. *Proc Mayo Clin* 1949; 24: 538–9.
25. Grindley JH, Claggett OR. Plastic sponge which acts as a framework for living tissue: experimental studies and preliminary report of use to reinforce abdominal aneurysms. *Arch Surg* 1951; 63: 288–97.
26. Cooley JC, Kirkland JW. The surgical treatment of persistent common atrioventricular canal; report of 12 cases. *Proc Mayo Clin* 1956; 31: 523.
27. Mortensen JD. Ivalon sponge vascular prosthesis. *Transplant Bull* 1956; 3: 8.
28. Dodge HW, Grindley JH, Craig W, Ross PJ. Use of polyvinyl-formal sponge in neurosurgery. *J Neurosurg* 1954; 11: 258.
29. Bryan RS, Janes JM, Grindley JH. The effect of polyvinyl-formal (Ivalon) sponge on cortical bone healing. *Proc Mayo Clin* 1958; 33: 453.
30. Pearlman MD. Recommendations for the utilization of polyvinyl plastic sponge as an orbital implant. *Trans Am Acad Ophthalmol* 1953; 57: 910.
31. Cooley JC, Grindley JH, Claggett OT. Esophageal hiatal hernia: anatomic and surgical concepts, with special reference to the experimental use of an Ivalon prosthesis in the repair. *Surgery* 1957; 41: 714.
32. Freeman BS. Complications following insertion of plastic sponge. *Plast Reconstr Surg* 1955; 15: 149–53.
33. Pangman WJ, Wallace RM. The use of plastic prosthesis in breast plastic and other soft tissue surgery. *West J Surg* 1955; 63: 503–12.
34. Brown JB, Fryer MP, Ohlweiler DA. Study and use of synthetic materials such as silicones and Teflon, as subcutaneous prostheses. *Plast Reconstr Surg* 1960; 26: 264–79.
35. Edwards FE. Teflon-silicone breast implants. *Plast Reconstr Surg* 1963; 32: 519–26.
36. Calnan J. The use of inert plastic material in reconstructive surgery. *Br J Plast Surg* 1963; 16: 1–22.
37. Arons MS, Sabesin SM, Smith RR. Experimental studies with Ethern sponge. *Plast Reconstr Surg* 1961; 28: 72–80.
38. Schwartz AW, Erich JB. Experimental study of polyvinylformal (Ivalon) sponge as a substitute for tissue. *Plast Reconstr Surg* 1960; 25: 1–14.
39. Edgerton MT, McClary AR. Augmentation mammoplasty: psychiatric implications and surgical indications (with special reference to the use of polyvinyl alcohol sponge (Ivalon)). *Plast Reconstr Surg* 1958; 21: 279.
40. Neuman Z. The use of the non-absorbable polyethylene sponge 'Polystan sponge', as a subcutaneous prosthesis. *Br J Plast Surg* 1957; 9: 195–99.
41. Hoopes JE, Edgerton MT. Organic synthetics for augmentation mammoplasty: their relation to breast surgery. *Plast Reconstr Surg* 1967; 39: 263–70.
42. Speirs AC, Blocksma R. New implantable silicone rubbers. *Plast Reconstr Surg* 1963; 31: 166–75.
43. Kiskadden WS. 'Operations on bosoms dangerous'. *Plast Reconstr Surg* 1955; 15: 79–80.
44. Harris HI. Survey of breast implants from the point of view of carcinogenesis. *Plast Reconstr Surg* 1961; 28: 81–3.
45. Gonzalea-Ulloa M. Correction of hypotrophy of the breast by means of exogenous material. *Plast Reconstr Surg* 1960; 25: 15–26.
46. Oppenheimer BS, Oppenheimer ET, Damshefsky I, Eirich FR. Further studies of polymers as carcinogenic agents in animals. *Cancer Res* 1955; 15: 333.
47. Oppenheimer BS, Oppenheimer ET, Stout AP. Sarcomas induced in rodents by implanting various plastic films. *Proc Soc Exp Biol* 1952; 79: 366–9.
48. Johnson HA, Grindley JH. Experimental alteration of nasal contour by the use of polyvinyl sponge. *Plast Reconstr Surg* 1954; 14: 293.
49. Struthers AM. An experimental study of polyvinyl sponge as a substitute for bone. *Plast Reconstr Surg* 1955; 15: 274.
50. Bering EA, McLaurin RL, Lloyd JB, Ingraham FD. Production of tumours in rats by implantation of pure polyethylene. *Cancer Res* 1955; 15: 300–10.
51. Laskin DM, Robertson IB, Weinmann JP. *Proc Soc Exp Biol* 1954; 87: 329.
52. Northdurft H. Über die sarkomauslösung durch fremdkörperimplantationen bei ratten in abh angigkeit von der form der Implantate. *Strahlentherapie* 1956; 100: 192.
53. Leighton J, Kline I, Orr HC. *Science* 1956; 123: 512.
54. Dukes CE, Mitchley BCV. Polyvinyl sponge implants: experimental and clinical observations. *Br J Plast Surg* 1962; 15: 225–35.
55. Oppenheimer BS, Oppenheimer ET, Stout AP. Sarcomas induced in rats by implanting cellophane. *Proc Soc Exp Biol Med* 1948; 67: 33.
56. Grasso P, Goldberg L, Fairweather FA. [Letter] *Lancet* 1964; 2: 96.
57. Hoopes JE, Edgerton MT, Shelley W. Organic synthetics for augmentation mammoplasty: their relation to breast cancer. *Plast Reconstr Surg* 1967; 39: 263–70.
58. Berkel H, Birdsell DC, Jenkins H. Breast augmentation: a

- risk factor for breast cancer? *N Engl J Med* 1992; 326: 1649–53.
59. Deapen DM, Pike MC, Casagrande JT, Brody GS. The relationship between breast cancer and augmentation: an epidemiological study. *Plast Reconstr Surg* 1986; 77: 361–7.
 60. Bryant H, Brasher P. Breast implants and breast cancer – reanalysis of a linkage study. *N Engl J Med* 1995; 332: 1535–9.
 61. Deapen DM, Brody GS. Augmentation mammoplasty and breast cancer: a five year update of the Los Angeles study. *J Clin Epidemiol* 1995; 48: 551–6.
 62. Rowe UK, Spencer HC, Bars SL. Toxicological studies on certain silicones. *J Ind Hygiene Toxicol* 1948; 30: 332–52.
 63. DeNicola RR. Permanent artificial (silicone) urethra. *J Urol* 1950; 63: 168–72.
 64. Brown JB, Fryer MP, Randall P, Lu M. Silicones in plastic surgery. *Plast Reconstr Surg* 1953; 12: 374–6.
 65. Brown JB. The effects of various agents on healing in controlled partial thickness skin loss. *Surg Forum* 1953; 620–32.
 66. Marzoni FA, Upchurch SE, Lambert CJ. An experimental study of silicone as a soft tissue substitute. *Plast Reconstr Surg* 1959; 24: 600–8.
 67. Mancini D, Buono G, Cusano M, Minucci M. Adjuvant effects of a crystalline silica on IgE and IgG1 antibody production in mice and their prevention by the macrophage stabilizer poly-2-vinylpyridine N oxide. *Int Arch Allergy Immunol* 1983; 71: 279–81.
 68. Dubois CM, Bissonette E, Rola-Pleszczynski M. Asbestos fibres and silica particles stimulate rat alveolar macrophages to release tumour necrosis factor. *Am Rev Respir Dis* 1989; 139: 1257–64.
 69. Allison AC, Harrington JS, Birbeck M. An examination of the cytotoxic effects of silica on macrophages. *J Exp Med* 1966; 124: 141–50.
 70. Mancinni, D, Bevilacqua, N. Adjuvant effect of amorphous silica on the immune response to various antigens in guinea pigs. *Int Arch Allergy Immunol* 1977; 53: 97–103.
 71. Koeger A, Lang T, Alcaix D et al. Silica-associated connective tissue disease. *Medicine (Baltimore)* 1995; 74: 221–37.
 72. Rodnan GP, Benedek TG, Medsger TA Jr, Cammartata RJ. The association of progressive systemic sclerosis (scleroderma) with coal miners pneumoconiosis and other forms of silicosis. *Ann Intern Med* 1967; 66: 323–34.
 73. Silman, AJ, Hochberg, MC. Scleroderma. In: *Epidemiology of the Rheumatic Diseases*. Oxford: Oxford University Press, 1993.
 74. Le Vier RR, Harrison MC, Cook RR, Lane TH. What is silicone? *Plast Reconstr Surg* 1993; 92: 163–7.
 75. Lane TH, Burns SA. Silica, silicon and silicones. Unraveling the mystery. *Curr Top Microbiol Immunol* 1996; 210: 3–12.
 76. Picha GJ, Goldstein JA. Analysis of the soft-tissue response to components used in the manufacture of breast implants: rat animal model. *Plast Reconstr Surg* 1991; 87: 490–500.
 77. Marcus DM. An analytical review of silicone immunology. *Arthritis Rheum* 1996; 39: 1619–26.
 78. Blocksma R, Brailey S. The silicones in plastic surgery. *Plast Reconstr Surg* 1965; 35: 366–70.
 79. Cronin TD, Gerow FJ. Augmentation mammoplasty: a new ‘natural feel’ prosthesis. In: *Transactions of the Third International Congress of Plastic and Reconstructive Surgery*. Amsterdam: Excerpta Medica, 1964.
 80. Williams JE. Experiences with a large series of Sialastic breast implants. *Plast Reconstr Surg* 1972; 49: 253–8.
 81. Gayou R, Rudolph R. Capsular contracture around silicone mammary prostheses. *Ann Plast Surg* 1979; 2: 62.
 82. Lilla JA, Vistnes LM. Long term study of reactions to various silicone breast implants in rabbits. *Plast Reconstr Surg* 1976; 57: 637.
 83. Rigdon RH, Dricks A. Reaction associated with silicone rubber: an experimental study. *Biomed Mater Res* 1975; 9: 645.
 84. Robertson G, Braley S. Toxicological studies, quality control, and efficacy of the Sialastic mammary prosthesis. *Med Instrum* 1973; 7: 100.
 85. Baker JL Jr. Classification of spherical contractures. Presented at the Aesthetic Breast Symposium, Scottsdale, Arizona, 1975. Also in Baker JL Jr. Augmentation mammoplasty. In: Owsley JQ Jr, Peterson RA, eds. *Symposium on Aesthetic Surgery of the Breast*. St Louis: Mosby, 1978, 256–63.
 86. Virden CP, Dobke MK, Stein P et al. Subclinical infection of the silicone breast implant surface as a possible cause of capsular contracture. *Aesth Plast Surg* 1992; 16: 173–9.
 87. Ransjö U, Asplund OA, Gylbert L, Jurell G. Bacteria in the female breast. *Scand J Plast Reconstr Surg* 1985; 19: 87–9.
 88. Ahn CY, Ko CY, Wager EA et al. Microbial evaluation of 139 implants removed from symptomatic patients. *Plast Reconstr Surg* 1996; 98: 1225–9.
 89. Burkhardt BR, Freid M, Schnur PL, Tofield JJ. Capsules, infection, and intraluminal antibiotics. *Plast Reconstr Surg* 1981; 68: 43–7.
 90. Burkhardt BR, Eades E. The effect of biocell texturing and povidine-iodine irrigation on capsular contracture around saline inflatable breast implants. *Plast Reconstr Surg* 1995; 96: 1317–25.
 91. Burkhardt BR, Dempsey PD, Schnur PL, Tofield JJ. Capsular contracture: A prospective study of the effect of local antibacterial agents. *Plast Reconstr Surg* 1986; 77: 919–30.
 92. Shah Z, Lehman JA, Tan J. Does infection play a role in breast capsular contracture? *Plast Reconstr Surg* 1981; 68: 34–7.
 93. Collis N, Mirza S, Stanley PRW, Sharpe DT. Reduction of potential contamination of breast implants by the use of ‘nipple shields’. *Br J Plast Surg* 1999; 52: 445–7.
 94. Caffee, HH. The influence of silicone gel bleed on capsular contracture *Ann Plast Surg* 1986; 17: 284–7.

95. Asplund, O. Capsular contracture in silicone gel and saline-filled breast implants after reconstruction. *Plast Reconstr Surg* 1984; 73: 270–5.
96. Asplund O, Gylbert L, Jurell G, Ward C. Textured or smooth implants for submuscular breast augmentation: a controlled study. *Plast Reconstr Surg* 1996; 97: 1200–6.
97. Grossman AR. The current status of augmentation mammoplasty. *Plast Reconstr Surg* 1973; 52: 1.
98. Ashley FL. A new type of breast prosthesis. *Plast Reconstr Surg* 1970; 45: 421–4.
99. Herman S. The MEME implant. *Plast Reconstr Surg* 1986; 73: 411–14.
100. Smahel J. Tissue reactions to breast implants coated with polyurethane. *Plast Reconstr Surg* 1978; 61: 80–5.
101. Collis N, Coleman DJ, Foo ITH, Sharpe DT. Ten-year review of a prospective randomised controlled trial of textured versus smooth sub-glandular silicone gel breast implants. *Plast Reconstr Surg* 2000; 106: 786–91.
102. Coleman DJ, Foo ITH, Sharpe DT. Textured or smooth implants for breast augmentation? A prospective controlled trial. *Br J Plast Surg* 1991; 44: 444.
103. Brohim RM, Foresman PA, Hidebrandt PK, Rodeheaver GT. Early tissue reaction to textured breast implant surfaces. *Ann Plast Surg* 1992; 28: 354–62.
104. Wyatt LE, Sinow JD, Wollman JS et al. The influence of time on human breast capsule histology: smooth and textured silicone-surfaced implants. *Plast Reconstr Surg* 1998; 102: 1922–31.
105. Smahel JS, Hurwitz PJ, Hurwitz NH. Soft tissue response to textured silicone implants in an animal experiment. *Plast Reconstr Surg* 1993; 92: 474–9.
106. Bucky LP, Ehrlich HP, Sohoni S, May JW. The quality of saline-filled smooth silicone, textured silicone, and polyurethane implants in rabbits: a long-term study. *Plast Reconstr Surg* 1994; 93: 1123–31.
107. del Rosario AD, Bui HX, Petrocine S et al. True synovial metaplasia of breast implant capsules: a light and electron microscopic study. *Ultrastruct Path* 1995; 19: 83–93.
108. Ko CY, Ahn CY, Ko J et al. Capsular synovial metaplasia as a common response to both textured and smooth implants. *Plast Reconstr Surg* 1996; 97: 1427–33.
109. Yeoh G, Russell P, Jenkins E. Spectrum of histological changes reactive to prosthetic breast implants: a clinicopathological study. *Pathology* 1996; 28: 232–5.
110. Kasper, CS. Histologic features of breast capsules reflect surface configuration and composition of silicone bag implants. *Am J Clin Pathol* 1994; 102: 655–9.
111. Wider TM, Yager JS, Rittenberg T et al. The inhibition of fibroblast-populated collagen lattice contraction by human amniotic fluid. A chronological explanation. *Plast Reconstr Surg* 1993; 91: 1287.
112. Raso DS, Schulte BA. Immunolocalization of keratin sulphate, chondroitin-4-sulphate, and chondroitin-6-sulphate in periprosthetic breast capsules exhibiting synovial metaplasia. *Plast Reconstr Surg* 1996; 98: 78.
113. McKinnley P, Tresley G. Long term comparison of patients with gel and saline mammary implants. *Plast Reconstr Surg* 1983; 72: 27–9.
114. Gylbert L, Asplund O, Jurell G. Capsular contracture after breast reconstruction with silicone gel and saline filled implants – a six year follow up. *Plast Reconstr Surg* 1990; 85: 373–7.
115. Rubin LR. The deflating saline implant. *Plast Reconstr Surg* 1980; 65: 665.
116. Rees T, Guy GL. The use of inflatable breast implants. *Plast Reconstr Surg* 1973; 52: 163–7.
117. Young VL, Lund H, Ueda K et al. Bleed of and biologic response to triglyceride filler used in radiolucent breast implants. *Plast Reconstr Surg* 1996; 97: 1179–93.
118. Camara DL, Sheridan JM, Kammer BA. Rupture and aging of silicone gel breast implants. *Plast Reconstr Surg* 1993; 91: 828–34.
119. Greenwald DP, Randolph M, May JW. Mechanical analysis of explanted silicone breast implants. *Plast Reconstr Surg* 1996; 98: 269–75.
120. Robinson OG, Bradley EL, Smith D. Analysis of explanted silicone implants: a report of 300 patients. *Ann Plast Surg* 1995; 34: 1–6.
121. Beekman WH, Feitz R, Hage JJ, Mulder JW. Life span of silicone gel-filled mammary prostheses. *Plast Reconstr Surg* 1997; 100: 1723–6.
122. Cohen BE, Biggs TM, Cronin ED, Collins DR. Assessment and longevity of the silicone gel breast implant. *Plast Reconstr Surg* 1997; 99: 1597–601.
123. Rohrich RJ, Adams WP, Beran SJ et al. An analysis of silicone gel-filled breast implants: Diagnosis and failure rates. *Plast Reconstr Surg* 1998; 102: 2304–8.
124. Peters W, Smith D, Lugowski S. Failure properties of 352 explanted silicone-gel breast implants. *Can J Plast Surg* 1996; 4: 1.
125. Collis N, Sharpe DT. Silicone gel filled breast implant integrity: a retrospective review of 478 explanted implants. *Plast Reconstr Surg* 2000; 105: 1979–85.
126. Reynolds HE. Evaluation of the augmented breast. *Radiol Clin North Am* 1995; 33: 1131–45.
127. Sergotti TJ, Limoli JP, Baldwin CM Jr, Laub DR. Human adjuvant disease, possible autoimmune disease after silicone implantation: a review of the literature, case studies and speculation for the future. *Plast Reconstr Surg* 1986; 78: 104–14.
128. Thomsen JL, Christensen L, Neilson M et al. Histologic changes and silicone concentrations in human tissue surrounding silicone breast prostheses. *Plast Reconstr Surg* 1990; 85: 38–41.
129. Evans GRD, Netscher DT, Schusterman MA et al. Silicon tissue assays: a comparison of nonaugmented cadaveric and augmented patient levels. *Plast Reconstr Surg* 1996; 97: 1207–14.
130. Schur PL, Weinzwieg J, Harris JB et al. Silicon analysis of breast and periprosthetic capsular tissue from patients with saline or silicone gel breast implants. *Plast Reconstr Surg* 1996; 98: 798–803
131. Kessler DA. The basis of the FDA's decision on breast implants. *N Engl J Med* 1992; 326: 1713–15.
132. Calnan KC. Silicone gel breast implants statement of the Chief Medical Officer. London: Department of Health, January 1992.

133. Medical Devices Agency. Silicone Implants and Connective Tissue Disease. London: Department of Health, December 1994.
134. Ferguson JH. Silicone breast implants and neurologic disorders. *Neurology* 1997; 48: 1504–7.
135. Hochberg MC, Perlmutter DL, Medsger TA et al. Lack of association between augmentation mammoplasty and systemic sclerosis (scleroderma). *Arthritis Rheum* 1996; 39: 1125–31.
136. Friis S, Mellekjær L, McLaughlin JK et al. Connective tissue disease and other rheumatic conditions following breast implants in Denmark. *Ann Plast Surg* 1997; 39: 1–8.
137. Sanchez-Guerrero J. Silicone breast implants and the risk of connective tissue disease and symptoms. *N Engl J Med* 1995; 332: 1667–70.
138. Sherine G, O'Fallon WM, Kurland LT et al. Risk of connective tissue diseases and other disorders after breast implantation. *N Engl J Med* 1994; 330: 1697–702.
139. Miller AS, Willard V, Kline K et al. Absence of longitudinal changes in rheumatological parameters after silicone breast implantation: a prospective 13 year study. *Plast Reconstr Surg* 1998; 102: 2299–303.
140. Nyren O, Yin L, Josefsson S et al. Risk of connective tissue disease and related disorders among women with breast implants: a nation-wide retrospective cohort study in Sweden. *Br Med J* 1998; 316: 417–22.
141. Silicone gel breast implants. The Report of the Independent Review Group. July 1998. Cambridge: Jill Rogers Associates. © Crown Copyright, ISBN 1 85839 909 2.
142. Science and technology. *The Economist*. 26 July 1997, 95–6.

3 Skin-sparing and skin-reducing mastectomy

Guidubaldo Querci della Rovere, Marco Greco, Maurizio Nava, Estratos P Kouskos, John R Benson

Introduction

Surgical techniques for breast cancer have evolved significantly in recent years. In the past it was customary practice to remove not only the glandular tissue of the breast but also the overlying skin, associated pectoral muscles and regional lymph nodes. The majority of patients can safely be treated with a breast conserving procedure which helps maintain body image and aesthetic appearance.

This shift in the surgical approach to breast cancer has been prompted and underpinned by several factors:

- Improved understanding of the natural history of breast cancer.
- The advent of effective adjuvant therapies.
- Diagnosis of disease at an earlier stage.

Although conservation surgery for breast cancer is widely practised and accepted, mastectomy is necessary for some patients. When mastectomy is indicated, immediate breast reconstruction should be offered to most patients with the aim of reproducing the shape and form of the contralateral breast, but with realistic expectations on the part of the patient in terms of cosmetic outcome. For those patients with larger or locally advanced tumours, radical mastectomy may be indicated with removal of all or part of the pectoralis major muscle, together with ample portions of skin. Postoperative radiotherapy is often recommended for these patients and this may restrict reconstructive options. It is essential that the management of these patients is entrusted to a multidisciplinary team.

It is implicit that for some breast cancers conservative surgery provides inadequate local control, whilst a traditional modified radical mastectomy might repre-

sent over-treatment for others. This dichotomy into ‘conservation surgery versus mastectomy’ has dominated surgical treatment of breast cancer for the past 20 years but may be outdated and inappropriate.

Skin-sparing mastectomy is a procedure which is intermediate in radicality between conventional breast conservation therapy and modified radical mastectomy. It provides good local control of disease but is associated with minimal scarring when combined with immediate breast reconstruction. The latter can vary from insertion of a sub-pectoral implant to more complex interventions involving use of pedicled or free myocutaneous flaps. Skin-sparing mastectomy was first described by Toth and Lappert in 1991¹ and is being increasingly adopted for patients with early breast cancer.

General principles of mastectomy

The following factors have a major influence on the cosmetic outcome following mastectomy and the first two are dependent upon the size, extent and location of the tumour:

- positioning of the skin incision
- amount of skin removed (extent of skin excision)
- preservation of the inframammary fold.

Skin incision

Skin incisions employed for standard mastectomy aim to incorporate the nipple–areola complex together with a variable amount of adjacent skin (Figure 3.1). These different types of traditional mastectomy incisions (oblique, vertical or transverse) are comparable from an oncological point of

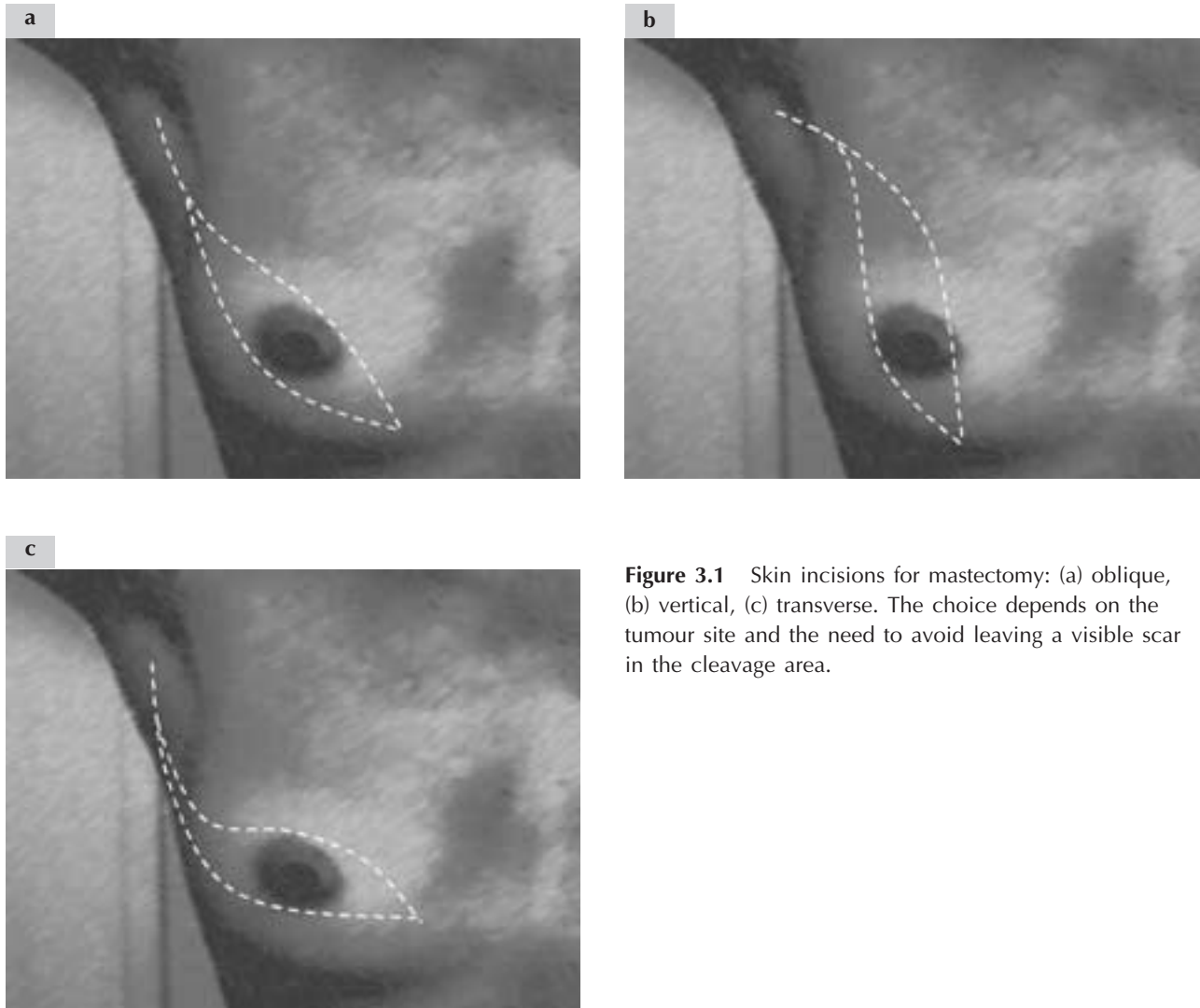


Figure 3.1 Skin incisions for mastectomy: (a) oblique, (b) vertical, (c) transverse. The choice depends on the tumour site and the need to avoid leaving a visible scar in the cleavage area.

view and ensure adequate tumour clearance whilst permitting primary skin closure. The incisions have long ‘tails’ and serve to:

1. remove skin overlying the tumour (which may be clinically or microscopically involved)
2. extend the incision into the axilla to facilitate axillary dissection
3. reduce the chance of formation of unsightly ‘dog ears’ which may occur if the upper and lower wounds lie at an angle which is too obtuse.

The cardinal principle is that as much skin as possible should be preserved, consistent with adequate extirpation of the tumour and oncological radicalism. The nipple–areola complex together with a variable amount of circumferential skin is removed thereby minimizing the possibility of potential spread of cancer from contiguous ducts. Amongst selected patients for whom nipple–areola conserva-

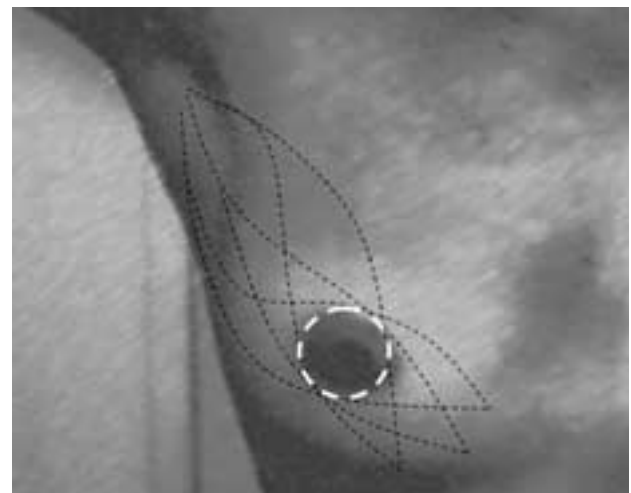


Figure 3.2 Circular periareolar incision typical of skin-sparing mastectomy (white dashes). Note that the excised skin is included within the traditional incisions (black dashes).

Table 3.1 Involvement of nipple–areola complex.

Authors (year)	No. of mastectomy specimens examined	Nipple–areola involvement (%)
Simmons et al (2002) ²	217	10.6
Laronga et al (1999) ³	286	5.6
Vyas et al (1998) ⁴	140	16
Verma et al (1997) ⁵	26	0
Menon and van Geel (1989) ⁶	33	58
Santini et al (1989) ⁷	1291	12
Luttges et al (1987) ⁸	166	38
Morimoto et al (1985) ⁹	141	31
Quin and Barlow (1981) ¹⁰	45	25
Wertheim and Ozzello (1980) ¹¹	1000	23.4
Lagios et al (1979) ¹²	149	30.2
Andersen and Pallesen (1979) ¹³	40	50
Parry et al (1977) ¹⁴	200	8
Smith et al (1976) ¹⁵	541	12.2

tion may be indicated, this area is involved at the microscopic level in up to 58% of cases (Table 3.1).

Extent of skin excision

Even when skin involvement is not clinically evident, skin overlying the tumour may be removed when the latter is relatively superficial. Under these circumstances this portion of skin is removed en bloc with the breast specimen and the incision around the nipple–areola complex is modified accordingly to incorporate this additional skin. In those cases where the risk of occult skin involvement is judged to be minimal (e.g. a small tumour lying deep within the breast) the excised skin may be confined to the nipple–areola complex and mastectomy undertaken with a circumareolar or peri-areolar 360° incision. Methods which attempt to ‘core out’ the nipple along with preservation of the areolar skin are likely to lead to incomplete duct excision and are not recommended. Furthermore, the position of a new nipple in the reconstructed breast may differ from that of the original breast.

Preservation of the inframammary fold

The inframammary fold is constituted from a complex system of collagen fibres which connect the superficial fascia to the dermis in the fold region. Some of these fibres project anteriorly from the fold region and emerge to envelop the lower part of the breast tissue. This fine system of fibres determines the shape of the lower pole of the breast and together

with the superficial fascia attaches the skin and subcutaneous tissue of the inferior breast to the thoracic wall. It is difficult to reproduce a natural ptosis and an aesthetically satisfactory breast reconstruction when this structure is breached or excised.^{16–18} Therefore the inframammary fold should be carefully preserved during mastectomy unless oncological considerations mandate removal, e.g. extensive tumour in the lower quadrants of the breast or tumour at the level of the inframammary fold.

Skin-sparing mastectomy

(by Marco Greco)

Definition: Removal of the entire glandular tissue, the nipple–areola complex, any previous biopsy scar and a limited amount of skin overlying the tumour (if superficial).

Skin incisions are generally conservative and in the most favourable cases a small circular incision around the areola will suffice. Nonetheless the skin incision must respect and be in accordance with the principles and criteria outlined above and its precise extent therefore will vary from patient to patient. In appropriately selected cases it is possible to perform a skin-sparing mastectomy in conjunction with immediate breast reconstruction using a subpectoral expander/prosthesis with minimal scarring. This technique involves a peri-areolar or circumareolar skin incision, preservation of the inframammary fold and limited dissection of the skin flaps beyond the breast tissue. Either formal axillary dissection or

sentinel node biopsy can be performed at the same time through either the areolar incision, a lateral extension thereof or a separate axillary incision.

Due to the limited approach to the operating field, both skin flap preparation and haemostasis are more complex than for standard breast surgery. The skin flaps tend to be longer and, consequently, the risk of necrosis higher. Access to the axillary region can be awkward and particular care must be taken to avoid damage to important vascular (axillary vein and thoracodorsal vessels) and neural (long thoracic and thoracodorsal nerves) structures, which should be identified early on and protected throughout the procedure.

Following reconstruction with a subpectoral tissue expander/prosthesis, the peri- or circumareolar incision may be closed either with a purse-string suture or in a linear fashion. Puckering associated with the former will disappear with time to leave a flat scar within the central part of the reconstructed breast. Sometimes this can be confined to the zone of the reconstructed nipple and areola and skilled tattooing can render this almost invisible.

Where autologous tissue has been imported as part of a myocutaneous flap, a disc of skin can be used from the donor site to replace the defect resulting from excision of the nipple–areola complex. Under these circumstances the skin is closed in a circumferential fashion to yield a scar of dimensions similar to the contralateral areola.

Indications

The indications for this relatively new technique of skin-sparing mastectomy continue to be defined. The technique can be adapted to individual situations by use of non-standard incisions which have been jointly planned by oncological and plastic surgeons preoperatively. As this technique is increasingly employed and evaluated, further indications or indeed limitations will become apparent.

Whenever extensive skin removal is not required on oncological grounds, skin-sparing mastectomy may be considered. The degree of skin saving is variable, but complete skin saving is compatible with oncological clearance and appropriate for smaller tumours lying deep within the parenchyma which are some distance from and not tethered to, or infiltrating, the skin. Insertion of a subpectoral implant should be avoided when radiotherapy to the chest wall is anticipated. Radiotherapy increases the chance of capsular contracture and distortion and will significantly compromise aesthetic outcome as well as increasing potential morbidity from the reconstructive procedure.

Skin-sparing mastectomy with immediate breast reconstruction may be considered in the following circumstances:

- Invasive carcinoma which is intraparenchymal but deemed unsuitable for breast conservation treatment due to size, location or an extensive in situ component.
- Multicentric carcinoma with no evidence of muscle or skin involvement.
- Centrally located carcinoma (as an alternative to a central segmental mastectomy ± dermoglandular pedicled flap).
- Paget's disease of the nipple associated with either invasive or in situ carcinoma in a peripheral location.
- Extensive ductal carcinoma in situ.
- Prophylactic surgery for those women with *BRCA-1* or *BRCA-2* gene mutations, lobular carcinoma in situ or high risk due to a family history of breast cancer.

Surgical technique

A circular skin incision is made which is typically centred on the nipple–areola complex. Where a surgical scar or needle biopsy tract lies in proximity to the nipple, this should be incorporated into the incision which therefore becomes eccentric and often elliptical in shape. This manoeuvre can improve access and when the incision is extended laterally will aid axillary dissection.

The incision is deepened through the subcutaneous tissues and the skin edges retracted by the assistant. A degree of tension on the skin flaps facilitates identification of the plane of dissection between the subcutaneous tissue and the breast tissue proper. This should be a relatively avascular plane and dissection is best carried out using scissors or cutting diathermy. As the edges of the breast are approached, retractors can be inserted to aid further dissection at the periphery of the gland. The superior, medial, inferior and lateral flaps are meticulously prepared and care taken to preserve the fold of superficial fascia forming the inframammary crease. This will ensure that the submuscular prosthesis does not migrate inferiorly and facilitates creation of a ptotic breast.

The medial flap is usually prepared last and the gland can then be detached from the fascia in a medial to lateral direction until it remains attached only by the axillary tail. It is optional whether the breast is removed at this stage from the surgical field or axillary surgery is performed in continuity. Formal axillary dissection or sentinel node biopsy may be undertaken via the primary incision or a

separate axillary incision (transverse or radial). In the former case, axillary dissection tends to be performed en bloc.

The subsequent steps in the operation depend upon the type of reconstruction being undertaken. With implant-based reconstruction the next stage involves preparation of the submuscular pouch (i.e. subpectoral). Access is either via the lateral border of the pectoralis major muscle, or more centrally through an incision made parallel to the fibres in the body of the muscle. Anterior insertions of serratus anterior are divided and the dissection should not proceed too far posterolaterally so as to avoid lateral displacement of the implant. Detachment of the inferior portions of the pectoralis major and serratus anterior permits the implant to lie at the correct level and helps reproduce ptosis. Following insertion of the prosthesis in the correct orientation, the pouch is closed with absorbable sutures. Drains are inserted in both the axilla and the subpectoral pouch and the skin incision closed with either a purse-string or subcuticular continuous suture (see Chapter 4).

When reconstruction involves a latissimus dorsi flap in conjunction with an implant, a pouch is fashioned from the latissimus dorsi muscle and the implant lies sandwiched between the latissimus dorsi and pectoralis major muscles. A disc of donor skin is tailored to match the defect corresponding to the mastectomy incision (see Chapter 6).

Outcomes

The technique of skin-sparing mastectomy facilitates breast reconstruction and yields aesthetic outcomes which must be compared with conservative surgery. However, oncological evaluation must be assessed against standard mastectomy techniques.

No clinical trials have yet been undertaken to compare the efficacy of skin-sparing mastectomy with more conventional surgical approaches. Nevertheless the technique has gained rapid popularity and is widely employed for breast reconstruction procedures. Nonetheless there has been

Table 3.2 Locoregional recurrence rates after skin-sparing mastectomy and non-skin-sparing mastectomy in retrospective series

Authors (year)	No. of mastectomies	T stage	Follow-up (months)	LRR (%)
Medina-Franco et al (2002) ¹⁹	173 SSM	T1, T2	73	4.5
Rivadeneira et al (2000) ²⁰	71 SSM	Tis, T1, T2	49	5.6
	127 NSSM			3.9
Kroll et al (1999) ²¹	114 SSM	T1, T2	72	7.0
	40 NSSM			7.5
Simmons et al (1999) ²²	77 SSM	T1, T2, T3	60	3.9
	154 NSSM			3.25
Newman et al (1998) ²³	372 SSM	T1, T2	50	6.2
Slavin et al (1998) ²⁴	32 SSM	Tis, T1, T2	45	2.0

LRR, locoregional rates; SSM, skin-sparing mastectomy; NSSM, non-skin-sparing mastectomy.

Table 3.3 Distant recurrence rates after skin-sparing mastectomy and non-skin-sparing mastectomy in retrospective series

Authors (year)	No. of mastectomies	T stage	Follow-up (months)	DRR (%)
Simmons et al (1999) ²²	77 SSM	T1, T2, T3	15.6	3.9
	154 NSSM			3.9
Kroll et al (1999) ²¹	104 SSM	T1, T2	60	12.5
	27 NSSM			25.9

DRR, distant recurrence rates; SSM, skin-sparing mastectomy; NSSM, non-skin-sparing mastectomy.

some concern that the technique has not been fully evaluated against standard mastectomy in randomized trials. There are theoretical arguments that restricted access and limited skin excision may increase the chance of residual breast tissue, particularly for more marginal parts of the gland. This may reduce local disease control, and in turn could lead to impaired disease-free survival should local recurrence be a determinant of distant disease.

Several retrospective studies show that skin-sparing mastectomy is similar to standard mastectomy in terms of both locoregional control and distant recurrence rates (Tables 3.2 and 3.3). There are limitations of retrospective comparisons which are subject to various sources of bias. Those studies which have reported a poorer prognosis for patients undergoing a standard mastectomy may reflect a selection bias with more favourable cases being offered skin-sparing techniques (see Table 3.2). Oncological considerations must take precedence over cosmetic issues and not be jeopardized by attempts to maximize aesthetic outcomes.

Local recurrence rates following skin-sparing mastectomy vary from 2 to 7%, with rates being highest in the first 3 years after surgery. Failure of local control can be attributed to several factors:

- local seeding of cancer cells during surgical manipulation
- retrograde passage of cancer cells from lymphatic vessels, supraclavicular lymph nodes or the internal mammary chain
- haematogenous dissemination from the primary tumour
- inadequate excision of extensive disease (namely in situ component).

Factors associated with increased risk of local recurrence after skin-sparing mastectomy include the following:

- stage II or III disease (American Joint Committee on Cancer (AJCC) classification)
- large tumour size
- lymph node involvement and lymphovascular invasion
- high grade tumours.

Where local recurrence occurs in the absence of distant disease, treatment should be multimodal involving surgery, radiotherapy or chemotherapy. Where reconstruction is implant-based only, local recurrence may mandate conversion to reconstruction with autologous tissue. Local control is achieved in approximately three quarters of patients with local recurrence, most of whom have a good prognosis.

In the absence of any trial data establishing the equivalence of this newer technique with standard mastectomy, skin-sparing mastectomy should not be considered an alternative to conventional modified radical mastectomy. The procedure should only be performed in specialist centres and ideally in collaboration with a plastic surgeon or be undertaken by a single surgeon with specific oncoplastic training. Moreover it is essential that longer-term evaluation is undertaken with accurate documentation of rates of locoregional and distant relapse. The European Society of Mastology (EUSOMA) has recommended that a data manager be a member of the extended breast cancer management team.²⁵ Registration of patient data not only facilitates research, but also permits monitoring and assessment of quality of care by comparison with standard quality control criteria such as those published by EUSOMA. These stipulate that for a mastectomy operation (i) the local recurrence for ductal carcinoma in situ should not exceed 5% after 10 years follow-up and (ii) the local recurrence rate for invasive carcinoma should not exceed 10% after 10 years follow-up.²⁵

Longitudinal studies on quality control are particularly important for skin-sparing mastectomy which has not been formally validated in controlled clinical trials. Patient selection rather than surgical technique is likely to have a major influence on longer-term outcome.

Skin-reducing mastectomy

(by *Maurizio Nava and
Guidubaldo Querci della Rovere*)

When breast reconstruction follows mastectomy in medium or large sized breasts, reduction of the skin envelope is usually required. The degree of skin reduction is variable, and may be done in conjunction with a contralateral reduction mammoplasty or mastopexy. The conventional method for achieving reduction of the skin envelope is removal of an ellipse of skin around the nipple-areola complex. An alternative technique²⁶ is presented which conforms with the oncological principles of skin-sparing mastectomy and reduces the outer envelope of the breast in a manner which optimizes cosmetic results.

Technique

The technique described combines the pattern of skin incision for a conventional inferior pedicle based breast reduction with preservation of an inferior dermal flap. The dermal flap is used to create and enlarge the sub-pectoral pouch into which the expander/prosthesis will be inserted.

Preoperative skin markings

The position of the new nipple is marked along the mid-clavicular line at a distance of between 19 cm

and 23 cm from the sternal notch. The exact position of this will depend on the degree of breast reduction. From this point, two vertical (oblique) lines are drawn, each 7 cm long, and lying at an angle of between 30° and 90° to one another (precise angle depending on the degree of reduction).

The distal ends of these two vertical lines are extended laterally and medially so as to intercept the inframammary line. The midclavicular point is marked below the inframammary fold (Figure 3.3a,b).

Surgical procedure

The skin is incised along these lines, joining the position of the new nipple to the inframammary line. These are full thickness skin incisions but the incision along the inframammary line itself should be partial thickness (epidermis only) with preservation of the dermal plane. A dermal flap is then created between the inframammary line and the medial and lateral extensions of the reduction pattern. A horizontal full thickness skin incision is made between the distal points of the two vertical

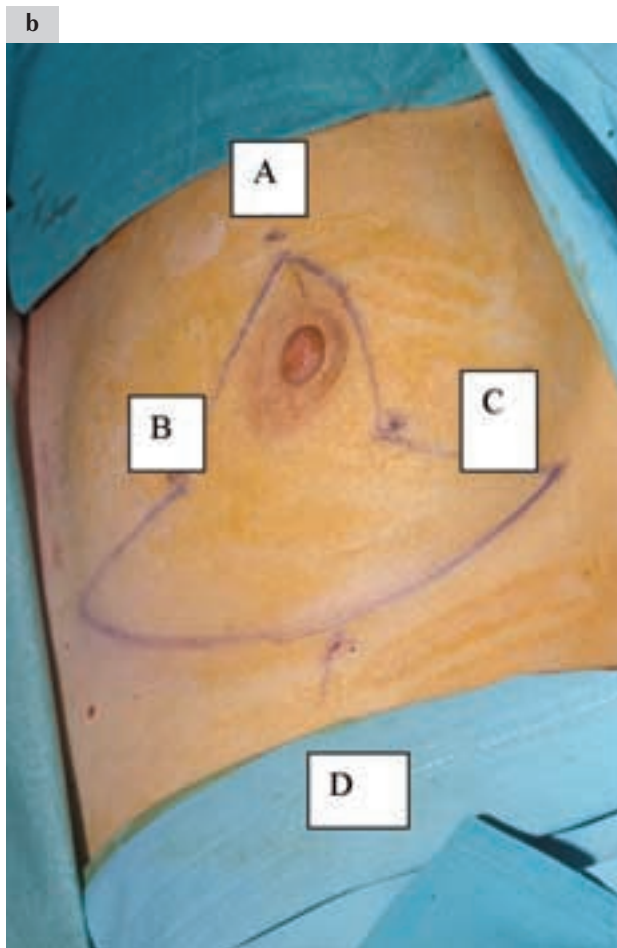
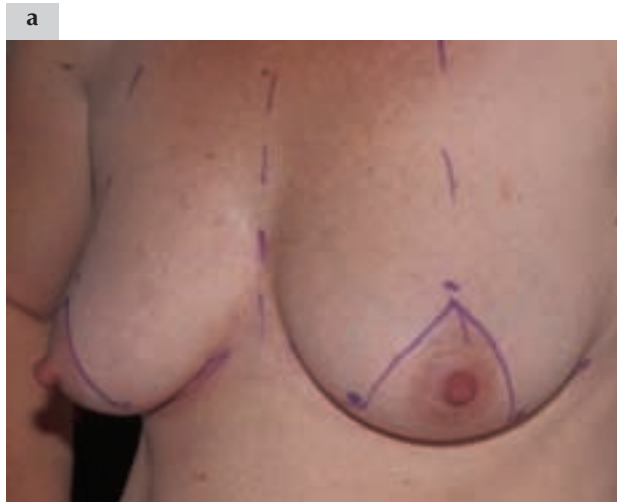

Figure 3.3 (a) Preoperative marking in a before bilateral prophylactic mastectomy. (b) Preoperative markings, left breast: (A) new nipple position; (B) medial and (C) lateral, lower ends of 7 cm long vertical lines of reduction pattern; (D) mid-clavicular point.

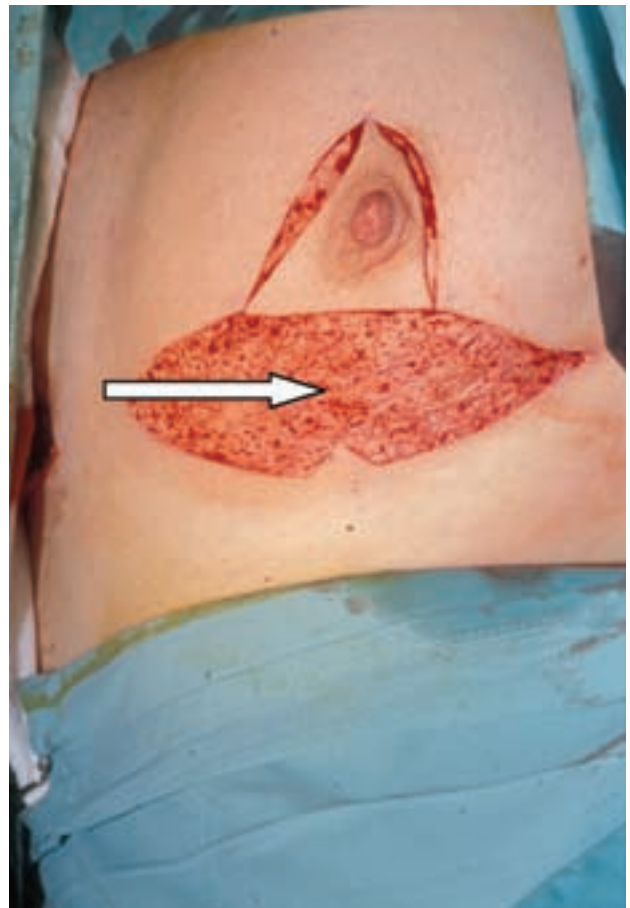


Figure 3.4 Skin incisions and dermal flap de-epithelialized (arrow).

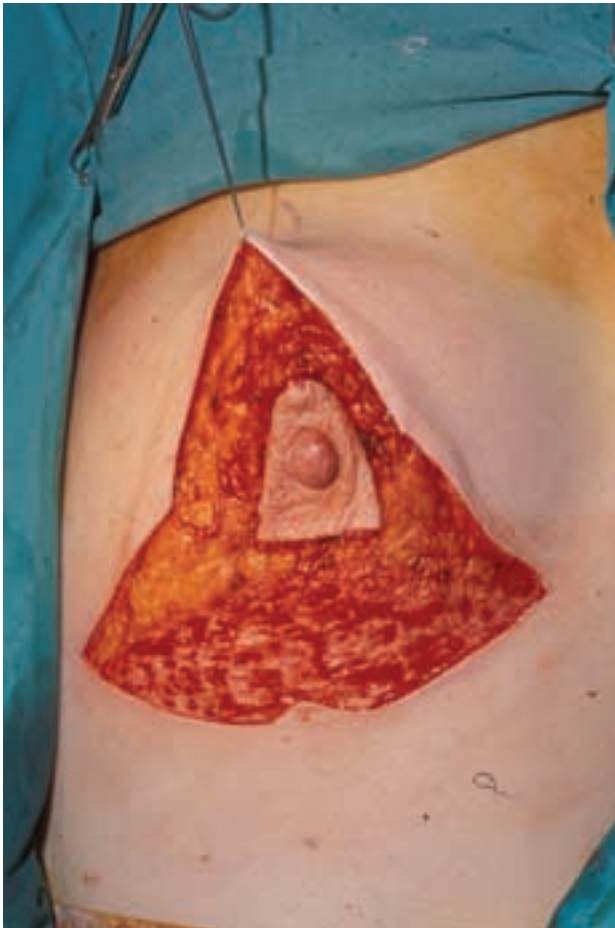

Figure 3.5 Mastectomy flaps prepared.

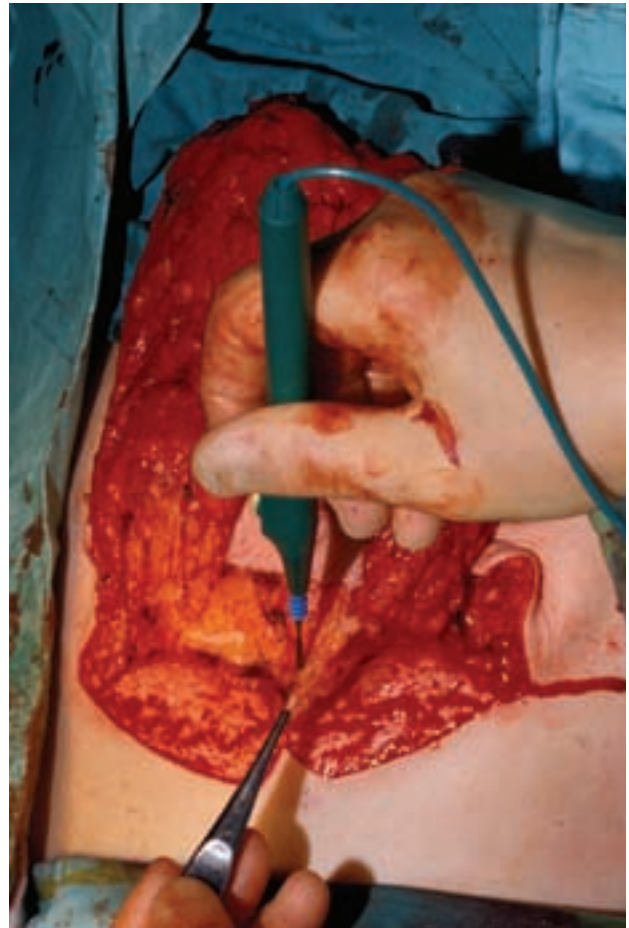


Figure 3.6 Dermal flap dissected from lower part of the breast.

lines drawn from the position of the new nipple (Figure 3.5). Mastectomy is subsequently undertaken with preservation not only of the skin flaps (as in a conventional skin saving procedure) but also the dermal flap in the inferior part of the breast (Figure 3.6).

Following completion of mastectomy an incision is made along the lateral border of the pectoralis major muscle and a submuscular pouch created deep to both pectoral and serratus muscles. The inferior and medial insertions of pectoralis major are divided and sutured to the superior border of the dermal flap, thus creating a pouch of adequate volume to accommodate the expander/prosthesis (Figure 3.7). The latter is inserted and orientated within the pouch and a suction drain placed within the submuscular/dermal pouch (Figures 3.8 and 3.9). The skin is closed by approximating the distal end of the two vertical lines to the infra-mammary line at the mid-clavicular point (Figure 3.10). Either one or two suction drains are placed in the subcutaneous layer.

In some circumstances it may be oncologically safe to conserve the nipple which can be advanced superiorly to the new nipple position by preserving the dermal bridge. When the nipple is sacrificed a delayed nipple reconstruction can be performed, though immediate nipple reconstruction is possible. Auto-transplantation of the nipple could be considered but it remains unclear whether the dermis of the mastectomy flaps can provide adequate and timely vascularization of the grafted nipple. Prosthetic silicone nipples are available and can be custom made to match the contralateral nipple.

Discussion

One of the technical challenges of immediate breast reconstruction with a sub-pectoral tissue expander/prosthesis is the relative lack of space at the inferior and medial aspects of the pouch due to the attachment of the pectoralis major muscle. This has necessitated correctional surgery in the past to improve

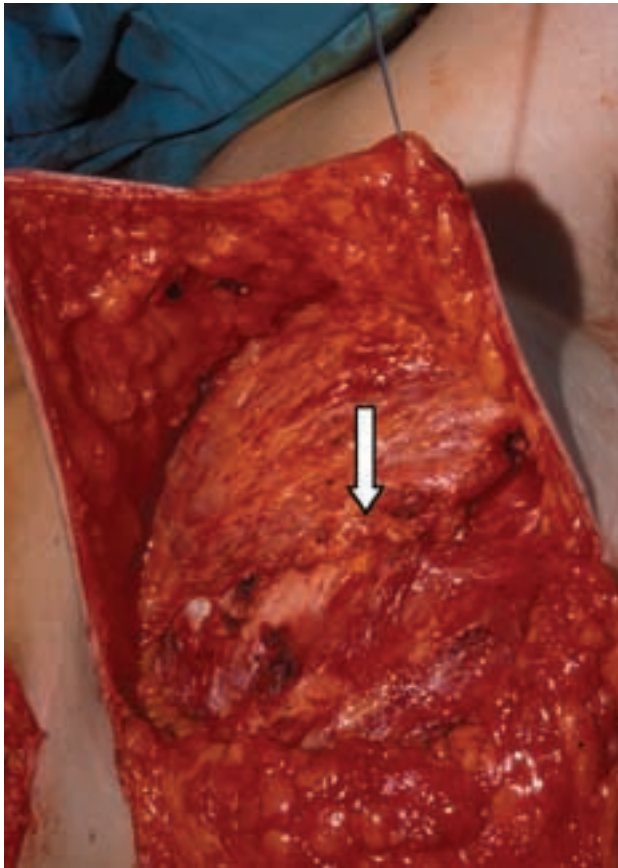


Figure 3.7 Lower and medial rib insertions of pectoralis major divided. Arrow points to inferior divided margin of pectoralis major.

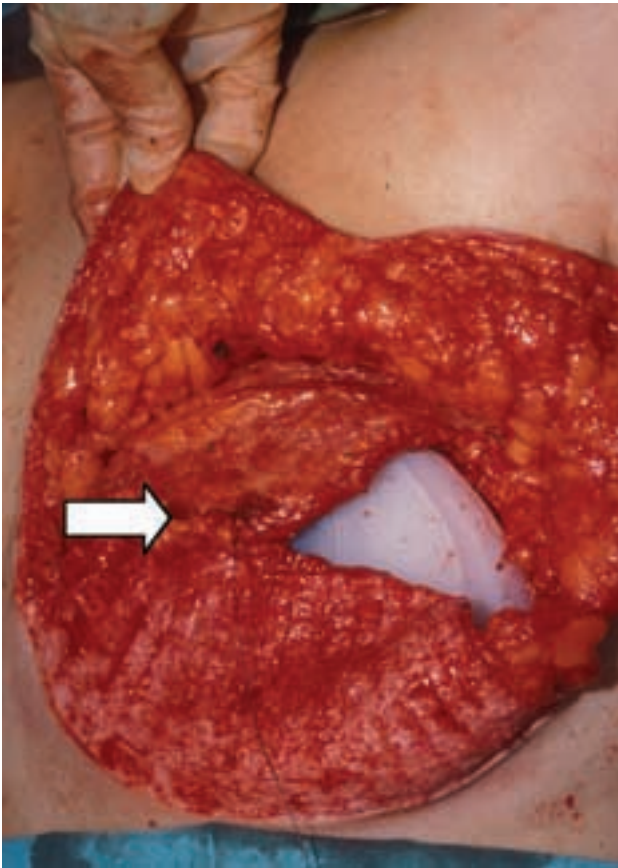


Figure 3.8 The inferior margin of the pectoralis major and the dermal flap are partially sutured (arrow) and a tissue expander is positioned under the dermo-pectoral pouch.

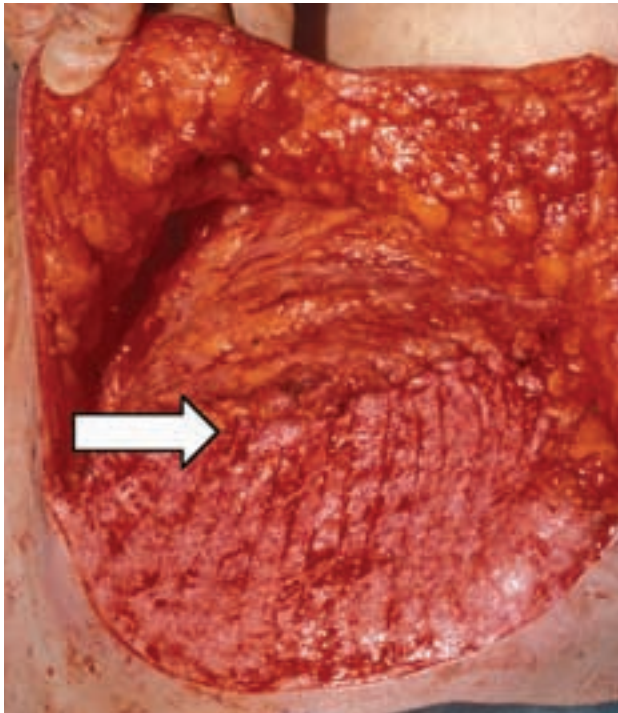


Figure 3.9 Completed suture of dermo-pectoral pouch (arrow).

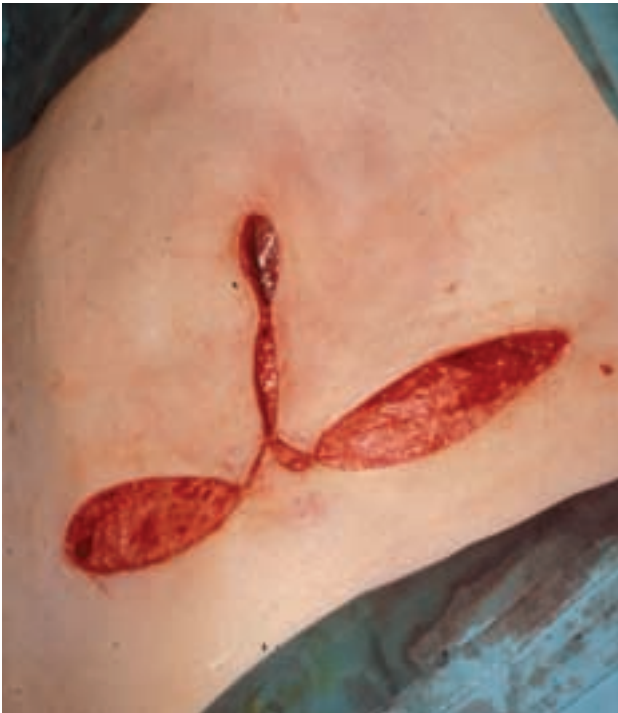

Figure 3.10 Skin closure.

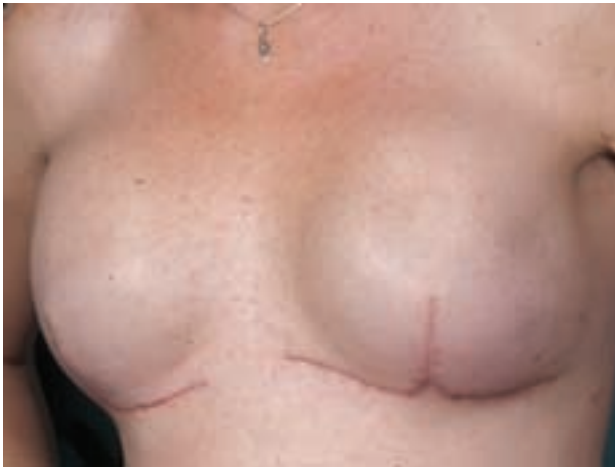

Figure 3.11 Early post-operative appearance after bilateral prophylactic mastectomies.

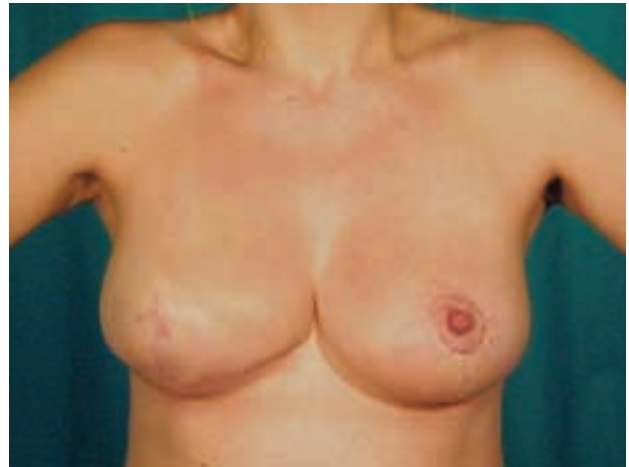

Figure 3.12 Early post-operative appearance after right skin reducing mastectomy with immediate reconstruction (500 cc expander) and simultaneous left breast reduction.

fullness in the lower inner quadrant of the reconstructed breast.

Some surgeons overcome this difficulty by dividing the lower-most insertions of the pectoralis major muscle and leaving the inferior portion of the prosthesis without muscle cover. However, this can increase the risk of implant failure in the event of skin necrosis. Loss of prosthesis due to infection is more likely when the subcutaneous portion of the implant lies directly beneath or in the vicinity of the skin incision.

The technique described herein overcomes this problem of implant cover by creating a pouch with adequate volume in the lower/medial quadrant which maintains coverage of the implant with a dermal flap (Figures 3.11 and 3.12). Furthermore, surgical scars are relatively inconspicuous with a characteristic inverted 'T' in which the lateral bars are hidden underneath the breast.

The indications for this technique are similar to those for skin-sparing mastectomy in which much of the dermal layer of the breast can be preserved. The procedure is particularly suited to cases of bilateral prophylactic mastectomy for women at increased risk of breast cancer.

References

- Toth BA, Lappert P. Modified skin incisions for mastectomy: the need for plastic surgical input in preoperative planning. *Plast Reconstr Surg* 1991; 87: 1048–53.
- Simmons RM, Brennan M, Christos P, King V, Osborne M. Analysis of nipple/areolar involvement with mastectomy: can the areola be preserved? *Ann Surg Oncol* 2002; 9: 165–8.
- Laronga C, Kemp B, Johnston D, Robb GL, Singletary SE. The incidence of occult nipple-areola complex involvement in breast cancer patients receiving a skin-sparing mastectomy. *Ann Surg Oncol* 1999; 6: 609–13.
- Vyas JJ, Chinoy RF, Vaidya JS. Prediction of nipple and areola involvement in breast cancer. *Eur J Surg Oncol* 1998; 24: 15–16.
- Verma GR, Kumar A, Joshi K. Nipple involvement in peripheral breast carcinoma: a prospective study. *Ind J Cancer* 1997; 34: 1–5.
- Menon RS, van Geel AN. Cancer of the breast with nipple involvement. *Br J Cancer* 1989; 59: 81–4.
- Santini D, Taffurelli M, Gelli MC et al. Neoplastic involvement of nipple-areolar complex in invasive breast cancer. *Am J Surg* 1989; 158: 399–403.
- Luttges J, Kalbfleisch H, Prinz P. Nipple involvement and multicentricity in breast cancer. A study on whole organ sections. *J Cancer Res Clin Oncol* 1987; 113: 481–7.
- Morimoto T, Komaki K, Inui K et al. Involvement of nipple and areola in early breast cancer. *Cancer* 1985; 55: 2459–63.
- Quinn RH, Barlow JF. Involvement of the nipple and areola by carcinoma of the breast. *Arch Surg* 1981; 116: 1139–40.
- Wertheim U, Ozzello L. Neoplastic involvement of nipple and skin flap in carcinoma of the breast. *Am J Surg Pathol* 1980; 4: 543–9.
- Lagios MD, Gates EA, Westdahl PR et al. A guide to the frequency of nipple involvement in breast cancer. A study of 149 consecutive mastectomies using a serial subgross and correlated radiographic technique. *Am J Surg* 1979; 138: 135–42.

13. Andersen JA, Pallesen RM. Spread to the nipple and areola in carcinoma of the breast. *Ann Surg* 1979; 189: 367–72.
14. Parry RG, Cochran TC Jr, Wolford FG. When is there nipple involvement in carcinoma of the breast? *Plast Reconstr Surg* 1977; 59: 535–7.
15. Smith J, Payne WS, Carney JA. Involvement of the nipple and areola in carcinoma of the breast. *Surg Gynecol Obstet* 1976; 143: 546–8.
16. Fan J, Raposio E, Wang J, Nordstrom RE. Development of the inframammary fold and ptosis in breast reconstruction with textured tissue expanders. *Aesthetic Plast Surg* 2002; 26: 219–22.
17. Muntan CD, Sundine MJ, Rink RD, Acland RD. Inframammary fold: a histologic reappraisal. *Plast Reconstr Surg* 2000; 105: 549–56.
18. Nava M, Quattrone P, Riggio E. Focus on the breast fascial system: a new approach for inframammary fold reconstruction. *Plast Reconstr Surg* 1998; 102: 1034–45.
19. Medina-Franco H, Vasconez LO, Fix RJ et al. Factors associated with local recurrence after skin-sparing mastectomy and immediate breast reconstruction for invasive breast cancer. *Ann Surg* 2002; 235: 814–19.
20. Rivadeneira DE, Simmons RM, Fish SK et al. Skin-sparing mastectomy with immediate breast reconstruction: a critical analysis of local recurrence. *Cancer J* 2000; 6: 331–5.
21. Kroll SS, Khoo A, Singletary SE et al. Local recurrence risk after skin-sparing and conventional mastectomy: a 6-year follow-up. *Plast Reconstr Surg* 1999; 104: 421–5.
22. Simmons RM, Fish SK, Gayle L et al. Local and distant recurrence rates in skin-sparing mastectomies compared with non-skin-sparing mastectomies. *Ann Surg Oncol* 1999; 6: 676–81.
23. Newman LA, Kuerer HM, Hunt KK et al. Presentation, treatment, and outcome of local recurrence after skin-sparing mastectomy and immediate breast reconstruction. *Ann Surg Oncol* 1998; 5: 620–6.
24. Slavin SA, Schnitt SJ, Duda RB et al. Skin-sparing mastectomy and immediate reconstruction: oncologic risks and aesthetic results in patients with early-stage breast cancer. *Plast Reconstr Surg* 1998; 102: 49–62.
25. Rutgers EJ, EUSOMA Consensus Group. Quality control in the locoregional treatment of breast cancer. *Eur J Cancer* 2001; 37: 447–53.
26. Bostwick J. Total mastectomy with breast skin and volume reduction using an inverted T incision. In: *Plastic and Reconstructive Breast Surgery*. St Louis, Missouri: Quality Medical Publishers Inc, 1990; 1048–54.

4 Breast reconstruction with subpectoral prosthesis or tissue expanders

Maurizio Nava, M Bonavita, N Arioli, A Colombetti, R Grillo, E Riggio

Introduction

Breast reconstruction using implant devices is a standard technique which can be undertaken as either an immediate or delayed procedure following mastectomy. As a form of immediate reconstruction it is a simpler procedure compared with reconstructive methods involving transfer of myocutaneous flaps which constitute more complex surgery. Most patients undergoing mastectomy are eligible for immediate reconstruction, even when the primary breast tumour has unfavourable characteristics and prognosis is limited. Patients should be jointly assessed by both plastic and general surgeons prior to surgery in order to plan the site of surgical incisions and select an appropriate implant. Prostheses can be either temporary or permanent and expansile devices are now available which can remain permanently once expansion is complete. Newer tissue expanders have a thick silicone envelope and a central chamber filled with saline, and are preferable to the thin walled saline filled implants used in the past which can lead to a 'rippling' effect. Some prostheses are bi-dimensional in an attempt to reproduce the natural ptosis of the breast and avoid excessive fullness in the upper quadrants. A tissue expander device is suitable for more than 90% of cases and is a popular choice of implant.

Attention to surgical technique at the time of mastectomy is important when reconstruction with subpectoral implants is to be carried out. Removal of large amounts of skin should be avoided if possible and the pectoral fascia preserved. The position of the inframammary skin crease is a seminal

landmark when creating the subpectoral pocket. When reconstruction is undertaken as a delayed procedure, the nature of the mastectomy scar and flaps will influence surgical technique; the implant must be placed beneath healthy viable myocutaneous flaps. Problems often arise when patients have previously received radiotherapy to the chest wall, which is considered by many surgeons to be a contraindication to reconstruction with implants alone.

The aims of reconstruction are as follows:

1. replacement of breast volume as close as possible to the contralateral breast with restoration of symmetry (Figure 4.1)
2. establishment of the superior mammary slope and the inferior pole of the breast
3. reconstitution of the inframammary fold (Figure 4.2)
4. reconstruction of the nipple-areola complex.

The greatest technical challenges in reconstruction of a breast relate to reproduction of projection, ptosis and the inframammary fold. The newer bi-dimensional prostheses (Figures 4.3 and 4.4) have helped achieve better projection and ptosis and the latter is aided by a degree of overexpansion and subsequent partial deflation of an expandable prosthesis. Following tissue expansion, it is usual to replace the expander with a definitive prosthesis, though permanent expander/implants are available for patients who wish to avoid a second operation. For those with small breasts and minimal ptosis, a permanent non-expansile prosthesis can sometimes be inserted *ab initio* without the need for preliminary tissue expansion.

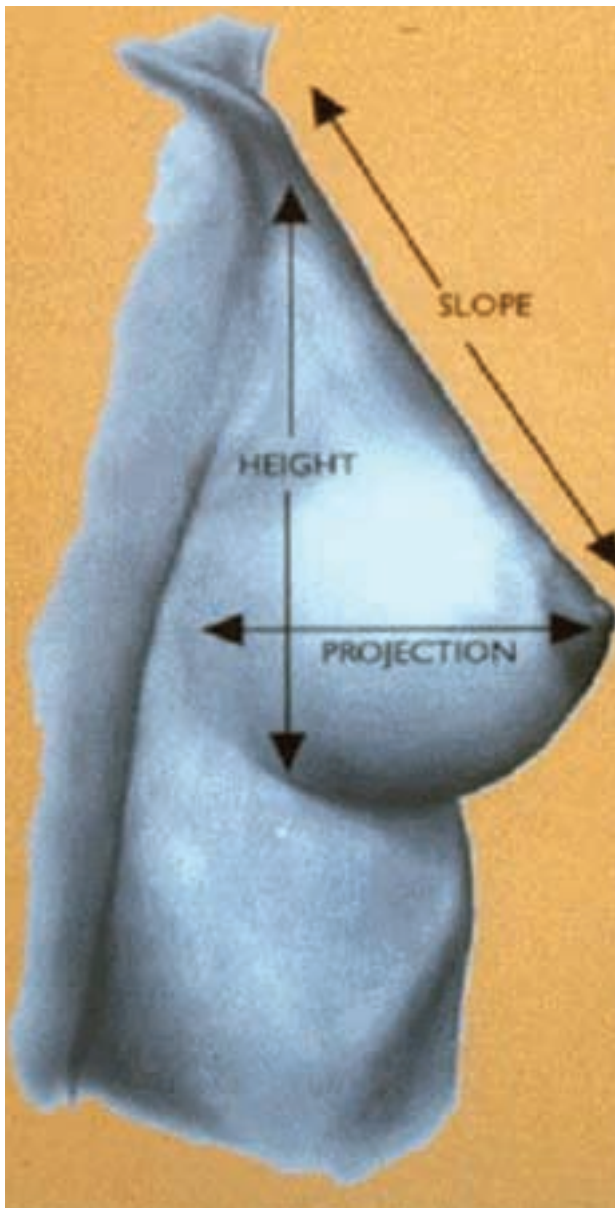


Figure 4.1 Breast reconstruction aims to restore not only volume, but also shape and contour of the breast. Establishment of the superior mammary slope and creation of adequate projection and ptosis are critical aspects of the reconstructive technique.

Opportunities for immediate breast reconstruction are increasing as patients become more aware of these techniques and cosmetic results improve. Furthermore, increasing numbers of surgeons are being trained in breast reconstruction, and subpectoral insertion of implants is a relatively safe and uncomplicated procedure compared with methods employing autologous tissue flaps. However, patients should be carefully selected in order to obtain optimal results with these techniques which have benefited in recent years from advances in implant design and technology.^{1,2}

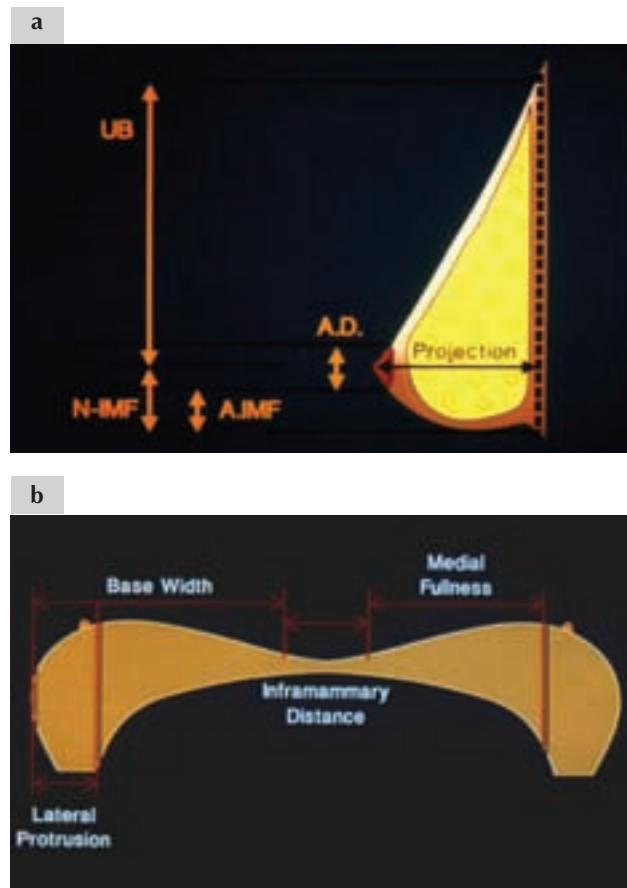


Figure 4.2 (a,b) Schematic diagrams illustrating proportional measurements for optimum reconstruction. Note the importance of height and projection (a) together with base width. The latter incorporates the two components of medial fullness and lateral protrusion. An adequate inframammary distance must be maintained to achieve a symmetrical cleavage and avoid symmastia. (UB, upper breast; AD, areola diameter; N, nipple; IMF, inframammary fold.)

Evolution of prosthetic implants

Mammary prostheses originated as rounded devices with silicone gel filled implants becoming commercially available in 1962, whilst saline filled implants were launched a few years later in 1969. Amongst the more commonly used breast implants, the Becker permanent expander has been in use for almost two decades. It has the advantage of permitting gradual tissue expansion without the need for subsequent replacement and therefore can be done as a one-stage procedure. However, it does have limitations, which include limited expansion of the lower portion of the breast, subcutaneous rippling (most evident in the upper quadrants) and lack of a natural ptotic shape. Nonetheless, it remains the most popular rounded prosthesis for breast recon-



Figure 4.3 Newer biodimensional prostheses of graduated thickness facilitate creation of the superior mammary slope. Both projection and ptosis are more readily achieved.

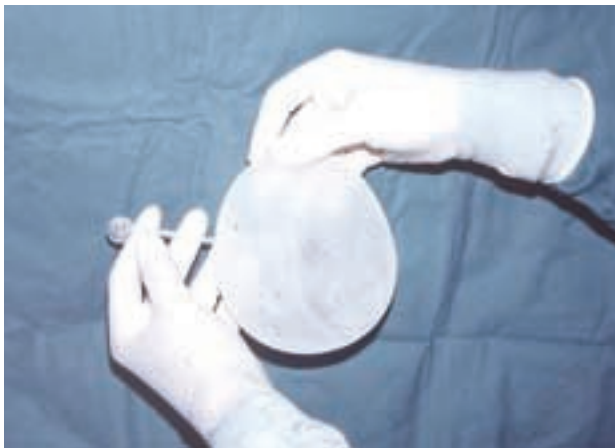


Figure 4.4 The current generation of permanent tissue expanders have a relatively small port which can be left in situ upon completion of expansion. Should this cause discomfort to the patient, it can either be removed or be relocated so as to lie deep to the prosthesis.

struction, although as with all such devices, increase in size and volume occurs equally in all directions.^{1,3} Textured anatomical implant designs were introduced to overcome the most difficult aspects of breast reconstruction, i.e. the creation of a natural breast contour, which is based on three parameters:

upper pole shape, breast projection and base width. Over the past decade reconstructive techniques have focused on the issue of shape and contour rather than volume replacement exclusively. This dimensional approach using anatomically shaped devices in conjunction with two-stage reconstruction has greatly enhanced the opportunity for reproduction of a more natural appearance using an implant alone. A combination of a new system of temporary expanders together with complementary permanent prostheses has greatly advanced the field of prosthetic breast reconstruction.^{4,5} Anatomical expanders permit more rapid expansion with lower pressures within the implant. They are less likely to migrate and lead to chest wall deformity. The infra-mammary fold is better defined and most devices have an integral injection port which does not require an additional procedure for removal. Expandable saline filled gel implants have been developed which provide more natural projection and give improved contour to the upper breast.⁶

The development of a cohesive silicone gel has yielded implants with enhanced durability, reduced capsule formation and less tendency to migrate within the chest wall (Figure 4.5). These implants are less influenced by gravitational forces than non-cohesive gel filled and saline filled implants.^{7,8} Recent innovations in implant design emphasize breast shape rather than simply volume and the more anatomically shaped prostheses permit reconstruction of breasts with a more natural feel and appearance. The newer cohesive gel filled implants are available in a broad range of specifications incorporating base width, height and projection (Figure



Figure 4.5 Cohesive silicone gel implants are textured, coated and associated with reduced capsule formation. In addition, these implants have enhanced durability and less tendency to migrate within the chest wall. Expansile variants contain an inner saline filled chamber and a relatively thick silicone envelope which avoids the 'rippling effect' observed with earlier saline filled implants.

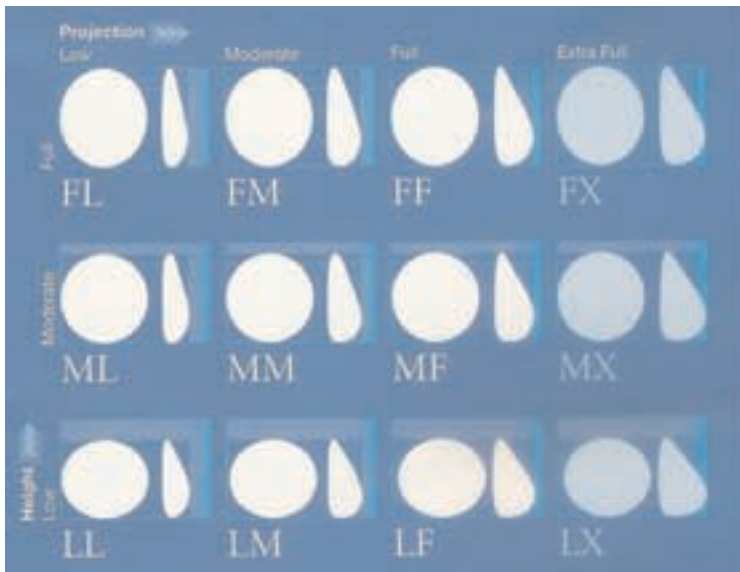


Figure 4.6 Modern textured, coated implants are available in a broad range of specifications incorporating base width, height and projection. Prostheses can therefore be appropriately selected for individual patients according to requirements. Custom-made implants are also available which must be ordered well in advance of the planned surgery.

4.6). This allows surgeons to plan more precisely a three-dimensional reconstruction and prostheses can be tailored to individual patients. With this variety of prostheses it is easier to match the reconstructed with the contralateral breast. These newer techniques permit breast reconstruction based increasingly on aesthetic considerations and greater expectations of patients. See Table 4.1 for a comparison of the various implants.

Indications for implant reconstruction

Immediate breast reconstruction

Immediate breast reconstruction should be offered to most patients undergoing either simple mastectomy or modified radical mastectomy. Partial

breast reconstructive techniques are being developed for patients undergoing breast conservation surgery. Preoperative (neoadjuvant) chemotherapy is not a contraindication to subsequent reconstruction post-mastectomy. Immediate reconstruction is oncologically safe and does not render detection of local recurrence more difficult (see Chapter 17). Chest wall irradiation can be administered following implant reconstruction, but a hypofractionated regimen is advisable to minimize cosmetic detriment. Where there is marked skin reaction to radiotherapy, inflation of the prosthesis can be deferred or undertaken over a more prolonged time period.^{9,10} Chemotherapy can be commenced once the surgical wounds are healed, although there is inevitably an increased risk of septic complications, which might necessitate removal of the implant. Immediate breast reconstruction benefits patients psychologically and improves quality of life. Poor prognosis per se is not a contraindication

Table 4.1 Advantages and disadvantages of the implant devices

	Advantages	Disadvantages
Simple prosthesis (single-stage reconstruction)	Easy procedure One operation	Projection defect No ptosis No inframammary fold Capsular contracture
Temporary expander (two-stage reconstruction)	Good projection Good ptosis Inframammary fold redefinition	Office visits for filling Two operations Long-lasting expansion
Permanent expander (single-stage reconstruction)	One operation	Minor projection Deficient ptosis Poor inframammary definition

Table 4.2 Differences between immediate and delayed expander insertion

Immediate reconstruction	Delayed reconstruction
Accurate intraoperative measurements	Accurate preoperative measurements
Technical aspects	Technical aspects
total submuscular pocket	subpectoral pocket
partial division of the lower pectoral insertions	complete division of the lower pectoral insertions
subcutaneous at inframammary level	subcutaneous pocket in the lower outer portion
Longer hospital stay	Shorter hospital stay
Higher postoperative morbidity	Reduced postoperative morbidity
Slower expander filling	Quicker expander filling
Feasible after irradiation	Difficult after irradiation
One operation after mastectomy	Two operations after mastectomy
Minor psychological morbidity	Psychosocial morbidity before definitive surgery

to breast reconstruction although reconstruction should be cautiously undertaken in those patients considered to be at particularly high risk of local recurrence. Immediate procedures avoid the additional costs of further hospitalization and implant only reconstruction adds only 60–90 minutes to the operating time.^{11,12}

Delayed breast reconstruction

The primary indication for delayed breast reconstruction is a prior mastectomy. The requirements for successful reconstruction in this context are generally more stringent than those for immediate reconstruction.^{13,14} The patient's oncological status should be updated prior to discussion of reconstruction to ensure there is no evidence of concomitant local or distant disease recurrence. The tissues of the chest wall must be carefully examined with attention to the quality of skin, scars and pectoralis major muscle. Where the chest wall musculature is severely atrophic and associated with thin, tight skin, implant insertion is contraindicated. Prior chest wall irradiation is not an absolute contraindication to use of an implant, but the risk of ischaemic complications is high. Large sized breasts are a relative contraindication to implant reconstruction due to constraints on volume with tissue expansion techniques alone. There are cost savings with prosthetic breast reconstruction compared with use of myocutaneous flaps, namely the TRAM (transverse rectus abdominis muscle) flap. Operating times and duration of inpatient stay are shorter and fewer revisional procedures are required overall for implant reconstruction. See Table 4.2 for a comparison of the two procedures.

Anatomical landmarks

The topographical anatomy of the chest wall changes dramatically after modified radical mastectomy. The mammary skin envelope together with the underlying subcutaneous tissue is preserved to a variable extent.^{13,15,16} The nipple–areola complex (usually with a surrounding ellipse of skin) is removed together with the glandular tissue of the breast and fascial attachments.^{17,18} It is unnecessary to routinely remove the fascia over the pectoralis major muscle, although this structure should be excised if tumour is attached.¹⁹ Pectoralis major and serratus anterior muscles are preserved whilst the pectoralis minor can be excised or divided if indicated to facilitate access to level III nodes lying medial to the muscle.

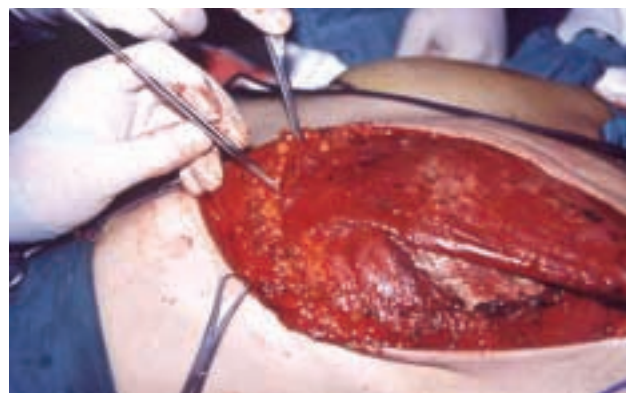

Figure 4.7 Preservation of the inframammary fold is critical for optimal cosmetic results. Such a practice does not compromise the oncological aspects of the extirpative procedure as breast tissue rarely lies distal to this level.

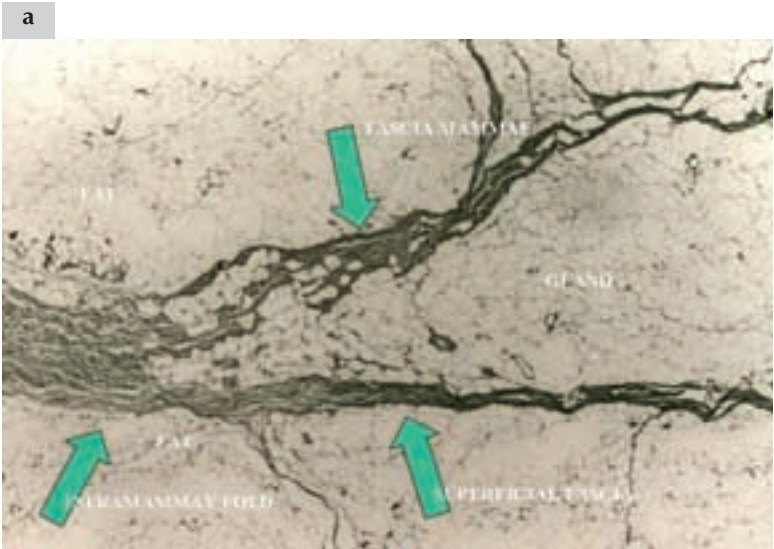
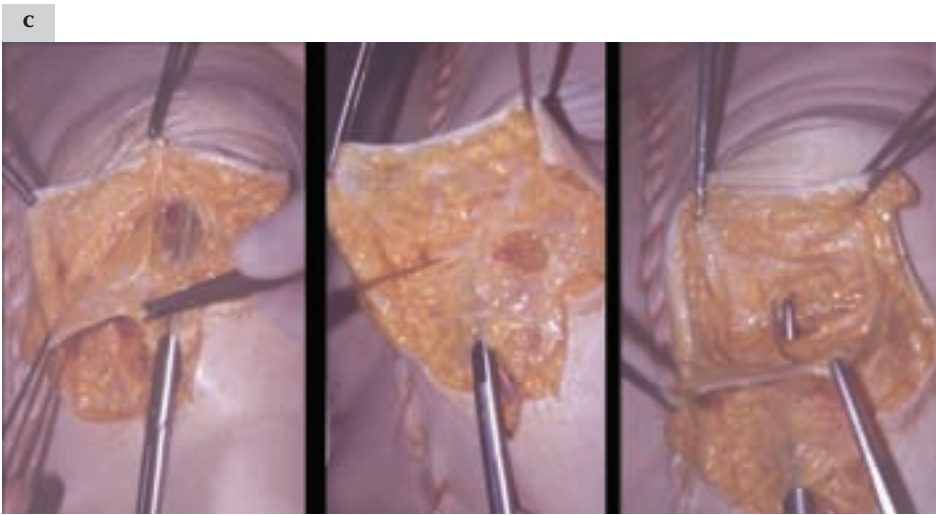
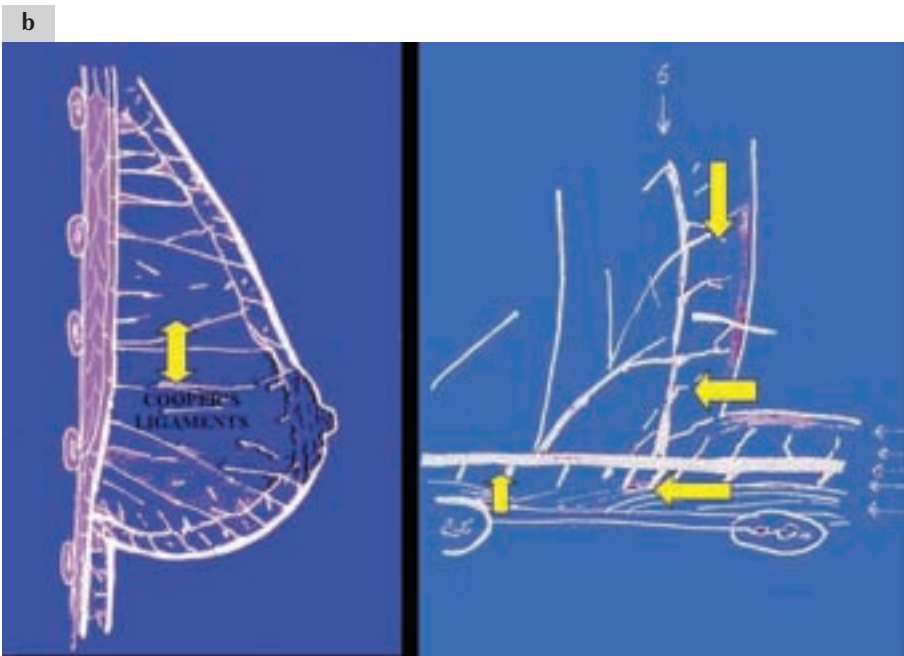


Figure 4.8 (a–c) The inframammary fold is a condensation of tissue within the superficial fascia system. It is composed of two subcutaneous layers and one superficial layer. Fusion between the superficial and mammary fascia yields the inframammary fold whilst fibrous retinaculae connecting both dermal and musculofascial layers to the superficial fascia determine the contour of the fold.



From the reconstructive point of view, certain anatomical features are critical for optimal results: (i) preservation of the inframammary fold frame, (ii) integrity of the pectoralis muscle, and (iii) the quality and tension of the skin flaps. Preservation of the inframammary fold is oncologically safe because breast parenchymal tissue rarely lies distal to this level (Figures 4.7 and 4.8a). This region is a specialized part of the superficial facial system being composed of two subcutaneous layers and one superficial fascia layer.^{20–22} The inframammary fold is formed by fusion between superficial and mammary fasciae (Figure 4.8b) whilst the contour of the fold is determined by the distribution of fine fibrous retinaculae which connect both the dermal and musculofascial layers to the superficial fascia (Figure 4.8c).^{23,24} The mammary fascia constitutes the natural envelope of the breast and is sometimes referred to as the anterior layer of the superficial fascia or the inframammary ligament. Loss of this structural network at the time of mastectomy will impair the cosmetic results of any subsequent breast reconstruction. The inframammary fold is an important aesthetic component of the breast and can readily be preserved without compromising oncological clearance of tumour. Nonetheless, where this structure has to be sacrificed, a new inframammary fold can be fashioned at the time of reconstruction or during subsequent surgery for revision of implant.^{25,27}

Minor disruption of the pectoralis major muscle should not interfere with any planned breast reconstruction. However, tears in the muscle must be closed with soluble sutures (preferably before insertion of an implant to avoid inadvertent needle puncture). There must be sufficient skin to allow primary closure without tension following insertion

of the implant. Where a tissue expander is used, minimal inflation is carried out at the time of initial placement to avoid excessive tension either within the skin and subcutaneous tissues or the pectoral muscles. The upper mastectomy flap can be further undermined superiorly if necessary but it is preferable to avoid dissection of the lower flap beyond the inframammary fold (Figure 4.7).^{28,29}

Breast reconstruction after mastectomy (first stage)

Following mastectomy, the tissues of the chest wall must be prepared for insertion of a prosthesis. The operative steps are similar irrespective of the type of implant employed (expandable or permanent). Reconstruction using an implant is technically more challenging when carried out as a delayed rather than immediate procedure.^{6,30}

Surgery is planned using a geometric approach; the overall shape and contour of the new breast relate to three parameters: width, height and projection. Base width and height are determined by the dimensions of the contralateral breast and are measured out on the chest wall corresponding precisely to the site of implant insertion (Figure 4.9). The projection of the breast can be predicted to some extent from the dimensions of the implant although the final result will only be apparent once expansion has occurred. Depending on the final volume of inflation, a permanent anatomical prosthesis can be selected which has the appropriate width, height and projection. The surgeon must learn to think in three dimensions when planning breast reconstruction.

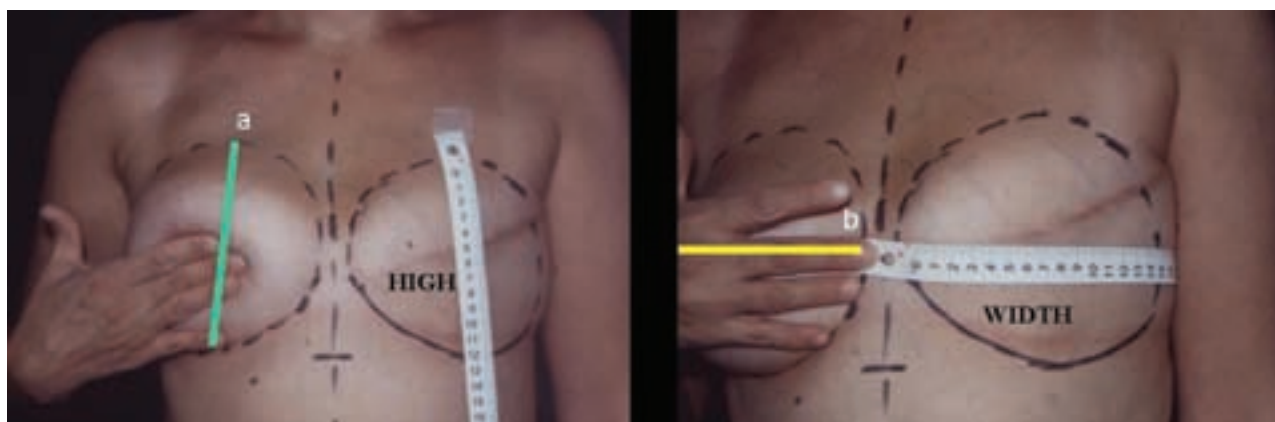

Figure 4.9 Height (see a) and base width (see b) must be accurately assessed and should correspond to the contralateral breast. These measurements are fundamental features of implant reconstruction and should be correctly sited on the chest wall.

Immediate reconstruction

Preoperative planning

The type of incision and amount of skin to be resected at the time of mastectomy should be jointly planned by the general (oncological) and plastic surgeons preoperatively (Figure 4.10). An appropriate type and size (base) of expander must be selected and this will be governed by the dimensions of the contralateral breast (Figure 4.11). Base width is a

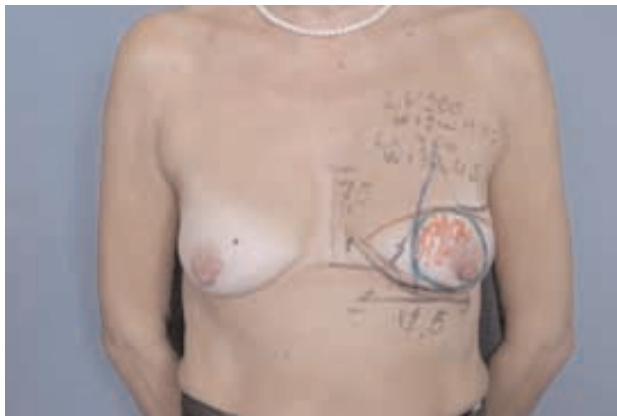

Figure 4.10 The type of incision to be employed for mastectomy and the amount of skin to be removed should be carefully planned as an oncoplastic approach. Skin-sparing techniques are increasingly being used, but often an area of skin directly overlying the tumour must be sacrificed to ensure adequate clearance of the anterior tumour margin. Narrow skin bridges should be avoided and usually additional skin is removed in continuity with the nipple–areola complex.

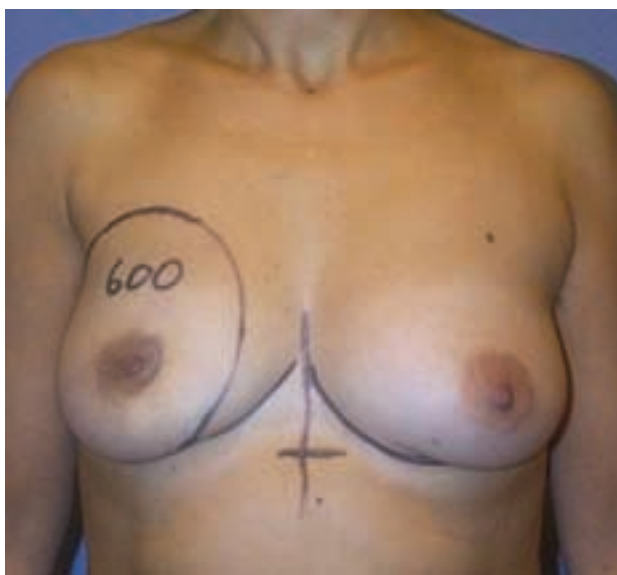

Figure 4.11 The type and size of implant selected is determined by dimensions of the contralateral breast. Surface markings of the subpectoral pocket can be outlined on the chest wall using standard templates.

critical measurement in determining overall cosmetic results, but expander volume is also important. Where the opposite breast is very large or will be augmented, then an expander one size bigger should be chosen. The surface markings of the subpectoral pocket can be outlined on the chest wall using the manufacturer's templates. The lower border of the pocket should lie just below the submammary crease but not by more than 1 cm, thus allowing for upward shift of the lower edge with inflation of the expander. The submuscular pocket will have the same dimensions as the selected expander and will reflect the base width and height of the contralateral breast.

Intraoperative planning

The patient must be correctly positioned on the operating table. Though initially in the supine position, this will be changed following mastectomy and prior to definitive reconstruction. The arms should lie at an angle of 60° to the operating table, thus completely relaxing the pectoralis major muscle and facilitating blunt dissection of the submuscular pocket. The contralateral breast is a useful guide to formation of the subpectoral pocket and in particular the position of the inframammary fold. Both breasts should therefore be prepared and exposed within the operative field. The amount of skin and quality of the pectoralis major muscle together with the definition of the inframammary fold and fascial attachments should be examined (Figure 4.12). The lower limit of the subpectoral pocket is marked and its transverse and vertical diameters guided by the dimensions of the prosthesis (Figure 4.13).

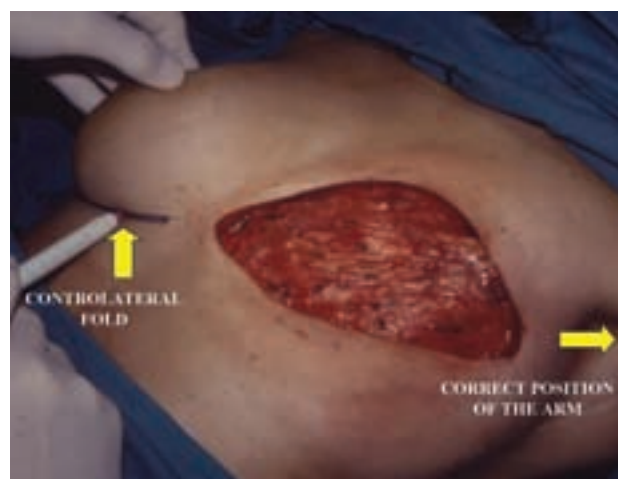

Figure 4.12 Following completion of mastectomy, the amount of skin and quality of the pectoralis major muscle must be assessed (thickness and integrity). The definition and position of the inframammary fold should be clarified.

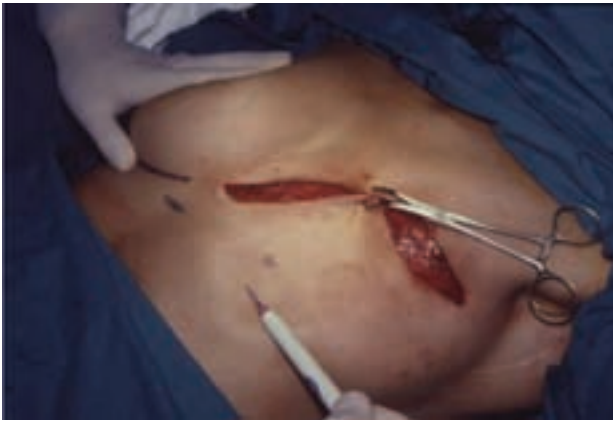

Figure 4.13 The lowermost limit of the subpectoral pocket is marked (note that the lower border of the pocket should lie just below the inframammary crease (≤ 1 cm)). The transverse and vertical diameters of the pocket will be guided by the dimensions of the implant.

Surgical steps for insertion of expander

1. Preparation of submuscular pocket.

The incision is made along the lateral border of the pectoralis major muscle (Figure 4.14). Progressive dissection is done beneath the pectoralis major muscle superiorly, medially and inferiorly (Figure 4.15). The inferior part of the dissection can include the anterior rectus sheath and the aponeurosis of the external oblique and continued beneath the serratus anterior muscle (Figure 4.16). Then dissection of the sternal attachments of the pectoralis major is done from the second intercostal space to the inferior edge of the pocket (Figure 4.17), and dissection of

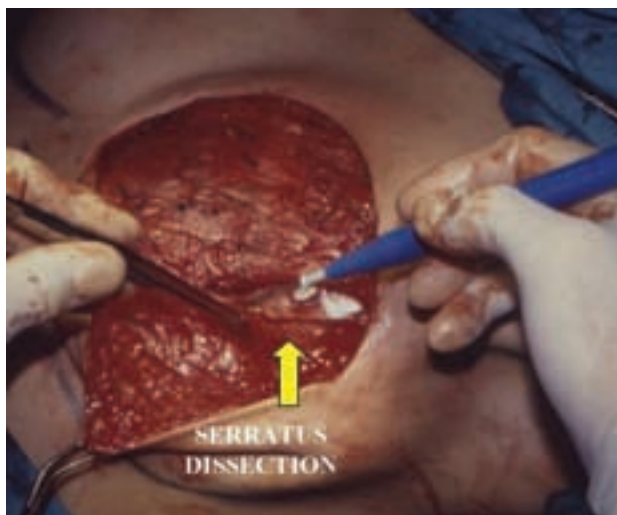


Figure 4.14 A subpectoral pocket may be created by making a short incision either along the lateral border of pectoralis major (illustrated here) or more centrally within the main muscle belly along the line of the muscle fibres.

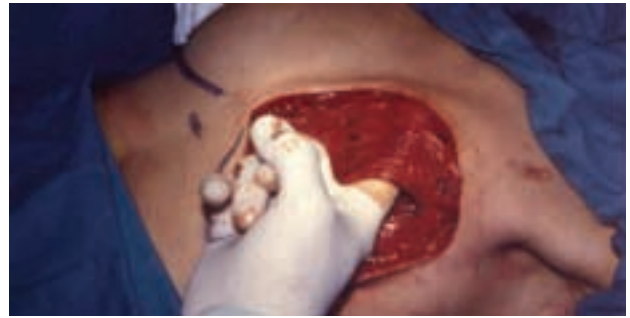

Figure 4.15 Dissection is carried out systematically in superior, inferior and medial directions using a combination of blunt and sharp techniques. The use of cutting diathermy helps minimize bleeding.

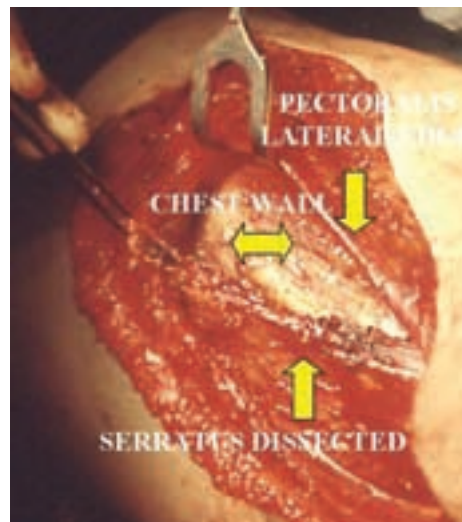


Figure 4.16 To ensure that the prosthesis lies at the correct level, the inferior part of the dissection can extend deep to the anterior rectus sheath and external oblique and be continued beneath the serratus anterior muscle (care must be taken to avoid tearing this muscle during the dissection).

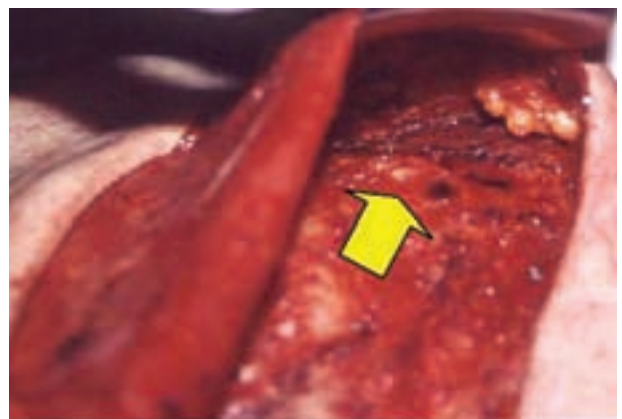


Figure 4.17 Dissection of the sternal attachments of pectoralis major proceeds from the second intercostal space to the inferior edge of the pocket. Troublesome bleeding can occur from branches of the internal mammary artery which may require ligation.

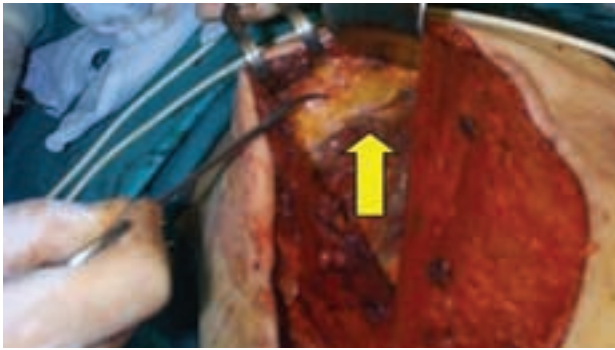


Figure 4.18 The lowermost attachments of pectoralis major muscle are freed and if necessary the inferomedial edge of the muscle can be detached to allow the implant to lie at the correct level (any subcutaneous component should not lie directly beneath the skin incision).

the lowermost attachments of the pectoralis major and the serratus anterior muscle at the same level as the contralateral inframammary fold (Figure 4.18).

The pocket should ideally be completely submuscular except at the inframammary fold where it should extend into the deep fascial layer avoiding direct continuity with the mastectomy site.^{8,11,12}

2. Preparation of the expander.

Complete evacuation of air with aspiration of any retained air within the inner expansion chamber is required (Figure 4.19a). Partially inflate the prosthesis with saline to ensure there is no leakage. A small amount of saline (up to 20% final volume) left within the prosthesis as a degree of partial inflation will aid insertion (Figure 4.19b and c). The prosthesis is then immersed in povidone iodine solution (Figure 4.19d).

3. Insertion of two suction drains.

Drains should be placed in the submuscular pocket and axilla following axillary dissection (Figure 4.20).

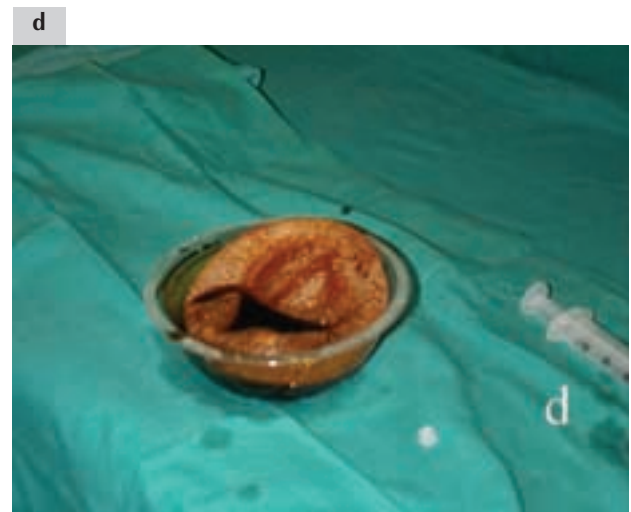
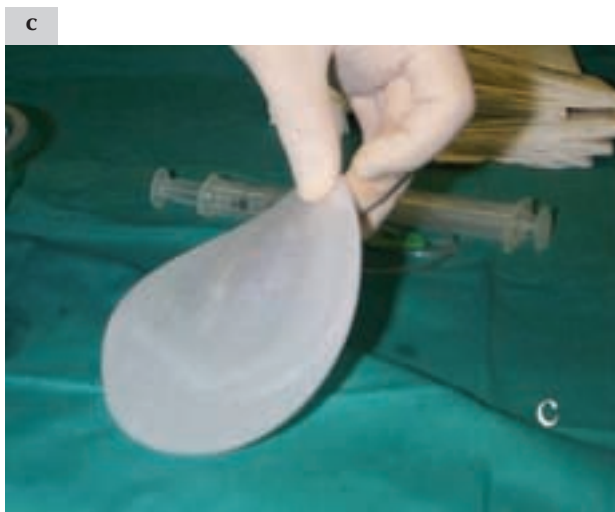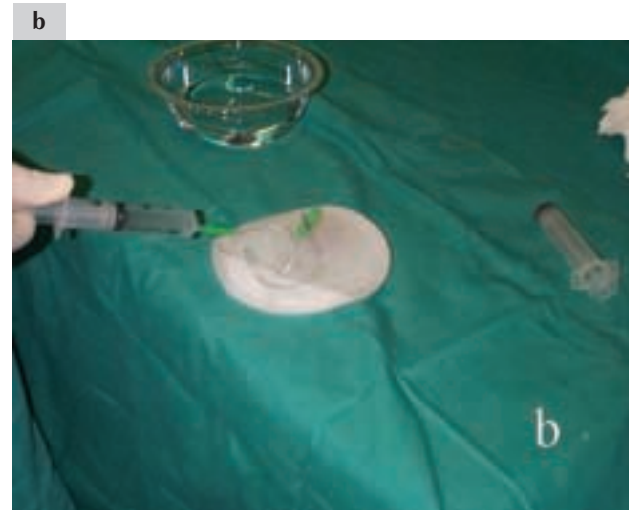
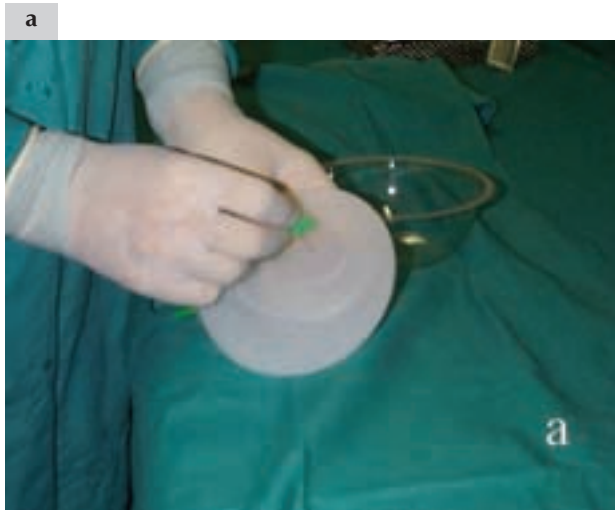


Figure 4.19 (a–d) Preparation of the expander (see text for details).

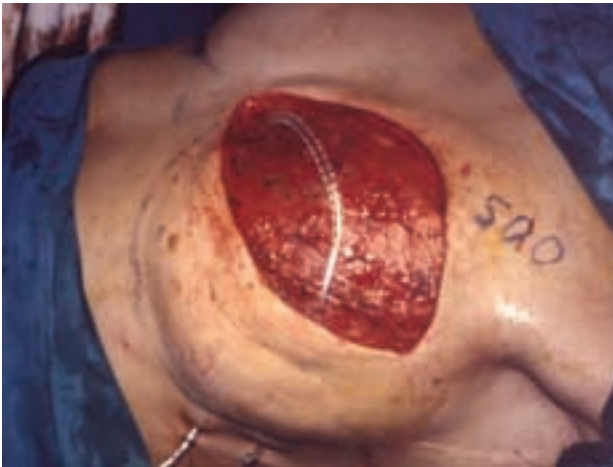

Figure 4.20 Suction drains should be placed both deep to the implant and in the subcutaneous tissues following insertion of the implant. In addition, an axillary drain is required when formal dissection of the axilla (level II/III) has been undertaken.

4. Insertion of the prosthesis partially inflated and correctly orientated (Figure 4.21)

Attention should be paid to filling the lower pole of the breast.

5. Closure of the submuscular pocket

Interrupted sutures can be pre-inserted before placement of the prosthesis to minimize risk of needle puncture.

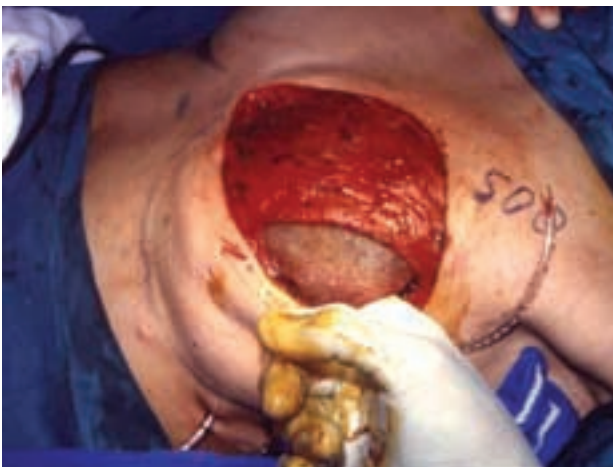

Figure 4.21 Bidimensional implants must be correctly orientated prior to insertion. Modern prostheses contain a small 'nodule' over the inferior aspect of the deep surface which facilitates maintenance of orientation during insertion. It is important to ensure that the lower edge of the prosthesis lies at the inferior extremity of the pocket.

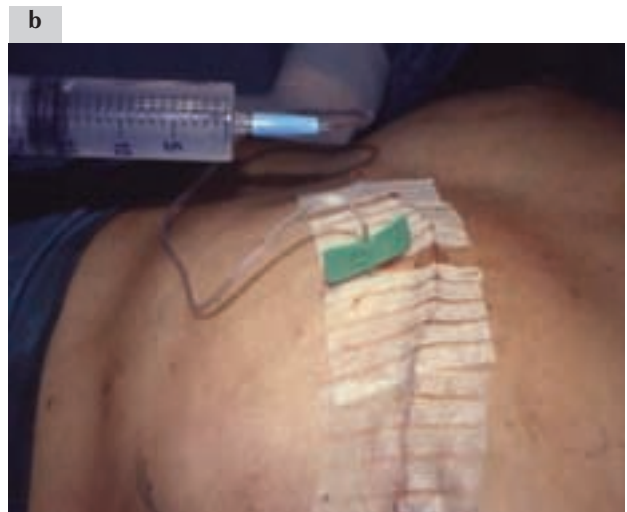
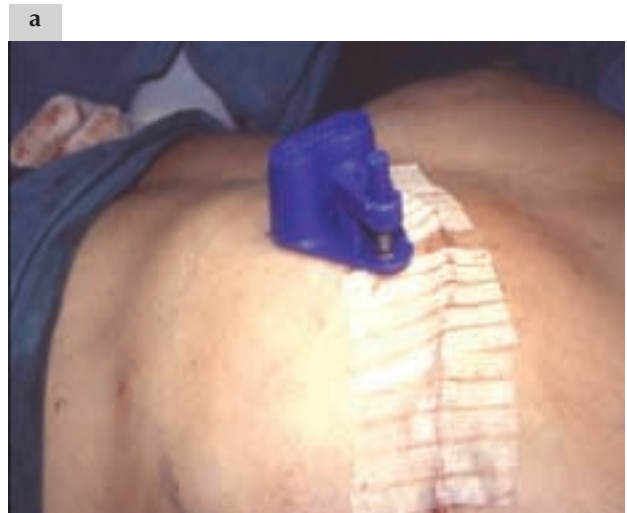
Figure 4.22 (a, b) The expander is inflated with 200–300 ml of saline, although the degree of initial expansion possible depends upon the tension within both the pectoralis muscle and the skin. Where a skin-sparing procedure has been carried out, skin tension is not usually a limiting factor with respect to rates of expansion. An implant containing an integral port is illustrated here: the port is located using a magnetic device. Expander prostheses with a separate port connected by tubing are popular, especially with the advent of permanent tissue expanders. These are now manufactured with smaller, discrete ports which can remain in situ once definitive breast size is attained.

6. Closure of both skin and subcutaneous tissues

7. Expander inflation (Figure 4.22)

Inflate the expander with 200–300 ml of saline. Initial expansion is desirable provided there is no skin tension.³¹

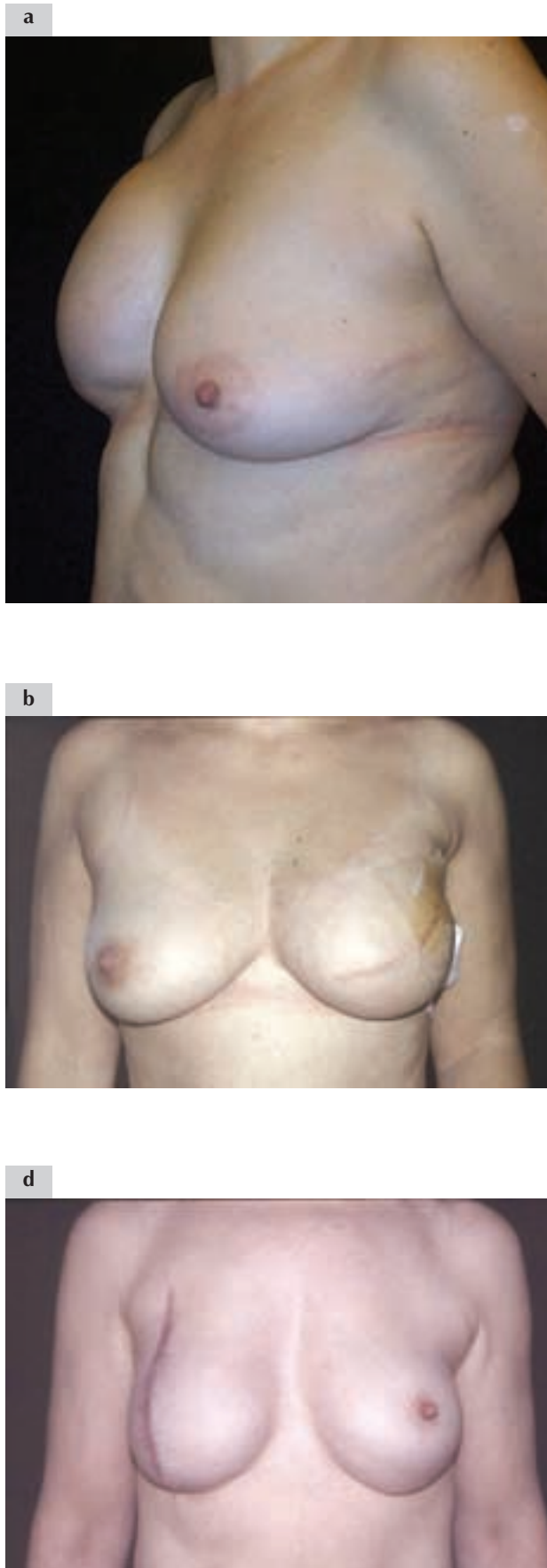


Figure 4.23 (a–c) Postoperative views following reconstruction with subpectoral prosthesis. The final outcome is conditioned by the mastectomy incision.

8. Postoperative views (Figure 4.23)

Delayed reconstruction

Preoperative planning

In order to satisfactorily place a tissue expander (within a submuscular pocket), the pectoralis major muscle together with skin and subcutaneous tissue must be adequately preserved following elevation from the chest wall. Muscle may be deficient inferiorly where prosthesis coverage is constituted of skin and subcutaneous layers only. As for immediate reconstruction, width and height of the contralateral breast guide the selection of an appropriately sized expander (Figure 4.24). Where the contralateral breast has marked ptosis and there is adequate skin, a larger expander can be chosen in order to better reproduce a ptotic breast (greater overexpansion). However, very large expanders should be avoided as these may be incompatible with chest wall dimensions. A template is positioned on the chest wall lying just inferior to the inframammary crease (not more than 1 cm below this line) (Figure 4.25).

Intraoperative planning

The patient is positioned supine with the arms out on a board. The contralateral breast should be within the operative field and the level of the inframammary fold marked (indelible pen or scratch mark).

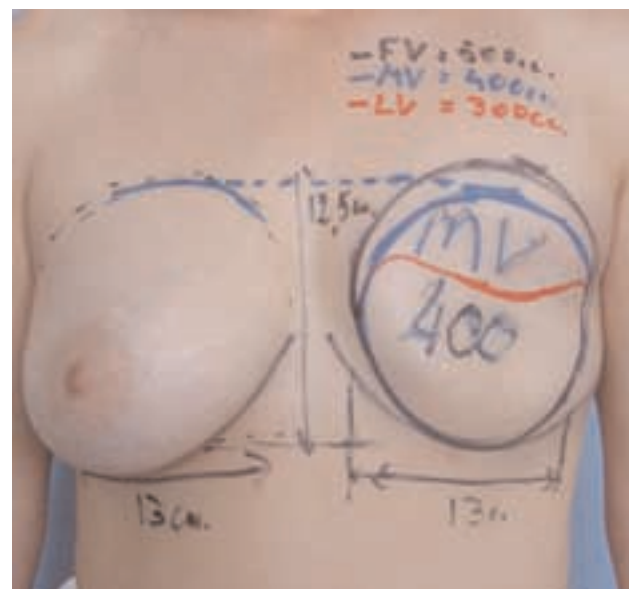


Figure 4.24 The dimensions of the contralateral breast (width and height) determine the size of the expander to be used (base width, height and projection).

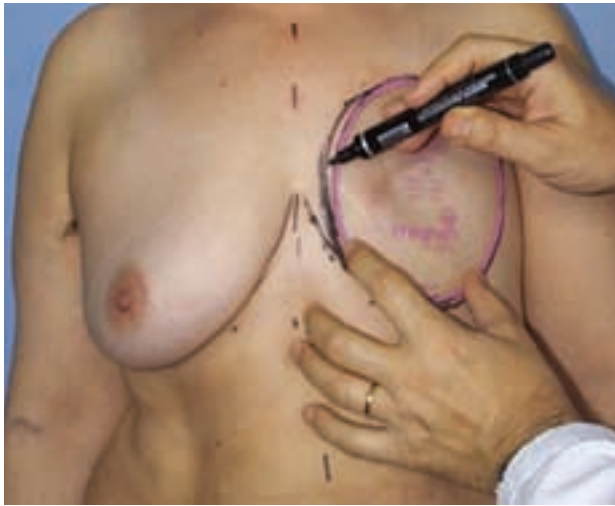

Figure 4.25 The subpectoral pocket can be accurately marked out on the chest wall using a template which should be positioned just below the inframammary crease (not more than 1 cm).

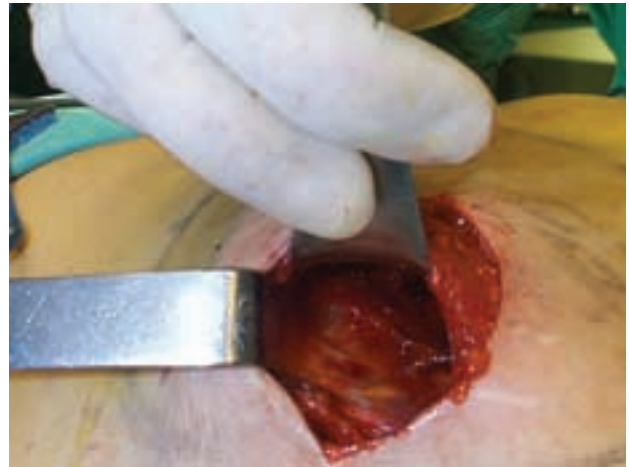

Figure 4.27 The pectoralis major muscle may be incised either along the lateral edge or more centrally parallel to the muscle fibres. The former approach is easier for delayed reconstruction where the skin and subcutaneous tissues are adherent to the pectoralis major muscle.

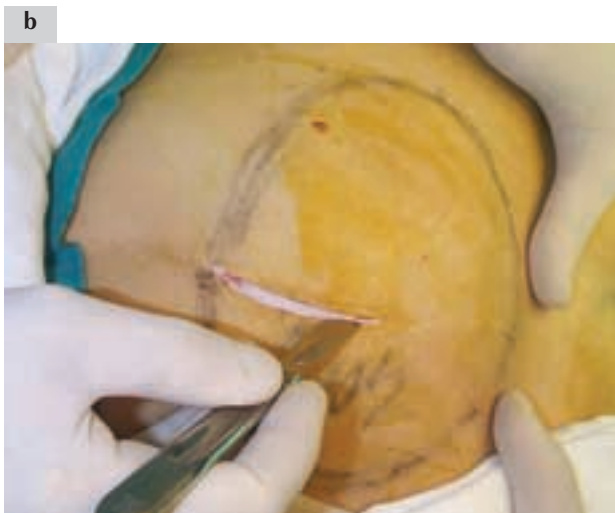
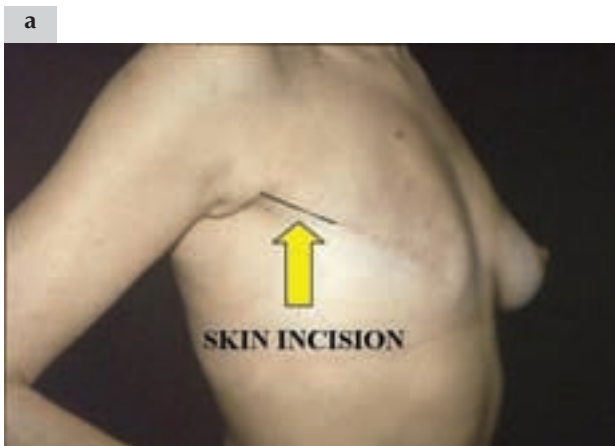
Figure 4.26 (a,b) With a delayed reconstruction, the skin incision should be placed along the lateral third of the mastectomy scar in order to be less conspicuous postoperatively.

The surgeon checks the chosen expander size in relation to the thorax and contralateral breast. The volume and shape of the latter can be modified at the time of reconstruction and this demands careful planning involving both patient and surgeon.

Surgical steps for expander insertion

1. Skin incision.

The skin incision is placed towards the lateral portion of the mastectomy scar (Figure 4.26). The pectoralis major muscle is incised along its free lateral edge or more centrally along the line of the muscle fibres (Figure 4.27).

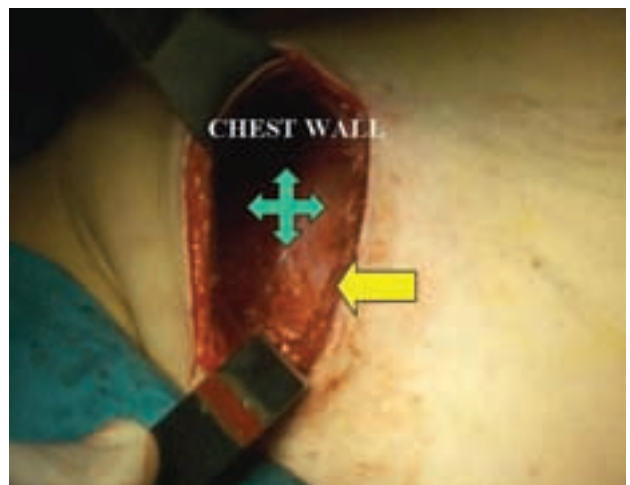


Figure 4.28 The subpectoral pocket is created by progressive dissection superiorly, medially and inferiorly.

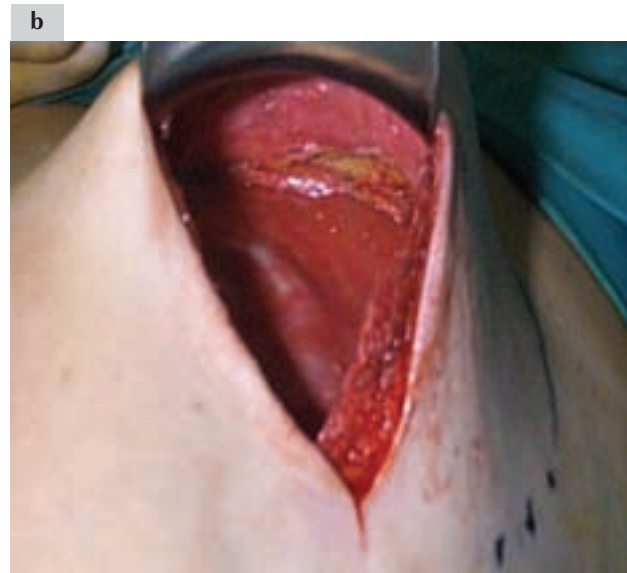
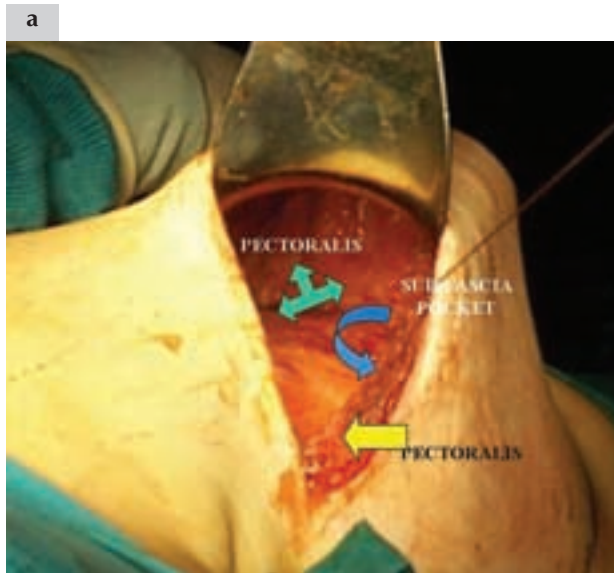
Figure 4.29 (a,b) The medial and inferior attachments of the pectoralis major muscle must be freed to allow the implant to be correctly positioned.

2. Preparation of the submuscular pocket.

Progressive dissection is done deep to pectoralis major muscle superiorly, medially and inferiorly (Figure 4.28). The medial and lowermost attachments of the pectoralis major are dissected from the level of the fourth to the sixth/seventh ribs (Figure 4.29). Any constricting scar tissue in the inframammary region is excised.

The remaining steps are similar to those described above for immediate implant reconstruction (see Figures 4.19–4.22). The wound is closed with absorbable sutures (Figure 4.30).

Breast reconstruction after expansion (second stage)

The second stage of implant reconstruction involves removal of the temporary tissue expander and its replacement with a permanent implant. Adjustments to the contralateral breast can be carried out at this stage. Furthermore, minor refinements to the reconstructed breast can be undertaken such as enlargement of the pocket and contouring of the breast.^{4,5}

This stage of reconstruction is identical for immediate and delayed procedures, and should be undertaken at least 6 months after final expander inflation. This delay permits a period of stabilization and improves the potential ptosis achiev-

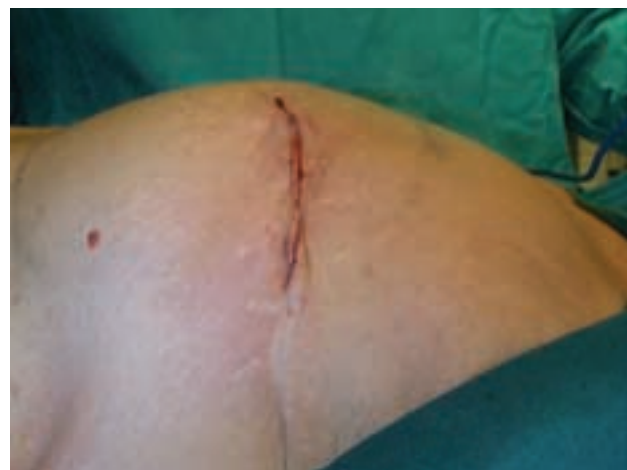

Figure 4.30 The subcutaneous tissues and skin are closed with absorbable sutures.

able with expansion. Moreover it allows for completion of adjuvant therapies. Experience is required in choosing an appropriate size and shape of prosthesis, and the current use of anatomical implants facilitates this selection process. Width, height and projection of the contralateral breast must be accurately assessed and are crucial parameters in planning the final stage of reconstruction. In addition to appropriate selection of an anatomically shaped implant, other factors are important in optimizing breast reconstruction. These relate to technical details of surgery, in particular fashioning of the inframammary fold.

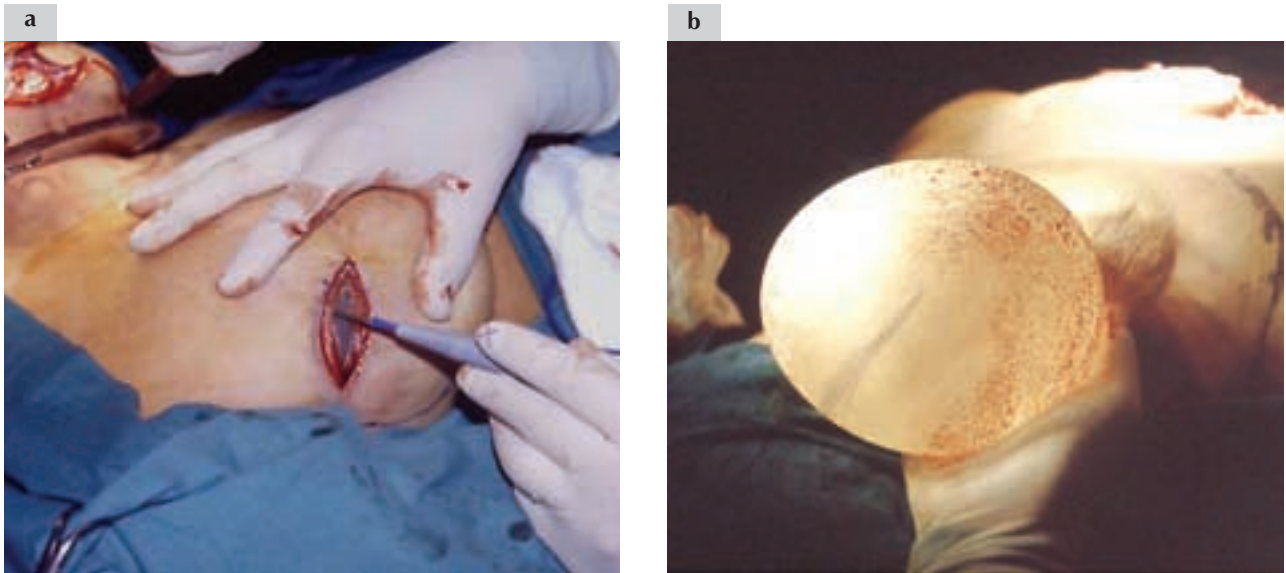


Figure 4.31 (a,b) An incision is made along the lateral aspect of the mastectomy scar and following incision of the pectoralis major muscle the temporary tissue expander is removed.

Preoperative planning

The final expander volume following inflation should correspond to approximately 70–80% of the potential expander volume. In circumstances where the desired volume of the contralateral breast is subsequently amended, this relationship will be modified and where contralateral size is overestimated, this percentage will be lower. Ideally, final volume adjustment should only be carried out following any contralateral surgery and the definitive size of the reconstructed breast can be determined intraoperatively.

Intraoperative planning

The result of augmentation, reduction or mastopexy will modify the surgical approach to definitive post-mastectomy reconstruction. Both breasts should be visible within the operative field and the level of the contralateral inframammary fold marked.

Surgical steps for prosthesis insertion

1. Skin incision.

The skin incision is placed towards the lateral end of the post-mastectomy scar, and an incision is made along the free edge of the pectoralis major muscle or in the line of its muscle fibres. The tissue expander is removed (Figure 4.31a).

2. Removal of temporary tissue expander (Figure 4.31b).

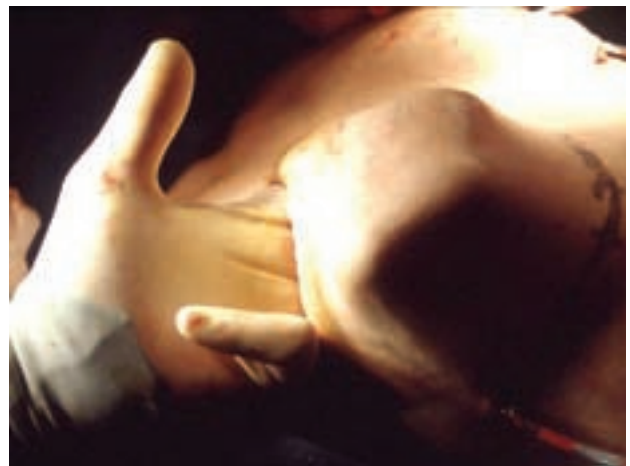

Figure 4.32 A pocket for the definitive prosthesis is prepared by carrying out multiple capsulotomies. Appropriately placed radial and transverse capsulotomies permit extension of the lower pole.

3. Preparation of pocket.

A pocket for the definitive prosthesis is prepared by creating multiple capsulotomies. The lateral, upper and lower incisions of the capsule edges are tailored according to the specific requirements for enlargement of the pocket. Extension of the lower pole of the new breast is carried out through a combination of radial and transverse capsulotomies positioned relative to the inframammary fold (Figure 4.32).

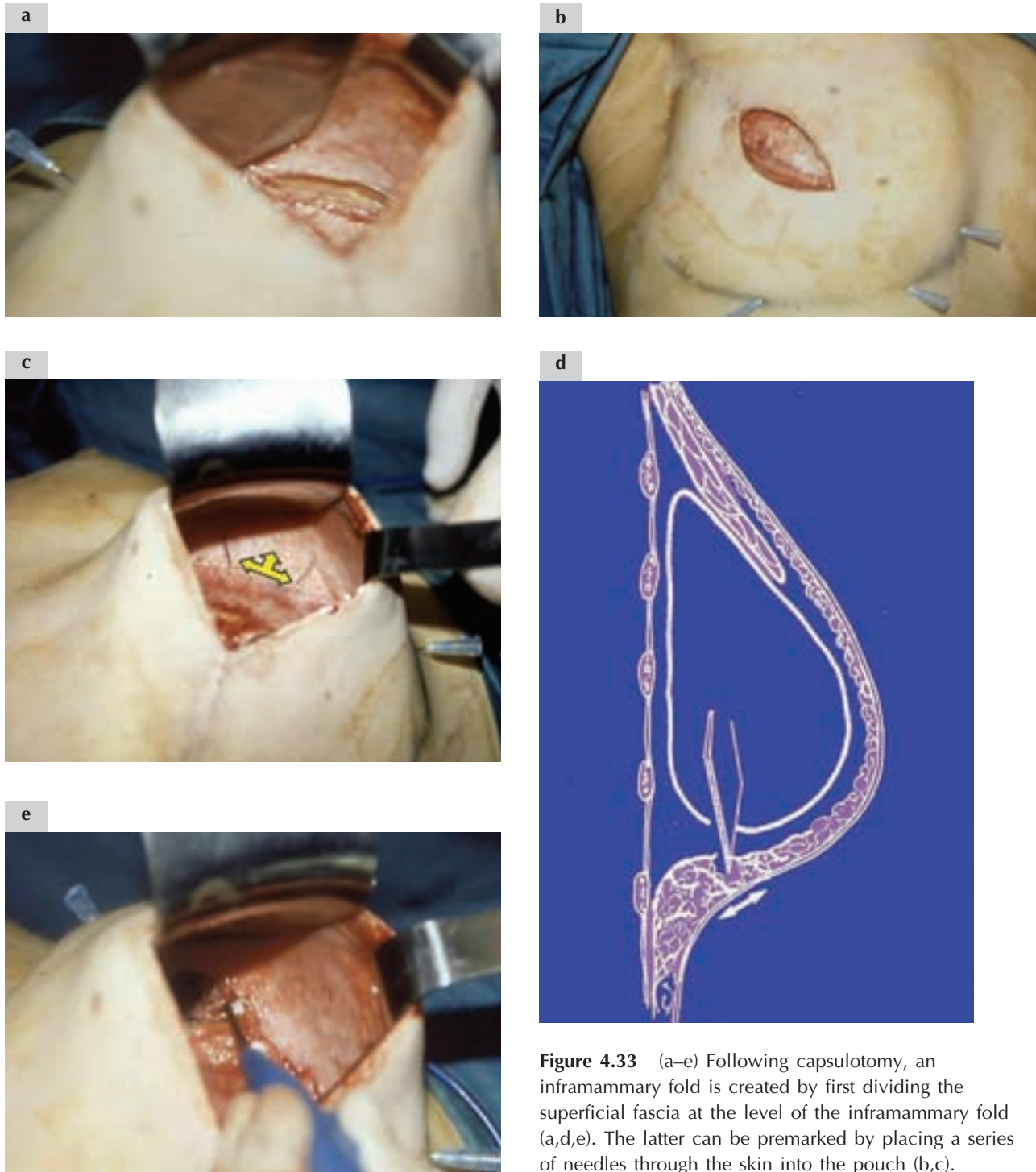


Figure 4.33 (a–e) Following capsulotomy, an inframammary fold is created by first dividing the superficial fascia at the level of the inframammary fold (a,d,e). The latter can be premarked by placing a series of needles through the skin into the pouch (b,c).

4. Creation of inframammary fold.

Following capsulotomy (Figure 4.33a), the superficial fascia is divided at the level of the inframammary fold which is marked by needles inserted into the pouch through the skin (Figure 4.33b and c). The lower edge of the superficial fascia is sutured to the chest wall musculature using continuous sutures of strong absorbable material (1/0) (Figures 4.33(d and e) and 4.34).^{32,33}

5. Insertion of drains.

6. Insertion of permanent prosthesis.

Following insertion of the definitive prosthesis, it is important to check the final result with the patient elevated to the sitting position.

7. Wound closure.

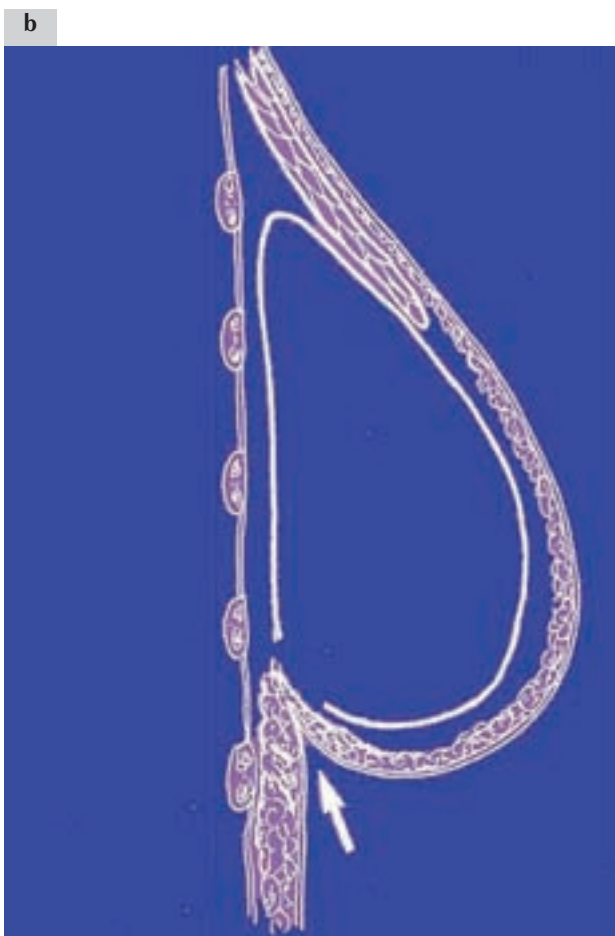
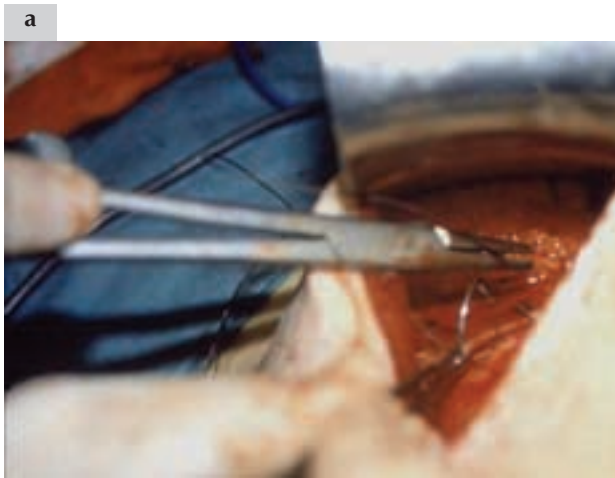


Figure 4.34 (a,b) The lower edge of the superficial fascia is sutured to the chest wall musculature to reconstitute the inframammary fold. Strong absorbable material should be used as these sutures can be placed under tension during tissue expansion.

The wound is closed in two layers using soluble suture material.

8. Pre and post-operative views (Figures 4.35–4.39)

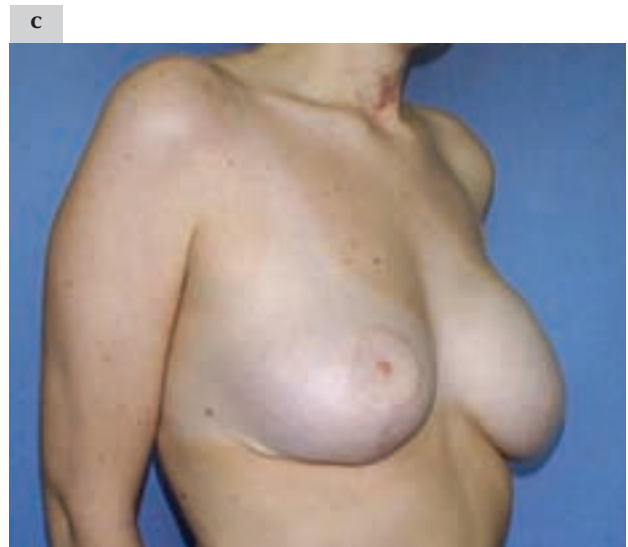
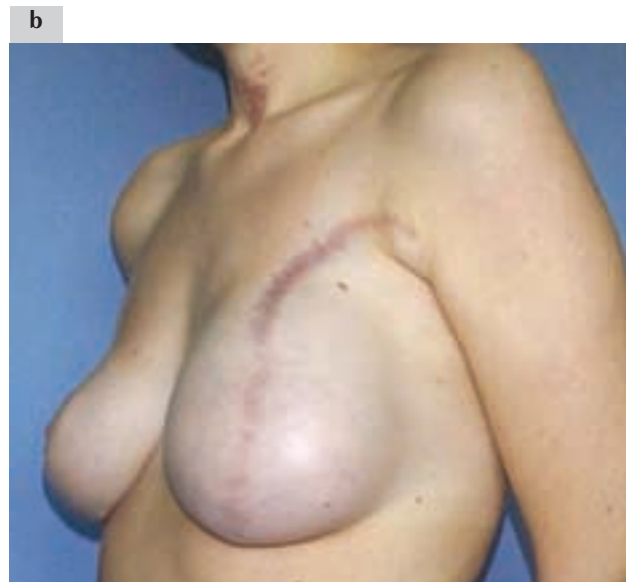
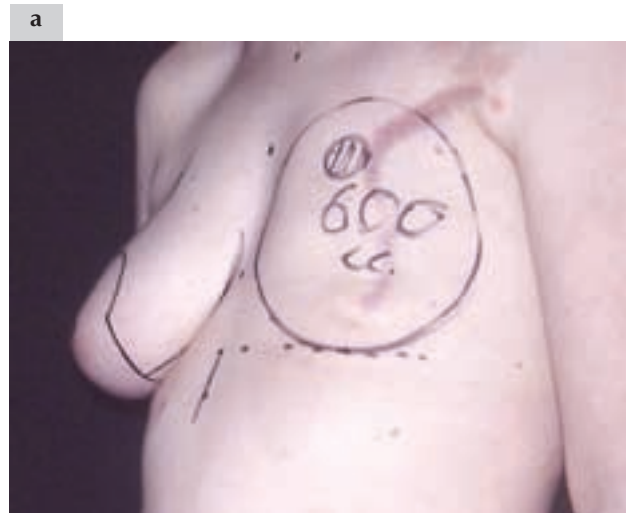Figure 4.35 (a) Preoperative view. (b) Postoperative view after left reconstruction and contralateral reduction (left side view). (c) Right side view.

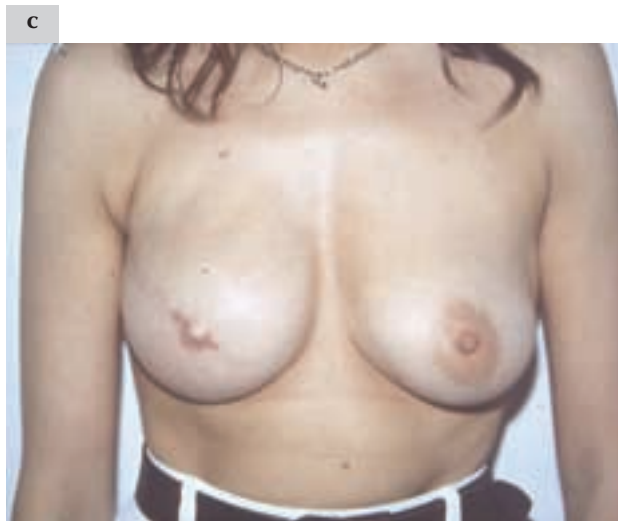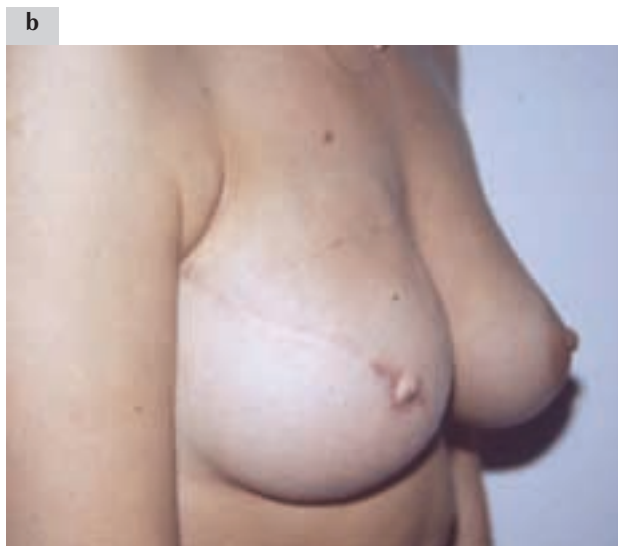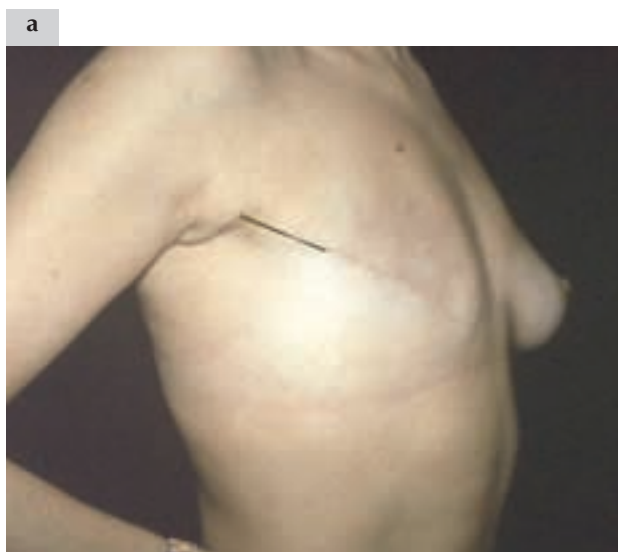


Figure 4.36 (a) Preoperative view (black line, site of incision). (b) Postoperative view after reconstruction of right breast and nipple. (c) Frontal view.

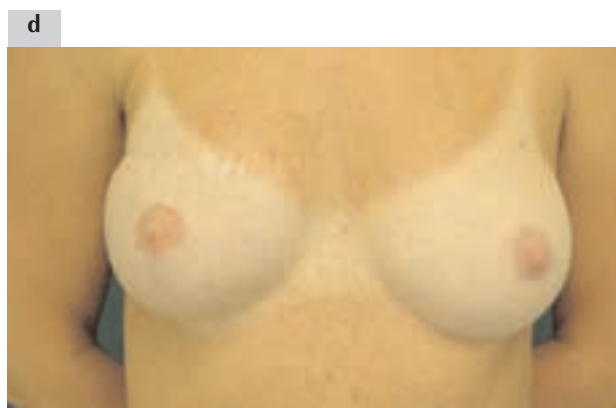
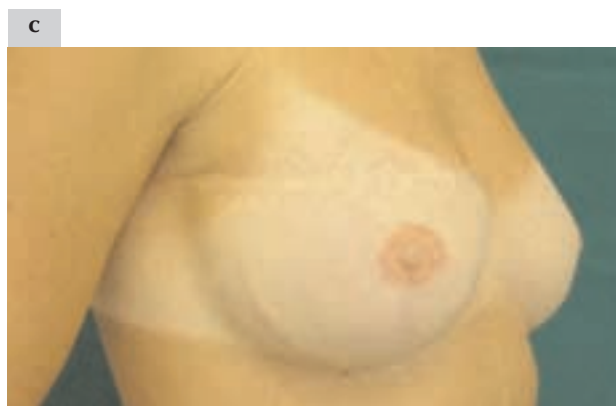
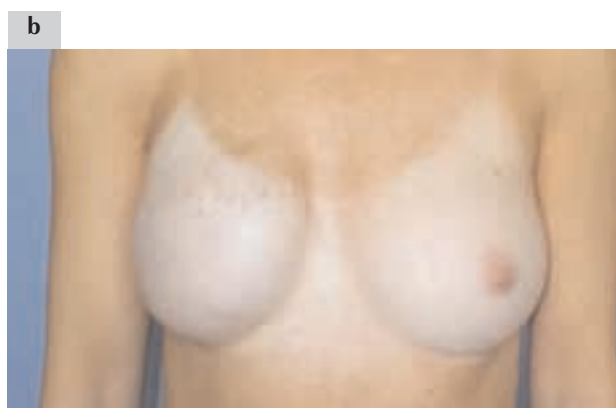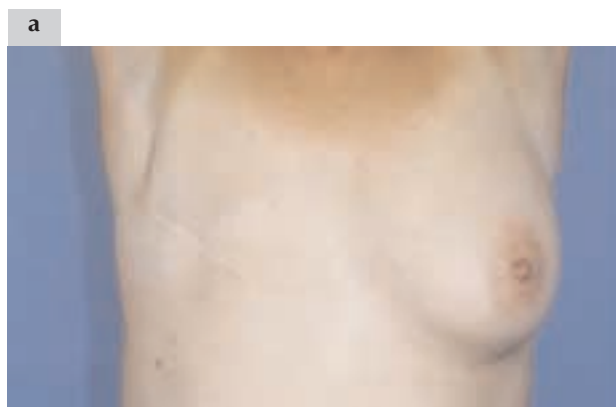Figure 4.37 (a) Preoperative view. (b) Postoperative view after left tissue expansion. (c) Postoperative view after replacement of expander, right nipple reconstruction and contralateral reduction (right side view). (d) Frontal view.

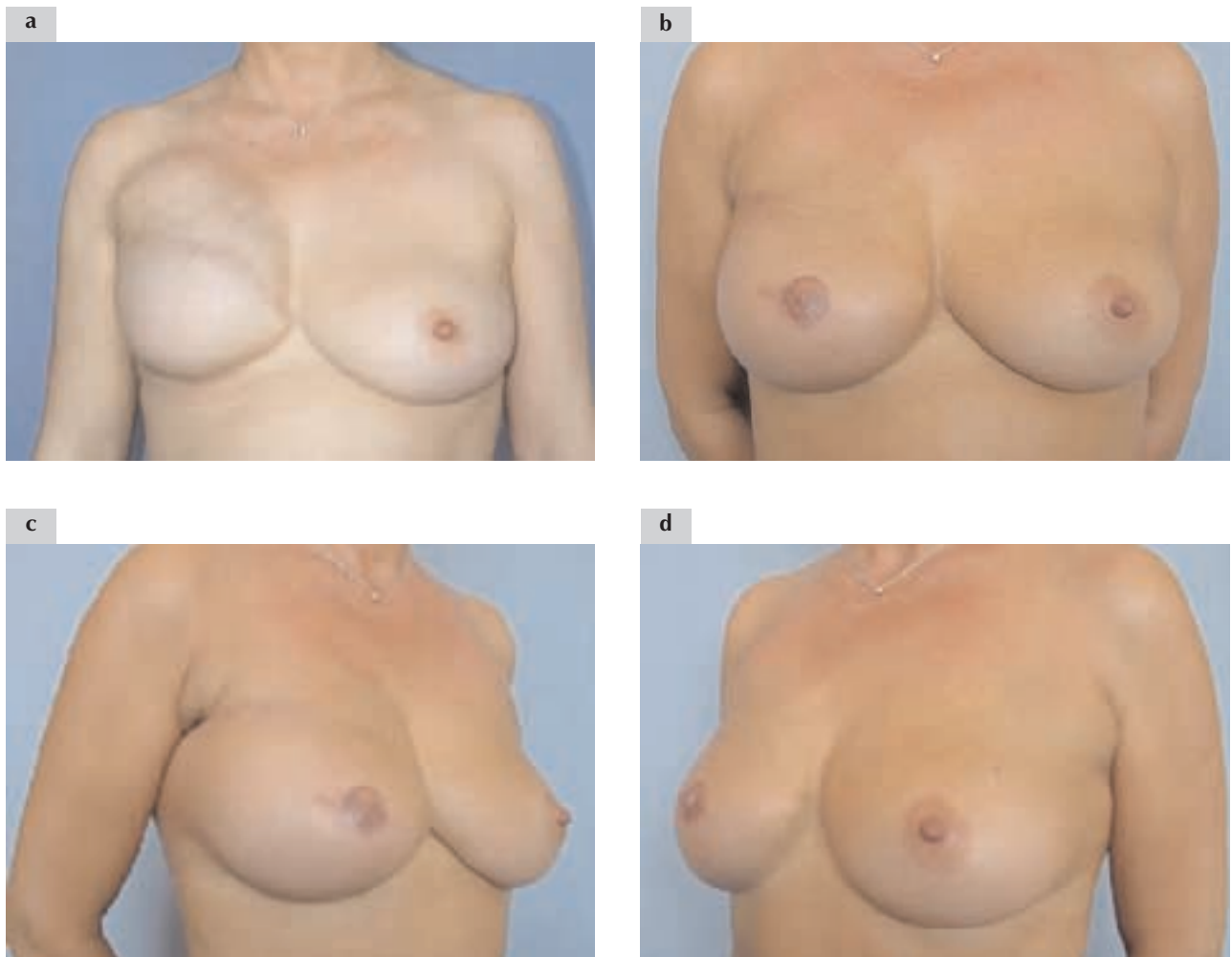


Figure 4.38 (a) Postoperative view after right tissue expansion. (b) After implant replacement and nipple reconstruction. (c) Right side view. (d) Left side view.

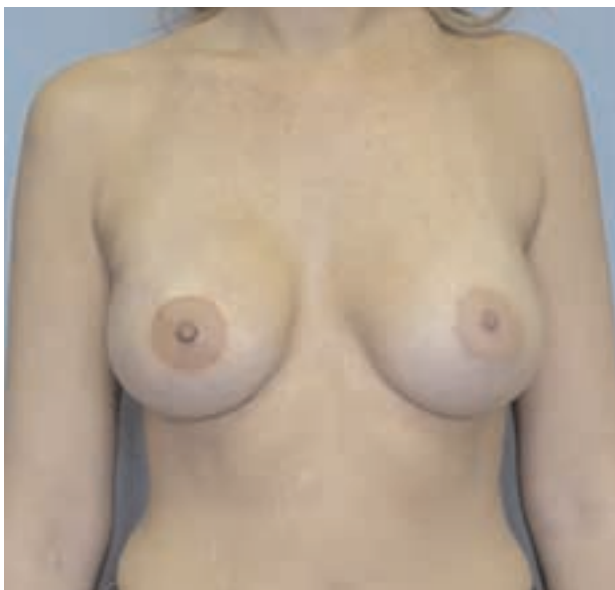

Figure 4.39 Postoperative view after right breast and nipple reconstruction.

Postoperative management

Prophylactic antibiotics with activity against staphylococcal bacteria should be routinely administered. Postoperative pain and discomfort is generally of short duration with this form of reconstruction (cf. TRAM flap reconstruction) and can be controlled with routine analgesia. Drains are removed when daily volumes are less than 30–40 ml. The mean duration of hospital stay is 10 days when immediate reconstruction is undertaken and 2–5 days for delayed reconstruction. A short period of hospitalization is required for exchange of a temporary with a permanent implant. Applying bandaging can help enhance the inframammary fold, but only surgical correction will create a durable fold in the long term. A well fitting sports bra should be worn following reconstruction and contralateral mastopexy or reduction. Intensive exercise should be avoided for 2–3 weeks, although arm and shoulder mobilization is important following formal axillary dissection.

Inflation of the prosthesis should be carried out weekly and ideally performed in a designated outpatient area. The rate of inflation is governed by patient comfort and excessive expansion can produce local pain and discomfort. Expansion takes place over a period of 4–8 weeks, and a temporary tissue expander should not be replaced with a permanent implant within the first 6 months. This allows time for the tissues to adapt and capsule formation to stabilize. Furthermore, the tissues in the lower pole of the breast are stretched by gravitational forces.

Complications

The incidence of local complications with implant reconstruction are lower than those for reconstruction involving autologous flaps. Immediate complications include haematoma formation, skin necrosis and pain. Adjuvant therapies including chemotherapy and radiotherapy can delay wound healing and postpone any planned programme of expansion. Later complications include infection, implant extrusion and capsular contracture. Complications are generally more frequent for immediate compared with delayed reconstruction. This is related to the administration of adjuvant treatments around the time of immediate reconstruction. Chemotherapy may compromise the immune system and influence processes such as regeneration and healing. Radiotherapy impairs the capacity of the skin to act as a natural barrier to exogenous insults. Irradiation induces excessive fibrosis and reduces tissue oxygen levels, thus promoting excessive capsular reaction. Pressure sores can develop in the region of the lower pole when skin is damaged by radiation. Persistent infection around the implant mandates removal and further attempts at reconstruction must be deferred until infection settles. Similarly a partially extruded implant must be removed. The degree of capsular contraction is greater than that occurring following breast augmentation (grade II, III, IV). When capsule formation leads to constriction or pain, open capsulotomy is required and sometimes exchange of implant. These complications are relatively uncommon, but secondary procedures to achieve breast symmetry and optimal shape are frequently necessary.

References

1. van Straalen WH, Hage JJ, Bloemena E. The inframammary ligament: myth or reality? *Ann Plast Surg* 1995; 35: 237.
2. Maillard GF, Garey LJ. An improved technique for immediate retropectoral reconstruction after subcutaneous mastectomy. *Plast Reconstr Surg* 1987; 80: 396.
3. Sterzi G. La Fascia superficiale. In: *Il Tessuto Sottocutaneo (Tela Subcutanea)*; Ricerche Anatomiche. Firenze: L. Niccolai, 1910: 62–8.
4. Colen SR. Immediate two-stage breast reconstruction utilizing a tissue expander and implant. In: Spear SL, ed. *Surgery of the Breast: Principles and Art* (1st edn). Philadelphia: Lippincott-Raven, 1998.
5. Spear SL, Spittler CJ. Breast reconstruction with implants and expanders. *Plast Reconstr Surg* 2001; 107: 177–88.
6. May JW Jr, Attwood J, Bartlett S. Staged use of soft-tissue expansion and lower thoracic advancement flap in breast reconstruction. *Plast Reconstr Surg* 1987; 79: 272.
7. Barone FE, Perry L, Keller T, Maxwell GP. The biomechanical and histopathologic effects of surface texturing with silicone and polyurethane in tissue implantation and expansion. *Plast Reconstr Surg* 1992; 90: 77.
8. Maxwell GP, Falcone PA. Eighty-four consecutive breast reconstructions using a textured silicone tissue expander. *Plast Reconstr Surg* 1992; 89: 1022.
9. Rosato RM, Dowden RV. Radiation therapy as a cause of capsular contracture. *Ann Plast Surg* 1994; 32: 342.
10. Schuster RH, Kuske RR, Young VL, Fineberg B. Breast reconstruction in women treated with radiation therapy for breast cancer: cosmesis, complications, and tumor control. *Plast Reconstr Surg* 1992; 90: 445.
11. Spear SL, Majidian A. Immediate breast reconstruction in two stages using textured, integrated-valve tissue expanders and breast implants: a retrospective review of 171 consecutive breast reconstructions from 1989 to 1996. *Plast Reconstr Surg* 1998; 101: 53.
12. Francel TJ, Ryan JJ, Manson PN. Breast reconstruction utilizing implants: a local experience and comparison of three techniques. *Plast Reconstr Surg* 1993; 92: 786.
13. Beasley ME. Two stage expander/implant reconstruction: delayed. In: Spear SL, ed. *Surgery of the Breast: Principles and Art* (1st edn). Philadelphia: Lippincott-Raven, 1998.
14. Spear SL. Primary implant reconstruction. In: Spear SL, ed. *Surgery of the Breast: Principles and Art* (1st edn). Philadelphia: Lippincott-Raven, 1998.
15. Charpy A. Peauciers et aponévroses. In: *Traité d'Anatomie Humaine* Publié sur la Direction de P. Poirier. T. II Fasc. I, Paris, 1896.
16. Sebileau P. *Demonstrations d'Anatomie*. Paris, 1892.
17. Cooper AP. *On the Anatomy of the Breast*. London: Longmans, 1940.
18. Lockwood TE. Superficial fascial system (SFS) of the trunk and extremities: a new concept. *Plast Reconstr Surg* 1991; 87: 1009.
19. Pennisi VR. Making a definite inframammary fold under a reconstructed breast. *Plast Reconstr Surg* 1977; 60: 523.
20. Rieffel H. L'appareil Génital de la Femme. In: *Traité d'Anatomie Humaine* Publié sur la Direction de P. Poirier et A. Charpy. T. V, Paris, 1901.
21. Chiarugi G. *Istituzioni di Anatomia Dell'uomo*. Milano, 1908.
22. Garnier D, Angonin R, Foulon P et al. Le sillon sous-mammaire: mythe ou réalité? *Ann Chir Plast Esthét* 1991; 36: 313.

23. Bayati S, Seckel BR. Inframammary crease ligament. *Plast Reconstr Surg* 1995; 95: 501.
24. Bostwick J III. Anatomy and physiology. In: *Plastic and Reconstructive Breast Surgery*. St Louis: Q, 1990: 67.
25. Bostwick J III. Finishing touches. In: *Plastic and Reconstructive Breast Surgery*. St Louis: Q, 1990: 1126.
26. Dowden RV. Achieving a natural inframammary fold and ptotic effect in the reconstructed breast. *Ann Plast Surg* 1987; 19: 524.
27. Handel N, Jensen JA. An improved technique for creation of the inframammary fold in silicone implant breast reconstruction. *Plast Reconstr Surg* 1992; 89: 558.
28. Ryan JJ. A lower thoracic advancement flap in breast reconstruction after mastectomy. *Plast Reconstr Surg* 1982; 70: 153.
29. Radovan C. Breast reconstruction after mastectomy using the temporary expander. *Plast Reconstr Surg* 1982; 69: 195.
30. Versaci AD. A method of reconstructing a pendulous breast utilizing the tissue expander. *Plast Reconstr Surg* 1987; 80: 387.
31. Noone RB. Adjustable implant reconstruction. In: Spear SL, ed. *Surgery of the Breast: Principles and Art* (1st edn). Philadelphia: Lippincott-Raven, 1998.
32. Pinella JW. Creating an inframammary crease with a liposuction cannula (Letter). *Plast Reconstr Surg* 1989; 83: 925.
33. Maillard GF, Montandon D, Goin J-L. Implant placed under an inverted abdominoplasty. In: *Plastic Reconstructive Breast Surgery*. Genève: Médecine et Hygiène, 1983: 210.

5 Commentary: materials, mastectomy and tissue expansion

Martin I Newman, Lloyd B Gayle

Breast reconstruction following ablative oncological surgery presents many challenges to the plastic and reconstructive specialist. The preceding three chapters (2–4) in this section collectively provide an excellent overview of the evolution of implantable breast prosthetics, oncoplastic reconstruction and reconstruction using tissue expanders with subsequent permanent prostheses. We review this material with attention to ongoing controversial issues, new developments and surgical technique. The viewpoint of a plastic surgeon specializing in the field of breast reconstruction is offered.

The history and development of breast prostheses and the silicone problem

The authors provide an outstanding and detailed summary of the evolution of breast prosthetics over the past century. The progression in the development of breast implants is, however, not yet complete. New innovations in breast reconstruction continue to emerge. They are fuelled by both controversy and complications and are supported by scientific study. In response to points and arguments put forth by Collis and Sharpe in Chapter 2, we offer commentary on the injection of alloplastic materials, the reported lower incidence of breast cancer in augmented patients, capsular contracture, smooth versus textured implants, submuscular versus subglandular placement of breast prosthetics and the ongoing ‘silicone controversy’.

The injection of alloplastic material is discussed in an historical sense. It should be pointed out, however, that silicone and other alloplastic materials continue to be injected today, subcutaneously and submuscularly, under illicit conditions for

‘quick-fix’ breast augmentations. Patients undergoing these procedures are most commonly transsexuals and present with complications including infection, scarring and deformity. Often on interview they report having had the materials placed by non-qualified, non-medical personnel.¹ Management of these patients can be challenging and most often involves removal of the foreign material and debridement of the infected and scarified tissues.

The authors comment that evidence suggests a lower risk and earlier presentation of breast cancer in the augmented patient. It is important to point out, however, that although some evidence may suggest these statements, multiple well designed studies continue to show no difference in the incidence and presentation of breast cancer in the previously augmented breast and subsequent survival.^{2,3}

Capsular contracture is an unfortunate late complication of breast reconstruction and is well described in this review. A strong argument is made for the role of the textured implants in decreasing the incidence of scar formation and contracture. The reader should be aware, however, of evidence contrary to the authors’ conclusions. Recent studies comparing textured to smooth implants find no difference in the incidence of capsular contracture related to implant design, when used for cosmetic augmentation.^{4,5} We argue that the causes of contracture are likely multifactorial and have yet to be fully elucidated. We therefore support the need for further investigation with respect to implant design as a causative factor of capsular contracture. In addition, with respect to the texturing of implant surfaces, we would further add that an irregular outer surface stimulates the fibrous ingrowth of connective tissue around the prosthetic material. This ingrowth helps to secure the position of the device in relation to surrounding structures – effectively locking it in place. Texturing thus benefits

those implants designed to simulate anatomical shape by stabilizing their position on the chest wall in a predetermined orientation.

Breast prostheses may be placed either in the submuscular or subglandular plane. Each has advantages and disadvantages as adequately described by the authors. It is important to note, however, that in breast reconstruction, as opposed to simple cosmetic augmentation, glandular tissue is most often ablated making subpectoral placement of prosthetic material the procedure of choice. If reconstruction is immediate, total muscle coverage should be achieved. However, if reconstruction is delayed partial coverage with muscle – and partial coverage with skin only – is acceptable providing the chest wall skin is of adequate quantity and quality for this purpose. For patients undergoing breast conservation surgery (lumpectomy), a small subglandular breast prosthesis may seem like an attractive option but should only be placed with the expectation of subsequent radiation therapy and its associated sequelae.

The authors' view on the 'silicone controversy' reflects the dogmatic and highly controversial nature of this ongoing discussion in the medical literature. Large prospective trials, sponsored by the United States Food and Drug Administration (FDA), are currently underway attempting to accurately identify the risks and benefits associated with silicone breast implants. Preliminary data from these studies support the safety and efficacy of silicone breast implants in breast reconstruction. Nevertheless, we consider it prudent to await the final results of these trials prior to forming a professional opinion as to long-term outcome. From a purely aesthetic point of view, however, we agree with the authors' stance that gel implants as opposed to saline implants provide the reconstructed breast with a more natural look and feel. We also wish to reinforce the fact that shells of implantable saline breast prosthetics are constructed of silicone polymer.

Skin-sparing and skin-reducing mastectomy

The term 'oncoplastic' surgery first appeared in the literature in 1996.⁶ The term in this context refers to the application of plastic surgical principles to oncological ablative breast surgery in an effort to avoid and correct the deformities associated with the traditional Halstedian approach.⁷

A reasonable concern regarding this new approach to breast cancer surgery is whether it can be employed without compromising the goals of the

oncological surgeon. Although oncoplastic surgery is a relatively new field, recent literature suggests that both oncological and aesthetic results have proved to be safe and satisfactory when the proper patient selection criteria is adhered to.^{7,8}

The authors of 'Skin-sparing and skin-reducing mastectomy' provide a short but concise description of one such approach to total mastectomy. Their technique as well as similar 'Wise pattern mastectomies' previously described are variations of the standard skin-sparing technique.^{9–13} The specific method outlined in Chapter 3 allows for immediate reconstruction, and it appears to result in a more aesthetically acceptable scar than the traditional mastectomy.

The practice of placing a permanent prosthesis at the initial surgery is also described. Our preference instead, with few exceptions, would be to place only tissue expanders after the described ablative procedure. A permanent prosthesis whether it is silicone or saline filled is most often designed and selected to provide the appearance of a full breast mound. We are concerned that an implant of this size and volume may place undue tension upon the unexpanded pectoralis muscle and newly created mastectomy skin flaps – possibly increasing the risk of epidermolysis, partial flap necrosis, or even full thickness skin and/or muscle loss. When performing procedures of this type, we place only tissue expanders in the submuscular pocket and limit our intraoperative expansion to less than 200 ml in the average sized patient. Subsequent expansions may be carried out in a routine fashion, and exchange for a permanent implant may be performed at a later date. The exception to the need for tissue expansion prior to placement of a permanent implant is seen in the patient with small, non-ptotic breasts. In this case, immediate reconstruction with satisfactory muscle coverage can usually be achieved with a small permanent implant without increasing the risk of complications.

With the exception of the above, we suspect that the skin-sparing, skin-reducing mastectomy is a reasonable and attractive option for patients with medium to large breasts qualifying for skin-sparing mastectomy. The reader should be made aware, however, of two critical considerations not discussed in the authors' presentation: patient selection criteria and the effects of radiation therapy.

It is important to reinforce proper patient selection criteria in any discussion related to breast conservation procedures. We would add to the material in Chapter 3 that factors such as tumour size and invasion of fascia or dermis, factors that help to either qualify or disqualify patients as candidates for

breast conservation and skin-sparing procedures, should be considered when evaluating a patient for possible oncoplastic intervention.

With respect to radiation therapy, we also believe it important to note that many breast cancer patients may have received or may be scheduled to receive radiation at a future date. The effects of ionizing radiation on the skin, muscle and wound healing are well documented. If a patient has already undergone radiation therapy, the skin of the involved breast must be carefully evaluated. Skin damaged by previous radiation therapy precludes its use in reconstruction. We therefore would not recommend the use of the skin-sparing mastectomy in these scenarios. Instead, we advocate the removal of the irradiated skin and replacement with skin from an unaffected location (e.g. latissimus dorsi or TRAM flap). Considering these facts – as well as Benson’s discussion of contraindications to implant reconstruction (Chapter 17) – we would avoid use of simple tissue expander placement for reconstruction in the previously irradiated patient. We would, however, make the reader aware of the controversial nature of this issue and cite literature which supports the use of simple implant reconstruction in this population of individuals.¹⁴

In contrast to patients who have previously undergone radiation therapy, patients planning to undergo radiation therapy in the future may be candidates for skin-sparing ablative procedures followed by simple implant reconstruction. These patients, however, should be made aware of the increased risks associated with this combination of therapies including suboptimal aesthetic results, skin flap ischaemia, poor skin expansion, implant extrusion and capsular contracture.^{15–20} In summary, we support the use of oncoplastic techniques in the appropriately selected and counselled patients.

Breast reconstruction with subpectoral prosthesis or tissue expanders

The last chapter in this section, ‘Breast reconstruction with subpectoral prosthesis or tissue expanders’, provides an excellent and thorough discussion of one of the more common forms of breast reconstruction following ablative surgery for breast cancer. This method of breast reconstruction is favoured by many patients and surgeons for its numerous advantages which include relative technical ease, lack of donor-site morbidity, the use of tissue with similar colour, texture and sensation, comparatively short operative times and reasonably

rapid recovery times.²¹ Much of the authors’ discussion revolves around the procedural and technical aspects of the operation which naturally vary between individual surgeons and institutions. Although the details of patient selection and operative technique described are perfectly appropriate, we offer the reader an alternative point of view based on our years of clinical experience.

With respect to patient selection criteria, in Chapter 4 the authors state that a history of radiotherapy to the chest wall is considered by many surgeons to be a contraindication to reconstruction with implants alone. The effects of radiation on the skin and underlying muscle of the chest wall are well documented as are the increased risks associated with placing a prosthetic device in the subpectoral plane.^{15–20} Although we agree that a history of radiation therapy to the chest wall imparts an increased risk of a suboptimal aesthetic result, skin flap ischaemia, poor skin expansion, implant extrusion, and capsular contracture, we are aware of studies in the literature suggesting the contrary¹⁴ and the existence of ongoing studies comparing these risks to the risks associated with alternative breast reconstructive procedures. Ultimately, we believe that a history of radiation therapy – in and by itself – is not an absolute contraindication to reconstruction with implants alone, and that the decision of reconstructive technique should be made on an individual basis between a well-informed patient and their surgeon.

The authors offer the option of placing a permanent implant in the submuscular plane immediately after an ablative breast procedure. As discussed in our response to ‘skin-sparing and skin-reducing mastectomy’ (Chapter 3), with the exception of the small, non-ptotic breast, our preference instead would be to place tissue expanders in this setting. We again cite our concern that an implant designed and selected to provide the appearance of a full breast mound may place undue tension upon the unexpanded, newly created mastectomy skin flaps. Such tension may increase the risk of epidermolysis, partial flap necrosis or even full thickness skin and/or muscle loss. In the setting of immediate reconstruction with submuscular implants, we place primarily tissue expanders and limit our intraoperative expansion to 200 ml in the average sized patient. Subsequent expansions may be carried out in a routine fashion, and exchange for permanent implant may be performed at a later date.

We would next comment on the use of combined implantable devices discussed in Chapter 4. These devices which serve as both tissue expanders and permanent implants are placed in the submuscular plane and inflated through a remote port placed in

a nearby location, usually laterally along the anterior axillary line. When expansion is complete, the port can be removed under local anaesthesia leaving the inflated device in situ as a permanent prosthesis. This appears to be an attractive option. It is technically very straightforward and its use obviates the need for a second procedure – exchanging the expander for a permanent implant. Yet in clinical practice we find that the use of this one-stage device deprives the surgeon of an opportunity to surgically correct the expanded skin and adjust the inframammary fold at the exchange procedure which most agree is a key step in achieving optimal aesthetic results. Its use also precludes the option of changing to a silicone prosthesis should the patient become dissatisfied with the look or feel of saline during expansion.

The authors next emphasize the importance of preserving the inframammary fold during ablative surgery as critical. We suggest that preservation of the fold is not critical to optimal reconstruction and its value in reconstruction is, at best, controversial. Anatomical studies have demonstrated extension of breast tissue below the inframammary fold. Therefore the caudal limit of dissection remains variable among subjects. In addition, because the implantable device is placed in the submuscular plane the newly created fold of the reconstructed breast is a function of the inferior margin of the device and not the anatomical inframammary fold.

With respect to the creation of the submuscular pocket, we believe it important to specifically state the limits of dissection which are dependent on anatomic landmarks, preoperative markings and the dimensions of the contralateral breast. Specifically, the base dimensions of the contralateral breast – independent of volume – should be the primary determinant in selecting the appropriately sized device for reconstruction. The superior limit of dissection should be guided by a preoperative marking placed on the skin at the junction of the chest wall and the superior pole of the breast. The lateral limit of dissection should be sub-serratus accommodating the width of the selected tissue expander to correspond to the base width of the breast being reconstructed. Dissection past this point may result in a laterally placed expander and subsequently the permanent prosthesis. The medial limit of dissection should be guided both by preoperative markings as well as the origin of the pectoralis major muscle along the costal–sternal junction. Medial dissection beyond this limit may result in synmastia, an aesthetically unpleasant complication. Our inferior dissection goes beyond the inferior border of

the pectoralis major muscle and continues in a plane between the rectus muscle and its anterior fascia. Traditionally, the fascia has been lifted off the muscle for a distance of approximately 1 cm inferior to the preoperative inframammary fold. However, with the advent of the new contoured tissue expanders, the inferior dissection may be limited to the level of the anatomical inframammary fold. In these cases a well-defined fold can be achieved in some circumstances with the textured, contoured device alone.

Other differences between the technique described in Chapter 4 and our methods worthy of mentioning include our aseptic technique and expansion methods. We prefer not to immerse either the expander or the prosthesis in povidone iodine. Manufacturers of these devices have warned against the ‘dipping’ or ‘painting’ of these devices with povidone iodine citing a possible increase in the risk of implant rupture. In addition, some suggest a correlation between the use of povidone iodine and capsular contracture. Instead, we choose to irrigate the pocket thoroughly with a heavily diluted solution of povidone iodine and double-antimicrobial wash which has been shown in Phase III trials to maximize control of the most common offending (bacterial) organisms and to minimize the detrimental effects on wound healing.²² With respect to tissue expansion methods, we do not perform serial expansions guided by volume alone. Instead, we inflate the expander weekly or every two weeks based upon a target volume but limit the amount infused based on the pressure generated by the injection of fluid. In our experience, a pressure of 30 mmH₂O should not be exceeded.

A striking difference between the methods described by the authors and our operandi concerns hospital admission and length of stay. Our practice is in the USA, and as opposed to the admission criteria and hospital course in Europe described by the authors our patients stay in the hospital for a much shorter duration. In the USA, the average patient undergoing mastectomy and immediate reconstruction with implantable tissue expander is discharged after a 48-hour uncomplicated hospital course, and exchange of tissue expander for permanent prosthesis is most often done on an outpatient basis. The hospital stay for an uncomplicated pedicled TRAM flap reconstruction is approximately 4 or 5 days.

In summary, Section I of this book offers an excellent overview of some of the more common materials and techniques involved in non-autologous breast reconstruction today.

References

1. Hage JJ, Kanhai RC, Oen AL et al. The devastating outcome of massive subcutaneous injection of highly viscous fluids in male-to-female transsexuals. *Plast Reconstr Surg* 2001; 107: 734–41.
2. Brinton LA, Lubin JH, Burich MC et al. Breast cancer following augmentation mammoplasty (United States). *Cancer Causes Control* 2000; 11: 819–27.
3. Holmich LR, Mellemkjaer L, Gunnarsdottir KA et al. Stage of breast cancer at diagnosis among women with cosmetic breast implants. *Br J Cancer* 2003; 88: 832–8.
4. Fagrell D, Berggren A, Tarpila E. Capsular contracture around saline-filled fine textured and smooth mammary implants: a prospective 7.5-year follow-up. *Plast Reconstr Surg* 2001; 108: 2108–12.
5. Tarpila E, Ghassemifar R, Fagrell D, Berggren A. Capsular contracture with textured versus smooth saline-filled implants for breast augmentation: a prospective clinical study. *Plast Reconstr Surg* 1997; 99: 1934–9.
6. Gabka CJ, Maiwald G, Baumeister RG. [Expanding the indications spectrum for breast saving therapy of breast carcinoma by oncoplastic operations]. *Langenbecks Arch Chir Suppl Kongressbd* 1997; 114: 1224–7.
7. Amanti C, Moscaroli A, Lo RM et al. [In Process Citation]. *G Chir* 2002; 23: 445–9.
8. Peyser PM, Abel JA, Straker VF et al. Ultra-conservative skin-sparing ‘keyhole’ mastectomy and immediate breast and areola reconstruction. *Ann R Coll Surg Engl* 2000; 82: 227–35.
9. Greco RJ, Dascombe WH, Williams SL et al. Two-staged breast reconstruction in patients with symptomatic macromastia requiring mastectomy. *Ann Plast Surg* 1994; 32: 572–9.
10. Skoll PJ, Hudson DA. Skin-sparing mastectomy using a modified Wise pattern. *Plast Reconstr Surg* 2002; 110: 214–17.
11. Toth BA, Lappert P. Modified skin incisions for mastectomy: the need for plastic surgical input in pre-operative planning. *Plast Reconstr Surg* 1991; 87: 1048–53.
12. Wise L, Mason AY, Ackerman LV. Local excision and irradiation: an alternative method for the treatment of early mammary cancer. *Ann Surg* 1971; 174: 393–401.
13. Wise L. Controversies in the management of potentially curable breast cancer. *Surg Annu* 1974; 6: 247–81.
14. Bacilious N, Cordeiro PG, Disa JJ, Hidalgo DA. Breast reconstruction using tissue expanders and implants in Hodgkin’s patients with prior mantle irradiation. *Plast Reconstr Surg* 2002; 109: 102–7.
15. Forman DL, Chiu J, Restifo RJ et al. Breast reconstruction in previously irradiated patients using tissue expanders and implants: a potentially unfavorable result. *Ann Plast Surg* 1998; 40: 360–3.
16. Mark RJ, Zimmerman RP, Greif JM. Capsular contracture after lumpectomy and radiation therapy in patients who have undergone uncomplicated bilateral augmentation mammoplasty. *Radiology* 1996; 200: 621–5.
17. Rosato RM, Dowden RV. Radiation therapy as a cause of capsular contracture. *Ann Plast Surg* 1994; 32: 342–5.
18. Spear SL, Majidian A. Immediate breast reconstruction in two stages using textured, integrated-valve tissue expanders and breast implants: a retrospective review of 171 consecutive breast reconstructions from 1989 to 1996. *Plast Reconstr Surg* 1998; 101: 53–63.
19. Vandeweyer E, Deraemaecker R. Radiation therapy after immediate breast reconstruction with implants. *Plast Reconstr Surg* 2000; 106: 56–8.
20. Victor SJ, Brown DM, Horwitz EM et al. Treatment outcome with radiation therapy after breast augmentation or reconstruction in patients with primary breast carcinoma. *Cancer* 1998; 82: 1303–9.
21. Spear SL, Spittler CJ. Breast reconstruction with implants and expanders. *Plast Reconstr Surg* 2001; 107: 177–87.
22. Adams WP Jr, Conner WC, Barton FE Jr, Rohrich RJ. Optimizing breast pocket irrigation: an in vitro study and clinical implications. *Plast Reconstr Surg* 2000; 105: 334–8.



Flaps

6 Breast reconstruction with the latissimus dorsi myocutaneous flap

Stefano Modena, Giuseppe Mangiante, Guidobaldo Querci della Rovere

Introduction

Breast reconstruction is an important component of breast cancer management and should be a safe procedure of appropriate complexity for the patient. No significant functional deficit should ensue and rates of complications must be minimized and any subsequent delays in commencement of adjuvant therapy following immediate reconstruction should be avoided.

Professor Iginio Tansini,¹ a surgeon in Pavia, Italy, first introduced the latissimus dorsi (LD) myocutaneous flap in 1896 as a method for compensating for tissue deficit following mastectomy, but only as recently as 1976–1977 has this method been employed with the intention of reconstructing a breast mound (Olivari,² Mulbauer and Olbrisch,³ and Schneider et al⁴)

Breast reconstruction using the LD flap in conjunction with a prosthesis was probably the commonest reconstructive procedure until the early 1980s when its popularity waned. This was because of three principal drawbacks of this procedure:

- problems with the prosthesis (migration and capsular formation)
- large scar on the back (seroma formation common)
- need for contralateral breast reduction to achieve symmetry.

The high rate of capsular contracture with the implant led to many surgeons abandoning this technique, but the advent of textured prosthesis

greatly reduced this particular complication especially when complete muscle coverage of the implant could be obtained. The scar at the donor site on the back can be very prominent in thin individuals and it may not always be possible to contain this within the territory of the bra strap. Preoperative planning and marking of the skin island on the back is very important. Notwithstanding these comments, the donor-site scar is not considered to be of major concern to many patients according to data collected by ourselves.

Breast symmetry is a principal objective in any form of breast reconstruction and is difficult to achieve in patients with large and ptotic breasts without carrying out a contralateral reduction. Greater bulk of tissue is potentially available with a rectus abdominis flap (transverse or vertical), but this is a more complex and lengthy procedure especially when a free graft involving microvascular anastomosis is chosen.

An LD flap reconstruction is suited to patients with moderate sized breasts and symmetry may be possible (without contralateral surgery) when an inflatable prosthesis is placed beneath the myocutaneous flap. This permits greater final volume together with a degree of ptosis which much enhances the ultimate appearance. The latissimus dorsi muscle is supplied by the thoracodorsal artery and vein; these are substantial vessels and the flap is generally robust. Upon entering the muscle, the main arterial trunk branches into a rich network of smaller tributaries which provide a rich blood supply both for the muscle itself and for the overlying skin. It is essential that the skin island actually lies within the

anatomical boundaries of the muscle to ensure that it receives vascular input from perforating vessels in the underlying muscle. Provided that these conditions are adhered to, complications such as flap necrosis are uncommon with this technique and functional deficits are only apparent in regular swimmers, golfers and tennis players. Reconstruction with the LD flap is now considered to be the primary procedure of choice for many patients for reasons of robustness, potential tissue bulk (with prosthesis) and low rates of complications.⁵⁻⁸

Surgical anatomy

The latissimus dorsi is a large muscle and arises from the lower six thoracic spines, the posterior layer of the lumbar fascia and the iliac crest. In addition there are muscle slips from the lower four

ribs and occasionally from the inferior angle of the scapula. The muscle converges towards the axilla where it wraps around the lower border of the teres major muscle and inserts into the floor of the bicipital groove of the humerus. The lateral part of the muscle is closely associated with the serratus anterior muscle on its deep aspect. The latissimus dorsi muscle has two free borders, (i) an upper border passing from the posterior axillary line to the sixth thoracic spine and (ii) a lateral border demarcating the midaxillary line (Figure 6.1).

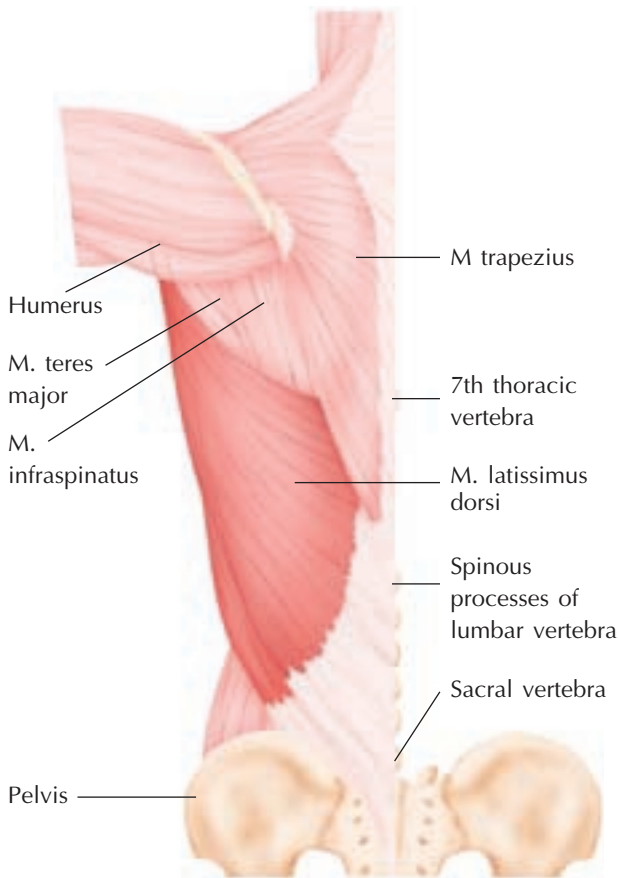


Figure 6.1 Anatomy of the latissimus dorsi muscle. Note that the muscle takes origin from the lower six thoracic, lumbar and upper sacral spinous processes via the thoracolumbar fascia together with the iliac crest. In addition there are muscle slips from the lower three or four ribs and the inferior angle of the scapula and there are fascial attachments to the serratus anterior muscle.

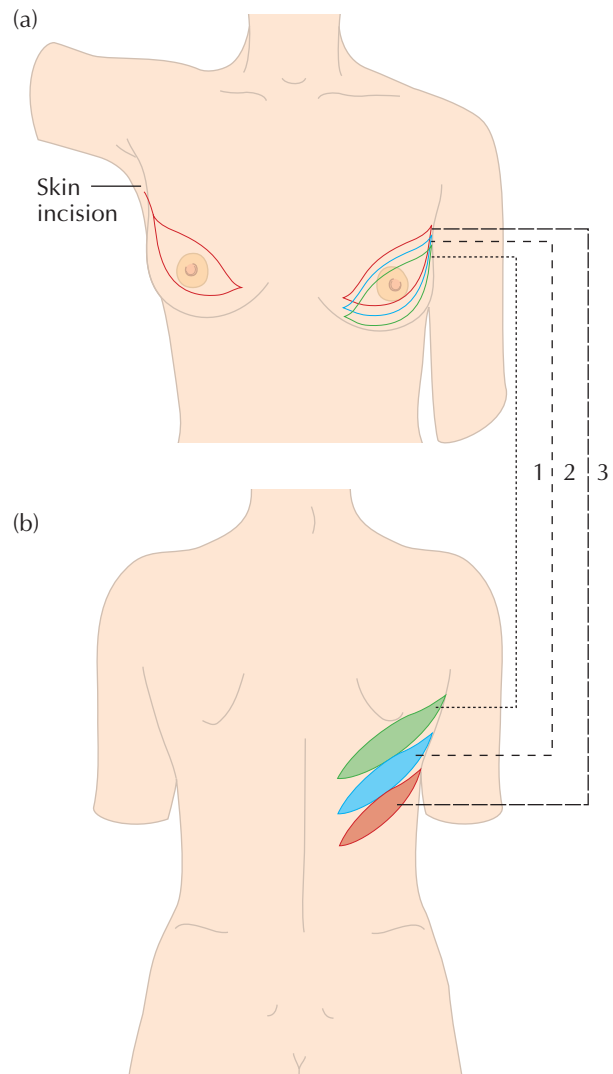


Figure 6.2 Position of skin incisions on the breast (a) and on the back (b) prior to surgery (patient should be fully cooperative and premedication withheld until marking is complete). (a) An elliptical breast incision is made centred around the nipple-areola complex and lying in an oblique direction. It can be extended into the axilla if necessary. The medial limit of the incision should be as close to the nipple as possible. (b) The donor ellipse on the back is placed relatively high when the breast ellipse is centred more inferiorly and placed lower when the breast lesion lies more superiorly.

The latissimus dorsi muscle is supplied by the thoracodorsal branches of the subscapular vessels which arise from the axillary trunk. The thoracodorsal vessels give off a branch to the serratus anterior muscle and when blood flow within the thoracodorsal vessels is interrupted, blood can pass from the serratus anterior muscle as an alternative source. Arterial branches entering the lateral border of the muscle divide into a rich network supplying the muscle and overlying skin. The skin paddle can be harvested in any orientation, but should not extend more than 2–3 cm beyond the edge of the underlying muscle (Figure 6.2).

The latissimus dorsi muscle is supplied by the thoracodorsal nerve which arises from the posterior cord of the brachial plexus and runs along the upper part of the muscle medial to the corresponding artery and vein.

Contraindications to LD flap reconstruction

Use of the latissimus dorsi muscle for reconstruction may be restricted on account of the following factors:

- previous thoracotomy
- atrophy of the muscle secondary to surgical damage of the vascular pedicle or radiation-induced injury.

The functional status of the muscle can be tested directly by asking the patient to touch the contralateral buttock against resistance. Assessment of muscle bulk will provide some indirect indication of function. The lateral edge of the muscle is difficult to palpate when atrophic, and tends to lie more horizontally. For those patients undergoing delayed reconstruction and who have already had a surgical intervention (\pm radiotherapy) it is prudent to check the integrity of the vascular pedicle with either Doppler ultrasonography or angiography (the former is non-invasive and the preferred method).

Immediate reconstruction

Preoperative marking of the skin

With the patient standing upright, the mastectomy incision (ellipse) is drawn on the anterior thoracic wall. It is crucial to mark the level of the inframammary fold, and this must be preserved during any subsequent mastectomy and reconstruction. The

mastectomy incision should not encroach upon the region of the anterior axillary fold, and the lateral part of the incision should lie within the mid/posterior region of the axilla. An obliquely directed incision is preferable to a transverse one as the medial end will be less visible when the patient wears a low V-neck dress. The maximum width of the skin island on the back should not exceed 12 cm (maximum) and usually ranges from 7 cm to 12 cm. Larger areas of skin create a defect which is difficult to close primarily without undue tension. Should the patient have large breasts, it is preferable to insert a tissue expander beneath the myocutaneous flap rather than a definitive prosthesis. It is our preferred method to place the skin paddle as low as possible (close to the ilium) so that the scar lies below the dress line. The precise position and orientation of the skin island will be governed by the features and position of the mastectomy defect. It is important to allow for rotation of the flap when planning the final position and angle of lie of the skin island. When performing immediate reconstruction, the lower mastectomy flap and inframammary fold should be carefully preserved. Skin-sparing mastectomy can be employed, via a small peri-areolar incision with a lateral extension if necessary to access the axillary contents. In this situation, only a relatively small area of skin need be harvested with the myocutaneous flap, but the siting of this must be carefully judged. In circumstances where no skin is required, a linear incision is made in a relatively lateral position. In very thin patients, it may be possible to harvest the muscle alone through the mastectomy incision thus avoiding any scar on the back.

Details of the operative procedure

Positioning

The patient should be placed in the lateral position with the side to be operated on uppermost. The ipsilateral arm is supported on a bracket.

Mastectomy

The mastectomy is performed first and this is facilitated by slightly rotating the patient posteriorly ensuring that they remain in a stable position on the operating table. The axillary contents should be cleared in continuity with the mastectomy and it is safest to identify and isolate the thoracodorsal trunk as a first step. With the patient in the lateral position the vascular pedicle lies more superficial than in the usual supine position and care is needed to prevent damage to this structure when dissecting deep to the clavipectoral fascia at the outer border of the muscle. The position of the patient's arm and pectoralis major muscle will facilitate access to the

apex of the axilla and the operator should beware of the vertical course of the axillary vein with the patient in the lateral position.

Harvesting of the flap

Upon completion of the mastectomy component of the operation, it is convenient to rotate the operating table slightly anteriorly (the patient is rotated away from the surgeon which facilitates dissection of the myocutaneous flap). As mentioned above, in the event that no skin island is required, the latissimus dorsi muscle can often be successfully harvested from the mastectomy wound with the aid of two large retractors. Otherwise the skin of the back is incised along the pre-marked lines with the blade angled obliquely away from the skin to avoid overhang. The dissection proceeds within the plane between the muscle fascia and subcutaneous tissue; excessive amounts of fat should not be left on the muscle and attempts made to harvest the whole of the muscle and at the very least, the skin island should be entirely encircled by muscle. The muscle dissection can commence along the anterior border which has already been freed and identified during the axillary dissection. The deep surface of the latissimus dorsi muscle is closely related to the serratus anterior muscle which must be carefully dissected free and not inadvertently elevated with the LD myocutaneous flap. Finger dissection can be used to free the muscle from loose areolar tissue in the region of the inferior border of the scapula. Once mobilized, the muscle can be divided along the inferior and medial borders to detach the muscle from the ilium and vertebral column. Extreme care is taken with the final stages of dissection as the insertion of the muscle in the humerus is approached. Division of the humeral attachment is not mandatory and is probably not warranted in the first instance if the flap can be adequately transposed to the appropriate position without undue tension. The flap is passed through the tunnel beneath the skin bridge separating the mastectomy and donor-site wounds. If the flap cannot reach across medially, then the insertion of the muscle at the humerus should be divided (with the pedicle seen and protected at all times). The back wound is closed with interrupted sutures to the deep fascia and a continuous subcuticular suture. A suction drain is placed at the donor site and orientated inferomedially towards the area of divided muscle.

Breast reconstruction

Once the donor site is closed and dressed, the patient can be repositioned supine with both arms abducted on arm boards and protected with padding. The edges of the transposed muscle are carefully sutured to the margins of the mastectomy cavity. The implant

is introduced into the resultant pocket and the remaining edge of the latissimus dorsi muscle is sutured to the margin of the pouch. It is helpful at this stage to sit the patient up at an angle of 45° to check the size, position and lie of the implant which can be compared with the contralateral breast (both breasts should be propped and draped). Where an inflatable prosthesis is to be used, the valve can be placed in the subcutaneous space in the region of the axilla or on the lower anterior chest wall (ease of access). Suction drains should be placed deep to the implant and within the axilla. Superficial drains can also be used if deemed necessary. Full antibiotic cover is essential (anti-staphylococcal agent) and additionally the implant can be soaked in an antibiotic or antiseptic solution prior to insertion. The skin of the mastectomy flaps is sutured to the donor skin island with a continuous subcuticular technique using monofilament material.

A prosthesis may not be required in patients with a small contralateral breast, and additional bulk from the autologous tissue alone can be obtained by folding redundant muscle underneath the skin island (Figure 6.3).

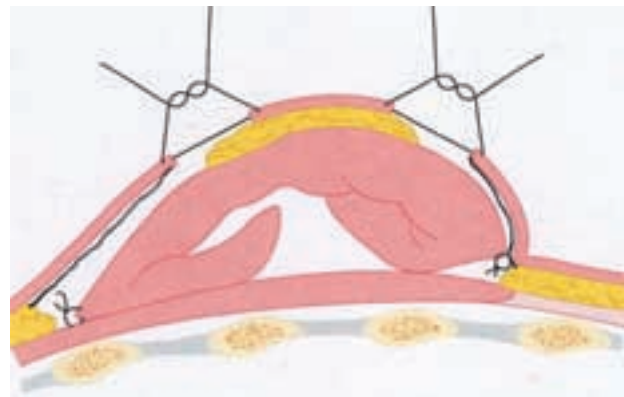


Figure 6.3 Folding of the latissimus dorsi muscle to provide bulk for the breast mound.

Patients can receive radiotherapy to the chest wall following reconstruction with an implant and latissimus dorsi flap; it is preferable that the implant is completely protected by muscle and does not lie partially subcutaneously. This may occur in the lower aspect of the reconstructed breast where the inferior border of the muscle is sometimes sutured directly to the subcutaneous tissue of the lower mastectomy flap rather than to the chest wall.

In patients without palpable disease in the axilla, the operation can be commenced by raising the LD flap with the patient in the lateral decubitus position. After the flap has been completely

mobilized it is positioned and fixed in a subcutaneous pouch just lateral to the breast which can be retrieved at the completion of the mastectomy. The donor site wound is then closed and the patient repositioned supine on the operating table. Adopting a supine position allows the mastectomy and reconstruction part of the operation to be undertaken with greater ease.

Delayed breast reconstruction

The surgical technique for delayed breast reconstruction is essentially similar to that for immediate reconstruction, but with some important differences. It is essential to reconstitute the inframammary fold, and on occasions it is preferable to make a fresh incision on the chest wall rather than open up the mastectomy scar. More commonly, the mastectomy scar is excised and the skin island placed within the space created at the site of the original mastectomy wound.

Following a radical mastectomy (Halsted) with sacrifice of the pectoralis major muscle, a new anterior axillary fold can be fashioned from the latissimus dorsi muscle. The humeral insertion is divided and reattached to the residual pectoralis tendon and clavicle. Where the pectoralis tendon cannot be located, the muscle is sutured directly to the humerus at the former site of insertion of the pectoralis major muscle. When this manoeuvre is necessary, it is useful to place the donor skin island more superiorly on the back in proximity to the tip of the scapula. Transposition of the muscle will then enable the skin paddle to fill any defect in the subclavicular space. Further tissue bulk may be obtained by de-epithelializing part of the skin island and placing this beneath the superior flap. This method can be employed in cases of congenital absence of the pectoralis muscles (Poland syndrome).

Step-by-step demonstration of an LD flap myocutaneous flap reconstruction and left modified radical mastectomy (Figures 6.4–6.28)

The operation commences with raising of the flap (left side of the patient). The patient is positioned in the right lateral decubitus position with the arm slightly abducted and flexed forward on the arm rest. The operating table is broken with a 20–30° angle to better expose the flank of the patient.

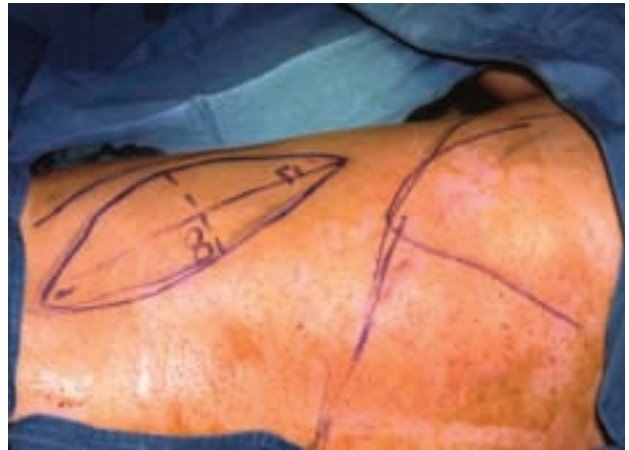

Figure 6.4 Left breast reconstruction with an LD flap. An oblique island (8 × 18 cm) of skin marked on the back.

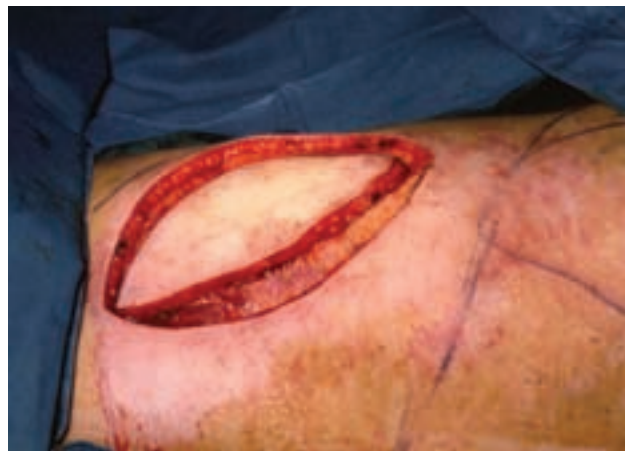

Figure 6.5 Skin incision down to the muscular fascial plane.

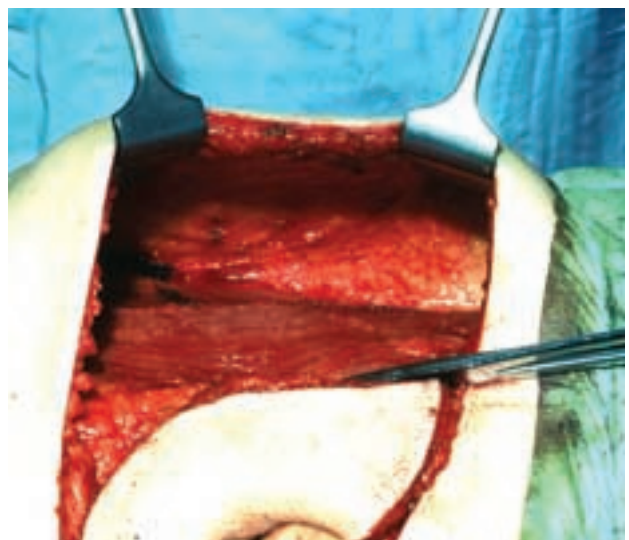


Figure 6.6 Anterior subcutaneous dissection as far as the anterior border of the latissimus dorsi muscle.

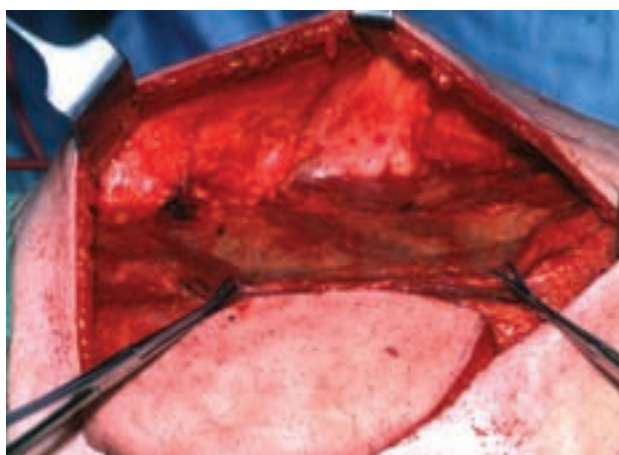


Figure 6.7 The anterior border of the latissimus dorsi is mobilized and dissected from the serratus anterior muscle.

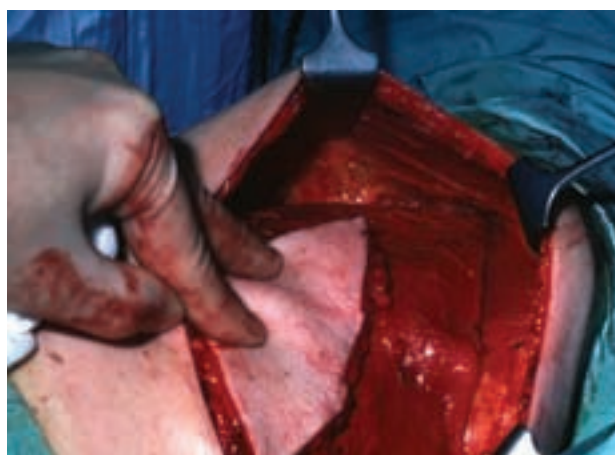

Figure 6.8 Subcutaneous dissection to expose the superior/posterior border of the latissimus dorsi muscle.

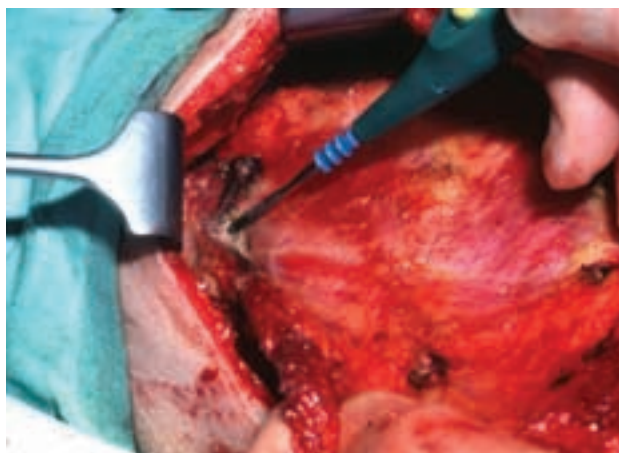


Figure 6.9 The lower/anterior insertions of the latissimus dorsi on the ribs are divided with cutting diathermy.

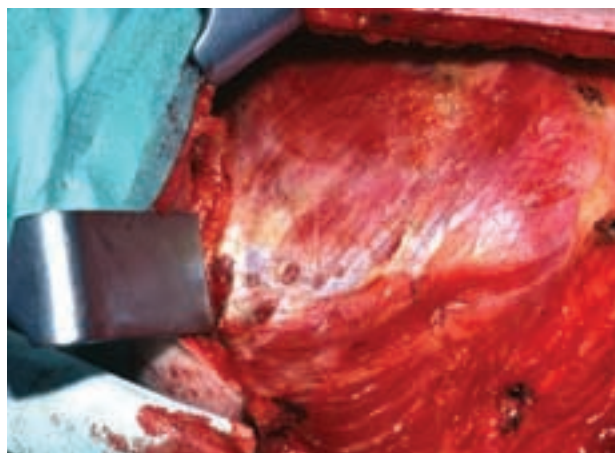

Figure 6.10 Lower/posterior dissection completed exposing the serratus posterior muscle.

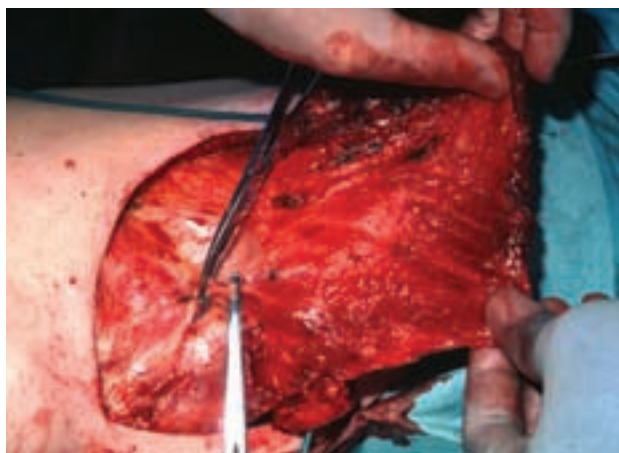

Figure 6.11 The mobilization of the latissimus dorsi muscle continues in an upward direction. Large vessels are clamped, divided and tied with absorbable material.

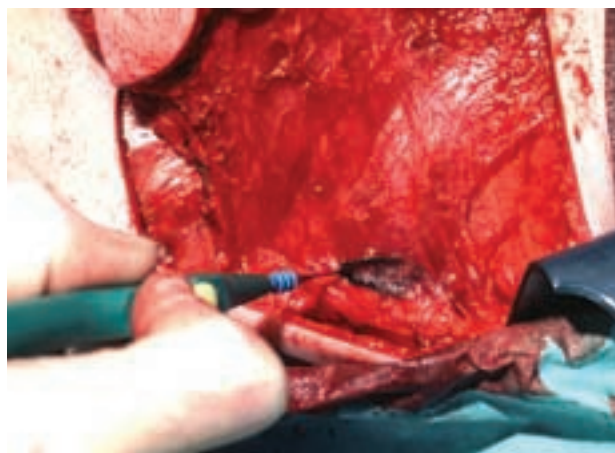


Figure 6.12 Cutting diathermy division of the medial insertions of the latissimus dorsi close to the spine. At this point one might find the lower end of the trapezius.

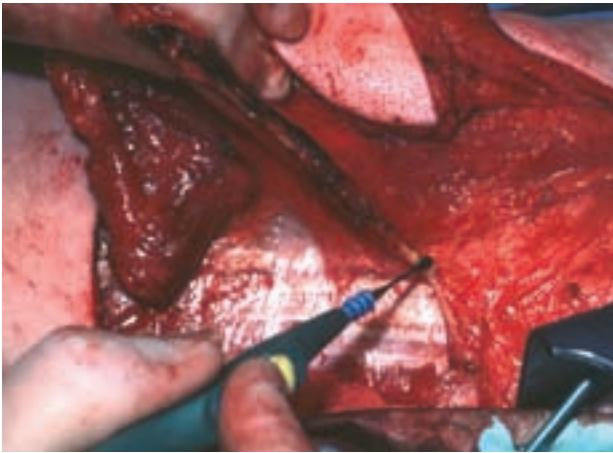


Figure 6.13 The dissection continues along the posterior/superior border of the latissimus dorsi.

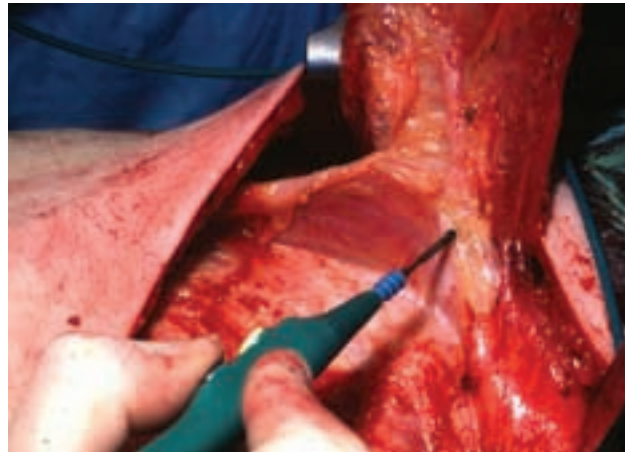

Figure 6.14 The latissimus dorsi is dissected free from the underlying serratus anterior muscle.

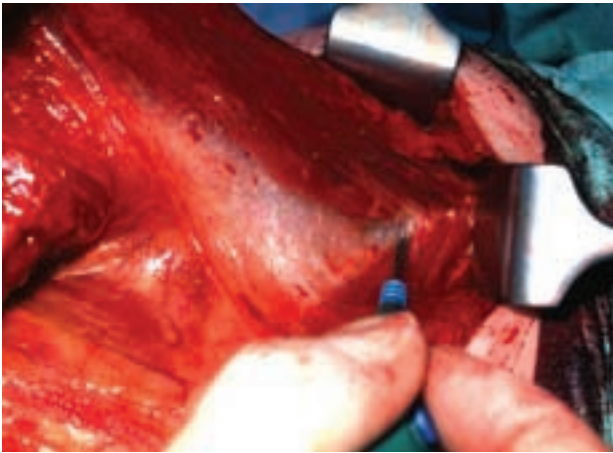

Figure 6.15 The dissection continues cranially separating the superior margin of latissimus dorsi from the teres major muscle.

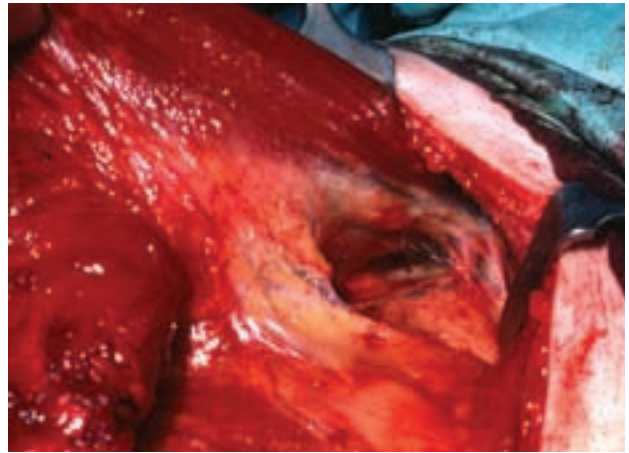


Figure 6.16 The dissection is continued as far as the exposure of the thoracodorsal bundle where it divides to supply a branch to the serratus anterior muscle.

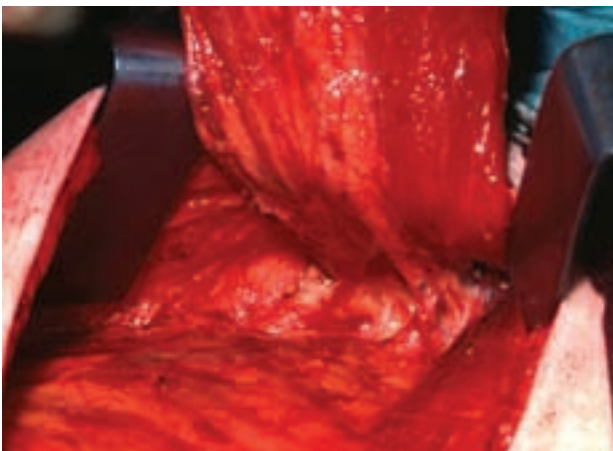


Figure 6.17 The latissimus dorsi flap completely mobilized.

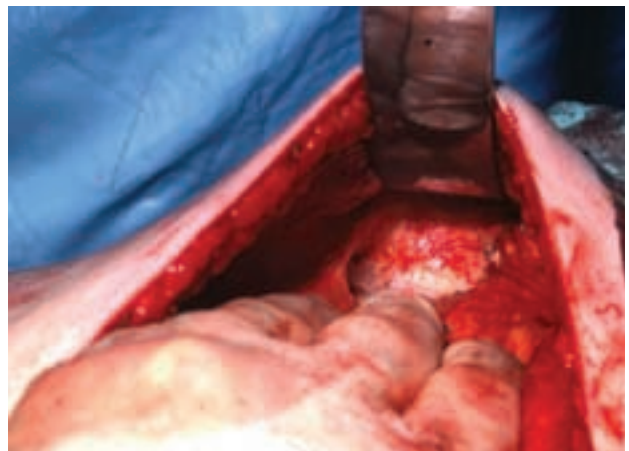

Figure 6.18 A pouch is now created on the upper lateral chest wall as far as the lateral margin of the breast disc.

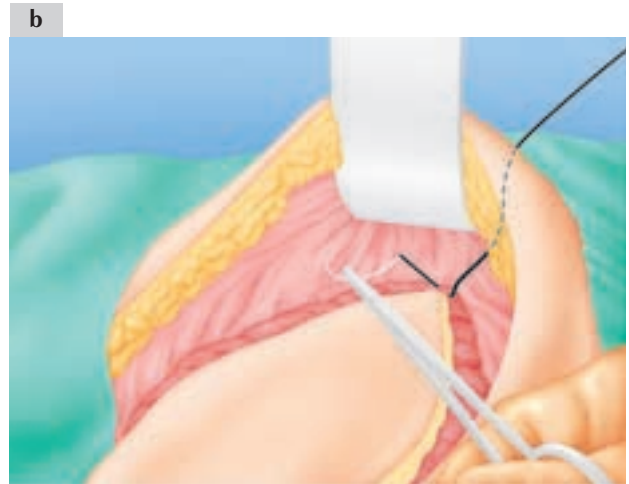
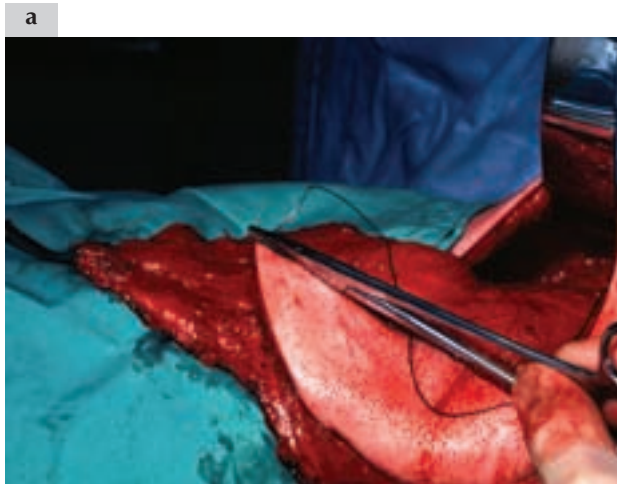


Figure 6.19 (a) A silk stitch is then inserted into the pouch from outside inside and then passed through the dermis of the distal end of the island of skin of the LD flap. (b) Diagram of the stitch passed through the dermis of the distal end of the skin of the flap.

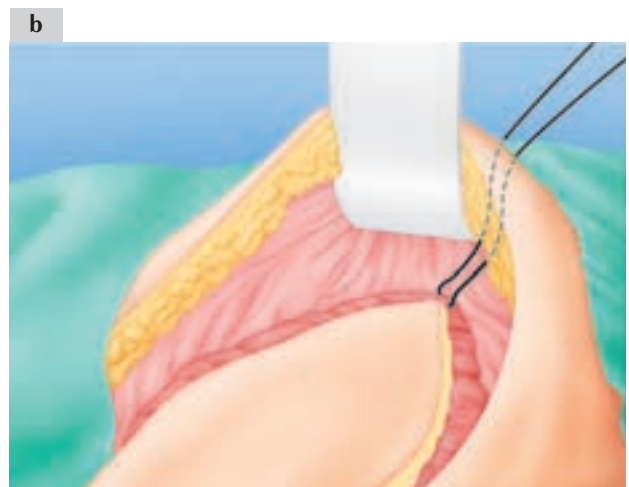
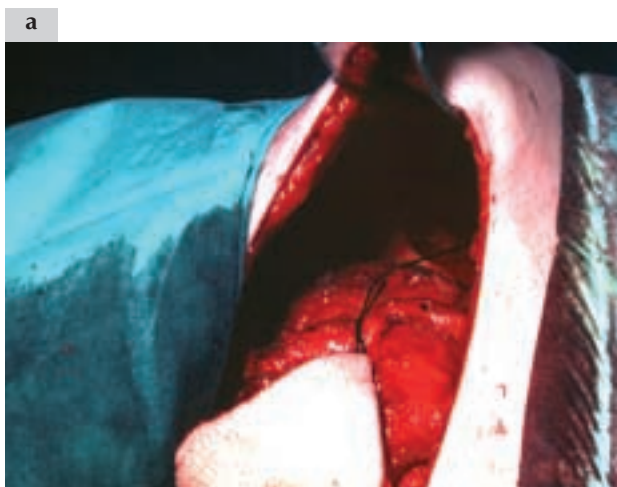


Figure 6.20 (a) The silk stitch is then passed from inside, out to the starting point. By traction on the stitch the LD flap is pulled and anchored in the pouch. The silk stitch is loosely tied on the outside. (b) Diagram showing the anchoring stitch.

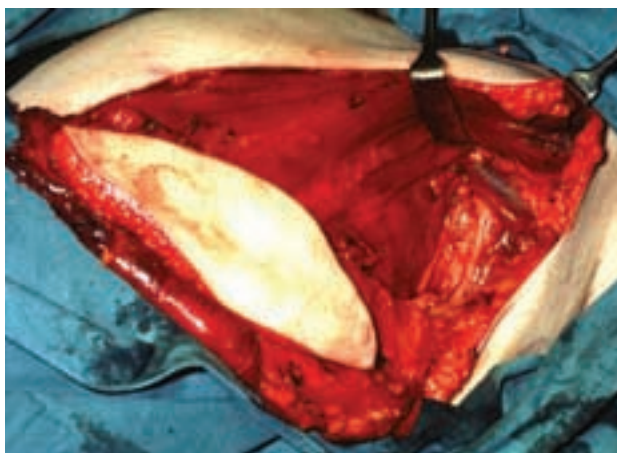


Figure 6.21 After completion of the mastectomy the LD flap will be retrieved and the stitch cut. The picture demonstrates the LD flap with its thoracodorsal pedicle in the dissected axilla.

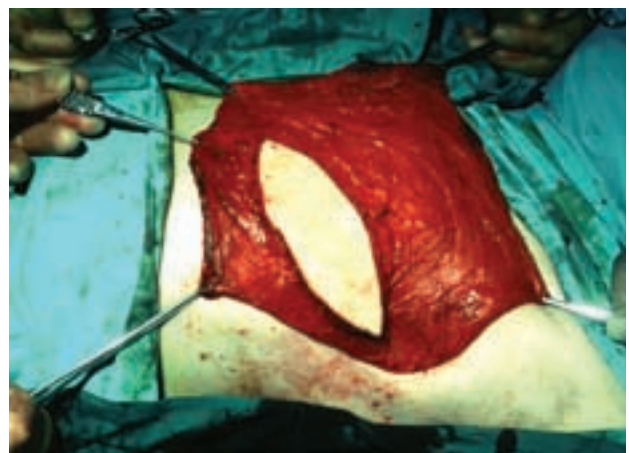


Figure 6.22 Demonstration of the area of anterior left chest wall that will be covered by the LD flap to reconstruct the breast.

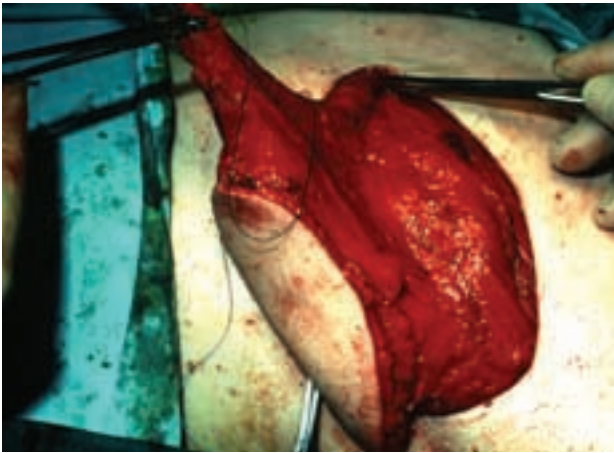


Figure 6.23 A stitch of absorbable material is passed through the distal end of the latissimus dorsi muscle.

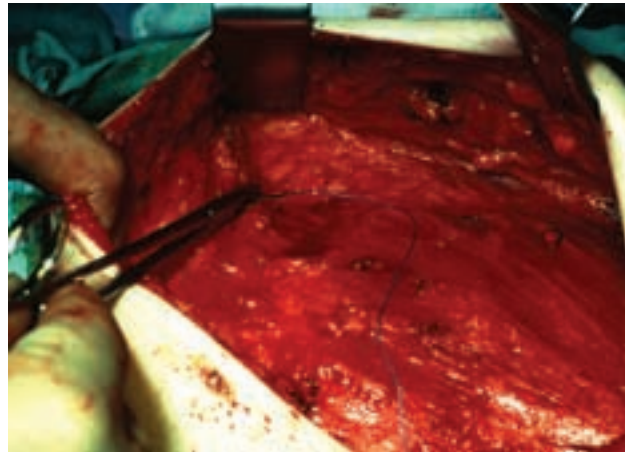


Figure 6.24 The same stitch is then fixed to the lower medial end of the mastectomy cavity (not to the pectoral muscle).

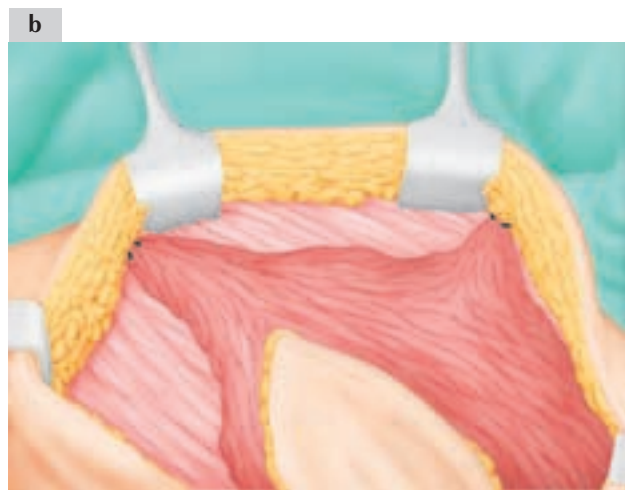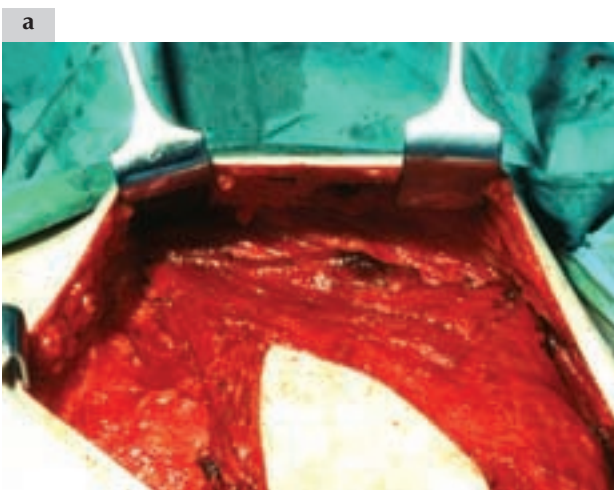


Figure 6.25 (a) The medial superior and inferior fixation of the muscle. (b) Diagram of upper and lower medial fixation of the latissimus dorsi muscle.

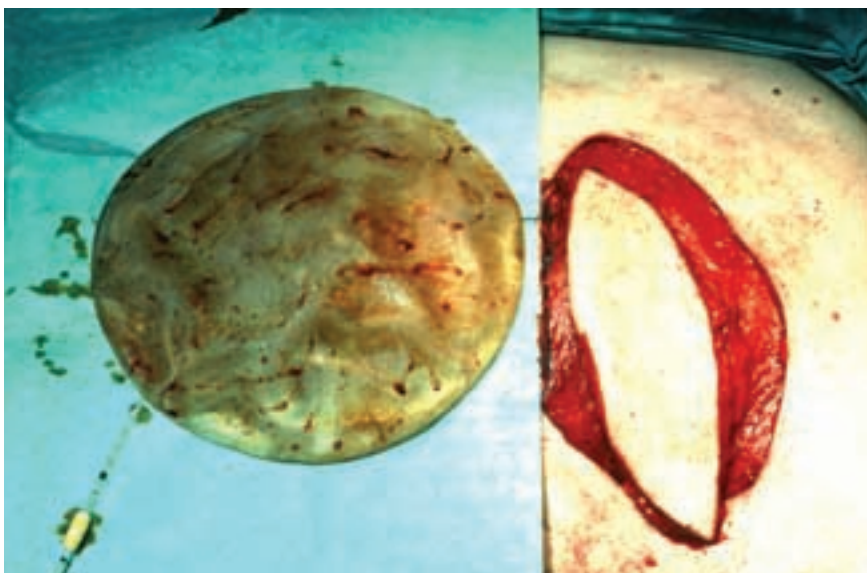


Figure 6.26 After suturing the medial superior and lateral borders of the muscle an opening is left at the inferior border to insert the tissue expander.

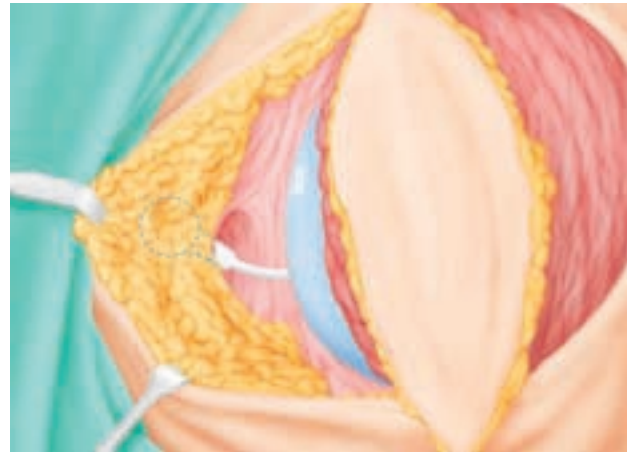
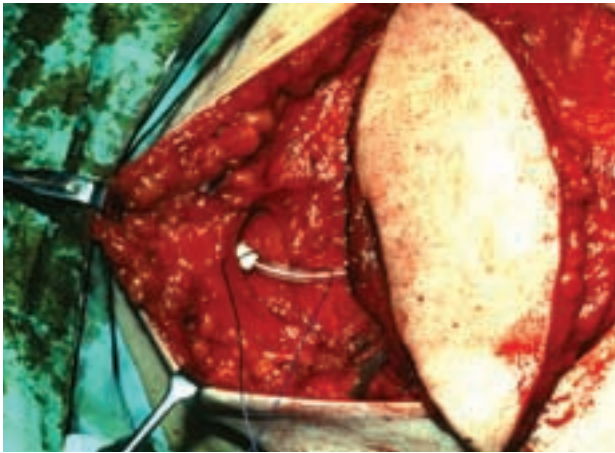


Figure 6.27 The port of the Becker tissue expander is positioned in a pouch created by blunt dissection on the lower anterior chest wall. The opening of the pouch is closed to prevent the displacement of the port.

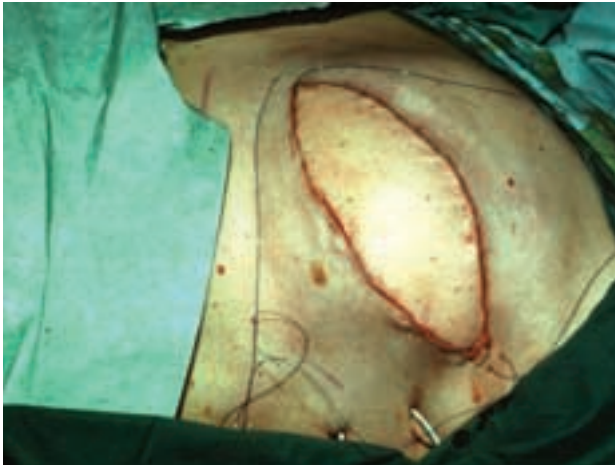

Figure 6.28 The completed operation.

Complications

Seroma formation

This is common at the donor site and can be readily managed by repeated aspiration. Ideally the drain should be retained postoperatively until the drainage volume is less than 30–40 ml. Smaller seroma collections will spontaneously absorb over a period of 3–4 weeks.

Flap necrosis

Total necrosis of the LD flap is a rare occurrence. It is usually a consequence of technical error and resultant surgical insult to the vascular pedicle at the time of reconstruction. Alternatively, the patient may have been inappropriately selected for this form of reconstruction on account of previous damage to

the pedicle. Partial loss of the flap can occur in up to 5% of patients and is more common in the distal portion of the flap. Infection and extrusion of any underlying implant can follow, necessitating removal of the implant with re-insertion 3–4 months later.

Malposition of the implant

Migration of the implant can occur in a superolateral direction. Placement of sutures between the latissimus dorsi muscle and lateral portion of the pectoralis major can help minimize the incidence of this complication. Displacement of the implant in other directions is uncommon.

Capsular contraction

This complication is now much less frequent with use of textured implants and with complete coverage of the implant with overlying muscle (either latissimus dorsi or pectoralis major). Use of an inflatable prosthesis can reduce capsule formation provided inflation is carried out regularly. Some recommend massage of the implant site 2–3 weeks after surgery. Once a definite capsule has formed, open capsulotomy should be carried out to remedy the situation, but recurrent capsule formation is high.

Conclusion

On the basis of results of others and ourselves, we would advocate breast reconstruction with a latissimus dorsi flap in conjunction with a prosthesis as the preferred reconstructive option for many patients. The following advantages are apparent:

- a relatively low complication rate
- minimal functional impairment
- good cosmetic results
- suitable method for a high proportion of patients.

In addition, this method of reconstruction often obviates the need for further reductive surgery to the contralateral breast, and symmetry can usually be achieved with a single operative procedure (Figures 6.29–6.38).

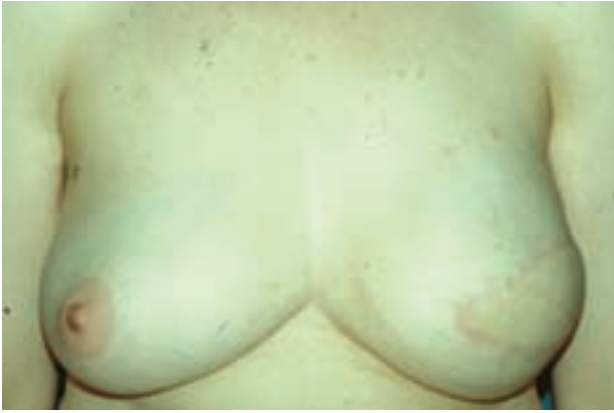

Figure 6.29 Postoperative view, immediate reconstruction.

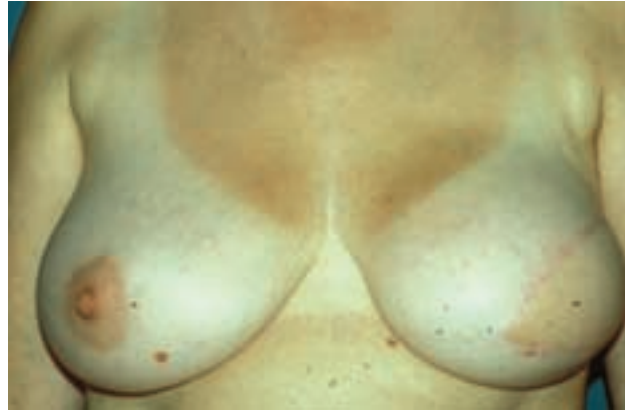

Figure 6.30 Postoperative view, immediate reconstruction.

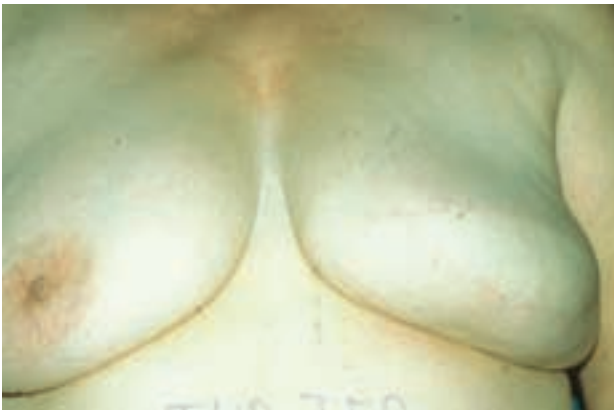

Figure 6.31 Postoperative view, immediate reconstruction.

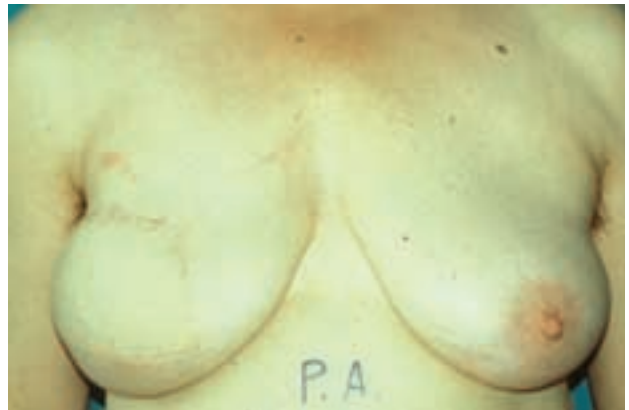


Figure 6.32 Postoperative view, immediate reconstruction.

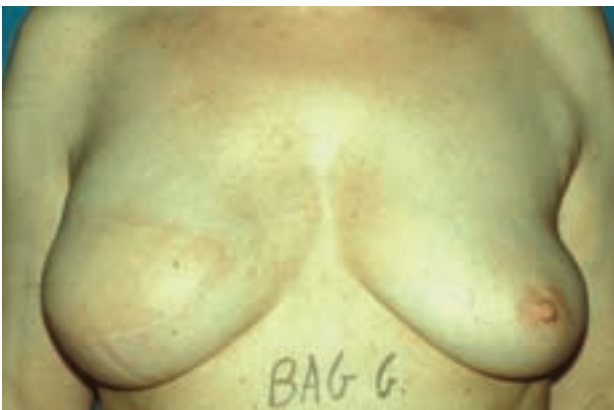

Figure 6.33 Postoperative view, immediate reconstruction.

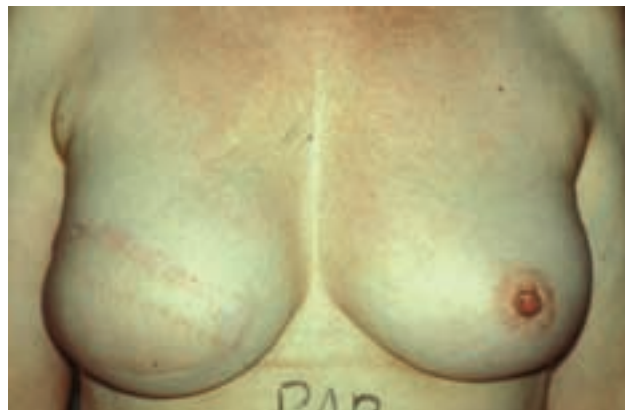

Figure 6.34 Postoperative view, immediate reconstruction.

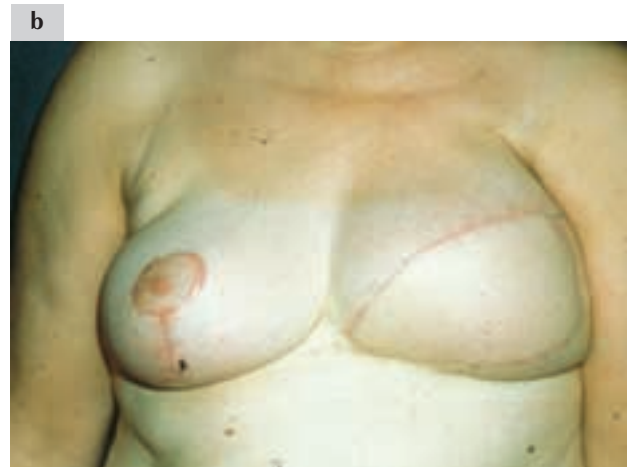
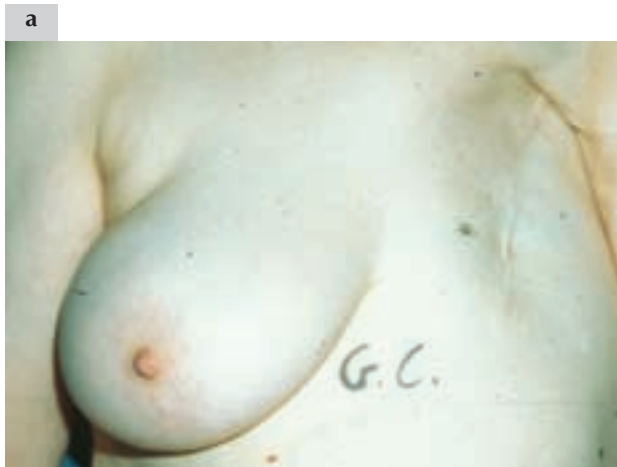
Figure 6.35 (a) Preoperative view, delayed reconstruction. (b) Postoperative view, delayed reconstruction and contralateral reduction.

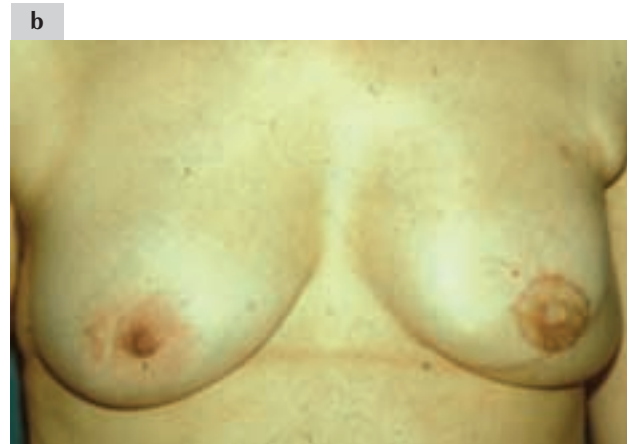
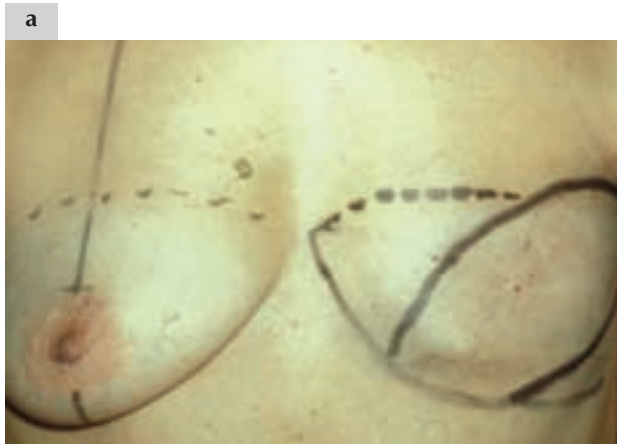
Figure 6.36 (a) Preoperative view and (b) postoperative view, delayed reconstruction.

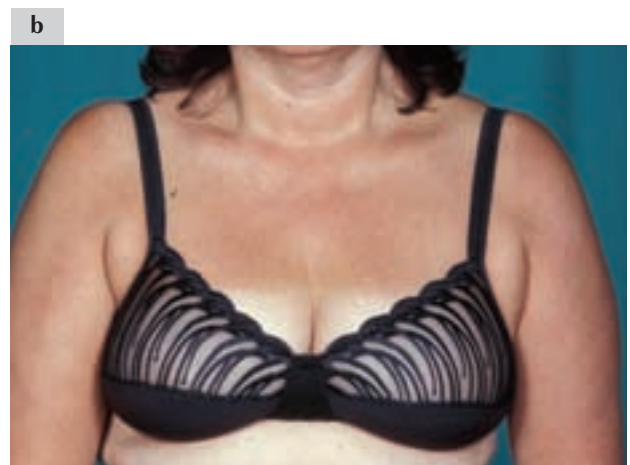
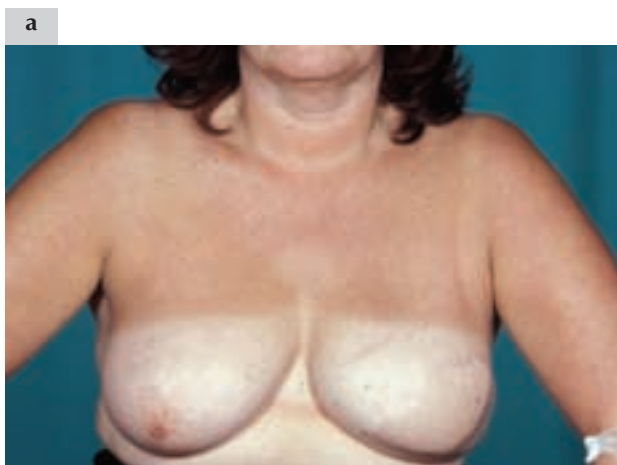

Figure 6.37 (a) Postoperative view, immediate reconstruction, without bras. (b) Postoperative view with bras.

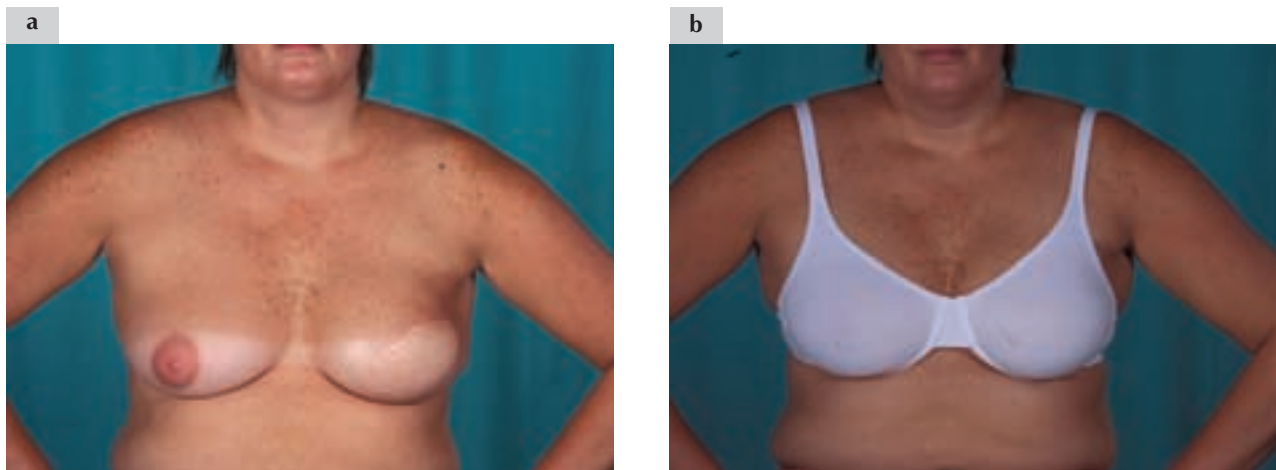


Figure 6.38 (a) Postoperative view, immediate reconstruction, without bras. (b) Postoperative view with bras.

References

1. Tansini I. Nuovo processo di amputazione della mammella per cancro. *Riforma Medica* 1896; 3–5.
2. Olivari N. The latissimus flap. *Brit J Plast Surg* 1976; 29: 126–8.
3. Muhlbauer W, Olbrisch R. The latissimus dorsi myocutaneous flap for breast reconstruction. *Chir Plast* 1977; 4: 27.
4. Schneider WJ, Hill LH, Brown RG. Latissimus dorsi myocutaneous flap for breast reconstruction. *Br J Plast Surg* 1977; 30: 277–81.
5. Webster D, Mansel R, Hughes L. Immediate reconstruction of the breast after mastectomy: is it safe? *Cancer* 1984; 53: 1416–19.
6. Frazier T, Noone R. An objective analysis of immediate simultaneous reconstruction in the treatment of primary carcinoma of the breast. *Cancer* 1985; 55: 1202–5.
7. Vinton A, Traverse W, Zehring D. Immediate breast reconstruction following mastectomy is as safe as mastectomy alone. *Arch Surg* 1990; 125: 1303–8.
8. Petit J-Y, Chretien B, Rigaut L, Griggio L. Bilan critique de la reconstruction mammaire par la technique du lambeau musculo-cutane pediculise sur ie muscle grand droit. A propos de 60 observations. *Ann Chir Plast Esthet* 1987; 32: 124–33.

7 Pedicled TRAM flap reconstruction

Jean-Yves Petit, M Rietjens, O Youssef, F de Lorenzi

Introduction

The use of the transverse rectus abdominis myocutaneous (TRAM) flap for breast reconstruction was first described by Hartrampf¹ in 1982. The flap had originally been employed as a method of obtaining skin and soft tissue cover of the chest wall following extensive surgical extirpation for breast cancer. Its potential use in recreating a breast mound was introduced shortly thereafter.

Anatomy

In contrast to the latissimus dorsi myocutaneous flap, the muscular component of the TRAM flap lacks both area and bulk which precludes its direct deployment in remodelling a reconstructed breast. Instead, the rectus muscle encases the superior epigastric vessels and its principal role relates to provision of an adequate blood supply to the skin and subcutaneous tissue of the flap. The superior and inferior epigastric vessels pass along the deep surface of the rectus muscle (Figure 7.1), from origin to insertion and anastomose around the para-umbilical region by fine collaterals. It is the perforators arising from the para-umbilical plexus which provide direct blood supply to the flap. The dominant blood supply to the infra-umbilical fold of tissue is from the inferior and not the superior epigastric vessels. The rectus abdominis muscle takes origin from the symphysis pubis and pubic crest and is inserted into the 5th, 6th and 7th costal cartilages together with the xiphoid process. The supra-umbilical portion of the muscle is regularly interrupted along its course by tendinous intersections in which the fascia of the anterior rectus sheath is closely adherent to the muscle. These intersections correspond with the segmental distri-

bution of the myotomes during embryological development and are usually three in number.

The fascia of the rectus abdominis muscle is relatively tough and fibrous around the origin of the muscle and progressively thins out at the level of the arcuate line, below which the posterior rectus sheath is deficient.² Above the level of the anterior superior iliac spine, the anterior rectus sheath is formed by fusion of the aponeuroses of three muscles (see Figure 7.1c). The sheath is deficient posteriorly and the muscle lies in direct contact with the fascia transversalis. Therefore, below the arcuate line, the muscle is separated from the peritoneal cavity by the fascia transversalis and peritoneum, together with a variable amount of extraperitoneal fat. It is important to understand these anatomical details to appreciate surgical repair of the abdominal wall following transposition of the rectus muscle and part of its sheath. The bulk of the TRAM flap is composed of a large island of skin and subcutaneous fat tissue which derives its blood supply from the superior epigastric pedicle. Initial reports of the technique advocated raising the flap on a single muscle pedicle which can adequately vascularize two-thirds of the flap. Subsequently, bipedicled flaps were employed in order to maximize the viable volumes of flap tissue.

Monopedicled TRAM flap

Flap design

The flap should be marked out the day prior to surgery with the patient in the standing, lying, and finally, sitting positions. This permits assessment of abdominal wall tissues and marking in the upright position ensures symmetry of the abdominal scar.

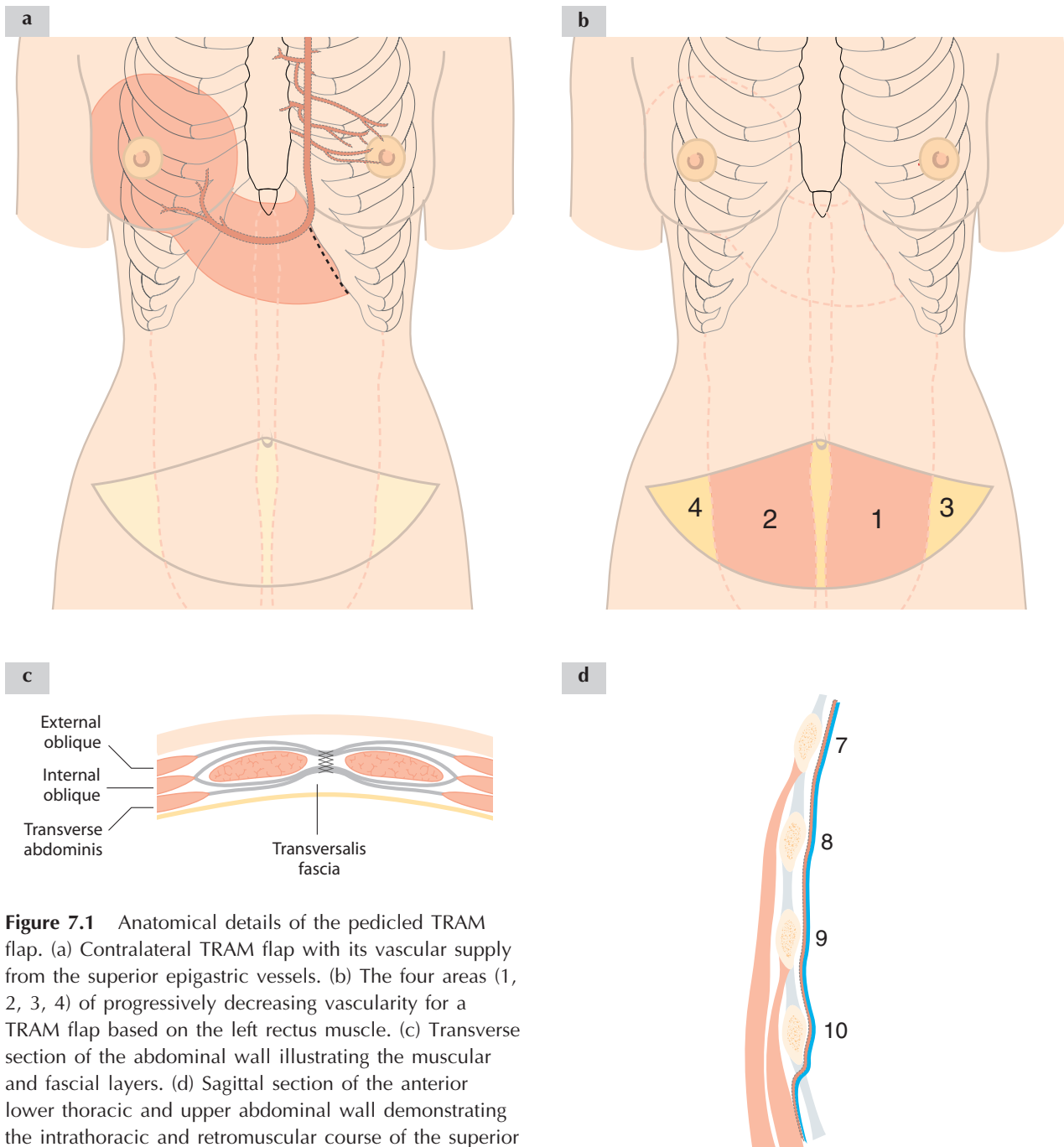


Figure 7.1 Anatomical details of the pedicled TRAM flap. (a) Contralateral TRAM flap with its vascular supply from the superior epigastric vessels. (b) The four areas (1, 2, 3, 4) of progressively decreasing vascularity for a TRAM flap based on the left rectus muscle. (c) Transverse section of the abdominal wall illustrating the muscular and fascial layers. (d) Sagittal section of the anterior lower thoracic and upper abdominal wall demonstrating the intrathoracic and retromuscular course of the superior epigastric vessels. It also illustrates how the upper insertions of the rectus muscle lie anterior to the ribs whereas the epigastric vessels are posterior. It is therefore safe to divide the lateral superior portion of the rectus muscle over the costal margin (dotted line in (a)) to allow an adequate rotation of the flap.

The anterior superior iliac spines will be at the same level, thus yielding a horizontal scar. This marking phase also provides an opportunity to clarify and reinforce details of the operation with the patient. It is imperative that the skin island is centred on the para-umbilical perforators to guarantee optimal blood supply to the flap. These can be identified

accurately with a Doppler ultrasound probe and preoperative marking provides a valuable guide whilst raising the flap. The majority of the sub-umbilical skin should be included and the upper margin of the flap should extend just proximal to the umbilicus in order to preserve the para-umbilical perforators.

Flap dissection

The upper skin incision is deepened down to the level of the aponeurosis. The incision should be bevelled to include umbilical perforators with more subcutaneous tissue on the flap side. The upper abdominal flap is undermined to the xiphoid process and inframammary sulcus. Use of cutting diathermy can help minimize blood loss during this stage of the operation. The lower flap incision is deepened to the aponeurotic plane and larger subcutaneous vessels are controlled with ligatures.

It is customary to select the contralateral rectus pedicle (although the ipsilateral pedicle can also be used) as this is less likely to be included within any subsequent radiotherapy field. The skin island is mobilized to the midline with successive division of para-umbilical perforators. The latter are often disposed symmetrically and their location on one side can predict the position of perforators on the other side. On the side of the pedicle, the flap is elevated until the lateral border of the rectus muscle is reached. Undermining is continued for a further 2–3 cm until the first perforator vessels are identified. Those perforators at the lateral border of the rectus can be safely sacrificed. The anterior rectus sheath is incised immediately lateral to the perforators, and the muscle pedicle mobilized. The rectus muscle should be isolated along its length from the lateral border and subsequently freed on this under-surface. The inferior epigastric pedicle should be identified and traced to below the arcuate line corresponding to the proposed level of division of the rectus muscle. There are no perforating vessels below the level of the arcuate line, and therefore harvesting muscle distal to this line is unnecessary. Attempts to do so will jeopardize abdominal wall integrity on account of the absence of any posterior rectus sheath at this level. Following division of the muscle, its border should be anchored to the flap with absorbable sutures to prevent shearing forces which might damage perforators passing to the flap from the underlying muscle. The muscle must be separated medially from the linea alba along its length and the umbilicus detached from the flap and left in situ on the anterior abdominal wall. The muscle is progressively mobilized proximally as far as the costal margin with freeing of the muscle at its costal insertion. Intercostal nerves and vessels passing laterally are divided including the 8th intercostal nerve which ensures atrophy of the rectus muscle and prevents unwanted contraction thereof.

With the flap fully mobilized on its pedicle, its blood supply can be assessed by observing the amount of bleeding from a small nick incision on the contralateral side of the flap. This part of the flap is furthest from the blood supply and if brisk red

bleeding is witnessed, the flap has a good blood supply. Dark red bleeding associated with bluish discoloration of the flap is an ominous sign and indicates poor venous return. This portion of the flap should be excised until bright red bleeding is apparent. Where viability of the flap is in doubt, the volume of tissue should be reduced and in extreme circumstances an implant can be used to supplement residual flap tissue.

Excision of mastectomy scar

When a delayed reconstruction is undertaken, the scar of the mastectomy is widely excised and submitted for complete histological examination. The inferior limit of the mastectomy flap dissection should correspond to the future inframammary fold. This should be placed slightly higher than the definitive position to allow for the effect of closure of the abdominal scar.

Transposition of the flap

In order to transpose the bulky flap from an abdominal to thoracic location, a subcutaneous tunnel must be created in the xiphisternal region. It is important not to undermine beyond the medial limit of the contralateral breast and the tunnel must be wide enough to admit an average sized hand and this will ensure ease of transposition without constriction of the pedicle. During transposition of the flap it is important to check the flap is neither twisted, strangulated nor under any tension. Moreover, prior to transposition, the tunnel should be meticulously inspected for haemostasis, as any collection of blood within the tunnel can restrict blood supply to the flap secondary to compression of the vascular pedicle. The flap is transposed in an anticlockwise direction if on the right, and clockwise if on the left. Ipsilateral and monopedicled flaps are becoming increasingly popular, but these involve some angulation and torsion of the muscle which can compromise venous return. An advantage of the ipsilateral pedicle is that it minimizes any epigastric bulge which can persist indefinitely.

The flap can be placed at different angles in order to judge the best orientation, although during the phase of remodelling and positioning of the flap, care is needed to avoid placing the muscle pedicle under any further tension. Excess tissue can be excised and additional skin is de-epithelialized and buried under the native chest wall skin. In delayed reconstruction the inframammary fold must be reconstructed and in the case of immediate reconstruction, this structure should be preserved during mastectomy in order to obtain optimal results.

Abdominal closure

Whilst the new breast is being modelled, the abdominal wall can be repaired simultaneously. Careful and accurate repair of the rectus fascia is very important. In those cases where much of the fascia has been preserved during harvesting of the flap and the quality of tissue is good, the defect can be closed primarily using non-absorbable, interrupted sutures which include all layers of fascia. This should be reinforced with a second continuous layer of non-absorbable suture (nylon or prolene). Where the aponeurotic defect is large (or for personal preference), synthetic mesh can be employed for closure of the abdominal fascia. This mesh is sutured laterally to the cut edge of the rectus sheath and medially to the linea alba (or cut medial edge of the rectus sheath) with non-absorbable sutures. This mesh will lie directly beneath the subcutaneous tissues and the latter together with skin are approximated after breaking the operating table. Two large suction drains are placed deep to the subcutaneous tissues prior to closure of superficial layers. Finally, the umbilicus is exteriorized and during closure of the aponeurotic defect care must be taken to avoid drawing this structure away from the midline. A contralateral plication of the anterior rectus sheath may be necessary to restore the position of the umbilicus when this structure has been pulled across from the midline. Alternatively, the umbilicus can be excised and a new one fashioned by the

technique of invagination. The new orifice for the umbilicus should be either triangular or rounded and not too large so as to encourage inversion of the scar which thereby becomes less conspicuous.

Bipedicled TRAM flap

When a large volume of tissue is required or there is an increased risk of flap necrosis, the flap can be raised on a dual pedicle using both muscle bellies of the rectus abdominis. This enhances the blood supply to the flap, but at the expense of abdominal wall integrity. The technique is similar to that for a monopedicled flap and the muscles are divided distally at or just beyond the arcuate line. Some surgeons¹ attempt to preserve a strip of muscle laterally (about 2 cm) rather than sacrificing the whole muscle. However, this is unlikely to confer any functional advantage as the residual muscle will be denervated and ultimately shrink and become fibrosed. Others contend that these muscle strips remain well vascularized and do contribute to the strength and security of abdominal wall closure. There is additional muscle bulk in the epigastric region following transposition with this approach. However, there tends to be muscle atrophy over the course of a few months and bulging of the muscle pedicles becomes less apparent. The abdominal wall should always be repaired with a mesh after harvesting a bipedicled TRAM flap.

Step-by-step demonstration of a bipedicled TRAM flap (Figures 7.2–7.20)

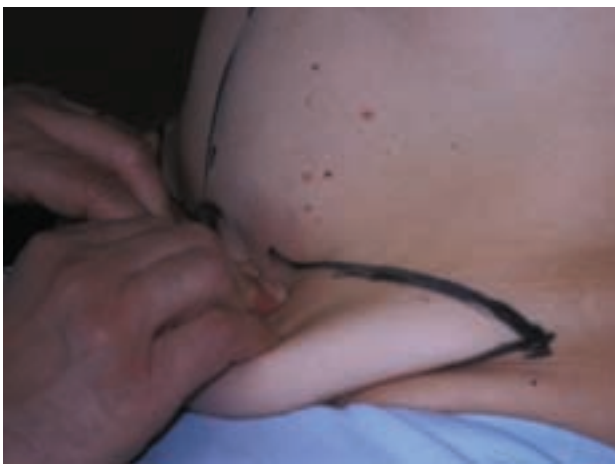

Figure 7.2 Preoperative assessment of the adequacy of redundant skin and subcutaneous tissue in the infra-umbilical region.

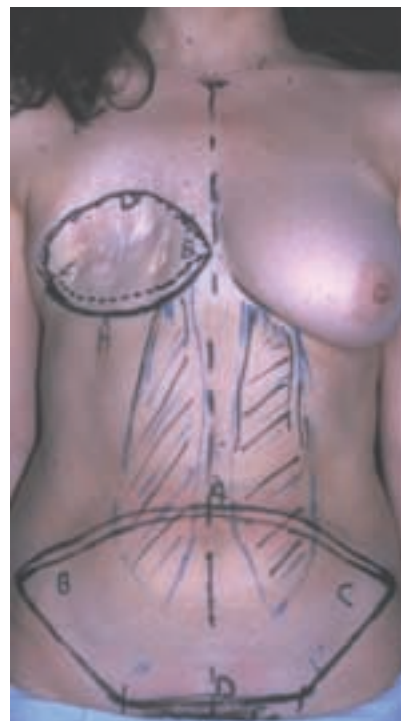

Figure 7.3 Preoperative marking for a bipedicled TRAM flap. Points A, B, C and D marked on the flap and chest wall indicate the direction of rotation of the flap.

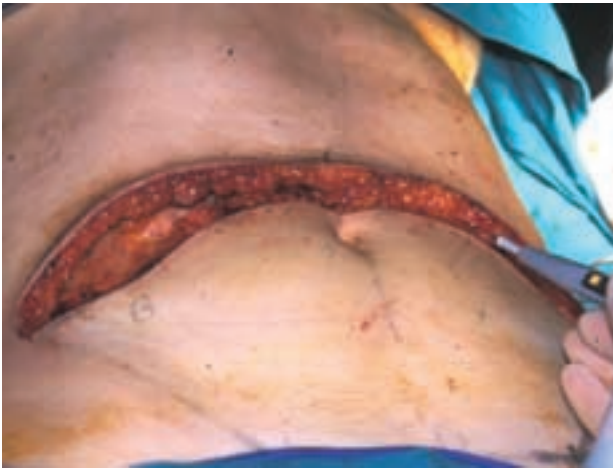

Figure 7.4 Incision of the skin and subcutaneous tissue along the upper margin of the flap just superior to the umbilicus.

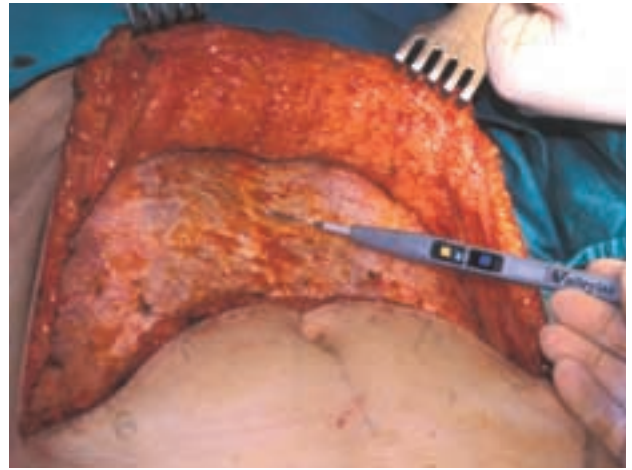

Figure 7.5 The upper abdominal wall is dissected free from the fascial layer up to the level of the costal margins.

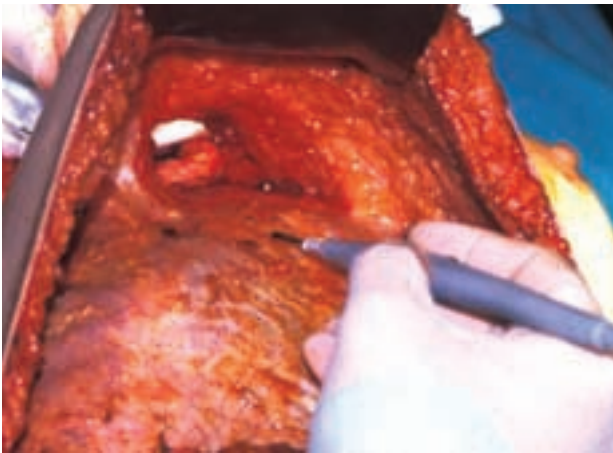


Figure 7.6 In the region of the xiphisternum on the side of the mastectomy, a subcutaneous tunnel is created to a size which admits a fist and through which the flap will be passed.

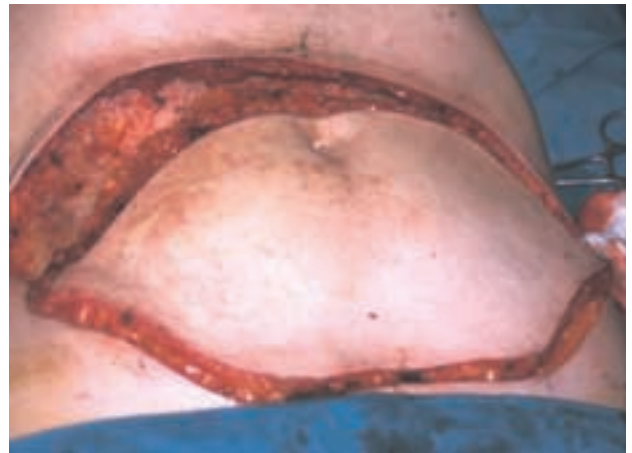


Figure 7.7 Incision along the inferior margin of the TRAM flap.

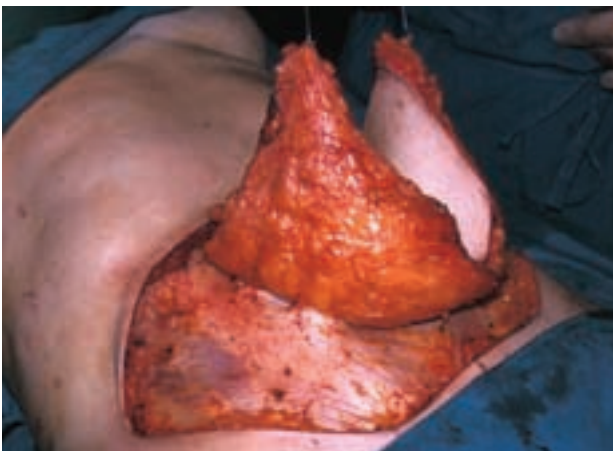


Figure 7.8 Lateral and inferior portions of the flap are dissected free from the fascia as far as the perforator vessels.

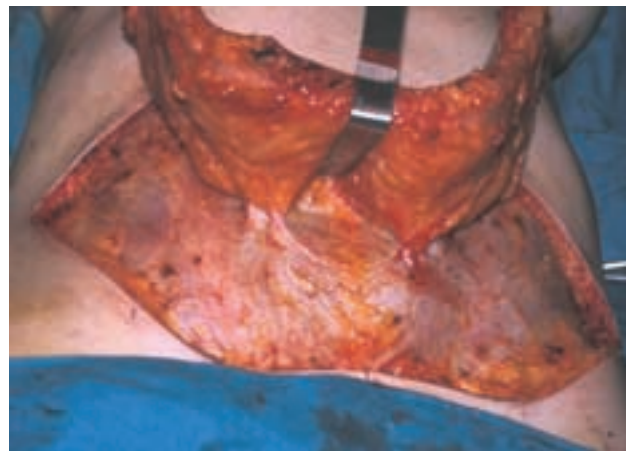


Figure 7.9 Demonstration of perforator vessels emerging through the fascia and passing into the flap.

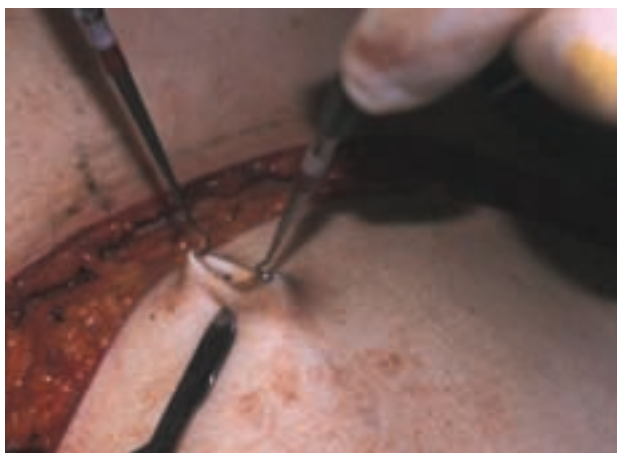

Figure 7.10 Circumcision of the umbilicus

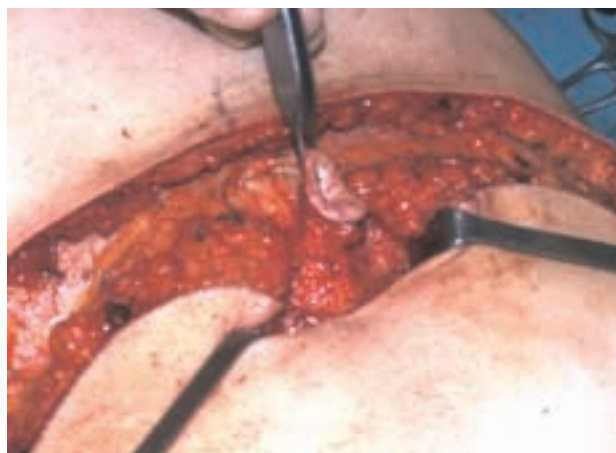

Figure 7.11 The umbilicus is fully mobilized and separated from the body of the TRAM flap.

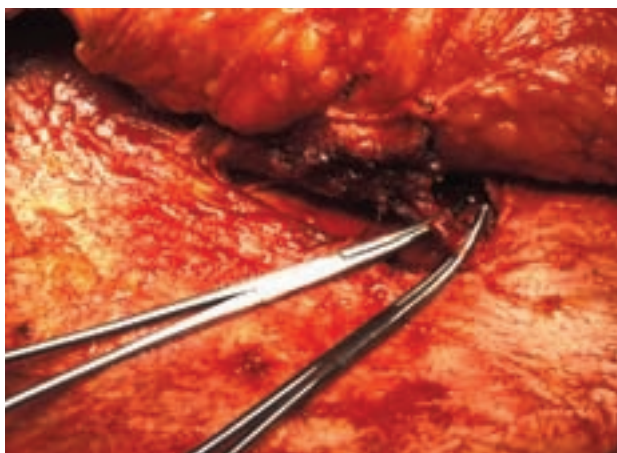

Figure 7.12 Following division of the lateral border of the rectus sheath, the inferior epigastric vessels are identified above the arcuate line and clamped prior to division.

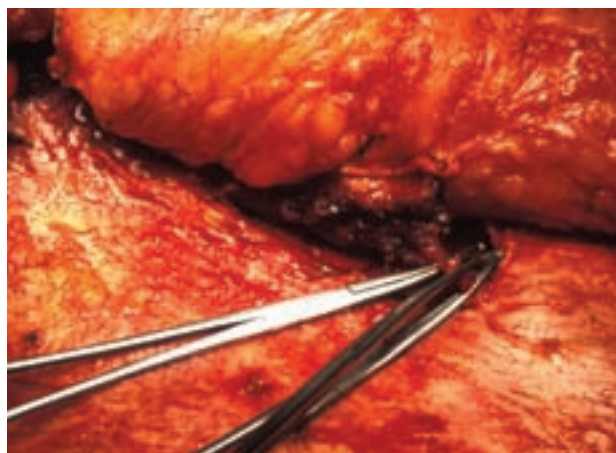

Figure 7.13 Division of the inferior epigastric vessels

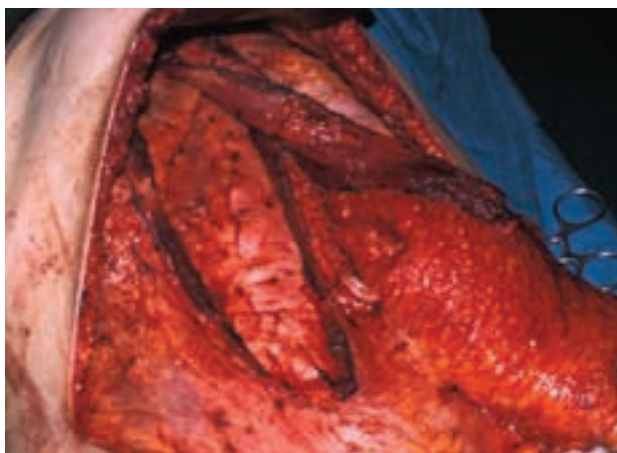


Figure 7.14 Mobilization of the right rectus muscle.

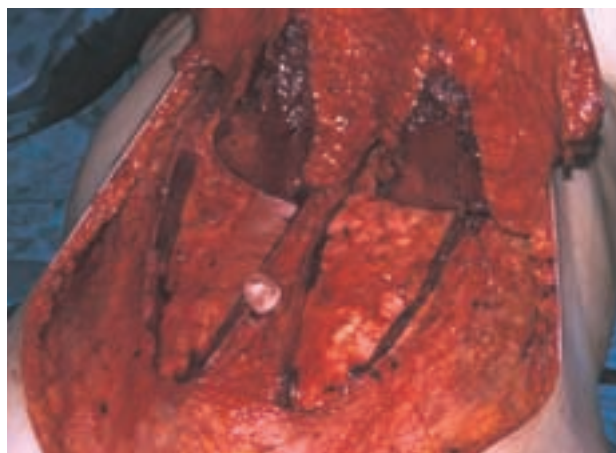

Figure 7.15 Mobilization of both rectus muscles.

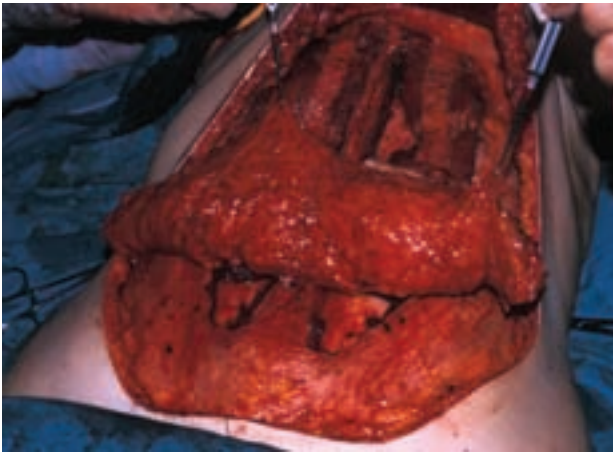


Figure 7.16 View of the mobilised TRAM flap on a dual pedicle in preparation

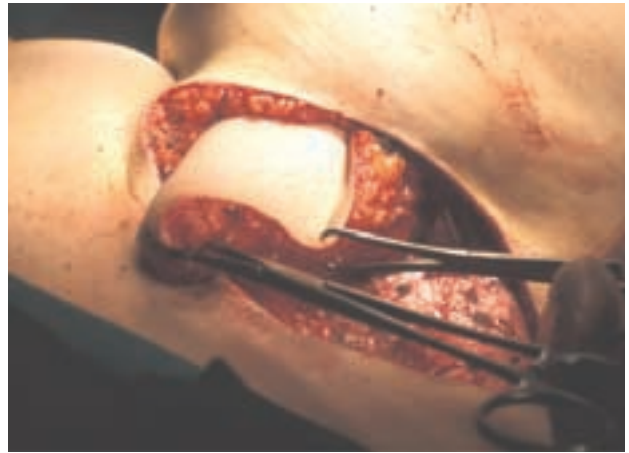

Figure 7.18 The TRAM flap is delivered into the mastectomy defect prior to reconstruction of the breast.

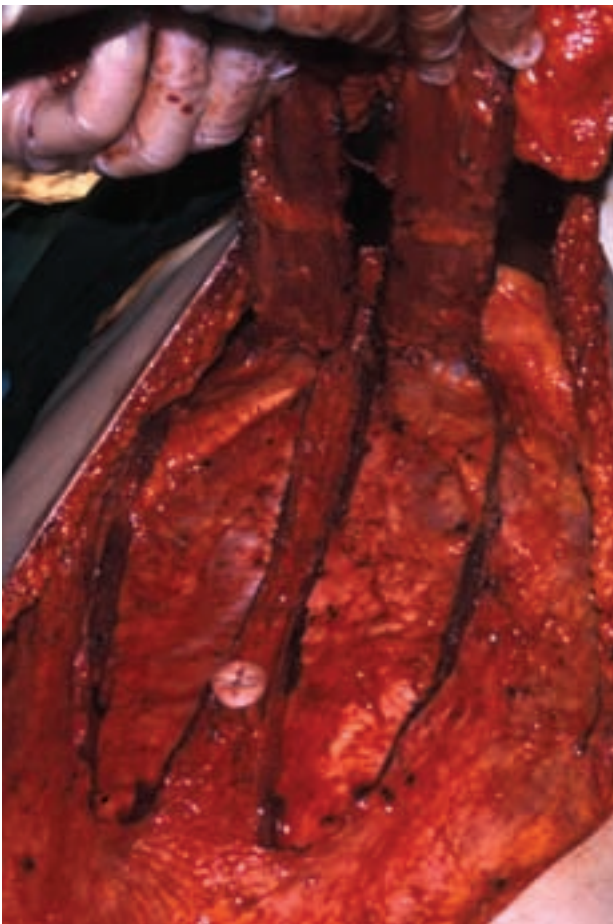


Figure 7.17 View of the two rectus muscles fully mobilized up to the level of the costal margins.

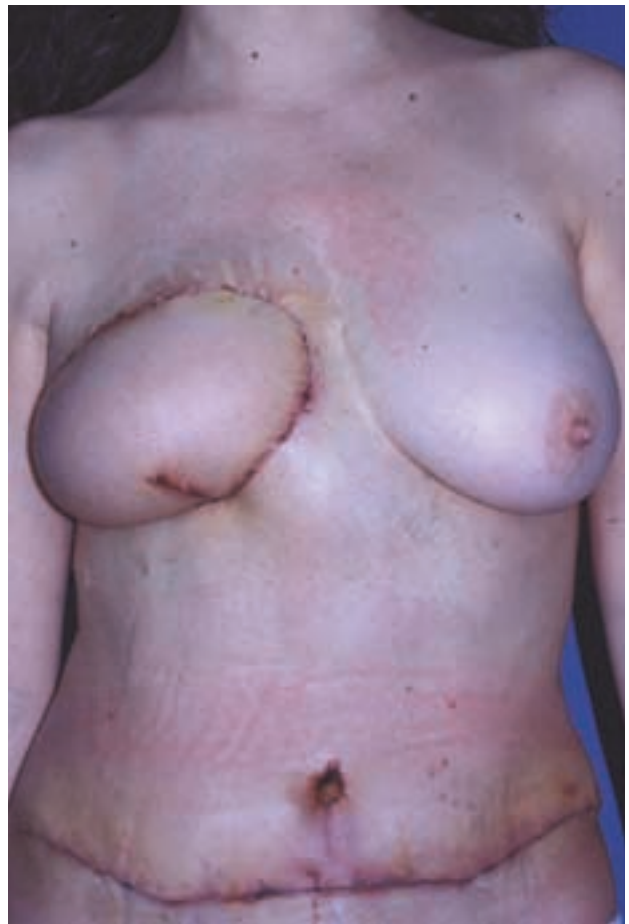

Figure 7.19 Appearance of the breast in the early post-operative period.

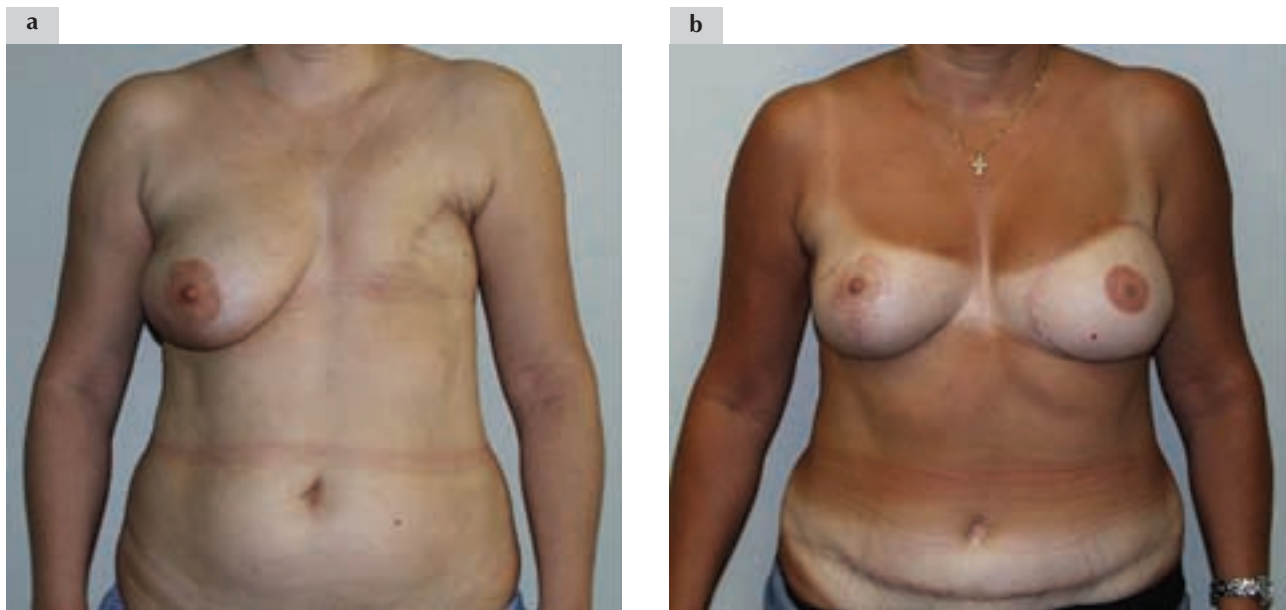


Figure 7.20 (a) Preoperative view prior to delayed TRAM flap reconstruction following left modified radical mastectomy. (b) Postoperative view following left (monopedicled) ipsilateral TRAM flap and simultaneous reduction of the left breast.

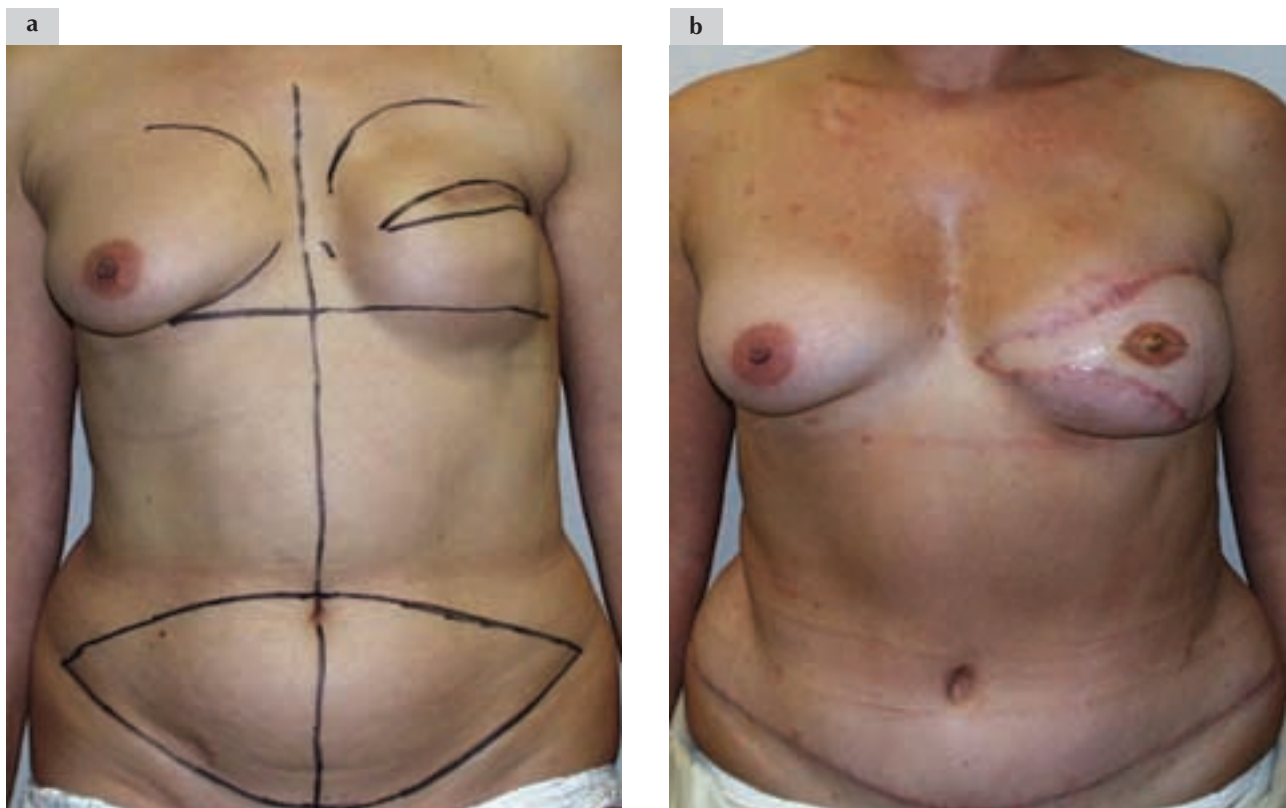


Figure 7.21 (a) Preoperative view of a patient with a grade 4 capsular contracture following reconstruction with simple tissue expansion. A revised reconstruction was undertaken with a TRAM flap. (b) Postoperative view of the same patient following a left monopedicled ipsilateral TRAM flap.

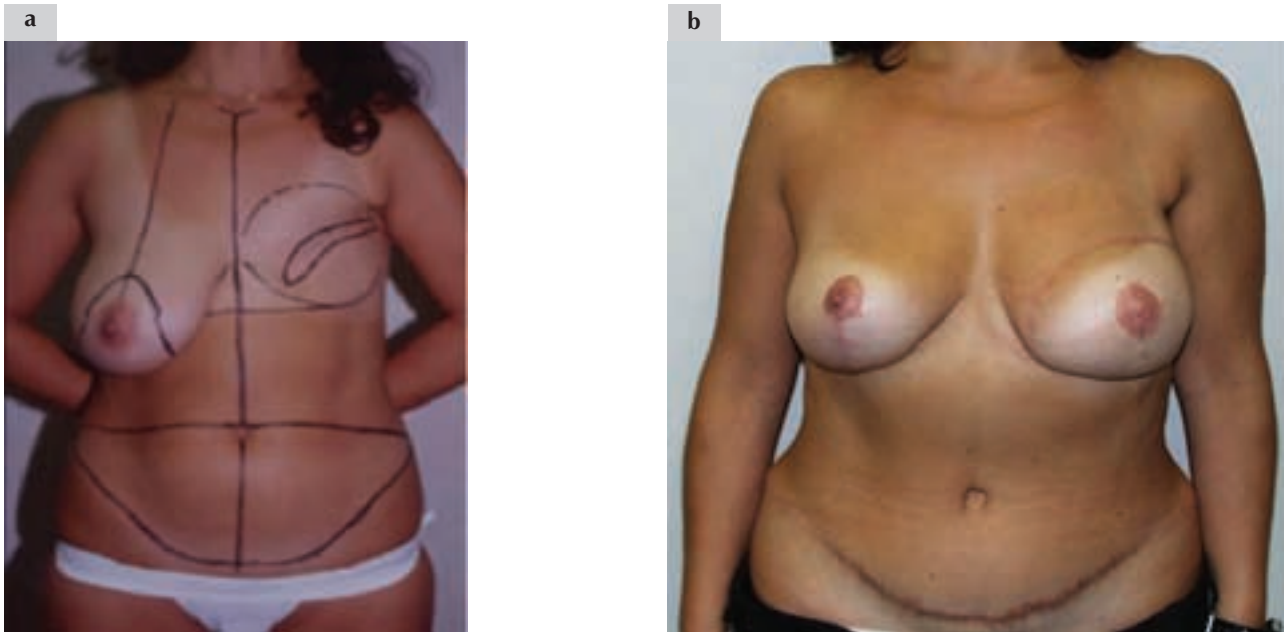


Figure 7.22 (a) Preoperative view of a patient prior to a delayed bipedicled TRAM flap reconstruction following a left mastectomy. (b) Postoperative view of the same patient after left bipedicled TRAM flap reconstruction and simultaneous contra-lateral breast reduction.

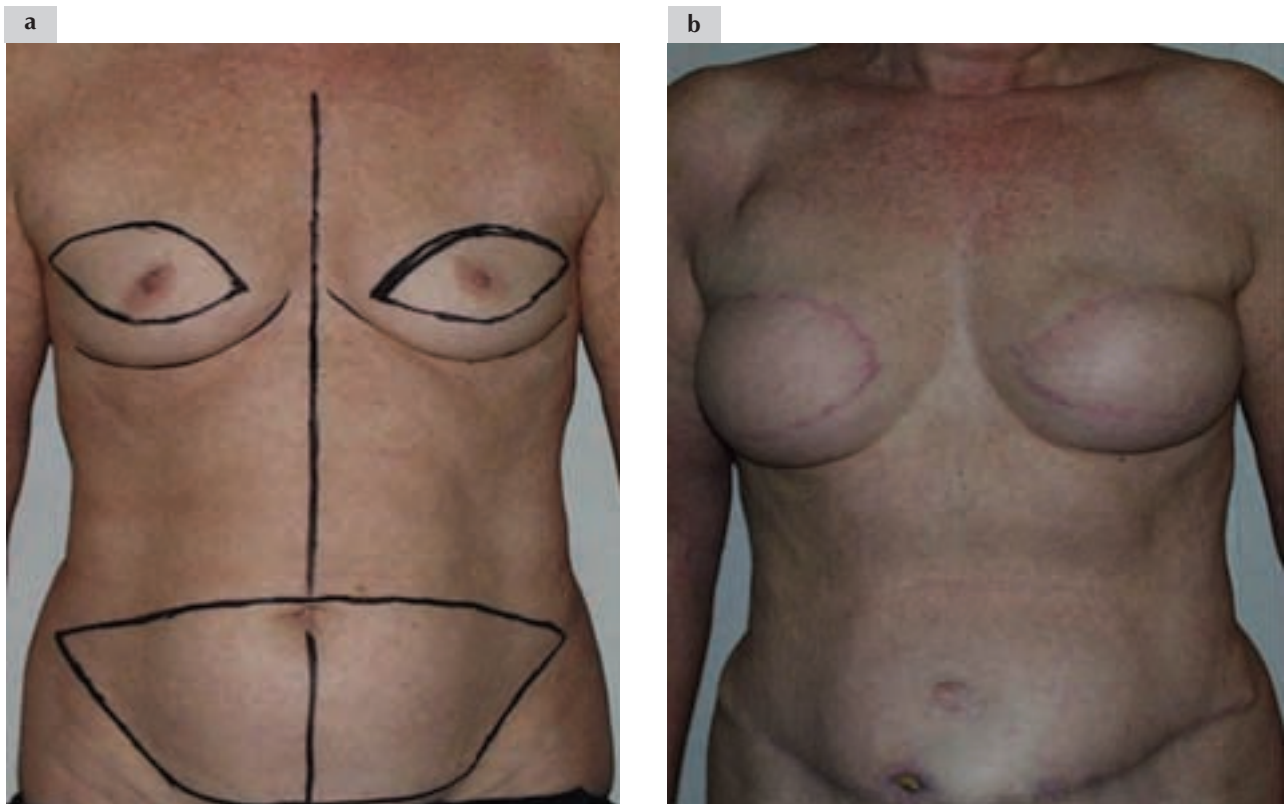


Figure 7.23 (a) Preoperative view of a patient prior to bilateral mastectomies and reconstruction with a split bipedicled TRAM flap. (b) Postoperative view of the same patient following reconstruction.

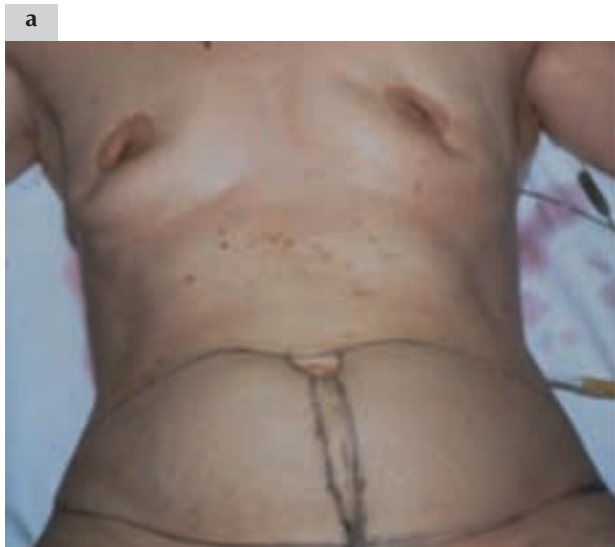
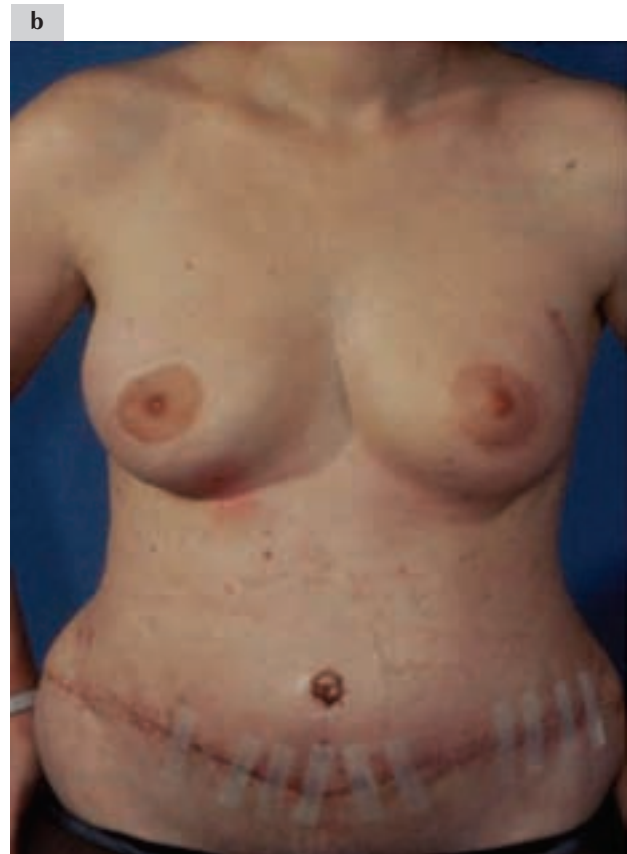
Figure 7.24 (a) Preoperative view of a patient having previously undergone bilateral prophylactic mastectomy and reconstruction with tissue expansion. Bilateral capsular contracture subsequently developed, leading to a revised reconstruction using autologous tissue. (b) Postoperative view of the same patient following reconstruction with totally deepithelialized bilateral TRAM flaps.



Variants of the pedicled TRAM flap

Skin sparing mastectomy

Skin-sparing forms of mastectomy are increasingly being undertaken in patients with both invasive and in situ breast cancer. When a strictly circumareolar incision is used, only a relatively small disc of epithelialised skin is required and the remainder of the flap skin can be de-epithelialised and buried beneath the native breast skin envelope. These techniques yield excellent cosmetic results and little 'sculpturing' of the TRAM flap is required.³

Bilateral reconstruction

The bipedicled flap can be divided and used for simultaneous bilateral breast reconstructions.

Delayed TRAM flap

The inferior epigastric vessels can be ligated 15 days prior to definitive surgery in order to increase blood flow within the superior epigastric system of vessels.⁴⁻⁵

Advantages and complications of TRAM flap reconstruction

Advantages

A principle advantage of TRAM flap reconstruction is creation of a breast using exclusively the patients own tissues and avoiding the need for any implant. Furthermore, the reconstructed breast has a shape and consistency which approximates much more closely to a natural breast than is attainable with implant reconstruction. In particular, it is possible to reproduce ptosis and a more natural slope to the upper part of the breast. Overall, TRAM flap reconstruction yields the best natural shape of the breast, possibly with long term lower costs.⁶

Specific complications

Abdominal wall herniation: The authors⁷ report a 10% incidence of abdominal wall herniae in their reconstructive practice (1980–1985), and this figure has fallen to 2% in recent years.⁸ The incidence of abdominal wall herniation is dependent on technique of abdominal wall repair; the selective and appropriate use of non-absorbable mesh is particularly relevant. Some surgeons always employ

mesh, whilst others never use prosthetic material to reconstitute the abdominal wall. Each case should be judged individually at the time of operation. Assessment of the size of the aponeurotic defect with the thickness and tension of the rectus sheath are important factors in deciding whether prosthetic mesh is required.

Donor site necrosis: Skin necrosis is prone to occur either at the mid-point of the abdominal wound (point of greatest tension) or at the umbilicus. It is often better to excise any necrotic zones rather than manage conservatively with prolonged periods of regular dressing which ultimately results in a broad, thickened and rather ugly scar.

Haematoma: Extensive undermining of the abdominal flaps predisposes to bleeding and haematoma formation. This can be minimised by use of cutting diathermy and adequate suction drainage. Similarly, bleeding beneath the mastectomy flaps may result in a discrete haematoma requiring surgical evacuation.

Infection: Infective complications occur secondary to a non-absorbed haematoma, fat necrosis or partial necrosis of skin and subcutaneous tissue at the flap extremity. Furthermore, use of prosthetic material to close the abdominal wall is associated with increase rates of infection and occasionally may necessitate removal of the mesh due to chronic infection of the abdominal wall with fistula formation (about 1% of the cases). Prophylactic antibiotics should always be used when mesh is employed.

Flap necrosis: Partial flap necrosis is more common with pedicled than free TRAM flap reconstruction. Small areas of superficial necrosis can be resected under local anaesthetic or left to heal by secondary intention. Larger degrees of necrosis (more than 15% total surface area of flap) usually demand resection

under general anaesthesia and formal re-shaping of the remaining flap tissue. The earliest signs of impending necrosis are a bluish discoloration of the flap at one or other apices. This may become apparent within a few hours of surgery and progress over the next 24 hours. The discoloured area darkens and eventually turns black. Necrosis supervenes after 2–3 days. Areas of necrosis should be excised to prevent secondary infection. A relatively small area of skin necrosis may be associated with a large volume of underlying ischaemic fat.

References

1. Hartrampf C, Schefflan M, Black P. Breast reconstruction with a transverse abdominal island flap. *Plast Reconstr Surg* 1982; 69: 216–25.
2. Hartrampf CR Jr. *Breast Reconstruction with Living Tissue*. New York: Raven Press, 1990.
3. Goes JCS. Mastectomy with immediate reconstruction by a periareolar approach. In: Spear SL, ed. *The Breast: Principles and Art*. Philadelphia: Lippincott-Raven Publishers, 1998: 555–63.
4. Morrissey WM Jr, Hallock GG. The increase in TRAM flap survival after delay does not diminish long term. *Annals of Plastic Surgery* 2000; 44: 486–90.
5. Towpik E, Mazur S, Witwicki T et al. Elevating the island: the simplest method of delaying the TRAM flap. *Ann Plast Surg* 2000; 45: 240–3.
6. Kroll SS, Baldwin B. A comparison of outcomes using three different methods of breast reconstruction. *Plast Reconstr Surg* 1992; 90: 455–62.
7. Petit JY, Rigaut L, Gareer W et al. Breast reconstruction without implant, experience of 52 cases. *Eur J Surg Oncol* 1987; 13: 219–23.
8. Petit JY, Rietjens M, Ferriera MA, et al. Abdominal sequelae after pedicled TRAM flap breast reconstruction. *Plast Reconstr Surg* 1997; 99: 723–9.

8 Autologous breast reconstruction using abdominal free flaps

Adam Searle

Introduction

Reconstruction of the breast demands accurate and thoughtful replacement of breast tissue by careful selection of volume provision combined with appropriate skin cover. Reconstruction demands symmetry of the breast mound, accuracy of contour, softness of feel and permanence of result. Reconstructive procedures must be reliable and planned with care and confidence such that any morbidity at the donor site is acceptable. These demands coupled with other factors including increased patient expectations, disappointing results with implant-only techniques and an unfounded fear of silicone use have, in recent years, encouraged the development of autologous methods of breast reconstruction.

In appropriately selected patients the latissimus dorsi muscle (usually in combination with an implant) can reproduce breast shape, form and consistency with high reliability. The donor site is generally acceptable and the flap is reliable and its anatomy well understood.

The pedicled TRAM (transverse rectus abdominus myocutaneous) flap can provide the volume and skin required for breast mound reconstruction but many surgeons familiar with this technique would testify to its sometimes fickle nature and potential for severe complications. Careful selection of patients and surgical planning is paramount for achieving success with a pedicled TRAM flap. Strict criteria must be applied to case selection and the procedure must be performed in an environment of adequate clinical support and anaesthetic management. Moreover, it is essential that surgeons undertaking such procedures possess an understanding of the basic principles of

flap anatomy and design, together with donor site management and finer details of technique. Many patients have unfortunately endured miserable and protracted episodes of complications due to lack of experience and knowledge on the part of their practitioner. Problems may arise from failure of the flap itself, but much morbidity can result from surgical insult at the donor site and this can be a source of distress to the patient. Harvesting a flap can involve extensive dissection and even sacrifice of both rectus abdominus muscles.

The pedicled rectus abdominus flaps are based on the superior deep epigastric system rather than the dominant inferior deep epigastric artery and vein. There are few other examples of flaps designed on secondary vascular axes but this has become common practice in breast reconstruction partly due to limited availability of reconstructive surgeons with microvascular skills. Some patients may therefore have undergone pedicled TRAM flap reconstruction when a free flap would have yielded optimal results. Free tissue transfers have the advantages of flexibility in flap design coupled with durability of tissue bulk with maintenance of volume based on the inferior deep epigastric supply. Flap failure rates are generally less than 5% and usually lead to the complete loss of flap in accordance with the 'all or nothing' concept. Attention to case selection, planning and technique will minimize the chance of flap failure.

In appropriate circumstances free tissue transfer can deliver a large volume of tissue to the anterior chest wall and provide sufficient tissue bulk to compensate for very substantial mastectomy defects. Abdominal free tissue transfer techniques fall into three main categories, which reflect different anatomical approaches to harvesting of the flap tissue:

- the basic free transverse rectus abdominus (free TRAM) flap
- the muscle sparing TRAM (msTRAM) flap
- the deep inferior epigastric perforator (DIEP) flap.

Anatomy of abdominal free flaps

The skin and adipose tissue of the trunk are vascularized through a network of microscopic and macroscopic vessel patterns. Unlike the extremities where systems of fasciocutaneous vessels dominate, the fat and the skin of the anterior abdominal wall is maintained on musculocutaneous vessels. In the lower anterior donor area the dominant blood supply comes from the deep inferior epigastric artery and vein which arise at the midinguinal point from the femoral axis. Several branches can be identified distally, however, the most important branches unite to form clearly defined conduits. These vessels can be up to 3 mm in diameter at their origin and are located deep to the rectus muscle in the extraperitoneal fat (Figure 8.1). Though previous abdominal surgery might compromise these vessels, routine appendectomy and caesarean section scars rarely affect the availability and suitability of these vessels for reconstruction.

It is possible to dissect up to 7–10 cm of deep inferior epigastric axis lying lateral and inferior to the rectus muscle. This well defined and dominant

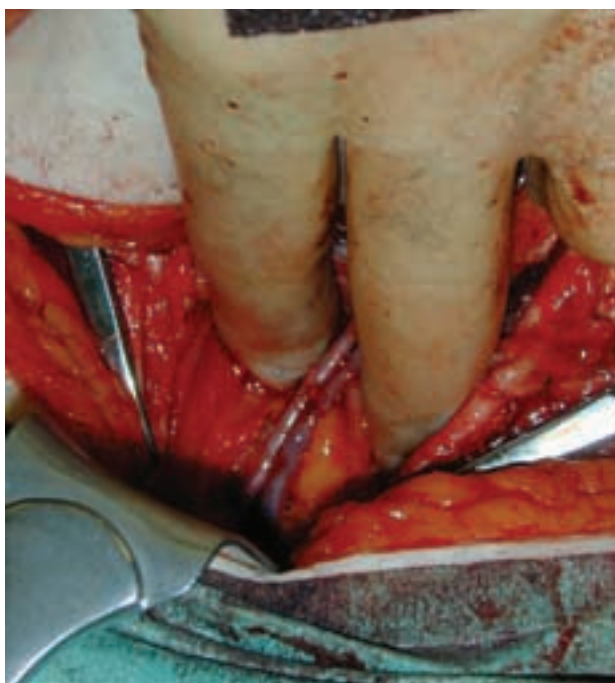


Figure 8.1 2.5 mm deep inferior epigastric vessels.

vascular pedicle passes deep to the lateral margin of the muscle between 6 and 10 cm superior to the attachment of this muscle to the pubic rim. The pedicle is relatively adherent to the under surface of the rectus muscle and gives rise to a variable pattern of branches which in turn pass through the muscle and the deep fascia to emerge through the superficial fascia where they arborize to form the superficial and subdermal plexus of vessels. The deep inferior epigastric vessels provide a variable pattern of muscular branches with anastomoses to lateral segmental vessels. The passage of the perforators through the muscle is also unpredictable with some pursuing a rather short and others a long intramuscular course.

Once denervated the rectus muscle provides no long term contribution to flap volume, which is entirely dependent upon the skin and adipose tissue supported by the vascular pedicle of the flap. The pattern of perforating vessels varies but they are generally arranged in two rows, one lateral and one medial. Large flaps can be maintained on three, two or even a single perforating complex. Preoperative ultrasound can aid localization of perforators, the largest of which may occupy the para-umbilical zone. According to the angiosome concept single perforators can supply their own and adjacent zones. Understanding these principles allows the surgeon to harvest a healthy flap on a very narrow base.

Support from perforators alone is possible leaving the muscle and its nerve supply intact – the pure DIEP flap. Sometimes the arrangement of perforators is such that a few fibres of muscle are unavoidably removed but muscle damage is minimal with these muscle-sparing flaps. In some circumstances a more substantial muscle harvest is undertaken with sacrifice of a muscle segment measuring up to 8 or 10 cm in length. Nonetheless, these options are less disruptive than a pedicled harvest and are based on an understanding of the anatomy to reduce any compromise of abdominal wall musculature.

Free abdominal flap transfer: selection and planning

In many cases failures of free tissue transfers at any site are attributable to poor case selection and inadequate planning, execution and postoperative support of these complex surgical procedures. Procedures involving free flaps are well tolerated by a broad spectrum of patients but the long duration of surgery demands that the general health status of the patient is good. Obesity represents a relative contraindication in patients undergoing free flap transfer with microvascular anastomosis. Similar considerations

apply to smoking which is an absolute contraindication for pedicled flaps but a relative contraindication for free flaps.

Cosmetic abdominoplasty is a secondary issue in patients undergoing breast reconstruction with either free or pedicled TRAM or DIEP flaps. Haemodynamic changes during lengthy surgical procedures are considerable and place great demands upon both patient and flap. These demands are more likely to be tolerated when the patient has a healthy cardiovascular and respiratory system. Poor cardiovascular management can irreversibly compromise a good microvascular procedure. A hyperdynamic circulation with vasodilation should be maintained together with an appropriate temperature. It is essential to ensure that these criteria are fulfilled before embarking on free tissue transfer techniques. It should also be noted that patients deemed unsuitable for microvascular transfer constitute a high risk for pedicled procedures.

Procedures involving free tissue transfer must be performed in an environment where personnel are familiar with the demands of microvascular reconstruction as an atmosphere of trial and error is more likely to result in flap failure. Programmes of preoperative fluid loading in conjunction with optimal perioperative support enhance the success of microvascular anastomosis. The majority of avoidable problems arise in the postoperative phase and high dependency support is recommended for the first 24 hours after surgery. This facilitates continuation of the operative support programme and, more importantly, helps identify problems at an early and rectifiable stage. Problems with fluid balance and temperature maintenance together with the development of haematoma or anastomotic failure can be corrected if recognized early. These measures may avert the catastrophic loss of a flap.

Therefore, appropriate patient selection coupled with optimum perioperative management and attention to technical detail will collectively minimize the chance of flap complications and ensure transplant success. In addition to these fundamental principles specific planning measures should be tailored to each patient and their individual circumstances.

An understanding of vascular anatomy will allow the surgeon to identify which area of the flap has the optimum blood supply. Areas of the flap are divided into zones based on the perforators. The area overlying the perforators is zone 1, those adjacent are zones 2 and 3, whilst the area furthest from the vascular input is zone 4. The latter has the most tenuous blood supply but may be viable if the deep epigastric system and its perforators are

adequate. Clinical assessment of this area requires experience and judgement (it will not survive as part of a unipedicled flap).

Having identified optimal zones a well-perfused flap can be harvested and subsequently shaped according to the required breast dimensions and contours of the breast skin envelope. With the trend towards skin-sparing mastectomy for immediate breast reconstruction the requirements for flap skin have lessened and much of the flap is de-epithelialized and buried beneath the native mastectomy flaps. In contrast, in delayed reconstruction there is a demand for greater skin replacement and this must be securely harvested over a well-perfused base.

Once the flap has been harvested it must be revascularized by the host vascular supply at the recipient site using microvascular techniques. Preoperative planning includes a careful assessment of the recipient vessels to ensure that they are of good quality and are readily accessible. The thoracodorsal trunk provides a familiar and anatomically predictable site for anastomosis. However, on account of its location, microvascular surgery has to be undertaken deep within the posterior axillary region which can be technically challenging. Furthermore, there is a risk of damage to the blood supply to the latissimus dorsi muscle which may be required at a later stage for any salvage procedure in the event of flap failure. Anastomosis of the inferior epigastric vessels to the thoracodorsal trunk can restrict positioning and shaping of the flap, tending to result in a rather laterally displaced reconstruction. It is therefore preferable to perform anastomosis on to the internal mammary system (Figure 8.2). This easily accessible vascular axis is reliable, tolerant of irradiation and provides good quality vessels which are well matched in size to the deep inferior epigastric vessels.

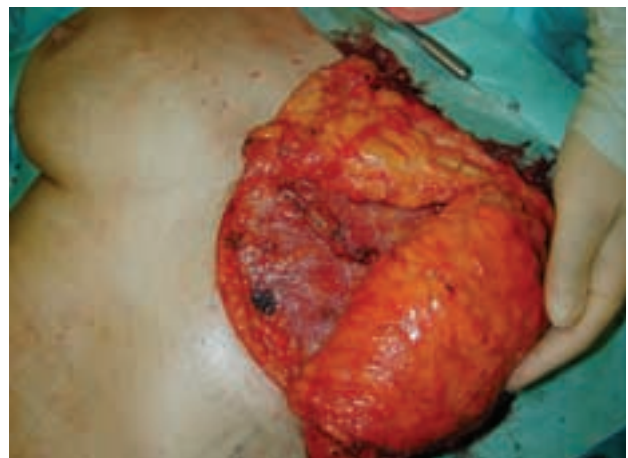


Figure 8.2 DIEP (deep inferior epigastric perforator) flap revascularized onto internal mammary perforators.

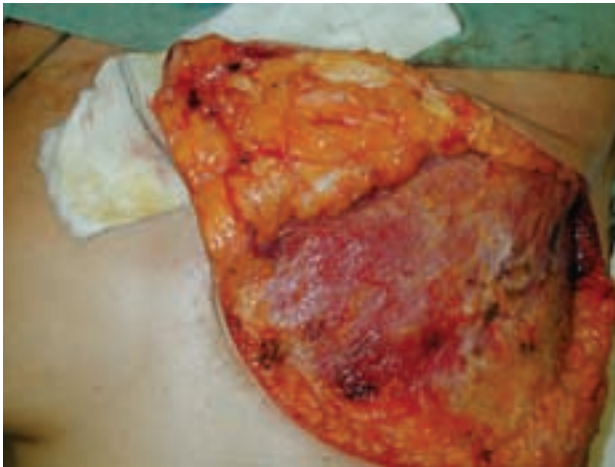


Figure 8.3 Internal mammary perforators are sometimes available for anastomosis.

Free tissue transfer: points of technique

It is important, particularly when initially embarking on free tissue transfer techniques, to be attentive and consider each step of the procedure carefully. This will help avoid inadvertent errors of technique which may be irretrievable and lead to flap failure. Microvascular surgery should be planned in a calm manner so as to facilitate what is otherwise a potentially difficult procedure. Flap ischaemia time should be kept to a minimum. Therefore whether reconstruction is immediate or delayed, the surgical team must ensure that appropriate recipient vessels are available prior to flap preparation. These basic principles apply to delayed, immediate or skin-sparing procedures. In some circumstances, internal mammary perforators are of a size and quality which permit them to be employed for the primary microvascular anastomosis (Figure 8.3). However, usually the internal mammary vessels need to be formally exposed and dissected. This relatively simple manoeuvre is performed by removing either the third or fourth costal cartilage (Figure 8.4).

Scalpel or diathermy incision through the perichondrium allows the subperichondrial space to be developed with blunt dissection, thus defining the costal cartilage which can be either excised or removed using bone 'nibblers'. Once a segment of cartilage has been removed, the posterior perichondrium is exposed at the base of the operative site. This must be opened and removed with great care to reveal the internal mammary vessels (the arteries are pale in colour compared with the dark purple vein). The vessels are prepared over a length of 1–2 cm by ligating small branches and clearing surrounding areolar tissue to permit the anastomosis to be performed with technical ease.

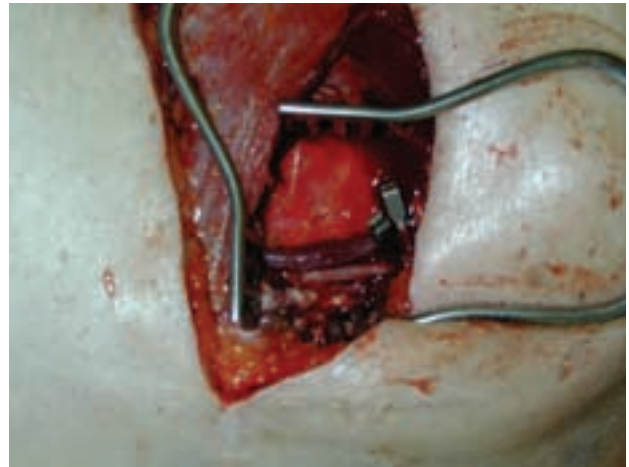


Figure 8.4 Internal mammary vessels exposed by removal of a costal cartilage.

Once the state of the recipient vessels has been established and their suitability for microvascular surgery confirmed, the flap can be raised on its vascular pedicle. Unilateral flap preparation is associated with limited muscle disruption on one side, but bilateral flap techniques incur more extensive muscle damage on both sides of the anterior abdominal wall.

Conventional free TRAM flaps are perhaps the easiest to design and harvest. The choice of axis, ipsilateral or contralateral, will depend on the site of the recipient vessels and the proposed extent of rotation of the flap at the time of transfer. A straightforward approach is to harvest a flap on the contralateral deep inferior epigastric artery and allow zones 1 and 2 to be 'coned' to form the central mass and projection. Zone 3 lies towards the axilla whilst zone 4 (least well vascularized) is discarded. Orientation of the flap in this way allows the deep inferior epigastric vessels to lie in proximity to the internal mammary system, thus facilitating anastomosis (Figure 8.5).

With this type of free TRAM flap, the central zone 1 overlies fascia and muscle which are harvested with the flap. The resulting abdominal wall defect is relatively large and must be carefully repaired, either with or without synthetic mesh. Weakness of the abdominal wall musculature is a potential problem and can be demonstrated clinically in a proportion of patients. Meticulous attention to surgical repair at the donor site can minimize hernia formation. The harvested flap contains a complete segment of transected rectus abdominus muscle, well-defined deep inferior epigastric vessels and an intact intervening portion of anterior rectus sheath. Although this method results in less donor site disruption than a pedicled TRAM flap, the proce-

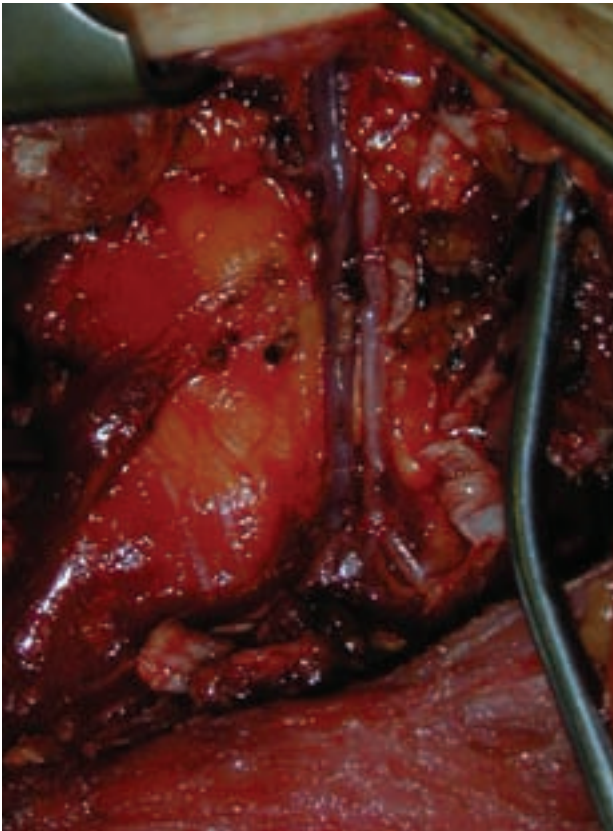


Figure 8.5 Anastomosis of the deep inferior epigastric vessels on to the internal mammary axis.

ture is associated with significant damage to muscle and nerves – characteristic of larger donor sites.

It becomes apparent from examining the pattern of blood supply to the flap that sacrifice of the entire rectus abdominus muscle is not necessary. Although there are variations between patients, the perforating vessels passing from the deep inferior axis through the muscle and into fat and skin are commonly arranged in medial and lateral rows. It is usually possible to identify two or three substantial perforators occupying a limited area of rectus muscle which are adequate for the supply of the whole flap. Under these circumstances, only that portion of muscle related to the perforators need be harvested and the remaining muscle fibres can be left intact. This limited muscle harvest also permits preservation of the segmental innervations which will help improve function at the donor site. The ‘muscle-sparing TRAM flap’ therefore has clear advantages and represents an advance in reconstructive techniques (Figure 8.6).

This theme has continued with development of techniques for complete muscle preservation which have refined methods of free tissue transfer greatly. Preoperative Doppler assessment of the anterior

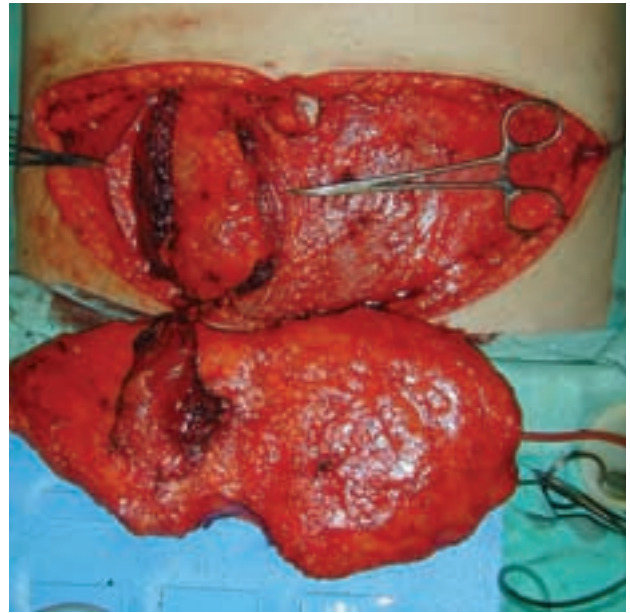


Figure 8.6 Subtotal rectus harvest in a muscle-sparing TRAM (transverse rectus abdominus myocutaneous) flap.

abdominal wall allows identification of the size and location of the deep inferior perforating vessels as they pass from beneath the rectus up through subcutaneous adipose tissue and into the dermal plexus. The abdominal wall flap can subsequently be raised with relative ease over a substantial area, leaving intact the area corresponding to selected perforators. Dissection then proceeds very cautiously as the surgeon identifies and isolates perforating vessels which will supply the entire flap. In small-to-moderate flaps, zones 1, 2 and 3 can be maintained on single perforators, whilst larger flaps require two or even three perforators and vessels should preferably be centrally placed, though the exact arrangement and size of vessels will vary. Clusters of perforating vessels may be seen in tight groups and are a welcome finding for the surgeon. Other arrangements are associated with widely spaced perforators and can be prepared only by extensive dissection. Some perforators have a short and direct transmuscular course, passing through clefts between muscle fibres whilst others have a long intramuscular course which demands careful exposure as their progress to the deep trunk is identified (Figure 8.7). Occasionally, large perforating vessels are found passing around the medial border of the rectus fibres allowing dissection thereof without any muscle damage. In addition to the benefits of muscle protection the DIEP flap allows exposure and preservation of nerve branches as they enter the lateral and deep surface of the muscle belly. These techniques which maintain innervation of the muscle segments, yield much reduced morbidity in comparison to the extensive muscle resections undertaken with pedicled flaps.

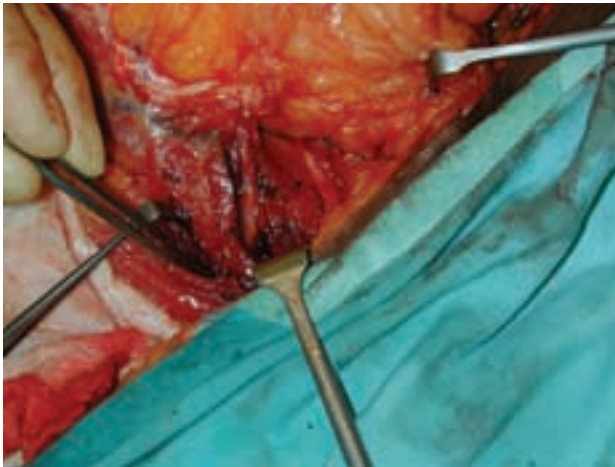


Figure 8.7 Perforator vessels dissected at their intramuscular course.

Once the free flap has been harvested, the general intraoperative progress should be reviewed and the microvascular procedure planned.

Haemostasis must be complete at the mastectomy site and native skin flaps viable. The recipient vessels (preferably the internal mammary artery and vein) should be free of any adventitial connections which may complicate microvascular anastomosis. The operating microscope must be in full working order and have been previously checked. Attention to these details, together with careful planning, will keep the ischaemia time of the flap to a minimum. Though flaps can survive ischaemic episodes of up to 4 hours, revascularization should ideally be re-established within 1 hour of detachment. A variety of technical ‘tricks and tips’ have been developed which have made microvascular anastomosis an efficient and satisfying procedure to perform. Inadequate preparation will increase the chance of an anastomotic failure with potentially catastrophic results for the patient.

An often neglected, but critical, aspect of TRAM flap techniques (pedicled and free) is the provision of effective and appropriate anaesthetic support. Maintenance of patient temperature and optimum haemodynamic parameters coupled with an understanding of flap dynamics, will greatly contribute to success. Patients in whom perfusion pressures and temperature are suboptimal will be at risk of inadequate tissue perfusion and partial or complete flap loss. Microvascular changes taking place during free flap surgery impose profound physiological demands which must be met by good perioperative care if irreversible tissue hypoxia is to be avoided.

These demands continue into the postoperative period when attentive support is required. It is

advisable to undertake free tissue transfer techniques only in an environment where high dependency support and understanding is available for at least the first 24 hours following surgery. A high level of vigilance must be maintained at all times over matters of fluid balance and drain care.

Summary

The transfer of large volumes of fat and skin from the anterior abdominal wall to the mastectomy defect has revolutionized breast reconstruction. In well structured and appropriate circumstances, carefully planned procedures permit the demands of reconstruction (softness, symmetry and shape) to be fulfilled. Free tissue transfer and refinements, including perforator flaps, have greatly reduced the clinical impact of donor site morbidity. Free tissue techniques are an integral part of reconstructive surgery and should be an option which is potentially available to all women requiring breast reconstruction.

Further reading

- Allen RJ, Treece P. Deep inferior epigastric perforator flap for breast reconstruction. *Ann Plast Surg* 1994; 32: 32–8.
- Allen RJ, Heitland AS. Superficial inferior epigastric artery flap for breast reconstruction. *Semin Plast Surg* 2002; 16: 1.
- Arnez ZM, Smith RW, Eder E et al. Breast reconstruction by the free lower transverse rectus abdominis musculocutaneous flap. *Br J Plast Surg* 1988; 41: 500–5.
- Blondeel PN, Vanderstaeten GG, Monstrey SJ et al. The donor site morbidity of free DIEP flaps and free TRAM flaps for breast reconstruction. *Br J Plast Surg* 1997; 50: 322–30.
- Blondeel PN. One hundred free DIEP flap breast reconstructions: a personal experience. *Br J Plast Surg* 1999; 52: 104–11.
- Futter CM, Webster MHC, Hagen S, Mitchell SL. A retrospective comparison of abdominal muscle strength following breast reconstruction with a free TRAM or DIEP flap. *Br J Plast Surg* 2000; 53: 578–83.
- Hamdi M, Weiler-Mithoff EM, Webster HC. Deep inferior epigastric perforator flap in breast reconstruction: experience with the first 50 flaps. *Plast Reconstr Surg* 1999; 103: 86–92.
- Koshima I, Soeda S. Inferior epigastric artery skin flaps without rectus abdominis muscle. *Br J Plast Surg* 1989; 42: 645–8.
- Nahabedian M, Dooley W, Singh N, Manson PN. Contour abnormalities of the abdomen after breast reconstruction with abdominal flaps: the role of muscle preservation. *Plast Reconstr Surg* 2002; 109: 91–8.

9 Commentary: flaps

Paul Roberto Leal, Jose Kogut

Breast reconstruction with the latissimus dorsi myocutaneous flap

Following initial proposals for use of the latissimus dorsi (LD) myocutaneous flap for breast mound reconstruction post-mastectomy, several publications have addressed various issues relating to autologous tissue reconstruction with the LD flap. Introduction of this method greatly increased the scope for breast reconstruction and it gained enormous popularity in the 1980s and was championed by the late John Bostwick III of Emory University in the United States.¹ One of the authors had the honour of learning the LD flap technique personally from him.

In Chapter 6, Modena and colleagues provide an accurate description of the technique and emphasize technical details which improve outcomes from reconstruction with the LD flap.

The popularity of the LD flap has faded somewhat with the advent of the transverse rectus abdominus myocutaneous (TRAM) flap which provides sufficient autologous tissue to permit reconstruction without an implant. However, sometimes contraindications to use of a TRAM flap prevail with a high risk of complications. Decisive patient selection is critical to the overall success of reconstruction.² There is a trend nowadays towards a return to reconstruction with the LD flap for which indications have broadened. In particular, improvements in implant design with textured coated prostheses have dramatically reduced the incidence of capsular contracture.

Scarring at the donor site can be minimized by careful preoperative planning and marking together with closure of the wound without tension.³ Seroma formation can be reduced by insertion of subcutaneous 'tacking' sutures in a manner akin to that suggested for abdominoplasties.⁴

Adjustment of the contralateral breast may be necessary, although symmetry can be attained at the time of reconstruction without any procedure to the remaining breast. However, with the passage of time, asymmetry may arise from ptosis of ageing and changes in body weight.

In our opinion, the LD flap is best suited to small or moderate sized breasts. Where ptosis is marked, a mastopexy can be undertaken of the remaining breast. Should a patient desire breast augmentation, then the reconstructed breast can be made larger than the normal side, into which an implant of the appropriate size can be inserted. Patients with larger breasts may benefit from reconstruction with an LD flap in conjunction with a tissue expander, which is usually sandwiched between the transposed LD muscle and the chest wall musculature.⁵ The LD flap should always be considered for reconstruction in selected patients and optimum results are obtained when carried out as part of an immediate reconstructive procedure. Furthermore, skin-sparing techniques permit transposition of a modest sized skin island to replace the relatively small skin deficit from mastectomy. These reduce size of the scar at the donor site.

Implant volume can sometimes be difficult to evaluate, especially when the normal breast is very ptotic. We avoid simultaneous adjustment of the contralateral breast at the time of immediate breast reconstruction and prefer to allow time for stabilization of size and shape of the reconstructed breast.

Postoperative radiotherapy is a cause for concern amongst many reconstructive surgeons. This can promote flap shrinkage and capsular contracture. Although the LD flap is relatively robust, where radiotherapy is a possibility, we advise that reconstruction be postponed and undertaken after irradiation (see comments Chapters 5 and 14).

We consider the inframammary fold as being one of the crucial aspects of breast reconstruction and

ideally it should be carefully preserved during mastectomy for immediate breast reconstruction. For delayed procedures, attention should be paid to creation of a new inframammary fold.

We aim to harvest the largest possible muscle flap in order to ensure complete coverage of the implant. The tendon of the latissimus dorsi muscle should be detached from the humerus to permit maximum mobility of the flap and enable optimum fashioning of the pocket and orientation of the skin paddle.

In conclusion, the LD flap has an important place amongst the various techniques for breast reconstruction and it will continue to be widely used by future generations of plastic surgeons.

Pedicled TRAM flap reconstruction

Since its original description by Carl Hartrampf,⁶ the pedicled TRAM flap has gained immense popularity and been employed extensively to manage post-mastectomy breast reconstruction. Petit and co-workers, in Chapter 7, provide an accurate and precise overview of pedicled TRAM flaps. We share many of their views and there is convergence of opinion between ourselves and these authors.

It is our belief that breast reconstruction using autologous tissue is the gold standard amongst methods of breast reconstruction following mastectomy. The newly constructed breast is cosmetically superior with great potential for matching the normal breast. This technique should be encouraged, although it does require a fully trained team and is a more complex procedure than some other types of reconstruction. Even though there are recognized risks, the pedicled TRAM flap reconstruction has many advantages, including a more natural feel with a soft consistency and attainment of satisfactory ptosis. In some circumstances, cutaneous sensation can improve and variations in body weight are reflected in the reconstructed breast. A large proportion of patients appreciate the concomitant abdominoplasty, although this is a secondary issue in selection of patients for TRAM flap reconstruction.

As pointed out by the authors, there are two variants of the pedicled TRAM flap. We prefer a mono-pedicled TRAM flap, which usually has sufficient volume of tissue to reconstruct a breast which matches the contralateral side. When additional volume is required to achieve a similar contralateral breast size, free flaps with microvascular anastomosis should be employed. When recipient vessels are not considered suitable, a bipedicled flap is a satis-

factory alternative. Some patients with large breasts prefer to undergo reduction of the contralateral breast at the time of reconstruction. However, it is advisable to plan a reductive mammoplasty/mastopexy as a secondary operation.

In order to optimize the vascularity of the abdominal segment to be transposed, the flap is fashioned using the extended pattern with the upper incision cut along a straight line backwards. This permits a larger amount of skin and fat in the flap although the final scar is longer.

Our personal preference is for the ipsilateral TRAM flap, even though kinking of the epigastric vessels is more accentuated. However, it avoids the troublesome epigastric bulge which can be a source of complaint for many patients. A pre-operative duplex Doppler ultrasound scan is recommended in order to identify the more robust perforators and the most reliable segment of abdominal tissue (this applies to both ipsilateral and contralateral TRAM flaps). Extensive scarring or postradiotherapy changes may preclude use of the ipsilateral flap for immediate or delayed procedures.

Immediate breast reconstruction is recommended in conjunction with a skin-sparing mastectomy (where oncologically feasible) and a TRAM flap probably yields the best results overall. The vascular supply to the flap can be enhanced by performing a delayed TRAM flap whereby the deep inferior epigastric vessels are ligated in advance of surgery (7–14 days preoperatively). This improves vascularity of the flap which is important for high-risk patients.

An additional concern in the use of a pedicled TRAM flap relates to abdominal wall weakness. This can be minimized by use of a muscle-sparing technique which involves conservative harvesting of the rectus abdominus muscle.⁷ The lateral third of the muscle is left untouched preserving the nerve supply; this is a significant factor in maintaining abdominal wall support.⁸ Alternatively, a prolene mesh can be used to repair the defect created by muscle elevation. This method not only strengthens the abdominal wall but helps avoid umbilical distortion.

Complications of a pedicled TRAM flap include:

- Haematoma – two large-bore vacuum suction systems are left in the wound for at least 3 days.
- Infection – extensive undermining of tissues promotes bacterial growth and the risk of infection is higher when a mesh is used. All patients should receive prophylactic antibiotics.
- Partial flap loss – this is more likely to occur in obese patients and smokers and other higher risk groups. Flap loss tends to occur when areas

of tissue with a poor blood supply are incorporated into the flap. Necrotic tissue must be debrided early and usually overlying skin does not have to be sacrificed. Lumps of necrotic fat can be mistaken for recurrent malignancy and biopsy may be necessary to exclude the latter.

- Total flap loss – complete loss of a pedicled TRAM flap is rare, but can occur secondary to bacterial emboli following extensive sepsis. Attention should be directed to the general status of the patient and any further reconstruction performed as a delayed procedure.
- Sloughing of the abdominal wall – several complications can affect the abdominal wall, including partial umbilical necrosis, which is more frequent in heavy smokers. Extensive undermining or tension on the abdominoplasty flap can lead to necrosis of varying severity with potentially serious consequences for the patient's general health.
- Abdominal weakness and hernias – bulging and weakness of the abdominal wall is more common than true hernias. Several papers have addressed the principal causes of abdominal wall weakness and hernias and the longer-term function of the abdominal wall following TRAM flap surgery. There is general consensus that insertion of a prolene mesh maintains optimal integrity of the abdominal wall. All women should be informed of potential problems with abdominal wall morbidity following TRAM flap reconstruction.
- Venous thrombosis and pulmonary embolism – patients undergoing TRAM flap reconstruction are at increased risk of deep vein thrombosis and pulmonary embolism and should receive prophylactic heparin perioperatively.

In conclusion, we advocate reconstruction with a TRAM flap for replacing large volumes of tissue removed at mastectomy. The technique yields excellent cosmetic results and provides the patient with the additional bonus of an abdominoplasty.

Autologous breast reconstruction using abdominal free flaps

Free TRAM flap

A crucial aspect of breast reconstruction is choosing the most appropriate operation for each patient. Technical skill and proficiency in the various methods of reconstruction are mandatory for those practising in this field. A capacity for good clinical judgement with careful selection of patients will

minimize the chance of major complications and optimize results. These considerations are particularly pertinent to free TRAM flap reconstruction with microvascular techniques. The principles of tissue transfer were pioneered by Holmstrom, who employed a segment of abdominal tissue to reconstruct a breast mound following mastectomy for cancer.⁹ Many others adopted these basic methods and variations of the technique have gradually evolved.

Some authors claim that the free TRAM flap is the most popular method of breast reconstruction.¹⁰ The procedure should only be undertaken when low failure rates and minor donor site morbidity can be achieved. Searle, in Chapter 8, rather wisely reminds us of the 'all or nothing' principle which applies to these procedures involving microsurgical anastomoses. They should only be undertaken by appropriately trained individuals.

In our institution, the following are considered suitable candidates for free TRAM flap reconstruction:

- Patients who are deemed high risk for pedicled TRAM flaps on account of more than two risk factors (smoking, moderate obesity, abdominal surgical scars).
- Patients who require reconstruction with large volumes of abdominal tissue.

The thoracodorsal vessels are occasionally used as recipient vessels in delayed procedures. Fibrosis and local radiotherapy damage tend to render these vessels adherent and difficult to dissect. In contrast, during an immediate reconstruction, they are more easily exposed and anastomosis can be relatively easily accomplished although the surgeon must operate deep within the posterior axilla. The internal mammary vessels are the preferred choice for anastomosis in delayed reconstruction and are exposed from the second to the fourth costal cartilages. Advantages include easy access, large calibre of vessels, greater freedom for positioning of the flap, resistance to radiotherapy and consistent location.

There are some disadvantages of this technique, notably the poor quality of the venous wall and sacrifice of vessels which could potentially be used at a later date for coronary revascularization.

Closure of the donor defect can be performed more easily due to preservation of the musculo-aponeurotic layer and a mesh is rarely required for reinforcement. The flap must be monitored continuously postoperatively with 2-hourly observations. Any evidence of impairment of blood flow to the flap is an indication for surgical re-exploration.

DIEP flap

The DIEP (deep inferior epigastric perforator) flap was first described in 1994 for breast reconstruction¹¹ and represents a new direction in microsurgical techniques. It is a free flap based solely on perforating vessels and permits transfer of a large amount of abdominal tissue for breast restoration. Minimal abdominal wall morbidity is particularly appealing but it is our impression that this method is associated with higher morbidity than the standard free flap. Further refinements are required before the method becomes more widely used.

References

1. Bostwick J, Vasconez LO, Jurkiewicz MJ. Breast reconstruction after a radical mastectomy. *Plast Reconstr Surg* 1978; 61: 682.
2. Kroll SS, Netscher DT. Complications of TRAM flap breast reconstruction in obese patients. *Plast Reconstr Surg* 1989; 84: 886–92.
3. Biggs TM, Cronin ED. Technical aspects of the latissimus dorsi myocutaneous flap in breast reconstruction. *Ann Plast Surg* 1981; 6: 382.
4. Pollock H. Progressive tension sutures: a technique to reduce local complications in abdominoplasties. *Plast Reconstr Surg* 2000; 105: 2583–6.
5. Lejour M. Reconstructive options after cancer surgery of the breast. *Eur J Surg Oncol* 1989; 15: 496.
6. Hartrampf CR, Schefflan M, Black PW. Breast reconstruction following mastectomy with a transverse abdominal island flap. *Plast Reconstr Surg* 1982; 69: 216.
7. Allen RJ, Treece P. Deep inferior epigastric perforator flap for breast reconstruction. *Ann Plast Surg* 1994; 32: 32–8.
8. Hammond DC, Larson DL, Severinac RN, Marcias M. Rectus abdominis muscle innervation: implications from TRAM flap elevation. *Plast Reconstr Surg* 1995; 96: 105–10.
9. Holmstrom H. The free abdominoplasty flap and its use in breast reconstruction. *Scand J Plast Reconstr Surg* 1979; 13: 423–7.
10. Schusterman MA, Kroll SS, Weldon ME. Immediate breast reconstruction: why the free TRAM over the conventional TRAM flap? *Plast Reconstr Surg* 1992; 90: 255–62.
11. Allen RJ, Treece P. Deep inferior epigastric perforator flap for breast reconstruction. *Ann Plast Surg* 1994; 32: 32–8.



Subcutaneous mastectomy and oncoplastic surgery of the breast

10 Breast reconstruction after conservative surgery

Jean-Yves Petit, O Youssef, C Garusi

Introduction

Reduction of the psychological distress accompanying breast cancer treatment is a primary aim in development of methods of breast conservation surgery and breast reconstruction post-mastectomy. Results of conservation surgery may deteriorate with time and a joint approach by plastic and oncological surgeons improves the longer-term cosmetic

results of conservation treatment for breast cancer. The criteria for breast preserving surgery are relative, and although initially confined to patients with smaller tumours (<3 cm), conservation surgery may be suitable for women with larger breasts in whom (i) tumours are up to 4 or 5 cm in diameter, (ii) multifocal tumours are confined to the same quadrant and (iii) large operable tumours have been downstaged by neoadjuvant chemotherapy.¹⁻⁴ The size of the tumour relative to the breast volume is a

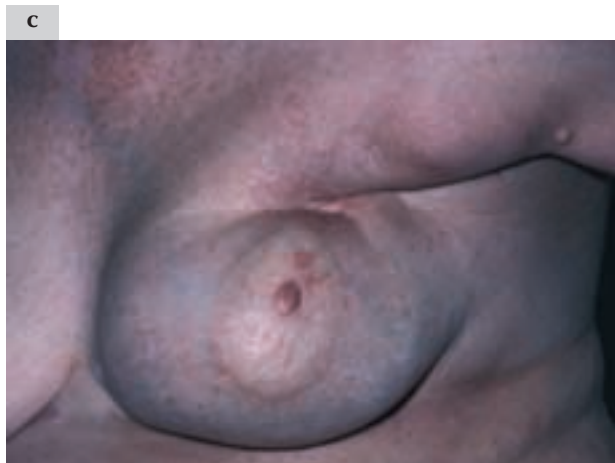
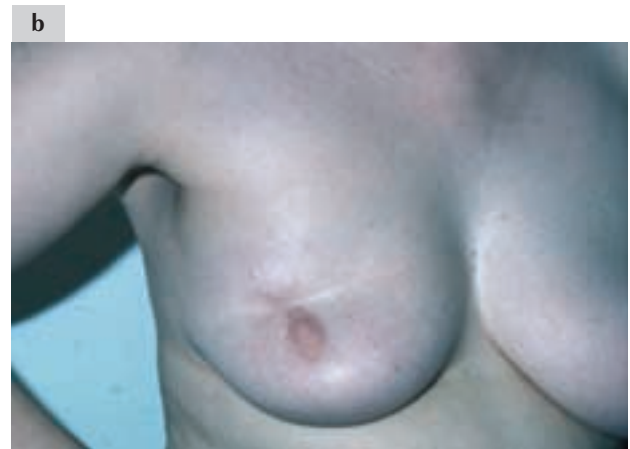
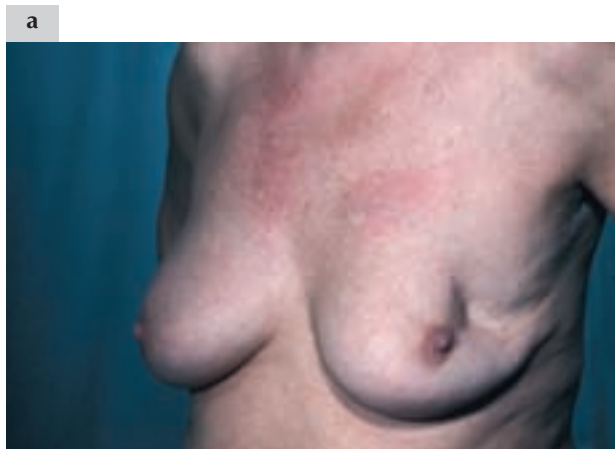
Figure 10.1 Deformity of the breast after wide excision without reconstruction of the glandular defect.

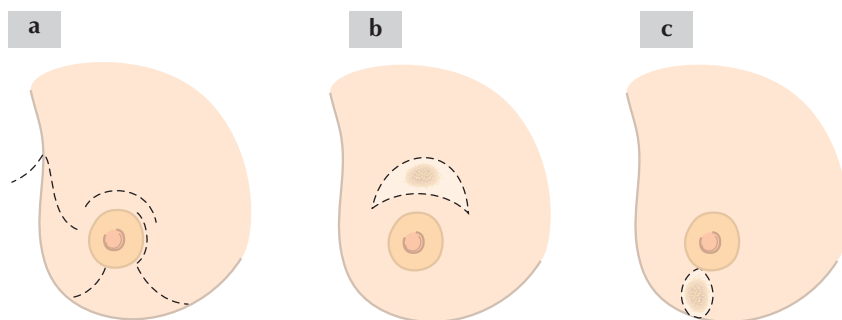


Figure 10.2 (a–c) Skin incisions.

critical factor in determining feasibility of conservation surgery and ensuring an optimal cosmetic result. Close collaboration between oncological and plastic surgical teams may in some circumstances broaden the opportunities for successful conservation surgery. Large deficits of glandular tissue can be compensated for by using techniques such as local transposition of glandular tissue or myocutaneous flaps and symmetry can often be improved by a contralateral reduction mammoplasty. Moreover, the use of plastic surgical techniques not only improves the final cosmetic result, but also permits the cancer surgeon to remove the tumour with a greater volume of surrounding normal breast tissue, thus increasing the chance of microscopic clearance with tumour-free margins and improved local control rates.

Techniques of partial breast reconstruction

Experience has shown that the majority of deformities following breast conservation result from scar

contracture and the local glandular defect which together lead to progressive asymmetry and distortion of the breast (Figure 10.1). Immediate partial reconstruction aims to restore the original volume and shape of the breast and to achieve a better match between the operated and contralateral breast.^{5–7}

The choice of incision is important from both oncological and cosmetic aspects; radial incisions in the lower part of the breast and circumlinear ones in the upper quadrants of the breast result in the least visible scars when closed with subcuticular (intra-dermal) absorbable sutures. Interrupted (or curved) incisions in the upper outer quadrant can help reduce excessively long scars which may subsequently contract (Figure 10.2).

Optimal results are obtained when the deeper glandular tissue has been carefully approximated to obliterate any major glandular defect. This is particularly important following larger resections such as quadrantectomy (Figures 10.3 and 10.4) and should be performed with local glandular flaps or even with distant fasciocutaneous or myocutaneous flaps.

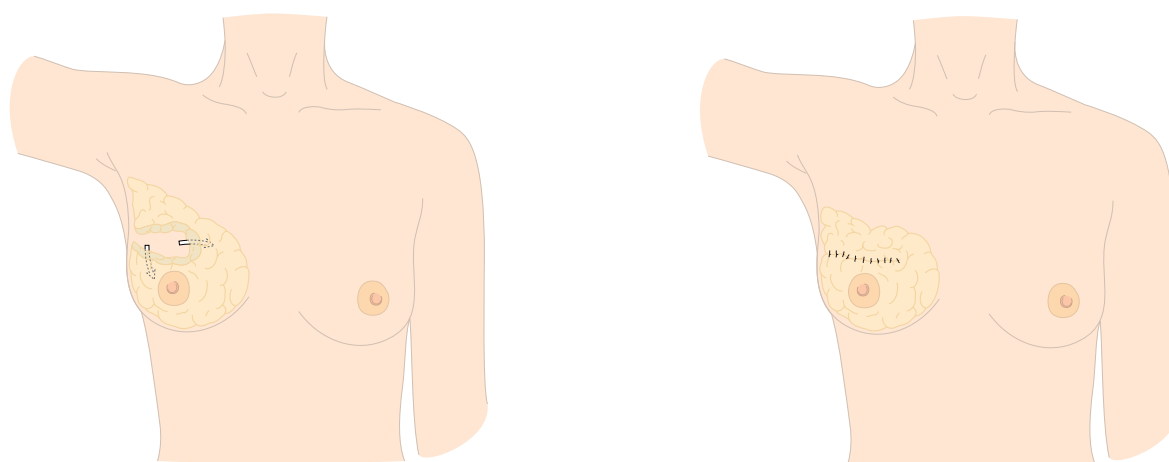


Figure 10.3 After wide excision of the cancer the glandular breast tissue is mobilized to reconstruct the breast mound.

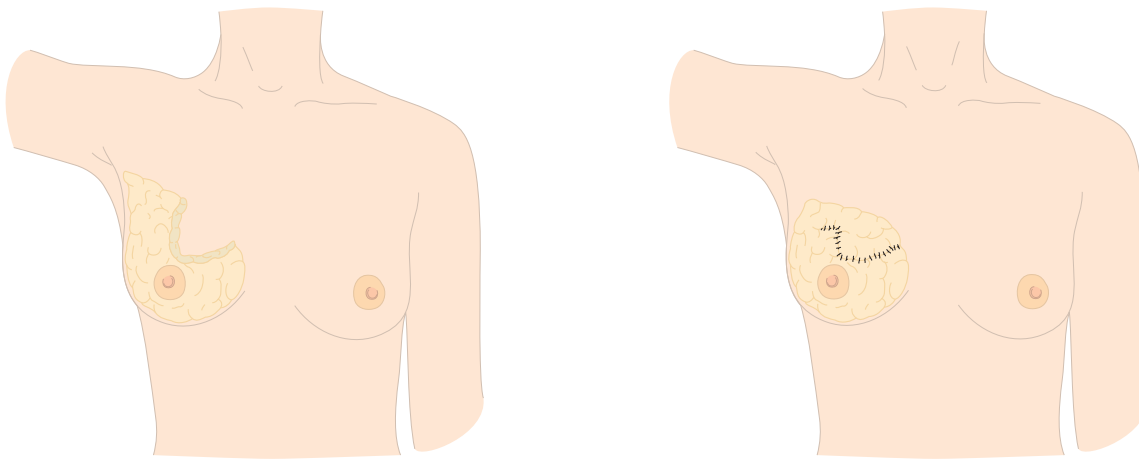


Figure 10.4 After wide excision of the cancer the glandular breast tissue is mobilized to reconstruct the breast mound.

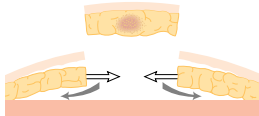


Figure 10.5 After excision of the cancer the glandular tissue is mobilized at the level of the pectoralis fascia and the skin to allow approximation of the edges of the breast.

Undermining the glandular tissue at the level of the pectoralis fascia facilitates mobilization of adjacent breast tissue to fill the defect (Figure 10.5). This undermining also permits more thorough assessment of the whole glandular tissue by peroperative bidigital palpation of the breast parenchyma. However, such extensive undermining can threaten the blood supply to glandular elements and thus increase the risk of postoperative necrosis and secondary sepsis.

For those patients with a tumour in relatively large breasts, reduction mammoplasty procedures can be fashioned using a nipple–areolar pedicle based either superiorly or inferiorly,^{8–10} depending on the site of the tumour (i.e. supra or infra-areolar) (Figures 10.6 and 10.7). For details of surgical technique see Chapter 12. Tumours located in the lower quadrants can be treated with the same technique (Figure 10.8).

Centrally located tumours mandate excision of the nipple–areolar complex in order to ensure tumour-free margins and minimize the risk of local recurrence.¹¹ Closure of the central defect can be achieved relatively easily by inserting purse-string style

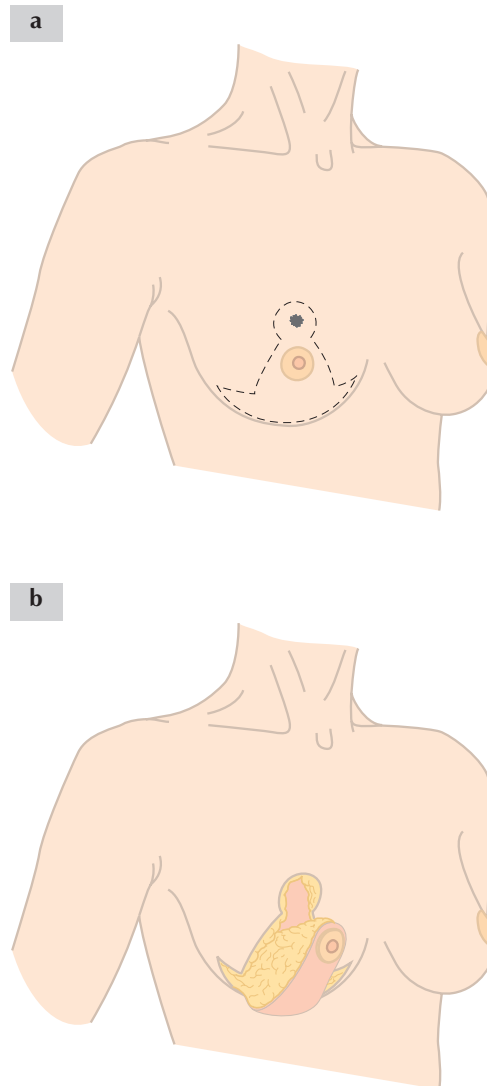


Figure 10.6 (a,b) Inferior pedicle breast reduction technique for carcinomas above the nipple or in the lower medial or lateral quadrants of the breast.

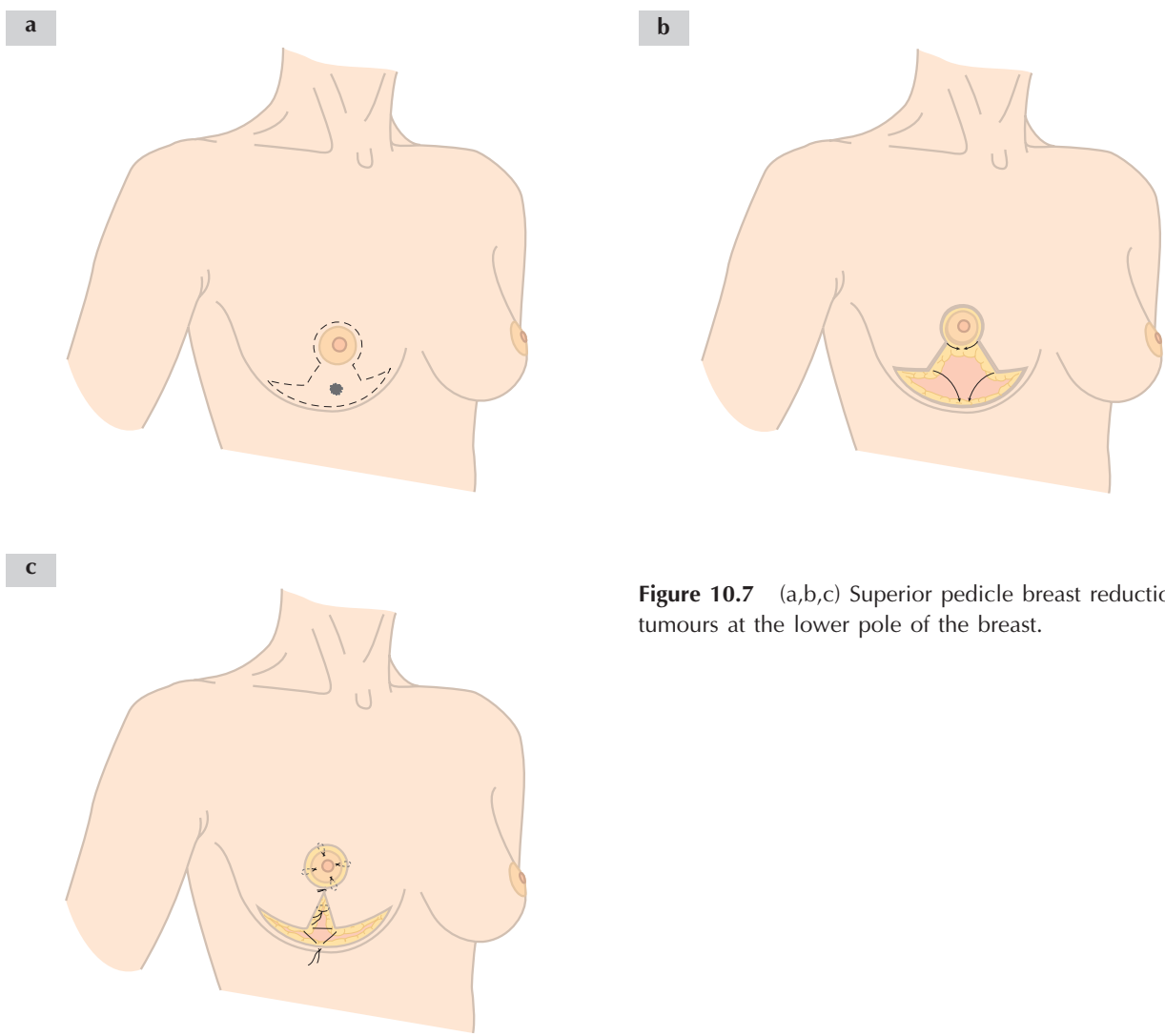


Figure 10.7 (a,b,c) Superior pedicle breast reduction for tumours at the lower pole of the breast.

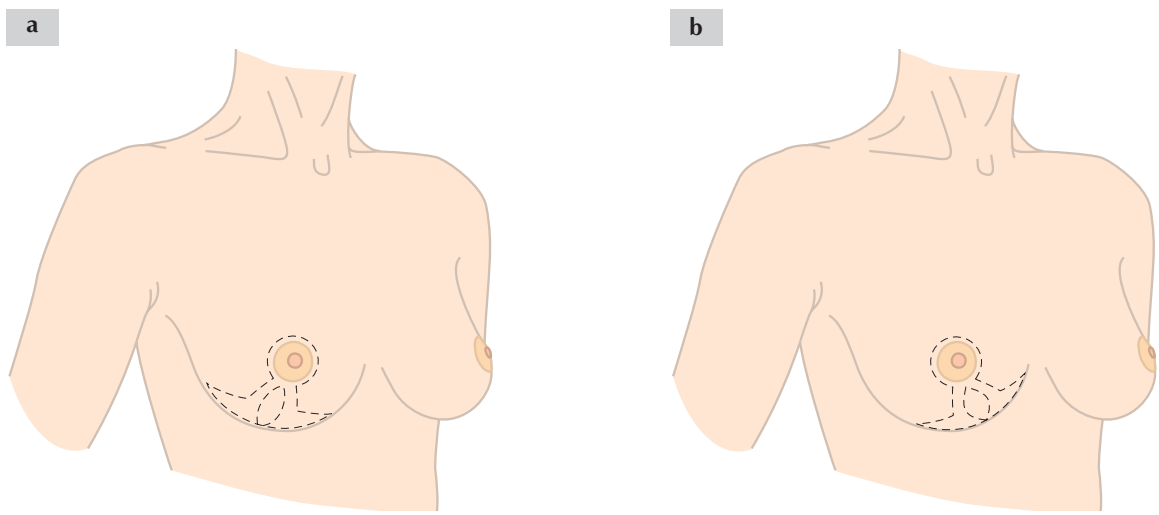


Figure 10.8 (a,b) Diagram showing the excision pattern for tumours in the lower quadrants.

sutures. Although the skin suture may appear prominent in the early postoperative period, this will ultimately be concealed behind the reconstructed nipple-areola complex. Where there is a

larger central defect, inferiorly based glandular flaps or fasciocutaneous flaps can be employed to fill the defect (e.g. Grisotti advancement rotation flap) (Figures 10.9–10.15).

Step-by-step demonstration of a Grisotti flap

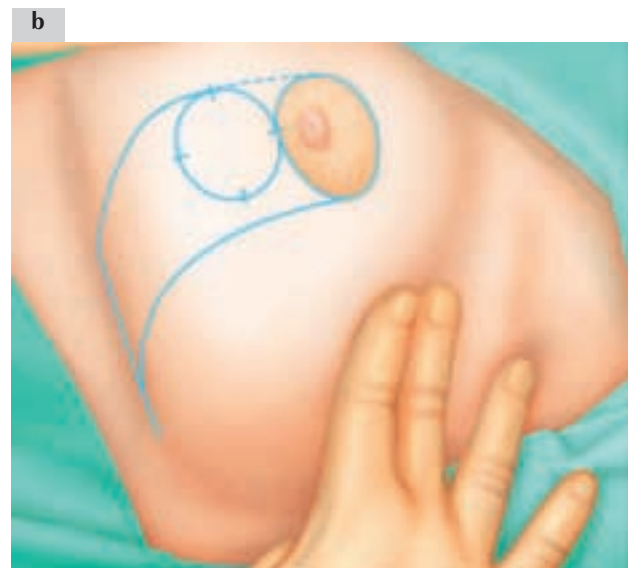
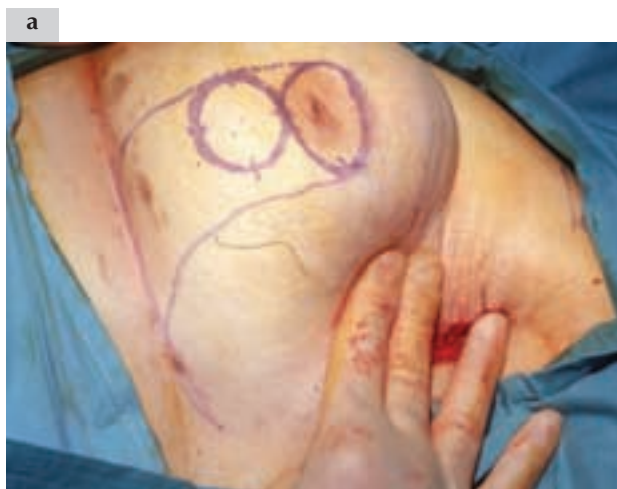

Figure 10.9 (a,b) Preoperative markings showing inferiorly based glandular-cutaneous flap with outline of the new nipple-areola complex lying adjacent to the native structure (left breast).

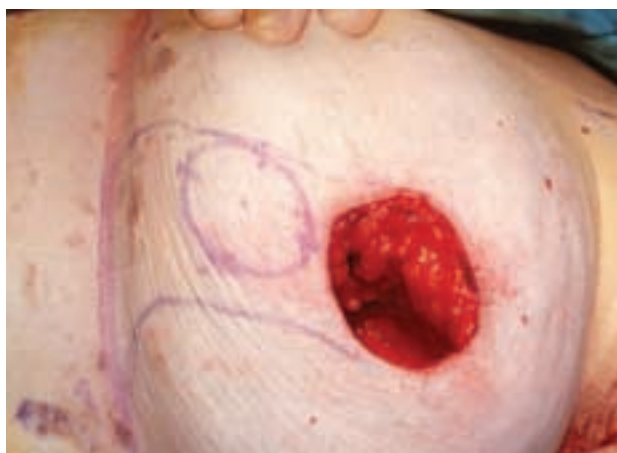

Figure 10.10 Excision of the nipple-areola complex with a column of tissue from subcutaneous tissue to pectoral fascia.

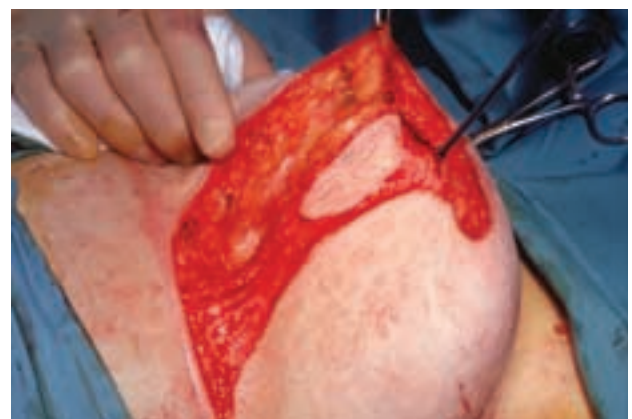

Figure 10.11 Mobilization of the skin disc, which will form the new nipple-areola complex. Viability of skin is maintained by creation of a dermoglandular bridge based inferiorly and corresponding in width to the diameter of the skin disc.

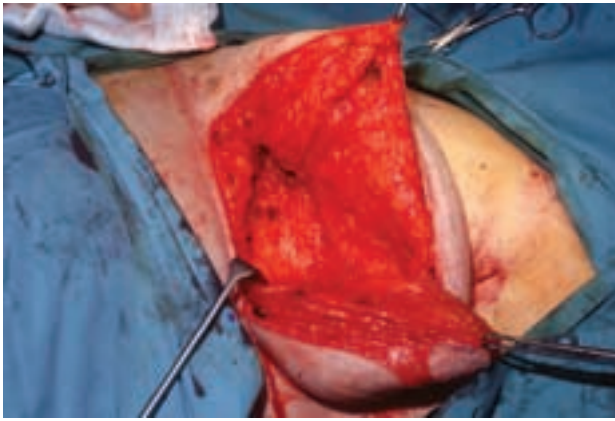


Figure 10.12 Undermining of glandular tissue of the remaining breast to facilitate advancement and rotation of the flap which will permit optimal position and orientation.

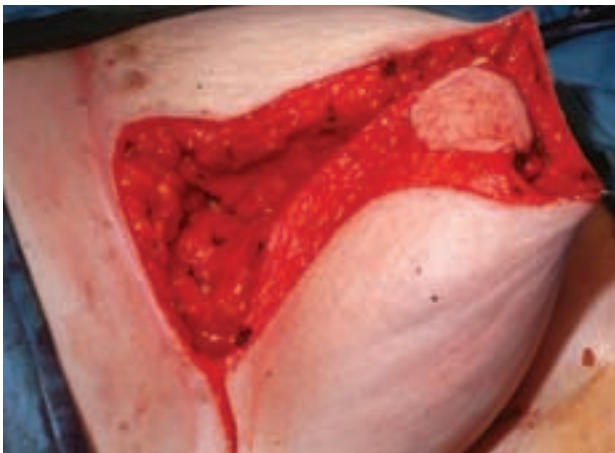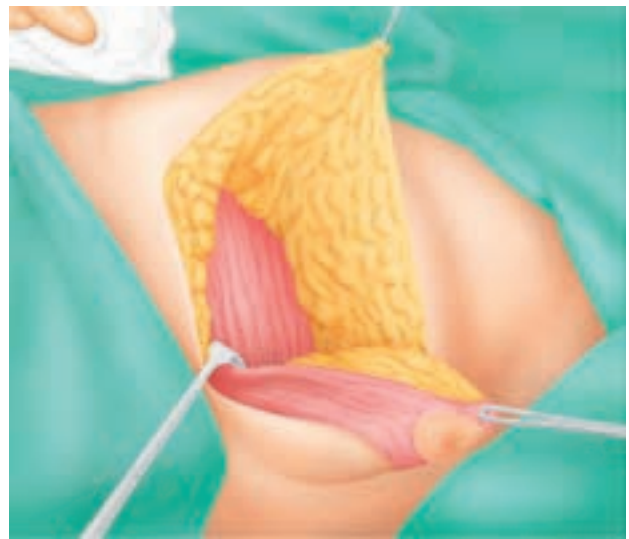


Figure 10.13 Demonstrating advancement and rotation into new position.

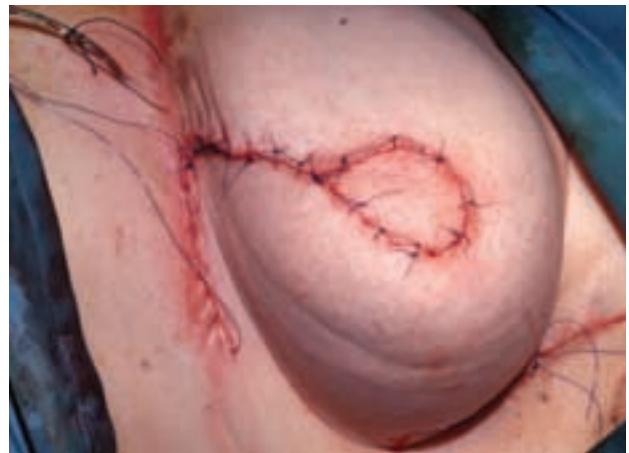

Figure 10.14 Appearance of the breast on completion of the procedure.

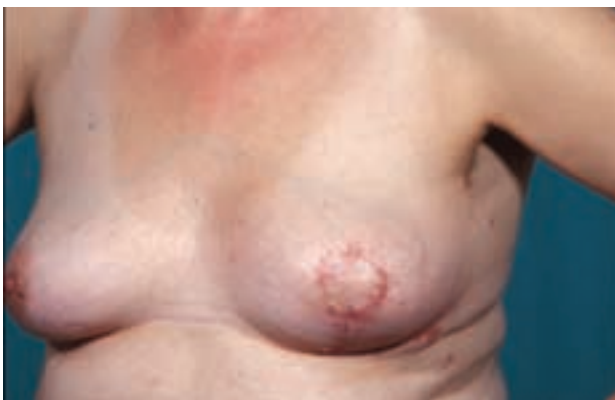

Figure 10.15 Postoperative view.

Step-by-step demonstration of the round block technique

The round block technique can be employed to remove most tumours except those located in the retro-areolar region. De-epithelialization of the peri-areolar region is done using a template which is adapted according to the degree of ptosis of the breast. A formal quadrantectomy allows removal of glandular tissue together with the tumour as a more anatomical resection.

The surrounding skin and subcutaneous tissues can be

undermined in order to facilitate greater resection of glandular tissue if indicated. The resulting defect is closed with approximation of the glandular tissue following mobilization of the breast from the pectoralis fascia. These quadrantectomies can be performed in any part of the breast, except for centrally located tumours. The margins of the resection should be cleanly incised in order to permit better approximation of glandular tissue and accurate assessment of margin status on histological examination.

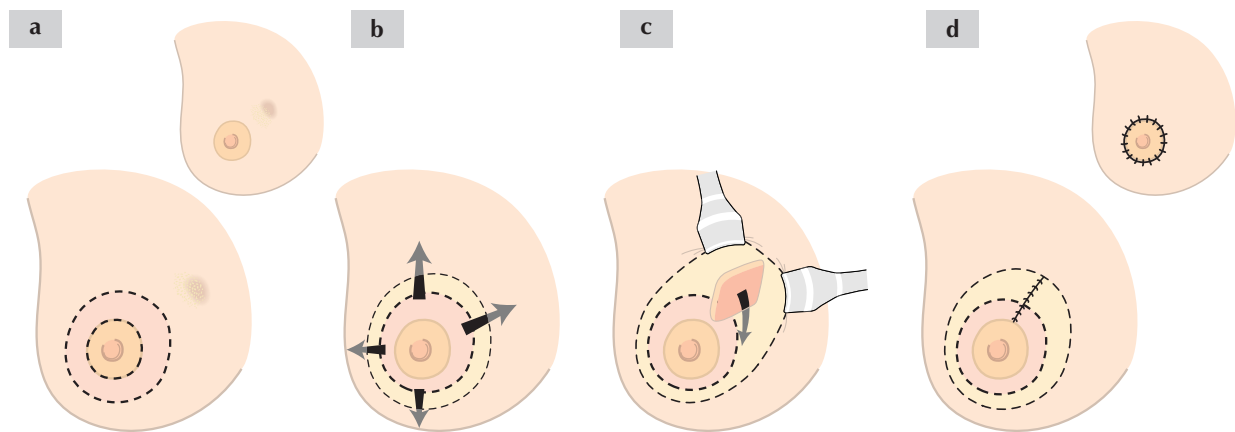


Figure 10.16 (a–d) Diagrammatic representation of the procedure.

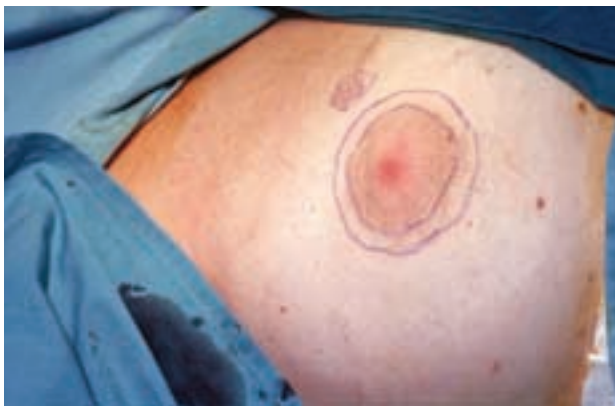

Figure 10.17 Preoperative skin markings for removal of tumour lying superomedial to nipple-areola complex.

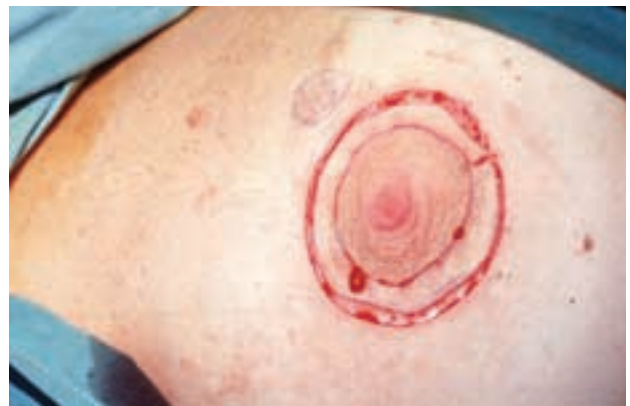

Figure 10.18 Circumareolar and peri-areolar incisions define the limits of the epidermal corona which represents the zone of de-epithelialization.

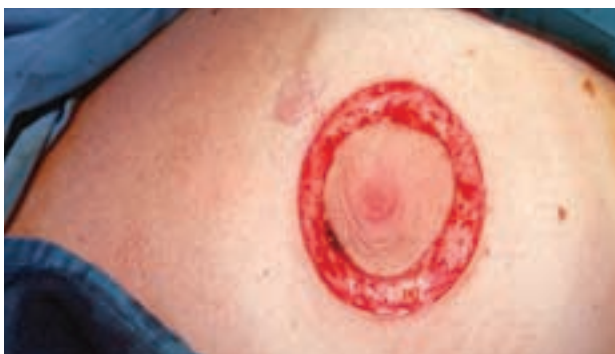

Figure 10.19 Dermal surface exposed.

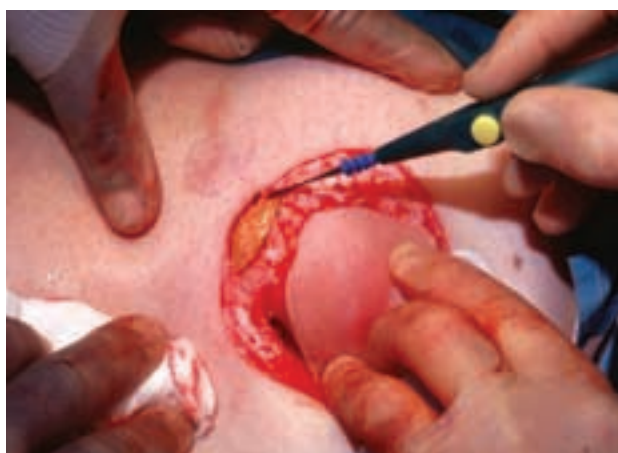

Figure 10.20 Deepening of the incision to mobilize nipple-areola complex.

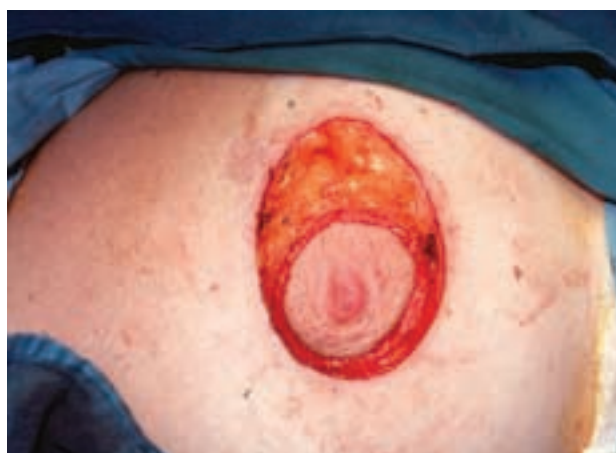

Figure 10.21 Dissection continued into the subcutaneous tissue in a circumferential manner.

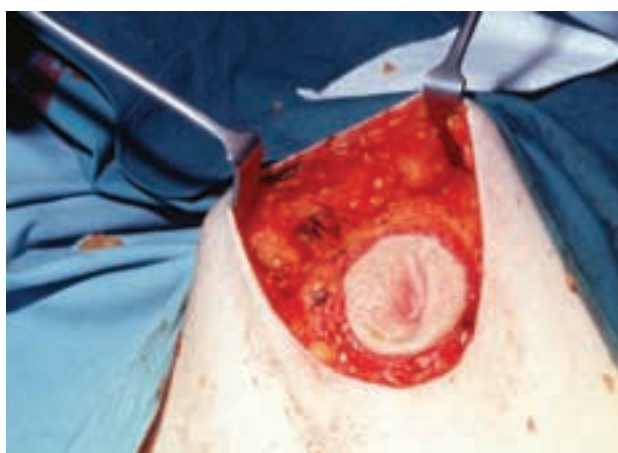


Figure 10.22 The dissection is extended in the direction of the quadrant with the cancer.

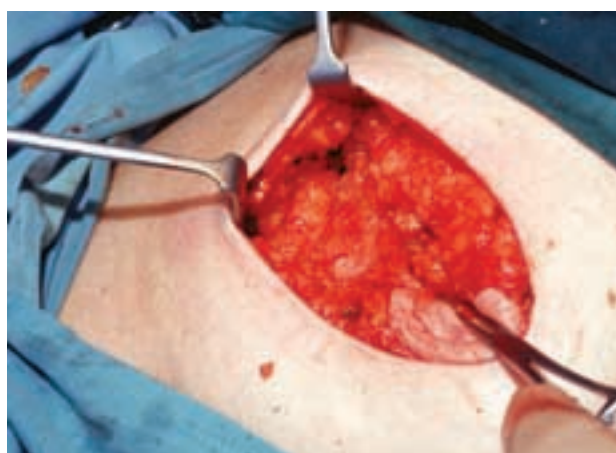

Figure 10.23 Dissection extended deep to the subcutaneous tissues in the direction of the quadrant bearing the tumour.

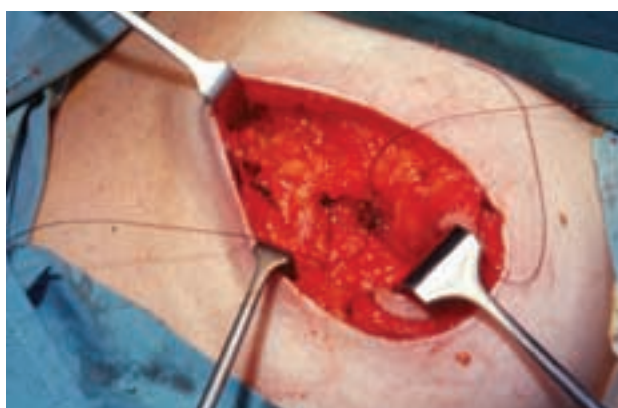


Figure 10.24 The tumour is widely excised and a quadrantic style excision may sometimes be appropriate; the defect is closed by mobilization of glandular tissue surrounding the site of excision which is approximated with absorbable suture material.

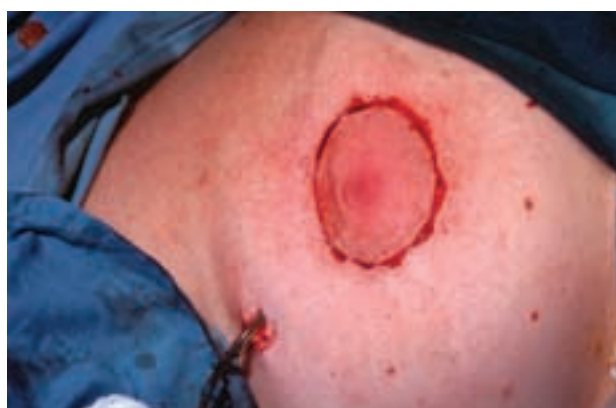

Figure 10.25 Appearance on completion of the operation.

Other techniques

More extensive resections in the outer or inferior part of the breast can be reconstructed using a mini latissimus dorsi (LD) flap.¹² However, patients should be carefully selected for this procedure as it entails additional donor site scarring together with cosmetic mismatch due to differences in colour and texture of the LD flap compared to the native breast envelope. Furthermore, the option of an LD flap reconstruction will be lost should the patient in the future develop a recurrence and require a mastectomy.

Partial breast reconstruction with a small prosthesis can yield excellent results following breast conservation surgery. Contracture rates and the risk of prosthetic extrusion are significantly higher than for conventional prosthetic reconstructions post-mastectomy. Final breast symmetry is best achieved by enhancing breast volume using additional sources of the patient's own tissue such as a distant myocutaneous flap. Breast augmentation after quadrantectomy can be achieved by transposition of an omental flap which is based on the right gastroepiploic vascular pedicle. The intra-abdominal dissection and mobilization of the flap may eventually be amenable to an endoscopic approach. The omental patch is placed under the glandular tissue on the pectoral muscle and used to fill the volume deficit.

Delayed cosmetic improvement of partial breast reconstruction

Remodelling of irradiated breast tissue is technically challenging and often associated with surgical complications and accompanying distress to patients. The glandular flaps are poorly vascularized and much less robust and subsequent scarring and distortion are common in the long term with progressive deterioration of cosmesis.^{5,7} Where asymmetry of volume is the principal issue, a contralateral reduction is probably the best approach and avoids surgical intervention within an irradiated field. Where there is marked distortion in shape of the treated breast, local glandular flaps should be avoided and myocutaneous flaps employed which bring fresh blood supply to the area.

Ideally, partial reconstruction should be undertaken as an immediate procedure following breast conservation surgery if optimal cosmetic results are to be achieved and maintained in the long term.

Conclusions

It is important that cosmetic results after conservation surgery are evaluated with recognized methodology.

These assessments should be as consistent and objective as possible. In addition to clinical evaluation by the attending physician, photographs can form part of the assessment exercise together with appropriate patient questionnaires. Differences of opinion may occur both between physicians themselves and between medical and nursing staff. Furthermore, different authors may attribute the final cosmetic results to various factors with differing degrees of emphasis.

A small breast is a relative contraindication to conservation surgery, but larger breasts can be associated with greater degrees of fibrosis and distortion. Both surgical technique and sequelae of radiotherapy have a major influence on cosmetic outcome. The former determines the degree of surface scarring and volume defects, whilst the latter are associated with telangiectasia and fibrotic changes within the breast tissue. Both factors collectively contribute to the final cosmetic result. Of interest, reports of chemotherapy effects on cosmesis following conservation surgery are inconsistent, but generally do not appear to have a negative impact. It is incumbent upon the general surgeon to seek the opinion of a plastic surgical colleague when poor results of conservation surgery are anticipated. Patients can then be reviewed by a plastic surgeon prior to embarking on any primary extirpative surgery. Any modification of technique or additional procedures designed to optimize cosmetic outcome can be fully discussed with the patient and the negative psychological impact of a poor cosmetic result minimized.

The results of several studies permit some general conclusions to be drawn:

- The axilla should not be irradiated when a full axillary dissection has been performed (level II or III).
- The radiation dose to the whole breast should be limited to a total of 45–50 Gy (usually administered at a daily dose of 2 Gy). Any booster dose should not exceed 18–20 Gy.
- Concomitant chemoradiation therapy should be avoided.
- Incisions should not be placed high in the breast and should ideally be within the bra line.
- Long radial scars should be avoided.
- Local or distant flaps should be employed to fill larger defects in breast tissue where possible, especially in the inferior portion of the breast.
- Wounds should be closed with continuous subcuticular (absorbable) sutures.

References

1. Fisher B, Redmond C et al. Eight year results of the NSABP randomised clinical trial comparing total

- mastectomy and lumpectomy with or without radiation in the treatment of breast cancer. *N Engl J Med* 1989; 320: 822.
- Holland R, Veling SHJ et al. Histological multifocality of Tis and T1-2 breast carcinoma. Implications for clinical trials of breast conserving surgery. *Cancer* 1985; 56: 979.
 - Veronesi U, Salvadori B et al. Conservative treatment of early breast cancer. Long term results of 1232 cases treated with quadrantectomy, axillary dissection and radiotherapy. *Ann Surg* 1990; 211: 250.
 - Sarrazin D, Fontaine M et al. Conservative treatment versus mastectomy in T1 or small T2 breast cancer: a randomised trial. In: Harris JR, ed. *Conservative Management of Breast Cancer*. Philadelphia: JB Lippincott, 1983: 101.
 - Petit J-Y, Rietjens M. Deformities following tumorectomy and partial mastectomy. In: Noone B, ed. *Plastic and Reconstructive Surgery of the Breast*. Philadelphia: BC Decker Inc, 1991.
 - Berrino P, Campora E, Santi PL. Post-quadrantectomy breast deformities. Classification and techniques of surgical correction. *Plast Reconstr Surg* 1987; 79: 567.
 - Garusi C, Petit J-Y, Rietjens M, Lanfrey E. La place de la chirurgie plastique dans le traitement conservateur du cancer du sein. *Ann Chir Plast Esthet* 1997; 42: 168.
 - Clough KB, Nos C, Salmon RJ et al. Conservative treatment of breast cancers by mammoplasty and irradiation: a new approach to lower quadrant tumours. *Plast Reconstr Surg* 1995; 96: 363.
 - Rietjens M, Petit J-Y, Contesso G et al. The role of the reduction mammoplasty in oncology. *Eur J Plast Surg* 1997; 20: 246.
 - Lejour M. Vertical mammoplasty without inframammary scar and with liposuction. *Perspect Plast Surg* 1990; 4: 67.
 - Galimberti V, Zurrida S et al. Central small size breast cancer: how to overcome the problem of nipple and areola involvement. *Eur J Cancer* 1993; 29: 1093.
 - Slavin S, Love S, Sadowsky N. Reconstruction of the radiated partial mastectomy defect with autogenous tissues. *Plast Reconstr Surg* 1992; 90: 854.

11

Subcutaneous mastectomy and reconstruction

Nicholas Breach

Introduction

The place of subcutaneous mastectomy in the management of breast disease remains controversial. Rice and Strickler first described this technique in 1951¹ and advocated a total adenomammectomy through an inframammary approach as a prophylactic operation for breast cancer. The operation was revived by Freeman² who recommended 'wider' removal of breast tissue with the immediate use of a silicone implant to restore the breast contour. Bader et al included excision of the pectoralis major fascia in addition to the central core of the nipple in an attempt to remove all breast tissue.³ They insisted that the skin flaps should be raised as thin as possible, but preservation of the subdermal vascular plexus was essential for maintenance of skin viability. These additional procedures aimed at complete extirpation of breast tissue thus providing patients with maximal sense of security and minimal chance of future development of malignancy.

In spite of progressively more extensive operations it is now acknowledged that no surgical procedure can remove 100% of breast tissue. Anatomical studies have confirmed that breast tissue invariably remains unless breast skin is removed.⁴

Notwithstanding these controversies, subcutaneous mastectomy does have a place in the management of breast disease and there are two situations where this form of mastectomy may be an appropriate operation to be considered and advocated. First, as a prophylactic procedure in women with a high risk of developing breast cancer who wish to preserve the nipple-areola complex and who recognize the risk posed by any residual breast tissue, and second, in those patients with invasive carcinoma who wish to avoid adjuvant radiotherapy and accept the

increased chance of local disease recurrence. In both these groups a small risk of breast cancer persists, but subcutaneous mastectomy is the preferred option for minimizing this risk and for many women great importance is attached to the retention of the nipple-areola complex.

There is consensus amongst surgeons that optimal cosmetic results are obtained when reconstruction is undertaken as an immediate procedure. Delayed reconstruction may have to be considered if adjuvant treatments are indicated and scheduling would be disrupted by reconstruction. Tissue changes such as subcutaneous scarring with displacement of the nipple-areola complex impact on the aesthetic outcome of any subsequent reconstructive procedure.

General considerations

When subcutaneous mastectomy is selected as the procedure of choice for management of breast conditions (see above), certain aspects of the mastectomy and reconstruction phases of the operation must be specifically addressed. Experience with breast augmentation suggests that the most satisfactory results are achieved when the skin envelope conforms with the size and shape of the prosthesis. The effect of the skin 'brassiere' appears to be essential in maintaining the position of the prosthesis with its broad base against the chest wall. In the majority of patients undergoing subcutaneous mastectomy reduction of the skin envelope is necessary for satisfactory long-term results. There is much debate as to what extent the natural ptosis of the breast can be reproduced when a prosthesis is used for reconstruction – whether placed in a subcutaneous or subpectoral pocket. Some authorities contend that the biomechanical properties of a

prosthesis preclude any natural 'droop', which can only occur as a consequence of excess skin and muscle. However, when inadequate pressure is applied to the prosthesis from the overlying muscle and skin, there is greater potential for capsular contracture.

When the nipple–areola complex is to be retained during mastectomy and breast reconstruction, maintenance of viability is of paramount importance. The vascular supply to the nipple–areola complex is particularly at risk when thin flaps have been raised. There is a fine margin of surgical error between a healthy nipple–areola complex and vascular insufficiency.

Where a substantial reduction of the skin envelope is required for patients with large breasts, the blood supply of the nipple–areola complex is dependent on pedicle design. When problems are anticipated in preserving vascular integrity, free grafting of the nipple–areola complex should be considered. The aim of a subcutaneous mastectomy is to remove as much breast tissue as possible, and generous access is essential with good visualization of the tissues during surgery.

Limited incisions may therefore result in persistent breast tissue, whilst excessively long incisions may compromise vascularity of the skin flaps. The lateral oblique incision allows excellent access to the axillary tail but restricts direct visualization of the lower medial quadrant. Similar reservations apply to the extended lateral incision as described by Wheeler and Masters.⁵ The inframammary approach gives limited access not only to the upper half of the breast but also the axillary tail and axilla itself. Moreover, the inframammary incision may threaten the vascularity of the subareolar skin. Using this incision, Ward and Edwards reported that almost a quarter of patients experienced some sloughing of skin overlying the implant, although in all cases the implant was placed in a subcutaneous pocket.⁶

Placement of the prosthesis in a subcutaneous pocket encourages ulceration of the skin overlying the implant. Experience has shown that additional coverage with muscle is necessary, particularly where the skin flaps are relatively thin. There are also reports of increased incidence of capsular contracture in cases where the implant is placed in a subcutaneous pocket.

Therefore the subpectoral plane (deep to the pectoralis major muscle) is the preferred position for the prosthesis and care is required in creating a subpectoral pocket and ensuring that the prosthesis is correctly positioned. A common error is for the prosthesis to lie either too high or too lateral on the

chest wall. Removal of the pectoralis fascia with the breast tissue frequently results in 'shredding' of the lower part of the muscle during dissection of the pocket, leading to a defect inferomedially. Ideally, total muscle coverage is required but where this is not possible, the zone between skin incision and prosthesis must be adequately covered by muscle to minimize the risk of implant failure. The issue of total muscle coverage is less of a problem in delayed reconstruction as the pectoralis major muscle tends to be adherent to overlying skin and subcutaneous tissue and shreds less readily.

The priority with a subcutaneous mastectomy is a thorough (though necessarily incomplete) resection of breast tissue and adequate access to all areas of the breast is important. In 1972, Pers and Bretteville-Jensen described a form of breast reduction in which the breast was approached across the meridian of the breast mound.⁷ This technique allowed for skin adjustment and resection of breast tissue with preservation of the nipple–areola complex on a vertical de-epithelialized pedicle and differed from other methods such as that of McKissock.⁸ An adaptation of the Pers and Bretteville-Jensen technique for breast reduction is described below and contrasts with the technique of Freeman.⁹ In the context of a subcutaneous mastectomy this technique has the advantage of providing excellent access to both the breast area and the axilla. It permits relatively thin upper and lower flaps to be created under direct vision without jeopardizing the vascularity of the skin. The breast skin can be trimmed to correspond with the reconstructed breast mound and the nipple–areola complex is preserved on either a vertical bipediced flap or a single upper or lower pedicle. A further important aspect of this technique is the preservation of the inframammary crease which is a complex fascial structure attaching the deep surface of the dermis to the anterior rectus sheath.

Surgical technique

The patient must be marked preoperatively in the sitting or standing position. When skin adjustment is required the new position of the nipple is marked at a distance of 18–22 cm from the sternal notch in the midclavicular (nipple) line. Lines are drawn medially and laterally from the new nipple position to the medial and lateral points of the meridian of the reconstructed breast. The transverse line corresponding to the upper margin of the inferior flap is drawn commencing 5 cm from the inframammary groove in the midclavicular line.

This point is continued medially and laterally to join with the marking previously drawn for the

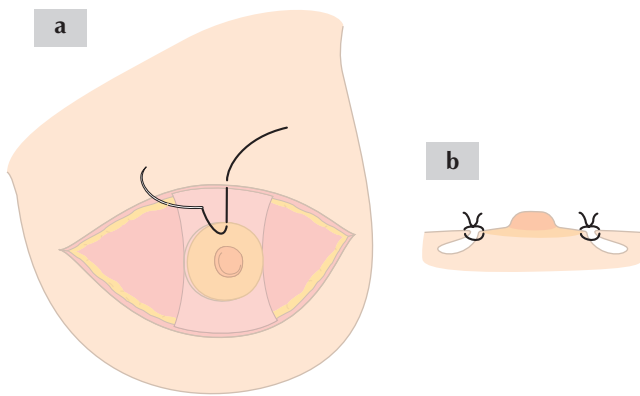


Figure 11.1 (a) Diagram showing a subcutaneous mastectomy with a bipedicled (superior and inferior) nipple preservation. (b) Sagittal section showing the skin sutures and the infolding of the vascular dermal bridges.

lower margin of the upper flap. There are several options for dealing with the nipple-areola complex: superior, inferior or both superior and inferior vascular dermal pedicles (Figure 11.1). By using a superior vascular dermal bridge the skin can be reduced by using the inferior inverted 'T' pattern of a conventional breast reduction.

For each option, the area between the markings, upper and lower skin margins, the peripheral margin of the areola and the edge of the pedicle will be de-epithelialized. The breast is removed once the skin flaps have been elevated and the vascular pedicle de-epithelialized. The margins of resection are bevelled to avoid any prominent contour deformity resulting from a step in the subcutaneous fat. A transverse incision facilitates identification of the breast margin and aids adequate resection of the axillary tail region of the breast.

When developing the subpectoral pocket continuity of the muscle overlying the implant is important. If the lateral margin of the pectoralis major muscle is used to gain access to the subpectoral space there may be difficulty in the closure of the tissues at this site once the prosthesis is in place. The preferred technique is to approach the subpectoral space through a muscle splitting incision. The size of the muscle split needs to be adequate to gain access to the space and for insertion of the prosthesis but it should not encroach upon the lower one-third of the pectoral muscle where tearing of muscle fibres is prone to occur leading to exposure of the prosthesis deep to the skin and subcutaneous tissues. Development of the superior aspect of the subpectoral pocket is usually straightforward (and should not extend beyond the second intercostal space), and the problem areas are medially, laterally and

inferiorly. The origin of the pectoralis major muscle must be detached from the anterior rib cage and lateral sternal edge to fashion the medial aspect of the pocket. Marking the peripheral margins of the contralateral breast preoperatively helps define the medial limit of dissection during development of the subpectoral pocket. Inferiorly the muscle is detached from its origin on the ribs and separated from the upper origin of the rectus abdominis muscle. The area of undermining is continued to below the inframammary crease in the submuscular plane in order to ensure that the prosthesis will not lie too high (especially when inflated). The dissection will continue inferolaterally deep to the external oblique and serratus anterior. A prosthesis placed too high will not 'drop' down at some later stage. Contraction of the pectoralis major muscle tends to displace the prosthesis in an upward and outward direction. It is important that the lateral limit of the pocket is sufficient to contain the prosthesis and the points of origin of the serratus anterior muscle from the ribs should be divided. The lateral limit of the dissection is the anterior axillary line. With careful dissection and a muscle splitting incision, an adequate pocket can usually be developed which provides complete musculofascial coverage of the prosthesis. Good illumination is essential during dissection of the pocket and facilitates adequate haemostasis.

An appropriate breast prosthesis is selected preoperatively; a biodimensional implant has the theoretical advantage of providing greater projection in the lower half of the reconstructed breast. A biluminal device permits tissue expansion postoperatively which may be required in some cases of delayed reconstruction. The limitations and potential problems associated with individual types of breast prostheses must be discussed with the patient. Often the base area of the prosthesis is less than the base area of the normal breast, but excessively large prostheses have intrinsic disadvantages and alternative forms of reconstruction (e.g. TRAM (transverse rectus abdominis myocutaneous) flap) should be considered in patients with very large breasts.

Following accurate placement of the implant the incision in the pectoralis major muscle is closed (sutures can be placed before insertion of the prosthesis to avoid inadvertent puncture of the latter). Suction drains should be placed in both the subpectoral and subcutaneous spaces and these are removed when drainage volumes are minimal. Subcuticular sutures are employed for skin closure with either non-absorbable or one of the newer soluble synthetic monofilament materials. The area into which the nipple-areola complex is to be set must be further de-epithelialized and despite a transverse incision across the meridian of the breast

together with a circumareolar incision the overall pattern of scarring is satisfactory. A compression brassiere worn for 3 months will enhance the quality of scarring and the final cosmetic outcome. Patients are routinely advised to restrict their activity in the immediate postoperative period to avoid excessive contraction of the pectoralis major muscle.

A similar technique is employed when alternative incisions are used. However, as previously mentioned, the breast tissue may be less accessible and there tends to be greater difficulty in adjustment of the skin envelope especially in those patients with breast hypertrophy or marked ptosis.

Results and complications

Modern techniques of breast reconstruction can now produce excellent cosmetic results with consistency and durability. Suboptimal results can be attributed to a variety of factors, but appropriate selection of patients and the method of choice are crucial aspects of any breast reconstruction. Other factors such as skin quality (texture and elasticity) influence results, in addition to the individual response of the patient to surgical intervention. When breast reconstruction follows subcutaneous mastectomy the size of the breast is an important factor determining aesthetic results. Breast symmetry per se can be more readily achieved when bilateral reconstruc-

tion is undertaken at the time of simultaneous right and left mastectomies.

References

1. Rice CO, Strickler JH. Adenomamectomy for benign breast lesions. *Surg Gynec Obstet* 1951; 93: 759–62.
2. Freeman BS. The technique of subcutaneous mastectomy with replacement, immediate and delayed. *Br J Plast Surg* 1969; 22: 161–6.
3. Bader KF, Pelletiere E, Curtin JW. Definitive surgical therapy for the premalignant or equivocal breast lesion. *Plast Reconstr Surg* 1970; 46: 120–4.
4. Goldman LD, Goldwyn RM. Some anatomical considerations of subcutaneous mastectomy *Plast Reconstr Surg* 1973; 51: 501–4.
5. Wheeler NR, Masters F. The lateral 'S' incision: an advantageous approach to subcutaneous mastectomy. *Plast Reconstr Surg* 1975; 55: 835.
6. Ward DC, Edwards MH. Early results of subcutaneous mastectomy with immediate silicone prosthetic implant for carcinoma of the breast. *Br J Surg* 1983; 70: 651–3.
7. Pers M, Bretteville-Jensen G. Reduction mammoplasty based on a vertical vascular pedicle and 'tennis ball' assembly. *Scand J Plast Surg* 1972; 6: 61.
8. McKissock P. Reduction mammoplasty with a vertical dermal flap. *Plast Reconstr Surg* 1972; 49: 245–52.
9. Freeman BS. Subcutaneous mastectomy for central tumours of the breast, with immediate reconstruction. *Plast Reconstr Surg* 1973; 51: 263–7.

12 Contralateral breast adjustment and nipple reconstruction

Alessandro Nannelli, Claudio Calabrese, Luigi Cataliotti, Guidobaldo Querci della Rovere

Introduction

The need for adjustment of the contralateral breast should be anticipated at the time of planning primary breast reconstruction. The procedure can be incorporated into the surgical programme and undertaken either at the time of immediate reconstruction or at a later stage when it can be carried out simultaneously with nipple reconstruction under general anaesthesia. Contralateral adjustment may be indicated following breast conservation surgery or mastectomy.

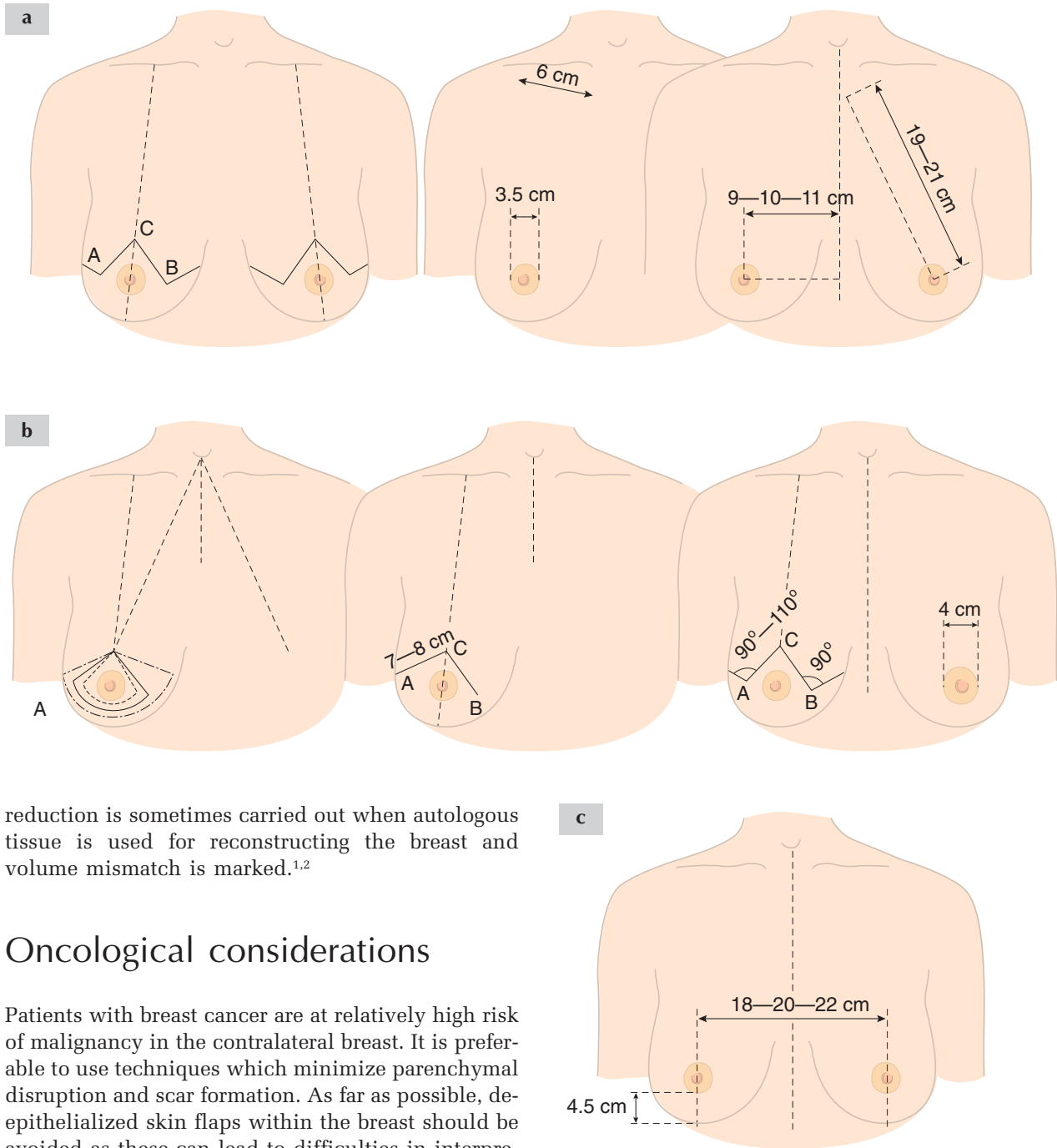
If the resectional procedure involves *partial removal of breast tissue*, a disparity in volume and contour can result between the operated and contralateral breasts, which detracts from the potential benefit of breast conservation surgery. Differences can become more obvious with time, usually as a consequence of late sequelae of radiation treatment. Radiotherapy leads to contraction in volume of the treated breast and can also induce changes in the shape and contour with loss of natural ptosis. In such circumstances, interventional surgery on the contralateral breast aims to restore symmetry by volume reduction coupled with elimination of excess ptosis. It may be apparent at the stage of planning the reconstruction that symmetry will not be achieved without a contralateral reduction. Ideally, this should be carried out at the same surgical sitting to avoid further major surgery and a second general anaesthetic.

In recent years, breast conservation procedures have only been carried out where breast resection can ensure favourable cosmetic results. Despite careful surgical technique and attention to aesthetic detail, often a contralateral procedure is necessary to

achieve acceptable breast symmetry and overall cosmesis. We have found that unfavourable cosmetic results occur following breast conservation surgery for two basic reasons, (i) location of the tumour in the lower quadrants of the breast and (ii) extensive resections in relatively small-to-medium sized breasts. Techniques are now available for partial breast reconstruction following breast conservation therapy and these should be considered in conjunction with a contralateral adjustment (see Chapter 10).

If the patient has undergone *mastectomy*, the need for adjustment of the contralateral breast is influenced by the type of breast reconstruction. Reconstruction using tissue expanders frequently necessitates contralateral breast surgery because prosthetic reconstruction has limitations in regard to size and degree of ptosis with a tendency for excessive fullness in the upper quadrants.

Where a temporary tissue expander has been employed, readjustment of the contralateral breast can be done simultaneously with the insertion of the definitive prosthesis. Should the final shape and volume of the reconstructed breast be difficult to predict, then it is preferable to perform a contralateral procedure at a later stage. Where a permanent expander is used (e.g. Becker type), it is essential to complete the overexpansion phase followed by definitive reduction in volume before embarking on any contralateral surgery. Final size and ptosis of the reconstructed breast is difficult to predict prior to final adjustment in volume of the tissue expander. Similarly, where reconstruction is undertaken with immediate insertion of a definitive implant, contralateral adjustment should be done as a delayed procedure in order to better judge the final volume and shape. Simultaneous contralateral



reduction is sometimes carried out when autologous tissue is used for reconstructing the breast and volume mismatch is marked.^{1,2}

Oncological considerations

Patients with breast cancer are at relatively high risk of malignancy in the contralateral breast. It is preferable to use techniques which minimize parenchymal disruption and scar formation. As far as possible, de-epithelialized skin flaps within the breast should be avoided as these can lead to difficulties in interpretation of subsequent mammograms. The aim of contralateral breast reduction is to achieve symmetry with the reconstructed breast, and this may sometimes involve aesthetic compromise. For example, the position of the nipple–areola complex may not be ideal, but must match the opposite side. Such surgery is performed on patients with a history of breast cancer who are often in an older age group than patients undergoing bilateral reduction mammoplasty for purely cosmetic purposes.

Contralateral surgery involves the following procedures:

- adjustment in position of the nipple–areola complex

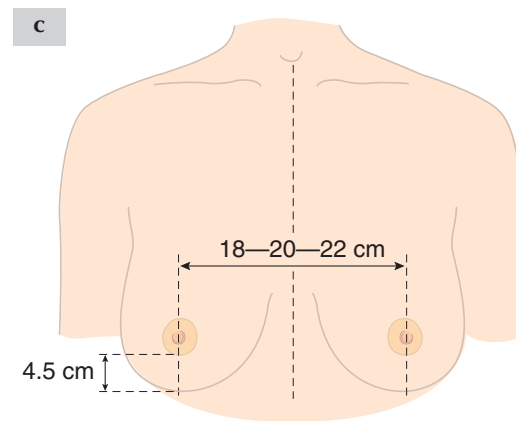


Figure 12.1 See text for details of a–c.

- mastopexy
- reduction mammoplasty
- augmentation mammoplasty.

The primary objective is to correct any asymmetry between the operated breast and the contralateral one. Slight asymmetry in the position of the two nipples can often be corrected by adjustment of the contralateral nipple–areola complex using a crescentic zone of de-epithelialization. This procedure is not suitable for more significant degrees of nipple asymmetry.

Greater degrees of asymmetry in nipple position must be corrected by mastopexy. The nipple–areola complex on the contralateral side lies at a lower position due to breast ptosis and this is associated with flattening of the upper quadrants. Both these aspects can be corrected with a mastopexy which lifts the breast and increases projection. Where there is a significant difference in volume between the treated and contralateral breasts, parenchymal tissue must be removed and a formal reduction mammoplasty undertaken. The choice between mastopexy and reduction mammoplasty is based on objective assessment, but details of operative technique will vary between surgeons and may be controversial.³ Breast surgeons should be familiar with a few basic techniques which they should practise regularly and in which they should accrue experience. More complex cases can be referred to a plastic surgeon with appropriate expertise.

Where possible, surgical incisions for adjustment of the contralateral breast should correspond to those on the treated side, e.g. an inverted T style incision or mirror image quadrantectomy. However, often this is not possible and then standard incisions should be employed.

Preoperative marking

Median sternal and inframammary lines are marked (Figure 12.1). A line is then drawn from the midclavicular point to the nipple and inframammary line.

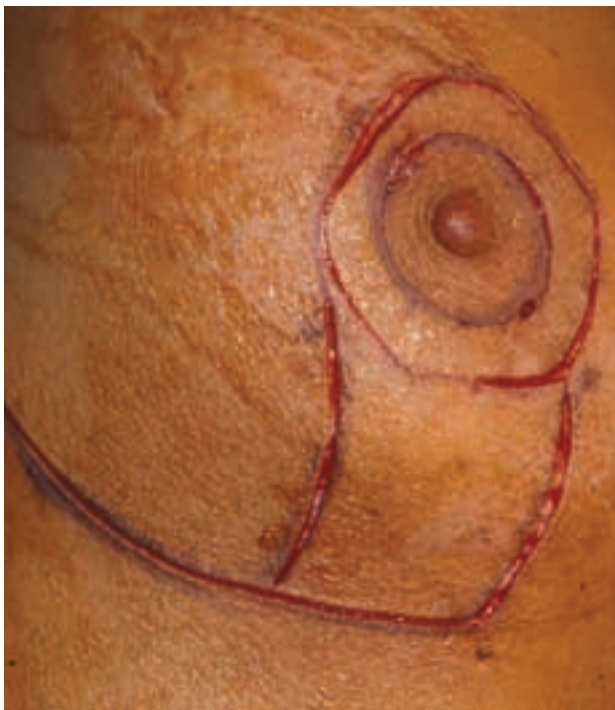

Figure 12.2 Skin incisions along the preoperative marking lines.

The site of the new nipple is positioned at a level corresponding to the contralateral side which is usually 19–21 cm from the sternal notch on the midclavicular line. From this point (C in Figure 12.1b) two lines are drawn at an angle of 90–140° (depending on the extent of reduction required) and 7–8 cm in length to points A and B. From points A and B lines are traced at an angle of 90–110° to intersect the inframammary line. The diameter of the new areola should be approximately 3.5–4.5 cm. Superior and inferior dermal pedicles are then fashioned accordingly.

Comma-shaped mammoplasty

In small or medium sized breasts without accentuated ptosis, the ‘comma technique’ of Regnaut⁴ can be used (Figures 12.2–12.8). This is suitable both for simple mastopexy and for those patients in whom only a small parenchymal reduction is required. Either mastopexy or reduction mammoplasty with limited parenchymal reduction can be carried out with the technique and the positioning of the nipple–areola complex can be easily determined during the planning stage.

This technique has the additional advantage of permitting removal of variable amounts of breast parenchyma. This technique allows for wide excision of tumours in the lower pole of the breast without deformity.

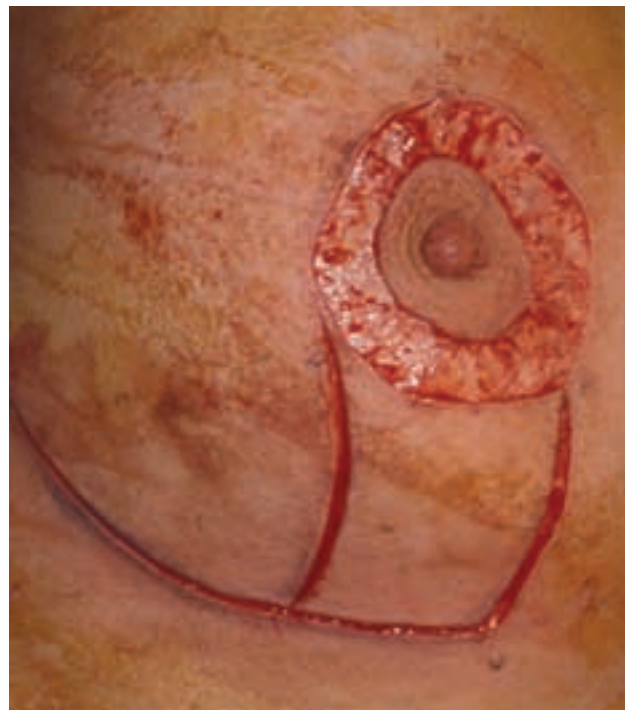


Figure 12.3 Zone of de-epithelialized skin around the areola.

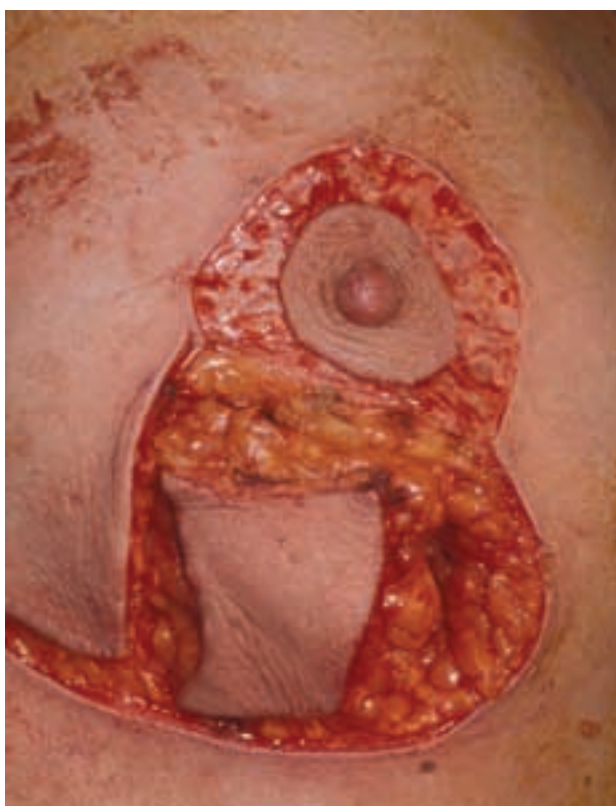

Figure 12.4 Incisions of the glandular tissue around the lower pole of the breast.

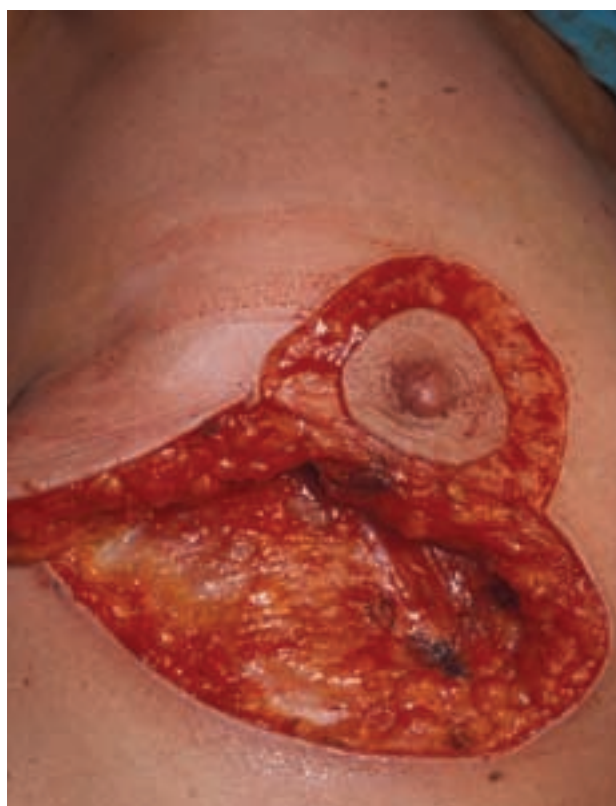

Figure 12.5 Operative view after excision of the lower pole of the gland and mobilization of the lower medial and lateral quadrants of the breast.

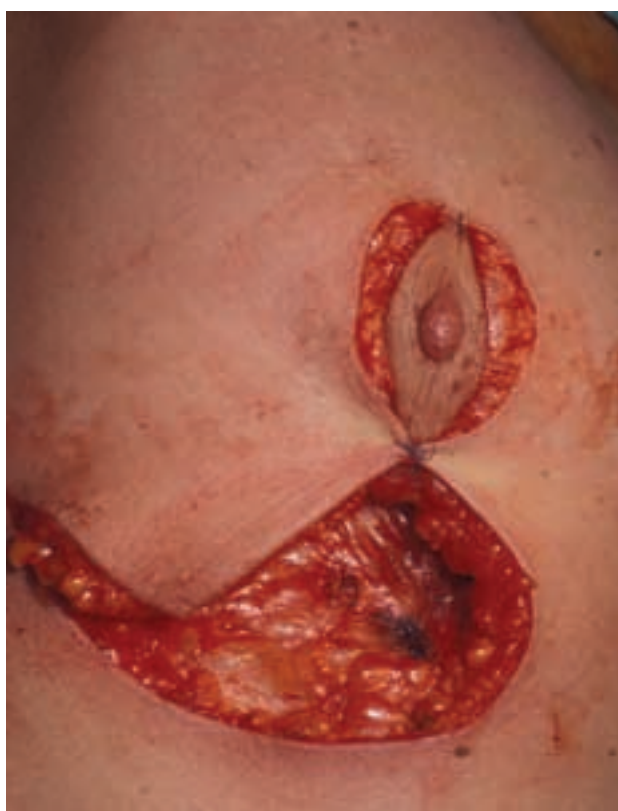

Figure 12.6 Temporary fixation of the areola in the 12 and 6 o'clock positions with interrupted sutures.

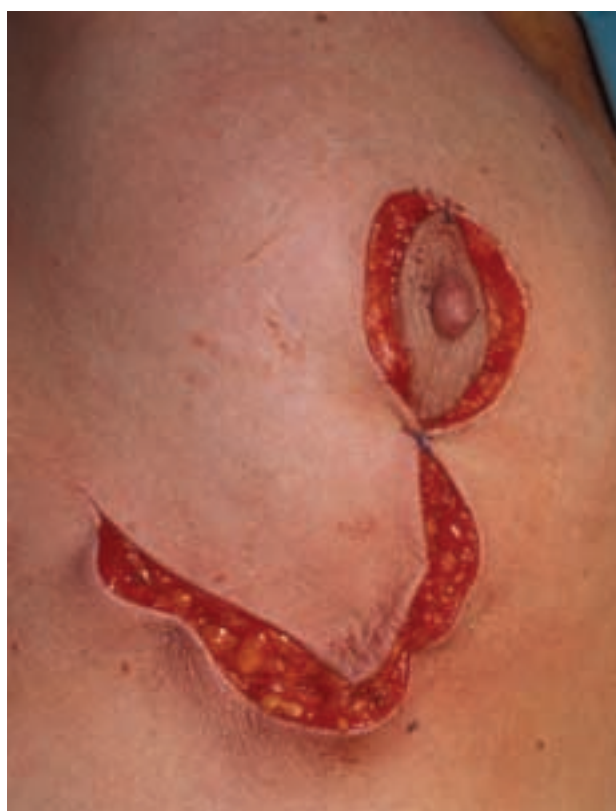

Figure 12.7 The medial and lateral lower quadrants are sutured together with interrupted absorbable sutures.

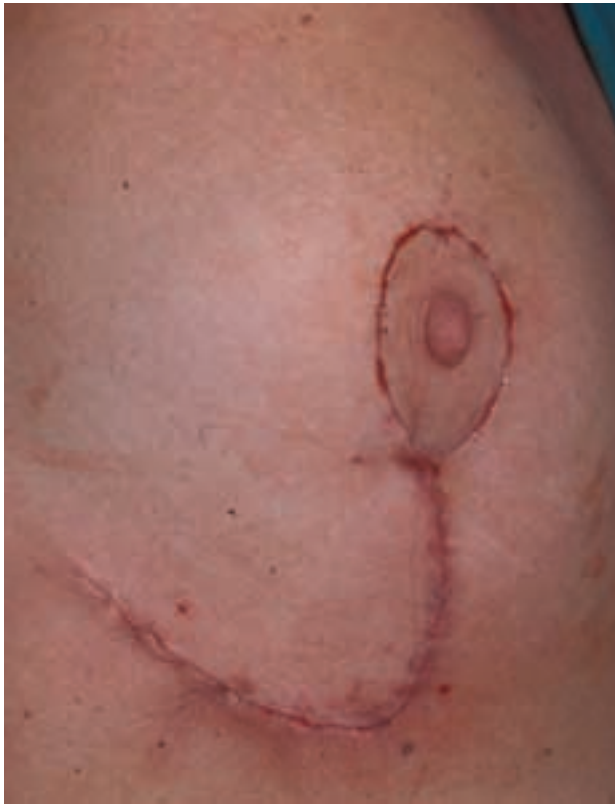

Figure 12.8 The skin is closed with absorbable 4/0 subcuticular material and the two temporary sutures holding the nipple in place are removed.

With greater degrees of ptosis and demand for volume reduction, a classical ‘inverted T’ (Wise pattern) technique is indicated which involves an upper or lower pedicled mammoplasty. An inferi-

only based pedicle, which minimizes the chance of ischaemic complications of the nipple–areola complex, should be planned for large pendulous breasts with extreme ptosis.⁵

Superior pedicled breast reduction/mastopexy (Figures 12.9–12.23)

This technique can also be used for wide excision of tumours in the lower pole of the breast.

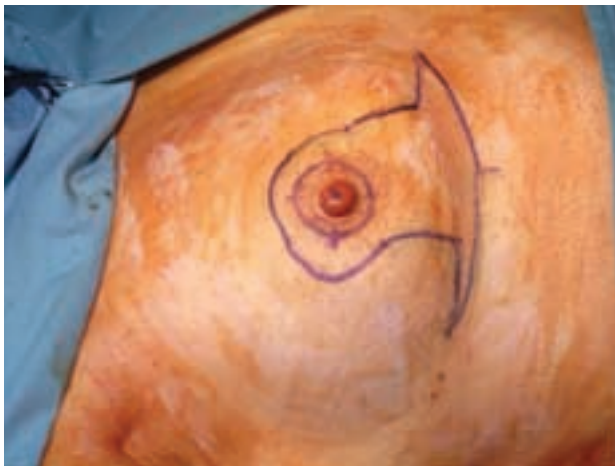

Figure 12.9 Preoperative skin marking.

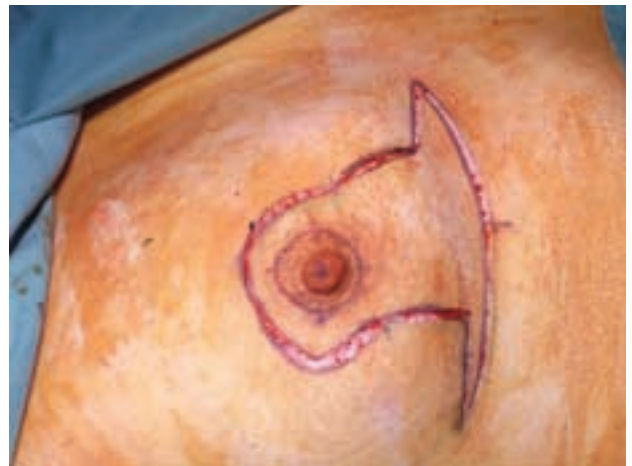

Figure 12.10 Epidermal skin incisions.

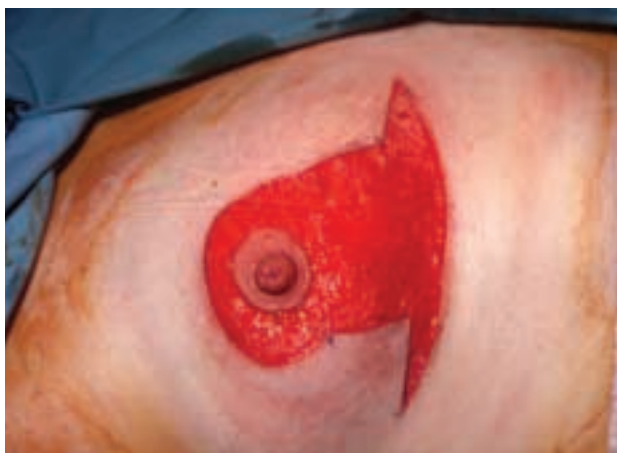

Figure 12.11 Zone of de-epithelialized skin.

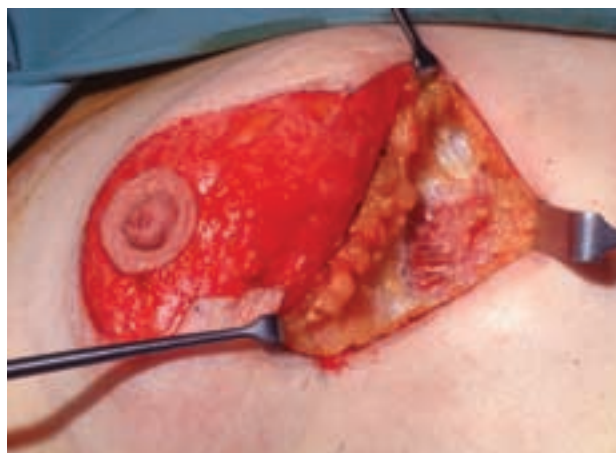

Figure 12.12 Dissection of the inferior pole of the breast down to the musculofascial layer.

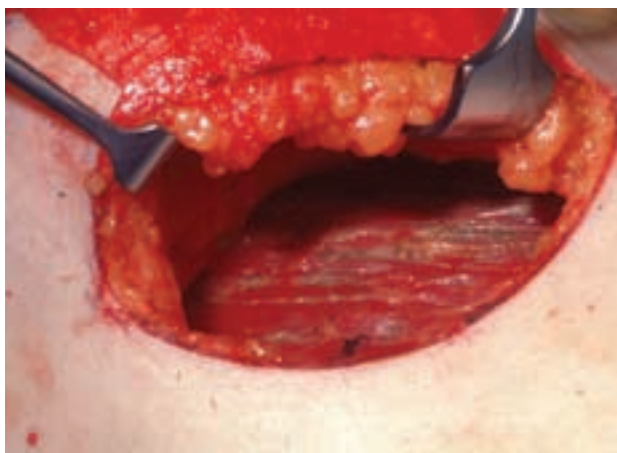

Figure 12.13 Development of the retromammary plane deep to the breast tissue.

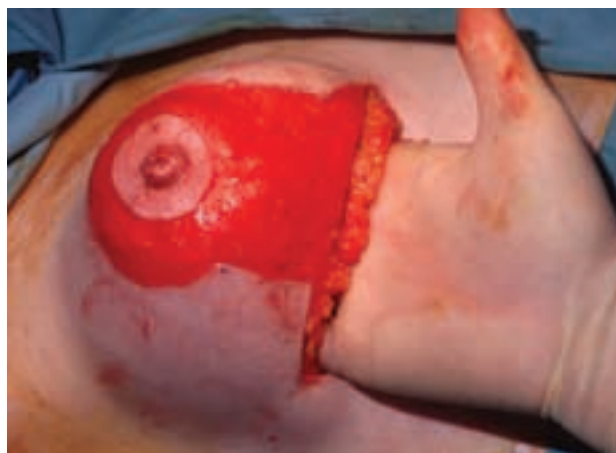


Figure 12.14 Retromammary dissection completed.

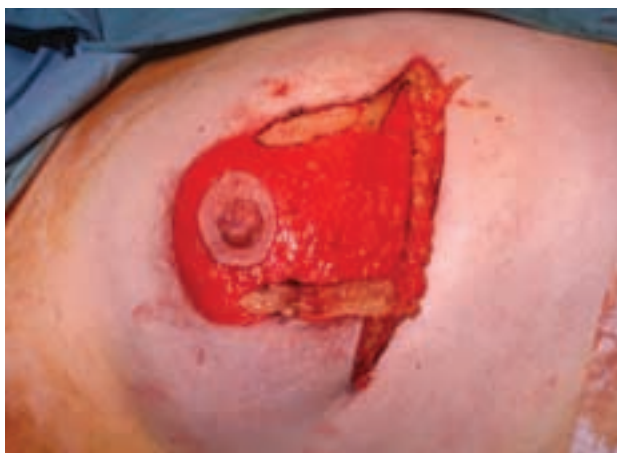

Figure 12.15 The inferior pole of the breast is divided in a vertical direction.

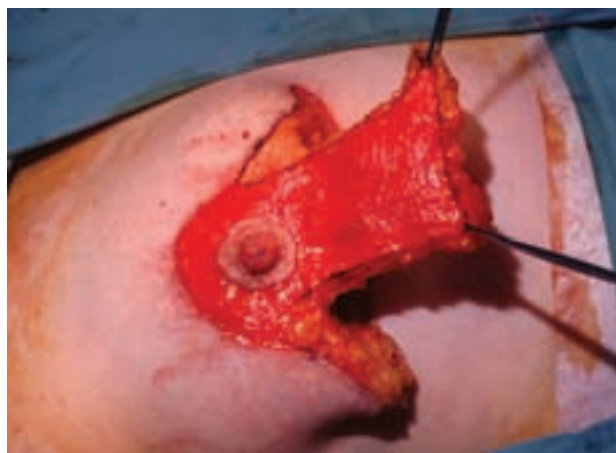

Figure 12.16 Resultant mobilization of the inferior pole of the breast is shown here.

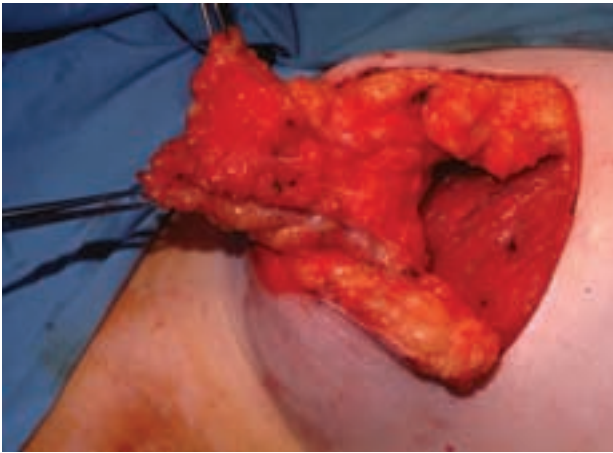


Figure 12.17 The under-surface of the breast tissue.

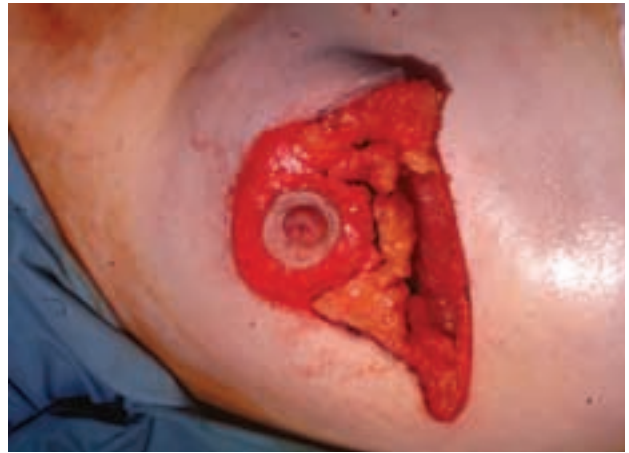

Figure 12.18 Amputation of the lower pole of the breast when the operation is undertaken as an oncological procedure or for reduction.

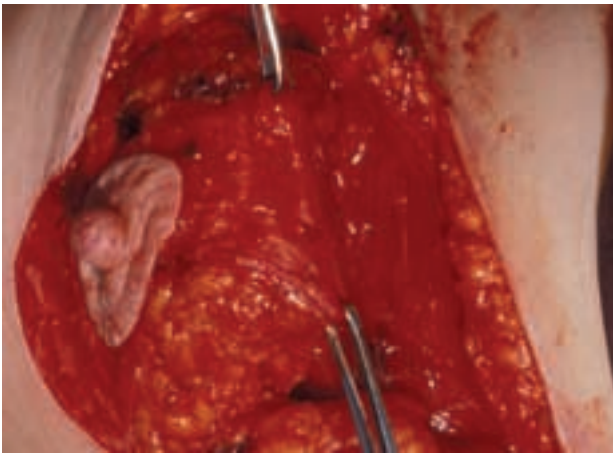


Figure 12.19 In cases undergoing surgery for contralateral symmetry where there is no need for breast reduction, the lower pole of the breast can be folded under the nipple to enhance the projection of the breast.

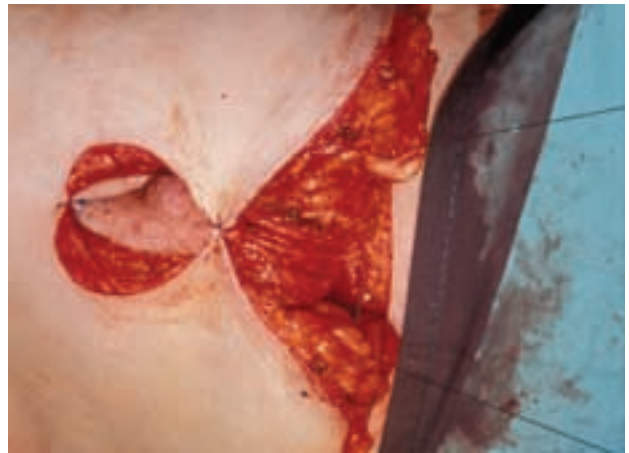

Figure 12.20 Closure of the lateral quadrants of the breast.

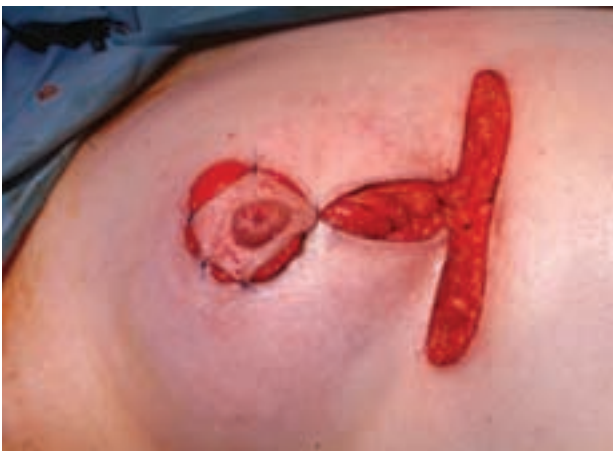

Figure 12.21 Skin closure.

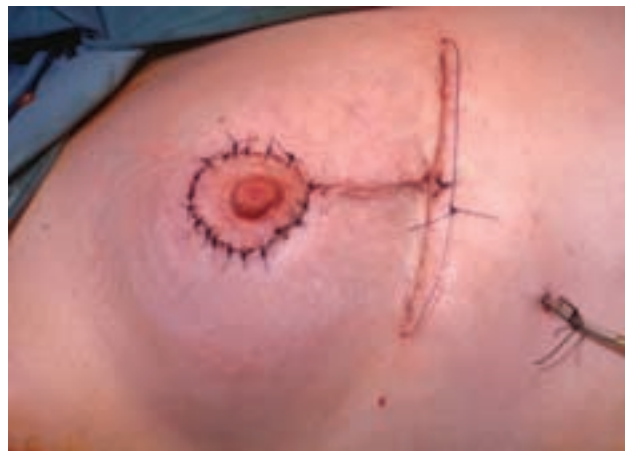

Figure 12.22 Skin closure completed.

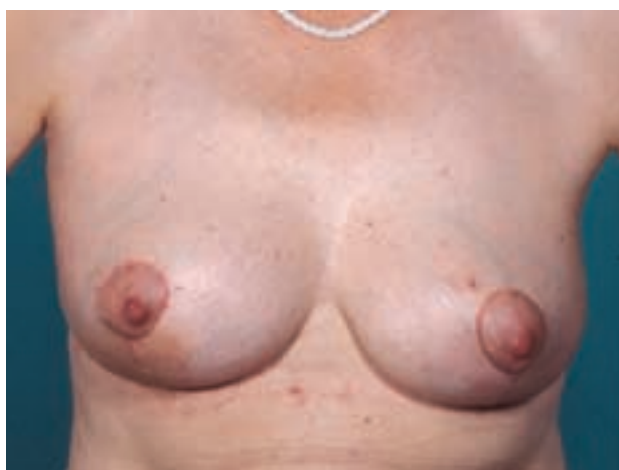

Figure 12.23 Postoperative view

Inferior pedicle breast reduction (Figures 12.24–12.39)

This technique can be used for wide excision of tumours located above the nipple or in the lower

quadrants of the breast (Figure 12.24 ab).

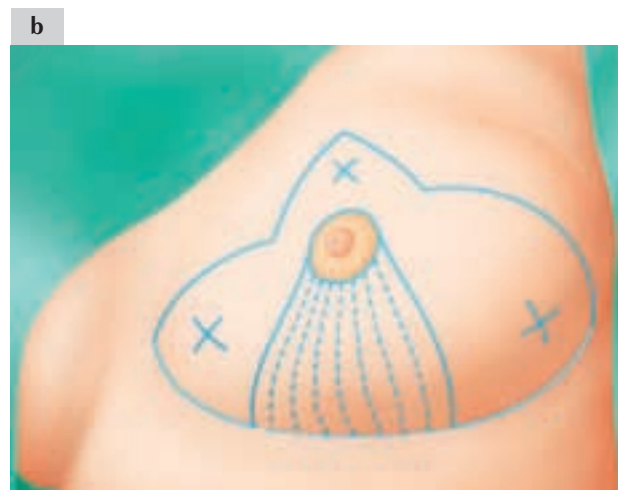
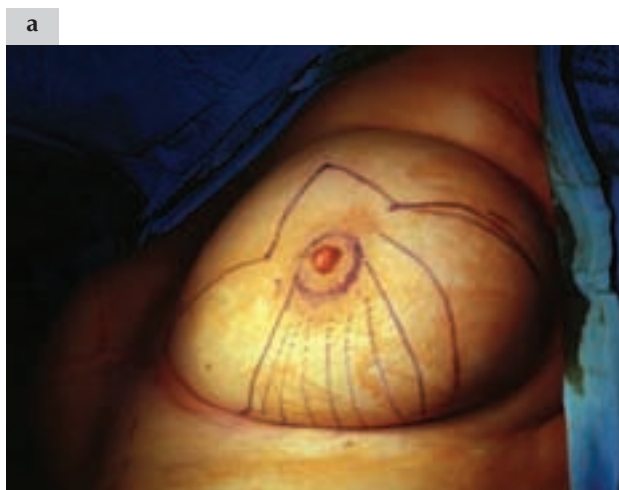

Figure 12.24 (a,b) Preoperative skin markings.

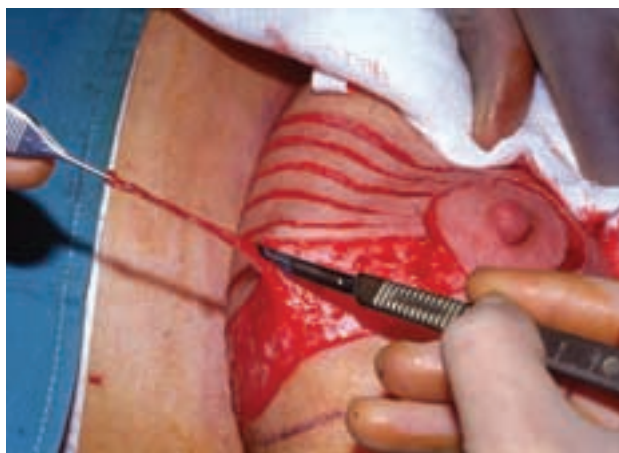


Figure 12.25 Creation of a dermal bridge inferiorly.

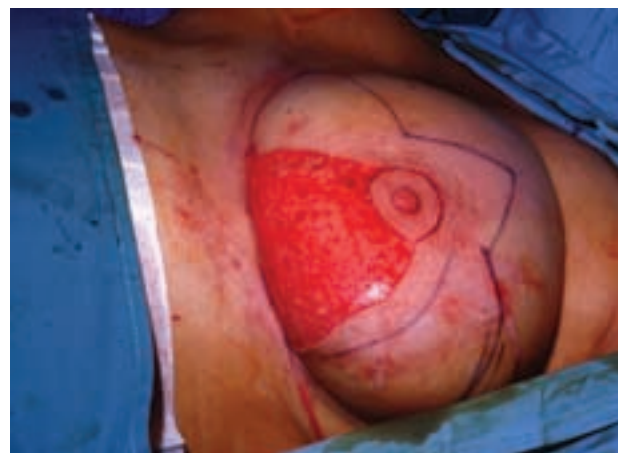

Figure 12.26 Completion of the dermal bridge.

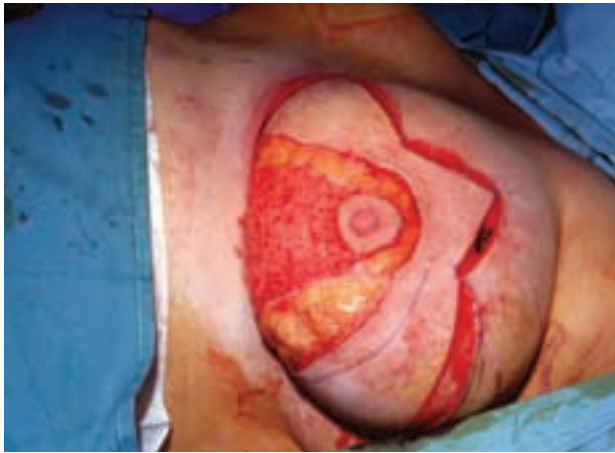

Figure 12.27 Skin incisions are completed in accordance with the reduction pattern.

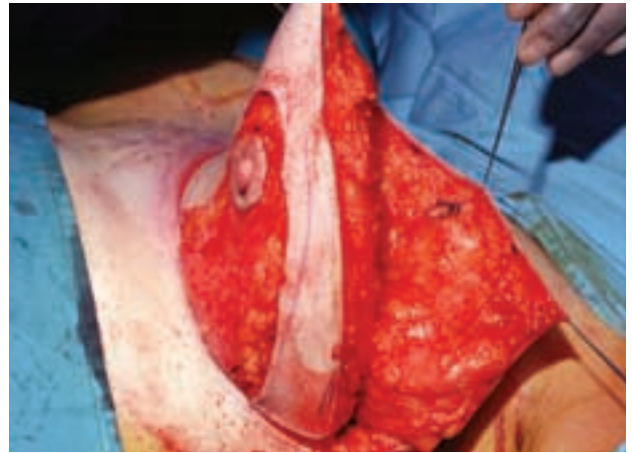


Figure 12.28 Parenchymal tissue is divided down to the chest wall at the level of the upper skin incisions.

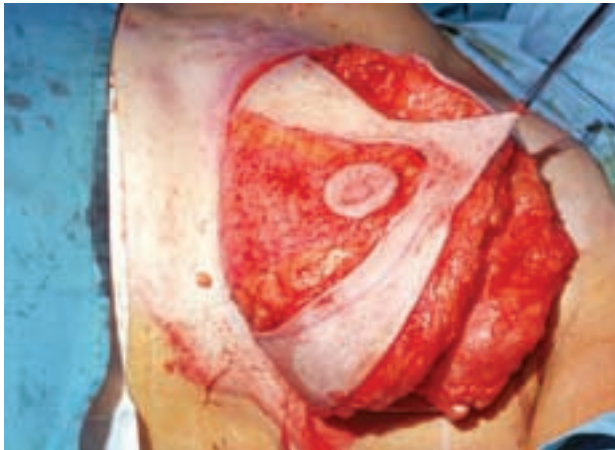


Figure 12.29 Division of glandular tissue is then continued in the inferior part of the reduction pattern with preservation of the nipple and dermo-glandular pedicle.

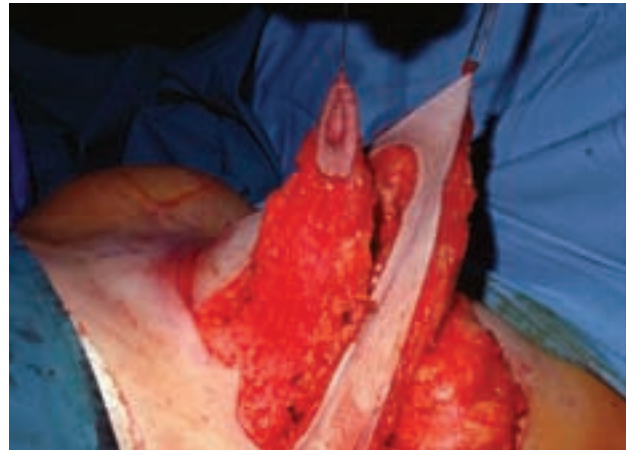


Figure 12.30 Dissection proceeds with separation of the dermo-glandular pedicle from the reduction specimen.

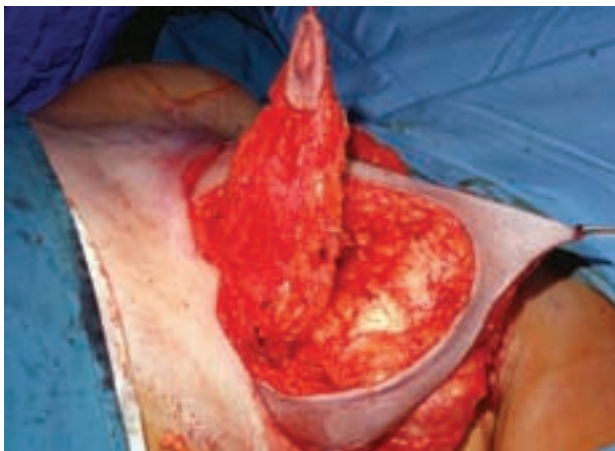

Figure 12.31 Further dissection completed.

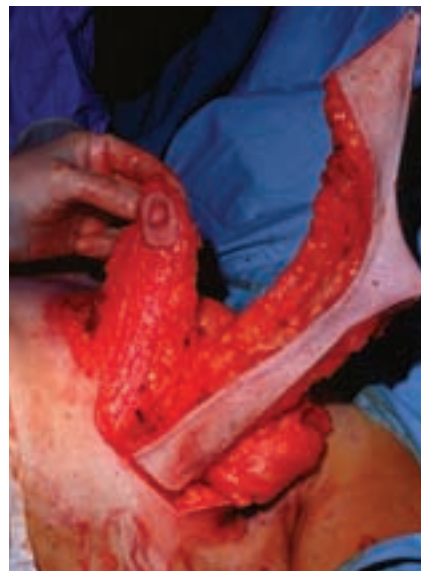

Figure 12.32 Reductional procedure almost completed.

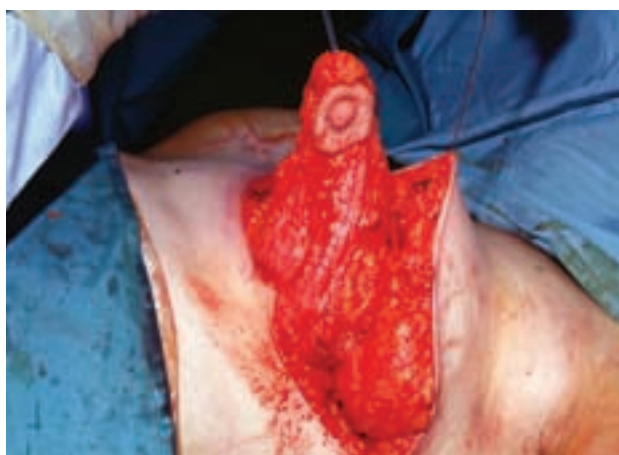

Figure 12.33 Residual breast tissue and dermo-glandular pedicle remains following excision of skin and reductive component of glandular tissue.

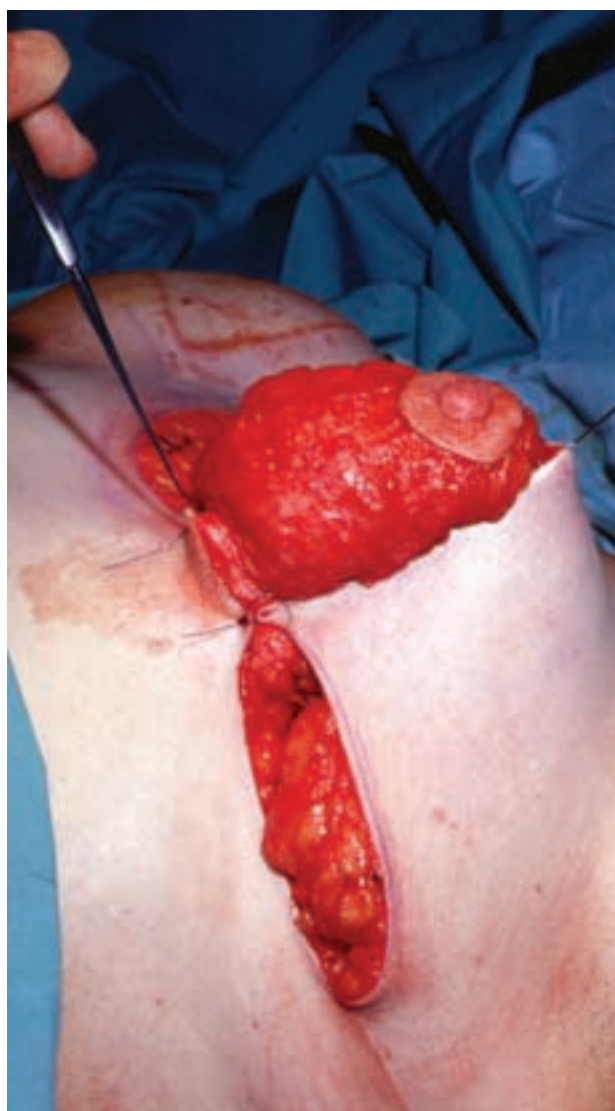


Figure 12.34 The lower ends of the vertical skin margins of the reduction pattern are sutured to the midclavicular point of the inframammary fold.

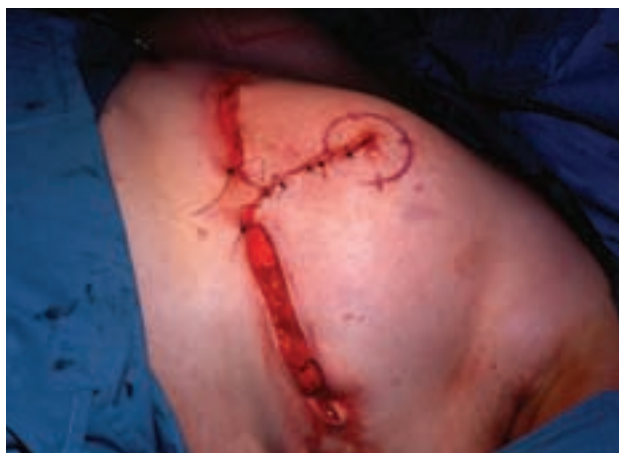

Figure 12.35 A disc of skin is marked with a nipple ring at the top of the vertical incision of the inverted 'T'.

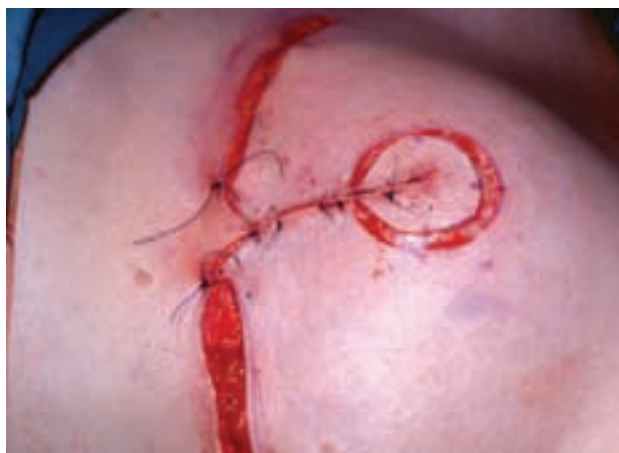

Figure 12.36 The disc of skin is excised.

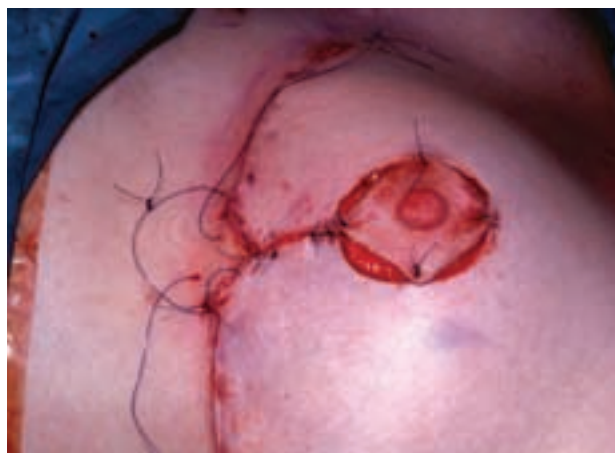

Figure 12.37 The nipple is retrieved and sutured to the skin.

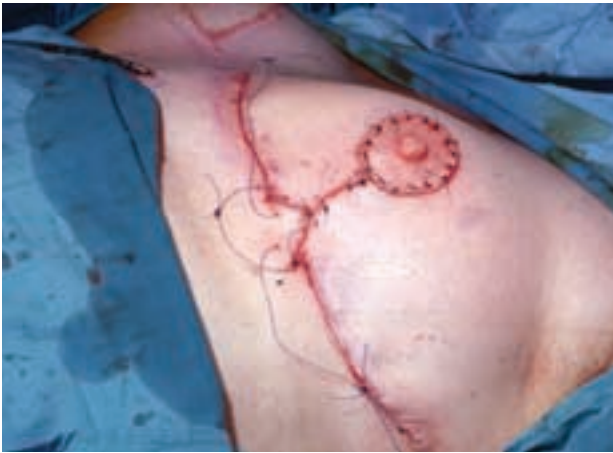

Figure 12.38 Appearance at completion of the operation.

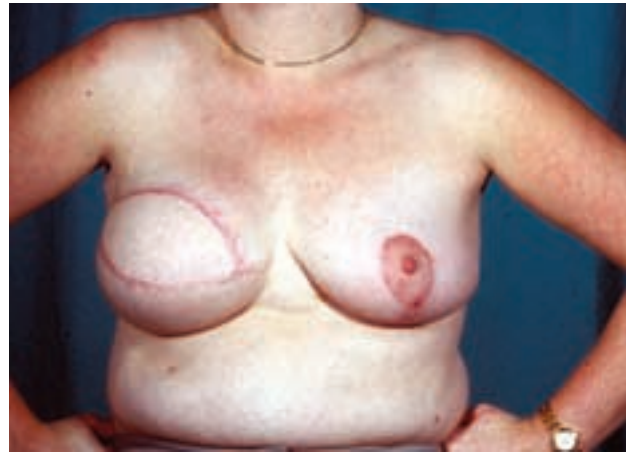

Figure 12.39 Postoperative view.

Final considerations

Remodelling of the contralateral breast following breast reconstruction post-mastectomy involves slightly different challenges and techniques are modified accordingly. Absence of a nipple–areola complex in the reconstructed breast to some extent facilitates remodelling of the contralateral breast. The position of the nipple–areola complex on the reconstructed breast can be finalized once a contralateral reduction has been performed. It is important that the nipple reconstruction is performed last with sufficient time interval to allow the reconstructed and contralateral breasts to settle following surgery (Figures 12.40 and 12.41). When reconstruction of the breast has been carried out using a temporary expander followed by insertion of a definitive prosthesis, contralateral surgery aims to achieve a firmer breast with increased fullness in the upper quadrants. The appearance of the contralateral breast should remain stable with the passage of time, although the reconstructed breast can change (e.g. due to capsule formation) with resultant loss of symmetry.

Sometimes the reconstructed breast appears greater in volume than the contralateral breast, and an augmentation mammoplasty is required to achieve symmetry. This can be combined with a mastopexy. This situation arises with reconstructions involving autologous flaps as well as implants. With the latter, an augmentation mammoplasty can be carried out to satisfy the patient's desire for larger breasts than previously.

It is often preferable to over-correct the contralateral breast to a moderate degree in order to achieve better

symmetry in the long term. It should always be remembered that a reconstructed breast, especially one containing an implant, can change with time. This must be taken into account when undertaking contralateral adjustment.

Remodelling of the contralateral breast may be undertaken as an immediate or deferred procedure. However, it is frequently carried out simultaneously with breast conservation surgery, but careful planning by both plastic and oncological surgeons is essential. Simultaneous contralateral surgery avoids the need for further anaesthesia and hospitalization.

For tumours in the inferior portion of the breast, the resection specimen can be incorporated within a classical mammoplasty procedure and in these circumstances symmetry can be achieved by performing a simultaneous mirror image procedure in the contralateral breast. Nonetheless, postoperative radiation therapy can result in subsequent loss of symmetry even when identical volumes of tissue have been removed from corresponding zones of each breast.

For patients undergoing mastectomy, contralateral surgery must not be commenced until breast reconstruction has been completed. Both breasts should be accurately marked preoperatively with a dermatographic pen. Important markings are the midline (from suprasternal notch to umbilicus) and the position of the submammary fold which indicates the point of projection of the nipple. On the operating table, the patient should be placed with her arms spread symmetrically; it must be possible to break the table in order to raise the patient into a semi-seated position and the upper torso should be completely exposed.

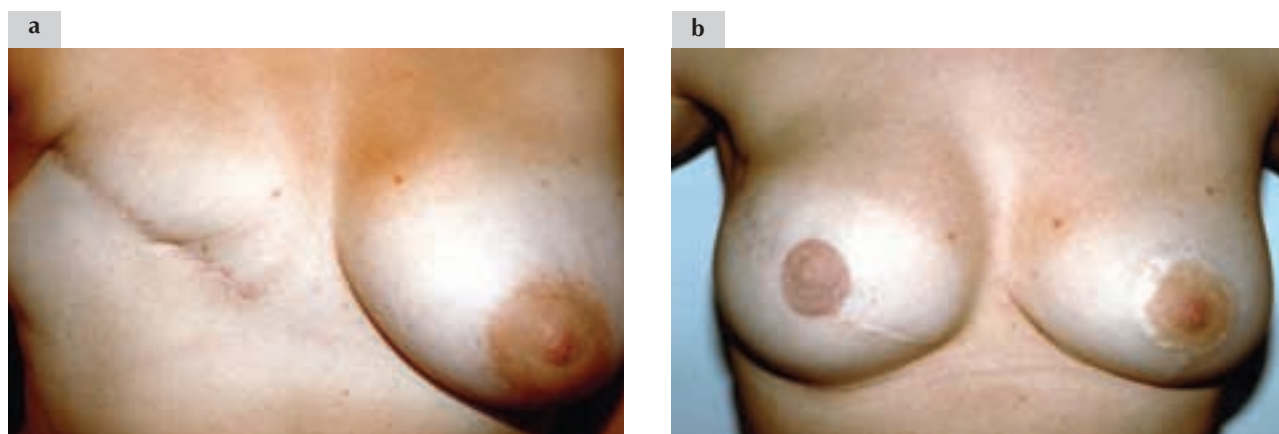


Figure 12.40 (a) Preoperative view before delayed breast reconstruction. (b) Postoperative view after reconstruction with tissue expander and contralateral adjustment

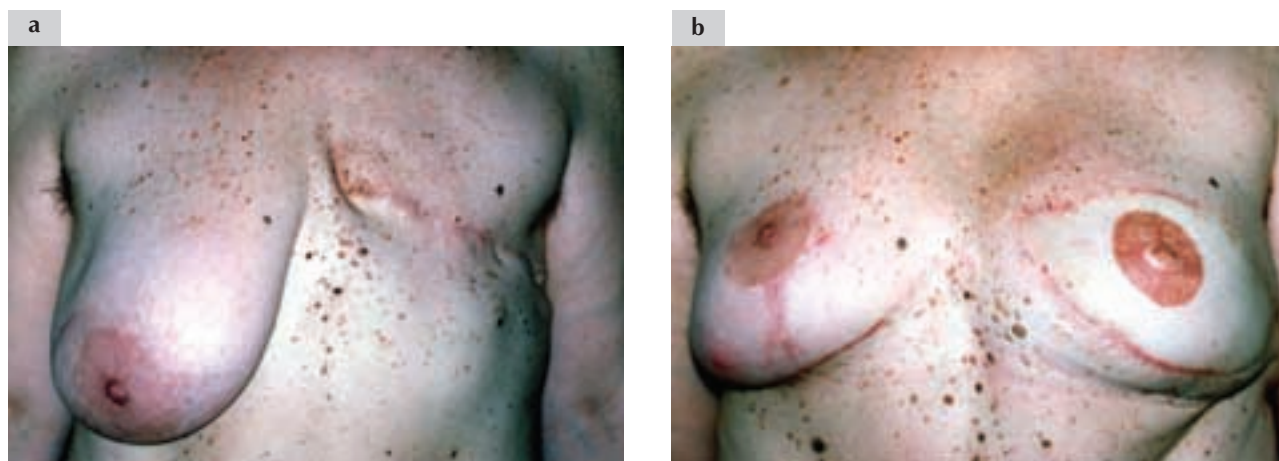


Figure 12.41 (a) Preoperative view before delayed breast reconstruction. (b) Postoperative view after reconstruction with TRAM flap and contralateral breast adjustment.

Reconstruction of the nipple–areola complex

This is the final stage of breast reconstruction and should be carried out only when the surgeon is confident that acceptable symmetry and shape of the reconstructed breast has been achieved. Nipple reconstructive techniques are relatively simple and can be carried out on an outpatient basis under local anaesthesia. Protruberance of the nipple is created with local skin flaps and once healed, colour matching of both nipple and areola can be achieved with tattooing. Alternatively, a skin graft can be taken from the inner thigh using an onlay technique.^{6,7}

Some of the techniques previously employed for

nipple reconstruction are being abandoned as it has become apparent that results are not durable with progressive flattening and loss of bulk of the reconstructed nipple. Not only may there be marked nipple asymmetry, but the reconstructed nipple can almost completely disappear. For this reason, some surgeons reconstruct an over-sized nipple to compensate for a degree of atrophy and to achieve long-term symmetry.⁸ The preferred methods of nipple reconstruction at present are those which use local flaps such as the skate flap or star flap (Figures 12.42–12.50). (An alternative to a surgically reconstructed nipple is the use of silicone prosthetic nipples.)

Nipple reconstruction: skate technique

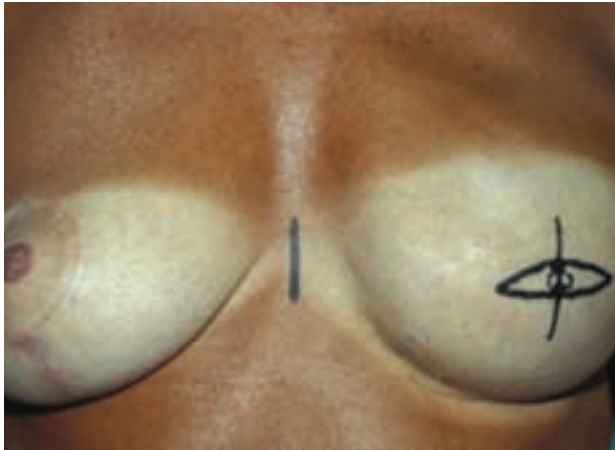

Figure 12.42 Preoperative skin marking.

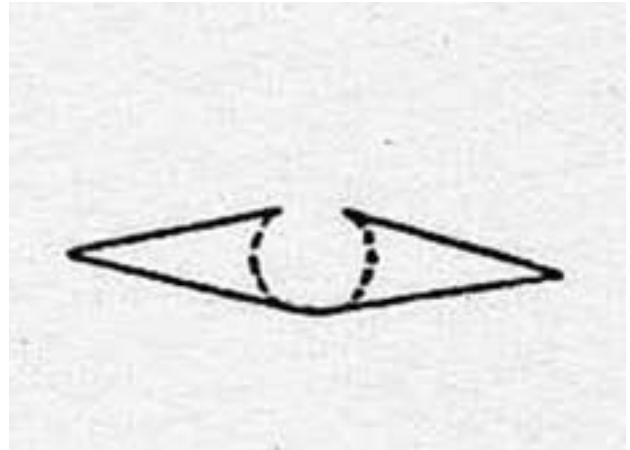


Figure 12.43 Diagram of the skin incision.

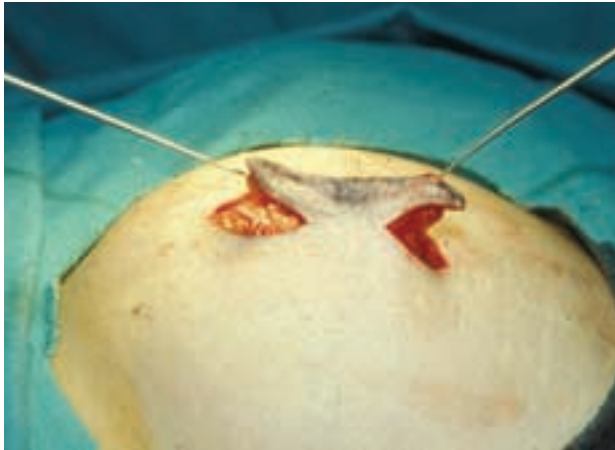


Figure 12.44 Skin flaps partially elevated.

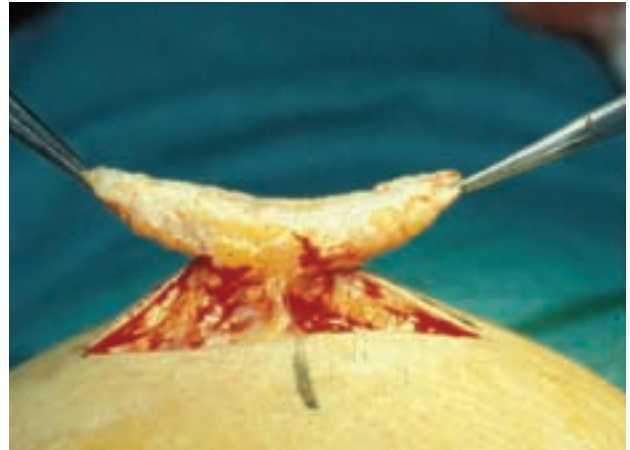

Figure 12.45 Complete elevation of skin flaps.

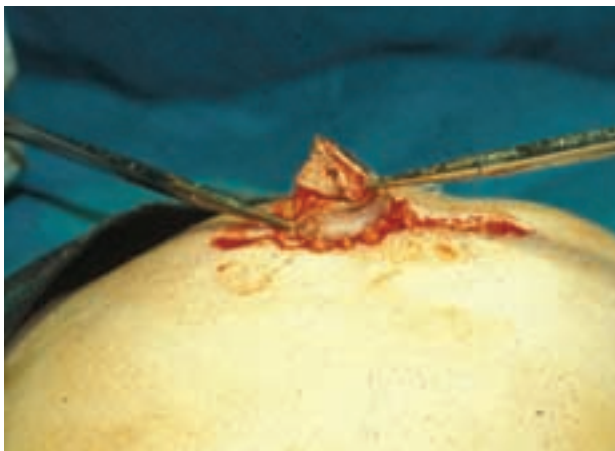

Figure 12.46 Skin flaps wrapped around central tissue core to form the new nipple.

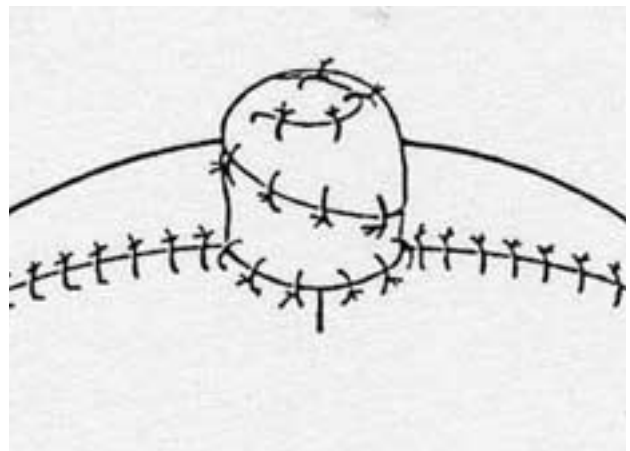


Figure 12.47 Diagram of the 'wrapping around' technique.

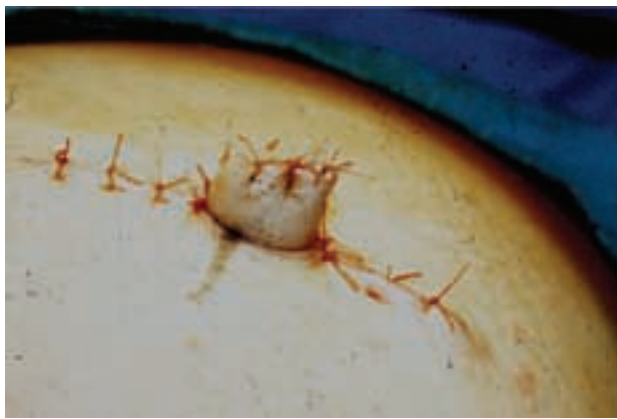


Figure 12.48 Wound closed to form nipple mound.



Figure 12.49 Postoperative view of nipple in profile to show the projection.

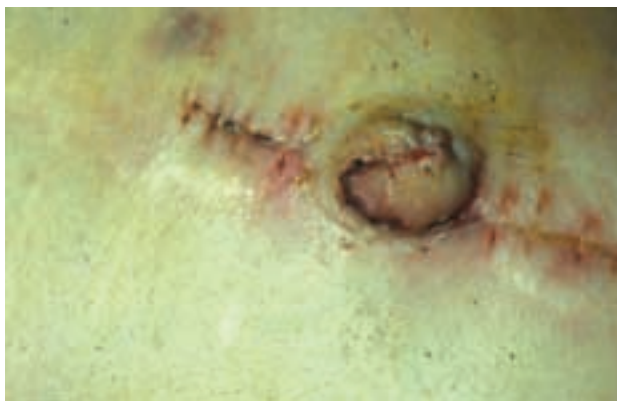

Figure 12.50 Appearance following removal of the sutures.

Conclusion

Surgical adjustment of the contralateral breast aims to achieve symmetry following partial or complete mastectomy for breast malignancy. Overall body image is improved but such procedures must be done in response to a patient's request and not on the insistence of the surgeon. Some patients may be content with the reconstructed breast even though symmetry and appearance could be enhanced by adjustment of the contralateral breast. Moreover, it should be borne in mind that surgery on the contralateral breast may render future clinical and radiological surveillance more difficult.

References

1. Hoffman S. Unilateral reduction mammoplasty. In: Goldwin MR, ed. *Reduction Mammoplasty*. Boston: Little, Brown and Company, 1990.
2. Kroll SS. Options for the contralateral breast in breast reconstruction. In: Spear SL, ed. *Surgery of the Breast: Principles and Art*. Philadelphia: Lippincott-Raven Publishers, 1998.
3. Hidalgo DA, Elliot LF, Palumbo S et al. Current trends in breast reduction. *Plast Reconstr Surg* 1999; 104: 806.
4. Regnault P. Reduction mammoplasty by the B-technique. *Plast Reconstr Surg* 1974; 53: 19.
5. Hidalgo DA. Improving safety and aesthetic results in inverted T-scar breast reduction. *Plast Reconstr Surg* 1999; 103: 874.
6. Little JW. Nipple-areolar reconstruction. In: Spear SL, ed. *Surgery of the Breast: Principles and Art*. Philadelphia: Lippincott-Raven Publishers, 1998.
7. Kroll SS. Nipple reconstruction with the double-opposing tab flap. *Plast Reconstr Surg* 1999; 104: 511.
8. Few JW, Marcus JR, Casas LA et al. Long-term predictable nipple projection following reconstruction. *Plast Reconstr Surg* 1999; 104: 1321.
9. Goldwin MR, Curtiss EH. Reduction mammoplasty by the inferior pedicle (pyramidal) technique. In: Goldwin MR, ed. *Reduction Mammoplasty*. Boston: Little Brown and Company, 1990.
10. Wiener DL. Breast reduction: the superior pedicle technique (dermal and composite). In: Goldwin MR. *Reduction Mammoplasty*. Boston: Little, Brown and Company, 1990.

13 Commentary: subcutaneous mastectomy and oncoplastic surgery of the breast

Scott L Spear

Breast reconstruction after conservative surgery

One of the most interesting areas in the surgery of breast cancer is the concept of breast reconstruction after breast conserving surgery. In fact, this is a broad subject which includes proper patient selection for breast conservation, proper planning for breast conservation, and management of complex and difficult situations for breast conservation. As breast conservation has become more widely applied in the treatment of breast cancer, the problems and challenges have become more complex. Perhaps the key to Chapter 10 and to this entire subject is the concept that patient selection, planning, and problem solving in breast conservation should include both an oncological breast surgeon and a plastic breast surgeon. In some environments this may be the same individual, but in many hospitals, in fact, this requires two different people with different perspectives and different expertise. The authors begin by describing what they feel to be the best incisions for breast conserving surgery. Essentially these are lower quadrant radial incisions and upper quadrant circumlineal incisions. They also emphasize the importance of avoiding long incisions, particularly ones above the bra line or extending into the axilla. They also emphasize the importance of a deep glandular repair when large amounts of tissue have been removed. This may require some undermining of the breast off the chest wall in order to mobilize the gland properly.

One of the most interesting concepts in this chapter is the idea of leaving the patient actually better than before the breast cancer by reducing or lifting the

large or pendulous breast as part of the breast conserving therapy. Thus, breast reduction techniques, or mastopexy techniques, can be applied to a large variety of tumours that may be found in the large pendulous breast. Flaps of breast tissue with or without the areola attached can be mobilized based upon a superior, inferior, superomedial, superolateral or a central pedicle.

One of the most controversial areas for breast reconstruction after breast conservation is the use of local or distant flaps to perform partial breast reconstruction. The authors recommend the application of an immediate latissimus dorsi (LD) flap at the time of the lumpectomy or quadrantectomy to be followed by postoperative radiation. They emphasize, however, that the use of this flap in reconstructing the partial mastectomy defect also results in the loss of the availability of this flap should it be needed for a total breast reconstruction, for example in the case of a recurrence. The authors do not mention the issue of how well these LD flaps hold up with post-quadrantectomy radiation therapy. The intriguing question remains as to whether or not the LD flap ultimately performs better as an immediate procedure or after a delay of some time after the lumpectomy and radiation therapy have been completed.

There is also mention in this chapter of placing an implant beneath the reduced breast after breast conservation therapy or the use of an omental flap to help augment a breast in those circumstances. I have not had personal experience in using the omental flap and so I can only say that that is an interesting concept that I have not needed in my experience. I will, however, mention that I have always been reluctant to use an implant to reconstruct the partial mastectomy defect because of

concerns of capsular contracture, implant extrusion and interference with postoperative surveillance. Nevertheless, in a small group of patients where the radiation damage seems to be modest and where the patient is insistent, I will agree to place an implant beneath the pectoralis muscle in order to restore volume and interfere as little as possible with subsequent mammography.

The authors also bring up the issue of remodelling the previously radiated breast. We have had some experience with that in the United States, and I agree with the authors that this should be done with great care and conservatism. One can predict that the irradiated breast will not tolerate remodelling surgery as well as would non-radiated tissue. For that reason, there should be a minimum of undermining or flap elevation, and the surgery should be kept as simple as possible. One should expect and warn the patient that the results of such remodelling surgery in the radiated breast are less predictable than in the non-radiated breast and will almost always yield a less successful outcome. Nevertheless, such remodelling procedures can still be quite worthwhile, particularly where there are significant deformities or asymmetries from the breast conserving treatment.

In summary, let me repeat the authors' admonition that it is incumbent upon general surgeons to seek the opinion of plastic surgical colleagues when poor results of breast conservation are anticipated. I would even expand this statement to include the principle that collaboration between general surgeons and plastic surgeons should be encouraged when planning and selecting patients for breast conserving therapy.

Subcutaneous mastectomy and reconstruction

The subject of subcutaneous mastectomy should be seen in the wider context of the role of mastectomy overall on the one hand, and the role of prophylactic mastectomy on the other. This subject has always been controversial and has become, if anything, more controversial in recent years as the identification of patients at high risk for developing breast cancer has become more precise. The most significant irony associated with prophylactic mastectomy has been the fact that for established breast cancer, breast conservation is often the recommended treatment, while for patients who do not have breast cancer, some recommend prophylactic mastectomy instead. Once prophylactic mastectomy is being considered, one variation would be prophylactic mastectomy done as a subcutaneous mastectomy or

as a nipple-sparing mastectomy. As the author of Chapter 11 points out, subcutaneous mastectomy may also be offered for a subset of individuals who have invasive breast cancer but who wish to avoid removal of the nipple on the one hand, or radiation therapy on the other. This subgroup is best defined by women who have a relatively small breast and a tumour located in the periphery of the breast, well away from the nipple.

This chapter mentions briefly the issue of general considerations regarding subcutaneous mastectomy. In fact, this subject deserves even greater attention than offered by the author. A review of much of the literature on subcutaneous mastectomy reveals that patient selection is rarely discussed adequately. The reality is that the issue of subcutaneous mastectomy or not is not simply an oncological issue but also a cosmetic issue. For some patients, preservation of the nipple-areola complex is technically difficult and probably not wise. For other patients, it may be cosmetically critical for the patient and give the possibility for the patient of a very good or excellent cosmetic result. The alternative in the same patient might be an average to poor result. Thus, balancing the cosmetic issues in any given patient is probably as important as balancing the oncological issues. As the author says, satisfactory results in breast augmentation or in breast reconstruction are often best achieved when a skin envelope conforms with the size and shape of the chosen breast prosthesis. However, I disagree with the claim in this chapter that in the majority of patients undergoing subcutaneous mastectomy, reduction of the skin envelope is necessary for satisfactory long-term results. In fact, there is no evidence presented in this chapter or in any paper that I am aware of that such reduction is necessary, and, in fact, this issue has a lot to do with proper patient selection. It would be my opinion that while some degree of ptosis of a prosthetic breast reconstruction is possible, on the other hand, a large amount of ptosis is probably undesirable and prone to developing deformities such as capsular contracture or the appearance of a breast implant in the distal portion of the skin envelope with a deficiency in the proximal portion, thus giving the appearance of a 'rock in a sock'.

The author is right in saying that there is a fine margin of surgical error between a healthy nipple-areola complex and vascular insufficiency when performing a subcutaneous mastectomy. In fact, this is true when performing any type of mastectomy, and it is also true that the larger the breast itself, the higher the risk of vascular insufficiency along the distal edge of these since the skin flaps must necessarily be longer in a larger breast. The author also mentions that when a substantial reduction of the skin envelope is required for the patient with large

breasts, the issue of blood supply becomes more complex and, therefore, free grafting of the nipple–areola should be a consideration.

Regarding incisions, the author mentions that limited incisions may result in persistent breast tissue while excessively long incisions may compromise vascularity of the nipple–areola complex or blood supply of the skin flaps. I agree that limited incisions may present obstacles to performing a subcutaneous mastectomy, and for that reason, the incision needs to be of sufficient length and in the best location to allow the surgery to proceed. However, with modern techniques including endoscopy, certainly incisions can be shorter than they used to be. On the other hand, the length of the incision probably is not critical to the blood supply of the flaps. Rather, the length of the flaps themselves and the plane of dissection as well as the underlying health of the patient are more critical. In my hands, I have found several incisions to be totally suitable for prophylactic mastectomy including a long inframammary incision in small-to-medium sized breasts, and a lateral oblique incision and an incision across the lateral equator of the breast, also in small-to-medium sized breasts. In larger breasts, a skin-sparing mastectomy with removal of the nipple–areola complex, with or without a linear extension, also can be suitable, particularly if the skin that has been removed with the nipple excision is replaced with a skin flap either from the back or the abdomen.

The author mentions that placement of the prosthesis in a subcutaneous pocket encourages ulceration of the overlying skin flap. I would have to disagree with this comment. In my opinion, most skin ulceration is not due to the presence of implant but rather to poor vascularity of the flap either from excessive length, overly aggressive dissection, or a patient with compromised health. The author would like to make the distinction between subcutaneous and subpectoral as being either totally on top of the muscle or totally underneath the muscle. His comments that the subcutaneous plane results in a higher incidence of capsular contracture is probably more true of the purely subcutaneous plane rather than a partially subcutaneous plane or a dual plane positioning.

The author then goes on to describe his special technique, which is a subcutaneous mastectomy down through a meridian incision where an ellipse of skin is removed centrally but a vertical bipedicle flap is created to hold the areola and to allow for it to be maintained on the breast. While this technique may have its indications and is certainly an interesting surgical manoeuvre, there are a number of things about it which are of concern. To begin with,

I have been disappointed with any pedicle procedures done at the same time as a subcutaneous or other type of mastectomy. The skin flaps are simply not reliable enough to allow them to be used for a flap procedure as well. In the author's technique, he also recommends total muscle coverage, which, in my opinion, is not the ideal solution for most patients. Total muscle coverage results in an overly tight muscle brassiere, superior malposition of the implant, inadequate projection of the lower pole as well as a poorly defined inframammary fold. The author also likes placement of an implant in the primary procedure, which is not my preference. I prefer to do this as a two-stage procedure with a tissue expander used as a temporary device followed later by a long-term implant. Certainly the use of a tissue expander allows more flexibility in the operation and greater safety as well as the ability to come back in stage two and improve the cosmetic result.

The subject of prophylactic mastectomy and subcutaneous mastectomy remains unresolved and, in fact, is of growing interest at the present time. Plastic surgeons tend to be far more favourable regarding both prophylactic mastectomy and subcutaneous mastectomy than do general surgeons or oncologists. The two best indications or techniques for subcutaneous mastectomy are in the small-to-medium sized breast using an inframammary or meridian incision connecting with a peri-areolar incision. In larger breasts where the nipple needs to be removed either for oncological, cosmetic, or vascular reasons, a small flap taken from the back can be used to carry a musculocutaneous flap which can be de-epithelialized to provide an appropriate recipient site for the nipple–areola graft. My preference is to avoid repositioning the nipple–areola either on a pedicle or as a skin graft on the mastectomy flaps. Both of those techniques have a higher complication rate and a greater risk of malposition of the nipple–areola complex.

The author also describes his preferred technique of placing the implant or device under total muscle coverage. While this is undoubtedly the safest thing to do from the point of view of exposure of the device or infection, it is probably the worst thing to do in terms of achieving good cosmetic results. Total submuscular placement prevents proper projection of the lower pole of the breast and inevitably leads to poor definition of the inframammary fold and an unnatural appearance. Our preference in most cases is for subpectoral or possible subserratus placement of the device leaving the lowermost portion of the device in the subcutaneous plane where hopefully it will be covered by a healthy skin flap. This does expose the patient to somewhat increased risk in terms of infection and exposure but, on the other hand, leads to better cosmetic results in terms of the

shape of the breast and a well-defined inframammary crease. The final decision regarding subpectoral placement versus total muscle coverage is a technical one which often must be made at the time of surgery depending upon the local tissue environment and the type and size of the breast that one is seeking to achieve.

The author tends to prefer an implant for the primary reconstruction using an adjustable device or a biluminal device. This is certainly an option depending upon what type of adjustable device is available. Currently in the United States, my preference is to use a single-chamber shaped textured expander with an integrated valve. Although this device must ultimately be replaced with an implant at a later date, it is an extremely convenient and reliable device to use and may be placed in the pocket in a deflated or partly inflated condition and filled postoperatively once good wound healing has been achieved.

Finally, in summary, I would agree that the more modern techniques of breast reconstruction can produce excellent or very good results in most patients. The best results are achieved in bilateral reconstructions and are also achievable in patients who have small-to-medium sized breasts. The larger the breast, the greater the challenge to obtain a good cosmetic reconstruction. In the era that we currently live in where the diagnosis of patients at high risk for breast cancer is becoming more precise, the option of subcutaneous mastectomy becomes particularly interesting, especially if and when we can achieve a high-quality result using prostheses with low rates of complications and good cosmetic outcomes.

Contralateral breast adjustment and nipple reconstruction

Adjustment of the contralateral breast as well as nipple reconstruction are critical elements in breast reconstruction. As the authors point out, these procedures are relevant both to post-mastectomy breast reconstruction as well as breast conservation surgery. The timing of these adjustments can be either during the first stage of surgery or at a later date after the oncological treatments have been completed.

When contralateral adjustment is done at the time of the mastectomy and immediate reconstruction, it is useful to think of this as a rough draft of the contralateral adjustment. Quite frequently, even having done the opposite side adjustment in the first operation, we will revisit that adjustment in the

second stage if a further revision will be helpful to achieve the best possible symmetry. Frankly, this option is true whether the initial operation for reconstruction is done with a tissue expander, an adjustable implant, or a simple implant. In the case of immediate reconstruction with autologous tissue, we sometimes postpone the contralateral surgery for several reasons. One is that autologous tissue reconstruction is a much longer operation than prosthetic reconstruction, and, therefore, in the interest of operating time, it may be wise to postpone the opposite breast surgery until later. In addition, the exact size and shape of the breast after autologous breast reconstruction is sometimes difficult to predict. Sometimes there is more tissue available than one has anticipated, and, unfortunately, at other times, some of the tissue that was expected does not have adequate circulation and ultimately must be trimmed off. For that reason, we are more reluctant to do the contralateral breast alteration at the time of autologous breast reconstruction.

The authors mention that when operating on the opposite breast they are concerned about masking malignancy. While we agree with this principle, this rarely affects our decision making in terms of mastopexy or breast reduction. However, when placing an implant beneath the opposite breast, we prefer whenever possible to place it subpectorally in order to interfere minimally with post-augmentation mammography.

When performing nipple reconstruction, we choose to pick the ideal location for the nipple on the reconstructed breast first and then when we are adjusting the opposite breast, use the reconstructed nipple as our baseline. Our preference for this strategy is because the opposite breast is easier to adjust than the reconstructed breast. On the other hand, when we are not planning to adjust the opposite breast, then we try to match the reconstructed nipple as much as possible to the unoperated side. The authors describe a preference for the comma-shaped mammoplasty, which is a derivative of the Regnaut procedure. We tend to avoid that operation because of its risk of moving the nipple-areola complex too medial. So our personal preference is to perform mastopexies and reductions using circumareolar, vertical or inverted T approaches. Even the inverted T approach often involves a circum-vertical approach. In the circum-vertical approach, we do not commit to the final transverse component until the nipple-areola and vertical limbs have been closed. Again, our preference is to avoid the comma technique because of the tendency to create peculiar breast shapes. The scar appearance, of course, is totally independent of the parenchymal surgery. Using any of the above scar patterns, the pedicle for the nipple-areola complex

itself can be superior, superomedial, superolateral, central, vertical, or even bipedicle vertical.

The authors are concerned about the tendency for the breast to change shape over time. One thing that we have learned over the years is that both reconstructed breasts and normal breasts do change shape over time. This is pretty much unpredictable and, therefore, ultimately cannot and should not occupy too much of the surgeon's time. It is fair to say, however, that an implant reconstruction rarely drops with time whereas a breast which has been reduced or lifted will probably become more pendulous over the years. Autologous breast reconstructions usually do not become more pendulous over time but can change size with general weight gain or loss. Because it is almost impossible to factor in all the possible changes that the breasts can undergo with time, we prefer instead to understand that both the reconstructed and adjusted opposite breast may need further alterations over the coming years.

One of the advantages of matching procedures and adjustments after breast conservation or mastectomy with reconstruction is the possibility of actually leaving the patient in a better anatomical condition than preoperatively. So, in many cases, by either enlarging the breast on the opposite side, lifting the breast in the form of a mastopexy, or reducing the breast, the patient can actually achieve a more attractive and youthful appearance than before the onset of breast cancer.

The authors also briefly discuss nipple reconstruction using the skate flap. I agree entirely with the authors that the decision to reconstruct the nipple should not be made until the final shape and position of the reconstruction is reasonably stable. While we would prefer to do the nipple reconstruction at the time of the second stage of breast reconstruction, there are times when we will postpone this decision until a third stage when we are not

confident of the ideal nipple position. Like the authors, we prefer to achieve colour match using tattooing after the nipple reconstruction has healed. We no longer take skin grafts from the upper inner thigh, and we reluctantly must discourage that procedure for several reasons. The donor site morbidity from the upper inner thigh is substantial and invariably the source of major complaints by the patient. In addition, the colour match is rarely ideal from the upper inner thigh and is often a short-term illusion which winds up with an areola in the long run which is not a good match to the opposite side. So even with an upper inner thigh skin graft, there is frequently, if not universally, the necessity for tattooing at a later date to achieve better colour match. Again, we agree with the authors that the skate flap and star flap are the preferred methods for nipple reconstruction. There are variations on this theme including the double-tab flap proposed by Steven Kroll or the fishtail flap proposed by John McCraw. Interestingly, the best nipple reconstructions in our hands remain composite grafts taken from the opposite nipple when there is sufficient tissue to harvest. The best case for opposite nipple composite grafts is the opposite nipple which is overly large to begin with. By sharing the distal one-half of that opposite nipple, it makes the other nipple a more appropriate size while at the same time providing a target which is now smaller than the original. The removed distal half of the nipple is the best possible source for nipple reconstruction because of the colour and texture match that it provides.

While it may be true that adjusting the opposite breast and reconstructing the nipple cannot salvage an otherwise mediocre or poor breast reconstruction, it is remarkably true that a good matching procedure combined with an excellent nipple-areola reconstruction can provide the final touches to a breast reconstruction such that the result can be quite impressive and deceive most observers.

IV The patient

14 Psychological issues in breast reconstruction

Margaret Watson

Introduction

Since Halsted conducted the first radical mastectomy in 1882, surgery has played a central role in the treatment of breast cancer. While providing a successful method for the treatment of early stage disease, improved rates of local control were at the cost of mutilating surgery. Psychological morbidity and disturbances in body image and sexual health are now well documented in the literature.¹ Evidence confirming the high levels of psychological morbidity has contributed to the exploration of more conservative surgical options. Improvements in surgical techniques now allow women to have a lumpectomy without any adverse impact on survival and reduce some of this morbidity, especially in relation to body image problems.² However, not all patients are eligible for breast conservation and mastectomy is still required to treat large centrally placed tumours or an extensive in situ component (EIC).

Major advances in surgical techniques and implant technology over the last decade have contributed to the increasing availability of breast reconstruction following mastectomy. Although rates for surgical reconstruction vary, depending on the source of the statistics, there has been a significant increase over the last decade. Women diagnosed with breast cancer are now beginning to expect reconstruction as an option. Although not well documented, there is some indication that women may opt for mastectomy plus reconstruction over lumpectomy. In some cases this may occur because it gives women greater reassurance that the cancer is gone and, at the same time, preserves an acceptable body image. This is an area that needs further investigation in order to clarify the psychological benefits. It is important to be aware of the psychological issues and how these impact on surgical management in relation to breast reconstruction.

The first section of this chapter deals with evidence on the psychosocial impact of breast reconstruction after surgery for breast cancer, while the second section reviews clinical guidelines for management of the patient's psychological care.

Psychological morbidity and reconstructive surgery

Despite the extensive literature on the psychological impact of mastectomy, there is a dearth of evidence on the effects of reconstructive surgery. However, studies examining the impact of mastectomy versus lumpectomy can be informative. In general these reveal high levels of distress around the time of breast cancer diagnosis.³ Much of this takes the form of anxiety with depression secondary and a substantial proportion of this psychological morbidity will remit spontaneously given time. However, a significant minority of women is known to have continuing problems of adjustment following breast surgery.⁴ Much of this relates to the threat to life but for some, this is linked to an inability to adjust to breast loss, post-surgical disfigurement and associated changes in body image, sexual functioning and perceived womanliness. The data now show that although anxiety and depression levels may be similar, regardless of whether a woman is treated by mastectomy or lumpectomy, there are differences in body image and sexual functioning.¹ Women having more conservative surgery tend to experience fewer problems in adjusting to body image changes with the less invasive procedure of lumpectomy.^{5,6} Body integrity is more likely to be maintained, thereby requiring less adjustment. Wellisch and colleagues⁷ have shown that, in addition to greater satisfaction with body image following lumpectomy, effects on sexual health were also improved compared to mastectomy. This, plus the evidence for equivalence

in survival rates, has contributed to the increased use of conservative surgical techniques.

Few studies have investigated the psychological impact of reconstruction in isolation from mastectomy alone and lumpectomy. A study by Mock revealed that patients undergoing breast conservation surgery (lumpectomy) derived most benefit in relation to body image.⁸ Other studies have compared women having breast conservation with those having reconstruction.⁹⁻¹¹ The evidence to date has not demonstrated any clear benefits of reconstruction over breast conservation and further research is needed. The psychological benefits of immediate reconstruction have been explored in a few studies. Where comparisons have been made between women who opt for immediate reconstruction and those with mastectomy alone, the benefits are in terms of lower levels of psychological morbidity and less impairment in physical attractiveness in the former, although Schain and colleagues¹² have observed that these differences disappear with time. However, Rowland and colleagues¹³ noted that satisfaction with the cosmetic effects was greater when length of time between mastectomy and reconstruction increased. This may reflect the fact that women who have lived with mastectomy for some time might take the attitude that any restoration of a breast shape is an improvement and apply different standards from those women having immediate reconstruction. The research findings are unclear, however, as women seeking later reconstruction are often a self-selecting group of those who have found it difficult to adjust to the impact of mastectomy. Generally speaking there is still a need for research on the psychosocial effects of delayed versus immediate reconstruction and, for the present at least, choices are likely to be driven by the medical benefits and patients' personal preferences.

Although it is often assumed that younger women in particular benefit psychologically from the offer of reconstruction age seems not to be the primary factor. As Rowland and Massie¹ point out '...attractiveness is not primarily a concern of younger women'. Consideration needs to be given to individual preferences in this instance rather than assuming that older women are less likely to want reconstruction.

Some women will express dissatisfaction with the cosmetic results or will be dismayed at the occurrence of post-surgical complications. These psychological effects are less well documented and further research is needed to help clarify why some women have difficulty in coming to terms with changes in body image following breast reconstruction. There is very little research on the psychosocial attributes of women who have difficulty adjusting to reconstruc-

tion that can be used to guide clinical decision making. However, adequate information and pre-surgical preparation is important.

One group of patients presents particular psychosocial issues that need to be considered. These are the increasing number of women who request prophylactic bilateral mastectomy due to either a strong family history of breast cancer or following a genetic testing which indicates that they are carriers of a breast cancer predisposition gene. Stefanek's¹⁴ study of a small group of women undergoing prophylactic mastectomy indicated that, while most reported satisfaction with their decision, post-operative attitudes towards reconstructive surgery were mixed. A recent study by Lloyd and colleagues¹⁵ indicated a difference in adjustment to mastectomy and reconstructive surgery was linked to whether or not study participants were known BRCA gene carriers. Due to the current limits in genetic technology the majority of women who presently seek prophylactic surgery do so on the grounds of a strong family history. However, where women have been tested and found to be a gene carrier they talked of surgery as a 'forced choice': something that followed naturally as the only sensible management choice. Such women appear to adjust better than those who felt they had opted for this procedure in the absence of a genetic test. In this instance women often felt that they were unable to express any lack of satisfaction post-surgically with the cosmetic effects. A substantial proportion felt that they had only themselves to blame because they had chosen this surgical option. This acted to inhibit any post-surgical expression of discontent about the cosmetic effects of the reconstructive surgery and sometimes impeded adjustment. Unhappiness about body image was also linked to self-blame; a sense of self-mutilation being sometimes expressed. Women also varied in the extent to which they experienced grief over the loss of their breasts.

A number of factors were identified within this study, which are protective of maintaining womanliness. Prior expectations about the cosmetic effect played an important part. Those who had been well prepared by seeing photographs, which depicted both short and long-term post-surgical effects, seemed better able to cope. Being well prepared and informed about the surgical procedure and what to expect afterwards appeared to aid adjustment.

A substantial minority of women found it difficult to adjust to the loss of their nipple. The absence of nipples and resulting loss of sensation was important in sexuality and this has also been noted amongst breast cancer patients. In Shover's¹¹ study women with immediate reconstruction were compared to those having breast conservation. There

were few differences between the groups but the former was more likely to report a loss of sensation and pleasure derived from the breasts. Some women in Lloyd's study¹⁵ reported that they did not feel properly 'finished', with a sense that body integrity had not been fully maintained by the loss of their nipples. Where there were pre-existing relationship or marital problems these seemingly subtle differences in the cosmetic effect became disproportionately distressing. The lack of nipples served as a reminder of their lack of physical perfection and undermined their womanliness.

Clinical management

Women with high expectations of reconstructive surgery require more pre-surgical information and counselling to ensure that it is clear what can be achieved. Preparation for surgery may be especially important for these women as the process of adjustment to body changes begins at this point and may aid post-surgical adjustment. Evidence from studies with women having mastectomy alone emphasises the importance of pre-surgical information and preparation. Women who feel well prepared have lower anxiety and improved post-surgical adjustment.¹⁶

Rowland and colleagues¹⁷ warn that women who pursue reconstruction in order to please others or try to improve pre-existing difficult relationships, are likely to be disappointed. In this respect it would be important to ascertain why reconstructive surgery is requested in those women previously treated by mastectomy so that realistic expectations can be encouraged.

While it is clear that further research is needed on the psychosocial aspects of reconstructive surgery the existing literature highlights a number of things which can be done.

- *Information:* in the form of leaflets and photographs will help prepare women. It is important that women be offered photographs showing a range of cosmetic results. Women who reject the offer of leaflets and photographs might be encouraged to discuss this further to clarify what they expect from surgery.
- *Nipples:* nipple-sparing techniques and methods of nipple reconstruction could be explained prior to surgery so women can consider the options. Where a prosthetic nipple is the only option it may be helpful to discuss what is available and whether a pre-surgical nipple mould can be used. It is wise to never under-estimate the importance of nipples and offer this infor-

mation routinely in order to avoid possible post-surgical sexual health and body image problems.

- *Cosmetic effects:* the issue of symmetry needs to be discussed. Lack of symmetry between the healthy and reconstructed breast, where this occurs, may cause subsequent body image problems especially if a woman has not been pre-warned. Patients also need to know what to expect during the immediate post-surgical period in terms of the cosmetic effects, especially if preparatory photographs show only the cosmetic effects once scars are fully healed. Some women (and their partners) find the post-surgical bruising from reconstructive surgery to be shocking if they have not been pre-warned
- *Pain:* patients are likely to cope better with post-surgical pain if they are well prepared and can have explained to them the pain management options available. Anxiety is known to exacerbate pain so methods of managing anxiety will also help improve pain management.
- *Cancer detection:* women may have concerns about the ability to detect chest wall recurrences should these occur. The issue of how clinical breast examination and mammograms are affected by reconstruction, especially if an implant is used, needs to be discussed with women. This information could be offered prior to surgery so that women may weigh all the costs and benefits of reconstruction before making a decision. Worry about recurrences being detected where an implant is in place is a problem for some women. They will need information to help them cope with these anxieties.
- *Implants:* the main issue is likely to revolve around the safety of implants. Adverse publicity about silicone implants is now widely disseminated and many women are aware of the controversy. Providing pre-surgical information will allow women to feel more involved in the decision-making process and help pre-empt subsequent anxiety about implant leakage. Women also need to be aware of possible complications such as implant rejection and encapsulation. Again, this information is best offered prior to surgery so that women can adjust expectations and weigh costs and benefits. Although not always discussed, some women do not have very clear expectations about the life-expectancy of implants nor do they have a clear understanding about aspects of modern implant technology to guide their pre-operative decision making.
- *Long-term effects:* particular long-term effects about which women need to know relate to the sensations created by having an implant. Feelings of tightness or of a 'foreign' body can occur. Women will cope better if they have

these effects acknowledged and discussed with them. In psychological terms women can also be prepared for the sense of regret in having lost their breast. Although not affecting all women having breast reconstruction, it is clear that some women grieve for the loss of their natural breast. These emotional ups and downs are part of post-operative adjustment and being prepared can aid this process. Where women fail to adjust to the altered body changes following reconstruction, access to a counsellor or clinical psychologist should be offered.

In summary, the improvement in surgical techniques and implant technology over the last decade now makes breast reconstruction a viable option. The psychological benefits are in terms of improved body image and sexual health. As breast reconstruction for women with breast cancer has increased dramatically over the last decade it would also be important to investigate further the short and long term psychological impact as this is an important factor in the surgical decision making process.

References

1. Rowland JH, Massie MJ. Breast Cancer. Psycho-oncology. In: Holland JC, ed. New York: Oxford University Press, 1998.
2. Ganz PA, Schag AC, Lee JJ et al. Breast conservation versus mastectomy: is there a difference in psychological adjustment or quality of life in the year after surgery? *Cancer* 1992; 69:1729–38.
3. Hughson AV, Cooper AF, McArdle CS et al. Psychosocial consequences of mastectomy: levels of morbidity and associated factors. *J Psychosoma Med* 1988; 32: 383–91.
4. Ford S, Lewis S, Fallowfield L. Psychological morbidity in newly referred patients with cancer. *J Psychosom Res*. 1995; 39: 193–202.
5. de Haes JCJM, Welvaart K. Quality of life after breast surgery. *J Surg Oncol* 1985; 28:123–5.
6. Lasry J-CM, Margolese RG, Poisson R et al. Depression and body image following mastectomy and lumpectomy. *J Chron Dis* 1987; 40: 529–34.
7. Wellisch DK, DiMatteo R, Silverstein M et al. Psychosocial outcomes of breast cancer therapies: lumpectomy versus mastectomy. *Psychosomatics* 1989; 30: 365–73.
8. Mock V. Body image in women treated for breast cancer. *Nurs Res* 1993; 42: 153–7.
9. Pozo C, Carver CS, Noriego V et al. Effects of mastectomy versus lumpectomy on emotional adjustment to breast cancer: a prospective study of the first year post-surgery. *J Clin Oncol* 1992; 10: 1292–8.
10. Noguchi M, Kitagawa H, Kinoshita K et al. Psychological and cosmetic self-assessments of breast conserving therapy compared with mastectomy and immediate breast reconstruction. *J Surg Oncol* 1993; 54: 260–6.
11. Schover LR, Yetmen RJ, Tuason LJ et al. Partial mastectomy and breast reconstruction: a comparison of their effects on psychosocial adjustment, body image and sexuality. *Cancer*. 1995; 75: 54–64
12. Schain WS, Wellisch DK, Pasnau RO, Landsverk J. The 'sooner the better': a study of psychological factors in women undergoing immediate versus delayed breast reconstruction. *Am J Psych* 1985; 142: 40–6.
13. Rowland JH, Dioso J, Holland JC, Chaglassian T, Kinne D. Breast reconstruction and mastectomy: who seeks it, who refuses? *Plastic Reconstr Surg* 1995; 95: 812–22.
14. Stefanek M, Helzisouer K, Wilcox P, Houn F. Predictors of and satisfaction with prophylactic mastectomy. *Prev Med* 1995; 24: 412–9
15. Lloyd S, Watson M, Oaker G et al. Understanding the experience of prophylactic bilateral mastectomy: a qualitative study of ten women. *Psycho Oncol* 2000; 9: 473–85.
16. Burton MV, Parker RW. Satisfaction of breast cancer patients with their medical and psychological care. *J Psychosocial Oncology* 1994; 12: 41–63.
17. Rowland JH, Holland JC, Chaglassian T, Kinne D. Psychological response to breast reconstruction: expectations for and impact on post-mastectomy functioning. *Psychosomatics*. 1993; 34: 241–50.

15 Breast reconstruction with myocutaneous flaps: biomechanical aspects

Gemma Martino, Hubert Godard, Maurizio Nava, John R Benson

Introduction

The biomechanical sequelae of breast reconstruction remain largely unexplored and attention to such issues may lead to improvements in overall results of reconstruction. When reconstruction involves transfer of autologous tissue such as myocutaneous flaps, biomechanical parameters relating to the following factors should be considered:

- changes in the antagonist/agonist balance of muscle groups
- alterations in direction of lines of force along which individual muscle groups act
- coordination of movement
- adjustments in gravitational forces
- alterations in gait.

Biomechanical interactions in mastectomy patients prior to reconstruction

The interaction and function of muscle groups of the shoulder, spine, pelvis and hip were studied in women who had previously undergone mastectomy and axillary dissection. Changes in coordination, posture and gait were examined. Even in women who report no functional impairment or reduction in range of motion of the shoulder, formal assessment may reveal sensory motor deficits together with changes in coordination and posture. These may worsen following reconstruction and become more evident clinically.^{1,2}

Shoulder region

Following mastectomy and axillary dissection changes in position and function of the ipsilateral shoulder have been documented in up to one-third of women. In women who are asymptomatic, biomechanical assessment conducted months or years after surgery reveals anterior displacement together with elevation of the shoulder in many cases. There is limitation of lateral rotation of the upper arm in 25% of cases and horizontal adduction of the arm involving the pectoralis major and minor together with the serratus anterior is impaired in one-fifth of cases. Abduction of the arm is reduced in 17% of patients. There may be demonstrable weakening of the serratus anterior with counter-resistance testing even when winging of the scapula is not evident.

More than 20% of women exhibit some compromise in stability of the humeral head following mastectomy which may be associated with micro-dislocations. In some cases the greater tubercle of the humerus may abut against the coraco-acromial ligament in association with weakness of the latissimus dorsi muscle and contracture of the coracobrachialis.

Spine and pelvis

Often pre-morbid conditions affecting the spine exist at the time of breast surgery. These include degenerative changes, disc disorders and malalignment. Following mastectomy over half of women have increased restriction of movement with contraction and pain at the level of the cervical, dorsal and lumbar spine. A quarter of women show

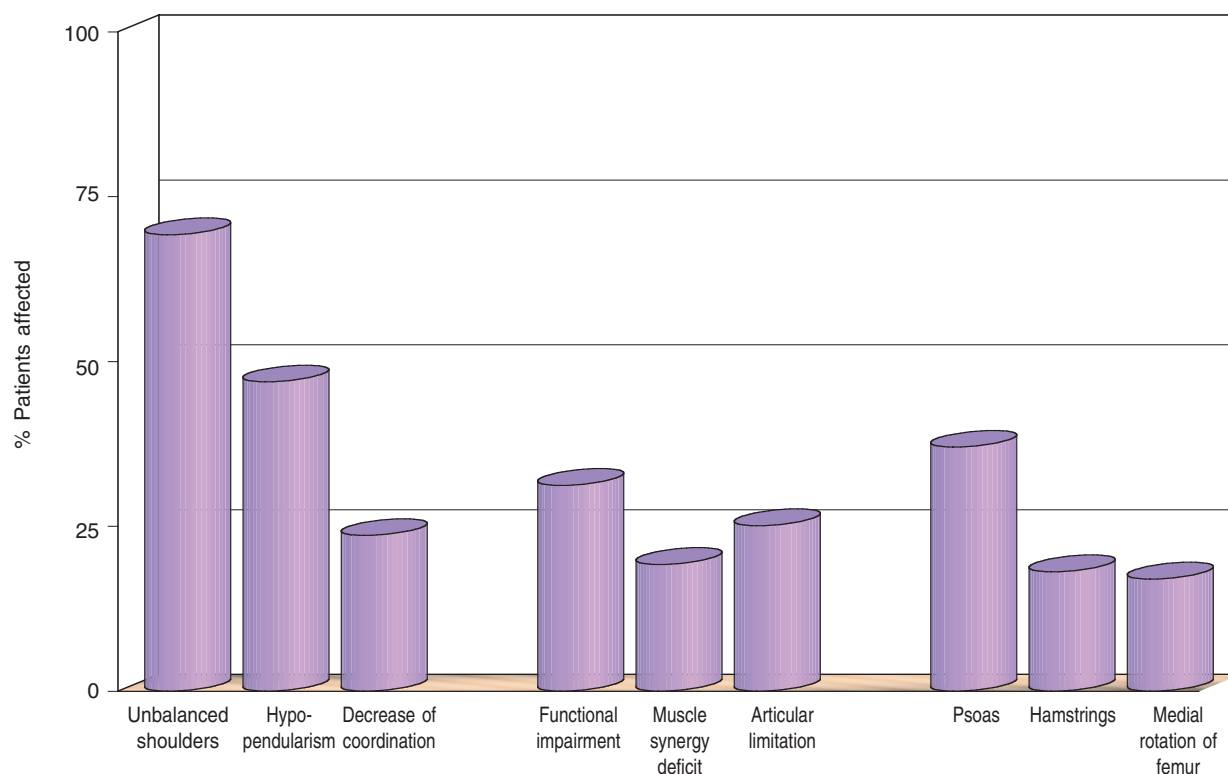


Figure 15.1 Biomechanical sequelae in 300 mastectomy patients prior to reconstruction.

either anteversion or retroversion of the pelvis with alteration in gait and the gravitational set point. Frequently there is difficulty in performing anterior flexion of the torso from the supine position.

Hip region

Asymmetry of the psoas muscle has been observed in 37% of women following mastectomy. Pelvic equilibrium is maintained by hypercontraction of the psoas major and shortening of the contralateral hamstring muscles. The latter is a consequence of the mechanics of walking whereby there is normally synchronization between contraction of the psoas major (which flexes the hip) and contraction of the hamstrings in the weight-bearing contralateral lower limb. Women who display shortening of the muscles in the hip region have loss of the usual pendular movement of the ipsilateral arm (operated side) during walking – the so-called hypopendularism.

With reference to the hip joint the most frequent abnormality is limitation in medial rotation of the femur resulting indirectly from shortening of the iliopsoas muscle. The lateral rotators of the hip joint compensate for increased tension within the psoas muscle, which is linked to functional deficits of the shoulder girdle following breast surgery. The proxi-

mal insertions of the iliopsoas are no longer properly stabilized during movements of the arm. Furthermore, shortening of the iliopsoas tends to promote hyperlordosis of the lumbar spine and the pelvis is inclined towards anteversion.

The incidence of biomechanical disturbances following breast surgery, but prior to any reconstruction are shown in Figure 15.1.

Postural observations and muscle synergy

In up to 20% of patients undergoing mastectomy there is an alteration of the gravitational set point (the centre of gravity of the trunk, head and arms is shifted forward or backward in relation to the head of the femur). This is accompanied by a change in the movements of the trunk relating to gait with a redistribution of movements in the horizontal and sagittal planes and corresponding adjustments in proprioceptive/exteroceptive balance.

Approximately half of the women demonstrate hypopendularism of the ipsilateral arm. Reduction in the pendular movement of the arm during walking is attributable to problems with sensorimotor organization in the absence of any objective neurological or mechanical lesion.³

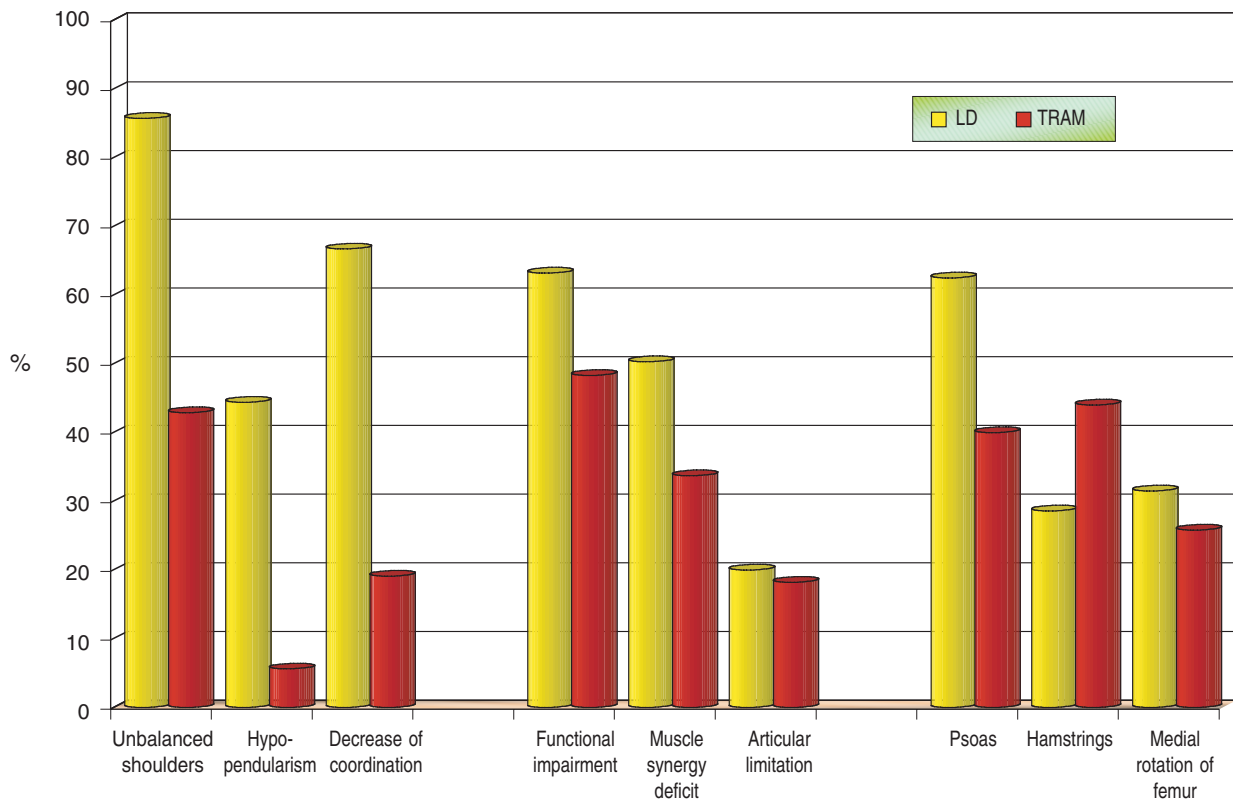


Figure 15.2 Biomechanical sequelae following reconstruction and mastectomy in asymptomatic women.

Coordination can be assessed by asking the patient to raise one arm and the contralateral leg simultaneously and determining whether equilibrium can be maintained satisfactorily during a unipodal stance. Following mastectomy there is difficulty in full coordination of movements in a unipodal stance. Coordination of movements of the upper and lower limbs is dependent upon synergistic actions of the latissimus dorsi and psoas major muscles.

Biomechanical sequelae following reconstruction with latissimus dorsi or TRAM myocutaneous flaps

Biomechanical disturbances following reconstruction with myocutaneous flaps (latissimus dorsi (LD) and transverse rectus abdominus myocutaneous (TRAM)) may exacerbate those already present after mastectomy alone.⁴

Shoulder region

Reconstruction with LD myocutaneous flap

In those women with no demonstrable abnormality in shoulder function following mastectomy there is

a degree of elevation and forward displacement of the shoulder in 90% of cases after delayed reconstruction with an LD flap (Figure 15.2). Where there is a pre-existing imbalance in shoulder function, this is worsened after reconstruction. Because the stabilizing action of the latissimus dorsi muscle is lost, arm flexion is limited in about 15% of patients. When the arm is elevated, the latissimus dorsi muscle is unable to pull the head of the humerus in a downwards and backward direction to counteract the dominant action of the deltoid muscle which moves the humeral head upwards and forwards in synergy with the brachialis. There is a worsening of lateral rotation of the humerus where a restriction already exists and up to one-third of patients with no previous abnormality lose between 30° and 60° in range of movement. Restriction in lateral rotation results from several factors when the insertion of the latissimus dorsi tendon remains intact and is not divided post-transposition:

1. The latissimus dorsi muscle may continue to influence medial rotation of the humerus, but instead of pulling backwards and downwards the direction of pull is forwards and upwards (micro-dislocation). This abnormal medial rotation weakens the lateral rotators.
2. Since the latissimus dorsi muscle no longer acts to pull the head of the humerus downwards and

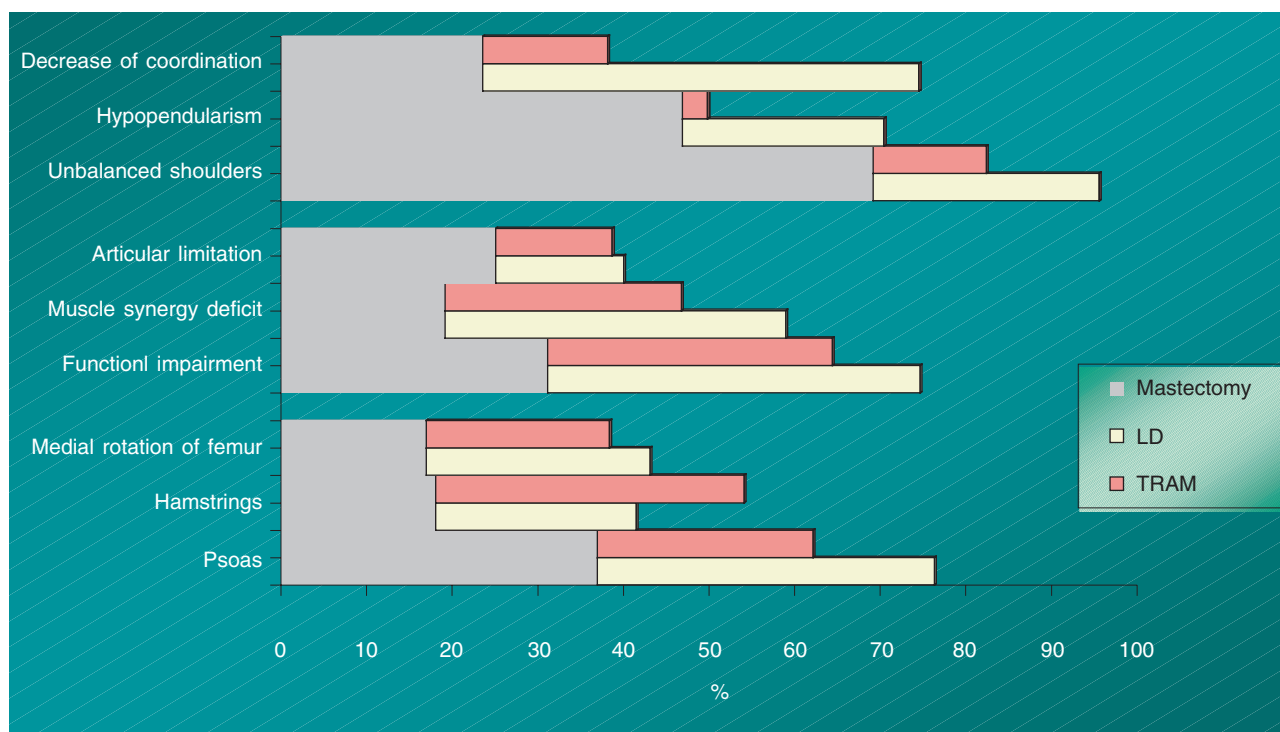


Figure 15.3 Biomechanical sequelae following reconstruction with LD or TRAM flaps and mastectomy in symptomatic women.

backwards, it moves it forwards and upwards. The greater tubercle dislocates upwards and the articular rima is reduced. The upwards pull of the deltoid is enhanced and this action further reduces lateral rotation.

3. The serratus anterior muscle tends to be weakened by adhesive fibrosis in the subcutaneous tissue and fails to stabilize the shoulder and, in particular, to elevate the acromion process to provide room for movement of the greater tubercle. With the acromion process in a lower position, the articular rima is reduced (micro-dislocation) and lateral rotation restricted. There is limited arm adduction (in the horizontal plane) in almost half of the women resulting from a combined deficit in functions of the latissimus dorsi and serratus anterior with displacement of the humeral head impeding full range of movement. A similar proportion of patients exhibit limitation in abduction in the horizontal plane which is a consequence of loss of the normal antagonist/synergistic functions of the latissimus dorsi and serratus anterior muscles with the deltoid muscle which is the principal abductor of the shoulder. In addition there is reduced activity of the lateral rotators.

Overall, approximately two-thirds of women experience limitation of movement in the shoulder region

following reconstruction with an LD myocutaneous flap. Approximately 20% of patients display some degree of micro-dislocation of the shoulder joint which can be detected clinically by palpation. The micro-dislocation occurs in an upwards direction (may be a forwards component) and is associated with reduction of the acromion/greater tubercle space. Micro-dislocation results from a combined effect of upward movement of the humeral head and lowering of the glenohumeral joint because of weakness of the serratus anterior. The upwards movement of the humeral head is due to the predominant action of the deltoid muscle which is no longer counter-balanced by the latissimus dorsi or by the lateral rotators. Excessive contraction of the brachialis contributes to this effect and the greater tubercle abuts against the coraco-acromial ligament.

Reconstruction with the TRAM flap

There is a lower incidence of shoulder abnormalities following reconstruction with a TRAM flap compared with an LD flap (see Figure 15.2). Thus about 43% of patients manifest elevation and forward displacement of the shoulder (90% for patients with latissimus dorsi flap reconstruction). Any pre-existing abnormalities are made worse by TRAM flap reconstruction (Figure 15.3). Both flexion and lateral rotation of the upper limb are

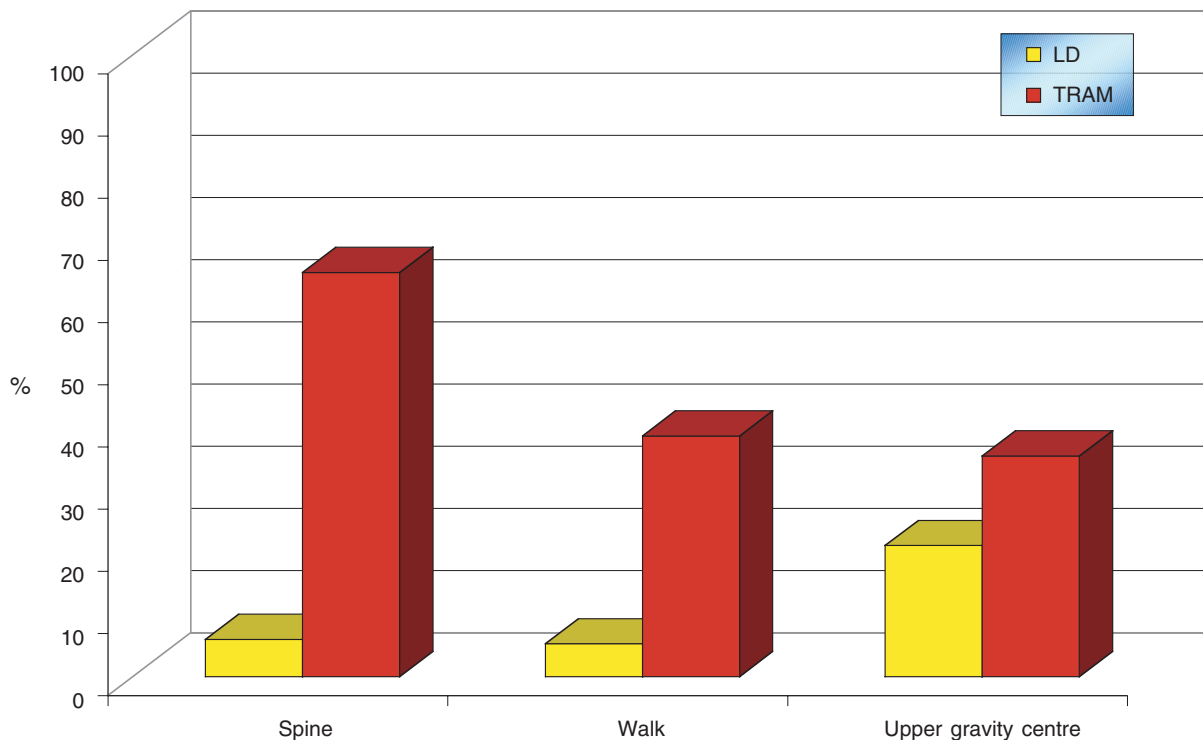


Figure 15.4 Biomechanical modifications following reconstruction with LD or TRAM flap.

worsened following TRAM flap reconstruction (13% and 12%, respectively). The rectus abdomini muscles stabilize adduction of the upper limb, which is reduced by about 25% in the horizontal plane. Half of the patients with TRAM flap reconstruction have limitation in abduction of the arm – a similar percentage as for those who had reconstruction with an LD flap. It results from loss of the stabilizing effect of the rectus abdomini on the chest wall. Overall, 48% of patients (without previous problems) show some limitation of movement of the upper limb following reconstruction with a TRAM flap (see Figure 15.2).

Interestingly, there is a similar incidence of functional deficit with ‘push forward’ of the arm after either TRAM or LD flap reconstructions (33.7%) although these tend to be less intense with TRAM flap reconstruction where there is less impact on the stabilization of the scapula. Micro-dislocation occurs with similar frequency (8%) but is of lesser degree following TRAM flap compared with LD flap reconstruction.

Spine and pelvis

Spine

Mobility of the spine is not compromised by LD flap reconstruction. In contrast, following TRAM flap

reconstruction the distribution of tension within the spinal column changes; there tends to be hyperlordosis of the upper three lumbar vertebrae with maintenance of alignment amongst the lower two vertebrae. Reduction in flexibility at the level of the lumbar spine is compensated by an increased kyphosis at the dorsal level. Almost two-thirds of patients with preoperative normal mobility of the lumbar spine will exhibit these changes which restrict the ability to forward flex the spine (Figure 15.4). Lateral flexion is also limited by increased contraction of other abdominal wall muscles such as the external and internal obliques which tend to compensate for loss of the epigastric muscle. Imbalance of the spinal column leads to alterations in the pelvic girdle and distribution of gravitational forces.

Pelvis

There is a slight tendency towards forward tilt of the pelvis following LD flap reconstruction, whilst there is a marked reduction in capacity to forward tilt the pelvis after TRAM flap reconstruction due to surgical scarring and a protective response which minimizes movement at the surgical site. There is a tendency to backward tilt of the pelvis which is seen in 20% of women and leads to straightening of the lumbar vertebrae and a reduction in the sacral angle of at least 7°.

Muscle synergy

There is minimal interference with active anterior and lateral flexion of the torso from the supine position following LD flap reconstruction. Any functional deficit is due to weakness of the serratus anterior accompanied by loss of function of the pectoralis minor (or absence thereof). These muscles normally work in synergy with the external oblique and intercostal muscles.

Following TRAM flap reconstruction the sit up movement from a supine position is severely weakened due to loss of contributory action of the transposed epigastric muscle. Indeed, up to 12% of patients can no longer perform a sit up movement at all, whilst in almost one-third of patients this movement involves contralateral torsion of the trunk. The majority of patients experience some degree of difficulty in performing a sit up movement after TRAM flap reconstruction.

Hip region**Hip joint**

Both LD and TRAM flap reconstructions are associated with limitation of medial rotation of the femur in approximately one-third of women with no prior deficit (see Figure 15.2). Furthermore, in the longer term this can lead to degenerative changes in the hip joint and half of the women develop signs of arthritis in the hip joint 3 years after surgery.

Psoas major

There is a reduction in efficiency of function of the psoas major which is no longer stabilized by the latissimus dorsi or anterior abdominal wall musculature. The muscle overcontracts to anteriorly flex the hip joint during walking which results in compensatory changes in the iliac muscle and lateral rotators of the hip (piriformis, gemelli, obturator internus and quadratus femoris muscles). These adjustments collectively result in limitation of medial rotation of the thigh and an imbalance of forces acting around the hip joint.

There is retraction of the hip flexors in 62.5% of patients following latissimus dorsi flap reconstruction and up to 40% of patients after TRAM flap reconstruction. These effects are exacerbated when they already exist before reconstructive surgery is undertaken.

Hamstrings

Changes in muscle tension within the hamstrings is observed following reconstruction with both LD and TRAM flaps (see Figure 15.2). Almost 30% of women exhibit differential muscle tension between

ipsilateral and contralateral hamstrings after LD flap reconstruction whilst 44% of patients have shortening of these muscles after TRAM flap reconstruction. The hamstrings compensate for loss of action of the anterior abdominal wall muscles which cause a backward tilt of the pelvis.

Assessment of posture and muscle synergy

Reconstructive surgery leads to predictable changes in the gravitational set point, gait and arm pendularism with alterations in coordination between the upper and lower body musculature. The centre of gravity and movements of the trunk during walking are modified in over one-third of patients. The precise changes depend upon the type of flap harvested for reconstruction. Following LD flap reconstruction the centre of gravity tends to shift posteriorly and maintains the pelvis in forward tilt. In contrast, the centre of gravity shifts anteriorly after TRAM flap reconstruction and maintains the pelvis in a backward tilt. These effects lead to a reduction in coordination between the upper and lower body musculature.

Natural pendular movement of the ipsilateral arm is reduced after breast reconstruction and this is most evident after LD flap reconstruction – 44.4% of patients are affected. For those with a pre-existing deficit the loss of pendular movement may become almost complete (see Figure 15.3). Changes in arm pendularism are seen much less frequently after TRAM flap reconstruction (5.6% of cases).

Impaired coordination of movements is the net result of changes in muscle synergy and antagonist balance around the hip and shoulder girdles. Two-thirds of patients display loss of coordination between the upper and lower limbs following LD flap reconstruction. There is a general reduction in reflex movements around the ipsilateral shoulder joint which is compounded by instability of the lumbar spine and abnormal tension in the psoas major muscle. Approximately one-fifth of patients undergoing TRAM flap reconstruction have any demonstrable loss of coordination between the upper and lower limbs. This disordered coordination is most pronounced in the contralateral lower limb (side opposite to reconstruction). Further functional sequelae result from changes in the centre of gravity, coordination and gait. Figures 15.2–15.4 summarize the biomechanical consequences of reconstruction using the two most common myocutaneous flaps.

Psychological aspects

The biomechanical changes associated with the physical aspects of surgery have an impact on a

patient's psychological state. In particular, a patient's self/extra-self-perception is influenced by these biomechanical factors which lead to significant alterations in the proprioceptive and motor pathways converging upon the central nervous system. These in turn are linked to the higher cortical centres controlling perception and emotional states.⁵ Psychological tests are available to evaluate these changes and are an important aspect of breast reconstruction.⁶

Biomechanical considerations in selection of a reconstructive technique

The general state of health of a patient together with their body habitus and psychological well being are of prime consideration when considering breast reconstruction. Other factors contribute to selection of patients for a particular type of reconstruction; the condition of the muscle which may form a component of any myocutaneous flap is relevant to the reconstructive surgeon. This applies particularly to a TRAM flap, where previous laparotomy may have breached the abdominal wall musculature and precludes use of one or both epigastric muscles for a TRAM flap reconstruction. In addition to these basic considerations, there are other factors which should be taken into account when choosing the optimal type of reconstruction for an individual patient.

The following features favour LD flap reconstruction:

- balanced shoulders
- glenohumeral and scapulothoracic stability
- absence of serratus anterior weakness
- no limitation in lateral rotation of upper limb
- absence of glenohumeral micro-dislocations
- good pendular movement of upper limb
- adequate function of psoas major.

It is preferable for patients to have a posteriorly positioned centre of gravity and movement of the trunk should be in the sagittal or frontal plane during walking.

The following features favour TRAM flap reconstruction:

- good mobility of spine
- shoulder stability
- adequate function of psoas major and hamstrings.

In contrast to those patients undergoing LD flap reconstruction, candidates for TRAM flap recon-

struction should have an anteriorly positioned centre of gravity and movement of the trunk in the horizontal plane during walking.

Conclusions

Formal biomechanical analysis can provide useful information when selecting patients for breast reconstruction using major myocutaneous flaps. Such analyses take into account various factors including muscle synergy, agonist/antagonist balance, planes of motion, centre of gravity, upper and lower body co-ordination, and gait. These are associated with fundamental changes in proprioceptive and motor function which influence perception and emotional states in important but poorly understood ways.

There are several well documented biomechanical consequences of both LD and TRAM flap reconstructions. These changes are most evident in the upper half of the body for LD flap reconstruction.

LD flap reconstruction can be associated with forward displacement and elevation of the shoulder. There is limitation in adduction and lateral rotation of the humerus with displacement of the greater tubercle and reduction of the articular rima promotes glenohumeral micro-dislocation. Although weakening of the serratus anterior is common, this is not associated with a winged scapula. There are important biomechanical alterations in the hip region. The ipsilateral psoas major muscle is contracted and shortened and leads secondarily to degenerative disease in the hip joint. The contralateral hamstrings are hypercontracted to compensate for the increased tension in the psoas major muscle whilst walking. There is limitation of medial rotation of the thigh in one-third of women and often heralds arthritic changes in the hip joint. In dynamic terms, there is a change in the gravitational set point with a tendency to posterior displacement of the centre of gravity, but the pelvis remains in anteversion. Alterations in gait involve a movement of the trunk in the sagittal plane and a reduction in pendular movement of the arm. Impaired coordination is best demonstrated by marked instability upon adoption of a unipodal stance. These effects are most evident in patients with an anteriorly placed centre of gravity and preferential movement of the trunk during walking in the horizontal plane (contralateral torsion of the trunk) prior to reconstructive surgery (Figure 15.5).

TRAM flap reconstruction is associated with fewer biomechanical disturbances in the upper half of the body. Nonetheless, half of all patients exhibit forward displacement of the shoulder with signifi-

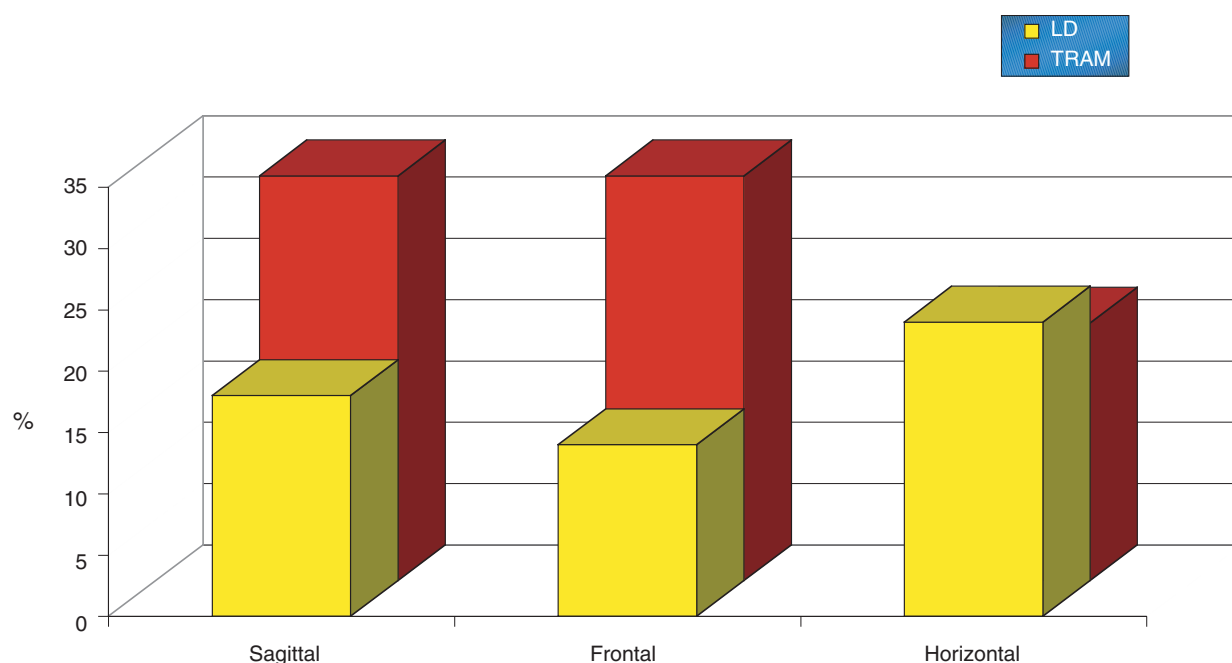


Figure 15.5 Biomechanical deficit following reconstruction with an LD or TRAM flap: correlation with trunk movement during walking.

cant functional limitation and reduction in strength of the serratus anterior. Both adduction and abduction of the shoulder is impaired and 20% of women have glenohumeral micro-dislocation.

The principal biomechanical changes after TRAM flap reconstruction are confined to the lower half of the body and involve the lumbar spine and pelvis. There is characteristic difficulty with forward and lateral sit up movements due to alterations, distribution of tension and alignment of the lumbar vertebrae and a tendency to maintain the pelvis in retroversion. Patients tend to hold themselves in a flexed position because of the large abdominal wound. The position of gravity is shifted anteriorly and persistent retroversion of the pelvis leads to incongruence between the upper and lower halves of the body.

The changes in pelvic position together with loss of function of the transposed ventral abdominal musculature are associated with contraction of the ipsilateral psoas major muscle and the contralateral hamstrings. There is shortening of the psoas major and impaired medial rotation of the femur, but these effects are much less pronounced than following LD flap reconstruction.

In dynamic terms the centre of gravity shifts forward and is not accompanied by a congruent anterior adjustment of the pelvis. Defects in coordination,

hypopendularism of the arm and instability upon unipodal stance are not as evident as for patients with a transposed LD flap. In general, biomechanical consequences following TRAM flap reconstruction are worse in patients with a posterior lie to their centre of gravity and movement of the trunk in the frontal (side-to-side movement of the trunk) or sagittal (anterior-posterior movement of the trunk) plane during walking prior to reconstructive surgery (see Figure 15.5).

The incorporation of biomechanical data of individual patients into the preoperative assessment may sharpen the selection process and ensure that a woman is offered the optimum form of reconstruction based on maximum information derived from both fundamental and less conventional parameters.

References

1. Martino G. Prevenzione e terapia degli esiti. In: Veronesi U, ed. *Senologia oncologica*. Milano: Masson, 1999, 555–65.
2. Godard H, Martino G et al. Sequele dopo ricostruzione con lembi miocutanei ed indicatori prognostici. In: Veronesi U, ed. *Senologia Oncologica*. Milano: Masson, 1999, 401–14.
3. Godard H. Le geste manquant. *Rev Intern Psychanalyse* 1994; 5: 63–75.

4. Martino G, Godard H et al. Study of biomechanical and symbolic functions in patients after oncological and reconstructive surgery for breast cancer. *New Trends in Experimental and Clinical Psychiatry* 1997; 15–17 (CNR Progetto ACRO n. 92.02361.PS39, 1992).
5. Godard H, Martino G. Motion e e-motion in oncologia: una lettura integrata del linguaggio del corpo e della sua relazione con il mondo. In: *Manuale di Psico-Oncologia*. Milano: Masson, 2001; 875–81.
6. Sensi R, Bedodi L et al. Breast cancer: psychological background of patients with non-oncological chronic symptoms. In: *the sixth European Conference on Clinical Oncology and Cancer Nursing*. *Eur J Cancer* 1991; 27: 5301.

16 Chronic pain after reconstructive surgery for breast cancer

John Williams, Jacqueline Filshie

Introduction

This chapter outlines the incidence, clinical features and pathophysiology of the development of chronic pain after breast reconstructive surgery and considers therapeutic options including standard pharmacological and non-pharmacological approaches.

It is expected that most patients will experience some pain immediately following a surgical operation. This 'acute pain', which may in part be caused by tissue disruption, typically lasts for a period of a few hours to several days. It usually responds to analgesics such as opioids and non-steroidal anti-inflammatory drugs. However, it is increasingly recognized that some patients experience pain which persists beyond these normal time limits and may continue for months or even years after surgery. Most researchers define chronic pain as persisting beyond the acute phase usually for a period in excess of 3 months.¹ Pain which persists into a chronic phase after an operation is known as chronic postsurgical pain (CPSP).

A number of surgical procedures for cancer and non-cancer conditions are well known to cause chronic pain problems, including thoracotomy, hernia repair, limb amputation and breast surgery.¹ Data from a number of large surveys indicate that approximately a quarter of women experience chronic pain following mastectomy and breast reconstructive surgery.

Incidence

Studies that have investigated chronic pain after breast surgery vary in both design and quality. Most

of the existing studies focus on pain after mastectomy for breast cancer, although one paper specifically examined chronic pain after breast reconstruction, which included patients with and without cancer.²

Overall 10 studies revealed significant long-term morbidity associated with breast surgery, with up to a quarter of women reporting pain more than 12 months following their operation (Table 16.1). All of the studies assessed pain after mastectomy, but in addition, Wallace et al² specifically analysed symptoms after breast reconstructive surgery.

Aetiology and pathophysiology

Pain after breast surgery is not one simple syndrome and involves several different potential causes which may be interrelated. Indeed, many patients will have more than one possible cause for their pain. CPSP is therefore not a specific diagnostic entity but represents a constellation of different symptoms and possible pathophysiological mechanisms. Any new symptoms can indicate either local or distant recurrence of disease and should be specifically investigated. Many patients will have pre-existing pain such as osteo- or rheumatoid arthritis and these should be identified, recorded and treated preoperatively. Table 16.2 lists the many different possible causes of chronic pain after breast surgery. Recurrent infections and seromas are causes for CPSP which are amenable to treatment. Table 16.2 lists the various different causes of chronic pain after breast surgery.

Intercostobrachial neuralgia

One pathophysiological mechanism for chronic pain after breast surgery is surgical damage to the inter-

Table 16.1 Summary of studies investigating chronic pain after breast surgery

Study type	Sample size	Duration of follow-up	Estimated prevalence of CPSP	Reference
Prospective cohort	120 110 at 1y	1 year	Phantom breast pain at 3 weeks 13%, 1 year 13%; scar pain at 3 weeks 35%, 1 year 23%	Kroner et al (1989) ³
Prospective cohort	120 110 at 1 year, 69 at 6 years	6 years	Phantom breast pain at 6 years 17%; scar pain at 6 years 1%	Kroner et al (1992) ⁴
Survey	223	16 months–32 years (mean 8 years)	Phantom breast 36%; numbness 39–78%; paraesthesia 19–35%; sensitivity 23–34%; pain 22–32%	Polinsky (1994) ⁵
Survey	42 at 54 months		62% at 36 months, 53% at 54 months	de Vries et al (1994) ⁶
Retrospective cohort	467	9–58 months	Pain 49%; paraesthesiae 54%; strange sensations 50%	Tasmuth et al (1995) ⁷
Survey	95	Not stated	Post-mastectomy pain 20%	Stevens et al (1995) ⁸
Survey	126	6 months–4 years	1 year 45%, 1–2 years 37%, 2–4 years 28%, >4 years 20%	Stevens et al (1995) ⁸
Retrospective cohort	282	2–6 years	Pain at 1 year after mastectomy 31%, mastectomy/reconstruction 49%; breast augmentation 38%; breast reduction 22%	Wallace et al (1996) ²
Survey	134	>3 months	27%	Carpenter et al (1998) ⁹
Retrospective cohort	408	6 years	Post-mastectomy pain 43%	Smith et al (1999) ¹⁰

CPSP, chronic postsurgical pain.
(Modified from Macrae WA. In: *Epidemiology of Pain*. Seattle: IASP Press.)

costobrachial nerve which is formed from the lateral branches of the first and second intercostal nerves. This nerve has up to four branches, supplies the posteromedial aspect of the upper arm and axillary region and has been reported to be injured in 80–100% of mastectomy patients undergoing routine axillary dissection.¹¹

It characteristically results in a sharp, shooting pain or burning sensation and may be associated with numbness in the posteromedial upper arm, upper lateral chest wall or axillary region (Figure 16.1). Patients may consequently restrict movement of the arm and shoulder, resulting in spasm of surrounding muscles (e.g. trapezius) (Figure 16.2), development of a frozen shoulder and worsening pain.

In a randomized controlled trial comparing two groups of patients undergoing axillary clearance with or without preservation of the intercostobrachial nerve, Abdullah et al¹² failed to show any reduction in chronic pain at 3 months follow up amongst patients randomized to nerve preservation.

However, this group of patients reported a lower incidence of sensory deficits. Others have shown a decrease in sensation and function following nerve sacrifice compared with preservation.^{13,14} Another prospective randomized controlled trial has failed to show any difference in pain scores or arm mobility between patients who had the intercostobrachial nerve sacrificed or preserved.¹⁵

Other neuralgias and complex regional pain syndrome

Several other nerves may be damaged during breast reconstructive surgery. The innervation of the breast and surrounding tissue includes nerves that originate from the brachial plexus. Nerves that supply the deep musculature of the chest wall include the long thoracic nerve together with lateral and medial pectoral nerves. These nerves are routinely spared during mastectomy but may be injured due to traction or scarring and though predominantly motor nerves, their section can contribute to chronic

Table 16.2 Possible causes of chronic pain after breast reconstructive surgery

Pre-existing pain

- osteo/rheumatoid arthritis¹⁶
- fibromyalgia¹⁷
- costochondritis (Tietze's syndrome)¹⁸
- cervical radiculopathy

Iatrogenic pain

- persistent 'acute' pain, e.g. due to wound infection, oedema, haematoma, necrosis, dehiscence, recurrent seromas
- phantom breast syndrome/pain^{3,4,11}
- scar pain, e.g. in wound, in axilla, around reconstructed nipple^{19–25}
- postradiotherapy, e.g. transient neuritis of brachial plexus, RIBP, cervical plexopathy, associated thrombosis of subclavian artery²⁶
- post-chemotherapy
- CPSP

Tumour involvement related pain

- recurrence, e.g. local, brachial plexus, neural or soft tissue infiltration
- metastasis, e.g. vertebrae, bone, brachial plexus, spinal cord, meninges^{27,28}

Neuropathic pain

- individual neuropathies, e.g. intercostobrachial neuralgia, intercostal neuromas, other neuromas, microneuromas, pressure on individual nerves, ischaemia, radiation fibrosis, scarring, trapping, traction, transection^{26,29,30}
- complex regional pain syndrome (or reflex sympathetic dystrophy) of upper extremity, pain swelling, vasomotor instability³¹
- carpal tunnel syndrome³²
- brachial neuritis/trauma

Pain due to implants

- implant-related, e.g. 'atypical chest pain syndrome' pressure/ischaemia on muscles or nerves resulting in neurogenic atrophy of pectoralis major, fasciitis, myositis, chronic inflammation, free silicone, neuroma³³
- capsulitis
- capsular contraction and hardening
- implant migration
- foreign body reaction, e.g. chronic inflammation, autoimmune, connective tissue disease
- referred pain¹⁸

Other causes of chronic pain

- lymphoedema-related discomfort and pain, brachial plexus/nerve entrapment
- pericapsulitis of shoulder/elbow joint (frozen shoulder/elbow)
- muscle spasm
- mastalgia (cyclical, non-cyclical)
- mastitis

Psychological factors causing pain

- anxiety, depression, somatization, fatigue, general stress, stress of pain, immobility in arm, and catastrophizing all increase pain due to any of the above causes

RIBP, radiation-induced brachial plexopathy; CPSP, chronic postsurgical pain.

pain. Moreover nerves may be inadvertently divided during surgery or may be damaged by ischaemia or radiation effects. Breast implants can affect nerves either by direct pressure or secondary to development of capsulitis. Pathophysiological mechanisms of neuropathic pain include demyelination, together with neuroma and microneuroma formation.

Chronic pain secondary to breast reconstructive procedures

Wallace et al² reported a higher incidence of chronic pain at 1 year in patients undergoing implant-only breast reconstruction after mastectomy, suggesting that implants themselves may be a source of pain.

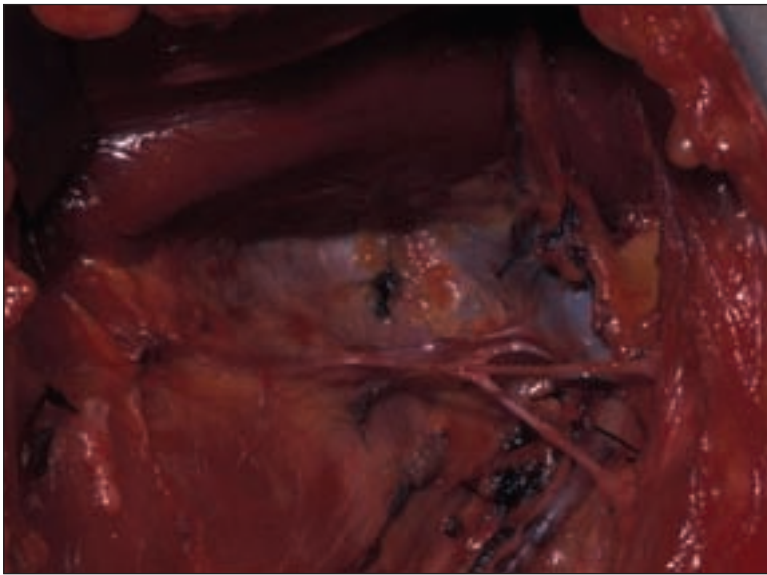


Figure 16.1 Intercostobrachial nerve dissected out.

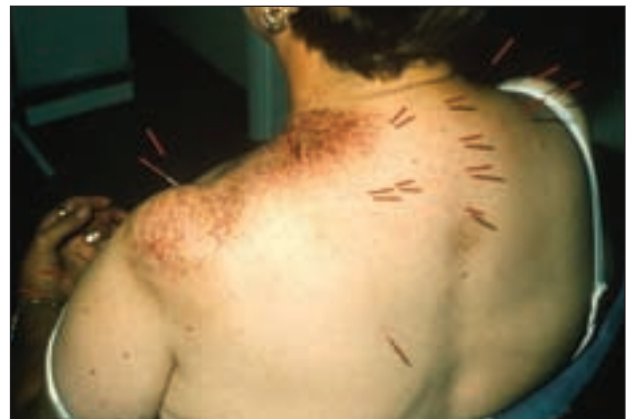
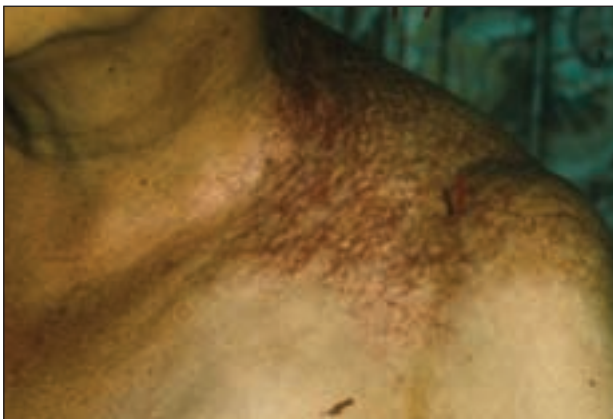
Figure 16.2 Anterior and posterior views of a patient with severe chronic pain after breast surgery. Severe trapezius spasm is seen.

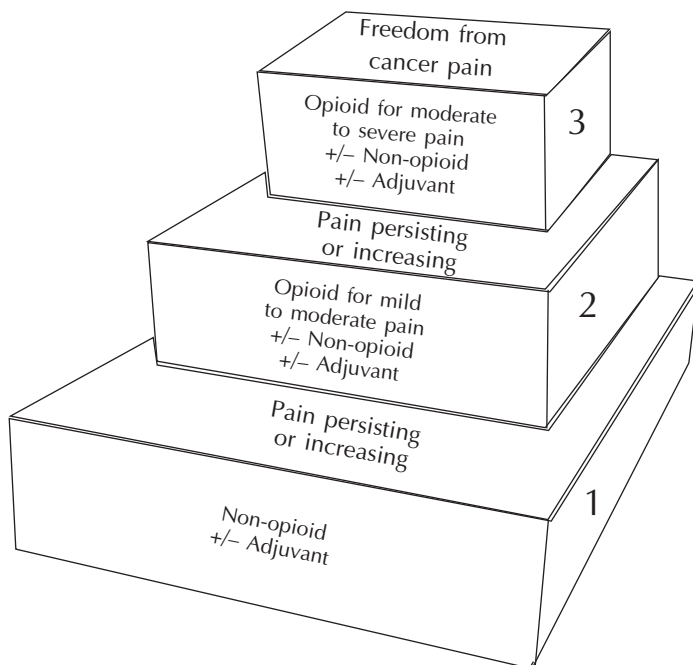


Figure 16.3 WHO's pain relief ladder

If pain occurs, there should be prompt oral administration of drugs in the following order: nonopioids (aspirin and paracetamol); then, as necessary, mild opioids (codeine); then strong opioids such as morphine, until the patient is free of pain. To calm fears and anxiety, additional drugs – 'adjuvants' – should be used. To maintain freedom from pain, drugs should be given 'by the clock', that is every 3–6 hours, rather than 'on demand'. This three-step approach of administering the right drug in the right dose at the right time is inexpensive and 80–90% effective.

Possible mechanisms include (i) tissue expansion resulting in nerve compression and ischaemia and (ii) capsule formation around the implant with subsequent contracture causing painful breasts.

Wallace et al² also reported a lower incidence of pain when the reconstructive procedure was performed immediately following mastectomy rather than as a delayed reconstructive procedure and cite two possible explanations. First, surgeons are aware that a patient is having immediate reconstruction and may be more meticulous in the surgical dissection (especially with skin-sparing techniques) and be less likely to cause extensive tissue damage. Second, some forms of breast reconstruction involve importing tissue as a pedicled or free flap. The immediate placement of autologous tissue provides an excellent source of blood supply which may enhance healing of tissues and promote nerve regeneration. Considerable tissue disruption occurs when submuscular implants are inserted, which can further contribute to any ongoing pain.

Atypical chest pain associated with silicone implants

Lu et al³³ describe a syndrome of 'atypical, non-cardiac chest pain associated with breast implants' and reported this in 11 patients receiving silicone breast implants.³³ The symptoms were described as muscular pain with burning and tenderness lasting from a few minutes to several days. In all cases there was improvement or even complete resolution of pain after removal of breast implants and five patients were found to have a degree of implant rupture. Chronic inflammatory changes were noted in all patients with capsule formation and biopsy of the pectoralis major muscle revealed inflammatory changes together with neurogenic atrophy or neuroma formation.

Management and treatment of chronic pain after breast reconstructive surgery

The first priority is to take a detailed history and conduct a physical examination. Recurrent carcinoma should be specifically excluded by appropriate investigation. Some conditions such as abscess formation, seromas and implant problems may be amenable to surgical intervention whilst antibiotics may be adequate for early stages of infection with cellulitis. It is important that symptomatic treatment of chronic pain is only initiated once other specific causes for the pain have been excluded and appro-

priate treatment implemented. A multidisciplinary approach to pain management combines analgesic medication with physical and psychological therapy and is more likely to yield successful outcomes.³⁴

The precise nature and character of the pain needs to be established and this will determine pharmacological treatment strategies. Nociceptive pain due to involvement of bone or soft tissue is typically dull and aching whilst neuropathic pain symptoms are characterized by sharp, shooting pains and burning sensations in association with dysaesthesia and pain in an area of numbness. Patients will often present with a mixture of both types of pain. Physical, psychological and emotional factors usually accompany and colour these symptoms and must be addressed accordingly.

Pharmacological treatment

Nociceptive pain usually responds to simple analgesics such as paracetamol or non-steroidal anti-inflammatory drugs. It may be necessary to use weak or even strong opioids for more persistent and severe pain (in accordance with the WHO (World Health Organization) classification of analgesics; Figure 16.3). Examples of WHO step 2 drugs include codeine, dihydrocodeine and tramadol whilst step 3 drugs are used for more severe pain and include morphine, oxycodone or methadone.

Neuropathic breast and arm pain responds well to secondary analgesics such as tricyclic antidepressants and anticonvulsants which should be tried initially before the weak and strong opioids according to the WHO step-wise approach (see Figure 16.8). Tricyclic antidepressants such as amitriptyline and dothiepin have proven efficacy for relief of neuropathic pain especially following treatment of breast cancer.³⁵ A low dose is administered initially and slowly titrated upwards. Maximum dosage may be limited by adverse side effects such as sedation and dry mouth although the sedative effects may help to improve sleep.

Some anticonvulsants including gabapentin, sodium valproate and carbamazepine are effective treatments for neuropathic pain and can be used in conjunction with antidepressants. Table 16.3 shows a summary of analgesic approaches commonly used for management of pain following breast reconstruction.

Perioperative analgesic techniques

There is much current interest in perioperative techniques to try to reduce both pain in the acute

Table 16.3 Summary of analgesic drug treatment for pain after breast reconstruction

Analgesic drug	Clinical use
Paracetamol	Initially used for mild pain. Can be given regularly or 'as required'. Can be used as a sole agent or in conjunction with other drugs
Paracetamol and codeine/dihydrocodeine/dextropropoxyphene combinations	As above, but also used for 'moderate' pain
Non-steroidal anti-inflammatory drugs	Can be used for mild/severe pain. Side effects such as gastrointestinal ulcers, bleeding and worsening of asthma may be problematical. These drugs should be avoided in patients with history of peptic ulcer, and in patients taking steroids
COX-2 inhibitors	The selective COX-2 inhibitors have a reduced incidence of gastrointestinal side effects
Tramadol	Used for moderate pain
Antidepressants such as amitriptyline, dothiepin	Often used in the first instance for treating neuropathic pain. Amitriptyline can be started as a low dose, e.g. 10 mg nocte and increased up to 100 mg nocte, or dothiepin 25–75 mg nocte
Anticonvulsants such as gabapentin, carbamazepine, sodium valproate	Used for treatment of neuropathic pain. Gabapentin, for example, is usually started in a low dose, e.g. 300 mg/day and slowly increased over a 4–6 week period up to 1800 mg/day and up to a maximum of 2400 mg
Strong opioids such as morphine, oxycodone, methadone, fentanyl patch	Used for severe pain, e.g. morphine, oxycodone, oral methadone. Initially should be used as immediate release preparation and then, if appropriate, converted to a low release preparation such as MST, oxycontin or fentanyl patch

COX, cyclo-oxygenase; MST, controlled release morphine; nocte, at night.

postoperative period and the progression from acute to chronic pain in patients undergoing breast surgery, including breast reconstruction.¹ Box 16.2 summarizes some of the approaches which have been used perioperatively for breast and reconstructive surgery.

Box 16.1 Perioperative analgesic techniques used to reduce the incidence of postoperative pain

Regional nerve blocks, paravertebral blocks, brachial plexus blocks, epidurals
 Amitriptyline
 Gabapentin
 EMLA local anaesthetic cream
 Topical capsaicin

Regional blockade

Regional nerve blockade reduces analgesic intake in the immediate postoperative period and the addition

of mexiletine reduces the total oral analgesic requirements in the first 5 postoperative days in patients undergoing breast surgery. Yet no significant difference in pain was found 3 months post-surgery although a combination of local anaesthetic block using ropivacaine plus mexiletine significantly reduced the incidence of absent or decreased sensation 3 months postoperatively.³⁶ A randomized controlled trial comparing local anaesthetic infiltration with bupivacaine versus topical application of lignocaine/prilocaine or no treatment after resection showed that local anaesthesia led to slightly lower overall pain scores. This was associated with reduced morphine consumption postoperatively and was of potential clinical value in patients with the highest pain scores.³⁷

Paravertebral blocks,^{38–40} brachial plexus blocks⁴¹ and epidurals^{42,43}

All these have been used as successful alternatives to general anaesthesia although any suppression of the acute to chronic progression of pain by any of these methods has yet to be formally documented.

Anecdotal reports suggest that these methods may help the acute to chronic pain progression but they have not been investigated in a clinical trial setting.

Amitriptyline

Amitriptyline reduced neuropathic pain in the arm and vicinity of the breast scar compared with placebo following breast surgery in a small randomized controlled crossover trial.³⁵

Gabapentin

Gabapentin, 1200 mg daily for 10 days has been shown to reduce burning pain at 3 months.

EMLA local anaesthetic cream

When EMLA was applied preoperatively to the chest wall and axilla and continued immediately postoperatively for a 4-day period it was found to reduce analgesic requirements in the first 6 days following either modified radical mastectomy or breast conservation therapy with lumpectomy and axillary lymph node dissection. EMLA also reduced the incidence and intensity of chronic pain measured at an interval of 3 months postoperatively.⁴⁵

Topical capsaicin

Topical capsaicin has been found to reduce post-mastectomy pain in a meta-analysis undertaken by Xhang and Wan.⁴⁶

Other treatment modalities for chronic pain after surgery

Psychological approaches

Pain following breast surgery can lead to psychological distress and impaired quality of life.^{9,47,48} The psychological impact of breast cancer on a patient is profound and encompasses fears about the consequences of a potentially fatal illness together with concerns about fertility, sexuality and femininity. These factors can collectively lead to both psychological and psychiatric morbidity.⁴⁹ Some of the existential dilemmas which confront a woman suffering from breast cancer and concomitant pain are described by Moore and Spiegel.⁵⁰

Clinically measured depression in breast cancer patients has been shown to lead to an increased risk of death or relapse at 5 years in one study.⁵¹ Early psychological evaluation and a formal programme of continuing support has been recommended for breast cancer patients.⁵² Up to a third of patients with breast cancer develop a major depressive

illness⁵³ and maladaptive coping may be a contributory factor to these patients.⁵⁴

Cohen et al⁵⁵ reviewed the literature on the psychological outcomes of breast conservation surgery compared with mastectomy. These authors carried out a prospective study on psychological adjustment amongst 183 patients according to surgery (including axillary lymph node dissection) and performed a mental health inventory and quality of life assessment. They noted that younger women had greater difficulty adjusting to breast cancer treatment than older women. Patients undergoing mastectomy had worse psychological distress initially but this steadily improved with the passage of time. In contrast, levels of psychological distress increased with time in the breast conservation group. The limitations and implications of this study have been discussed and the findings are consistent with those of Fallowfield et al⁵⁶ and Levy et al.⁵⁷

Younger patients were more prone to catastrophize and reported higher levels of postoperative pain than older groups.⁵⁸ Higher preoperative measurements of anxiety and depression were recorded for breast cancer patients compared with healthy individuals.⁵⁹ Furthermore, those women who developed chronic pain 'remembered' more severe postoperative pain compared with those women without chronic pain. However, determining 'memory of pain' is not as accurate as formal pain scores.

Cognitive behavioural approaches are commonly used for patients with breast cancer and involve methods which have a high rate of success for patients with chronic pain. Short-term interventions improve mood and quality of life, but longer-term efficacy has been questioned in patients with metastatic breast cancer.^{60,61}

Physiotherapy

There is no general consensus on the optimum schedule of physiotherapy following breast surgery with or without reconstruction. In one study, delaying physiotherapy for 7 days after modified radical mastectomy reduced seroma formation compared with a similar group of patients commencing physiotherapy on the first postoperative day without detriment to shoulder function.⁶²

Administration of formal physiotherapy in the postoperative period resulted in a more rapid return of shoulder abduction compared with a controlled group issued with an exercise instruction booklet only.⁶³ Interestingly this same group of patients also showed a reduction in development of secondary lymphoedema compared with the control group.⁶⁴

Transcutaneous electrical nerve stimulation

Transcutaneous electrical nerve stimulation (TENS) is a popular form of electrostimulation and a recent study employed 240 volunteers to determine optimal parameters for maximal hypoalgesic effect.⁶⁵ Low frequency, high intensity extrasegmental stimulation provided rapid onset hypoalgesia which progressively increased throughout the stimulation and was sustained for 30 minutes post-stimulation. High frequency, high intensity segmental stimulation produced similar pain relief during the stimulation period but no post-stimulation analgesia was observed. Preliminary results of a study comparing TENS with TSE (transcutaneous spinal electroanalgesia) favoured TENS in preference to other modes of treatment in patients with symptoms of post-mastectomy pain syndrome or radiation-induced brachial plexopathy (RIBP).⁶⁶

TENS has been found in a controlled trial to improve blood flow within ischaemic flaps and improved capillary refilling with less tendency to necrosis in breast reconstruction patients.⁶⁷ Increased blood flow within the flap correlated with longer-term flap survival.⁶⁸

Lymphoedema treatment

Lymphoedema of the arm or breast can lead to discomfort and aching in association with tightness and heaviness which can contribute to postsurgical or treatment-related pain. The pathophysiology of this symptom complex has been described.⁶⁹ A combination of manual lymphatic massage, multi-layered compression bandaging, exercise and meticulous skin care has been shown to reduce primary and secondary lymphoedema. Furthermore, self-care measures with a variety of sleeves and exercises further reduces the chance of lymphoedema.⁷⁰ Clinical practice guidelines have been developed for lymphoedema in breast cancer patients.⁷¹ Patients undergoing mastectomy with axillary node dissection together with adjuvant therapy such as radiotherapy and chemotherapy are at higher risk of developing lymphoedema.⁷² Early recognition and referral to a lymphoedema clinic with access to nurse specialists provides optimal control of symptoms with relevant advice on treatment and preventative measures.

Acupuncture

Acupuncture is based on sound neurophysiological studies and there is an accumulating evidence base for this modality of treatment.^{73,74} Acupuncture given perioperatively has been shown to reduce

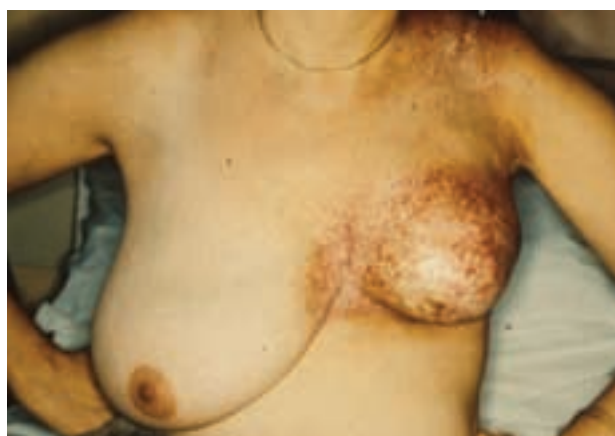

Figure 16.4 A patient who was a tertiary referral to the hospital with severe pain and paraesthesia down the left arm following an extreme form of RIBP (radiation-induced brachial plexopathy) and who subsequently had reconstructive surgery.

acute postoperative pain.⁷⁵ He and colleagues undertook a randomized controlled trial of acupuncture in patients undergoing breast cancer surgery with axillary lymph node dissection and found a reduction in levels of postoperative pain and a concomitant increase in mobility (especially arm abduction) in the early postoperative period.⁷⁶

Acupuncture was found to have effects in breast cancer patients similar to sympathetic blockade with increases in arm circulation and improvement of mobility in patients with RIBP.⁷⁷ Figures 16.4 and 16.5 illustrate a patient with pain from severe post-irradiation changes which was greatly helped by acupuncture. Four weeks of treatment with acupuncture has been reported to improve symptoms of pain, distress and reduce interference with lifestyle and depression.⁷⁸ Patients with pain following reconstructive surgery present a greater clinical challenge than those undergoing ablative surgery alone and complete pain control may be difficult to achieve. A combination of acupuncture and medication may be necessary for optimal control in this group of patients.

Conclusion

Clinical guidelines for the management of chronic pain in patients with breast cancer have been formulated.³⁴ A key recommendation was that 'all patients should be informed at the time of surgery that pain may occur'.⁷⁹ Studies have shown that patients generally cope better with postoperative pain when forewarned of potential symptoms during preoperative counselling. It is likely that not all patients

receive such information and there is an urgent need to implement these recommendations. Further prospective randomized controlled trials comparing

various pharmaceutical and non-pharmaceutical approaches should be carried out to identify which treatments yield optimum pain relief, not only in the acute perioperative period but also in the longer term following breast reconstructive surgery. Patients with chronic symptoms should be referred to a pain clinic for advice and treatment as appropriate. It is important that accompanying symptoms of chronic pain do not overshadow the cosmetic benefits of reconstruction.

Acknowledgements

We would like to thank Roxaneh Zarnegar for her help in compiling Table 16.2 and Jane Brooks for her secretarial help in preparing this chapter.

References

1. Macrae WA, Davies HTO. Chronic postsurgical pain. In: Crombie IK, Croft PR, Linton SJ, LeResche L, Von Korff M, eds. *Epidemiology of Pain*. Seattle: IASP Press, 1999; 125–42.
2. Wallace MS, Wallace AM, Lee J, Dobke MK. Pain after breast surgery: a survey of 282 women. *Pain* 1996; 66: 195–205.
3. Kroner K, Krebs B, Skov J, Jorgensen HS. Immediate and long-term phantom breast syndrome after mastectomy: incidence, clinical characteristics and relationship to pre-mastectomy breast pain. *Pain* 1989; 36: 327–34.
4. Kroner K, Knudsen UB, Lundby L, Hvid H. Long-term phantom breast syndrome after mastectomy. *Clin J Pain* 1992; 8: 346–50.
5. Polinsky ML. Functional status of long-term breast cancer survivors: demonstrating chronicity. *Health Soc Work* 1994; 19: 165–73.
6. de Vries JE, Timmer PR, Erfteemeier EJ, van de Weele LT. Breast pain after breast conserving surgery. *Breast* 1994; 3: 151–4.
7. Tasmuth T, von Smitten K, Hietanen P et al. Pain and other symptoms after different treatment modalities of breast cancer. *Ann Oncol* 1995; 6: 453–9.
8. Stevens PE, Dibble SL, Miaskowski C. Prevalence, characteristics, and impact of postmastectomy pain syndrome: an investigation of women's experiences. *Pain* 1995; 61: 61–8.
9. Carpenter JS, Andrykowski MA, Sloan P et al. Postmastectomy/postlumpectomy pain in breast cancer survivors. *J Clin Epidemiol* 1998; 51: 1285–92.
10. Smith WC, Bourne D, Squair J et al. A retrospective cohort study of post mastectomy pain syndrome. *Pain* 1999; 83: 91–5.
11. Jamison K, Wellisch DK, Katz RL, Pasnau RO. Phantom breast syndrome. *Arch Surg* 1979; 114: 93–5.
12. Abdullah TI, Iddon J, Barr L et al. Prospective

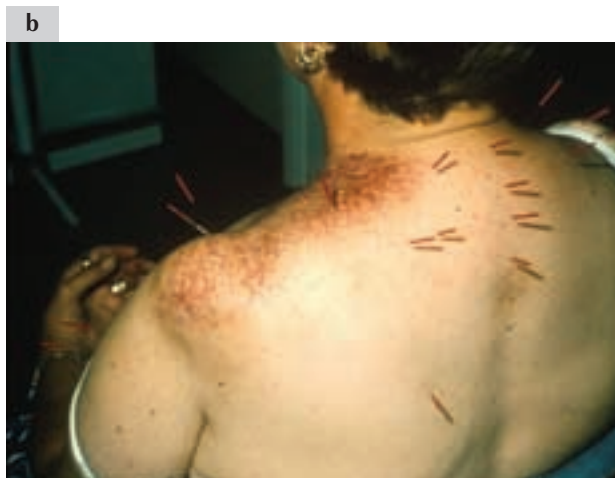
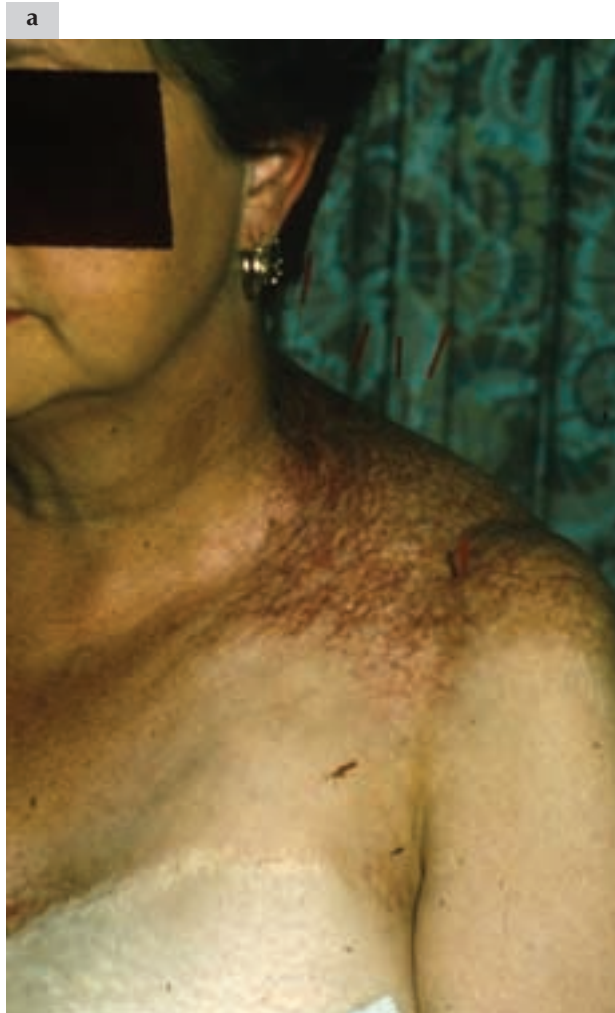
Figure 16.5 (a,b) Placement of needles for pain relief. Note that the use of needles in the ipsilateral arm has been avoided. The patient had no pain following a course of treatment, although mild paraesthesia persists. Intermittent 'top ups' are required.

- randomized controlled trial of preservation of the intercostobrachial nerve during axillary node clearance for breast cancer. *Br J Surg* 1998; 85: 1443–5.
13. Temple WJ, Ketcham AS. Preservation of the intercostobrachial nerve during axillary dissection for breast cancer. *Am J Surg* 1985; 150: 585–8.
 14. Freeman SR, Washington SJ, Pritchard T et al. Long-term results of a randomised prospective study of preservation of the intercostobrachial nerve. *Eur J Surg Oncol* 2003; 29: 213–15.
 15. Salmon RJ, Ansquer Y, Asselain B. Preservation versus section of intercostal-brachial nerve (IBN) in axillary dissection for breast cancer – a prospective randomized trial. *Eur J Surg Oncol* 1998; 24: 158–61.
 16. Doherty M, Jones A. ABC of rheumatology. Fibromyalgia syndrome. *BMJ* 1995; 310: 386–9.
 17. Twycross RG, Fairfield S. Pain in far advanced cancer. *Pain* 1982; 14: 303–10.
 18. Mansel RE. Breast pain (in: Dixon JM, ed. ABC of Breast Diseases). *BMJ* 1994; 309: 866–8.
 19. Jarvis JH. Post mastectomy breast phantoms. *J Nerv Ment Dis* 1967; 144: 266–72.
 20. Weinstein S, Vetter RJ, Sersen EA. Phantoms following breast amputation. *Neuropsychol* 1970; 8: 185–97.
 21. Ackerly W, Lhamon W, Fitts WT. Phantom breast. *J Nerv Ment Dis* 1955; 121: 177–8.
 22. Bressler B, Cohen SI, Magnussen F. The problem of phantom breast and phantom pain. *J Nerv Ment Dis* 1956; 123: 181–7.
 23. Downing R, Windsor CWO. Disturbance of sensation after mastectomy. *BMJ* 1984; 288: 1650.
 24. Staps T, Hoogenhout J, Wobbes T. Phantom breast sensations following mastectomy. *Cancer* 1985; 15: 2898–901.
 25. Karydas I, Fentiman IS, Habib F, Hayward JL. Sensory changes after treatment of operable breast cancer. *Breast Cancer Res Treat* 1986; 8: 55–9.
 26. Kori SH, Foley KM, Posner JB. Brachial plexus lesions in patients with cancer: 100 cases. *Neurology* 1981; 31: 45–50.
 27. Coleman RE, Rubens RD. The clinical course of bone metastases from breast cancer. *Br J Cancer* 1987; 55: 61–6.
 28. Iddon J, Bundred N, Howell T. Pamidronate disodium in the treatment of osteolytic lesions and bone pain in patients with bone metastases associated with breast cancer. *Rev Contemp Pharmacother* 1998; 9: 183–93.
 29. Vecht CJ, van de Brand HJ, Wajer OJ. Post-axillary dissection pain in breast cancer due to a lesion of the intercostobrachial nerve. *Pain* 1989; 38: 171–6.
 30. Wong L. Intercostal neuromas: a treatable cause of postoperative breast surgery pain. *Ann Plast Surg* 2001; 46: 481–4.
 31. Saddison DK, Vanek VW. Reflex sympathetic dystrophy after modified radical mastectomy: a case report. *Surgery* 1993; 114: 116–20.
 32. Ganel MD, Engel J, Sela M, Brooks M. Nerve entrapment associated with post mastectomy lymphedema. *Cancer* 1979; 44: 2254–9.
 33. Lu LB, Shoaib BO, Patten BM. Atypical chest pain syndrome in patients with breast implants. *South Med J* 1994; 87: 978–84.
 34. The management of chronic pain in patients with breast cancer. The Steering Committee on Clinical Practice Guidelines for the Care and Treatment of Breast Cancer. Canadian Society of Palliative Care Physicians. Canadian Association of Radiation Oncologists. *Can Med Assoc J* 1998; 158(Suppl 3): S71–S81.
 35. Kalso E, Tasmuth T, Neuvonen PJ. Amitriptyline effectively relieves neuropathic pain following treatment of breast cancer. *Pain* 1995; 64: 293–302.
 36. Fassoulaki A, Sarantopoulos C, Melemini A, Hogan Q. Regional block and mexiletine: the effect on pain after cancer breast surgery. *Reg Anesth Pain Med* 2001; 26: 223–8.
 37. Pettersson N, Perbeck L, Hahn RG. Efficacy of subcutaneous and topical local anaesthesia for pain relief after resection of malignant breast tumours. *Eur J Surg* 2001; 167: 825–30.
 38. Greengrass R, O'Brien F, Lyerly K et al. Paravertebral block for breast cancer surgery. *Can J Anaesth* 1996; 43: 858–61.
 39. Coveney E, Weltz CR, Greengrass R et al. Use of paravertebral block anesthesia in the surgical management of breast cancer: experience in 156 cases. *Ann Surg* 1998; 227: 496–501.
 40. Najarian MM, Johnson JM, Landercasper J et al. Paravertebral block: an alternative to general anesthesia in breast cancer surgery. *Am Surg* 2003; 69: 213–18.
 41. Fassoulaki A. Brachial plexus block for pain relief after modified radical mastectomy. *Anesth Analg* 1982; 61: 986–7.
 42. Yeh CC, Yu JC, Wu CT et al. Thoracic epidural anesthesia for pain relief and postoperation recovery with modified radical mastectomy. *World J Surg* 1999; 23: 256–60.
 43. Doss NW, Ipe J, Crimi T et al. 0.2% ropivacaine epidurally provides better analgesia and recovery than general anesthesia for patients undergoing oncological mastectomy. *Proc West Pharmacol Soc* 2001; 44: 191–3.
 44. Fassoulaki A, Patris K, Sarantopoulos C, Hogan Q. The analgesic effect of gabapentin and mexiletine after breast surgery for cancer. *Anesth Analg* 2002; 4: 985–91.
 45. Fassoulaki A, Sarantopoulos C, Melemini A, Hogan Q. EMLA reduces acute and chronic pain after breast surgery for cancer. *Reg Anesth Pain Med* 2000; 25: 350–5.
 46. Zhang WY, Li Wan PA. The effectiveness of topically applied capsaicin. A meta-analysis. *Eur J Clin Pharmacol* 1994; 46: 517–22.
 47. Hack TF, Cohen L, Katz J et al. Physical and psychological morbidity after axillary lymph node dissection for breast cancer. *J Clin Oncol* 1999; 17: 143–9.
 48. Ververs JM, Roumen RM, Vingerhoets AJ et al. Risk, severity and predictors of physical and psychological morbidity after axillary lymph node dissection for breast cancer. *Eur J Cancer* 2001; 37: 991–9.

49. Morrow VR. Psychological aspects of breast cancer. *Conn Med* 1999; 63: 35–9.
50. Moore RJ, Spiegel D. Uses of guided imagery for pain control by African-American and white women with metastatic breast cancer. *Integrative Med* 1999; 2: 115–26.
51. Watson M, Haviland JS, Greer S et al. Influence of psychological response on survival in breast cancer: a population-based cohort study. *Lancet* 1999; 354: 1331–6.
52. Charles L. Integrating psychological services with medical treatment for patients with breast cancer. *Curr Prob Cancer* 2000; September/October: 281–90.
53. Maguire P. Late adverse psychological sequelae of breast cancer and its treatment. *Eur J Surg Oncol* 1999; 25: 317–20.
54. Parle M, Jones B, Maguire P. Maladaptive coping and affective disorders among cancer patients. *Psychol Med* 1996; 26: 735–44.
55. Cohen L, Hack TF, de Moor C et al. The effects of type of surgery and time on psychological adjustment in women after breast cancer treatment. *Ann Surg Oncol* 2000; 7: 427–34.
56. Fallowfield LJ, Baum M, Maguire GP. Effects of breast conservation on psychological morbidity associated with diagnosis and treatment of early breast cancer. *BMJ (Clin Res Edn)* 1986; 293: 1331–4.
57. Levy SM, Haynes LT, Herberman RB et al. Mastectomy versus breast conservation surgery: mental health effects at long-term follow-up. *Health Psychol* 1992; 11: 349–54.
58. Jacobsen PB, Butler RW. Relation of cognitive coping and catastrophizing to acute pain and analgesic use following breast cancer surgery. *J Behav Med* 1996; 19: 17–29.
59. Tasmuth T, Estlanderb AM, Kalso E. Effect of present pain and mood on the memory of past postoperative pain in women treated surgically for breast cancer. *Pain* 1996; 68: 343–7.
60. Cunningham AJ, Edmonds CV, Jenkins GP et al. A randomized controlled trial of the effects of group psychological therapy on survival in women with metastatic breast cancer. *Psycho-oncology* 1998; 7: 508–17.
61. Edmonds CV, Lockwood GA, Cunningham AJ. Psychological response to long-term group therapy: a randomized trial with metastatic breast cancer patients. *Psycho-oncology* 1999; 8: 74–91.
62. Schultz I, Barholm M, Grondal S. Delayed shoulder exercises in reducing seroma frequency after modified radical mastectomy: a prospective randomized study. *Ann Surg Oncol* 1997; 4: 293–7.
63. Box RC, Reul-Hirche HM, Bullock-Saxton JE, Furnival CM. Shoulder movement after breast cancer surgery: results of a randomised controlled study of postoperative physiotherapy. *Breast Cancer Res Treat* 2002; 75: 35–50.
64. Box RC, Reul-Hirche HM, Bullock-Saxton JE, Furnival CM. Physiotherapy after breast cancer surgery: results of a randomised controlled study to minimise lymphoedema. *Breast Cancer Res Treat* 2002; 75: 51–64.
65. Chesterton LS, Barlas P, Foster NE et al. Sensory stimulation (TENS): effects of parameter manipulation on mechanical pain thresholds in healthy human subjects. *Pain* 2002; 99: 253–62.
66. Robb K. TENS versus TSE (transcutaneous spinal electroanalgesia) for pain following breast cancer treatments: an RCT (abstract). Bournemouth: British Medical Acupuncture Society, Spring Scientific Meeting, 2001.
67. Lundeborg T, Kjartansson J, Samuelsson U. Effect of electrical nerve stimulation on healing of ischaemic skin flaps. *Lancet* 1988; 2: 712–14.
68. Kjartansson J, Lundeborg T. Effects of electrical nerve stimulation (ENS) in ischemic tissue. *Scand J Plast Reconstr Surg Hand Surg* 1990; 24: 129–34.
69. Mortimer PS. The pathophysiology of lymphedema. *Cancer* 1998; 83(12 Suppl Am): 2798–802.
70. Ko DS, Lerner R, Klose G, Cosimi AB. Effective treatment of lymphedema of the extremities. *Arch Surg* 1998; 133: 452–8.
71. Harris SR, Hugi MR, Olivotto IA, Levine M. Clinical practice guidelines for the care and treatment of breast cancer: 11. Lymphedema. *Can Med Assoc J* 2001; 164: 191–9.
72. Lee YM, Mak SS, Tse SM, Chan SJ. Lymphoedema care of breast cancer patients in a breast care clinic: a survey of knowledge and health practice. *Support Care Cancer* 2001; 9: 634–41.
73. *Medical Acupuncture: A Western Scientific Approach*. Filshie J, White A, eds. Edinburgh: Churchill Livingstone, 1998.
74. *Acupuncture: A Scientific Appraisal*. Ernst E, White A, eds. Oxford: Butterworth-Heinemann, 1999.
75. Aldridge S. Acupuncture helps breast cancer patients (abstract). American Society of Anaesthesiologists Annual Scientific Session, 2001.
76. He JP, Friedrich M, Ertan AK et al. Pain-relief and movement improvement by acupuncture after ablation and axillary lymphadenectomy in patients with mammary cancer. *Clin Exp Obstet Gynecol* 1999; 26: 81–4.
77. Filshie J, Redman D. Acupuncture and malignant pain problems. *Eur J Surg Oncol* 1985; 11: 389–94.
78. Filshie J, Scase A, Ashley S, Hood J. A study of the acupuncture effects on pain, anxiety and depression in patients with breast cancer (abstract). Newcastle: Pain Society Meeting, 1997.
79. Emery C, Gallagher R, Hugi M, Levine M. Clinical practice guidelines for the care and treatment of breast cancer: the management of chronic pain in patients with breast cancer (summary of the 2001 update). *Can Med Assoc J* 2001; 165: 1218–19.

17 Contraindications to breast reconstruction

John R Benson

Introduction

There are few absolute contraindications to breast reconstruction per se, but for individual types of reconstruction specific contraindications may apply. Careful selection of patients for reconstruction and the choice of method is crucial to outcome. Not all patients are suitable for reconstruction and some elect for mastectomy only with the option of delayed reconstruction. Despite detailed explanation of the procedures involved, not all patients accept the offer of reconstruction and of those who opt for a delayed procedure, a proportion will subsequently decline further surgery.^{1,2} In addition to patient choice, compliance is important and patients must be aware of the short-term restrictions and inconvenience of more complex reconstructive surgery that demand time for healing of wounds. In recent years there has been a trend towards liberalization of selection criteria for reconstruction, particularly in relation to stage of disease. Reconstruction can justifiably be undertaken for psychological palliation with acceptable levels of risk and age alone should not preclude consideration of reconstructive options. However, age together with general health will influence the appropriateness of any method selected.³

General contraindications

Age

Despite an ageing population, it is physiological rather than chronological age which governs anaesthetic risk. Most reported series of breast reconstructions cite an average age of 45–50 years with a range from 25 to 75 years.^{2,4,5} Occasionally reconstruction is indicated in very young women (<20 years) who may suffer rare conditions such as Poland's syndrome. Many surgeons would not deny patients reconstruction exclusively on the basis of

advanced age, but most would restrict more complex forms of reconstruction (namely TRAM (transverse rectus abdominis myocutaneous flaps) which incur blood loss of 2–4 units and may last up to 6–8 hours) to patients under 65–70 years of age. Failure rates for alloplastic reconstruction with implant/expanders have been reported to be a function of age, with older patients having a more attenuated and fragile chest wall musculature.⁶ It has been suggested that the ideal upper age limit for reconstruction is 55 years, but this is not supported by objective evidence or statistical rigor.

Medical illness

Breast reconstructive procedures are carried out under general anaesthesia and lengthen operating time (compared with mastectomy alone) between 1 and 6 hours depending on the type of reconstruction. Subpectoral insertion of an expander prosthesis incurs an additional 60–90 minutes of operating time, whilst autologous tissue reconstruction using a free flap with microvascular anastomosis may require up to 8–10 hours. Relatively large cumulative volumes of blood may be lost during these procedures which can constitute a significant physiological insult in patients with a compromised cardiovascular system.

Concomitant medical conditions which threaten patient safety both during and immediately following surgery may preclude any form of reconstruction. Patients with severe cardiorespiratory or other systemic disease (American Association of Anesthetists classification III/IV) may be intolerant of even brief anaesthesia and are not eligible for the simplest forms of reconstruction. Medical conditions including chronic obstructive airways disease, cardiovascular disease, hypertension, insulin-dependent diabetes mellitus and collagen vascular disease are particularly important risk factors for TRAM flap reconstruction where both viability of the flap and

life of the patient may be potentially threatened.^{7,8} Heavy smokers should refrain from smoking for at least 2 weeks prior to surgery, whether this be implant reconstruction or transfer of a myocutaneous flap.^{9,10} Similarly, all patients will benefit from reduction of excess weight, irrespective of the type of reconstruction though this is most applicable to TRAM flap reconstruction for which the rate of complications is related to degree of obesity in a linear fashion.¹¹

Stage of disease

Breast reconstruction should ideally be undertaken in patients with early stage disease (0, I, IIa). Not only do these patients have longer disease-free and overall rates of survival,^{12,13} but they are less likely to require adjuvant therapies. Radiotherapy and chemotherapy (or a combination thereof) may influence the final cosmetic result of any reconstruction, and conversely, reconstruction itself may impact upon the timing and administration schedules for adjuvant therapies. These issues are discussed in more detail below for individual types of reconstruction.

Though it is desirable to undertake breast reconstruction in patients with early stage disease and a favourable prognosis, the extent of local or systemic disease is not a contraindication to reconstruction unless the disease process itself influences anaesthetic risk. Patients with diffuse metastatic disease are not candidates for reconstruction, but those with a solitary metastatic deposit can benefit from reconstruction. The psychological benefits of reconstruction in patients with more advanced disease (stages IIb and III) are well documented.¹⁴⁻¹⁶ Despite poor prognosis and survival, worthwhile psychological palliation can be achieved in these patients and it should be remembered that the next year of life may be the patient's last.⁴ Quality of life during these limited though cherished periods is enhanced by reconstruction which improves body image, and the promise of reconstruction may motivate patients and help them come to terms with their cancer.¹⁷

Several studies have now confirmed that reconstruction does not influence the chances of detection of local recurrence or outcome, with disease-free and overall survival being comparable in patients with breast reconstructions to those with similar stage disease who have not had reconstructions.^{2,18-22} This applies to both immediate and delayed reconstruction with survival being equivalent for patients undergoing immediate or delayed reconstruction.⁴ Earlier concerns that ablative procedures involving immediate breast reconstruction may be oncologically compromised with incomplete mastectomy have not been substantiated and recent skin-sparing

mastectomy techniques are not associated with increased rates of local recurrence in the short term²³ or at 5 years.^{24,25} Evidence is now available in the literature from many groups indicating that immediate breast reconstruction with autologous flaps can be safely performed without significantly interfering with the timing or efficacy of adjuvant therapies. Conversely, the cosmetic results of autogenous tissue reconstruction are not consistently impaired by either radiotherapy or chemotherapy. Patients with more advanced disease often require both chemotherapy and radiotherapy. An immediate reconstruction should be performed so as to avoid another surgical procedure following a course of chemotherapy. Subsequent radiotherapy has minimal effects upon an autologous flap and this is the preferred method of reconstruction when chest wall radiotherapy is anticipated.

There is no evidence that immediate breast reconstruction increases the rate of or masks the detection of local recurrence.^{4,20,21} Rates of local recurrence in patients with reconstructions at 5 years were reported by Noone et al to be comparable to those for unreconstructed patients.²⁰ Though these rates were relatively high (20.1%), more than 90% of recurrences occurred within the first 5 years. The interval from mastectomy to first local recurrence was not increased by reconstruction.²⁰ In the case of implant reconstruction with subpectoral placement of an expander prosthesis, the sites of local recurrence are essentially lifted forwards, i.e. the skin, subcutaneous tissue and pectoralis major muscle. However, for TRAM flap reconstruction, there is a theoretical risk that the flap may conceal local recurrences which are more deeply situated on the muscles of the chest wall. However, in an analysis of 300 patients, Hartrampf and Bennet found that detection of only one of five local recurrences was potentially hampered by the overlying tissue flap.²⁶ Longer follow-up is required for more recent series of TRAM flap reconstructions to determine whether any subgroup of patients developing local recurrence are disadvantaged by the transfer of a myocutaneous flap to a zone where potential local relapse will occur. However, the presence of an implant does not interfere with treatment of local recurrence by surgical excision; a portion of the pectoralis major muscle can be removed without breaching the capsule around the implant.²⁰

Thus the stage of the disease is not in general a contraindication to breast reconstruction, but the final decision for an individual patient may depend more upon psychosocial rather than medical issues. There are less tangible factors involved in decision making; it is incumbent upon both oncological and plastic surgeons to take account of these in conjunction with technical factors. A balanced judgement

should be reached for each patient – whose safety and wishes are paramount.

Psychological factors

There are no clear psychological differences between patients who choose immediate breast reconstruction and those who do not. In a study of psychological and cosmetic sequelae of immediate breast reconstruction, data gathered from semistructured interviews revealed no apparent differences in the psychological profiles of women electing to undergo immediate breast reconstruction compared with those of general breast cancer patients.² In contrast, some groups have reported stratification of profiles in women randomized to either immediate or delayed breast reconstruction.²⁷ In those patients offered complete choice and information about reconstructive options, it is possible that there is an element of self-selection for immediate breast reconstruction.

Reconstruction is probably unwise in patients displaying emotional instability and in those with unrealistic expectations. Some patients have a well documented history of medical dependency and are prone to minor symptoms and complaints which can lead to persistent and continuing care. Moreover, these patients are potentially litigious and in the current climate of a ‘complaints culture’ caution should be exercised. These patients are likely to tolerate any complications of surgery badly and may direct any innate anger against the surgeon who becomes an outlet for cumulative grievances.²⁸ It is important to explain the extent of scarring to patients, especially those undergoing reconstruction with autologous tissue. Fully informed consent is mandatory prior to undertaking reconstruction in these patients. In those patients with poor general health or mental impediment, fully informed consent may be difficult. Those who indulge in substance abuse may be unsuitable for several reasons including poor compliance. Where psychological problems have a reactive component, for example emotional lability associated with a diagnosis of cancer, a delayed reconstruction may be appropriate. Such patients are likely to require maximal emotional support and empathy in the postoperative period.²

Specific contraindications

Implants and tissue expanders

Radiotherapy

The most important contraindication to the use of tissue expansion and implants is previous radiother-

apy to the chest wall.²⁹ Radiation induces a perivascular inflammation which has long-term sequelae including impaired vascularity of skin flaps secondary to endarteritis obliterans. There is scarring between skin and muscle and although these structures may survive submuscular dissection and elevation, there is a risk of ischaemic ulceration and necrosis. Dickson and Sharpe reported an overall complication rate of 70% in patients undergoing implant reconstruction with tissue expansion who had received radiotherapy to the chest wall.²⁹ Complications included necrosis, wound breakdown and infection with an implant failure rate (removal of implant) of 30%. Failure was most likely in those patients with marked post-radiation skin changes which are a reflection of the general state of chest wall tissues including underlying musculature.²⁹ Barreau-Ponhauer and colleagues reported an almost 30-fold increase in local failure rate (defined as removal of prosthesis) in patients undergoing implant reconstruction following chest wall irradiation.⁶ In a prospective study of 32 patients undergoing immediate breast reconstruction with a subpectoral tissue expander, von Smitten and Sundell evaluated the effects of postoperative radiotherapy.³⁰ In addition to a higher rate of complications including infection around the implant and extrusion thereof, irradiated patients suffered more pain and discomfort during expansion. As a consequence, the average number of expansions was significantly higher for patients receiving adjuvant therapy (radiotherapy ± chemotherapy). Radiotherapy not only resulted in muscle stiffness which impaired expansion, but also thinning of the skin with bluish discoloration and telangiectasia. Overall cosmetic outcome was worse for the irradiated group with significantly fewer ‘good’ results and a breast mound, which was smaller, harder and less ptotic. The authors concluded that tissue expander reconstruction should be avoided in patients who are likely to receive radiotherapy to the chest wall based on tumour size and grade together with nodal status. Often this information is not available until definitive histological examination of the mastectomy specimen has been carried out postoperatively. It may be advisable to restrict implant reconstruction to patients with ductal carcinoma in situ (DCIS) (± microinvasion) or small (T1 NO) invasive tumours.

Capsular contracture is more common in irradiated tissue which is less pliant and expansile.²⁹ The incidence of capsular contracture has been greatly reduced with the advent of textured, coated prostheses.^{31,32} Nonetheless, radiotherapy in conjunction with chemotherapy induces fibrosis, impairs wound healing and leads to increased infection rates with both tissue expanders and permanent implants. Rates of extrusion and implant loss are ultimately higher in patients receiving adjuvant treatments and neither

hypofractionated regimens nor prophylactic antibiotics can prevent these complications. In the absence of radiation therapy, capsular contracture is more frequent when implants are placed subcutaneously rather than within a submuscular pocket.³³ Ryu and colleagues assessed capsule formation in patients receiving breast (native or reconstructed) irradiation for primary or recurrent breast cancer following prior breast augmentation or reconstruction. Three cases of encapsulation were reported amongst nine patients followed up for a minimum period of 2 years. All three patients had a subcutaneous implant and none of the five patients with a subpectoral implant developed late capsular contracture. Overall, six out of the nine patients had either good or excellent cosmetic results. The timing of radiotherapy in relation to insertion of the prosthesis may be an important factor in determining incidence of late sequelae of radiation treatment on prosthetic reconstruction.³⁴ Halpern et al advocated avoidance of radiotherapy immediately following reconstruction with prosthetic material. Almost 50% (five out of 11) of patients had poor cosmetic results amongst whom two had radiotherapy within 1 month of reconstruction.³⁵ Similarly, Kuske and colleagues reported that administration of radiotherapy within 6 weeks of reconstruction was less likely to yield good to excellent results compared with a delayed schedule (32% versus 55%, respectively).³⁶ Other factors such as the total dosage of radiotherapy and the use of a booster dose may influence final cosmetic outcome. The latter, in particular, has been reported to be detrimental to cosmesis due to late tissue effects on the skin.^{36,37} In a recent analysis of patients receiving breast irradiation following conservation surgery in an augmented breast or modified radical mastectomy and immediate implant reconstruction, Victor and colleagues conclude that most patients with augmented breasts can safely undergo radiotherapy with good to excellent cosmetic results in a high proportion of cases (100% cited therein).³⁷ For patients with reconstructed breasts, a smaller proportion (54%) were reported to have good to excellent results. Implant reconstruction was undertaken at a median of 7 months prior to adjuvant radiotherapy (range 1–12 months).³⁶ Of interest, there was no statistically significant difference in cosmetic outcome between reconstruction with subcutaneous placement and submuscular placement of implant, and no patients underwent reconstruction with tissue transfer (with or without an implant). The results are in accordance with previous (and more recent) conclusions on the use of radiation therapy in patients with implant-only reconstruction.^{6,30}

Although prior irradiation is not an absolute contraindication to implant reconstruction, the tissues overlying an implant should have a good blood supply. It is preferable to bring in fresh blood

supply to the area using autologous tissue such as a latissimus dorsi (LD) flap. Similarly, when postoperative radiotherapy is anticipated, reconstruction using a myocutaneous TRAM flap and avoidance of any prosthetic material should be considered. Patients undergoing implant reconstruction may receive other forms of adjuvant therapy, namely systemic chemotherapy.

Yule and colleagues found no evidence for increased rates of complications in patients undergoing immediate breast reconstruction with a subpectoral tissue expander and receiving postoperative adjuvant chemotherapy commencing 2–4 weeks post-surgery.⁵ No statistically significant difference in rates of flap necrosis, infection, contracture or extrusion were observed between the chemotherapy and non-chemotherapy groups. Others have concurred that no additional complications of reconstruction are attributable to chemotherapy.²⁰

Other factors

If a large area of skin is excised at mastectomy and skin flaps are tight, tissue expansion is more difficult. Optimal results are achieved when minimal amounts of skin have been removed with the mastectomy specimen (skin-sparing mastectomy) and where a radical mastectomy has been performed. The absence of the pectoralis major muscle precludes simple tissue expansion.

A history of allergy or autoimmune disease may be a relative contraindication to the use of implants. The Scleroderma Task Force of the American Medical Association (amongst others⁴⁰) reported no association between silicone implants and autoimmune disease. It has been suggested that prosthetic silicone implants may modify the capacity of the immune system to respond to a tumour challenges,⁴¹ but overall there is no evidence that silicone prostheses suppress the body's natural immunological responses.⁴²

Tissue expansion and implant reconstruction is best suited to patients with small-to-moderate sized breasts (volume <400 ml; cup size A/B). Minimal degree of ptosis is preferable and modern bi-dimensional (anatomical) prostheses can yield excellent results in appropriately selected patients. For those with larger breasts, volume match and symmetry may be difficult to achieve using local tissue and prosthetic material alone. A myocutaneous flap provides additional tissue bulk and a contralateral reduction procedure can often be avoided.

The use of implants may be relatively contraindicated for certain occupations and activities such as airline cabin staff and female wrestlers.

Latissimus dorsi flap

The LD flap is generally robust and technically easier to perform than a TRAM flap. It is sometimes employed in conjunction with a prosthesis for reconstruction in patients who are unsuited to simple tissue expander reconstruction or a more complex TRAM flap reconstruction. Thus patients who have large amounts of skin excised at the time of mastectomy or have minimal redundant lower abdominal tissue are candidates for an LD flap reconstruction. Similarly, any patient with moderate-to-large breasts in whom a TRAM flap is contraindicated for surgical or medical reasons should be considered for this form of reconstruction. Advances in implant design in recent years have provided further impetus for methods of reconstruction employing an LD flap, and indeed a total autologous LD flap reconstruction without the need for an associated implant has been described.^{32,43–45} As discussed above reconstruction with tissue expansion techniques alone should be avoided in patients who are likely to require postoperative irradiation. Historically, approximately 10–15% of patients have been eligible for radiotherapy following mastectomy,⁴⁶ but with the publication of two papers showing substantial reduction in the odds of any recurrence or death of between 30–40%⁴⁷ and 25–30%,⁴⁸ the indications for post-mastectomy radiotherapy have broadened and this shift in oncological strategy will impact upon options for reconstruction (see Implants and tissue expanders, Radiotherapy, p.159). The effects of chest wall irradiation on longer-term outcome following reconstruction with an LD flap and implant remain unclear and indeed controversial. Some surgeons prefer to carry out complete autologous tissue reconstruction without any prosthetic material when radiotherapy is anticipated (Malata, personal communication). However, in the experience of others (including the present author), there is no current evidence for any significant detriment to cosmesis in patients receiving postoperative radiotherapy following reconstruction with LD flap and implant (whether tissue expander or permanent device). Radiotherapy techniques have improved in recent years and some earlier reports on effects of radiation therapy were based on outdated techniques which were more likely to be associated with tissue injury and later complications. Modern radiotherapy techniques together with implant design (textured coating) minimize the chance of capsular contracture.

Radiotherapy can be given using a hypofractionation regimen with the total dose administered in smaller fractions over a longer period of time. It is important to ensure that the implant is completely covered by muscle at the time of reconstruction; the implant

can either be ‘sandwiched’ between the pectoralis major and latissimus dorsi muscles or alternatively a composite pocket can be fashioned by suturing the latissimus dorsi muscle to the inferolateral border of the pectoralis major. This technique is useful when the volume of muscle harvested is modest and there is a risk of the pouch being deficient superiorly. Complete muscle coverage may offer protection to any implant from external beam radiotherapy and minimizes any longer-term sequelae.

There is currently a paucity of data on the incidence of capsular contracture in patients undergoing implant reconstruction in conjunction with transfer of a myocutaneous LD flap who receive postoperative radiotherapy. It remains unproved whether contracture is less likely when implants are inserted within a pocket fashioned from an LD flap compared with a subpectoral pocket. Often the latter is associated with suboptimal coverage of the implant whereas an LD flap provides well vascularized and sturdy tissue which may protect any underlying implant from the adverse effects of external beam radiotherapy. Instead of risking exposure of an implant to radiation, this can be administered post-mastectomy and reconstruction performed as a delayed procedure. However, a delayed procedure would preclude use of a skin-sparing technique and the final result may be inferior cosmetically due to more extensive scarring from conventional mastectomy incisions.

The LD flap is based on the dorsal scapular vessels and any insult to the thoracodorsal trunk can potentially threaten the viability of this flap. Thus the thoracodorsal vessels can be traumatized at the time of formal axillary dissection, especially if nodal tissue is adherent posteriorly to the thoracodorsal pedicle. Diathermy of smaller branches of the main thoracodorsal vessels should be undertaken with care and appropriate adjustment of current intensity. The thoracodorsal axis can also be damaged secondary to radiotherapy administered to the axilla either directly (for positive nodes on sampling) or to the chest wall following mastectomy for higher risk primary tumours or local recurrence. Mobilization of the thoracodorsal trunk can be difficult due to scarring and further damage to the vessels may be incurred. The surgeon should proceed with caution when any previous intervention may have jeopardized the thoracodorsal pedicle or rendered dissection more difficult. Flap necrosis, which is otherwise a rare occurrence with an LD flap, may result under these circumstances.^{49,50}

There is a relatively high incidence of seroma formation (up to 33%^{49,50}) which may be reduced when endoscopic methods of flap harvest are employed.⁵²

Transposition of the latissimus dorsi muscle from the back usually results in no significant functional deficit. However, swimmers, golfers and tennis players may notice some impairment of performance following this procedure.

Transverse rectus abdominis myocutaneous flap

The TRAM flap is the most widely used autologous tissue flap for breast reconstruction and provides a large volume of tissue which yields a ptotic breast with a natural texture. This form of reconstruction avoids the need for prosthetic material and in recent years has become more popular partly as a consequence of the perceived risks of alloplastic implants. However, this is a major surgical procedure taking up to 6–8 hours depending on whether the flap is pedicled or a free graft in which case a microvascular anastomosis is required. The former is based on the superior epigastric vessels which are not the dominant blood supply to the infra-umbilical fold of abdominal skin. Indeed, blood flow within the superior system of vessels falls in a progressive stepwise fashion at each tendinous intersection where a series of ‘choke’ vessels exist. The principal physiological blood supply to this portion of the abdominal tissue is via the inferior epigastric vessels which are therefore a more natural choice for sustaining any TRAM flap.^{53,54} The free TRAM flap is based on the inferior epigastric vessels which provide a more reliable blood supply to the flap, which may be advantageous in patients with specific risk factors for a conventional TRAM flap.^{55,56} However, there is a finite risk of total flap failure which is up to 10%⁵⁵ although rates of less than 1% have been achieved in experienced centres performing approximately 300 procedures annually.⁵⁷ Other methods have therefore been developed for augmenting blood supply and avoiding degrees of flap necrosis. These include the delayed TRAM flap^{54,58} and the bipedicled TRAM flap,⁵⁹ which are both associated with increasing the blood flow within the superior epigastric pedicle at the time of tissue transfer; in a delayed TRAM, the inferior epigastric vessels are ligated 2–3 weeks in advance of surgery. This improves the blood flow within the superior system which is connected to the inferior system of vessels via a wide arborization.⁵⁴ This enhances the viability of a pedicled flap.^{54,58}

It is particularly important that patients are carefully selected for this type of reconstruction and that the surgery is performed by those with appropriate training and expertise. Optimal results are obtained when oncological and plastic surgeons work in close collaboration and the reconstruction is undertaken as an immediate rather than a delayed procedure.^{60,61}

General conditions previously discussed may preclude patients from undergoing TRAM flap reconstruction, but certain specific risk factors pertain to this form of reconstruction.⁶²

Obesity

Although some redundant skin and subcutaneous tissue in the lower abdomen is essential to provide tissue bulk for a TRAM flap reconstruction, extremes of obesity increase operative risk. Hartrampf defined two categories of obese patients: moderately obese (less than 25% above ideal body weight) and severely obese (more than 25% above ideal body weight).⁷ The latter group of patients have a risk estimate of 5 on an arbitrary scale of 0–10. Kroll and Netscher reported that patients with ‘morbid’ obesity (defined as a height weight index of >49) have a high incidence of complications (41.7%).¹¹ These included partial or major flap necrosis, hernias, abdominal bulge, deep vein thrombosis and infected prosthetic mesh. In addition, seromas, haematomas and wound infections are more common in obese patients and the complication rate is related proportionately to the degree of obesity.¹¹ This also applies to patients undergoing general surgical procedures where the complication rate may be as high as 40%.⁶¹ Patients who are morbidly obese or more than 25% above their ideal body weight should diet prior to surgery, though there is limited opportunity for weight reduction in patients undergoing immediate reconstruction following mastectomy for breast cancer for whom surgery is usually scheduled within 2–3 weeks. These very obese patients often have large volumes of extraperitoneal fat which can hinder aponeurotic repair and abdominal closure. Furthermore, splinting of the diaphragm can lead to respiratory complications in the early postoperative period.¹¹

Smoking

Smoking increases the failure rate of skin flaps in experimental animal models.^{9,10} Some surgeons advocate that regular, heavy smokers should be excluded from surgery with conventional TRAM flap reconstruction. Cessation of smoking 2 weeks prior to surgery may reduce the chance of flap necrosis, but a minimum period of 6 weeks abstinence has been advocated.⁵⁵ For those patients undergoing immediate breast reconstruction, both the myocutaneous flap and mastectomy flaps (especially with a skin-sparing procedure) are at risk of ischaemic complications. A free TRAM flap is preferable in heavy smokers, many of whom will continue smoking up to the day of surgery (the risks of this practice should be fully explained to the patient).⁹ Where microvascular facilities and exper-

tise are not available, delayed (or possibly bipediced) TRAM flap reconstruction should be carried out to minimize the risk of flap necrosis in smokers.^{54,58}

Microvessel disease

Conditions associated with compromise of the microvascular circulation threaten viability of the flap. Diabetes mellitus is the most common factor, but autoimmune and collagen vascular diseases (scleroderma, Raynaud's) may be implicated.

Previous abdominal surgery

A prior subcostal incision with transection of the superior epigastric vessels is an absolute contraindication to an ipsilateral TRAM flap, although a contralateral flap is possible. Other types of abdominal incision present relative contraindications. A previous incision may not have divided the superior epigastric artery, but could interfere with peri-umbilical perforators and lead to subsequent difficulties with mobilization and transposition of the flap. Furthermore, extensive abdominal scarring may potentiate any tendency towards abdominal wall herniation, and multiple incisions are a contraindication to TRAM flap reconstruction. Similarly, irradiation with a field encompassing the base of the flap pedicle can jeopardize patency of the epigastric vessels. Blood flow within the epigastric territories can be measured with Doppler ultrasound.

Chronic back pain

The rectus abdominis muscle stabilizes the back, and TRAM flap reconstruction may be contraindicated in patients with chronic back problems. This applies particularly to the bipediced TRAM flap where a major breach of integrity of the anterior abdominal wall occurs.

Pregnancy

For younger patients who may subsequently become pregnant, violation of the abdominal wall may result in considerable morbidity. Under these circumstances, a limited amount of fascia should be harvested with the flap in order to preserve abdominal wall competence. The free deep inferior epigastric perforator (DIEP) flap in which the tissue is raised on two to three perforating vessels may be advantageous for this group of patients as there is minimal disruption of the abdominal wall musculature.^{64,66}

Thin patients

TRAM flap reconstruction exploits the infra-umbilical fold of redundant tissue which is commonly

present in patients. When absent, there may be insufficient tissue bulk to reconstitute a breast and an LD flap (with implant) should be used instead.

Adjuvant therapy

In contrast to implant reconstruction, there is little evidence for significant effects of radiation on the final outcome of TRAM flap reconstruction. Williams et al analysed the effects of radiation therapy before and following pedicled TRAM flap reconstruction and compared these with patients undergoing breast reconstruction without radiotherapy.⁶⁷ Complications of those fat necrosis or fibrosis occurred in just over half of 19 patients receiving post-reconstruction radiation treatment, six of whom required revisional surgery. There was no statistically significant difference in the incidence of fat necrosis between the two irradiated groups, although rates were higher than for the non-irradiated group. However, fibrosis was more common in post-TRAM irradiated patients – occurring in almost one-third of patients. The overall complication rate was not increased by TRAM flap irradiation, but fibrosis rather than fat necrosis was observed.⁶⁷ In contrast, others have found no significant increase in rates of complications attributable to TRAM flap irradiation and cosmetic outcomes are very favourable with minimal flap shrinkage.^{68,69} Therefore patients who are likely to require post-operative radiotherapy should be considered for autogenous tissue reconstruction which avoids the need for prosthetic material.

Increasing numbers of node negative patients are now being offered chemotherapy.⁷⁰ Adjuvant chemotherapy was previously given only to node positive patients and commenced a few weeks post-operatively. An earlier concern with conventional pedicled TRAM flaps was the delay in instituting adjuvant therapy consequent upon complications of flap necrosis, some patients required revisional surgery or developed infective complications which precluded initiation of adjuvant therapy.⁷¹ The free TRAM flap with its more reliable blood supply was developed partly to overcome these potential problems of adjuvant therapy in patients with reconstructions. Schusterman et al found a non-significant trend towards less delay in administration of chemotherapy in a retrospective non-randomized comparison of relatively small numbers of pedicled and free TRAM flaps.⁵⁶ This improved timing of adjuvant therapy schedules was attributed to a lower incidence of partial or fat necrosis in the free TRAM flap group of patients. Notwithstanding this potential advantage of free TRAM flap reconstruction, several groups have reported no significant delays in commencement of chemotherapy following pedicled TRAM flap procedures.^{72,73}

Cost

Although the initial costs of immediate reconstruction with a conventional TRAM flap may be higher than for implant reconstruction, the overall costs in the longer term are comparable (replacement of implants, etc.). Of interest, Kroll's group have recently shown that the total resource cost for immediate TRAM flap reconstruction is US\$17 957 compared with US\$17 514 for immediate tissue expansion. This latter figure does not include any later costs relating to implant complications such as contracture (approximately 10% for textured, coated prostheses), which may necessitate prosthetic exchange.⁷²

Free TRAM flap reconstruction is popular in the United States but much less widely practised in Europe. As this method involves a microvascular anastomosis, it is perceived as being a procedure of high risk and long duration which by implication it is more expensive than conventional TRAM flap reconstruction. However, in a comparison of resource costs between pedicled and free TRAM flaps, Kroll and co-workers calculated the mean difference in total resource cost for free TRAM to be small (4.1%) and not statistically significant.⁷⁴ Moreover, the mean operating time for a free TRAM flap reconstruction was only 41 minutes longer than for a pedicled TRAM whilst mean duration of hospital stay was shorter (0.6 days less). Surgical violation of the anterior abdominal wall is less for the free TRAM flap and this may permit earlier mobilization and discharge from hospital. This analysis was based on results from a single centre where a large number (>300 per annum) of free flaps are performed.⁷⁵ Other centres with less experience are likely to have longer operating times and higher failure rates for free TRAM flaps. At the present time, free TRAM flaps are probably too complex and expensive to be offered as a routine service in the National Health Service or any managed healthcare system.

Conclusion

The majority of patients undergoing mastectomy for breast cancer are eligible for, and should be offered some form of breast reconstruction. In particular, immediate breast reconstruction is safe and reliable and, as with all types of reconstruction, judicious selection of patients is mandatory for optimal results. Individual patients should be jointly assessed by the oncological and plastic surgeons and the ideal form of reconstruction judged in the context of technical, medical and psychosocial factors. It is anticipated that in the future an increasing proportion of reconstructions will be carried out as a joint procedure with breast surgeons working in close collaboration with plastic surgery colleagues.

References

1. Dean C, Chetty U, Forrest AMP. Effects of immediate breast reconstruction or psychosocial morbidity after mastectomy. *Lancet* 1983; 1: 459–62.
2. Rosenqvist S, Sandelin K, Wickman M. Patients' psychological and cosmetic experience after immediate breast reconstruction. *Eur J Surg Oncol* 1996; 22: 262–6.
3. Questions, controversies and decisions. In: Silen W, Matory W.E, Love S, eds. *Atlas of Techniques in Breast Surgery, Part IV Postmastectomy reconstruction*. Philadelphia and New York: Lippincott Raven Publishers, 1996: 107–14.
4. Johnson CH, van Heerden JA, Donohue JH et al. Oncological aspects of immediate breast reconstruction following mastectomy for malignancy. *Arch Surg* 1989; 124: 819–24.
5. Yule GJ, Concannon MJ, Croll GH. Is there liability with chemotherapy following immediate breast reconstruction? *Plast Reconstr Surg* 1996; 97: 969–73.
6. Barreau-Pouhaer L, Le MG, Rietjens M et al. Risk factors for failure of immediate breast reconstruction with prosthesis after mastectomy for breast cancer. *Cancer* 1992; 70: 1145–51.
7. Hartrampf CR Jr. The transverse abdominal island flap for breast reconstruction: a 7-year experience. *Clin Plast Surg* 1988; 15: 703.
8. Bailey MH, Smith JW, Casas L et al. Immediate breast reconstruction reducing the risks. *Plast Reconstr Surg* 1989; 83: 845–51.
9. Nolan J, Jenkins RA, Kurihara K, Schultz RC. The acute effects of cigarette smoke exposure on experimental skin flaps. *Plast Reconstr Surg* 1985; 75: 544–51.
10. Craig S, Rees TD. The effects of smoking in experimental skin flaps in hamsters. *Plast Reconstr Surg* 1985; 75: 842.
11. Kroll SS, Netscher DT. Complications of TRAM flap breast reconstruction in obese patients. *Plast Reconstr Surg* 1989; 84: 886.
12. Berg JW, Robbins GF. Factors influencing short and long term survival of breast cancer patients. *Surg Gynecol Obstet* 1966; 122: 1311.
13. Saez RA, Dark GM, McGuire WL. Prognostic factors in breast cancer. *Semin Surg Oncol* 1989; 5: 102.
14. McGuire GP, Lee EG, Bevington DJ et al. Psychiatric problems in the first year after mastectomy. *BMJ* 1978; 1: 963–5.
15. Meyerowitz BE. Psychosocial correlations of breast cancer and its treatment. *Psychol Bull* 1980; 87: 108–31.
16. Irvine D, Brown B, Crooks D et al. Psychosocial adjustment in women with breast cancer. *Cancer* 1991; 67: 1097–117.
17. Godfrey PM, Godfrey NV, Romita MC. Immediate autogenous breast reconstruction in clinically advanced disease. *Plast Reconstr Surg* 1995; 95: 1039.
18. Radovan C. Breast reconstruction after mastectomy using the temporary expander. *Plast Reconstr Surg* 1982; 69: 195–206.

19. Dowden RV, Blanchard JM, Greenstreet RL. Breast reconstruction – selection, timing and local recurrence. *Ann Plast Surg* 1983; 10: 265–9.
20. Noone RB, Farzier TG, Noone GC et al. Recurrence of breast carcinoma following immediate breast reconstruction: a 13 year review. *Plast Reconstr Surg* 1994; 93: 96–106.
21. Webster DJT, Mansel RE, Hughes LE. Immediate reconstruction of the breast after mastectomy. Is it safe? *Cancer* 1984; 53: 1416–19.
22. Noguchi DM, Fukushima W, Ohta N et al. Oncological aspects of immediate breast reconstruction in mastectomy patients. *J Surg Oncol* 1992; 50: 241–6.
23. Kroll SS, Ames F, Singletary SE, Shusterman MA. The oncological risks of skin preservation at mastectomy with immediate breast reconstruction. *Surg Gynaecol Obstet* 1991; 172: 17.
24. Kroll SS, Shusterman MA, Tradjalli HE et al. Risk of recurrence after treatment of early breast cancer with skin-sparing mastectomy. *Ann Surg Oncol* 1997; 4: 193.
25. Rosen PP, Saigo PE, Braun DW et al. Prognosis in stage I (T1N1M0) breast cancer. *Ann Surg* 1981; 194: 576.
26. Hartrampf CR Jr, Bennett GK. Autogenous tissue reconstruction in the mastectomy patient. A critical review of 300 patients. *Ann Surg* 1987; 205: 508.
27. Dean C. Psychiatric morbidity following mastectomy. *J Psychosom Res* 1987; 31: 385–92.
28. McCraw JB, Papp C, Cramer A et al. Breast reconstruction following mastectomy. In: Bland KI, Copeland ME, eds. *The Breast*, 2nd edn, Vol 2. Philadelphia: WB Saunders, 000; 962–93.
29. Dickson MG, Sharpe DT. The complications of tissue expansion in breast reconstruction. A review of 75 cases. *Br J Plast Surg* 1987; 40: 629–35.
30. von Smitten K, Sundell B. The impact of adjuvant radiotherapy and cytotoxic chemotherapy on the outcome of immediate breast reconstruction by tissue expansion after mastectomy for breast cancer. *Eur J Surg Oncol* 1992; 18: 119–23.
31. Burkhardt BR, Eades E. The effect of Biocell texturing and povidone-iodine irrigation on capsular contracture around inflatable breast implants. *Plast Reconstr Surg* 1994; 93: 123–8.
32. Maxwell GP, Falcone PA. Eighty four consecutive breast reconstructions using a textured silicone tissue expander. *Plast Reconstr Surg* 1992; 89: 1022–34.
33. Papillon J. Pros and cons of subpectoral implantation. *Clin Plast Surg* 1976; 3: 321–7.
34. Ryu J, Yahalom J, Shank B et al. Radiation therapy after breast augmentation in early or recurrent breast cancer. *Cancer* 1990; 66: 844–7.
35. Halpern J, McNeese MD, Kroll SS, Ellerbrock N. Irradiation of prosthetically augmented breasts: A retrospective study on toxicity and cosmetic results. *Int J Radiat Oncol Biol Phys* 1990; 18: 189–91.
36. Kuske RR, Schuster R, Klein E et al. Radiotherapy and breast reconstruction: clinical results and dosimetry. *Int J Radiat Oncol Biol Phys* 1991; 21: 339–46.
37. Victor SJ, Brown DM, Horwitz EM et al. Treatment outcome with radiation therapy after breast augmentation or reconstruction in patients with primary breast carcinoma. *Cancer* 1998; 82: 1303–9.
38. Vandermeeyer E, Deraemeecker R. Radiation therapy after immediate breast reconstruction with implants. *Plast Reconstr Surg* 2000; 105: 56–8.
39. Tallet AV, Salem N, Moutardier V et al. Radiotherapy and immediate two-stage breast reconstruction with a tissue expander and implant: complications and esthetic results. *Int J Radiat Oncol Biol Phys* 2003; 57: 136–42.
40. Gabriel SE, O'Fallon WM, Kurland LT et al. Risk of connective tissue diseases and other disorders after breast implantation. *N Engl J Med* 1994; 33: 1697.
41. Schuler FA, Rosato FE, Miller E. Silicone prostheses and anti-tumor immunity. *Plast Reconstr Surg* 1978; 61: 762.
42. Fisher JC. The silicone controversy – when will science prevail? *N Engl J Med* 1992; 36: 1696.
43. Hokin JA. Mastectomy reconstruction without a prosthetic implant. *Plast Reconstr Surg* 1997; 100: 1418–24.
44. Hokin JA, Silfverskiold KL. Breast reconstruction without an implant: results and complications using an extended latissimus dorsi flap. *Plast Reconstr Surg* 1987; 79: 58–66.
45. Papp C, Zanon E, McCraw J. Breast volume replacement using the de-epithelialized latissimus dorsi flap. *Eur J Plast Surg* 1988; 11: 120.
46. Fowbie B, Gray R, Gilchrist K et al. Identification of a subgroup of patients with breast cancer and histologically positive nodes receiving adjuvant chemotherapy who may benefit from post-operative radiotherapy. *J Clin Oncol* 1988; 6: 1107–17.
47. Overgaard M, Hansen PS, Overgaard J et al. Post-operative radiotherapy in high-risk pre-menopausal women with breast cancer who receive adjuvant chemotherapy. *N Engl J Med* 1997; 337: 949–55.
48. Ragaz J, Jackson SM, Le N et al. Adjuvant radiotherapy and chemotherapy in node-positive premenopausal women with breast cancer. *N Engl J Med* 1997; 337: 956–62.
49. DeMey A, LeJour M, Declety A, Meythiaz AM. Late results and current indications of latissimus dorsi breast reconstructions. *Br J Plast Surg* 1991; 44: 1–4.
50. Song R, Yang P, Yu H, Huang H. Breast reconstruction without a silicone implant. *Clin Plast Surg* 1982; 9: 85–9.
51. Moore TS, Farrell LD. Latissimus dorsi myocutaneous flap for breast reconstruction – long term results. *Plast Reconstr Surg* 1992; 89: 666–72.
52. Bostwick J III, Carlson GW. Reconstruction of the breast. *Surg Oncol Clin North Am* 1997; 6: 71–89.
53. Harris NR II, Webb MS, May JW. Intra-operative physiological blood flow studies in the TRAM flap for immediate breast reconstruction. *Plast Reconstr Surg* 1992; 90: 553.
54. Moon HK, Taylor GI. The vascular anatomy of the rectus abdominis musculocutaneous flaps based on the superior epigastric system. *Plast Reconstr Surg* 1988; 82: 815.
55. Grotting JC, Urist MM, Maddox WA et al. Conventional

- TRAM flap versus free microsurgical TRAM flap for immediate breast reconstruction. *Plast Reconstr Surg* 1989; 83: 828–41.
56. Schusterman MA, Kroll SS, Weldon ME. Immediate breast reconstruction: why the free TRAM over the conventional TRAM flap? *Plast Reconstr Surg* 1992; 90: 255–61.
 57. Slavin SA, Goldwyn RM. The mid-abdominal rectus abdominis myocutaneous flap: review of 236 cases. *Plast Reconstr Surg* 1988; 81: 189–97.
 58. Boyd JB, Taylor GI, Corlett R. The vascular territories of the superior epigastric and the deep inferior epigastric systems. *Plast Reconstr Surg* 1984; 73: 1–16.
 59. Ischii CH Jr, Bostwick J III, Raine TJ et al. Double pedicled transverse rectus abdominis myocutaneous flap for unilateral breast and chest wall reconstruction; reducing the risks. *Plast Reconstr Surg* 1985; 76: 901–7.
 60. Kroll SS, Coffey JA Jr, Winn RJ, Shusterman MA. A comparison of factors affecting cosmetic outcomes of TRAM flap breast reconstructions. *Plast Reconstr Surg* 1995; 96: 860.
 61. Grotting JC. Immediate breast reconstruction using the free TRAM flap. *Clin Plast Surg* 1994; 21: 207.
 62. Beasley MF. The pedicled TRAM as preference for immediate autogenous tissue breast reconstruction. *Clin Plast Surg* 1994; 21: 191–205.
 63. Abdel-Moneim RI. The hazards of surgery in the obese. *Int Surg* 1985; 70: 101.
 64. Koshima I, Soeda S. Inferior epigastric artery skin flaps without rectus abdominis muscle. *Br J Plast Surg* 1989; 42: 645–8.
 65. Alien RJ, Treece P. Deep inferior epigastric perforator flap for breast reconstruction. *Ann Plast Surg* 1994; 32: 32–8.
 66. Blondeel PN, Boeckx WD. Refinements in free flap breast reconstruction: the free bilateral deep inferior epigastric perforator flap anastomosed to the internal mammary artery. *Br J Plast Surg* 1994; 47: 495–501.
 67. Williams JK, Carlson GW, Bostwick J et al. The effects of radiation treatment after TRAM flap breast reconstruction. *Plast Reconstr Surg* 1997; 100: 1153–9.
 68. Hunt KK, Baldwin BJ, Strom EA et al. Feasibility of postmastectomy radiation therapy after TRAM flap breast reconstruction. *Ann Surg Oncol* 1997; 4: 377–84.
 69. Zimmerman RP, Mark RJ, Kim AI et al. Radiation tolerance of transverse rectus abdominis myocutaneous – free flaps used in immediate breast reconstruction. *Am J Clin Oncol* 1998; 21: 381–5.
 70. Early Breast Cancer Trialists' Collaborative Group. Polychemotherapy for early breast cancer: an overview of the randomised trials. *Lancet* 1998; 352: 930–42.
 71. Holstrom H. The free abdominoplasty flap and its use in breast reconstruction. An experimental study and clinical case report. *Scand J Plast Reconstr Surg* 1979; 13: 423–42.
 72. Rosen PB, Jabs AD, Kister SI, Hugo NE. Clinical experience with immediate breast reconstruction using tissue expansion or transverse rectus abdominis musculocutaneous flaps. *Ann Plast Surg* 1990; 25: 249–57.
 73. Furey PC, Macgillivray DC, Castiglione CL, Alien L. Wound complications in patients receiving adjuvant chemotherapy after mastectomy and immediate breast reconstruction for breast cancer. *J Surg Oncol* 1994; 55: 194–7.
 74. Kroll et al. A comparison of resource costs of immediate and delayed breast reconstruction. *Plast Reconstr Surg* 1998; 101: 964–8.
 75. Kroll SS, Evans GR, Reece GP et al. Comparison of resource costs of free and conventional TRAM flap breast reconstruction. *Plast Reconstr Surg* 1996; 98: 74–7.

18 Breast reconstruction from a woman's point of view: experience of a male breast surgeon

Alfonso M Pluchinotta

'What are your breasts filled with now?' said eight-year-old Elisabeth.

'Saline, like salt water,' I said.

'Oh,' said Elisabeth, after a moment, 'you mean like tears.'

'Yes, my darling, my breasts are filled with tears.'
Heather Ann Gilchrist¹

Breast cancer represents a heterogeneous disease and develops in an equally heterogeneous group of patients. Considering the broad spectrum of clinical scenarios, Virchow commented that the breast is like a 'teaching mother' for the oncologist² and Handley declared himself to be a lifelong student of breast cancer.³ Certain elements of clinical practice proceed from unwritten testimonials of women, whilst others emanate from written documentation. A woman's personal account can eloquently express her experience of this disease and can reflect her innermost feelings in addition to observational commentary.

With regard to breast reconstruction, cultural beliefs and practices influence both a woman's choice of treatment as well as outcome. In view of recent changes in surgical practice which include (i) increased use of breast conservation surgery, (ii) preference for immediate rather than delayed breast reconstruction and (iii) greater use of autologous tissue reconstruction, previous studies should arguably be repeated and re-evaluated in the context of contemporary cultural attitudes. Moreover, with the advent of technological medicine and increasing levels of specialization, the emphasis in medical practice has to some extent shifted from the patient

to a specific disease and may involve highly technical issues. Specialization does not necessarily represent an obstacle to a holistic medical approach and criticism of specialization is often used as a pretext.

Against the mistake of those who are afraid of harmful consequences of an excessive specialisation, I distinguish between a helpful or rather necessary specialisation, which is the technical one, and a detrimental specialisation, which is the cultural one.

Claude Bernard⁴

Although breast cancer has a variable and unpredictable emotional impact, it may be assumed that a psychologically well balanced woman can cope with a diagnosis of this disease without developing serious psychological problems. An important concept is for the patient to envisage cancer as a temporary event or a 'transitional' process, which will exert only relative and limited changes in her life. Reconstructive surgery may improve the patient's psychological status and help reduce the impact of mutilating surgery.

The reconstructive surgeon should be aware of what has previously been discussed between their oncological colleagues and the patient. Important issues relating to breast cancer per se should be reinforced, and relevant reconstructive options fully explained without overloading the patient with excessive amounts of information. Attempts should be made to ensure that the patient's expectations are not unrealistically high. In particular, it should be emphasized that the reconstructed breast will be a

variable approximation to a normal breast, but any mimicry will never be complete.

Plastic surgery does not have an unlimited competence. When a woman feels uncomfortable in her skin it is of little use to put something else in her breasts, no surgeon is able to give her charm or to modify a glance.

Dominique Gros⁵

Consultation with the patient

In order to achieve fully informed consent and to involve the patient actively in the decision making process, careful explanation is required. Patients are increasingly forearming themselves with knowledge of breast cancer and its management. They may have certain preconceived ideas of treatment and a physician may have to dispel these before conveying their own opinion, judgement and advice.

A patient's response to the diagnosis and her ability to cope with various forms of treatment will be influenced by her own experience of previous illnesses, her personal values and philosophies, together with various social and cultural mores. Information sharing is not synonymous with shared decision making and current models and methodology are unsatisfactory. Doctors may require formal training in this area in order to guide patients through the process of shared decision making. The principle of empowering patients with knowledge and information for the purpose of allowing them to participate in management decisions may not be appropriate for all patients. Three basic approaches are recognized:

- paternalism
- informed choice
- shared decision making.

Paternalism

The doctor assumes complete responsibility for the decision making process and involvement of the patient is minimal. This is considered a protective approach based on the premise that 'the doctor knows best'. The doctor essentially makes decisions on behalf of and with the patient's best interests foremost in mind. Paternalism was common in the past, and indeed the norm, and reflects the dominance of the doctor over the patient. However, this approach is now outdated and patients no longer exhibit the same degree of dependency upon their physicians as in previous generations.

Benign and well intentioned it may be, paternalism has the effect of creating and maintaining a dependency which is out of step with other currents in society.

Susan Love⁶

The 'stoical passivity' of the patient has been superseded by an assertiveness and in some cases, a 'clamour of discontent'.

The patient may derive some psychological comfort from the paternalistic approach and believe that what the doctor has advised is the best option for her. Some patients are reluctant to accept any degree of responsibility for their choice of treatment.

Informed choice

With this approach, the patient is provided with sufficient information to allow her to make a calculated decision about her own treatment options. The final choice is ultimately left to the patient and the doctor acts as a facilitator who resists intervening directly in the decision making process. This approach restores the balance in favour of the patient, who assumes an active role in her own management. This method echoes the free market ideology of the 1980s, with patients being redefined as 'consumers' or 'users'. However, such consumerism encourages patients to make demands and claims for individual rights, but often ignores any concomitant responsibilities.

Norbert Bensaïd alluded to the risks of providing inadequate explanation to patients, when he wrote:

Medicine takes advantages of our fear of death and tries to provide us with all the necessary knowledge, in order to keep us healthy. On the contrary, rather than protect us from the fear of death, it makes us die of fear, its intention is noble and portrays the ambition and the challenge undertaken through the centuries to eliminate the suffering and fight death, instead abusing this method may become an alibi for the doctor; on the one hand tends to eliminate the problems that cannot be resolved, but burdens the patient himself with the responsibility and self-reproach.

Shared decision making

This is a compromise between paternalism and informed consent which are extremes of a continuum involving a balance of power and responsibility between doctors and patients. Shared decision making implies a partnership between doctor and patient. There is evidence that patients will better

adjust to their diagnosis and cope with their disease when they possess adequate information and understand the treatment decisions. Furthermore, rates of compliance and patient satisfaction are increased, and costs of treatment may ultimately be reduced. Doctors must listen to patients and respect their views and opinions and be prepared to incorporate these into the overall management plan.

As part of this shared decision making process, patients will come to realize that there is intrinsic uncertainty about outcomes of various treatment options and corroborative or definitive data are often lacking. Some clinical decisions can more readily and appropriately be taken without significant patient involvement and the doctor must recognize when such circumstances occur. When input from the patient is required, their contribution to the decision making process must not be underestimated and the whole interaction must not be rushed. Patients must be allowed adequate time to absorb and assimilate the information and unfamiliar concepts such as numeracy and probability, which may be difficult to convey in a clinical consultation.

Diagrams may be useful in explaining some of the technical aspects of reconstruction, e.g. the TRAM (transverse rectus abdominis myocutaneous) flap. The consultation may impose special demands upon the doctor who must gauge the patient's level of understanding and adjust the content and style of the consultation accordingly. Susan Love has summarized these aspects of the consultation succinctly.⁸

Decisions must be shared with an aware patient, the doctor is neither infallible or omniscient, at best he is a skilled consultant with a useful specialised knowledge. He can tell people what options are open to them in a given situation and he can give them statistical information about how these options have worked for others. A doctor cannot tell a particular patient which option she should follow. It is her body and her life and what is right for one patient, may be wholly wrong for another.

The manner in which a doctor discusses and champions certain treatment options over others may unconsciously reflect their own attitudes, beliefs and biases. Patients may sense that a doctor favours one option over another from the way they 'sell it' even though there may be no data to support this apparent preference. Mark Lippman wrote of a surgeon's performance during the interview:⁹

It is a good idea from time to time to see a patient with another colleague, who is a peer rather than a trainee. To have the opportunity to ask that

colleague to critique one's own performance can be eye opening and astoundingly useful. I also believe that it is essential to be a careful observer of the patient and the individual with whom she arrives. A useful maxim is that we never get a patient in high wind. It is almost as important to be a careful observer of the accompanying family and friends as it is of the patient herself. It seems clear that there is no one path of style, formality and information shown, that is appropriate for all patients. Our response to the individual arises with highlighted references, has got to be very different from the response from the patient, who states from the outset that she wants you to tell her what to do.

A woman's opinion of doctors

A woman's viewpoint of her disease and her reaction to mastectomy and reconstruction is greatly influenced by her own body image and any alterations thereof, together with her perceived loss of femininity which will affect sexual and personal relationships. A male doctor has limited appreciation of such issues although a female doctor may more readily identify and empathize with such matters.

The meanings attributed to the breast throughout history have rarely expressed women's feelings about themselves, only recently in a medley of distinctive voices, have women begun to talk openly about their breasts. How a woman regards her breasts is a good indicator of her personal self-esteem, as well as the collective status of women in general.

Marilyn Yalom¹⁰

Whether male or female, a surgeon may have accrued much clinical and technical acumen from years of experience, yet may still lack a deeper understanding of complex human emotions and the capacity for introspection. *Apropos* the latter, a physician's psychological flexibility may be compromised or even stunted by regular contact with the disease and a traditional background of objectivity and scientific rigour. In particular, doctors may sometimes fail to appreciate the trinity of the breast ~ as an organ of maturity, fertility and sexuality.

In Karen Michaelis' novel, *The Dangerous Age* (1911), the chief character is heard to say: 'I spoke with many celebrated gynaecologists and admired their knowledge; but intimately, I mocked their simplicity. They are able to split our interiors like girls do with their dolls, but they are not able to see beyond.'¹¹ This theme of limitations in human

comprehension has parallels in a theological context. Michaelis further comments:¹¹

Probably and in spite of common belief, the same thing happens with the priests. Theology is a magnifying glass with little suitable to examine the human spirit. I have spoken with many really respectable priests who have no central idea of women, even though they had received confessions, that many of them have fallen into sin. Sin, like disease, is something exteriorly so thick that nobody can see beyond, inside the intimacy of human spirit and accessible to the professional approach by physician or minister.

The feminist writer and essayist, Germaine Greer, warns women to beware of potential ignorance amongst doctors on the subject of female health and symptomatology.¹²

Historically, there has been a tendency for doctors to be criticized for failing to fully evaluate and objectively assess symptoms relating to hormonal imbalance, such as the menopause. More recently, breast screening programmes have been accused of recruiting patients without adequately explaining the disadvantages, such as heightened anxiety on recall, false positive results which may entail unnecessary biopsies, together with potential overdiagnosis and treatment. The majority of breast surgeons continue to be male and, as Susan Love points out:⁸

Even the most sensitive sympathetic men cannot understand a woman's complex emotional relationship to her breast. They do not know in their own bodies what it means to have breasts and they have not faced the nightmare of mastectomy that haunts almost every woman in our culture, and surfaces with even the most harmless breast problem.

Notwithstanding such comments, some women, if offered the choice, would opt for a male doctor. The reasons for this are unclear and several studies addressing this issue have failed to reach any consistent and definitive conclusion. For some women, a male doctor represents a figure of trust and authority with whom the patient feels secure and confident. Interestingly, in the case of reconstructive surgery, men are sometimes considered a better judge of shape and form with a more natural sense of aesthetic appreciation. Undoubtedly, some women have an innate distrust of women doctors. Women may perceive a surgeon as a specialist who voices relatively few words.

The surgeon who uses a knife to cure thinks that words are accessory instruments; after all this is what he makes of the word in the operating room.

From there comes the difficulty in understanding that words are otherwise useful. ... words have an extraordinary efficacy, they have a fundamental role in defining the therapeutic success.

W Pasini¹³

Breast surgeons have developed methods of involving the patient in decision making and are aware of the potential benefits, both for the patient and for themselves. With increasing experience they are better able to effect an evolution in methodological approach during the continued interaction with the patient. Some surgeons are sceptical about the concept of shared decision making and they may feel that they already communicate effectively with their patients, and do not readily welcome progressive methods of interaction. However, there is evidence that women nowadays seek knowledge and information and wish to be well informed about their disease. They may consider the attitude of older generations of surgeons to be laconic and sententious. Some surgeons convince patients to accept and abide by their advice by an act of 'friendly persuasion'. They justify such an approach to themselves by believing that they are shielding the patient from unnecessary anxiety. Constraints associated with a conventional doctor-patient relationship may hamper any exploratory gestures on the part of the doctor, which might otherwise help him respond to patient preferences. Time is always a limiting factor in clinical practice but the more time spent with a patient in the preoperative period, the less time is required for further explanation following surgery. Some patients clearly require more time than others but no consultation should be excessively long. Written consent should be obtained for all procedures, although a signed document is no substitute for a clear and comprehensive explanation in the setting of a good doctor-patient relationship.

A woman's opinion of surgery

Surveys are often used to canvas patients' opinions and listen to their concerns. However, they do not necessarily lead to increased patient satisfaction or expectations of improved quality of care.

Previous satisfaction surveys have little impact because they often did not meet minimal standards of conceptual or methodological rigour and were not designed to facilitate quality improvement efforts. Responses to such surveys are subjective and difficult to interpret, since they are a complex function of expectations that may vary greatly among patients with comparable care.

PD Clearly¹⁴

It might be argued that there is a need for more structured questions which are less subjective and dependent on patient characteristics. These may be easier to interpret and translate into practical improvements in patient care.

Breast reconstruction is most frequently requested by younger patients, although older women may enquire about this option. The psychological impact of breast loss is not necessarily diminished with increasing age. However, certain types of reconstruction may not be appropriate in the older age group (see Chapter 17).

Once breast cancer is diagnosed, the first decision a patient has to face is whether to undergo mastectomy or breast conservation. Even when the surgeon considers the latter feasible, a woman may choose mastectomy for personal reasons. These include cancer phobia and adverse anecdotal experiences of friends or relatives. Some patients are strongly guided by their surgeons.

Women who get breast cancer find themselves dealing with a largely male dominated medical establishment that is often astoundingly insensitive to the double terror that women feel; the terror of the death and the terror of mutilation. Ironically, the male culture that emphasises the importance of beautiful breasts often becomes extremely cavalier about removing those breasts. Despite the years of research showing that many mastectomies are unnecessary, a frightening number of male surgeons still recommend them when a less severe operation would be equally helpful, and some even recommend 'preventive' mastectomies for women who feel they might get cancer.

Susan Love⁸

Similarly, not all women undergoing mastectomy seek reconstruction. It is important that patients are not coerced into reconstruction, and when there is an element of uncertainty a delayed reconstruction can be carried out at a later date. Often women adapt to mastectomy and come to terms with their altered body image (with or without an external prosthesis). Such women decline the offer of a delayed procedure which involves further hospitalization (see Chapter 4, section 1). The poet Audrey Lorde wrote of her mutilation:¹⁵

I looked strange and uneven and peculiar to myself but somehow, ever so much more myself and therefore, so much more acceptable than I looked with that thing stuck inside my clothes. For not even the most skilful prosthesis in the world could, under that reality, or feel the way my breasts had felt and either I would love my body, one breast did now or remained forever alien to myself.

Teimourian and Adham surveyed patients' responses to reconstruction and found that some patients viewed reconstruction as a 'reverse mastectomy' which could partially overcome the psychological detriment of breast loss.¹⁶ This is most apparent for immediate breast reconstruction. Clifford and colleagues showed that women seeking delayed breast reconstruction exhibited positive coping with an assertive manner associated with effective problem solving behaviour.¹⁷ The artist Jo Raksin, compares her experience of mastectomy to women of Amazonia:¹⁸

According to Greek mythology, the Amazons were female warriors who removed a breast so they could draw a bow more easily. The tale gives me a sense of empowerment when I lost the breast to cancer. Wanting to share this story I draw the symbol to capture their power.

Reaby's study illustrates how difficult it can be for women to decide whether to undergo breast reconstruction or use an external breast prosthesis.¹⁹ The most common reasons for not choosing breast reconstruction were (i) no increase in physical well-being; (ii) not considered essential for emotional well-being; (iii) inadequate information about the procedure; and (iv) fear of having unnatural materials within the body. A major concern was the risk of complications from the surgical procedure, together with a perception by patients of being 'too old' for reconstruction. Reasons for choosing breast reconstruction included avoidance of an external prosthesis, increased range and choice of clothing, restoration of femininity, and a feeling of being whole again (which was the principal reason cited by this group of patients for selecting reconstruction). Of interest, perceived improvements in sexual relationships was not given high priority.¹⁹

Breast reconstruction should ideally be offered as an immediate procedure as this is associated not only with improved psychological outcome, but also superior cosmetic results. In particular, patients avoid experiencing absence of a breast. Schain and colleagues reported that women having immediate breast reconstruction were less anxious and depressed and tended to exhibit less hostility to their diagnosis, compared with those undergoing delayed reconstruction.²⁰ However, overall rates of patient satisfaction were not correlated with timing of breast reconstruction and those patients who sought reconstruction with the intention of enhancing sexual and social relations, were more likely to be disappointed. At a time when breast conservation has become more widespread, the options for, and results of, breast reconstruction have greatly improved. Sometimes patients may benefit from a mastectomy and reconstruction, rather than attempts

at breast conservation surgery which may ultimately yield a poorer cosmetic result. This applies particularly to skin-sparing procedures where much of the breast envelope is preserved and scarring is minimal.

How to reach a shared decision

Before embarking on a process of shared decision making, surgeons must familiarize themselves with all pertinent facts relating to any individual case, including stage of disease and psychosocial aspects. A formal psychological profile may be indicated in some cases and assessment of a patient's social and cultural background are valuable. A practical division of psychological types is the Miller Behavioural Style Scale.²¹ Essentially, patients are divided into 'monitors' or 'blunters'. The former group of patients request much information whilst the latter avoid asking questions. Yet, although some patients may demand information, they do not wish to be burdened with responsibility for any final decisions on treatment. Other patients express little interest in obtaining information about their disease or appear unreceptive to any information that is offered, either in verbal or written form.

It may be difficult for a doctor to convey information of appropriate quantity and clarity within the time constraints of the clinic consultation. Doctors are very aware of time pressures in an outpatient setting and spending more than 15–20 minutes with each cancer patient may significantly disrupt the clinic schedule. In this regard, the role of a breast care nurse specialist can be invaluable as they are likely to have more time to spend with patients' and their discussions will complement and reinforce the consultation which has taken place with the breast surgeon.

Patients vary greatly in the amounts of information they are able to understand and assimilate within a single consultation. This will be influenced by their level of intelligence and educational attainment. Information overload is counter-productive and the patient may recall very little upon conclusion of the consultation; even worse, they may feel very confused. With the advent of easy access to information technology (e.g. the internet) patients are increasingly well informed about their disease. However, there are potential risks that information accessed by patients may be inaccurate or misleading. Furthermore, patients may understand such information to varying degrees and misinterpret certain aspects or extrapolate inappropriately. Ideally, some doctors prefer to have a 'clean slate' rather than being faced with either a misinformed

patient or one with certain preconceptions about their disease and its management.

George Bernard Shaw stated that 'to overcome fear is the beginning of wisdom'. It is important to allay both fear and prejudice; fear of cancer per se is usually more paramount than specific fears relating to treatment such as breast reconstruction. The patient is usually more concerned about saving her life than her breast. A patient may be so psychologically overwhelmed by the diagnosis of cancer, that her mind becomes blocked to receipt of any detailed information on management. This is illustrated in the following citation from Reaby.¹⁹

The day after my mastectomy, the plastic surgeon came to see me. That was the first time I realised that I had the reconstruction done. He was totally surprised and told me that he talked to me the night before surgery; I guess I was so emotionally distressed that I completely blanked out that period of my life. He even showed me where I had signed the consent form; it just shows you what tricks the mind can play when you are really upset.'

Sometimes it may be useful to pause and allow the patient to openly express her reaction to the diagnosis of cancer and to pour forth her inner emotions. She can then compose herself before proceeding further with the consultation.

As a surgical procedure, all forms of reconstruction are associated with risks and patients must be informed of these. However, with modern anaesthesia and recent technical developments in plastic surgery, reconstructive methods today are relatively safe. Where there are potentially serious risks such as total flap failure (e.g. the free TRAM flap), it is imperative that patients understand these in quantitative terms and are aware of alternative methods.

Many women decline breast reconstruction because they perceive themselves as being too old. Interestingly, this attitude may reflect underlying psychological problems such as low self esteem, but may also indicate a sense of security from a supportive family. 'My husband said I did not need reconstruction, that he loved me, and that my losing the breast did not make any difference. He said that if I wanted it, that was up to me and whatever I decided was alright by him.'²² As previously stated, age of itself is not a contraindication to breast reconstruction, 'I just felt that I was too old to even think about it but I think it would be necessary for younger women. They should not have to live without a breast.'¹⁹

Intervention from members of the family can sometimes hinder the decision making process and

advice which may be given with good intent may not ultimately be in the patient's best interests. For example, they may feel intuitively that breast cancer mandates mastectomy and dissuade the patient from attempting breast conservation. Similarly, they may be sceptical of the potential benefits derived from breast reconstruction and may even accuse the patient of being vain or selfish: 'I got really excited about the prospect of reconstruction until I talked to my parents. They took me aside and said . . . you have really got to think about what you are doing. They felt that it was totally unnecessary with me being on my own with the children and that I was being selfish and vain.'¹⁹

Once fear, prejudice and conditioning have been assuaged, decision making becomes easier and management proposals more acceptable to the patient. 'The biggest reason for me was that the surgeon wanted me to have the breast reconstruction. I had complete trust in him and he felt it would be the best solution for me.'¹⁹

Maintaining and encouraging a sense of humour is a useful coping mechanism for some patients. Constance Richardson wrote a humorous little poem in which she thanked her body for being so adaptable following a TRAM flap breast reconstruction:²³

I am a work in progress, not diminished or finished, re-engineered, thank you I say to my abdominal muscle for accommodating its move north, its capillaries a river of new life, hooray I say for having too much belly that became the donor site and now my left breast. Pull, I ordered my flaccid obliques, reach, I croon to one arm as it struggles up, up, up. Patience, I say to tight tendons, fascia, sore arms and torso as we metamorphose in recovery together.

Conclusions

Breast cancer has profound psychological sequelae as alluded to by Andrykowski when he wrote that breast cancer 'is a traumatic event that alters an individual's assumptive world with the potential to produce long lasting changes of both a positive as well as a negative nature'.²⁴

Reconstructive surgery is of great psychological benefit and has a favourable effect on the impact of the disease. This applies particularly to immediate breast reconstruction in which a chain of adverse psychological events may be averted. However, breast reconstruction is not a panacea which will compensate for the physical and emotional scars

experienced by the patient throughout the course of her diagnosis and treatment. The relationship between patient and surgeon not only helps a woman come to terms with her disease, but may also influence her satisfaction with the final aesthetic result.⁹

A careful consideration of attention and relationship with patients can be an immense help in allowing us to improve this situation for our patients, and indirectly for ourselves as well. Being respectful and observant of the individual, we have the greatest possible opportunity to lessen the psychological impact of the treatment on the patient and thus, ensure better compliance and almost certainly a better outcome.'

The majority of decisions involve consensus between patient and doctor with an occasional element of negotiation. Sometimes doctors have to deal with extremes of emotions, ranging from depression to anger, but these situations can be minimized by ensuring that a doctor's style and approach are in accord with the patient's frame of reference. The words of Marguerite Yourcenar provide a final thought:²²

You cannot understand disease without considering its singular affinity with war and love, without recognising its compromises, pretences, the absolute necessities, mixed up in a bizarre and unique amalgam of temperament and evil.

References

1. Gilchrist HA. In: *Art. Rage. Us. Art and Writing by Women with Breast Cancer*. San Francisco: Chronicle Books, 1998.
2. Quoted by De Moulin D. *A Short History of Breast Cancer*. Dordrecht: Nijhoff M, 1983.
3. Handley R. Symposium on Breast Cancer: opening address. *Br J Surg* 1976; 61: 757.
4. Bernard C. *Introduction à l'étude de la médecine expérimentale*. Paris: Baillière, 1865.
5. Gros D. *Le Sein Dévoilé*. Paris: Stock/L Pernaud, 1987.
6. Coulter A. Paternalism or partnership? *BMJ* 1999; 7212: 719–20.
7. Bensaïd N. *Les illusions de la prévention*. Editions du Seuil, Paris: 1981.
8. Love SM. *Dr. Susan Love's Breast Book*, 2nd edn. Reading MA: Addison-Wesley, 1995.
9. Lippman ME. Editorial comment in Rowland JH, Psychological impact of treatment for breast cancer. In: Spear SL, ed. *The Breast, Principles and Art*. Philadelphia: Lippincott-Raven, 1998.
10. Yalom M. *A History of the Breast*. New York: A Knopf, 1997.

11. Michaelis K. Quoted in Marañon G. *L'Age critique*, 2nd edn. Paris: F Alcan, 1934
12. Greer G. *The Change, Women, Aging and the Menopause*. New York: Fawcett, 1991.
13. Pasini W. *La qualità dei sentimenti*. Milano: Mondadori, 1991.
14. Clearly PD. The increasing importance of patient surveys. *BMJ* 1999; 7212: 720–1.
15. Lorde A. *The Cancer Journal*. Argyle NY: Spinsters, 1990.
16. Teimourian B, Adham MN. Survey of patients: responses to breast reconstruction. *Ann Plast Surg* 1982; 9: 321–325.
17. Clifford E, Clifford M, Georgiade NC. Breast reconstruction following mastectomy. *Ann Plast Surg* 1980; 5: 343–6.
18. Raksin J. In: *Art. Rage. Us. Art and Writing by Women with Breast Cancer*. San Francisco: Chronicle Books, 1998.
19. Reaby LL. Reasons why women who have mastectomy decide to have or not to have breast reconstruction. *Plast Reconstr Surg* 1998; 101: 1810–18.
20. Schain WS, Wellisch DK, Pasnau RO et al. The sooner the better: a study of psychological factors in women undergoing immediate versus delayed breast reconstruction. *Am J Psychiatry* 1985; 142: 40–6.
21. Johnson JD, Roberts CS, Cox CE et al. Breast cancer patient's personality style, age and treatment decision making. *J Surg Oncol* 1996; 63: 183–6.
22. Richardson C. In: *Art. Rage. Us. Art and Writing by Women with Breast Cancer*. San Francisco: Chronicle Books, 1998.
23. Andrikowsky MA, Curran SL, Studts JL et al. Psychosocial adjustment and quality of life in women with breast cancer and benign problems: a controlled comparison. *J Clin Epidemiol* 1996; 49: 827.
24. Yourcenar M. *Mémoires d'Hadrien*. Paris: Plon, 1951.

19 Breast reconstruction from a woman's point of view: experience of a female Clinical Nurse Specialist – Breast Care

Lisa Wolf

Introduction

The offer of immediate breast reconstruction to a woman undergoing mastectomy for breast cancer is usually viewed as 'good news' at an emotionally traumatic moment in her life. Breast reconstruction significantly reduces the psychological morbidity associated with mastectomy with improvements in emotional, social and functional well-being.¹⁻³ Nonetheless, the decision whether to accept reconstruction or not remains a matter of individual choice and the patient herself is the final arbiter. Reconstruction does not enhance survival or impact on mortality, yet ameliorates some of the associated psychological morbidity. Unlike procedures such as cosmetic enhancement, it should not be regarded as a 'luxury' operation.

The breasts constitute an integral component of a woman's identity and for those women who endure a mastectomy for breast cancer, the potential threat is double edged. Not only does she lose a breast but she also has to live with the fear that having a life-threatening disease encompasses. Breast cancer therefore jeopardizes not only a woman's self-esteem and body image but also her femininity, which collectively impact in a negative manner on sexual functioning and self-perception.^{4,5} These issues are further explored in Chapter 20.

The following account reflects personal experiences and impressions gleaned from working with breast

cancer patients, each of whom has a different story to tell.

The role of the Clinical Nurse Specialist – Breast Care

The breast care nurse is a designated Clinical Nurse Specialist and an integral member of the multi-disciplinary team. The role of the breast care nurse primarily involves provision of supportive information to women with early or advanced breast cancer. In addition, the physical and psychological well-being of patients is continually monitored from the time of diagnosis and a variety of practical advice is offered. In particular, patients have access to the breast care nurse at the time when decisions about breast reconstruction are being made. With her knowledge base of breast cancer and its management, the breast care nurse has an educational role and can reinforce information already conveyed to patients by doctors. The breast care nurse should be in a position to assess the psychological needs and information requirements of individual patients and to provide appropriate levels of emotional support and practical help. The breast care nurse can also act as an advocate on behalf of the patient.⁶ One of the fundamental aspects of the role of the breast care nurse is that of assessment of the woman's response to her diagnosis and her social/family support network. In addition, an assessment must be made of individual coping style and capacity for decision

making. The breast care nurse can help clarify a woman's understanding of her diagnosis and management pathway and will gain some insight into what factors govern the patient's decision to proceed with reconstruction or otherwise.

It might be argued that the role of a breast care nurse can only be optimally accomplished by a female who has a greater appreciation and understanding of the significance of breast surgery to another woman. The breast care nurse has the opportunity to establish a unique relationship with a breast cancer patient, based on empathy, trust and advocacy. Many women consider the breast care nurse to be a confidante who can understand their emotional tribulations, but who also possesses the knowledge to facilitate decision making on the part of the patient. The role of the breast care nurse is most effective when harmonized with that of other members of the breast care team. In particular, the role of the breast care nurse should complement that of the surgeon in order to provide maximum benefit to patients. Although a surgeon may declare a patient suitable for reconstruction, the final decision rests with the patient themselves. It is essential that women have appropriate perceptions of what reconstruction will mean to them and must therefore be well informed with realistic expectations. The breast care nurse has a crucial role in guiding this process of shared decision making which is greatly facilitated when empathy and rapport have been established between patient and nurse. A level of trust may be fostered which enables a woman to express herself more comprehensively to a breast care nurse than possibly to her surgeon. The breast care nurse can help a patient to formulate pertinent questions and can act as advocate by focusing on specific issues or indeed challenging the surgeon when discordant advice is given or conflict is sensed.

The information giving process

The aim of educating the woman who has been offered breast reconstruction is to enable her to decide whether to have the procedure in the first place, to prepare her for it and to help her adjust afterwards. Information giving demands both sensitivity to the needs of an individual and flexibility on behalf of the provider of that information.⁷ The requirements of a patient undergoing immediate reconstruction differ from those seeking delayed reconstruction, from those coming to terms with a recent diagnosis of breast cancer and the prospect of a mastectomy, and from those experiencing the shock and disappointment of a local recurrence. Information giving should extend beyond simple disclosure and should be designed to help patients

process the information by encouraging them to ask questions, thus clarifying facts and understanding. Furthermore partners, family and friends can be incorporated into discussions as considered appropriate.⁸ Information can be customized to provide specific and personalized advice on how reconstruction will affect daily life and sufficient time must be allocated to complete the information giving process without any impression of haste. It is particularly important to obtain some feedback from the patient to confirm that information has been comprehended and retained. It should never be assumed that just because the information has been provided it will necessarily have been comprehended or in fact retained.⁷

Areas of anxiety should be cautiously unearthed, and those of confusion or misinformation clarified. An enormous volume of information is conveyed which is difficult to assimilate during a single session and follow-up consultations with either the surgeon or breast care nurse should be offered. It is important that the breast care nurse is present at the initial consultation with the surgeon in order to be aware of what has already been discussed and to assess how much information the patient has understood and remembered. Moreover, this co-presence of surgeon and breast care nurse ensures consistency of information disclosure. Once a close working relationship is established, their respective roles of information giving become complementary within this framework.

An important aspect of information giving in the context of breast reconstruction is establishing realistic outcomes. It must be emphasized that a woman is not obtaining another breast but rather a shape that may mimic a breast form and create a cleavage. Breast reconstruction yields a facsimile of a breast and cannot replicate the feel and texture of the normal breast. The degree of satisfaction with surgery is inextricably linked to expectation and as such a balanced and realistic attitude avoids the disappointment of idealization.⁹ At the time of discussion on breast reconstruction, it is valuable for women to have the opportunity of considering non-surgical options. A range of external prostheses is now available which women should be made aware of. In addition, the use of drawings or photographs may be extremely useful and is most effective when the photographs pertain to outcomes achieved by the same surgeon who will perform that woman's operation and are not confined exclusively to 'best' results. Talking to other women who have undergone reconstruction can be useful, although a balanced perspective should be sought and patients must not be unduly influenced by one individual's surgical misfortune. Similarly, patients should appreciate that reconstruction is a process which

evolves rather than a single event in time, and the final outcome is usually not achieved for several months. Patients may require serial inflation of a prosthesis or sometimes further surgical procedures such as contralateral breast surgery or nipple reconstruction, which necessitate additional visits to hospital.

The decision making process

Information can be viewed as an antecedent to decision making.¹⁰ Many, though not all, patients will wish to be active participants in the decision making process. Determining a patient's preference and engaging in shared decision making demands a high level of communication skills, supported by good quality information material (leaflets/packages). Levels of anxiety and depression are reduced when patients are actively involved in decision making¹¹ and non-participation in decision making (paternalism) should not imply that patients have relinquished any information requirements which are important for patient autonomy.¹² The degree of participation and decision making must be carefully judged on an individual basis and patients' wishes always respected. Those who defer decision making responsibility to others should have their wishes respected and those who prefer to be more actively involved should be offered appropriate decision making support. In addition, these preferences are not static and changes may occur over time as the healthcare relationship evolves and as the woman moves further away from the point of diagnosis. These issues are further discussed in Chapter 18. The breast care nurse should provide a balanced view of breast reconstruction, which will aid a woman in assessing her reasons for considering such surgery. She should arrive at a decision based on her personal needs and beliefs and not be overly influenced or even coerced by others. In particular, breast reconstruction should not be requested at the command of a partner. A breast care nurse is well placed to ascertain the patient's motives for and expectations from reconstruction.

There are several reasons why a woman may seek reconstruction, or indeed decline any offer thereof. The following reasons are based on personal testimonials of individual women whose experiences were shared with the present author and pertain mostly to women who have chosen immediate rather than delayed reconstruction. A review of the literature supports the author's experience.^{13–19}

Most women express a strong desire to feel 'normal' again and return to their previous lifestyles as far as possible with what is perceived as an acceptable

compromise. For some women this can be achieved by using an external prosthesis only whilst for others this is dependent upon a surgically reconstructed breast. Reconstruction is considered to improve the ability to cope with loss of a breast, as a woman regains symmetry and 'wholeness'. Similarly, restoration of body image allows patients to feel more comfortable with their bodies and self-esteem is improved. They feel that their sense of femininity is preserved, but few women believe that reconstruction will save a faltering relationship. However, surgery can impact favourably upon a woman's general level of confidence, which can improve personal interactions. Women who have young children may select reconstruction to avoid their children seeing them in a deformed state. Conversely, reconstruction, particularly when delayed, may be considered an unnecessary risk and further hospitalization and recuperation can pose problems with childcare.

Some woman may choose delayed reconstruction to eliminate the need for an external prosthesis, or in the case of immediate reconstruction, to avoid the need for one. External prostheses can be uncomfortable but more specifically they restrict the choice of clothing. These women lack a cleavage and must wear clothes with a higher neck line and special types of swimwear. The desire for a cleavage is a strong incentive to some women for selecting surgical breast reconstruction and they often feel secure in the belief that 'no one can tell' which is the affected side when dressed. Finally, some women report that the presence of an external prosthesis is a constant reminder of their disease.

The breast care nurse also plays an important role in discussing breast reconstruction with women considering bilateral prophylactic mastectomy. This is an option for women at high risk for breast cancer and has been shown to significantly reduce the incidence of breast cancer.²⁰ In addition, positive outcomes include decreased emotional concern about developing breast cancer and favourable psychological and social outcomes.^{21,22} However, this must be weighed against potential adverse effects, both physical and emotional, and the irreversibility of the decision. The breast care nurse can play a vital role, along with the multi-disciplinary team, in providing the woman considering bilateral prophylactic mastectomy, with or without reconstruction, with the best available information. Encouraging her to take time to consider all the options available to her, including surveillance and participation in a chemoprevention trial, is crucial. For this group of women breast reconstruction can provide substantial psychosocial benefits and as such should be offered as a matter of routine.

Patients tend to view reconstruction as part of the rehabilitative phase of the cancer experience. The offer of reconstruction may be interpreted as a positive gesture, which indicates a likely favourable prognosis.

Age is not necessarily a deterrent to women seeking reconstruction. Some patients maintain that having lived so long with a pair of breasts, they find it more difficult to accept the loss of one. Nonetheless the sense of loss consequent upon mastectomy is great, irrespective of age. Older patients may express concern over possible allegations of vanity if they request reconstruction. It is important that such individuals receive appropriate support and reassurance from family and friends.

Apart from age, patients may also decline reconstruction because of fears about potential risks and complications associated with surgery, in addition to uncertainties relating to cosmetic outcome. Others express concern that breast reconstruction may impair survival and interfere with postoperative follow-up and monitoring (despite reassurance to the contrary). Not all patients consider reconstruction to be essential for either physical or emotional well-being and refuse reconstructive surgery at the outset. The idea of having 'unnecessary' cosmetic surgery may hinder a woman's decision to proceed with reconstruction. She must give priority to her own needs even if these appear to be at the expense of those of partners and children. A woman needs to evaluate her options and determine what is right for her. Difficulties with decision making can be compounded by a recent diagnosis of breast cancer with the associated anxiety, stress and fear of making an inappropriate decision. This can be particularly severe when a woman has taken much responsibility for decision making and things have not turned out well. In such circumstances, patients must be reassured that when outcomes are adverse, they are personally not at fault. Women must always be provided with sufficient time to make a final decision and realize that minor delays in surgery will not jeopardize final outcomes from an oncological viewpoint. Patients should not feel under pressure to arrive at a decision hastily.

Therefore, in reaching a decision about reconstruction some women will be influenced by practical considerations such as comfort and convenience, whilst others will focus on aesthetic and psychological aspects of reconstruction. For most patients the final decision is based on a synthesis of multiple factors, which ultimately emphasize the positive benefits of reconstruction regarding femininity, self-confidence and attractiveness.

The information given

Box 19.1 lists the subject areas that should be routinely covered by the breast care nurse when a patient is contemplating reconstructive surgery. This list aims to serve as a guide which needs to be approached with flexibility and is aimed at the appropriate level and focus of information required by the woman.

Box 19.1 Topics a breast care nurse should cover

- Immediate versus delayed surgery
- Correct fears about detection of recurrence post-reconstruction
- Different options in reconstructive surgery and why a particular method is being recommended
- Advantages and disadvantages of different methods
- What the operation involves – mastectomy with or without axillary surgery, and the methods of reconstruction
- The surgical procedure explained in language and manner that patients can relate to
- Scarring – expected and possible complications
- Cosmetic outcomes – symmetry, size, position, height, ptosis
- Sensations – insensate, cooler, firmer, numbness
- Pain – post-operatively, phantom, long-term complications
- Complications – short term, e.g. haematoma, seroma, infection, necrosis, delayed wound healing
- Complications – long term, e.g. capsular contracture, pain
- Implants and silicone – issues, complications and risks, aftercare
- With expander implants – valve discomfort, removal, failure and length of time to complete process
- Nipple replacement options
- Role of physiotherapy
- Recovery – short and long term, emotional and physical
- Post-operation information – recovery, drains, PCA, dressings, sutures
- Outpatient care and follow-up
- Aftercare, e.g. massage
- Bra advice and use of partial prosthesis if necessary
- Additional future surgery – valve removal, scar revision, implant change, contralateral augmentation, reduction
- Effects of other treatments, e.g. radiotherapy
- Effects of weight change
- 'Showing' others
- Expectations, reactions
- Use of diagrams and photographs
- PCA, patient controlled analgesia

Personal experience of being a Clinical Nurse Specialist – Breast Care within the context of breast reconstruction

An important aspect of the role of a breast care nurse is provision of information and support to patients at the time of deciding upon breast reconstruction. Both the breast care nurse and surgeon must be committed to maintaining a partnership which benefits patients under their care. They should liaise regularly and the surgeon should not put pressure upon the breast care nurse to hasten a patient's decision on reconstruction. The breast care nurse must not be partisan and should deliver guidance and information in an unbiased manner. The breast care nurse must learn to cope with being asked, 'What would you do if you were in this situation?'.²³ Similarly, the breast care nurse may have to deal with postoperative regret and a sense of having 'let the woman down'.

The breast care nurse must constantly undertake self-evaluation and maintain high standards of integrity. A balanced perspective is essential despite constant media reports that may distort the significance of a mastectomy and expectations from reconstruction. The breast care nurse can accrue much experience from personal accounts of women undergoing mastectomy and breast reconstruction that contributes to a process of continual learning and self-development.

Personal experience of women's views of breast reconstruction and of their surgeon

The majority of women are satisfied with the cosmetic outcome of breast reconstruction, and this is more likely to be the case when patients have received adequate information, preparation and support preoperatively. Those who remain disappointed usually have unrealistically high expectations or have suffered unexpected complications. Many women regard breast reconstruction as a compromise, which is preferable to a mastectomy scar but clearly only an approximation to the 'real thing'. Most women acknowledge the skill and expertise of surgery in achieving an 'illusion' of a breast, and usually exhibit feelings of gratitude to their surgeon. Rarely, patients may express resentment towards their surgeon when the latter is perceived as lacking understanding and acknowledgement of their loss. Sometimes these may be mixed feelings that fluctuate between a sense of

appreciation and admiration on the one hand and to an impression of complacency and lack of compassion on the other. A woman's response to her reconstruction is partly determined by the attitude and the disposition of the surgeon towards her.

While breast reconstruction is an essential treatment component for some women it can equally be irrelevant for others. Women opt for reconstruction for a variety of reasons and individual patient choice must be respected. A common theme is that reconstruction shifts a patient's focus away from the disease and sense of loss towards the recovery phase of the cancer experience. The breast care nurse is ideally placed to provide both information and support throughout this physically and emotionally traumatic journey.

References

1. Dean C, Chetty U, Forrest APM. Effects of immediate breast reconstruction on psychological morbidity after mastectomy. *Lancet* 1983; 26: 459–62.
2. Schain JWS. Breast reconstruction. Update of psychosocial and pragmatic concerns. *Cancer* 1991; 68(Suppl 5): 1170–5.
3. Wilkins EG, Cederna PS, Lowery JC et al. Prospective analysis of psychosocial outcomes in breast reconstruction: one-year postoperative results from the Michigan Breast Reconstruction Outcome Study. *Plast Reconstr Surg* 2000; 106: 1014–25.
4. Mock V. Body image in women for breast cancer. *Nurs Res* 1993; 42: 153–7.
5. Schover LR. The impact of breast cancer on sexuality, body image and intimate relationships. *Cancer* 1991; 41: 112–20.
6. Cancer Relief Macmillan Fund. *Breast Cancer. How to Help Yourself*. Cancer Relief Macmillan Fund, 1994
7. Van der Molen B. Relating information needs to the cancer experience: 2. Themes from six cancer narratives. *Eur J Cancer Care* 2000; 9: 48–54.
8. Reaby LL. Breast restoration decision making: enhancing the process. *Cancer Nurs* 1998; 21: 196–204.
9. Ferrario R. After mastectomy: breast reconstruction. The nurse's counselling role. *Eur J Cancer* 1998; 34: 27.
10. Lenz ER. Information seeking: a component of client decisions and health behaviour. *Adv Nurs Sci* 1984; 6: 59–72.
11. Morris J, Royale G. Offering patients a choice of surgery for early breast cancer: a reduction in anxiety and depression in patients and their husbands. *Soc Sci Med* 1988; 27: 1257–62.
12. Sutherland HJ, Llewellyn-Thomas HA, Lockwood GA et al. Cancer patients: their desire for information and participation in treatment decisions. *J R Soc Med* 1989; 82: 260–3.

13. Al-Ghazal SK, Sully L, Fallowfield L et al. The psychological impact of immediate rather than delayed breast reconstruction. *Eur J Surg Oncol* 2000; 26: 17–19.
14. Anderson SG, Rodin J, Ariyan S. Treatment considerations in postmastectomy reconstruction: their relative importance and relationship to patient satisfaction. *Ann Plast Surg* 1994; 33: 263–70.
15. Berger K, Bostwick J III. *A Woman's Decision. Breast Care, Treatment, and Reconstruction*. St Louis, Missouri: Quality Medical Publishing, Inc. 1994.
16. Constant CME, van Wersch AMEA, Wigges T et al. Motivations, satisfaction and information of immediate breast reconstruction following mastectomy. *Patient Educ Couns* 2000; 40: 201–8.
17. Neill KM, Armstrong N, Burnett CB. Choosing reconstruction after mastectomy: a qualitative analysis. *Oncol Nurs Forum* 1998; 25: 743–50.
18. Reaby LL. Reasons why women who have mastectomy decide to have or not to have breast reconstruction. *Plast Reconstr Surg* 1998; 101: 1810–18.
19. Reaby LL, Hort LK, Vandervord J. Body image, self-concept and self-esteem in women who had a mastectomy and either wore an external breast prosthesis or had breast reconstruction and women who had not experienced mastectomy. *Health Care Women Int* 1994; 15: 361–75.
20. Hartmann LC, Schaid DJ, Woods JE et al. Efficacy of bilateral prophylactic mastectomy in women with a family history of breast cancer. *N Engl J Med* 1999; 340: 77–84.
21. Bebbington Hatcher M, Fallowfield L, A'Hern R. The psychological impact of bilateral prophylactic mastectomy: prospective study using questionnaires and semistructured interviews. *BMJ* 2001; 322: 1–6.
22. Frost MH, Schaid DJ, Selles TA et al. Long-term satisfaction and psychological and social function following bilateral prophylactic mastectomy. *JAMA* 2000; 284: 319–24.
23. Caroll S. Role of the breast care Clinical Nurse Specialist in facilitating decision-making for treatment choice: a practice profile. *Eur J Oncol Nurs* 1998; 2: 34–42.

20 Breast reconstruction following mastectomy: patients' expectations

Guidubaldo Querci della Rovere

Introduction

The expectations of patients undergoing immediate breast reconstruction may be different from those undergoing a delayed procedure. Although the desire for an acceptable cosmetic result is the same for both groups of women, the former may have greater emotional and psychological requirements induced by the simultaneous need to cope with the loss of her breast, to come to terms with the diagnosis of breast cancer and its implications, and to deal with multiple treatment modalities. On the other hand, the latter is more likely to have overcome the acute phase of anxiety caused by the fear of death from breast cancer, has completed the treatment phase which can last more than 6 months, has commonly recovered from the unpleasantness of side effects and may have resumed a more normal lifestyle. Recovering to this extent may result in many women choosing not to have delayed reconstruction because they do not want to become 'patients' again or undergo surgery which may result in more pain, anxiety and possible complications; they may have adjusted to their breast loss and simply prefer to get on with their lives. The women seeking a delayed breast reconstruction are in my experience more complex, as they form a selected group determined to risk further surgery for the benefit of an improved cosmetic result without which life could be unbearable. Furthermore, sometimes the surgical aspects of a delayed reconstruction are more difficult than an immediate one, which has the advantage of the availability of more and better quality skin. These considerations can explain why sometimes satisfaction with the outcome of delayed reconstruction is lessened. This is also the reason why, whenever feasible and acceptable to the patient, I prefer to do an immediate breast reconstruction.

Expectations also vary from patient to patient and it is imperative that surgeons understand this fact and adapt their clinical and technical expertise to the patient's needs and not vice versa – 'adapting the patient to their preferred surgical procedure'.

On the one hand, for the woman who wants a reconstruction solely to avoid the need for an external prosthesis and who wants a quick recovery with minimal chance of complications, the use of a tissue expander represents the best option, provided a reasonable symmetry of the two breasts can be achieved. On the other hand, for the woman who wants a nearly perfect result with a soft feeling breast, ideally without the use of implants and without the risk of capsule formation or of an abdominal hernia, the technique of a free TRAM flap, in spite of the possible complications, may be appropriately recommended.

Expectations: the reasons

The expectations of women undergoing breast reconstruction are closely related to the reasons why the patient chooses to have the cosmetic procedure. The reasons can be described as practical and emotional.

Practical reasons

The two most commonly cited practical reasons are:

- *To avoid the use of an external prosthesis.* For the majority of patients, particularly young women and those who lead a fairly active life and/or take part in sporting activities the use of

an external prosthesis is very inconvenient. The external prosthesis may feel less secure and somewhat limits the choice of clothing that can be worn. This expectation is usually met by breast reconstruction as equality of volume is usually achievable and there is no need for an external prosthesis.

- *To avoid changes in sexual relations.* It is obviously every patient's desire that the result of the treatment of her breast cancer does not change her sexual life. This is a very delicate subject for the patient to discuss with a male surgeon and the subject may be more easily approached by a female breast care nurse specialist, who can then liaise with the surgeon. Although this is a practical expectation, its achievement depends not only on the final cosmetic result but also on the emotional status of the patient herself and her partner. Sometimes the opinion and advice of a professional psychologist can be very useful.

Emotional reasons

The most frequent emotional reasons cited by women having a breast reconstruction are:

- to feel feminine
- to remain sexually attractive
- to have more confidence
- to feel oneself again.

Although apparently different, these expectations are all part of the deeply rooted biological, emotional and cultural need of a gender identity which is threatened by the mutilation of a mastectomy and which reconstructive surgery is trying to re-establish. In my experience this objective is achieved by breast reconstruction to various degrees in the majority of cases. One should not forget, however, that progress in this field is a slow and gradual one. The patient will need considerable support not only from the medical and nursing team but also, more importantly, from her partner and her family. It is worth remembering that whilst breast reconstruction may help restore altered body image and sexuality, it still at best only mimics the natural breast. Therefore even excellent surgical outcomes will result in scarring, and altered sensation and movement.

Expectations: the cosmetic result

Patient's expectations of the final cosmetic result depend to a great extent on their prior knowledge of breast surgery. Contrary to some years ago,

nowadays the majority of patients are more fully informed, although they may still have misperceptions derived from friends, the media and the internet.

It is essential that before the patient makes her final decision (not only about whether to have or not have a breast reconstruction) but also about which technical option to choose, she is fully informed and given plenty of time to make a decision. The breast care nurse specialist, in conjunction with the surgeon, is the ideal person to help the patient to reach a fully informed consent to the procedure of her choice. She can reiterate and expand the information provided by the surgeon and discuss aspects that the surgeon might not have covered in depth. The opportunity to see postoperative photographs and of talking to women who have had the same surgical procedure can be very useful to the patient to give her a realistic sense of what can be achieved.

The patient must be informed not only about the expected length of recovery time, possible surgical side effects and complications, but also that the final cosmetic result might take a few months to achieve and might require, even in the absence of major complications, further corrective surgical procedures. The need for these will depend on the patient's desire for 'perfection' and symmetry. The surgeon and the breast care nurse will play crucial and highly relevant roles in advising the patient what is realistically achievable – I have seen patients' quest for perfection ending in extreme disappointment.

How can the reconstructive breast surgeon meet the patient's expectations?

Obviously the better the cosmetic results the more likely that the patient's expectations are met. It is, however, imperative to be realistic with the patient regarding the outcome of breast reconstruction, reiterating that a reconstructed breast is never like having a new 'normal breast'. There are aims that can be achieved easily, others which are only achievable with more complex procedures or interventions on the contralateral breast and some which are unattainable.

Breast symmetry

Symmetry is the single most important aim in breast reconstruction. This will conceal the mutilation caused by the mastectomy and will help the patient

to return to a normal social and emotional life. Two types of equality must be considered: equality of volume and equality of shape. Nowadays the first is fairly easy to achieve with the use of permanent expanders or adjustable implants and procedures such as reduction or augmentation of the contralateral breast. The second is sometimes more difficult to achieve. For example, a tuberous type of breast is almost impossible to match in shape. Very good results can be achieved by mammoplasty, reduction or augmentation of the contralateral breast. It is my experience, however, that the majority of women prefer to avoid surgery to the contralateral breast and are content with equality of shape only that is achieved when they wear a bra. This usually allows them to show an equal cleavage even with a low neck line. The possibility to be able to show a good cleavage is so important that I prefer the use of an oblique incision for a mastectomy as this does not cut across the cleavage line. Temporary alteration of the shape of the breast can occur after reconstruction with an LD flap or with a subpectoral tissue expander. This is because the implant is squashed by the muscular contraction during certain activities. This problem can be prevented by division of the motor nerve which supplies the muscle; this however has the disadvantage of muscular atrophy. It is preferable to warn the patient about this possibility.

Skin sensation

Skin sensation is the weakest point as far as breast reconstruction is concerned. The surgeon cannot prevent the area of anaesthesia present in the LD or TRAM flap. Patients need to be warned in advance that this will be the case. For the patient having breast reconstruction with tissue expansion the initial areas of numbness will gradually improve spontaneously.

The nipple

The greatest loss for a woman undergoing mastectomy is the loss of the nipple. This is the most erogenous part of the breast and its sensory function cannot be re-created with any surgical technique. In some cases, for example women undergoing prophylactic mastectomies, the surgeon can offer a subcutaneous mastectomy with nipple preservation. This might, however, increase the risk of developing breast cancer and, if the breasts are ptotic, might require a simultaneous mastopexy, which can jeopardize the sensation and viability of the nipple. The surgeon can surgically re-create a nipple for cosmetic reasons. It is my experience, however, that most reconstructed

nipples eventually become paler and lose the projection. This is why nowadays I advise patients to use a prosthetic nipple.

Radiotherapy

Post-mastectomy radiotherapy is becoming more frequent after two randomized controlled trials showed a survival benefit in premenopausal women with node positive breast cancer.^{1,2} The current guidelines in the USA are to use post-mastectomy radiotherapy in women with T3 tumours or with four or more positive axillary lymph nodes.³ Previous studies have shown that tissue expansion is not the procedure of choice either pre or post-radiotherapy. Better cosmetic results are obtained with myocutaneous flaps. Some surgeons are quite happy to use radiotherapy after breast reconstruction with a myocutaneous flap, others are reluctant. I am not aware of any randomized study comparing breast reconstruction before or after radiotherapy and therefore I am not sure what is the best practice. My personal experience with post-reconstruction radiotherapy is a bit disappointing. At present, if I know in advance that the patient will need radiotherapy I prefer her to have it prior to the mastectomy and reconstruction. Although there is a higher risk of postoperative breast skin flap necrosis, there is the advantage of preoperative assessment of the effect of radiotherapy on the skin of the breast. The surgeon can then decide whether to go ahead with the reconstruction and choose the most appropriate technique or to delay it.

Scarring

Some women falsely believe that plastic surgery means a scarless result though this is far from the truth despite good placement of incisions and accuracy of skin suturing. Patients must therefore be adequately informed and forewarned.

Complications

Complications are not amongst patients' expectations or in the surgeon's interests. However, like scarring, we know they can occur. Their incidence varies according to the magnitude of the surgical procedure and the experience of the surgeon. Patients must be adequately informed about this possibility and information must be properly recorded in the medical records. Minor complications can delay recovery or require further treatment and can be the cause of severe frustration for the patient and her family. The occurrence of a complete failure, like total flap necrosis or the need to remove a silicone implant due to

infection are uncommon. However, when this happens, it has a devastating effect on the patient and her expectations are temporarily destroyed and only restored after a few months when a new procedure can be carried out.

Conclusions

Patients' needs and expectations can be very different; surgeons must therefore take this into consideration and adapt their surgical techniques to patients' requirements. Knowledge and correct information are the foundations for informed consent to a specific surgical procedure. Patients' expectations depend on it and are met by taking an honest and realistic approach of what can be achieved by a surgical reconstructive technique and by adapting the surgeon's repertoire to the individual patient's

needs. Very often a patient is satisfied more by good information and counselling than by an excellent technical result.

Further reading

1. Ragaz J, Jackson SM, Le Nhu et al. Adjuvant radiotherapy and chemotherapy in node positive premenopausal women with breast cancer. *N Engl J Med* 1997; 337: 956–62.
2. Overgaard M, Hansen PS, Overgaard J et al. Postoperative radiotherapy in high risk premenopausal women with breast cancer who receive adjuvant chemotherapy. *N Engl J Med* 1997; 337: 949–55.
3. Recht A, Edge SB, Robinson LJ et al. Postmastectomy radiotherapy: clinical practice guidelines of the American Society of Clinical Oncology. *J Clin Oncol* 2001; 19: 1539–69.

Appendix: Types of prosthesis

Arikoge J Ogedegbe, Delilah Hassanally

Introduction

The two major companies involved in the manufacture of silicone implants for breast reconstruction are Mentor Corporation (Santa Barbara, CA, USA) and McGhan Medical Corporation (Santa Barbara, CA, USA). The range of products available includes simple round implants, contour profile implants and a variety of temporary and permanent tissue expanders of different shapes and sizes. The most important recent advance is the development of textured-coated contour or anatomically shaped permanent expanders, which have the flexibility to modify prosthesis shape and size postoperatively via their integrated ports. These are either incorporated within the dome of the prosthesis or attached separately by a plastic tube.

For simplicity, products will be discussed under the broad subheading of 'the manufacture', and important advantages and disadvantages will be highlighted.

Mentor implants

Silicone low bleed gel filled mammary implant (slightly cohesive; not liquid gel)

Textured (Siltex) round gel

These are round, available in 'moderate', 'moderate plus' or 'high' profile depending on the desired projection and vary in transverse diameter. They are of no fixed volume. They have the advantage of being relatively simple to use, and require no complicated calculations preoperatively. The textured implants are associated with a low incidence of capsule formation. An obvious disadvantage is the inability to

adjust implant size postoperatively. Sizes (volume) range from 100 ml to 800 ml.

Smooth round gel

These implants are not textured; they are round and available in various profiles (projection). There is a direct relationship between the implant's transverse diameter and projection. They are straightforward to use but more likely to undergo capsule formation when compared with the textured implants. Sizes range from 100 ml to 800 ml.

Round cohesive gel

These are round implants with a moderate, moderate plus or high profile in projection and are available in various transverse diameters. They are textured implants ranging from 100 ml to 800 ml. This level of gel cohesion minimizes leakage.

Contour profile gel (cohesive)

The contour implant is a 'tear-drop' shape (as opposed to round), to provide a more anatomical and natural appearance. Implants are textured and filled with cohesive silicone gel. They are characterized in three dimensions (width, height and projection) and tend to be of moderate-high profile. The volume ranges from 120 ml to 775 ml. This gel allows shape retention but provides a soft, natural feel.

Saline implants

Smooth round implants

These are round implants with smooth exteriors, available in various projections and sizes. The volumes range from 150 ml to 775 ml. These

implants are inflated with saline at the time of surgery and are suitable for cosmetic augmentation. They are easy to insert, and do not require a subsequent procedure for port removal. The major disadvantage is the inability to adjust implant size postoperatively.

Siltex round implants

These are round in shape and have a textured silicone shell and an inner chamber filled with saline. Sizes range from 150 ml to 525 ml. The projection is comparable to that of other implants. They are suitable for patients who prefer to avoid silicone gel. Saline implants are not as 'natural feeling' as the silicone implants and tend to be associated with rippling; these are not adjustable postoperatively.

Adjustable saline implants

Smooth spectrum implants

These are saline filled, round implants without texturing and have detachable ports. There is one basic model with a minimum fill and a maximum fill with the latter providing a greater projection compared with the former. The sizes available range from 125 ml to 575 ml. With the maximum fill an extra 25–115 ml can be added to the recommended device volume to increase the projection (range 150 ml–690 ml.)

The major advantage of these spectrum devices over the fixed volume, round implants is the ability to adjust size postoperatively. This is, however, associated with the need for port removal. The round spectrum implants are not shaped and may produce an inferior cosmetic result compared with the contour profile spectrum implants, which are shaped. The absence of texturing may increase the risk of capsule formation. However, these implants are appropriate for women who express concern about the silicone content of their prostheses.

Siltex spectrum implants

These are similar to the smooth spectrum implants except for the textured shell. Advantages and disadvantages are similar to the smooth spectrum implants except for the reduced risk of capsule formation.

Contour profile spectrum implant (adjustable sizes)

This prosthesis has a detachable port in addition to the other features of the contour profile implant described above. It is available in one form with a minimum fill and maximum fill, depending on the desired projection. The advantage of this over the

non-spectrum saline implants is the ability to adjust projection, shape and size by altering the volume of saline in the implant. The volume ranges from 275 ml to 650 ml for minimum fill and 330 ml to 780 ml for the maximum fill.

Tissue expanders

Siltex Becker expander/mammary implant

These are biluminal devices and are of two types: the Siltex Becker 25 (25% silicone gel in outer lumen, 75% saline in inner lumen) and the Siltex Becker 50 (50% silicone gel in outer lumen, 50% saline inner lumen). All Becker implants have detachable remote ports which contain a diaphragm to prevent inadvertent puncture and pneumothorax.

Becker 25: is available in different sizes from 150 ml to 800 ml with a broad range of projections. The advantages of these implants include texturing to reduce capsule formation and a detachable port, which provides flexibility to adjust size postoperatively. A wide variety of sizes are available but a disadvantage is the need for a second operation to remove the port. This can be performed under local anaesthesia.

Becker 50: the ratio of saline to gel is 50:50. Advantages of this implant are similar to the Becker 25 but with the additional benefit of improved inferior projection and ptosis in a proportion of women. Women with very small breasts will not benefit from this implant, as the smallest device available is 300 ml. The projection ranges from 3 cm to 5 cm. Like the Becker 25 an additional procedure is required to remove the port.

Temporary expanders without silicone gel

The Contour profile tissue expanders are designed to provide the desired shape and projection. These are manufactured with an integral port to enable easy inflation of the expander.

Round tissue expanders with detachable ports are used to create the appropriate pocket size to accommodate simple implants for patients having two-stage procedures, especially when subpectoral reconstruction is indicated. These expanders are smooth or textured, round or shaped and usually saline filled.

McGhan implants

The McGhan system includes a variety of expanders and permanent breast implants. These implants are

'biodimensional' and offer a comprehensive range of shapes and sizes to meet virtually all patients' needs. The 'biocell' texture promotes mild tissue adherence that maintains implant position and reduces the risk of capsule formation. The implants incorporate soft cohesive silicone gel for shape control and an 'Intrashiel' shell designed to minimize silicone gel diffusion. There are three main types of McGhan implants:

- Saline filled, silicone shell implants
- Silicone gel filled implants
- Silicone gel with adjustable saline filled inner chamber.

Textured silicone gel filled implants (Styles 110 and 120)

These are round silicone gel filled implants, available in either moderate profile (Style 110) or high profile (Style 120) projection. The high profile is available in larger sizes (range 180 g–650 g) compared with the lower profile devices (90 g–510 g). Appropriate calculations are required before use, as these implants have no injection ports for size adjustment. The textured shell is associated with a lower risk of capsule formation, and these implants are associated with fewer complications in general.

Textured silicone shell saline filled implants (Style 168)

These round implants are saline filled, with a silicone shell, and are similar to Styles 110 and 120. They are available in moderate profile only, and have an anterior diaphragm valve for filling before use. They are available in a range of base diameters, and volumes range from 120 ml to 540 ml. Style 168 is useful for patients who will not accept silicone gel implants. Though the textured shell reduces capsule formation, the saline content may not feel as soft and natural as the silicone implants.

Smooth surface silicone gel filled implants (Styles 40 and 45)

These are manufactured in two separate styles, standard profile (Style 40) and high profile (Style 45), both of which are round silicone gel filled implants with a smooth non-textured outer shell. A range of sizes is available (measured in grams), depending on the base diameter and desired projection. Style 40 ranges from 140 g to 360 g, and Style 45 ranges from 120 g to 400 g. These implants may be associated with increased risk of capsule formation due to the absence of texturing, but they are straightforward to use and no

complex measurements are required pre-operatively.

Biodimensional (Style 468)

The McGhan Style 468 breast implants are anatomically designed to achieve a more natural appearance. They are saline filled with a silicone shell and are suited especially for women who prefer not to have silicone gel. The shell is textured to minimize capsule formation and displacement. This style is available in a range of height, width and projection to suit most women with small to moderate sized breasts.

A relative disadvantage of this implant is the requirement for precise and accurate measurements preoperatively; with specific implant sizes for each patient. The size range available is 195 ml–650 ml.

Cohesive gel filled implants (Style 410 and Style 410 soft touch)

The Style 410 implants are cohesive gel filled anatomical implants, manufactured with a textured silicone shell and anatomical shape. A newly developed 'Soft touch' gel offers a softer feeling implant. Implants are produced in a range of sizes, which vary in width, height and projection. An additional range (Style 410XP), has been recently introduced which provide extra projection. The implants are categorized in terms of height and projection (low, moderate, full and extra full, for both parameters). The following combinations are available for height and projection:

Style 410 LL: low height, low projection, 135–300 g

Style 410 LM: low height, moderate projection, 140–320 g

Style 410 LF: low height, full projection, 125–595 g

Style 410 LX: low height, extra full projection

Style 410 ML: moderate height, low projection, 140–320 g

Style 410 MM: moderate height, moderate projection, 160–450 g

Style 410 MF: moderate height, full projection, 140–600 g

Style 410 MX: medium height, extra full projection

Style 410 FL: full height, low projection, 140–320 g

Style 410 FM: full height, moderate projection, 155 g–670 g

Style 410 FF: full height, full projection, 160 g–740 g

Style 410 FX: full height, full projection

Table 1 summarizes the range of McGhan Style 410, Style 410 soft touch, and Style 410XP breast implants. A disadvantage of Style 410 implants is the inability to alter size postoperatively and therefore accurate measurements are mandatory before selection of implants.

Table 1 Available range of McGhan cohesive gel filled implants

Height	Projection			
	Low (L)	Moderate (M)	Full (F)	Extrafull (X)
Full (F)	FL	FM	FF	FX
Moderate (M)	ML	MM	MF	MX
Low (L)	LL	LM	LF	LX

Permanent adjustable implants (Style 150)

This prosthesis features a textured silicone shell together with an inner lumen, which is saline filled and a silicone gel outer lumen. It is manufactured with two height options (full and short) to suit a range of breast sizes. Volumes range from 230 ml to 760 ml for full height and from 135 ml to 655 ml for short height. The textured surface reduces capsule formation and the design of this implant aims to maintain its position and improve infra-mammary fold definition. The connectors between the port and implant are integrated within the prosthesis. The Style 150 implant eliminates the need for additional surgery to remove the injection port. Style 150 has a uniquely controlled expansion of the lower pole and better approximates the natural contour of the breast. The injection port has a titanium needle guard to prevent puncture through the injection site base.

Both the short and full height Style 150 implants require accurate measurements before surgery to ensure optimum cosmetic outcome. Size templates for the Style 150 are also available. The adjustable saline filled inner lumen is approximately half the total implant size.

Expanders (Style 133)

This expander is for two-stage reconstruction. It comes in three basic configurations of full (FV), moderate (MV) and low (LV) heights with variable projection. It is textured with a variety of base widths and heights and in particular has an integrated injection port within the dome of the expander. This device has a magna finder (magnetic locating device) to locate the port site accurately and prevent puncture of the expander while injecting. The volume range is:

FV: 300 ml–850 ml

MV: 250 ml–700 ml

LV: 150 ml–500 ml

Saline filled implants (Style 363)

This is an anatomically shaped saline filled implant, with measurements similar to Style 133 described above. It is designed to fit the exact pocket created by the corresponding base width McGhan Style 133 tissue expander. The silicone shell is textured to reduce the risk of capsule formation and promotes full dimensions with greater emphasis on the lower pole (designed to be slightly shorter than it is wide). They range in size from 230 ml to 685 ml. Saline filled implants may not feel as smooth and natural as the silicone ones.

CUI 'DRIE' brand implants**Silicone gel filled (MLP high and low profile)**

This is a Microcell textured, surface cohesive silicone gel filled implant. It is essentially a round silicone implant available in different sizes (110 g–505 g), to suit women with small breasts. The main advantage is that the texturing minimizes capsule formation by disturbing the linearization of fibrotic collagen. This style of implant incorporates a 'diffusion rate inhibiting envelope' (DRIE) as a barrier shell to reduce silicone diffusion. The sizes available range from 100–525 g with variable diameter and projection.

Silicone gel filled (SLD low profile and SHD high profile)

These are silicone filled implants, which are round with a smooth surface, and the advantage of incorporated DRIE, which reduces silicone diffusion. The size range is (i) low profile 110 g–800 g and (ii) high profile 100 g–500 g. These implants vary in diameter and projection and have similar properties to the Style 40 and Style 45 McGhan implants.

Saline-filled (CUI Microcell RTT and RTV style implants)

The Microcell RTT implants are textured surface, saline filled implants manufactured to minimize shell crease fold failure. This is made possible by

the technology of room temperature vulcanization (RTV) of the shell. The texturing reduces capsule formation. These are round implants with a variety of base dimensions and projections, and a volume range of 90 ml–510 ml. The implant has an anterior diaphragm valve for saline filling. The principle advantage of these implants is reduced crumpling of the envelope due to the RTV of the shell.

The RTV implant is the smooth surface version,

saline filled with anterior diaphragm valve. It is similar to the RTT except for the ‘smooth’ outer shell. This implant also possesses the room temperature vulcanized outer shell similar to the RTT style but the absence of texturing may be associated with a higher risk of capsular formation.

Saline implants in general should not be under-filled in order to avoid problems with crease fold failure.

Index

- abdominal free flaps 97–8
 - advantages 90
 - anatomy 90
 - autologous breast reconstruction 89–94
 - blood supply
 - epigastric vessels 89, 90
 - microvascular reconstruction 91, 94
 - perforators 90, 92, 93
 - categories 89–90
 - contraindications 90–1
 - nerve supply 93
 - preparation, importance of 94
 - revascularization 91
 - risks 89, 91
 - selection/planning 90–1
 - technique
 - anastomosis 92, 93, 94
 - haemostasis 94
 - perichondria, dissection of 92
 - unilateral vs bilateral flaps 92
 - vascular anatomy 91
- abdominal surgery, previous 169
- abdominal wall herniation 86–7
 - with pedicled TRAM flaps 97
- abdominal wall integrity/weakness
 - with free TRAM flaps 92
 - with pedicled TRAM flaps 79, 80, 97
- abdominoplasty, cosmetic 91
- acupuncture 158
- adjuvant therapies
 - and postoperative complications 52
 - and reconstruction 164, 169
 - contraindications to 169
 - delayed 46
 - see also* chemotherapy; radiotherapy
- age
 - and psychological issues 138, 177, 178
 - and reconstruction 184
 - as contraindication 163
 - options 177
- allergy 166
- alloplastic implants 8
 - preformed sponge 8–9
- alloplastic injections 8
 - illicit 55
- amitriptyline 156, 157
- anaesthesia
 - local 157
 - for TRAM flaps 94
- analgesics for CPSP 155, 156
- anatomical landmarks 37–9
- anatomical shaped implants 11, 46
- antibiotics, prophylactic
 - implant-based reconstruction 51
 - in LD flap reconstruction 66
 - in TRAM flaps, pedicled 87
- anticonvulsants 155, 156
- antidepressants 155, 156
- arm pendularity 142, 146
- autoimmune disease 166
- autologous tissue transplantation 8, 89
 - abdominal free flaps 89–94
 - and contralateral breast modification 116, 132
 - vascular supply 166
- back pain, chronic 169
- Baker classification 11
- base width of breast 34
 - assessment after mastectomy 39, 40
 - contralateral 44, 46
- Becker permanent expanders 34–5, 192
 - in LD flap reconstruction 72
- Biocell implant texturing 193
- biodimensional implants 193
- biological predetermination 1
- biomechanical interactions/sequelae
 - LD flap surgery 143–4
 - mastectomy
 - hip/pelvis 141–2
 - muscle synergy 142–3
 - postural changes 142–3
 - shoulder region 141
 - spine 141–2
 - psychological aspects 146–7
 - and reconstruction 141–9
 - and surgical technique selection 147
- TRAM flap surgery
 - hip/pelvis 145–6
 - muscle synergy 146
 - postural changes 146
 - shoulder region 144–5
 - spine 145

- body image and breast surgery 137, 138, 140, 181, 183
 - factors influencing 138
 - loss of nipple 138–9
 - reconstruction, reasons for 188
- brachial plexus blocks 156–7
- BRCA gene carriers 138
- breast augmentation 55
 - of contralateral breast 95
 - history of materials 8
 - after quadrantectomy 109
- breast cancer
 - clinical behaviour/pathobiology 1
 - presentation in augmented patients 55
 - symptomatic, management of 2
- breast care nurse specialists 178
 - on breast reconstruction 181–6
 - topics covered 184
 - personal experience in reconstruction 185
 - role of 181–2, 188
- breast conservation *see* conservative surgery
- breast preserving surgery *see* conservative surgery
- breast prostheses/implants 33, 35
 - biocompatibility 7
 - biodimensional 33, 35, 193
 - orientation 43
 - in subcutaneous mastectomy 113
 - contraindications 37
 - encapsulation 7, 11
 - evolution 34–6
 - external prostheses 182
 - history/development 7–19, 55–6
 - in LD flap reconstruction 65, 66
 - materials
 - development 8
 - suitability 7
 - orientation 43
 - permanent
 - insertion 47–9
 - timing of placement 56
 - rigid vs mobile 7
 - in subcutaneous mastectomy 113
 - submuscular vs subglandular placement 56
 - tissue tolerance 7
 - type/size selection 40, 44, 46, 58
 - see also specific implant types*
- breast surgeons *see* surgeons, specialist
- cancer detection worries 139
- capsaicin, topical 157
- capsular contracture 11–13, 55
 - after implant-based reconstruction 52
 - and implant placement 13, 166
 - and implant surface 12–13
 - after LD flap reconstruction 63, 72, 167
 - multifactorial causes 55
 - in partial reconstructions with small implants 109
 - and radiotherapy/chemotherapy 165
- capsule formation 11–13
- capsulotomies 47, 52
- carcinogenicity
 - implant materials 9
 - polyurethane coated implants 12
- cardiovascular status and free tissue transfer 91
- chemotherapy 165–6
 - postoperative complications 52
 - preoperative (neoadjuvant) 36
 - and reconstruction 35, 164, 169
- chest pain associated with silicone implants 155
- choice
 - of surgeon 3
 - of treatment
 - patient's 137, 174, 177–8
 - surgeon's 33, 56–7
- chronic postsurgical pain (CPSP) 151–61
 - aetiology/pathophysiology 151–5
 - causes 153
 - immediate vs delayed reconstruction 155
 - incidence 151
 - management/treatment 155–7
 - perioperative analgesia techniques 155–7
 - pharmacological 155
 - other modalities 157–8
 - mechanisms 155
 - pre-existing pain 151, 153
 - studies 152
 - trapezius spasm 154
- circumlinear incisions 102
- Clinical Nurse Specialist *see* breast care nurse specialists
- closed capsulotomy 11, 12
- codeine 156
- cohesive gel implants
 - anatomical 11, 191, 193–4
 - dimensions of 35–6
 - round 191
- collagen 12–13
- comma technique 117–19
 - advantages 117
 - areolar fixation, temporary 118
 - postoperative appearance 119
 - skin/glandular tissue incisions 118
- complications
 - information/preparation of patients 189–90
 - see also specific techniques*
- consent, written 176
- conservative surgery
 - breast reconstruction after 101–10, 129–30
 - choice of 177–8
 - criteria 101–2
 - extent of resection 2
 - glandular tissue deficits after 102
 - improved body image 137
 - incisions 129
 - skin incisions, choice of 102
 - submuscular vs subglandular implant 56
 - survival 1
- consultation with patient 174–5

- contour profile implants 191, 192
- contralateral breast
- assessment 44
 - modification 45, 47, 115–25, 130
 - commentary 132–3
 - after conservative surgery 102
 - implant placement 132
 - incisions matching treated side 117
 - with LD flap reconstruction 63
 - multiple reconstructions 132
 - oncological considerations 116–17
 - patient positioning 125
 - pre/postoperative views 126
 - procedures 116
 - size 95
 - skin marking 117, 125
 - timing 95, 115, 125
 - tissue expansion 115
- Cooper's ligaments 38
- cosmetic considerations
- vs oncological surgery principles 1
 - see also* plastic surgery
- cosmetic effects, explaining 139
- COX-2 inhibitors 156
- CPSP *see* chronic postsurgical pain
- cultural influences 1–2
- reconstruction 173
- curved incisions 102
- Dacron fixation patches 11
- de-epithelialization
- in free tissue transfer 91
 - in nipple positioning 116, 117
 - in round block technique 107
 - in subcutaneous mastectomy 113
 - in superior pedicled mastopexy 120
 - in TRAM flaps, pedicled 79, 86
- decision-making, shared 174–5, 178–9
- and breast care nurses 182, 183–4
 - family intervention 178–9
 - psychological issues 179
- deep inferior epigastric perforator flaps *see* DIEP flaps
- deep inferior epigastric vessels 90
- deformity after wide excision 101
- derma-fat-fascia grafts 8
- detection rates 164
- dextran filled implants 12
- dextropropoxyphene 156
- di-isocyanate polyether (Etheron) implants 8
- DIEP flaps 98
- advantages/disadvantages 98
 - revascularized 91
- diffusion rate inhibiting envelope (DRIE) 195
- donor site
- closure 97
 - necrosis 87
 - scarring 95
 - see also under specific technique*
- Doppler ultrasound *see* ultrasound, Doppler
- Dow Corning
- Centre for Aid to Medical Research 10
 - medical grade silicone 10
 - Sialastic S9711 9
- drains, surgical
- insertion
 - in LD flap reconstruction 66
 - in reconstruction 42–3, 48
 - in subcutaneous mastectomy 113
 - in TRAM flaps, pedicled 80
 - removal 51
- Dupuytren's disease 12
- EMLA local anaesthetic cream 157
- encapsulation 7, 11
- epidurals 156–7
- epigastric vessels 89, 90
- Etheron sponge implants 8
- excision patterns for conservative surgery 103–5
- exercise, post-reconstruction 51
- expanders *see* tissue expander devices
- explantation 14
- external prostheses 182, 183
- avoidance 187–8
- family
- and breast care nurses 181, 182
 - and decision-making 178–9, 182, 183, 184
 - support from 184
- fear and decision-making 178
- financial aspects
- immediate reconstruction 37
 - of TRAM flaps, pedicled 37
- flap loss/failure
- information/preparation of patients 178, 189
 - partial 96–7
 - total 97
- flap necrosis 72
- latissimus dorsi flaps 167
 - with radiotherapy 189
 - and smoking 168
 - TRAM flaps, pedicled 87
- flaps
- commentary 95–8
 - and radiotherapy 57
 - see also specific techniques*
- fluid balance in free tissue transfer 91
- free flaps
- advantages 89, 90
 - failure rates 89, 97
 - postoperative management 97
 - technique 92–4
 - see also* abdominal free flaps; TRAM flaps, free
- free TRAM flaps *see* TRAM flaps, free
- gabapentin 156, 157
- gait changes after surgery 142, 146, 147, 148
- glandular breast tissue mobilization 102, 103

- glass ball implants 8
- Grisotti advancement rotation flaps 105
 - postoperative views 106
 - skin marking 105
 - skin viability 105
 - undermining of glandular tissue 106
- haematoma 87, 96
- haemodynamics in TRAM flap surgery 94
- hamstrings, biomechanics of 146, 148
- height of breast 34
 - assessment after mastectomy 39
 - contralateral 44, 46
- hip region, biomechanics of 142, 146, 147, 148
- hospital admission 51, 58
 - free tissue transfer 94
- human adjuvant disease 14, 15
- hydrocephalus shunts 10
- hydrocodeine 156
- hydrogel filled implants 11
- iatrogenic pain 153
- implants
 - contraindications to 165–6
 - information to patients 139
 - rupture
 - diagnosis 13, 14
 - and povidone iodine immersion 58
 - see also specific types*
- implant-based reconstruction 33–53, 57–8
 - aims 33
 - aseptic technique 42, 58
 - breast size 166
 - challenges 33
 - complications 51, 165
 - after conservative surgery 129–30
 - contraindications/indications 36–7, 57
 - and contralateral adjustment 126
 - delayed 37
 - choice of surgical technique 33
 - muscle coverage 56
 - patient positioning 44
 - planning 44–5
 - pre/postoperative views 44
 - skin incision 45
 - subpectoral pocket preparation 45
 - surgical steps 45–6
 - immediate 36–7
 - muscle coverage 56
 - patient positioning 40
 - patient selection 34
 - planning 40
 - postoperative views 44
 - surgical steps 41–3
 - tissue expanders vs permanent implants 56
 - important factors 46
 - information to patients 139–40
 - long-term effects 139–40
 - after mastectomy
 - postoperative management 51–2
 - stage 1 (tissue expansion) 39–46
 - chest wall preparation 39
 - planning 39–40
 - stage 2 (after expansion) 46–51
 - drain insertion 48
 - expander removal 47
 - planning 47
 - prosthesis insertion 47, 48
 - skin incision 47, 50
 - submuscular pocket preparation 47
 - wound closure 48–9
 - proportional measurements 34
 - shape/contour, recent focus on 35
 - subpectoral implants vs tissue expanders 56, 57
 - three-dimensional 36
 - implant-related pain 153
 - infection
 - and chronic pain 151
 - implant-based reconstruction
 - intraoperative 12
 - postoperative 52
 - and total muscle coverage of implant 131
 - TRAM flap reconstruction 87, 96
 - inferior pedicle breast reduction 103, 122–5
 - breast reconstruction 124
 - dermal bridge creation 122
 - dissection 123
 - postoperative views 125
 - skin incisions, choice of 123
 - skin marking 122
 - inflatable implants, permanent 51, 57–8
 - Simaplast 11, 12
 - see also tissue expander devices*
 - inflation
 - of permanent prosthesis 51
 - of tissue expander 43
 - information to patients 139, 163, 175, 178
 - from breast care nurses
 - process 182–3
 - topics covered 184
 - on risk 178
 - skin-sparing/-reducing surgery 57
 - informed choice 174
 - inframammary distance 34
 - inframammary fold
 - assessment after mastectomy 40
 - composition 38, 39
 - creation
 - after tissue expansion 48
 - after TRAM flap surgery 79
 - postoperative management 51
 - preservation for reconstruction 37, 39
 - in implant-based reconstruction 58
 - in LD flap reconstruction 65, 95–6
 - in subcutaneous mastectomy 112
 - and total muscle coverage of implant 131
 - inframammary skin crease 33
 - intercostobrachial nerve 154

- intercostobrachial neuralgia 151–2
 internal mammary artery 41
 internal mammary perforators, anastomosis of 92, 93
 interrupted incisions 102
 Intrashiel implant shell 193
 ‘inverted T’ technique 119
 Ivalon sponge implants 8, 9
 carcinogenicity 9
- lateral protrusion of breast 34
 latissimus dorsi (LD) flaps 63–75, 95–6
 advantages 72–3, 89
 axillary disease, patients without 66–7
 biomechanical sequelae 143–4, 147
 breast reconstruction 66–7
 completed operation 72
 breast size 167
 complications 72
 contraindications 65, 167–8
 delayed 67
 pre/postoperative views 74, 75
 demonstration, step-by-step 67–72
 flap fixation 70, 71
 flap harvesting 67–9
 implant insertion 72
 pouch creation 69
 thoracodorsal pedicle 70
 donor site/skin island 64
 harvesting 65
 marking 63
 position 63–4, 65
 scarring 63
 size 65, 96
 flap harvesting 66
 functional deficits following 64, 166, 168
 immediate 65–7
 postoperative views 73, 74–5
 mastectomy 65–6
 incision 64, 65
 patient positioning 65–6, 67
 patient selection 63, 95
 planning 63
 with prosthesis 63
 radiotherapy 167
 skin marking 65
 skin-sparing/skin-reducing 95
 with tissue expansion 95
 vascular supply 166, 167
 latissimus dorsi (LD) muscle
 anatomy 64–5
 blood supply 63, 65
 dissection/mobilization 67–9
 folding to provide bulk 66
 functional status, testing 65
 nerve supply 65
 leisure activities and implant surgery 166
 latissimus dorsi flaps 168
 ‘linguine’ sign 13
 LipoMatrix implants 13
- local anaesthetic cream 157
 local pedicled fat flaps 8
 lymphoedema treatment 158
- magnetic resonance imaging (MRI) 13
 malposition of implants 72
 mammary fascia 38, 39
 mammography 13
 mammoplasty
 augmentative 125
 comma-shaped 117–19
 reduction 103, 117
 management
 breast cancer 2
 options, discussion of 3, 139–40
 pain 155–8
 postoperative
 free tissue transfer 94, 97
 implant-based reconstruction 51–2, 58
 mastectomy
 biomechanical sequelae 141–3
 contralateral breast modification 125
 men’s understanding of 176
 prophylactic 131, 138
 bilateral 183
 psychological issues 137, 138, 140
 radical 21
 and reconstruction
 choice of 177–8
 eligibility 33
 skin-sparing/skin-reducing 21–31, 40, 56–7
 complications 166
 in LD flap reconstruction 65
 patient selection 56–7
 subcutaneous *see* subcutaneous mastectomy
 survival 1
 women’s reactions to 175, 181
 mastopexy
 comma-shaped 117–19, 132–3
 alternative approaches 132
 areolar fixation, temporary 118
 postoperative appearance 119
 skin/glandular tissue incisions 118
 contralateral breast 125
 for contralateral nipple positioning 117
 for ptosis 95
 superior pedicle *see* superior pedicle breast
 reduction
- McGhan implants
 CUI ‘DRIE’ brand implants 194–5
 saline filled implants 194, 195
 silicone gel filled implants 193–4
 tissue expander devices 194
 measurements of breasts *see* proportional
 measurements
 media influences 1–2
 medial fullness of breast 34
 medical illness 163–4
 Mème implants 11

- Mentor implants
 - saline implants 192
 - silicone low bleed gel filled
 - smooth 191
 - textured 191–2
 - tissue expander devices 192–3
- mesh, synthetic 80, 87
- Microcell implant texturing 194, 195
- microvascular reconstruction
 - in free tissue transfer 91
 - planning 92
 - staff competence 89, 91
- microvessel disease 169
- mini latissimus dorsi (LD) flaps 109
- MLP implants 194
- monitoring by specialist nurses 181
- moratorium on gel filled implants 11, 14
- multidisciplinary approach
 - to pain management 155–7
 - to planning/surgery 2, 21, 33
- muscle-sparing TRAM flaps *see* TRAM flaps, muscle-sparing
- muscle synergy 142–3, 146, 147

- Natural Y implants 11, 12
- nerve damage with free TRAM flaps 93
- neuralgias 151–3
 - intercostobrachial 151–2
- neuropathic pain 153
 - management/treatment 155
- NHSBSP (NHS Breast Screening Programme) 2
- nipple–areola complex
 - adjustment to loss 138–9
 - and contralateral breast modification 125
 - excision 103, 105
 - grafting 131
 - preservation 112
 - reconstruction 115, 126–8, 132–3
 - colour matching 126, 133
 - flap types available 126, 133
 - inner thigh grafts 126, 133
 - methods 126
 - postoperative views 128
 - skate flap technique 126–7, 133
 - skin flap ‘wrapping’ 127
 - skin marking/incision 127
 - star flaps 126, 133
 - timing 132
 - removal 37, 40
 - in subcutaneous mastectomy 113
 - vascular supply 112
- nipple–areola pedicles 103
- nipple preservation 113
- nipple reconstruction 115, 132–3
 - patient expectation/realistic outcome 189
 - postoperative views 51
- nociceptive pain 155
- non-steroidal anti-inflammatory drugs 156
- numbness 189

- nurse specialists *see* breast care nurse specialists

- obesity 164, 168
- occupations and implant surgery 166
 - latissimus dorsi flaps 168
- omental flaps 109
- omentum 8
- oncological factors in choice of surgery 56–7
- oncological surgery vs cosmetic considerations 1, 2–3
- oncoplastic surgery 56
- opioids 156
- ‘Oppenheimer effect’ 9

- pain
 - back, chronic 169
 - chest 155
 - iatrogenic 153
 - implant-related 153
 - infection-related 151
 - management 155–8
 - neuropathic 153, 155
 - nociceptive 155
 - postoperative
 - chronic *see* chronic postsurgical pain
 - implant-based reconstruction 51
 - information to patients 139
 - and radiotherapy/chemotherapy 165
 - psychological factors causing 153
 - tumour involvement related 153
- pain relief ladder 154, 155
- para-umbilical perforators
 - in free flap harvesting 90
 - in TRAM flaps, pedicled 78
- paracetamol 156
- paraffin injections 8
- paravertebral blocks 156–7
- partial breast reconstruction *see* reconstruction, partial
- paternalism 174
- pathobiology of breast cancer 1
- patient expectations 139, 173–4, 182
 - and aims of surgeon 188–90
 - cosmetic results 188
 - information from nurse specialists 140, 185
 - reconstruction after mastectomy 187–90
 - reasons for choosing 187–8
 - technique, choice of 188
- patient selection
 - abdominal free flaps 91, 97
 - mini LD flaps 109
 - reconstruction 95, 163
 - immediate 34
 - implant-based 56–7
 - psychological issues 165
 - skin-sparing/-reducing surgery 56–7
 - subcutaneous mastectomy 111
 - TRAM flaps 168
- pectoralis muscles 39
 - major

- assessment after mastectomy 40
- attachments, dissection of 41, 42, 46
- and reconstruction 37, 39
 - delayed 44, 45, 46
 - immediate 41–2, 43
- minor 37
- pelvis, biomechanics of 141–2, 145–6, 148
- perforators
 - in free flap harvesting 90, 92, 93
 - revascularized 78
 - in TRAM flaps, pedicled 78
 - ultrasound detection 90
- perichondria, dissection of 92
- Pers and Bretteville-Jensen technique 112–14
- physiotherapy for CPSP 157
- plastic surgeons
 - in breast conserving therapy 130
 - lack of 2
 - oncological training 3
 - vs oncologists 3
 - and prophylactic/subcutaneous mastectomy 131
- plastic surgery
 - cosmetic considerations 1
 - techniques for tumour removal 102
 - vs oncological surgery 2–3
 - see also* oncoplastic surgery
- polydimethylsiloxanes (PDMS) *see* silicone
- polyester implants *see* polyurethane/polyester implants
- polyethylene (Polystan) implants 8
 - carcinogenicity 9
- Polystan sponge implants 8
 - carcinogenicity 9
- polyurethane coated implants 11, 12
- polyurethane/polyester implants 8
- polyvinyl alcohol (Ivalon) implants 8
 - carcinogenicity 9
- postoperative management *see under* management
- postoperative views
 - delayed reconstruction 49–51
 - with contralateral adjustment 126
 - Grisotti flaps 106
 - immediate reconstruction 44
 - inferior pedicle breast reduction 125
 - LD flap reconstruction
 - delayed 74, 75
 - immediate 73, 74–5
 - with/without bra 74–5
 - nipple reconstruction 51, 128
 - superior pedicled breast reduction 122
 - after tissue expansion 50
 - tissue expansion/contralateral adjustment 126
 - TRAM flap/contralateral adjustment 126
 - TRAM flaps, pedicled
 - bilateral 85–6
 - bipedicled 85
 - delayed 84
 - early appearance 83
 - monopedicled ipsilateral 84
 - postural changes after surgery 142–3, 146, 147
 - pre/postoperative views
 - delayed reconstruction 49–51
 - with contralateral adjustment 126
 - LD flap reconstruction 74, 75
 - TRAM flaps, pedicled 84–6
- pregnancy 169
- pressure sores 52
- primary surgery *see* oncological surgery
- projection of breast
 - achievement of 33, 34
 - contralateral 46
- prophylactic mastectomy 131
 - bilateral 183
 - psychological issues 138
- proportional measurements 34
- psoas major, biomechanics of 146, 148
- psychological approaches to CPSP 157
- psychological aspects/issues
 - adjustment to surgery/reconstruction 138
 - of biomechanical changes 146–7
 - and breast care nurses 182
 - in breast reconstruction 137–40, 173
 - choice of treatment 137, 177
 - conservative surgery 101
 - decision-making 178–9
 - immediate reconstruction 36
 - mastectomy vs lumpectomy 137–8
 - patient profiling 178
 - preparation for 139, 140
 - prophylactic mastectomy 138
 - reconstruction 138
 - threat to life 137
- psychological factors
 - causing pain 153
 - contraindications to reconstruction 165
- psychological palliation 163, 164
- psychosocial aspects of reconstruction 139
- ptosis of breast
 - achievement of 33, 34
 - and delayed reconstruction 44
 - and LD flap reconstruction 63
 - mastopexy for 95
 - reproduction of 111–12
 - and subcutaneous mastectomy 130
 - and tissue expansion 56
- pulmonary embolism 97
- quadrantectomy 102, 107
 - breast augmentation after 109
- quality of life 164
- radial incisions 102
- radiation-induced brachial plexopathy (RIBP) 158
- radiotherapy
 - adjuvant local control 2
 - and breast contraction 115
 - and capsular contracture 165–6
 - contraindication to surgery 165–6

- radiotherapy (*cont.*)
- and contralateral breast modification 125
 - and free tissue transfer 91
 - and implant-based reconstruction 57
 - and LD flap reconstruction 66, 95
 - post-mastectomy 2–3
 - and reconstruction options 21
 - post-reconstruction 36, 125, 189
 - postoperative complications 52
 - and reconstruction 164, 169
 - and remodelling 109
 - and skin-sparing/-reducing surgery 56, 57
- reconstruction 58, 179, 184
- and adjuvant therapies 164
 - and biomechanics 141–9
 - clinical management 139–40
 - after conservative surgery 101–10, 129–30
 - local vs distant flaps 129
 - contraindications 163–72
 - abdominal surgery, previous 169
 - adjuvant therapy 169
 - age 163
 - back pain, chronic 169
 - cost 170
 - to implants 165–6
 - to LD flaps 167–8
 - medical illness 163–4
 - microvessel disease 169
 - obesity 168–9
 - pregnancy 169
 - psychological factors 165
 - radiotherapy 165–6
 - stage of disease 164–5
 - to tissue expander devices 165–6
 - to TRAM flaps 168–70
 - cultural influences 173
 - as evolutionary process 183
 - immediate 21
 - vs delayed 2, 177, 182, 187
 - psychological issues 138
 - and LD flap reconstruction 167
 - with myocutaneous flaps
 - biomechanical aspects 141–9
 - see also specific techniques*
 - operating times 163
 - partial 102–5, 109
 - patient selection 163
 - and post-mastectomy radiotherapy 2–3
 - prediction of final size/shape 115
 - as psychological palliation 163, 164
 - psychosocial aspects 139
 - reasons for choosing
 - emotional 188
 - practical 187–8
 - reasons for declining 178
 - vs external prostheses 183
 - woman's point of view
 - female specialist nurse's experience 181–6
 - male surgeon's experience 173–80
 - women's opinions of 185
 - see also specific types and techniques*
- rectus abdominis flap reconstruction 63
- rectus abdominis muscles
- anatomy 77
 - blood supply 77, 81, 89
 - testing 79
 - mobilized 82, 83
 - pedicles 77, 79
- recurrence, local, of breast cancer 1, 164
- fear of 184
 - and survival 2
- regional blockade for CPSP 156–7
- 'rock in a sock' appearance 130
- room temperature vulcanization *see* RTV
- round block technique
- nipple–areola complex mobilization 108
 - postoperative appearance 108
 - skin marking/incisions 107
 - wide excision of tumour 108
- RTT/RTV implants 195
- RTV 8, 10
- catalysts 10
 - saline filled implants 195
- saline filled implants 12
- and capsular contracture 13
 - expandable 35, 192, 194
 - McGhan 193, 194, 195
 - Mentor 192
- satisfaction surveys 176–7
- scarring 189
- seroma formation 72, 95
- and chronic pain 151
 - latissimus dorsi flaps 167
- serratus major muscle 37
- in subpectoral pocket preparation 41, 42
- sexual health and breast surgery 137, 140, 181
- reconstruction, reasons for 188
- SHD implants 195
- shoulder region, biomechanics of 141, 144–5, 147
- Sialastic 2000 9
- hydrocephalus shunts 10
- Sialastic gel filled implant G1 11
- silicon/silica/silicates 10
- silicon tissue assays 14
- silicone
- controversy 8, 14–15, 56, 139
 - exposure to 11
 - properties/uses of 9–10
 - silicon, relationship to 10
 - and wound healing 10
- silicone breast implants 7
- advantages/disadvantages 36
 - controversy over 8, 14–15, 56, 139
 - development 11–13
 - innovations/problems 11
 - double lumen 11, 12, 113
 - explantation 14

- gel filled
 - G2 low bleed 11, 12
 - G3 11
- moratorium on 11, 14
- history 9–10
- lifespan 11–14
- litigation over 14–15
- McGhan 193–4
- Mentor 191
- nature/properties of material 10–11
- nipple reconstruction 126
- placement and capsular contracture 12
- removal 190
- rupture/leakage 12, 13
 - clinical diagnosis 13
- seamless 11
- smooth walled 11, 191, 192, 195
- surface textured 11, 12, 35, 191–2
 - and capsular contracture 55–6
 - coated 36
 - integrity 13
- see also* saline filled implants
- silicone elastomer gel implants 8
- silicone injections 8
 - human adjuvant disease 14
- silicone rubber 10
- Siltex Becker expanders 34–5, 72, 192
- Siltex saline implants 192
- Siltex textured round gel implants 191
- Simaplast inflatable implants 11, 12
- skin flaps
 - and reconstruction 39
 - see also specific techniques*
- skin sensation 189
- skin-sparing/-reducing surgery
 - latissimus dorsi flaps 95
 - mastectomy 21–31, 40, 56–7, 65
 - complications 166
 - patient counselling 57
 - patient selection 56–7
 - and radiotherapy 56, 57
 - TRAM flaps, pedicled 86, 96
- SLD implants 195
- slope of breast *see* superior mammary slope
- smoking and reconstruction 164, 168–9
- smooth round implants
 - gel filled 191, 195
 - saline filled 192
- 'Soft touch' silicone gel 193
- specialist breast surgeons *see* surgeons, specialist
- spine, biomechanics of, after surgery 141–2, 145, 147, 148
- stannous octoate 10
- 'stepladder' sign 13
- subcutaneous fat grafts 8
- subcutaneous mastectomy
 - with bipedicled nipple preservation 113, 131
 - commentary 129–33
 - complications 114
 - cosmetic considerations 130
 - delayed 113
 - immediate 111
 - muscle coverage 131
 - patient selection 130
 - Pers and Bretteville-Jensen technique 112–14
 - advantages 112
 - limits of dissection 113
 - postoperative care 113
 - prosthesis placement 113
 - skin closure 113
 - skin marking 112–13
 - and reconstruction 111–14, 130–2
 - implant placement 112, 131–2
 - implant type 132
 - results 114
 - risks/indications 111
 - skin envelope reduction 111, 130–1
 - skin incisions, choice of 112, 131
- submuscular/-pectoral pocket
 - closure 43
 - creation/preparation 58
 - preparation 40–2, 46
 - in subcutaneous mastectomy 112, 113
 - surface marking by template 40, 44, 45
- subpectoral implants
 - postoperative views 44
 - reconstruction with *see* implant-based reconstruction
 - surgical steps 41–3
 - surgical technique 33
- superficial fascial system 38, 39
 - division after tissue expansion 48, 49
- superior mammary slope 33, 34
- superior pedicle breast reduction 104, 119–22
 - inferior pole amputation 121
 - inferior pole mobilization 120
 - postoperative views 122
 - retromammary dissection 120
 - skin marking/incisions 119
 - skin/tissue closure 121
- support
 - family/social 184
 - assessment of 181
 - from nurse specialists 185
- surgeons
 - attitudes/bias 175
 - involving patients 176
 - specialist 1–4
 - choice for reconstruction 3
 - neoplastic surgeons 3
 - plastic surgery 3
 - training 2, 3
 - women's opinions of 175–6, 185
 - surgery, women's opinions of 176–8
 - symmetry 188–9
 - synmastia, avoidance 34
 - synthetic mesh 80, 87
 - systemic disease 15

- teflon-coated silicone sponge implants 8, 9
- textured surface implants 11, 12, 35, 191–2
 - and capsular contracture 55–6
 - coated 36
 - integrity 13
- tissue expander devices 33
 - contraindications 165–6
 - immediate vs delayed reconstruction 37
 - indications 187
 - in LD flap reconstruction 65, 95
 - permanent 35–6, 192
 - advantages/disadvantages 36
 - insertion 46
 - port location 43
 - detachable 192–3
 - magnetic 194
 - permanent 35
 - reconstruction with *see* implant-based reconstruction
 - and subcutaneous mastectomy 131, 132
 - surgical steps of insertion 41–4
 - disinfection 42, 58
 - inflation 43
 - insertion, partially-inflated 43
 - preparation 42
 - skin incision 45
 - skin/subcutaneous tissue closure 43, 46
 - subpectoral pocket closure 43
 - subpectoral pocket preparation 41–2, 46
 - temporary 35, 192–3, 194
 - advantages/disadvantages 36
 - removal 46, 47
- tissue tolerance of rigid vs mobile implants 7
- TRAM flaps
 - biomechanical sequelae 144–6, 147–8
 - contraindications to 168–70
 - indications 187
 - patient selection 168
 - recurrence, masking of 164
 - in smokers 168–9
- TRAM flaps, free 97–8
 - advantages 97, 170
 - design/harvesting 92–3
 - disadvantages 92, 93, 97
 - donor site repair 92
 - failure rates 97
 - patient selection 97
 - postoperative management 97
 - in smokers 168
 - staff competence 97
- TRAM flaps, muscle-sparing 93
- TRAM flaps, pedicled 77–87, 96–7
 - abdominal closure 80
 - advantages 86, 89
 - bilateral 85–6
 - bipedicled 80, 83
 - blood supply 96
 - complications 86–7, 96–7
 - and contralateral adjustment 126
 - contralateral flap 78
 - delayed 79, 84, 86, 96
 - demonstration, step-by-step 80–6
 - donor site assessment/markings 80
 - flap dissection 81–3
 - flap positioning 83
 - disadvantages 89, 96
 - flaps
 - anatomy/sections 78
 - composition 77
 - design 77–8
 - dissection 79, 81–3
 - transposition/orientation 79
 - viability 79
 - ipsilateral pedicle 79, 96
 - mastectomy flap excision 79
 - monopedicled 77–80, 96
 - pedicle selection 79
 - postoperative views
 - bilateral 85–6
 - bipedicled 85
 - delayed 84
 - early appearance 83
 - monopedicled ipsilateral 84
 - preoperative views 84–6
 - skin-sparing 86, 96
 - and surgical competence 89
 - synthetic mesh, use of 80, 87
 - after tissue expansion failure 84, 86
 - tunnel creation 81
 - umbilicus mobilization 82
 - see also* rectus abdominis muscles
- tramadol 156
- transcutaneous electrical nervous stimulation (TENS) 158
- transexuals, breast augmentation in 55
- transverse rectus abdominis myocutaneous (TRAM) flaps *see* TRAM flaps
- trilucent lipid filled implants 11, 13
 - toxicity/recall 13
- tumour involvement related pain 153
- tumour removal
 - excision patterns for conservative surgery 103–5
 - in inferior portion of breast 125
 - using plastic surgery techniques 102
- tumour size 2
- ultrasound
 - Doppler
 - abdominal wall assessment 93
 - muscle testing 65
 - in TRAM flap positioning 78, 96
 - implant rupture diagnosis 13, 14
 - perforator detection 90
- umbilicus 80, 82
- uncertainty 175
- vascular insufficiency 130–1
- venous thrombosis 97

-
- vulcanization
 - heat 10
 - RTV 8, 10
 - WHO's pain relief ladder 154, 155
 - wide excision
 - deformity after 101
 - at lower pole of breast 119
 - in lower quadrants 122
 - mobilization of glandular tissue after 102, 103
 - of tumours above nipple 122
 - women's view of reconstruction
 - female specialist nurse's experience 181–6
 - male surgeon's experience 173–80