

# Nursing Care of the Pediatric Neurosurgery Patient

Third Edition

Cathy C. Cartwright  
Donna C. Wallace  
*Editors*

 Springer

---

# Nursing Care of the Pediatric Neurosurgery Patient

---

Cathy C. Cartwright • Donna C. Wallace  
Editors

# Nursing Care of the Pediatric Neurosurgery Patient

Third Edition

 Springer

*Editors*

Cathy C. Cartwright  
Childrens Mercy Hospital  
Kansas City  
Missouri  
USA

Donna C. Wallace  
Division of Pediatric Neurosurgery  
Banner Children Specialists at Cardon  
Children's Medical Center  
Mesa  
Arizona  
USA

ISBN 978-3-319-49318-3      ISBN 978-3-319-49319-0 (eBook)  
DOI 10.1007/978-3-319-49319-0

Library of Congress Control Number: 2017938118

© Springer International Publishing AG 2017

© Springer-Verlag Berlin Heidelberg 2007, 2013

This work is subject to copyright. All rights are reserved by the Publisher, whether the whole or part of the material is concerned, specifically the rights of translation, reprinting, reuse of illustrations, recitation, broadcasting, reproduction on microfilms or in any other physical way, and transmission or information storage and retrieval, electronic adaptation, computer software, or by similar or dissimilar methodology now known or hereafter developed.

The use of general descriptive names, registered names, trademarks, service marks, etc. in this publication does not imply, even in the absence of a specific statement, that such names are exempt from the relevant protective laws and regulations and therefore free for general use.

The publisher, the authors and the editors are safe to assume that the advice and information in this book are believed to be true and accurate at the date of publication. Neither the publisher nor the authors or the editors give a warranty, express or implied, with respect to the material contained herein or for any errors or omissions that may have been made. The publisher remains neutral with regard to jurisdictional claims in published maps and institutional affiliations.

Printed on acid-free paper

This Springer imprint is published by Springer Nature

The registered company is Springer International Publishing AG

The registered company address is: Gewerbestrasse 11, 6330 Cham, Switzerland



---

## Foreword

Caring for the pediatric patient requires nurses who understand the specific challenges and possess specialized knowledge. A solid knowledge base of not only disease states but also developmental milestones is critical in the delivery of care to these young patients and their families. With contributors from across the USA and Canada, Cathy C. Cartwright and Donna Wallace have once again provided us their expertise in this latest edition of the textbook *Nursing Care of the Pediatric Neurosurgery Patient*.

In addition to the 12 chapters in the previous edition that covered assessment, development anomalies, injury, and disease entities, the editors have added four new chapters: “Neuroimaging,” “Skull Anomalies,” “Abusive Head Trauma,” and lastly “Pediatric Athletic Concussion” which has become a hot topic in recent years. The authors and editors have captured the complexity of pediatric patient care and added excellent figures and case studies to create a text that meets the needs of not only nurses but all healthcare providers.

As a neuroscience clinical nurse specialist, mother, and now grandmother, I have thumbed and pored over my previous edition of this invaluable book often, and it made a significant contribution to shaping my knowledge. I know this new edition will add even more, and I hope that every neuroscience nurse will have their own copy and use it as often as I have done to reference pediatric care wherever it is needed.

AANN Past President

Linda R. Littlejohns, MSN, RN, CNRN, SCRNP, FAAN  
San Juan Capistrano, California

---

## Preface

We are so pleased that Springer requested a third edition of “the book”! With improvements in each successive edition, we have tried to remain true to our original intent: to provide a reference for nurses who care for children with neurosurgical conditions. Thus, we are also pleased that it will be available online to nurses worldwide.

This edition has been expanded to include four new chapters. Common and unusual lumps and bumps found on the head are discussed in the chapter on skull and scalp anomalies. The increasing concern over abusive head trauma and pediatric athletic concussion warrants that those topics have their own separate chapters. And a basic knowledge of neuroimaging is key in helping the nurse understand their patient’s condition and can be instrumental when explaining that condition to parents.

None of this would be possible without the fine work of the authors who have taken the time to share their expertise. Many thanks to them for their contributions – some participating for the second or third time and some for the first. As always, we thank the families who have allowed us to be part of their lives during the times when they are most vulnerable. It is our hope that neurosurgery nurses use this book as a resource as they support these families on their journey.

Kansas City, MO, USA  
Mesa, AZ, USA  
2017

Cathy C. Cartwright  
Donna C. Wallace

---

## Acknowledgments

I wish to acknowledge the American Association of Neuroscience Nurses (AANN) for providing opportunities for my professional development and Linda Littlejohns for her support throughout my neuroscience career. Especially Zach for his editorial efforts and being my partner in all things.

Cathy C. Cartwright

I wish to acknowledge and offer gratitude and thanks to family and friends who are ever supportive of this project. This book could not have been possible without the encouragement of neuroscience nursing colleagues and mentors, those bright people that I wanted to be like early in my career, those who said the right thing when it needed to be said, and those who always believed in me when the road became bumpy.

Donna C. Wallace

---

# Contents

<b>1</b>	<b>Neurological Assessment of the Neonate, Infant, Child, and Adolescent</b> . . . . .	1
	Jennifer A. Disabato and Dee A. Daniels	
<b>2</b>	<b>Hydrocephalus</b> . . . . .	39
	Nadine Nielsen and Amanda Breedt	
<b>3</b>	<b>Craniosynostosis and Plagiocephaly</b> . . . . .	91
	Cathy C. Cartwright and Patricia D. Chibbaro	
<b>4</b>	<b>Skull and Scalp Anomalies</b> . . . . .	133
	Donna C. Wallace and Lindsey N. Weak	
<b>5</b>	<b>Neural Tube Defects</b> . . . . .	151
	Mary L. Dexter and Teresa Schultz	
<b>6</b>	<b>Chiari Malformation and Syringomyelia</b> . . . . .	177
	Ambre' L. Pownall	
<b>7</b>	<b>Tumors of the Central Nervous System</b> . . . . .	195
	Stephanie Smith	
<b>8</b>	<b>Traumatic Brain Injury</b> . . . . .	255
	Angela Hoersting and Jodi E. Mullen	
<b>9</b>	<b>Pediatric Athletic Concussion</b> . . . . .	317
	Jill Kouts and Tanya Filardi	
<b>10</b>	<b>Abusive Head Trauma</b> . . . . .	335
	Jodi E. Mullen	
<b>11</b>	<b>Spine</b> . . . . .	351
	Anne Stuedemann and Valorie Thomas	
<b>12</b>	<b>Neurovascular Disease</b> . . . . .	395
	Theresa M. Gabay and Davonna Ledet	
<b>13</b>	<b>Surgical Management of Epilepsy</b> . . . . .	457
	Patti L. Batchelder	
<b>14</b>	<b>Surgical Management of Functional Disorders</b> . . . . .	493
	Herta Yu	

---

<b>15 Infections of the Central Nervous System</b> . . . . .	515
Gina Weddle	
<b>16 Perioperative Care</b> . . . . .	529
Sarah M. Lagergren and Gail C. Dustman	
<b>17 Transition from Pediatric to Adult Care</b> . . . . .	555
Theresa M. Gabay, Jennifer A. Disabato, and Teresa Schultz	
<b>18 Neuroimaging</b> . . . . .	573
Angela Forbes	
<b>Index</b> . . . . .	597

# Neurological Assessment of the Neonate, Infant, Child, and Adolescent

1

Jennifer A. Disabato and Dee A. Daniels

## 1.1 Introduction

### 1.1.1 Importance of Neurological Assessment

Serial, consistent, and well-documented neurological assessments are the most important aspect of nursing care for the pediatric neurosurgical patient. A bedside nurse is often the first to note a subtle change in a child's level of responsiveness, pattern of movement, or signs and symptoms of decline in neurological function. Both keen observation skills and knowledge of the patient's baseline neurological function are essential tools for the pediatric neurosurgical nurse. Rapid response and escalation of care in response to changes in assessment are necessary to prevent

secondary complications that can further impede recovery from a neurological disease or traumatic injury. Potential complications include the inability to protect the airway leading to aspiration, immobility leading to venous stasis and thrombosis, endocrine disorders related to central hormonal regulation, impaired communication, and behavioral issues, among others (Hickey 2009).

It is understood that children are not always under the care and custody of their parents. As used in this book, however, the term "parent(s)" is intended to include family members who have custody of a child, foster parents, guardians, and other primary caregivers.

### 1.1.2 Nursing Approach to the Pediatric Neurological Assessment

Neurological assessment should be an integral part of the entire physical assessment, and aspects can be integrated into the general exam of patients in both inpatient and outpatient settings. The approach to neurological assessment should be systematic and includes pertinent health history, e.g., coexisting conditions, developmental status of the child, the nature and extent of the injury or surgery performed, and potential complications (Amidei et al. 2010). Sources of this information are broad and include the verbal report provided in care transitions, the medical record, the parent

---

J.A. Disabato, DNP, CPNP-PC, AC (✉)  
Department of Child Neurology,  
Children's Hospital Colorado, Aurora, CO, USA

University of Colorado College of Nursing,  
13120 E. 19th Avenue, 4126,  
Aurora, CO 80045, USA  
e-mail: [jennifer.disabato@ucdenver.edu](mailto:jennifer.disabato@ucdenver.edu)

D.A. Daniels, MS, RN, CPNP  
Department of Pediatrics,  
Sie Center for Down Syndrome,  
Children's Hospital Colorado,  
University of Colorado School of Medicine,  
13123 East 16th Ave, B-745,  
Aurora, CO 80045, USA  
e-mail: [dee.daniels@childrenscolorado.org](mailto:dee.daniels@childrenscolorado.org)

caregiver, and the nursing and medical colleagues, including the neurosurgeon, neurologist, and other health-care providers.

Knowledge of physical and developmental disorders not directly associated with the neurological condition, such as renal, cardiac, or pulmonary status, is important to a comprehensive approach and enhancing the patient's outcome. Care planning should be a team approach that involves the parents and the multidisciplinary team to assure optimal communication of key information, and avoid unnecessary repetition of tests, or oversight of important clinical findings.

Factors that impact the nurse assessment of the child will be the age and developmental stage of the child. The history should include antenatal, perinatal, and postnatal information as well as developmental milestones (Sables-Baus and Robinson 2011). Other factors include the nature of the child's diagnosis (chronic, acute, static, progressive), the setting in which the assessment takes place (critical care unit, general care are, outpatient clinic, school nurse office), and the information available at the time of the assessment from other members of the multidisciplinary team. Family dynamics and social circumstances can also impact the nurses' approach to the assessment.

### 1.1.3 Diagnostic Imaging and Testing in Neurological Assessment

Diagnostic imaging and other laboratory and electrical testing of the nervous system play an important role in understanding the nature of neurological disorders. The brain, spinal cord, and peripheral neurological system are organs of both intricate structure and complex metabolic, vascular, and cellular function. Diagnostic tools are generally focused on one aspect of the structure or function, but several tests incorporated with a neurological assessment of the child are often the key to an accurate diagnosis and appropriate treatment. Ongoing advances in medicine, technology, and pharmacology have contributed to safer outcomes for children who may need

sedation for diagnostic imaging, and the speed of imaging has increased substantially in recent years.

Advancements in imaging techniques make it easier to consider repeat studies as treatment or recovery progresses, so that changes can be monitored through comparisons to the baseline imaging. However, the use of diagnostic testing in an era of health-care reform calls for all involved to consider the costs associated with a test and query whether the results will truly change the plan or outcome for the patient.

In general, radiographic or digital imaging (such as MRI) are tools to evaluate the structure of the brain and spinal cord, while other diagnostic tests like EEG, SPECT scanning, nuclear medicine scans, and Wada test (intracarotid sodium amobarbital procedure to lateralize language and memory) are evaluating specific functions of the brain. PET scans look at metabolic function and utilization of glucose by the brain. Some tests serve both diagnostic and therapeutic outcomes (Hedlund 2002). Magnetoencephalography (MEG) or magnetic source imaging (MSI) and functional MRIs (fMRI) are methods of localizing areas of abnormality associated with ictal (seizure) onset (Knowlton 2008). Newer technologies allow for evaluation of cerebral blood flow and brain perfusion. Three methods currently in use for monitoring cerebral ischemia include Doppler ultrasound, near-infrared spectroscopy (NIRS), and amplitude-integrated electroencephalogram (aEEG) (Greisen 2006; Iaia and Barker 2008). Table 1.1 is a listing of the most common neurological diagnostic tests and imaging modalities used in pediatrics.

---

## 1.2 Developmental Assessment: Growth and Developmental Tasks by Age

Knowledge of human growth parameters and normal developmental landmarks is critical to the assessment of each age group. The Individuals with Disabilities Education Act (IDEA) Amendments of 1997 (U.S. Department of

**Table 1.1** Neurological diagnostic and imaging modalities

Diagnostic or imaging modality	Technology utilized	Nursing and patient considerations
X-rays of the skull and vertebral column	X-rays to look at boney structures of the skull and spine, fractures, integrity of the spinal column, and the presence of calcium intracranially	Patient should be immobilized in a collar for transport if there is a question of spinal fracture
Cranial ultrasound	Doppler sound waves to image through soft tissue. In infants it can only be used if fontanel is open	No sedation or intravenous access needed. Used to follow ventricle size/bleeding in neonates/infants
Computerized tomography with/without contrast	Differentiates tissues by density relative to water with computer averaging and mathematical reconstruction of absorption coefficient measurements	Noninvasive unless contrast is used or sedation needed. Complications include reaction to contrast material or extravasation at injection site
Computerized tomography – bone windows and/or three-dimensional reconstruction	Same as above with software capabilities to subtract intracranial contents to look specifically at the bone and reconstruct the skull or vertebral column in a three-dimensional model	No changes in study for patient. Used for complex skull and vertebral anomalies to guide surgical decision-making
Cerebral angiography	Intra-arterial injection of contrast medium to visualize blood vessels; transfemoral approach most common; occasionally brachial or direct carotid is used	Done under deep sedation or anesthesia; local reaction or hematoma may occur; systemic reactions to contrast or dysrhythmias; transient ischemia or vasospasm; patient needs to lie flat after and CMS checks of extremity where injection was done are required
MRI with or without contrast (gadolinium)	Differentiates tissues by their response to radio-frequency pulses in a magnetic field; used to visualize structures near bone, infarction, demyelination, and cortical dysplasias	No radiation exposure; screened prior to study for indwelling metal, pacemakers, braces, electronic implants; sedation required for young children because of sounds and claustrophobia; contrast risks include allergic reaction and injection site extravasation
MRA MRV	Same technology as above used to study flow in vessels; radio-frequency signals emitted by moving protons can be manipulated to create the image of vascular contrast	In some cases it can replace the need for cerebral angiography; new technologies are making this less invasive study more useful in children with vascular abnormalities
Functional MRI	Technique for imaging activity of the brain using rapid scanning to detect changes in oxygen consumption of the brain; changes can reflect increased activity in certain cells	Used in patients who are potential candidates for epilepsy surgery to determine areas of cortical abnormality and their relationship to important cortex responsible for motor and speech functions
<i>Physiologic imaging techniques – nuclear medicine imaging</i>		
SPECT	Nuclear medicine study utilizing injection of isotopes and imaging of the brain to determine if there is increased activity in an area of abnormality; three-dimensional measurements of regional blood flow	Often used in epilepsy patients to diagnose areas of cerebral uptake during a seizure (ictal SPECT) or between seizures (intraictal SPECT)
SISCOM	Utilizing the technology of SPECT with MRI to look at areas of increased uptake in conjunction with MRI images of the cortex and cortical surface	No significant difference for patient; software as well as expertise of radiologist is used to evaluate study

(continued)



**Table 1.1** (continued)

Diagnostic or imaging modality	Technology utilized	Nursing and patient considerations
PET	Nuclear medicine study that assesses perfusion and level of metabolic activity of both glucose and oxygen in the brain; radiopharmaceuticals are injected for the study	Patient should avoid chemicals that depress or stimulate the CNS and alter glucose metabolism (e.g., caffeine); patient may be asked to perform certain tasks during study
<i>Electrical studies</i>		
EEG	Records gross electrical activity across surface of the brain; ambulatory EEG used may be used for 24–48 h with data downloaded after study; video combines EEG recording with simultaneous videotaping	Success of study dependent on placement and stability of electrodes and ability to keep them on in children; routine studies often miss actual seizures but background activity can be useful information
Routine		
Ambulatory		
Video		
Evoked responses	Measure electrical activity in specific sensory pathways in response to external stimuli; signal average produces waveforms that have anatomic correlates according to the latency of wave peaks	Results can vary depending on body size, age, and characteristics of stimuli; sensation for each test will be different for patient – auditory clicks (BAER), strobe light (VER), or electrical current on the skin – somatosensory (SSER)
SSER		
VER		
BAER		
MEG (magnetoencephalography) mapping	Noninvasive functional brain imaging that uses electrodes on the scalp to measure tiny changes in magnetic fields between groups of neurons and projects them onto MRI brain imaging for correlation. Used to assist in localization of seizure foci in evaluation of patients for epilepsy surgery and to determine the language dominant hemisphere	Patients will need to remove all metals prior to entry into the room. Pacemakers or vagus nerve stimulators (VNS) will cause artifact. VNS should be turned off prior to the study and any magnetic field can affect the function of the VNS
MSI (magnetic source imaging)	Using a weak magnetic field, images normal and abnormal electrical activity and produces clear images. Messages are sent to the brain via small stimulators on lips and fingers of the patient and measured and recorded as electrical activity	
aEEG (amplitude-integrated EEG)	Filtered and compressed EEG data used to evaluate long-term trends in background patterns	Used primarily in neonates to predict neurological outcome following perinatal asphyxia
<i>Cerebral perfusion studies</i>		
Near-infrared spectroscopy (NIRS)	Using light, monitors changes in cerebral tissue oxygenation through functional measurements of differential absorption of hemoglobin at multiple wave lengths	
Transcranial Doppler (TCD) ultrasound	A noninvasive method of monitoring cerebral circulation (flow velocity) over the middle, anterior and posterior cerebral, ophthalmic, and carotid arteries	Results indicating low flow velocities after head injury are consistent with low cerebral blood flow, high ICP levels, and a poor prognosis

Adapted from Iaia and Barker (2008)

*MRI* magnetic resonance imaging, *MRA* magnetic resonance angiography, *MRV* magnetic resonance venography, *SPECT* single photon emission computerized tomography, *SISCOM* subtracted ictal spectroscopy co-registered with MRI, *PET* positron emission tomography, *EEG* electroencephalogram, *SSER* somatosensory evoked potentials, *VEP* visual evoked potentials, *BAER* brainstem auditory evoked potentials, *CNS* central nervous system

Education Special Education and Rehabilitative Services 2005) mandates the “early identification of, and intervention for developmental disabilities through the development of community-based systems.” This law requires physicians to refer children with suspect developmental delays to appropriate intervention services in a timely manner. Early identification and intervention can have significant impact on later developmental outcomes (Hamilton 2006).

Development is the essential distinguishing feature of pediatric nursing. Normal development is a function of the integrity and maturation of the nervous system. Only with a working knowledge of age-related developmental standards can the examiner be sensitive to the deviations that indicate slight or early impairment of development and an abnormal neurological assessment. An abnormality in development from birth suggests an intrauterine or perinatal cause. Slowing of the rate of acquisition of skills later in infancy or childhood may imply an acquired abnormality of the nervous system or metabolic disease. A loss of skills (regression) over time strongly suggests an underlying degenerative disease of the central nervous system (Volpe 2009).

Serial measurements can indicate the normal or abnormal dynamics of the child’s growth. One key growth measurement important to the neurological assessment of the child is the head circumference. The measurement is taken around the most prominent frontal and occipital bones that which offers the maximal circumference. How rapidly the head circumference accelerates or decelerates away from the percentile curve can determine if the underlying cause of the growth change is more benign or serious. An example of a benign finding is the presence of extra-axial fluid collections of infancy, which often present with an accelerating head circumference. Generally, the infant with this finding is observed over time, but no intervention is warranted. On the other hand, an accelerating head circumference can also be a sign of increasing intracranial pressure in uncompensated hydrocephalus, which would require immediate evaluation and treatment. A child with a large head in the setting of normal development and normal neurologic exam could be explained by measuring

the parents’ head circumference, as large heads can be familial.

Voluntary motor skills generally develop in a cephalocaudal and proximodistal progression, as it parallels the process of myelination. Myelin is a phospholipid layer that surrounds the axons of many neurons, which regulate the speed of transmission. First the head, then the trunk, arms, hands, pelvis, legs, bowel, and bladder are brought under voluntary control. Early in life motor activity is largely reflexive, and generalized movements predominate. Patterns emerge from the general to the specific; for example, a newborn’s total body response to a stimulus is contrasted with the older child, who responds through simply a smile or words. So as the neuromuscular system matures, movement gradually becomes more purposeful and coordinated (Schultz and Hockenberry 2011). The sequence of development is the same for all children, but the rate of development varies from child to child.

Finally, as important to a complete neurological exam is an assessment of the child’s cognitive and emotional development. These abilities impact directly on expectations of the child’s behavioral, social, and functional capabilities. The younger the child, the more developmental history is needed from the parents. Accurate identification of the child’s mastery of cognitive and emotional developmental milestones, as it relates to chronological age, is necessary for a comprehensive neurological assessment. It is imperative to note if the child is making steady developmental progress or has experienced regression. If regression has occurred, then it is important to note the onset of regression. Documenting examples of regression and the temporal relationship to current symptoms gives further context that may influence the evaluation, diagnosis, and subsequent treatment plan. If the child had significant regression in speech at 18 months of age followed by seizure onset at 3 years of age, this knowledge may lead to further consideration of autism spectrum disorder rather than simply a seizure disorder. This history is imperative in planning a comprehensive evaluation and future treatment plan that would span many health-care disciplines.

### 1.2.1 Developmental Assessment Tools

With the diagnosis of a neurosurgical condition comes the awareness of potential or realized developmental delays. A comprehensive approach to assessment with a family history, developmental observations, comprehensive neurological assessment, and developmental screening is indicated. Selected screening tools can aid in identification of developmental disorders defined by prevalence (Rydz 2004).

Spencer and Daniels (2015) stress the importance of developmental screening with documented developmental surveillance at each encounter. An important part of this assessment is the use of parent-report developmental screening tools. Refer to Table 1.2 adapted by Spencer and Daniels (2015) from Rydz (2004) to review currently used evidence-based tools. This table is a useful reference for finding the most appropriate screening tool for identifying a developmental delay in a young child, so that referral can be made for further evaluation by a specialist, and early intervention can occur. The goal of a com-

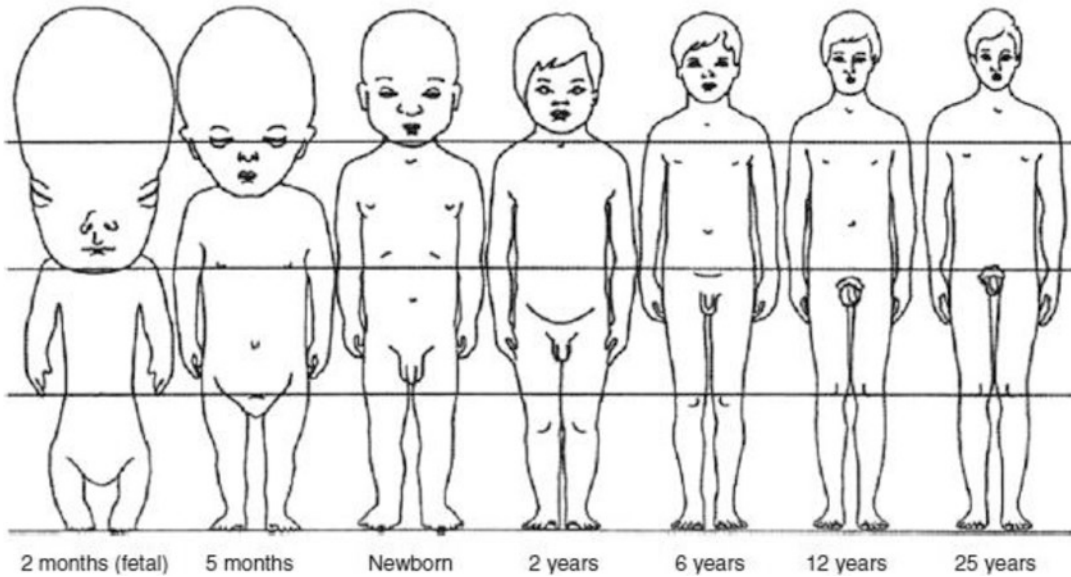
prehensive developmental approach in the hospital or outpatient setting is to determine the most appropriate developmentally based neurosurgical care for the patient. Treatment for identified needs can be better directed toward the developmental age of the child that, if different from the chronological age, will impact the assessment and patient care of the child. This developmental information can guide the nurse in planning for the child's home care, including targeted resources such as early intervention services, adapted educational plans, and rehabilitation and therapy services.

### 1.2.2 Neonate

Aside from head shape and size and assessment of fontanels, there are other aspects unique to the neurological exam of the neonate and/or infant. These are important to understanding the integrity of the nervous system early in life and are detailed in this section. The proportional changes in head and body growth from fetal life to adulthood are depicted in Fig. 1.1 (Sanrock 1998).

**Table 1.2** Comparison of commonly used parent-report developmental screening tools (Spencer and Daniels 2016)

Instrument	Age appropriate	Developmental areas screened	Sensitivity and specificity	Language availability
Ages and Stages Questionnaires (3rd Ed.) ASQ-3	3–66 months	Global communication, gross and fine motor, problem-solving, personal-social, autonomy, affect	Sensitivity 71–86% Specificity 90–98%	English Spanish
Modified Checklist for Autism in Toddlers (M-CHAT)	18–60 months	Screens for autism spectrum disorder	Sensitivity 90% Specificity 99%	English Spanish Others
Infant-Toddler Checklist for Language and Communication	6–24 months	Language, social and communication	Sensitivity 78% Specificity 84%	English Spanish Others
Parents' Evaluation of Developmental Status (PEDS)	Birth to 8 years	Global: fine motor, gross motor, self-help, expressive language, receptive language and social-emotional	Sensitivity 70–94% Specificity 77–93%	English Spanish Vietnamese Others
Parents' Evaluation of Developmental Status Developmental Milestones (PEDS:DM)	Birth to 8 years	Global: fine/gross motor, self-help, academics, expressive/receptive language, social-emotional	Sensitivity 75–87% Specificity 71–88%	English Spanish Vietnamese Others
Child Development Review: Parent Questionnaires (CDR-PQ)	18 months to kindergarten	Social, self-help, gross motor, fine motor, language	Sensitivity 88% Specificity 88%	English Spanish Vietnamese



**Fig. 1.1** Changes in proportions of the human body during growth (Santrock 1998)

### 1.2.2.1 Maternal and Pregnancy/Labor and Delivery History

An interview with the biological mother, or another familiar with the pregnancy, should include questions about any maternal illness, nutrition status, drug and/or alcohol use, chronic diseases, and any medications taken routinely, including prescription, over-the-counter, and herbal supplements. Important factors to know about the delivery include the administration of anesthesia or drugs and difficulties with the delivery like the need for forceps or vacuum devices.

Note the infant's Apgar scores. A need for supplemental oxygen, intubation/ventilation, glucose, and abnormalities of bilirubin levels is also important. A history of post-birth infections, a need for medication/oxygen, feeding difficulties, and/or seizures may also indicate underlying problems.

### 1.2.2.2 Physical Appearance

The neonatal period is defined as the first 4 weeks of life. The neonate may be term or premature, and the physical characteristics of neonates vary with their gestational age. Inspection of the shape, symmetry, and mobility of the head of the neonate is critical for evaluating cranial abnormalities or soft tissue injuries. Head circumference at term will

range from 34 to 36 cm within the 25–75% ranges. Neonates outside this range should be accurately plotted on the appropriate growth chart and serially measured (Nellhaus 1968). Further examination of the neonate's head for a patent fontanel, tautness, and approximation of cranial sutures is vital. Fontanels are best palpated when the neonate is in the upright position and not crying. The cranial sutures should be well approximated, especially the coronal, squamosal, and lambdoid sutures, and should not admit a fingertip. The sagittal suture may be wider in normal newborns, especially if the baby is premature. A soft, flat, or sunken anterior and posterior fontanel should be palpated. The posterior fontanel may be palpated up to 4 weeks of age. More detailed information and illustrations regarding cranial sutures and related abnormalities can be found in Chapter 3.

Spine assessments include evaluation for abnormal midline lumps, dimples, tufts of hair on the spine, and palpation for vertebral anomalies. Skin markings such as petechiae, hemangiomas, and hypopigmented or hyperpigmented lesions may be present at birth and indicative of neurological congenital conditions. It is important to note the size, location, and number of hypo- or hyperpigmented lesions. In addition, congenital

anomalies of the heart, lungs, and gastrointestinal tract may suggest abnormalities of brain development. However, optic or facial dysmorphisms more accurately predict a brain anomaly (American Academy of Pediatrics 1996). Some facial dysmorphisms to note include hyper- or hypotelorism, flat philtrum, thin upper lip, epicanthic folds, unequal size of the eyes, nystagmus, microphthalmia, hypoplastic face or facial droop, micrognathia, abnormal shape/size of the nose, asymmetry of smile, high-arched palate, congenital cataracts, small or simple ears, and preauricular skin tag/dimple and cleft lip/palate.

### 1.2.2.3 Functional Capabilities

Neonatal function is primarily reflex activity and necessitates the assessment of infantile automatisms, i.e., those specific reflex movements which appear in normal newborns and disappear at specific periods of time in infancy. Table 1.3 outlines the primitive reflexes in more detail (Slota 1983a). Functional examination may begin by observation of the neonate in supine and prone positions, noting spontaneous activity in each position and the presence of primitive reflexes. The posture of the neonate is one of partial flexion with diminishing flexion of the legs as the neonate ages. Observe for hypotonia, which could indicate neurologic deficit or a genetic/metabolic disorder. Look for random movements of the extremities and attempt to distinguish single myoclonic twitches, which are normal, from repetitive movement seen with seizures. Observe for symmetry of movements. Care should be taken to observe for infantile spasms characterized by atonic head drops accompanied by the arms rising upward. Some neonates have an excessive response to arousal with “jitteriness” or tremulousness. This is a low-amplitude, rapid shaking of the limbs and jaw. It may appear spontaneously and look like a seizure. However, unlike seizures, jitteriness usually follows some stimulus, can be stopped by holding the limb or jaw, and does not have associated eye movements or respiratory change. When prominent, slow, and coarse, it may be related to central nervous system stress or metabolic abnormalities, but otherwise it is often a

normal finding (Kramer et al. 1994; Shuper et al. 1991).

Strength is assessed by observing the newborn’s spontaneous and evoked movements and by eliciting specific newborn reflexes. Neonates with neuromuscular conditions may manifest with abnormally low muscle tone (hypotonia), paradoxical breathing, hip dislocation, or contractures. The neonate is capable of reacting to moving persons or objects within sight or grasp, both for large and small objects. Neonates can visually fixate on a face or light in their line of vision (American Academy of Pediatrics 1996). The quality of the cry can suggest neurological involvement. A term newborn’s cry is usually loud and vigorous. A weak or sedated neonate will cry only briefly and softly or may just whimper. A high-pitched cry is often associated with a neurological abnormality or increased intracranial pressure (Freedman et al. 2009). Functional capabilities of the preterm infant will vary by gestational age. Premature infants demonstrate less strength and decreased muscle tone compared to a term infant. Table 1.3 provides some of the key changes and the approximate time when selected milestones appear in most premature infants (McGee and Burkett 2000).

### 1.2.2.4 Vulnerabilities

The most critical need of both the term and premature neonate is for the establishment of adequate respiratory activity with appropriate oxygenation. Respiratory immaturity added to the neurological insults from seizures, congenital conditions such as spina bifida and genetically linked syndromes, as well as intraventricular hemorrhage and hydrocephalus all have the capability to severely limit the neonates’ ability to buffer these conditions. Infections, an immature immune system, and gastrointestinal deficiencies also can severely compromise the neonate’s ability to dampen the physiological effects of neurological conditions. For the preterm neonate with a neurological disorder, dampening the effects becomes even more crucial and makes the preterm infant vulnerable to multisystem failures. Developmental care teams can be mobilized to augment the neonate’s capacity for optimal growth and interaction with his or her environment.

**Table 1.3** Interpreting the neurological examination in the neonate/infant

Reflexes	Methods of testing	Responses/comments
Palmar grasp P – birth D – 3–4 months	Press index finger against palmar surface; compare grasp of both hands	Infant will grasp the finger firmly. Sucking facilitates grasp. Meaningful grasp occurs after 3 months
Plantar grasp P – birth D – 8–10 months	Press index finger to sole of the foot	Toes will flex in an attempt to grasp the finger
Acoustic – cochleopalpebral	Create loud noise	Both eyes blink. This reflex may be difficult to elicit in first few days of life
Rooting P – birth D – 3–4 months when awake D – 3–8 months when asleep	Stroke perioral skin or cheek	Mouth will open and infant will turn to stimulated side
Sucking P – birth D – 10–12 months	Touch lips of infant	Infant will suck with the lips and the tongue
Trunk incurvation (Galants) P – birth D – 2 months	Hold infant prone in one hand and stimulate one side of the back about 3 cm from midline	Trunk will curve to stimulated side
Vertical suspension positioning P – birth D – 4 months	Support baby upright with hands under axillae	Legs flex at hips and knees. Legs extend after 4 months. Scissoring of legs indicates spastic paraplegia
Placing response P – few days after birth D – 10–12 months	Hold baby upright with hands under axillae and allow dorsal surface of foot to touch undersurface of table without plantar-flexing foot	Infant will flex hip and knee and place the foot on table with stepping movement
Stepping response P – birth D – 3 months	Hold infant upright with hands under axillae and feet flat on table	Infant will pace forward alternating feet
Tonic neck reflex P – birth to 6 weeks D – 4–6 months	Turn the head to one side	Arm and leg on same side extend and others flex
Traction response	Pull infant from supine position to sitting with his hands	Shoulder muscle movement will be noted
Perez reflex P – birth D – 3 months	Hold in prone position with one hand and move the thumb from sacrum to the head	Infant will extend the head and spine, flex knees on the chest, cry, and urinate
Moro reflex P – birth D – 4–6 months	Create loud noise or sudden movement such as extension of the infant's neck	Infant stiffens, extremities extend, index finger and thumb form C shape, and fingers and toes fan

Obtained from McGee and Burkett (2000)

*P* present, *D* disappears

In the United States, all 50 states have laws that require car seats for infants and toddlers. Since the implementation of such passenger safety laws, hospitals and health-care providers have played an important role in providing awareness, education, and access to equipment (Elliott

et al. 2013; Knoeker et al. 2015). Despite this, motor vehicle accidents continue to be one of the leading causes of death for children and youth. These statistics emphasize the need to provide appropriate car safety education to caregivers during the assessment.



### 1.2.2.5 Tips in Approach to Child/Family

Observation of the neonate at rest is the first step in a comprehensive approach to neurological assessment of the neonate. Usually, the head can be inspected and palpated before awakening the neonate and measuring the head circumference. Most neonates arouse as they are unwrapped, and responses to stimuli are best assessed when the neonate is quietly awake. As the neonate arouses further, the strength of his spontaneous and active movement can be observed and cranial nerves assessed. Stimulation of selected reflexes, like the Moro reflex, and eye exam are reserved for last, since they usually elicit vigorous crying. The typical cry of an infant is usually loud and angry. Abnormal cries can be weak, shrill, high pitched, or catlike. Crying usually peaks at 6 weeks of age, when healthy infants cry up to 3 h/day, and then decreases to 1 h or less by 3 months (Freedman et al. 2009). The ability to console, including the sucking response, can be evaluated whenever the neonate is agitated. The sequence of the examination can always be altered in accordance with the newborn's state or situation. Excessive stimulation or cooling may cause apnea or bradycardia in the preterm neonate, and components of the exam may need to be postponed until the neonate is stabilized.

## 1.2.3 Infant

### 1.2.3.1 Physical Development

Infancy is defined as 30 days to 12 months of age. An infant's head grows at an average rate of 1 cm per month over the first year. Palpation of the head should reveal soft and sunken fontanels when quiet and in the upright position. A bulging fontanel in a quiet infant can be a reliable indicator of increased intracranial pressure. However, vigorous crying of an infant can cause transient bulging of the fontanel. The posterior fontanels will close by 1–2 months of age with wider variability in the anterior fontanel, often closing between 6 and 18 months of age. If the sutures close prematurely and skull shape becomes abnormal, evaluate for craniosynostosis. Delayed

closure of the sutures may indicate increased intracranial pressure or hydrocephalus, warranting further evaluation. Inspection of the scalp should include observation of the venous pattern, because increased ICP and thrombosis of the superior sagittal sinus can produce marked venous distention (Dlamini et al. 2010).

Observation of the spine should include an examination for lumps, bumps, dimples, midline hemangiomas, and tufts of the hair. Examination of rectal tone for an anal wink should be performed, especially when suspicion is present for an occult spinal dysraphism. The absence of an anal wink is noted when the anal sphincter does not contract when stimulated or there is a lack of contraction of the anal sphincter during the rectal examination. Identification of a sensory level of function in an infant with a spinal abnormality can be very difficult. If decreased movement of extremities is noted, observe the lower extremities for differences in color, temperature, or perspiration, with the area below the level of spinal abnormality usually noted to be cooler to touch and without perspiration (McGee and Burkett 2000).

### 1.2.3.2 Functional Capabilities

Assessment of the infant's function requires knowledge of normal developmental landmarks. Refer to Table 1.4.

### 1.2.3.3 Vulnerabilities

When typical ages for maturation of selected milestones are not reached and/or primitive reflexes persist beyond their expected disappearance, neurological problems may be implicated. Most primitive reflexes such as the Moro reflex have disappeared by the age of 4–6 months, with reflexes of sucking, rooting during sleep, and placing responses lingering until later in infancy. Specifically if there are persistent rigid extension or flexion of the extremities, opisthotonos positioning (hyperextension of the neck with stiffness and extended arms and legs), scissoring of the legs, persistent low tone of all or selected extremities, asymmetry of movement or reflexes, and asymmetrical head rotation to one side, these behaviors alone can suggest central nervous system disease or insult during this rapid period of growth and development (Hobdell 2001).

**Table 1.4** Age-appropriate neuro assessment table (Wallace and Disabato)

Age	Gross motor	Fine motor	Personal/social	Echoes two or more words
Newborn	Head down with ventral suspension	Hands closed	With sounds, quiets if crying; cries if quiet; startles; blinks	Crying only monotone
	Flexion posture	Cortical thumbing (CT)		
	Knees under abdomen – pelvis high			
	Head lag complete			
4 weeks	Head to one side prone			
	Lifts chin briefly (prone)	Hands closed (CT)	Indefinite stare at surroundings	Small, throaty noises
6 weeks	Rounded back sitting head up momentarily		Briefly regards toy only if brought in front of the eyes and follows only to midline	
	Almost complete head lag		Bell sound decreases activity	
2 months	In ventral suspension head up momentarily in same plane as body	Hands open 25% of time	Smiles	Social smile (first cortical input)
	Prone: pelvis high but knees no longer under the abdomen			
3 months	Ventral suspension; head in same plane as body	Hands open most of the time (75%)	Alert expression	Cooing
	Lifts head 45° (prone) on flexed forearms	Active grasp of toy	Smiles back	
	Sitting, back less rounded, head bobs forward		Vocalizes when talked to	Single vowel sounds (ah, eh, uh)
	Energetic arm movements		Follows dangled toy beyond midline	
4 months	Ventral suspension; head in same plane as body	Hands open most of the time (75%)	Follows moving person	Chuckles
	Lifts head 45° (prone) on flexed forearms	Active grasp of toy	Smiles spontaneously	
	Sitting, back less rounded, head bobs forward		Hand regard	“Talks back” if examiner nods head and talks
	Energetic arm movements		Follows dangled toy 180°	Vocalizes with two different syllables (a-a, oo-oo)
4 months	Head to 90° on extended forearms	Active play with rattles	Promptly looks at object in midline	
	Only slightly head lag at beginning of movement		Glances at toy put in hand	
	Bears weight some of time on extended legs if held standing	Crude extended reach and grasp	Body activity increased at sight of toy	Laughs out loud increasing inflection
	Rolls prone to supine	Hands together	Recognizes bottle and opens mouth for nipple (anticipates feeding with excitement)	No tongue thrust
	Downward parachute	Plays with fingers		
		Toys to the mouth when supine		

(continued)



Table 1.4 (continued)

Age	Gross motor	Fine motor	Personal/social	Echoes two or more words
6 months	Bears full weight on legs if held standing	Reaches for toy	Displeasure at removal of toy	Shy with strangers
	Sits alone with minimal support	Palmar grasp of cube	Puts toy in the mouth if sitting	Imitates cough and protrusion of the tongue
	Pivots in prone	Lifts cup by handle		Smiles at mirror image
7 months	Rolls easily both ways	Plays with toes		
	Anterior propping		Stretches arms to be taken	Murmurs "mom" especially if crying
	Bears weight on one hand prone		Keeps the mouth closed if offered more food than wants	Babbles easily (Ms, Ds, Bs, Ls)
9 months	Held standing, bounces		Smiles and pats at mirror	Lateralizes sound
	Sit on hard surface leaning on hands	Picks up small objects with index finger and thumb (pincer grasp)	Feeds cracker neatly	Listens to conversation
	Sits steadily for 15 min on hard surface		Drinks from cup with help	Shouts for attention
10 months	Reciprocally crawls			Reacts to "strangers"
	Forward parachute			
	Pulls to stand	Pokes with index finger, prefers small to large objects	Nursery games (i.e., pat-a-cake), picks up dropped bottle, waves bye-bye	Will play peekaboo and pat-a-cake to verbal command
12 months	Sits erect and steadily (indefinitely)			Says Mama, Dada appropriately, finds the hidden toy (onset of visual memory)
	Sitting to prone			
	Standing: collapses and creeps on hands and knees easily			
12 months	Prone to sitting easily			
	Cruises – laterally			
	Squats and stoops – does not recover to standing position			
12 months	Sitting: pivots to pick up object	Easy pinch grasp with the arm off the table	Finds hidden toy under cup	One other word (noun) besides Mama, Dada (e.g., hi, bye, cookie)
	Walks, hands at shoulder height	Independent release (e.g., cube into cup)	Cooperates with dressing	
	Bears weight alone easily momentarily	Shows preference for one hand	Drinks from cup with two hands	
			Marks with crayon on paper	
			Insists on feeding self	

13 months	Walks with one hand	Mouthing very little	Helps with dressing	Three words besides Mama, Dada			
				Larger receptive language than expressive			
14 months	Few steps without support	Explores objects with fingers	Offers toy to mirror image	Three to four words expressively minimum			
		Unwraps small cube	Gives toy to examiner				
		Imitates pellet bottle	Holds cup to drink, tilting the head				
			Affectionate				
		Points with index finger					
		Plays with washcloth, bathing					
		Finger feeds well but throws dishes on the floor					
		Appetite decreases					
		Should be off bottle					
		Puts toy in container if asked					
		Throws and plays ball					
		Feeds self fully leaving dishes on tray					
		15 months	Creeps up stairs		Deliberately picks up two small blocks in one hand	Uses spoon turning upside down, spills much	Four to six words
Opens small square box							
Tower of two cubes							
“Helps” turn pages of book							
Scribbles in imitation							
Completes round peg board with urging							
Kneels without support	Tower of three to four cubes			Uses spoon without rotation but still spills			
18 months	Gets to standing without support			Completes round peg board with urging			
		Stoop and recover					
		Cannot stop on round corners suddenly					
		Collapses and catches self					
		Runs stiffly					
		Rarely falls when walking					
		Walks upstairs (one hand held one step at a time)					
		Climbs easily					
Walks, pulling toy or carrying doll	Throws ball without falling	Knee flexion seen in gait	Likes to take off shoes and socks	Knows “hello” and “thank you”			
					More complex “jargon” rag		
					Attention span 1 min		
					Points to one picture		

(continued)

Table 1.4 (continued)

Age	Gross motor	Fine motor	Personal/social	Echoes two or more words
21 months	Runs well, falling some times	Tower of five to six cubes	May briefly resist bathing	Knows 15–20 words and combines 2–3 words
	Walks downstairs with one hand held, one step at a time	Opens and closes small square box	Pulls person to show something	Echoes two or more
	Kicks large ball with demonstration	Completes square peg board	Handles cup well	Knows own name
	Squats in play		Removes some clothing purposefully	Follows associate commands
	Walks upstairs alternating feet with rail held		Asks for food and drink	
			Communicates toilet needs	
			Helps with simple household tasks	
			Knows three body parts	
24 months	Rarely falls when running	Tower of six to seven cubes	Uses spoon, spilling little	Attention span 2 min
	Walks up and down stairs alone one step at a time	Turns book pages singly	Dry at night	Jargon discarded
	Kicks large ball without demonstration	Turns door knob	Puts on simple garment	Sentences of two to three words
	Claps hands	Unscrews lid	Parallel play	Knows 50 words
	Overthrow hand	Replaces all cubes in small box	Assists bathing	Can follow two-step commands
		Holds glass securely with one hand	Likes to wash and dry hands	Refers to self by name
			Plays with food + body parts	Understands and asks for “more”
			Tower of 8	Asks for food by name
			Helps put things away	Inappropriately uses personal pronouns (e.g., me want)
				Identifies three pictures
3–5 years	Pedals tricycle	Copies circles	Group play	Uses three-word sentences
	Walks upstairs alternating feet	Uses overhand throw	Can take turns	
5–12 years	Tiptoe jump with both feet			
	Activities of daily living	Printing and cursive writing	Group sports	Reads and understands content
				Spells words

Wallace and Disabato (2014)

### 1.2.3.4 Tips in Approach to Child/ Family

A comprehensive review of the infant's developmental milestones, activity level, and personality is critical when obtaining a history from the parent. Pictures of the infant at birth, home videos, and baby book recordings may trigger additional input to supplement the history. Approach to the physical exam in early infancy (before infant sits alone at 4–6 months) differs from the older infant. During early infancy, they can be placed on the examining table assessing for positioning abilities in prone and supine. Reflexes can be elicited as extremities are examined. The onset of stranger anxiety at 6–8 months of age presents new challenges and can result in clinging and crying behaviors for the infant. Reducing separations from the parent by completing most of the exam on the parent's lap can diminish these responses. This is a time to gain cooperation with distraction, bright objects, smiling faces, and soft voices (Schultz and Hockenberry 2011). The use of picture books between infant and parent can provide an environment to demonstrate language abilities. The assessment should proceed from the least to the most painful or intrusive to maximize the infant's cooperation and is often performed in a toe-to-head fashion. Evaluation of muscle strength, tone, and cerebellar function should precede the cranial nerve examination with palpation, auscultation, and measurement of the head reserved for last.

## 1.2.4 Toddler

### 1.2.4.1 Physical Development

During the toddler years of ages 1–3, brain growth continues at a more gradual rate. Head growth measurements for boys average 2.5 cm and girls slightly less with a 2-cm increase. From ages 24 to 36 months, boys and girls both slow to only 1 cm per year. The toddler's head size is only one-quarter the total body length. The toddler walks with a wide-based gait at first, knees bent as feet strike the floor flat. After several months of practice, the center of gravity shifts back and trunk stability increases, while the knees extend

and the arms swing at the sides for balance. Improvements in balance and agility emerge with mastery of skills such as running and stair climbing. Inspection of the toddler head and spine is aimed at recognition of subtle neurological abnormalities like new-onset torticollis, abnormal gait patterns, and loss of previously achieved milestones. Cortical development is 75% complete by the age of 2 years; therefore, the neurological response of the child over 2 years old is similar to that of the adult. Most toddlers are walking by the first year, though some do not walk until 15 months. Assessment of language close to the age of 3 is the first true opportunity for a cognitive assessment.

### 1.2.4.2 Vulnerabilities

Greater mobility of the toddler gives them access to more and more objects, and, as exploration increases, this makes them more at risk for injury. Physical limits on their explorations become less effective; words become increasingly important for behavior control as well as cognition. Delayed language acquisition can be identified at this age and may represent developmental issues previously unrecognized. If language delay is suspected, then a referral to speech therapy for a formal evaluation should be initiated by 9–15 months of age.

### 1.2.4.3 Tips in Approach to Child/ Family

The neurological exam is approached systematically beginning with an assessment of mental/emotional status and following with evaluation of cranial nerves and motor and sensory responses and reflexes. Much of the neurologic examination can be completed by careful observation before ever laying hands on the child. Watch as the child plays and interacts with his environment. Interactive games such as peekaboo, reaching for toys, and turning to the sound of the bell can make the examination fun and less traumatic. The toddler may interact better on the parent's lap or floor of the exam room. Initially, minimal physical contact is urged. Later inspection of the body areas through play with "counting toes" and "tickling fingers" can enhance the outcomes of

the exam. Exam equipment should be introduced slowly and inspection of equipment permitted. Auscultate and palpate the head when quiet. Traumatic procedures such as head measurements should be performed last. Critical portions of the exam may require patient cooperation, and consideration should be given to completing those components first (e.g., walking and stooping abilities).

## 1.2.5 Preschooler

### 1.2.5.1 Physical Development

This period is defined as ages 3–5 years. Visual acuity reaches 20/30 by age 3 and 20/20 by age 4. Handedness is usually established after age 3. If handedness is noted much earlier, spasticity or hemiparesis should be suspected. Note if the child is left-handed and if there is familial history of left-handedness. Bowel and bladder control emerge during this period. Daytime bladder control typically precedes bowel control, and girls precede boys. Bed-wetting is normal up to age 4 years in girls and 5 years in boys (American Academy of Pediatrics 2011). Although the brain reaches 75% of its adult size by the age of 2 years, cortical development is not complete until the age of 4 years.

### 1.2.5.2 Vulnerabilities

Highly active children face increased risks of injury. Helmet and bike safety programs are essential ingredients to reducing such risks. Given the escalating language abilities of the preschooler, speech and language delays can be detected with a greater assurance than in the toddler period. Persistent bowel or bladder incontinence may indicate a neurogenic bladder that can be a sign of spine anomalies such as a tethered cord.

Preschoolers can control very little of their environment. When they lose their internal controls, tantrums result. Tantrums normally peak in prevalence between 2 and 4 years of age. Tantrums that last more than 15 min, or if they are regularly occurring more than three times a day, may reflect underlying medical, emotional, or social problems as well as expressive language delay.

### 1.2.5.3 Tips in Approach to Child/Family

To maximize the preschooler's cooperation during the neurological assessment, many approaches can be offered. The presence of a reassuring parent can be more comforting to a preschooler than words. The older preschooler may be willing to stand or sit on the exam table, while the younger preschooler may be content to remain in the parent's lap. If the preschooler is cooperative, the exam can proceed from the head to toe; if uncooperative, the approach should be as for the toddler exam. Equipment can be offered for inspection and a brief demonstration of its use. Fabricating a story about components of the assessment, such as "I'm checking the color of your eyes," or making games out of selected portions, can maximize the child's cooperation. Using positive statements that expect cooperation can also be helpful (e.g., "I know you can open your mouth" or "Show me your pretty teeth").

## 1.2.6 School-Age Child

### 1.2.6.1 Physical Appearance

This is the phase of the middle childhood years aged 5–12. The head grows only 2–3 cm throughout the entire phase. This is a reflection of slower brain growth with myelination complete by 7 years of age (Amidei et al. 2010). Muscular strength, coordination, and endurance progressively increase throughout this growth period. School children's skills at performing physical challenges like dribbling soccer balls and playing a musical instrument become more refined with age and practice. School-aged children are able to take care of their own immediate needs and are generally proficient in the activities of daily living. Motor skills are continuing to be refined. Children at this age participate in extra-curricular and competitive activities outside of school in arenas such as academic clubs, sports, art, and music, and a history of socialization should be obtained. Their world is expanding, and accomplishments progress at an individual pace.

School makes increasing cognitive demands. Mastery of the elementary curriculum requires that a large number of perceptual, cognitive, and language processes work efficiently. By third grade, children need to be able to sustain attention through a 45-min period. The goal of reading becomes not only sounding out the words but also understanding the content, and the goal of writing is no longer spelling but composition. By the third or fourth grade, the curriculum requires that children use these fundamentals to learn increasingly complex materials. If this critical leap in educational capabilities is not made, then what appear as subtle deficits in academic performance in third or fourth grade can translate into insurmountable academic challenges in grades 5 and 6. Recognition and early intervention can minimize deficits and increase self-esteem.

### 1.2.6.2 Vulnerabilities

The most significant vulnerabilities of children this age are to injury. They are now mobile, in neighborhoods, playing without constant supervision. Children with physical disabilities may face special stresses because of their visible differences. However, children with silent handicaps (e.g., traumatic brain injury, seizure disorders, hearing deficit) may experience acute and daily stressors, leading to difficulties in peer relationships and school performance.

The safety of children in playgrounds is a complex interaction between the height, structure, and surface of the playground equipment (Howard 2010). Safety on the playground must not only take into account playground equipment and design but also consider that children's behaviors are often the cause of accidents. Of particular concern is the number of arm fractures related to playground equipment like monkey bars that require a combination of upper body strength and coordination. Careful design of play equipment and the environment can change behavior and thereby reduce the rate of injuries. Current research shows that reducing the height of playground equipment below 1.5 m (4.9 ft) can reduce the risk of injury (Wakes and Beukes 2012).

### 1.2.6.3 Tips in Approach to Child/Family

For the neurological exam of school-age children, they usually prefer sitting and are cooperative in most positions. Most children this age still prefer a parent's presence. The assessment usually can proceed in a head-to-toe direction. Explaining the purpose of the equipment and significance of the procedure, such as the fundoscopic exam, can further reduce anxiety and maximize consistent findings. The use of stories to prepare them for parts of the exam or a procedure increases their awareness of what to expect and is also helpful in decreasing anxiety.

## 1.2.7 Adolescent

### 1.2.7.1 Physical Development

Adolescence is generally considered the time when children undergo rapid changes in body size, shape, physiology, and psychological and social functioning. For both sexes, acceleration in stature begins in early adolescence, but peak growth velocities are not reached until middle adolescence. Boys typically peak 2–3 years later than girls and continue their growth in height for 2 or 3 years after girls have stopped. The development of secondary sex characteristics is usually classified by Tanner's stages of sexual maturity (or sexual maturity ratings) that defines sequential changes in pubic hair, breast changes, and testicular and penile growth (National Institute of Child Health and Human Development 2012). Motor skills are refined into an adult pattern. Functional development of this age group is marked by pubertal changes that can affect self-esteem. They are able to construct a reasonable evaluation of consequences for risk-taking behaviors.

### 1.2.7.2 Vulnerabilities

Adolescents are vulnerable to traumatic brain and spinal cord injuries due to frequent engagement in risk-taking behaviors. Injury prevention programs are geared to reduce teens' participation in behaviors like drinking and driving, but knowledge does not consistently control behavior. As an age group, adolescents sustain the highest number of

traumatic brain injuries from motor vehicle collisions due to factors including inexperience, distractions from cell phones and texting, peer pressure, and failure to wear seatbelts.

The growth of competitive sports has also contributed to increasing injuries. Sports-related concussions are common and of particular concern due to the effects of concussions on the developing pediatric brain and repeated injury over a lifetime. The effect of multiple concussions on the developing brain appears to be cumulative (Halstead and Walter 2010; Karlin 2011). The young athlete is more susceptible to concussion, and research has shown that they need more time to recover. It is important that cognitive assessment be included such as the Standardized Assessment of Concussion and the Sports Concussion Assessment Tool (SCAT) (McCroory 2009). The child should have medical follow-up. It is recommended that the child with a concussion be removed from play on the day of the injury and receive both cognitive and physical rest followed by a monitored return-to-play plan. Cognitive rest includes reduction or discontinuation of activities such as watching television, reading, using the computer, texting, music by headphones and frequent use of telephone, as well as time away from school. The CDC has created a concussion awareness program, “HEADS UP” aimed at educating parents, teachers, coaches, and physicians ([www.cdc.gov/headsup](http://www.cdc.gov/headsup)). See Chapter 7 for further information on pediatric athletic concussion.

Teenagers are also vulnerable to the onset of a seizure disorder in the presence of a previously known or unknown low seizure threshold compounded by major hormonal changes that occur during this developmental phase. Adolescents who suffer from chronic neurological disorders face the additional challenge of transitioning from pediatric to adult care settings and providers, which is the topic discussed in Chap. 17.

The incidence of firearm injuries among children in the United States is the highest of all industrialized countries in the world (Safavi et al. 2014; Bergen et al. 2008). According to the Centers for Disease Control and Prevention, the incidence of firearm injuries among children has increased and become a leading cause of death in children in the

United States (Centers for Disease Control and Prevention 2013). The American Pediatric Surgical Association supports counseling on gun safety in the home and preventing child access to guns.

### 1.2.7.3 Tips in Approach to Child/Family

The assessment of an adolescent can proceed in the same position and sequence as for a school-aged child. Offering the option of a parent’s presence is important when developmentally appropriate. If the parent is interviewed alone, it should be done first before the interview with the child to avoid undermining the adolescent’s trust. This is also the time to introduce adolescents to taking ownership for their health care by encouraging them to start making their own appointments, learning how to refill their own prescriptions, and writing down their health questions. For many neurosurgical conditions, the teenager may be anxious about the outcome of the assessment and will want the parent(s) present. It remains important to continue to respect the need for privacy during the spine assessment, along with ongoing explanations of the findings.

---

## 1.3 Hands-on Neurological Assessment

The importance of a well-documented neurological assessment on a child with a neurological diagnosis cannot be understated. Repeated observations over time can give the nurse information regarding a child’s level of neurological irritability, motor function, and changes in intracranial pressure. A systematic approach is essential. Repeating the assessment in the same order each time avoids the pitfall of missed information. Bedside assessment should be done when changing caregivers to give the nurse a framework on which to base her description of changes in the assessment (Haymore 2004). The order of the pediatric neurological assessment is generally as follows:

- Appearance and observation
- Level of consciousness



- Cranial nerve assessment (appropriate to the setting)
- Vital signs
- Motor sensory function
- Assessment of reflexes
- Gait and balance
- Assessment of external monitoring apparatus

### 1.3.1 Appearance and Observation

#### 1.3.1.1 Head Size, Shape, and Fontanels

Accurate measurement of occipital-frontal circumference (OFC) reported in centimeters is vital. If the child is unconscious, careful placement of the tape while the patient is supine is important. In children under the age of 2 with a normally shaped skull, this measurement is taken just above the eyes and over the occipital ridge. Growth charts with OFC norms for age and some genetic syndromes (e.g., trisomy 21) should be used in less acute settings. The widespread use of the electronic medical record (EMR) has made viewing measurements over time significantly easier, regardless of the setting.

Palpation of the scalp is done to look for any alteration in skin integrity and abnormal ridging or splitting of the sutures. In the injured child, care should be taken to both visually examine and palpate the entire scalp for the presence of skin lacerations and/or subgaleal blood or fluid collections that contribute to skin breakdown. In children with thick hair, adequate light and assistance with alignment while moving the child are important. Pressure sores can develop in the posterior scalp over the occipital protuberance, from subcutaneous edema and prolonged dependent position of the scalp.

Microcephaly is the term used to describe infants whose head does not grow secondary to lack of brain growth. Causes include acquired factors occurring during pregnancy (intrauterine infection, radiation exposure, alcohol, or drug teratogenic effects) and familial syndromes such as familial microcephaly, which is an autosomal recessive disorder. The definition is a head circumference that falls more than 2 standard deviations

below the mean for age and sex, when compared with other growth parameters (Nellhaus 1968). The head appears disproportionately small, and many of these children have significant neurological disabilities that may include mental retardation and seizures.

Megalencephaly or macrocephaly refers to an unusually large head and skull with a circumference that is greater than 2 standard deviations above the mean for age and sex. There are many causes for this including hydrocephalus, expanding cysts or tumors, endocrine disorders, congenital syndromes, or chromosomal abnormalities. Asymptomatic familial megalencephaly is when the head is large but follows the shape of the growth curve, appears to be genetically determined, and does not result in increased intracranial pressure or other neurological or developmental problems (Purugganan 2006).

#### 1.3.2 Level of Consciousness: Level of Arousal and Content of Response

The assessment of level of consciousness is the most important task that the nurse will perform as part of the overall patient assessment. Level of consciousness (LOC) is described in terms of specific to both level of arousal and content of response. The primary goal is to identify changes that may indicate deterioration, so that early intervention can prevent further complications that diminish the patient's recovery of function. Most institutions use a standardized tool for serial assessments of level of consciousness. Although adapted from adult versions of tools, early versions were initially used to assess and prognosticate for children who had sustained a traumatic brain injury. However, the use of a standardized tool quickly gained acceptance and began to be used to assess LOC for all hospitalized children with a neurological alteration and is commonly referred to as a "neuro check." The frequency of neuro checks will depend on the neurological problem, patient acuity, and potential for deterioration and is ordered by the managing physician or other provider team member.



**Table 1.5** Modified Glasgow Coma Scale for infants and children

Activity	Score	Infant/nonverbal child (<2 years)	Verbal child/adult (>2 years)	
Eye opening	4	Spontaneous	Spontaneous	
	3	To speech	To verbal stimuli	
	2	To pain only	To pain only	
	1	No response	No response	
Motor response	6	Normal/spontaneous movement	Obeys commands	
	5	Withdraws to touch	Localizes pain	
	4	Withdraws to pain	Flexion withdrawal	
	3	Abnormal flexion (decorticate)	Abnormal flexion	
	2	Extension (decerebrate)	Extension (decerebrate)	
	1	No response	No response	
			2–5 years	>5 years
Verbal response	5	Cries appropriately, coos	Appropriate words	Oriented
	4	Irritable crying	Inappropriate words	Confused
	3	Inappropriate screaming/crying	Screams	Inappropriate
	2	Grunts	Grunts	Incomprehensible
	1	No response	No response	No response

Obtained from Marcoux (2005)

Coma scoring system appropriate for pediatric patients

In pediatrics, the most commonly used tool is the Modified Glasgow Coma Scale for Infants and Children. See Table 1.5 for this commonly used scale (Marcoux 2005). There are many variants of this scale in use around the country, and newer scales are available as alternatives. These include the Glasgow-Pittsburgh Coma Scale (GCS-P), which has been shown to have similar prognostic accuracy rates when compared to the modified GCS in very small samples (He et al. 2008). Another scale gaining use is the **FOUR – Full Outline of UnResponsiveness** – score created and published by Wijdicks and colleagues at the Mayo Clinic (Wijdicks et al. 2005). This scoring system was validated in pediatrics with inter-rater reliability slightly greater than that of the GCS, in the prediction of poor outcomes and morbidity (Cohen 2009) (Fig. 1.2).

The neuroanatomic location of consciousness specific to arousal is located in the reticular activating system of the brainstem, just above the midbrain. The assessment of consciousness is closely tied to the assessment of eye findings because of the anatomic proximity of the midbrain to the nuclei of cranial nerves III, IV, and VI – which together control pupillary responses and extraocular eye movements (EOM). Anatomic

correlates of the content of the response (once the child has been aroused) are located in the cerebral cortex. If a patient has an altered level of consciousness, the first step will be to assess arousal (Haymore 2004). The nurse should first attempt to arouse the child from sleep using the least amount of stimulation necessary to evoke a response from the child. Often, the first stimulus is the turning on of a light over the child, followed by auditory stimuli like saying the child's name, and finally tactile by touching the child. Each of these should be applied in increasing levels of intensity with a dim light, soft voice, and gentle touch first, followed by a brighter light, louder voice, and firmer tactile stimulation. In cases where this level of stimulus does not cause arousal, noxious stimuli, which would be considered painful to a child who is fully aware, are used.

Noxious stimuli should be forceful, yet not injure the child. Central stimulus should be applied before peripheral stimulus. Three commonly used central stimuli are the trapezius squeeze, mandibular pressure, and sternal rub. The sternal rub is the most common central stimulus used in pediatrics. A single-fisted hand is used with the knuckles lightly applied to the child's sternum. Pressure should be for a minimum of

**Eye response (E)**

E4 Eyelids open or opened, tracking, or blinking to command

E3 Eyelids open but not tracking

E2 Eyelids closed, open to loud voice, not tracking

E1 Eyelids closed, open to pain, not tracking

E0 Eyelids remain closed pain

**Motor response (M)**

M4 Thumbs up, fist, or peace sign to command

M3 Localizing to pain

M2 Flexion response to pain

M1 Exterior posturing

M0 No response to pain or generalized myoclonus status epilepticus

**Brain stem reflexes (B)**

B4 Pupil and corneal reflexes present

B3 One pupil wide and fixed

B2 Pupil or corneal reflexes absent

B1 Pupil and corneal reflexes absent

B0 Absent pupil, corneal, and cough reflex

**Respiration (R)**

R4 Not intubated, regular breathing pattern

R3 Not intubated, Cheyne-Stokes breathing pattern

R2 Not intubated, irregular breathing pattern

R1 Breathing above ventilator rate

R0 Breathes at ventilator rate or apnea

**Fig. 1.2** The FOUR score instructional card (Full Outline of Unresponsiveness) coma scale (Wijdicks et al. 2005)

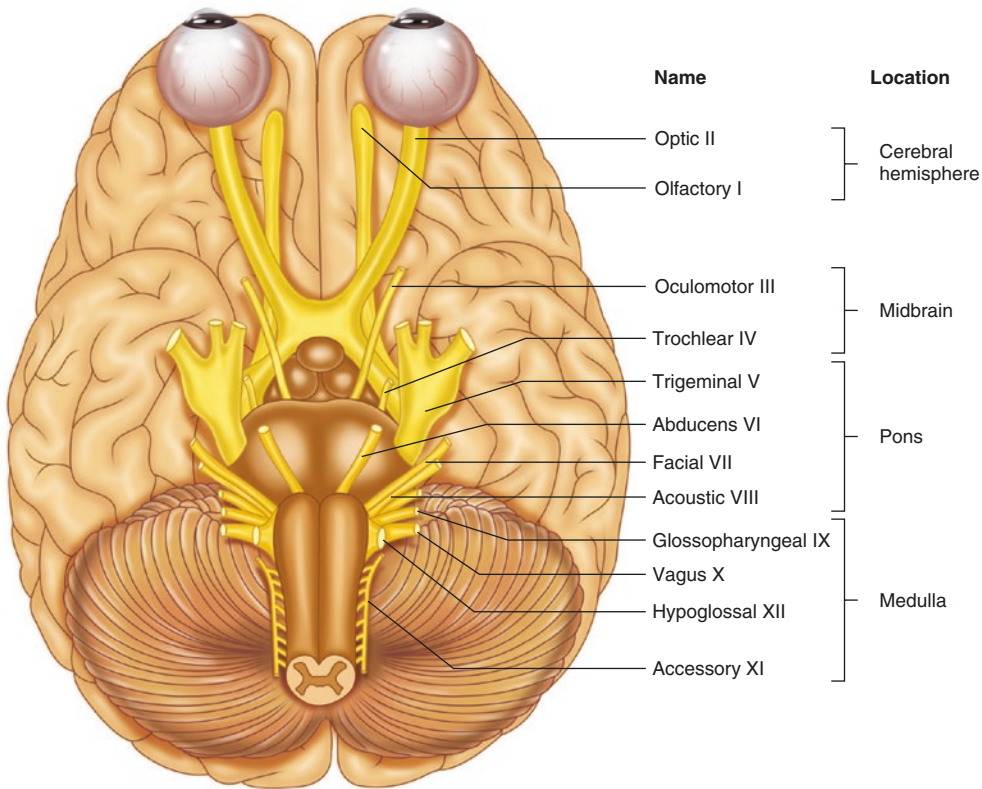
15 s or until a response is obtained and no longer than 30 s. A response to central stimulus indicates that the movement is a result of a cortical response rather than a spinal or reflex response. If there is no response to central stimulus or the

response indicates asymmetry of motor movements, peripheral stimulus to the affected limbs should be applied; for example, place a pencil between two fingers and squeeze the fingers together (Cook and Woodward 2011).

With any stimulus in the less than fully conscious patient, observation of how the child responds is thought of in terms of either a generalized or localized response. A generalized response is one where the child shows general agitation or has increased overall body movement to the stimulus. A localized response is one where the child shows clear evidence of an awareness of where the stimulus is coming from (localizes it). This is evident because the child either reaches to the limb where the stimulus is applied or tries to pull the limb away from the examiner.

Once it has been determined that the child can be aroused, the level or degree of response (content) to the stimulus is assessed. Determining whether a child is oriented to person, place, and time is more challenging because of developmental influences. The pediatric nurse is more likely to report that the child is oriented to the presence of known caregivers, favorite objects (toys or stuffed animals), and other developmentally appropriate stimuli. The ability to follow commands may rely more on the examiner's knowledge of what commands a certain age child would be likely to follow. This assessment distinguishes between simple and more complex commands. Examples of simple commands are "stick out your tongue" and "squeeze my hand." More complex commands involve two or three steps and require a higher level of processing. An example would be, "can you kiss your bear and give it to your mommy." Parents and others who know the child well are often helpful in assessing subtle changes in awareness.

With fully awake children, in either the hospital or clinic setting, awareness is assessed by asking questions related to place and time, assessing memory by giving them three simple words to remember, and asking them to repeat them several minutes later. Children are more likely to be engaged if the examiner is utilizing current events, holidays or school routines, questions about pets, or other topics that are familiar to the child (Amidei et al. 2010).



**Fig. 1.3** Diagram of base of the brain showing entrance and exits of the cranial nerves (Hickey 2009)

### 1.3.3 Cranial Nerve Assessment: Brainstem Function

Cranial nerve assessment is an assessment of brainstem function, because nuclei of 10 of the 12 cranial nerves arise in the brainstem. The proximity of these nuclei to the reticular activating system (arousal center) located in the midbrain is the anatomic rationale for assessing cranial nerves in conjunction with level of consciousness. Important neurological functions and protective reflexes are mediated by the cranial nerves, and many functions are dependent on more than one nerve. Some of the cranial nerves have both motor and sensory functions. See Fig. 1.3 for a diagram of the base of the brain illustrating the location of the 12 cranial nerves and Table 1.6 for an overview of all 12 cranial nerves and their functions (Hadley 1994).

The two cranial nerves that do not arise in the brainstem are the olfactory nerve (CN I) and the

optic nerve (CN II). The olfactory nerve is located in the medial frontal lobe and is responsible for the sense of smell. This can be difficult to assess in the younger child, so it is often omitted unless there is specific concern that there has been damage by swelling or traumatic injury in that area. Taste may also be affected with injuries to CN I. The optic nerve (CN II) is assessed through testing of visual acuity. This may be done more formally with visual screening or more generally by noting if children can see objects placed in front of them. The approach to assessing visual acuity depends on the setting where the person doing the examination is seeing the patient (American Academy of Pediatrics 1996).

The optic (CN II) and oculomotor (CN III) nerves and the sympathetic nervous system mediate pupillary size and constriction to direct light. Many factors can affect the pupillary response, including damage to the eye or cranial nerves, pressure on the upper brainstem, local and systemic

**Table 1.6** Assessment of cranial nerves in the child

Cranial	Test for function
<b>I Olfactory (S)</b>	
Olfactory nerve, mucous membrane of nasal passages and turbinates	With eyes closed, child is asked to identify familiar odors such as peanut butter, orange, and peppermint. Test each nostril separately
<b>II Optic (S)</b>	
Optic nerve, retinal rods, and cones	Check visual acuity, peripheral vision, color vision, perception of light in infants; fundoscopic examination for normal optic disk
<b>III Oculomotor (M)</b>	
Muscles of the eyes (superior rectus, inferior rectus, medial rectus, inferior oblique)	Have child follow an object or light with the eyes (EOM) while the head remains stationary. Check symmetry of corneal light reflex. Check for nystagmus (direction elicited, vertical, horizontal, and rotary). Check cover-uncover test
Muscles of iris and ciliary body	Reaction of pupils so light, both direct and consensual, accommodation
Levator palpebral muscle	Check for symmetric movement of upper eyelids. Note ptosis
<b>IV Trochlear (M)</b>	
Muscles of the eye (superior oblique)	Check the range of motion of the eyes downward (EOM). Check for nystagmus
<b>V Trigeminal (M, S)</b>	
Muscles of mastication (M)	Palpate the child's jaws, jaw muscles, and temporal muscles for strength and symmetry. Ask child to move lower jaw from side to side against resistance of the examiner's hand
Sensory innervation of the face (S)	Test child for sensation using a wisp of cotton, warm and cold water in test tubes, and a sharp object on the forehead, cheeks, and jaw. Check corneal reflex by touching a wisp of cotton to each cornea. The normal response is blink
<b>VI Abducens (M)</b>	
Muscles of the eye (lateral rectus)	Have child look to each side (EOM)
<b>VII Facial (M, S)</b>	
Muscles for facial expression	Have child make faces: look at the ceiling, frown, wrinkle forehead, blow out cheeks, and smile. Check for strength, asymmetry, paralysis
Sense of taste on anterior two-thirds of tongue. Sensation of external ear canal, lachrymal, submaxillary, and sublingual glands	Have a child identify salt, sugar, bitter (flavoring extract), and sour substances by placing substance on anterior sides of tongue. Keep tongue out until substance is identified. Rinse mouth between substances
<b>VIII Acoustic (S)</b>	
Equilibrium (vestibular nerve)	Note equilibrium or presence of vertigo (Romberg sign)
Auditory acuity (cochlear nerve)	Test hearing. Use a tuning fork for the Weber and Rinne tests. Test by whispering and use a watch
<b>IX Glossopharyngeal (M, S)</b>	
Pharynx, tongue (M)	Check elevation of palate with "ah" or crying. Check for movement and symmetry. Stimulate posterior pharynx for gag reflex
Sense of taste on posterior third of the tongue	Test sense of taste on posterior portion of tongue
<b>X Vagus (M, S)</b>	
Mucous membrane of the pharynx, larynx, bronchi, lungs, heart, esophagus, stomach, and kidneys	
Posterior surface of external ear and external auditory meatus	Note same as for glossopharyngeal. Note any hoarseness or stridor. Check uvula for midline position and movement with phonation. Stimulate uvula on each side with tongue depressor – should rise and deviate to stimulated side. Check gag reflex. Observe ability to swallow

(continued)

**Table 1.6** (continued)

Cranial	Test for function
XI Accessory (M)	
Sternocleidomastoid and upper trapezius muscles	Have child shrug the shoulders against mild resistance. Have child turn the head to one side against resistance of examiner's hand. Repeat on the other side. Inspect and palpate muscle strength, symmetry for both maneuvers
XII Hypoglossal (M)	
Muscle of tongue	Have child move the tongue in all directions and then stick out the tongue as far as possible: check for tremors or deviations. Test strength by having child push the tongue against inside the cheek against resistance on outer cheek. Note strength, movement, symmetry

Obtained from Hadley (1994)

*S* Sensory, *M* motor, *EOM* extraocular movement

effects of certain drugs, anoxia, and seizures. Pupil size varies with age and is determined by the amount of sympathetic input, which dilates the pupil and is balanced by the parasympathetic input to the oculomotor nerve, which constricts the pupil. Pupillary response in the eye that is being checked with direct light as well as the other pupil (consensual response) is significant in that they can point to where damage to nerves exists. This is an objective clinical sign that can be followed over time (Hickey 2009).

### 1.3.3.1 Visual Field Testing and Fundoscopic Examination

Visual field testing and examination of the optic nerve using an ophthalmoscope (fundoscopic exam) are not performed by the bedside or clinic nurse but may be done at the bedside by physicians or advanced practice nurses. In the outpatient setting, if the child is awake and able to cooperate, the examiner will position themselves about 2–3 ft in front of the patient and ask the child to fix their gaze directly in front (usually at the examiner's nose) while bringing a brightly colored object from the periphery (right, left, upper, and lower) into the central visual area. The child is asked to indicate verbally when they see the object entering into view, and this is compared with the timing of the examiner's visualization of the object to determine if there is a gross defect in the visual field. In the non-acute setting, formal visual field testing is done by a pediatric

ophthalmologist and generates a computerized report showing whether the visual field is full or has areas where vision is absent. This baseline determination is required in patients undergoing surgical resection of a lesion and in particular epilepsy surgery, where cortical resection in the area of the temporal lobe often is proximate to, or overlaps with, the optic nerves as they project from the retina in a posterior fashion to the occipital lobe (Asato et al. 2011). It is also done prior to other surgeries around the optic pathway, so that a baseline assessment can be compared to repeat exams done after surgical intervention.

Fundoscopy examination in the acute setting is utilized to look for evidence of papilledema and/or retinal hemorrhages. The former is a sign of increased intracranial pressure (IICP), generally of a gradual and long-standing nature. The latter is a sign of traumatic injury to the retina as a result of infant shaking in cases of non-accidental trauma or child abuse (Togioka et al. 2009).

Extraocular eye movements (EOMs) are mediated by three cranial nerves (III, IV, and VI), as well as the medial longitudinal fasciculus tract of the midbrain and pons, and the vestibular system. Eye movements are observed by using either a light, object (toy works well for younger children), or by having the child follow the examiner's finger. The primary descriptors used to describe EOMs are "intact" or "conjugate" if they are normal, indicating that the eyes move

together, and “dysconjugate” when they do not move together. Fixed eye movements, a gaze preference (eyes seeming to fix on either a right or left gaze even if briefly tracking), or roving eye movements indicate damage to nerves and other brain structures. Nystagmus is defined as involuntary back and forth or cyclical movements of the eyes. The movements may be rotatory, horizontal/lateral or vertical, and often most noticeable when the child gazes at objects in the periphery or that are moving by rapidly. Two to three “beats” of nystagmus in far lateral gaze are considered normal if it is an isolated finding. The presence of persistent nystagmus indicates structural lesions or changes in the brainstem, cerebellum, or vestibular system but can also be present as a result of drug intoxications, notably phenytoin (Schultz and Hockenberry 2011).

The motor component of the trigeminal nerve (CN V) innervates the chewing muscles. The sensory component of this nerve has three branches, each supplying sensation to the eye, face, and jaw. Trigeminal nerve function is evaluated in comatose patients when corneal sensation is tested with a wisp of cotton (referred to as the corneal reflex). A lack of response indicates pressure on or damage to CN V.

The facial nerve (CN VII) innervates the muscles of the face, as well as supplying the anterior two-thirds of the tongue with sensory input allowing for taste of sweet, sour, and salty foods. Looking for symmetry while asking the child to smile, frown, and make a face or “blow up” their cheeks is the best way to test this nerve. Formal testing of taste is usually deferred in the acute care setting.

The acoustic nerve (CN VIII) is comprised of two divisions. The cochlear division innervates the inner ear and auditory function (hearing). The vestibular division is responsible for balance. A quick, albeit gross, method of testing hearing is to hold a ticking watch or rubbing strands of hair together near the child’s ear and ask if they can hear the sound and describe what it is they are hearing.

Three of the lower cranial nerves IX, X, and XII, glossopharyngeal, vagus, and hypoglossal, respectively, contribute to the function of swallowing and the ability to gag and cough which safeguards the integrity of the airway. Clinicians often refer to these nerves collectively in discussions of “lower cranial nerve dysfunction” rather than individually. These cranial nerves are especially important in pediatrics because the airway structures are less developed and more at risk for dysfunction and slow recovery if damaged. Damage to these nerves results in impaired swallowing, a decrease in tongue mobility, and speech articulation problems. These problems lead to excessive drooling, frequent aspiration, and nutritional deficits related to poor oral intake. The usual method of assessing these three nerves is to observe for excessive drooling (indicating inability to swallow secretions), cough and gag with suctioning, and/or use a tongue blade to illicit the gag reflex.

The spinal accessory nerve (CN XI) innervates the sternocleidomastoid and trapezius muscles. It can only be tested in the child who is conscious. Having children shrug their shoulders and push their heads against the examiner’s hand in both directions is the easiest way to assess CN XI. To test children in the supine position, have them raise their heads off the bed and flex forward against the force of the examiner’s hand (Hadley 1994).

### 1.3.4 Assessment of Motor Function

Motor function is assessed in all children with neurosurgical diagnoses. Those with a depressed level of consciousness will be observed for the type and quality of movement that occurs to noxious stimuli. The nursing assessment of motor function over time will be integral to the determination of long-term outcome for the child. Motor movements that indicate more significant damage to the neurological system are called abnormal motor reflex posturing or pathological posturing and are covered in greater detail in the



chapter “Traumatic Brain Injury” (Chap. 8) of this text.

In the child *without* a depressed level of consciousness, assessment of motor function involves observation of the patient’s spontaneous movements as well as responses to direct commands and tactile stimuli. Key things to observe are the presence of any asymmetries of movement or unusual postures of either the upper or lower extremities. Overall bulk of the muscles and tone is important, especially if there is any question of limb atrophy. In infants, testing of primitive reflexes like the Babinski, Moro, and grasp reflexes assists in the identification of any asymmetries.

Toddlers and preschool-age children respond to the examiner engaging them in play activities. Assessment of spontaneous motor function is done by observation after the child is given objects, toys, or other items to manipulate. Strategies include asking them to give a “high five” with both hands and having them push their feet against your hands. School-age children will enjoy games of strength and are easily encouraged to cooperate. In the ambulatory, clinic, or school setting, having children run after a tennis ball, climb onto an exam table, draw a picture or write their name, heel-and-toe walk, hop, skip, gallop, and/or walk a few stairs while observing is the best way to get an accurate functional motor assessment. Asking children to hold both hands upright in front of their body for several seconds with their eyes closed will give the examiner the opportunity to look for a drifting down (“drift”) of one extremity, which can indicate subtle weakness on one side that may not be noted when testing hand grasp strength (Lucille Packard Children’s Hospital 2012).

### 1.3.5 Assessment of Sensory Function

Sensory function is usually assessed in conjunction with motor function. Certain populations of children with neurological abnormalities are more likely to undergo routine assessment of sensory function. These populations include those

with spina bifida, spinal cord lesions, or injuries as well as those with indwelling epidural analgesia for postoperative pain management.

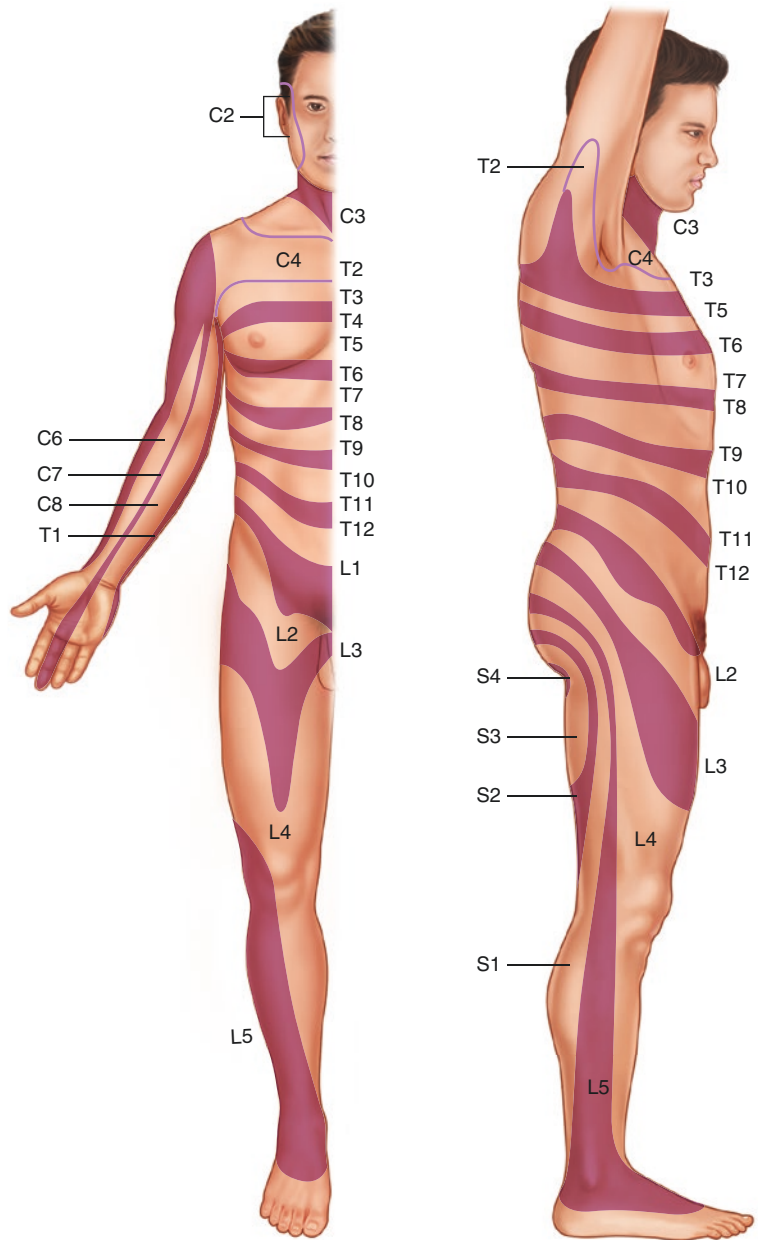
The response to superficial tactile stimulation is the most common technique used to assess sensation. More complex testing involves using objects that are both sharp and/or dull to determine if the child can discriminate between them. Assessment of the child’s ability to feel a vibration can be done with a tuning fork. Proprioception (awareness of the body in space) is tested by having the child identify flexion or extension of a toe while blocking visualization of the motion (“Is your toe going up or down?”).

Like motor function, any asymmetries of sensory function should be noted. In cases of brain or spinal cord injury or after spinal cord surgery, sensation may be asymmetric and should be documented as such. A baseline exam should be documented so accurate comparisons can be made. The accepted tool for documentation of the spinal level where sensation is felt is the dermatome chart, shown in Fig. 1.4 (Conn 1995). A nurse should identify the spinal level at which sensation is present by utilizing either a sharp object or crushed ice in a glove. The examiner first confirms the sensation of the chosen stimulus on a part of the body with normal sensation and then uses the stimulus on the affected area and asks the child to compare with what he or she has confirmed is “normal.” Both anterior and posterior levels are pictured on the chart, which should be readily accessible to nurses who care for these patients. Dermatome levels are also routinely assessed and documented on children with epidural catheters in place to deliver regional analgesia for pain relief in the postoperative period (Pasero et al. 2008).

### 1.3.6 Assessment of Motor Reflexes

Both superficial and deep tendon reflexes (DTR) will be assessed as part of a comprehensive neurological exam. The bedside nurse may not be directly testing the reflexes but is often present during the exam. Superficial reflexes

**Fig. 1.4** Dermatome chart used to localize level of spinal nerve function through assessment of cutaneous sensation (Conn 1995)



include the abdominal, cremasteric, and gluteal (anal wink) reflex. Deep tendon reflexes include tapping a reflex hammer on the respective tendons in the bicep, tricep, brachioradialis, patella, and Achilles. Deep tendon reflexes are usually the following scoring system: 0 =

absent, +1 = sluggish, +2 = active, +3 = hyperactive, +4 = transient clonus, and +5 = permanent clonus.

The Babinski reflex is a neurological sign elicited by stimulating the lateral aspect of the sole of the foot with a blunt point or fingernail. A



positive response is when the toes fan and the great toe dorsiflexes (goes up). Usually the child can dorsiflex the foot and flex the knee and hip. A positive Babinski is normal in an infant and child up to about 18 months of age, around the time a child begins ambulating. After then, the response is considered abnormal and should be documented, and any asymmetry noted (Slota 1983b).

### 1.3.7 Assessment of Gait and Balance

Gait and balance are controlled in part by the cerebellum. Assessment of cerebellar function includes the ability to move limbs smoothly in space and the steadiness of the gait. The extent of the assessment of a child's gait and balance will depend on the ability of the child to cooperate with the assessment. Children who are seen in the acute care setting may be too critically ill or sedated to fully assess, although as the child arouses, some simple tests can be done at the bedside if the child will cooperate.

Ataxia is the term to describe a lack of muscular coordination and can be termed truncal, appendicular (relating to an appendage), or gait ataxia. It often occurs when voluntary muscle movements are attempted. Cerebellar lesions and drug intoxications can be etiologies of ataxia. Children may exhibit ataxia after a seizure in the postictal phase. Some children will exhibit ataxia as a result of a high serum level of an anticonvulsant (Caplin et al. 2009).

Asking children to walk in their usual casual gait, both forward and backward, is an easy method to test for ataxia. Follow this with a request for the child to walk heel to toe on a straight line. A normal heel-to-toe walk requires children to hold their arms out from their body to maintain balance. Standing balanced on one foot and then the other is also a way to challenge a child's balance. Children generally respond best when these requests are made into a game, using counting techniques and encouragement or doing the tests with the child.

Testing for appendicular ataxia can be done while seated by having the children touch their fingers to your finger held about 12–18 in. in front of them and then touch their nose and go back and forth. This is often more appealing to the child when a stuffed animal is used as a prop. Ask the child to touch the nose several times while moving the animal. It is normal for the child to be slightly less coordinated in the non-dominant hand, but movements should be smooth. A coarse tremor while doing this finger to nose testing is called *dysmetria*, which refers to the inability to control the range of a movement. Often the tremor will worsen when the child is near the target, which is referred to as an *intentional* tremor.

Ataxia may be more noticeable when a child is fatigued or late in the day, especially if the child is recovering from a neurological trauma. The same individual should conduct and document the assessment at the same time of the day, so as to not confound the exam findings and to more accurately assess progress in recovery.

### 1.3.8 Assessment of Vital Signs

Concepts related to IICP, including vital sign and fluid balance alterations, are covered in greater detail in Chap. 8 of this text. A brief more general overview is contained here. Neurological alterations can and often do affect vital signs, particularly in the acute care setting. Vital sign assessment is usually done in conjunction with neurological assessment so that the child is disturbed once, and the information obtained can be evaluated as a whole to determine if changes in vital signs indicate pending deterioration. Fluid balance, intake, and output are also assessed at this time. Awareness of the relationships between neurological assessment findings, fluid balance, and vital signs in the postoperative neurosurgery patient is essential to avoiding an ominous slide from an alteration in level of consciousness to brainstem herniation and death (Marcoux 2005).

Changes in vital signs are a late sign of increased intracranial pressure (IICP) and require immediate response from the bedside nurse and

medical team. Cushing's triad is a descriptor for a pattern of vital sign changes that includes a widening pulse pressure, bradycardia, and altered respiratory patterns including central hyperventilation. These three vital sign changes are seen in close proximity, or simultaneously, before the more ominous signs of pressure affecting the lower medulla, which manifest as a very deep coma evidenced by flaccid muscles, absent reflexes, and fixed and dilated pupils. At this point, vital signs display a low blood pressure, a low pulse, and spontaneous respiration cease. This is termed brainstem herniation and leads to brain death (Hickey 2009).

Temperature dysregulation in the form of hyperthermia occurs because of damage to or pressure around the hypothalamus where the regulation of body temperature occurs. Fever without accompanying signs of infection is often referred to as "central" fever, meaning that it has a neurological origin rather than an infectious cause. In the acutely ill child, it is important that all diagnostic testing (labs, imaging, and cultures including CSF) to rule out infectious causes of elevated temperature have been completed and results are known prior to assuming a fever in a neurosurgical patient is central in origin.

Fluid balance, in particular the signs and symptoms of the syndrome of inappropriate antidiuretic hormone (SIADH) and diabetes insipidus (DI), should be assessed and carefully documented in the acutely ill child with a neurological disorder. Frequent measurements of urine output via an indwelling catheter and labs including serum sodium and osmolality are essential to a determination of whether SIADH or DI is present. Factors such as the administration of diuretics, fluid restrictions imposed to decrease the risk of IICP, and trending of serum electrolyte and osmolality values should be considered when making a determination of the presence of one of these syndromes. Pressure on or damage to the anterior pituitary gland can lead to SIADH or DI and may have a significant impact on recovery and outcomes. Diabetes insipidus in particular can persist after recovery from acute illness and requires lifelong treatment with synthetic vasopressin (Schultz and Hockenberry 2011).

### **1.3.9 Assessment of Brainstem Function in the Acute Care Setting: External Monitoring Apparatus, Herniation Syndromes, and Brainstem Reflexes**

More detailed information on aspects of neurological assessment that are common in pediatric or neonatal critical care settings is included in Chap. 8 on "Traumatic Brain Injury." The information here is provided as a brief overview. Progression of brain insult without appropriate identification and treatment will continue to manifest down the brainstem affecting the cranial nerves in succession. As noted above, vital sign changes usually occur late in the cascade of acute progressive neurological deterioration. Assessment of brainstem function in the acute or critical care setting is accomplished with repeated systematic neurological examination and incorporates the use of equipment and technology including intracranial pressure (ICP) monitors, external ventricular drains (EVD), and cerebral perfusion monitors. Careful interpretation of data obtained from these devices is essential. Children with brain injuries, traumatic or otherwise, are at risk for brain herniation from the primary or secondary effects of their injury. In situations where herniation is suspected, clinical tests to determine brainstem function through the assessment of what are referred to as brainstem reflexes are useful for clinical decision-making in regard to prognosis for survival.

#### **1.3.9.1 Assessment of External Monitoring Apparatus**

The bedside nurse should assess equipment used for neurological monitoring at regular intervals. This is usually done in the same time interval as scheduled for vital signs and neurological assessments. Any concern regarding malfunction or leakage around a monitoring device should be reported immediately, following the specific institutional protocol so that patient safety is assured and risk for infection is minimized. Biomedical technicians should be available for routine equipment evaluation so that equipment is ready and in working order.

An important rule to follow in dealing with equipment or any other technology is to always *look at the patient first*, rather than the machine, for the definitive answer in the interpretation of the findings and their meaning in regard to the patient's status. This is an important lesson as machines can malfunction. If something does not "make sense," the nurse should seek opinions from others and not always assume that the equipment is correct.

### 1.3.9.2 Herniation Syndromes

Displacement of brain structures resulting from increased intracranial pressure and compromised cerebral blood flow leads to herniation of brain tissue and an ominous sequence of neurological signs and symptoms. Herniation syndromes are categorized by supratentorial and infratentorial locations. Supratentorial herniation includes cingulate herniation, central herniation, and uncal herniation. These types of herniation syndromes result from expanding lesions in one hemisphere of the brain causing pressure medially, downward, or by displacement against the skull. Infratentorial herniation is from displacement of the cerebellar tonsils below the foramen magnum or in rare cases upward herniation of the brain across the tentorium from an expanding lesion in the posterior fossa. Herniation can be reversed with early identification and treatment of the signs and symptoms of IICP but ends in brain death if the rapid progression of events is not halted.

### 1.3.9.3 Brainstem Reflexes

One commonly used test for determination of brainstem function in the unconscious child in a comatose state is the assessment of the oculocephalic reflex, which is also referred to as "doll's eyes." This maneuver can only be done if a patient is unconscious and is performed by holding the patient's eyelids open and briskly rotating the head laterally in one direction and then the other. A normal response is conjugate eye deviation to the opposite side of the head position with return to midline. This is usually documented as "doll eye's present." An abnormal response is the eyes moving in the same direction as the head

and/or dysconjugate movements and is documented as "doll eyes absent." The latter indicates damage to the brainstem (Hickey 2009; Schultz and Hockenberry 2011).

Another commonly used test for brainstem function in the comatose child is the assessment of the oculovestibular reflex, referred to as iced-water calorics. This test assesses the function of the vestibular branch of cranial nerve X, the vagus nerve. The test involves irrigating each ear canal with iced water. The child's head is elevated to about 30° and kept midline. Approximately 5 ml of ice water is drawn into a syringe and attached to a butterfly catheter with the needle cutoff. Another individual holds the child's eyes open during the rapid injection of the water into the ear canal. A normal response is nystagmus to the opposite side of the ear being irrigated and then a return of the eyes to midline. There is no response in the patient who is brain dead (Schultz and Hockenberry 2011).

Other brainstem reflexes include the corneal reflex which tests the sensory branch of the trigeminal nerve (CNV) through sensory stimulation of the cornea and the gag reflex, which tests the sensory branch of the vagus nerve (CN X) using stimulation of the posterior palate and pharynx. Chapter 8 on "Traumatic Brain Injury" includes a table with greater detail about these brainstem reflexes.

### 1.3.10 Criteria for Determination of Brain Death in Infants and Children

Testing of brainstem reflexes as described above is one aspect of the clinical exam required for the determination of brain death in pediatrics. The manner and timing of the clinical exam and the examiners performing it are outlined in the recently revised criteria published by the Society of Critical Care Medicine (SCCM) and the American Academy of Pediatrics (AAP) in 2011. These guidelines were initially established by consensus of a multi-society task force, published in 1987, and considered the standard of practice throughout the country for over two decades. The

Society of Critical Care Medicine and the American Academy of Pediatrics convened a multidisciplinary committee that included nurses, to update the guidelines using current evidence, with a goal of addressing gaps and weaknesses of the original recommendations.

The 2011 recommendations for the diagnosis of brain death in neonates, infants, and children include six areas where evidence was gathered, scored, and summarized. These areas are (1) the determination of brain death; (2) prerequisites for initiating a brain death evaluation; (3) number of examinations, examiners, and observation periods; (4) apnea testing; (5) ancillary studies; and (6) declaration of death. The determination is a "... clinical diagnosis based on the absence of neurologic function with a known irreversible cause of coma. Coma and apnea must coexist to diagnose brain death" (Nakagawa et al. 2011, p.722).

The brain death examination calls for 24 h to pass following cardiopulmonary resuscitation or severe acute brain injury if the neurological exam is not clear or clinical judgment dictates. Two separate exams are (not were) conducted by two different attending physicians, with 24 h of interval between exams for neonates (37-week gestation to 30-day postnatal life) and 12 h for infants (31 days to 18 years). If the EEG or cerebral blood flow testing is consistent with brain death, the interval between exams can be decreased. Two apnea tests are required (Nakagawa et al. 2011).

The guidelines for determination of brain death aim to assure that the clinical exam is consistent with other electrical and radiographic findings to guide health-care providers in their discussions with families about removing a child from life-sustaining technology and declaring death. The possibility of organ harvest and donation should be discussed with the family prior to this, according to institutional guidelines, and can proceed if it is deemed appropriate by the organ and tissue donor organization interfacing with the facility, and consent has been given by the child's family or legal guardians. Table 1.7 succinctly summarized the 2011 guidelines for easier reference and clarification regarding the nationally established criteria for determination of brain death in infants and children.

**Table 1.7** 2011 guidelines for determination of brain death in infants and children

Guideline element	
Number of exams	Two, regardless of other studies completed
Length of time to wait prior to first exam	24 h following CPR or severe acute injury suggested if clinical judgment dictates or if there are concerns about the exam
Number of examiners	Two different attending MDs for first and second exam
Core body temperature	>35 °C (95°F)
Apnea testing	Two tests required unless clinically contraindicated; PaCO <sub>2</sub> parameters are specified
Ancillary study recommended	Not required unless clinical exam and apnea test cannot be completed  Newborn to 30 days of age: <i>EEG or CBF less sensitive, CBF may be preferred</i>
Time of death	Time of the second exam and apnea test/ancillary study

Adapted from Nakagawa et al. (2011)

*EEG* electroencephalogram, *CBF* cerebral blood flow

## 1.4 Pain Assessment in the Child with a Neurological Diagnosis

Children with neurological abnormalities may suffer pain from either their primary diagnosis, in the postoperative period after neurological surgery, or during procedures that must be performed in the course of medical care (lumbar punctures, IV starts, shunt taps, dressing changes). Some children will unfortunately suffer chronic pain related to peripheral nerve injury or a defect in the ability of the central nervous system to "turn off" the pain impulses and alter the function of the normal negative feedback loop. The last three decades have seen a significant growth in the understanding of pain and how it is manifested, physiologically understood, and treated in the pediatric population. These advances have led to the availability of comprehensive pain management programs available at most pediatric tertiary care centers in the United States and abroad (Brislin and Rose 2005). Yet, the management of pain in

the pediatric neurosurgery patient remains a challenging and complex task.

Neurologically impaired children present a challenging dilemma to health-care providers who are entrusted to assess and manage their pain. One obvious challenge is the difficulty of assessing pain in a developmentally delayed child. Confounding this issue is the relationship of anxiety to pain and how to determine which is having more of an impact on the child's overall level of comfort. A further challenge is the desire to not "oversedate" so that an accurate neurological assessment can occur while still providing adequate pain relief for the child. Another important factor in the neurologically impaired child is the input of the parents and other primary care providers who may have specific experiences and insights that may enhance or diminish their ability to "speak" for the child. Pain in this population of children is very likely undertreated.

A child's perception of pain is related to both anatomic and physiologic factors and cognitive and behavioral factors. Many involved in pain research agree that a child's response to pain is in part a learned response. Infants and young children may have more atypical responses, whereas older children's pain behaviors are more likely to produce actions from others that lead to pain relief (Stapelkamp et al. 2011). Despite the fact that many children suffer pain needlessly, there are still many barriers that exist to providing adequate pain relief to children. These barriers include personal family beliefs, institutional cultures, and individual nurse, physician, and other health-care provider beliefs.

Pain assessment should be done using validated, age-appropriate scales when the child is able to participate. For those who cannot report their pain because of age and/or injury, physiologic parameters, observation, and response to ordered pain relief measures should be carefully documented and communicated to promote optimal pain relief. Parent report may also be a reliable indicator when the child is unable to participate or is uncooperative.

Although there are many tools now available for assessment of pain in infants and children, because of space constraints, only a few will be

highlighted here as examples. Institutional approaches should utilize published evidence and input from specialists from multiple disciplines (nurses, physicians, child life specialists, psychologists, etc.) to determine the best tools for each setting. Many institutions use the Faces Pain Scale (FPS) – Revised for young children. For children over the age of 10 years, the most common approach to pain assessment is the use of the numerical rating scale. A score of one being no pain and ten being the most pain you could ever experience. One recent study validated the use of the NRS for pediatric patients in comparison to the Faces Pain Scale – Revised and found an acceptable level of validity in two different samples (Miró et al. 2009).

Educating nurses and medical staff regarding the use of pain tools is an ongoing endeavor. The use of a validated pain tool does not necessarily correlate with improved outcomes for children in pain. The use of these tools must be tied to protocols for pain management, so evaluation of pain relief measures, both pharmacological and non-pharmacological, can occur (Greco and Berde 2005). As complementary and alternative approaches to pain management become more widely accepted, many centers have access to therapists skilled in hypnosis, biofeedback, guided imagery, relaxation techniques, acupuncture, and music and art therapy, among others. Tables 1.8, the FLACC Pain Scale, and Table 1.9, the Premature Infant Pain Profile, illustrate the scoring used for these tools for different age groups (Merkel et al. 1997; Stevens et al. 2010).

Pharmacologic management of pain in children undergoing neurosurgical procedures includes the use of nonsteroidal anti-inflammatory drugs (NSAIDs), opioids, local anesthetics, antispasmodics, and other drugs that are continually being developed and trialed in the clinical arena (Teo et al. 2011). Safety in the use of pain medication is a paramount concern, and nurses should follow institutional guidelines and work closely with pharmacists to address questions about dosage and potential adverse events of these and all medications. In the past several years, novel medications have become available, as a way to target more than one cellular mechanism for pain,

**Table 1.8** FLACC (face, legs, activity, cry, and consolability) pain assessment tool

Categories	0	1	2
Face	No particular expression or smile	Occasional grimace or frown, withdrawn, disinterested	Frequent-to-constant quivering chin, clenched jaw
Legs	Normal position or relaxed	Uneasy, restless, tense	Kicking or legs drawn up
Activity	Lying quietly, normal position, moves easily	Squirming, shifting back and forth, tense	Arched, rigid, or jerking
Cry	No cry (awake or asleep)	Moans or whimpers, occasional complaint	Crying steadily, screams or sobs, frequent complaints
Consolability	Content, relaxed	Reassured by occasional touching, hugging, or being talked to, distracted	Difficult to console or comfort
Total score:			

From Merkel et al. (1997)

The FLACC is a behavioral observational tool for acute pain that can be used for infants, toddlers, and preschool children. It may also be useful for cognitively impaired children and adolescents. The patient is observed and the score noted for each category (i.e., face, legs, activity, cry, and consolability). The sum of all categories will give score out of maximum 10

**Table 1.9** Premature infant pain profile (PIPP) assessment tool

Procedure	Indicator	0	1	2	3	Score
	Gestational age	>36 weeks	32–36 weeks	28–32 weeks	<28 weeks	
Observe infant or 15 s for baseline, heart rate, and O <sub>2</sub> sat	Behavioral state	Active awake (eyes open, facial movements)	Quiet awake (eyes open, no facial movements)	Active sleep (eyes closed, facial movements)	Quiet sleep (eyes closed, no facial movements)	
Observe infant for 30 s	Heart rate	0–4 bpm increase	5–14 bpm increase	15–24 bpm increase	>25 bpm increase	
	O <sub>2</sub> sat	0–2.4% decrease	2.5–4.9% decrease	5.0–7.4% decrease	>7.5% decrease	
	Brow bulge	None (0–9% of the time)	Min (10–39% of the time)	Mod (40–69% of the time)	Max (>70% of the time)	
	Eye squeeze	None (0–9% of the time)	Min (10–39% of the time)	Mod (40–69% of the time)	Max (>70% of the time)	
	Nasolabial furrow	None (0–9% of the time)	Min (10–39% of the time)	Mod (40–69% of the time)	Max (>70% of the time)	
					Total	

From Stevens et al. (2010)

The PIPP is a biobehavioral observational tool for acute and procedural pain. It can be used to assess full- and preterm neonates. The infant is observed as indicated and their score noted. The sum of all categories will give a score out of a maximum of 21

O<sub>2</sub> sat oxygen saturation, *Min* minimal, *Mod* moderate, *Max* maximal

although many are not approved for children less than 12 years of age. In the setting of a comprehensive pain management team approach, there may be a role for these agents in certain cases (Randive and Mehta 2012). For children with chronic or neuropathic pain, tricyclic antidepressants like amitriptyline and GABA agonists like gabapentin and pregabalin may be used. Administration of medications can be oral, intra-

venous via intermittent dosing or patient-controlled analgesia (PCA), regional via epidural catheters, transcutaneous (dermal patches), transmucosal (oralettes), and rectal (Rosen and Dower 2011).

Whatever pain medications are chosen, the nurse plays the most important role of any caregiver in assessing, evaluating, documenting, preventing, and educating about pain in the ill



child. No medication can ever replace a caring, comforting, confident, reassuring, and truly present nurse to both the child and family in improving the overall comfort and recovery of the hospitalized child experiencing pain for any reason. Close follow-up after hospitalization is needed so that pain continues to abate, and medication use is carefully and consistently coordinated by health-care professionals in the transition between hospital care and primary care (Ali et al. 2010). The nurse in the neurosurgery clinic, or the hospital case manager doing telephone follow-up after surgery and discharge from the acute care setting, should work closely with home and primary care providers in more complex cases, to assure that pain management is sustained in the transition home.

Over the last decade, many groups, including pediatric health-care providers, professional organizations, and federal agencies, have brought the prevalence of prescription drug abuse to national attention. Medication abuse and misuse rates have grown significantly, and surveys among youth indicate that the overall prevalence of nonmedical use of opioids is an issue from the standpoint of concern for dependence and addiction and leads to the potential for providers to undertreat pain in this population. Prescriptions provided to older pediatric patients may be diverted to others like friends and family members. In addition, youth in pain may borrow others' medications, in place of making a follow-up appointment if their pain is not managed (Frese and Eiden 2011). Pediatric neurosurgical patients, particularly older children with chronic or recurring pain complaints, may need to be referred to pain specialists for comprehensive pain management.

### Conclusion

The twenty-first century witnessed rapid advancements in technology and successful treatments in the field of pediatric neurosurgery. These advances coincided with the evolution of expanded roles and responsibilities of nurses and an increasing number of advanced practice nurses. As members of

health-care teams, nurses have the most direct contact with patients and often the best opportunity to note signs of neurological abnormalities or subtle clinical changes in a child's condition. Thorough, accurate, and consistently documented neurological assessments can make the difference between recovery and complication and even life and death. Nurses who have accepted the responsibility of caring for children should strive to develop and consistently apply their neurological assessment skills.

### Pediatric Practice Pearls: Pediatric Neuro Assessment Tools # 1: Examination Tool

One useful and inexpensive tool for neurological assessment of both infants and young children is a *small retracting tape measure with a brightly colored push button* for tape retrieval. This simple tool can be kept in a pocket and used for the following:

- Assessment of occipital-frontal circumference (OFC).
- Assessment of extraocular eye movements (EOMs) by moving the retracted tape in all visual fields while holding the child's head steady.
- Assessment of cerebellar function by looking for tremor or dysmetria when asking the child to take their "pointer finger" and touch the button and then touch their nose. You can test both hands individually.
- Assessment of dexterity when you ask them to pull the tape out and then push the button to let it go back in with each hand.
- Assessment of cognitive skills by asking them to put it back into your bag or pocket – hint: toddlers and preschool-aged children may resist giving a toy or object back to the examiner but often will put an item back into an exam bag or basket.

### **Pediatric Practice Pearls: Pediatric Neuro Assessment Tools # 2: LOC Assessment Technique**

Assessing level of consciousness (LOC) for hospitalized pediatric neurology or neurosurgery patients can be challenging and so much depends on an accurate assessment. One tip is to “stage” your LOC assessment in the same order for each patient to allow for objectivity. As you move through this, note what stimuli is needed to arouse the patient, document as per agency protocol, and use the same pattern of escalating stimulation each time the patient is assessed.

- Start by approaching the bedside quietly and stating the child’s name, once softly and again more loudly.
- If there is no response, turn on bright light over patient.
- If no response with both of these, bring the bed or crib rail down (will create motion and often noise).
- If no response, touch the child on the arm or hand while calling their name.
- Increase to more significant motor stimulation and note what it takes to arouse the child; and if they stay responsive or immediately, fall back to sleep.
- If patient has a change from prior assessments or does not arouse, seek verification of your assessment immediately and call medical personnel as per agency policy.

### **Pediatric Practice Pearls: Pediatric Neuro Assessment Case # 3: External Ventricular Drain**

#### **Case Exemplar:**

A patient returns to the PICU from the OR after a craniotomy for septum pellucidotomy and endoscopic third ventriculostomy.

An external ventricular drain is in place. There is no CSF drainage, and the child is difficult to waken. “Not to worry,” states the resident over the phone, “...we lost a lot of CSF in the OR, and bumped the thalamus with the endoscope. She’ll be fine. Call me back later and update me.”

The seasoned PICU RN calls back 4 h later to report that though the child does respond to deep stimulus, there continues to be no CSF output. The resident is in surgery and tells the circulator to relay that she will see the patient when done with surgery. And, “Not surprising, thank you for the update.”

The neurosurgical PNP rounds early in the AM and finds RNs signing off to next shift. There is no CSF output, pressure wave is flat, child is difficult to arouse, and VS: HR 60, BP elevated. RNs note that they have been in touch with neurosurgery, regularly, and “we are not worried because of the type of surgery she had...” The neurosurgery NP double checks the child head to toe and checks all lines/equipment. She finds a stopcock that is located distal to the setup (not close to the CSF drip chamber) is closed. The child had suffered a massive stroke and was rushed back to surgery.

#### **Assessment Pearls**

In children whose exam/vital signs are not “making sense,” the bedside nurse needs to verify the findings with a colleague.

- Call the neurosurgeon and insist that she come to see the patient if you are concerned.
- Verify function of all equipment, i.e., that all stopcocks are open and drains are patent if there is no CSF output.
- Call attending if there is no drainage, if drainage is expected, and if neurological status changes.



## References

- Ali S, Drendel AL, Kircher J, Beno S (2010) Pain management of musculoskeletal injuries in children: current state and future directions. *Pediatr Emerg Care* 26(7):518–524. doi: [10.1097/PEC.0b013e3181e5c02b](https://doi.org/10.1097/PEC.0b013e3181e5c02b) [pii]; quiz 525–518
- American Academy of Pediatrics (1996) Eye examination and vision screening in infants, children, and young adults. *Pediatrics* 98(1):153–157
- American Academy of Pediatrics (2011) Health issues: bedwetting (enuresis). Healthy Children Website. <http://www.healthychildren.org/English/health-issues/conditions/emotional-problems/Pages/Bed-Wetting-Enuresis.aspx>. Accessed 21 Mar 2012
- Amidei C, Blissett P, Brooks L (2010) Assessment. In: Amidei C (ed) AANN core curriculum for neuroscience nursing, 5th edn. American Association of Neuroscience Nurses, Glenview, pp 107–157
- Asato MR, Nawarawong N, Hermann B, Crumrine P, Luna B (2011) Deficits in oculomotor performance in pediatric epilepsy. *Epilepsia* 52(2):377–385
- Bergen G, Chen LH, Warner M, Fingerhut LA (2008) Injury in the United States: 2007 Chartbook. National Center for Health Statistics, Hyattsville
- Brislin RP, Rose JB (2005) Pediatric acute pain management. *Anesthesiol Clin North America* 23(4):789–814 x
- Caplin DA, Austin JK, Dunn D (2009) Epilepsy. In: O'Donohue WT, Tolle LW (eds) Behavioral approaches to chronic disease in adolescence: a guide to integrative care. Springer, New York, pp 143–152
- Centers for Disease Control (2013) Web-based Injury Statistics Query and Reporting System. National Center for Injury Prevention and Control. [www.cdc.gov/ncipc/wisqars](http://www.cdc.gov/ncipc/wisqars)
- Cohen J (2009) Interrater reliability and predictive validity of the FOUR score coma scale in a pediatric population. *J Neurosci Nurs* 41(5):261–267 quiz 268–269
- Conn PM (1995) Neuroscience in medicine. J.B. Lippincott, Philadelphia
- Cook N, Woodward S (2011) Assessment, interpretation and management of altered consciousness. In: Woodward S, Mestecky A-M (eds) Neuroscience nursing: evidence based practice. Blackwell Publishing Ltd, West Sussex
- Dlamini N, Billingham L, Kirkham FJ (2010) Cerebral venous sinus (sinovenous) thrombosis in children. *Neurosurg Clin N Am* 21(3):511–527
- Elliott, L (2013) et al An inpatient child passenger safety program. *Clin Pediatr* 52 (11) 1022-1028
- Freedman SB, Al-Harthy N, Thull-Freedman J (2009) The crying infant: diagnostic testing and frequency of serious underlying disease. *Pediatrics* 123(3):841–848
- Frese WA, Eiden K (2011) Opioids: nonmedical use and abuse in older children. *Pediatr Rev* 32(4):e44–e52. doi:[10.1542/pir.32-4-e44](https://doi.org/10.1542/pir.32-4-e44)
- Greco C, Berde C (2005) Pain management for the hospitalized pediatric patient. *Pediatr Clin North Am* 52(4):995–1027, vii–viii
- Greisen G (2006) Brain monitoring in the neonate – the Rationale. *Clin Perinatol* 33:613–618 v–vi
- Hadley J (1994) Assessing child health. In: Betz C, Hunsberger M, Wright S (eds) Family centered nursing care of children, 2nd edn. Saunders, Philadelphia, pp 458–512
- Hamilton S (2006) Screening for developmental delay: reliable, easy-to-use tools. *J Fam Pract* 55(5):415–422. doi: [jfp\\_0506\\_5505c](https://doi.org/10.1097/00006123-200605000-00011) [pii]
- Halstead MD, Walter KD (2010) Clinical report: sports related concussion in children and adolescents. *Pediatrics* 126:597–615
- Haymore J (2004) A neuron in a haystack: advanced neurologic assessment. *AACN Clin Issues* 15(4):568–581. doi: [0004067-200410000-00008](https://doi.org/10.1004/0004067-200410000-00008) [pii]
- He YZ, Wang ZP, Wang J (2008) Value of Glasgow-Pittsburgh Coma scale scoring in childhood coma. *Zhongguo Dang Dai Er Ke Za Zhi* 10(5):614–616. doi: [1008-8830\(2008\)05-0614-03](https://doi.org/10.1008-8830(2008)05-0614-03)[pii]
- Hedlund GL (2002) Neuroradiology of the central nervous system in childhood. *Neurol Clin* 20(4):965–981 vi
- Hickey J (2009) Neurological assessment. In: Hickey J (ed) The clinical practice of neurological and neurosurgical nursing, 6th edn. Wolters Kluwer/Lippincott Williams & Wilkins, Philadelphia, pp 154–180
- Hobdell E (2001) Infant neurologic assessment. *J Neurosci Nurs* 33(4):190–193
- Howard AW, MacArthur C, Willan A, Rothman L, Moses-McKeag A, MacPherson AK (2005) The effect of safer play equipment on playground injury rates among school children. *CMAJ : Canadian Medical Association Journal* 172(11):1443–1446. <http://doi.org/10.1503/cmaj.1041096>
- Iaia A, Barker E (2008) Neurodiagnostic studies. In: Barker E (ed) Neuroscience nursing a spectrum of care, 3rd edn. Mosby/Elsevier, St. Louis, pp 99–130
- Karlin A (2011) Concussion in the pediatric and adolescent population: different population, different concerns. *Am Acad Pediatr Phys Med Rehabil* 3:S369–S379
- Knoeker A, Teddy A, et al (2015) Car seat inspection among children older than 3 years of age: using data to drive practice child passenger safety. *J Trauma Acute Care Surg* 79(3 Suppl 1):S48–54
- Knowlton RC (2008) Can magnetoencephalography aid epilepsy surgery? *Epilepsy Curr* 8(1):1–5. doi:[10.1111/j.1535-7511.2007.00215.x](https://doi.org/10.1111/j.1535-7511.2007.00215.x)
- Kramer U, Nevo Y, Harel S (1994) Jittery babies: a short-term follow-up. *Brain Dev* 16(2):112–114. doi: [10.1016/0387-604\(94\)90045-0](https://doi.org/10.1016/0387-604(94)90045-0) [pii]
- Lucille Packard Children's Hospital (2012) Neurological Examination. Retrieved from <http://www.lpch.org/DiseaseHealthInfo/HealthLibrary/neuro/neurexam.html>. Accessed 20 Mar 2012
- Marcoux KK (2005) Management of increased intracranial pressure in the critically ill child with an acute neurological injury. *AACN Clin Issues* 16:212–231
- McCrory P, Meeuwisse W, Johnston K et al (2009) Consensus statement on concussion in sport, Zurich,

- Switzerland, November 2008. *Br J Sports Med* 43(Suppl):76–90
- McGee S, Burkett KW (2000) Identifying common pediatric neurosurgical conditions in the primary care setting. *Nurs Clin North Am* 35(1):61–85
- Merkel SI, Voepel-Lewis T, Shayevitz JR, Malviya S (1997) The FLACC: a behavioral scale for scoring postoperative pain in young children. *Pediatr Nurs* 23(3):293–297
- Miró J, Castarlenas E, Huguet A (2009) Evidence for the use of a numerical rating scale to assess the intensity of pediatric pain. *Eur J Pain* 13(10):1089–1095. doi: S1090-3801(09)00151-7 [pii] [10.1016/j.ejpain.2009.07.002](https://doi.org/10.1016/j.ejpain.2009.07.002)
- Nakagawa, TA, Ashwal, S, Mathur, M, & Mysore, MR. (2011) Guidelines for the determination of brain death in infants and children: an update of the 1987 task force recommendations. *Soc Crit Care Med, Sect Crit Care Sect Neurol Am Acad Pediatr, Child Neurol Soc, Crit Care Med*, 39(9):2139–2155. doi: 00003246-201109000-00016 [pii] [10.1097/CCM.0b013e31821f0d4f](https://doi.org/10.1097/CCM.0b013e31821f0d4f)
- National Institute of Child Health and Human Development (2012) *Pediatr Endocrinol Train Program Tanner Staging Females Males*. Retrieved from <https://science.nichd.nih.gov/confluence/display/pe/Clinical+Resources>. Accessed on 21 Mar 2012
- Nellhaus G (1968) Head circumference from birth to eighteen years. Practical composite international and interracial graphs. *Pediatrics* 41(1):106–114
- Pasero C, Eksterowicz N, Primeau M, Cowley C (2008) The registered nurse's role in the management of analgesia by catheter techniques. *J Perianesth Nurs* 23(1):53–56
- Purugganan OH (2006) Abnormalities in head size. *Pediatr Rev* 27(12):473–476 doi: [10.1542/pir.27-12-473](https://doi.org/10.1542/pir.27-12-473) [pii]
- Randive S, Mehta V (2012) Breakthrough pain—novel analgesics. *Curr Clin Pharmacol*. doi: [10.2174/157488412800228893](https://doi.org/10.2174/157488412800228893) [pii]
- Rosen DA, Dower J (2011) Pediatric pain management. *Pediatr Ann* 40(5):243–252 doi:[10.3928/00904481-20110412-05](https://doi.org/10.3928/00904481-20110412-05)
- Rydz D et al (2004) Screening for developmental delay in the setting of a community pediatric clinic; a prospective assessment of parent-report questionnaires. *Pediatrics* 113(6):1926–1933
- Sables-Baus S, Robinson M (2011) Pediatric neurological exam. *Int Emerg Nurs* 19:199–205
- Safavi A, Rhee P, Pandit V et al (2014) Children are safer in states with strict firearm law; a national inpatient study. *Trauma Acute Care Surg* 76(1):146–150
- Santrock, JW (1998) Physical growth and development in infancy. In: Santrock JW (ed) *Physical and cognitive development in infancy*. Chapter 3. Retrieved from [highered.mcgraw-hill.com/sites/0073405515/519572/Santrock\\_ch3.pdf](http://highered.mcgraw-hill.com/sites/0073405515/519572/Santrock_ch3.pdf). Accessed on 27 Oct 2012
- Schultz R, Hockenberry M (2011) The child with cerebral dysfunction. In: Hockenberry MJ, Wilson D (eds) *Wong's nursing care of infants and children*, 9th edn. Elsevier/Mosby, St. Louis, pp 1507–1566
- Shuper A, Zalzburg J, Weitz R, Mimouni M (1991) Jitteriness beyond the neonatal period: a benign pattern of movement in infancy. *J Child Neurol* 6(3):243–245
- Slota MC (1983a) Neurological assessment of the infant and toddler. *Crit Care Nurse* 3(5):87–92
- Slota MC (1983b) Pediatric neurological assessment. *Crit Care Nurse* 3(6):106–112
- Spencer D, Daniels J (2016) Pediatric developmental screening: what constitutes evidence-based practice? *Ad Nurse Pract Phys Assist*. Retrieved on 26 Sept 2016: <http://nurse-practitioners-and-physician-assistants.advanceweb.com>
- Stapelkamp C, Carter B, Gordon J, Watts C (2011) Assessment of acute pain in children: development of evidence-based guidelines. *Int J Evid Based Healthc* 9(1):39–50 doi:[10.1111/j.1744-1609.2010.00199.x](https://doi.org/10.1111/j.1744-1609.2010.00199.x)
- Stevens B, Johnston C, Taddio A, Gibbins S, Yamada J (2010) The premature infant pain profile: evaluation 13 years after development. *Clin J Pain* 26(9):813–830 doi:[10.1097/AJP.0b013e3181ed1070](https://doi.org/10.1097/AJP.0b013e3181ed1070)
- Teo JH, Palmer GM, Davidson AJ (2011) Post-craniotomy pain in a paediatric population. *Anaesth Intensive Care* 39(1):89–94
- Togioka BM, Arnold MA, Bathurst MA, Ziegfeld SM, Nabaweesi R, Colombani PM, Abdullah F (2009) Retinal hemorrhages and shaken baby syndrome: an evidence-based review. *J Emerg Med* 37(1):98–106. doi: S0736-4679(08)00617-3[pii] [10.1016/j.jemermed.2008.06.022](https://doi.org/10.1016/j.jemermed.2008.06.022)
- U.S. Department of Education Special Education and Rehabilitative Services (2005) *Individuals with disabilities education act*. U.S. Department of Education, Washington, DC. Retrieved from [www.ed.gov/about/offices/list/osep](http://www.ed.gov/about/offices/list/osep)
- Volpe JJ (2009) The encephalopathy of prematurity – brain injury and impaired brain development inextricably intertwined. *Semin Pediatr Neurol* 16(4):167–178. doi: S1071-9091(09)00063-1[pii] [10.1016/j.spn.2009.09.005](https://doi.org/10.1016/j.spn.2009.09.005)
- Wakes S, Beukes A (2012) Height fun and safety in the design of children's playground equipment. *Int J Inj Control Saf Promot* 19(2):101–108
- Wallace D, Disabato J (2014) Age appropriate assessment table. Adapted from children's rehabilitative services. St. Joseph's Hospital, Phoenix
- Wijdicks EF, Bamlet WR, Maramattom BV, Manno EM, McClelland RL (2005) Validation of a new coma scale: the FOUR score. *Ann Neurol* 58(4):585–593 doi:[10.1002/ana.20611](https://doi.org/10.1002/ana.20611)

Nadine Nielsen and Amanda Breedt

---

## 2.1 Hydrocephalus

Hydrocephalus is a condition resulting from an imbalance between the production and absorption of cerebral spinal fluid (CSF). This imbalance results in an increased volume of spinal fluid, often dilation of the ventricular system, and often increased intracranial pressure. Hydrocephalus onset can be acute and occur over hours or days. It may also be chronic and occur over months or years. Hydrocephalus can occur as an isolated condition or one associated with numerous other neurological conditions and diseases.

---

## 2.2 History of Hydrocephalus

The term hydrocephalus is derived from the Greek words “hydro” meaning water and “cephalus” meaning head. The description and treatment of hydrocephalus date back to the eras of Hippocrates and Galen. Galen (130–200 AD) identified the ventricles. He believed that the soul

was purified through the pituitary gland. Waste was discharged via the nose as “pituita.” During the renaissance, Vesalius (1514–1564) described the ventricular system in his original text on human anatomy. A century later, Franciscus Sylvius (1614–1672) described the cerebral aqueduct. Morgagni (1682–1771) described the pathology of hydrocephalus, and Monro (1733–1817) named the intraventricular foramen. In 1768, Whytt distinguished internal and external hydrocephalus.

Early treatment included bleeding, purging, surgical release of the fluid, puncturing the ventricles to drain the fluid, injection of iodine or potassium hydriodate into the ventricles, binding of the head, application of a plaster of herbs to the head, application of cold wraps to the head, lumbar puncture, and diuretics. Confusion about hydrocephalus persisted into the 1800s. It was thought to be caused by fevers, rheumatism, pulmonary consumption, and worms; however, treatment did not change.

The earliest attempts at surgery occurred during the late 1800s. The first shunts diverted spinal fluid from the ventricles to the subcutaneous or subdural spaces. During the early 1900s, other surgical procedures were attempted to treat the condition. These procedures included surgical removal of the choroid plexus, diversion of spinal fluid through a third ventriculostomy, and continued attempts at shunting, including attempts to shunt into the vascular space. Most of these patients did poorly, and either suffered the consequences of

---

Katherine Pearce, Elisabeth Limbacher, and Donna C. Wallace were authors on the first edition but did not contribute to the revision of this chapter.

N. Nielsen, MN, ARNP (✉) • A. Breedt, MN, ARNP  
Department of Neurosurgery, Seattle Children’s  
Hospital, 4800 Sand Point Way N.E., 5371/6E-1,  
Seattle, WA 98105, USA  
e-mail: [nadine.nielsen@seattlechildrens.org](mailto:nadine.nielsen@seattlechildrens.org);  
[mandy.breedt@seattlechildrens.org](mailto:mandy.breedt@seattlechildrens.org)

prolonged increased intracranial pressure or died. Many institutions cared for and housed these disabled children with very large heads, small bodies, and severe mental retardation.

Modern shunting procedures began in the 1950s with the introduction of the antireflux valve. The first valves, developed by Nulson and Spitz in 1952, used a spring and steel ball valve. Holter then developed the first slit valve. He was particularly interested in shunt development, as he had a son with a myelomeningocele and hydrocephalus. These first modernized shunts diverted CSF from the ventricles to the right atrium of the heart. The ventricular to peritoneal shunt became the preferred shunt in the 1970s because it allowed for the child to grow and not outgrow the length of the shunt tubing. This has remained the preferred shunt procedure among modern neurosurgeons. Neurosurgeons have also placed shunts leading from the ventricle to the pleural space, gall bladder, ureter, or fallopian tube if the abdominal cavity is not a suitable place to terminate the shunt. Numerous improvements of shunt hardware have occurred in the last four decades.

A genetic understanding of hydrocephalus and diseases associated with hydrocephalus has occurred in the last decade. Such knowledge of genetics has allowed for improved prenatal diagnosis and genetic counseling.

---

### 2.3 Incidence of Hydrocephalus

Hydrocephalus is the most common neurosurgical problem encountered by pediatric neurosurgeons. The overall incidence is difficult to determine, as hydrocephalus can occur as an isolated condition or in conjunction with many other neurological diseases and conditions. The overall incidence of hydrocephalus at birth is 0.5–4 per 1,000 live births. As an isolated congenital disorder, the incidence of hydrocephalus is 0.5–1.5 per 1,000 live births. Hydrocephalus occurs in about 80–85% of infants born with a myelomeningocele. Because hydrocephalus is associated with so many other diseases and conditions, it is impossible to know how many such

children actually exist in the general population. A recent study revealed that pediatric hydrocephalus results in 38,200–39,900 annual hospital admissions, with total hospital charges of \$1.4–2.0 billion dollars. Hydrocephalus accounts for 3.1% of all pediatric hospital charges (Simon et al. 2008). Surgeries to place and revise shunts comprise approximately half of a pediatric neurosurgeon's annual operative cases (McLone 2001).

---

### 2.4 Prognosis

The prognosis for children with hydrocephalus has markedly improved with modern shunting. The natural history of unshunted hydrocephalus was studied, and it revealed a 46% survival rate for 10 years (Laurance and Coates 1962). Of the surviving population, 62% suffered from intellectual impairment (Laurance and Coates 1962). Children who are adequately treated for hydrocephalus have a considerably better outcome. Prognosis is challenging to measure given the integrated sources of hydrocephalus, in combination with brain tumor or myelomeningocele. Paulsen et al. (2015) followed patients with hydrocephalus through into their fourth decade of life. At that time approximately half of patients were still alive; mortality rate was 48% (including brain tumor and myelomeningocele patients). Thirty-one (24%) patients died during the first 2 years after initial shunt insertion, and 15 of these were patients with tumors. Thus, the 2-year mortality rate in nontumor patients was 12%. Vinchon et al. (2012) found a mortality rate of 18.1% at 20 years.

As mentioned the prognosis of an infant or child with hydrocephalus is mostly dependent on the underlying cause of the hydrocephalus. Prognosis may also be related to the complications that occur, such as shunt malfunctions and infections. The best predictors of a good outcome are the prompt treatment of the hydrocephalus and the ability of the brain to grow normally in the newborn once a functioning shunt is placed. Shunt dependency is associated with a 1% mortality rate per year (Ditmyer 2004).

## 2.5 Classifications of Types of Hydrocephalus

Hydrocephalus is subdivided into several different categories. Communicating and noncommunicating are the most common categories. These terms were previously used interchangeably with obstructive and nonobstructive. The latter terms have fallen from use, as it is believed that in almost all cases of hydrocephalus, there is some obstruction of CSF reabsorption; the exception is the rare state of overproduction of CSF. Hydrocephalus is also subdivided into congenital versus acquired and internal versus external (Table 2.1). Other categories include normal pressure hydrocephalus and ex vacuo hydrocephalus.

### 2.5.1 Communicating Hydrocephalus

Communicating hydrocephalus is a condition that results when the arachnoid villi are unable to adequately reabsorb cerebral spinal fluid. Intraventricular or subarachnoid hemorrhage may cause the arachnoid villi to become unable to function adequately, either temporarily or permanently. This is a consequence of the effect of the end products of red blood cell breakdown on the arachnoid villi. Infectious processes such as meningitis may also render the arachnoid villi to be nonfunctional (due to, e.g., toxins or scarring). Communicating hydrocephalus may also be due to the overproduction of CSF. This is rare and is usually associated with a choroid plexus papilloma or a choroid plexus carcinoma.

### 2.5.2 Noncommunicating Hydrocephalus

Noncommunicating hydrocephalus is a condition that results when the ventricular system does not communicate with the arachnoid villi due to some obstruction in the normal pathways of CSF flow. Consequently, CSF is produced in the ventricular system but cannot flow to the arachnoid villa to be

**Table 2.1** Classifications of hydrocephalus

Communicating
Congenital
Achondroplasia
Associated with craniofacial syndromes
Acquired
Posthemorrhagic: intraventricular or subarachnoid
Choroid plexus papilloma or choroid plexus carcinoma
Venous obstruction as in superior vena cava syndrome
Postinfectious
Noncommunicating
Congenital
Aqueductal stenosis
Congenital lesions (vein of Galen malformation, congenital tumors)
Arachnoid cyst
Chiari malformations either with or without myelomeningocele
X-linked hydrocephalus
Dandy-Walker malformation
Acquired
Aqueductal gliosis (posthemorrhagic or postinfectious)
Space-occupying lesions such as tumors or cysts
Head injuries

reabsorbed. Such obstruction can occur when pathways are blocked by a tumor, congenital abnormalities of the brain, cysts, inflammation from infection, or any other condition that interferes with the patency of these pathways. Some consider the failure of the arachnoid villi to reabsorb CSF to be an obstruction at the level of the arachnoid villi.

### 2.5.3 Congenital Hydrocephalus

Congenital hydrocephalus is caused by any condition that existed before birth. The hydrocephalus may or may not be present at birth. Examples include aqueductal stenosis, Dandy-Walker malformation, and X-linked hydrocephalus. Congenital hydrocephalus is also associated with myelomeningocele, Chiari malformations, encephalocele, and prenatal infections such as cytomegalo inclusion virus (CMV) or rubella.



### 2.5.4 Acquired Hydrocephalus

Acquired hydrocephalus is hydrocephalus resulting from a condition that did not previously exist in the patient. The condition either obstructs normal spinal fluid flow, causes overproduction of CSF, or prevents reabsorption of CSF. Examples include tumors that obstruct CSF flow and other space-occupying lesions that were not congenital. Infection in the brain may also occlude small passageways. Overproduction of spinal fluid may be caused by a choroid plexus tumor. Acquired conditions that interfere with reabsorption of CSF include intraventricular hemorrhage (IVH) and subarachnoid hemorrhage.

### 2.5.5 Internal Hydrocephalus

Internal hydrocephalus refers to ventricular dilation and the associated pathophysiology. The term hydrocephalus is used most commonly to refer to internal hydrocephalus.

### 2.5.6 External Hydrocephalus

External hydrocephalus refers to the accumulation of spinal fluid in either the subarachnoid or subdural spaces. CSF collection in the subarachnoid space may be a benign condition in infancy, which is called benign subdural hygromas of infancy or idiopathic external hydrocephalus of infancy. The neuroimaging characteristics of this condition typically show enlarged frontal subarachnoid spaces and moderately enlarged ventricles. Infants present with rapidly increasing head circumference and sometimes developmental delays. Some children may show temporary or permanent psychomotor delays (Zahl et al. 2011). This is usually a self-limiting condition. The child is usually treated conservatively, although some may require a shunt.

CSF mixed with blood in the subdural space may not be benign and usually requires further investigation and treatment, as it may be related to trauma (possibly nonaccidental trauma). If these fluid collections exert pressure on the brain and cause symptoms or cause very accelerated head growth, surgical treatment may be necessary.

### 2.5.7 Ex Vacuo Hydrocephalus

Ex vacuo hydrocephalus refers to a condition of brain volume loss. The condition may be present at birth. It may be the result of failure of the fetal development of the brain as in schizencephaly (abnormal development of the brain, leading to the characteristic appearance of abnormal clefts in either one or both cerebral hemispheres) or hydranencephaly (abnormal development of the brain, leading to the absence of the cerebral hemispheres of the brain). The brain may also undergo destruction or atrophy from infections, very poor nutrition, or unknown causes. The ventricles become large to “fill the space” where there is an absence of brain tissue and may or may not be under increased pressure. There is technically not an imbalance of CSF production and absorption but rather the actual loss of brain matter.

### 2.5.8 Idiopathic Normal Pressure Hydrocephalus

Idiopathic normal pressure hydrocephalus is primarily a condition of the elderly. It is a condition that occurs with normal intracranial pressure and ventricular dilation. These patients develop symptoms slowly over time. The classic symptoms include dementia, gait difficulties, and urinary incontinence. A shunt may be helpful if the symptoms improve after a lumbar puncture or lumbar drain.

---

## 2.6 Pathophysiology of Hydrocephalus

### 2.6.1 Overview of CSF Production and Flow Dynamics

Most of the CSF (approximately 60%) is produced in the choroid plexus; the rest is produced in the ependymal of the cerebral ventricles, the aqueduct of Sylvius, and the subarachnoid space. Studies by Milhorat looking at CSF production after choroid plectomy demonstrated that the total amount of produced CSF was reduced by only one-third, thus suggesting that other sites can produce larger amount of CSF (Milhorat 1982). He proposed that CSF is also produced as the result of cellular

metabolism of periventricular cortical gray matter. These other areas account for 20–50% of CSF production. CSF production requires the expenditure of energy (Albright et al. 2007).

### 2.6.2 CSF Pathways

CSF flows from the ventricles, passes through a series of channels, and exits the ventricular system via the fourth ventricle. There are two lateral foramina on the lateral aspect of the fourth ventricle, named the foramen of Luschka, and medially located opening called the foramen of Magendie. After exiting the fourth ventricle, the CSF flows into the subarachnoid space and up over the convexities of the brain, to be absorbed into the large intracranial sinuses (Albright et al. 2007). Alternative pathways for CSF have been scientifically supported and include lymphatic drainage into the cervical lymphatic chain and paranasal sinuses. After being absorbed, the CSF is returned to the right atrium via the superior vena cava (Albright et al. 2007).

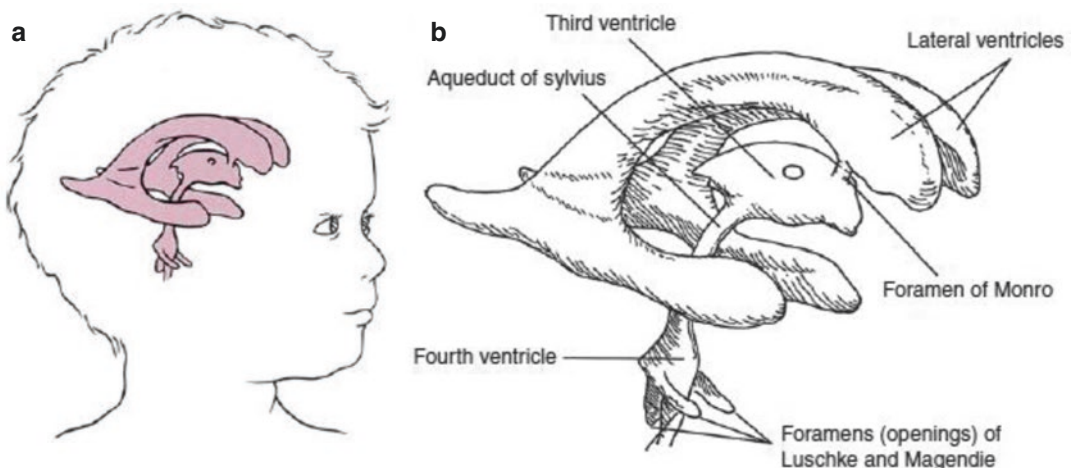
### 2.6.3 Intracranial Pressure

A study of rabbits by Dr. McComb found that CSF flows passively and absorption of CSF does not require the expenditure of energy (Albright et al. 2007). For each drop of CSF that is produced, the same amount should be absorbed. Several factors affect the flow of CSF, including resistance, which

may result from an obstruction or restriction of a pathway. Other considerations include the plasticity of the brain itself, as well as the flexibility of the intracranial venous structures.

Neuroplasticity refers to the ability of the brain to change in structure or function. For example, an increase in the intraventricular volume will enlarge the ventricles, causing distortion of the cerebral cortex. As we age, our brain may become stiffer. Neonatal brains are very elastic. Anoxic injury can change the brain's ability to maintain its normal stiffness and can also be hydroplastic. The intracranial venous system includes the dural sinuses which are more rigid than the cortical veins. Cortical veins join the dural sinuses at such an angle that a valvular mechanism is created and a pressure gradient is maintained. The jugular veins, returning the blood to the heart, have no valves. When we stand, negative pressure produced in the jugular veins causes them to collapse and assist humans in maintaining normal intracranial pressure. Shunting systems are used when the CSF pathways are somehow obstructed. The valves that are used to regulate the flow attempt to mimic normal flow.

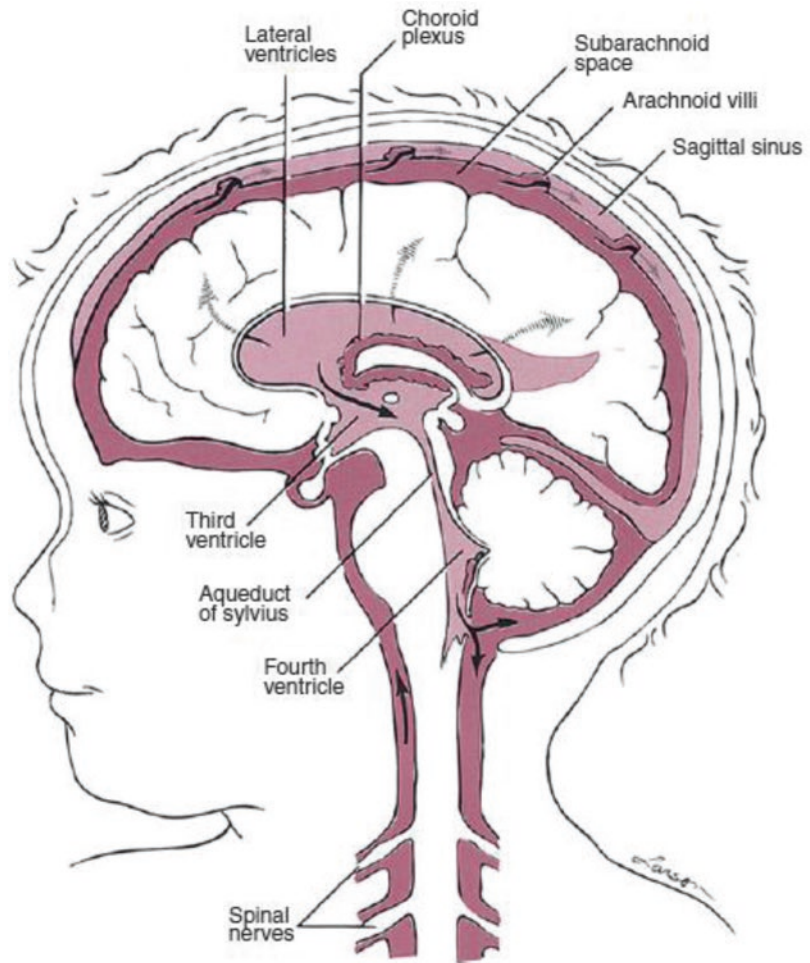
The normal rate of CSF production in infants and children is about 0.33 ml/kg/h. Normal newborns have about 5 ml total volume of CSF. Adults have about 125 ml of total CSF, with about 20 ml located within the ventricles. CSF is produced continually by the choroid plexus, which is located within the ventricles. It is continually reabsorbed by the arachnoid villi (Figs. 2.1 and 2.2).



**Fig. 2.1** Illustration of position and configuration of intracranial ventricles



**Fig. 2.2** Illustration of cross section of the brain and ventricles shows pathways of CSF flow



The pathophysiology of hydrocephalus is much more complex than the radiographic picture. The computed tomography (CT) or magnetic resonance imaging (MRI) scan may reveal many structural changes including enlarged ventricles, thinning of the cortical mantle, distortion of structures, and possible transependymal flow of CSF. These visible changes may also affect the biochemistry, metabolism, and maturation of the brain. Adequate treatment and resolution of the dilated ventricles does not always reverse the other injuries that have occurred to the brain.

Three factors are critical in determining the severity of injury caused by hydrocephalus: age at onset, underlying cause (etiology), and duration of the hydrocephalus. Age is a salient factor because hydrocephalus may affect the normal maturation processes of the brain in addition to

the other expected effects of increased intracranial pressure. Furthermore, the underlying disease process responsible for the hydrocephalus may have its own destructive effects on maturation and brain function. Examples of such diseases are encephalitis, meningitis, tuberous sclerosis, and tumors. Treatment of these diseases may also have destructive effects on the brain and brain maturation. For example, radiation treatment of brain tumors in very young children can interrupt normal maturation permanently, and development does not always proceed normally, even after the resolution of the hydrocephalus. The duration of the hydrocephalus has a critical role in determining the long-term recovery. Long-standing ventricular dilation and increased intracranial pressure tend to lead to poor recovery of function, even after ventricular size normalizes.

### 2.6.4 Structural Changes

Ventricular dilation seen on the CT or MRI is the hallmark of hydrocephalus. The temporal and frontal horns of the lateral ventricles usually dilate first and are sometimes asymmetrical. This is due to the accumulation of spinal fluid and leads to distortion of the adjacent structures, compression of the nearby white matter, reduction of cerebral cortex, and thinning of the cortical mantle. The ependymal cells lining the ventricles may become damaged and allow transependymal flow of CSF. The septum pellucidum may become damaged, leading to its disappearance and the formation of one large ventricular cavity. In some situations, ventricular size may not change even though pressure is elevated and symptoms are present.

### 2.6.5 Vascular Changes

The distortion of the brain tissue that occurs with hydrocephalus also affects the arteries, veins, and capillaries. Deep vessels are affected the most as they may be directly compressed from the increased ventricular size. Peripheral vessels are also affected as they try to supply the brain tissue that is suffering from the insult of increased intracranial pressure. Blood flow has been shown to be globally decreased to the brain in acute hydrocephalus (Da Silva et al. 1995). Blood flow is primarily decreased to the periventricular white matter in chronic hydrocephalus (Da Silva et al. 1995). Hypoperfusion may cause damage to neurons and glia and interfere with normal maturation of all brain structures.

### 2.6.6 Metabolic Changes

The brain of a child consumes about 50% of total body oxygen, and an infant's brain consumes more than 50%. The adult brain consumes only about 20% (Sokoloff 1989). The brain uses glucose as its primary source of energy with few exceptions. Therefore, any decrease in cerebral blood flow that decreases the amount of oxygen and glucose available can markedly alter metabo-

lism. This impairment of metabolism may lead to damage to the brain. Furthermore, during infancy and childhood, a significant portion of the energy used by the brain is used for maturational activities such as myelination, neuronal maturation, and protein production. Normal maturation may be disturbed and possibly permanently altered, due to these metabolic alterations.

### 2.6.7 Cerebral Spinal Fluid Changes

Abnormal amounts of spinal fluid in the brain may lead to changes in the CSF itself. Metabolites may accumulate in the CSF during hydrocephalus. Protein levels in the CSF may be altered by the underlying cause of the hydrocephalus. For example, after an IVH, protein levels may be very elevated. If the hydrocephalus damages the ependymal cells lining the ventricles, the CSF may flow out of the ventricles into the periventricular white matter. CSF production may or may not decrease as intracranial pressure increases. As intracranial pressure increases, reabsorption of CSF may increase assuming that the arachnoid villi are functional.

### 2.6.8 Brain Tissue Changes

The white matter surrounding the enlarged ventricles is called the periventricular white matter. As the ventricles dilate, the white matter may become compressed, saturated with CSF, and possibly damaged. Periventricular leukomalacia may result from ischemia to affected white matter. The corpus callosum may also become thinned.

The myelination process may also be delayed in children with hydrocephalus. Myelination occurs in a stepwise fashion during development. If one step is interrupted, it cannot occur at a later time, and this prevents subsequent steps in the overall process.

The cerebral cortex is also markedly affected by hydrocephalus. The cortex is thinned as it is pushed out by the ventricles and restricted by the skull. Histological changes within the cortex are usually subtle, but damage to cells occurs and results in a change in function.

The goal of treatment of hydrocephalus is to prevent further damage and to restore function. Treatment usually reverses symptoms of acute hydrocephalus. However, timing is critical, and treatment should occur before vascular, metabolic, and other changes described interfere with normal maturation and brain function. Without prompt treatment, acute hydrocephalus and increased intracranial pressure can lead to brain stem herniation and death.

## 2.7 Etiologies of Hydrocephalus

Hydrocephalus is primarily a condition of obstructed CSF circulation or absorption. In infants and children, it may be congenital or associated with other congenital abnormalities. It may also be associated with central nervous system (CNS) infection, hemorrhage, tumors, or cysts.

### 2.7.1 Aqueductal Stenosis

In 1900, Bourneville and Noir noted an association between hydrocephalus and stenosis of the aqueduct of Sylvius (Cinalli et al. 2004). The aqueduct of Sylvius is a narrow passageway connecting the third and fourth ventricles. The most common cause of hydrocephalus in children is aqueductal stenosis, and it accounts for 70% of cases (Greenberg 2010). Hydrocephalus due to aqueductal stenosis is characterized by enlargement of the lateral and third ventricles with a normal fourth ventricle. This constriction of the aqueduct of Sylvius is best seen on MRI scan (sagittal view).

Stenosis of this passageway may be congenital or acquired, although in 50–75% of cases, the cause may be unknown. It may be associated with Chiari I malformation, vein of Galen malformation (VGAM), or Dandy-Walker malformation. Aqueductal stenosis may also be due to an X-linked recessive gene, *LICAM* mutation, (Langingham et al. 2009) occurring only in males. This is rare and is associated with characteristic adducted thumbs, spastic paraparesis, and mental retardation. Acquired cases of aqueductal

stenosis may be the result of hemorrhage, inflammation from infection, or obstruction from a nearby tumor or cyst.

### 2.7.2 Myelomeningocele and Chiari II Malformation

Myelomeningocele is a neural tube defect that occurs during embryonic development resulting in failure of the neural tube to close. This malformation involves the entire CNS. At the level of the spinal defect, there is a midline lesion containing meninges, spinal cord, nerves, and CSF. The bony structures of the spine may be abnormal or absent. Associated abnormalities in the brain include Chiari II malformation, hydrocephalus, and possibly other structural abnormalities.

Chiari II malformation occurs in almost all infants born with myelomeningocele.

It is a malformation of the hindbrain, fourth ventricle, and brain stem and includes herniation of these structures into the cervical spinal canal. Herniation of the brain stem and fourth ventricle may result in obstruction of CSF flow. The development of hydrocephalus is related to the Chiari II malformation, aqueductal stenosis, venous hypertension in the posterior fossa, and closure of the myelomeningocele (Sgouros 2004a, b).

Hydrocephalus develops in about 85% of children with myelomeningocele. Approximately 50% have significant hydrocephalus at birth (Wang and Avellino 2005). About 80–90% will eventually require a CSF shunt (Dias 2005) or an endoscopic third ventriculostomy (ETV). Before modern shunting of these infants in the 1960s, only about 20% of non-shunted children lived into adulthood. Today, hydrocephalus can usually be adequately treated. Infants and children who die from this complex condition usually die from the Chiari II malformation and brain stem dysfunction. New research shows that patients who have undergone prenatal closure of the myelomeningocele have lower rates of hydrocephalus, and in some patients, there was no formation of a Chiari II malformation (Adzick et al. 2011).

Myelomeningocele is discussed in detail in Chap. 5.

### 2.7.3 Chiari I Malformation

Chiari I malformation is one of the four types of Chiari malformations. In Chiari I, the cerebellar tonsils are elongated and herniated into the cervical spinal canal. Chiari I is not associated with myelomeningocele and may be acquired from increased intracranial pressure or occur as an isolated condition.

Hydrocephalus occurs in 10% of children with Chiari I malformation, most likely due to blockage of CSF flow at the craniovertebral junction. A small posterior fossa may also alter CSF flow. Treatment for patients with symptomatic Chiari I malformation is often a posterior fossa decompression. A small percentage of children develop hydrocephalus after the decompression.

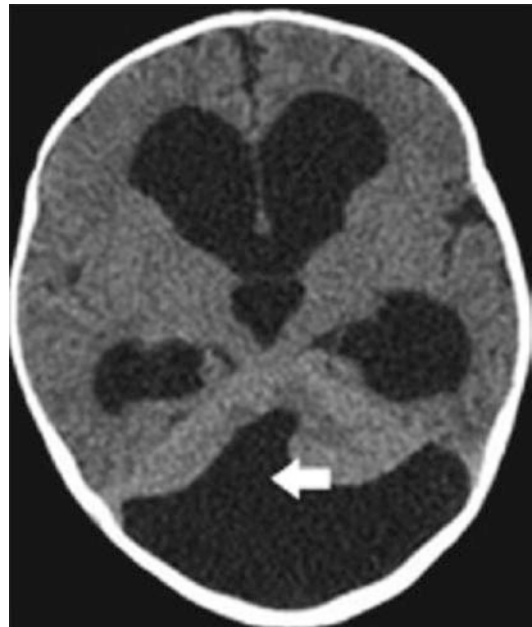Chiari malformations are discussed in detail in Chap. 6.

### 2.7.4 Dandy-Walker Malformation

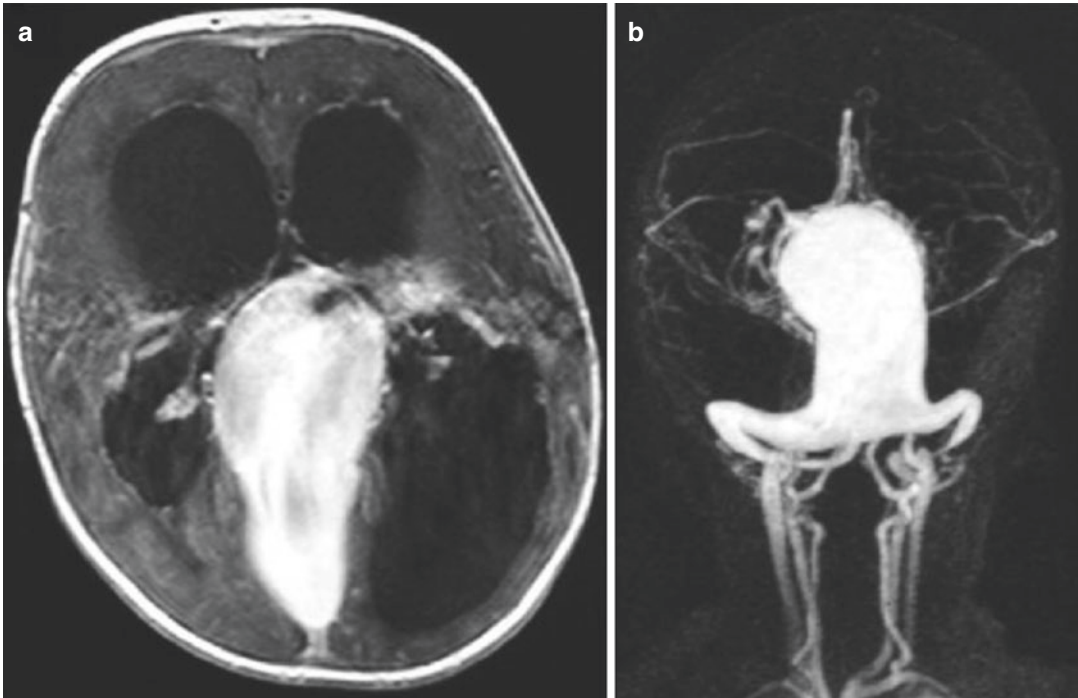
Dandy-Walker malformation is a continuum of posterior fossa abnormalities including Dandy-Walker malformation and Dandy-Walker variants. The abnormalities associated with these conditions include cystic dilation of the fourth ventricle, partial or complete absence of the cerebellar vermis, upward displacement of the tentorium, and usually hydrocephalus. Dandy-Walker may be differentiated from a posterior fossa cyst by the atrophy or agenesis of the vermis seen on MRI scan. Dandy-Walker malformation/variant may also be associated with other intracranial abnormalities in 70% of patients. These abnormalities include agenesis of the corpus callosum, aqueductal stenosis, schizencephaly, holoprosencephaly (failure of the prosencephalon, the embryonic forebrain, to sufficiently divide into the double lobes of the cerebral hemispheres, resulting in a single-lobed brain and severe craniofacial defects), neural tube defect, and occipital encephalocele. Dandy-Walker is found in 2–4% of all children with hydrocephalus (Greenberg 2010). Other abnormalities associated with Dandy-Walker malformation/variant include congenital heart

defects, renal malformations, polydactyly/syndactyly, cleft palate, perineal malformations, Klippel-Feil malformation, and facial hemangiomas.

Hydrocephalus occurs in 90% of children with Dandy-Walker malformation/variant (Greenberg 2010). Initially, it was believed that associated hydrocephalus was caused by obstruction of the foramina of Luschka and Magendie. Dandy and Blackfan (1914) believed that the foramina failed to develop or were obstructed due to a prenatal inflammatory process. However, in some cases, the foramina are found to be patent. Also, about 80% of infants with Dandy-Walker malformation do not have hydrocephalus at birth (Cinalli et al. 2004). The pathophysiology of hydrocephalus associated with Dandy-Walker is now felt to be multifactorial. Contributing factors include aqueductal stenosis, basal arachnoiditis from an inflammatory process, abnormally developed subarachnoid space, and venous hypertension from direct pressure from the posterior fossa cyst (Cinalli et al. 2004) (Fig. 2.3).



**Fig. 2.3** A 2-month-old female with Dandy-Walker malformation. MRI shows a posterior fossa cyst of the fourth ventricle and subsequent development of severe hydrocephalus



**Fig. 2.4** A 4-month-old male with vein of Galen malformation: (a) MRI shows the dilated vein of Galen; (b) cerebral angiogram shows the dilated vein of Galen and the surrounding vasculature

### 2.7.5 Vein of Galen Malformation

A vein of Galen malformation is a rare vascular malformation. It is a venous aneurysm of the vein of Galen fed by numerous aberrant branches of the carotid or vertebrobasilar vessels. In addition, arteriovenous malformations may occur within the feeding vessels.

Infants with a vein of Galen malformation often present at birth with congestive heart failure and hydrocephalus. They may also develop hydrocephalus later. Hydrocephalus may be caused by the venous malformation causing obstruction of the cerebral aqueduct. Elevated intracranial venous pressure may also decrease CSF reabsorption and cause hydrocephalus (Fig. 2.4a, b).

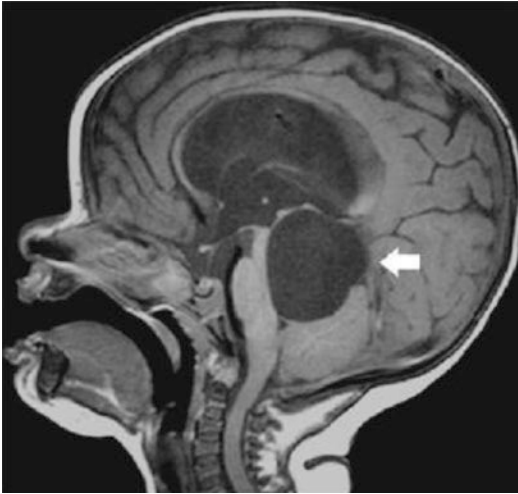Cerebrovascular diseases are discussed in detail in Chap. 12.

### 2.7.6 Arachnoid Cysts

An arachnoid cyst is a benign congenital cyst occurring within the brain. The cyst forms dur-

ing fetal development with the splitting of the arachnoid membrane (Raffel and McComb 1994), creating an intra-arachnoid space and the resultant cyst. Most of these cysts do not change or cause any other problems. Such cysts are often found incidentally when a child has a scan for some other reason (i.e., head injury). If the cyst enlarges, it may compress the surrounding structures and cause symptoms from mass effect. Depending on the location, as the cyst expands, it may compress nearby CSF pathways and cause hydrocephalus. A suprasellar cyst may expand upward pressing on the floor of the third ventricle and obstruct the foramen of Monro or aqueduct of Sylvius. A cyst in the quadrigeminal cistern or supracollicular region may cause obstruction of the aqueduct of Sylvius. A posterior fossa arachnoid cyst can cause obstruction at the level of the fourth ventricle. A posterior fossa cyst can be differentiated from a Dandy-Walker malformation by the presence of the cerebellar vermis and a normal appearing fourth ventricle on an MRI. The etiology of expansion of the cyst is unknown.





**Fig. 2.5** MRI shows a large posterior fossa cyst which effaces the aqueduct of Sylvius and fourth ventricle causing severe hydrocephalus

Surgical intervention is required if hydrocephalus occurs or there are symptoms of mass effect from the cyst. What appears to be an arachnoid cyst may also be associated with a brain tumor. Therefore patients with a newly found cyst require a full MRI of the brain, possibly with contrast, to rule out a tumor. An arachnoid cyst identified before the age of two typically presents with macrocephaly. These cysts are thought to be affected by CSF dynamics, requiring a greater rate of treatment. In Zada et al.'s (2007) study, after fenestration, 57% of patients still required shunt placement (Zada et al. 2007) (Fig. 2.5).

### 2.7.7 Posthemorrhagic Hydrocephalus of Prematurity

The most common cause of hydrocephalus in the premature infant is a germinal matrix hemorrhage. The germinal matrix is a very vascular area in the fetal brain, in the subependymal region located at the level of the foramen of Monro. It is from the very thin-walled germinal matrix vessels that the bleeding is thought to occur in preterm infants. Bleeding can

**Table 2.2** Grading of intraventricular hemorrhage

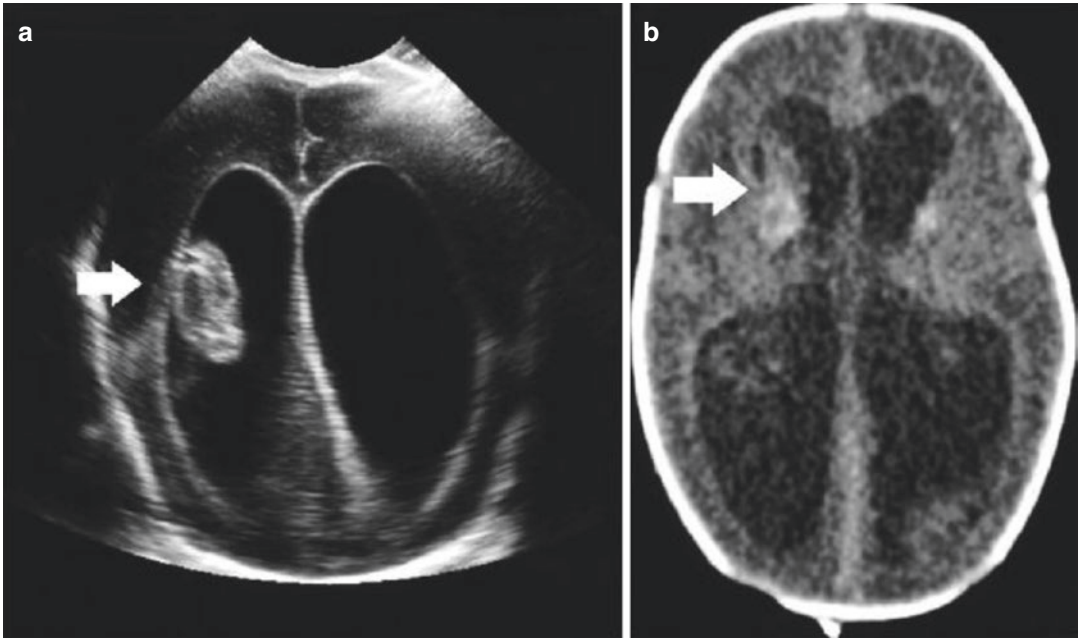
Grade	Extent of hemorrhage (IVH)
I	Subependymal germinal matrix hemorrhage
II	IVH without ventriculomegaly
III	IVH with ventriculomegaly
IV	IVH with parenchymal hemorrhage

Wang and Avellino (2005)

spread, most often to the adjacent ventricles and into the surrounding parenchyma. The germinal matrix gradually involutes after 34 weeks' gestation and nearly disappears by 40 weeks. A Papile grading system was devised to describe the severity of the bleeding – Grades I–IV (Wang and Avellino 2005) (Table 2.2).

Premature infants less than 34 weeks' gestation with very low birth weight (<1,500 g) are at greatest risk for developing intraventricular hemorrhage (IVH). With current management, 20% of these preterm infants will develop an IVH (Boop 2004). The risk of developing post-hemorrhagic hydrocephalus (PHH) is directly related to the extent of the hemorrhage. Hydrocephalus develops in 9% of infants with IVH (Christian et al. 2016). In infants with Grade III and IV IVH, 25% and 28%, respectively, went on to develop hydrocephalus, whereas in patients with Grade I and Grade II, only 1% and 4%, respectively, developed hydrocephalus (Christian et al. 2016). PHH may develop as a result of the accumulation of blood and hemorrhagic debris within the ventricles and subarachnoid spaces (Fig. 2.6). Obstruction of the aqueduct of Sylvius or foramen of Monro may occur. The breakdown of the blood may also render the arachnoid villi unable to reabsorb the CSF. Multiloculated hydrocephalus may occur after IVH due to ventriculitis. Ventricular septations may develop causing isolated compartments of fluid within the ventricles.

Many premature infants require surgical intervention to treat the hydrocephalus until it is resolved. Thirty-eight percent of patients with PHH had a permanent shunt inserted (Christian et al. 2016). Figure 2.6 illustrates IVH and PHH of prematurity.



**Fig. 2.6** A 25-week premature male with an intraventricular hemorrhage and subsequent development of hydrocephalus: (a) CUS shows the right-sided intraventricular hemorrhage; (b) CT also shows parenchymal hemorrhage

### 2.7.8 Postinfectious Hydrocephalus

Intracranial infection at any age may cause hydrocephalus. Hydrocephalus may follow bacterial, fungal, viral, and parasitic infections of the CNS. In utero, CNS infections may cause intracranial injury leading to obstruction of CSF flow. Toxoplasmosis may cause inflammation and blockage of the CSF pathways and blockage within the subarachnoid spaces (Ciurea et al. 2004). During the neonatal period, gram-negative bacteria are the leading cause of bacterial meningitis (Ciurea et al. 2004). Gram-negative bacteria may also cause ventriculitis (Ciurea et al. 2004) leading to hydrocephalus.

After the neonatal period, gram-positive bacteria are the leading cause of meningitis. Meningitis and ventriculitis may lead to multiloculated hydrocephalus, a condition where non-communicating pockets of CSF occur within the ventricles. Viral infections, including CMV, parainfluenza, and influenza A, can affect ependymal cells leading to acquired aqueductal stenosis and hydrocephalus (Ciurea et al. 2004). Tuberculosis meningitis may cause obstructive hydrocephalus from mass effect of a tuberculoma or cause a communicating type of hydrocephalus by affecting the basal cisterns. Hydrocephalus may

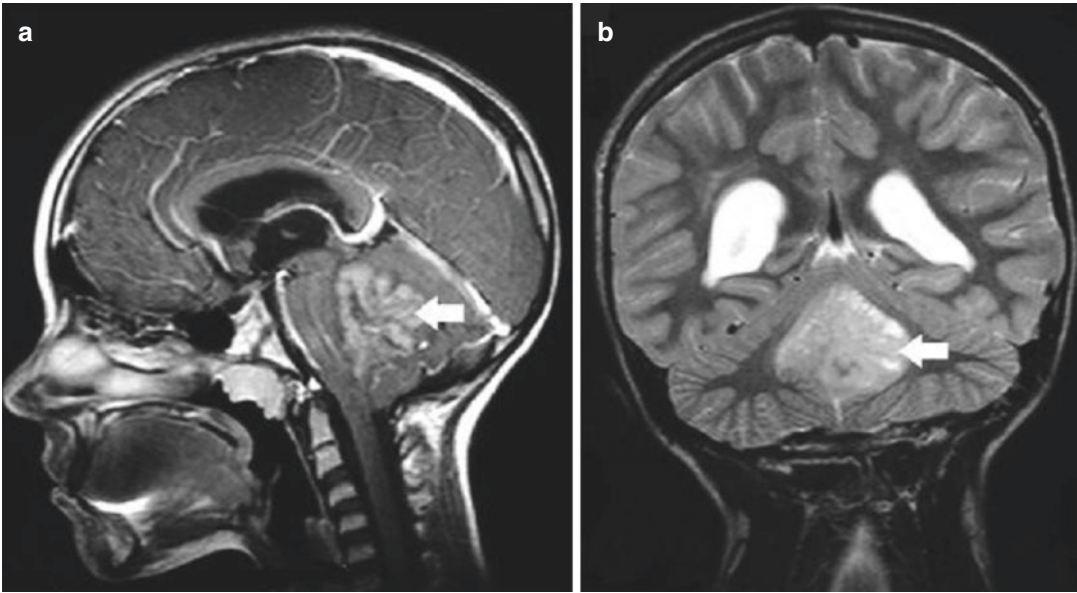
develop in conjunction with the intracranial infection or much later after recovery.

Cysticercosis occurs throughout the world. It is uncommon in the United States but is found throughout Central/South America. Humans can acquire the pork tapeworm, *Taenia solium*, by eating undercooked pork or by consuming the tapeworm eggs from food contaminated with human feces. The tapeworm larva enters the body and forms cysticerci. Neurocysticercosis results when the cysts enter the brain. The cysts can implant in the parenchyma, ventricles, subarachnoid space, or cisterns. Hydrocephalus can occur when cysts are in the ventricles, subarachnoid space, and cisterns or cause arachnoiditis. In areas such as southern California, Arizona, and New Mexico, neurocysticercosis must be considered as an etiology of hydrocephalus.

### 2.7.9 CNS Tumors

Hydrocephalus can be a complicating factor of pediatric brain tumors. It may be present at the time of diagnosis of the tumor, may occur during or after tumor treatment, or may develop if the tumor reoccurs. Most of the time, hydrocephalus





**Fig. 2.7** (a, b) An 8-year-old female with a posterior fossa brain tumor and hydrocephalus

associated with tumors is due to the obstruction of CSF pathways.

About 60% of brain tumors in children are located infratentorially or in the posterior fossa, occurring in the cerebellum, fourth ventricle, or brain stem. The most common tumors of this region include medulloblastoma, astrocytoma, and ependymoma. Hydrocephalus is common with tumors in this area. It results from obstruction of CSF flow, particularly if the tumor is in the fourth ventricle or exerting pressure on the fourth ventricle. A tectal plate tumor is an indolent tumor of the midbrain and results in hydrocephalus. In all of these tumors, hydrocephalus is often a major contributor to symptoms at the time of diagnosis. If the hydrocephalus is severe, urgent treatment is needed to relieve increased intracranial pressure. Hydrocephalus may also occur from blood and debris in the CSF after tumor resection. Approximately 25–50% of children will require placement of a permanent shunt (Wang and Avellino 2005) or endoscopic third ventriculostomy after the tumor resection. Certain factors are associated with the need for permanent CSF diversion including age less than 10 years, midline tumors, incomplete tumor resection, CSF infection, and persistent pseudomeningocele (Sainte 2004).

About 40% of pediatric brain tumors occur in the supratentorial area. The most common site is the suprasellar region, followed by the cerebral

hemispheres, thalamus and basal ganglia, pineal region, intraventricular spaces, and meninges. Hydrocephalus is associated with some of these tumors and is usually due to obstruction of CSF flow at the aqueduct of Sylvius. Tumors in the suprasellar region most commonly associated with hydrocephalus are craniopharyngioma and optic pathway glioma. Craniopharyngiomas can also form cysts that exert mass effect that causes symptoms and/or hydrocephalus. Pineal region tumors are commonly associated with hydrocephalus. Tumors that grow within the ventricles may cause hydrocephalus as a result of overproduction of CSF. There are two types of choroid plexus tumors: choroid plexus papilloma and choroid plexus carcinoma. They arise from the choroid plexus, located within the lateral, third, and fourth ventricles. Occasionally, germ cell tumors and pituitary adenomas may cause hydrocephalus. Hydrocephalus may also occur in patients with neurofibromatosis or tuberous sclerosis secondary to obstruction of CSF flow.

Spinal cord tumors are rare in children. They may be associated with hydrocephalus due to arachnoiditis and elevated protein in the CSF (Fig. 2.7).

Brain and spinal cord tumors are discussed in detail in Chap. 7.

## 2.7.10 Head Trauma

Hydrocephalus may occur after head injury if there is intracranial blood. This is particularly true if there is subarachnoid hemorrhage or IVH. The breakdown of the blood may alter the ability of the arachnoid villi to absorb CSF. Debris and blood may also obstruct normal CSF pathways and cause obstructive hydrocephalus.

## 2.8 Signs and Symptoms of Hydrocephalus

The signs and symptoms of hydrocephalus in infants and children vary depending on their age, the degree of hydrocephalus at presentation, the primary etiology, and the time over which the hydrocephalus develops. Because of the plasticity of the infant brain and the ability of the cranium to expand, ventriculomegaly can progress without obvious signs of increased intracranial pressure. In premature infants, in which hydrocephalus is caused predominately by IVH, there is a general correlation between the severity of hemorrhage and the degree of hydrocephalus (Table 2.3). Infants with PHH may have minimal symptoms or may exhibit increasing spells of apnea and bradycardia. They may also have hypotonia, sunseting eyes, ophthalmoplegia, and seizures. As the ventriculomegaly progresses, the fontanel will bulge become tense and nonpulsatile, and the cranial sutures become splayed. In a healthy premature infant, the head circumference generally increases about 1 cm a week. In premature infants with progressive ventriculomegaly, the head circumference may increase more rapidly than normal (when charted on the head growth chart) but may not accurately reflect the rate of increase in ventricular size.

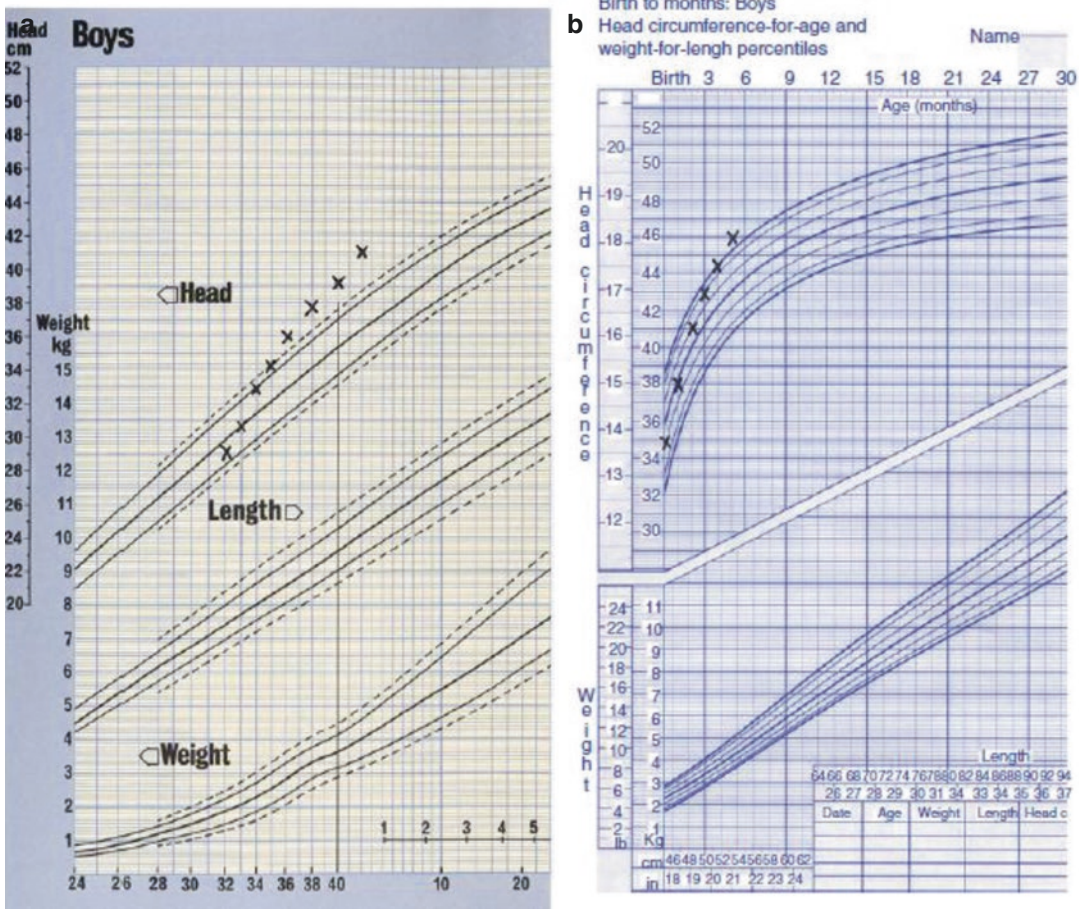
In full-term infants, signs often include macrocephaly and progressively increasing occipital frontal head circumference, crossing percentile curves. Normal head circumference for a full-term infant is 33–36 cm at birth. A normal head circumference increases by approximately 2 cm/month during the first 3 months, by 1.5 cm/month during the fourth and fifth months, and by about 0.5 cm/month from months 6 to 12 (Fig. 2.8).

**Table 2.3** Signs and symptoms of hydrocephalus in children

Premature infants	Full-term infants	Toddlers and older
Rapid head growth	Macrocephaly	Headache
Tense fontanelle	Tense fontanelle	Nausea
Apnea	Rapid head growth	Vomiting
Bradycardia	Splayed cranial sutures	Irritability
Splayed cranial sutures	Decreased feeding	Lethargy
Sunseting eyes	Vomiting	Delayed development
Vomiting	Distended scalp veins	Decreased school performance
Hypotonia	Increased drowsiness	Behavioral disturbance
Acidosis	Poor head control	Papilledema
Seizures	Parinaud's sign	Parinaud's sign
	Sunseting eyes	Sunseting eyes
	Frontal bossing	Bradycardia
		Hypertension
		Irregular breathing patterns

Other common signs in full-term infants include a bulging, tense anterior fontanel; splayed cranial sutures; irritability; poor feeding; episodes of spitting up or vomiting; increased sleeping; distended scalp veins; and, if the head is large relative to size, poor head control. Visual changes may also be noted and include paralysis of upward gaze (Parinaud's sign) and sunseting eyes.

Children older than 2 or 3 years may have a more acute presentation of symptoms since the cranial fontanels and sutures are closed, and the skull is no longer able to compensate for the increasing ventricular size. The predominant symptom is usually a persistent headache that typically occurs upon waking and is often associated with nausea, vomiting, and lethargy. The child is often irritable. A child who has a gradual onset of hydrocephalus may have more subtle signs, such as delayed development in both motor and cognitive functions. Older children often present with decreased



**Fig. 2.8** Growth charts show the head circumference rapidly crossing percentile curves: (a) premature male infant growth chart and (b) full-term male growth chart

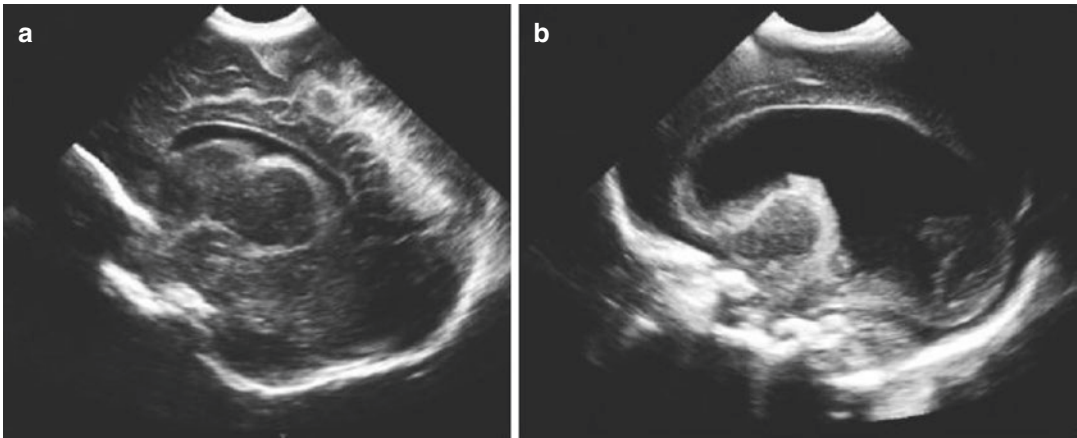
school performance and behavioral disturbance. Other less common signs may include papilledema and visual complaints. If hydrocephalus is severe, Cushing’s triad of bradycardia, systemic hypertension, and irregular breathing patterns may occur. This triad denotes a severe case of increased intracranial pressure and requires emergent treatment.

## 2.9 Diagnosis of Hydrocephalus by Imaging Studies

The three major techniques used for diagnosis and evaluation of hydrocephalus are ultrasonography (US), CT, and MRI.

### 2.9.1 Ultrasonography

Prenatal US can be highly reliable and accurate in diagnosing hydrocephalus. Hydrocephalus can be detected in a fetus as early as the later part of the first trimester of pregnancy, although abnormal dilation of the fetus’ ventricles are more clearly detectable after 20–24 weeks’ gestation (University of California, San Francisco 2000). Although prenatal US can detect an abnormal CSF collection, it may not show the precise site or cause of obstruction. Amniocentesis can often detect the presence of open neural tube defects, such as myelomeningocele, chromosome abnormalities, and in utero infections, and may also help indicate the overall health of the fetus. In



**Fig. 2.9** (a) Normal CUS in a 1-month-old female and (b) hydrocephalus in a 3-week-old male

general, the first trimester development of significant hydrocephalus can be a poor prognostic sign for infant mortality and developmental progress. In some cases, mild ventricular dilation identified by US will resolve by the third trimester (University of California, San Francisco 2000).

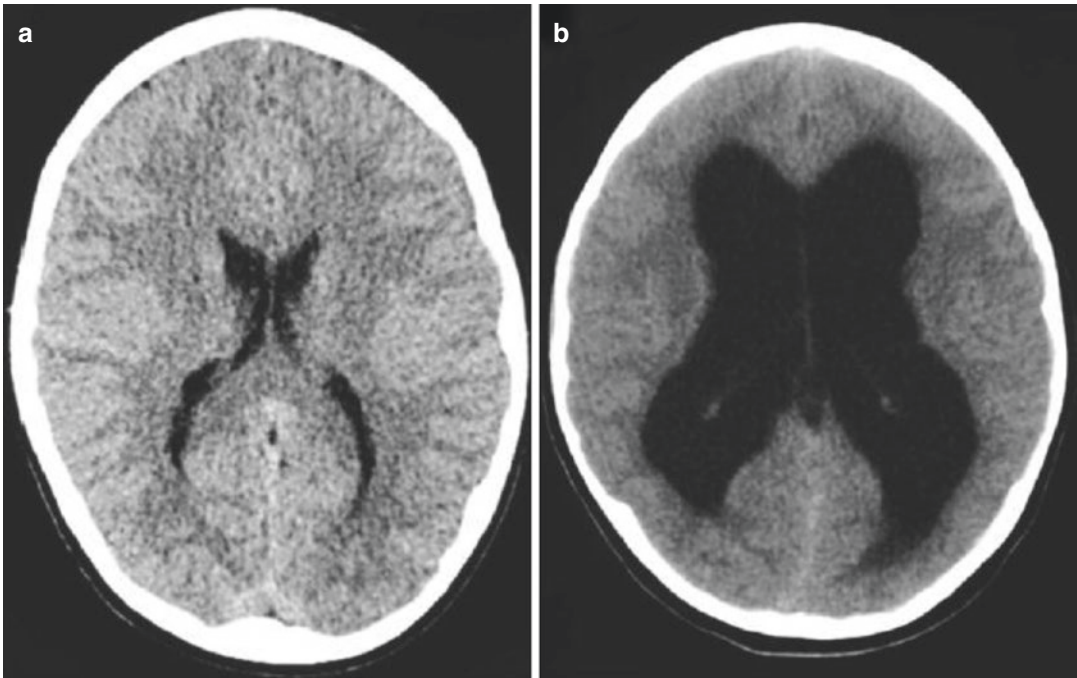
Cranial US (CUS) is useful in infants and young children while the anterior fontanel is still open, usually under the age of 18 months (Fig. 2.9). Through the open fontanel, CUS can demonstrate lateral ventricular morphology and intraventricular clots. It is less accurate in its ability to look at the third and fourth ventricles and subarachnoid spaces. For this reason, the precise diagnosis and cause of hydrocephalus are rarely made by CUS alone. It is particularly useful, however, for follow-up screening of infants with untreated and treated hydrocephalus. The equipment is portable, involves no radiation, does not require sedation, and is considerably less expensive than CT/MRI.

### 2.9.2 Computed Tomography (CT)

Since the advent of CT scanning in 1976, it is a common radiologic technique for the diagnosis and follow-up of hydrocephalus. CT images

can accurately demonstrate the ventricular size and shape the presence of blood and calcifications, cysts, and shunt hardware. With hydrocephalus, an enlarged ventricular system is usually seen and is typically first seen in the lateral ventricles (Fig. 2.10). CT images can also accurately reflect signs of increased intracranial pressure, such as compressed cerebral sulci, absent subarachnoid spaces over the convexity, and transependymal reabsorption of CSF into the white matter. When contrast enhancement is used, tumors, abscesses, and some vascular malformations can be visualized. It is a diagnostic screening tool, taking only a few minutes, and few children need to be sedated for the procedure. CT does expose the patient to radiation, and little is known about the long-term effects of multiple scans. Many providers have concern about the effects of repeated CT scan on the growing brain. Alternatives include low-dose CT or HASTE (limited T2) MR scans. These are acceptable methods for following ventricular size. The Alliance for Radiation Safety has created the “Image Gently” campaign ([www.imagegently.com](http://www.imagegently.com)) to assist providers in obtaining the images they need while decreasing the radiation exposure to the patient.





**Fig. 2.10** (a) Normal CT in a 9-year-old male and (b) hydrocephalus in a 2-week-old male

### 2.9.3 Magnetic Resonance Imaging (MRI)

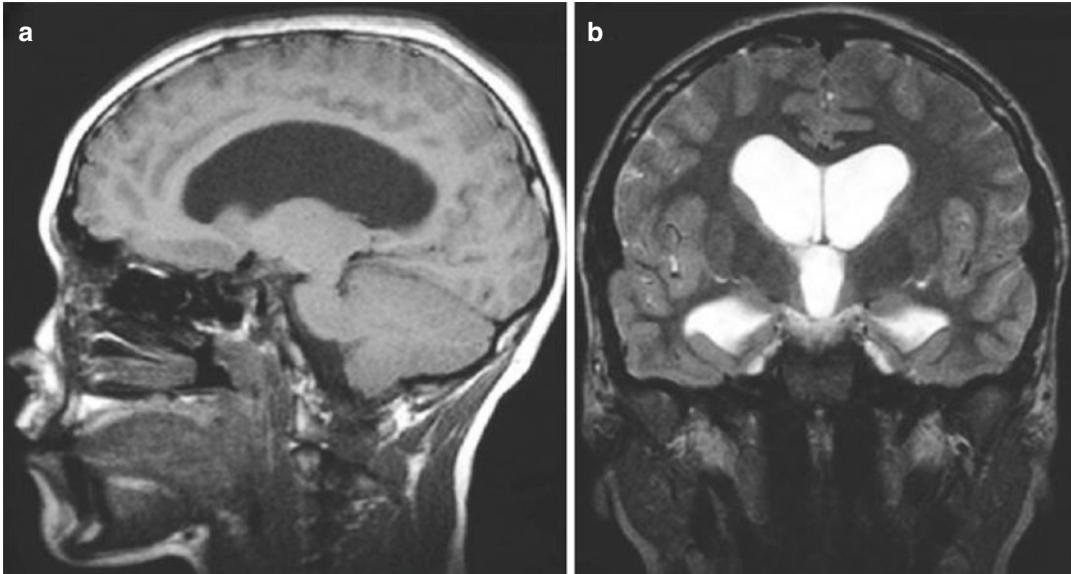
Commercially available MRI was introduced in 1986 and is the examination of choice for revealing the underlying cause of hydrocephalus. It allows anatomical visualization in the axial, coronal, and sagittal planes, providing detailed information regarding the anatomy and the position and extent of lesions. Subtle findings, such as white matter pathology, dysmorphic anatomy, and characteristics of lesions, can be readily demonstrated. In addition, the aqueduct of Sylvius can be visualized, as well as membranes and loculated ventricular systems. With the addition of gadolinium (an intravenous contrast medium), some neoplasms, infectious and vascular lesions, can be better visualized. CSF flow dynamics can be visualized through the use of phase-contrast cine MRI. This sequence takes

only a few extra seconds and allows for real-time flow measurements that are demonstrated on the sagittal plane of the MRI. Furthermore, constructive interference in the steady state (CISS) sequence MRI may be used. This sequence provides great detail of the ventricular system and basal cisterns and may show membranes not otherwise seen on conventional MRI. Both phase-contrast cine MRI and CISS sequence MRI can be very helpful in determining the underlying cause of hydrocephalus. They can also provide valuable preoperative information related to the potential success of endoscopic third ventriculostomy, as well as postoperative information by being able to visualize the CSF flow pattern. MRI takes approximately 45 min or longer, and therefore, young children need to be sedated or anesthetized for the exam. Typically developing children over the age of 5 or 6 can often do the exam without sedation.

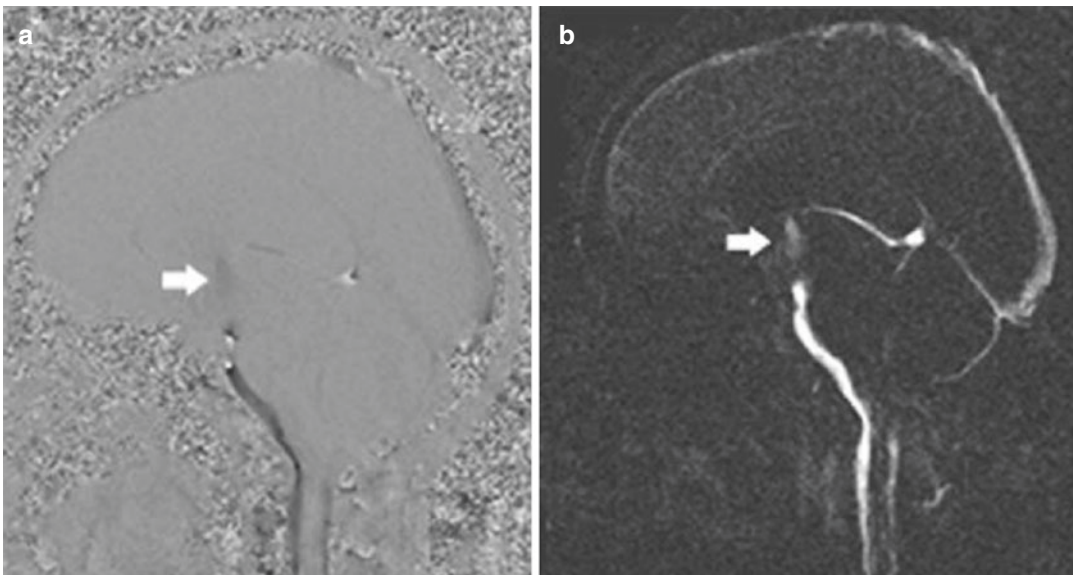
The half-Fourier single-shot turbo spin-echo (HASTE) MRI is a limited T2 image that provides good visualization of ventricular anatomy. It is an alternative to CT, does not expose the child to radiation, and requires no sedation as it is

a short study lasting less than 20 s to 3 min (O'Neill et al. 2013).

Aqueductal stenosis and hydrocephalus are shown in Figs. 2.11, 2.12, and 2.13, along with cine and CISS MRI scans.

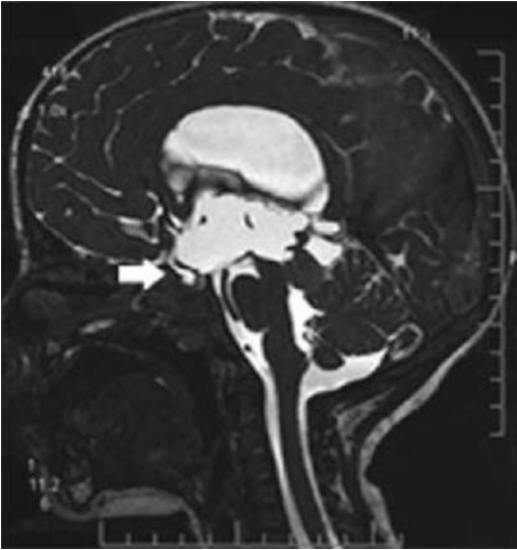


**Fig. 2.11** A 13-year-old male with aqueductal stenosis and hydrocephalus: (a) Sagittal T1 MRI shows enlarged lateral ventricles (CSF appears *black*); (b) coronal T2 MRI shows enlarged lateral and third ventricles (CSF appears *white*)



**Fig. 2.12** A 13-year-old male with hydrocephalus secondary to aqueductal stenosis, status post endoscopic third ventriculostomy (ETV). CSF cine flow study demon-

strates CSF flow across the fenestration in the anterior third ventricle: (a) phase-contrast magnitude cine MRI and (b) phase-contrast directional cine MRI



**Fig. 2.13** A 13-year-old male with hydrocephalus secondary to aqueductal stenosis. Preoperative CISS (constructive interference in the steady state) MRI demonstrates the floor of the third ventricle and the position of the basilar artery

## 2.10 Treatment of Hydrocephalus

### 2.10.1 Medical Therapy

There is currently no medical therapy that definitively treats hydrocephalus effectively. Occasionally, in borderline cases of progressive hydrocephalus and in PHH, diuretics may be useful as a temporizing measure to try to avoid the need for a permanent shunt. Acetazolamide, a carbonic anhydrase inhibitor, has been shown to decrease CSF production. The dose may be as high as 100 mg/kg/day, and in order for it to be effective, more than 99% of carbonic anhydrase must be blocked before CSF production decreases significantly. Furosemide, 1 mg/kg/day, has also been used. The mechanism of action is unknown, but it is thought to decrease brain extracellular fluid. Although these have been used historically as temporizing measures, comprehensive analysis of data from clinical trials on diuretic therapy for PHH by the Cochrane Collaboration concluded that acetazolamide and furosemide were neither effective nor safe for the treatment of PHH (Whitelaw et al. 2001).

Serial lumbar or ventricular punctures to evacuate CSF are also used as a temporizing measure. The efficacy of these punctures is controversial, but some centers routinely use them in infants until they are stable enough to tolerate a surgical intervention. The goals are to decrease the ICP and help clear the CSF of toxic chemicals produced by the breakdown of blood. If the infant continues to have inadequate CSF reabsorption, a more permanent shunt may be implanted.

### 2.10.2 Surgical Intervention

#### 2.10.2.1 Shunts

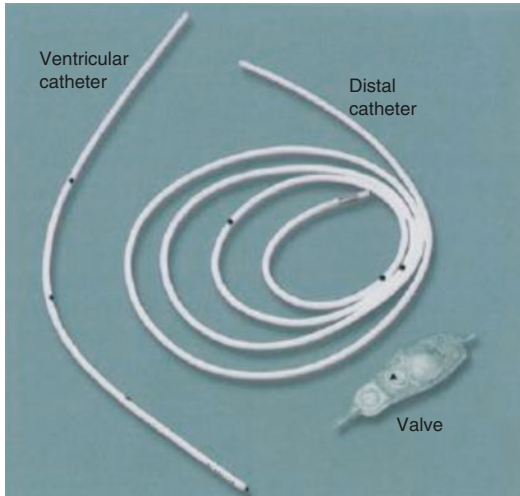
CSF shunting is the most common standard treatment in the long-term management of hydrocephalus. It involves the placement of a ventricular catheter to divert CSF to another body cavity, where it can be absorbed. There are many different shunting devices with different components, all having similar features. The three main components of a shunt are a proximal (ventricular) catheter, a valve, and a distal catheter (Fig. 2.14). The ventricular catheter is a Silastic tube that is placed either through a frontal or parieto-occipital approach, usually in the right nondominant cerebral hemisphere, as shown in Fig. 2.15. via a burr hole.

There are many different valves made by many different manufacturers. They all regulate the flow of CSF by means of a one-way valve. The valves most commonly used in the pediatric setting today are differential pressure valves, flow-regulating valves, and siphon-resisting valves. The pressure at which the valves open is termed the opening pressure. Typically there are low-, medium-, and high-pressure valves in each category, referring to opening pressures of approximately 5, 10, and 15 cm H<sub>2</sub>O, respectively. Most valves are differential pressure valves and are designed to open and allow drainage of CSF as the intraventricular pressure rises above the valve's opening pressure. Once the pressure falls below the closing pressure, the valve closes and the flow of CSF ceases. Flow-regulating valves attempt to keep the CSF flow constant despite changing pressure differentials

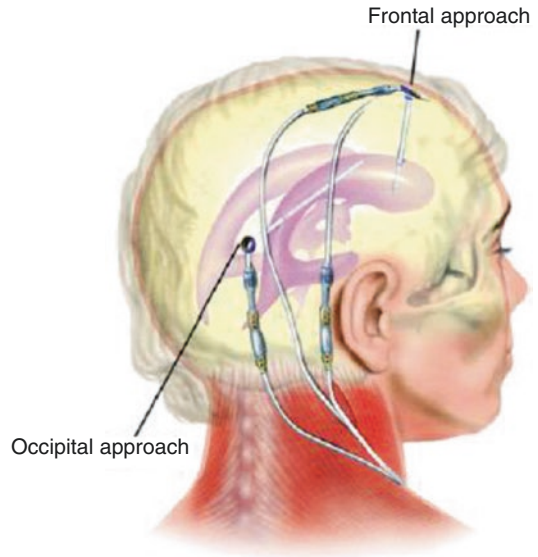


and patient position. Siphon-resisting valves are used to avoid siphoning of CSF and the complication of over-drainage. Siphoning is a phenomenon that occurs in some patients in whom there is gravity-enhanced flow of CSF when the patient is in an upright position. The choice of which

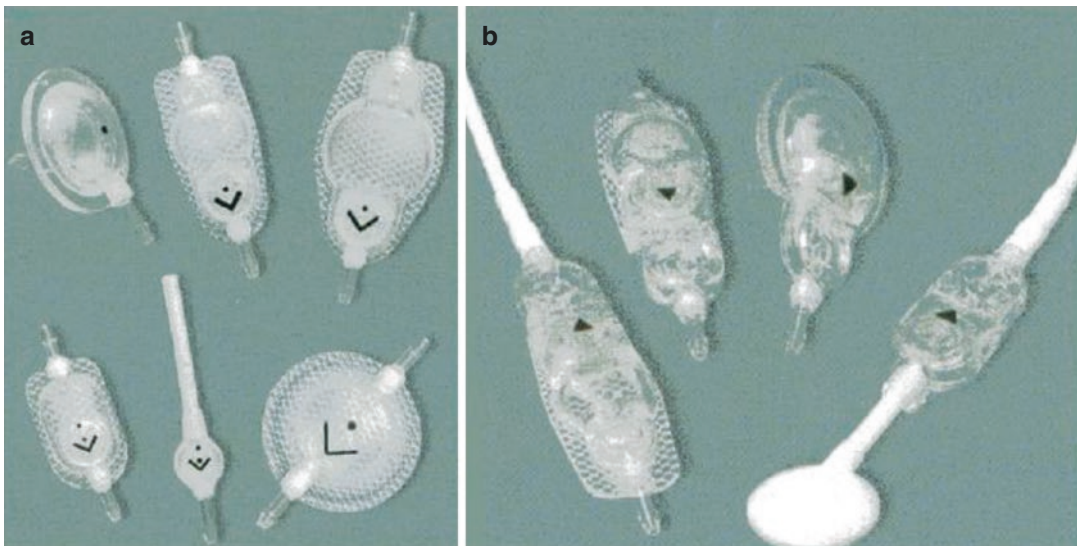
valve to use is based on the personal preference of the neurosurgeon and is usually based on training and personal experience. No data exists to support a recommendation of one particular shunt design or valve over another. Fixed pressure valves are shown in Fig. 2.16.



**Fig. 2.14** Shunt components (Courtesy of Medtronic Neurologic Technologies)



**Fig. 2.15** Illustration demonstrates that proximal catheter placement is generally through a frontal or occipital approach



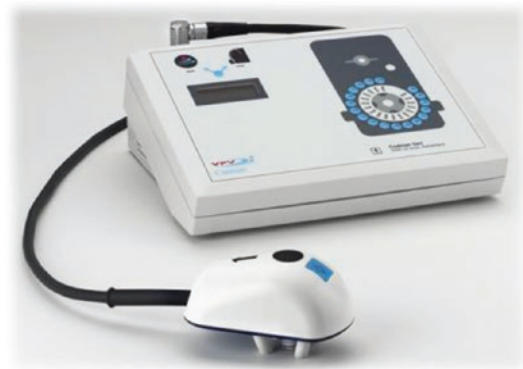**Fig. 2.16** (a) Fixed pressure valves and (b) delta valves with siphon control (Courtesy of Medtronic Neurologic Technologies)

A recent advance in shunt valve technology has been the introduction of programmable valves (Figs. 2.17, 2.18, 2.19, 2.20, and 2.21). Programmable valves allow the opening pressure of the valve to be adjusted externally with the use of a special magnetic device. This avoids the need for an operative procedure should the patient need a valve with a different pressure. This type of valve tends to be well suited for the management of difficult cases of over-drainage or underdrainage or in children whose pressure needs are expected to change over time. It is not clear that the benefits outweigh the increased cost in all patients. Since the programmable valve contains a magnet, most valves need to be reprogrammed immediately after all MRIs. Several programmable valves that are not altered by a magnetic field are also available. In these valves, the setting is locked and can only be changed with the manufacturer's specific magnetic programmer. Special precautions should be taken when the patients are around strong magnetic sources; patients and families should be directed to the manufacturer's recommendations on magnetic considerations.

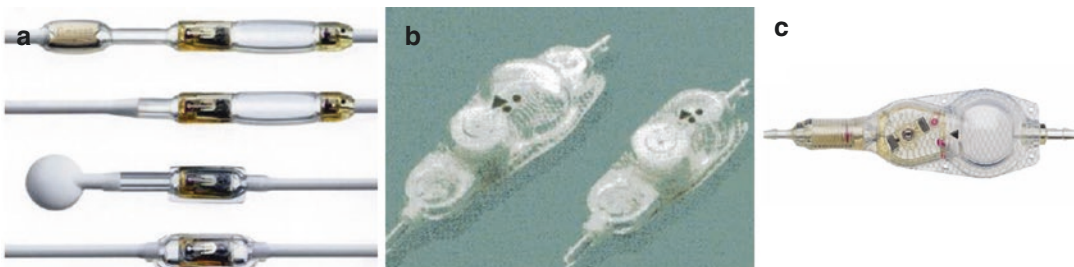
Distal catheters are also made of Silastic material. The peritoneal cavity is the preferred and most commonly utilized location for the shunt to terminate. There are two main advantages to placing the distal tubing in the peritoneum. First, if an infection develops, it usually stays localized rather than disseminating, as can happen with shunts placed in the heart. Second, a large amount of tubing can be placed in the peritoneal cavity to allow for growth of the child and minimize the need for revisions during

expected childhood growth. In addition, the peritoneal cavity is an extremely efficient site of absorption and is also easily accessible to the surgeons. If the peritoneal cavity is not appropriate for placement of the distal tubing, either due to an abdominal malformation, postsurgical adhesions, infection, or inadequate reabsorption, the second and third choices for the distal catheter placement are the right atrium of the heart and the pleural cavity.

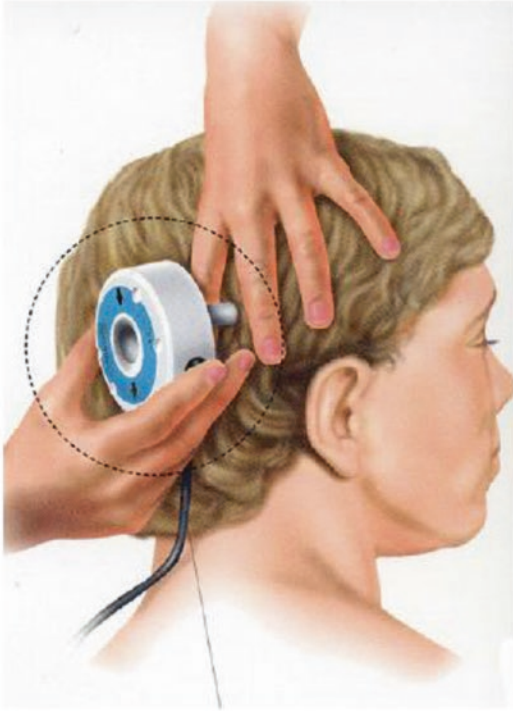Ventriculoatrial (VA) shunts are placed through the neck, into the jugular vein to the superior vena cava and into the right atrium. The shunt tip should lie just above the tricuspid valve and on plain chest radiograph should be at the superior vena cava/right atrial interface. The tip of the catheter can also be evaluated by looking for it at the level of the sixth/seventh thoracic vertebrae. If it is above this level, a shunt-lengthening procedure may be indicated. Infants should have a chest x-ray every 6 months



**Fig. 2.18** Codman Hakim valve programmer



**Fig. 2.17** (a) Codman Hakim programmable valves, (b) strata programmable valves, and (c) Certas valves (Courtesy of Medtronic Neurologic Technologies/Codman)

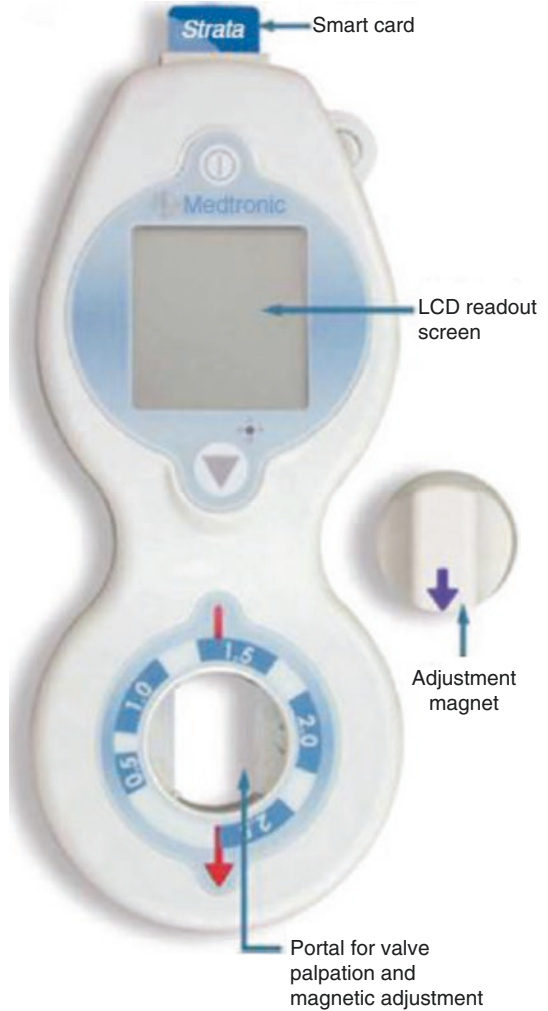


**Fig. 2.19** Illustration demonstrates programming a Codman Hakim programmable valve

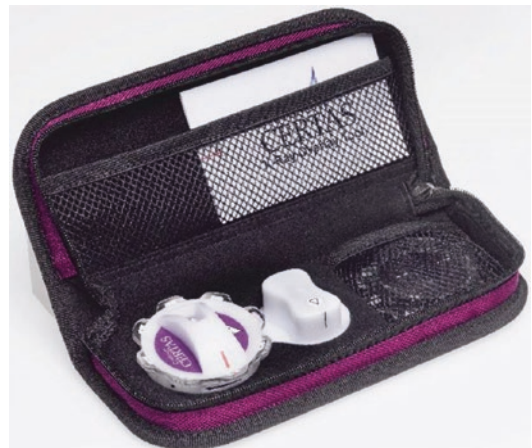and older children every year to make sure the distal placement is adequate.

Ventriculopleural shunts are placed subcutaneously and the tube is inserted into the pleural space. There is concern that pleural shunting may be poorly tolerated in the young child due to lack of adequate absorptive pleural surface. In addition, the length of time the pleural cavity retains its absorptive capacity varies from individual to individual. Complications may include respiratory compromise secondary to hydrothorax. Other less common distal placements include the gallbladder and ureter.

Less frequently used in the pediatric population, lumboperitoneal shunts (LPS) are sometimes used in patients with communicating hydrocephalus, slit ventricle syndrome, or benign intracranial hypertension (pseudotumor cerebri). Although classically performed using a limited laminectomy, percutaneous placement is now the preferred method of insertion of the catheter into the intradural space (Greenberg 2010) (Figs. 2.22 and 2.23).

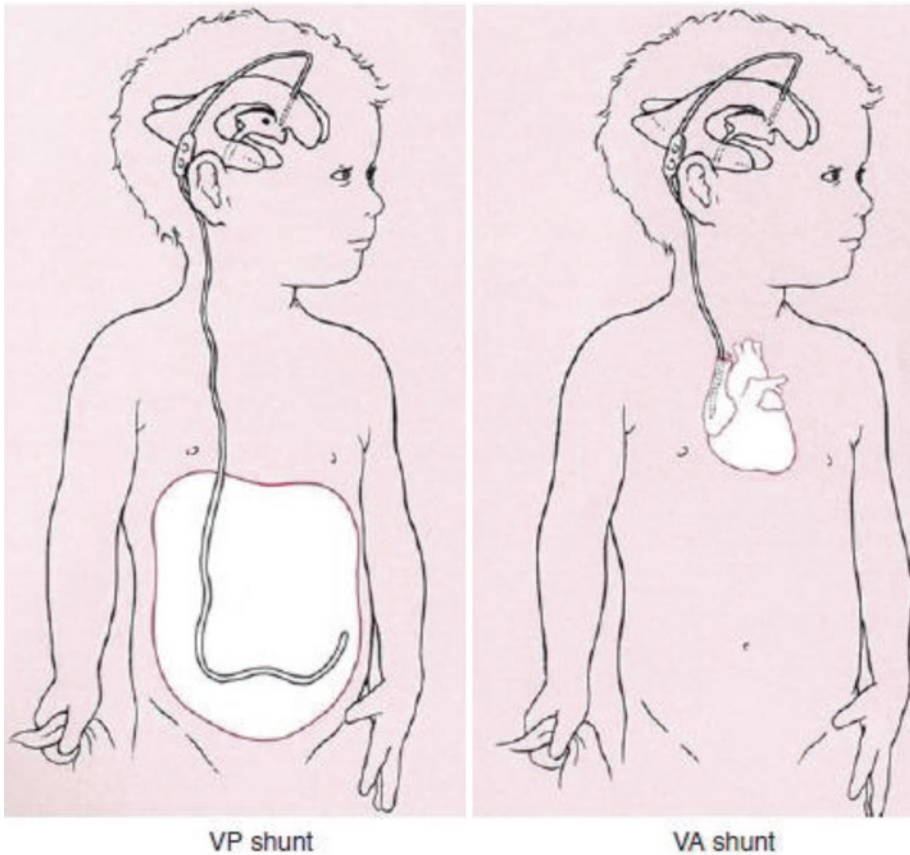


**Fig. 2.20** Strata valve programmer (Courtesy of Medtronic Neurologic Technologies)

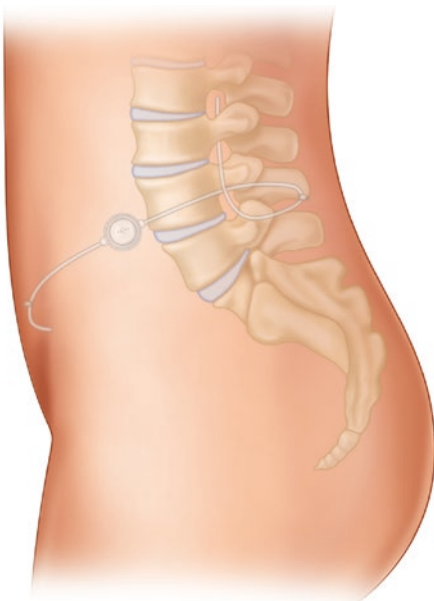


**Fig. 2.21** Certas valve programmer (Courtesy of Codman)





**Fig. 2.22** Illustration shows placement of ventriculoperitoneal (VP) and ventriculoatrial (VA) shunts



**Fig. 2.23** Illustration shows lumboperitoneal shunt (LPS) placement

### 2.10.2.2 Surgical Endoscopy

A significant development in pediatric neurosurgery has been the evolution of neuroendoscopy and its application in the management of hydrocephalus. It has been used for endoscopic third ventriculostomy, cyst fenestration and septostomy, and shunt placement and retrieval. The pioneering stage of neuroendoscopy began in the early 1900s but quickly fell out of favor due to poor equipment and a high rate of associated morbidity and mortality. In the 1970s, there was renewed enthusiasm for its use because of improvement in endoscopes, light sources, camera equipment, and instrumentation. In the past two decades, there has been a marked increase in the use of endoscopy.

### 2.10.2.3 Endoscopic Third Ventriculostomy

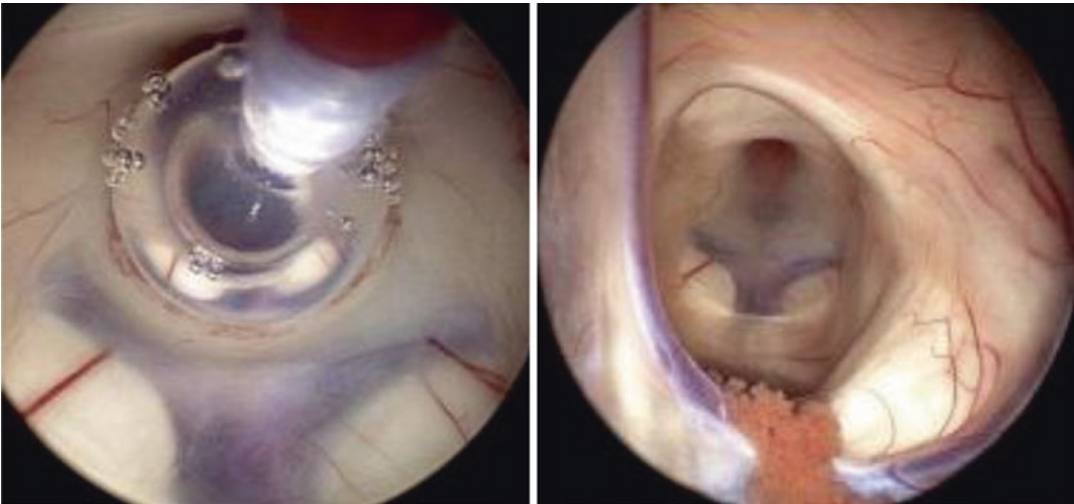
Endoscopic third ventriculostomy (ETV) is used as an alternative to shunting in selected

patients with noncommunicating hydrocephalus. The success of the procedure depends largely on proper patient selection. The patients most likely to benefit from the procedure are those with significant obstruction of CSF flow between the ventricles and the subarachnoid space and those with normal CSF absorption between the subarachnoid space and the venous system. An MRI should be done as part of the work-up to confirm that the basilar artery does not lie below the floor of the third ventricle. Such placement of the artery is usually a contraindication for a third ventriculostomy due to the added risk of hemorrhage at the time of surgery. Correct patient selection for an ETV has been shown in multiple studies to be vital in the success of the ETV. Many neurosurgeons now consider the factors identified in the ETV Success Score to identify patients based on the criteria of age, etiology, and previous exposure to shunt hardware (Kulkarni et al. 2009; Oertel et al. 2009). Based on these factors, a score is easily calculated and estimates the percentage probability of a successful ETV. This score finds that patients under the age of 6 months do not uniformly have good results. ETV Success Score is the strongest predictor of ETV success. It is also found that visualization of a

naked basilar artery was independently associated with ETV success (Kulkarni et al. 2016). Patients with aqueductal stenosis are, in general, excellent candidates for the procedure. It has also been used successfully in patients with tectal plate tumors.

The goal of ETV is to bypass the obstruction of CSF by diverting it through the floor of the third ventricle and returning it to the normal subarachnoid space. An endoscope is introduced into the lateral ventricle via a coronal burr hole and advanced through the foramen of Monro and into the third ventricle. Once the thin translucent floor of the third ventricle is visualized, a probe is used to puncture the membrane, and the fenestration is enlarged (Fig. 2.24). A laser may also be used to fenestrate the floor of the third ventricle. An external ventricular drain (EVD) with an intracranial pressure monitor may be placed after the procedure and is usually kept clamped (to drainage). This allows monitoring of the ICP and possible diversion of CSF should the ETV be unsuccessful. Another option is placement of a ventricular catheter and reservoir for emergent future access.

Patency of the third ventriculostomy can be confirmed noninvasively using phase-contrast



**Fig. 2.24** Surgical view of the endoscopic third ventriculostomy

cine MRI or CISS sequence MRI, to identify the CSF flow through the fenestration. However, the finding of a patent fenestration does not guarantee that the procedure has been successful. If there is an obstruction to the circulation of CSF further downstream or inadequate absorption within the subarachnoid space, it is possible for the procedure to fail, even in the setting of a patent fenestration. Ventricular size often does not change after an ETV, even though the pressure is normalized in the ventricles.

ETV has an overall success rate of approximately 75% after 3 years (Teo and Mobbs 2005). With improved selection of patients, this success rate may be as high as 83% at 5 years (Kulkarni et al. 2009). Failure of ETV can occur early or late. Early failure may be the result of factors including bleeding around the fenestration site, unnoticed additional arachnoid membranes occluding the flow of CSF, or an inadequate size of the fenestration. Late failure can be caused by subsequent closure of the fenestration by gliotic tissue or arachnoid membrane. Tumor progression and inadequate CSF absorption at the level of the arachnoid villi may result in either early or late failure.

Patients with an ETV require the same neurosurgical follow-up as they can exhibit deterioration after months or years of successful ETV. The problem can be potentially serious because failure can develop over a short period of time and may be unpredictable. The patient develops signs and symptoms of increased intracranial pressure and requires further intervention, either another ETV or a shunt.

Choroid plexus cauterization (CPC) may be coupled with ETV. CPC is a process by which the choroid plexus is cauterized bilaterally within the lateral ventricles through an endoscope. This helps to reduce the rate of CSF production. It has been found that combining the CPC with ETV may be more successful than ETV alone for treating hydrocephalus in infants less than 1 year of age (Warf and Campbell 2008); however, this work may need further study (Box 2.1).

### **Box 2.1 Case Study: A 1-Month-Old with an Attempted ETV with CPC**

AF was a 1-month-old infant with prenatally diagnosed ventriculomegaly. He was seen in neurosurgery clinic at 2 weeks of age with a haste MRI. His head growth was slightly accelerated and his fontanelles were full and soft. He returned 10 days later with another haste MRI. At that time his OFC had increased 3 cm, his fontanelle was full, and his sutures were splayed. The MRI showed that the ventricles were larger. It was decided that AF needed some intervention. His parents met with the neurosurgeon as well as the nurse practitioner. The options of a shunt versus an endoscopic third ventriculostomy and choroid plexus coagulation were discussed in detail with the parents. His parents were anxious to avoid a shunt if possible. It was decided to do an ETV/CPC and the procedure was done 2 days later. AF did well and was discharged on post-op day 2. Three days later his mother called and said there was some swelling under the incision and clear fluid was leaking from the wound. She said it was worse when he cried. She was told to come back to the clinic immediately, and AF was admitted to the hospital. He went to the operating room that afternoon for placement of an external ventricular drain and CSF sampling. After 3 days of sampling, his CSF remained sterile; white cells were 0–1. Thus a VP shunt was planned for. AF went to the OR and a new VP shunt was placed. A programmable valve was placed and set at 1.5. AF went home the following day and was seen 2 weeks later. His head growth was unchanged. His fontanelle was soft and slightly sunken. He was starting to smile and his mother felt that he was doing well.



## 2.10.3 Treatment of Hydrocephalus in Specific Malformations/ Diseases

### 2.10.3.1 Posthemorrhagic Hydrocephalus

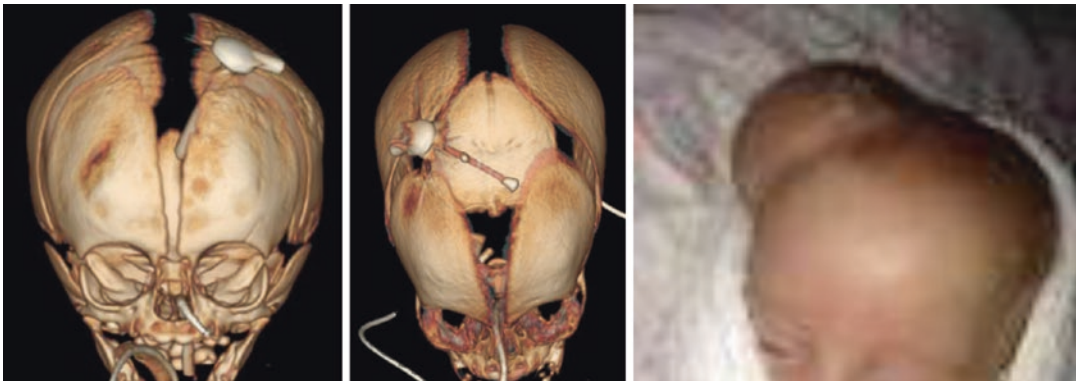
Infants who develop increasing PHH or become symptomatic need temporizing treatment initially. Some centers will treat these small infants with serial lumbar or ventricular punctures; however, infection is a risk. Repeated ventricular taps may lead to porencephaly (cyst or cavity in the cerebral hemisphere).

In infants who have PHH and are able to tolerate a surgical intervention, a ventricular access device (VAD) can be implanted. This is a catheter that is surgically placed into the ventricle with an attached subcutaneous reservoir. The reservoir can be tapped as often as needed through the skin using a 23-gauge butterfly needle. Most infants with a VAD require a tap every 2–3 days, but some may require taps as often as twice daily.

Another procedure that may be used is the placement of a subgaleal shunt (Fig. 2.25). This is similar to a VAD, but the distal limb of the catheter is left to drain into a subgaleal pocket, which is created at the time of the placement of the device. The CSF under pressure drains through the catheter and distends the scalp, which allows absorption of the CSF by the galea. In some cases, CSF production may exceed the absorptive capability of the subgaleal space, and

intermittent taps of the pocket may be required. When repeated taps are needed through either the VAD or the subgaleal shunt, there is a risk of infection. Alternatively, some providers use a temporary external ventricular drainage device in the management of PHH. This has the advantage of maintaining a constant intraventricular pressure, whereas with the other aforementioned treatments, intraventricular pressure can alternate between being very high and very low. The disadvantage of all of these devices is that the catheters can become clogged from the blood or its by-products or, as previously mentioned, infected.

Eventually, over time, it will become clear whether the PHH is resolving or if the infant will need a permanent shunt placed. It has been demonstrated by studies on temporary measures to treat PHH that lumbar punctures and ventricular taps showed no reduction in ongoing need for shunt placement. Despite temporizing measures about 38% of patients will require a permanent shunt (Christian et al. 2016). In the majority of these infants, the shunt dependency is usually lifelong. There is currently some debate as to the most appropriate timing for a permanent shunt placement. There is insufficient evidence to recommend a specific infant weight or CSF parameter to direct the timing of shunt placement in premature infants with PHH (Mazzola et al. 2014). However many neurosurgeons believe that a shunt should be considered when the CSF is cleared of posthemorrhagic



**Fig. 2.25** Subgaleal shunt seen on a 3d CT scan, subgaleal pocket

debris and blood and the CSF protein is <500 mg/dl (Rekate 1999) and the infant should weigh >1.5 kg (variable), have progressive hydrocephalus (Wang and Avellino 2005), and be otherwise stable (Box 2.2).

**Box 2.2 Case Study: A 27-Week Premie with IVH**

Baby P was born at 27 weeks' gestation. The patient was born via an emergency C-section due to maternal hypertension and preeclampsia. The patient required CPR at birth and was intubated. An initial cranial ultrasound (CUS) revealed bilateral IVH, Grade III on the right and Grade IV on the left.

Baby P was initially watched closely by the NICU team with daily OFC and twice weekly CUS. The patient was extubated and started on high-flow nasal cannula. The patient was noted to have a gradual increase in head size. The patient was also noted to have an increase in bradycardic and apneic events. CUS revealed slight increase in ventricles.

On day 24 of life, the patient weighed 1.1 kg. Baby P was taken back to the operating room for a placement of a left frontal subgaleal shunt with a Rickham reservoir, which entailed creation of a subgaleal pocket. The patient initially had a stable subgaleal pocket that was fluid filled and soft. The OFC and US remained stable.

However, over the next several weeks, the subgaleal pocket lessened. By 6–7 weeks of life, Baby P was noted to have a rising OFC and fuller fontanel, with splayed sutures. A CUS, done on week 8 of life, revealed the ventricles to be larger. The patient also demonstrated episodic desaturations. The subgaleal reservoir was tapped using sterile technique. 10 cc/kg of CSF was withdrawn per this hospital's policy. The patient tolerated procedure well and his/her clinical status improved.

Baby P's weight was now 2.2 kg. Therefore, the decision was made to take the patient back to the operating room. The patient underwent placement of a ventricular-peritoneal shunt with a programmable valve. The patient tolerated the procedure well and continued to be followed while inpatient with daily OFCs and weekly CUSs. The patient's shunt valve resistance was increased (resulting in decreased flow of CSF) once due to sunken fontanel and overriding sutures. Baby P did well and was discharged home at 3 months of age.

### 2.10.3.2 Myelomeningocele

About 80–90% of children with myelomeningocele will eventually require surgical CSF diversion (Dias 2005). The treatment of hydrocephalus in the infant with a myelomeningocele usually involves placement of a ventriculoperitoneal (VP) shunt. The timing of the shunt placement depends on the severity of the hydrocephalus but historically has been deferred until after the myelomeningocele repair. Waiting until the hydrocephalus clearly progresses allows for the proper selection of infants who need permanent shunting. Placing a shunt at the time of the back closure may also be more difficult, since the infant should not be positioned on the newly closed myelomeningocele repair site. The advantages to doing it simultaneously with the myelomeningocele repair include a decreased risk of a CSF leak from the repair site and a decreased risk of CSF infection. Some neurosurgeons perform an endoscopic third ventriculostomy instead of a shunt, although performing an ETV in infants is debated.

Placement of an external ventricular drain (EVD) at the time of closure is another option; this allows for the decision of a permanent shunt to be deferred and minimizes the risk of leaking from the back closure (Box 2.3).

### **Box 2.3 Case Study: An Infant Born with Myelomeningocele and Hydrocephalus**

CR was born at 38 weeks' gestation with a prenatally diagnosed lumbar myelomeningocele. She was born at adult high-risk maternity center and transferred shortly after birth to a nearby pediatric tertiary care center with a level one NICU. CR was admitted to the NICU and seen by neurosurgery as well as other specialists, including neurodevelopment. She underwent a head CT, renal ultrasound, and cardiac echo. CR had minimal movement of her lower extremities at the hip flexors only, no movement distally, and a club foot on the right. Surgery was planned with neurosurgery and plastics later that day to close her back. A head CT revealed mildly enlarged ventricles. The back closure was somewhat difficult due to the size of the lesion, and during the procedure, the neurosurgeon decided to place an external ventricular drain so as to minimize the risk of a leak from the newly closed myelo. Baby CR did well and was transferred back to the NICU after being extubated in the PACU. The EVD was positioned at 5 cm to allow for adequate drainage. On the third post-op day, the EVD was raised to 7 cm and continued to drain. The following day it was raised to 10 cm. The EVD drainage slowed considerably. The following day the back wound began to have some mild underlying bogginess. There was no actual leaking thru the incision. This was watched for a few hours and increased slightly. It was decided to lower the EVD back to 0 and plan for a shunt. The following day a VP shunt was placed. A programmable valve was installed and set at 1.0 so as to allow for adequate drainage and to minimize the risk of any leak from the back. CR did well; the incisions from both the shunt and back wound healed without further issues. She was ready to be discharged on post-op day 8 with a plan to follow up in the neurosurgery clinic in 2 weeks.

The in utero surgical repair of myelomeningocele was studied in a multicenter study funded by the National Institutes of Health (MOMS study). The purpose of the study was to determine efficacy, safety, and benefit of in utero closure of the back (Sutton 2005). Prenatal surgery for the myelomeningocele repair performed before 26 weeks' gestation was found to be associated with decreased risk of death, decreased need for a shunt by 12 months of age, improved scores on mental and motor function, and decreased degree of hindbrain herniation associated with Chiari II malformation (Adzick et al. 2011). This procedure is available at limited medical centers.

### **2.10.3.3 Vein of Galen Malformation (VGAM)**

Initial treatment for the neonate is supportive and may include immediate resuscitative efforts with ventilatory support. The goal is stabilization until a transvenous and/or transarterial endovascular approach for embolization can reduce blood flow through the malformation and feeding vessels. The infant often presents with, or develops, hydrocephalus. However, the placement of a cerebrospinal shunt in an infant or child with a vein of Galen malformation has a very high risk of associated intracranial hemorrhage (Schneider et al. 1992). Many neurosurgeons will try to avoid placing a shunt by initially treating the malformation with embolization. If the malformation can be successfully embolized, it may shrink and the hydrocephalus may resolve. Although treatment has greatly improved outcome, mortality and morbidity of these malformations remain high. These patients can have a wide range of cardiac symptoms related to the increase in venous return to the right atrium and chronically increased preload. Patient's cardiac symptoms can range from mild volume overload to congestive heart failure or cardiogenic shock (Hoang et al. 2009). For further details on VGAM, refer to Chap. 12.

### **2.10.3.4 Intracranial Cysts**

Many types of intracranial cysts may occur including arachnoid cysts, choroid plexus cysts, neoplastic cysts, and multiloculated cysts associ-

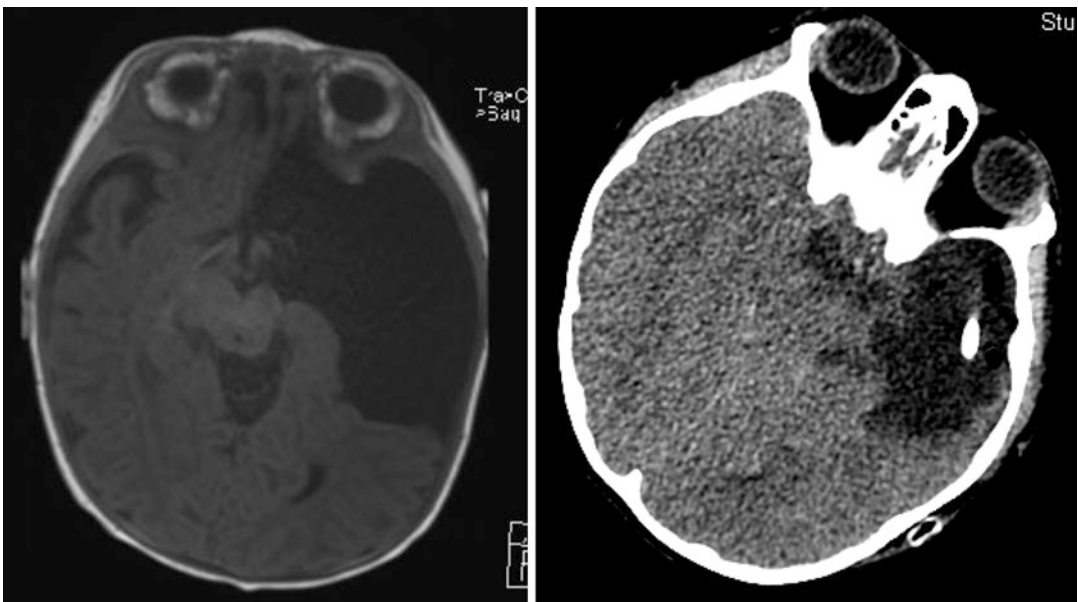
ated with infection, tumors, hemorrhage, or trauma. Arachnoid cysts are often diagnosed as an incidental finding when a CT is done for another reason. At the time of the initial diagnosis of an arachnoid cyst, an MRI is often done to rule out a tumor. An intracranial cyst may cause no mass effect or symptoms. Conservative treatment of such a cyst, including follow-up scans to verify that there is no change, may be adequate. The cyst can cause mass effect with symptoms and noncommunicating hydrocephalus from obstruction of normal CSF pathways (Fig. 2.26). In these cases, surgical intervention is required. Rarely, patients present with hemorrhage into the cyst that may also require surgical intervention.

Neuroendoscopic fenestration of the cyst wall may eliminate the need for a shunt. The surgeon breaks the cyst wall with an endoscope, and the fluid in the cyst is allowed to drain into normal CSF passageways. The goal is to reduce the cyst size and avoid placement of a shunt or, if a shunt is necessary, to avoid placing multiple shunts into noncommunicating spaces. Some surgeons may decide to shunt the cyst first because of the high rate of cyst recurrence after fenestration (Abtin and Walker 1999). If a ventricular shunt is needed, a shunt catheter can be placed into the

cyst(s) and another into the ventricle. These catheters can be “y’ed” together into a distal catheter terminating in the peritoneal cavity. The failure rate of multiple shunt catheters is high, and it is difficult to determine which catheters are functional and which are not at the time of malfunction. If the lateral ventricles are loculated (isolated) by membranes or cysts, the surgeon may fenestrate the septum pellucidum (septostomy) to eliminate the need for more than one shunt catheter.

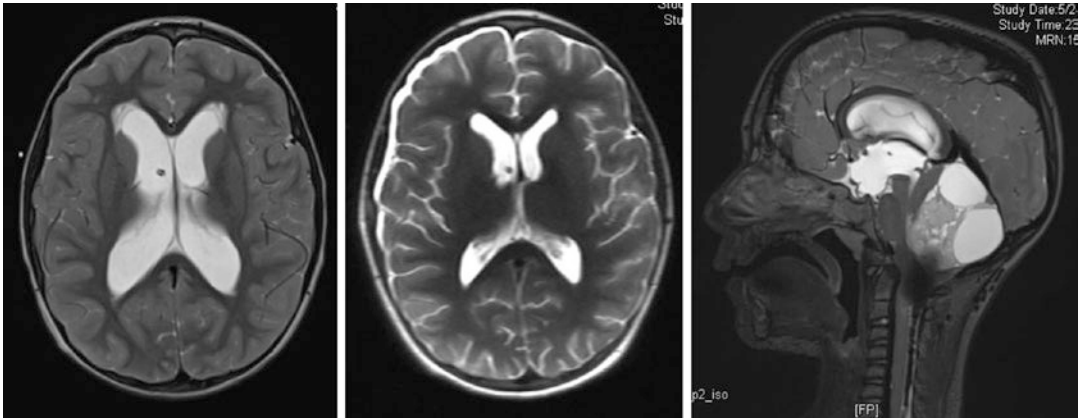
### 2.10.3.5 Brain Tumors

Approximately two-thirds of children who present with a posterior fossa tumor will have hydrocephalus. A smaller number of children with supratentorial tumors will have associated hydrocephalus at the time of diagnosis. If the hydrocephalus is severe and the child is very symptomatic, an emergent external ventricular drain or shunt may need to be placed (Figs. 2.27 and 2.28). When the surgeon anticipates a resection of the tumor, an external ventricular drain is usually the most appropriate choice because of the risk of shunt failure after tumor surgery due to blood and debris in the CSF from the surgery. If hydrocephalus is present,

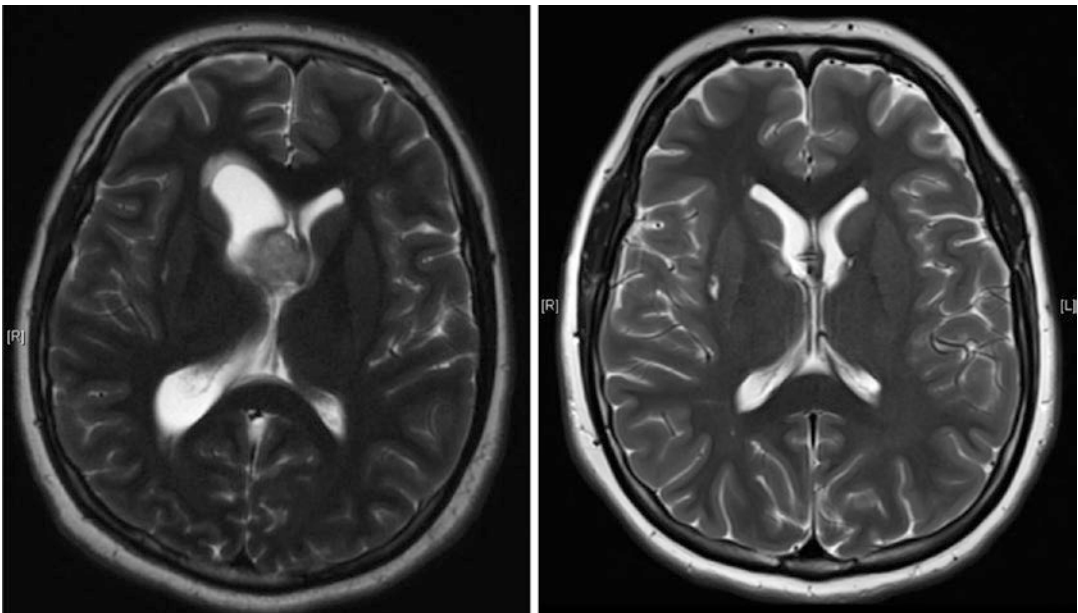


**Fig. 2.26** Arachnoid cyst (with mass effect) before and decreased mass effect post shunting





**Fig. 2.27** Obstructive hydrocephalus from a brain tumor now shunted



**Fig. 2.28** Obstructive hydrocephalus from a brain tumor now shunted

most neurosurgeons will place an external ventricular drain immediately before a posterior fossa tumor resection. The CSF is allowed to drain for 48–96 h postoperatively, and then the child is gradually weaned from the drainage device over several days. Approximately 25–50% of these children will be unable to tolerate weaning or removal of the external ventricular drain and will need a permanent shunt (Wang and Avellino 2005) or endoscopic third ventriculostomy (Box 2.4).

#### **Box 2.4 Case Study: An 8-Year-Old Boy with Fourth Ventricular Mass**

J is an 8-year-old boy who presented with headaches and nausea/vomiting for 1 month. The patient had CT scan that revealed a fourth ventricular mass, measuring  $3 \times 3 \times 2.5$  cm with significant ventriculomegaly and transependymal flow. J was immediately flown to a pediatric neurosur-

gery center. An MRI of the brain and spine was subsequently done on arrival which showed a homogenous and uniformly enhancing fourth ventricular mass with restricted diffusion and severe hydrocephalus. Spine MRI was normal.

On arrival at this center, J was emergently taken to the operating room for placement of a right frontal external ventricular drain (EVD). J tolerated the procedure well and his symptoms improved. The EVD was drained at a level of 15 cm H<sub>2</sub>O above the external auditory meatus. The patient was started on intravenous antibiotics for prophylactic coverage of the drain and high-dose steroids (dexamethasone).

The following day, J was taken back to the operating room for a suboccipital craniotomy and resection of a posterior fossa tumor. Postoperatively, the EVD was set at a level of 10 cm H<sub>2</sub>O. The CSF output initially was bloody and pinkish in color. He had daily sodiums checked which remained stable.

Over the next 3 days, the patient's EVD continued to be monitored. The CSF had less blood products and became straw colored. The patient continued to recover and did remarkably well. Therefore, on day 4 postoperatively, his EVD was raised to 15 cm H<sub>2</sub>O. The patient continued to have no headaches or other symptoms, and the following day, the drain was raised to 20 cm H<sub>2</sub>O, while at 20 cm H<sub>2</sub>O, he started to develop headaches and became sleepy. A pseudomeningocele developed at the site of his incision. A limited MRI (HASTE MRI) revealed enlarged ventricles. The patient's EVD was lowered to 15 cm H<sub>2</sub>O since he had failed the attempted wean.

The patient was taken to the operating room the following morning for a placement of a right ventricular-peritoneal shunt which he tolerated well. He was able to be

discharged home 4 days later after receiving further therapies.

Pathology revealed the tumor was an ependymoma, Grade II. The patient was enrolled in a study involving treatment with chemotherapy and radiation; he continued to be followed by the neurosurgery team.

## 2.11 Complications of Shunts and Treatment

Complications of cerebrospinal fluid (CSF) shunts include mechanical failure of the shunt, infection, and over-shunting. Depending on the location of the distal catheter of the CSF shunt, risks of other complications are possible. Procedures with the highest rate of unplanned readmission were CSF shunt revision or removal and CSF shunt placement (Sherrod et al. 2016). Shunt failure is a common and often unpreventable phenomenon, occurring in approximately 12% of pediatric shunt procedures within 30 days or less, and up to 46% of procedures had reported failure rates when the follow-up period lasted up to 1 year (Sherrod et al. 2016).

### 2.11.1 Shunt Malfunction

Mechanical failure of the shunt can be due to improper placement, obstruction, disconnection, fracture, and migration of the hardware. Malfunctions may occur in the operating room, soon after surgery or years later. However, the most common time for a malfunction is within the first 6 months after placement or revision (McLone 2001). Recent study showed that being under 6 months of age, a preexisting cardiac comorbidity, and the use of the intraoperative endoscope for proximal catheter placement had correlated with higher risks of initial CSF shunt failure (Riva-Cambrin et al. 2016).

Obstruction of the shunt hardware is a common cause of malfunction. Most often, the

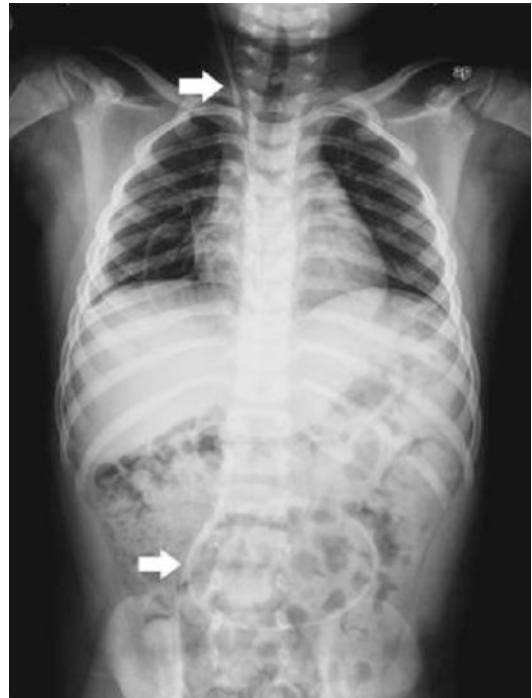


obstruction occurs in the proximal portion of the shunt. Total proximal obstruction of the shunt is frequently associated with rapidly increasing intracranial pressure and requires emergent intervention. The proximal catheter may become obstructed in the operating room or shortly thereafter with blood or air. Proximal occlusion may also be the result of the choroid plexus growing around the proximal portion of the catheter or from blood or other proteinaceous materials within the catheter or valve. Occlusion may also be from the catheter being improperly placed during surgery or slipping out of the ventricle later.

If the proximal catheter is obstructed or partially occluded, there may be swelling along the shunt tract over the skull and neck, with minimal signs of shunt failure. Such swelling may also occur with a functional or partially occluded shunt if there is a large hole in the dura around the shunt catheter, resulting in a CSF leak around the shunt. Obstruction of the distal catheter may be the result of distal infection, scarring, adhesions, or fat occluding the shunt. As the child grows, the distal end of the catheter may slip out of the abdominal cavity. A tract may form allowing CSF to flow beyond the shunt tip, usually failing slowly over time.

Disconnections happen most often at connection sites between components of the shunt. A disconnection may occur between the proximal catheter and valve or between the valve and distal catheter. Tubing that has been in place for a long time may become fixed by the development of scar tissue around the catheter. Over time, calcification may also develop around the catheter and the catheter itself may degrade. Both the fixation and calcification may lead to catheter breakage with growth, particularly in the neck where there is constant motion (Fig. 2.29). The patient may also develop pain along an old calcified shunt tract.

Migration of the distal catheter may occur to a number of sites, including the scrotum, umbilicus, stomach, mouth, intestine, chest, anus, uterus, internal jugular vein, and coronary sinus. When migration occurs, malfunction of shunt often results from blockage of CSF flow and/or lack of



**Fig. 2.29** Radiograph shows a broken ventriculoperitoneal shunt catheter near the clavicle. The most distal portion of the catheter can be seen in the *bottom* of the peritoneal cavity

reabsorption of CSF (Greenberg 2010). Infection may also occur in conjunction with migration to another site. Other complications may occur depending on where the distal shunt is located.

### 2.11.1.1 Evaluation and Treatment of Shunt Malfunctions

The initial work-up of the patient with a suspected shunt malfunction includes a thorough history and physical exam. The radiological exam includes shunt series x-rays of the shunt hardware and a CT (without contrast) of the head or limited T2 (HASTE) MRI.

Shunt series x-rays include anterior/posterior and lateral films of the skull, neck, abdomen, and pelvis. These are done to evaluate the continuity of the shunt hardware, location of the hardware, valve type, and any other abnormalities that may be present. There may be areas of the shunt system that seem translucent on plain films, particularly over the valve and connec-

tors. Comparing the films to previous postoperative films may provide further information about how the shunt hardware appears at baseline. Comparing the films to x-rays of the most common shunt valves and connectors may also be helpful.

The head CT, MRI, or US can also be compared with previous scans. If the patient is symptomatic and the ventricles have increased in size, a shunt failure is usually confirmed. The scan may also reveal other intracranial complications such as improper placement of the proximal catheter or extra-axial fluid or blood.

Ventriculomegaly does not always occur with shunt malfunctions. In some patients, the ventricles remain small due to decreased ventricular compliance. The child who does not demonstrate increased ventricle size with shunt failure needs further testing to evaluate shunt function.

Additional information about shunt function may be obtained by tapping the shunt and measuring the intracranial pressure. This can be done by accessing the shunt via the reservoir or valve with a small needle connected to a manometer. When the shunt is working, there is usually spontaneous flow of CSF through the catheter into the manometer with good respiratory variation; sometimes pulsation will be seen. The lack of CSF flow from the shunt in the presence of normal or dilated ventricles suggests proximal obstruction. If the ventricles are slit-like, no flow may be normal. Intracranial pressure is measured manually with the manometer. The pressure is measured with the “0” on the manometer at the level of the external auditory meatus (see Sect. 2.13.5 “External Ventricular Drains”). Pressure will vary depending on age and activity of the child (Box 2.1). To obtain a true pressure, the child must be calm. Intracranial pressure measured with a manometer is measured in cm of water (cm H<sub>2</sub>O) (Table 2.4).

A nuclear medicine study (shuntogram) is another test that may be useful in the evaluation of shunt function. A small needle is inserted into the shunt reservoir or valve and the opening pressure is measured. A radioisotope is then injected into the shunt, and gamma camera images are taken of the head, neck, and abdo-

**Table 2.4** Normal intracranial pressure for infants and children

Age	Pressure, cm of H <sub>2</sub> O	Pressure, mm of Hg
Neonate	<3	<2
Newborn	2–8	1.5–6
Young child	4–9	3–7
	1.36 cm of H <sub>2</sub> O = 1 mm of Hg	

Adapted from Wang and Avellino (2005)

men to evaluate movement of the tracer. Normal findings of a shuntogram include an opening pressure between 0 and 20 cm of H<sub>2</sub>O (dependent on the age and activity of the child), and radioisotope flows out of the needle hub, clears out of the reservoir and shunt, and disperses freely into the peritoneal cavity (the half-time should be less than 5 min). Both a shunt tap and a nuclear medicine study can sometimes provide confusing results.

If a shunt malfunction is confirmed, the child is taken to the operating room for a shunt revision. Sometimes, a very symptomatic patient without clear diagnostic findings during the work-up may be taken to the operating room to explore the shunt. During a shunt revision, all parts of the shunt are evaluated. Shunt hardware parts that are malfunctioning are replaced (Box 2.5).

#### Box 2.5 Case Study: A 6-Year-Old with Shunt Malfunction

CS is a 6-year-old male who has a shunt in place due to a history of congenital hydrocephalus caused by aqueductal stenosis. He was shunted at birth. He underwent an endoscopic third ventriculostomy after shunt failure at the age of 3. He did well and then developed symptoms of hydrocephalus again at the age of 5. An MRI was done and revealed that the ETV had closed. He then underwent another shunt placement.

CS presented to the ED with an 18-h history of headache, vomiting, and 6 h of increasing lethargy. He was seen in the ED

by the neurosurgical nurse practitioner. Upon exam, he was arousable but sleepy. He was not sure where he was but was asking for his mother. The mother stated that he is a typically developing child and in the first grade. He was complaining of headache and vomited in the ED. His heart rate was in the 60s, and his other VS were normal for age. He could follow some directions such as moving an extremity, but he was not consistently following directions and at times just cried or whimpered. An urgent low-dose CT was done that showed enlarged ventricular size. A shunt series showed that the shunt system was intact, and his Strata valve was set at 1.0, as it had been previously. When he returned from CT, he seemed slightly more somnolent to his mother. His heart rate was occasionally dipping into the 50s. A shunt tap was done, and there was no flow from the shunt. The pressure was measured and found to be  $-10$  cm of water.

Due to the enlarged ventricles, no flow from the shunt tap and negative pressure in the shunt system, a proximal shunt malfunction was presumed. He was taken urgently to the operating room for a shunt revision. He was found to have occlusion of the proximal catheter, and the intracranial pressure was found to be 30 cm of water. A new catheter was placed and attached to the existing valve and distal catheter. Postoperatively, CS was awake and alert. He denied headache and had complaints of being hungry later in the evening. He also denied any memory of the events in the ED. He stayed in the hospital overnight and was discharged the following morning in good condition.

### 2.11.2 Shunt Infection

Infection is the second most common complication of cerebrospinal fluid shunts. The incidence is greatest in the first year after placement, with

80% appearing in the first 6 months. Rates of infection range from 4.1% to 20.5% per patient and 2.5–12.3% per procedure (Simon et al. 2009a). Patient characteristics can influence risk. Infants and younger children, those with concurrent infection, those who have had a recent shunt revision, those with previous shunt infection, and those with postoperative disruption of the incision exposing the shunt hardware, have a higher risk of shunt infection.

The most common infecting organism is Staphylococci. *Staphylococcus epidermidis* (coagulase-negative *Staphylococcus*) is seen in 50–75% of all shunt infections (Haines 1999). *Staphylococcus aureus* (coagulase-positive *Staphylococcus*), gram-negative organisms (usually *Escherichia coli*, *Klebsiella*, *Proteus*, and *Pseudomonas*), streptococcal species, *Neisseria*, *Haemophilus influenzae*, and fungi make up the remainder of most infections. Infections with gram-positive organisms correlate with a better outcome than those with gram-negative organisms. The infection usually occurs in one of three ways: (1) via intraoperative contamination, (2) via the bloodstream, or (3) via retrograde travel from a contaminated distal catheter.

#### 2.11.2.1 Evaluation and Treatment of a Cerebrospinal Shunt Infection

If the child has had a recent shunt procedure or a history of shunt infections and presents with symptoms of infection, one should have a high index of suspicion of a shunt infection. If the child is stable and has not had a shunt procedure in the last several months, the most common diseases of childhood should be ruled out. A thorough physical exam and laboratory work (including complete blood count, C-reactive protein, erythrocyte sedimentation rate, blood cultures, urinalysis, and chest films) may help locate the source of the infection. Most neurosurgeons are reluctant to tap a shunt unless there is clearly no other source of infection, due to the risk of infecting the shunt with the tap.

The child presenting with a shunt infection may range from minimally to gravely ill. The child may have one or more signs and symptoms of infection: fever, irritability, redness and/or

swelling over the shunt tract, or redness and/or drainage from shunt incisions. The infected shunt may or may not fail. Therefore, the child may or may not have signs and symptoms of a shunt malfunction, including headaches, nausea, vomiting, and lethargy. If the distal portion of the shunt is infected, the child may have abdominal symptoms, including pain, tenderness to palpation, and distension. An abdominal CT or US may reveal an intra-abdominal loculated CSF collection.

Diagnosis of a shunt infection is confirmed by a positive CSF culture from the shunt (or a positive culture from explanted hardware). The shunt reservoir is aspirated via a shunt tap for CSF and sent to the lab for glucose, protein, cell count, Gram stain, and culture. The CSF with infection usually shows mild to marked elevation of WBCs. The Gram stain may show the presence of polymorphonuclear leukocytes and bacteria. The glucose may be decreased and the protein elevated. Infection in the tissues surrounding the reservoir is usually a contraindication to tapping the shunt. Even presumed sterile aspiration of the shunt in this setting could lead to contamination and subsequent infection of the shunt.

The treatment of a shunt infection varies, but in general principles of treatment of infection in the setting of a foreign body are followed. Cultures are obtained, and intravenous broad-spectrum antibiotics are started to cover the most likely organisms. The shunt hardware is either externalized or totally removed and replaced with an external ventricular drain. Some neurosurgeons may not remove the shunt if it is functional and treat the patient only with intravenous antibiotics. However, this is controversial.

Once the infecting organism's sensitivities are known, the antibiotics may be altered. The child is treated with intravenous antibiotics until the CSF has been sterile for several days. There is no consistent agreement about the number of days that the CSF should be sterile before the shunt hardware can be reimplanted. Many neurosurgeons also prefer for the CSF to have less than 50/mm<sup>3</sup> white blood cells and the protein to be less than 500 mg/dl before replacing the shunt. Most commonly, the child will receive 5–14 days of treatment before the shunt is replaced. There is also no consistent agreement as to the length of antibiotic

treatment after the shunt has been replaced. Factors such as the specific organism, the severity of the infection, and previous history of infections may all affect the length of antibiotic treatment.

Preventing infection is the best way to improve outcome. At present, adherence to meticulous intraoperative aseptic technique and perioperative prophylactic systemic antibiotics are accepted procedures. There is no proven drug of choice or length of treatment after a shunt revision. Most neurosurgeons use intravenous cefazolin, nafcillin, vancomycin, ceftriaxone, or methicillin. Length of treatment varies from one dose to multiple doses (up to 72 h). Antibiotic-impregnated shunt material has been shown to decrease infection rates (Kestle et al. 2011). These catheters may be impregnated with vancomycin, rifampin, clindamycin, or iodine. More studies are currently being done on standardizing protocols to reduce CSF infections. These studies standardize how the room is set up, the number of personnel in the room, double gloving, preparation of the skin, antibiotics (vancomycin and gentamicin) injected into the shunt intraoperatively, and postoperative care. These protocols have been proven to decrease overall infection rates (Kestle et al. 2011) (Box 2.6).

#### **Box 2.6 Case Study: A 4-Year-Old Child with Shunt Infection**

AB is a 4-year-old female who was born with congenital hydrocephalus. A shunt was placed shortly after birth and revised once in the first year of life and again 5 weeks ago at 4 years of age. She did well after the most recent revision and was discharged on the first postoperative day. She returned for a wound check 2 weeks later. The wound appeared to be healing. She had vague complaints of abdominal pain. Her mother also reported some issues with constipation. The neurosurgery nurse practitioner counseled the mother on constipation management.

She returned 1 week later, still complaining of abdominal pain. On exam, the incisions were healing normally. Palpation of her

abdomen revealed that it was soft, slightly distended, and mildly tender. She was afebrile. Labs were ordered, and her WBC was normal; CRP was elevated at 5.4. A low-dose head CT and shunt series were done that showed resolution of her increased ventricle size. An abdominal CT was done showing a loculated fluid collection around the tip of the catheter. A shunt tap was done: glucose 28, protein 140, RBC 2, and WBC 190. Gram stain shows moderate polymorphonuclear leukocytes and gram-positive cocci. A diagnosis of a shunt infection was made. She was taken to the operating room where all the shunt hardware was removed and an external ventricular drain was placed. She was started on vancomycin and ceftriaxone. The original culture eventually grew out *Staphylococcus epidermidis*, and sensitivities showed it was sensitive to nafcillin. The antibiotics were changed to nafcillin. CSF cultures were drawn daily and were negative after the shunt was removed. She received a total of 8 days of IV vancomycin/nafcillin. She was then taken back to the OR for placement of a new ventricular to peritoneal shunt. She received the standard post-op dose of antibiotics. She was discharged home the following day.

### 2.11.3 Complications Related to Distal Catheter Location: Ventriculoperitoneal Shunts

The abdominal cavity is the preferred area to place the distal end of a cerebral spinal fluid shunt in most cases. However, the abdomen may be the site of other surgical procedures or diseases. This is particularly an issue in young children with chronic medical conditions. These children may need frequent urological procedures, gastrostomy tube placement and revisions, or other bowel surgeries. Intra-abdominal adhesions, scarring from old procedures, or previous shunt infections may decrease the absorptive capability of the peri-

toneum. Pseudocysts may develop around the tip of the catheter, with or without infection. The presence of an intra-abdominal infection, such as appendicitis, may or may not infect the shunt and make the abdominal cavity unsuitable for another shunt. The distal catheter may erode into the bowel leading to shunt infection and peritonitis. Other complications that may occur from intra-abdominal shunts include a 17% risk of inguinal hernia development (if the shunt is placed in young infants whose process vaginalis is still patent) or the development of a hydrocele.

#### 2.11.3.1 Ventriculoatrial Shunts

If the abdomen is not an appropriate site for the distal shunt catheter, it may be placed in the right atrium of the heart. Ventriculoatrial catheters potentially have more serious complications than ventriculoperitoneal catheters. Complications include migration of the shunt into the superior vena cava (usually with failure of the shunt), pneumothorax, endocarditis, shunt nephritis, pulmonary embolism, septicemia, septic emboli, cardiac arrhythmias, cardiac tamponade, detachment of the catheter with migration into the coronary sinus, and obstruction of the vena cava system. Shunt nephritis is an unusual complication that can cause proteinuria, hematuria, and decreased kidney function and is often caused by a low-grade infection of the shunt. If shunt infection is suspected, blood cultures and 24-h urine for protein are obtained in addition to the other labs to rule out shunt nephritis. If the patient with a ventriculoatrial shunt presents with fever, blood cultures are always performed to rule out systemic bacteremia.

Another problem with ventriculoatrial shunts is that extra tubing cannot be placed into the right atrium to allow for growth. Therefore, infants and young children may outgrow these shunts in months resulting in shunt failure. A ventriculoatrial shunt may require frequent revisions to allow for growth. By examining the chest x-ray, one can diagnose the distal catheter being dislodged from the right atrium. The catheter tip should be visible on plain x-ray at the level of the sixth/seventh thoracic vertebrae.



When examined at autopsy, multiple complications may have occurred around a ventriculoatrial catheter: fibrinous material may surround the catheter, vegetation may be seen within the wall of the right atrium, and there may be evidence of pulmonary emboli (Marlin and Gaskill 1994).

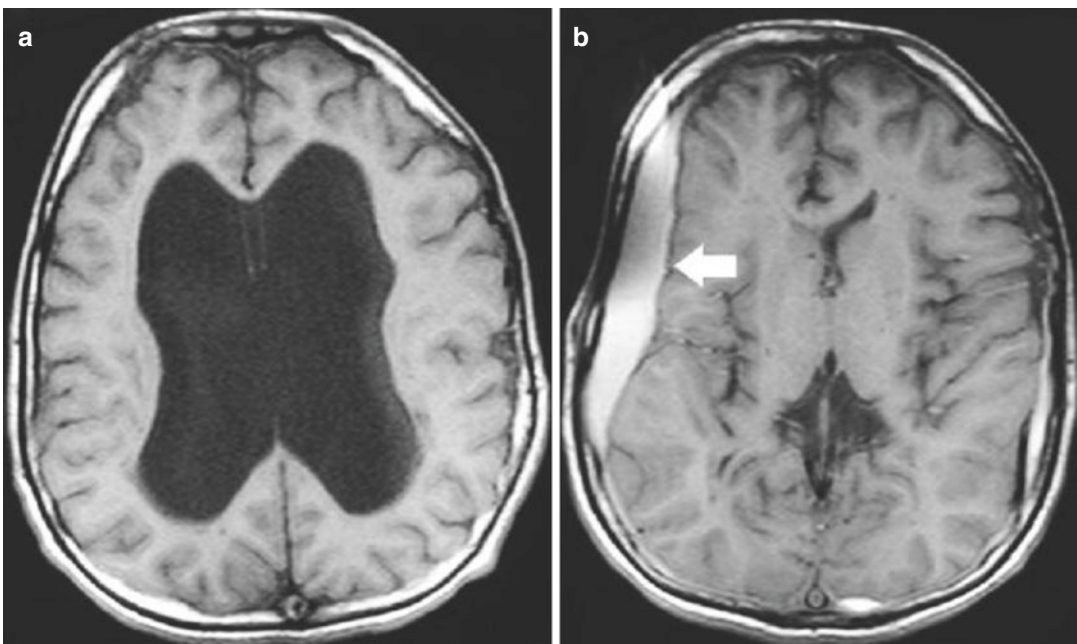
#### 2.11.4 Lumboperitoneal Catheter Complications

Historically, a number of complications have been associated with lumboperitoneal shunts, including frequent shunt failure, scoliosis, arachnoiditis, back stiffness, back pain, sciatica, neurological changes in the lower limbs, and hindbrain herniation (Olson 2004). These complications have been reduced with changes in shunt hardware and careful preoperative screening. First, with the introduction of percutaneously implanted shunts and improved shunt catheters, the need to perform a laminectomy for shunt placement is now rare. This has reduced the rate of scoliosis and arachnoiditis. Second,

preoperative evaluation of patients for hindbrain herniation, including a CSF flow study, can help determine when posterior fossa decompression prior to placement of the LP shunt is appropriate. Thorough preoperative evaluation and the use of a higher-pressure valve may decrease the risk and incidence of hindbrain herniation and decrease lumboperitoneal shunt complications (Rekate and Wallace 2003).

#### 2.11.5 Over-Drainage Causing Extra-Axial Fluid Collection

After a CSF shunt is placed, if the ventricles decompress excessively or too rapidly, extra-axial fluid collections and/or a subdural hematoma may occur. Fragile bridging veins on the brain's surface may tear as the brain falls away from the dura and bleeding can occur creating a subdural hematoma (Fig. 2.30). This is a risk when shunts are placed for the first time in older children. Treatment depends on severity, symptoms, and the type of valve used. If the valve is programmable, the



**Fig. 2.30** A 15-year-old male with achondroplasia and chronic hydrocephalus: (a) preoperative MRI shows enlarged ventricles; (b) postoperative MRI shows col-

lapsed ventricles with subsequent development of bilateral (right greater than left) subdural hematomas



pressure may be temporarily increased. If not, the valve may need to be replaced with a higher-pressure valve. By allowing the ventricles to remain more dilated, the brain will resume its normal position against the dura and skull. If a subdural hematoma is present, it may need to be drained.

### 2.11.6 Slit Ventricle Syndrome

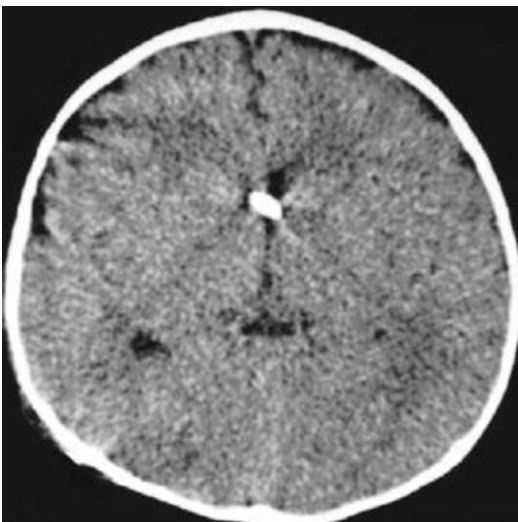
Slit ventricle syndrome (SVS) occurs in patients with shunted hydrocephalus. It is typically characterized on imaging by small or “slit-like” ventricles (Fig. 2.31) and symptomatically by severe headaches. However, most patients with slit ventricles on scan have no symptoms, while others have SVS-like symptoms but normal-sized ventricles (Rekate 2008; Buxton and Punt 1999). Of children with radiologically slit ventricles and headaches, only an estimated 6–22% have this syndrome (Olson 2004). SVS has been used in the literature to describe a number of different conditions that include symptomatic small ventricles. This has led to confusion in choosing the

most effective treatment option and evaluating the outcome. To avoid confusion, using the term noncompliant ventricle syndrome instead of SVS has been recommended (Olson 2004; Buxton and Punt 1999).

SVS usually occurs after a shunt has been in place for many years, making it more common in the older child and adolescent, although younger children and infants may also be affected. Symptoms are those associated with shunt malfunction (intermittent headaches, nausea, vomiting, and other signs of increased intracranial pressure). Headaches are the most common complaint. In some patients, being upright worsens the symptoms, and lying down improves them.

In a review of the literature, Olson (2004) found at least five different clinical scenarios in which children have radiologically slit ventricles and headaches. Patterns include an on-off (intermittent) symptom complex, over-drainage and siphoning with negative intracranial pressure (particularly when the patient is upright), recurring proximal ventricular catheter dysfunction/obstruction, chronic subdural collections due to shunt over-drainage, and headaches unrelated to shunt function. Most authors applied the syndrome to an on-off (intermittent) symptom complex. This has further been defined as “severe intermittent headaches lasting 10–90 min associated with smaller than normal ventricles on imaging studies, and a slow refill on valve pumping devices” (Rekate 1999, 2008). The pathophysiology supporting these symptoms is that with slit ventricles, the catheter becomes intermittently obstructed with surrounding tissue, the pressure rises, and when it is high enough, the ventricles minimally dilate, allowing the catheter to function again.

The exact mechanism underlying the syndrome is not known and may be a combination of proposed theories. First, because there is a relationship between ventricular pressure and intracranial pressure, when CSF pressure drops, there is an increase in venous congestion and brain elasticity. Second, an increased pressure with subependymal flow can cause subependymal gliosis and periventricular gliosis with increased ventricular wall stiffness. Consequently, a higher than normal intracranial pressure is needed to dilate



**Fig. 2.31** An 11-month-old male with a ventriculoperitoneal shunt and slit ventricle syndrome. He had many months of irritability and trouble feeding and also had several shunt revisions, including the placement of programmable valves and a lumboperitoneal shunt. He eventually underwent a cranial expansion procedure, and his symptoms improved

the ventricles. Third, in newborns, over-shunting leads to radiologically slit ventricles, as well as the development of microcephaly and suture synostosis. Because of the small ventricles, catheters become easily plugged. With a small cranial compartment, ventricular dilatation is restricted and can lead to increased intracranial pressure.

Evaluation initially involves the typical work-up for shunt malfunction. When the CT is normal, but significant symptoms persist, further studies are warranted. A shuntogram may confirm CSF patency and flow but can be misleading due to the intermittent nature of the problem. Continuous invasive intracranial pressure monitoring may correlate symptoms with pressure. This may be done via a fiber-optic intracranial monitoring device or via an external ventricular drainage catheter attached to an intracranial monitoring device.

Some patients may benefit from antimigraine therapy using propranolol, dihydroergotamine, or amitriptyline. The mechanism by which these drugs work is probably by reducing venous congestion. Propranolol, a beta-blocker, cannot be used in children with asthma, as it will render asthma medications (beta-adrenergic agonist bronchodilators such as albuterol) ineffective.

A revision of the shunt is the most common treatment for SVS, particularly in those patients with a normal-sized calvarium. If headaches occur with low pressure, an antisiphon device may be added, and the valve may also be changed to a higher-pressure or programmable valve (Rekate 2008). These shunt changes may decrease over-drainage and promote slightly larger ventricles, allowing for more consistent shunt function. Multiple changes in ventricular valve pressure are often needed during the evaluation and treatment of SVS. Programmable valves have made this possible without repeated surgical procedures. Before any such changes in an infant, it is important to rule out craniosynostosis, as increasing the valve pressure in this situation could cause a pathological increase in intracranial pressure. Shunt replacement in the setting of small ventricles can be difficult and may require the use of endoscopy.

Success has recently been reported with the placement of a lumboperitoneal shunt in addition

to a ventriculoperitoneal shunt (Olson 2004). This may occur due to an added increase in CSF drainage when an increase in intracranial pressure occurs. A potential risk factor with a lumbar shunt in addition to a VP shunt is that if the ventricular catheter fails, hindbrain herniation may occur (acquired Chiari I).

Other surgical procedures have been utilized, including subtemporal decompression, calvarial expansion, and third ventriculostomy or EVT. Subtemporal decompression reduces intracranial pressure by removing a portion of the skull. The procedure can be accomplished with low risks, and some recommend this as a first-line treatment for patients with synostosis and a small calvarium (Olson 2004). Calvarial expansion is a much more extensive procedure, and bleeding is a significant risk. EVT is an option for some patients who still experience headaches after valve upgrade and placement of an antisiphoning device, but not those with Chiari II malformation (Rekate 2008).

---

## 2.12 Nursing Care of the Hydrocephalus Patient After Surgery

The most common operations that children with hydrocephalus undergo are shunt placement, shunt revision, and endoscopic third ventriculostomy (ETV). Because these children frequently have other diseases related to the hydrocephalus, they often undergo other surgeries to treat a multitude of other problems.

### 2.12.1 Neurological Assessment

Neurological assessment of the child after surgery to treat the hydrocephalus needs to be done frequently to detect any changes. The surgeon will usually specify the frequency, but assessment should occur every 1–4 h, depending on the condition of the child. An exam that is changing subtly over time may be an indication of failure of the surgical treatment or postoperative complication. The first signs of increasing intracranial

pressure are usually subtle and related to mildly increasing somnolence, lack of interest in activities (feeding) or play, and subtle behavioral changes. Level of consciousness is the most important single indicator of neurological status. Altered level of consciousness may progress to confusion, disorientation, somnolence, lethargy, obtundation, stupor, and coma.

Parents and families are an excellent resource to provide information about their particular child's developmental level. The signs and symptoms of increasing intracranial pressure may initially be very subtle. Hence, the child's caretaker is a valuable resource in such assessment and may notice subtle changes before nursing and medical staff.

A thorough neurological assessment starts with watching the child play and interact with those around him. Assessment also includes asking the child if he has a headache. Nonverbal infants and children may exhibit behavioral signs of headache. The child should be examined for his ability to answer questions appropriately and follow directions. Asking a child to move his arms and legs will also allow the examiner to assess muscle strength, tone, and movement. Vital signs should also be assessed. Bradycardia is a sign of increased intracranial pressure and should be closely monitored in the presence of other symptoms. Increased blood pressure is usually not a common finding in children until late in the process of increasing intracranial pressure.

It is important to carefully examine the eyes; checking pupils without further exam is never an adequate exam. The pupils are checked for equality, roundness, and reactivity to light. Dilated and nonreactive pupils are a very late sign of increased intracranial pressure. A "sunsetting" appearance to the eyes or the loss of the upward gaze is an abnormal finding and indicative of increased intracranial pressure. The extraocular movements should be intact.

The infant's head should be examined. The occipital frontal circumference should be measured and documented on a daily basis to determine appropriate head growth. The fontanelles should be palpated with the child upright and calm. The anterior fontanelle should feel soft and

pulsatile. A tense or bulging fontanel is suspicious for increased intracranial pressure. The suture lines of the skull should also be examined. Normal suture lines are palpable and apposed. If they are overriding, the infant may have over-drainage of the shunt. If the sutures are splayed, there is likely increased intracranial pressure.

### 2.12.2 Wound and Dressing Care

The child may come from the operating room with a dressing over the incision. The dressing is normally removed or changed during the first few postoperative days. If a dressing is soiled or saturated with blood, most surgeons agree that it should be replaced. If the child is likely to pick at the incision, a dressing may be kept over the incision to prevent infection. Before a child goes home, most surgeons agree the dressing should be changed and the wound inspected for any erythema, drainage, swelling, or infection.

### 2.12.3 Medications

The majority of neurosurgeons will order intravenous postoperative antibiotics to prevent shunt infection. Cefazolin and nafcillin are the most commonly used antibiotics, as gram-positive organisms demonstrate sensitivity to them. Vancomycin or clindamycin may also be used for resistant organisms. Length of treatment is variable.

Pain management starts with good pain assessment. Age-appropriate pain assessment scales such as the CRIES (crying, requires increased oxygen administration, increased vital signs, expression, sleeplessness), Objective Pain Scale, and Oucher scale may be used. There is a wide variety of pain experienced by children after surgery for hydrocephalus. Pain may be related to the cranial incision(s), the abdominal incision, the amount of intra-abdominal manipulation, and the tunneling of the distal catheter through the subcutaneous tissue. Other factors influencing pain may include the age of the child, the child

and/or family's experience with pain, and the child and family's anxiety. Pain is usually managed with medications although other techniques may be helpful. The first drug of choice is usually acetaminophen. It should be adequately dosed at 10–15 mg/kg/dose, maximum dose of 75 mg/kg/day not to exceed 4,000 mg/day, and can be given orally or rectally. Nonsteroidal anti-inflammatory drugs (NSAIDs) may be used, but they can inhibit platelet aggregation and prolong bleeding time. For this reason, some neurosurgeons do not use NSAIDs during the immediate postoperative period.

If the child needs additional medication for pain, the surgeon's beliefs about pain control in neurosurgical patients may be a factor. Some neurosurgeons will order opiates such as morphine sulfate, oxycodone, or codeine, while others do not want to alter the patient's neurological exam with these drugs. The nurse should not administer these drugs if she is concerned that the pain is due to increasing intracranial pressure or the neurological exam is changing. Other modalities to relieve pain may include age-appropriate relaxation techniques, play therapy, music therapy, massage, distraction, and acupuncture or acupressure.

Some children will experience nausea and vomiting from anesthesia that may be worsened by extensive intra-abdominal manipulation during the surgery. Medications to treat this include metoclopramide and ondansetron. The nurse should not administer these drugs repeatedly if there is a possibility that the nausea and vomiting are due to increasing intracranial pressure. Treating the symptoms and ignoring the underlying cause may result in further increased pressure and delay of needed treatment.

Children who are on antiseizure medications preoperatively should have these resumed as soon as possible. Often, because of vomiting before or after the surgery, doses are missed, so it is helpful to check blood levels of the drugs to ensure they are therapeutic. If the levels are subtherapeutic, extra doses may be ordered. Children with low levels of their antiseizure medications are at increased risk for seizures.

Infants and children require some intravenous fluids after surgery until they can take adequate fluids orally. Fluid loss from vomiting should be replaced. Electrolytes should also be monitored during periods of vomiting. The nurse should assess the child for symptoms of adequate hydration. Usually the child will receive maintenance fluids postoperatively for at least 12 h. The child with a shunt in place should never have an intravenous line placed into the scalp because of the risk of introducing bacteria to the area around the shunt hardware.

#### 2.12.4 Other Nursing Care

The surgeon will usually specify the position that the child should assume. Elevating the head of the bed 30–45° will enhance shunt function by gravity aiding the flow of the CSF through the shunt. The surgeon may specify that the infant or child be placed flat if he is concerned about overdrainage of the ventricles. If the ventricles are allowed to drain too quickly, the outside of cerebral cortex may pull away from the dura. This may cause tearing of the fragile bridging veins and result in a subdural hematoma. Infants with overriding sutures are usually placed flat to minimize overdrainage. If overriding sutures are allowed to occur for a long period of time, the sutures may fuse prematurely. The nurse should also position the infant or child off of the incision and shunt hardware. Young infants who are allowed to lie on the hardware may experience skin breakdown and shunt infection within hours. X-rays of the shunt system are also done during the postoperative period to assure correct placement of the shunt, that the system is intact, and for any other potential complications (i.e., pneumothorax associated with a ventriculoatrial shunt).

These children have all the other usual postoperative needs of pediatric surgery patients. Nurses should be concerned with adequate diet, good pulmonary care, mobilization issues, skin care, adequate rest, and emotional care.

### 2.12.5 Extraventricular Drainage

CSF can be temporally diverted outside the body using an extraventricular drain (ventriculostomy or EVD) and may be used with or without intracranial pressure monitoring. It is commonly used in the treatment of shunt infections, in which the colonized shunt tubing, as well as the infected CSF, needs to be removed in order to completely eradicate the infection. Usually the entire shunt system is removed, although occasionally just the distal portion of the shunt is externalized. An EVD is also commonly used after posterior fossa tumor resections, to help drain blood and surgical debris out of the ventricular system. Other uses may include the administration of intrathecal antibiotics, emergent diversion of CSF in acute hydrocephalus, and intracranial pressure monitoring after endoscopic third ventriculostomy and in association with head injury.

Several different drainage systems are available for an EVD, but all have similar features (Fig. 2.26). The ventricular catheter is usually placed in the operating room, which allows for maximal aseptic technique at placement and tunneling of the catheter under the skin before it exits the skin. These two factors may decrease the infection rate with external drains. The ventricular catheter is generally inserted into the frontal horn of the lateral ventricle (on the nondominant side of the brain) and is connected to the CSF collection chamber via a closed sterile setup.

The surgeon should specify the level that the chamber needs to be placed, as well as the level of the head of bed, in the postoperative orders. The chamber is generally placed in reference to the external auditory meatus, which is at the level of the foramen of Monro. Careful attention needs to be made to assure that the system is set up and measured properly and that the catheter does not become kinked, dislodged, or disconnected. In addition, it is important to clamp the system before the patient changes position (Fig. 2.32).

The details of CSF drainage need to be monitored regularly, and the amount, color, and presence of blood or sediment must be recorded on a frequent basis. The normal amount of CSF that is produced daily is approximately 350–700 ml in



**Fig. 2.32** External ventricular drain (EVD) (Courtesy of Medtronic Neurologic Technologies)

adults (Brack et al. 1994). Infants and children produce less, about 0.33 ml/kg/h. Excessive or insufficient CSF drainage is a common complication that may occur. Excessive drainage results when the pressure at which the drainage occurs is too low. This may be caused by the movement of the child above the predetermined ordered level or increased intracranial pressure secondary to coughing, crying, sneezing, or the Valsalva maneuver. Excessive draining may cause the ventricles to rapidly collapse, leading to a subdural or subarachnoid hemorrhage.

Insufficient CSF drainage may cause increased intracranial pressure, with associated symptoms.



Inadequate drainage may be caused by the child moving to a position that is lower than the ordered level, by kinks in the catheter, or by occlusion of the catheter from blood or cellular debris. Occlusion should be suspected if there is no fluctuation of CSF in the catheter with respirations or with lowering of the chamber. If there is no drainage or fluctuation within the tubing, the neurosurgery team should be notified immediately. If the occlusion in the catheter cannot be dislodged by flushing it, the patient may need to return to the operating room and have a new drain placed. If the system is accidentally pulled apart or broken, the proximal catheter should be clamped immediately, the open tip placed in a sterile covering, and the neurosurgery team notified.

CSF is generally clear and has the same consistency as water. In the presence of infection, it may become cloudy, darker in color, and more viscous. CSF samples are often drawn on a regular basis to monitor the treatment of infection or to rule out infection. The studies completed normally consist of a cell count, levels of glucose and protein, Gram stain, and culture. In the presence of infection, protein and white blood cells are usually elevated, and glucose is usually decreased. Blood is often present after posterior fossa tumor resections. The amount of blood present should be noted as well as any new bleeding.

CSF contains approximately 120 mEq/l of sodium. Therefore, the child's electrolytes should be monitored closely. Some surgeons may want to replace CSF with intravenous normal saline, particularly in younger children.

Other nursing considerations include keeping the head dressing clean, dry, and intact, as well as pain control. Distraction techniques or restraining the child may be necessary to keep the patient from moving or dislodging the catheter.

In patients with posterior fossa tumor resections, there is a chance that the ventricular drain may be weaned and removed completely. This is often done once the cellular debris and blood have cleared. The chamber is raised slowly over 24–96 h and may eventually be clamped. If the patient does not develop signs and symptoms of increased intracranial pressure and a CT or HASTE MRI does not show enlargement of the

ventricular system, the drain may be removed. If there are signs and symptoms of increased pressure and enlargement of the ventricles, the patient will most likely need a permanent shunt or may be a candidate for endoscopic third ventriculostomy.

### 2.12.6 Discharge

Most infants and children can be discharged 24–48 h after a shunt placement or revision. The child undergoing a third ventriculostomy may be in the hospital longer while evaluation of the efficacy of the procedure is carried out. In preparation for discharge, the nurse should discuss with the parents, or other caregiver, wound care, pain management, signs and symptoms of shunt failure and infection, and other issues that may be relevant. The caregiver should be instructed on how to take care of the dressing and/or wound. The surgeon will usually specify recommendations regarding dressings, bathing, and suture removal. The nurse should know what those specifications are and relay them to the family verbally and in writing. Often, families need to go home with dressing supplies if a dressing is to be kept in place.

Most children can be discharged with acetaminophen or ibuprofen for pain. The nurse should give the care provider the appropriate dose for the child. Some surgeons will prescribe a stronger pain medication such as oxycodone or codeine if it is necessary. Parents should be instructed to use any medication cautiously. If the child's pain is increasing over time, the child may be experiencing another shunt failure or infection. Pain is usually expected to be incisional or related to distal catheter implantation by the time of discharge.

The family needs to be instructed on the signs and symptoms of shunt failure and infection. The signs and symptoms may be subtle and confusing in a child already recovering from surgery. The caregivers should be told that an infected shunt may or may not function. Parents should also be advised that any fever during the first month after shunt placement could be related to a shunt infection. The patient's family also needs instruction on



what to do if they suspect shunt failure or infection or have other concerns. If the shunt fails at night or on the weekend, the child still needs immediate evaluation. Each surgeon handles this somewhat differently, and the nurse should know the expectations of the particular surgeon. Follow-up appointments should also be scheduled.

### 2.12.7 Family Support

The family of a child with hydrocephalus is often quite anxious because the child may need to undergo repeated surgeries, and there are often other major illnesses or conditions associated with hydrocephalus. They may also be concerned about the lifelong implications of hydrocephalus, whether the infant or young child will be normal have delays, cerebral palsy, or other conditions related to hydrocephalus (or its etiology). The nurse or physician may not be able to adequately answer such questions and that only further increases parental anxiety.

Families need anticipatory guidance and teaching about hydrocephalus, including what the signs and symptoms are, why they occur, and what needs to be done. They need to understand what tests are done to diagnose hydrocephalus and shunt failure. Sometimes these tests are confusing or inconclusive for the provider. This further confuses families and causes more anxiety. Families also need to know the importance of prompt treatment of suspected shunt failure and have a plan as to how that will occur.

A child with a shunt should be encouraged to live as normal of a life as is possible. If the child does not have other associated conditions or delays, there will usually be no restrictions. If the child is delayed, in a wheelchair, blind, or otherwise disabled, many restrictions will be needed because of the underlying issues. Parents should still be encouraged to treat the child as normally as possible. Some surgeons do not want children with shunts to play rough contact sports such as football or wrestling because of the possibility of damaging the shunt hardware. There is no contraindication to flying in commercial pressurized aircraft.

Children with shunts need good primary care. The primary care provider as well as the parent can follow head growth in infants. A primary provider or nurse may help the family with all the standard issues that parents face including discipline, toileting, sleep issues, child care, and schooling. These children need all the regular immunizations. The diphtheria-tetanus-pertussis vaccine should be administered to an infant or child with stable neurological conditions, including controlled seizures (Committee on Infectious Diseases 2000). They need good dental care to avoid the possibility of dental carries seeding a shunt infection during a shunt revision. Current American Dental Association guidelines do not recommend any prophylactic antibiotics for any patients containing neurosurgical hardware (including ventriculoatrial shunts) (Lockhart et al. 2007). Some surgeons may still recommend antibiotics before dental work in children who have had repeated shunt infections. Children also need routine vision screening because of the associated visual abnormalities.

Families who have children with hydrocephalus may benefit from a support group. Families may also benefit from information from national organizations such as the following:

#### 2.12.7.1 Organizations and Web Sites

Hydrocephalus Association

340 East-West Hwy

Bethesda, MD 20814

415-732-7040; 888-598-3789

[www.hydroassoc.org](http://www.hydroassoc.org)

Hydrocephalus Clinical Research Network (HCRN)

[www.HCRN.org](http://www.HCRN.org)

National Hydrocephalus Foundation

562-924-6666

[www.nhfonline.org](http://www.nhfonline.org)

Pediatric Hydrocephalus Foundation

10 Main Street, Suite 335

Woodbridge, NJ 07095

732 634 1283

[www.hydrocephaluskids.org](http://www.hydrocephaluskids.org)

National Information Center for Children and Youth with Disabilities

PO Box 1492

Washington, DC 20013  
[www.nichcy.org](http://www.nichcy.org)  
 Spina Bifida Association of America  
 1600 Wilson Blvd, #800  
 Arlington, VA 22209  
 202-944-3285  
[www.sbaa.org](http://www.sbaa.org)

## 2.13 Living with Hydrocephalus

Hydrocephalus is a chronic, lifelong condition. Untreated hydrocephalus has a mortality rate of 50–60%. Surgically treated hydrocephalus in children is associated with a mortality rate of 18% (Vinchon et al. 2012) at 20 years and 48% at 40 years (Paulsen et al. 2015). Some infants have a shunt placed at birth, require few revisions, and grow to be cognitively and physically normal. Others have a shunt placed and require many revisions, experience complications, and are mildly or markedly developmentally delayed. These ongoing issues with the shunt are not usually the only cause of the developmental abnormalities, but they may contribute to them. Some children with hydrocephalus have other chronic diseases that are associated with or are the cause of the hydrocephalus. Such illnesses include brain tumors, neurofibromatosis, myelomeningocele, craniofacial abnormalities, cerebral palsy, and various brain malformations. The treatment of hydrocephalus is just one aspect of the complicated care that these children require. Many factors affect the outcome of children with hydrocephalus, such as the age at onset, the underlying cause, the timing of the surgical intervention, complications such as repeated shunt failures and infections, and the associated comorbidities of other diseases.

All children with hydrocephalus are at risk for certain associated problems, including cognitive delays, learning disabilities, motor delays, behavioral abnormalities, visual abnormalities, seizures, precocious puberty, and diabetes insipidus. Vinchon et al. (2012) followed pediatric hydrocephalus into adulthood. The study found that 60% had motor disabilities, 13% requiring walking aides and 17% a wheelchair, and 13.6% had

significant visual impairment. Hoppe-Hirsch et al. (1998) found that 30% had seizures. Sixty percent were in school, some with special services, and their IQs were highly variable. Thirty percent had IQs that were in the normal range above 90, 30–60% had mild to moderate mental retardation, and 7–20% had severe mental retardation (Hoppe-Hirsch et al. 1998). Many were 1–2 years behind their peers. Behavioral disorders were common. Vinchon et al. (2012) reported a 43% rate of depression.

### 2.13.1 Cognitive Abnormalities

Intellectual function is difficult to predict in the infant and young child. Abnormalities of, and insults to, the CNS may both contribute greatly to impaired function. The younger the child at the age of the onset of hydrocephalus, the greater the risk for intellectual abnormalities. Cognitive difficulties can also be caused by the underlying condition and associated treatment. Shunt infections, especially with gram-negative organisms, can further impair cognitive function. Some infants have extreme hydrocephalus at birth, but once shunted, the brain may grow into the existing space. Some of these children can develop normally. It has been suggested that a cortical mantle of less than 5 mm in thickness can be a predictive of a poor outcome. Cognitive function is also impossible to predict from radiographic studies. Some children are remarkably functional despite markedly abnormal appearing brains on CT and/or MRI scans. Other children have severe intellectual impairment with relatively normal appearing scans.

Sgouros et al. (1995) followed 70 patients with shunts for 16 years. He found that children with IVH and meningitis as the underlying cause of their hydrocephalus did the worst cognitively. Thirty to 40% of these children had cognitive delays. He also found that two-thirds of these patients were socially independent but living with their parents.

Among children with myelomeningocele and hydrocephalus, cognitive abnormalities are more pronounced in those with a higher-level defect, as

compared to those with a sacral defect. Those that require a shunt (80–85%) have overall lower IQ scores than those who do not require shunting (Mapstone et al. 1984).

Children with hydrocephalus also have a higher risk of learning disabilities. These children have difficulty with encoding and retrieval in both verbal and nonverbal tasks (Scott 1998). In addition, such children may have difficulty with reading comprehension (Yamada 2002). They also have difficulties with concentration, nonverbal learning, processing complex language, short-term memory, and poor spatial relations. These children are at a higher risk of attention deficit hyperactivity disorder than the general population. Dysmorphology of the cerebellum may be associated with oral and motor speech deficits (Huber-Okraïnc et al. 2002).

Neuropsychological testing of the child will help to better define where the deficits exist. With such knowledge, learning and activities of daily living can be modified to fit the needs of the individual child. Special therapy, such as speech or occupational therapy, may help the child to become more functional.

The importance of social factors must also be considered when evaluating the intellectual function of these children. Those who have access to the most state-of-the-art medical care, therapy services, and educational services may do better functionally than those who do not. Some of these children also need complex care from their families on a daily basis. While some families are well equipped to deal with these demands, other families seem to be in a continual state of crisis, have several children with special needs, have one or both parents absent, or many other problems that make it difficult to care for these children.

### 2.13.2 Motor Disabilities

Sixty percent of children with hydrocephalus have varying degrees of motor abnormalities (Vinchon et al. 2012). The motor deficits are often related to the underlying etiology of the hydrocephalus. Children with hydrocephalus may have global motor delays and achieve milestones, such as sit-

ting and walking late, or not at all. Hydrocephalus may also affect fine motor control. Such fine motor difficulty may be exacerbated by visual impairments. These children may have trouble learning to write, so keyboards and communication boards may be useful. Premature infants with IVH may develop hydrocephalus and cerebral palsy. The cerebral palsy may be mild and affect only the lower extremities (spastic diplegia), or it may be severe and affect the entire body (spastic quadriplegia).

### 2.13.3 Ocular Abnormalities

Optic atrophy from chronic papilledema was the leading cause of blindness from congenital malformations, before the successful treatment of hydrocephalus. Increased intracranial pressure from hydrocephalus causes pressure on the cranial nerves. The cranial nerves that are involved in eye function are II (optic), III (oculomotor), IV (trochlear), and VI (abducens). As intracranial pressure increases, signs and symptoms become evident as these nerves are affected. Common findings include limited upward gaze, extraocular paresis, decreased vision, and diplopia (Table 2.5).

Papilledema is a less common finding and is difficult to diagnose in young children. The child is often referred to an ophthalmologist for a complete eye exam, including dilation of the pupil, to correctly diagnose papilledema. Papilledema is not a common finding in children with increased intracranial pressure unless it is chronic.

Ocular abnormalities are a common finding in infants and children with untreated hydrocephalus and during periods of shunt malfunction. If treatment is not prompt, visual damage is a risk, including blindness. Visual deficits are common in children with hydrocephalus. Refractive and accommodative errors are found in 25–33% of these children. Gaze and movement disorders, such as nystagmus, astigmatism, strabismus, and amblyopia, are found in 25–33% (Rosen 1998). Abnormalities in vision may be associated with lower IQ scores. Correctable vision issues should be identified and treated as early as possible so that they do not add to developmental and learning difficulties.

**Table 2.5** Cranial nerves and eye symptoms

<b>II. Optic nerve</b>
Responsible for transmitting visual images from the eye to the brain
Test: check for light perception, visual acuity, peripheral vision, and normal appearance of the optic disk
<b>III. Oculomotor nerve</b>
Responsible for controlling four of the six muscle groups that move the eye
Medial rectus: moves eye inward
Superior rectus: moves eye upward and in
Inferior rectus: moves eye downward and in
Inferior oblique: moves eye upward and out
Responsible for constriction and accommodation of the pupil and closing of eyelid
Test: have the child follow object in six cardinal positions of gaze; check for pupil reaction to light; check for closing of the eyelid
<b>IV. Trochlear nerve</b>
Responsible for controlling superior oblique muscle that moves the eye inward and down
Test: have the child look down and in
<b>VI. Abducens nerve</b>
Responsible for lateral rectus muscle that moves the eye temporally
Test: have the child look temporally

### 2.13.4 Seizures

Hydrocephalus alone is not commonly recognized as a cause of seizures. However, seizures are associated in children with hydrocephalus who have shunts implanted. The incidence of epilepsy in the general population is 1% in children. The incidence of seizures in children with shunted hydrocephalus is 20–50% (Sato et al. 2001). Since modern shunting became the standard treatment for hydrocephalus, controversy has existed about shunt procedures and complications of shunts leading to seizures. Children with hydrocephalus have numerous risk factors that increase the risk of seizures. These include age at the original shunt placement, the location of the shunt catheter in the brain, the actual placement of the shunt catheter, repeated revisions of the proximal catheter, the presence of the hardware itself in the brain, the location of the burr hole, shunt infections, intracranial hemorrhage at the time of shunt placement or revision, repeated episodes of increased intra-

cranial pressure, the presence of tumors or cysts, the underlying etiology of the hydrocephalus, and any associated developmental delay. When a child has seizures, a work-up is indicated including an electroencephalogram. Seizures are not usually a symptom of shunt malfunction although a very small percentage of patients will present with seizures as the main symptom of shunt malfunction.

### 2.13.5 Precocious Puberty

Precocious puberty is defined as the onset of puberty 1–2 years before the expected age. Normal onset of puberty may occur as young as eight in girls and nine in boys. Precocious puberty is fairly common in children with hydrocephalus, myelomeningocele, cerebral palsy, and microcephaly. It can start as early as 5 years of age.

Precocious puberty is presumed to be caused by chronic or intermittent increased intracranial pressure that affects the hypothalamus and pituitary gland. These two areas deep in the brain are responsible for timing the release of gonadotropins and sex hormones. Children who have had many shunt revisions when they are very young are at greater risk for precocious puberty.

Precocious puberty causes the growth plates to close early in the long bones leading to short stature. Additionally, precocious puberty is associated with risk of pregnancy in young children with associated cognitive and behavioral difficulties.

### 2.13.6 Transition to Adulthood

Hydrocephalus is a chronic disorder that will follow children into adulthood. Specifically in a shunted patient, it is a condition that requires regular follow-up and established care in case of a medical emergency, such as a shunt malfunction. A study by Simon et al. (2009a, b) showed that the number of young adults aged 18–35 with hydrocephalus that need treatment in the United States is predicted to exceed 40,000 annually within the next two decades. These young adults need access to both expert surgical and medical providers. As pediatric providers, it is vital to

prepare patients for transition to adulthood. Studies show that one-half to two-thirds of patients failed to maintain adequate shunt follow-up after transitioning to adult care (Simon et al. 2009a). It is recommended to start discussions with families as young as 16 years of age, to establish who their adult provider will be and how transition of care will happen. The hope is to have the young adult establish care while in a healthy state if possible and not have first contact with their new provider in an emergency. It is also important to discuss with families the issue of private insurance versus qualifying for a government-funded program, to ensure adequate accessibility to the healthcare system.

---

## 2.14 Special Diagnostic and Treatment Considerations: Pseudotumor Cerebri in the Pediatric Population

Another type of CSF absorption problem is a condition known as pseudotumor cerebri (PTC). It is described as elevated intracranial pressure without hydrocephalus, mass lesion, infection, or hypertensive encephalopathy (Cinalli et al. 1999). PTC is the result of CSF malabsorption or obstruction in the intracranial venous system. Sometimes an exact cause can be found, such as thrombosis, which may be the source of the obstruction. Many times, however, a cause is not found. Thus, PTC is usually a diagnosis of exclusion (Brack et al. 1994).

There are three types or classifications of PTC: primary, secondary, and atypical pseudotumor. The most common form, primary PTC, is idiopathic, and thus the cause is unknown. This is also referred to as idiopathic intracranial hypertension. Secondary PTC presents as the result of another illness or cause. Secondary PTC may be associated with a known neurological disease, the result of a systemic illness (e.g., clotting disorder), or caused by the ingestion or withdrawal of exogenous agents (e.g., vitaminosis A, antibiotics, and others). Notably, the use of tetracycline-class medications to control acne has been linked to PTC in adolescents (Paley et al. 2015). Finally,

atypical PTC presents without papilledema or may be seen in infants. The most common known causes of PTC in children include venous thrombosis, steroid withdrawal, malnutrition, or exogenous substances.

In the general population, PTC is predominately found in obese adult females. Lessell (1992) concluded that obesity did not appear to be a factor in pediatric PTC. However, the following 25 years has witnessed an epidemic in childhood obesity. Not surprisingly, more recent studies have found that obesity is strongly associated with an increased risk of PTC in adolescents (Bara et al. 2012; Paley et al. 2015). Ninety percent of children are diagnosed between 5 and 15 years of age, and PTC is rarely seen in infants (Boop 2004). Visual loss is a significant complication of PTC.

### 2.14.1 Nursing Care for PTC Patients

Sometimes, children are admitted to the hospital for several days, while their intracranial pressure is monitored via an intracranial device. It is usually inserted in the operating room, under anesthesia, to maintain strict asepsis and to reduce anxiety. The nurse plays an important role in monitoring elevations in pressure and assisting the family to keep a “headache diary” during their stay. Monitoring of visual changes is also very important.

Patient and family education is needed so that lifestyle changes can be made to prevent loss of vision and the adaptation to the possible shunt systems. There are several Web sites that provide education to families and allow patients to communicate with one another. Patient and family support are provided by nursing, social service, and psychological intervention as needed.

---

### Conclusion

The Nurse’s Dictionary of Medical Terms and Nursing Treatment (Morton, circa 1898) stated the following about hydrocephalus: “water on the brain, a disease most common in children, and causing the head to swell to an enormous size. The victim is always idiotic. Nourishing



diet – cod liver oil; as little fluid as possible.” As this chapter has shown, nurses today need to know far more about the condition and its treatment. Most importantly, they need to know that many children with hydrocephalus can lead normal lives because of available surgical treatment. Despite advances in technology and surgical technique, nurses have and will continue to play major roles in achieving the best possible outcomes for these patients.

### Pediatric Practice Pearls

- If the mother thinks that the child is acting abnormally or that the shunt is not working, there is a high probability that she is right.
- Small ventricles do not assure adequate shunt function.
- Altered mental status is the first and most salient symptom of increased intracranial pressure, thus the child needs to be wakened for serial neurological assessments.
- Mental status should be assessed over time for changes. Never give patients with altered mental status, or an unstable exam, medications that could mask the exam and symptoms.

## References

- Abtin K, Walker ML (1999) Congenital arachnoid cysts and the Dandy-Walker complex. In: Albright AL, Pollack IF, Adelson PD (eds) Principles and practice of pediatric neurosurgery. Thieme, New York, pp 125–139
- Adzick NS, Thom EA, Spong CY, Brock JW et al (2011) A randomized trial of prenatal versus postnatal repair of myelomeningocele. *N Engl J Med* 364(11): 993–999
- Albright A, Pollack I, Adelson P (eds) (2007) Principles and practice of pediatric neurosurgery. Thieme, New York
- Bara S et al (2012) Pediatric idiopathic intracranial hypertension. *J Pediatr* 161(4):602–607
- Boop F (2004) Posthemorrhagic hydrocephalus of prematurity. In: Cinalli G, Maixner WJ, Sainte-Rose C (eds) Pediatric hydrocephalus. Springer, Milano, pp 121–131
- Brack M, Taylor AG, Walker ML (1994) Hydrocephalus: etiology, pathologic effects, diagnosis and natural history. In: Cheek WE, Marlin AE, McLone DG, Reigel DH, Walker ML (eds) Pediatric neurosurgery. Surgery of the developing nervous system. WB Saunders, Philadelphia, pp 185–199
- Buxton N, Punt J (1999) Subtemporal decompression: the treatment of noncompliant ventricle syndrome. *Neurosurgery* 44:513–519
- Christian E, Jin D, Attenello F, Wen T, Cen S, Mack W, Kreiger M, McComb J (2016) Trends in hospitalization of preterm infants with intraventricular hemorrhage and hydrocephalus in the United States, 2000–2010. *J Neurosurg Pediatr* 63:260–269
- Cinalli G, Saint-Rose C, Chumas P, Zerah M, Brunelle G, Lot G, Pierre-Kahn A, Renier D (1999) Failure of third ventriculostomy in the treatment of aqueductal stenosis in children. *J Neurosurg* 90:448–453
- Cinalli G, Spennato P, Basso De Caro ML, Buonocore MC (2004) Hydrocephalus and the Dandy-Walker malformation. In: Cinalli G, Maixner WJ, Sainte-Rose G (eds) Pediatric hydrocephalus. Springer, Milano, pp 259–277
- Ciurea AV, Coman TC, Mircea D (2004) Postinfectious hydrocephalus in children. In: Cinalli G, Maixner WJ, Sainte-Rose G (eds) Pediatric hydrocephalus. Springer, Milano, pp 201–218
- Committee on Infectious Diseases (2000) Report of the committee of infectious diseases, 25th edn. The American Academy of Pediatrics, Elk Grove Village
- Da Silva MD, Michowicz S, Drake JM et al (1995) Reduced local cerebral blood flow in periventricular white matter in experimental neonatal hydrocephalus restoration with CSF shunt. *J Cereb Blood Flow Metab* 15:1057–1065
- Dandy WE, Blackfan KD (1914) Internal hydrocephalus. An experimental, clinical and pathological study. *Am J Dis Child* 8:406–482
- Dias MS (2005) Neurosurgical management of myelomeningocele spina bifida. *Pediatr Rev* 26:50–58
- Ditmyer S (2004) Hydrocephalus. In: Jackson PL, Vessey JA (eds) Primary care of the child with a chronic condition. Mosby, St. Louis, pp 543–559
- Greenberg MS (2010) Handbook of neurosurgery. Thieme, New York
- Haines SJ (1999) Shunt infections. In: Albright AL, Pollack IF, Adelson PD (eds) Principles and practice of pediatric neurosurgery. Thieme, New York, pp 1177–1185
- Hoang S, Chowdhri O, Edwards M, Guzman R (2009) Vein of Galen malformation. *Neurosurg Focus* 27(5):E8
- Hoppe-Hirsch E, Laroussinie F, Burnett L, Sainte-Rose C, Reiner D, Cinalli G et al (1998) Late outcome of the surgical treatment of hydrocephalus. *Childs Nerv Syst* 14:97–99
- Huber-Okraïnec J, Dennis M, Brettschneider J, Spiegel BJ (2002) Neuromotor speech deficits in children and adults with spina bifida and hydrocephalus. *Brain Lang* 80:592–602

- Kestle JR, Riva-Cambrin J, Wellons JC, Kulkarni A, Whitehead WE et al (2011) A standardized protocol to reduce cerebrospinal fluid shunt infection: the hydrocephalus clinical research network quality improvement initiative. *J Neurosurg Pediatr* 8:22–29
- Kulkarni AV, Drake JM, Mallucci CL, Sgouros S, Roth J, Constantini S (2009) Endoscopic third ventriculostomy in the treatment of childhood hydrocephalus. *J Pediatr* 155(2):254–259
- Kulkarni AV et al (2016) Endoscopic third ventriculostomy in children: prospective, multicenter results from the Hydrocephalus Clinical Research Network. *J Neurosurg Pediatr* 3:1–7
- Langingham MV, Nguyen TV, Robert A, Parent AD, Zhang J (2009) Risk factors of congenital hydrocephalus: a 10 year retrospective study. *J Neurol Neurosurg Psychiatry* 80:213–217
- Laurance LM, Coates S (1962) The natural history of hydrocephalus. Detailed analysis of 182 unoperated cases. *Arch Dis Child* 37:345–361
- Lessell S (1992) Pediatric pseudotumor cerebri (idiopathic intracranial hypertension). *Surv Ophthalmol* 37(3):155–166
- Lockhart PB, Loven B, Brennan MT, Fox PC (2007) The evidence base for the efficacy of antibiotic prophylaxis in dental practice. *J Am Dent Assoc* 138:458–465
- Mapstone TB, Rekate HL, Nulson FE (1984) Relationship of CSF shunting and IQ in children with myelomeningocele: a retrospective analysis. *Childs Brain* 11:112–118
- Marlin AE, Gaskill ST (1994) Cerebrospinal fluid shunts: complications and results. In: Cheek WR, Marlin AE, McLone DG, Reigel DH, Walker ML (eds) *Pediatric neurosurgery. Surgery of the developing nervous system*. W. B. Saunders Company, Philadelphia, pp 221–231
- Mazzola C, Choudhri A, Auguste K, Limbrick D, Rogido M, Mitchell L, Flannery A (2014) Pediatric hydrocephalus: systematic literature review and evidence-based guidelines. Part 2: management of posthemorrhagic hydrocephalus in premature infants. *J Neurosurg Pediatr* 14:8–23
- McLone DG (2001) *Pediatric neurosurgery. Surgery of the developing nervous system*, 4th edn. W. B. Saunders Company, Philadelphia
- Milhorat TH (1982) Hydrocephalus historical notes, etiology, and clinical diagnosis. In: *Section of Pediatric Neurosurgery of the American Association of Neurological Surgeons* (ed) *Pediatric neurosurgery. Surgery of the developing nervous system*. Grune & Stratton, New York, pp 192–210
- Oertel JM, Mondork J, Baldauf J, Schroeder HW, Gaab MR (2009) Endoscopic third ventriculostomy for obstructive hydrocephalus due to intracranial hemorrhage with intraventricular extension. *J Neurosurg* 111:1119–1126
- Olson S (2004) The problematic slit ventricle syndrome. *Pediatr Neurosurg* 40:264–289
- O'Neill B, Pruthi S, Bains H, Robison R, Weir K, Ojemann J, Ellenbogen R, Avellino A, Browd S (2013) Rapid sequence magnetic resonance imaging in the assessment of children with hydrocephalus. *World Neurosurg* 80:E307–E312
- Paley G et al (2015) Overweight and obesity in pediatric secondary pseudotumor cerebri. *Am J Ophthalmol* 159(2):344–352
- Paulsen A, Lunder T, Lindegaard K (2015) 40-year outcomes in 128 hydrocephalic patients treated with shunts in childhood. Assessment of surgical outcome, work participation, and health-related quality of life. *J Neurosurg Pediatr* 16(6):633–641
- Raffel C, McComb G (1994) Arachnoid cysts. In: Cheek WR, Marlin AE, Reigel DG, Walker ML (eds) *Pediatric neurosurgery. Surgery of the developing nervous system*. W. B. Saunders Company, Philadelphia, pp 104–110
- Rekate HL (1999) Treatment of hydrocephalus. In: Albright A, Pollack I, Adelson D (eds) *Principals and practice of pediatric neurosurgery*. Thieme Medical Publishers, New York, pp 47–73
- Rekate HL, Wallace D (2003) Lumboperitoneal shunts in children. *Pediatr Neurosurg* 38:41–46
- Rekate HL (2008) Shunt related headaches: the slit ventricle syndromes. *Childs Nerv Syst* 24:423–430
- Riva-Cambrin et al (2016) Risk factors for shunt malfunction in pediatric hydrocephalus: a multicenter prospective cohort study. *J Neurosurg Pediatr* 17(4):382–390
- Rosen S (1998) Educating students who have visual impairments with neurological disabilities. In: Sacks SZ, Silberman RK (eds) *Educating students who have visual impairments with other disabilities*. Paul H. Brooks, Baltimore
- Sainte R (2004) Hydrocephalus in pediatric patients with posterior fossa tumours. In: Cinalli G, Maixner WJ, Sainte-Rose G (eds) *Pediatric hydrocephalus*. Springer, Milano, pp 155–162
- Sato O, Yamguchi T, Ketaaka M, Toyoma (2001) Hydrocephalus and epilepsy. *Childs Nerv Syst* 17:76–86
- Schneider SJ, Wiscoff JS, Epstein FJ (1992) Complications of ventriculoperitoneal shunt procedures or hydrocephalus associated with vein of Galen malformations in childhood. *Neurosurgery* 30:906–908
- Scott MA (1998) Memory functions in children with early hydrocephalus. *Neuropsychology* 12:578–589
- Sgouros S (2004a) Management of spina bifida, hydrocephalus and shunts. *E-Medicine*. Retrieved 9 Sept 2005, from <http://www.emedicine.com/ped/topic2976.htm>
- Sgouros S (2004b) Hydrocephalus with myelomeningocele. In: Cinalli G, Maixner WJ, Sainte-Rose G (eds) *Pediatric hydrocephalus*. Springer, Milano, pp 133–144
- Sgouros S, Malluci C, Walsh AR, Hockley AD (1995) Long term complications of hydrocephalus. *Pediatr Neurosurg* 23:127–132
- Sherrod B, Johnston J, Rocque B (2016) Risk factors for unplanned readmission within 30 days after pediatric neurosurgery: a nationwide analysis of 9799 procedures from the American College of Surgeons National Surgical Quality Improvement Program. *J Neurosurg Pediatr* 14:1–13

- Simon TD, Riva-Cambrin J, Srivastava R, Bratton SL, Dean JM, Kestle JR (2008) Hospital care for children with hydrocephalus in the United States: utilization, charges, comorbidities, and death. *J Neurosurg Pediatr* 1:131–137
- Simon TD, Hall M, Riva-Cambrin J, Albert E, Jeffries HE, LaFleur B, Dean M, Kestle J (2009a) Infection rates following initial cerebrospinal fluid shunt placement across pediatric hospitals in the United States. *J Neurosurg Pediatr* 4(2):156–165
- Simon TD, Lamb S, Murphy NA, Hom B, Walker ML, Clark EB (2009b) Who will care for me next? Transitioning to adulthood with hydrocephalus. *Pediatrics* 125:1431–1438
- Sokoloff L (1989) Circulation and energy metabolism of the brain. In: Siegel GJ, Agranoff BW, Albers RW (eds) *Basic neurochemistry. Molecular, cellular and medical aspects*. Ravens Press, New York, pp 565–590
- Sutton LN (2005) Spinal dysraphism. In: Rengachary SS, Ellenbogen RG (eds) *Principles of neurosurgery*. Elsevier Mosby, New York, pp 99–115
- Teo C, Mobbs R (2005) Neuroendoscopy. In: Rengachary SS, Ellenbogen RG (eds) *Principles of neurosurgery*. Elsevier Mosby, New York, pp 145–156
- University of California, San Francisco (2000) *About hydrocephalus – a book for families*. (Brochure). Editor, Fudge
- Vinchon M, Baroncini M, Delestret I (2012) Adult outcome of pediatric hydrocephalus. *Childs Nerv Syst* 28:847–854
- Wang PP, Avellino AM (2005) Hydrocephalus in children. In: Rengachary SS, Ellenbogen RG (eds) *Principles of neurosurgery*. Elsevier Mosby, New York, pp 117–136
- Warf B, Campbell JW (2008) Combined endoscopic third ventriculostomy and choroid plexus cauterization as primary treatment of hydrocephalus for infants with myelomeningocele: long-term results of a prospective intent-to-treat study in 115 East African infants. *J Neurosurg Pediatr* 2:310–316
- Whitelaw A, Kennedy CR, Brion LP (2001) Diuretic therapy for newborn infants with posthemorrhagic ventricular dilation. *Cochrane Database Syst Rev* (2):CD002270
- Yamada J (2002) Neurological origins of poor reading comprehension despite fast word decoding. *Brain Lang* 80:253–259
- Zada G, Krieger MD, McNatt SA, Bowen I, McComb JG (2007) Pathogenesis and treatment of intracranial arachnoid cysts in pediatric patients younger than 2 years of age. *Neurosurg Focus* 22(2):1–5
- Zahl S, Egge A, Helseth E, Wester K (2011) Benign external hydrocephalus: a review, with emphasis on management. *Neurosurg Rev* 34:417–432

Cathy C. Cartwright and Patricia D. Chibbaro

## 3.1 Craniosynostosis

Craniosynostosis is the premature closure of one or more of the cranial sutures. Sometimes the entire suture is fused, but even a partial fusion can cause a deformity as the skull growth is restricted. Although the clinical condition of craniosynostosis was described by Hippocrates 400 years BC, effective treatments have only been developed in the last century (Cohen 1986). In 1800, Sömmering described the anatomic structures of calvarial sutures and the results of premature closure (Sömmering 1800). However, it was the German pathologist Rudolf Virchow who first used the term craniostenosis and proposed that “outward growth of the skull is restricted in a direction perpendicular to the prematurely fused suture and compensatory growth occurs in the patent sutures” (Virchow 1851). This restriction of growth in one direction and compensatory growth in others accounts for the classic skull deformities seen in craniosynostosis.

---

C.C. Cartwright, RN, MSN, PCNS, FAAN (✉)  
Department of Neurosurgery, Children’s Mercy  
Hospital, 2401 Gillham Road, Kansas City,  
MO 64108, USA  
e-mail: [c2cartwright@gmail.com](mailto:c2cartwright@gmail.com)

P.D. Chibbaro, RN, MS, CPNP  
Department of Craniofacial Surgery, Institute of  
Reconstructive Plastic Surgery, NYU Langone  
Medical Center, 307 East 33rd Street, New York,  
NY 10016, USA  
e-mail: [patricia.chibbaro@nyumc.org](mailto:patricia.chibbaro@nyumc.org)

The most common type of craniosynostosis is nonsyndromic craniosynostosis, which is a congenital disorder. Craniosynostosis also occurs in over 90 syndromes, but these usually involve more than one cranial suture and occur far less frequently than nonsyndromic craniosynostosis (Cohen 1993). Cohen listed the known causes of craniosynostosis as genetic conditions (e.g., mutations in fibroblast growth factor receptors); metabolic disorders, such as hyperthyroidism, mucopolysaccharidoses,  $\beta$ -glucuronidase deficiency, and mucopolipidoses; hematological disorders; teratogens; and malformations, including microcephaly and encephalocele (Cohen 1986). Secondary craniosynostosis can result from overshunting hydrocephalus; however, true bony fusion of the suture does not occur in shunt-related craniosynostosis (Sun and Persing 1999).

Craniosynostosis is usually recognizable at birth, and the parents may suspect that their baby’s head “just doesn’t look right.” Although molding of the skull can occur during the birth process, this usually normalizes by 3 months of age, whereas the deformities from craniosynostosis continue to worsen as the child’s brain continues to grow. Infants with craniosynostosis have unique characteristics that are not to be confused with birth trauma. Recognizing craniosynostosis early, before 3 months of age, is important so that minimally invasive surgery can be considered instead of the more extensive calvarial vault remodeling required for the older child.

### 3.2 Nonsyndromic Craniosynostosis

Nonsyndromic craniosynostosis, the predominant type of suture fusion, occurs in 1 of every 2,000–2,500 newborns (Lajeunie et al. 1995; Slater et al. 2008). The sagittal suture is involved in 40–60 % of these fusions, though some recent studies have found it to be in the lower part of that range. Traditionally, the coronal suture was considered to have the second highest incidence of premature closure, with the metopic suture being the third highest (Hunter and Rudd 1984; Lajeunie et al. 1995; Shillito and Matson 1968). Lambdoid synostosis, while often mistaken for positional plagiocephaly, is rare, occurring in 1–2 % of all craniosynostosis (Vander Kolk and Carson 1994). Multiple suture synostoses involving two or more cranial sutures were thought to occur in 4–8 % of nonsyndromic craniosynostosis (Chumas et al. 1997; Hoffman and Raffel 1989), but higher percentages have been found (Lee et al. 2012).

Multiple studies have found that metopic synostosis has been on the rise since the mid-1990s and is now the second most frequently occurring craniosynostosis. Those studies were conducted in locations as diverse as Philadelphia, PA, where the metopic suture was found to be involved in

27 % of all cases (Selber et al. 2008); to Paris, FR, where a 420 % increase in the incidence of metopic synostosis was found in comparison to a 170 % increase overall (Di Rocco et al. 2009), to Melbourne, AU (Lee et al. 2012). Further, a pan-European study also found a substantial increase in the incidence of metopic synostosis (van der Meulen et al. 2009). Several factors have been proposed to account for this increased incidence, but it remains unexplained. Table 3.1 has been revised from previous editions to reflect the statistics derived from these more recent studies. The specific cause of simple nonsyndromic craniosynostosis has not yet been identified. Simple craniosynostosis is usually random in occurrence, but 2–6 % of isolated sagittal synostosis and 8–14 % of coronal synostosis were found to be familial (Cohen 1986; Lajeunie et al. 1996). In utero head restraint has also been named as a cause of craniosynostosis, although it is more commonly seen as positional plagiocephaly (Graham et al. 1979, 1980; Higgenbottom et al. 1980).

The diagnosis is made by physical examination and can be confirmed with radiographs if there is any question about the diagnosis. Plain skull films allow a look at the patency of the suture in question, but a CT of the head is preferable as the suture can be identified more easily. A CT scan with three-dimensional reconstruction (3D recon) pro-

**Table 3.1** Classifications of craniosynostosis

Type of craniosynostosis	Suture involved	Incidence	Characteristics
Scaphocephaly (dolicocephaly)	Sagittal	40–60 %	Bitemporal narrowing
			Frontal bossing
			Occipital cupping
			Palpable sagittal ridge
Anterior plagiocephaly	Coronal	10–20 %	Nasional deviation Flattening of frontal bone on affected side
Trigonocephaly	Metopic	20–30 %	Triangular shape
			Bitemporal narrowing
			Parietal bossing
			Hypotelorism Metopic ridge
Posterior plagiocephaly	Lambdoid	1–2 %	Trapezoid shape Tilted skull base Occipitomastoid bulge
Multiple sutures	Combination	5–15 %	Depends on sutures involved



vides further clarity of the skull shape, skull base, and suture patency. Radiodiagnostic testing should be used judiciously, however, because radiation can have deleterious effects on the growing brain (Frush et al. 2003; Didier et al. 2010; Paterson and Frush 2007; Pearce et al. 2012). There are several campaigns (e.g., Image Gently, Image Wisely) as well as a major focus in the medical and lay press on the importance of increasing efforts to reduce exposure, especially in infants and children (McCarthy et al. 2012). For example, use of the ALARA guidelines (“as low as reasonably achievable”) is recommended in order to achieve the correct dose of radiation (The Joint Commission 2011).

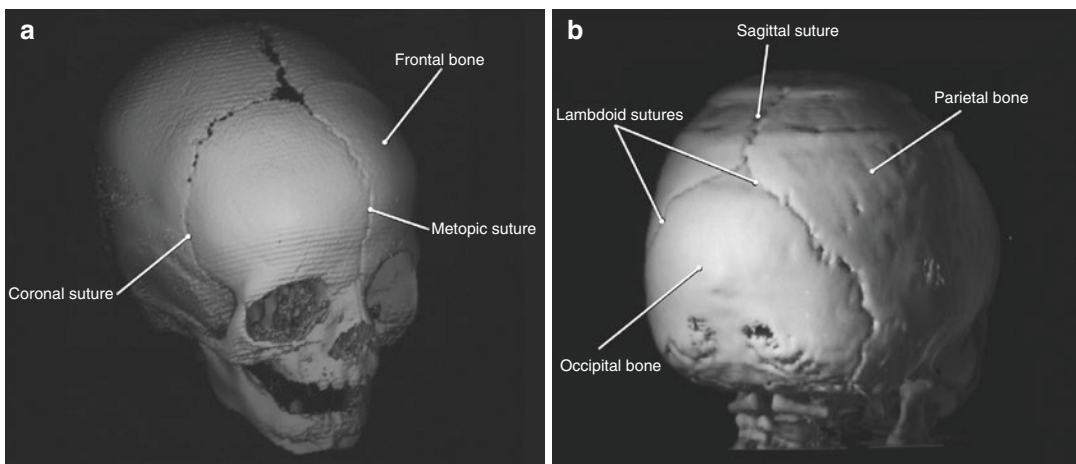
### 3.2.1 Pathophysiology

The brain is contained in the neurocranium, which comprises the skull base and cranial vault. Each of these two components of the neurocranium develops in different ways. The calvarial vault develops via intramembranous ossification as fibrous membrane (ectomeninx) over the brain, while the skull base develops through endochondral ossification. After the second month of gestation, ossification centers in the ectomeninx differentiate into an outer periosteum and inner dura. These ossifica-

tion centers eventually expand or fuse to form the frontal, parietal, and occipital bones (Lemire 1986; Pritchard et al. 1956) (Fig. 3.1). The edges of these sutures contain special cells called the osteogenic front (Decker and Hall 1985). At 16 weeks gestation, sutures form as these osteogenic fronts approach each other (Vermeij-Keers 1990).

Sutures allow the infant’s head to reshape during the birth process and accommodate the expanding brain during rapid growth. Open sutures may also absorb stresses from trauma (Cohen and MacLean 2000). The dura (membrane covering the brain) is essential for suture and calvarial bone growth. The site of suture formation is related to the location of major dural reflections. Dural reflections are bands of dural attachment to the skull base that conform to the early recesses of the brain (Sun and Persing 1999). In infants with brain malformations, these early recesses may be absent and the suture will not form.

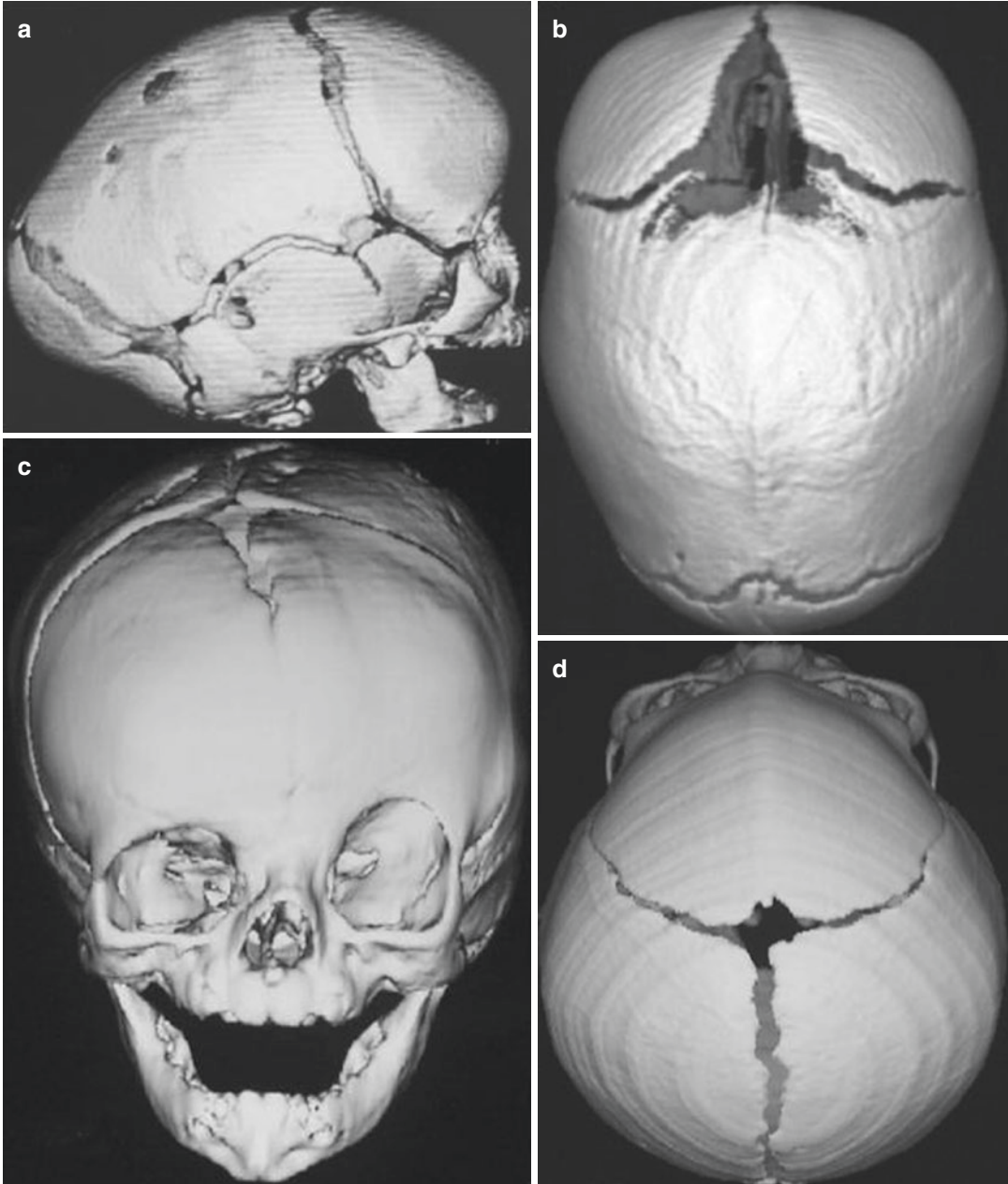
Removing the skull in a neonate with intact dura results in the dura regenerating the skull with sutures placed as dictated by the dura (Drake et al. 1993; Mabutt and Kokick 1979). In other words, neonates and young infants can have portions of or their entire skull removed, and an intact dura will regrow the skull bone with appropriate suture locations. This ability to reossify the skull diminishes as the infant ages.



**Fig. 3.1** (a, b) Skull bones and sutures most commonly involved in craniosynostosis

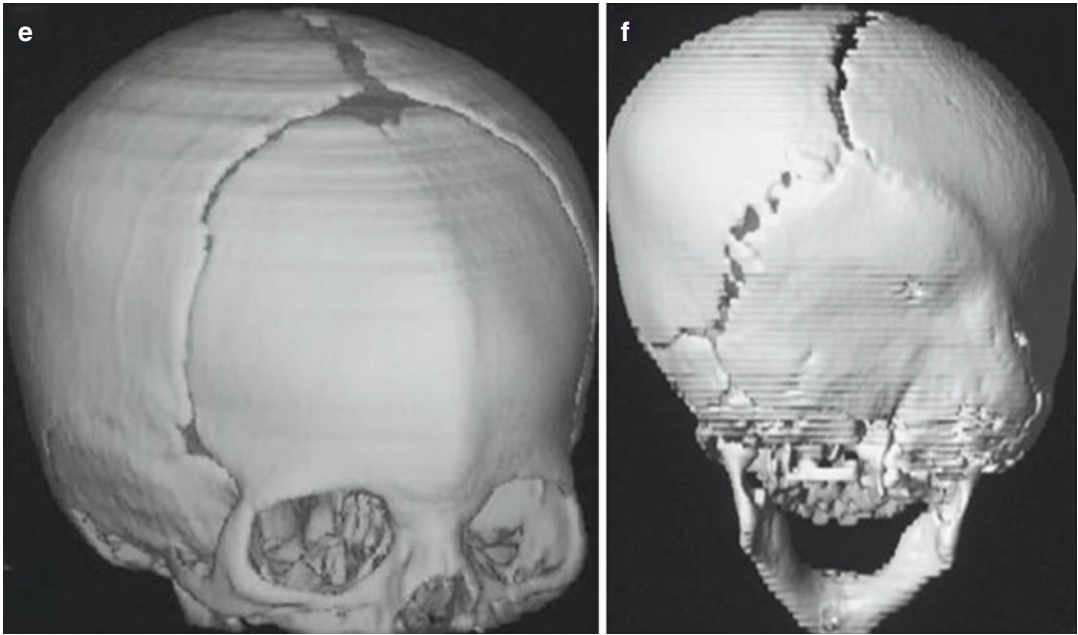
As the brain grows, overall calvarial bone growth occurs from the expanding brain. New bone is deposited at the osteogenic fronts of the open sutures, and this bone deposition at the suture

margins is driven by the expanding brain (Sun and Persing 1999). The skull is 35 % of adult size at birth, two thirds of adult size by 2 years of age, and reaching adult size between 6 and 10 years of age



**Fig. 3.2** 3D CT reconstructions clearly show the stenosed sutures and skull shapes. (a) In sagittal synostosis the open sutures compensate for brain growth. (b) Top of skull shows sagittal synostosis with a closed sagittal suture, open anterior fontanel, and open coronal and lambdoid sutures.

(c) Left coronal synostosis showing closed left coronal suture, nasal deviation, and elongation of the left superior orbital rim. (d) Metopic synostosis with trigonocephalic shape to the skull. (e) Closed metopic suture causes a vertical ridge or keel. (f) Right lambdoid synostosis



**Fig. 3.2** (continued)

(Ohman and Richtsmeier 1994; Zollikofer 2009). The metopic suture can fuse normally in infants by as early as 2 months of age, but the other sutures remain open to accommodate brain growth into adulthood. A layer of capsular fibrous tissue surrounding the osteogenic fronts normally keeps the other sutures from fusing (Sun and Persing 1999). Even partial closure of one or more sutures during the period of rapid cranial growth can cause significant skull deformities (Fig. 3.2).

A discussion of the characteristics of each of the four most common single suture closures follows. Bicoronal synostosis and a multiple suture condition known as Mercedes Benz are also discussed, but other combinations involving multiple sutures can occur.

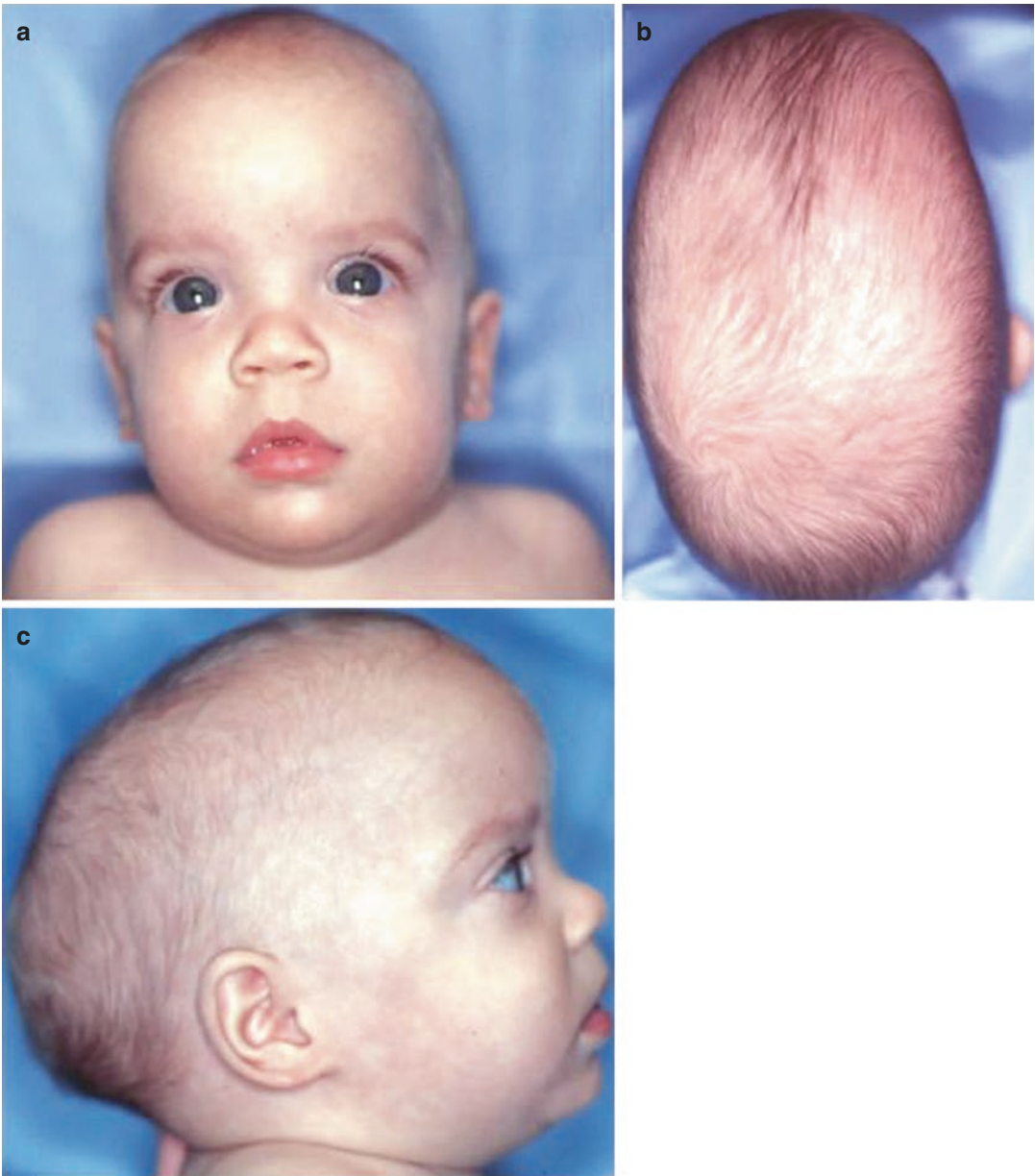### 3.2.2 Sagittal Synostosis

The most common type of craniosynostosis is sagittal, characterized by a scaphocephalic or “boatlike” shape to the skull, various degrees of bitemporal narrowing, frontal bossing, occipital cupping, and a palpable sagittal ridge (Fig. 3.3).

Sometimes, the scaphocephalic shape, and especially the occipital cupping, is so prominent that when the infant is lying supine with the back of the head on the mattress, the head is flexed in a way that causes the airway to be compromised. The degree of scaphocephaly is determined by measuring cranial index. Using spreading cranial calipers (GPM Instruments, Switzerland), the distance is measured from euryon to euryon, divided by glabella to opisthocranium and multiplied by 100 (Fig. 3.4). A cephalic index between 75 and 85 would be normal, with higher numbers indicating a rounder head and lower numbers indicating a more scaphocephalic shape (Proctor 2014). A special laser scanner can also be used to get measurements and a 3D picture of the skull.

### 3.3 Mercedes-Benz Syndrome

Mercedes-Benz syndrome, also known as craniofacial dysynostosis in the genetics literature, results in a characteristic head shape with frontal bossing, turribrachycephaly, biparietal narrow-

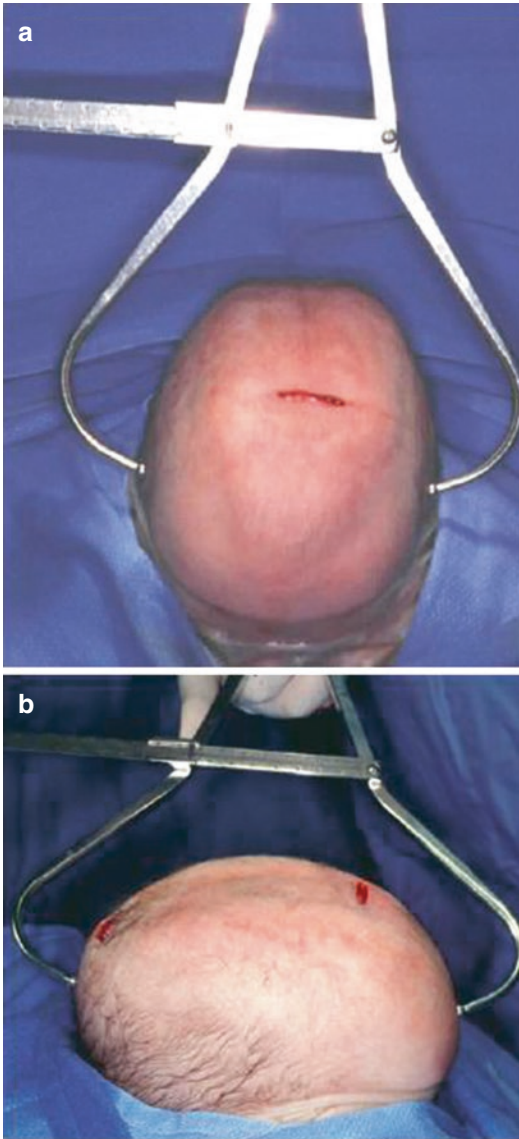


**Fig. 3.3** (a–c) Sagittal synostosis: note the long, narrow shape to the skull, bitemporal narrowing, occipital cupping, and frontal bossing

ing, occipital concavity, and inferior displacement of the ears (Hing et al. 2009). The term “Mercedes-Benz” is derived from the appearance of the bilateral lambdoid and sagittal synostosis (BLSS) as seen on 3D CT (Fig. 3.5). Although

development in these children can be normal, some have short stature, developmental delays, and chromosomal abnormalities. Genetic testing is recommended in these patients as well as any patient with multiple suture synostosis.

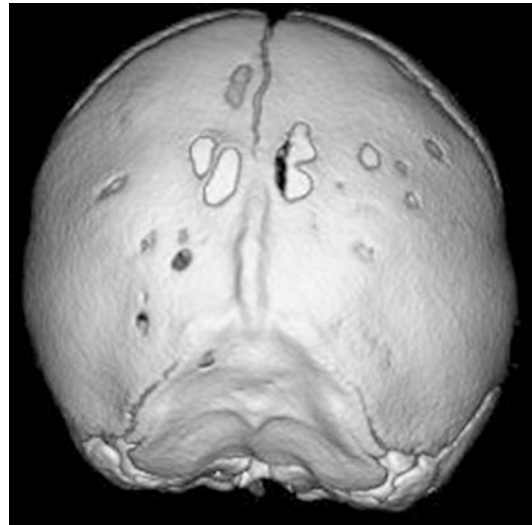



**Fig. 3.4** Cranial calipers are used to measure the cephalic index. (a) Euryon to euryon. (b) *Glabella* to opistocranium

### 3.4 Coronal Synostosis

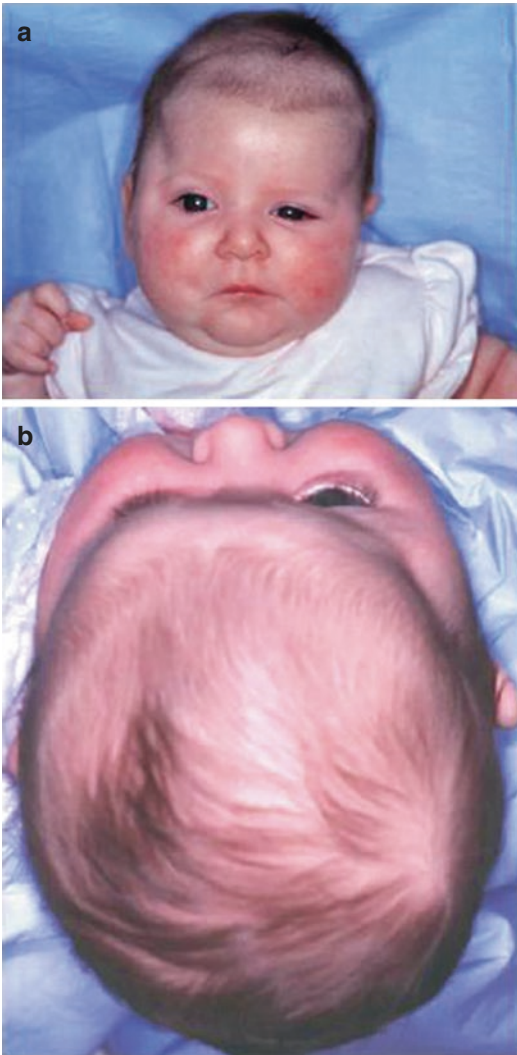
Coronal synostosis, or anterior plagiocephaly, is characterized by vertical dystopia, nasional deviation to the ipsilateral (affected or same) side,



**Fig. 3.5** 3D CT showing partially fused lambdoid and posterior sagittal sutures giving the appearance of a Mercedes-Benz sign

flattening of the frontal bone on the ipsilateral side, and bulging of the frontal bone on the contralateral (opposite) side (Figs. 3.6 and 3.7). The tips of the nose and chin point to the contralateral side in some cases. Strabismus from ipsilateral superior oblique paresis and compensatory contralateral head tilt is present in 50–65 % of unilateral coronal synostosis (Gosain et al. 1996; O'Daniel et al. 1993). It is recommended that the patient see an ophthalmologist familiar with craniofacial disorders for preoperative evaluation. Strabismus surgery is usually needed, as it rarely improves after craniofacial reconstruction (Sun and Persing 1999). However, strabismus surgery corrects or improves the head tilt (Gosain et al. 1996). MacKinnon et al. (2013) found a significant improvement in strabismus after endoscopic strip craniectomy and postoperative helmet therapy. These patients also had fewer strabismus surgeries than those who underwent a fronto-orbital advancement. An anteroposterior (AP) skull film shows a harlequin appearance to the ipsilateral orbit as the superior orbital rim is elongated (Fig. 3.8).

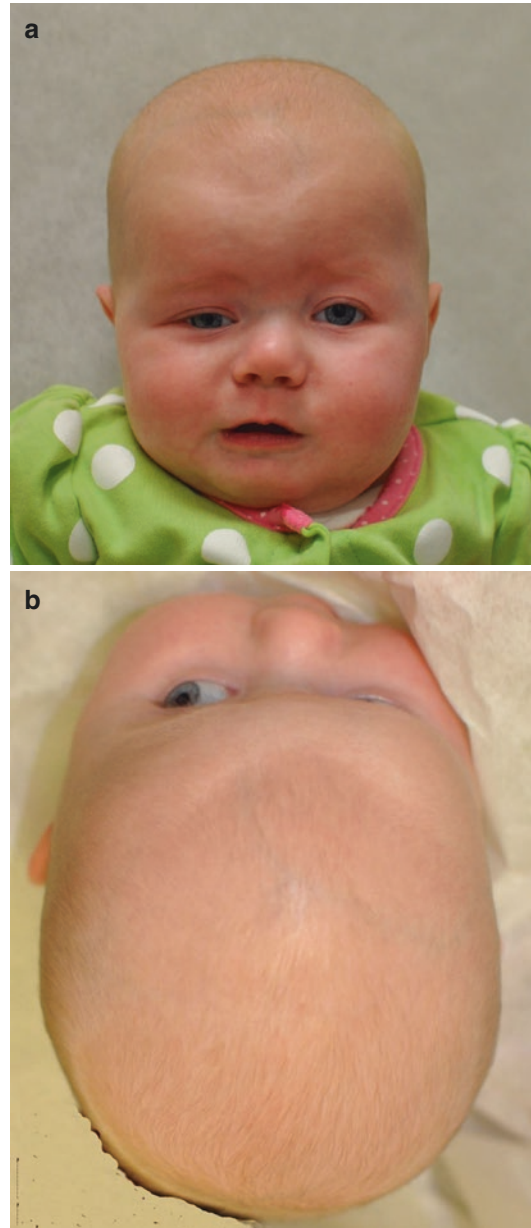




**Fig. 3.6** (a, b) Right coronal synostosis: note the nasal deviation, flattening of the frontal bone on the ipsilateral side and vertical dystopia

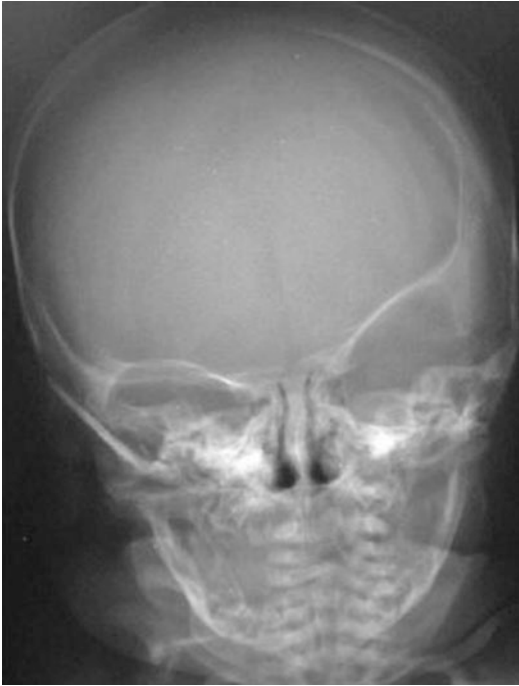### 3.5 Bicoronal Synostosis

Although bicoronal synostosis can occur sporadically, there is a much higher association in syndromic patients as compared to single suture craniosynostosis (Proctor 2014). Patients with bicoronal synostosis have turribrachycephaly or a “tower-shaped” head with



**Fig. 3.7** (a, b) Left coronal synostosis. Note the nasal deviation, flattening of the frontal bone on the ipsilateral side, and vertical dystopia

flattening of the frontal area. Although all children with craniosynostosis should have genetic screening, these patients need to be referred to



**Fig. 3.8** Skull film shows “harlequin sign” as the superior orbital rim of the affected left eye is elongated

a geneticist because of the high association with genetic mutations (MacKinnon et al. 2009) (Fig. 3.9).

### 3.6 Metopic Synostosis

Metopic synostosis is characterized by a trigonocephalic or triangular shape to the head when viewed from above. There are various degrees of bitemporal narrowing, parietal bossing, hypotelorism (close-set eyes), and ridging of the metopic suture that can resemble a keel (Fig. 3.10). The metopic suture is the only suture that truly fuses, usually by 2 years of age. When it closes in utero, the baby can be born with the characteristic trigonocephalic head shape (Proctor 2014). If the suture fuses in infancy, a common variation can occur, characterized by a normal shape to the skull, absence of hypotelorism, slight ridging of the metopic suture, and

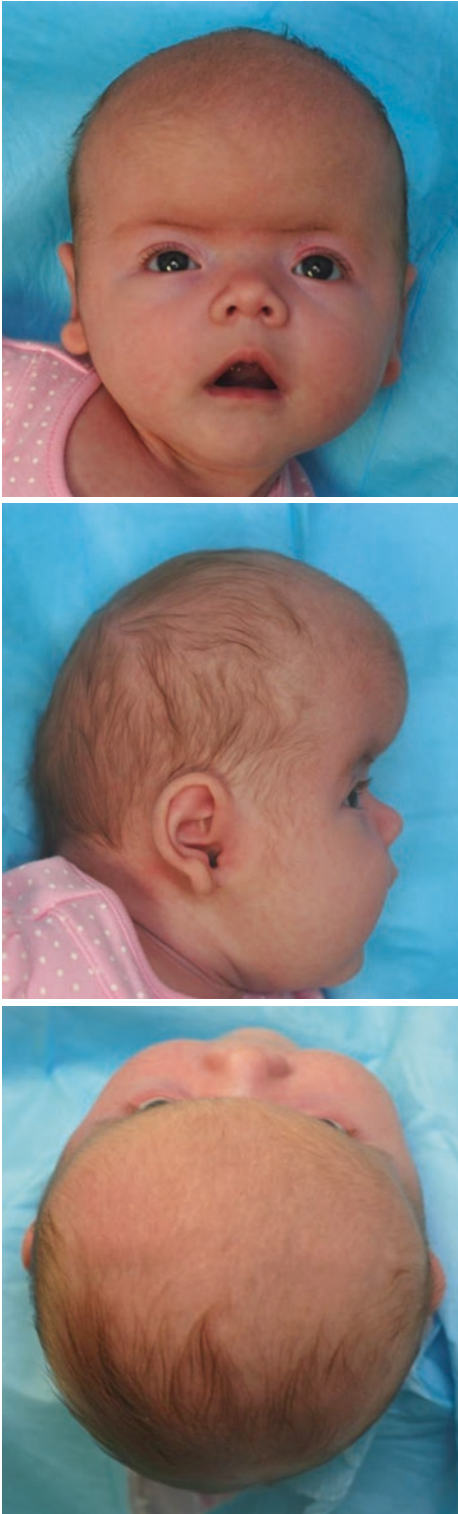radiographic evidence of a fused metopic suture. This ridge will usually disappear over 2–3 years as the frontal bones thicken (Proctor 2014). Surgery is not necessary in this instance and the head shape remains normal. The ridge can be “burred down” at a later date if it is still prominent (Fig. 3.11).

### 3.7 Lambdoid Synostosis

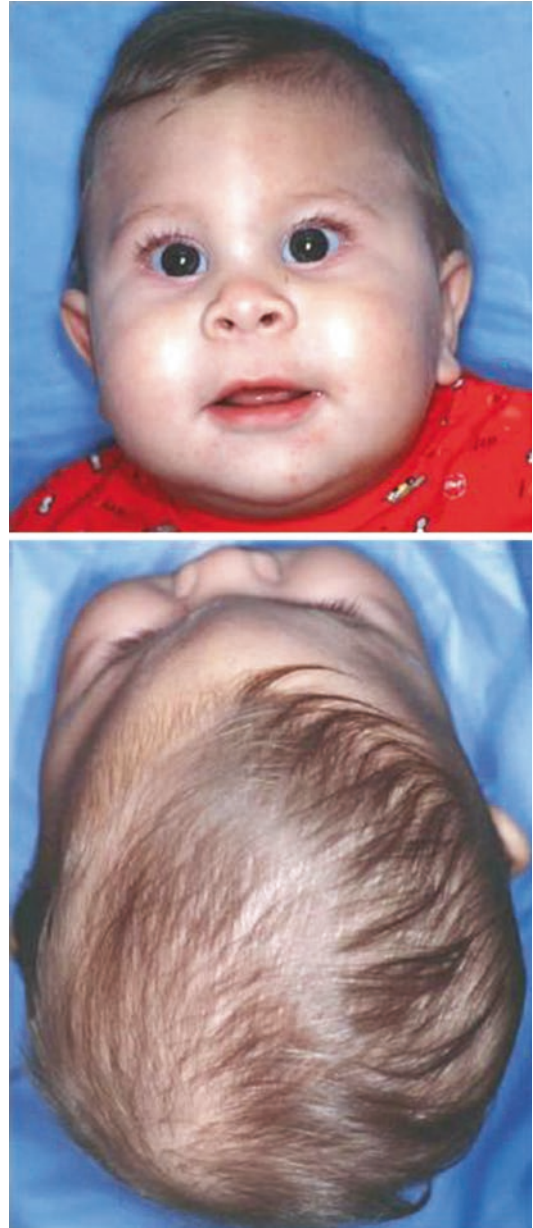
Lambdoid synostosis or occipital plagiocephaly is characterized by a trapezoid shape to the head when viewed from above, tilted skull base (ipsilateral side displaced inferiorly), and ipsilateral ear displaced inferiorly and posteriorly. The fused lambdoid suture has a palpable ridge, and there is an ipsilateral occipitomastoid bulge. When viewed from behind, the skull base appears tilted (Fig. 3.12). Care must be taken not to confuse true lambdoid synostosis with positional plagiocephaly (Table 3.2). Radiographically, a Towne’s view skull film or CT scan will show a closed lambdoid suture.

### 3.8 Positional Plagiocephaly

Deformational forces, such as the prenatal head on the mother’s pelvic bone or the birth process itself, can shape the skull. The infant brain grows rapidly during the first several months after birth, and it is this growth that expands the skull into its normocephalic shape. Infant head circumference increases 9 centimeters (cm) during the first 6 months and grows approximately 12 cm during the first year. In comparison, the head circumference increases by only 2.25 cm during the second year after birth and just 0.75 cm between the second and third years. Therefore, deformational forces encountered when an infant head lies on a mattress; against a car seat, swing, or stroller; or on any firm surface for prolonged periods of time can have a significant influence during the period of rapid skull growth.



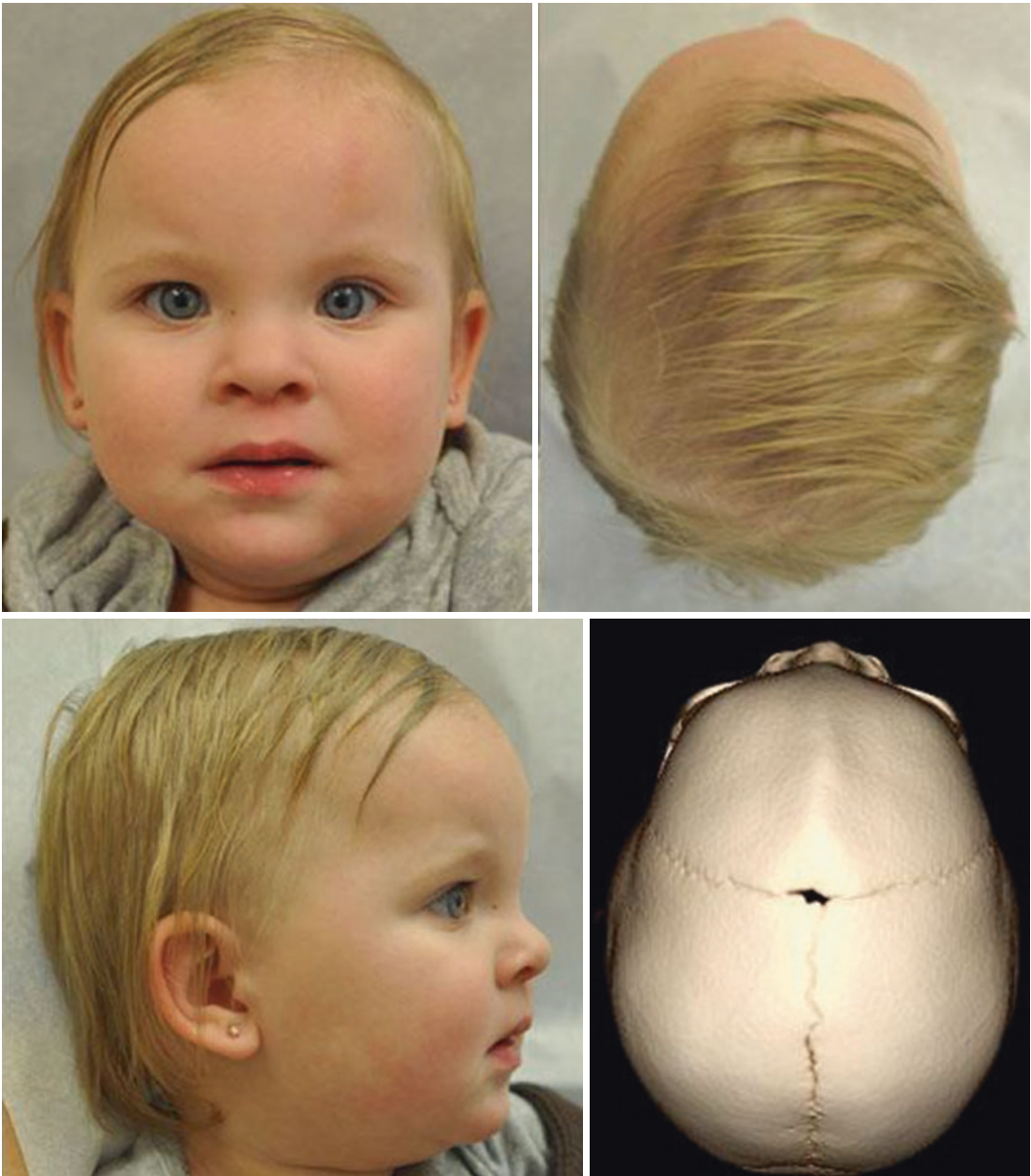
**Fig. 3.9** Bicoronal synostosis



**Fig. 3.10** Metopic synostosis. Note the trigonocephalic shape of the skull, bitemporal narrowing, hypotelorism and ridging of the metopic suture

Most babies are born with normocephaly, but their skulls may become progressively more misshapen during the first several weeks after birth because of deformities from unrelieved pressure on the occipital bone. By 2 months of age, a baby may have spent approximately 700 h sleeping. If



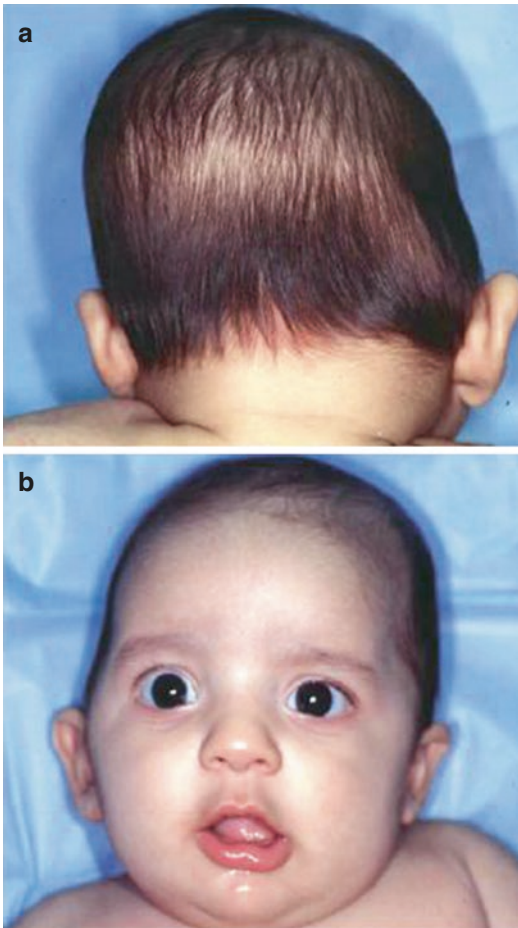


**Fig. 3.11** Infant with metopic ridge and radiographic evidence of fused metopic suture. This is a normal nonsurgical variant

the baby lies supine with the head turned to one side, either from preference or the head has not been rotated to redistribute the deformational forces of gravity, positional plagiocephaly (PP) can result. This condition can be further aggravated by torticollis, which is a tightening of the sternocleidomastoid or cervical muscles that pre-

vent the infant from turning the head 180° (Rekate 1997).

There has been a significant increase in “deformational” or “positional” plagiocephaly since 1992, when the American Academy of Pediatrics initiated the “Back to Sleep” (BTS) campaign and recommended that infants sleep on their backs or



**Fig. 3.12** (a, b) Lambdoid synostosis. Note the tilted skull base

sides to decrease the incidence of sudden infant death syndrome (SIDS) (Kane et al. 1996; Majnemer and Barr 2006; Moon et al. 2011). One referral center reported a tenfold increase in referrals for occipital plagiocephaly compared with 1991 (Carson et al. 1997). Positional plagiocephaly occurs in 18–19.7 % of healthy infants, depending on age. Thirteen percent of newborns present with PP, and the incidence increases to 16 % and 19 % at 6 weeks and 4 months of age, respectively (Hutchinson et al. 2004; Peitsch et al. 2002). There is much controversy in the literature regarding the association between positional plagiocephaly and developmental delays (Collett et al. 2005; Majnemer and Barr 2006).

It is important to differentiate positional plagiocephaly from craniosynostosis, as the treat-

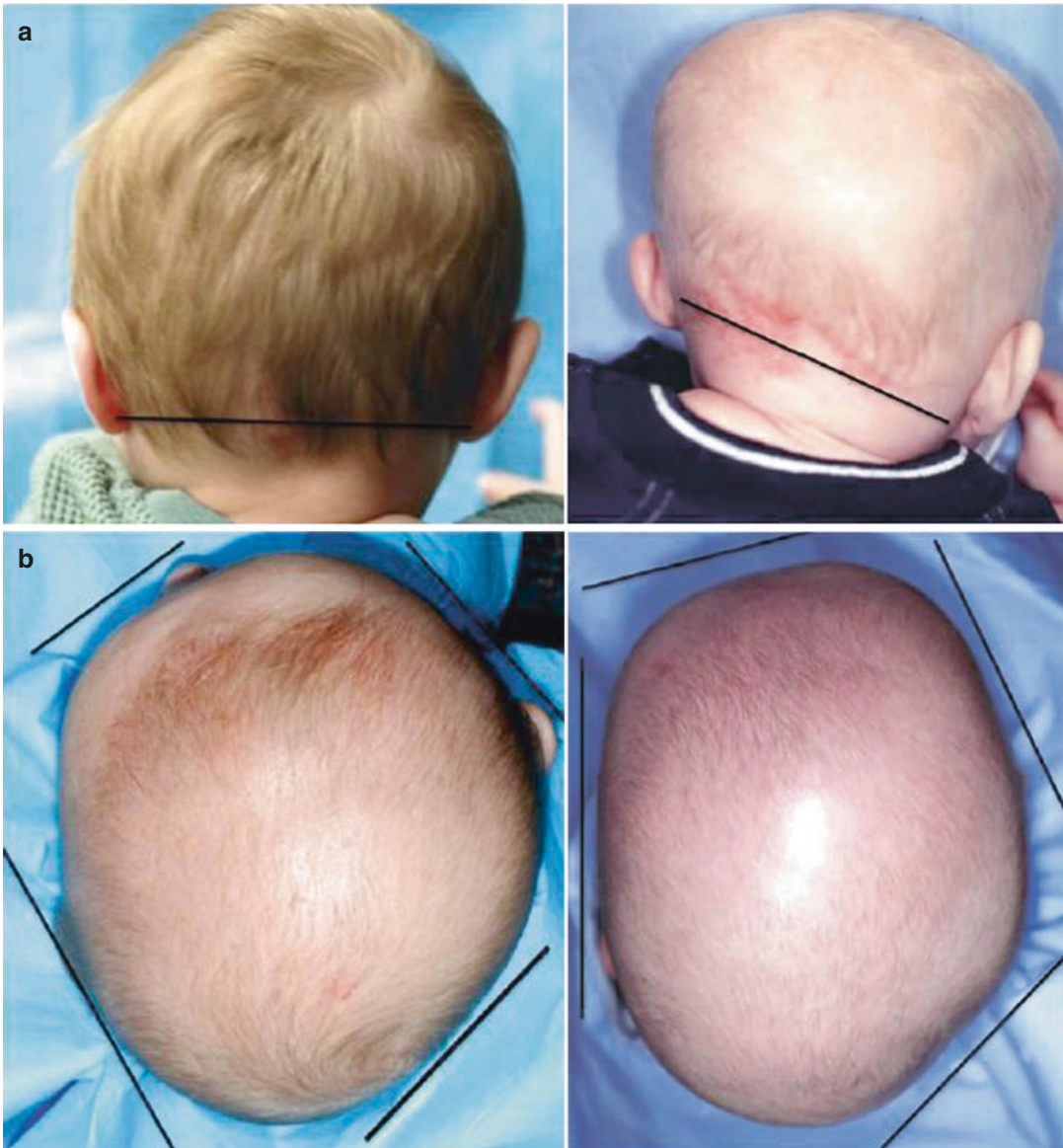**Table 3.2** Comparison of lambdoid synostosis and positional (deformational) plagiocephaly

Lambdoid synostosis	Positional plagiocephaly
Usually present at birth	Usually not present at birth
Trapezoid shape when viewed from above	Parallelogram shape when viewed from above
Ipsilateral ear displaced posteriorly and inferiorly	Ipsilateral ear displaced anteriorly
Bony ridge palpable over closed lambdoid suture	No bony ridge over lambdoid suture
Unilateral occipitoparietal flattening posteriorly	Usually unilateral occipitoparietal flattening but can be bilateral
When viewed posteriorly there is an ipsilateral occipitomastoid bulge and the skull base appears tilted	When viewed posteriorly the skull base is horizontal and no occipitomastoid bulge
Contralateral frontal bossing	Ipsilateral frontal bossing
Radiographic evidence of closed suture (Towne's view, CT with bone windows, CT with 3D recon)	Radiographic evidence of open sutures May have torticollis

ment for craniosynostosis is surgery and the treatment for plagiocephaly is, with rare exception, nonsurgical. A thorough history and physical examination will help differentiate between the two. Parents of infants with plagiocephaly frequently report that the head shape was normal at birth and that the occipital flattening was noticed later, often by the pediatrician at the 2-month well-baby exam. They also recall their baby preferred to sleep in one position with the head turned to one side. Some babies may prefer to sleep with the back of the head on the mattress, not turning it to either side. These infants can have flattening of the entire occipital bone, which causes the face to appear very round when viewed from the front.

With positional plagiocephaly, there is no bony ridge palpated along the lambdoid suture, and the base of the skull will be horizontal when viewed from behind. When viewed from above, there is occipitoparietal flattening on the affected side with anterior displacement of the ear, forehead, and malar eminence on the ipsilateral side. This appears to resemble the shape of a parallelogram as one side of the skull is shifted for-





**Fig. 3.13** These pictures illustrate the differences between positional plagiocephaly (*left*) and lambdoid synostosis (*right*). (a) When the skull is viewed from behind, the skull base is horizontal with positional plagiocephaly and tilted

with lambdoid synostosis. (b) When viewed from above, the skull with positional plagiocephaly (*left*) takes the shape of a parallelogram, while the skull with lambdoid synostosis (*right*) takes the shape of a trapezoid

ward (Fig. 3.13). A Towne's view x-ray or CT of the brain with bone windows will clarify the diagnosis by showing open lambdoid sutures. However, if a thorough history and physical examination clearly supports the diagnosis of positional plagiocephaly, imaging is often not necessary. The severity of cranial vault asymmetry can be evaluated by obtaining transcranial

anthropometric measurements with a sliding caliper. Two oblique transverse cranial diameters are measured – from the midpoint of the supraorbital rim to the midpoint of the contralateral parieto-occipital scalp. The larger the difference between these two points, the greater the asymmetry (Mulliken et al. 1999; Farkas 1996; Dec and Warren 2011).

**Table 3.3** Recommendations for a safe sleeping environment/principles of “back to sleep”

Place infant supine for all naps and at bedtime – “back to sleep for every sleep”
Vary the head position by alternating the infant’s head from side/side but do not position on the side
Use a firm sleep surface, covered by a tight fitted sheet
No wedges, crib bumpers, blankets, pillows, loose bedding, or stuffed animals in the crib
Do NOT use devices that are marketed to decrease the risk of SIDS – e.g., special wedges, positioners, sleep surfaces
If infant falls asleep in a seat/swing, move her to a crib/ other flat surfaces as soon as practical
Room-sharing without bed-sharing (avoid the risk of entrapment/suffocation) is recommended
Offer a pacifier at bedtime/nap time
Avoid overheating
Avoid smoke exposure, alcohol/illicit drug use during pregnancy and after birth
Breastfeeding is recommended
Do not use home cardiorespiratory monitors as a SIDS-reduction strategy
Infants should be immunized in accordance with the AAP and CDC recommendations
Health care professionals in all settings and child care providers should endorse the SIDS risk reduction recommendations from birth
Task Force on Sudden Infant Death Syndrome (2011) and Koren et al. (2010)

### 3.9 Prevention and Treatment for Positional Plagiocephaly

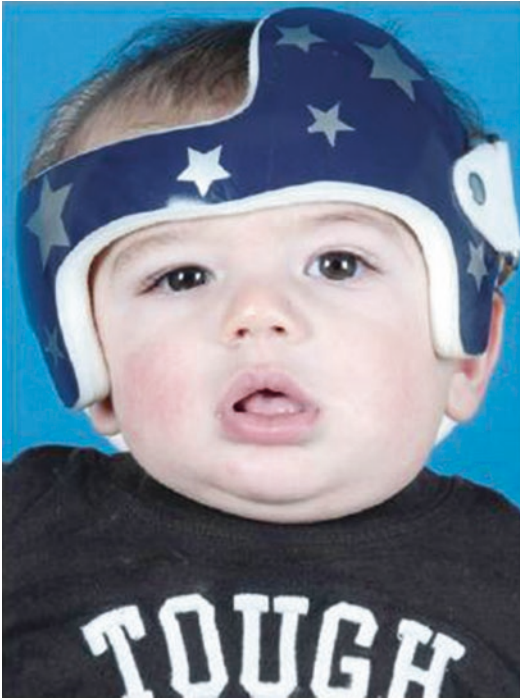The prevention of positional plagiocephaly should begin at birth, with education provided by the postpartum nursing staff and continuing at each pediatric well-child care visit by the pediatrician or pediatric Advanced Practice Nurse (Table 3.3). Before leaving the hospital, parents should be instructed in principles of “back to sleep/tummy to play.” Although babies should be supine for sleep or naps, it is important to provide “tummy time” to allow strengthening of neck muscles and promote optimal development (Table 3.4). Parents should be taught to reposition their infant’s head when lying supine, starting from birth. Mild cases of flatness will resolve over weeks to months if the infant’s head is repositioned on a flat surface. Toys or objects of interest can be placed on the nonpreferential side to encourage the infant to turn his head in the nonpreferential direction. Alternating arms to hold the

**Table 3.4.** Strategies to prevent/manage positional plagiocephaly

<b>Tummy time</b>
Tummy time activities – with the infant in the prone (on the stomach) position – should begin at birth
These activities must always occur with the infant awake and supervised
Start with a few minutes per day, 2–3 times per day, and increase the time/frequency as the infant grows
A rolled blanket may be placed under the chest and upper arms for added support
<i>Examples of tummy time/prone to play activities include:</i>
Burping/soothing your infant face down on your lap
Getting down level with her to encourage eye contact
Lying on your back with her, face to face on your chest or tummy
Sliding your hand under tummy/between her legs and carrying her tummy down
Placing her on her tummy for 1–2 min after each diaper change
Lying her on her tummy with a blanket rolled under her and dangling a toy in her face ( <a href="https://pathways.org/growth-development/tummy-time/6/26/2016">https://pathways.org/growth-development/tummy-time/6/26/2016</a> )
<b>Additional strategies to prevent/manage positional plagiocephaly</b>
Carry infant in front/back carriers or infant slings – ensure that the head is up and above fabric, the face is visible, and the nose and mouth are clear of obstructions
Limit time spent in:
Infant seats
Car seats
Bouncy seats
Swings
Strollers
Place toys or objects of interest on infant’s nonpreferential side
Hold/carry infant on nonpreferential side
Alternate arms when bottle feeding to encourage head turning to both sides

baby when feeding will also encourage head turning to both sides. “Tummy time,” or placing the baby prone while awake and observed, will decrease gravitational forces on the skull (Koren et al. 2010).

A cranial orthotic device such as a band or molding helmet may be used to correct moderate to severe cases of positional plagiocephaly (Kluba et al. 2014), but only after the parents have attempted all other repositioning strategies without significant improvement in the head shape (Fig. 3.14). Molding therapy is most effec-



**Fig. 3.14** Cranial orthotic device to correct positional plagiocephaly

tive between 4 and 12 months of age, during the time of rapid brain growth. The helmet helps to reshape the skull by restricting the growth in one direction, thus allowing it to expand in the other direction. It is critical to refer these patients to an orthotist experienced in cranial orthotic devices for positional plagiocephaly. The orthotist will closely monitor the patient for changes in head measurements and pressure points and instruct the parents in cleaning and caring for the helmet. Infants typically show significant improvement in head shape over the first several weeks, and significant correction is usually achieved by 3 months (Robinson and Proctor 2009). However, the helmet must be worn at least 23 h each day to get best results. Surgery may be considered in extremely rare cases where a severe deformity still exists despite repositioning, correction of torticollis, and use of a cranial orthotic device.

Torticollis, or unilateral shortening and fibrosis of the sternocleidomastoid, can prevent an infant from turning his head to the nonpreferential side and cause further deformity to the face. Congenital muscular torticollis is associated with

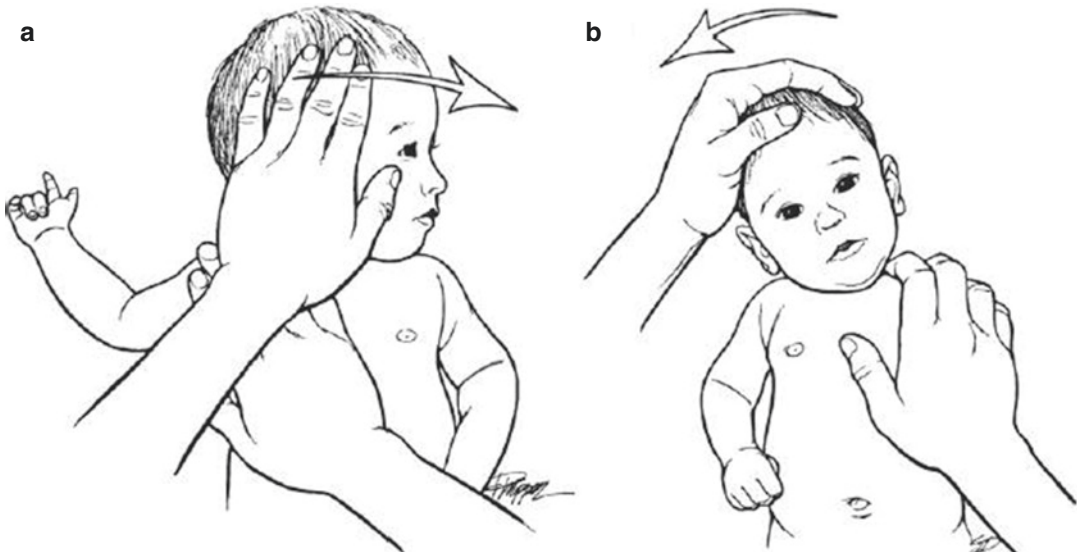
PP in up to 90 % of infants (Rogers 2011). Static stretching exercises can be done to gently stretch the affected sternocleidomastoid muscle. Confirm that there is no cervical spine defect before doing these exercises. A pediatric physiotherapist should be consulted, though parents can be taught to do these exercises at home five to six times a day. With the infant lying supine on a flat surface and the head in midline position, the parent can slowly turn the head 90° toward the nonpreferential side, holding the stretched position for 10 s, and then slowly turn the head back to midline. A second person may need to hold the shoulders so they don't turn with the head. If a head tilt is present, the parent should slowly tilt the head to the contralateral side and hold that position for 10 s (Fig. 3.15). Parents should be informed that these exercises should be done slowly to prevent trauma to the muscle and that the baby will cry the first few times. However, within a few days, the muscle will relax and it will be easier to turn the head. The torticollis should resolve within a couple of weeks.

In sternocleidomastoid tumor of infancy, a tumor is palpable in the muscle and can restrict the infant's ability to turn the head. Stretching exercises may improve this condition, but surgery is usually necessary to remove the mass and lyse the muscle (Kane et al. 1996; ReKate 1997).

Although preventing positional plagiocephaly is ideal, treatment should be instituted as soon as the diagnosis is made. Early intervention during the period of rapid skull growth (first few months of age) will have the best results.

### 3.10 Syndromic Craniosynostosis

Infants with craniosynostosis “syndromes” or “conditions” present with a characteristic group of clinical findings. They have multiple cranial suture synostoses, including the sutures of the cranial base, which result in complex skull and forehead deformities (Bartlett and Mackay 1997). The cranial base abnormalities are manifested by hypoplasia of the midface and maxilla. These children often have hypertelorism, exorbitism, syndactyly, cleft palate, cardiac anomalies, and eye muscle abnormalities (e.g., strabismus). Depending on the



**Fig. 3.15** Static stretching exercises (Used with permission from Littlefield et al. (2001)). (a) Slowly turn the head to the nonpreferential side, holding the stretch position for 10 s and then returning it to the midline.

(b) Slowly tilt the head to the contralateral side and hold that position for 10 s (Used with permission from Barrow Neurological Institute. © Barrow Neurological Institute 2001. All Rights Reserved)

degree of severity, there are frequently associated medical problems, including hydrocephalus, papilledema, respiratory distress, and failure to thrive.

The most common of these conditions are Crouzon, Apert, and Pfeiffer syndromes. Although their etiology is not totally clear and the majority of the reported cases are sporadic, it is known that they have an autosomal dominant mode of inheritance. An affected individual always has a 50 % chance of parenting a child who will be born with the same condition. Mutations in specific fibroblast growth factor receptor (FGFR) gene types for these syndromes have been identified (Ridgeway and Weiner 2004; Rossi et al. 2003).

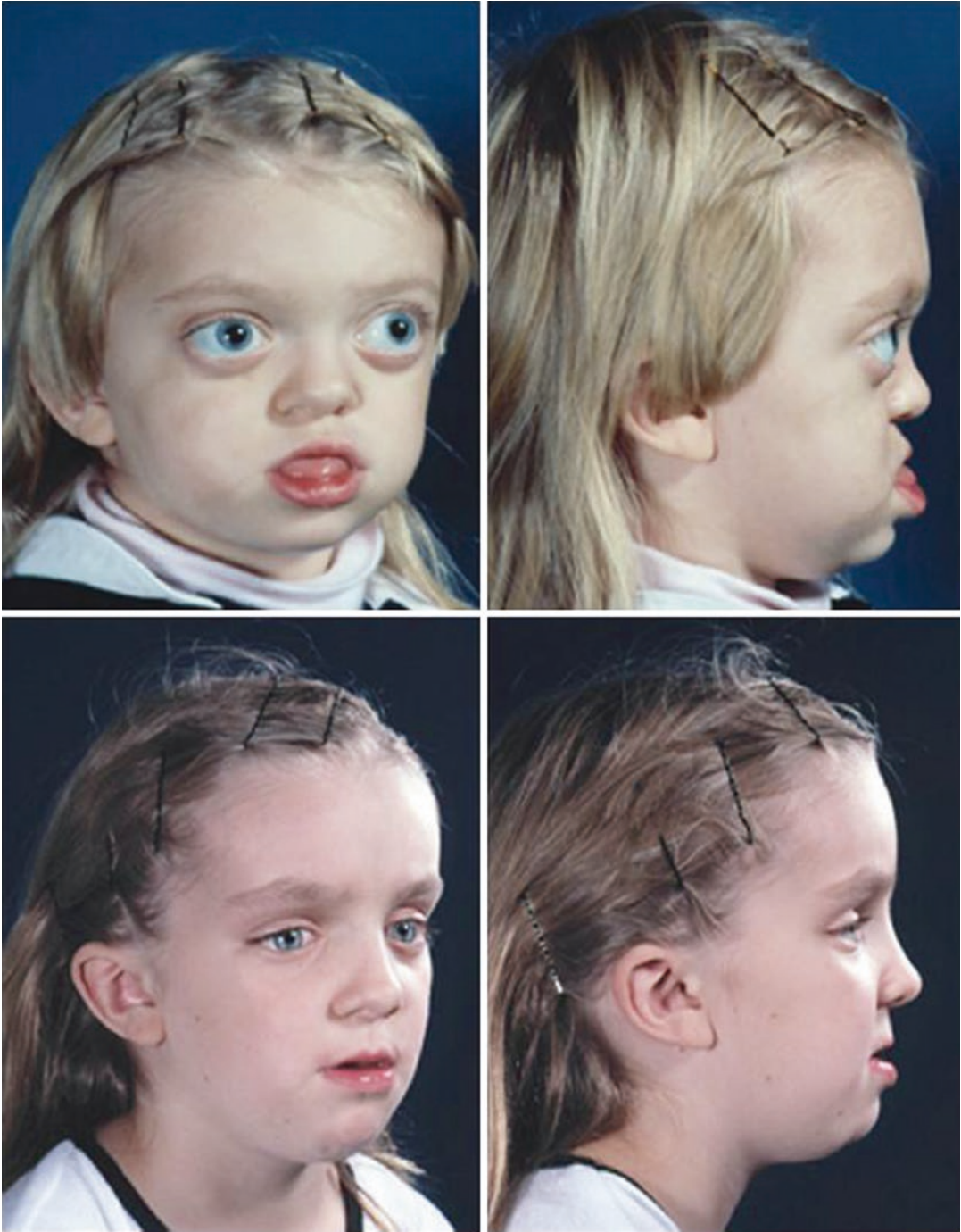
### 3.10.1 Crouzon Syndrome

First described by a French neurologist in 1912, this autosomal dominant condition has an approximate incidence of 1 in 25,000 births. It is caused by multiple mutations in the fibroblast growth factor receptor 2 (FGFR2). Common clinical findings in infants with Crouzon syndrome may

include bicoronal craniosynostosis, with a resulting short cranium, a broad/flat forehead, sometimes in combination with sagittal and/or lambdoid synostosis (often very severe, as in a child with a cloverleaf deformity), and varying degrees of exorbitism, hypertelorism (wide-set eyes), and maxillary/midface hypoplasia – resulting in a “froglike” face (Fig. 3.16). They are at very high risk for serious ocular abnormalities, including papilledema, optic atrophy, corneal exposure, and proptosis. In severe cases, the globe can actually herniate through the eyelids, often requiring emergency reduction or tarsorrhaphy (partial or complete suturing of the eyelids). They may also have a conductive hearing loss. In general, these children do not have anomalies of the hands or feet (Bartlett and Mackay 1997).

Depending on the severity of the midface hypoplasia (and whether there is choanal atresia), the child may have serious airway compromise and challenges with oral feeding, often requiring management by supplemental oxygen therapy, CPAP (continuous positive airway pressure), tracheostomy, and/or gastrostomy placement. They





**Fig. 3.16** Patient with Crouzon syndrome. Preoperative (*top*) – note the exorbitism and midface hypoplasia. Postoperative (*below*) – following cranial vault remodeling and midface advancement surgeries



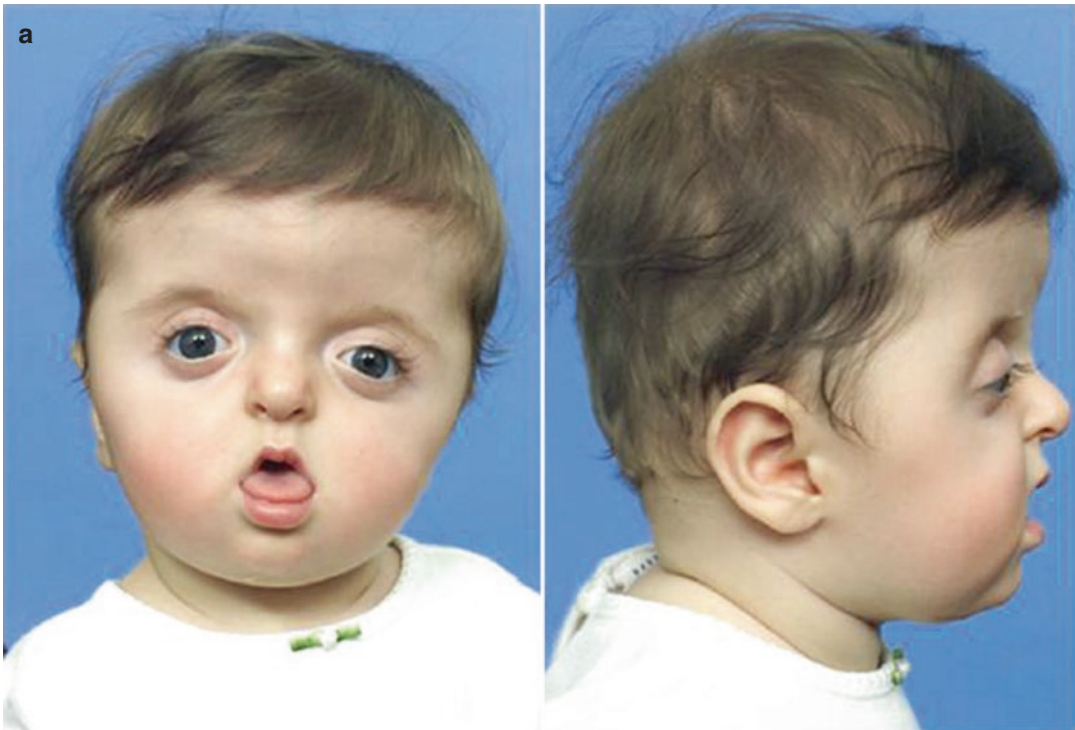are also at risk for development of hydrocephalus and/or a symptomatic Chiari malformation, possibly requiring early neurosurgical intervention (Ridgeway and Weiner 2004).

### 3.10.2 Apert Syndrome

Acrocephalosyndactyly type 1, more commonly known as Apert syndrome (after the French neurologist who described the syndrome in 1906), is the most complex of the craniosynostosis syndromes (McCarthy et al. 1990a). The incidence of this autosomal dominant condition is reported as 1/50,000–1/160,000 (Gosain et al. 1996; Bartlett and Mackay 1997). As with Crouzon syndrome, this condition results from a mutation of the *FGFR2* gene. Infants with Apert syndrome also characteristically have multiple suture craniosynostosis. Their skulls are often very tall and turricephalic (tower-like). They usually present with an

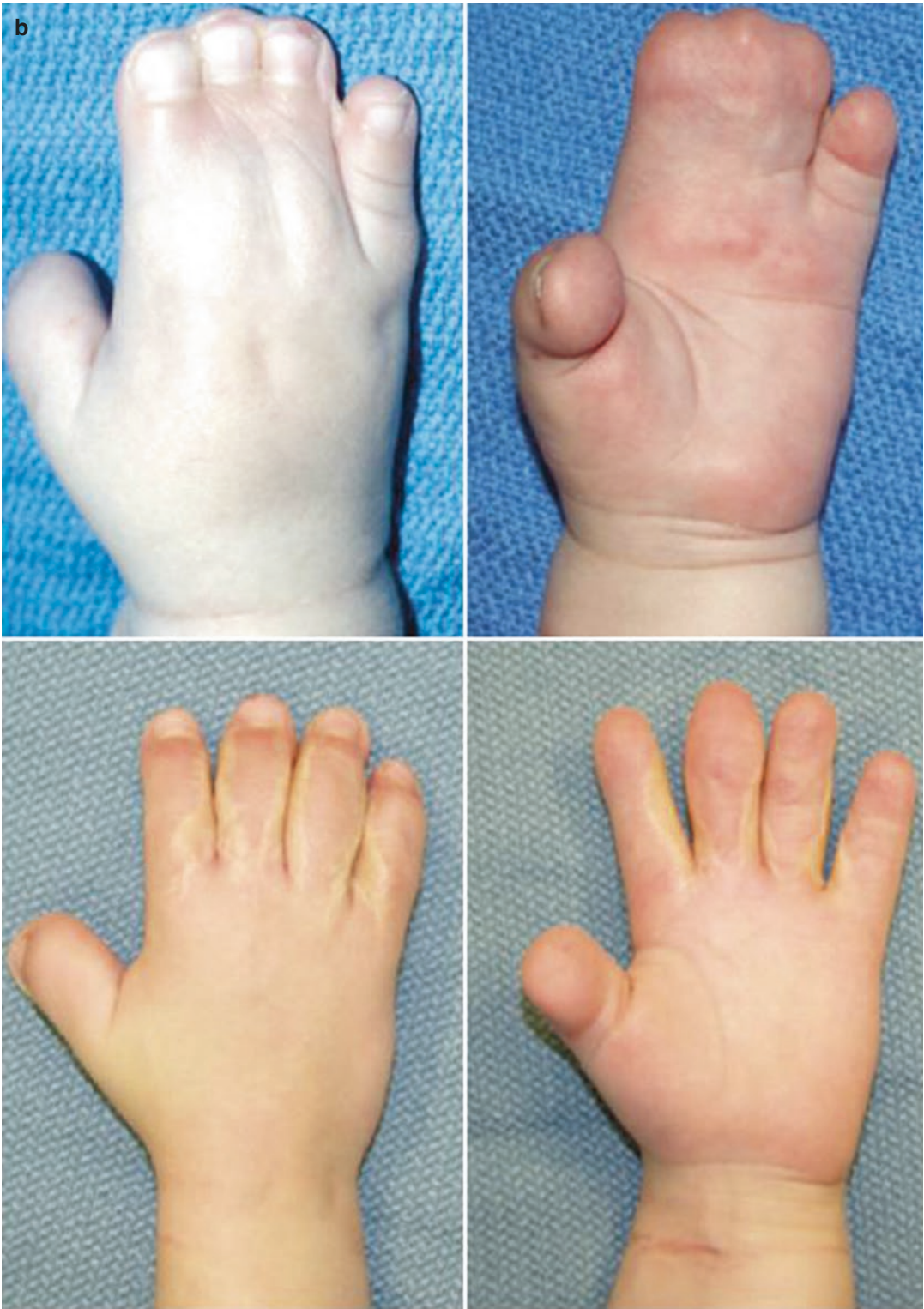extremely flat and elongated forehead, bitemporal widening, and bilateral flattening of the occiput. The nose has a “beaked” appearance (Fig. 3.17). Hydrocephalus and agenesis of the corpus callosum are not uncommon in these children. They also have varying degrees of exorbitism, proptosis, midface/maxillary hypoplasia, and hypertelorism.

The classic distinguishing finding in infants with Apert syndrome is soft tissue and bony syndactyly (fusion) of the digits of the hands and feet. Many of these infants also have shortening of the upper extremities, dental abnormalities (e.g., anterior open bite), clefts of the secondary palate (they almost always have a very high arched palate), conductive hearing loss, cardiac anomalies, and chronic acne (first noted in infancy). Mental retardation and learning disabilities are higher in this group than in children with Crouzon syndrome, although many of these children develop normal intelligence (Bartlett and Mackay 1997).

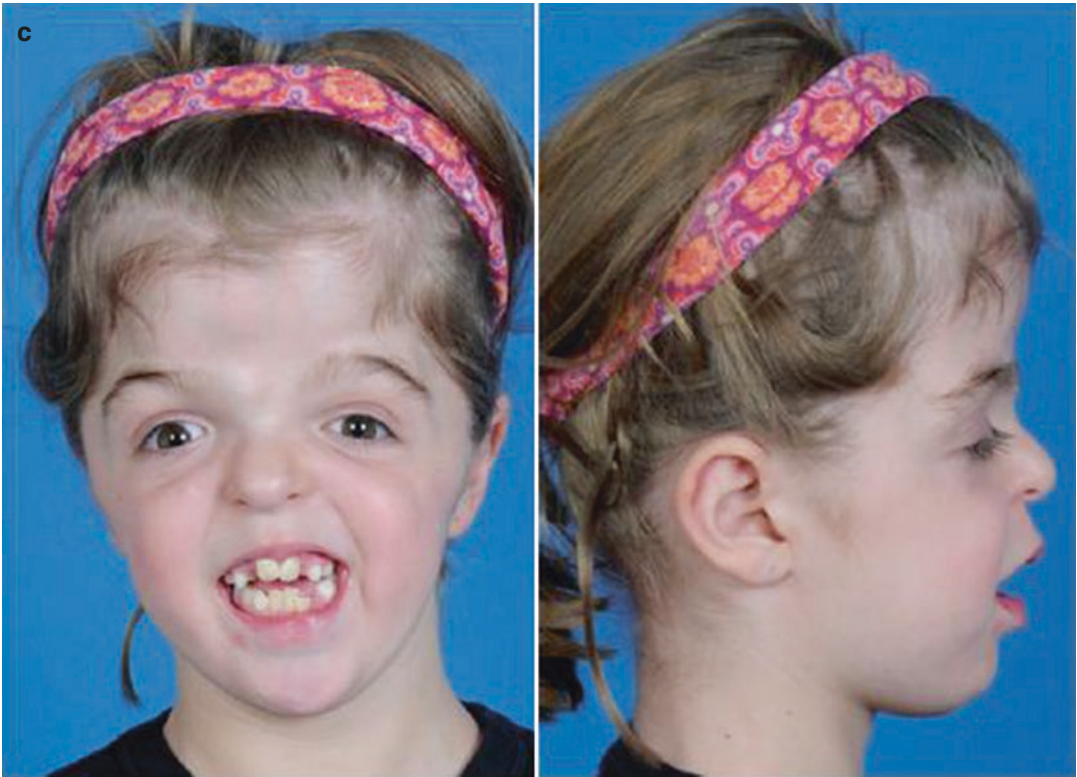

**Fig. 3.17** (a) Preoperative patient with Apert syndrome. Note the turricephaly and exorbitism. (b) Same patient (bilateral syndactyly) pre- and postoperative views

(Photos courtesy of Dr. Joseph Upton). (c) Same patient after cranial vault remodeling and midface advancement



**Fig. 3.17** (continued)



**Fig. 3.17** (continued)

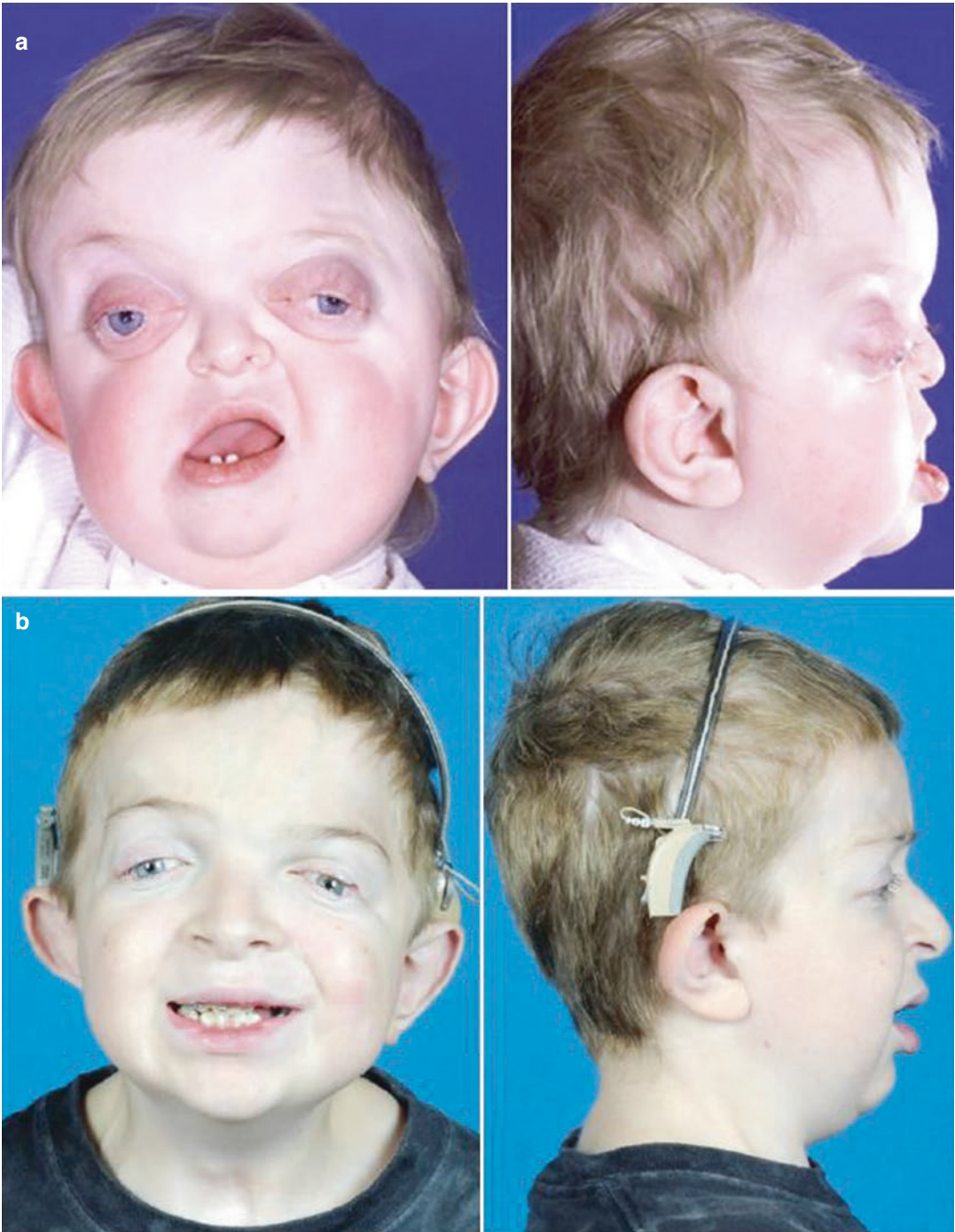### 3.10.3 Pfeiffer Syndrome

This syndrome, also autosomal dominant, has an incidence of approximately 1 in 200,000. It is caused by mutations in *FGFR1* or *FGFR2* (Mooney and Siegel 2002) and, like Apert syndrome, is characterized by multiple suture craniosynostosis, varying degrees of mental retardation, midface hypoplasia, and upper airway anomalies (Ridgeway and Weiner 2004) (Fig. 3.18). These children commonly have very broad thumbs and great toes and sometimes have syndactyly. They can be mistaken for a child with Apert syndrome and require careful assessment and diagnosis by an experienced craniofacial team.

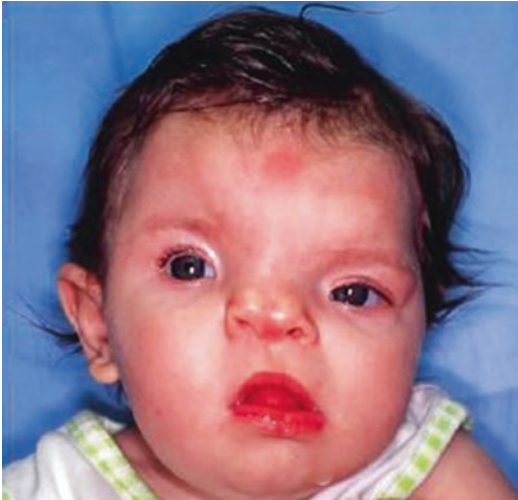### 3.10.4 Other Syndromes

There are several less commonly occurring craniosynostosis syndromes, including Carpenter, Antley-Bixler, Saethre-Chotzen, and Jackson-Weiss syndromes and craniofrontonasal dysplasia (Fig. 3.19). They are also characterized by craniosynostosis and midface deformities, and the affected infants can have associated neurosurgical, airway, and ophthalmologic problems, requiring assessment and management by a craniofacial team. Additionally, there are almost 100 other “noncraniosynostosis” syndromes in which craniosynostosis may be a finding. Two common examples are Treacher Collins syndrome and craniofacial microsomia.





**Fig. 3.18** (a) Patient with Pfeiffer syndrome. Bilateral tarsorrhaphies were performed to prevent herniation of the globes. (b) Same patient after cranial vault reconstruction and midface advancement



**Fig. 3.19** Infant with frontonasal dysplasia and right coronal synostosis. Note the hypertelorism and bifid nose

**Table 3.5** Craniofacial team

Craniofacial surgeon	Nurse specialist
Neurosurgeon	Pediatrician
Orthodontist	Psychologist
Geneticist	Otolaryngologist
Speech pathologist	Ophthalmologist
Social worker	Prosthodontist
Audiologist	Pediatric dentist
Oral-maxillofacial surgeon	Team coordinator

### 3.11 Comprehensive Diagnosis/ Assessment of the Infant with Syndromic Craniosynostosis

In order to comprehensively manage the syndromic child, there must be a team approach to diagnosis and assessment (Table 3.5). When a new patient is referred to a craniofacial center, the team assembles and obtains a full patient history, including the prenatal and birth course, and all medical/surgical information. A detailed feeding history is also obtained. The team psychologist and social worker interview the family in private and complete a psychosocial profile. A complete physical examination is done, including measurement of head circumference and intraoral evaluation. Any medical records brought to the consult by the family are reviewed, as well as skull films and CT or MRI scans. All members

of the team are given the opportunity to question the family and to examine the child.

The family is encouraged to express their concerns and to ask questions. The team then discusses the child and reviews all records without the family in the room, in order to allow for an open discussion and exchange of opinions. Treatment options will be prioritized, based on the patient's individual clinical findings. The team director meets with the family and presents a treatment plan. This may involve further medical workup, especially if there is a concern about airway, eye, or neurosurgical problems (e.g., if there is a suspicion of increased intracranial pressure, hydrocephalus, or a Chiari malformation). Initial surgical intervention will depend on the age of the child at presentation to the team as well as the presence of any medical problems. Often, prior to the initial cranial reconstruction, an infant might require placement of a tracheostomy, gastrostomy, and ventriculoperitoneal shunt or could need to undergo a posterior fossa decompression.

### 3.12 Treatment for Craniosynostosis

If parents choose to correct craniosynostosis, the treatment is surgical. It is important to differentiate between cosmetic surgery and reconstructive surgery. The American Medical Association defines cosmetic surgery as "surgery performed to reshape normal structures of the body in order to improve the patient's appearance and self-esteem. Reconstructive surgery is performed on abnormal structures of the body, caused by congenital defects, developmental abnormalities, trauma, infection, tumors or disease. It is generally performed to improve function, but may also be done to approximate a normal appearance" (American Medical Association Policy of House of Delegates 1989, 2013). Craniosynostosis is usually a congenital defect, and surgery to correct it is reconstructive. This may be an issue of importance for insurance companies or others with authority to approve treatment.

Although surgery for craniosynostosis is reconstructive, it is also done for the cosmetic and psychological benefits, as well as to prevent neurological injury. Children with untreated craniosynostosis



look “different” than their peers and are often teased and ostracized. Hats and protective helmets for sports such as biking, football, and baseball don’t fit a misshapen head. Visual disturbances have been reported, especially the characteristic vertical dystopia seen in patients with coronal synostosis. Some children with craniosynostosis can have elevated intracranial pressure which impairs mental development and can lower IQ (Renier 1989; Renier et al. 1982, 1987). Research on the incidence and extent of increased intracranial pressure is limited, due to the ethical considerations of placing intracranial monitors in healthy infants for research purposes. However, Cartwright and Jimenez studied 89 infants with untreated craniosynostosis and found a significant decrease in fussiness and irritability after suture release by endoscopic strip craniectomy as compared to preoperatively (Cartwright and Jimenez 2002).

---

### 3.13 Surgical Intervention

In 1888, L.C. Lane performed the first craniectomy to remove a stenosed suture on a 9-month-old infant with microcephaly (Lane 1892). Lannelongue, a French surgeon, performed bilateral strip craniectomies to treat sagittal synostosis in 1890 (Lannelongue 1890). In 1894, Jacobi reported treatment of 33 microcephalic patients with poor results and high mortality rates (Jacobi 1894). This ended surgery for craniosynostosis for the next 30 years. Faber and Town proposed reviving the surgery in 1927 to prevent blindness and other complications (Faber and Towne 1927). In 1943, Faber and Town recommended operating at 1–3 months of age for optimal results, and this became generally accepted (Faber and Town 1943).

Many craniofacial centers do not intervene surgically prior to age 3 months (except in the case of an infant with increased intracranial pressure which requires urgent decompression). The typical age range to operate is between 3 and 12 months, depending on the protocol of the center (Bartlett and Mackay 1997; Kabbani and Raghuvver 2004; Panchal and Uttchin 2004). Some delay these procedures until the baby is 8–12 months of age as substantial blood loss with coagulopathy are the most frequent serious com-

plications in extensive open procedures to correct craniosynostosis (Erb and Meier 2016). There are several surgical techniques, both open and closed, to correct craniosynostosis. These include strip craniectomy (endoscopic or non-endoscopic approaches), fronto-orbital advancement with calvarial vault remodeling (for correction of metopic, unicoronal, bicoronal, and syndromic craniosynostoses), and the pi (extended strip craniectomy) and hung span procedures (specifically for correction of severe sagittal craniosynostosis) (McCarthy et al. 1995, 2002). In syndromic infants with multiple suture synostoses, staged circumferential procedures may be required (Bartlett and Mackay 1997).

Infants with isolated craniosynostosis may be candidates for minimally invasive endoscopic craniectomy, or a more simple strip craniectomy in the case of sagittal synostosis, if diagnosed early – at least before the age of 3–4 months. Infants older than 4–6 months, as well as most with syndromic craniosynostosis, will require an intracranial fronto-orbital advancement with cranial vault remodeling. However, some infants with multiple suture nonsyndromic synostosis have undergone endoscopic strip craniectomy with good results (Jimenez and Barone 2010). If the child is over age 18 months, bone grafting may be needed at the same time (rib or split cranium), as they are less likely to generate new bone to adequately cover the cranial defects which result from the fronto-orbital advancement. Children with Apert syndrome often require secondary cranial vault remodeling because of the severity of their abnormality (specifically the turricephaly of the skull).

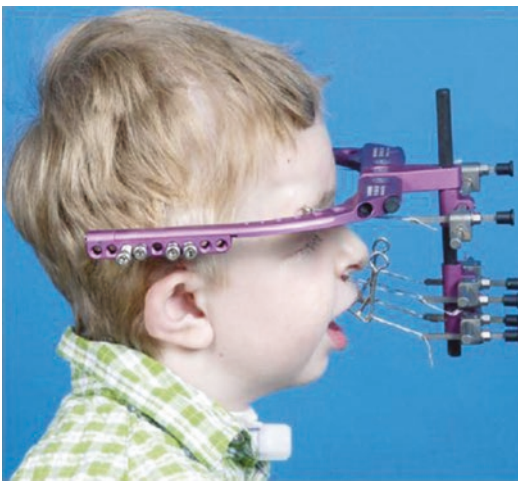
In addition to cranial surgeries, syndromic children may require any one or more of the following: shunt placement, correction of Chiari malformation, eye muscle surgery, choanal atresia repair, syndactyly reconstruction (several stages of surgery to separate the soft tissue and/or bony fusion of the hands), midface advancement, and definitive nasal reconstruction. They also will need many years of specialized orthodontic treatment (Richards 1994).

Between ages 4 and 6 (as early as age 3 in tracheostomy-dependent children), the syndromic patient will often need to undergo correction of their midface hypoplasia, known as a

midface advancement. This surgery accomplishes many things, including better eye coverage, improvement in breathing, correction of dental occlusion, and a more “acceptable” facial appearance. If the forehead requires further advancement, it can be addressed at the same time. The surgery can be performed by a “traditional” approach, using rib grafts to stabilize the advanced midface segments (McCarthy et al. 1990a, b), or by a more gradual process, distraction osteogenesis, using either a rigid external halo-type fixation device or an internal device (Cohen and Holmes 2001) (Fig. 3.20). Once the patient reaches skeletal maturity (age 16–21), definitive midface or maxillary advancement (as well as nasal reconstruction) may be indicated.

### 3.14 Preoperative Preparation for Cranial Reconstructive Surgery

Prior to intracranial surgery, all patients have a very specific and detailed preoperative workup, with some of the requirements being specific to the syndromic patient (Table 3.6). An MRI scan (brain and cervical spine) will document whether there is hydrocephalus or a Chiari malformation. If either is detected, the cranial reconstruction may need to be postponed until after a neurosur-



**Fig. 3.20** Boy with Crouzon syndrome with rigid external distraction (RED) for midface advancement

**Table 3.6** Preoperative workup for intracranial surgery

MR scan (brain and cervical spine) <sup>a</sup>
CT scan with 3D reconstruction
Fundoscopic eye evaluation
Pediatric ENT evaluation <sup>a</sup>
Anesthesia consult <sup>a</sup>
Genetics evaluation <sup>a</sup>
Medical photographs
Blood donation
Presurgical testing
Psychosocial consult
Preoperative nursing consult
Family networking

<sup>a</sup>Mandatory for syndromic patients

gical intervention (shunt placement or posterior fossa decompression). A CT scan can also detect hydrocephalus but is most important in confirming the extent of the sutural synostosis, and the 3D reconstructions will assist in surgical planning. A complete eye evaluation, including a dilated fundoscopic examination, is essential to identify the presence of papilledema. This finding will often result in performing an emergency strip craniectomy or in doing a cranial vault reconstruction prior to age 6 months. Other eye abnormalities, such as strabismus (a very common finding in patients with both syndromic and nonsyndromic craniosynostosis), should be identified preoperatively, as over 60 % of children will require eye muscle repair after recovering from their cranial surgery (Gosain et al. 1996).

A child with a tracheostomy or any breathing problems must have a thorough evaluation by a pediatric otolaryngologist as well as a presurgical consult with a pediatric anesthesiologist. Preoperative medical photographs (all views) are essential for medical documentation. A complete genetics evaluation should be done prior to surgery, as the child’s clinical examination will obviously be affected by the surgery. Presurgical screening (pediatric medical clearance, blood work, history/physical examination, obtaining surgical consent) and appointments with the craniofacial surgeon and the neurosurgeon are scheduled within 3–4 weeks of the procedure. The family is encouraged to donate blood for the patient.

**Table 3.7** Preoperative nursing consult

Review of pre-/postoperative photographs	
Networking to families and support groups/craniofacial websites	
Hospital information	Location of OR, waiting/recovery room, ICU, pediatric unit, visiting policies, rooming-in for parents
Procedure/post-op	Length, description, possible complications, postoperative appearance (drains, IVs, dressings, swelling of eyes, overcorrection of forehead, Foley catheter), length of stay (ICU, hospital)
Home issues	Discharge instructions, signs/symptoms of infection/dehydration, prevention of swelling, activity, diet, postoperative appointments, return to child care, parents' return to work

The entire family (including siblings and grandparents) are offered the opportunity to meet with the team psychologist and social worker in order to discuss any concerns and to receive support in dealing with the surgical experience, which has an impact on everyone. Finally, the craniofacial advanced practice registered nurse (APRN) meets with the parents for an extensive preoperative teaching session (Table 3.7). This includes written and verbal information/explanations about the hospitalization, the surgical procedure, postoperative course, and at-home management (Chibbaro 1994). Pre- and postoperative photos of children who underwent the same procedure are shown, and networking to other families by phone or email is offered, as well as a tour of the pre-op waiting area and the pediatric units. The family is referred to craniofacial support groups and websites (Table 3.8).

### 3.15 Surgical Experience

Whenever possible, any type of intracranial procedure should be scheduled as a first case, in order to minimize the physiologic and psychological stress of waiting on the patient and family

**Table 3.8** Craniofacial resources/support groups

About face <a href="http://www.aboutfaceinternational.org/800-665-FACE">www.aboutfaceinternational.org/800-665-FACE</a>
American Academy of Pediatrics <a href="http://www.aap.org">www.aap.org</a> <a href="http://www.healthychildren.org">www.healthychildren.org</a>
American Cleft Palate-Craniofacial Association Cleft Palate Foundation <a href="http://www.acpa-cpf.org/">www.acpa-cpf.org/</a>
Ameriface <a href="http://www.ameriface.org">www.ameriface.org</a>
CAPPS – Craniosynostosis and Positional Plagiocephaly Support <a href="http://www.cappskids.org">www.cappskids.org</a>
Children’s Craniofacial Association <a href="http://www.ccakids.org/800-535-3643">www.ccakids.org/800-535-3643</a>
Craniosupport <a href="http://www.craniosupport.net">www.craniosupport.net</a>
FACES – The National Craniofacial Association <a href="http://www.faces-cranio.org/800-332-2373">www.faces-cranio.org/800-332-2373</a>
Foundation for Faces of Children <a href="http://www.facesofchildren.org/617-355-8299">www.facesofchildren.org/617-355-8299</a>
Genetic Alliance <a href="http://www.geneticalliance.org/">www.geneticalliance.org/</a>
The Jorge Posada Foundation <a href="http://www.jorgeposadafoundation.org">www.jorgeposadafoundation.org</a>
National Foundation for Facial Reconstruction <a href="http://www.nffr.org/212-263-6656">www.nffr.org/212-263-6656</a>
National Organization for Rare Disorders <a href="http://www.rarediseases.org/800-999-6673">www.rarediseases.org/800-999-6673</a>
Pathways Awareness <a href="http://www.pathways.org">www.pathways.org</a>
Torticollis Kids <a href="http://www.torticolliskids.org">www.torticolliskids.org</a>
WCF – World Craniofacial Foundation <a href="http://www.worldcf.org">www.worldcf.org</a>

(Chibbaro 1994). Many centers allow a parent to carry the infant into the operating room, in order to decrease separation anxiety. Once anesthesia is induced by mask, the parent is safely escorted back to the waiting area by the circulating nurse.

After the child is induced with inhaled anesthetic and the parent leaves the room, he or she undergoes a “prep” period, which involves intubation, placement of cardiac and respiratory monitors, multiple intravenous lines (peripheral, central, arterial), a Foley catheter, and corneal protectors. The hair is parted but generally not shaved.

In order to minimize bleeding, the anesthesiologist will maintain the child in a hypotensive state,

but one or two units of packed cells are often transfused during the procedure. Once the surgery is completed, one or two Jackson-Pratt drains may be placed, and the incision is closed with absorbable sutures. A gauze head dressing is applied, the corneal protectors are removed, and the child is usually extubated and, once stable, is transferred either to the recovery room or the pediatric intensive care unit for initial observation. The total length of the procedure, including patient preparation, surgical intervention, extubation, and transfer to the postoperative unit, is approximately 4–6 h. This will obviously differ by the specific type of procedure as well as by the surgeon – the most important factor is that the family is prepared for what to expect (Box 3.1).

### **Box 3.1. A Mother's Journey with a Child Who Has Crouzon Syndrome**

The day Olivia was born, we were so care-free we missed our exit to the hospital and had to do a complete loop to get back. My water had broken after a long walk on a beautiful day and the delivery had gone fairly well. We heard her cry, that moment of joy all parents hold their breaths for, and then saw the looks and knew something was wrong. What everyone immediately saw was this new baby's prominent eyes. They were quick to call it birth trauma because she was born face up, but something unspoken was wrong. The nurse we developed a relationship with became distant. Our OB disappeared. Everyone around us deflected, except our pediatrician. He took our concerns seriously; he listened with compassion and care, and at our follow-up appointment, he got out a book and pointed to a picture of a person with Crouzon syndrome. "Does this look like Olivia?" Yes. Olivia's features were a match. A geneticist confirmed as much through genetic testing, but he amiably told us Olivia was so mild this would be "our little secret." It felt good to hear at the time, but it was tremendously disappointing

later. This time, not unspoken, but a whispered truth: Olivia had a facial difference.

We began to Google everything we could about Crouzon and joined a Yahoo! support group. We learned Olivia needed to see a craniofacial team – a group of doctors, nurses, psychologists, sociologists, etc., with unique expertise treating the physical and emotional needs of people with craniofacial conditions. When we left our first meeting at the hospital, we knew Olivia would need her first surgery at 11 months, as her brain would eventually be strangled by her tightening skull. Olivia is now 3 years old and just completed her fifth operation, this time to remove the halo that has brought the bones of her midface forward to a normal position. Her normal looks now match her vibrant, lovely self, and she can breathe at night without constant apneas. Even with her Crouzon face, Olivia was beautiful. It was easy to discover if you were looking for the right thing. We have always treated Olivia like a normal kid (because she is aside from small bones), but taking a lesson from those who ignored and covered up at first, we are honest with her and those around us, and all of us are better for it. We educate when we can and protect when we can't.

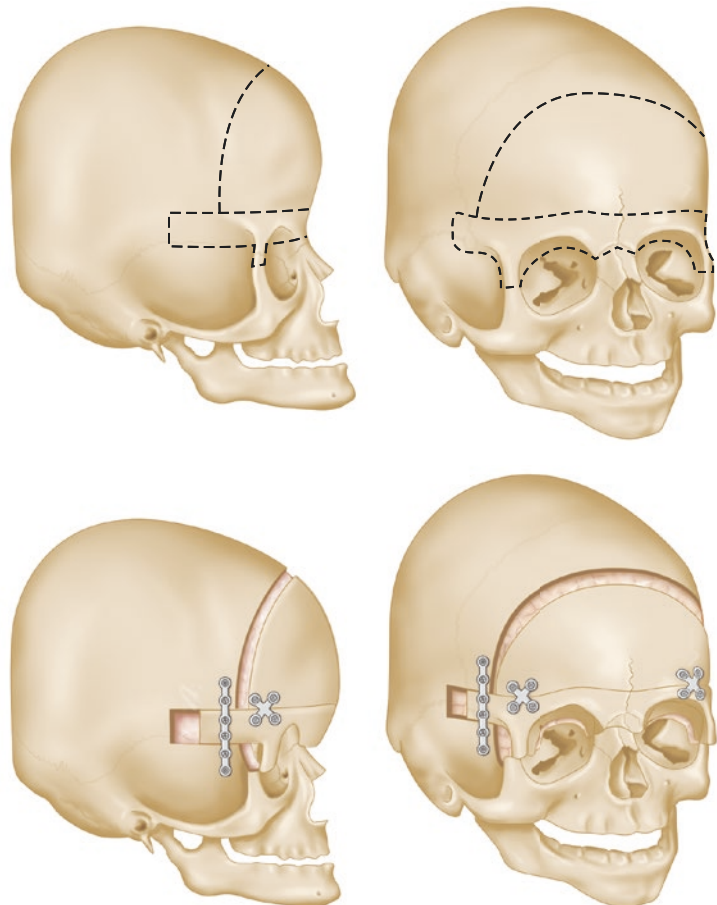
The group of doctors, nurses, and other care providers on Olivia's craniofacial team give us a great sense of security. Many of the nurses and several doctors have become like family to us. They are quick to give their email address and then happy to keep in touch when a question or concern arises. It's the compassion and understanding these folks provide that you can't necessarily teach. It's the same thing we felt from Olivia's pediatrician when everyone else was more content to retreat. They understand the human element of the care they provide, and they support us in teaching Olivia that her facial difference doesn't have to be a handicap to a healthy, happy life.

### 3.16 Technique: Fronto-orbital Advancement/Calvarial Vault Remodeling

The primary goal of this procedure is to expand the cranial vault (which increases the intracranial volume) by releasing the prematurely fused suture(s), thus maximizing brain growth and minimizing the possibility of increased intracranial pressure, hydrocephalus, and optic nerve damage. A second goal, which is especially important for the syndromic child, is to advance the retruded supraorbital bar, in order for the globe to receive more adequate coverage and protection. A third, very critical goal (sometimes the primary motivation to intervene surgically in the nonsyndromic infant) is to perform the above procedure in an attempt to normalize the appearance of the child (Bartlett and Mackay 1997; Ridgeway and Weiner 2004).

Once the above prep is completed, a coronal incision (across the top of the head, from ear to ear, often in a “zigzag” pattern to facilitate closure and help with scar camouflage) is made, and the flap is “turned down” over the lower face (Richards 1994). The surgery is done as a “team,” by a pediatric neurosurgeon and a craniofacial surgeon. The neurosurgeon performs the frontal craniotomy. The frontal bone is removed and placed in sterile, saline-soaked gauze. The craniofacial surgeon creates a fronto-orbital bony segment (the “bandeau” or supraorbital bar). The brain is retracted, and the bandeau and cranial bone plates (which are often split in two) are reshaped and advanced into an overcorrected position to allow for increased cranial vault growth (Bartlett and Mackay 1997). The segments are then secured with sutures, wires, and/or absorbable miniplates/screws (Fig. 3.21). The child with a significant turricephaly will require a

**Fig. 3.21** Drawing of intracranial fronto-orbital advancement/calvarial vault remodeling surgery





circumferential reshaping, involving advancement/remodeling of the frontal bone and supraorbital rim, as well as reduction of the vertical height of the skull. In the more mildly affected patient, only the frontal bone and supraorbital bar are remodeled and advanced into an overcorrected position.

### 3.17 Techniques for Sagittal Synostosis

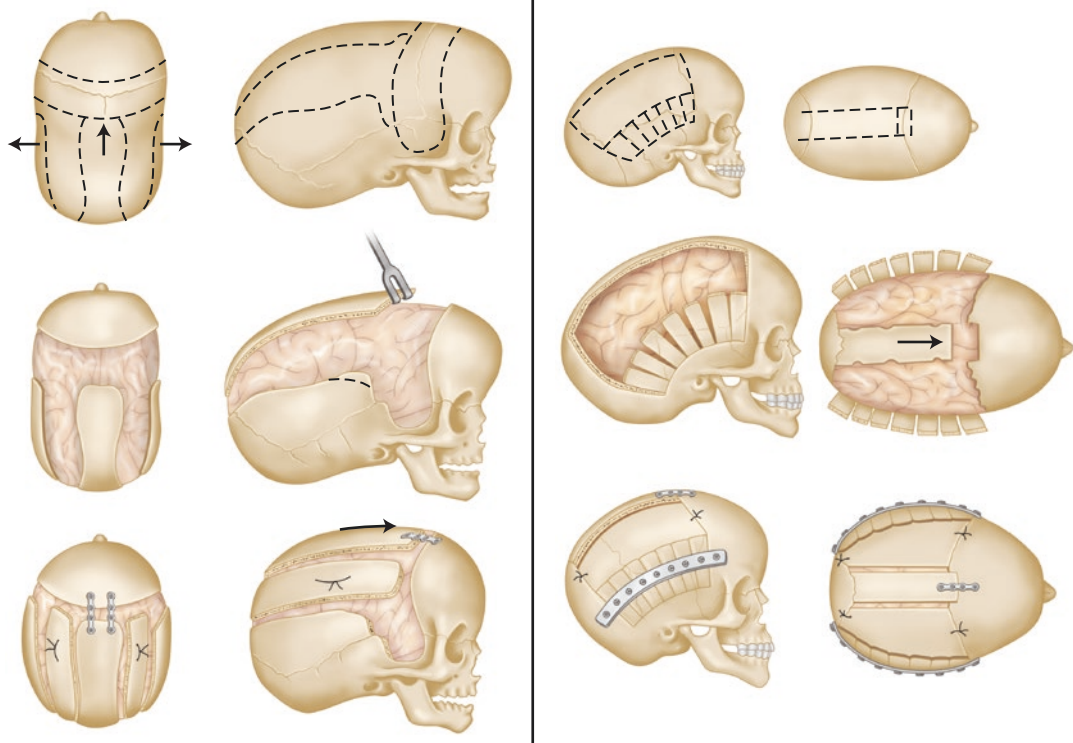
The hung span procedure is frequently performed on children who require a secondary surgery for sagittal synostosis due to increased intracranial pressure. In some centers, it is the primary surgical intervention in very severely affected infants (McCarthy et al. 2002). The extent of the cranial remodeling depends on the severity of the deformity.

The pi procedure is another type of cranial vault reconstruction to correct sagittal synostosis. It is so named because the craniectomy is made in the shape of the Greek letter  $\pi$ . Barrel-stave osteotomies are made across the parietal bones,

and the skull is foreshortened to correct the scaphocephalic shape (Figs. 3.22 and 3.23).

#### 3.17.1 Postoperative Nursing Management

Following an intracranial procedure, initial nursing care should focus on assessment of neurologic status, postoperative hemostasis, fluid and electrolyte balance, pain management, and presence of infection. Frequent neurologic checks are needed to monitor the child's level of consciousness and to observe for any signs of seizure activity and for a possible CSF leak (keeping in mind that the craniotomy performed carries the potential risk of a dural tear). The drains and suture line need very close monitoring as well as assessment of anemia (frequent hematocrit checks, evidence of hematuria, tachycardia, arrhythmia, pale skin color). An additional blood transfusion may be needed on the operative day or on the first postoperative day. Intravenous antibiotics may



**Fig. 3.22** Pi (*left*) and hung span (*right*) procedures for correction of sagittal craniosynostosis



**Fig. 3.23** Custom molding helmet is worn after endoscopic strip craniectomy for approximately 6 months to 1 year to overcome dural forces and reshape the skull

continue until discharge; the child may remain on oral antibiotics for approximately 1 week.

The child is usually transferred to the general pediatric unit on the first or second postoperative day. In almost all children, severe swelling of the forehead and eyelids will occur (the eyes will swell shut). Elevating the head of the bed may help make the child feel more comfortable; they often reject iced compresses and should not be forced to use them, as they will not prevent the edema. Parents are prepared for this preoperatively but are often very anxious about it and need reassurance that the swelling will peak on the second postoperative day and will then resolve over a period of 1–2 weeks. The goal is to remove the Foley and most of the intravenous lines on post-op day one and all remaining IVs and the drains/head dressing by the second postoperative day, with hospital discharge by day three or four, depending on the child's ability to tolerate oral fluids (Chibbaro 1994, 1996). Throughout the hospitalization, the APRN is in contact with the family and serves as a resource to the nursing staff.

### 3.17.2 Postdischarge Management

Prior to discharge, the APRN will meet with the family and review with them the signs and symptoms of postoperative infection and dehydration.

Suture line care is reviewed (this is also center dependent, although most centers advocate showering upon discharge, with gentle shampooing to avoid formation of a hematoma). It is advised that the child should avoid contact with playmates or family members who may be ill for the first 2 weeks after surgery. They are reminded that the forehead and eye swelling will resolve and that elevation of the head is helpful. Reassurance is given to parents that injury to the operative site is very unlikely (the bones are very well secured!) and that the child should be allowed to resume ambulation with their supervision. Parents are often very anxious about returning to work and bringing the child back to a caregiver or to a day care setting, and this will often require additional support and counseling. Postoperative visits are scheduled at 1–2 weeks and then as per the protocol of the craniofacial team.

## 3.18 Spring-Mediated Cranioplasty

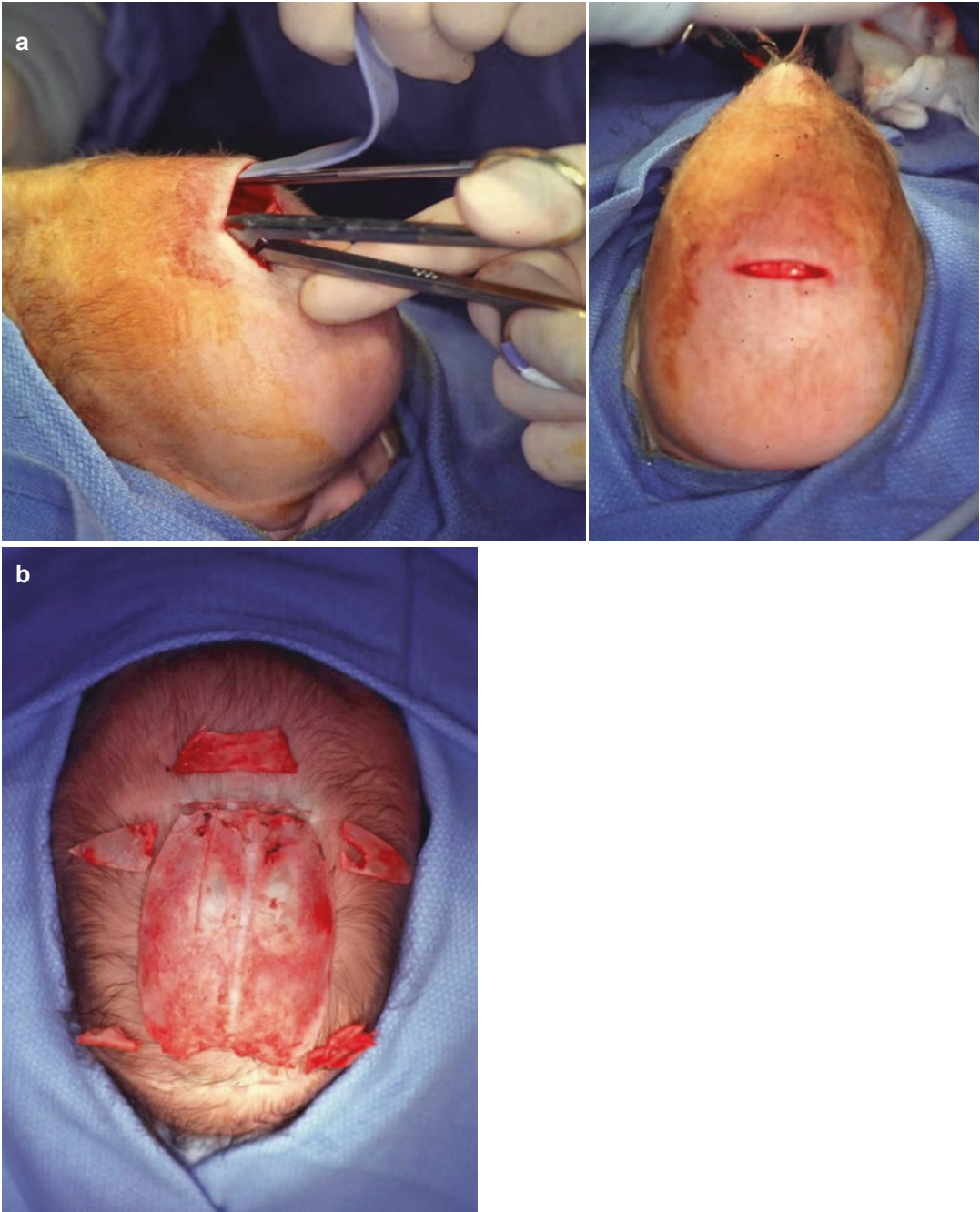
Some craniofacial centers have adopted the spring-assisted correction of sagittal synostosis. This is usually done before the infant is 6 months of age and involves removing the fused sagittal suture and placing springs on the opposing parietal bones as a means of distraction (Simpson et al. 2015). Although this can offer minimal blood loss, shorter operative time and hospital stay, a second surgery is required to remove the springs in approximately 5 months (Simpson et al. 2015).

## 3.19 Strip Craniectomy

Although the extensive cranial vault remodeling for correction of craniosynostosis has shown good results, the lengthy operating times and blood transfusions to correct estimated blood loss from 25 % to 500 % have led surgeons to use less invasive techniques (Jimenez et al. 2004). The strip craniectomy, traditionally only done for sagittal synostosis, involves removing the stenosed sagittal suture. Blood loss is minimal and the hospital stay is 2–3 days. This is done in the young infant, preferably before 4 months of age,

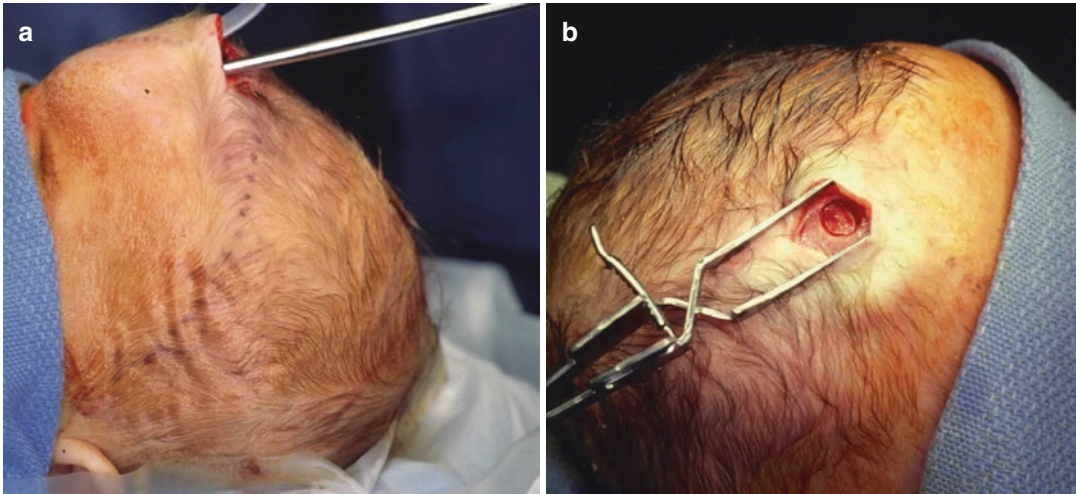
to take advantage of the rapid brain growth during that time as well as the dura's ability to regrow the bone. A custom-made molding helmet, worn postoperatively, helps to reshape the head during this time (Fig. 3.23).

The endoscopic strip craniectomy (endoscopy-assisted wide-vertex craniectomy) is a minimally invasive technique that uses endoscopes to visualize the intracranial area, while a strip of the bone containing the stenosed suture is removed



**Fig. 3.24.** (a) Sagittal – intraoperative approach with baby in sphinx position. (b) Wide-vertex craniectomy with barrel stave osteotomies





**Fig. 3.25.** Intraoperative approach. (a) Metopic and (b) coronal

(Jimenez and Barone 1998; Ridgeway et al. 2011; Shah et al. 2011; Proctor 2014; Erb and Meier 2016). This has been done successfully on the sagittal, coronal, metopic, and lambdoid sutures (and combinations thereof) with blood losses averaging less than 43 cc and usually just an overnight stay in the hospital (Cartwright et al. 2003; Jimenez et al. 2002, 2004; Jimenez and Barone 2010; Rivero-Garvia et al. 2011; Proctor 2014). These strip craniectomies should be performed as early as reasonably possible, but at least before the baby is 4 months of age for best results. A custom-made molding helmet is worn for approximately 6 months to 1 year postoperatively. The surgery for endoscopic removal of the sagittal suture involves making two incisions approximately 2 cm in length, one on the vertex of the skull just behind the coronal sutures and the other just above the lambdoid sutures. Surgeons remove the sagittal suture and 1–6 cm of the surrounding bone (Fig. 3.24a, b). For metopic and coronal synostosis, a 2 cm incision is made behind the hairline and only a 1 cm strip of the bone is removed. (Fig. 3.25a, b). The surgery time is less for the endoscopic strip craniectomy as compared to the more extensive calvarial vault remodeling. Shorter surgeries can mean less blood loss and less need for transfusion. Additionally, there have been concerns about the use of anesthesia in infants due to the

potential for neurotoxicity, so the shorter surgery results in less time under anesthesia (Proctor 2014).

The cost of this procedure is substantially less than that of the traditional calvarial vault remodeling (Cartwright et al. 2003; Abbott et al. 2012; Vogel et al. 2014). With cosmetic results at least equal to those of the open calvarial vault remodeling coupled with the minimal blood loss, decrease in anesthesia and operative times, and decreased hospital stay, the choice of endoscopic strip craniectomy should be discussed with parents whose children are young enough to be candidates.

As previously discussed, strip craniectomies were first performed over 100 years ago. These earlier surgeons obviously did not have the benefits of today's imaging and less invasive surgical techniques. Moreover, they did not utilize the other key component of a successful procedure – the cranial molding helmet. Strip procedures take advantage of the rapid brain growth in infants. Once the stenosed suture is removed, brain growth forces the head to conform to the shape of the helmet. Since the most rapid brain growth occurs before the age 6 months, strip craniectomies are performed prior to that age. But the helmet must be worn by the infant and replaced at appropriate times. When the helmet has been used properly, the technique has demonstrated

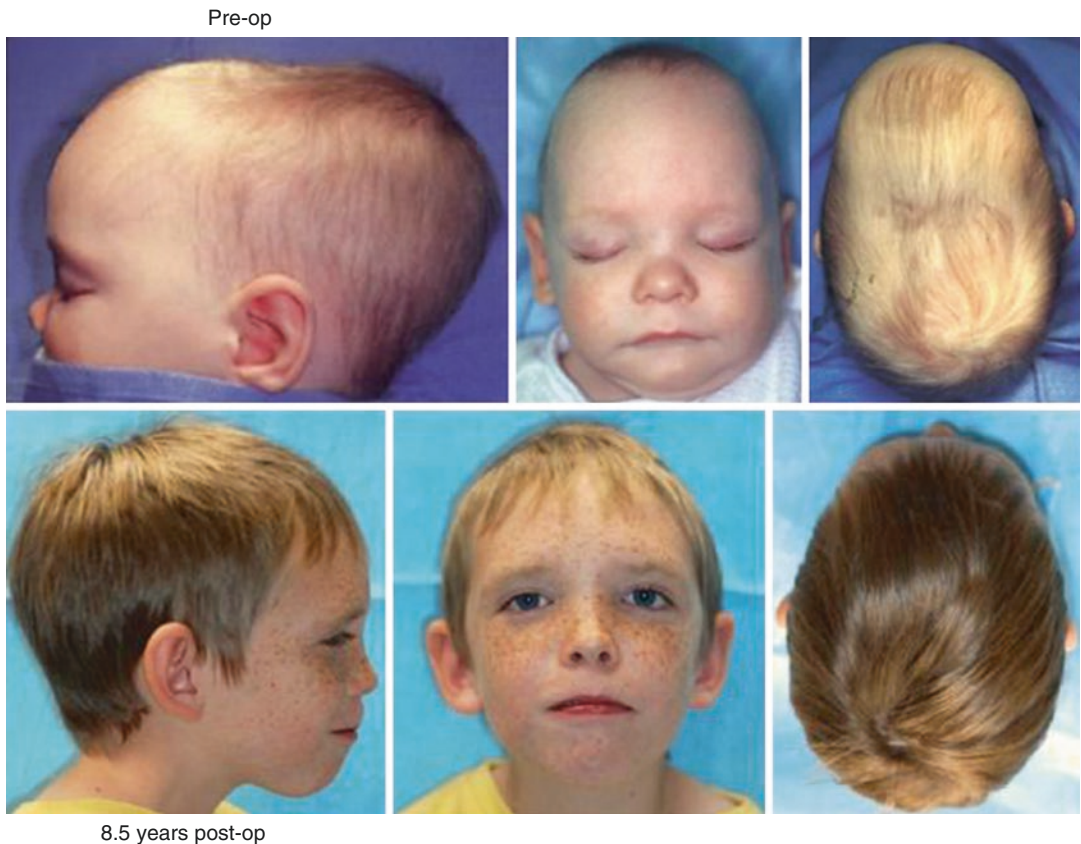excellent results, both short and long term (Figs. 3.26, 3.27, 3.28, 3.29, 3.30, 3.31, and 3.32) (Boxes 3.2 and 3.3). Many centers proficient in both open and endoscopic techniques consider this minimally invasive surgery the standard of care for young infants with craniosynostosis (Proctor 2014).

### 3.20 Nursing Care

Although strip craniectomies are generally less of a surgical risk than cranial vault remodeling, they are not without risk. Preoperative preparation is similar to what is described for cranial

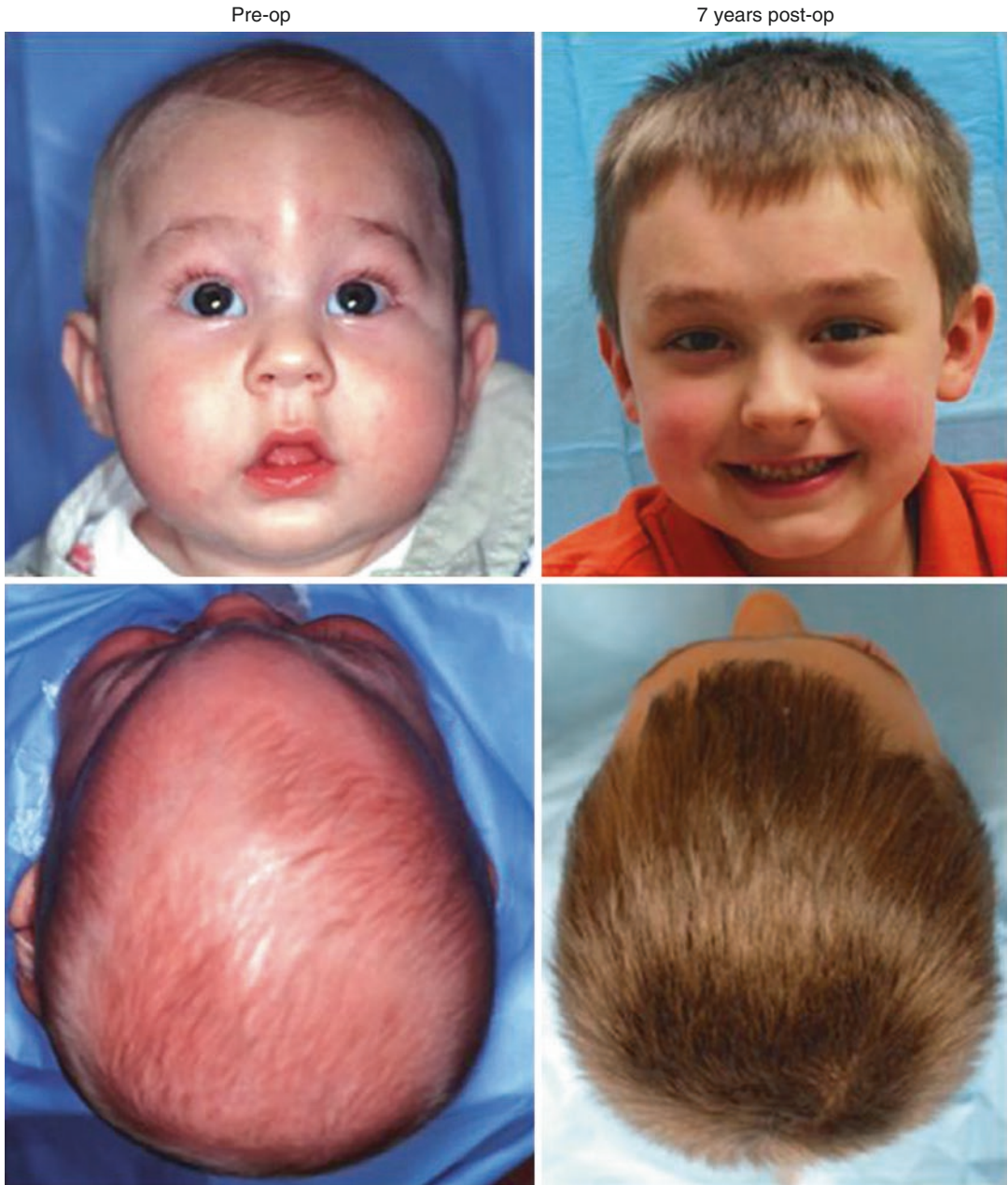vault remodeling, as these patients are also evaluated by members of the craniofacial team. Parents that prefer their infant not receive a blood transfusion for personal or religious reasons may choose the endoscopic strip craniectomy because of the minimal blood loss. Preoperative administration of erythropoietin may be considered to increase the baby's hematocrit. Preoperative photos and anthropometric measurements are taken.

Postoperatively, these infants also need frequent vital signs with neurological assessment to detect any early signs of blood loss, electrolyte imbalance, or neurologic deterioration. Any bleeding from the incision site should be immediately reported to the neurosurgeon. Although

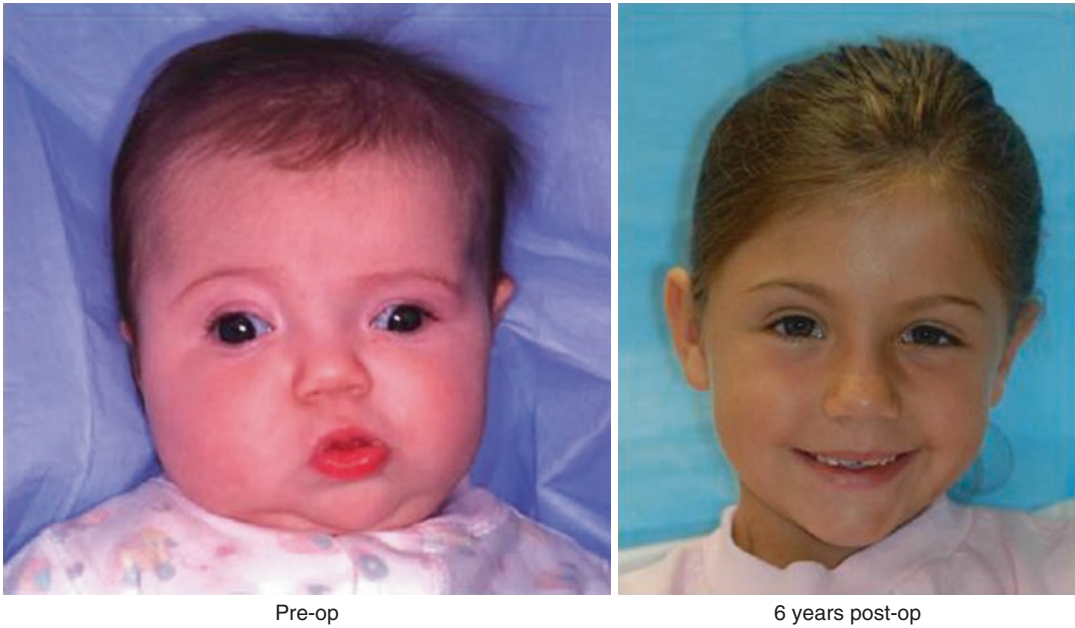


**Fig. 3.26** Boy with sagittal synostosis preoperatively and 8.5 years after endoscopy-assisted wide-vertex craniectomy and postoperative helmet therapy

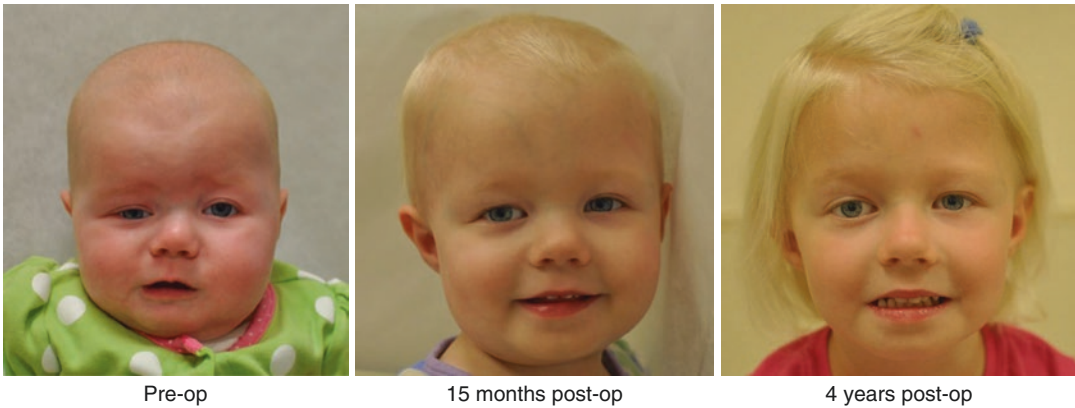



**Fig. 3.27** Boy with metopic synostosis preoperatively and 7 years after endoscopic strip craniectomy and postoperative helmet therapy



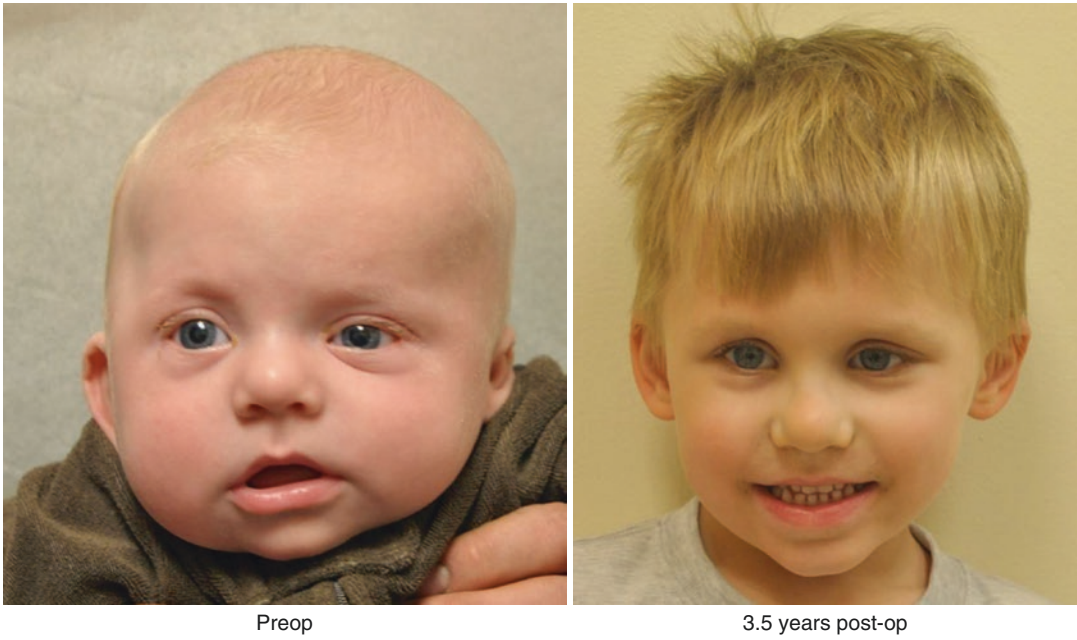**Fig. 3.28** Girl with *right* coronal synostosis preoperatively and 6 years after endoscopic strip craniectomy with postoperative helmet therapy



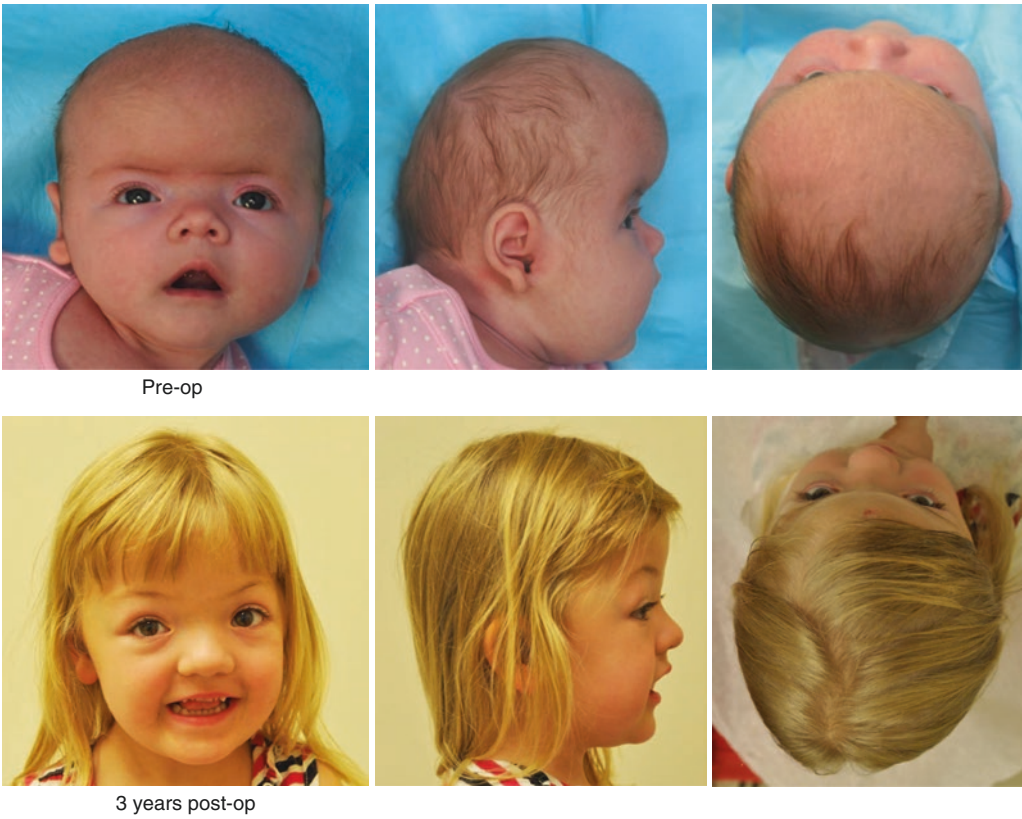**Fig. 3.29** Progression of correction of left coronal synostosis in girl who underwent endoscopic strip craniectomy with postoperative helmet therapy at 5 months of age

some swelling of the head is expected, it usually peaks on postoperative day 2 or 3 and has subsided by 1 week. Rarely do the eyes swell shut. A subgaleal drain may be placed intraoperatively to decrease postoperative swelling and removed the next day. Babies with sagittal synostosis should lie with the back of the head on the mattress to decrease the anterior-posterior (AP) diameter. Preoperative diet and activity are usu-

ally resumed on the same day as surgery and no later than the first postoperative day. Pain can be controlled with acetaminophen and oxycodone, with fentanyl for breakthrough pain. Care should be taken to prevent oversedation, whereby the baby is too sleepy to eat. Frequently, these babies are hungry and want to be held and fed, so comfort measures should be used before narcotics. Discharge criteria include a stable hematocrit and

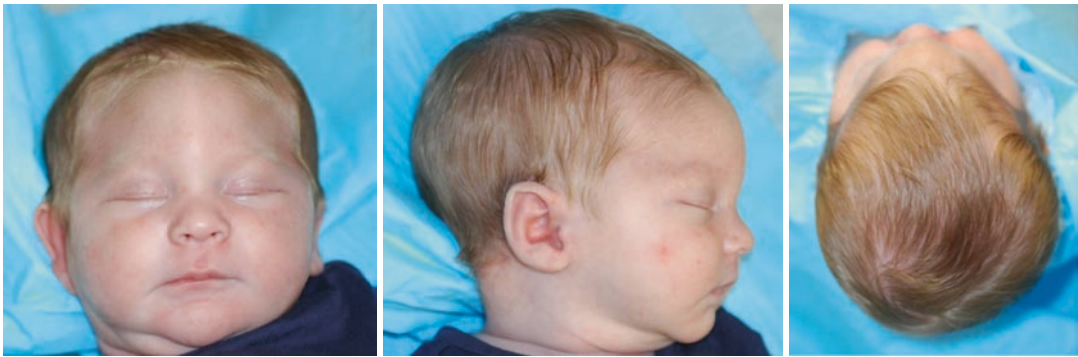

**Fig. 3.30** Baby with right coronal synostosis shown preoperatively and at 3.5 years post-op endoscopic strip craniectomy and helmet therapy

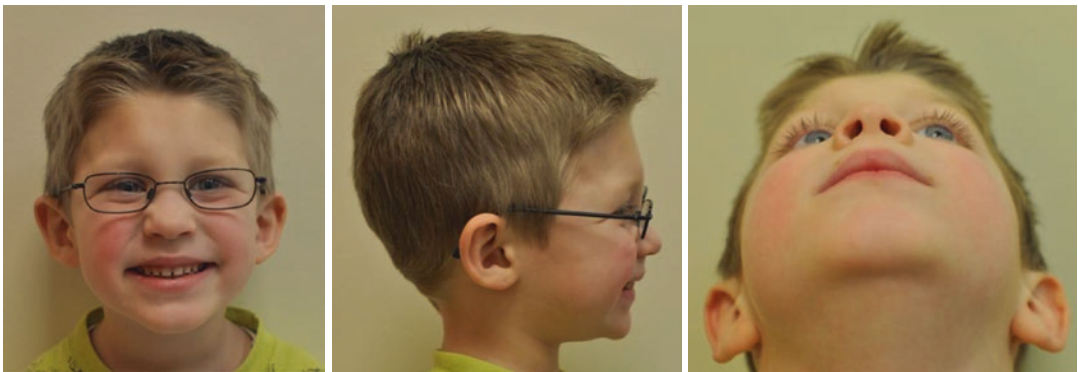

**Fig. 3.31** Top row: baby with bicoronal synostosis. Bottom row: same child 3 years post-op endoscopic strip craniectomy with helmet therapy





Preoperative



5 years post-op

**Fig. 3.32** *Top row:* baby with metopic synostosis. *Bottom row:* Same child 5 years post-op endoscopic strip craniectomy with helmet therapy

### Box 3.2. A Mother's Story: Endoscopic Strip Craniectomy

My husband and I knew exactly what sagittal craniosynostosis was because he had surgery for it when he was only 6 weeks old. So, when our son Dexter was diagnosed with it at 3 weeks, we had an idea of what we were in for.

We set his surgery for the 6-week mark, and my mother-in-law tried to prepare us on what to expect after his surgery. From her description of how my husband looked afterward, we were expecting a swollen gray-colored head and face that would be unrecognizable to us. Well, all I can say is

that we were pleasantly surprised to see how far this surgery has come over the last 30 years! Dexter looked amazing! We immediately saw a dramatic improvement in the shape of his head, and with very minimal swelling. His skin color was beautiful, and his temperament changed from fussy to easy going. We are so thankful for this new procedure and would gladly have him wear a helmet for a year, as opposed to the more invasive option from 30 years ago! The doctors and nurses were wonderful. We are so blessed to have had such skilled and caring professionals taking care of our precious baby boy!

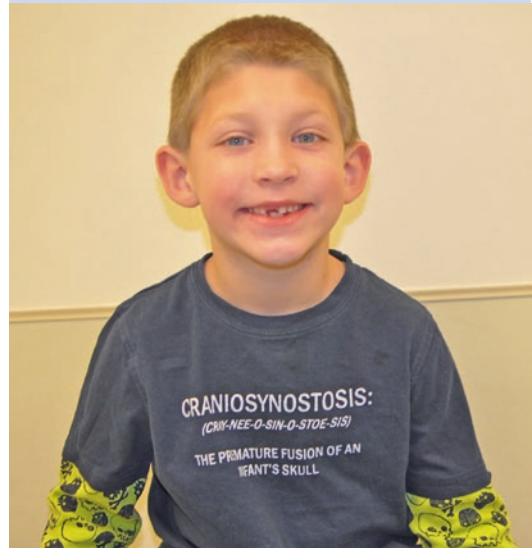**Box 3.3. A Mother's Story: Endoscopic Strip Craniectomy for Metopic Synostosis**

When Cameron was born, we could tell immediately that something was wrong with his skull. As a parent, it was one of the hardest things I have ever been faced with. There is always a fear for the unknown, and I was definitely afraid. I was blessed to have my options placed before me when he was just days old. When we went for his first checkup a few days after being born, I discussed with his pediatrician my fears and she agreed things did not look right. Immediately, we scheduled an appointment with the pediatric neurosurgeon and his pediatric clinical nurse specialist. As soon as I walked through the door of their office, I was told Cameron had metopic synostosis.

Not quite sure what to do, they explained everything so I could understand it and gave me my options. I had the option of having a more invasive surgery to reconstruct his skull, which would involve more blood transfusions and scarring than I was prepared for. The second option I had was an endoscopic strip craniectomy. This involved making a very small incision with very little blood loss and very little scarring. With the second option, he would have to wear a helmet for about a year if all went well. The helmet would put the necessary pressure where it was needed in order to protect his skull and help it grow and form properly. I chose the second option, believing it would be in Cameron's best interest in the years to come. He went in for surgery, when he was just 21 days old, and did amazing. I was so scared when I first saw him after his surgery but knew that I had made the right choice. Cameron only had to spend about 24 h in the hospital to be sure there were no complications, and a

week later, he had his first helmet. He handled everything so well, probably even better than I did. I was very lucky to have an amazing doctor and nurse that were willing to answer all of my questions, day or night, and help me make what I now know was the right decision for my son.

Cameron is now 4 years old and will be starting prekindergarten in the fall. He's very smart and is doing everything his older brother and sister did when they were his age if not more since he is always there doing everything they do. He catches on quickly and is very active; he loves to play outside and get dirty like most kids do. The only time you see his scar is when you are looking for it. I am very happy with the decision I made, and I would do it again if I had to. By looking at him now, you would never know that there was ever anything wrong with him when he was born. Figure 3.33 is a photo of Cameron at 7.5 years (Fig. 3.33).



**Fig. 3.33** Cameron at 7.5 years after endoscopic strip craniectomy for metopic synostosis



vital signs, adequate oral intake, and pain controlled by oral medication. Parents should be instructed to call for increased fussiness not relieved by oral pain medication, decreased level of consciousness or lethargy, vomiting, or drainage from the incision site.

The infants are measured for and receive a custom-made molding helmet within 1 week after surgery. Because a strip of the bone is missing, many parents become alarmed that their baby's brain may become injured during the time before they receive the helmet. Assure them that no extra precautions need to be taken, other than what they would usually do to protect a baby's head, as the dura, or covering to the brain, is very tough (dura mater means "tough mother").

The molding helmet is worn 23 h a day for 6 months to 1 year, with new helmets made as the head grows and changes shape. Usually, two to three helmets are required over that year, if the baby wears the helmet that long. Visits to craniofacial clinic and the orthotist will be scheduled to check the head shape and fit of the helmet over the course of the year. Anthropometric measurements and pictures will be taken at each visit and compared to those preoperatively. Patients whose parents are not compliant with helmet use, or discontinue it too soon, will have less than optimum results. Parents should be reminded of the importance that the helmet be worn as directed to overcome the dural forces that continue to dictate skull growth and could recreate the deformity.

### 3.21 Conclusion

The diagnosis of craniosynostosis can be a frightening one for the parents of a child with a skull deformity. It is essential that craniosynostosis is differentiated from positional plagiocephaly early on, so the appropriate treatment can be instituted.

The patient with craniosynostosis requires comprehensive management by an experienced craniofacial team, with surgical intervention being the core component of their treatment. The nursing roles of provider of

direct care, patient/family educator, and liaison between the patient, their family, and the rest of the team are key to a successful outcome.

#### Pediatric Practice Pearls

- Positional plagiocephaly can be prevented or minimized by following the back to sleep and tummy time strategies recommended by the AAP.
- Early recognition and treatment of craniosynostosis vs. positional plagiocephaly lead to improved outcomes.
- Children with craniosynostosis should receive comprehensive care provided by a craniofacial team.

### References

- Abbott MM, Rogers GF, Proctor MR, Busa K, Meara JG (2012) Cost of treating sagittal synostosis in the first year of life. *J Craniofac Surg* 23:88–93
- American Medical Association Policy of House Delegates (2013) Definitions of "cosmetic" and "reconstructive" surgery, H-475.992.
- American Medical Association Policy of House of Delegates (1989) Definitions of "cosmetic" and "reconstructive" surgery, H-435.992. Council of medical services annual meeting, Chicago, p A-89.
- Bartlett SP, Mackay GJ (1997) Craniosynostosis syndromes. In: Aston SJ, Beasley RW, Thorne CH (eds) *Grabb and Smith's plastic surgery*, 5th edn. Lippincott-Raven, Philadelphia, pp 295–304
- Carson BS, James CS, VanderKolk CA, Guarnieri M (1997) Lambdoid synostosis and occipital plagiocephaly: clinical decision rules for surgical intervention. *Neurosurg Focus* 2:e10
- Cartwright CC, Jimenez, DF (2002) Fussiness and irritability in patients with craniosynostosis. Paper presented at the AANS/CNS section on pediatric neurological surgery annual meeting, Phoenix, Dec 2002
- Cartwright CC, Jimenez DF, Barone CM, Baker L (2003) Endoscopic strip craniectomy: a minimally invasive treatment for early correction of craniosynostosis. *J Neurosci Nurs* 35(3):130–138
- Chibbaro P (1994) Understanding and managing stressors facing the pediatric craniofacial patient and family. *Plast Surg Nurs* 14(2):86–91
- Chibbaro P (1996) Nursing care of patients with craniofacial anomalies. In: Goodman T (ed) *Core curriculum*

- for plastic and reconstructive surgical nursing. Anthony J. Jannetti, Pitman
- Chumas PD, Cinalli G, Arnaud E (1997) Classification of previously unclassified cases of craniosynostosis. *J Neurosurg* 86:177–181
- Cohen MM (1986) Craniosynostosis. Diagnosis, evaluation and management. In: Cohen MM (ed) *Perspectives on craniosynostosis*. Raven, New York, pp 21–56
- Cohen MM Jr (1993) Sutural biology and the correlates of craniosynostosis. *Am J Med Genet* 47(5):581–616
- Cohen SR, Holmes RE (2001) Internal Lefort III distraction with biodegradable devices. *J Craniofac Surg* 12(3):264–272
- Cohen MM, MacLean RE (2000) *Craniosynostosis: diagnosis, evaluation and management*, 2nd edn. Oxford University Press, New York
- Collett B, Breiger D, King D, Cunningham M, Speltz M (2005) Neurodevelopmental implications of “deformational” plagiocephaly. *J Dev Behav Pediatr* 26:379–389
- Dec W, Warren S (2011) Current concepts in deformational plagiocephaly. *J Craniofac Surg* 22(1):6–8
- Decker JD, Hall SH (1985) Light and electron microscopy of the new born sagittal suture. *Anat Rec* 212:81–89
- Di Rocco F, Arnaud E, Renier D (2009) Evolution in the frequency of nonsyndromic craniosynostosis. *J Neurosurg Pediatr* 4:21–25
- Didier RA, Kuang AA, Schwartz DL, Selden NR, Stevens DM, Bardo DME (2010) Decreasing the effective radiation dose in pediatric craniofacial CT by changing head position. *Pediatr Radiol* 40(12):1910–1917
- Drake DB, Pershing JA, Berman DE, Ogle RC (1993) Calvarial deformity regeneration following subtotal calvariectomy for craniosynostosis: a case report and theoretical implications. *J Craniofac Surg* 4:85–89
- Erb TO, Meier PM (2016) Surgical treatment of craniosynostosis in infants: open vs closed repair. *Pediatr Anesth* 29(3):345–351
- Faber HK, Town EB (1943) Early operation in premature cranial synostosis for the prevention of blindness and other sequelae. Five case reports with follow up. *J Pediatr* 22:286
- Faber HK, Towne EB (1927) Early craniectomy as a preventive measure in oxycephaly and allied conditions. With special reference to the prevention of blindness. *Am J Med Sci* 173:701
- Farkas LG (1996) Accuracy of anthropometric measurements: past, present and future. *Cleft Palate Craniofac J* 33:10–18; discussion 19–22
- Frush DP, Donnelly LF, Rosen NS (2003) Computed tomography and radiation risks: what pediatric health care providers should know. *Pediatrics* 112(4):951–957
- Gosain AK, Steele MA, McCarthy JF, Thorne CH (1996) A prospective study of the relationship between strabismus and head posture in patients with frontal plagiocephaly. *Plast Reconstr Surg* 97:881–891
- Graham JM, deSaxe M, Smith DW (1979) Sagittal synostosis: fetal head restraint as one possible cause. *J Pediatr* 95:747–750
- Graham JM, Bardura RJ, Smith DW (1980) Coronal synostosis: fetal head restraint as one possible cause. *Pediatrics* 65:995–999
- Higgenbottom MC, Jones KL, James HE (1980) Intrauterine constraint and craniosynostosis. *Neurosurgery* 6:39–49
- Hing A, Click E, Holder U, Seto ML, Vessey K, Gruss J, Hopper R, Cunningham ML (2009) Bilateral lambdoid and sagittal synostosis (BLSS): a unique craniosynostosis syndrome or predictable craniofacial phenotype? *Am J Med Genet Part A* 149A:1024–1032
- Hoffman H, Raffel C (1989) Craniofacial surgery. In: McLaurin R, Venes JL, Schut L et al (eds) *Pediatric neurosurgery: surgery of the developing nervous system*. WB Saunders, Philadelphia
- Huang MH, Gruss JS, Clarren SK, Mouradian WE, Cunningham ML, Roberts TS, Loeser JD, Cornell CJ (1996) The differential diagnosis of posterior plagiocephaly: true lambdoid synostosis versus positional molding. *Plast Reconstr Surg* 98(5):765–774 discussion 775–776
- Hunter AG, Rudd NL (1984) Craniosynostosis I. Sagittal synostosis: its genetics and associated clinical findings in 214 patients who lacked involvement of the coronal suture. *Teratology* 14:185–194
- Hutchinson BL, Hutchinson LA, Thompson JM, Mitchell EA (2004) Plagiocephaly and brachycephaly in the first two years of life: a prospective cohort study. *Pediatrics* 114:970–980
- Jacobi A (1894) Non nocere. *Med Rec* 45:609
- Jimenez DF, Barone CM (1998) Endoscopic craniectomy for early surgical correction of sagittal craniosynostosis. *J Neurosurg* 88:77–81
- Jimenez DF, Barone CM (2010) Multiple-suture nonsyndromic craniosynostosis: early and effective management using endoscopic techniques. *J Neurosurg Pediatr* 5:223–231
- Jimenez DF, Barone DM, Cartwright CC, Baker L (2002) Early management of craniosynostosis using endoscopic assisted strip craniectomies and cranial orthotic molding therapy. *Pediatrics* 110:97–104
- Jimenez DF, Barone CM, McGee ME, Cartwright CC, Baker L (2004) Endoscopic-assisted wide-vertex craniectomy, barrel stave osteotomies, and postoperative helmet molding therapy in management of sagittal suture craniosynostosis. *J Neurosurg* 100:407–417
- Kabbani MD, Raghuvver TS (2004) Craniosynostosis. *Am Fam Physician* 69(12):2863–2870
- Kane AA, Mitchell LE, Craven KP, Marsh JL (1996) Observations on a recent increase in plagiocephaly without synostosis. *Pediatrics* 97:877–885
- Kluba S, Wiebke K, Calgeer B, Reinert S, Krimmel M (2014) Treatment of positional plagiocephaly – helmet or no helmet? *J Cranio-Maxillofac Surg* 42(5):683–688
- Komotar RJ, Zacharia BE, Ellis JA, Feldstein NA, Anderson RC (2006) Pitfalls for the pediatrician: positional molding or craniosynostosis? *Pediatr Ann* 35(5):365–375

- Koren A, Reece SM, Kahn-D'angelo L, Medeiros D (2010) Parental information and behaviors and provider practices related to tummy time and back to sleep. *J Pediatr Health Care* 24:222–230
- Lajeunie E, Le Merrer M, Bonaiti-Pellie C, Marchac D, Renier D (1995) Genetic study of nonsyndromic coronal craniosynostosis. *Am J Med Genet* 55:500–504
- Lajeunie E, Le Merrer M, Bonaiti-Pellie C, Marchac D, Renier D (1996) Genetic study of scaphocephaly. *Am J Med Genet* 62:282–285
- Lane LC (1892) Pioneer craniectomy for relief of mental imbecility due to premature sutural closure and microcephalus. *J Am Med Assoc* 18:49–50
- Lannelongue M (1890) De la craniectomie dans la microcephalie. *C R Acad Sci* 110:1382–1385
- Lee H, Hutson J, Wray A, Lo P, Chong D, Holmes A, Greensmith A (2012) Changing epidemiology of nonsyndromic craniosynostosis and revisiting the risk factors. *J Craniofac Surg* 23(5):1245–1251
- Lemire LJ (1986) Craniosynostosis. Diagnosis, evaluation and management. In: Cohen MM (ed) *Embryology of the skull*. Raven, New York, pp 105–130
- Littlefield TR, Reiff JL, Rekate HL (2001) Diagnosis and management of deformational plagiocephaly. *BNI Q* 17(4):18–25
- Mabutt LW, Kokick VG (1979) Calvarial and suture development following craniectomy in neonatal rabbit. *Anatomy* 129:413–422
- MacKinnon S, Proctor MR, Rogers GF, Meara JG, Whitecross S, Daqi LR (2013) Improving ophthalmic outcomes in children with unilateral coronal synostosis by treatment with endoscopic strip craniectomy and helmet therapy rather than fronto-orbital advancement. *J AAPOS* 17:259–265
- MacKinnon S, Rogers GF, Gregas M, Proctor MR, Mulliken JB Daqu LR (2009) Treatment of unilateral coronal synostosis by endoscopic strip craniectomy or fronto-orbital advancement: Ophthalmologic findings. *J AAPOS* 13:155–160.
- Majnemer A, Barr RG (2006) Association between sleep position and early motor development. *J Pediatr* 149:623–629
- McCarthy JG, Epstein FJ, Woodsmith D (1990a) Craniosynostosis. In: McCarthy JG (ed) *Plastic surgery*. Saunders, Philadelphia, pp 3013–3053
- McCarthy JG, LaTrenta GS, Breitbart AS (1990b) The le fort III advancement osteotomy in the child under 7 years of age. *Plast Reconstr Surg* 86:633
- McCarthy JG, Glasberg SB, Cutting CB, Epstein FJ, Grayson BH, Ruff G, Thorne CH, Wisoff Z, Zide BM (1995) Twenty year experience with early surgery for craniosynostosis. I. Isolated craniofacial synostosis – results and unsolved problems. *Plast Reconstr Surg* 96:272–284
- McCarthy JG, Bradley JP, Stelnicki EJ, Stokes T, Weiner HL (2002) Hung span method of scaphocephaly reconstruction in patients with elevated intracranial pressure. *Plast Reconstr Surg* 109(6):2009–2018
- McCarthy JG, Warren SM, Bernstein J, Burnett W, Cunningham ML, Edmond JC, Figueroa AA, Kapp-Simon KA, Labow BI, Peterson-Falzone SJ, Proctor MR, Rubin MS, Sze RW, Yemen TA (2012) Parameters of care for craniosynostosis. *Cleft Palate Craniofac J* 49(1 Supplement):1S–24S
- Moon RY, Darnall RA, Goodstein MH, Hauck FR, American Academy of Pediatrics, Task Force on Sudden Infant Death Syndrome (2011) Technical report – SIDS and other sleep-related infant deaths: expansion of recommendations for a safe infant sleeping environment. *Pediatrics* 128(5):1030–1039. doi:10.1542/peds.2011-2284
- Mooney MP, Siegel MI (2002) *Understanding craniofacial anomalies*. Wiley-Liss, New York
- Mulliken JB, Vanderwoude SL, Hanson M (1999) Analysis of posterior deformational plagiocephaly: deformational vs. synostotic. *Plast Reconstr Surg* 103:371–380
- O'Daniel TC, Milder BO, Marsh JL (1993) Ophthalmologic screening of infants with craniosynostosis. Scientific program of the American Cleft Palate-Craniofacial Association, 50th anniversary meeting, Pittsburgh, 1993.
- Ohman JC, Richtsmeier JT (1994) Perspectives on craniosynostosis facial growth. *Clin Plast Surg* 21:489–499
- Opperman LA, Chhabra A, Nolen AA, Bao Y, Ogle RC (1998) Dura mater maintains rat cranial sutures in vitro by regulating suture cell proliferation and collagen production. *J Craniofac Genet Dev Biol* 18(3):150–158
- Panchal J, Uttchin V (2004) Management of craniosynostosis. *Plast Reconstr Surg* 111:2032–2048
- Paterson A, Frush DP (2007) Dose reduction in paediatric MDCT: general principles. *Clin Radiol* 62(6):507–517. <https://pathways.org/growth-development/tummy-time/accesssd>. 26 June 2016.
- Pearce MS, Salotti JA, Little MP et al (2012) Radiation exposure from CT scans in childhood and subsequent risk of leukemia and brain tumours: a retrospective cohort study. *Lancet* 380:499–505
- Peitsch WK, Keefer CH, LaBrie RA, Mulliken JB (2002) Incidence of cranial asymmetry in healthy newborns. *Pediatrics* 110:e72
- Pritchard JJ, Scott JH, Girgis FG (1956) The structure and development of cranial and facial sutures. *J Anat* 90:73–86
- Proctor M (2014) Endoscopic craniosynostosis repair. *Transl Pediatr* 3(3):247–258
- Rekate H (1997) Occipital plagiocephaly: a critical review of the literature. *J Neurosurg* 2:1–14
- Renier D (1989) Intracranial pressure in craniosynostosis: pre- and postoperative recordings-correlation with functional results. In: Persing, JA, Edgerton, MT, Jane, JA (eds) *Scientific foundations and surgical treatment of craniosynostosis*. Williams and Wilkins, Baltimore, p 263. <http://pathways.org/awareness/parents/tummy-time/tummy-time-help/>. Accessed 20 Oct 2012.

- Renier D, Sainte-Rose C, Marchac D, Hirsch JF (1982) Intracranial pressure in craniostenosis. *J Neurosurg* 57:370
- Renier D, Brunet L, Marchac D (1987) IQ and craniostenosis: evolution in treated and untreated cases. In: Marchac D (ed) *Craniofacial surgery*. Springer, Berlin, p 114
- Richards M (1994) Common pediatric craniofacial reconstructions. In: McKenna CJ, Black JM (eds) *The nursing clinics of North America*. W.B. Saunders Co, Philadelphia, pp 791–799
- Ridgeway EB, Weiner HL (2004) Skull deformities. In: Piatt JH (ed) *Pediatric Clin North Am* 51(2): 359–387.
- Ridgeway EB, Berry-Candelario J, Grondin RT, Rogers GF, Proctor MR (2011) The management of sagittal synostosis using endoscopic suturectomy and postoperative helmet therapy. *J Neurosurg Pediatr* 7:620–626
- Rivero-Garvia M, Marquez-Rivas J, Rueda-Torres AB, Ollero-Ortiz A (2011) Early endoscopy-assisted treatment of multiple-suture craniosynostosis. *Childs Nerv Syst* 28(3):427–431
- Robinson S, Proctor M (2009) Diagnosis and management of deformational plagiocephaly. *J Neurosurg Pediatr* 3:284–295
- Rogers GF (2011) Deformational plagiocephaly, brachycephaly, and scaphocephaly. Part I: terminology, diagnosis, and etiopathogenesis. *J Craniofac Surg* 22:9–16
- Rossi M, Jones RL, Norbury G, Bloch-Zupan A, Winter RM (2003) The appearance of the feet in Pfeiffer syndrome caused by FGFR1 P252R mutation. *Clin Dysmorphol* 12(4):269–274
- Selber J, Reid RR, Chike-Obi CJ, Sutton LN, Zackai EH, McDonald-McGinn D, Sonnad SS, Whitaker LA, Bartlett SP (2008) The changing epidemiologic spectrum of single-suture synostoses. *Plast Reconstr Surg* 122:527–533
- Shah MN, Kane AA, Petersen JD, Woo AS, Nadoo SD, Smyth MD (2011) Endoscopically assisted versus open repair of sagittal craniosynostosis: the St. Louis Children's Hospital experience. *J Neurosurg Pediatr* 8:165–170
- Shillito J, Matson DD (1968) Craniosynostosis: a review of 519 surgical patients. *Pediatrics* 41:829
- Simpson A, Wong AL, Bezuhyl M (2015) Surgical correction of nonsyndromic sagittal craniosynostosis: Concepts and controversies. *Annals of Plastic Surgery*;1–8.
- Slater BJ, Lenton KA, Kwan MD, Gupta DM, Wan DC, Longaker MT (2008) Cranial sutures: a brief review. *Plast Reconstr Surg* 121:170e–178e. doi:10.1097/01.prs.0000304441.99483.97
- Sömmering ST (1800) *Vom Baue des Menschlichen Körpers*, 1st edn. Voss, Leipzig
- Sun PP, Persing JA (1999) Craniosynostosis. In: Albright L, Pollack I, Adelson D (eds) *Principles and practice of pediatric neurosurgery*. Thieme, New York, pp 219–242
- Task Force on Sudden Infant Death Syndrome (2011) SIDS and other sleep-related infant deaths: expansion of recommendations for a safe infant sleeping environment. *Pediatrics* 128(5):1030–1039. doi:10.1542/peds.2011-2284
- The Joint Commission (2011) Sentinel event alert: radiation risks of diagnostic imaging. [www.jointcommission.org/sea\\_issue\\_47/](http://www.jointcommission.org/sea_issue_47/). Accessed 20 Oct 2012, Accessed 4 Aug 2011.
- van der Meulen J, Hulst R, Adrichem L, Arnaud E, Chin-Shong D, Duncan C, Habets E et al (2009) The increase in metopic synostosis: a pan-European observation. *J Craniofac Surg* 20:283–286
- Vander Kolk C, Carson B (1994) Lambdoid synostosis. In: Vander Kolk C (ed) *Clinics in plastic surgery*, 21st edn. WB Saunders, Philadelphia, p 575
- Vermeij-Keers C (1990) Craniofacial embryology and morphogenesis: normal and abnormal. In: Strickler M, van der Meulen J, Rapheal B et al (eds) *Craniofacial malformations*. Churchill Livingstone, New York, pp 56–57
- Virchow R (1851) Über den cretinism, namentlich in franken und-ber pathologische schadelformen. *Verh Phys Med Ges Wurzburg* 2:230–244
- Vogel TW, As W, Kane AA, Patel KB, Naidoo SD, Smyth MD (2014) A comparison of costs associated with endoscope-assisted craniectomy versus open cranial vault repair for infants with sagittal synostosis. *J Neurosurg Pediatr* 3:324–331
- Warschausky S, Angobaldo J, Kewman D, Buchman S, Muraszko KM, Azengart A (2005) Early development of infants with untreated metopic craniosynostosis. *Plast Reconstr Surg* 115(6):1518–1523
- Zollikofer CPE, Ponce de Leon MS (2009) The evolution of hominin ontogenies. *Semin Cell Dev Biol* 21:441–452

Donna C. Wallace and Lindsey N. Weak

---

## 4.1 Introduction

Anomalies of the pediatric skull and scalp can be thought of as congenital or acquired. Though most lesions in the pediatric population are benign, there are a few malignant types as well.

Typically, an anomaly may be found upon palpation by a parent (Fig. 4.1) or the primary care provider. The child may then be referred to the pediatric neurosurgery practice for a more thorough evaluation. Identification and examination of a lesion would include the size and location, color, whether it is mobile or fixed, and whether it is pulsatile or painful to touch. A lesion with clear drainage may be leaking CSF.

---

## 4.2 Diagnostic Testing

Once the child is referred to pediatric neurosurgery, the provider may order a computed tomography (CT) scan or a magnetic resonance imaging (MRI). It is not uncommon for newborns to undergo ultrasonography (US); however, ultrasounds are usually considered preliminary tests, and more eloquent testing is usually needed. CT scans are ordered judiciously because of radiation exposure to the growing cranium. Most pediatric facilities limit the amount of radiation by using specific formatting. CT scans are ordered to assess bony lesions, whereas MRIs are ordered to assess soft tissue lesions, as well as possible intracranial involvement. Swift and Trumble (1999) note that up to one third of patients with solitary nontraumatic lumps on the head have some degree of intracranial extension.

Lesions that are noted to be in the midline or pedunculated (a stalk-like structure) should be evaluated with an MRI to assess the degree of probable intracranial extension. Midline structures that are pulsatile should be considered vascular and may be connected to a dural sinus (e.g., sinus pericranii). Further testing of possible vascular lesions may require specialized magnetic resonance imaging studies that include venous and arterial structures, known as MRI/MRVs. Arteriograms may also be performed (Table 4.1).

---

D.C. Wallace, MS, RN, CPNP (✉)  
L.N. Weak, DNP, RN, CPNP  
Division of Pediatric Neurosurgery,  
Banner Children Specialists at Cardon Children's  
Medical Center, 1432 S Dobson Road Suite 403,  
Mesa, AZ 85202, USA  
e-mail: [Dcwallace001@gmail.com](mailto:Dcwallace001@gmail.com);  
[Lindsey.weak@gmail.com](mailto:Lindsey.weak@gmail.com)





**Fig. 4.1** Finding a new bump while washing hair

### 4.3 Neoplastic

The term neoplasm refers to an abnormal growth of tissue caused by the rapid division of cells that have undergone some form of mutation. Benign neoplasms are usually localized and do not invade other tissues, while malignant neoplasms are usually invasive.

Benign skull lesions are typically seen as a single lesion on radiographs, and CT scans or skull X-rays are typically performed as the bone is more clearly identified in these studies. Malignant lesions tend to have ragged margins and usually occur in multiples.

#### Benign

Examples of benign tumors of the skull include epidermoid and dermoid cysts, fibrous dysplasia,

**Table 4.1** Lesions of the skull and scalp overview

Lesion	Histology	Imaging features	Signs/symptoms	Treatment
Cutis aplasia	Varies depending on depth of defect. Fibrovascular stomas and/or edematous stroma	N/A	Well-demarcated, noninflammatory ulceration	Smaller lesions will re-epithelialize without tx, larger lesions require surgical repair (skin grafting)
Cranial dermal sinus tract	Stratified squamous epithelium	Inferiorly directed tract, enlarged foramen cecum may be present with nasal cranial dermal sinuses	Dimple usually located along the middle, with/without clear or yellow drainage	Surgical resection if intracranial
Epidermoid/dermoid cyst	Squamous epithelium and keratin, dermoids also include hair and sebaceous/sweat glands	Lytic with sclerotic margins and bone erosion	Soft or hard, nonmobile nodule. Usually appears over suture lines	Surgical resection
Ewing's sarcoma	Compact and uniform cells with distinct nuclei. Sheets of round blue cells with increased nucleus-to-cytoplasm ratio	Bone destruction with irregular and poorly defined borders, "onion-peel" arrangement. Associated soft tissue mass	Intermittent at site, worse at night. Size of tissue mass can fluctuate. Leukocytosis, anemia, fevers	Local radiation with systemic chemotherapy. Surgical resection depending on the site of the disease
Fibrous dysplasia	Fibroblastic collagen mixed with immature woven bone	Sclerotic, cyst-like, or "ground glass" appearance	Painless, boney skull deformity	Conservatively followed or surgical excision if symptomatic
Neuroblastoma	Sheets of neuroblasts with small round blue cells, dark nuclei, and little cytoplasm	"Sunburst" appearance of bone spicules with elevation in periosteum seen on CT. Often present near cranial suture lines in children	Headache, pain, fever. "Raccoon eyes" with orbital bone involvement	Radiation and chemotherapy

**Table 4.1** (continued)

Lesion	Histology	Imaging features	Signs/symptoms	Treatment
Neurofibromas	Proliferation of all aspects of peripheral nerves. Wavy serpentine nuclei with pointed ends. Stromal mucin deposition and fibroplasia	Sphenoid wing dysplasia, pseudarthrosis	Axillary freckles, café au lait spots, dermal fibromas	Surgical excision
Langerhans cell histiocytosis	Large cells with eosinophilic cytoplasm and irregular nuclei	Lytic or “punched-out” appearance, with/without soft tissue mass	Asymptomatic or with localized pain over a raised, soft, and tender area	Low-dose radiation, surgical excision, or conservative tx with immobilization (lesions of the spine and long bones)
Osteoma	Similar to normal bone, decreased marrow	Hyperdense and expansile	Asymptomatic or with pain over lesion	Biopsy and/or surgical excision
Osteoblastoma	Large epithelioid osteoblasts	Well-demarcated, mixed lytic/sclerotic lesion with enlarged diploe	Asymptomatic or with pain over lesion	Biopsy and/or surgical excision
Sinus pericranii	Endothelial lining with congenital etiology. Connective tissue with traumatic etiology	Soft tissue mass with extracranial and intracranial venous communication seen with venogram. Associated skull defect	Compressible, painless mass. Enlarged in recumbent position and diminished in erect position	Surgical resection

histiocytosis (eosinophilic granuloma), osteomas and chondromas, as well as neurofibromas. Benign vascular lesions include hemangiomas, sinus pericranii, encephaloceles, and aneurysmal bone cyst.

Acute neoplasms of the scalp are unusual in children; congenital lesions of the scalp are more common. Lesions that are not attached to the cranium may be referred to a pediatric plastic surgeon for evaluation. An example of an interesting and rare benign lesion of the scalp is cranial fasciitis (Halder et al. 2012).

### Malignant

Malignant lesions of the skull include chordomas, sarcomas, neuroblastomas with inner osseous involvement, and some leukemias.

Malignant lesions of the scalp are rare, but there are a few examples of congenital lesions that could become malignant. These include nevus sebaceous lesions that could lead to basal cell carcinoma. Some moles or nevi could also become malignant.

### 4.3.1 Neurofibromas

Craniofacial neurofibromas can involve peripheral nerves of the face, orbit, and cranial base. Facial lesions can be disfiguring and are usually taken care of by plastic surgeons. Neurofibromas are seen in patients who have neurofibromatosis (NF), which is classified into two distinct clinical groups based on the pattern of clinical presentation. These are multi-system disorders.

#### 4.3.1.1 Epidemiology

NF 1 is one of the most commonly occurring genetic disorders and is seen frequently in the neurology and neurosurgery clinic. It occurs in 1 in 3,000–4,000 people (Pollack 2008). It is an autosomal dominant condition with the effected gene on chromosome 17 (17q11.2). Spontaneous mutation is high, with 30–50% of cases representing new mutations.

NF2 is one tenth as common, affecting only 1 in 50,000 patients (Pollack 2008).

### 4.3.1.2 Evaluation

Children with NF1 often have lesions of the skin such as freckles in unusual places (i.e., axillary), multiple café au lait spots, or dermal fibromas. Eye lesions can include glaucoma, optic pathway gliomas, and Lisch nodules. Sometimes pulsatile exophthalmos is also present.

Children with NF 2 can present with either unilateral or bilateral cranial nerve VIII lesions. They may also present with a meningioma.

Neurofibromas of the scalp may be seen in NF 1 and sometimes NF 2.

Patients who have neurodermatoses are often screened with CT scan or MRIs. It is during the screening processes that lesions of the skull and scalp may be found. The Committee on Genetics of the American Academy of Pediatrics has published guidelines on how these children should be screened and monitored (Hersh and Committee on Genetics 2008).

Bony lesions of the skull in children with NF include sphenoid wing dysplasia seen on head CT scan. Other bony lesions include tibial bowing as well as pseudarthrosis.

### 4.3.1.3 Treatment

Focal, resectable, or symptomatic lesions are surgically removed. Other lesions are usually followed with routine radiographs. The nurse is mindful to observe for lesions that are growing or changing in characteristics. Clinical coordination includes making sure the children are seen by the appropriate disciplines including neurology, genetics, orthopaedics, and neurosurgery.

## 4.3.2 Fibrous Dysplasia

### 4.3.2.1 Etiology and Pathophysiology

Fibrous dysplasia is another example of a lesion that though benign can become malignant (Greenberg 2014). Normal bone is replaced with fibrous connective tissue. The abnormal tissue is composed of fibroblastic collagen, and it is mixed with immature woven bone.

The etiology is not clear. There are three types: (1) cystic, though not an actual cyst, there is wid-

ening of the diploe with thinning of the outer table and little involvement of the inner table; (2) sclerotic, usually seen in the skull base and facial bones; and (3) mixed.

Fibrous dysplasia accounts for approximately 2.5% of all bone tumors (Swift and Trumble 1999). It is most commonly seen at puberty and has equal distribution between boys and girls. As is seen with other bone tumors, the disease becomes more prominent during periods of growth.

### 4.3.2.2 Evaluation

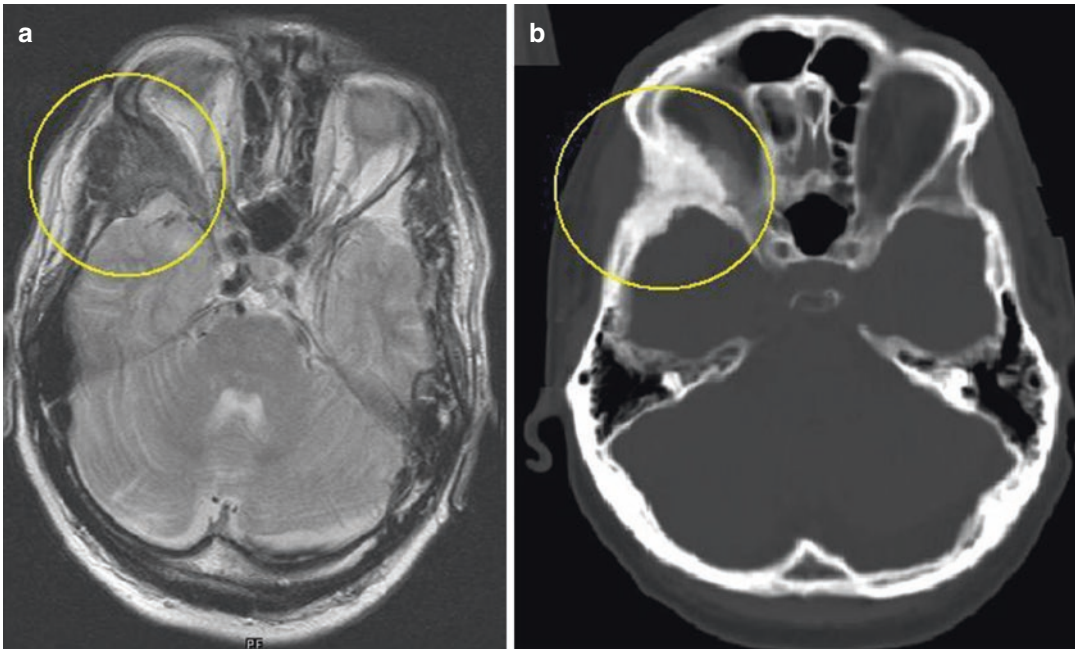
Initially, the child presents with a progressive and painless deformity of the skull. Various parts of the craniofacial skeleton may be involved including the orbit and foramina of other cranial nerves. Thus, there is concern of visual impairment when it involves the orbit because of distortion of the globe. These children are usually seen by a craniofacial team (Fig. 4.2).

As this is a bony lesion, the most appropriate test would be a CT. On plain radiographs and on CT, the lesion has a “ground glass” appearance due to the spicules of woven bone. An MRI may be performed to rule out intracranial involvement, including the involvement of cranial nerves.

### 4.3.2.3 Treatment

These can be slow-growing lesions and may be followed conservatively. If the lesion is impairing vision or impedes other cranial nerves, surgical excision is planned.

A meta-analysis of surgery versus watchful waiting by Amit et al. (2011) looked at several trials, studies, and individual case presentations. It was determined that surgeons prefer “watchful waiting” if the patient was asymptomatic, and surgery would be preferred for those who were symptomatic (i.e., visual changes). Asymptomatic patients with lesions of the optic nerve who underwent optic nerve decompression usually had some loss of vision. Thus, it was determined that watchful waiting would be more appropriate for those patients without impaired vision.



**Fig. 4.2** Fibrous dysplasia seen on (a) MRI and (b) CT with bone windows

### 4.3.3 Langerhans Cell Histiocytosis

Langerhans cell histiocytosis (LCH) is an entity that has been referred to as histiocytosis X or eosinophilic granuloma. When seen as a single lesion, it is classically known as eosinophilic granuloma.

LCH is a nonneoplastic type of histiocytic disorder that is most commonly characterized by a single lesion but also can be seen as multiple osteolytic bone lesions. Multiple lesions are more frequently seen in children under age 3 years.

LCH can be seen as a systemic entity, disseminating into the CNS and through the viscera. Lesions can present as skin lesions, pulmonary infiltrates, hepatosplenomegaly, and lymphadenopathy.

There is a subgroup of malignant histiocytic disorders, and these include the monocyte-related leukemias (acute monocytic leukemia, acute myeloid/myelomonocytic leukemia) and other tumors.

#### 4.3.3.1 Etiology

LCH is a rare histiocytic disorder that accounts for 7–10% of all reported skull lesions. It is seen in all

age groups but it is most common in children from 1 to 3 years of age. The incidence appears to be three to five cases per million children, which is the same as pediatric Hodgkin's lymphoma, and in one to two cases per million in adults.

The genetics of LCH is not well defined at this time. There is no current evidence that relatives of the patients with this condition are at increased risk of developing it.

#### 4.3.3.2 Pathophysiology

LCH is named because of a presumed derivation of the morphology similar to Langerhans cells, which are specialized dendritic cells found in the skin and mucosa.

Gene expression array data has shown that Langerhans cell is not the actual cell origin for LCH. Rather it is a myeloid dendritic cell that expresses the same antigens (CD1a, CD207) as the actual Langerhans cell.

A few studies reported evidence of viruses within the LCH lesions, but at this time, viral etiology debate is ongoing. It is now thought to be an inflammatory myeloid neoplasia because of

two mutations found in up to 75% of all biopsies. Some studies support that LCH is a reactive condition due to immunological dysfunction stemming from regulatory T-cell expansion and a lack of mutations and tumor suppressor genes. However, there is also support that LCH is a neoplasm which comes from finding cancer-associated proto-oncogene mutations seen in a high percentage of LCH biopsies (McClain 2016).

#### 4.3.3.3 Clinical Presentation

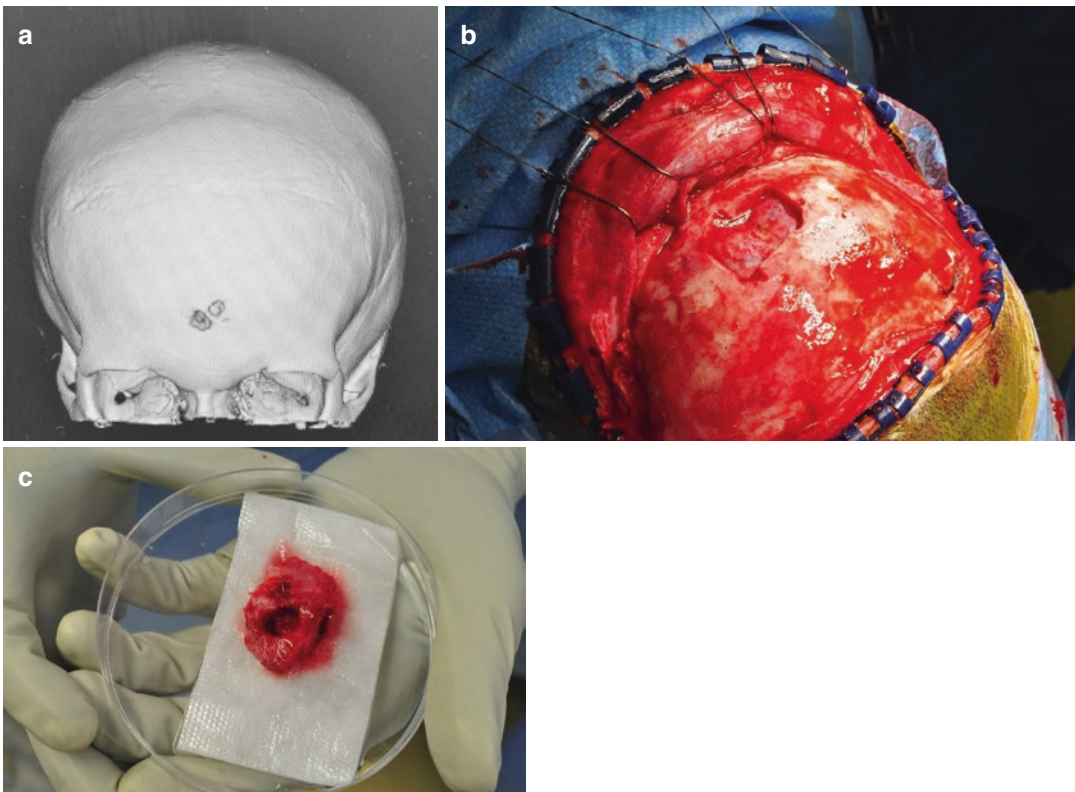
The areas of involvement vary with age. Acute disseminated multisystem disease is most commonly seen in children less than 3 years of age, while a more indolent disease involving the single origin is more common in older children and adults. Presenting symptoms in patients depend on the organ system involved. Most patients with bone marrow involvement are young children

with diffuse disease in the liver, spleen, lymph nodes, and skin. LCH patients under 2 years of age with two or more “risk organs,” such as hematopoietic organs, have a poor prognosis.

#### 4.3.3.4 Lytic Bone Lesions of LCH

Bone involvement occurs in the majority of patients with this condition. The most frequent sites of bony involvement are the skull (40–80%), femur, ribs, vertebrae, and humerus.

It is interesting to note that some lesions may be asymptomatic, while other patients may complain of pain in a localized area of the bone. Examination of the area usually reveals a lesion that is raised, soft, and tender to palpation. Skull radiographs typically demonstrate a lytic or “punched out” appearance with unequal involvement of the outer and inner tables. Typically there is a sclerotic rim. Sometimes there is an accompanying soft tissue mass (Fig. 4.3a–c).



**Fig. 4.3** (a) A 12-year-old girl with recurrent frontal skull lesions from histiocytosis. (b) Intraoperative view of excision of skull lesions. (c) Excised lesion with the surrounding bone



#### 4.3.3.5 Treatment

Treatment depends on presentation. For example, in cases where children have pain without neurologic deficit, immobilization may be tried (such as in lesions of the spine or long bones). Studies indicate that younger children may spontaneously regress with arrest of further bony destruction. The pain usually resolves when the disease arrests. Low-dose radiation is sometimes used for these lesions with good result.

Parent and Shiflett (2011) state that management of LCH skull lesions usually requires wide surgical resection. These lesions may be attached to dura and subcutaneous tissues and can be friable. These lesions can be persistent and recur. Chemotherapy or low-dose radiation may be considered.

#### 4.3.4 Osteoma and Osteoblastoma

Osteomas are more commonly seen in young adults and rarely in children. These lesions have a distinctive appearance on CT of being hyperintense and expansile. If the lesions are essentially asymptomatic, they are followed. If surgery is performed, the entire lesion is removed and is repaired with a split-thickness graft (Swift and Sacco 2008).

Osteoblastomas are more commonly seen in children than adults and are considered benign. These account for about 1% of benign tumors and about 10–20% of tumors of the skull.

Testing with radiographs may be inconclusive, and a biopsy is usually required. This is an example of a benign lesion that can grow and cause pain or discomfort. As with other such lesions, the entire lesion is removed and replaced with a split-thickness cranial bone graft.

#### 4.3.5 Ewing's Sarcoma

This childhood bone cancer was described as early as 1866 and has been associated with Dr. James Ewing because of his extensive work. This lesion is rarely a primary lesion of the skull, but it frequently metastasizes to the calvaria.

#### 4.3.5.1 Epidemiology

Ewing's sarcoma is the second most common bone cancer found in children, but it is also relatively uncommon. It accounts for about 1% of all childhood cancers. Though seen at any age, it rarely occurs in adults over age 30 years.

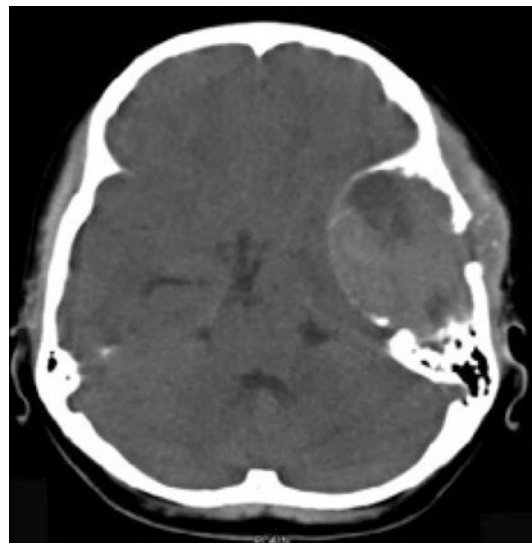
#### 4.3.5.2 Evaluation

The most common presenting symptom is pain, which can be intermittent. It is usually worse at night, and the size can fluctuate as well, enlarging when it is more painful. It is associated with leukocytosis, anemia, and fevers.

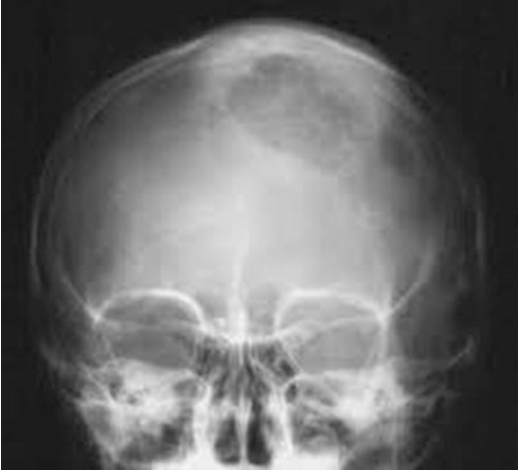Radiographic appearance shows destruction of the bone with irregular and poorly defined borders. There is usually an associated soft tissue mass. It may appear to be inflammatory in nature, yet bone destruction is a hallmark feature (Figs. 4.4 and 4.5).

#### 4.3.5.3 Treatment

Identification of the cell type is imperative. The cellular structure is composed of compact and uniform cells with distinct nuclei. The neuropathologist must differentiate this tumor from other sarcomas, as the 5-year survival rate with Ewing's sarcoma is less than 5% where as other sarcomas have better prognoses. The lesion is radiosensitive, so initial treatment includes local radiation therapy along



**Fig. 4.4** Ewing's sarcoma on CT showing destruction of the bone and painful scalp mass



**Fig. 4.5** Ewing's sarcoma on skull X-ray showing bony destruction

with systemic chemotherapy. Recurrences are common, and prognosis is poor with any type of treatment (Kieffer et al. 1989). Surgical resection is considered depending on the site and may be performed after chemotherapy.

## 4.4 Congenital

### 4.4.1 Cutis Aplasia

#### 4.4.1.1 Epidemiology and Pathophysiology

Cutis aplasia (also known as aplasia cutis congenita) is a rare, congenital, localized skin defect that can occur on any part of the body but is most commonly found on the scalp. Although the exact incidence is unknown, it is believed to occur in approximately 1 in 10,000 births (US National Library of Medicine 2016). There are several etiologic causes for this defect that can be categorized into non-syndrome related and syndrome related.

Non-syndrome-related causes include intra-uterine exposure to teratogenic drugs such as methimazole or misoprostol, viral infections in the perinatal period, intrauterine vascular ischemia, and amniotic adhesions. Familial cases have also been reported and are mostly inherited through an autosomal dominant pattern. Mutations in the ribosomal GTPaseBMS1 gene have been linked to cutis aplasia (Wan 2016).

While cutis aplasia is usually isolated, it has also been noted to appear with other malformations and syndromes including Adams-Oliver syndrome, Johanson-Blizzard syndrome, trisomy 13, and Wolf-Hirschhorn syndrome.

Due to the various, multifactorial causes of cutis aplasia, Frieden (1986) proposed a classification system consisting of nine groups characterized by the number, location, and pattern of the defect and the presence of associated malformations and/or genetic components.

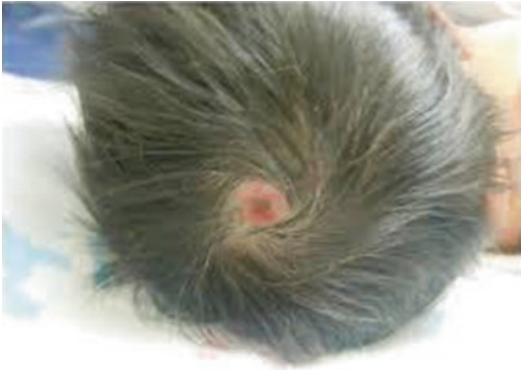#### 4.4.1.2 Evaluation

Cutis aplasia occurs most frequently on the scalp (80% of cases) along the vertex but can also appear on the face, trunk, and limbs. It appears as a well-demarcated ulceration or open wound and sometimes involves the underlying tissue and bone. It varies in size from <1 to >10 cm, as well as in shape. It can appear circular, linear, oval, or stellate in configuration. Defects that occur early in gestation may heal before birth and be covered with a thin, smooth, and atrophic membrane, fibrous tissue, or a parchment-like scar with associated alopecia. Defects that occur later in gestation appear more ulcerative (Wan 2016).

A comprehensive physical examination should be performed to evaluate for any associated malformations or syndromic manifestations. Medical imaging is not usually indicated, unless evaluation of structural lesions that may require neurosurgical intervention is desired (Fig. 4.6).

#### 4.4.1.3 Treatment

Smaller lesions (<3 cm) will usually re-epithelialize spontaneously and sometimes heal with an atrophic scar or an area of alopecia. With these smaller lesions, the treatment plan may include an antibiotic ointment and wet gauze dressing. However larger lesions, or lesions with associated bone and dural defects, are at risk for infection and hemorrhage and require surgical repair. Surgical intervention may include skin rotation flaps, tissue expanders, or skin grafts (Parent and Shiflett 2011). There have been literature reports where the defect can expose the sagittal sinus, in which case immediate surgical intervention is warranted due to the high risk of fatal hemorrhage (Kim et al. 2001).



**Fig. 4.6** Cutis aplasia of the scalp

#### 4.4.2 Epidermoid and Dermoid Cysts

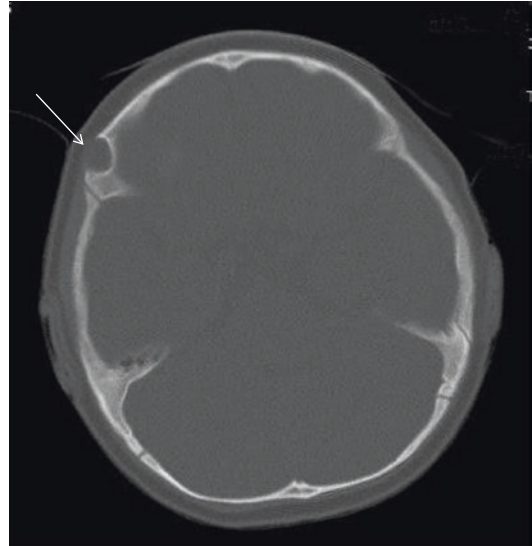
##### 4.4.2.1 Epidemiology and Pathophysiology

Epidermoid and dermoid cysts are common findings in the pediatric neurosurgical clinic, accounting for 50–60% of all pediatric scalp lesions (Parent and Shiflett 2011). Although epidermoid and dermoid cysts have similar presentations, they differ in their cell makeup. They are both ectoderm-lined inclusion cysts that develop when the surface ectoderm fails to properly separate during neural tube closure. Epidermoid cysts are primarily made up of squamous epithelium and keratin, while dermoid cysts contain hair, sebaceous and sweat glands, as well as squamous epithelium. They can present intradurally or extradurally, but for the purposes of this chapter, we will focus on the extradural lesions.

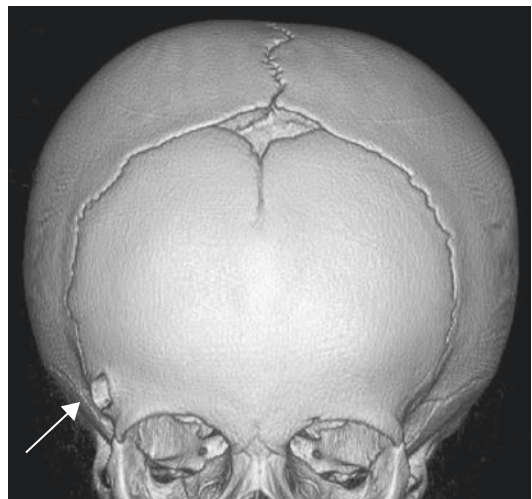
Epidermoid and dermoid cysts are mainly unilocular and slow growing (Smirniotopoulos and Chiechi 1995). They typically grow to be 1–2 cm by the time of discovery but will continue to grow if not surgically removed. As they grow, they tend to involve more and more of the inner table of the bone and can erode through the bone if not removed.

##### 4.4.2.2 Evaluation

Epidermoid and dermoid cysts are among the most common masses of the scalp and skull. Most commonly, they form along sites of fusion with 50% of them involving the frontozygomatic suture of the

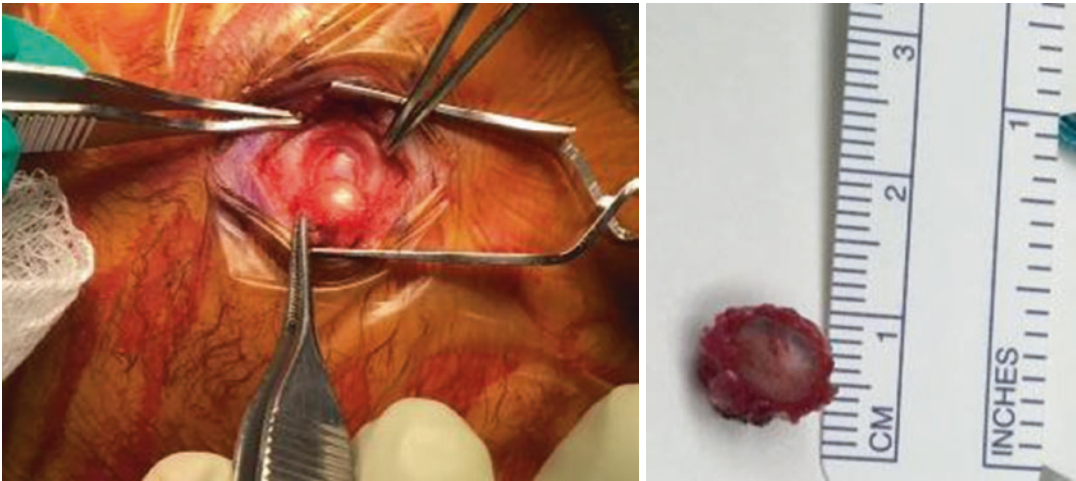


**Fig. 4.7** Erosion of the bone by dermoid cyst seen on CT with bone windows



**Fig. 4.8** Erosion of the bone by dermoid cyst seen on 3D CT

orbit (Veselinovic et al. 2010). Upon palpation, they can feel soft and partially compressible, or they can feel hard. This is dependent on the amount of bone bordering the edges of the cyst. They are most commonly nonmobile masses because they are fixed to the underlying bone periosteum. Although diagnosis can usually be made upon physical examination, a skull X-ray or head CT scan may be ordered by the provider as additional preoperative workup. This is helpful with surgical planning to understand how much of the inner



**Fig. 4.9** Intraoperative excision of epidermoid

table of the bone is involved if any and if there is intracranial involvement (Figs. 4.7 and 4.8).

#### 4.4.2.3 Treatment

Surgical removal is the treatment of choice with epidermoid and dermoid cysts. If left untreated, they can potentially erode through the skull, and because of their superficial location, they are at risk for injury or rupture. Surgery is done on an outpatient basis and involves little postoperative pain or recovery time. If the cyst is removed intact without rupture, recurrence is rare (Fig. 4.9).

### 4.4.3 Cranial Dermal Sinus

#### 4.4.3.1 Etiology and Pathophysiology

Dermal sinus tracts are a common pediatric finding that can be present anywhere along the neural axis. Although they are most commonly found in the lumbosacral area, they can also be found on the cranium. Of those that present on the cranium, 85% are found along the midline in the occipital region, while the remainder can be found in the nasofrontal area or, very rarely, the posterior parietal area (Jimenez and Barone 1999) (Fig. 4.10a, b).

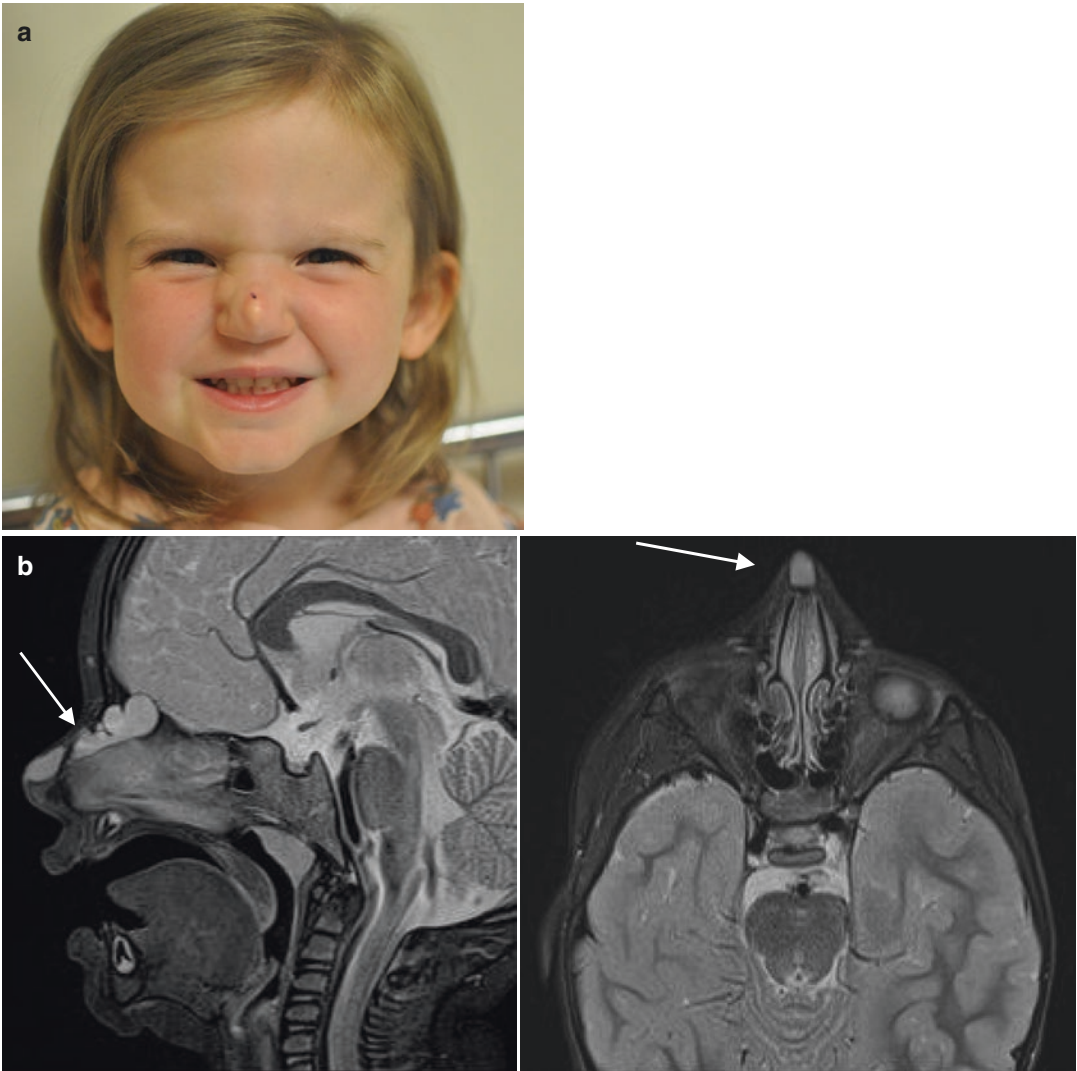
Dermal sinuses are formed when there is an interruption in the separation of the neural ectoderm and the epithelial ectoderm during the time of normal midline fusion at 3–5 weeks of

gestation. This interruption results in a focal segmental adhesion lined with stratified squamous epithelium. Cranial dermal sinus tracts have variable depth depending on their degree of separation. They may end subcutaneously or extend deeper to include central nervous system structures that reflect its ultimate embryologic level. This would include the fourth ventricle for those found in the occipital level or the crista galli for those found in the nasofrontal area. Of those found in the nasofrontal area, 90% end extracranially (Dias and Partington 2011).

An associated dermoid or epidermoid cyst may form anywhere along the dermal sinus tract but most commonly occur at its terminus. Although rare, if an inclusion cyst does occur intracranially, mass effect and local compression could lead to serious complications including hydrocephalus and signs and symptoms associated with increased intracranial pressure (headache, vomiting, ataxia, nystagmus, papilledema, unsteady gait, etc.).

The most commonly associated risk with cranial dermal sinuses is infection as the tract serves as a constant portal for pathogens to enter. For sinuses that end subcutaneously, an infection may present with localized erythema, edema, or purulent drainage. However, sinuses that extend intracranially are at risk for much more serious infections that lead to meningitis or abscesses, with *Staphylococcus aureus* being the most common pathogen.





**Fig. 4.10** (a) A 2-year-old girl with nasal dermoid marked for surgery. (b) Sagittal and axial T2 images of nasal dermoid. Note sagittal view of dermoid extending intracranially

#### 4.4.3.2 Evaluation

Cranial dermal sinuses are easily seen when they present on the nasofrontal area and appear as a small dimple. Sometimes there is an associated abnormal hair pattern surrounding the tract and/or clear or yellow drainage. Cranial dermal sinuses located in the occipital or parietal area are more disguised by normal hair growth and may not be discovered on initial routine exam. In fact, it is not uncommon for occipital dermal sinuses to be found only after recurrent

unexplained episodes of meningitis have presented. In this case, close examination of the midline of the scalp should be done and may require shaving of the head in order to completely visualize the sinus. Anytime there is a report of an area of hair that is wet without explanation; the area should be shaved and examined for a cranial dermal sinus tract.

A brain MRI is recommended for evaluation of the depth of the dermal sinus tract. If meningitis is suspected, a lumbar puncture is performed.



### 4.4.3.3 Treatment

Cranial dermal sinuses that end subcutaneously, if able to be kept properly clean, do not require surgical excision. However, sometimes these sinuses become infected or form abscesses. In these cases, surgical excision is recommended to avoid recurrent infections. Cranial dermal sinuses that extend intracranially are surgically explored, and the tract is excised, including any associated cysts. In the presence of meningitis, the patient usually completes a course of antibiotic therapy before surgery is recommended, given there is not declining neurological status.

## 4.5 Acquired Lesions

### 4.5.1 Hematomas

A cephalohematoma is a collection of blood between the skull and the pericranium, confined within the borders of cranial sutures. These are sometimes referred to as subperiosteal hematomas. Bleeding elevates the periosteum, and at the time of the injury, the site is more firm. It becomes more ballotable after a few days (Fig. 4.11).

A calcified cephalohematoma is one that and has not resorbed, but rather has hardened in its original form. A calcified hematoma has an inner and outer layer of the bone. The inner layer consists of the fetal inner and outer table of the intramembranous calvarial bone, while the outer layer is made up of sub-pericranial bone (Figs. 4.12 and 4.13).

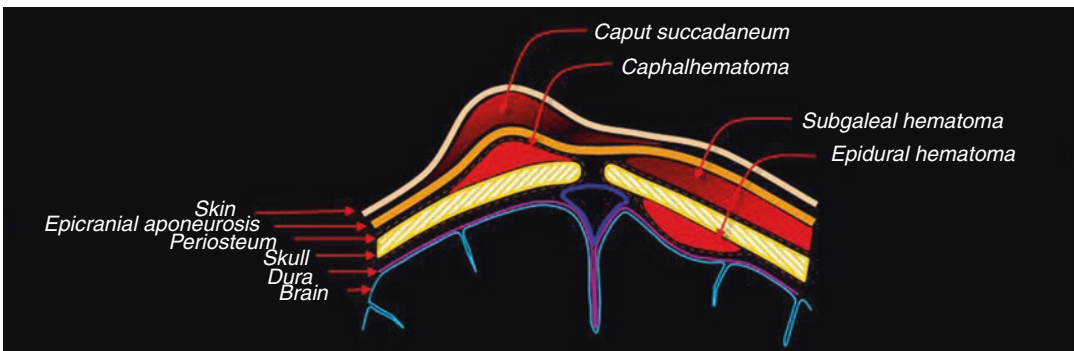
The most common cause of the cephalohematoma that becomes calcified is the result of trauma associated with an instrument-assisted vaginal birth, occurring in 1–2% of spontaneous vaginal deliveries. These injuries are usually noticed within the first 24 h but can be found up to 72 h after birth. Most of these hematomas spontaneously resorb within 1 month, with 80% of them absorbing within 2–3 weeks (Greenberg 2010). Other causes of cephalohematomas include trauma in childhood (Fig. 4.14).

A caput succedaneum is edema at the neonate's presenting part of the head as a result of pressure against the mother's cervix during labor. The edema in caput succedaneum crosses suture lines. It may involve wide areas of the head or may be the size of a large egg (Fig. 4.15).

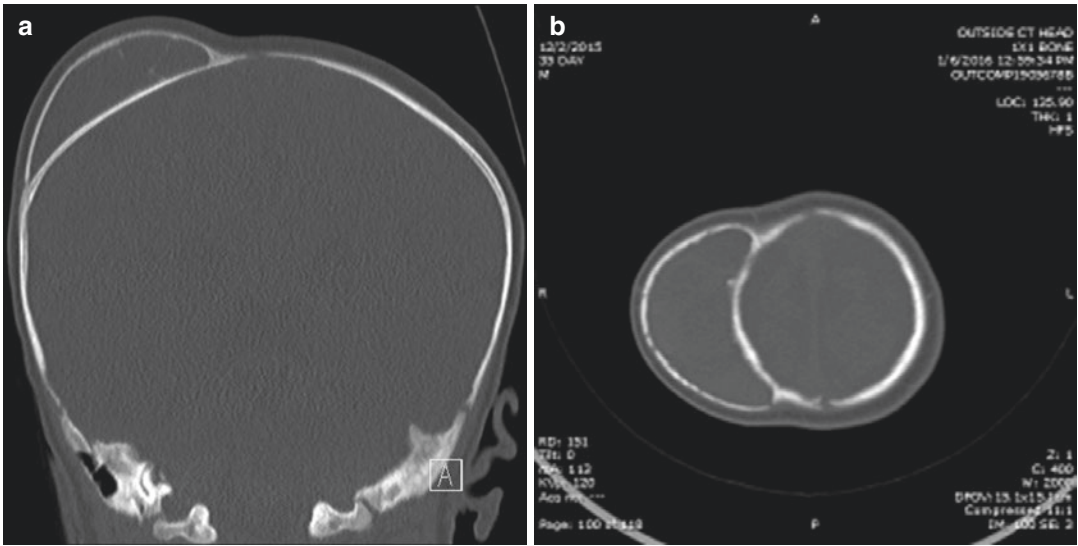
A subgaleal hematoma may occur without any bony trauma or may be associated with a linear skull fracture especially in a small child under 1 year of age. It is caused from bleeding into the loose connective tissue that separates the scalp from the periosteum. This type of hematoma typically does cross suture lines. It is not uncommon for the care provider or examiner to not notice much of a hematoma right after the injury, because it is still solid at this point. Within a day or 2, the lesion is noted to be a soft fluctuant mass similar to a "water balloon." These lesions do not calcify, because they occur above the bony layers.

#### 4.5.1.1 Treatment

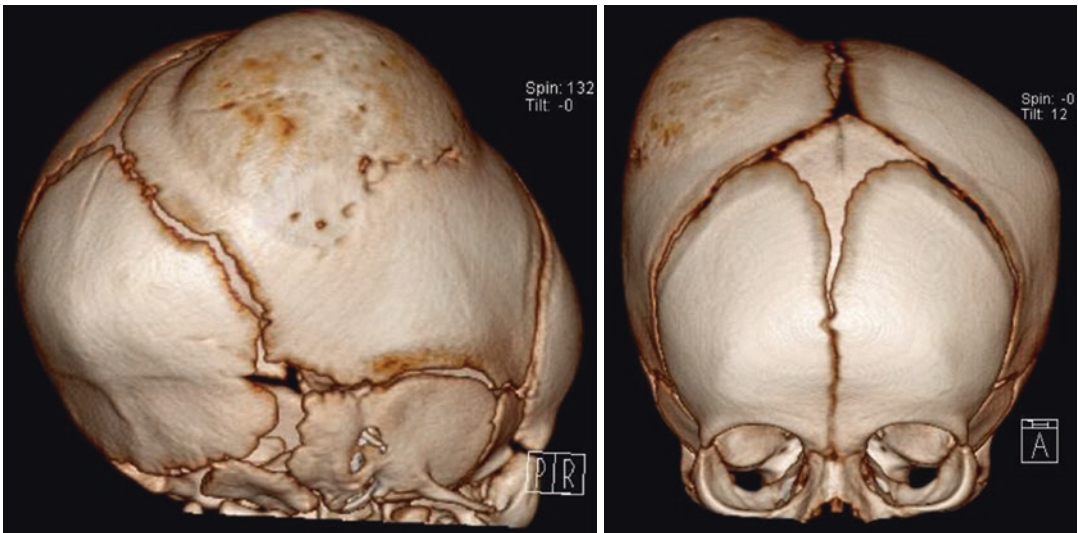
The nurse caring for an infant or small child with a hematoma needs to be mindful of several things.



**Fig. 4.11** Diagram of various skull injuries and their locations



**Fig. 4.12** (a) Coronal CT with bone windows showing right parietal calcified cephalohematoma. (b) Calcified hematoma on CT scan



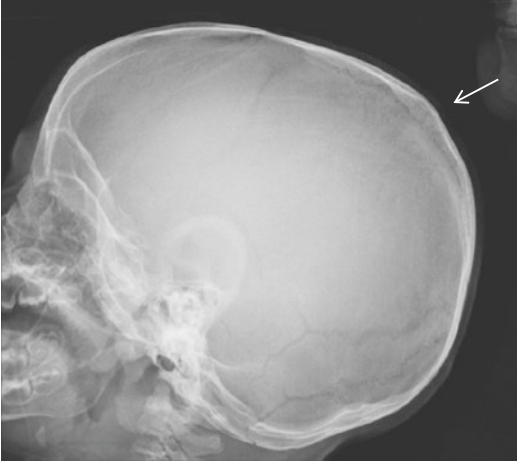
**Fig. 4.13** CT head with 3D recon showing calcified right parietal cephalohematoma

First of all, small children have small circulating volumes, so large hematomas can cause hypovolemia and later anemia. In an infant with a large hematoma, one must be mindful of hyperbilirubinemia as the blood is resorbed. This can occur up to 10 days after an injury. Occasionally an infant may require a blood transfusion.

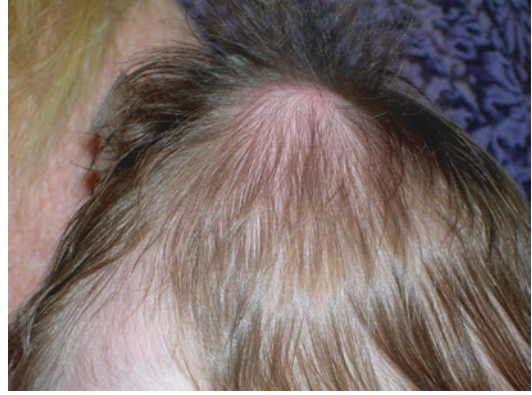Infection of a hematoma is rare but has been documented. In one case, a 1-month-old female

presented with febrile illness and was found to have *E. coli* sepsis. She had a cephalohematoma that was fluctuant, and it also grew *E. coli*. (Weiss et al. 2009). It was presumed the hematoma became infected via hematologic seeding (Fig. 4.16).

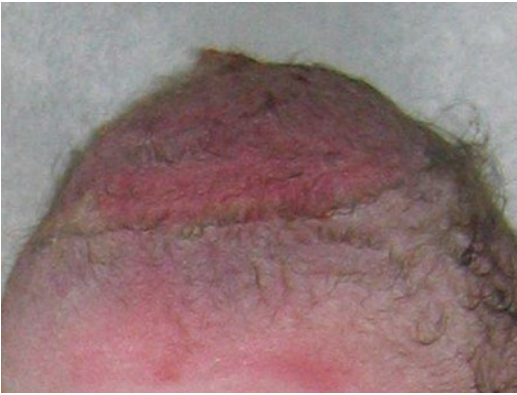One review suggests that there may be an elevated incidence of intracranial hemorrhage (ICH) in babies with cephalohematomas. It was found that 7/19 infants who underwent neuroimaging



**Fig. 4.14** Small calcified hematoma due to trauma



**Fig. 4.16** Infected calcified cephalohematoma (Courtesy of Dr. Weiss)



**Fig. 4.15** Caput succedaneum

(36.8%) had ICH including two epidural hematomas (Kim et al. 2014).

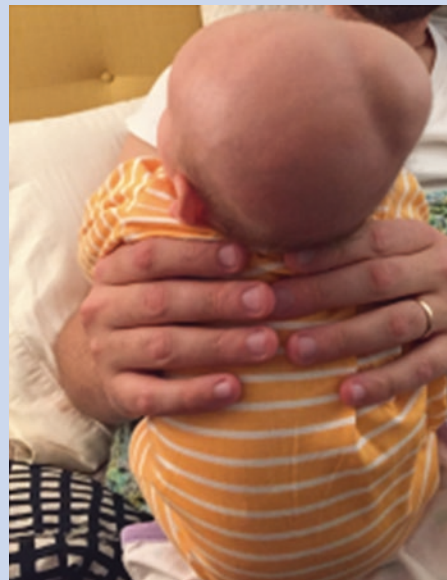
Sometimes a calcified hematoma can be quite large and unsightly. These children are often referred to the pediatric neurosurgery office. Typically a low-dose CT scan is ordered to make sure that there are no underlying intracranial injuries as well as to document the condition of the skull. The pediatric neurosurgeon then meets with the parents. Many times these lesions need to be surgically excised, and hearing that your baby needs surgery can be quite traumatic. Other lesions are small and do not require surgical intervention.

Occasionally the pediatric office will see an older child with a calcified hematoma that was

not operated on in early childhood or infancy. Sometimes the calcified hematoma remains quite large, and the surgeon must decide along with the parents whether or not it is beneficial to have it removed. If small enough and the hair covers it, most likely it will not be removed. However, larger bony defects may require surgery.

#### Box 4.1

##### Baby with calcified cephalohematoma



### 4.5.2 Growing Fracture of Childhood

An interesting and unusual late complication of skull fractures seen small children is what is known as a growing fracture of childhood. These are also known as growing skull fractures and posttraumatic leptomeningeal cysts (Fig. 4.17). It was first described in 1816 and has been reported to occur in less than 0.05–1.6% of cases. It occurs more commonly in children under age 12 months, but 90% of patients with these complications are under the age of 3 years (Dutcher et al. 2001; Liu et al. 2012).

There are several theories as to the cause. It is known that in some skull fractures, there may be dural tearing and entrapment of the arachnoid membrane or brain tissue within the fracture margin. Some experts also feel that as the rapid growth of the brain and skull occurs, the dura adheres more tightly to the bone and thus is more easily torn when the skull is fractured in a small child. The protruding intracranial contents may prevent the fracture from healing.

#### 4.5.2.1 Treatment

Treatment requires surgery. This includes resection of the leptomeningeal cyst or pro-

truding tissue. The surgeon then performs a meticulous watertight repair of the dura, followed by a cranioplasty. The surgeon is mindful that the child may have increased intracranial pressure as one of the causes of intracranial contents protruding through a fracture. Thus, once the defect is closed, the patient is monitored closely in the pediatric intensive care unit postoperatively.

Nursing care for these children would be the same for any craniotomy patient, with close monitoring of vital signs, mindful for signs and symptoms of increased intracranial pressure. Neuro checks are performed regularly, and any change should be brought to the neurosurgeon's attention right away.

## 4.6 Vascular

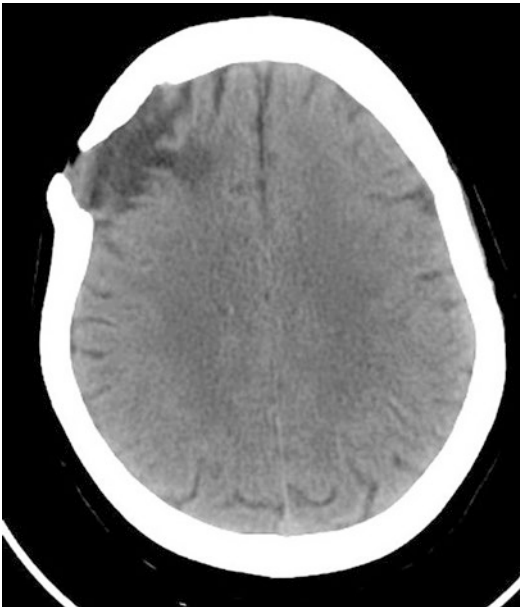
### Vascular Lesions of the Scalp

Vascular lesions are actually quite common in children, occurring in up to 75% of newborns. We commonly see small pink to red lesions over the face, head, and neck, and these are sometimes known as “stork bites” (nevus flammeus). They are usually small, less than 2 cm, and are not raised. Most of these small lesions disappear within the first or second year of life.

Lesions known as port wine stains contain abnormal blood vessels. These lesions can be quite large and disfiguring. They also do not involute, but rather can continue growing.

### Clinical Concerns

As noted above, the smaller lesions usually disappear without intervention. Larger lesions may indicate intracranial abnormalities that include lesions of the cortex. One such diagnosis is Sturge-Weber syndrome. These children can have devastating seizures and developmental delays. Thus, it is imperative that larger lesions are evaluated by the neurology or neurosurgery team. Evaluation would include appropriate radiographs such as MRI and MRA/MRV (Fuchs and Tomita 2001).



**Fig. 4.17** Leptomeningeal cyst



## 4.6.1 Sinus Pericranii

### 4.6.1.1 Etiology and Pathophysiology

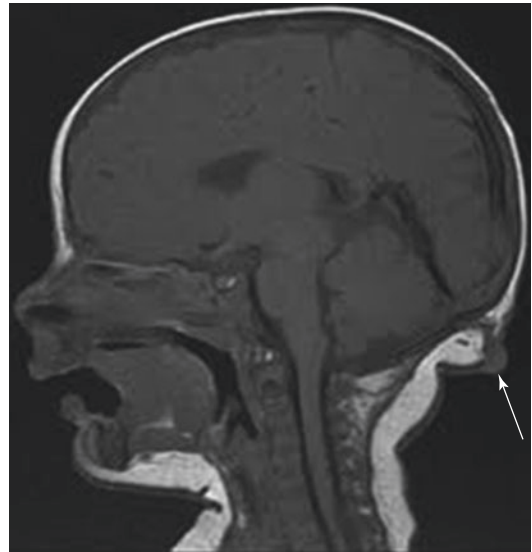
Sinus pericranii is a rare, slow-flow venous anomaly that presents when there is an abnormal communication between extracranial and intracranial venous pathways. More specifically, the communication is usually seen between the sagittal sinus and dilated transosseous emissary veins. The nature of this vascular abnormality may be congenital, spontaneous, or acquired by trauma. Congenital cases are present at birth and reveal an endothelial lining on close pathological examination. Traumatic sinus pericranii usually present after a head injury which results in a skull fracture, a torn emissary vein, or a direct injury to the sagittal sinus. Spontaneous sinus pericranii occur after an intrinsic defect in the skull itself causes erosion through the skull table. These are also thought to be congenital with a late diagnosis in some cases (Bollar et al. 1992; David et al. 1998; St. Clair and McCutcheon 2011).

Although the majority of cases present in young childhood, they can also present in adolescence or adulthood, especially with post-traumatic etiology. Sinus pericranii can present as an isolated incidence or in association with a syndrome such as Crouzon's syndrome, Apert's syndrome, or Hunter's syndrome. Association with craniosynostosis has also been documented in the literature (Nobuyuki et al. 2007) (Fig. 4.18).

### 4.6.1.2 Evaluation

Sinus pericranii are usually found on the cranial vault at the midline or just off center, proximal to the sagittal sinus. They present as a soft mass or scalp swelling that is easily compressible and painless. They are noted to swell and appear engorged while lying in the recumbent position or during a Valsalva maneuver (such as crying in the infant child) and decrease in size in the upright or erect position. Over time they tend to increase in size; however, there have been some reports of spontaneous regression (Rozen et al. 2008).

The underlying skull defect associated with sinus pericranii is best visualized on a head CT, but a CT venogram is also required to evaluate



**Fig. 4.18** Sinus pericranii

the communication between the venous pathways. An MRI and MR venogram are also useful in evaluation.

### 4.6.1.3 Treatment

In the case of progressive disease, surgical resection is indicated. Because of the risk for serious complications such as hemorrhage, infection, or air embolism, some surgeons recommend prophylactic resection (Bollar et al. 1992; David et al. 1998; St. Clair and McCutcheon 2011). Although surgical resection is the most common treatment approach, endovascular embolization has also been utilized in some cases.

## 4.7 Inflammatory/Reactive

### 4.7.1 Cranial Fasciitis

#### 4.7.1.1 Etiology and Pathophysiology

This is a rare, benign lesion that is thought to be the result of possible trauma. It is considered a reactionary process. There may be a history of a delivery by forceps or vacuum extraction. The most common site is the temporal bone, followed then by the frontal, parietal, and temporoparietal



area. There is no family history, and the lesion does not return once removed.

The lesion arises from the deep fascia (hence the name), periosteum, or the fibromembranous layer covering the sutures and fontanel. Though most lesions are found in the scalp, there have been a few reported cases of intracranial lesions. The intracranial lesions can arise from the dura without scalp involvement.

#### 4.7.1.2 Evaluation

Most patients, up to 95%, present with an asymptomatic lesion in the scalp. There is almost always a history of trauma, and the lesion can grow rapidly. Radiographs showing erosion of the outer table is a common finding; however, there are a few reported cases where cranial fasciitis has penetrated the calvarium through to the epidural space. There are also a few reports of intracranial lesions found exclusively intracranially after head trauma or tumor removal (Halder et al. 2011). These tend to be slow-growing lesions and are thought to be the result of altered blood supply to lesion within the cranium.

#### 4.7.1.3 Treatment

These scalp and skull lesions are totally resected, and intracranial lesions require surgical planning depending on the location.

#### Conclusion

Unusual new masses found on a child's scalp or skull usually eventually referred to the Pediatric Neurosurgery service. Though only a few may be malignant, even benign lesions can grow and should be evaluated by the neurosurgeon for definitive treatment.

#### Pearls

- Unresolving cephalohematomas should be referred to neurosurgery for early treatment to prevent calcification.
- Cranial dermal sinus should be included in the differential diagnosis of any patient with unexplained meningitis and/or an

area of wet hair that cannot be explained. Sometimes shaving of the head must be done before the sinus is visualized.

- Any lesion or mass that is noted to progress or grow in size should be referred to the neurosurgical clinic for further evaluation.
- Neuroscience nurses caring for infants with scalp hematomas should be mindful of possible anemia and hyperbilirubinemia.

## References

- Amit M, Collins MT, FitzGibbon EJ, Butman JA, Fliss DM, Gil Z (2011) Surgery versus watchful waiting in patients with craniofacial fibrous dysplasia: a meta-analysis. Database of abstracts of reviews of effects, 2015 Issue 2. University of New York, Wiley. <http://onlinelibrary.wiley.com/doi/10.1002/111006500/sect0.html>
- Bollar A, Allut A, Prieto A, Gelabert M, Becerra E (1992) Sinus pericranii: radiological and etiopathological considerations. *J Neurosurg* 77(3):469–472
- David L, Argenta L, Venes J, Wilson J, Glazier S (1998) Sinus Pericranii. *J Craniofac Surg* 9(1):3–10
- Dias MS, Partington MD (2011) Normal and abnormal embryology of the brain. In: Winn HR (ed) *Youmans neurological surgery*. Elsevier Saunders, Philadelphia, pp 1883–1897
- Dutcher A, Sood A, Ham S, Canady A (2001) Skull fractures and penetrating brain injury. In: McLone, Marlin, Scott, Steinbok, Reigel, Walker, Cheek (eds) *Pediatric neurosurgery*. Saunders, Philadelphia
- Frieden IJ (1986) Aplasia cutis congenital: a clinical review and proposal for classification. *J Am Acad Dermatol* 4(14):646–660
- Fuchs HE, Tomita T (2001) Neurocutaneous syndromes and meningiomas of childhood. In: David M (ed) *Pediatric neurosurgery*. 4th edn. Saunders, Philadelphia, p 778
- Greenberg MS (2010) *Handbook of neurosurgery*. Thieme, New York, p 918
- Greenberg MS (2014) *Handbook of neurosurgery*. Thieme, New York, p 701
- Halder A, Greene C, Rivard D, Shao L (2012) Cranial fasciitis presenting as an intracranial mass in a 10-year-old girl. *Pediatr Dev Pathol* 15:146–150
- Hersh JH, Committee on Genetics (2008) Health supervision for children with neurofibromatosis. *Pediatrics* 121:633
- Jimenez D, Barone C (1999) Encephaloceles, meningoceles and dermal sinuses. In: Albright, Pollack,

- Adelson (eds) Principles and practice of pediatric neurosurgery. Thieme, New York, pp 202–206
- Kim CS, Tatum SA, Rodziewicz G (2001) Scalp aplasia cutis congenita presenting with sagittal sinus hemorrhage. Arch Otolaryngol Head Neck Surg 127(1): 71–74
- Kim HM, Kwon SH, Park SH, Kim YS, Oh KW (2014) Intracranial hemorrhage in infants with cephalohematoma. Pediatr Int 56:378–381 (Official journal of the Japan Pediatric Society)
- Liu X, You C, Lu M, Liu J (2012) Growing skull fracture stages and treatment strategy. J Neurosurg Pediatr 9:670–675
- McClain KL (2016) Clinical manifestations, pathologic features, and diagnosis of Langerhans cell histiocytosis. In: Boxer L, Park J (eds). Wolters Kluwer, UpToDate. Retrieved from <http://www.uptodate.com/home>
- Nobuyuki M, Kaneshige S, Takashi H, Yoshihiko F, Tadayuki S, Tetsuji U, Yoshiaki H (2007) Sinus Pericranii associated with craniosynostosis. J Craniofac Surg 18(1):78–84
- Parent AD, Shiflett JM (2011) Skull tumors and fibrous dysplasia. In: Winn HR (ed) Youmans neurological surgery. Elsevier Saunders, Philadelphia, pp 2136–2143
- Pollack I (2008) Neurofibromatosis 1 and 2. In: Albright, Pollack, Adelson (eds) Principles and practice of pediatric neurosurgery. Thieme, New York, pp 735–736
- Rozen W, Joseph S, Lo P (2008) Spontaneous involution of two sinus pericranii- a unique case and review of the literature. J Clin Neurosci 15(7):833–835
- Smirniotopoulos JG, Chiechi MV (1995) Teratomas, dermoids, and epidermoids of the head and neck. Radiographics 6(15):1437–1455
- St. Clair EG, McCutcheon IE (2011) Skull tumors. In: Winn HR (ed) Youmans neurological surgery. Elsevier Saunders, Philadelphia, pp 1667–1691
- Swift D, Sacco D (2008) Scalp and Skull neoplasms. In: Albright, Pollack, Adelson (eds) Principles and practice of pediatric neurosurgery. Thieme, New York, p 484
- Swift D, Trumble E (1999) Scalp and skull neoplasms. In: Albright, Pollack, Adelson (eds) Principles and practice of pediatric neurosurgery. Thieme, New York, p 450
- U.S. National Library of Medicine (2016) Genetics home reference: nonsyndromic aplasia cutis congenita. Retrieved from <https://ghr.nlm.nih.gov/condition/nonsyndromic-aplasia-cutis-congenita#statistics>
- Veselinovic D, Krasic D, Stefanovic I, Veselinovic A, Radovanovic Z, Kostic A, Cvetanovic (2010) Orbital dermoid and epidermoid cysts: case study. Serbian Arch Med 138(11–12):755–759
- Wan J (2016) Aplasia cutis congenita. Retrieved from <http://emedicine.medscape.com/article/1110134-overview#a4>
- Weiss KJ, Edwards MS, Hay LM, Allen CH (2009) *Escherichia coli*-infected cephalohematoma in an infant. Clin Pediatr 48(7):763–766

Mary L. Dexter and Teresa Schultz

---

## 5.1 Introduction

Neural tube defects persist as a common and potentially devastating birth defect affecting the central nervous system, with an incidence rate that varies worldwide but is generally considered to be 1 in 1,000 live births (Toriello 2011; Deak et al. 2008). This spectrum of congenital anomalies is caused by the failure of the neural tube to close during the early weeks of intrauterine development. The outcomes or clinical impacts of neural tube defects are multifaceted: dependent on the anatomic level of the defect, associated brain malformations, severity of hydrocephalus, and whether it is an open or closed defect. A neural tube defect impacts motor and cognitive skills and can range from a mild to severe disability, paralysis, and possibly death. The defect may occur anywhere in the head and spine and is defined by the degree of involvement of the spinal cord, neural tissue, and vertebral bodies as an open (visible) or

closed (hidden) defect. Many terms are applied to each (Table 5.1).

---

## 5.2 Etiology

Despite extensive studies, the precise etiology of neural tube defects (NTDs) is not completely understood. Multiple factors, genetic, nutritional, and environmental, are believed to be involved (Nat. Inst. of Neuro. Dis. and Stroke n.d.). The MTHFR (methylentetrahydrofolate reductase) gene has been the most studied genetic influence. This gene is involved in the processing of folate in the body. Folate, a B vitamin, is necessary for synthesis of DNA during cell division. Dietary intake of folate may be inadequate to reach demand during pregnancy, or there may be a genetic inability to properly process folate due to one or more variants of the MTHFR gene (Zhang et al. 2013; Wenstrom et al. 2000). Either can contribute to the failure of the neural cells to fuse and complete the formation of the neural tube.

The genetic role may also involve mutations in genes that contribute to an abnormal or lack of closure of the neural tube between the third and fourth week of uterine development. Clinical studies have shown that families with a known history of a neural tube defect are at a 2–5 % higher risk for a recurrence, which is a 25–50 times higher prevalence than in that of the general population (Detrait et al. 2005; Elwood et al. 1992). Neural tube

---

Shona Lens was the author of the original chapter and 2nd edition, but did not participate in this revision.

M.L. Dexter, BSN, RN (✉)  
Children's Rehabilitative Services, District Medical  
Group, Phoenix, AZ 85013, USA  
e-mail: [mary\\_dexter@dmgaz.org](mailto:mary_dexter@dmgaz.org)

T. Schultz, CNP, APRN  
Gillette Children's Specialty Healthcare,  
St. Paul, MN 55101, USA  
e-mail: [TSchultz@gillettechildrens.com](mailto:TSchultz@gillettechildrens.com)

**Table 5.1** NTD terminology

	Defect	Open	Closed
Anencephaly	Fatal condition where neonate missing parts of the brain and skull	x	
Encephalocele	Sacklike protrusions of the brain and the membranes that cover it	x	
Meningocele	Sac of fluid protruding through the back	x	
Myelomeningocele	Part of the spinal cord and nerves in sac protruding through the back	x	
Occult spinal dysraphism	General term including tethered spinal cord		x
Spina bifida	General term that means “split spine”	x	x
Spina bifida occulta	Small gap in spine but no opening on back or sac, cutaneous anomalies may be present	x	
Spinal dysraphism	Term related to malformations of spinal cord	x	x
Tethered cord syndrome	Disorder caused by stretching of spinal cord attached to spinal canal		x

defects can be linked to various genetic syndromes, including Meckel syndrome; trisomies 13, 18, and 21; and other chromosomal abnormalities or deletion (Detrait et al. 2005).

The environmental risk factors associated with neural tube defects are the maternal health concerns of hyperthermia, malnutrition, maternal obesity or diabetes (Detrait et al. 2005), or medication use, specifically valproic acid. Additionally but rare is the exposure to other teratogens, including thalidomide and Agent Orange (Detrait et al. 2005).

### 5.3 Folic Acid

Folic acid has shown the strongest link in the reduction of neural tube defects. Research has shown that prenatal folic acid use can decrease the prevalence of open neural tube defects by 50–70 % (AAP 1999, 2012; CDC 2004; Detrait et al. 2005). Folate is the natural form of folic acid and is found in leafy green vegetables (spinach), beans, liver, and citrus fruits. It is not absorbed at a 100 % ratio of the food that is ingested; thus, vitamin supplementation is recommended. Folic acid is a water-soluble synthetic compound used in vitamin supplements and fortified foods. The Centers for Disease Control and Prevention (CDC) and the US Public Health Service (USPHS) recommend that all women of childbearing age who are capable of becoming pregnant should take 400 mcg of folic acid daily, whether or not they are planning a pregnancy, and that women who have had a previous pregnancy or a family history of a neural

**Table 5.2** Folic acid for prevention of neural tube defects

0.4 mg (400 mcg)	All women capable of becoming pregnant should take 0.4 mg (400 mcg) of folic acid daily
4 mg (4,000 mcg)	All women who have a family history of neural tube defect or have had a previous pregnancy affected by a neural tube defect should take 4.0 mg (4,000 mcg) of folic acid daily

From Centers for Disease Control and Prevention (2004)  
 \*This is ten times the usual dose and must be prescribed by a qualified practitioner

tube defect take 4,000 mcg of folic acid daily (Table 5.2) (AAP 1999; CDC 2004). After reviewing the evidence, the American College of Medical Genetics reaffirmed its position in support of that policy in 2010 (Toriello 2011). These recommendations are extremely important because the neural tube develops by gestational day 28, often before a woman discovers that she is pregnant, and approximately 45 % of all pregnancies in the United States in 2011 were unintended (Finer and Zolna 2016).

In 1998, the US Food and Drug Administration (FDA) mandated food manufacturers to fortify certain grain products with folic acid (AAP 1999; Honein et al. 2001). Foods enriched with folic acid may include breads, breakfast cereals, flours, rice, and pasta. The CDC reported a reduction in the prevalence of spina bifida and anencephaly together of 28 % in the period of 1999–2011, as opposed to the period immediately preceding mandatory fortification (CDC 2015). Studies in

other countries with mandatory or voluntary folic acid fortification have shown higher rates of reduction (Toriello 2011). In April 2016, the Food and Drug Administration approved a change in the food additive regulations to allow the safe use of folic acid in corn masa flour. This will have an impact on the growing Hispanic population in the United States to decrease the risk of spina bifida (Federal Register).

Although the use of folic acid greatly reduces the risk of a neural tube defect, it does not eliminate the risk altogether. Nurses working with women who are capable of pregnancy can be highly effective in educating them about the importance of folic acid supplementation.

## 5.4 Epidemiology

Collectively, birth defects are the leading cause of death in infants under 1 year of age in the United States and account for up to 121.5 infant deaths per 100,000 live births (National Vital Statistics Reports 2015). Neural tube defects are the second leading birth defect and can result in devastating outcomes in infants and children. Generally, NTDs are more common in females than males and particularly anencephaly (Deak et al. 2008). In the United States, children born to Hispanic mothers have the highest prevalence of NTDs. Data from 12 birth defects tracking centers from 1997 to 2007 showed a prevalence of spina bifida among three ethnic groups: Hispanic, 3.80 per 10,000 live births; non-Hispanic black or African-American, 2.73 per 10,000 live births; and non-Hispanic white, 3.09 per 10,000 live births (Canfield et al. 2014).

Fortunately, the overall incidence of neural tube defects in the United States has steadily declined during the past few decades. This is likely attributable to an increased awareness of the need for additional folic acid supplementation, mandatory fortification, and improved prenatal diagnosis with elective termination of pregnancy. Prior to 1980, the incidence of neural tube defects in the United States was 1–2 per 1,000 live births (Lary and Edmonds 1996), and it had decreased to 0.6 per 1,000 live births in

1989 (Yen et al. 1992). As noted above, the current incidence is in the range of 0.3–0.4.

## 5.5 Pathophysiology

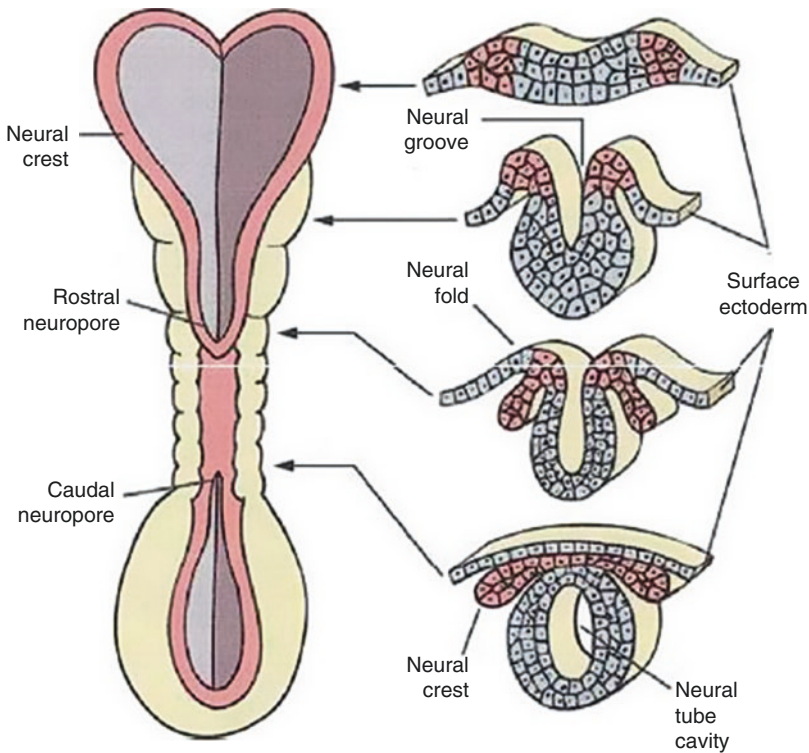
Neurulation is the embryologic formation of the neural plate, neural folds, and neural tube (Table 5.3). The neural tube is the cellular structure that later differentiates into the brain and spinal cord. (Fig. 5.1) This process of human embryonic development occurs in 23 stages, each stage lasting 2–3 days. The development of the neural tube is complete by 28 days of gestation. The neural tube is formed by two different processes called primary and secondary neurulation. Primary neurulation begins immediately after fertilization, or day one of gestation, and consists of the formation of the neural tube from the rostral (head) to the caudal (bottom) neuropore, which forms into the brain and most of the spinal cord (Park 1999).

Secondary neurulation is the process by which the caudal end of the neural tube develops into the lower sacral and coccygeal segments (part of the conus medullaris or end of the spinal cord) (Park 1999). The development of the neural tube begins around 17–19 days of gestation with dorsal thickening of the ectoderm, forming into the neural plate. During days 19–21, the neural plate unfolds and forms a neural groove, and neural

**Table 5.3** Neural development terminology

Ectoderm	The outer layer of cells in the developing embryo
Neural crest	A band of cells in the ectoderm at the margins of the neural tube that form into the cranial and spinal ganglia
Neural fold	One or two longitudinal elevations of the neural plate of an embryo that unite to form the neural tube
Neural groove	A narrow midline groove in the neural tube
Neuropore	An opening of the neural tube
Neural plate	A dorsal thickening of ectoderm in the developing embryo that develops into the nervous system
Neural tube defect	A defect in the embryologic development of the anterior or posterior neuropore during neural tube formation





**Fig. 5.1** Neural tube at the end of the third week. Neural folds have begun to fuse at the cervical level of the future spinal cord. *Right*, cross sections of the neural tube at four

different levels. Total length of the neural tube at this time is about 2.5 mm (Printed with permission from McCance and Huether 2002)

foldings begin to develop laterally. During days 21–23, the neural folds continue to grow to mid-line which allows closure of the tube. The neural folds develop into a rostral neuropore and a caudal neuropore. Finally, the closure of the neural tube takes place over 4–6 days. Traditionally, researchers have thought the neural tube closed in the midline cervical area, and then closure extended up and down. More recently, evidence seems to indicate that the neural tube closes at several points simultaneously and then extends to the rostral and caudal ends to complete the closure.

## 5.6 Spina Bifida and Spinal Dysraphism

Spina bifida is a general term that means “split spine.” The term encompasses three major types of NTDs: meningocele and myelomeningocele (MM), which are both open defects; and spina

bifida occulta, which describes “hidden” or closed defects. All involve incomplete closures of the spine, but the consequences of each are significantly different. MM and spina bifida are often used interchangeably, but not all spina bifida results in a myelomeningocele.

Spinal dysraphism is another general term used to describe a collection of NTDs, both open and closed. It can be used synonymously with spina bifida, but that is not always the case. Sometimes the term is used in a broader sense including spina bifida and other defects, while other times, it is used in discussing a tethered spinal cord (which is a type of occult spinal dysraphism). These various usages occur in both the literature and the parlance of neurosurgeons, nurses, and other medical providers, depending on their education and training. Hence, when you see or hear the terms spina bifida or spinal dysraphism used, consider the context or inquire further to avoid potential confusion.

## 5.7 Open Defects

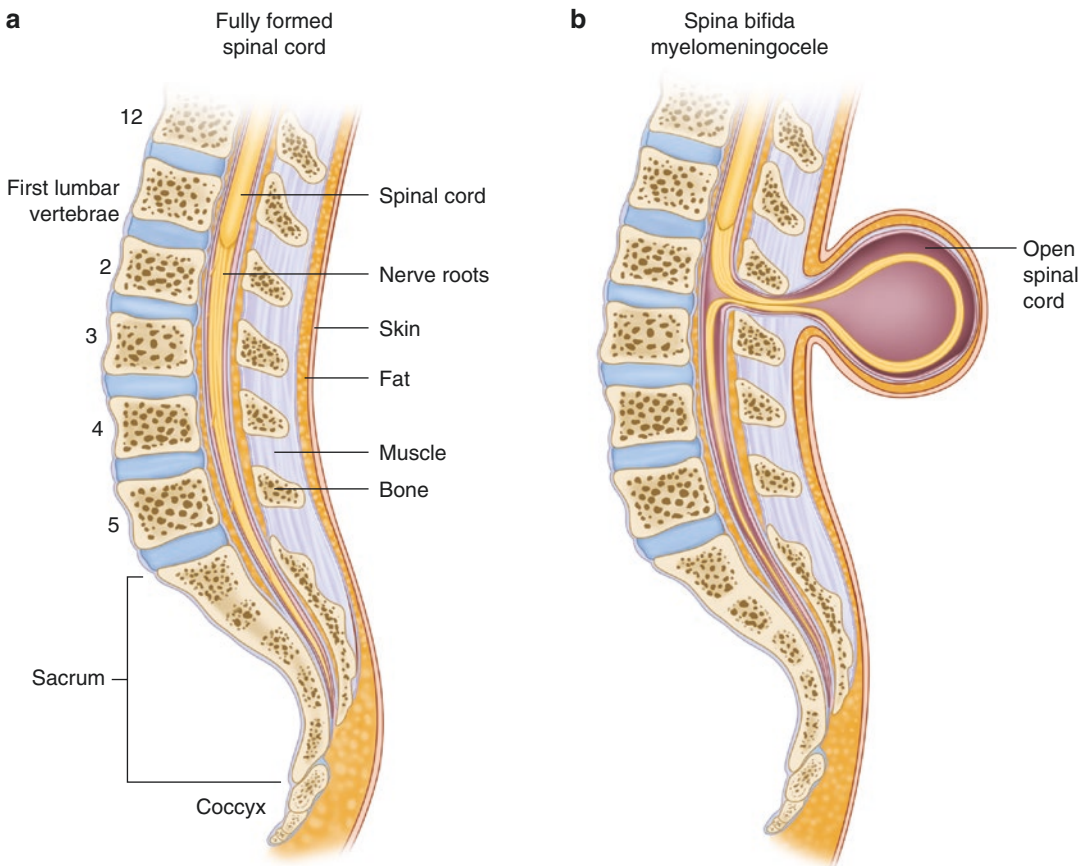
An open neural tube defect is a complex neurological defect of the central nervous system that results in permanent and potentially severe disabilities. This defect is the result of a deficiency in primary neurulation. Open defects include MM, meningocele, encephalocele, and anencephaly.

### 5.7.1 Myelomeningocele

When the spinal column does not fuse together, allowing outward growth of the spinal contents, including cerebral spinal fluid (CSF), spinal cord, nerves lined with meninges, and sometimes skin (Fig. 5.2), this defect in the spine is called a myelomeningocele, and the disease process is

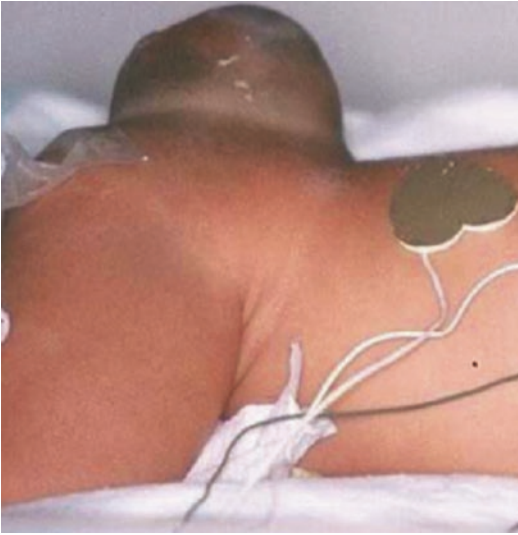spina bifida (Fig. 5.3). The defect can occur anywhere in the spinal axis, with 85 % in the lumbosacral spine, 10 % in the thoracic spine, and 5 % in the cervical spine (Cohen and Robinson 2001).

The prognosis of a myelomeningocele is highly dependent on the size and location of the spinal defect and on the severity of its comorbidities, which include hydrocephalus and Chiari II malformation. The most common clinical complications are paralysis, hydrocephalus, and bowel and bladder incontinence. The survival rate of spina bifida has increased with advanced and more aggressive surgical intervention. Historically, dating back to the 1960s, infants born with spina bifida were managed conservatively without surgery. Many infants died from perinatal problems, hydrocephalus, or infection. A study by Laurence in South Wales evaluated



**Fig. 5.2** Normal spinal cord and myelomeningocele. (a) Anatomic diagram showing normal anatomy of spine and spinal cord. (b) A myelomeningocele defect (Printed with

permission from University of Wisconsin Hospitals & Clinics Authority, Madison, WI)



**Fig. 5.3** Myelomeningocele (Courtesy of Bermans Iskandar, M.D., Director of Pediatric Neurosurgery, University of Wisconsin, Madison, WI)

children born between 1956 and 1962 that were not surgically treated and found that only 11 % of the children survived to 10–16 years of age (Laurence 1974). Although this is a high rate of mortality demonstrating the natural progression of untreated MM, the percentage of survival gave thought to more aggressive treatment. Throughout the 1960s, continued research showed a substantially higher rate of survival for infants who had immediate surgical repair of the MM and surgical treatment of hydrocephalus (Park 1999). Ames and Shut (1972) evaluated 171 patients with myelomeningocele that were treated surgically between 1963 and 1968. They found the survival rate continued to improve, climbing to 50–80 % for children 3–8 years old (Ames and Shut 1972).

Later, in the 1970s and 1980s, the trend for aggressive and immediate surgical intervention continued and became the current standard of care. Throughout the 1990s, researchers learned more about the untoward effects of hindbrain herniation and hydrocephalus to the fetus and the overall impact on lifetime livelihood. Currently, there is the “two-hit” pathogenesis theory of MM. Not only is the incomplete neural tube the cause, but also the exposed part of the cord is further injured during gestation by exposure to

amniotic fluid, direct trauma, and hydrodynamic pressure, especially in the third trimester. This theory brought about the idea of fetal MM surgery (Adzick 2010; Meuli and Moehrien 2014). If the defect can be repaired prenatally, the spinal cord will be protected during remaining gestation and labor. To determine whether early fetal surgery would be a greater benefit than risk, a landmark 7-year National Institutes of Health-funded trial called the Management of Myelomeningocele Study (MOMS) was conducted from 2003 to 2010. The outcome of this study continues to mold and shape the care of these patients. Results of the MOMS two study are due out in November, 2016, which will further guide the direction of care for patients with myelomeningocele.

Today, we understand that although these infants are often born with significant neurological deficits, many have normal intelligence and the capability to enjoy a productive and fulfilling life. Major factors that affect long-term clinical outcomes are intelligence quotient (IQ), ambulatory function, degree of bowel and bladder function, the presence of hydrocephalus, or symptomatic Chiari II malformation, and upward to 20 % may have seizures in childhood (Liptak 1997). Intellectual ability is strongly influenced by the presence and severity of hydrocephalus, the level of the defect and associated handicap, and a history of having central nervous system infection (e.g., meningitis). Individuals with myelomeningocele may have below-average cognitive abilities or mild intellectual disability. It is understood that a lower level lesion may correlate with less motor deficit and higher intellectual capability. The ability to ambulate is directly correlated to the anatomic level of the spinal defect and subsequent neurological deficit. Children with a lower spinal defect have a greater chance of ambulating. Approximately 95 % of children with lower lumbar or sacral level defects can achieve walking, with or without assistive devices (Sakakibara et al. 2003). The ability to ambulate ranges from independent walking, or requiring assistive mobility devices (orthotic braces, crutches, or walker), to complete dependence on a wheelchair (Fig. 5.4e). Bowel and bladder dysfunction is a notable determinant of social acceptance. Some patients may be



**Fig. 5.4** Mobility devices. (a) Solid ankle foot orthosis (AFO). (b) Lofstrand crutches. (c) Posterior walker. (d) Fixed frame lightweight manual wheelchair (Photos courtesy of Jim Miedaner, MS, PT, University of Wisconsin

Hospital & Clinics, Rehabilitation Clinics, Madison, WI), (e) gait trainer (Photo courtesy of Wikipedia Commons and Rifton Products)





**Fig. 5.4** (continued)

incontinent of bowel and bladder, while others can achieve “social continence.”

## 5.7.2 Comorbidities of Myelomeningocele

### 5.7.2.1 Hydrocephalus

Hydrocephalus is the accumulation of cerebral spinal fluid (CSF) inside the ventricles of the brain, causing increased intracranial pressure (ICP). Hydrocephalus can be diagnosed prenatally with an ultrasound or fetal magnetic resonance image (MRI) to determine the presence and severity measured by the size of the ventricles in the fetus. Coniglio et al. (1997) have hypothesized that moderate to severe ventriculomegaly determined by a prenatal high-resolution ultrasound shows a correlation to an overall lower cognitive development quotient (Coniglio et al. 1997). Largely, literature alludes to the fact that progressive hydrocephalus may impinge on brain development. Clinically, it is noted that a higher incidence of hydrocephalus occurs with a high-level myelomeningocele lesion, such as those in the thoracic spine, as opposed to those in the sacral spine.

In the past, up to 90 % of infants with spina bifida required surgical treatment for hydrocephalus (McLone 1998). Beginning in the mid-1990s, more

stringent policies for shunt placement (symptomatic hydrocephalus, severe ventricular dilation at the time of presentation, and/or unequivocal progressive ventriculomegaly after primary closure) were developed in one center, which brought the VP shunt rate down to the 50–60 % range (Chakraborty et al. 2008). In another, fontanelle characteristics, head circumference at birth, and head growth velocity were associated with the need for shunt placement in 75 % of the study participants (Phillips et al. 2014). MOMS (Management of Myelomeningocele Study) showed that with prenatal surgery for closure of myelomeningocele, VP shunt rates dropped to as low as 44 % (Tulipan et al. 2015).

More recent research has shown encouraging findings that support the treatment of hydrocephalus from a myelomeningocele with an endoscopic third ventriculostomy (ETV) and choroid plexus cauterization (CPC) (Warf 2005). An ETV is a procedure to create an opening in the floor of the third ventricle to create free-flowing communication between the ventricular system and basal subarachnoid spaces (Petronio and Walker 2001). A CPC is a procedure that destroys the choroid plexus, where CSF is made within the ventricles. Warf’s most recent study (2011) found that ETV/CPC successfully treated hydrocephalus without any further surgery in 76 % of patients with myelomeningocele and was superior to shunting in regard to the incidence of treatment failure, operative mortality, and infection in over a decade of experience in Sub-Saharan Africa. Please see Chap. 2 for a more in-depth description of Hydrocephalus.

### 5.7.2.2 Chiari II Malformation

A Chiari II malformation is a downward herniation of the posterior fossa structures (medulla and cerebellum) into the spinal canal and is present in nearly all infants with myelomeningocele. This may be the most serious comorbidity as it increases the mortality risk significantly due to potential apnea, stridor, vocal cord paralysis, and difficulty with feeding. It can also cause nystagmus and a lower cranial nerve palsy. Up to 30 % of infants have mild symptoms from compression on the brainstem, feeding difficulties, or gastroesophageal reflux, and fewer have severe symptoms of weak or absent cry, stridor, apnea or color change, drooling, increased tone in the arms and legs, or arching of the neck (Rekate 1999; Sandler 2010).



If untreated, Chiari II can lead to death. Surgical decompression of a Chiari malformation can resolve these symptoms, except when they present immediately after birth, which may indicate irreversible problems from brainstem compromise. The surgery involves removal of part of the upper cervical vertebrae and expansion of the dura overlying the malformation in order to decompress the herniating brain. A review of the MOMS participants at Children's Hospital of Philadelphia showed that the posterior fossa in patients with myelomeningocele is smaller than patients without myelomeningocele. Prenatal surgery resolved both the smaller posterior fossa and the tonsillar herniation (Grant 2011).

Another complication that can occur with the presence of a Chiari II malformation is syringomyelia, which is a fluid-filled cyst (syrinx) that expands within the spinal cord causing neurological symptoms. The center of the spinal cord is a CSF filled canal. This central canal can expand secondary to pressure of spinal fluid. This may occur during prenatal development or as a result of progressive hydrocephalus prior to shunt placement. A syrinx can develop associated with growth, spinal cord tethering, or a shunt malfunction. The presence of the Chiari II Malformation may contribute to the formation of a syrinx. A change in motor and sensory function may be noted at the level of the syrinx and below. This is more fully discussed in Chap. 6.

### 5.7.2.3 Bowel and Bladder Dysfunction

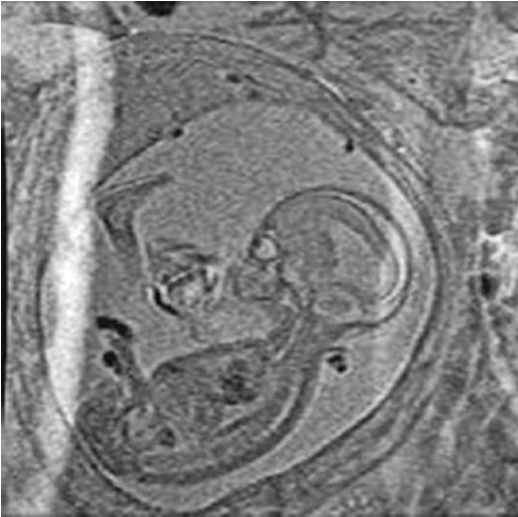
The majority of patients with a myelomeningocele have some degree of neurogenic bladder and bowel dysfunction (Anderson and Travers 1993; Cohen and Robinson 2001). The level of the defect is not always predictive of the degree of dysfunction. A urologist is vital to the multidisciplinary team and will evaluate the kidneys and the bladder integrity (elasticity and filling capacity) and initiate a bowel and bladder maintenance program. Common urological tests to evaluate these concerns are a renal ultrasound, voiding cystourethrogram (VCUG), and urodynamics, known as video urodynamic studies. Often, early management of the bowel and bladder dysfunction begins with baseline diagnostic evaluation and testing throughout the lifetime to prevent deterioration of the urinary tract, preserve current

level of function, and ultimately decrease the risk of renal complications. The primary goal of a neurogenic bladder program is to prevent scarring of the kidneys from increased bladder pressures caused by decreased compliance. The secondary goal is to provide socially acceptable continence or "social continence" in the future. Clean intermittent catheterization (CIC) several times a day has improved regulation of bladder function and resulted in greater social continence.

A sub-study of the MOMS study showed that although prenatal surgery did not significantly change the number of patients requiring CIC, there was less bladder trabeculation and open bladder neck (Brock et al. 2015). The MOMS II study, to be released in November 2016, may include further longitudinal information about bladder continence/incontinence.

### 5.7.3 Prenatal Screening for Myelomeningocele

Prenatal screening is helpful in the detection of an open neural tube defect and is extremely important in planning a timely and safe delivery. Screening and a consequent diagnosis can be determined with a maternal serum alpha-fetoprotein (MSAFP), ultrasound, or amniocentesis (Coniglio et al. 1997). The MSAFP is done between 14 and 21 weeks and is optimal between 16 and 18 weeks of gestation. If this number is higher than the normal value range, it may be an indicator of a possible neural tube defect. This is a screening test, and a normal AFP does not completely exclude the possibility of a myelomeningocele. An ultrasound is done between 15 weeks and up to the end of pregnancy for the assessment of the fetal age and general anatomy of the brain and spine (d'Ercole et al. 2003). If a neural tube defect is found, the patient is referred to a perinatologist for a high-resolution ultrasound and possible amniocentesis. Some medical facilities have the capability to do a prenatal ultrafast MRI of the mother's abdomen for structural assessment of the fetus and the severity of hydrocephalus (Fig. 5.5). Fetal blood sampling and chorionic villi sampling are not useful in the determination of an open neural tube defects.



**Fig. 5.5** MRI of the fetus showing ventriculomegaly (hydrocephalus) (Courtesy of Bermans Iskandar, M.D., Director of Pediatric Neurosurgery, University of Wisconsin Madison, WI)

## 5.7.4 Management

### 5.7.4.1 Medical Management

In many cases, an infant with a myelomeningocele is delivered by a planned cesarean section to minimize trauma to the defect during delivery. The infant is immediately assessed by neonatologists, neurosurgeons, and nurses. Initial evaluation of hydrocephalus is done by palpating the fontanel, measuring a baseline head circumference, and obtaining pertinent imaging. A cranial ultrasound can be helpful to determine a baseline assessment of ventricle size, although a CT or MRI will offer a more detailed assessment of the severity of hydrocephalus. A thorough neurological exam is done, the defect is carefully examined, and the spine is assessed for abnormal curvature. The myelomeningocele may appear as an obvious bubble that sits midline somewhere on the spine, filled with CSF, spinal cord, and nerves, with a membranous covering. It can also appear with a ruptured membrane or as an open defect with no membrane covering. Motor function is assessed by observing upper and lower extremities for spontaneous active movements, symmetry, muscle bulk, and tone. The sensory level is evaluated in the trunk and lower extremities. Assess anal wink (gluteal reflex) as a predictor of bowel control. A thorough preoperative

examination and appropriate diagnostic testing of medical abnormalities are important to ensure the best possible circumstance prior to surgery.

### 5.7.4.2 Surgical Management

#### Fetal Surgical Management

Dating back to the 1930s, infants born with a myelomeningocele underwent postnatal surgery to close the spinal defect. Over the years, it became understood that closure of the defect is optimally done within hours after birth. Delay in surgical treatment can increase both morbidity and mortality because of the increased risk of meningitis. The major goals of surgery are to anatomically restore the already damaged spinal cord, surrounding nerves and tissues, and to ultimately preserve the current neurologic function of the neonate.

For a surgical repair of a myelomeningocele, the infant is placed in a prone position. The neurosurgeon will open the sac, close the neural structures, and then close the dura, the fascia, the subcutaneous tissues, and finally the skin. Some defects are so large or complex that a plastic surgeon is consulted to assist in the closure.

Starting in the 1970s, early sonogram screening allowed the opportunity for serial monitoring of the fetal movement as pregnancy progressed. Physicians began to recognize decreased fetal movement in the legs and feet throughout pregnancy, leading to the idea of progressive damage to the open portion of the exposed spinal cord causing increased neurologic damage. Additionally, it was theorized that the hindbrain herniation may result from leakage of cerebrospinal fluid through the open neural tube during a critical time of posterior fossa formation (Manning et al. 2000).

In 1994, physicians conceptualized early closure of the defect to minimize further neurological damage and began intrauterine repair (Box 5.1). Fetal surgery was improved and performed by talented neurosurgeons in the United States, but the potential morbidity and mortality to both fetus and mother raised the question of whether the overall benefit outweighed the overall risk factors. This question launched a major clinical trial designed to compare the outcome of surgical prenatal repair to that of postnatal repair. The Management of Myelomeningocele Study (MOMS) was a randomized controlled trial funded by the National

### Box 5.1 A Parent's Perspective: Bowel and Bladder Continence

Our son was born with a sacral level myelomeningocele. When others see him, they don't see a child with a disability because he does not have any outward signs of spina bifida. He walks normally and has a shunt, but his biggest struggle is with bowel and bladder continence.

We have tried many things over the past 7 years to achieve bowel and bladder continence. We started catheterizing our son when he was 3.5 years old. We were taught how to catheterize him during a clinic visit and were sent home with supplies and our memory of what we had learned. After a few difficult weeks, we were on our way to a lifelong routine of cathing every 3–4 h. The bowel issues have been extremely difficult. We have tried several types of bowels programs: enemas and drinks that made him gag from the taste or texture. We were diligent patients as we could be with each program, but our emotions went up and down as each new promising method failed. After repeated failure to gain control of the bowel continence, we were told about a surgical procedure called the Malone antegrade continence enema (MACE) to help in bowel flushing.

He had the surgery when he was 8 years old. After surgery, things had improved, but he still has daily struggles. Every day after our son comes home from school, he has just enough time to do his homework and to eat supper before we begin our daily bowel program. We go to the "cinematography room" (what we call our bathroom) equipped with a TV/DVD player that is kept in the bathtub behind the shower curtain. He spends the next hour or more on the toilet while we do the "cleanout" procedure.

Our life revolves around the "cleanouts." He has little time to spend with friends or extracurricular activities, and overnights are almost impossible. We have to plan everything in advance. The stress of his situation is shared by the entire family. It has changed our family routine; mom quit her job to stay

home and tend to medical needs, dad is the sole financial provider for the family, and his little sister feels left out at times.

We hope this helps medical professionals understand what goes on behind the scenes of a family dealing with ongoing medical needs. When doctors tell us, it's time to try something new, we brace ourselves for the implications this will have on our family life for the weeks to come.

Institute of Child Health and Human Development (a part of the National Institutes of Health) conducted between February 2003 and December 2010 at three designated maternal-fetal surgical centers: the University of California in San Francisco, The Children's Hospital of Philadelphia in Pennsylvania, and Vanderbilt University Medical Center in Nashville, Tennessee (Adzick et al. 2011). No other hospitals throughout the United States performed prenatal surgery while the trial was ongoing.

The researchers recruited 183 of a planned 200 pregnant women, and the results were based on 158 women. All women enrolled were to deliver at the designated MOMS center by cesarean section around the 37th week of pregnancy, and surgery was done by a study-approved surgeon. Women were randomly assigned to a prenatal group; one group would undergo fetal repair of myelomeningocele at a MOMS center and were required to stay near the site for the duration of their pregnancy, and the comparison group went home for prenatal care until their return to the MOMS center around the 37th week to undergo conventional surgical repair after birth. Inclusion criteria were that of a singleton pregnancy, a defect from T1 and S1, evidence of hindbrain herniation, and maternal age of at least 18 years. Exclusion criteria were a fetal anomaly other than myelomeningocele, severe kyphosis, risk of preterm labor, placental abruption, a body mass index of 35 or more, and contraindication to surgery (Adzick et al. 2011; Danzer and Flank 2008).

The results were based on 158 children that were evaluated at 12 and 30 months of age on the basis of physical, neurologic, and developmental

testing at the center in which they had either the prenatal or postnatal repair. These children underwent thorough physical examinations, MRI of the head and spine, renal ultrasound and urodynamics, spinal x-ray, and neurodevelopment testing with regard to social, fine, and gross motor skills. One primary outcome at 12 months was a composite of fetal or neonatal death, or the need for cerebrospinal shunting, which occurred in 68 % of the infants in the prenatal surgery group and in 98 % of those in the postnatal surgery group. A second primary outcome at 30 months was a composite score of the mental development and the child's motor function, which also resulted in improvement in the scores collectively. Although the score was based on motor function, there was no significant improvement in mental development alone (Adzick et al. 2011; Danzer and Flank 2008). Overall, reported results compared the prenatal to postnatal group in the rates of shunt placement, no hindbrain herniation, moderate to severe hindbrain herniation, and ability to ambulate independently (Table 5.4). The study was powerful in demonstrating decreased incidence of shunt placement, less severe Chiari II, and increased abilities to ambulate in the prenatal group, yet there were some infants that did not benefit and had poor neuromotor outcome.

Prenatal surgery was associated with increased risk of preterm delivery and uterine dehiscence at delivery. Specifically, the prenatal surgery group had higher rates of complications compared to the postnatal group in both the mother and fetus, such as spontaneous membrane rupture, oligohydramnios, and complications associated with prematurity. More than a third of mothers showed dehiscence

or a thin uterine wall at the hysterotomy site, which increased risk of subsequent pregnancy (Adzick et al. 2011; Simpson and Greene 2011).

The overall results of this study cannot be generalized to all patients with myelomeningocele. It is also recognized that an experienced surgical team is vital for positive outcome of prenatal surgery and that not all geographic locations can provide this level of expertise. These factors, combined with the significance of fetal and maternal risk, support the belief that this option of treatment is a step in the right direction, but may not be considered the gold standard of care in all cases of infants with myelomeningocele.

### Postnatal Surgery

As nurses care for families who have a newborn with a myelomeningocele, it is important to assess the parents' current level of understanding of the disease and their ability or willingness to learn. Although the majority of parents have had time to prepare for the birth if the diagnosis was made through prenatal testing, others may have learned about the diagnosis for the first time after delivery. Obviously, in both instances, this is a stressful and overwhelming time for the family. It is important to educate the family about what to expect during the first hours of their baby's life. The newborn infant will be examined by many professionals to determine the presence of other associated abnormalities such as genetic disorders, cardiac, urologic, or orthopedic problems. Preoperative care of the infant with myelomeningocele may vary at each medical center, but there are many basic similarities: (1) cover the myelomeningocele defect with a sterile saline-soaked dressing and avoid drying of the dressing by keeping it moist; (2) place the infant in a prone or lateral recumbent position until surgery; (3) withhold oral feedings to maintain an "aseptic bowel," thereby decreasing risk of infection to the open defect; (4) administer intravenous antibiotics if ordered by the surgeon; and (5) administer intravenous fluids in lieu of no oral intake until after surgery. Nurses can help a new mother to understand that impending surgery should not be a deterrent to breast-feeding. If the mother is interested in breast-feeding, nurses or a lactation consultant can help to initiate pumping and storing of milk

**Table 5.4** Results of prenatal repair as compared to postnatal repair of children with spina bifida at 12 months of age (Adzick et al. 2011)

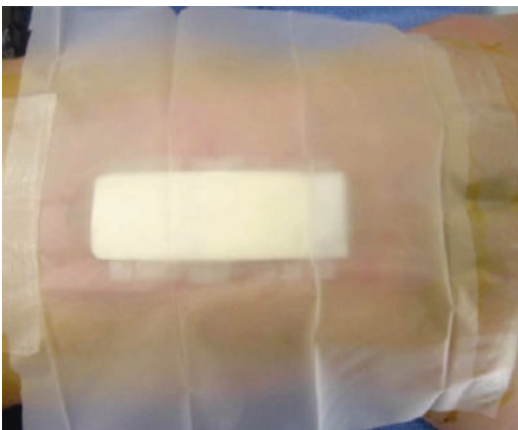Prenatal and postnatal myelomeningocele repair		
	Prenatal (%)	Postnatal
Rates of shunt placement at 12 months	40	82
No hindbrain herniation at 12 months	36	4
Moderate to severe hindbrain herniation	25	67
Walk independently	42	21



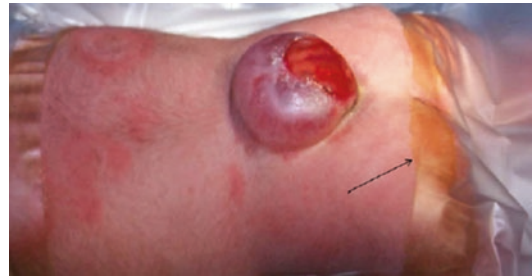until the baby can be put to breast. Last, educate parents about the surgery, anesthesia care, and what to expect for the immediate recovery.

Patients with spina bifida are at high risk for developing a latex sensitivity or allergy. The natural history of a latex allergy is not well understood. It is believed that an allergy or sensitivity to latex develops from repeated exposure in the hospital environment and from multiple surgeries, particularly when latex comes in contact with mucous membranes (i.e., urinary catheter). Latex is a form of rubber derived from a plant source, the *Hevea brasiliensis* tree, and is found in many medical and home supplies. Latex reactions vary from mild contact dermatitis to anaphylactic shock or death (Mazagri and Ventureyra 1999). Latex precautions should always be used for patients with neural tube defects.

Routine postoperative care of the infant after surgery to close the myelomeningocele may include the following: (1) place the infant in a prone or side-lying position for up to 3 days (or per surgeon's preference) to minimize the risk of CSF leaking or wound compromise, (2) cover the incision with a dressing to protect the wound from soiling of urine and feces (Fig. 5.6), (3) administer intravenous antibiotics (per surgeon preference) to minimize risk of infection, and (4) administer intravenous fluids for the first 24 h or



**Fig. 5.6** Example of occlusive dressing and drape. The incision is covered by a 4 × 4 gauze and occlusive dressing. A plastic drape is secured to the *top* of the buttocks and draped over the *back* and torso to avoid soiling from the diaper (Courtesy of Bermans Iskandar, M.D., Director of Pediatric Neurosurgery, University of Wisconsin, Madison, WI)



**Fig. 5.7** Plastic “Mudflap” adhered to skin over buttocks to prevent stool and urine from soiling the myelomeningocele

until the infant is breast-feeding or taking oral feedings well. Lying flat or horizontal keeps CSF distributed somewhat evenly along the spinal cord and decreases pressure on the myelomeningocele closure, allowing it to heal. Breast-feeding can still be accomplished if the baby is positioned horizontally on a pillow on the mother's lap. A “mud flap” placed between the myelomeningocele and the rectum can keep stool out of the incision (Fig. 5.7). If the infant must be placed supine for any reason, a foam “donut” can be placed around the closed myelomeningocele to prevent pressure on the incision.

Beyond the initial postoperative period, it is important to educate the family about care of the infant at home so they feel more confident transitioning out of the hospital. The family is instructed to monitor the infant for signs and symptoms of infection including fever or redness, swelling or drainage from the incisions, and progressive hydrocephalus. Signs or symptoms of hydrocephalus include fullness of the fontanel, irritability, decreased interest in feedings, lethargy, or projectile vomiting. Daily measurement of head circumference is useful to detect rapid head growth. It is equally important to observe the infant for symptoms indicative of problems caused by the Chiari malformation including abnormal breathing, such as stridor, apnea, choking, or gagging. Prospectively, scarring from spinal surgery can result in retethering of the spinal cord that is evidenced by back pain or a change from baseline in bowel and bladder control or degree of mobility. It is important that families understand when to seek immediate medical attention with concerns of progressive hydrocephalus or breathing difficulties.



### 5.7.4.3 Nursing Considerations

Prenatal diagnosis of a chronic and debilitating disease is a time of shock, anxiety, and despair for families. Nurses can play an instrumental role, offering supportive care to prospective parents and families affected with a congenital malformation. This support can be derived by models of care focusing on emotional, spiritual, and social needs that match the affected family needs (Munson and Leuthner 2007). Nurses have a dual responsibility in caring for a patient with special medical needs: the first is to provide quality nursing care to the patient and the second is to care for the emotional needs of the family (Box 5.2). It is important to assess the family's ability to

#### Box 5.2 A Parent's Perspective: An Unexpected Journey

After settling my three small boys for the night, I was beyond my typical nervous laughter when I told my husband that we were expecting our fourth child. I was definitely surprised and cautiously guarded as I wondered how I was going to manage four children under the age of 5. Nothing seemed out of the ordinary, until the day of my scheduled ultrasound. We learned that our baby had spina bifida. We were told of our options: to continue or terminate the pregnancy. After sharing our strong desire to continue the pregnancy, we were told about maternal-fetal surgery. Initially, we were not interested because of the risks involved, but after learning more about some of the promising medical outcomes and the reduced need for a shunt to treat hydrocephalus, we decided to learn more about how the risks outweighed the benefits. We traveled over 1,000 miles away to a center where it was done.

After an agonizing 3-day consultation and medical tests, we decided to undergo the surgery, at 24 weeks' gestation. We hoped that we made a good decision to improve the quality of life for our unborn child. Four days after the surgery as I was flying back home, my thoughts turned to my other children as I looked down at the

terbutaline pump-flowing medicine into my body and keeping me from going into premature labor. Our commitment to surgery required many volunteers, friends, and family to keep things going at home. It seemed to be going alright, but what came later tested my strength and endurance.

My unborn son was doing fairly well until around the 28th week of gestation when I started losing amniotic fluid internally from a tear in my uterus at the surgical site. I was hospitalized until my son's delivery at 34 weeks' gestation. When he was born, his lungs were underdeveloped, and he was immediately placed on a ventilator. He was hospitalized for 3 weeks and sent home on oxygen and oral tube feedings. Ironically, I had met another family during my pregnancy, and they too were expecting a son with spina bifida. He was born a day later than my son, by a planned C-section with surgery immediately after birth. It was hard *not* to compare our babies. I thought about fetal surgery impacted our situation. While their baby had the typical closure at birth and was discharged from the hospital a few days later, my son was still in the neonatal ICU on a ventilator and very sick from prematurity.

Both my son and I had multiple complications as a result of the fetal surgery, and it was one of the most challenging experiences I have gone through. I am glad we had the option of surgery, but my husband and I still wonder if this was the best decision, especially since he ended up requiring a shunt for hydrocephalus. It was difficult to come to terms with having a child with spina bifida. And it was more difficult with the added stressors of having gone through a prenatal surgery, complicated recovery, premature delivery, and our son's ongoing medical issues.

Our son is 4 years old now, and he is doing great and making progress by leaps and bounds. When I look at him, it is hard to believe that he had so many challenges early on in his life.

cope with their stress and emotions; naturally they may feel overwhelmed or in a state of shock (Box 5.3). Nurses can have a positive impact on the commencement of this life-changing event as they offer support and reassurance throughout the process of educating the family. It is important to have a well-organized discharge plan in mind as you care for the infant and family for the remainder of the hospitalization. Nursing education is best achieved by the use of a variety of teaching modalities: written materials and verbal instruction and demonstration as you are prepare a family for discharge.

**Box 5.3 A Parent's Perspective:  
A Myelo – What?**

My second pregnancy seemed to be going along without complications. The triple screen was negative, and I had three ultrasounds, ordered by my physician: the first to confirm a due date, second for routine screening at 20 weeks' gestation, and a third late in pregnancy to evaluate amniotic fluid; they were all "normal"! However, the day my daughter was born was the day we learned that she had spina bifida.

After a short, but difficult delivery, the medical staff whisked away a somewhat "purple" looking newborn to the next room with my husband following behind. After several moments of silent panic, I sighed in relief as I heard her cry for the first time. "Thank You, God." I remember mumbling as the doctor worked to repair the trauma my body had endured. Several more minutes passed before a very calm and reassuring female neonatologist approached my bedside to inform me that my daughter had a lesion on her back called a myelomeningocele. A myelo-what, I thought to myself? She explained that my daughter would need surgery to repair the lesion as soon as possible. They gave me a quick peek at my daughter, and then they took her to neonatal intensive care to prepare her for surgery.

My husband and I sat together in a quiet hospital room. He tried to explain what the surgeon had told him about the surgery and complications of hydrocephalus and the possibility of needing a shunt. The staff gave us a book and some other literature to read as we waited for her to get out of surgery. I hadn't even held my daughter, and here I was, looking at lifeless diagrams and words that would affect the rest of our lives. Although we knew this was important information, nobody wants their child defined by a book or pamphlet. We didn't need to know that this happens one in every 1,000 births. When it comes to any newborn, it is more important for medical professionals to remember that the "human connection" needs to come first. What we needed, right then, was to know that our daughter was going to be ok. We didn't need a book to tell us who our daughter was. We knew that she would show us who she is and that each detail would emerge in its own order, not like a book divided neatly into chapters.

From our experience, we believe that medical professionals should pass on information with great compassion. Preface the information with the fact that all cases are based on the individual and the unique characteristics of the type of myelomeningocele they have. Shortly after birth, we told our pediatrician that "She is going to write her *own* book, the story of *her* life, and Spina Bifida will only be part of it." Now 5 years old, each day we learn that our daughter has defied many of the "statistics" that we first read about.

#### 5.7.4.4 Care Coordination

Myelomeningocele is a complex congenital condition that is static. There are changes which occur as a result of growth and development which need to be evaluated and monitored. Any changes occurring need to be evaluated as normal growth and development or potentially problematic due to

pathology. Changes require prompt evaluation and exploration to define the cause. Hydrocephalus, Chiari malformation, syrinx, and tethered spinal cord may contain symptoms that overlap. Issues in one area may suggest a problem in another area. For example, increased Chiari symptoms may be related to shunt function. An increase in the size of a syrinx may be related to the shunt function or a tethered spinal cord. A shunt malfunction may present as a variety of symptoms. A urinary or bladder infection may present as headache or like a shunt malfunction. Constipation may affect the efficiency of ventriculoperitoneal shunt function and may present as possible shunt malfunction. A thorough evaluation and consideration of all symptoms is needed to order to understand changes in this complex condition.

A multidisciplinary care approach is vital for long-term management of the complex medical needs of a child with spina bifida. The team often consists of a neurosurgeon, orthopaedic surgeon, rehabilitation specialist, urologist, nurses or nurse practitioners, physical and occupational therapists, nutritionist, social worker, child life specialist, orthotist, wound specialist, and a psychologist. Sometimes, collaborative care with neurology, neuropsychology, and endocrine specialists is required. This approach to healthcare is essential to offer each child the greatest potential to lead a healthy and productive life. The multi-specialty team works closely with the patient's Primary Care Provider and Medical Home to coordinate care so the patient and family can achieve optimal function.

The primary provider and the parents/guardians are the first observers and monitors of growth, development, and change. The primary providers are the coordinators of the specialty care while providing standard primary care. The neurosurgeon and neurosurgery team provide the primary closure of the defect. They continue to monitor and manage hydrocephalus, monitor the developing nervous system, and observe for changes. Physical evaluations are needed as well as periodic imaging studies. The urologist and urology team manage and monitor the developing urologic system. Bladder studies, renal and bladder ultrasound, urodynamic testing, and

voiding cystourethrogram, measure the functional ability of the bladder and identify kidney involvement. The orthopedist and the orthopedic team monitor and manage skeletal development. Unbalanced muscle tone affects bone and joint alignment. Club foot, talipes equinovarus, may be present at birth and requires early orthopedic evaluation. This may be managed by serial casting or require eventual surgical intervention. The orthopedic team provides ongoing monitoring for developmental changes affecting bone and joint alignment with particular consideration to effect on function.

---

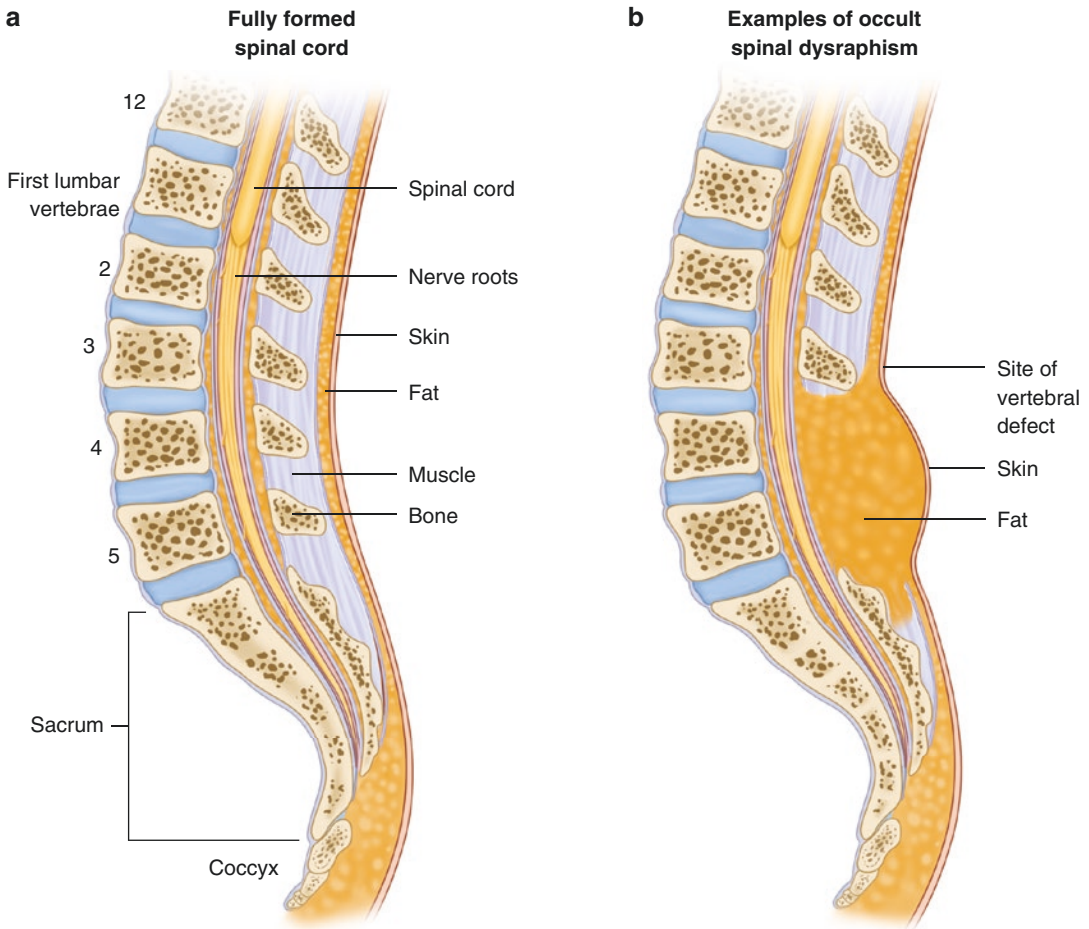
## 5.8 Other Open Defects

### 5.8.1 Meningocele

Meningocele is another type of spina bifida. It is like MM in the sense that there is a protruding sac along the spinal column, but the sac only contains fluid and not any nerves or part of the spinal cord (Fig. 5.8). Although it may cause minor disabilities, it rarely results in any serious long-term health consequences if repaired. Surgery is typically performed within 2 days after birth to prevent infection. The surgical procedure is similar to but less complex than that for MM, as the neurosurgeon does not have to deal with the spinal cord and nerves. In general, the excess CSF drained from the sac, any damage near the spinal cord is repaired, and the opening in the back is closed. It is possible that a tethered cord will subsequently develop at the site of the repair, so the patient will need to be followed periodically. Nursing care is similar to that for myelomeningocele. Mothers should be educated about taking 4 mg of folic acid daily to protect against another NTD in a later pregnancy.

### 5.8.2 Encephalocele

Encephalocele, a neural tube defect of the skull, presents as a saclike structure containing the brain and other neural elements protruding through a midline gap of the bone. This most



**Fig. 5.8** Normal spinal cord and occult spinal dysraphism. (a) Anatomic diagram showing normal anatomy of spine and spinal cord. (b) Spinal cord with closed neural

tube defect (Printed with permission from University of Wisconsin Hospitals & Clinics Authority, Madison, WI)

commonly occurs at the occiput in the United States but also occurs between the skull and nasal bones or at the top of the head. Cleft palate may also be involved, with protrusion of the brain into the oral cavity. Occipital encephalocele carries the highest mortality. According to the CDC, about 1 in 10,000 babies born in the United States have some form of encephalocele. Females are more likely to have an encephalocele at the back of the head, whereas males are more likely to have them in the front of the skull. Surgical correction is complex but essentially involves opening the skull and dura, placing the brain tissue back into the skull, repairing the dura, and removing the sac. Prognosis depends upon the type of

brain tissue involved, the extent of damage to that tissue, whether the brain can reorganize to accommodate that damage, and any other brain malformations that may have occurred. Encephalocele is associated with Chiari III malformations.

### 5.8.3 Anencephaly

Anencephaly is the most serious and second most common neural tube defect. It results from the failure of the rostral end of the neural tube to close properly. The neonate is born with part of one or both cerebral hemispheres of the brain

absent and not covered by skull. The infant can have an intact brainstem which may allow vital function to continue for a short period, although these infants are often stillborn or die within days after birth. This is not technically a neurosurgical condition, as there is no viable medical or surgical treatment. As previously noted, the prevalence of anencephaly has been reduced following mandatory folic acid fortification. Nursing care consists primarily of support for the parents.

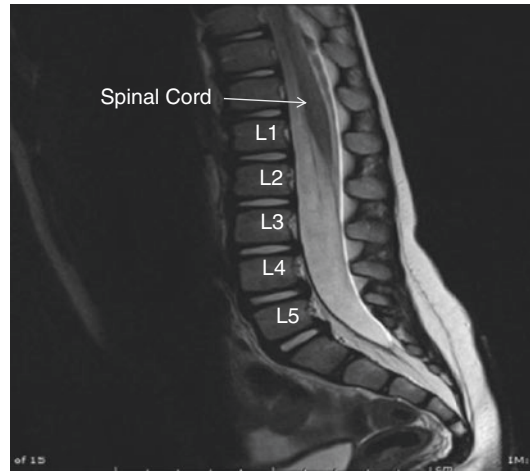
### 5.9 Spina Bifida Occulta (Closed Defect) and Tethered Cord Syndrome

A closed neural tube defect may be called either spina bifida occulta or occult spinal dysraphism (OSD). It results from the incomplete formation of the bony spine ring and predominantly occurs in the lumbosacral spine. A closed defect is less devastating than an open defect, but can result in a progressive and possibly permanent disorder known as tethered cord syndrome. There are a spectrum of clinical abnormalities of OSD, and each has a different clinical presentation. These abnormalities include a lipoma or lipomyelomeningocele, dermal sinus tract, split cord malformation (diastematomyelia or diplomyelia), dermoid cysts and tumors, and a tight or fatty filum terminale.

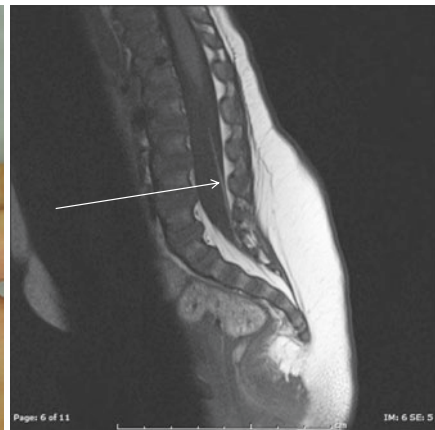
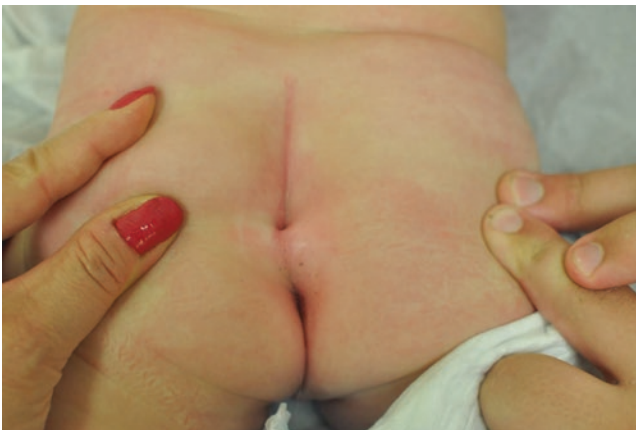Normally, the end of the spinal cord (conus medullaris) floats freely in the spinal column (Fig. 5.9). At birth, the conus is located at verte-

bral level L3 and ascends to its normal position of vertebral level L1–2 by 2–3 months of age. A tethered cord is characterized on imaging by a conus medullaris that is positioned abnormally low in the spinal canal because it is attached to the surrounding structures (Dias and Partington 2015). There is a persistent anatomic connection between the neuroectoderm and the cutaneous ectoderm that causes this attachment or tethering (Fig. 5.10).

Tethering can occur anywhere along the spinal cord depending on the level of the dysraphism. The tethering can also be caused by scarring from infection or trauma, keeping the spinal cord from hanging freely in the spinal canal. Once a tethering has occurred, the spinal cord stretches



**Fig. 5.9** Normal termination of the spinal cord



**Fig. 5.10** Patient with sacral dimple and sagittal spine MRI showing fatty filum and tethered cord



abnormally as the child grows. This abnormal stretching of the cord causes decreased blood flow, diminished oxidative metabolism and glucose utilization, and metabolic failure at the level of the mitochondrial respiratory chain. This in turn causes the neurological deficits seen in children with a tethered cord. The degree of impairment correlates with the degree and duration of the stretching of the cord (Yamada et al. 2004, 2007). The prognosis of tethered cord syndrome is good when it is diagnosed and surgically treated before neurological deficits occur.

### 5.9.1 Clinical Presentation

Unlike the open defect, the clinical presentation of OSD is variable. In the majority of patients, signs are obvious on examination, but in some cases, there are no signs until symptoms occur. The common presentation of signs and symptoms are a skin lesion, pain or weakness of the legs, back pain, change in bowel or bladder control, or orthopedic problems such as scoliosis. The majority of patients diagnosed with a tethered cord will present with one or more of the six characteristic skin lesions of OSD. These are a hemangioma, hypertrichosis, atretic meningocele, dermal sinus tract, subcutaneous lipoma, or a caudal appendage. Other medical problems that have an association with tethered spinal cord are imperforate anus, cloacal exstrophy, and history of previous spinal surgery. Previous spinal surgery, such as myelomeningocele repair, causes scar tissue and subsequent risk of retethering of the spinal cord. The incidence for a patient with a myelomeningocele to retether at some point in their lifetime is 15–20 % (Gaskill 2004).

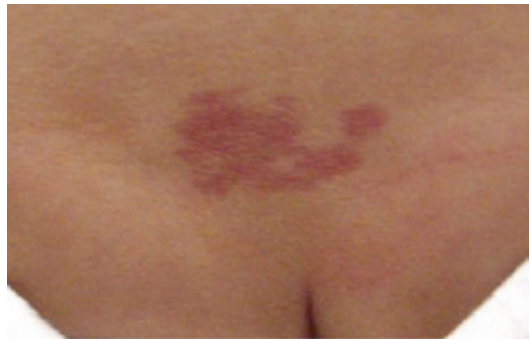#### 5.9.1.1 Cutaneous Anomalies of OSD

One or more of the six characteristic cutaneous lesions occur in up to 70 % of patients diagnosed with a tethered spinal cord (James and Lassman 1981). All midline lesions on the spine are clinically significant for a possible tethered cord, making it important to distinguish between abnormal and benign skin markings. All the skin lesions described in the section to follow are

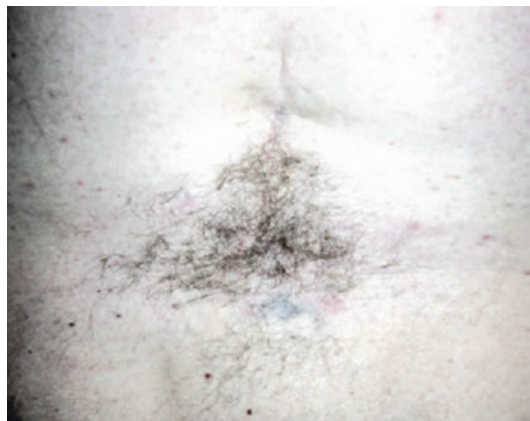clinically significant for OSD when observed on the back and located in the midline lumbosacral spine.

A *hemangioma* is a flat or raised, pink or red skin lesion that consists of capillary vessels (Fig. 5.11). The examiner needs to distinguish differences between common skin findings and a true hemangioma. For example, infants commonly have a nevus at the base of the skull called a “stork bite” (nevus flammeus), which is benign. A Mongolian spot (a pigmented black or blue spot) or a nevus (pigmented circumscribed area on skin) may be found in the lumbosacral region and has no clinical significance for OSD.

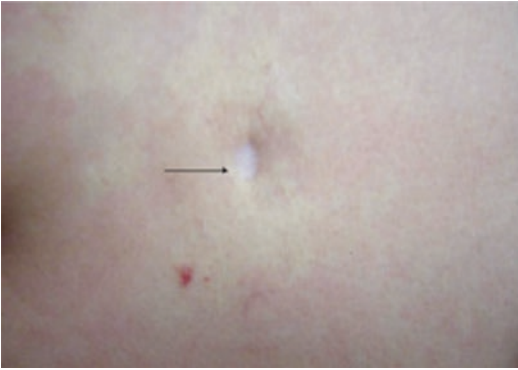
*Hypertrichosis* is a localized patch or tuft of hair (Fig. 5.12). Hair that is localized and sometimes diffuse is “baby” hair that dissipates over



**Fig. 5.11** Lumbar hemangioma (Courtesy of Bermans Iskandar, M.D., Director of Pediatric Neurosurgery, University of Wisconsin, Madison, WI)



**Fig. 5.12** Hypertrichosis (Courtesy of Bermans Iskandar, M.D., Director of Pediatric Neurosurgery, University of Wisconsin, Madison, WI)

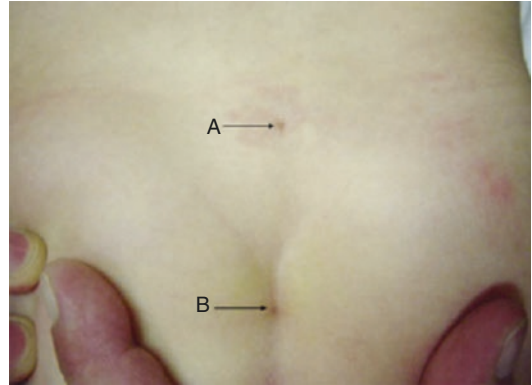


**Fig. 5.13** Atretic meningocele (Courtesy of Bermans Iskandar, M.D., Director of Pediatric Neurosurgery, University of Wisconsin, Madison, WI)

the first months of life and is not indicative of OSD. Hypertrichosis is highly correlated to the malformation called diastematomyelia, which is a split or double spinal cord (James and Lassman 1981).

An *atretic meningocele* (*meningocele manque*) is a skin lesion that looks like a scar and is sometimes called a “cigarette burn” (Fig. 5.13). The skin over this lesion may be sensitive to touch. An atretic meningocele presumably indicates that a meningocele (malformation of the meninges) was once present during fetal life and had partially repaired itself. The lesion can be connected to the spinal cord by a tract of fixed fibrous band that extends from the skin to the spinal cord. It is often connected to underlying structures by a subcutaneous tract lined with epithelium, bone, dura, or the spinal cord.

A *dermal sinus* is a small hole or opening in the skin that appears as a dimple and lies along the midline, most often at S2. It is the result of a remnant of cutaneous ectoderm attached to the neuroectoderm at primary closure of the neural tube. It appears most often as a dimple well above the upper end of the gluteal cleft (Ackerman and Menezes 2003). An innocent coccygeal dimple is more caudally located and usually is invisible unless the buttocks are parted (Fig. 5.14). Generally, if a dimple appears above an imaginary line between the tops of the two forks of the gluteal cleft, it is abnormal (Fig. 5.15). If it appears below this line, it is most likely benign (Dias and Partington 2015).



**Fig. 5.14** Dermal sinus and sacral dimple. (a) Dermal sinus with flat hemangioma. (b) Sacrococcygeal dimple (Courtesy of Bermans Iskandar, M.D., Director of Pediatric Neurosurgery, University of Wisconsin, Madison, WI)

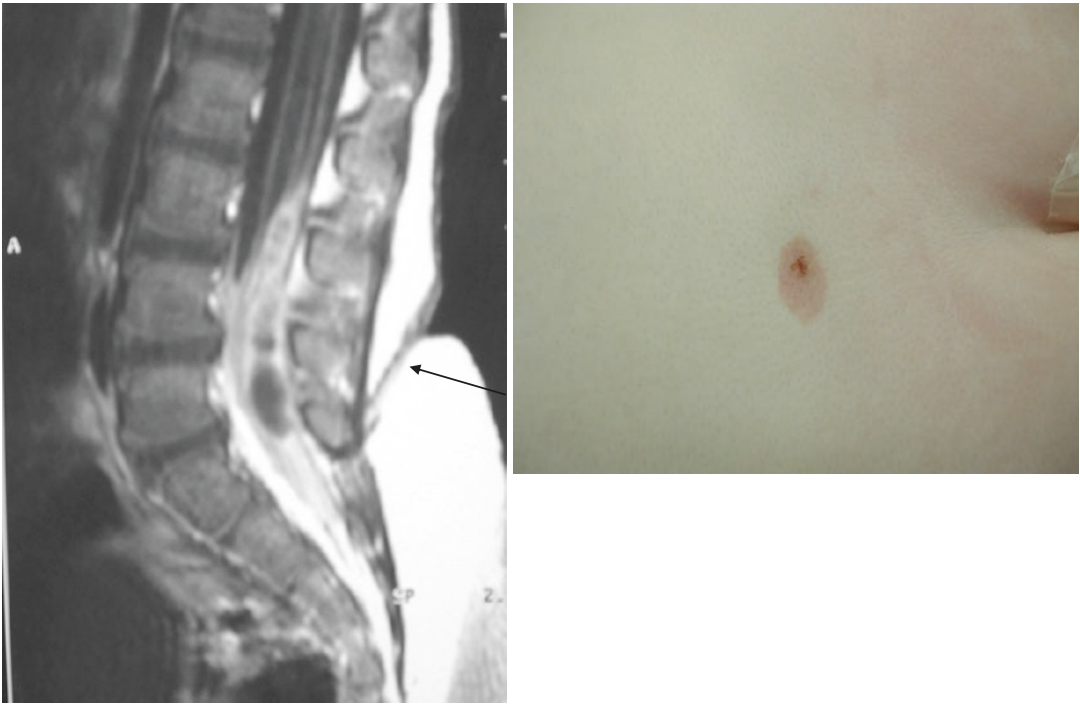A *lipoma* or *lipomyelomeningocele* is a soft tissue mass that is completely covered with skin (Fig. 5.16). It can grow larger over time as fat grows in proportion to the patient’s body weight. A lipoma or lipomyelomeningocele may be an extension of an intramedullary mass within the spinal cord.

A *caudal appendage* appears as a tail or “pseudotail” which presents as a skin-covered round structure that is attached to the skin of the back (Fig. 5.17). It can be discolored or covered with hair, and sometimes it contains cartilage, fat, or other organ-specific tissues. In contrast, a “true” human tail is the remains of an embryonic structure that may contain vertebrae, spinal cord, notochord, sacral artery and vein, muscle, fat, or connective tissue.

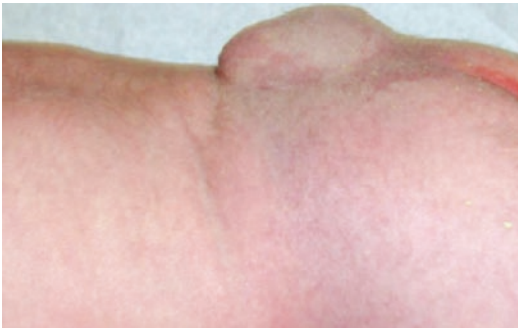
*Asymmetrical gluteal folds* may also be an indication of a tethered cord.

### 5.9.1.2 Orthopedic Findings of OSD

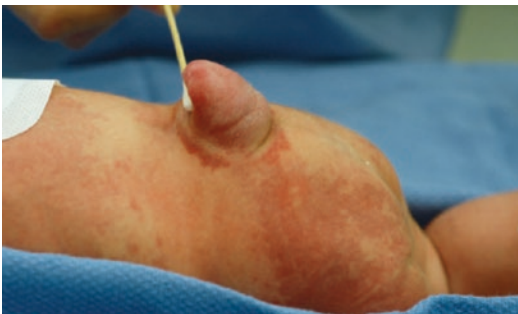The orthopedic signs of OSD may vary and are not always identified at birth. In fact, clinical signs or symptoms may not be evident until a child has a growth spurt or is walking. Scoliosis or kyphosis, asymmetry of the legs and feet, or deformities of the feet are signs of OSD. For example, one calf may be thinner, and the foot on the same side may be smaller or have a higher arch or hammering of the toes. Another orthopedic finding is asymmetry of the buttocks,



**Fig. 5.15** Cutaneous dimple above the gluteal cleft and sagittal MRI of lumbar spine showing dermal sinus tract



**Fig. 5.16** Lipomyelomeningocele (Courtesy of Bermans Iskandar, M.D., Director of Pediatric Neurosurgery, University of Wisconsin, Madison, WI)



**Fig. 5.17** Pseudotail

identified by lateral curve of the upper part of the gluteal crease. On examination, evaluate the spine for abnormal curve, and assess soles of the feet for asymmetry, difference in size or arch, unilateral or bilateral club feet, or for the presence of valgus or varus positioning. If the child is walking, evaluate for inversion or forefoot adduction. It is important to identify the underlying cause of orthopedic anomalies and refer to a specialist for further evaluation if appropriate. Last, vertebral deformities are commonly present with OSD and include anomalies of the laminae, vertebral bodies, disk space, pedicles, or sacrum (sacral agenesis/dysgenesis).

### 5.9.1.3 Urologic Dysfunction of OSD

Urinary dysfunction may be the first sign of OSD if it has not already been diagnosed from other presenting signs and symptoms. Bladder dysfunction occurs from neurologic injury or defective development of the spinal cord. The overall incidence of urinary problems associated with OSD is not clear. Urinary symptoms may not be evident until a child cannot learn to toilet train. In the presence of OSD, bladder dysfunction can

present at any time throughout life as urgency, urinary retention, or enuresis (Sakakibara et al. 2003). Another presenting sign of OSD can be recurrent urinary tract infections.

## 5.9.2 Management

### 5.9.2.1 Surgical Management

Surgery is the treatment of choice for OSD to prevent future neurological deterioration or complications from a tethered spinal cord. There is little data in the literature that compares the natural progression of OSD to cases that are treated surgically, due to ethical considerations of conducting such studies. It is known, however, that management without surgery can be associated with neurological deterioration and that surgical intervention can halt this progression and sometimes improve function. Early surgical treatment is important to prevent permanent neurological deficits, and surgery can be done any time after birth. The surgical procedure is called a “tethered cord release,” and it releases the spinal cord so that it can hang freely in the spinal column. Intraoperative monitoring, somatosensory evoked potentials (SSEPs), electromyography (EMG), and bladder cystometry are done to monitor the bladder, anal sphincter, and nerve conduction to the lower extremities. Overall, the outcome of surgery is positive. There are many research studies that demonstrate low risk of developing neurological deterioration from the surgery (Anderson 1975; James and Lassman 1981; Keating et al. 1988).

### 5.9.2.2 Medical Management

After surgery, the patient is followed by a neurosurgeon and urologist. The urologist monitors bowel and bladder function through the use of diagnostic testing if necessary. Urodynamic testing is the most sensitive indicator for tethered cord. The neurosurgeon monitors neurological status through examination and surveillance with imaging of the lumbar sacral spine postoperatively. Future radiographic imaging is done if there is a return of symptoms suggestive of re-tethering of the spinal cord. If there are chronic problems with lower extremity weakness or difficulties

with ambulation, a rehabilitation physician or physiatrist will provide continued medical care.

## 5.9.3 Nursing Considerations

In a patient with inability to toilet train with or without chronic constipation, the possibility of tethered cord must be considered. An enuresis work up often will find urodynamic abnormalities leading to the diagnosis. New foot deformities in a patient with a known spinal defect can also be one of the first indications of tethering.

The diagnosis of any medical condition is stressful for the patient and family. Nurses can guide families through this process while promoting a positive experience. It is important to provide age-appropriate education to the patient and family about the tethered cord, diagnostic testing, and about referrals, if any, to other specialists. Many parents are concerned about the surgery and the possibility of a permanent bowel and bladder deficit or weakness in the lower extremities.

The preoperative nursing care of a patient with TCS is limited. After the diagnosis is made, appropriate referrals and outpatient diagnostic studies are done. Presenting symptoms determine whether or not surgery for detethering needs to be performed sooner rather than later. Loss of previous bladder function usually indicates surgery is to be performed as soon as possible. However, usually repair of a tethered cord is not an emergency, and the patient may need to limit activities until surgery is scheduled. Prior to surgery, the patient should avoid repetitive flexion and extension of the spine or sudden forceful movements of the body. Back or leg pain is managed with oral medications. Many surgeons will withhold NSAIDs for up to 1 week prior to surgery to minimize intraoperative bleeding.

The postoperative care of a patient with a tethered cord is similar to that of a patient with a myelomeningocele (Table 5.5). As with any hospitalized patient, it is important to have a discharge plan in mind as you prepare the patient and family for transition to home. The family is instructed to monitor their child for signs and symptoms of infection including fever or wound changes of drainage, swelling, or redness and to



**Table 5.5** Postoperative care guidelines tethered cord release

Observe for adverse effects from anesthesia (irritability, nausea, vomiting)
Assess pain and medicate as needed
Obtain frequent vital signs and neurologic checks
Keep the head of bed flat for up to 5 days to minimize risk of CSF leak
Log roll every 2 h
Apply protective barrier to incision to avoid exposure to stool or urine
Observe dressing frequently for discharge; if present observe amount, color and notify surgeon
Administer IV hydration until taking PO fluids well
Foley catheter care if needed
Latex precautions (if applicable)

notify medical staff immediately with concerns. After a surgery for tethered cord release, when applicable, the child is to avoid all contact sports for a minimum of 4–6 weeks.

## 5.10 Diagnostic Studies for Neural Tube Defects

An ultrasound is low cost and often readily available. It can be used for screening of OSD in newborns before 5–6 months of age, before the posterior elements of the spine are ossified, which obstructs visualization of the spinal cord (Hughes et al. 2003; Korsvik and Keller 1992). An ultrasound, however, does not show the detail for complex anatomy of the spine and possibly the complicated spinal cord abnormalities associated with tethered cord. Postnatal ultrasound is not a common diagnostic test for a myelomeningocele.

### 5.10.1 Radiographic Imaging

Evaluation with plain radiograph anteroposterior (AP) and lateral views of the affected part of the spine can be helpful in determining vertebral anomalies. This is beneficial as an initial screening for OSD but is not diagnostic in either the open or closed defect.

An MRI is a noninvasive and radiation-free test that is commonly used for screening of spinal anomalies. It shows complete and clear anatomical

detail of the spine, spinal cord, filum terminale, fat, tumors, or dermoids (Figs. 5.10 and 5.16). A disadvantage to traditional MRI is that it takes a long time and may require sedation of the infant.

A CT scan is an excellent screening tool for detail of bony anatomy. It is commonly used for the diagnosis of hydrocephalus in a patient with a myelomeningocele. A CT scan is quick and does not require sedation; however, there is exposure to radiation with each scan.

## 5.11 Transition to Adulthood

Due to advanced medical technology, patients with neural tube defects are living longer healthier lives. Advanced urologic care and clean intermittent catheterization prevent the severe and end-stage renal disease due to high bladder pressures seen in earlier generations. Shunted hydrocephalus and the radiologic technology to monitor this complication have reduced the number of deaths due to increased intracranial pressure and herniation. Improved spinal surgery technologies are preventing the loss of pulmonary function due to severe scoliosis. Consequently, clinics are finding their patients' need to transition to adult care.

There has been an emphasis on patient acquisition of life skills and assessment of patient readiness to transition to adult medical providers. Evaluation of this readiness can be calculated with questionnaire tools such as the STARx (Cohen et al. 2015) or the TRAQ (Transition Readiness Assessment Questionnaire). Common components of transition clinics include a transition coordinator, a specific transition program, and educational materials (Davis et al. 2014). Some are specifically nurse-led (Betz et al. 2016). There is agreement that such programs are needed, but evaluation of goals to determine success has yet to be established.

### Conclusion

Neural tube defects affect thousands of children in the United States each year. Over the past five decades, there have been progressive changes in medical practices, and we have



observed greater longevity and overall improved quality in the life in these patients. A major breakthrough in research proved that prenatal folic acid use can prevent the incidence of neural tube defects in up to 70 % of children. Recent studies on prenatal surgery demonstrated improvement of the severity of comorbidities of myelomeningocele, and although there are untoward risks to both the fetus and mother, this study demonstrates advancement in care for these patients. Continued advances in our knowledge of timely treatment and appropriate diagnostic tests for occult spina bifida can decrease the occurrence of long-term neurological deficits.

In conclusion, spina bifida and spina bifida occulta can be devastating to the lives of many children. Through the continued research and implementation of evidence-based practice, we can continue to make great strides in the treatment of this potentially devastating neurological disorder.

#### Pediatric Practice Pearls

1. Become familiar with the multidisciplinary care needs of a patient with spina bifida to better address their educational and emotional needs while providing holistic nursing care.
2. Cover the surgical incision with an occlusive dressing and rectangular drape secured to the buttocks under the top of the diaper and drape upward over the back to avoid soiling from feces and urine.
3. Provide timely nursing education through a variety of teaching modes at a time that is “right” for the family. An overwhelmed parent has less readiness to learn. Observe nonverbal cues in order to pace your “teachable moments.”
4. Suspect OSD whenever child presents with a cutaneous anomaly on the lower back.

## References

- AAP Policy Statement Committee on Genetics (1999, Reaffirmed 2012), American Academy of Pediatrics: folic acid for the prevention of neural tube defects. *Pediatrics* 104(2):325–327
- Ackerman LL, Menezes AH (2003) Spinal congenital dermal sinuses: a 30 year experience. *Pediatrics* 112(3 pt 1):641–647
- Adzick NS, Thom EA, Spong CY, Brock JW III, Burrows PK, Johnson MP, Howell LJ, Farrell JA, Dabrowiak ME, Sutton LN, Gupta N, Tulipan NB, D’Alton ME, Farmer DL (2011) A randomized trial of prenatal versus postnatal repair of myelomeningocele. *N Engl J Med* 364(11):993–1004
- Adzick NS (2010) Fetal myelomeningocele: natural history, pathophysiology, and in-utero intervention. *Semin Fetal Neonatal Med* 15(1):9–14
- Ames MD, Shut L (1972) Results of treatment of 171 consecutive myelomeningoceles, 1963 to 1968. *Pediatrics* 50:466–470
- Anderson FM (1975) Occult spinal dysraphism. A series of 73 cases. *Pediatrics* 55:826–835
- Anderson PA, Travers AH (1993) Development of hydro-nephrosis in spina bifida patients: predictive factors and management. *Br J Urol* 72:958–961
- Betz CL, Smith KA, Van Speybroeck A, Hernandez FV, Jacobs RA (2016) Movin’ on up: an innovative nurse-led interdisciplinary health care transition program. *J Pediatr Health Care* 30(4):323–338
- Brock JW 3rd, Carr MC, Adzick NS, Burrows PK, Thomas JC, Thom EA, Howell LJ, Farrell JA, Dabrowiak ME, Farmer DL, Cheng EY, Kropp BP, Caldamone AA, Bulas DI, Tolifaisa S, LS B, MOMS Investigators (2015) Bladder function after fetal surgery for myelomeningocele. *Pediatrics* 136(4):e906–e913
- Canfield M, Mai C, Wang Y, O’Halloran A, Marengo L, Olney R, Borger C, Rutkowski R, Fornoff J, Irwin N, Copeland G, Flood T, Meyer R, Rickard R, Alverson C, Sweatlock J, Kirby R (2014) The association between race/ethnicity and major birth defects in the United States, 1999–2007. *AJPH* 104(9):e14–e23
- Centers for Disease Control and Prevention (2004) Spina bifida and anencephaly before and after folic acid mandate – United States, 1995–1996 and 1999–2000. *MMWR Morb Mortal Wkly Rep* 53(17):362–365
- CDC (2015) Updated estimates of neural tube defects prevented by mandatory folic acid fortification – United States, 1995–2011. *MMWR* 64(01):1–5
- Chakraborty A, Crimmins D, Hayward R, Thompson D (2008) Toward reducing shunt placement rates in patients with myelomeningocele. *J Neurosurg Pediatr* 1(5):361–365
- Cohen AR, Robinson S (2001) Early management of myelomeningocele. In: McLone DG (ed) *Pediatric neurosurgery; surgery of the developing nervous system*. W.B. Saunders Company, Philadelphia, pp 241–259
- Cohen SE, Hooper SR, Javalkar K, Haberman C, Fenton N, Lai H, Mahan JD, Massengill S, Kelly M,

- Cantú G, Medeiros M, Phillips A, Sawicki G, Wood D, Johnson M, Benton MH, Ferris M (2015) Self-management and transition readiness assessment: concurrent, predictive, and discriminant validation of the STARx questionnaire. *J Pediatr Nurs* 30(5):668–676
- Coniglio SJ, Anderson SM, Ferguson JE (1997) Developmental outcomes of children with myelomeningocele: prenatal predictors. *Am J Obstet Gynecol* 177(2):319–324
- d'Ercole C, Shojai R, Desbriere R, Chau C, Bretelle F, Piechon L (2003) Prenatal screening: invasive diagnostic approaches. *Childs Nerv Syst* 19:444–447
- Danzer E, Flank AW (2008) In utero repair of myelomeningocele: rationale, initial clinical experience and a randomized controlled prospective clinical trial. *Neuroembryology Aging* 4:165–174
- Davis AM, Brown RF, Taylor JL, Epstein RA, MPheeters MI (2014) Transition care for children with special healthcare needs. *Pediatrics* 134:900–908
- Deak KL, Siegel DG, George TM, Gregory S, Ashley-Koch A, MC S, NTD Collaborative Group (2008) Further evidence for a maternal genetic effect and a sex-influenced effect contributing to the risk for human neural tube defects. *Birth Defects Res A Clin Mol Teratol* 82(10):662–669
- Detrait ER, George TM, Etchevers HC, Gilbert JR, Vekemans M, Speer MC (2005) Human neural tube defects: developmental biology, epidemiology, and genetics. *Neurotoxicol Teratol* 27:515–524
- Dias M, Partington M (2015) Congenital brain and spinal cord malformations and their associated cutaneous markers. *Pediatrics* 136:e1105
- Elwood JM, Little J, Elwood JH (1992) *Epidemiology and control of neural tube defects*. Oxford University Press, Oxford
- Federal Register (2016) Food Additives Permitted for Direct Human Consumption; Folic Acid 81(73): 22176–83
- Finer LB, Zolna MR (2016) Declines in unintended pregnancy in the United States, 2008–2011. *N Engl J Med* 374:843–852
- Gaskill SJ (2004) Primary closure of open myelomeningocele. *Neurosurg Focus* 16(2):1–4
- Grant RA, Heuer GG, Carrion GM, Adzick NS, Schwartz ES, Stein C, Storm PB, Sutton LN (2011) Morphometric analysis of posterior fossa after in utero myelomeningocele repair. *J Neurosurg Pediatr* 7(4):362–368
- Honein MA, Paulozzi LJ, Mathews TJ, Erickson JD, Wong LY (2001) Impact of folic acid fortification of the us food supply on the occurrence of neural tube defects. *J Am Med Assoc* 285(23):2981–2986
- Hughes JA, De Bruyn R, Patel K, Thompson D (2003) Evaluation of spinal ultrasound in spinal dysraphism. *Clin Radiol* 58:227–233
- James CCM, Lassman LP (1981) *Spina bifida occulta: orthopaedic, radiological and neurosurgical aspects*. Academic Press/Grune & Strattons, London/New York
- Keating MA, Rink RC, Bauer SB (1988) Neurological implications of the changing approach in management of occult spinal lesions. *J Urol* 140:1299–1301
- Korsvik HE, Keller MS (1992) Sonography of occult dysraphism in neonates and infants with MR imaging correlation. *Radiographics* 12:297–306
- Lary JM, Edmonds LD (1996) Prevalence of spina bifida at birth – United States, 1983–1990: a comparison of two surveillance systems. *Morb Mortal Wkly Rep Surveill Summ* 45:15–26
- Laurence KM (1974) Effect for early surgery for spina bifida cystica on survival and quality of life. *Lancet* 1:301–304
- Liptak GS (1997) Neural tube defects. In: Batshaw ML (ed) *Children with disabilities*, 4th edn. Paul H Brookes, Baltimore, pp 529–552
- Manning SM, Jennings R, Madsen JR (2000) Pathophysiology, prevention, and potential treatment of neural tube defects. *Ment Retard Dev Disabil Rev* 6:6–14
- Mathews TJ, MacDorman MF, Thoma ME. Infant mortality statistics from the 2013 period linked birth/ infant death data set. National vital statistics reports; vol 64 no 9. National Center for Health Statistics. 2015
- Mazagri R, Ventureyra EC (1999) Latex allergy in neurosurgical practice. *Childs Nerv Syst* 15:404–407
- McCance KM, Huether SE (2002) *Pathophysiology the biologic basis for disease in adults & children*, 4th edn. Mosby, St. Louis
- McLone DG (1998) Care of the neonate with a myelomeningocele. In: *Neurosurgery of the neonate*. *Neurosurg Clin North Am* 9(1):111–120. Saunders, Philadelphia
- Meuli M, Moehrieh U (2014) Fetal surgery for myelomeningocele is effective: a critical look at the whys. *Pediatr Surg Int* 30(7):689–697
- Munson D, Leuthner SR (2007) Palliative care for the family carrying a fetus with a life-limiting diagnosis. *Pediatr Clin N Am* 54:787–798
- National Institute of Neurological Disorders and Stroke (n.d.) Spina bifida, retrieved 19 Sept 2016, from [www.ninds.nih.gov/disorders/spina\\_bifida](http://www.ninds.nih.gov/disorders/spina_bifida)
- Park TS (1999) Myelomeningocele. In: Albright AL, Pollack IF, Adelson PD (eds) *Principles and practice of pediatric neurosurgery*. Thieme, New York, pp 125–139
- Petronio J, Walker ML (2001) Ventriculoscopy. In: McLone DG (ed) *Pediatric neurosurgery; surgery of the developing nervous system*. W.B. Saunders Company, Philadelphia, pp 559–562
- Phillips BC, Gelsomino M, Pownall AL, Ocal E, Spencer HJ, O'Brien MS, Albert GW (2014) Predictors of the need for cerebrospinal fluid diversion in patients with myelomeningocele. *J Neurosurg Pediatr* 14(2):167–172
- Rekate HL (1999) Treatment of hydrocephalus. In: Albright AL, Pollack IF, Adelson PD (eds) *Principles and practice of pediatric neurosurgery*. Thieme, New York, pp 125–139

- Sakakibara R, Hattori T, Uchiyama T, Kamura K, Yamanishi T (2003) Uroneurological assessment of spina bifida cystica and occulta. *Neurorol Urodyn* 22:328–334
- Sandler AD (2010) Children with spina bifida: key clinical issues. *Pediatr Clin N Am* 57:879–892
- Simpson JL, Greene MF (2011) Fetal surgery for myelomeningocele? Editorial. *N Engl J Med* 364(11):1076–1077
- Toriello HV, for the Policy and Practice Guideline Committee of the American College of Medical Genetics (2011) Policy statement on folic acid and neural tube defects. *Genet Med* 13(6):593–596
- Tulipan N, Wellons JC 3rd, Thom EA, Gupta N, Sutton LN, Burrows PK, Farmer D, Walsh W, MP J, Rand L, Tolivaisa S, D'alton ME, Adzick DS, MOMS Investigators (2015) Prenatal surgery for myelomeningocele and the need for cerebrospinal fluid shunt placement. *J Neurosurg Pediatr* 16(6):613–620
- Warf BC (2005) Comparison of endoscopic third ventriculostomy alone and combined with choroid plexus cauterization in infants younger than 1 year of age: a prospective study in 550 African children. *J Neurosurg Pediatr* 103:475–481
- Warf BC (2011) Hydrocephalus associated with neural tube defects: characteristics, management, and outcome in sub-Saharan Africa. *Childs Nerv Syst* 27(10):1589–1594
- Wenstrom KD, Johanning GL, Owen J, Johnston KE, Acton S, Tamura T (2000) Role of amniotic fluid homocysteine level of fetal 5, 10-methylenetetrahydrofolate reductase genotype in the etiology of neural tube defects. *Am J Med Genet* 90(1):12–16
- Yamada S, Won DJ, Yamada SM (2004) Pathophysiology of tethered cord syndrome: correlation with symptomatology. *Neurosurg Focus* 16(2):1–5
- Yamada S, Won DJ, Pezeshkpour G, Yamada BS, Yamada SM, Siddigi J, Zouros A, Colohan AR (2007) Pathophysiology of tethered cord syndrome and similar complex disorders. *Neurosurg Focus* 23(2):E6
- Yen IH, Khoury MJ, Erickson JD, James LM, Waters GD, Berry RJ (1992) The changing epidemiology of neural tube defects: United States, 1968–1989. *Am J Dis Child* 146:857–861
- Zhang T, Lou J, Zhong R, Wu J, Sun Y, Xuzai L, Liu L, Xiaoping M, Xiong G (2013) Genetic variants in the folate pathway and the risk of neural tube defects: a meta-analysis of the published literature. *PLoS One* 8(4):e59570

---

# Chiari Malformation and Syringomyelia

# 6

Ambre' L. Pownall

---

## 6.1 Introduction

Chiari malformations are a group of structural abnormalities of the hindbrain which were originally described by John Cleland in 1883 and then classified in 1891 by Hans Chiari, a German professor. His work, based on autopsy results, created the classic definitions of hindbrain herniation now described as Chiari I (CM-I), Chiari II (CM-II), and Chiari III (CM-III). Although named similarly to the other Chiari malformations, Chiari IV malformation (CM-IV) is now recognized as cerebellar hypoplasia and unrelated to the others; thus, it will not be discussed (Greenberg 2010; Khoury 2015; Oakes et al. 2011; Weprin and Oakes 2001).

Syringomyelia refers to the development of a cyst or a cavity filled with cerebrospinal fluid (CSF) within the spinal cord. The cyst is also known as a syrinx. Despite advances in neuroimaging and embryological work, the natural his-

tory of Chiari malformation and syringomyelia remains incompletely understood.

CM-I consists of displacement of the cerebellar tonsils below the foramen magnum and is often associated with syringomyelia. CM-II, also known as the Chiari malformation, is associated with myelomeningocele (MM) and includes caudal displacement of the inferior cerebellar vermis, the fourth ventricle, and the medulla into the cervical canal. CM-III, the rarest and most severe form, includes a low occipital or high cervical encephalocele in combination with downward displacement of most of the cerebellum, the fourth ventricle, and possibly portions of the brainstem. Two other subtypes have been described. The Chiari 0 malformation exhibits normally located cerebellar tonsils in the presence of syringomyelia, abnormal posterior fossa anatomy, and altered CSF dynamics, analogous to Chiari I malformation. The Chiari 1.5 malformation mimics Chiari II in the absence of spina bifida (Khoury 2015). The CM-0, 1.5 and III are not often seen, with CM-I and CM-II being the most common.

---

Susan McGee and Diane Baudendistel wrote the original chapter and the 2nd edition but did not participate in this revision.

A.L. Pownall, MSN, APRN, PPCNP-BC  
Division of Pediatric Neurosurgery, Arkansas  
Children's Hospital, 1 Childrens Way, Slot 838,  
Little Rock, AR 72202, USA

Department of Neurosurgery, University of Arkansas  
for Medical Sciences, Little Rock, AR 72202, USA  
e-mail: [alpownall@uams.edu](mailto:alpownall@uams.edu)

---

## 6.2 Chiari I Malformation

Historically, Chiari malformations were described as developmental anomalies. However, there is currently evidence to indicate that some CM-Is are acquired (Oakes et al. 2011). In addi-

tion, debate exists about whether the term malformation, implying faulty formation and supporting the etiology as a developmental process, accurately describes the range of the Chiari phenomena (Novegno et al. 2008; ReKate 2008). Although the true incidence of CM-I is unknown, studies have reported approximately 0.1–0.05% in diagnosis since the availability of MRI (Milhorat et al. 2007).

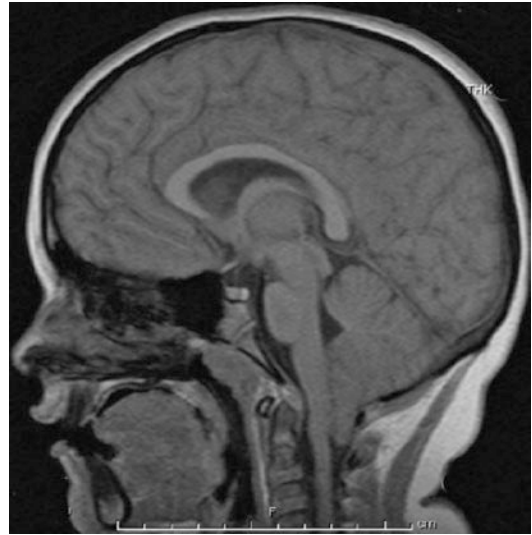
CM-I has historically been considered to occur sporadically. However, familial clustering suggests inheritable genetic factors may be present in a small number of cases. Other genetic syndromes have been associated with CM-I, such as achondroplasia and Williams syndrome. To identify potential inheritable cases, it is important to obtain a thorough family history and consult with a genetics specialist, when needed (Fig. 6.1).

### 6.2.1 Developmental Anomaly

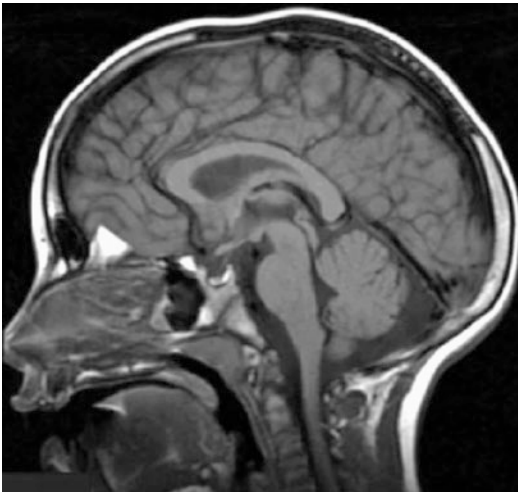
CM-I is anatomically the simplest of the Chiari malformations. Magnetic resonance imaging demonstrates descent of the cerebellar tonsils 5 mm or more below the foramen magnum and occasionally below the second cervical (C2) level (Figs. 6.2 and 6.3). Cerebellar tonsils that enter the cervical canal but descend less than 5 mm are

considered cerebellar ectopia, not meeting the criteria for the diagnosis of Chiari malformation.

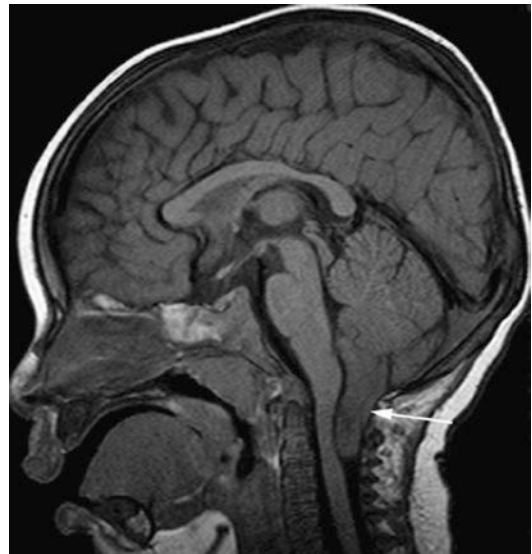Skull-based deformities, such as a small posterior fossa and steep incline of the tentorium, may be present. Basilar impression or invagination, concavity of the clivus, and atlantoaxial assimilation have been associated with CM-I (Weprin and Oakes 2001). Although this historically was considered a condition of adulthood,



**Fig. 6.2** Chiari I



**Fig. 6.1** Normal T1 sagittal MRI of a 5-year-old



**Fig. 6.3** Chiari I



CM-Is have been identified in all age groups, including the neonatal population (Lazareff et al. 2002; Menezes 1995; Nohria and Oakes 1991; Yundt et al. 1996).

The prevalence of hydrocephalus associated with CM-I is approximately 10% and may be caused by fibrous adhesions or scarring that develop between the dura, the arachnoid, and the cerebellar tonsils (Nohria and Oakes 1991). This in turn may cause obstruction of the flow of CSF from the fourth ventricle.

### 6.2.2 Acquired Anomaly

CM-I may develop in patients treated for hydrocephalus or pseudotumor with a ventriculoperitoneal shunt or lumboperitoneal shunt (Payner et al. 1994; Weprin and Oakes 2001). Chronic shunting of CSF from the lumbar subarachnoid space to the peritoneal cavity may cause the cerebellar tonsils to move caudally below the foramen magnum. This descent of the cerebellar tonsils may be reversed by removing the shunt. In patients with ventriculoperitoneal shunts, it has been reported that the overdrainage of the ventricles caused increased CSF in the subarachnoid space, theoretically changing the pressure gradient and contributing to the downward movement of the cerebellar tonsils. Other authors report that, with specific patients and techniques to prevent overshunting, this phenomenon can be avoided (Rekate and Wallace 2003).

## 6.3 Chiari II Malformation

The Chiari II malformation is present in nearly all children with myelomeningocele (MM) (Dias 1999). CM-II is probably a primary dysgenesis of the brainstem associated with the neural tube defect and multiple other developmental anomalies present in these patients (Greenberg 2010). However, there is evidence that patients undergoing intrauterine repair of the MM may not have the typical low-lying tonsils of the CM-II (Adzick et al. 2011; Sutton et al. 1999; Tulipan et al. 1998, 1999), thus placing into question the

theory that this is a primary dysgenesis and giving support to the hydrodynamic theories of Chiari malformations. Indeed, the Management of Myelomeningocele Study (MOMS) (Adzick et al. 2011) demonstrated that 36% of the prenatal surgery group had no evidence of hindbrain herniation at the age of 12 months compared to 4% of the postnatal surgery group. Up to 90% of MM patients also develop symptomatic hydrocephalus, with 50% of infants showing evidence of hydrocephalus at birth (Detwiler et al. 1999). In the MOMS study, fewer CSF shunts were placed in infants in the prenatal surgery group by 12 months (40%) compared to the postnatal group (82%) ( $p < 0.001$ ) (Adzick et al. 2011).

For these patients, the Chiari malformation appears to be more than hindbrain herniation but also includes anatomic changes in the supratentorial structures and the skull as well. The posterior fossa abnormalities include caudal descent of the pons, medulla, cerebellar vermis and fourth ventricle, “kinking” of the brainstem, “beaking” of the tectum, and aqueductal stenosis (Fig. 6.4). Some associated anomalies of the cerebral hemispheres include polymicrogyria, cortical heterotopias, dysgenesis of the corpus callosum, and a large massa intermedia. Skull deformities include “luckenschadel” or craniolacunia, shortening of

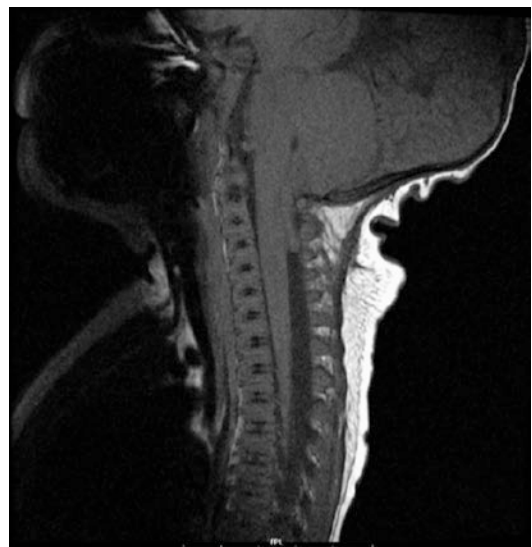


Fig. 6.4 Chiari II

bony clivus, and enlargement of the foreman magnum (Greenberg 2010). Hindbrain and lower cranial nerve dysfunction is the leading cause of death in children with myelodysplasia (Oakes et al. 2011).

## 6.4 Chiari III Malformation

The Chiari III malformation involves descent of most of the cerebellum and brainstem below the foramen magnum and may be associated with a cervical or occipital encephalocele. The encephalocele may contain cerebellum, occipital lobes, and brainstem. Herniation of the fourth and lateral ventricles may occur. Hydrocephalus is often present (Oakes et al. 2011; Weprin and Oakes 2001).

### 6.4.1 Etiology

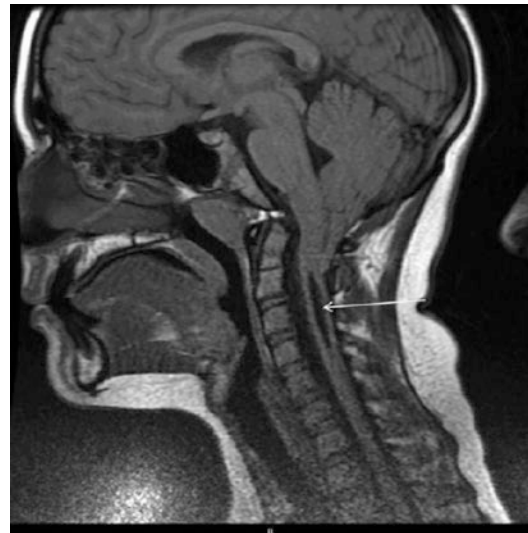Despite being identified in the 1800s, a debate still continues about the cause of Chiari malformations. Although these malformations have abnormalities of the cerebellum and the cranio-cervical junction in common, they are thought to be distinct conditions with differing etiologic factors (Greenberg 2010; Strayer 2001). Many theories about the etiology have been proposed. Ongoing research brings hope for information that will help in determining best treatment options for this challenging spectrum of disorders (Table 6.1).

### 6.4.2 Syringomyelia

Syringomyelia (or syrinx) refers to a cavitation or cyst within the substance of the spinal cord extending over many spinal levels (Figs. 6.5 and 6.6). Hydromyelia is a term that describes a distended central canal lined by ependymal tissue. The technical difference between these two terms has little clinical significance because the hydrodynamics of both types of cavitations are identical as evaluated by MRI. Therefore, medical literature currently uses the term syringomyelia to describe all intramedullary cysts with cerebrospinal fluidlike content (Oakes et al. 2011).

**Table 6.1** Etiology of Chiari malformations Nohria and Oakes (1991), Oakes et al. (2011), Fic and Eide (2015)

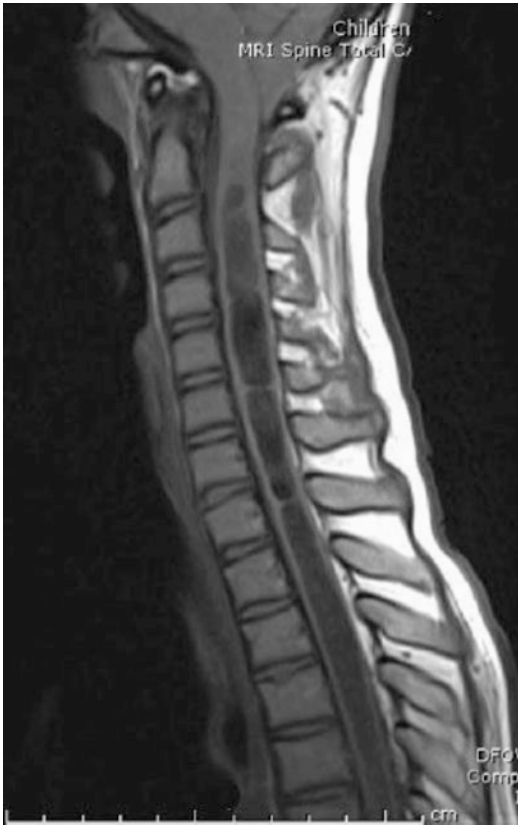Theory	Mechanism
Hydrodynamic	Hydrocephalus the primary cause
Mechanical	(a) Spinal cord tethering causing abnormal development (b) Abnormal bony structures not providing enough space in the posterior fossa (cephalocranial disproportion)
Variation in pressure gradient	Pressure gradient between the intracranial and spinal compartments forcing the cerebellar tonsils to migrate caudally (craniospinal pressure gradient)
Traumatic birth	Birth trauma causing tonsillar edema and arachnoid scarring



**Fig. 6.5** T1 sagittal MRI showing cervical syrinx

Although syringomyelia most often occurs in association with a posterior fossa abnormality, a syrinx can also be associated with tumors, injury, and inflammatory processes or may simply be idiopathic.

Syringomyelia is present in 30–85% of patients with Chiari I malformation (Schijman 2004) and is found most often in the older female child who has a larger degree of tonsillar descent with CSF flow impairment (Strahle et al. 2011). Oftentimes the syrinx is found in the cervical spine (Strahle et al. 2011).



**Fig. 6.6** T1 sagittal MRI showing cervical and thoracic syrinx

The medical literature has posed a variety of mechanisms for the development of the syrinx in patients with Chiari malformations. In general, there is agreement that the abnormal CSF dynamic associated with Chiari malformations produces a net bulk flow of CSF into the central canal (rather than a balanced bidirectional flow through the parenchyma) that creates the syrinx. The presence of syringomyelia will have an impact on symptom presentation, treatment options, and long-term outcomes (Dias 1999; Oakes et al. 2011; Weprin and Oakes 2001). Also, it is important to realize that a new syrinx in patients with CM-II with a ventriculo-peritoneal shunt may represent a shunt malfunction causing altered spinal cord CSF dynamics.

Presyrinx, first described in 1999, is a reversible state of spinal cord edema caused by alterations in CSF flow, typically in the cervical region. Ongoing clinical examination and serial MRI imaging are used to monitor progression. The

presyrinx may advance to a syrinx if untreated (Goh et al. 2008; Khoury 2015).

## 6.5 Presentation

### 6.5.1 Chiari I Malformation

Before the use of MRI, Chiari I malformations were thought to be a condition that is presented in late childhood or adolescence. Occipital and upper cervical headache is the most common presenting symptom in this age group, occurring in 63–69% of patients (Dias 1999; Hida et al. 1995). The headache may be triggered or exacerbated by Valsalva maneuver, extreme neck movement, or during exertional activities such as sports. Headaches may progress over time and, primarily in younger children, may cause nighttime awakening. Weakness or numbness of one or both arms may be present. Some patients report gait unsteadiness, sensory changes, and dysphagia.

On physical exam, nystagmus, facial hyperesthesia, dysarthria, palatal weakness, or tongue atrophy may be present. Vocal cord paralysis may be present in rare cases. Other possible findings include hyperactive upper extremity reflexes, positive Babinski, weakness of the upper and lower extremities, scoliosis, spasticity, and ataxia (Oakes et al. 2011; Weprin and Oakes 2001). The literature indicates, however, that 10% of all patients with CM-I present with headache only and have a normal neurological examination. This percentage may be higher in the pediatric population. A recent study reported findings of about 130 children with CM-I, of whom 21% presented with headache only and a normal neurological examination (Yeh et al. 2006). Diagnoses of CM-I in children and adolescents are often based on history, symptoms, and radiographic studies, in the absence of focal neurological findings.

In rare cases, ventral brainstem compression (VBSC) can occur when there is compression on the brainstem and upper spinal cord (Fig. 6.7). These patients will present with signs and symptoms similar to a CM-I such as neck pain and occipitalcervical headache. Other signs and

symptoms include myelopathy or quadraparesis, brainstem dysfunction, lower cranial nerve abnormalities, basilar migranes, ataxia, facial pain, and nystagmus (Menezes 2008; Rider et al. 2015). Treatment for VBSC includes close observation as well as surgery. Two different surgical approaches, open transoral and endoscopic transnasal, may be performed depending on the size of the patient and their imaging studies.

The availability of MRI has assisted in the identification of Chiari malformations in the younger child. Infants and the nonverbal child may present with persistent crying and irritability as well as arching of the neck. Respiratory irregularities and recurrent aspirations may, in addition to the brainstem signs noted above, mark the presentation of the youngest patients (Benglis et al. 2011; Oakes et al. 2011). One recent study identified significant differences in the presentation of children 2 years and younger compared to those 3–5 years of age. The younger age group was more likely to present with oropharyngeal symptoms (77.8–38.1%,  $p = 0.01$ ), while the 3- to 5-year-old subjects were more likely to present with scoliosis (38.1–16.7%,  $p = 0.03$ ) or with syrinx (85.7–27.8%,  $p = 0.002$ ). Although more of their older subjects (3- to 5-year-olds) presented with headache, this dif-

ference was not statistically significant (Albert et al. 2010) (Table 6.2).

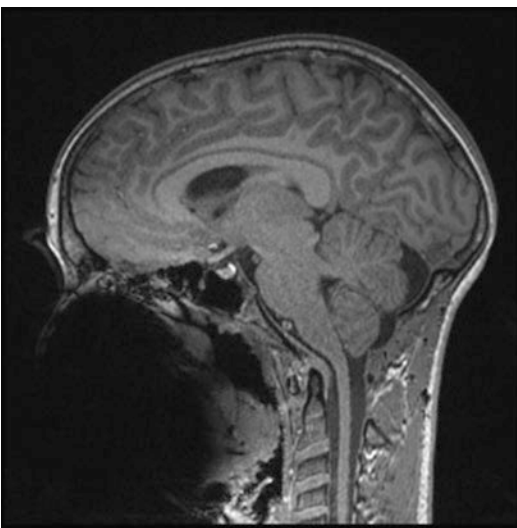
### 6.5.2 Chiari II Malformation

Chiari II malformations are present at birth in patients with an open neural tube defect. The literature reports that 18–33% of these patients will demonstrate Chiari II symptoms (Dias 1999; Weprin and Oakes 2001). The MOMS study provides evidence that prenatal repair of open neural tube defects may lessen the incidence of CM-IIs (Adzick et al. 2011). Infants with a symptomatic CM-II have a more rapid and severe onset of symptoms than those who present later in childhood. Symptom presentation early in life is related to higher morbidity and mortality.

Most patients are asymptomatic at birth, but a small group of neonates have respiratory distress. These patients demonstrate a poor respiratory drive, likely related to brainstem dysfunction. In infancy, respiratory distress including cyanotic spells, central or obstructive apnea, inspiratory stridor, and hoarse or high-pitched cries are the most common presenting signs. New or worsening stridor, accompanied by oxygen desaturation, in an infant with CM-II is considered a medical emergency.

Swallowing dysfunction is the second most common sign of a symptomatic CM-II (Dias 1999). Infants demonstrate poor suck and swallow coordination, nasal regurgitation, projectile emesis, choking, drooling, or pooling of food in the posterior pharynx. As a result, these children may suffer from failure to thrive, repeated episodes of aspiration pneumonia, and chronic gastroesophageal reflux. Nystagmus and vocal cord paralysis may also be present. This combination of symptoms reflects brainstem and lower cranial nerve dysfunction (Dias 1999; Weprin and Oakes 2001). Decreased upper extremity tone is another common sign in young children with a symptomatic CM-II.

The clinical presentation of a symptomatic CM-II in the older child is usually more gradual, with milder symptoms that are often responsive to surgical intervention. Symptoms in this age group include upper extremity weakness, spasticity, decreased function of the lower extremities, headache, neck pain, nystagmus, ataxia, and



**Fig. 6.7** Sagittal MRI of 12-year-old boy showing ventral compression and Chiari I. He presented with new onset of progressive left-sided esotropia and blurry vision

**Table 6.2** Categories of patients with Chiari I malformation based on predominant clinical symptoms

Headache	98%	Arm pain	27%
Dizziness	84%	Abdominal pain	23%
Difficulty sleeping	72%	Photophobia	21%
Weakness of an upper extremity	69%	Decrease or loss of hearing	16%
Neck pain	67%	Tachycardia	16%
Numbness/tingling of an upper extremity	62%	Fever	15%
Fatigue	59%	Word-finding problems	14%
Nausea	58%	Vision loss	7.2%
Shortness of breath	57%	Blackout spells	6.8%
Blurred vision	57%	Apnea	5.7%
Tinnitus	56%	Vertigo	5.6%
Difficulty swallowing	54%	Peripheral vision loss	5%
Weakness of a lower extremity	52%	Nystabmus	5%
Depression	47%	Earache	4.5%
Vomiting	15%	Epistaxis	3.8%
Diplopia	15%	Increased snoring	3.7%
Generalized body weakness	46%	Thoracic pain	2.6%
Disequilibrium	46%	Hypotension	1.9%
Memory problems	45%	Wakes up choking	1.9%
Numbness/tingling of a lower extremity	43%	Leg pain	1.7%
Hoarseness in voice	41%	Palpitations	1.5%
Chest pain	39%	Hypertension	1.5%
Numbness in the face	32%	Absent gag	1.1%
Anxiety	30%	Face pain/tingling	0.3%
Slurred speech	28%		

Mueller and Oro (2004)

scoliosis. This group of symptoms is related to dysfunction of the cerebellum and spinal cord. Because these symptoms may progress very slowly, a complete history to identify subtle and gradual changes is vital. Presentation in adulthood is rare but would mimic the progression of symptoms of the older child (Table 6.3).

### 6.5.3 Chiari III Malformation

Chiari III malformations are present at birth and are identified by an occipital or high cervical encephalocele. Multiple anomalies of the cerebellum and brainstem accompany the encephalocele, which contains varying amounts of brain tissue. This anomaly is associated with poor prognosis due to the severity of the cranial nerve deficits and developmental and neurological impact. Even with supportive treatment, patients have a short life expectancy (Oakes et al. 2011; Weprin and Oakes 2001).

#### 6.5.3.1 Syringomyelia

The neurological examination should include a thorough sensory evaluation and testing of the reflexes, in addition to strength testing. Syringomyelia should be suspected in patients that present with scoliosis, leg or foot asymmetries, or abnormal sensory examination. Dysesthetic pain of the trunk or extremities may be present. New or progressive spasticity is another symptom of concern for syrinx. Clumsiness, weakness, and atrophy of the upper extremities also may occur. In myelomeningocele patients, a worsening of urodynamics or changes in baseline motor function should be noted. In patients with CM-1, urinary incontinence may be a late sign of syringomyelia (Nohria and Oakes 1991; Oakes et al. 2011; Weprin and Oakes 2001).

#### 6.5.3.2 Diagnostic Tests

The creation of the MRI provided a breakthrough in the diagnosis of Chiari malformations, which often present with vague and nonspecific signs and



**Table 6.3** Comparison of Chiari I and II malformations

	Chiari I malformation	Chiari II malformation
Brain	Caudal descent of cerebellar tonsils > than 5–7 mm below foramen magnum Peg like or pointed Often asymmetric	Caudal descent of cerebellar vermis, brainstem, and fourth ventricle below the foramen magnum
Common associated radiographic findings		
Skull	Underdeveloped occiput	Craniolacunaria luckenschadel
	Small posterior fossa	Lemon sign on fetal ultrasound
	+/- Enlarged foramen magnum	Small posterior fossa
	Basilar impression	Enlarged foramen magnum +/- Basilar impression
Spine	Assimilation of the atlas	+/- Assimilation of the atlas
	Progressive scoliosis (10% in those who also have syringomyelia)	Enlarged cervical canal
	Klippel-Feil deformity	Klippel-Feil deformity Scoliosis
Ventricles and cisterns	Hydrocephalus (3–10%)	Hydrocephalus (90%)
		Intrinsic malformation of ventricles including asymmetry, pointed frontal horns, and colpocephaly (enlarged occipital horns)
Spinal cord	Syrinx (40–75%)	Syrinx (20–95%)

Khoury (2015), Menezes (1999), Nohria and Oakes (1991)

symptoms. Identifying the compression of the hindbrain and cervical spine as the possible cause of discomfort in these pediatric patients, especially those that are nonverbal, aided clinicians in providing useful treatment options. Recognition of Chiari I malformation in the very young children provides them with an opportunity to benefit from advances made in the surgical approach to this condition. Cine MRI may be used to assess CSF flow around the cerebellar tonsils. The location and extent of syringomyelia is best defined by a non-contrasted spinal MRI (Sherman et al. 1999).

CT is of limited value in diagnosing Chiari malformations but provides information about the presence of hydrocephalus. In addition, cerebellar tonsillar ectopia may be noted as an incidental finding on a CT scan obtained for new symptoms such as headache or head injury. Sleep and swallow studies may be indicated prior to surgery to further evaluate the signs of brainstem or cranial nerve compression. Vocal cord motility may be evaluated if indicated.

Cervical radiographs can identify potential bony instability of the neck. Ultrasonography may provide identification of Chiari malformations and syringomyelia in the neonate and infant, but decisions about surgical intervention are based on MRI findings. Intraoperative ultrasound is used to identify whether bony decompression establishes adequate CSF flow. If CSF flow remains impaired with bony decompression, the surgery may proceed to include duraplasty and fourth ventricular stent (Sherman et al. 1999).

## 6.6 Treatment Options for Chiari I Malformation

### 6.6.1 Medical

A child diagnosed with CM-I presents a variety of challenges related to developmental considerations and the nonspecific symptoms often associated with this condition. Because the CM-I

may present with only headache, care must be taken to confirm that the malformation itself is causing the headaches. Children, as well as adults, are subject to a variety of types of headaches. Taking a thorough history of the type, pattern, and location of the headache and evaluating the effect of conservative treatment are key components of the medical management of these patients. If the headaches can be managed medically, the child may avoid a major surgical procedure. One recent review concluded that children with Chiari I malformation who are not clearly symptomatic and do not have scoliosis or syrinx can be followed conservatively. The development of symptoms and new neurological deficits were extremely uncommon in a group of 124 children followed retrospectively for 1.0–8.6 years (mean 2.83 years) without surgery (Benglis et al. 2011).

Children with known CM-I should be followed annually for evaluation of symptom development or progression. MRI imaging with cine of the craniocervical junction to assess CSF flow may be indicated. The parents and child should be advised that the child should avoid lumbar punctures that could worsen the herniation of the cerebellum tonsils.

### 6.6.2 Surgical

Early surgery is recommended for symptomatic patients (Hida et al. 1995). Patients who have CM-I identified on MRI, and have occipital headaches unrelieved by medical management and/or other signs/symptoms associated with Chiari I malformation, are candidates for surgery. MRI evidence of a syrinx is an additional reason for surgical intervention. Common goals are improvement of presenting symptoms, radiographic reduction of syringomyelia, and arrest or remission of associated scoliosis (Greenberg 2010). If the patient also has hydrocephalus, treatment with a CSF diversionary shunt should precede surgery to treat the CM-I.

The surgical procedure is planned to decompress the posterior fossa sufficiently to allow room for CSF to circulate around the cerebellum and the cervical spinal cord (Boxes 6.1 and 6.2). Electrophysiologic neuromonitoring is generally employed. A vertical occipital incision is made to

#### Box 6.1 Chiari I Malformation: Case Study

LL is a 4-year-old boy with a 2-month history of suboccipital headaches with vomiting.

He was evaluated by his primary care provider who ordered an MRI of the brain and spine. The MRI showed herniated tonsils projecting 6 mm below the foramen magnum, upper cervical cord compression, and medullary kink. Cine images demonstrated restricted CSF flow at the cervicomedullary junction. MRI of the spine showed no syrinx. LL was referred to the pediatric neurosurgery clinic for further evaluation.

Upon evaluation in the pediatric neurosurgery clinic, the patient was found to have a normal neurological exam except for an absent gag reflex. He was doing well with potty training, and his suboccipital headaches had increased in frequency, and he was now vomiting daily.

The patient was scheduled for surgery, and a suboccipital craniectomy with C1–C2 laminectomy was performed. The patient was found to have large cerebral tonsils with severe compression at the craniocervical junction. Appropriate bony decompression and dural opening were achieved; the patient then had CSF flowing freely from the fourth ventricle through the craniocervical junction. Spinal monitoring was done during the entire procedure. After the surgery, the patient was transferred to the pediatric intensive care unit in stable condition.

### Box 6.2 One Family's Chiari Malformation Story

It was October 31, 2001 when we first got the diagnosis of Chiari malformation for our 1-year-old son. When I heard the words “brain surgery,” I felt like the air was sucked right out of my lungs. I can honestly say I remember nothing else that was told to us that day at the doctor’s office. Looking back though, I guess I knew all along something was wrong but was not sure what to do because at that time Jacob was our only child and I had never been a mother before. As a baby, Jacob never really slept well, and there would be periods of crying with his eyes closed or banging his head on things that would last for hours over night. After numerous visits to our pediatrician and being told that our son was just a bad sleeper, I began to assume I was maybe not the best mother. One afternoon after a morning of crying, I decided to put Jacob down for nap. I went downstairs and heard a very loud noise. Upon entering his room, I realized Jacob had fallen out of his bed and knocked himself unconscious. In the emergency room, we were told that his CT scan looked fine from the fall but that there was a malformation at the base of his brain. Further testing was necessary, and we were told to follow up with our pediatrician to get those things scheduled. As a parent, you believe that you can protect your child from anything, but in this circumstance, that is not true. I found myself totally helpless and lost. I would be holding my son as he was put to sleep for an MRI and having no knowledge as to what they were looking at. All I needed was someone to show me a little compassion and knowledge about what was coming next, to take the time to answer my questions and put some of my fears to rest. Surgery was scheduled, and I was introduced to an angel that will always be a part of my life. A nurse at the neurosurgeon’s office who was our surgeon’s right-hand lady began to take the time and explain in so much detail about the steps we were beginning to take. She spent hours (it felt like) listening and answering questions. Whenever we called

scared, nervous, or lost, she made us feel like no one was more important at that moment than our family. If we had not been prepared for surgery and the days after, I do not honestly think we could have survived it. For Jacob, it took two surgeries to create excellent CSF flow, and today he is just like any other 11-year-old boy. Both surgeries were different though; in the second one, we had an idea of what to expect but still spent every night watching the monitors on Jacob to make sure that he was breathing. The fear after the second surgery was not about hoping we got him home. It was about wondering if we were going to have to do this again in the future. Two and a half years after Jacob had his last surgery, our second son, Dylan, was beginning his Chiari journey. Dylan’s symptoms were totally different than Jacob’s, but this time I knew in my gut without a doubt what was going on. Dylan never really spoke or made sounds as an infant, had extreme difficulty drinking his bottles, and, when began moving, always dragged his left leg. As soon as I saw the leg dragging, I called this nurse who I trusted as much as our neurosurgeon. Instead of telling me I was just seeing things or that I was jumping to a conclusion too quickly, she listened to me and offered me resources to find out what was going on. Once we had an MRI showing his Chiari, we scheduled surgery. Dylan’s case has always been much worse than Jacob’s. To date, he has had four decompressions, and it looks like things have finally resolved. Every night though in the hospital, I would sit by his bed and cry because I felt so guilty that I could not make things better with a kiss (like moms are supposed to), and the following day, that same nurse would check in and remind me that things will get better. Chiari malformation is a frightening diagnosis to any parent and is not an easy recovery the first couple of days after surgery. At that moment in a family’s life, the only thing they focus on is their child and getting him or her healed. Compassion, knowledge, and recognition are things that can assist every family during their journey.

allow for bony decompression of the foramen magnum. Initial suboccipital craniectomy may be followed by cervical laminectomy (Greenberg 2010). If the removal of bone allows for adequate CSF flow, as determined by intraoperative ultrasound, the procedure may be completed at this stage (Sherman et al. 1999). If there is continued evidence of impingement on the brainstem and cerebellum, the surgeon may perform a variety of procedures to further decompress the space (Fig. 6.8). This may include intradural exploration, partial dural removal or scoring, duraplasty with graft material or pericranium, plugging of the obex, shunting of the fourth ventricle, and coagulation of the cerebellar tonsils (Dias 1999; Narvaro et al. 2004; Sherman et al. 1999).

### 6.6.3 Nursing Care

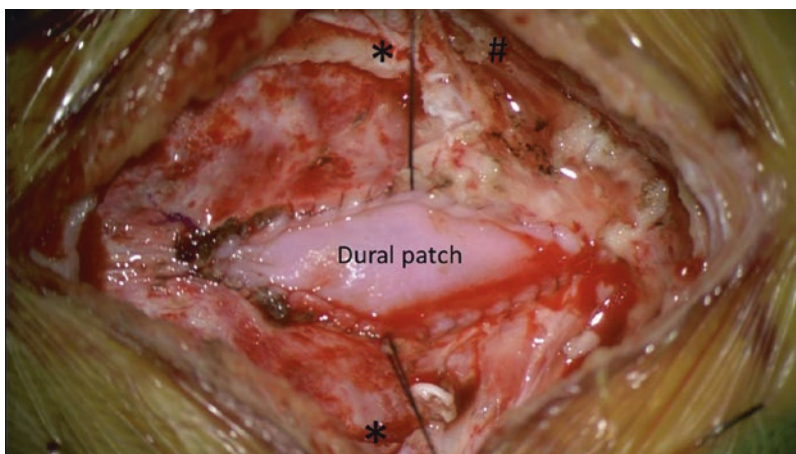
The main concerns for nurses taking care of these patients postoperatively are pain management and respiratory compromise, which may be aggravated by narcotic pain medications. In addition, if the dura was opened, the patient is at risk for CSF leak and infection. Surgical treatment without disrupting the dura is limited to the pediatric population and has decreased the incidence of postoperative complications (Sherman et al.

1999). The patient is monitored in the intensive care unit (ICU) for prevention and early detection of potential complications and initiation of pain management.

Pain and stiffness of the neck are due to the incision through the semispinalis capitis and splenius capitis muscles, as well as from opening the dura. Pain management in the early postoperative period includes use of narcotics, either from “as-needed” medications or by patient (or parent)-controlled analgesia (PCA). When the patient is able to tolerate oral medications, adding nonsteroidal anti-inflammatory medication scheduled around the clock can improve pain scores and decrease the need for narcotics for breakthrough pain. Antispasmodics for neck spasm may also be indicated. Encouraging the patient to turn his or her head frequently so it doesn’t stay in a “fixed” position is recommended.

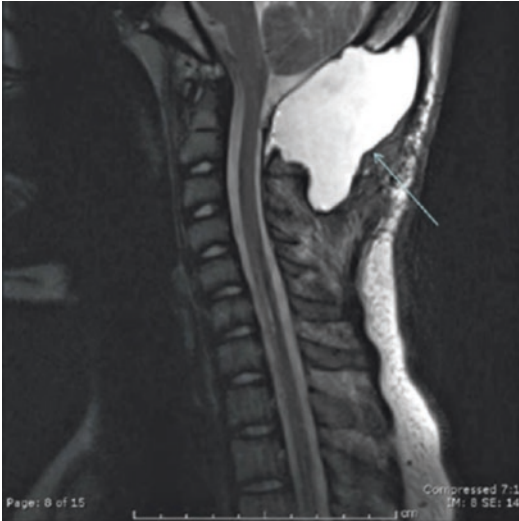
When surgery includes duraplasty and a fourth ventricular stent, intraoperative stimulation of the area postrema located near the fourth ventricle often causes nausea and vomiting. Scheduled antiemetic medications given around the clock are indicated.

Monitoring patients for respiratory compromise is vital. The combination of potential irritation to the brainstem and the need for narcotics can make these patients susceptible to having a



\* Bone edges of suboccipital bony decompression at foramen magnum; # one end of C1 laminectomy;

**Fig. 6.8** Dural patch graft (Courtesy of Dr. Rongsheng Cai)



**Fig. 6.9** T2 sagittal MRI of pseudomeningocele

decreased respiratory drive. ICU monitoring until most of anesthesia effects are eliminated allows for close assessment and early intervention to decrease the risk of complications.

Pseudomeningocele is the most common surgical complication when the dura has been disrupted (Fig. 6.9). This occurs when CSF leaks into the subcutaneous space, causing a fullness of the surgical site (Sherman et al. 1999). To minimize the risk of CSF leak in patients with dural compromise, the operative site should be closely monitored. A short course of dexamethasone may minimize symptoms from postoperative edema. Another possible complication is chemical meningitis (or aseptic meningitis). The symptoms include nuchal rigidity, low-grade fever, and headache. If bacterial meningitis has been ruled out, a short course of dexamethasone is the treatment of choice. Chemical meningitis after surgery for Chiari I malformation may be related to the use of dural graft material and/or tissue sealants (Parker et al. 2011).

The usual hospital length of stay after a Chiari decompression is 3–5 days. Discharge criteria include normothermia, adequate oral fluid intake, and pain control with oral medications. In addition, it is particularly important for patients who have undergone duraplasty to have a bowel regime that keeps their bowel movements soft

and regular to prevent disruption of the surgical site by straining.

Resolution of symptoms such as headache may be immediate, but other symptoms may take up to 3 months to begin to resolve. Symptoms resulting from long-standing brainstem compression do not always completely resolve (Oakes et al. 2011).

## 6.7 Treatment Options for Chiari II Malformation

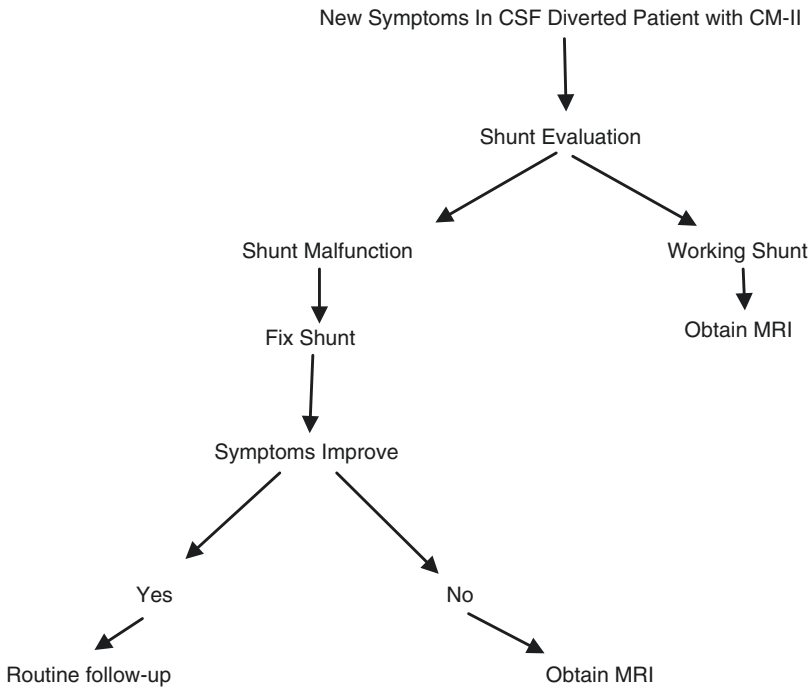
### 6.7.1 Medical

Imaging for the Chiari II malformation is indicated only when new symptoms occur or when baseline status deteriorates. Symptoms of concern may include swallowing difficulties, weakness or increased weakness of the upper extremities, new spasticity, or occipital headaches. If the child has shunted hydrocephalus, the shunt should be evaluated first and revised if it is malfunctioning. In the presence of a functioning CSF shunt, evaluation of the CM-II by an MRI of the brain and craniocervical junction is the next step. If the symptoms persist and the MRI shows brainstem compression or obstruction of CSF flow, surgical treatment is indicated. In CM-II, early surgical intervention in the child with symptoms may prevent significant morbidity and mortality (Oakes et al. 2011).

### 6.7.2 Surgical

The surgical intervention for the CM-II parallels that for the Chiari I malformation. Based on the need for extensive dissection of the brainstem and cranial nerve structures, electrophysiologic neuromonitoring is generally employed. A suboccipital incision is made to allow for removal of the posterior arch of C1 and excision of any extradural constrictive band. Laminectomy is performed to the level of descent of the cerebellar tonsils, which may require a 1-, 2-, or 3-level laminectomy. Myelomeningocele patients, unlike the Chiari I malformation patients, have an elongated





foramen magnum and, thus, do not require further expansion. The dura should be opened to create CSF flow around the CM-II. Commonly, extremely dense arachnoidal adhesions require lysis. The herniated tonsils may require fulguration (cauterization). A stent spanning the obex, lying within the fourth ventricle proximally and the cervical subarachnoid space distally, is frequently placed. Finally, a dural augmentation graft (allograft or autograft pericranium) is typically sutured into the opened dural margins.

### 6.7.3 Nursing Care

As with the CM-I, these patients are monitored after surgery in the ICU or the neonatal intensive care unit. Extensive microsurgical manipulation, involving multiple lower cranial nerves and brainstem structures, places the patient at risk for postoperative neurological deterioration, especially regarding swallowing and ventilation. These patients must be monitored for late extubation, apnea, swallowing dysfunction, and feeding problems after surgery. The risk for CSF leak and infection exists when the dura has been opened.

Neck movement limitation and steroids may be indicated to minimize symptoms related to dural opening and postoperative edema. Neck pain and stiffness occur in these patients and must be managed carefully in light of the presence of respiratory compromise preoperatively, especially in the very young patients.

Like CM-I patients, discharge criteria include normothermia, adequate oral fluid intake, and pain controlled with oral medications. A bowel regime is needed to keep stool soft and regular to prevent disruption of the surgical site by straining.

## 6.8 Treatment Options for Syringomyelia

Left untreated, a syrinx can enlarge or elongate over time causing damage to the spinal cord. When syringomyelia is associated with a Chiari malformation, treatment by posterior fossa decompression of the hindbrain malformation may result in resolution of the syrinx. Primarily in CM-II, symptomatic syringomyelia may persist despite decompressive surgery. In the absence of Chiari malformation, asymptomatic syringomyelia may

be observed clinically with yearly clinical examinations and intermittent MRI.

Direct shunting of the syrinx may improve symptoms in those patients who have persistent symptoms after successful posterior fossa decompression, or in those patients who have a symptomatic syrinx without a Chiari malformation. Options include syringoperitoneal, syringopleural, and syringosubarachnoid shunts. The shunt acts to decompress the fluid buildup within the spinal cord, diverting the fluid to another space for reabsorption (Menezes 1999). Similarly, stenting across the obstructed fourth ventricular obex can prevent “water hammering” of CSF into the proximal cervical central canal.

### 6.8.1 Nursing Care

Postoperative care includes incision care, pain management, and evaluation of shunt function. With syringoperitoneal shunting, there will be an incision over the spine at the level of the syrinx and an incision over the abdomen for insertion of the distal catheter. Abdominal pain and bowel function are key areas for nursing assessment.

The syringopleural shunt will have a similar back incision with the distal catheter incision in the lateral chest. Observation of respiratory status is important with this treatment option. Decreased breath sounds and oxygen desaturation may indicate a symptomatic pleural effusion. Indeed, small pleural effusions are typical and generally well tolerated. The patient may have mild tachypnea and low oxygen saturations and may require nasal cannula oxygen supplementation for up to 1 week. If tachypnea or desaturations worsen, the patient may need more intervention including thoracentesis or removal of shunt from the pleural space. Serial chest radiographs may be used to evaluate the patient’s ability to accommodate the pleural fluid being diverted by the shunt.

The syringosubarachnoid shunt requires only one incision to accommodate both the proximal and distal catheters and may be effective in symptom relief. The use of a shunt to treat syringomyelia requires ongoing follow-up to observe for signs of shunt failure (Boxes 6.3, 6.4, and 6.5).

#### Box 6.3 Case Study Progress Note

S: Pt’s mom and dad at bedside, state he did well after surgery but has really struggled with pain since around 0200. N/V has been better controlled since MN. Pt is resting comfortably at the moment, in NAD.

O: HR: 1150, BP: 102/72, RR: 19.

Pt wakes easily, states pain is a 5/10, mainly at incision area.

Dressing has a scant amount of old blood on it, no fluid collection noted.

Medications: acetaminophen 420 mg IV, every 6 h.

Valium 3 mg IV, every 6 h.

Oxycodone 3 mg PO, every 4 h, PRN mild pain (received three doses in past 24 h).

Morphine 3 mg IV, every 2 h, PRN severe pain (received five doses in past 24 h).

Zofran 4 mg IV, every 6 h PRN nausea/vomiting (received two doses in past 24 h).

A: 4-year-old CM with CM-I, POD 1 Chiari decompression.

P: Keep in the PICU this morning.

Will add ketorolac (Toradol) 15 mg IV every 6 h, PRN moderate pain, if pain is better controlled, O2 sats stable and requiring less IV narcotics and then pt. can tx to floor.

Encourage clear liquid diet as tolerated, keep MIVF. Will add stool softener.

#### Box 6.4 Cont. Case Study Progress Note

S: Pt’s mom at bedside, pt. is on his way back from the playroom. Mom states he had a great night and is much improved. Minimal n/v (only when taking pain medications on empty stomach).

O: HR: 80, BP: 100/69, RR: 18.

Pt AAO x3. States pain is a 2/10, mainly at incision area.

Dressing was removed, no fluid collection. Incisions is clean, dry, and intact. No

redness, drainage, or swelling noted. Sensate to light touch. Stiff neck with ROM.

Medications: acetaminophen 350 mg PO, every 4 h, PRN (received three doses in past 24 h).

Valium 3 mg PO, every 6 h, PRN (received two doses in past 24 h).

Oxycodone 3 mg PO, every 4 h, PRN mild pain (received one doses in past 24 h).

Morphine 3 mg IV, every 2 h, PRN severe pain (received 0 doses in past 24 h).

Zofran 4 mg IV, every 6 h, PRN nausea/vomiting (received two doses in past 24 h) docusate 50 mg, once daily.

A: 4-year-old CM with CM-I, POD 3 Chiari decompression, doing well with limited n/v, good pain control.

Limited ROM of neck.

P: Ok to D/C home with mom and dad.

Will send home with valium and oxycodone in limited quantities since he is not taking many at this time. Encouraged patient to take tylenol and colace as needed for pain and constipation.

Encouraged oxycodone to be taken with food to avoid upset stomach and for severe pain.

Incision care instructions were given.

Return to school note, and sports and activities restrictions were given. Follow-up appointment was made. PT consult prior to D/C for home exercise.

### Box 6.5 Cont. Case Study

At LL's first postoperative appointment 2 weeks after surgery, his parents reported improved sleep and headaches as well as a resolution of the vomiting. His surgical site was healing well without redness, drainage, or swelling, and the absorbable sutures were beginning to fall out spontaneously.

He had full ROM of his neck and was taking acetaminophen one to two times a day.

Six months after surgery, a follow-up brain MRI revealed "near-complete resolution of the brainstem and upper cervical cord compression with resolved medullary kink, adequate CSF at the craniocervical junction, and resolution of low-lying tonsil".

LL will have follow-up with the neurosurgeon again in 18 months.

### Patient and Family Education

1. Informed consent: major risks of surgery include bleeding, CSF leak, infection, persistence of symptoms, neurological deficit, and anesthesia complications.
2. Preoperative history and physical examination.
3. Preoperative diagnostic tests that may include swallow evaluation, sleep study, MRI, and developmental assessment.
4. Educational handouts about Chiari malformations and website information recommendations.
5. Incision care after dressing removed.
6. Sutures either dissolvable or removed in about 2 weeks.
7. Activity restrictions: no driving while on narcotics or while neck is stiff; return to school or work once cleared by neurosurgeon, usually between 2 and 4 weeks.
8. Follow-up imaging: MRI in 4–6 weeks and then annually for 5 years (more frequently if syrinx present).
9. Signs and symptoms of shunt failure, for patients requiring shunting of the syrinx.
10. Discharge instructions: incision care with observation for infection or pseudomeningocele; call surgeon's office for headache not responsive to medication and fever greater than 101 °F.

## 6.9 Outcomes: Short and Long Term

CM-I: Successful decompression can provide relief of headache. Symptoms due to cranial nerve or brainstem dysfunction can show improvement over several weeks to months. Follow-up swallow studies are useful to evaluate the effects of treatment when done 6 or more weeks postoperatively. Ataxia or weakness may also gradually improve. Patients with symptoms other than isolated headaches on presentation benefit from appropriate therapies postoperatively, such as occupational, physical, and/or speech therapy.

MRI imaging should demonstrate improvement in CSF flow around the craniocervical junction by approximately 6 weeks after surgery. A syrinx should radiographically resolve or decrease in size within 3–6 months of posterior fossa decompression. Symptoms may persist in spite of the radiographic improvement (Dias 1999).

CM-II: Better outcomes occur with older children who present with cerebellar dysfunction, spasticity, and weakness. Results in the neonatal and infant population have been varied, but in general, their outcomes are poorer. CM-II may cause death by respiratory failure (Dias 1999). The rapidity of neurological decline and immediate preoperative neurological status are the most important factors affecting prognosis.

### Conclusion

The spectrum of Chiari malformations and syringomyelia present a continuum of challenges to the pediatric patient. The range of effect on quality of life varies from mild, with effective treatments available, to very severe, with minimal or no benefit from medical intervention. Advances in radiographic imaging and surgical techniques have provided opportunities to improve the health status of many of these patients. Advances in nursing research provide the opportunity for nurses and the allied health professionals to further enhance

functional level and optimal development of children with this varied spectrum of disorders. Incorporating best practice for the pediatric neurosurgical patient in the areas of wound healing, pain management, prevention of postoperative complications, and effects of hospitalization on development and psychosocial wellness will further enhance the quality of life of this young population.

### Pediatric Practice Pearls

1. For pain management after posterior fossa decompression, start nonsteroidal anti-inflammatory medications when the patient is taking fluids orally. Starting scheduled IV acetaminophen immediately postoperatively can significantly reduce the amount of opioids taken and controls pain well.
2. May need antispasmodics ordered due to muscle spasm after Chiari decompression.
3. Straining with constipation can disrupt the surgical site and is particularly a risk when the dura has been disrupted. Start a bowel regime when the patient is taking fluids orally to avoid constipation.
4. Relaxation techniques and gentle massage can be helpful during recovery from posterior fossa decompression. Muscle spasms often complicate the pain cycle.
5. For patients recovering from Chiari decompressions, place devices such as the TV remote, tablets, and phones on the side of the bed to encourage the patients to turn their heads once outside of the acute postoperative stage to avoid their necks becoming stiff.
6. Involve physical therapy prior to discharge for range of motion exercises to be done at home to avoid a stiff neck.
7. Avoid wearing hats, especially in summer months, that could result in skin breakdown and introduce bacteria on sweaty skin until incisions are well healed.

## References

- Adzick NS, Thom EA, Spong CY, Brock JW 3rd, Burrows PK, Johnson MP (2011) A randomized trial of prenatal versus postnatal repair of myelomeningocele. *N Engl J Med* 364(11):993–1004
- Albert GW, Menezes AH, Hansen DR, Greenlee JD, Weinstein SL (2010) Chiari malformation type I in children younger than age 6 years: presentation and surgical outcome. *J Neurosurg Pediatr* 5(6):554–561
- Benglis D, Covington D, Bhatia R, Bhatia S, Elhammady MS, Ragheb J et al (2011) Outcomes in pediatric patients with chiari malformation type I followed up without surgery. *J Neurosurg Pediatr* 7(4):375–379
- Detwiler PW, Porter RW, Rekate HL (1999) Hydrocephalus-clinical features and management. In: Choux M, DiRocco C, Hockley AD, Walker ML (eds) *Pediatric neurosurgery*. Churchill Livingstone, London, pp 253–271
- Dias MS (1999) Myelomeningocele. In: Choux M, DiRocco C, Hockley AD, Walker ML (eds) *Pediatric neurosurgery*. Churchill Livingstone, London, pp 33–59
- Fric R, Eide PK (2015) Comparison of pulsatile and static pressures within the intracranial and lumbar compartments in patients with Chiari malformation type I: a prospective observational study. *Acta Neurochir* 157:1411–1423
- Goh S, Bottrell CL, Aiken AH, Dillon WP, Wu YW (2008) Presyrinx in children with chiari malformations. *Neurology* 71(5):351–356
- Greenberg MS (2010) *Handbook of neurosurgery*, 7th edn. Thieme Medical Publishers, New York
- Hida K, Iwasaki Y, Koyanagi I, Sawamura Y, Abe H (1995) Surgical indication & results of foremen magnum decompression versus syringosubarachnoid shunting for syringomyelia associated with Chiari I malformation. *Neurosurgery* 37(4):637–639
- Khoury C (2015) Chiari malformation. In: Patterson MC (ed) *UpToDate*. Wolters Kluwer Health, Philadelphia
- Lazareff JA, Galarza M, Gravori T, Spinks TJ (2002) Tonsillectomy without craniectomy for the management of infantile Chiari I malformation. *J Neurosurg* 97:1018–1022
- Menezes AH (1995) Primary craniovertebral anomalies and the hindbrain syndrome (Chiari I): data base analysis. *Pediatr Neurosurg* 23:260–269
- Menezes AH (1999) Craniovertebral anomalies and syringomyelia. In: Choux M, DiRocco C, Hockley AD, Walker ML (eds) *Pediatric neurosurgery*. Churchill Livingstone, London, pp 151–184
- Menezes AH (2008) Craniovertebral junction database analysis: incidence, classification, presentation, and treatment algorithms. *Childs Nerv Syst* 24:1101. doi:10.1007/s00381-008-0605-9
- Milhorat TH, Bolognese PA, Nishikawa M, McDonnell NB, Francomano CA (2007) Syndrome of occipitoatlantoaxial hypermobility, cranial settling, and Chiari malformation Type I in patients with hereditary disorders of connective tissue. *J Neurosurg Spine* 7(6):601–609
- Mueller DM, Oro JJ (2004) Prospective analysis of presenting symptoms among 265 patients with radiographic evidence of Chiari malformation type I with or without syringomyelia. *J Am Acad Nurse Pract* 16:134–138
- Narvaro R, Olavarria G, Seshadri R, Gonzales-Portillo G, McLone DG, Tomita T (2004) Surgical results of posterior fossa decompression for patients with Chiari I malformation. *Childs Nerv Syst* 20:349–356
- Nohria V, Oakes WJ (1991) Chiari I malformation: a review of 43 patients. *Pediatr Neurosurg* 16:222–227
- Novogno F, Caldarelli M, Massa A, Chieffo D, Massimi L, Pettorini B et al (2008) The natural history of the chiari type I anomaly. *J Neurosurg Pediatr* 2(3):179–187
- Oakes WJ, Pugh JA, Tubbe RS (2011) Chiari malformations. In: Winn HR (ed) *Youmans neurological surgery*, 6th edn. Saunders, Philadelphia, pp 1918–1927
- Parker SR, Harris P, Cummings TJ, George T, Fuchs H, Grand G (2011) Complications following decompression of Chiari malformation Type I in children: dural graft or sealant? *J Neurosurg Pediatr* 8:177–183
- Payner TD, Prenger E, Berger TB, Crone KR (1994) Acquired Chiari malformations: incidence, diagnosis, and management. *Neurosurgery* 34(3):429–434
- Rekate HL (2008) Natural history of the chiari type I anomaly. *J Neurosurg Pediatr* 2(3):177–178
- Rekate HL, Wallace D (2003) Lumboperitoneal shunts in children. *Pediatr Neurosurg* 38:41–46
- Rider T, Anderson RCE, Hankinson, TC (2015) Ventral decompression in Chiari malformation, basilar invagination, and related disorders. *Neurosurg Clin N Am* 26:571–578. <http://dx.doi.org/10.1016/j.nec.2015.06.011> 1042–3680/15/\$
- Schijman E (2004) History, anatomic forms, pathogenesis of Chiari I malformation. *Childs Nerv Syst* 20:323–328
- Sherman J, Larson JJ, Crone KR (1999) Posterior fossa decompression without dural opening for the treatment of Chiari I malformation. In: Rensachary SS, Wilkins RH (eds) *Neurosurgical operative atlas*, vol, 8th edn. American Association of Neurological Surgeons, Park Ridge, pp 179–183
- Strahle J, Muraszko KM, Kapurch J, Bapuraj JR, Garton HR, Maher CO (2011) Chiari malformation Type I and syrinx in children undergoing magnetic resonance imaging. *J Neurosurg Pediatr* 8(2):205–213



- Strayer A (2001) Chiari I malformation: clinical presentation & management. *J Neurosurg Nurs* 33(2):90–104
- Sutton LN, Adzick NS, Bilaniuk LT, Johnson MP, Crombleholme TM, Flake AW (1999) Improvement in hindbrain herniation demonstrated by serial fetal magnetic resonance imaging following fetal surgery for myelomeningocele. *JAMA* 282(19):1826–1831
- Tulipan N, Hernanz-Schulman M, Bruner JP (1998) Reduced hindbrain herniation after intrauterine myelomeningocele repair: a report of four cases. *Pediatr Neurosurg* 29(5):274–278
- Tulipan N, Hernanz-Schulman M, Lowe LH, Bruner JP (1999) Intrauterine myelomeningocele repair reverses preexisting hindbrain herniation. *Pediatr Neurosurg* 31(3):137–142
- Weprin BE, Oakes WJ (2001) The Chiari malformations and associated syringohydromyelia. In: McClone DG (ed) *Pediatric neurosurgery*. WB Saunders Co, Philadelphia, pp 214–235
- Yeh DD, Koch B, Crone KR (2006) Intraoperative ultrasonography used to determine the extent of surgery necessary during posterior fossa decompression in children with chiari malformation Type I. *J Neurosurg* 105(1 Suppl Pediatrics):26–32
- Yundt KD, Park TS, Tantuwaya VS, Kaufman BA (1996) Posterior fossa decompression without duraplasty in infants and young children for treatment of Chiari malformation and achondroplasia. *Pediatr Neurosurg* 25:221–226

Stephanie Smith

## 7.1 Introduction

Central nervous system (CNS) tumors are the most common solid tumors in children and the leading cause of cancer-related deaths in childhood (Pollack 2011). For example, there are approximately 2500 brain tumors diagnosed in children each year in the United States (Gajjar et al. 2013). The incidence of CNS tumors is higher in males than females and higher among white and Asian/Pacific islanders than any other group (Ostrom et al. 2015). The incidence of reported pediatric brain tumors has gradually increased over the past few decades by 1.37% annually. Some researchers theorize that the increase in CNS tumors is a result of better diagnostic imaging, while others believe that it is a result of changes in the histological classification of “benign” and “malignant” tumors resulting in a more accurate picture of the true incidence rate (Patel et al. 2014). Recent advances in diagnostic capabilities, aggressive surgical techniques, and multimodal therapy, including radiation and/or chemotherapy, have led to improved cure rates

for some tumors with no change in outcomes for other tumors (Gajjar et al. 2015). The World Health Organization’s (WHO) four-tier grading system is commonly used to classify all tumors according to their histologic features (Adesina 2010). Significant improvements in the identification and understanding of the genetic mutations of tumors and the molecular alterations leading to tumor formation have prompted a recent update in the WHO’s classification (Fig. 7.1) (Louis et al. 2016). The identification of the molecular pathogenesis of some tumors will provide an opportunity for a more personalized therapeutic approach, in an effort to improve survival rates while also decreasing long-term morbidity (Gajjar et al. 2015).

Because there are many different kinds of brain tumors, the number of children diagnosed with each particular type is small (Fig. 7.2). Advances in successfully treating each subset of tumor have been a direct result of children being enrolled in clinical trials. The majority of those trials are part of the Children’s Oncology Group (COG). Such trials accurately evaluate treatments and recommend standard best treatments for each tumor type. In addition to clinical treatments, COG also conducts biological research focused on identifying possible causes of CNS tumors (Khatua and Jalali 2005). Neurosurgical and technological advances in diagnostic capabilities, radiation techniques, and the use of chemotherapy have radically improved the prognosis for

---

Tania Shiminski-Maher wrote the original chapter and the 2nd edition but did not participate in this revision.

S. Smith, MS, CPNP  
Department of Pediatric Neurosurgery,  
Dayton Children’s Hospital,  
One Children’s Plaza, Dayton, OH 45404, USA  
e-mail: [smithsj@childrensdayton.org](mailto:smithsj@childrensdayton.org)

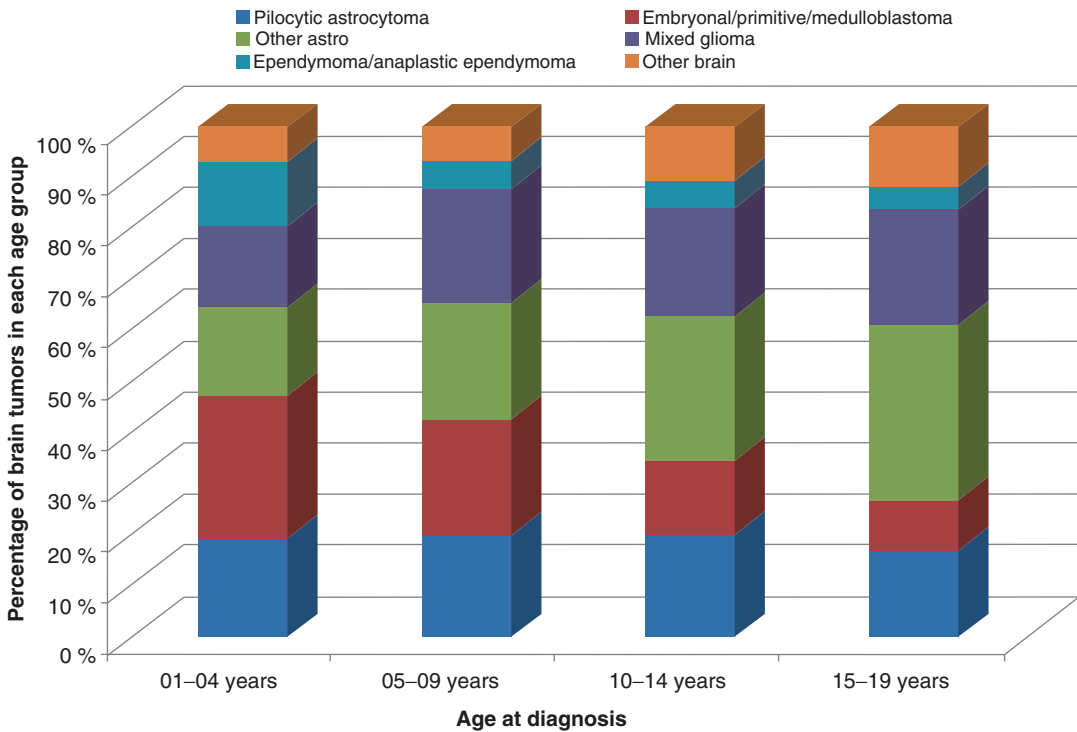
WHO classification of tumours of the central nervous system

WHO classification of tumours of the central nervous system	ICD-O-3 code	ICD-O-3 code	ICD-O-3 code
<b>Diffuse astrocytic and oligodendroglial tumours</b>			
Diffuse astrocytoma, IDH-mutant	9400/3	Neuronal and mixed neuronal-glia tumours	9413/0
Gemistocytic astrocytoma, IDH-mutant	9411/3	Dysembryoplastic neuroepithelial tumour	9492/0
Diffuse astrocytoma, IDH-wildtype	9400/3	Gangliocytoma	9505/1
Diffuse astrocytoma, NOS	9400/3	Anaplastic ganglioglioma	9505/3
Anaplastic astrocytoma, IDH-mutant	9401/3	Dysplastic cerebellar gangliocytoma	9493/0
Anaplastic astrocytoma, IDH-wildtype	9401/3	(Lhermitte-Duclos disease)	
Anaplastic astrocytoma, NOS	9401/3	Desmoplastic infantile astrocytoma and ganglioglioma	9412/1
Glioblastoma, IDH-wildtype	9404/3	Papillary glioneuronal tumour	9509/1
Giant cell glioblastoma	9441/3	Rosette-forming glioneuronal tumour	9509/1
Gliosarcoma	9442/3	Diffuse leptomeningeal glioneuronal tumour	9506/1
Ependymoid glioblastoma	9440/3	Central neurocytoma	9506/1
Glioblastoma, IDH-mutant	9445/3*	Extraventricular neurocytoma	9506/1
Glioblastoma, NOS	9440/3	Cerebellar liponeurocytoma	8693/1
		Paraganglioma	
<b>Tumours of the pineal region</b>			
Diffuse midline glioma, H3 K27M-mutant	9385/3*	Pineocytoma	9381/1
Oligodendroglioma, IDH-mutant and 1p/19q-codeleted	9450/3	Pineal parenchymal tumour of intermediate differentiation	9362/3
Oligodendroglioma, NOS	9450/3	Pineoblastoma	9362/3
Anaplastic oligodendroglioma, IDH-mutant and 1p/19q-codeleted	9451/3	Papillary tumour of the pineal region	9395/3
Anaplastic oligodendroglioma, NOS	9451/3		
Oligoastrocytoma, NOS	9382/3	<b>Embryonal tumours</b>	
Anaplastic oligoastrocytoma, NOS	9382/3	Medulloblastomas, genetically defined	
		Medulloblastoma, WNT-activated and TP53-mutant	9475/3*
		Medulloblastoma, SHH-activated and TP53-wildtype	9476/3*
<b>Other astrocytic tumours</b>		Medulloblastoma, SHH-activated and TP53-wildtype	9471/3
Pilocytic astrocytoma	9421/1	Medulloblastoma, non-WNT/non-SHH	9477/3*
Plexiform astrocytoma	9425/3	Medulloblastoma, group 3	
Subependymal giant cell astrocytoma	9394/1	Medulloblastoma, histologically defined	
Pleomorphic xanthoastrocytoma	9424/3	Medulloblastoma, classic	9470/3
Anaplastic pleomorphic xanthoastrocytoma	9424/3	Medulloblastoma, desmoplastic/nodular	9471/3
		Medulloblastoma with extensive nodularity	9471/3
<b>Ependymal tumours</b>		Medulloblastoma, large cell / anaplastic	9474/3
Subependymoma	9383/1	Medulloblastoma, NOS	9470/3
Myxopapillary ependymoma	9394/1		
Ependymoma	9391/3	Embryonal tumour with multilayered rosettes, C19MC-altered	9478/3*
Papillary ependymoma	9393/3	Embryonal tumour with multilayered rosettes, NOS	9478/3
Clear cell ependymoma	9391/3	Embryonal tumour with multilayered rosettes, NOS	9501/3
Tanycytic ependymoma	9391/3	CNS neuroblastoma	9500/3
Ependymoma, RELA fusion-positive	9396/3*	CNS ganglioneuroblastoma	9493/3
Anaplastic ependymoma	9392/3	CNS embryonal tumour, NOS	9473/3
		CNS embryonal tumour with rhabdoid features	9508/3
<b>Other gliomas</b>			
Choroid glioma of the third ventricle	9444/1	<b>Tumours of the cranial and paraspinal nerves</b>	
Angiocentric glioma	9431/1	Schwannoma	9560/0
Astroblastoma	9430/3	Cellular schwannoma	9560/0
		Plexiform schwannoma	9560/0
<b>Choroid plexus tumours</b>			
Choroid plexus papilloma	9390/1		
Atypical choroid plexus papilloma	9390/1		
Choroid plexus carcinoma	9390/3		

Fig. 7.1 The 2016 World Health Organization classification of tumors of the central nervous system

WHO classification of tumours of the central nervous system	ICD-O-3 code	ICD-O-3 code	ICD-O-3 code
Melanotic schwannoma	9560/1		92100
Neurofibroma	9540/0		9180/3
Atypical neurofibroma	9540/0		
Plexiform neurofibroma	9550/0		
Perineurioma	9571/0		
Hybrid nerve sheath tumours	9540/3		
Malignant peripheral nerve sheath tumour	9540/3		
Epileptoid MPNST	9540/3		
MPNST with perineurial differentiation	9540/3		
<b>Meningiomas</b>			
Meningioma	9530/0		9680/3
Meningothelial meningioma	9531/0		
Fibrous meningioma	9532/0		
Transitional meningioma	9537/0		
Psammomatous meningioma	9533/0		
Angiomatous meningioma	9534/0		
Microcystic meningioma	9530/0		
Secretory meningioma	9530/0		
Lymphoplasmacyte-rich meningioma	9530/0		
Metaplastic meningioma	9538/1		
Chordoid meningioma	9538/1		
Clear cell meningioma	9539/1		
Atypical meningioma	9538/3		
Papillary meningioma	9538/3		
Rhabdoid meningioma	9538/3		
Anaplastic (malignant) meningioma	9538/3		
<b>Mesenchymal, non-meningothelial tumours</b>			
Solitary fibrous tumour / haemangiopericytoma**			
Grade 1	8815/0		
Grade 2	8815/1		
Grade 3	8815/3		
Haemangioblastoma	9161/1		
Haemangioma	9120/0		
Epithelioid haemangiopericytoma	9133/3		
Angiosarcoma	9120/3		
Kaposi sarcoma	9140/3		
Ewing sarcoma / PNET	9864/3		
Lipoma	8850/0		
Hibernoma	8861/0		
Liposarcoma	8850/3		
Desmoplastic fibromatosis	8821/1		
Myofibrosarcoma	8820/0		
Inflammatory myofibroblastic tumour	8825/1		
Benign fibrous histiocytoma	8830/0		
Fibrosarcoma	8810/3		
Undifferentiated pleomorphic sarcoma / malignant fibrous histiocytoma	8802/3		
Lelomyoma	8800/0		
Leiomyosarcoma	8803/0		
Rhabdomyoma	8900/0		
Rhabdomyosarcoma	8903/0		
Chondroma	9220/0		
Chondrosarcoma	9223/3		
Osteoma	9180/0		
<b>Germ cell tumours</b>			
Germinoma	9064/3		
Embryonal carcinoma	9070/3		
Yolk sac tumour	9071/3		
Choriocarcinoma	9100/3		
Teratoma	9080/1		
Mature teratoma	9080/0		
Immature teratoma	9080/3		
Teratoma with malignant transformation	9084/3		
Mixed germ cell tumour	9085/3		
<b>Tumours of the sellar region</b>			
Craniopharyngioma	9350/1		
Adamantinomatous craniopharyngioma	9351/1		
Papillary craniopharyngioma	9352/1		
Granular cell tumour of the sellar region	9452/0		
Pituitaryoma	9432/1		
Spindle cell oncocyoma	8290/0		
<b>Metastatic tumours</b>			

The morphology codes are from the International Classification of Diseases for Oncology (ICD-O) [17A2]. Behaviour is coded 0 for benign tumours; 1 for unspecified, borderline, or uncertain behaviour; 2 for carcinoma in situ and grade III intracapsular neoplasms; and 3 for malignant tumours. \*These new codes were approved by the IARC/WHO Committee for ICD-O. \*\*These new codes were approved by the IARC/WHO Committee for ICD-O. IARC Provisional tumour entities. \*Grading according to the 2013 WHO Classification of Tumours of Soft Tissue and Bone.



**Fig. 7.2** The percentage of tumor histologies for the four pediatric age subgroups in the SEER database between 1973 and 2008. The “other astro” category includes diffuse, anaplastic, unique, and not otherwise specified

(NOS) astrocytomas. The “other brain” category includes choroid plexus tumors, germ cell tumors, nerve sheath tumors, craniopharyngiomas, hemangiomas, and chordomas (Used with permission from Patel et al. 2014)

children with CNS tumors over the past few decades. Many CNS tumors carry a greater than 75% chance of long-term survival. Unfortunately, for those malignant tumors that have been refractory to treatment, there still has been minimal progress in identifying effective therapies (Parsons et al. 2016).

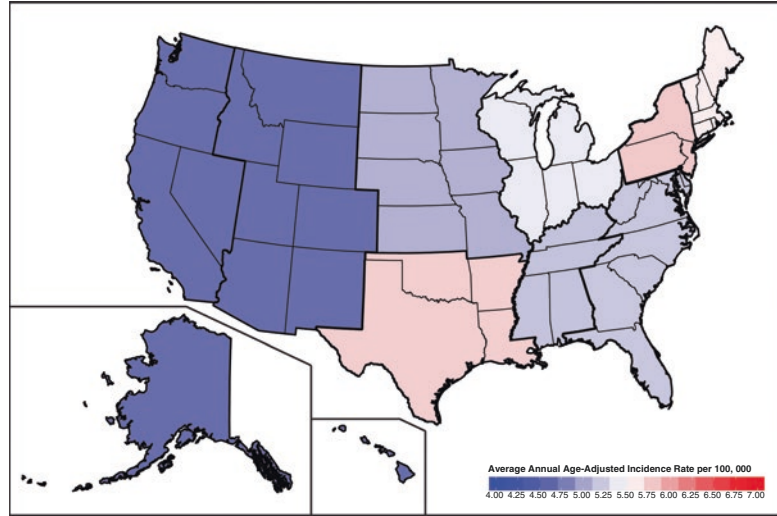
## 7.2 Etiology

Despite the research to date, the cause of pediatric central nervous system tumors remains unknown, though age, gender, hereditary, and environmental factors may be involved (Fig. 7.3). Some CNS tumors have been associated with phakomatoses or hereditary syndromes in children. Examples of tumors with hereditary causes include tuberous sclerosis, which may have tubers within their ventricular system or astrocytomas called subependymal giant cell astrocyto-

mas (SEGAs). Hemangioblastomas are common in children who have von Hippel–Lindau syndrome. Optic nerve gliomas and other CNS astrocytomas can be associated with neurofibromatosis type 1 (also known as von Recklinghausen’s disease). Schwannomas, meningiomas, and spinal cord ependymomas can be associated with neurofibromatosis type 2. Cowden’s disease, Gorlin syndrome (also known as nevoid basal cell syndrome), Turcot syndrome, and Li–Fraumeni syndrome can each be associated with medulloblastomas and other CNS tumors (Kun et al. 2011).

Radiation exposure has been linked to children with pediatric brain tumors. Children who received cranial irradiation in either low or moderate doses have had a higher incidence of brain tumors (Vinchon et al. 2011). While there has also been discussion regarding the use of cellular phones and high-power electrical wires being associated with CNS tumors, to date there has

**Fig. 7.3** Average annual age-adjusted incidence rates of all primary brain and CNS tumors by region of the United States (0–14 years) ( $N = 16,044$ ) (CBTRUS 2007–2011)



New England: Connecticut, Maine, Massachusetts, New Hampshire, Rhode Island, Vermont; Middle Atlantic: New Jersey, New York, Pennsylvania; South Atlantic: Delaware, District of Columbia, Florida, Georgia, Maryland, North Carolina, South Carolina, Virginia, West Virginia; East North Central: Illinois, Indiana, Michigan, Ohio, Wisconsin; East South Central: Alabama, Kentucky, Mississippi, Tennessee; West North Central: Iowa, Kansas, Minnesota, Missouri, Nebraska, North Dakota, South Dakota; West South Central: Arkansas, Louisiana, Oklahoma, Texas; Mountain: Arizona, Colorado, Idaho, Montana, New Mexico, Utah, Wyoming; Pacific: Alaska, California, Hawaii, Nevada, Oregon, Washington.

been no scientific research to confirm this (Kieran et al. 2015).

Recent advances in molecular biology and cytogenetics have begun to identify possible sites of oncogenesis. Mutations in tumor suppressor genes can lead to unregulated and rapid cellular division, and mutations in oncogenes lead to the conversion of normal cells into cancer cells (Ruccione 2011). Alterations in chromosome 17 have been associated with medulloblastoma and astrocytoma, and loss of chromosome 10 has been associated with glioblastoma. Clinical research in pediatric CNS tumors on the cooperative group level is focusing on biology, not only to identify causes but also as a step to develop new treatment strategies (Gajjar et al. 2015).

### 7.3 Nervous System Anatomy

It is essential to have an understanding of normal anatomy to understand the diagnosis and treatment of CNS tumors. The brain sits inside a solid calvarium, the bony structure that is a fixed volume once the sutures are fused. The spinal cord sits inside the hollow vertebrae of the spine. It is the brain and spinal cord that make up the central nervous system. The brain and spinal cord communicate with the arms, legs, and other organs

through the peripheral nervous system (PNS). Control of blood pressure, breathing, and hormonal function is carried out primarily in the brainstem by the autonomic nervous system (ANS) (Hickey 2014).

The largest region in the brain is called the supratentorial region which contains the cerebrum, basal ganglia, and the diencephalon. Symptoms of CNS tumors in this area can be generalized (from changes in intracranial pressure regulation) or focal (from tissue destruction or compressions from the tumor). Focal symptoms include seizures, memory difficulties, headaches, weakness or paralysis of arms and legs, speech abnormalities, personality changes, and visual loss or changes. Generalized symptoms include irritability, lethargy, early morning vomiting, headache, loss of appetite, and behavioral changes (Shiminski-Maher et al. 2014).

The cerebrum is divided into left and right cerebral hemispheres by the great longitudinal fissure and is connected by two bundles of fibers, called the corpus callosum and the anterior commissure. The corpus callosum and the anterior commissure transmit information between the two hemispheres. The cerebrum interprets sensations, controls body movements, and is essential for emotional awareness, memory, acquisition of language, reasoning, and other higher mental

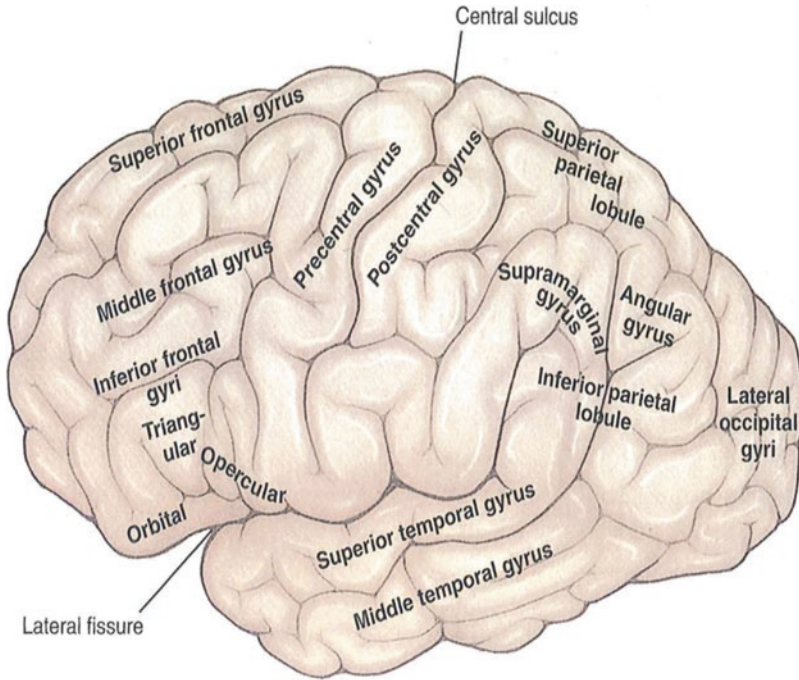


functions (Young et al. 2015). In general, motor function for one side of the body is controlled by the opposite cerebral hemisphere. For example, movement of the arms and legs on the right side of the body is controlled by the left cerebral hemisphere. By early school age, around 5 years, a hand preference is usually identified. A person's speech center is located in the hemisphere opposite hand dominance. This is important when planning treatment for a tumor which is within or adjacent to the speech or motor cortex. In this situation, special preoperative testing may be needed, along with intraoperative monitoring to minimize damage to that area. Younger children have the ability to switch dominance after an injury to the dominant side has occurred or have mixed dominance in terms of speech or motor functioning (Shiminski-Maher et al. 2014).

The frontal lobes make up about 40% of the cerebral cortex and contain the following six functional areas: primary motor, premotor, supplementary motor, frontal eye field, prefrontal, and the Broca speech area. The primary motor cortex controls voluntary movements by sending neural impulses to produce movement in the contralateral side. A lesion on the primary motor cortex that is located in the region that controls facial movement would result in paralysis of the facial muscles on the opposite side. The premotor cortex is located anterior to the primary motor cortex and, when stimulated, produces slower generalized movements of the larger muscles on the contralateral side. A lesion in this area would result in the inability to perform skilled movements on the contralateral side. The supplementary motor area is located anterior and medially to the primary motor area and is responsible for motor planning. A lesion in this area will often result in the inability to perform purposeful movement known as motor apraxia. The frontal eye field is located anterior to the supplementary motor area and is responsible for conjugate eye movements to the contralateral side. A lesion here would result in paralysis of the contralateral gaze. The prefrontal cortex is located anterior to the frontal eye field and extends inferiorly, medially, and laterally making up approximately one-third of the cerebral cortex. It is responsible for

social behavior and cognitive abilities. Bilateral lesions on the prefrontal cortex may result in personality changes and inability to concentrate or to solve problems. Broca area is located in the inferior frontal gyrus and is responsible for the motor control of speech. A lesion here would result in the inability of a person to express his or her thoughts, known as nonfluent aphasia (Young et al. 2015; Hickey and Kunusky 2014). (Figs. 7.4 and 7.5).

The temporal lobes are located on the sides of the brain and make up about 25% of the cerebral cortex. Each temporal lobe contains the following five functional areas: primary auditory receptive area, Wernicke's area (also known as the auditory association area), interpretive area, amygdala, and hippocampus. The primary auditory receptive area is located in the transverse temporal gyrus and is responsible for emotions, speech, and memory. A lesion in this area would cause difficulty determining the direction or distance of sound especially in the contralateral ear. Wernicke's area is located in the posterior part of the temporal gyrus, is larger in the dominant hemisphere, and is responsible for speech formation and comprehension. A lesion in this area would result in a person substituting meaningless words or phrases that is characterized as fluent aphasia. The lesion would also result in difficulty understanding written or spoken language characterized as receptive aphasia. The interpretive area is located where the temporal, parietal, and occipital lobes meet and is responsible for memory, olfaction, visual, auditory, and emotions. A lesion here would result in significant cognitive impairment. The amygdala is located near the dorsomedial tip of the temporal lobe and is responsible for controlling social behavior and emotions. Bilateral lesions here could result in behavioral changes such as a loss of fear. The hippocampus is located in the floor of the temporal horn of the lateral ventricle and is responsible for short-term memory and ability to learn. Lesions here could result in the loss of short-term memory and ability to learn (Young et al. 2015; Hickey and Kunusky 2014). Seizures are a common presenting symptom in tumors of the temporal lobe (Kun et al. 2011).



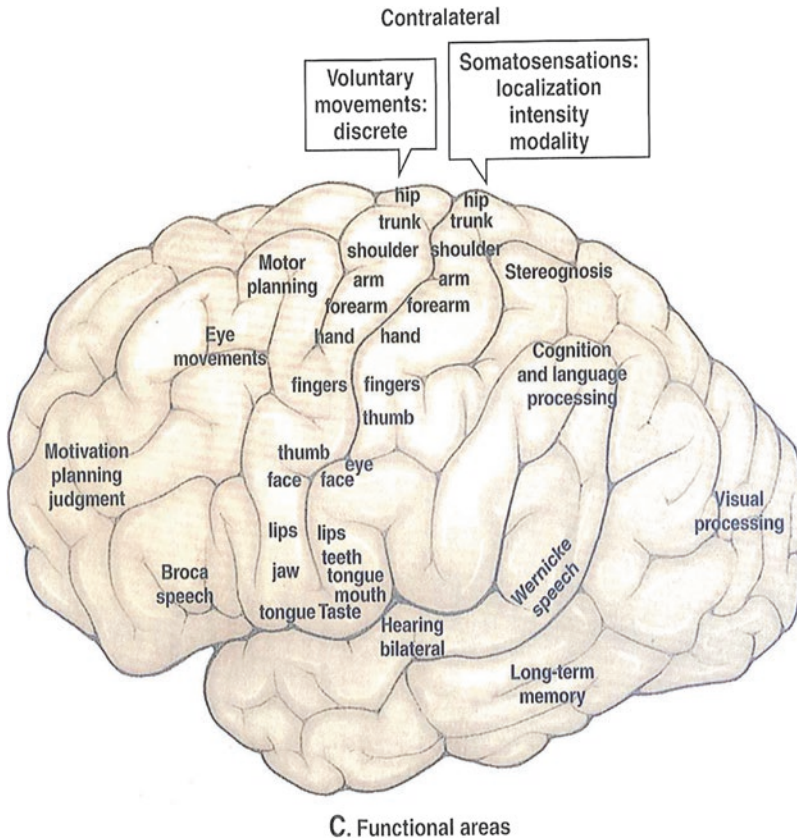
**A. Principal gyri and sulci**

**Fig. 7.4** Principal gyri and sulci in the cerebrum (Used with permission from Wolters Kluwer Health)

The parietal lobes are located posterior to the frontal lobes and make up about 20% of the cerebral cortex. The parietal lobes contain the following three functional areas: primary somatosensory area, secondary somatosensory area, and association area. The primary somatosensory area is located in the postcentral gyrus and part of the paracentral lobule and is responsible for interpreting contralateral tactile sensory information such as pinprick and temperature as well as position of body parts known as proprioception. A lesion in this area would result in a loss of tactile discrimination or proprioception on the contralateral side. The secondary somatosensory area is located in the cortex that extends from the parietal operculum into the posterior part of the insula and is also responsible for the interpretation of tactile sensation. The association area is located posterior to the somatosensory area and is responsible for stereognosis, awareness of body parts, and orderly motor movements. This area is also responsible for visual and auditory processing that is needed for language and cogni-

tion. A lesion in the superior region of this area can result in the denial of parts of the body on the contralateral side, also known as neglect syndrome. Lesions in the inferior region of this area can result in the inability to read, write, and perform simple math (Young et al. 2015). Tumors in the parietal lobes can result in seizures, weakness, uncontrolled movements, or sensory changes such as pain or tingling known as paresthesia in the extremities (Shiminski-Maher et al. 2014).

The occipital lobes are located posterior to the parietal lobes and make up about 15% of the cerebral cortex. The occipital lobes contain the primary visual cortex and the visual association area which are responsible for receiving and interpreting information received from the optic nerves, visual fixation, and involuntary smooth eye movements. The left occipital lobe receives information from the right eye, and the right occipital lobe receives information from the left eye (Shiminski-Mayer et al. 2014; Hickey and Kunusky 2014). A lesion in the primary visual



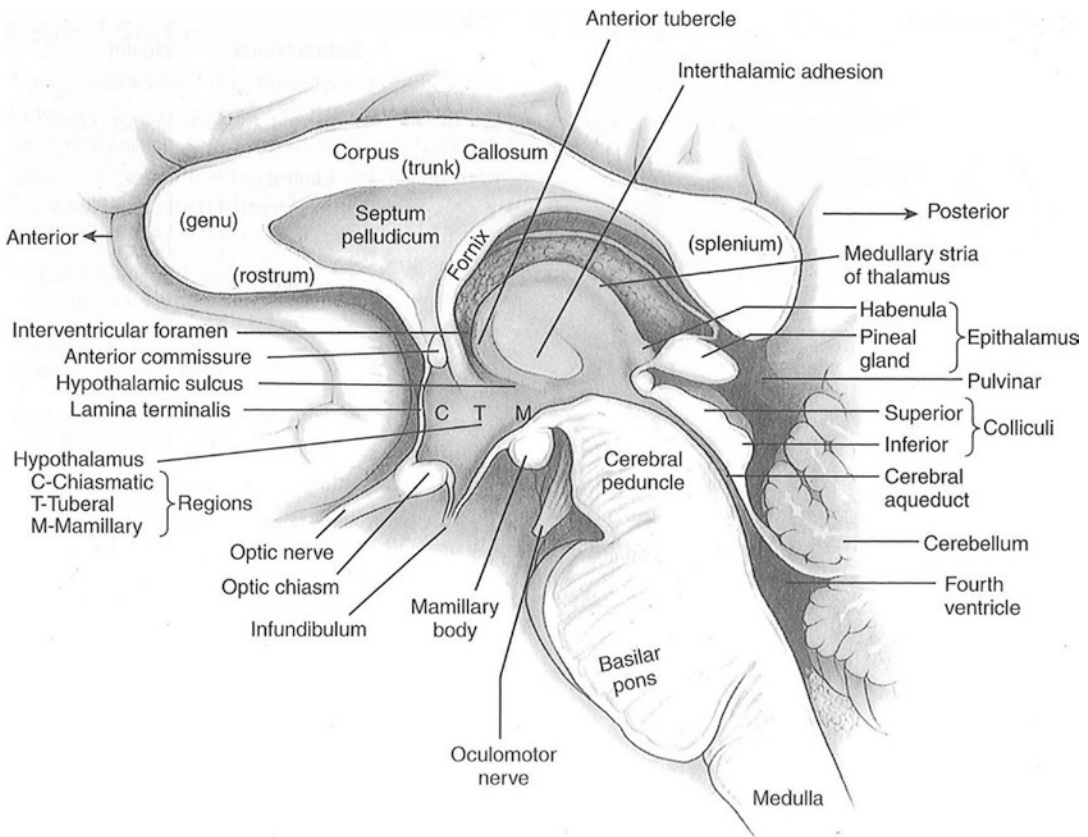
**Fig. 7.5** Functional areas of the cerebrum (Used with permission by Wolters Kluwer Health)

cortex would result in loss of peripheral vision of the contralateral side known as a visual field cut. Bilateral lesions in the visual association area would result in loss of color vision and loss of spatial relationships (Young et al. 2015).

The basal ganglia is located deep within the cerebral hemispheres and is interconnected with the thalamus, cerebral hemispheres, and the midbrain. The basal ganglia help to control fine motor movements in the hands and lower extremities. A lesion involving the basal ganglia can result in weakness, abnormal movements, or spasticity (Young et al. 2015).

The diencephalon is divided into four regions: hypothalamus, thalamus, epithalamus, and subthalamus, and it is located in the middle cranial fossa below the cerebral hemispheres (Fig. 7.6). The hypothalamus is located in front of the third ventricle and behind the optic chiasm. It is responsible for many roles in the endocrine,

reproductive, and autonomic systems including regulation of temperature, water balance, food intake, emotions, and circadian rhythms. The thalamus consists of a left and right thalami that are connected across the third ventricle by the interthalamic adhesions or massa intermedia in most brains. The thalamus is responsible for the reticular activating system (RAS), limbic system, and the sensory pathways (except smell). It is also responsible for pain awareness and the ability to focus one's attention. The epithalamus is located behind the thalamus and contains the pineal body which secretes melatonin that helps to regulate circadian rhythms. The epithalamus also helps to regulate the intake of food and water. The subthalamus is located below the thalamus, and its responsibilities are similar to the basal ganglia. A lesion within the diencephalon could result in disturbances of behavior, vision, circadian rhythms, fever, and endocrine abnormalities such



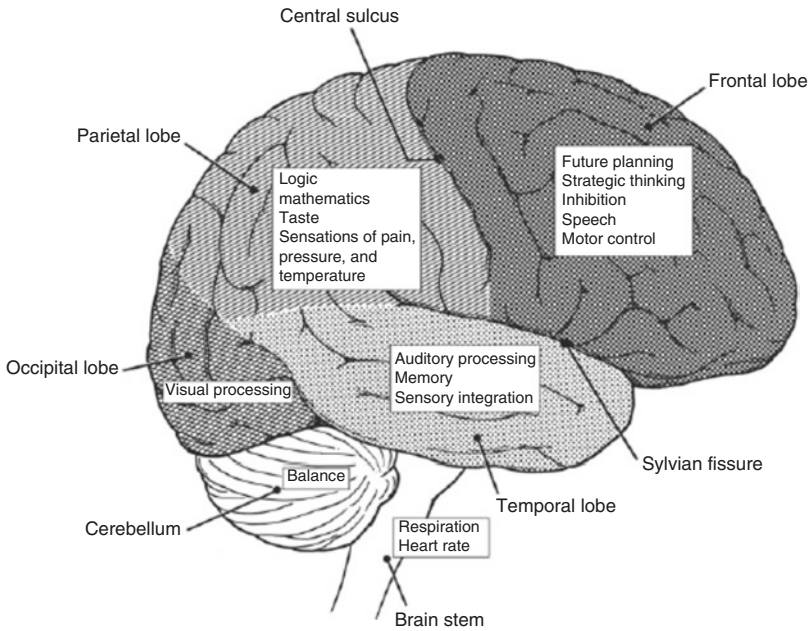
**Fig. 7.6** Median view of right diencephalon and adjacent parts of the brainstem and cerebral hemisphere (Used with permission from Wolters Kluwer Health)

as diabetes insipidus (Young et al. 2015; Hickey and Kunusky 2014).

The posterior fossa or infratentorium contains the cerebellum, the brainstem, and the fourth ventricle. It is located below the occipital lobe and under a double layer of dura mater called the tentorium (Hickey and Kanusky 2014). Nearly half of all child and adolescent brain tumors originate in the posterior fossa (Kun et al. 2011). The cerebellum controls balance, coordination, the ability to judge distances, and cadence and rhythm of speech. A lesion in this area would result in problems with balance and/or lack of coordinated movements known as ataxia (Young et al. 2015). The brainstem, which contains cranial nerves, is the relay center responsible for transmitting and coordinating messages between the brain and other parts of the body. The brainstem is located behind the clivus and in front of the

cerebellum and contains the midbrain, the pons, and the medulla oblongata. The brainstem is also continuous with the spinal cord distally. The midbrain is located at the top of the brainstem and contains cranial nerve nuclei responsible for processing vision and hearing. It also coordinates the sleep and wake cycles. The pons is directly below the midbrain and contains cranial nerve nuclei that control eye and facial movements and also serves as a link between the cerebrum and the cerebellum. The medulla is below the pons and contains the cranial nerves that control breathing, swallowing, heart rate, and blood pressure. The fourth ventricle is a fluid space that connects the upper fluid chambers to the spinal cord and subarachnoid space surrounding the brain and contains the vagal motor center that controls vomiting (Shiminski-Maher et al. 2014). A lesion here could result in impaired gag, swallowing





**Fig. 7.7** Normal brain anatomy (Used with permission from Barrow Neurological Institute. © Barrow Neurological Institute 2000. All Rights Reserved)

dysfunction, and signs of hydrocephalus such as headache, vomiting, and lethargy (March and Hickey 2014; Cahill and Armstrong 2014).

The spinal cord contains the 31 pairs of spinal nerves that exit at various levels in the cervical, thoracic, lumbar, and sacral regions. The spinal cord sits inside the vertebral column, a series of bones that are stacked upon one another. Nerve impulses travel from the brain down the spinal cord and exit at various levels. They provide sensory and motor stimulation, which result in contraction of muscles in organs in the body as well as movement of the extremities (Hickey and Kanusky 2014).

Figure 7.7 illustrates normal brain anatomy.

## 7.4 Presenting Symptoms

The diagnosis of a CNS tumor in a child is often difficult to establish. The presenting symptoms of a CNS tumor may be vague or similar to the symptoms of many common childhood illnesses. As there are only approximately 2500 children diagnosed with CNS tumors annually in the

United States, the likelihood of a pediatrician seeing a CNS tumor in the practice in his/her career is remote. It is not unusual to get a history from the family of many trips to a health-care provider before the actual diagnosis is made. Many parents express a sense of frustration that they knew something was wrong with their child, and if they had not been persistent in expressing their concerns to the physician, the diagnosis may have been “even more delayed” (Wilne et al. 2010).

Signs and symptoms vary depending upon the rate of growth and location of the tumor. Table 7.1 summarizes symptoms based upon tumor location and tissue type. Tumors with an acute onset of symptoms tend to be more rapidly growing and may be described as aggressive, high grade, or histologically malignant (Watrall 2014). Those with a long history of vague symptoms or those picked up incidentally tend to be slower growing, low grade, or histologically benign (Petriccione and Gilger 2011).

On physical examination, the child with a CNS tumor may have specific neurological deficits, which correlate with the tumor location.



**Table 7.1** Brain tumors: diagnosis based on location and symptoms

Part of the CNS	Symptoms of tumors	Types of tumors
Frontal lobes (cerebral hemispheres)	Problems with learning and concentration, changes in behavior, personality changes, seizures, weakness of an arm or leg on opposite side of tumor	Astrocytoma Glioma Rarely PNET or ependymoma
Parietal lobes (cerebral hemispheres)	Seizures, difficulty processing information, language difficulties	Astrocytoma Glioma DNET
Temporal lobes (cerebral hemispheres)	Atypical/partial complex seizures, behavior problems (aggressiveness, impulsiveness)	Astrocytoma Glioma DNET
Occipital lobes (cerebral hemispheres)	Loss of peripheral vision	Astrocytoma Glioma
Cerebellum (posterior fossa) including the fourth ventricle	Problems with balance, uncoordinated gait, increased intracranial pressure, nausea and vomiting	Astrocytoma Glioma Medulloblastoma Ependymoma
Brainstem (posterior fossa) including the fourth ventricle	Increased intracranial pressure, headache, nausea and vomiting, cranial nerve problems including eye movement disruption, decreased hearing, facial asymmetry, breathing or swallowing difficulties, and problems with balance and strength	Astrocytoma Glioma Ependymoma Medulloblastoma (rare)
Midbrain/thalamus	Altered level of consciousness, memory problems, weakness of arms or legs	Astrocytoma Glioma
Diencephalon (hypothalamus, sella, pituitary)	Hormonal secretion disruption (decreased growth, diabetes insipidus, thyroid deficiency, puberty problems), memory and academic problems	Astrocytoma Gliomas Craniopharyngioma Germ cell
Optic pathway	Visual changes: acuity or field cut	
Ventricular system	Increased intracranial pressure, hydrocephalus, memory or academic problems, hormonal changes	Ependymoma Choroid plexus Astrocytoma Glioma Medulloblastoma
Spinal cord	Back pain, scoliosis, weakness in arms or legs, bowel and bladder problems	Astrocytoma Ependymoma

Source: Adapted from Shiminski-Maher et al. (2014)

It is possible for a child to have a normal examination, for example, in a situation where the tumor is diagnosed incidentally because of a diagnostic test being performed for another reason (Shiminski-Maher et al. 2014).

will be discussed in detail in the next section. Other signs associated with infratentorial tumors include ataxia, nystagmus, and cranial nerve problems. Cranial nerve deficits are indicative of brainstem involvement (Parsons et al. 2016).

## 7.5 Diagnosis: Tumors of the Infratentorium

Symptoms of infratentorial tumors are most commonly associated with increased intracranial pressure. Signs of increased intracranial pressure

### 7.5.1 Diagnosis: Tumors of the Supratentorium

Symptoms of supratentorial tumors include hemiparesis, hemisensory loss, seizures, visual field changes, personality changes, and intellectual

problems. Midline tumors, such as those in the thalamus, hypothalamic, or pituitary region, are associated with increased intracranial pressure, visual changes, motor deficits, and seizures. Endocrine issues such as diabetes insipidus or precocious puberty may also exist (Petriccione and Gilger 2011).

### 7.5.2 Diagnosis: Tumors of the Spinal Cord

Spinal cord tumors usually present with scoliosis, back or leg pain (which often awakes the child from sleep), weakness or sensory changes in the arms or the legs, and/or bowel and bladder dysfunction. Occasionally, a brain tumor will metastasize to the spinal cord and produce similar symptoms to those mentioned above (Shiminski-Maher et al. 2014).

### 7.5.3 Diagnosis: Increased Intracranial Pressure and Hydrocephalus

Increased intracranial pressure occurs from the mass of the tumor occupying space within the brain. It can also occur when the tumor causes an obstruction in the flow of CSF, resulting in hydrocephalus. Symptoms of increased intracranial pressure include headache (that awakens from sleep), nausea, vomiting (which often temporarily relieves the nausea and headache), lethargy, double vision or other visual changes, gait instability, memory problems, and decline in academic functioning. Nausea is especially problematic, as the nausea centers are located near the medulla that may be compressed or infiltrated by a tumor. Infants whose sutures are open can increase their head circumference to compensate for the pressure (Petriccione and Gilger 2011). Infants and children have the ability to compensate for increased intracranial pressure, especially if the tumor is slower growing and pressure increases are subtle. In addition, these symptoms are typical of many childhood illnesses and, therefore, may go unnoticed (Watral 2014). Late signs of increased pressure are papilledema, vital sign

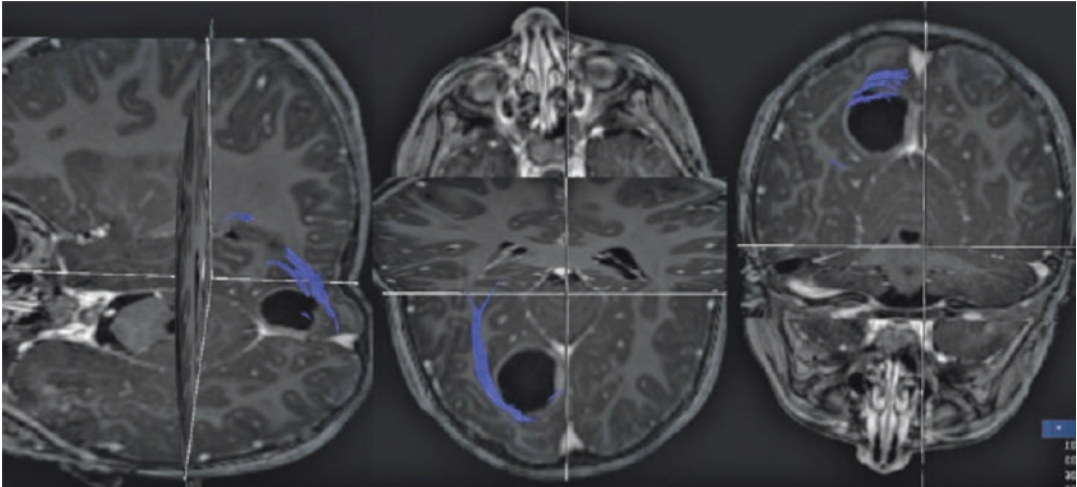
changes, and severe altered level of consciousness (Cahill and Armstrong 2014).

### 7.5.4 Diagnosis: Diagnostic Tests

The diagnosis of a CNS tumor is confirmed with a radiographic study, which is usually ordered by the primary care provider in a child with symptoms suggestive of intracranial or intraspinal pathology. Several other diagnostic tests may also be performed prior to treatment. Obviously, the extent of testing will depend upon the clinical condition of the patient. In general, the more information available to the treating team, the more thorough the plan for maximal surgical removal of the tumor, followed by appropriate adjunctive therapy (Eche 2014).

Until the late 1980s, the computed tomography (CT) scan was the most frequently ordered imaging test. Magnetic resonance imaging (MRI) of the brain is now the gold standard neuroimaging for brain tumors (Watral 2014). Nurses are generally familiar with this diagnostic test, but not necessarily with how it works. A patient having an MRI scan is placed in a machine that contains a strong magnetic field. This magnetic field causes protons in the water molecules in the body to align parallel or antiparallel within the field, and this generates an image (Krishnamurthy et al. 2016).

MRI is a much more sensitive diagnostic test than the previously utilized computed tomography (CT) scans. Its sensitivity allows for detection of smaller tumors that may be missed with a CT scan. In addition, an MRI provides greater anatomic detail in multiple planes. The administration of a contrast agent (gadolinium diethylenetriaminepentaacetic acid: Gd-DTPA) allows for better visualization of enhancing tumors. Moreover, newer imaging sequences are continually being developed to assist in determining whether a tumor's pathology is malignant or benign or to differentiate between recurrent tumor and treatment changes. In addition, specific sequences may allow the radiologist to predict specific tumor diagnosis. For example, diffusion tractography, a variant of diffusion-weighted MRI, allows tracing of functional tracts



**Fig. 7.8** Diffusion tractography of the right optic radiation in a 3-year-old girl with right occipital endependymoma. The right optic radiation (shown in blue) abuts the ring-enhancing endependymoma

in the cerebral white matter, and the optic radiations can be traced through the occipital lobes. This allows planning a surgical route that avoids the optic radiations, limiting the risk for postoperative visual deficit. Figure 7.8 shows this technique (Hastings et al. 2012).

MR angiography utilizes the magnetic field to display blood vessels within the brain. It is helpful in visualizing the blood supply to a tumor or in identifying vessels that may be compromised because of the tumor. It is a noninvasive way of looking at the blood supply within the CNS and has replaced the conventional angiography in many situations. Angiography is used in a small group of CNS lesions whose differential diagnosis includes tumor versus aneurysm/cavernoma or tumors where hemorrhage into the tumor cavity is suspected (Krishnamurthy et al. 2016).

Because the quality of the MRI images is dependent upon the patient lying motionless throughout the study, younger children and some older ones will require conscious sedation or anesthesia to perform the test. Sedation protocols vary with the institution, and larger pediatric centers may have blocks of time set aside with anesthesiologists present to efficiently utilize scanner time. If the child shows clinical signs of increased ICP or has hydrocephalus, it may be the physician's preference to insert a drain prior to the

MRI scan, especially if the child is intubated (Ramaswamy et al. 2015).

A CT scan may be the first diagnostic test performed. Some tumors, especially small ones, may not be seen on a CT scan, and most tumors will not be visualized on a CT scan unless contrast is given. CT scans are most often used during the treatment processes as a screening tool for children who have experienced a change in their neurological status. It can be performed in less than 5 min and is not as sensitive to the child moving as an MRI. The CT scan does expose the child to radiation during the test, and there is a growing awareness of the potential harmfulness of cumulative radiation after many CT scans during the course of the illness (Leonard 2011). For this reason, clinicians will consider alternative testing, such as a fast MRI scan, when ordering a CT scan to avoid the risk of unnecessary radiation exposure (Krishnamurthy et al. 2016).

Other radiodiagnostic tests include positive emission tomography (PET), single-photon emission computed tomography (SPECT), and magnetic resonance spectroscopy (MRS), which focus on a tumor's metabolism. These tests help clinicians determine the rate of cell growth and to differentiate between active tumor cells and treatment effects such as radiation necrosis. During a PET scan, radiotracer fluorodeoxyglucose

(FDG) or methionine (MET) is injected in a vessel, and approximately 30 min later, CT scans are obtained (Bryant et al. 2010). These radiotracers demonstrate low uptake in normal brain tissue and increased uptake in primary brain tumors (Sharma et al. 2016). SPECT also uses radiotracers followed by CT scan to further evaluate lesions (Bryant et al. 2010). If there is concern on imaging following surgery and radiation therapy, MRS provides a noninvasive way to differentiate between tumor recurrence and radiation necrosis (Sanghvi 2009). MRS measures the following four principle metabolites within a tumor: choline, N-acetyl aspartate (NAA), lactate, and creatine. Pediatric brain tumors typically demonstrate elevated choline levels and decreased or absent NAA levels. Lactate levels vary with the degree of necrosis within the tumor (Krishnamurthy et al. 2016).

An electroencephalogram (EEG) measures the electrical activity within the brain and may be performed on a patient whose clinical presentation includes a seizure. Patients with tumors that are associated with difficult to control or generalized seizures undergo continuous EEG monitoring with videotaping in a special epilepsy-monitoring unit. Subdural grids are inserted in some cases to localize speech or motor centers prior to surgical removal of the tumor. A Wada test (intracarotid sodium amobarbital test) may be performed to determine which side of the brain is responsible for speech and memory. This test is slowly being replaced with the functional MRI scan or magnetoencephalography (MEG), which attempts to obtain the same information in a noninvasive manner (Smyth and Vogel 2015). Please refer to the Chap. 13 for more information.

Visual acuity and visual field studies performed by an ophthalmologist are utilized if a patient presents with visual abnormalities. Laboratory tests, including blood and CSF necessary to look for tumor markers or endocrine abnormalities, may also be part of the initial workup. Serum electrolytes, thyroid levels, and growth hormone levels are necessary for hypothalamic/pituitary tumors. Serum and CSF tumor markers of human chorionic gonadotropin (HCG) or alpha-fetoprotein (AFP) are needed for supra-

sellar tumors which may be germ cell tumors (Shiminski-Maher et al. 2014).

## 7.5.5 Treatment

Technical advances in medicine and surgery have dramatically changed the management of pediatric CNS tumors over the past several decades. Imaging allows for early diagnosis and treatment of tumors, in addition to monitoring the effects of those treatments. Evolution in the surgical equipment, radiation therapy equipment, and use of chemotherapy for CNS tumors has improved long-term survival and the quality of that survival. Treatment consists of any combination of surgery, radiation therapy, chemotherapy, and observation. Treatment depends upon the location and type of CNS tumor. The tumor location determines the surgical approach. Tumors near eloquent areas may require special planning. The type of tumor refers to its cellular makeup and rate of growth (Parsons et al. 2016).

### 7.5.5.1 Surgery

Surgery is the primary and frontline treatment for virtually all CNS tumors. On radiology confirmation of a tumor, the child is seen by a neurosurgeon and evaluated for surgery. The goals of surgery are for maximal safe surgical removal and also to provide a tissue diagnosis. It is optimal for a child diagnosed with a CNS tumor to be operated on by a pediatric neurosurgeon. This is because pediatric neurosurgeons are more likely to extensively remove pediatric tumors than general neurosurgeons, and the extent of surgical resection is a significant prognostic indicator (Rosetto and Cartwright 2011).

Ideally, surgery should be carried out as efficiently as possible under elective, controlled conditions. This is possible for the child who has minimal clinical symptoms or for whom medical management can temporize symptoms. Placing a child with subtle symptoms of ICP on steroids may temporarily relieve the symptoms as they decrease edema around the tumor. Diuretics such as mannitol may also be utilized to decrease ICP. The child should be monitored carefully for

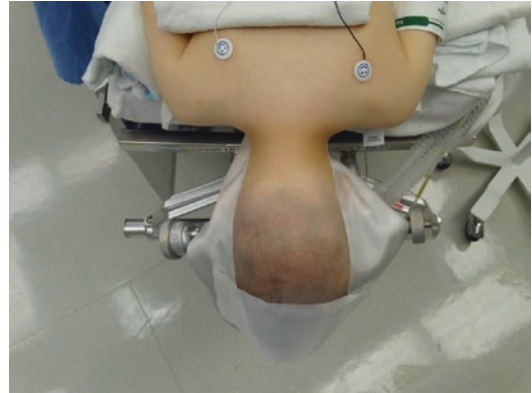

any change in status. In severe situations of increased ICP, intubation with mechanical ventilation is necessary to assure adequate oxygenation to the brain. Any child with significant symptoms or who is unstable should be operated upon immediately. If the child has hydrocephalus, the surgeon may place a ventricular drain to relieve the symptoms prior to the craniotomy for tumor removal. Simply removing the tumor, however, may open blocked CSF pathways and thus relieve the hydrocephalus (Ramaswamy and Taylor 2015).

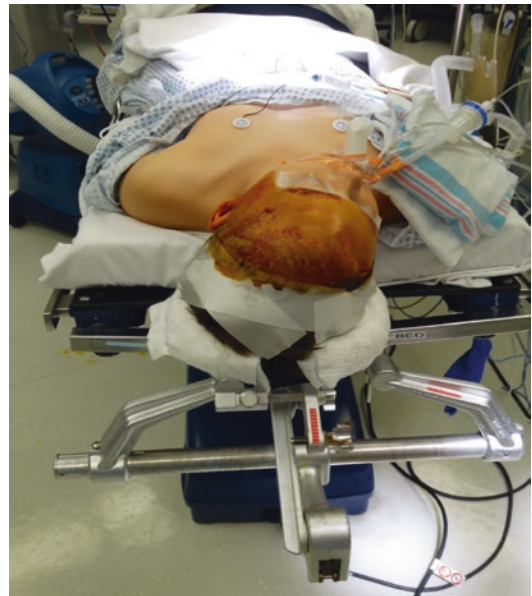Tumors of the hemispheres and posterior fossa are often readily accessible, allowing for gross total surgical resections (Figs. 7.9 and 7.10). Surgical debulking of tumors in the areas of the third ventricle, hypothalamus, optic nerve, and pituitary regions has also become possible. Surgery is not indicated in children with diffuse intrinsic brainstem tumors (most of which are malignant in histology) in which the surgical risks outweigh the benefits of a radical surgical procedure, because the overall prognosis is not changed with surgery. The exception is the focal tumor that is isolated to one area within the brainstem (either only in the medulla or only in the pons or those at the cervicomedullary junction). These tumors are benign in histology and are possible to remove surgically, thus delaying or avoiding adjunctive treatments (McCrea and Souweidane 2015).

Staged surgical procedures and second-look operations have become a frequently used modality to increase extent of tumor resection and to decrease morbidity. Deep tumors can be approached from two different trajectories to maximize the resection. A surgeon will choose to perform a second operation when the postoperative imaging study shows residual tumor and the pathology is low grade. Second-look operations after a specific treatment modality has been given to allow for evaluation of tumor response to the treatment as well as the potential for rendering the patient free of disease (Gupta et al. 2010).

Standard neurosurgical tools utilized by the surgeon in the operating room include the operating microscope, loupes, ultrasonic surgical aspirator, carbon dioxide laser, ultrasound, endoscopy,



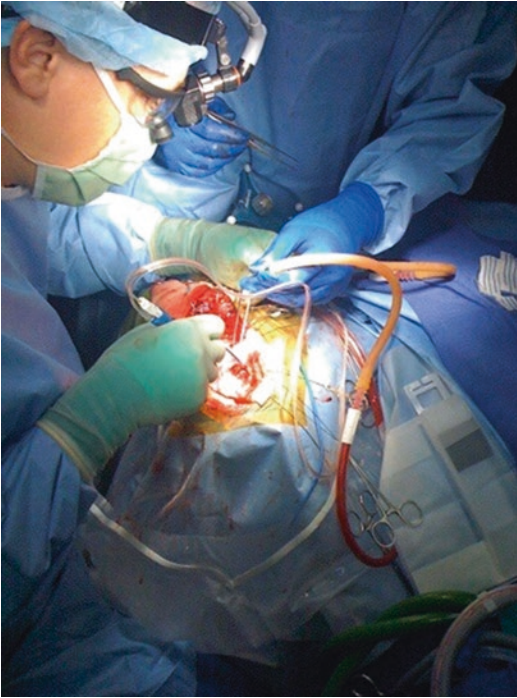**Fig. 7.9** Child in prone position in cranial fixation pins in preparation for removal of a posterior fossa tumor



**Fig. 7.10** Child in Mayfield head rest prior to a pterional craniotomy (Photo courtesy of Dr. Robert Lober)

and intraoperative monitoring, such as electrocorticography and sensory and motor evoked potentials (Fig. 7.11). An MRI scan obtained prior to surgery can provide preoperative and intraoperative localization using a frameless navigational system, as shown in (Fig. 7.12). In some situations, this allows the surgeon to use a smaller craniotomy to maximally remove the tumor (Pollack 2015). An ultrasound is used to localize the tumor, and it is usually removed with the ultrasonic surgical aspirator. An endoscope may



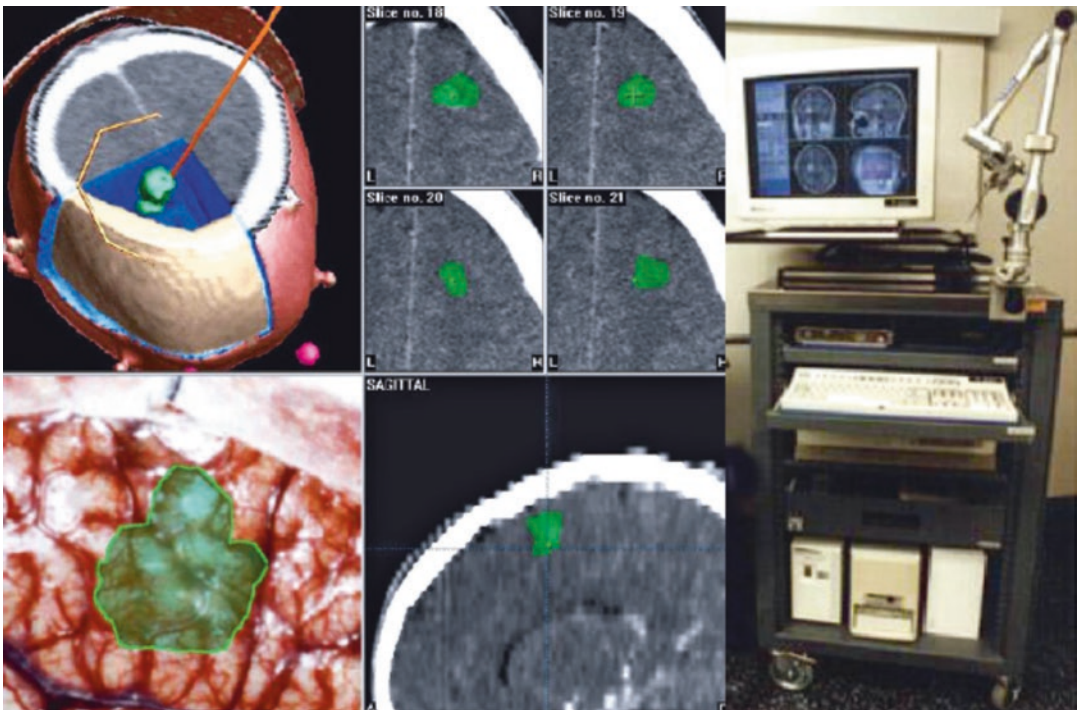


**Fig. 7.11** Neurosurgeon in OR using loupes, a magnifying device used to visualize intricate neuroanatomy (Photo courtesy of Dr. Robert Lober)

be used to remove or biopsy a tumor within the ventricular system. The endoscope can also be used to perform an anterior third ventriculostomy to treat obstructive hydrocephalus, thus avoiding insertion of a ventriculoperitoneal shunt (Fig. 7.13) (Rosetto and Cartwright 2011). The laser is commonly used to remove spinal cord tumors (Wetjen et al. 2015) (Fig. 7.14).

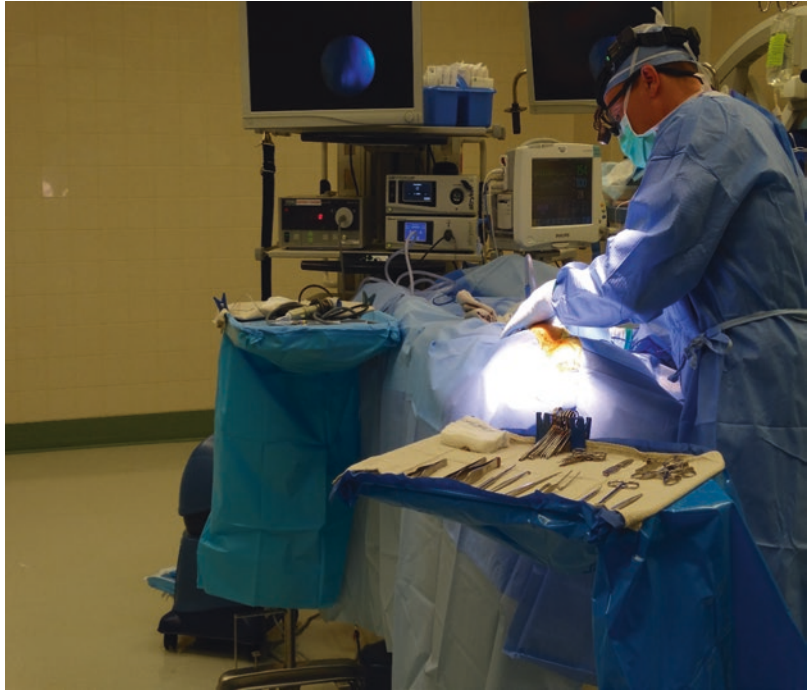Intraoperative monitoring (called motor evoked potentials) involves watching the nerve impulses travel from the brain to important functional areas, such as arms, legs, face, eyes, bowels, and bladder (Fig. 7.15). By using this technology during the operation, the surgeon can determine the location of the tumor in relation to important body function, thus maximizing resection while attempting to minimize injury (Groves and Jallo 2015). Electrocochography, as shown in Fig. 6.6, allows the surgeon to place electrodes or grids into the cavity after a tumor resection to ensure that any abnormal tissue that can generate a seizure is also removed (Pollack 2015) (Fig. 7.16).

Localization of the tumor using intraoperative guidance systems has become common in the last

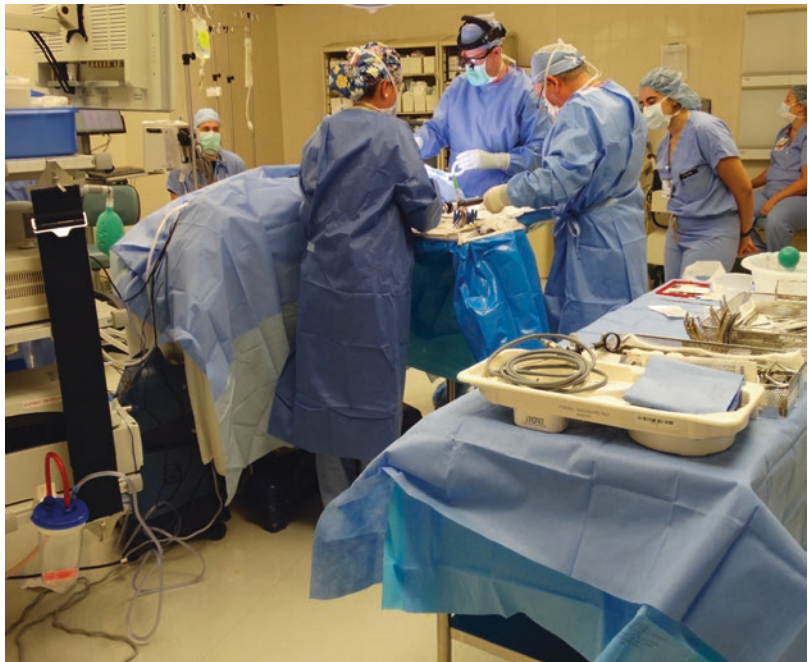

**Fig. 7.12** Intraoperative guidance systems

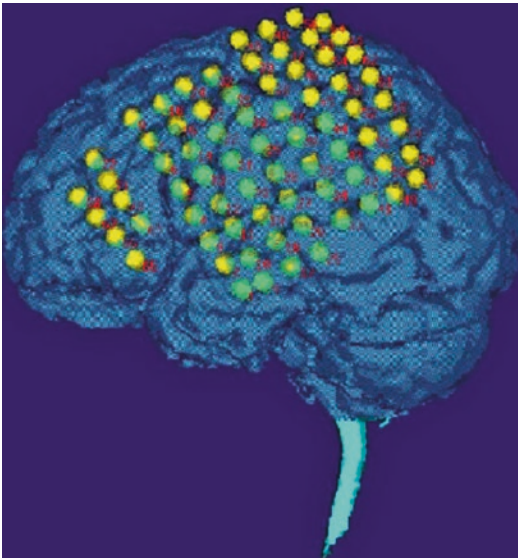
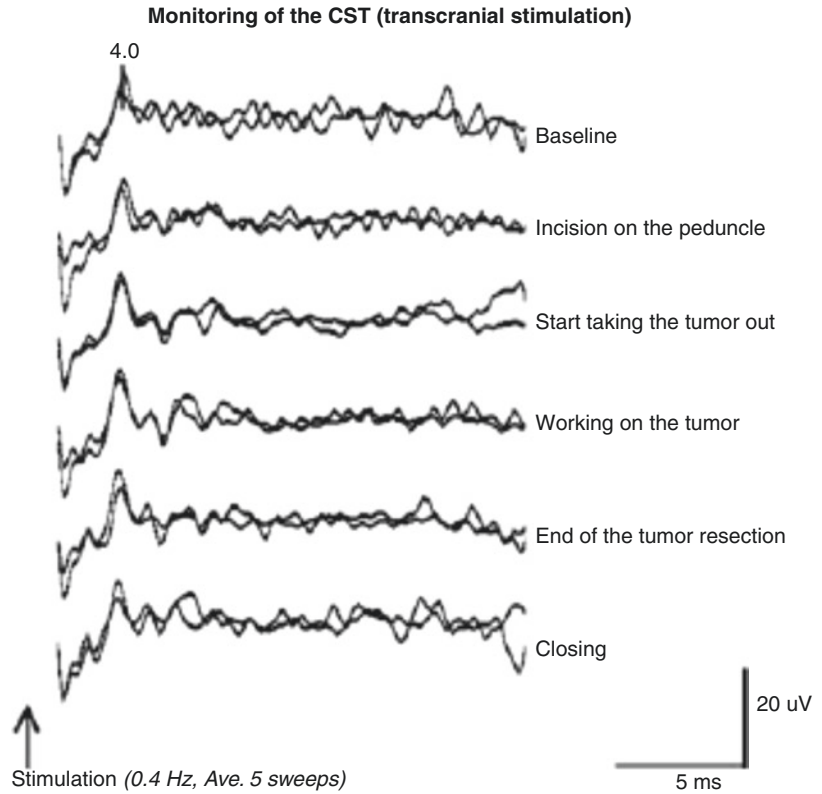**Fig. 7.13** Neurosurgeon preparing to use an endoscopic



**Fig. 7.14** Operating room setup



**Fig. 7.15** Use of evoked potentials during tumor resection to monitor motor function



**Fig. 7.16** Grid placement for evaluation of seizure focus outside tumor cavity

decade. An MRI scan is obtained preoperatively using neuronavigational MRI protocol which includes contiguous, non-overlapping, thin slices (1.0–3.0 mm). If present, surface markers on the scalp must also be included in the MRI. The computerized scan is then sent to the navigational system in the operating room. In the operating room, the surgeon can touch the scalp or surface markers upon the scalp with a stylet, and the computer then generates a picture of the lesion in relation to that specific marker. This allows for surgical removal of a tumor through a much smaller craniotomy, reducing recovery time and length of hospitalization. It is extremely efficient in localizing small lesions within the brain (Ganslandt et al. 2002). Specific MRI scans such as functional MRI and diffusion MR tractography are noninvasive techniques that can be obtained preoperatively to localize the tumor in



relation to eloquent areas, such as visual or motor pathways (Shaikh et al. 2015).

Hydrocephalus that does not resolve with the removal of tumor, and for which an endoscopic third ventriculostomy is not possible, is treated with insertion of a ventriculoperitoneal shunt (Madden et al. 2014). The clinicians must also monitor for the development of hydrocephalus in the weeks or months following surgery as approximately 10–35% of patients following posterior fossa tumor removal will require CSF diversion (Morgenstern and Souweidane 2012). See Chap. 2.

#### 7.5.5.2 Observation

A postoperative MRI is performed, usually within the first few days after surgery. The purpose of the scan is to evaluate the amount of tumor removed. This scan, combined with the histology of the tumor, will determine the next treatment step. For tumors that are very slow growing and for which a significant surgical removal has been possible, observation with frequent MRIs may be the only recommendation. The ability to detect subtle changes in tumor growth with the MRI has made clinicians more comfortable in observing these tumors. Observation may delay the use of more surgery or other treatments (Shiminski-Maher et al. 2014).

Observation may be the treatment of choice at the original diagnosis if the tumor is very small and/or was diagnosed incidentally. MRI is again utilized to monitor the lesion for any change in size over time. Observation is also required following any adjunctive treatment that may be used following surgery. Once a child or adolescent has completed additional treatments for their tumor, MRI scans and other pertinent diagnostic tests are performed on an interval basis (Shiminski-Maher et al. 2014).

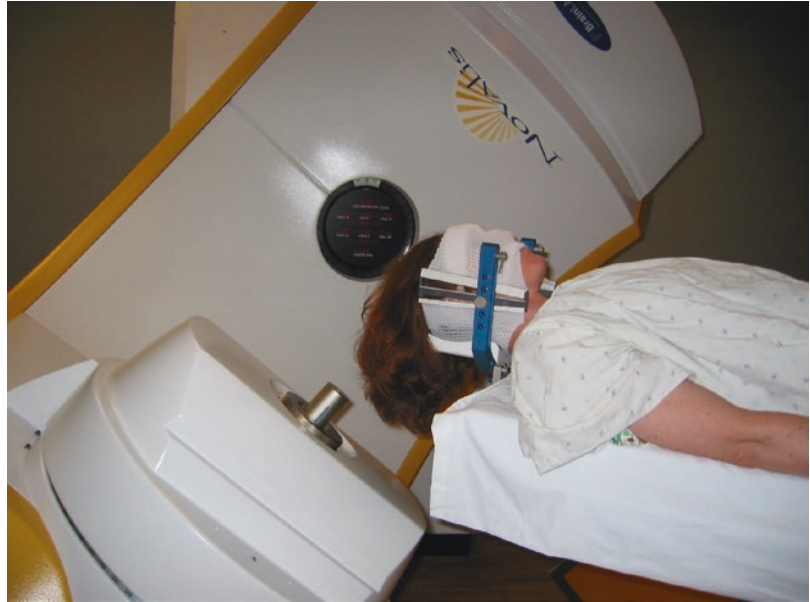
#### 7.5.5.3 Radiation

Many CNS tumors are very sensitive to radiation treatments, also called radiotherapy. Prior to the technical advances in surgery, radiation was the primary treatment for CNS tumors in children. It became clear as children began to survive their CNS tumors, however, that radiation treatments

also carried acute and long-term side effects that dramatically impacted the individual's ability to function. The intensity of the side effects was directly related to the age of the child at the time radiation was given. In general, younger children were much more vulnerable to significant toxicity than were older children. Common long-term effects include delays in cognition and growth, hormone deficiencies, and hearing deficits. Children who have had radiation therapy may develop vascular abnormalities and secondary malignancies many years after the completion of therapy. Radiation treatments can only be administered once and, therefore, should be employed at the time of minimal disease based upon tumor type and age of the patient. Beginning in the late 1980s, clinicians chose to treat younger children requiring adjunctive treatment with chemotherapy first in an attempt to withhold radiation for as long as possible. This past quarter century has brought about technological advances, which allow for MRI and CT computerized planning of radiation treatments. This allows for focused treatments to the tumor while sparing as much normal brain tissue as possible. Currently, radiation treatments (especially more targeted treatment plans) are being considered for younger children if the tumor is not responsive to chemotherapy (Ermoian et al. 2016).

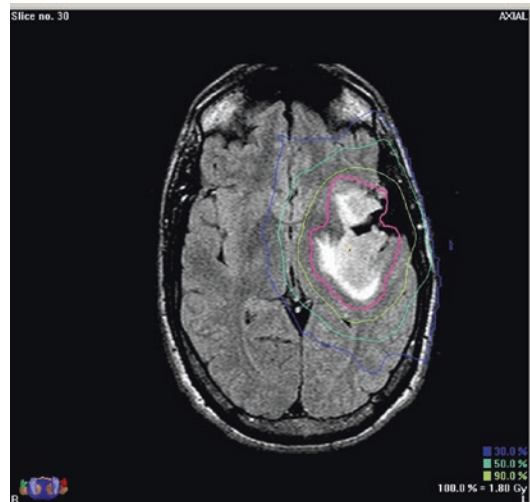
Radiotherapy directs high-energy x-rays called photons at targeted areas within the CNS to destroy tumor cells. Radiation can be given internally or externally, with the majority of pediatric CNS tumors treated with external radiation. A large machine called a linear accelerator delivers external radiation via x-rays (photons) to the precise portion of the CNS where the tumor is located (Fig. 7.17). These photons enter the patient at a high dose and deposit that radiation to the tumor target and beyond. Radiation doses are measured in Gray (Gy) or centiGray (cGy) (Ermoian et al. 2016). Treatment doses for CNS tumors range between 18 and 60 cGy with the dose determined based on presentation and the type of tumor. If the tumor has the potential of spreading or already has spread beyond the primary site, the entire CNS will receive external radiation dosing up to 23.4 cGy. Radiation

**Fig. 7.17** Child undergoing radiation therapy with a stereotactic face mask in place to hold the head perfectly still (Photo courtesy of Dr. John Breneman)



treatments are normally given once a day at around the same time. Twice a day treatments (called hyperfractionation) are another way of delivering radiation treatments. The daily dose is split into two fractions and delivered at least 6 hours apart with the intent on hitting the tumor cells at different times of their cycles and increasing cell death (Kun et al. 2011).

Conformal radiation therapy is a technique used to target radiation doses to the tumor while limiting the dose to normal tissues. Conformal radiation therapy requires brain imaging with MRI and CT so that the tumor target and critical normal structures can be accurately defined (Fig. 7.18). It is now the accepted standard for radiation treatments for pediatric CNS tumors. There are several specific types of conformal radiation therapy that utilize photons. 3D conformal radiation therapy uses radiation fields from several directions that overlap at the tumor. In this manner, the tumor receives the high-dose radiation, while the normal tissue surrounding it receives a smaller dose. Intensity-modulated radiation therapy (IMRT) is a sophisticated type of 3D conformal therapy that modifies the radiation beam based on the shape of the target to be treated. Another type of sophisticated 3D technique is stereotactic radiosurgery/radiotherapy,



**Fig. 7.18** Intensity-modulated radiotherapy plan for treatment of a glioma (Photo courtesy of Dr. John Breneman)

which delivers radiation to a small, precisely defined target. Stereotactic radiosurgery is delivered as one single treatment, while stereotactic radiotherapy is multiple fractionated treatments (Ermoian et al. 2016).

Proton beam radiation therapy (PBRT) is another type of conformal treatment. Unlike the other therapies that utilize photons, this



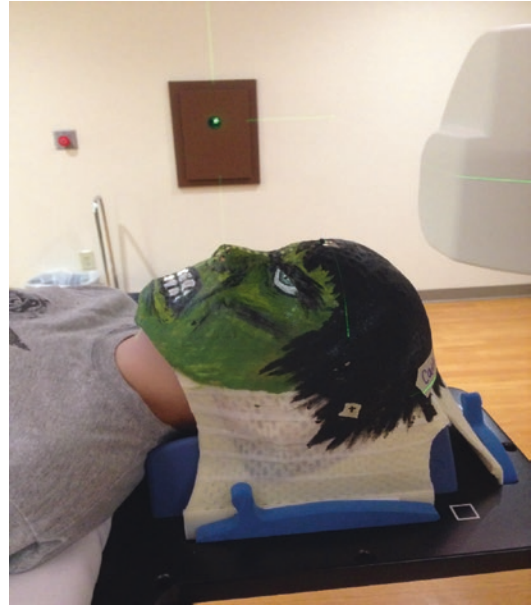uses protons. Protons, unlike photons, enter the patient with a relatively low dose and deposit their energy within the tumor with no exit dose of radiation to the normal tissues beyond the tumor. Pencil-beam scanning proton therapy is a second-generation PBRT. In addition to preventing an exit dose beyond the tumor, pencil-beam scanning proton therapy helps to decrease radiation exposure proximal to the tumor. New studies have demonstrated that verbal comprehension, perceptual reasoning, and working memory remain stable following PBRT; however, processing speed can decline over time. PBRT is a promising alternative over traditional radiation therapy (XRT) in helping to decrease the long-term neurocognitive effects (Sands 2016). Although PBRT centers have increased in numbers over the past decade, the overall number of centers are few and unable to provide treatment for all seeking care (Vega et al. 2015).

Internal radiation, or brachytherapy, implant therapy, or interstitial therapy is used much less than external radiation to treat childhood CNS tumors. Brachytherapy uses radioactive seeds or implants which are surgically placed into the tumor cavity. Brachytherapy may be useful in treating CNS tumors because it delivers high-dose radiation directly to the tumor site while sparing surrounding healthy tissue. Unlike external radiation, it provides a continuous low dose of radiation to the tumor rather than intermittent bursts once or twice a day (Parsons et al. 2016).

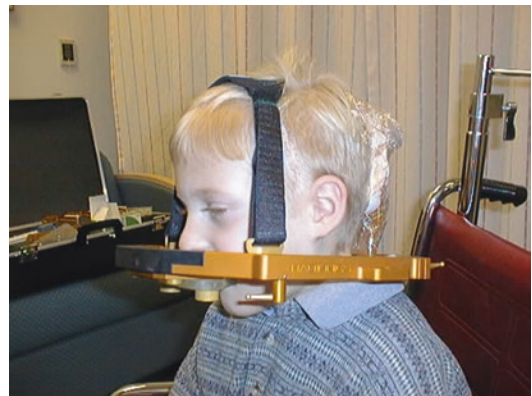Children should receive radiation therapy at major medical centers with experience in treating children with CNS tumors. This will ensure that treatments conform to the standards set up by COG. Immobilization devices are necessary to ensure that the radiation beam is directed with precision (Figs. 7.19 and 7.20). Sedation or anesthesia may be required on a daily basis for those who cannot tolerate the immobilization process (Shiminski-Maher et al. 2014).

#### 7.5.5.4 Chemotherapy

Until the 1980s, chemotherapy was not used to treat pediatric CNS tumors. It was felt that the blood–brain barrier would prevent the penetration of chemotherapy into a tumor within the



**Fig. 7.19** Custom stereotactic radiation mask on a child preparing for radiation therapy (Photo courtesy of Dr. John Breneman)



**Fig. 7.20** Child in a stereotactic radiotherapy ring (Photos courtesy of Dr. John Breneman)

CNS. Chemotherapy, either alone or as part of a multimodality treatment, is used to treat all malignant CNS tumors and has also been shown to be effective in the treatment of some benign tumors. Cooperative group studies within COG have allowed for testing of specific chemotherapeutic protocols and have been responsible for increasing the progression-free survival in children with CNS tumors. In the past decade, higher

doses of chemotherapy followed by stem cell rescue have been used in treating tumors in infants (while delaying radiation treatments) or resistant tumors (Watrall 2014). In addition, researchers have begun to look at the genetic components of specific resistant tumors and tailoring treatments based upon this research (Gajjar et al. 2015).

The goal of chemotherapy includes destruction or interruption in growth of tumor cells. The destruction occurs when the chemotherapeutic agent enters the cell and disrupts its proliferative process. In addition to destroying the abnormally growing tumor cells, the chemotherapy also affects normal growing cells such as the hair, skin, and blood cells, with common adverse effects that include immunosuppression, hair loss, nausea, and vomiting. For more information, see Table 7.3 (Shiminski-Maher et al. 2014).

Chemotherapy is given either as a single agent alone or in combination with other drugs. Most treatment plans have a schedule or road map that outlines the drugs given over the treatment plan. When these drugs are given in high doses or at frequent intervals over a long period of time, bone marrow suppression can be a major side effect. Autologous stem cell reinfusion can regenerate the bone marrow, thus allowing for dose-intensive treatments (Watrall 2014). Chemotherapy is sometimes given simultaneously with radiation therapy in an attempt to increase the radiation's effectiveness. In this case, the chemotherapy is referred to as a radiosensitizer (Hanson and Atlas 2016).

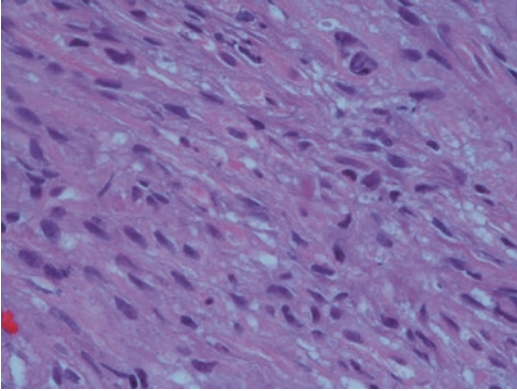
#### 7.5.5.5 Rehabilitation

Rehabilitation services are a necessary treatment for the majority of children with CNS tumors. The tumor itself or effects of treatments may impair the use of or coordination in an extremity. Problems with speech, language, memory, and processing may also occur. Physical, occupational, and speech therapy as indicated should be initiated immediately and often will continue for months or years depending upon individual needs. Therapies are incorporated into school educational plans with exercise supplements built into daily activities (Shiminski-Maher et al. 2014).

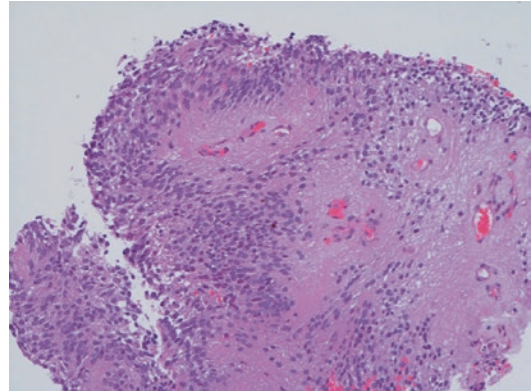
#### 7.5.5.6 Types of Tumors: Malignant Versus Benign

CNS tumors develop from astrocytes or neuroglial cells. Other tumors develop from neuronal or germ cell lines. After a sample of the tumor is obtained during surgery, a neuropathologist looks at the tumor under a microscope. He determines the type of tumor, depending upon the cell from which it develops and the rate of cell growth. There is no single uniform classification system for pediatric brain tumors. More than one pathologist may look at the same tumor and assign it a different name. This can be very frustrating and confusing for the families. The WHO recently restructured their classification of CNS tumors to include not only histology but also the molecular features of each tumor (Figure 7.1). Although this is an improvement in reaching a uniform classification of CNS tumors, there will still be some tumors that do not meet the criteria for any one specific class of tumors (Louis et al. 2016). Names for different types of CNS tumors include astrocytomas, gliomas, glioblastoma multiforme, ependymomas, oligodendrogliomas, gangliocytoma, ganglioglioma, medulloblastoma, PNET, pineal cell tumors, choroid plexus tumors, germ cell tumors, craniopharyngiomas, hemangioblastomas, and dermoid and epidermoid tumors (Petriccione and Gilger 2011).

The terms malignant and benign are confusing when applied to many CNS tumors. In order to identify if a tumor is malignant or benign, it must be looked at in terms of rate of growth and location. The WHO four-tier grading system is used to classify all tumors according to their histologic features, with the higher grades demonstrating more atypical cellular characteristics that are frequently seen in the highly malignant tumors (Adesina 2010). Unlike adult brain tumors, which are primarily histologically malignant or fast growing, childhood brain tumors have a greater likelihood of being histologically benign or slow growing. When surgically removed, slow-growing tumors rarely regrow and do not require chemotherapy or radiation. However, some slow-growing tumors are found deep within the brain or brainstem where aggressive surgery is not possible because of significant risk of damaging adjacent



**Fig. 7.21** Histology of slow-growing tumor (Photo courtesy of Dr. L. David Mirkin)



**Fig. 7.22** Histology of fast-growing tumor (Photo courtesy of Dr. L. David Mirkin)

structures. In these cases, other treatments (chemotherapy and/or radiation) are used in an attempt to shrink or halt further tumor growth. Thus, even if a tumor deep in the brain is slow growing, it may require the same treatments as malignant brain tumors—and these treatments can cause the same long-term side effects. Some health-care providers call this “malignant by location.” Figure 7.21 shows the microscopic histology of a slow-growing tumor (Shiminski-Maher et al. 2014).

All fast-growing tumors are considered malignant and cancerous. Figure 7.22 shows the microscopic histology of a malignant CNS tumor. Malignant tumors contain undifferentiated cells that display increased cellular proliferation, significant mitotic activity, and microscopic seeding of tumor cells into surrounding tissue. These tumors can invade surrounding tissue without forming a definite mass. Even if totally removed with surgery, these tumors will usually grow back without further treatment, including radiation and/or chemotherapy. Malignant CNS tumors rarely spread to other parts of the body (Hickey 2014).

#### 7.5.5.7 Based Upon Histology

Once the tissue diagnosis has been made with a surgical procedure, the next step is to formulate a treatment plan. Postoperative imaging is obtained to determine the extent of tumor removal that has been obtained. This information, along with any other preoperative testing, is summarized, and the next step of care is recommended. Many large

centers utilize a tumor board to make treatment decisions. This is a multidisciplinary group including surgeons, oncologists, neuro-oncologists, radiation therapy physicians, radiologists, and other appropriate specialists. A case may be presented to the tumor board at various times during the course of the illness when treatment decisions need to be made. A summary of treatments based upon tumor histology is found in Table 7.2. A discussion of treatment plans based on specific pathologic diagnosis follows (Shiminski-Maher et al. 2014).

#### Low-Grade Astrocytomas

Low-grade astrocytomas (LGAs) are slow-growing tumors that rarely metastasize and have low cellularity and low mitotic activity. LGAs are also called low-grade gliomas as they are made up of a type of glial cell called astrocytes. Based on their histology, LGAs are classified as grade I or grade II under the WHO classification system and are the most common type of CNS tumor in children (Petriccione and Gilger 2011). The average age at diagnosis is between 6 and 9 years, and males are more frequently affected than females. Approximately 70% of the low-grade gliomas occur in the cerebellum, but they can occur anywhere in the brain and spinal cord (Parson et al. 2016). The following tumors are included in this group: pilocytic astrocytoma or juvenile pilocytic astrocytoma, pilomyxoid astrocytoma, diffuse astrocytoma, pleomorphic xanthoastrocytoma

**Table 7.2** Brain tumors: treatment based upon type and location of tumor

Part of the CNS	Type of tumor	Treatment
Frontal lobes	Astrocytoma	Maximal surgical removal using intraoperative guidance, monitoring, electrocorticography, and MRI; observation between surgical treatments for tumors that are slow growing; chemotherapy and/or radiation may be considered for disease progression in low-grade lesion or for adjunctive treatment for high-grade astrocytomas or gliomas, PNET, or ependymoma
Parietal lobes	Glioma	
Temporal lobes	DNET	
Occipital lobes	Rarely PNET or ependymoma	
Cerebellum	Astrocytoma	Maximal surgical removal; observation following surgery for slow-growing tumors with reoperation at progression; chemotherapy and/or radiation for medulloblastoma and ependymoma
	Glioma	
	Medulloblastoma	
	Ependymoma	
Brainstem/fourth ventricle	Astrocytoma	Radiation $\pm$ chemotherapy is standard treatment for diffuse brainstem tumors. Surgery is possible for focal lesions followed by observation, chemotherapy, or radiation
	Glioma	
	Ependymoma	
	Medulloblastoma	
Midbrain/thalamus	Astrocytoma	Conservative surgery or observation for low-grade tumors; observation $\pm$ chemo for low grade; chemotherapy and radiation for germ cell or other high-grade tumors
Diencephalon	Glioma	
Optic pathway	Craniopharyngioma	
Ventricular system	Germ cell	
	Choroid plexus	
Spinal cord	Astrocytoma	

Source: Adapted from Shiminski-Maher et al. (2014)

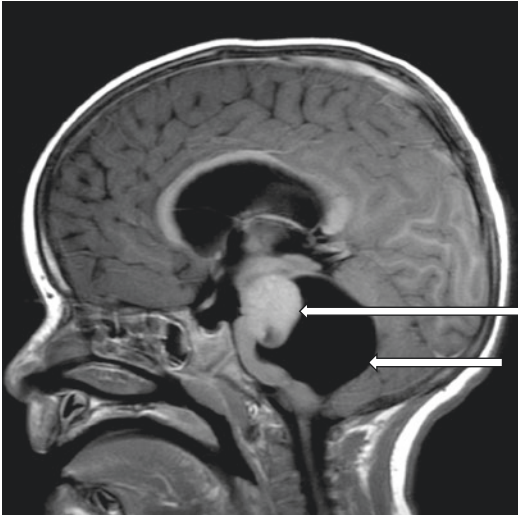
(PXA), low-grade diffuse astrocytoma, optic glioma, and subependymal giant cell astrocytoma (SEGA). Activation of the mitogen-activated protein kinase (MAPK) pathway by a mutation in the BRAF protein is the most common genomic alteration in low-grade astrocytomas in children (Gajjar et al. 2015). Surgery is the primary treatment for slow-growing astrocytomas. This is possible in many areas of the cerebrum and always possible in the cerebellum. If there is question of residual tumor after surgery, the surgeon can either reoperate or follow closely with frequent MRI scans and reserve surgery unless there is an increase in tumor size. Surgery is also possible with astrocytomas located at the cervicomedullary junction and gliomas growing out of the posterior brainstem (also known as exophytic gliomas) (Parsons et al. 2016).

Pilocytic astrocytomas (PAs) are the most frequently diagnosed WHO grade I astrocytoma with 80% occurring in the cerebellum (Gan and Haas-Kogan 2010). The histologic diagnosis is made with the presence of Rosenthal fibers, eosinophilic granular bodies, and a biphasic pat-

tern of packed bipolar cells mixed with loosely packed astrocytes (Glod et al. 2016). Children with cerebellar pilocytic astrocytomas will often present with signs of hydrocephalus, as the location and size of the tumor will cause obstruction of the outflow of CSF (Kieran et al. 2015). On MRI, most pilocytic astrocytomas have a classic presentation of a cyst with a minimal or non-enhancing mural nodule. Despite sometimes being very large in size, these tumors will have little or no surrounding vasogenic edema (Chapman 2016) (Fig. 7.23). Following complete resection, cerebellar astrocytomas are potentially the most curable form of LGA with 5-year progression-free survival rates as high as 95% (Petriccione and Gilger 2011).

Diffuse low-grade astrocytomas (also known as fibrillary astrocytomas) are the most common WHO grade II astrocytoma (Gan and Haas-Kogan 2010). The WHO divides diffuse astrocytomas into three molecular subtypes: diffuse astrocytoma, NOS (not otherwise specified); diffuse astrocytoma, IDH-mutant; and diffuse astrocytoma, IDH-wild type (Louis et al. 2016). These



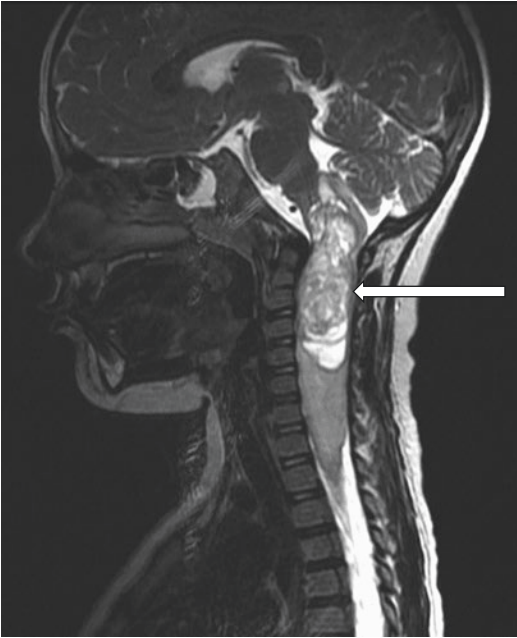


**Fig. 7.23** Pilocytic astrocytoma: Sagittal view T1 FLAIR of a solid-enhancing mural nodule arising from the midbrain and pons as indicated by the *long white arrow*. The tumor is surrounded by a large posterior fossa cyst, indicated by the *short white arrow*. There is anterior displacement of the brainstem, posterior displacement of the cerebellum and hydrocephalus

tumors can be found anywhere in the brain and spinal cord with the majority found in the frontal and temporal lobes of the cerebrum (Petriccione and Gilger 2011). The histologic diagnosis is made with the presence of long thin fibrillary cells that comprise a microcytic tumor matrix (Pfister et al. 2009). This tumor is more widely infiltrative of the surrounding normal brain parenchyma and is more likely to undergo malignant transformation compared with the WHO grade I astrocytomas (Parsons et al. 2016). Seizures are a common presenting symptom, especially if the tumor is located in the temporal lobe. On MRI, diffuse low-grade astrocytomas will typically not enhance; however, new post-contrast enhancement will be present if progression to a WHO grade III or grade IV astrocytoma has occurred. Surgery is the primary treatment for this tumor with a goal of a gross total resection (Kun et al. 2011). In cases where the tumor is located in an eloquent area of the brain, chemotherapy or radiation is the primary treatment (Parsons et al. 2016). The 5-year progression-free survival for diffuse astrocytomas is 80% (Kun et al. 2011).

Optic gliomas account for about 3–5% of all pediatric intracranial tumors with the majority of these tumors found in the first decade of life. Most optic gliomas are pilocytic astrocytomas, and some are diffuse or fibrillary astrocytomas (Parsons et al. 2016). Optic gliomas are found in the optic pathway region in the diencephalon and may involve the optic chiasm, optic nerves, optic tracts, and optic radiations (Kieran et al. 2015). Optic gliomas may also invade surrounding structures such as the thalamus, hypothalamus, and frontal and temporal lobes (Imbach 2014). Over 70% of patients with optic gliomas have NF type 1 (Hanson and Atlas 2016). These patients have a mutation of the NF1 gene located on chromosome 17q which encodes neurofibromin, a protein that helps to control astrocyte proliferation (Pfister 2009). Presenting symptoms of optic gliomas are progressive vision loss, nystagmus, proptosis, and strabismus. If the tumor involves other nearby structures, symptoms may include endocrinopathies and signs of hydrocephalus. On MRI, there is a post-contrast enhancing mass that frequently contains cysts and involves at least one of the optic nerves. Surgery is the primary treatment indicated for unilateral tumors of the optic nerve in cases where vision is absent and debulking of the tumor is required to treat hydrocephalus. Surgery is also indicated if vision is deteriorating and there is a cystic or exophytic component of the tumor that is causing compression of nearby structures and is surgically accessible. In patients who are asymptomatic, visual assessments every 6 months and serial MRIs are the recommended treatment (Hanson and Atlas 2016). Following surgery, or if surgery is not an option, chemotherapy has become the next line of treatment for symptomatic patients with optic glioma. This is largely in part due to the risk of developing cognitive impairment, vasculopathies, and endocrinopathies that may occur following radiation therapy (Ertiaei et al. 2016). Radiation is often reserved for tumor progression following chemotherapy (Imbach 2014). Many optic gliomas become dormant in adulthood. Unfortunately, the location of the tumor leads to progressive vision loss resulting in serious long-term morbidity (Kieran et al. 2015).





**Fig. 7.24** Pilocytic astrocytoma: sagittal view T2 FSE of a large enhancing mass of the medulla and cervical spinal cord, indicated by the *white arrow*

Progression-free survival is poorest in optic gliomas patients that do not have NF type 1 (Kalin-Hajdu et al. 2014).

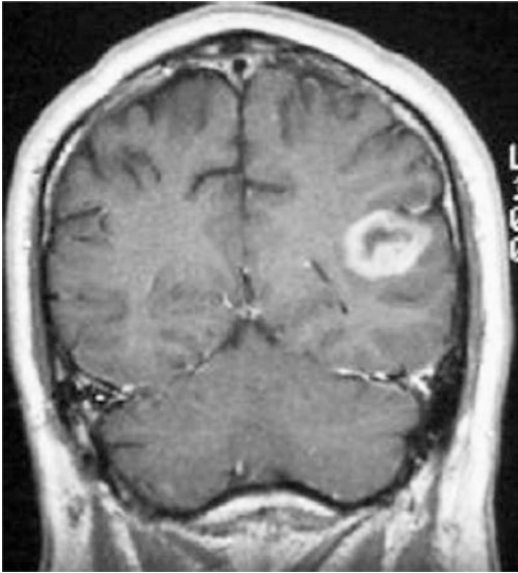
Low-grade astrocytomas of the spinal cord account for over 80% of all spinal cord tumors in children (Fig. 7.24). Most are diffuse (fibrillary) and less commonly the pilocytic type. Presenting symptoms may be a long history of pain or weakness corresponding to the level of the lesion. On MRI, these tumors are discrete, well circumscribed, non-enhancing intraspinal tumors with more than 30% also occurring with intraspinal cysts. Surgery is the primary treatment, and multiple surgical procedures may be needed to maintain tumor control. The use of intraoperative spinal evoke potentials to safely guide the dissection of the tumor and prevent injury to the spinal cord has helped to achieve a gross total resection and improve long-term morbidity. Chemotherapy has shown to be effective in children with progressive low-grade spinal spinal astrocytomas (Kun et al. 2011). Radiation therapy is used for progression of tumors despite surgery and chemotherapy (Kieran et al. 2015). The 5-year

progression-free survival following surgery for this tumor ranges from 64% to over 90% (Petriccione and Gilger 2011; Kun et al. 2011).

### Malignant Astrocytomas

Malignant astrocytomas make up about 20% of all childhood CNS tumors and are the most common malignant glial neoplasm (Kieran et al. 2015). These tumors consist of astrocytes that demonstrate hypercellularity, rapid mitosis, necrosis, and endothelial proliferation that invade nearby normal brain tissue and can disseminate throughout the CNS. They are referred to as high-grade gliomas and are classified by the WHO as grade III or grade IV. Approximately two-thirds of malignant astrocytomas occur in the cerebral hemispheres, with the remainder occurring throughout the CNS (Petriccione and Gilger 2011). Malignant astrocytomas include the following: anaplastic astrocytoma, glioblastoma multiforme (GBM), gliomatosis cerebri, diffuse intrinsic pontine glioma (DIPG), anaplastic oligodendroglioma, anaplastic oligoastrocytoma, anaplastic ganglioglioma, and gliosarcoma. The vast majority of malignant astrocytomas occur sporadically with only a minority occurring in those with Li–Fraumeni syndrome, Turcot syndrome, tuberous sclerosis, and neurofibromatosis type 1. Clinical presentation of a high-grade astrocytoma is often a recent onset of rapidly progressing symptoms of increased ICP and focal neurological deficits that correspond to the tumor location and/or mass effect.

On MRI, high-grade astrocytomas demonstrate post-contrast enhancement, have poorly defined borders, and have edema surrounding the tumor (Fuller 2010a). High-grade astrocytomas are difficult to cure even with the most aggressive treatments and have an extremely poor prognosis. Maximal surgical resection appears to be the only significant variable in extending time to progression for this resistant tumor (MacDonald et al. 2011). Radiation therapy remains the standard adjunctive treatment for children with malignant astrocytomas and, when given after aggressive surgery and with chemotherapy, will prolong time to progression. Chemotherapy windows have included single



**Fig. 7.25** Anaplastic astrocytoma: enhancing tumor adjacent to motor strip

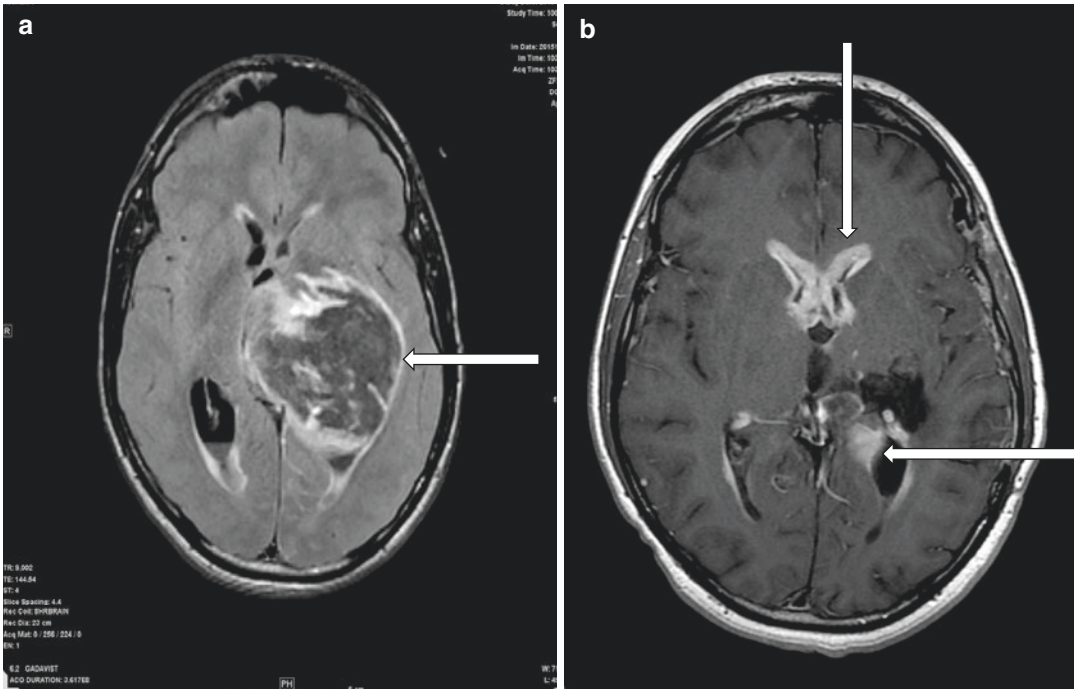
and multiple agents, along with high-dose chemotherapy with autologous marrow or stem cell rescue. To date, despite multiple cooperative group clinical trials where chemotherapy was given before, during, and following radiation therapy, there has been no significant improvement in event-free survival (Shiminski-Maher et al. 2014).

Anaplastic astrocytoma is an infiltrative tumor that grows rapidly and is classified by the WHO as grade III (Fig. 7.25). The following three molecular subtypes are as follows: anaplastic astrocytoma, IDH-mutant; anaplastic astrocytoma, IDH-wild type; and anaplastic astrocytoma-NOS (Louis et al. 2016). They occur predominantly in the cerebrum and to a lesser extent the cerebellum and brainstem (Pfister et al. 2009). Histologic characteristics of anaplastic astrocytoma include atypical nuclei, increased cellularity, and increased mitotic activity (Glod et al. 2016). Pediatric anaplastic astrocytomas and glioblastomas are nearly identical at the molecular level, with both found to have an over-expression of the alpha-type platelet-derived growth factor receptor (PDGFR $\alpha$ ) and a mutation in the tumor suppressor gene TP53 (Nageswara Rao and Packer 2012). Anaplastic astrocytomas

that show a gain of chromosomal material at chromosome arm 1q have a significantly shorter survival. The overall survival rate for anaplastic astrocytomas is between 30 and 40% (Pizer et al. 2013).

Glioblastoma (previously referred to as glioblastoma multiforme) is a highly infiltrative tumor that grows rapidly and is classified by the WHO as grade IV (Fig. 7.26a, b). Two molecular subtypes of glioblastoma have been identified: glioblastoma, IDH-wild type, and glioblastoma, IDH-mutant (Louis et al. 2016). Glioblastoma occurs 1.5 times more often than anaplastic astrocytoma in children (Pfister 2009). Glioblastoma frequently occurs in the cerebrum extending deep into the gray matter or crossing midline. They are the most common pediatric brainstem tumor, occurring predominantly in the pons (Fuller 2010a). The histology is the same as anaplastic astrocytoma but includes the additional presence of necrosis or microvascular proliferation (Mueller and Haas-Kogen 2010). Pediatric glioblastoma has the same histology as adult glioblastoma but with very different molecular pathways leading to tumor formation (Parsons et al. 2016). Inactivation of the tumor suppressor gene phosphatase and tensin homolog (PTEN) and amplification of the highly oncogenic epidermal growth factor receptor (EGFR) are commonly found in adult glioblastoma (Hatanpaa et al. 2010). The majority of pediatric glioblastomas do not have these mutations, and they rarely progress from a low-grade to a high-grade astrocytoma, which commonly occurs in adults (Parsons et al. 2016). A loss of the chromosome 10q23 locus and a mutation of PTEN are both associated with a poor prognosis (Pfister et al. 2009). The long-term survival rate for glioblastoma is 10% (Pizer et al. 2013).

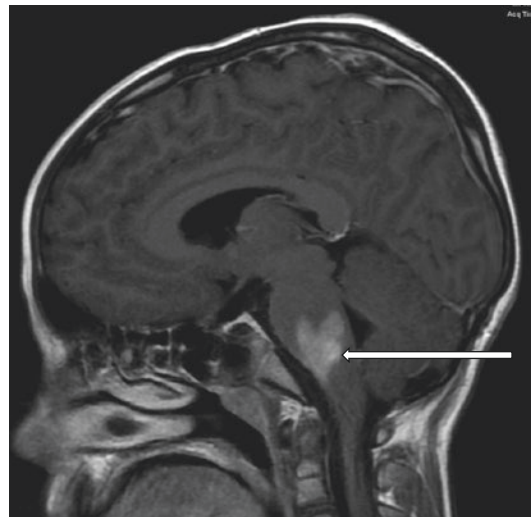
Diffuse intrinsic pontine glioma (DIPG) is an infiltrative glial tumor located in the pons and makes up 80% of all childhood brainstem tumors. The majority of DIPGs are classified as WHO grade III (anaplastic astrocytoma) or WHO grade IV (glioblastoma) (Kieran et al. 2015). Presenting symptoms of DIPG are cranial nerve deficits (especially CN VI and CN VII), long tract signs, and ataxia (Mueller and Haas-Kogan 2010).



**Fig. 7.26** (a) Glioblastoma: axial view post-contrast T2 FLAIR of a large left thalamic and temporal hemorrhagic tumor as indicated by the *white arrow*. The tumor crosses midline and is compressing the posterior third ventricle. (b) Same patient 6 months later following radiation ther-

apy with tumor progression throughout the ventricles: axial view post-contrast T1 FLAIR of significant abnormal enhancement and abnormal nodularity throughout the ventricular system as indicated by the *white arrows*

On MRI, there is hypointense enlargement of the pons on T1-weighted images and diffuse hyperintense enlargement of the pons on T2-weighted images (Fig. 7.27). Calcifications and hemorrhages are rare on initial diagnosis, although expansion to the midbrain or medulla may be present (Parsons et al. 2016). Due to the eloquent location of the tumor, DIPGs are not resectable. Historically, tumor tissue for research studies has been obtained during autopsies. Recently, biopsy using stereotactic guidance by an expertly trained neurosurgeon under very controlled circumstances has provided new information about the biology of DIPGs. Due to the increased risk of morbidity and potential mortality, biopsies are reserved for only a select few patients, and parents must be made aware that the biopsy is for confirmation of tumor identity and research purposes only (Jansen et al. 2012). The use of chemotherapy in conjunction with radia-



**Fig. 7.27** Diffuse intrinsic pontine glioma (DIPG) sagittal view post-contrast T1 FLAIR of tumor in the pons, as indicated by the *white arrow*. Patient died 6 months after diagnosis

tion therapy has not demonstrated improved outcomes in DIPG, and, therefore, radiation therapy remains the standard of care (Gajjar et al. 2015). DIPG is the leading cause of mortality in children with brain tumors with an average overall survival of 10–12 months (Glod et al. 2016).

## 7.5.6 Types of Central Nervous System Tumors

### 7.5.6.1 Spinal Cord Malignant Astrocytomas

Anaplastic astrocytomas or glioblastoma in the spinal cord is a rare entity in children, accounting for less than 0.2% of primary CNS tumors in children. Anaplastic astrocytomas represent just slightly more than half of the high-grade spinal astrocytomas (HGSCAs). Like the high-grade astrocytomas of the brain, the extent of surgical resection may impact time to progression, and radiation treatments may temporarily reduce the size of the tumor. Children who are diagnosed with HGSCA under the age of 5 years have a better overall survival when compared to older children. Median survival for those with anaplastic HGSCAs was 12 months compared to 7 months with glioblastoma (Lam et al. 2012).

### 7.5.6.2 Subependymal Giant Cell Astrocytomas (SEGAs)

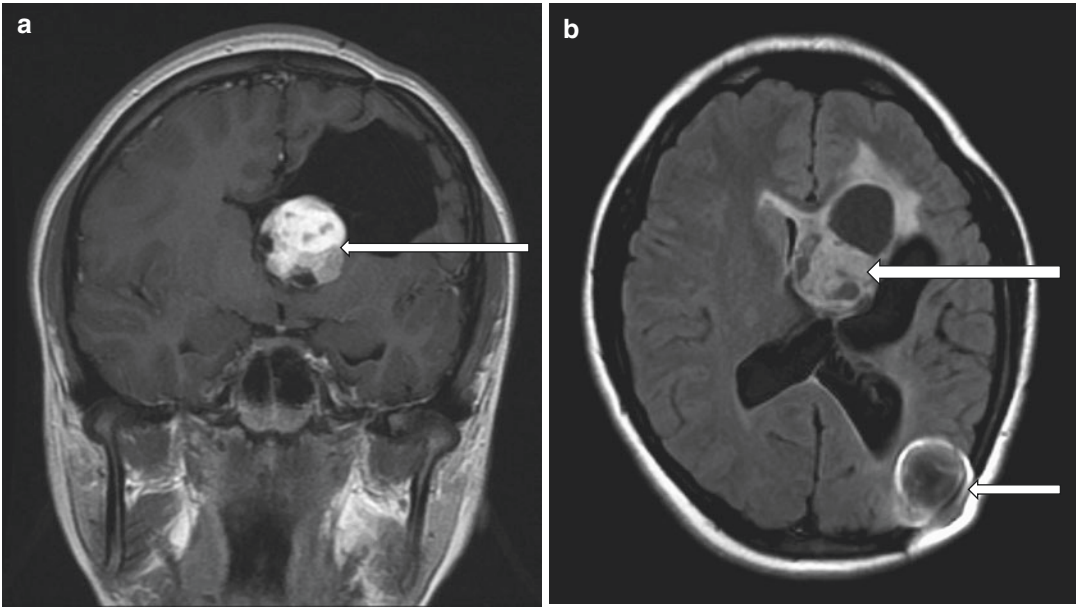
Subependymal giant cell astrocytomas (SEGAs) are tumors that are always associated with tuberous sclerosis, an autosomal dominant inherited phakomatosis. SEGAs are classified by the WHO as grade I (Louis et al. 2016). Approximately 20% of patients with tuberous sclerosis will develop SEGAs in the first two decades of life (Wheless and Klimo 2014). Many tuberous sclerosis patients develop seizures, mental retardation, hamartomas, adenoma sebaceum, intracranial cortical tubers, and subependymal nodules. Most SEGAs arise in the wall of the lateral ventricle near the foramen of Monro and generally exceed 1 cm in diameter (Fig. 7.28a, b) (Grajkowska et al. 2010). Presenting symptoms are focal neurological deficits that correspond to the level of the lesion and signs of hydrocephalus if the tumor

has obstructed the outflow of CSF (Wheless and Klimo 2014). Patients diagnosed with tuberous sclerosis have mutations of the TSC1 gene on chromosome 9q34 and on TSC2 gene on chromosome 16p13. Hamartin and tuberin are tumor suppressor proteins, and mutations here lead to activation of the mTOR pathway that leads to tumor formation (Mueller and Haas-Kogan 2010). The histologic diagnosis is made with the presence of dysmorphic glial and giant cells arranged in sheets, clusters, or pseudorosettes that make up a rich vascular stroma (Grajkowska et al. 2010). A gross total resection of the tumor is usually possible and can be curative. Everolimus, a rapamycin inhibitor, has been shown to halt tumor progression or reverse tumor growth in pediatric patients. Because death can occur from an undiagnosed tumor and hydrocephalus, all children with tuberous sclerosis should be screened radiographically every 2 years for the presence of a lesion (Wheless and Klimo 2014).

### 7.5.6.3 Gangliogliomas/ Gangliocytomas/Desmoplastic Infantile Ganglioglioma

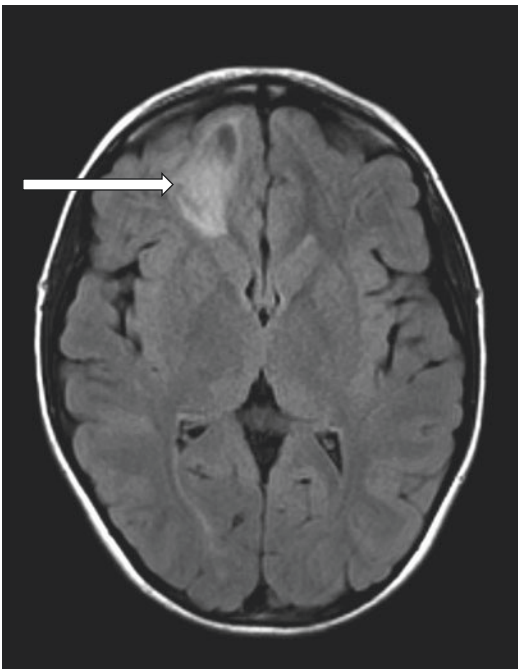This group of slow-growing glioneuronal tumors represents about 4–8% of all tumors in children. This group of tumors are classified as WHO grade I with the exception of anaplastic ganglioglioma, which is classified as WHO grade III (Louis et al. 2016). Gangliogliomas and gangliocytomas are most commonly located in the temporal or parietal lobes but may occur anywhere in the CNS (Kieran et al. 2015). Desmoplastic infantile gangliogliomas (DIGs) occur in the supratentorium, often in the frontal or parietal lobes. They involve the leptomeningeal surface and, if located peripherally, can erode the inner table of the calvarium (Chapman 2016). Gangliogliomas often occur prior to the age of 30 years, with a mean age at diagnosis of less than 10 years (Fig. 7.29). The first presenting symptom in 50% of all gangliogliomas is seizure, and upon further review of the past medical history, there is often a 2-year history of seizures prior to diagnosis. The majority of DIG tumors occur in children under the age of 2 years (Fig. 7.30). Presenting symptoms of DIG are increasing head circumference, bulging fonta-



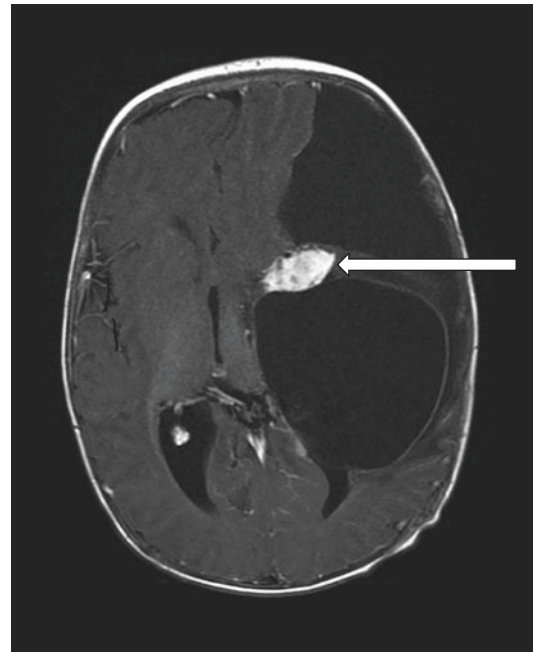


**Fig. 7.28** (a) SEGA: coronal view post-contrast T1 FLAIR with tumor located in the left lateral ventricle near the foramen of Monroe, as indicated by the *white arrow*. (b) Recurrent SEGA: axial view T2 FLAIR of the tumor in the left lateral ventricle and left parietal region as indi-

cated by the long *white arrow*. The tumor is obstructing CSF flow and hydrocephalus is present. There is artifact from her programmable VP shunt as indicated by the short *white arrow*

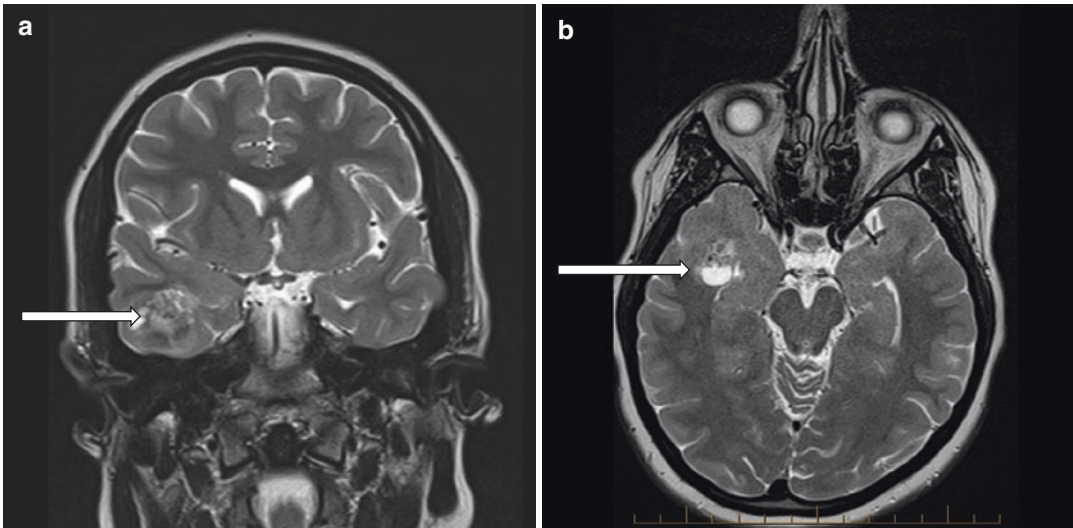


**Fig. 7.29** Ganglioglioma: axial view T2 FLAIR of a variable enhancing lesion with peripheral cystic area, indicated by the *white arrow*



**Fig. 7.30** Desmoplastic infantile glioma (DIG): axial view post-contrast T1 FLAIR of a large multicystic partially enhancing mass lesion in the left cerebral hemisphere, indicated by the *white arrow*. There is significant midline shift





**Fig. 7.31** (a) Oligodendroglioma: coronal view T2 image with *white arrow* pointing to a right temporal grade II oligodendroglioma. (b) Oligodendroglioma: axial view

T2 image with *white arrow* pointing to a right temporal grade II oligodendroglioma

nel, lethargy, and, in older children, focal motor deficits (Kieran et al. 2015).

On MRI, these tumors will have a curvilinear pattern of enhancement of the solid tissue with one or more cysts that may be quite large (Chapman 2016). Gangliocytomas contain well-differentiated ganglion cells, whereas gangliogliomas also contain neoplastic glial cells. DIGs are very similar to the gangliogliomas but also contain desmoplasia (fibrous tissue) and some poorly differentiated neuroepithelial cells (Ellison et al. 2013). A BRAF V600E oncogene mutation has been found in a significant number of gangliogliomas and less frequently in DIG tumors. Targeting this mutation has become the focus for international clinical trials (Kieran et al. 2015). Observation, with further surgery or radiation therapy if the tumor begins to grow, is recommended (Greenburg 2016). Malignant transformation is rare with this group of tumors. Following surgical removal, gangliogliomas have a 10-year disease-free survival rate of 97% (Kun et al. 2011).

#### 7.5.6.4 Oligodendrogliomas

Oligodendrogliomas are a group of diffusely infiltrative gliomas that account for less than 1%

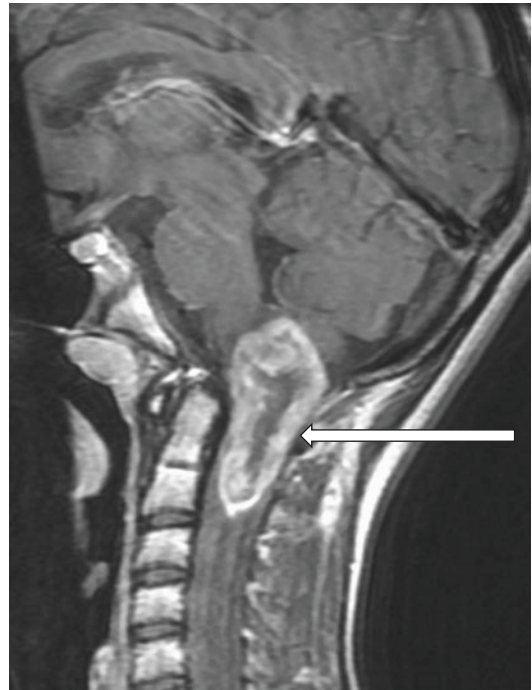of all pediatric tumors (Parsons et al. 2016). Recent changes in the WHO classification system have identified three categories of oligodendrogliomas. Oligodendroglioma, IDH-mutant and 1P/19q-codeleted, and also oligodendroglioma, NOS (not otherwise specified), are WHO grade II. Anaplastic oligodendroglioma, IDH-mutant and 1P/19q-codeleted, is WHO grade III (Louis et al. 2016). Oligodendrogliomas can occur anywhere in the CNS but frequently are found in the frontal and temporal lobes and involve the white matter (Fig. 7.31a, b) (Fuller 2010b). The average age at diagnosis is between 10 and 13 years, and males are more frequently affected. Presenting symptoms are often dependent on the location and size of the tumor and may include seizures, visual deficits, headache, cranial nerve palsies, and paresis (Kieran et al. 2015).

On MRI, oligodendrogliomas are well-demarcated tumors with minimal surrounding vasogenic edema that are hypointense on T1-weighted and hyperintense on T2-weighted and FLAIR images (Fuller 2010b). Contrast enhancement is more common in solid masses and less so in infiltrative tumors. Oligodendrogliomas contain cells with small round nuclei with clear nuclear halos giving it the appearance of a “fried

egg.” They may also demonstrate increased mitotic activity and microvascular proliferation (Kieran et al. 2015). Oligodendrogliomas that occur in childhood are poorly understood at the molecular level as they often do not have IDH gene mutation and the 1p/19q codeletion typically found in adult oligodendrogliomas. Therefore, the WHO recommends these pediatric tumors be included in the oligodendroglioma, NOS category (Louis et al. 2016). The 10-year survival after GTR of oligodendrogliomas is 60 and 31% after subtotal resection followed by irradiation (Kun et al. 2011).

### 7.5.6.5 Ependymoma

Ependymomas are neuroepithelial tumors that make up 6–10% of childhood brain tumors (Lin and Chintagumpala 2015). WHO grading for ependymomas ranges from grade I to grade III. WHO grade I subtypes include myxopapillary ependymomas that typically occur in the spine and subependymomas that can occur anywhere in the CNS. WHO grade II is classic ependymoma with subtypes that include cellular, clear cell, papillary, and tancytic ependymoma. WHO grade III is anaplastic ependymoma (Glod et al. 2016). The highest incidence of ependymoma occurs in children under the age of 7 years with up to 51% of all children diagnosed under 3 years of age (Lin and Chintagumpala 2015). Ependymoma tumors arise from the cells within or adjacent to the ependymal lining of the ventricular system or the central canal of the spinal cord. More than 85% of ependymomas occur in the fourth ventricle of the posterior fossa, with the remainder occurring in the cerebral hemispheres or spinal cord. Recent data demonstrates that there is now a higher incidence of ependymomas in females, with a male-to-female ratio of 1.3:2.0 (Parsons et al. 2016). NF type 2 is the only inherited genetic disorder known for having an increased tendency for developing ependymomas, and in these cases, the tumors primarily occur in the spinal cord (Plaza et al. 2013). Presenting symptoms include headache, vomiting, papilledema, ataxia, swallowing dysfunction, and torticollis. Ependymomas of the spinal cord can lead to scoliosis, back pain, and motor



**Fig. 7.32** Ependymoma: sagittal view post-contrast FSE T1 of enhancing tumor in the posterior fossa and extending below the foramen magnum, indicated by the *white arrow*

deficits that correspond to the level of the tumor (Kieran et al. 2015).

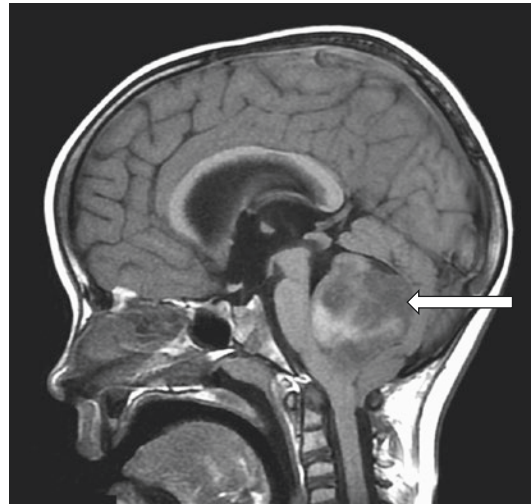
Posterior fossa ependymomas on MRI appear as a well circumscribed, uniformly enhancing tumor extending out of the fourth ventricle by way of the foramina of Magendie or Luschka (Fig. 7.32). Ependymomas have a tendency to wrap around the brainstem or extend down the foramen magnum and hemorrhage, or calcifications may also be observed (Kieran et al. 2015). Because of the risk of spread of tumor to other areas of the neuroaxis, either preoperative or postoperative imaging of the entire CNS is recommended (Wait et al. 2015b). The classic histologic finding of ependymomas is perivascular pseudorosettes forming a fibrillary zone around vessels and classic rosettes located in the ependyma. Anaplastic ependymomas also have necrosis, mitoses, and vascular proliferation (Parsons et al. 2016). There are multiple chromosomal anomalies that have been identified within ependymoma tissue with the most common being structural abnormalities of chromosome 22q

(Kieran et al. 2015). A better prognosis is associated with a loss of 6q25.3 in anaplastic ependymoma, whereas a poor prognosis is associated with ependymomas that have a gain of chromosome 1q (Pfister 2009).

Surgery is the first treatment for ependymomas with the extent of surgery being the most important prognostic factor (Plaza et al. 2013). Surgical management of hydrocephalus is also required because of the tumor obstructing flow through the fourth ventricle. It is difficult, however, to totally remove an ependymoma in the fourth ventricle because it is close to the brainstem. As with other tumor types, the extent of surgical removal correlates with increased progression-free survival; thus, a child with fourth ventricular ependymomas tends to have a worse prognosis. Treatment of ependymomas after surgery is controversial. Local radiation has been shown to increase the overall survival rates from up to 73% at 5 years to 85%. Chemotherapy has shown some efficacy and continues to be considered along with radiation for tumors that cannot be surgically removed. Chemotherapy in older children and those with recurrent ependymomas has not shown an improvement in the overall survival rate (Parsons et al. 2016). Progression-free survival (PFS) for subtotal resection is 25% compared with 66% for those with a gross total resection (Kieran et al. 2015).

#### 7.5.6.6 Medulloblastoma

Medulloblastomas are the most common malignant tumor in children and account for 20–25% of all CNS tumors. They are embryonal tumors that are classified as WHO grade IV (Pfister 2009). These tumors originate in the cerebellum with the potential to extend into the fourth ventricle and/or brainstem (Fig. 7.33). Nearly 80% of patients present with headache and vomiting at the time of diagnosis, secondary to obstruction of CSF pathways that occur either at the level of the third or fourth ventricle. Unsteadiness, papilloedema, nystagmus, and sixth cranial nerve palsies are also common presenting symptoms. Familial cancer syndromes such as Turcot, Li-Fraumeni, and Gorlin can be associated with medulloblastoma. Eighty percent of all children



**Fig. 7.33** Medulloblastoma: sagittal view T1 FLAIR of a large heterogeneously enhancing fourth ventricular tumor as indicated by the short *white arrow*. There is anterior displacement of the brainstem and obstructive hydrocephalus

diagnosed with medulloblastoma are non-Hispanic white children (Chintagumpala et al. 2016). The peak incidence of medulloblastoma occurs around age 6 years of age (Gajjar 2013).

Approximately one-third of cases have CNS metastases at the time of diagnosis, and, for this reason, both a brain and spine MRI should be performed (Glod et al. 2016). Obtaining a spine MRI along with a CSF sample via lumbar puncture (LP) is necessary to assess for seeding of the tumor to the subarachnoid space. An LP may be contraindicated preoperatively if there is mass effect of the tumor and potential for cerebellar herniation. In these situations, the LP would be deferred until at least 2 weeks following surgical resection of the tumor. Bone marrow metastases are rare with medulloblastoma, but if extraneural disease is suspected, a bone marrow aspirate should be obtained (Ramaswamy and Taylor 2015).

On MRI, medulloblastomas typically appear as a solid mass that is hypointense or isointense to gray matter on T1-weighted images and has variable signal on T2-weighted images. They also demonstrate restricted diffusion, and following contrast, there is moderate diffuse

nonhomogenous enhancement (Adesina and Hunter 2010).

Medulloblastomas have five histological variants: classic medulloblastoma, desmoplastic (nodular) medulloblastoma, anaplastic medulloblastoma, large cell medulloblastoma, and medulloblastoma with extensive nodularity (Pfister 2009). The classic variant consists of monotonous sheets of small cells with nuclear irregularity, scant cytoplasm, and apoptosis. Desmoplastic variants have a similar appearance to the classic variant with the addition of pale nodules of neurocytic cells (Adesina and Hunter 2010). Anaplastic variants have pleomorphic, enlarged nuclei, and increased cytoplasm-to-nucleus ratio compared to the classic variant. The large cell variant has a high mitotic rate and extensive apoptosis (Pfister 2009). The extensive nodularity variant has florid nodularity and neurocytic differentiation (Adesina and Hunter 2010). The desmoplastic (nodular) variants have a much better prognosis compared to the large cell and anaplastic variants (McLendon et al. 2011). A deletion of 17p with isochromosome 17q is the most common cytogenetic abnormality and is present in 30–40% of medulloblastomas (Pfister 2009).

Significant research over the past several years has led to the identification of four molecular subtypes: sonic hedgehog (SHH), wingless (WNT), and group 3 and group 4 (Gajjar et al. 2015). Research has identified that each molecular subtype has a distinct pattern of genetic expression, signaling pathway, and biological behavior which may impact how it will respond to certain treatment regimens (Pollack 2011). Knowledge at the molecular level has led to improved stratification of medulloblastomas and identified therapeutic targets that may lead to improved patient care (Glod et al. 2016).

Nearly all of the WNT subtypes display the classic histology and rarely metastasize (Gajjar et al. 2015). Greater than 90% WNT subtypes have a deletion of one copy of chromosome 6 and a mutation of the CTNNB1 ( $\beta$ -catenin) gene which leads to a protein that is resistant to break down and accumulates in the nucleus of tumor cells (Chintagumpala et al. 2016). The WNT sub-

type has the best prognosis with a 5-year event-free survival of greater than 90% (Gajjar et al. 2015).

The SHH subtype is further broken down into three variants: infant SHH, childhood SHH, and adult SHH. The infant SHH frequently has the PTCH1 or the SUFU mutation. Both PTCH1 and SUFU regulate the sonic hedgehog signaling pathway which is essential for normal cerebellar development and is dysregulated in medulloblastoma (Slade et al. 2011). The prognosis for infant SHH is excellent when treated with chemotherapy alone. Childhood SHHs have the PTCH1 mutation or the germline TP53 mutation; the latter is associated with Li–Fraumeni syndrome. The prognosis for childhood SHH with TP53 mutations have the worst outcome, and those without this mutation have a 60% 5-year progression-free survival. Adult SHH has mutations in the SMO or mTOR signaling pathway and has a 40% 5-year survival rate (Gajjar et al. 2015).

Both group 3 and group 4 subtypes are more common in males. Group 3 subtypes display the large cell or anaplastic histology, and 50% have metastatic disease. The majority of group 3 subtypes have the isochromosome 17q cytogenetic abnormality or the oncogene MYC amplification (Gajjar et al. 2015). MYC is a regulator gene that codes for transcription factor and plays a role in cell cycle progression, apoptosis, and cellular transformation (Fiaschetti et al. 2011). Of the four molecular subtypes, group 3 has the poorest prognosis with a 50% 5-year overall survival (Glod et al. 2016). The majority of group 4 subtypes display classic histology and some that have large cell histology (Gajjar et al. 2015). This subtype is associated with MYCN amplification. The MYCN gene helps to regulate cell growth, proliferation, apoptosis, and inhibition of cell differentiation (Gorlick et al. 2016). Group 4 subtypes are common in males with the male-to-female ratio 3:1. Group 4 has a 35% metastases rate and has an intermediate survival rate of approximately 75% (Chintagumpala et al. 2016).

Surgery (in one or several operations) is the first treatment for medulloblastoma. Total removal is the goal. This is sometimes difficult if the tumor has spread to the brainstem or the floor

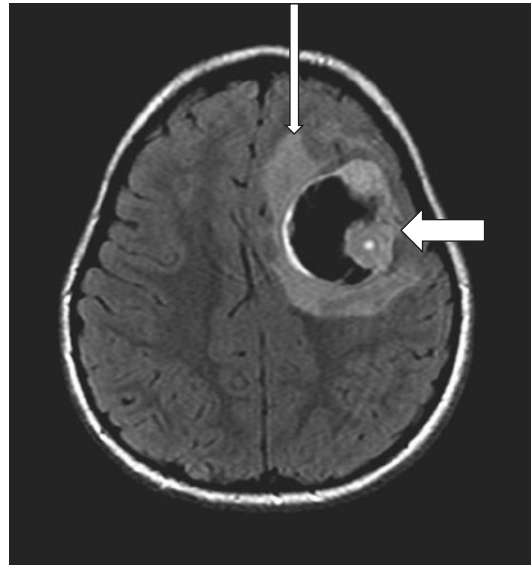


of the fourth ventricle. Treatment plans vary depending upon the child's age at diagnosis, amount of tumor removed, and extent of tumor spread. Postoperatively, about 10–40% of all children will require treatment for hydrocephalus with either a shunt or an endoscopic third ventriculostomy (Ramaswamy and Taylor 2015). If not done preoperatively, a neuroaxis MRI scan for drop metastases should be obtained. Medulloblastoma is very responsive to radiation therapy and to many chemotherapy drugs (Ramaswamy and Taylor 2015).

Medulloblastoma tumors are grouped into two broad categories: standard risk and high risk. A tumor that has been completely removed by surgery and has not spread to other areas of the CNS is called standard risk. Children with standard-risk medulloblastoma receive craniospinal radiation and chemotherapy during induction, with a chemotherapy backbone for maintenance. Progression-free survival for this group of children is approximately 80–85% at 5 years. Those children who are younger than 3 years of age at diagnosis, who have spread of their disease within the neuroaxis, or who have greater than 1.5 cm<sup>2</sup> of tumor after surgery are considered high risk. Progression-free survival for this group of children is 60–70% at 5 years (Gajjar 2015). Treatment for these children varies with age. For those younger than age 3, intensive chemotherapy with a tandem stem cell rescue is indicated to achieve a remission, until the child is older than 3 years of age when radiotherapy can be used. Older children receive radiation with or without a radiosensitizing chemotherapy, followed by intensive chemotherapy with autologous stem cell rescue, if necessary (Chintagumpala et al. 2016).

#### 7.5.6.7 Supratentorial Primitive Neuroectodermal Tumors (sPNETs)

sPNETs are a group of supratentorial embryonal tumors with undifferentiated neuroepithelial cells that account for up to 2.5% of childhood brain tumors (Chintagumpala et al. 2016). They are also referred to as CNS PNETs. Historically, these tumors have been hard to classify and have included the following subtypes: cerebral neuro-



**Fig. 7.34** Supratentorial primitive neuroectodermal tumor (sPNET): axial view T2 FLAIR of a large heterogeneously enhancing left frontal cystic, solid tumor as indicated by the *short white arrow*. There is vasogenic edema surrounding the tumor as indicated by the *long white arrow*

blastoma, ganglioneuroblastoma, medulloepithelioma, and ependymblastoma (Pfister et al. 2009). The WHO has recently removed the term PNET from their diagnostic lexicon and now identifies the following as individual embryonal tumors: embryonal tumor with multilayered rosettes C19MC-altered, embryonal tumor with multilayered rosettes-NOS, CNS neuroblastoma, CNS ganglioneuroblastoma, medulloepithelioma, and CNS embryonal tumor-NOS. Each are classified as WHO grade IV (Louis et al. 2016). Pineoblastomas were previously considered a type of sPNET that occurred in the pineal region, and they are now considered a subtype of a pineal region tumor (Chintagumpala et al. 2016). Historically, sPNETs and medulloblastomas were considered the same tumor but labeled differently based on their location, with SPNETs located above the tentorium (Fig. 7.34) and medulloblastomas located below the tentorium (Keiran et al. 2015). Recent molecular studies have revealed that medulloblastomas are embryonal tumors but are biologically different from sPNET (Chintagumpala et al. 2016). The majority of sPNETs occur before the age of 10 years

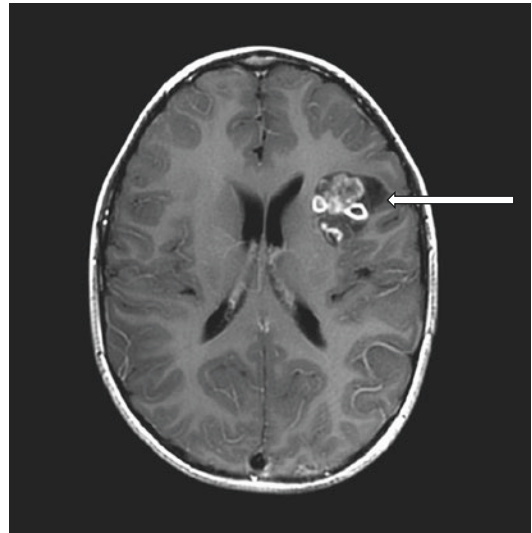


with more cases reported in Caucasian people (Kieran et al. 2015). Dissemination to the CNS is less frequent than medulloblastoma with a rate of 10–15% at the time of diagnosis (Chintagumpala et al. 2016). Presenting symptoms correspond with the location of the tumor and may include hemiparesis, seizures, mood changes, and signs of hydrocephalus (Kieran et al. 2015).

On MRI, sPNETs are dark on T1-weighted images unless hemorrhage has occurred and dark on T2-weighted images. They enhance with contrast and may have cysts, necrosis, and surrounding edema (Kieran et al. 2015). CNS embryonal tumor-NOS contains small blue round cells of undifferentiated or poorly differentiated neuroepithelial cells with scant cytoplasm. CNS neuroblastomas are similar but have neuronal differentiation present. CNS gangliogliomas have the addition of ganglion cells, and medulloepithelial tumors are characterized by papillary, tubular arrangements of neoplastic neuroepithelium. Ependyoblastomas contain multilayered rosettes and now are classified as embryonal tumor with multilayered rosettes C19MC-altered or NOS type (Miller et al. 2012). A gross-total resection is possible depending on the location but occurs less frequently as they are large, highly vascular tumors that may involve eloquent areas of the brain. Following surgery, the standard treatment is craniospinal irradiation (CSI) and chemotherapy using the same treatment regimen used for medulloblastomas. The 5-year progression-free survival for older children following chemotherapy and CSI is approximately 50%, and for infants the rates are less favorable with the range between 20% and 40% (Chintagumpala et al. 2016).

#### 7.5.6.8 Dysembryoplastic Neuroepithelial Tumors (DNETs)

DNETs are neuroepithelial tumors located in the supratentorium that make up fewer than 1% of pediatric brain tumors. Two-thirds of DNETs are located in the temporal lobe and almost always present with partial complex seizures that are refractory to anticonvulsant medications (Fig. 7.35). They are classified as WHO grade I. DNETs present in the first two decades of life



**Fig. 7.35** Dysembryoplastic neuroepithelial tumor: axial view post-contrast T1 FLAIR propeller of a left parietal solid cystic tumor, as indicated by the *white arrow*

and occur more frequently in males (Kieran et al. 2015). NF type 1 and XYY syndrome are associated with a higher risk of developing DNETs (Adesina and Rauch 2010). On gross examination, they have the appearance of a megagyrus or expanded cortex. MRI reveals well-demarcated lesions that are non-enhancing and hypodense on FLAIR and T2-weighted imaging. Histologically, there is disorganized glial and neuronal elements arranged in columns perpendicular to the cortical surface with 50–90% of all cases positive for cortical dysplasia. Surgery is the only treatment and employed not only to remove the tumor but to treat the seizure disorder as well. If the entire tumor is not removed, the patient may require further surgical resection if symptomatic or may be followed with serial imaging if asymptomatic. DNETs are typically reported in terms of seizure outcomes with reports of 86% of patients seizure-free at 1 year (Wait et al. 2015a).

#### 7.5.6.9 Craniopharyngiomas

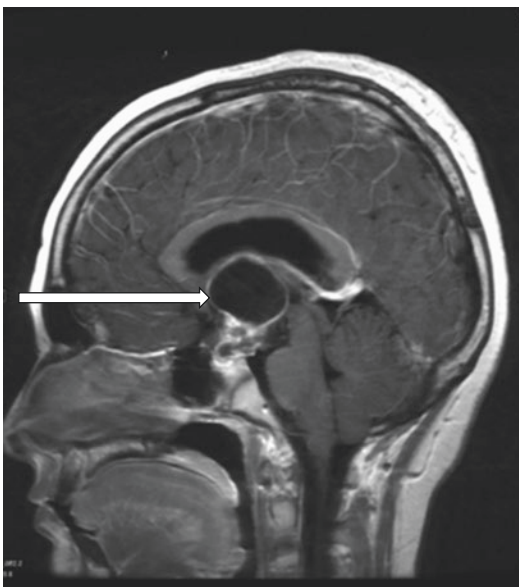
Craniopharyngiomas are suprasellar epithelial tumors that are believed to be residual embryonic tissue from the Rathke's pouch (Imbach 2014). They are slow-growing tumors that are classified as WHO grade I. Despite clinically benign

features, their location in the sella is in close proximity to the hypothalamus, pituitary, optic chiasm, and vessels of the circle of Willis which can result in significant morbidity and mortality (Kieran et al. 2015).

Craniopharyngiomas account for 6–9% of all pediatric CNS tumors with no gender predilection. The peak age at diagnosis is between 8 and 10 years of age, and rarely do they occur in infants (Parsons et al. 2016). Approximately 70% of children present with visual impairment at the time of diagnosis (Drimtzias et al.). Other presenting symptoms include endocrine abnormalities and signs of hydrocephalus.

On MRI, craniopharyngioma will appear as multicystic and solid-enhancing suprasellar mass, often with the optic chiasm stretched over the tumor (Fig. 7.36). A classic distinction from other suprasellar tumors is the presence of calcifications on head CT. Craniopharyngiomas are divided into two histologic subtypes: papillary and adamantinomatous. Papillary subtypes are found almost exclusively in adults, and adamantinomatous subtypes occur in both

adults and children. The presence of squamous epithelium bordered by palisading columnar epithelium confirms the diagnosis of adamantinomatous craniopharyngiomas (Kieran et al. 2015). Craniopharyngiomas often have a thick glial layer of tissue that can form a tight adherence to surrounding structures, greatly increasing the risk of injury and long-term morbidity with complete resection. Treatment is controversial because aggressive surgery often cures the child but can cause seizures and lifelong memory, visual, behavioral, and hormonal problems. Taking out part of the tumor, followed by radiation therapy, is a treatment option that can lessen the long-term side effects. The cystic portion of craniopharyngiomas frequently contains an oily substance that has the appearance of machine oil, and if the contents of the cyst are spilled, it can lead to intense chemical meningitis. Treatment depends upon the location and the size of the tumor and may include surgery from an intracranial or transsphenoidal approach, observation, or focused radiation therapy (Parsons et al. 2016). Long-term survival following a GTR is 50–90% with a 60–85% long-term survival following a subtotal resection followed by radiation therapy (Imbach 2014).



**Fig. 7.36** Craniopharyngioma: coronal view T1 FLAIR of a multilobulated, multicystic, partially calcified suprasellar retrochiasmatic mass, indicated by the *white arrow*

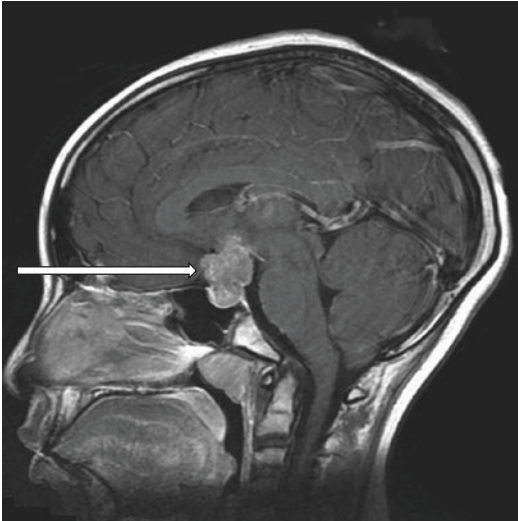
#### 7.5.6.10 Germ Cell Tumors

Germ cell tumors (GCTs) are a group of embryonal tumors that typically grow in the pineal or suprasellar regions and represent 3–5% of all intracranial tumors in children. GCTs are presumed to be the result of abnormal migration of primitive germ cells early in embryogenesis within the gonadal ridge (Kieran et al. 2015). There are two major groups: pure germinomas and non-germinoma germ cell tumors (NGGCTs) which include embryonal carcinoma, yolk sac tumor, choriocarcinoma, teratoma (mature and immature), teratoma with malignant transformation, and mixed germ cell tumor (Louis et al. 2016). Approximately 90% of all CNS GCTs occur prior to the age of 20 years, with mature and immature teratomas the most prevalent in the neonatal period (Echevarría et al. 2008). These

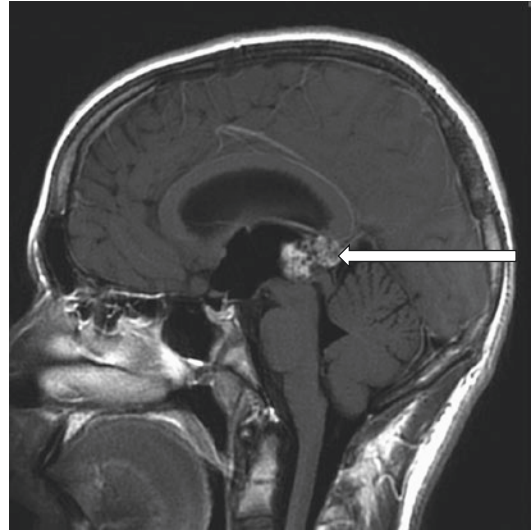
tumors are more commonly found in Asia, particularly in Japan. There is a significant male predominance in GCTs with the male-to-female ratio approximately 14:1. Syndromes associated with GCTs are Down syndrome and males with Klinefelter syndrome (Kieran et al. 2015). Presenting symptoms are directly related to the location and size of the tumor. The most frequent findings are increased ICP, visual changes, and endocrine abnormalities (Echevarría et al. 2008).

On MRI, pineal region germinomas appear as well-delineated tumors that are hypointense on T1-weighted images and iso- or hyperintense on T2-weighted images, with uniform contrast enhancement. Germinomas located in the suprasellar region appear infiltrative and less well defined (Figs. 7.37 and 7.38). Mixed germ cell tumors and mature and immature teratomas may have both hyper- and hypointense areas on T2-weighted images, with heterogeneous enhancement (Figs. 7.39 and 7.40) (Tihan 2010). Up to 37% of GCTs can have CSF metastases; thus a spine MRI and CSF cytology are required (Wait et al. 2015a).

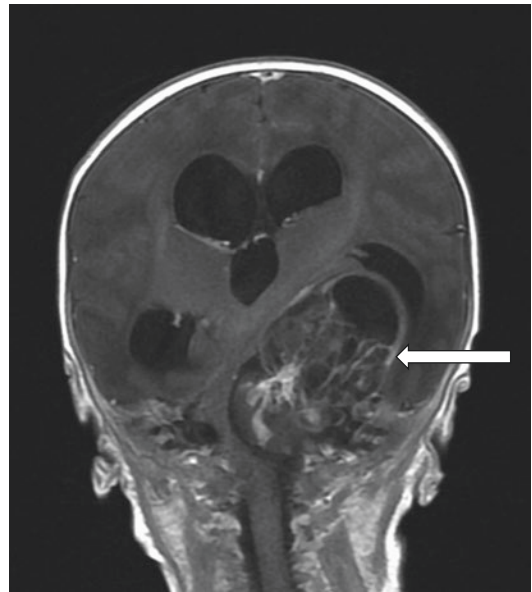
Pure germinomas make up 60–70% of all GCTs and have a more favorable prognosis



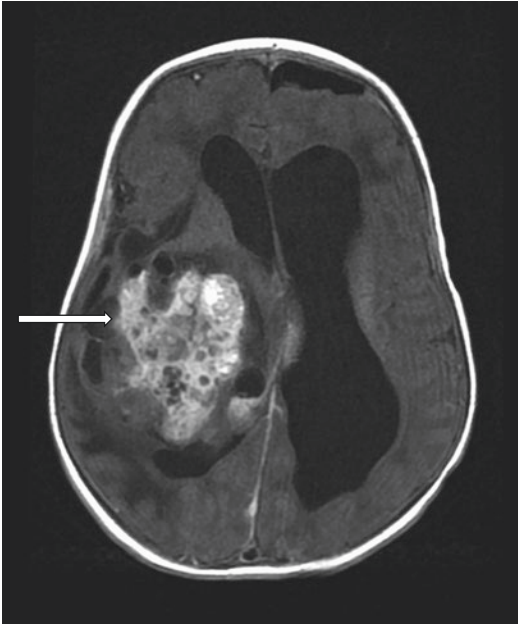
**Fig. 7.37** Germinoma: sagittal view post-contrast T1 FLAIR sella and suprasellar tumor with punctate calcifications, as indicated by the *white arrow*



**Fig. 7.38** Mixed germ cell tumor: sagittal view post-contrast T1 FLAIR propeller of a small lobulated mass with calcifications in the pineal region and the posterior third ventricle, indicated by the *white arrow*. There is moderate enlargement of the lateral and third ventricles



**Fig. 7.39** Mature teratoma: coronal view post-contrast T1 FLAIR of a large heterogeneously enhancing solid tumor in the left middle fossa and posterior fossa, as indicated by the *white arrow*. The brainstem is shifted toward the right and there is hydrocephalus



**Fig. 7.40** Immature teratoma. Axial view post-contrast T1 FLAIR of an enhancing tumor involving the right frontal, temporal, and parietal lobes. There are cystic and solid components of the tumor, and it is causing a midline shift and hydrocephalus

compared to NGGCTs which are histologically “malignant” (Kun et al. 2011). On histology, germinomas consist of mitotically active large cells with vacuolated cytoplasm, round vesicular nuclei, central macronucleoli, and mature lymphocytes (Titan 2010). Germinomas that do not secrete tumor markers will require a biopsy to confirm diagnosis. These tumors respond to both chemotherapy and radiation but are highly responsive to radiation. In many cases, a complete response can be achieved with radiation therapy alone (Echevarría et al. 2008). Germinomas, following craniospinal irradiation, have the best prognosis with 5-year overall survival rates over 90% (Wait et al. 2015a).

NGGCTs secrete substances called tumor markers. Doctors can diagnose these tumors by checking the blood or CSF for two markers, called alpha-fetoprotein (AFP) and beta human chorionic growth factor (bHCG). Therefore, surgery to confirm the diagnosis of a NGGCT is not required. If the tumor is very large, however, part of it is removed (debulked) if the neurosurgeon

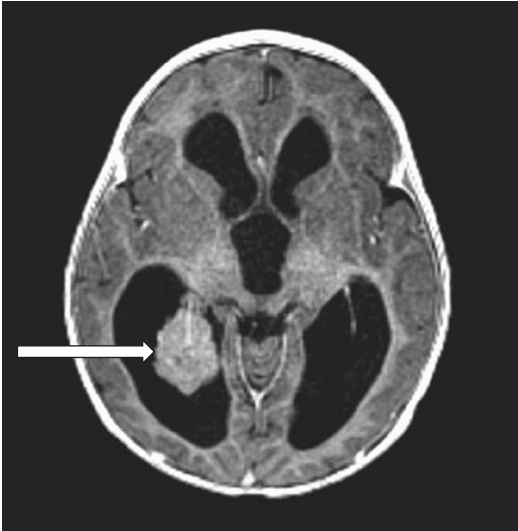
feels it can be done with few to no side effects. Treatment for NGGCTs includes chemotherapy followed by surgical resection and/or radiation. NGGCTs with complete resection, no CSF or leptomeningeal spread, and aggressive radiation can have a 5-year progression-free survival of 60% (Wait et al. 2015a).

The second most common GCTs are mature and immature teratomas (Tihan 2010). Histology for mature teratomas consists of mature tissue that differentiates along all three germ layers of the ectoderm, mesoderm, and endoderm. Immature teratomas contain variable amounts of tissue that resembles fetal tissue that often includes immature neural elements with rosettes. A grading system based on the amount of neuroepithelial tissue present is used with immature teratomas. Grade 1 contains <10% of immature neuroepithelium and grade 3 contains >50%. On gross examination, teratomas may include the hair, bone, cartilage, and pigmented skin (Frazier et al. 2015). Mature teratomas are best treated with surgery as they continue to grow and cause mass effect on surrounding structures (Wait et al. 2015a). The treatment of choice for immature teratomas is surgery, as prepubertal children do not respond to chemotherapy. If AFP levels are elevated, this may indicate a malignant component and chemotherapy may be indicated (Olson 2016). A gross total resection of a mature teratoma is often curative (Echevarría et al. 2008). An 80% event-free survival following GTR has been reported with immature teratomas (Frazier et al. 2015).

#### 7.5.6.11 Choroid Plexus Tumors

Choroid plexus tumors account for 2–6% of all pediatric brain tumors with the majority arising from the choroid plexus within the lateral ventricles (Wait et al. 2015a). Seventy percent of choroid plexus tumors are diagnosed in the first 2 years of life (Parsons et al. 2016). Choroid plexus tumors include choroid plexus papillomas (CPP), atypical CPPs, and choroid plexus carcinomas. Choroid plexus papillomas are WHO grade I, atypical choroid plexus papillomas are WHO grade II, and choroid plexus carcinomas are WHO grade III (Louis et al. 2016). The





**Fig. 7.41** Choroid plexus papilloma: axial view post-contrast SPGR 3D of an enhancing right intraventricular mass indicated by the *white arrow* and enlarged ventricles indicative of hydrocephalus

number of choroid plexus papillomas outnumber choroid plexus carcinomas 4:1. Choroid plexus carcinomas are commonly found in families with Li–Fraumeni syndrome, as they have the TP53 germline alteration. Presenting symptoms include a rapidly increasing head circumference, vomiting, and excessive irritability, as the tumor leads to an overproduction of CSF resulting in hydrocephalus (Fig. 7.41) (Parsons et al. 2016).

On MRI, choroid plexus papillomas are solid, well-demarcated intraventricular masses that are isointense to gray matter on T1-weighted images and hyperintense on T2-weighted images. Choroid plexus carcinomas are typically larger and have irregular enhancement, edema, cysts, and areas of intratumoral hemorrhage and/or necrosis (Fuller et al. 2010). In patients with choroid plexus carcinomas, spinal screening is necessary as up to 30% have metastatic disease at the time of diagnosis (Wait et al. 2015a). Histology of choroid plexus papillomas is similar to normal choroid plexus with cuboidal or columnar epithelium with a well-preserved epithelial-stromal border. Choroid plexus carcinomas have a poorly differentiated epithelial-stromal border and grow in sheets that contain pleomorphic cells that have frequent mitoses and necrosis. Surgery is the

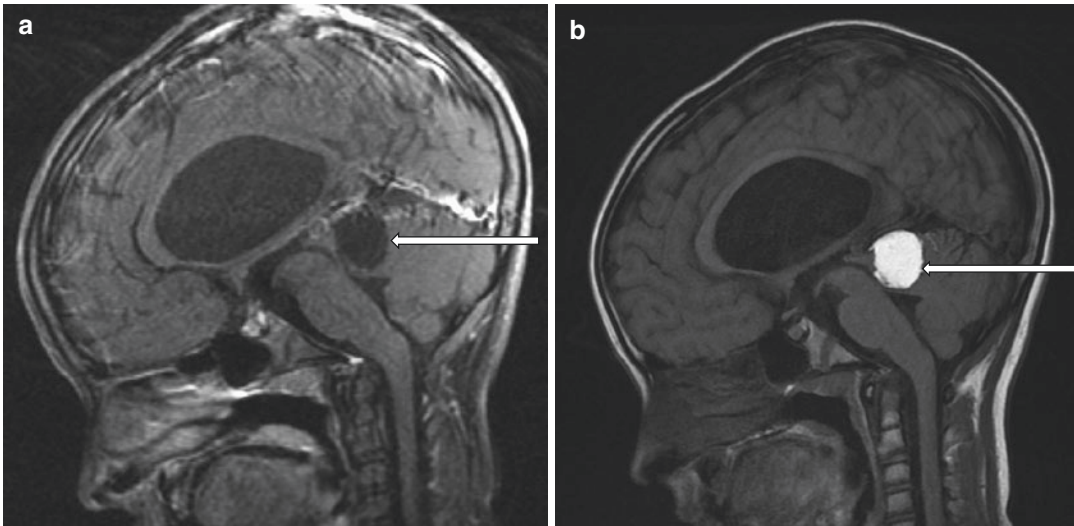
primary treatment for all choroid plexus tumors. A GTR of choroid plexus papillomas are often curative, although up to 60% of patients will have persistent hydrocephalus requiring a CSF shunt (Parsons et al. 2016). A GTR of a subset of choroid plexus carcinomas can be curative; however, for most, the 5-year survival rate ranges from 30% to 50% (Wait et al. 2015a). Postoperative radiation following resection of this tumor is frequently used, especially if there is an incomplete resection or if there is leptomeningeal spread. Research has demonstrated that chemotherapy may potentially contribute to higher chances of survival (Parsons et al. 2016).

#### 7.5.6.12 Dermoids and Epidermoids

Dermoid and epidermoid cysts/tumors are benign congenital lesions that account for 0.3–0.8% of all pediatric intracranial masses. They are thought to arise from ectodermal and mesenchymal cell nests entrapped within the neuroectodermal fold during its closure between third and fifth week of embryonic development (Schneider et al. 2012). Dermoids and epidermoids occur commonly on the scalp and calvaria (Swift and Sacco 2015). Intracranial dermoids and epidermoids can be found in the posterior skull base and suprasellar or parasellar region (Heger et al. 2016). Dermoids can be associated with Klippel-Feil anomaly and Goldenhar syndrome (Fig. 7.42a, b). Dermoids often have a dermal sinus tract that extends from the skin to the cyst, which can lead to meningitis (Raghunath et al. 2013). Epidermoids do not have a dermal sinus tract, which is a differential diagnostic marker during the histological evaluation (Schneider et al. 2012). Presenting symptoms correspond with the location and size of the cyst and may include seizure, headache, fever, dizziness, cranial nerve deficits, and signs of hydrocephalus (Orakcioglu et al. 2008).

On MRI, the dermoids and epidermoids are non-contrast enhancing and on T2-weighted images are usually hyperintense. They are signal-free in the fat-suppressed sequence. The contents of the cyst include sebaceous gland secretions, fat, oil, and hair. If dermoids/epidermoids rupture, they can lead to meningitis, vasospasm, cerebral ischemia, seizures, and hydrocephalus





**Fig. 7.42** (a) Dermoid: sagittal view post-contrast SE T1 fat saturation. Pineal region lesion as indicated by the white arrow. There is low signal on fat saturation imaging

identifying the lesion as predominantly fatty tissue. (b) Sagittal view T1 FLAIR of the same pineal region tumor as indicated by the white arrow

(Heger et al. 2016). Complete resection of the dermal sinus tract is recommended to prevent infection. A GTR of the dermoid/epidermoid, taking care not to spill its contents, is typically curative. If the dermoid/epidermoid is near an eloquent area or vessels, observation is preferred (Orakcioglu et al. 2008).

### 7.5.6.13 Infant Tumors

Children diagnosed with a CNS tumor in infancy should be discussed separately. These tumors are more difficult to treat because they are often aggressive histologically and any treatment will have an effect on the rapidly developing brain. The most common types of tumors associated with infancy, starting with the most common, are astrocytomas, medulloblastomas, ependymomas, choroid plexus tumors, sPNETs, and teratomas. Surgery is the primary treatment for all infant CNS tumors. Seventy percent of all tumors diagnosed in infants under 1 week of age are supratentorial. If adjunctive treatment is necessary, most clinicians advocate utilizing chemotherapy in an attempt to delay radiation therapy. Radiation is recommended for children less than 3 years of age only as a last resort (Kieran et al. 2015).

## 7.6 Posterior Fossa Syndrome

Posterior fossa syndrome (also called cerebellar mutism syndrome) is a complication of posterior fossa (cerebellum or brainstem) surgery. The actual cause is not clear. The most common tumors in this area are medulloblastomas, astrocytomas, and ependymomas. Posterior fossa syndrome occurs in up to 25% of patients following medulloblastoma surgery (Kieran et al. 2015). Most children wake up from the surgery moving their arms and legs and responding to questions. In some cases, 24 or more hours later, the child stops talking and may develop weakness of arms and legs, changes in respiratory function, incontinence, ataxia, and cranial nerve deficits. Emotionally, the children seem disconnected from their environment and may respond by simply crying. These symptoms improve over a period of days in the minimally affected child, but improvement may take months in the severely affected child. Some patients may benefit from glucocorticoids (Kelly et al. 2014). Preliminary research findings have demonstrated steady improvement of symptoms with the use of zolpidem (Shyu et al. 2011). Physical, occupational, and speech therapy should be started immediately.

Children who have severe posterior fossa syndrome require transfer to an inpatient rehabilitation center (Shiminski-Mayer et al. 2014).

---

## 7.7 Nursing Care

### 7.7.1 Overview

Nursing management for the child with a CNS tumor is dependent upon many variables, including age at diagnosis, specific type of tumor, neurological deficits, treatments required, and the individual family dynamics present to deal with the illness. All patients and families have a need for education and emotional support throughout all facets of the illness. The management of children with CNS tumors involves a large multidisciplinary team, including nurses, pediatricians, pediatric neurosurgeons, neurologists, oncologists, endocrinologists, radiologists, social work, child life, and radiation oncologists to name a few. Nurses and nurse practitioners are the health-care providers who have the majority of contact with the patient and families both in the hospital and as coordinators of outpatient care. Thus, nurses serve as patient advocates, case managers, and educators in a liaison role between patient/family and various members of the medical team throughout the course of the illness. They are also responsible for coordination of reentry to school and normal life once the acute treatment phase is completed. Nursing intervention is indeed critical at diagnosis and throughout the treatment of pediatric CNS tumors (Shiminski-Maher 1993).

### 7.7.2 Developmental Considerations

It is uniformly accepted that children need to be told of their diagnosis and plan of treatment as soon as possible. Delay in providing information will only escalate the child's fears. Parents may delude themselves into thinking that the diagnosis is a secret, but children are very perceptive. Nurses, along with child-life specialists, can assist parents in providing developmentally

appropriate information to their children. Nurses can also ensure that age-appropriate explanations are provided to patients prior to any procedure or treatment given. Educational materials should be provided for the families whether written, video, or by access to the Internet. The children and families should be encouraged to ask questions and keep a notebook with information regarding the diagnosis and treatment as well as tests that have been performed and results (Shiminski-Maher et al. 2014).

### 7.7.3 Diagnosis

The nurse's main responsibility during the diagnostic period is to provide the child and family with information about why various tests are being performed and how to prepare their child for each test. Nursing management of the patient undergoing diagnostic studies includes a large amount of patient/family education and coordination of diagnostic activities. Most young children (and older children whose level of consciousness is altered) receive conscious sedation or anesthesia for their MRI scans (Eche 2014). The nurse must monitor the child closely for signs and symptoms of increased intracranial pressure and seizures. If the child is not hospitalized during the diagnostic testing phase, instructions should be given to the family regarding the signs and symptoms of increased intracranial pressure and seizure precautions as indicated. Patient/family education should reinforce information given to the parents, including information on how to contact the medical team with any questions or concerns (Shiminski-Maher and Rosenberg 1990).

Obviously, the acuity of the situation will determine the extent of preparation the nurse can provide for the child and family. A neurologically unstable child may go from the emergency room, to the scanner, and then to the operating room. In other situations, the surgery is planned as an elective procedure with the child at home prior to the surgery. Whenever possible, nurses should be present when the physician presents the information about diag-

nosis and treatment to the child and family. The nurse will be able to reinforce and clarify information communicated as well as answer some of the many questions that will arise later. The nurse can provide preoperative education, including location of incision, bandages, presence of a drain or shunt postop, and other tubes that may be needed. Diagrams, booklets, and other audio-video tools assist in this preparation. Nurses can also refer the child and family to social work and child-life teams to reinforce this information (Shiminski-Maher 1993).

### 7.7.4 Surgery

Nursing care of the postoperative pediatric CNS tumor patient depends upon the location of the tumor, the extent of surgical removal, and clinical condition of the patient. Intraoperative guidance systems have dramatically reduced the size of many craniotomies and thus impacted positively on the recovery period for these children. Where children with CNS tumors would spend two to five postoperative days in an intensive care setting 10 years ago, today they spend on average 1–4 days. Intensive care monitoring is based upon level of consciousness. Most children are able to maintain their own airway and are extubated at the end of the surgery. For those children, it is a matter of careful hourly assessment for changes in level of consciousness or increased intracranial pressure for the first 24 h postoperatively. Hourly neurological checks and vital signs will allow nurses to alert the physicians of change in neurological status. Intracranial pressure monitoring is utilized for operations where the child is neurologically impaired preoperatively, if there is a sudden bleed or change in intracranial dynamics during the operation, or if intraoperative monitoring shows a change in the integrity of the nervous system in a specific region. Intracranial pressure can be monitored from a transducer through an externalized drain or, if no hydrocephalus is present, through an external ICP monitor called an intraparenchymal wire, inserted between the bone and the brain tissue (March and Hickey 2014).

Surgically removing some or all the tumor is the first step in treating increased intracranial pressure. The presence of an external drain to remove CSF allows for further controlling the intracranial pressure. Intravenous steroids, most commonly dexamethasone, are used to combat swelling. Further medical management includes the addition of osmotic diuretics such as mannitol and the utilization of intubation. A brief intervention of hyperventilation is recommended for an acute episode of increased ICP. The use of prophylactic or prolonged hyperventilation is not recommended. Maintaining euthermia decreases metabolic demand, and maintaining normal blood glucose levels prevents neurological changes. Analgesics and appropriate sedation to treat pain and agitation help to decrease the metabolic demand and prevent exacerbations of increased ICP (March and Hickey 2014).

Children are released from the intensive care unit when they are neurologically stable, usually within 24–48 h postoperatively. A steroid taper is begun with the intent to stop steroids as soon as possible. The long-term side effects of steroids have to be weighed with the side effects of long-term steroid use. These side effects of steroids include increased appetite and weight gain, irritability, difficulty sleeping, and muscle weakness. In addition, long-term steroids can adversely weaken the immune system. It is understood that the use of postoperative steroids makes the exam of a child “better than reality.” Steroids are only increased if there is a severe loss of function in a short period of time in a particular patient (Shiminski-Maher et al. 2014).

The use of postoperative anticonvulsants is necessary for children who presented with seizures preoperatively or for those who have tumors in areas of the brain where seizures can occur because of location. Intra- or postoperative seizures can occur in an area of the brain prone to epileptical activity that is associated with the removal of the tumor or associated interference with normal electrical activity in adjacent areas. Pre- and postoperative 24-h electrocorticography may be necessary for tumors where removal of the tumor and removal of an adjacent seizure focus are necessary. The recent advances in

monitoring activity have resulted in long-term remission from the tumor as well as eventual cure of a seizure problem, with removal of all anticonvulsants, in a tumor associated with seizures (Wells et al. 2012).

Patients who have hypothalamic and pituitary tumors are at risk for the development of diabetes insipidus (DI), or syndrome of inappropriate secretion of antidiuretic hormone (SIADH), as a result of either the tumor or the surgeon injuring the pituitary stalk (Wisoff and Donahue 2015). In the normal individual, water balance is controlled by the release of vasopressin from the posterior pituitary gland. The hypothalamus produces and releases the hormone, which travels via the pituitary stalk to the posterior pituitary gland where it is stored. Vasopressin is circulated to the kidney where it controls the amount of water retained or excreted. Vasopressin's hormonal influence controls the salt and water balance within the body. Imbalance in this system secondary to increased or decreased amounts of circulating vasopressin is commonly associated with DI or SIADH. Children with suprasellar, hypothalamic, or pituitary tumors are at risk for primary DI, while SIADH can occur as a result of overtreatment of DI, or because of confusion with salt-wasting issues which occur in injury to the posterior fossa and brainstem. Careful monitoring of fluid intake and output, as well as serum and urine sodium levels, is necessary for regulation of water and sodium balance in the body. DI may be permanent or transient depending on the extent of injury to the pituitary stalk. If resolution of this problem is to occur, it usually will do so in the first 2 weeks after surgery (Kelly 2014). For nursing management of sodium problems, see Chap. 8.

The majority of the suprasellar tumors are approached from an intracranial approach. Some tumors, such as pituitary or craniopharyngiomas, may be approached from a transsphenoidal approach or in a two-step transsphenoidal and intracranial procedure. This approach is utilized in older children whose sphenoid sinuses are large enough to accommodate the approach. Postoperatively these children must be monitored carefully for leakage of CSF. Often, their noses

are packed for 3–6 days, and they are prohibited from nose blowing or sneezing (Greenburg 2016). A temporary lumbar drain may be placed for postoperative drainage of CSF to prevent a CSF leak from the nose.

For those children without significant intracranial pressure, seizure, or hormonal problems, careful monitoring is necessary for 24–48 h. Postoperative imaging is necessary within the first 2 days to determine the extent of tumor resection. For those children requiring sedation or anesthesia, nursing coordination is essential. Physical and occupational therapies are ordered in the immediate postoperative period to begin working with any physical weaknesses that may be evident (Madden et al. 2014).

Pain management is different depending upon location of the surgical site in the CNS. Brain tumor surgery is generally less painful than spinal cord tumor surgery. Postoperative analgesics for intracranial surgery include a short period of opiates such as morphine, with a rapid switch to codeine or oxycodone, with or without acetaminophen. Nonsteroidal anti-inflammatory drugs such as ketorolac or ibuprofen are often used to potentiate the narcotic effects. Spinal cord operations usually require a longer course of opiates, usually with a patient-controlled analgesia (PCA). By the second postoperative day, the patient becomes increasingly mobile, with a decrease in intravenous narcotics and an increase in oral drugs. Switching from opioids to nonsteroidal anti-inflammatory medications while the dexamethasone (steroid) is decreased further aids in mobility (Jacob 2014).

Children with severe alteration in intracranial pressure or altered level of consciousness preoperatively, or those who are unstable during surgery, will require longer-term intensive care management postoperatively. Placement in an intensive care unit setting with intensive nursing monitoring is required. Airway, breathing, and circulation are the priorities. These are linked closely with intracranial pressure, which must be monitored constantly. Intake and output, management of fluid and electrolytes, especially sodium, and fluid balance are a key nursing function. Continued interface with the family

members by the nurses to keep them up to date on the current clinical situation, as well as providing ongoing education about the illness, is also important. As an individual's clinical condition improves, the patient transitions into a less intensive level of care that focuses on maximal recovery (March and Hickey 2014).

The goal with all postoperative patients is to minimize the time spent in the intensive care unit and initiate rehabilitative treatments while decreasing steroids and any other pain medications as soon as possible. This goal will allow for maximization of physical function with the least amount of medical support as the next step of the treatment process is identified. Nurses must assist patients and families in participating in physical therapy while minimizing medical support. They must also provide education as to the diagnosis of the tumor and the plan for further treatment (Shiminski-Maher et al. 2014).

### 7.7.5 Observation

For many children with CNS tumors, surgery is the only initial treatment. The next phase of treatment is simply clinical and radiographic observation. Other children get to the observation phase after having any combination of surgery, radiation, and chemotherapy. Whatever the course, families of children with CNS tumors who reach a period of observation do so with a certain amount of fear and anxiety about not having an "active treatment" plan. This period may include treatments which focus on residual clinical issues caused by the tumor and its treatment, such as physical, occupational, and speech therapies, seizure medications, or hormonal replacements. MRI scans are needed at specific intervals based upon previous scans (Shiminski-Maher et al. 2014).

Nurses play a key role in the coordination of care in the observation phase. At this time, families often rely on the nurses for emotional support and to answer questions that may arise. They coordinate the scheduling of diagnostic tests and appointments with various medical teams. Nurses educate the parents or caregivers so that they can effectively advocate for their children within the

medical and community systems. Education should emphasize return to school and other normal activities as soon as possible. To facilitate this, nurses can provide information and education to the school community regarding the illness and treatment and the importance of the child returning to school with as few limitations as possible (Hockenberry et al. 2016).

### 7.7.6 Radiation Therapy

Nursing intervention throughout radiation treatment involves coordination of the treatment along with providing education to the child and family regarding the radiation and its potential adverse affects. Coordination also includes gaining the cooperation of the children to participate in the radiation treatments. Nurses collaborate with child life and social work in using play therapy to gain cooperation (Hesselgrave and Chordas 2014). Coordination of treatment is more complex for younger children who will require daily anesthesia. Ideally, these children should be scheduled in the morning to minimize the time of NPO status. Children who require positioning in a mold may be allowed to take a sample mold home in the evening to practice with it, thus increasing the child's comfort level. Allowing the child to visit the facility several times before the beginning of treatments will also decrease anxiety and increase cooperation (Light and Halperin 2011).

School-age and adolescent patients need support in coping with body issues of hair loss or other physical changes that may occur. Nurses can provide education about protecting the skin with hats or scarfs and sunscreen and refer for a wig if the patient wishes (Hesselgrave and Chordas 2014). While these children may not require sedation or anesthesia for daily treatments, they may need medication to help with the simulation of radiation, a lengthy session, which is the technical planning and measuring session. At this session, the child is marked so that he can be aligned in the same position for each treatment. Radiation markings are small ink marks that should not be scrubbed off in the bath. They



do fade over time, and the technologist will mark over them as needed during the treatment (Light and Halperin 2011).

Nursing intervention throughout radiation treatment involves monitoring the patient for any side effects of radiation as well as educating patients and families. Patients need to be instructed to watch for signs and symptoms of brain swelling as the treatments begin to take effect. Pain and anemia are common side effects of radiation therapy and should be treated. If the symptoms are dramatically interfering with the child's activities of daily living, a short course of steroids, or boosting of existing steroid dose with a subsequent taper, may improve things. As with surgical patients, steroids are important to treat acute problems but should be tapered as quickly as possible to prevent side effects (Shiminski-Mayer et al. 2014).

Nutritional support of these children during radiation is important. Nurses should be monitoring for any decreased appetite or weight loss. Patients receiving craniospinal radiation therapy experience nausea, vomiting, anorexia, and diarrhea and may require antiemetics or antispasmodics to relieve symptoms. Mucositis can occur with radiation therapy leading to inflammation and/or painful ulcers in the mouth or esophagus. Meticulous mouth care using a saline soaked gauze or soft bristle toothbrush is imperative to prevent infection. Nurses should develop an oral hygiene regimen and provide daily assessment of the oral cavity. Children who lose an excessive amount of weight may require enteral feedings. In this situation, nurses must educate the family on how to provide the feedings (Hockenberry et al. 2016).

Toward the end of treatment and for a few weeks after treatment, it is not unusual for the patient to feel fatigue and increased sleepiness. This is usually short-lived, and, as with acute symptoms, severe cases can be treated with a short pulse of steroids. Nurses should monitor for signs of fatigue and encourage rest breaks or naps throughout the day. Lastly, children who are receiving craniospinal irradiation must have their complete blood count (CBC) monitored because bone marrow suppression is possible during the

spine component of the treatment. Weekly CBCs and other appropriate blood tests are performed on children who are receiving chemotherapy at the same time as the radiation (Lafond et al. 2011).

### 7.7.7 Chemotherapy

The majority of children who receive chemotherapy will follow some type of treatment protocol. This includes very specific road maps or recipes for timing of drug administration and monitoring for side effects (Shiminski-Maher 2014). Nursing care of the child receiving chemotherapy includes the actual administration of the drugs in most cases and, as with radiation therapy, involves coordination of care and patient/family education and support. Monitoring for side effects of chemotherapy and educating the family about these side effects are another key nursing function. Common chemotherapy drugs and their side effects are listed in Table 7.3 (Toomey 2014).

Many chemotherapy drugs are emetogenic (induce nausea and vomiting) and can lead to severe fluid imbalances. Some patients will have nausea and vomiting that develop several days after receiving cisplatin and carboplatin (Hockenberry et al. 2016). Nursing care includes administration of antiemetics and monitoring for adequate nutrition and hydration. Small, frequent meals may ensure adequate nutrition rather than traditional meal times. Families should be educated about avoiding fatty or spicy foods to help decrease nausea and vomiting. Fluid and electrolyte imbalances can occur during administration of chemotherapy and can be intensified in the child with endocrine issues such as diabetes insipidus (Hooke et al. 2011).

Immunosuppression is one of the common side effects of chemotherapy; therefore, blood counts are monitored on a frequent basis as per the individual protocol. When blood counts are low, packed red blood cells may be given to treat anemia and platelets given to treat very low platelet levels. Children with decreased white blood cell counts must be isolated from sick people and must be hospitalized if they have fever or any

**Table 7.3** Common chemotherapy drugs and side effects

Chemotherapy group	Specific drug in group	Side effects of group
<i>Alkalyting agents</i> : poison cancer cells by interacting with DNA to prevent cell reproduction	Busulfan	Common side effects:
	Carmustine (BCNU)	Myelosuppression
	Carboplatin	Nausea and vomiting
	Cisplatin	Anorexia and weight loss
	Cyclophosphamide (cytoxan)	Stomatitis
	Dacarbazine (DTIC)	Alopecia
	Ifosfamide	Less common but potential side effects:
	Lomustine (CCNU)	Hearing loss (cisplatin, carboplatin)
	Procarbazine	Kidney damage (cisplatin, carboplatin)
	Temozolomide (temodar)	Hemorrhagic cystitis (cytoxan, ifosfamide)
<i>Antimetabolites</i> : starve cancer cells by replacing essential cell nutrients necessary during synthesis phase of the cell cycle	Hydroxyurea	Myelosuppression
	Methotrexate	Skin rashes Photosensitivity Mouth sores
<i>Antibiotics</i> : prevent cell growth by blocking reproduction, weakening the membrane of the cell, or interfering with certain cell enzymes	Bleomycin	Alopecia
		Mouth sores
		Nausea and vomiting
		Anorexia and weight loss Lung toxicity
<i>Alkaloids</i> : derived from plant, interrupt cell division by interfering with DNA synthesis, specific enzyme activities, cell division, or disrupting the membrane of the cell to cause cell damage or death	Irinotecan (CPT-11)	Anorexia
	Topotecan	Myelosuppression
	Vinblastine	Nausea and vomiting
	Vincristine	Alopecia Peripheral neuropathy Constipation
<i>Hormones/steroids</i> : create a hostile environment that slows cell growth	Dexamethasone	Increased appetite
	Methylprednisolone	Mood changes
	Prednisone	Weight gain Sleep loss
<i>Antiangiogenesis</i> : disrupt the blood supply to a tumor, depriving of nutrients necessary to grow	Thalidomide	Peripheral neuropathy
		Drowsiness
		Constipation
		Myelosuppression

Source: Adapted from Shiminski-Maher et al. (2014)

sign of infection (Hockenberry et al. 2016). Immunosuppression is even more pronounced in the patient who receives craniospinal irradiation therapy following chemotherapy, as it can affect the bone marrow's ability to recover (Arush 2011).

Several of the commonly used chemotherapies for the treatment of pediatric brain tumors also adversely affect hearing and kidney func-

tion. Up to 60% of patients treated with cisplatin and carboplatin chemotherapy agents have ototoxicity and hearing loss can progress up to 20 years following treatment (Langer et al. 2013). The COG has recommendations for post-chemotherapy monitoring to assess for any change in hearing (Fig. 7.43). Changes, if they occur, will do so in the high-frequency sounds first. Kidney function is monitored with blood

CHEMOTHERAPY		HEAVY METALS				
Sec #	Therapeutic Agent(s)	Potential Late Effects	Risk Factors	Highest Risk Factors	Periodic Evaluation	Health Counseling/ Further Considerations
20	<p><b>HEAVY METALS</b> Carboplatin (myelosuppressive doses OR any dose if age at diagnosis &lt; 1 year) Cisplatin</p> <p><b>Info Link</b>  <ul style="list-style-type: none"> <li>In general, patients who received carboplatin in nonmyelosuppressive doses do not appear to be at risk for clinically significant ototoxicity.</li> <li>Some studies have observed hearing loss among infants (with retinoblastoma) exposed to nonmyelosuppressive doses of carboplatin.</li> </ul> </p>	<p><b>Ototoxicity</b> Sensorineural hearing loss Tinnitus Vertigo</p> <p><b>Host Factors</b> Age &lt; 4 years at treatment</p> <p><b>Treatment Factors</b> Combined with: - Cranial/ear radiation - Ototoxic drugs (e.g., aminoglycosides, loop diuretics)</p> <p><b>Medical Conditions</b> Chronic otitis Cereum impaction Renal dysfunction</p>	<p><b>Host Factors</b> CNS neoplasia</p> <p><b>Treatment Factors</b> Cumulative cisplatin dose &gt; 360 mg/m<sup>2</sup> High dose cisplatin (i.e., 40 mg/m<sup>2</sup> per day &gt; 5 days per course) Cisplatin administered AFTER cranial/ear radiation Carboplatin conditioning for HCT Radiation involving ear &gt; 30 Gy</p>	<p><b>HISTORY</b> Hearing difficulties (with/without background noise) Tinnitus Vertigo Yearly</p> <p><b>PHYSICAL</b> Otoscope exam Yearly</p> <p><b>SCREENING</b> <b>Complete audiological evaluation</b> Baseline at entry into long-term followup. If hearing loss is detected, test at least yearly, or as recommended by audiologist. If clinical suspicion of hearing loss at any time, test as clinically indicated. If audiogram is inconclusive or unrepeatable, refer to audiologist for consideration of electrophysiologic testing e.g., otoacoustic emissions (OAEs).</p> <p><b>Info Link</b>  <ul style="list-style-type: none"> <li>A complete audiological evaluation includes pure tone air and bone conduction, speech audiometry, and tympanometry for both ears.</li> <li>Frequency-specific auditory brainstem response (ABR) can be performed if the above is inconclusive.</li> </ul> </p>	<p><b>Health Links</b> Hearing Loss Educational Issues</p> <p><b>Considerations for Further Testing and Intervention</b> Audiology consultation for amplification in patients with hearing loss. Speech and language therapy for children with hearing loss. Otolaryngology consultation in patients with chronic infection, eumen impaction, or other anatomical problems exacerbating or contributing to hearing loss. Refer patients with auditory deficits to school liaison in community or cancer center (psychologist, social worker, school counselor) to facilitate provision of educational resources. Consider specific needs and/or preferential classroom seating, FM amplification system, and other educational assistance as indicated.</p> <p><b>SYSTEM = Auditory</b> <b>SCORE = 1</b></p>	
<p><b>SECTION 20 REFERENCES</b></p> <p>Bertolini P, Lassalle M, Mercier G, et al. Platinum compound-related ototoxicity in children: long-term follow-up reveals continuous worsening of hearing loss. <i>J Pediatr Hematol Oncol</i>. Oct 2004;26(10):649-655.</p> <p>Block PR, Bellman SC, Yomans EC, Pritchard J, Cisplatin ototoxicity in children: a practical grading system. <i>Med Pediatr Oncol</i>. 1991;19(4):295-300.</p> <p>Cushing B, Ciller R, Cullen JW, et al. Randomized comparison of combination chemotherapy with etoposide, bleomycin, and either high-dose or standard-dose cisplatin in children and adolescents with high-risk malignant germ cell tumors: a pediatric intergroup study—Pediatric Oncology Group 9049 and Children's Cancer Group 8882. <i>J Clin Oncol</i>. Jul 1 2004;22(13):2691-2700.</p> <p>Foullad M, Gururangan S, Moghrabi A, et al. Carboplatin-based primary chemotherapy for infants and young children with CNS tumors. <i>Cancer</i>. Jul 15 2009;115(14):3243-3253.</p> <p>Gilmer Knight KR, Kraemer DF, Neuvel EA. Ototoxicity in children receiving platinum chemotherapy; underestimating a commonly occurring toxicity that may influence academic and social development. <i>J Clin Oncol</i>. 2005;Dec 1 23(34):8588-8596.</p> <p>Gurney JG, Tarsak JM, Mess KK, Landler W, Matthey KK, Schmitt ML. Hearing loss, quality of life, and academic problems in long-term neuroblastoma survivors: a report from the Children's Oncology Group. <i>Pediatrics</i>. Nov 2007;120(5):e1229-1236.</p> <p>Jehanne M, Lumbroso-Le Rouic L, Savignoni A, et al. Analysis of ototoxicity in young children receiving carboplatin in the context of conservative management of unilateral or bilateral retinoblastoma. <i>Pediatr Blood Cancer</i>. May 2009;52(5):837-843.</p>						

**Fig. 7.43** Chemotherapy guidelines from the Children's Oncology Group Long-Term Follow-up Guideline for Survivors of Childhood, Adolescent, and Young Adult Cancers, Version 4.0, October 2013, used with permission

and urine tests. Dose modifications of the chemotherapy are outlined in the protocols if adverse toxicity occurs. Nurses are responsible for checking these results prior to administration of chemotherapy and administering reduced doses as necessary (Toomey 2014). Peripheral nerve toxicity resulting in pain in the extremities and difficulty walking can also occur with some of the chemotherapies. This is exaggerated in children with CNS tumors who may have weakness from steroids and/or surgery. Nurses must ensure that these children are receiving physical and occupational therapy, and, if toxicity is severely impairing activities of daily living, a dose modification as per the individual protocol may be required (Hooke et al. 2011).

Nursing care for the child receiving high-dose chemotherapy with peripheral stem cell reinfusion involves all of the above interventions, with toxicities being expected. Such children have a greater chance at fever and neutropenia admissions, increased transfusion requirements, nutritional issues, and neurological complications. These children also spend more time in the hospital and thus are removed from school and other normal activities (Norville and Staton 2014).

### 7.7.8 The Multidisciplinary Team

Care of children with CNS tumors requires a multidisciplinary approach. These patients are cared for by neurosurgeons, neurologists, pediatricians, nurses/advance practice nurses, radiologists, endocrinologists, dieticians, neuro-ophthalmologists, neuropsychologists, social workers, child-life specialists, and psychologists to name a few. Primary responsibility for treatment and coordination of care may shift from one subspecialty to another depending upon whether the child is on active or inactive (observation) treatment. It is essential that the patient and family know which health-care team(s) is coordinating care at any given time. Communication must exist within and between members of each team. This coordination most often falls to the patient, parents, or caregivers. Nurses and advanced practice nurses are instru-

mental in providing parents the information and education that they need to advocate for their children. They are also able to assess when teaching is not appropriate with families, such as in times of great stress or emotional vulnerability. In situations where patients and/or caregivers are unable to coordinate or advocate, the nurse/practitioner can assume that role. Patients and families look to nurses for coordination of diagnostic testing, explanation, and reinforcement of all procedures and surgery and integration of information given to them regarding the treatment plan and side effects. The nurse can coordinate physician-patient-family conferences as necessary to clarify the current plan of care. In addition, the nurse can identify communication inconsistencies between members of consulting teams (Mosadegh 2014) (Box 7.1) (Figs. 7.44, 7.45, 7.46, 7.47, 7.48, and 7.49).

#### Box 7.1 A Mother's Perspective of Her Child's Journey When Diagnosed with a Brain Tumor

The emergency department was the last place I expected to be. My son Jules had been sick off and on for a couple of months. But occasional vomiting and swelling around his eye couldn't add up to anything more serious than allergies. Could it?

Initial tests were inconclusive, until Jules underwent a magnetic resonance imaging (MRI) scan. My mind almost couldn't comprehend the words as they came out of the doctor's mouth: "You were right to bring him in. Jules is very sick—he has a brain tumor."

Jules, then just 18 months old, was admitted to the hospital immediately, and I spent a restless night at his side. The next morning, I met with the pediatric neurosurgeon and he explained that the tumor, which was larger than a golf ball, was causing a harmful buildup of cerebrospinal fluid in Jules' brain. It had to be removed—immediately.

**A long, anxious day**

The eight-hour brain surgery took place very early the next morning. We received a call every hour to update us on how the surgery was going and a final call to let me know that the surgery was done and I could see him shortly. Before I went to see Jules in the postoperative suite, a nurse gently told me what to expect—but it was still a shock. Jules was hooked up to all these machines, with a tube in his mouth, and his head was bandaged. He was all puffy just lying there, so small in his bed. But he moved his hands, both of them, to wave at me, and I started to feel a little hopeful.

And there was reason to hope, the neurosurgeon told me that he had been able to remove the entire tumor, and the cancer had not spread to other parts of Jules' body. The bad news: a routine post-surgery X-ray revealed a second, eight-millimeter brain lesion, which had not been visible in the earlier scan. Rather than recommending an immediate second surgery to remove the lesion, Jules' doctors advised sticking to the original plan of having Jules undergo an intense course of high-dose chemotherapy. Ideally, the chemo would kill any remaining cancer cells, including the residual lesion.

**Part of the family**

Chemotherapy began in March. Every other week, Jules was admitted to the inpatient oncology unit, where he would receive chemotherapy drugs through a port in his chest. During the weeks that he did not receive chemotherapy, we would have to go to the outpatient oncology clinic for lab tests and a checkup.

During the tedious days of chemotherapy treatment, child life specialists enter-

tained Jules with toys and games. Nurses watched Jules closely for signs of distress, doing everything they could to keep him comfortable. Doctors took time to answer any questions and remembered to treat Jules not as just a patient but as a little boy who always wore a smile and was sure to leave you with one.

Throughout the spring and summer months, Jules responded well to the chemotherapy. But in September, I received another blow when an MRI scan showed that the residual lesion no longer seemed to be responding to treatment. Jules' cancer specialist and neurosurgeon recommended another brain surgery to remove the residual lesion for testing. Jules underwent the second surgery, and the result was that the lesion was scar tissue, not cancer.

**Uncertainty and hope**

Posttreatment, Jules is doing great! He's progressing and developing well. We still have to go back for routine MRIs, and I still get anxiety. I don't believe that will ever go away. I think about the future a lot. I see Jules doing anything, everything, and that might have been an impossible thing. I see him living a full, healthy, normal life. A life free from cancer and without obstacles or disabilities. Jules loves music; maybe he'll be a musician. He's very loving, so I definitely see him having a family of his own. Having had so much early experience with doctors, nurses, and hospitals—maybe he will choose to become a nurse or even a cancer specialist. Whatever the future holds, Jules has a future thanks to his medical staff and much prayer. This experience will never fade; we will always remember the special people who took care of Jules and I and treated us like family.



**Box 7.2 Second Mother's Perspective of Her Child's Journey During the Diagnosis of a Brain Tumor**

My second pregnancy was uneventful. Delivery was another story. During an induced labor that failed to progress, Naomi's heart rate dropped dramatically. She made her appearance by way of an emergency C-section. She struggled with respiratory issues immediately and was whisked away to the special care nursery before I could get more than a glance of her precious face. A neonatologist informed me that there were also some cardiac concerns and that my daughter had trisomy "of some kind." A cardiac ultrasound revealed four heart defects, all of which spontaneously resolved within six months. Genetic testing confirmed trisomy 21, or Down syndrome. Naomi had a difficult time feeding, and insufficient weight gain kept her in the hospital until she was ten days old. Once released, she thrived at home. We continued to monitor her overall growth with frequent visits to the pediatrician. It became apparent, rather quickly, that her head circumference was increasing at a disproportionate rate. I caressed her head constantly while she was nursing and noticed that her sutures had split. Then, I noticed tiny new veins appearing on her beautiful little head. The pediatrician referred us for an ultrasound, which was done through the fontanel. I saw all the black—and all the white—on that screen. If I had known how to read it at the time, I would have known what horrible news we were about to receive. Neither the ultrasound technician nor the radiologist was able to deliver their findings. Instead, a pediatrician from our regular office had to explain it to me over the phone, "your daughter has a massive brain tumor; you need to go to the ER right now."

We did just that and were visited by far more medical professionals than seemed necessary. The neurosurgeon was

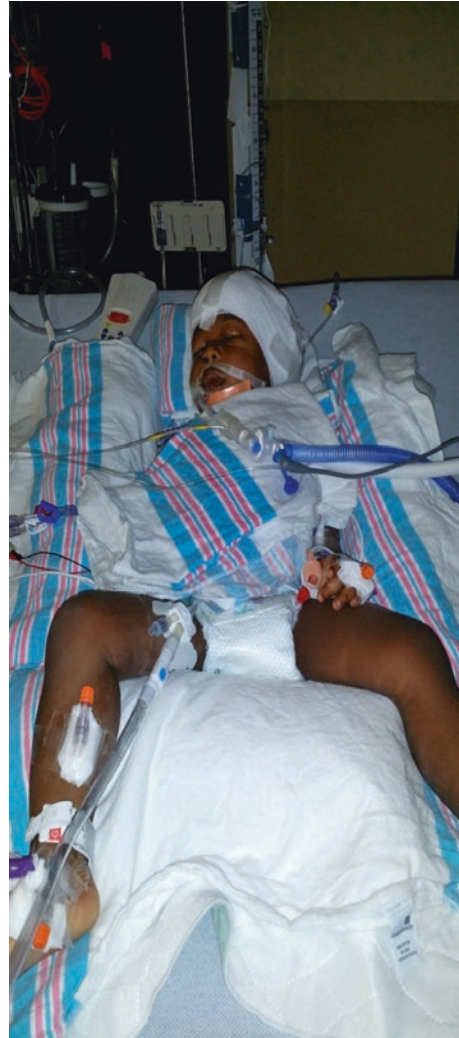astounded that Naomi had not had any seizures and that she continued to nurse well with no vomiting. He said, "Her head couldn't possibly get any bigger." His plan was to place a drain to relieve the elevated ICP, which would make her more stable for a tumor resection. On the day of the resection, the anesthesia team arrived to transport her to surgery. The neurosurgeon explained that Naomi would "likely require resuscitation during the procedure." Those words are what finally shook me to the core, bringing me to the reality of the situation that my seven-week-old baby girl may not survive. It was an understandably lengthy surgery, one in which Naomi lost more than half of her blood volume, yet she never did require resuscitation. I credit both the anesthesia team and the neurosurgeon for saving her life that day.

We were in the hospital for a couple of weeks initially. I stayed in Naomi's room the entire time, leaving only to shower and deliver pumped milk to the refrigerator in the PICU. I stood in the doorway of Naomi's room during rounds every morning and was often asked for my opinion as to Naomi's condition. I became familiar with a few of the nurses, but there were so many, it was difficult to keep track. I took notes, asked a lot of questions, and cried a lot. The hospital chaplain came to visit, too. In spite of the whirlwind of visitors, both medical and personal, I felt very alone. At one point, I did ask one of the residents why it seemed like Naomi was such a spectacle. I asked, "Haven't you all seen babies with brain tumors before?" His reply was that they had but never a tumor that large in a baby so small. Naomi returned to the hospital on an inpatient basis several times to place/remove shunts or drains. Her final inpatient stay was almost three months post resection. The subdural peritoneal shunt placed that day remains in place, although it is no longer needed.

The magnitude of Naomi’s journey with brain cancer, the sheer miracle that she continues to thrive, fills my heart with so many emotions—relief, pride, and joy to name a few. She is now seven years old and has remained cancer-free since the resection at seven weeks of age. She does have many disabilities as a result of the tumor and/or the surgery to remove it. The list includes cerebral palsy (left side hemiparesis/hemiplegia), left hemianopsia, cortical vision impairment, cognitive impairment (far beyond what is typical in a child with Down syndrome), leg length discrepancy, speech/feeding issues, and sensory processing disorders. In spite of these challenges, she is a happy and loving little girl who has had a positive impact on many people, most of all her sister and me.

## 7.8 Late Effects of CNS Tumors and Treatment

It is rare that a child manages to complete treatment for a CNS tumor and walks away without some type of late effect. Each child and family will end a treatment phase and need to carve out a new “normal” life pattern. For some, physical changes or handicaps are a constant reminder of the diagnosis and treatment. This new life often includes physical, occupational, and/or speech therapy and coping with learning issues. Others require hormonal replacement or medications for seizure disorders. All survivors of CNS tumors are seen periodically for imaging studies and follow-up with their individual physicians or in a multidisciplinary follow-up clinic (Hobbie et al. 2011). Between 40% and 100% of all pediatric brain tumor survivors experience psychosocial issues and cognitive delays which have a profound effect on their quality of life and self-esteem. Screening for psychosocial issues should be performed at regular intervals in order to provide individual, tailored support (Ruiter et al. 2016).



**Fig. 7.44** Jules immediately following the removal of his brain tumor

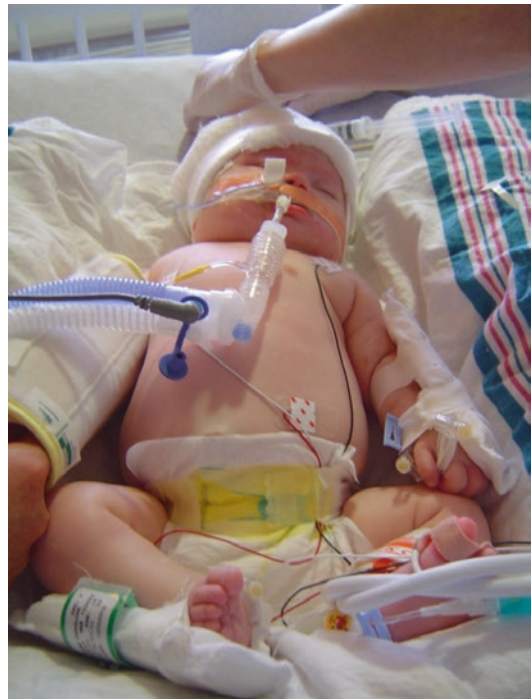## 7.9 School Reentry: Physical and Neurocognitive Sequelae

Children with CNS tumors often experience disruptions in their education due to repeated hospitalizations, cycles of treatment and therapy, physical weakness and fatigue, and the cumulative effects of medications, surgery, chemotherapy, and radiation. In addition, many children also have neurological changes, including seizures, behavior disorders, memory problems, or visual deficits. For many children, school is a

**Fig. 7.45** Jules at the hospital following his chemotherapy



**Fig. 7.46** Jules is doing well and having fun with sidewalk chalk



**Fig. 7.47** Naomi immediately following the removal of her brain tumor

refuge from the life of a CNS tumor with hospitalizations and procedures. Other children, especially teenagers or those with visible impairments, may dread returning to school. Lastly, subtle learning issues, when not handled in a

sensitive manner, can affect a child's confidence and self-esteem. All of these issues can be managed with good planning and communication via the parents, educators, and health-care providers. Nurses can provide information, guidance, or be



an advocate for the parents and/or child. They can also provide the school professionals with information regarding CNS tumors in general

and specific issues related to a given child's plan of care (Shiminski-Maher et al. 2014).

It is helpful for children with CNS tumors to maintain some connection to the school throughout the diagnosis and treatment. Being able to attend school during windows of no active treatment or even during treatment on "off days" is helpful in maintaining relationships. Home schooling or tutoring is often necessary even if the child can attend school some of the time. The majority of children with CNS tumors will ultimately have some type of physical or cognitive impairment, and this requires assessment for an individual education plan (IEP) (Shiminski-Maher et al. 2014). The extent of the needs will depend upon the location of the tumor and treatments utilized. Those children who have received radiation therapy will have more intensive cognitive issues, specifically with visual spatial skills, memory, attention, speed of information processing, and verbal fluency (Sands 2016).

The IEP mechanism evaluates all aspects of the individual's learning styles and physical needs, and then a plan is developed as collaboration between parents and professional educators to determine the curriculum and how it will be taught. It may be focused on preparation for college, vocational training, or simply independent living skills with education (special or mainstream), speech therapy,



**Fig. 7.48** Naomi is a happy 3-year-old! (Photo credit: Debbie Rankey)



**Fig. 7.49** Naomi at age five and all smiles! (Photo credit: Amanda Barbosa)

physical and occupational therapy, and counseling. Nurses, as part of the health-care team, can interface with the family and school and advocate for an IEP to happen (Shiminski-Maher et al. 2014).

### 7.9.1 Ototoxicity Late Effects

Children who have received cranial radiation or ototoxic chemotherapy have a significant risk of hearing problems that can interfere with their learning potential. High-frequency sound is the first to be affected and interferes with children's ability to sort out background noise. In a classroom situation, this prevents children from hearing the teacher above peripheral noise. Amplification systems for the child in the classroom may help the child with this problem. More severe ototoxicity can result in substantial hearing loss requiring hearing aids (Matson 2014).

### 7.9.2 Neuroendocrine Late Effects

The most common neuroendocrine effects of CNS tumors and their treatment are hormone deficiencies. This can happen in children who have midline tumors but can also happen after treatment with chemotherapy alone and almost always occurs in the child who has received radiation treatments. Endocrine problems include growth, thyroid, and secondary sex hormonal deficiencies. An endocrinologist who will monitor growth rate and pubertal status, as well as obtain blood tests to check for thyroid and growth hormone deficiency, must follow all children and adolescents with CNS tumors. Films to determine bone age are obtained, prior growth curves evaluated, and linear growth closely monitored. Hormonal replacement is necessary for many of these children, with thyroid replacement taken by mouth and growth and secondary sex hormones given by injection. Nurses can coordinate follow-up appointments and also can teach the child and family about the administration of hormonal replacement (Hobbie et al. 2011).

### 7.9.3 Psychological/Social Late Effects

The diagnosis and treatment of CNS tumors can bring with them significant psychological and social sequelae. Body image changes that are visible such as a hemiparesis, facial weakness, or hair loss can adversely affect the development of a positive self-esteem. If the child has missed a lot of school or is having educational difficulties, then completing the educational process is difficult. Nurses can play an integral role in mainstreaming children as early as possible and in connecting these patients with educational specialists and rehabilitation early on to foster as normal a life as possible. As the number of long-term survivors of CNS tumors increases, as has happened with other childhood cancers, there will be a greater need for such specialized clinics and programs of which nursing can have an integral role (Shiminski-Maher et al. 2014).

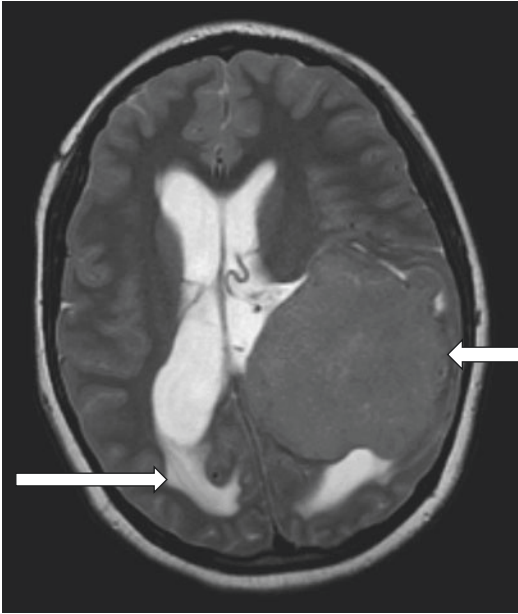
### 7.9.4 Secondary Cancers: Late Effects

As the long-term survival for all childhood cancers has increased with improvements in treatment, so has the incidence of second primary cancers as a side effect of chemotherapy and more commonly radiation therapy. The most commonly reported CNS tumors following brain irradiation are meningiomas and gliomas (Fig. 7.50). There are also reports of secondary medulloblastomas and primitive neuroectodermal tumors after brain irradiation. The Childhood Cancer Survivor Study (CCSS) is a North American multi-institutional group that follows the late effects of cancer survivors through data obtained in long-term follow-up clinics. The information obtained is used to evaluate therapeutic approaches and the associated outcomes (Vrooman et al. 2015).

### 7.9.5 Recurrence, Death and Dying, and Hospice

Recurrence or progression can happen at any time during treatment or after therapy is completed.





**Fig. 7.50** Meningioma: axial view FSE T2 of a large left parietal slightly enhancing mass as indicated by the *short white arrow*. There is midline shift, hydrocephalus and transependymal spread of CSF as indicated by the *long white arrow*

When this occurs, the patient's history, clinical information, pathology, and sequential radiology studies are presented at the tumor board and a new treatment plan designed. This may include surgery, radiation (if it has not already been given), or chemotherapy. Experimental drugs including new chemotherapeutic drugs may be tried in patients who have undergone multiple previous standard treatment modalities. As with all aspects of care, nurses can provide education and emotional support to families in this situation (Shiminski-Maher et al. 2014).

For some children with CNS tumors, there comes a time where treatments have stopped working and the tumor continues to grow. Some families want to try every available treatment and exhaust all possible medical remedies. For those who choose to discontinue active treatment, the focus shifts to end-of-life care, either in the hospital setting, at home on hospice, or a combination of both. Hospice programs not only assist the child in comfort but also allow the family to

receive support and counseling as their family member dies (Shiminski-Maher et al. 2014).

### Conclusions

The diagnosis of a CNS tumor in the pediatric population does not always carry the poor prognosis that it did several decades ago. Technology is now available to successfully diagnose, treat, and cure many children with CNS tumors. The MRI helps surgeons plan delicate surgeries and radiation treatments that allow newer machines to deliver more focused doses of radiation and hopefully minimizing side effects. Chemotherapy has been shown to penetrate the blood–brain barrier, and many drugs have been found effective in destroying CNS tumor cells. The enrollment and participation in national clinical trials have significantly impacted our understanding of various subsets of CNS tumors and customizing treatment protocols (Shiminski-Maher et al. 2014). Molecular understanding of the tumor and the signaling pathways that lead to tumor formation has provided researchers with the opportunity to develop novel therapeutic approaches that are tailored to each specific tumor (Gajjar et al. 2015).

We know that each tumor is different and that tumors within the same disease groups may behave differently. Children with tumors that are maximally removed with surgery have a much better prognosis and longer period to progression of disease than do tumors that cannot be removed. Slow-growing tumors may remain dormant for months or years without treatment, and some slow-growing tumors will shrink in size with chemotherapy treatments. The greatest success in the treatment of malignant CNS tumors comes in the area of medulloblastoma. Radiation treatments are withheld in younger children whenever possible and also delayed in children with slower-growing tumors in an attempt to spare intellectual development. Rehabilitation advances and the existence of special education programs have fostered independent living for long-term survivors of CNS tumors who have neurological impairment. As technology continues to explode,

there is good reason to believe that our results in the next generation will continue to improve (Shiminski-Maher et al. 2014).

The complex issues associated with pediatric CNS tumors demand a multidisciplinary health-care team to ensure optimal patient/family care. Nurses and advanced practice nurses are the consistent members of the team (along with the parents or primary caregivers), from diagnosis, through various treatment or observation periods through long-term follow-up. Parents or an identified advocate needs to be in charge to ensure checks and balances in the system so that optimal care is delivered. Patients and families look to nurses for coordination of diagnostic testing, explanation, and reinforcement of all procedures and surgery, integration of information given to them by members of the medical team, education regarding the treatment plan and side effects, discharge teaching and planning, and, most important, caring and support throughout the course of the illness and follow-up. As with most things in life, those with the strongest, consistent, and most cohesive team will win the championship (Shiminski-Maher 1993).

### Pediatric Practice Pearls

- The extent of tumor resection is the most significant factor in predicting long-term outcome.
- New advances in radiology and treatments have changed and will continue to positively impact the prognosis for children with central nervous system tumors.
- Knowledge of long-term sequelae related to treatment, along with careful screening, prevention when possible, and coordination of services will help to ensure that children with CNS tumors have the best quality of life.
- Care of children with CNS tumors requires a multidisciplinary team with nurses serving in the role of educator, coordinator, and advocate.

## References

- Adesina AM (2010) Introduction and overview of brain tumors. In: Adesina AM, Tihan T, Fuller C, Poussaint T (eds) Atlas of pediatric brain tumors. Springer, New York, pp 1–2
- Adesina AM, Hunter J (2010) Medulloblastoma. In: Adesina AM, Tihan T, Fuller C, Poussaint T (eds) Atlas of pediatric brain tumors. Springer, New York, pp 75–93
- Adesina AM, Rauch RA (2010) Dysembryoplastic neuroepithelial tumor. In: Adesina AM, Tihan T, Fuller C, Poussaint T (eds) Atlas of pediatric brain tumors. Springer, New York, pp 171–180
- Arush MWB (2011) Blood count depression in the child with cancer. In: Halperin EC, Constine LS, Tarbell NJ, Kun LE (eds) Pediatric radiation oncology. Lippincott Williams & Wilkins, Philadelphia, pp 434–438
- Bryant SO, Cha S, Barkovich AJ (2010) Modern neuroimaging of pediatric brain tumors. In: Gupta N, Banerjee A, Haas-Kogan D (eds) Pediatric CNS tumors. Springer, Heidelberg, pp 247–272
- Cahill J, Armstrong T (2014) Nursing management of patients with neoplasms of the neurological system: brain tumors. In: Hickey J (ed) The clinical practice of neurological and neurosurgical nursing. Lippincott Williams & Wilkins, Philadelphia, pp 471–495
- Chapman T (2016) Brain tumors. In: Iyer R, Chapman T (eds) Pediatric imaging: the essentials. Wolters Kluwer, Philadelphia, pp 432–455
- Chintagumpala MM, Paulino A, Panigrahy A, Hawkins C, Jae A, Parsons DW (2016) Embryonal and pineal region tumors. In: Pizzo PA, Poplack DG (eds) Principles and practice of pediatric oncology. Wolter Kluwer, Philadelphia, pp 671–699
- Eche IJ (2014) Diagnostic and staging procedures. In: Kline NE, Bryant R, Carlson CA, Hooke MC, Nixon C (eds) Essentials of pediatric hematology/oncology nursing: a core curriculum. APHON, Chicago, pp 102–106
- Echevarría ME, Fangusaro J, Goldman S (2008) Pediatric central nervous system germ cell tumors: a review. *Oncologist* 13:690–699
- Ellison D, Love S, Chimelli L, Harding BN, Lowe JS, Vinters HV, Brandner S, Yong WH (2013) Neuroepithelial neoplasms displaying neuronal features. *Neuropathology: a reference text of CNS pathology*. Mosby, Edinburgh, pp. 743–754
- Ermoian RP, Fogh SE, Braunstein S, Mishra KK, Kun LE, Haas-Kogan DA (2016) General principles of radiation oncology. In: Pizzo PA, Poplack DG (eds) Principles and practice of pediatric oncology. Wolters Kluwer, Philadelphia, pp 362–382
- Ertiaei A, Hanaei S, Habibi Z, Moradi E, Nejat F (2016) Optic pathway gliomas: clinical manifestations, treatment and follow-up. *Pediatr Neurosurg* 51:223–228
- Fiaschetti G, Castelletti D, Zoller S, Schramm A, Schroeder C, Nagaishi M, Stearns D, Mittelbronn M, Eggert A, Westermann F, Ohgaki H, Shalaby T, Pruschy M, Arcaro A, Grotzer MA (2011) Bone morphogenetic protein-7 is a MYC target with prosurvival functions in childhood medulloblastoma. *Oncogene* 30:2823–2835

- Frazier AL, Billmire D, Amatruda J (2015) Pediatric germ cell tumors. In: Orkin SH, Fisher DE, Ginsburg D, Look AT, Lux SE, Nathan DG (eds) *Nathan and Oski's hematology and oncology of infancy and childhood*. Elsevier Saunders, Philadelphia, pp 2056–2099
- Fuller C (2010a) Infiltrative astrocytomas: diffuse astrocytoma, anaplastic astrocytoma and glioblastoma. In: Adesina AM, Tihan T, Fuller CE, Poussaint TY (eds) *Atlas of pediatric brain tumors*. Springer, New York, pp 25–38
- Fuller C (2010b) Oligodendroglial tumors. In: Adesina AM, Tihan T, Fuller CE, Poussaint TY (eds) *Atlas of pediatric brain tumors*. Springer, New York, pp 39–46
- Fuller CE, Narendra S, Tolocica I (2010) Choroid plexus neoplasms. In: Adesina AM, Tihan T, Fuller CE, Poussaint TY (eds) *Atlas of pediatric brain tumors*. Springer, New York, pp 269–279
- Gajjar A, Packer R, Foreman N, Cohen K, Hass-Kogan D, Merchant T (2013) Children's Oncology Group's 2013 blueprint for research: central nervous system tumors. *Pediatr Blood Cancer* 6(60):1022–1026
- Gajjar A, Bowers D, Karajannis M, Leary S, Witt H, Gottardo N (2015) Pediatric brain tumors: innovative genomic information is transforming the diagnostic and clinical landscape. *J Clin Oncol* 33(27):2986–2998
- Gan G, Haas-Kogan D (2010) Low grade gliomas. In: Gupta N, Banerjee A, Haas-Kogan D (eds) *Pediatric CNS tumors*. Springer, Heidelberg, pp 1–35
- Ganslandt O, Behari S, Gralla J, Fahlbusch R, Nimsky C (2002) Neuronavigation: concept, techniques and applications. *Neurol India* 50:244
- Glod J, Rahme GJ, Kaur H, Raabe EH, Hwang EI, Israel MA (2016) Pediatric brain tumors: current knowledge and therapeutic opportunities. *J Pediatr Hematol Oncol* 38(4):249–259
- Gorlick R, Janeway K, Marina N (2016) Osteosarcoma. In: Pizzo PA, Poplack DG (eds) *Principles and practice of pediatric oncology*. Wolters Kluwer, Philadelphia, pp 877–898
- Grajkowski W, Kotulska K, Jurkiewicz E, Matyja E (2010) Brain lesions in tuberous sclerosis complex: review. *Folia Neuropathol* 48(3):139–149
- Greenburg MS (2016) *Handbook of neurosurgery*. Thieme, New York, pp. 584–799
- Groves ML, Jallo G (2015) Intramedullary spinal cord tumors. In: Albright AL, Pollack IF, Adelson PD (eds) *Principles and practice of pediatric neurosurgery*. Thieme, New York, pp 605–613
- Gupta N, Auguste KI, Berger MS (2010) Current surgical management. In: Gupta N, Banerjee A, Haas-Kogan D (eds) *Pediatric CNS tumors*. Springer, Heidelberg, pp 273–285
- Hanson DR, Atlas MP (2016) Central nervous system malignancies. In: Lankowsky P, Lipton JM, Fish JD (eds) *Lanzkowsky's a manual of pediatric hematology and oncology*. Academic Press, London, pp 453–472
- Hantanpaa KJ, Burma S, Zhao D, Habib AA (2010) Epidermal growth factor receptor in glioma: signal transduction, neuropathology, imaging and radioresistance. *Neoplasia* 12(9):675–684
- Hastings CA, Torkildson JC, Agrawal AK (2012) *Handbook of pediatric hematology and oncology: Children's Hospital and Research Center Oakland*. Wiley-Blackwell, West Sussex, pp. 157–165
- Heger D, Scheer F, Andresen R (2016) Ruptured, intracranial dermoid cyst: a visual diagnosis? *J Clin Diagn Res* 10(4):TD08–TD09
- Hesselgrave J, Chordas C (2014) Radiation therapy. In: Kline NE, Bryant R, Carlson CA, Hooke MC, Nixon C (eds) *Essentials of pediatric hematology/oncology nursing: a core curriculum*. APHON, Chicago, pp 151–159
- Hickey JV (2014) *The clinical practice of neurological and neurosurgical nursing*, 7th edn. Lippincott Williams & Wilkins, Philadelphia
- Hickey JV, Kunsky JT (2014) Overview of neuroanatomy and neurophysiology. In: Hickey JV (ed) *The clinical practice of neurological and neurosurgical nursing*. Wolters Kluwer, Philadelphia, pp 48–93
- Hobbie WL, Carlson C, Harvey J, Ruccione K, Moore IM (2011) Care of the survivor of childhood cancer. In: Baggott C, Fochtman D, Foley GV, Kelly KP (eds) *Nursing care of children and adolescents with cancer and blood disorders*. APHON, Glenview, pp 694–763
- Hockenberry MJ, Kline NE, Rodgers C (2016) Nursing support of the child with cancer. In: Pizzo PA, Poplack DG (eds) *Principles and practice of pediatric oncology*. Wolters Kluwer, Philadelphia, pp 1094–1107
- Hooke MC, Baggott C, Robinson D, Woolery M, Maloney AM, Dulczak S, Madsen L (2011) Managing disease- and treatment-related complications in pediatric oncology. In: Baggott C, Fochtman D, Foley GV, Kelly KP (eds) *Nursing care of children and adolescents with cancer and blood disorders*. APHON, Glenview, pp 510–584
- Imbach P (2014) Brain tumors. In: Imbach P, Kühne T, Arceci RJ (eds) *Pediatric oncology*. Springer, New York, pp 95–118
- Jacob E (2014) Pain. In: Kline NE, Bryant R, Carlson A, Hooke MC, Nixon C (eds) *Essentials of pediatric hematology/oncology nursing: a core curriculum*. APHON, Chicago, pp 244–252
- Jansen MHA, van Vuurden DG, Vandertop WP, Kaspers GJL (2012) Diffuse intrinsic pontine gliomas: a systematic update on clinical trials and biology. *Cancer Treatment Review* 38:27–35
- Kalin-Hajdu E, Décarie J, Marzouki M, Carret A, Ospina L (2014) Visual acuity of children treated with chemotherapy for optic pathway gliomas. *Pediatr Blood Cancer* 61:223–227
- Kelly T (2014) Central nervous system complications. In: Kline NE, Bryant R, Carlson A, Hooke MC, Nixon C (eds) *Essentials of pediatric hematology/oncology nursing: a core curriculum*. APHON, Chicago, pp 207–214
- Khatua S, Jalali R (2005) Recent advances in the treatment of childhood brain tumors. *Pediatr Hematol Oncol* 5:361–371
- Kieran M, Chi S, Manley P, Green A, Bandopadhyay P, Berghthold G, Robison N, Madrid A, Sauer N, Prabhu

- S, Ligon K, Goumnerova L, Marcus K, Segal R (2015) Tumors of the brain and spinal cord. In: Orkin S, Fisher D, Ginsburg D, Look A, Lux S, Nathan D (eds) *Nathan and Oski's hematology and oncology of infancy and childhood*. Elsevier Saunders, Philadelphia, pp 1779–1885
- Krishnamurthy R, Daldrup-Link HE, Jones JY, Voss SD, Khanna G, Golriz F, Guillerman RP (2016) Imaging studies in the diagnosis and management of pediatric malignancies. In: Pizzo PA, Poplack DG (eds) *Principles and practice of pediatric oncology*. Wolters Kluwer, Philadelphia, pp 185–238
- Kun L, MacDonald S, Tarbell N (2011) Supratentorial brain tumors and tumors of the posterior fossa and the spinal cord. In: Halperin E, Constine L, Tarbell N, Kun L (eds) *Pediatric radiation oncology*. Lippincott, Williams & Wilkins, Philadelphia, pp 26–84
- Lafond DA, Bolton RM, Mannix CM (2011) Radiation therapy. In: Baggott C, Fochtman D, Foley GV, Kelly KP (eds) *Nursing care of children and adolescents with cancer and blood disorders*. APHON, Glenview, pp 298–325
- Lam S, Lin Y, Melkonian S (2012) Analysis of risk factors and survival in pediatric high-grade spinal cord astrocytoma: a population-based study. *Pediatr Neurosurg* 48:299–305
- Langer T, Zehnhoff-Dinnesen A, Radtke S, Meitert J, Zolk O (2013) Understanding platinum-induced ototoxicity. *Trends Pharmacol Sci* 34(8):458–469
- Leonard, M (2011) Nursing implications of diagnostic and staging procedures. In: Baggott C, Fochtman D, Foley GV, Kelly KP (eds) *Nursing care of children and adolescents with cancer and blood disorders*. APHON, Glenview, pp 236–267
- Light KL, Halperin EC (2011) Stabilization and immobilization devices. In: Halperin EC, Constine LS, Tarbell NJ, Kun LE (eds) *Pediatric radiation oncology*. Wolters Kluwer, Philadelphia, pp 425–428
- Lin FY, Chintagumpala M (2015) Advances in management of pediatric ependymomas. *Curr Oncol Rep* 17(47):1–7
- Louis D, Perry A, Reifenberger G, von Diemling A, Figarella-Branger D, Cavenee W, Ohgaki H, Wiestler O, Kleihues P, Ellison D (2016) The 2016 World Health Organization classification of tumors of the central nervous system: a summary. *Acta Neuropathol* 131:803–820
- MacDonald TJ, Aquilera D, Kramm CM (2011) Treatment of high-grade glioma in children and adolescents. *Neuro-Oncology* 13(10):1049–1058
- Madden LK, Tham PK, Shahlaie K (2014) Management of patients undergoing neurosurgical procedures. In: Hickey JV (ed) *The clinical practice of neurological and neurosurgical nursing*. Wolter Kluwer, Philadelphia, pp 300–324
- March K, Hickey J (2014) Intracranial hypertension: theory and management of increased intracranial pressure. In: Hickey J (ed) *The clinical practice of neurological and neurosurgical nursing*. Lippincott Williams & Wilkins, Philadelphia, pp 266–299
- Matson K (2014) Ototoxicity. In: Kline NE, Bryant R, Carlson CA, Hooke MC, Nixon C (eds) *Essentials of pediatric hematology/oncology nursing: a core curriculum*. APHON, Chicago, pp 215–216
- McCrea HJ, Souweidane MM (2015) Brainstem gliomas. In: Albright AL, Pollack IF, Adelson PD (eds) *Principles and practice of pediatric neurosurgery*. Thieme, New York, pp 553–562
- McLendon RE, Adekunle A, Rajaram V, Kocak M, Blaney SM (2011) Embryonal central nervous system neoplasms arising in infants: a pediatric brain tumor consortium study. *Arch Pathol Lab Med* 135(8):984–993
- Miller S, Ward J, Rogers HA, Lowe J, Grundy RG (2012) Loss of INI1 protein expression defines a subgroup of aggressive central nervous system primitive neuroectodermal tumors. *Brain Pathol* 23:19–27
- Morgenstern PF, Souweidane MM (2012) Pediatric intraventricular brain tumors: endoscopic neurosurgical techniques. In: Hayat MA (ed) *Pediatr Cancer: Teratoid/rhabdoid, brain tumors, and glioma*. Dordrecht, pp 155–163
- Mosadegh S (2014) The pediatric hematology/oncology nurse as educator. In: Kline NE, Bryant R, Carlson CA, Hooke MC, Nixon C (eds) *Essentials of pediatric hematology/oncology nursing: a core curriculum*. APHON, Chicago, pp 361–363
- Mueller S, Haas-Kogan D (2010) Neurocutaneous syndromes and associated CNS tumors. In: Gupta N, Banerjee A, Haas-Kogan D (eds) *Pediatric CNS tumors*. Springer, Heidelberg, pp 223–246
- Nageswara Rao AA, Packer RJ (2012) Impact of molecular biology studies on the understanding of brain tumors in childhood. *Curr Oncol Rep* 14:206–212
- Norville R, Staton S (2014) Hematopoietic stem-cell transplantation. In: Kline NE, Bryant R, Carlson CA, Hooke MC, Nixon C (eds) *Essentials of pediatric hematology/oncology nursing: a core curriculum*. APHON, Chicago, pp 160–180
- Olson TA (2016) Germ cell tumors. In: Lanzkowsky P, Lipton JM, Fish AD (eds) *Lanzkowsky's manual of pediatric hematology and oncology*. Academic, London, pp 555–568
- Orakcioglu B, Halatsch ME, Fortunati M, Unterberg A, Yonekawa Y (2008) Intracranial dermoid cysts: variation of radiological and clinical features. *Acta Neurochir* 150:1227–1234
- Ostrom Q, de Blank P, Kruchko C, Petersen C, Liao P, Finlay J, Stearns D, Wolff J, Wolinsky Y, Letterio J, Barnholtz-Sloan J (2015) Alex's Lemonade Stand Foundation infant and childhood primary brain and central nervous system tumors diagnosed in the United States in 2007–2011. *Neuro-Oncology* 17:x1–x35
- Parsons DW, Pollack IF, Hass-Kogan DA, Poussaint TY, Adesina AM, Chintagumpala MM (2016) Gliomas, ependymomas, and other nonembryonal tumors of the central nervous system. In: Pizzo P, Poplack D (eds) *Principles and practice of pediatric oncology*. Wolters Kluwer, Philadelphia, pp 628–670



- Patel S, Bhatnagar A, Wear C, Osiro S, Gabriel A, Kimball D, John A, Fields P, Tubbs R, Loukas M (2014) Are pediatric brain tumors on the rise in the USA? Significant incidence and survival findings from the SEER database analysis. *Childs Nerv Syst* 30:147–154
- Petriccione MM, Gilger EA (2011) Central nervous system tumors. In: Baggott C, Fochtman D, Foley G, Kelly K (eds) *Nursing care of children and adolescents with cancer and blood disorders*. Association of Pediatric Hematology/Oncology Nurses, Glenview, pp 987–1012
- Pfister S, Hartmann C, Korshunov A (2009) Histology and molecular pathology of pediatric brain tumors. *J Child Neurol* 24(11):1375–1386
- Pizer B, Salehzadeh A, Brodbelt A, Mallucci C (2013) Prolonged survival associated with the use of intraoperative carmustine (Gliadel®) in a pediatric patient with recurrent grade III astrocytoma. *Br J Neurosurg* 27(4):516–518
- Plaza MJ, Borja MJ, Altman N, Saigal G (2013) Conventional and advanced MRI features of pediatric intracranial tumors: posterior fossa and suprasellar tumors. *Am J Roentgenol* 200(5):1115–1124
- Pollack I (2011) Multidisciplinary management of childhood brain tumors: a review of outcomes, recent advances, and challenges. *J Pediatr Neurosurg* 8:135–148
- Pollack IF (2015) Supratentorial hemispheric gliomas. In: Albright AL, Pollack IF, Adelson PD (eds) *Principles and practice of pediatric neurosurgery*. Thieme, New York, pp 445–459
- Ragunath A, Devi BI, Bhat DI, Somanna S (2013) Dermoid cysts of the posterior fossa: morbid associations of a benign lesion. *Br J Neurosurg* 27(6):765–771
- Ramaswamy V, Taylor M (2015) Medulloblastomas. In: Albright AL, Pollack IF, Adelson PD (eds) *Principles and practice of pediatric neurosurgery*. Thieme, New York, pp 527–534
- Rosetto CL, Cartwright CC (2011) Pediatric surgical oncology. In: Baggott C, Fachtman D, Foley GV, Kelly KP (eds) *Nursing care of children and adolescents with cancer and blood disorders*. APHON, Glenview, pp 268–295
- Ruccione K (2011) The biological basis of cancer. In: Baggott C, Fochtman D, Foley GV, Kelly KP (eds) *Nursing care of children and adolescents with cancer and blood disorders*. APHON, Glenview, pp 36–113
- Ruiter MA, Schouten-van Meeteren YN, van Vuurden DG, Maurice-Stam H, Gidding C, Beek LR, Granzen B, Oosterlan J, Grootenhuis MA (2016) Psychosocial profile of pediatric brain tumor survivors with neurocognitive complaints. *Qual Life Res* 25:435–446
- Sands SA (2016) Proton beam radiation therapy: the future may prove brighter for pediatric patients with brain tumors. *Am Soc Clin Oncol* 34(10):1024–1026
- Sanghvi DA (2009) Recent advances in imaging of brain tumors. *Indian J Cancer* 46(2):82–87
- Schneider UC, Koch A, Stenzel W, Thomale UM (2012) Intracranial, supratentorial dermoid cysts in paediatric patients: two cases and a review of the literature. *Childs Nerv Syst* 28:185–190
- Shaikh R, Prabhu SP, Voss SD (2015) Imaging in the evaluation and management of childhood cancer. In: Orkin SH, Fisher DE, Ginsburg D, Look AT, Lux SE, Nathan DG (eds) *Nathan and Oski's hematology and oncology of infancy and childhood*. Elsevier Sanders, Philadelphia, pp 2146–2254
- Sharma R, D'Souza M, Jaimini A, Hazari PP, Saw S, Pandey S, Singh D, Solanki Y, Kumar N, Mishra AK, Mondal A (2016) A comparison study of Cmethylene and F-fluorodeoxyglucose positron emission tomography-computed tomography scans in evaluation of patients with recurrent brain tumors. *J Nucl Med* 31(2):93–102
- Shiminski-Maher T (1993) Physician-patient-parent communication complications. *Pediatr Neurosurg* 19:104–108
- Shiminski-Maher T, Rosenberg M (1990) Late effects associated with treatment of craniopharyngiomas in children. *J Neurosci Nurs* 22:220–226
- Shiminski-Maher T, Woodman C, Keene N (2014) *Childhood brain and spinal cord tumors: a guide for families, friends and caregivers*. Childhood Cancer Guides, Bellingham
- Shyu C, Burke K, Souweidane MM, Dunkel IJ, Gilheeny SW, Gershon T, Khakoo Y (2011) Novel use of Zolpidem in cerebellar mutism syndrome. *J Pediatr Hematol Oncol* 33(2):148–149
- Slade I, Murray A, Hanks S, Kumar A, Walker L, Hargrave D, Douglas J, Stiller C, Izatt L, Rahman N (2011) Heterogeneity of familial medulloblastoma and contribution of germline PTCH1 and SUFU mutations to sporadic medulloblastoma. *Familial Cancer* 10:337–342
- Smyth MD, Vogel TW (2015) Extratemporal epilepsy surgery. In: Albright AL, Pollack IF, Adelson PD (eds) *Principles and practice of pediatric neurosurgery*. Thieme, New York, pp 951–968
- Swift DM, Sacco DJ (2015) Scalp and skull neoplasms. In: Albright AL, Pollack IF, Adelson PD (eds) *Principles and practice of pediatric neurosurgery*. Thieme, New York, pp 408–422
- Tihan T (2010) Germ cell tumors. In: Adesina AM, Tihan T, Fuller CE, Poussaint TY (eds) *Atlas of pediatric brain tumors*. Springer, New York, pp 291–296
- Toomey C (2014) Chemotherapy. In: Kline NE, Bryant R, Carlson CA, Hooke MC, Nixon C (eds) *Essentials of pediatric hematology/oncology nursing: a core curriculum*. APHON, Chicago, pp 111–140
- Vega RM, Kim J, Hollander A, Hattangadi-Gluth J, Michalski J, Tarbell NJ, Yock TI, Bussiere M, MacDonald SM (2015) Cost effectiveness of proton versus photon radiation therapy with respect to the risk of growth hormone deficiency in children. *Cancer* 121:1694–1702
- Vinchon M, Leblond P, Caron S, Delestret I, Baroncini M, Coche B (2011) Radiation-induced tumors in children irradiated for brain tumor: a longitudinal study. *Childs Nerv Syst* 27:445–453



- Vrooman L, Diller L, Kenney LB (2015) Childhood cancer survivorship. In: Orkin SH, Fisher DE, Ginsburg D, Look AT, Lux SE, Nathan DG (eds) *Nathan and Oski's hematology and oncology of infancy and childhood*. Elsevier Saunders, Philadelphia, pp 2397–2434
- Wait SD, Taylor M, Boop FA (2015a) Ependymomas. In: Albright AL, Pollack IF, Adelson PD (eds) *Principles and practice of pediatric neurosurgery*. Thieme, New York, pp 535–552
- Wait SD, Boop FA, Klimo P (2015b) Supratentorial non-glial hemispheric neoplasms. In: Albright AL, Pollack IF, Adelson PD (eds) *Principles and practice of pediatric neurosurgery*. Thieme, New York, pp 460–472
- Watral M (2014) Central nervous system tumors. In: Kline N (ed) *Essentials of pediatric hematology/oncology nursing*. Association of Pediatric Hematology/Oncology Nurses, Chicago, pp 44–50
- Wells EM, Gaillard WD, Packer RJ (2012) Pediatric brain tumors and epilepsy. *Semin Pediatr Neurol* 19:3–8
- Wetjen NM, Raffel C, Murphy M (2015) Spinal extradural neoplasms and intradural extramedullary neoplasms. In: Albright AL, Pollack IF, Adelson PD (eds) *Principles and practice of pediatric neurosurgery*. Thieme, New York, pp 594–604
- Wheless JW, Klimo P (2014) Subependymal giant cell astrocytomas in patients with tuberous sclerosis complex: considerations for surgical or pharmacotherapeutic intervention. *J Child Neurol* 29(11):1562–1571
- Wilne S, Koller K, Collier J, Kennedy C, Grundy R, Walker D (2010) The diagnosis of brain tumours in children: a guideline to assist healthcare professionals in the assessment of children who may have a brain tumour. *Arch Dis Child* 95(7):534–539
- Wisoff JH, Donahue B (2015) Craniopharyngiomas. In: Albright AL, Pollack IF, Adelson PD (eds) *Principles and practice of pediatric neurosurgery*. Thieme, New York, pp 483–502
- Young P, Young P, Tolbert D (2015) *Basic clinical neuroscience*, 3rd edn. Wolters Kluwer, Philadelphia

Angela Hoersting and Jodi E. Mullen

## 8.1 Introduction

Traumatic brain injury (TBI) is a leading cause of death and disability in children. The anatomy and unique activity of children differ from adults and result in different types of injuries. Anatomic development and the maturing pediatric brain determine neurological deficits, recovery, and disability following traumatic brain injury.

### 8.1.1 Epidemiology

The routine play of children at any given age results in characteristic age-related causes of injury and death. Unintentional injuries in 2014 accounted for 30% of deaths in ages 1–4 years and 40% of deaths in ages 4–24 years (Health, United States 2015). Due to prevention efforts (i.e., bike helmets and child safety restraints), the

total number of unintentional injuries in children (birth to 24 years) decreased by greater than 50% from 1980 to 2014. Despite prevention efforts, unintentional injuries continue to be the leading cause of death in the United States (USA) for children from ages 1 to 19 years and the fifth leading cause of death in infants <1 year. Rates remain much higher in the USA compared to other countries (Centers for Disease Control 2010).

Injuries to the brain contribute to 30% of all injury-related deaths in children (Faul et al. 2010). Most pediatric traumatic brain injury (TBI) is mild in severity, although central nervous system (CNS) injury is the most common cause of pediatric traumatic death (Greenberg 2016). The leading causes of TBI-related deaths for all ages are motor vehicle accidents (MVAs) and falls (CDC 2010). School-aged children have high incidence of injury related to a bicyclist or pedestrian being struck by a motor vehicle. TBI-related deaths from MVAs are higher in adolescents from 15 to 24 years old than for any other age group throughout the life span (Coronado et al. 2011). Among children aged 0–15 years in the USA, TBI results in nearly half a million (473,947) emergency department (ED) visits, 35,136 hospitalizations, and 2,174 deaths annually (Faul et al. 2010). Epidemiological studies and prevention efforts remain important to raise awareness and to reduce the incidence, related suffering, and financial burden of TBI in children.

---

A. Hoersting, MS, RN, CPNP-AC/PC (✉)  
Neurosurgery, Dayton Children's Hospital,  
One Children's Plaza, Dayton, OH 45404, USA  
e-mail: [hoerstinga@childrensdayton.org](mailto:hoerstinga@childrensdayton.org)

J.E. Mullen, MS, RN-BC, CCRN, CCNS, ACCNS-P  
Pediatric Intensive Care Unit, Shands Children's  
Hospital, University of Florida,  
Gainesville, FL 32610, USA  
e-mail: [muljod@shands.ufl.edu](mailto:muljod@shands.ufl.edu)

## 8.2 Pediatric Anatomy and Physiology in Head Trauma

The adage “children are not just small adults” holds true when discussing pediatric head trauma. The physically larger and proportionately heavier pediatric cranium, together with the greater laxity of the cervical spine, creates a fulcrum and predisposes children to traumatic injury of the head and cervical spine. In general, children tend to fare better than adults with head injury (Emami et al. 2016; Luerson et al. 1988). But very young children do not fare as well as school-aged children (Kriel et al. 1989). “Early and aggressive treatment” is recommended for children with severe TBI, as children admitted with motor deficits and fixed and dilated pupils have better survival and functional outcome than adults (Emami et al. 2016). Providers need to maintain a higher level of suspicion in children under the age of 2 years, who are nonverbal and fall victim to inflicted injury at a higher frequency. They lack the ability to communicate what has happened to them and what they are feeling. In addition, the examination in young or developmentally delayed children is often less revealing.

### 8.2.1 Skull

The skull of an infant consists of many small bones which are connected by sutures (strips of connective tissue). Larger areas of connective tissue, called fontanels, separate the bones. The open sutures and fontanels allow for molding of the skull during the birth process and also for rapid brain growth over the first 2 years of life. The posterior fontanel closes by 8 weeks of life. The anterior fontanel closes between 12 and 18 months (Barkovich and Raybaud 2012). The skull becomes a closed system around 4 years of age.

Open cranial sutures are protective against a gradual increase in intracranial volume (Pinto et al. 2012), but rapidly expanding mass lesions are not tolerated and result in increased intracra-

nial pressure (ICP). The head circumference of infants should be measured and compared with the normal child head growth curve and the child’s previous measurements. Rapidly increasing head circumference can be indicative of increased ICP or hydrocephalus. Head circumference is measured upon admission and daily in infants with neurological diagnoses. The presence of bulging or firm fontanels, with the infant calm and in an upright posture, can also be an indicator of increased ICP.

The infant’s skull is thinner, softer, and more deformable. The thinnest cranial bones are the temporal and parietal, which are common sites of accidental fracture. The thickest cranial bones are the frontal and occipital. Occipital fractures are related to more serious brain injury due to the increased force necessary to generate a fracture in the thickest bone of the skull and an inability to protect oneself when falling backward (Greenberg 2016). The pediatric skull can absorb a significant impact with little external evidence of significant intracranial injury. Intracranial injury often occurs without skull fracture. When evaluating the head-injured child, the nurse must consider all external indications, such as bruising, swelling, and lacerations, as well as the mechanism of injury and the degree of neurologic deficit.

### 8.2.2 Brain

The pediatric brain is softer due to higher water content and less white matter myelination. The subarachnoid space is wider. The thin pediatric skull, soft brain, and large subarachnoid space allow increased movement of the brain within the skull, which makes the child more susceptible to brain injury, including extraparenchymal hemorrhage, shearing or tearing of neuronal processes, and diffuse axonal injury. The pressure–volume curve is shifted to the left, meaning that children tolerate acute increases in intracranial volume poorly. Children have a smaller intracranial space, in which smaller increases in volume produce exponentially larger increases in ICP.

## 8.3 Classification of Traumatic Brain Injury

### 8.3.1 Grading of Injury

Level of severity of TBI is assigned based on the immediate post-resuscitation Glasgow Coma Scale (GCS) score. A GCS score of 14–15 defines a mild TBI, a score of 9–13 defines a moderate TBI, and a score of 8 or less defines a severe TBI. The GCS scale is discussed further in Sect. 8.5.4.

### 8.3.2 Location: Supratentorial Versus Infratentorial Injury

The dura mater (“tough mother”) is a tough fibrous membrane which separates the intracranial space into compartments and splits to form the venous sinuses. The tentorium cerebelli is a fold of the dura mater, separating the cerebral hemispheres from the cerebellum and brainstem. The “tent” is an important landmark, as assessment for deterioration of neurologic status differs based on whether the injury is above the tentorium (supratentorial) or below the tentorium (infratentorial). The tentorium also contains the tentorial notch through which uncal or brainstem herniation occurs with increased ICP. Impending herniation must be recognized early to prevent brain death. Unilateral supratentorial mass lesions cause uncal herniation, evidenced initially by ipsilateral (same side) sluggish pupillary response, progressing to ipsilateral pupillary dilation, contralateral (opposite side) hemiparesis, trochlear and abducens cranial nerve paralysis, and a decreased level of responsiveness with eventual rostral–caudal deterioration. The mass effect causes lateral displacement of the mid-brain, forcing the opposite cerebral peduncle against the tentorium, producing Kernohan’s notch. This is important to remember when attempting to identify the location of a lesion, as it results in hemiparesis ipsilateral to the expanding mass lesion. Bilateral supratentorial lesions, which cause mass effect and increased ICP, progress in a rostral (head) to caudal (tail) progression

with impending herniation of the brainstem through the tentorial notch (see Sects. 8.5.10 and “Epidural Hemorrhage”).

An expanding mass lesion in the posterior fossa (rare in children) results in direct compression on the brainstem and cerebellum, upward herniation, or downward herniation. A primary infratentorial injury affects the reticular activating system (consciousness) directly. Downward compression on the vital cardiac and respiratory centers in the medulla oblongata results in pathologic alteration in vital signs, with respiratory and cardiac arrest. More often, posterior fossa lesions in children show progressive deterioration, with or without development of obstructive hydrocephalus, and present with rostral–caudal deterioration or lower cranial nerve deficits. Ataxia (decreased muscle coordination) and dysarthria (discoordinated speech) also occur with cerebellar injury.

### 8.3.3 Primary Versus Secondary Brain Injury

Pediatric TBI can be divided into two types of injury: primary and secondary. Primary TBI occurs at the time of the trauma or impact and includes extra-axial hemorrhage (i.e., subdural hemorrhage (SDH), epidural hemorrhage (EDH), subarachnoid hemorrhage (SAH), parenchymal injury (i.e., contusion, diffuse axonal injury (DAI), or vascular injury such as cerebral hemorrhage, dissection). Secondary injury develops as a subsequent complication of the primary injury and includes cerebral swelling, ischemia or infarction, and brain herniation (Pinto 2012). Secondary injury can cause significant worsening of prognosis and outcome. Patient management decisions and interventions are directed at preventing secondary injury.

### 8.3.4 Mechanism of Injury

Healthcare providers use mechanism of injury (energy transferred from the environment to the

patient) to help determine how likely it is that a serious injury has occurred. History taking is important to determine the type and severity of mechanism. Terms used to describe mechanism of injury include:

- Rotational
- Deceleration
- Acceleration (pedestrian struck by car)
- Combination of acceleration–deceleration
- Blunt versus penetrating
- Closed versus open
- Fall from a height versus ground level
- High- or low-speed MVA, ejection, or rollover

---

## 8.4 Initial Evaluation and Resuscitation

Following traumatic injury involving the head or neck, the child should arrive in an emergency department secured on a backboard and wearing a well-fitted cervical collar. A comprehensive multidisciplinary trauma evaluation should be performed to assess for multiple injuries. Immediate baseline neurologic examination should occur simultaneously with evaluation and resuscitation of circulation, airway, and breathing (CAB). Neurologic examination should be performed consistently and be clearly documented on arrival and at frequent intervals. Critical evaluation of trends in the neurologic exam, vital signs, and ICP measurements is the most sensitive method of detecting early neurologic deterioration.

Infants and young children lack the ability to communicate the circumstances of their injuries. Therefore, the caregiver must rely on the report of parents or other historians regarding previous medical history, baseline neurologic/cognitive/developmental deficits, and vital information to determine the circumstances of the child's injury. Circumstances of the accident or trauma are vital to determine the mechanism of injury and the potential severity of the child's injuries. First responders provide vital information such as a photograph, description of the

scene, or a police report. Witnessed loss of consciousness (LOC); amnesia before (retrograde) or after (anterograde) the event; posttraumatic seizures; post-resuscitation Glasgow Coma Scale (GCS) score; cardiorespiratory collapse; interventions to maintain or restore airway, breathing, and circulation; interventions to correct hypoxia, hypotension, or hypoglycemia; and patient's response (worsened or improved) should be included in the paramedic's report to the trauma team (Badjatia et al. 2008). Table 8.1 includes elements of the initial TBI history and physical examination.

---

## 8.5 Neurologic Assessment and Deterioration in Pediatric Traumatic Brain Injury

### 8.5.1 General Assessment

Inspection for external trauma, such as scalp or facial swelling, abrasions, laceration, or ecchymosis, can indicate traumatic brain injury. Palpable step-off or depression indicates skull fracture, which may be associated with contusion of brain, laceration of dura or brain, and CSF leak. Open, depressed skull fracture may present with scalp laceration, CSF leak, and avulsed brain tissue. Significant scalp swelling in the highly vascular scalp of an infant may be indicative of hemorrhage and can cause anemia with pallor and tachycardia. A basilar skull fracture in the base of the anterior fossa causes "raccoon eyes" or periorbital ecchymoses and can be associated with rhinorrhea (CSF leak from the nares). Fracture in the base of the middle fossa causes "Battle's sign," or postauricular ecchymoses, and can be associated with otorrhea (leak of CSF from the ear). Hemotympanum (blood behind the tympanic membrane) can indicate temporal or basilar skull fracture. Otorrhea indicates disruption of the tympanic membrane (TM) related to temporal skull fracture. See Chap. 11 for spine immobilization and clearance recommendations.



**Table 8.1** Initial history and physical in TBI

Subjective: witness to mechanism of event (i.e., police, EMT, parent report, photographs), loss of consciousness (LOC), anterograde or retrograde amnesia, witnessed posttraumatic seizure, abnormal behavior or vomiting, cardiorespiratory compromise/resuscitation, immobilization of cervical spine, and improved or worsened exam after initial resuscitation
Objective: general survey for multiple traumatic injuries, including spine. Survey for cranial injury: scalp hematoma; laceration, contusion, or abrasion; and open or penetrating intracranial injury. Evidence of basal skull fracture includes Battle's sign, raccoon eyes, otorrhea, rhinorrhea, and hemotympanum. Facial fractures (Le Fort – facial instability or step-off) may indicate serious neurologic injury
Physical examination: general assessment provides suspicion of location and severity of injury
Vital signs, LOC/mental status, GCS, orientation
Cranial nerve exam:
Olfactory nerve (CN I)
Optic nerve (CN II) – assess vision (Snellen card, finger counting, hand motion, light perception). Note: may have temporary cortical blindness 1–2 days after blow to back of the head
Oculomotor nerve (CN III) – pupillary size and reaction to light, ptosis, abducted gaze
Oculomotor (CN III), trigeminal (CN IV), and abducens (CN VI) nerves – extraocular eye movements
Trochlear nerve (CN V) – facial sensation, sensory portion of corneal reflex
Facial nerve (VII) – facial movement, motor portion of corneal reflex
Acoustic nerve (CN VIII) – hearing
Glossopharyngeal (CN IX) and vagus (CN X) nerves – intact gag and cough
Motor exam: if cooperative, assess strength ×4 extremities; if uncooperative, assess movement to noxious stimuli (caution: differentiate seizure from posturing, and avoid mistaking spinal cord reflexive movement as indication of cerebral function)
Sensory exam: if cooperative, differentiate tickle and pinch in all extremities; if uncooperative, assess for grimace and vocalization to central painful stimuli
Reflexes: DTRs, Babinski reflex, clonus
History: any previous head injury – timing, frequency, severity, other PMH such as bleeding dyscrasias, seizures, medications and allergies, NPO status, alcohol or drug use, and metabolic abnormality (i.e., IDDM)
Previous developmental or cognitive impairments

## 8.5.2 Vital Functions

Every patient assessment must begin with evaluation of adequate airway, breathing, and circulation, which are vital to sustain life. A decreased level of consciousness after TBI can interfere with protection of the pediatric airway and adequate ventilation. Inadequate ventilation results in hypercarbia and hypoxia, which cause vasodilation and secondary ischemic brain injury. Vasodilation and resultant ischemia contribute to further increases in ICP. Vital control centers located within the brainstem regulate respiratory and cardiac functions. Brainstem pathophysiology can be identified by changes in the vital signs. The following abnormal respiratory rate and patterns indicate neurologic dysfunction secondary to progressive brainstem compression in increasing ICP (Greenberg 2016):

- Cheyne–Stokes: rhythmic cycles of breaths, which gradually increase in amplitude and then trail off, followed by an expiratory pause; indicates diencephalic injury or bilateral hemispheric dysfunction.
- Central neurogenic hyperventilation (rare): increased rate and depth of respirations, indicates pons dysfunction.
- Apneustic (rare): a pause at full or prolonged (slow and deep) inspiration, indicates injury to the pons.
- Ataxic: no pattern in rate or depth, indicates medulla or lower brainstem dysfunction with impending herniation, and injury to the respiratory centers in the medulla (also known as agonal respirations).
- Apnea: respirations cease with herniation.

Following loss of autoregulation (the ability of the brain to maintain perfusion despite changes in systemic perfusion), the cerebral blood flow is dependent on the systemic blood pressure. Adequate systemic perfusion is critical following pediatric TBI because hypotension causes secondary injury and is associated with poor outcome (Badjatia et al. 2008; Krishnamoorthy et al. 2015; Stocchetti et al. 2010; Zebrack et al. 2009).

Prevention and immediate correction of hypoxia and hypotension are imperative. A study by Zebrack et al. (2009) found that the odds of death and long-term disability were both more than three times higher for children who did not have their hypotension addressed in the field. In children, hypotension is a late sign, which indicates compromised systemic and likely cerebral perfusion. Other earlier indications of poor systemic perfusion include tachycardia, decreased LOC, signs of inadequate skin perfusion (capillary refill >2 s), and decreased urine output (less than 1 cm<sup>3</sup>/kg/h). Hypertension occurs as a compensatory mechanism to maintain cerebral perfusion in the face of increased ICP. This mechanism, known as Cushing's response, is activated by decreased cerebral blood perfusion and includes increased systolic blood pressure, widened pulse pressure, and bradycardia. Cushing's triad is a classic presentation of vital signs, including hypertension, bradycardia, and increasingly abnormal respiratory pattern, which is a late and ominous sign of severe increased ICP and impending herniation.

### 8.5.3 Level of Consciousness

The child's level of consciousness (LOC), and whether it is worsening or improving, is the most important indicator of neurologic status. The neurologically intact child is awake, alert, and responsive to his/her surroundings. Level of responsiveness varies with the developmental age of the child. Infants should respond to feeding and measures to console them. Toddlers and older children should recognize and respond to their parents. Older children and adolescents should be able to follow commands. Children of all ages should localize to and withdraw from painful stimulus. After neurologic injury, pediatric head-injured victims may have degradation in LOC as follows: subtle restlessness, disorientation, and agitation, somnolence (arouses to full consciousness and resumes sleep if not stimulated), lethargy (requires vigorous stimulation to arouse to full consciousness), stupor (nearly unconscious, may moan or withdraw from pain),

and finally coma (unresponsive). A worsening LOC suggests neurologic deterioration. Caution should be exercised not to mistake neurologic deterioration for pain or anxiety, as treatment of the same with narcotics or antianxiety agents will further blunt the neurologic exam and delay treatment. Any subtle change from documented baseline, including parental concern that child is "not acting right," must be taken seriously and reported to the provider.

### 8.5.4 Glasgow Coma Scale

The Glasgow Coma Scale (GCS) was developed in 1974 (Teasdale and Jennett 1974) to measure the level of consciousness after TBI. As pediatric responses differ from those of adults, the GCS was modified to incorporate the young child's developmental level of verbal and motor responses (APLS 1998). See Table 8.2. The modified GCS for the child and infant allows for reliable, serial measurements of the child's level of neurologic responsiveness following TBI. The scale considers the child's best response, following adequate central stimulation for eye opening, motor, and verbal responses, with each assigned a score and the three scores totaled. The scores range from 3 (lowest score indicating no response) to 15 (highest score indicating intact neurologic status). A worsening GCS and decreased level of responsiveness indicate a rise in ICP (Dias 2004). A change of two or more points on the GCS score is very significant and should be reported to the provider immediately.

It is important when assessing responsiveness for the nurse to use an adequately painful, central stimulus to elicit the child's best response. Examples of an appropriate stimulus include application of firm pressure to the mandible, sternum, supraorbital area, or sternocleidomastoid muscle (Marcoux 2005). Peripheral painful stimulation should be avoided, as it can elicit a spinal reflex. The spinal reflex arc is a response to peripheral sensory stimulation, in which the sensory afferent fibers carry stimulation to the dorsal root and spinal cord. The signal synapses in the cord

**Table 8.2** Modified Glasgow Coma Scale for Infants and Children

Response	Child	Infant	Score
Eye opening	Spontaneous	Spontaneous	4
	Verbal stimuli	Verbal stimuli	3
	Pain only	Pain only	2
	No response	No response	1
Verbal response	Oriented, appropriate	Coos and babbles	5
	Confused	Irritable cry	4
	Inappropriate words	Cries to pain	3
	Incomprehensible words or sounds	Moans to pain	2
	No response	No response	1
Motor response	Obeys commands	Moves spontaneously and purposeful	6
	Localizes painful stimulus	Withdraws to touch	5
	Withdraws to pain	Withdraws to pain	4
	Flexion to pain	Decorticate posture (abnormal flexion) to pain	3
	Extension to pain	Decerebrate posture (abnormal extension) to pain	2
	No response	No response	1

with the motor neuron in the anterior horn. Motor efferent fiber signals travel back to the neuromuscular junction, which elicits a muscle contraction (Young et al. 2015). The spinal reflex should not be confused as a demonstration of cerebral function.

GCS score should be assessed after restoration of the ABCs with correction of hypoxia and hypotension and prior to administration of sedatives. The immediate post-resuscitation modified Glasgow Coma Scale for Infants and Children score is used as a reliable indicator of the severity of pediatric TBI and should be used repeatedly to assess neurologic improvement or deterioration (Badjatia et al. 2008). Studies have also shown a relationship between GCS score and outcomes following TBI (Massagli et al. 1996; Holmes et al. 2005).

The severity of head trauma is determined by the following scale:

- GCS 14–15 = mild TBI
- GCS 9–13 = moderate TBI
- GCS < or equal to 8 = severe TBI

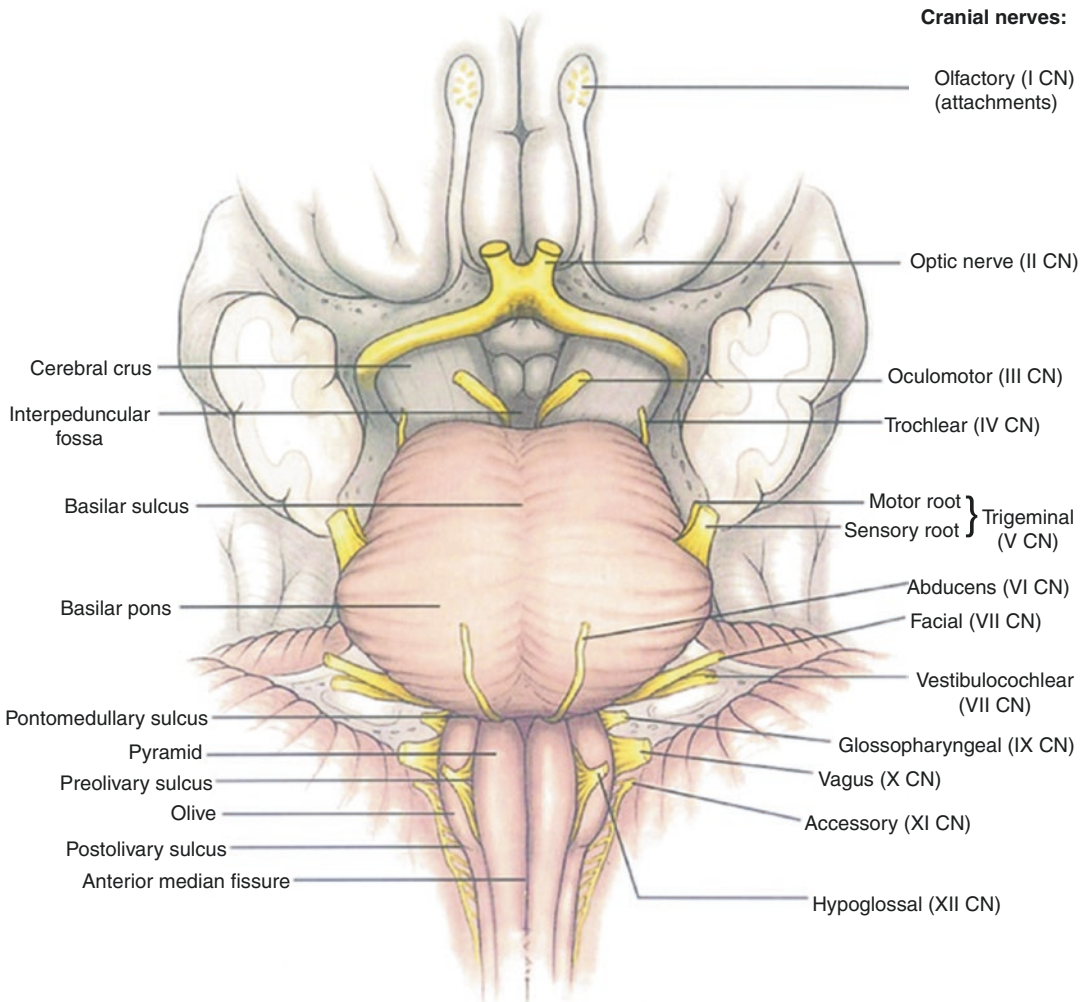
Coma is defined as the inability to arouse or interact with the environment. A GCS of 8 or less is an operational definition of coma.

### 8.5.5 Cranial Nerve (CN) Evaluation

The cranial nerves originate in the brainstem, with CN I through IV from the midbrain, CN V through VIII from the pons, and CN IX through XII from the medulla. See Fig. 8.1. Evaluation of cranial nerve and brainstem function is valuable to locate neurologic injury. Rostral–caudal deterioration with worsening increased ICP manifests as an anatomic “picking off” (dysfunction) of the cranial nerves in chronologic order as the pressure progresses downward through the brainstem. It is critical for the nurse to recognize this subtle deterioration early so that there is potential to reverse the process before herniation and death occur.

### 8.5.6 Visual Acuity

Optic nerve injury (CN II) can be either direct (penetrating injury to the nerve) or indirect (injury to nerve from a blow to the head). Following TBI, it is essential to assess for the presence of bilateral vision as an indicator of bilateral optic nerve function. The methods used to assess vision in children vary with age and level of consciousness. In the conscious older



**Fig. 8.1** The image depicts the anterior surface of the brainstem and shows which cranial nerves originate from the midbrain, pons, and medulla (Reprinted with permission from Young et al. 2015)

child, reading of the Snellen vision chart (or printed material) is best. If the child is unable to see the chart, or unable to cooperate, vision is assessed on a continuum progressing from normal to abnormal, including finger counting, hand motion, and light perception. In an infant or small child, the ability to “fix and follow” a face or toy, squint to bright light, or blink to visual threat indicates intact vision. In the unconscious child, check for afferent pupillary defect by performing the swinging flashlight test to assess for optic nerve injury (Greenberg 2016). Children may have transient posttraumatic cortical blindness

for 1–2 days following a blow to the back of the head.

Fundoscopy exam is performed to assess for papilledema or retinal hemorrhage. The presence of papilledema on a fundoscopic exam indicates the presence of increased ICP. This finding presents 12–24 h after injury, however, and its absence should not delay treatment when other findings are consistent with severe brain injury (Dias 2004). The presence of retinal hemorrhages with subdural hematomas is a classic finding in abusive head trauma (AHT) (Vinchon et al. 2005) but can also be seen with high-impact accidental injuries.

### 8.5.7 Pupillary Response

Pupillary response represents a balance between sympathetic and parasympathetic systems, wherein dysfunction in one system results in unopposed action of the other. Pupillary response is innervated by the optic or second cranial nerve (CN II). The pupils are normally equal in size, round, and reactive to light and accommodation, thus the acronym PERRLA. When assessing pupillary response, darken the room. Bring the light in from the periphery, and note direct (same side) and consensual (opposite side) response to light; repeat with the other eye. Accommodation maintains focused vision when gaze shifts from a near object to a far object. Three components include convergence (simultaneous inward movement of the eyes), pupillary constriction, and thickening of the lens (Young et al. 2015). The reflex is assessed by directing gaze at a distant object, which causes pupillary dilatation, and then shifting gaze to a near object, which causes the pupils to constrict and converge on the near object. The accommodation–convergence reflex is innervated by the CN II, the oculomotor or third cranial nerve (CN III), and the parasympathetic nervous system. Parinaud’s syndrome, caused by a lesion (hemorrhage, tumor) or pressure (increased ICP or hydrocephalus) exerted on the tectum of the midbrain, results in upward gaze palsy, lid retraction (“setting sun sign”), and loss of accommodation (may be associated with unreactive pupils) (Greenberg 2016).

Abnormal mydriasis (pupillary dilation) is caused by unopposed sympathetic input, whereas miosis (pupillary constriction) is due to unopposed parasympathetic input. Bilateral fixed (nonreactive) and dilated (mydriatic) pupils indicate unopposed sympathetic input, due to injury to either the Edinger–Westphal nucleus of CN III in the tectum of the midbrain or direct CN III injury from trauma or increased intracranial pressure (Dias 2004). Anisocoria (inequality of the pupil size) is a variant of normal in approximately 20% of the population. Physiologic anisocoria is a pupillary difference of <1 mm, whereas pathologic anisocoria due to increased ICP will mani-

fest as a pupillary difference of >1 mm. Unilateral mydriasis (pupillary dilation) in TBI suggests either direct orbital trauma, transtentorial (uncal) herniation, or expanding mass hemorrhage on the same (ipsilateral) side as the dilated pupil. A new finding of pupillary inequality, even by only 1 mm, must be taken seriously and reported to the provider.

Bilateral mydriasis can also occur following seizure or administration of medications, such as atropine, that mimic the sympathetic response. A pharmacologically dilated pupil is very large (7–8 mm), whereas mydriasis due to CN III compression is typically 5–6 mm (Greenberg 2016). The nurse should be aware of what medications are given and notify other caregivers of iatrogenic pupillary dilatation. Miosis occurs with injury to the pons or carotid artery and with administration of opioids and other miotic drugs.

Hippus is a spasmodic, rhythmic pupillary response to light manifested as alternating dilation and constriction. Hippus is usually a normal variant but can indicate altered mental status. Hippus “confuses the exam” and initial response should be recorded (Greenberg 2016).

### 8.5.8 Extraocular Eye Movements

Eye position and movement are controlled by CN III (oculomotor), CN IV (trochlear), and CN VI (abducens), as well as the cerebral hemispheres and the brainstem. Extraocular eye movements (EOM) are assessed by having the conscious child follow the examiner’s finger in the pattern of an “H” (cardinal fields of gaze). Cranial nerve injury following TBI is manifested as extraocular eye muscle weakness, resulting in abnormal eye position in the conscious or unconscious child. The third CN innervates four of the six ocular muscles, which control all directions of gaze except downward and inward (CN IV) and lateral (CN VI). When control of eye movement in one direction is lost, there is overcompensation of positioning of the eye in the opposite direction. Table 8.3 is a limited review of abnormal eye position, which includes location of causative



**Table 8.3** Etiology of pathologic eye deviation in pediatric head trauma

Location of lesion	Pathologic eye deviation	Associated findings	Etiologies
Frontal lobe injury	Toward lesion		
Expanding mass hemorrhage	Toward lesion		
Occipital injury	Toward lesion	Hemianopsia (contralateral loss of vision)	
Seizure	Away from side of seizure focus, toward jerking		
CN III (oculomotor motor palsy)	Down and out (exotropia), ptosis, mydriasis, proptosis		Trauma, uncal herniation – extrinsic compression of nerve
CN IV (trochlear)	Inability to look up and in); diplopia	Tilt head to side opposite the palsy to alleviate diplopia	Isolated injury is rare
CN VI (abducens)	Lateral rectus palsy with loss of lateral gaze; diplopia exaggerated with gaze to side of palsy	Squint and head tilt	↑ICP secondary to trauma; sensitive due to longest intracranial course
Parinaud’s syndrome	Upward gaze palsy and lid retraction (setting sun sign), loss of accommodation; pupils may be nonreactive	Infants unable to fix/follow	Pressure on the tectum of midbrain due to elevated ICP, hydrocephalus

lesion, etiology, and associated findings (Young et al. 2015; Dias 2004). Saccadic eye movements (rapid, voluntary movements to search a field) are controlled by the frontal gaze centers, where injury causes deviation toward the lesion. Pursuit movements (slow, involuntary movements keeping the eyes fixated on a moving target) are controlled by the occipital gaze centers.

### 8.5.9 Brainstem Reflex Exam

Cranial nerves originate in the brainstem. See Figs. 8.1 and 8.3 and Table 8.4. Testing of CN function and the presence of brainstem reflexes is used to assess brainstem function and as part of the exam to document brain death criteria (Greenberg 2016; Young et al. 2015). Pupillary response is innervated by CN III, and intact pupillary response indicates midbrain function. The trigeminal nerve (CN V) innervates the sensory portion of the corneal reflex, where stimulation of blowing into the child’s eye elicits eye closure. The motor response of blinking is innervated by the facial nerve (CN VII). Intact corneal reflex indicates pons function. Integrity of the

vestibulocochlear nerve function (CN VIII) is assessed by performing oculovestibular (“cold calorics”) and oculocephalic (“doll’s eyes”) reflex testing, which indicates the presence or absence of brainstem function in the comatose patient (Greenberg 2016; Young et al. 2015). Intact gag and cough reflexes assess continuity of the glossopharyngeal (CN IX) and vagus (CN X) nerves and function of the medulla. Table 8.4 summarizes the brainstem reflexes.

The vestibular system maintains equilibrium (vestibulospinal reflex) and visual fixation (vestibulo-ocular reflex). The nuclei of CN VIII are located in the brainstem at the level of the junction between the pons and the medulla (pontomedullary junction), near the fourth ventricle. Vestibular testing stimulates the vestibular reflex, which stimulates nystagmus. Nystagmus includes two components of rhythmic eye movements: slow movement of the eye away from a target (vestibular response) and fast movement of the eye back to a target (cerebral component). The results of vestibular testing are described according to the fast (cerebral) component of nystagmus. The oculovestibular reflex (“cold calorics”) is tested in a comatose

**Table 8.4** Brainstem reflexes assess function between the cranial nerve nuclei and the brainstem

CN	Brainstem reflex	Conscious	Comatose	Brain death
III	Pupillary reflex	Normal		Fixed
V and VII	Corneal reflex	Stimulation of cornea produces a blink		Absent
VIII	Oculo-vestibular (cold calorics). Caution: must have intact TM	Fast nystagmus (cerebral component) to side opposite of cold. “COWS” (cold opposite, warm same)	Deviate to side of irritant only. No fast (cerebral component) nystagmus	Absent
	Elevate HOB, 60–100 ml ice water instilled into ear			
VIII	Oculocephalic (doll’s eyes). Caution: do not perform unless C-spine clearance obtained	Eyes move with or away from (contraversive to) lateral head rotation	Eyes move away (contraversive to) lateral rotation for classic “doll’s eyes” response	Absent
IX and X	Gag and cough	Intact		Absent

patient by ensuring the TM is intact, raising the head of bed 30°, and injecting 60–100 ml ice water into the ear. The oculocephalic reflex (doll’s eyes) is tested only after clearance of the cervical spine, by assessment of the eye movements in response to lateral head movement. Table 8.4 lists the CN’s and associated brainstem reflexes and explains how to interpret results of vestibular reflex testing in conscious and comatose patients, as well as expected finding in brain death.

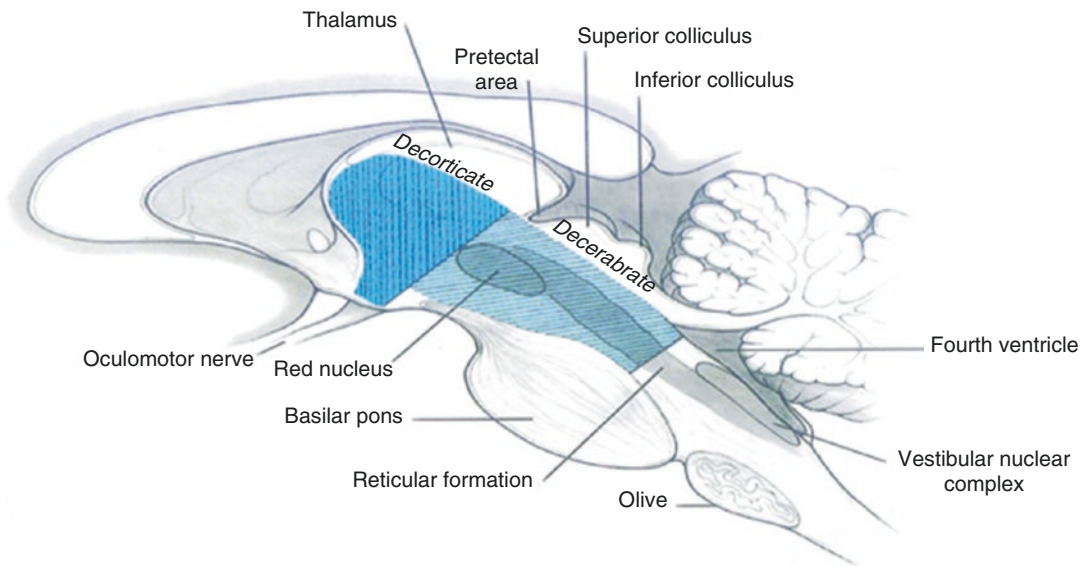
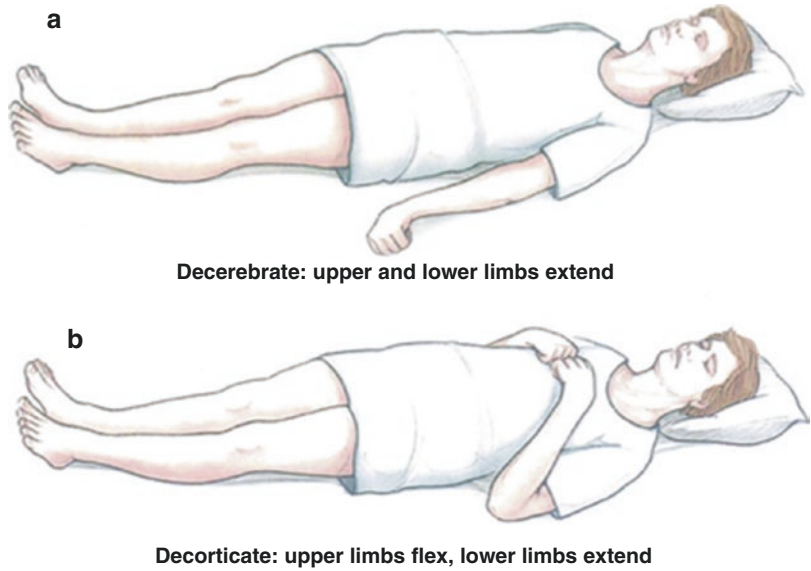
### 8.5.10 Motor Exam

The infant should have dominant flexor tone but relax to easily perform full range of motion. The older infant and toddler will cry, push away examiner, or attempt to retreat to a safe distance or to a parent. The older child has the cognitive ability to cooperate and follow verbal command. Ability to follow command is assessed by asking them to perform a purposeful and reproducible task, such as holding up two fingers. Note whether the child initiates movement spontaneously or what stimulus is required to elicit movement. Table 8.2 shows the child and infant GCS, in which the “motor response” section provides gradation of motor response from normal motor response to absence of motor response. Note the symmetry and quality of strength using the motor strength scale: 0, no muscle contraction; 1, palpation of trace contraction; 2, movement without

gravity; 3, movement against gravity, but not resistance; 4, movement against some resistance; and 5, movement against full resistance. Weakness on the side opposite the lesion with hypertonicity and hyperreflexia indicates cerebral or upper motor neuron (UMN) injury. A lower motor neuron injury presents with weakness or paralysis, on the same side as the lesion or bilaterally, hypotonia, and areflexia. Cerebellar injury results in hyporeflexia, ataxia, and dysarthria (Young et al. 2015).

Abnormal flexion or extension posturing indicates severe traumatic brain injury. Posturing indicates neurologic activity (or inactivity) secondary to brainstem compression and impending herniation in comatose patients (Young et al. 2015). Remember that deterioration of neurologic status occurs in a rostral to caudal progression. This is true of cranial nerve and brainstem dysfunction with impending herniation. Decorticate posturing implies a more rostral lesion and a better prognosis (Greenberg 2016). Decorticate posture (abnormal flexion of the upper extremities with extension of the lower extremities) is indicative of disinhibition of the corticospinal pathways above the midbrain, whereas decerebrate posture (abnormal extension of the upper and lower extremities) indicates disinhibition of the pons and medulla, implying further (caudal) deterioration and impending herniation. See Fig. 8.2. Posturing may be reversible but is associated with a more ominous outcome. Progression from decorticate to decerebrate

**Fig. 8.2** (a) Abnormal posturing indicates brainstem compression in the comatose patient. Decerebrate posturing with abnormal upper extremity (UE) and lower extremity (LE) extension (*late*). (b) Decorticate posturing with abnormal UE flexion and LE extension (*early*) (Reprinted with permission from Young et al. 2015)



**Fig. 8.3** Brainstem compression occurs in a rostral (*head*) to caudal (*toe*) progression. Median view of brainstem showing levels of impairment associated with abnormal posturing: Decorticate indicates a more rostral lesion

(above *red nucleus*); decerebrate indicates a more caudal lesion (midbrain or pons) (Reprinted with permission from Young et al. 2015)

indicates worsening brainstem function, whereas progression from decerebrate to decorticate indicates improvement. Figure 8.3 illustrates the brainstem centers that are compressed by downward herniation, progressing from decorticate to decerebrate posturing, and finally herniation (brain death) (Young et al. 2015).

### 8.5.11 Deep Tendon Reflexes

A reflex is an autonomic nervous system motor response to stimulation. The stimulus (striking tendon) travels via sensory (afferent) fibers to the dorsal ganglion and anterior horn of the spinal cord. The ventral horn relays the motor (efferent)

signal back to the muscle, causing a reflexive contraction. This chain of events is referred to as the reflex arc. Deep tendon reflexes (DTR) or muscle stretch reflexes are assessed to determine the presence and location of nervous system dysfunction in both conscious and unconscious children. Injury can occur to the central nervous system – brain and spinal cord (upper motor neurons) or the peripheral nervous system (PNS; lower motor neurons).

With upper motor neuron (UMN) injury, signals (both excitatory and inhibitory) from the cortex are diminished or cut off, causing the spinal cord to become hyperreflexic. Hyperreflexia indicates injury to the CNS corticospinal tract with resultant irritability in the spinal cord. UMN injury is associated with increased tone, spasticity, clonus (muscle spasm with forceful dorsal flexion of the ankle), and a present Babinski. Unilateral hyperreflexia indicates a CNS injury, such as an expanding mass hemorrhage on the opposite side of the brainstem or cerebral cortex, resulting in increased ICP. Injury to the peripheral nervous system (PNS), or lower motor neurons (LMN), is associated with hyporeflexia or areflexia (loss of efferent motor fibers), as well as muscle weakness, flaccidity, and atrophy (Greenberg 2016; Young et al. 2015). Hypotonia and atrophy occur due to the loss of LMNs, which innervate muscles and maintain normal tone. Preserved reflexes in a flaccid limb indicate CNS (UMN) injury, not a PNS (LMN) injury.

Babinski sign is present when stroking the plantar surface of the foot, results in dorsiflexion of the great toe and fanning of the other toes. This is a primitive reflex seen normally in infants and usually disappears by 10 months of age (range 6–12 months) (Greenberg 2016). The presence of a Babinski sign after age 6 months in TBI is pathologic and indicates injury to the corticospinal tract at any level.

---

## 8.6 Radiographic Imaging in Pediatric Head Trauma

For the purpose of this chapter, traumatic cranial injuries are discussed individually, but in reality any combination of lesions can and does

occur. The neuroimaging modality of choice will be discussed in greater detail in Sect. 8.8.7 Types of Traumatic Brain Injuries. Table 8.5 contains a general comparison of neuroimaging modalities.

The non-contrast head computed tomography (CT) is the study of choice for evaluation of acute pediatric TBI. Obtaining CT imaging is an efficient method of imaging a child for TBI, especially when the child is acutely ill or less cooperative due to age, developmental level, or altered mental status. CT scan is sensitive to skull fracture, hemorrhage, mass effect or shift, hydrocephalus, and pneumocephalus. While CT scans are the best study for evaluation of acute TBI, practitioners should also consider that exposure to ionizing radiation during CT carries an increased risk of secondary radiation-induced cancer.

Advances in neuroimaging have led to earlier, more specific diagnoses of the full extent of TBI (Pinto et al. 2012). One such advance, the fast helical CT, has led to the use of the head CT as the study of choice for acute TBI. The ease of obtaining head CT in the USA led to a “nearly sevenfold increase in the number of CT’s performed” from 1981 to 1995 (Brenner et al. 2001). CT scan exposes the patient to a dose of radiation, which remains with the patient, and is cumulative over the patient’s lifetime. In children, the combination of higher radiation doses (for body size) and the much larger lifetime risk (number of years following exposure per unit dose of radiation) has resulted in significantly higher lifetime cancer mortality risk in children than in adults (Brenner et al. 2001). Children under the age of 2 years are most sensitive to the effects of radiation (Kupperman et al. 2009). Strategies are being implemented to reduce radiation exposure in pediatric CT, without compromising the diagnostic quality of CT images (Strauss et al. 2010; Zacharias et al. 2013). A validated “CT algorithm” was born out of the Pediatric Emergency Care Applied Research Network (PECARN) study, which helps practitioners identify children *without* “clinically important TBI” for whom CT scans can be omitted (Kupperman et al. 2009). See Sec. 8.7.2.1.

**Table 8.5** Comparison of neuroimaging modalities in pediatric traumatic brain injury

	X-ray	Ultrasound	CT scan	MRI
Timing	Early, especially if scalp swelling, trauma is present	Useful with open fontanel; portable	Gold standard for acute, posttrauma imaging	Subacute or chronic imaging
Type of injury	Skull fracture	Hemorrhage	Extraparenchymal hemorrhage (EDH, SDH, SAH, IVH)	Nonhemorrhagic contusion
	Pneumocephalus	Ventricular size (hydrocephalus or small, obliterated ventricles with ICP)	Intraparenchymal hemorrhage (ICH, hemorrhagic contusion)	Brainstem injury
	Foreign body	Cranial Doppler for vasospasm secondary to SAH	Cerebral swelling obliteration of ventricles and cisterns	White matter changes: diffuse axonal injury
	Split cranial sutures with increased ICP		Shift of midline structures	Early ischemic injury (cerebral infarct)
Follow-up			Cerebral anoxia: loss of gray-white differentiation	CT scan does not explain neurologic deficit
			Skull fracture/pneumocephalus/splitting of cranial sutures	Injury dating in child abuse
Additional considerations			Hydrocephalus	MRA (posttraumatic aneurysm)
			Indications for follow-up CT: within 24 h for severe TBI, within 4–6 h for EDH, within 8–12 h for SDH, persistent elevated ICP or low CPP, new focal neurologic deficit, pupillary change >2 mm	Rapid sequence MRI avoids ionizing radiation exposure; no sedation
		Less detail, “shadows of shadows”	Ionizing radiation exposure	Longer scan time
		Window limited by size of fontanel		Often requires sedation
				Safety with ferrous metal implants



Magnetic resonance imaging (MRI) is more sensitive and more likely than CT to show the full extent of injury in pediatric TBI. Due to longer scan times and the probable need for sedation, MRI is more useful in the subacute or chronic stage of injury. MRI should be performed if CT findings do not fully explain the extent of neurologic deficit. Skull radiographs are minimally useful. When obtained in the presence of scalp swelling or other injury, x-rays can reveal skull fractures or intracranial air, which may indicate more serious intracranial injuries. The presence or absence of skull fracture is not predictive of intracranial injury (Schutzman and Greenes 2001). In neonates and infants with open fontanels, cerebral ultrasound is useful in identifying the presence of intracerebral hemorrhage (ICH) and intraventricular hemorrhage (IVH), as well as assessment of ventricular size with hydrocephalus.

---

## 8.7 Types of Traumatic Brain Injury

### 8.7.1 Birth-Related Traumatic Brain Injury

Traumatic injury to the brain may occur during the birth process. Infants with greater risk for birth-related injuries include those above the 90th percentile for weight. The rate of birth injury is higher in infants weighing more than 3,500 g (Ditzenberger and Blackburn 2014). Birth injuries may also be related to the infant's position during labor and delivery (e.g., breech presentation), as well as cephalopelvic disproportion, where the mother's pelvis size or shape is not adequate for vaginal birth; difficult labor or delivery; prolonged labor; fetal anomalies; and very low birth weight or extremely premature infants. Some of the more common birth injuries to the neonatal head and brain include extracranial hemorrhage (caput succedaneum, subgaleal hemorrhage, or cephalohematoma), skull fracture, and intracranial hemorrhage (epidural, subarachnoid, subdural, or intracerebellar hemorrhage) (see Fig. 8.4).

#### 8.7.1.1 Caput Succedaneum

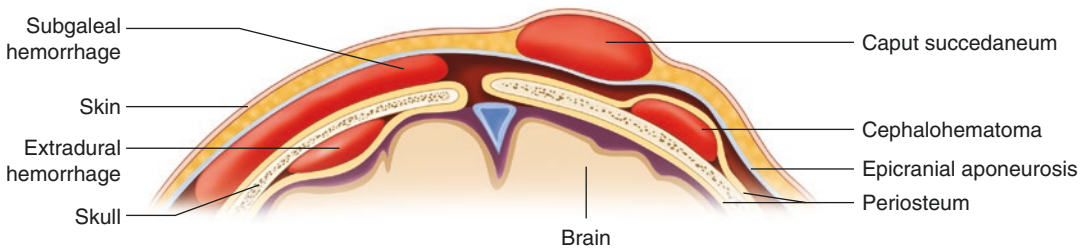
Caput succedaneum, a common finding in the newborn, involves soft tissue swelling of the presenting part of the head in a vertex (head first) delivery. The scalp edema consists of serum, blood, or both and may have ecchymosis, petechiae, or purpura. Caput succedaneum may occur after spontaneous delivery due to pressure of the fetal head against the uterine wall, the cervix, or the vaginal wall or after use of a vacuum extractor. The scalp edema may cross over suture lines and does not continue to increase in size after delivery. This injury heals in hours to days and rarely has complications. Nursing care involves parent education about the cause of the tissue swelling and/or discoloration (Cavaliere and Sansouci 2014).

#### 8.7.1.2 Cephalohematoma

Cephalohematoma is a subperiosteal collection of blood secondary to the rupture of blood vessels between the skull and the periosteum. It is typically over the parietal bone, and is usually unilateral, but can occur bilaterally. Cephalohematoma occurs most often in infants after a prolonged, difficult, or forceps-assisted delivery. The characteristic finding is a firm, tense mass that does not cross the suture lines. It may enlarge slightly by 2–3 days of age and takes weeks to months to resolve, occasionally with residual calcification. The calcified “lump” gradually subsides as bones grow and reshape. Approximately 10–25% of cephalohematomas have an underlying linear skull fracture (Parsons et al. 2016). Rarely, the cephalohematoma may contain enough blood to affect hematocrit and bilirubin levels. Nursing care involves monitoring and parent teaching about the expected time course for resolution. Anemic infants should also be evaluated for symptoms of intracranial hemorrhage. Generally, there are no long-term sequelae from a cephalohematoma.

#### 8.7.1.3 Subgaleal Hemorrhage

Subgaleal hemorrhage is the most serious extracranial hemorrhage in newborns, though it occurs much less frequently than caput succeda-



**Fig. 8.4** Various neonatal birth-related hemorrhages

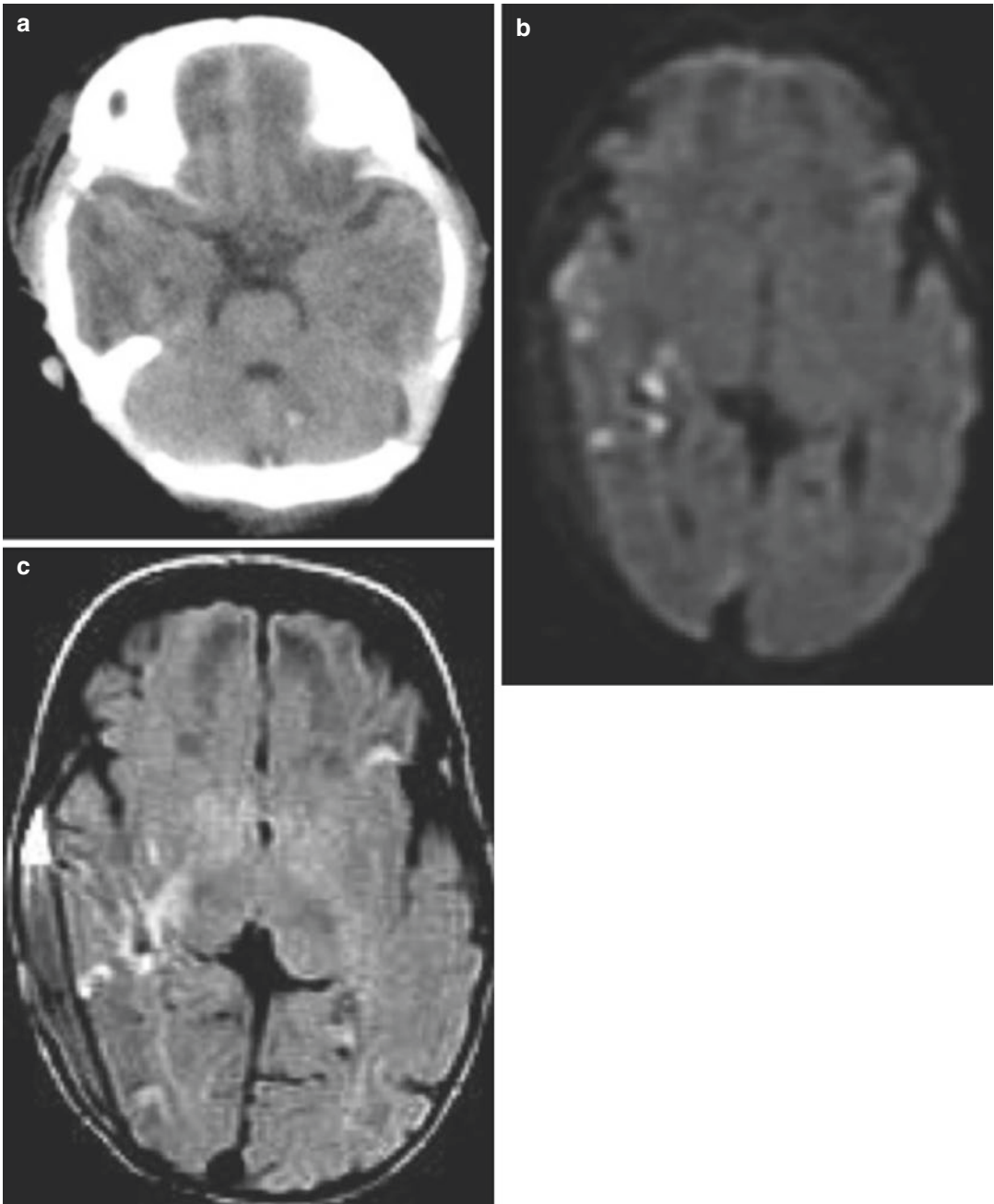
neum and cephalohematoma. Blood collects below the epicranial aponeurosis, which is a tough layer of dense fibrous tissue that covers the upper part of the cranium, and may spread beneath the entire scalp and down the subcutaneous tissue in the neck. There is a strong association between vacuum extraction and forceps-assisted delivery and subgaleal hemorrhage (Swanson et al. 2012). The hemorrhage may be from suture diastasis, linear skull fracture, or fragmentation of the superior margin of the parietal bone. Subgaleal hemorrhage presents as a firm fluctuant mass, crosses suture lines, and may increase in size after birth. Blood loss can be significant, possibly 260–280 ml, exceeding the total blood volume of a full-term infant (Colditz et al. 2015; Ditzenberger and Blackburn 2014). This volume loss into the large potential space between the galea aponeurotica and the periosteum of the skull can necessitate urgent blood transfusion and may contribute to hyperbilirubinemia (Colditz et al. 2015; Ditzenberger and Blackburn 2014). Early detection of this clinical emergency is vital, and the nurse should maintain a high level of suspicion for this injury after a difficult delivery. Nursing interventions include serial measurements of head circumference, inspection of the back of the head and neck for increasing edema, and observation of the ears being pushed forward and lateral. The nurse should also monitor for changes in LOC and decrease in hematocrit along with signs of hypovolemic shock (Barkovich and Raybaud 2012; Schierholz and Walker 2014). Parent teaching includes preparing them for the swelling and discoloration of the face, head, and neck and emotional support.

Lesser lesions resolve in 2–3 weeks, while moderate to severe lesions may require intensive care, and up to 25% of these babies may die (Colditz et al. 2015).

#### 8.7.1.4 Neonatal Skull Fracture

Skull fractures, both depressed and linear, are occasionally seen in the newborn. The fetal skull is flexible, malleable, and poorly ossified when compared to the adult skull and thus is often able to tolerate mechanical stressors relatively well. Skull fractures can occur in utero, during labor, with forceps delivery (Fig. 8.5), or during a prolonged or difficult labor. The fetal skull can be compressed against the maternal ischial spines, sacral promontory, or symphysis pubis. Cerebral injury should be suspected when neurologic signs are apparent and there is a history of a difficult delivery. While neonatal skull fractures are generally diagnosed with skull x-rays, skull films are challenging to interpret in neonates, as they have widened sutures and decreased bone mineralization (Merhar et al. 2016). Low-dose CT scan may be a better first line of imaging, as it can be accomplished quickly without the need for sedation, and used to identify space-occupying hematomas and injury to the underlying brain (Fig. 8.5).

Depressed skull fractures may occur after forceps delivery but are occasionally observed after a spontaneous vaginal or cesarean delivery (Parsons et al. 2016). A birth-related depressed skull fracture is a visible and palpable dent in the skull, usually over the right parietal bone, which does not cross suture lines. This type of depressed skull fracture may be referred to as a “ping-pong” lesion, as it



**Fig. 8.5** (a–c) Neonate with significant birth trauma after vaginal delivery with forceps. (a) Infant sustained a right parietal depressed skull fracture, scalp swelling (caput succedaneum), bilateral extra-axial hematomas (SDH subdural hemorrhage), and right temporal and left cerebellar hemorrhage as seen on computed tomography (CT) images. Subarachnoid hemorrhage was also seen on the tentorium and at the vertex (not shown). (b) Diffusion-weighted magnetic resonance imaging on DOL 7 shows

brain contusion with injury in the right temporal lobe and corpus callosum (not shown). (c) Fast fluid-attenuated inversion recovery (FLAIR) MRI reveals right temporoparietal SDH and scattered white matter hemorrhage bilaterally (right temporal, bilateral occipital, and left frontal). The infant was treated with observation only; the lesions resolved, and the child did well, without development of hydrocephalus

resembles a dent in a ping-pong ball (Fig. 8.6). There may be no other symptoms unless there is an underlying cerebral contusion or hemorrhage. Depressed skull fractures that are small or treated early have a good prognosis. The uncomplicated depressed fracture can be manually elevated if it does not resolve spontaneously in the first few days of life (Parsons et al. 2016). Manual elevation becomes more difficult later on. Methods to elevate the fracture include gentle pressure or use of a breast pump or vacuum extractor. As recently demonstrated, elevation can be accomplished by use of a pediatric CPR mask and negative pressure from a 50 mL syringe (Lopez-Elizalde et al. 2013). Surgical intervention is necessary when the depressed fracture cannot be elevated manually, when bone fragments are in the cerebrum, if neurologic deficits exist, or if intracranial pressure is increased. If there is CSF leakage, antibiotics may be prescribed for prophylaxis. Some infants will require treatment for shock and hemorrhage.

Linear skull fractures usually occur in the frontal and parietal bones and are often associated with extracranial hemorrhage, such as cephalohematoma. They are typically asymptomatic. The exact incidence is unknown as routine x-rays in otherwise healthy newborns are uncommon. Linear fractures are rarely complicated by intracranial hemorrhage (Ditzenberger and Blackburn 2014). Linear skull fractures in infants may spontaneously heal in 6 months with no sequelae (Barkovich and Raybaud 2012), unless a dural tear allows the leptomeninges to protrude into the fracture site (i.e., growing fracture of childhood). A cyst may form and grow, causing the fracture to enlarge. Leptomeningeal cyst is rare, occurring in less than 1% of linear fractures in children under age 3 years (Greenberg 2016). Larger fractures have a greater risk of sequelae, especially if treatment is delayed. Sequelae are related to the cerebral injury, from either dural hemorrhage or hypoxic event, or both, not from the fracture itself (Ditzenberger and Blackburn 2014).

Nursing interventions for neonatal skull fractures include supportive care and monitoring of

the infant for signs of neurologic dysfunction, such as increased ICP from hemorrhage, seizures, apnea, and meningitis. If there is a depressed fracture, parents may be concerned about brain damage and their infant's appearance. Parents should be educated to observe their infant for and report signs of increased ICP, which would include irritability, poor feeding, vomiting, and hypersomnolence. Parents should also report a growing bulge at the fracture site, which could indicate a growing fracture. The fracture site should be examined at each newborn visit.

#### 8.7.1.5 Intracranial Hemorrhage

Intracranial hemorrhage may occur in the neonate secondary to trauma or hypoxia in the perinatal period (epidural hemorrhage (EDH), primary subarachnoid hemorrhage (SAH), subdural hemorrhage (SDH), intracerebellar hemorrhage) or due to immature structures and hemodynamics in the premature infant (periventricular/intraventricular hemorrhage (P/IVH)), especially those under 32-week gestational age at birth. The pathophysiology of P/IVH involves disruption to the autoregulation of CBF, which is affected by hypoxia and acidosis, leaving the germinal matrix area vulnerable to systemic blood pressure changes. Systemic blood pressure changes may be caused by handling, suctioning, positive-pressure ventilation, hypercapnia, and rapid volume expansion (Ditzenberger and Blackburn 2014).

#### 8.7.1.6 Epidural Hemorrhage

EDH is a rare occurrence and may be associated with cephalohematoma. An EDH in the newborn is a blood collection above the dura mater and below the periosteum. Most cases are associated with a linear skull fracture. Nearly all affected infants have a history of difficult delivery. Signs of increased ICP, including a bulging fontanel, may be apparent within the first hours of life. An emergent CT scan should be performed, and surgical evacuation may be required, depending on the size of the EDH and the associated symptoms of increased ICP. Aspiration of any accompanying cephalo-

hematoma has been reported as a means of reducing the epidural lesion (Smets and Vanhauwaert 2010). Significant untreated lesions may result in death within 48 h.

Nursing care involves prompt recognition and reporting, timely preparation and transport for CT scan, transfer to the appropriate facility, and preparation for surgery. Postoperative nursing care includes supportive care for oxygenation, ventilation, thermoregulation, fluids and nutrition, pain management, and monitoring of neurologic signs. Parents will need support and teaching to understand their infant's condition and participate in the treatment plan. Complications range from none to permanent neurologic deficits and/or seizures.

#### **8.7.1.7 Subarachnoid Hemorrhage**

Primary SAH is the most common intracranial hemorrhage in the neonate. SAH is more common in the premature infant but also occurs in full-term infants. Primary SAH consists of venous bleeding into the subarachnoid space, unlike SAH in older children and adults, which is usually the result of arterial bleeding. The cerebral convexities, especially in the posterior fossa, are the usual sites for SAH in the neonate (Parsons et al. 2016).

Trauma causing increased intravascular pressure and capillary rupture is associated with SAH in the full-term infant. Asphyxia may cause SAH in the premature infant. Risk factors for SAH include birth trauma, prolonged labor, difficult delivery, fetal distress, and perinatal asphyxia.

The most common presentation of SAH is the asymptomatic premature infant with a minor SAH. The SAH is discovered incidentally with a bloody lumbar puncture during a sepsis work-up or cerebral ultrasound to rule out intraventricular hemorrhage. SAH can also present in a full-term or preterm infant as seizures or apnea at 2–3 days of age. Between seizures, the infant appears healthy. Rarely, infants with a massive SAH associated with birth trauma and severe asphyxia have a rapid and fatal course (Ditzenberger and Blackburn 2014).

Ultrasonography or CT is useful to confirm the diagnosis of SAH. If the infant has seizures, other causes of seizures must be eliminated. Blood in the CSF on lumbar puncture may be from SAH or from a bloody tap. Although rare, a severe, acute SAH may require a craniotomy. Infants with minor or asymptomatic SAH survive and generally have good developmental outcomes. Up to half of infants with symptomatic SAH, with sustained traumatic and hypoxic injury, have neurologic sequelae. Occasionally, SAH results in hydrocephalus due to CSF obstruction at the level of the arachnoid villi. Periodic cerebral ultrasound evaluation for ventricular size may be indicated. Nursing care involves assessment for seizures and other neurologic signs. Parents will need support and teaching about SAH, so they can understand the needs of their infant.

#### **8.7.1.8 Subdural Hemorrhage**

SDH is not unusual after vaginal delivery. Small posterior fossa subdural hematomas are common after uncomplicated vaginal deliveries (Barkovich and Raybaud 2012). The most likely site for hemorrhage is over the cerebral hemispheres. Significant bleeding over the posterior fossa causes compression of the brainstem, as do dural tears near the great vein of Galen. SDH affects full-term infants more often than preterm infants, usually as a result of precipitous, prolonged, or difficult delivery, use of forceps, cephalopelvic disproportion, breech delivery, or a large infant (Parsons et al. 2016).

Excessive head molding results in stretching of the falx (folds of dura mater that separate the two cerebral hemispheres and the two cerebellar hemispheres) and tentorium (dura mater between the cerebrum and cerebellum), and venous sinuses, with tearing of the vein of Galen or cerebral or cerebellar veins (Lynam and Verklan 2015). As with SAH, SDH diagnosis depends upon the history and presentation of the infant. If seizures are present, other causes must be excluded. SDH can occur along with SAH; cephalohematoma; subgaleal, subconjunctival, and retinal hemorrhages; skull fractures; and brachial plexus and facial palsies. MRI or CT will help to



confirm the diagnosis, while ultrasound is less reliable.

Clinical signs are related to the site and severity of the bleeding. Infants with minor hemorrhage will either be asymptomatic or have minor neurological signs, such as irritability and hyperalertness. If the posterior fossa SDH is small, there may be no signs for 3–4 days. As the subdural clot enlarges, signs of increased ICP appear and the infant's condition deteriorates. With more significant hemorrhage, the infant may demonstrate seizures in the first 2–3 days of life. These seizures are usually focal, and other neurologic signs may or may not be present, such as hemiparesis, unequal or sluggish pupils, full or tense fontanel, bradycardia, and irregular respirations. Infants with significant posterior fossa SDH have abnormal neurologic signs from birth, including stupor or coma, eye deviation, asymmetric pupil size, altered pupillary reaction to light, tachypnea, bradycardia, and opisthotonos (prolonged, sustained posture with leg extension, trunk arching, and variable arm posture, often extended). As the clot enlarges, there is rapid deterioration with signs of shock in minutes to hours. The infant becomes comatose, with fixed, dilated pupils, altered respirations and heart rate, and finally respiratory arrest.

A subset of infants have no or nonspecific signs in the neonatal period, but then present at 4 weeks to 6 months of age with increasing head size as a result of continued hematoma formation, poor feeding, failure to thrive, altered LOC, and, occasionally, with seizures due to chronic subdural effusion.

Care is primarily supportive, including oxygenation and perfusion, thermal management, and fluids and nutrition. Surgical evacuation of bleeding over the temporal convexity associated with increased ICP may be necessary for infants unable to be stabilized neurologically. Massive posterior fossa hemorrhage requires neurosurgical intervention. Infants at risk for SDH should be monitored for 4–6 months for head size, growth, feeding, activity, LOC, and seizure activity. Aside from supportive nursing care, nurses provide parents education about the cause and

prognosis for their infant. Referral to early intervention services is recommended at discharge.

Prognosis varies with the size and severity of the hemorrhage. Infants with SDH, who are asymptomatic or have transient seizures in the neonatal period, do well if there is no associated cerebral injury. Minor posterior fossa hemorrhages rarely have clinical significance (Barkovich and Raybaud 2012). Early diagnosis of large posterior fossa hemorrhage with MRI and CT has improved the outcome for those infants. Most infants with massive bleeding over the tentorium or falx cerebri near the great vein of Galen die. Those who survive usually have hydrocephalus and neurologic sequelae.

#### **8.7.1.9 Intracerebellar Hemorrhage**

Intracerebellar hemorrhage is more common in preterm than full-term infants. Although rare, it is generally associated with hypoxia in the preterm infant and associated with trauma in the full-term infant.

Intracerebellar hemorrhage may be caused by intravascular factors (vitamin K deficiency, thrombocytopenia), vascular factors (damage due to hypoxia, followed by hypertensive spikes, e.g., from too rapid intravenous colloid infusion), and extravascular factors (mechanical deformation of the occiput during forceps or breech delivery in the full-term infant, compression of the compliant skull during caregiving, or the use of constrictive bands around the head, especially in the preterm infant) (Lynam and Verklan 2015). Intracerebellar hemorrhage may be a primary bleed or extension of a hemorrhage into the cerebellum.

Infants with intracerebellar hemorrhage either present critically ill from birth, with apnea, a declining hematocrit, and death within 24–36 h, or present less ill with symptoms developing at up to 2–3 weeks of age. Clinical signs include apnea, bradycardia, hoarse or high-pitched cry, eye deviations, facial paralysis, opisthotonos or intermittent tonic extension of the limbs, seizures, vomiting, hypotonia, diminished or absent Moro reflex, and hydrocephalus (Ditzenberger and Blackburn 2014).

Cranial ultrasound and/or CT scan is used for diagnosis. Lack of echogenicity of the cerebellum may be an important finding (Lynam and Verklan 2015). Intracerebellar hemorrhage is frequently diagnosed at autopsy. Treatment is primarily supportive. Surgery may be indicated, including hematoma evacuation or ventriculoperitoneal shunt for hydrocephalus. Nursing care involves supportive care for the infant and care and comfort for the parents/family, including referral for early intervention services after discharge. Prognosis is poor in preterm infant survivors. Full-term infants have more favorable outcomes, but generally with subsequent neurologic deficits, especially motor and variable involvement of intellect.

### 8.7.2 Pediatric Traumatic Brain Injury

Concussion and mild TBI are interchangeable terms. Concussion does not necessarily involve a loss of consciousness, and imaging is typically negative. Yet it can have devastating consequences for children if not diagnosed or treated properly. A child can suffer a concussion as a result of a fall, a fistfight, a motor vehicle accident, an athletic injury, or any other accidental or non-accidental trauma. However, due to the recent interest in sports-related concussions, a separate chapter is devoted to that topic. See Chap. 9.

The question then is which children with concussion, or MTBI, meet clinical criteria to warrant CT and which can be safely observed without CT. A prospective study of over 42,000 children with minor blunt head trauma, performed by the Pediatric Emergency Care Applied Research Network (PECARN), “derived and validated highly accurate prediction rules for children at very low risk of clinically important TBI for whom CT can be avoided.” Negative predictors in children younger than 2 years were normal mental status, no scalp hematoma except frontal, no loss of consciousness or loss of consciousness for less than 5 s, non-severe injury mechanism, no palpable skull fracture, and acting normally

according to the parents. In children older than 2 years, they were normal mental status, no loss of consciousness, no vomiting, non-severe injury mechanism, no signs of basilar skull fracture, and no severe headache. An algorithm was created to assist providers in deciding which patients with minor head trauma should have a CT (Kupperman et al. 2009).

Management of nonsports-related concussion or mild TBI includes admission for observation and symptomatic treatment, including intravenous fluids, analgesia for headache, and antiemetics. Children with mild TBI (GCS 14–15) and an intracranial lesion are monitored and require follow-up imaging. Recommended intervals for repeat imaging of nonsurgical lesions are as follows: EDH, 6 h; SDH, 8–12 h; and contusion, 12–24 h. A retrospective review of 118 pediatric patients with mild TBI (GCS 14–15) and traumatic ICH found that patients without EDH, IVH, coagulopathy, or concern for a high-risk neurosurgical lesion (e.g., arteriovenous malformation) were less likely to develop clinically important neurologic decline (CIND) and therefore suggests that such patients may be monitored on a general neurosurgery floor rather than in the intensive care (Greenberg et al. 2014).

#### 8.7.2.1 Skull Fractures (Pediatric)

The pediatric skull provides a protective box, which houses the brain. Forces exerted on the skull are absorbed initially in a centrifugal configuration and then directed inward toward the brain. Fractures occur when the skull cannot withstand the force of impact. As mentioned previously, the pediatric skull is thinner and more deformable when compared to the adult skull, which predisposes the child to significant traumatic brain injury with or without the presence of a skull fracture. As summarized by Pinto et al. (2012), the incidence of skull fractures in children with TBI ranges from 2% to 26%. Of these, 75% occur in severe TBI as opposed to less than 10% in mild TBI. Almost half of all intracranial injury occurs without skull fracture. The most common location for pediatric skull fracture is parietal (60–70%), followed by occipital, frontal, and temporal locations. Skull fractures are

described as linear, closed/open, depressed, or basilar. The majority of pediatric skull fractures are linear.

The nursing assessment should include inspection and gentle palpation of the scalp to check for findings consistent with a skull fracture. External evidence of skull fracture includes swelling, hematoma, depression of the scalp, laceration with or without hemorrhage or cerebrospinal fluid (CSF) leak, or extruding brain. Basilar skull fractures are identified by external clinical findings. Basilar fracture of the temporal bone results in “Battle’s sign,” which is postauricular ecchymoses and can be associated with CSF leak from the ear (otorrhea). A frontal basilar fracture results in “raccoon eyes,” which is periorbital ecchymoses. CSF leak from the nares (rhinorrhea) can result secondary to frontal basilar fracture. The majority of cerebrospinal fluid leaks resolve within a few days without surgical intervention. Nursing care of the patient with CSF leak includes elevation of the head of the bed, restriction of nose blowing, and reporting of fever or other signs of meningitis. The neurosurgeon may need to place a lumbar drain to allow the leak to seal or perform surgical closure if conservative management is unsuccessful. Check with the neurosurgeon before placement of a nasogastric tube, as a frontal fracture through the cribriform plate can allow placement of the catheter into the brain.

*Linear nondepressed skull fractures* occur in the calvaria (upper portion of the frontal, parietal, and occipital bones) and heal without intervention (Gaynor et al. 2015). Only 15–30% are associated with intracranial injury (Schutzman and Greenes 2001). Complex fractures – multiple, stellate (multiple linear fractures radiating from the site of impact) (Farlex Medical Dictionary 2012), or crossing a venous sinus – are more often associated with intracranial hemorrhage or injury (Gaynor et al. 2015). Initial management of skull fractures is identification of any serious underlying acute hemorrhage or brain injury. While skull fractures are readily visible on skull radiographs as thin, dark lines, CT is the gold standard to determine if there is any underlying brain injury (Pinto et al. 2012). The middle men-

ingeal artery is housed in a groove of the temporal bone. Laceration by the sharp bony edge of the fracture causes serious life-threatening epidural hematoma formation and need for emergent surgical intervention following temporal bone fracture (Greenberg 2016).

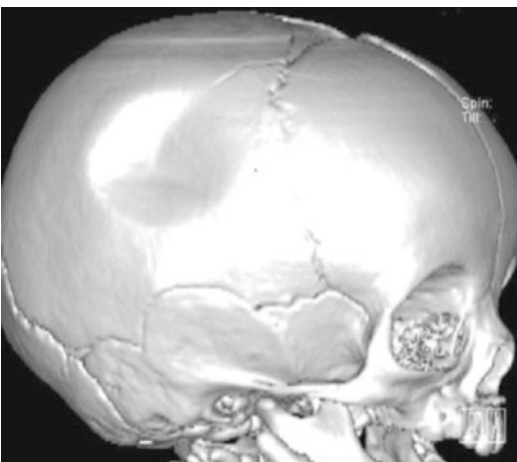
Young children with a diastatic skull fracture (occurring along or widening a cranial suture line) and an underlying dural tear may develop a *leptomeningeal cyst or growing fracture of childhood*. This is rare, occurring less than 1% of the time in children less than 3 years of age. The opening in the dura allows the cerebrospinal fluid (CSF), dura, and brain to pulse outwardly into the area of the fracture, preventing healing and causing outward eversion or “growth” of the fracture margins. A new soft, pulsatile swelling on the scalp is suspicious for a growing skull fracture and requires imaging with a head CT to assess the fracture and brain MRI to determine the extent of brain changes and dural tear (Pinto et al. 2012). Leptomeningeal cysts require early craniotomy, repair of the torn dura, and cranioplasty, as delayed diagnosis or surgical correction may lead to progressive skull defect and brain damage (Pinto et al. 2012).

*Depressed skull fractures* (bone depressed below the inner table of the skull) occur in 7–10% of children with head injury. The depressed fragment can cause hemorrhage secondary to tearing of a venous sinus and injury (contusion) to underlying brain (Pinto et al. 2012). Minimally depressed fractures (less than full thickness of skull), without skin laceration or underlying brain injury, do not require surgery. Nonsurgical management in this case is not associated with increased risk for seizures, neurologic impairment, or cosmetic deformity (Gaynor et al. 2015). In younger children with growing skulls, these fractures tend to remodel to a cosmetically pleasing appearance. *Closed, open (compound) depressed skull fractures* with skin laceration, dural tear, parenchymal injury, CSF leak, brain extruding through laceration, and focal neurologic deficit require surgical elevation, debridement of pulped brain, evacuation of hemorrhage, and dural repair. The case study in this chapter (see case study and Fig. 8.11a–f) gives an example,

including radiographic imaging, of a patient with a depressed skull fracture and severe underlying brain injury.

*Ping-pong fractures* are a subset of depressed skull fractures which occur in newborns and young infants due to the thin, pliable skull and consist of a greenstick fracture and skull depression which resembles a depression in a ping-pong ball (see Fig. 8.6). Due to rapid skull growth, most ping-pong fractures heal well without surgery and mold to become cosmetically acceptable. Elevation is required for underlying brain injury, parenchymal bone fragments, neurologic deficit, or cosmesis in older infants (Gaynor et al. 2015).

*Basilar skull fractures* occur in the anterior, middle, or posterior fossa at the base of the skull and frequently extend from temporal bone or from paranasal sinus fractures. They occur in about 6–14% of pediatric traumas, and 80% of those have associated complications (Pinto et al. 2012). Cerebrospinal fluid leak via the ear or nose occurs in about a quarter of basilar skull fractures and most often resolves within a few days. Persistent CSF leak requires surgical closure. Meningitis can occur secondary to CSF leak. The use of antibiotics is controversial and not often recommended due to the risk of selecting out resistant organisms. Structures at the



**Fig. 8.6** Ping-pong skull fractures occur in newborns and young infants due to the thin, pliable skull and consist of a greenstick fracture and skull depression which resembles a depression in a ping-pong ball

skull base are susceptible to injury and include the carotid artery (dissection), venous sinus, cranial nerves, and the middle ear (Gaynor et al. 2015). Basilar skull fractures may be difficult to see on CT, but findings of pneumocephalus and opacification of the mastoid air cells are suggestive. Plain films and clinical findings such as CSF otorrhea or rhinorrhea, hemotympanum, Battle's sign, raccoon eyes, and cranial nerve injuries are more sensitive indicators (Greenberg 2016).

*Temporal bone fractures* are classified as transverse (extending across the petrous portion) or longitudinal (extending lateral to medial). Complications associated with transverse temporal bone fracture include sensorineural hearing loss (CN VIII) and facial nerve dysfunction (CN VII), whereas longitudinal temporal fracture can cause hemotympanum, torn tympanic membrane, CSF leak, and conductive hearing loss secondary due to bony disruption. In most cases, the hearing loss resolves, but it can be permanent. Most basilar skull fractures resolve without surgery (Pinto et al. 2012). Inner ear injury and hearing loss are typically referred to an ENT specialist.

### 8.7.2.2 Extra-axial Hematomas

Extra-axial hematomas are those occurring outside the brain itself and are defined by etiology (venous, arterial), location in relationship to the meninges (epidural, subdural, subarachnoid), speed of occurrence, and size. The presentation and acuity level varies based on the child's age, as well as location and size of the hemorrhage. Rapidly expanding hemorrhage results in an increase in intracranial volume and causes mass effect with shift of the midline brain structures. Mass effect compounded with associated cerebral swelling and injury results in increased ICP. The classic presentation in a child with a rapidly expanding mass lesion is reduced level of consciousness, ipsilateral mydriasis (same-side, fixed, and dilated pupil), and contralateral hemiparesis (opposite-side weakness). Small hemorrhages with minimal or no clinical deterioration may be observed with close monitoring and follow-up imaging. Venous-origin hematomas can present in delayed fashion (Figaji 2015), making serial neurologic assessment and

follow-up imaging important in order to catch deterioration early. Hematomas of arterial origin (accumulate rapidly), posterior fossa location (small space, pressure on brainstem, hydrocephalus secondary to occlusion of fourth ventricle), and those that are large or associated with underlying brain swelling are higher risk lesions (Figaji 2015). Large hematomas with significant mass effect, underlying brain injury, and in a deteriorating or comatose patient require emergent craniotomy and surgical decompression.

### Epidural Hemorrhage

Bleeding separates the dura and the inner table of the skull, creating a virtual space above the dura, where mass hemorrhage accumulates. EDHs occur in 3% of all head traumas, with the highest incidence in children 10 years and older (Pinto et al. 2012). Mortality rate is ~5% (Greenberg 2016). The typical locations of pediatric EDHs are parietotemporal and in the posterior fossa (Pinto et al. 2012). Epidural hematomas can be either venous or arterial in origin. Arterial EDHs develop rapidly in the first 6–8 h following trauma. Classic arterial EDH results from a tear of the middle meningeal artery (MMA), which is housed within a groove of the temporal and parietal bones. The MMA is lacerated by a depressed sharp bony edge at the time of impact. EDHs are less common in infants and young children than in adults due to anatomic adherence of the dura to the inner table of the skull, and the MMA lies loosely in a more shallow skull groove, allowing it to be easily displaced rather than torn. In children, EDHs are more common in the posterior fossa than in adults, occur with or without occipital skull fracture, are frequently venous secondary to tearing of the dural venous sinus, and have mortality rates as high as 26% (Greenberg 2016). Venous-origin EDHs develop slowly over 24 h, along the dural sinuses, and are associated with better outcomes than arterial EDHs.

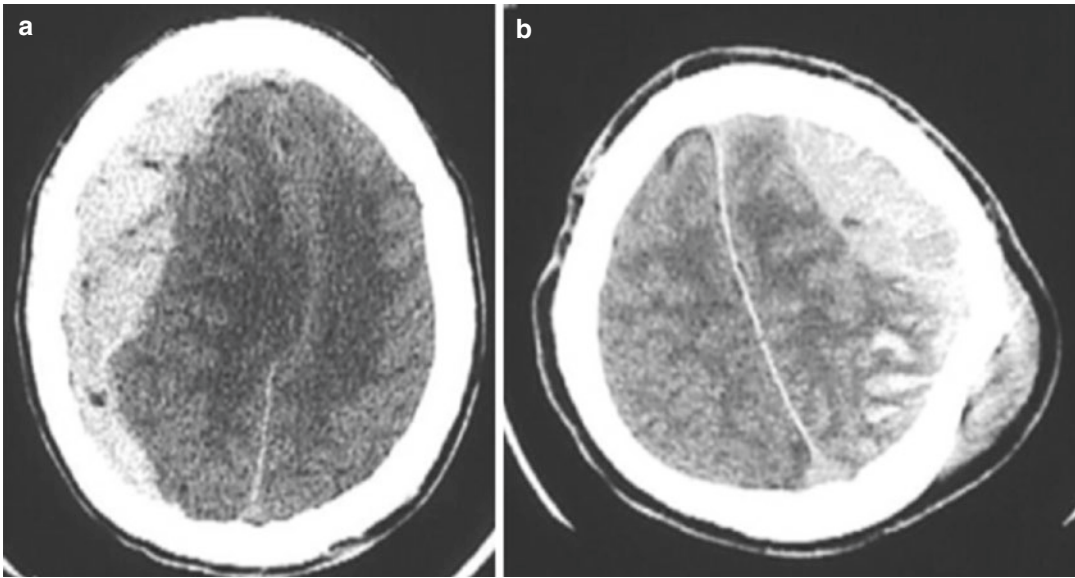
The hallmark presentation is brief loss of consciousness (child may only appear stunned), followed by “lucid interval,” and then rapid neurologic deterioration to obtunded with unequal pupils and hemiparesis. Other presenting symptoms may include headache, vomiting,

unilateral seizure, hemi-hyperreflexia, unilateral Babinski, and in young children, a 10% drop in hematocrit (Greenberg 2016). Clinical presentation of EDH in pediatrics can be delayed due to venous origin, and, to a point, the plasticity of the child’s skull. The volume of a rapidly expanding mass lesion (or hemorrhage) is not well tolerated, however, even in the more plastic pediatric cranium. The increased intracranial volume results in increased intracranial pressure. Posterior fossa EDHs present with rapid loss of consciousness and cardiorespiratory collapse, due to small anatomic space in the posterior fossa and direct compression on the vital centers in the brainstem. Compression on the outlet of the fourth ventricle can also cause acute obstructive hydrocephalus.

Radiographic evaluation of EDH is best accomplished with a CT scan, which reveals a lentiform, hyperdense (bright white), extraparenchymal fluid collection that is contained within the cranial suture lines (see Fig. 8.7b). The blood is contained within the sutures because of the attachment of the dura to the periosteum. Epidural hematomas are often also associated with CT scan findings of scalp swelling and the presence of a skull fracture in the frontal, temporal, or parietal regions (Barkovich 2012). Common practice is to repeat the radiographic imaging within 6 h for small, nonsurgical EDH. Indications for conservative, neurosurgical management are listed in Table 8.6.

Most EDHs are emergent surgical lesions. Management priorities are resuscitation and control of ICP, early imaging, and emergent craniotomy for evacuation, as delay leads to herniation, cerebral ischemia, and death (Figaji 2015). There is little or no underlying brain injury, so timing of surgery is critical in determining survival and outcome (Figaji 2015). Expedient evacuation can result in full recovery. Epidural hematomas in the posterior fossa of children are more dangerous due to the smaller anatomic space and potential for direct mass effect on the brainstem; thus surgery is highly recommended (Greenberg 2016). Complications, and therefore nursing assessments and nursing care, vary depending on the location of the EDH. Location, supratentorial (above) or infratentorial (below) the tentorium cerebelli,





**Fig. 8.7** (a, b) Extraparenchymal hemorrhage. (a) Subdural hematoma shown on CT scan as an acute, crescent-shaped blood collection that crosses suture lines.

(b) Epidural hematoma seen on CT scan as a hyperdense, lentiform collection, contained within the suture lines. Also note significant scalp swelling

results in varied clinical presentation and neurologic deterioration (see Sect. 8.3.2, “Location of Injury”).

### Subdural Hemorrhage

The subdural space is located below the dura mater and above the arachnoid membrane. The potential subdural space (created by hemorrhage) is not limited to the suture lines and, therefore, results in large, bilateral blood collections over the entire convexity (see Fig. 8.7a). Subdural hematomas (SDHs) can become chronic via a mechanism where the body walls off the collection with a vascular membrane that is prone to rebleed. Occurrence of SDHs is opposite that of EDHs in that they are more common in infants

and less common in older children, with the risk of SDHs ranging from 3.5% to 10.8% (Pinto et al. 2012). Presentation and prognosis are often worse with SDHs due to more underlying brain injury. Mortality rates may be as high as 40–60% (Figaji 2015). Common mechanisms of acute traumatic SDHs in children include acceleration–deceleration forces caused by falls from height, MVAs, and child abuse (see Chap. 10 on abusive head injury). This type of hemorrhage is due to either stretching and tearing of the bridging veins in the subdural space or accumulation around a brain laceration or severe primary brain injury (Greenberg 2016). The unique pediatric anatomy, including deformable skull, soft brain, and wider extra-axial space, creates traction force on the veins, making them more susceptible to tearing (Pinto et al. 2012). Most are supratentorial in location, occurring along the convexities, the falx, or the tentorium.

The presence of acute blood in the subdural space is well visualized on CT scan. Subdural hematomas appear as an acute, crescent-shaped, extraparenchymal blood collection, which crosses the suture lines (see Fig. 8.7a). Severity of an SDH is based on the size, location, and the

**Table 8.6** Nonsurgical management of epidural hematomas (Figaji 2015)

Requirements for nonsurgical management of EDH
Minimal mass effect (<1–1.5 cm thickness)
An awake patient
Close neurologic observation
Repeat imaging within 6 h
Small posterior fossa clot without compression of cortex, fourth ventricle, or brainstem (Greenberg 2016)

presence of mass effect. Mass effect with any intracranial lesion is manifested as a right or left shift of the cerebral hemispheres (away from the lesion), effacement (compression) of the ventricles, displacement of the brainstem, and obliteration of the sulcal pattern and is indicative of increased ICP. There may also be underlying brain injury, which is less visible until the clot is surgically decompressed. MRI can be useful to determine the timing (acute versus chronic) of subdural hemorrhages, which can be helpful in an investigation for child abuse (Barkovich et al. 2012). See Chap. 10.

Large expanding mass lesions of subdural origin significantly increase intracranial volume and thereby intracranial pressure. Infants with SDH present with seizures, irritability, lethargy, vomiting, and increased head circumference. Older children have decreased level of consciousness, pupil asymmetry, and hemiparesis. Severe increased intracranial pressure results in an irregular respiratory pattern, hypertension, and bradycardia, also known as “Cushing’s triad” (see Sect. 8.5.2). Presenting symptoms may be due to the mass effect exerted by the subdural hemorrhage or by the underlying brain injury, and possibly cerebral edema. Expansile subdural collections require emergent craniotomy and evacuation to prevent herniation and death. In contrast, a small SDH in a child with minimal neurologic deficits can be observed closely with follow-up imaging within 8–12 h. Size, location, and patient presentation are considered when weighing indications for surgery. Guidelines for surgical evacuation are as follows (Figaji 2015; Bullock et al. 2006; Greenberg 2016):

- At least considered for SDH thickness >5 mm
- Thickness <10 mm or midline shift <5 mm; and drop in GCS by two or more points, pupils asymmetric/fixed and dilated, or ICP >20 mmHg
- Thickness of 10 mm or more and/or midline shift 5 mm or more, regardless of GCS

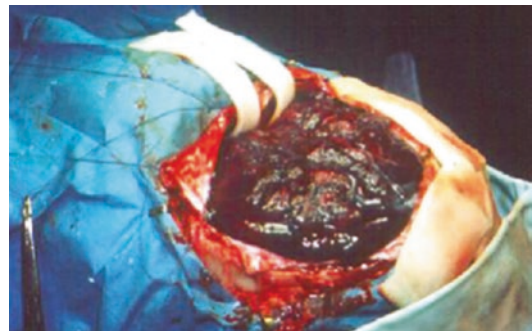
Care must be taken at the time of surgery to avoid herniation of the swollen, hyperemic (increased cerebral blood flow) brain (see

Fig. 8.8). Measures to prevent herniation of the brain through the craniotomy and dural opening include maximum measures by the anesthesiologist to control ICP, slow decompression of the clot and brain, and duraplasty with craniectomy (Figaji 2015). Needle aspirations can be performed in infants with an open fontanel to temporarily relieve pressure.

### Subarachnoid Hemorrhage

The subarachnoid space is located between the arachnoid and pia mater (a thin membrane that is adhered to the brain’s surface). In children, acute traumatic subarachnoid hemorrhage (SAH) occurs due to a direct tear of vessels in large, vascular subarachnoid space, an extension of intraventricular hemorrhage (IVH), or subarachnoid rupture of a cerebral contusion or hemorrhage (Pinto et al. 2012). SAH often coexists with extra-axial hemorrhage and IVH in severe TBI. Cerebrospinal fluid (CSF) is made primarily in the ventricles and then circulates out of the fourth ventricle and around the brain within the subarachnoid space. Circulation of CSF allows delivery of metabolic substrates, cushions the brain from trauma, and removes waste products. Clearance of subarachnoid blood is fairly rapid as the blood is “washed out” with the circulation of CSF.

On CT scan images, SAH appears hyperdense (bright white) and is seen within the sulci on the brain’s surface, in the interhemispheric fissure, along the tentorium, and within the basal cisterns.



**Fig. 8.8** Intraoperative photograph demonstrating a large open craniotomy after severe head trauma. Note swollen appearance of the brain and the large SDH clot on the surface of the brain

SAH is difficult to visualize on MRI, with the exception of MRI FLAIR sequence where blood and protein enhance the signal intensity of the subarachnoid CSF. MRI can be useful to identify nonhemorrhagic intraparenchymal lesions in children with substantial SAH and severe neurologic deficits (Pinto et al. 2012).

The child with SAH should be observed for irritability, headache, stiff neck, and other signs of irritation to the meninges, similar to the presentation of meningitis. Children with traumatic SAH or IVH rarely develop posttraumatic or posthemorrhagic hydrocephalus. Clinical presentation of hydrocephalus is identical to that of increased intracranial pressure. Hydrocephalus can be seen on limited-sequence MRI as dilation of the cerebral ventricles and when present requires CSF diversion to prevent increased ICP and possible herniation. Temporary CSF diversion techniques include transfontanel tap in an infant with an open fontanel or drainage via ventriculostomy. Permanent CSF diversion requires placement of a shunt, consisting of a ventricular catheter, a one-way pressure-regulated valve, and a distal catheter to divert CSF to the peritoneum, pleural space, or right atrium. See Chap. 2, “Hydrocephalus.”

### 8.7.2.3 Parenchymal Injury

Generalized brain swelling is more common in children than adults following severe head trauma (Barkovich et al. 2012). This is thought to occur due to edema and a process of dysautoregulation (see Sect. 8.8.5). Neuroimaging with CT scan completed 12 h after the injury may not show brain swelling, whereas repeat imaging with CT or MRI at 24 h post-injury may reveal poor gray-white matter differentiation, compressed or absent ventricles, cisterns, and sulci, focal injury on diffusion-weighted imaging (DWI) (see Fig. 8.9), cerebral herniation (see Sect. 8.8.11), and infarction (Barkovich et al. 2012).

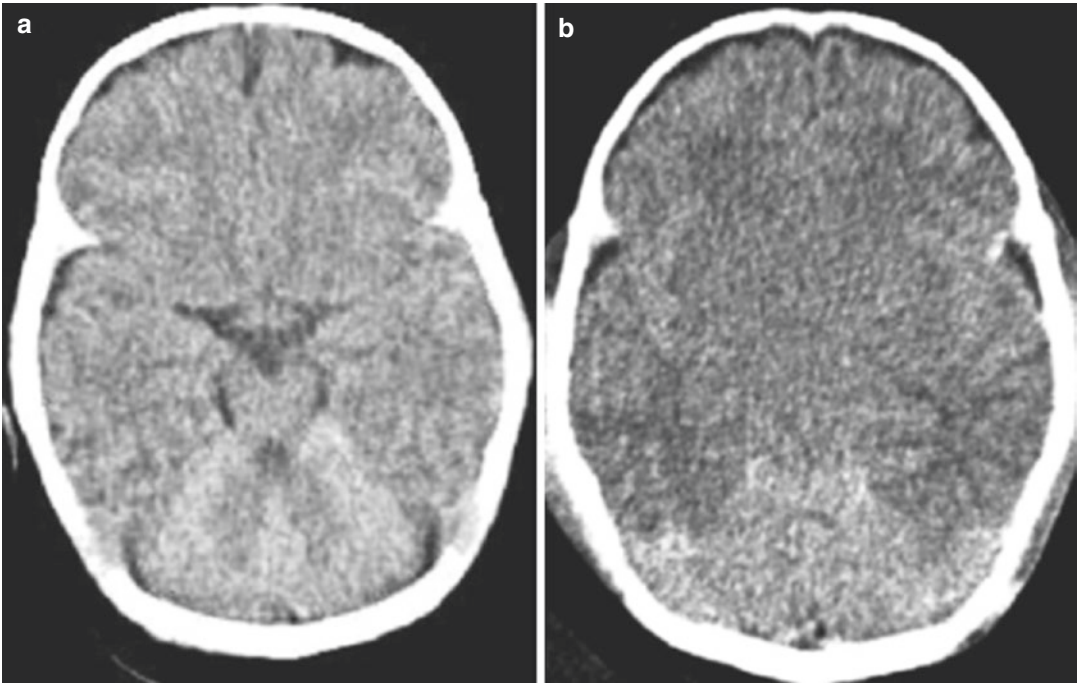
Mass effect following parenchymal injury can be compartmentalized or global. Mass effect from hemorrhage and surrounding cerebral edema, when confined to the temporal (middle) cranial fossa, is concerning and can lead to transtentorial (or uncal) herniation. Surgical intervention becomes necessary to prevent impending uncal

herniation or other neurologic deterioration. The child with an expanding contusion or mass lesion on the right side and pending uncal herniation will present with a right unilateral dilated pupil and contralateral motor weakness, hyperreflexia, Babinski, clonus, or posturing. The goal of neurosurgical intervention is to remove the hemorrhage, as well as the injured portion of the brain, to decompress the compartment and reduce related volume and, therefore, pressure (Greenberg 2016). It is paramount for the nurse to carry out interventions to prevent secondary injury due to hypoxemia, hypotension, cerebral edema, increased ICP, and life-threatening cerebral herniation. Any deterioration in the child’s level of consciousness, GCS, and pupillary or motor responses indicates increasing ICP and should be reported to the provider immediately and documented. Types of parenchymal injury include cerebral contusion (hemorrhagic and nonhemorrhagic), laceration, and axonal shearing.

### Contusion

A contusion is a focal bruise (hemorrhagic or nonhemorrhagic) to the surface of the brain or gray matter. Contusion occurs after a focal impact with overlying skull fracture or when the skull impacts a stationary object with sudden deceleration. Deceleration causes sudden impact of the brain against irregular or sharp internal bony prominences of the frontal, temporal, or occipital skull. Contusions are less common in young children due to the smoother internal surface of the skull (Pinto et al. 2012). The point of initial impact of the brain on the internal skull is referred to as the “coup” contusion. The brain, being suspended in fluid, then strikes the opposite side of the skull, which can cause a “contrecoup” contusion. The French meaning of the word contrecoup is “counterblow.” Coup and contrecoup injuries are less common in children <4 years of age, when the soft brain is more likely to tear than contuse (Pinto et al. 2012). Thirty percent have mass effect and swelling of adjacent brain (Pinto et al. 2012).

Nonhemorrhagic contusions appear as a hypodense (dark) area on head CT representing associated edema, whereas hemorrhagic



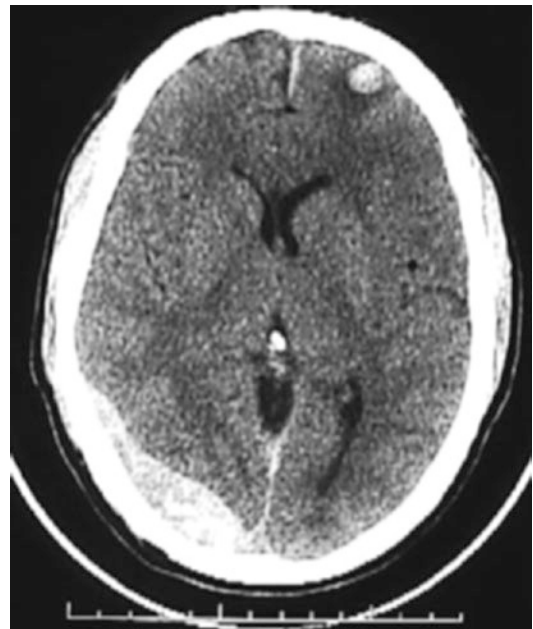
**Fig. 8.9** (a) Severe traumatic brain injury (TBI). Early CT scan without evidence of injury, cisterns, and normal extra-axial fluid is maintained. (b) Follow-up CT scan on day 2 showing what is referred to as a “tight” brain, with

generalized edema, poor gray-white matter differentiation, and obliteration of the ventricles, cisterns, and sulcal pattern

contusions appear as a hyperdense (bright white) area surrounded by edema (see Fig. 8.10). MRI, specifically diffusion-weighted imaging (DWI), is more sensitive to identify nonhemorrhagic contusions (see section “Diffuse Axonal Injury”). It is the hallmark for contusions to enlarge subacutely and, therefore, require repeat CT imaging within 12–24 h of the injury or 4–6 days post-injury when associated edema can be most severe (Pinto et al. 2012).

The child with a focal contusion in an eloquent area of brain, such as speech or motor centers, will likely have worsening of their neurologic function specific to the area of injury as the contusion enlarges. Nurses should be aware of the location of injury and anticipate what deficits may develop. Any change in neurologic function should be reported to the provider immediately. The family should also be warned that the deterioration may occur.

Close observation in an intensive care unit and repeat imaging is required, but contusions typically coalesce and resolve without surgical inter-



**Fig. 8.10** CT scan demonstrating a typical surface contusion in the left frontal lobe, which was likely a contrecoup injury. Note right posterior SDH. The ventricles are asymmetric secondary to the mass effect of the SDH



vention. Lesions may “blossom” with progressive hemorrhage or brain swelling, resulting in secondary injury such as herniation and ischemia. Progression in temporal lobe can result in uncus herniation. Progression in the hypothalamus may result in downward transtentorial herniation. And progression in the posterior fossa may cause tonsillar herniation and obstruction of the outlet of the fourth ventricle resulting in hydrocephalus. Surgical decompression is indicated for threat of cerebral herniation (Greenberg 2016).

*Posttraumatic seizures* (PTS) occur in about 10% of pediatric TBIs, with higher incidence in younger children and with more severe injury (Gaynor et al. 2015). The majority occurs in the first 24 h post-injury and is referred to as *impact* seizures. Risk factors associated with higher occurrence of PTS include location of the lesion, cerebral contusions, retained bone and metal fragments, depressed skull fracture, focal neurologic deficits, loss of consciousness, Glasgow Coma Scale (GCS) score <10, severity of injury, length of posttraumatic amnesia, subdural or epidural hematoma, penetrating injury, chronic alcoholism, and age (Kochanek et al. 2012). Seizures result in increased cerebral metabolism and increased ICP and can cause secondary brain injury with worsened outcomes. The Guidelines from the Society of Pediatric Critical Care Medicine (Kochanek et al. 2012), based on a single class III study (Lewis et al. 1993), recommend “prophylactic anticonvulsant therapy with phenytoin may be considered to reduce the incidence of early posttraumatic seizures in pediatric patients with severe TBI.” No data has shown that the use of anticonvulsants for early PTS in severe TBI reduces the long-term risk of posttraumatic epilepsy or improves long-term neurologic outcome.

### Case Study (See Fig. 8.11a–f)

Scene: A 9-year-old male was struck in the head by a line-drive foul-tip baseball. He was witnessed to have immediate LOC, followed by combative behavior and vomiting.

Pediatric ED: He was brought in by squad and presented in coma with extensor posturing. Exam revealed a “boggy” depression in left posterior temporal scalp. Pupils 2–3, ERRLL, “erratic” respiratory effort, HR 65–75 with good perfusion. GCS = 8 (eyes open but not responding, no verbalization, no purposeful movement/extensor posturing).

ED diagnosis: Severe TBI, coma with extensor posturing, concern for increased ICP and inability to protect airway.

Treatment: Intubated and mechanically ventilated, fentanyl and versed given for hypertension following intubation. Fosphenytoin added for seizure prophylaxis. See Fig. 8.11a–b.

Social history: The mother was hysterical in the ED. She is a single mother whose support system resides outside of the USA. An 8-year-old sibling witnessed the injury. The chaplain and social work were involved to provide support to the family.

Operation: Emergent left frontotemporal parietal craniectomy for elevation of a depressed skull fracture.

PICU medical management: Noninvasive measures for cerebral swelling, mechanical ventilation, temperature control, HOB elevation, seizure prophylaxis, mannitol q6, and 3% NS at 1 ml/kg/hr. See Fig. 8.11c.

*PTD #2* (24 h post-op) – A stat limited-sequence MR is performed for low GCS and elevated ICP; high teens to low 20s (highest witnessed at 27) responded to pentobarbital q2–3, 3% NS infusion, and mannitol q12. CPP in the low 60s. Limited MRI is similar to CT with severe left temporal and parietal hemorrhagic contusions and edema with mass effect. See Fig. 8.11d. He fails extubation and is reintubated. Surgeon performs craniotomy, clot evacuation, and placement of an ICP monitor.



**PTD #3** – Post-op head CT (Fig. 8.11e) shows the ventricles are less effaced, with less MLS. He remains sedated and intubated. Exam reveals pupils 2 mm and slightly reactive, moves all extremities (left > right) to stimulation, ICP 18–27, serum Na 143, serum Osm 297. Medical management continues in the PICU with 3% NS at 1.5 ml/kg/h, mannitol 0.5 gm/kg/dose q12 and prn q6, fentanyl and versed gtt, and pentobarbital q2 prn. If pentobarbital is needed more frequently for sustained ICP > 20 for more than 5 min, switch to pentobarbital gtt with load of 2 mg/kg and gtt at 1 mg/kg/h. Goal CPP >55. Will tolerate as low as 50 in order to avoid SBP > 120. Fosphenytoin for seizure prophylaxis. Goal ICP = 20. Goal sodium 145–155.

### Example of a Progress Note

**PTD #5** – 7-year-old male struck in the head by a baseball, POD #3 elevation of a depressed left temporal skull fracture and POD #2 evacuation of a left temporal clot and placement of an ICP monitor. Head CT from yesterday showed less effacement of the ventricles and less midline shift. The left temporal lobe is macerated and swollen.

Ventilated with goal pCO<sub>2</sub> of 35.

Sedation: Fentanyl 3 mcg/kg/h, versed 0.2 mg/kg/h, Precedex gtt. Also received pentobarbital bolus at midnight and 0500.

Osmotherapy: Mannitol 0.5 g/kg every 8 h and 3% NS at 30 ml/h.

ICP ranged 20–22 (spiked to 26–29 this morning with stimulation; resolved with pentobarbital bolus).

CPP ranged 55–65.

Fosphenytoin for seizure prophylaxis.

Tylenol scheduled (tmax 37.3).

Sosm = 311.

Na = 150.

Hb = 8.4

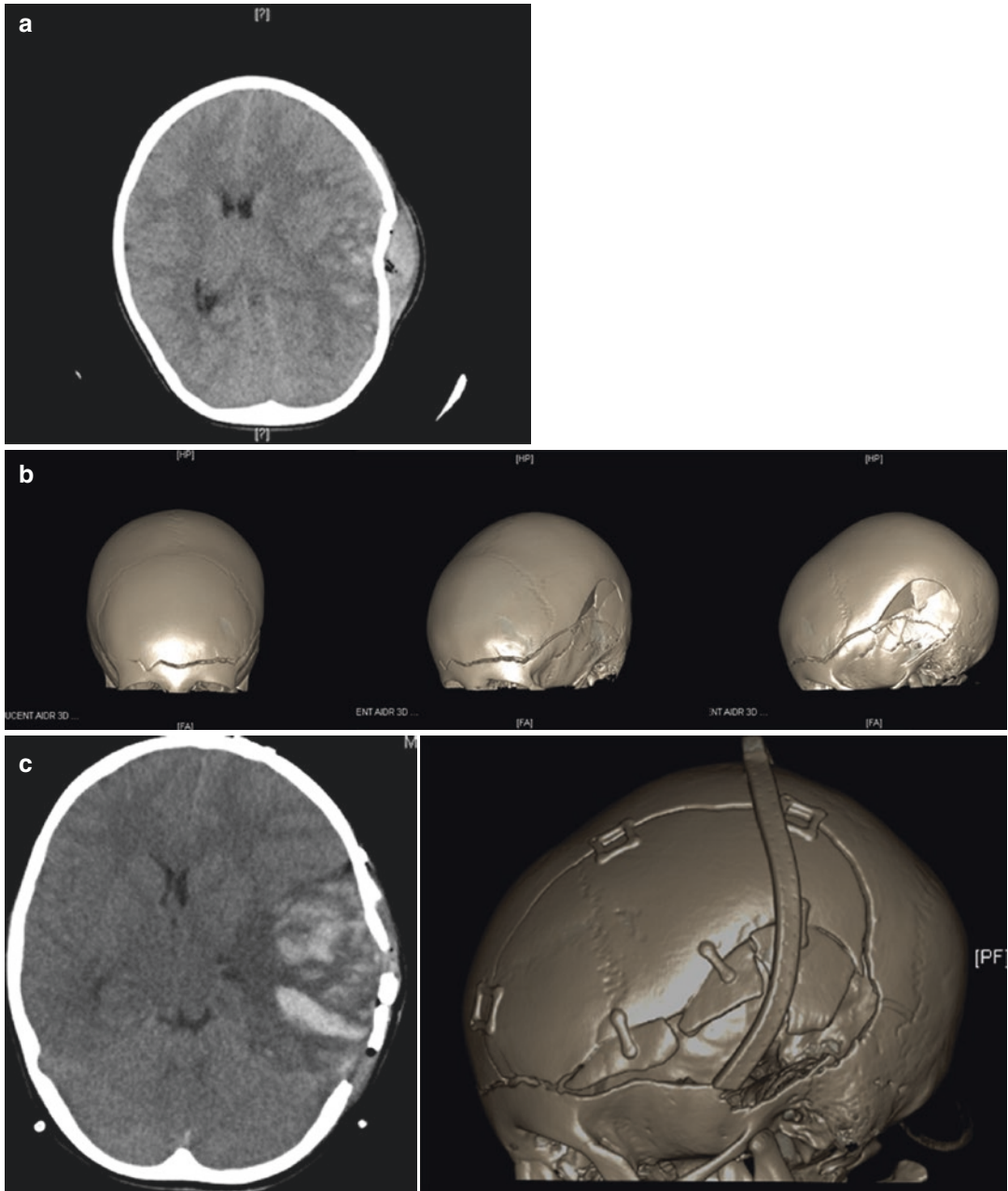
Sedated but spontaneously raises left arm off bed. No eye opening. Pupils 2 mm ERRL,

+ cough reported. No movement of right arm or BLE. Toes equivocal, nonclonic.

A/P: Status post-severe head trauma. ICP and CPP fairly stable with therapies. Imaging yesterday was improved s/p surgery. Plan is to continue all therapies. Will transfuse with PRBC today to maximize cerebral perfusion and oxygenation. Reviewed with mother that goal of current therapies is to prevent secondary brain injury. Mother is asking appropriate questions and is tearful.

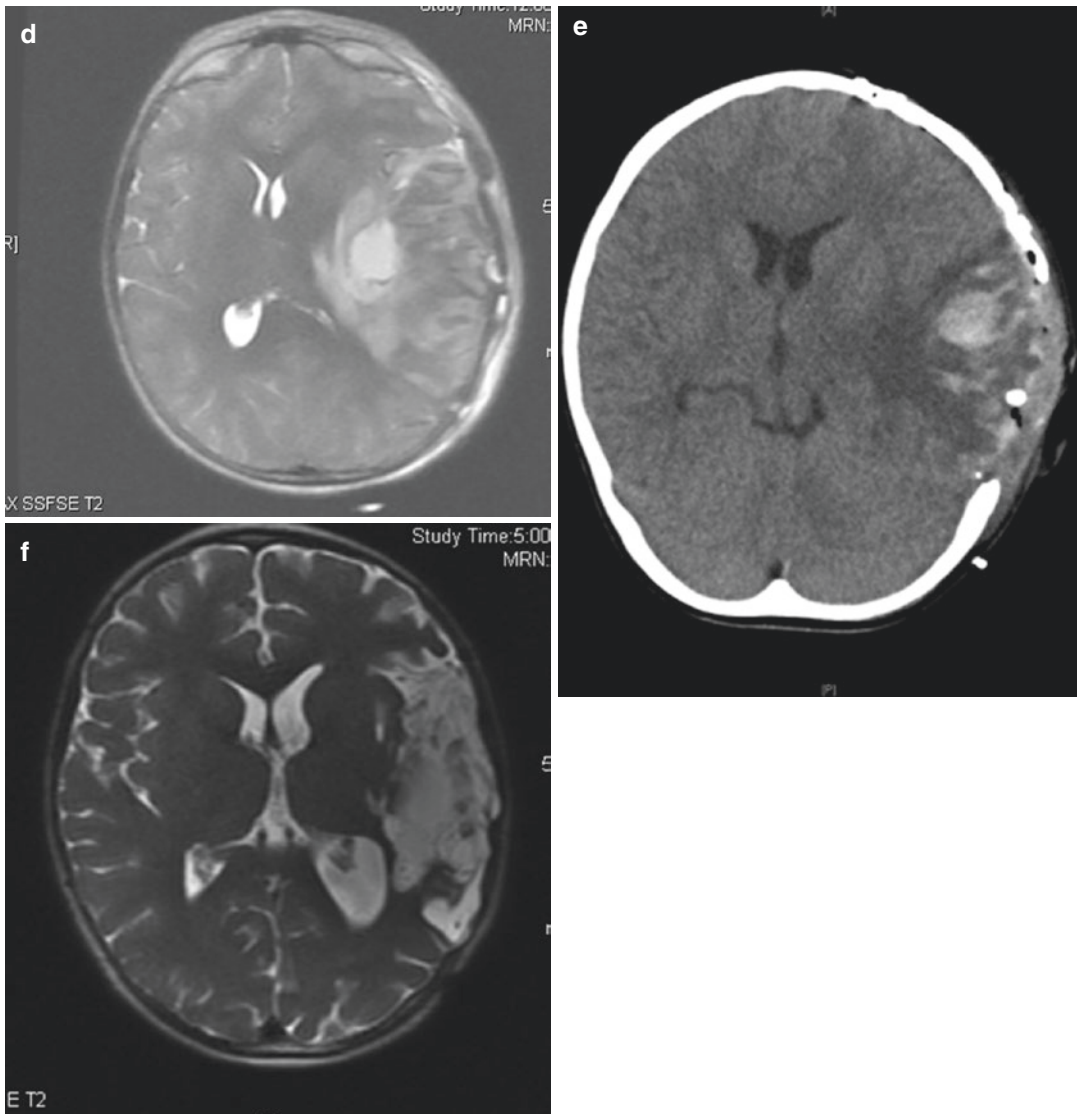
### Summary PTD #7 to PTD #14

ICP normalized and therapies to reduce ICP were weaned. He was extubated and the ICP monitor was removed. The patient progressed from opening eyes to stimulation to following simple commands; aphasia improved. He continued to improve; writing his name legibly, more cognizant, and taking foods by mouth. He was emotionally labile, with persistent but improving right facial and right hemiparesis. Physical, occupational, and speech therapies evaluated and began therapy. Psychology service became involved to assist with family and patient coping. Throughout the hospitalization, the family participated in bedside rounds. The neurosurgery and intensivist staff provided daily support to the family, which included updates on patient condition, imaging, treatment plans, and prognosis, as well as, emotional support. A reference book, *Children with Traumatic Brain Injury: A Parent's Guide* (Schoenbrodt 2001), was provided for the family. The patient was admitted to an inpatient rehabilitation program. MRI performed 1 year after the injury (Fig. 8.11f) shows a large area of cystic encephalomalacia in the left temporal and parietal lobes. There is ex vacuo dilatation of the left lateral ventricle. Two years post-injury, he has mild cognitive impairment and dizziness. Expressive aphasia, hemisensory deficit, and hemiparesis resolved completely.



**Fig. 8.11** Case study images. Head CT (a) showed an acute frontoparietal subdural hemorrhage (8 mm), a hyperdense hemorrhagic contusion in the left temporal lobe with adjacent hypodense surrounding edema. Midline shift (MLS) of 9 mm and effacement of the left lateral ventricle indicate significant mass effect, but the cisterns remained open (not pictured). (b) Reconstructed 3D images from the head CT which show a large left temporal comminuted, depressed (9 mm) skull fracture with extension across the frontal bone above the orbits. (c) Repeat head CT <6 h after surgery; left temporoparietal hemorrhage (hyperdense) and edema (hypodense) remain

with similar mass effect and MLS. 3D reconstruction shows the construct of the fracture repair with plating system and a JP drain. (d) Limited-sequence MRI shows severe left temporal and parietal hemorrhagic contusions and edema with mass effect and MLS in face of worsening intracranial hypertension. (e) Post-op head CT following repeat craniotomy with evacuation of blood and macerated brain shows ventricles are less effaced (expanded and more symmetric) and there is less MLS (f) MRI performed 1 year post-injury with large left temporoparietal cystic encephalomalacia and ex vacuo dilatation of left lateral ventricle



### Diffuse Axonal Injury

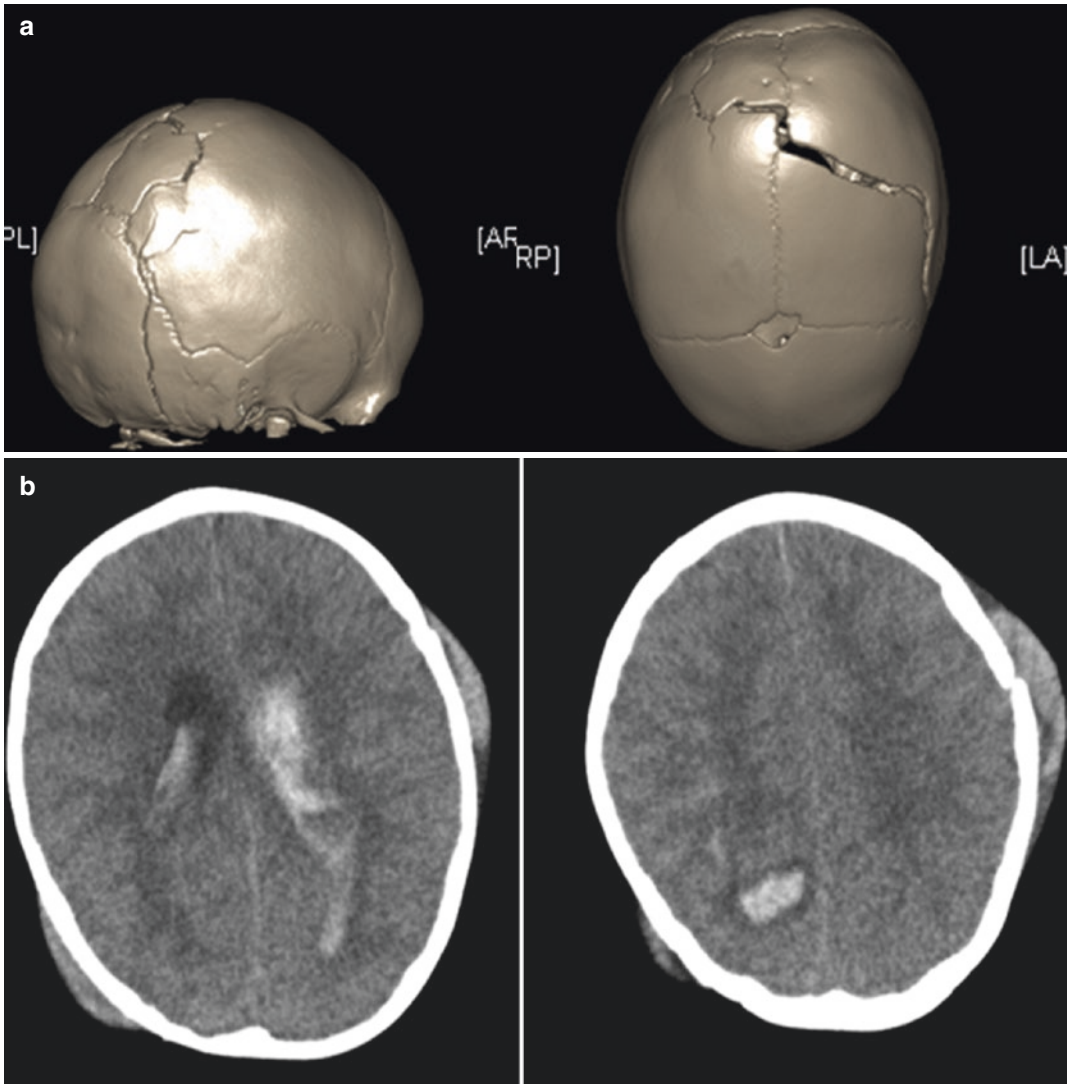
Diffuse axonal injury (DAI) is described as widespread axonal injury in subcortical areas, where gray and white matter interface. Axons are projections which carry signals away from the neuron cell body and lack the ability to regenerate (Young et al. 2015). DAI occurs when the pediatric skull is subjected to high-velocity, rotational, acceleration–deceleration forces, such as motor vehicle accidents (MVAs) and bicycles or pedestrians versus MVA. High-velocity force causes the skull to rotate but the brain lags behind. Gray and white matter differ in density and deform at different rates, causing shear forces to stretch and disrupt

vessels (hemorrhagic) and nerve fibers tracts (non-hemorrhagic) (Barkovich et al. 2012; Gaynor et al. 2015). DAI occurs because shear forces typically disrupt axons in the subcortical frontoparietal white matter, corpus callosum, brainstem, basal ganglia, and internal capsule. DAI is more common in infants and young children due to the softer, unmyelinated brain which is more susceptible to distortion and increased movement within the wider subarachnoid space. The hallmark presentation for DAI is immediate loss of consciousness (LOC) that often lasts greater than 6 h. Abnormal flexion (decorticate) posturing or extension (decerebrate) posturing often accompany LOC. Children

may also have pupillary and other cranial nerve dysfunction and brainstem abnormalities on exam.

Computed tomography (CT) does not show the full extent of DAI, with CT findings ranging from normal to the presence of small hemorrhagic contusions, SAH, or blood in the cisterns.

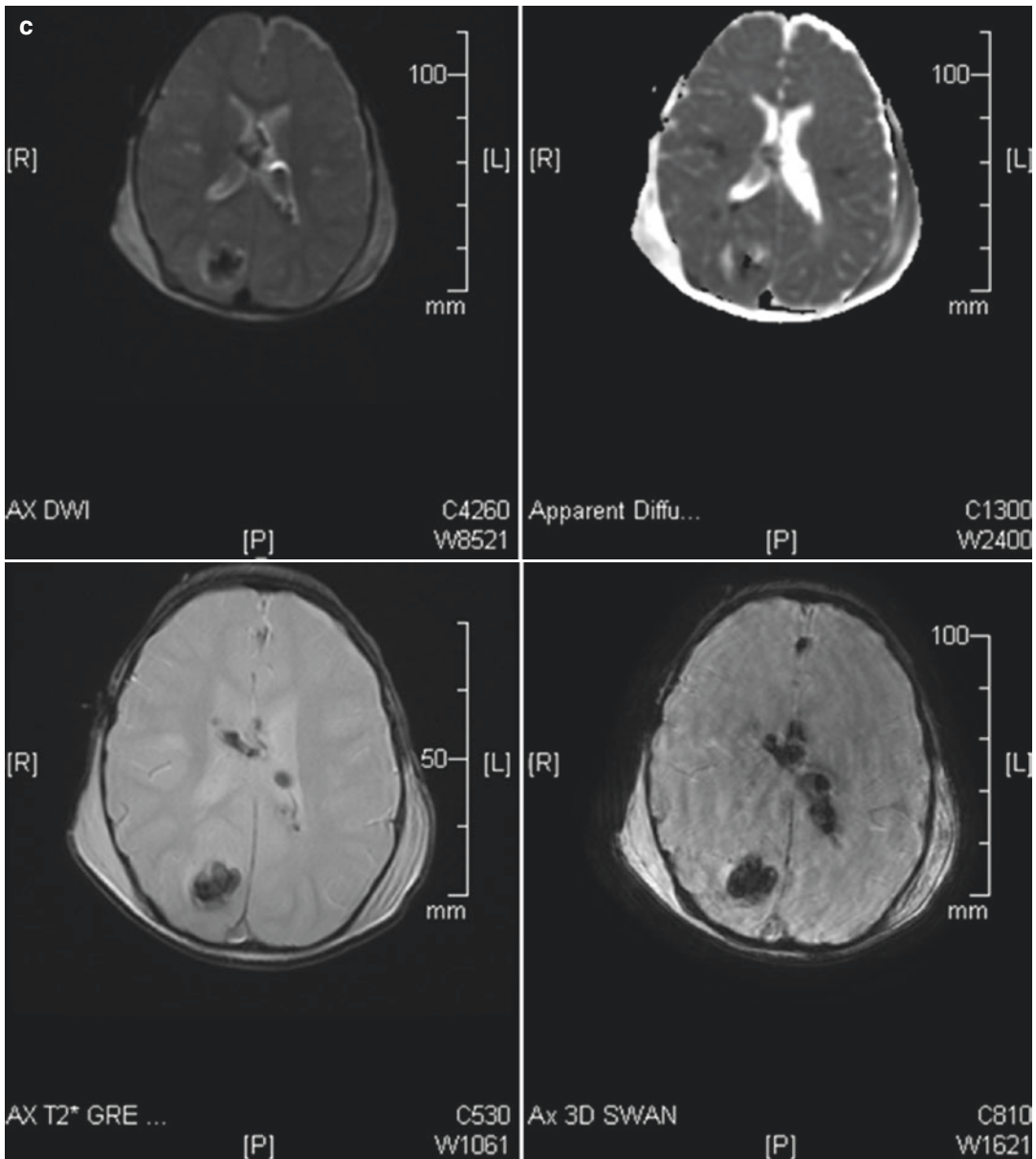
Magnetic resonance imaging (MRI) is most sensitive to shearing (nonhemorrhagic) injury and should be performed if the CT scan does not reveal injury sufficient to explain the degree of neurologic deficit and when the mechanism is severe enough to suggest DAI (see Fig. 8.12).



**Fig. 8.12** (a–d) A 15-month-old fell from a second story balcony, head first onto concrete. He had loss of consciousness and decorticate posturing, GCS = 8 (Images demonstrate differences between CT and T2-weighted MRI sequences in severe TBI with DAI). (a) Skull fractures on reconstructed 3D CT: biparietal, diastatic, crossing sagittal suture, right occipital, and skull base. (b) Head CT: scalp hematomas overlie fractures; bilateral IVH (L > R), large right parieto-occipital hemorrhagic contusion; and effacement of subarachnoid spaces. MRI sequences for compar-

ison: (c) DWI sequence shows multiple areas of restricted diffusion (hypodense or *dark*) in right cerebral hemisphere and left temporoparietal lobe (not seen on CT), which indicate shear injury. (d). GRE and SWI sequences are more sensitive than CT when showing (hypodense or *dark*) right parieto-occipital hemorrhagic contusion and IVH. The child was managed with an ICP monitor and aggressive medical management for intracranial hypertension. Following inpatient rehabilitation, the child has mild developmental delay and improved right hemiparesis





**Fig. 8.12** (continued)

T2-weighted MRI sequences – T2 and FLAIR – have higher sensitivity to hemorrhagic and non-hemorrhagic lesions than CT. Diffusion-weighted imaging (DWI) can identify additional shearing injuries but is less sensitive to hemorrhagic lesions. Gradient echo (GRE) and susceptibility-weighted imaging (SWI) are exquisitely sensitive to micro hemorrhage seen in DAI (Barkovich

et al. 2012; Gaynor et al. 2015; Pinto et al. 2012). SWI shows 640% more lesions and 200% greater hemorrhage volume than conventional 2D gradient echo (Pinto et al. 2012).

There is no definitive treatment for DAI other than supportive care. ICP monitor is placed for  $GCS \leq 8$ , although ICP is not usually elevated (Gaynor et al. 2015). Elevated intracranial



pressure is managed as discussed later in this chapter. Greatly increased ICP in children with DAI requires repeat imaging with CT scan for suspected expanding mass lesion (Barkovich et al. 2012). Injury and loss of axons in DAI account for most of the neurocognitive injury sustained from TBI. Recovery is a slow, gradual, and often incomplete process and can continue for weeks or months following DAI (Gaynor et al. 2015). Outcomes depending on the severity of DAI can vary from cognitive and neurologic deficits to severe disability and death. A lower number of lesions on SWI seem to correlate well with better neurological outcome (Barkovich et al. 2015). Brainstem involvement strongly correlates with duration of coma and outcome (Woischneck et al. 2003).

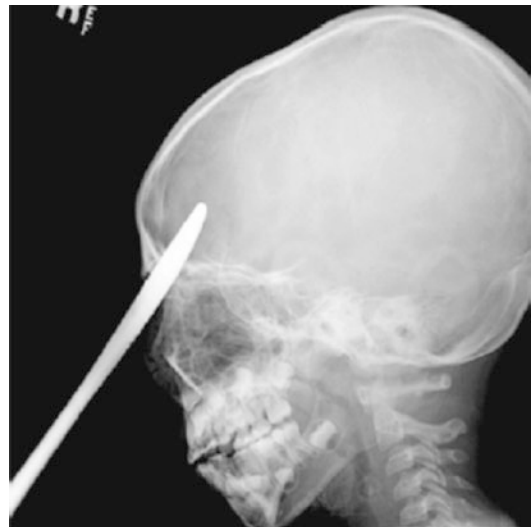#### 8.7.2.4 Penetrating Craniocerebral Injury

Penetrating craniocerebral injuries (PCI) are increasingly common and more often fatal in children. A 138% increase in pediatric PCI has been reported over the past decade, as well as a 4% increase in gunshot wounds (GSW) to the head (Bowen et al. 2015). Many societal factors are cited to have contributed to the increased incidence: accidental firearm discharge in the home (70%), individual's perceived need for protection, illegal drug culture, gang activity, availability of powerful weapons, and increased incidence of homicide and suicide. Causes of PCI include accidental impalement with a random sharp object or firearm injury, suicide, and homicide. Gunshot wounds are classified by the caliber or velocity at which the missile (bullet) enters the brain. Low-velocity injuries occur with most handguns and cause tissue injury (laceration and maceration) along a path slightly wider than the bullet. High-velocity PCI occurs with military weapons and hunting rifles and causes additional damage by "shock waves and temporary cavitation (pushes the brain tissue away from the bullet causing a conical cavity of injury many times the size of the bullet, and causing low pressure whereby debris is pulled into the wound)" (Greenberg 2016). Secondary brain injury occurs with cerebral edema, increased ICP (higher with

high-velocity GSW), a decrease in cardiac output and therefore a decrease in CPP, disseminated intravascular coagulation (DIC), and intracranial hemorrhage from lacerated vessels (Greenberg 2016).

Head CT will reveal the gamut of intracranial injuries as well as help distinguish the entry (small, in-driven fragments and beveled edges) and exit wounds (larger and irregular), bone and metal fragments, trajectory, and number of lobes traversed. Repeat head CT is performed in 3–8 h for detection of delayed hemorrhage (Bowen et al. 2015). Skull films identify fractures and location of skull or bullet fragments. MRI is not recommended for early evaluation. The presence or non-presence of ferrous metal in the foreign object must be confirmed prior to performance of an MRI, as movement of the object due to magnetic force of MRI poses risk for further neurovascular injury.

Early aggressive hemodynamic stabilization and ICP management are vital. (See Sect. 8.9.) According to Bowen et al. (2015), two key factors with impalements are penetration through the thin calvarium with high risk for vascular and cranial nerve injuries and infection risk with the foreign body (see Fig. 8.13). In impalement, the



**Fig. 8.13** Skull x-ray reveals a penetrating cerebral injury, after a 3-year-old fell and was impaled onto a butter knife

protruding object must be stabilized during transport and evaluation until surgical removal can be accomplished. With GSWs to the head, the decision for surgical intervention is complicated but generally recommended for patients who are considered salvageable. Patients with post-resuscitative GCS 3–5 and fixed pupils have mortality rates greater than 80% and very poor outcomes. Simultaneous to surgery is continued control of elevated ICP and administration of anticonvulsants and antibiotics.

Goals of surgery include:

- Removal of foreign object (bullet or bone fragments) to prevent infection, seizures, and aneurysm
- Debridement of necrotic brain to prevent hemorrhage, edema, and scar
- Elimination of mass effect to protect viable brain
- Evacuation of hematomas
- Repair of vascular injury (hemostasis)
- Closure of dura and scalp
- Placement of ICP monitor (Bowen et al. 2015)

Complications of PCI include DIC, infection (with or without abscess), and seizures (Bowen et al. 2015). DIC is an abnormal coagulation/thrombolytic cascade secondary to thrombin release from an injured brain and leads to uncontrolled cerebral hemorrhage. Treatment includes replacement of clotting factors such as fresh frozen plasma, cryoprecipitate, and platelets. Infection is common after PCI, especially in low-velocity GSW and impalement, where the rate of infection approaches 43% (Bowen et al. 2015). Removal of the object does not prevent infection. Early broad-spectrum antibiotic prophylaxis is recommended. Repeat cerebral imaging is important to assess for abscess, especially in the face of fever, new focal neurologic deficits, and change in mental status. Incidence of posttraumatic seizures following PCI has been found to be as high as 50% (Greenberg 2016); therefore, treatment with anti-epileptic medications for 3–6 months is recommended (see section “Contusion” “Posttraumatic Seizures”). Late complications include abscess,

traumatic aneurysm, seizures, wandering fragment, hydrocephalus (obstructive or posthemorrhagic), and lead toxicity (Greenberg 2016).

Poor prognostic factors associated with GSW to the head include presentation in coma (most important) and the path of the bullet (crossing midline, pass through center of the brain, traverse ventricles, more lobes traversed) (Greenberg 2016). Concomitant anoxia results in a grave prognosis. Child survivors of PCI commonly have neurologic deficits, but improvements can be seen over the first year following injury (Bowen et al. 2015).

---

## 8.8 Concepts of Cerebral Physiology

### 8.8.1 Intracranial Dynamics

The skull forms a protective vault, which houses the brain and other cerebral structures. The protection offered by the cranial vault is finite. In infants and toddlers, the skull is a less rigid structure. The cranial sutures are open in infants allowing for a finite degree of expansion or “tolerance” of increased intracranial volume. Rapid increases in intracranial volume, however, result in increased ICP. Severe TBI results in cerebral edema, increased intracranial volume, and eventually increased ICP, leading to decreased perfusion, decreased oxygen delivery, and cell death.

The Monro–Kellie doctrine recognizes that the skull is a rigid structure and that the sum of the intracranial volumes is nearly constant. Intracranial components consist of the brain (80%), cerebrospinal fluid (CSF) (10%), blood within the cerebral vasculature (10%), and other lesions (hematoma, tumor, etc.). The intracranial pressure is determined by the total intracranial volume and intracranial compliance (the ratio of change in volume to the resulting change in pressure). When any of the components increase in volume, there must be an equal decrease in the others to maintain equilibrium and to prevent an increase in intracranial pressure.

### 8.8.2 Compensatory Mechanisms

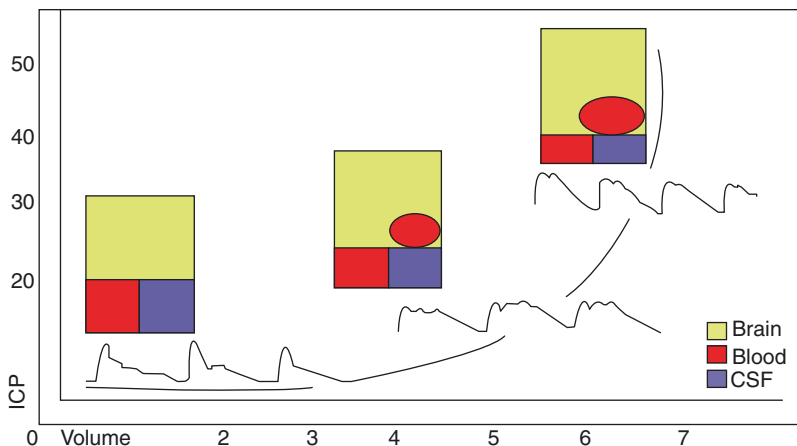
Compensatory mechanisms exist to maintain the intracranial volume. In the face of increased intracranial volume, CSF and blood are displaced to maintain equilibrium between the brain, CSF, and blood. The compensatory mechanisms that maintain the intracranial volume include the following:

- CSF is displaced from the intracranial spaces, through the foramen magnum (FM), into the spinal subarachnoid space. As ICP increases, the intracranial CSF spaces – ventricles and cisterns – are easily compressed and become shifted or absent on neuroimaging.
- Blood is displaced from the low-pressure venous system through the internal jugular veins.
- Intracranial volume is further decreased by vasoconstriction which displaces oxygen-rich arterial blood. Cerebral perfusion decreases, and diffuse cerebral ischemia occurs. Blood flow ceases when the ICP equals the mean arterial pressure (MAP). The result is massive infarction (Greenberg 2016).

The brain's ability to compensate for increased volume is limited. Severe cerebral edema or expanding mass lesion results in increased intracranial volume that surpasses the compensatory mechanisms and results in increased ICP. Severe increased pressure can force the brain and brainstem downward through the FM, causing cerebral herniation. Two therapeutic interventions which are utilized to maintain intracranial volume and prevent raised ICP and secondary injury are external ventricular drainage and osmotic diuresis.

### 8.8.3 Intracranial Compliance

Cerebral compliance can be thought of as a measure of the brain's ability to respond to injury, or a volume increase due to injury, while avoiding a rise in ICP. By definition, cerebral compliance is the ratio of change in volume to the resulting change in pressure (compliance = change in volume/change in pressure). Compliance is limited in that ICP will rise once the compensatory mechanisms are exhausted. The pressure–volume curve (see Fig. 8.14) demonstrates how initial increases in intracranial volume are tolerated with little



**Fig. 8.14** Pressure–volume curve. The Monro–Kellie doctrine demonstrates the intracranial contents (brain, yellow; CSF, blue; blood, red). With expanding mass lesion (hemorrhage) in TBI, intracranial volume rises. Pressure rises once compensatory mechanisms fail (pressure–volume curve). Corresponding ICP waveforms are also pictured. The normal ICP waveform depicts P1 (percussion wave) as the initial highest sharp peak, which indicates

cardiac ejection. The tidal wave, or P2, is the second lower and more rounded peak, which reflects normal brain compliance. With rising ICP and poor compliance, there is a progressive rise in P2, while P1 and P3 rise much less, giving a rounded appearance to the overall pulse wave. The bedside nurse should monitor the ICP waveform for worsening intracranial compliance and as an indication of patient intolerance to nursing interventions

increase in pressure, indicating that intracranial compliance is high. Further increases in volume, especially after compensatory mechanisms are exhausted, result in low compliance, and ICP rises quickly. After compliance is lost, progressively smaller increases in intracranial volume are associated with significant increases in ICP. In addition to compliance being influenced by intracranial volume, it can also be influenced by how rapidly the volume increases (slow-growing tumor versus rapidly expanding mass lesion) and also by the size of the intracranial compartment (i.e., brain atrophy, craniectomy, smaller overall size of pediatric skull, cranial sutures open or closed).

Intracranial compliance can be estimated clinically by evaluating changes in the ICP waveform. This requires availability of continuous ICP monitoring with ICP waveforms and nurses' knowledge to evaluate the waveforms and intervene. Transient increases in ICP are less injurious than sustained increased ICP. Activities such as coughing and treatments such as suctioning temporarily raise ICP. Nursing observations and knowledge of ICP waveforms can be utilized to safely guide nursing care. The ICP waveform has three peaks as follows:

- P1 (percussion wave) – originates from cardiac ejection, is sharply peaked, is fairly constant in amplitude, and represents ejection of blood from the heart into the brain
- P2 (tidal wave) – is more variable, changes with compliance, terminates in the dicrotic notch, and represents compliance of the brain, CSF, and venous volume
- P3 (dicrotic wave) – follows the dicrotic notch and represents closure of aortic valve

With rising ICP and poor compliance, there is a progressive rise in P2, while P1 and P3 rise much less, giving a rounded appearance to the overall pulse wave. see Fig. 8.14.

### 8.8.4 Cerebral Blood Volume

Cerebral blood volume (CBV) is the amount of blood in the brain. Blood makes up about 10% of

the total intracranial volume; of this, 80% is venous and 20% arterial. Arterial CBV is affected by autoregulation, a homeostatic mechanism which controls CBF via dilation or constriction of cerebral arteries. Dilation of the cerebral arteries results in increased CBV and increased ICP. Low-pressure venous blood is displaced into the spinal canal to decrease cerebral blood volume. Once this compensatory mechanism is exhausted, venous pressure rises causing a decrease in cerebral venous return. Decreased cerebral venous return increases cerebral blood volume and further increases ICP. Improper positioning of the child's neck in a rotated position causes compression of the internal jugular vein (IJV) and impedes venous return. The child's head should be positioned midline with the head of the bed elevated to 30° to optimize venous return via the internal jugular vein (IJV). Increased intrathoracic pressures secondary to high positive end-expiratory pressure (PEEP) with mechanical ventilation can also impede cerebral venous return.

### 8.8.5 Cerebral Blood Flow

Cerebral blood flow and autoregulation in children is complicated and not completely understood. Much of what is known about normal cerebrovascular physiology and pathophysiology after TBI has been gained from adult research and applied to children. In this section, a review by Udomphorn et al. (2008) will be utilized to summarize the body of knowledge pertaining to normal pediatric cerebral blood flow and autoregulation, as well as the alterations to cerebrovascular physiology that occur following TBI. Further research is needed in this area to make treatment recommendations which may improve outcomes in children after TBI.

Maintenance of cerebral blood flow (CBF) and oxygen delivery is critical to maintain normal cerebral metabolism and to prevent neuronal injury and ischemic cell death. The average brain receives about 15% of the cardiac output and uses 20% of oxygen and 25% of glucose at

rest (Udomphorn et al. 2008; Hickey 2014). Normal CBF in children has been measured using a noninvasive imaging tool, called transcranial Doppler (TCD) ultrasonography. Udomphorn cites multiple studies using TCD to document that CBF is highest in early childhood. Cerebral blood flow volume (CBFV) is lowest in healthy newborns (24 cm/s), increases and peaks at 6–9 years (97 cm/s), and beyond 10 years decreases to adult values (50 cm/s) (Udomphorn et al. 2008). This is important because hypotension may be more poorly tolerated in children after TBI.

Cerebral blood flow may be abnormally decreased (hypoperfusion), abnormally increased (hyperemia), or both following TBI in children. Derangement in CBF after TBI may be triphasic: hypoperfusion and ischemia in first 6–12 h, followed by hyperperfusion and increased ICP, and finally poor perfusion (White et al. 2001). Too little blood flow, a condition known as hypoperfusion, is most common following pediatric TBI and results in cerebral ischemia (CBF less than metabolic demand) and poor outcome. Adelson et al. (1997) demonstrated that hypoperfusion was common in the first 24 h after pediatric TBI, when cerebral metabolic demand is highest, and is associated with poor outcomes. Hypotension must be treated aggressively to prevent secondary ischemic injury. Hyperemia is a less common condition following severe TBI in children, where too much blood volume exists in the brain (CBF in excess of metabolic demand). Hyperemia following pediatric TBI increases the risk of intracerebral hemorrhage and further increases intracranial pressure, causing secondary ischemic injury. Hyperemia is associated with impaired cerebral autoregulation and poor outcome (Vavilala et al. 2004). Hypercarbia, fever, agitation, and acidosis may contribute to hyperemia and should be avoided.

Cerebral perfusion pressure (CPP) is a measure of the adequacy of CBF following TBI. It represents the difference between the mean arterial pressure (MAP) and the resistance from the opposing ICP. The equation looks like this:  $CPP = MAP - ICP$ . Cerebral perfusion pressure is used to clinically measure CBF. Depending on the child's

age, a CPP threshold of 40–60 mmHg should be maintained at all times during head injury management (Kochanek et al. 2012). New evidence shows that CPP targets should be age specific (Allen et al. 2014). The data showed decreased survival in patients 18 years and older who experience prolonged CPP below 50 or 60 mmHg, in patients 6–17 years old with prolonged CPP below 50 mmHg, and in patients 0–5 years old with prolonged CPP below 40 mmHg.

*Control of cerebral circulation is regulated by the following homeostatic mechanisms, as summarized by Udomphorn et al. (2008):*

1. *Metabolism.* Rate of cerebral metabolism for oxygen and glucose mirrors CBF and peaks during early childhood. Flow-metabolism coupling is the most important control of cerebral circulation. CBF is tightly coupled to metabolism and therefore a “high metabolic rate probably leads to high CBF” (Udomphorn et al. 2008). TBI results in “flow-metabolism uncoupling” which, according to Udomphorn, further results in cerebral ischemia or cerebral hyperemia. Presence of fever and seizure activity increases cerebral metabolic demand and causes vasodilation to meet the increased demand. Vasodilation increases intracranial blood volume and, after compliance is lost, increases intracranial pressure.
2. *PaCO<sub>2</sub>.* PaCO<sub>2</sub> is the most potent cerebral vasodilator. CO<sub>2</sub> reactivity is higher in children than adults (10.3–13.8% change in cerebral blood flow volume (CBFV) per 1 mmHg change in end-tidal CO<sub>2</sub> in children compared to 2–4% in adults). The responsive vasodilation occurs within seconds after an increase or decrease in PaCO<sub>2</sub> and equilibrates within 2 min. CO<sub>2</sub> vasoreactivity can be impaired for 4–7 days after TBI, causing hyperemia, ischemia, and intracranial hypertension. Intentional hyperventilation to induce hypocarbia and vasoconstriction to lower ICP may unintentionally cause ischemia. Hyperventilation is generally reserved as a last resort to prevent impending cerebral herniation.



3. *PaO<sub>2</sub>*. Minimal changes in CBF occur with PaO<sub>2</sub> >50 mmHg, but below 50 mmHg cerebral blood flow slowly increases to maintain oxygen delivery. This may take up to 6 min after onset of hypoxia.
4. *Anemia*. During anemia, CBF increases to improve oxygen delivery.
5. *Autoregulation*. Cerebral autoregulation is a homeostatic mechanism, which balances vasoconstriction and vasodilation of cerebral arteries and arterioles, to maintain CBF nearly constant despite changes in systemic blood pressure. In other words, cerebral autoregulation is a protective process where large changes in systemic circulation result only in small changes in the cerebral circulation. Failure of autoregulation after TBI renders the cerebral circulation completely dependent on the MAP and the CPP. Vasomotor dysfunction occurs, and the resultant ischemia causes secondary cerebral injury (Kennedy and Moffatt 2004).

Changes in mean arterial pressure (MAP) between 60 and 160 mmHg or CPP between 50 and 150 mmHg produce little or no change in CBF in the adult brain (Udomphorn et al. 2008). Autoregulation ensures that as MAP/ CPP increase, resistance increases in the small cerebral arteries and arterioles. Conversely, this adaptive mechanism maintains constant (adequate) CBF by decreasing cerebrovascular resistance or vasodilation when MAP/ CPP decreases. Beyond limits of autoregulation, CBF depends on MAP/ CPP; hypotension results in cerebral ischemia, and hypertension results in cerebral hyperemia.

Studies on cerebral autoregulation in children are very limited. Vavilala et al. (2004) reported children 6 months to 2 years to have a lower limit of cerebral autoregulation. “This is of importance,” according to Udomphorn et al. (2008), “because tolerating lower blood pressure and therapeutic techniques such as deliberate hypotension in young children may not be appropriate and, in fact, result in cerebral ischemia.” A prospective cohort study by Vavilala et al. (2004) measured cerebral autoregulation with transcranial Doppler ultrasonography in 36 children with TBI and found that impaired

cerebral autoregulation was greater after moderate to severe (42%) TBI than with mild (17%) TBI in children and was associated with poor outcome. Udomphorn describes a “vicious cycle” known as the “vasodilator cascade” where decrease in MAP causes vasodilation, increase in CBV, and increase in ICP. Increase in ICP decreases CPP, leading to more vasodilation, and so on. Autoregulation changes and worsens during the first 9 days after injury, and worsening cerebral autoregulation may mirror worsening TBI (Udomphorn et al. 2008).

6. *pH*. A low body pH, or acidosis, also causes vasodilation.

Nursing assessments and interventions following TBI are focused on early detection of neurologic deterioration, maximization of cerebral blood flow, and prevention of secondary brain injury. The following are examples of nursing considerations which impact CBF. As mentioned previously, the patient is positioned with head midline and HOB elevated to allow for cerebral venous return. Hourly monitoring and reporting of fluid balance allows for normovolemia, including prevention of hypovolemia or hypotension and prevention of hypervolemia. Delivery of sedatives and analgesia assists with control of the ICP and optimization of cerebral blood flow (CPP). As pCO<sub>2</sub> is the most potent vasodilator, the nurse also ensures the security of the endotracheal tube and monitors adequacy of ventilation (pCO<sub>2</sub>) by obtaining blood gases.

### 8.8.6 Cerebral Metabolism

The brain is dependent on constant delivery of glucose and oxygen for energy production. The neural cells lack the ability to store these critical substrates. Neurons utilize glucose to produce energy, in the form of adenosine triphosphate (ATP), to meet metabolic demand and maintain aerobic metabolism. Oxygen is required to activate the Krebs cycle. Glucose is required to energize the Krebs cycle. Without oxygen and glucose, the Krebs cycle does not function properly, leading to anaerobic metabolism. Anaerobic

metabolism produces excess lactate and pyruvate, which contributes to tissue acidosis, decreased ATP, decreased energy, and cell death. Lack of ATP causes failure of the sodium–potassium pump and its protection of the cellular membrane. Seizure control, sedation, analgesia, fever prevention, and barbiturate administration are examples of therapies which aim to decrease the cerebral metabolic demand.

### 8.8.7 Pathophysiology of Intracranial Hypertension

Primary traumatic brain injury is caused by an impact that directly disrupts brain tissue. Secondary injury is caused by late effects of the primary injury or new injury due to processes which compromise cerebral blood flow and tissue oxygenation. The pathophysiology of secondary injury is complex with many interrelated processes that interfere with cerebral function. These secondary processes include failure of compensatory mechanisms, altered cerebral blood flow (dysautoregulation and resultant hypoperfusion or hyperemia), anaerobic metabolism, excitotoxicity (excitatory amino acids such as glutamate), inflammation (increased permeability of the blood–brain barrier and resultant swelling), cerebral edema, oxidative stress (excess free radicals), and ischemic cascade resulting ultimately in cerebral infarction (Kennedy and Moffatt 2004; Hickey 2014). The final fatal pathway is malignant intracranial hypertension. The majority of our knowledge about increased ICP and the treatments employed is directed at therapies which attenuate cerebral inflammation, prevent or reduce intracranial hypertension, control cerebral hemodynamics, and facilitate substrate delivery (Bell et al. 2015).

#### 8.8.8 Cerebral Edema

Cerebral swelling is defined as an increase in cerebral blood flow from regional or generalized hyperemia or CBF in excess of metabolic demand. Cerebral edema is an increase in brain tissue volume, either local or generalized, due to

increased intracellular and extracellular water content. There are three types of cerebral edema:

- Vasogenic – extracellular edema of the white matter. Diffuse injury produces an alteration in the permeability of the capillaries of the blood–brain barrier, which is more vulnerable to disruption in the pediatric brain. Plasma and protein leak into the extracellular space locally around brain tumors, infarction, and abscess. Vasogenic edema can also be generalized following TBI.
- Cytotoxic – increased intracellular swelling as a result of the ATP-dependent sodium–potassium pump failure, allowing fluid and sodium to accumulate in the cells. Cytotoxic edema results in diffuse brain swelling in both the gray and white matter. Cytotoxicity occurs after hypoxic-ischemic injury and in conditions of hypo-osmolality, such as hyponatremia and SIADH. Edema secondary to hypoxic-ischemic injury peaks at 48–72 h or longer after injury. Vasogenic and cytotoxic edema occur within hours of injury and often coexist after TBI. The use of osmotic diuretics (mannitol) is useful in acute treatment of vasogenic and cytotoxic edema.
- Interstitial – occurs in severe hydrocephalus where CSF (under pressure) crosses the ependymal tissue, out of the ventricle and into the periventricular white matter.

#### 8.8.9 Intracranial Hypertension

Intracranial pressure is the pressure exerted on the intracranial contents. Normal fluctuations of ICP occur with any mechanism that increases cerebral venous pressure, such as coughing, crying, and the Valsalva maneuver. The normal value for ICP varies with age in children:

- Infants = 1.5–6 mmHg
- Children = 3–7 mmHg
- Adolescents = less than 10–15 mmHg (Greenberg 2016)

Prevention or treatment of intracranial hypertension in severe TBI is critical to maximize a

child's outcome and potentially ensure survival. The threshold for treatment of intracranial hypertension is any sustained ICP of 20 mmHg or higher. No data exists to support treating children at lower thresholds (Kochanek et al. 2012). It is theorized, however, that the optimal ICP treatment threshold may be age dependent, given that normal blood pressures and ICP values are age dependent. Further investigation is needed.

### 8.8.10 Cerebral Perfusion Pressure

Cerebral perfusion pressure (CPP) is an estimated measure of the adequacy of cerebral perfusion. CPP is the difference between the mean arterial pressure (MAP) to perfuse the brain and the opposing intracranial pressure (ICP) [thus,  $CPP = MAP - ICP$ ]. The optimal CPP threshold and therapeutic approach to achieve it both remain to be defined. A minimum CPP of 40 mmHg may be considered in children with TBI. Age-specific thresholds in the range of 40–50 mmHg may be considered, with infants at the lower end and adolescents at the upper end of this range (Kochanek et al. 2012). CPP should be determined in a standard fashion with ICP zeroed at the tragus (foramen of Monro or midventricular level) and MAP zeroed to the right atrium of the heart with the head of the bed elevated 30°. Cerebral perfusion pressure can be improved through measures that lower the ICP (see Sect. 8.9) and by measures that raise the MAP (volume or vasopressor administration).

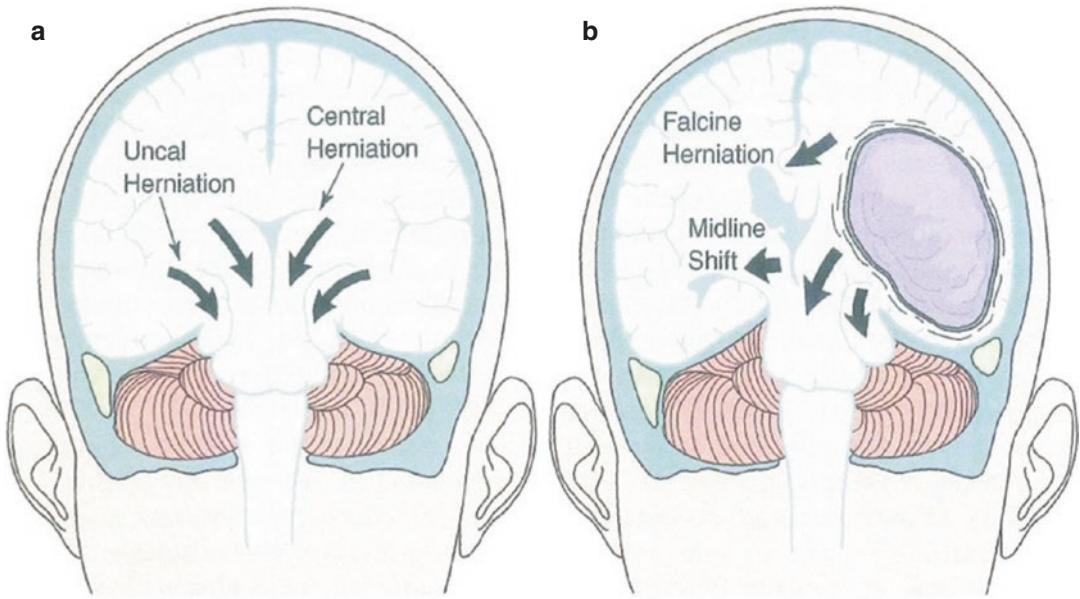
### 8.8.11 Cerebral Herniation Syndromes

The brain is not acutely compressible, but it will shift within the cranium. Excessive pressure gradients between compartments lead to herniation, where part of the brain is herniated into an adjacent compartment (i.e., supratentorial, infratentorial) or into the spinal column. It is important to consider the anatomic landmarks, which separate the intracranial compartments. The tentorium cerebelli is a tent-like partition between the cere-

brum and the cerebellum. The space above the tentorium is referred to as the supratentorial space, while the space below the tentorium is referred to as the infratentorial space. The falx cerebri divides the left and right cerebral hemispheres within the longitudinal fissure. The falx cerebelli separates the cerebellum into a left and right side. The foramen magnum (FM) is the opening at the base of the skull through which the brainstem and spinal cord are connected. Cerebral herniation syndromes, described by Plum and Posner, are demonstrated in Fig. 8.15. The cerebral herniation syndromes include cingulate herniation (cingulate gyrus under the falx), uncal herniation (the medial, inferior portion of the temporal lobe, uncus, herniates down through the incisura or tentorial notch into the infratentorial compartment), and central herniation of the cerebellar tonsils and brainstem down through the foramen magnum into the spinal column. Cingulate herniation usually is not clinically significant. Uncal herniation, evidenced initially by ipsilateral sluggish pupillary response, progresses to ipsilateral pupillary dilation, contralateral hemiparesis, trochlear and abducens cranial nerve paralysis, and a decreased level of responsiveness with eventual rostral–caudal deterioration. The mass effect causes lateral displacement of the midbrain, forcing the opposite cerebral peduncle against the tentorium, producing Kernohan's notch (resulting in hemiparesis ipsilateral to the expanding mass lesion). Central herniation causes deterioration in a rostral–caudal pattern, eventually causing cessation of cerebral blood flow and brain death (see Sect. 8.8.5).

## 8.9 Collaborative Management of Intracranial Hypertension

Treatment of the child with a TBI focuses on preventing secondary insults and obtaining best possible functional outcomes. Maintaining CBF and optimizing oxygen and substrate delivery and utilization, while preventing or effectively managing intracranial hypertension, accomplish these goals. Additionally, the child needs to have adequate airway support, effective oxygenation



**Fig. 8.15** A drawing represents the different cerebral herniation syndromes. (a) Global supratentorial mass effect causes uncal herniation (uncus or medial, inferior portion of the temporal lobe herniates downward through the incisura of the tentorium) and central herniation (cerebellar tonsils and brainstem herniate downward through the

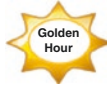foramen magnum into the spinal column, causing cessation of cerebral blood flow and brain death). (b) Unilateral mass lesion causes falcine herniation (herniation of the ipsilateral cingulate gyrus under the falx) or unilateral uncal herniation. (Reprinted with permission from Posner et al. 2007)

and ventilation, and good perfusion. When these fundamental needs are addressed, the child's chances of meaningful recovery and effective brain injury management are improved.

The main focus of management is to prevent or minimize secondary injuries, such as cerebral ischemia, cerebral edema, and neurochemical alterations. Since hypoxia and hypotension are known to worsen secondary injury by causing cerebral vasodilatation, care must be taken to quickly recognize and treat these mitigating factors. In general, the goal of treatment is to maintain an ICP <20 mmHg, along with age-appropriate CPP. ICP management interventions include therapies to decrease cerebral volume, control CSF volume, control cerebral blood volume, and decrease cerebral metabolic rate. Because there exists a lack of data from well-designed and controlled pediatric studies to direct the treatment of children with brain trauma, guidelines have been released that assimilate the research results that are available

and provide expert consensus on therapies (Kochanek et al. 2012). There is some evidence in adult studies (Arabi et al. 2010; Cnossen et al. 2015; Timmons 2016; Vavilala et al. 2014), as well as a pediatric study (O'Lynnger et al. 2016), to suggest that adherence to evidence-based treatment guidelines in severe TBI can lead to improved outcomes. Figure 8.16 shows an example of a severe TBI treatment guideline utilized in a pediatric intensive care unit. The guideline is based on a tiered gradation system, where tier I is the initial intervention and then intervention progresses to tier II and tier III as the maximum level of intervention for each category. The level of intervention is advanced to the next tier if set ICP and CPP parameters are not met. In addition, children with severe TBI are more likely to survive when they are transported to a pediatric trauma center, if one is available, or an adult trauma center with added capabilities to treat children (Badjatia et al. 2008; Mills et al. 2015).

## Intracranial Pressure Management Guidelines (GCS <8)



### EMERGENCY DEPARTMENT

Rapid assessment and stabilization of airway, breathing and circulation. Intubation should be accomplished with use of rapid sequence intubation, using drugs that do not further increase intracranial pressure (ICP). Deliver 100% FIO2 to avoid hypoxia. Mechanical ventilation is provided to maintain normocapnia (pCO2 35–40 mmHg). Maintain adequate blood pressure with administration of fluid volume resuscitation and inotropic support as needed to ensure adequate end-organ cerebral perfusion and avoid secondary cerebral insult. Stat head CT is obtained.

### DECISION FOR IMMEDIATE INTRACRANIAL INTERVENTION

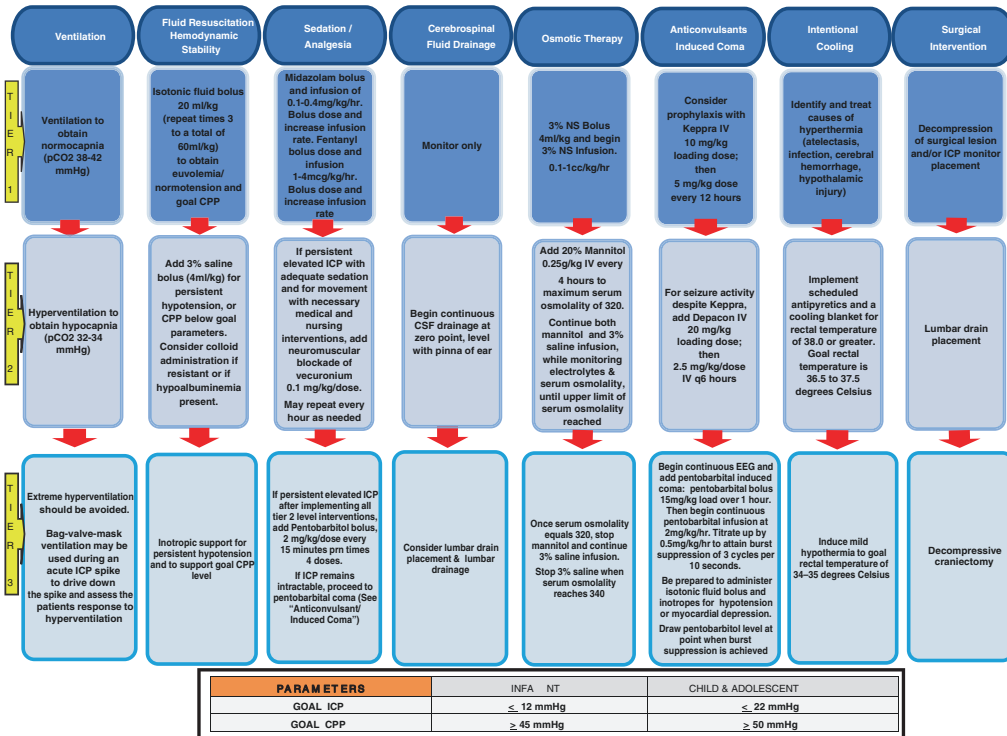
The neurosurgeon will determine if a surgical lesion is present requiring emergent surgical evacuation. If so, the patient will be transferred immediately to the operating room for surgical address of the lesion and placement of an ICP monitor. In the absence of a surgical lesion requiring immediate decompression, the patient will be transferred to the PICU for ICP monitor placement.

### PICU ICP MANAGEMENT

This protocol is based on a tiered gradation system, where tier I is the initial intervention; and then intervention progresses to tier II and then tier III as the maximum level of intervention for each category. The level of intervention is advanced to the next tier if the following ICP and cerebral perfusion pressure (CPP) parameters are not met.

PARAMETERS	INFANT	CHILD & ADOLESCENT
<b>GOAL ICP</b>	≤ 12 mmHg	≤ 22 mmHg
<b>GOAL CPP</b>	≥ 45 mmHg	≥ 50 mmHg

Formulated: 11/2011, Reviewed 6/2016

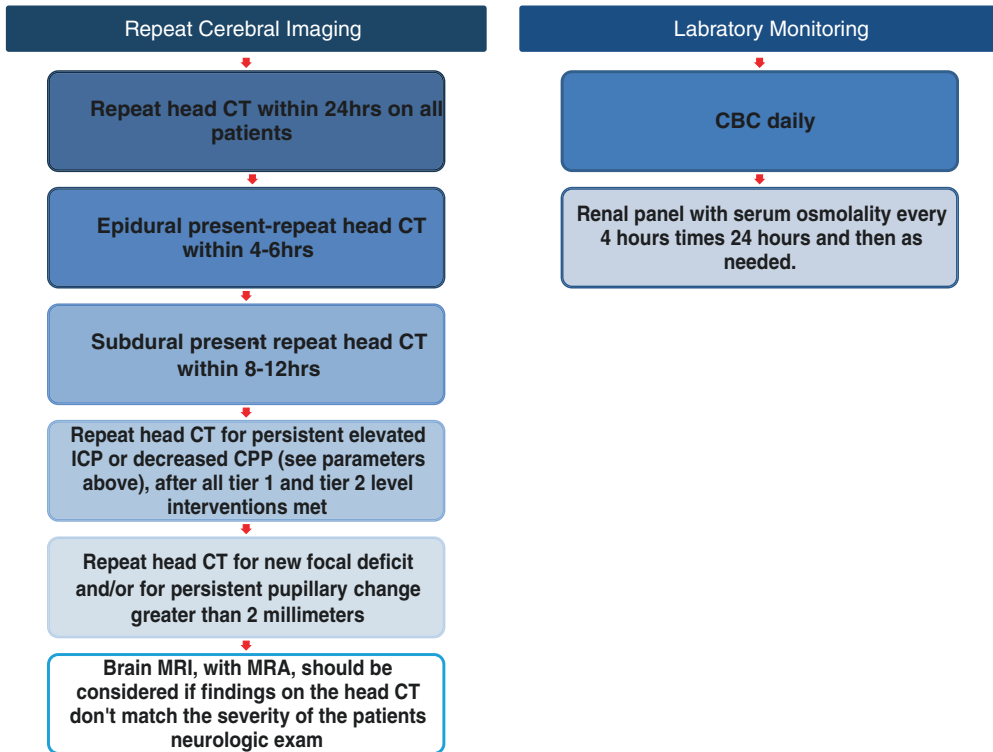


Formulated: 11/2011, Reviewed 6/2016

**Fig. 8.16** Evidence-based treatment guideline for severe pediatric TBI with Glasgow Coma Scale (GCS) score <8. The guideline is based on a tiered gradation system, where tier I is the initial intervention; and then intervention pro-

gresses to tier II and tier III as the maximum level of intervention for each category. The level of intervention is advanced to the next tier if set ICP and CPP parameters are not met (Used with permission from Dayton Children’s Hospital)





Formulated: 11/2011, Reviewed 6/2016

## General Guidelines

- Central venous access is obtained with central venous pressure (CVP) monitoring. Arterial line placement is performed.
- Maintain order to elevate head of bed 30 degrees, unless instructed otherwise by neurosurgeon.
- Basal metabolic expenditures are now believed to be normal with severe Traumatic Brain Injury. Adequate and early nutrition is vital to recovery. The goal is to begin trophic feeds within 24hrs. In the absence of a basilar skull fracture, a nasoduodenal tube should be placed and trophic feeds started within 72 hours of the injury. If basilar fracture is present, an orogastric tube is preferred. Consider hyperalimmentation if aggressive sedation and /or barbiturates are in use.
- Zantac 1mg/kg IV every 8 hours is provided to avoid gastric stress ulcer.
- Prophylactic antibiotic coverage of the ICP monitor: A dose of Zinacef (50mg/kg or max. 1 gram) should be given 0 – 60 minutes prior to placement; and then three doses spaced every 8 hours following placement; then discontinued.
- Lidocaine 1 mg/kg (maximum 50mg/dose and 300mg/day) will be ordered to administer via the ETT prior to endotracheal suctioning to blunt the cough response and associated ICP spikes.
- Avoid glucose containing fluids in the first 48 hours following injury as hyperglycemia has been associated with poor outcome in severe TBI. Treat persistent hyperglycemia aggressively with insulin infusion. Monitor for hypoglycemia, particularly in neonates and infants < 6 months of age.
- Consider pneumatic stockings for patients weighing greater than 50 kilograms, or greater than 14 years of age.

## Nursing Guidelines

- Implement nursing interventions to attain goals for MAP, ICP & CPP:
- Maintain patient in quiet environment with minimal noxious stimuli. Encourage family presence and quiet interaction with patient. Avoid prolonged periods of elevated ICP or plateaus in the ICP waveform with interventions, as this is indicative of decreased cerebral perfusion. Provide general skin care, mouth care, and repositioning as tolerated.
- Maintain head midline and HOB elevated as ordered.
- Monitor for and maintain adequate sedation/analgesia/paralysis.
- Titrate sedative and inotropic infusions to maintain patient parameters within ordered goal.
- Ensure integrity of ICP monitor and change dressing routinely per protocol.
- Assess EVD and troubleshoot if ordered to be open to drain, but no drainage.
- Avoid hyperthermia: Monitor temperature and maintain adequate patient temperature by administering antipyretics as ordered. External cooling blanket as ordered to maintain rectal temp 36.5 – 37.5 C. Avoid patient shivering as this can increase heat generation.
- Avoid seizure activity: administer antiepileptics and report seizure activity immediately to MD/NP.
- Liquid tears as ordered.
- Pneumatic stockings as ordered to prevent DVT.
- Do not suction ETT routinely, but rather on as needed basis, and with use of endotracheal or intravenous lidocaine as ordered to blunt cough response and associated ICP spikes.

Formulated:11/2011, Reviewed 6/2016

### 8.9.1 Initial Resuscitation

Pre-hospital care of the child with TBI begins at the scene with rapid assessment and support of airway, breathing, and circulation. Supplemental oxygen should be administered and hypoxia (oxygen saturation <90% or PaO<sub>2</sub> <60 mmHg) avoided. In general, if the GCS is ≤8, endotracheal intubation should be considered, although there is no research evidence that supports endotracheal tube intubation over bag-valve-mask ventilation for pre-hospital management. Upon arrival at a medical center, rapid-sequence intubation should be performed if the CT scan demonstrates diffuse cerebral edema, as there is risk of neurologic decompensation, respiratory instability, or loss of protective airway reflexes. The intubation procedure should include medications to facilitate the process which do not further increase ICP, such as thiopental, etomidate, lidocaine, and a short-acting, non-depolarizing neuromuscular blocking agent (American Heart Association 2012). Normoventilation (PaCO<sub>2</sub> 35–40 mmHg) should be ensured during initial resuscitation (Badjatia et al. 2008; Kochanek et al. 2012).

Hypotension has been shown to increase the morbidity and mortality of traumatically brain-injured children (Badjatia et al. 2008; Krishnamoorthy et al. 2015; Stocchetti et al. 2010). Because hypotension is a serious and potentially preventable secondary insult, signs of inadequate perfusion should be recognized and treated aggressively. Cerebral perfusion is partially dependent on an adequate MAP; therefore, age-appropriate blood pressure must be maintained to ensure adequate end-organ perfusion and CPP to prevent ischemia and resultant infarction. The following formula is used to determine median blood pressure (50th percentile) for children greater than 1 year of age:  $90 + (2 \times \text{age in years})$  (American Heart Association 2012). Table 8.7 shows ranges for median to 90th percentile age-related blood pressures in children. Because of the risk of poor outcome for children with systolic blood pressure below the 75th percentile for age, a higher blood pressure should be targeted initially (Badjatia et al.

**Table 8.7** Normal blood pressure in children (50–90th percentile)

Age	Systolic pressure <sup>a</sup> (mmHg)	Diastolic pressure <sup>a</sup> (mmHg)
Birth (3 kg)	50–70	25–45
Neonate (96 h)	60–90	20–60
Infant (6 months)	87–105	53–66
Toddler (2 years)	88–102	42–59
School age (7 years)	97–111	57–72
Adolescent (15 years)	103–127	61–79

Falkner and Daniels (2004)

<sup>a</sup>For 50th percentile of height

2008). Children can be severely hypovolemic without demonstrating decreased blood pressure, and so rapid fluid volume resuscitation should occur both at the scene and upon arrival at the hospital. If appropriate amounts of fluid volume resuscitation do not improve signs of inadequate perfusion, vasopressor support should be initiated (American Heart Association 2012).

### 8.9.2 Intensive Care Management

The child with TBI should be initially evaluated in the emergency department and then taken to the medical imaging department for further evaluation. Radiographic testing may include cervical spine evaluation, CT scan, and possible MRI. From there, the child may proceed to the operating room for removal of expanding lesions, control of hemorrhage, evacuation of significant hematomas, insertion of an ICP monitor or catheter for extraventricular drainage, or decompressive craniectomy (Csokay et al. 2012; Oluigbo et al. 2012). Although randomized controlled trials of the safety and efficacy of decompressive craniectomy in pediatric patients with severe brain injury have not been undertaken, there are instances when this procedure may lower ICP and improve outcomes (Jacob et al. 2011; Oluigbo et al. 2012). Table 8.8 lists criteria to guide the surgeon in determining if the child is a candidate for decompressive craniectomy. After

**Table 8.8** Criteria for decompressive craniectomy

1. Severe traumatic brain injury
2. Refractory intracranial hypertension
3. Diffuse cerebral edema on CT imaging within 48 h of injury
4. No episodes of sustained ICP >40 mmHg prior to surgery
5. GCS $\leq$ 4 at any point prior to surgery
6. Secondary clinical deterioration
7. Evolving cerebral herniation syndrome

Some or all may be present

determining if any surgical intervention is necessary, further head injury management then generally takes place in the intensive care unit.

### 8.9.3 Intracranial Pressure Monitoring

The ability to identify rapidly increasing pressure is crucial in the treatment of severe TBI and in the prevention of cerebral ischemia and infarction. ICP monitoring is recommended for the child with a traumatic brain injury that has a GCS  $\leq$  8 (Kochanek et al. 2012). It should be noted that the presence of an open fontanel in an infant does not negate the utility of ICP monitoring or preclude the development of intracranial hypertension. In addition, a monitor may be placed in the child that has clinical signs of increasing ICP, after major neurosurgical procedures, or when serial neurologic assessments may be masked by sedation, neuromuscular blockade, or anesthesia.

Either a fiber-optic-tipped wire, a microchip sensor, or a fluid-filled catheter system can be placed in the intracranium, which allows for the continuous measurement of ICP. Fiber-optic-tipped devices can be placed in the intraventricular, parenchymal, and less often epidural, subdural, and subarachnoid spaces. Fluid-filled ICP catheters are generally placed in the intraventricular space, particularly if CSF drainage is desired. Table 8.9 lists potential complications associated with the use of intracranial catheters.

**Table 8.9** Potential complications associated with ICP monitoring catheters

Hemorrhage
Infection
Overdrainage of cerebrospinal fluid
Catheter misplacement
Catheter migration
Catheter obstruction

**Table 8.10** Nursing priorities for the child undergoing ICP monitoring

1. Keep the ICP monitoring system operational and intact, ensuring that all connections are secure
2. Prevent strain on the tubing and cables, particularly during patient repositioning and transport
3. Zero and level the system according to manufacturer's recommendations
4. Ensure the transducer of a fluid-filled system is leveled at the appropriate anatomical location, especially after patient repositioning and transport
5. If draining CSF, maintain the drainage chamber at the level ordered
6. Empty the drainage chamber regularly, recording the amount of CSF output
7. Do not allow the air filter of the drainage chamber to get wet
8. Document ICP and CPP readings
9. Note child's ICP response to interventions and ICP trends over time
10. Maintain a dry sterile dressing around the insertion site per hospital policy
11. Monitor for and notify the neurosurgeon of CSF leakage around the insertion site, other drainage, and signs of infection

The fiber-optic-tipped catheter and microchip sensor are zeroed before insertion and require a monitoring unit supplied by the manufacturer for ICP readings. Alternatively, a fluid-filled ventriculostomy catheter system can be set up to allow for the continuous drainage of CSF. This system contains an external strain-gauge transducer that is coupled to the patient's intracranial space through a fluid-filled line. The transducer must be secured at a fixed reference point, usually the foramen of Monro or midventricular level, which can be approximated by positioning the transducer level with the tragus or external auditory

meatus. The system must be zeroed to atmospheric pressure and leveled to ensure accuracy of the ICP data. Nursing care of the patient with an ICP monitor is outlined in Table 8.10.

Intracranial hypertension is defined as an ICP  $\geq 20$  mmHg, and treatment designed to reduce ICP and improve cerebral perfusion should be initiated at this point (Brain Trauma Foundation 2007). Prolonged periods of increased ICP and dramatic elevations in ICP are associated with poor outcomes in the pediatric patient. Increased intracranial pressure is significantly related to low cerebral perfusion pressure (Allen et al. 2014). Depending on the child's age, a CPP threshold of 40–60 mmHg should be maintained at all times during head injury management (Kochanek et al. 2012). In addition to ICP data, evidence of intracranial hypertension should be corroborated by frequent patient assessment, other physiologic parameters, and cranial imaging studies.

### 8.9.4 Jugular Venous Oxygenation Saturation Monitoring

Continuous measurement of venous saturation can be obtained using a fiber-optic catheter placed retrograde into the internal jugular bulb, which is located just below the base of the skull. This monitoring technique can provide information on cerebral oxygen delivery and consumption and the effectiveness of therapies. Because the cerebral circulation drains into the internal jugular bulb, oxygen saturation that is measured here reflects oxygen extraction that occurred during cerebral perfusion. Normal jugular venous oxygen saturation ( $S_{jv}O_2$ ) values are 55–70%. Values below 55% indicate inadequate oxygen delivery or utilization within the injured brain, and treatment interventions should be initiated when the jugular venous saturation is  $< 50\%$  (Brain Trauma Foundation 2007). Conditions that decrease  $S_{jv}O_2$  are hypoxia, hypotension, increased ICP, and hypocarbia.  $S_{jv}O_2$  monitoring provides a global picture of CBF and metabolic need, but does not provide any information about oxygen consumption at the site of injury.

### 8.9.5 Monitoring Partial Pressure of Oxygen

$P_{bt}O_2$  is a measure of cerebral (brain tissue) oxygenation. A microprobe is inserted into uninjured parenchymal brain tissue or the area of primary injury (penumbra) of an intracerebral lesion. While placing the microprobe into uninjured brain tissue will more closely assess global cerebral oxygenation, placement in an intracerebral lesion will provide data regarding cerebral oxygenation in an area most at risk (Martini et al. 2013; Nangunoori et al. 2012). Either method should give an indication of cerebral oxygenation and ischemia (Martini et al. 2013; Nangunoori et al. 2012). Normal values for noninjured brain tissue range from 20 to 35 mmHg. Instances that can decrease  $P_{bt}O_2$  are hypocarbia, hypoxemia, hyperthermia, decreased CBF and ischemia, decreased CPP, and elevated ICP (Martini et al. 2013). Treatment interventions to improve cerebral oxygenation should begin when  $P_{bt}O_2$  values are  $< 15$  mmHg (Brain Trauma Foundation 2007; Martini et al. 2013). Values below this have been associated with poor outcomes and death.

### 8.9.6 CSF Drainage

External ventricular drainage of CSF is a common management therapy that is often used in conjunction with ICP monitoring. The CSF is drained to reduce intracranial fluid volume and thus decrease ICP. Drainage can be continuous or intermittent, depending on the child's situation and the neurosurgeon's preference. For instance, drainage may be ordered any time the ICP is above a preselected value for a specified time. Moving the CSF collection device up or down in relation to the reference level point will control the amount of drainage. The higher the drain is above the reference level, the higher the ICP must be for CSF to flow into the collection device. Conversely, lowering the drain will cause CSF to flow at a lower ICP. Care must be taken when draining CSF to treat elevated ICP, as excessive drainage of CSF may cause the lateral ventricles to collapse. In addition, excessive CSF output

may lead to hyponatremia, particularly in younger patients, which is corrected with intravenous fluid administration of normal saline, designed to replace the CSF fluid volume.

The use of lumbar CSF drainage has occasionally been reported in pediatric patients with increased ICP refractory to other management therapies (Kochanek et al. 2012; Kukreti et al. 2014; Murad et al. 2012). The lumbar drain is used simultaneously with a functioning ventricular catheter when the basilar cisterns are open. Patients for whom lumbar drainage is contraindicated include those with intracranial masses or shifts because transtentorial herniation could result (Kochanek et al. 2012).

### 8.9.7 Analgesia, Sedation, and Neuromuscular Blockade

Analgesia and sedation are important adjuncts to other treatments for the brain-injured child. Because pain and anxiety contribute to increased ICP and the cerebral metabolic rate, it is imperative to provide relief from pain, anxiety, and agitation. Additionally, the use of these agents can also facilitate the child's tolerance of other therapies, such as mechanical ventilation and suctioning, intradepartmental transport, and monitoring devices. The nurse is in a vital position to assess, advocate for, and effectively manage the child's level of sedation and analgesia. Depending on practitioner preference, common agents used are opiates, benzodiazepines, and barbiturates. Although routinely used in the adult with traumatic brain injury, the use of continuous infusions of propofol is not recommended for sedation of patients in the pediatric intensive care unit because it has been associated with fatal metabolic acidosis, rhabdomyolysis, and hypoxia.

While the use of short-acting neuromuscular blockade agents may facilitate intubation and the tolerance of therapies, the patient's neurologic exam is blunted. Therefore, these agents are generally used only when the child's agitation and increased ICP persist despite adequate doses of sedation and analgesia. The paralytic agent is generally allowed to wear off at intervals to allow for a complete

neurologic examination. Neuromuscular blocking agents should never be used without the concomitant administration of a sedative or analgesia.

### 8.9.8 Hyperosmolar Therapy

Osmotic diuresis for the treatment of the head-injured child is accomplished through the use of mannitol and/or hypertonic saline (HS), such as a 3% saline solution. While mannitol has been the mainstay of therapy for many years, there is increasing evidence that using HS in children with intractable intracranial hypertension results in a decrease in ICP and subsequent increase in CPP (Gonda et al. 2013; Upadhyay et al. 2010). The nurse should keep in mind that the overall goal is euvolemia (fluid balance); therefore, hyperosmolar therapy may be contraindicated in the presence of hypotension (Brain Trauma Foundation 2007).

After mannitol administration, an osmotic gradient between plasma and parenchymal tissue develops, drawing fluid from brain tissue into the vascular space. Osmotic diuresis then occurs, which results in a net reduction of brain water content. Further, because of fluid movement, mannitol reduces hematocrit and blood viscosity, improving CBF and reducing blood vessel diameter. ICP and cerebral blood volume decrease almost immediately. Therefore, because of its rapid onset of action, a 20% mannitol solution is usually administered as a bolus dose of 0.25–1 g/kg body weight (Brain Trauma Foundation 2007). The nurse should be aware that mannitol may crystallize, so an in-line filter should be used to prevent the administration of any crystals. Serum osmolarity must be monitored when using hyperosmolar therapies. The maximum recommended serum osmolarity when using mannitol is 320 mOsm/l. Because mannitol is excreted unchanged in the urine, renal failure can result with higher serum osmolarity. With chronic administration, mannitol may cause rebound cerebral edema because it is believed to disrupt the blood–brain barrier and accumulate in the interstitial space of the brain parenchyma, causing a reverse osmosis. Additional side effects of



mannitol therapy are dehydration with resultant hypotension following overly effective osmotic diuresis and electrolyte imbalance.

Hypertonic saline works by increasing serum sodium and serum osmolarity, creating an osmotic gradient to pull water from the intracellular and interstitial compartments of the brain, which reduces cerebral edema and ICP. Sodium chloride creates a driving force to bring water from the brain into the intravascular compartment in regions with intact blood–brain barrier, thus reducing water content, mass effect, and ICP. In addition, intravascular volume expansion occurs after administration of HS solutions. While there is no change in systemic vascular resistance, MAP rises because of increases in cardiac output and intravascular volume. This increase in MAP can further improve CPP. For acute management of intracranial hypertension, the recommended dose of 3% HS is 6.5–10 ml/kg (Kochanek et al. 2012). Subsequently, 3% saline can be administered via continuous infusion at a dose of 0.1–1 ml/kg/h as needed to maintain ICP <20 mmHg (Kochanek et al. 2012). An osmolarity up to 360 mOsm/l has been well tolerated in children receiving HS (Kochanek et al. 2012). A potential side effect in patients with preexisting chronic hyponatremia is osmotic demyelination syndrome (ODS), which involves demyelination, primarily of the pons, that can be noted clinically by the onset of lethargy and quadriparesis. Other possible side effects of the use of HS, particularly when serum sodium levels exceed 165 mEq/L, include coagulopathy, rebound rises in intracranial hypertension, electrolyte imbalance, hyperchloremic acidosis, and the risk of phlebitis if the solution is administered via a peripheral vein.

### 8.9.9 Hyperventilation

During hyperventilation,  $P_a\text{CO}_2$  decreases, resulting in cerebral vasoconstriction and a reduction in cerebral blood volume. Although ICP rapidly decreases in this situation, cerebral perfusion is compromised and ischemia can result. Because of these concerns, prophylactic hyperventilation and hypocarbia should be avoided. Mild

hyperventilation ( $P_a\text{CO}_2$  30–35 mmHg) may be instituted when other therapies such as adequate sedation and analgesia, neuromuscular blockade, hyperosmolar therapy, and CSF drainage have not been effective in correcting intracranial hypertension. Depending on practitioner preference, aggressive hyperventilation may be used in the event of acute brain herniation or significant ICP elevation. However, prophylactic severe hyperventilation ( $P_a\text{CO}_2$  <30 mmHg) should be avoided for 48 h after injury (Kochanek et al. 2012). In this instance,  $P_{bt}\text{O}_2$  and/or  $S_{jv}\text{O}_2$  may be monitored to allow for immediate detection of cerebral ischemia.

### 8.9.10 Temperature Regulation

Hyperthermia is known to increase cerebral metabolic rate as well as ICP and should be avoided in the traumatically brain-injured child. Core body temperature may be measured via the bladder or rectal route or through a pulmonary artery catheter. Brain temperature can also be assessed during both  $P_{bt}\text{O}_2$  and  $S_{jv}\text{O}_2$  monitoring. Because core body temperature measurement may be lower than actual brain temperature (McIlvoy 2012), the nurse may need to institute treatment for fever at a rectal temperature of 37.5 °C, instead of the usual 38.5 °C. Fever can be treated with antipyretics and external cooling devices, although shivering must be avoided because it will further increase cerebral metabolic rate and ICP. Furthermore, it is important to identify and treat the cause of the elevated temperature. Some common causes of fever after a TBI include atelectasis, infection, cerebral irritation from hemorrhage, and injury to the hypothalamus.

Hypothermia (32–34 °C) as a treatment for intracranial hypertension has been considered in both adults and children. The goal of hypothermia therapy is to slow the body's metabolic processes. In addition, induced hypothermia may improve ICP, increase oxygen supply to areas of ischemic brain, and help prevent seizures. The sequelae of induced hypothermia include increased risk of acquired infection, lactic acidosis, sludging blood flow, cardiac arrhythmias,

some effects on drug metabolism, and seizures. During the rewarming phase, patients may experience hemodynamic instability, the reemergence of seizures, and rebound intracranial hypertension (Kochanek and Bell 2016). A recent pediatric study comparing maintenance of normothermia to hypothermia that involved rapid cooling to 32–33 °C for 48–72 h, followed by slow rewarming by 0.5–1.0 °C every 12–24 h, was terminated early for futility (Adelson et al. 2013). Multicenter studies have failed to demonstrate the efficacy of moderate hypothermia in severe TBI (Kochanek and Bell 2016). Should hypothermia therapy be initiated, care should be taken to avoid short periods of cooling (<24 h) and the patient rewarmed at a rate of <0.5 °C/h (Kochanek et al. 2012).

### 8.9.11 Barbiturate Therapy

Barbiturates (e.g., pentobarbital) have been used for many years as a therapy for intracranial hypertension that is not responsive to other treatments. Despite this history of use, limited clinical trials have been performed in children, and other studies in adults have not consistently demonstrated improved outcomes (Brain Trauma Foundation 2007). However, in the pediatric patient with a potentially recoverable brain injury that has elevated ICP which is not responsive to other management strategies, barbiturate coma therapy may be used (Mellion et al. 2013).

Barbiturates decrease cerebral blood flow and the cerebral metabolic requirements of the brain with a resultant decrease in ICP. As a side effect, barbiturate therapy causes myocardial depression and vasodilation, which results in hypotension. The child who is receiving barbiturate therapy should have cardiovascular parameters monitored continuously, including blood pressure and central venous pressure. The nurse should be prepared to administer fluids and inotropic agents as needed during barbiturate therapy. Continuous electroencephalogram (cEEG) monitoring is needed to evaluate burst suppression. The barbiturate is administered via continuous intravenous infusion following a loading dose. The infusion is titrated

based on the patient's ICP response and cEEG tracing. Since rebound intracranial hypertension can occur after discontinuation of barbiturate therapy, the medication should be weaned slowly over a few days (Brain Trauma Foundation 2007).

### 8.9.12 Hydration and Nutrition

During the first 48–72 h, the child with a TBI should receive intravenous fluid therapy to maintain a euvoletic state. Fluid boluses, including blood products as indicated, may be administered to maintain adequate perfusion, age-appropriate blood pressure, central venous pressure, and urine output. A bladder catheter is essential for monitoring accurate urinary output. The intravenous fluid of choice is usually normal saline, lactated Ringer's, or hypertonic saline. Hypotonic fluids should be avoided and hyponatremia prevented, since both contribute to cerebral edema.

Research results suggest a relationship between hyperglycemia and poor outcome from pediatric TBI (Elkon et al. 2014; Smith et al. 2012). Because of this, glucose-containing parenteral fluids are normally not used during the first 48 h after injury. Serum glucose must be monitored and appropriate glucose correction therapy initiated prior to the patient becoming hypoglycemic (serum glucose <75 mg/dl) since this may also result in harm (Faust et al. 2011). The current recommended blood glucose target for most critically ill patients is 140–180 mg/dl (Moghissi et al. 2009).

Meeting nutritional requirements is of utmost importance, as children with severe TBI who have nutrition started early have better outcomes (Meinert et al. 2015; Vavilala et al. 2014). Patients with a TBI require approximately 130–160% of their expected metabolic expenditures (Bratton et al. 2007). Enteral feedings should begin by 72 h after injury (Vizzini and Aranda-Michel 2011), with full caloric feeds established within 7 days (Bratton et al. 2007). Nutritional formula appropriate for age and caloric requirements is administered via a gastric or transpyloric tube, which can be inserted by the nurse at the bedside

(Mehta 2009). In cases where enteral feeding cannot be initiated, total parenteral nutrition should be started. Having a nutritionist facilitate the dietary regimen results in an earlier time to overall nutrition start (Malakouti et al. 2012). In addition, because the patient is likely to be immobile and receiving opiates, a bowel regimen should be established early and should include a stool softener.

### 8.9.13 Additional Nursing Care

The nurse at the bedside caring for the traumatically brain-injured child has an important role in preventing secondary injury and optimizing outcomes. The nurse must also balance the care needs of the patient with the requirement not to further increase ICP. Vigilance to proper patient positioning is necessary. The head of the bed should be elevated 30°. Moreover, the patient's head should be maintained in a midline position to prevent obstruction of venous outflow, which can further worsen intracranial hypertension. The nurse should check that the cervical collar or tracheostomy ties are not so tight that they constrict venous outflow. Complications from immobility should be assessed and prevented. The child will need to be repositioned as tolerated, keeping the head in midline with the body. The risk of skin breakdown should be assessed, skin integrity routinely monitored, and prevention measures started for at-risk patients (Schindler et al. 2011). Preventive measure for deep vein thrombus, such as passive range of motion or sequential compression devices, should be initiated as indicated based on the child's age and body size.

Depending on the child's response to stimuli, the environment should be quiet and free from extraneous noise. The nurse will need to determine if the child will tolerate the clustering of care activities or if care needs must be met in increments with rest periods between activities. The child's response, vital signs, ICP, and CPP parameters should be monitored during care activities (Olson et al. 2013). For instance, if the ICP rises significantly during care, the nurse may need to cease care and allow the ICP to return to

baseline for a period of time before meeting further care needs (Tume et al. 2011). Also, the nurse should assess the child's need for additional analgesia or sedation during care activities that must take place.

Because this child is likely to be intubated and ventilated, the nurse should institute measures to prevent ventilator-associated pneumonia, such as oral care and head of bed elevation. Endotracheal tube suctioning should be initiated based on the child's clinical assessment and should not be performed on a scheduled basis if the patient does not demonstrate the need for suctioning (Tume and Copnell 2015). Coughing during suctioning can increase ICP. Endotracheal lidocaine may need to be administered before endotracheal tube suctioning to blunt the gag and cough response. Preoxygenation is necessary during the suctioning procedure so that hypoxia can be avoided.

During this time of intensive care, the child's family will need much support and education. They are likely to experience uncertainty and fear about their child's recovery and future. The nurse will need to describe the equipment surrounding the child and should provide the family with anticipatory guidance on what to expect during the child's initial care and recovery. The family may need to be given direction on the role they can assume in the intensive care unit. A family-centered intensive care unit environment that establishes a partnership between the family and the healthcare team is vital. The family may be encouraged to interact with their child and touch the child as appropriate. The nurse should observe the patient's response to this interaction, including ICP response. The presence of family has not been shown to be detrimental to patient outcomes and should be evaluated on a case-by-case basis.

---

## 8.10 Perioperative Nursing Care and Complications

Surgical interventions for pediatric head trauma were discussed throughout this chapter and include placement of an ICP monitor with external ventricular drain (EVD) or lumbar drain; craniotomy for elevation of depressed skull

fractures; evacuation of hematomas, bony fragments, and pulped brain; and decompressive craniectomy. Postoperative nursing care following neurosurgery includes observation of the patient's vital signs, baseline as well as frequent ongoing neurologic assessments, management of neuro-monitoring devices, observation for postoperative complications, and good general postoperative care to include pain management, prevention of infection, nutritional status optimization, and psychosocial support of the child and family.

### 8.10.1 Preoperative Baseline

The preoperative and immediate postoperative assessment provides a baseline for comparison when assessing for postoperative deterioration or complications. For consistency, it is ideal for the same nurse to care for the child before and after neurosurgery. When this is not possible, the nurse assuming care should seek knowledge of the preoperative assessment from the previous caregiver, surgeon, anesthesiologist, postanesthesia care unit nurse, the medical record, and the parents in order to recognize and anticipate changes in the child's postoperative neurologic assessment.

Conscious children should be prepared for the operative experience in a developmentally appropriate manner. Reassure these children that they will remain asleep and be unable to feel pain during surgery and will awaken afterward to see their parents. Educate them that pain is expected and that medications will be available to alleviate their pain. Advise them to anticipate a large number of people and equipment to help take the best care of them when they awaken. Parents need to be prepared for the appearance of the child postoperatively with a head turban dressing, ICP/EVD monitor, multiple intravenous lines, monitors, and possible endotracheal tube and ventilator.

### 8.10.2 Assuming Postoperative Nursing Care

Hand-off report following surgery should include the type of neurosurgical procedure and region of brain affected, intraoperative complications,

anesthetic and analgesic agents used, preexisting medical problems and neurologic deficits, presence of new neurologic deficits since surgery, surgeon's insight on what new deficits may develop, fluid/electrolyte status, lab values, and postoperative orders. Appropriate monitoring equipment should be attached and may include any or all of the following: cardiorespiratory, pulse oximetry, end-tidal CO<sub>2</sub>, arterial and central venous pressure, ICP, EVD, SjvO<sub>2</sub>, and PbtO<sub>2</sub>. Ideally, the reporting nurse and the oncoming nurse should assess the patient together to facilitate a clear understanding of the patient's baseline exam, to decrease the chance of miscommunication, and to prevent missed signs of subtle deterioration.

### 8.10.3 Vital Functions

Protection of the pediatric airway following neurosurgery is paramount, whether the child is extubated immediately following neurosurgery or remains intubated and on mechanical ventilation. The nurse should monitor for signs of respiratory distress and assist with bag-valve-mask ventilation and reintubation if required. Possible causes of abrupt airway or ventilatory deterioration in the intubated child include tube displacement, tube obstruction, pneumothorax, and equipment failure (American Heart Association 2012). Inadequate ventilation results in hypoxia and hypercarbia, which cause increased CBF, ischemia, and increased ICP.

Vital signs should be recorded frequently, according to your institution's policy. Normothermia should be maintained, remembering that infants can become cold-stressed very quickly. Fever should be avoided as it increases cerebral metabolic demand. Postoperative tachycardia is expected secondary to the stress response, but it can also indicate anemia, hypovolemia, cardiorespiratory distress, fever, or pain. Bradycardia is very concerning in this child and may indicate increased ICP or hypoxemia, which requires immediate evaluation and treatment. Cushing's response is a late ominous sign of impending cerebral herniation and includes hypertension, bradycardia, and an irregular respi-

ratory pattern. When appropriate, monitor ICP values, evaluate the ICP waveform, and calculate the CPP at frequent intervals.

Euvolemia should be maintained as the nurse calculates the intake and output totals from surgery and alerts the healthcare team of indications of hypovolemia. Hypovolemia occurs in the neurosurgery postoperative period due to fluid loss, the use of osmotic diuretics, and fluid shifts as a result of endocrine complications, such as diabetes insipidus. Indicators of hypovolemia include low CVP and signs of low cardiac output, including tachycardia; rapid respirations; cool, pale, or mottled skin; low urine output; change in mental status; and finally hypotension (American Heart Association 2012). Administration of fluid boluses and vasopressors may be necessary to prevent and treat hypotension, which is a known cause of secondary brain injury and ischemia, resulting in further increased ICP and poor outcome (Krishnamoorthy et al. 2015).

### 8.10.4 Neurologic Function

A full discussion of neurologic assessment and management of increased ICP precedes this section. The general neurologic assessment includes assessment of level of consciousness and responsiveness, including scoring the GCS, pupillary and CN assessment, and motor exam. Serial neurologic assessments are completed as ordered and as the child's condition warrants. A general guideline is to assess every 15 min if the child's condition is deteriorating and then every hour and beyond once the child's condition stabilizes.

### 8.10.5 General Postoperative Nursing Care

Good general postoperative care includes pain management, prevention of infection, nutritional status optimization, and psychosocial support of the child and family. Multiple scales exist for assessment of pediatric pain (see Chap. 1). The scale selected should be used consistently to assess pain in the postoperative neurosurgery

patient. Pain physiologically increases ICP and should be adequately controlled with administration of analgesics. It is important to note that administration of narcotics and anxiolytics will decrease the patients LOC and responsiveness, blunting the neurologic assessment.

The surgical site should be evaluated for the presence of bleeding, dehiscence, wound infection, and CSF leak, all of which should be reported to the neurosurgeon. Bandages should be changed according to institution policy. Enteral nutrition should be started as early as possible to promote wound healing and improve outcomes (Meinert et al. 2015).

### 8.10.6 Postoperative Complications

Postoperative deterioration, including worsening neurologic status compared to preoperative assessment, requires emergency evaluation and treatment as indicated. Worsening neurologic assessment in the postoperative period warrants repeat imaging with CT scan to rule out hematoma formation, worsening cerebral edema, and acute hydrocephalus.

#### 8.10.6.1 Intracranial Hypertension

Increased ICP can develop or become worse during neurosurgery or in the postoperative period. Intracranial pressure, ICP waveforms, and calculated CPP values must be monitored and recorded, with deterioration reported to the physician immediately. Cerebrospinal fluid can be drained via an EVD, either intermittently or continuously, to therapeutically lower ICP. See previous Sects. 8.8, 8.9, and 8.10 for full discussion of the pathophysiology, assessment, and management of increased ICP.

#### 8.10.6.2 Seizure

The incidence of seizures following TBI in children may be as high as 19% and can occur during or following neurosurgery (Arango et al. 2012). Seizure activity increases cerebral metabolic demand and, therefore, must be prevented or treated immediately. Prophylactic administration of antiepileptic medications is recommended (see section "Contusion"). Management of postoperative



seizures includes administration of intravenous antiepileptic medications and insertion of an artificial airway and ventilation if the child is unable to protect the airway. A stat CT scan may be necessary to rule out postoperative development of a hematoma. Seizure should be considered as a potential cause of increasing or refractory ICP.

#### **8.10.6.3 Complications After Supratentorial Craniotomy**

Complications related to supratentorial neurosurgery include hemorrhage, cerebral edema, and cerebral ischemia secondary to increased ICP (Von Lehe et al. 2013). Swelling is an expected finding after neurosurgery and peaks within 72 h. Postoperative hemorrhage should be considered when there is a rapid increase in ICP and bloody output from an EVD or drain. An unexpected decrease in hemoglobin can indicate intracranial hemorrhage. The presence of coagulopathies in the postoperative period should also be considered as a cause for hemorrhage and managed rapidly. Clinical manifestations of supratentorial complications include symptoms of increased ICP (headache, emesis, decreasing LOC), signs of rostral–caudal deterioration, cranial nerve dysfunction (II, visual deficit; III, ptosis; III, IV, and VI, EOM deficit), focal motor deficits, and seizures. Stat repeat imaging with CT scan is performed. Neurologic deterioration due to an expanding mass lesion requires rapid intubation and control of ventilation, administration of an osmotic diuretic, such as mannitol or hypertonic saline, and emergent surgical intervention.

#### **8.10.6.4 Complications After Posterior Fossa Craniotomy**

Postoperative complications after posterior fossa (PF), or infratentorial, craniotomy deserve further discussion. Complications include acute bleeding or clot formation, cerebral edema or swelling, and CSF fistula. Often the first indication of posterior fossa complications is respiratory arrest, prompting some neurosurgeons to delay extubation in the postoperative period for 24–48 h. Hypertension after PF craniotomy can cause hemorrhage from tenuous vessels and pre-

cipitates postoperative use of antihypertensive medications. The child's blood pressure should be monitored closely, with any sudden increases reported to the neurosurgeon immediately.

The PF is a physically small compartment, which contains important structures such as the cerebellum and the brainstem. Cerebral swelling or postoperative hematoma with mass effect on the brainstem can be rapidly fatal. Increased pressure in the PF can cause obstruction of the outlet of the fourth ventricle, resulting in acute hydrocephalus (see Chap. 2). Increased pressure in the PF is associated with rapid change in respiratory pattern and hypertension. Headache, lower cranial nerve dysfunction (III to X), and cerebellar findings, such as ataxia and fine motor or coordination deficits, are common. Pupillary reflexes, level of consciousness, and ICP are not affected until late. An immediate reoperation is indicated to prevent cerebral herniation and is often not delayed to obtain neuroimaging or transport the patient to the operating room.

CSF fistula can occur following posterior fossa craniotomies and is evidenced by a persistent leak of clear fluid from the wound (Tsitouras and Sgouros 2015). CSF can also accumulate beneath the surgical skin flap (pseudomeningocele) without external leak or fistula. Pseudomeningocele can be observed and may resolve spontaneously. CSF fistula or active leak of CSF requires surgical wound revision. Lumbar drainage or placement of a ventricular shunt may be required if the leak is persistent or to promote healing of the surgical wound. CSF leak is a potential source for infection or meningitis, and prophylactic antibiotics are administered.

---

## **8.11 Endocrine Complications**

### **8.11.1 Diabetes Insipidus**

Diabetes insipidus (DI) can occur after a traumatic head injury or intracranial surgery because of damage to the cells in the hypothalamus that produce antidiuretic hormone (ADH). DI can also occur after injury to the posterior pituitary gland, whereby the injured gland does not release

**Table 8.11** Selected laboratory values associated with DI<sup>a</sup>, SIADH<sup>b</sup>, and CSW<sup>c</sup>

	DI	SIADH	CSW
Urine			
Specific gravity	<1.005	>1.020	>1.010
Osmolality	<250	>500	>300
Urine output (ml/kg/h)	>3	<1	≥1
Sodium (mEq/l)	<40	>60	>120
Serum			
Osmolality	>305	<275	<275
Sodium	>150	<130	<130

<sup>a</sup>Diabetes insipidus<sup>b</sup>Syndrome of inappropriate secretion of antidiuretic hormone<sup>c</sup>Cerebral salt wasting

ADH. When there is not enough ADH present, the collecting ducts and the distal tubules of the kidneys do not reabsorb free water, which results in intravascular volume depletion. Signs and symptoms of DI include large amounts of very dilute urine, severe dehydration, thirst, hypernatremia, and elevated serum osmolality. Excessive thirst in an alert child may also be indicative of DI and often is an effective mechanism to prevent severe dehydration. Table 8.11 lists laboratory values associated with DI.

The treatment for DI includes frequent assessment of laboratory values, as well as accurate calculation of fluid administration and urine output. Fluid resuscitation with isotonic solutions may be needed initially to treat severe volume depletion. After stabilization, fluid volume deficits and ongoing urine volume losses are replaced hourly. An intravenous infusion of vasopressin may become necessary if fluid replacement therapy alone is unsuccessful. For chronic management of DI, desmopressin is administered via the nasal or oral route.

### 8.11.2 Syndrome of Inappropriate Secretion of Antidiuretic Hormone

SIADH involves overproduction or release of ADH from the pituitary. This excess ADH increases the permeability of the collecting ducts and the distal tubules of the kidneys, caus-

ing water to be retained. The child can become fluid overloaded, and fluid can further shift from the intravascular to interstitial spaces, worsening cerebral edema. Clinically, the child will demonstrate decreased urine output, nausea and vomiting, dilutional hyponatremia with the risk of seizures, and mental status changes. Table 8.11 lists laboratory values associated with SIADH.

The treatment for SIADH, like that for DI, also includes frequent assessment of laboratory values and accurate calculation of fluid administration and urine output. Fluid restriction therapy is usually initiated. The child is also monitored frequently for changes in mental status and seizures. Severe hyponatremia, especially when associated with seizures, is treated with 3% hypertonic saline via the intravenous route. Rapid correction of sodium levels should be avoided because this can cause CNS osmotic demyelination syndrome.

### 8.11.3 Cerebral Salt Wasting

Cerebral salt wasting (CSW) is a condition characterized by true loss of body sodium through natriuresis. Though the exact mechanism by which CSW occurs is unclear, it is theoretically caused by natriuretic peptides (Leonard et al. 2015). This sodium loss results in decreased plasma volume, increased concentration of nitrogen (in the form of urea) in the blood, and a negative salt balance. Treatment of this condition involves first distinguishing it from SIADH. Fluid and sodium replacement therapies are then initiated, along with ongoing monitoring of serum sodium levels. Table 8.11 lists laboratory values associated with CSW.

## 8.12 Outcomes

Outcomes for children with traumatic brain injury can be difficult to predict. Children tend to have better outcomes, especially as compared to adults (Emami et al. 2016). Children

with more severe injuries have higher mortality rates (Alhelali et al. 2015; Stewart et al. 2013). Other factors associated with increased mortality include arriving at the hospital comatose, with a CPP <40 mmHg, and remaining in that state for at least 6 h (Davis et al. 2015; Fulkerson et al. 2015; Ramesh Kumar et al. 2012). It is also known that for the duration of hours that the ICP is more than 20 mmHg and CPP less than 45 mmHg, the presence of hypotension and the number of hypotensive episodes have an effect on outcome (Guiza et al. 2015; Hutchison et al. 2010; A. Mehta et al. 2010; Miller Ferguson et al. 2016).

Children with TBI tend to have more impairment than those with other injuries (Martin-Herz et al. 2012; Winthrop and Health-related quality of life after pediatric trauma 2010). Because of this, rehabilitation must begin early in the recovery period, ideally in the intensive care unit. An interdisciplinary team that includes the child's family is necessary to coordinate treatment. Physical, occupational, and speech therapists should participate in the child's care as soon as possible. Families will need anticipatory guidance about potential impairments and disabilities their child may experience, as well as about behaviors the child may display. They will also need to develop strategies to advocate for their child's maximal recovery and ongoing needs (Aitken et al. 2009; Kirk et al. 2015). Because the child's brain is still developing, it is difficult to predict final functional outcome. Children may experience neurocognitive delays or may never reach milestones related to visual-motor abilities, language, cognition, intelligence and school achievement, and behavior (Li and Liu 2013; Max et al. 2015; Ryan et al. 2016; Schachar et al. 2015). Some behavior problems may persist into adulthood (Scott et al. 2015). Additionally, these children may experience posttraumatic stress disorder in response to their medical trauma, depression, and anxiety (Marsac et al. 2014; Max et al. 2012, 2015). A structured rehabilitation program will provide the child with the best opportunity to meet his or her potential following a TBI.

### 8.13 Prevention Efforts

Major prevention efforts have included reduced speed limits, seat belt laws to include a lap and shoulder harness, proper use of child safety seats, and use of safety helmets for bicycling and other activities on wheels. Many local communities and states have passed mandatory bike helmet laws. The difficulty for law enforcement officials becomes how to enforce the law and what, if any, penalty or reward should be placed on the minors and their parents. Nurses should take an active interest in lobbying legislators to continue head trauma prevention efforts and encourage parents and children to use seat belts and other safety devices.

#### Pearls

1. Neurologic assessment should be performed consistently and be clearly documented on arrival, at change of shift, and at regular intervals. Critical evaluation of trends in the neurologic exam, vital signs, and ICP measurements is the most sensitive method of detecting early neurologic deterioration.
2. It is critical for the nurse to recognize early signs of neurologic (rostral (head)-caudal (tail)) deterioration, such as worsening LOC, cranial nerve dysfunction, and posturing, so that there is potential to reverse the process before herniation and death occur.
3. Due to their developmental age, young children are more difficult to assess than older children and adults. Young children may have significant intracranial injury with little external evidence.
4. Strategies to reduce radiation exposure in young children, and therefore reduce secondary malignancies, include creation of algorithms to determine children in whom CT scan can be avoided and also reduced radiation CT protocols.
5. Recommended intervals for repeat imaging of nonsurgical lesions are as

follows: EDH, 6 h; SDH, 8–12 h; and contusion, 12–24 h.

6. Minimal stimulation must not prevent a good assessment and intervention when necessary: base interventions on patient's response, ICP value, and waveform.
7. When evaluating child for causes of increased ICP, assure that the head of bed is elevated 30° with head midline, that adequate sedation and analgesia are provided as ordered, and that the ventilator and EVD/ICP monitor are functioning appropriately, prior to calling provider.
8. A worsening LOC suggests neurologic deterioration. Caution should be exercised not to mistake neurologic deterioration for pain or anxiety, as treatment of the same with narcotics or anti-anxiety agents will further blunt the neurologic exam and delay treatment. By the same token, abnormal motor posturing should not be mistaken as seizure activity.
9. The classic presentation of an expanding mass lesion is decreased LOC, ipsilateral pupillary dilation, and contralateral hemiparesis.
10. With expanding mass lesions, resuscitation and control of ICP, early imaging, and emergent surgical evacuation are important, as delay results in herniation, cerebral ischemia, and death.
11. Following loss of autoregulation (the ability of the brain to maintain perfusion despite changes in systemic perfusion), the cerebral blood flow is dependent on the systemic blood pressure. Adequate systemic perfusion is critical following pediatric TBI because hypotension causes secondary injury and is associated with poor outcome.
12. Adherence to evidence-based treatment guidelines in severe TBI can lead to improved outcomes. An example is included.

## References

- Adelson PD, Clyde B, Kochanek PM et al (1997) Cerebrovascular response in infants and young children following severe traumatic brain injury: a preliminary report. *Pediatr Neurosurg* 26:200–207
- Adelson PD, Wisniewski SR, Beca J, Brown SD, Bell M, Muizelaar JP et al (2013) Comparison of hypothermia and normothermia after severe traumatic brain injury in children (cool kids): a phase 3, randomised controlled trial. *Lancet Neurol* 12(6):546–553. doi:[10.1016/S1474-4422\(13\)70077-2](https://doi.org/10.1016/S1474-4422(13)70077-2)
- Aitken ME, McCarthy ML, Slomine BS, Ding R, Durbin DR, Jaffe KM et al (2009) Family burden after traumatic brain injury in children. *Pediatrics* 123(1):199–206. doi:[10.1542/peds.2008-0607](https://doi.org/10.1542/peds.2008-0607)
- Alhelali I, Stewart TC, Foster J, Alharfi IM, Ranger A, Daoud H, Fraser DD (2015) Basal skull fractures are associated with mortality in pediatric severe traumatic brain injury. *J Trauma Acute Care Surg* 78(6):1155–1161. doi:[10.1097/TA.0000000000000662](https://doi.org/10.1097/TA.0000000000000662)
- Allen BB, Chiu YL, Gerber LM, Ghajar J, Greenfield JP (2014) Age-specific cerebral perfusion pressure thresholds and survival in children and adolescents with severe traumatic brain injury\*. *Pediatr Crit Care Med: J Soc Crit Care Med World Fed Pediatr Intensive Crit Care Soc* 15(1):62–70. doi:[10.1097/PCC.0b013e3182a556ea](https://doi.org/10.1097/PCC.0b013e3182a556ea)
- American Heart Association (2012) Pediatric advanced life support: provider manual. American Heart Association, Dallas
- APLS—The Pediatric Emergency Medicine Course. American College of Emergency Physicians and American Academy of Pediatrics, 1998.
- Arabi YM, Haddad S, Tamim HM, Al-Dawood A, Al-Qahtani S, Ferayan A et al (2010) Mortality reduction after implementing a clinical practice guidelines-based management protocol for severe traumatic brain injury. *J Crit Care* 25(2):190–195
- Arango JI, Deibert CP, Brown D, Bell M, Dvorchik I, Adelson PD (2012) Posttraumatic seizures in children with severe traumatic brain injury. *Childs Nerv Syst: ChNS: Off J Int Soc Pediatr Neurosurg* 28(11):1925–1929. doi:[10.1007/s00381-012-1863-0](https://doi.org/10.1007/s00381-012-1863-0)
- Badjatia N, Carney N, Crocco TJ, Fallat ME, Hennes HM, Jagoda AS et al (2008) Guidelines for prehospital management of traumatic brain injury 2nd edition. *Prehospital Emerg Care: Off J Nat Assoc EMS Phys Natl Assoc State EMS Dir* 12(Suppl 1):S1–52. doi:[10.1080/10903120701732052](https://doi.org/10.1080/10903120701732052)
- Barkovich AJ, Raybaud C (eds) (2012) Pediatric neuroimaging, 5th edn. Lippincott, Williams, & Wilkins, Philadelphia
- Bell MJ, Adelson D, Forbes ML, Kochanek PM (2015) Traumatic brain injury in children: critical care management. In: Albright AL, Pollack IF, Adelson PD (eds) *Principles and practice of pediatric neurosurgery*, 3rd edn. Thieme, New York, pp 729–742
- Bowen IE, McComb JG, Krieger MD (2015) Penetrating craniocerebral injuries. In: Albright AL, Pollack IF,

- Adelson PD (eds) Principles and practice of pediatric neurosurgery, 3rd edn. Thieme, New York, pp 706–717
- Bratton SL, Chestnut RM, Ghajar J, McConnell Hammond FF, Harris OA, Hartl R et al (2007) XII. nutrition. *J Neurotrauma* 24(Supplement 1):S-77–S-82
- Brenner DJ, Elliston CD, Hall EJ, Berdon WE (2001) Estimated risks of radiation-induced fatal cancer from pediatric CT. *Am J Radiol* 176(2):1–18
- Bullock MR, Chestnut R, Ghajar J, Surgical Management of Traumatic Brain Injury Author Group et al (2006) Surgical management of acute subdural hematomas. *Neurosurgery* 58(Suppl):S15–S24 discussion Si-iv
- Cavaliere TA, Sansouci DA (2014) Assessment of the newborn and infant. In: Kenner C, Lott JW (eds) *Comprehensive neonatal nursing care*, 5th edn. Springer, New York, pp 71–112
- Centers for Disease Control (2010) Morbidity and Mortality Weekly Report (MMWR). Vital signs: unintentional injury deaths among persons aged 0–19 years – United States, 2000–2009. <http://www.cdc.gov/mmwr/preview/mmwrhtml/mm6115a5.htm>
- Cnossen MC, Scholten AC, Lingsma H, Synnot A, Tavender E, Gantner D et al (2015) Adherence to guidelines in adult patients with traumatic brain injury: a living systematic review. *J Neurotrauma*. doi:10.1089/neu.2015.4121
- Colditz MJ, Lai MM, Cartwright DW, Colditz PB (2015) Subgaleal haemorrhage in the newborn: a call for early diagnosis and aggressive management. *J Paediatr Child Health* 51(2):140–146. doi:10.1111/jpc.12698
- Coronado VG, Xu L, Basavaraju SV et al (2011) Surveillance for traumatic brain injury-related deaths – United States, 1997–2007. *MMWR Surveill Summ* 60:1–32
- Csokay A, Emelifeonwu JA, Fugedi L, Valalik I, Lang J (2012) The importance of very early decompressive craniectomy as a prevention to avoid the sudden increase of intracranial pressure in children with severe traumatic brain swelling (retrospective case series). *Childs Nerv Syst* 28(3):441–444. doi:10.1007/s00381-011-1661-0
- Davis AL, Wales PW, Malik T, Stephens D, Razik F, Schuh S (2015) The BIG score and prediction of mortality in pediatric blunt trauma. *J Pediatr* 167(3):593–8. e1. doi:10.1016/j.jpeds.2015.05.041
- Dias MS (2004) Traumatic brain and spinal cord injury. *Pediatr Clin N Am* 51:271–303
- Farlex Medical Dictionary (2012) Retrieved 5 Aug 2016 from <http://medical-dictionary.thefreedictionary.com/stellate+skull+fracture>
- Ditzenberger GR, Blackburn ST (2014) Neurologic system. In: Kenner C, Lott JW (eds) *Comprehensive neonatal nursing care*, 5th edn. Springer, New York, pp 392–437
- Elkon B, Cambrin JR, Hirshberg E, Bratton SL (2014) Hyperglycemia: an independent risk factor for poor outcome in children with traumatic brain injury\*. *Pediatr Crit Care Med: J Soc Crit Care Med World Fed Pediatr Intensive Crit Care Soc* 15(7):623–631. doi:10.1097/PCC.000000000000170
- Emami P, Czorlich P, Fritzsche FS, Westphal M, Rueger JM, Lefering R, Hoffmann M (2016) Impact of glasgow coma scale score and pupil parameters on mortality rate and outcome in pediatric and adult severe traumatic brain injury: a retrospective, multi-center cohort study. *J Neurosurg*:1–8. doi:10.3171/2016.1.JNS152385
- Falkner B, Daniels SR (2004) Summary of the fourth report on the diagnosis, evaluation, and treatment of high blood pressure in children and adolescents. *Hypertension* 44(4):387–388. doi:10.1161/01.HYP.0000143545.54637.af
- Faul M, Xu L, Wald MM, Coronado VG 2010 Traumatic brain injury in the United States: emergency department visits, hospitalizations, and deaths. Centers for Disease Control and Prevention, National Center for injury Prevention and Control, Atlanta. <http://www.cdc.gov/traumatic-braininjury/pdf/blue-book.pdf>
- Faust AC, Attridge RL, Ryan L (2011) How low should you go? The limbo of glycemic control in intensive care units. *Crit Care Nurse* 31(4):e9–e18. doi:10.4037/ccn2011188
- Figaji A (2015) Intracranial and extracranial hematomas in children. In: Albright AL, Pollack IF, Adelson PD (eds) Principles and practice of pediatric neurosurgery, 3rd edn. Thieme, New York, pp 718–728
- Brain Trauma Foundation (2007) Guidelines for the management of severe traumatic brain injury, 3rd edn. *J Neurotrauma* 24:S1–S106
- Fulkerson DH, White IK, Rees JM, Baumanis MM, Smith JL, Ackerman LL et al (2015) Analysis of long-term (median 10.5 years) outcomes in children presenting with traumatic brain injury and an initial glasgow coma scale score of 3 or 4. *J Neurosurg Pediatr* 16(4):410–419. doi:10.3171/2015.3.PEDS14679
- Gaynor BG, Zoeller GK, Ragheb J (2015) Accidental head injuries in children. In: Albright AL, Pollack IF, Adelson PD (eds) Principles and practice of pediatric neurosurgery, 3rd edn. Thieme, New York, pp 700–705
- Gonda DD, Meltzer HS, Crawford JR, Hilfiker ML, Shellington DK, Peterson BM, Levy ML (2013) Complications associated with prolonged hypertonic saline therapy in children with elevated intracranial pressure. *Pediatr Crit Care Med: J Soc Crit Care Med World Fed Pediatr Intensive Crit Care Soc* 14(6):610–620. doi:10.1097/PCC.0b013e318291772b
- Greenberg MS (ed) (2016) Handbook of neurosurgery, 8th edn. Thieme, New York
- Greenberg JK, Stoey IT, Park TS, Smyth MD, Leonard JR, Leonard JC, Pineda JA, Limbrick DD (2014). Management of children with mild traumatic brain injury and intracranial hemorrhage. *J Trauma Acute Care Surg* 2014 Apr; 76(4): 1089–1095.
- Guiza F, Depreitere B, Piper I, Citerio G, Chambers I, Jones PA et al (2015) Visualizing the pressure and time burden of intracranial hypertension in adult and paediatric traumatic brain injury. *Intensive Care Med* 41(6):1067–1076. doi:10.1007/s00134-015-3806-1



- Hickey JV (2014) The clinical practice of neurological and neurosurgical nursing, 7th edn. Lippincott, Williams & Wilkins, Philadelphia
- Holmes JF, Palchak MJ, MacFarlane T. et al (2005) Performance of the pediatric Glasgow coma scale in children with blunt head trauma. *Acad Emerg Med* 12:814–819
- Hutchison JS, Frndova H, Lo TY, Guerguerian AM, Hypothermia Pediatric Head Injury Trial Investigators, & Canadian Critical Care Trials Group (2010) Impact of hypotension and low cerebral perfusion pressure on outcomes in children treated with hypothermia therapy following severe traumatic brain injury: a post hoc analysis of the hypothermia pediatric head injury trial. *Dev Neurosci* 32(5–6):406–412. doi:10.1159/000323260
- Jacob AT, Heuer GG, Grant R, Georgoff P, Danish SF, Storm PB, Stein SC (2011) Decompressive hemicraniectomy for pediatric traumatic brain injury: long-term outcome based on quality of life. *Pediatr Neurosurg* 47(2):81–86. doi:10.1159/000329624
- Kennedy CS, Moffatt M (2004) Acute traumatic brain injury in children: exploring the cutting edge in understanding, therapy, and research. *Clin Pediatr Emerg Med* 5:224–238
- Kirk S, Fallon D, Fraser C, Robinson G, Vassallo G (2015) Supporting parents following childhood traumatic brain injury: a qualitative study to examine information and emotional support needs across key care transitions. *Child Care Health Dev* 41(2):303–313. doi:10.1111/cch.12173
- Kochanek PM, Bell MJ (2016) Traumatic brain injury 2016. In: Turner DA, Killinger JS (eds) Current concepts in pediatric critical care 2016. Society of Critical Care Medicine, Mount Prospect, pp 175–181
- Kochanek PM, Carney N, Adelson PD, Ashwal S, Bell MJ, Bratton S et al (2012) Guidelines for the acute medical management of severe traumatic brain injury in infants, children, and adolescents – second edition. *Pediatr Crit Care Med: J Soc Crit Care Med World Fed Pediatr Intensive Crit Care Soc* 13(Suppl 1):S1–82. doi:10.1097/PCC.0b013e31823f435c
- Kriel RL, Krach LE, Panser LA (1989) Closed head injury: comparison of children younger and older than 6 years of age. *Pediatr Neurol* 5:296–300
- Krishnamoorthy V, Vavilala MS, Mills B, Rowhani-Rahbar A (2015) Demographic and clinical risk factors associated with hospital mortality after isolated severe traumatic brain injury: a cohort study. *J Intensive Care*:3
- Kukreti V, Mohseni-Bod H, Drake J (2014) Management of raised intracranial pressure in children with traumatic brain injury. *J Pediatr Neurosci* 9(3):207–215. doi:10.4103/1817-1745.147572
- Kupperman N et al (2009) Identification of children at very low risk of clinically-important brain injuries after head trauma: a prospective cohort study. *Lancet* 374(9696)
- Leonard J, Garrett RE, Salottolo K, Slone DS, Mains CW, Carrick MM, Bar-Or D (2015) Cerebral salt wasting after traumatic brain injury: a review of the literature. *Scand J Trauma Resuscita Emerg Med* 23:98
- Lewis RJ, Yee L, Inkelis SH et al (1993) Clinical predictors of post-traumatic seizures in children with head trauma. *Ann Emerg Med* 22:1114–1118
- Li L, Liu J (2013) The effect of pediatric traumatic brain injury on behavioral outcomes: a systematic review. *Dev Med Child Neurol* 55(1):37–45. doi:10.1111/j.1469-8749.2012.04414.x
- Lopez-Elizalde R, Leyva-Mastrapa TF, Munoz-Serrano JF, Godinez-Rubi MF, Preciado-Baron KF, Velazquez-Santana HF, Santana-Ramirez A (2013) Ping pong fractures: treatment using a new medical device. doi:10.1007/s00381-012-1979-2
- Luerson TG, Klauber MR, Marshall LF (1988) Outcome from head injury related to patient's age: a longitudinal prospective study of adult and pediatric head injury. *J Neurosurg* 68:409–416
- Lynam L, Verklan MT (2015) Neurological disorders. In: Verklan MT, Walden M (eds) Core curriculum for neonatal intensive care nursing, 5th edn. Elsevier Saunders, St. Louis, pp 734–766
- Malakouti A, Sookplung P, Siriussawakul A, Philip S, Bailey N, Brown M et al (2012) Nutrition support and deficiencies in children with severe traumatic brain injury. *Pediatr Crit Care Med: J Soc Crit Care Med World Fed Pediatr Intensive Crit Care Soc* 13(1):e18–e24. doi:10.1097/PCC.0b013e31820aba1f
- Marcoux KK (2005) Management of increased intracranial pressure in the critically ill child with an acute neurological injury. *AACN Clin Issues* 16:212–231
- Marsac ML, Kassam-Adams N, Delahanty DL, Widaman KF, Barakat LP (2014) Posttraumatic stress following acute medical trauma in children: a proposed model of bio-psycho-social processes during the peri-trauma period. *Clin Child Fam Psychol Rev* 17(4):399–411. doi:10.1007/s10567-014-0174-2
- Martin-Herz SP, Zatzick DF, McMahon RJ (2012) Health-related quality of life in children and adolescents following traumatic injury: a review. *Clin Child Fam Psychol Rev* 15(3):192–214. doi:10.1007/s10567-012-0115-x
- Martini RP, Deem S, Treggiari MM (2013) Targeting brain tissue oxygenation in traumatic brain injury. *Respir Care* 58(1):162–172. doi:10.4187/respcare.01942
- Massagli TL, Michaud LJ, Rivara FP (1996) Association between injury indices and outcome after severe traumatic brain injury in children. *Arch Phys Med Rehabil* 77:1125–1132
- Max JE, Keatley E, Wilde EA, Bigler ED, Schachar RJ, Saunders AE et al (2012) Depression in children and adolescents in the first 6 months after traumatic brain injury. *Int J Dev Neurosci: Off J Int Soc Dev Neurosci* 30(3):239–245. doi:10.1016/j.ijdevneu.2011.12.005
- Max JE, Lopez A, Wilde EA, Bigler ED, Schachar RJ, Saunders A et al (2015) Anxiety disorders in children and adolescents in the second six months after traumatic brain injury. *J Pediatr Rehabil Med* 8(4):345–355. doi:10.3233/PRM-150352

- McIlvoy L (2012) Fever management in patients with brain injury. *AACN Adv Crit Care* 23(2):204–211. doi:[10.1097/NCL.0b013e31824db1c6](https://doi.org/10.1097/NCL.0b013e31824db1c6)
- Mehta NM (2009) Approach to enteral feeding in the PICU. *Nutr Clin Pract: Off Publ Am Soc Parenter Enter Nutr* 24(3):377–387. doi:[10.1177/0884533609335175](https://doi.org/10.1177/0884533609335175)
- Mehta A, Kochanek PM, Tyler-Kabara E, Adelson PD, Wisniewski SR, Berger RP et al (2010) Relationship of intracranial pressure and cerebral perfusion pressure with outcome in young children after severe traumatic brain injury. *Dev Neurosci* 32(5–6):413–419. doi:[10.1159/000316804](https://doi.org/10.1159/000316804)
- Meinert E, Bell M, Adelson P, Buttram S, Kochanek P, Balasubramani G, Wisniewski S (2015) 17: early nutritional support is associated with favorable outcome in pediatric traumatic brain injury. *Crit Care Med* 43(12 Suppl 1):5
- Mellion SA, Bennett KS, Ellsworth GL, Moore K, Riva-Cambrian J, Metzger RR, Bratton SL (2013) High-dose barbiturates for refractory intracranial hypertension in children with severe traumatic brain injury. *Pediatr Crit Care Med: J Soc Crit Care Med World Fed Pediatr Intensive Crit Care Soc* 14(3):239–247. doi:[10.1097/PCC.0b013e318271c3b2](https://doi.org/10.1097/PCC.0b013e318271c3b2)
- Merhar SL, Kline-Fath BM, Nathan AT, Melton KR, Bierbrauer KS (2016) Identification and management of neonatal skull fractures. *J Perinatol: Off J Calif Perinatal Assoc.* doi:[10.1038/jp.2016.53](https://doi.org/10.1038/jp.2016.53)
- Miller Ferguson N, Shein SL, Kochanek PM, Luther J, Wisniewski SR, Clark RS et al (2016) Intracranial hypertension and cerebral hypoperfusion in children with severe traumatic brain injury: thresholds and burden in accidental and abusive insults. *Pediatr Crit Care Med: J Soc Crit Care Med World Fed Pediatr Intensive Crit Care Soc.* doi:[10.1097/PCC.0000000000000709](https://doi.org/10.1097/PCC.0000000000000709)
- Mills B, Rowhani-Rahbar A, Simonetti JA, Vavilala MS (2015) Facility characteristics and in-hospital pediatric mortality after severe traumatic brain injury. *J Neurotrauma* 32(11):841–846. doi:[10.1089/neu.2014.3733](https://doi.org/10.1089/neu.2014.3733)
- Moghissi ES, Korytkowski MT, DiNardo M, Einhorn D, Hellman R, Hirsch IB et al (2009) American association of clinical endocrinologists and american diabetes association consensus statement on inpatient glycemic control. *Diabetes Care* 32(6):1119–1131. doi:[10.2337/dc09-9029](https://doi.org/10.2337/dc09-9029)
- Murad A, Ghostine S, Colohan AR (2012) A case for further investigating the use of controlled lumbar cerebrospinal fluid drainage for the control of intracranial pressure. *World Neurosurg* 77(1):160–165. doi:[10.1016/j.wneu.2011.06.018](https://doi.org/10.1016/j.wneu.2011.06.018)
- Nangunoori R, Maloney-Wilensky E, Stiefel M, Park S, Andrew Kofke W, Levine JM et al (2012) Brain tissue oxygen-based therapy and outcome after severe traumatic brain injury: a systematic literature review. *Neurocrit Care* 17(1):131–138. doi:[10.1007/s12028-011-9621-9](https://doi.org/10.1007/s12028-011-9621-9)
- National Center for Health Statistics (US). Health, United States (2015) With special feature on racial and ethnic health disparities. National Center for Health Statistics (US), Hyattsville 2016 May. Available from: <http://www.ncbi.nlm.nih.gov/books/NBK367640/>
- O’Lynnnger TM, Shannon CN, Le TM, Greeno A, Chung D, Lamb FS, Wellons JC (2016) Standardizing ICU management of pediatric traumatic brain injury is associated with improved outcomes at discharge. *J Neurosurg Pediatr* 17:19–26
- Olson DM, McNett MM, Lewis LS, Riemen KE, Bautista C (2013) Effects of nursing interventions on intracranial pressure. *Am J Crit Care Off Publ Am Assoc Crit-Care Nurses* 22(5):431–438. doi:[10.4037/ajcc2013751](https://doi.org/10.4037/ajcc2013751)
- Oluigbo CO, Wilkinson CC, Stence NV, Fenton LZ, McNatt SA, Handler MH (2012) Comparison of outcomes following decompressive craniectomy in children with accidental and nonaccidental blunt cranial trauma. *J Neurosurg Pediatr* 9(2):125–132. doi:[10.3171/2011.11.PEDS09449](https://doi.org/10.3171/2011.11.PEDS09449)
- Parsons JA, Seay AR, Jacobson M (2016) Neurologic disorders. In: Gardner SL, Carter BS, Enzman-Hines J et al (eds) *Merenstein and gardner’s handbook of neonatal intensive care*, 8th edn. Elsevier, St. Louis, pp 727–762
- Pinto PS, Meoded A, Poretti A, Tekes A, Huisman TA (2012) The unique features of traumatic brain injury in children. Review of the characteristics of the pediatric skull and brain, mechanisms of trauma, patterns of injury, complications, and their imaging findings – Part 2. *J Neuroimaging* 22:e18–e41
- Posner JB, Saper CB, Schiff ND, Plum F (2007) *Plum and Posner’s diagnosis of stupor and coma*, 4th edn. Oxford University Press, New York
- Ramesh Kumar R, Singhi SC, Singhi P (2012) Raised Intracranial Pressure (ICP): Management in Emergency Department. *The Indian Journal of Pediatrics* 79(4):518–524.
- Ryan NP, Catroppa C, Godfrey C, Noble-Haesslein LJ, Shultz SR, O’Brien TJ, Anderson V, Semple BD (2016) Social dysfunction after pediatric traumatic brain injury: a translational perspective. *Neurosci Biobehav Rev* 64:196–214
- Schachar RJ, Park LS, Dennis M (2015) Mental health implications of traumatic brain injury (TBI) in children and youth. *J Can Acad Child Adolesc Psychiatry* 24(2):100
- Schierholz E, Walker SR (2014) Responding to traumatic birth: subgaleal hemorrhage, assessment, and management during transport. *Adv Neonatal Care: Off J Natl Assoc Neonatal Nurses* 14(Suppl 5):S11–S15. doi:[10.1097/ANC.0b013e3181fe9a49](https://doi.org/10.1097/ANC.0b013e3181fe9a49)
- Schindler CA, Mikhailov TA, Kuhn EM, Christopher J, Conway P, Ridling D, ..., Simpson VS (2011) Protecting fragile skin: nursing interventions to decrease development of pressure ulcers in pediatric intensive care. *Am J Crit Care Off Publ, Am Assoc Crit Care Nurses* 20(1):26–34; quiz 35. doi:[10.4037/ajcc2011754](https://doi.org/10.4037/ajcc2011754)
- Schoenbrodt L (ed) (2001) *Children with traumatic brain injury: a parent’s guide*. Woodbine House, Bethesda
- Schutzman SA, Greenes DS (2001) Pediatric minor head trauma. *Ann Emerg Med* 37:65–74

- Scott C, McKinlay A, McLellan T, Britt E, Grace R, MacFarlane M (2015) A comparison of adult outcomes for males compared to females following pediatric traumatic brain injury. *Neuropsychology* 29(4):501–508
- Smets KJ, Vanhauwaert D (2010) Treatment of cranial epidural hematoma in a neonate by needle aspiration of a communicating cephalohematoma. *Eur J Pediatr* 169(5):617–619. doi:10.1007/s00431-009-1071-4
- Smith RL, Lin JC, Adelson PD, Kochanek PM, Fink EL, Wisniewski SR et al (2012) Relationship between hyperglycemia and outcome in children with severe traumatic brain injury. *Pediatr Crit Care Med J Soc Crit Care Med World Fed Pediatr Intensive Crit Care Soc* 13(1):85–91. doi:10.1097/PCC.0b013e3182192c30
- Stewart TC, Alharfi IM, Fraser DD (2013) The role of serious concomitant injuries in the treatment and outcome of pediatric severe traumatic brain injury. *J Trauma Acute Care Surg* 75(5):836–842. doi:10.1097/TA.0b013e3182a685b0
- Stocchetti, N., Conte, V., Ghisoni, L., Canavesi, K., & Zanaboni, C. (2010). Traumatic brain injury in pediatric patients. *Minerva Anestesiol*, 76(12), 1052–1059. doi:R02106334 [pii]
- Strauss KJ, Gopske MJ, Kaste SC, Bulas D, Frush DP, Butler P, Morrison G, Callahan MJ, Applegate KE (2010) Image gently: ten steps you can take to optimize image quality and lower CT dose for pediatric patients. *Am J Radiol* 194(4):1–11
- Swanson AE, Veldman A, Wallace EM, Malhotra A (2012) Subgaleal hemorrhage: risk factors and outcomes. *Acta Obstet Gynecol Scand* 91(2):260–263. doi:10.1111/j.1600-0412.2011.01300.x
- Teasdale G, Jennett B (1974) Assessment of coma and impaired consciousness. A practical scale. *Lancet* 2:81–84
- Timmons SD (2016) Adherence to traumatic brain injury guidelines-linkages to outcomes. *World Neurosurg* 90:663–664. doi:10.1016/j.wneu.2016.02.057 S1878-8750(16)00302-8 [pii]
- Tsitouras V, Sgouros S (2015) Postoperative care following surgery for posterior fossa tumors. *Posterior fossa tumors in children*. Switzerland: Springer; pp 841–845
- Tume LN, Copnell B (2015) Endotracheal suctioning of the critically ill child. *J Pediatr Intensive Care* 4(02):056–063
- Tume LN, Baines PB, Lisboa PJ (2011) The effect of nursing interventions on the intracranial pressure in paediatric traumatic brain injury. *Nurs Crit Care* 16(2):77–84. doi:10.1111/j.1478-5153.2010.00412.x
- Udomphorn Y, Armstead WM, Vavilala MS (2008) Cerebral blood flow and autoregulation after pediatric traumatic brain injury. *Pediatr Neurol* 38(4):225–234 <http://doi.org/10.1016/j.pediatrneurol.2007.09.012>
- Upadhyay P, Tripathi VN, Singh RP, Sachan D (2010) Role of hypertonic saline and mannitol in the management of raised intracranial pressure in children: a randomized comparative study. *J Pediatr Neurosci* 5(1):18–21. doi:10.4103/1817-1745.66673
- Vavilala MS, Lee LA, Boddu K et al (2004) Cerebral autoregulation in pediatric traumatic brain injury. *Pediatr Crit Care Med* 5:257–263
- Vavilala MS, Kernic MA, Wang J, Kannan N, Mink RB, Wainwright MS et al (2014) Acute care clinical indicators associated with discharge outcomes in children with severe traumatic brain injury. *Crit Care Med* 42(10):2258–2266. doi:10.1097/CCM.0000000000000507
- Vinchon M, Defoort-Dhellemmes S, Desurmont M et al (2005) Accidental and nonaccidental head injuries in infants: a prospective study. *J Neurosurg Pediatr* 102:380–384
- Vizzini A, Aranda-Michel J (2011) Nutritional support in head injury. *Nutrition (Burbank, Los Angeles County, Calif)* 27(2):129–132. doi:10.1016/j.nut.2010.05.004
- Von Lehe M, Kim H, Schramm J, Simon M (2013) A comprehensive analysis of early outcomes and complication rates after 769 craniotomies in pediatric patients. *Childs Nerv Syst* 29(5):781–790
- White JRM, Farukhi Z, Bull C, Christenson J, Gordon T, Paidas C, Nichols DG (2001) Predictors of outcome in severely head injured children. *Crit Care Med* 29:534–540 [PubMed: 1137346]
- Winthrop AL (2010) Health-related quality of life after pediatric trauma. *Curr Opin Pediatr* 22(3):346–351. doi:10.1097/MOP.0b013e3283394351
- Woischnack D, Klein S, Reissberg S et al (2003) Prognosis of brainstem lesion in children with head injury. *Childs Nerv Syst* 19:174–178
- Young PA, Young PH, Tolbert DL (2015) *Basic clinical neuroscience*, 3rd edn. Wolters Kluwer, Philadelphia
- Zacharias C, Alessio AM, Otto RK, Iyer RS, Philips GS, Swanson J, Thapa MM (2013) Pediatric CT: strategies to lower radiation dose. *Am J Radiol* 200(5):1–7
- Zebrack M, Dandoy C, Hansen K et al (2009) Early resuscitation of children with moderate-to-severe traumatic brain injury. *Pediatrics* 124:56–64

Jill Kouts and Tanya Filardi

---

## 9.1 Introduction

In the twenty-first century, considerable publicity, legislation, and research have been devoted to the problem of concussion in sports. Much effort has also gone into educating parents and coaches about concussion and implementing return to play (RTP) and learn (RTL) protocols for young athletes who exhibit concussion-like symptoms. Of course, children and adolescents can sustain concussions from many forms of accidental or non-accidental trauma and not just from sports or recreational activities. The information in this chapter is generally applicable to all pediatric concussions.

---

## 9.2 Definition

The term concussion is used to describe a brain injury resulting from a blow or force to the head or body that is often radiographically silent with standard imaging. As defined by the Zurich Consensus Statement on Concussion in Sport of 2012, it is a “complex pathophysiological process affecting the

brain, induced by direct or indirect biomechanical forces” (McCrory et al. 2013). The mechanism may occur from a direct or indirect blow to the face, head, neck, or elsewhere in the body that transmits energy to the brain and causes damage to brain cells and/or their function. Although classified as a mild form of traumatic brain injury, concussions can have long-term effects on children or even result in death, if not identified and treated appropriately. Due to the unique characteristics of the pediatric population, including the rapid development and vulnerability of the young brain, this can be even more challenging.

---

## 9.3 Epidemiology

Traumatic brain injury (TBI) is the leading cause of disability and death in children and adolescents in the USA according to the Centers for Disease Control and Prevention (CDC 2011). Concussion is the largest subset of TBI, though exactly how large is hard to say because it often goes unreported and the symptoms resolve without treatment.

The epidemiology of sports-related concussion is speculative. Bryan et al. (2016) estimated that between 1.1 and 1.9 million concussions occur annually in the USA involving children injured in recreational and sports activities. The authors claim their study provides the “most accurate and precise estimate to date” and that very well may be true. However, the study

---

J. Kouts, BSN, RN (✉)  
University of Kansas Medical Center,  
Kansas City, KS, USA  
e-mail: [jkouts@kumc.edu](mailto:jkouts@kumc.edu)

T. Filardi, MD  
Department of Neurosurgery,  
University of Kansas Medical Center,  
Kansas City, KS, USA

includes estimates for concussions that were unreported and untreated, and those estimates were based on studies with small cohorts. For example, one study found that 52.7% of 234 tackle football players who claimed to have suffered a concussion did not report it (McRea et al. 2004), whereas another found that it was just 22.5% (9 of 40) of football players who failed to report (Kelleher et al. 2014). While those two studies may be indicative of a positive trend in the reporting of concussions among American high school football players, it is questionable whether they should be used to estimate the overall number of unreported concussions among young athletes.

In contrast, the American Medical Society for Sports Medicine relied on an estimate of 3.8 million concussions per year in sports and recreational activities (all ages), which is an oft-cited figure originally calculated by Langlois et al. (Harmon et al. 2013). According to Selassie et al. (2013), approximately 61% of sports-related concussions occur in children aged 18 or younger. If you multiply 3.8 million by 61%, that results in an estimated 2.3 million pediatric athletic concussions annually in the USA.

Tackle football is far and away the leading cause of pediatric concussions in competitive sports in the USA, although cycling is the most common overall cause of TBI in children aged 5–14 (AANS 2014). In most of the world, football is a sport played with the feet and a round ball. That sport is typically called soccer in the USA, whereas football is played with pads and helmets that are intended to protect participants from injuries resulting from violent collisions. To avoid confusion, we will use the term “football” here to mean the American or tackle version.

The high school sports where concussions most frequently occur in the USA are football for boys and soccer for girls (Marar et al. 2012; Gessel et al. 2007). Statistics compiled by the Missouri State High School Activities Association are illustrative. During the 2014–2015 school year, 1,332 boys were withheld from practice or competition due to head injuries and concussion symptoms in football and 273 girls in soccer. The overall percentages of reported injuries were foot-

ball, 46.7%; soccer (boys and girls), 16.6%; basketball (boys and girls), 12.5%; wrestling, 8.3%; and cheerleading, 8.0% (MSHSAA 2015). With regard to soccer, more injuries occur from contact with other players, the goalposts, and the ground than from “heading” the ball (Meehan 2009).

The Centers for Disease Control and Prevention (CDC) estimates that 1.1 million persons with traumatic brain injury (TBI) are treated and released from emergency departments in the USA every year with an additional 235,000 being hospitalized (Langlois et al. 2006). Pediatric patients are often admitted for observation and treatment of extreme symptoms such as nausea and vomiting (Albright 2008). Over the time period of 2001–2005, the CDC reported that an estimated 207,830 patients with sports- and recreation-related TBIs were treated each year, with the highest rate in the 10–14-year-old age group without gender difference (CDC 2011). In the same time period, expanding the age range from 5 to 18 years of age, these patients accounted for 2.4 million sports- and recreation-related emergency room visits with 134,959 of those categorized as TBI related. In the past, the total number of concussions was estimated at 300,000 a year in the high school age group alone. However, these numbers only included athletes with a loss of consciousness (Thunнан et al. 1998). With only 10% of concussions associated with a loss of consciousness, this leaves the total number of concussions severely underestimated (CDC 2011). The two age groups at greatest risk for TBI are ages 0–4 and 15–19 (CDC 2011). The spikes in these age groups are felt to be due to anatomical differences from adults.

What do all of these statistics mean? Regardless of the actual numbers, pediatric athletic concussion is a common occurrence, and a substantial percentage of them go unreported and untreated. How do these statistics apply to the rest of the world? Although tackle football is primarily an American sport, other countries have popular sports that involve violent contact such as ice hockey and rugby. Soccer is the world’s most popular sport and children fall off bicycles everywhere. Although the incidence by sport may change, the problem of pediatric concussion



remains. What are the nursing implications apparent in this epidemiology? Many pediatric nurses will be caring for patients with concussions, whether they specialize in neurosurgery or not. Nurses can also be educators about the problem of pediatric athletic concussions, as well as advocates for improvements in safety rules and the use of protective helmets.

---

## 9.4 The Pediatric Brain

The pediatric population presents unique concerns due to the rapid development of the young brain (Konrad et al. 2011). Those concerns include the vulnerability of the developing brain to injury, and particularly concussion, because of factors such as the disproportionately larger head-to-body ratio until about age 4, a softer brain due to higher water content, a thinner skull, and a wider subarachnoid space. The thinner skull not only provides less protection to the brain but also combines with the wider subarachnoid space to make the pediatric brain more susceptible to acceleration-deceleration or rotational injuries (which will be more fully discussed in Pathophysiology).

There are additional concerns about neuronal plasticity and immature myelination (Norton et al. 2013). The neuronal plasticity (or neuroplasticity) of the developing brain also allows for the possibility of neuronal pathway reorganization after injury, if given time for recuperation. Reorganization allows activities performed by a part of the brain that is injured to be transferred to another part of it. Pediatric brains have more capacity for this than do adults. But as with any healing process, reorganization takes energy. Hence, a child or adolescent who suffers a concussion needs good nutrition and rest, including cognitive rest. And if the brain sustains additional trauma during the healing process, recovery will be prolonged or may never fully occur. Myelination is a process that begins in utero and generally continues into adolescence or even adulthood. Myelin forms an insulating sheath around axons, which enhances the speed at which electrical impulses can travel in the brain.

Disruption of this process via injury before it is complete can interfere with the formation of nerve connections within the brain.

---

## 9.5 The Female Athlete

There is considerable evidence that females participating in high school sports sustain a higher incidence rate of concussions than males (Gessel et al. 2007). Marar et al. (2012) not only found that girls had a higher concussion rate (1.7) to boys (1.0) in gender-comparable sports but that girls were also more susceptible to subsequent concussions. Interestingly, Broshek et al. (2005) found the same ratio: that females were cognitively impaired 1.7 times more frequently than males after suffering a concussion. Further, the Michigan High School Athletics Association reported that, “Girls soccer had 58% more concussions than boys soccer, despite having fewer players” (Bernreuter, mlive.com, 6/28/16). However, at least one author has questioned whether the difference is “true...or influenced by reporting bias” (i.e., females are more honest in reporting subjective symptoms) (Dick 2009). And while it would be logical to expect that same difference to exist in younger children, this is an area in need of further study.

Cheerleading is an athletic activity which involves primarily female participants from elementary school through college-age. Although the Wisconsin Supreme Court held that cheerleading is a “contact sport” in *Noffke v. Bakke* (2009), some states do not classify it as a sport at all. Likewise, some research studies and articles on concussion do not include cheerleading as a sport (Gessel et al. 2007), while others do so (Marar et al. 2012). Cheerleading stunts have become more complex and emergency department visits more frequent over the years, and it results in the largest number of catastrophic sports injuries among girls and young women in the USA (Lovell and Solomon 2013). From a nursing perspective, it does not matter how cheerleading is classified. A significant risk of concussion exists, and the same return to play and learn guidelines are applicable.

## 9.6 Pathophysiology

Whether a concussion is caused by a fall from a bicycle, a skateboard, or a cheerleading pyramid or a collision in football, ice hockey, or soccer, the mechanism of injury is the same. This mechanism is not exclusive to a blow to the head but can be any injury that generates enough force to cause an energy transfer to the brain. As discussed, the pediatric skull is thinner and there is more subarachnoid space surrounding the brain. This allows for increased movement of the brain within the skull, which also makes it more susceptible to whiplash, acceleration-deceleration, or coup-contrecoup injuries. For example, a young boy falls off his skateboard and strikes his head on the sidewalk. The direct blow is a coup, and the energy transfer causes the brain to accelerate (instantly) and then decelerate when it strikes the opposite side of the skull, which is called a contrecoup.

The same factors that make the pediatric brain more susceptible to acceleration-deceleration injuries also apply when the head is subjected to rotational forces (or angular acceleration). The brain is suspended in CSF, so it will tend to keep moving after the head stops. As noted, the wider subarachnoid space permits for more such movement. But there are also nerves and blood vessels in the subarachnoid space. These can be stretched or torn when the brain moves violently, whether by rotational or acceleration-deceleration forces, which can result in injuries like axonal shearing and subarachnoid bleeds or less obvious damage at the cellular level.

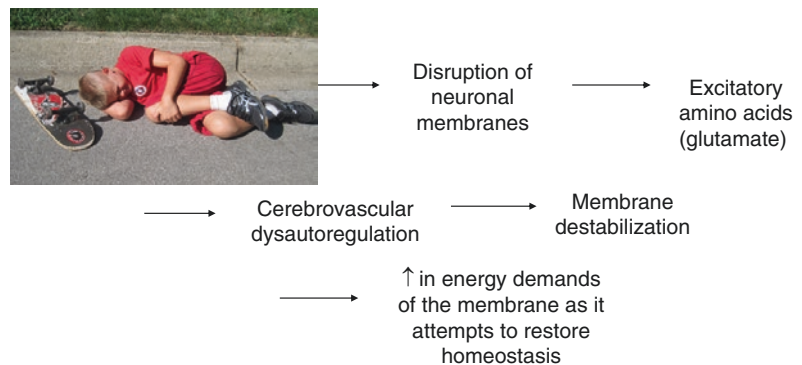
The disproportionate head size and laxity of the immature neck muscles in infants and toddlers increase the potential for head movement and damage from jarring forces (Mason 2013). This is a key factor in children aged 0–4 being one of two groups at greater risk for TBI (CDC 2011). Likewise, female athletes generally have thinner and weaker necks than males, which allows for greater angular acceleration of the head after impact (Harmon 2013).

Adolescents aged 15–19 are the other group at greater risk for TBI (CDC 2011). They begin operating motor vehicles during this time, often engage in more reckless behaviors, and are more likely to participate in contact sports. As young athletes become bigger, stronger, and faster, they also become potential victims of Newton's second law:  $f = ma$ . A larger mass moving at a higher speed (acceleration) creates a greater force. And in the case of two larger, faster athletes colliding, the resulting force transmitted to their respective brains creates a higher potential for concussive injury. Simply put, exposure to greater forces means a greater risk for concussion.

A concussion alters the cerebral metabolism. The mechanical trauma experienced with a concussion transfers energy that breaks down the cell structure and metabolism of brain cells. This type of cellular injury can also hinder the blood flow to the cells, disrupting the autoregulation of the cerebrovascular metabolism as well as recovery after injury (Fig. 9.1).

The force of the blow and resulting energy transfer sets off a complex cascade of neuro-

**Fig. 9.1** Concussion pathophysiology



chemical events that lead to the disruption of cell membranes and an indiscriminate efflux of ions. The disorganized efflux of ions results in an unregulated release of neurotransmitters that disrupts the ionic balance of the cell. Potassium goes to the extracellular space which results in the calcium-dependent release of excitatory amino acids (glutamate). This drives more potassium to the extracellular space. The Na/K ATP-dependent pump actively attempts to reestablish homeostasis which requires a large amount of energy, depleting cell energy stores (Barkhoudarian et al. 2016). This leads to an energy crisis. The depletion of glucose used for energy necessitates a trigger of anaerobic metabolism that leads to an accumulation of lactate. Further dysfunction leads to the activation of enzymes that cause cellular dysfunction and cell death. The excitatory neurotransmitters further cause a disruption of the ion transport and cellular membranes. The disrupted cascades impair the ability to metabolize glucose, and in the pediatric population, this is even more increased due to the ongoing maturation changes of the developing brain (Prins and Matsumoto 2016). The mitochondrial oxidative function is noted to be diminished up to 10 days after injury requiring alternative energy sources (Barkhoudarian et al. 2016). After this increase in metabolism, there is a hypometabolic state that may persist for up to 4 weeks after injury (Yoshino et al. 1991; Sunami et al. 1989; Halstead and Walter 2010; Barkhoudarian et al. 2016). The pediatric brain is extremely vulnerable to further injury during this time period.

The developing brain is more sensitive to glutamate-induced NMDA excitotoxicity than the fully developed adult brain. Animal models have shown NMDA receptors appear to play a role in the disruption of normal brain development and disruption of plasticity. The theories draw strongly on the diffuse brain injury temporarily arresting the capacity for plasticity due to the decreased NMDA receptor function (Fineman et al. 2000). Although there are many theories about the particular differences between pediatric and adult brain injury pathophysiology, as of yet there are few scientific studies.

## 9.7 Physical Exam

### 9.7.1 Initial Evaluation

The first step of concussion management is recognizing the concussion. Since there are no clear radiographic findings associated with concussion diagnosis and management, it is especially critical to use a multifaceted approach when assessing and treating concussion (Guskiewicz et al. 2013; Resch et al. 2013). It is not unusual that the signs of concussion present subtly, such as walking to the wrong side of the field after the hit or being amnesic to the injury event. The player may describe the event as having his/her “bell rung” or “seeing stars.” The player may appear stunned or dazed or have no recollection of the recent play. Retrograde (before the event) or anterograde (after the event) amnesia may be one of the only signs. Often the initial provider is a parent, trainer, coach, or even school nurse, and for this reason, it is important they be aware of the signs and symptoms of a concussion.

On field assessment tools can and should be used in order to ascertain if a player qualifies for return to play. There should be a systematic approach to on-field and sideline evaluation, first by using a basic neurological assessment to distinguish a more serious injury such as a neck injury or intracranial injury. Once the more serious injury has been excluded, the sideline evaluation can be as basic as reviewing a symptom checklist and cognitive evaluation including orientation, immediate memory, and fundamental balance testing. There are also more sophisticated tools such as the Maddocks Questions, the Standardized Assessment of Concussion, and the modified Balance Error Scoring System. Each of these provides a component of the concussion assessment.

Players frequently resist being withdrawn from play for concussion assessment. Despite their protestations, they should be removed and not allowed to return to play the same day or until symptom-free. It is also important to determine what is a concussive injury versus a more serious injury requiring immediate medical attention.

### 9.7.2 History of Injury

Acquiring a detailed history is extremely important for the evaluation of a concussion as well as the postconcussion management. The history should include the mechanism of injury; the initial signs and symptoms; amnesia; past diagnosed concussions; previous associated symptoms; any past injury that involved the head, face, and/or cervical spine; and the state of consciousness. The history should also include the use of protective equipment for sports-related injury. It is also important to note the severity of the concussive symptoms and if they are disproportionate to the injury as this may indicate an increased susceptibility to concussive injury. This information appraises the provider for current and ongoing care.

### 9.8 Signs and Symptoms

While most concussions are mild, there are some that require emergent attention. It is vital to identify these signs especially in the first 24–48 h. The child should be taken to the nearest emergency room if there is persistent headache that increases in severity or a neurological change such as drowsiness or lethargy. Other signs that require emergency attention include persistent vomiting, slurring of speech, any loss of consciousness, seizures, or increased agitation (Table 9.1). Any of the symptoms can manifest in varying degrees of severity and should be taken seriously. Children should be observed closely by a responsible adult for the first 24 h after a concussion to assess for any decrease in neurological status.

**Table 9.1** Warning signs requiring immediate medical attention

Warning signs
Loss of consciousness
Agitation
Confusion
Slurred speech
Persistent headache
Persistent vomiting
Unequal pupils (new onset)

### 9.9 Concussion Symptoms

Concussion symptoms can be physical, cognitive, and emotional and can disturb sleep. The physical symptoms include headache, nausea, vomiting, photophobia, tinnitus, visual disturbance, balance problems, and dizziness. Rarely, these symptoms include loss of consciousness. The cognitive symptoms include fogging, psychomotor retardation, difficulty with concentration, reduced short-term memory, irritability, sleep disturbance, and emotional lability (Table 9.2).

In the very young, many of these same symptoms may be present; however, the infant, toddler, or preschool-age child may not have the vocabulary or communication skills required to express a severe headache or visual disturbances. A headache and irritability may be represented by inconsolability and increased crying. These factors should be taken into consideration in the decision-making for treatment management. If there is a suspicion of a concussion in the very young, then immediate medical attention should be sought. Small children are often admitted to the hospital for symptomatic treatment with antiemetics, intravenous fluid administration, and close monitoring for any neurological decline.

Frequently, someone with a concussion will exhibit a multitude of symptoms that can be self-limited and short lived but cause acute impairment of neurologic function. This is a functional disturbance rather than a structural injury, as the radiographic imaging is negative. These symptoms do not necessarily require the loss of consciousness and in most cases the symptoms are self-reported with a variability in severity. Usually the patient returns to baseline anywhere from several days to several weeks. The vast majority of concussions (80–90%) are reported to resolve within 7–10 days, although children and adolescents may take a longer time to recover (McCroory et al. 2013). However with the fluctuation in symptoms and severity, there must be appropriate care by a medical provider knowledgeable about concussion management.

**Table 9.2** Symptoms of concussion

Physical	Cognitive	Emotional	Sleep
Headache	Foggy	Irritability	Drowsiness
Nausea/vomiting	Slowed down	Sadness	Sleeping more than usual
Balance problems	Difficulty concentrating	More emotional	Sleeping less than usual
Visual problems	Difficulty remembering	Nervousness	Difficulty falling asleep
Fatigue	Forgetful		
Sensitive to light and noise	Confused		
Dazed	Answers slowly		
Stunned	Repeats questions		

Harmon et al. (2013)

### 9.9.1 Physical Examination and Objective Assessments

A full physical exam should be completed to ensure that no other injuries are missed. Special attention should be paid to the neurological exam with particular consideration to balance and cognitive testing.

Initial management incorporates a period of brain rest such as refraining from the use of computer, phone, or television screens. This includes abstaining from reading and minimizing situations that would overstimulate the patient with sound or lights. If there is no improvement of symptoms after 7–10 days, there should be serious consideration made to referring the patient for specialized concussion care and further testing.

### 9.9.2 Balance

Significant balance problems or postural instability has been noted in patients with concussion (McCrary et al. 2012, 2013). Balance testing is used as an objective assessment tool (Furman et al. 2013; McCrary et al. 2012). The most common assessment of balance is the Balance Error Scoring System (BESS).

The BESS entails testing the patient on a firm surface, in addition to an irregular surface such as foam, for three separate sections that last 20 seconds each. The first section has the patient standing with feet together and hands on the hips while the eyes are closed. The test is scored based on any fluctuation from this stance such as opening

eyes, hands off hips, a step, a stumble, a fall, or movement of the hips more than 30°. Each of these is considered an error. The test is repeated with single leg stance on the nondominant leg and then once again with a heel-toe stance with the dominant leg in front (a tandem stance). The BESS best separates the healthy participant from a patient with a concussion (Furman et al. 2013). The BESS has been noted to be highly specific but with low sensitivity rate (Giza et al. 2013). The BESS data is most useful when there is an established baseline for comparison, and there should be some consideration to the fatigue of the patient as well as any injury that may impede participation such as ankle or leg instability or pain.

There are several other balance assessment tools that obtain computerized posturography data to assess the amount of sway in certain positions on a force plate. Although these tests may provide greater sensitivity, the equipment can be cost prohibitive and has not been studied to the degree of the BESS. These other technological methods will require further investigation before definitive conclusions can be drawn.

### 9.9.3 Cognitive Assessment

The cornerstone of concussion diagnosis and evaluation is subjective symptom reporting. Since the diagnosis is made on the basis of subjective symptoms, the cooperation of the athlete is paramount. However, standardized cognitive measures of memory can be used as possible indicators of concussion. There are objective



measures to assess short-term memory, working memory, attention, and concentration, all areas that can be affected by a concussion. Neuropsychological and cognitive testing has been a useful tool for determining return to play and return to learn decisions. This testing is especially useful when there is a baseline for comparison. Many schools do cognitive testing before the season and use that as a baseline after concussion or at the end of the season.

Neuropsychological testing can be done with paper and pencil as well as in a computerized setting. One example of computerized testing is the Immediate Post-Concussion Assessment and Cognitive Testing (ImPACT). The ImPACT test is a 20 min computerized test used to assess verbal memory, visual memory, reaction time, impulse control, and information processing. The greatest advantage of computerized testing is the ease of administration and scoring. However, the disadvantages include the need for specialized training for evaluation and the cost. The Sport Concussion Assessment Tool 3rd edition (SCAT3) is a paper and pencil tool for use only by medical professionals to evaluate for concussion in athletes 13 years and older. It assesses cognitive function, level of consciousness, balance, and symptoms. For children 12 years and younger, the Child SCAT3 can be used (bjsm.bmj.com 2016). The Zurich Consensus Statement recommends neuropsychological testing be administered and interpreted by a licensed neuropsychologist (McCrory et al. 2013). The use of neuropsychological testing in the pediatric population is especially useful for determining readiness for return to school. Since most concussion management strategies often include some extended cognitive rest, such as “screen rest” and restricted school/class attendance, testing can direct the extent of modification for academic accommodations. This testing is also useful in the identification of attention deficit disorders as well as learning disabilities.

### 9.9.4 Vestibular Testing

Vestibular and ocular motor deficiencies have been noted in patients with concussions. As of

yet there is still not a gold standard clinical screening tool for assessing and monitoring these abnormalities. The King-Devick (K-D) test is a visual recognition and reaction time test to track rapid eye movements and detect reading difficulty. The K-D requires the participant to read unevenly spaced single digits left to right as quickly and accurately as possible. The results provide objective measures of brain function and eye movement impairments, as well as balance, attention, language, and visual recognition skills. The K-D test is also sensitive to neurological changes seen in concussion. It can be used to identify patients who have not reported or shown signs or symptoms of a concussion but actually have sustained a meaningful head injury (Galetta et al. 2011; King et al. 2013).

Vestibulo-oculo dysfunction (VOD) has been detected in the pediatric population with acute concussions and postconcussion syndrome (PCS) (Ellis et al. 2015). Vestibular/Ocular Motor Screening (VOMS) includes assessment of smooth pursuit, horizontal and vertical saccades, near point convergence distance, horizontal vestibular reflex, and visual motion sensitivity. VOMS testing has demonstrated the ability to identify patients with a concussion (Anne Mucha et al. 2014), but there is still not enough data to incorporate into a concussion treatment and management strategy.

---

## 9.10 Treatment

### 9.10.1 Management Strategies

Although most concussed athletes can be managed on an outpatient basis, initial management may include addressing severe symptoms, such as nausea and vomiting that may require an antiemetic or intravenous fluid resuscitation. Headache may be managed with non-sedating medication such as acetaminophen. Nonsteroidal medication should be avoided in the very early period due to possible risk of bleeding. Increased severity in these symptoms may need to be further explored with a CT or MRI to rule out more severe intracranial pathology.

The mainstay of management includes cognitive and physical rest (McCrory et al. 2013). Cognitive rest requires minimizing unnecessary auditory and visual stimulation. The concussed brain needs to rest, much like resting a physical injury such as a sprained ankle. The patient may need to refrain from schoolwork or work and abstain from reading, television viewing, use of computers, texting, video games, or cell phone use. Lights may need to be dimmed and noise level may need to be reduced. There may need to be a reduction in social outings and trips out of the home, with an environment that promotes rest as well as a restful sleeping environment (Moser et al. 2012). Care must be taken when recommending cognitive rest. Not only can the effects of concussion cause depression, but keeping the athlete away from their sport, school, and friends can further contribute to their depression.

Physical activity and exertion should be introduced slowly with coach/trainer input for return to play decisions after return to learn has been completed. The reintroduction of physical activity should be done at a graduated level not all at once (Meehan et al. 2011). Exposure to activities that may cause a concussion should also be eliminated until there has been resolution of symptoms and clearance from a medical professional experienced in concussion management (Majerske et al. 2008).

Vestibular rehabilitation is used for evaluation and as a treatment modality of select concussion symptoms such as dizziness and gait instability. Improvement has been noted for self-reported symptoms as well as objective evaluation of dizziness and gait in all age groups (Alsalaheen et al. 2010; Thornton and Carmody 2009).

The upper cervical spine is more vulnerable to trauma due to the increased mobility in this particular region of the vertebral column (Kristjansson and Treleaven 2009). There has been a noted difference in the strength of male and female athletes (Tierney et al. 2005). The neck strength of the male athlete is stronger than in the female athlete and also stronger in the collegiate athlete as compared to the high school athlete (Hildenbrand and Vasavada 2013). Cervical therapy has been integrated with vestibular rehabilitation with reported results of quicker return to baseline (Hugentobler

et al. 2015; Leddy et al. 2012; Schneider et al. 2014). The use of cervical therapy focuses on the positioning of the cervical joint position into a neutral position and assisting with the range of motion of the cervical spine (Kristjansson and Treleaven 2009). This therapy has had some success with cervicogenic headaches, and the treatment has been extrapolated for use with postconcussion symptoms (Racicki et al. 2013).

Biofeedback and neurofeedback have also been proposed as treatment modalities for concussion symptoms. There are select studies indicating some success with feedback therapy involving headache and concussion (Andrasik 2010; Thornton and Carmody 2009).

Neuropsychology testing, as all other testing, should not be attempted until the patient is able to tolerate the stimuli testing might introduce. Neuropsychological testing is most useful when interpreted by a neuropsychologist and compared to baseline studies but is beneficial for return to learn and return to play decisions (McCrory et al. 2013).

---

## 9.11 Diagnostic Findings

Conventional neuroimaging is usually normal in patients with concussion as the injury is metabolic rather than structural. However, computed tomography (CT) and magnetic resonance imaging (MRI) are diagnostic tools for acute brain injury management and should be obtained for symptoms such as severe headache, seizures, focal deficits, repeated emesis, significant drowsiness or difficulty awakening, slurred speech, poor orientation, or significant irritability. CT is most useful for radiographically visible changes such as acute hemorrhage, contusions, or skull fractures but does not show structural damage related to concussion diagnosis. The accessibility and ease of acquiring a CT is often why it is obtained in the acute period, but it has the risk of radiation exposure. Standard MRI is also helpful in showing acute changes such as blood and cerebral edema and in some instances diffuse axonal injury, but it too lacks the ability to indicate concussion-related structural changes (Lee et al. 2008). An MRI takes longer than a CT scan and can require seda-

tion in the pediatric population. A CT scan is recommended for patients with altered mental status (LOC), severe mechanism of injury, or acute worsening of symptoms. This tool is more for differentiating a more underlying serious injury from a concussion.

Functional MRI (fMRI) evaluates the measures of brain function based on changes in blood flow in the cranial capillaries (Raichle and Mintun 2006) and may be helpful in identifying concussion injury not seen on standard CT or MRI and may provide information of residual deficits (Chen et al., 2004).

There have been some preliminary studies using diffusion tensor imaging (DTI), an advanced neuroimaging modality that is based on tissue water diffusion rate. DTI views soft tissue on a microstructural scale and can detect subtle changes in a three-dimensional visualization of white matter tracts. The focus of these studies is to determine any correlation of postconcussive symptoms with white matter integrity (Toledo et al. 2012). Although studies have demonstrated changes in the white matter integrity, it is still unclear what this signifies or what it might mean in the short or long term to concussion management or diagnosis (Mayer et al. 2013).

Recently, there has been some work toward identifying TBI biomarkers present in human serum. The biomarker glial fibrillary protein (GFAP) is found in the serum of patients with TBI at high levels within a few hours of injury (Papa et al. 2012). It is still early days in the study of biomarkers, and it is unclear what role this will have in managing TBI patients during initial injury or subsequent injuries, or if this could be an indicator for return to play or return to school. Although preliminary studies have indicated some positive results for human serum biomarkers, there is still no clinical indication for use, and further study will be needed (Papa et al. 2015).

### 9.11.1 Nursing Care

Pediatric concussion patients may be seen in the emergency department but are typically not admitted. Many centers now have nurse-led con-

cussion clinics where children and adolescents are managed on an outpatient basis.

The developmental age of the child needs to be considered, as well as symptoms such as amnesia, depression, LOC, and female gender. Determining a concussion evaluation should be based on the ability of the patient to advocate for themselves and individual considerations. Pediatric vs. adolescents require different tools to determine efficacy. An age-appropriate pain scale may be used for pediatric patients that are not able to verbalize feelings, whereas a symptom checklist would be appropriate in the adolescent population. Anxiety or depression may affect recovery. The patient should be evaluated as a whole by utilizing symptom checklists, neurocognitive evaluations (testing memory and recall), and neurological exam including balance and reaction (Apps and Walter 2012).

Pain control (pharmacological and nonpharmacological) should be considered for patients using self-reported and parent-reported symptoms. However medication intervention should be restricted to nonnarcotic medication such as acetaminophen. Nonsteroidal and aspirin-containing products should be avoided in the acute period. Narcotics can mask symptoms of neurological decline, and nonsteroidal medication such as ibuprofen or aspirin may cause bleeding. Antiemetics can be given for persistent nausea and vomiting.

Managing the environment is key for inpatient care. Environmental stimulation should be minimized and nursing care bundled so as not to inundate the patient and allow time for rest. Lowering the lights and decreasing noise and activity are also significant components. If the patient must have a roommate, assign a patient with similar issues that would benefit from a restful environment. Encourage ice packs at the base of the neck and fluid intake to flush proteins from the brain.

### 9.11.2 Patient and Family Education

Nurses play an essential role in the treatment and education of patients and their families after a concussion (Evans 2014). From the standpoint of education, Table 9.3 shows some of the common

**Table 9.3** Common concussion myths

Myth: everyone with a concussion needs a CT scan or MRI right away
Fact: while there is damage to the brain cells in a concussion, the damage is at a microscopic level and cannot be seen on MRI or CT scans. The concussed brain looks normal on these tests, even though it has been seriously injured. These modalities are reserved to ensure there is not a more serious intracranial injury.
Myth: do not treat the headache from concussion with any medications because it may mask some symptoms
Fact: over-the-counter pain relievers, as ordered by the physician, are fine to use. At times prescription medicine may be needed
Myth: someone with a concussion should be awakened every 2–3 h
Fact: drowsiness and fatigue are common symptoms of concussion. Getting plenty of sleep and allowing the brain to heal are necessary for recovery
Myth: children recover at the same rate as adults
Fact: children and teenagers actually recover more slowly due to their developing brain. They are also more prone to complications from concussion and more susceptible in the acute phase
Myth: a concussion requires loss of consciousness
Fact: loss of consciousness is not the only indicator of concussion. Approximately 10% of concussions involve loss of consciousness
Myth: there are no long-term effects of concussion
Fact: a concussion that is not properly treated at the beginning can lead to postconcussion syndrome, with prolonged symptoms that affect memory and physical and emotional functioning for many months to years
Myth: a concussion is not a brain injury
Fact: a concussion is a mild traumatic brain injury (mTBI). Since the mid-1990s, mTBI has been the standard term of use instead of mild closed head injury by professionals and the Brain Injury Association of America
Myth: male and female athletes have the same chance of sustaining a concussion
Fact: female athletes are more prone to concussions than their male counterparts in studies. Possible explanations for this are that female athletes are more open to report concussion and there are gender differences in anatomy and physiology
Myth: athletes will acknowledge when they have sustained a concussion
Fact: some players are hesitant to report injury and want to return to sport
Myth: an athlete needs to be hit on the head to sustain a concussion
Fact: concussions can occur with any movement or jostling of the head or body, as in whiplash injuries (front to back) or rotational force (side to side)

Courtesy of University of Kansas Hospital

myths or misconceptions that nurses should be aware of. Care extends to the home environment. Decreasing visual stimulation in the early days postconcussion encourages brain rest. Decreased visual stimulation includes decreased screen time (phones, television, computer, etc.). It also includes decreased reading. Cognitive rest breaks are also encouraged. When the patient has a trigger that brings on a symptom (such as light, noise, activity, computer activity, or walking), it is advisable to take a cognitive rest break. Recognizing activities that trigger symptoms and stepping back from the activity for a 5 min break may be a sufficient amount of time for the patient's symptoms to decrease.

It is important to encourage normal sleep patterns and sleep hygiene prior to bedtime to

encourage restful sleep. Having the patient go to bed at a consistent time and avoid napping during the day keep the body in normal patterns. By resting, the brain has time to heal. Provide education to parents that distractions at bedtime should be minimized to promote scheduled rest.

During the academic year, it may be important to look for additional resources within the school community for short-term and long-term issues. Good communication between the teacher, guidance counselor, school administrators, school psychologist, student, family, nurse, athletic trainer, and physician is important to help with integration of back to school and normal activities. A modified class schedule may benefit the concussed athlete when integrating back into

**Table 9.4** Return to Learn after a concussion

Take rest breaks as needed
Spend fewer hours at school
Be given more time to take tests or complete assignments
Receive help with schoolwork
Reduce time spent on computer, reading, writing

<http://www.cdc.gov/headsup> 2016

school (Table 9.4). If the student plays sports, the coach, athletic director, and physical education teacher should also be involved. Box 9.1 gives an example of a typical high school football player suffering from a concussion and his management before returning to play.

### Box 9.1

A 14-year-old male football player took a hit to the head during practice while playing linebacker. He was hit in the frontal parietal area of his helmet and suffered no loss of consciousness but complained of an immediate headache with disorientation. He was immediately taken out of practice and evaluated by the team athletic trainer. His mother was notified and he was taken home for observation. The next day he was evaluated by a doctor with complaints of a headache, difficulty with concentration, mild dizziness, and fatigue. He denied memory loss, sleep disturbance, or other symptoms. His neurological exam was normal with some mild balance unsteadiness.

He was prescribed a return to learn program that included cognitive rest, sleep hygiene, good nutrition intake, and hydration. Any increasing symptoms were to be reported for urgent evaluation. He was also given school accommodation and a 1-week follow-up.

After 1 week, he completed his return to learn program without incident and was back to school full-time without symptoms. His neurological exam was normal, and he was released to start a five-step return to play program under the authority of an athletic trainer at the high school.

On the third step of return to play, he experienced headaches while in his math and science classes: his two favorite subjects. He experienced some resolution of his headache with acetaminophen but did not take it on a regular basis. Upon return to a medical provider he denied exertional headaches or dizziness and his neurological exam was normal. It was recommended that he resume his return to play program on the second step. Over the next 3 weeks, he progressed through all his steps without the recurrence of symptoms and was cleared to return to play a full 28 days later.

### 9.11.3 Eating Healthy and Recovery

Healthy fat intake with proteins that include nuts, fish, avocados, seeds, and nuts will help replace the nutrients and chemicals that are causing a disruption in the brain. It is important to eat small meals. The patient may not feel up to eating or forget, so try to keep a schedule with eating to help optimize recovery. Encourage proper hydration. Alcohol, caffeine, salty foods, candy and treats should be avoided.

### 9.11.4 Complications of Concussion

Concussions can cause a multitude of complications of varying severity that can resolve in



7–10 days or become more long term. These difficulties can include problems with memory, thinking, and mood alterations that can make academics and work challenging. Other problems may include depression and even early-onset dementia, necessitating further medical management.

Once a child or adolescent has had a concussion, he or she is more likely to sustain a second one (Guskiewicz et al. 2000). Various studies have found 2–5.8 times higher risk of subsequent concussion in individuals who have already had one (Harmon et al. 2013). Whatever the increased likelihood may be, multiple concussions can result in serious health consequences. The most serious is second impact syndrome (SIS) which will be discussed below. While SIS is rare, subsequent concussions can also prolong recovery or lead to persistent symptoms and long-term cognitive impairment (Moser et al. 2012; Harmon et al. 2013). Among these are an increased incidence of posttraumatic seizures, headaches, and depression that may require pharmacologic management. It is essential to recognize these potential long-term complications in order to intervene with appropriate treatment.

Although most concussions resolve within 7–10 days, symptoms can persist for longer than that, whether as a result of a single concussion or multiple ones. This can lead to what has been called postconcussion syndrome (PCS). There does not appear to be a consensus on the definition of PCS. Some say that PCS is the persistence of symptoms for at least a month (Ellis et al. 2015). Others say that three or more symptoms must exist for at least 3 months (Halstead and Walter 2010), while others simply define it as signs and symptoms of concussion that persist for weeks or months after the incident (Harmon et al. 2013). However it may be defined, pediatric nurses should be mindful that, when a young athlete presents with complaints of recurrent headaches or other concussion-like symptoms, PCS should be part of the differential diagnosis. A thorough history should include any incidents that may have resulted in a sports-

related concussion. This could save a child or adolescent from unnecessary exposure to ionizing radiation and other invasive or expensive diagnostic tests.

One of the most devastating consequences of concussion is second impact syndrome (SIS), which is more prevalent in the pediatric population. SIS is a potentially lethal condition that affects an individual who suffers a second head injury before recovering from the first one (Cantu 1998; McCrory et al. 2012). It is believed that the subsequent injury disables the cerebral autoregulation system causing diffuse swelling and severe cerebral edema, resulting in 50% morbidity and mortality (Wetjen et al. 2010). It is likely that the most well-known case of SIS involved Zackery Lystedt, a 13-year-old middle school football player who sustained successive concussions in a 2006 game. He “shook off” the first concussion and reentered the game about 15 min later. After the second blow, he collapsed, sustaining a permanent brain injury. In 2009, the State of Washington adopted the “Zackery Lystedt Law,” which requires education about concussions be made available to coaches, young athletes and parents, and that any youth showing signs of concussion be removed from play and not allowed to return until cleared by a licensed health-care provider. Similar laws have since been adopted in the other 49 states in the USA.

Another much talked about possible long-term consequence of repeated concussion is chronic traumatic encephalopathy (CTE). This term is used to describe a tauopathy or a progressive neurodegenerative disease thought to be caused by chronic or repetitive brain trauma. This phenomenon has not been exclusive to athletic concussions but has been most studied in this context. It can only be diagnosed at autopsy with very specific immunoreactive stains for tau proteins. Among athletes, CTE was originally thought to only be found in boxers. But over the time frame of 2002–2005, a neuropathologist named Bennet Omalu noted these changes in the brain autopsies of several former National

Football League players (Omalu et al. 2005). His efforts helped raise awareness of the potential long-term consequences of multiple concussions. Although CTE is rare in young athletes, much is still not known and it is being studied within the context of head injury and concussion (Stern et al. 2011).

### 9.11.5 Return to Play Guidelines

Concussions have undoubtedly been occurring in sports for as long as there have been sports, certainly prior to the first Olympic Games in 776 BCE. Although recent publicity and new laws have raised general awareness of the problem, it has been a concern of neurosurgeons, neurologists, sports medicine physicians, nurses, and athletic trainers for decades. In 1986, Robert Cantu published his first guidelines for return to contact sports after a concussion (Cantu 1986). Since then, there have been many other return to play (RTP) guidelines proposed and four international conferences on the issues related to concussion in sport. The most recent of those was the 4th International Conference on Concussion in Sport, which took place in Zurich, Switzerland, in 2012. The recommendations developed at that conference were included in a Consensus Statement on Concussion in Sport (McCrory et al. 2013).

Among those recommendations was RTP protocol or guidelines which have been adopted or endorsed by organizations like the American Medical Society for Sports Medicine, the American Academy of Pediatrics (2008 guidelines), and the US Centers for Disease Control and Prevention (see [cdc.gov/headsup](http://cdc.gov/headsup)). The RTP protocol is found in Table 9.5. It provides for a gradual, stepwise progression from “no activity” to full “return to play.” The Consensus Statement further recommended that an athlete should only proceed to the next level if asymptomatic at the current level, and no RTP should occur on the day of the concussive injury, especially for young athletes. And children should not be permitted to return to play until com-

**Table 9.5** Return to play (stepwise fashion). If any post-concussive symptoms return, drop back to previous asymptomatic level and try to progress again after 24 h

Rehabilitation stage	Functional exercise
No activity	Symptom-limited physical and cognitive rest
Light aerobic activity	Walking, swimming, stationary cycling at <70% maximum heart rate; no resistance training
Sports-specific exercise	Skating drills in ice hockey, running drills in soccer but no head impact
Noncontact training drills	More complex drills, passing drills in football and ice hockey; may start progressive resistance training
Full-contact practice	After medical clearance, participate in normal training
Return to play	Normal game play

McCrory et al. (2012)

pletely symptom-free at rest or on exertion (McCrory et al. 2013). May et al. (2014) further proposed sports-specific RTP guidelines for cheerleading, gymnastics, football, wrestling, soccer, basketball, boys’ and girls’ lacrosse, baseball/softball, and ice hockey.

It may take long-term studies to determine the impact of education efforts and RTP guidelines on pediatric athletic concussions. But available evidence is promising. For example, the Colorado School of Public Health at the University of Colorado Denver has conducted the National High School Sports-Related Injury Surveillance Study since the 2005/2006 school year. That study compiles data on time-loss injuries in a national sample of US high school athletes. Its summary report for the 2015/2016 school year contains a table which shows the percentages of various injuries reported over the life of the study. Concussion was at 9.1% in 2005/2006, increased to 14% in 2009/2010 and then to 20% in 2010/2011 (which coincided with the period when most of the Lystedt Laws were adopted), and has been at 24.6% of injuries reported for the 2014–2016 school years NHSSRISS (2016). This reflects better diagnosis and reporting of concussions.

**Table 9.6** Adapted from MSHSAA Interscholastic Youth Sports Brain Injury Reports

	Schools	Injury reports	Injury reports	Avg. no. of reports/school	Avg. days withheld	Avg. days withheld
		Males	Females		Males	Females
2011–2012	505	881	242	2.2	6.5	10.3
2012–2013	522	2097	635	5.2	10.8	12.4
2013–2014	578	2220	827	5.3	11.5	11.6
2014–2015	530	2078	773	5.4	11.7	13.1
2015–2016	526	2003	848	5.4	12.8	13.1

mshsaa.org

Furthermore, the State of Missouri adopted its version of the Lystedt Law in 2011. Among its provisions was a requirement that schools supply certain data to the Missouri State High School Activities Association, including the number of head injury reports, gender of the athlete, sport, and amount of time the athlete was withheld from practice or competition. MSHSAA then compiles the data into annual reports. Table 9.6 shows a summary of some of that data for 2011–2012 to 2015–2016 school years. The data indicates that athletes are generally being withheld for longer periods of time, which was a primary goal that the proponents of the legislation and RTP guidelines were hoping to achieve.

**9.11.6 Helmets**

Helmets generally provide protection from TBI by absorbing an impact and distributing the energy from that impact over a larger surface area (Sone et al. 2016). As previously discussed, however, the mechanisms of concussion injuries do not always involve a direct blow to the head. Hence, helmets will not always prevent concussions (any more than seatbelts will always prevent traffic fatalities). But that’s hardly the basis for an argument that children do not need to wear helmets when participating in sports and recreational activities.

Bergenstal et al. (2012) found that the concussion rate of patients involved in bicycle crashes who wore helmets was 19.4%, compared to a rate of 37.4% in unhelmeted riders. There was also a significant difference in the

incidence of skull fractures and intracranial hemorrhage between the two groups. Helmets have also been demonstrated to reduce the incidence of concussion in skiing and snowboarding, but a similar reduction in concussion incidence has not been consistently found in other studies (Sone et al. 2016; Halstead and Walter 2010). All such studies suffer from the inability to perform truly blinded, randomized trials, with identical forces applied to helmeted and unhelmeted heads, due to ethical and common sense considerations. Further, there is no good way for researchers to determine whether a helmeted person who sustains a concussion would have sustained a worse one, or a more severe TBI, if the helmet had not been worn.

Another consideration with helmets is that some athletes may actually use their helmets as weapons, thinking the helmet affords them protection from injury. Recent rule changes in American football have increased the penalties for “targeting” another player’s head with a helmet. The penalties include the potential ejection of the offender from the game. These rules are primarily intended to protect against concussions.

Given the vulnerabilities of the pediatric brain, anything that reduces the potential for head injury is desirable. Nurses should be advocates for helmet use among children who ride bicycles (Fig. 9.2) and skateboards and those who participate in other activities with a risk of head trauma, as well as proponents of safety rules and laws directed toward reducing the occurrence and severity of concussions.



**Fig. 9.2** “My mom’s a nurse and I always wear my bike helmet”

### Conclusion

There is still much that we do not know about concussions and their long-term effects. But several points are obvious: (1) while a child’s brain is developing, it is more susceptible to injury; (2) once injured, the brain may be more susceptible to reinjury, especially if the first injury has not fully resolved; and (3) the more frequent and/or severe concussions a child may sustain, the more likely there will be long-term effects. Thus, a pediatric nurse should be able to identify signs and symptoms of a concussion and give appropriate guidance to children and their parents, coaches, and teachers about such matters as when the child

may return to school and return to play. Further, in order to minimize the injury and the potential for further morbidity such as PCS, SIS, or CTE, it is important to continue research focused on concussions. Pediatric neurosurgical nurses are well positioned to be principal investigators on such research.

### References

- Albright AL, Pollack IF, Adelson PD (2008) Principles and practice of pediatric neurosurgery. Thieme, New York
- Alsalaheen BA, Mucha A, Morris LO, Whitney SL, Furman JM, Camiolo-Reddy CE et al (2010) Vestibular rehabilitation for dizziness and balance disorders after concussion. *J Neurol Phys Ther* 34(2):87–93
- American Association of Neurological Surgeons (2014) Patient information/sport-related head injury. [aans.org](http://aans.org)
- Andrasik F (2010) Biofeedback in headache: an overview of approaches and evidence. *Cleve Clin J Med* 77:S72–S76
- Anne Mucha D, Collins MW, Elbin R, Furman JM, Kontos AP (2014) A brief Vestibular/Ocular Motor Screening (VOMS) assessment to evaluate concussions. *Am J Sports Med* 42(10):2479–2486
- Apps JN, Walter KD (eds) (2012) Pediatric and adolescent concussion diagnosis, management, and outcomes. Springer, New York. ISBN: 978-0-387-89544-4 (Print) 978-0-387-89545-1 (Online)
- Barkhoudarian G, Hovda DA, Giza CC (2016) The molecular pathophysiology of concussive brain injury – an update. *Phys Med Rehabil Clin N Am* 27(2):373–393
- Bergental J, Davis SM, Sikora R, Paulson D, Whiteman C (2012) Pediatric bicycle injury prevention and the effect of helmet use: the West Virginia experience. *W V Med J* 108(3):78–81
- Broshek DK et al (2005) Sex differences in outcome following sports-related concussion. *J Neurosurg* 102(5):868–863
- Bryan MA, Rowhani-Rahbar A, Comstock RD, Rivara F (2016) Sports-and recreation-related concussions in US youth. *Pediatrics* 138(1):e20154635
- Cantu RC (1986) Guidelines for return to contact sports after a cerebral concussion. *Phys Sportsmed* 14:75–83
- Cantu RC (1998) Second-impact syndrome. *Clin Sports Med* 17(1):37–44
- Chen JK, Johnston KM, Frey S, Petrides M, Worsley K, Ptito A (2004) Functional abnormalities in symptomatic concussed athletes: an fMRI study. *NeuroImage* 22(1):68–82. doi:10.1016/j.neuroimage.2003.12.032
- Control, Center for Disease, & Prevention (2011) Nonfatal traumatic brain injuries related to sports and recreation activities among persons aged ≤ 19 years – United



- States, 2001–2009. *MMWR Morbidity Mortality Weekly Report* 60(39):1337–1342.
- Dick RW (2009). Is there a gender difference in concussion incidence and outcomes?. *British journal of sports medicine*, 43(Suppl 1): i46–i50
- Ellis MJ, Cordingley D, Vis S, Reimer K, Leiter J, Russell K (2015) Vestibulo-ocular dysfunction in pediatric sports-related concussion. *J Neurosurg Pediatr* 16(3):248–255
- Evans V (2014) Recognizing and managing concussion in school sport. *J Neurosurg Nurs* 46(4):e25–e32
- Fineman I, Giza CC, Nahed BV, Lee SM, Hovda DA (2000) Inhibition of neocortical plasticity during development by a moderate concussive brain injury. *J Neurotrauma* 17(9):739–749
- Furman GR, Lin C-C, Bellanca JL, Marchetti GF, Collins MW, Whitney SL (2013) Comparison of the balance accelerometer measure and balance error scoring system in adolescent concussions in sports. *Am J Sports Med* 41(6):1404–1410
- Galetta K, Barrett J, Allen M, Madda F, Delicata D, Tennant A et al (2011) The King-Devick test as a determinant of head trauma and concussion in boxers and MMA fighters. *Neurology* 76(17):1456–1462
- Gessel L et al (2007) Concussions among United States high school and collegiate athletes. *J Athl Train* 42(4):495–503
- Giza CC, Kutcher JS, Ashwal S, Barth J, Getchius TS, Gioia GA et al (2013) Summary of evidence-based guideline update: Evaluation and management of concussion in sports report of the guideline development subcommittee of the American Academy of Neurology. *Neurology* 80(24):2250–2257
- Guskiewicz K, Weaver N et al (2000) Epidemiology of concussion in collegiate and high school football players. *Am J Sports Med* 28:643–650
- Guskiewicz KM, Register-Mihalik J, McCrory P, McCrea M, Johnston K, Makdissi M et al (2013) Evidence-based approach to revising the SCAT2: introducing the SCAT3. *Br J Sports Med* 47(5):289–293
- Halstead ME, Walter KD (2010) Sport-related concussion in children and adolescents. *Pediatrics* 126(3):597–615
- Harmon KG, Drezner JA, Gammons M, Guskiewicz KM, Halstead M, Herring SA, Roberts WO (2013). American Medical Society for Sports Medicine position statement: concussion in sport. *British journal of sports medicine*, 47(1):15–26.
- Hildenbrand KJ, Vasavada AN (2013) Collegiate and high school athlete neck strength in neutral and rotated postures. *J Strength Cond Res* 27(11):3173–3182
- Hugentobler JA, Vegh M, Janiszewski B, Quatman-Yates C (2015) Physical therapy intervention strategies for patients with prolonged mild traumatic brain injury symptoms: a case series. *Int J Sports Phys Ther* 10(5):676
- Kelleher E, Taylor-Linzey E, Ferrigno L, Bryson J, Kaminski S (2014) A community return-to-play mTBI clinic: Results of a pilot program and survey of high school athletes. *Journal of pediatric surgery*, 49(2):341–344.
- King D, Brughelli M, Hume P, Gissane C (2013) Concussions in amateur rugby union identified with the use of a rapid visual screening tool. *J Neuro Sci* 326(1):59–63
- Konrad C, Geburek A, Rist F, Blumenroth H, Fischer B, Husstedt I et al (2011) Long-term cognitive and emotional consequences of mild traumatic brain injury. *Psychol Med* 41(6):1197–1211
- Kristjansson E, Treleaven J (2009) Sensorimotor function and dizziness in neck pain: implications for assessment and management. *J Orthop Sports Phys Ther* 39(5):364–377
- Langlois JA, Rutland-Brown W, Wald MM (2006) The epidemiology and impact of traumatic brain injury: a brief overview. *J Head Trauma Rehabil* 21(5):375–378
- Lovell MR, Solomon GS (2013) Neurocognitive test performance and symptom reporting in cheerleaders with concussions. *J Pediatr* 163:1192–1195
- Leddy JJ, Sandhu H, Sodhi V, Baker JG, Willer B (2012) Rehabilitation of concussion and post-concussion syndrome. *Sports Health Multidiscip Approach* 4(2):147–154
- Lee H, Wintermark M, Gean AD, Ghajar J, Manley GT, Mukherjee P (2008) Focal lesions in acute mild traumatic brain injury and neurocognitive outcome: CT versus 3 T MRI. *J Neurotrauma* 25(9):1049–1056
- Majerske CW, Mihalik JP, Ren D, Collins MW, Reddy CC, Lovell MR, Wagner AK (2008) Concussion in sports: postconcussive activity levels, symptoms, and neurocognitive performance. *J Athl Train* 43(3):265–274
- Marar M et al (2012) Epidemiology of concussions among united states high school athletes in 20 sports. *Am J Sports Med* 40(4):747–755
- Mason C (2013) Mild traumatic brain injury in children. *Pediatr Nurs* 39(6):267–272
- May KH et al (2014) Pediatric sports specific return to play guidelines following concussion. *Int J Sports Phys Ther* 9(2):242–255
- Mayer A, Ling J, Yang Z, Pena A, Yeo R, Klimaj F (2013) Diffusion abnormalities in pediatric mild traumatic brain injury. *J Neurosci* 32(50):17961–17969
- McCrea, M., Hammeke, T., Olsen, G., Leo, P., & Guskiewicz, K. (2004). Unreported concussion in high school football players: implications for prevention. *Clinical Journal of Sport Medicine*, 14(1):13–17.
- McCrea M, Iverson GL, Echemendia RJ, Makdissi M, Raftery M (2013) Day of injury assessment of sport-related concussion. *Br J Sports Med* 47(5):272–284
- McCrory P, Davis G, Makdissi M (2012) Second impact syndrome or cerebral swelling after sporting head injury. *Curr Sports Med Rep* 11(1):21–23
- McCrory P, Meeuwisse W, Aubry M, Cantu B, Dvorak J, Echemendia R et al (2013) Consensus statement on Concussion in Sport – The 4th International Conference on Concussion in Sport held in Zurich, November 2012. *Phys Ther Sport* 14(2):e1–e13. doi:10.1016/j.ptsp.2013.03.002
- Meehan WP, Bachur RG (2009) Sport-related concussion. *Pediatrics* 123:114–123



- Meehan WP, d'Hemecourt P, Collins CL, Comstock RD (2011) Assessment and management of sport-related concussions in United States high schools. *Am J Sports Med* 39(11):2304–2310
- Missouri State High School Activities Association (2015) Interscholastic Youth Sports Brain Injury Report, [www.mshsaa.org/sportsmedicine](http://www.mshsaa.org/sportsmedicine).
- Moser RS, Glatts C, Schatz P (2012) Efficacy of immediate and delayed cognitive and physical rest for treatment of sports-related concussion. *The Journal of pediatrics*, 161(5):922–926.
- National High School Sports-Related Surveillance Study (2015–2016) Summary report, school year, table 13.4. [www.ucdenver.edu/piper](http://www.ucdenver.edu/piper)
- Noffke ex rel. Swenson v. Bakke, 2009 WI 10, 760 N.W.2d 156 (Wis. 2009)
- Norton C, Feltz S, Brocker A, Granitto M (2013) Tackling long-term consequences of concussion. *Nursing* 43(1):50–55
- Omalu BI, DeKosky ST, Minster RL, Kamboh MI, Hamilton RL, Wecht CH (2005) Chronic traumatic encephalopathy in a National Football League player. *Neurosurgery* 57(1):128–134
- Papa L, Lewis LM, Falk JL, Zhang Z, Silvestri S, Giordano P et al (2012) Elevated levels of serum glial fibrillary acidic protein breakdown products in mild and moderate traumatic brain injury are associated with intracranial lesions and neurosurgical intervention. *Ann Emerg Med* 59(6):471–483
- Papa L, Ramia MM, Edwards D, Johnson BD, Slobounov SM (2015) Systematic review of clinical studies examining biomarkers of brain injury in athletes after sports-related concussion. *J Neurotrauma* 32(10):661–673
- Prins ML, Matsumoto J (2016) Metabolic response of pediatric traumatic brain injury. *J Child Neurol* 31(1):28–34
- Racicki S, Gerwin S, DiClaudio S, Reinmann S, Donaldson M (2013) Conservative physical therapy management for the treatment of cervicogenic headache: a systematic review. *J Manip Ther* 21(2):113–124
- Raichle ME, Mintun MA (2006) Brain work and brain imaging. *Annu Rev Neurosci* 29:449–476
- Resch J, Driscoll A, McCaffrey N, Brown C, Ferrara MS, Macciocchi S et al (2013) ImPact test-retest reliability: reliably unreliable? *J Athl Train* 48(4):506–511
- Schneider KJ, Meeuwisse WH, Nettel-Aguirre A, Barlow K, Boyd L, Kang J, Emery CA (2014) Cervicovestibular rehabilitation in sport-related concussion: a randomised controlled trial. *Br J Sports Med* 48:1294 . [bjsports-2013-093267](http://bjsports-2013-093267)
- Selassie AW, Wilson DA, Pickelsimer EE, Voronca DC, Williams NR, Edwards JC (2013). Incidence of sport-related traumatic brain injury and risk factors of severity: a population-based epidemiologic study. *Annals of epidemiology*, 23(12): 750–756.
- Sone JY, Kondziolka D, Huang J, Smadani U (2016) Helmet efficacy against concussion and traumatic brain injury: a review. *J Neurosurg* 27:1. doi:[10.3171/2016.2.JNS151972](https://doi.org/10.3171/2016.2.JNS151972)
- Stern RA, Riley DO, Daneshvar DH, Nowinski CJ, Cantu RC, McKee AC (2011) Long-term consequences of repetitive brain trauma: chronic traumatic encephalopathy. *PM R* 3(10 Suppl 2):S460–S467. doi:[10.1016/j.pmrj.2011.08.008](https://doi.org/10.1016/j.pmrj.2011.08.008)
- Sunami K, Nakamura T, Ozawa Y, Kubota M, Namba H, Yamaura A (1989). Hypermetabolic state following experimental head injury. *Neurosurgical review*, 12(1):400–411
- Thornton KE, Carmody DP (2009) Traumatic brain injury rehabilitation: QEEG biofeedback treatment protocols. *Appl Psychophysiol Biofeedback* 34(1):59–68
- Thunman DJ, Branche CM, Sniezek JE (1998) The epidemiology of sports-related traumatic brain injuries in the United States: recent developments. *J Head Trauma Rehabil* 13(2):1–8
- Tierney RT, Sitler MR, Swanik CB, Swanik KA, Higgins M, Torg J (2005) Gender differences in head-neck segment dynamic stabilization during head acceleration. *Med Sci Sports Exerc* 37(2):272–279
- Toledo E, Lebel A, Becerra L, Minster A, Linnman C, Maleki N et al (2012) The young brain and concussion: imaging as a biomarker for diagnosis and prognosis. *Neurosci Biobehav Rev* 36(6):1510–1531
- Wetjen NM, Pichelmann MA, Atkinson JL (2010) Second impact syndrome: concussion and second injury brain complications. *J Am Coll Surg* 211(4):553–557
- Yoshino A, Hovda DA, Kawamata T, Katayama Y, Becker DP (1991). Dynamic changes in local cerebral glucose utilization following cerebral concussion in rats: evidence of a hyper- and subsequent hypometabolic state. *Brain research*, 561(1):106–119.

---

## Resources

- [http://link.springer.com/chapter/10.1007/978-0-387-89545-1\\_12#page-2](http://link.springer.com/chapter/10.1007/978-0-387-89545-1_12#page-2)
- <http://bjsm.bmj.com/> 22 Sept 2016, published by group. [bjsm.com](http://bjsm.bmj.com)
- <http://bjsm.bmj.com/content/47/5/250.short> Zurich guidelines 2012
- <http://bjsm.bmj.com/content/48/7/563.3.abstract>
- <http://www.cdc.gov/headsup/>
- <http://www.ncbi.nlm.nih.gov/pubmed/25789439>
- <http://my.clevelandclinic.org/services/concussion-center/symptom-management>
- <http://www.nationwidechildrens.org/academic-concussion-management>
- <http://www.kumed.com/medical-services/concussion-management/myths-facts>

Jodi E. Mullen

---

## 10.1 Introduction

### 10.1.1 Overview

The Centers for Disease Control and Prevention defines abusive head trauma (AHT) as an injury to the skull or intracranial contents of an infant or child younger than age 5, which is caused by inflicted blunt impact, violent shaking, or both (Parks et al. 2012). The child with AHT may present with cerebral, cervical, or cranial injuries as a result of inflicted injury to the head (Sieswerda-Hoogendoorn et al. 2012). The classic triad of injuries depicting AHT includes subdural hemorrhage (SDH), retinal hemorrhage (RH), and fractures, especially in the ribs and long bones, although not all victims will present with this triad (Kemp 2011; Piteau et al. 2012). It is of vital importance that pediatric nurses understand the epidemiology and pathophysiology of AHT, recognize the signs and symptoms, and maintain a high level of suspicion for these types of injuries in young children.

---

J.E. Mullen, MS, RN-BC, CCRN, CCNS,  
ACCNS-P  
Pediatric Intensive Care Unit, Shands Children's  
Hospital, University of Florida,  
Gainesville, FL 32610, USA  
e-mail: [muljod@shands.ufl.edu](mailto:muljod@shands.ufl.edu)

### 10.1.2 Historical Context

Children have not always been recognized as being the victims of abuse or inflicted traumatic injury. It was not until the middle of the nineteenth century that French pathologist Auguste Ambroise Tardieu first described injuries he saw in 32 young children in Paris and attributed the cause of their trauma to their caretakers (Roche et al. 2005). Nearly 100 years later, pediatric radiologist John Caffey reported on the association between long bone fractures in children who had chronic subdural hemorrhages but who had no history of trauma or other systemic diseases (Caffey 1946). Additionally, he identified trauma as the possible cause of the retinal hemorrhages that were observed in several of these cases.

The term “battered child syndrome” was coined in 1962 to describe a child with a pattern of injuries including fractures, subdural hematoma, skin bruising, soft tissue swelling, and failure to thrive (Kempe et al. 1962). These injuries were identified in children who either had no history of trauma or in whom the degree and type of injuries were not adequately accounted for with the history provided. Parents and other caregivers were identified as the probable perpetrators of these injuries. Over time the medical community increasingly accepted the concept of child abuse as a legitimate cause of injury, and multiple case reports continued to be published, which associated the presence of concurrent subdural

hemorrhages, retinal hemorrhages, and fractures in young children without external signs of trauma (Narang and Clarke 2014). Further work subsequently proposed shaking or whiplash-type injury as a possible mechanism for these injuries because of an infant's relatively large head and weak neck muscles (Caffey 1972; Guthkelch 1971). Also known by such descriptors as shaken baby syndrome, inflicted brain injury, and non-accidental trauma, the term now preferred by the American Academy of Pediatrics is abusive head trauma, because it is a better descriptor of the clinical findings, rather than the mechanism of injury (Christian et al. 2009).

### 10.1.3 Epidemiology

The annual incidence of abusive head trauma in the United States is 33.4–38.8 cases per 100,000 children under the age of 1 (Shanahan et al. 2013). This estimate is likely low because not all abused infants will come into contact with the medical system or need/seek medical help. The United Kingdom's estimated incidence of AHT ranges 12.5–24.1 per 100,000 children (Hobbs et al. 2005). Children in other countries also experience AHT, with reported rates of 14.7–19.6 per 100,000 children in New Zealand (Kelly and Farrant 2008) and 24.6 per 100,000 children in Scotland (Barlow and Minns 2000). The challenge with comparing statistics across countries arises from the varying definitions and terms used to identify AHT.

It is estimated that over 1,600 children die yearly in the United States as the result of child maltreatment and AHT accounts for nearly 80% of these deaths (US Department of Health and Human Services et al. 2012). A vast majority of the child maltreatment victims that die of their injuries are under the age of 3 years (US Department of Health and Human Services et al. 2012), and when the primary cause is AHT, children tend to be less than 6 months of age (Sieswerda-Hoogendoorn et al. 2012). Fifty-one percent of children with fatal injuries are likely to have been evaluated in a clinic or emergency department in the previous 2 months (Ortega et al. 2013), and up to 27% of abused infants

under 1 year of age have a previous injury reported in their medical history that was suspicious for abuse because the baby was not mobile or the explanation for the injury was unlikely (Sheets et al. 2013). This represents missed opportunities for intervention prior to a child being severely or fatally injured.

### 10.1.4 Risk Factors

Several factors have been associated with an increased risk for AHT, and these can be described as arising from the child, the caregiver or adult perpetrator, and the environment (Christian and Committee on Child Abuse and Neglect. 2015; Liley et al. 2012; Narang and Clarke 2014). These factors are not the *cause* of child abuse, but rather it is the dynamic interrelatedness of these factors that result in AHT. Child factors include male gender and younger child age, particularly those under 6 months. Other risk factors include premature birth, physical or developmental disabilities, and being from an unwanted pregnancy (Sieswerda-Hoogendoorn et al. 2012). Caregiver factors, such as a young mother, unmarried/unrelated caregivers, male caregiver, substance abuse, and caregiver mental health disease, have been identified as being associated with an increased risk for AHT, as has caregivers having unrealistic developmental expectations for the child (Christian and Committee on Child Abuse and Neglect 2015; Lopes et al. 2013; Narang and Clarke 2014). Race and ethnicity have not been consistently linked to an increased risk of AHT (Narang and Clarke 2014). Among the environmental factors are lower socioeconomic status, social isolation, and other domestic violence (Lopes et al. 2013; Narang and Clarke 2014). Additionally, a triggering event, such as crying and the caregiver's resultant anger and frustration, can create an environment where abuse occurs (Adamsbaum et al. 2010; Narang and Clarke 2014).

### 10.1.5 Etiology

Inconsolable crying is often a trigger for shaking an infant (Adamsbaum et al. 2010). The caregiver

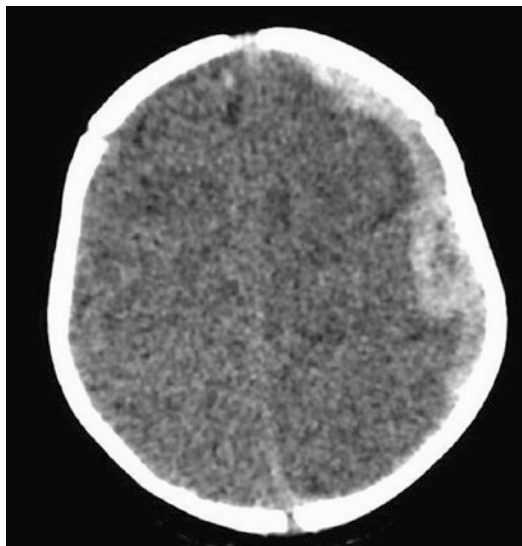
becomes frustrated by failed attempts to console the baby, loses emotional control, and grabs the infant either by the arms, under the arms, or by the chest and proceeds to violently shake the baby. This shaking episode may range from a few to several seconds and may involve shaking alone or shaking and then an impact against a surface, such as a bed, table, or wall. Perpetrators who confess often describe violently shaking the child on repeated episodes over a time period of days to months (Adamsbaum et al. 2010).

## 10.2 Pathophysiology

### 10.2.1 Brain Injury

Shaking with acceleration/deceleration and rotational forces applied to the child's head and neck, along with a sudden angular deceleration of the child's head at the time of an impact, causes stretching of the veins that bridge from the dura to the brain. Once these vessels exceed their elasticity, they tear and bleed. These veins are normally fixed to the inside of the skull and when torn the resultant bleeding creates subdural and/or subarachnoid hemorrhages. Subdural hemorrhage is the most common intracranial finding associated with AHT, occurring in 77–89% of patients (Kemp et al. 2011; Maguire et al. 2009, 2011; Sieswerda-Hoogendoorn et al. 2012) (Fig. 10.1). The presence of multiple SDH and those within the interhemispheric fissure or over the convexities is often found with AHT (Kemp et al. 2011). SDH with mixed density on CT imaging is more frequently associated with AHT, while accidental SDH will appear as homogeneous hyperdensity (Roach et al. 2014). Other than birth-related SDH, which resolves by 4–6 weeks of age, SDH in children is most commonly due to trauma, and the presence of a SDH in an infant with a history inadequate to explain the injury is highly suspicious for AHT (Kemp et al. 2011; Maguire et al. 2009, 2011).

During shaking, the brain strikes the inner surfaces of the skull which causes direct trauma to the brain itself and can result in parenchymal



**Fig. 10.1** Subdural hemorrhage. Left-sided moderate subdural hemorrhage observed in a 4-month-old who experienced abusive head trauma

hemorrhages. The deeper axons can twist and shear during shaking, and may ultimately break off, resulting in diffuse axonal injury. Secondary brain injury subsequently results from ischemia, hypoxia, and the cascade of metabolic disruptions in the brain cells, which includes oxidative stress. The damaged cells of the brain take up water and swell, with resultant cerebral edema and increases in intracranial pressure (ICP). Death results from intracranial hypertension and brain herniation.

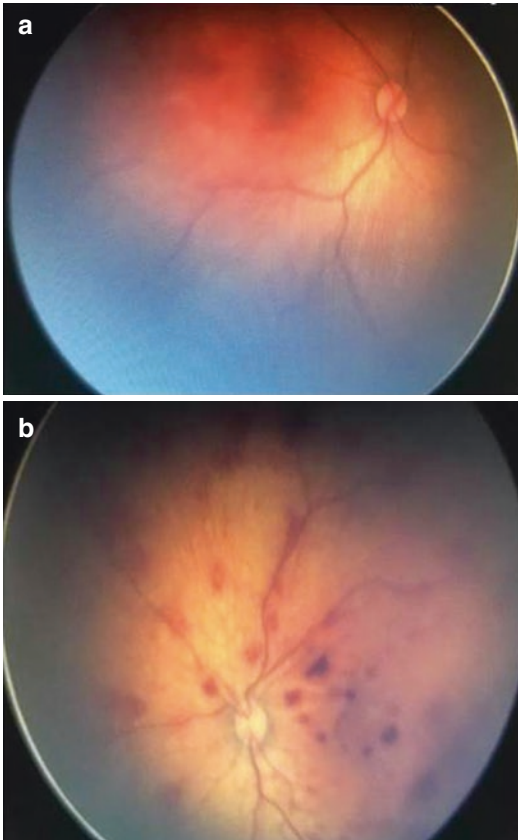
### 10.2.2 Spine Injury

Victims of AHT may also have cervical spinal and ligamentous injuries. Infants have a proportionally larger head and weaker neck muscles, making them vulnerable to cervical injuries that result from high-energy rotational forces as the head moves violently back and forth. Cervical injuries observed with AHT include cervicomedullary junction injury, vertebral body subluxations or fractures, traumatic axonal damage of the cervical spine, and primary cervical cord injury (Kadom et al. 2014; Narang and Clarke 2014).

### 10.2.3 Retinal Hemorrhages

Another common injury related to AHT are retinal hemorrhages, which results from the violent rotational movements of the eyes during shaking that causes the vitreous humor to exert extreme traction on the retina (Yamazaki et al. 2014). Retinal hemorrhages occur in 50–95% of children who are victims of AHT (Binenbaum and Forbes 2014) and have a 71% positive predictive value (Maguire et al. 2009). These hemorrhages tend to be bilateral, widespread to the outer margins of the retina, too numerous to count, and present in all layers of the retina (Maguire et al. 2013) (Fig. 10.2). Retinal hemorrhages also

occur in other pediatric conditions, including unidirectional/blunt head trauma, infections, bleeding disorders, metabolic disorders, vaginal births, and after cardiopulmonary resuscitation (Shaahinfar et al. 2015). However, these hemorrhages are usually unilateral, fewer in number, and localized to the optic disks and posterior pole of the retina (Shaahinfar et al. 2015). The majority of RH associated with vacuum-assisted birth resolve within 1 week and all resolve within 4 weeks of age (Laghmari et al. 2014). Up to 15% of non-abused children in the pediatric intensive care unit may have RH, but these are mild, located only on the posterior pole, and found only in the retinal layer (Agrawal et al. 2012; Longmuir et al. 2014). In the absence of a documented history of major trauma, retinal hemorrhages should be considered highly suspicious for AHT.



**Fig. 10.2** (a, b) Fundoscopic exam. (a) Right eye with normal retinal image. (b) Left eye with multiple small preretinal and intraretinal hemorrhages in the macula with innumerable preretinal and intraretinal hemorrhages extending from the posterior pole throughout the midperiphery and far periphery

### 10.2.4 Fractures

Fractures may occur as a result of child maltreatment, and rib fractures are strongly associated with AHT, having a 73% positive predictive value (Maguire et al. 2009). These fractures are thought to occur from squeezing around the infant's chest during shaking. Healing rib fractures may be seen when the abuse has occurred over time. Other fractures, such as metaphyseal injuries, may occur along with AHT, with the most common type of long bone fractures associated with AHT being those of the humerus and femur, particularly in nonmobile infants. Osteogenesis imperfecta, prematurity, vitamin and mineral deficiencies, and previous injuries can make a child vulnerable to bone fractures, and these should be considered on the list of differential diagnoses (Table 10.1) when evaluating the child for AHT and abuse (Flaherty et al. 2014).

Skull fractures can occur with and without intracranial bleeding, and intracranial bleeding can be present without associated related skull fracture. Skull fractures that result from accidental injuries tend to be unilateral, be linear, and occur in the thinner parietal bones, as the mechanism of injury is generally from lateral move-



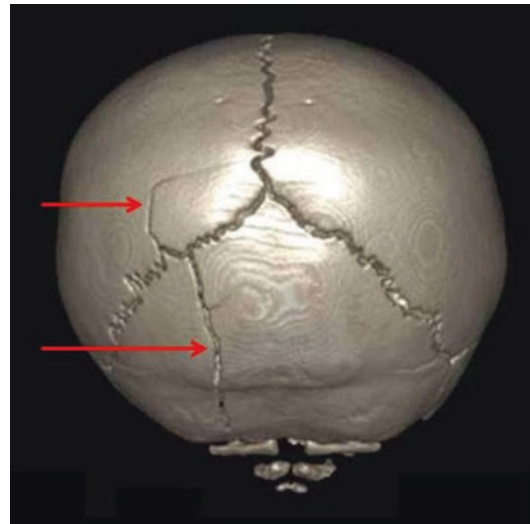
**Table 10.1** Differential diagnosis for abusive head trauma

Category	Examples
Bleeding disorders	Vitamin K deficiency in newborns
	Hemophilia
	Factor deficiencies (V, XII, XIII)
	von Willebrand disease
	Disseminated intravascular coagulation
	Alpha 1-antitrypsin deficiency
Accidental trauma	Falls, motor vehicle crash, etc.
Perinatal conditions	Birth trauma
	Intrauterine trauma
	Maternal preeclampsia
Congenital malformations	As previously diagnosed
Metabolic disorders	Glutaric aciduria type 1
	Pyruvate carboxylase deficiency
Genetic disorders	Osteogenesis imperfecta
	Menkes kinky hair syndrome
	Alagille syndrome
	Ehlers-Danlos syndrome
	Sickle cell anemia
Infectious diseases	Encephalitis
	Meningitis
	Kawasaki disease
	Toxoplasmosis
Poisonings	Lead poisoning
	Anticoagulant therapy

ment during accidental falls. Skull fractures in other locations and those that cross suture lines are associated with more severe impact, result in significant brain injury, and thus may be indicative of AHT (Roach et al. 2014) (Fig. 10.3).

### 10.2.5 Seizures

Both clinical and subclinical seizures may arise from cellular injury in the brain (Narang and Clarke 2014). Over 50% of victims of AHT develop seizures (Hasbani et al. 2013), and younger age and intraaxial bleeding are risk factors for both status epilepticus and subclinical



**Fig. 10.3** Skull fracture. Skull fracture that originates in the occipital bone (*large arrow*) and crosses the lambdoid suture to the parietal bone (*small arrow*). This fracture occurred as a result of significant energy forces when a 6-month-old baby was violently shaken before his head impacted a wood table

status epilepticus (Arndt et al. 2013). Seizures are best determined when the child undergoes continuous electroencephalographic (cEEG) monitoring as soon as possible after admission for suspected AHT (Paul and Adamo 2014).

## 10.3 Clinical Presentation

Presenting signs and symptoms of AHT will vary depending on the extent of brain injury and the type and severity of accompanying injuries. Manifestations may include nonspecific clinical findings such as an altered level of consciousness, lethargy, irritability, seizures, poor feeding, vomiting, and respiratory changes, including apnea. Apnea is a critical distinguishing feature for AHT compared to accidental head injury, having a positive predictive value of 93% (Maguire et al. 2009). Other conditions that may be associated with AHT include expanding head circumference, failure to thrive, and developmental delay. Since AHT is the most common cause of brain injury in children less than 2 years old, it should be suspected in all children who present with signs of

**Table 10.2** Injury patterns associated with abusive head trauma versus non-abuse etiologies

Injury type	Abusive head trauma	Non-abusive injuries
Brain injury	Subdural hemorrhages	Epidural hemorrhages
Diffuse axonal injury	More likely to be present	Less likely to be present
Retinal hemorrhages	Bilateral, widespread, multilayered, extending to the periphery of the retina	Unilateral, confined to the optic nerve and posterior poles, single layered in the retina
Skull fractures	Can occur anywhere, but occipital more likely to be abusive	Isolated, unilateral, linear parietal
Rib fractures	More likely to be present	Less likely to be present
Bruises	May or may not be present; patterned bruises more likely to be abusive; bruises unlikely to be accidental in non-cruising infants	Less likely to be patterned

Maguire et al. (2013) and Roach et al. (2014)

neurologic trauma, unless that trauma is unquestionably accidental (Narang and Clarke 2014). Bruising may be observed, depending on the mechanism of injury, with patterned bruising being more commonly associated with child maltreatment. However, since bruising occurs <50% of the time in AHT, the absence of bruises does not rule out AHT (Fanconi and Lips 2010). Bruising in nonmobile infants and bruising of the head and neck are concerning for AHT (Pierce et al. 2010). It can be challenging to differentiate inflicted from accidental injuries. Table 10.2 further compares injury patterns common to accidental versus abusive injuries (Maguire et al. 2009; Piteau et al. 2012).

## 10.4 History

### 10.4.1 History of the Event

A detailed and thorough history must be obtained when evaluating the child who presents with possible AHT. The history given by caregivers may be incomplete or even incorrect. A changing history, particularly when key factors change, is also common with AHT (Christian and Committee on Child Abuse and Neglect 2015; Hettler and Greenes 2003). Caregivers of victims of AHT often describe a relatively small trauma, such as falling from arms or falling from a short height, or they deny any trauma at all (Narang and Clarke 2014). If an accident is described, the caregiver(s) should

**Table 10.3** Historical concerns for abusive head trauma

Delay in seeking medical care
No history given for an injury
Absence of a history of trauma in the presence of significant injury
Absence of an adult when the injury occurred
History inconsistent with the injury pattern or severity (e.g., history of a short fall resulting in clinically significant intracranial injury)
Different caregivers/witnesses relay conflicting or inconsistent history
History and/or injuries inconsistent with physical or developmental capabilities of the child
History that changes over time, especially as injuries are revealed
History of the child or sibling inflicting the injury

be asked about when and where the injury occurred, who was present with the child at the time, what happened right before the event, and to describe the response to the injury. As detailed a timeline as possible should be obtained, including how much time elapsed between the incident and seeking medical assistance. If no trauma or accident is described, or if the child is portrayed as suddenly appearing in a poor condition or being found in such a state, the caregiver(s) should be asked about the last time the child was in good condition and how much time elapsed between those states. AHT should also be suspected in the child who presents with a history that does not match the observed injuries. Certain other historical indicators may raise concerns for AHT and these are further detailed in Table 10.3.

## 10.4.2 Medical History

The child's medical history, including prior traumas, or symptoms attributed to injury, should be obtained. The child's growth curve history, medical history of siblings, history of family violence, and previous contact with child protective services should be assessed. A detailed history will aid in quickly eliminating many items on the list of differential diagnoses, which can include accidental trauma, bleeding disorders, and other genetic and metabolic disorders (Table 10.1). Most of these conditions are rare, can be identified from the medical history, and are accompanied by other signs and symptoms or can be ruled out by laboratory tests.

---

## 10.5 Diagnosis

### 10.5.1 Physical Examination

The initial physical examination should include the child's general appearance, level of consciousness, and a primary survey for life-threatening injuries. Injury location and description should be assessed and documented. The injury location and other factors, such as multiple fractures, burns, injuries in various stages of healing, and patterned injuries/marks, should raise concern for child maltreatment and the possibility of AHT. Pattern marks on the skin may reflect the object which caused the injury and patterned injuries generally do not occur as a result of normal play. Additional examination will also differentiate conditions that may mimic child maltreatment and AHT.

### 10.5.2 Medical Imaging

The American College of Radiology recommends non-contrast head computed tomography (CT) as the initial study of choice for suspected AHT (Campbell et al. 2015; Christian and Committee on Child Abuse and Neglect 2015; Ryan et al. 2014). This exam can quickly diagnose life-threatening brain injuries that require

urgent intervention. Brain magnetic resonance imaging (MRI) may be used to detect small extra-axial fluid collections not seen on CT, to observe diffuse axonal injury and determine the extent of parenchymal brain injuries, while more accurately estimating the time of injury (Campbell et al. 2015; Christian and Committee on Child Abuse and Neglect. 2015; Ryan et al. 2014). MRI can distinguish between fresh blood in an acute SDH and older blood that is undergoing resorption in subacute and chronic SDH. MRI of the spine may be needed to determine associated injuries.

The American Academy of Pediatrics recommends that a skeletal survey, which is a complete set of radiographs with examination of each bone for possible fracture, be completed for all children under 2 years of age who are being evaluated for possible physical abuse (Campbell et al. 2015; Christian and Committee on Child Abuse and Neglect. 2015; Ryan et al. 2014). To detect healing fractures and those not visible on the initial radiographs, the skeletal survey is often repeated 2 weeks after the initial study.

### 10.5.3 Retinal Examination

A dilated fundoscopic exam is the accepted standard for identifying retinal hemorrhages. A pediatric ophthalmologist should be consulted whenever possible to examine the retinas for hemorrhage (Campbell et al. 2015). In some situations a susceptibility-weighted MRI can also detect RH when fundoscopic exam is not possible, for instance, when eyelids are swollen shut or when pupil dilation would interfere with serial neurological exams (Zuccoli et al. 2013).

### 10.5.4 Laboratory Evaluation

Initial laboratory evaluation should include a comprehensive metabolic panel, complete blood count, and basic coagulation panel to include prothrombin time (PT) and partial thromboplastin time (PTT) (Christian and Committee on Child Abuse and Neglect. 2015; Narang and

Clarke 2014). Subsequent testing will vary depending on the child's specific injuries and may include liver and pancreatic enzymes to detect any occult abdominal trauma and bleeding studies to rule out any bleeding disorders that may predispose the child to intracranial bleeding (Campbell et al. 2015). Metabolic and bone health studies, such as serum amino acids, phosphorous, and vitamin D 25-OH levels, may be needed as the injury evaluation progresses (Christian and Committee on Child Abuse and Neglect 2015; Narang and Clarke 2014). A routine urinalysis and urine toxicology screen are indicated in the child who presents with an altered level of consciousness.

---

## 10.6 Management of Abusive Head Trauma

### 10.6.1 Medical Interventions

Interventions to stabilize the child's cardiorespiratory status are given immediate attention. Then the child is taken for radiographic imaging to determine life-threatening intracranial bleeding or injuries that may be amenable to neurosurgical intervention. Potential indications for urgent surgery include large hematomas with a size greater than 10 mm, signs of intracranial hypertension, and low Glasgow Coma Scale (GCS) score  $\leq 12$  (Shaahinfar et al. 2015). Interventions include placement of an intraventricular drain and/or intracranial pressure monitor, depressive craniectomy, and craniotomy (Melo et al. 2014). Further management of AHT does not differ from the management of accidental head injury. Chapter 8 further details the specific management of traumatic brain injury.

### 10.6.2 Collaboration

Each case of suspected abusive head trauma should be managed using a multidisciplinary team approach in order to collect information on the facts that led to the clinical manifestations and appropriately manage the child's physical

and emotional needs, as well as the needs of the family. Team members include bedside nurses and physicians and advance practice nurses with specialty in child abuse pediatrics, pediatric critical care, neurosurgery, trauma, neurology, ophthalmology, and radiology. Social workers and the child protection team, which may include members from law enforcement, will facilitate the legal investigation.

The healthcare team's primary role is to evaluate and respond to a child's medical needs. This evaluation and treatment is a part of the entire child maltreatment investigation, which goes beyond the healthcare evaluation and includes the child's environment and the people and situations to which the child is exposed. The role of the healthcare team is not to determine who was the abuser or perpetrator but, along with the child protection team, to identify the medical problems, determine what injuries are present and treat those injuries, and offer honest medical information to parents and families. Caring for the victim of AHT can be emotionally challenging for the entire healthcare team. Nurses should confront their own perceptions and beliefs about AHT and child abuse, as it may have an impact on the care provided to abused children and their families. Nurses must treat this patient and family the same as the other patient and family with a different diagnosis.

### 10.6.3 Legal Implications

All 50 states in the United States have statutes that require the reporting of suspected child abuse or neglect by all healthcare providers, including nurses, though the process for making such reports may vary by state. There need only be *suspicion* of inflicted injury or abuse, and not certainty of proof, to meet mandatory reporting requirements. All states have eliminated the right of confidentiality when child abuse is suspected. Failure to report suspected abuse leaves the child at risk for further physical abuse and death and may potentially put other children at risk for abuse (Hornor 2012). Healthcare providers who fail to report suspicions of abuse place themselves at risk of professional liability.

Other nations such as Australia, Brazil, Canada, and most of the European Union also have reporting requirements. Nurses should be familiar with their local laws and advocate for the enactment of such laws where they don't exist.

---

## 10.7 Care of the Family

### 10.7.1 Patient and Family Education

The family of the child experiencing AHT will need information to help them understand the child's condition, medical plan, and anticipated prognosis. Because the investigation required when AHT is suspected evolves over time, families will need anticipatory guidance about what to expect and the roles of the various healthcare team members. Social services or other family support workers may be needed to assist with managing emotional family dynamics.

### 10.7.2 Siblings

Any siblings of the patient will need special consideration. After their safety has been assured, they will likely need to undergo a physical examination to make certain they are not also injured. As possible witnesses to abuse and violence, siblings will need developmentally appropriate support and interventions to meet their emotional needs. Nurses, child life therapists, and social workers are in prime positions to provide this type of care.

---

## 10.8 Prevention Efforts

The personal costs to the victim, coupled with the financial costs to society, make preventing child abuse and abusive head trauma a priority.

### 10.8.1 Primary Prevention

Primary prevention activities are those designed to raise the awareness of the general public about

the scope and magnitude of the problems associated with AHT. For instance, parental education should take place in the newborn nursery and at routine newborn examinations (Allen 2014; Altman et al. 2011; Dias et al. 2005; Simonnet et al. 2014). These are ideal opportunities to provide anticipatory guidance about dealing with the frustration of a crying baby and the harm that can result from shaking an infant (Flaherty et al. 2010). The *Period of PURPLE Crying* (<http://purplecrying.info>) is an intervention that can educate parents about why infants cry, what increases the infant's risk of trauma, and skills adult caregivers can use to soothe a crying baby and manage their frustration and anger (Allen 2014). Many states also have telephone hot lines that parents can call if they are feeling stressed and overwhelmed. Emphasis should also be placed on the importance of leaving a young infant or toddler in the care of adults whom the parents trust will not harm their child.

Home-visiting programs focus on educating parents on child development and parenting skills, so they can provide a safe home environment. One example is the Nurse-Family Partnership (<http://nursefamilypartnership.org>), which is a free, voluntary program that partners first-time parents with a nurse, who visits the home until the child is 2 years of age (Nurse-Family Partnership 2016). There are locations in over 43 states and the US Virgin Islands. Additional education services include the National Center on Shaken Baby Syndrome (<http://dontshake.org>), which has a mission to "Prevent shaken baby syndrome and promote the well-being of infants generally through the development and implementation of programs, policy and research; and to support and educate families, caregivers and professionals" (National Center on Shaken Baby Syndrome 2016). The center serves as a resource for prevention programs, training courses, and public education campaigns for professionals and families.

### 10.8.2 Secondary Prevention

Secondary prevention involves initiatives that are geared toward children and families who are



known to be at higher risk for maltreatment and AHT. Those considered at risk include substance-abusing parents, young mothers, those with developmental disabilities, and those living in socioeconomic stress (Chevignard and Lind 2014). For example, because of the high concordance between domestic violence and child maltreatment, families should be screened for domestic violence at every entry into the health-care system. Screening can and should occur during well-child visits, as a part of routine social histories, and when a child presents with findings or a history worrisome for possible maltreatment (Institute of Medicine and National Research Council 2014).

### 10.8.3 Tertiary Prevention

Finally tertiary prevention focuses on families in which abuse or neglect has already occurred. The goal at this point is to prevent the recurrence of maltreatment and reduce the long-term consequences and burden of abuse. Activities can include counseling, parent mentor programs, and programs designed to improve family communication and functioning (Institute of Medicine and National Research Council 2014).

## 10.9 Outcomes

### 10.9.1 Victim Outcomes

Outcomes for children experiencing AHT range from mild disability to death, depending on the severity of the head injury and other concomitant injuries. Factors associated with an increased risk of dying from AHT include an initial GCS of  $\leq 5$ , retinal hemorrhage, intraparenchymal hemorrhage and cerebral edema, and refractory intracranial hypertension with cerebral hypoperfusion (Miller Ferguson et al. 2016; Shein et al. 2012). Of survivors, approximately one third will have a good outcome. The remaining two thirds will experience some level of disability, with half of those having severe problems, such as microcephaly, chronic subdural hematoma, obstructive

hydrocephalus, epilepsy, hemiparesis, quadriplegia, psychomotor impairment, and visual deficit, including blindness (Fanconi and Lips 2010; Miller et al. 2014). Many of these severely affected children become dependent on technology such as tracheostomy tubes, ventilators, and gastrostomy tubes. More than half of severely injured victims of AHT die before the age of 21 (Miller et al. 2014). Other effects of child abuse and AHT include delayed development, poor school performance, and other mental health problems such as depression, suicidal ideation, and post-traumatic stress disorder.

### 10.9.2 Costs

All of these outcomes carry tremendous family and society costs. The dollar value attributed to AHT for one child over the first 4 years following diagnosis is nearly \$48,000 (Peterson et al. 2014). It is estimated that it costs over \$69 million yearly in the United States to care for victims of AHT (Peterson et al. 2015). These estimates do not include related nonmedical costs such as special education, and many children will need extensive medical care for the remainder of their lives. Victims of AHT have greater need for medical services, are more frequently hospitalized, and require more medication than non-abused children, all of which have financial implications (Peterson et al. 2014).

#### Box 10.1 Abusive Head Trauma: Case Study

##### History:

CP was a previously healthy 6-month-old male who by history was found limp after his father returned from outside where he had been smoking a cigarette around 8:00 pm. The father indicates he was watching the child while the mother was at work and that he had placed the baby in a bouncy seat prior to going outside. After finding the baby unresponsive, he ran two blocks to a convenience store and called

911. On arrival, EMS noted decerebrate posturing. Oxygen was applied and the child was transported from the scene to a pediatric emergency room.

**Physical exam findings:**

*General:* Well nourished, high-pitched irritable weak cry

*HEENT:* Pupils equal and reactive, right eye deviation

*Lungs:* Irregular respiratory pattern with periods of apnea, RR 16–30

*CV:* HR 140, sinus tachycardia, BP 96/42, capillary refill <2 s

*Abdomen:* Soft, non-tender, no organomegaly or palpable masses

*Extremities:* Decerebrate posturing of all extremities

*Neurologic:* Fontanel full, weak cry, GCS 8 (eye opening to pain only, 2 points; verbal response irritable cry, 4 points; motor response decerebrate (abnormal extension) posture, 2 points)

*Skin:* Bruising on left temporal area and soft tissue swelling over left parietal and occipital areas, mucus membranes moist

**Diagnostic findings:**

*Head CT:* Left subdural and subarachnoid hemorrhages, nondisplaced left posterior skull fracture (Fig. 10.3), loss of gray-white differentiation consistent with hypoxic injury and cerebral edema

*Abdominal/pelvic CT:* Normal

*Skeletal survey:* Left second rib with healing posterior fracture

*Ophthalmology:* Bilateral preretinal and intraretinal hemorrhages too numerous to count, extending from the posterior pole

*Laboratory:* Complete metabolic panel normal. Hemoglobin and hematocrit, platelet count, and urinalysis all normal

**Assessment:**

Abusive head trauma with severe traumatic brain injury

**Additional information:**

The baby's father was detained at the scene by law enforcement and was then taken to the police station for further questioning. His initial story was vague, describing the child as suddenly becoming unresponsive. During further questioning, he gave various and changing stories about how the baby was injured.

When the child's mother arrived at the hospital, she was visibly upset and concerned about her son's condition. She was initially supported by the social worker in the emergency department and interviewed in further detail later in the pediatric intensive care unit (PICU).

The baby is the result of an unplanned pregnancy. The parents are in their early 20s and unmarried, though they have been in a relationship for 2.5 years. They have no other children. The mother works second shift full-time at a grocery store, while the father provides child care. The father is unemployed but is looking for a job. There are no other caretakers and the baby is not in daycare. In terms of stressors, the mother reports some financial strain since the father is unemployed. She also reports that the father suffers from ADHD and bipolar disorder and is supposed to be on medication, which he takes inconsistently. She indicates that she and the baby's father regularly drink alcohol but denies drug use. There is also a reported history of domestic violence by the father against the mother, but she states that she has never witnessed the father being violent with the baby.

Before the baby's mother went to work on the day of the event, she noted that the child was playful and happy. She did not notice any bruising and said that she was not aware of any injuries the baby might have sustained over the past several days.

### Management:

Because of the child's periodic breathing and low GCS, he was intubated in the emergency room and subsequently received a 20 mL/kg normal saline bolus. After completing medical imaging, the baby was admitted to the PICU where central venous and arterial catheters were placed for invasive monitoring. Neurosurgical intervention consisted of placement of a ventriculostomy with ICP monitoring. The ICP was initially in the single digits, but the child developed intracranial hypertension over the next few days, which was treated with appropriate traumatic brain injury management interventions, including sedation and cerebral spinal fluid drainage. The baby developed seizures within 24 h of admission, was placed on cEEG monitoring, and started on antiepileptic medication. He was ultimately placed on pentobarbital and hypertonic saline infusions to control the seizures and refractory intracranial hypertension.

The child slowly improved and required ICP monitoring for 15 days. After 3 weeks of intubation, he was successfully extubated without the need for a tracheostomy tube. During hospitalization enteral nutrition was delivered via a transpyloric feeding tube, and he was subsequently transferred out of the PICU to the general pediatric unit with this tube still in place.

### Outcomes:

The baby remained hospitalized for just over 3 months. During that time, it was determined that he could not eat by mouth and a gastrostomy tube was placed for enteral nutrition. His vision is questionable and he does not focus or track. He has hypertonia and does not sit up, does not hold his head up unassisted, and does not grasp toys. He continues to need antiepileptic medication. The baby's mother received ongoing support from the hospital social worker and pediatric nurses and she

was taught to care for her son so he could be discharged home. He will continue to need ongoing physical, occupational, and speech therapy and will need an early intervention program and ongoing support indefinitely. The child's father ultimately plead guilty to child endangering, was fined \$10,000, and sentenced to 4 years in prison.

### Pearls

- Accidental injury is uncommon in children under 2 years of age. Strongly consider an inflicted mechanism when the caregiver(s) explanation does not match the resultant injuries or when key aspects of the history/story change over time.
- Classic injuries associated with abusive head trauma are subdural hematoma, retinal hemorrhages, and rib fractures. However, not all injuries may be present.
- Be cognizant of potential opportunities to identify abusive injuries. Over half of children who are fatally abused are evaluated in a clinic or emergency department in the 2 months prior to their death. Detecting sentinel injuries early may prevent additional abusive events.
- It can be difficult to distinguish accidental injury from abusive head trauma. Apnea is a critical distinguishing feature for AHT compared to accidental head injury, having a positive predictive value of 93%.
- Preventing abusive head trauma is paramount, and additional research is needed to determine effective strategies for primary, secondary, and tertiary prevention.

## References

- Adamsbaum C, Grabar S, Mejean N, Rey-Salmon C (2010) Abusive head trauma: Judicial admissions highlight violent and repetitive shaking. *Pediatrics* 126(3):546–555. doi:[10.1542/peds.2009-3647](https://doi.org/10.1542/peds.2009-3647)
- Agrawal S, Peters MJ, Adams GG, Pierce CM (2012) Prevalence of retinal hemorrhages in critically ill children. *Pediatrics* 129(6):e1388–e1396. doi:[10.1542/peds.2011-2772](https://doi.org/10.1542/peds.2011-2772)
- Allen KA (2014) The neonatal nurse's role in preventing abusive head trauma. *Adv Neonatal Care Off J Natl Assoc Neonatal Nurses* 14(5):336–342. doi:[10.1097/ANC.0000000000000117](https://doi.org/10.1097/ANC.0000000000000117)
- Altman RL, Canter J, Patrick PA, Daley N, Butt NK, Brand DA (2011) Parent education by maternity nurses and prevention of abusive head trauma. *Pediatrics* 128(5):e1164–e1172. doi:[10.1542/peds.2010-3260](https://doi.org/10.1542/peds.2010-3260)
- Arndt DH, Lerner JT, Matsumoto JH, Madikians A, Yudovin S, Valino H et al (2013) Subclinical early posttraumatic seizures detected by continuous EEG monitoring in a consecutive pediatric cohort. *Epilepsia* 54(10):1780–1788. doi:[10.1111/epi.12369](https://doi.org/10.1111/epi.12369)
- Barlow KM, Minns RA (2000) Annual incidence of shaken impact syndrome in young children. *Lancet* 356(9241):1571–1572
- Binenbaum G, Forbes BJ (2014) The eye in child abuse: key points on retinal hemorrhages and abusive head trauma. *Pediatr Radiol* 44(Suppl 4):S571–S577. doi:[10.1007/s00247-014-3107-9](https://doi.org/10.1007/s00247-014-3107-9)
- Caffey J (1946) Multiple fractures in the long bones of infants suffering from chronic subdural hematoma. *Am J Roentgenol Radium Ther* 56(2):163–173
- Caffey J (1972) On the theory and practice of shaking infants. its potential residual effects of permanent brain damage and mental retardation. *Am J Dis Child* 124:161–169
- Campbell KA, Olson LM, Keenan HT (2015) Critical elements in the medical evaluation of suspected child physical abuse. *Pediatrics* 136(1):35–43. doi:[10.1542/peds.2014-4192](https://doi.org/10.1542/peds.2014-4192)
- Chevignard MP, Lind K (2014) Long-term outcome of abusive head trauma. *Pediatr Radiol* 44(Suppl 4):S548–S558. doi:[10.1007/s00247-014-3169-8](https://doi.org/10.1007/s00247-014-3169-8)
- Christian CW, Committee on Child Abuse and Neglect (2015) The evaluation of suspected child physical abuse. *Pediatrics* 136(3):583–2010. doi:[10.1542/peds.2015-2010](https://doi.org/10.1542/peds.2015-2010)
- Christian CW, Block R, Committee on Child Abuse and Neglect, American Academy of Pediatrics (2009) Abusive head trauma in infants and children. *Pediatrics* 123(5):1409–1411. doi:[10.1542/peds.2009-0408](https://doi.org/10.1542/peds.2009-0408)
- Dias MS, Smith K, DeGuehery K, Mazur P, Li V, Shaffer ML (2005) Preventing abusive head trauma among infants and young children: a hospital-based, parent education program. *Pediatrics* 115(4):e470–7. doi:[10.1154/e470](https://doi.org/10.1154/e470) [pii]
- Fanconi M, Lips U (2010) Shaken baby syndrome in Switzerland: results of a prospective follow-up study, 2002–2007. *Eur J Pediatr* 169(8):1023–1028. doi:[10.1007/s00431-010-1175-x](https://doi.org/10.1007/s00431-010-1175-x)
- Flaherty EG, Stirling J Jr, American Academy of Pediatrics, Committee on Child Abuse and Neglect (2010) Clinical report—the pediatrician's role in child maltreatment prevention. *Pediatrics* 126(4):833–841
- Flaherty EG, Perez-Rossello JM, Levine MA, Hennrikus WL, American Academy of Pediatrics Committee on Child Abuse and Neglect, Section on Radiology, American Academy of Pediatrics et al (2014) Evaluating children with fractures for child physical abuse. *Pediatrics* 133(2):e477–e489. doi:[10.1542/peds.2013-3793](https://doi.org/10.1542/peds.2013-3793)
- Guthkelch AN (1971) Infantile subdural haematoma and its relationship to whiplash injuries. *Br Med J* 2(5759):430–431
- Hasbani DM, Topjian AA, Friess SH, Kilbaugh TJ, Berg RA, Christian CW et al (2013) Nonconvulsive electrographic seizures are common in children with abusive head trauma\*. *Pediatr Crit Care Med J Soc Crit Care Med World Feder Pediatr Intens Crit Care Soc* 14(7):709–715. doi:[10.1097/PCC.0b013e3182917b83](https://doi.org/10.1097/PCC.0b013e3182917b83)
- Hettler J, Greenes DS (2003) Can the initial history predict whether a child with a head injury has been abused? *Pediatrics* 111(3):602–607
- Hobbs C, Childs AM, Wynne J, Livingston J, Seal A (2005) Subdural haematoma and effusion in infancy: an epidemiological study. *Arch Dis Child* 90(9):952–955. doi:[10.1093/adc/90/9/952](https://doi.org/10.1093/adc/90/9/952) [pii]
- Hornor G (2012) Medical evaluation for child physical abuse: what the PNP needs to know. *J Pediatr Health Care Off Publ Natl Assoc Pediatr Nurse Assoc Pract* 26(3):163–70; quiz 171–3. doi:[10.1016/j.pedhc.2011.10.001](https://doi.org/10.1016/j.pedhc.2011.10.001)
- Institute of Medicine, National Research Council (2014) New directions in child abuse and neglect research. The National Academies Press, Washington, DC
- Kadom N, Khademi Z, Vezina G, Shalaby-Rana E, Rice A, Hinds T (2014) Usefulness of MRI detection of cervical spine and brain injuries in the evaluation of abusive head trauma. *Pediatr Radiol* 44(7):839–848. doi:[10.1007/s00247-014-2874-7](https://doi.org/10.1007/s00247-014-2874-7)
- Kelly P, Farrant B (2008) Shaken baby syndrome in New Zealand, 2000–2002. *J Paediatr Child Health* 44(3):99–107
- Kemp AM (2011) Abusive head trauma: Recognition and the essential investigation. *Arch Dis Child Educ Pract* 96(6):202–208. doi:[10.1136/adc.2009.170449](https://doi.org/10.1136/adc.2009.170449)
- Kemp AM, Jaspan T, Griffiths J, Stoodley N, Mann MK, Tempest V, Maguire SA (2011) Neuroimaging: What neuroradiological features distinguish abusive from non-abusive head trauma? A systematic review. *Arch Dis Child* 96(12):1103–1112. doi:[10.1136/archdischild-2011-300630](https://doi.org/10.1136/archdischild-2011-300630)
- Kempe CH, Silverman FN, Steele BF, Droegemueller W, Silver HK (1962) The battered-child syndrome. *JAMA* 181:17–24

- Laghmari M, Skiker H, Handor H, Mansouri B, Ouazzani Chahdi K, Lachkar R et al (2014) Birth-related retinal hemorrhages in the newborn: incidence and relationship with maternal, obstetric and neonatal factors. prospective study of 2,031 cases. [Hemorragies retiniennes liees a l'accouchement chez le nouveau-ne : frequence et relation avec les facteurs maternels, neonataux et obstetricaux. Etude prospective de 2031 cas]. *J Fr D'Ophthalmol* 37(4):313–319. doi:10.1016/j.jfo.2013.06.005
- Liley W, Stephens A, Kaltner M, Larkins S, Franklin RC, Tsey K et al (2012) Infant abusive head trauma – incidence, outcomes and awareness. *Aust Fam Physician* 41(10):823–826
- Longmuir SQ, McConnell L, Oral R, Dumitrescu A, Kamath S, Erkonen G (2014) Retinal hemorrhages in intubated pediatric intensive care patients. *J AAPOS Off Publ Am Assoc Pediatr Ophthalmol Strabismus Am Assoc Pediatr Ophthalmol Strabismus* 18(2):129–133. doi:10.1016/j.jaapos.2013.12.005
- Lopes NR, Eisenstein E, Williams LC (2013) Abusive head trauma in children: a literature review. *J Pediatr* 89(5):426–433. doi:10.1016/j.jpeds.2013.01.011
- Maguire S, Pickerd N, Farewell D, Mann M, Tempest V, Kemp AM (2009) Which clinical features distinguish inflicted from non-inflicted brain injury? A systematic review. *Arch Dis Child* 94(11):860–867. doi:10.1136/adc.2008.150110
- Maguire SA, Kemp AM, Lumb RC, Farewell DM (2011) Estimating the probability of abusive head trauma: a pooled analysis. *Pediatrics* 128(3):e550–e564. doi:10.1542/peds.2010-2949
- Maguire SA, Watts PO, Shaw AD, Holden S, Taylor RH, Watkins WJ et al (2013) Retinal haemorrhages and related findings in abusive and non-abusive head trauma: a systematic review. *Eye (London, England)* 27(1):28–36. doi:10.1038/eye.2012.213
- Melo JR, Di Rocco F, Bourgeois M, Puget S, Blauwblomme T, Sainte-Rose C et al (2014) Surgical options for treatment of traumatic subdural hematomas in children younger than 2 years of age. *J Neurosurg Pediatr* 13(4):456–461. doi:10.3171/2014.1.PEDS13393
- Miller Ferguson N, Shein SL, Kochanek PM, Luther J, Wisniewski SR, Clark RS et al (2016) Intracranial hypertension and cerebral hypoperfusion in children with severe traumatic brain injury: thresholds and burden in accidental and abusive insults. *Pediatr Crit Care Med J Soc Crit Care Med World Feder Pediatr Intens Crit Care Soc*. doi:10.1097/PCC.0000000000000709
- Miller TR, Steinbeigle R, Wicks A, Lawrence BA, Barr M, Barr RG (2014) Disability-adjusted life-year burden of abusive head trauma at ages 0–4. *Am Acad Pediatr* 134(6):1545–1550. doi:10.1542/peds.2014-1385
- Narang S, Clarke J (2014) Abusive head trauma: past, present, and future. *J Child Neurol* 29(12):1747–1756. doi:10.1177/0883073814549995
- National Center on Shaken Baby Syndrome (2016) National center on shaken baby syndrome: about us Retrieved from <http://dontshake.org/about-us>
- Ortega HW, Vander Velden H, Kreykes NS, Reid S (2013) Childhood death attributable to trauma: is there a difference between accidental and abusive fatal injuries? *J Emerg Med* 45(3):332–337. doi:10.1016/j.jemermed.2013.03.020
- Parks SE, Annett JL, Hill HA, Karch DL (2012) Pediatric abusive head trauma: recommended definitions for public health surveillance and research. Centers for Disease Control and Prevention, Atlanta
- Nurse-Family Partnership (2016) Nurse-family partnership fact sheet Retrieved from [http://www.nursefamilypartnership.org/getattachment/about/fact-sheets/NFP\\_February\\_2016\\_Snapshot-\(6\).pdf.aspx](http://www.nursefamilypartnership.org/getattachment/about/fact-sheets/NFP_February_2016_Snapshot-(6).pdf.aspx)
- Paul AR, Adamo MA (2014) Non-accidental trauma in pediatric patients: a review of epidemiology, pathophysiology, diagnosis and treatment. *Transl Pediatr* 3(3):195–207. doi:10.3978/j.issn.2224-4336.2014.06.01
- Peterson C, Xu L, Florence C, Parks SE, Miller TR, Barr RG et al (2014) The medical cost of abusive head trauma in the united states. *Pediatrics* 134(1):91–99. doi:10.1542/peds.2014-0117
- Peterson C, Xu L, Florence C, Parks SE (2015) Annual cost of U.S. hospital visits for pediatric abusive head trauma. *Child Maltreat* 20(3):162–169. doi:10.1177/1077559515583549
- Pierce MC, Kaczor K, Aldridge S, O'Flynn J, Lorenz DJ (2010) Bruising characteristics discriminating physical child abuse from accidental trauma. *Pediatrics* 125(1):67–74. doi:10.1542/peds.2008-3632
- Piteau SJ, Ward MG, Barrowman NJ, Plint AC (2012) Clinical and radiographic characteristics associated with abusive and nonabusive head trauma: a systematic review. *Pediatrics* 130(2):315–323. doi:10.1542/peds.2011-1545
- Roach JP, Acker SN, Bensard DD, Sirotnak AP, Karrer FM, Partrick DA (2014) Head injury pattern in children can help differentiate accidental from non-accidental trauma. *Pediatr Surg Int* 30(11):1103–1106. doi:10.1007/s00383-014-3598-3
- Roche AJ, Fortin G, Labbe J, Brown J, Chadwick D (2005) The work of ambrose tardieu: the first definitive description of child abuse. *Child Abuse Negl* 29(4):325–334
- Ryan ME, Palasis S, Saigal G, Singer AD, Karmazyn B, Dempsey ME et al (2014) ACR appropriateness criteria head trauma – child. *J Am Coll Radiol JACR* 11(10):939–947. doi:10.1016/j.jacr.2014.07.017
- Shaahinfar A, Whitelaw KD, Mansour KM (2015) Update on abusive head trauma. *Curr Opin Pediatr* 27(3):308–314. doi:10.1097/MOP.0000000000000207
- Shanahan ME, Zolotor AJ, Parrish JW, Barr RG, Runyan DK (2013) National, regional, and state abusive head trauma: application of the CDC algorithm. *Pediatrics* 132(6):e1546–e1553. doi:10.1542/peds.2013-2049
- Sheets LK, Leach ME, Koszewski IJ, Lessmeier AM, Nugent M, Simpson P (2013) Sentinel injuries in infants evaluated for child physical abuse. *Pediatrics* 131(4):701–707. doi:10.1542/peds.2012-2780
- Shein SL, Bell MJ, Kochanek PM, Tyler-Kabara EC, Wisniewski SR, Feldman K et al (2012) Risk factors for



- mortality in children with abusive head trauma. *J Pediatr* 161(4):716–722.e1. doi:[10.1016/j.jpeds.2012.03.046](https://doi.org/10.1016/j.jpeds.2012.03.046)
- Sieswerda-Hoogendoorn T, Boos S, Spivack B, Bilo RA, van Rijn RR (2012) Educational paper: abusive head trauma part I. clinical aspects. *Eur J Pediatr* 171(3):415–423. doi:[10.1007/s00431-011-1598-z](https://doi.org/10.1007/s00431-011-1598-z)
- Simonnet H, Laurent-Vannier A, Yuan W, Hully M, Valimahomed S, Bourennane M, Chevignard M (2014) Parents' behavior in response to infant crying: abusive head trauma education. *Child Abuse Negl* 38(12):1914–1922. doi:[10.1016/j.chiabu.2014.06.002](https://doi.org/10.1016/j.chiabu.2014.06.002)
- US Department of Health and Human Services, Administration for Children and Families, Administration on Children, Youth, and Families, Children's Bureau (2012) *Child maltreatment 2012*. Government Printing Office, Washington, DC
- Yamazaki J, Yoshida M, Mizunuma H (2014) Experimental analyses of the retinal and subretinal haemorrhages accompanied by shaken baby syndrome/abusive head trauma using a dummy doll. *Injury* 45(8):1196–1206. doi:[10.1016/j.injury.2014.04.014](https://doi.org/10.1016/j.injury.2014.04.014)
- Zuccoli G, Panigrahy A, Haldipur A, Willaman D, Squires J, Wolford J et al (2013) Susceptibility weighted imaging depicts retinal hemorrhages in abusive head trauma. *Neuroradiology* 55(7):889–893. doi:[10.1007/s00234-013-1180-7](https://doi.org/10.1007/s00234-013-1180-7)

Anne Stuedemann and Valorie Thomas

---

## 11.1 Introduction

This chapter will address pediatric spinal anomalies, spine trauma, and the potential neurologic implications related to these conditions from an orthopedic perspective. A child diagnosed with a spine anomaly, be it congenital or trauma related, has the potential of neurologic injury either from the deformity, the injury itself, or from complications of surgical intervention.

Pediatric patients may present with spinal abnormalities resulting from multiple conditions including congenital or idiopathic anomalies, skeletal dysplasias, syndromes, underlying neuromuscular conditions, or spinal injuries sustained from trauma. Many spine abnormalities are not present at birth and may be challenging to diagnose and treat. The spine deformities may be progressive and cause neurologic deficits, as well as cardiovascular and pulmonary compromise (Wiggins et al. 2003). Spinal trauma may be difficult to diagnose due to the differences in the development of the pediatric spine compared to the adult spine. Congenital spinal anomalies may also not be diagnosed until the child is older, which may result in irreversible neurological

damage. Spinal cord injuries from trauma can be understated but severe. Children with spinal anomalies or traumatic injury to the spine require specialized care. The care providers must have knowledge and understanding of spine development and the potential neurologic impact of the trauma and the congenital deformity. The goal of this chapter is to provide nurses with the necessary information and knowledge to assess and care for these children safely while promoting optimal outcomes.

---

## 11.2 Pediatric Spinal Deformity and Trauma

Pediatric patients may suffer from congenital spinal anomalies or spinal injuries from trauma. Abnormalities such as spine infections, tumors, and vascular lesions are discussed in other chapters. Spinal cord injuries can be complex and debilitating. Because of these concomitant injuries, treatment does not stop when the patient leaves the hospital or the rehabilitation facility; it may require a life-long commitment from the family and patient.

---

## 11.3 Congenital Spine Deformity and Spinal Cord Disorders

In the pediatric age group, spinal deformity may result from, or be related to, various conditions, including congenital anomalies, neuromuscular conditions, connective tissue disorders, neurofibromatosis, and skeletal dysplasias including

---

Laurie Baker, Suzan R. Miller-Hoover, Donna C. Wallace and Sherry Kahn were authors on the first edition but did not contribute to the revision of this chapter.

A. Stuedemann, MSN, RN, CPNP (✉)  
V. Thomas, MSN, RN, PPNP-BC  
Division of Orthopaedic Surgery,  
Children's Mercy Hospitals and Clinics,  
2401 Gillham Road, Kansas City, MO 64108, USA  
e-mail: [astuedemann@cmh.edu](mailto:astuedemann@cmh.edu); [vthomas@cmh.edu](mailto:vthomas@cmh.edu)

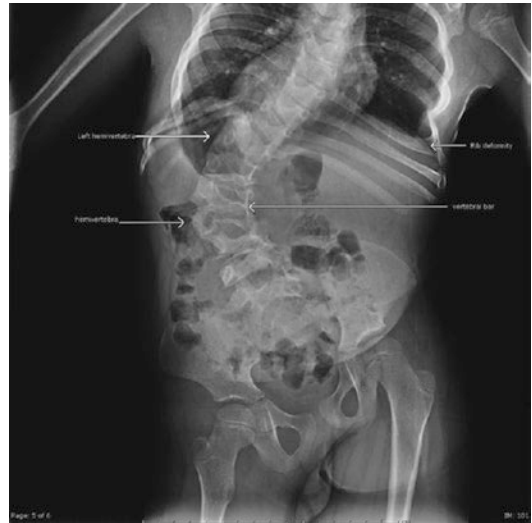© Springer International Publishing AG 2017

C.C. Cartwright, D.C. Wallace (eds.), *Nursing Care of the Pediatric Neurosurgery Patient*,

DOI 10.1007/978-3-319-49319-0\_11

dwarfism (Wiggins et al. 2003). Congenital spine deformity is caused by anomalous vertebral development in the embryo. The actual spinal deformity may not be obvious at birth but progresses in proportion to spinal growth resulting in unbalanced growth of the spine. The rate of curve progression depends on the age of the patient, type and location of the anomaly, and location of the curve (Hedequist and Emans 2007). Minor deformities may seldom be apparent and may be noted for the first time during periods of rapid growth (first 5 years of life and again at adolescence), later in life as they progress, or on a routine radiograph for work up of an unrelated problem. More severe congenital malformations that may result in progressive deformity and multisystem problems, including neurologic complications, have a high incidence of other associated conditions which will be discussed in more detail throughout this chapter (Dewald et al. 2003).

Predominant congenital deformities typically exist as scoliosis, kyphosis, or lordosis. Most are multiplane deformities. A description of a congenital deformity should include the involved area of the spine, the type of vertebral anomaly, and the configuration of the deformity, as these factors will have a direct effect on further evaluation and treatment. Congenital scoliosis or kyphosis is classified as failure of formation, failure of segmentation, or mixed anomalies (Wiggins et al. 2003) (Fig. 11.1). Approximately 60% of individuals with vertebral malformations have associated anomalies either within or outside the spine. The importance of thoroughly searching for associated anomalies cannot be emphasized enough, as a vertebral anomaly that appears relatively benign may be associated with a much more severe and possibly life-threatening condition (Devlin 2012). There is also an increased incidence of spinal cord disorders related to the congenital defect that are more common to some specific syndromes. A few of the more common conditions that are seen in the neurosurgery and orthopedic patients are achondroplasia, Klippel-Feil syndrome, connective tissue disorders, and mucopolysaccharide disorders (MPS). These will be discussed in more detail later in this section.



**Fig. 11.1** Defects of segmentation

### 11.3.1 Etiology

Development of the vertebrae begins at 4–6 weeks of gestation. This is when the mesenchymal mold is formed which is the model for the framework for the secondary cartilaginous and osseous development of the vertebrae (Dewald et al. 2003). Subsequent chondrification and ossification follow this mold. The neural axis is developing at the same time, which explains why children with vertebral anomalies may potentially have neural anomalies as well. The embryologic insult resulting in the vertebral anomaly is unknown, and there has been no clear-cut genetic etiology of congenital scoliosis to date. In animal models, it has been demonstrated that deformities have been linked with maternal hypoxia at the critical time of gestation (Devlin 2012). There have also been associations with maternal diabetes, ingestion of antiepileptic drugs during pregnancy, and maternal exposure to toxins (Hedequist and Emans 2007).

Congenital vertebral anomalies are rare. The prevalence rate of congenital scoliosis is approximately 1 in 1,000 live births (Hedequist and Emans 2007). Isolated anomalies (hemivertebra) are sporadic with no familial or genetic tendencies. However, there is a 5–10% risk of similar lesions in siblings or subsequent generations, as

well as an increased risk of neural tube defects when there are complex anomalies in multiple locations (Dewald et al. 2003).

### 11.3.2 Related Conditions

Organ systems that are developing during the same gestational period as the spine may also be at risk for developing malformations. There are some common malformations that are associated with congenital spinal anomalies, including intraspinal abnormalities. Neural axis abnormalities, such as tethered cord, spinal stenosis, diastematomyelia (split cord), diplomyelia (complete or incomplete doubling of the spinal cord), and syringomyelia (fluid-filled space within the spinal cord), are present in up to 38% of patients with congenital vertebral anomalies. Clinical findings of posterior midline skin lesions like hairy patches or dimples, foot deformity (especially unilateral), muscle weakness, or spasticity may be a red flag as to an underlying intraspinal anomaly. Other anomalies associated with vertebral abnormalities are vertebral anomalies at another level, urinary tract structural abnormalities, cranial nerve palsy, upper extremity hypoplasia, clubfoot, dislocated hip, and congenital cardiac disease. Specifically, the vertebral malformation most often associated with an abnormality of the neural axis is a unilateral unsegmented bar and a same-level contralateral hemivertebra. It has been estimated that approximately 50% of this population have an associated neural axis abnormality (Devlin 2012). These may often be occult anomalies such as a tethered cord, intradural lipoma, syringomyelia, or diastematomyelia, which is the most common (Dewald et al. 2003). The clinical signs and radiographic findings of these spinal cord anomalies are discussed in the physical assessment and imaging sections of this chapter.

### 11.3.3 Evaluation of the Child with a Congenital Spine Deformity

As high as 35% of children with a congenital spine deformity may also have a congenital

anomaly of the neural axis or a spinal dysraphism. Some of the forms of spinal dysraphism include spina bifida (spina bifida occulta, meningocele, and myelomeningocele), diastematomyelia, and tethered cord (Hedequist and Emans 2007). The symptoms of spinal dysraphisms are difficult to generalize as they are quite varied depending on the type and severity of the malformation. A thorough past medical history with focus on the physical exam should be obtained, keeping in mind the correlation of the congenital spine deformity and other congenital anomalies. Detailed questions should be directed as to the child's neurologic status. Age-appropriate questions related to development history, toilet training, bed wetting, changes in bowel or bladder habits, and complaints of lower extremity pain, numbness, or weakness are all of great importance in the evaluation of the child's neurologic status. A complete evaluation of the patient should include a comprehensive exam of the patient as well as a close evaluation of the spine itself with a thorough neurologic exam.

General patient evaluation should occur throughout the encounter with the child. A full exam should include sitting and standing heights or supine measurements for infants and head circumference. Take note of any alterations in head shape, along with size, shape, and symmetry of the ears and eyes. Assessment of the neck and cervical spine should be noted for range of motion. There are some syndromes, such as Klippel-Feil syndrome, which have congenital cervical fusions thus limiting cervical range of motion. The spine exam itself should focus on trunk and pelvic balance, including the coronal and sagittal planes (Hedequist and Emans 2007). The finding of abnormal kyphosis on physical exam may be postural or congenital and thus should be thoroughly evaluated. Complaints of back pain, muscle fatigue, and stiffness are common in kyphosis. In severe cases, there can be compression of the spinal cord with neurologic symptoms that include weakness, altered sensation, and loss of bowel and bladder control. The chest should be examined for symmetry and deformity. Observation of inspiration, expiration, and the abdominal

wall for movement, masses, and hernias may be an indication of a fixed chest wall deformity (Dewald et al. 2003). Lastly, secondary sexual development should be noted with examination of the genitalia and Tanner staging.

### 11.3.4 Neurologic Evaluation

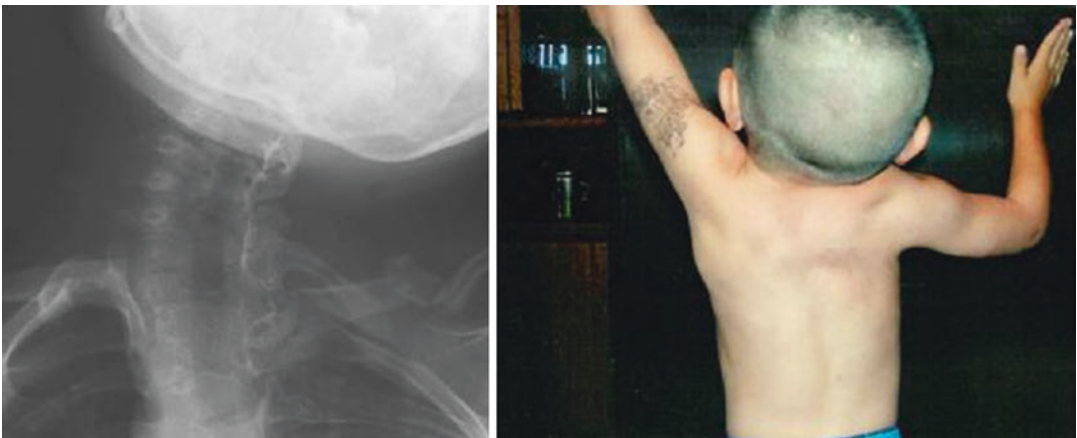Neurologic evaluation can quickly and easily be performed throughout the physical exam. Extremity development, length, and symmetry should be noted, as well as anomalies of the feet. Feet abnormalities may include extra or absent toes, cavus (high arch), or flat feet. Remember that flat feet alone may be a benign common finding in young children. These can be red flags as to underlying neurologic conditions. Congenital deformities of the upper body and extremities such as Sprengel's deformity (undescended scapula) and syndactyly should also be noted (Fig. 11.2). Further neurologic exam can be performed simply by observing the child walk, run, and move, noting overall general motor function. Testing of reflexes should be carefully performed. Abdominal reflexes should be symmetric. Asymmetric or depressed reflexes can be symptomatic of a spinal dysraphism. Hyperactive reflexes can be indicative of spinal cord compression (Dewald et al. 2003).

### 11.3.5 Associated Anomalies

Children with congenital scoliosis are also at risk for abnormalities of the cardiac and genitourinary systems. Congenital heart disease may be observed in up to 25% of children with congenital scoliosis and genitourinary anomalies in as many as 20% of these patients (Hedequist and Emans 2007). These abnormalities may be benign and asymptomatic. They are typically detected during a routine screening or preoperative appointment. Alternatively, these anomalies may be severe and have possibly already required treatment. If it is determined through the medical history that these patients have not previously been evaluated for possible cardiac and/or urologic anomalies, they should be referred to a cardiologist or urologist for further screening and evaluation.

### 11.3.6 Diagnostic Studies

When anomalies of the spine are suspected, radiologic study is essential, especially for anomalies of the cervical spine. Early identification may significantly reduce potential major complications (Albright et al. 1999). Plain x-rays are always a recommended and reliable starting point for radiographic evaluation; how-



**Fig. 11.2** A 4-year-old boy with Sprengel's deformity associated with Klippel-Feil syndrome



ever, they may give limited information depending on the age of the patient and the type of anomaly present.

Ultrasound, a simple and very useful type of study, can be a good screening tool in neonates and infants when physical findings suggest an underlying dysraphic lesion. Prenatal findings, family history, and other anomalies may also be an indication for an ultrasound (Albright et al. 1999). Normal vertebral growth and ossification can demonstrate many patterns, as well as be difficult to read on plain films due to the many overlying structures. CT scans are often needed to assess congenital anomalies. This is true especially in the cervical spine. Both CT and MR are especially useful in studying the entire spinal cord and the cervical spine. If any anomaly or malformation is suspected, it is important to image the entire spine as multiple spinal anomalies can commonly present. (Albright et al. 1999).

The incidence of intraspinal abnormalities associated with congenital spine anomalies as detected by MRI has become better defined. In a study by Suh, Sarwark, Vora, and Huang in 2001, there was an incidence of intraspinal anomalies in 31% in children with congenital spine anomalies. A screening MRI is indicated in patients with a spinal deformity that is known to be associated with neural axis abnormalities because of its capacity to detect clinically unsuspected dysraphia in asymptomatic patients. Other indications would include patients with a progressive deformity, abnormal reflexes, neurological deficits, or major extremity anomalies (Hedequist and Emans 2007). Angiography may be required if vertebral circulation is a concern. Some of the intraspinal pathologic conditions that may be found in patients with such conditions include congenital spinal stenosis, tethered cord, syrinx, Chiari malformation, diastematomyelia, and spinal cord tumor (Devlin 2012). Again, as clinical manifestations may not be detectable initially, MR imaging of the entire spinal cord and vertebral column from the foramen magnum to the distal sacrum is essential for complete evalua-

tion. The advantages of MR imaging is that it is a technique that avoids invasive procedures and high radiation exposure.

All systems should be thoroughly reviewed and examined. Frequently, a renal and cardiac consultation is a part of an expanded evaluation.

Computed tomography (CT) is not typically used for serial monitoring and observation of scoliosis; however, it is routinely used in preoperative assessment and planning. CT scans are extremely useful in clearly defining the anatomy and identification of previously unrecognized malformations (Hedequist and Emans 2007). There are concerns regarding high radiation exposure during a CT scan. Today, most institutions typically have written protocols for various scans in order to minimize the amount of radiation that children are exposed to during their scans.

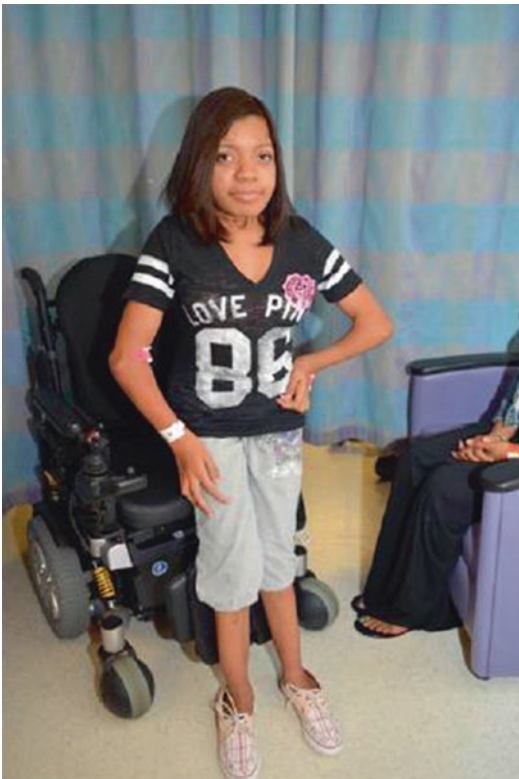Treatment of congenital scoliosis focuses on early recognition, diagnosis, and treatment. Surgical treatment may include early arthrodesis and the routine use of spinal instrumentation for progressive curves. Younger children with congenital deformities may be treated with fusionless surgery by using a growing rod technique. Further discussion of various surgical corrections, fusion, and instrumentation is beyond the scope of the chapter.

### 11.3.7 Skeletal Dysplasias

All conditions of skeletal dysplasia share a common theme of some systemic defect in skeletal development. The categories of spine-related problems common to many of the skeletal dysplasias are instability, stenosis, and deformity, although they may occur concurrently at different levels of the spine and in different planes. Any type of dysplasia may manifest one or more of these problems with some exceptions. The phenotypic variability seen in genetic diseases makes it difficult to predict specific patterns of problems within the skeletal dysplasia groups (Dewald et al. 2003).

The first issue of instability may be a bony or ligamentous issue and usually occurs at the C1–C2 level. Instability is most common in the

mucopolysaccharidoses, spondyloepiphyseal dysplasia, and metatropic dysplasia (Dewald et al. 2003). Baseline flexion and extension films of the cervical spine are always indicated. Also, a clinical exam evaluating spasticity, strength, and coordination should be included. An MRI in neutral, flexion, and extension would be indicated if it is not clear whether cord compression is developing. Stenosis may occur at any level of the spine. It is most commonly found in the patient with achondroplasia (80–90%) (Dewald et al. 2003). Treatment, typically decompression of the affected region, is determined by the extent and location of the neurologic deficit (Fig. 11.3 and Box 11.1).



**Fig. 11.3** A young lady with Larsen syndrome, a connective tissue/skeletal dysplasia disorder associated with congenital spinal instability and spinal cord injury. This young lady went on to have a posterior cervical fusion as well as spinal fusion from T2 to L4 for her cervical kyphosis, cervical myelopathy, and progressive lordoscoliosis. She mostly mobilizes with her wheelchair but is able to walk with a walker

### Box 11.1 Our Angel

This story begins the same as many, following the joyous birth of an expected-to-be-healthy child. The delivery was a bit challenging, but it was well worth knowing we had a beautiful baby girl! Immediately, grandmother noticed that the baby had unusually long fingers and hands, but we were not concerned at first. We also noticed that she was not meeting developmental milestones, even the simple ones like being able to hold her head up. This was the beginning of our journey, meeting with many specialists and undergoing multiple examinations. Finally, a geneticist identified her problem, and it was called Larsen syndrome or Larsen’s syndrome.

We learned that this is a very rare diagnosis that is one of a group of conditions known as “skeletal dysplasias.” It is an inherited condition characterized by congenital interruption of multiple body joints and connective tissue. The children have a characteristic appearance of the face, hands, and multiple skeletal problems. They may have learning disabilities as well.

Identifying the diagnosis was just the beginning. We had to find out who could provide the very best care for her. We began by going online and reaching out to other parents. We found specialists in orthopedics who could stabilize her spine that was compressed by almost 97%! She underwent a fusion and was placed in halo traction for the first 4 years of her life.

We have never lost faith that our little girl would grow up – she is now a freshman in high school! You can see by her beautiful

picture that she cares about all the things that most teens do. She chose the picture because she wanted to look her best.

We do have a wonderful support system in place that includes our family, our church, and our many friends. We also have sought out what we feel is the best care possible with the help of other parents from around the country. We have also counted on the surgical specialists, the orthopedic and neuroscience nurses, the many therapists, and her schools to guide and support us.

Most important of all throughout her 14 years of life, the resilience of our daughter and granddaughter has endured. No challenge is too great, no obstacle too much for us to overcome. We have come together and endured it all for our “little angel” because she is worth it all.

## 11.4 Larsen Syndrome

Larsen syndrome is a heterogeneous, rare genetic disorder occurring in approximately 1 in 100,000 births. It was first recognized as an entity by Larsen in 1950 (Hennekam 2010). It is known to follow an autosomal-dominant or autosomal-recessive mode of inheritance, although sporadic occurrences have also been described in the literature (Becker et al. 2000).

Symptoms and severity in Larsen syndrome may vary greatly, ranging from a lethal form of the disorder to a mild clinical expression where there is an absence of major diagnostic features. Characteristic findings include skeletal and large joint abnormalities with distinctive facial features, cleft palate, hearing loss, and spinal abnormalities. Classic facial features of the syndrome are flattened, hypoplastic midface, a prominent forehead, depressed nasal bridge, and hypertelorism (Becker et al. 2000). Some symptoms

are present at birth such as dislocation of large joints, especially the hips, knees, and elbows. Club foot is present in 75% of affected individuals. Spine abnormalities occur in about 84% of those with Larsen syndrome. This includes scoliosis and cervical kyphosis. Cervical kyphosis can occur from subluxation or fusion of the cervical vertebral bodies associated with dysplasia of the vertebral laminae and hypoplasia of the lateral processes of the cervical vertebrae. This is potentially the most life-threatening manifestation due to the impingement of the spinal cord at the apex of the kyphosis (Johnston et al. 1996). Early diagnosis and intervention of cervical kyphosis can help patients avoid potential neurologic deficits.

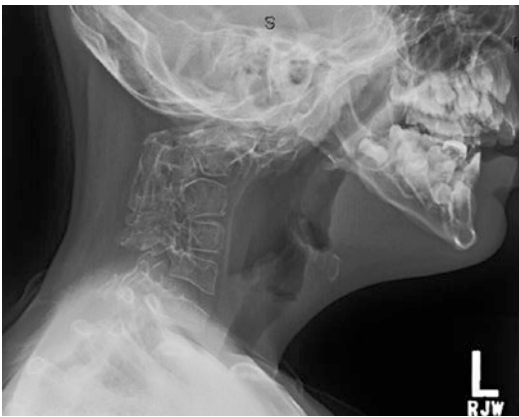
## 11.5 Loey-Dietz Syndrome

Loey-Dietz syndrome (type 1–5), also referred to as LDS or Marfan 2, is a rare genetic disorder. The exact prevalence of LDS is unknown. Its characteristic features of craniofacial, vascular, and musculoskeletal malformations are also common to Marfan syndrome. Although LDS has been called Marfan 2, there are some significant differences between Loey-Dietz and Marfan syndrome (The Marfan Foundation 2016).

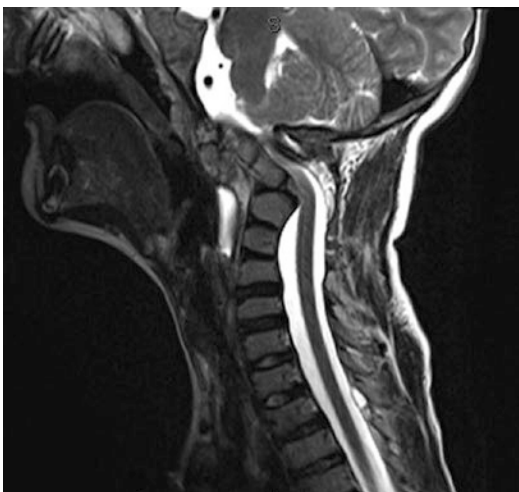
Loey-Dietz is an autosomal-dominant connective tissue disorder. It is caused by a mutation in the transforming growth factor-beta receptor 1 or 2 (TGF-BR1 or TGF-BR2) genes (Fuhrhop et al. 2015). Loey-Dietz syndrome, first described in 2005, is characterized by a triad of aggressive aneurysm formation, bifid uvula or cleft palate, and hypertelorism. Other common physical features in Loey-Dietz include translucent skin, easy bruising, and craniofacial abnormalities such as craniosynostosis, retrognathia, and malar hypoplasia. Vertebral anomalies and cervical instability also have a high prevalence in Loey-Dietz syndrome. Cervical instability especially at C2–C3 is associated with C3 vertebral body hypoplasia and C2–C3 kyphosis (Fig. 11.4). Other spine malformations may include scoliosis and spondylolisthesis. Deformity of the extremities including arachnodactyly, talipes equinovarus,

and joint hypermobility are also noted. Pectus excavatum or carinatum deformities may also be present (Fuhrhop et al. 2015).

As evidenced by the literature, cervical mid-line defects are common in Loeys-Dietz syndrome as are vascular abnormalities. With these patients having a high prevalence of cervical instability, there is a very important need for frequent imaging to monitor for progression and subsequent neurologic sequelae from the deformity (Fig. 11.5). Early diagnosis is critical for appropriate and timely intervention (Fuhrhop et al. 2015).



**Fig. 11.4** Preoperative x-ray of a 12-year-old male with Loeys Dietz. Note the cervical kyphosis



**Fig. 11.5** Preoperative MRI demonstrates stenosis and compression of the spinal cord

## Box 11.2 Devin's Story

(Told by Devin's mother)

*Our story began the same as many, however changed and became a high-risk pregnancy. Many tests were being done in the last 3 months of the pregnancy. We were never told anything was wrong with our sweet baby boy. The delivery was like many others, but we only got a few minutes to see our son before he was taken to the NICU (neonatal intensive care unit.) After 11 days of being in NICU, our baby was able to come home, with a lots of issues and doctors.*

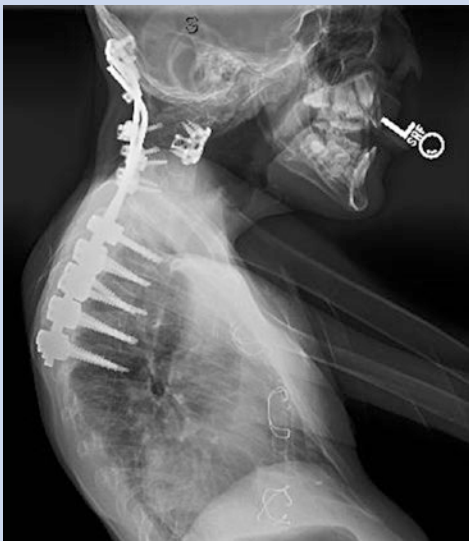*After 7 years of his life, we requested a test to be done on our son to see if he has Loeys-Dietz syndrome. The geneticist looked him over to see if he met the criteria and she believed he did. Two weeks later, we finally had a diagnosis. After many appointments and surgeries with many doctors and specialists, we then knew we were dealing with Loeys-Dietz syndrome (Fig. 11.6).*



**Fig. 11.6** 12 year old male with Loeys-Dietz



*Our son was born with many skeletal issues from his head to his feet, ligament issues in his knees and ankles, and an enlarged aorta. After three head surgeries, his skull was reshaped (due to having two soft spots at birth), two jaw surgeries to pull his jaw forward (the jaw was pushed back and crushing his airway), one heart surgery to replace the section of the aorta that was enlarged, and two neck surgeries due to two extra vertebrae, causing the neck to curve and smash his spinal cord (Fig. 11.7). Both knees had to have ligaments tightened to stop dislocating. A screw was placed in his left foot to help straighten it, and through all of these bad experiences, he still has a great outlook on life! He is an inspiration to all of us when we think that our own problems are bad!*



**Fig. 11.7** Note postoperative spinal fixation extending into the cervical spine to correct the pre-existing kyphosis and instability

## 11.6 Spinal Manifestations of Achondroplasia

Achondroplasia is an autosomal-dominant genetic disorder affecting endochondral bone

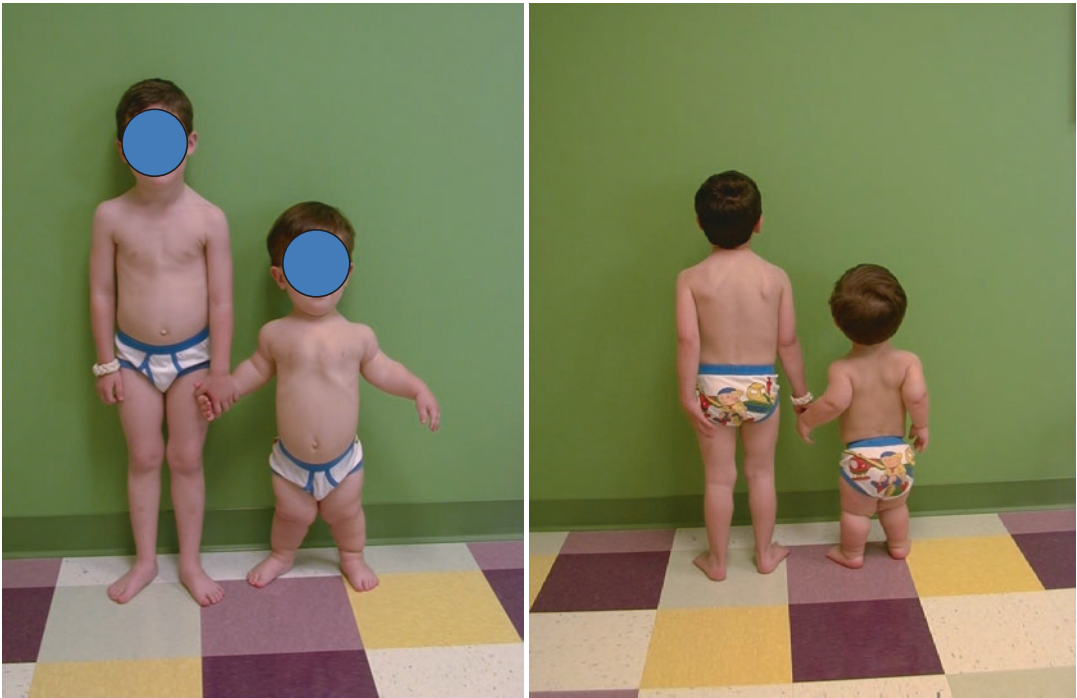formation. It is the most common form of short-limbed dwarfism. The prevalence rate is approximately 1 in 26,000 live births (Wright et al. 2000). The mutation of the gene which is involved in the growth and development of bone results in abnormal stunting of bone formation at the epiphyseal plates (Alman 2002; Shiang et al. 1994). The bones in the face, skull base, spine, hands, feet, and proximal long bones, such as the humerus and femur, are especially affected resulting in characteristic features involving these structures (Fig. 11.8) (Alman 2002; Poseti 1988). Hydrocephalus, upper cervical spinal cord compression, and spinal stenosis are three neurological problems seen in achondroplasts (Park et al. 2003). The spinal manifestations of achondroplasia will be the primary focus of this section.

Abnormal development of the bones of the skull base results in abnormalities of the foramen magnum, posterior fossa, and brain stem. These abnormalities contribute to compression at the cervicomedullary junction. The diameter of the foramen magnum is significantly decreased in achondroplasia leading to compression of the upper cervical spinal cord and distal medulla (Schnuerer et al. 2001). The foramen magnum is also displaced anteriorly resulting in a shallow posterior fossa. As a result, the brainstem is displaced upward and posteriorly, simulating hyperextension of the neck. The compression on the upper cervical spinal cord is exacerbated further because it is often stretched over the edge of the occipital bone (Kokoska et al. 2001; Kopits 1988).

### 11.6.1 Cervicomedullary Compression

Cervicomedullary compression resulting from foramen magnum insufficiency is usually identified in young achondroplastic patients and is a common cause of early morbidity and mortality in this patient population. It is also thought to be a contributing factor in the hypotonicity and motor developmental delay common in achondroplastic infants. The manifestations of this





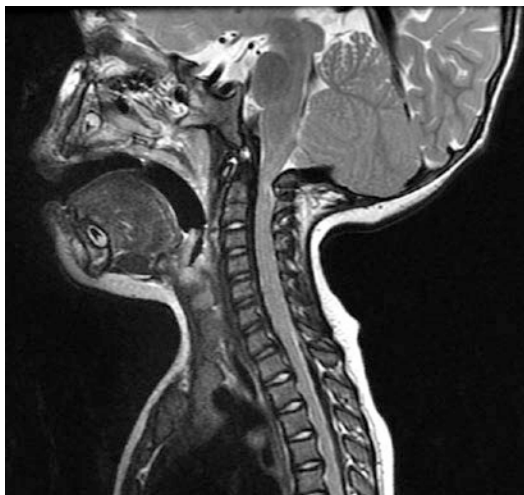
**Fig. 11.8** Twins, one with achondroplasia. Notice the classic physical features of achondroplasia

chronic neurological compression can be wide ranging. Patients may be asymptomatic initially but may develop signs and symptoms of upper spinal cord compression, including paresthesias and paresis, which can be progressive, even leading to quadriplegia. Signs of myelopathy including hyperreflexia and clonus may be evident even in the patient who is apparently asymptomatic. Symptoms such as spastic quadriparesis may not manifest until adulthood in patients with mild, chronic compression. Respiratory manifestations such as hypoventilation and apnea may also occur because of medullary compression. Simple extension of the neck can cause acute compression of the spinal cord at the cervicomedullary junction which could lead to sudden death of the achondroplastic infant (Hunter et al. 1998; Hurko et al. 1988; Morgan and Young 1980; Reid et al. 1988). The foramen magnum eventually increases in size as the child grows, easing the compression at the cervicomedullary junction (Rimoin 1988).

Radiographic evaluation should be undertaken if there is any question of cervicomedullary compromise. Computed tomography (CT) can provide

detailed imaging of the bony architecture of the skull base, foramen magnum, and upper cervical spinal column. Measurements of the foramen magnum can be taken from these scans to determine the degree of stenosis. Magnetic resonance imaging (MRI) provides information on the soft tissue structures including the brain stem and upper cervical spinal cord. Compression of these structures is evident with this study and changes within the upper cervical spinal cord can be identified, including atrophy and abnormal signal within the spinal cord itself (Fig. 11.9) (Hurko et al. 1988). Any patient who exhibits respiratory abnormalities should undergo a thorough evaluation to determine if there is a neurologic component to their respiratory dysfunction. Additional studies which may be helpful in evaluation of these patients include somatosensory evoked potentials to evaluate brain stem and spinal cord dysfunction and sleep apnea studies to rule out central versus obstructive apnea (Hurko et al. 1988; Reid et al. 1988).

Caution should be exercised in positioning the achondroplastic infant until better control of the head and neck muscles develops. Any position or



**Fig. 11.9** MRI of patient with achondroplasia. Note the upper cervical cord compression and spinal stenosis

activity that results in hyperextension of the neck could cause additional impingement of the spinal cord and distal medulla at the craniocervical juncture. Sitting or standing postures without adequate support of the neck and head should be avoided, as well as the use of bouncing type seats (Hurko et al. 1988).

### 11.6.2 Thoracolumbar Kyphosis and Lumbosacral Hyperlordosis

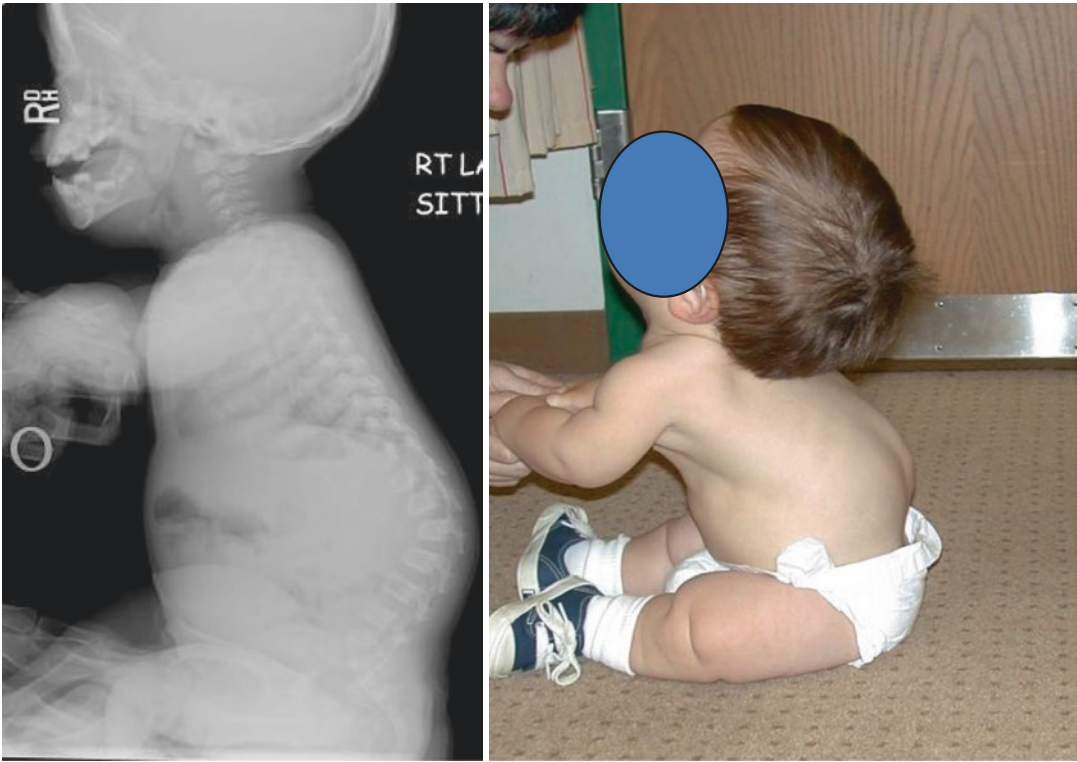
Abnormal alignment of the spine, including kyphosis in the thoracolumbar junction and hyperlordosis at the lumbosacral junction, is also frequently seen in this patient population and contributes to the congenital spinal stenosis common in achondroplasia. Kyphosis is very common in the achondroplastic child, with more than 90% of achondroplastic infants under 1 year of age exhibiting a kyphotic deformity (Pauli et al. 1997). Truncal hypotonicity, ligamentous laxity, the large size of the infant's head, flat chest, and protuberant abdomen are thought to be contributing factors to the development of this deformity. Abnormalities of the vertebral body, such as wedging at the apex of the kyphotic deformity, may be evident in some, but not all, of these

patients (Ain et al. 2004). Many children will have spontaneous improvement in this deformity once they begin to sit upright and walk; however, up to one-third of these patients will develop a progressive kyphosis into adulthood (Ain and Shirley 2004; Lonstein 1988; Pauli et al. 1997).

Hyperlordosis of the lumbosacral juncture, present in children with achondroplasia, becomes evident as the achondroplastic child begins to walk. The incidence of this deformity increases as these children reach adulthood. This deformity is not thought to be a primary disorder of the spine but rather occurs as a result of abnormal forward flexion of the pelvis and a horizontally oriented sacrum (Giglio et al. 1988; Kopits 1988).

Patients with thoracolumbar kyphosis and hyperlordosis of the lumbosacral spine have a very distinct posture. The kyphotic deformity is most notable while patients are in the seated position. The spine assumes a C shape and the patient appears to sit with a slumped posture (Reid et al. 1988). In the standing position, the kyphotic deformity becomes much less noticeable, but exaggeration of the lordotic curve becomes evident. Plain, lateral view x-rays illustrate these abnormalities well (Fig. 11.10).

Parents of achondroplastic children should be instructed to avoid having the child sit in an unsupported position until truncal hypotonia improves. The back should be supported utilizing counter-pressure with the hand when the child is held, and only hard-backed seating devices should be used. Periodic radiographic follow-up is important during this time to assess for continued progression of the kyphosis. If the kyphosis is determined to progress or if vertebral body wedging is evident, then bracing utilizing a firm brace such as a thoracolumbosacral orthosis (TLSO) can be instituted (Kopits 1988; Pauli et al. 1997). In many patients, the kyphotic deformity will improve with these measures; however, approximately 11% of these patients will develop persistent and progressive kyphosis (Ain and Shirley 2004; Kopits 1988). In these cases, surgical intervention involving stabilization with fusion and instrumentation is often necessary. Surgery of this nature in the achondroplastic patient carries a significant risk of neurologic injury (Ain and Shirley 2004).



**Fig. 11.10** Lumbar kyphosis

### 11.6.3 Spinal Stenosis

The overall diameter of the spinal canal in achondroplastic patients is diminished as a result of abnormalities in the development of the bone of the spinal column.

Symptoms related to spinal stenosis below the cervicomedullary juncture usually do not become problematic until the late teens. In most cases, symptomatic spinal stenosis does not occur until later in adulthood with the average age of symptom onset occurring late in the third decade of life (Ain et al. 2000; Hunter et al. 1998; Hurko et al. 1988). Low back pain is a very common complaint in patients with achondroplasia. Neurogenic claudicatory-type symptoms are typical in patients with symptomatic spinal stenosis. These symptoms include pain, paresthesias, and weakness involving the lower extremities with walking. The symptoms are often relieved by rest, bending forward, or squatting. A typical scenario is the patient who must lean on a shopping cart in order to complete the task of grocery

shopping. The symptoms usually affect both lower extremities and can progress to the point where they are present even at rest. If the stenosis is severe and ongoing, neurologic changes including weakness, abnormal reflexes, spasticity, alterations in sensation and proprioception below the level of the stenosis, and bladder dysfunction may be present (Hurko et al. 1988).

Radiographic evaluation is warranted in any patient experiencing symptoms of spinal stenosis. Plain x-rays are often the first line of evaluation. These x-rays can determine if abnormalities of spinal alignment, degenerative changes such as the presence of osteophytes, degenerative disk disease, and abnormalities of the shape and configuration of the vertebral body complex are present. CT will provide a detailed evaluation of the bony structure of the spine. Myelogram is very useful in evaluating the spinal canal; however, performing the lumbar puncture necessary for the myelogram may prove difficult because of the anatomical changes of the spine in achondroplasia. Magnetic resonance imaging (MRI) provides very detailed

information about the soft tissue structures including the spinal cord, ligaments, and intervertebral disks (Morgan and Young 1980).

### 11.6.4 Conclusion

Achondroplasia is a complex genetic disorder involving bone and cartilage formation. The manifestations of this disorder result in abnormalities of the craniocervical juncture and the spine. These abnormalities can become problematic at any time throughout the achondroplast's lifespan; however, cervicomedullary insufficiency and abnormalities of spinal alignment, including thoracolumbar kyphosis and lumbosacral hyperlordosis, are most common in early childhood. Stenosis below the cervicomedullary juncture often does not become symptomatic until later into adulthood, but can begin to manifest in the teen years. Early recognition and treatment of these disorders is important to promote normal growth and development of the achondroplastic child.

## 11.7 Klippel-Feil Syndrome

Klippel-Feil syndrome (KFS) was first described in 1912 by Maurice Klippel and Andre Feil (Sullivan and O'Donoghue 2005). This syndrome is a rare congenital disorder that affects the spine as well as many other body systems. This disorder is characterized by "the congenital fusion of any two of the seven cervical vertebrae" (Sullivan and O'Donoghue 2005). The resulting fusion is caused by a failure of the normal division of the cervical somites vertebrae during early fetal development. Patients with Klippel-Feil syndrome present with a triad of symptoms: short neck, low hairline at the back of the head, and restricted mobility of the upper spine (Fig. 11.2).

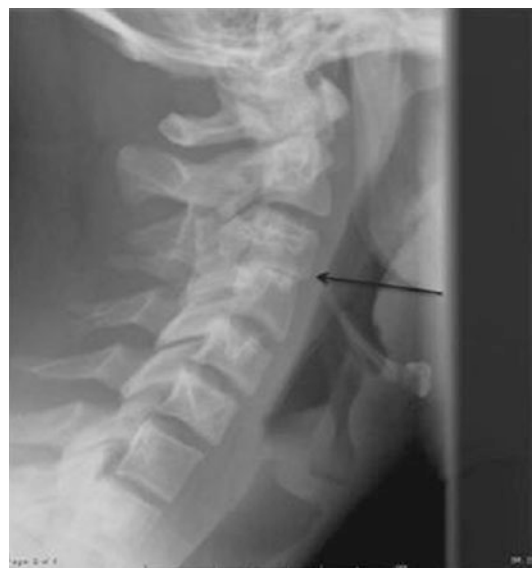### 11.7.1 Diagnosis

Diagnosis is based on clinical presentation and radiographic exam. The clinical presentation varies because of the number of associated syndromes and anomalies that can occur. Associated abnor-

malities may include scoliosis, spina bifida, anomalies of the kidneys and the ribs, cleft palate, respiratory problems, and heart malformations. The disorder also may be associated with abnormalities of the head and face, skeleton, sex organs, muscles, brain and spinal cord, arms, legs, and fingers (Curcione and Mackenzie 1995). Careful evaluation is essential as some associated anomalies may be fatal if not recognized and treated.

### 11.7.2 Radiographic Evaluation

Anteroposterior (AP) and lateral views of the cervical spine are done to determine the presence of anomalies. Flexion-extension radiographs should be done if instability or anomalies are suspected or if two fused segments are separated by an open segment (Fig. 11.11). AP and lateral chest radiographs may be done to rule out rib fusions and cardiac involvement. CT scans of the entire spine are useful to determine associated abnormalities. MRI scans are indicated in patients with neurological deficits. These scans may reveal cord compression, spinal stenosis, and central nervous system anomalies such as syringomyelia. Renal ultrasounds are used to determine renal involvement, and an intravenous pyelography is done to delineate any abnormality found on ultrasound.



**Fig. 11.11** Fused segment of Klippel-Feil syndrome (arrow)



### 11.7.3 Treatment

Treatment for KFS is focused on relieving associated symptoms. Medical treatment may involve a wide variety of specialists depending on which anomalies are present. A patient with KFS may be seen by a cardiologist, audiologist, and urologist among others. Physical therapy may be useful. Because the spinal anomalies are often progressive in nature, surgical intervention is often necessary to relieve cervical or craniocervical instability and constriction of the spinal cord and to correct scoliosis. Depending on the type of surgery needed, neurosurgery, orthopedic surgery, or both may be necessary to correct the anomalies.

KFS may be found at any stage of life. This syndrome may be progressive and may involve other specialty care. As with the previously discussed syndromes and skeletal dysplasias, it is important to educate the parents of possible related anomalies and symptoms associated with those anomalies. Early diagnosis, consistent follow-up, and multidisciplinary care are important for positive outcomes.

## 11.8 Mucopolysaccharide Disorders

Mucopolysaccharide disorders (MPS) were first identified in 1917 (website MPS Society). These inherited disorders are errors of metabolism that are progressive in nature and may not become

apparent until later in childhood. The disorder may also be referred to as lysosomal storage disorder (LSD). The lysosomal enzyme normally found in each cell is needed to degrade and recycle glycosaminoglycans. If these enzymes are not degraded and recycled, they accumulate within the cells causing the disease process with progressive damage to the body (Vogel et al. 2004). People affected with these disorders either do not produce enough of any one of the 12 identified enzymes that normally degrade and recycle the sugar chains into proteins, or the enzymes do not work correctly to produce the enzyme necessary for degradation.

### 11.8.1 Inheritance

The nature of the disease has an autosomal-recessive inheritance and an abnormal gene is inherited from each parent. The odds of receiving the disorder if both parents are affected are one out of every four pregnancies. The unaffected child of parents with the gene has two in three risks of being a carrier and a one in three chances of being a noncarrier of the disorder. The sole exception is MPS type II (Hunter syndrome) as this is X-linked and recessive inheritance. The Hunter gene is carried by a normal female and there is a 50/50 chance of transmission to each of the male offspring. Estimates have the occurrence in population at 1 birth in 31,000 (NCBI website, MPS Society website) (Table 11.1).

**Table 11.1** Syndromes associated with MPS

Type/syndrome	Disease name	Deficiency
MPS I	Hurler/Hurler-Scheie syndrome	$\alpha$ -L-Iduronidase
MPS II	Hunter syndrome	Iduronate sulfatase
MPS III A	Sanfilippo syndrome	Heparan-N-sulfatase
MPS III B	Sanfilippo syndrome	$\alpha$ -N-Acetylglucosaminidase
MPS III C	Sanfilippo syndrome	Acetyl CoA: $\alpha$ -glycosaminide
MPS III D	Sanfilippo syndrome	N-Acetylglucosamine-6-sulfatase
MPS IV A	Morquio syndrome	Glactose-6-sulfatase
MPS IV B	Morquio syndrome	Galactosidase
MPS VI	Maroteaux-Lamy syndrome	N-Acetylgalactosamine-4-sulfatase
MPS VII	Sly syndrome	Glucuronidase
MPS IX		Hyaluronidase
ML II	I-Cell	N-acetylglucosamine-1-phosphotransferase
ML III	Pseudo-Hurler polydystrophy	N-acetylglucosamine-1-phosphotransferase

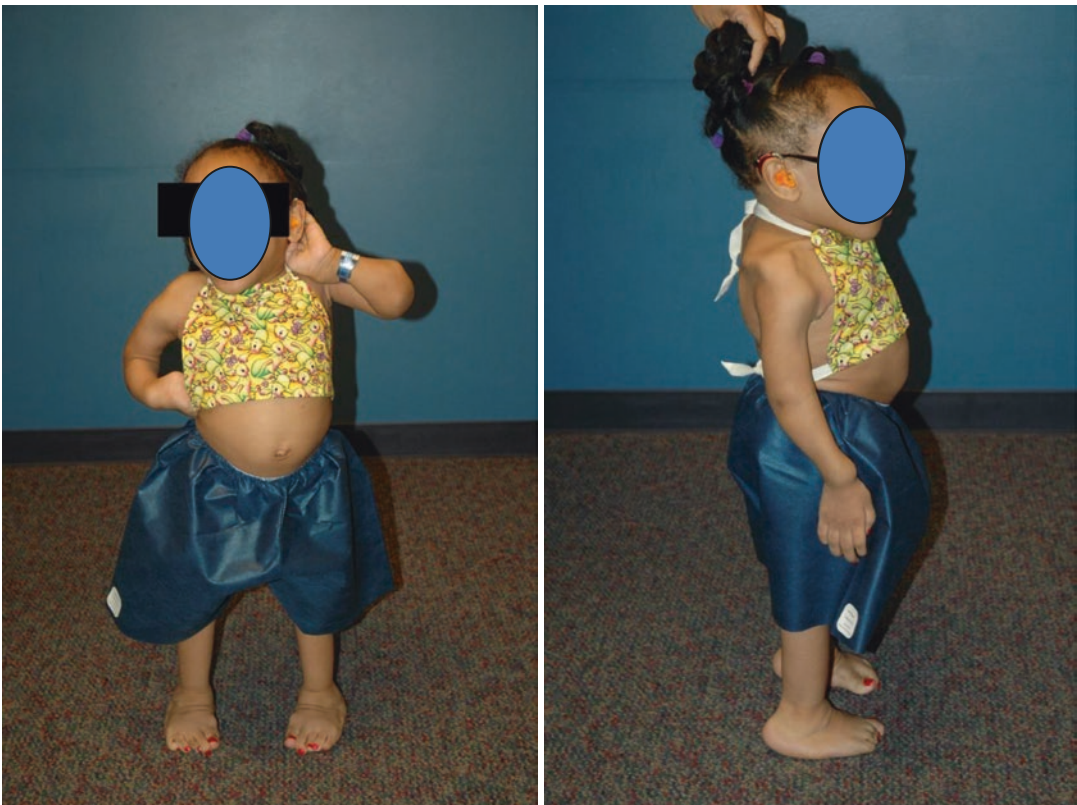

### 11.8.1.1 Characteristics

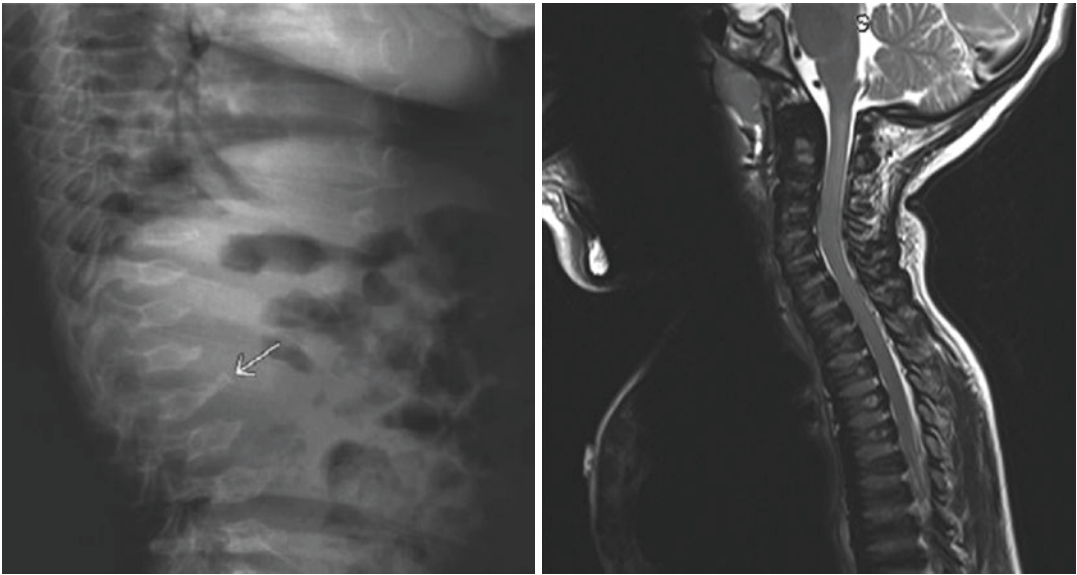The children with MPS may appear normal at birth and develop normally for the first few years of life. The slow progression of this disorder is related to the gradual buildup of metabolites. Usually, the symptoms that prompt further clinical investigation are the repeated upper respiratory infections, colds, runny noses, and ear infections (MPS Society website). Clinical features may produce neurological complications through impaired signals as damage occurs to neurons affecting motor function and pain receptors. Children with MPS often have mental retardation, hyperactivity, depression, and pain, and their growth and development may be stunted (Fig. 11.12). All children with MPS have coarse facial features and skeletal involvement, such as skeletal dysplasia (Cleary and Wraith 1995; Menezes et al. 2001; Neufeld and Muenzer 2001; Scheie et al. 1962). Some may have an absence of the odontoid process or odontoideum. They may have a thoracic gibbus deformity, a form of

structural kyphosis. The curvature is not smooth, as the posterior curve is angled sharply, and results in a humpback that is more prominent on forward bend.

Morquio syndrome, MPS type IV, is another disorder that involves skeletal and spinal problems. Death commonly occurs by age 7 years from hypoxia secondary to a cervical myelopathy and subsequent effects upon the respiratory system (Cleary and Wraith 1995; Menezes 1999). Atlanto-axial instability, scoliosis, and kyphosis of the thoracolumbar spine are problems. There is also a characteristic flattening of the vertebrae with a flame-shaped pattern of ossification (Fig. 11.13). Other characteristics of MPS may include general ligamentous laxity, thought to contribute to atlanto-axial subluxation (Menezes et al. 2001); corneal clouding; speech or hearing impairment; chronic runny nose; hernias; heart disease; development of hydrocephalus; stiff joints; splenomegaly; liver enlargement; diarrhea; and shortened life expectancy. Symptoms appear as the storage



**Fig. 11.12** 13-year-old female with mucopolysaccharide disorder, Morquio syndrome



**Fig. 11.13** Flame-shaped vertebrae (*arrow*) with spinal cord narrowing on MRI characteristic of MPS in Morquio syndrome

of the enzymes increases. The projected life expectancy of children with MPS is 10–20 years (Cleary and Wraith 1995; Neufeld and Muenzer 2001; Scheie et al. 1962; MPS Society website).

### 11.8.2 Diagnosis

The diagnosis of MPS may be made through clinical examination, and urine and tissue testing. Genetic counseling and reviewing family history for at least three generations may assist couples in determining if they are carrying the mutated gene responsible for the development of the disorders (Clarke 2005). Prenatal diagnosis utilizing amniocentesis and chorionic villus sampling at 14–17 weeks gestation should be done to determine if the fetus has the defective gene or is affected by the disorder. Clinical signs and symptoms do not demonstrate a diagnosis. Further definitive testing such as enzyme-specific assays for alpha-L-iduronidase, peripheral blood leukocytes, and plasma or cultured fibroblasts should be ordered (Hall et al. 1978; Neufeld and Muenzer 1995, 2001). For an infant suspected of having an inborn error of metabolism, laboratory studies should include complete blood counts, urinalysis, capil-

lary blood gases, electrolytes, glucose, ammonia, urine-reducing substances, urine ketones, plasma and urine amino acids (quantitative), urine organic acids, and plasma lactate (Burton 1998).

### 11.8.3 Treatment

Currently there is not a cure for MPS; therefore, treatment is focused on relieving and treating symptoms as they arise. The FDA has approved several medications for use in MPS. Some of the enzyme replacement therapies are specific for a particular disease: Aldurazyme (Iaronidase) in 2003 and Naglazyme in 2005. These enzyme replacement therapies for MPS types I and IV are proving to be useful in the reduction of pain and non-neurological symptoms of MPS. They replace the deficient enzymes and are given IV once a week for life. Bone marrow transplant has been utilized to replace lost enzymes; however, some of the children have heart disease due to the syndrome and cannot withstand the chemotherapy required for the transplantation of bone marrow. Bone marrow transplantation, along with umbilical cord blood transplants, is showing limited success with improved survival.

## 11.9 Traumatic Spinal Cord

### 11.9.1 Pathophysiology

#### 11.9.1.1 The Pediatric Spinal Column

The immature pediatric spinal column has unique features that increase the spinal cord's susceptibility to injury without obvious evidence of abnormality in alignment or bony integrity. Among those are a higher fulcrum of cervical movement, a larger head to body ratio, wedge-shaped vertebral bodies, underdeveloped unciniate processes, increased elastic interspinous ligaments, and underdeveloped neck and paraspinous muscles. Those anatomic features increase the mobility of the pediatric spinal column, causing it to be hypermobile and more susceptible to flexion and extension type injuries.

Pediatric spinal trauma patients can be divided into two unique groups. The first group is from birth to 8 years of age. The spinal anatomy of children becomes more similar to adults by age 8 but may not reach full maturity until age 16–18 years (Bosch et al. 2002; Ergun and Oder 2003). As mentioned, there are specific anatomic differences in the younger age group. First, the fulcrum of cervical movement is higher (C2–C3), as opposed to the adult level (C5–C6) (Grabb 2008). Accordingly, there is a high percentage of cervical spine injuries between occiput and C3 in children under 8 years of age. In a study of 227 children with spinal cord injury (SCI), 87% of those less than 8 years old had an injury C3 or higher (Khanna and El-Khoury 2006).

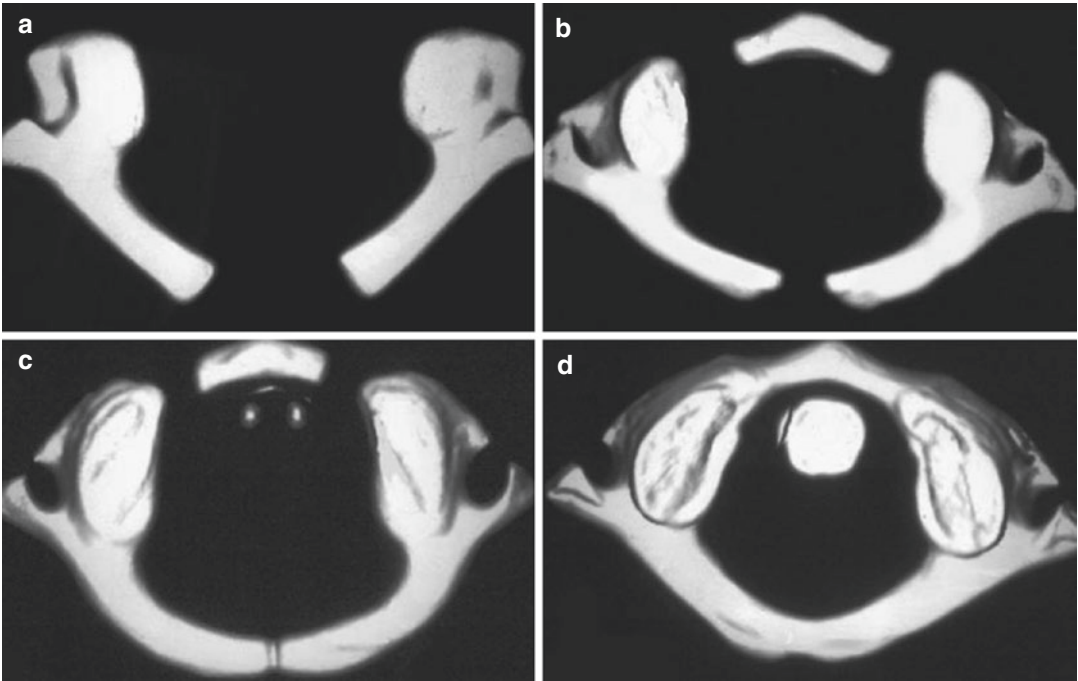
The disproportionate size of the head also contributes to the risk of spinal cord injury in children under age 9 (Grabb 2008). The development of head to body ratio is illustrated in Fig. 1.1 in the Assessment chapter. Additionally, the large head is not well supported because the neck muscles are underdeveloped in the younger child. Those factors put the young child at greater risk for flexion-extension injuries to the C-spine.

The spine is also hypermobile related to both the laxity of the intraspinal ligaments and the underdevelopment of the paraspinous musculature (Carreon et al. 2004; Lang and Bernardo 1993; Pang et al. 1982). In comparison, the spinal

cord is much less elastic. This accounts for higher incidence of subluxation without fractures and spinal cord injury without radiographic abnormality (SCIWORA) in children.

Pediatric bony development of long bones includes growth plates called epiphyses and ossification centers (which are the areas where cartilage is turning to bone). Similar to long bones, the spinal column also has 11 growth centers known as synchondroses and ossification centers. In the upper cervical spine, C1 (Atlas) forms from three primary ossification centers: the anterior arch and two neural arches (Fig. 11.14). These don't fuse until between 3 and 6 years of age. Similar to ossification centers in long bones being a point of weakness because they are not hard bone yet, ossification centers in the spine are also a weak point for trauma. C2 (axis) develops from five primary ossification centers. The body of the peg-like odontoid (also known as dens) and two neural arches typically fuse to the bone between 3 and 6 years of age as well. This makes odontoid injuries in younger children much more prevalent due to the weakness through this ossification center (Khanna and El-Khoury 2006).

Other anatomic features that increase the mobility of the pediatric spine involve the shape of certain parts of the spinal column. The vertebral bodies are wedge-shaped in children, allowing for slippage anteriorly during flexion. With age, the vertebral bodies mature. They evolve through four basic types: type I, oval immature; type II, rounded upper corner; type III, anterior wedging; and type IV, rectangular, more mature (Eubanks et al. 2006) (Fig. 11.15). Also, the facet joints are much more horizontally oriented in the pediatric spine in comparison to the adult spine. This again allows for translation of the vertebral bodies as the spine is flexed forward or extended back. Further, the unciniate processes, which serve to limit spinal mobility at C3–C7 and T1, particularly as to rotational and lateral movement, are underdeveloped in children under age 10 (Brockmeyer 2006). By contrast, in the adult spine, they are hooklike, projecting upward and articulating with the vertebral level above.



**Fig. 11.14** Axial reconstructed CT images of C1 (atlas) (a) 1 month old: ossification centers of both the neural arches are present, but the ossification center for the anterior arch is not yet seen (because it is still cartilage and not turned to bone). (b) 1-year-old: ossification centers of the anterior arch and both neural arches are seen but are still

open and not yet fused. (c) 3-year-old: the neural arches in the back are almost fused, while the growth centers (synchondroses) of the anterior arch are still open. (d) 6-year-old: anterior arch and neural arches are completely fused (Khanna and El-Khoury 2006)

<p><b>Type I</b> <i>immature, oval</i></p>	
<p><b>Type II</b> <i>rounded upper corner</i></p>	
<p><b>Type III</b> <i>anterior wedging</i></p>	
<p><b>Type IV</b> <i>mature rectangular</i></p>	

**Fig. 11.15** Vertebral shapes (Eubanks et al. 2006)



## 11.10 Traumatic Spinal Cord Injuries

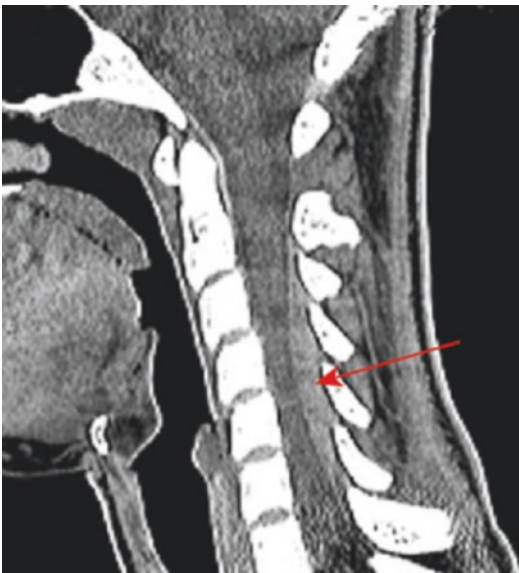
### 11.10.1 Etiology

Pediatric spine trauma is not common but can be catastrophic if misdiagnosed. Therefore, in the case of high-energy or polytrauma, a child should be assumed to have a spine injury until proven otherwise (Skaggs and Flynn 2006). Trauma from birth accounts for a high prevalence of spinal cord injury in children less than 2 years of age. For children who are 3 up to 8 years of age, common mechanisms include motor vehicle collisions, fall from heights, and abuse or non-accidental trauma. For the age group of 8 and older, additional mechanisms include sports-related injuries, diving, and violence, such as gunshot wounds (Cramer and Scherl 2004).

Traumatic injury to the spinal cord can result in contusion (bruising) or transection or hemisection (complete/partial cutting or tearing) of the cord. Epidural bleeding from trauma can result in cord compression (Fig. 11.16). Any injury to the cord can have a temporary or permanent effect on the functions of the body below the level of the

injury. The cord is less elastic than the pediatric spine. Studies of autopsies have shown that the infantile spinal column could be stretched up to 2 in. without disruption, yet the cord can sustain damage or even rupture at a quarter of an inch (Bosch et al. 2002; Dickman et al. 1991). Think of this like pulling on a rubber band. When stretched to the max, the band doesn't break at first; it frays and then breaks. When released, the rubber band remains frayed, permanently affected. This is similar to the spinal cord. When stretched it may not break, but the cord can be permanently damaged nonetheless. This elasticity of the spinal column compared to the cord helps explain the higher frequency of cord injury in the absence of bony injury (Khanna and El-Khoury 2006).

Injuries to the spinal column include vertebral fractures and/or dislocations, with or without related cord damage. Similar to other bony injuries in children, cervical fractures tend to be avulsions or growth plate separations. The synchondroses (growth centers) tend to be the weak links in the cervical spine (Khanna and El-Khoury 2008). The soft tissues of the spinal column, such as the blood vessels, intraspinal ligaments, and intervertebral disks, can also sustain traumatic injury.



**Fig. 11.16** MRI showing cord compression with epidural bleeding

### 11.10.2 Epidemiology

Less than 5% of all spinal injuries involve the pediatric patient (Cramer and Scherl 2004). Since the patient may be treated by neurosurgeons and/or orthopedic surgeons, the statistics vary on the number and types of injuries. The neurosurgeon often focuses on the neurologic components of the spinal cord, while the orthopedic surgeon focuses more on the bony injury. Although it is important that spinal cord injury (SCI) statistics be reviewed, the caregiver must be cognizant of these differences and what they may mean to the patient population being studied. Neurosurgery literature reports that 61% of pediatric spinal injuries are in the cervical region, 11% are in the thoracic region (T1–11), 14% are in the thoracolumbar region (T12–L1), and 14% occur in the



lumbar region (L2–S1) (Grabb 2008). Research reports that approximately 30% of traumatic SCI in pediatrics present as a trauma to the cord with no bony injury, also known as a SCIWORA (spinal cord injury without radiographic abnormality) (Cramer and Scherl 2004).

Traumatic SCIs are the fourth leading cause of death in the United States in all age groups (Vogel et al. 2004). These injuries are predominantly found in males in their late teens and early 1920s. In children under the age of 5, the incidence of females equals males. Before puberty, the unique physical and developmental characteristics of children predispose them to SCI from lap-belt injuries, injuries related to birth, child abuse, delayed onset of neurologic deficits, and high cervical injuries (Vogel et al. 2004). There is a high mortality associated with SCI, and a significant percentage of individuals with SCI will expire prior to reaching the hospital. The mortality rate for pediatric SCI is estimated to be 2.5 times greater than that for adults (Alden and Ellenbogen 2008). Survival is based on the severity and level of the neurologic injury. Quality of life and ability to function in society may be severely affected, especially in those patients who suffer a neurologic and/or motor deficit post SCI.

---

## 11.11 Injury Classifications

### 11.11.1 Spinal Cord Injury Without Radiographic Abnormality

#### 11.11.1.1 Symptomology

Spinal cord injury without radiographic abnormality (SCIWORA) is a syndrome of traumatic SCI without evidence of bony injury like fracture or dislocation on plain radiographs, computed tomography (CT), or myelogram (Dickman et al. 1991). This phenomenon was first described before the advent of magnetic resonance imaging (MRI). Now, MRI is finding abnormalities in some SCIWORA patients, such as ligamentous edema, central disk herniation, epidural hemorrhage, or injuries to the spinal cord itself. But there remain a significant number of patients with

normal MRIs. Up to two-thirds of patients diagnosed with SCIWORA are under age 8 (Alden and Ellenbogen 2008). It is rare to see SCI without bony abnormality in patients older than 16 years because of the anatomic and biomechanical differences of the spinal column (Pang 1982).

SCIWORA is most commonly seen in the cervical spine region, but it has also been documented in other areas of the spine (Cirak et al. 2004). Traumatic events such as the application of traction to the neonatal spinal column during delivery, child abuse, falls, sports injuries, or motor vehicle accidents may result in this SCI (Brown et al. 2001; Pang 1982). This injury may occur when the spinal column deforms elastically, stretching it beyond its limits. The spinal column then returns to its normal anatomic alignment without bony injury but with evidence of SCI. As previously discussed, the elasticity of the ligaments of the pediatric spine contributes to this laxity of the spinal column. Another injury that may occur without bony injury due to the elasticity of the spinal column is a concussive injury resulting from a transmission of kinetic energy or concussive force applied to the spine (Bosch et al. 2002; Dickman et al. 1991).

#### 11.11.1.2 Prognosis

The prognosis for recovery following a SCIWORA injury is dependent on the severity of injury at the time of presentation. Incomplete injuries have the best prognosis for a good recovery, whereas complete injuries have the worst prognosis (Bosch et al. 2002; Ergun and Oder 2003). In one study, external immobilization for 12 weeks resulted in complete recovery for 39% of the study population (90% pediatric), but no recovery in 44% (Alden and Ellenbogen 2008).

#### 11.11.2 C-Spine Injuries

In children, C-spine injuries occurring in the upper C-spine account for more than 60% of all spinal injuries (Greenberg 2001; Van de Pol et al. 2005). C-spine injuries may be caused by motorcycle crashes, pedestrian accidents, sports activities, bicycle accidents, falls, and motor vehicle

accidents. It is estimated that 25–50% of all SCIs have a related severe head injury (Van de Pol et al. 2005). Whenever a head injury is suspected, both the rescue team and hospital personnel should have a high diagnostic suspicion for C-spine injury, as the risk of C-spine injuries is 8.5 times greater with a head injury than without (Dibsie 1998; Morris and McCoy 2004). C-spine injuries, which alter or sever the communication between the brain and sympathetic nervous system in the cord, may lead to hypotension, bradycardia, and/or death (Mattera 1998). The most common level of injury will change with the age of the child (Table 11.2). This pattern generally corresponds with the location of the fulcrum of cervical movement at various ages. The most important intervention provided by the rescue team and hospital personnel is stabilization of the spine or C-spine precautions. Stabilization of the spine at the scene of the accident has been shown to reduce the extent of complete SCIs by 10% (Dibsie 1998; Mattera 1998).

### 11.11.2.1 Diagnosis

In the initial evaluation of a pediatric trauma victim, it is important to first assess the CABs (chest compressions, *airway*, and *breathing*) (2010, American Heart Association & International Liaison Committee on Resuscitation). Then obtain a thorough past medical history, including any history of trauma, and do a thorough physical exam. Eight key risk factors associated with your physical exam include (1) unconscious patient;

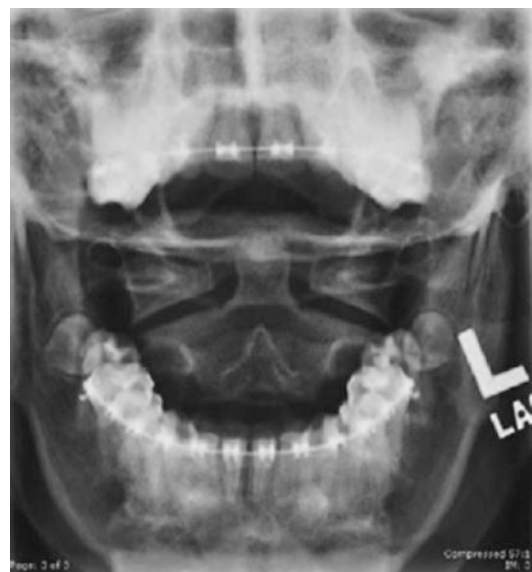(2) complaints of neck pain; (3) focal neck tenderness; (4) abnormal neurologic findings; (5) reports on transient neurologic symptoms, such as weakness, paresthesias, or a burning sensation; (6) physical signs of neck trauma, such as bruising, abrasions, deformity, swelling, or tenderness; (7) significant trauma to head or face; and (8) an inconsolable child (Eubanks et al. 2006). Children with any of these listed risk factors should be considered to have a potential cervical spine injury and be treated with immobilization. A meticulous neurologic exam is important to help determine the possible level of injury and other differential diagnosis (Skaggs and Flynn 2006). In addition, a child who presents with cardiorespiratory instability or arrest may have a high cervical injury and should be evaluated accordingly (Eubanks et al. 2006).

### 11.11.2.2 Radiographic Evaluation

All children with suspected cervical spine injury warrant radiographic evaluation. This always begins with plain radiographs (with the patient in a cervical collar) consisting of the anteroposterior view (AP) and cross table lateral of the cervical spine. This can be combined with an odontoid view (open mouth view) if the child is old enough to cooperate (Fig. 11.17). CAT scan (CT) should

**Table 11.2** Age-related injuries and symptoms (Adapted from Dziurzynski (2005))

Age	Level of injury	Possible symptoms
All-age children	Occiput-C2	Respiratory arrest, quadriplegia
Infants and toddlers	C1–C2 or C2–C3	Respiratory arrest, quadriplegia
Children 3–8 years	C3–C5	Respiratory arrest, quadriplegia
Children 9–15 years	C4–C7	High injuries: respiratory arrest, quadriplegia
		Low injuries: some spontaneous respirations and some upper extremity movement may persist



**Fig. 11.17** Open-mouth view of odontoid

be utilized in children who are too young to obtain an odontoid view or in any child who is also having a head CT (Eubanks et al. 2006). If the plain radiographs reveal abnormalities, further investigation utilizing CT and/or MRI is warranted (Pediatric Orthopaedic Society of North America 2006). As mentioned earlier, plain radiographs may appear normal in young children with a cervical spine injury, i.e., SCIWORA. This is why the physical exam becomes so important in children, as children with a spinal cord injury will have pain on physical exam. Any child with a positive physical exam and normal plain films warrants cervical spine immobilization (Pediatric Orthopaedic Society of North America 2006).

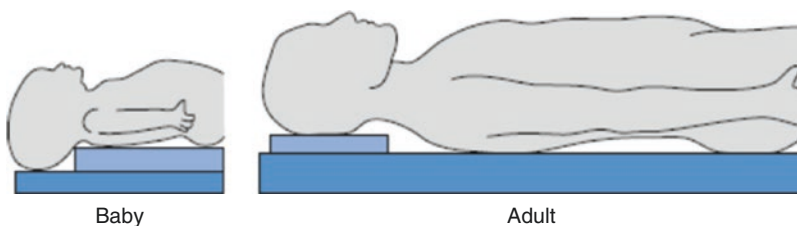
### 11.11.2.3 Cervical Spine Precautions

Cervical spine precautions (stabilization) help prevent further spinal cord and vertebral column damage as well as ensure an adequate airway, ventilation, and perfusion. Immobilization of the spine in the neutral position is the goal of this treatment. To achieve neutral positioning in children, you must take note and accommodate for physical differences due to age and physical maturity. For children under the age of 8 years, one must consider that the head is larger than the torso. It has been shown that the large head and relatively small chest in children force the head and neck into a position of kyphosis. This positioning in flexion may place the immobilized child at risk for further injury. Thus, it is important that backboards with an occipital recess or a double mattress pad under the body be used to raise the torso and assist in lifting the neck out of forward flexion (Eubanks et al. 2006) (Fig. 11.18). Cervical spine immobilization should

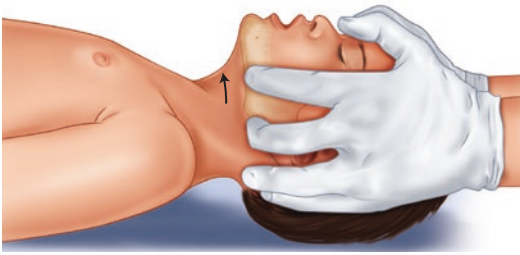
continue throughout the evaluation process. Correct immobilization includes a combination of a hard cervical collar, appropriate backboard, head and neck blocks, and tape to fix the head (Eubanks et al. 2006).

It is important to maintain a safe airway through the spine immobilization process. The “jaw thrust method” is used to open the airway while maintaining cervical spine stabilization. This technique will place the patient’s head in the recommended position for simultaneous airway opening (American Heart Association 2002) (Fig. 11.19). Another consideration is intubation versus bag-mask ventilation. Although intubation is the preferred method of airway management, not all providers are skilled in this area (American Heart Association 2000). Children can be ventilated easily and for extended periods of time with a bag-mask, especially if a provider skilled in intubation is not readily available (Proctor 2002). A randomized study by Turkstra et al. in 2005 demonstrated, under fluoroscopy, that normal patients who were positioned utilizing cervical spine stabilization demonstrated less cervical spine motion during bag-mask ventilation than during intubation (Turkstra et al. 2005). These findings help support pediatric advanced life support teaching that only providers experienced in intubation of pediatric trauma victims should perform this procedure in the field (American Heart Association 2000).

Clearing the cervical spine is an important step to avoid missed or delayed diagnosis. First, a physician must rule out any bony or ligamentous injury that may cause instability. Instability that is missed could be disastrous and cause additional cervical cord or nerve root injury. Utilization of a multidisciplinary team can



**Fig. 11.18** Spinal alignment (Reprinted with permission from Hadley (2002))



**Fig. 11.19** Jaw thrust method, airway management (Reprinted with permission from Dziurzynski et al. (2005))

effectively support rapid clearance of the cervical spine. Literature shows on average clearance of a cervical spine takes around 7.5 h in the nonintubated patients and 19.4 h in the intubated child (Eubanks et al. 2006).

There is no national protocol for clearing a pediatric cervical spine. However, there are adult protocols that provide guidelines. It is important with children to focus more closely on clinical assessment than on radiographic clearance, as it is not desirable to expose infants and children to unnecessary radiation. On the other hand, failure to use imaging can lead to missed diagnoses.

In 2001, a study by Viccellio et al. suggested that cervical spine imaging in children could be reduced by approximately 20%, if the five low-risk criteria in the National Emergency X-Radiography Utilization Study (NEXUS) decision instrument were utilized to clear the C-spine (Viccellio et al. 2001). While the study urged caution in applying the decision instrument to individual patients, a number of centers adopted it. However, later research found that of 539 children cleared by the NEXUS criteria without radiographs, 90 cervical spine injuries were missed, and 58 of those were in children younger than 8 years of age (American College of Emergency Physicians 2008). That data was compiled in a study that identified eight risk factors associated with C-spine injury: altered mental status, focal neurologic findings, neck pain, torticollis, substantial torso injury, predisposing conditions, diving, and high-risk motor vehicle crash (Leonard et al. 2011). Further research is necessary to refine and validate that eight-variable model. Consequently, it is not recom-

mended that either the NEXUS criteria or the eight-variable model be used to clear the C-spine unless the patient is awake, alert, and able to effectively communicate pain.

Clearing the C-spine in the conscious pediatric patient starts with systematically reviewing any plain radiographs that may have been taken to identify any abnormalities. Again, the child's level of consciousness and developmental age must allow for the appropriate communication of pain. The cervical spine exam is again repeated in the hard collar looking for pain, visible deformity, or notable muscle spasms. If this exam is normal, the physician will remove the collar and repeat the exam. The physician will have the patient perform gentle active range of motion focusing on flexion, extension, and lateral rotation. If this exam is normal, the cervical spine precautions may be cleared and the collar removed. For the child who complains of cervical tenderness on exam, the hard collar is continued and a repeat exam along with further imaging (MRI) may be used to clear the cervical spine (Eubanks et al. 2006).

On the unconscious patient, radiographs and a CT of the cervical spine follow immediate immobilization and clinical examination. A head CT is often combined with cervical spine scans on a trauma victim. The patient may be taken off back board (still in spine precautions and rigid collar) when both the plain films and CT demonstrate no abnormalities. They are then kept on spine precautions and in rigid collar with close neurologic exam for the next 24 h. If the patient regains normal mental status, the conscious pathway listed above may be followed. If the patient remains unconscious, an MRI is then performed. Normal MRI findings with unremarkable plain films and CT scan permit cervical spine clearance (Eubanks et al. 2006).

#### 11.11.2.4 Common Pediatric Cervical Spine Injuries

As stated prior, less than 5% of all spine injuries involve children. The most common etiology in all age groups is motor vehicle trauma, while other typical causes in children include falls from heights, sports-related injuries, diving, and

non-accidental trauma (Khanna and El-Khoury 2006). The more frequent types of cervical spine injuries in children include atlanto-occipital dislocation (AOD), atlanto-axial (AA) rotatory fixation, atlas fracture, odontoid (dens) injury, and compression fractures. Mortality with cervical spine injury in pediatrics is higher with children than in adults. In a study of 216 children with spinal injuries, a mortality rate of 28% was reported when compared with a reported 11% in adults. In contrast, when looking at head injuries, mortality is less in children than with adults (Khanna and El-Khoury 2006).

### 11.11.3 Atlanto-Occipital Dislocation (AOD)

#### 11.11.3.1 Pathophysiology

The axial (load bearing) strength of the craniovertebral junction is provided by an intricate system of ligaments at the level of the superior facets of the atlas. This system is compiled of the anterior and posterior atlanto-occipital membranes and two lateral atlanto-occipital ligaments. The atlanto-occipital ligamentous structure supplies the majority of the strength at the craniovertebral junction. The atlas ring is seated within a ligamentous complex joining the occiput to the axis. This complex consists of the tectorial membrane, the anterior longitudinal ligament, and the uncial ligament. Stability is also supported by the apical dental ligament and the paired alar ligament (Kenter et al. 2001). These structures are underdeveloped in children thus less resistant to translational forces. In AOD, the force through the spine causes a disruption through the stabilizing ligaments and causes the occiput of the skull to dislocate from the atlanto-axial joint of the cervical spine. This injury is commonly seen in high-energy traumas such as motor vehicle accidents or falls (Beaty and Kasser 2010).

This dislocation of the skull from the spine was once thought to be rare and often these children were found dead on arrival. Increased awareness of this injury in pediatric patients along with prompt cervical spine immobilization

and rapid transport has increased the survival rate of this injury.

#### 11.11.3.2 Classifications

Three types of AOD have been described and account for 85% of the cases:

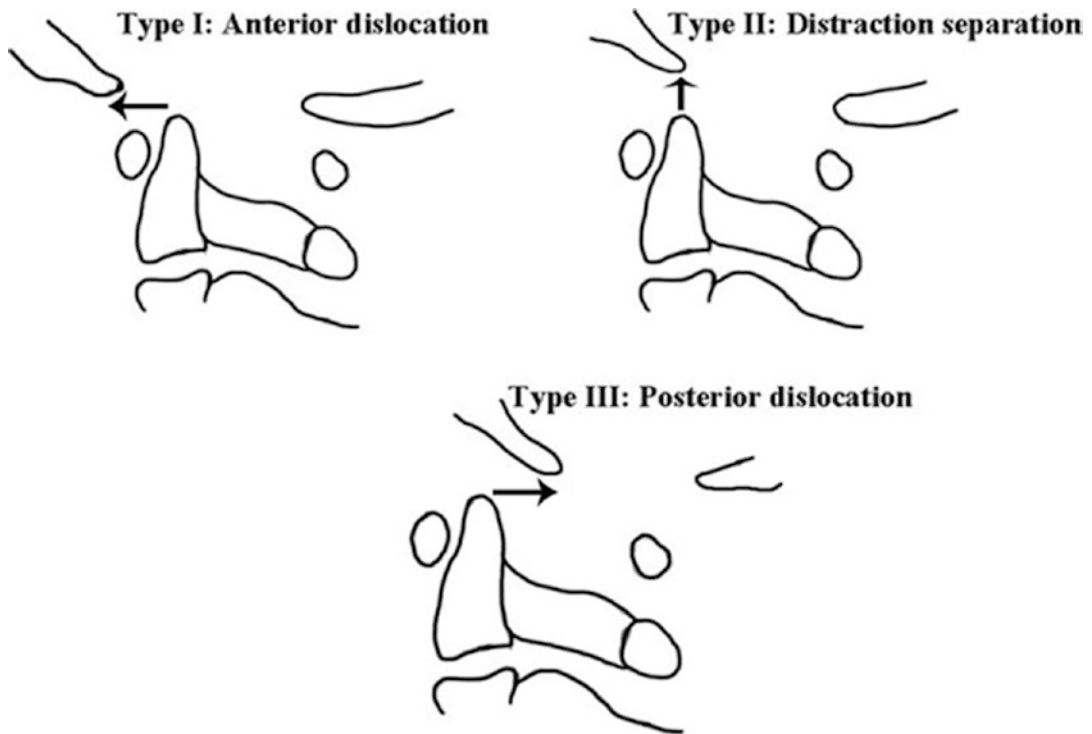
- Type I: anterior dislocation with the occiput displaced ventrally to the atlas (40% of cases)
- Type II: longitudinal dislocation (40% of cases); most unstable (Fig. 11.20)
- Type III: posterior dislocation of the occiput (5% of cases)
- The remaining 15% consists of other types of nonclassified, rotational dislocations (Van de Pol et al. 2005).

In a study of 14 patients diagnosed with AOD, the mean age at the time of injury was around 5 years. The most common mechanism of injury was a motor vehicle accident in which the victim was a passenger. Eleven (78%) had an associated brain injury, and nearly half sustained a spinal cord injury. In this population of patients, eight patients (57%) had a type II (longitudinal) atlanto-occipital dislocation, five (35%) had a type I (anterior) dislocation, and one (7%) had a type III (posterior) dislocation. This study demonstrates that patients with atlanto-occipital dislocation may survive the initial trauma but still have a high percentage of associated injuries, and many have neurological impairment. (Astur et al. 2013).

#### 11.11.3.3 Diagnosis

Initial symptoms of an AOD may be masked by other distracting injuries. Diagnosis is difficult because this is a ligamentous injury. Common red flags on the physical exam may include the following: cranial nerve dysfunction, vomiting, headache, torticollis, and motor or sensory deficits. Similar to other cervical spine injuries, there is a high association of this injury with head trauma and facial injuries. If the dislocation is severe, the child may have brain stem symptoms such as ataxia and vertigo and have difficulty being ventilated (Beaty and Kasser 2010).





**Fig. 11.20** Three types of AOD (Hosalkar et al. 2005) | spine

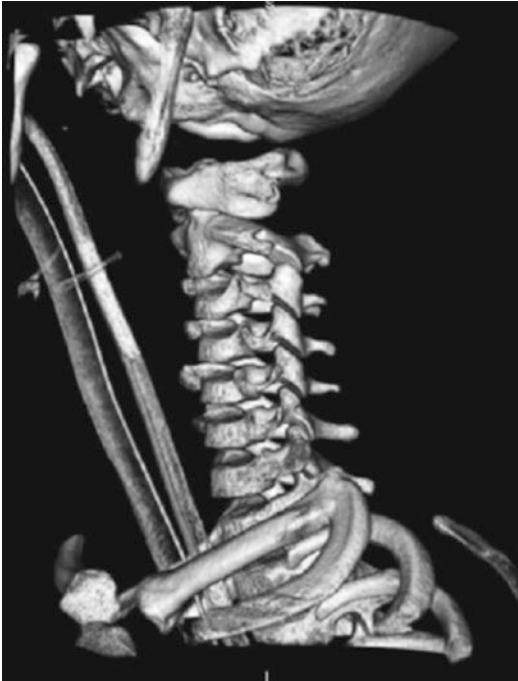#### 11.11.3.4 Radiographic Evaluation

There has been much discussion about which radiographic test and which cervical angle measurement techniques should be used to determine AOD. In 1999, Berne et al. demonstrated that complete cervical helical CT scans, in addition to the routine radiographs, should be used when a C-spine injury is suspected in a patient with multiple severe injuries (Berne et al. 1999). This study also concluded that complete cervical helical (spiral) CT scans are superior to plain radiographs. In a blinded study done by Dziurzynski et al. in 2005, five methods commonly used to diagnose AOD were compared using plain x-rays and CT scans of the C-spine (Dziurzynski et al. 2005). The objective of the study was to determine the best method to diagnosis AOD. The conclusion of the study was that the sensitivity, specificity, and positive and negative predictive values of all the methods improved, when applied to CT scan, because of better visualization of anatomic landmarks. Thus, CT scans of C-spine may be warranted in all trauma patients thought to have cervical spine injuries.

Lateral cervical spine films can reveal soft tissue swelling and widening of the disks, facet joints, or posterior elements (Beaty and Kasser 2010). CT scans offer better visualization of the anatomic landmarks thus making identification of AOD easier (Fig. 11.21). MRI is sensitive in detecting ligamentous disruption and instability not readily seen on radiographs (Proctor 2002). A magnetic resonance angiogram (MRA) can also be used to evaluate the vertebral and carotid circulation, as disruption can occur with C-spine injuries (Beaty and Kasser 2010).

#### 11.11.3.5 Treatment

Acute treatment should be directed to airway management and support of respiratory and cardiac function. Stabilization of the neck is most often done via surgery with insertion of posterior implants. Acute stabilization of the cervical spine is a top priority (Beaty and Kasser 2010, Astur et al. 2013). The child should remain in a rigid collar until seen by a neurosurgeon and an orthopedic surgeon for further treatment recommendations.



**Fig. 11.21** 3-D CT scan showing AOD

#### 11.11.4 Atlanto-Axial Rotary Subluxation (AA Rotary Fixation)

The atlanto-axial joint is the most active joint in the body. It is between C1 (the atlas) and C2 (the axis). Normal range of motion for this joint is about 45° to each side. Trauma to this area is also known as atlanto-axial rotatory dislocation and atlanto-axial rotatory fixation. In most cases of AA rotatory subluxation, the amount of rotation between C1 and C2 is within the normal range, yet the patient is unable to return the head to a neutral (forward facing) position. Thus, the term “fixation” can be used in place of “subluxation” as the patient’s joint is in a fixed position within the normal range of motion (Khanna and El-Khoury 2006).

##### 11.11.4.1 Pathophysiology

AA rotatory subluxation is typically caused by inflammation. This can be inflammation from a minor or even unnoticed trauma, infection, or rheumatologic condition. Examples of infectious etiology include an upper respiratory infection or

retropharyngeal abscess. The facet joints at C1 and C2 are nearly horizontal to each other. There are two ligaments that stabilize this joint, the transverse ligament and alar ligament. The transverse ligament prevents anterior translation and the alar ligament prevents excessive rotatory motion of the joint. A disruption in either of these ligaments results in AA rotatory subluxation.

##### 11.11.4.2 Classification

Fielding and Hawkins (1977) identified four types of AA rotatory fixation based on how they appear on radiographs (Fig. 11.22).

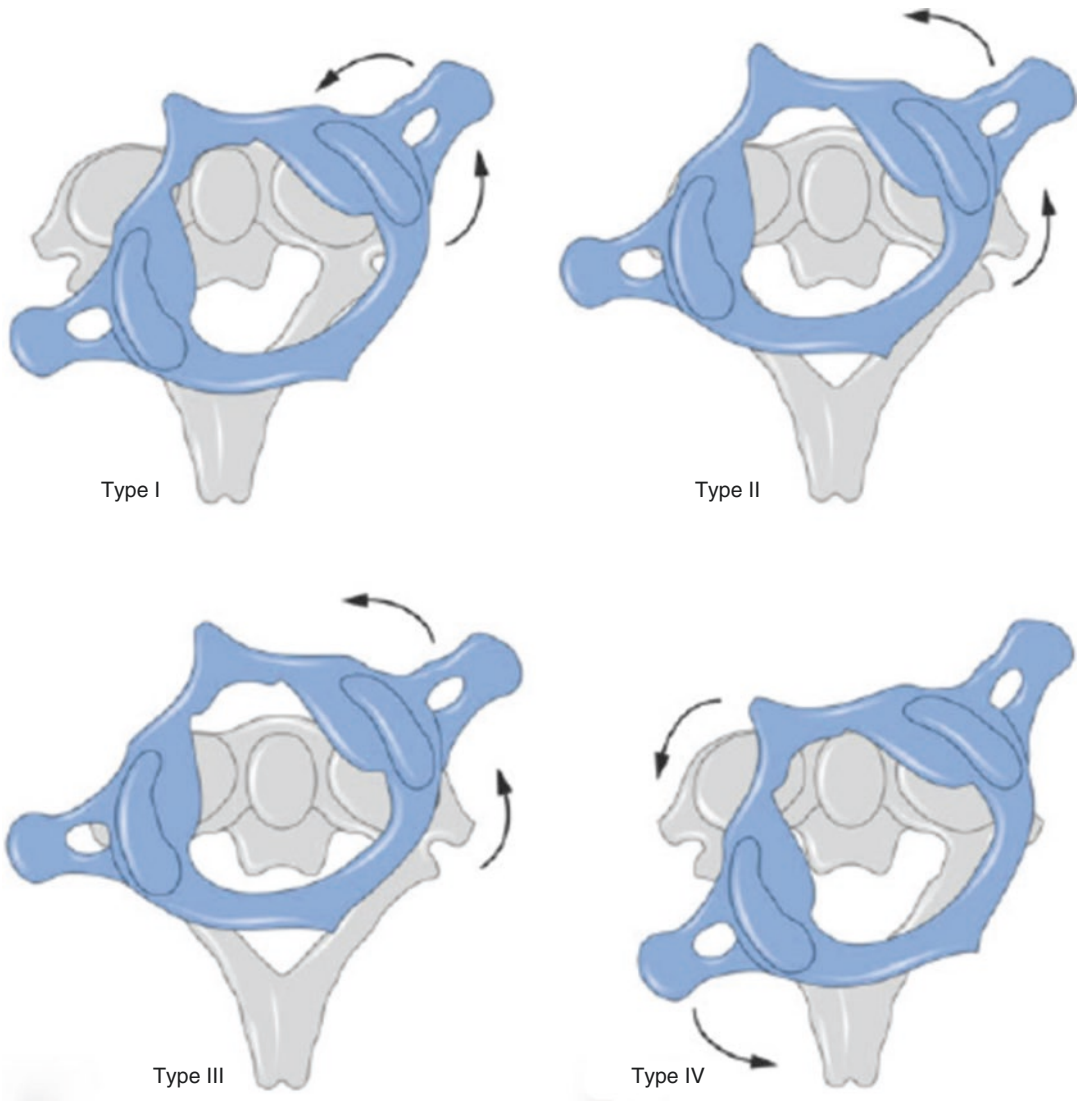
- Type I: unilateral anterior rotation of the atlas pivoting around the dens with a competent transverse ligament. This is the most common type of fracture (Fig. 11.23).
- Type II: unilateral anterior rotation of the atlas pivoting around the contralateral C1–C2 facet (Fig. 11.24). The atlanto dens interval is increased to no more than 9 mm.
- Type III: anterior subluxation of both C1 facets with an incompetent transverse ligament.
- Type IV: posterior displacement of C1 relative to C2 with an absent or hypoplastic odontoid process.

##### 11.11.4.3 Diagnosis

When examining a child with AA rotatory fixation, you will first notice the limited range of motion of the cervical spine. The child will have his/her head rotated to one side in lateral flexion to the other. This is often referred to as the “cocked robin” position. The child will resist any attempt to correct his/her head position (Beaty and Kasser 2010). Often you can see the longer sternocleidomastoid (SCM) muscle spasm from a traumatic torticollis (Khanna and El-Khoury 2006).

##### 11.11.4.4 Radiographic Evaluation

Adequate plain radiographs are difficult to obtain since the child’s head is fixed in a flexed position. Physicians will often recommend a CT scan to look for malrotation. A dynamic CT scan may also be done in place of a regular CT. During a dynamic CT, the patient is actively looking from the right to the left. These images will help



**Fig. 11.22** Four types of atlanto-axial rotary subluxation. *Type I*: unilateral anterior rotation of the atlas pivoting around the dens with a competent transverse ligament. This is the most common type of fracture. *Type II*: unilateral anterior rotation of the atlas pivoting around the contralateral C1–C2 facet. The atlantodens interval is

increased to no more than 5 mm. *Type III*: anterior subluxation of both C1 facets with an incompetent transverse ligament. *Type IV*: posterior displacement of C1 relative to C2 with an absent or hypoplastic odontoid process (Reprinted with permission from Cleary and Wraith (1995))

diagnose the findings of rotary fixation (Beaty and Kasser 2010).

#### 11.11.4.5 Treatment

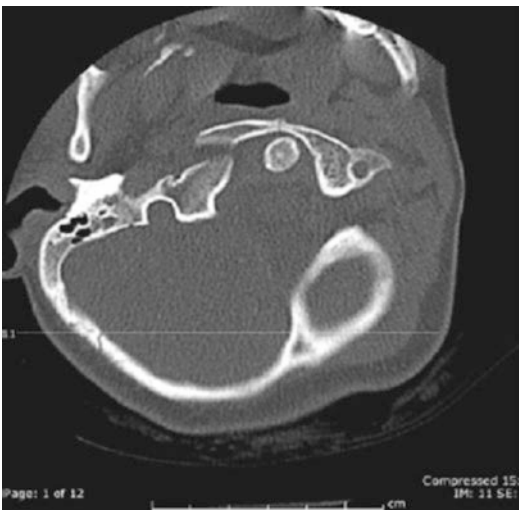
Treatment depends on the type of AA rotary fixation and the duration of the symptoms. If the patient has been symptomatic for 1 week or less, a soft collar paired with nonsteroidal

anti-inflammatory drugs (NSAIDs) and physical therapy should be an adequate treatment plan. When the symptoms have been present for more than 1 week but less than 1 month, the child may be admitted for head halter traction (chin traction) and treated with muscle relaxants and pain medications to help guide C1 back onto C2. If the symptoms have been present for greater than

1 month, more aggressive treatment may be required such as application of halo traction or a pinless halo (Beaty and Kasser 2010) (Fig. 11.25).

### 11.11.5 Jefferson or Atlas Fractures

The atlas fracture is less common than AA rotary fixation and AOD. It only comprises 5% of all cervical spine injuries. The C1 burst fracture (Jefferson fracture) is the more common. It is due



**Fig. 11.23** Type I: unilateral anterior rotation of the atlas pivoting around the dens with a competent transverse ligament

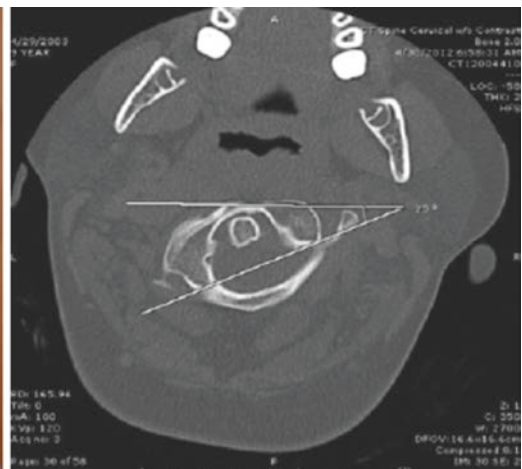

to an axial load on the spine such as when diving or from hitting the head on the roof of the car in motor vehicle accident (Beaty and Kasser 2010). Open mouth radiographs will show the displacement of the lateral mass(es) of C1 away from the odontoid (dens) of C2. A distance of greater than 6 mm suggests ligamentous injury (Fig. 11.26) (Lustrin et al. 2003).

#### 11.11.5.1 Diagnosis

Presenting symptoms consist of complaints of upper neck pain, although patients are usually neurologically intact. In cases of vertebral artery injury, neurologic injury can occur. This neurologic injury may manifest as Wallenberg's syndrome with ipsilateral loss of cranial nerves, Horner's syndrome (meiosis, anhidrosis, and ptosis), ataxia, and loss of contralateral pain and temperature sensation.

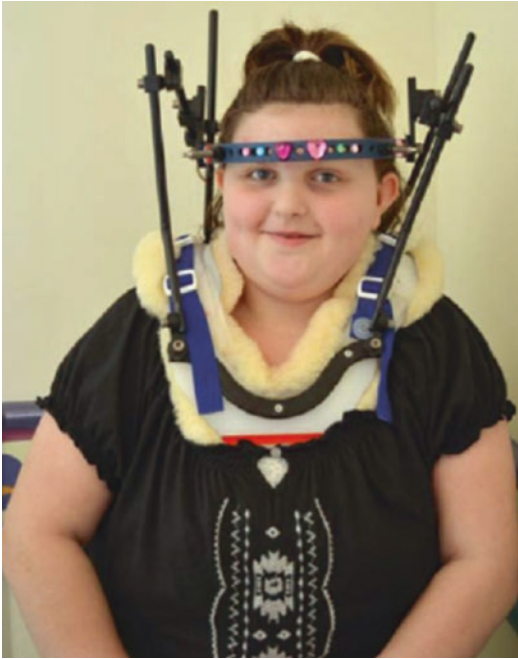#### 11.11.6 Radiographic Evaluation

An odontoid view shows overlapping of C1 facets on C2 facets. Lateral view shows prevertebral soft tissue widening. Flexion and extension views are usually required to determine transverse ligament disruption. A CT scan is often helpful in delineating the exact displacement of fragments and to help diagnose transverse

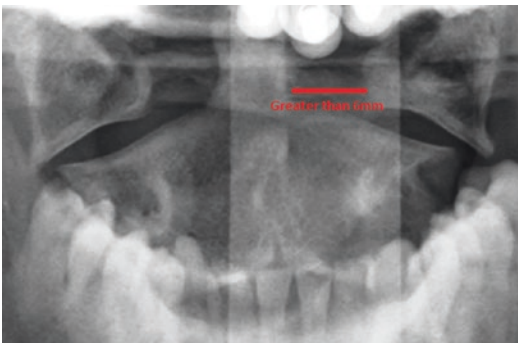


**Fig. 11.24** A 9-year-old female with C1–C2 rotary fixation after streptococcal infection





**Fig. 11.25** A 9-year-old female in halo vest after inpatient hospitalization and traction as part of treatment for C1–C2 rotary fixation



**Fig. 11.26** Open mouth radiograph demonstrating the lateral mass displacement of C1 from the odontoid of C2

ligament disruption if the odontoid views are not conclusive.

#### 11.11.6.1 Treatment

Stable fractures with an intact transverse ligament and nondisplaced or minimally displaced fractures are usually treated in a rigid neck brace for a period of 3 months. Unstable fractures with a ruptured transverse ligament may require place-

ment of a halo. Halo braces may be applied after reduction, but care should be taken to recognize late atlanto-axial instability. Unstable fractures with a greater than 5-mm subluxation of C1 to C2 may require a C1 to C3 fusion (Duke 2005).

#### 11.11.7 Odontoid (Dens) Fracture

Odontoid fractures (also known as dens fractures) are the most common fracture of the cervical spine in children. The average age of occurrence is usually around 4 years of age. In one study, out of 15 fractures of the cervical spine seen in children 0–7 years of age, 11 of these (73%) involved the odontoid (Beaty and Kasser 2010). There is a positive outcome with no neurologic or growth disturbances if the fracture is located below the blood supply to the odontoid.

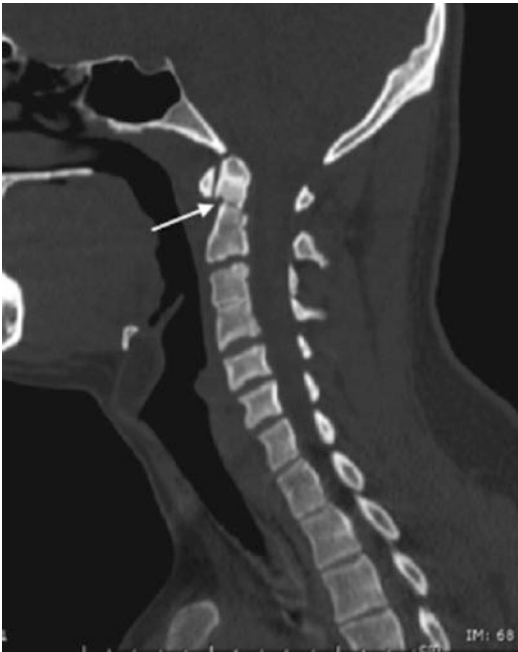#### 11.11.8 Pathophysiology

The odontoid fuses with the axis around 6 years of age, but the synchondrosis (growth center) may be visible on radiographs up to 11 years of age. In young children, the fracture tends to run through the weak link of the odontoid which is the synchondrosis. This is below the blood supply and usually given an anterior displacement of the odontoid. In older children, the fracture is typically above the synchondrosis and can interrupt the blood supply to the odontoid. This can result in the fracture not healing well causing a nonunion or pseudoarthrosis. This fracture is often from high-velocity injuries such as motor vehicle accidents, head trauma, or fall from heights. During motor vehicle crashes, the sudden deceleration of the body as it is strapped into the car seat while the large young child's head continues to move forward causes this fracture (Beaty and Kasser 2010).

### 11.12 Diagnosis, Radiographic Evaluation, and Treatment

A child with an odontoid fracture will have neck pain, particularly with extension. They may be reluctant to move their head and/or become





**Fig. 11.27** Odontoid fracture



**Fig. 11.29** A 2.5-year-old female in pinless halo after sustaining a type 2 displaced odontoid fracture in a motor vehicle accident



**Fig. 11.28** Pinless halo (OrtoPed 2005)

distressed when not lying flat (Kim et al. 2015). This fracture can be seen on plain radiographs but may be better visualized with an MRI or CT scan (Fig. 11.27). Treatment depends on the displacement of the fracture. A nondisplaced odontoid fracture requires immobilization using a halo or Minerva orthosis for 6–8 weeks. The surgeon may also choose to use a pinless halo for a nondisplaced odontoid fracture that does not require corrective forces (Figs. 11.28, 11.29, and 11.30). A displaced odontoid fracture may require surgery to reduce the fracture into better alignment (Beaty and Kasser 2010). Young children have a great remodeling potential when it comes to bony displacement. Although age should be taken into



**Fig. 11.30** A 2.5-year-old female with transition from pinless halo hard cervical collar

consideration, a recent case study indicated that a displaced type 2 odontoid process fracture in a 2-year-old was successfully treated conservatively in an Aspen collar (semirigid cervical orthosis) (Kim et al. 2015).

or (2) three-column injuries. Lumbar spine injuries in children are frequently associated with lap seat belt use in a motor vehicle accident. This is a flexion-distraction type of injury that too often goes undiagnosed or undertreated (Grabb 2008).

## 11.13 Spinal Cord Injuries Other Than Cervical Spine

### 11.13.1 Thoracic and Lumbar Spine Injuries

Thoracic spinal column injuries are relatively uncommon compared with C-spine injuries in children. They generally fall into one of two types: (1) uncomplicated anterior wedge fractures

### 11.13.2 Chance Fracture

The spine consists of three columns: the anterior, middle, and posterior columns.

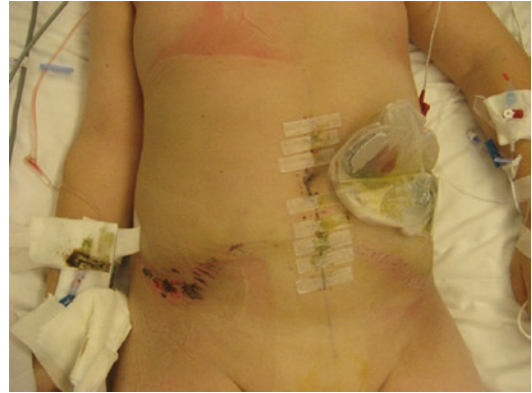
- Anterior column
  - Anterior longitudinal ligament, anterior annulus fibrosus (intervertebral disk), and the anterior part of the vertebral body
- Middle column

- Posterior longitudinal ligament (PLL), posterior annulus fibrosus (intervertebral disk), and the posterior wall of the vertebral body
- Posterior column
  - Everything posterior to the PLL: posterior arch of the body, pedicles, supraspinous ligament, interspinous ligament, capsule, and ligamentum flavum (Denis 1983)

Chance fractures occur as a result of a forceful acute forward hyperflexion with a resulting distraction injury of the spine that involves all three levels of the spinal column. The most common mechanism of injury is a head-on motor vehicle collision while wearing a lap belt (Mechanism of Chance Fracture 2012). It is particularly prevalent in accidents where the lap belt only was being used without a shoulder restraint, or where the lap belt was worn incorrectly (lap belts should be worn below the level of the anterior superior iliac spine) (Chance Fracture 2012). The force from the accident propels the patient forward while immobilizing their abdomen with the lap belt. The force exerted on spine distracts it with the anterior vertebral body acting as a fulcrum. Initially the force pulls apart the posterior column, then the middle column, and finally in the anterior column (Mechanism of Chance Fracture 2012). A soft-tissue Chance injury disrupts the disk or vertebral body and continues through the posterior ligament or capsule. The bony Chance injury involves a compression-type injury of the vertebral body, while the posterior bony elements of the body (spinous processes) are typically distracted (Price 2014).

Clinical findings from this injury are often a result from wearing the lap belt. These include abdominal wall ecchymoses (“seat belt sign”) (Fig. 11.31), intra-abdominal organ injuries, and vertebral fractures with spinal cord injury. The most common injury seen from seat belts are intra-abdominal. The organs are compressed between the posterior bony spinal column and the anterior lap belt. Children have thinner abdominal walls and are smaller in anterioposterior diameter; this makes them more prone to injury against blunt trauma (Price 2014).

Treatment choices are based on the extensiveness of the injuries. In the young child with a bony Chance injury without spinal cord involvement,



**Fig. 11.31** Classic “seat belt sign” with abdominal wall ecchymoses and subsequent intra-abdominal injuries

an extension brace may be used for 6–8 weeks. With a soft tissue Chance injury, the posterior elements are involved and this creates instability and often requires operative fixation (Price 2014) (Denis 1983).

## 11.14 Contusions

Spinal cord contusion is the complete or incomplete transient spinal cord dysfunction which generally resolves in 1–2 days but can also cause permanent damage. A contusion results from the stretching and compression of the spinal cord, which disrupts the gray matter in the spinal cord while preserving the white matter tracks (Adelson and Resnick 1999). Contusions can be associated with edema and/or hemorrhage and can be caused by blunt force, axial loading, flexion-extension, or other mechanism that results in stretching or compression of the cord. Since contusions do not appear on radiographs, they can also be associated with SCIWORA.

## 11.15 Brown-Sequard Syndrome

Brown-Sequard syndrome is an injury to the right or left side of the spinal cord where movements are lost below the level of the injury on the injured side, but pain and temperature sensation are lost on the opposite side of the injury. It is a rare

disorder resulting from a lesion on the spinal cord. Prognosis is variable depending upon the cause of the disorder.

---

### 11.16 Anterior Cord Syndrome

Anterior cord syndrome is an incomplete injury to the motor and sensory pathways in the anterior parts of the spine. Patients are able to feel crude sensation, but movement and detailed sensation are lost in the posterior part of the spinal cord below the level of injury. It is usually caused by compression of the artery that runs along the anterior part of the spinal cord. There is no cure or standard course of treatment, and prognosis is poor for functional recovery.

---

### 11.17 Central Cord Syndrome

Central cord syndrome is an injury to the center of the cervical spinal cord, producing weakness, paralysis, and sensory deficits in the arms but not the legs. It is the most common incomplete SCI. It results from damage to large nerve fibers, usually secondary to hyperextension or bony instability in pediatric patients. There is no cure or standard course of treatment (though rest, stabilization, drug therapy, and/or surgery may be part of a program). Most patients recover some neurologic function, according to the fact page of the National Institute for Neurological Disorders and Stroke.

#### 11.17.1 Assessment

A thorough initial neurological assessment is essential to delineate the level of injury and to obtain a baseline for comparison of subsequent assessments. Continuing assessments will be used to determine improvement or deterioration. Assessments should include basic vital signs, Glasgow Coma Scale, motor function of all muscle groups, sensation levels, and reflexes. It is important to include checking the anal sphincter for contracture, in addition to diaphragmatic

function, to delineate respiratory effort and efficacy. The dermatome chart should be used to assess the level of sensation. Any deterioration noted on subsequent examinations should be reported to the care provider, and the appropriate treatment should begin to insure that any secondary injury is minimal (Moloney-Harmon and Adams 2001).

#### 11.17.2 Treatment

Treatment begins at the scene of the accident with resuscitation, immobilization, and transport. The main consideration of treatment should be to maintain the patient's airway, breathing, and circulation while decompressing the neural elements and stabilizing the spine to prevent further injury. Basic anatomical and developmental considerations such as future growth, recuperative powers of children, and difficulty in achieving adequate internal or external fixation (halo) in the young child must be a part of the treatment plan.

Halo immobilization has been used successfully in patients <5 years of age and older. The halo ring has more pins (6–8) than the adult version to distribute the pin pressure around the thinner pediatric skull. The pressure applied by the pins ranges from finger tight to two pounds. Most of the orthosis or vests are custom made using thermoplastic compounds molded to the child and attached with straps. The neurosurgeon, orthotist, or other trained individual will most likely be the ones who tighten pins. Pin site care is done per institutional policy (Carreon et al. 2004).

#### 11.17.3 Surgical Treatment

Injury that requires surgical treatment in the adult patient may only need immobilization in the pediatric patient. Bone and tissue thickness may have a major impact on what orthosis may be applied and what internal constructs may be possible. The vertebrae are partially cartilaginous in the young child, and it may not be possible to



apply the same kind of screws or plates that would easily fit a larger patient. Spinal fusion may have a major impact on the developing spine. The spine may not grow normally and scoliosis could result. Therefore, it is important to limit the number of levels fused and to consider the effects of an isolated anterior or posterior fusion on subsequent development of excessive lordosis or kyphosis (Proctor 2002).

### 11.17.4 Role of Steroids

Several studies are currently looking at the efficacy of high-dose steroids in the initial treatment of spinal cord injury. Despite early enthusiasm, much controversy exists concerning their effectiveness. It should also be noted that there were no pediatric patients included in the National Acute Spinal Cord Injury Study data and that no recommendations were made regarding pediatric patients (Proctor 2002). Each institution will vary in their use of steroids post spinal cord injury.

Corticosteroids, specifically methylprednisolone, received an enormous amount of attention in the 1990s as a powerful neuroprotective agent. The National Acute Spinal Cord Injury Study (NASCIS) II and III were designed as class I prospective, randomized trials and were critical studies in guiding treatment. In post hoc analysis, their conclusions on the benefit of corticosteroid treatment did verify downgrading the level of evidence. These studies also showed a trend toward greatly increased morbidity and mortality rates in patients treated with corticosteroids, specifically for pneumonia, sepsis, acute respiratory distress syndrome, gastrointestinal hemorrhage, and death (Ropper et al. 2015).

## 11.18 Nursing Care of the Spinal Cord Injury Patient

### 11.18.1 Cervical Collar Care

Cervical collars support and limit the movement of the neck during the healing process. They may

be worn 24 h a day or for comfort depending on the injury. Always refer to your attending physician's recommendation for collar care and guidelines. Common cervical collar types are as follows: Soft, Philadelphia, Miami J, Aspen, DeRoyal, Cervical-Thoracic Orthotic (CTO), and Cervical-Thoracic-Lumbar Orthotic (CTLSSO). Nurses should perform "collar care" at least once per day, if not more often. This includes making sure the collar is fitting well and there are no areas of skin breakdown. Pads are changed when soiled, damp, malodorous, soiled, and otherwise every 24 h. A mild soap and water is all that is needed to clean the pads and collars. Avoid using bleach and other harsh chemicals.

Patients with highly unstable cervical spine injuries should have a provider present at the time of collar care for the first change. Patients with stable cervical spine fractures can have their collar care done by a qualified RN alone. If there is any question about the stability of the cervical fracture, ask the attending physician and document their recommended guidelines for collar care.

Every institution has guidelines for collar care (Louisiana State University Health Sciences Center 2009):

1. Lay patient supine.
2. Unfasten the outside colored Velcro strap on the patient's left side.
3. Lift open the front portion of the collar to the opposite (right) side.
4. Clean the skin on the anterior portion of the neck.
5. Dry skin and inspect for skin integrity.
6. Reapply the anterior portion of the collar.
7. Roll patient prone.
8. Unfasten the outside colored Velcro closure on patient's left side.
9. Lift open the opposite (right) side.
10. Clean the posterior portion of the neck as done for the anterior side.
11. After drying and inspecting skin, reapply collar.

The patient's chin should be flushed with the end of collar chin piece. The inner trach bar



should not be touching the airway. All slack should be removed from collar and back panel should be centered to the front. The back Velcro straps should be symmetrical (Aspen Medical Products 2008).

### 11.18.2 Pin Site Care for Halos

Pin care for halo immobilization is also dependent on an institution's guidelines. Typically, pin care is done daily with either mild soap and water or half/half-strength hydrogen peroxide and normal saline. Pins should be assessed every shift for soreness and increasing erythema or drainage. If these are noted, the provider should be notified to assess the patient and determine the next course of action. If the halo and pins are loose, radiographs may be ordered to assess if the pins are in proper alignment. Redness or drainage at the pin site may indicate infection.

### 11.18.3 Developmental Considerations

Children and adolescents who have sustained spinal cord injuries (SCI) experience unique manifestations and complications related to their injury based on the dramatic developmental changes that occur as they grow (Adelson and Resnick 1999). The pediatric neurosurgery nurse must have a thorough understanding of the child's typical growth and development, complications of SCI, and specific care related to the level and mechanism of injury. This will alleviate unrealistic expectations related to the child's ability to participate in the examination that may cause frustration for the patient, family, and nurse. The pediatric neurosurgery nurse is mindful that small children may not be able to describe their pain or symptoms very well, depending on their age, cognitive function, and injury. A thorough history, when appropriate to obtain, is a vital component to prudent care and will help the nurse understand the child's cognitive level, socioeconomic status, and support system. A baseline and regular head to toe nursing assess-

ments should be performed, including respiratory and cardiovascular status, skin condition, bowel and bladder management, motor and neurovascular status, nutritional status, and emotional well-being. A multidisciplinary medical team, in conjunction with the patient and family, will provide comprehensive care and management after a spinal cord injury. This management will be individualized to each child and family and include developmentally appropriate education, family-centered care, and anticipatory guidance to address future issues related to growth and development.

Children develop along predictable patterns of physical, intellectual, and emotional growth, thus requiring their care to be dynamic, developmentally sensitive, and appropriate for each age group. SCI patients require long-term care and an essential part of rehabilitation is appropriate patient and family education. The patient needs to be made accountable for his or her own care whenever possible based on age and developmental level. If the child or adolescent is unable to perform their own care, they should be taught to direct their care. Family-centered care is also essential and family members should take control of the patient's care when appropriate. Parents also need to be taught to transition control of care to the patient as he or she becomes an adult (see Chap. 17). This education must be individualized to the child's and family's needs. The SCI patient's rehabilitation plan should also include plans to return to school.

### 11.18.4 Secondary Medical Conditions

SCI leads to a variety of changes in the systemic physiology of the child that can cause a number of complications. These complications, or secondary medical conditions, can rival the initial neurologic deficits in their impact on function and quality of life. Secondary medical conditions after SCI are common, severe, and may be as devastating as the underlying injury if not properly cared for. These complications include, but are not limited to, pneumonia, neurogenic bladder

and bowel, pressure ulcers, autonomic dysreflexia, spasticity, latex allergy, or deep vein thrombosis. The nurse needs to be able to care for the patient with the following conditions as well as teach the patient and family how to care for themselves.

#### **11.18.4.1 Neurogenic Bladder**

SCI disrupts both the storage and emptying functions of the bladder, causing a condition referred to as neurogenic bladder. This is the loss of sensation of bladder fullness and the inability to voluntarily initiate urination and to completely empty the bladder, resulting in urinary retention and/or incontinence. The goal of an SCI bladder program is to preserve renal function while eliminating urine at regular and socially acceptable times, avoiding high bladder pressures, retention, incontinence, and infection. Treatment for this is clean intermittent catheterization (CIC). Emptying the bladder is important for protecting the kidneys from refluxing of the urine upward from the full bladder. Patients should be taught how to self-catheterize as soon as they are developmentally ready. They must be able to tell time, recognize the equipment, follow step-by-step instructions, and understand the purpose of equipment. This program can typically be started by the parents at 3 years of age and then taught to the patient around age 5–7, if developmentally appropriate. Managing incontinence is very important to children and adolescents, and they should be motivated to manage this aspect of their own care. Parental or parental designee supervision is necessary for school age children, whereas adolescents may only need assistance with problem solving. Continence is an expectation for school age children and adolescents and must be achieved for the individual to move on to a productive and satisfying adult life, including issues of sexuality and positive self-esteem.

#### **11.18.4.2 Neurogenic Bowel**

Patients with neurogenic bowel syndrome do not feel the urge to have bowel movements and are often unable to control them. To manage a neurogenic bowel, a regular program of bowel care must be instituted. The goal of this program

should be to prevent constipation, provide adequate elimination, and preserve bowel function while providing a convenient, regular, and complete emptying of the bowel. This may be as simple as placing the child on the commode at the same time every day and instructing him or her to bear down, although more detailed programs are often necessary. Stool softeners, laxatives, suppositories, enemas, and digital stimulation may be needed to expedite the process. Privacy, consistency, proper seating, and regularity mixed with patience help ensure success. This program can begin at age 3 years, be supervised during the school age period, and be proficiently performed by adolescents.

#### **11.18.4.3 Pressure Ulcers**

Pressure ulcers commonly occur from unrelieved pressure over bony prominences that results in tissue damage. Because of loss of sensation below the level of the spinal cord lesion, patients often are not aware of skin breakdown. Contributing factors to the development of pressure ulcers include shear, friction, poor nutrition, and changes in the skin physiology below the level of the lesion. Pressure ulcers add tremendous cost to already expensive medical care by causing increased hospital stays, surgical repair, and loss of school or work. If left untreated or undertreated, pressure ulcers may lead to death from sepsis. Good skin care, including prevention of skin breakdown, is essential and begins on day one of hospitalization. Strategies for prevention include daily examination of skin over vulnerable areas; avoidance of immobility and excess moisture in susceptible regions; the use of pressure-relieving wheelchairs, cushions, or other devices; and maintenance of adequate nutritional intake and weight. Children and adolescents should have their positions changed every 2 h while in bed and every hour while sitting in a chair. Their skin needs to remain clean and dry. Treatment for pressure ulcers consists of cleansing, debridement, nutritional support, and management of tissue loads. Parents and patients should be taught the signs of skin breakdown and how to treat them if they should occur.

#### 11.18.4.4 Autonomic Dysreflexia

Autonomic dysreflexia is a life-threatening complication of SCI that is most often seen in pediatric patients with T6 or higher injuries. It is a phenomenon manifested by the loss of coordinated autonomic responses to demands on heart rate and vascular tone. An exaggerated response of the sympathetic nervous system to a noxious stimulus below the level of the injury can lead to vasoconstriction and hypertension. A compensatory parasympathetic response produces bradycardia and vasodilation above the level of the lesion. This is due to the lack of supraspinal control of the major splanchnic outflow that leaves the spinal cord at the thoracic vertebrae 6–12 level. Symptoms include elevation of blood pressure by 24–51 mmHg above baseline (depending on the age of the patient), pounding headache, age-defined bradycardia or tachycardia in young children, profuse sweating, piloerection, cardiac arrhythmias, flushing, blurred vision, nasal congestion, or anxiety. Infants and very young children may exhibit sleepiness or irritability.

The most common trigger is bladder distention; however, becoming overheated, kidney stones, urinary tract infections, bowel distention or impaction, pressure ulcers, tight clothing, burns, ingrown toe nails, deep vein thrombosis, menses, pregnancy, labor, fractures, trauma, heterotopic ossification, surgery or invasive procedures, hyperthermia, or any other painful stimulus may also trigger autonomic dysreflexia. Recognition and treatment of symptoms is paramount to preventing this life-threatening process. Assessing and alleviating the triggers is essential. Heart rate and blood pressure measurements should be taken every 2–5 min, and antihypertensive medications should be instituted as needed. Caregiver education is essential with children and adolescents prone to this complication. A medical alert bracelet or identification card should be worn or carried at all times.

#### 11.18.4.5 Spasticity

Spasticity is thought to result from the disruption of descending inhibitory modulation of the alpha motor neurons, causing hyperexcitability, which manifests as increased muscle tone and spasms.

Fifty percent of all children with SCI are affected by spasticity, and it is usually seen within 1 year after injury, although it tends to lessen in subsequent years. Spasticity causes pain, decreased mobility, contractures, and muscle spasms, all of which can interfere with activities of daily living and sleep. The goals of spasticity management include improved function, prevention of complications, and alleviation of discomfort and embarrassment. Some potential benefits of spasticity include decreased muscle atrophy, increased tone to facilitate standing and transfers, promotion of venous return, and decreased risk of deep venous thrombosis and orthostatic hypotension. These positive aspects should be considered when determining the plan of care for the child or adolescent. A comprehensive program of range of motion, stretching, positioning, and use of braces is essential in the management of spasticity to maintain movement and prevent contractures. Relief of triggers is an important part of the management plan and any noxious stimulus may exacerbate spasticity. An example of noxious stimuli which may occur with spasticity and is unique to the pediatric population is hip dislocation.

Baclofen is the drug of choice to manage spasticity that interferes with functioning and is refractory to conservative treatment. Other drugs such as diazepam, clonidine, and tizanidine may be beneficial in spasticity management. A baclofen pump (intrathecal) is an option when other methods of management are not effective. Please refer to the Chap. 14 on spasticity for a more in-depth discussion.

#### 11.18.4.6 Sexuality and Fertility

One of the most socially important topics to cover with SCI patients is the ability to enjoy sexual intimacy and bear children. Common consequences of SCI related to sexual function include decreased libido, impotence, and infertility. Males may experience difficulties with erections, ejaculation, and fertility. These are important topics for discussion with the patient, covering why problems occur and how they may be treated. Females usually have fewer issues. Sexual response is typically impaired, but ovulation and fertility are generally unaffected. Menstruation, lubrication,

pregnancy, labor, and delivery should all be discussed. Personal hygiene surrounding incontinence is an issue for both sexes. This information should also be presented to the parent of a child with SCI as part of the long-term treatment plan. This will help the parents come to terms with the reality of the injury implications and also help them see that there is a future for their child in terms of love, dating, marriage, and children.

## 11.19 Summary

Pediatric traumatic spinal cord injuries are often difficult to diagnose due to the differences in the development of the pediatric spine, inconsistent radiographic quality, and because SCIs are relatively rare. Despite the fact that the pediatric spine offers some natural protection from SCI due to its bony and ligamentous structure compliance, SCIs are often severe. These severe injuries are likely due to the high magnitude of force that is necessary to disrupt the tolerance of the pediatric spine. As a result, children often have concomitant neurological injuries that complicate the recovery.

Secondary medical conditions after SCI are both common and severe leading to rehospitalizations and decreased life expectancy. Treatment does not stop when the patient leaves the hospital or the rehabilitation facility; it requires a life-long commitment from the family and patient. The cost to the family and patient is astronomical in terms of support, time, effort, and money. Because these injuries are permanent and devastating, injury prevention is paramount.

### Pediatric Practice Pearls

- Younger children are more prone to cervical spine injuries with flexion-extension forces because of the large size of their heads, increased spine mobility, and ligament laxity.
- Children require appropriate head support and immobilization when on a

spine board because of the size and shape of the head that could cause extreme flexion of the cervical spine, further injuring the spine or obstructing the airway.

- Autonomic dysreflexia is an exaggerated and possibly life-threatening autonomic response to normal innocuous stimuli seen in injuries of the spinal cord at T6 or above. The offending stimulus must be sought and reversed as soon as possible.
- Congenital spine anomalies may be asymptomatic early in life and become apparent with growth or subsequent to injury or inflammation.
- Congenital vertebral anomalies are often associated with renal, cardiac, and spinal cord abnormalities and syndromes, having an insidious onset with slow progression.
- Most motor and sensory signs and symptoms occur below the involved vertebrae.
- Early recognition, diagnosis, referral, and treatment are extremely important for a congenital spinal anomaly. A very thorough history and physical exam is critical in every child who is referred for a congenital vertebral anomaly. This should include screening with MRI/CT imaging and possibly ultrasound, urologic exam, genetics, and cardiology referral. Testing early in life is recommended with frequent follow-up.

## Case Study

### *History of present illness:*

A 17-year-old non-English speaking male was an unrestrained passenger in a vehicle which collided with an electric pole and the patient was ejected. He was admitted to the pediatric intensive care unit with acute respiratory failure, traumatic brain injury, pneumothorax, and rib fractures following the motor vehicle accident.

On arrival, he had notable extensive abrasions along his entire right side and back and diminished breath sounds throughout. During the exam, he would arouse to open his eyes and move all extremities, including reaching for medical devices and could follow commands. He was reported to have vomited on the scene of the accident and complained of head and neck pain. He was placed into a rigid hard collar. With exam he also had noted shortness of breath. Related to concern for a right-sided pneumothorax on chest x-ray, a chest tube was placed with adequate decompression and improved aeration.

### *Physical exam:*

Temperature celsius:	36.5 °C
Heart rate monitored:	102 bpm
Respiratory rate monitored:	15 BR/min
Blood pressure monitored:	125/71
SpO <sub>2</sub> :	99%

General: well developed and well nourished (WDWN), no apparent distress (NAD), sedated and intubated, moves extremities with exam

Head: normocephalic, no obvious deformities, abrasions on left cheek and chin, bilateral edema, and bruising around eyes

Eyes: pupils small and equal, reactive bilaterally, conjunctiva clear

Ears, nose, throat (ENT): oral mucosa moist, orally intubated

Chest: mechanically ventilated with good aeration bilaterally, clear breath sounds, right chest tube in place

Cardiovascular (CV): heart regular rate and rhythm (HRRR), no murmur, peripheral pulses +2, cap refill <2 s

Abdomen: soft, non-tender (NT), non-distended (ND), bowel sounds (BS) positive, no organomegaly

Extremities: no deformities, warm peripherally with good perfusion. When asked to squeeze hands, patient has noted weakness on right side

Neuro: Sedated but responsive to exam

Skin: numerous and large abrasions throughout right side (flank, UE, LE) along with back

### **What bony injuries would you be most concerned about?**

- Femur fracture
- Odontoid fracture
- Atlas fracture
- Atlanto-occipital dislocation (AOD)



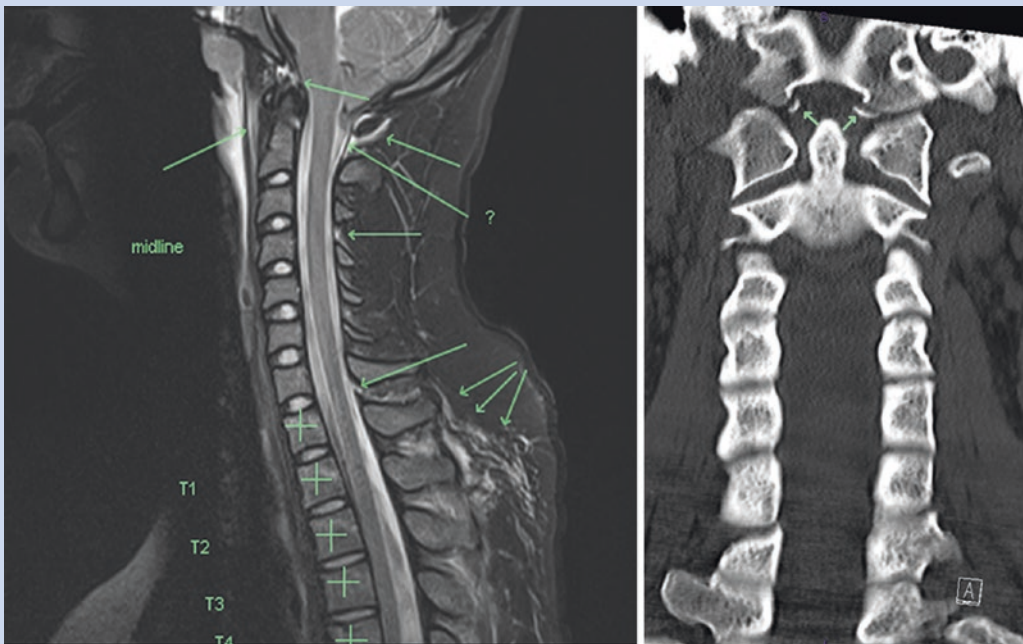
**When stable, what radiographic imaging would help you diagnose the problem best?**

- (a) Lateral cervical spine films
- (b) CT scan of the head and neck
- (c) MRI of the head and neck
- (d) Bilateral femur films

**Answers and radiographic imaging:**

The diagnosis you would be most concerned about is (d) atlanto-occipital dislocation (AOD) related to the vomiting, headache, and motor deficit. Once the patient is stable, the imaging of choice would be (c) MRI. MRI is sensitive in detecting ligamentous disruption and instability which may not be readily seen on plain radiographs or CT.

MRI shows different densities in fluid, which in turn helps identify areas of inflammation. On the left MRI image, note the green arrows (Fig. 11.32). They demonstrate all the areas of ligamentous injury of the spine. The most concerning is the disruption of the tectorial membrane and suspected disruption of the odontoid apical ligament. On the right CT of the same patient, you can see the arrows pointing to occipital condyle avulsions. The mechanism of this injury is typically forced rotation, usually combined with lateral bending (Fig. 11.32). After occipital condylar avulsion, the contralateral alar ligament and tectorial membrane may be stressed resulting in a partial tear or complete disruption as seen with atlanto-occipital dislocation (AOD) (Leone et al. 2000).



**Fig. 11.32** Note the multiple ligamentous injuries as noted by arrows on left image. Observe the arrows on the right image pointing towards the occipital condyle avulsions

## References

- Adelson PD, Resnick DK (1999) Spinal cord injury in children. In: Albright AL, Pollack IF, Adelson PD (eds) *Principles and practice of pediatric neurosurgery*. Thieme, New York, pp 955–972
- Ain C, Shirley E (2004) Spinal fusion for kyphosis in achondroplasia. *J Pediatr Orthop* 24:541–545
- Ain MC, Elmaci I, Hurko O, Clatterbuck RE, Lee RR, Rigamonti D (2000) Reoperation for spinal stenosis in achondroplasia. *J Spinal Disord* 13:168–173
- Albright AL, Pollack IF, Adelson PD (1999) *Principles and practice of pediatric neurosurgery*. Thieme Medical Publishers, New York, pp. 399–411
- Alden TD, Ellenbogen RG (2008) Spinal cord injuries. In: Albright AL, Pollack IF, Adelson PD (eds) *Principles and practice of pediatric neurosurgery*, 2nd edn. Thieme, New York, pp 925–938
- Alman BA (2002) A classification of genetic disorders of interest to orthopaedists. *Clin Orthop Relat Res* 401:17–26
- American Academy of Orthopaedic Surgeons (2006) *Orthopaedic knowledge update: pediatrics*, 3rd edn. American Academy of Orthopaedic Surgeons, Rosemount
- American College of Emergency Physicians (2008) ACEP News. Studies challenge spine injury criteria for children
- American Heart Association (2000) Trauma resuscitation and spinal immobilization. In: Hazinski MF, Zaritsky AL, Nadkarni VM, Hickey RW, Schexnayder SM, Berg RA (eds) *PALS provider manual*. American Heart Association, Dallas, pp 253–283
- American Heart Association, American Academy of Pediatrics (2002) *PALS provider manual*. American Heart Association
- Aspen Medical Products (2008) Expanded pad care. Retrieved from [http://www.aspencollar.com/products/collar/epc\\_instructions.html](http://www.aspencollar.com/products/collar/epc_instructions.html). Accessed 2 Feb 2010
- Astur N, Klimo P Jr, Sawyer JR, Kelly DM, Muhlbauer MS, Warner WC Jr (2013) Traumatic atlanto-occipital dislocation in children: evaluation, treatment, and outcomes. *J Bone Joint Surg Am* 95(24):e194(1–8). doi: 10.2106/JBJS.L.01295. PubMed PMID: 24352780
- Beaty J, Kasser J (eds) (2010) *Rockwood and Wilkins' fractures in children*, 7th edn. Lippincott Williams & Wilkins, Philadelphia
- Becker R, Wegner R-D, Kunze J, Runkel S, Vogel M, Entezami M (2000) Clinical variability of Larsen syndrome: diagnosis in a father after sonographic detection of a severely affected fetus. *Clin Genet* 57: 148–150
- Berne JD, Velmahos GC, El-Tawil Q, Demetriades D, Asensio JA, Murray JA et al (1999) Value of complete cervical helical computed tomographic scanning in identifying cervical spine injury in the unevaluable blunt trauma patient with multiple injuries: a prospective study. *J Trauma Injury Infect Crit Care* 47:896–903
- Bosch PP, Vogt MT, Ward WT (2002) Pediatric spinal cord injury without radiographic abnormality (SCIWORA): the absence of occult instability and lack of indication for bracing. *Spine* 32:2788–2800
- Brockmeyer D (2006) *Advanced pediatric craniocervical surgery*. Thieme, New York
- Brown RL, Brunn MA, Garcia VF (2001) Cervical spine injuries in children: a review of 103 patients treated consecutively at a level 5 pediatric trauma center. *J Pediatr Surg* 37:1107–1114
- Burton BK (1998) Inborn errors of metabolism in infancy: a guide to diagnosis. *Pediatrics* 102:69–73
- Carreon LY, Glassman SD, Campbell MJ (2004) Pediatric spine fractures: a review of 137 hospital admissions. *J Spinal Disord Tech* 22:477–482
- Chance Fracture (2012). Retrieved 19 July 2016, from The Northern Hospital: <http://www.emergucate.com/wp-content/uploads/2015/05/Chance-Fracture.pdf>
- Cirak B, Ziegfeld S, Knight VM, Chang D, Avellino AM, Paidas CN (2004) Spinal injuries in children. *J Pediatr Surg* 39:607–612
- Clarke JTR (2005) *A clinical guide to inherited metabolic diseases*, 3rd edn. Cambridge University Press, New York
- Cleary MA, Wraith JE (1995) The presenting features of mucopolysaccharidosis type IH (Hurler syndrome). *Acta Paediatr Int J Paediatr* 84:337–339
- Cramer K, Scherl S (eds) (2004) *Orthopaedic surgery essentials: pediatrics*. Lippincott Williams & Wilkins, Philadelphia
- Curcione PJ, Mackenzie W (1995) Klipper-Feil a clinical case presentation at The Alfred I. Dupont Institute in Wilmington, Delaware
- Denis F (1983) Spinal instability as defined by the three-column spine concept in acute spinal trauma. *Clin Orthop Relat Res* 189:65–74
- Devlin VJ (2012) *Spine secrets plus*, 2nd edn. Elsevier, Mosby, pp. 291–293
- Dewald RL, Arlet V, Carl A, O'Brien M (2003) *Spinal deformities, the comprehensive text*. Thieme Medical Publishers Inc., New York
- Dibsie GL (1998) Clearing cervical spine injuries: a discussion of the process and the problems. *Crit Care Nurs Q* 2:26–41
- Dickman CA, Zabranski JM, Hadley MN, Reke HL, Sonntag VK (1991) Pediatric spinal cord injury without radiographic abnormalities: report of 26 cases and review of the literature. *J Spinal Disord* 4:296–305
- Duke Orthopaedics (2005) *Atlas fracture/Jefferson fracture*. *Wheeless' textbook of orthopaedics*. Retrieved from <http://www.whelessonline.com>. Accessed 4 Dec 2005
- Dziurzynski K, Anderson PA, Bean DB, Choi J, Levenson GE, Marin RL et al (2005) A blinded assessment of radiographic criteria for atlanto-occipital dislocation. *Spine* 30:1427–1432
- Ergun A, Oder W (2003) Pediatric care report of spinal cord injury without radiographic abnormality (SCIWORA): case report and literature review. *Spinal Cord* 41:249–253

- Eubanks J, Gilmore A, Bess S, Cooperman D (2006) Clearing the pediatric cervical spine following injury. *J Am Acad Orthop Surg* 14:552–564
- Fielding JW, Hawkins RJ (1977) Atlanto-axial rotary fixation: fixed rotatory subluxation of the atlanto-axial joint. *J Bone Joint Surg Am* 59A:45–55
- Fuhrhop SK, McElroy MJ, Dietz h C III, MacCarrick GL, Sponseller PD (2015) High prevalence of cervical deformity and instability requires surveillance in Loays-Dietz Syndrome. *J Bone Joint Surg Inc* 97:411–119
- Giglio GC, Passariello R, Pagnotta G, Crostelli M, Ascani E (1988) Anatomy of the lumbar spine in achondroplasia. In: Nicoletti B, Kopits SE, Ascani E, Mckusick VA (eds) *Human achondroplasia: a multidisciplinary approach*. Plenum, New York, pp 227–239
- Grabb PD (2008) Spinal column trauma in children. In: Albright AL, Pollack IF, Adelson PD (eds) *Principles and practice of pediatric neurosurgery*, 2nd edn. Thieme, New York, pp 908–924
- Greenberg MS (2001) Spine injuries. In: Greenberg MS (ed) *Handbook of neurosurgery*, 5th edn. Thieme, Stuttgart, pp 686–735
- Hadley MN (2002) Management of pediatric cervical spine and spinal cord injuries. *Neurosurgery* 50:S85–S99
- Hall CW, Liebaers I, Di Natale P, Neufeld EF (1978) Enzymatic diagnosis of the genetic mucopolysaccharide storage disorders. *Methods Enzymol* 50:439–456
- Hedequist D, Emans J (2007) Congenital scoliosis: a review & update. *J Pediatr Orthop* 27:106–116
- Hennekeam RCM (2010) *Gorlins' syndromes of the head and neck*, 5th edn. Oxford University Press, Oxford/ New York
- Hosalkar HS, Cain EL, Horn D, Chin KR, Dormans JP, Drummond DS (2005) Traumatic atlanto-occipital dislocation in children. *J Bone Joint Surg Am* 87(11):2480–8. PubMed
- Hunter A, Bankier A, Rogers J, Silience D, Scott C (1998) Medical complications of achondroplasia: a multicenter patient review. *J Med Genet* 35:705–712
- Hurko O, Pyeritx R, Uematsu S (1988) Neurological considerations in achondroplasia. In: Nicoletti B, Kopits SE, Ascani E, Mckusick VA (eds) *Human achondroplasia: a multidisciplinary approach*. Plenum, New York, pp 153–162
- Johnston CE, Birch JG, Daniels JL (1996) Cervical kyphosis in patients who have Larsen syndrome. *J Bone Joint Surg*:538–545
- Kenter K, Worley G, Griffin T, Fitch RD (2001) Pediatric traumatic atlanto-occipital dislocation: five cases and a review. *J Pediatr Orthop* 21:585–589
- Khanna G, El-Khoury G (2006) Imaging of cervical spine injuries of childhood. *Skelet Radiol* 36:477–494
- Kim W, O'Malley M, Kieser DC (2015) Noninvasive management of an odontoid process fracture in a toddler: case report. *Global Spine J* 5(1):59–62. doi: 10.1055/s-0034-1384817. Epub 2014 Jul 30. PubMed PMID: 25649544; PubMed Central PMCID: PMC4303473
- Kokoska ER, Keller MS, Rallo MC, Weber TR (2001) Characteristics of pediatric cervical spine injuries. *J Pediatr Surg* 37:100–105
- Kopits SE (1988) Thoracolumbar kyphosis and lumbosacral hyperlordosis in achondroplastic children. In: Nicoletti B, Kopits SE, Ascani E, Mckusick VA (eds) *Human achondroplasia: a multidisciplinary approach*. Plenum, New York, pp 241–255
- Lang SM, Bernardo LM (1993) SCIWORA syndrome: nursing assessment. *Dimens Crit Care Nurs* 12:247–254
- Leonard JC et al (2011) Fractures associated with cervical spine injury in children after blunt trauma. *Ann Emerg Med* 58(2):145–155
- Leone A, Cerase A, Colosimo C, Lauro L, Puca A, Marano P (2000) Occipital condylar fractures: a review. *Radiology* 216(3):635–44. Review. PubMed PMID: 10966689
- Lonstein JE (1988) Anatomy of the lumbar spinal canal. In: Nicoletti B, Kopits SE, Ascani E, Mckusick VA (eds) *Human achondroplasia: a multidisciplinary approach*. Plenum, New York, pp 219–226
- Louisiana State University Health Sciences Center (2009) Cervical collars: skin care. Retrieved from [http://www.sh.lsuhsu.edu/policies/policy\\_manuals\\_via\\_ms\\_word/Nursing/C-33.pdf](http://www.sh.lsuhsu.edu/policies/policy_manuals_via_ms_word/Nursing/C-33.pdf). Accessed 2 Feb 2010
- Lustrin S, Karakas S, Ortiz O, Cinnamon J, Castillo M, Vaheesan K et al (2003). Pediatric cervical spine: normal anatomy, variants, and trauma. *RadioGraphics* 23(3):539–560
- Mattera C (1998) Spinal trauma, new guidelines of assessment management in the out hospital environment. *J Emerg Nurs* 24:523–538
- Mechanism of Chance Fracture (2012) Retrieved 19 July 2016, from *Wheeless' textbook of orthopaedics*: [http://www.wheelessonline.com/ortho/mechanism\\_of\\_chance\\_frx](http://www.wheelessonline.com/ortho/mechanism_of_chance_frx)
- Menezes AH (1999) Craniovertebral anomalies and syringomyelia. In: Choux M, DiRocco C, Hockley AD, Walker ML (eds) *Pediatric neurosurgery*. Churchill Livingstone, New York, pp 151–183
- Menezes AH, Ryken TC, Brockmeyer DL (2001) Abnormalities of the craniocervical junction. In: McLone DG, Marlin AE, Scott RM, Steinbok P, Reigel DH, Walker LM (eds) *Pediatric neurosurgery – surgery of the developing nervous system*, 4th edn. WB Saunders, Philadelphia, pp 400–422
- Moloney-Harmon PA, Adams P (2001) Trauma. In: Curley MAQ, Moloney-Harmon PA (eds) *Critical care nursing of infants and children*, 2nd edn. Saunders, Philadelphia, pp 947–980
- Morgan DF, Young BF (1980) Spinal neurological complications of achondroplasia: results of surgical treatment. *J Neurosurg* 52:463–472
- Morris CG, McCoy E (2004) Clearing the cervical spine in unconscious polytrauma victims, balancing risks and effective screening. *Anesthesia* 59:464–482
- Nelson MA (1988) Kyphosis and lumbar stenosis in achondroplasia. In: Nicoletti B, Kopits SE, Ascani E, Mckusick VA (eds) *Human achondroplasia: a multi-*

- disciplinary approach. Plenum, New York, pp 305–312
- Neufeld EF, Muenzer J (1995) The mucopolysaccharidoses. In: Scriver CR, Beaudet AL, Sly WS, Valle D (eds) *The metabolic and molecular bases of inherited disease*, 7th edn. McGraw-Hill, New York, pp 2465–2487
- Neufeld EF, Muenzer J (2001) The mucopolysaccharidoses. In: Scriver CR, Beaudet AL, Sly WS, Valle D (eds) *The metabolic and molecular bases of inherited disease*, 7th edn. McGraw-Hill, New York, pp 3421–3465
- OrtoPed (2005) Lerman noninvasive pediatric halo system (Model C-24). Retrieved 2012, from OrtoPed: [http://www.ortoped.ca/pdf/Becker\\_C-24-Lerman-Noninvasive-Pediatric-Halo.pdf](http://www.ortoped.ca/pdf/Becker_C-24-Lerman-Noninvasive-Pediatric-Halo.pdf)
- Pang D, Wilberger JE Jr (1982) Spinal cord injury without radiographic abnormalities in children. *J Neurosurg* 57(1):114–29
- Park H, Kim H, Hahn S, Yang K, Choi C, Park J, Jung S (2003) Correction of lumbosacral hyperlordosis in achondroplasia. *Clin Orthop Relat Res* 414:242–249
- Pauli RM, Breed A, Horton VK, Glinski LP, Reiser CA (1997) Prevention of fixed angular kyphosis in achondroplasia. *J Pediatr Orthop* 17:726–733
- Pediatric Orthopaedic Society of North America (2006) *Orthopaedic Knowledge Update: Pediatrics* (3rd ed.)
- Posetti IV (1988) Bone formation in achondroplasia. In: Nicoletti B, Kopits SE, Ascani E, Mckusick VA (eds) *Human achondroplasia: a multidisciplinary approach*. Plenum, New York, pp 109–122
- Price N (2014) Principles of treatment of spine stability in children with spinal cord injury. In: Vogel L, Zebracki K, Betz R, Mulcahey M (eds) *Spinal cord injury in the child and young adult*. Mac Keith Press, London, pp 102–105
- Proctor MR (2002) Spinal cord injury. *Crit Care Med* 30:S489–S499
- Reid CS, Pyeritz RE, Kopitz SE, Maria BL, Wang H, McPherson RW, Hurko O, Phillips JA (1988) Cervicomedullary cord compression in young children with achondroplasia: value of comprehensive neurologic and respiratory function. In: Nicoletti B, Kopits SE, Ascani E, Mckusick VA (eds) *Human achondroplasia: a multidisciplinary approach*. Plenum, New York, pp 199–206
- Rimoin DL (1988) Clinical variability in achondroplasia. In: Nicoletti B, Kopits SE, Ascani E, Mckusick VA (eds) *Human achondroplasia: a multidisciplinary approach*. Plenum, New York, pp 123–127
- Ropper AE, Neal MT, Theodore N (2015) Acute management of traumatic cervical spinal cord injury. *Pract Neurol* 15(4):266–272. doi:10.1136/practneurol-2015-001094 Epub 2015 May 18. Review. PubMed PMID: 25986457
- Scheie HG, Hambrick GW, Barness LA (1962) A newly recognized form of Hurler's disease (Gargoylism). *Am J Ophthalmol* 67:753–769
- Schnuerer AP, Gallego J, Manuel C (2001) Basic anatomy and pathology of the spine: core curriculum for basic spinal training. Medtronic Sofamor Danek, Memphis
- Shiang R, Thompson LM, Zhu Y, Church DM, Fielder TJ, Bocian M, Winokur ST, Wasmuth JJ (1994) Mutations in the transmembrane domain of FGFR3 cause the most common genetic form of dwarfism, achondroplasia. *Cell* 78:335–342
- Skaggs D, Flynn J (2006) *Staying out of trouble in pediatric orthopaedics*. Lippincott Williams & Wilkins, Philadelphia
- Sullivan JA, O'Donoghue DH (2005) Klippel-Feil syndrome. e-medicine. <http://www.emedicine.com/orthoped/topic408.htm>. Accessed 18 May 2006
- The Marfan Foundation (2016) Loeys-Dietz Syndrome. Retrieved from THE Marfan Foundation: <http://www.marfan.org/loeys-dietz>
- Turkstra TP, Craen RA, Pelz DM, Gelb AW (2005) Cervical spine motion: a fluoroscopic comparison during intubation with lighted stylet, GlideScope, and Macintosh laryngoscope. *Anesth Analg* 101:910–915
- Uematsu S, Wang H, Hurko O, Kopits SE (1988) The subarachnoid fluid space in achondroplastic spinal stenosis: the surgical intervention. In: Nicoletti B, Kopits SE, Ascani E, Mckusick VA (eds) *Human achondroplasia: a multidisciplinary approach*. Plenum, New York, pp 275–281
- Van de Pol GJ, Hanlo PW, Oner FC, Catelein R (2005) Redislocation in a halo vest of an atlanto-occipital dislocation in a child: recommendations for treatment. *Spine* 30:E424–E428
- Viccellio P et al (2001) A prospective multicenter study of cervical spine injury in children. *Pediatrics* 108(2):e20
- Vogel LC, Hickey KJ, Klass SJ, Anderson CJ (2004) Unique issues in pediatric spinal cord injury. *Orthop Nurs* 23:300–308
- Wiggins GC, Shaffrey C, Abel M, Menezes A (2003) Pediatric spinal deformities. *Neurosurg Focus* 14(1): 1–14, Article 3
- Wright MJ, Ain MC, Clough MV, Bellus GA, Hurko O, McIntosh I (2000) Achondroplasia and nail-patella syndrome: the compound phenotype. *J Med Genet* 37(9):E25

Theresa M. Gabay and Davonna Ledet

---

## 12.1 Introduction

Neurovascular malformations are generally congenital lesions that may or may not have a hereditary or familial origin. They can be associated with other pathologies, such as infection or cardiac disorders, or can be a result of trauma or medical treatments (Vananman et al. 2010). Although considered a rare occurrence in the pediatric population, these anomalies have the potential for significant morbidity and mortality, given the life expectancy in this age group (Moore and Agur 1995). The vast majority of pediatric malformations fall into one of the following groups: AVM, cavernous malformation, vein of Galen malformation, aneurysms, venous angiomas, and moyamoya.

---

T.M. Gabay, RN, MSN, APRN, CNRN (✉)  
Advanced Neurosurgery Associates,  
Rutherford, NJ, USA  
e-mail: [tgabay@advancedneurosurgeons.com](mailto:tgabay@advancedneurosurgeons.com)

D. Ledet, RN, MSN, MBA, DNP, APN-BC, CNRN  
Neuroscience Institute, LeBonheur Children's  
Hospital, Memphis, TN, USA  
e-mail: [davonna.ledet@lebonheur.org](mailto:davonna.ledet@lebonheur.org)

---

## 12.2 Vascular Anatomy

Vessels within the vascular blood supply are composed of arteries, veins, and capillaries. Table 12.1 describes the characteristics of these three types of vessels.

---

## 12.3 Cerebral Blood Supply

The cerebral circulation is composed of two very distinct circulatory systems: the arterial and venous systems. The two systems work in unison to maintain appropriate pressure and perfusion within the brain. There are many physiologic and pathologic factors that can affect blood flow in the arteries and veins of the brain, including acid-base balance, oxygen saturation, and systemic blood pressure. Under normal conditions of autonomic regulation, the mean arterial pressure is maintained at 0–10 cm H<sub>2</sub>O (McCance and Huether 2002). This ensures adequate perfusion of the cerebral capillary beds despite changes in systemic blood pressure.

### 12.3.1 Arterial Supply

Arterial blood enters the cranial cavity anteriorly (via the carotid arteries) and posteriorly (via the vertebral arteries). They feed into an



**Table 12.1** Description of arteries, capillaries, and veins

Arteries	Artery walls are composed of three layers: tunica intima, tunica media, and tunica adventitia. There are three types of arteries: elastic arteries, muscular arteries, and arterioles. Thickness of wall layers and differences in makeup of these layers – particularly the tunica media – are elements that further distinguish the different artery types from one another (Moore and Agur 1995)
Elastic arteries	Elastic arteries are the largest type of artery. They expand synchronously with heart contractions and resume their normal shape between contractions (Moore and Agur 1995)
Muscular arteries	These arteries distribute blood to various parts of the body, and for this they are often referred to as <i>distributing arteries</i> . Muscular artery walls consist of circularly disposed smooth muscle fibers. The smooth muscle fibers constrict their lumina upon contraction (Moore and Agur 1995)
Arterioles	Arterioles are the smallest of the arteries. They have a narrow lumina and thick muscular walls. The degree of tonus of the smooth muscle in arteriole walls is primarily responsible for arterial pressure (Moore and Agur 1995)
Capillaries	Capillaries connect arteries to veins. They are made of endothelial tubes and are arranged in a network known as capillary bed (Moore and Agur 1995). The makeup of a capillary wall consists of a single layer of endothelial cells that are surrounded by a thin basement membrane of the tunica intima. Some capillary walls consist of a single endothelial cell with no tunica of the tunica externa. Other capillaries contain oval windows known as fenestrations within the endothelial cells. A thin diaphragm covers the fenestrations (McCance and Huether 2002)
Veins	Vein wall are thinner than artery walls because of the lower blood pressure in the venous system. They are also fibrous and have a larger diameter. The tunica externa of veins has less elastic tissue than arteries, and as a result, veins do not possess the capacity to recoil as seen in arteries (McCance and Huether 2002). Valves work to permit blood to flow toward the heart and prevent blood from flowing in the opposite direction. There are three types of veins: small, medium, and large. The adventitia of large veins is composed of wide bundles of longitudinal smooth muscle. Venules are the smallest type of vein (Moore and Agur 1995). The smallest venules that are closest to capillaries have an inner lining made up of the endothelium of the tunica intima and surrounded by fibrous tissue. The largest venules that are furthest from the capillaries are made of a thin tunica media that consists of a few smooth muscle fibers (Moore and Agur 1995)

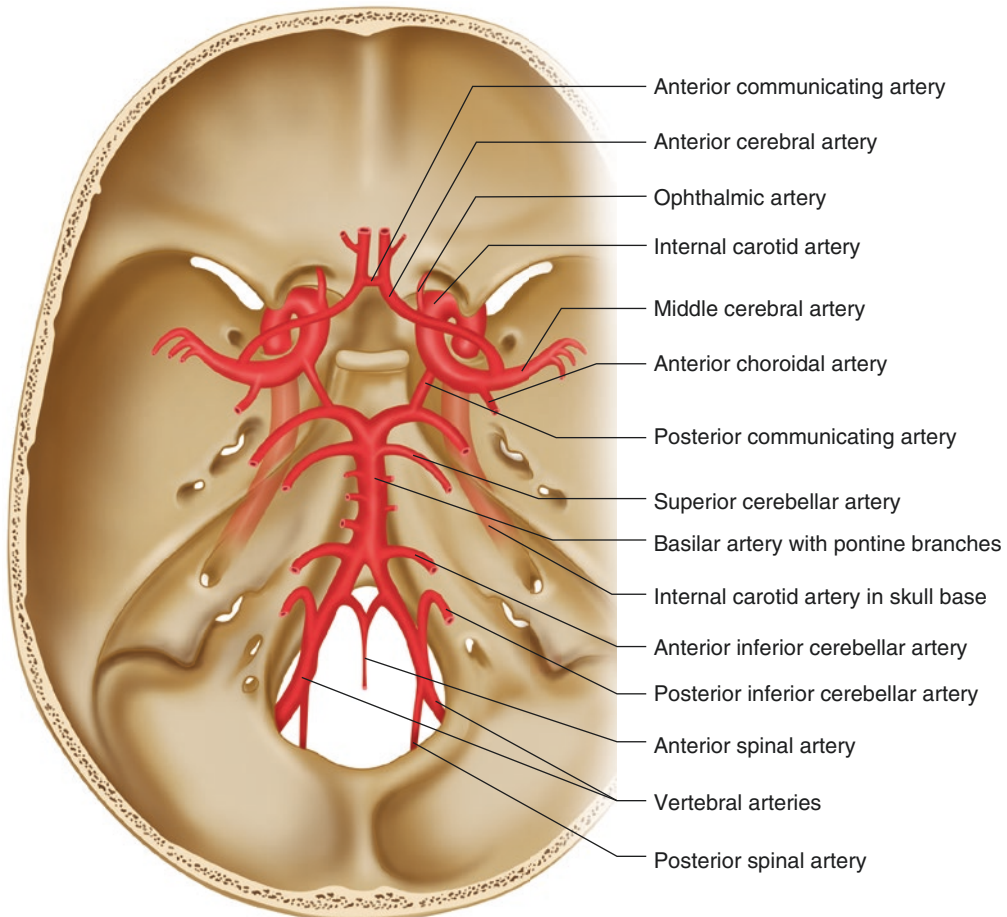
anastomotic ring of vessels called the circle of Willis, which gives rise to all the major cerebral arteries (Fig. 12.1). The origin of the brain's anterior arterial system is the right and left common carotids arising from the innominate artery and aortic arch, respectively. Each of these large vessels further branches into the external and internal carotid arteries. The external carotid is responsible for blood supply to the face and scalp. The internal carotid enters the base of the skull via the foramen lacerum. It then twists and divides into several segments (i.e., cervical, petrous) and terminates by dividing into the anterior cerebral artery and middle

cerebral artery (MCA). Main branches include the ophthalmic artery, the posterior communicating artery, and the anterior choroidal artery (Hinkle et al. 2010). The cortical areas are supplied by the anterior and middle cerebral arteries, as well as the anterior choroidal arteries (Table 12.2).

The two vertebral arteries, which originate from the subclavian arteries, enter the skull through the foramen magnum and then unite at the level of the pons to form the basilar artery. The posterior inferior cerebellar arteries branch off the vertebrals and the anterior inferior cerebellar arteries, superior cerebellar arteries, and

**Table 12.2** The cortical areas supplied by the major cerebral arteries

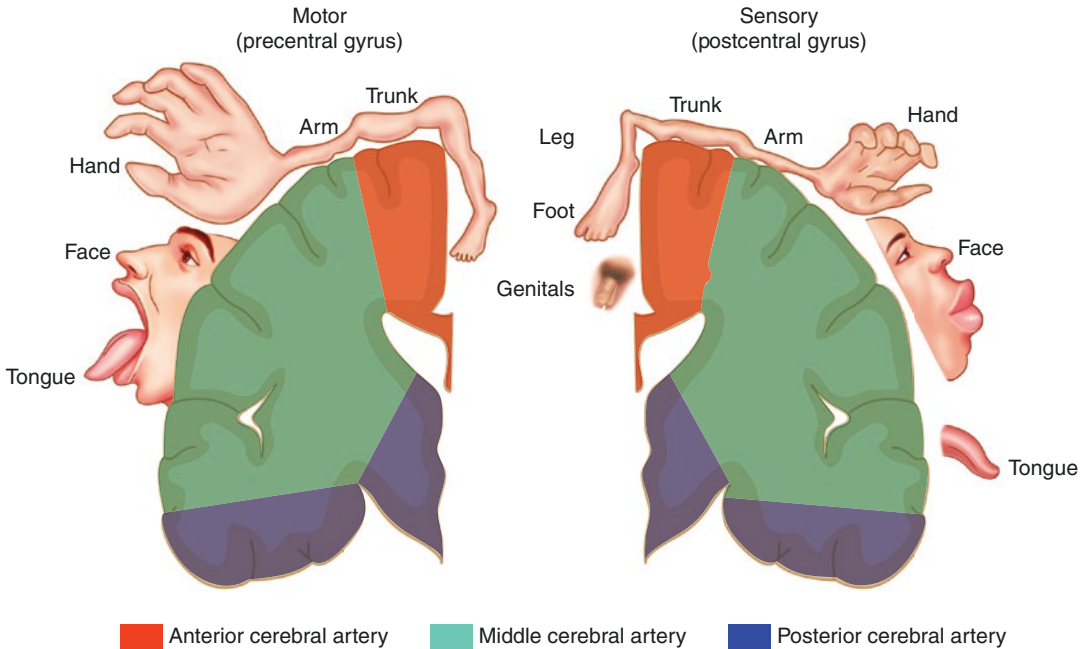
Middle cerebral artery	Supplies many deep lateral aspect of the cerebrum
Anterior cerebral artery	Supplies the anterior frontal lobe and the medial aspects of the hemisphere
Posterior cerebral artery	Supplies the occipital lobe and choroid plexus of the third and lateral ventricles and the lower surface of the temporal lobe
Anterior choroidal artery	Supplies the choroid plexus of the lateral ventricles and the adjacent brain structures supplied by the major cerebral arteries

**Fig. 12.1** Circle of Willis. Principal arteries on the floor of the cranial cavity (From Waxman (2003))

posterior cerebral arteries arise from the basilar artery (Fig. 12.1).

The posterior circulation, or the vertebral basilar system, supplies the brainstem, cerebellum, occipital lobe, and parts of the thalamus. The anterior circulation, as described above, supplies the remainder of the forebrain (Hinkle et al. 2010).

Occlusion of a specific artery often leads to a characteristic clinical picture (Fig. 12.2). Each major artery supplies a certain territory which is separated from other territories by watershed areas (the border of two vascular territories lying adjacent to each other). The two anterior cerebral arteries are joined together by the anterior



**Fig. 12.2** Arterial supply and homunculus

communicating artery. This allows for communication of the right and left hemispheres and is important in compensation for blood flow in the event of an occlusion of one of the carotid arteries.

### 12.3.2 Venous System

The venous system of the brain and coverings is a network of drainage systems that include the veins of brain tissue, dural venous sinuses, dural meningeal veins, and veins between the skull tables (diploic veins). The majority of these veins communicate and, unlike systemic veins, have no valves.

The cerebral veins consist of the superficial cerebral veins and the deep cerebral veins. The superficial cerebral veins, also known as the cortical veins, drain blood from the outer surface of the brain into the large venous channels: the superior and inferior sagittal sinuses, the great cerebral vein of Galen, the straight sinus, and the tentorial veins. Blood from the cerebellar surface

is drained by way of the cerebellar veins into the superior vermician vein and then into the great cerebral vein, straight sinus, and transverse sinuses. Blood from the inner regions of the brain is drained by the deep cerebral veins (or central veins). The inner regions include the hemispheric white matter, basal ganglia, corpus callosum, and choroid plexus. The deep cerebral veins also drain blood from several cortical areas (Moore and Agur 1995).

Blood supply from the brain drains into the dural venous sinuses and subsequently into the internal jugular veins. The dural venous sinuses are lined with endothelial cells and are found between the endosteal and meningeal layers of the dural mater (Moore and Agur 1995).

### 12.3.3 Pediatric Stroke

Stroke is the sudden occlusion or rupture of cerebral arteries or veins resulting in focal cerebral damage and clinical neurological deficits.

A hemorrhagic stroke is one involving the rupture of a blood vessel, while ischemic stroke involves an occlusion that restricts the flow of blood to part of the brain, thus causing the tissue to die. Although it is commonly thought of as an “old person’s disease,” stroke also strikes infants and children and can occur in utero. Strokes in children are markedly different than strokes in adults, both in terms of risk factors and treatment, but the need to urgently recognize and treat within a short time period is vital for both populations.

The risk of stroke is greatest in the perinatal period, occurring in 1 out of every 4,000 live births (Lloyd-Jones et al. 2009), and the overall incidence of stroke in children is 1–6 per 100,000 children per year (Mallick et al. 2014). Breaking it down, the incidence of cerebral venous strokes is 0.5–1 per 100,000 children (Agrawal et al. 2009), 5.11/100,000 for hemorrhagic strokes (Giroud et al. 1995), and 2–13/100,000 for arterial ischemic strokes. The rates may even be higher as it remains an under-recognized disease entity in childhood. Boys are at greater risk of stroke than girls, and African American children are at greater risk than Caucasian and Asian children (Lloyd-Jones et al. 2009).

Neonatal risk factors include a maternal history of infertility, chorioamnionitis, premature rupture of membranes, and preeclampsia. In older children, sickle cell disease and congenital or acquired heart disease, head trauma, and major infections, such as encephalitis, meningitis, and stroke, are the most common risk factors (Roach et al. 2008), although arteriopathies, vasculitis, coagulopathies, and hematologic and metabolic disorders raise the risk as well. However, in the majority of children, strokes are idiopathic, with no underlying systemic disease found (Amlie-Lefond et al. 2009).

Symptoms of stroke in children are different than in adults and differ between age groups. Perinatal strokes that may occur anywhere from birth to 28 days after birth generally present less specifically as poor feeding, irritability, apnea, hypotonia, or with seizures (Kirton et al. 2011). Early handedness (before age 3 years) or devel-

opmental delay may also be a sign of perinatal stroke (Roach et al. 2008). As the child ages, focal neurological deficits are the more common presenting signs including hemiplegia or hemiparesis, an acute change in speech pattern, headaches, vomiting, hemianopsia, ataxia, or abrupt change in level of consciousness. The middle cerebral artery (MCA) is the most affected. Fifty to 80% of children who survive stroke will often have permanent neurological deficits, usually hemiplegia/hemiparesis – the most common symptom of cerebral palsy in term infants (Kirton and deVeber 2006).

A noncontrast CT may be performed in the acute presentation to rule out a hemorrhagic stroke, but within the first 12 hours of an acute ischemic stroke, the CT will likely be normal. Consequently, an MRI of the brain with diffusion-weighted imaging is considered the diagnostic gold standard.

Treatment of acute ischemic stroke is directed at minimizing further injury to prevent future developmental, cognitive, or functional impairment. Although there is a significant lack of pediatric data for the clear treatment of stroke, there are management guidelines available (Monagle et al. 2008; Roach et al. 2008). Generally, after hemorrhagic stroke has been ruled out, acute thrombotic treatment is recommended although the specific indications and type of therapy remain controversial. Anticoagulation with unfractionated heparin is safe for secondary prevention (Coutinho et al. 2011).

Children presenting with hemorrhagic stroke should have a thorough evaluation for vascular malformations and any arteriovenous malformations should be treated. Due to the significant chance of lifelong disability accompanied by the potential for considerable devastating effects on the family and society, pediatric stroke should be highly considered in the differential diagnosis. When the child presents with neurologic signs and symptoms, aggressive data collection should be performed to make an accurate diagnosis in this extremely significant disease entity (Gardner et al. 2010; Goldenberg et al. 2009; Perkins et al. 2009).

### Pearls

- Risk of stroke is greatest in the perinatal period.
- Newborns with stroke present with:
  - Poor feeding
  - Irritability
  - Apnea
  - Hypotonia
  - Seizures
  - Early handedness (before age 3 years)
  - Developmental delay
- Older children with stroke present with:
  - Hemiplegia or hemiparesis
  - Acute change in speech pattern
  - Headaches
  - Vomiting
  - Hemianopsia
  - Ataxia
  - Abrupt change in level of consciousness
- Noncontrast CT may be used in the acute stage to rule out hemorrhagic stroke, but diffusion-weighted MRI is the gold standard for diagnosis.
- Treatment is directed at minimizing further injury and may include thrombotic treatment and/or prolonged anticoagulation for cases of ischemic stroke.

### Ronnie's Story

Ronnie is a happy, healthy 13-year-old African American male who loves playing sports and hanging out with his friends. One summer morning, he began to experience a headache but decided it wasn't bad enough to stay at home, so he went to the gym to play basketball with his friends. Once there though, his headache worsened and he experienced a syncopal episode. He was taken by EMS transport to the closest children's hospital and diagnosed with an acute stroke. He was given tissue plasminogen activator (tPA), and his clot was

embolized in the catheterization lab. He was diagnosed with dextrocardia as well as a moderate to large secundum atrial septal defect with left to right shunt. Surprisingly, he had been asymptomatic up to this event. Ronnie was discharged home with physical therapy secondary to his left-sided hemiparesis and placed on low-molecular-weight heparin (LMWH) until he could have surgical repair of his heart defect. Four months later, Ronnie underwent successful surgical intervention. He demonstrates minimal residual neurological deficits, and he is playing sports, going to school, and thankful for his life returning to normal.

## 12.4 Vein of Galen Aneurysmal Malformations

### 12.4.1 Pathophysiology

A vein of Galen aneurysmal malformation (VGAM) is a rare intracranial vascular anomaly typically found in neonates and infants but can also present in older children and adults. It accounts for approximately 1% of all cerebrovascular lesions overall (Huhn et al. 2006), although it is estimated to account for approximately 30% of all pediatric vascular malformations (Long et al. 1974). The vein of Galen, or great cerebral vein, lies under the cerebral hemispheres in the subarachnoid space dorsal to the midbrain and drains the anterior and central regions of the brain into the sinuses of the posterior cerebral fossa (Santos et al. 2005). The vein of Galen extends embryologically from the posterior segment of the median prosencephalic vein of Markowski (MProsV) and drains into the vein of Galen (Huhn et al. 2006). The MProsV can be identified between the 8th and 11th weeks of gestation, during which time the VGAM is thought to develop. The MProsV is the persistent embryonic channel that forms the aneurysmal or dilated component of the VGAM



**Table 12.3** Vein of Galen aneurysmal malformation: neonatal evaluation scoring system

Score	Cardiac function	Cerebral function	Hepatic function	Respiratory function	Renal function
5	Normal	Normal	Normal	Normal	Normal
4	Untreated overload	Subclinical EEG abnormalities	Normal	Tachypnea but finishes bottle feed	Normal
3	Stable treated failure	Intermittent neurological signs	No hepatomegaly, normal function	Tachypnea, does not normally finish bottle feed	
2	Unstable treated failure	Isolated seizure	Hepatomegaly, normal function	Ventilated, normal saturations <25% added O <sub>2</sub>	Transient anuria
1	Ventilated treated failure	Continuing seizures, neurological signs	Abnormal function	Ventilated, normal	Unstable
0	Resistant to treatment		Coagulopathy, raised enzymes	Ventilated, desaturated	Anuric

(Raybaud and Strother 1986). Most of the arterial supply of a VGAM comes from the choroidal arteries or feeders, which include the anterior and posterior choroidal arteries, the pericallosal artery, transmesencephalic branches from the basilar tip, and the proximal posterior cerebral arteries (Gailloud et al. 2005). The VGAM results from multiple fistulous connections or arteriovenous shunts that drain into the MProsV. It is still not known how these arteriovenous shunts actually form. Consequently, the MProsV becomes progressively dilated from the high-pressure flow from the choroidal feeders (Gailloud et al. 2005).

VGAMs can be classified into categories based on their angioarchitecture: choroidal and mural (Lasjaunias 1997). The simplest or choroidal type receives its arterial contribution from the choroidal arteries and a typical interposed network is present before opening into the large venous pouch. This choroidal type has been found mostly in neonates with poor clinical scores (Table 12.3). The second, or mural type, represents direct arteriovenous fistulas within the wall of the MProsV, and it can either be single or multiple. There may also be mixed forms when direct shunts and arterial networks combine (Hoang et al. 2009). Mural VGAMs tend to occur in infants with higher clinical scores. A score between 8 and 12 entails emergency endovascular management (Lasjaunias 1997).

## 12.4.2 Presenting Symptoms

The clinical features of VGAM differ characteristically with the age of presentation (Gold et al. 1964). The larger the arteriovenous shunt, the earlier the anomaly will manifest itself clinically. Symptomatic neonates can present with severe or progressive high-output congestive heart failure with cardiomegaly, as a result of the large volume of blood exerted by a VGAM with high-flow arteriovenous shunts (Gold et al. 1964; Fullerton et al. 2003). Severe pulmonary hypertension can also be a complication. Infants may present with an increasing head circumference secondary to hydrocephalus, seizures, and/or hemorrhage, albeit rare (Gold et al. 1964). Vein of Galen malformation should always be ruled out in neonates born with high-output cardiac failure (Hoang et al. 2009).

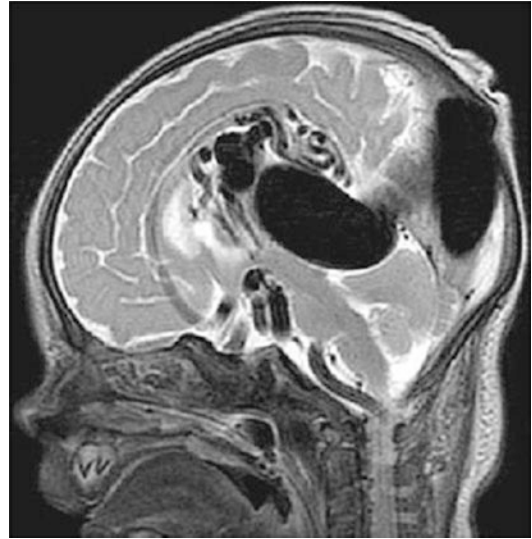A cerebral “steal” phenomenon, or the siphoning of blood flow away from adjacent brain tissue, can result in cerebral atrophy and periventricular leukomalacia (Pasqualin et al. 1982). The most severe form of the cerebral “steal” phenomenon is often referred to as the melting brain (Alvarez et al. 2007). Mild symptoms in the neonate may include feeding difficulties, tachycardia, and cardiomegaly on chest x-ray (Alvarez et al. 2007). More severe presentations include cardiorespiratory failure, hydrops, (a large amount of fluid buildup in the infant’s brain tissue), and renal failure (Gailloud et al. 2005).

Cardiac manifestation is typically milder in infants, and they are usually treated symptomatically with diuretics until the embolization procedure can be performed (Alvarez et al. 2007). Milder symptoms in this age group are usually due to a smaller shunt. Other symptoms may include failure to thrive, cranial bruits, dilated scalp veins, proptosis, prominent scalp veins, and epistaxis (Gailloud et al. 2005; Gulati and Kalra 2002; Gupta and Varma 2004). Noncommunicating hydrocephalus results from aqueductal obstruction or compression of the posterior third ventricle by the VGAM itself, whereas impaired cerebrospinal fluid absorption caused by subarachnoid hemorrhage (SAH) could contribute to communicating hydrocephalus (Jaegar et al. 1937). Intracranial venous hypertension induced by the VGAM has also been postulated to contribute to the development of hydrocephalus (Zerah et al. 1992).

In older children and adults, headaches tend to be the presenting symptom, which may be attributed to subarachnoid hemorrhage (Gold et al. 1964). Older children may also present with focal seizures and developmental delay. Poorer outcomes are demonstrated when prenatal diagnoses with ultrasound showed associated cardiomegaly and ventriculomegaly rather than isolated VGAM (Deloison et al. 2012). Preoperative sudden deaths in patients with VGAM have gradually declined, while the rate of emergency operations has gradually increased. Urgent medical attention to these malformations has demonstrated improved outcome (Yan et al. 2016).

### 12.4.3 Diagnostic Tests

Transcranial ultrasound will help to localize or identify the lesion, and color Doppler studies can help to delineate the hemodynamics of the lesion (Deeg and Scarf 1990; Rodesch et al. 1994). A typical Doppler finding is that of a large, midline cystic structure with arterialized flow and visualization of the feeding arteries (Blaser et al. 2003). Cranial MRI and/or CT scan, with and without contrast administration, will help to establish the



**Fig. 12.3** Magnetic resonance image (MRI) of the vein of Galen malformation

venous and arterial vascular anatomy of the lesion, as well as to confirm the diagnosis and define the degree of involvement (Fig. 12.3) (Blaser et al. 2003; Gailloud et al. 2005; Huhn et al. 2006). Imaging studies in infants will also help determine whether the patient has accompanying hydrocephalus.

MR angiography (MRA) will be able to delineate feeding arteries, nidus, and draining veins, as well as distinguish the high-flow feeding vessels from the low-flow venous lesions (Blaser et al. 2003; Santos et al. 2006). CT angiogram is another modality of diagnostic imaging that may be helpful. In patients being considered for surgery or for endovascular therapy, cerebral angiography may be required to define the extent of aneurysmal dilatation and details for arterial feeders (Huhn et al. 2006). Angiography findings typically show anterior and posterior circulation fistulae supplying a markedly dilated vein of Galen (Blaser et al. 2003). However, cerebral angiography should only be undertaken as a prelude to therapeutic intervention and is not required purely for diagnosis, as the nature of the condition can be confirmed by MRI (Punt 2004). Cardiac ultrasound may be indicated to assess left ventricular function (Chevret et al. 2002).

## 12.4.4 Treatment Options

### 12.4.4.1 Endovascular Treatment

VGAMs have proven to be very difficult to treat using standard surgical procedures. Fortunately, this condition can now be treated with endovascular embolization, with improved neurodevelopmental outcomes (Chow et al. 2015). Endovascular embolization involves the injections of embolic agents, such as synthetic cyanoacrylate glue (*N*-butyl-cyanoacrylate or NBCA) or a variety of coils. Embolic agents encourage blood clotting and closure of the VGAM (Lasjaunias et al. 1991). Onyx (one of the more recently developed liquid embolic substances) has also been used to occlude the arteriovenous fistula on the arterial side (Gailloud et al. 2005; Jankowitz et al. 2008; Lasjaunias et al. 2006). The transarterial approaches are preferred over transvenous endovascular treatments. The literature clearly indicates an improved outcome and fewer complications associated with the arterial approach, such as potentially impairing normal deep venous pathways (Levrier et al. 2004; TerBrugge 1999, 2006). Using x-ray guidance, this procedure involves the insertion of a microcatheter through the femoral artery that is threaded through the arteries until the tip reaches the site of the arterial feeder. The embolic agent is then injected through the catheter. Sometimes several staged endovascular embolizations are required to help avoid the occurrence of parenchymal bleeds, secondary to “perfusion breakthrough phenomenon,” or massive venous thrombosis potentially endangering the normal venous supply (Gailloud et al. 2005). “Perfusion breakthrough” refers to a hemorrhage or swelling that develops from abnormal perfusion of the vessels surrounding the recently embolized lesion. Perfusion breakthrough is more prevalent in patients who are hypertensive. Given that most of these hemorrhages occur within the first week after treatment, strict management of the blood pressure in the days post-procedure is imperative.

Non-neurological complications related to embolization are rare (Lasjaunias 1997). Asymptomatic occlusion of the internal iliac

artery and the microcatheter getting glued in place have been reported. Repeated punctures of the femoral artery do not seem to cause significant problems.

The timing of endovascular management is usually determined by the severity of the clinical presentation (Gupta and Varma 2004). Emergency embolization in the newborn is considered necessary in cases where congestive heart failure is present and does not respond to medical management (Gupta et al. 2006). Some clinicians feel that the therapeutic window for optimal endovascular management is between 4 and 6 months of age, as long as the infant is hemodynamically stable (Gailloud et al. 2005; TerBrugge 1999). However, excessive delay may lead to intractable hydrocephalus. There are a minority of patients who experience spontaneous thrombosis of the malformation (Cheng et al. 2003; Lasjaunias 1997; Lasjaunias et al. 1991).

### 12.4.4.2 Surgical Treatment

As a result of advances in endovascular management, surgical obliteration of a VGAM is now only considered in case of failure of, or as an adjunct to embolization (Gailloud et al. 2005; Huhn et al. 2006). Surgical interventions are indicated for the evacuation of intracranial hematomas and for the management of hydrocephalus. This can be treated either by endoscopic third ventriculostomy or insertion of a ventriculoperitoneal shunt (Gailloud et al. 2005). Shunt placement is associated with mortality and morbidity so should be considered if the treatment of the VGAM does not address the hydrocephalus.

## 12.4.5 Nursing Care

One of the primary goals of the nursing care for the neonate with a VGAM is maintaining optimal neurological function. Head circumference measurements should be obtained regularly and monitored carefully to detect hydrocephalus. Patients should be monitored for seizures and managed with antiepileptic medications. Usually, neonates are given phenobarbital and phenytoin. Respiratory interventions should include chest

physiotherapy and suctioning to maintain the airway in the ventilated patient. Cardiac management of high-output heart failure is essential. Clinical care includes monitoring of physical activity, oxygen requirements, adequate caloric intake, and strict maintenance of input and output records. Pharmacological management can include inotropic agents (digoxin, dopamine, dobutamine), diuretics (loop diuretics, such as furosemide), and afterload-reducing agents (angiotensin-converting enzyme inhibitors such as captopril and enalapril). Other important nursing interventions include maintaining skin integrity, infection prevention and early recognition of sepsis, and providing comfort measures of frequent repositioning and pain medications as needed. Additionally, facilitation of parent-infant bonding, normal grieving and coping, and open communication are other means of providing holistic nursing care (TerBrugge 1999).

#### 12.4.6 Family Education

Parents must face the ethically and morally difficult decision of whether or not to treat the child's lesion, particularly for parents of children whose available medical information does not clearly indicate the benefit of one choice over the other (Gaillood et al. 2005). Parents may not fully understand the potentially devastating outcome of a child who is unresponsive to treatment, yet survives, and therefore are ill-prepared to adapt to life with a severely debilitated child. Problems include obtaining medical equipment, financial assistance, and certain support services often occur. It is of utmost importance that therapeutic decision-making is a shared process between the clinician and parents. All elements defining the child's best interests must be considered and discussed.

#### 12.4.7 Outcomes

Prior to the advent of endovascular embolization, the prognosis for patients presenting as neonates with congestive heart failure was poor. An earlier review reported mortality rates of 100% (9/9) for

neonates, 68% (13/19) for infants, and 45% (5/11) for older children and adults (Gold et al. 1964). Modifications in the application of newer microcatheters, acrylic polymer NBCA, and neonatal care, such as modern imaging and intensive care environment, improved the outlook in a series of 11 patients (Friedman et al. 1993). No mortality had occurred, and 6 out of the 11 patients were functionally normal up to 30-month follow-up. In a series of 78 neonates, infants, and children that were treated and followed, seven of these patients died, but 66% of the 71 patients remaining were neurologically normal, 14% had transient neurological symptoms, 11.5% had mild permanent deficits, and 8.5% had severe permanent deficits (Lasjaunias et al. 1991). In a more recent series of 27 children undergoing endovascular treatment, four of whom died in hospital, 61% of the 23 surviving patients had no or minor developmental delay, and 64% had no or mild abnormalities on neurological examination (Fullerton et al. 2003).

Resolution of cardiac failure has also been achieved favorably with embolization. In a series of five symptomatic neonates, one died of intractable cardiac failure (20%), whereas control of cardiac failure was achieved by embolization without neurological symptoms in the surviving four patients. One of the patients (20%) demonstrated moderate developmental delay in follow-up (Mitchell et al. 2001). In a larger series of nine symptomatic neonates who underwent endovascular treatment, six patients (66%) obtained control of cardiac failure and normal neurological functioning, one patient died from intractable cardiac failure, and two patients (33%) died later as a result of severe hypoxic-ischemic neurological injury. At 6-month to 4-year follow-up, five infants had no evidence of either neurological or cardiac deficits, and one (11%) child had mild developmental delay (Frawley et al. 2002).

In another series with 15 patients who underwent embolization, 66% (10/15) had a complete obliteration of the fistula with an overall mortality rate of 20% (3/15) secondary to meningitis and intracranial hemorrhage. At 6-year follow-up, these patients were stable cognitively with overall improvement of their delayed developmental milestones (Gupta et al. 2006).

In a series of 233 patients, endovascular embolization was utilized via the transfemoral approach in patients where angiographic studies demonstrated a 90–100% occlusion in 55% of the patients. The neonatal mortality outcome was 52% (12/23), while the general mortality rate was 10.6% (23/216). Of note, only three of these deaths were caused by the embolization procedure. In the neonatal population, most of the deaths represented patients whose clinical presentation score was <8, and intervention was not expected to be successful. This study also demonstrated that persistent shunts, if small, can be tolerated and may even resolve spontaneously over time (Lasjaunias et al. 2006).

In a prospective review spanning 21 years, one large center treated 26 patients with VGAMs. At presentation, 12 of the patients presented with congestive heart failure, while ten presented with hydrocephalus. Five patients did not qualify for surgical interventions because of either mild or severe symptomatology. Of the remaining patients, 12 underwent embolization, and the remaining nine underwent endovascular surgery. Overall survival rate was 76.9% (20/26). Of the 21 patients who underwent endovascular treatment, 66/7% (14/21) went on to experience no delay in development. Those patients who were older at the time of embolization were noted to have more developmental delay as compared to those who were younger at the time of embolization (Li et al. 2010).

In summary, the more current reviews have shown improvement in both morbidity and mortality for the neonatal and pediatric populations. With continued advances in imaging and staged transarterial and transvenous embolizations, infants and children can have promising long-term cognitive and functional outcomes (Ellis et al. 2012).

---

## 12.5 Cerebral Arteriovenous Malformation in Children

### 12.5.1 Etiology

Cerebral arteriovenous malformation (AVM) is a relatively uncommon vascular lesion. Within the general population, the prevalence is estimated

to be between 1.34 and 18 cases per 100,000 (Boone et al. 2016). Although AVMs are considered to be congenital in origin, few are diagnosed in the first two decades of life. The average age of presentation is 32–40 years old. In the less than 20-year-old age group, rate of occurrence is between 0.014% and 0.028%. This translates to a 20% rate of all AVMs diagnosed (Darsaut et al. 2011; Singhal et al. 2011; Foy et al. 2010; Buckley and Hickey 2014; Boone et al. 2016). The main difference between adults and children with regard to this lesion is the dramatic presentation of spontaneous hemorrhage as the initial symptom. This is as high as 80–85% in the pediatric population versus 50–65% in adults (Niazi et al. 2010) and accounts for more than half of the various presentation symptoms. Despite improvement of medical and surgical management, there is still a high mortality rate of 20–25% in children due to this phenomenon (Boone et al. 2016).

The majority of cerebral AVMs occur sporadically, are generally single lesions, and have no predilection for race or gender. Multiple AVM (MAVM) has been reported in the literature. These are two or more nidi that are separated by brain parenchyma and often present with neurological findings versus hemorrhage (Boone et al. 2016). Additionally, familial cases have been documented but are very rare (Yokoyama et al. 1991). AVMs are known to be associated with a few syndromes, specifically hereditary hemorrhagic telangiectasia (HHT) or Osler-Weber-Rendu disease. About 3.4% of children with AVM have HHT (Smith 2015). Recent investigations into this comorbid phenomenon have implicated a genetic mutation process along the transforming growth factor-beta signaling pathway causing AVM development (Smith 2015). In children diagnosed with multiple AVMs, HHT should be considered (Griffiths et al. 1998; Horgan et al. 2006; Roach and Riela 1995). Additionally, Wyburn-Mason syndrome (Bonnet-Dechaume-Blanc) is a rare congenital, nonhereditary disorder characterized by multiple cutaneous nevi and brain and retinal AVM (Roach and Riela 1995).



## 12.5.2 Pathophysiology

AVMs are often very complex neurovascular lesions. They are defined as a cluster of arteries and veins in the brain or on its surface that directly shunts arterial blood to the venous system. There is an absence of normal intervening capillary beds between the two systems causing the vessels to become dilated and tortuous forming a central nidus (Ali et al. 2003; Kondziolka et al. 1999; Roach and Riela 1995).

There is no brain parenchyma contained within the nidus. The tangled nidus of the AVM receives direct high-flow arterial blood from multiple feeding arteries. Blood is then shunted straight into the venous drainage system, which is subserved by veins that vary considerably in number, size, and configuration. The blood vessels become progressively dilated, thereby increasing the risk of rupture and subsequent spontaneous intracranial hemorrhage. In addition to dilatation, blood vessels are further weakened by dynamic remodeling of the structure from inflammatory and angiogenic processes (Smith 2015).

AVMs have been predominantly described as congenital abnormalities arising from persistent embryonic patterns with failure of normal involution of blood vessel networks (Buckley and Hickey 2014). It is hypothesized that a defect in the formation of the normal arteriolar capillary network occurs somewhere around the third to 12th week of embryogenesis which leads to the malformation (Niazi et al. 2010). Others postulate that AVMs are a consequence of stimulation of vascular growth by blood shunting, genetic errors, and mutations in the genes controlling angiogenesis (Zaidat and Alexander 2006). They may enlarge in childhood through early adulthood when new blood vessels are recruited during brain growth and development (Buckley and Hickey 2014).

These factors result in a propensity for AVM hemorrhage. The annual incidence of AVM rupture in children is 2–4% per year (Niazi et al. 2010; Yen et al. 2010; Darsaut et al. 2011). Mortality rate for children is 25% versus 6–10% in adults. Often AVMs in children are located in the posterior fossa or are deep seated in areas such

as the basal ganglia or thalamus. Hemorrhages in these regions are generally less tolerated because of the valuable “real estate” in these areas than in the supratentorial areas seen as common AVM sites for adults. It is suspected that AVMs in children may be prone to bleeding due to a more active angiogenesis mediated by vascular endothelial growth factor (VEGF) as opposed to their adult counterparts (Niazi et al. 2010).

Tissues adjacent to the AVM may also be mildly hypoxic as the malformation may be stealing blood from the bordering healthy tissue causing chronic ischemia (Roach and Riela 1995; Smith and Sinson 2006). This steal phenomenon results in less devastating neurological symptoms initially but may herald an impending bleed. This phenomenon is generally not seen in children.

Secondary pathological changes can occur and include cerebral aneurysms; approximately 7% of patients with an AVM develop an aneurysm (Smith and Sinson 2006). Most commonly, aneurysms are found on the artery feeding the AVM and are considered pre-nidal. Aneurysms may also occur within the nidus or post-nidal veins. It has been reported that associated aneurysms are higher in adults with AVM than children –41% versus 26% in one series (Niazi et al. 2010).

## 12.5.3 Presenting Symptoms

Mentioned earlier, the primary symptom of AVM in the pediatric population is intracranial hemorrhage (ICH) (Griffiths et al. 1998; Horgan et al. 2006; Humphreys et al. 1996; Kondziolka et al. 1992, 1999; Muszynski and Berenstein 2001; Punt 2004; Zaidat and Alexander 2006). These lesions account for 30–50% of hemorrhagic stroke in children (Buckley and Hickey 2014). Since the majority of AVMs lie within the cerebral parenchyma, hemorrhages usually present as a subarachnoid or intraparenchymal bleeds. Clinical symptoms of an intracranial hemorrhage include sudden and severe headache that is often described as the “worst headache ever,” nausea and vomiting, neck stiffness, progressive neurological decline, and rapidly progressing coma (Punt 2004).

Some patients with AVMs may have intermittent or progressive symptoms rather than a single catastrophic event. Occasionally, the evolution may be more gradual and characterized by episodes of moderate headache, followed by focal neurological features over the next several hours. Hemiparesis, hemianopsia, and focal seizures are typically seen. This presentation may lead clinicians to believe that the child has sustained a characteristic occlusive episode rather than a hemorrhagic one (Punt 2004). It may, in fact, be periodic small hemorrhages that have occurred or thrombosis of a portion of the AVM, causing an infarct in the surrounding brain parenchyma (Roach and Riela 1995).

Some patients develop progressive neurological deficits over time without evidence of hemorrhage. This presentation may be attributed to the steal phenomenon mentioned earlier. In one series, other than ICH (71.6%), children presented with seizures (15.6%), headache (5.9%), and other neurological deficits including cranial nerve palsies (4.3%). Approximately 2.7% children were asymptomatic with the AVM found incidentally in this same series (Niazi et al. 2010).

Seizures without features of spontaneous intracranial hemorrhage or fixed neurological deficit are seen in 14–20% of patients (Humphreys et al. 1996; Kondziolka et al. 1999; Punt 2004). The seizures are presumably a result of gliosis of the brain due to chronic ischemia adjacent to the AVM (Kondziolka et al. 1999; Punt 2004). Very large AVMs may produce audible cranial bruits. AVMs with large arteriovenous shunts can also present with heart failure in the neonatal and infant populations (Elixson 1992; Levy et al. 2000; Punt 2004). Those located in the basal ganglia may produce movement disorders (Punt 2004). Macrocephaly and prominent scalp veins may also be evident.

### 12.5.4 Diagnostic Imaging

Upon initial presentation of a symptomatic ICH, CT scan should be the first radiological study completed. It is readily available at most hospitals, takes a few minutes to complete, and is most appropriate for identification of hemorrhage and

any resulting hydrocephalus or mass effect. A noncontrast CT may also suggest the presence of an AVM if calcifications or dilated vessels are seen. Contrast CT (Horgan et al. 2006; Kondziolka et al. 1999; Meyer et al. 2000), specifically CT angiogram or CTA, will often reveal the vascular nature of the lesion. It will give a rough estimate of the location, size, and drainage of the lesion that is especially useful if other imaging such as MRI/MRA or cerebral angiography cannot be done due to emergent nature of surgical intervention (Niazi et al. 2010; Smith 2015).

When clinically feasible, MRI and MRA imaging may prove very helpful in diagnosis and planning management strategies. The higher resolution of this technique compared to CT is more specific regarding size and location, as well as helping differentiate from other sources of bleeding such as tumor or cavernoma. MRA may identify anatomy of the feeding arteries, possible aneurysms, venous drainage patterns, and nidus location/characteristics. Lastly, MRI/MRA technology preoperatively can assist with stereotactic guidance intraoperatively (Niazi et al. 2010).

The gold standard for AVM diagnosis is conventional four-vessel cerebral angiography. Angiography of an AVM will show abnormally dilated feeding arteries, draining veins, and the location of the tangle nidus (Horgan et al. 2006; Wolfe et al. 2009). Additionally, the presence of associated aneurysm or venous anomalies such as ectasia or varices can be identified. Dynamic blood flow through and around the AVM can be evaluated by angiography and helps the medical team determine feasibility of treatments such as endovascular therapy, surgery options, and radiosurgery (Buckley and Hickey 2014). The presence of a hematoma may lead to failure to visualize all of the malformation and its feeding vessels. The hematoma may compress and obscure the AVM, so for this reason, it is advisable to perform angiography once the clot retracts/dissolves (Punt 2004; Niazi et al. 2010).

In addition to imaging and clinical assessment, a thorough review of all systems, full coagulation profile, cardiovascular examination, and hematology profile should be completed on every child in order to establish a diagnosis (Ali et al. 2003; Punt 2004).

### 12.5.5 Treatment

The primary goals of treatment of AVMs in children are to eliminate the risk of future hemorrhage, control seizures, and relieve symptoms related to vascular steal (Horgan et al. 2006). Hemorrhage rates for children are close to 4% the first year after an initial hemorrhage and 2–4% annually thereafter (Smith 2015). Some literature shows the rebleeding rate higher in the first 1–3 years, from 6% to 17% (Buckley and Hickey 2014). The success of treatment is dependent on the size of the AVM, its location, and vascular tendencies. The clinical condition of the patient at the time of diagnosis also plays a major role (Niazi et al. 2010). Treatment options of AVMs include microsurgical resection, radiosurgery, endovascular embolization, or a combination of treatment modalities. The focus of a recent investigation of AVMs in the adult population during the ARUBA study (A Randomized Trial of Unruptured Brain AVMs) was examination of the best outcomes of interventional versus conservative treatments 5 years from discovery of the unruptured lesion. Many AVMs in adults are found incidentally and don't have the propensity for hemorrhage like those in children (Buckley and Hickey 2014). The option for conservative management of AVM in children is essentially not recommended, except where high morbidity risk or ineffective treatment is determined (Darsaut et al. 2011; Niazi et al. 2010; Ali et al. 2003; Horgan et al. 2006; Kondziolka et al. 1999; Zaidat and Alexander 2006).

The Spetzler-Martin (SM) grading system (Table 12.4) is a scale that was developed to predict the results of surgical intervention in adults (Spetzler et al. 2002). It is used in pediatric patients and has also been helpful in predicting outcomes of surgical and other interventions (Darsaut et al. 2011). This grading system assigns points to three features of an AVM: the size, area of the brain (eloquent and non-eloquent), and the presence or absence of deep venous drainage. The sum of the points determines the grading. Figure 12.4 is the proposed Spetzler-Martin grading scale with visual depictions of each grade.

Lesions with SM grades I-III tend to have acceptable surgical outcomes: a rate of 86-100% radiographic obliteration (Smith 2015), average

**Table 12.4** Spetzler and Martin grading system (Spetzler et al. 2002)

Graded feature	Point assigned
Size of AVM	
Small (<3 cm)	1
Medium (3.1–6 cm)	2
Large (>6 cm)	3
Eloquence of adjacent brain	
Non-eloquent	0
Eloquent <sup>a</sup>	1
Deep venous drainage	
Not present	0
Present <sup>b</sup>	1

<sup>a</sup>Eloquent brain: brainstem, cerebellar peduncles, deep cerebellar nuclei, internal capsule, basal ganglia/thalamus, motor strips, speech area, visual cortex

<sup>b</sup>Deep drainage is internal cerebral veins, basal vein of Rosenthal, and precentral cerebellar veins

complication rate of 10%, and low mortality rate (0-8%) (Yen et al 2010). Patients who receive SM scores of IV and V should only be considered for surgery when significant repetitive hemorrhage occurs since rates of morbidity and mortality are proportionately higher. The high mortality rate in pediatric AVM is mainly associated with the initial sudden and catastrophic bleeding (Smith 2015). Hence, children who present with an acute intracerebral hemorrhage and associated progressive neurological deficit and/or brainstem compression require immediate surgery (Horgan et al. 2006; Kondziolka et al. 1992). The main goal of the surgery in acute presentation is to relieve the immediate increased intracranial pressure by evacuation of hematoma and removal of the AVM if possible. Patients often require a cerebral spinal fluid (CSF) diversionary procedure, specifically insertion of an external ventricular drain at the time of evacuation.

Ideally, surgical resection of the AVM should be delayed for 2–4 weeks post hemorrhage if a child is clinically stable (Horgan et al. 2006). This allows for resolution of the hematoma and the opportunity for a complete diagnostic workup to be done. MRI/MRA including navigation imaging and cerebral angiogram prior to surgery assists the surgeon in locating the nidus and feeding and draining vasculature that may have been previously occult due to the hematoma.

Surgery eliminates the risk of immediate bleeding and improves seizure control (Ali et al. 2003; Hoh et al. 2000; Horgan et al. 2006; Smith and Sinson 2006). Adjuncts to surgery that assist the neurosurgical team with planning and limit surgical complications are stereotactic localization, functional testing, and cortical localization. Monitoring of the patient during the procedure with somatosensory evoked potential (SSEP), motor evoked potential (MEP), electroencephalogram (EEG), and/or brainstem auditory evoked response (BAER) is indicated, especially in higher grade lesions where the potential for significant deficit exists (Darsaut et al. 2011). Intraoperative complications include hemorrhage, parenchymal injury due to sacrificing of vessels or retraction, and incomplete resection. Intraoperative angiography should be considered to assess for residual AVM during the procedure, but it isn't always readily available.

Immediate complications related to surgical excision of an AVM are hemorrhage, seizures, vasospasm, and retrograde vascular occlusion, with either an arterial or venous thrombosis within the first 12–24 h after surgery (Horgan et al. 2006). These children will require postoperative management in the pediatric intensive care setting. Postoperative hemorrhage may be due to residual malformation or insufficient occlusion of the major arterial inputs and normal perfusion breakthrough phenomenon (Horgan et al. 2006; Smith and Sinson 2006). Normal perfusion breakthrough can occur after AVM resection, when blood flow that was directed through the AVM is now redistributed. If the perfusion pressure is greater than the autoregulatory capacity of the surrounding brain, swelling or hemorrhage may occur (Horgan et al. 2006).

Stereotactic radiosurgery (SRS) is a treatment modality utilized in children that uses high-energy radiation aimed directly on the nidus of the AVM. The radiation induces sclerosis or thickening of the blood vessel walls and ultimately obliterates the AVM by proliferation and thrombosis (Roach and Riela 1995; Niazi et al. 2010; Darsaut et al. 2011). SRS is a noninvasive procedure that is usually done in the outpatient setting. It is often administered in a single ses-

sion, but depending on age of the child, location, and size of the lesion, the treatment may be staged to deliver smaller doses at intervals rather than one larger dose.

Whereas microsurgical intervention has the advantage of immediate and definitive treatment in lower SM grade lesions, SRS is recommended for AVMs in deep brain locations and eloquent cortical areas where safe surgical resection is questionable (Niazi et al. 2010; Yen et al. 2010; Darsaut et al. 2011; Buckley and Hickey 2014). There is also a role for radiosurgery for recurrent AVM and as part of a combined treatment approach for multiple AVMs (Boone et al. 2016). The main disadvantage of SRS is that obliteration of the malformation occurs over 3–5 years. During this period of time, the child continues to be at risk for recurrent hemorrhage (Hoh et al. 2000; Levy et al. 2000; Punt 2004; Smith and Sinson 2006; Smyth et al. 1997). An interesting finding over the last several years is that when total low-dose treatments are utilized in children to minimize radiation, there have been reported rebleed rates as high as 25% at 5 years versus a less than 2% annual rate (Smith 2015).

Because of the need for placement of a stereotactic frame utilizing some radiotherapy systems, children under 13–16 years of age often do best with sedation or anesthesia initiated prior to frame placement. Stereotactic MRI and/or biplanar stereotactic angiography is then utilized for dose planning. There are several SRS delivery systems, including Gamma Knife© (GKS), CyberKnife©, and linear accelerator (LINAC) (Darsaut et al. 2011; Niazi et al. 2010) and more recently greater use of proton beam (Smith 2015).

Over the last two decades, there have been several studies that retrospectively examined the clinical outcomes of SRS treatment. Radiosurgery has proven to be most efficacious in smaller lesions (less than 3 cm in size) and in those that receive a mean marginal dose of 20 Gy. Complete obliteration of AVM for these select patients has been reported in the 65–88% range (Levy et al. 2000; Smith 2015). With proton beam, these numbers are slightly less (Smith 2015). Surveillance of the lesion after treatment varies by center. Typically, angiogram is performed

immediately to and within the first year of the procedure, followed by annual MRI until the nidus is no longer visualized. At that juncture, or by at least year 5, another angiogram is performed to assess the AVM. Retreatment or alternate treatment should be considered if there is obliteration failure or rebleeding in this time period (Niazi et al. 2010; Foy et al. 2010).

Radiosurgery is seldom performed in children under 2 years of age (Niazi et al. 2010; Levy et al. 2000). Side effects associated with radiation that present around the time of treatment are at a rate of 15%, are often transient, and are due to cerebral edema. AVM size, radiation dose, and AVM location also may influence presence and severity of symptoms (Levy et al. 2000). After radiosurgery has been performed, patients may present with headache, nausea, vomiting, and new onset or increase of seizure activity. Treatment with corticosteroids in the post-procedure phase may help with symptom management, but a small percentage (1–6%) of these issues may become permanent. Additionally, there have been a few cases of cyst formation and meningioma identification in follow-up (Yen et al. 2010; Darsaut et al. 2011).

The delayed effects of radiation on children can occur weeks to years after treatment. Although there is limited data available given the short history of this treatment modality, complications include hemorrhage, progressive edema, radionecrosis, seizures, and neurological deterioration (Friedlander 2007). So far, the rate of developing neoplasia status post-treatment seems to be less than 1% (Yen et al. 2010).

Embolization is rarely a solitary treatment option for children with AVMs (Roach and Riela 1995). It is usually an adjunct therapy prior to a surgical resection (Roach and Riela 1995; TerBrugge 1999), and it is helpful in removing the deep vessels that feed the malformation by inducing partial thrombosis of the malformation. By occluding the flow through the malformation, embolization helps to prevent excessive blood loss during surgery and avoid normal perfusion pressure breakthrough postoperatively (Horgan et al. 2006; Zaidat and Alexander 2006). In large AVMs, complete embolization in one session carries a higher risk of embolization-related hem-

orrhage so a staged treatment approach is recommended (Roach and Riela 1995; Zaidat and Alexander 2006; Buckley and Hickey 2014).

During embolization, a catheter is placed inside the blood vessel and blocks off the abnormal vessels supplying the AVM. Various materials can be used for this procedure, including thrombogenic coils, silk threads, polyvinyl alcohol (PVA) particles, *N*-butyl cyanoacrylate (NBCA) glue, and Onyx-34 liquid embolic. In some institutions, interventionalists use combinations of coils and glue (Lv et al. 2009). The chance of complete obliteration by this method alone is anywhere from 5% to 20% in recent series, with Onyx showing early promise for higher success rates (Darsaut et al. 2011; Yen et al. 2010; Friedlander 2007). Onyx has theoretical slower filling times allowing for a more solid cast to occlude the vessel than other agents. As with many treatments in pediatrics, it is approved for adults and is off-label in pediatrics. In a recent study by Soltanolkotabi et al. (2013), of 38 embolizations, 12% had complete obliteration, while 88% had partial obliteration. Preoperative devascularization occurred in 72% of patients which made surgery safer.

For all endovascular methods, low obliteration rates result from the inability to embolize all vessels, and over time, AVMs can recanalize, recruit new vasculature, and reestablish AV shunting. Although the patient may have relief of some of the symptoms caused by the AVM after embolization, it is important to keep in mind that the risk of hemorrhage in a partially treated AVM may be reduced but not eliminated (Niazi et al. 2010).

The advantages of embolization over radiosurgery are the elimination of brain edema from radiation and a more immediate effect of lesion reduction prior to surgery. There is, however, a reported complication rate of almost 8% with embolization, including hemorrhage and other unexpected neurological deficits (Darsaut et al. 2011). AVMs in eloquent areas may have negative outcomes from vessel thrombosis. Some centers perform sodium amytal assessment prior to embolization or opt for radiosurgery instead.

Mentioned earlier, rare conservative management is used only in cases where the AVM is not



treatable due to size or location and is generally associated with poor outcome (Zaidat and Alexander 2006). Patients and families should be counseled to have the child avoid activities that elevate blood pressure excessively, avoid medications or alternative therapies that may have blood thinning properties, and have regular medical monitoring and follow-up. Infants with congestive heart failure from shunting through the low-resistance AVM should be stabilized. Seizures should be treated with anticonvulsant medication. All treatment modalities require angiographic follow-up at appropriate intervals to confirm successful and complete obliteration (Ali et al. 2003; Punt 2004).

### 12.5.6 Outcomes

In the general population, nontreated lesions carry a 10–15% mortality and 30–50% morbidity rates (Horgan et al. 2006; TerBrugge 1999). Risk of hemorrhage from an unruptured AVM is 2–4% per year, which translates into a 30–40% risk of serious morbidity and a 10–15% risk of mortality per decade (Horgan et al. 2006; Levy et al. 2000; Maity et al. 2004; Roach and Riela 1995; Smith and Sinson 2006). The greatest risk to a child with an AVM is hemorrhage. Without treatment, the risk for re-hemorrhage is nearly 6% or higher in the first year after the initial hemorrhage, with a return to 1.5–3% per year thereafter. Hemorrhage results in damage to normal brain tissue that can lead to loss of normal functional abilities which may be temporary or permanent. The impact of a hemorrhage depends on the location and the extent of associated brain injury. Successful management depends on many factors, including presentation, clinical condition, the age of the child, and neuroanatomical features (size, location, and angioarchitecture) of the lesion (Horgan et al. 2006). Complete surgical excision of the AVM eliminates the risk of bleeding almost immediately. Nearly 50% of patients with preoperative seizures are eventually seizure-free and off anticonvulsants after resection of the AVM (Horgan et al. 2006).

Excellent or good outcomes can now be achieved in 95% of children with AVMs who survive a hemorrhagic event with complete angio-

graphic obliteration achieved in over 90% (Horgan et al. 2006). A multidisciplinary approach to these malformations, with selection of appropriate treatment modalities done on a case-by-case basis by comprehensive teams, has proved invaluable in these successes. Additionally, young children have brain plasticity and the ability to overcome initially poor neurological presentations better than adults (Niazi et al. 2010).

It is imperative that radiological evaluation in the posttreatment period is completed, as there is a risk of incomplete resection or recurrence. Severe complications are reported in approximately 10% of children, and operative mortality is between 0% and 8% (Horgan et al. 2006; Roach and Riela 1995). Despite the recent advances in treatment options approximately 10% of cases are unable to utilize these options. Prognosis for these children continues to be poor (Horgan et al. 2006; Singhal et al. 2011).

#### Pearls

- AVM in pediatrics is rare, but up to 85% present with hemorrhage with a mortality rate of up to 25% in this population.
  - Congenital and complex lesions with direct shunting of arterial blood into venous system and have rate of rupture 2–4% per year.
- Imaging includes CTA and MRI, with cerebral angiogram as the gold standard.
- Treatments
  - Aggressive in children due to high risk for bleeding over lifetime.
  - Conservative management only in very high-risk patients.
- Endovascular embolization
  - Used mainly as adjunct therapy for many years prior to surgical resection by occluding deep vessels and limiting bleeding during surgery.
  - Incomplete obliteration may encourage reestablishment of AV shunting over time.

- Solitary therapy for AVM that is surgically risky or inaccessible.
- Surgery
  - May be required urgently to evacuate large hematoma after rupture.
  - Ideally surgical resection after rupture planned with angiogram, embolization prior to surgery.
- Stereotactic radiosurgery
  - Not used in children under 2 years old.
  - Delayed obliteration (up to 5 years later), brain edema after treatment risks of treatment.
  - May be used for deep AVM or in eloquent brain area.
- Outcomes
  - Up to 90% of children who survive initial rupture achieve obliteration of AV.
  - Brain plasticity in young children leads to better outcomes.
  - Ten percent of AVM patients have poor outcome due to eloquent, deep location of lesion, rebleeding, and morbidity of survivors.

### Mariana's Story

Mariana is an 11-year-old girl who suffered a sudden and severe headache after playing a soccer game. She was taken by her parent to the local emergency room where she proceeded to display worsening neurological symptoms. Brain CT was positive for a large left temporal/parietal hemorrhage. She was immediately airlifted to a major children's hospital where upon arrival her right pupil became dilated and fixed. She was immediately taken for a craniectomy and evacuation of the hematoma, and a ventricular drain was placed. Postoperatively, she had expressive aphasia and right hemiparesis but was stabilized hemodynamically and neurologically.

Although an AVM was suspected, because of the urgency of surgery to decompress her, MRI/MRA and cerebral angiogram was done postoperatively. These studies confirmed an AVM as the source of her hemorrhage. After several days, she was able to utter some words, but this was not consistent for several weeks. During that time period, she began to increase her motor function on her right side and her speech improved. The neurosurgical plan was to do another angiogram electively in 6–8 weeks to determine the status of the AVM and attempt embolization of an accessible vessel. It was deemed to not be safe to embolize any vessels so the neurosurgeon performing the resection had to do so surgically. The surgery resulted in complete removal of the AVM that was confirmed on postoperative angiogram.

Mariana has taken about a year to regain the majority of her motor strength with some fine motor deficits of her right hand that she has ongoing therapy for. Her expressive aphasia has dramatically improved, but she still needs speech therapy for continued achievement. Her 1-year anniversary after AVM rupture is bitter-sweet for her parents: an emotional reminder as to how close she was to death and her long journey back to baseline combined with one of pure joy and thankfulness for the team that gave Marianna and her family all the care and support through this crisis.

## 12.6 Cerebral Arteriovenous Fistulas in Children

### 12.6.1 Etiology

Cerebral arteriovenous fistulas (AVFs), excluding the vein of Galen malformation (VGAM), are extremely rare and account for only 1.6–4.7% of all brain AV malformations in the gen-

eral public (Lv et al. 2009). Among all intracranial arteriovenous lesions in children, AVFs account for approximately 10% (Horgan et al. 2006; Zaidat and Alexander 2006). Arteriovenous fistulas can be acquired or congenital in origin (Hoh et al. 2000; Horgan et al. 2006). The exact etiology is unknown, but most AVFs are thought to be multifactorial. Conditions associated with dural AVFs include intracranial venous hypertension, previous sinus thrombosis, thrombophlebitis, tumor, previous neurosurgical intervention, and cranial trauma. Much like arteriovenous malformations, AVFs have a relationship to some childhood syndromes, including hereditary hemorrhagic telangiectasia (HHT) (Osler-Weber-Rendu disease), Wyburn-Mason syndrome (Bonnet-Dechaume-Blanc), and Klippel-Trenaunay-Weber syndrome (Hoh et al. 2000; Horgan et al. 2006).

### 12.6.2 Pathophysiology

Arteriovenous fistulas are abnormal connections between a dural arterial supply and a dural venous channel. There is no intervening capillary channel between the arterial and venous supply which creates conditions for rapid high flow through the vessels (Lv et al. 2009). Unlike the AVM, which has a well-circumscribed discrete nidus, AVFs are composed of a diffuse network of numerous arteriovenous microfistulae (Kondziolka et al. 1992; Zaidat and Alexander 2006). Arteriovenous fistulas are commonly found in the sigmoid-transverse sinus, cavernous sinus, and superior sagittal sinus (Horgan et al. 2006; Kondziolka et al. 1992). Approximately 50% of all dural AVFs are found in the occipital-suboccipital region (Kondziolka et al. 1992).

In children, AVFs are often solitary entities, but they may also be multiple entities with multiple feeding arteries (Horgan et al. 2006; Kondziolka et al. 1992). Arterial supply and venous drainage patterns vary depending on the location of the fistula (Zaidat and Alexander 2006). Transverse-sigmoid dural AVFs are usually supplied by the ipsilateral occipital artery, with additional supply from the anterior and pos-

terior division of middle meningeal arteries, posterior auricular artery, neuromeningeal trunk of the ascending pharyngeal artery, posterior meningeal branches of the ipsilateral vertebral artery, and possibly the meningohypophyseal trunk from the internal carotid artery (ICA) (Zaidat and Alexander 2006). Venous drainage is variable and can involve the ipsilateral sinus, depending on the degree of sinus obstruction into the contralateral transverse sigmoid sinus or cortical veins (Zaidat and Alexander 2006). Arterial supply from the coronal segments of either or both middle meningeal arteries or superficial temporal artery primarily supplies fistulas that are found in the superior sagittal sinus. Additional supply may be from the anterior falcine artery of the ophthalmic artery and the posterior meningeal branch of the vertebral artery.

Ethmoidal dural AVFs are those along the anterior cranial fossa floor, are primarily fed by anterior and posterior ethmoidal branches of the ophthalmic artery, and receive a secondary supply from the internal maxillary artery. Venous drainage is usually via a pial vein commonly associated with a venous varix that is directed toward the superior sagittal sinus (Horgan et al. 2006). Cavernous dural AVFs are rarely found in the pediatric population. These fistulas receive arterial supply from dural branches of the cavernous segment of the internal carotid artery and also from distal internal maxillary artery branches, middle/accessory meningeal arteries, and distal branches of the ascending pharyngeal artery. Venous drainage is via superior ophthalmic vein, cavernous sinus, or cortical veins.

Pial AVFs occur in the subpial space. These lesions are mainly congenital but can be associated with trauma or iatrogenic factors. They resemble AVMs in structure with direct arterial connection to a pial venous channel, although without a nidus that is distinctive of AVM. They are located most often in the supratentorial area of the brain (Paramasivam et al. 2013). There is up to 25% association with HHT – hemorrhagic hereditary telangiectasia – reported in the literature (Walcott et al. 2013). This association has led to the hypothesis that this anomaly results from failure of the primitive endothelial tubes of

venous development to regress as proper capillary networks are developed. The abnormally dilated capillary nets form fistulas that persist. In HHT, the auxiliary receptor for normal vascular development and maintenance, endoglin, is deficient. Especially in cases where multiple pial AVFs are present, this deficiency is suspect (Paramasivam et al. 2013).

AVFs can be associated with other vascular lesions such as AVMs and aneurysms (Horgan et al. 2006). Neonates and children with dural AVFs develop cerebellar tonsillar prolapse that results from hydrovenous dysfunction of the posterior fossa and is reversible after therapy (Horgan et al. 2006).

### 12.6.3 Presenting Symptoms

Clinical presentation in children with AVFs is variable and specific to age, location, size of the fistula, and the presence of other vascular lesions (Hoh et al. 2000; Horgan et al. 2006; Kondziolka et al. 1992). Location and pattern of drainage are key components of the clinical presentation. Cardiac involvement is absent in the adult population, but in children it is often seen and may be the sole presenting feature (Zaidat and Alexander 2006). Neonates typically present with symptoms of heart failure, cyanosis, and cranial bruits, whereas children outside of the neonate period present with neurological symptoms (Hoh et al. 2000; Horgan et al. 2006; Kondziolka et al. 1992). Children between 1 and 15 months of age are the largest group of patients, with hydrocephalus and macrocrania, increased intracranial pressure (ICP), developmental delay, seizures, and subarachnoid hemorrhage (SAH) as typical symptomatology (Horgan et al. 2006). In one series reporting on pial AVF, 8 out of 16 cases were diagnosed before 1 year of age, and 80% had congestive heart failure (Paramasivam et al. 2013). If a child is 2–15 years of age at time of presentation, their clinical symptoms would often include headaches, focal neurological deficits, syncope, seizures, and SAH (Horgan et al. 2006; Paramasivam et al. 2013; Hacin-Bey et al. 2014).

Hemorrhage from an AVF is relatively uncommon (Hoh et al. 2000; Kondziolka et al. 1992). In

one series of 41 patients with 63 AVFs, there was a 17.1% hemorrhage rate (Weon et al. 2004). Anterior cranial fossa and tentorial dural AVFs almost always drain into a cortical vein and are associated with a high degree of intracranial hemorrhage (Zaidat and Alexander 2006). Pial AVFs also are high risk for bleeding due to high-flow shunting and the absence of varix (Paramasivam et al. 2013). A dural AVF occurring in the cavernous sinus usually presents with proptosis, cranial bruit, increased intraocular pressure, diplopia, or diminished visual acuity (Kondziolka et al. 1992; Zaidat and Alexander 2006).

AVFs can be classified into three types (Djindjian system):

*Type 1* (least risk): Drain via the ipsilateral sinus; these usually present with headaches and bruits but rarely with neurological deficits or hemorrhage.

*Type 2* (higher risk): Drain toward the contralateral sinus; these present with more severe symptoms mostly related to increased ICP or papilledema.

*Type 3* (highest risk): Drain via cortical veins; these are at greatest risk of ICH or venous infarction.

Some dural AVFs can spontaneously progress from type 1 to either type 2 or 3 (Zaidat and Alexander 2006).

Alternatively, the Cognard classification system adds two additional types of lesions to this grading system (Buckley and Hickey 2014):

*Type 4*: Drainage into cortical veins with venous dilatation (ectasia).

*Type 5*: Drainage into spinal perimedullary veins, associated with progressive myelopathy – spinal AVF will be discussed later in this chapter.

### 12.6.4 Diagnostic Imaging

Conventional cerebral angiography remains the preferred diagnostic test for AVFs. Additionally, this is necessary for treatment planning especially

in complex anatomical areas of the brain (Hacien-Bey et al. 2014). A complete evaluation of head and neck vasculature is required (Zaidat and Alexander 2006). Plain chest x-rays are utilized to screen for signs of congestive heart failure: cardiomegaly, pulmonary vascular congestion, and edema.

CT angiogram (CTA) is newer technology that has recently been enhanced by four-dimensional renderings. This imaging modality not only diagnoses the lesion but can also have a role in visualizing major arterial feeders to the lesion. If a cerebral angiogram is still indicated for treatment, this test does add more radiation exposure to a young child – it has about two-thirds the amount of radiation as cerebral angiography – and would not add additional information to the cerebral angiography. Therefore, it should not be utilized in this situation.

CT scan is generally not the best imaging for diagnosing AVF; however, features that may raise suspicion include prominent enlargement of arteries or veins, a large varix, and the lack of an obvious nidus (Horgan et al. 2006; Buckley and Hickey 2014). CT is valuable for assessing ventricular size or the presence of ischemic infarctions and is also used to rule out parenchymal edema related to venous hypertension, SAH, subdural hematoma, and intraparenchymal hemorrhage (Horgan et al. 2006). Pediatric dural AVFs can have rather large draining sinuses or veins. Sometimes, the draining sinus may be so massive on imaging that it can be misinterpreted as an extra-axial mass (Zaidat and Alexander 2006).

MRI or cranial ultrasound can adequately establish diagnosis of these lesions. MRI is preferred and can delineate abnormally enlarged dural arteries, normal pial arteries, thrombosis of the dural sinus, venous varix, possible feeders, and multiple parenchymal serpentine vessels without a vascular nidus (Zaidat and Alexander 2006; Paramasivam et al. 2013). MRI is also effective in delineating cerebellar tonsillar prolapse and cerebral malacia. This is important when assigning prognosis – diffuse cerebral malacia equates to poor outcomes since it is irreversible (Paramasivam et al. 2013). MRA may demonstrate flow-related enhancement of serpentine vessels. High-field 3-tesla time-resolved

MRA has been reported to have excellent sensitivity and specificity in screening for and follow-up of AVF (Hacien-Bey et al. 2014). The role of MRV is to evaluate for the presence of a thrombosis in the recipient sinus (Zaidat and Alexander 2006) (Fig. 12.4).

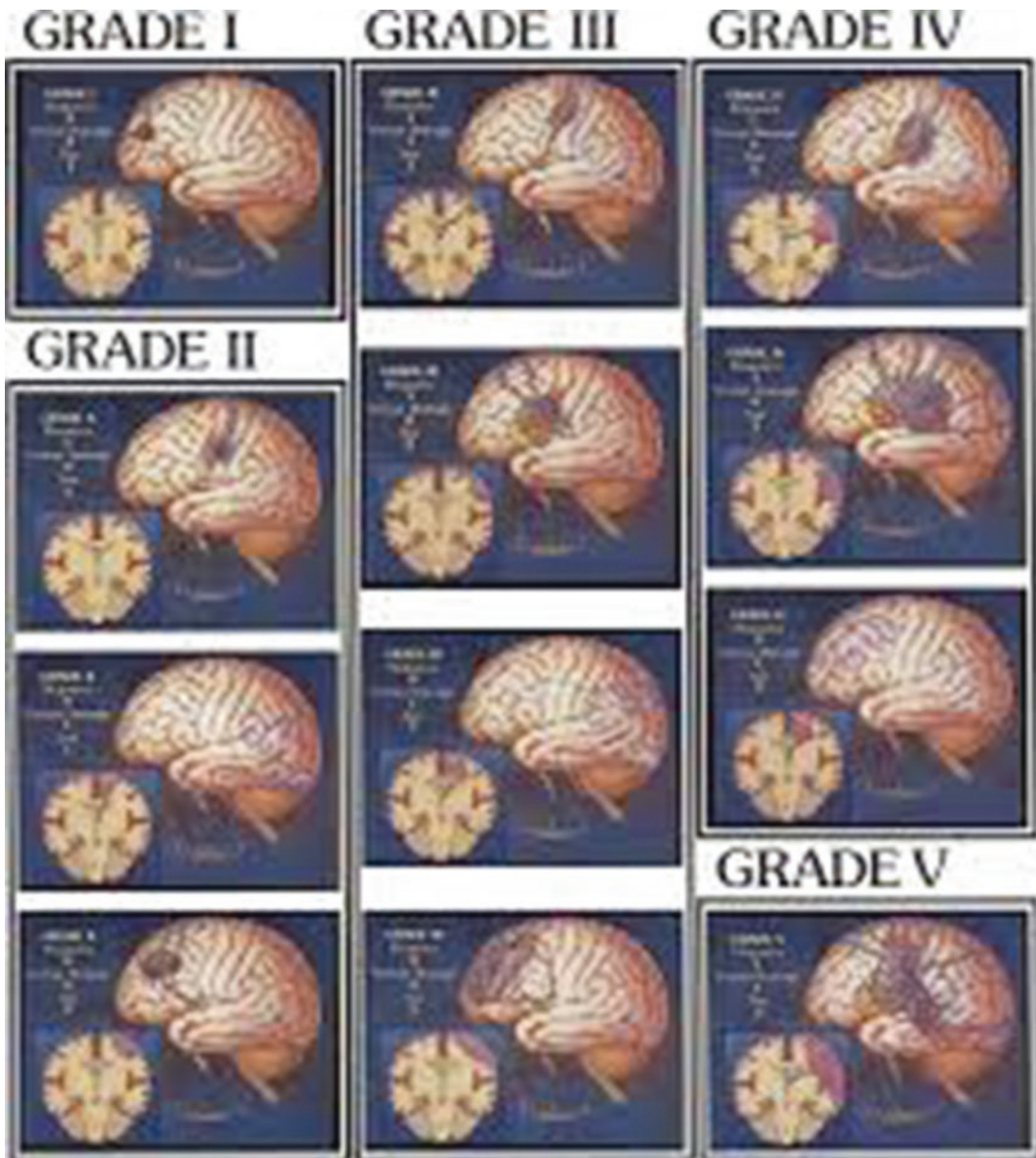
### 12.6.5 Treatment

Therapy for dural AVFs in the pediatric population must be performed with the understanding that they are potentially life-threatening lesions. The goal of treatment is to interrupt all the feeding arteries as closely as possible to the fistula while leaving the venous drainage intact, thereby obliterating the fistula (Hoh et al. 2000). Medical management with inotropic agents and diuretics is often vital at the onset of cardiac manifestations (Kondziolka et al. 1992).

Treatment options for the AVF include surgical resection, endovascular treatment, or a combination of treatment modalities. Surgery has traditionally been the treatment approach but has been replaced more and more by endovascular embolization. Many brain AVFs are deep and located in eloquent areas that carry high risk for neurological morbidity when addressed surgically. There has been significant improvement of microcatheters, guidewires, and experience by endovascular practitioners over the last two decades that have resulted in better outcomes. Reported in a literature review by Yang and associates (2011), obliteration in endovascular treatment is 86.5%. Although obliteration rate in surgical resection in the same review was 96.9%, caution was given since many were superficial AVF (Paramasivam et al. 2013).

Because there may often be several arterial connections for a single venous channel, endovascular embolization is often done as a staged transarterial approach (Lv et al. 2009). The use of various agents has been employed, such as balloons, coils, glue, and Onyx-34. The procedure is generally done under general anesthesia via a percutaneous femoral puncture (Weon et al. 2004). Complications that may occur include arterial collateral recruitment from an occlusion too proximal or decreased venous outflow and





**Fig. 12.4** Proposed Grading System for Arteriovenous Malformations (Spetzler and Martin 1986)

venous hypertension from an occlusion too distal. Other complications include cerebral edema and hemorrhage. Radiation has been utilized in adults with localized slow flow dural lesions but is not an appropriate treatment in infants or children with extensive dural AVFs (Kondziolka et al. 1992). Depending on the complexity of the fistula, treatment may be either palliative for symptom relief or curative.

### 12.6.6 Outcomes

Irreversible brain injury was found in cases where dural AVFs were undiagnosed and where cerebral venous hypertension went unchecked for a long period of time. In cases of early presentation in neonates, no presence of lasting radiological or clinical deficits was seen (Kondziolka et al. 1992).

Posttreatment hydrocephalus has been documented in the literature and should be evaluated during scheduled medical follow-up (Walcott et al. 2013).

#### Pearls

- AVFs are rare in children but usually present within the first 1–5 years of life.
- Conventional diagnostic cerebral angiography remains the gold standard for certain vascular malformations including AVF and AVM when complete and thorough evaluation of head and neck vasculature is required.
- The goal of treatment (endovascular and surgery) is to interrupt all the feeding arteries as close as possible to the fistula while leaving the venous drainage intact.

research that has evaluated the natural history of aneurysms (The International Study of Unruptured Intracranial Aneurysms and the Unruptured Cerebral Aneurysm Study). The International Subarachnoid Aneurysm Trial, a multicenter randomized trial, evaluated aneurysm treatments specifically endovascular coiling and neurosurgical clipping. The findings of these studies have improved care in adults with these lesions. For pediatric patients, data has been mostly case studies and reports in the literature. In a comprehensive review of the literature by Beez et al. (2016), current management of pediatric aneurysms is reviewed. They caution, however, that neither generalizations from adult data nor information from the review can replace research, and they encourage multicenter registries and clinical trials in children for the future.

Features of childhood aneurysms which are different than those of adults include:

1. A predominant incidence in males versus females
2. A higher incidence of unusual sites, specifically the posterior circulation, and especially the carotid bifurcation location
3. A predominance of complex aneurysms with giant aneurysms accounting for 20% of the aneurysm types seen in children
4. A lower incidence of multiple aneurysms
5. A higher incidence of posttraumatic and infectious causes
6. A tendency toward a higher frequency of spontaneous thrombosis aneurysms
7. An absence of familial aneurysms that typically present in adulthood (TerBrugge 1999; Beez et al. 2016)

## 12.7 Intracranial Aneurysms

### 12.7.1 Incidence

The incidence of intracranial aneurysms in children under the age of 18 years has been estimated between 0.5% and 4.6% (Asaithambi et al. 2014). There is a bimodal age pattern, with a peak occurring in the first 2–6 years of life and the second peak occurring in the second decade. The mean age of diagnosis in the pediatric population is 7.6 years (Beez et al. 2016). Intracranial aneurysms occur predominantly in males, with a male to female ratio of 1.8:1 (Buckley and Hickey 2014). A recent review of the literature found that pediatric aneurysms account for 5% of all aneurysms. Cerebral aneurysms are very rare in patients 18 years old or younger but are even rarer in the infant and toddler age group (Huang et al. 2005).

In the adult population where aneurysms are more commonly seen, there is high-quality

### 12.7.2 Aneurysm Subtypes

There are four different subtypes of aneurysms that are defined by their shape and form: saccular aneurysms (berry aneurysms), fusiform aneurysms (including giant aneurysms), infectious or mycotic aneurysms, and traumatic aneurysms.

### 12.7.2.1 Saccular Aneurysms (Berry Aneurysms)

Saccular aneurysms are nontraumatic, noninfectious lesions. They are often round with a well-defined neck that connects to a parent artery but also can be broad-based with no stalk or cylindrical. Thought likely to be a result of congenital abnormalities in the media of the arterial wall, saccular aneurysms occur more commonly in the general population, up to 80% of all aneurysms in some literature (Hinkle et al. 2010). They occur less so in children, but overall have a high incidence of spontaneous rupture or hemorrhage. Statistics of this phenomenon range from 35% to 75% (Jian et al. 2010).

### 12.7.2.2 Fusiform Aneurysms

Fusiform aneurysms are circumferential dilations involving the arterial wall. They occur in cerebral arteries, as well as other parts of the body. Often called “dissecting aneurysms,” these lesions have a lower incidence of hemorrhage than saccular aneurysms, but their neurological impact is commonly embolic stroke as acute and subacute dissection events in the vessel wall occur (Hinkle et al. 2010). Although they only account for approximately 5% of intracranial aneurysms in the general population, fusiform lesions occur more frequently in children. A recent review showed 16% incidence of fusiform lesions in pediatrics (Beez et al. 2016). In children, they are associated with connective tissue disorders, radiation to the pituitary region, and after resection of craniopharyngiomas (Hetts et al. 2009). Fusiform aneurysms are commonly found in the basilar arteries or terminal portions of the internal carotid arteries and often result from diffuse arteriosclerotic changes.

“Giant aneurysm” is a term given to lesions that are >25 mm in size. They are rare in adults but were documented in 11–23% of the cases in the literature (Kakarla et al. 2010). Common sites were the basilar artery and the terminal portions of the ICAs and represent the largest subgroup (54%) of posterior circulation aneurysms in literature review (Beez et al. 2016). They also tend to produce symptoms typical of space-occupying lesions due to their potential size and can be mis-

taken for a tumor on neuroimaging (McCance and Huether 2002; Jian et al. 2010; Hetts et al. 2009).

### 12.7.2.3 Mycotic or Infectious Aneurysms

Mycotic aneurysms are rare and result from arteritis caused mainly by bacterial emboli, although fungal infections can also be a source (McCance and Huether 2002). These lesions tend to have a lower hemorrhage potential as compared to saccular and fusiform aneurysms. Associated infections include endocarditis and meningoen- cephalitis and immunodeficiencies, both congenital and acquired (Hetts et al. 2009; Lasjaunias et al. 2006; Buckley and Hickey 2014). In addition to endovascular and surgical management of these aneurysms, treatment of the underlying infectious process with appropriate systemic antibiotic therapy is indicated (Jian et al. 2010; Hetts et al. 2009).

### 12.7.2.4 Traumatic Aneurysms

Traumatic aneurysms occur as a result of sustained trauma to the arterial wall, causing a fracture that weakens the wall (McCance and Huether 2002). As would be expected given the mechanism of injury, these aneurysms are commonly seen in vessels near the skull base versus the supratentorium.

## 12.7.3 Etiology

The risk factors of aneurysms in the pediatric population differ from the classic risks seen in adults. In adults, these potentially modifiable risk factors include hypertension, shear stress, high fat and high cholesterol diets, oral contraceptive use and cocaine, and alcohol and tobacco use (Khoo et al. 1999; Lasjaunias et al. 2006). In addition, typical diseases of the vascular system seen during the fifth, sixth, and seventh decade of life, such as atheromatosis and degenerative vascular conditions, account for aneurysm peak during these age groups in adults. For this reason, it has been proposed that a vasculopathy (congenital or acquired) predisposes the cerebral vascula-

ture to aneurysm development (Hinkle et al. 2010). Associated conditions of intracranial aneurysms in children include vascular anomalies, cardiac lesions, connective tissue abnormalities (Ehlers-Danlos most often), hematological disorders (with sickle cell predominance), infections, immunodeficiencies, and phakomatoses syndromes (e.g., neurofibromatosis type I and tuberous sclerosis) (Beez et al. 2016). Other miscellaneous causes, such as surgical complications, penetrating head injuries, and radiation therapy, have been reported. As with their adult counterparts, intracerebral aneurysms in children may be due to a combination of genetic and acquired factors (Khoo et al. 1999). Refer to Table 12.5 for a list of causes and pathologies that may be associated with intracranial aneurysms in childhood.

### 12.7.4 Pathophysiology

In general, pathogenesis of aneurysms is not completely understood. Two main hypotheses for formation are (1) hemodynamic or luminal factors – high blood flow or turbulent flow or shear stress – that are based on bifurcation sites of many aneurysms and arterial anatomic variants and (2) morphological abnormality of vessel walls from congenital anomaly, infectious or systemic process, and head injury, including birth trauma (TerBrugge 1999; Beez et al. 2016). Specific conditions in children give insight into such mechanisms for aneurysm development. For example, abnormal erythrocytes cause an endothelial weakening of the arterial wall in sickle cell patients. In children with tuberous sclerosis and polycystic kidney disease, mutation of the PKD1 gene is thought to alter vascular smooth muscle that can ultimately weaken vessel walls. Additionally, mutation of the COL3A1 gene encoding procollagen in children with Ehlers-Danlos likely is responsible for weakening of arterial walls. Without a known comorbidity, it is still unclear what causes aneurysm formation, but histological analysis of these lesions reveals inflammatory and structural abnormalities similar to those seen in adult sac-

**Table 12.5** Causes and associated pathologies of intracranial aneurysms

<i>Vascular anomalies</i>
Cerebral AVM
Moyamoya
<i>Cardiac lesions</i>
Coarctation of the aorta
Bacterial endocarditis
Atrial myxoma
<i>Connective tissue abnormalities</i>
Marfan's syndrome
Ehlers-Danlos type IV syndrome (rarely in types I and IV)
Fibromuscular dysplasia
Pseudoxanthoma elasticum
<i>Hematological disorders</i>
Sickle cell disease
G-6-PD deficiency
Thalassemia
<i>Infections and immunodeficiency</i>
HIV/AIDS
Syphilis
Severe combined immunodeficiency
X-linked immunodeficiency
<i>Phakomatoses</i>
NF-1 (especially after radiation therapy)
Tuberous sclerosis
<i>Miscellaneous</i>
Surgery for craniopharyngioma
Radiation therapy
Polycystic kidneys
Penetrating or blunt head injury
Neurocutaneous disorder

Proust et al. (2001), Hetts et al. (2009), Vananman et al. (2010)

cular lesions. In adult research, new insight into aneurysm formation such as high collagen turnover has been discovered (Beez et al. 2016).

The internal carotid artery (ICA) bifurcation is the most common site for pediatric aneurysms and accounts for 27% in literature review (Beez et al. 2016). Some researchers feel that this may be due to the large bifurcation angle. Hemodynamic stress with subsequent impingement of an axial stream of blood causes high shear forces and fenestration of the internal elastic lumina at the apex of the bifurcation. Another theory implicates the augmented blood flow in the vessel wall due to associated vascular



anomalies, such as arteriovascular malformations (AVM) or coarctation of the aorta, to be causes of aneurysms in younger age groups (Krishna et al. 2005). A close second location in literature reviews with a 26% occurrence is the middle cerebral artery (MCA). This is followed by the anterior communicating artery (ACoA) at 11% and the basilar artery at 8% (Beez et al. 2016). The concept of aneurysmal vasculopathies and a redirection of focus to understanding the biology of the type of arterial wall disease that is associated with an aneurysm come on the heels of the adult research (Beez et al. 2016). Aneurysmal subtypes add to the complexity of etiologic theories of aneurysm formation as most case series that examine specific aneurysm subtypes are too small to arrive at a definitive conclusion (Lasjaunias et al. 2006). However, there are reports of trends in subtypes. For example, Gross et al. (2014) noted that of the children in their cohort of 22 patients, those under the age of 10 years most often had fusiform/dissecting lesions, whereas those 11 years and older had saccular lesions. Researchers are hopeful that age, location, and presentation factors will lead to better information about aneurysms in children.

### 12.7.5 Presenting Symptoms

It is important to note that most intracranial aneurysms in children are not found incidentally, although with more recent availability of neuroimaging for other neurological issues, some studies report as much as 35% are incidental findings (Kakarla et al. 2010). The most common presenting symptom (55%) in children with an aneurysm is sudden massive intracranial hemorrhage, more specifically subarachnoid hemorrhage (SAH). Like adults, severe and sudden onset of headache, vomiting, meningeal irritation, and increased intracranial pressure occur as a result of the blood from the ruptured aneurysm entering the subarachnoid space. In 30% of children, focal neurological deficits can be seen due to mass effect or compression effect by the aneurysm (Beez et al. 2016). Deterioration in consciousness, seizures, coma, and retinal hemorrhages

occur as a result of progressive bleeding, expansion of the aneurysm, or, in the case of large lesions, mass effect. Retinal hemorrhages are found near blood vessels and may appear flame shaped, or they may be ovoid and located close to the optic disk. Subhyaloid hemorrhage (blood between the retina and vitreous humor) may occur if the retinal hemorrhages dissect between retinal layers. A sudden increase in intracranial pressure caused by an intracerebral hematoma occurs in approximately one-fourth to one-half of all children (Khoo et al. 1999; Santos et al. 2005).

In cases of giant aneurysms or large fusiform lesions that do not hemorrhage, more subtle signs related to space-occupying lesions may be present, such as intermittent headache, seizures, visual changes, and sensory and motor deficits.

### 12.7.6 Diagnostic Tests

In the case of ruptured aneurysms, cranial CT is used for initial evaluation (Buckley and Hickey 2014). Subarachnoid hemorrhage (SAH) is the hallmark finding, and within 48 hours of rupture, there is a 90% sensitivity for it on CT. Lumbar puncture (LP) is used to detect blood or xanthochromia in the cerebrospinal fluid (CSF), which is indicative of SAH. The LP is only done if there is no evidence of SAH on imaging and the child is still symptomatic. Performing an LP is contraindicated if a child has signs and symptoms of increased intracranial pressure (ICP). If either the CT or LP is positive for SAH, contrast-enhanced imaging is indicated. Depending on the child's clinical condition and availability of imaging, this may be MRI/MRA, digital subtraction CT angiography (CTA), or cerebral catheter angiography (Jian et al. 2010; Buckley and Hickey 2014).

MRI/MRA is capable of visualizing aneurysms that are greater than 5 mm. MRI is a good tool for demonstrating the aneurysm and for delineation of complications in the case of an aneurysmal bleed, such as intraventricular hemorrhage, subdural hemorrhage, intracerebral hematoma, or acute hydrocephalus. Although it is a source of radiation, CTA is faster and diagnosti-



cally more sensitive for aneurysm identification than MRI according to latest literature. CTA can usually detail vascular anatomy related to the aneurysm and can provide the neuro team with valuable information for treatment in a critically ill child. If the patient is stable, the gold standard, catheter angiography, is performed. The advantage of angiography is greater detail of the aneurysm shape, type, location, its vasculature makeup, and the presence of vasospasm which needs to be addressed immediately (Buckley and Hickey 2014).

MRI/MRA is used to screen children with non-SAH headaches or seizures and those with strong family history of aneurysms and significant risk factors or comorbidities (such as Ehlers-Danlos syndrome or polycystic kidney disease). Additionally, this modality is utilized to follow patients with conservative management treatment plans or those that are posttreatment.

### 12.7.7 Treatment Options

Over the last 20–30 years, there has been a significant evolution of microneurosurgical techniques and endovascular treatments in pediatric aneurysm management. Moreover, the availability of pediatric neurosurgeons, neuroradiologists/interventionalists, and neurologists has optimized management for this population (Jian et al. 2010; Hetts et al. 2009).

#### 12.7.7.1 Medical Management

With the evolution of improved and more widely used treatment modalities in children, expectant conservative medical management, or “watchful waiting,” is no longer widely used as a definitive therapy (Huang et al. 2005; Asaithambi et al. 2014). This may be considered in cases of very complex, eloquent location or multiple/extensive disease but is by far the exception rather than the rule in pediatric patients. Aneurysms in children should be regarded as both an acute and chronic disease. Increased growth of untreated lesions can often be seen in children, as well as recurrence and de novo formation of additional aneurysms, supporting the philosophy of aggressive

management and follow-up (Kakarla et al. 2010; Hetts et al. 2009; Jian et al. 2010; Asaithambi et al. 2014).

The goal of medical management of children with ruptured and suspected intracranial aneurysms is to provide prompt stabilization to prevent secondary complications of hemorrhage. This includes aggressive control of systolic and mean arterial blood pressure in order to prevent continued oozing and rebleeding. Strict fluid control and monitoring is required with the aid of indwelling arterial catheters, central venous lines, and an indwelling urinary catheter. In some children, hydrocephalus and resulting increased ICP may occur due to blood or clot, impairing normal CSF reabsorption. This may require placement of an externalized ventricular catheter (EVD), and drainage of CSF is carefully titrated (Hinkle et al. 2010). Provision of adequate sedation or analgesia to minimize anxiety and headache must be considered against the need for frequent neurological assessment. This may require airway protection via intubation to keep the child calm and normotensive. Antihypertensive agents, including calcium channel blockers, beta-blockers, and vasodilators, may be required to manage marked hypertension. Anticonvulsant therapy to prevent seizures is often routinely administered.

In the postoperative phase, anticonvulsant therapy is often continued for a period of 6 months or indefinitely. Situations where extensive cortical destruction has occurred after subarachnoid hemorrhage or there have been seizures observed require long-term consideration. High-dose glucocorticoids are often given in the presence of acute aneurismal subarachnoid hemorrhage. Minimization of fluctuations in intracranial pressure as a result of straining, coughing, and vomiting are controlled with stool softeners, breathing treatments, and antiemetic medications (Khoo et al. 1999). Bed rest may be indicated in children who are unable to have immediate surgery.

In cases of SAH, vasospasm is commonly seen in 30% of adults. Although concerning for pediatric patients as well, the literature demonstrates a better tolerance of SAH by children

with decreased vasospasm events (Jian et al. 2010; Hetts et al. 2009). Literature review by Beez and colleagues (2016) revealed a 9.4% incidence of vasospasm after ruptured aneurysm with 64% seen in the anterior circulation. Angiographic vasospasm occurred in 81% of the cases, and 19% were diagnosed with delayed cerebral ischemia. The majority of these cases were treated aggressively with good outcomes in all but 12%. It has been proposed that the phenomenon responsible is abundance of leptomeningeal collateral supply to watershed areas in children's brains that prevent ischemia/stroke. Others have postulated that elasticity of the cerebral vasculature in young children and well-preserved autoregulation in this age group are factors (Sharma et al. 2007). Clinical studies have shown increased cerebral blood flow (CBF) in children (50–85% more) peaks at about 5 years of age. It then declines until it is similar to adult CBF at 15–19 years of age (Beez et al. 2016). This said, the potential for vasospasm is significant due to morbidity and mortality and should be monitored for but, more importantly, prevented.

Volume expansion and the use of cerebroselective calcium channel blockers have been known to help. "Triple-H therapy" (hemodilution, hypervolemia, and hypertension) is used at many neurovascular centers as treatment for vasospasm although recent controlled trials did not produce conclusive evidence that it directly impacts cerebral blood flow in SAH (Buckley and Hickey 2014). Close monitoring and prompt identification and treatment of underlying issues is key. Hyponatremia has also been implicated as risk factor for vasospasm so correction is important (Buckley and Hickey 2014). Peak incidence for vasospasm is generally 7–10 days after rupture but can occur between 3 and 14 days post-rupture. The use of transcranial Doppler assessment daily to watch for increasing velocities is recommended during the peak period, often for 10–14 days after the event. Any signs of vasospasm, clinically or on imaging, require immediate angiography and possible angioplasty to prevent infarct (Hinkle et al. 2010).

### 12.7.7.2 Surgical Management

Management of aneurysms in children is either microsurgery or endovascular treatment and may be a combination of both. The cohort of patients from the literature review by Beez and colleagues (2016) had a 53% surgical treatment rate and 35% endovascular rate. The surgical procedure most often performed was clipping of the aneurysm with coiling (with or without stent assist) as the most performed endovascular procedure. It was noted by the reviewers that there was a shift toward publication of endovascular cases in more recent years. The results of the International Subarachnoid Aneurysm (ISA) Trial comparing surgical clipping versus endovascular coiling were published in 2002, and positive results supporting endovascular therapy may have had an impact on treatments in pediatric aneurysm.

Gross and associates (2014) reported on a cohort of 33 children with aneurysms and treatments employed. There were an endovascular treatment rate of 45% (15/33 patients), a surgical rate of 24% (8/33), and 31% being observed or in the process of workup for treatment. The higher proportion of endovascular procedures was also attributed to results of adult clinical trials. Additionally, due to the increased posterior circulation lesions that were often giant aneurysms and surgically challenging, endovascular modalities became initial treatment choice in many cases.

Utilizing the Kids' Inpatient Database, Asaithambi and colleagues (2014) analyzed unruptured intracranial aneurysms (UIA) from 2003 to 2009. There was a large cohort of 818 patients identified with 111 undergoing microsurgical treatment and 200 patients undergoing endovascular treatment. The decision to treat was based on a symptom rate of 62% in this population with the main objective to minimize symptoms and prevent hemorrhage. Comparison of the two modalities had similar outcomes in short-term follow-up according to the study. Long-term follow-up was not part of this report but encouraged by the authors for future consideration as long life expectancy exists in children.

The primary goal in surgical treatment of aneurysms is to remove the abnormality from the

circulation while preserving normal vasculature, including the perforating arteries. Up until the last 15–20 years, surgery was the standard of aneurysm management. More recently, endovascular techniques have been used with greater frequency and confidence in pediatrics, either solely or as an adjunct to surgery and in ruptured and unruptured aneurysm (Hetts et al. 2009; Jian et al. 2010; Asaithambi et al. 2014). An important aspect of the ISA Trial is long-term follow-up results. Reassessment revealed a small increased risk of rebleeding in the aneurysm coiling group. For children, durability of treatment is a concern given their young age (Beez et al 2016).

The conventional surgical approach to treating intracranial aneurysms in children is direct clipping of the aneurysm neck through an open craniotomy. For lesions not amenable to clipping, aneurysm trapping and bypass techniques may be employed (Kakarla et al. 2010). Improvements in neurosurgical equipment (e.g., microsurgical instruments and immobilization devices), as well as pediatric appropriate critical care management, have affected outcomes favorably in children with aneurysms (Kakarla et al. 2010).

Interventional angiography and endovascular occlusion are methods used to treat unusual sites that are commonly seen in children, especially in the posterior circulation (basilar artery aneurysms) and in the treatment of giant aneurysm. This was an established standard of care even before the findings of the International Subarachnoid Trial were published in 2002 (Beez et al. 2016). In recent years, significant developments have been made in the utilization of selective coiling and balloon occlusion techniques in children by neurointerventionalists. Although these techniques have been used many years in the adult population, history of use in pediatrics has increased in the last two decades (Jian et al. 2010). In the Gross and colleagues cohort (2014), initial occlusion of aneurysms was 80% in the endovascular group versus 88% in the surgical group demonstrating similar outcomes of both treatments.

Recurrence rate for any treatment needs to be incorporated into the long-term outcomes in the pediatric population. A large study (Kakarla et al.

2010) followed patients treated microsurgically for an extended period of time (range 5–120 months), and recurrence rate for this population was 8.6%. Sanai and colleagues (2010) evaluated microsurgical treatment versus endovascular treatment with both being equally successful, but recurrence rate in the endovascular population was reported to be 20–40%. This suggests that over time, no single treatment is curative for a select number of pediatric patients. Many centers now use a combination of modalities to increase obliteration rates and decrease recurrence rates. In a 27-year retrospective medical record review, Hetts et al. (2009) documented crossovers of patients treated initially by coiling to microneurosurgical treatment, as well as incomplete neurosurgical obliterations requiring future endovascular treatment.

As suggested by many pediatric studies, intracranial aneurysms in children have both acute and chronic implications given their potential life span. Longitudinal management suggested for these lesions includes angiography at 3–6 months post initial treatment. If no residual aneurysm or recanalization is seen, yearly MRA is proposed, gradually decreasing to every 5 years (after three to five negative annual exams) (Jian et al. 2010). With either evidence of incomplete surgical treatment or new aneurysms/recanalization documented, more frequent evaluation is required.

### 12.7.8 Assessment of Intracranial Aneurysms

Vigilant assessment of children with ruptured intracranial aneurysms is critical in attaining the best possible outcomes as rapidly as possible. The use of grading scales to assess the severity of a ruptured intracranial aneurysm is valuable. Two outcome predication scales commonly used to assess clinical outcomes are the Hunt and Hess Scale and the World Federation of Neurological Surgeons Scale (Cavanagh and Gordon 2002).

#### 12.7.8.1 Hunt and Hess Scale

The Hunt and Hess (HH) Scale is the most commonly used tool to assess subarachnoid

hemorrhage. The grades of the scale correspond with the neurological deficits with the level of consciousness and focal deficits (Cavanagh and Gordon 2002). The HH scale is used to predict prognosis and timing of surgical or endovascular intervention (Table 12.6) (Drucker 2006).

**12.7.8.2 World Federation of Neurological Surgeons Scale**

The World Federation of Neurological Surgeons (WFNS) Scale is based on the Glasgow Coma Scale (GCS) with a correction for motor deficits to the GCS (Cavanagh and Gordon 2002) (Table 12.7).

**12.7.9 Outcomes**

A good or excellent outcome can be expected in 70–80% of all children who have intracerebral aneurysms (Khoo et al. 1999). In recent series, favorable outcomes were seen in up to 95% of the children followed (Aryan et al. 2006; Sanai et al. 2006). Children tend to have better clinical outcomes than their adult counterparts. In one large

study, mortality reported was 1.3%, with morbidity as 8% for infarction and 4% for new-onset seizures (Hetts et al. 2009). In the review by Beez and colleagues (2016), 88% of microsurgically treated children had good outcomes, 9% had poor outcomes, and 3% died. For children treated with endovascular therapy, it was 86%, 3%, and 11%, respectively.

**Table 12.6** Hunt and Hess Scale

Grade	Clinical condition
0	Unruptured
I	Asymptomatic or minimal headache, nuchal rigidity
II	Moderate to severe headache, nuchal rigidity, no neurological deficit other than cranial nerve palsy
III	Drowsiness, confusion, mild focal deficit
IV	Stupor, moderate to severe hemiparesis, possible early decerebrate rigidity, and vegetative disturbances
V	Deep coma, decerebrate rigidity, moribund appearance (Cavanagh and Gordon 2002)

**Table 12.7** World Federation of Neurological Surgeons Grading Scale

WFNS grade	Glasgow Coma score	Motor deficit
I	15	Absent
II	14–13	Absent
III	14–13	Present
IV	12–7	Present or absent
V	6–3	Present or absent

**Pearls**

- Aneurysms are rare in children and differ from adult counterparts.
  - Higher in males versus females in kids
  - Posterior circulation lesions higher than adults
  - Increased incidence of giant aneurysms, lower incidence in multiple aneurysms in children
- Congenital etiology versus associated pathologies exist.
  - Vascular anomalies
  - Cardiac lesions
  - Connective tissue abnormalities
  - Hematological disorders
  - Infections, immunodeficiencies
  - Phakomatoses
  - Miscellaneous causes
- Most frequently present as massive ICH, less often incidentally diagnosed.
- Medical management limited and due to increased growth and potential for bleeding not recommended.
- Endovascular treatment.
  - As adjunct therapy to surgery, recently utilized more often for high surgical risk areas
- Surgical treatment.
  - Still has highest rate for obliteration but higher rates for morbidity and mortality than endovascular treatment
- Outcomes improved over last two decades and surpass adult rates of favorable outcomes.

## 12.8 Venous Angiomas (Developmental Venous Anomaly, Vascular Malformation)

### 12.8.1 Etiology

Developmental venous angiomas (DVA) are considered a subset of developmental venous anomalies that occur because of arrested development. The cause of this arrested development is not known. They are the most common form of vascular malformation and are found at autopsy in approximately 3% of cases (McCance and Huether 2002), although with new imaging techniques, the prevalence is considered to be much higher at 6.4% (Gokce et al. 2014). It is generally accepted that they form during intrauterine life (Ruiz et al. 2009). They are viewed by some as anatomical variations resulting from a “hemodynamic need” which causes a subsequent recruitment of “transhemispheric anastomotic pathways” (Lasjaunias et al. 1986). Others consider that these lesions are malformative in nature, formed by an occlusion such as a thrombosis of normal parenchymal veins (Saito and Kobayashi 1981). It is also postulated that these may represent the expression of disturbed fetal angiogenesis and regression (Wilson 1992). DVAs are often seen during MRI and CT as an incidental finding (Cohen et al. 2010; Ruiz et al. 2009). They are found in both the pediatric and adult populations, with a slightly greater incidence in males (San Millan Ruiz et al. 2007). A retrospective review by Jones et al. (2015) also demonstrated that the prevalence of DVAs in children with brain tumors is significant, greater than that of children without brain tumors.

### 12.8.2 Pathophysiology

A venous angioma is an extreme variation of veins that drain normal brain tissue within its region of distribution (Khurana 2005). Venous angiomas consist of primitive embryologic veins that form in a radial pattern and feed a central vein or “collector vein” (McCance and Huether 2002).

The collector vein is often located on the surface of the brain, but it may also be found in the deeper regions (Khurana 2005). Venous angiomas are often found near the frontal horns of the ventricles or in the cerebellum (Khurana 2005). While brain parenchyma tissue in between the veins that make up the venous angioma was considered to be normal in the past, histological and radiological studies now indicate that this is not always the rule (Courville 1963; San Millan Ruiz et al. 2007).

The most frequent abnormality noted in a recent series of 84 DVAs was locoregional cerebral atrophy in 29.7% of the cases, followed by white matter lesions in 28.3% of the cases, and dystrophic calcification in 9.6% of CT cases (San Millan Ruiz et al. 2007). In this series, the most frequent locations of DVAs were at the supratentorial level with a frontal predominance (Lee et al. 1996; San Millan Ruiz et al. 2007). Of note, DVAs are often associated with other cerebrovascular lesions, the most common and clinically significant being the cavernous malformation (Cohen et al. 2010). Because of this association, when a DVA is diagnosed, other vascular malformations should be considered.

### 12.8.3 Presenting Symptoms

Unless combined with another type of vascular malformation, venous angiomas alone rarely become symptomatic. The most common presenting sign of a venous angioma is seizures without hemorrhage (Khurana 2005). Hemorrhage is rarely seen with venous angiomas. In the rare case of rupture of a venous angioma, signs and symptoms of a hemorrhage would include sudden onset of headache that may be associated with nausea, vomiting, somnolence, hemiparesis, or other focal neurological deficit. The formation of a thrombus in one or more veins can cause local venous hypertension, resulting in a headache. Regional cavernous malformations (CMs) are associated with DVAs in 13–40% of cases (Huber et al. 1996; San Millan Ruiz et al. 2007), and the CMs are considered to be the likely cause of symptoms that were previously attributed to DVAs (McLaughlin et al. 1998; Rigamonti and Spetzler 1988).



## 12.8.4 Diagnostic Tests

Venous angiomas are primarily detected using neuroimaging, as they are usually not problematic. Because most DVAs can be diagnosed with routine CT or MRI, this is the first method utilized. When using MR imaging, the hemodynamic behavior of DVAs is best imaged by digital subtraction angiography (DSA) because of its higher temporal resolution. However, this should only be utilized in cases where hemorrhagic or ischemic infarctions or other associated vascular malformations are suspected (Ruiz et al. 2009; San Millan Ruiz and Gailloud 2010). Cerebral angiography is the best method to detect a venous angioma. Angiography shows the caput medusae pattern (a cluster of veins that resemble a “head of snakes”) that drains into a collector vein. The caput medusae originate from a main venous trunk (Rodesch et al. 2005). MRI with and without contrast is another good way to image a venous angioma, as it shows the venous angioma along with any other vascular abnormality through multiple imaging sequences. However, small DVAs can be overlooked even in contrast-enhanced MRI if the images are not reviewed carefully (Gokce et al. 2014) (Fig. 12.5).

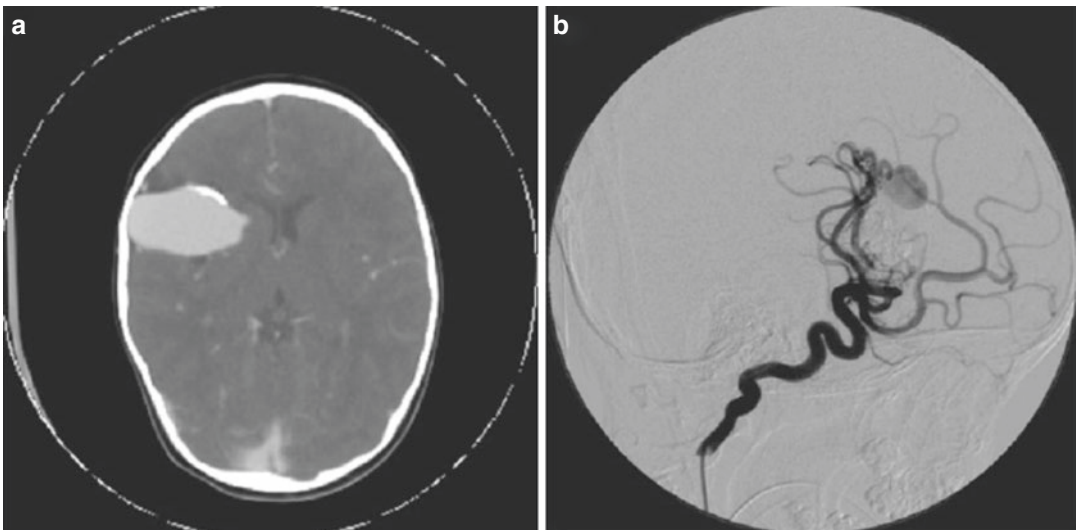
Magnetic resonance venography (MRV) may be able to detect a VA if it is not too small. Time-

resolved magnetic resonance arteriography (MRA) utilizing a 3.0 tesla magnet has been demonstrated to provide sufficient results to identify, localize, and classify lesions, especially for screening and follow-up, reducing the potential risk of arterial catheterization in patients (Liu et al. 2015). CT angiography (CTA) may also be used though it is not effective in detecting commonly associated vascular malformations, such as a cavernous hemangioma, if it is too small (Khurana 2005).

## 12.8.5 Treatment Options

### 12.8.5.1 Medical Management

Venous angiomas are primarily benign and do not require any form of treatment unless they cause seizures. If seizures are present, neuroimaging can ensure there is no other underlying arteriovenous malformation. If no other arteriovenous malformation is present, anticonvulsant medications are used to treat seizures (Khurana 2005). Although there is a lack of large or controlled studies evaluating conservative management versus management with systemic anticoagulation, medical management of thrombosed DVAs should be guided by experience gained from treating venous sinus thrombosis. This suggests prolonged, systemic



**Fig. 12.5** (a) Computed tomography scan (b) angiogram of a saccular aneurysm

anticoagulation could be of benefit in the prevention of clot propagation, improving recanalization, and promoting reversibility of symptoms (Ferro and Canhao 2008; Schaller and Graf 2004).

### 12.8.5.2 Surgical Management

Venous angiomas are frequently associated with cavernous malformations that tend to be problematic and often require surgical intervention. Surgical resection of venous angiomas alone without an associated vascular malformation is only recommended in cases where a patient has suffered a massive or recurrent hemorrhage due to rupture of the angioma or if the venous malformation is causing debilitating seizures. Resection of venous malformations yields a risk of venous stroke due to venous congestion as these malformations are thought to drain normal brain tissue (Khurana 2005). The surgical removal of DVAs may result in detrimental ischemic and hemorrhagic complications due to their role in the normal cerebral venous drainage system for the patient (Abe et al. 2003).

#### Pearls

- Most common form of vascular malformation.
- When a DVA is diagnosed, other vascular malformations should be considered, especially cavernous malformations.
- Most common presenting signs:
  - Headache
  - Seizures
  - Focal neurological deficits
- Best imaged by digital subtraction angiography.
- Most often do not require treatment, but long-term anticoagulants may be considered.
- Surgical treatment is not indicated (and may be harmful) unless there is the presence of an associated cavernous malformation which requires treatment.

#### Lydia's Story

Lydia, a 10-year-old healthy female presented to a neurologist with an approximate 3-month history of headaches and near-syncopal events that primarily occurred later in the day, especially during or after physical activity, and worsened when she became overheated. The events began to occur abruptly at the beginning of the school year. The family denied any morning vomiting, seizure events, cognitive decline, or focal neurological deficits. In fact, Lydia is an excellent student and a very active child who excelled on her cheer team. There was no significant history of head injury and no history of early strokes in her family. However, due to the acute onset and headaches in association with near-syncopal events of less than 1-year duration, Lydia was referred for a noncontrast brain MRI, which was performed on a first available basis since Lydia's exam was not concerning for any acute neurologic process. The imaging demonstrated a DVA in the right temporal parietal area, which was not associated with her headache or near-syncopal events. She was educated on improving her lifestyle habits including increasing her water intake and eating small regular meals throughout the day. With this therapy, Lydia's headaches and near-syncopal events were totally resolved, and there was no indication for any further treatment of the DVA. She continues to perform well in the academic setting and participate in cheerleading without limitations.

## 12.9 Capillary Angiomas and Telangiectasia

Capillary angiomas and telangiectasias are two distinct entities. They are often mistakenly thought to be interchangeable terms (Santos et al. 2005).

### 12.9.1 Capillary Angiomas

Intracranial capillary angiomas are extremely rare, with less than 0.1% reported in infants (Metry et al. 2006; Viswanathan et al. 2009) and only 36 cases reported in the literature (Kang et al. 2016). They are most commonly associated with PHACES, a rare neurocutaneous disorder characterized by posterior fossa abnormalities of the brain and arterial, cardiac, and eye abnormalities (Heyer and Garzon 2008; Judd et al. 2007; Metry et al. 2004, 2006; Oza et al. 2008; Poindexter et al. 2007). They are most often treated with corticosteroids (Balaci et al. 1999; Bar-Sever et al. 1994; Ersoy and Mancini 2005; Heyer and Garzon 2008; Judd et al. 2007; Metry et al. 2004; Song et al. 2007; Tortori-Donati et al. 1999; Viswanathan et al. 2009), interferon therapy (Bar-Sever et al. 1994; Viswanathan et al. 2009), and surgery (Daenekindt et al. 2008; Jalloh et al. 2014; Karikari et al. 2006; Philpott et al. 2012; Uyama et al. 2008; Willing et al. 1993; Zheng et al. 2012), and there has been a case report of significant reduction in size with the use of propranolol (Kang et al. 2016). In capillary angiomas, the neural tissue is usually gliotic and contains no neurons. The vessels in angiomas tend to be variable in diameter and thin-walled, and they resemble the smaller vessels seen in cavernous angiomas. Capillary angiomas are found in the posterior fossa, primarily in the pons or medulla and occasionally in the cerebellum. They are also found in the subependymal deep cortical region where they are solitary. Capillary angiomas, like telangiectasias, are often discovered as an incidental finding at autopsy. Capillary angiomas may lead to catastrophic hemorrhages because of their location in the brainstem or subependymal region (Santos et al. 2005).

#### Pearls

- Are extremely rare
- May be treated with:
  - Corticosteroids
  - Interferon
  - Surgical therapy

### 12.9.2 Telangiectasias

Cerebral telangiectasias are “localized collections of multiple thin-walled vascular channels interspersed within normal brain parenchyma” (Tang et al. 2003). The parenchyma between the vessels in the telangiectasia is normal, and there are normal neurons, a normal concentration of glial cells, and normal fibers with variable ratios, depending on the region of the brain involved. Vessels in telangiectasias tend to be more constant in size and are morphologically consistent with capillaries found in telangiectasias.

It is difficult to identify these on most imaging modalities, including serial cerebral angiography, CT, conventional MRI, fluid-attenuated inversion-recovery (FLAIR) imaging, or diffusion-weighted imaging (Sayama et al. 2009). They are best visualized as small, faintly enhancing lesions on T1-weighted MR imaging with gadolinium enhancement (Sayama et al. 2009).

Telangiectasias are commonly found in the basis pontis. They make up about 4–12% of vascular formations, but it is rare to encounter symptomatic capillary telangiectasias (Sayama et al. 2009). Usually, they are discovered as an incidental finding at autopsy. However, not all capillary telangiectasias are asymptomatic. A study by Sayama et al. (2009) reviewed a series of 105 cases of capillary telangiectasias. Seven (6.7%) of the 105 cases demonstrated large capillary telangiectasias. Large telangiectasias were considered to measure over 1 cm. Two of the seven patients were identified as having symptoms likely related to their capillary malformations (Sayama et al. 2009). When symptomatic, the symptoms can include seizures, cranial nerve palsy, confusion, dizziness, visual changes, vertigo, tinnitus, or even progressive spastic paraparesis (Lee et al. 1997; Milandre et al. 1987; Tang et al. 2003). They may often be misdiagnosed as glial tumors or other more serious disease processes (Sayama et al. 2009). Interestingly, in a meta-analysis performed by Gross and Du (2014), 37% cerebral capillary telangiectasias were associated with a prominent draining vein and 11% with a developmental venous anomaly (DVA). With long-term follow-up, the telangiect-

tasia remained stable without surgical or medical intervention over a 65.7 patient-years of follow-up.

---

## 12.10 Cavernous Malformations

### 12.10.1 Etiology

Cavernous malformations, also known as cavernous angiomas or cavernous hemangiomas, are vascular lesions that can be asymptomatic or present with varying neurological symptoms. Cavernous malformations are found in 0.5% of the general population and make up 5–10% of all vascular lesions (Bhardwaj et al. 2009). These lesions are found more frequently with the increased use of imaging studies for surveillance imaging for various disease entities. They are most commonly seen in the third to fourth decade of life but about 25% of cavernomas present in childhood (Bigi et al. 2011) and up to 18% of the vascular lesions are seen in this population (von der Brellie et al. 2014). Fortuna et al. (1989), in a retrospective review of cavernomas in children, found a bimodal pattern of distribution at 0–2 years of age and 12–14 years of age. In a later review by Gross and colleagues (2015), age was not a specific risk factor. There is generally no preference for gender, although some studies show higher female population in very young and spinal cavernomas more prevalent in males than females (Bigi et al. 2011).

The causes of cavernomas are both congenital and de novo. Although the exact cause of cavernomas is unknown, factors associated with de novo formations of cavernous malformations are previous irradiation, genetics, and hormones (Fortuna et al. 1989; Larson et al. 1998; Pozzati et al. 1996). In patients with brain tumors that have received radiotherapy, there is a 3.4% incidence of these lesions (Bhardwaj et al. 2009). Gastelum and colleagues (2015) noted in a retrospective review that the majority of patients had a CRT dose >50 Gy, although literature supports the presence of cavernoma in children exposed to lower doses (12–24 Gy). The median latency period for detection of cavernous malformation

was 12.7 years for child post-radiation in the same review warranting longer follow-up in this population. The genetic predisposition for cavernomas is associated with an autosomal pattern of inheritance, with predominance within the Hispanic population. This familial tendency to develop cavernomas has been linked to the CCM 1 locus on the long arm of chromosome 7 in Hispanic families and 7q21–22 in non-Hispanic families (Frim et al. 2001; Yeh and Crone 2006). Additional loci have also been mapped to chromosomes 7p and 3 q (Buckley and Hickey 2014).

### 12.10.2 Pathophysiology

Cavernous malformations are vascular lesions that are composed of cystic vascular spaces lined by a single layer of endothelial cells. There is a distinct absence of smooth muscle elastic fibers which signifies the immaturity of the vessels. The sinusoidal vessels form a compact mass with no intervening neural parenchyma between the vascular structures. The immaturity of the blood vessels, no intervening neural parenchyma, and the lack of recognizable arteries and veins differentiate the cavernoma from other vascular lesions. The appearance of a cavernous malformation is that of a discrete, well-circumscribed, reddish mass with distinct lobulations. It is a low-flow lesion which lacks arterial supply and is composed of thin-walled vascular channels in a honeycomb pattern. It has both cystic and calcified components and is often characteristically referred to as a cluster of mulberries or “popcorn-like.” Cavernomas are separated typically from normal brain tissue by a gliotic plane (Bhardwaj et al. 2009). Several forms have been identified in childhood. They have been classified as solitary, multiple, iatrogenic, and familial lesions. Cavernous malformations most commonly occur in the supratentorial region (DiRocco et al. 1996) and less commonly in the spine and posterior fossa area. In the cerebral hemisphere, cavernomas have been reported in the parietal lobes, periventricular area, temporal lobes, and occipital lobes. They are generally independent lesions but have been found to occur with associated venous

malformations, specifically developmental venous anomalies (Kamezawa et al. 2005; Larson et al. 1998). Infratentorial lesion location includes the brainstem with the majority found in the pons versus the medulla or midbrain. Pediatric brainstem malformations account for 13.3–14.5% of all brainstem CM (Li et al. 2014). In the spine, they are seen more in the cervical and thoracic areas versus lumbosacral. Usually, these lesions are identified mid-childhood to adolescence (Bhardwaj et al. 2009.)

Most cavernomas show evidence of recent or remote hemorrhage. They often contain clots and blood products of various stages of evolution within the lesion, as well as calcification and gliosis. There also may be thrombosis in some of the dilated venules (Buckley and Hickey 2014). These lesions have a propensity to hemorrhage because of the fragility of the sinusoidal channels. Microhemorrhages may not manifest clinically; however, overt hemorrhages result in neurological deterioration. The risk of bleeding of a cavernous malformation is 0.6% but increases to 4.5% per year for cavernous malformations with a history of hemorrhage (Frim et al. 2001; Yeh and Crone 2006). In the cohort studied by Gross and colleagues (2015), incidental CCM had an annual hemorrhage rate of 0.5%, but for hemorrhagic CCM, the rate was 11.3%. This increased to 18.2% over the first 3 years for this population. There has been some evidence in the literature to suggest that the location of the cavernous hemorrhage influences the rate of hemorrhage, specifically brainstem cavernomas (Larson et al. 1998; Porter et al. 1997, 1999). In the literature, risk of rebleeding of cavernomas in the brainstem has been as high as 34% (Bhardwaj et al. 2009). However, this may be more related to the eloquence and sensitivity of the surrounding brain to show clinical events, as opposed to other areas of the brain (Larson et al. 1998).

The natural history of cavernomas is that they have a tendency to grow over time. This is one of the characteristics that differentiate them from other vascular lesions (Yeh and Crone 2006). One of the theories regarding the growth of the cavernoma is the hemorrhagic angiogenic proliferation theory. This theory suggests that recurrent

microhemorrhages are followed by fibrosis, reorganization, or calcification that leads to growth (Frim et al. 2001; Yeh and Crone 2006). It has also been theorized that cysts occur with clot absorption and re-hemorrhage. The cysts enlarge because of osmotic forces favoring movement of fluid into the cyst cavity. Biological factors, such as estrogen, have also been found to play a role in the growth of cavernous malformations (Frim et al. 2001; Yeh and Crone 2006).

### 12.10.3 Presenting Symptoms

As previously indicated, cavernomas can be asymptomatic. Those that are symptomatic generally present with seizures, hemorrhage, and neurological deficits. In a review of the natural history of CCM in children, hemorrhage is the most common presenting symptom in children. Of the 167 patients in the cohort, 62% of patients with a cavernoma presented with hemorrhage, followed by 35% with seizures, and 26% were incidental finding (Gross et al. 2015). The seizures have been theorized to be related to cortical irritation, the presence of calcification and gliosis around the surrounding parenchyma, or the accumulation of iron-containing substances produced by silent microhemorrhages (Fortuna et al. 1989; Yeh and Crone 2006). Headaches and focal neurological deficits are less evident in children versus adults, but when accompanied with nausea and vomiting, deterioration in the level of consciousness, and irritability, they are generally related to acute increased intracranial pressure from hemorrhage. Neurological deficits will be dependent on the location of the cavernoma and often are acute or progressive. The deficit can be a symptom of overt bleeding or gradual enlargement of the lesion causing the brain to become dysfunctional. Although extremely rare in children, patients with spinal cavernomas present with hydrocephalus and myelopathies secondary to small hemorrhages and a spinal cord compression. Progressive paraparesis and sensory changes are often usually seen in symptomatic patients with spinal cavernous malformations (Kondziolka et al. 1999).



### 12.10.4 Diagnostic Imaging

Cavernomas are detectable both on CT imaging and on MRI. Noncontrast CTs show cavernous malformations as focal areas of increased density, representing calcium or blood within the brain without any signs of mass effect. The high resolution afforded by MRI makes it the diagnostic tool of choice for identifying cavernous malformations. On MRI, cavernous malformations are best seen on T2-susceptibility-weighted images, which show high-intensity lobulated lesions (resembling popcorn kernel) surrounded by a low-intensity hemosiderin ring (resembling a bloom). Hemorrhages can produce areas of encephalomalacia, cyst, or calcification. The absence of large flow voids, suggestive of feeding arteries or draining veins, strongly suggests the diagnosis of cavernous malformation (Fig. 12.6). Cavernous malformations can be classified into four types based on their appearance on MR imaging (Table 12.8). Additionally, MRI technology is essential for follow-up of these patients to identify any recurrence, changes in existing

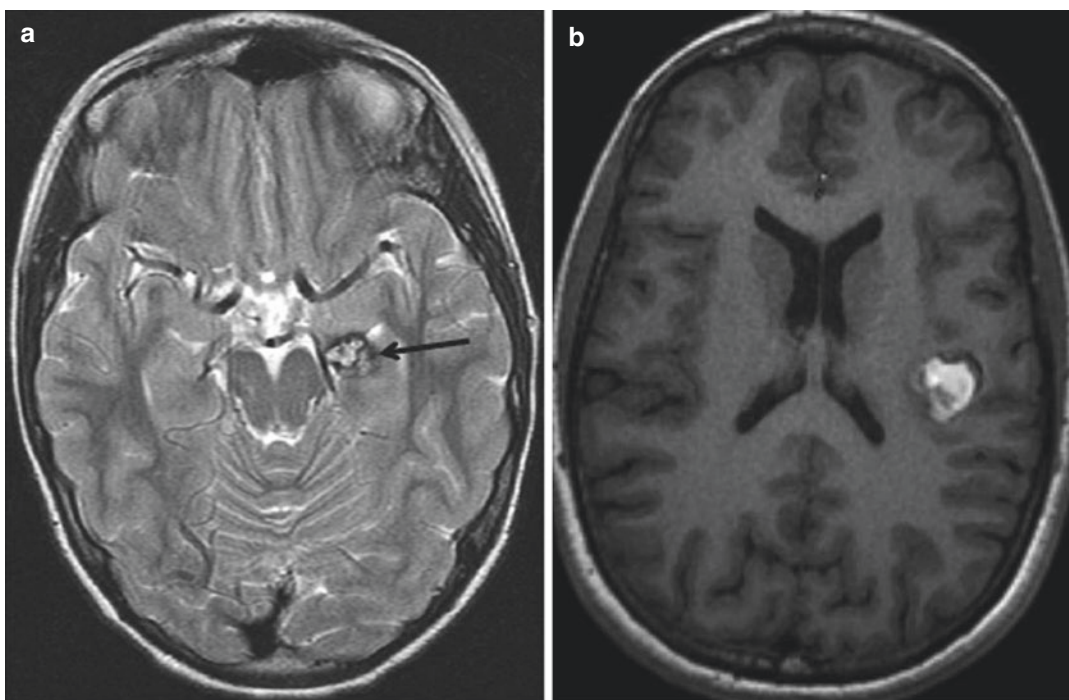
lesion, or hemorrhage. There is no role for angiography for these lesions because cavernous malformations do not have the high arterial blood flow. In the face of an acute hemorrhage and concern for AVM, angiography is often done to eliminate that possibility.

### 12.10.5 Treatment

There is no standard treatment for children with cavernous malformations. Each cavernoma needs to be assessed on an individual basis using a

**Table 12.8** Classification of cavernous malformations based on magnetic resonance imaging

Type I	Subacute bleed hyperintense on T1-weighted sequences
Type II	Popcorn appearance, heterogeneous T1- and T2-weighted sequences
Type III	Isointense/hypointense T1- and T2-weighted images chronic blood products
Type IV	Tiny punctuate foci, hypointense T1- and T2-weighted sequences



**Fig. 12.6** (a) MRI of cavernous malformation. (b) Cavernoma

risk-benefit approach. It has been generally accepted that cavernomas found incidentally and are asymptomatic do not require treatment. Surveillance for these lesions is recommended with follow-up MRI imaging.

Treatment options for a symptomatic cavernoma can be either medical or surgical. Medical conservative management involves the use of antiepileptic drugs for seizures, headache drugs, and physiotherapy. It is considered for lesions with medically controlled seizures, lesions in critical areas without severe symptoms, and cases of multiple cavernous malformations for which the actual symptomatic lesion is unidentified (Yeh and Crone 2006). When considering medical/conservative management, one needs to take into account the cumulative risk of hemorrhage for the child, lifetime costs associated with antiepileptics, and the long-term effects of being on antiepileptics. This becomes controversial because the curative rate from seizures with a surgical procedure is between 65% and 100% (Fortuna et al. 1989; Kondziolka et al. 1999). In recent literature, control in children who had seizures less than 2 years had a 100% response to surgery, but only 64% had good control in children with long-standing seizures, i.e., greater than 2 years (von der Brélie et al. 2014). In addition to medical management, patients with multiple lesions should have genetic counseling.

Surgical management is generally considered for symptomatic lesions, intractable epilepsy, lesions showing growth, and those with hemorrhage (Yeh and Crone 2006; Li et al. 2014). Location of the lesion near eloquent or superficial areas of the brain needs to be taken into consideration when deciding upon surgical management. The 4–5% rate for surgical morbidity in non-eloquent areas jumps to 12–25% in more vital areas such as the brainstem. Ideally, any surgical resection of a cavernoma should be delayed for 4–6 weeks after hemorrhagic event to allow for decreased swelling. Utilization of stereotactic navigation for surgical planning is typical to help with approach and trajectory. Additionally, the use of electrophysiological monitoring of the cranial nerves and somatosen-

sory motor components and brainstem auditory evoked potentials are routinely applied for minimization of risk in complex resections (Li et al. 2014). Optimal resection includes the cavernoma and the hemosiderin ring, which has correlated with better outcomes (Smith and Scott 2010).

The use of stereotactic radiosurgery for the treatment of cavernomas remains controversial. There have been studies pertaining to the adult population using radiation for inaccessible lesions (Tung et al. 1990). But because of the reluctance to expose young children to radiation of the brainstem or cortex, there is limited experience in pediatrics. In this small population, there has been a 3% mortality rate and a 16% morbidity seen (Smith and Scott 2010).

For all children with a cavernoma, whether treated or not, initial follow-up MRI is recommended in a 6-week to 6-month time period then annually after that for 2–5 years to look for rebleeding and regrowth of the cavernoma (Smith and Scott 2010).

### 12.10.6 Outcomes

Patients who undergo complete surgical resection of their cavernous malformation are often relieved of their symptoms (Kondziolka et al. 1999). The literature regarding seizure resolution indicated that 65–100% of patients postoperatively show resolution of their seizures (Fortuna et al. 1989; Kondziolka et al. 1999; von der Brélie et al. 2014). In a pediatric series, von der Brélie et al. (2014) had excellent seizure control (100%) in those with shorter-term seizure symptoms, typically less than 2 years. In the same study, those with longer seizure symptoms greater than 2 years, there was a 63.6% rate of becoming seizure-free. Location of the cavernoma will also affect the outcome. Deep cavernomas, or those involving the brainstem, are associated with significant morbidity and mortality. In a review of 20 pediatric patients with brainstem cavernomas who underwent surgical excision, six had excellent results, ten had good results with neurological improvement, and two had worsening of symptoms (DiRocco et al. 1996). In the review

by Li and associates (2014), they found that of the 52 patients who underwent surgery for brainstem cavernoma, 19.2% had full recovery of neurological symptoms. Improvement occurred in 61.5% overall, while 38.5% had no improvement.

Recovery from the neurological deficit is dependent on the number of hemorrhagic events. Tung et al. (1990) reported that of patients who had experienced a single hemorrhagic event, 80% of the patients also experienced a transient deficit. Conversely, Porter et al. (1997) report that one-third of patients experiencing an event will recover fully, one-third will have no significant recovery, and one-third will have partial recovery.

For patients with spinal cavernomas that present with hydrocephalus, the hydrocephalus resolves post-resection (Drucker 2006; Rivera et al. 2003). In regard to functional ability post-resection, the more functional the patient is pre-operatively, the more likely the patient is to do well after the surgical excision of the lesion (Box 12.1).

### Pearls

- Five to 10% of all vascular lesions, 25% present in childhood
- Low-flow lesion, no arterial supply, “cluster of mulberries”
- Can be congenital or de novo formations secondary to irradiation, hormones, genetics/familial
- Presenting symptoms
  - Hemorrhage
  - Seizures
  - Incidental finding
- Treatment
  - Incidental – can watch closely
  - Hemorrhagic, intractable seizures, severe neurological deficits – surgical resection
- Outcomes best in non-eloquent locations and seizures/symptoms <2 years versus chronic symptoms

### Box 12.1 Matthew’s Story

Matthew was a typical high school junior. He was popular, played sports, had a girlfriend, and was looking forward to junior prom and applying to college. So when he had his first seizure, Matthew and his family were unprepared for the battery of tests that yielded his diagnosis of a cavernous angioma (cavernoma) in his left temporal lobe. The neurologist caring for Matthew started him on antiepileptic medication and referred him to a pediatric neurosurgeon.

“We were so blown away by all this,” says his mother. “We never had anyone in the family have something so serious at such a young age. Matthew was afraid that he would have a seizure when he was out with his friends or in front of his girlfriend. He had to stop playing sports. We didn’t know what to do.”

The neurosurgeon evaluated Matthew and his imaging and video EEG results. He recommended surgical resection as his best chance for seizure control with the potential of becoming free of medications in the future. Matthew and his family agreed to the procedure. Since that time, he has been seizure-free and has been weaned from his antiseizure drug.

His dad gets emotional when he talks about the experience: “Matthew is now entering his second year in college. He has his life back and we are forever grateful to our medical team.”

## 12.11 Moyamoya Syndrome

### 12.11.1 Etiology

Moyamoya is a rare vascular disorder that leads to irreversible blockage of the internal carotid arteries. It is a chronic occlusive cerebrovascular disorder of unknown etiology that was initially reported and discovered in Japan (Takeuchi and

Shimuzu 1957). Moyamoya in Japanese means “puff of smoke” and was named this due to its characteristic appearance of abnormally fine collateral vessels on angiography. The disease is predominantly found in children, has a bimodal presentation at the first and fourth decade of life, and has a female preponderance of 1:1.8 male/female ratio. Although the exact etiology is unknown, the disease has a genetic link carried on chromosomes 1–22 (Ipone et al. 2000). Clinical syndromes and conditions that have been associated with moyamoya include prior radiation therapy to the head or neck, Down syndrome, neurofibromatosis type 1, tuberous sclerosis, primordial dwarfism, large facial hemangiomas, Fanconi’s anemia, sickle cell disease, and other hemoglobinopathies, autoimmune disorders including Grave’s disease, collagen vascular disorders (including Marfan’s syndrome), congenital cardiac anomalies, renal artery stenosis, infections including tuberculous meningitis and leptospirosis, and fibromuscular dysplasia (Scott and Smith 2009; Smith 2009).

Moyamoya disease refers to the idiopathic form, while moyamoya syndrome refers to those cases where a causative clinical condition has been identified (Ibrahimi et al. 2010). It accounts for approximately 6% of all causes of pediatric ischemic stroke (Nagaraja et al. 1994; Soriano et al. 1993). Reported incidence of moyamoya in the United States is 0.086 per 100,000, while the incidence in Japan is 0.35 per 100,000 (Uchino et al. 2005; Wakai et al. 1997).

### 12.11.2 Pathophysiology

Moyamoya disease is characterized by progressive intracranial vascular stenosis due to thickening of the intima of the vessel. It is commonly seen in the distal carotid artery, proximal anterior artery, and the middle cerebral arteries (Ohaegbulam et al. 1999). The progressive narrowing leads to a decrease in arterial blood flow resulting in cerebral ischemia. The brain induces the growth of netlike moyamoya vessels in order to establish collateral blood flow to areas distal to the site of vascular stenosis (Hannon 1996).

Although the exact cause of the thickening of the intima is unclear, it has been suggested that it is related to elevated basic fibroblast growth factor, platelet activation, and systemic alterations in cellular function (Ohaegbulam et al. 1999).

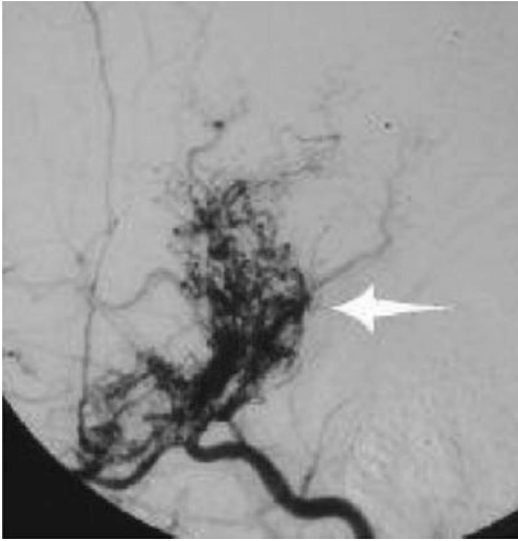
### 12.11.3 Presenting Symptoms

Children with moyamoya present with ischemic symptoms, whereas adult patients tend to present with cerebral hemorrhage (Kitamura et al. 1998). Intracranial hemorrhage associated with moyamoya is infrequently encountered in the pediatric population (Ibrahimi et al. 2010).

Children present with cerebral ischemia that manifests as monoparesis, hemiparesis, sensory deficits, and dysphasia (Yonekawa and Kahn 2003). Initially, children will develop transient ischemic attacks (TIAs) which can progress to cerebral infarction. TIAs can be precipitated by crying, coughing, hyperventilation, or straining, which ultimately reduces cerebral blood flow. Generally, 40% of children present with TIAs, 40% present with stroke, and 80% present with extremity weakness (Ohaegbulam et al. 1999). Repeated TIAs are manifested predominantly by seizure (20–30%) and motor hemiparesis (70–80%), as well as headache and speech difficulties, which are strongly indicative, although not pathognomonic, of moyamoya (Fukui 1997). Choreiform movements have been associated with moyamoya disease, occurring in 3–6% of patients (Zheng et al. 2006).

### 12.11.4 Diagnostic Test

Radiologic criteria for moyamoya are (1) stenosis or occlusion at the terminal portion of the internal carotid artery and proximal portion of the anterior cerebral artery and middle cerebral artery, (2) abnormal vascular network near the arterial occlusion, and (3) bilateral involvement (Fukui 1997). The gold standard for both the diagnosis and surgical planning is conventional angiography (Ibrahimi et al. 2010); however, multiple diagnostic techniques can be used to diagnose moyamoya. This



**Fig. 12.7** Lateral view of a right carotid angiogram showing proliferation of the lenticulostriate arteries forming a moyamoya or “puff-of-smoke” pattern

disease entity can be characterized radiologically on either angiograms, MRI, or magnetic resonance angiography (MRA) (Fig. 12.7). CT findings may demonstrate hypodensities in the watershed areas, suggestive of prior infarctions (Scott and Smith 2009; Smith and Scott 2005; Smith 2009); however, MRI can detect infarcts too small to be seen on CT imaging alone. MRIs show flow voids, and MRAs show stenosis of the cerebral arteries. Positron emission tomography (PET) and single-photon emission CT (SPECT) are diagnostic tests used that give important information regarding the cerebral hemodynamics. The findings are indicative of cerebral perfusion and metabolism which are important factors to take into consideration when planning surgical intervention. EEG is also a helpful diagnostic tool, demonstrating posterior and/or centrottemporal slowing, with a re-buildup phenomenon after the end of hyperventilation (Kodama et al. 1979).

### 12.11.5 Treatment Options

Currently, there is no curative medical/surgical treatment for moyamoya. Treatment is based on symptom management and begins with medical

management transitioning to surgical management. Initially, when the child presents with their first TIA, they may be started on medical therapy. This may include antiplatelets, anticoagulants, NSAIDs, and calcium channel blockers (Ohaegbulam et al. 1999). Treatment transitions to surgical as ischemic episodes progress. The goal of surgical therapy is to increase blood supply to the hypoperfused brain by establishing collateral circulation for the ischemic brain to prevent cerebral infarct. Multiple types of bypass procedures have been effective for moyamoya and can be classified as direct or indirect bypass. Ultimately, bypass procedures bring blood to the brain and bypass areas of blockage.

Direct bypass, namely, superficial temporal artery middle cerebral artery anastomosis (STA-MCA), is a procedure in which a scalp artery is directly sutured to a brain surface artery and burr holes are placed in the skull to allow for regrowth. This procedure is generally not used in children for they do not have a recipient cerebral artery large enough for anastomosis and are at increased risk for stroke (Ventureya and Vassilyadi 2001).

Indirect bypass involves leptomeningeal anastomosis from the external carotid artery directly on the ischemic brain. Indirect procedures can be either single or multiple depending on the number of vessels used. Single procedures such as encephaloduroarteriosynangiosis and encephalomyoarteriosynangiosis (EDAS, EMAS) are limited in their abilities to form collaterals and cover the ischemic area. Failure rate for a single procedure is 20–30% (Hannon 1996). Hence, multiple indirect bypass procedures have been developed to improve the possibility of revascularization and have a success rate of 94% (Hannon 1996).

Postoperatively, success is determined by the change in frequency and clinical presentation of the TIAs in the patient. If sufficient collaterals form, TIAs may decrease or disappear within months. However, this is difficult to predict, as patient factors influencing collateral formation are unknown. Postoperative imaging entails angiograms (during the follow-up period), MRA to demonstrate collateral revascularization, and SPECT and PET scans to show improvements in cerebral perfusion.



### 12.11.6 Outcomes

In the 5-year period following diagnosis, approximately 66% of patients with moyamoya disease experience symptomatic progression, demonstrating a poor long-term outcome in this population (Imaizumi et al. 1998; Scott and Smith 2009). Without surgical intervention, prognosis is poor, with the majority of individuals experiencing cognitive decline and multiple strokes because of the progressive narrowing of arteries. The incidence of TIAs may decrease, but the intellectual and motor disturbances tend to increase.

For those patients undergoing surgical revascularization, the neurological status at the time of the surgery appears to be the best prognosticator for favorable long-term outcome (Scott and Smith 2009). Patients who have sustained extensive ischemic morbidity preoperatively do not recover their abilities postoperatively. The risk of stroke in the postoperative period is highest in the first 30 days (Ibrahimi et al. 2010); the risk significantly decreases, with a 96% chance of being stroke-free over the next 5-year period (Smith and Scott 2005). Not surprisingly, the largest study of pediatric moyamoya admissions (Titsworth et al. 2016) demonstrated that those hospitals that admitted and treated the largest volumes of moyamoya disease demonstrated a reduced mortality rate, especially in those admissions who underwent surgical revascularization. The most important prognostic indicators for poorer outcomes included young age and longer duration of disease. Consequently, early intervention provides the most promising long-term outcomes (Shim et al. 2015).

### 12.11.7 Nursing Care

Close monitoring after surgery is vital in these children. Children postoperatively should initially be managed in an ICU environment. Patient should be sedated and remain normotensive and well hydrated. In the immediate postoperative period, neurological status, arterial blood pressure reading, and fluid status should be carefully monitored to prevent serious ischemic complications. Refer to Sect. 12.4.5 for vascular lesions for further nursing care issues.

### 12.11.8 Patient and Family Education

Prior to surgical intervention, the family should be educated on risk factors for hypoxemia, including those that cause hyperventilation and the need for appropriate hydration. After surgery, the family should be educated on signs and symptoms of cerebral ischemia, CVA, and seizures, as well as the importance of follow-up with the neurosurgeon. Follow-up angiography is done during the first year after surgery in order to evaluate the growth of cerebral circulation.

#### Pearls

- Rare vascular disorder that leads to irreversible blockage of the internal carotid arteries.
- Risk factors include:
  - Prior radiation therapy to the head or neck
  - Down syndrome
  - Neurofibromatosis type 1
  - Tuberous sclerosis
  - Primordial dwarfism
  - Large facial hemangiomas
  - Fanconi's anemia
  - Sickle cell disease
  - Hemoglobinopathies
  - Autoimmune disorders
    - Grave's disease
    - Collagen vascular disorders (including Marfan's syndrome)
  - Congenital cardiac anomalies
  - Renal artery stenosis
  - Infections
    - Tuberculous meningitis
    - Leptospirosis
  - Fibromuscular dysplasia
- Children generally present with ischemic symptoms and hyperventilation should be avoided in this population.
- Repeated TIA's may present with predominantly by seizure, motor hemiparesis (70–80%), and headache and speech difficulties.

- Gold standard for treatment and diagnosis is conventional angiography.
- No curative medical or surgical treatment for moyamoya although there are many surgical treatments utilized for reperfusion of the affected area.
- Early recognition and intervention provide the best opportunity in a disease process which generally has poor long-term outcomes.

## 12.12 Sinovenous Thrombosis

### 12.12.1 Pathophysiology

Cerebral sinovenous thrombosis (CSVT) is a disease characterized by a blood clot in the sinovenous system. The obstruction can result in increased ICP and subsequent stroke. The most common sites involved in CSVT are the transverse, superior sagittal, sigmoid, and straight sinuses, and the superficial system is more frequently involved than the deep (Dlamini et al. 2010).

Cerebrovascular venous drainage occurs through both superficial and deep systems via a network of veins and sinuses. Cortical veins that drain into the superior sagittal sinus make up the superficial venous system. The superior sagittal sinus then predominantly drains into the right lateral sinus and the jugular vein in most people. The deep system is comprised of the inferior sagittal sinus and the paired internal cerebral veins, which then join and form the vein of Galen and the straight sinus. This system predominantly drains into the left lateral sinus and jugular venous system (Dlamini et al. 2010; Swaiman and Ashwal 1999).

Because there are no venous valves, cerebral venous drainage is passive, and, consequently, venous flow may potentially reverse and is unresponsive to changes in systemic blood pressure. Cerebrospinal fluid (CSF) is primarily absorbed through the superior sagittal sinus by the arachnoid granulations that protrude into it. When these granulations are not able to absorb CSF,

such in the cases of sinus hypertension or venous thrombosis, outflow is obstructed. The consequence of this obstructed outflow includes venous congestion and an increase in capillary hydrostatic pressure, which then drives fluid into the interstitium and produces edema. Ultimately, obstruction of the venous system may present as a mild venous congestion and edema, cortical or subcortical parenchymal ischemia (with or without infarction), and hemorrhage. In some cases, noncommunicating hydrocephalus may be seen (Dlamini et al. 2010; Swaiman and Ashwal 1999).

There are many risk factors for the development of CSVT in the pediatric population, but any time there is local venous stasis, thrombosis can develop. Acute processes include fever, infection (particularly otitis media and mastoiditis), dehydration, anemia, head trauma, or recent intracranial surgery. Chronic processes include congenital heart disease, diabetes, nephrotic syndrome, systemic lupus erythematosus, inflammatory bowel disease, Cushing's syndrome, thyrotoxicosis, and malignancy (Dlamini et al. 2010). Prothrombotic disorders, such as protein C, protein S, and antithrombin deficiencies, factor V Leiden mutation, and high factor VIII levels, must also be considered as risks.

Sinovenous thrombosis may be under-recognized in both neonates and children because of the frequent presentation of nonfocal neurological signs and symptoms. In one series, 2.6 neonatal cases per 100,000 were noted, while between 0.4 and 0.7 per 100,000 childhood cases were noted (Dlamini et al. 2010). Other factors that may contribute to the underdiagnosis of this process include nonspecific imaging techniques, rapid reversal of the thrombosis, and variable anatomy of the cerebral venous system (Dlamini et al. 2010). An international study of 170 children admitted for CSVT demonstrated that 60% that presented were males and that the median age was 7.2 years. Hemorrhagic stroke occurred in 31% of the patients, while ischemic stroke occurred in 37%. Neurologic status was normal in 48% of those admitted. Mortality was 4%, and there was a relationship between it and no treatment

with anticoagulation. Poor discharge outcomes and death were associated with a decreased level of consciousness and the presence of a prothrombotic state at initial presentation (Ichord et al. 2015). Further study of treatment was recommended.

Clinical presentation may be nonspecific, non-focal, or subtle. Seizures, altered levels of consciousness, encephalopathy, and focal neurological deficits including cranial nerve palsies, hemiparesis, hemisensory loss, and diffuse neurological symptoms (including headache, nausea, vomiting) may be present. While seizures are more common in the neonatal population, focal and diffuse neurological signs are more common in infants and older children (Dlamini et al. 2010).

Neurological deficits are present at the time of discharge or at follow-up in 17–79% of survivors. Even in cases where aggressive treatment with antithrombotic agents, antibiotics, and surgery are used, many children may suffer chronic neurological problems due to increased intracranial pressure (including headache, visual disturbances, and cranial nerve VI palsy). Others may be affected by their venous infarction with developmental delays, learning disabilities, hemiparesis, and hemisensory loss. Many of these patients require long-term rehabilitative regimens. Overall, sinovenous mortality is less than 10% in children, but more than 50% of neonates have a poor outcome with a high mortality (Dlamini et al. 2010). Neonates that present with CVST may have up to a 6% mortality rate although the neurologic disability has been found to be 61% with epilepsy in 19% despite complete thrombus resolution in 90% of those patients. The 6% of the patients who died had been left untreated with antithrombotics. Of those who were untreated but survived, one in three experienced propagation and new venous infarction. Only 5.6% on neonates experienced anticoagulant-related bleeding, and none of these cases were fatal. While full recanalization was present in 89% of the neonates at 3 months, 61% of these demonstrated sensorimotor, language, and cognitive deficits significant enough to adversely affect quality of life and daily function. Because of these significant outcomes, sinovenous thrombosis should be

strongly considered in sick newborns with new onset neurologic symptoms (Moharir et al. 2011).

### 12.12.2 Diagnostic Imaging

Imaging must be done prior to recanalization. CT without contrast may demonstrate linear densities in the area of thrombosis, but as the lesion becomes less dense, a contrasted CT may demonstrate the “empty delta” sign. However, even a CT with contrast may miss the diagnosis of CSVT in 40% of patients. MRI with diffusion and perfusion is helpful in detecting venous congestion and in the differentiation of vasogenic and cytotoxic edema, but does not differentiate venous from arterial infarction well. The diagnostic imaging method of choice for CSVT is either CT venography or MRI with venography (MRV), which demonstrates a lack of flow in the cerebral veins (Dlamini et al. 2010). MRI and MRV may demonstrate flow artifacts, and if the diagnosis is in question, high-resolution CT venography or conventional digital subtraction angiography may be required.

### 12.12.3 Medical Treatment

Treatment usually consists of supportive measures and correction of the underlying problem, including correction of dehydration and infectious processes and control of seizures with anti-convulsant medications. There is a lack of controlled trials of anticoagulation in the pediatric population, and case studies in the last 10 years vary on the utilization of antithrombotic agents. While treatment may vary by center, overall it appears that older infants and children receive treatment with either parenteral unfractionated heparin, subcutaneous low-molecular-weight heparin (LMWH), or oral warfarin in the acute care setting for a period of 3–6 months. Hematological parameters should be followed closely during this time, and the risk of further worsening or causing intracranial hemorrhage should be weighed against the risk of supportive treatment only. As noted earlier, however, more recent studies are demonstrating greater mortal-

ity in those that do not receive antithrombotic treatment. The European Paediatric Neurology Society and Society for Paediatric Neurology have recommended that in the absence of any contraindication, anticoagulation may be utilized in the acute phase of CSVT in children and may be continued for 3–6 months according to individual factors. Neonates may also be treated with anticoagulation during the acute phase which may be continued up to a period of 6–12 weeks (Lebas et al. 2012).

#### 12.12.4 Surgical Treatment

Thrombolysis, thrombectomy, and surgical decompression have been used with success in isolated cases and small series, but no large, controlled, randomized studies have been performed, either in the adult or the pediatric population (Dlamini et al. 2010).

##### Pearls

- Characterized by a blood clot in the intracranial venous system, most commonly in transverse, superior sagittal, sigmoid, and straight sinuses, and the superficial system is more frequently involved than the deep.
- Obstruction results in increased ICP and hemorrhagic or ischemic stroke.
- Risk factors include:
  - Acute processes
    - Fever
    - Infection
      - Otitis media
      - Mastoiditis
    - Dehydration
    - Anemia
    - Head trauma
    - Recent intracranial surgery
  - Chronic processes include:
    - Congenital heart disease
    - Diabetes
    - Nephrotic syndrome

Systemic lupus erythematosus

Inflammatory bowel disease

Cushing's syndrome

Thyrototoxicosis

Malignancy

– Prothrombotic disorders

Protein C

Protein S

Antithrombin deficiencies

Factor V Leiden mutation

High factor VIII levels

- Clinical presentation may be subtle, nonfocal, or nonspecific but may include:
  - Seizures
  - Headaches
  - Reduced LOC
  - Encephalopathy
  - Focal neurological deficits
- CT venography or MRV are imaging studies of choice.
- Treatment includes correction of the underlying problem and/or anticoagulation.

### 12.13 Nursing Care for Ruptured Vascular Brain Lesions

Depending on the lesion, extent of rupture, and location of bleeding, the child may present with a variety of symptoms, from focal neurological deficits to a truly compromised clinical condition. Nursing care focus is on comprehensive assessment and identification of significant neurological changes, as well as prevention of further insults and deterioration of the patient's clinical status.

#### 12.13.1 Monitoring of Neurological Status

Careful monitoring of neurological status and vital signs is critical in assessing the child with a vascular anomaly. Nurses should monitor for signs of

increased intracranial pressure (ICP) by observing for signs of changes in the child's level of consciousness, abnormal cranial nerve findings, pupillary abnormalities, focal motor deficits, and increasing headache. Signs of headache and focal neurological deficits may indicate rebleed or vasospasm. Consistent documentation and communication of the patient's neurological status must exist among all caregivers assessing the child so that subtle changes in neurological status can be appreciated. Any changes indicative of worsening neurological function need be reported to the neurosurgical team.

### **12.13.2 Cerebral Perfusion: Monitoring and Maintenance**

Cerebral perfusion requires careful maintenance and monitoring. Specific neurological signs of decreased cerebral perfusion include complaints of diplopia, headache, and blurred vision. To increase cerebral perfusion, the administration of hypervolemic and/or hypertensive therapy may be required. In addition to monitoring for signs of decreased cerebral perfusion, children should be monitored for signs and symptoms of vasospasm including the insidious onset of confusion, disorientation, focal neurological deficits corresponding to a specific vascular territory, and decreased level of consciousness. It is also important to maintain the child's blood pressure or BP within the parameters indicated as per institutional protocols. Most often, there is a narrow acceptable window to ensure perfusion, but not hypertension, while a neurovascular lesion is unsecured, or not yet treated, as rebleeding can occur (Hinkle et al. 2010). Administration of hypertensive medications and vasopressors may be required after a hemorrhagic event and post-treatment for a vascular malformation, and, if used, their effect must be carefully monitored to keep the BP as close to normal for age as possible. Positioning of the patient in midline position with the head of bed elevated to 30° assists in perfusion and venous drainage (Hinkle et al. 2010).

### **12.13.3 Monitoring for Seizures**

Children with vascular lesions have a high propensity for seizure activity in both the preoperative and postoperative phase. Surgical intervention may involve stimulation of the parenchyma that in turn can provoke seizure activity in the postoperative stage, therefore necessitating careful observation of the child for seizure activity. If the child is seizing, anticonvulsants are to be administered, and therapeutic drug monitoring of anticonvulsants is important to ensure adequate dosing. Depending on the type of lesion, location, and treatment, the potential for recurrent seizures must be assessed to determine length of therapy. In many cases, risks for seizure may decrease significantly after definitive treatment for the vascular anomaly is performed, and anti-seizure medication may be weaned or stopped. In one series evaluating outcomes of children with various sources of intracranial hemorrhage (ICH), 11% of the cohort studied went on to develop epilepsy afterward (Beslow et al. 2010). It is important to educate the family and child regarding seizures and their management.

### **12.13.4 Management of Increased ICP and Hydrocephalus**

Some neurovascular lesions, such as aneurysm with significant SAH or AVM with extensive hemorrhage, can result in hydrocephalus and increased intracranial pressure. These patients may require placement of an EVD either prior to securing of the lesion, intraoperatively, or postoperatively. CSF drainage can then be titrated to keep ICP at prescribed parameters. It is important to note that over-drainage of CSF prior to aneurysm clipping or coiling can lead to sudden rebleeding of the aneurysm by alleviating the tamponade effect of normal to slightly elevated ICP. As the child is stabilized posttreatment, CSF drainage can be slowly decreased and eventually clamped to determine the need for more permanent shunting. It is not often, but a child may require ventricular-peritoneal shunting for unresolved hydrocephalus (Hinkle et al. 2010).



### 12.13.5 Management of Environmental Stress

To avoid complications related to vascular lesions, precautions should be instituted to decrease the environmental stimulus and minimize stress. Depending on the institution, patients may have an extended stay in the critical care unit during their postoperative period to allow for the child to remain ventilated, sedated, and hemodynamically stable. Further precautions include maintaining the child on bed rest and minimizing stimulus such as bright light, noise, anxiety, and pain. For example, noxious procedures like routine suctioning of endotracheal tubes should be limited. It is also important to limit activities to avoid elevation in blood pressure and ICP. Administration of stool softeners will minimize an increase in ICP from straining. Children who experience extreme agitation may require medication to reduce their level of agitation.

### 12.13.6 Management of Pain and Anxiety

Pain management needs to be addressed along the continuum of care for these patients. Obtaining a child's pain history is critical in helping to gauge their response to pain. Speak with the child and his/her parents to determine how they have responded to pain in the past and what modes of pain management were successful and unsuccessful. This will help in the assessment and treatment of the child's pain. The use of age-appropriate pain scales (e.g., OUCHER scale, Faces scale, numeric rating scale) and observation of physical manifestations such as increased BP, increased respirations, alteration in mood or behavior, and monitoring of vital signs should be completed on an ongoing basis. Particular attention should be given to signs of worsening of headache. Pain management is individualized and can vary from acetaminophen to opioids, depending on institution and surgeon preference. As the field of pediatric pain management expands, the use of patient-controlled analgesia (PCA) has been utilized for patients that cannot be managed with bolus doses of analgesics. Identification of intrac-

table pain and appropriate referrals to pain and palliative care teams is important to ensuring comfort for these patients.

Nonsteroidal anti-inflammatory drugs (NSAIDs) can inhibit platelet aggregation and prolong bleeding time. For this reason, it is not generally used in patients with vascular anomalies, particularly if they have had a hemorrhage or are in the immediate postoperative period. The nurse should discuss concerns regarding pain management with the neurosurgical team. In addition to the administration of analgesics, techniques should be employed to provide non-pharmacological modes of pain management through methods like distraction (e.g., engage in therapeutic play with the child life specialist, experience a visit with a therapy dog, listen to favorite music, and establishment of a quiet, dark environment that is conducive to rest).

Anxiety often accompanies pain and can intensify pain. To reduce anxiety in children, it is important to explain all procedures that will occur, ensure parental presence when possible for comfort, or provide an anxiolytic if clinical indicated. Risks in muting the symptoms of increased ICP must be weighed against the benefits of providing an anxiolytic. Sedatives such as midazolam, diazepam, and lorazepam may be administered for management of anxiety. As for opioid administration, selection of agent and titration of dosing to ensure acceptable response while preventing oversedation have become a standard of care in the pediatric ICU. However, cardiorespiratory equipment must be available at the bedside to manage respiratory distress or oversedation, with ready access to benzodiazepine antagonists (Humphreys et al. 1996).

The Bromage Sedation Scale (Table 12.9) is a tool often used (in addition to traditional pain scales) to assess the level of sedation in children who receive opioids or sedatives.

**Table 12.9** Bromage Sedation Scale

0	Awake
1	Occasionally drowsy, easily arousable
2	Frequently drowsy, easily arousable
3	Somnolent, difficult to arouse
S	Normal sleep

From Cheng et al. (2003)

### 12.13.7 Management of Nausea and Vomiting

Children often experience nausea and vomiting at presentation of a vascular event and throughout treatment, including postoperatively. Administration of antiemetics such as dimenhydrinate, metoclopramide, and ondansetron may be effective. The nurse should not administer these drugs repeatedly if there is suspicion that the child's nausea and vomiting are due to increased ICP. Intravenous fluids may be required if the child is unable to take adequate fluid orally. For some patients, such as those in the immediate postoperative period, IV fluids are run above maintenance to allow for adequate cerebral perfusion. With prolonged IV hydration, electrolytes need to be closely monitored.

### 12.13.8 Monitoring for Signs of Infection

Post-neurosurgical or endovascular intervention, the child should be observed of signs of infection. These include fever, discharge from the wound, redness or swelling around incision site, stiff neck, vomiting, irritability, and headache. Upon discharge, parents need to be educated regarding signs and symptoms of infection, as some infections may be insidious and have latent clinical effects.

### 12.13.9 General Posttreatment Care

Other needs that require attention include an adequate diet, good pulmonary care, mobilization issues, skin care, adequate rest, and emotional care. Many children who have had an ICH or clinical course of neurological significance will require inpatient rehabilitation once stable. Predictors of poor neurological outcome in this population are age <12 years old, poor functional status prior to treatment, left-sided (supratentorial) and brainstem (infratentorial) location, and high-grade lesion with bleed >2% of total brain volume (Darsaut et al. 2011; Beslow et al. 2010). Pediatric specific facilities are optimal for these children for the best outcomes. Referral to other professional services, such as social work, occu-

pational therapy, physical therapy, speech and swallowing specialists, neuropsychology/cognitive therapy, and child life services, should be initiated if clinically indicated.

### 12.13.10 Patient and Family Education

Always assess for the level of readiness in a parent of child when providing teaching regarding neurovascular lesions and the treatment. The level of anxiety may prohibit the intake of information and will often require a step-by-step approach to information exchange and teaching. Repeating or re-explaining the child's condition and treatment is often required to ensure adequate understanding by parents and children. Teaching aids in the form of handouts, diagrams, web-based teaching tools, or physical models of the brain are excellent tools to use in helping parents and children understand their condition. Allowing parents and child to view their own neuroimaging is often a very effective way to teach about the child's condition.

Parents and children (if age appropriate) should be provided with information on their vascular malformation in both written and verbal forms. In situations where the child is being managed by observation, the parents and children (if age appropriate) should be taught to watch for any potential signs and symptoms of seizure activity or signs of hemorrhage such as severe headache and the emergency action they need to take. Thorough instructions regarding activity restrictions need to be reviewed.

Parents and children should be taught emergency management of seizures – particularly prolonged seizures lasting greater than 5 minutes. Education regarding a prescribed anticonvulsant medication, side effects, and adverse reactions should be reviewed. Consider prescription of rectal diazepam to be used in case of prolonged seizure in high-risk patients. Daily assessment for the parents' level of understanding of their child's clinical status, treatment plan, and opportunities for teaching needs to be an ongoing process.

At the time of discharge, it is important to again provide written information that indicates the exact name of the child's condition, the type of treatment the child received (including the surgical procedure), the medications required for ongoing man-

agement, instructions for dressing and wound care, information on level of activity, follow-up appointments, and contact numbers in case of emergency or questions. In situations where ongoing care will be required in the home, arrangements for nursing care, physical and occupational therapy, and other care will need to be made. This includes providing the home care agency with accurate and detailed instructions and also the name of a contact nurse whom the home care agency can collaborate with to ensure appropriate management is provided. If a parent or child is to perform ongoing care in the home, teaching of the procedure and opportunities for return demonstrations must be provided during the child's admission.

When providing web-based information to parents and children, ensure that the information comes from a credible site. Warn parents and children about websites that may provide inaccurate information or are based on mainly anecdotal and personal experiences. While peer support is sometimes appropriate, try to direct families to sites where exchanges are monitored by reliable medical persons or organizations. Many children's hospitals have access to a medical library service within the institution that may provide patients and families with reliable information and resources appropriate to a child's individual condition at no charge or minimal fee. For a list of websites pertaining to neurovascular disease in children, see Appendix 12.1.

#### Pearl

- The Glasgow Coma Scale is the most effective tool that should always be utilized in ongoing monitoring of a child's neurological status whether in the preoperative or postoperative phase.

## 12.14 Pediatric Spinal Vascular Malformations

Spinal vascular malformations in children are rare. They consist of the same malformations seen in the brain and include cavernous malformations (CMs), arteriovenous fistulas (AVFs), and arteriovenous malformations (AVMs). There have been only a handful of cases of CM of the spinal cord

in the literature. The majority of spinal vascular malformations seen in the pediatric population are AVMs (Mawad 1994; Muszynski and Berenstein 2001; Riina et al. 2006; Spetzler et al. 2002) which will be the focus of this section.

### 12.14.1 Etiology

AVMs in the spine are similar in structure to their cerebral counterparts. They are congenital malformations that result from failure of arteriovenous connections to differentiate properly early in embryogenesis. An AVM is a tangle of arteries and veins without the typical intervening capillaries. The result is a so-called high-flow lesion where blood is shunted directly and quickly from the arterial side to the venous (Mawad 1994; Muszynski and Berenstein 2001; Riina et al. 2006; Spetzler et al. 2002; Ventureya and Vassilyadi 2001). AVMs of the spine can have varying numbers of feeding arteries and draining veins. The number and size of vessels involved can vary considerably. As in brain AVMs, the core of these vessels is the nidus where the arterial and venous components meet (Murasko and Oldfield 1990; Spetzler et al. 2002; Ventureya and Vassilyadi 2001). A nidus can be small and compact or large and diffuse. AVMs in children have been shown to increase in size over time secondary to increased flow through poorly differentiated vessels and the ability to recruit collateral vessels or proliferate new ones (Ventureya and Vassilyadi 2001). Poorly differentiated and dilated vessels in an AVM have a propensity for hemorrhage. The overall risk of hemorrhage is 2–4% per year, and the incidence is cumulative with age. Therefore, children with spinal AVMs have a high lifetime risk of hemorrhage (Ventureya and Vassilyadi 2001). In children, hemorrhage tends to occur bimodally: under the age of 4 years or over the age of 10 years (Kitagawa et al. 2009).

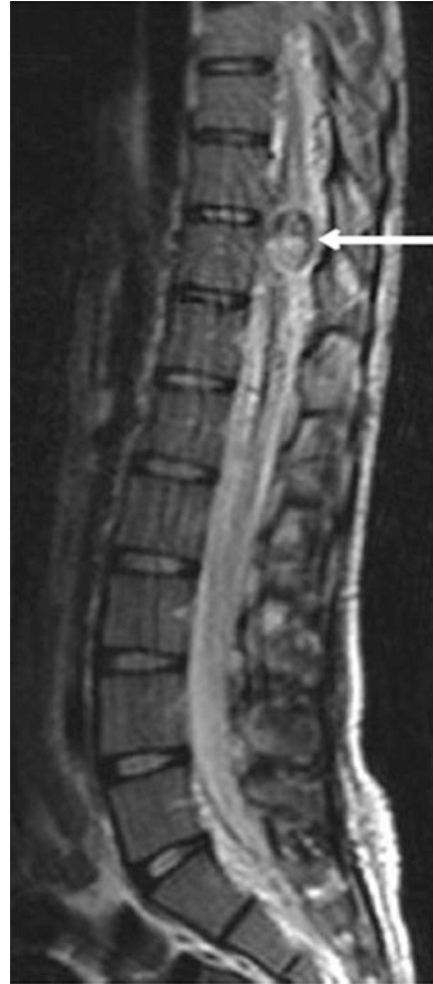AVMs of the spine can exist with a familial tendency. They can also be associated with syndromes including HHT (hereditary hemorrhagic telangiectasia) (Muszynski and Berenstein 2001; Ventureya and Vassilyadi 2001). Most occurrences, however, are often the

first within a family. Like their cerebral counterparts, spinal AVMs can have an associated aneurysm; however, such occurrences are rare (Riina et al. 2006; Spetzler et al. 2002; Ventureya and Vassilyadi 2001).

### 12.14.2 Pathophysiology

Spinal AVMs can occur anywhere along the spinal axis, and location of the AVM relative to cord parenchyma can vary. AVMs can arise from vessels on the surface of the cord or within the cord parenchyma itself. AVMs with the nidus involving the cord parenchyma are called intramedullary and are the most frequently occurring in adolescence or young adults (Fig. 12.8) (Riina et al. 2006). They derive their arterial blood supply directly from the spinal cord vasculature, either the anterior or posterior spinal arteries, and often involve very high blood flow and high pressure (Muszynski and Berenstein 2001; Spetzler et al. 2002). Juvenile AVM has an intramedullary nidus, but it is large and compromises the entire spinal cord at that level. Hemorrhage in either type results in acute neurological deterioration, but given the complex nature of the juvenile lesions, they often have a less favorable prognosis (Hinkle et al. 2010).

Extradural-intradural and paraspinal AVMs can involve not only the cord itself but the surrounding tissues including the paravertebral muscles, nerve root foramina, prevertebral area, and the spinal canal (Riina et al. 2006). These AVMs can have an intramedullary component to them but often are on the surface of the cord. Their arterial blood supply typically comes from multiple medullary arteries which, in turn, branch off the spinal arteries (Murasko and Oldfield 1990). They can be large with many arterial feeders and are associated with very high flow. When the AVM involves all tissue types, it is referred to as Cobb's syndrome (Riina et al. 2006; Rodesch et al. 2002; Spetzler et al. 2002). These are very rare but do occur more frequently in the pediatric population than adults.



**Fig. 12.8** Picture of intramedullary AVM

AVMs affecting the terminal portion of the spinal cord are called conus arteriovenous malformations. They involve the conus medullaris and the cauda equina. The blood supply tends to be from one or more of the spinal arteries, and they are also a high-flow lesion (Riina et al. 2006).

Spinal AVMs can produce symptoms secondary to hemorrhage, compression, vascular steal, and venous congestion (Murasko and Oldfield 1990; Spetzler et al. 2002; Riina et al. 2006; Ventureya and Vassilyadi 2001). Hemorrhage can occur in one catastrophic event or in repeated smaller ones. Symptoms produced will vary

depending on the location and extent of the hemorrhage. Compression on the cord or nerve roots can result from hemorrhage, the mass of the AVM itself, or largely dilated vessels. Compression can also result from surrounding edema that may be a result of hemorrhage or cord ischemia. Vascular steal is a result of blood being shunted into the malformation and away from arteries supplying the surrounding healthy tissue. Vascular steal leads to ischemia, which can lead to cell death and cord atrophy. Venous congestion leads to venous hypertension which results in impaired perfusion pressure to the cord and ischemia. Venous congestion can also lead to venous thrombosis causing a spinal cord infarct (Murasko and Oldfield 1990).

### 12.14.3 Presenting Signs and Symptoms

The presenting clinical picture is dependent on the location, size, and the pathophysiology of the AVM. The majority of children will present with an acute hemorrhage. The hemorrhage may be into the subarachnoid space, into the cord parenchyma, or both. Signs and symptoms of an acute hemorrhage include sudden onset of back or neck pain, extremity weakness or loss of function, sensory changes, and bowel and bladder dysfunction. If repeated smaller hemorrhages occur, the pain and neurological deterioration may be non-specific and subtle in onset. In such cases, the symptoms may go overlooked (Muszynski and Berenstein 2001).

Compression and ischemia can also present with pain and loss of motor and sensory function. Pain from compression or ischemia is more likely to be present in affected limbs. The exact location and nature of pain and neurological deficit is dependent on the location of the AVM. For example, an AVM in the cervicothoracic area will cause symptoms in the upper extremities, whereas a conus AVM will cause lower extremity and bowel and bladder dysfunction. Motor dysfunction can range from weakness to paralysis in the affected extremities. Tone may also be affected

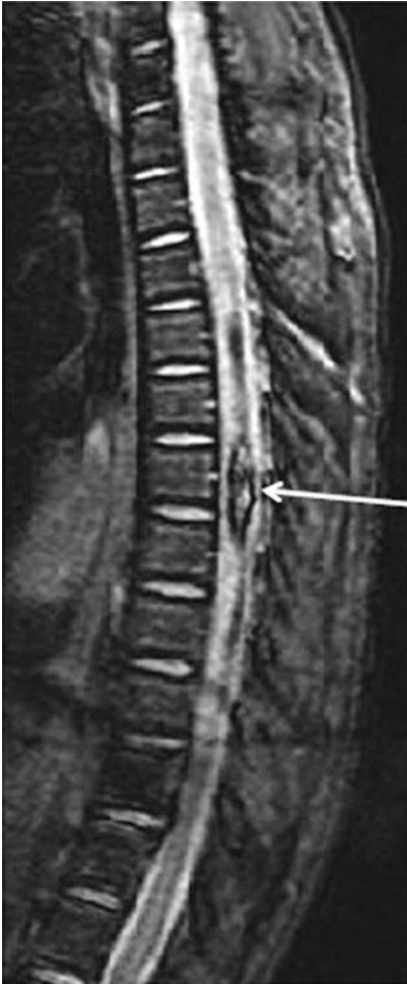and can be increased or decreased. Clonus can be a finding in these patients, as well as eventual spasticity requiring intervention if long-standing. Sensory manifestations can result in diminished or heightened perception of stimuli. Diminished sensation can result in a loss of discrimination to touch, temperature, sharpness, and proprioception. Hypersensitivity can result in neuropathic pain with minimal stimulation. Paresthesias such as tingling and numbness may be present. Because of the fragility of the spinal cord, most patients will present with some degree of neurological dysfunction. The nature and severity of the dysfunction depend on the location of the AVM, presence of hemorrhage, and damage done to the cord.

### 12.15 Cavernous Malformations and Arteriovenous Fistulas of the Spine

Cavernous malformations of the spine are rare in children but do occur. They have been described to occur more frequently in children who have received spinal radiation. They typically present secondary to signs and symptoms following repeated hemorrhages but occasionally are an incidental finding (Riina et al. 2006). Presentation usually occurs in the school-age to adolescent child and most often with an acute paraplegia syndrome (Bigi et al. 2011). The location of spinal CMs is mainly at the cervical or thoracic levels and has a typical appearance on MRI with a focal area of abnormal signal with surrounding hemorrhage of various ages and hemosiderin ring (Fig. 12.9) (Riina et al. 2006). They are angiographically occult. The only treatment option is surgery which is reserved for cases of an easily accessible lesion or significant neurological compromise.

Arteriovenous fistulas of the spine are similar in physiologic structure to their cerebral counterparts. They can occur anywhere on the spine; however, certain types do occur more frequently in the thoracic region (Spetzler et al. 2002). They tend to occur on the surface of the





**Fig. 12.9** Cavernoma of the spine

cord, typically in the dura mater around sensory ganglion of proximal nerve roots. (Rodesch et al. 2002; Spetzler et al. 2002; Hacein-Bey et al. 2014). There are two types of spinal AV fistulas. Dural AVFs occur in the dural root sleeve and account for the majority of spinal vascular malformations. They more often present in fourth to sixth decade of life rather than in childhood and have slow neurological deterioration in the form of progressive myelopathy from cord compression or vascular steal as they generally do no hemorrhage. Symptoms occur when there is reversal of flow in perimedullary veins causing venous hypertension, venous ischemia, and possible necrosis (Hacein-Bey

et al. 2014). The second type, perimedullary AVF, is a congenital lesion for the most part and within the dura. These can hemorrhage acutely. Rapid neurological deterioration from subarachnoid hemorrhage -SAH may be seen. These lesions also have a tendency to present in adulthood rather than in children (Hinkle et al. 2010). Treatment of spinal AV fistulas is most often accomplished with endovascular techniques alone. Surgery is less often required (Rodesch et al. 2005).

### 12.15.1 Diagnostic Tests

All patients with a suspected cord lesion will undergo an MRI of the spine. The MRI will often be performed with and without gadolinium to help differentiate an AVM from other vascular abnormalities or tumor. The presence of blood and its acute or subacute nature, as well as associated edema, syrinx, or cord atrophy, can be determined on MRI (Mawad 1994; Murasko and Oldfield 1990; Muszynski and Berenstein 2001; Porter et al. 1999).

MR angiography can be performed at the time of the MRI and may be useful in helping to identify the anatomy of the malformation. However, selective angiography remains the gold standard in defining the vascular architecture of the AVM and is absolutely necessary for treatment planning (Mawad 1994; Murasko and Oldfield 1990; Muszynski and Berenstein 2001; Ventureya and Vassilyadi 2001). In the case of an acute hemorrhage, angiography may be postponed until after the clot has resolved, generally in 4–6 weeks, as the presence of the clot can make defining the structure of the AVM difficult.

### 12.15.2 Treatment Options

As with cranial AVMs, the goal of treatment is complete obliteration of the malformation to eliminate the risk of future hemorrhage. However, because of the vulnerability of the spinal cord, this is not always possible. Treatment options include conservative management, surgical exci-

sion, and embolization. Often, a combination of these options is used.

Surgery in the acute presentation phase is typically reserved for children who are experiencing continued neurological deterioration, and an emergent need for decompression of the cord exists. This generally is evacuation of the clot. Once decompression is achieved, further workup with angiography and stabilization of neurological function should be done in an attempt to plan for resection of the residual AVM. Sometimes, especially in the case of small AVMs, the AVM may be removed with the clot at the time of the original surgery. AVMs that sit close to or on the cord surface, with a compact nidus, are most amendable to surgery. Some AVMs, given their location and relationship with the cord, are not surgically treatable.

Potential risks of surgery include new hemorrhage and injury to the spinal cord or nerve roots. Either of these would result in worsening neurological dysfunction. There is also a risk of infection and postoperative CSF leak.

As with cerebral AVMs, endovascular embolization is an important treatment option. Embolization is rarely solely curative with spinal AVMs but may be the only treatment option in lesions that are surgically inaccessible (Riina et al. 2006). Embolization is often used prior to surgery to decrease the number of feeder vessels to the AVM, thus decreasing the risk of hemorrhage. Embolization in the spine involves the same technique and materials used with cerebral lesions. The same risks of post-embolization hemorrhage, venous congestion, and edema exist. All of these could lead to further cord injury and loss of function (Mawad 1994; Muszynski and Berenstein 2001).

When a child presents with acute hemorrhage, a conservative approach is often taken initially if they are neurologically stable. During this phase, symptoms are managed, and neurological function is allowed to stabilize. Also during this phase, the clot is allowed to resolve so that a full diagnostic workup can take place. Angiography and treatment planning can proceed most effectively after the hemorrhage has resolved. All treatments pose a risk of causing new deficits or worsening existing ones. Therefore, careful plan-

ning and weighing of the risk-benefit ratio will help determine an individual treatment course for each patient.

### 12.15.3 Nursing Care

The most important aspect of nursing care for children with spinal AVMs is serial neurological examinations. The frequency of exams will vary depending on the stage of treatment and should be documented thoroughly. Neurological examination in children is detailed elsewhere in Chapter 1. The key point of the neurological exam is to know the child's baseline (or pretreatment) deficits and thus be able to note changes from that. Following surgery or embolization, it is critical to note changes in existing deficits and whether the changes are for the better or worse. Good and descriptive communication must exist between all caregivers assessing the child so that subtle changes can be noted. Any sign of worsening neurological function should be reported to the neurosurgical team.

Pain management is important throughout all stages of the patient's care. Pain is most acute following the initial hemorrhage or surgery. In these instances, a combination of narcotics and nonsteroidal anti-inflammatory medications is typically used. A muscle relaxant like diazepam may be added if muscle spasms are an issue.

Pain originating from the cord or nerves, called neuropathic or radicular pain, can be particularly difficult to control. Narcotics often are not completely effective in these situations. Certain neuroleptic drugs, like gabapentin, can be beneficial in helping to control this type of pain. Dosages typically start off once for first day, twice for second day, and then three times daily for third day. If a response is not realized in the next 2–3 days, increase each dose to therapeutic response.

Depending on the location of the spinal surgery, the neurosurgeon may request that the patient remain flat for a period of time, typically 24–48 hours. The purpose of this restriction is to help prevent a CSF leak. Generally with this type of resection, the dura is opened and sutured as part of closing the wound and can leak with

pressure from sitting and upright positioning. Typically, the patient can lay on their side, prone, or supine, as long as they remain flat. Other positioning or activity restrictions may be imposed dependent on the location of the incision and nature of the surgery. These are usually meant to help protect the integrity of the incision and prevent the complication of a CSF leak.

Postoperatively, diligent monitoring of the incision must be part of the nursing assessment, and a CSF leak reported should it occur. Any drainage from the wound that appears watery or leaves a ring sign is concerning for CSF. Additionally, a CSF leak can also present itself as swelling under the incision that continues to grow. Patients with a CSF leak will often experience a severe headache accompanied by nausea. They may also experience dizziness and photophobia. The symptoms are often worse when the patient is upright and improve when lying down. Managing a CSF leak may include timely resuturing of the incision if there is an external leak to prevent infection, along with strict bed rest. In some cases, a lumbar drain may be placed to drain CSF off and encourage sealing of the leak. On rare occasions, the leak must be surgically repaired.

Positioning and mobility are essential components of nursing care. Care must be taken to ensure frequent turning and range of motion, especially in children who have paralysis or have positioning and activity restrictions. Children who are not immobilized should begin moving as soon as cleared by the neurosurgery team.

Children who have undergone angiography with embolization will have a brief period of immobilization. Typically, the child is required to lie flat for 6 hours following the procedure. This is to prevent bleeding from the arterial puncture site and decrease the risk of thrombus formation. Post-embolization care involves serial neurological checks to monitor for signs of complications as the hemodynamics in the AVM change. It is important to monitor perfusion in the limb where arterial access was gained. Serial checks of pulses and perfusion distal to

the puncture site are necessary to monitor for signs of a clot.

Many children who present with spinal AVMs also present with neurological deficits. These deficits may improve or possibly resolve with treatment. However, a significant number of these children will have neurological deficits that do not completely resolve and therefore will need initiation of therapies and involvement of the rehabilitation team. Physical and occupational therapy should be consulted and involved from the onset of care. Other disciplines, such as urology and gastroenterology, may be needed depending on the exact deficits. The sooner a multidisciplinary team is brought together to address each child's specific needs, the sooner discharge planning can become a reality.

Paying attention to the emotional care is an aspect that should not be overlooked. Many of these children will present with new and, likely, life-altering deficits. Coupled with physical pain and the anxiety of the situation, coping may be difficult. It is important to monitor how the patient and their family are dealing with the situation and offer assistance at an early juncture. Involvement of social work and child life at the onset of diagnosis and treatment is essential. Anger and depression are not uncommon, especially if progress is slow and multifaceted. Providing encouragement to the patient and family is important.

#### **12.15.4 Outcomes**

Complete obliteration of the spinal AVM is not always possible. If residual AVM is present, so is a continued risk for hemorrhage. Secondary to the fragility of the cord, presenting deficits are often permanent. However, neurological improvement can continue over several weeks to months.

Family education should focus on not only the disease process and treatments but also on the deficits the child may have and how life adaptations may be possible. The patient and family will rely on the health care team to guide them in address-

ing such issues as mobility and care at home and school. There may be a need for adaptive equipment or learning new bowel and bladder management. Good communication between the multidisciplinary team and the family is essential.

### Conclusions

Neurovascular disease in children is typically the result of a congenital lesion that may be hereditary, inherited, or idiopathic in origin. Although each of these lesions has a low rate of incidence individually, vascular malformations are regularly seen in the pediatric neurosurgery population. Symptoms may be insidious and vague in nature or may present as acute, life-threatening events and can occur at any time. Accurate assessment and diagnosis is essential in ensuring that appropriate treatment is rendered.

It is important for the nurse to have an understanding of neurovascular malformations, their treatment, and potential outcomes in order to provide these patients with the best possible care. Treatment of neurovascular disease in pediatrics is improving rapidly. The refinement of neurosurgical instruments and surgical techniques, increased experience in endovascular and radiosurgical treatments, and evolution of medical management philosophies have all contributed to more favorable outcomes in children. Keeping abreast of current “best practice management” by nurses is an important component of comprehensive care for children with neurovascular disease.

### Pearls

- VGAMs typically present in neonates with high-output cardiac failure and during infancy with hydrocephalus, seizures, and rarely hemorrhage. Headaches tend to be the presenting symptom in older children and adults. Older children may also present with focal seizures and developmental delay.

- MRI can be used to diagnose and determine the nature of a VGAM, and cerebral angiography can be used to plan definitive endovascular or surgical intervention.
- Therapeutic decision-making regarding management of VGAM should be a shared process between the clinician and the parents.
- AVMs are congenital in origin, relatively uncommon, with no sex predilection.
- Hemorrhage and seizures are the most common presenting features in children presenting with AVMs.
- The greatest risk to a child with an AVM is potential for hemorrhage.
- Children with ruptured aneurysm and other vascular lesions often have significant headache as a presenting symptom, as well as altered neurological status. Pain management is required; however, the level of sedation must be considered to ensure adequate neurological assessment.
- Neuroscience nurses play a pivotal role in initial and posttreatment management. Appropriate monitoring and interventions can impact morbidity and mortality in these critically ill children.
- Support of the patient and family through the process of recovery and rehabilitation is paramount.

## 12.16 Appendix 12.1 Neurovascular Websites for Parents

[www.aboutkidshealth.ca/EN/HOWTHEBODYWORKS/Pages/default.asp](http://www.aboutkidshealth.ca/EN/HOWTHEBODYWORKS/Pages/default.asp) (Hospital for Sick Children website – good site for brain anatomy and physiology).

[www.ninds.nih.gov](http://www.ninds.nih.gov) (National Institute for Neurological Disorders and Stroke).

[www.novanews.org](http://www.novanews.org) (National Organization of Vascular Anomalies – NOVA).

## References

- Abe M, Hagihara N, Tabuchi K, Uchino A, Miyasaka Y (2003) Histologically classified venous angiomas of the brain: a controversy. *Neurol Med Chir (Tokyo)* 43:1–11
- Agrawal N, Johnston SC, Wu YW, Sidney S, Fullerton HJ (2009) Imaging data reveal a higher pediatric stroke incidence than prior US estimates. *Stroke* 40(11):3415–3421. doi:10.1161/strokeaha.109.564633
- Ali MJ, Bendok B, Rosenblatt S et al (2003) Recurrence of pediatric cerebral arteriovenous malformations after angiographically documented resection. *Pediatr Neurosurg* 39:32–38
- Alvarez H, Garcia Monaco R, Rodesch G, Sachet M, Krings T, Lasjaunias P (2007) Vein of Galen aneurysmal malformations. *Neuroimaging Clin N Am* 17(2):189–206. doi:10.1016/j.nic.2007.02.005 [Review]
- Amlie-Lefond, C., Bernard, T. J., Sebire, G., Friedman, N. R., Heyer, G. L., Lerner, N. B.,... Fullerton, H. J. (2009). Predictors of cerebral arteriopathy in children with arterial ischemic stroke: results of the International Pediatric Stroke Study. *Circulation*, 119(10), 1417–1423. doi:10.1161/circulationaha.108.806307
- Aryan HE, Giannotta SL, Fukushima T, Park MS, Ozgur BM, Levy ML (2006) Aneurysms in children: review of 15 years experience. *J Clin Neurosci* 13:188–192
- Asaithambi G, Advil MM, Shah KM, Jordan LC, Qureshi AI (2014) Patterns of treatment and associated short-term outcomes of unruptured intracranial aneurysms in children. *Childs Nerv Syst* 30:1697–1700
- Balaci E, Sumner TE, Auringer ST, Cox TD (1999) Diffuse neonatal hemangiomas with extensive involvement of the brain and cervical spinal cord. *Pediatr Radiol* 29(6):441–443. doi:10.1007/s002470050612
- Bar-Sever, Z., Horev, G., Lubin, E., Kornreich, L., Naor, N., Ziv, N.,... Grunebaum, M. (1994). A rare coexistence of a multicentric hepatic hemangioendothelioma with a large brain hemangioma in a preterm infant. *Pediatr Radiol*, 24(2), 141–142.
- Beez T, Steiger H, Hanggi D (2016) Evolution of management of intracranial aneurysms in children: a systemic review of the modern literature. *J Child Neurol* 31(6):773–783
- Beslow LA, Licht DJ, Smith SE, Storm PB, Heuer GG, Zimmerman RA, Feiler AM, Kasner SE, Ichord RN, Jordan LC (2010) Predictors of outcome in childhood intracerebral hemorrhage. *Stroke*. doi:10.1161/STROKEAHA.109.568071
- Bhardwaj RD, Auguste KI, Kulkarni AV, Dirks PB, Drake JM, Rutka JT (2009) Management of pediatric brainstem cavernous malformations: experience over 20 years at the Hospital for Sick Children. *J Neurosurg Pediatr* 4:458–464
- Bigi S, Capone Mori A, Steinlin M, Remonda L, Landolt H, Boltshauser E (2011) Cavernous malformations of the central nervous system in children: presentation, treatment and outcome of 20 cases. *Eur J Paediatr Neurol* 15:109–116
- Blaser SI, Illner A, Castillo M, Hedlund GL, Osborn AG (2003) Pocket radiologist *Peds Neuro top 100 diagnoses*, 1st edn. WB Saunders, Utah
- Boone C, Caplan JM, Garzon-Muvdi T, Yang W, Ye X, Groves ML, Tamargo RJ, Ahn ES, Huang J (2016) Hemorrhage risk in pediatric patients with multiple intracranial arteriovenous malformations. *Pediatr Neurosurg*. doi:10.1159/000444286
- Buckley DA, Hickey JV (2014) Cerebral aneurysms and arterial venous malformations and other cerebrovascular anomalies. In: Hickey JV (ed) *The clinical practice of neurological and neurosurgical nursing*, 7th edn. Lippincott Williams & Wilkins, Philadelphia
- Cavanagh SJ, Gordon VL (2002) Grading scales used in the management of aneurismal subarachnoid hemorrhage: a critical review. *J Neurosurg Nurs* 34:288–295
- Cheng A, Williams BA, Sivrahan BV (eds) (2003) *The HSC handbook of pediatrics*, 10th edn. Elsevier/Saunders, Toronto
- Chevret L, Durand P, Alvarez H, Lambert V, Caeymax L, Rodesch G, Devictor D, Lasjaunias P (2002) Prognosis significance of hemodynamic parameters in neonates presenting with severe heart failure owing to vein of Galen arteriovenous malformations. *Intensive Care Med* 28:1126–1130
- Chow, M. L., Cooke, D. L., Fullerton, H. J., Amans, M. R., Narvid, J., Dowd, C. F.,... Hettis, S. W. (2015). Radiological and clinical features of vein of Galen malformations. *J NeuroInterv Surg*, 7(6), 443–448. doi:10.1136/neurintsurg-2013-011005
- Cohen JE, Boitsova S, Moscovici S, Itshayek E (2010) Concepts and controversies in the management of cerebral developmental venous anomalies. *Isr Med Assoc J* 12(11):703–706
- Courville CB (1963) Morphology of small vascular malformations of the brain. With particular reference to the mechanism of their drainage. *J Neuropathol Exp Neurol* 22:274–284
- Coutinho J, de Bruijn SF, Deveber G, Stam J (2011) Anticoagulation for cerebral venous sinus thrombosis. *Cochrane Database Syst Rev* (8):Cd002005. doi:10.1002/14651858.CD002005.pub2
- Daenekindt T, Weyns F, Kho KH, Peuskens D, Engelborghs K, Wuyts J (2008) Giant intracranial capillary hemangioma associated with enlarged head circumference in a newborn. *J Neurosurg Pediatr* 1(6):488–492. doi:10.3171/ped/2008/1/6/488
- Darsaut TE, Guzman R, Marcellus ML, Edwards MS, Tian L, Do HM, Chang SD, Levy RP, Adler JR, Marks MP, Steinberg GK (2011) Management of pediatric intracranial arteriovenous malformations: experience with multimodality therapy. *Neurosurgery*. doi:10.1227/NEU.0b013e3182181c00
- Deeg K, Scarf J (1990) Colour Doppler imaging of arteriovenous malformation of the vein of Galen in a newborn. *Neuroradiology* 32:60–63
- Deloison B, Chalouhi GE, Sonigo P, Zerah M, Millischer AE, Dumez Y et al (2012) Hidden mortality of prenatally diagnosed vein of Galen aneurysmal malformation: retrospective study and



- review of the literature. *Ultrasound Obstet Gynecol* 40(6):652–658. doi:10.1002/uog.11188
- DiRocco C, Iannelli A, Tamburrini G (1996) Cavernomas of the central nervous system in children. *Acta Neurochir* 138:1267–1274
- Dlamini N, Billingham L, Kirkham FJ (2010) Cerebral venous sinus (sinovenous) thrombosis in children. *Neurosurg Clin N Am* 21(3):511–527
- Drucker DE (2006) Neurologic disorders. In: *Nettina S* (ed) Lippincott manual of nursing practice, 8th edn. Lippincott Williams Wilkins, Philadelphia, pp 465–557
- Elixson EM (1992) Intracerebral arteriovenous malformations presenting as neonatal congestive heart failure. *Crit Care Nurs Clin North Am* 4:537–542
- Ellis JA, Orr L, Ii PC, Anderson RC, Feldstein NA, Meyers PM (2012) Cognitive and functional status after vein of Galen aneurysmal malformation endovascular occlusion. *World J Radiol* 4(3):83–89. doi:10.4329/wjr.v4.i3.83
- Ersoy S, Mancini AJ (2005) Hemifacial infantile hemangioma with intracranial extension: a rare entity. *Pediatr Dermatol* 22(4):309–313. doi:10.1111/j.1525-1470.2005.22405.x
- Ferro JM, Canhao P (2008) Acute treatment of cerebral venous and dural sinus thrombosis. *Curr Options Neurol Treat* 10(2):126–137
- Fortuna A, Ferrante L, Acqui L, Mastronardi L, Acqui M, d'Addetta R (1989) Cerebral cavernous angioma in children. *Childs Nerv Syst* 5:201–207
- Foy AB, Wetjen N, Pollock BE (2010) Stereotactic radiosurgery for pediatric arteriovenous malformations. *Neurosurg Clin N Am* 21:457–461
- Frawley GP, Dargaville PA, Mitchell PJ, Tress BM, Loughnan P (2002) Clinical course and medical management of neonates with severe cardiac failure related to vein of Galen malformation. *Arch Dis Child Fetal Neonatal Ed* 87:144–149
- Friedlander RM (2007) Arteriovenous malformations of the brain. *N Engl J Med* 356(26):2704–2712
- Friedman DM, Verma R, Madrid M, Wisoff JH, Berenstein A (1993) Recent improvement in outcome using transcatheter embolization techniques for neonatal aneurysmal malformations of the vein of Galen. *Pediatrics* 91:583–596
- Frim DM, Gupta N, Scott RM (2001) Cavernous malformations. In: McLone DG (ed) *Pediatric neurosurgery. Surgery of the developing nervous system*. Saunders, Philadelphia, pp 1097–1104
- Fukui M (1997) Current state of study on Moyamoya disease in Japan. *Surg Neurol* 47:138–143
- Fullerton HJ, Aminoff AR, Ferriero DM, Gupta N, Dowd CF (2003) Neurodevelopmental outcome after endovascular treatment of vein of Galen. *Neurology* 61:1386–1390
- Gailloud P, O'Riordan DP, Burger I, Levrier O, Jallo G, Tamargo RJ, Murphy KJ, Lehmann CU (2005) Diagnosis and management of vein of Galen aneurysmal malformations. *J Perinatol* 25:542–551
- Gardner MA, Hills NK, Sidney S, Johnston SC, Fullerton HJ (2010) The 5-year direct medical cost of neonatal and childhood stroke in a population-based cohort. *Neurology* 74(5):372–378. doi:10.1212/WNL.0b013e3181cbcd48
- Gastelum E, Sear K, Hills N, Roddy E, Randazzo D, Chettout, Hess C, Cotter J, DA H-K, Fullerton H, Mueller S (2015) Rates and characteristics of radiographically detected intracerebral cavernous malformations after cranial radiation. *J Child Neurol* 30(7):842–849
- Giroud M, Lemesle M, Gouyon JB, Nivelon JL, Milan C, Dumas R (1995) Cerebrovascular disease in children under 16 years of age in the city of Dijon, France: a study of incidence and clinical features from 1985 to 1993. *J Clin Epidemiol* 48(11):1343–1348
- Gökçe E, Acu B, Beyhan M, et al. Magnetic resonance imaging findings of developmental venous anomalies. *Clin Neuroradiol* 2014;24:135–43
- Gold AP, Ransohoff J, Carter S (1964) Vein of Galen malformation. *Acta Neurol Scand* 40:1–31
- Goldenberg NA, Bernard TJ, Fullerton HJ, Gordon A, deVeber G (2009) Antithrombotic treatments, outcomes, and prognostic factors in acute childhood-onset arterial ischaemic stroke: a multicentre, observational, cohort study. *Lancet Neurol* 8(12):1120–1127. doi:10.1016/s1474-4422(09)70241-8
- Griffiths PD, Blaser S, Armstrong D et al (1998) Cerebellar arteriovenous malformations in children. *Neuroradiology* 40:324–331
- Gross BA, Du R (2014) Diagnosis and treatment of vascular malformations of the brain. *Curr Treat Options Neurol* 16(1):279. doi:10.1007/s11940-013-0279-9
- Gross BA, Du R, Orbach DB, Scott RM, Smith ER (2015) The natural history of cerebral cavernous malformations in children. *Neurosurg Pediatr* 16:1–6
- Gross BA, Smith ER, Scott RM, Orbach DB (2014) Intracranial aneurysms in the youngest patients: characteristics and treatment challenges. *Pediatr Neurosurg* 15(50):18–25
- Gulati S, Kalra V (2002) An uncommon variety of vein of Galen malformation. *Indian Pediatr* 39(3):307–308 [Case Reports]
- Gupta AK, Varma DR (2004) Vein of Galen malformations: review. *Neurol India* 52(1):43–53 [Review]
- Gupta AK, Rao VR, Varma DR, Kapilamoorthy TR, Kesavadas C, Krishnamoorthy T, Purkayastha S (2006) Evaluation, management, and long-term follow up of vein of Galen malformations. *J Neurosurg* 105(1):26–33. doi:10.3171/jns.2006.105.1.26 [Case Reports]
- Hacein-Bey L, Konstas AA, Pile-Spellman J (2014) Natural history, current concepts, classification, factors impacting endovascular therapy, and pathophysiology of cerebral and spinal dural arteriovenous fistulas. *Clin Neurol Neurosurg* 121:64–75
- Hannon K (1996) Pial synangiosis for treatment of Moyamoya syndrome in children. *AORN J* 64:540–560
- Hetts SW, Narvid J, Sanai N, Lawton MT, Gupta N, Fullerton HJ, Dowd CF, Higashida RT, Halba VV (2009) Intracranial aneurysms in childhood. *AJNR Am J Neuroradiol* 33:1315–1324

- Heyer GL, Garzon MC (2008) An infant with a facial hemangioma and more. *Semin Pediatr Neurol* 15(4):160–163. doi:10.1016/j.spen.2008.10.001
- Hinkle JL, Guanci MM, Stewart-Amidei C (2010) Cerebrovascular events of the nervous system. In: Bader MK, Littlejohns LR (eds) AANN core curriculum for neuroscience nurses, 5th edn. AANN, St. Louis
- Hoang S, Choudhri O, Edwards M, Guzman R (2009) Vein of Galen malformation. *Neurosurg Focus* 27(5):E8. doi:10.3171/2009.8.FOCUS09168 [Comparative Study Review]
- Hoh B, Ogilvy C, Butler W et al (2000) Multimodality treatment of nongalenic arteriovenous malformations in pediatric patients. *Neurosurgery* 47:346–358
- Horgan M, Florma J, Spetzler RF (2006) Surgical treatment of arteriovenous malformations in children. In: Alexander M, Spetzler RF (eds) Pediatric neurovascular disease: surgical, endovascular, and medical management. Thieme, New York, pp 104–115
- Huang J, McGirt MJ, Gaillood P, Tamargo RJ (2005) Intracranial aneurysms in the pediatric population: case series and literature review. *Surg Neurol* 63:424–433
- Huber G, Henkes H, Hermes M, Felber S, Terstegege K, Piepgras U (1996) Regional association of developmental venous anomalies with angiographically occult vascular malformations. *Eur Radiol* 6(1):30–37
- Huhn SL, Lee JA, Steinberg GK (2006) Surgical treatment of vein of Galen malformations in children. In: Alexander M, Spetzler RF (eds) Pediatric neurovascular disease. Thieme, New York, pp 116–128
- Humphreys RP, Hoffman H, Drake J, Rutka J (1996) Choices in the 1990s for the management of pediatric cerebral arteriovenous malformation. *Pediatr Neurosurg* 25:277–285
- Ibrahimi DM, Tamargo RJ, Ahn ES (2010) Moyamoya disease in children. *Childs Nerv Syst* 26(10):1297–1308. doi:10.1007/s00381-010-1209-8 [Review]
- Ichord RN, Benedict SL, Chan AK, Kirkham FJ, Nowak-Gottl U (2015) Paediatric cerebral sinovenous thrombosis: findings of the International Paediatric Stroke Study. *Arch Dis Child* 100(2):174–179. doi:10.1136/archdischild-2014-306382
- Imaizumi T, Hayashi K, Saito K, Osawa M, Fukuyama Y (1998) Long-term outcomes of pediatric moyamoya disease monitored to adulthood. *Pediatr Neurol* 18(4):321–325 [Comparative Study Research Support, Non-U.S. Gov't]
- Ipone T, Ikezaki K, Susuzaki T (2000) Linkage analysis of Moyamoya disease on chromosome 6. *J Child Neurol* 15:179–182
- Jaegar JR, Forbes RP, Dandy WE (1937) Bilateral congenital cerebral arteriovenous communication aneurysm. *Trans Am Neurol Assoc* 63:173–176
- Jalloh I, Dean AF, O'Donovan DG, Cross J, Garnett MR, Santarius T (2014) Giant intracranial hemangioma in a neonate. *Acta Neurochir* 156(6):1151–1154. doi:10.1007/s00701-014-2007-y
- Jankowitz BT, Vora N, Jovin T, Horowitz M (2008) Treatment of pediatric intracranial vascular malformations using Onyx-18. *J Neurosurg Pediatr* 2(3):171–176
- Jian BJ, Hetts SW, Lawton MT, Gupta N (2010) Pediatric intracranial aneurysms. *Neurosurg Clin N Am* 21:491–501
- Jones BV, Linscott L, Koberlein G, Hummel TR, Leach JL (2015) Increased prevalence of developmental venous anomalies in children with intracranial neoplasms. *AJNR Am J Neuroradiol* 36(9):1782–1785. doi:10.3174/ajnr.A4352
- Judd CD, Chapman PR, Koch B, Shea CJ (2007) Intracranial infantile hemangiomas associated with PHACE syndrome. *AJNR Am J Neuroradiol* 28(1):25–29
- Kakarla UK, Beres EJ, Ponce FA, Chang SW, Deshmukh VR, Bambakidis NC, Zabramski JM, Spetzler RF (2010) Microsurgical treatment of pediatric intracranial aneurysms: long-term angiographic and clinical outcomes. *Neurosurgery* 67:237–249
- Kamezawa T, Hamada J, Niuro M, Kai Y, Ishimaru K, Kuratsu J (2005) Clinical implication of associated venous drainage in patients with cavernous malformations. *J Neurosurg* 102:24–28
- Kang E, Friedman N, Mamoun I, Tamburro J, Golden A (2016) Beta blockade as treatment for intracranial infantile hemangioma: case report and literature review. *Pediatr Neurol*. doi:10.1016/j.pediatrneurol.2016.01.018
- Karikari IO, Selznick LA, Cummings TJ, George TM (2006) Capillary hemangioma of the fourth ventricle in an infant. Case report and review of the literature. *J Neurosurg* 104(3 Suppl):188–191. doi:10.3171/ped.2006.104.3.188
- Khoo LT, Wallace MJ, McComb JG, Levy ML (1999) Pediatric aneurismal disease. In: Albright AL, Pollack I, Adelson PD (eds) Principles and practice of pediatric neurosurgery. Thieme, New York, pp 1133–1152
- Khurana VG (2005) Venous angiomas: developmental venous anomaly (DVA). Retrieved from <http://www.brainaneurysm.com/dva.html>. Accessed on 2011 Sept 19.
- Kirton A, deVeber G (2006) Cerebral palsy secondary to perinatal ischemic stroke. *Clin Perinatol* 33:367–386
- Kirton, A., Armstrong-Wells, J., Chang, T., DeVeber, G., Rivkin, M. J., Hernandez, M.,... Ferriero, D. M. (2011). Symptomatic neonatal arterial ischemic stroke: the International Pediatric Stroke Study. *Pediatrics*, 128(6), e1402–1410. doi:10.1542/peds.2011-1148
- Kitagawa RS, Mawad ME, Whitehead WE, Curry DJ, Luerssen TG, Jea A (2009) Paraspinal arteriovenous malformations in children. *J Neurosurg Pediatr* 3:425–428
- Kitamura F, Fuku M, Oka K, Masushima T, Kurokawa T, Hasuo K (1998) Moyamoya disease. *Handb Clin Neurol* 2:293–306
- Kodama N, Aoki Y, Hiraga H, Wada T, Suzuki J (1979) Electroencephalographic findings in children with moyamoya disease. *Arch Neurol* 36(1):16–19
- Kondziolka D, Humphreys RP, Hoffman H et al (1992) Arteriovenous malformations of the brain in children: a forty year experience. *Can J Neurol Sci* 19:40–45

- Kondziolka D, Pollock B, Lunsford LD (1999) Vascular malformations: conservative management, radiosurgery and embolization. In: Albright A, Pollack I, Adelson PD (eds) *Principles and practice of pediatric neurosurgery*. Thieme, New York, pp 1017–1031
- Krishna H, Wani AA, Behari S, Banerji D, Chhabra DK, Jain VK (2005) Intracranial aneurysms in patients 18 years of age or under, are they different from aneurysms in adult population? *Acta Neurochir* 147:469–476
- Larson J, Ball W, Bove K, Crone K, Tew J Jr (1998) Formation of intracerebral cavernous malformations after radiation treatment for central nervous system neoplasia in children. *J Neurosurg* 88:51–56
- Lasjaunias P (1997) Vein of Galen aneurysmal malformation. In: Lasjaunias P (ed) *Vascular diseases in neonates. Infants and children*. Springer, Berlin, pp 67–202
- Lasjaunias P, Burrows P, Planet C (1986) Developmental venous anomalies (DVA): the so-called venous angioma. *Neurosurg Rev* 9(3):233–242 [Review]
- Lasjaunias PL, Chng SM, Sachet M, Alvarez H, Rodesch G, Garcia-Monaco R (2006) The management of vein of Galen aneurysmal malformations. *Neurosurgery* 59(5 Suppl 3):S184–S194 discussion S183–S113
- Lasjaunias P, Garcia-Monaco R, Rodesch G, TerBrugge K ZM, Tardieu M, de Victor D (1991) Vein of Galen malformation. Endovascular management of 43 cases. *Childs Nerv Syst* 7:360–367
- Lebas, A., Chabrier, S., Fluss, J., Gordon, K., Kossorotoff, M., Nowak-Gottl, U.,... Tardieu, M. (2012). EPNS/SFNP guideline on the anticoagulant treatment of cerebral sinovenous thrombosis in children and neonates. *Eur J Paediatr Neurol*, 16(3), 219–228. doi:10.1016/j.ejpn.2012.02.005
- Lee RR, Becher MW, Benson ML, Rigamonti D (1997) Brain capillary telangiectasia: MR imaging appearance and clinicohistopathologic findings. *Radiology* 205(3):797–805
- Lee C, Pennington MA, Kenney CM 3rd (1996) MR evaluation of developmental venous anomalies: medullary venous anatomy of venous angiomas. *AJNR Am J Neuroradiol* 17(1):61–70
- Levrier O, Gailloud P, Souei M, Manera L, Brunel H, Raybaud CA (2004) Normal galenic drainage of the deep cerebral venous system in 2 cases of vein of Galen aneurysmal malformations (VGAM). *Childs Nerv Syst* 20:91–97
- Levy E, Niranjan A, Thompson T et al (2000) Radiosurgery for childhood intracranial arteriovenous malformations. *Neurosurgery* 47:834–842
- Li A-H, Armstrong D, terBrugge KG (2010) Endovascular treatment of vein of Galen aneurysmal malformation: management strategy and 21-year experience in Toronto. *J Neurosurg Pediatr* 7(1):3–10. doi:10.3171/2010.9.peds0956
- Li D, Shu-Yu H, Tang J, Xiao X, Jia G, Wu Z, Zhang L, Zhang J (2014) Surgical management of pediatric brainstem cavernous malformations. *J Neurosurg Pediatr* 13:484–502
- Liu MC, Chen HC, Wu CH, Chen WH, Tsuei YS, Chen CC (2015) Time-resolved magnetic resonance angiography in the evaluation of intracranial vascular lesions and tumors: a pictorial essay of our experience. *Can Assoc Radiol J* 66(4):385–392. doi:10.1016/j.carj.2015.05.001
- Lloyd-Jones D, Adams R et al (2009) Heart disease and stroke statistics 2009 update: a report from the American Heart Association Statistics Committee and Stroke Statistics Subcommittee. *Circulation* 119:e1–e161
- Long DM, Seljeskog EL, Chou SN, French LA (1974) Giant arteriovenous malformations of infancy and childhood. *J Neurosurg* 40(3):304–312. doi:10.3171/jns.1974.40.3.0304
- Lv X, Li Y, Jiang C, Wu Z (2009) Endovascular treatment of brain arteriovenous fistulas. *AJNR Am J Neuroradiol* 30:851–856
- Maher CO, Meyer FB (2006) Surgical treatment of cerebral aneurysms in children. In: Alexander MJ, Spetzler RF (eds) *Pediatric neurovascular disease*. Thieme, New York, pp 83–89
- Maity A, Shu H, Tan J et al (2004) Treatment of pediatric intracranial arteriovenous malformations with linear-accelerator-based stereotactic radiosurgery: the University of Pennsylvania experience. *Pediatr Neurosurg* 40:207–214
- Mallick, A. A., Ganesan, V., Kirkham, F. J., Fallon, P., Hedderly, T., McShane, T.,... O’Callaghan, F. J. (2014). Childhood arterial ischaemic stroke incidence, presenting features, and risk factors: a prospective population-based study. *Lancet Neurol*, 13(1), 35–43. doi:10.1016/s1474-4422(13)70290-4
- Mawad ME (1994) Interventional radiology. In: Cheek WR (ed) *Pediatric neurosurgery: surgery of the developing nervous system*. WB Saunders, Philadelphia, pp 539–544
- McCance KL, Huether SE (2002) *Pathophysiology: the biologic basis for disease in adults children*, 4th edn. Mosby, St. Louis
- McLaughlin MR, Kondziolka D, Flickinger JC, Lunsford S, Lunsford LD (1998) The prospective natural history of cerebral venous malformations. *Neurosurgery* 43(2):195–200 discussion 200–201
- Metry, D. W., Haggstrom, A. N., Drolet, B. A., Baselga, E., Chamlin, S., Garzon, M.,... Frieden, I. J. (2006). A prospective study of PHACE syndrome in infantile hemangiomas: demographic features, clinical findings, and complications. *Am J Med Genet A*, 140(9), 975–986. doi:10.1002/ajmg.a.31189
- Metry DW, Hawrot A, Altman C, Frieden IJ (2004) Association of solitary, segmental hemangiomas of the skin with visceral hemangiomatosis. *Arch Dermatol* 140(5):591–596. doi:10.1001/archderm.140.5.591
- Meyer P, Orliaguet G, Zerah M et al (2000) Emergency management of deeply comatose children with acute rupture of cerebral arteriovenous malformations. *Can J Anaesth* 47:758–766
- Milandre L, Pellissier JF, Boudouresques G, Bonnefoi B, Ali Cherif A, Khalil R (1987) Non-hereditary multiple telangiectasias of the central nervous system. Report of two clinicopathological cases. *J Neurol Sci* 82(1–3):291–304
- Mitchell PJ, Rosenfeld JV, Dargarville P, Loughnan P, Ditchfield MR, Frawley G, Tress BM (2001)

- Endovascular management of vein of Galen aneurismal malformations presenting in the neonatal period. *AJNR Am J Neuroradiol* 22:1403–1409
- Moharir MD, Shroff M, Pontigon AM, Askalan R, Yau I, Macgregor D, Deveber GA (2011) A prospective outcome study of neonatal cerebral sinovenous thrombosis. *J Child Neurol* 26(9):1137–1144. doi:10.1177/0883073811408094
- Monagle P, Chalmers E, Chan A, DeVeber G, Kirkham F, Massicotte P, Michelson AD (2008) Antithrombotic therapy in neonates and children: American College of Chest Physicians Evidence-Based Clinical Practice Guidelines (8th edition). *Chest* 133(6 Suppl):887s–968s. doi:10.1378/chest.08-0762
- Moore KL, Agur AM (1995) Essential clinical anatomy. Williams Wilkins, Toronto
- Murasko K, Oldfield E (1990) Vascular malformations of the spinal cord and dura. *Neurosurg Clin N Am* 1:631–652
- Muszynski C, Berenstein A (2001) Interventional radiology. In: McClone D (ed) *Pediatric neurosurgery: surgery of the developing nervous system*. WB Saunders, Philadelphia, pp 1155–1171
- Nagaraja D, Verma A, Taly AB, Kumar MV, Jayakumar PN (1994) Cerebrovascular disease in children. *Acta Neurol Scand* 90(4):251–255
- Niazi TN, Klimo P, Anderson RCE, Raffel C (2010) Diagnosis and management of arteriovenous malformations in children. *Neurosurg Clin N Am* 21:443–456
- Ohaegbulam C, Magge S, Scott M (1999) Moya Moya disease. In: Albright AL, Pollack I, Adelson PD (eds) *Principles and practice of pediatric neurosurgery*. Thieme, New York, pp 1077–1089
- Oza VS, Wang E, Berenstein A, Waner M, Lefton D, Wells J, Blei F (2008) PHACES association: a neuro-radiologic review of 17 patients. *AJNR Am J Neuroradiol* 29(4):807–813. doi:10.3174/ajnr.A0937
- Paramasivam S, Toma N, Niimi Y, Berenstein A (2013) Development, clinical presentation and endovascular management of congenital intracranial pial arteriovenous fistulas. *J Neurointervent Surg* 5:184–190. doi:10.1136/neurintsurg-2011-010241
- Pasqualin A, Mazza C, Da Pian R, Dala BB (1982) Midline giant arterio-venous malformations in infants. *Acta Neurochir* 64:259–271
- Perkins E, Stephens J, Xiang H, Lo W (2009) The cost of pediatric stroke acute care in the United States. *Stroke* 40(8):2820–2827. doi:10.1161/strokeaha.109.548156
- Philpott C, Wray A, MacGregor D, Coleman L (2012) Dural infantile hemangioma masquerading as a skull vault lesion. *AJNR Am J Neuroradiol* 33(6):E85–E87. doi:10.3174/ajnr.A2752
- Poindexter G, Metry DW, Barkovich AJ, Frieden IJ (2007) PHACE syndrome with intracerebral hemangiomas, heterotopia, and endocrine dysfunction. *Pediatr Neurol* 36(6):402–406. doi:10.1016/j.pediatrneurol.2007.01.017
- Porter R, Detweiler P, Spetzler R, Lawton M, Baskin J, Derksen P, Zabramski J (1999) Cavernous malformations of the brainstem: experience with 100 patients. *J Neurosurg* 90:50–58
- Porter P, Willinsky R, Harper W, Wallace C (1997) Cerebral cavernous malformations: natural history and prognosis after clinical deterioration with or without hemorrhage. *J Neurosurg* 87:190–197
- Pozzati E, Acciarri N, Tognetti F, Marliani F, Giangaspero F (1996) Growth, subsequent bleeding and de novo appearance of cerebral angiomas. *Neurosurgery* 38:662–670
- Proust F, Toussaint P, Garnieri J, Hannequin D, Legars D, Houtieville J, Freger P (2001) Pediatric cerebral aneurysms. *J Neurosurg* 94:733–739
- Punt J (2004) Surgical management of paediatric stroke. *Pediatr Radiol* 34:16–23
- Raybaud CA, Strother CM (1986) Persisting abnormal embryonic vessels in intracranial arteriovenous malformations. *Acta Radiol Suppl* 369:136–138
- Rigamonti D, Spetzler RF (1988) The association of venous and cavernous malformations. Report of four cases and discussion of the pathophysiological, diagnostic, and therapeutic implications. *Acta Neurochir* 92(1–4):100–105
- Riina H, Lemole M, Spetzler R (2006) Surgical treatment of spinal vascular malformations in children. In: Alexander MJ, Spetzler RF (eds) *Pediatric neurovascular disease*. Thieme Medical, New York, pp 129–134
- Rivera P, Willinsky R, Porter P (2003) Intracranial cavernous malformations. *Neuroimag Clin North Am* 13:27–40
- Roach ES, Riel A (eds) (1995) *Pediatric cerebrovascular disorders*, 2nd edn. New York, Futura
- Roach ES, Golomb MR, Adams R, Biller J, Daniels S, Deveber G, Smith ER (2008) Management of stroke in infants and children: a scientific statement from a special writing group of the American Heart Association Stroke Council and the Council on Cardiovascular Disease in the Young. *Stroke* 39(9):2644–2691. doi:10.1161/strokeaha.108.189696
- Rodesch G, Hui F, Alvarez H, Tanaka A, Lasjaunias P (1994) Prognosis of antenatally diagnosed vein of Galen aneurysmal malformations. *Childs Nerv Syst* 10:79–83
- Rodesch G, Hurth M, Alvarez H, Tadie M, Lasjaunias P (2002) Classification of spinal cord arteriovenous shunts: proposal for a reappraisal – the bicetre experience with 155 consecutive patients treated between 1981 and 1999. *Neurosurgery* 51:374–380
- Rodesch G, Hurth M, Alvarez H, Tadie M, Lasjaunias P (2005) Spinal cord intradural arteriovenous fistulae: anatomic, clinical, and therapeutic considerations in a series of 32 consecutive patients seen between 1981 and 2000 with emphasis on endovascular therapy. *Neurosurgery* 57:973–981
- Ruiz DS, Yilmaz H, Gailloud P (2009) Cerebral developmental venous anomalies: current concepts. *Ann Neurol* 66(3):271–283. doi:10.1002/ana.21754 [Review]
- Saito Y, Kobayashi N (1981) Cerebral venous angiomas: clinical evaluation and possible etiology. *Radiology* 139(1):87–94



- San Millan Ruiz D, Gailloud P (2010) Cerebral developmental venous anomalies. *Childs Nerv Syst* 26(10):1395–1406
- San Millan Ruiz D, Delavelle J, Yilmaz H, Gailloud P, Piovani E, Bertramello A, Rufenacht DA (2007) Parenchymal abnormalities associated with developmental venous anomalies. *Neuroradiology* 49(12):987–995. doi:10.1007/s00234-007-0279-0
- Sanai N, Auguste KI, Lawton MT (2010) Microsurgical management of pediatric intracranial aneurysms. *Childs Nerv Syst* 26:1309–1318
- Sanai N, Quinones-Hinojosa A, Gupta NM et al (2006) Pediatric intracranial aneurysms: durability of treatment following microsurgical and endovascular management. *J Neurosurg* 104:82–89
- Santos CC, Sarnat HB, Roach ES (2005) Cerebrovascular disorders. In: Menkes JM, Sarnat HB, Maria BL (eds) *Child neurology*. Lippincott Williams Wilkins, Philadelphia, pp 1–76
- Santos CC, Sarnat HB, Roach ES (2006) Cerebrovascular disorders. In: Menkes JM, Sarnat HB, Maria BL (eds) *Child neurology*. Lippincott Williams Wilkins, Philadelphia, pp 843–844
- Sayama CM, Osborn AG, Chin SS, Couldwell WT (2009) Capillary telangiectasias: clinical, radiographic, and histopathological features. *J Neurosurg* 113(4):709–714. doi:10.3171/2009.9.jns09282
- Schaller B, Graf R (2004) Cerebral venous infarction: the pathophysiological concept. *Cerebrovasc Dis* 18(3):179–188
- Scott RM, Smith ER (2009) Moyamoya disease and moyamoya syndrome. *N Engl J Med* 360(12):1226–1237. doi:10.1056/NEJMra0804622 [Review]
- Sharma BS, Sinhas S, Mehta VS, Suri A, Gupta A, Manapatra AK (2007) Pediatric intracranial aneurysms: clinical characteristics and outcome of surgical treatment. *Childs Nerv Syst* 23:327–333
- Shim KW, Park EK, Kim JS, Kim DS (2015) Cognitive outcome of pediatric moyamoya disease. *J Korean Neurosurg Soc* 57(6):440–444. doi:10.3340/jkns.2015.57.6.440
- Singhal A, Adirim T, Cochrane D, Steinbok P (2011) Pediatric patients with poor neurological status and arteriovenous malformation hemorrhage: an outcome analysis. *J Neurosurg Pediatr* 7:462–467
- Smith JL (2009) Understanding and treating moyamoya disease in children. *Neurosurg Focus* 26(4):E4. doi:10.3171/2000.01.FOCUS08306 [Review]
- Smith ER (2015) Structural causes of ischemic and hemorrhagic stroke in children: moyamoya and arteriovenous malformations. *Curr Opin Pediatr* 27:706–711
- Smith ER, Scott RM (2005) Surgical management of moyamoya syndrome. *Skull Base* 15(1):15–26
- Smith ER, Scott RM (2010) Cavernous malformations. *Neurosurg Clin N Am* 21:483–490
- Smith M, Sinson G (2006) Intracranial arteriovenous malformations. <http://www.emedicine.com/med/topic3469.htm>. Retrieved 9 Jan 2006.
- Smyth M, Sneed P, Ciricillo S et al (1997) Stereotactic radiosurgery for pediatric intracranial arteriovenous malformations: the University of California at San Francisco experience. *J Neurosurg* 97:48–55
- Soltanolkotabi M, Schoeneman SE, Alden TD, Hurley MC, Ansari SADP, AJ, Tomita T, Shaibani A (2013) Onyx embolization of intracranial arteriovenous malformations in pediatric patients. *J Neurosurg* 11:431–437
- Song JK, Niimi Y, Kupersmith MJ, Berenstein A (2007) Postnatal growth and development of a cerebral arteriovenous malformation on serial magnetic resonance imaging in a child with hemangiomas. Case report. *J Neurosurg* 106(5 Suppl):384–387. doi:10.3171/ped.2007.106.5.384
- Soriano SG, Sethna NF, Scott RM (1993) Anesthetic management of children with moyamoya syndrome. *Anesth Analg* 77(5):1066–1070
- Spetzler RF, Martin NA (2010) A proposed grading system for arteriovenous malformations. *J Neurosurg* 16(2):476–483
- Spetzler RF, Detwiler P, Riina H, Porter RW (2002) Modified classification of spinal cord vascular lesions. *J Neurosurg Spine* 96:145–156
- Swaiman KF, Ashwal S (1999) *Pediatric neurology principles & practice*, from <http://books.google.com/books?id=BNpsAAAAMAAJ>. Accessed on 19 Sept 2011.
- Takeuchi K, Shimizu K (1957) Hypoplasia of bilateral internal carotid arteries. *Brain Nerve* 19:37–43
- Tang S-C, Jeng J-S, Liu H-M, Yip P-K (2003) Diffuse capillary telangiectasia of the brain manifested as a slowly progressive course. *Cerebrovasc Dis* 15(1–2):140–142
- TerBrugge K (1999) Neurointerventional procedures in the pediatric age group. *Childs Nerv Syst* 15:751–754
- TerBrugge K (2006) Endovascular treatment of vein of Galen malformations in children. In: Alexander M, Spetzler RF (eds) *Pediatric neurovascular disease: surgical, endovascular and medical management*. Thieme, New York, pp 176–185
- Titsworth WL, Scott RM, Smith ER (2016) National analysis of 2454 pediatric moyamoya admissions and the effect of hospital volume on outcomes. *Stroke* 47(5):1303–1311. doi:10.1161/strokeaha.115.012168
- Tortori-Donati P, Fondelli MP, Rossi A, Bava GL (1999) Intracranial contrast-enhancing masses in infants with capillary haemangioma of the head and neck: intracranial capillary haemangioma? *Neuroradiology* 41(5):369–375
- Tung H, Giannotta SL, Chandarasoma P (1990) Recurrent intraparenchymal hemorrhages from angiographically occult vascular malformations. *J Neurosurg* 73:174–180
- Uchino K, Johnston SC, Becker KJ, Tirschwell DL (2005) Moyamoya disease in Washington State and California. *Neurology* 65(6):956–958. doi:10.1212/01.wnl.0000176066.33797.82 [Research Support, N.I.H., Extramural Research Support, U.S. Gov't, P.H.S.]
- Uyama, A., Kawamura, A., Akiyama, H., Nakamizo, S., Yamamoto, K., Nagashima, T.,... Yoshida, M. (2008). A case of cerebellar capillary hemangioma with mul-



- multiple cysts. *Pediatr Neurosurg*, 44(4), 344–349. doi:10.1159/000138375
- Vananman MJ, Hervey-Jumper SL, Maher CO (2010) Pediatric and inherited neurovascular diseases. *Neurosurg Clin N Am* 21:427–441
- Ventureya E, Vassilyadi M (2001) Arteriovenous malformations. In: McLone D (ed) *Pediatric neurosurgery: surgery of the developing nervous system*. WB Saunders, Philadelphia, pp 1105–1111
- Viswanathan V, Smith ER, Mulliken JB, Fishman SJ, Kozakewich HP, Burrows PE, Orbach DB (2009) Infantile hemangiomas involving the neuraxis: clinical and imaging findings. *AJNR Am J Neuroradiol* 30(5):1005–1013. doi:10.3174/ajnr.A1478
- Von der Brölie C, Kuczaty S, von Lehe M (2014) Surgical management and long-term outcome of pediatric patients with different subtypes of epilepsy associated with cerebral cavernous malformations. *J Neurosurg Pediatr* 13:699–705
- Wakai K, Tamakoshi A, Ikezaki K, Fukui M, Kawamura T, Aoki R, Ohno Y (1997) Epidemiological features of moyamoya disease in Japan: findings from a nationwide survey. *Clin Neurol Neurosurg* 99(Suppl 2):S1–S5 [Research Support, Non-U.S. Gov't]
- Walcott BP, Smith ER, Scott RM, Orbach DB (2013) Pial arteriovenous fistulae in pediatric patients: associated syndromes and treatment outcome. *J Neurointervent Surg* 5:10–14. doi:10.1136/neurintsurg-2011-010168
- Waxman SG (2003) *Clinical neuroanatomy*, 25th edn. Lange Medical Books/McGraw Hill, New York, p. 171
- Weon YC, Yoshida Y, Sachet M, Mahadevan J, Alvarez H, Rodesch G, Lasjaunias P (2004) Supratentorial cerebral arteriovenous fistulas (AVFs) in children: review of 41 cases with 63 non choroidal single-hole AVFs. *Springere, Austria* Published online 13 Dec 2004
- Willing SJ, Faye-Petersen O, Aronin P, Faith S (1993) Radiologic-pathologic correlation. Capillary hemangioma of the meninges. *AJNR Am J Neuroradiol* 14(3):529–536
- Wilson CB (1992) Cryptic vascular malformations. *Clin Neurosurg* 38:49–84
- Wolfe TJ, Hussain SI, Lynch JR, Fitasimmons B, Zaidat OO (2009) Pediatric cerebral angiography: analysis of utilization and findings. *Pediatr Neurol* 40(2):98–101
- Yan J, Gopaul R, Wen J, Li XS, Tang JF (2016) The natural progression of VGAMs and the need for urgent medical attention: a systematic review and meta-analysis. *J Neurointerv Surg*. doi:10.1136/neurintsurg-2015-012212
- Yang WH, Lu MS, Cheng YK (2011) Pial arteriovenous fistula: a review of literature. *Br J Neurosurg* 25:580
- Yeh D, Crone K (2006) Cavernous malformations in children. In: Alexander M, Spetzler RF (eds) *Pediatric neurovascular disease: surgical, endovascular, and medical management*. Thieme, New York, pp 65–71
- Yen CP, Monteith SJ, Nguyen JH, Rainey J, Schlesinger DJ, Sheehan JP (2010) Gamma knife surgery for arteriovenous malformations in children. *J Neurosurg Pediatr* 6:426–434
- Yokoyama K, Asano Y, Murakawa T et al (1991) Familial occurrence of arteriovenous malformations of the brain. *J Neurosurg* 74:585–589
- Yonekawa Y, Kahn N (2003) Moyamoya disease. *Adv Neurol* 92:113–118
- Zaidat O, Alexander M (2006) Endovascular treatment of cerebral arteriovenous malformations in children. In: Alexander M, Spetzler RF (eds) *Pediatric neurovascular disease: surgical, endovascular, and medical management*. Thieme, New York, pp 167–175
- Zerah M, Garcia-Monaco R, Rodesch G, TerBrugge K, Tardieu M, de Victor D, Lasjaunias P (1992) Hydrodynamics in vein of Galen malformations. *Childs Nerv Syst* 8:111–117
- Zheng SP, Ju Y, You C (2012) Giant intracranial capillary hemangioma in a 3-year-old child: case report and literature review. *Clin Neurol Neurosurg* 114(9):1270–1273. doi:10.1016/j.clineuro.2012.02.052
- Zheng W, Wanibuchi M, Onda T, Liu H, Koyanagi I, Fujimori K, Houkin K (2006) A case of moyamoya disease presenting with chorea. *Childs Nerv Syst* 22(3):274–278. doi:10.1007/s00381-004-1104-2 [Case Reports Research Support, Non-U.S. Gov't]

Patti L. Batchelder

### 13.1 Introduction

Epilepsy is the most common neurologic disorder of childhood, affecting 1 in every 100 children (Karsy et al. 2016; Ramey et al. 2013). Epilepsy has historically been defined as two or more unprovoked seizures separated by at least 24 h (Linehan and Berg 2011). An unprovoked seizure is one that occurs in the absence of an acute event, such as a traumatic brain injury or metabolic disturbance. The International League Against Epilepsy (ILAE) further expanded this definition to include individuals with epilepsy syndromes and individuals who are at higher risk for recurrent seizures (Fisher et al. 2014). The majority of individuals with epilepsy will obtain good seizure control with antiepileptic medications. However, up to 30% will be intractable to medical therapy (Karsy et al. 2016; Ramey et al. 2013). Medically intractable epilepsy can have devastating consequences on the developing

brain, as can side effects from antiepileptic medications. Certain persons with medically intractable epilepsy, particularly those with identifiable lesions, malformations of brain parenchyma, or associated syndromes, may be candidates for surgery to help treat or even cure their epilepsy. Undertaken in the right patient, epilepsy surgery can allow for improved neurological outcomes, independence, and overall better quality of life.

### 13.2 Seizures

Initially, in a child's workup, it is important to distinguish true epileptic seizures from non-epileptic behaviors. Non-epileptic events like breath-holding spells, syncope, and rhythmic self-stimulatory behaviors can be confused with seizures (Jette and Wiebe 2016; Asano et al. 2013). A complete and detailed history, thorough physical exam, and adjunct testing such as an electroencephalogram (EEG) can help diagnose seizure activity. An EEG records the electrical onset and progression of a seizure.

A seizure is a change in neurological functioning secondary to hypersynchronous discharges in cortical neurons (Linehan and Berg 2011). The specific neurologic changes that are seen during a seizure depend on the areas of brain affected. Seizure semiology is a description of the signs and symptoms displayed by a patient during a seizure. A universal classification

#### Electronic supplementary material

Supplementary material is available in the online version of this chapter at [10.1007/978-3-319-49319-0\\_13](https://doi.org/10.1007/978-3-319-49319-0_13). Videos can also be accessed at <http://www.springerimages.com/videos/978-3-319-49318-3>.

P.L. Batchelder, RN, MSN, PPCNP-BC (✉)  
Department of Neurosurgery, Children's Hospital  
Colorado, University of Colorado School of  
Medicine, 13123 E. 16th Ave, 330,  
Aurora, CO 80045, USA

system for seizures was first developed in 1964 by the Commission on Classification and Terminology of the International League Against Epilepsy (ILAE). The International Classification of Epileptic Seizures (ICES) was then revised in 1981 and 1989 to include epilepsies and epileptic syndromes. A more recent reclassification occurred in 2010 (Berg et al. 2010). The classification system defines seizures based on EEG findings and clinical manifestations. It provides a common nomenclature for providers across disciplines to describe seizures and the possible underlying pathology (Kellinghaus and Luders 2011; Loddenkemper 2011). Other classification systems, such as the semiology seizure classification (SSC) by Luders et al. (1998), have been proposed, which classifies seizures solely on semiology. Proponents of this system argue that it is more descriptive and applicable for everyday clinical use and can be used successfully to lateralize and localize seizure onset (Hirfanoglu et al. 2006; Parr et al. 2001). However, critics state that it is simply a list of descriptive epileptic features and not a classification system (Kim et al. 2002). The ILAE classification remains the more widely used, but some argue that it remains incomplete in its comprehensiveness and descriptions (Panayiotopoulos 2012).

---

### 13.3 Seizure Types

Globally, seizures can be classified as partial or generalized with further subdivisions within these classifications. Partial seizures involve an area of cortex that can vary in size but are isolated to one hemisphere. Simple partial seizures tend to involve a small area of cortex and consciousness is not impaired. Complex partial seizures involve a larger area of cortex and consciousness is impaired. Often, there is memory loss around the seizure event. Clinical manifestations in both types of partial seizures can be motor, sensory, somatosensory, autonomic, or psychic in nature depending on the area of cortex involved. Both types of seizures can stay limited to the initial area of onset, or they can spread. Simple partial

seizures can progress into complex partial, which in turn can progress into a generalized seizure (Kellinghaus and Luders 2011).

Generalized seizures occur when both hemispheres are affected. Generalized seizures can be idiopathic (with onset in both hemispheres), or they can be the result of secondary spread from one hemisphere to the other (generalization). Generalized seizures are further described as tonic-clonic, tonic, clonic, myoclonic, atonic, and absence. Tonic-clonic seizures are the most common type of generalized seizure and are frequently referred to as grand mal. They are manifested by a loss of consciousness and an abrupt sustained contraction of multiple muscles (tonic phase), including respiratory muscles. The patient may fall, be incontinent, and often becomes cyanotic. A clonic phase then follows which involves repetitive convulsive movements throughout the body (Kellinghaus and Luders 2011).

Tonic seizures involve an abrupt contraction of muscles resulting in rigidity of the extremities and neck. There can be turning of the head and deviation of eyes to one side. Clonic seizures are typically characterized by repetitive muscle contractions. Myoclonic seizures, often called myoclonic jerks, are sudden, brief, and very strong muscle contractions that last less than 2 s. They may be confined to a specific area of the body or they may occur all over. Atonic seizures are a sudden and complete loss of muscle tone. They too can manifest in a specific area of the body or they can affect many muscle groups. When this occurs, they are referred to as drop attacks. Absence seizures are characterized by a sudden arrest in the individual's activity. A blank stare or slight deviation of the eyes is accompanied by a lack of response to any external stimuli. Absence seizures can be accompanied by tonic, clonic, and atonic components (Kellinghaus and Luders 2011; Tatum 2011).

Seizures of all types can last a few seconds to several minutes. Some are self-limiting, with the seizure activity stopping on its own. Others require the administration of antiepileptic drugs to stop them. Status epilepticus is recurring seizure activity without a period of recovery in

between. All individuals with epilepsy are at risk for status epilepticus.

Careful identification of the semiology of seizures helps to determine appropriate treatment. Initial treatment of epilepsy begins with placement on an antiepileptic drug (AED). The choice of particular AED is based on the type of seizure, possible seizure etiology, frequency of seizures, and the presence of associated syndromes. A single AED will control seizures for the majority of individuals with epilepsy (Tsur et al. 2011). In a study by Kwan and Brodie (2000), 64% of newly diagnosed patients with epilepsy had their seizures controlled with medication. Of these patients, 47% responded to the first AED tried. Another 13% responded to a second drug when the first failed, but only 1% became seizure free when trying a third. An additional 3% became seizure free with the combination of two AEDs, leaving 36% of their study population with medically intractable seizures (Kwan and Brodie 2000; Holmes 2002).

Medical management of seizures beyond the use of AEDs is fairly limited. The ketogenic diet can be an effective treatment for some individuals but is not without drawbacks and risk (Nordli and De Vivo 2011; Neal et al. 2008). High-dose vitamin B supplementation may control seizures for a very small number of patients with a rare form of vitamin B deficiency (Neubauer et al. 2011). However, the number of patients well controlled on either of these therapies is small. The mainstay of medical management is AEDs, and there is a high risk of becoming intractable for those not responding to the first one or two medications tried.

---

### 13.4 Intractable Epilepsy

Making the diagnosis of medically intractable, or drug-resistant epilepsy (DRE), can vary among providers. The diagnosis is made based on multiple factors including number of antiepileptic medications tried, duration of treatment, degree of response, and tolerance of the medications. Other important factors include the number and characteristics of the seizures, the impact of the

seizures on the patient, and the presence of an identified epilepsy syndrome (Go and Snead 2008; Ramey et al. 2013). Ambiguity in the diagnosis exists because the impact DRE has on a specific individual and family can vary greatly, as seizure frequency and semiology may be more disruptive for one patient than another (Schuele and Luders 2008). A grand mal seizure occurring three to four times a month in an older child with repeated absences from school as a result has a different impact than the same seizure frequency in an infant.

In an effort to improve patient care and facilitate research, the ILAE in 2010 released a consensus definition for DRE as “failure of adequate trials of two tolerated, appropriately chosen and used antiepileptic drug schedules (whether as monotherapies or in combination) to achieve sustained seizure freedom” (Kwan et al. 2010). This definition is now widely accepted and has shown interrater reliability in its use (Hao et al. 2011; Brodie et al. 2013).

Up to one third of patients diagnosed with epilepsy are at risk of having DRE (Karsy et al. 2016; Pittau et al. 2014; Ramey et al. 2013). Certain risk factors have been identified that are associated with the development of intractable epilepsy. The first is a patient’s initial response to medical management. Kwan and Brodie (2000) found that response to the first AED tried was a strong predictor of intractability. Of the 53% of patients who did not respond to the first AED tried, only 17% went on to become seizure free with the use of other medications. Further, patients who experience failure at higher dosages are also more likely to be resistant (Brodie et al. 2013). The number of seizures a person experiences before treatment was also found to be a strong predictor of drug-resistant epilepsy. Among patients who had more than 20 seizures prior to initiating treatment, 51% experienced intractable epilepsy, as compared to only 29% of patients who had experienced fewer seizures (Kwan and Brodie 2000; Holmes 2002). There are also specific etiologies of epilepsy and epilepsy syndromes that are known to be associated with intractability. These include temporal lobe epilepsy, cortical dysplasia, hemimegalencephaly,

tuberous sclerosis, Sturge-Weber syndrome, Rasmussen's syndrome, and the presence of focal lesions such as tumors (Go and Snead 2008; Cross et al. 2006; Kwan and Brodie 2000).

It is important to identify individuals with intractable epilepsy as early as possible. The sooner such individuals are identified, the earlier other therapies, such as surgery, can be considered. Drug-resistant epilepsy typically exists with other comorbidities either as a result of the underlying etiology of epilepsy, side effects of antiepileptic drugs, or effects of the seizures themselves. These comorbidities include cognitive impairment, developmental delays, attention deficit, depression, anxiety, and increased risk of death (Karsy et al. 2016; Kim and Ko 2016; Brooks-Kayal et al. 2013). The longer DRE goes untreated, the more significant these comorbidities can become.

Studies have shown that the effect of poorly controlled seizures on the brain, particularly the developing brain, can be devastating and result in significant cognitive decline (Shurtleff et al. 2015; Berg et al. 2012; Farwell et al. 1985). Not only are children with intractable epilepsy more likely to have lower IQs than their healthy counterparts, but their IQs have also been shown to decline progressively over time the longer their seizures are uncontrolled (Farwell et al. 1985). Similarly, antiepileptic medications can adversely affect cognitive and behavioral development (Jenny et al. 2016; Aldenkamp et al. 2016). Antiepileptic drugs work by decreasing the excitability of neurons; thus, they can also impair cognition. These effects are heightened when polypharmacy and increased doses are needed (Kim and Ko 2016; Meador 2011).

Seizures also have a tremendous social and financial impact on affected children and their families. Not only can the actual occurrence of seizures socially isolate a child and his or her family, but the social stigmata that still exist around epilepsy can be isolating as well. Seizures persisting into adolescence and adulthood can severely limit independence and overall quality of life (Puka and Smith 2015; Cross et al. 2006). Finally, although rare, sudden unexplained death in epilepsy (SUDEP) affects

approximately 1 person in 1,000 individuals per year and remains the leading cause of epilepsy-related death (Maguire et al. 2016; Seneviratne 2016). Sanchez et al. (2015) found that across all age groups, epilepsy surgery yielded a higher life expectancy than medical treatment alone.

---

### 13.5 Surgical Candidate Selection and Preoperative Workup (Phase I)

Surgical treatment should be considered in all individuals who have proven themselves to have drug-resistant epilepsy (Jette and Wiebe 2016; Pittau et al. 2014). In the appropriately chosen patient, epilepsy surgery can result in improved cognitive and quality of life outcomes by decreasing exposure to antiepileptic medications and continued seizure activity (Guan et al. 2016; Karsy et al. 2016; Ramey et al. 2013). Yet, some debate still exists on the which patients should be referred for surgery and when (Engel 2013; Ramey et al. 2013; Go and Snead 2008). Research supports earlier referral and intervention, if appropriate, to achieve the best outcomes (Jenny et al. 2016; Engel 2013; Ramey et al. 2013). In particular, studies have shown better cognitive outcomes and seizure control in toddlers and preschoolers (Shurtleff et al. 2015). The goal of epilepsy surgery is to eliminate or decrease the number of seizures, without causing a permanent neurological deficit, and limit the long-term effects of continued seizures and exposure to AEDs. (Karsy et al. 2016; Engel 2013; Vendrame and Loddenkemper 2010; Schuele and Luders 2008). This goal can be achieved in over 80% of appropriately chosen patients (Ryvlin and Rheims 2016; Karsy et al. 2016). Identifying appropriate surgical candidates requires a thorough and systematic workup. The goal of this workup is to identify the epileptogenic zone, or area of seizure onset, and determine if it is resectable. The success of epilepsy surgery is directly related to accurate identification of this zone and ability to remove it (Guan et al. 2016; Nissen et al. 2016).



All patients being considered for epilepsy surgery should be referred to a center with the necessary resources available for appropriate evaluation and workup. Appropriate evaluation requires a multidisciplinary team with specific expertise in pediatric surgical epilepsy. This team includes epileptologists, neurosurgeons, advanced practice providers, neuropsychologists, therapists, EEG technicians, and psychiatrists. Phase one of the evaluation involves gathering information from a detailed history, physical exam, EEG, and imaging. A detailed history can provide information regarding behaviors observed before, during, and after a seizure. It also provides information regarding age at onset, progression of seizures, and seizure semiology. The physical exam can reveal neurologic deficits that may be associated with the affected areas of the brain. A scalp EEG can show areas of epileptiform discharges and can often lateralize onset and show other areas of potential onset. However, the scalp EEG in and of itself is limited, as rapid generalization of seizure activity and distortion by tissue can misrepresent the area of onset.

### 13.5.1 Imaging

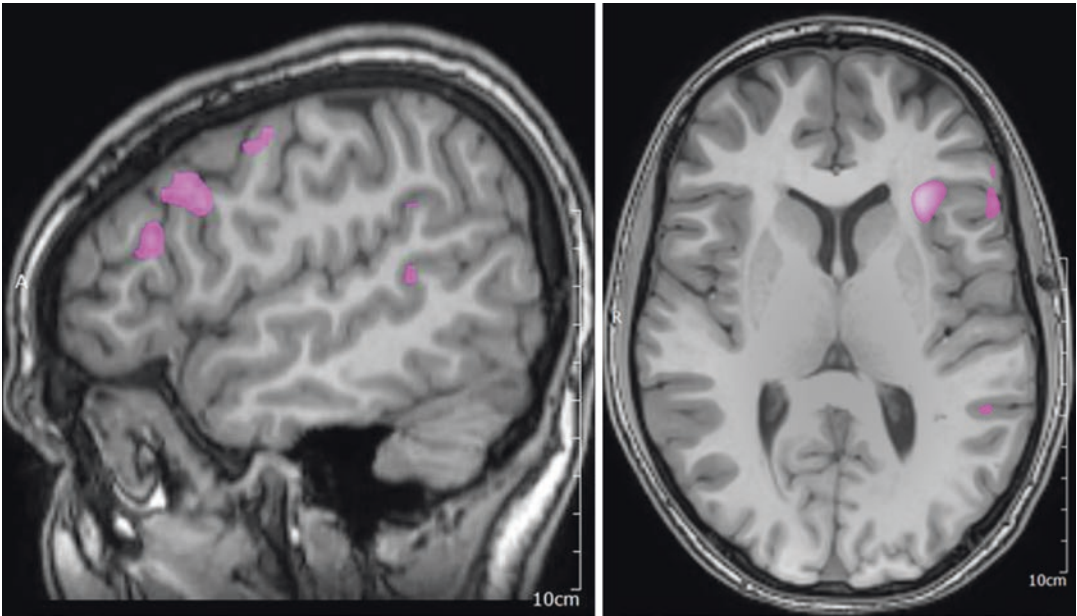
The goal of neuroimaging in the workup of patients with DRE is to identify the epileptogenic zone and any related structural abnormalities, as well as the location of eloquent brain in surrounding areas. Workup tends to proceed from least invasive to maximally invasive, and multiple modalities are often used to accurately define the epileptogenic zone (Pittau et al. 2014; Go and Snead 2008). Various imaging modalities have become increasingly more sophisticated and sensitive at not only detecting structural abnormalities but also in identifying areas of differing metabolism that are associated with seizure onset. The ILAE has recommended that all patients with DRE should undergo a high-resolution brain MRI, done with a specified epilepsy protocol, as the primary imaging study (Go and Snead 2008). MRI can help identify structural abnormalities that may be causing seizures. Examples of structural abnormalities include

neoplastic or vascular lesions, cortical anomalies like cortical dysplasia (abnormally formed cortex) and heterotopias (normal gray matter in an abnormal location), or mesial temporal sclerosis (neuron loss and scarring in the temporal lobe). As MRI technology has advanced, the ability to detect even very subtle abnormalities has increased. CT can be useful in identifying areas of calcification, which are not well visualized on MRI.

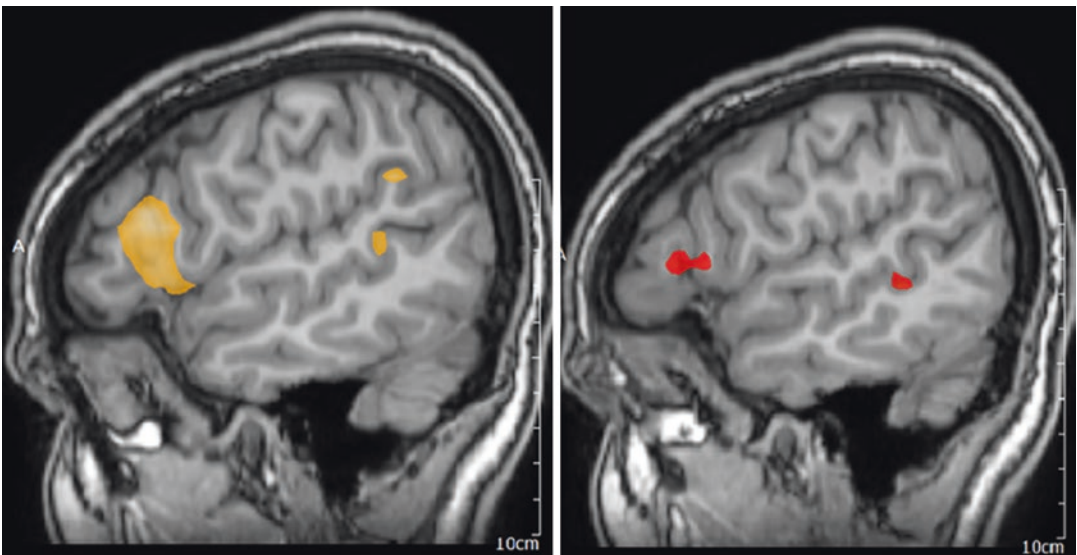
Functional MRI (fMRI) works on the principle that increased neuronal activity is associated with increased blood flow. The primary role of fMRI in the workup of a potential surgical candidate is to identify areas of eloquent brain. fMRI has shown efficacy in lateralizing language and identifying motor and sensory tracks (Widjaja and Raybaud 2008) (Figs. 13.1 and 13.2).

Positive emission tomography (PET) and single-proton emission tomography (SPECT) scan also work on the principle that increased neuronal activity results in increased blood flow and increased metabolic demand. Areas of epileptogenic focus tend to be hypometabolic during times when a seizure is not actively occurring (interictal) and hypermetabolic with increased blood flow during a seizure (ictal). PET scan is generally performed interictally. An agent, typically FDG (fluorodeoxyglucose), is injected intravenously, and the brain is then scanned looking for areas of hypometabolism, as evidenced by decreased agent uptake. SPECT uses a different agent (HMPAO) which is often injected during the ictal phase. Scans are then obtained looking for areas of increased uptake. A second SPECT scan can be obtained interictally looking for areas of decreased uptake. Often, the two scans are compared, and the subtraction between the two can provide additional information (Go and Snead 2008; Widjaja and Raybaud 2008) (Figs. 13.3 and 13.4). Both FDG and HMPAO are radiopharmaceuticals and expose children to ionizing radiation.

Magnetoencephalography (MEG) is a noninvasive imaging technique that can help localize the epileptogenic zone. MEG measures neuronal activity by measuring the magnetic fields produced by electrical activity. Unlike scalp



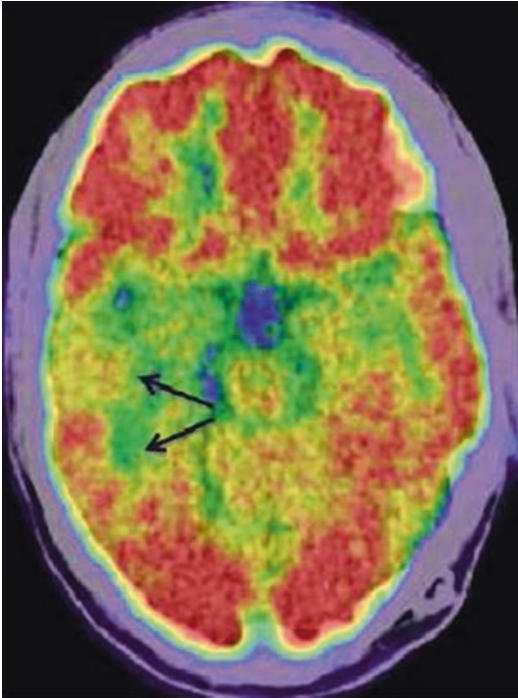
**Fig. 13.1** fMRI showing activation with word generation



**Fig. 13.2** *Left:* sentence completion. *Right:* verb generation

EEG monitoring, MEG allows for direct measurement of the electrical activity without distortion from surrounding tissues (Englot et al. 2015; Pittau et al. 2014). Potential areas of seizure onset are seen as spikes on MEG and have been shown to correlate with epileptogenic areas identified with subdural electrodes. MEG

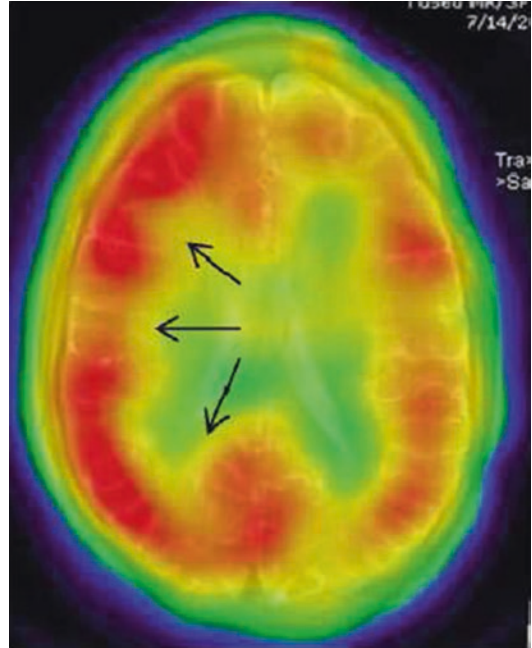
can be helpful in defining the epileptogenic zone in patients who have a normal MRI (Guan et al. 2016; Pittau et al. 2014). MEG is a relatively newer diagnostic tool, but its efficacy in identifying the epileptic zone and association with good surgical outcomes is being established (Englot et al. 2015).



**Fig. 13.3** Interictal PET scan showing decreased uptake in right posterior temporal occipital lobes (note the lack of redness shown by the *arrows*)

### 13.5.2 vEEG Monitoring

Imaging and initial scalp EEG are essential pieces of information to begin localizing seizure onset. However, the gold standard for characterizing seizures is inpatient video-EEG monitoring (vEEG). With vEEG monitoring, a patient is admitted for a minimum of 24 h to a neuromonitoring unit (NMU). Scalp electrodes are placed and the patient is monitored continuously. An NMU has patient rooms specially equipped to provide continuous EEG and video monitoring. A camera captures the clinical manifestations of seizures, while simultaneous continuous EEG captures the electrical activity of the brain during and between seizures. vEEG is an invaluable source of information, as it records not only the electrical onset and spread of the seizure but also the corresponding physical behaviors. Patients are monitored until they have had enough seizures to provide information regarding localization of seizure onset, spread, and duration. If need be, medica-



**Fig. 13.4** Ictal SPECT showing increased uptake in right hemisphere (note increased redness in area shown by *arrows*)

tions are withdrawn to help promote seizures. vEEG provides information regarding likely areas of seizure onset. It also allows for the correlation of behaviors seen during ictal and interictal activity. It can also identify seizure-like behaviors that are not a result of abnormal brain electrical activity (pseudoseizures).

### 13.5.3 Cognitive Evaluations

Another critical piece to the workup of a potential surgical candidate is neuropsychological testing. This involves various cognitive tests performed by a psychologist experienced in the needs and concerns of the pediatric epilepsy patient. One purpose of this testing is to establish a baseline of preoperative functioning. It also identifies problem areas that may be made worse by surgery. Identifying the presence of premorbid deficits can also help in making the decision whether to proceed with surgery. For example, if certain deficits that would be expected postoperatively already exist, that can be key information

in the decision to proceed. Neuropsychological testing can also help to determine cerebral dominance for language and memory. However, if the patient is old enough to cooperate, a much more sensitive test for establishing dominance is the Wada test.

A Wada test, when indicated, can be used to help determine hemispheric dominance of language and memory. Depending on the proposed surgical procedure, this information is important in determining whether or not surgical resection would impair these functions. The procedure is technically a cerebral angiogram. The internal carotid is accessed with a catheter from the femoral artery, and a barbiturate, typically sodium amobarbital, is then injected. Patients are put through a series of age-appropriate language and memory tasks looking for impairment caused by the medication. If language ceases or memory is impaired while injecting one hemisphere, then dominance is established. If the seizure focus is felt to arise in that hemisphere, then the patient may be at more risk for language and cognitive deficits postoperatively. One limitation of this study is that patients must be old enough to participate as they must be awake for the actual testing. The arterial accessing can be done under anesthesia with reversal of agents prior to testing. As functional MRI has improved, it has been shown to be a noninvasive alternative to the Wada test in lateralizing language dominance for some patients (Dym et al. 2011). But it too has limitations related to age of the patient and cooperation. Additional limitations exist for both studies in children less than 10 years of age as language lateralization is not always identifiable in this age group (Schevon et al. 2007).

The goal of the preoperative evaluation is to attempt to identify the focus of seizure onset in relation to eloquent cortex for functions such as memory, language, cognition, and sensorimotor (Guan et al. 2016; Schuele and Luders 2008; Harvey et al. 2008). Data from the various sources is compared and analyzed in an attempt to “map out” eloquent cortex and seizure onset and their relationship to each other. Factors complicating this in children include incomplete functional maturation, level of patient coopera-

tion, and the abnormal functional organization that can result secondary to malformed cortex and lesions (Yang et al. 2014; Schevon et al. 2007). Data gleaned from the various sources is reviewed and compared by the multidisciplinary epilepsy group. At times, the information is concordant with regard to localization of seizure onset, but other times it is not. More often, the information may lateralize to a single hemisphere but have imprecise or discordant data regarding specific localization of onset. For example, imaging may reveal a subtle abnormality in the left temporal lobe, but vEEG may suggest onset in the left frontal or parietal lobes. If all data is concordant and associated with a specific lesion, surgery may proceed without further testing. Conversely, if concordant data shows multifocal or bilateral onset, no further testing is needed because that patient is not a candidate for potentially curative surgery. A patient may, however, be a candidate for palliative procedures such as corpus callosotomy or vagus nerve stimulator. If the information obtained from a potential candidate for resective surgery requires further clarification, the patient will need additional invasive monitoring (phase II). Also, if the seizure onset lies near eloquent brain, invasive monitoring is indicated so that cortical mapping can occur.

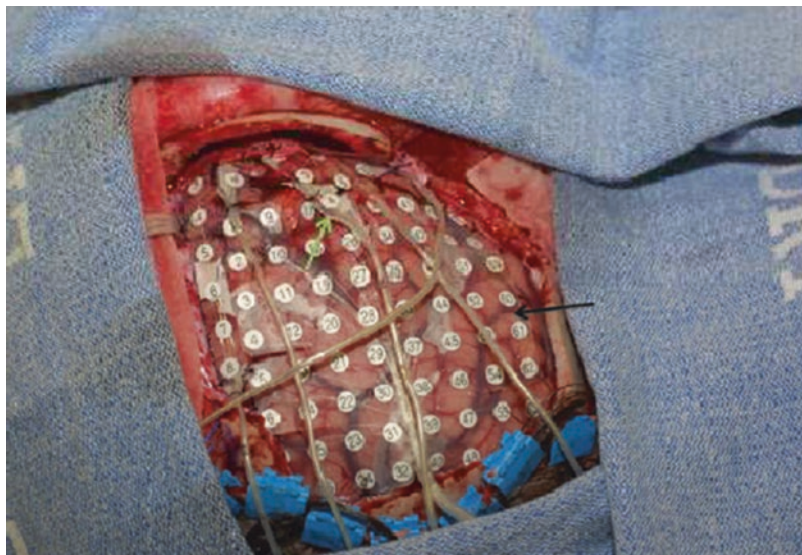---

### 13.6 Phase II Monitoring

Phase II monitoring involves direct recording from electrodes surgically placed in or on the brain. There are two main approaches to placing electrodes intracranially. One is through an open craniotomy for implantation of subdural strip or grid electrodes on the surface of the brain. The other is depth electrodes placed through individual burr holes. (Mullin et al. 2016a, b). Surgically implanted electrodes have been successfully placed in children of all ages, from infancy through adolescence. Which method to use, and where to place the electrodes, is dictated by the information obtained during Phase I monitoring. There are benefits and drawbacks to each method. The goal of Phase II monitoring is to define the epileptogenic zone and its relationship to elo-



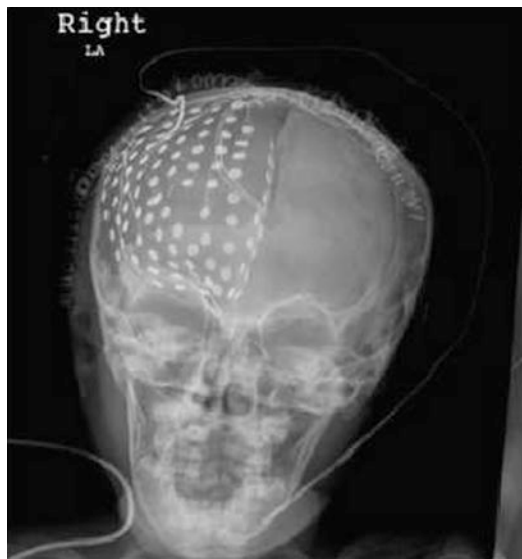**Fig. 13.5** Subdural electrodes in place. *Black arrow* denotes large grid. *Green arrow* denotes a strip electrode



quent brain as precisely as possible. Then the decision can be made as to whether or not the epileptogenic zone can be safely removed with minimal deficits and, if so, the likelihood of seizure freedom as a result. Regardless of the method used to place intracranial electrodes, one drawback is common to both: at least one more surgery is required to remove the electrodes.

Subdural electrode placement involves an open craniotomy with implantation of various grid and strip electrode configurations to cover a wide area over the suspected epileptogenic zone (Fig. 13.5). The exact number and configuration of electrodes used varies depending on the areas of the brain to be monitored. Typically, electrodes are only placed over one hemisphere (Fig. 13.6). However, single strip electrodes may be placed over the other hemisphere if there is concern for an area of onset in the contralateral hemisphere. Subdural electrodes are limited to placement on the surface of the brain; however, depth electrodes can be placed in conjunction to monitor suspected seizure foci deep within brain parenchyma.

The benefits of subdural electrode placement include the ability to monitor a large area of cortex. Subdural placement also allows the ability to perform cortical stimulation and mapping of eloquent areas such as language, sensorimotor, and memory (Yang et al. 2014) (Fig. 13.7). This method is often



**Fig. 13.6** Skull x-ray showing postoperative subdural electrode placement

used when it is suspected that, if fully defined, the epileptogenic zone will be resected at the same time as electrode removal. Drawbacks to subdural placement include the need for a large craniotomy and the inability to adequately define an area of onset that may lie in deeper or contralateral cortex (Mullin et al. 2016a, b).

Depth electrodes are individually placed through small incisions and holes in the skull. These are typically used when the area of seizure



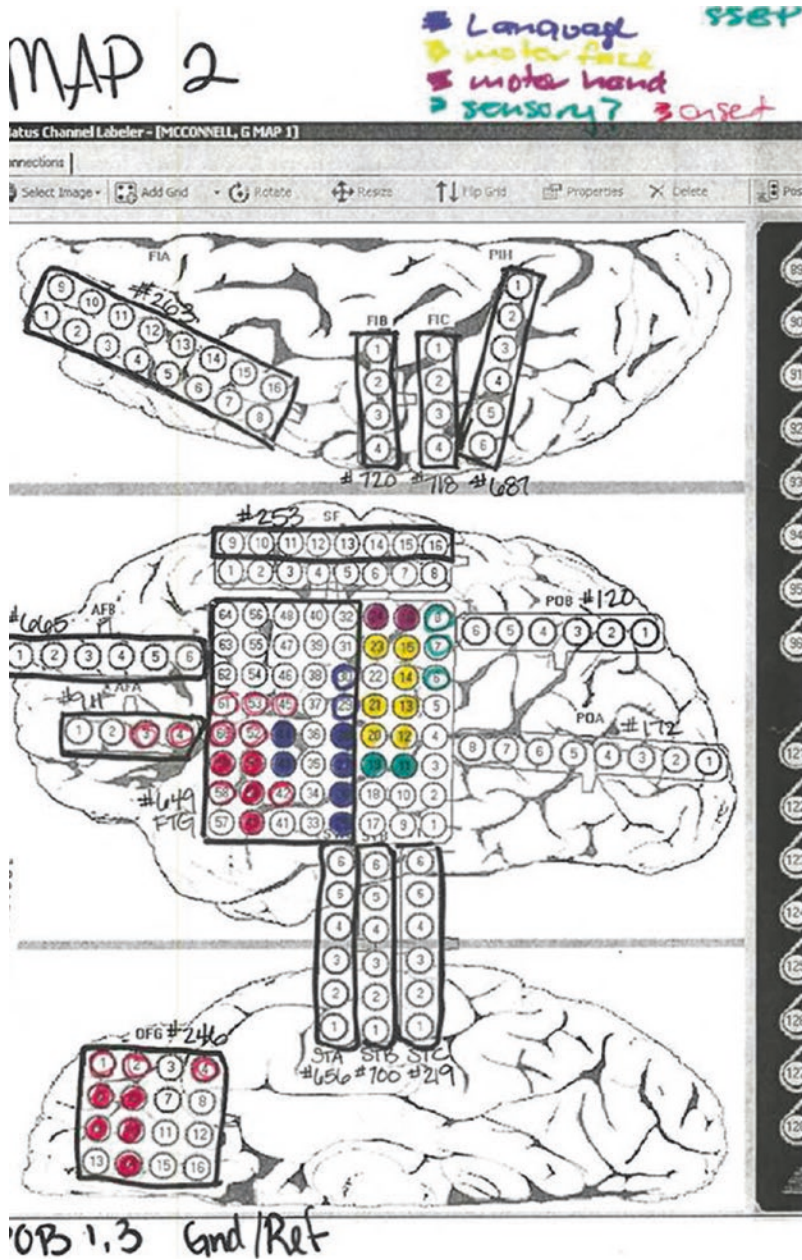
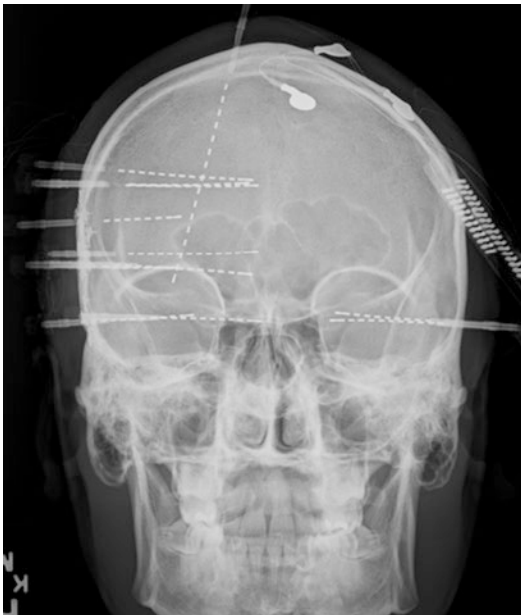


Fig. 13.7 Brain “map” showing eloquent functions in monitoring area

onset is thought to be located in deep or difficult to access cortex. Depth electrodes are also used when prior workup has failed to clearly lateralize onset and bilateral monitoring is needed. Depth electrodes can help define the epileptogenic zone when subdural monitoring has failed to do so and in patients with difficult to localize epilepsy

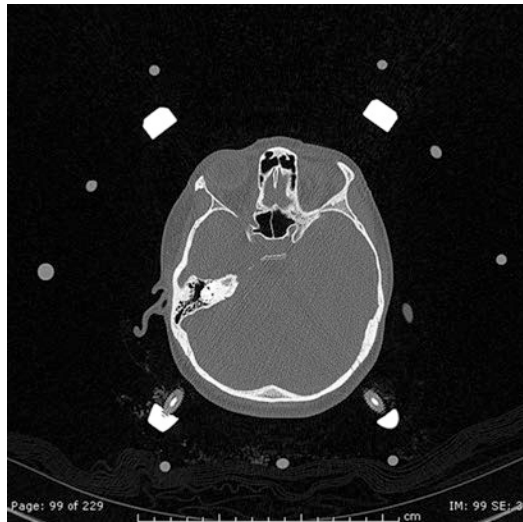
(Mullin et al. 2016a, b; Vadera et al. 2013; Gonzalez-Martinez et al. 2013) (Fig. 13.8). The benefits of depth electrodes include less invasive placement and the ability to monitor bilateral hemispheres, multiple lobes, and deep structures. Depth electrodes are limited in their ability to map eloquent cortex, though some studies have



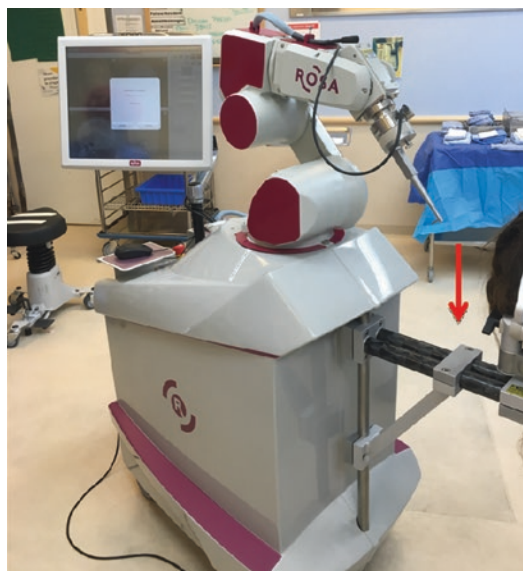**Fig. 13.8** X-ray showing SEEG depth electrodes in place

shown the ability to lateralize language using bilateral frontal electrodes (Alonso et al. 2016). Depth electrodes, like subdural electrodes, require additional surgeries, one more to remove the electrodes and an additional surgery if resection of the epileptogenic zone is undertaken.

Depth electrodes are typically placed stereotactically and are commonly referred to as SEEG (stereoelectroencephalography). The technique was developed in Europe in the 1960s, but did not become widely used in the United States until 2009 (Vadera et al. 2013; Gonzalez-Martinez et al. 2014). Stereotactic placement can be done using frameless stereotaxy or with traditional frame-stereotaxy (Fig. 13.9). Frame-based stereotaxy generally is more accurate but can be time intensive. More recently, robotic stereotaxy has come into use making the placement of SEEG leads faster, safer, and more accurate (Karsy et al. 2016). One such system is the ROSA™ (MedTech Surgical Inc., Newark, NJ) (Fig. 13.10). Electrode placement and trajectories are planned preoperatively using the system's software and high-resolution imaging. Prior to surgery, fiducials are placed on the patient, and a new scan is obtained that is then fused with the preoperative planning scan. In

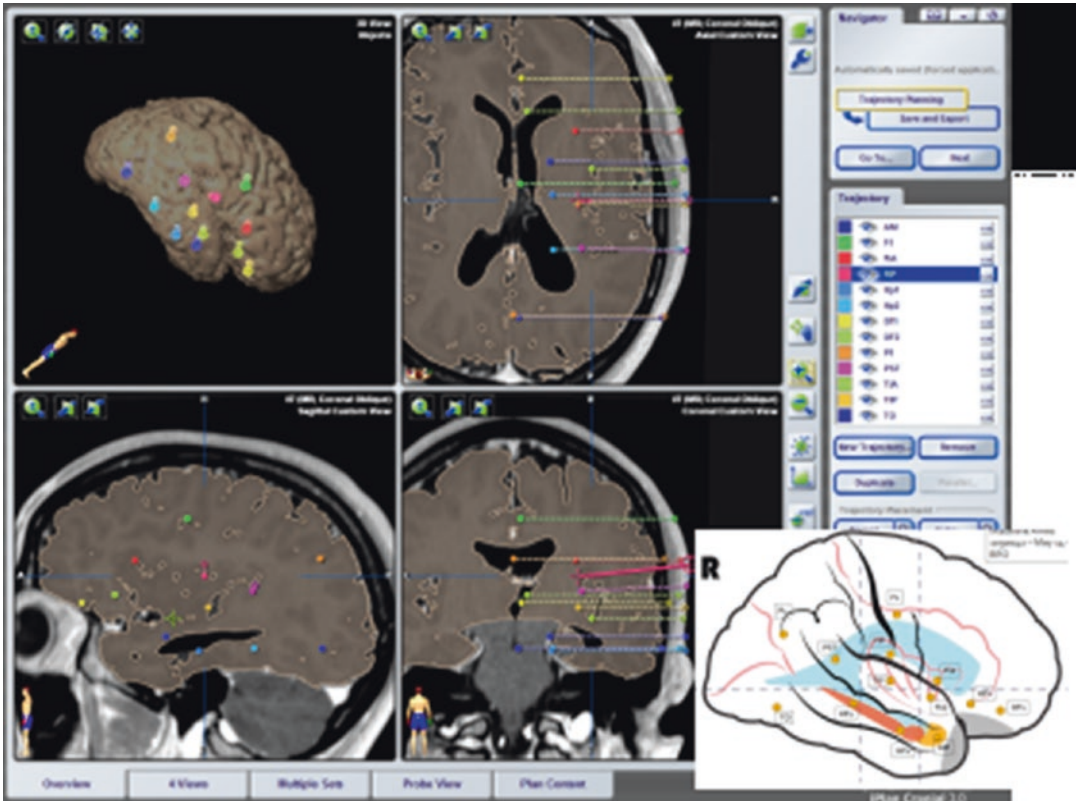


**Fig. 13.9** CT showing stereotactic frame in place.



**Fig. 13.10** Rosa™ (MedTech Surgical Inc., Newark, NJ). Red arrow showing arm where robot attaches to patient head holder

surgery, the patient is “registered” to the robot, and the robot guides the exact location and trajectory of the electrode placement. The exact location and number of depth electrodes placed is guided by a predetermined hypothesis, based on Phase I workup, of where potential epileptogenic sites are located (Fig. 13.11) (Video 13.1).



**Fig. 13.11** Planning software showing proposed electrode targets based on identified epileptogenic foci

Following electrode placement, the wounds are closed with the electrodes in place. The patient then undergoes continuous vEEG monitoring. This provides the most direct EEG monitoring without distortion caused by the meninges, skull, and scalp. Medications can be withdrawn if needed to induce seizures. Electrodes can be left in place for days to weeks in order to capture a sufficient number of seizure events to define the area of seizure onset and spread. Once enough seizures have been captured, the same electrodes can be used for direct stimulation of the brain and “mapping” of surrounding eloquent cortex if possible. This information is then used in planning the resection.

Depending on the location of onset, this information allows resection to occur safely without deficit or for appropriate planning with the family regarding what deficit to expect. At times, such mapping and monitoring will show that resection is not possible as too significant of a deficit will

be inflicted. It is important that the area of seizure onset is established prior to undertaking cortical mapping, as mapping can trigger episodes of status epilepticus resulting in the need to administer AEDs.

### 13.6.1 Nursing Care of the Patient Undergoing Phase II Monitoring

If a craniotomy is performed, the patient will typically spend their first postoperative night in the PICU. Ideally, continuous EEG recordings should take place during this time. Often, patients will not experience seizure activity during this initial phase, but if they do it should be captured. If medically stable on postoperative day number one, the patient will be transferred to the NMU. Following SEEG placement, the patient can often go directly to the

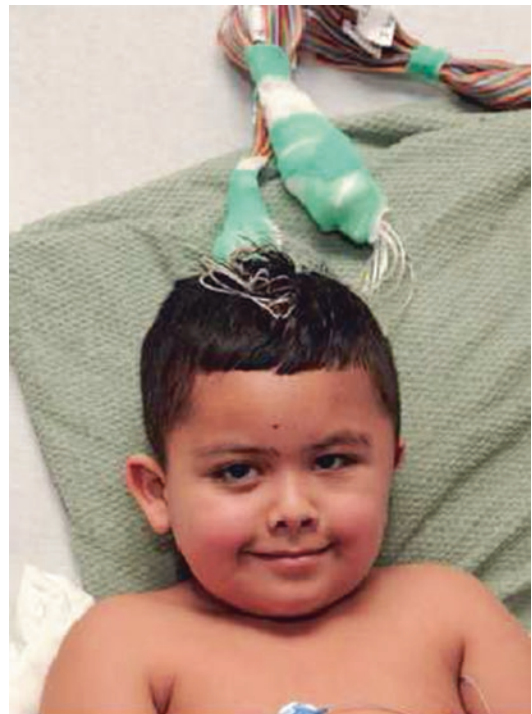


NMU. The NMU should be staffed by nurses who are not only proficient in caring for neurosurgical patients but also in recognizing and responding to seizure activity. NMU rooms are equipped with monitoring systems that alert nursing staff to seizure activity on the continuous EEG. Family members are also instructed to push an “alert button” when they feel that seizure activity is occurring. These patients are at risk for episodes of status epilepticus, especially as AEDs are weaned or when mapping is occurring. Each patient must have a clearly outlined rescue plan stating which AED is to be used, in what order, and after what length of time. With the risk of status epilepticus, all patients must have IV access throughout the monitoring process. Given the length of time often required, strong consideration should be given to placing a peripherally inserted central catheter (PICC) at the time of electrode placement.

Pain management is an important aspect of postoperative care. A combination of narcotic and non-narcotic medications seems to provide the best control, and nurses must be constantly sensitive to this. Narcotics typically do not deter seizures from occurring and need not be withheld. All patients are different in their tolerance of implanted electrodes. Some patients experience pain that is easily controlled, resume normal diets, and have fairly uneventful postoperative courses. Other patients may have poorly controlled pain, experience protracted nausea and vomiting, or display irritability and some degree of cognitive depression throughout the entire time the electrodes are in place. These side effects are seen more commonly with subdural grid and strip electrodes, as the risk of cortical irritation and swelling is greater given a larger area of the brain is in contact with the electrodes. When this occurs, a short course (24–72 h) of dexamethasone may be used in the initial postoperative period and may need to be extended in some cases.

In some centers, following a craniotomy to implant electrodes, the bone flap is left off. It is important for all caregivers to be alert for this and avoid pressure or trauma to that side of the head.

Drainage from the incision while the electrodes are in place is not uncommon and can vary greatly from large to small amounts on a daily basis. The need for prolonged antibiotics with implanted electrodes is a matter of surgeon preference but largely is not done. Most children inherently leave their leads alone, but restraints may be needed if wound and electrode integrity are threatened. EEG monitoring is continuous and should not be disconnected unless an absolute emergency warrants it. As such, the patient is restricted to the bed and immediate surrounding area. This can be challenging for the patient and family, and distractive activities should be employed. Careful attention to developmental and emotional needs is essential. Family members are encouraged to stay with the patient and be an active member of the team. The participation of therapists, child life specialists, school specialist, and other ancillary services is invaluable for the overall success of the monitoring process (Fig. 13.12).



**Fig. 13.12** Patient with implanted subdural electrodes

### 13.6.2 Complications of Cortical Electrodes

There are risks with surgically implanted electrodes. The electrodes themselves are thin and pliable and are generally well tolerated. However, especially in the immediate postoperative period, there is the risk of acute hematoma formation, cerebral edema, vascular compression, and inflammation (Mullin et al. 2016a, b; Gonzalez-Martinez et al. 2013). Any of these can cause varying degrees of mass effect on the brain, resulting in increased intracranial pressure, and possible need for emergent return to the OR for electrode removal. Complications such as these are uncommon and typically seen only in the first 24–48 h postoperatively. A meta-analysis review of the complications seen with SEEG and subdural electrode placement showed that the risk of these complications was less in SEEG (Mullin et al. 2016a, b). There exist small risks of infection and cerebral spinal fluid leak. There is a risk that electrodes will be implanted – only to show that resective surgery is not possible due to multiple areas of onset, seizure onset in eloquent cortex, or seizure onset outside the area being monitored. It is possible that despite withdrawal of medication and various activities to induce seizures, seizures may not occur during the monitoring period. Implanted electrodes can be left in place for up to 3–4 weeks, but concerns for infection or complications may warrant removal sooner. Status epilepticus may occur as AEDs are withdrawn or during mapping.

## 13.7 Epilepsy Surgery

Once the focus of seizure onset has been identified and surrounding brain has been mapped, if necessary, decisions are made regarding the type of surgery that can be offered. Generally, there are two types of epilepsy surgery, potentially curative and palliative. Potentially curative procedures are offered to those with onset within one hemisphere. The exact procedure offered is dependent not only on the area of seizure onset but also on the underlying cause of the epilepsy. Potentially curative

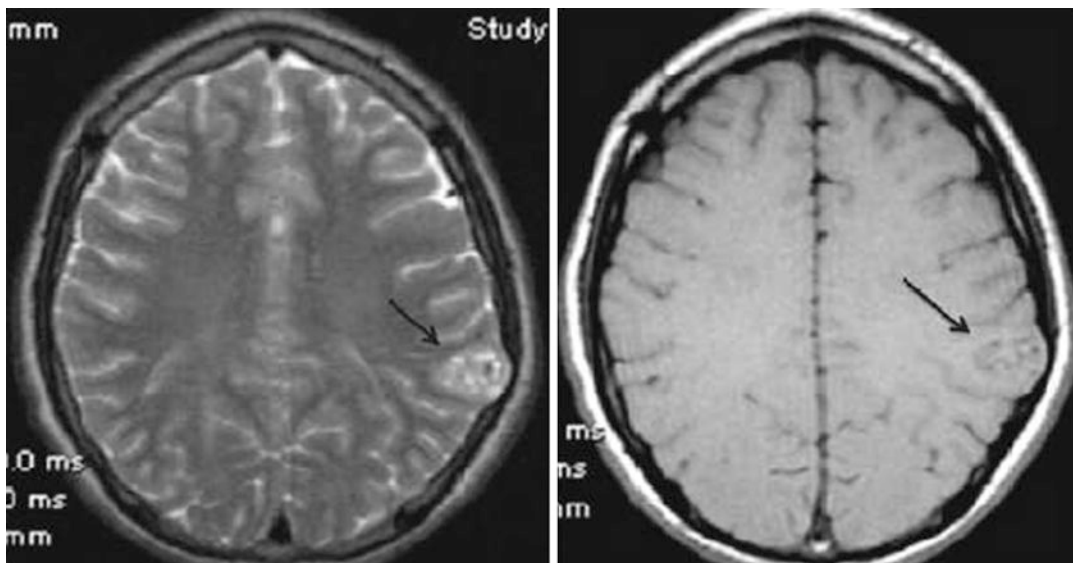
procedures include lesionectomy, temporal lobectomy, extratemporal resections, and hemispherectomy. Individuals who have bilateral or multifocal onset are not candidates for potentially curative surgery. However, they may be candidates for palliative procedures, including corpus callosotomy or vagus nerve stimulator.

### 13.7.1 Lesionectomy

A lesionectomy is the removal of a well-defined lesion, such as a tumor, vascular malformation, or hamartoma, which has been shown to be the site of seizure onset. Resection may take place with or without phase II monitoring. Phase II monitoring may be needed if there is concern for potential seizure onset in the surrounding cortex, if the margins of the lesion are not clearly defined, or if the lesion's location does not fully explain seizure semiology. Phase II monitoring also allows for cortical mapping so that potential postoperative deficits can be fully understood and avoided if possible. The most common tumor types seen in association with intractable epilepsy are DNET (dysembryoplastic neuroepithelial tumor), ganglioglioma, and astrocytoma, but any tumor can be epileptogenic. Benign tumors that may not require resection from an oncology perspective may need resection in order to treat intractable epilepsy. If a tumor is present, but seizures are well controlled on easily managed and well-tolerated AEDs, resection may not be necessary. Individuals undergoing epilepsy surgery for a well-defined lesion have the highest likelihood of becoming seizure free (Guan et al. 2016; West et al. 2016; Kunieda et al. 2013; Tellez-Zenteno et al. 2010) (Fig. 13.13).

Risks specific to a lesionectomy include injury to eloquent brain. The exact deficits seen depend on the area of brain affected. There is also a risk of incomplete resection of epileptogenic zone resulting in continued seizures. This is more likely if the lesion is not clearly defined, lies close to eloquent cortex, or if it is associated with other unseen abnormalities like mild cortical dysplasia. Results from a lesionectomy may be improved with intraoperative electrocorticogra-





**Fig. 13.13** T2 (left)- and T1 (right)-weighted MRI images showing epileptogenic lesion (ganglioglioma) in left posterior parietal lobe as indicated by the arrows

phy which allows direct recording from the brain to identify areas of abnormal electrical activity near the lesion that may be epileptogenic.

### 13.7.2 Temporal Lobectomy

Temporal lobe epilepsy (TLE) is one of the most common epilepsy syndromes amenable to surgical treatment. While it accounts for up to 75% of all surgically treated epilepsy in adults and adolescents, it accounts for only 15–20% in children (Englot et al. 2013). Surgery for TLE dates back to 1886. Because of this and its commonality, it is one of the most studied forms of epilepsy surgery (Ramey et al. 2013; Rzezak et al. 2014; Velasco and Mather 2011). As research has progressed, and more has been learned about underlying pathology, it has become clear that pediatric and adult TLE are quite different. Mesial temporal sclerosis (MTS), particularly hippocampal sclerosis, is the most frequent pathology found in intractable TLE in adults (Deleo et al. 2016; Guan et al. 2016; Velasco and Mather 2011). Mesial temporal structures include the hippocampus, parahippocampal gyrus, and the amygdala. Sclerosis is scarring and atrophy secondary

to neuronal loss that can be caused by such insults as infection, traumatic injury, or hypoxic events. In pediatric TLE, the pathology is more likely to be low-grade tumors (ganglioglioma or DNET) or cortical malformations, primarily dysplasia. Another difference in pediatric TLE is the high prevalence of dual pathology. Dual pathology refers to seizures arising from mesial temporal structures as well as from the surrounding temporal cortex and adjacent structures (Ryvlin and Rheims 2016). Dual pathology, or “temporal plus epilepsy,” is much more common in children than in adults (Guan et al. 2016; Ryvlin and Rheims 2016). Dual pathology may not always be readily evident during the presurgical workup. Seizures arising within the temporal lobe spread quickly to involve all of the temporal lobe, medial structures, adjacent lobes (frontal and parietal), and the contralateral temporal lobe, making the exact identification of ictal onset difficult. Different techniques are used for temporal lobectomy. Resection can involve just the mesial structures (amygdalohippocampectomy) with or without varying degrees of temporal lobe resection, from full to partial (Guan et al. 2016; Ramey et al. 2013). The extent of resection can also vary depending on whether or not dominance has been

established. The temporal lobe plays a significant role in language, and if the child is old enough for dominance to have been established, a more limited resection of the lateral posterior temporal lobe will be done on the dominant side. Outcomes for temporal lobectomy are generally very good in both children and adults, with reported rates of seizure freedom ranging from 60 to greater than 90% (Englot et al. 2016; Guan et al. 2016; Lee et al. 2015; Ramey et al. 2013). Rates are slightly lower in children compared to adults. This is likely related to the frequency of dual pathology and greater difficulty in completely defining the epileptogenic zone.

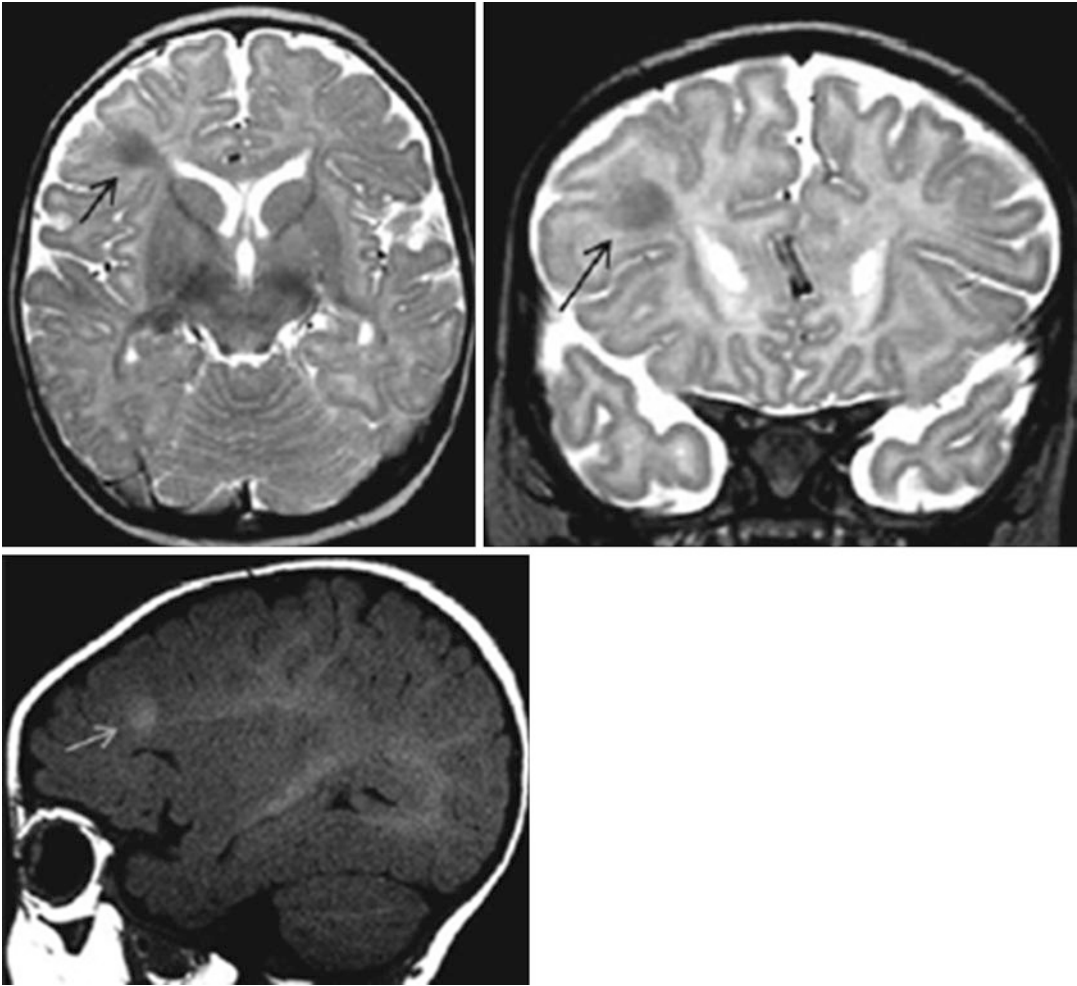
### 13.7.2.1 Complications of Temporal Lobe Surgery

The temporal lobe is responsible for many memory and language functions. Therefore, potential complications following temporal lobe surgery involve deficits in these areas. The temporal lobe is the location of the primary auditory cortex and plays a role in auditory perception. Postoperatively, patients having undergone a temporal lobectomy are at risk for problems with comprehension of verbal stimuli, naming, and verbal memory impairment. The hippocampus is involved in long-term memory and in making new memories, so impairment can be seen there as well. In the younger child, language is less likely to be affected or may recover more quickly, as language rarely completely lateralizes before age 10 (Lee et al. 2015; Englot et al. 2015). In individuals where the anterior temporal lobe has been resected, a partial homonymous superior quadrantanopia can be expected postoperatively secondary to disruption of the optic radiations (Lee and Adelson 2004). Sometimes referred to as the “pie in the sky” defect, this visual field cut involves the left or right upper quadrant in each eye and affects the side opposite of the resection. For example, a right temporal lobectomy will result in a defect in the left upper quadrant in both eyes. There is also a risk of CN III (oculomotor) injury resulting in impaired eye movements and a ptosis, as medial temporal structures lie immediately adjacent to the third nerve at the tentorial edge (Holmes 2002).

### 13.7.3 Extratemporal Resections

The temporal lobe is the most common site of seizure onset in adults, but extratemporal onset is more common in children (Englot et al. 2013). Extratemporal lobe epilepsy (ETLE) can include the frontal, parietal, or occipital lobes. The most common pathology seen is malformations of cortical development, particularly cortical dysplasia. ETLE is also involved in multifocal epilepsy syndromes such as Sturge-Weber and tuberous sclerosis complex (Guan et al. 2016; Ramey et al. 2013). Resection of the seizure focus can involve a full or partial lobectomy as well as portions of multiple lobes, depending on the causative pathology and its location. Seizure onset in extratemporal epilepsy typically occurs early in life, often in infancy, and can be quite severe. Therefore, extratemporal resections account for the largest number of epilepsy operations among younger children (Vendrame and Loddenkemper 2010).

Malformations of cortical development (MCD), in particular cortical dysplasia, are a leading cause of extratemporal epilepsy in children (Ramey et al. 2013; Bower et al. 2015; Rowland et al. 2012; Blumcke et al. 2011). Malformations of cortical development are the result of neurons failing to migrate in their proper formation during development, leading to an area of disorganized cortex. The area can vary in size from quite small to involving an entire hemisphere, as in hemimegalencephaly (Blumcke et al. 2011; Phi et al. 2010) (Figs. 13.14 and 13.15). Polymicrogyria and schizencephaly are also forms of cortical malformation that are often associated with epilepsy. The term cortical dysplasia is used to describe a wide variety of cortical malformations that can involve not only varying amounts of the brain but also a broad spectrum of histopathology. A classification system has been developed to better characterize cortical dysplasia. The system separates the spectrum of dysplasias into three types with further subdivisions for each type. The classifications are based on histopathology, the presence of other associated lesions, and location and extent of the malformation (Blumcke

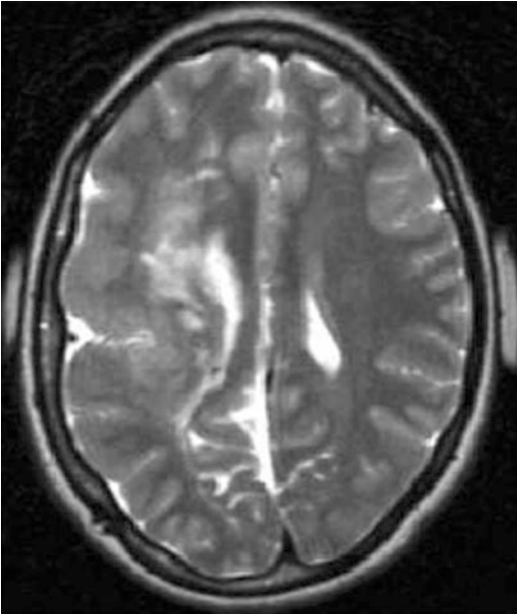


**Fig. 13.14** Focal cortical dysplasia of the frontal lobe (indicated by *arrow*)

et al. 2011). The different classifications have been associated with differing seizure outcomes (Ryvlin and Rheims 2016; Rowland et al. 2012; Blumcke et al. 2011). The pathology, location, and association with other epileptic syndromes greatly affect both the surgical approach and the outcomes following resection.

Extratemporal resections are more challenging than temporal. The seizure focus is more difficult to localize given the large surface area, deep structures, and abundance of eloquent cortex (Guan et al. 2016; Englot et al. 2013; Diaz et al. 2008). Furthermore, areas of malformation can be difficult to see on MRI, and functional studies do not always correlate to these abnor-

malities. Even when a focal area of cortical abnormality is seen, it is not always clear how much of the surrounding brain is also epileptogenic. When seizures have been ongoing, it is likely that some degree of surrounding neocortex has been irritated or damaged and contributes as a seizure focus. Seizure foci in extratemporal epilepsy are more likely to overlap with eloquent cortex, which is more difficult to map in the parietal and occipital lobes (Ramey et al. 2013; Englot et al. 2013; Rowland et al. 2012). Because of these challenges, most patients with extratemporal onset will usually require phase II monitoring to help define the full area of seizure onset and its relation to eloquent cortex.



**Fig. 13.15** *Right hemimegalencephaly. Note the widened gyral pattern and dysmorphic ventricle on the right*

Seizure outcomes for extratemporal resections can vary dramatically, with seizure-freedom rates reported as low as 14% and as high as 63%. Numbers improve to 75% when patients having a significant reduction in seizures are included (Ramey et al. 2013; Phi et al. 2010; Zupanc et al. 2010). The main prognostic indicator of seizure freedom postoperatively is the ability to completely resect the epileptogenic zone. This is difficult to do with cortical dysplasia where boundaries are ill defined and lie near or within eloquent brain. Multiple studies have shown that complete resection of the epileptogenic focus results in the highest seizure-free percentages (Ryvlin and Rheims 2016; West et al. 2016; Bower et al. 2015; Puka and Smith 2015; Englot et al. 2013). Repeat resections may be needed and should be considered, as they can result in seizure freedom when the original resection did not (Bower et al. 2015; Kunieda et al. 2013).

### 13.7.3.1 Complications of Extratemporal Resections

Injury to eloquent cortex is the main risk of extratemporal resections. Deficits seen can vary greatly depending on the part of the brain

involved. Cortical mapping during phase II identifies functions within and surrounding the epileptogenic area. Resections are undertaken with the attempt to resect all of the seizure focus while sparing function. This can lead to incomplete resection of seizure focus, acquired neurologic deficit, or both. Depending on the deficit and the severity of the seizures, choices are made regarding how much of a deficit is acceptable in an attempt to make the patient seizure free. Clearly, seizure freedom becomes irrelevant if a patient is neurologically devastated postoperatively. Undertaking a major surgery without any improvement in seizure control, even with sparing of neurologic function, is likewise of no benefit. Such decisions require close counsel of epilepsy team members, the family, and patient if possible. Motor sensory deficits recover fairly well following insult in younger children, as do language skills. In the child less than 8 years, the plasticity of the brain allows for good recovery. Significant visual deficits, however, may be more difficult to overcome. Loss of visual fields as a result of cortical resection is permanent. However, with therapy, the deficit becomes functionally less noticeable. Incomplete resections of seizure focus lead to incomplete seizure control. Studies have shown that long-term seizure control rates (>5 years) are lowest among extratemporal resections (Englot et al. 2014; Ramey et al. 2013; Phi et al. 2010; Zupanc et al. 2010).

### 13.7.4 Hemispherectomy

Hemispherectomy was first described by Walter Dandy in 1928 to treat malignant brain tumors. The procedure did not achieve tumor control, but the patients had fair neurologic outcomes, and the technique continued to evolve (Beier and Rutka 2013). Its use in the treatment of intractable epilepsy began in the 1980s (Limbrick et al. 2011). Traditional hemispherectomies involve removal of the entire hemisphere and are now less commonly used. A functional hemispherectomy is more commonly done and involves a complete temporal lobectomy and amygdalohippocampectomy, with disconnection of the

frontal, parietal, and occipital lobes. The affected hemisphere is disconnected from the other but structurally still present.

A hemispherectomy should be considered in a child with a congenital or acquired abnormality that affects one entire hemisphere resulting in severe unilateral seizures. Seizures should clearly lateralize to one hemisphere with poor localization of onset due to multiple sites within the hemisphere. They must have a relatively normal contralateral hemisphere to be a candidate. Often, the seizures are not only intractable but quite debilitating. Patients usually must show baseline motor impairment with a contralateral hemiparesis too. In such children, the affected hemisphere is likely providing little useful function. Most display some degree of developmental delay from multiple seizures which can number over 100 per day.

In the correct patients, hemispherectomies render a seizure-free outcome ranging from 43% to 100% (Guan et al. 2016; Vadera et al. 2015; Ramey et al. 2013; Beier and Rutka 2013; Schramm et al. 2012). Long-term follow-up (>5 years) shows that seizure freedom is maintained, and late seizure reoccurrence rates are much lower than in extratemporal resections (Vendrame and Loddenkemper 2010). In the majority of hemispherectomy patients, even without complete abolishment of seizures, improved cognitive and motor functioning is seen (Schramm et al. 2012). Widespread cortical dysplasia, hemimegalencephaly (hemispheric cortical dysplasia), encephalomalacia, neonatal or perinatal infarction, Rasmussen's encephalitis, and Sturge-Weber syndrome are all etiology associated with progressive catastrophic epilepsies leading to hemispherectomy (Guan et al. 2016; Vadera et al. 2015; Beier and Rutka 2013). The best seizure-free outcomes are typically seen in patients with Sturge-Weber, Rasmussen's encephalitis, and peri- or neonatal infarcts (Beier and Rutka 2013).

#### 13.7.4.1 Complications of Hemispherectomy

Complications unique to hemispherectomy include the certainty of a hemiparesis and homonymous hemianopsia on the contralateral side.

Candidates undergoing hemispherectomy generally have a hemiparesis of varying degrees to begin with. Postoperatively, the deficit can be unchanged or significantly worse. With physical and occupational therapy, it is remarkable how quickly and to what extent motor function recovers. Over the course of weeks to a few months, the majority of hemispherectomy patients regain motor function that is equal to or better than their preoperative baseline. Particularly in younger patients, the recovery is often nearly complete, except that full function of the hand, particularly fine motor, rarely recovers.

Homonymous hemianopsia is a field cut in one-half of the visual field in both eyes. The field cut exists on the contralateral side from the operation. Though the defect does not recover, functional improvement is clearly seen as the brain compensates for the defect. Postoperatively, patients may be noted to have a "gaze preference" to the same side as the surgery raising concern for cranial nerve dysfunction. However, in hemispherectomy patients, this "gaze preference" is likely related to the field cut.

Depending on the degree of function in the resected hemisphere, postoperative patients may display varying degrees of disturbances in language, memory, or cognition. Again, these defects typically recover quite well, especially in the younger child where dominance has not yet been established (Moosa et al. 2013). Good recovery is expected in most patients, if the deficits exist at all, as many of the eloquent functions have likely lateralized to the good hemisphere as a result of their disease. Hydrocephalus is another risk associated with hemispherectomy. Although rates are lower with functional compared to traditional hemispherectomies, the rate is still reported between 18% and 30% (Vadera et al. 2015; Schramm et al. 2012). Hydrocephalus can develop weeks, months, or even years after a hemispherectomy.

#### 13.7.5 Stereotactic Laser Ablation

Stereotactic laser ablation, or MRI-guided laser interstitial thermal therapy, is a minimally



invasive option for treating small, well-defined epileptogenic foci. A small diameter fiberoptic applicator is used to deliver laser light into the lesion. Heat is generated through light absorption which causes damage to intracellular DNA and DNA-binding structures leading to cell death (Tovar-Spinoza et al. 2013; Rolston and Chang 2016; Lewis et al. 2015). Lesions amenable to laser ablation are focal tumors, hamartomas, and focal areas of cortical malformations including dysplasia, mesial temporal sclerosis, and tubers. The lesions must be well circumscribed and small, roughly 2 cm across. For larger lesions, serial ablations can be completed along the same trajectory.

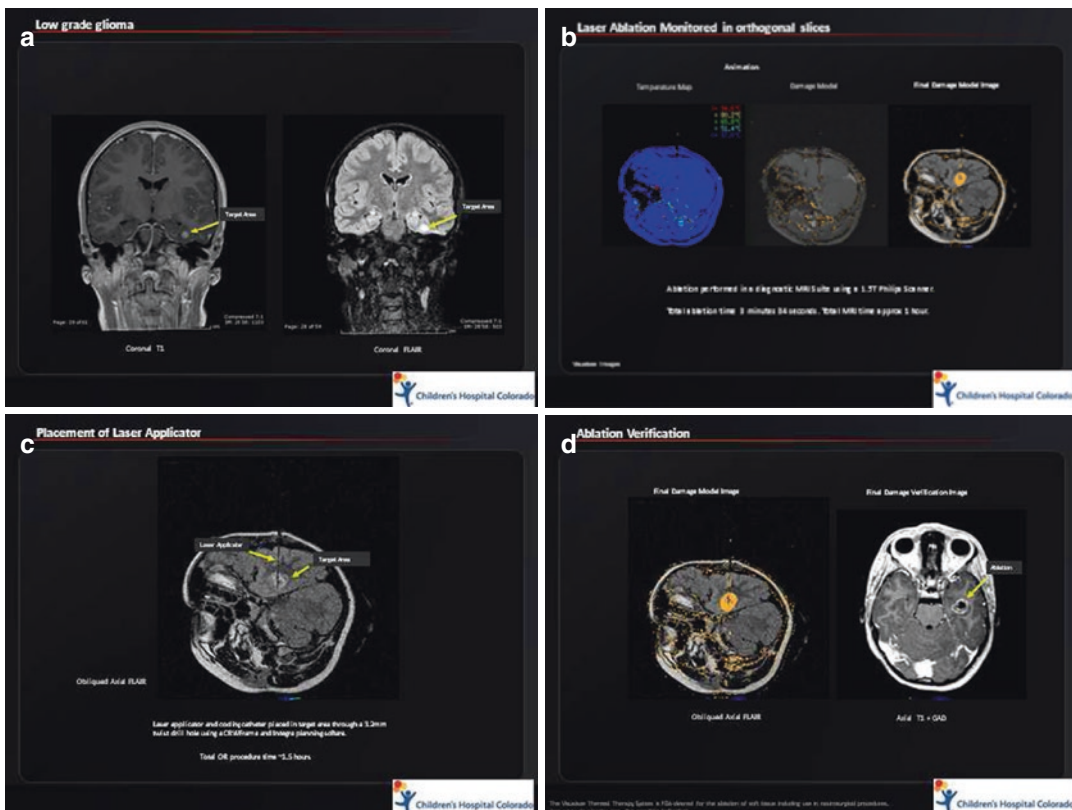
The laser is placed under stereotactic guidance into the lesion. Frameless, frame-based, or robotic stereotaxy may be used to obtain the high level of accuracy that is needed. The laser is inserted through a stereotactically placed anchor bolt which is placed in the operating room. The actual ablation takes place in MRI under the guidance of real-time thermal mapping. High temperature limits are set near the applicator tip and near the margin of the desired treatment zone. A small dose is given to confirm applicator position prior to the full dose. Laser irradiation is stopped either by the surgeon when it is felt that the predicted ablation zone is sufficient or by the system if any temperature limit is exceeded. Once the ablation is completed, more images are acquired to confirm the margins of the ablation (Fig. 13.16).

The main benefit of laser ablation is that it is minimally invasive. For most patients there is no need for intensive care postoperatively, and the majority patients are discharged home the next day. Risks associated with laser ablation include inaccurate applicator position, breakage of laser tip, and edema in the lesion and surrounding tissues. Other risks do include neurologic deficit and hemorrhage, though these risks are much less than with an open resection. Seizure outcomes in laser ablation appear similar to traditional operative techniques in appropriately selected patients. Rates of long-term seizure control are not yet known as the therapy is too new.

## 13.8 Epilepsy Syndromes

### 13.8.1 Rasmussen's Encephalitis

Rasmussen's encephalitis (RE) is a rare, progressive, chronic inflammatory disorder of the brain that is characterized by unilateral hemispheric atrophy, progressive decline in neurologic function, and intractable epilepsy. It was first described in 1958 by Theodore Rasmussen and his colleagues (Varadkar et al. 2014). The cause is not known. Both viral and autoimmune etiologies have been researched, but the cause remains unclear. Histopathology of involved brain tissue does show lymphocyte infiltration. RE typically only involves one hemisphere, although bilateral involvement has been reported (Bien et al. 2005; Dubeau 2011). Onset is predominantly in childhood, with an average age at onset of 6 years. The disease begins with a prodromal phase with infrequent seizures and possible mild hemiparesis. The diagnosis can be difficult to make during this phase as EEG and MRI are often normal (Hoffman et al. 2016; Varadkar et al. 2014). The acute phase is characterized by marked escalation of seizures, progressive hemiplegia and hemianopsia, as well as progressive cognitive decline. Imaging in the acute phase shows inflammatory response in the affected hemisphere with progressive atrophy. The third and final phase is the residual phase characterized by stable, often severe, neurologic deficit and intractable epilepsy (Bien et al. 2005). About 10% of cases present in adolescence or adulthood. These cases tend to have a slower course and permanent deficits are typically not as severe (Hoffman et al. 2016; Varadkar et al. 2014). Semiology of seizures in RE can vary depending on what areas of the hemisphere are involved. The semiology can change over time as the disease progresses and involves more of the hemisphere (Varadkar et al. 2014). Seizures caused by RE are intractable to AEDs. Immunosuppressive and immunomodulating medications have been tried to treat RE with limited success. Hemispherectomy remains the only treatment for RE that has provided long-term seizure relief (Hoffman et al. 2016; Varadkar et al. 2014; Dubeau 2011). In their series of RE



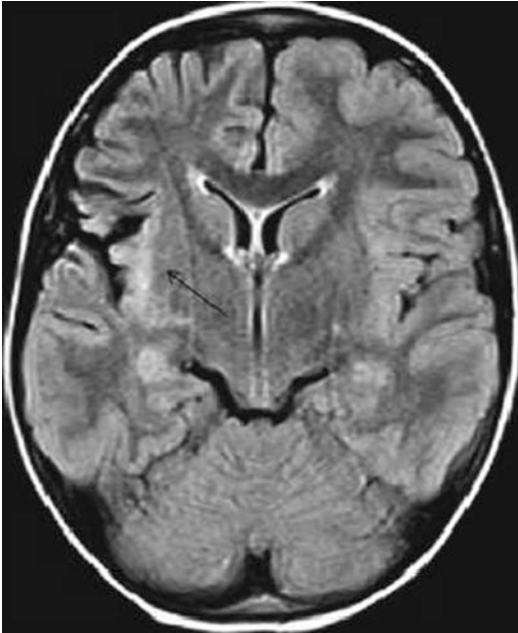**Fig. 13.16** Stereotactic laser ablation using visualase TM. (a) Target area. (b) Thermal monitoring during treatment. (c) Laser in lesion. (d) Treatment verification

patients undergoing hemispherectomy, Hoffman et al. (2016) showed a 63% seizure freedom rate and 100% improved seizure control rate postoperatively. Ninety percent of their patients had improved cognitive function and 83% showed improved language (Fig. 13.17).

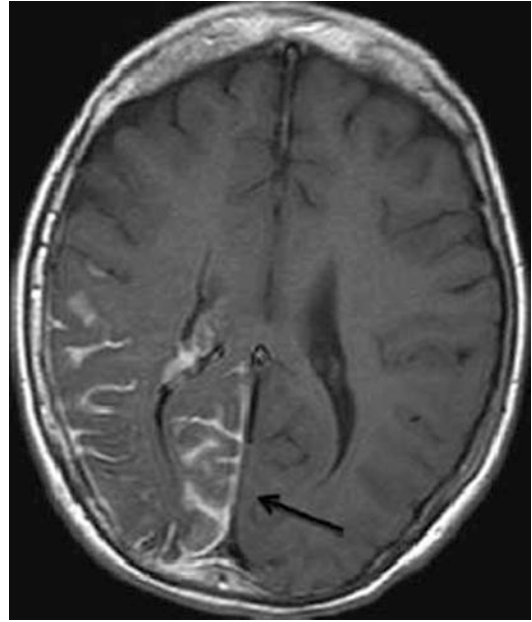
### 13.8.2 Sturge-Weber Syndrome

Sturge-Weber syndrome (SWS), also known as encephalotrigeminal angiomatosis, is a rare neurocutaneous syndrome affecting approximately 1 per 50,000 live births. The syndrome is now known to be caused by a somatic mosaic mutation in GNAQ gene. This same mutation is also responsible for isolated port-wine birthmarks (PWB) (Comi et al. 2016). SWS is characterized by vascular malformations of the

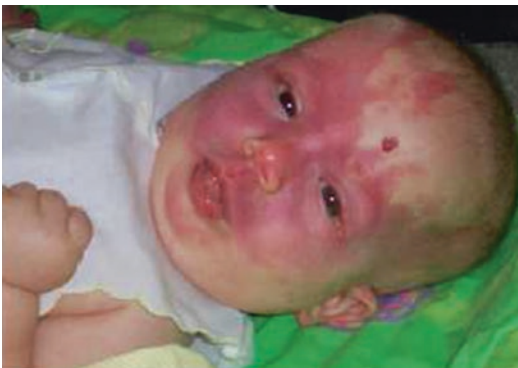skin, brain, and eye. These malformations typically include a unilateral facial nevus (port-wine stain), dural and leptomeningeal angiomatosis, hemangiomas of the choroid, and angioma of the eye (Comi 2015; Sudarsanam and Arden-Holmes 2014). The nevi can vary in size and are generally located on one side of the face. Distribution is usually along the region of the trigeminal nerve innervation (Fig. 13.18). The leptomeningeal angiomatosis is typically present on the same side as the nevus but has been reported bilaterally in as many as 15% of cases (Sudarsanam and Arden-Holmes 2014). Angiomatosis can cause chronic cortical ischemia leading to calcification and laminar cortical necrosis (Gupta 2011) (Figs. 13.19 and 13.20). Epilepsy is a common symptom in SWS, affecting 75–100% of patients. Seizure onset can occur at any age, but typically occurs



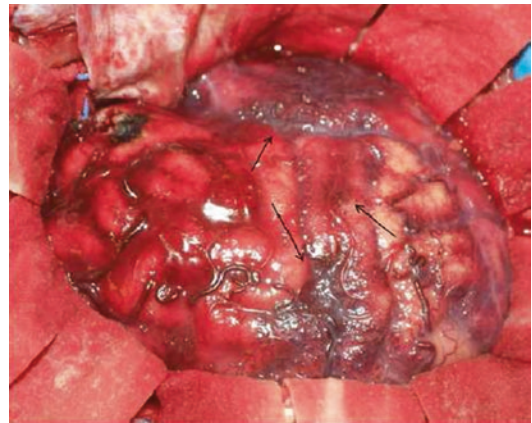
**Fig. 13.17** Rasmussen's encephalitis. MRI FLAIR image showing *right-sided* atrophy as evidenced by a widened Sylvian fissure. Also note the increased signal in the area indicating inflammation (indicated by *arrow*)



**Fig. 13.19** MRI of SWS patient showing right occipital hypervascularity as indicated by *arrow*



**Fig. 13.18** Patient with Sturge-Weber syndrome. Most nevi are unilateral but can be bilateral



**Fig. 13.20** Intraoperative photo of patient with SWS. Note abnormal blood vessels over the surface of the cortex (indicated by *arrows*)

in infancy with 75% of patients having seizures by 1 year and 90% by age 2 (Comi 2015; Sudarsanam and Arden-Holmes 2014).

Pharmacological control of seizures has been reported in up to 40% of patients with SWS, but many will be medically intractable. Seizure onset in the first year of life has been associated with a higher risk of intractability (Di Rocco and Tamburrini 2006). In patients with unilateral

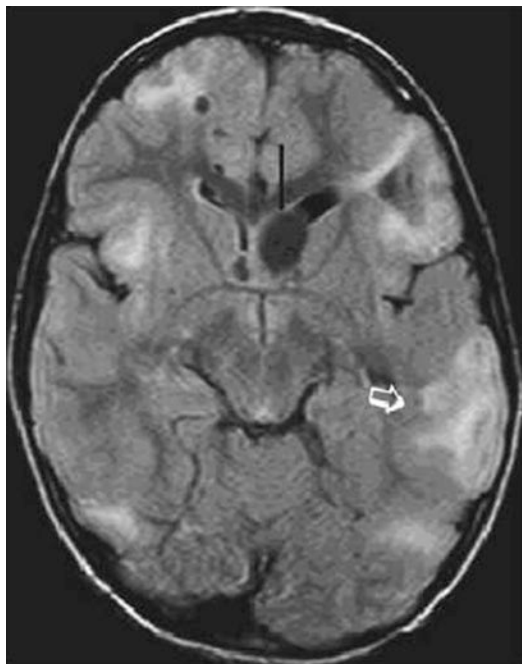hemispheric involvement and intractable epilepsy, surgical intervention should be considered. The decision should be made as soon as possible, since there is some evidence that the angiomas can be progressive. These patients are also at risk for ischemic brain injury, strokes, and development of calcifications (Comi 2015). Early intervention can not only treat the seizures but

also stop the progression of brain involvement and neurologic decline (Gupta 2011). The extent of involvement, and the information obtained from the preoperative workup, will dictate what surgical procedure is recommended. Procedures include lobectomies, tailored resections, and hemispherectomies. All surgical techniques have shown improvement in seizure outcome, but hemispherectomy patients have the highest seizure-free rate at long-term follow-up with a 90% seizure-free rate (Comi 2015).

### 13.8.3 Tuberos Sclerosis

Tuberous sclerosis complex (TSC) is an autosomal dominant genetic disorder that affects multiple systems with variable phenotypic expression. TSC results from a mutation in the TSC1 gene on chromosome 9p34 or the TSC2 gene on chromosome 16p13. The TSC1/TSC2 genes help regulate cortical development and growth. Mutations in one or both of these genes result in dysregulated cell size, differentiation, and migration (Curatolo et al. 2015; Fallah et al. 2015). TSC occurs in 1 of 10,000 births (Fallah et al. 2015). TSC is characterized by various lesions involving the skin, heart, retina, kidneys, and brain. The most common neurologic manifestation is seizures, affecting 85% of patients with TSC. Seizure onset occurs by 3 years of age in 80% of patients (Curatolo et al. 2015). Seizures are caused by cortical tubers which are lesions made up of dysplastic neurons, giant balloon cells, and glial components (Connolly et al. 2006; Gupta 2011). Tubers are epileptogenic in differing degrees. They can occur in multiple locations throughout the brain, so the seizure type and pattern seen can vary. Medical management with AEDs is the initial treatment of seizures for TSC patients, but patients may become intractable and should be considered for surgery (Curatolo et al. 2015; Fallah et al. 2015).

Surgical resection of a single tuber shown to be the focus of onset can result in good seizure control. Unfortunately, many patients with TSC have multiple tubers, and the removal of one may result in another becoming the epileptogenic



**Fig. 13.21** Diffusion-weighted MRI of tuberous sclerosis patient. *White arrow* shows a large tuber. The other high-signal areas are also tubers. The *black arrow* shows a subependymal giant cell tumor

focus. Therefore, preoperative workup and candidate selection becomes challenging and requires careful identification of the number of tubers present, and whether one or several are the epileptogenic focus. As in all surgical candidates, this information will dictate what surgery, if any, is proposed. Patients with TSC are at risk for developing obstructive hydrocephalus secondary to two types of lesions typical of TSC: SEN (subependymal nodule) and SEGAs (subependymal giant cell astrocytoma). SEN are present in 80% of patients with TSC and are generally located along the wall of the lateral and third ventricles. SEGAs are present in up to 15% of patients with TSC but tend to occur near the Foramen of Monro and grow over time (Curatolo et al. 2015). Both can result in obstructive hydrocephalus (Fig. 13.21).

Research has shown high rates of seizure alleviation or significant reduction in TSC patients with epilepsy surgery (Fallah et al. 2015; Gupta 2011). Timing of surgery is important as TSC can



be a progressive disease. TSC patients exhibit a higher incidence of mild to moderate intellectual disabilities that are likely associated to the duration and severity of seizures (Curatolo et al. 2016). Again, earlier identification of potential candidates is better. Not all TSC patients will be candidates for resective surgery, but even those that are not may be candidates for a palliative surgery, such as corpus callosotomy or vagus nerve stimulator.

## 13.9 Palliative Surgical Procedures

### 13.9.1 Corpus Callosotomy

In individuals with intractable generalized seizures without an identifiable epileptogenic focus, corpus callosotomy may be a surgical option. Corpus callosotomy is a palliative, not curative, procedure involving resection of the corpus callosum. By resecting the corpus callosum, the most important tracts that allow seizure spread from one hemisphere to the other are removed. The procedure is primarily indicated for patients suffering from intractable drop attacks secondary to generalized tonic or atonic seizures (Graham et al. 2016; Malmgren et al. 2015). Most patients considered for this procedure are cognitively impaired with severe and debilitating epilepsy.

There are two approaches to this procedure, partial and complete resection. If the child possesses any meaningful language, an anterior two-thirds resection is undertaken, thereby preserving the posterior tracts and language. If a child is severely disabled without any meaningful language, then a complete resection is recommended as it provides the best control (Jalilian et al. 2010). The goal of corpus callosotomy is not to achieve freedom from seizures but to improve quality of life. Therefore, outcome data focuses not on seizure freedom but on significant reduction in drop attacks and improved quality of life measures. When looked at from this perspective, the corpus callosotomy can be quite successful, with reduction rates reported in nearly 100%

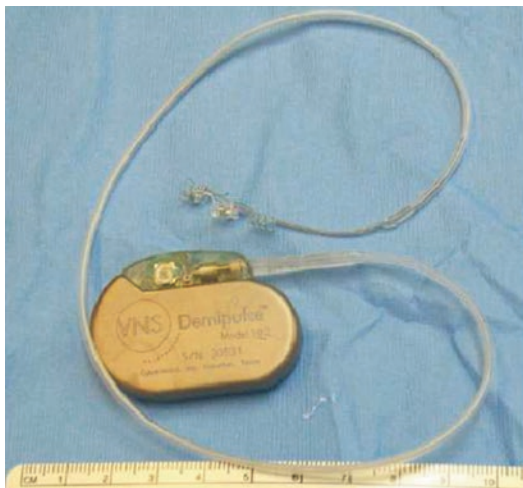
of complete resections and 75% of partial (Englot et al. 2016; Graham et al. 2016; Malmgren et al. 2015; Sood et al. 2015).

Complete resection carries the risk of a disconnection syndrome that results from the somatosensory, auditory, and visual disorientation caused by removing the corpus callosum (Graham et al. 2016; Malmgren et al. 2015). Cutting the tracks that prevent seizures from spreading also disconnects the pathway of information sharing from one hemisphere to the other. Thus, patients undergoing this operation may experience a period of being “stunned” where existing cognitive abilities will be diminished. The more functional a patient was prior to surgery, the more severe these deficits may seem. Most deficits will improve significantly over a period of weeks to months with therapies.

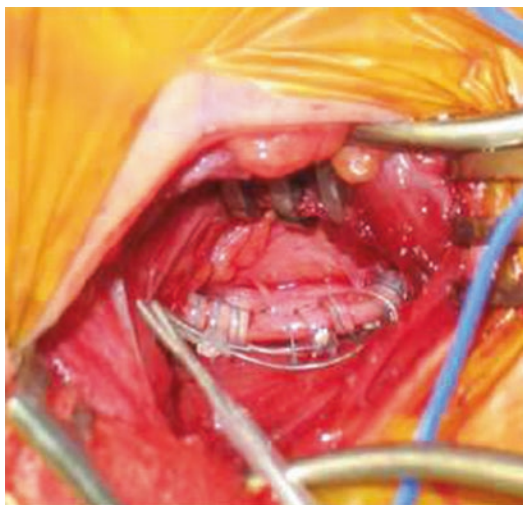
### 13.9.2 Vagal Nerve Stimulator

The vagal nerve stimulator (VNS) is another palliative option in children with medically intractable epilepsy who are not candidates for surgical resection. An impulse generator that emits electrical impulses is implanted under the skin in the chest. Attached to the generator are leads that are wrapped around the vagus nerve (Figs. 13.22 and 13.23). The generator emits an intermittent current in an on/off pattern. Patients can also place a magnet over the device and trigger an impulse during a seizure. A newer model of VNS (model 106) senses increases in heart rate that occur with a seizure and will deliver the impulse once the tachycardia is detected (El Tahry et al. 2016). It is not clear why the VNS works, but it is thought that the electrical impulses increase the excitability of neurons, thereby increasing their inhibition and reducing seizures (Serdaroglu 2016; Bodin et al. 2016). A reduction of seizures by 50% or greater is reported in as many as 75% of patients. Few patients will be rendered seizure free with a VNS, but improved seizure control and improved quality of life scores are reported by the majority of patients and families (Bodin et al. 2016; Serdaroglu et al. 2016; El Tahry et al. 2016; Mapstone 2008).





**Fig. 13.22** VNS generator



**Fig. 13.23** VNS leads attached to vagus nerve

Placement of the VNS is a well-tolerated procedure that is normally done as an outpatient. The device is placed on the left side, as stimulation of the left vagus nerve has fewer cardiac affects. The device and leads are typically placed through a single incision above the left clavicle. Once the device is in place, some centers will turn on the device at a low voltage while in the operating room. Others will turn the device on at later date in clinic. In either scenario, every 1–2 week follow-up visits are planned while the device is “ramped up.” Impulse output is

increased until desired effects on seizure frequency are seen or side effects prevent further increase. Care must be taken when patients with a VNS in place undergo MRI. The device must be turned off prior to going into the magnet and then turned back on afterward. Typically, the higher strength magnets (T3) are not used on patients with a VNS in place.

Side effects from stimulation of the vagus nerve can include bradycardia when stimulation is first initiated. This tends to be brief, immediately upon starting the device, and generally does not reoccur. A hoarse voice, hiccupping, coughing, and drooling have been seen in association with vagal nerve stimulation. Side effects tend to be voltage dependent and often remit once the nerve gets used to the current. It is not uncommon to see temporary reappearance of the symptom each time the VNS is turned up. The risks of VNS implantation are small and include injury to the vagus nerve (1–2%), postoperative hematoma (<2%), and infection (1–3%). Infection results in the need to explant the device (Revesz et al. 2016; Serdaroglu et al. 2016; Kabir et al. 2009). There is also the risk that the surgery is undertaken to implant the device without any noticeable improvement in seizures. The VNS contains a lithium battery that will eventually wear out, requiring the device to be changed. Average battery life is 6 years but depends greatly on the particular device and individual generator settings.

Deep brain stimulation for treatment of drug-resistant epilepsy is a relatively newer modality. An impulse generator is implanted extracranially and is attached an electrode typically placed in the anterior thalamic nuclei. Studies have shown a decrease in seizure frequency. DBS is not yet approved in the United States for treatment of DRE, though it is in several other countries (Englot et al. 2016).

### 13.9.3 Complications of Epilepsy Surgery

Complications specific to individual procedures have already been discussed, but there are potential complications that are inherent to all resective

epilepsy surgeries. With the exception of VNS, all epilepsy surgeries carry the risk of problems with cerebral spinal fluid (CSF) dynamics. This can range from a CSF leak to hydrocephalus. It is not uncommon for CSF to collect under the skin in what is called the subgaleal space following an open craniotomy. Typically, a CSF collection here will decrease over time and resolve on its own. If a subgaleal fluid collection fails to resolve over time or is continuing to increase in size, then concerns for hydrocephalus are raised. If CSF leaks through the incision, then there is an increased risk for infection, and sutures may need to be applied to stop the leak. As noted previously, hemispherectomy has the highest association of hydrocephalus, but it can develop after any resective seizure surgery.

Infection is a risk inherent to any surgical procedure, and epilepsy surgery carries infection rates that are similar to other neurosurgical procedures. The overall rate of infection is quite low, with studies reporting rates from 2% to 9%. There is no statistical difference between patients who underwent phase II monitoring and those who did not (Johnston et al. 2006; Zupanc et al. 2010). When infections occur, there is the added concern of involvement of the bone flap in the infection. Therefore, these children are often treated with several weeks of antibiotics.

There are surgical risks involved with every craniotomy. These include the risk of acute hemorrhage causing mass effect, cerebral edema, and vascular compromise that could lead to stroke. The risk of new neurologic deficits is also inherent to any resective surgery, as addressed elsewhere in this chapter. The exact deficits seen depend on the area of the brain that has been injured either by the resection itself or as a result of secondary events such as stroke or ischemic injury. When undertaking epilepsy surgery, the goal is always to have a significant reduction or elimination of seizures without inflicting significant neurologic injury. Most of the epilepsy surgeries have a significant degree of risk to them. It is essential that families have a full understanding of these potential risks before proceeding with the surgery. They must understand the characteristics of potential complications and what that may mean for them and their child should the

complication occur. This information is as critical, if not more so, than understanding the likelihood of seizure freedom.

### 13.9.4 Nursing Care Following Resective Surgeries

Following resective surgeries, patients may be monitored in the PICU, if indicated, until they are stable enough to be cared for in the general pediatric areas. The most important aspect of postoperative nursing care is serial neurologic examinations. A comprehensive description of a neurological examination for children is described elsewhere in this book (Chap. 1) so will not be detailed here. The frequency of the exam will vary depending on what stage of recovery the patient is in. Obviously, neurological exams should be performed very frequently as the child emerges from anesthesia so that a new postoperative baseline can be established. It is important for the nurses in the immediate postoperative phase to be familiar with the patient's preoperative baseline as comparison. New deficits, as well as any neurologic improvements, should be noted. Once a new baseline is established, it is essential that good and descriptive communication exists between all caregivers assessing the child so that subtle changes can be noted. Any sign of worsening neurologic function should be discussed with the neurosurgical team. Nurses caring for these patients need to be familiar with the various operations and the potential complications inherent to them.

Pain management is important throughout the child's postoperative course. All patients are different in the degree of pain they experience as well as the length of time they experience it. A combination of narcotics and non-narcotics is used. IV medications are required initially with transition to enteral routes once the patient can tolerate it. Various pain scales exist, but the same scale should be used for the same patient to allow for consistent assessments between care providers. This also allows for the establishment of a pain medication "routine" that can be followed across shifts for consistent pain control. Nurses should take an active role in anticipating pain needs and use a combination of patient

parameters to help make decisions about medications and dosing. Patients with neurologic compromise can have behaviors that appear to be associated with pain but may actually represent agitation, global disorganization, or even seizures. It is essential that nurses caring for these patients be able to discern the difference. The ability to do so makes the nurse an even more valuable part of the team. Having a good understanding of the child's baseline neurologic exam and level of functioning can help in differentiating the source of behaviors. Good communication between individual care providers and the family is also essential.

Postoperative craniotomy patients are at risk for disorders associated with fluid and electrolyte balance, such as DI, SIADH, or cerebral salt wasting. It is important to monitor both fluid intake and output, as well as lab values for serum sodium. Hyponatremia can develop quite quickly over the course of a shift and can lead to increased brain swelling, altered mental status, and seizures. Electrolytes are typically monitored closely within the first 24–48 h and, once stability is established, can be followed less closely. Nurses should recognize that most patients will exhibit a transient large increase in their urine output somewhere between 12 and 24 h after surgery. This can be concerning but usually represents the normal diuresis of intraoperative fluids and should not last more than a few hours. The nurse should be aware of urine output parameters that would warrant notification of the neurosurgical team.

The use of postoperative drains, particularly external ventricular drains (EVD), is not uncommon with epilepsy surgery. Jackson-Pratt (JP) drains and subdural drains may also be used. It is important for the nurse to understand the function of the drain and its collection system, as well as what space the drain is draining. This allows for the nurse to know what type of fluid and how much output is expected. The exit site should be carefully monitored for drainage. If drainage does exist, then it is essential to assess whether or not the drainage is CSF. Drainage of CSF through an incision, or around an exiting catheter, can increase the risk of infection. The neurosurgery team should be notified whenever this occurs so that appropriate measures can be taken to stop it.

Fever occurring in the first 72 h postoperatively is expected and is not a concern for infection. Fever in this time frame is often seen as a reaction to general anesthesia, most likely from atelectasis, and should be treated accordingly. Nurses should be aware that fever can significantly impact the neurologic exam of a postoperative neurosurgical patient. It is not uncommon to see a fairly significant decline in the neurologic exam of a febrile patient, and care must be taken to assure that the exam returns to baseline when the fever abates. After the initial 72 h, fevers carry a different significance and should prompt investigation of the source. Postoperative infections typically do not present within the first week of surgery, but postoperative complications like atelectasis or urinary tract infection could be the source.

Specific postoperative incision care will vary greatly by institution and surgeon. In general, the wound and operative area should be monitored for the presence of drainage, swelling, or erythema. Some degree of drainage is often present in the first 24 h following surgery. However, drainage persisting past that time needs to be monitored closely by the surgical team. Characteristics of the drainage should be noted to help determine whether it represents expected serosanguinous drainage or if it is CSF. The nurse should have a good understanding of when the surgical team needs to be notified regarding drainage. Any drainage that occurs after the immediate post-op period, especially if the wound had been dry for a period of time, is concerning for wound breakdown, infection, or CSF leak. Wound breakdown can result from poor healing or a broken stitch, but it can also be a sign of developing infection or hydrocephalus.

Patients remain at risk for seizures postoperatively. Nurses caring for these patients must be comfortable with recognizing and treating seizures. A rescue medication plan must exist for each patient following surgery. Postoperative seizures are fairly uncommon following epilepsy surgery; however, they do occur. When they do, that does not mean that the operation has failed. There is a risk for seizures associated with any brain surgery, as the operation causes irritation and inflammation in the brain. The nurse can play an important role in the reassurance of parents who

are understandably concerned over the presence of a seizure. Postoperative neurosurgical patients can also display behaviors that can look like seizures but are not. Again, nurses experienced in caring for epilepsy patients can help decipher seizures from non-epileptiform behaviors. Continuous EEG may be used postoperatively to determine whether seizures are truly occurring.

Postoperative care of the epilepsy patient involves a large, multidisciplinary team. Many patients will require an extended hospital stay for rehabilitation needs. This can be stressful to the family and child. Paying attention to the emotional aspects of care is important. Nurses are the constant provider among a larger group that will change over time. They are in the perfect position to provide support and education to the family and child. Nurses play an important role as advocates and liaisons for the family. Families are not only dealing with the stress of a prolonged hospital stay but are also coping with understanding the needs of their children postoperatively and what changes (good and bad) are going to occur in their lives. It is important to monitor how the patient and family are coping with the overall situation and offer assistance at an early juncture. Anger, frustration, and depression can occur even when the outcome has been good. The nurse is essential in providing encouragement, support, and resources to the family and child.

### 13.9.5 Outcomes of Epilepsy Surgery

When discussing outcomes of epilepsy surgery, it is important to consider not only seizure frequency but also quality of life. Classification systems to categorize outcomes are important so that results from different therapies can be compared. The most commonly used classification system for defining seizure outcome is the classification developed by J. Engel in 1993 (Engel et al. 1993) (Table 13.1). This system is widely used and provides a uniform method to analyze outcomes. In this system, seizure outcome is based on the number of seizure events a patient experiences postoperatively. It excludes seizures seen in the first few weeks postoperatively and includes four

**Table 13.1** Engel's classification of postoperative outcome

<i>Class I: free of disabling seizures<sup>a</sup></i>
A. Completely seizure free since surgery
B. Nondisabling simple partial seizures only since surgery
C. Some disabling seizures after surgery but free of disabling seizures for at least 2 years
D. Generalized convulsions with AED discontinuation only
<i>Class II: rare disabling seizures ("almost seizure free")</i>
A. Initially free of disabling seizures but has rare seizures now
B. Rare disabling seizures since surgery
C. More than rare disabling seizures since surgery but rare seizures for the last 2 years
D. Nocturnal seizures only
<i>Class III: worthwhile improvement<sup>b</sup></i>
A. Worthwhile seizure reduction
B. Prolonged seizure-free intervals amounting to greater than half the follow-up period but not <2 years
<i>Class IV: no worthwhile improvement</i>
A. Significant seizure reduction
B. No appreciable change
C. Seizures worse

Source: Engel et al. (1993)

<sup>a</sup>Excludes early postoperative seizures (first few weeks)

<sup>b</sup>Determination of "worthwhile improvement" will require quantitative analysis of additional data such as percentage seizure reduction, cognitive function, and quality of life

classes, ranging from "free of disabling seizures" to "no worthwhile improvement" (Jehi et al. 2011). Criticisms of this system include the use of ambiguous terms like "disabling seizures," "almost seizure-free," and "worthwhile improvement" (Weiser et al. 2001). These category headings are subject to interpretation and lead to a high variability in reported results. One center may consider any reduction in seizures over 50% to be worthwhile, whereas another center may require greater than 75%. Furthermore, the definition of disabling seizures can vary greatly. Another criticism is that centers may not utilize the subcategories that exist for each classification (Weiser et al. 2001). These criticisms led the International League Against Epilepsy to propose a revised classification system in 2001 (Table 13.2). This system more clearly defines seizure occurrence by distinctly categorizing



**Table 13.2** ILAE classification of postoperative outcome

Class 1. Completely seizure free; no auras
Class 1a. Completely seizure free since surgery; no auras
Class 2. Only auras; no other seizure
Class 3. 1–3 seizure days/year $\pm$ auras
Class 4. 4 seizure days/year to 50% reduction in baseline number of seizure days/year; $\pm$ auras
Class 5. <50% reduction in baseline seizure days to 100% increase in baseline seizure days; $\pm$ auras
Class 6. >100% increase in baseline number of seizure days; $\pm$ auras

Source: Weiser et al. (2001)

those who are completely seizure free from those with just auras. It also defines seizures based on seizure days per year rather than events, thus classifying patients who may seize infrequently but do so with clusters. The ILAE system also added a category for patients with worsening seizures which was lacking in Engel's system (Weiser et al. 2001). Both systems are easy to use and provide a way to systematically classify seizure outcomes. Further, they have both been shown to have excellent interrater reliability and have been found to be comparable to each other (Durnford et al. 2011).

In looking at all surgical procedures to treat epilepsy, seizure freedom (or significant reduction in seizures) is highest among patients with temporal lobectomies, followed by hemispherectomies, with resections for cortical dysplasia showing some of the lowest rates for non-palliative procedures (Ryvlin and Rheims 2016; Kunieda et al. 2013; Phi et al. 2010; Zupanc et al. 2010). Patients having a defined, identifiable lesion on MRI are 2.5 times more likely to be seizure free after surgery than those without a defined lesion, and those with a lesion in the temporal lobe do best of all (Wasade et al. 2015; Ramey et al. 2013; Tellez-Zenteno et al. 2010). The presence of a well-defined lesion allows for a higher probability of complete resection of the epileptogenic focus. Epileptogenic foci defined by vague imaging findings, metabolic studies, and cortical EEG mapping carry a higher probability of leaving epileptogenic tissue behind. Also, resections near eloquent areas have a higher

risk of incomplete resection (Ryvlin and Rheims 2016; Wasade et al. 2015; Ramey et al. 2013). Cortical dysplasia, as noted, carries one of the lowest seizure-free rates. This is due to the fact that the extent of the dysplasia is not always evident on imaging or EEG monitoring allowing for incomplete resection.

Multiple factors certainly play into seizure outcome, particularly the etiology of the epilepsy, age of the child, duration of the seizures, and the presence of dual pathologies or syndromes. Long-term seizure control has been shown to decline at 2 and 5 years post surgery. One explanation for this is recruitment of new epileptogenic foci. The cortex surrounding an identified epileptic focus may not appear to be epileptogenic on initial workup, but it may become so once the main seizure focus is removed. Then, as AEDs are being withdrawn, it becomes active. It is also thought that AED resistance worsens over time, thus allowing for recurrence of seizures (Wasade et al. 2015; Kunieda et al. 2013).

Quality of life (QOL) outcomes are as important as seizure outcomes. QOL outcomes look at cognitive, behavioral, and social functioning. More recent studies are showing that early surgical intervention can result not only in seizure reduction but improvements in quality of life as well (Jenny et al. 2016; Shurtleff et al. 2015). No QOL outcome classification system exists, although this has been proposed by the ILAE (Weiser et al. 2001). There are some surveys available that measure QOL based on parent and patient perception of such things as well-being, cognitive functioning, behavioral functioning, and social activity. They generally include assessments of seizure impact on quality of life (Zupanc et al. 2010). As would be expected, better QOL scores are reported postoperatively by patients with seizure-free or near-seizure-free outcomes. QOL scores are also significantly higher for surgically treated patients than for patients worked up for surgery but not operated on (Lee et al. 2015; Wasade et al. 2015; Kunieda et al. 2013). Families of patients operated on at a younger age with good outcomes also report better quality of life (Jenny et al. 2016; Shurtleff et al. 2015; Zupanc et al. 2010).



QOL outcomes showed no change or limited change among teenagers and young adults, however, regardless of seizure outcome. Despite good or complete seizure control, this age group still reported low QOL outcomes (Shurtleff et al. 2015; Zupanc et al. 2010). This is likely due to the fact that despite improved seizures, many of these individuals experienced social isolation, poor performance in school, high unemployment, and low rates of independence. It is believed that when control of seizures comes in adolescents or adulthood, these individuals have likely had long-standing intractable epilepsy leading to significant effects on cognition, academic performance, self-esteem, and social skills. Corrective surgery may have come at too late of a juncture to have an impact on major life skills (Sanchez et al. 2015; Widjaja et al. 2011; Mikati et al. 2010; Zupanc et al. 2010). Depression and other psychiatric disturbances are common with epilepsy and may not improve even after a successful surgery. Results such as these serve as another argument for considering epilepsy surgery earlier rather than later in children with intractable seizures. Early intervention prevents injury to the developing brain from intractable seizures and medications, allowing the child to develop more normally (Berg et al. 2012). As epilepsy surgery continues to be considered earlier in an individual's disease, it will be interesting to see if QOL data improve among adolescents and adults (Box 13.1).

### Box 13.1 Epilepsy Surgery Case Study

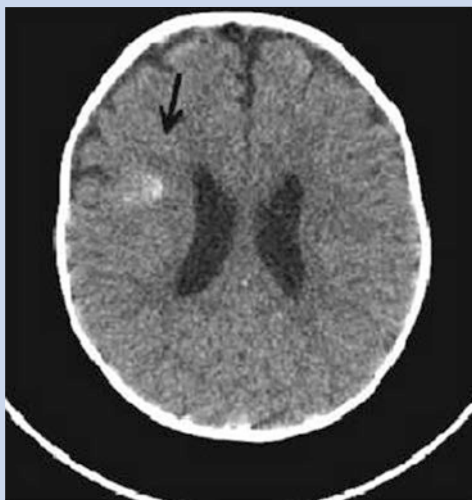
M. A. was born at 29 weeks gestation requiring initial care in the NICU. Neonatal complications included mild respiratory distress, feeding disturbance, and a PDA which was closed with indomethacin. He did well, without lasting effects, and was discharged home at 2 months. Head ultrasounds had been performed as part of his neonatal care and were found to be normal. He experienced no seizures. He was growing well, and developing normally, until 7 months of age. He had no known medical problems, and he had never experienced a febrile seizure. There was no family history of seizures.

At 7 months, he had his first seizure which involved left-sided twitching and gaze deviation to the left. An EEG was scheduled by his PCP, but, before this could be done, he acutely developed an episode of dense left hemiparesis and leftward gaze. His parents brought him to the emergency department where, by that time, he was found to have a normal neurologic exam. A CT scan showed a 3-cm area of abnormality in the inferior frontal region with calcifications and vague abnormal density. An MRI was done showing focal cortical dysplasia in the right frontoparietal region. There was also an area of cortical abnormality in the right inferior occipital lobe. He was started on Tegretol and discharged home.

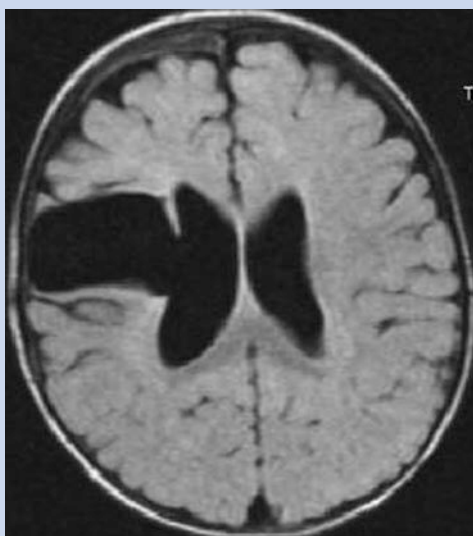
M. A. continued to experience multiple daily seizures despite the Tegretol, so he was started on Trileptal. He had better seizure control but continued to experience daily seizures. He was admitted to the NMU for vEEG monitoring. His AEDs were withdrawn and he experienced several typical seizures. Video monitoring showed his seizures to consist of a blank stare, eye movements back and forth, twitching in the left side of his face, and snorting noises. The EEG showed ictal onset from the right cerebral hemisphere, particularly the right parietal and temporal regions. Interictal EEG showed normal background EEG for his age. Because of the focal cortical abnormalities on imaging, and EEG onset from the same area, he was felt to be a candidate for resective surgery.

At 9 months of age, he underwent phase II monitoring with a right frontotemporal parietal craniotomy for implantation of subdural electrodes. He was monitored and mapped in the NMU. His seizures were found to be arising from the frontoparietal area of dysplasia.

No seizures were noted to arise from the occipital area. Four days later, he was taken back to surgery where the electrodes were removed and the area of seizure focus was resected (Figs. 13.24 and 13.25). He spent his first postoperative night in the PICU and then was transferred to the neurosurgery floor. He had an uneventful postoperative course. He had no seizures following surgery. He was discharged home on postoperative day number 5 on Dilantin and Trileptal.



**Fig. 13.24** Area of calcification and subtle cortical abnormality suggesting cortical dysplasia



**Fig. 13.25** Postoperative MRI showing resection of seizure focus

Prior to surgery, he had a normal neurological and developmental exam for a 9-month-old, corrected 2 months for his prematurity. He was vocal, playful, rolling over, and pushing up on all fours. He had no neurologic deficits. Postoperatively, he had a moderate left-sided weakness, greater in arm than leg, but no other deficits. The weakness improved postoperatively. At his 2-month post-op visit, he was noted to use the left arm purposefully. He would bear weight and try to “cruise” when put into a standing position. He was noted to have mildly increased tone on the left.

M. A. is now 11 years old and has been seizure free since surgery (Engel class Ia). He is off all seizure medications. His Dilantin was stopped 10 days postoperatively, and his Trileptal was stopped 2 years postoperatively. He does have a residual mild left hemiparesis, but he is fully ambulatory and active. He runs, is on a soccer team, and has purposeful use of his left arm and hand. He is in the fifth grade and is performing above grade level in core subjects. His neuropsychological testing has been in the normal to above normal range on all measures.

### Conclusions

Epilepsy surgery is a safe and effective treatment option for individuals with intractable seizures. New and continually improving imaging, monitoring, and operative techniques make epilepsy surgery an option for patients of all ages. Careful workup and consideration of surgical candidates is leading to a high success rate of seizure control and improved quality of life outcomes. Once reserved for only the most severe cases, epilepsy surgery is now being considered as a treatment option earlier in a child’s disease. With earlier intervention comes improved cognitive outcomes, as the brain is spared detrimental exposure to seizures and AEDs. Though there are risks associated with

epilepsy surgery, the overall reported outcomes are still superior to reported outcomes for continued trials of antiepileptic medications. The goal of epilepsy surgery remains curing or significantly decreasing the number of seizures while preserving the child's development, intellect, and quality of life. As advancements in workup and surgical technique continue, this goal will be reached in all surgical patients, not just the majority. Nurses will continue to play an essential role in reaching that goal.

### Pediatric Pearls

1. All patients being monitored in the NMU are at risk for episodes of status. Make sure that a clear plan of action is readily available should status occur. The action plan should include what AEDs to give, in what order, after what length of time, as well as who is to be notified. The plan should also clearly identify which concerns to address with neurosurgery and which to address with neurology.
2. Given that epilepsy surgery patients require a multidisciplinary team, nurses need to play a consistent role as communicator, liaison, and advocate for the family.
3. Differentiating between seizures and behaviors related to pain or altered mental status can be difficult. It is important to know each child's typical seizure semiology and their baseline neurologic functioning to help with this distinction.
4. Narcotics will not deter seizures during monitoring and should not be withheld for this reason.
5. Surgical epilepsy patients typically require long hospital stays. It is important to involve ancillary services such as child life specialists, play therapists, and school resources.

6. Hemispherectomy patients can develop hydrocephalus years after their procedure. Therefore, any patient with a history of hemispherectomy who is displaying signs and symptoms of elevated intracranial pressure needs to be evaluated for this.
7. Increased seizure activity in a patient with a VNS in place could be an indication of VNS malfunction and should warrant investigation.

### References

- Aldenkamp A, Besag F, Gobbi G, Caplan R, Dunn D, Sillanpaa (2016) Psychiatric and behavioral disorders in children with epilepsy (ILAE Task Force Report): adverse cognitive and behavioural effects of antiepileptic drugs in children. *Epileptic Disord* 18(supplement):555–567
- Alonso F, Sweet J, Miller J (2016) Speech mapping using depth electrodes: the “electric wada”. *Clin Neurol Neurosurg* 144:88–90
- Asano E, Brown EC, Csaba J (2013) How to establish causality in epilepsy surgery. *Brain Dev* 35:706–720
- Beier AD, Rutka JT (2013) Hemispherectomy: historical review and recent technical advances. *Neurosurg Focus* 34:E11
- Berg AT, Berkovic SF, Brodie MJ, Buchhalter J, Cross JH, vanEmde BW, Engel J, French J, Glauser TA, Mathern GW, Moshe SL, Nordli D, Plouin P (2010) Revised terminology and concepts for organization of seizures and epilepsies: report of the ILAE Commission on Classification and Terminology 2005–2009. *Epilepsia* 51:676–685
- Berg AT, Zelko FA, Levy SR, Testa FM (2012) Age at onset of epilepsy, pharmacoresistance, and cognitive outcomes. *Neurology* 79:1384–1388
- Bien CG, Granata T, Antozzi C, Cross JH, Dulac O, Kurthen M, Lassman H, Mantegazza R, Villemure JG, Spreafico R, Elger CE (2005) Pathogenesis, diagnosis and treatment of Rasmussen encephalitis: a European consensus statement. *Epilepsia* 46:454–471
- Blumcke I, Thom M, Aronica E, Armstrong DD, Vinters HV, Palmieri A, Jacques TS, Avanzini G, Barkovich AJ, Battaglia G, Becker A, Cepeda C, Cendes F, Colombo N, Crino P, Cross JH, Delalande O, Dubeau F, Duncan J, Guerrini R, Kahane P, Mathern G, Najm I, Ozkara C, Raybaud C, Represa A, Roper SN, Salamon N, Schulze-Bonhage A, Tassi L, Vessani A, Spreafico R (2011) The clinicopathologic spectrum of focal cortical

- dysplasias: a consensus classification proposed by an ad hoc Task Force of the ILAE Diagnostic Methods Commission. *Epilepsia* 52:158–174
- Bodin E, Le Moing AG, Bourel-Ponchel E, Quere L, Toussaint P, Berquin P (2016) Vagus nerve stimulation in the treatment of drug-resistant epilepsy in 29 children. *Eur J Pediatr Neurol* 20:346–351
- Bower RS, Wirrell EC, Eckel LJ, Wong-Kisiel LC, Nickels KC, Wetjen NM (2015) Repeat resective surgery in complex pediatric refractory epilepsy: lessons learned. *J Neurosurg Pediatr* 16:94–100
- Brodie MJ, Barry SJ, Bamagous GA, Kwan P (2013) Effect of dosage failed of first antiepileptic drug on subsequent outcome. *Epilepsia* 54:194–198
- Brooks-Kayal AR, Bath KG, Berg AT, Galanopoulou AS, Holmes GL, Jensen FE, Kanner AM, O'Brien TJ, Whittemore VH, Winawer MR, Patel M, Scharfman HE (2013) Issues related to symptomatic and disease-modifying treatments affecting cognitive and neuropsychiatric comorbidities of epilepsy. *Epilepsia* 54(suppl 4):44–60
- Comi A (2015) Current therapeutic options in Sturge-Weber syndrome. *Semin Pediatr Neurol* 22:295–301
- Comi AM, Sahin M, Hammill A, Kaplan EH, Juhasz C, North P, Ball KL, Levin AV, Cohen B, Morris J, Lo W, Roach ES (2016) 2015 Sturge-Weber syndrome research workshop. *Pediatr Neurol* 58:12–24
- Connolly MB, Henderson G, Steinbok P (2006) Tuberous sclerosis complex: a review of the management of epilepsy with emphasis on surgical aspects. *Childs Nerv Syst* 22:896–908
- Cross JH, Jayakar P, Nordli D, Delalande O, Duchowny M, Wieser HG, Guerrini R, Mathern G (2006) Proposed criteria for referral and evaluation of children for epilepsy surgery: recommendations of the Subcommission of Pediatric Epilepsy Surgery. *Epilepsia* 47:952–959
- Curatolo P, Moavero R, Roberto D, Graziola F (2015) Genotype/phenotype correlations in tuberous sclerosis complex. *Semin Pediatr Neurol* 22:259–273
- Curatolo P, Aronica E, Jansen A, Jansen F, Kotulska K, Lagae L, Moavero R, Jozwiak S (2016) Early onset epileptic encephalopathy or genetically determined encephalopathy with early onset epilepsy? *Eur J Pediatr Neurol* 20:203–211
- Deleo F, Garbelli R, Milesi G, Gozzo F, Bramerio M, Villani F, Cardinale F, Trinagali G, Spreafico R, Tassi L (2016) Short- and long-term surgical outcomes of temporal lobe epilepsy associated with hippocampal sclerosis: relationships with neuropathology. *Epilepsia* 57:306–315
- Di Rocco C, Tamburrini G (2006) Sturge-Weber syndrome. *Childs Nerv Syst* 22:909–921
- Diaz RJ, Sherman EMS, Hader WJ (2008) Surgical treatment of intractable epilepsy associated with focal cortical dysplasia. *Neurosurg Focus* 25:E6
- Dubeau F (2011) Rasmussen encephalitis (chronic focal encephalitis). In: Wyllie E (ed) *Wyllie's treatment of epilepsy: principles and practice*, 5th edn. Lippincott Williams & Wilkins, Philadelphia
- Durnford AJ, Rodgers W, Kirkham FJ, Mullee MA, Whitney A, Previtt M, Kinton L, Harris M, Gray WP (2011) Very good inter-rater reliability of Engel and ILAE epilepsy surgery outcome classifications in a series of 76 patients. *Seizure*. doi:10.1016/j.seizure.2011.08.004
- Dym RJ, Burns J, Lipton ML (2011) Is functional MR imaging assessment of hemispheric language dominance as good as WADA test? *Radiology* 261:446–455
- El Tahry R, Hirsch M, Van Rijckevorsel K, Santos SF, de Tourchaninoff M, Rooijakkers H, Coenen V, Schulze-Bonhage A (2016) Early experiences with tachycardia-triggered vagus nerve stimulation using the AspireSR stimulator. *Epileptic Disord* 18:155–162
- Engel JJ (2013) Why is there still doubt to cut it out? *Epilepsy Curr* 13:198–204
- Engel JJ, Van Ness PC, Rasmussen TB, Ojemann LM (1993) Outcome with respect to epileptic seizures. In: Engel JJ (ed) *Surgical treatment of the epilepsies*, 2nd edn. Raven Press, New York, pp 609–621
- Englot DJ, Breshears JK, Sun PP, Chang EF, Auguste KI (2013) Seizure outcomes after resective surgery for extra-temporal lobe epilepsy in pediatric patients. *J Neurosurg Pediatr* 12:126–133
- Englot DJ, Rolston JD, Wang DD, Sun PP, Chang EF, Auguste KI (2013) Seizure outcomes after temporal lobectomy in pediatric patients: a systematic review. *J Neurosurg Pediatr* 12:134–141
- Englot DJ, Seunggu JH, Rolston JD, Ivan ME, Kuperman RA, Chang EF, Gupta N, Sullivan JE, Auguste KI (2014) Epilepsy surgery failure in children: a quantitative and qualitative analysis. *J Neurosurg Pediatr* 14:386–395
- Englot DJ, Nagarajan SS, Imber BS, Raygor KP, Honma SM, Mizuiri D, Mantle M, Knowlton RC, Kirsch HE, Chang EF (2015) Epileptogenic zone localization using magnetoencephalography predicts seizure freedom in epilepsy surgery. *Epilepsia* 56:949–958
- Englot DJ, Harjus B, Chang EF (2016) Seizure outcomes in nonresective epilepsy surgery: an update.
- Fallah A, Rodgers SD, Weil AG, Vadera S, Monsouri A, Connolly MB, Major P, Ma T, Devinsky O, Weiner HL, Gonzalez-Martinez JA, Bingaman WE, Najm I, Gupta A, Ragheb J, Bhatia S, Steinbok P, Witiw CD, Widjaja E, Snead OC, Rutka JT (2015) Resective epilepsy surgery for tuberous sclerosis in children: determining predictors of seizure outcomes in a multicenter retrospective cohort study. *Neurosurgery* 77:517–524
- Farwell JR, Dodrill CB, Batzel LW (1985) Neuropsychological abilities of children with epilepsy. *Epilepsia* 26:395–400
- Fisher RS, Acevedo C, Arzimanoglou A, Bogacz A, Cross JH, Elger CE, Engel JJ, Forsgren L, French JA, Glynn M, Hesdorffer C, Lee BI, Mathern GW, Moshe SL, Perucca E, Scheffer IE, Tomson T, Watanabe M, Wiebe S (2014) A practical clinical definition of epilepsy. *Epilepsia* 55:475–482



- Go C, Snead OC (2008) Pharmacologically intractable epilepsy in children: diagnosis and preoperative evaluation. *Neurosurg Focus* 25(E2):1–7
- Gonzalez-Martinez J, Bulacio J, Alexopoulos A, Jehi L, Bingaman W, Najm I (2013) Stereoelectrocephalography in the “difficult to localize” refractory focal epilepsy: early experience from a North American epilepsy center. *Epilepsia* 54:323–330
- Gonzalez-Martinez J, Mullin J, Bulacio J, Gupta A, Enatsu R, Najm I, Bingaman W, Wyllie E, Lachhwani D (2014) Stereoelectroencephalography in children and adolescents with difficult to localize refractory focal epilepsy. *Neurosurgery* 75:258–267
- Graham D, Tisdall MM, Gill D (2016) Corpus callosotomy outcomes in pediatric patients: a systematic review. *Epilepsia* 57:1053–1068
- Guan J, Karsy M, Ducis K, Bollo R (2016) Surgical strategies for pediatric epilepsy. *Transl Pediatr* 5:55–66
- Gupta A (2011) Epilepsy in the setting of neurocutaneous syndromes. In: Wyllie E (ed) *Wyllie’s treatment of epilepsy: principles and practice*, 5th edn. Lippincott Williams & Wilkins, Philadelphia
- Hao X, Wong ISM, Kwan P (2011) Interrater reliability of the international consensus definition of drug-resistant epilepsy: a pilot study. *Epilepsy Behav* 22:388–390
- Harvey S, Cross JH, Shinnar S, Mathern BW, ILAE Pediatric Epilepsy Surgery Survey Taskforce (2008) Defining the spectrum of international practice in pediatric epilepsy surgery patients. *Epilepsia* 49:146–155
- Hirfanoglu T, Serdaroglu A, Cansu A, Bilir E, Gucleyener K (2006) Semiological seizure classification: before and after video-EEG monitoring of seizures. *Pediatr Neurol* 36:231–235
- Hoffman CE, Ochi A, Snead BC, Widjaja E, Hawkins C, Tisdall M, Rutka JT (2016) Rasmussen’s encephalitis: advances in management and outcomes. *Childs Nerv Syst* 32:629–640
- Holmes G (2002) Epilepsy surgery in children: when, why, and how. *Neurology* 58(suppl 7):S13–S20
- Jalilian L, Limbrick DD, Steger-May K, Johnston J, Powers AK, Smyth MD (2011) Complete versus two-thirds corpus callosotomy in children: analysis of outcome. *J Neurosurg Pediatr* 6:257–266
- Jehi L, Martinez-Gonzalez J, Bingaman W (2011) Outcome and complications of epilepsy surgery. In: Wyllie E (ed) *Wyllie’s treatment of epilepsy: principles and practice*, 5th edn. Lippincott Williams & Wilkins, Philadelphia
- Jenny B, Smoll N, Hassani YE, Momkian S, Pollo C, Korff CM, Seock M, Schaller K (2016) Pediatric epilepsy surgery: could age be a predictor of outcomes? *J Neurosurg Pediatr* 29:1–7
- Jette N, Wiebe S (2016) Initial evaluation of the patient with suspected epilepsy. *Neurol Clinics* 34:339–350
- Johnston JM, Mangano FT, Ojemann JG, Park TS, Trevathan E, Smyth M (2006) Complications of invasive subdural electrode monitoring at St. Louis Children’s Hospital 1994–2005. *J Neurosurg* 105(5 Suppl):343–347
- Kabir SMR, Rajaraman C, Ritty C, Zaki HS, Kemeny AA, McMullan J (2009) Vagus nerve stimulation in children with intractable epilepsy: indications, complications, and outcome. *Childs Nerv Syst* 25:1097–1100
- Karsy M, Guan J, Ducis K, Bollo RJ (2016) Emerging surgical therapies in the treatment of pediatric epilepsy. *Transl Pediatr* 5:67–78
- Kellinghaus C, Luders HO (2011) Classification of seizures. In: Wyllie E (ed) *Wyllie’s treatment of epilepsy: principles and practice*, 5th edn. Lippincott Williams & Wilkins, Philadelphia
- Kim EH, Ko TS (2016) Cognitive impairment in childhood onset epilepsy: up-to-date information about its cause. *Kor J Pediatr* 59:155–164
- Kim KJ, Lee R, Chae JH, Hwang YS (2002) Application of semiological seizure classification to epileptic seizures in children. *Seizure* 11:281–284
- Kunieda T, Mikuni N, Shibata S, Inano R, Yamao Y, Kikuchi T, Matsumoto R, Takahashi J, Ikeda A, Fukuyama H, Miyamoto S (2013) Long-term seizure outcome following resective surgery for epilepsy: to be or not to be completely cured? *Neurol Med Chir (Tokyo)* 53:805–813
- Kwan P, Brodie M (2000) Early identification of refractory epilepsy. *N Engl J Med* 342:314–319
- Kwan P, Arzimanoglou A, Berg AT, Brodie MJ, Hauser WA, Mathern G, Moshe SL, Perucca E, Wiebe S, French J (2010) Definition of drug resistant epilepsy: consensus proposal by the ad hoc Task Force of the ILAE Commission on Therapeutic Strategies. *Epilepsia* 51:1069–1077
- Lee J, Adelson P (2004) Neurosurgical management of pediatric epilepsy. *Pediatr Clin N Am* 51:441–456
- Lee YJ, Kang HC, Kim HD, Kim DS, Shim KW, Ma SE, Lee JS (2015) Neurocognitive function in children after anterior temporal lobectomy with amygdalohippocampectomy. *Pediatr Neurol* 52:88–93
- Lewis EC, Weil AG, Duchowny M, Bhatia S, Ragheb J, Miller I (2015) MR-guided laser interstitial thermal therapy for pediatric drug-resistant lesional epilepsy. *Epilepsia* 56:1590–1598
- Limbrick DD, Narayan P, Powers AK, Ojemann JG, Park TS, Bertrand M, Smyth MD (2011) Hemispherotomy: efficacy and analysis of seizure recurrence. *J Neurosurg Pediatr* 4:323–332
- Linehan C, Berg AT (2011) Epidemiologic aspects of epilepsy. In: Wyllie E (ed) *Wyllie’s treatment of epilepsy: principles and practice*, 5th edn. Lippincott Williams & Wilkins, Philadelphia
- Loddenkemper T (2011) Classification of the epilepsies. In: Wyllie E (ed) *Wyllie’s treatment of epilepsy: principles and practice*, 5th edn. Lippincott Williams & Wilkins, Philadelphia
- Luders HO, Acharya J, Baumgartner C et al (1998) Semiological seizure classification. *Epilepsia* 39:1006–1013
- Maguire MJ, Jackson CF, Marson AG, Nolan SJ (2016) Treatments for the prevention of Sudden Unexpected Death in Epilepsy (SUDEP). *Cochrane Database Syst Rev* (7):CD011792
- Malmgren K, Rydenhag B, Hallbook T (2015) Reappraisal of corpus callosotomy. *Curr Opin Neurol* 28:175–181



- Mapstone TB (2008) Vagus nerve stimulation: current concepts. *Neurosurg Focus* 25(E9):1–4
- Meador KJ (2011) Cognitive effects of epilepsy and anti-epileptic medications. In: Wyllie E (ed) *Wyllie's treatment of epilepsy: principles and practice*, 5th edn. Lippincott Williams & Wilkins, Philadelphia
- Mikati MA, Ataya N, Ferzli J, Kurdi R, El-Banna D, Rahi A, Shamseddine A, Sinno D, Comair Y (2010) Quality of life after surgery for intractable partial epilepsy in children: a cohort study with controls. *Epilepsy Res* 90:207–213
- Moosa A, Jehi L, Marashly A, Cosmo G, Lachhwani D, Wylie E, Kotagoal P, Bingaman W, Gupta A (2013) Long-term functional outcome and their predictors after hemispherectomy in 115 children. *Epilepsia* 54:1771–1779
- Mullin JP, Sexton D, Al-Omar S, Bingaman W, Gonzalez-Martinez J (2016a) Outcomes of subdural grid electrode monitoring in the stereoencephalography era. *World Neurosurg* 89:255–258
- Mullin JP, Shriver M, Alomar S, Najm I, Bulacio J, Chauvel P, Gonzalez-Martinez J (2016b) Is SEEG safe? A systematic review and meta-analysis of stereo-electroencephalography-related complications. *Epilepsia* 57:386–401
- Neal EG, Chagge H, Schwartz RH, Lawson MS, Edwards N, Fitzsimmons G, Whitney A, Cross JH (2008) The ketogenic diet for the treatment of childhood epilepsy: a randomized control trial. *Lancet Neurol* 7:500–506
- Neubauer BA, Hahn A, Tuxhorn I (2011) Progressive and infantile myoclonic epilepsies. In: Wyllie E (ed) *Wyllie's treatment of epilepsy: principles and practice*, 5th edn. Lippincott Williams & Wilkins, Philadelphia
- Nissen IA, Stam CJ, Citroen J, Reijneveld JC, Hillebrand A (2016) Preoperative evaluation using magnetoencephalography: experience in 382 epilepsy patients. *Epilepsy Res* 124:23–33
- Nordli DR, De Vivo DC (2011) The ketogenic diet. In: Wyllie E (ed) *Wyllie's treatment of epilepsy: principles and practice*, 5th edn. Lippincott Williams & Wilkins, Philadelphia
- Panayiotopoulos CP (2012) The new ILAE report on terminology and concepts for the organization of epilepsies: critical review and contribution. *Epilepsia* 53:399–404
- Parr J, Augustijn PB, Geerts Y, vanEmde BW (2001) Classification of epileptic seizures: a comparison of two systems. *Epilepsia* 42:476–482
- Phi JH, Cho BK, Wang KC, Lee JY, Hwang YS, Kim KJ, Chae JH, Kim IO, Park SH, Kim SK (2010) Longitudinal analyses of the surgical outcomes of pediatric epilepsy patients with focal cortical dysplasia. *J Neurosurg Pediatr* 6:49–56
- Pittau F, Grouiller F, Spinelli L, Seeck M, Michel CM, Vulliemoz S (2014) The role of functional neuroimaging in pre-surgical epilepsy evaluation. *Front Neurol* 5:1–16
- Puka K, Smith ML (2015) Predictors of long-term quality of life after pediatric epilepsy surgery. *Epilepsia* 56:873–881
- Ramey WL, Martirosyan NL, Lieu CM, Hasham HA, Lemole GM, Weinand ME (2013) Current management and surgical outcomes of medically intractable epilepsy. *Clin Neurol Neurosurg* 115:2411–2418
- Revesz D, Rydenhag B, Ben-Menachem E (2016) Complications and safety of vagus nerve stimulation: 25 years of experience at a single center. *J Neurosurg Pediatr* 18:97–104
- Rolston JD, Chang EF (2016) Stereotactic laser ablation for hypothalamic hamartoma. *Neurosurg Clin N Am* 27:59–67
- Rowland NC, Englot DJ, Cage TA, Sughrue E, Barbaro NM, Chang EF (2012) A meta-analysis of predictors of seizure freedom in surgical management of focal cortical dysplasia. *J Neurosurg* 116:1035–1041
- Ryvlin P, Rheims S (2016) Predicting epilepsy surgery outcome. *Curr Opin Neurol* 29:182–188
- Rzezak P, Valente KD, Duchowny MS (2014) Temporal lobe epilepsy in children: executive and mnemonic impairments. *Epilepsy Behav* 31:117
- Sanchez F, An S, Loddenkemper T (2015) Pediatric refractory epilepsy: a decision analysis comparing medical versus surgical treatment. *Epilepsia* 56:263–272
- Schevon CA, Carlson C, Zaroff C, Weiner HJ, Doyle WK, Miles D, Lajoie J, Kuzniecky R, Pacia S, Vazquez B, Luciano D, Najjar S, Devinsky O (2007) Pediatric language mapping: sensitivity of neurostimulation and WADA testing in epilepsy surgery. *Epilepsia* 48:539–545
- Schramm J, Kuczaty S, Sassen R, Elger CE, von Lehe M (2012) Pediatric functional hemispherectomy: outcome in 92 patients. *Acta Neurochir (Wien)* 154:2017–2028
- Schuele SU, Luders HO (2008) Intractable epilepsy: management and therapeutic alternatives. *Lancet Neurol* 7:514–524
- Seneviratne U (2016) Sudden unexpected death in epilepsy: a silent killer. *Ceylon Med J* 61(2):47–51
- Serdaroglu A, Arhan E, Kurt G, Erdem A, Hirfanoglu T, Aydin K, Bilir E (2016) Long term effect of vagus nerve stimulation in pediatric intractable epilepsy: an extended follow-up. *Childs Nerv Syst* 32:641–646
- Shurtleff HA, Barry D, Firman T, Warner MH, Aguilar-Estrada RL, Saneto RP, Kuratani JD, Ellenbogen RG, Novotny EJ, Ojemann JG (2015) Impact of epilepsy surgery on development of preschool children: identification of a cohort likely to benefit from early intervention. *J Neurosurg Pediatr* 16:383–339
- Sood S, Marupudi NI, Asano E, Haridas A, Ham SD (2015) Endoscopic corpus callosotomy and hemispherectomy. *J Neurosurg Pediatr* 16:681–686
- Sudarsanam A, Arden-Holmes SL (2014) Sturge-Weber syndrome: from the past to the present. *Eur J Pediatr Neurol* 18:257–266
- Tatum WO (2011) Atypical absence seizures, myoclonic, tonic, and atonic seizures. In: Wyllie E (ed) *Wyllie's treatment of epilepsy: principles and practice*, 5th edn. Lippincott Williams & Wilkins, Philadelphia
- Tellez-Zenteno JF, Ronquillo LH, Moien-Afshari F, Wiebe S (2010) Surgical outcomes in lesional and

- non-lesional epilepsy: a systematic review and meta-analysis. *Epilepsy Res* 89:310–318
- Tovar-Spinoza Z, Carter D, Ferrone D, Eksioglu Y, Huckins S (2013) The use of MRI-guided laser-induced thermal ablation for epilepsy. *Childs Nerv Syst* 29:2089–2094
- Tsur VG, O'Dell C, Shinnar S (2011) Initiation and discontinuation of antiepileptic drugs. In: Wyllie E (ed) *Wyllie's treatment of epilepsy: principles and practice*, 5th edn. Lippincott Williams & Wilkins, Philadelphia
- Vadera S, Mullin J, Bulacio J, Najm I, Bingaman W, Gonzalez-Martinez J (2013) Stereoelectroencephalography following subdural grid placement in difficult to localize epilepsy. *Neurosurgery* 72:723–728
- Vadera S, Griffith SD, Rosenbaum BP, Seicean A, Kshetry ML, Weil RJ, Bingaman W, Jehi L (2015) National trends and in-hospital complication rates in more than 1600 hemispherectomies from 1988 to 2010: a nationwide inpatient sample study. *Neurosurgery* 77:185–191
- Varadkar S, Bien CG, Kruse CA, Jensen FE, Bauer J, Pardo CA, Vincent A, Mathem GW, Cross JH (2014) Rasmussen's encephalitis: clinical features, pathobiology, and treatment advances. *Lancet Neurology* 13(2):195–205
- Velasco TR, Mather GW (2011) Surgical treatment of refractory temporal lobe epilepsy. In: Wyllie E (ed) *Wyllie's treatment of epilepsy: principles and practice*, 5th edn. Lippincott Williams & Wilkins, Philadelphia
- Vendrame M, Loddenkemper T (2010) Surgical treatment of refractory status epilepticus in children: candidate selection and outcome. *Semin Pediatr Neurol* 17:182–189
- Wasade VS, Elisevich K, Tahir R, Smith B, Schultz L, Schwalb J, Spanaki-Varelas M (2015) Long-term seizure and psychosocial outcomes after resective surgery for intractable epilepsy. *Epilepsy Behav* 43:122–127
- Weiser HG, Blume WT, Fish D, Goldensohn E, Hufnagel A, King D, Sperling MR, Luders H (2001) ILAE commission report: proposal for a new classification of outcome with respect to epileptic seizures following epilepsy surgery. *Epilepsia* 42:282–286
- West S, Nolan SJ, Newton R (2016) Surgery for epilepsy: a systematic review of current evidence. *Epileptic Disord* 18:113–120
- Widjaja E, Raybaud C (2008) Advances in neuroimaging in patients with epilepsy. *Neurosurg Focus* 25(E3):1–11
- Yang PF, Zhang HJ, Pei JS, Tian J, Lin Q, Mei Z, Zhong ZH, Jia YZ, Chen ZQ, Zheng ZY (2014) Intracranial electroencephalography with subdural and/or depth electrodes in children with epilepsy: techniques, complications, and outcomes. *Epilepsy Res* 108:1662–1670
- Zupanc ML, dos Santos Rubio EJ, Werner RR, Schwabe MJ, Mueller WM, Lew SM, Marcuccilli CJ, O'Connor SE, Chico MS, Eggener KA, Hecox KE (2010) Epilepsy surgery outcomes: quality of life and seizure control. *Pediatr Neurol* 42:12–20

Herta Yu

---

## 14.1 Introduction

Functional disorders are rarely life-threatening, but have great impact on quality of life of patients and their families. Functional neurosurgery is a subspecialty of neurosurgery that provides surgical intervention for these disorders. The interventions and procedures performed are not directed toward saving lives or curing diseases but rather aim to improve the quality of life for patients suffering with these chronic and debilitating conditions. Functional neurosurgery procedures are mainly divided into two types: one directed toward epilepsy surgery which is discussed in Chap. 13 and the other intended for managing symptoms associated with movement disorders. This chapter focuses on the management of movement disorders, namely, spasticity and dystonia.

---

## 14.2 Spasticity

### 14.2.1 Pathophysiology

Spasticity is a disorder of motor function characterized by an increase in muscle tone and exagger-

ated deep tendon reflexes. Increased muscle tone makes performing simple activities of daily living very difficult and impacts the quality of life of the affected person (Thompson et al. 2005). Over recent decades, both clinical and laboratory research offer various theories to explain the mechanism of spasticity; yet the anatomy and pathophysiology are still not fully understood. The studies suggest that spasticity is complex, dynamic, and multifactorial. In general, spasticity is related to the function of two interconnected mechanisms: the supraspinal mechanism and the spinal mechanism, including the non-neural muscular system.

The supraspinal mechanism involves the cortical structures that mediate the impulses down the descending spinal pathways. An imbalance of excess excitatory impulses is propagated down the motor pathway and prevents muscle relaxation. Inhibitory impulses are controlled by the dorsal reticulospinal tract. Loss of function from this tract will leave excitatory impulses from the medial reticulospinal and vestibulospinal tracts unopposed, resulting in an increase in spasticity (Martins 2016; Danner and Dimitrijevic 2012; Priori et al. 2006; Mullarkey 2009).

The spinal mechanism includes the excitatory and inhibitory functions of motor neurons and interneurons and their effects on the muscular system. Spasticity is the result of a failure to inhibit a nerve impulse within the reflex arc (Fig. 14.1). There must be a reflex arc for muscle

---

H. Yu, RN, MN, CNN(C), NP-Paeds  
Department of Neurosurgery, Hospital for Sick  
Children, 555 University Ave., Toronto,  
ON M5G 1X8, Canada  
e-mail: [herta.yu@sickkids.ca](mailto:herta.yu@sickkids.ca)

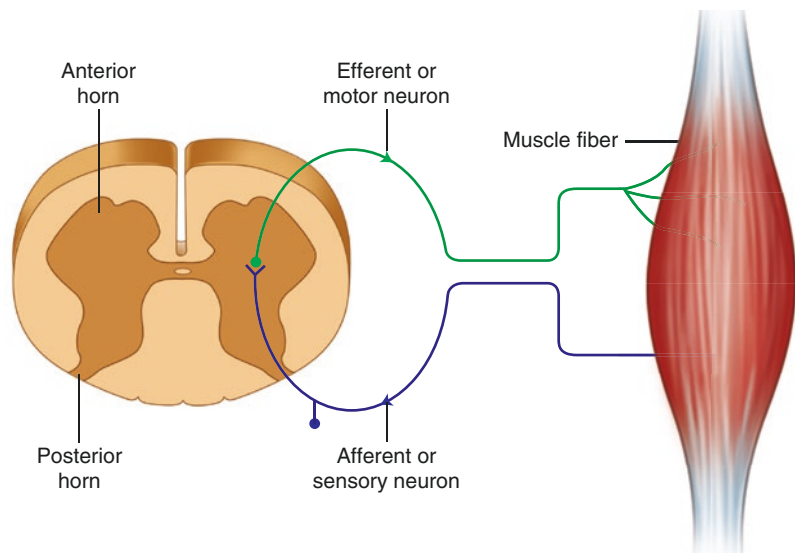
movement to occur. The reflex arc is the neural pathway that a nerve impulse follows and is thought to be the basic neural circuit that contributes to spasticity. It contains an afferent or sensory neuron, an efferent or motor neuron, and an effector muscle. The sensory neurons originate in the muscle spindles of the muscle. The afferent (or sensory) neurons are also located in the gray matter of the dorsal (or posterior) horn of the spinal cord and transmit impulses from the receptors to the central nervous system (CNS).

The efferent neurons have their cell bodies in the ventral (or anterior) horn of the spinal cord and carry impulses from the CNS to the effector muscle. An interneuron, which transmits the impulse from one neuron to another, may or may not be present depending on the location. Interneurons also rise from the dorsal horn of the spinal cord. Stimulation of the sensory neuron causes the flow of chemical transmitters across the synaptic space to depolarize the next neuron and continue the flow of the impulse to the muscle cell. The muscle cell sends a signal back to the sensory neuron that the action is completed, and inhibition occurs, creating relaxation. Spasticity occurs when there is an increase in activation of the reflex arc and lack of inhibition. This creates a loop which continues to stimulate the muscles fibers and may spread to other mus-

cle groups (Moss and Manwaring 1992; Satkunam 2003).

Spasticity presents as an involuntary, velocity-dependent increase in tonic stretch reflexes, meaning that a sudden rapid stretch would elicit greater resistance to movement than a slow steady sustained stretch (Sheean 2002). Spasticity also manifests other symptoms including increased muscle tone, exaggerated reflexes, flexor and extensor spasms, clonus, and decreased coordination. The initial neural insult causes muscle immobilization and limb paresis. This immobility shortens the muscle's spindles and increases the resistance of the muscle to passive stretch, resulting in joint and musculoskeletal deformity, contractures, and pain (Trompetto et al. 2014). In addition, many patients with spasticity experience fatigue, sleep disturbance, anxiety, depression, immobility, infections, and decreased cognitive development. Spasticity has devastating consequences affecting function, comfort, care delivery, and quality of life (Dietz 2000). Table 14.1 shows the clinical presentation of spasticity and the symptomatic and functional problems created.

Spasticity may have a cerebral or spinal origin, with damage located in the cerebral cortex, brainstem, or spinal cord levels. Cerebral causes of spasticity include cerebral palsy, intracranial hemorrhage, hydrocephalus, brain tumor, multi-



**Fig. 14.1** Reflex arc

**Table 14.1** Clinical presentation and complications of spasticity

Clinical presentation	Complications
Increased muscle tone, stiffness	Symptomatic problems:
Increased deep tendon reflexes	Fatigue, sleep disturbance
Persistent primitive reflexes	Stress
Contractures	Bone deformity
Clonus	Pain
Clasp-knife rigidity	
Decrease coordination, strength, and endurance	Functional problems:
	Daily personal care
	Difficulty with positioning and mobility
	Impaired ambulation
	Depression and anxiety
	Psychosocial deficits

ple sclerosis, stroke, or head injury. Spinal causes of spasticity include spinal injury, inflammatory disease, and nontraumatic conditions resulting in spinal compression (Vanek et al. 2010).

### 14.2.2 Assessment

Diagnosis and treatment of spasticity is highly dependent on the accurate assessment of the degree of spasticity and resultant effect on the affected limb or limbs. The effect of spasticity may not always have negative consequences. A degree of tone may be helpful in a weak or paretic limb to promote function by enabling standing, transfer, and even walking. Thorough assessment requires the use of standardized scales for both diagnostic and functional purposes (Rekand 2010).

The Ashworth scale or modified Ashworth scale is the most widely used scale to measure spasticity for diagnostic purposes for both children and adults. It measures the passive resistance of a joint subjectively from the examiner's viewpoint. The Ashworth scale is a five-level scale that ranges from "no increase in tone" to "limb rigid in flexion and extension." Another scale used for clinical diagnosis is the Tardieu scale which is also a subjective scale to measure passive resistance. The major criticism of these

**Table 14.2** Ashworth scale

Score	Description of spasticity level
1	No increase in tone
2	Mild increase in tone, giving a catch when affected limb is moved in flexion or extension
3	More marked increase in tone, but affected limb can be easily flexed
4	Considerable increase in tone; passive movements difficult with affected limb
5	Affected limbs are rigid in flexion or extension

scales is that they rely on subjective perception of the examiner. These scales also have limited utility to assess functional effects of spasticity on the patient (Rekand 2010; Yam and Leung 2006; Awaad et al. 2003). Table 14.2 outlines the Ashworth scale and the spasticity levels.

## 14.3 Dystonia

### 14.3.1 Pathophysiology

Dystonia is defined as a syndrome that presents with sustained or intermittent muscle contractions resulting in abnormal repetitive, twisting, patterned movements and abnormal postures. Dystonic movements or postures are initiated or aggravated by voluntary movement (DiFrancesco et al. 2012; Lubarr and Bressman 2010; Roubertie et al. 2000; Madhusudanan 1999; Albanese et al. 2013).

The etiology and pathophysiology of dystonia are not clearly understood. Research suggests that dystonia is a motor system disease rather than disease within a particular motor structure (Lubarr and Bressman 2010). Historically, dysfunction of the basal ganglia was believed to be the cause of the condition, since the basal ganglia is responsible for integration of motor control. However, dystonia had been presented in patients with normal brain structure, with lesions in other areas of the brain or in association with other neurodegenerative syndromes or diseases. Studies suggest that the abnormal twisting movements may be the result of co-contraction of agonist and antagonist muscles. Electromyography (EMG) studies show that



there are excessive and overlapping activities in the agonist and antagonist muscles that are not normally involved in a voluntary movement, resulting in prolonged and complex innervations of opposing muscles causing the involuntary dystonic movements and postures (Berardelli et al. 1998). Tempel and Perlmutter (1993) suggested that there may be a sensory feedback component in activation and suppression of dystonia. Vibrations of the dystonic regions can induce involuntary contractions to reproduce dystonic movements and posture. Sensory tricks, such as stroking or touching the affected body part, will reduce the contraction.

Dystonia may involve any body region or combinations of body regions, and the distribution may change over time and spread to previously unaffected regions (Albanese et al. 2013). The distribution of dystonia may be focal, affecting a single body part which often presents as cramps. Dystonia may also be segmental, involving two or more contiguous regions, or it may be generalized to one side of the body or the entire body (Albanese et al. 2013; DiFrancesco et al. 2012; Berardelli et al. 1998).

There are few methods proposed to classify dystonia; however, two classifications are commonly accepted at the present time, primary and secondary dystonia. Primary dystonia presents as the only clinical sign, whether there is a focal or generalized distribution. There is no evidence of an acquired lesion or trauma, and it is not associated with any neurological or metabolic disease or syndrome. (Albanese et al. 2013; Lubarr and Bressman 2010; Berardelli et al. 1998). A number of DYT gene abnormalities have been identified in relation to primary dystonia (Camargo et al. 2015).

Secondary dystonia occurs in association to another disease or is acquired via a lesion or trauma. There may be numerous other neurological symptoms such as spastic dystonia presenting in children with cerebral palsy. There may or may not be an identified gene associated with the condition (Lubarr and Bressman 2010; Albanese et al. 2013). Other methods to classify dystonia may be related to age of onset or associated condition. Table 14.3 outlines the proposed classification of dystonia.

**Table 14.3** Classification of dystonia

Primary dystonia	Secondary dystonia
Early onset	Dystonia – plus syndromes
Onset in childhood or adolescence	Inherited syndromes but no evidence of neurodegeneration
Mixed phenotype	Inherited disordered associated neurologic symptoms
Onset in adolescence or early adulthood	Autosomal dominant disorders (i.e., Hunting’s disease)
Starts in one body region and spreads	Autosomal recessive disorders (e.g. juvenile Parkinsonism, Wilson’s, etc.)
	X-linked syndromes
	Mitochondrial (i.e., lactic acidosis)
Late onset – adult	Acquired conditions and disorders
Usually focal or segmental distribution	Perinatal cerebral injury (i.e., CP)
Unlikely to spread	Infections, encephalitis, MS
	Stroke, tumor, CNS injury
	Associated movement disorders
	Parkinson’s disease, multisystem atrophy
	Progressive; supranuclear palsy
	Paroxysmal dyskinesia disorder

Adapted from Lubarr and Bressman (2010)

Secondary dystonia may also be caused by preventable conditions related to dietary, metabolic, or chemical imbalances. For example, kernicterus is a condition caused by bilirubin toxicity in newborn babies. The developing brain is vulnerable to exposure to moderate – high levels of bilirubin over time. This exposure results in damage to specific structures including the basal ganglia and cerebellum, thus causing neurological deficits and movement disorders such as dystonia (Ross and Vasser 2015; Okumura et al. 2009). Kernicterus is preventable with careful monitoring and management of hyperbilirubinemia in the neonate.

### 14.3.2 Assessment and Diagnosis

The presentation of dystonia interferes with performance of general activities of daily living and

may cause great pain and discomfort. Dystonia may be present alone or be the clinical manifestation of many associated neurological, metabolic, or acquired conditions. The treatment of dystonia is guided by a thorough history and careful assessment of both clinical and functional effects that include the topography of dystonia, severity of abnormal movements, functional impairments, and progression of disease (Roubertie et al. 2000). Screening tests, laboratory assessments, and diagnostic imaging are needed to distinguish associated diseases and rule out treatable conditions. A number of medications may induce dystonia such as various dopamine antagonists, antiepileptic agents, antihistamines, tricyclic antidepressants, adrenergic agents, monoamine oxidase inhibitors (MAOIs), and caffeine. Therefore, correcting or treating the underlying cause or condition may eliminate the dystonia (Albanese et al. 2006; Geyer and Bressman 2006).

The use of a standardized scale to rate and measure the degree of dystonia is helpful to determine the most appropriate treatment strategies and also to evaluate the effectiveness of treatment modalities. Several scales are used to measure dystonia. The most commonly used scale for primary dystonia is the Burke-Fahn-Marsden (B-F-M) rating scale, and the Barry-Albright Dystonia (BAD) scale is the most popular for secondary dystonia (Comella et al. 2003; Barry and Van Swearingen 1999). Each scale identifies body parts and an ordinal scale is used to rate the severity of the dystonia of individual patients. The scores measure dystonia of individual body parts and the overall total. The scores provide a standard to design treatment plans and offer comparisons to assess the effectiveness of such treatments.

---

## 14.4 Treatment Modalities

A multidisciplinary approach is required to manage either spasticity, dystonia, or both. Decisions are made with input from a diverse team that includes the patient, family, and members of the health-care team including medical provider, nurses, social worker, and rehabilitative team.

The focus of care is on the needs of the patient. The primary goal of treatment for both spasticity and dystonia is to improve the quality of life for the patient and his/her family. Treatment plans will differ according to the underlying condition, severity of the disorder, and the debilitating effect of the symptoms. The objective of treatment may be directed to increase function and mobility, prevent further detrimental effects, prevent complications caused by the disease, promote comfort, and/or facilitate ease of care (Goldstein 2001; DiFrancesco et al. 2012; Yu and Neimat 2008).

There are various therapeutic treatment modalities focused on the management of spasticity or dystonia or both. There is no one single treatment that is appropriate for all patients. Some patients may require a succession of various treatments as they age or as the disorder progresses. Selection of the treatment modality or combinations of modalities should focus on what is most appropriate for each individual patient. All parties involved need to have a clear and uniform understanding of the objectives and expectations of the treatment (Steinbok 2006; Adams and Hicks 2010).

The literature suggests that treatment and management procedure should be the least invasive to meet the patient's goals (Lubarr and Bressman 2010; Steinbok 2006). Treatment strategies include rehabilitative therapies, pharmacological treatments, denervation and neuromodulation, and invasive surgical procedures (Trompetto et al. 2014; Mullarkey 2009; Roubertie et al. 2000; Yu and Neimat 2008; Tabbal 2015).

### 14.4.1 Conservative Therapies

Rehabilitative services and pharmaceuticals are conservative therapies that are effective in management of spasticity and dystonia in the early and mild stages of disease. Rehabilitation with physiotherapy and occupational therapy are also important in combination with more invasive procedures to manage movement disorders. Pharmacotherapy is helpful for selected patients and easy to administer. However, both therapies lose effectiveness as the conditions progress, and

increasing medication doses pose dangerous adverse effects that are hard to control making it necessary for more invasive therapies (Goldstein 2001).

#### 14.4.2 Botulinum A Toxin

The use of botulinum A toxin (Botox) to treat focal spasticity and focal or segmental dystonia has been gaining favor over the past 10–15 years. Botox is a mildly invasive, non-neurosurgical, and temporary treatment for moderate movement disorder. Botox is injected directly into the targeted muscle and causes temporary paralysis of the muscle. It acts by inhibiting acetylcholine release at the neuromuscular junction and affects the muscle spindles and afferent nerve fibers (Koman et al. 2003; Ward et al. 2006; Wong 2003; Guettard et al. 2009).

The effects of Botox are temporary, with effects initiated within 1–2 weeks after the injection and peaking at about 4–6 weeks. The effects last about 4–6 months but are very individualized to the specific patient. The dosing of Botox is calculated by the patient's weight. There is a mild risk for development of resistance to the toxin that is dependent on the interval and total dose administered. Administrations of doses higher than recommended may cause dysphagia, decreased gastrointestinal motility, and respiratory muscle compromise (Tabbal 2015).

#### 14.4.3 Intrathecal Baclofen

Baclofen is recognized as a medication that is effective in reducing the tone and symptoms of spasticity. It is structurally similar to gamma-aminobutyric acid (GABA) which is the primary inhibitory neurotransmitter in the CNS that promotes relaxation. Baclofen is a GABA agonist and binds to presynaptic GABA receptors to restrict calcium influx at the presynaptic terminal, thereby inhibiting the release of excitatory neurotransmitters across the synaptic junction at the level of the spinal cord to decrease muscle tone (Albright 2003).

Baclofen can be administered both orally and intrathecally via an implanted pump. The primary goals for treatment with baclofen are to decrease muscle tone and improve the functional status of the patient. With dystonia, baclofen helps with relaxation and improves the pain sensation associated with the abnormal movements and postures (Tabbal 2015).

Major adverse effects of baclofen administered orally or intrathecally include sedation, somnolence, seizure activity, muscle weakness, orthostatic hypotension, dizziness, headaches, and ataxia. However, withdrawal of baclofen is the most serious concern related to treatment. Baclofen withdrawal may result in rebound severe spasticity, rigidity, tachycardia, hypotension, hyperthermia, and/or seizures. Thus, it is important that the medication be given at the appropriate dose, at regular intervals, and continuously without abrupt interruptions.

When baclofen is administered orally, the drug is rapidly absorbed and partially metabolized in the liver and then excreted in the kidneys. The half-life is about 3.5 h. Oral baclofen does not readily cross the blood-brain barrier and requires large doses to reach therapeutic concentrations in the cerebrospinal fluid (CSF) at the desired spinal levels.

Intrathecal baclofen (ITB) was first approved in the United States for use to treat spasticity of spinal origin in 1992 and subsequently to treat spasticity of cerebral origin in 1996 (Albright and Ferson 2006). ITB infuses directly into the CSF at the targeted spinal level at high concentrations, although the dose is only a fraction of the oral dose necessary to achieve the same therapeutic effects (Albright and Ferson 2006; Rizzo et al. 2004). Clearance of ITB is via caudal-cephalic bulk flow similar to the flow of CSF in the spine at about 30 ml/h. The drug concentration in the cerebral or brainstem levels is only about one quarter of the concentration found in the lumbar spine region following ITB administration. The risks of dose-related adverse effects and overdose are greatly minimized (Bergenheim et al. 2003; Fitzgerald et al. 2004; Vitzum and Olney 2000). Table 14.4 shows the characteristics of oral baclofen contrasted to intrathecal baclofen.

**Table 14.4** Overview of baclofen

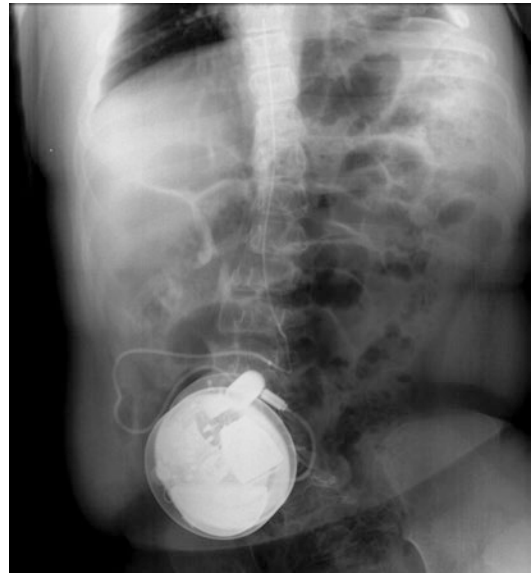
Oral baclofen	Intrathecal baclofen
Lipophilic	Delivered directly into the spinal subarachnoid, intrathecal space
Rapidly absorbed and partially metabolize in liver	No systemic effect
Excreted by kidneys	Diffuses within the spinal canal
Barely passes the blood-brain barrier	Low cerebral concentration; low cerebral effect
Low concentrations in spinal cord and CSF	
Large doses to achieve effect	Only fractions or oral dose to achieve similar or better effect
Withdrawal occurs with symptoms relieved once medications reestablished	Withdrawal symptoms are more severe and may become life-threatening if left untreated for greater than 24–48 h

Withdrawal symptoms are more severe and much more problematic with ITB as compared to oral administration. In addition, abrupt disruption of baclofen administration may result in rhabdomyolysis with elevated plasma creatinine kinase level, renal and hepatic failure, disseminated intravascular coagulation, and sometimes death, if therapy is not restarted promptly. This condition is also known as neuroleptic malignant syndrome and can be life-threatening (Douglas et al. 2005; Mohammed and Hussain 2004).

The literature highly supports ITB for the management of spasticity in both cerebral and spinal origin. Recent longitudinal studies support both efficacy and safety in the continuous use of ITB for children with spasticity or other movement disorders caused by various underlying conditions including cerebral palsy, stroke, multiple sclerosis, myelomeningocele, and head or spinal injury (Bergenheim et al. 2003; Krach et al. 2009; Morton et al. 2011; Ramstad et al. 2010; Ward et al. 2009).

#### 14.4.3.1 Intrathecal Baclofen Pump System

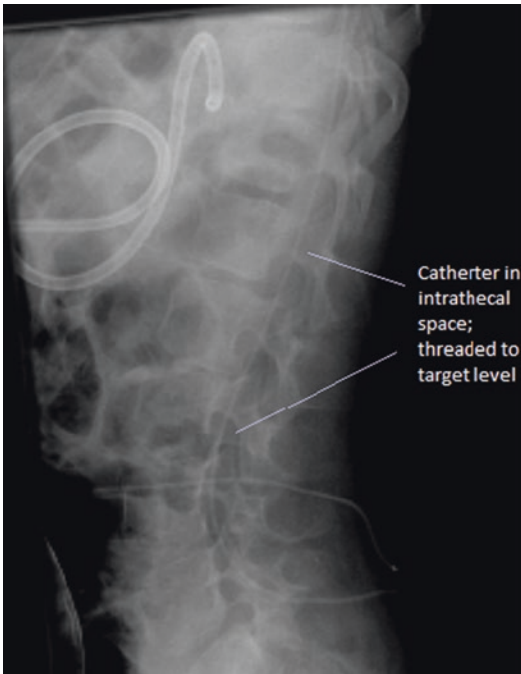
ITB therapy is administered via an implantable pump system. The implantable pump is inserted



**Fig. 14.2** Pump implanted in the abdomen. The pump is implanted into the subcutaneous tissue in the abdomen. The catheter is connected to the exit port and threaded around to the back and inserted in the intrathecal space in the lumbospine (Courtesy of Dr. Drake)

into the subcutaneous tissue of the abdominal wall. A catheter is connected to the exit port, then tunneled around to the back through the subcutaneous tissue, and inserted into the intrathecal space at the level of the lumbar spine. Once the catheter is in the intrathecal space, its tip is threaded up to the appropriate targeted spinal level predetermined by the neurosurgeon, usually within the upper thoracic levels. In the management of dystonia, the targeted spinal level is higher and may reach the cervical levels (Pin et al. 2011). Figures 14.2 and 14.3 illustrate the location of pump implantation and catheter placement.


The ITB pump is a circular device that contains a reservoir to hold the medication and has both an injection port for instillation of the medication and a catheter access port (Fig. 14.4). Contrast may be injected through this access port to radiographically assess pump function and catheter integrity when complications are suspected. The pump is powered by a battery that lasts about 5–7 years. When the battery runs low, the pump would need to be replaced. An external



**Fig. 14.3** Catheter threaded into the spine. Catheter is threaded from the catheter exit site of the pump and runs across the abdomen to the spine lumbar site where it enters the intrathecal space and threaded upward to the appropriate predetermined thoracic or cervical levels. The targeted levels are higher for treating dystonia and lower for spasticity alone (Courtesy of Dr. Drake)

handheld programmer (Fig. 14.5) that includes a computer, printer, and programming head is used to interrogate the pump or to program the pump to deliver desired prescribed doses of medication to meet the needs of the patient. The pump has programmable audible alarms that alerts when the reservoir is low and needs refilling and when the end of battery life is approaching.

Regular refills of ITB are required to ensure continuous supply of medication and should be scheduled 1–2 weeks prior to the low reservoir alarm. It is important to know the maximum capacity of the pump reservoir in order to facilitate appropriate refill schedules. There are two different-sized pumps which have the capacity of 20 ml or 40 ml. Care and adherence to sterile procedures are necessary during pump refill as there has been report of pump infections related to repeat refills (Dario and Tomei 2004; Dario et al. 2005; Vender et al. 2005).



**Fig. 14.4** Photograph of Medtronic SynchroMed II pump (Photo courtesy of Medtronic, Inc.)



**Fig. 14.5** Photograph of Medtronic SynchroMed II handheld programmer (Photo courtesy of Medtronic, Inc.)

#### 14.4.3.2 Patient Selection

ITB therapy is indicated for those patients with medically intractable spasticity or dystonia.



Patients suffering from unacceptable adverse effects from doses of oral antispasmodics may also be considered for ITB (Dario and Tomei 2004). A severity level of three on the Ashworth scale or moderate dystonia is sufficient to consider ITB therapy. A baseline functional assessment and determination of level of spasticity and dystonia is helpful to compare effectiveness of treatment. Continuous education is provided to ensure that clear and uniform functional goals are discussed and established early to ensure success of treatment. The family needs to understand the probable complications if the patient does not get refills as scheduled, as well as how to recognize the signs of pump malfunction. The patient and family must accept the responsibility for continued repeat medication refills and assessment.

#### 14.4.3.3 Trial Dosing

Selected patients need to undergo a screening process or trial dosing to ensure they will respond positively to ITB prior to surgically implanting the pump. Traditionally, the child will be admitted into hospital for surgical insertion of a temporary lumbar drain and receive three consecutive increasing doses of ITB over 2–3 days. The test doses are usually 50, 75, and 100 mcg. The effects peak at about 4 hours and the patient is assessed for any signs of improved spasticity or dystonia in response to the medication (Vitzum and Olney 2000). During this time, the child will be on bed rest which poses potential risks including leakage of CSF from the lumbar drain site, respiratory compromise related to bed rest, infection, and repeated admission for implantation.

The more recent approach to testing is a same-day admission where the patient receives a single ITB dose of 50–100 mcg via lumbar puncture. If there is a response, the patient is discharged to evaluate and prepare for pump implantation. This latter testing method is the current desired method for experienced practitioners as it minimizes potential risks posed by the traditional method. In addition, the test dose does not determine the eventual dosing for treatment but only that the patient shows a response (Keenan 2010).

#### 14.4.3.4 Complications of ITB Therapy

There are many complications associated with intrathecal administered baclofen. Similar to CSF shunts, ITB delivery systems are foreign devices with connecting parts and, therefore, pose inherent risks for complications. These complications can be classified into three categories: skin or wound related, catheter related, and pump related. Infection is a persistent risk and may be associated with all categories.

Skin- or wound-related complications are associated with the physical and overall health of the child. Many children with cerebral palsy or other movement disorders are malnourished, suffer physical deformities, and are immobilized or bedridden. These factors compromise skin integrity and predispose them to poor healing and wound complications. In many cases, a seroma (fluid or edema) develops around the pump pocket in response to inflammation after surgery. The seroma may become excessive and cause related problems such as skin breakdown, dehiscence of the incision, CSF leakage, and superficial or deep wound infection. Careful wound closure and minimizing the space of the pump pocket during surgery may decrease the risk of seroma formation. Pocket effusions can occur at a later date resulting in CSF tracking along the catheter to the abdominal pocket (Vender et al. 2005). Sometimes, wearing an abdominal binder for a short period of time helps prevent this risk. Skin breakdown or erosion of the skin around the pump can result from stretching and continuous compression of the skin by the implanted pump (Boviatsis et al. 2004; Atiyeh et al. 2006).

Catheter-related complications are by far the most frequent problems with baclofen pumps. These complications include catheter breakages, microfracture, puncture, kinking, migration from the intended spinal level, or disconnections, either at the port or connection sites (Dawes et al. 2003; Follett et al. 2003; Ridley and Rawlins 2006). These complications cause disruption of ITB flow to the patient. The patients usually presents in the emergency room with increased spasticity, decreased level of consciousness, pain, and

other symptoms indicative of ITB withdrawal. X-rays can assess the placement of catheter and any disconnections or kinks within the catheter system. If no disconnections or possible kinking is noticed, then the integrity of the catheter should be investigated further by injecting contrast in the catheter access port to identify breakage or microfractures.

Pump-related complications are few but may be serious. There are reports of cases where the pump flips over in the abdominal cavity (Gooch, et al. 2003). The phenomenon is associated with the development of seromas creating a space for the pump to move from its implanted space. Other pump-related complications are linked to the electronic mechanism of the pump itself, resulting in pump failure and under- or over-delivery of the medication. Any confirmed catheter or pump complications necessitate surgical intervention to repair, reinsert, and reestablish appropriate medication infusion.

#### 14.4.3.5 Infection

The most serious complication associated with ITB therapy is infection. Infection can originate from the pump, the catheter, or the wound bed (Fitzgerald et al. 2004). Possible causes of pump infection can be attributed to the surgical procedure, contamination of the pump apparatus at the time of surgery, and poor sterile technique when accessing the port for medication refill. Untreated, or poorly treated surgical wound site infections may eventually contaminate the pump and catheter.

Pump infections pose the greatest threat to patients, as they may potentially lead to a series of adverse consequences. Bacteria invading the wound and pump may spread along the catheter and enter the spinal canal causing CSF infection or meningitis. Treatment of pump infections involves a process that needs to be initiated promptly to avoid such consequences. If pump infections occur, ITB must be weaned rapidly but safely and the pump should be removed. The patient should receive an effective course of intravenous antibiotics to sterilize the pump pocket (Botiatsis et al. 2004).

#### 14.4.3.6 Management of Abrupt ITB Cessation

Baclofen cannot be stopped abruptly, because life-threatening withdrawal symptoms will develop. Withdrawal symptoms are greatly exaggerated with ITB treatment. Rebound spasticity is the earliest symptom and can induce excess pain and discomfort for the patient. When cessation of treatment or weaning of the medication is required in order to remove the infected pump, oral baclofen and other antispasmodic agents such as benzodiazepines must be started immediately at substantial doses to prevent withdrawal symptoms (Watve et al. 2012). Weaning of ITB is recommended at 10–15 % decrease of the standing dose every 1–2 days to the lowest dose allowable by the pump. At this minimal dose, it is considered turned off. Some pumps, depending on the manufacturer, cannot be turned completely off by the handheld device. A special code needs to be obtained from the manufacturer and entered via the handheld device in order to turn off the pump. Once the pump is turned off, it cannot be turned on again. Increasing oral baclofen should precede subsequent ITB dose decreases. This process may result in very high final doses of oral baclofen above the regular dosing limit. In extreme case, intravenous benzodiazepines may be necessary to prevent withdrawal (Watve et al. 2012; Haranhalli et al. 2010).

In a case at the Hospital for Sick Children in Toronto, the pump had protruded through the abdominal pocket due to the inflammation process during infection of a 10-year-old boy. The pump was removed immediately upon presentation. The spinal catheter at the lumbar exit site was connected to an external peripheral intravenous catheter and ITB was administered intrathecally via external continuous infusion and weaned. This was the first and only case at this hospital for external intrathecal ITB administration for weaning to prevent life-threatening withdrawal symptoms in relation to the abrupt removal of the pump. The clinical pharmacist provided guidance to ensure safe dilution of the ITB and calculations for infusion rates during the weaning process. The patient was initially on very high daily dose of ITB. The period for wean-

ing was about 10 days and the remainder of the spinal intrathecal catheter was removed when the patient was completely weaned off ITB. Luckily there was no progression of infection to the CSF or brain. The resultant oral baclofen dose was 35 mg given four times daily for a daily total of 140 mg, well over the recommended daily oral dose for adults. The spasticity level of the patient returned to baseline as compared to the patient's status prior to pump insertion, and at that time the patient's oral dose was only 10 mg three times daily. (Permission to illustrate this case is given by the patient's guardians.)

#### 14.4.3.7 Nursing Considerations

Nurses play an important role in the care of patients with spasticity treated with baclofen pump. Nurses are in a unique position to coordinate necessary resources and communicate with members of the multidisciplinary team. Nurses are able to provide appropriate education to patients and their families to help them understand test procedures, as well as the potential benefits and complications. Nurses can help patients and families identify their goals for treatment and evaluate if ITB is the appropriate therapy.

Nurses should perform a thorough assessment of the patient's physical condition, nutritional status, clinical presentation, and family readiness, all of which can help minimize the risk for potential complications. Children with spasticity tend to have poor nutritional intake as a result of their underlying disease. Compounding poor intake, these children are in nutritional catabolic states, burning calories at greater rates than intake (Stallings et al. 1995). The resulting picture presents undernourished children with low body weights, disturbed immune systems, and poor skin integrity. All these conditions predispose the children to infection and seroma development. Therefore, coordinating a team of dietician/nutritionist, physical therapists, occupational therapists, and social worker can help optimize the physical condition of the patients and address any health problems.

After pump implantation, the priority of care is focused on prevention of both surgical and

pump-specific complications. The Centers for Disease Control (1999) recommends a 24-h course of prophylactic antibiotics postoperatively.

The contractures and physical deformity associated with spastic disease predispose patients to develop postoperative complications associated with surgery such as atelectasis, aspiration pneumonia, ileus, and hemodynamic and electrolyte imbalances. Nursing care should encourage mobility, hygiene, and nutrition to facilitate healing. Meticulous skin care that includes frequent turning and repositioning, along with provision of adequate nutrition and comfort measures, is an essential postoperative nursing intervention.

A child with a baclofen pump requires dedication and commitment on the part of the patient and family. It is important that the family keep regularly scheduled follow-up appointments with the entire health-care team (Motta et al. 2007; Plassat et al. 2004).

Maintenance of ITB therapy should follow a systematic approach and a multidisciplinary team perspective. The patient requires continuous care from a trained primary practitioner or expert physiatrist to assess, monitor, and titrate the medication dosing according to the patient's changing needs. The neurosurgeon not only inserts the pump but is also required to follow up on possible complications and ensure pump function. Of course, the most important partner will be the caregiver(s) who will assume responsibility to care for the patient and ensure the patient continues with follow-up appointments for assessment, monitoring, and refills (Thompson et al. 2005).

When considering ITB therapy, the family must be aware and understand the time commitment and the persistent financial cost of maintenance of therapy, as well as the unexpected emergency costs should complications arise. Though most insurance companies in the United States cover the cost of care surrounding the insertion of the ITB pump and maintenance of treatment, in some countries or regions, the insurance may not cover this cost, especially those countries with government-regulated universal health-care coverage. For example, in Canada only certain provinces such as Ontario and British

Columbia provide coverage of the operation and pump apparatus in limited pediatric cases for compassionate reasons.

The decision for ITB therapy must consider the family's emotional, physical, and financial commitment, as well as considerations of the patient-focused goals of therapy. It is not an easy decision and the family requires continued support and encouragement especially when dealing with potential complications. The following case illustrates the family's emotional toll and ambiguity with ITB treatment. (Permission is given by the patient's mother to use the case and his actual name in the following passage.)

Owen was a premature baby born around 32 weeks of gestation. He was diagnosed with hydrops fetalis at about 28 weeks. There was an abnormal accumulation of fluid in his fetal chest and abdominal cavities. Owen was delivered cyanotic and unresponsive. He was resuscitated and had a long and complex stay in the neonatal intensive care unit. As a result, the sequence of events had left him severely physically impaired with little or no mobility. Not only did he develop severe spasticity but also severe dystonia.

The spasticity and dystonia made it extremely difficult for Owen to sit in his wheelchair and required a custom-fitted seating system. He was unable to swallow properly and required a gastric tube for nutrition. As his tone increased, he would sometimes break off pieces from his wheelchair, but the worse was the disturbance of sleep. Mom described the endless nights she spent cuddling and rocking him to sleep. Owen eventually had a baclofen pump implanted to help his hypertonia as he was on extremely high doses of oral baclofen.

Owen's mother had hopes for the treatment with intrathecal baclofen, even though she was not exactly sure that the decision was in Owen's best interest.

Bending him at the hips and cradling him like a baby would relieve the overall, full-body thrusting. Effective yes, but a lot of work. Owen's dystonia and spasticity would continue in his sleep. Movement and tightness would prevent him from falling asleep or would wake him in the night. Baclofen [oral] helped to make him very sleepy, but it suppressed his breathing/coughing response,

so his medication dosing required careful monitoring and ongoing assessment.

Our hope was that the baclofen pump would administer the medication efficiently with acceptably few side effects, helping calm Owen's body for better sleeping, ease of positioning and improved function ... Owen's body was so small that the baclofen pump stuck out like an appendage. The outline of the hockey puck-sized device could be seen and felt through the skin, nestled snugly in the space between his right hipbone and lower ribs. If you put your ear to it, you could hear it ticking.

I would never have admitted to regretting putting it in. Indeed, I had pushed for it, thought it a good preventive measure. And it did help; Owen was softer, looser, he slept more. Actually, slept much more ... Still, I was deeply conflicted. There were many reasons: the permanence of the device; the invasiveness of the surgery; the ugly scars and unpleasant post-op infection.

I had gotten what I wanted – he was easier to manage. And I was sorry. I felt my regret most keenly on those occasions that we returned home from the clinic after having had the amount of medication adjusted. The regret followed me around day and night. I transmitted my regret to Owen every night while he slept.

I like to imagine that he knew this, and forgave me. [written by mom, excerpt from book she wrote about Owen]

#### 14.4.4 Selective Dorsal Rhizotomy

Selective dorsal rhizotomy (SDR) is a neurosurgical procedure performed mainly to relieve spasticity in the lower extremities of children with cerebral palsy. The surgery is targeted at the lower lumbar levels, ideally from L2 to S1 (Grunt et al. 2011; Steinbok et al. 2009). SDR has a very limited role in treatment of dystonia. It may be indicated for extreme cases of spastic dystonia where only a few muscle groups are involved (Yu and Neimat 2008). SDR incompletely severs the posterior or sensory lumbosacral rootlets and reduces the excitatory impulses to the spinal cord from the lower extremities. At present, rhizotomy is the only treatment that provides permanent reduction in spasticity quickly and effectively (Hesselgard et al. 2005).

The idea of rhizotomy was first suggested in 1888 by a New York neurologist named Dr. Charles Dana in a letter to Dr. Robert Abbe to

treat “violent neuralgic pains.” This idea was put into action by Dr. Abbe on a select few patients. He found that, indeed, cutting nerves relieved spasticity and the accompanying pain, but also resulted in loss of needed sensation and function (Moss and Manwaring 1992; Hays et al. 1997). In 1908, Foerster, a German neurologist, used rhizotomy to treat spasticity in cerebral palsy by sectioning the posterior lumbar nerve roots. However, this procedure resulted in less than favorable outcomes. The procedure was later revised in the late 1970s by Fasano and his colleagues in Italy, to develop a technique that separated the dorsal root into individual nerve fibers called fascicles or rootlets. By using electrical stimulation, he cut selected fascicles, relieving the most severe spastic symptoms without losing the desirable sensory function. This procedure was further modified by Peacock and his colleagues in 1987 to include multilevel laminectomy to provide better visualization of the rootlets (Hesselgard et al. 2005; Ou et al. 2010; Steinbok et al. 2009).

#### 14.4.4.1 Patient Selection

Currently, patients are carefully evaluated and selected for SDR. Ideal candidates are usually children that have walked, have the potential to attain ambulation with rhizotomy, have spasticity that interferes with functions such as sitting, or have hip dislocations caused by spasticity (Abbott 1999). Review of patient records and a physical examination is done by a team consisting of a neurologist, physical and occupational therapists, orthopedist, developmental specialist, and a pediatric neurosurgeon. Patients are screened based on their muscle strength and contractures as well as their ability to cooperate with therapists. Although previous orthopedic procedures may not exclude the child from selection, they will need to have more extensive testing to qualify. Selected candidates for SDR should be motivated to work with their therapist post surgery as therapy is a major component for success with SDR. Patients who have dystonia in conjunction with spasticity, truncal ataxia, and contracture are contraindicated for SDR (Goldstein 2001).

Patients are usually between the ages of 4 and 9 years, as they have been found to have the best response. Children younger than 4 years generally are not able to cooperate fully with physical therapy, nor do they have the developed muscle strength to get the full benefit of the surgery. MacWilliams et al. (2011) compared functional outcomes in children chosen for surgery that were older than 10 years of age to younger cohorts and also compared age-matched cohorts who were undergoing orthopedic procedures and nonsurgical procedures. The results demonstrated that children who underwent orthopedic procedures had greater gait improvements and children over 10 years with SDR had a decline in function. Although selection for SDR may include other factors, age and desired outcomes should be carefully considered.

#### 14.4.4.2 Procedure

A rhizotomy is performed to relieve spasticity in the areas where the reflex arcs are the most pathological. The patient is taken to the operating room and given a short-acting muscle relaxant for intubation and to allow the neurosurgeon to access the area. The paralysis from the muscle relaxant is then reversed to permit electric stimulation and recording. The patient continues under anesthesia and may also be given a narcotic to relieve the pain of the electric stimulation. Electrical stimulation and recording are done to identify the specific root level and differentiate between motor and sensory nerve bundles as they exit the foramen. The sensory bundles are separated into rootlets. Then the rootlets are gently separated and stimulated to test the effect on various muscles to find the ones responsible for the spasticity. The rootlets that stimulate an abnormal reflex arc to the muscles and cause tetany are cut (Cheek 1996).

#### 14.4.4.3 Outcomes

Long-term results from rhizotomy are as varied as the patients themselves. Approximately 80 % of rhizotomy patients have some improvement in spasticity. Some children require further surgeries to correct shortened tendons or hip dislocations. Longitudinal studies identify sustained



improvements in spasticity over 5–10 years following SDR, but it is unclear whether this sustained improvement is purely the result of SDR or is it a combination of therapy and other treatments. Outcomes of SDR in regard to the neurologic changes are very specific. The effects are mostly consistent with dysfunction in the spinal reflex arc and not the supraspinal reflexes. The changes include decreased deep tendon reflexes, clonus, and the velocity-dependent hypertonia thereby improving gait function and possible ambulation.

All children who undergo SDR need rigorous physiotherapy. Some patients may later also require Botox injections (Tedroff et al. 2011; Grunt et al. 2011). Further work on measuring the effectiveness of SDR targeting the improvements of spasticity and functional outcomes is required.

#### 14.4.4.4 Nursing Considerations

Postoperatively, pain control is a vital part of nursing considerations. Aside from the incisional pain and soft tissue pain from the laminectomy, there may be dysesthesia of the lower extremities resulting from manipulation of the nerve rootlets (Hesselgard et al. 2005). The patient may feel a burning sensation in the back and legs from the severed nerves. It is exacerbated with movement or any change in sensations, such as hot or cold, or movement of clothing or linens. Once the burning pain subsides, there may be a change in sensations such as feelings of “pins and needles” or a patchy numbness to the legs and/or feet. This change in sensation may resolve or may be permanent (Abbott 1999; Institute for Neurology and Neurosurgery 2004).

There are several interventions for managing postoperative pain: continuous intravenous or intrathecal infusion of opioids and epidural morphine or fentanyl. Scheduled oral analgesic can be an adjunct to the aforementioned methods. The goal is to provide steady maximum pain control to achieve comfort while limiting side effects (Hesselgard et al. 2005). The patient should be monitored for undesirable side effects during pain management, such as respiratory depression, excessive sedative, excessive nausea and

vomiting, itchiness, and muscle spasms. Valium may be used to control muscle spasms.

Postoperatively, the patient is positioned on either side or prone for the first 1–2 days. The patient often wants to curl up in a fetal position after surgery, which is highly contraindicated for recovery. The application of knee splints may help this situation and hold the legs in a natural extended position. The children usually have an indwelling catheter inserted or are diapered since they are on strict bed rest. Physical therapy is started on the third postoperative day and will continue after discharge.

Complications from SDR include general postsurgical risks in regard to the incision, CSF leak, and urinary tract infection. Bowel maintenance and hygiene is important. Stool softeners can prevent constipation caused by opioids and immobility. Closely monitor patients for urinary retention. Patients with a history of asthma or recent respiratory infection should be monitored closely for respiratory complications. The bed-rest protocol and positioning may increase the risk of aspiration and pneumonia.

#### 14.4.5 Deep Brain Stimulation

The concept of deep brain stimulation (DBS) is to deliver an electrical current to targeted regions of the brain by placement of implanted electrodes. DBS was adapted from traditional ablation surgeries, such as pallidotomy and thalamotomy, which create permanent lesions in the deep structures of the brain to relief movement disorders (Yu and Neimat 2008; Keen et al. 2014). It was during these permanent destructive surgeries that suppression of abnormal movements was noted when high frequency stimulation for localization purposes was applied to the targeted structures. This prompted the idea of deep brain stimulation (Vercueil et al. 2002). While DBS mimics the effect of the traditional ablation surgeries, the effects are reversible and flexible giving it added safety for pediatric use. The stimulation may be titrated during the child’s development and preserves the functional anatomy for future treatments when necessary

(DeFrancesco et al. 2012). Currently DBS is highly recommended for children with dystonia. Future implications for the use of DBS include epilepsy, psychiatric conditions, pain management, and even management of obesity (DiFrancesco et al. 2012; Awan et al. 2009; Lipsman et al. 2010).

#### 14.4.5.1 Patient Selection

DBS has made great advances over the past two decades for treatment of movement disorders in adults and pediatric populations. The literature supports the efficacy and durability of DBS in management of various types of movement disorders. In the pediatric population, it is most commonly used for treatment of dystonia. Much success has been reported for DBS used for effective treatment of primary dystonia with the target of stimulation in the globus pallidus internus (GPI). The effectiveness of treatment for secondary dystonia remains variable in relation to the heterogeneous symptoms and associated causes of disease (Keen et al. 2014; DiFrancesco et al. 2012; Lipsman et al. 2010; Yu and Neimat 2008). DBS is recommended for children with primary dystonia who have failed medical management or those patients whose medical treatment is no longer effective. A second group recommended for DBS are those with secondary dystonia related to spastic dystonia symptoms caused by cerebral palsy (Awan et al. 2009; Keen et al. 2014; Lipsman et al. 2010; Lubarr and Bressman 2010).

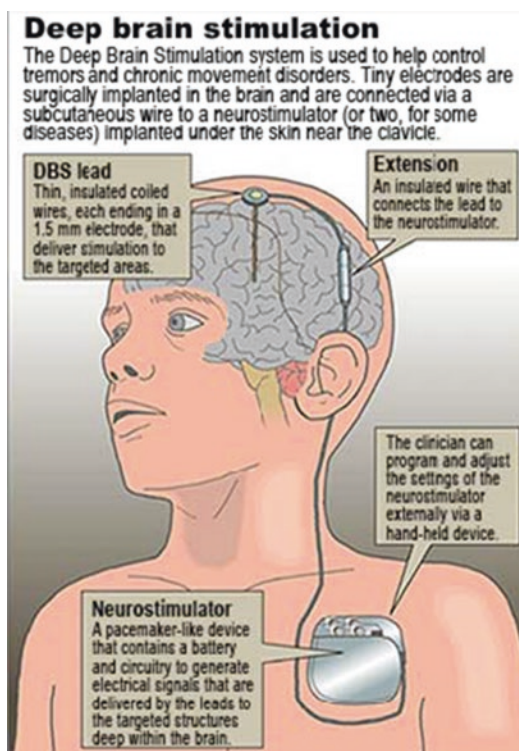
#### 14.4.5.2 Surgical Procedure

The DBS system includes electrode leads that are implanted into the brain, with wires connecting to a programmable pulse generator that is implanted under the skin in the chest region close to the clavicle. The pulse generator may be programmed by a handheld programming device to deliver the impulse of a desired frequency. Figures 14.6 and 14.7 show the DBS and the location of implantation.

Implantation of the DBS system involves three basic steps: (1) identification of the target site, (2) localization and physiologic confirmation (via specialized MRI location programs such

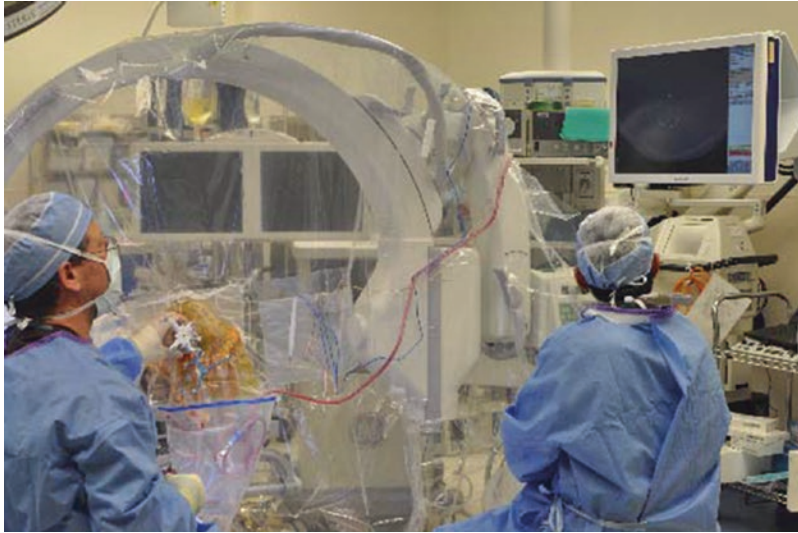


**Fig. 14.6** Deep brain stimulator (Photo courtesy of Medtronic, Inc.)



**Fig. 14.7** Deep brain stimulation: implantation (Picture courtesy of Medtronic, Inc.)

as “stealth”) of the target, and (3) implantation of the DBS leads and connection to the programmable internal pulse generator (Yu and Neimat 2008). Efficacy of DBS depends largely on how



**Fig. 14.8** Intraoperative preparation: defining the trajectory for DBS electrode (leads) insertion

accurate the leads are placed at the target. Figure 14.8 shows the intraoperative preparation and localization of the target site with specialized MRI.

The use of microelectrode recordings (MER) or macrostimulation to localize and confirm physiologic target is helpful to accurately place the leads (Yu and Neimat 2008; Heppard et al. 2014). To use MER or macrostimulation, the patient is usually awake during this part of the procedure in order to test the motor response of the stimulation when the leads are accurately placed. In the pediatric population, the entire procedure is done under general anesthesia in order to prevent sudden adverse movements that may harm the child. Therefore, MER and macrostimulation will be difficult for children. The literature supports the use of intraoperative MRI for target localization. MRI is also ideal to align the entry point and trajectory for lead implantation by visualization of the brain and vascular structures to reduce bleeding risks (Vayssiere et al. 2000; Larson et al. 2008; Fenoy and Simpson 2014; Martin et al. 2016).

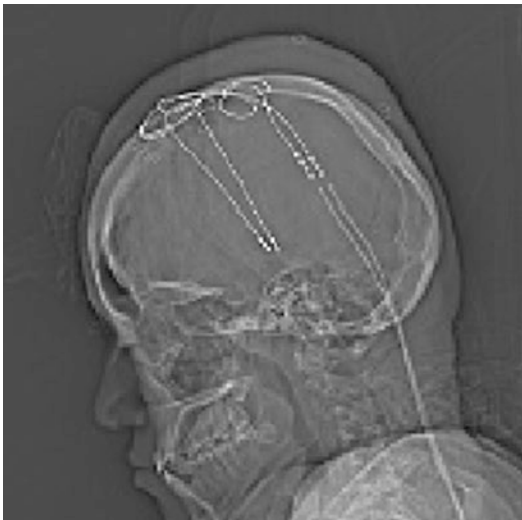CT and MRI scans may be performed with the DBS electrodes in place. A postoperative CT is often obtained to show the placement of the electrodes. The electrodes, wires, and implanted stimulator are made of materials generally com-

patible with MRI, however, some models, depending on manufacturer, may not be compatible for all machines, full body MRIs, or high Tesla settings. The main concern is heating of the implanted metal during MRI which may cause severe and permanent injuries. The manufacturer should provide guidelines for MRI imaging as well as an ID card for patients. Radiology personnel and nursing staff should be familiar with these guidelines and instruct patients to bring their ID cards with them every visit and alert radiology to their implanted device (Medtronic Inc. 2015). Figures 14.9 and 14.10 show the use of CT to show placement of the electrode leads.

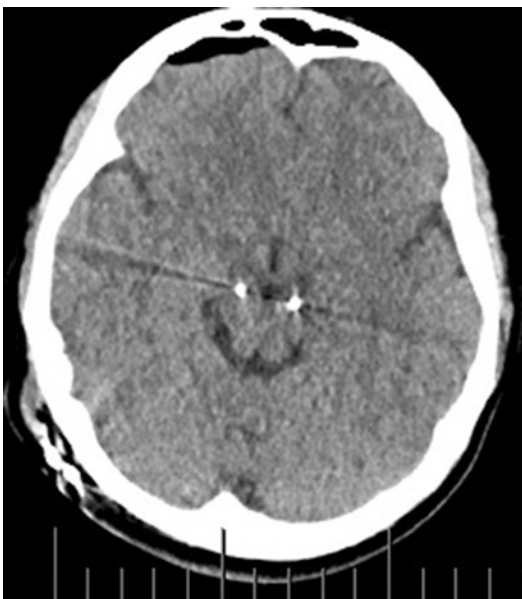### 14.4.5.3 Complications

The most concerning complication of DBS implantation is hemorrhage. Yu and Neimat (2008) reported 3 % bleeding after electrode placement with 0.7 % of the bleeds causing permanent deficits in patients. Further development of the procedural technique and localization targeting accuracy will decrease bleeding risks.

Infection is another major complication associated with DBS implantation. Infection may occur at the site of lead implantation or at the site of the pulse generator, and other infections may be related to superficial wound issues. In the pediatric population, the risk of infections



**Fig. 14.9** Scout CT showing placement of two DBS electrodes with leads



**Fig. 14.10** Axial CT showing electrode placement

appears to be much higher than in the adult population. Infection rates of greater than 10 % have been published (Fenoy and Simpson 2014; Keen et al. 2014). In many cases of infection, another surgery is required for debridement, removal, or revision of the apparatus. Therefore, a stringent antibiotics prophylaxis protocol is highly recommended to include peripheral vancomycin and

cephalosporin (Olaya et al. 2013; Larson et al. 2008; Yu and Neimat 2008).

Hardware complications occur in about 1–2 % of cases reported in the literature (Fenoy and Simpson 2014; Hippard et al. 2014; Larson et al. 2008). These complications include lead migration, lead misplacement, lead fracture, lead malfunction, skin erosion, and flipped generator. All hardware complications will require surgery.

#### 14.4.5.4 Adverse Effects

DBS may produce adverse effects which are attributed to stimulation or placement of the leads. Most common adverse effects are dysarthria and worsening gait. Other adverse effects include declining cognitive function, confusion, blurry vision, depression, dizziness, headaches, dysphagia, dyskinesia, and emotional changes (Kenney et al. 2007). For the most part these symptoms are transient or may be relieved by adjusting the stimulation.

#### 14.4.5.5 Nursing Implications

Nursing care of DBS treatment is primarily focused on pain management and prevention of postoperative complications such as infection. Nurses can assist in managing any complications related to the surgical procedure and should be alert for any signs or symptoms of hemorrhage such as a decrease in level of consciousness or focal neurological deficit. Additionally, nurses have a role in educating patients and families both before and after surgery, including risks, benefits, potential complications to watch for, and any change in neurological function.

#### Conclusion

There are many treatment modalities for the treatment of functional neurological conditions resulting in movement disorders in children. The key to effective management is a thorough assessment of the movement disorder and its effect, both clinical and functional, on the patient and family. It is beneficial to have clearly identified patient and family-focused goals to select the most appropriate treatment modality or combination of modalities. Neurosurgical nurses need to have a good



understanding of their patients' conditions and treatments available to effectively advocate for care and treatments that are patient and family focused.

### Pediatric Practice Pearls

1. Rapid withdrawal of intrathecal baclofen, whether from pump removal, pump malfunction, or incorrect dosing, can result in severe withdrawal symptoms and death. Appropriate doses of oral baclofen should be used in the interim.
2. It is imperative that parents of children that are candidates for ITB understand the long-term commitment they must make for follow-up.
3. Videotaping the patient before rhizotomy and at 6 weeks, 3 months, etc. after surgery will show the parents how much progress has been made.
4. Explain to parents that after undergoing a rhizotomy, some children may lose previously obtained function. It takes a while to regain back some skills, such as walking, as it is necessary to retrain muscle groups to do these functions.

## References

- Abbott R (1999). Selective dorsal rhizotomy. Retrieved August 16, 2005, from <http://cerebnet.netfirms.com/selective.htm>
- Adams M, Hicks AL (2010) Spasticity: pathophysiology, assessment, and management. In: Lin VW (ed) *Spinal cord medicine: principles and practice*. Demos Medical Publishing, New York
- Albanese A, Barnes MP, Bhatia KP, Fernandez-Alvarez E, Fillipini G, Gasser T et al (2006) A systematic review on the diagnosis and treatment of primary (idiopathic) dystonia and dystonia plus syndromes: report of an EFNS/MDS-ES task force. *Eur J Neurol* 13(5):433–444. doi:10.1111/j.1468-1331.2006.01537.x
- Albanese A, Bhatia K, Bressman SB, DeLong MR, Fahn A, Fung VSC et al (2013) Phenomenology and classification of dystonia: a consensus update. *Mov Disord* 28(7):863–873
- Albright AL (2003) Neurosurgical treatment of spasticity and other pediatric movement disorders. *J Child Neurol* 18:S67–S78
- Albright AL, Ferson SS (2006) Intrathecal baclofen therapy in children. *Neurosurg Focus* 21(2):1–6
- Atiyeh BS, Hayek SN, Skaf GS, Araj AA, Chamoun RB (2006) Baclofen pump pocket infection: a case report of successful salvage with muscle flap. *Int Wound J* 3:23–28
- Awaad Y, Tayem H, Munoz S, Ham S, Michon AM, Awaad R (2003) Functional assessment following intrathecal Baclofen therapy in children with spastic cerebral palsy. *J Child Neurol* 18:26–34
- Awan NR, Lozano A, Hamani C (2009) Deep brain stimulation: current and future perspectives. *Neurosurg Focus* 27(1). doi:10.3171/2009.4.FOCUS0982
- Barry MJ, Van Swearingen JM (1999) Reliability and responsiveness of the Barry-Albright Dystonia Scale. *Dev Med Child Neurol* 41(6):404–411
- Berardelli A, Rothwell JC, Hallett M, Thompson PD, Manfredi M, Marsden CD (1998) The pathophysiology of primary dystonia. *Brain* 121:1195–1212
- Bergenheim AT, Wendelius M, Shahidi S, Larsson E (2003) Spasticity in a child with myelomeningocele treated with continuous intrathecal Baclofen. *Pediatr Neurosurg* 39:218–221. doi:10.1159/000072476
- Boviatsis EJ, Kouyialis AT, Boutsikakis I, Korfas S, Sakas DE (2004) Infected CNS infusion pumps: is there a chance for treatment without removal? *Acta Neurochir* 146:463–467
- Camargo CH, Camargos ST, Cardoso FEC, Teive HAG (2015) The genetics of the dystonias – a review based on the new classification of the dystonias. *Arq Neuropsiquiatr* 73(4):350–358. doi:10.1590/0004-282XX20150030
- Center for Disease Control and Prevention; Mangram AJ, Horan TC, Pearson ML, Silver LC, Jarvis WR (1999) The Hospital Infection Control Practice Advisory Committee. Guideline for prevention of surgical site infection. *Infection control and Hospital Epidemiology* 20(4):247–278
- Cheek WR (1996) *Atlas of pediatric neurosurgery*. W.B. Saunders Company, Philadelphia
- Comella CL, Leurgans S, Wu J, Stebbins GT, The Dystonia Study Group (2003) Rating scales for dystonia: a multi-center assessment. *Mov Disord* 18(3):303–312
- Danner SM, Dimitrijevic MR (2012) Spasticity: pathophysiology and neural control. In: Kusimastuli P, Tular ABM (eds) *3rd Asia-Oceanian Conference of Physical and Rehabilitation Medicine in Conjunction with XI Annual Scientific of Indonesian Association of Physical Medicine and Rehabilitation*. Medimond, Bologna ISBN978–88–7587-655-5, pp 9–15
- Dario A, Tomei G (2004) A benefit-risk assessment of Baclofen in severe spinal spasticity. *Drug Saf* 27(11):799–818
- Dario A, Scamoni C, Picano M, Fortini G, Cuffari A, Tomei G (2005) The infection risk of intrathecal drug



- infusion pumps after multiple refill procedures. *Neuromodulation* 8(1):36–39
- Dawes WJ, Drake JM, Fehlings D (2003) Microfracture of a baclofen pump catheter with intermittent under- and overdose. *Pediatr Neurosurg* 39(3):144–148
- Dietz V (2000) Spastic movement disorder. *Spinal Cord* 38:389–393
- DiFrancesco MF, Halpern CH, Hurig HH, Raltuch GH, Heuer GG (2012) Pediatric indications for deep brain stimulation. *Childs Nerv Syst* 28:1701–1714
- Douglas AF, Weiner HL, Schwartz DR (2005) Prolonged intrathecal baclofen withdrawal syndrome. *J Neurosurg* 102:1133–1136
- Fenoy AJ, Simpsons R (2014) Risks of common complication in deep brain stimulation surgery: management and avoidance. *J Neurosurg* 120:132–139
- Fitzgerald JJ, Tsegaye M, Vloeberghs (2004) Treatment of childhood spasticity of cerebral origin with intrathecal Baclofen: a series of 52 cases. *Br J Neurosurg* 18(3):240–245
- Follett KA, Burchiel K, Deer T, Dupen S, Prager J, Turner MS et al (2003) Prevention of intrathecal drug delivery catheter-related complications. *Neuromodulation* 6(1):32–41
- Geyer HL, Bressman SB (2006) The diagnosis of dystonia. *Lancet Neurol* 5(9):780–790. doi:10.1016/S1474-4422(06)70547-6
- Goldstein EM (2001) Spasticity management : an overview. *J Child Neurol* 16:16–23
- Gooch JL, Oberg WA, Grams B, Ward LA, Walker ML (2003) Complications of intrathecal Baclofen pumps in children. *Pediatr Neurosurg* 39:1–6
- Grunt S, Becher JG, Vermeulen RJ (2011) Long-term outcome and adverse effects of selective dorsal rhizotomy in children with cerebral palsy: a systematic review. *Dev Med Child Neurol* 53:490–498. doi:10.1111/j.1469-8749.2011.03912.x
- Guetard E, Roze E, Abada G, Lemesle C, Vidailhet M, Laurent-Vannier A et al (2009) Management of spasticity and dystonia in children with acquired brain injury with rehabilitation and botulinum toxin A. *Dev Neurorehabil* 12(3):128–138. doi:10.1080/17518420902927994
- Haranhalli N, Ammand D, Wisoff JH, Harter DH, Weiner HL, Blate M, Roth J (2010) Intrathecal baclofen therapy: complication avoidance and management. *Childs Nerv Syst* 27:421–427. doi:10.1007/s00381-010-1277-9
- Hays RM, McLaughlin JF, Geiduschek JM, Bjornson KF, Graubert CS (1997) Evaluation of the effects of selective dorsal rhizotomy. *Mental Retardation and Development Disabilities Research Reviews*, 3:168–174
- Hippard HK, Watcha M, Stocco AJ, Curry D (2014) Preservation of microelectrode recordings with non-GABAergic drugs during deep brain stimulator placement in children. *J Neurosurg Pediatr* 14:279–286
- Hesselgard K, Reinstrup P, Stromblad LG, Uden J, Romner B (2005) Selective dorsal rhizotomy and post-operative pain management. *Pediatr Neurosurg* 43:107–112. doi:10.1159/000098382
- Institute for Neurology & Neurosurgery (2004). Rhizotomy. Retrieved August 16, 2005, from <http://nyneruurgery.org/cp/thizhist.html>
- Keen JR, Przekop A, Olaya JE, Zouros A, Hsu FP (2014) Deep brain stimulation for the treatment of childhood dystonic cerebral palsy. *J Neurosurg Pediatr* 14(6):585–593. doi:10.3171/2014.8.PEDS141
- Keenan E (2010) Spasticity management, Part 3: surgery and the use of intrathecal baclofen. *Br J Neurosci Nurs* 6(1):12–18
- Kenney C, Simpson R, Hunter C, Ondo W, Almaguer M, Davidson A, Jankovic J (2007) Short-term and long-term safety of deep brain stimulation in the treatment of movement disorders. *J Neurosurg* 106:621–625
- Krach LE, Kriel R, Day SM, Strauss DJ (2009) Survival of individual with cerebral palsy receiving continuous intrathecal baclofen treatment: a matched-cohort study. *Dev Med Child Neurol* 52:672–676. doi:10.1111/j.1469-8749.2009.03473.x
- Koman LA, Smith B, Balkrishnan (2003) Spasticity associated with cerebral palsy in children. *Pediatr Drug* 5(1):11–23
- Larson PS, Richardson RM, Starr PA, Martin AJ (2008) Magnetic resonance imaging of implanted deep brain stimulators: experience in a large series. *Stereotact Funct Neurosurg* 28:92–100
- Lipsman N, Ellis M, Lozano AM (2010) Current and future indications for deep brain stimulation in pediatric populations. *Neurosurg Focus* 29(2):1–7
- Lubarr N, Bressman S (2010) Advances in our understanding of dystonia – pathophysiology and treatment outcome. *US Neurol* 6(2):115–121. doi:10.17925/USN.2010.06.02.115
- Madhusudanan M (1999) Dystonia: emerging concepts in pathophysiology. *Neurol India* 47:263
- MacWilliam BA, Johnson BA, Shuckra AL, D’Astous JL (2011) Functional decline in children undergoing selective dorsal rhizotomy after age 10. *Dev Med Child Neurol* 53:717–723. doi:10.1111/j.1469-8749.2011.04010.x
- Martins A (2016) The role of spasticity in functional neurorehabilitation – Part 1: the pathophysiology of spasticity, the relationship with neuroplasticity, spinal shock and clinical signs. *Arch Medication* 8(3):1–7
- Martin AJ, Larson PS, Ziman N, Levesque N, Volz M, Ostrem JL, Starr PA (2016) Deep brain stimulator implantation in a diagnostic MRI suite: infection history over a 10-year period. *J Neurosurg*, Published online March 25, 2016; doi:10.3171/2015.7.JNS15750
- Medtronic Inc (2015) MRI guidelines for Medtronic deep brain stimulation systems, 2014-12-01 - instructions for use. <http://www.zaloker-zaloker.si/assets/Uploads/MR-smernice.pdf>
- Mohammed I, Hussain A (2004) Intrathecal baclofen withdrawal syndrome – a life-threatening complication of baclofen pump: a case report. *BMC Clin Pharmacol* 4(6):1–5. doi:10.1186/1472-6904-4-6

- Morton RE, Gray N, Vloeberghs M (2011) Controlled study of the effects of continuous intrathecal baclofen infusion in non-ambulant children with cerebral palsy. *Dev Med Child Neurol* 53:736–741. doi:10.1111/j1469-8749.2011.04009.x
- Moss SD, Manwaring KH (1992) Relief of spasticity for children with cerebral palsy using selective posterior rhizotomy. *Phoenix Child Hosp Pediatr Rev* 4(1):5–11
- Motta F, Buonaguro V, Stignani C (2007) The use of intrathecal baclofen pump implants in children and adolescents: safety and complications in 200 consecutive cases. *J Neurosurg* 107:32–35. doi:10.3171/PED-07/07/032
- Mullarkey T (2009) Considerations in the treatment of spasticity with intrathecal baclofen. *Am J Health-Syst Pharm* 66(Suppl. 5):s14–s22. doi:10.2146/ajhp0108c
- Kumura A, Kidokoro H, Shoji H, Nakazawa T, Mimaki M, Fujil K et al (2009) Kernicterus in preterm infants. *Pediatrics* 123:1052–1058. doi:10.1542/peds.2008.2791
- Olaya JE, Christian E, Ferman D, Luc Q, Krieger MD, Sanger TD, Liker MA (2013) Deep brain stimulation in children and young adults with secondary dystonia: the Children's Hospital Los Angeles experience. *Neurosurg Focus* 35(5):1–13
- Ou C, Kent S, Miller S, Steinbok P (2010) Selective dorsal rhizotomy in children: comparison of outcomes after single-level versus multi-level laminectomy technique. *Can J Neurosci Nurs* 32(3):17–24
- Pin TW, McCartney L, Lewis J, Waugh M (2011) Use of intrathecal baclofen therapy in ambulant children and adolescents with spasticity and dystonia of cerebral origin: a systematic review. *Dev Med Child Neurol* 53:885–895. doi:10.1111/j.1469-8749.2011.03992.x
- Plassat R, Verbe BP, Menei P, Menegalli D, Mathe JF, Richard I (2004) Treatment of spasticity with intrathecal Baclofen administration: long-term follow-up, review of 40 patients. *Spinal Cord* 42:686–693
- Priori F, Cogiamanian f, sPposta SM (2006) Pathophysiology of spasticity. Vol 27 supplement 4, s307–s309
- Ramstad K, Jahnsen R, Lofterod B, Skjeldal OH (2010) Continuous intrathecal baclofen therapy in children with cerebral palsy – when does improvement emerge? *Acta Paediatr* 99:1661–1665. doi:10.1111/j.1651-2227.2009.01596x
- Rekand T (2010) Clinical assessment and management of spasticity: a review. *Acta Neurol Scand Suppl* (190):62–66. doi:10.1111/j.1600-0404.2010.01378.x
- Roubertie A, Echonne B, Cif L, Vayssiere N, Hemm S, Coubes P (2000) Treatment of early-onset dystonia: update and a new perspective. *Childs Nerv Syst* 16:334–340
- Ridley B, Rawlins PK (2006) Intrathecal baclofen therapy: ten steps toward best practice. *J Neurosci Nurs* 38(2):72–82
- Rizzo MA, Hadjimichael OC, Preinigherova J, Vollmer TL (2004) Prevalence and treatment of spasticity reported by multiple sclerosis patients. *Mult Scler* 10:589–595
- Rose J, Vassar R (2015) Movement disorders due to bilirubin toxicity. *Semin Fetal Neonatal Med* 20(1):20–25. doi:10.1016/j.siny.2014.11.002
- Satkunam LE (2003) Rehabilitation medication: 3. Management of adult spasticity. *CMAJ* 169(11):1173–1179
- Sheehan G (2002) The pathophysiology of spasticity. *Eur J Neurol* 9(Suppl. 1):3–9
- Stallings VA, Cronk CE, Zemel BS, Charney EB (1995) Body composition in children with spastic quadriplegic cerebral palsy. *J Pediatr* 126:833–839
- Steinbok P (2006) Selection of treatment modalities in children with spastic cerebral palsy. *Neurosurg Focus* 21(2):1–8. doi:10.3171/foc.2006.21.2.5
- Steinbok P, Tidemann AJ, Miller S, Mortenson P, Bowen-Roberts T (2009) Electrophysiologically guided versus non-electrophysiologically guided selective dorsal rhizotomy for spastic cerebral palsy: a comparison of outcomes. *Childs Nerv Syst* 25:1091. doi:10.1007/s00381-009-0908-5
- Tabbal SD (2015) Childhood dystonias. *Curr Treat Options Neurol* 17(12):1–15. doi:10.1007/s11940-015-0339-4
- Tedroff K, Lowing K, Jacobson DN, Astrom E (2011) Does loss of spasticity matter? a 10-yr follow-up after selective dorsal rhizotomy in cerebral palsy. *Dev Med Child Neurol* 53(8):724–729. doi:10.1111/j.1469-8749-2011.03969.x
- Tempel LW, Perlmutter JS (1993) Abnormal cortical responses in patients with writer's cramp. *Neurology* 43:2252–2257
- Thompson AJ, Jarrett L, Lockley L, Marsden J, Stevenson VL (2005) Clinical management of spasticity. *J Neurol Neurosurg Psychiatry* 76:459–463. doi:10.1136/jnnp.2004.035972
- Trompetto C, Marinelli L, Mori L, Pelosin E, Curra A, Molfetta L, Abbruzzes G (2014) Pathophysiology of spasticity - implication for neurorehabilitation. *BioMed Research International*. Volume 2014, <http://dx.doi.org/10.1155/2014/354906>
- Vanek ZF, Menkes JH, Carcione J, Talavera F, Lopate G, Benbadis S, Berman SA (2010) Spasticity. *eMedicine Neurology*. Retrieved January 21, 2012, from <http://www.emedicine.com/neuro/topic706.htm>
- Vayssiere N, Hemm S, Zancel M, Picot MC, Bonafe A, Cif L et al (2000) Magnetic resonance imaging stereotactic target localization for deep brain stimulation in dystonic children. *J Neurosurg* 93:784–790
- Vender LR, Hester S, Rekito A, Lee MR (2005) Baclofen intrathecal pump delivery systems, avoidance and management of complications in adult and pediatric patients: part 2. *Contemp Neurosurg* 27(2):1–5
- Verceuil L, Krack P, Pollak P (2002) Results of deep brain stimulation for dystonia: a critical reappraisal. *Mov Disord* 17(S3):S89–S93. doi:10.1002/mds.10148
- Vitzum C, Olney B (2000) Intrathecal baclofen therapy and the child with cerebral palsy. *Orthop Nurs* 19(1):43–48

- Ward A, Hayden S, Dexter M, Scheinberg (2009) Continuous intrathecal baclofen for children with spasticity and/or dystonia: goal attainment and complications associated with treatment. *J Paediatr Child Health* 45:72–726. doi:[10.1111/j.1440-1754.2009.01601.x](https://doi.org/10.1111/j.1440-1754.2009.01601.x)
- Ward AB, Molenaers G, Colosimo C, Berardelli A (2006) Clinical value of botulinum toxin in neurological indications. *Eur J Neurol* 13(Suppl. 4):20–26
- Watve SV, Sivan M, Raza WA, Jamil FF (2012) Management of acute overdose or withdrawal state in intrathecal baclofen therapy. *Spinal Cord* 50:107–111
- Wong V (2003) Evidence-based approach of the use of botulinum toxin A (BTX) in cerebral palsy. *Pediatr Rehabil* 6(2):85–96. doi:[10.1080/1363849031000139306](https://doi.org/10.1080/1363849031000139306)
- Yam WKL, Leung MSM (2006) Interrater reliability of modified Ashworth scale and modified Tardieu Scale in children with spastic cerebral palsy. *J Child Neuol*. 21:1031–1035. doi:[10.23107010.2006.00222](https://doi.org/10.23107010.2006.00222)
- Yu H, Neimat JS (2008) The treatment of movement disorders by deep brain stimulation. 89u. *J Am Soc Exp Neurother* 5:26–36

Gina Weddle

## 15.1 Brain Abscess, Epidural Abscess, and Subdural Empyema

Intracranial abscess is a complication of common pediatric conditions including meningitis, sinusitis, dental disease, and otitis media (Hicks et al. 2011; Menon et al. 2008). Intracranial abscess affects areas from superficial to deep including the epidural space, subdural space, and parenchyma tissue. Although rare in pediatrics, intracranial abscess poses a serious life-threatening condition for the child that can lead to permanent sequelae. This section will focus on these processes and their relationships to one another.

### 15.1.1 Etiology

Brain abscesses account for 8 % of CNS masses in developing countries and up to 2 % in developed countries (Bonfield et al. 2015). One-fourth of brain abscesses occur in children less than 15 years of age with a peak incidence between 4 and 7 years (Leonard et al. 2006). The incidence

for both subdural empyema and epidural abscess combined approximates 13–25 % of all intracranial infections, with epidural abscesses being rare (McLone 2001).

The infective process depends on (1) the quantity of microorganisms that are involved, (2) their virulence, (3) the immunological status of the patient, and (4) the timeliness of clinical diagnosis and treatment (McLone 2001). With improved treatment of sinus and otogenic conditions, there has been a recent decline seen with pediatric CNS infectious complications (Bonfield et al. 2015). The most common organism seen in intracranial abscesses is *Streptococci*, specifically the viridians *Streptococci* group which is a common nasal/oral colonizer (Long et al. 2008; Bonfield et al. 2015). After *Streptococci*, *Staphylococci* are the second most common organisms, followed by gram-negative organisms, anaerobic organisms, and common pathogens that cause meningitis particularly *Pneumococcus* and group B beta-hemolytic *Streptococci* (Long et al. 2008). In the case of intracranial abscess caused as a complication of sinusitis, polymicrobial infections are not uncommon.

Intracranial abscesses originate from many different sources, which include contiguous site infections accounting for over half of the cases (i.e., chronic otitis media, mastoiditis, dental procedures, sinusitis, or ruptured dermoid tumor), distant pathological states (i.e., cyanotic congenital heart disease, chronic lung infections,

---

G. Weddle, DNP, RN, CPNP-PC/AC  
Department of Infectious Diseases,  
The Children's Mercy Hospital,  
2401 Gillham Road, Kansas City, MO 64108, USA  
e-mail: [gweddle@cmh.edu](mailto:gweddle@cmh.edu)

pulmonary arteriovenous fistulae from Osler-Weber-Rendu syndrome), head trauma (i.e., open depressed skull fractures, gunshot wound), neurosurgical procedures, and cryptogenic sources (Saez-Llorens 2003; Bonfield et al. 2015). Hematogenous seeding is responsible for 25 % of cases, while around 25 % have identifiable etiology (Bonfield et al. 2015; Lu et al. 2006). Those with congenital heart disease, especially tetralogy of Fallot, will have an increased risk of abscess with prevalence between 6 and 51 % (Frazier et al. 2008). This is due to the lack of filtering provided by the lungs and hypoxic brain tissue, which is favorable for abscess formation (Greenberg 2006). Brain abscess rarely occurs in children less than 2 years of age, but when it does occur, it is usually secondary to meningitis (Albright et al. 1999; Heilpern and Lorber 1996; Long et al. 2008).

### 15.1.2 Pathophysiology

Contiguous spread of an infection to the brain leads to an area of infection adjacent to the source and is a common cause of intracranial abscess (Long et al. 2008). This is evident by the fact that a brain abscess, or subdural empyema, from otitis media will most likely occur in the temporal lobe, while those originating from the frontal or ethmoid sinus will occur in the frontal lobe. This type of spread results from direct extension through the bone, between bony sutures, or via extension through venous structures (Heilpern and Lorber 1996). Epidural abscesses can occur in conjunction with osteomyelitis of the skull. Subdural abscess as a complication of meningitis can occur in conjunction with thrombophlebitis, venous stasis, ischemia, and infarction. Common organisms of contiguous spread include *Streptococcus*, *Staphylococcus*, Enterobacteriaceae, and anaerobic bacteria (Long et al. 2008; McLone 2001).

Hematological spread usually originates from a cardiac or pulmonary source and usually extends through the distribution of the middle cerebral artery. Hematogenous seeding accounts for 25 % of brain abscess in children (Long et al. 2008;

Bonfield et al. 2015). A risk factor for hematogenous seeding is a child with a congenital heart defect, specifically a defect with right to left shunting (i.e., tetralogy of Fallot or transposition of the great vessels). Hematogenous seeding can additionally occur as a result of endocarditis or septic thrombophlebitis where septic vegetations are dislodged from the heart valve and seed the brain. This type of spread tends to form at the gray-white matter junction, and abscesses due to this process are usually multiple, which makes this type unique. Common organisms associated with hematogenous seeding include *Streptococcus*, *Staphylococcus*, and *Haemophilus* species (Tekkok and Erbenig 1992).

Head trauma and neurosurgical procedures produce abscesses and empyemas, which contain organisms native to the skin. The most common organisms include *Staphylococcus*, *Streptococcus*, and gram-negative species. In the setting of penetrating trauma, polymicrobial infections and unusual environmental organisms can be seen. Fungal infective processes are rare in the child and are usually associated with immunodeficiency, immunological suppression after organ transplantation, chemotherapy, or from congenital disease (Osenbach and Loftus 1992). Other factors that place a child at risk for invasive fungal disease include broad-spectrum antibiotics, total parenteral nutrition, steroid use, and penetrating trauma.

There are four stages of abscess maturation. Days 1–3 consist of early inflammatory changes, with some necrosis and edema. Days 4–9, inflammatory changes increase as fibroblasts, and leukocytes are recruited to the area of central necrosis and edema. Early capsule formation begins on days 10–13, with maturation complete on day 14 (Heilpern and Lorber 1996).

### 15.1.3 Presenting Symptoms

Initial presentation can be vague but typically will progress to focal neurologic findings (Bonfield et al. 2015). The most common presenting signs and symptoms include headache (92 %), fever (85 %), nausea/vomiting (62 %),



and lethargy (23 %) (Hicks et al. 2011). Focal neurological deficits that are seen are related to the affected area of the brain. Frontal lobe includes behavioral changes, speech disorder, hemiparesis, and papilledema. Temporal lobe involvement can manifest as third cranial nerve palsy, aphasia, and motor dysfunction of the face or arm. Parietal lobe manifestation includes visual field defects, dyspraxia, and homonymous hemianopia. Neurological deficit, including cranial nerve palsies, hemiparesis, or decreased mental status, can occur in up to 50 % of cases. Most problems seen are due to increased intracranial pressure and can result in vomiting, lethargy, and even seizures.

In interviewing the patient or the family, it is important to recognize any recent or chronic infections, especially of the head, ears, nose, or throat. Current and any recent antibiotic use is additionally important when obtaining a history as antibiotic use may play a role in emergence of resistant organisms, and pretreatment with antibiotics may affect culture results. History should additionally include a comprehensive review of systems including fevers, headache, nasal or ear drainage, and earache.

Nurses should note any recent dental procedures, head trauma, and neurosurgical or otolaryngology procedures. Further, the caregiver needs to inquire about history regarding congenital disease, immune deficiencies, as well as sick contacts.

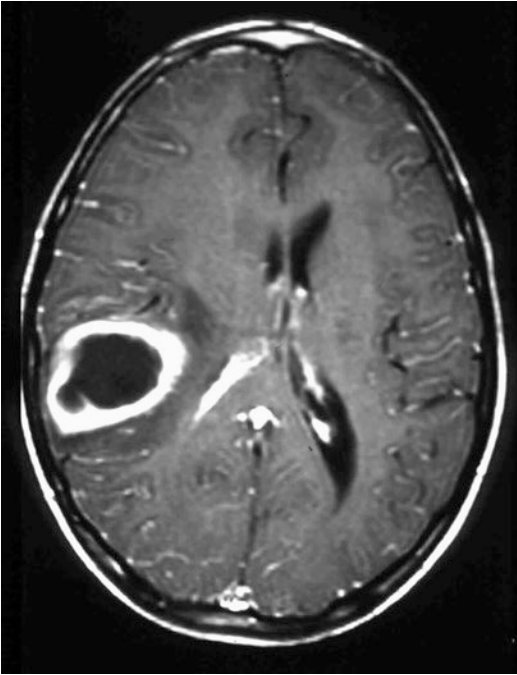
On exam, note the general appearance of the child, and document whether the child is interactive, lethargic, or irritable. Inspect and palpate the skull for tenderness, trauma, or swelling. Check the ears for drainage, and look at the mouth and throat for exudate, erythema, dental caries, or swelling. Be sure to perform a full cranial nerve exam and look for asymmetry or dysfunction. For infants, it should be determined if there are any signs of failure to thrive (i.e., poor growth, lack of appetite, or delay in development). In an infant, inspect for reactivity of pupils, check for conjugate gaze, measure head circumference, and note whether the fontanelles are bulging or if the sutures are splayed. Assess motor strength and sensation in all four

extremities. If the child has concurrent meningitis, you may notice signs of meningismus including neck stiffness, Kernig sign, Brudzinski sign, altered consciousness, or photophobia. Auscultate the heart for murmurs, clicks, or dysrhythmias. Observe for clues of right to left heart shunting such as cyanosis, clubbing, and tachypnea.

#### 15.1.4 Diagnostic Test

Initial testing will involve obtaining a serum white blood count (WBC), baseline chemistries, blood cultures, erythrocyte sedimentation rate (ESR), and C-reactive protein (CRP). Unfortunately, the serum WBC may be normal or mildly elevated in 60–70 % of cases, while blood cultures are only positive in 25 % of cases. ESR will become elevated but may be normal in some cases, such as congenital cyanotic heart disease, whereas polycythemia lowers the ESR. CRP becomes elevated with any type of infection and is more of an acute phase protein but is nonspecific like ESR (Greenberg 2006). The yield of a lumbar puncture depends on whether the infection is in contact with the intracranial CSF spaces. A lumbar puncture may reveal an elevated WBC, decreased glucose, elevated protein, or isolation of infective organism, all of which provide valuable information indicating an infective process. If a lumbar puncture is to be considered, it must be done with caution due to the concern of herniation, especially in the presence of increased ICP.

Contrasted head computed tomography (CT) or magnetic resonance imaging (MRI) is recommended with MRI being preferable due to superior visualization of brain matter and fluid collections (Figs. 15.1 and 15.2). In infants, cranial ultrasonography may reveal fluid collections with echogenic boundaries obtained through the fontanel. Operative biopsy or drainage of the abscess for all ages will bring forth a diagnosis and in most cases identify the pathogen. Aerobic, anaerobic, fungal, and acid-fast bacilli cultures are recommended to help identify an organism.



**Fig. 15.1** T-1-weighted MRI with contrast demonstrating a ring-enhancing lesion suspicious for intracranial abscess

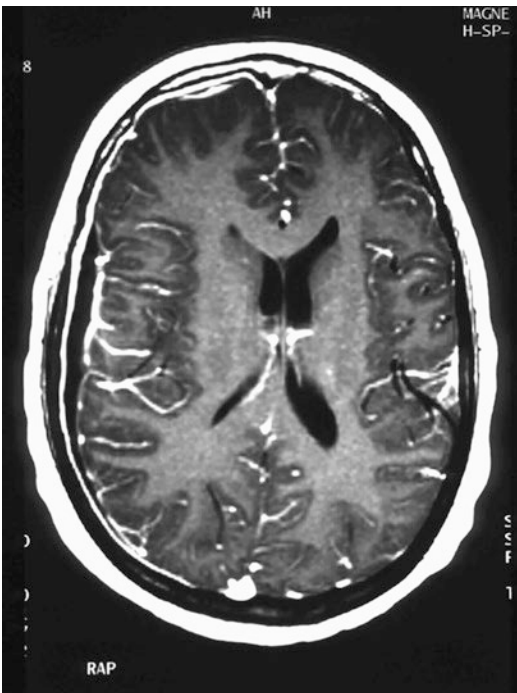
### 15.1.5 Treatment Options

For brain abscesses, surgical treatment is determined based on clinical status, mass effect, location of the abscess, failure of lesions to improve with 1–2 weeks of antibiotic therapy, or the need to obtain organism for culture and susceptibilities. Surgical treatment consists of needle aspiration or excision. Medical management may be considered if treatment is begun early in the infection, improvement is seen with initiation of treatment, the lesions are smaller than 3 cm, or the abscess is located in an eloquent brain area.

For subdural empyemas and epidural abscesses, surgical treatment is indicated in most cases. But like brain abscesses, surgical drainage will depend on the size of the abscess and clinical status of the patient. The surgical therapy can range from simple burr holes to a large craniotomy, with possible conversion to a craniectomy if the bone flap is infected. In infants with subdural empyemas, medical management usually suffices, but in certain cases, transfontanel needle aspiration or burr holes are needed.

Antibiotic therapy should be started immediately upon determination of intracranial infection. Initial antibiotics for empiric therapy for all intracranial suppurative processes should include medications that cross the blood–brain barrier. Typically, vancomycin is used for gram-positive organisms, a third-generation cephalosporin for gram-negative organisms, and metronidazole for anaerobic coverage (Long et al. 2008). Clindamycin is increasingly being used for *Staphylococcus*, *Streptococcus*, and anaerobic infections. However, clindamycin does not have any gram-negative coverage and does not cross the blood–brain barrier, so it would not be a treatment option with intracranial abscess.

Once the bacteria is cultured and identified, antibiotic therapy may be narrowed although caution should be used in narrowing antibiotic coverage too far as some intracranial abscess are polymicrobial in nature and certain organisms can be difficult to grow, particularly anaerobic organisms. Intravenous antibiotic therapy is usually needed for 6–8 weeks. Length of therapy will depend on the clinical course, organisms identified, and whether the patient underwent surgical drainage.



**Fig. 15.2** T-1-weighted MRI with contrast revealing right-sided enhancement along the cortical surface of the brain with a hypointense (*dark appearing*) fluid collection representing a subdural empyema

A distinctive form of posttraumatic brain abscess seen in children results from penetrating injuries to the orbital region, as well as other areas of the skull. These injuries are caused by such things as pencil tips, wooden sticks, wooden toys, and lawn darts. Treatment involves prompt surgical debridement. The use of prophylactic antibiotic therapy for penetrating brain injury to prevent meningitis or abscess depends on the degree of contamination and location. A broad-spectrum cephalosporin with good blood–brain barrier penetration with metronidazole would be recommended, or a carbapenem such as meropenem would give gram-positive, gram-negative, and anaerobic coverage. In general, prophylaxis should consist of a short course of therapy, typically 5–7 days. Prophylaxis will not totally eliminate the risk of infection, and a prolonged course of prophylaxis will only encourage infections with multidrug-resistant organism. With all penetrating trauma, tetanus status should be documented and vaccine updated as needed. Additionally depending on the location of the penetrating trauma, Pneumococcal vaccine should be considered particularly if the penetration involves the sinus region or CSF leak.

### 15.1.6 Nursing Care

Nursing care is focused on observation of the patient, with special attention paid to any change in the neurological exam. Serial exams will allow the nurse to distinguish any signs of deterioration which should be reported immediately. Age-appropriate neurological exam is key to the nursing care of these patients. Mental status, irritability, cranial nerve exam (especially pupil reactivity), motor and sensory testing, reflexes, as well as fever curves will help dictate care. Inspect incisions or wounds for increasing tenderness, erythema, drainage, and dehiscence. Ensure proper and timely delivery of antibiotics. Monitor fluid and electrolyte status closely, since this can change drastically with deleterious effects. Attempt to keep head of bed raised to at least 30° to help protect against elevated ICP, and provide a quiet environment that does not overstimulate the patient. Be sure all caregivers and visitors undergo thorough handwashing before and after visiting.

### 15.1.7 Patient and Family Education

Upon discharge to home, educate the patient and family to monitor for any type of change in neurological status. For infants, family should call the physician if they detect any change in alertness, difficulty in arousing, irritability, decreased feeding, bulging fontanel, seizures, or intractable vomiting. Also, the family should note fevers, and any temperature greater than 100.8 F warrants a call to the physician. The patients should be kept away from sick contacts during their convalescence. Discharge instructions should cover wound care, activity, follow-up, and medications. Home health nursing care may be needed for long-term intravenous antibiotic therapy.

### 15.1.8 Outcome

The prognosis for survival and neurological morbidity depends on the patient's level of consciousness at presentation, rapid onset, or rapid progression of disease (Long et al. 2008). Mortality rates range from 5 to 15 % (Long et al. 2008; Menon et al. 2008). Morbidity remains a problem, with patients experiencing seizures (10–30 %), hemiparesis (10–15 %), cranial nerve palsy (5–10 %), hydrocephalus (5–10 %), and behavioral or intellectual problems (Long et al. 2008). The younger population, especially those under 2 years of age, has a high risk of learning disability. Delayed diagnosis, immunocompromised host, abscess rupture into ventricular space, and fungal etiology are associated with worse outcomes (Bonfield et al. 2015):

- Treatment consists of antibiotic therapy, as well as surgical intervention when indicated.
- Time is essential because rapid intervention leads to improved outcome.

---

## 15.2 Neurocysticercosis

Cysticercosis is a common parasitic infection accounting for 50 million infections worldwide with the most common manifestation being neurocysticercosis, but extraneural infections can

additionally be seen (Ndimubanzi et al. (2010)). Neurocysticercosis is a leading cause of seizures and epilepsy in developing countries (Leonard et al. 2006). It dates back to the time of ancient Greece, where it was known as the disease of the swine. Since the seventeenth century, it has been recognized as a disease which affects humans, and only since the second half of the nineteenth century has this pathogen been studied and understood. It is one of the few conditions included in a list of potentially eradicable infectious disease of public health concern, but it still remains a problem in our world today (Garcia and Del Brutto 2005).

### 15.2.1 Etiology

Worldwide distribution is higher in areas with poor sanitation. Neurocysticercosis is highly endemic in Central and South America, sub-Saharan Africa, India, and Asia. Hispanic race has more prevalence of neurocysticercosis due to countries of origin. Neurocysticercosis is the leading cause of foodborne disease and it is estimated by the World Health Organization estimates that 50 million people are infected with 2.8 million disability-adjusted life years worldwide. Because immigration rates have continued to increase in the United States along with increasing international adoption, the incidence of this disease is on the rise in the United States. Neurocysticercosis is currently one of the most common parasitic diseases of the central nervous system in the United States and a leading cause of epilepsy among Hispanic children living in US metropolitan areas along the Mexican border (Gershon et al. 2004).

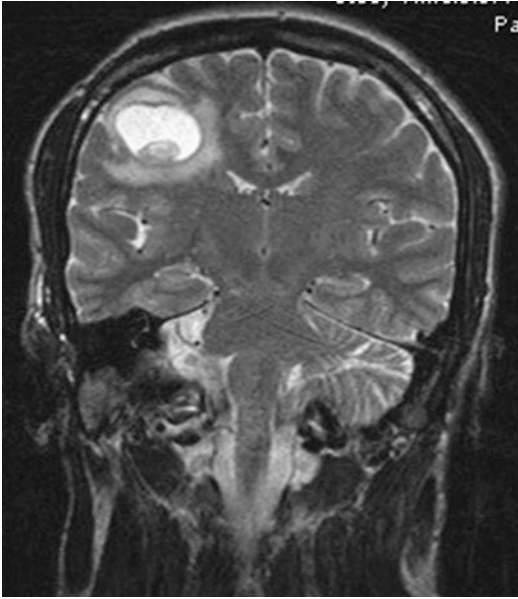
*Taenia solium* is the parasite responsible for neurocysticercosis. Parasite infections result when the adult pork tapeworm ingestion occurs from eating undercooked pork contaminated with the organism called *Taenia solium* (Leonard et al. 2006; Ndimubanzi et al. 2010). The pig is the intermediate host, where ingested larvae cysts embed themselves in the pig's muscle. Transmission can occur by ingesting eggs of the pork tapeworm or via the fecal-oral route (Wallin and Kurtzke 2004).

Incubation period from time of infection to presenting symptoms can be years. This has nursing implications as many born in developing countries do not know they are infected and can present with symptoms once settled in the United States (Wallin and Kurtzke 2004). Due to the long incubation period, age does not seem to predispose a person, although it is rare to see a child under the age of 2 years diagnosed with neurocysticercosis.

### 15.2.2 Pathophysiology

Upon reaching the human GI tract, the egg's thin outer membrane will dissolve, releasing the inner oncosphere or larvae. Oncospheres are released into the intestines and then migrate through the blood and lymphatic system before being distributed into tissues where they form cysts (Wallin and Kurtzke 2004). The oncospheres readily cross the intestinal lining but are usually destroyed by the immune system. They will escape the defenses of the host if they reach immunologically privileged sites, such as the central nervous system or eyes. In the CNS, the larvae tend to lodge in the small arterioles at the gray-white interface of the cerebral hemispheres and at the leptomeninges (Albright et al. 1999; Choux et al. 1999). However, the larvae can invade any part of the central nervous system, and once they invade, they will each mature into a cysticercus with a life span of approximately 18 months. The cysticercus is characterized by a head, body, four suckers, and some 20 pairs of hooks arranged as a crown (Choux et al. 1999).

The immunological response to the cysticercus lays the foundation for what is known as neurocysticercosis and manifests pathological changes like gliosis, necrosis, vasculitis, blockage of CSF drainage, meningitis, intracranial hypertension, and demyelination. Specifically with neurocysticercosis, the cysts form in the central nervous system. The types of infestation can be categorized according to location. These are parenchymal, meningeal, intraventricular, spinal, or mixed. Even once the cysticercus has died, inflammatory reactions can continue to occur for years (Fig. 15.3).



**Fig. 15.3** T2-weighted MRI showing a cystic lesion in the right parietal lobe with a nodule on the inferior aspect which represents the larvae of *Taenia solium*

### 15.2.3 Presenting Symptoms

The most common presenting symptoms are seizures, headache, and intracranial hypertension. Parenchymal forms manifest as convulsive disorders, motor or sensory deficit, or deterioration of consciousness. Meningeal involvement presents with photophobia, headache, nausea, vomiting, nuchal rigidity, and cranial nerve palsies (particularly II, V, VI, VII). Intraventricular infestation may manifest as intermittent acute hydrocephalus, which may result in loss of consciousness with position changes as the cyst blocks the flow of spinal fluid. Hydrocephalus with increased intracranial pressure is associated with a higher mortality rate. Spinal involvement has not been documented in children but presents in adults as motor or sensory deficit, with a combination of upper and lower motor neuron pathology.

### 15.2.4 Diagnostic Tests

Diagnosing is made with neuroimaging with CT or MRI (Saenz et al. 2006). Imaging can reveal

active cysts with or without calcified granulomas that represent nonviable cysts. In active disease, a ring-enhancing cyst is noted on CT or MRI, which may have surrounding edema. On these images, the larvae can sometimes be seen within the walls of the cyst (Fig. 12.3).

Confirmation can be obtained on serum and cerebral spinal fluid (CSF) with the enzyme-linked immunotransfer blot (EITB) assay that is used to detect the antibody to *T. solium* (Mody et al. 2005). This type of testing has a sensitivity of 98 % and specificity of 100 %, but in patients with only a single brain lesion, up to 30 % test negative (Garcia et al. 1991; Richards and Schantz 1991). CSF enzyme-linked immunosorbent assay (ELISA) for detection of antibodies or antigens to *T. solium* is also available and has a sensitivity of 87 % and specificity of 95 % (Rosas et al. 1986).

### 15.2.5 Treatment Options

Treatment is controversial and is based on the number of viable cysts seen on imaging. Symptomatic management is a mainstay with seizure control and reducing intracranial pressure a priority. Treatment with antiparasitic drugs can cause an inflammatory host response, and, therefore, if antiparasitic therapy is initiated, it should be done in combination with steroid therapy (Marconi et al. 2006). Antiparasitic agents that are used for treatment include albendazole (15 mg/kg/day) and praziquantel (50–100 mg/kg/day) and should only be considered when multiple viable cysts are seen (Sotelo 2004). The risks and benefits must be weighed before initiation of therapy. Patients without evidence of active disease, as evident by only calcified granulomas, do not require treatment and should receive supportive care with anticonvulsant therapy. In cases of encephalitis and intracranial hypertension, antiparasitic therapy is contraindicated because treatment may cause exacerbation of cerebral swelling and edema, leading to herniation and death (Gershon et al. 2004). Other medical management focuses on antiepileptic drugs (AEDs), steroids, analgesics, and osmotic agents. As stated,



steroids have a significant role with the initiation of antiparasitic therapy, since the destruction of the cysticerci may lead to significant and devastating inflammatory responses, resulting in increased intracranial pressure and even death.

Surgical therapy is indicated for the removal of space-occupying lesions causing significant mass effect and for the removal of seizure foci that are refractory to AEDs. Endoscopic removal is an option for ventricular lesions, and CSF diversion is often needed to treat communicating or obstructive hydrocephalus. In the case of obstructive hydrocephalus due to intraventricular neurocysticercosis, an attempt should be made to remove the lesion before shunting.

### 15.2.6 Nursing Care

Nursing care is essential during the administration of antiparasitic agents. Analgesics will play a major role, since many will experience headaches during antiparasitic therapy. One must also be on guard for signs of increased intracranial pressure, such as lethargy, vomiting, increasing headache, and unresponsiveness. Steroid administration should be initiated prior to antiparasitic therapy. Seizure precautions should be enforced to protect the child from injury.

### 15.2.7 Patient and Family Education

Neurocysticercosis can cause rapid deterioration, which can ultimately result in death. During discharge education, this needs to be emphasized, and the family should be instructed to seek immediate medical attention for any change in neurological status. Education should also focus on medications, since the child may be discharged on an AED, an antiparasitic agent or steroids.

Since a large proportion of pediatric patients inflicted with neurocysticercosis may be of Hispanic descent or from a part of the world other than the United States, an interpreter may be needed to help overcome the communication barrier. In addition, cultural issues may need to be

addressed, and special help may be sought from the hospital or community to help bridge any gaps. The family members should be screened for disease, especially if the family comes from an endemic part of the world. Also, the patient and family should be taught how the disease is transmitted. Education should focus on frequent handwashing and sanitary handling of food. If the family and patient plan to travel to endemic areas or areas with poor sanitation, caution should be undertaken in the consumption of foods from unsanitary restaurants or street vendors.

### 15.2.8 Outcome

Morbidity and mortality are based on whether the disease process is complicated or not. Most cysts are benign and resolve in 2–3 months. Children with a single cyst that can be controlled symptomatically have a favorable prognosis. If neurocysticercosis is treated properly, a cure rate of 90 % can be achieved in children. The real cure will not come from the treatment of the disease but only with the eradication of the parasite. Complications include increased intracranial pressure and difficulty controlling seizures, resulting in hydrocephalus, papilledema, and headaches; therefore, symptomatic management is crucial. Although complications are on the rare end of the spectrum, prognosis is less favorable when they are present.

With proper treatment, lesions will often disappear, seizures will resolve, and imaging studies will normalize. For these patients, AEDs may be tapered off in 2 years (Gershon et al. 2004). However, in one study, there was a reported rate of 50 % for seizure recurrence following cessation of AEDs after 2 years of treatment, indicating that the effects of neurocysticercosis on epilepsy may be lifelong (Nash et al. 2004). This may be the result of a permanent structural abnormality caused by neurocysticercosis that is responsible for the seizure foci. It is not known for certain the long-term effects on mental and cognitive development, but it is suspected that it plays a negative role.

## 15.3 Shunt Infections

Shunts continue to be the mainstay of treatment for hydrocephalus. These devices have reduced the morbidity and mortality of hydrocephalus but can become the target of infection. When this occurs, the child may suffer serious negative consequences, and treatment is needed immediately. The care of patients experiencing a shunt infection is, unfortunately, a common event that nurses will encounter often in a neurosurgical setting.

### 15.3.1 Etiology

The incidence of shunt infections averages between 5 and 15 % (Rehman et al. 2010) with 90 % occurring in the first month following surgery (Gutierrez-Murgas and Snowden 2014). Shunt infections most often result from colonization of the device by normally nonpathogenic skin flora. Ascending infections can occur, specifically with a ventricular peritoneal shunt in the setting of intra-abdominal infection, a ventricular pleural shunt in the setting of complicated pneumonia, and a ventricular atrial shunt in the setting of bacteremia. The main risk factors for shunt infection that have consistently been reported in the literature are length of procedure, frequent revisions, skin condition, defects causing communications with the CSF, etiology of the hydrocephalus, younger age, and number of people in the operating room (Choux et al. 1999; Gutierrez-Murgas and Snowden 2014; Klimo et al. 2014).

### 15.3.2 Pathophysiology

Shunt infections are unique from other types of CNS infections because they involve a foreign body. Often, the shunt becomes colonized at time of placement. Infection can also occur from wound breakdown, retrograde colonization from the distal end, or hematogenous seeding. The bacteria are able to adhere to the foreign body and secrete a biofilm made of glycolipids, which help protect the bacteria from host defenses (Albright et al. 1999; Gutierrez-Murgas and

Snowden 2014). The most common organism to cause a shunt infection is *Staphylococcal* species, specifically coagulase-negative *Staphylococcus* (i.e., *Staphylococcus epidermidis*), followed by *Staphylococcus aureus*. Other organisms that cause shunt infections include *Corynebacterium* and *Propionibacterium* which are typical skin colonizers. Less commonly would include gram-negative organism and *Candida* species.

### 15.3.3 Presenting Symptoms

Symptoms at presentation can initially be subtle and then progress to signs of increased intracranial pressure, including headache, lethargy, nausea, vomiting, irritability, seizure, and mental status changes. Additionally, due to the infection, fever can be seen. In neonates, the presentation may manifest as apneic spells, irritability, lethargy, or a bulging fontanel. A patient may additionally present with tenderness, erythema, or cellulitis over the shunt tract. Further, depending on the site of the distal end of the shunt, bacteremia can be seen with a vascular shunt or intra-abdominal infection with a peritoneal shunt. Shunt nephritis is unique to a ventriculovascular shunt in which immune complexes are deposited in the renal glomeruli causing proteinuria and hematuria.

### 15.3.4 Diagnostic Tests

Initial evaluation begins with serum white blood cell count (WBC), erythrocyte sedimentation rate (ESR), C-reactive protein (CRP), and blood cultures. In 25 % of shunt infections, the WBC will be normal, while in another 33 %, it will be greater than 20,000 cells/mm (McLone 2001). ESR and CRP are nonspecific but are rarely normal in shunt infections particularly if fever is present. Blood cultures are often negative with shunt infections, unless the distal end is in a vascular structure, which brings the rate of positive cultures to 90 % (Greenberg 2006). Collection of CSF via a shunt tap is desirable, since the fluid collected is in direct contact with the shunt. The fluid is sent for glucose,

**Table 15.1** CSF normal CSF values according to age (Gardner et al. 1985)

Age group	WBC/mm <sup>3</sup>	Protein (mg/dl)	Glucose (mg/dl)	Glucose ratio (CSF:plasma)
Preemie	10	150	20–65	0.5–1.6
Term infant	7–8	80	30–120	0.4–2.5
Infant 1–12 months	5–6	15–80	40–80	0.5
Infant 1–2 years	2–3	15	40–80	0.5
Young child	2–3	20	40–80	0.5
Child 5–15 years	2–3	25	40–80	0.5
Adolescent and adult	3	30	40–80	0.5

protein, cell count with differential, gram stain, and culture. Depending on the clinical suspicion, in addition to routine aerobic cultures, anaerobic, fungal, and acid-fast bacilli cultures may be necessary. CSF studies suggestive for infection include low glucose, high protein, and elevated WBC (Table 15.1). Head CT is not useful to determine infection but can show worsening hydrocephalus indicating shunt malfunction secondary to possible infection. Ultrasound or CT of the abdomen may be useful to determine the presence of a peritoneal cyst or fluid collection, also known as pseudocyst, which is suggestive of infection. If infection of a VA shunt is suspected, an echocardiogram should be obtained to assess for the presence of vegetations.

### 15.3.5 Treatment Options

Treatment of shunt infections includes removal of the device, external drainage, and parenteral antibiotics followed by replacement once sterilization has been achieved. External drainage can be provided by means of an external ventricular drain (EVD), intermittent ventricular taps, or lumbar punctures in the case of a communicating hydrocephalus. If the existing shunt is externalized, it is done distal to the site of ventricular insertion, usually at the level of the clavicle. Initial antibiotic therapy consists of vancomycin for gram-positive coverage and a third-generation cephalosporin for gram-negative coverage. Once identification of an organism is obtained, antibiotic therapy can be tailored to the organism, and the addition of rifampin or an aminoglycoside can be added for synergistic effect. Intraventricular injection of preservative-free antibiotics via an externalized shunt or EVD should be used with

caution and only in the setting where parenteral therapy has failed. The patient is reimplanted with a new shunt based on clearance of CSF and preference of the surgeon (Box 15.1).

Subacute bacterial endocarditis (SBE) prophylaxis is not indicated for patients with a shunt (American Academy of Pediatric Dentistry Clinical Affairs Committee 2009). VP shunts are not in the vascular space, and although a ventricular atrial shunt is in the vascular space, the American Heart Association has found no evidence of an increased risk of infection following dental procedures. Indications for SBE prophylaxis are patients with a prosthetic cardiac valve, prosthetic material used for cardiac valve repair, previous history of endocarditis, unrepaired cyanotic congenital heart disease, completely repaired congenital heart disease with prosthetic material, repaired congenital heart disease with residual defects at the site of a prosthetic patch, and cardiac transplant recipients who develop valvulopathy (American Academy of Pediatric Dentistry Clinical Affairs Committee 2009).

### 15.3.6 Nursing Care

Antibiotic therapy must remain on a tight schedule with no interruptions in treatment. Delay or missed antibiotics could lead to resurgence of the pathogen and delay the time for reimplantation. If the child's shunt is externalized or an external ventricular drain is placed, care should be taken to keep the exit site clean and dry. It is acceptable to place antibiotic or betadine ointment on the shunt wound initially, but more than 3 days of this treatment may cause the skin to macerate and prevent good healing. It is best to keep it clean

**Box 15.1 Case Study**

Laura is a 3-year-old girl with a right ventriculoperitoneal (VP) shunt admitted to the hospital for headache and purulent drainage from her scalp incision. She had a VP shunt placed at 1 year of age, and her last revision was 3 weeks prior to admission. The neurosurgeon took her to the operating room for removal of her VP shunt and placement of a ventriculostomy. Her CSF and wound were cultured and grew methicillin-resistant *Staphylococcus aureus* (MRSA). CSF glucose = 54, protein = 110, WBC = 150, and RBC = 2050. The infectious disease service was consulted, and initially she was started on IV vancomycin at 15 mg/kg every 6 h and IV ceftriaxone 50 mg/kg every 12 h. The ceftriaxone was discontinued when the cultures grew MRSA. Serial CSF sampling from the ventriculostomy every other day, weekly screening labs consisting of liver function tests (LFT), complete blood count with differential (CBC with diff), basic metabolic panel (BMP), and vancomycin trough were ordered. Also infectious disease recommended continuing vancomycin for 2 weeks after her first negative CSF culture although the shunt could be replaced after 5–7 days of negative CSF cultures. A PICC (peripheral intravenous central catheter) was placed to facilitate administration of the vancomycin. On hospital day 3, her CSF cultures were negative and remained so through her treatment.

On hospital day 3, the EVD site began growing staph aureus and rifampin 200 mg PO BID was added. Laura went back to the operating room so the EVD site could be changed. She had her shunt replaced 7 days after the EVD was changed per infectious disease recommendations. She was eventually discharged with home health continuing her course of vancomycin and rifampin for 2 weeks post-EVD removal and a return to neurosurgery clinic in 2 weeks.

and dry and to keep it covered with a sterile occlusive dressing, especially if the child is likely to pick and touch the wound or catheter.

Keeping the child occupied through playtime, schoolwork, or child life activities will help distract the child during their hospitalization. Pain and irritability are issues with shunt infections, and the child may experience headaches and fevers. Treatment with acetaminophen and ibuprofen helps to alleviate these symptoms in most children, but occasionally you may need to employ stronger agents, such as hydrocodone, morphine, or nalbuphine.

**15.3.7 Patient and Family Education**

It is vital to instruct parents and patients on the warning signs of shunt infections. Fever, headache, lethargy, anorexia, nausea, vomiting, irritability, and redness along the shunt track are all possible signs of oncoming shunt infection. After the shunt is revised, inform the family that infection recurrence is highest during the first 6 months, so constant surveillance is needed during this critical time. If the child is to be discharged on antibiotics, careful instruction needs to be given on proper delivery and schedule. Instructions on wound care and activity, as well as follow-up, will ensure a smooth transition from the hospital to home.

**15.3.8 Outcome**

Most children do well with proper and timely treatment. Mortality and morbidity depend on the virulence of the pathogen and underlying host factors, including immunosuppression (Long et al. 2008). A history of a shunt infection predisposes a child to future shunt infections and malfunctions, as opposed to those without a history (Kanev and Sheehan 2003; Gutierrez-Murgas and Snowden 2014). Chronic and repeated shunt infections are associated with intellectual, psychological, and neurological deficits with a lower IQ by 20 points, but little evidence supports this outcome for a single infection that is treated promptly and successfully (Albright et al. 1999; Fobe 1999; Kanev and

Sheehan 2003; Klimo et al. 2014)). Instruct parents to look for signs of developmental delay, and encourage them to seek assistance quickly if such issues arise.

## 15.4 Postoperative Infections

Postoperative infections are always a concern but can usually be prevented. Nursing plays a big role in this process.

### 15.4.1 Etiology

The etiology for postoperative infections depends on anatomical location of the infection. Keep in the mind the five Ws of postoperative fevers: wind, water, wound, walking, and wonder drug. The timing after surgery when a fever occurs dictates which process is the most likely etiology. For wind, this usually refers to lung processes, which occur in the first 48 hours postoperative. Atelectasis is the most common etiology in this setting and, if not properly addressed, will evolve into pneumonia by postoperative days 3–5. Water involves urinary processes from indwelling foley catheters, which become the source of fevers around postoperative days 3–5. Wound processes, such as wound infection and meningitis, can also present by postoperative days 3–5, while abscesses present later in the hospital course, usually starting after postoperative day 10. Walking refers to deep venous thrombosis and thrombophlebitis, which are a common finding in older children during postoperative days 6–10 but less common with the younger pediatric population. Wonder drug does not refer to an infective process but simply refers to medications that can cause fever in patients, such as phenytoin, or those which induce an allergic reaction.

### 15.4.2 Pathophysiology

The usual source for infection is bacterial, with viral and fungal being less likely. Pulmonary infections occur most often due to the underinflation of lungs

postoperatively, limited mobility, or from aspiration. The pathogen will vary depending on the mechanism involved. Urinary tract infections occur due to the foley acting as a conduit for bacteria to enter or from urinary retention that can result from opioid use. Sepsis can arise from bacterial introduction into the circulatory system from a central venous catheter but also can arise from a secondary source such as complex UTI. Postoperative wound infections occur from introduction of bacteria into the surgical bed during surgery. Skin flora is usually the culprit, but other pathogens not native to the skin are also implicated. More indolent skin pathogens such as coagulase-negative *Staphylococcus*, *Corynebacterium*, and *Propionibacterium* can take longer to present.

### 15.4.3 Diagnostic Tests

Initial evaluation involves fever curves and a white blood cell count with differential. Further testing can include blood culture, urinalysis, urine culture, sputum culture, and chest x-ray depending on the clinical manifestations. If a postoperative CNS infection such as meningitis is suspected, a lumbar puncture or sampling of a shunt can be diagnostic. Other studies for postoperative wound infections may include a wound culture, needle aspiration of fluid, CT with contrast, or MRI with contrast.

### 15.4.4 Treatment Options

The best treatment is prevention. Immediate mobilization after surgery, removal of indwelling catheters, and initiation of functional pulmonary toilet are key maneuvers in this preventive effort. Once infection is diagnosed, antibiotic therapy is indicated and should be tailored to the causative pathogen. If the infection involves the wound, surgical incision, drainage, and debridement may be indicated. In the unfortunate case of an infected prosthesis, such as a shunt or spinal hardware, removal is usually the treatment if possible, as infections can be difficult to eradicate in this setting.



### 15.4.5 Nursing Care

Nursing care has the main responsibility of prevention. This involves ambulating or getting the patient up into a chair in the immediate postoperative period. Some children refuse to use incentive spirometry or are too young to do so. Encouraging the children to blow soap bubbles, a pinwheel, or party horn also helps to expand the lungs and prevent atelectasis. Removal of indwelling devices, such as foley catheters, arterial blood pressure lines, and central venous catheters, in a timely manner is essential.

Surgical dressing should be left intact until the surgeon does the initial dressing change. If the initial dressing becomes soiled or is saturated, the physician should be notified immediately. In some cases, it suffices to keep the wound open to air after the initial surgical dressing is removed, but in other situations where the incision can become contaminated from bodily fluids, or if the patients continue to touch the incision, a dry dressing may be in order. If vigilance from the nursing staff or parents is not effective in preventing a child from touching his wound, elbow restraints or mitten gloves may be utilized. Avoid frequent prolonged use of wound ointments because they can delay healing or cause wound breakdown.

Antibiotics need to be kept on a tight time schedule, and antipyretics such as acetaminophen and ibuprofen are utilized to keep the patient comfortable. Routine use of antipyretics is not recommended because it may mask fevers and blunt the body's attempt to rid itself of infection.

### 15.4.6 Patient and Family Education

Instructing the family and patient on signs of infection will assist in early detection. Postoperative wound care should be a primary focus on discharge teaching. Problems with wounds that require reporting to the physician include erythema, drainage, increased pain, fever, and dehiscence. If the patient is to be discharged on antibiotics, teaching regarding the administration, timeliness, and duration should be addressed.

### 15.4.7 Outcome

Postoperative infections resolve with proper and timely treatment. The morbidity and mortality remain low, except in cases where detection and treatment were delayed.

#### Pediatric Practice Pearls

- In the presentation of fever, headache, and focal neurological deficit, nurses must be suspicious for infective intracranial process.
- Neurocysticercosis can occur anywhere in the CNS, and its presentation usually manifests as seizures or symptoms and signs related to increased intracranial pressure.
- *Taenia solium* is the parasite responsible for neurocysticercosis, and its transmission occurs via the fecal-oral route seen in the improper handling of foods.
- The average incidence of shunt infection is 5–15 %.
- In neonates, infection may manifest as apneic spells, irritability, and bulging fontanel.
- Once the infection is cleared, the shunt can be reimplanted, but the child will be at a higher risk for future infections.
- Most postoperative infections are preventable.
- Maintain good pulmonary toilet, encourage incentive spirometry as well as deep breathing and coughing, and mobilize the patient as soon as possible.
- When appropriate, remove all indwelling catheters and tubes promptly.
- Report fevers immediately; avoid routine use of antipyretics because this will mask fevers which cause a delay in detection.

## References

- Albright AE, Pollack IF, Adelson PD (1999) Principles and principles of pediatric neurosurgery. Thieme, New York
- American Academy of Pediatric Dentistry Clinical Affairs Committee (2009) Guideline on antibiotic prophylaxis for dental patients at risk for infection. *Pediatr Dent* 30(7 suppl):215–218
- Bonfield C, Sharma J, Dodson S (2015) Pediatric intracranial abscesses. *J Infect* 71(suppl):42–26
- Choux M, Concezio DR, Hockley A, Walker M (1999) Pediatric neurosurgery. Churchill Livingstone, New York
- Fobe JL (1999) IQ in hydrocephalus and myelomeningocele. Implications of surgical treatment. *Arq Neuropsiquiatr* 57:44–50
- Frazier J, Ahn E, Jallo G (2008) Management of brain abscesses in children. *Neurosurg Focus* 24(6):E8
- Garcia HH, Del Brutto OH (2005) Neurocysticercosis: updated concepts about an old disease. *Lancet Neurol* 4:653–661
- Garcia HH, Martinez M, Gilman R et al (1991) Diagnosis of cysticercosis in endemic regions. *Lancet* 338:549–551
- Gardner P, Leipzig T, Phillips P (1985) Infections of central nervous system shunts. *Med Clin North Am* 69:297–314
- Gershon AA, Hotez PJ, Katz SL (2004) Krugman's infectious diseases of children. Mosby, Inc, St Louis
- Greenberg MS (2006) Handbook of neurosurgery. Thieme, New York
- Gutierrez-Murgas Y, Snowden J (2014) Ventricular shunt infections: immunopathogenesis and clinical management. *J Neuroimmunol* 276:1–20
- Heilpern KL, Lorber B (1996) Focal intracranial infections. *Infect Dis Clin N Am* 10:879–898
- Hicks C, Weber J, Reid J, Moodley M (2011) Identifying and managing intracranial complications of sinusitis in children. *Pediatr Infect Dis* 30(3):220–226
- Kanev PM, Sheehan JM (2003) Reflections on shunt infection. *Pediatr Neurosurg* 39:285–290
- Klimo P, Thompson C, Baird L, Flannery A (2014) Pediatric hydrocephalus: systematic literature review and evidence based guidelines. Part 7: antibiotic impregnated shunt system versus conventional shunts in children: a systematic review and meta-analysis. *J Neurosurg Pediatr* 14:53–59
- Leonard R, Adickes ED, Brumback RA (2006) Neurocysticercosis. *J Child Neurol* 21(7):589–590
- Long SS, Pickering LK, Prober CG (2008) Principles and practice of pediatric infectious diseases, 3 edn. Churchill Livingstone, New York
- Lu C, Chang W, Lui C (2006). Strategies for the management of bacterial brain absces. *Journal of Clinical Neuroscience*, 13(10):979–985.
- Marconi VC, Garcia HH, Katz JT (2006) Neurocysticercosis. *Curr Infect Dis Rep* 8(4):293–300
- McLone DG (2001) Pediatric neurosurgery: surgery of the developing nervous system. WB Saunders, Philadelphia
- Menon S, Bharadwaj R, Chowdhary A, Kaundinya DV, Palande DA (2008) Current epidemiology of intracranial abscesses: a prospective 5 year study. *J Med Microbiol* 57:1259–1268
- Mody R, Nield L, Stauffer W, Kamat D (2005) Seizures in a 20-month-old native of Minnesota: a case of neurocysticercosis. *Pediatr Emerg Care* 21(12):860–862
- Nash TE, Del Brutto OH, Butman JA (2004) Calcific neurocysticercosis and epileptogenesis. *Neurology* 62:1934–1938
- Ndimubanzi P, Carabin H, Budke C, Nguyen H, Qian Y, Rainwater E, Dickey M, Reynolds S, Stoner J (2010) A systematic review of the frequency of neurocysticercosis with a focus on people with epilepsy. *PLoS Negl Trop Dis* 4(11)
- Osenbach R, Loftus C (1992) Diagnosis and management of brain abscess. *Neurosurg Clin N Am* 3:403
- Rehman A, Rehman T, Bashir H, Gupta V (2010) A simple method to reduce infection of ventriculoperitoneal shunts. *J Neurosurg Pediatr* 5(6):569–572
- Richards E, Schantz PM (1991) Laboratory diagnosis of cysticercosis. *Clin Lab Med* 11:1011–1028
- Rosas N, Sotelo J, Nieto D (1986) ELISA in the diagnosis of neurocysticercosis. *Arch Neurol* 43:353–356
- Saenz B, Ruiz-Garcia M, Jimenez E, Hernandez-Aguilar J, Suastegui R, Larralde C, Scitutto E, Fleury A (2006) Neurocysticercosis: clinical, radiologic, and inflammatory differences between children and adults. *Pediatr Infect Dis J* 25(9):801–803
- Saez-Llorens X (2003) Brain abscess in children. *Semin Pediatr Infect Dis* 14:108–114
- Sotelo J (2004) Neurocysticercosis – is the elimination of parasites beneficial? *N Engl J Med* 350(3):280–282
- Tekkok IH, Erbeni A (1992) Management of brain abscess in children: review of 130 cases over a period of 21 years. *Childs Nerv Syst* 8:411–416
- Wallin M, Kurtzke J (2004) Neurocysticercosis in the United States: review of an important emerging infection. *Neurology* 63(9):1559–1564

Sarah M. Lagergren and Gail C. Dustman

## 16.1 Preoperative Care

### 16.1.1 Providing Information and Guidance: Family-Centered Care

While the following sections separate parental and child preparation for surgery, it is important to realize that a family-centered approach is ideal. As Chorney and Kain (2010) state, “Families are an integral part of the perioperative care team and should be treated as such.” Utilization of preoperative preparation programs that are family-centered has been shown to lower preoperative anxiety for both child and parents and produce better child postoperative outcomes (less emergence delirium, decreased need for analgesics, and shortened time to discharge) (Chorney and Kain 2010).

### 16.1.2 Parental Preparation: Information Giving

An important part of the perioperative process is providing information to the parents of children

undergoing surgery. Parents frequently are more concerned with their child’s health than with their own and thus desire detailed information regarding the anesthesia process and surgery itself (Kain et al. 1997). Of particular concern to parents is the induction of anesthesia, emergence from anesthesia, and postoperative pain and nausea (Wisselo et al. 2004). A study by Kain et al. (1997) demonstrated that providing parents of children undergoing general anesthesia very detailed information regarding the anesthesia process and potential risks did not increase parental anxiety, and by doing so, parents have the opportunity to make a fully informed choice.

The perioperative nurse and anesthesia provider should ensure that information is given to the parents regarding premedication, induction of anesthesia, side effects of anesthesia, and postoperative pain management. A variety of modalities should be utilized when providing education to parents prior to surgery, such as combinations of written, audiovisual, and verbal information. Parents can also be involved in the meeting with a child-life specialist, who provides information regarding the perioperative period to the child through demonstration and role-play.

Ideal timing of parental preparation is 5–7 days prior to surgery (Wisselo et al. 2004). With scheduled neurosurgical procedures, this preparation can occur through mailings of written materials and/or videotape, during a health-screening telephone call made by a nurse, or as

---

S.M. Lagergren, MSN, APRN, ACCNS-P, CPN (✉)  
 G.C. Dustman, BSN, RN, CNOR, RNFA  
 Children’s Mercy Hospital, 2401 Gillham Road,  
 Kansas City, MO 64108, USA  
 e-mail: [smlagergren@cmh.edu](mailto:smlagergren@cmh.edu); [gdustman@cmh.edu](mailto:gdustman@cmh.edu)

part of a preoperative visit to the hospital to meet with an anesthesiologist and the neurosurgery team. Even prior to emergent procedures, it is important to provide time for parents to receive adequate information, time to process that information, and an opportunity to have their questions answered. Providing parents with additional preparation and information lessens anxiety and increases overall satisfaction with the perioperative period (Hatava et al. 2000).

### 16.1.3 Psychological Preparation of the Child

It is estimated that as many as 60 % of children undergoing anesthesia and surgery in the United States experience significant anxiety preoperatively (Kain et al. 2002). Anxiety and fear prior to surgery can prolong the induction of anesthesia, increase postoperative pain and analgesic requirements, and lengthen the recovery period (Kain et al. 2002). Moreover, this anxiety and fear may also lead to maladaptive postoperative changes in behavior that interfere with the daily functioning of the child. Thus, preparation of the child before surgery is an important part of the perioperative process. Both behavioral interventions (such as preparation programs that utilize education through therapeutic play) and pharmacological interventions (such as premedication with sedatives) are available to treat preoperative anxiety in children.

Behavioral preoperative preparation programs for children are highly recommended in the psychological and medical literature (Leack 2007). Most major pediatric hospitals offer such programs to children and their parents. These preparation programs may provide narrative information; a tour of the preoperative holding area, the operating suite, and recovery room; therapeutic role play using dolls; child-life preparation or coping skills education; and relaxation skills for children and their parents. Similar to adults, children benefit the most if they participate in the program 5–7 days prior to surgery (Wisselo et al. 2004). It is important to consider each child's age and developmental needs to

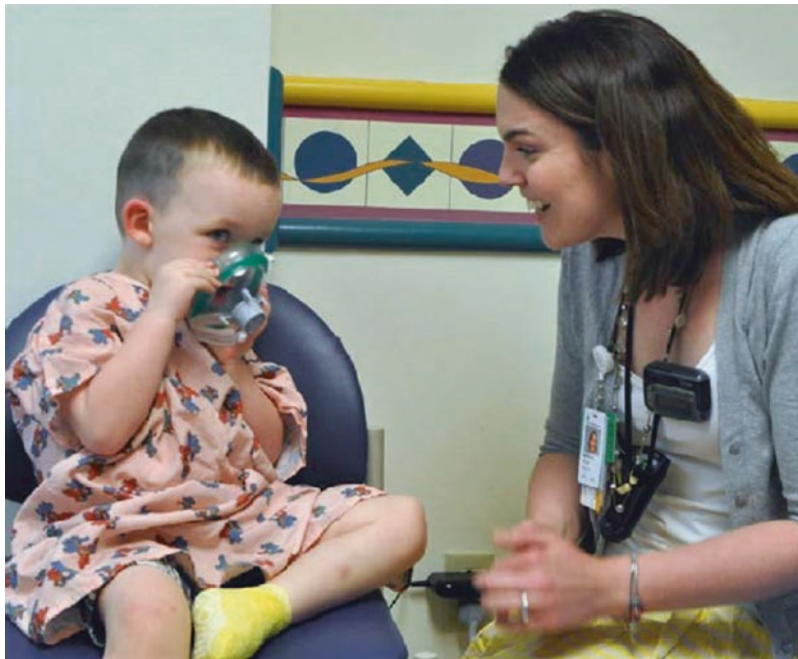provide a program that will be effective in reducing preoperative anxiety.

Literature has also shown that having a consistent anesthesia provider (anesthesiologist or nurse anesthetist) that provide ongoing dialogue and care during the perioperative process can reduce postoperative stress in children (Wennstrom et al. 2011). Wennstrom and colleagues found that by having continuity of care with the same anesthesia provider being at the preoperative, intraoperative, and postoperative encounter with the child led to decreased postoperative stress as measured by salivary cortisol levels. Moreover, they also found a reduction in the need for morphine as a postoperative analgesic (Wennstrom et al. 2011). Focusing on having continuity of care in providers, therefore, is important in the perioperative setting.

Child-life specialists play an important role in the behavioral preoperative preparation programs as well as preoperatively on the day of surgery. Child-life specialists facilitate coping and the adjustment of children and parents by providing play experiences, presenting information about the events and procedures, and establishing supportive relationships with children and parents (Kain et al. 1998a). To make information accessible to children, child-life specialists incorporate descriptions of the sensations that children will experience, provide opportunities for children to examine and manipulate equipment to be used in their care, and encourage rehearsal with dolls (Kain et al. 1998a). Child-life preparation has been shown to effectively reduce anxiety in the preoperative holding area and upon separation from parents (Kain et al. 1998a) (Fig. 16.1).

### 16.1.4 Preoperative Consultations and Assessment

Historically, the primary care pediatrician was asked to “clear” the patient for surgery and anesthesia (Ferrari et al. 2015). This practice is becoming obsolete as most major pediatric hospitals have created a perioperative process that includes this initial evaluation of the patient and much more. Ferrari and colleagues call such an



**Fig. 16.1** Child-life specialist helps patient become more familiar with oxygen mask

approach a “Perioperative Surgical Home.” Such a model “will result in a more comprehensive and integrated approach to surgical care, promoting standardization and integration in perioperative systems that will improve clinical outcomes, ensure high-quality patient-centered shared decision making, and decrease inefficient resource utilization” (Ferrari et al. 2015).

### 16.1.5 Surgeon/Anesthesiologist

The preoperative consultation and evaluation may occur on the day of the procedure or at a separate visit up to 1 month before the surgical date. This visit is often referred to as preoperative testing. The preoperative surgical evaluation should focus on identification of potential factors associated with frequently occurring perioperative complications and on those with high potential morbidity or mortality (Burd et al. 2006). In most cases, children at risk can be identified by a detailed history and physical examination performed by a qualified health-care provider, such as the surgeon, the advanced practice nurse, or

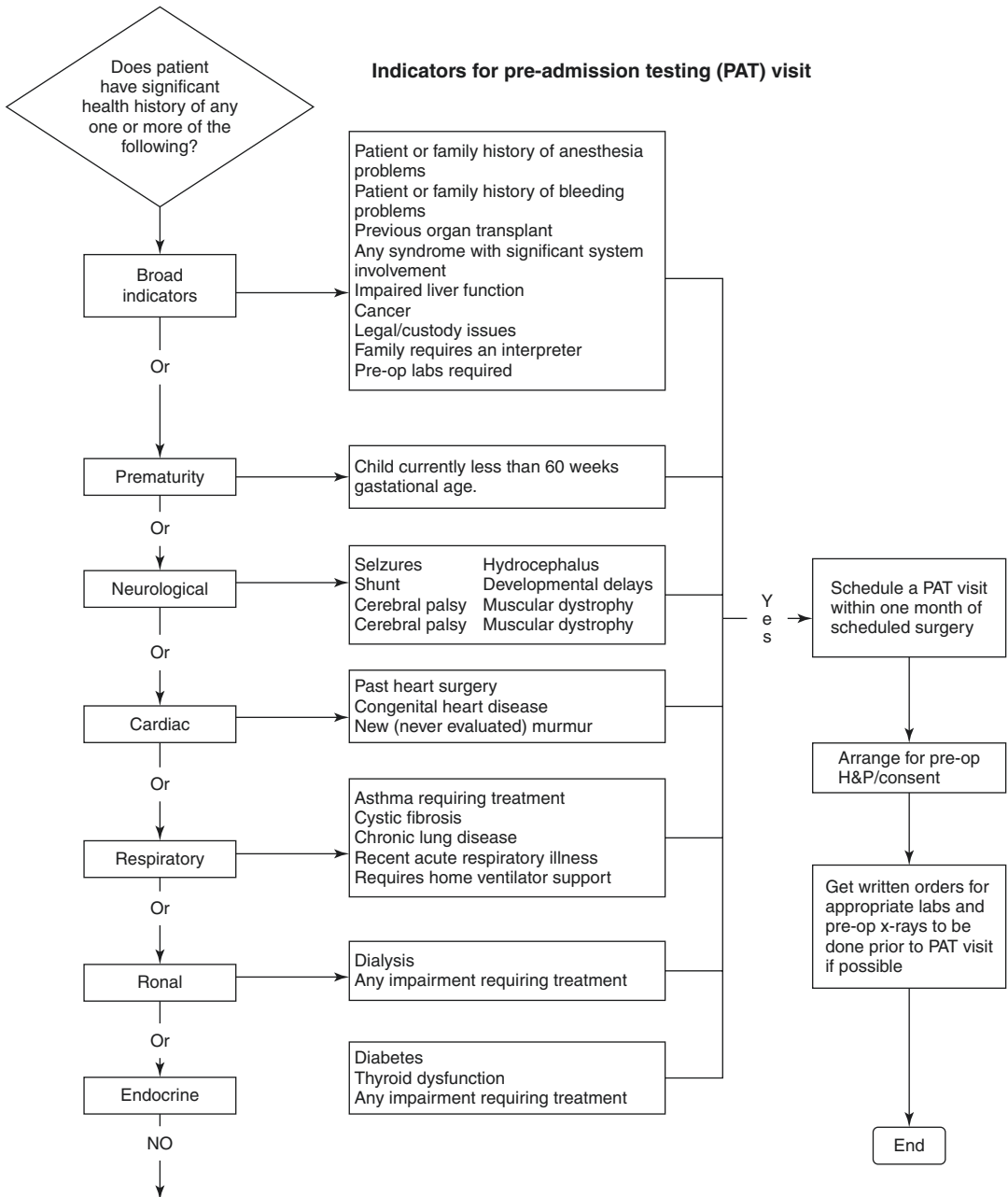
the anesthesiologist. Additional laboratory studies or other investigational studies are typically not necessary (Burd et al. 2006).

However, the pediatric neurosurgery patient may require additional studies. A preoperative visit and testing, therefore, is recommended for the scheduled pediatric neurosurgical patient, particularly for patients that are high risk with comorbidities. Any laboratory or additional studies will be ordered at this visit and obtained prior to the day of surgery. Even if additional studies are not needed, any surgical patient with a health history and a surgical procedure that inherently raises the risk of undergoing anesthesia should have a preoperative visit. The following figure provides an algorithm of indicators for a preadmission testing visit (Table 16.1).

In addition to a detailed history and physical, the surgeon and the anesthesiologist will obtain informed consent from the parent(s) or legal guardian of the child. The surgeon will discuss with the family the underlying condition for which the surgery has been recommended, a detailed description of the procedure, the risks, benefits and alternatives to the procedure, and the



**Table 16.1** Indicators for preadmission testing (PAT) (Developed at Children’s Mercy Hospitals and Clinics, Kansas City, MO)



possible outcomes that may occur after surgery. Aspects of the anesthetic are similarly presented by the anesthesiologist. Opportunity is provided for questions and clarification prior to the signing of consent. Although much of the informed consent discussion occurs between the surgeon or

anesthesiologist and the parent, the input of the patient must also be solicited, as may be developmentally appropriate. The procedure should be explained to the child in a manner that the child understands. For older children, assent (the agreement of someone who is not competent to

give legally valid informed consent) should be sought. During the consent process with the anesthesia provider or during the visit with the child-life specialist, the child is also given the opportunity to choose the “flavoring” or scent of anesthesia gas that will be used during induction. Standard options include bubble gum, strawberry, banana, grape, and orange. Consent for blood products, if applicable, is also obtained at this time.

### 16.1.6 Nursing

If the pediatric neurosurgical patient does not have a preoperative visit, typically a nurse working in the perioperative area will make a telephone call to obtain a health screening as well as to provide helpful information about what the parents and child can expect on the day of surgery. Standard questions asked during the health-screening phone call or during the initial nursing health history obtained on the day of surgery include:

- Presence of any allergies or adverse reactions to food, medications, or latex
- Current medications including any over-the-counter medicines, inhalers, ointments, vitamins, or herbal supplements
- Birth history
- Meeting developmental milestones/developmentally appropriate for age
- Review of systems, specifically the presence of heart, lung, liver, or kidney issues
- Diagnosis of a seizure disorder, thyroid disorder, diabetes, or asthma
- Diagnosis of any other health conditions or syndromes
- Use of medical equipment (ventilator, CPAP, oxygen, monitors, etc.)
- Previous surgeries
- History of any problems with anesthetics (specifically malignant hyperthermia, more below) or bleeding disorders in the patient and/or biological family
- Immunization status
- Recent exposures to contagious illnesses

- Presence of recent or chronic illness, particularly respiratory illnesses
- If an adolescent female, start of menarche and date of last menstrual period

One specific condition, though rare, that is very important for the nurse performing the preoperative intake to identify is a personal or family history of malignant hyperthermia (MH). MH is a rare life-threatening condition that is usually triggered by exposure to certain drugs used for general anesthesia—specifically the volatile anesthetic agents and succinylcholine, a neuromuscular blocking agent. According to the Malignant Hyperthermia Association of the United States (MHAUS), MH is not usually associated with other serious medical problems. MH or MH-like events, however, can occur in patients who have underlying muscle diseases, such as muscular dystrophy, when exposed to triggering anesthetic agents (MHAUS 2016). For example, in patients with Duchenne muscular dystrophy, succinylcholine should always be avoided as rhabdomyolysis can occur (MHAUS 2016).

At the preoperative visit, if any, and on the day of surgery, a nurse will perform a physical assessment on the pediatric surgical patient. The nurse’s physical assessment includes a brief head-to-toe examination, focusing in detail on the condition of the skin, particularly at the proposed surgical site, neurological status and function, and cardio-respiratory status and function. The nurse will obtain the child’s current height and weight and, if under 3 years of age, or if indicated, head circumference. The child’s vital signs, including blood pressure, heart rate, respiratory rate, oxygen saturation, and temperature, are also obtained and recorded preoperatively and used as baseline data for the perioperative period.

---

## 16.2 Physical Preparation

### 16.2.1 Labs

Routine laboratory testing of the pediatric surgical patient is no longer recommended. Laboratory testing should be determined by the medical con-

dition of the child and the nature of the surgery to be performed. For the pediatric neurosurgery patient, laboratory tests that may be necessary for surgical management include a complete blood count (CBC) with differential (including hemoglobin and hematocrit), a complete or basic metabolic panel (CMP/BMP), and any others specifically indicated for the patient. Depending on the facility, females over the age of 10 years may need to provide a urine sample for a UCG or blood sample for an HCG pregnancy test.

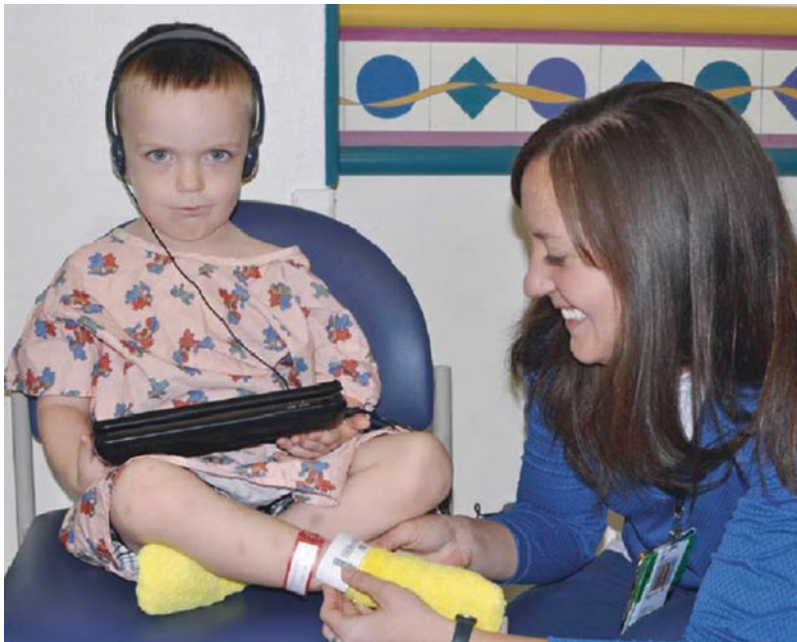### 16.2.2 Blood

Depending on the type of neurosurgery, it may be necessary for the child to undergo blood typing in case of the need for a blood transfusion during the procedure. For the patient who has little or no need for a blood transfusion, a type and screen should be ordered and completed. In a type and screen, the blood bank will determine the patient's blood type and screen for antibodies, but no units of blood will be crossmatched and set aside in the blood bank for that patient until

requested by the advanced practice nurse or physician. If the need for blood is expected or likely, then a type and cross is necessary. With a type and cross, units of blood will be crossmatched and held for the patient in the blood bank. If a child needs a transfusion, packed red blood cells are the preferred product, as it provides the benefits of increasing the oxygen-carrying part of the blood without adding too much extra volume. The patient who undergoes a type and screen or cross will obtain a special blood identification band that should be on the patient at all times. Care must be taken to maintain the integrity of the blood band so that identification information is readable (Fig. 16.2). It is important to note that blood bands have an expiration date, with few exceptions, which varies from facility to facility but is usually 72 h or 3 days.

### 16.2.3 Images

Imaging tests may be necessary for a pediatric neurosurgery patient before proceeding to surgery. Depending on the nature of the condition,



**Fig. 16.2** Nurse checks identification and blood bands on day of surgery

the patient, and the preference of the surgeon, the child may undergo x-rays, a CT or MRI scan with or without contrast, or with an image-guided protocol to help guide the surgeon. It may be necessary for the child to undergo sedation in order to obtain these images. Imaging provides the neurosurgeon with vital information necessary to perform the procedure as well as a baseline in order to monitor changes in the patient's condition over time.

### 16.2.4 Dietary Restrictions

Prior to surgery, it is necessary for the patient to fast in order to reduce the risk of aspiration while under anesthesia. Children have higher fluid requirements for size than adults, and prolonged preoperative fasting may cause dehydration, hypoglycemia, ketosis, and discomfort from hunger. Therefore, the standard preoperative fasting for pediatric patients as recommended by the American Society of Anesthesiologists is clear liquids up to 2 h before surgery, breast milk up to 4 h before surgery, and infant formula, milk, or regular diet up to 6 h before surgery. It is important that the perioperative nurse clearly communicate and review the preoperative dietary restrictions with the patient and family. Utilizing the teach-back method in which the parent repeats back the eating and drinking instructions can help to ensure that the information has been clearly communicated and received. A violation of these dietary restrictions could result in a delay or cancelation of surgery or, if not detected, an increased aspiration risk to the patient.

### 16.2.5 Preoperative Medication

Anxiolytic medications can be used in conjunction with or as an alternative to behavioral programs to reduce preoperative anxiety in the pediatric surgical patient. In addition to decreasing anxiety, preoperative anxiolytics provide amnesia for the separation of the patient from the family, create a quiet environment during the induction of anesthesia, and can also provide

analgesia. Midazolam is the most common anxiolytic used preoperatively in children, as it has a rapid onset of action, is highly effective, and has low toxicity. The preferred method of administration of midazolam is orally in the preoperative holding area. Within 10–20 min of oral administration, patients experience amnesia (typically will not remember separation from parents or induction of anesthesia), decreased anxiety, and light sedation.

Other common preoperative anxiolytics used in pediatrics include clonidine and diazepam. Like midazolam, both can be given orally. Clonidine and diazepam take about 30–45 min to begin to take effect and thus must be given earlier than midazolam in the preoperative intake process. Both clonidine and diazepam have the additional benefit of also acting as analgesics.

Children who receive a preoperative medication for anxiety should be continually monitored in the holding area in order to ensure the child's safety. They should be held by their parents or placed on a cart. Heart rate, respiratory rate, and oxygen saturation should be monitored. It is important to note that in susceptible individuals, anxiolytic medications, particularly midazolam, can cause a paradoxical reaction with increased anxiety, aggressive or violent behavior, uncontrollable crying or verbalization, and similar effects. Thus, it is important for clinicians and parents of the child to determine if utilizing a premedication will be advantageous for the well-being of the child.

### 16.2.6 Separation from Parents Versus Parental Presence upon Induction of Anesthesia

Some facilities permit a parent to accompany the child to the operating room and be present during the induction of anesthesia, while others do not. At facilities in which parental presence at induction is not the norm, children may receive a premedication anxiolytic to aid in the separation and induction process. The practice of parental presence at induction is a common method used to decrease perioperative anxiety, and this practice

has significantly increased in the United States during the past decade (Burd et al. 2006). Early studies of this practice showed that parental presence at induction was less effective at reducing anxiety, when compared to premedication with oral midazolam (Kain et al. 1998b). But more recent studies have shown that, if selectively applied and proper parental preparation is done, it can be an effective alternative to premedication (Kain et al. 2002).

For parental presence during induction, it is primarily important to ensure patient safety. If the anesthesia provider suspects that the child may have airway problems during induction, or the child is too young to warrant parental presence, then no parent will be present. Studies have shown that children who benefit the most from parental presence are those older than 4 years of age who have either a calm baseline personality or a mother who has a calm baseline personality (Kain et al. 1998b). If parental presence is acceptable to the anesthesia provider and family, the parent selected must want to be present and willing to undergo preoperative preparation for the experience (Romino et al. 2005). The parent should be informed about the sequence of events, how the child will look during anesthesia induction, and how the child may react, as well as what the parent's role will be. The parent may sit next to the child or comfort the child in the parent's lap as inhalation anesthesia commences. Parents are encouraged to touch, sign, tell stories, and reassure their child during anesthesia induction. The parent is escorted from the induction area/operating room when the child is no longer aware of his/her surroundings. It is helpful for a nurse to act as a support for the parent during this process and to guide them as necessary.

The potential benefits of parental presence during induction include avoiding the need for premedication, avoiding the child's resistance to separation from parents, and decreasing perioperative anxiety and postoperative behavioral problems related to perioperative anxiety (Kain et al. 2002). An additional benefit is a more positive perioperative experience for the family. Presence at induction is viewed favorably by parents as most believe that they have contributed to

reducing their child's stress and are themselves less anxious and more satisfied (Kain et al. 2000). Patients and parents who will benefit from presence at induction should be considered on a case-by-case basis, and as stated, it is key that proper parent selection and preparation occur in order to be effective.

### **16.2.7 Advance Preoperative Activities of OR Nurses**

It is incumbent on the perioperative nurse to ensure that everything that could be needed is present on the day of surgery for each scheduled patient. In the days or even weeks before the scheduled surgical procedure, any instruments, implantable devices, and other special equipment requested by the surgeon will be ordered. This could involve customization of an implant for a specific patient, which would require that the nurse send scans, radiographs, and/or measurements to the company manufacturing the implant. It may also be necessary to educate the nursing staff on the specifics of a particular item so that all will be familiar with it on the day of surgery.

---

## **16.3 Intraoperative Care**

### **16.3.1 Introduction**

The intraoperative care of the pediatric neurosurgical patient is a collaborative effort involving the nursing staff, anesthesia providers, surgeons, and other health-care professionals with the goal to achieve the best possible outcome for patients and their families. Nurses in the perioperative setting are multifaceted, and they function in various capacities. They may scrub or circulate. They may be assistants during surgery, or registered nurse first assistants (RNFA), acting in collaboration with and under the direction of the surgeon. They may also be advanced practice nurses, such as pediatric nurse practitioners (PNP) or clinical nurse specialists (CNS). Each role is vital to the team as a whole. These nurses are educators and preceptors, teaching new operating room nurses



their respective roles and responsibilities and educating future health-care professionals about the scope of practice of the perioperative nurse. Perioperative nurses provide patient care within the framework of the nursing process, utilizing skill in patient assessment, care planning, intervention, and assessing patient outcomes (Spry 2005). The perioperative nurse depends on knowledge of surgical anatomy, physiologic alterations, and their consequences for the patient, intraoperative risk factors, potentials for patient injury and the means of preventing them, and psychosocial implications of surgery for the patient and significant others. This knowledge enables the perioperative nurse to anticipate needs of the patient and surgical team and rapidly initiate appropriate nursing interventions. This is part of patient advocacy, of doing for the patient what needs to be done to provide a safe and caring environment (Meeker and Rothrock 1999).

### 16.3.2 Day of Surgery: Preparation of the Operating Room

On the day of surgery, each member of the surgical team arrives at the operating room suite and dons hospital-approved, facility-laundered surgical attire. All head hair is covered by a surgical hat, and a surgical mask is required once a sterile field is created (Association of Perioperative Registered Nurses (AORN) 2016). Each member of the team has an assigned task. There may be a scrub nurse, an RNFA, and one or two circulating nurses, depending on the acuity of the case. All members of the team participate in getting the operating room readied for the procedure.

The air-handling system is assessed to ensure that a positive air pressure environment is maintained in the operating room in which the procedure will occur. Appropriate ventilation systems are important in controlling infection by minimizing microbial contamination (Meeker and Rothrock 1999). The ambient air temperature is elevated to assist in the patient's thermoregulation during anesthetic induction. Each flat surface and operating light in the room is wiped with germicidal cloths and allowed to air-dry. All equip-

ment in the operating room is placed in position for the scheduled procedure and tested to ensure it is in optimal operating condition. These may include the suction apparatus, fluid warming/slush unit, smoke evacuation system, electrocautery unit, microscope, power drill, neuronavigation system, the ultrasonic aspirator, lasers and the Mayfield, and DORO or horseshoe headrest apparatus. The arrangement of the equipment in the room is determined by the procedure to be performed.

The operating table is prepared for the patient, taking into consideration the patient's size and the procedure being performed. A warming/cooling device is placed on the operating table to assist in the maintenance of normothermia. Perioperative hypothermia is estimated to occur in 50–90 % of all cases. It can lead to increased intraoperative bleeding, postoperative tachycardia, impaired wound healing, and greater postoperative discomfort (Meeker and Rothrock 1999). An impervious drape and then the bed linens are applied to the table. Positioning of the patient for the procedure is carefully considered, and all needed positioning aids are secured. These may include gel rolls, gel pads, gel head rings, foam head rings, foam padding, bean bags, Z-flo fluidized positioners, and arm boards to aid in positioning and prevent skin breakdown during the procedure. A forced-air machine and appropriate-size warming blanket are made available for anesthesia's use during each procedure.

If the neuronavigation system is to be utilized, the team ensures that the correct MRI scan is loaded into the system and that the needed attachments are verified by the unit and are ready for use. Surgeon-specific irrigating solutions and intraoperative medications are retrieved from the pharmacy, paying careful attention to any documented allergies or sensitivities. Anti-embolism stockings or sequential compression devices are brought to the room to be placed on the patient for prevention of venous pooling and subsequent formation of deep vein thromboses.

The patient's most recent MRI, CT scan, US, or radiographs are displayed for review by the surgical team. If the patient has been typed and screened or crossmatched for blood products, a

call is placed to the blood bank to determine how many units of blood product are available for the patient. If neurophysiologic monitoring or corticography has been requested, the technician's availability is ascertained. The same is true for any manufacturer's representative who might accompany a piece of new equipment or an implantable device. If intraoperative radiographs are to be taken, the radiology technician is notified of the projected start time of the surgery.

Each surgical specialty may have surgeon-specific preference cards. It is the responsibility of the scrub nurse to ensure that the appropriate instruments and supplies are gathered for each procedure. The surgical team then prepares the sterile field, using strict sterile technique. Every piece of equipment or item to be placed on the sterile field is examined for any breach in sterility. Each product expiration date is examined. Sterile drapes are utilized to create the sterile field, and every item introduced to the field is done so in a manner that maintains the item's sterility and integrity. Once a sterile field is created, it is constantly guarded and maintained (Association of Perioperative Registered Nurses AORN 2010). This is the responsibility of the entire surgical team, throughout the procedure. Traffic flow is kept to a minimum, with as little movement as possible, to diminish the number of airborne microbial contaminants entering the field.

Next, the entire surgical team gathers for a daily surgical briefing or "huddle." This allows the team to discuss the plan of care for each of their scheduled patients. This will include a review of the medical record and past medical/psychosocial history, allergies and sensitivities, laboratory test results, pertinent radiographs/scans, the planned surgical procedure, special equipment or implants needed, and any anesthesia concerns, including regional anesthesia. Teamwork and effective communication are essential to safe perioperative patient care (Rothrock 2015). Meeting in a daily "huddle" also allows for any changes to the plan of care to be discussed and begins the discussion of postoperative care for each patient. The "huddle" also helps to build a more cohesive surgical team.

With the operating room ready, the scrub nurse goes to the scrub sink and performs a

surgical hand scrub, using an antimicrobial surgical scrub agent with a sponge/brush and nail cleaner. The scrub should last at least 5 min and includes all surfaces of the nails, fingers, hands, and arms up to 2 in. above the elbow. During this process, the arms are held away from the body, in a flexed position, with the fingertips pointing upward (Spry 2005). In recent years, alcohol-based hand rub products have become available. Prior to use of these products, it is necessary to perform a thorough nail cleaning and hand washing with soap and water. The hands and arms are rinsed and dried, using a clean towel. The product is applied and rubbed until dry. The scrub nurse reenters the operating room and dons a sterile gown, with the assistance of the circulating nurse, and sterile gloves and begins to organize the sterile field.

### 16.3.3 Readyng the Patient for the Operative Procedure

It is the circulating nurse who goes to preoperative holding to retrieve the patient. Usually, this nurse is the last member of the perioperative team to interview the patient and family, and it is *this* nurse who is the patient's advocate throughout the entire intraoperative process. By now, the surgeon has visited the patient and family and has obtained consent for the procedure. If laterality (right or left side) is an issue for the scheduled surgical procedure, the surgeon will have marked the surgical site with his or her initials. The anesthesia provider has interviewed the family and has determined that the patient is well enough to undergo the scheduled procedure and has met the NPO parameters. The anesthesia provider has also obtained consent for a general anesthetic, administration of blood products, and any planned regional anesthetics.

The circulating nurse introduces himself or herself to the patient and family and reviews the patient's chart. Of primary concern to the circulating nurse is the proper identification of the patient. It is best practice that the patient's identity be confirmed by using at least two identifiers (name, date of birth, and medical record or account number) (The Joint Commission 2012).

The circulating nurse will verify that the child's wristband is in place and accurate. Some hospitals may also issue wristbands to parents, while others have different policies regarding parental identification. Whatever the institutional policy, the circulating nurse must verify the identity of the parent/legal guardian so that information about the child is obtained from and given to proper, legally authorized persons. If the use of blood products is anticipated, the nurse also checks to see that an identification blood band is present on the patient and this number is documented on the patient's chart.

The preoperative nursing documentation is reviewed, as is the anesthesia assessment and anesthesia consent. A current history and physical should be present and signed by the surgeon. The circulating nurse assesses the developmental level of the child, checks motor function, checks the condition of the child's skin, and is sure that all metallic objects, such as hair adornments, and jewelry have been removed. All home medications are reviewed. Results of any ordered lab tests are present and reviewed with the anesthesia provider and the surgeon as necessary. Baseline vital signs are reviewed and any preoperative medication administration is noted.

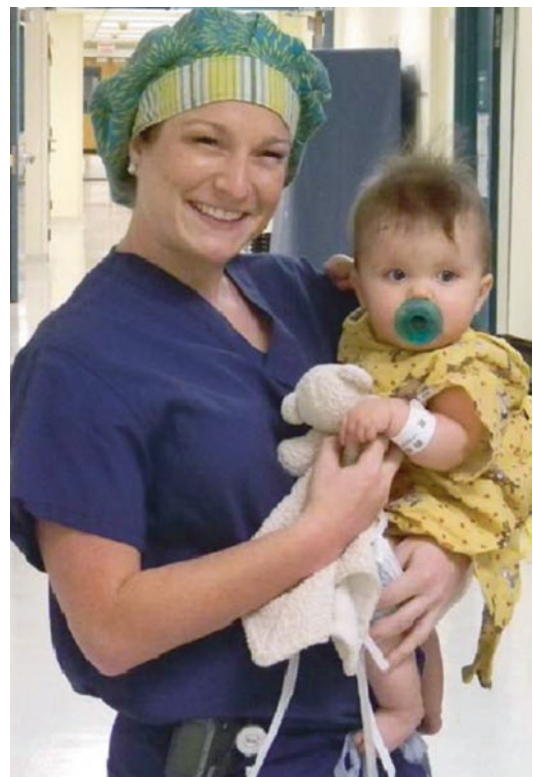A verbal confirmation of the NPO status and any allergies or sensitivities are received from the parent/legal guardian. The parent is asked to describe the procedure that their child will be undergoing, to acknowledge their understanding of the procedure, and their signature is verified on the operative consent. The circulating nurse then explains what will happen to the child from the time the family unit is separated until they are reunited once again. The family is told that they will be notified by phone when the procedure has begun and that they will be given updates as the procedure progresses. The child's and family's anxiety levels are assessed, and every attempt is made to develop a comfortable relationship with this family unit in a very short amount of time. All of the family's questions are answered as honestly as possible.

Allowing the child to bring a toy or blanket with them to the operating room gives the child a familiar item in foreign surroundings and may increase their sense of security (Association of

Perioperative Registered Nurses (AORN) 2010). The goal is always to minimize the ordeal of separating the child from the family, and, as previously discussed, some facilities even permit a parent to accompany the child into the OR. To allow the child a sense of autonomy, they may walk to the operating room, if able. If unable or premedicated, they may be carried or brought in their hospital bed, radiant warmer, wagon, wheelchair, stroller, or a stretcher, utilizing safety straps to prevent falls during transport (Fig. 16.3).

### 16.3.4 Anesthesia

Upon entering the operating room with the patient, the circulating nurse will introduce the patient to the operative team. The patient will have assistance transferring to the operating table, if needed, and noise will be kept to a minimum, providing a quiet and calm environment. The patient's modesty will be protected at all



**Fig. 16.3** Carrying the child to the operating room can sometimes be less scary than riding on a cart

times. Care of the patient at this time is under the direction of the anesthesia provider and his or her team. The circulating nurses and RNFA are present to support their efforts and to protect the patient. Warm blankets are placed over the patient and a seat belt is utilized as a safety measure.

An oxygen saturation probe is attached to the finger, EKG pads and leads are placed, a temperature monitor is placed in the patient's axilla, and a blood pressure cuff is applied. Anesthetic induction may be accomplished with an IV induction or with anesthetic gasses and a mask. Once the patient is asleep, an appropriately sized endotracheal tube or laryngeal mask is placed by the anesthesia provider, with the assistance of the circulating nurse, and it is secured. If a peripheral IV is not present, one is started at this time by the anesthesia team. For craniotomies, it is preferable to have two, large-bore peripheral IVs and an arterial line placed. A CVP line may be placed, as well. The patient's eyes are lubricated and gently kept closed with tape or a Tegaderm. A urinary catheter, with urometer, is placed by the circulating nurse and secured. Sequential compression stockings or anti-embolism stockings are applied, if indicated (Raffini et al. 2009).

A dispersive electrocautery pad is applied over clean and dry skin, preferably over a large muscle mass, on the incision side and as close to the surgical incision site as possible. Care is taken to avoid tattooed skin, as some tattoos may contain metallic dyes, to avoid placement over implantable devices, and to avoid placement over hairy surfaces. If hair removal is necessary, care is taken to utilize clippers to minimize injury to the skin (Rothrock 2015). The dispersive pad is a disposable, adhesive foil pad, covered with foam and impregnated with electrolyte gel. Electrosurgery utilizes electric current to cut and coagulate tissue. The purpose of the dispersive pad is to return current released from the electrosurgery handpiece, thereby diminishing the heat that builds in the surrounding tissues and returning the current to the generator (Phillips 2007). It acts as a ground pad for the patient, preventing electrical burns.

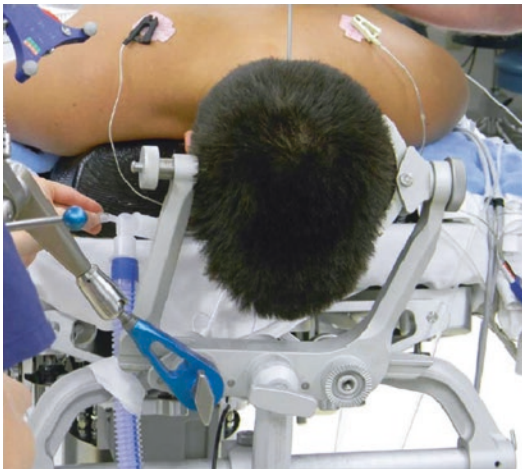
### 16.3.5 Positioning

With the assistance of the surgeon, the patient is positioned on the operating table for the procedure. The team takes into consideration the potential for tissue injury, peripheral nerve injury, musculoskeletal stress and strain, and crush injury from moving table parts. The patient's dignity is maintained as much as possible during the positioning process. Also of consideration are the surgeon's need for adequate exposure of the surgical site and the anesthesiologist's accessibility to the patient (Phillips 2007). It is the responsibility of the entire surgical team to assure that each patient leaves the operating room with no injury related to intraoperative positioning. This is accomplished under the direction of the anesthesia provider. The patient is positioned safely, maintaining proper body alignment. Care is taken to protect the patient's skin, especially over bony prominences, and to ensure that peripheral nerves are not stretched or depressed, which can cause permanent damage. All extremities are secured to prevent them from falling from the operating table or resting on any hard surfaces (Meeker and Rothrock 1999). Many types of positioning aids are utilized to accomplish this in the safest manner possible for the patient.

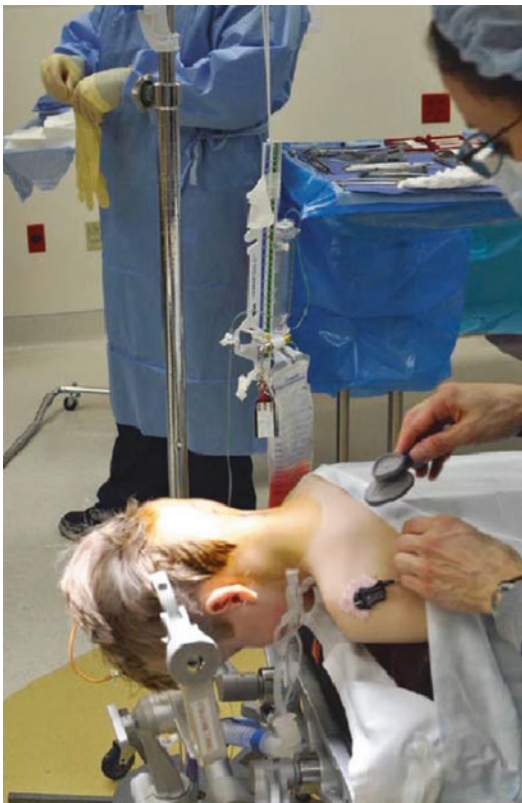For most craniotomies for tumor resection, the Mayfield or DORO headrest is utilized (Fig. 16.4). It attaches to the head of the operating table and is a three-point skull fixation apparatus. It is applied by the surgeon as a final step in the positioning process and can be utilized with the patient in the supine, lateral decubitus, or prone position. For Chiari decompression and posterior fossa tumor resection, the patient is in the prone position with the head fixed in the Mayfield or DORO headrest (Fig. 16.5). Although care is taken to apply appropriate pin pressure, occasionally a CSF (cerebrospinal fluid) leak or epidural hematoma can result from penetrating the inner table of the skull.

For ventriculoperitoneal shunt placement and vagal nerve stimulator placement, the patient is





**Fig. 16.4** The patient's head is secured in a Mayfield headrest, a three-point fixation device



**Fig. 16.5** Anesthesia provider checks for breath sounds in preparation for posterior fossa tumor resection. Note the ventriculostomy

usually in the supine position with the head turned to the left or right (Fig. 16.6). For lumbar shunt placement and baclofen pump placement, the patient is in the lateral decubitus position (Fig. 16.7).

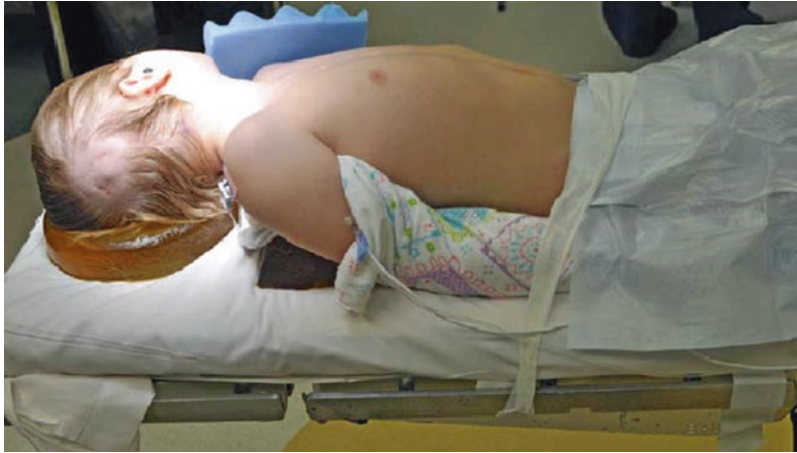### 16.3.6 Hair

Hair should not be removed from the surgical site unless required (Rothrock 2007). The need to remove hair is based upon surgeon preference and the procedure to be performed. Cranial surgery without hair removal does not increase the risk of infection (Simona et al. 2016; Winston 2011). If hair is to be removed, it is done with clippers, not a razor, by the surgeon after the child is secured on the operating table. Shaving is not recommended as it has been shown that postoperative wound infection rates are higher for those patients that are shaved preoperatively as compared to those who have no shave prep or a small amount of hair clipped (Rothrock 2007). Hair that is clipped is placed in a bag with a patient label and sent out of the operating room with the patient for the family. Sometimes this is a child's first haircut and may become part of a baby book! Every attempt is made to clip as little hair as possible as we know that this loss of hair affects each patient's body image. At the close of the procedure, the nurses will perform a hair wash, if needed, to remove blood and proteins that have collected in the hair during the surgery, and a dressing may be applied to the surgical incisions. The first glimpse of their child after a surgical procedure can be very overwhelming and emotional for parents, and loss of hair may be the first thing they see.

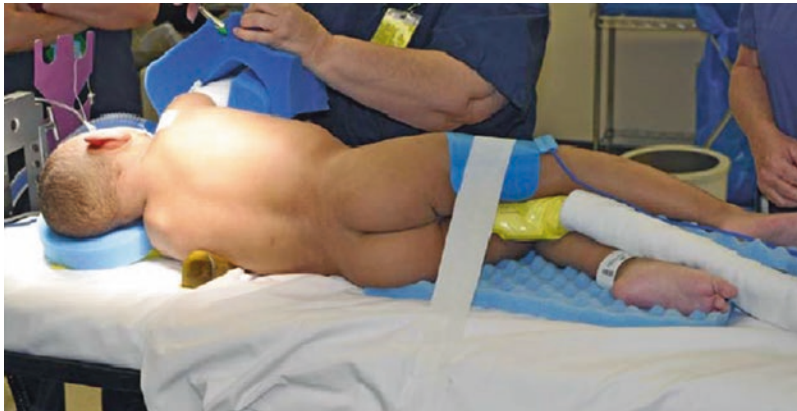### 16.3.7 Surgical Time-Out

The Joint Commission, which accredits and certifies health-care organizations in the United States, has established a 2012 National Patient





**Fig. 16.6** Positioning for revision of right occipital ventriculoperitoneal shunt. A gel ring is used to position the head



**Fig. 16.7** Intraoperative positioning for baclofen pump or lumbar drain. Note the *blue* electrocautery pad placed on right thigh and foam padding to prevent skin breakdown over bony prominences

Safety Goal as the elimination of wrong site, wrong patient, and wrong procedure surgery (The Joint Commission 2012). Accordingly, it is recommended that, once the patient is positioned and secured, the entire surgical team participates in a surgical time-out. This includes, but is not limited to, review of the patient's name, allergies, procedure, position, whether antibiotics have been given, and the presence of any special instruments, implants, or services. Each member of the team must verbalize their agreement in order for the procedure to go forward.

### 16.3.8 Surgical Procedure

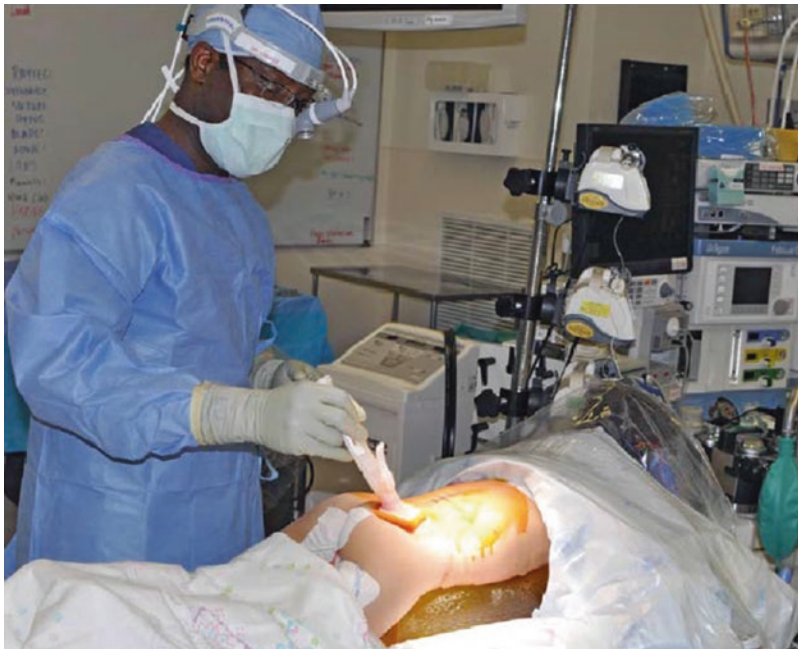The surgical site should be confirmed before the preparation of the skin for surgery, and the surgical site mark should remain visible after skin antisepsis. The preparation of the patient's skin is a two-step process. In the first step, the circulating nurse performs a sterile scrub preparation of the skin around the site of the surgical incision. The circulating nurse dons sterile gloves and uses sterile supplies during the scrub prep. The prep site is dried utilizing dry, sterile towels. The purpose of this scrub is to reduce the number of gross con-

taminants and oils that may block penetration of the antiseptic agent on and near the incision site (Association of PeriOperative Registered Nurses (AORN) 2010). The choice of scrub agent is determined by the surgeon, taking into account any patient allergies or sensitivities, the condition of the skin, and the type of contaminants and the age of the patient. An odorless agent that produces a nice lather effect and is nonirritating to the skin is most typically preferred (Rothrock 2007).

The second step is for the scrub nurse or the surgeon to apply an antiseptic or antimicrobial agent. While the patient's skin is being scrubbed by the circulating nurse, the surgeon and the surgical assistant will perform surgical hand scrubs and don sterile gowns and gloves. The surgeon will then apply a topical antiseptic agent to the surgical site (Fig. 16.8), being careful to prevent soaking the patient's hair and pooling of the solution beneath the patient. Prolonged contact with antiseptic solutions has been shown to produce chemical burns, and pooling of flammable skin antiseptics is a fuel

source and poses a fire hazard. (Association of PeriOperative Registered Nurses (AORN) 2016). The selected solution should decrease the microbial count of the skin rapidly, be applied quickly, remain effective throughout the procedure, and be nonirritating. Alcohol preparations, tincture of iodine, chlorhexidine preparations, and iodophors meet these criteria (Fox et al. 2000). The applied antimicrobial agent is allowed to air-dry prior to draping the patient with sterile towels and sheets (Association of PeriOperative Registered Nurses (AORN) 2010).

Once the patient's skin has been prepared and sterile drapes have been applied, the scrub nurse and the circulating nurse accomplish the initial counts of sharps and sponges. These numbers are documented on a dry-erase board in clear sight of the surgical team and will reflect any changes made to these counts throughout the procedure. Counts will be meticulously performed by the scrub and circulating nurses throughout the procedure, when there is a change in scrub personnel



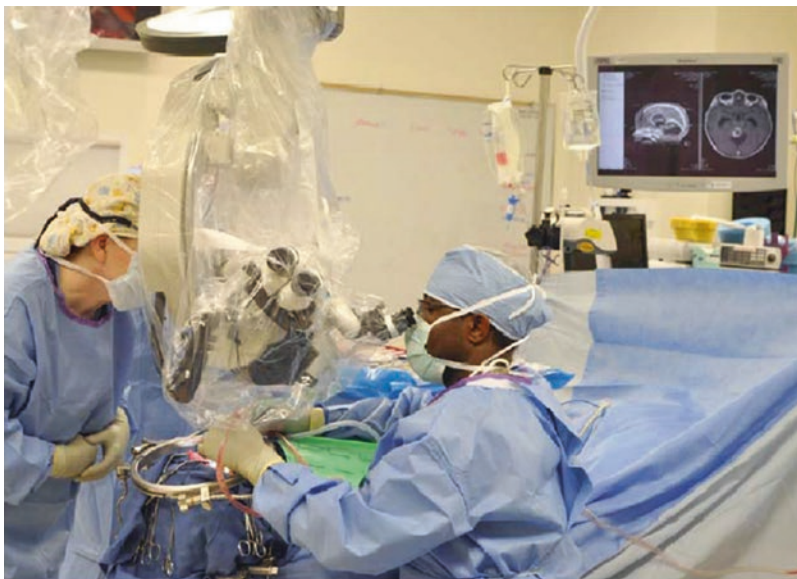**Fig. 16.8** The neurosurgeon applies an antimicrobial agent to the skin in preparation for lumbar laminectomy and tethered cord release

and at the completion of the procedure. These counts protect the patient from an injury caused by a retained foreign object (Association of Perioperative Registered Nurses (AORN) 2010). When the surgical procedure begins, the circulating nurse calls the waiting family and gives them a brief report. The family is updated throughout the procedure by the circulating nurses or the neurosurgical advanced practice nurses.

The circulating nurse documents what happens to the patient from the moment of entry into the operating room until the moment of departure. The patient assessment and nursing diagnoses are recorded, and each specific nursing intervention in the plan of care has an expected, desired outcome. The patient's responses to these interventions and deviations from the expected outcomes are recorded, as well. For example, an expected outcome would be that the patient is free from signs and symptoms of injury related to positioning. Other information documented includes, but is not limited to, times in and out of the operating room; times of incision and closure; the persons present during the procedure and their roles; patient positioning and positioning aids utilized; placement of catheters and drains, personnel placing them, and their sizes and lot numbers; place-

ment of the electrocautery dispersive pad and the personnel placing it; electrocautery unit used with the selected settings; warming/cooling devices used, type of unit, and their respective temperature settings; location of skin preparation; skin preparation solutions used and the personnel applying them; intraoperative medication administration, including dose and mode of application and personnel applying; specimen and culture collection; placement of implanted medical devices and all FDA tracking information; wound classification; instruments, sharps, and sponge counts; and times of communication with waiting family members.

All specimens taken during the procedure are sent immediately to pathology or to the surgeon's lab of choice. All sent specimens include a patient label, a description of the specimen, the time and date the specimen was procured, and the initials of both the scrub nurse and the circulating nurse. If the surgeon is requesting that a frozen section be taken, the phone number into the operating room is also included so that the pathologist and the surgeon can communicate about the results. A frozen section provides the surgeon with a preliminary tissue identification and can aid in determining the scope of the tumor resection (Fig. 16.9).



**Fig. 16.9** The neurosurgeon uses the microscope and image-guided MRI to assist with tumor resection

The circulating nurse is also attuned to the physiologic changes occurring to the patient while in the operating room. In collaboration with the anesthesia provider, close attention is paid to the patient's temperature, heart rate, blood pressure, oxygen saturation, ventilation, IV fluid administration, intraoperative laboratory results, urine output, and estimated blood loss. Estimated blood loss is documented on the same dry-erase board as the sharp and sponge counts and is meticulously updated by the circulating nurse.

At the conclusion of the surgical procedure, the drapes will be removed and the dispersive electrocautery pad will be removed. Positioning devices will be removed, and the patient will then be returned to the supine position under the direction of the anesthesia provider. The urinary catheter will then be secured for transport. The patient will be examined for any pressure ulcers or any interruption to skin integrity. The surgical team will lastly participate in a surgical debriefing. It is here that postoperative plans for the patient will be discussed which the circulating nurse will report to the PACU nurse.

### 16.3.9 Transfer of Care

Prior to leaving the operating room, the circulating nurse will call the pediatric intensive care unit (PICU) and give a verbal report to the nurse who will care for the patient. If the patient is to be recovered in the postanesthesia care unit (PACU), a verbal report will be given upon arrival by the circulating nurse to the nurse recovering the patient. The anesthesia provider will give a verbal report to these nurses as well. Any personal items brought to the operating room by the patient will be labeled with a patient identification sticker and transferred with the patient to these units.

There is widespread consensus that using a structured, standardized handover whenever a patient is being transferred from one hospital location to another (for instance, OR to PACU or PACU to ICU/surgical unit) is critical for

safe patient care (Kalkman 2010). By using a standardized tool in the patient handoff process for postoperative pediatric cardiac surgery patients, Agarwal et al. (2012) found a decrease in loss of patient information, an improvement in the quality of communication among care providers, a decrease in postoperative complications, and an overall improvement in 24-h patient outcomes. Many facilities are utilizing the electronic health record (EHR) to automatically pull key patient information to support the verbal handover process (Kalkman 2010). Regardless of the handoff tool or checklist used, it should be tailored to fit the specific care setting and handover type (Kalkman 2010).

---

## 16.4 Postoperative Care

### 16.4.1 Criteria for PACU Recovery

During the neurosurgical procedure, it is important for the surgeon and anesthesiologist to collaborate together, not only to ensure optimum patient outcomes but also to determine what will be the best immediate recovery course for the patient. The surgeon and anesthesiologist should take into account the complexity of the neurosurgical procedure, intraoperative occurrences, age of the child, preoperative condition of the child, and other comorbidities when deciding where the patient will go after the OR. Options include patient recovery in the postanesthesia care unit (PACU), and then transfer of care to the pediatric intensive care unit (PICU) or to a regular inpatient medical/surgical unit, or the patient may require an immediate transfer of care to the PICU. Reasons pediatric neurosurgical patients may require an immediate transfer to the PICU include the need for continued mechanical ventilation to manage increased intracranial pressure, substantial blood loss during the procedure, or high potential for neurologic deterioration.

Historically, patients who underwent a neurosurgical procedure required at least an overnight stay in the intensive care unit (ICU) to



ensure close monitoring and frequent neurologic assessments. Many facilities, however, are transitioning from this practice of routine post-neurosurgery ICU stays to a regular surgical unit stay for postoperative patients who meet an established set of criteria. This change in practice arose due to challenges with access to ICU beds and the cancellation of surgeries because of lack of available nurses for the ICU setting (Douglas and Rowed 2005). Criteria to determine which postoperative neurosurgical patients should go to the ICU or the surgical unit immediately following their anesthetic recovery in the PACU are based on patient diagnosis, preoperative condition, comorbidities, the surgical procedure, intraoperative complications, and postoperative status (Douglas and Rowed). Regardless of whether the patient goes to the PICU or the surgical unit, the standard of care should remain the same. Moreover, as Westcott and Dunn (1998) state, “the demands of neurosurgical nursing require that nurses manage acute situations and pick up subtle changes in a patient’s condition to ensure proper treatment is given promptly. The nature of many neurosurgical conditions is such that small changes in function are often early signs of life-threatening conditions.” It is important, therefore, that if the patient is transferred to a surgical unit rather than the PICU in the immediate postoperative period, nurses specifically trained to care for pediatric neurosurgical patients are available to provide care. Additionally, an appropriate nurse-to-patient ratio that is based on acuity level of the patient should be utilized to ensure safe care is provided on the surgical unit.

### 16.4.2 PACU Recovery

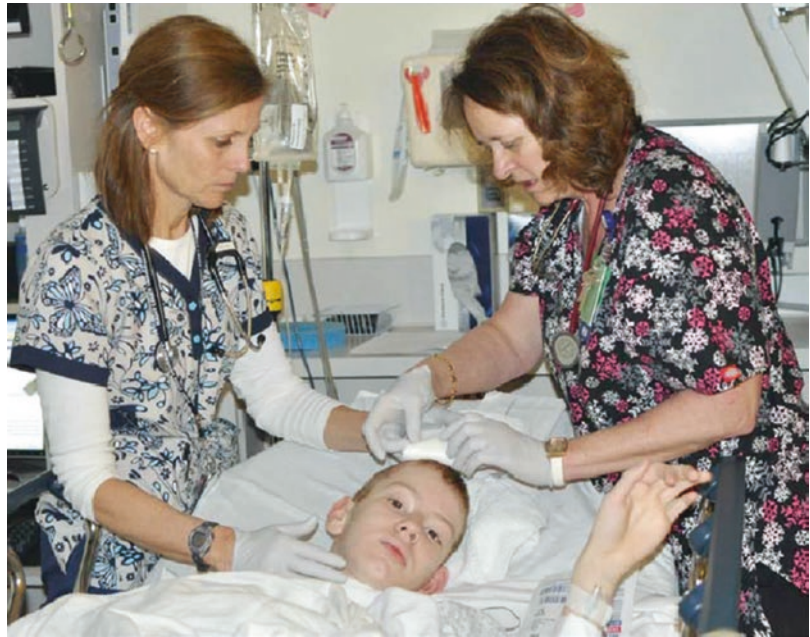The typical duration of stay in the PACU after a neurosurgical procedure is 1–2 h. Upon arrival to the PACU, a primary nurse and one to two secondary nurses are ready to take over caring for the patient. The circulating OR nurse and

anesthesia provider provide a detailed report to the primary PACU nurse, including surgical procedure, dressing, drains, intraoperative fluids and blood products given, medications administered, urine output, blood loss, and any other important occurrences during the intraoperative period. The PACU nurses apply monitors to the patient, including cardiorespiratory, continuous oxygen saturation, and blood pressure, and obtain a full set of vital signs. An end-tidal carbon dioxide monitor may also be utilized if indicated. An end-tidal carbon dioxide monitor provides important information regarding the respiratory status of the intraoperative and postoperative child by measuring the amount of carbon dioxide in exhaled gas. It can alert the PACU nurse if the child is experiencing hypoventilation due to oversedation or possibly from neurologic compromise. Once report has been completed and all questions and concerns have been addressed, the care of the patient now resides in the PACU nursing staff, who reports to and consults directly with the anesthesia providers as needed during the patient’s PACU stay (Fig. 16.10).

While the patient recovers in the PACU, the nursing staff is responsible first and foremost in maintaining the patient’s airway. Depending on the facility, patients may arrive to the PACU still intubated with an endotracheal tube or laryngeal mask airway, or they may be extubated and require supplemental oxygen, whether via blowby oxygen or other more aggressive airway interventions. PACU nurses are specially trained to assess and manage airway complications and provide necessary interventions including breathing treatments, chin lifts, jaw thrusts, use of continuous positive airway pressure, and oral or nasal airways and provide manual ventilation via bag and mask as needed. In instances in which the PACU nurse is not able to maintain the airway, the anesthesia providers are immediately available to intervene and provide assistance. Other key aspects of the care provided in the PACU include a focused assessment of the patient, routine checks of vital signs, monitoring



**Fig. 16.10** Nurses in PACU redress craniotomy incision



for potential complications, and treatment of pain and/or nausea and vomiting.

The primary nurse caring for the patient initially determines when the patient is ready for discharge from the PACU and transfer to the PICU or medical/surgical unit. Once the patient has met certain criteria, such as a maintained airway, is arousable and able to respond appropriately, has stable vital signs, and has achieved an adequate level of pain relief and the surgical site remains secure, the primary nurse initiates a bedside consult with the anesthesia provider to obtain a discharge order. The anesthesia provider in collaboration with the neurosurgery team and PACU nurse determines at this final step in the perioperative process that the patient is ready for transfer and that the postoperative level of care required (ICU or medical/surgical unit) remains appropriate for this patient.

### 16.4.3 Parental Presence

Similar to parental presence at induction of anesthesia, the presence of parents in the PACU

varies from facility to facility. Regardless of facility policy, parental presence is always dependent on the postoperative condition of the child and the psychological preparation of the parent(s). The ability of the anesthesia provider and perioperative nurses to anticipate which children may develop serious postoperative complications requiring critical intervention, thereby postponing parental presence in these cases until the child is stabilized, is also key when implementing a program of parental presence upon anesthesia emergence (Hall et al. 1995).

Findings from a study by Burke et al. (2009) found that parents felt comfortable in the PACU setting and reported a high degree of helpfulness in comforting their children. While the Burke et al. study found that parental presence did not decrease agitation upon emergence from anesthesia in young children, there was a significant psychosocial benefit to the parents. Nurses in the study rated parent helpfulness as high, and parent upset, anxiety, and fear very low, indicating that parental presence does not hinder patient care (Burke et al. 2009). In the case of children with

special health-care needs, the parent can assist the child and enhance the staff's ability to assess the child. The anesthesia provider and perianesthesia nurses should consider these potential benefits of the presence of parents in the immediate postanesthesia period, but must also ensure that patient safety comes first.

#### 16.4.4 Parental and Patient Guidance

Whether or not parents will be present in the PACU, it is important that a member of the neurosurgery or perioperative team provide information to the parents and patient (as is developmentally and age appropriate) about what to expect postoperatively. Typically, the neurosurgery patient will have at least one intravenous catheter, if not multiple, and may have an arterial and/or central line too. The patient will be on a continuous cardiorespiratory monitor and pulse oximetry monitor, as well as have blood pressure monitored at intervals. The patient may have an indwelling urine catheter in place to closely monitor output and may have drains coming from the surgical site that drain blood or cerebral spinal fluid. If the patient goes directly to the ICU from the OR, he or she will likely still have an endotracheal tube in place and will be manually ventilated until placed on a mechanical ventilator.

In addition to the medical monitors and devices in place, it is also important to provide parents a general description about what to expect in regard to the child's appearance. The child may appear pale. There may be dressings at the surgical site that have drainage ranging from bloody to serous. The child may also have facial swelling due to prone positioning during the procedure, the particular procedure itself, or an imbalance in fluid status. Parents and the child should be reassured, as needed, concerning postoperative appearance and the presence of monitors or devices in order to alleviate any anxiety or fears.

#### 16.4.5 Assessment

After a neurosurgical procedure, close observation with serial neurologic examinations and hemodynamic monitoring is helpful for the prevention and early detection of postoperative complications. In the PACU and the immediate postoperative period, a full set of vital signs including heart rate, respiratory rate, blood pressure (arterial pressure if invasive monitoring is present), oxygen saturation, temperature, and pain should be obtained and a focused neurologic exam performed every 15 min or more often if needed. Refer to Chap. 1 regarding how to perform a neurologic assessment. In the immediate postoperative period, a full neurologic assessment may not be possible, as the patient will be sedated and/or drowsy. The nurse should at the minimum monitor responsiveness (alert, verbal, tactile, pain, unresponsive), pupil size, symmetry and reaction to light, as well as symmetry and strength of movement of facial muscles and extremities if the patient is able to follow commands.

Postoperatively, the surgeon will place a specific set of orders regarding the care of the child. For the neurosurgery patient, the nurse should pay particular attention to how high to elevate the head of the bed (such as 15° or 30°) or specific positioning and movement of the patient (e.g., supine, prone, or log roll). If the patient has any surgical drains, including an external ventricular drainage (EVD) system, the nurse should note whether the drains should be opened or closed, and what level they should be set at, and monitor the output for amount, color, and clarity. Prior to moving or repositioning the patient, care should be taken that the EVD is closed to the patient to prevent sudden changes in the drainage of cerebral spinal fluid and intracranial pressure. The patient may require postoperative labs. These should be obtained as soon as possible and results provided to the ordering physician, as further interventions may be needed.

### 16.4.6 Monitoring and Treatment of Potential Complications

Key complications that nurses and other health-care providers should monitor for in the immediate postoperative period include respiratory dysfunction, bleeding, seizures, diabetes insipidus, cerebral salt-wasting syndrome, nausea and vomiting, and pain. Airway edema may occur from the presence of an endotracheal tube for intubation during the procedure, particularly with procedures that require prone positioning. Use of intravenous steroids (e.g., dexamethasone), nebulized breathing treatments with racemic epinephrine, or continued endotracheal intubation may be required to treat the airway edema. With surgery to the posterior fossa region of the brain, early postoperative swelling may cause respiratory control to be compromised, leading to postoperative respiratory failure and the need for continued intubation and mechanical ventilation.

Postoperative bleeding may occur after any surgical procedure. To detect postoperative bleeding in the post-neurosurgical patient, close monitoring and frequent assessments for changes in the neurologic exam are important, as well as monitoring the output of any surgical drains. A decrease in responsiveness/level of consciousness, the presence of posturing, and a change in pupil size, symmetry, and reaction to light are key indicators of a postoperative head bleed. The surgeon should be immediately notified. The patient will likely need to return to the OR as soon as possible in order to obtain the best possible outcome.

Seizures may occur postoperatively in the patient with or without a known history of seizures. Patients who undergo insertion of a vagal nerve stimulator (VNS) for seizure control continue to be at risk for seizures in the postoperative period. Lobectomies are another neurosurgical procedure in the PACU nurse should closely monitor for seizures. A new onset of seizures in the postoperative period may be indicative of neurologic compromise, possibly from bleeding, and

requires the immediate attention of the neurosurgeon.

Diabetes insipidus is another possible complication after neurosurgery in the region of the hypothalamus and pituitary gland. Nurses should monitor for excessive dilute urine output. This condition can be managed acutely with an intravenous infusion of vasopressin.

Cerebral salt-wasting syndrome and resulting hyponatremia may also occur after a surgical procedure in the brain. In cerebral salt-wasting syndrome, excessive renal sodium is excreted from a centrally mediated process. Hyponatremia results, with primary symptoms being polyuria, or excessive urine output due to inadequate sodium retention in the body, polydipsia (excessive thirst), and dehydration. Severe hyponatremia can be detected by the following symptoms: muscle cramps, dizziness, tachycardia or bradycardia, hypotension, facial flushing, nausea/vomiting, decreased level of consciousness, and seizures. Treatment includes hydration via IV fluids and administration of sodium to correct the deficiency.

Postoperative nausea and vomiting can occur after any surgical procedure but is particularly harmful in the post-neurosurgery patient as it can cause sudden rises in intracranial pressure. Postoperative nausea and vomiting should be treated with a nonsedating antiemetic. Prophylactic treatment of postoperative nausea and vomiting with a 5-HT<sub>3</sub> serotonin reuptake inhibitor (e.g., ondansetron) is often used as well. Following craniotomies in children, however, the use of ondansetron prophylactically was not effective in decreasing the incidence of vomiting (Furst et al. 1996). Alternative antiemetics may need to be utilized.

### 16.4.7 Assessment and Treatment of Pain

After any surgical procedure, the assessment and treatment of pain is key to a successful recovery. In the past 20 years, many changes in the under-

standing and treatment of acute pain in infants and children have occurred. It is now understood that infants and children experience a severity of postoperative pain similar to adults and thus should be provided with adequate treatment.

To assess pain in the immediate postoperative period, health-care providers utilize a variety of methods. Vital signs are examined for indication of pain, such as elevated heart rate, respiratory rate, and blood pressure. Behaviors are observed, including facial expression, movement of legs/ extremities, activity (posturing/movement), cry, and consolability (FLACC pain scale). If awake and able to comprehend and cooperate, the child may also be able to indicate his or her pain by utilizing a scale, such as FACES or VAS (visual analogue scale) which indicates the intensity of pain on a continuum from no pain to the most pain one could possibly experience (Hockenberry and Wilson 2009).

The World Health Organization provides a clinical ladder for pain treatment depending on the degree of pain from mild to severe. For mild pain, nonsteroidal anti-inflammatory drugs (NSAIDs) or acetaminophen should be given via the oral route. NSAIDs and acetaminophen act through inhibition of the enzyme cyclooxygenase, thereby blocking the synthesis of prostaglandins that stimulate free nerve endings of the peripheral nervous system. These agents have a ceiling effect so that after a certain plasma concentration is achieved, no further analgesia is provided by increasing the dose.

For moderate pain, NSAIDs or acetaminophen with a weak opioid (such as oxycodone, hydrocodone, or codeine) can be given orally. Or IV opioids may be used via patient-controlled analgesia (PCA), which is a continuous infusion of opioid with as needed rescue doses, or fixed-interval dosing of an opioid. In pediatrics, common opioids used include fentanyl, morphine, and hydromorphone. Opioids can cause respiration depression when administered, and thus care must be taken to closely monitor the patient's respiratory status.

For severe pain, IV opioid by PCA or regional anesthetic techniques (such as nerve blocks or a continuous epidural infusion) should be used

along with continued use of an NSAID or acetaminophen. If a patient is unable to tolerate an oral prostaglandin inhibitor, IV ketorolac (NSAID) may be used. Ketorolac is contraindicated in patients who have kidney dysfunction and bleeding disorders or in settings in which acute hemorrhage is a concern; therefore, it may not be indicated for use in the postoperative neurosurgery patient.

When opioids are chosen for postoperative analgesia, three choices must be made: (1) which opioid to use, (2) the mode of administration, and (3) the route of administration. For the immediate postsurgical pediatric patient, fentanyl is usually the first choice of anesthesia providers for treatment of moderate to severe pain, administered via IV on an "as needed" basis in intervals up to every 5 min, at a dose of 0.5 mcg/kg. If fentanyl is contraindicated or ineffective, morphine or hydromorphone is utilized. Most neurosurgical patients will not have a PCA, regional block, or continuous epidural infusion, but rather will be treated with IV narcotics on an "as needed" basis in order to accurately monitor the child's neurological status (Box 16.1).

#### Box 16.1 Case Study

A 4-year-old child named Sophia presents at the neurosurgery clinic after a referral from her pediatrician. Over the past month, her mother reports that she has a sudden loss of appetite, vomiting, and headaches. She has taken her child to the pediatrician three times in the last month with the symptoms being attributed to a virus and then her vision. After an eye exam revealed normal vision, Sophia's mother insisted on referral to a specialist. Normally a bubbly little girl who likes to play with Barbie dolls, she is now quiet and listless.

After a normal neurologic exam, the neurosurgeon orders an MRI to try to determine the cause of Sophia's symptoms, particularly the worsening and debilitating headaches. Results of the MRI reveal Sophia has a ping-pong-sized tumor press-

ing on her brainstem in the posterior fossa region. Posterior fossa tumors are the most common childhood brain tumor.

With a diagnosis of a brain tumor, the neurosurgeon informs Sophia's mother of the need for surgery. A surgery date is selected and preoperative visit planned. At the preoperative visit, Sophia and her parents meet with a perioperative nurse who asks health history questions, performs a head-to-toe assessment, obtains height/weight and vital signs, and provides general information about what to expect on the day of surgery. The anesthesia provider and neurosurgeon provide information regarding their particular roles in the procedure and obtain consent. Preoperative labs are ordered including a complete blood count (CBC), basic metabolic panel (BMP), and a type and cross as posterior fossa tumors pose a high risk for blood loss. Sophia meets with a child-life specialist, who gives her a tour of the preoperative area, the OR, and the PACU and helps Sophia role-play with her favorite Barbie doll on how to obtain vital signs and the induction of anesthesia.

The day before Sophia's surgery, her preoperative labs are completed and a blood band placed on her wrist. Instructions are provided to keep the band clean and dry. Her parents are also informed of when Sophia needs to stop eating and drinking.

On the day of surgery, Sophia and her parents are anxious but prepared. The preoperative nurse obtains a set of vital signs and places the family in the preoperative holding room. The anesthesiologist and neurosurgery team meet with the family to answer any further questions or concerns. At this facility, parental presence is

allowed at induction and in the PACU. Sophia's mother is provided with instructions by the preoperative nurse on what to expect and on her role in the process. When it is time for surgery, Sophia and her mother follow the OR nurses back to the OR suite. Sophia lies down the OR table, with her mother holding her hand, and the two sing a favorite song together as Sophia goes to sleep with anesthesia gas administered via a mask, just as Sophia did with her doll at her preoperative visit with the child-life specialist. Sophia's mother is then escorted to the OR waiting room where she and her husband will receive hourly updates from the OR nurse.

After completion of the surgery, it is determined by the neurosurgeon and anesthesiologist that Sophia is stable enough to recover in the PACU. She had minimal blood loss, vital signs were stable throughout the procedure, and she was a healthy child prior to her diagnosis with the posterior fossa tumor. Sophia arrives to the PACU still intubated, and the PACU nurse decides to wait until Sophia is extubated and stable before having her parents present. Sophia is extubated without complication and is reunited with her parents in the PACU. She is pale and drowsy with some facial swelling but overall stable. After approximately 1 h in the PACU, she is transferred to the ICU for continued care. Sophia's parents, while they underwent a very stressful day with their child undergoing surgery for a brain tumor, were overall satisfied by the perioperative experience because of the preparation, high level of communication, and incorporation of their presence in the process.



### Pediatric Practice Pearls

- Include the child in preoperative conversations with the family, as chronological and developmental age allows.
- A preoperative visit is highly encouraged for the neurosurgical pediatric patient who is high risk with other comorbidities.
- Preparation of the parent and guidance during the process are keys if a parent will be present at induction and/or during the initial recovery period. Remember, patient safety always comes first.
- Make the separation of the child from the family as gentle as possible. Make the trip to the operating room a fun one for the child. Blowing some bubbles and a piggyback ride go a long way toward helping make the child feel at ease!
- Always call the family at the start of the procedure and continue to give them updates at regular intervals. Waiting family members feel very helpless as the care of their child is now out of their control. Regular communication with the family does much to allay their fears.
- If the intraoperative plan of care changes from what has been previously discussed with the family, alert them of the change. Let them know if their wait time will be increased.
- Honesty is always the best policy. If you cannot answer a question, find someone who can!
- Have the family write down any questions they may have so that they can discuss them with the surgeon postoperatively.
- The neurosurgical team and anesthesia provider should make a collaborative decision regarding the initial plan of care for the recovery process. Factors that should be considered when deciding where the patient will initially recover after surgery include the com-

plexity of the neurosurgical procedure, intraoperative occurrences, age of the child, preoperative condition of the child, and other comorbidities.

- After a neurosurgical procedure, close observation and frequent vital sign and neurologic assessments should be performed by nurses specifically trained to care for pediatric neurosurgical patients.
- Key complications that nurses and other health-care providers should monitor for in the immediate postoperative period include respiratory dysfunction, bleeding, seizures, diabetes insipidus, cerebral salt-wasting syndrome, nausea and vomiting, and pain.

### 16.4.8 Transitioning from Pediatric to Adult Care in the Perioperative Setting

A special topic associated with perioperative care is the transition of the pediatric patient to the adult health-care system. As increasing numbers of children with congenital and chronic diseases are living into adulthood, the need has arisen to ensure their safe transition of care (Brennan and Rolfe 2011). Unfortunately, the perioperative area has lagged behind in facing this challenge of optimizing care in this transitional period.

There are several aspects of perioperative care that can pose an issue to the young medically complex person who is transitioning to the adult world of care. In the pediatric perioperative setting, the following are commonplace; in the adult setting, however, these practices may not be high involvement of parents, a team that guides the child and is specifically trained for age and developmentally specific care (child-life specialists), use of inhalation agents for induction of anesthesia, and preoperative oral sedation medicine or intramuscular ketamine for anti-anxiolytic administration (Brennan and Rolfe 2011). Another key difference is the technical skills and training necessary to provide anesthesia and

other perioperative care to young adults with diagnoses and genetic syndromes that may have short stature, dysmorphism, and low body weight (Brenna and Rolfe 2011). For the young adult transitioning, these differences in perioperative care can be a substantial psychological hurdle to overcome and can significantly affect the quality of care they receive.

When the child should make the transition varies from facility to facility. Some pediatric facilities cease providing care after the age of 18, whereas others may provide care for the patient who is well into their twenties for specific conditions. As Brennan and Rolfe (2011) indicate, it is important for pediatric surgeons and anesthesiologists to make connections and collaborate with the appropriate adult providers to help provide continuity of care upon transfer. Additionally, they suggest that the transfer to adult care should be a flexible process that takes into account the specific needs of the young adult, not driven solely on chronological age (Brennan and Rolfe 2011).

## References

- Agarwal HS, Saville BR, Slayton JM, Donahue BS, Daves S, Christian K, Bichell DP, Harris ZL (2012) Standardized postoperative handover process improves outcomes in the intensive care unit: a model for operational sustainability and improved team performance. *Crit Care Med* 40(7):2109–2115. doi:10.1097/CCM.0b013e3182514bab
- Association of PeriOperative Registered Nurses (AORN) (2010) Perioperative standards and recommended practices. Association for Perioperative Registered Nurses, Denver
- Association of PeriOperative Registered Nurses (AORN) (2016) Guidelines for perioperative practice. Association for PeriOperative Registered Nurses, Denver
- Brennan LJ, Rolfe PM (2011) Transition from pediatric to adult health services: the perioperative care perspective. *Pediatr Anesth* 21:630–635. doi:10.1111/j.1460-9592.2011.03560.x
- Burd RS, Mellender SJ, Tobias JD (2006) Neonatal and childhood perioperative considerations. *Surg Clin North Am* 86:227–247. doi:10.1016/j.suc.2005.12.010
- Burke CN, Voepel-Lewis T, Hadden S, DeGrandis M, Skotcher S, D'Agostino R, Walton S, Malviya S (2009) Parental presence on emergence: effect on postanesthesia agitation and parent satisfaction. *J Perianesth Nurs* 24:216–221. doi:10.1016/j.jopan.2009.03.014
- Chorney JM, Kain ZN (2010) Family-centered pediatric perioperative care. *Anesthesiology* 112(3):751–755. doi:10.1097/ALN.0b013e3181cb5ade
- Douglas M, Rowed S (2005) The implementation of a postoperative care process on a neurosurgical unit. *J Neurosurg Nurs* 37:329–333
- Ferrari LR, Antonelli RC, Bader A (2015) Beyond the preoperative clinic: considerations for pediatric care redesign aligning the patient/family-centered medical home and the perioperative surgical home. *Anesth Analg* 120(5):1167–1170. doi:10.1213/ANE.0000000000000627
- Fox VJ, Rothrock JC, Vaiden RE (2000) Core curriculum for the RN first assistant, 3 edn. AORN, Denver
- Furst SR, Sullivan LJ, Soriano SG, McDermott JS, Adelson PD, Rockoff MA (1996) Effects of ondansetron on emesis in the first 24 h after craniotomy in children. *Anesth Analg* 83:325–328
- Hall PA, Payne JF, Stack CG, Stokes MA (1995) Parents in the recovery room: survey of parental and staff attitudes. *Br Med J* 310:163–164
- Hatava P, Olsson GL, Lagerkanser M (2000) Preoperative psychological preparation for children undergoing ENT operations: a comparison of two methods. *Paediatr Anaesth* 10:477–486
- Hockenberry MJ, Wilson D (2009) Wong's essentials of pediatric nursing, 8 edn. Mosby, St. Louis
- Kain ZN, Wang SM, Caramico LA, Hofstadter M, Mayes LC (1997) Parental desire for perioperative information and informed consent: a two-phase study. *Anesth Analg* 84:299–306
- Kain ZN, Caramico LA, Mayes LC, Genevro JL, Bornstein MH, Hofstadter MB (1998a) Preoperative preparation programs in children: a comparative examination. *Anesth Analg* 87:1249–1255
- Kain ZN, Mayes LC, Wang SM, Caramico LA, Hofstadter MB (1998b) Parental presence during induction of anesthesia versus sedative premedication: which intervention is more effective? *Anesthesiology* 89:1147–1156
- Kain ZN, Mayes LC, Wang SM, Caramico LA, Krivtza MA, Hofstadter MB (2000) Parental presence and a sedative premedicant for children undergoing surgery: a hierarchical study. *Anesthesiology* 92:939–946
- Kain ZN, Caldwell-Andrews A, Wang SM (2002) Psychological preparation of the parent and pediatric surgical patient. *Anesthesiol Clin North Am* 20:29–44
- Kalkman CJ (2010) Handover in the perioperative care process. *Curr Opin Anaesthesiol* 23(6):749–753. doi:10.1097/ACO.0b013e3283405ac8
- Leack KM (2007) Perioperative preparation of the child and family. In: Browne NT, McComiskey CA, Flanigan LM, Pieper's P (eds) *Nursing care of the pediatric surgical patient*, 2 edn. Jones and Bartlett Publishers, Boston, pp 3–16
- Malignant Hyperthermia Association of the United States (MHAUS). (2016) MH susceptibility and associated conditions. Retrieved from <http://www.mhaus.org/healthcare-professionals/be-prepared/associated-conditions>

- Meeker MH, Rothrock JC (1999) Alexander's care of the patient in surgery, 11 edn. Mosby, St. Louis
- Phillips N (2007) Berry and Kohn's operating room technique, 11 edn. Mosby, St. Louis
- Raffini L, Huang YS, Witmer C, Feudtner C (2009) Dramatic increase in venous thromboembolism in children's hospitals in the United States from 2001 to 2007. *Pediatrics* 24(4):1001–1008
- Romino S, Keatley V, Secrest J, Good K (2005) Parental presence during anesthesia induction in children. *AORN J* 81:780–792
- Rothrock JC (2007) Alexander's care of the patient in surgery, 13 edn. Mosby, St. Louis
- Rothrock JC (2015) Alexander's care of the patient in surgery, 15 edn. Mosby, St. Louis
- Simona V, Pinotti S, Fillipo F, Barbara S, Giacomo P, Lorenzo G (2016) Cranial neurosurgery without hair removal and shampoo care: retrospective analysis of 450 cases. *Pediat Ther* 6(2):1–4
- Spry C (2005) Essentials of perioperative nursing, 3 edn. Jones and Bartlett Publishers, Sudbury
- The Joint Commission (2012) [http://www.jointcommission.org/standards\\_information/npsg.aspx](http://www.jointcommission.org/standards_information/npsg.aspx). Accessed on 3 May 2012
- Wennstrom B, Tornhage CJ, Nasic S, Hedelin H, Bergh I (2011) The perioperative dialogue reduces postoperative stress in children undergoing day surgery as confirmed by salivary cortisol. *Pediatr Anesth* 21:1058–1065. doi:10.1111/j.1460.9592.2011.03656.x
- Westcott E, Dunn V (1998) An exploration of the value of specialist neurosurgical nurses. *NT Res* 3:421–431
- Winston K (2011) Neurosurgery and shaving. *J Neurosurg* 115:669
- Wisselo TL, Stuart C, Muris P (2004) Providing parents with information before anaesthesia: what do they really want to know? *Paediatr Anaesth* 14:299–307
- Wollin S, Plummer J, Owen H, Hawkins R, Materazzo F, Morrison V (2004) Anxiety in children having elective surgery. *J Pediatr Nurs* 19:128–132

Theresa M. Gabay, Jennifer A. Disabato,  
and Teresa Schultz

## Amanda's Story

Amanda is an 18-year-old female who has been under pediatric neurosurgical care since infancy. She was born at 26 weeks gestation and, like many premature babies, suffered a bilateral grade II intraventricular hemorrhage. She developed progressive hydrocephalus and had a ventricular-peritoneal shunt placed. Her medical history includes several other chronic health problems including seizures, immunity issues, and liver issues. She has had several shunt revisions throughout her life.

In addition to her medical problems, Amanda has cognitive deficits. She is mainstreamed in school with special education classes to supplement her learning experience. Because of her limited mental capacity, her mother is concerned that she cannot make medical decisions on her own. Mom has thought about legally pursuing guardianship for Amanda for the last few years, but has not acted on it until she turned 18 years old. Furthermore, many of Amanda's specialists (immunology, gastroenterology, and neurology) and her primary care physician are pediatric practitioners. Although her neurosurgical team is able to provide care throughout her life span, there is concern that Amanda's family is reluctant to transition to adult care for most of her health-care needs. When mother is asked as to her plans for transition, she has no clear pathway for doing so.

---

T.M. Gabay, RN, MSN, APN-BC, CNRN (✉)  
Advanced Neurosurgery Associates,  
Rutherford, NJ, USA  
e-mail: [tgabay@advancedneurosurgeons.com](mailto:tgabay@advancedneurosurgeons.com)

J.A. Disabato, DNP, CPNP-PC, AC  
Department of Child Neurology, Children's Hospital  
Colorado, Aurora, CO, USA

University of Colorado College of Nursing,  
13120 E. 19th Avenue, 4126, Aurora, CO, 80045,  
USA  
e-mail: [jennifer.disabato@ucdenver.edu](mailto:jennifer.disabato@ucdenver.edu)

T. Schultz, RN, MSN, CPNP-PC, AC  
Department of Neurosurgery, Gillette Children's  
Specialty Healthcare, St. Paul, MN, USA  
e-mail: [tschultz@gillettechildrens.com](mailto:tschultz@gillettechildrens.com)

---

## 17.1 Introduction

Many children are now able to survive into adulthood with conditions that only a few decades ago lead to early demise. Nurses are now seeing these children thriving and becoming productive adults.

This chapter reviews the most updated state of transition care in the United States, citing evidence, challenges, and proposed models in current national and international literature. Examples of how health-care providers are handing patients off to the adult care system are included. In addition to overview and current recommendations regarding transition management, identification of the neuroscience nurse's role is included.

The transition from adolescence to adulthood is challenging for any youth. The psychological, behavioral, and social growth that occurs during this stage of life allows for gradual assumption of personal responsibility and independence (Mennito and Clark 2010). For the majority of adolescents, the transition is successful when they are productive and meaningfully engaged in society (Park et al. 2011). This is different for each individual but is often measured by financial independence, gainful employment, and the ability to care for oneself. For youth with special needs, transition into adulthood is challenging. Many will continue to live with their families and often have significant impairments of cognitive, psychological, and social skills.

Despite these limitations, the transition to adult health-care providers is inevitable. It is an expected and desired outcome of all pediatric care in the general adolescent population. It should be purposeful and planned and occur over a period of years. The Society for Adolescent Medicine advocates for transition as a clinical care standard with the ultimate goal of developmentally appropriate, uninterrupted, and accessible health care for young adults (Blum et al. 2002). For those who have multiple medical issues, however, transfer of care is more complicated.

With the advances in health care over the last three to four decades, there has been an increase in the survival of children with chronic childhood-onset diseases. It is estimated that 30% of adolescents in the United States report a chronic medical condition and 18.4% report having a special health-care need (Okumura et al. 2013). The literature also states that in the United States approximately 600,000 16- to 17-year-olds have serious mental illness (Hergenroeder et al. 2015). It is estimated that over 500,000 youth with special health-care needs (YSHCN) will become adults with

special health-care needs (ASHCN) annually here in the United States. As survival rates for many chronic diseases are expected to continue to increase in the future, so will the numbers of the ASHCN population (Okumura et al. 2013).

Those with neurosurgical and neurological disorders that persist into adulthood are significant in numbers and encounter frequent and multiple barriers to adequate care once they have "aged out" of pediatric services (Camfield and Camfield 2011; Rothstein and Li 2015). For the diagnosis of hydrocephalus alone, it is predicted that the number of young adults between the ages of 18 and 35 that will need treatment in the United States will exceed 40,000 annually in the next two decades (Simon et al. 2009).

Young adults with myelomeningocele (spina bifida), hydrocephalus, intractable epilepsy, acquired brain injury, and childhood neoplasms of the central nervous system are now commonly seen in neurosurgical practices. In many of these patients, even though the initial disorder is stabilized during childhood, problems commonly arise during the normal aging process and transitions in both living and health-care arrangements.

For the myelomeningocele patient, the value of a multidisciplinary approach is significant. There is coordinated care from primary care providers, neurosurgery, urology, orthopedics, and physical and occupational therapy that is the bare minimum standard in this population. Studies have shown that disruption to this standard results in complications that are potentially preventable such as urinary sepsis, renal calculi, pneumonia, osteomyelitis, shunt malfunction, tethered spinal cord, and gait deterioration. Additionally, this population is high risk for Chiari II malformation and syringomyelia that can present later as the child ages. Symptoms are uniquely different in these patients and are detected as part of ongoing medical monitoring (Rothstein and Li 2015). Loss of access to specialized pediatric spina bifida clinic programs once the patient becomes an adult is common, and therefore multidisciplinary care is also lost.

In patients with hydrocephalus, endoscopic third ventriculostomy and shunt devices have been known to fail with aging. Without neurosurgical monitoring or availability, failure of



recognition of urgent surgical intervention results in increased mortalities (Rothstein and Li 2015). Lastly, approximately 4,500 children with tumors of the brain or spine are newly diagnosed annually in the United States. Over the last 20 years, there have been advances in treatments that have increased survival rates dramatically. Delayed sequelae from treatments, however, have been documented in survivors. These include new or recurrent brain lesions, spinal problems secondary to radiation, growth and cognitive deficits, pituitary insufficiency, and infertility in later years (Rothstein and Li 2015). In a retrospective study by Vinchon and associates (2012), the outcome of pediatric hydrocephalus was evaluated. Significant findings in their cohort of 456 patients include 81 (17.8%) subjects requiring shunt revision in adulthood and death in 13 of the subjects (five were documented as shunt related). Sequelae commonly identified in this population were motor (46.5%) and cognitive (47.6%) – only 82 (18%) subjects had no long-term sequelae at all. This study supports the strong argument for continued neurosurgical monitoring through adulthood.

Chronic neurological disorders starting in childhood can exhibit a greater impact on individuals as they age. Cerebral palsy (CP) is the most common pediatric motor disorder that is the result of a disturbance in normal brain development occurring in the perinatal period. Disability of motor function with or without cognitive impairment is seen and is relatively stable and nonprogressive throughout the life span. Death in this population is uncommon unless severely disabled and is often the result of other causes. Transition to adult practitioners who have little experience with CP is concerning to these patients. In a qualitative study by Carroll (2015), the lived experiences of nine high-functioning subjects with CP provided insight into this process. Common themes included having expertise in CP while a novice in the world of adult medicine, negotiating accessibility and insurance issues, continuing to rely on parents and peers for assistance in finding appropriate providers into adulthood, and recognizing that their experiences of transition fell short of their expectations. Despite the nonprogressive nature of the disease,

CP patients can experience deterioration of mobility and increased pain as adults in addition to common medical issues of all aging adults (Camfield and Camfield 2011; Carroll 2015).

The list of pediatric neurological conditions that carry the need for monitoring and possibly intervention into adulthood includes Chiari malformations, congenital spinal deformities, arachnoid cysts, vascular disorders, and craniofacial deformities to name a few (Rothstein and Li 2015). Epilepsy presents many new challenges in the young aging adult including social isolation, unemployment, and depression. In addition, poor adherence to antiepileptic medications, safety issues, and sudden unexplained death in epilepsy (SUDEP) are all concerns in young adults with epilepsy. The developmentally delayed or autistic child can become increasingly difficult to manage over time for aging parents and care providers who have little resources or new therapies to offer (Camfield and Camfield 2011). The concern that the modern adult health-care system is deficient in comprehensive care models for these special needs patients has become a “hot topic” of society here in the United States and around the world.

---

## 17.2 Historical Milestones

As children began to survive diseases that they once previously died from prior to the 1970s and 1980s, it became apparent to the United States and the rest of the world that there were service disparities among adolescents and young adults with special health-care needs (Slap 2009). This was attributed to various factors: individual state policies, institutions, insurance coverage, training of care providers, and patient and family issues. In 1984, Surgeon General C. Everett Koop cohosted the first national invitational conference that focused on the needs of older adolescents who had chronic or disabling disorders. This led to a subsequent Surgeon General conference in 1989: “Growing Up and Getting Medical Care: Youth with Special Health Care Needs (YSHCN)” (Blum 1995). It established a national agenda for training, research, and program development with a goal of establishing a health-care system allowing for seamless transition of care for YSHCN.

Additionally, both the Individuals with Disabilities Education Act (IDEA) of 1997 and *Healthy People 2010* (Mennito and Clark 2010) included specific standards for YSHCN. They stipulated that these individuals receive services that will result in successful transition not only in health care but also in all aspects of adult life including education, work, and independent living.

In 2002, the US Department of Health and Human Services developed a joint consensus statement that was coauthored by the American Academy of Pediatrics (AAP), the American Academy of Family Physicians (AAFP), and the American College of Physicians (ACP) – American Society of Internal Medicine. The committee identified multiple deficiencies in transition care specific to special health-care need youths and young adults including lack of patient preparation, lack of pediatric providers prepared to assist patients and families with transition, less than adequate communication between subspecialists and the medical home, and adult health-care system not prepared to accept the influx of young adults with special health-care needs. The goals of the policy statement were to ensure that by the year 2010, all physicians who provide primary or subspecialty care to YSHCN understand the rationale for transition from child-oriented to adult-oriented health care, have the knowledge and skills to facilitate that process, and know if, how, and when transfer of care is indicated (AAP et al. 2002).

In a subsequent policy statement issued by the AAP in 2005, the recommendation that primary care physicians provide a “medical home” for children with special needs was a core concept (Slap 2009). Recognizing the uncoordinated care that often precedes transition, the pediatrician is central to this model of delivering primary care that is accessible, comprehensive, coordinated, continuous, family centered, and culturally effective (Labhard 2010).

In 2008, the American Academy of Pediatrics issued a report on the state of transition that documented progress on the initiatives set forth by the 2002 and 2005 consensus statements. This report included current literature review, parallel initiatives, and active programs targeting the transition of care for YSHCN. One of the most

important findings that came out of the document was that despite the vested interest of the medical community effecting change on this subject, there was a lack of evidence-based data regarding best practices (Mennito and Clark 2010).

Most recently, the same group that coauthored the original consensus statement in 2001 (AAP, AAFP, and ACP) published a clinical report in 2011 that focused on guidelines for planning, preparation, and implementation of transition within the medical home framework. An algorithm that outlines clear steps, interventions, and newer key components such as electronic health records (EHR) for successful transition is core to this report (Hess et al. 2015).

Subsequent to this publication, clinical quality tools supporting the transitional care process were developed by Got Transition, a federally funded resource center. The current “Six Core Elements of Health Care Transition (2.0)” tool was published in 2014 and has been tested in several national learning collaboratives. The core components address transition policy, tracking and monitoring, readiness for transition, planning, actualization of transfer of care, and assurance of completion of transition (McManus et al. 2013). Later in this chapter, programs that utilize these core elements will be discussed.

---

## 17.3 Barriers to Successful Transition

### 17.3.1 Patient and Family

Transition to adult care is a coordinated process that is ideally addressed early in adolescence to ensure success (AAP et al. 2011; (Sanders et al. 2009)). For the youth with special and complex medical needs, the process is more cumbersome and labor intensive. Transition that is not well coordinated leaves patients and families often in the driver’s seat of finding appropriate adult providers and coordination of care with specialists. Parents who have dedicated their lives to the care of their special needs children often express fear, frustration, and abandonment during transition when they leave the pediatric health-care system (Hopper et al. 2014).

Additionally, adult care rarely engages the entire family which is conversely basic to child-centered care. The “adult culture” is disease-focused with the expectation of independence of patients, whereas the “pediatric culture” is attentive to the needs of the patient within a family system (Mennito and Clark 2010). Hopper and associates (2014), citing the experiences of patients and families with transition, noted that parents in the series repeatedly expressed this concern. From not having accommodations for parents in the hospital rooms to asking them to “step back” from care participation and having a general lack of knowledge about diseases originating in childhood left families struggling with trust in the adult health-care system. Recognizing that interdependence between YSHCN and their parents and families has been lifelong, successful transition occurs when there is a gradual transfer of care from the parent to the child while keeping the parent as a partner in the process (Carroll 2015).

Caregivers who have a low level of expectation for YSHCN will often have impact on the youth’s self-image, motivation, self-determination, and ability to manage responsibly. If parents have difficulty envisioning successful attainment of generic skills needed to be a responsible adult, they will put off the transition process. Retention in a pediatric-oriented health-care system sends the message that adolescents with a disability are incapable of being adults and effects how they are viewed by society (Ried 2010).

Many children with neurological diseases often have significant cognitive impairment. They may never have the ability to become responsible for themselves on any level and generally remain under the care of their families. For this group of youth, their clinical condition precludes them from participation in the transition process. For others, there are various levels of cognitive function and ability as they mature. Having an environment that fosters function and social independence as much as possible despite the challenge of a disability is paramount (Ried 2010). Lastly, many parents of children with significant cognitive impairments obtain legal guardianship so that their participation in obtaining clinical information and health-care decision-making is not an issue (Hopper et al. 2014).

Cognitively appropriate adolescents with neurological and neurosurgical issues often have the same concerns as their developing peers. They may have low self-esteem, feelings of inadequacy about their bodies, and experience social isolation (Labhard 2010). These may be magnified, especially in a youth who has spina bifida or spinal cord injury or has frequent seizures. Medical self-care (intermittent bladder catheterizations, taking medications, etc.) is not a priority but a nuisance to the teen and further separates them from their peers (Labhard 2010). In addition to asking the YSHCN to assume responsibility for their care, this is also the time they are asked to eventually leave the medical team that has come to know and accept them. Cerebral palsy subjects in the study by Carroll (2015) identified key challenges of transition including lack of professionals’ knowledge of their disease, limited health-care access, lack of information, and guidance regarding the transition process.

### 17.3.2 Primary and Specialty Care Providers

Pediatric providers’ difficulty with “letting go” of their YSHCN is often a barrier to the transition process. There is a vested interest in the child with complex medical needs after many years of involvement in various aspects of care, and transition can therefore be emotionally discomfiting for the provider as well as the patient/family. In a series by O’Sullivan-Oliveira et al. (2014), pediatric providers cite issues with attachment and grief with their patients moving on, negative perceptions of adult providers and the lack of coordination of specialty care, and poor structural support. Conversely, many pediatric practitioners express lack of experience and comfort managing adult health issues for YSHCN as they age. Adoption of established guidelines for transition planning and development of a transition policy by pediatricians is key to success (Hergenroeder et al. 2015).

Often, there is ambivalence by the pediatric team in identifying adult providers who will provide continuity of care similar to what the child has had during childhood (O’Sullivan-Oliveira et al. 2014). In a national survey that evaluated physicians’ views on barriers to primary care in YSHCN (Okumura et al.

2008), 62% of pediatric providers thought that it would be difficult to find an internist that would care for a young adult with a childhood-onset disorder. Additionally, adult care is often fragmented and lacks the multidisciplinary team approach that young adults with disorders like spina bifida or cerebral palsy desperately need (Hopper et al. 2014; Rothstein and Li 2015). Health insurance coverage issues, identifying adult providers available to assume care, and completion of legal documents for guardianship of patients who are unable to manage their own affairs are other very important tasks necessary for successful transition (Jurasek et al. 2010).

System challenges in the pediatric setting include both a lack of resources to coordinate and communicate information about care transfer and a clear written procedure or pathway to follow. The development of readiness assessment tools that evaluate independence and self-care abilities of adolescents within the pediatric practice has been helpful according to patients that have made successful transitions (O'Sullivan-Oliveira et al. 2014). Strategies to operationalize the transfer plan include the utilization of other professionals (nurses, social workers, therapists) to support the plan, use of interactive media for informational resources, and accessibility to electronic health records (Hergenroeder et al. 2015).

On the receiving end, adult care providers often have limited training, knowledge, and experience (and sometimes limited interest) in caring for young adults with childhood disease processes (Hergenroeder et al. 2015). In the national survey published by Okumura and associates (2010), 24% of general internists reported lack of training as a significant barrier to caring for young adults with special health-care needs (ASHCN). Additionally, adult primary care physicians cite lack of time, reimbursement, and transition coordination as major barriers to providing quality care for YSHCN.

Noted by Camfield and Camfield (2011), there are many types of chronic neurological disorders starting in childhood that have anticipatory issues in adulthood. Some disorders are static or manageable in childhood, cerebral palsy and neurofibromatosis, for example, but become progressive with more serious manifestations as a natural course. Brain tumors may have been cured in

childhood, but the young adult may have late effects from chemotherapy and radiation treatments, including new malignancies, intractable epilepsy, and cognitive deficits. Children who have significant developmental delays are often more difficult to manage as adults. Consider the child with severe autistic disorder who has limited communication and exhibits aggressive behaviors. These examples illustrate just some of the challenges in assuming care of young ASHCN.

Strategies for addressing some of the barriers seen by adult providers revolve around education and coordination. Improving medical education training from undergraduate studies through residency in care management for YSHCN has been recommended (Sharma et al. 2014). Communication between pediatric care teams and their counterpart adult teams is especially important for patients with complex medical and surgical histories. Providing a current medical record abstract or summary is helpful to eliminate the receiving provider's need to wade through a sea of medical records. In addition, the adult provider needs to know who makes medical decisions for the patient and identifies any confidentiality concerns. Lastly, including the adult provider as part of "the team" early on provides the opportunity to be educated about the patient's disease management needs resulting in a smooth transition (Hergenroeder et al. 2015; O'Sullivan-Oliveira et al. 2014).

### 17.3.3 Environment

During the 2008 American Society of Pediatric Neurosurgeons (ASPN) meeting, members in attendance were polled about views and practices regarding transition of their patients (Rekate 2009). One of the demographics components was practice facility. Of the responders, 78% practiced in freestanding children's hospitals where they could not continue to care for patients once they reached a certain age of maturity. This was usually at 18 or 21 years old. For the remainder of the respondents, the neurosurgeon practiced in a children's hospital within a larger hospital or in a general facility with pediatric units. Although 89% of the hospitals took patients greater than

18 years of age, only 44% took patients over 21 years of age.

For YSHCN, the majority will receive care in an adult facility once they mature. The patient and family may find themselves suddenly in unfamiliar surroundings. These facilities tend to focus on the patient and treating health issues that arise through a siloed medical specialty approach, rather than integrated disease management that includes the family or other caregivers, using a holistic approach. Additionally, hospitals that primarily serve adults may not have the equipment or resources to care for a patient that is 26 years old yet has the developmental ability of a toddler and weighs 20 kg (Berkowitz 2009).

In the qualitative study by Hopper and associates (2014), the parents of YSHCN discussed their anxiety related to adult-based facilities. They verbalized that at the children's hospital, there were often "other children" with the same diagnosis on the units. The staff was very familiar with diseases such as epilepsy and sickle cell, and, therefore, a level of confidence was extended to them by parents. In the adult facilities, caregivers noted that staff was not accustomed to caring for the same patients. Parents related the need to not leave their children's side while in these facilities and the need to explain their concerns repeatedly to the adult team and generally scattered care providers for children with complex and specialized needs.

Goodman and associates (2011) analyzed data on patients hospitalized in 30 academic children's hospitals over a 10-year period. The growth rate of admissions/discharges was examined for three age groups: pediatric (<18 years old), transitional (18–21 years old), and adult (>21 years old). Although individuals above the pediatric age group were a small portion of inpatients within these facilities, this amounted to thousands of "adults" annually. These groups had higher numbers of inpatient days, disproportionately higher charges, and were more frequently readmitted than their pediatric counterparts. Over the course of the study, admissions of patients aged 18–21 increased steadily and disproportionately to increases in pediatric populations. This led to the prediction that both transitional and adult groups will continue to increase in numbers in years to come.

### 17.3.4 Insurance

Readiness for transition is typically evaluated using physical, social, and cognitive meters to determine the ability to care for oneself. The financial component, i.e., insurance status, can often dictate when YSHCN must be transitioned and to what provider. Prior to the passing of the 2010 Patient Protection and Affordable Care Act, approximately one half of young adults with chronic illness had gaps in insurance coverage between the ages of 18 and 24 resulting often in adverse effects (Okumura et al. 2013; Hergenroeder et al. 2015). The legislation has improved health coverage for this population until the age of 25, but it is still not clear if reimbursement for lengthy and complex care will be provided for specialists such as pediatric neurosurgeons on a consistent basis, especially when there are adult providers participating in health plans (Simon et al. 2009; Rothstein and Li 2015). Additionally, lack of care has shifted to the 26- to 34-year-old age group at this present time. Programs including expansion of Medicaid benefits in all 50 states for those significantly affected are being evaluated for these young adults (Sharma et al. 2014; Hergenroeder et al. 2015).

As a result of the Affordable Care Act, accountable care organizations (ACOs) were developed. There are provider-led organizations that manage the full continuum of care for a specific population. Providing high-quality care including pediatric to adult care transition while controlling costs is part of the mission of the ACO (Lemly et al. 2013). Financial reimbursement is closely tied to ACO success.

Despite expansion of medical coverage for adolescents and young adults as mentioned above, transition to an adult provider may be limited to those that will accept the expanded payment programs (Sanders et al. 2009). Additionally, there is no obligation on the part of private payers to continue covering services at a pediatric facility when they could be rendered at a contracted adult-based hospital (Simon et al. 2009). For adolescents and young adults without coverage, care often needs to take place in the area's primary care center or local health department utilizing charity care programs.



### 17.3.5 Health Information and Records

Children who have long-standing neurosurgical and neurological disorders can have extensive medical records. It is not unusual for them to have various health-care providers over the years and in multiple geographic locations. Although the current pediatrician and neurosurgical team has a good handle on the child's medical history and events, adult providers assuming care will have a daunting task of familiarizing themselves with the patient who comes with several forms of records. Electronic health records (EHRs) that are now common in private practices as well as health-care facilities should be readily available to the patient to share with other providers. This can be inval-

able to the new medical team and ensure an accurate history is communicated (Hergenroeder et al. 2015). In addition, sharing of personal medical information with the parents was not an issue when the patient was a child under the age of 18. Once a patient becomes of age, the Health Insurance Portability and Accountability Act legally binds providers to share information with the patient and whomever he or she designates. In the absence of a durable medical power of attorney or permission by the individual, requests for medical records and information must be made by the patient rather than a parent (Rekate 2009). For patients with significant neurological disease, this may not be feasible. Ensuring that the appropriate legal rights of the patient and parent are addressed before transition is completed is important.



## 17.4 Programs, Clinics, and Care Models

### 17.4.1 Care Model: The Medical Home

The “medical” or “patient-centered health-care” home is a nationally recognized primary care model established to ensure the delivery of high-quality, coordinated, comprehensive, and cost-efficient health-care services. This concept of providing care especially to those with special health-care needs encompasses the core values – care that is coordinated, continuous, accessible and comprehensive, compassionate, culturally appropriate, and family centered (McManus et al. 2013). Top on the list of the critical steps to transition to adult care, the American Academy of Pediatrics (AAP) supports providers in establishment of this model for their patients through websites, literature, and formal training opportunities (AAP website, [www.medicalhome.org](http://www.medicalhome.org)). The American College of Physicians (2010) has also adopted a concept of a Patient-Centered Medical Home with guidelines for interface between primary care delivery models with subspecialty practices.

There are three distinct processes of the medical home that are interrelated but central to this model: preventative care, acute illness management, and chronic condition management. For adolescents and young adults with complex medical needs, there may need to be comanagement of certain aspects of care. The primary care physician, in conjunction with various specialists, will work with the patient and family to ensure complete and continuous care (AAP Clinical Report 2011). It is this unique partnership between the family unit and health-care professionals that will be instrumental in developing an individualized transition plan. Furthermore, the process and timing of transition to adult primary care and specialists should follow the algorithm included in the Clinical Report by the AAP on Medical Home Transition, 2011. It reflects the latest guidelines and recommendations on transition of all adolescents to adult health care but has an expanded component addressing those with special and chronic health-care needs.

The pediatric primary care medical home should establish office policy regarding transition for all adolescents as recommended by the AAP guidelines. By doing so, core elements can be addressed at the appropriate ages and a plan for transition established based on the individual’s needs. This is helpful as each provider in the practice can follow and adjust the plan as needed and document steps followed and goals achieved. Assessing readiness of the patient and family to proceed with the tasks of transition is the responsibility of the medical home.

Although the provider, patient, and family are always core members of the “transition team,” the receiving provider and other medical subspecialists (pediatric and adult) will need to be intimately involved in the process for YSHCN. This may result in many clinical challenges for the medical home. Stated previously, adult providers have verbalized their inexperience and lack of education as a barrier to care of ASHCN. In addition, the lack of adult medical subspecialists, financial incentives, and care coordination support has also been cited. Often, even with the best planning and attention to the transition process, ASHCN may end up with “ad hoc” medical care due to system barriers that impact the adult medical home care model.

In a series by McManus and associates (2013), results of the 2009–2010 National Survey of Children with Special Health Care Needs are examined. With regard to the 40% of YSHCN that met transition outcomes, children in medical homes were substantially at an advantage. Transition discussions, comprehensive assessments, support for self-care management, updated clinical summaries, and development of adult referral networks were key factors of preparation provided within the medical home model. Federal, state, and community expansion of medical home access for all children and young adults with special health-care needs is recommended for improved outcomes in the future.

### 17.4.2 Evolving Models and Programs for Transition

Over the last decade, published evidence on the topic of pediatric to adult transition has evolved

and moved beyond recognition of the scope of the problem to reporting of transition care models for specific populations, with varying degrees of success. Existing transition program and models vary depending on the focus of the entity that develops the program. There are those established by state health departments, health-related foundations, hospital systems, and individual specialty departments within larger health-care organizations, to name a few.

This chapter will provide examples of implementation in health-care organizations or within subspecialty practices. The six core elements are now widely disseminated through Got Transition™ as the evidence base for the six core elements of pediatric to adult transition (National Alliance to Advance Adolescent Health 2016). All models contain some, if not all, of the elements: a transition readiness assessment, self-management education, a medical summary/“passport” summarizing disease-specific care, and coordination between the pediatric and adult practices are common starting places for many groups addressing this issue. Many transition care programs or models include electronic medical record tools to streamline communication, reporting, and internal and external sharing of transition care planning (Hergenroeder et al. 2015).

### 17.4.3 Position and Consensus Statements

Specialty organizations are recognizing the need for established guidelines for health-care transition which has led to the publication of position or consensus statements confirming the critical aspects of transition that are essential to care and improving patient outcomes. Key among these for the population of children with neurological disorders is the recently published consensus statement endorsed by the American Academy of Neurology, the Child Neurology Society, and the American Academy of Pediatrics (Brown et al. 2016). Through the efforts of an interdisciplinary panel, the group adopted eight common principles to be incorporated into transition models implemented for child and adult neurology practices. Included in the eight principles are early initiation of a transition discussion between the ages of 12 and 13, engaging youth and

caregivers in early discussions about genetics and reproductive concerns and driving and alcohol or other substance abuse and discussing the youth’s expected legal competency and potential need for guardianship (Brown et al. 2016).

Another initiative by a primarily adult care-focused organization is an initiative by the American College of Physicians (ACP) to facilitate more effective transition and transfer of young adults to adult health-care settings. Under the umbrella of high-value care coordination, the initiative developed condition-specific tool kits. Currently there are seven subspecialty kits and others being developed. Based on established evidence put forth through Got Transition™ 2.0, this initiative is an example of the recognition among adult health-care groups of the magnitude of the problem and the need for action to address it (American College of Physicians 2016) (National Alliance to Advance Adolescent Health 2016). This relatively recent availability of readily accessible and varied tools online has enhanced opportunities for health-care teams in hospitals, clinics, and community settings to focus on adapting existing documents for patient populations without having to “start from scratch.”

Got Transition™ (2016) showcases ongoing work with several large health systems to implement the Six Core Elements of Health Care Transition (National Alliance to Advance Adolescent Health 2016). Quality improvement methodologies are frequently used for implementation with pilot studies in small specialty populations leading to successive trials and refinement of processes. Common themes discussed at national meetings among organizations that implement transition programs are poor patient outcomes secondary to gaps in care and inappropriate utilization of urgent and emergent care setting when adult care transition is not well planned. These events often precede larger system-wide discussions and support the inclusion of transition care into strategic planning.

### 17.4.4 Clinic Models

One example is the work from the University of Rochester, where a 17-month pilot to incorporate the six core elements into workflow for patients

in diabetes, sickle cell, and cystic fibrosis clinics improved relationships between pediatric and internal medicine specialists, led to the transfer of twice as many patients to adult care over the baseline, and decreased the time to first adult appointment (National Alliance to Advance Adolescent Health 2016).

A quality improvement pilot project with epilepsy patients on an academic medical campus at the University of Colorado leads to a significant decrease in time to first adult appointment in the adult care setting, a consistent improvement in the transfer of patient information through templated electronic medical record (EMR) summary letters, and an interdisciplinary team approach using clinical decision support in the EMR to integrate a social work transition assessment and ongoing support for adolescents and young adults with refractory epilepsy (Disabato et al. 2015). The project was expanded to all epilepsy patients with similar success using team-based quality improvement methodologies.

A recently published program for patients with spina bifida in a metropolitan area in California highlighted a nurse-led interdisciplinary model that utilizes an HCT nursing specialist and is built on the philosophy that transition is a complex, continuous, and long-term process of care coordination. Key elements of this plan are an interdisciplinary HCT plan that begins with an assessment of needs and strengths and is reviewed routinely during clinic visits. The organizational structure of the model incorporates all disciplines involved in the complex care of these patients, outlines the specific role of the HCT nursing specialist within the context of clinic visits to decrease the burden on patients and families, and is responsive to developmental and clinical modifications for the young adult (Betz et al. 2016).

#### **17.4.5 The Gillette Children's Specialty Healthcare Experience**

Comprehensive clinics caring for adults with childhood-onset disabilities are rare, but some do exist. Gillette Children's Specialty Healthcare in St. Paul, Minnesota, has a 100-year history of

caring for children with disabilities. In 2001, Gillette Lifetime Specialty Healthcare opened to include adults with developmental and childhood-onset disabilities.

At Gillette, the transition process begins at around the age of 14. As discussed above, this process can – and should – take several years. Collaboration between the patients, the pediatric and adult providers, and the family is important in planning comprehensive care that reflects the preferences, needs, and priorities of the patient and the family. Therefore, Gillette utilizes a team approach. That means that a pediatric subspecialty provider may see an adult patient in the Lifetime Clinic as part of their continued care. It is also the case that pediatric subspecialists transition the patient to an adult provider to be seen in the Lifetime Clinic. Gillette also employs adult providers at Lifetime to assist in coordinating care for these complex patients, working with their subspecialists and their primary care provider.

As a result of transitioning from the pediatric-focused Gillette Children's, Gillette Lifetime aims to improve the quality of life of adults with childhood-onset disabilities while educating about potential health risks, preventative measures, and personal care. Patients have access to a therapy kitchen, where daily activities such as cooking and cleaning are explored and practiced. Education regarding sexuality and relationships is made available, and women have access to female exams. Preventative measures, such as examining the skin and feet routinely for wounds which if left un- or undertreated can become life-threatening, are also taught. Gillette Lifetime specializes in treating people who have cerebral palsy, neuromuscular conditions, and spina bifida.

Gillette Children's Specialty Healthcare offers inpatient care for adults with childhood-onset disabilities as a part of continued care. The adult inpatient unit utilizes Gillette Lifetime providers as needed to care for individual patients. Most, but not all, of these patients are seen and followed in the Gillette Lifetime Clinic. Adult medical providers are available to assist subspecialists with management of adult-onset medical issues and care, such as hypertension, diabetes, and pregnancy.

As these examples illustrate, there is established evidence for the six core elements of pediatric to adult transition. In contrast the evidence for specific and effective tools and models for transitioning youth with chronic illness and special health-care needs (YSHCN) is less definitive and evolving over time and in various sectors of the health-care system. It is the authors' hope that the next decade of work in this area clarifies successful models and outcome measures for high-quality, effective, efficient, and adaptable transition programs to remove the existing gaps in care for youth and young adults during a vulnerable juncture in their lives.

#### **17.4.6 Physician and Health-Care Professional Curriculum**

Curriculum changes in medical and other health-care education programs have increased content on disabilities and management of complex-related health issues over the last several years (Sharma et al. 2014). One of the barriers to comprehensive care of ASHCN is the lack of knowledge and training that internal medicine residents receive during their educational years for this population.

To address this, Patel and O'Hare (2010) created the Working Initiative for Special Health Education Services (WISHES) curriculum. The goals of this program are (1) to create and administer a health curriculum pertinent to YSHCN, (2) to train internal medicine and pediatric residents as care providers for YSHCN and educate health-care professionals about the importance of transitions to adult care, and (3) to facilitate the transition of YSHCN from pediatric to adult providers.

These goals are actualized utilizing several strategies. Participation in formal joint conference series with disease-specific transition presentations and core seminars on advocacy is the expectation of both residency programs. Additionally, all residents work with patients in inpatient and outpatient settings, focusing on some of the chronic, lifelong conditions such as spina bifida, cerebral palsy, autism, and epilepsy. There is also a training program for ancillary health-care professionals that is linked to this

curriculum. Although this program is in its early stages of implementation, future goals for WISHES are evaluation of effectiveness of the current training and expansion of existing successful components to a national level.

Other curriculum efforts are being reported and include a program tested in two US medical schools educating medical students about caring for people with disabilities. The evaluation of the program was favorable indicating that exposure to a longitudinal curriculum leads to significant improvements in student comfort and attitudes toward those with disabilities (Symons et al. 2014).

#### **17.5 Special Considerations for Transition of Pediatric Neurosurgery Patients to Adult Care**

Transition to adult care providers is a process that takes several years in the best of circumstances, and stakeholders (patients, families, and providers) still may face significant barriers for success, even with early discussion and planning. For YSHCN, specifically those with childhood neurosurgical issues, obstacles that are unique to this population have been identified in current literature (Vinchon et al. 2012; Rothstein and Li 2015; ReKate 2009).

First, the spectrum of neurosurgical disease in children is different from their adult counterparts. The clinical significance of certain brain insults, such as brain cysts and neurovascular disorders, tends to be more dramatic and requires neurosurgical intervention in pediatric patients. Additionally, CNS tumors of childhood, craniofacial deformities, and congenital spine disorders may present in young adulthood but are not commonly treated by adult providers versus their pediatric counterparts (Rothstein and Li 2015).

Hydrocephalus, which is one of the most common lifelong neurosurgical conditions that develop in early childhood, presents unique challenges. Although the exact number of persons currently with this condition is unknown, annually it is the diagnosis for 69,000 patients at discharge in the United States, of which half are children (Patwardhan and Nanda 2005). As a sole



diagnosis, hydrocephalus in children accounts for nearly 40,000 admissions, upward of 433,000 inpatient days, and cumulative hospital charges of 2.0 billion US dollars each year (Simon et al. 2008). Based on current treatment patterns and numbers, it is projected that young adults (ages 18–35) will exceed 40,000 in the next two decades (Simon et al. 2009).

For the pediatric neurosurgeon, management of hydrocephalus and placement and revision of CSF shunts are significant components of practice (Rekate 2009). In general neurosurgery, adult-onset hydrocephalus is infrequent by comparison and is often acquired after trauma or brain tumor. With extensive experience, the pediatric neurosurgeon is adept at troubleshooting shunt issues that may have subtle or atypical symptoms commonly seen in childhood-onset disease.

With the advancement of neurosurgical procedures in the last 30–40 years, one of the greatest medical challenges today is caring for young adults with myelomeningocele (Rothstein and Li 2015; Rekate 2009). During childhood, health care for these patients is often coordinated and comprehensive. Many are followed in spina bifida clinics utilizing a multidisciplinary approach to patient and family care. The literature notes that once transferred to adult care, there is limited access to medical subspecialties, and care is reported as fragmented, resulting in untoward patient effects (Rothstein and Li 2015). Primary care providers are overwhelmed, complications are overlooked, and, as parent advocates age, there is decreased involvement in care (Camfield and Camfield 2011). Furthermore, the child with myelomeningocele who was functionally and medically stable through childhood and early adolescence can have significant deterioration of gait and walking, premature aging of the bones, and neuro-orthopedic issues such as kyphosis and scoliosis in young adulthood. There is increased morbidity and mortality in this population during or shortly after transition from tethered cord, syringomyelia, and failure of shunts and endoscopic third ventriculostomies (Rothstein and Li 2015). How much the lack of medical resources plays a part in this is unclear.

As mentioned earlier in this chapter, the survival rate for many of the pediatric CNS tumors diagnosed annually has been steadily increasing. For the survivors, latent effects of disease and treatment often become apparent years later in adolescence or young adulthood. Sequelae include secondary malignancies, fertility issues, seizures, cognitive disorders, and pituitary deficiencies (Rothstein and Li 2015). The ability for adult practitioners to recognize and appropriately manage these patients becomes challenging with little experience to guide them. Mental health concerns such as depression and anxiety are frequently under diagnosed in this young adult population. Potential reasons are decreased access to care, concern about medication interactions and adherence, and/or drug diversion. This is another contributor to a potential decline in health and overall quality of life for these emerging adults.

So what to do about transitioning these special children to adult neurosurgical practices? For some patients, they are fortunate in that their neurosurgeons have “double citizenship” and can take care of them cradle to grave. For many others, their pediatric practitioners must hand them off to adult providers due to regulations and resource limitations that restrict their scope of practice. A solution that is utilized by many pediatric neurosurgeons is to have privileges at institutions that provide care for patients older than 21 years so that continuity of neurosurgical care can be maintained (Rothstein and Li 2015).

From a professional standpoint, there are several organizations that are heavily involved in examining issues related to childhood-onset neurosurgical disorders. The section on neurological surgery of the AAP has been vocal in advocating for transition planning and defining strategies for this complex patient population. The Joint Section of Pediatric Neurological Surgery of the American Association of Neurological Surgeons (AANS) and Congress of Neurological Surgeons (CNS), which was established as a forum for sharing pediatric neurosurgical experiences and promotes education, research, and patient care standards, also has put

the topic of transition high on their list of priorities. The American Society of Pediatric Neurosurgeons (ASPN) has recently updated their vision statement to include the reality of pediatric neurosurgical problems persisting into adulthood. The role these professional societies play in the support of viable care models is an important one. Although there is most likely not one care model that will fit all regions and situations, these organizations can establish guidelines that can be customized to individual neurosurgical practices (Rekate 2009).

---

## 17.6 Issues Specific to Nursing and Scope of Practice

Similar to their physician counterparts, nursing professionals will undoubtedly experience increased exposure to the growing number of youth and adults with special health-care needs. These complex patients are no longer limited to pediatric or subspecialty practices. Adult primary care, occupational medicine, and other various inpatient and outpatient environments of care will continue to see an influx of this population.

In response to this phenomenon, nursing curricula need to include education and clinical training that will prepare future providers to meet the needs of adults with childhood-onset neurological disease. Most often, nurses are in the position of having sustained contact with this patient population and can be the main facilitators of transition (Sharma et al. 2014). Important skills will include the ability to interact with patients who have cognitive and communication deficits and specific strategies to incorporate patient advocates during the patient encounter. Nurses who traditionally practice the “clinician-patient” model may need to learn how to incorporate an advocate while fostering autonomy and acceptance of the ASHCN. In addition, development of a transition nurse specialist role in primary care and hospital facilities that care for adolescents and young adults with special health-care needs can be helpful (Carroll 2015).

Experienced pediatric neuroscience nurses have the advantage of practicing under this model

of care. Many of the common neurological and neurosurgical conditions start at birth or early childhood and are typically managed in primary care and subspecialty environments. Pediatric neuroscience nurses who care for the transitioning adult have experience in clinical assessment related to the neurosurgical condition, patient and family teaching, and developmental knowledge, all which are an asset to facilitating a plan of care. Referrals to community resources, coordination of care with other providers, and facilitation/implementation of therapies are well within the nurses’ scope of practice. The value of nursing support to any program that manages YASHCN cannot be understated.

With regard to advanced practice, nurses have been integral to many transition programs. Betz and Redcay (2003) described an innovative nursing model for a transition clinic led by family nurse practitioners and is based in part on the Creating Healthy Futures model used in the educational system. The clinic was unique in that it provided comprehensive services to adolescents and young adults and involved extensive prescreening, identification of unique needs, and follow-up to assure successful transition (Betz and Redcay 2003). Outlined in a later report, the role of the advanced practice registered nurse (APRN) as a transition services coordinator for the clinic was described, as well as the skills necessary to provide care and serve as a case manager and community liaison for this underserved population (Betz and Redcay 2005). Most transition clinic models reinforce the unique role of the nurse, clinical nurse specialist, or nurse practitioner as key to the success of the clinic and the confidence of the patient.

Certain limitations of APRN scope of practice have become an issue as the pediatric population ages. Pediatric nurse practitioners (PNPs) who have traditionally cared for the child with hydrocephalus and spina bifida or other chronic neurological disorders may be prohibited from doing so once the patient exceeds the age of 21. Depending on the State Board of Nursing Regulations, which vary from state to state, a PNP may be practicing outside her/his scope of practice by managing a 23-year-old. In another

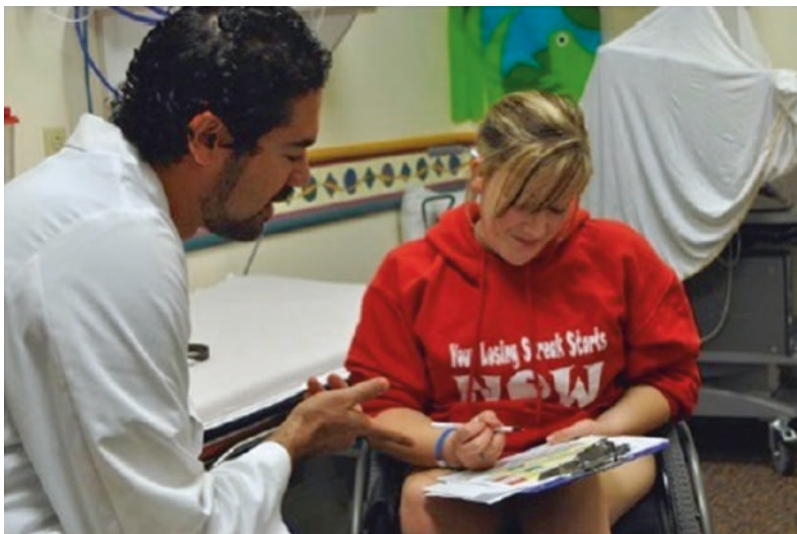state, it may be within the scope if the patient has a chronic “pediatric onset” problem. It is vital that each APRN knows what the practice statement or policy is for the state she/he practices in.

### Conclusion

The pediatric neurosurgical patient often has chronic lifelong conditions such as hydrocephalus, spina bifida, or epilepsy that require comprehensive and competent health care through adulthood. As discussed in this chapter, there are often significant barriers to successful transition that need to be addressed universally. Planning for the process of transition and ensuring that health-care providers are adequately educated in care of complex patients with childhood-onset diseases are essential. Additionally, the support services of nursing and social work need to be included in these programs. Their roles are vital to ensure coordination of services and specialists as needed by the individual patients. Financial considerations and the environment of care need to also be in line with the aging of these YSHCN as they move into the adult health-care arena. Although there are many innovative programs and clinics in existence, lack of “best practice” evidence for a program model that consistently leads to positive outcomes is a major gap in the realization of national standards of care.

### Pediatric Practice Pearls

- The transition planning process for pediatric neurosurgical patients should be presented and implemented around 14 years of age.
- Assessment of readiness and identification of any potential barriers early in the process are essential.
- Electronic health records, especially those with transition plan included, increase communication between pediatric care providers and adult care providers.
- Education of physicians and other health-care providers as to the specialized needs of pediatric neurosurgical patients that “grow up” can reduce mortality and morbidity associated with childhood neurological disorders in adulthood.
- Neuroscience nurses often have sustained relationships with their neurosurgical patients and families – they can provide invaluable insight, counseling, and problem-solving skills resulting in a positive transition outcome.
- There is a national resource available online for pediatric neuroscience nurses interested in pursuing transition program development through [www.got-transition.org](http://www.got-transition.org).



## References

- American Academy of Pediatrics American Academy of Family Physicians, & American College of Physicians – American Society of Internal Medicine (2002) A consensus statement on health care transitions for young adults with special health care needs. *Pediatrics* 110(6 pt 2):1304–1306
- American Academy of Pediatrics, American Academy of Family Physicians, & American College of Physicians, Transitions Clinical Report Authoring Group (2011) Supporting the health care transition from adolescence to adulthood in the medical home. *Pediatrics* 128:182–200. doi:10.1542/peds.2011-0969
- American College of Physicians (2010) The patient-centered medical home neighbor: the interface of the patient-centered medical home with specialty/subspecialty practices. American College of Physicians Policy Paper, Philadelphia
- American College of Physicians (2016) ACP pediatric to adult care transitions initiative. Retrieved 9/27/16: <https://www.acponline.org/clinical-information/high-value-care/resources-for-clinicians/pediatric-to-adult-care-transitions-initiative/about>
- Berkowitz S (2009) Transitioning adolescents to adult care: putting theory into practice. *Minn Med* 92(3):42–44
- Betz CL, Redcay G (2003) Creating healthy futures: an innovative nurse-managed transition clinic for adolescents and young adults with special health care needs. *Pediatr Nurs* 29(1):25–30
- Betz CL, Redcay G (2005) Dimensions of the transition service coordinator role. *J Spec Pediatr Nurs* 10(2):49–59. doi: JSPN010 [pii] 10.1111/j.1744-6155.2005.00010.x
- Betz CL, Smith KA, VanSpeybroeck A, Hernandez FV, Jacobs RA (2016) Movin' on up: an innovative nurse-led interdisciplinary health care transition program. *J Pediatr Nurs* 30(4):323–338
- Blum R (1995) Transition to adult health care: setting the stage. *J Adolesc Health* 17:3–5
- Blum RW, Hirsch D, Kastner TA, Quint RD, Sandler AD, Anderson SM, American Academy of Pediatrics American Academy of Family Physicians, & American College of Physicians – American Society of Internal Medicine (2002) A consensus statement on health care transitions for young adults with special health care needs. *Pediatrics* 110(6):1304–1306
- Brown LW, Camfield P, Capers M, Cascino G, Ciccarelli M, de Gusmao C, Downs SM, Mainemer A, Brin Miller A, SanInocencio C, Schultz R, Tilton A, Winokur A, Zupanc M (2016) The neurologist's role in supporting transition to adult health care: a consensus statement. *Neurology*. doi:10.1212/WNL.0000000000002965
- Camfield P, Camfield C (2011) Transition to adult care for children with chronic neurological disorders. *Ann Neurol* 69:437–444. doi:10.1002/ana.22393
- Carroll EM (2015) Health care transition experiences of young adults with cerebral palsy. *J Pediatr Nurs* 30:157–164. doi:10.1016/j.pedn.2015.05.018
- Disabato J, Cook P, Hutton L, Dinkel T, Levisohn P (2015) Transition from pediatric to adult specialty care for adolescents and young adults with refractory epilepsy: a quality improvement approach. *J Pediatr Nurs* 30:e37–e45 <http://dx.doi.org/10.1016/j.pedn.2015.06.014>
- Goodman D, Hall M, Levin A, Watson R, Williams R, Shah S, Slonim A (2011) Adults with chronic health conditions originating in childhood: inpatient experience in children's hospitals. *Pediatrics* 128:5–13. doi:10.1542/peds.2010-2037
- Hergenroeder AC, Wiemann CM, Cohen MB (2015) Current issues in transitioning from pediatric to adult-based care for youth with chronic health care needs. *J Pediatr* 167(6):1196–1201
- Hess JS, Straub DM, Mateus JS, Pelaez-Velez C (2015) Preparing for transition from pediatric to adult care. *Adv Pediatr* 62:137–161. doi:10.1016/j.jpapd.2015.04.003
- Hopper A, Dokken D, Ahmann E (2014) Transitioning from pediatric to adult health care: the experience of patients and families. *Pediatr Nurs* 40(5):249–252
- Jurasek L, Ray L, Quigley D (2010) Development and implementation of an adolescent epilepsy transition clinic. *J Neurosci Nurs* 42(4):181–189
- Labhard S (2010) Transitioning to adulthood with disabilities: a holistic approach. *Top Spinal Cord Inj Rehabil* 16(1):1–16. doi:10.1310/sci1601-1
- Lemly DC, Weitzman ER, O'Hare K (2013) Advancing healthcare transitions in the medical home: tools for providers, families and adolescents with special healthcare needs. *Adolesc Med* 25(4):439–446
- McManus MA, Pollack LR, Cooley WC, McAllister JW, Lotstein D, Strickland B, Mann MY (2013) Current status of transition preparation among youth with special needs in the United States. *Pediatrics* 131(6):1090–1097. doi:10.1542/peds2012/3050
- Mennito S, Clark J (2010) Transition medicine: a review of current theory and practice. *South Med J* 103(4):339–342
- National Alliance to Advance Adolescent Health (2016) Got Transition™, [www.gottransition.org](http://www.gottransition.org). Retrieved on 9.27.2016
- O'Sullivan-Oliveira J, Fernandes SM, Borges LF, Fishman LN (2014) Transition of pediatric patients to adult care: an analysis of provider perceptions across discipline and role. *Pediatr Nurs* 40(3):113–120
- Okumura MJ, Heisler M, Davis M, Cabana M, Demonner S, Kerr E (2008) Comfort of general internists and general pediatricians in providing care for young adults with chronic illnesses of childhood. *J Gen Intern Med* 23(10):1621–1627. doi:10.1007/s11606-008-0716-8
- Okumura MJ, Kerr E, Cabana M, Davis M, Demonner S, Heisler M (2010) Physician views on barriers to primary care for young adults with childhood-onset chronic disease. *Pediatrics* 125:e748–e754. doi:10.1542/peds.2008-3451

- Okumura MJ, Hersh AO, Hilton JF, Lotstein DS (2013) Change in health status and access to care in young adults with special health care needs: results from the 2007 national survey of adult transition and health. *J Adolesc Health* 52:413–418. doi:[10.1016/j.jadohealth.2012.08.005](https://doi.org/10.1016/j.jadohealth.2012.08.005)
- Park M, Adams S, Irwin C (2011) Health care services and the transition to young adulthood: challenges and opportunities. *Acad Pediatr* 11(2):115–122
- Patel M, O'Hare K (2010) Residency training in transition of youth with childhood-onset chronic disease. *Pediatrics* 126:S190–S193. doi:[10.1542/peds.2010-1466P](https://doi.org/10.1542/peds.2010-1466P)
- Patwardhan R, Nanda A (2005) Implanted ventricular shunts in the United States: the billion-dollar-a-year cost of hydrocephalus treatment. *Neurosurgery* 56(1):139–144
- Rekate H (2009) The pediatric neurosurgical patient: the challenge of growing up. *Semin Pediatr Neurol* 16(1):2–8. doi:[10.1016/j.spenn.2009.03.004](https://doi.org/10.1016/j.spenn.2009.03.004)
- Ried S (2010) Transition of youth from pediatric to adult care: physician's perspective and recommendations. *Top Spinal Cord Inj Rehabil* 16(1):38–47. doi:[10.1310/sci1601-38](https://doi.org/10.1310/sci1601-38)
- Rothstein DH, Li V (2015) Transitional care in pediatric neurosurgical patients. *Semin Pediatr Surg* 24:79–82. doi:[10.1053/j.sempedsurg.2015.01.005](https://doi.org/10.1053/j.sempedsurg.2015.01.005)
- Sanders R, Kuo D, Levey D, Cheng T (2009) Transitioning adolescents to adult care and adulthood: is it time yet? *Contemp Pediatr* 26(12):46–55
- Sharma N, O'Hare K, Antonelli RC, Sawicki GS (2014) Transition care: future directions in education, health policy, and outcomes research. *Acad Pediatr* 14(2):120–127
- Simon T, Riva-Cambrin J, Srivastava R, Bratton S, Dean J, Kestle J (2008) Hospital care for children with hydrocephalus in the United States: utilization, charges, comorbidities, and deaths. *J Neurosurg Pediatr* 1(2):131–137
- Simon T, Lamb S, Murphy N, Hom B, Walker M, Clark E (2009) Who will care for me next? Transitioning to adulthood with hydrocephalus. *Pediatrics* 124(5):1431–1437. doi:[10.1542/peds.2008-3834](https://doi.org/10.1542/peds.2008-3834)
- Slap G (2009) Promoting lifelong health for adolescents and young adults with special health care needs. *Pediatrics* 124:1469–1470. doi:[10.1542/peds.2009-1662](https://doi.org/10.1542/peds.2009-1662)
- Symons AB, Morley CP, McGuigan D, Akl EA (2014) A curriculum on care for people with disabilities: effects on medical student self-reported attitudes and comfort level. *Disabil Health J* 7(1):88–95
- Vinchon M, Baroncini M, Delestret I (2012) Adult outcome of pediatric hydrocephalus. *Childs Nerv Syst* 28:847–854



Angela Forbes

## 18.1 History of Radiographic Imaging

The first radiographic images were produced by German physicist Wilhelm Röntgen in 1895. Röntgen's lab records were all burned at his request after his death, but it is speculated that he accidentally discovered x-rays during experimenting with electromagnetic rays (Waters et al. 2011). Röntgen was unsure of the type of rays he was dealing with so he temporarily called them x-rays, but many others referred to them as "Röntgen rays" and to the radiographic images produced by x-rays as "Röntgenograms" after their discovery. They are still referred to as Röntgenograms in his native language of German, as well as many other languages. At the end of 1895, Röntgen published his observations in a paper entitled "On a New Kind of Rays: A Preliminary Communication" and mailed his colleagues a photograph of his wife's hand and skeletal structure. The x-ray machines from this time period used large radiation doses, 1,500 times greater than today's doses, often resulting in burns and loss of hair to those who received the x-rays or worked with the equipment (Sansare et al. 2011). The time it took to take an x-ray was also much longer, for example, it took about 90 min to image a hand (Waters et al. 2011).

---

A. Forbes, MN, ARPNP, C-PNP  
Seattle Children's Hospital, Seattle, WA, USA  
e-mail: [angela.forbes@seattlechildrens.org](mailto:angela.forbes@seattlechildrens.org)

Since this discovery x-rays have been used for medical imaging but have had limited application in the field of neurosurgery, particularly for imaging of the brain, without adaptation. One such adaptation was pneumoencephalography, which was introduced in 1919 by American neurosurgeon Walter Dandy. That technique involved draining CSF by means of a lumbar puncture and replacing it with air. The patient was maneuvered until the air displaced CSF in the subarachnoid spaces and/or in parts of the ventricular system, which could then be visualized by x-rays. This permitted neurosurgeons to identify the location and size of certain tumors and other lesions based on the shape of these air-outlined CSF spaces. The procedure is very painful, especially for children, and provided only limited appreciation of brain abnormalities. Though it remained in use at some facilities until the late 1970s, when it was replaced by modern imaging techniques.

Modern neuroimaging began in the 1970s with the development of computed tomography (CT also known as CAT for computerized axial tomography) and magnetic resonance imaging (MRI), as well as the first uses of ultrasound to image the neonatal brain. The first CT scanner was built by British engineer Godfrey Hounsfield, and the first diagnostic brain scan occurred on October 1, 1971. Hounsfield was unaware that South African physicist Allan Cormack had previously made and published the theoretical calculations supporting CT scanning technology. Both gentlemen shared a 1979 Nobel Prize for their contributions to the field of medicine. The CT scan was revolutionary, as it used x-rays to

provide an almost photographic replica of the internal structures of the body.

MRI is often the preferred imaging modality for children, because it does not utilize x-rays or ionizing radiation. Two researchers also shared a Nobel Prize for their discoveries concerning MRI: American chemist Paul Lauterbur and English physicist Peter Mansfield. Interestingly, Armenian-American physician Raymond Damadian, who invented and patented the first MRI machine, did not share the prize (Kaufmann 2014). MRI was first used to scan a human body in 1977 and started becoming commercially available in the early 1980s. CT and MRI were two of the most important medical inventions of the twentieth century.

---

## 18.2 Neuroradiology

Imaging, like any test performed on a patient, should be used as a tool to aid in diagnosis and guide treatment options. Neuroradiology refers specifically to a subspecialty of radiology that focuses on diagnosing abnormalities of the central nervous system, i.e., the skull, brain, and spine, as well as the vascular system supplying all of these entities. With the introduction of CT, MRI and related imaging techniques, extensive evaluations of the brain and spine that were not previously possible can now be obtained. Imaging of the central nervous system is most commonly done using x-ray, CT, MRI, and ultrasound. Angiography can also be used in conjunction with other imaging for the diagnosis of vascular anomalies in cases where MRI and other imaging do not provide a clear answer. No single imaging technique can be used to replace all of the modalities of imaging. Instead, the best mode of imaging should be determined on the basis of the particular pediatric patient and the differential diagnosis (see Table 18.1).

Patients and their families who are undergoing imaging will need an explanation of the procedure, as well as what to expect before, during, and after. There may be a great amount of anxiety of the unknown from these patients and families, as the purpose is often to obtain a

diagnosis. Although some explanation of the procedure will be given by the ordering provider, there will be a need for proper education from nurses with knowledge of the tests, as well as emotional support before and after the imaging. As more and more imaging is being completed on an outpatient basis, it can be challenging to provide the necessary education to families. If education cannot be provided in person, it should be done through a telephone call or by written material.

---

## 18.3 Radiation

Medical imaging has become a primary tool in diagnosis of injury and illness in children. However, it is important to remember that the decision to obtain imaging tests needs to be based on the potential benefits versus the potential risks. Among those risks is exposure to ionizing radiation. Common neuroimaging techniques that use radiation include x-ray (plain films), angiogram, radionuclide CSF shuntogram, proton emission tomography (PET) scan, and the CT scan. MRI does not use ionizing radiation but generally involves longer imaging times, requiring greater patient cooperation that can necessitate sedation. CT has the advantage of speed and greater sensitivity in evaluation of some pathologies, particularly in trauma.

We are all exposed to small amounts of radiation on a daily basis. There are risks involved with radiation exposure, the greatest concern being the risk of developing cancer. The low levels of radiation patients are exposed to during medical tests can be measured in units called millisieverts (mSv). There have been no published studies that show a link between radiation exposure of less than 10 mSv and cancer. However, there have been studies done on atomic bomb survivors, as well as workers who are exposed to radiation, which suggest that radiation exposure levels of 10–100 mSv can increase the risk of developing cancer (Miglioretti et al. 2013; Pearce et al. 2012). For comparison, a child who receives multiple CT scans during their lifespan can easily exceed

**Table 18.1** First line imaging

What	Goal	First line imaging	Special considerations
Brain tumor	Diagnosis and treatment/therapy/planning/posttreatment follow-up	MRI brain with and without contrast	Strongly consider obtaining spine imaging to rule out any metastatic disease
Spine tumor	Diagnosis and treatment/therapy/planning/posttreatment follow-up	MRI spine with and without contrast	Strongly consider obtaining brain imaging
Hemorrhage	Diagnosis and treatment	CT head without contrast	Consider 3D reconstruction to evaluate for skull fracture
Ventriculomegaly/hydrocephalus	Diagnosis and treatment/follow-up	Acute – CT head without contrast	CISS/CINE to evaluate anatomy that might favor an ETV
		Non acute – MRI brain without contrast	
		HASTE MRI – follow-up imaging	
Chiari malformation	Diagnosis and treatment/follow-up	MRI brain without contrast	CISS sequence to assess CSF flow around cervicomedullary junction
Syrinx	Diagnosis and treatment/follow-up	MRI spine without contrast	
Vascular malformation	Diagnosis and treatment	CT and CTA or MRI and MRA	
Craniosynostosis	Confirm diagnosis (initial diagnosis usually made on physical examination)	CT head without contrast	
Abscess	Diagnosis/treatment/follow-up	MRI brain or spine with and without contrast	
Non-accidental trauma	Diagnosis and management	CT head without contrast	
Spine trauma	Diagnosis and management	CT spine without contrast	

10 mSv. Modern CT scanners have substantially reduced the dose required for imaging.

The Pediatric Emergency Care Applied Research Network (PECARN) published a study that evaluated over 42,000 children cared for in 25 different emergency rooms, who had experienced head trauma within the previous 24 h and presented with a Glasgow Coma Scale of 14–15. The primary goal of this study was to identify children who had a minimal risk of developing a clinically important traumatic brain injury (ciTBI) after a head injury and, therefore, decrease the number of unnecessary CT scans that are performed on these children. For the purpose of the study, a ciTBI was defined as death from a TBI, need for a neurosurgical intervention following a TBI, intubation for more than 24 h following a TBI, or hospital admission for two or more nights associated with evidence of TBI on CT scan. From this very large study, an algorithm was developed to help guide whether or not a child with a traumatic head injury should undergo a head CT. The PECARN algorithm has guidelines for children younger than 2 years of age and for those 2 years and older. Children who are younger than 2 years should undergo a CT if they have a GCS of less than 14, altered mental status, or a palpable skull fracture. A CT should be considered in children younger than 2 years who have an occipital, parietal, or temporal hematoma, loss of consciousness (LOC) for greater than 5 s, a severe mechanism of injury, or an abnormal behavior reported by parents. In children 2 years and older, a head CT should be obtained for children with a GCS of less than 14, altered mental status, or signs of a basilar fracture. A head CT should be considered in this population if there has been vomiting, LOC, and severe mechanism of injury or the child self-reports a severe headache (Kuppermann et al. 2009). If this algorithm is applied, it can result in a reduction in the number of CT scans being done on children with minor head injuries.

Nurses should have a basic knowledge of the risks involved with radiation exposure, since the increasing media attention on the subject will likely result in questions and concerns from parents. Nurses must know how to educate patients

**Table 18.2** Radiation exposure in mSv

Exposure source	Level of radiation
Natural radiation per year	3.0 mSv
Cross country flight	0.04 mSv
Single chest x-ray	0.01 mSv
Spine x-ray	1.5 mSv
CT scan – head	2–4 mSv
Low-dose CT scan – head	0.5–1.0 mSv
CT scan – spine	6–10 mSv

and families about those risks while also explaining the necessity of the imaging. Nurses should be vigilant about reviewing medical records to ensure that patients are not receiving duplicate images that would expose them to additional radiation. It is important to consider that children are more sensitive to radiation than adults. It is essential that the “as low as reasonably achievable” (ALARA) principle be used in pediatric patients whenever safely possible. The goal of the ALARA principle is to achieve the best imaging using the least amount of radiation by utilizing weight-based protocols, improved shielding, consideration of alternative imaging methods (including MRI), use of limited view and reduced dose images, and avoidance of repeated images (Strauss and Kaste 2006).

The simplest way for us to think of medical radiation exposure is to compare it to the radiation we are exposed to on a day-to-day basis. Some examples of different levels of radiation exposure are listed on Table 18.2.

## 18.4 Contrast

Dense parts of the body such as bone are easily imaged using an x-ray or CT, but soft tissue structures (including tumors) are often difficult to see. Intravenous contrast agents can assist with visualization of these structures and improve the accuracy of diagnosis prior to any surgical intervention. For example, contrast can help evaluate different types, sizes, and locations of brain or spine tumors for diagnosis and surgical planning. Contrast can also help characterize infections and vascular anomalies. After diagnosis and treatment

of an infection, it can be used to determine response to the therapy and monitoring over the long term. It can also be used to follow vascular anomalies such as arteriovenous malformations (AVMs) or cavernous malformations over time and also to detect new anomalies before symptoms occur.

Iodinated (iodine-containing) contrast is most commonly used with CT. It can greatly enhance the clarity of vascular structures and provide improved visibility of tumors or abscesses. Gadolinium-based contrast has magnetic properties that are used to enhance brain and spine images created by MRI.

Prior to the administration of any contrast agent, nurses should consider the degree of renal function in children with known renal disease and whether they are receiving nephrotoxic medications like chemotherapy or some antibiotics. Use of iodinated contrast needs to be carefully considered for children who are dehydrated or who have impaired kidney function. Gadolinium contrast should be avoided in the child with significantly impaired kidney function.

In very rare cases, children can have an allergic reaction to both iodinated and gadolinium-based contrast, although allergic reactions, especially anaphylaxis, are much less common with gadolinium than to iodinated contrast. The current literature shows that there is no relationship between a shellfish or iodine allergy and an allergy to contrast agents (Schabelman and Witting 2010). Patients should be asked if they have any allergies or have had a previous reaction to contrast (Schabelman and Witting 2010). Patients who have had a reaction to contrast in the past, such as hives, pruritus, or shortness of breath, should be premedicated if contrast use cannot be avoided (e.g., steroids, antihistamine). When a patient has had a previous anaphylactic reaction, such as airway edema or difficulty breathing, alternative imaging should be considered.

---

## 18.5 Sedation

One of the most important things about obtaining quality images in pediatric patients is ensuring that they stay still during the procedure. Every

consideration should be made to avoid the use of sedation, as there are risks involved, most commonly respiratory depression. Additionally, there is some concern for the possible effects of sedation on the developing brain. There have been many studies done on rodents and primates demonstrating that there can be an effect on neuronal development when anesthesia is administered during the critical period of brain growth (Reddy 2012).

There is no consensus on how these animal studies translate to humans, and specifically children, undergoing anesthesia. A study of 2,608 children in Australia, of whom 321 had been exposed to anesthesia before age 3, found that children in the exposed group had an increased long-term risk of deficits in language and abstract reasoning at age 10 compared to unexposed children (Ing et al. 2012). In contrast, the Pediatric Anesthesia and Neurodevelopment Assessment Study (PANDA) was recently published and showed no evidence of any link between a single exposure to anesthesia in children below the age 3 and cognitive delays (Sun et al. 2016). Similarly, an international multicenter study also revealed no connection between a short period of general anesthesia (under 1 h) in children under two and neurocognitive delays (Davidson et al. 2016). The level of concern with the use of anesthesia in children is continuously evolving.

The American Academy of Pediatrics (AAP) defines the goals of sedation in the pediatric patient for diagnostic procedures as follows: to ensure the patient's safety, to reduce physical discomfort and pain, to keep anxiety to a minimum, to limit movement to allow safe completion of the procedure, and to return the patient to their baseline prior to discharge (Charles and Stephen 2007; Coté and Wilson 2016). When a child must be sedated for imaging, it is preferable that it be done under the care of a trained pediatric anesthesiologist (Coté and Wilson 2016).

In most cases, sedation is not needed for a CT scan. Younger children can be safely restrained for the duration of the imaging, and older children are able to cooperate and hold still for the time needed to obtain a CT scan of the head or spine.



Sedation is usually required for an MRI in children younger than 6–8 years of age, with the exception of a half-Fourier acquisition single-shot turbo spin echo (HASTE), also known as a rapid sequence MRI. An MRI can cause a great amount of fear in children, as the machines are very loud and it requires laying still and alone in a small space (Arlachov and Ganatra 2012). Children are, however, less prone to claustrophobia which can be a problem with adults. Most children 8 years and older can be distracted with the use of a movie or music. Neonates can usually be scanned using a fast and feed protocol, where the infant is fed immediately prior to the study and will usually sleep for the duration of the scan. At around 3 months of age, sedation is usually necessary to obtain adequate imaging. With patience on the part of the nursing staff and cooperation from the technicians, nonsedated imaging can be achieved in many cases. Centers around the world are looking at alternative options to sedation, including sleep deprivation, hypnosis, distraction, melatonin, play therapy, and parental involvement (Arlachov and Ganatra 2012). Allowing a family member to be present during the exam can often be a great calming mechanism for children.

Limited imaging techniques that would be performed in a rapid manner are currently under development. These will have various clinical applications such as evaluation for only the presence of hydrocephalus.

### 18.5.1 Nursing Care

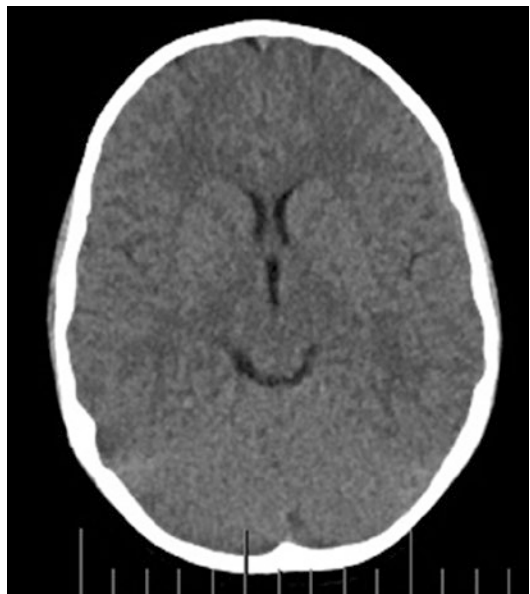- Baseline assessment prior to sedation: respiratory rate, oxygen saturations, blood pressure, pulse, and neurological exam.
- Is sedation needed?
- Has patient adhered to fasting guidelines? (These instructions should be given to family several days before the procedure if possible.)
- Prepare the patient and family, including an explanation of the possible complications.
- Has informed consent been obtained from the patient's parent or legal guardian for both the sedation and the procedure being performed?
- Monitor throughout the procedure and during the recovery period, including respiratory rate, oxygen saturation, blood pressure, and pulse and that the child returns to their pre-sedation neurological baseline.
- Educate patient and family about post-sedation side effects, including nausea, vomiting, sleepiness, confusion, chills, and throat pain if the patient needed intubation for general anesthesia. If patient is being discharged after sedation, instructions should be given including phone numbers to call if the family has questions or concerns.

## 18.6 Neuroimaging Techniques

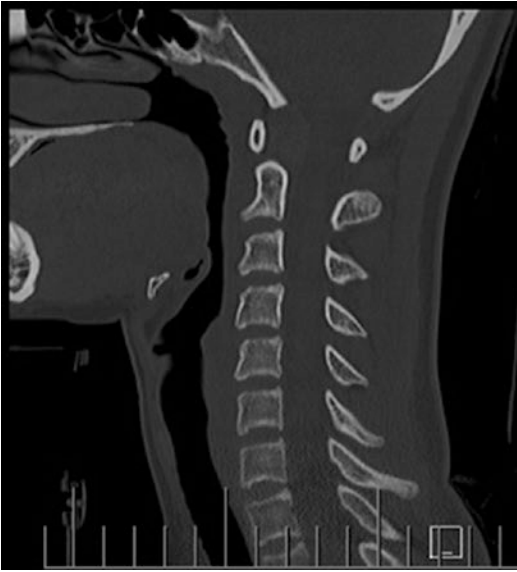
### 18.6.1 Computed Tomography (CT) (Figs. 18.1 and 18.2)

#### 18.6.1.1 How Does It Work/Procedure

A plain film x-ray will depict a skull fracture but is of little value for imaging the brain. Tomography refers to imaging by sections. CT works in a similar way to an x-ray, but with a CT scan, multiple images are taken from multiple angles as the



**Fig. 18.1.** Normal head CT



**Fig. 18.2** Normal cervical spine CT

x-ray tube rotates around the patient's body. A computer then reconstructs the images into cross-sectional images or "slices." These slices can either be viewed individually or stacked on top of each other to create a 3D image of the brain or spine. The provider then has the ability to rotate and view the images to find the exact location of the abnormality.

The density of the tissue or fluid that the x-ray passes through will determine how it appears on the CT scan. The denser the object, the brighter it will be on the image. Hence, bone will show up on a scan as a very bright white. Acute blood will be white as well. This brightness is referred to as "hyperdense." Air will be dark, and water or CSF will be relatively dark, all referred to as hypodense. Normal brain shows up as gray (isodense). For viewing, CT images need to be adjusted (referred to as window and level) for the particular range of structural density being assessed, e.g., "brain window" or "bone window." CT demonstrates less contrast differentiation of soft tissue than MRI, for example, when looking at brain tumors or for infections. CT is also compromised in evaluation of the posterior fossa due to effects of the bone in the skull base (Fig. 18.3 shows a

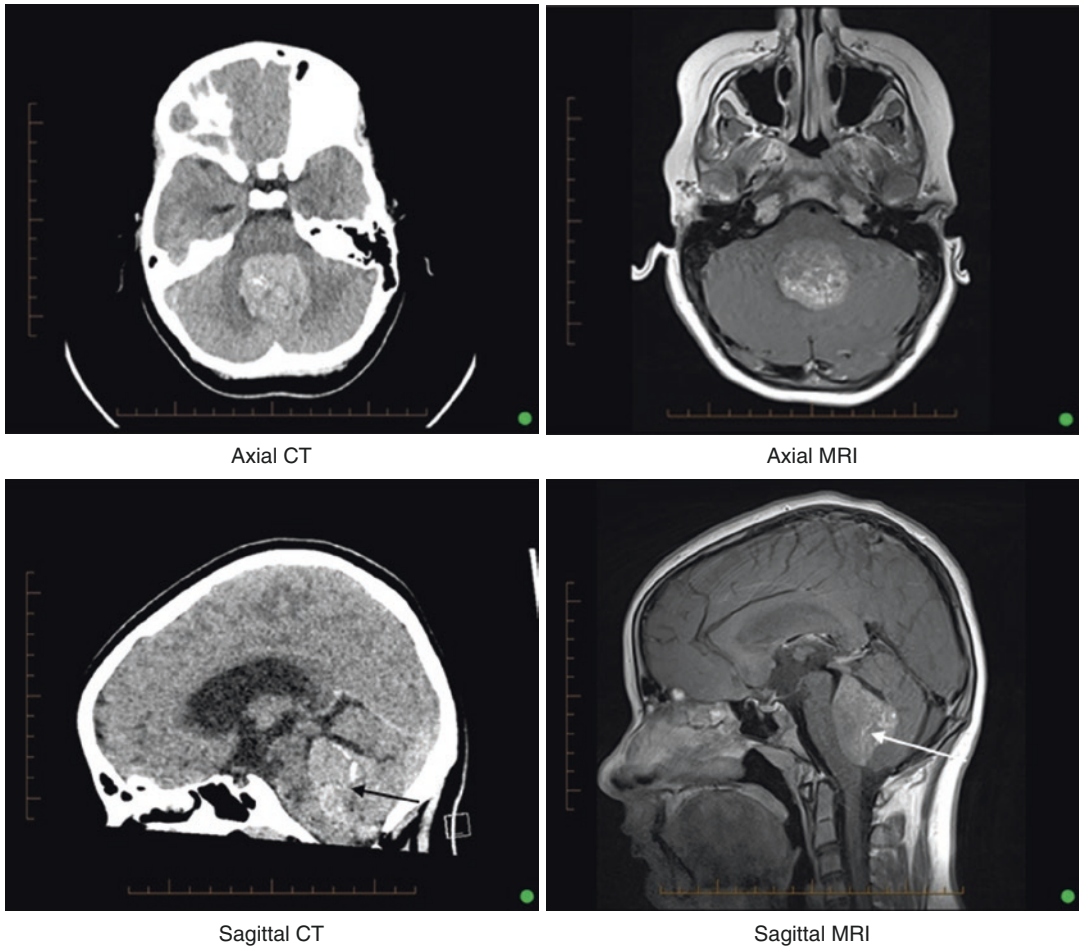
comparison of CT and MRI scans of the same patient with a posterior fossa tumor).

If contrast is going to be administered, an IV will either need to be placed before the test begins or it can be given through a butterfly needle during the scan. The patient lies on a moving table which slides inside a circular opening (CT gantry). Restraints may be used with younger children to reduce movement during the procedure. The x-ray will then start to rotate around the patient. A CT scan of the head or spine can be done in about 2–10 sec.

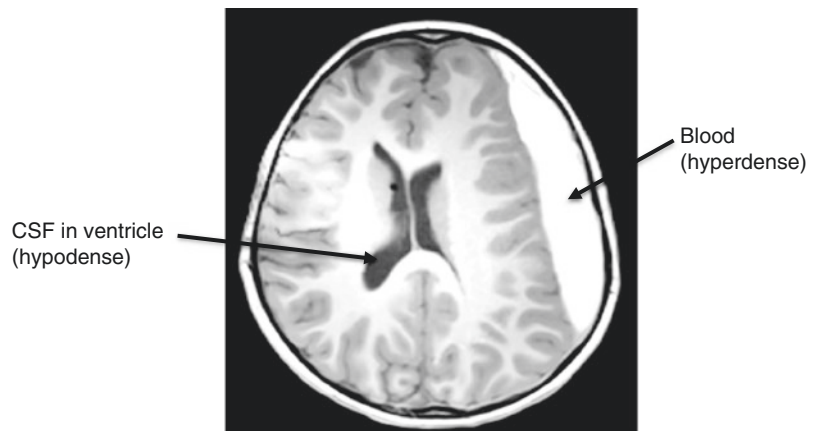
### 18.6.1.2 Clinical Application

CT scan is the most commonly used imaging in trauma cases. It is the fastest way to obtain images of the brain and spine in a critical period. CT scanners are also widely available and can be found even in many rural facilities. Also because it is quick, CT can be performed without the use of sedation in most cases. Blood and CSF show up well on CT, so it can be used to look for an intracranial hemorrhage (Fig. 18.4) caused by a trauma (both accidental and non-accidental), as well as hydrocephalus (Fig. 18.5). It is also used to evaluate skull and spinal fractures. CT will generally be able to rule out most intracranial abnormalities that would require neurosurgical intervention. A CT scan of the brain and spine can also be used to look for tumors, abscesses/infection, and vascular anomalies that may be responsible for strokes or bleeds in children who present with neurological deficit. A CT scan is often obtained to confirm the diagnosis of craniosynostosis and provide operative planning, although the diagnosis can usually be made on physical exam alone. CT scan can be used to evaluate bony abnormalities in the spine, such as craniovertebral junction abnormalities and vertebral anomalies.

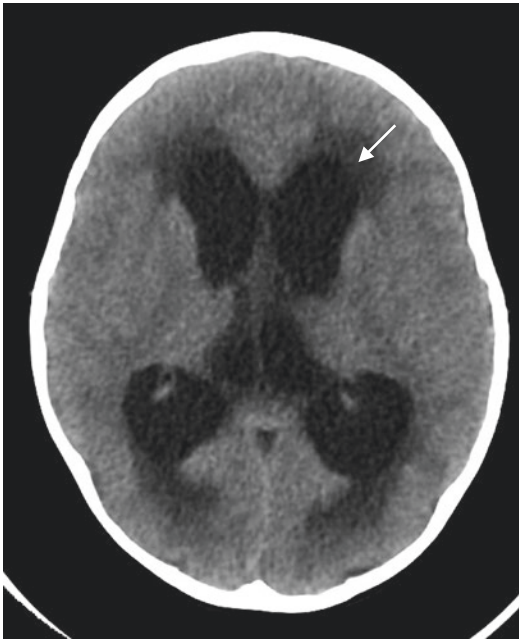CT scans are used for guidance during brain and spine surgery, as they can provide coordinates for the navigation system in the operating room. Such navigation systems allow surgeons to track the location of their surgical instruments in relation to the anatomy of the brain. This helps the surgeon to perform more precise and less invasive surgical interventions.



**Fig. 18.3** Comparison of CT and MRI of same patient with posterior fossa tumor



**Fig. 18.4** CT head without contrast showing intracranial hemorrhage



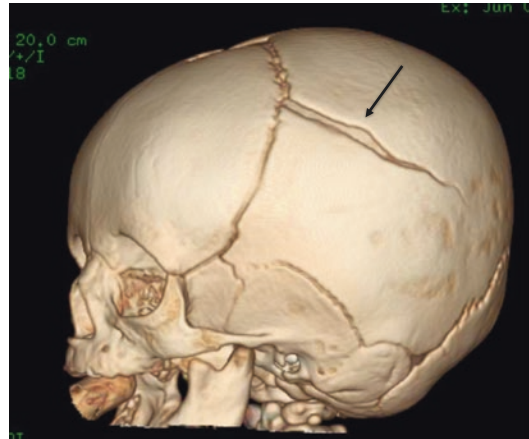**Fig. 18.5** CT head without contrast. Hydrocephalus and transependymal flow

### 18.6.1.3 Additional Considerations

CT scans use medical radiation, but it is important to remember that the benefit of obtaining a head or spine CT usually outweighs any potential risk. Low-dose protocols are being utilized more frequently in CT scans, especially as providers and radiologists consider the ALARA principle.

### 18.6.1.4 Nursing Care

- Ensure that no metal is worn in the area being imaged during the study, as this can produce artifact and interfere with the accuracy of the imaging.
- Sedation is rarely necessary to perform a CT scan of the brain or spine.
- An important job of the nurse is to help decrease the patient and family's anxiety by explaining the procedure and what will happen during the test. They should be assured that CT scan is not painful, but remember that having to lie still in the setting of an injury can be painful and anxiety producing.
- If patient is receiving contrast, identify any problems with renal function prior to the scan.



**Fig. 18.6** CT head with 3D reconstruction showing skull fracture

- Identify allergies, particularly to contrast.
- Tell patient that if contrast is being administered, the contrast may cause a flushing sensation, salty or metallic taste in their mouth, a mild headache, or nausea but that these side effects are usually very short lasting.
- Patients do not need to be NPO for CT scanning of the brain or spine even if contrast is being administered, as the contrast is given through an IV and does not need to be ingested.
- Patients should be well hydrated following the procedure to ensure proper clearance of the contrast.

### 18.6.1.5 Special Considerations

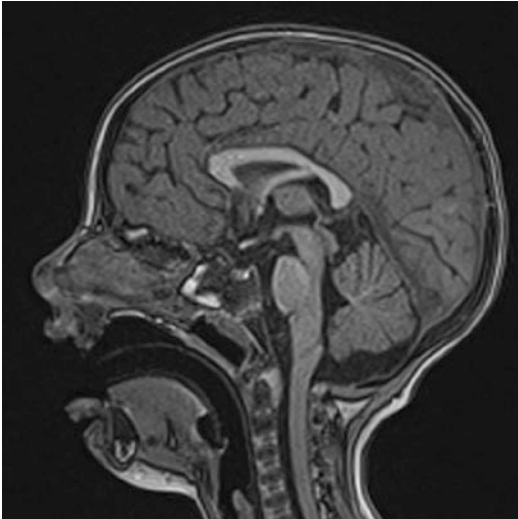
3D reconstruction of a head CT can be helpful to further evaluate the bone structure of the head and to evaluate for abnormalities including better characterization of skull fractures (Fig. 18.6).

## 18.6.2 Magnetic Resonance Imaging (MRI)

### 18.6.2.1 How Does It Work/Procedure

An MRI can provide incredibly detailed images of the brain (Fig. 18.7) and spine (Fig. 18.8) that cannot be seen on plain x-rays or CT scans. It not only permits the identification of abnormalities undetected by other imaging modalities but also facilitates the further evaluation of those that

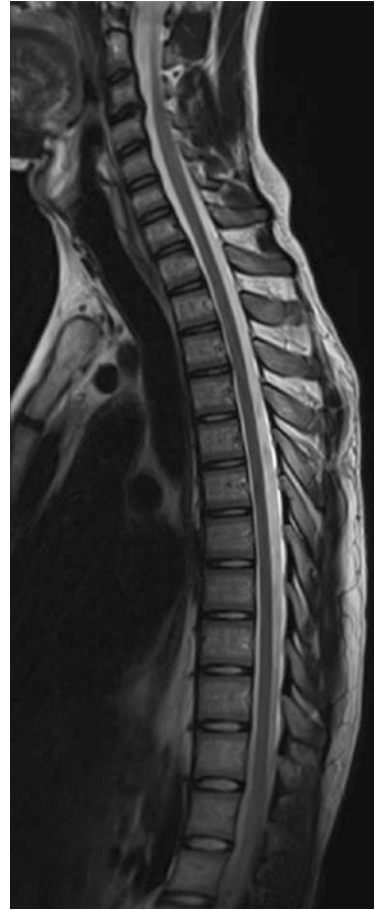




**Fig. 18.7** Normal brain MRI (T1 sagittal view)

were detected otherwise. MRI is an exceptional imaging technique because it provides information about both anatomy and the actual physiologic process of the body.

MRI utilizes a large magnet along with radio waves (pulse) to exploit an atomic phenomena known as magnetic resonance. Since the human body is largely composed of water, hydrogen is a major component of all tissues and bodily fluids. A fractional percentage of it exists as hydrogen ions, which carry a positive charge. The MRI scanner creates a strong magnetic field, causing those hydrogen ions to “line up” along its axes. A radio frequency pulse is used along with manipulation of the magnetic field (through gradient coils) to alter the precession of the ions. Following the pulse, the hydrogen ions “relax” and emit energy which can be detected. The rate of relaxation differs depending upon the type of tissue or fluid they exist in. To oversimplify, MRI maps the differences in the relaxation rates (measured in milliseconds). Indeed, it was the discovery that ions in cancerous tissue generally relaxed at a slower rate than those in healthy tissue that led Damadian to first propose that nuclear magnetic resonance could be used for medical diagnostic purposes (Damadian 1971).



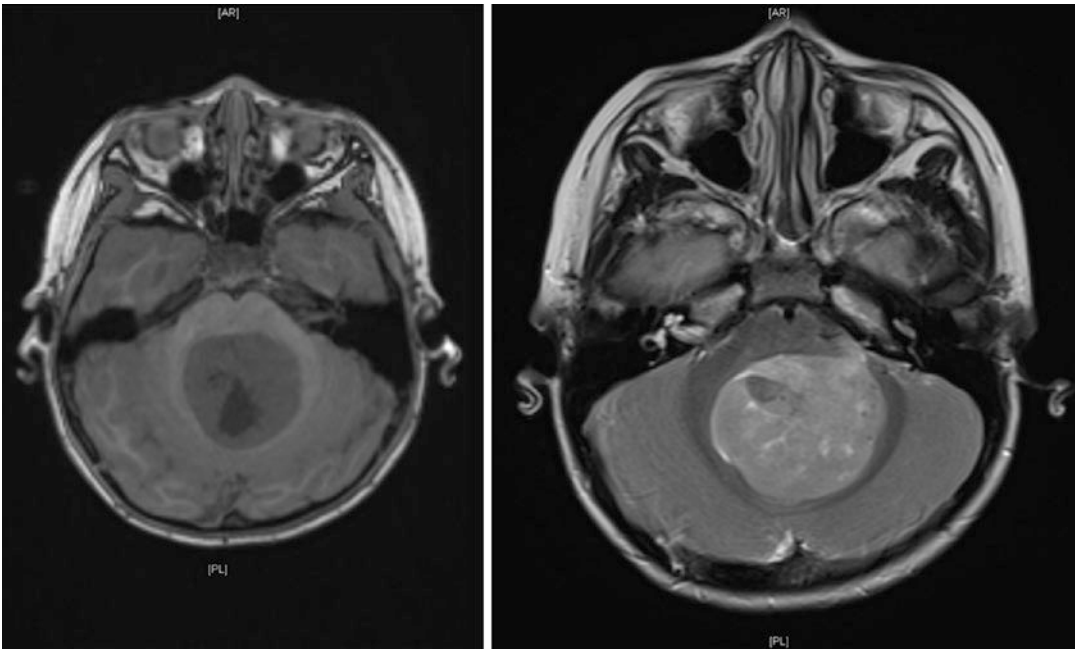
**Fig. 18.8** Normal spine MRI (T2 sagittal image)

An MRI image differentiates various tissues and fluids by signal intensity:

- Low signal intensity – black (or dark), hypointense
- Intermediate signal intensity – gray, isointense
- High signal intensity – white (or bright), hyperintense

The signals are emitted by the ions/protons existing in those tissues and fluids, and the intensity of the respective signals can be manipulated by radiologists through the frequencies and pulse sequences used (e.g., water appears black on T1 and white on T2). The contrast is distinctly different on T1 and T2 images (Fig. 18.9), but both





**Fig. 18.9** MRI brain comparison of T1 (*left*) and T2 (*right*) sequences of same brain tumor

**Table 18.3** Comparison of MRI intensity and CT density

Anatomy	MRI T1 (intensity)	MRI T2 (intensity)	CT (density)
Air	Hypointense (dark)	Hypointense (dark)	Hypodense (dark)
Bone	Hypointense (dark)	Hypointense (dark)	Hyperdense (white)
Water/CSF	Hypointense (dark)	Hyperintense (white)	Hypodense (dark)
Blood	Acute – hypointense (dark)	Acute – hypointense (dark)	Hyperdense (white)
Brain	Gray matter – isointense (gray)	Gray matter – isointense (gray)	Isodense (gray)
	White matter – isointense (darker than gray)	White matter – isointense (darker than gray)	
Tumor	Hypointense (dark)	Hyperintense (white)	Hypodense (dark)

T1 and T2 are typically performed on most brain MRIs. Proton density can also be a factor in MRI, but that is different than tissue density which is important for CT. Keep in mind that CT reflects the *density* of the anatomical structures scanned, while MRI differentiates by signal *intensity* (see Table 18.3).

*T1 sequence* is often the most basic spin sequence. T1 is the sequence used to show the anatomy of the central nervous system, reproducing an almost photographic image of the structures. T1 is the optimal sequence to use with

gadolinium enhancement which can be utilized to identify lesions such as tumors or abscesses.

T1 signal intensities:

- Fluid – black
- Muscle – gray
- Fat – white
- Brain gray matter – gray
- Brain white matter – white

*T2 sequence* is another basic sequence performed in nearly all MRI scans. T2 is excellent

for showing abnormalities such as tumors, edema, or infection.

T2 signal intensities:

- Fluid – white
- Muscle – gray
- Fat – black
- Brain gray matter – gray
- Brain white matter – gray

### 18.6.2.2 Special MR Sequences

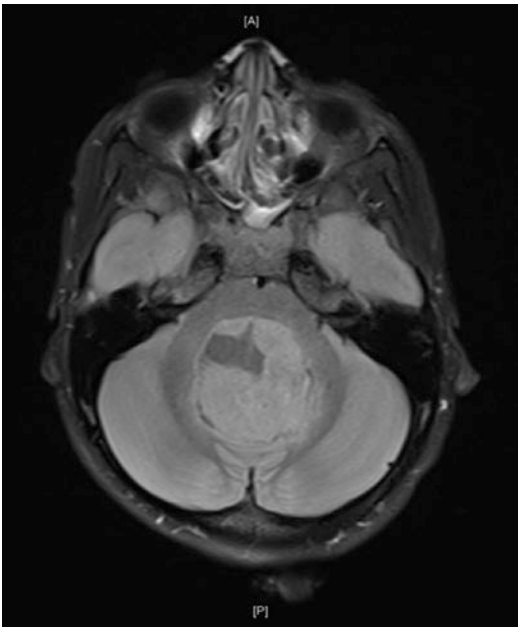
*FLAIR sequence* is an acronym for fluid attenuation inversion recovery. It makes normal CSF black, but not fluids with other levels of protein, which makes it useful when evaluating pathology in the brain (Okuda et al. 1999). It is also helpful to determine if there is edema surrounding the abnormality (Fig. 18.10). Flair sequence can also identify subarachnoid hemorrhages that may not be obvious on a CT scan (Abdel Ghaffar et al. 2014).

*Diffusion-weighted imaging (DWI)* detects the molecular motion of water in tissues (Brownian motion). The diffusion rate of water molecules in brain tissue is altered by disease or infarct. Much like MRI generally looks at differences in relaxation rates, DWI analyzes differences in the diffusion rates. DWI uses rapid sequences and is more

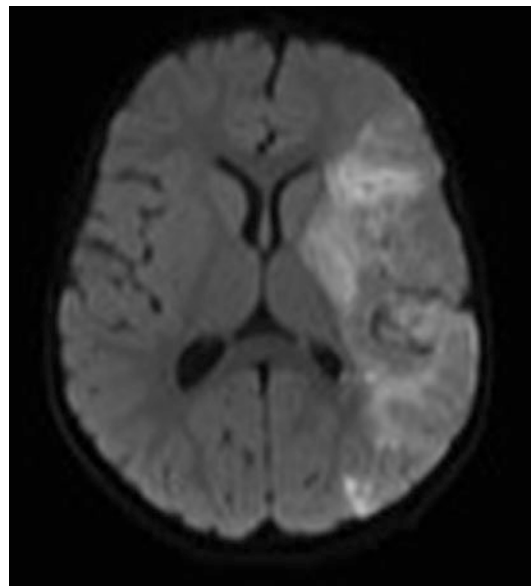
resistant to patient movement than most standard sequences. DWI is highly sensitive to acute and subacute ischemic stroke (Fig. 18.11) (Schaefer et al. 2000). It can also provide additional information on edema, infections, and tumors.

*Functional MRI (fMRI)* can be used to visualize changes in blood oxygen levels during various tasks, thereby mapping the functional activity of the brain during the activity (e.g., having the patient speak or move a body part). Thus, areas of eloquent brain can be identified prior to surgery.

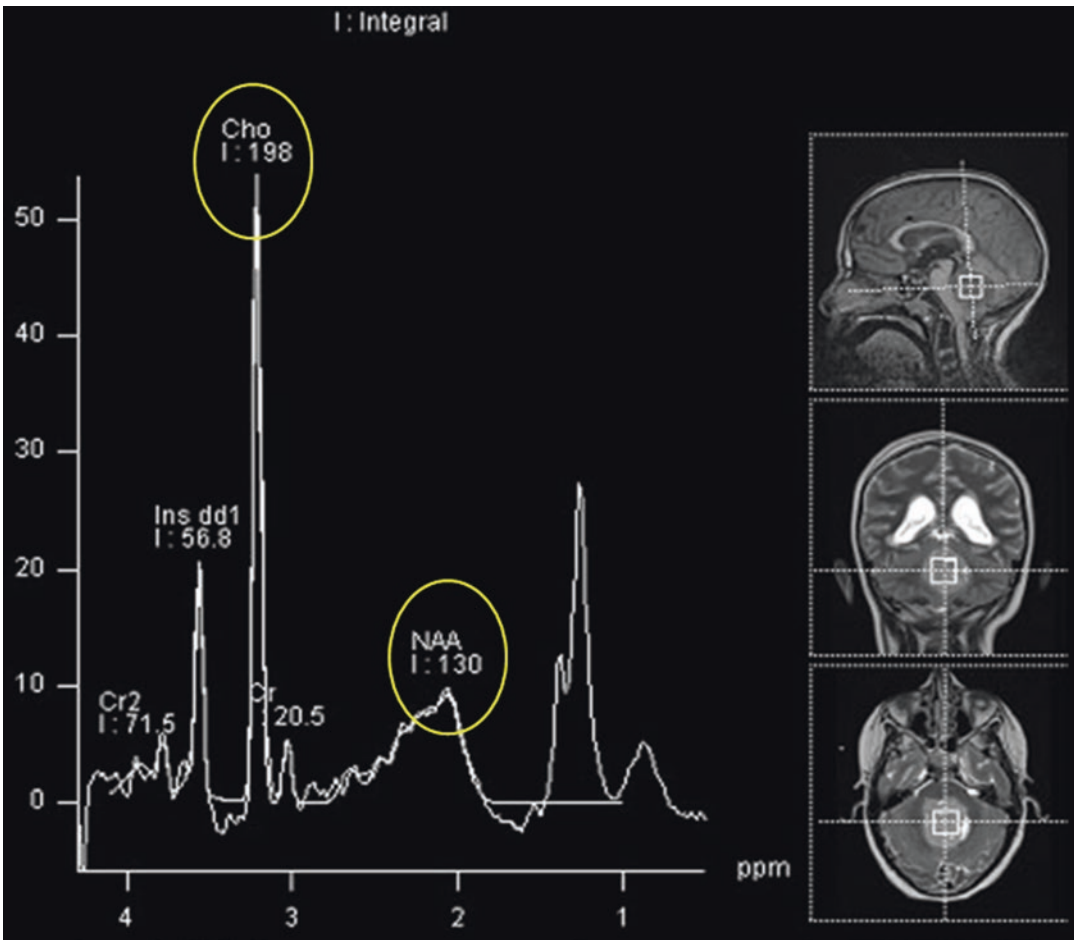
*MR spectroscopy (MRS)* measures biochemical changes in the brain and can provide information about tissue changes. MRS is done at the same time and on the same machine as an MRI, but instead of providing information about the location of abnormalities, MRS looks at the products of metabolism (specifically amino acids, lipids, lactate, alanine, N-acetyl aspartate or NAA, choline, creatine, myoinositol). These products or metabolites are measured in parts per million (ppm) and are then placed on a graph (Fig. 18.12). One of the main uses of MRS is with brain tumors. It can provide additional information about tumor type and grade, as well as help differentiate between tumor recurrence and changes secondary to radiation (Bertholdo et al. 2013). MRS can also be helpful in differentiating between brain tumors and infection.



**Fig. 18.10** MRI flair signal – brain tumor with surrounding edema



**Fig. 18.11** MRI with DWI showing ischemic stroke



**Fig. 18.12** MR spectroscopy showing abnormal choline to NAA ratio providing information for tumor grading

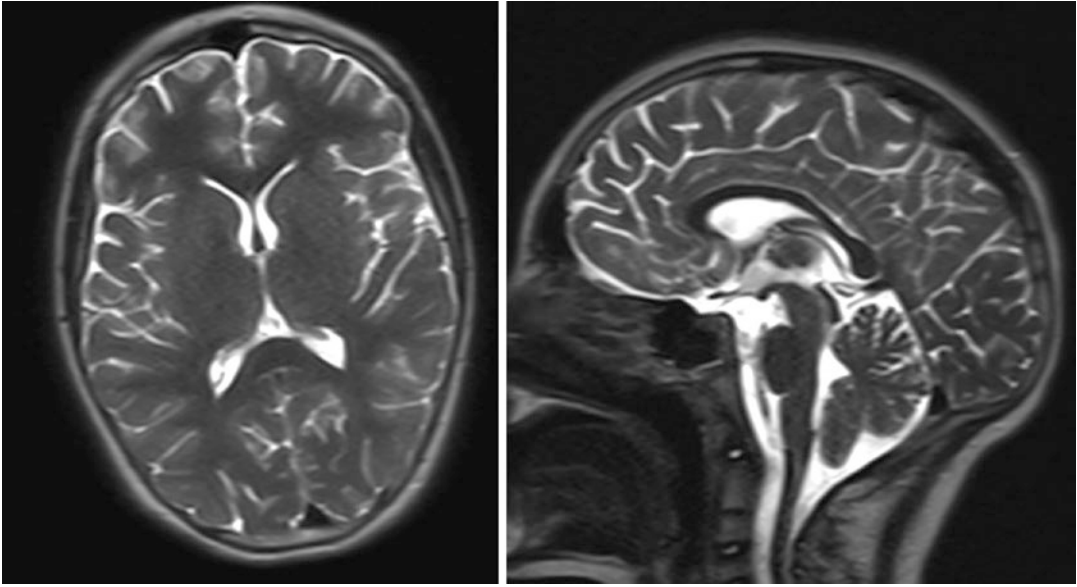
*Magnetic resonance angiography/venography (MRA/MRV)* is used to image arterial or venous blood vessels. It is noninvasive, so it can be used as an alternative to invasive techniques like angiography when imaging is needed on an emergent basis.

*Half-Fourier acquisition single-shot turbo spin echo (HASTE) MRI* is a rapid sequence MRI that produces axial T2-weighted images (Fig. 18.13). The advantage of this technique is that it can be performed very quickly (less than 1 min). As the term “single-shot” indicates, it uses a single radio frequency pulse instead of a sequence of them. And each slice is acquired sequentially, rather than the standard MRI sequence that is acquiring a component of each slice. As a result, the patient often does not need sedation. Studies have shown that, when compared to a head CT, a HASTE MRI can effectively evaluate ventricular size (see Fig. 18.14) without exposing a child to

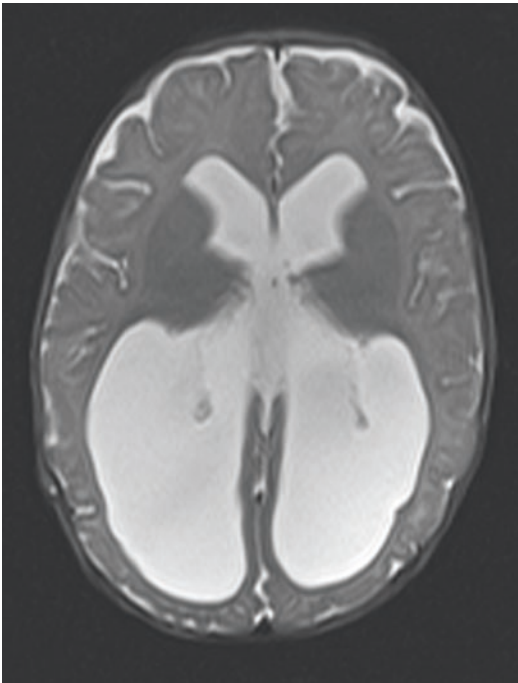
ionizing radiation (Niederhauser et al. 2013; O’Neill et al. 2013; Koral et al. 2012). This makes it an excellent tool for assessing hydrocephalus.

### 18.6.2.3 Clinical Application

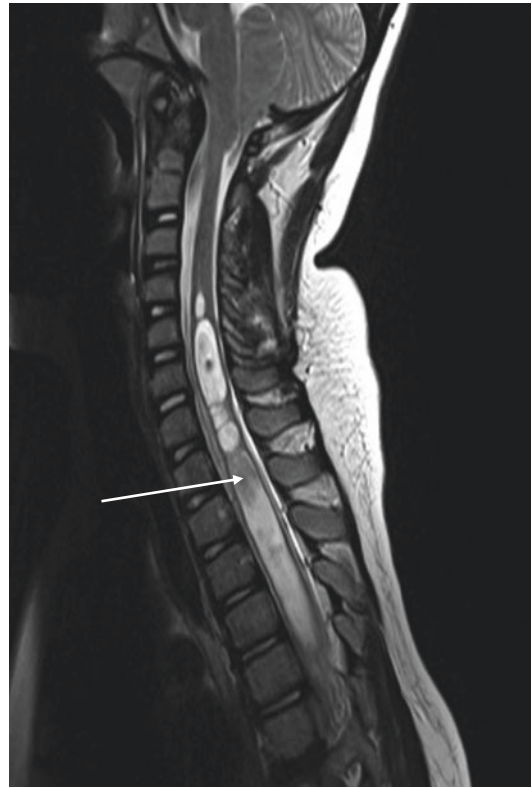The high definition and detail provided by an MRI makes it the imaging of choice in the evaluation of many diagnoses, including tumors, congenital malformations, vascular malformations, hemorrhages, and ischemic strokes, without exposure to ionizing radiation. It does not, however, provide good bone images, so CT scans are preferred for imaging the skull and bony spine. However, MRI is the preferred imaging modality when looking for spine pathology, such as a myelomeningocele, a tethered spinal cord, intraspinal cysts, syringomyelia (Fig. 18.15), infections, abscesses, or tumors (Figs. 18.16 and 18.17). Another important use of MRI is to eval-



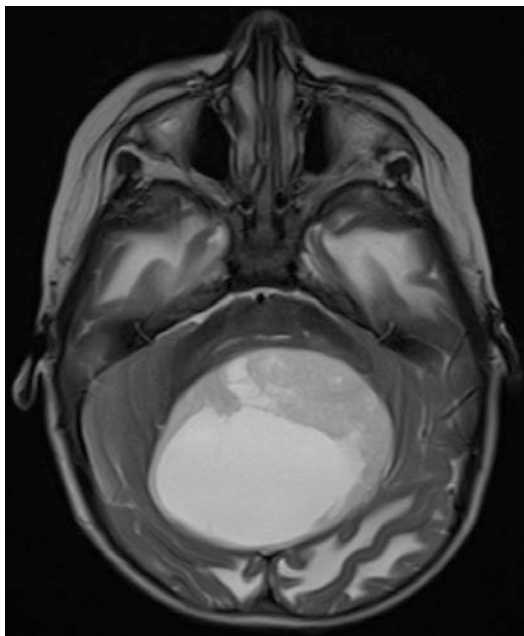
**Fig. 18.13** HASTE MRI of normal brain



**Fig. 18.14** HASTE MRI showing enlarged ventricles



**Fig. 18.15** T2 MRI of cervical spine showing multiloculated syrinx



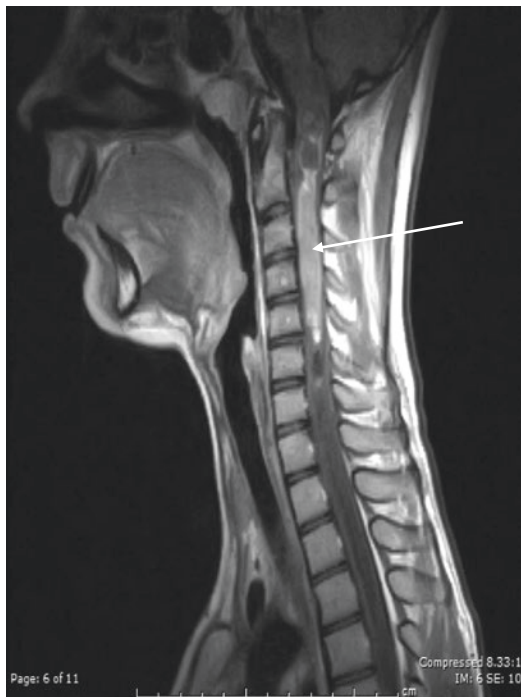**Fig. 18.16** MRI brain showing brain tumor

uate the cause of hydrocephalus. MRI can also be used in the preoperative setting to evaluate candidacy for endoscopic third ventriculostomy and as an evaluation tool in preparation for epilepsy surgery. MRI with contrast can be used to detect infections, including bacterial infections, such as epidural and subdural abscesses and meningitis. When a child presents with neurological dysfunction or following a trauma, a CT remains the best scan to obtain in the acute setting, as it usually can be done faster than an MRI.

There are special imaging sequences, including constructive interference in steady state (CISS) and “cine” or cinema, which can be used to visualize CSF flow during an MRI. The following clinical situations can benefit from such CSF flow studies:

- Aqueductal stenosis
- Patency of third ventriculostomy
- Flow at the cervicomedullary junction, for example, with a Chiari malformation or achondroplasia

These sequences are further discussed in Sect. 2.9.3 of the “Hydrocephalus” chapter, which includes images at Figs. 2.12 (cine) and 2.13 (CISS).



**Fig. 18.17** MRI cervical spine intramedullary tumor

#### 18.6.2.4 Additional Considerations

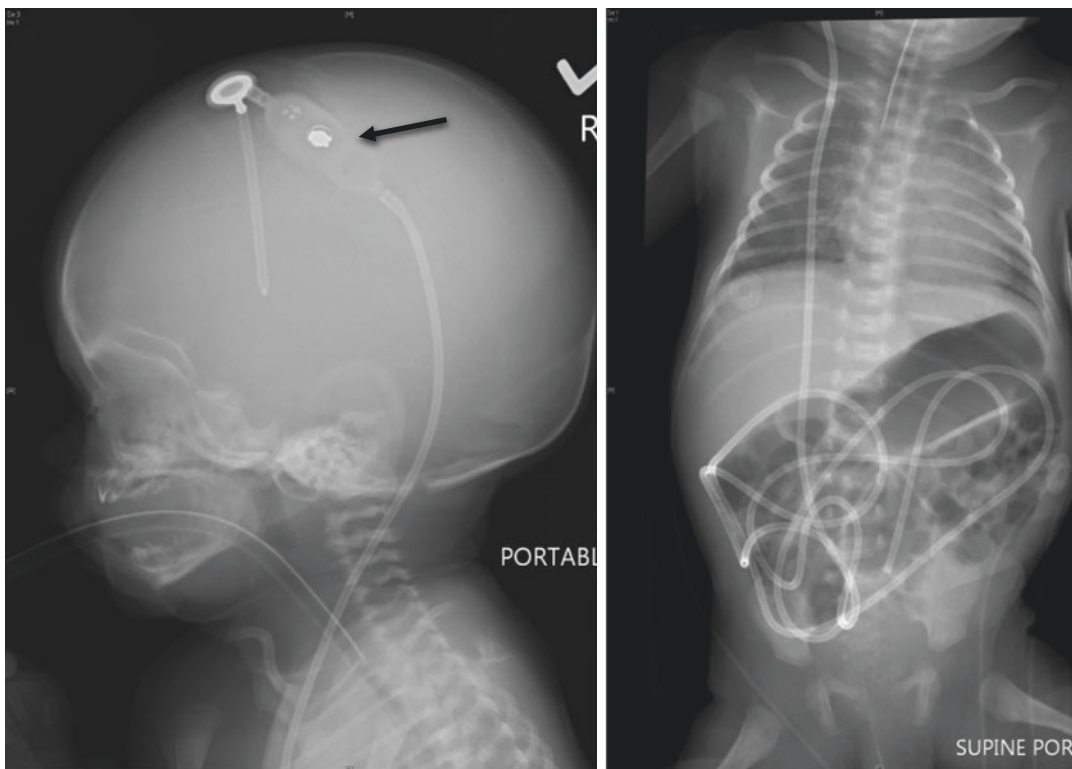
As noted, a major advantage to using an MRI instead of a CT scan is that it does not entail exposure to ionizing radiation. But it is important to remember that the development of MRI technology is very recent when compared to x-rays. Although at this time it does appear that MRI is safe, there has not been an opportunity to study the long-term effects of MRI. Further, most younger children will require sedation for an MRI, unless a HASTE or rapid sequence MRI is being performed. An MRI does take longer than a CT scan, and it can be challenging to keep patients still enough to obtain optimal images.

#### 18.6.2.5 Nursing Care

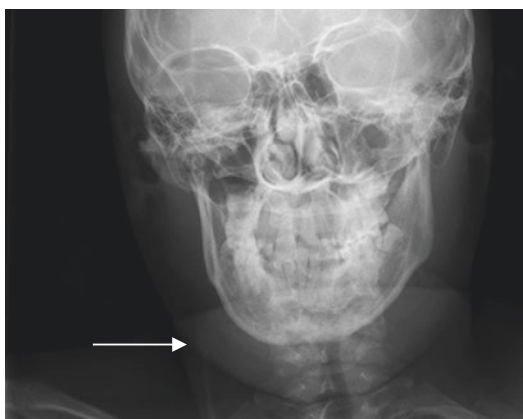- Due to the length of the test and the need for the patient to stay very still, sedation will probably be required for children under the age of 8 or for children with behavioral difficulties or developmental delays.
- The MRI machine utilizes very high-powered magnets. If the patient has metallic implants (e.g., a pacemaker, VP shunt, baclofen pump,







**Fig. 18.19** X-ray shunt series. Note the programmable valve

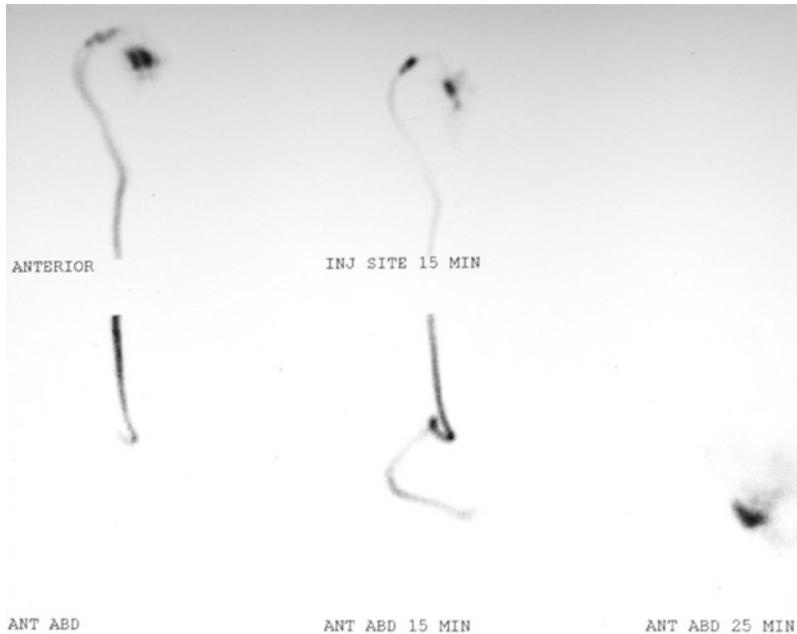


**Fig. 18.20** Skull x-ray – fractured shunt tubing

Immediately after the radiotracer is injected, a series of images are taken over a short time period (10–15 min) at intervals of approximately 1 min. This documents the flow of contrast from the shunt reservoir all the way to the tip of the distal tubing in the peritoneal cavity, the atrium, or

pleural cavity. Imaging may also be performed with the patient in the upright position to encourage CSF flow. Studies have shown that a single variable called half time or  $T_{1/2}$  can be used to determine patency of a shunt. A ventricular catheter obstruction or valve malfunction should be considered if there is no free flow of CSF once the needle is inserted into the valve, or if CSF is not able to be easily aspirated from the reservoir. A normal or elevated opening pressure should be considered proof that the proximal tubing is patent. A distal occlusion should be considered when the radiotracer does not spill freely into the peritoneal cavity or if it takes a prolonged period of time (despite placing child in the upright position) for the radiotracer to enter the peritoneal cavity.

During the test the patient is positioned supine and the head is positioned for optimal access to the shunt system. X-rays of the head should be readily available to identify the location of the reservoir valve and shunt system. Once the shunt reservoir



**Fig. 18.21** CSF flow study/shuntogram

or valve is located, the hair over the area may be clipped. A small needle is sterilely inserted into the reservoir. Free flow of clear CSF confirms proper placement (and rules out proximal obstruction). An opening pressure can be obtained using a manometer when the reservoir is first accessed with the needle. Once the opening pressure has been measured, the radiopharmaceutical is injected. A small amount of CSF (1–2 ml) can be withdrawn and used for laboratory analysis.

#### 18.6.4.2 Clinical Application

When a shunt series, CT scan, or MRI does not clearly show a shunt malfunction, a CSF shuntogram can be used to evaluate the patency of a shunt and rule out an obstruction. The CSF shuntogram can reveal malfunction of several components of the shunt, including the proximal catheter, valve, or distal tubing. Studies have shown that the utilization of both a CT and a CSF shuntogram for evaluation of a shunt malfunction can provide a higher sensitivity and negative predictive value than when either test is used alone (Ouellette et al. 2009).

#### 18.6.4.3 Additional Considerations

Although the radionuclide CSF shuntogram can provide a minimally invasive method of

evaluating shunt patency, this study can often be inconclusive or produce a false-negative reading. The CSF shuntogram can put children at risk for a shunt infection if the procedure is not performed in a sterile manner.

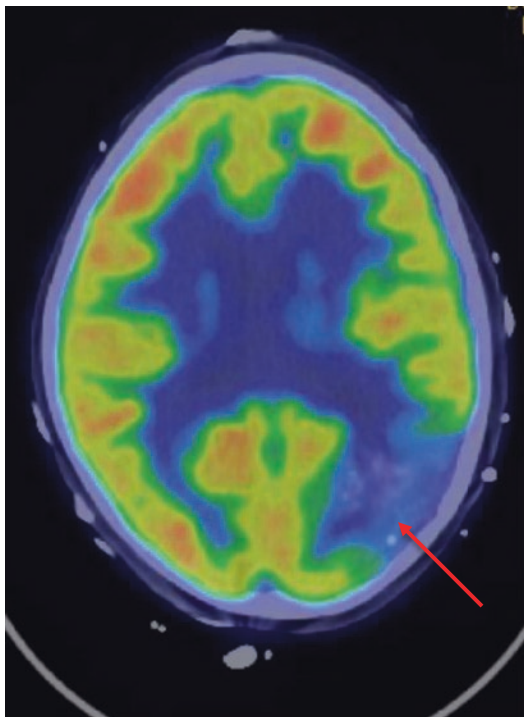
#### 18.6.4.4 Nursing Care

- Children under the age of 6–8 years or children with developmental delays may need to have sedation for this test.
- The child and family will need to be told that a needle will be inserted into the shunt reservoir, and the child will need to lie still during insertion. The child will also need to be able to lay flat for about 30 min. It is very important that the child is able to stay still while the images are being taken.

### 18.6.5 Proton Emission Tomography (PET)

#### 18.6.5.1 How Does It Work/Procedure

A PET scan (see Fig. 18.22) is a nuclear medicine study that shows the metabolic process of the body. Patients are injected with a radio-tracer, most commonly the glucose analogue



**Fig. 18.22** PET/CT arrow indicates hypometabolism in the left temporal occipital lobe/seizure focus

18-fluorodeoxyglucose (FDG). The PET scan then measures the distribution of FDG in the brain. These images can show blood flow, oxygenation, and glucose metabolism. Brain tumors, especially highly malignant tumors, have an increased metabolic rate in comparison to normal brain tissue (Hunter 2016). There are also benign tumors such as pilocytic astrocytoma, choroid plexus papilloma, and pleomorphic xanthoastrocytoma (Hunter 2016) that have faster metabolic rates than that of normal tissue. In these cases, PET scans can provide important information about prognosis and in selection of chemotherapy and/or radiation therapy. When seeking a diagnosis of the central nervous system, PET scans are usually combined with a CT scan, known as a PET/CT.

The radiotracer is injected intravenously and it usually takes about an hour for it to be absorbed. After that time, the patient lies on a table and slides under the scanner. The test itself can take about 1–2 h, so younger children or children with developmental delays may require sedation.

### 18.6.5.2 Clinical Application

The most common use for PET scan is to provide additional information about central nervous system tumors. PET scans can also be used preoperatively for surgical planning in neurosurgical procedures for epilepsy, vascular malformations, and tumors. PET scans are used to evaluate areas of the central nervous system involved in visual, sensory, motor, auditory, memory, attention, and language functions. A PET scan allows the surgeon to evaluate the location of a lesion in relation to eloquent areas of the brain, therefore maximizing the extent of the resection and minimizing any neurological complications to the child.

### 18.6.5.3 Additional Considerations

Radiation exposure from a PET scan actually comes from the FDG injection and not the PET scan itself. When the PET scan is combined with a CT, as is the case with most neurosurgical imaging, there is additional radiation exposure from the CT scan. The radiation dose will depend on the amount of FDG administered, which in turn is dependent on the age/size of the child and whether the brain and/or the spine are being scanned. Because of the length of the test, many young children will need to receive sedation in order to stay still for the duration of the test.

### 18.6.5.4 Nursing Care

- Patient must lie still for 60–120 min.
- Patient's family should encourage child to avoid intensive activity 24 h prior to test.
- The PET scan works on the principle of glucose metabolism; therefore, patients with diabetes and who are receiving insulin will require the guidance of a pediatric endocrinologist to ensure accuracy of the test.

### 18.6.5.5 Single Photon Emission Computed Tomography (SPECT)

SPECT scan is another nuclear medicine study commonly used in some centers. In comparing the two modalities, a SPECT scanner is considerably less expensive, and the radiotracers it uses have a much longer half-life, thus allowing more imaging time. On the other hand, PET scan

images are clearer (compare Figs. 13.3 and 13.4), and it can use some radiotracers with very short half-lives, which means that higher amounts can be injected without causing any additional radiation exposure for the patient, thus providing more detectable radiation in a shorter time (Rahmim and Zaidi 2008). From the standpoint of nurses, the same considerations apply to both PET and SPECT, except that the length of the procedures may be different.

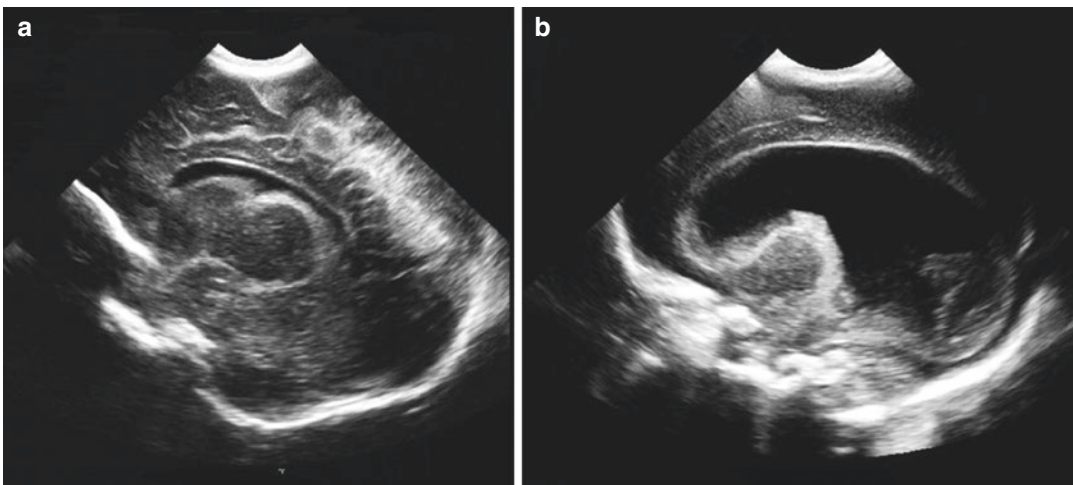
## 18.6.6 Ultrasound

### 18.6.6.1 How Does It Work/Procedure

Cranial ultrasounds have been used since the 1970s to provide information about the neonatal brain. An ultrasound uses sound waves and their echoes to provide images. The ultrasound machine sends out waves using an ultrasound probe or transducer. The sound waves travel into the head through the open fontanelles and then bounce off fluid, soft tissue, and bone. When the sound waves are returned to the transducer, the transducer translates those sound waves into electric pulses that are sent to the scanner and transformed into an image. There is no evidence of a link between ultrasound and any poor long-term outcomes, making it a very low-risk imaging technique.

### 18.6.6.2 Clinical Application

Cranial ultrasound is the first choice of imaging in premature infants. Premature infants, younger than around 32–34 weeks gestation, are at higher risk for both germinal matrix and intraventricular hemorrhages. Therefore, a screening cranial ultrasound should be considered on preterm infants who have additional risk factors including an increasing head circumference or abnormal neurological examination (Ballardini et al. 2014; Islam et al. 2016). Technicians can use the anterior fontanel and posterior fontanel to visualize information about the germinal matrix and intraventricular hemorrhages. It is also used to evaluate ventriculomegaly (see Fig. 18.23). The advantage of the cranial ultrasound in premature infants is that it is portable and can be done in the neonatal intensive care unit without requiring transport out of the unit. The test is noninvasive and, because the test happens very quickly, no sedation needed. Ultrasound is helpful for initial imaging and identification of critical abnormalities but should be followed up with an MRI to evaluate the extent of any injury or defect (Blankenberg et al. 1996; Genedi et al. 2016; Raets et al. 2014). Ultrasound is also used intraoperatively for biopsy guidance and drainage of cysts and other fluid collections. It can provide real-time information to the surgeon and assist with intraoperative planning.



**Fig. 18.23** Cranial ultrasound normal (a) vs ventriculomegaly (b)



### 18.6.6.3 Additional Considerations

Ultrasound does not travel through bone, so once a child's fontanel is closed, the cranial ultrasound should no longer be used. Ultrasounds are very operator dependent, and the quality of the image can often be reliant on skill and experience.

### 18.6.6.4 Nursing Care

Nurses should provide education to families about the purpose of test and how it is performed.

## 18.7 Interventional Radiology

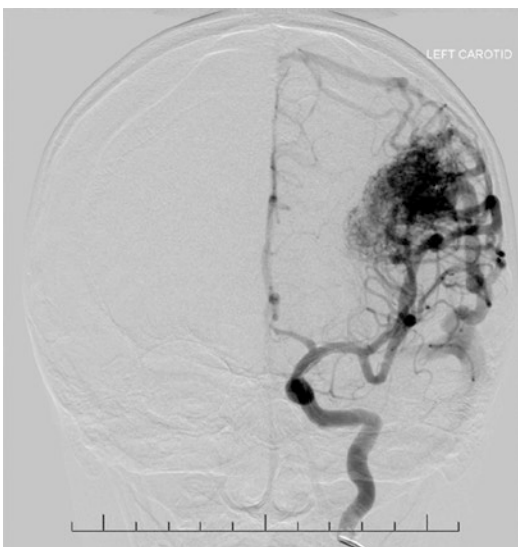
Interventional radiology is subspecialty of pediatric neurosurgery that is growing at a rapid rate. Interventional radiology specializes in diagnostic and/or treatment using neuroimaging as a guide including fluoroscopy, CT, US, MRI, and plain film x-rays.

One example of this is a cerebral angiogram.

### 18.7.1 Cerebral Angiogram

#### 18.7.1.1 How Does It Work/Procedure

An interventional radiologist performs cerebral angiograms (Fig. 18.24) to diagnose and some-



**Fig. 18.24** Cerebral angiogram – left parietal arteriovenous malformation

times treat vascular abnormalities, such as arteriovenous malformations (AVMs), aneurysms, cavernous malformations, and vein of Galen malformation (see Chap. 12). A cerebral angiogram, or intra-arterial digital subtraction angiography (IADSA), is an invasive test in which contrast is injected into an artery (most commonly the femoral artery) and images are taken to provide information about the vascular system. Cerebral angiography uses fluoroscopy to create a moving picture that shows the contrast in the cerebrovascular system. (Figure 12.5 shows a comparison of a CT and angiogram.)

It is important that all previously obtained images are available and are carefully reviewed to ensure the necessity and purpose of the angiogram. Most pediatric patients undergoing angiogram will need to have conscious sedation or general anesthesia. The patient is positioned supine on the table. Arterial access is most commonly obtained in children through the femoral artery. The catheter is inserted into the femoral artery and contrast is injected. The interventional radiologist is then able to visualize the contrast moving through the vascular system of the brain and to identify and treat many abnormalities that are seen.

#### 18.7.1.2 Clinical Application

In some instances, treatment such as embolization of a vascular malformation can be done during the angiogram through the catheter. Cerebral angiogram can be helpful in the diagnosis or postoperative follow-up of vascular malformations including AVM, cavernous malformations, vein of Galen malformations, stroke, moyamoya disease, or hemorrhagic events.

#### 18.7.1.3 Additional Considerations

Although the risks of a cerebral angiogram including hematoma and thrombosis are low in pediatric patients (Hoffman et al. 2014; Burger et al. 2006; Wolfe et al. 2009), it is an invasive procedure so the risks and benefits should be carefully considered and explained to the parents. CT and MR angiography are noninvasive tests, and that should be considered before the utilization of a cerebral angiogram. Radiation exposure

should be considered when performing any interventional neurosurgical procedure. The amount of radiation exposure is dependent on the type of procedure performed, and the ALARA principle should always be taken into consideration (Alexander et al. 2009).

#### 18.7.1.4 Nursing Care

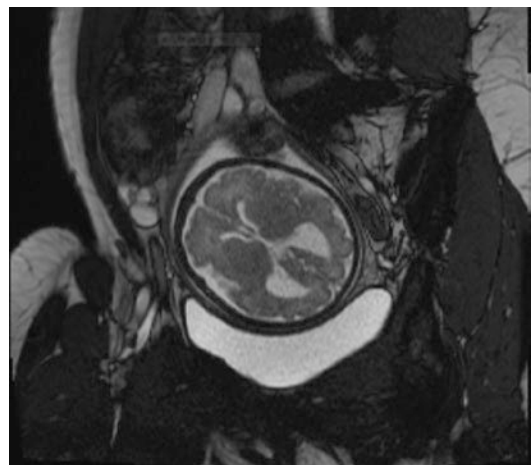
- Assessment of patient prior to procedure and sedation including respiratory rate, oxygen saturations, blood pressure, pulse, and baseline neurological exam.
- Review patient's medications to ensure that the patient is not receiving any anticoagulation medications including aspirin.
- Blood work should be obtained or reviewed prior to the procedure including a coagulation screen and complete blood count.
- If patient is receiving contrast, it is important to know if your patient has any problems with renal function.
- Note any allergies and inquire about any previous allergic reaction from contrast administration.
- Educate patient that if contrast is being administered, the contrast may cause a flushing sensation, salty or metallic taste in their mouth, a mild headache, or nausea but that these side effects are usually very short lasting.
- Any metal including jewelry should be removed prior to the test to avoid artifact.
- Post-procedural care
  - Pressure should be applied with a pressure dressing to the catheter insertion site.
  - Perform frequent evaluation of the catheter insertion site and assess for bleeding or bruising
  - Assess pedal pulses and temperature of the extremity if the entry site was femoral.
  - Patient should lay flat for about 6–8 h.
  - Patients should be well hydrated using IV or oral fluids to help clear the contrast and prevent kidney damage.
  - Most common side effects to educate patients and their families about include headache, dizziness, hypotension, and bleeding.

## 18.8 Special Topics

### 18.8.1 Fetal Neuroimaging

Ultrasound remains the screening tool of choice during pregnancy and is used to evaluate the anatomy of a fetus. There is exciting new imaging available such as fetal MRIs that are being obtained more frequently when fetal ultrasounds show abnormalities. A fetal MRI (Fig. 18.25) can be performed as early as the second trimester. Central nervous system abnormalities that are diagnosed in utero need to be approached using a multidisciplinary team. Families will need to have prenatal counseling, as well as access to a high-level care center that can provide experts in neonatology, neurology, and pediatric neurosurgery in case surgical intervention is required, either in utero or after delivery. Families should also be provided assistance in obtaining a termination if indicated or desired.

Congenital anomalies, including ventriculomegaly, agenesis of the corpus callosum, holoprosencephaly, intraventricular hemorrhage, and abnormalities of the posterior fossa are best evaluated with fetal MRI, as it provides a clearer picture than ultrasound. These detailed images provide information about diagnosis and, therefore, can help provide adequate prenatal counseling to families about their child's prognosis.



**Fig. 18.25** Fetal MRI showing axial view of fetal brain

## Conclusion

Shurtleff (1964) recommended that a child be taken into a dark closet and a flashlight shined through an open fontanel to assess for hydrocephalus. Seasoned pediatric nurses may recall assisting with this transillumination procedure as late as the 1970s. With the recent introduction of CT, MRI, and US scans, we are able to visualize detailed images of the brain and its vasculature allowing us to diagnose problems early on, sometimes even prior to birth. Nevertheless, all current imaging modalities suffer from one or more of the following limitations: (1) does not provide good images of certain structures and anomalies, (2) subjects the child to ionizing radiation, (3) is an invasive procedure with risks of infection and allergic reaction to contrast agents, and/or (4) requires sedation. By having an understanding of the available modalities and their limitations, nurses can be better advocates for their patients and better educators for the families.

## References

- Abdel Ghaffar MK, Eleya RZ, Nassef MA (2014) Detection of acute small amount of subarachnoid hemorrhage: Comparison between fluid-attenuated inversion recovery MR imaging and CT. *Egypt J Radiol Nucl Med* 45(3):833–839
- Alexander MD, Oliff MC, Olorunsola OG, Brus-Ramer M, Nickoloff EL, Meyers PM (2009) Patient radiation exposure during diagnostic and therapeutic interventional neuroradiology procedures. *J NeuroInterv Surg* 2(1):6–10
- Arlachov Y, Ganatra RH (2012) Sedation/anaesthesia in paediatric radiology. *Br J Radiol* 85(1019):e1018–e1031
- Ballardini E, Tarocco A, Baldan A, Antoniazzi E, Garani G, Borgna-Pignatti C (2014) Universal cranial ultrasound screening in preterm infants with gestational age 33–36 weeks. A retrospective analysis of 724 newborns. *Pediatr Neurol* 51(6):790–794
- Bertholdo D, Watcharakorn A, Castillo M (2013) Brain proton magnetic resonance spectroscopy. *Neuroimaging Clin N Am* 23(3):359–380
- Blankenberg FG, Norbash AM, Lane B, Stevenson DK, Bracci PM, Enzmann DR (1996) Neonatal intracranial ischemia and hemorrhage: diagnosis with US, CT, and MR imaging. *Radiology* 199(1):253–259
- Burger IM, Murphy KJ, Jordan LC, Tamargo RJ, Gailloud P (2006) Safety of cerebral digital subtraction angiography in children: complication rate analysis in 241 consecutive diagnostic angiograms. *Stroke* 37(10):2535–2539
- Charles C, Stephen W (2007) Guidelines for monitoring and management of pediatric patients during and after sedation for diagnostic and therapeutic procedures: an update. *Pediatr Anesth* 18(1):9–10
- Coté CJ, Wilson S (2016) Guidelines for monitoring and management of pediatric patients before, during, and after sedation for diagnostic and therapeutic procedures: update 2016. *Pediatrics* 138(1):e20161212–e20161212
- Damadian R (1971) Tumor detection by nuclear magnetic resonance. *Science* 171(3976):1151–1153
- Davidson AJ, Disma N, Graaff JC, Withington DE, Dorris L, Bell G, ..., Mccann ME (2016) Neurodevelopmental outcome at 2 years of age after general anaesthesia and awake-regional anaesthesia in infancy (GAS): an international multicentre, randomised controlled trial. *Lancet* 387(10015):239–250
- Genedi EAS, Osman NM, El-deeb MT (2016) Magnetic resonance imaging versus transcranial ultrasound in early identification of cerebral injuries in neonatal encephalopathy. *Egypt J Radiol Nucl Med* 47(1):297–304
- Hoffman CE, Santillan A, Rotman L, Gobin YP, Souweidane MM (2014) Complications of cerebral angiography in children younger than 3 years of age. *J Neurosurg Pediatr* 13(4):414–419
- Hunter J (2016) Approach to neuroimaging in children. Retrieved 13 July 2016, from <http://www.uptodate.com/contents/approach-to-neuroimaging-in-children>
- Ing C, DiMaggio C, Whitehouse A, Hegarty MK, Brady J, von Ungern-Sternberg BS, ... Sun LS (2012) Long-term differences in language and cognitive function after childhood exposure to anesthesia. *Pediatrics* 130(3):e476–e485
- Islam MMZ, Hossain MM, Khan NZ (2016) Cranial ultrasound in preterm neonates: screening of at risk infants for long term neurodevelopmental impairments. *J Enam Med Coll* 6(1):28
- Kaufmann G (2014) Nobel prize for MRI imaging denied to Raymond V. Damadian a decade ago. *Chem Educ* 19:73–90
- Koral K, Blackburn T, Bailey AA, Anderson J (2012) Strengthening the argument for rapid brain MR imaging: estimation of reduction in lifetime attributable risk of developing fatal cancer in children with shunted hydrocephalus by instituting a rapid brain MR imaging protocol in lieu of head CT. *Am J Neuroradiol* 33(10):1851–1854
- Kuppermann N, Holmes JF, Dayan PS, Hoyle JD, Atabaki SM, Holubkov R, ..., Wootton-Gorges SL (2009) Identification of children at very low risk of clinically-important brain injuries after head trauma: a prospective cohort study. *Lancet* 374(9696):1160–1170
- Miglioretti DL, Johnson E, Williams A, Greenlee RT, Weinmann S, Solberg LI, ..., Smith-Bindman R (2013) The use of computed tomography in pediatrics and the associated radiation exposure and estimated cancer risk. *JAMA Pediatr* 167(8):700

- Niederhauser BD, McDonald RJ, Eckel LJ, Keating GF, Broomall EM, Wetjen NM, ..., Kallmes DF (2013) Retrospective review of rapid pediatric brain MR imaging at an academic institution including practice trends and factors affecting scan times. *Am J Neuroradiol* 34(9):1836–1840
- Okuda T, Korogi Y, Shigematsu Y, Sugahara T, Hirai T, Ikushima I, ..., Takahashi M (1999) Brain lesions: when should fluid-attenuated inversion-recovery sequences be used in MR evaluation?. *Radiology* 212(3):793–798
- O'Neill BR, Pruthi S, Bains H, Robison R, Weir K, Ojemann J, ..., Browd SR (2013) Rapid sequence magnetic resonance imaging in the assessment of children with hydrocephalus. *World Neurosurg* 80(6):e307–e312
- Ouellette D, Lynch T, Bruder E, Everson E, Joubert G, Seabrook JA, Lim RK (2009) Additive value of nuclear medicine shuntograms to computed tomography for suspected cerebrospinal fluid shunt obstruction in the pediatric emergency department. *Pediatr Emerg Care* 25(12):827–830
- Pearce MS, Salotti JA, Little MP, McHugh K, Lee C, Kim KP, ..., Berrington de González A (2012) Radiation exposure from CT scans in childhood and subsequent risk of leukaemia and brain tumours: a retrospective cohort study. *Lancet* 380(9840):499–505
- Raets M, Plaisier A, Ecury-Goossen G, Govaert P, Feijenoort M, Reiss I, ..., Dudink J (2014) PS-331 serial cranial ultrasonography or early MRI for detecting pre-term brain injury? *Arch Dis Child*, 99(Suppl 2):A231–A232
- Rahmim A, Zaidi H (2008) PET versus SPECT: strengths, limitations and challenges. *Nucl Med Commun* 29(3):193–207
- Reddy S (2012) Effect of general anesthetics on the developing brain. *J Anaesthesiol Clin Pharmacol* 28(1):6–10
- Sansare K, Khanna V, Karjodkar F (2011) Early victims of x-rays: a tribute and current perception. *Dentomaxillofacial Radiol* 40(2):123–125
- Schabelman E, Witting M (2010) The relationship of radiocontrast, iodine, and seafood allergies: a medical myth exposed. *J Emerg Med* 39(5):701–707
- Schaefer PW, Grant PE, Gonzalez RG (2000). Diffusion-weighted MR imaging of the brain. *Radiology*, 217(2): 331–345.
- Shurtleff DB (1964) Transillumination of skull in infants and children. *Am J Dis Child* 107(1):14–24
- Strauss KJ, Kaste SC (2006) The ALARA (as low as reasonably achievable) concept in pediatric interventional and fluoroscopic imaging: striving to keep radiation doses as low as possible during fluoroscopy of pediatric patients – a white paper executive summary. *Pediatr Radiol* 36(S2):110–112
- Sun LS, Li G, Miller TLK, Salorio C, Byrne MW, Bellinger DC, ..., McGowan FX (2016) Association between a single general Anesthesia exposure before age 36 months and Neurocognitive outcomes in later childhood. *JAMA* 315(21):2312
- Waters H, Grant B, Offord C, Lewis T (2011). The first x-ray, 1895. Retrieved 13 July 2016, from <http://www.the-scientist.com/?articles.view/articleNo/30693/title/The-First-X-ray--1895/>
- Wolfe TJ, Hussain SI, Lynch JR, Fitzsimmons B-F, Zaidat OO (2009) Pediatric cerebral angiography: analysis of utilization and findings. *Pediatr Neurol* 40(2):98–101

# Index

## A

- Abusive head trauma (AHT)
  - assessment, 345
  - child's medical history, 341
  - clinical presentation, 339–340
  - diagnostic findings
    - laboratory evaluation, 341–342
    - medical imaging, 341
    - physical examination, 341, 345
    - retinal examination, 341
  - differential diagnosis, 338, 339
  - epidemiology, 336
  - etiology, 336–337
  - family care
    - patient and family education, 343
    - patient siblings, 343
  - financial implications, 344
  - historical concerns, 335–336, 340, 344–345
  - incidence, 336
  - management
    - collaboration, 342
    - legal implications, 342–343
    - medical interventions, 342
  - vs. non-abuse etiologies, injury patterns, 340
  - pathophysiology
    - brain injury, 337
    - clinical and subclinical seizures, 339
    - fractures, 338–339
    - retinal hemorrhages, 338
    - skull fracture, 339
    - spine injury, 337
  - prevention efforts
    - primary prevention activities, 343
    - secondary prevention, 343–344
    - tertiary prevention, 344
  - retinal hemorrhages, 335
  - risk factors, 336
  - signs and symptoms, 339
  - society and family costs, 344
  - subdural hemorrhage, 337
  - victim outcomes, 344, 346
- AED. *See* Antiepileptic drug (AED)
- After surgery
  - neurological assessment, 34, 77–78, 172
  - nursing implications, 509
  - organizations and web sites, 82, 83
  - seroma (fluid/edema), 501
  - wound and dressing care, 78
- Analgesia, sedation, and neuromuscular blockade, 303
- Anencephaly
  - complications, 155
  - historically, 155
  - prognosis, 155
  - survival rate, 155
- Anesthesia
  - anesthetic induction, 55, 529, 530, 535–537, 540, 552
  - dispersive electrocautery pad, 540
  - positioning, 238, 540–541
  - sequential compression stockings, 540
- Anesthesia provider
  - parental preparation, 529
  - preoperative preparation programs, 114, 536
  - psychological preparation of the child, 547
- Angiomatosis, 477, 478
- Antiepileptic drug (AED), 352, 432, 458–460, 468–470, 521, 522
- Antley-Bixler, 110
- AOD. *See* Atlanto-occipital dislocation (AOD)
- Apert syndrome
  - syndactyly, 108, 110
  - turricephalic, 108
- Aplasia cutis congenita, 140–141
- Apnea, 10, 21, 31, 52, 116, 158, 163, 182, 189, 259, 272–274, 360
- Apneustic, 259
- Aqueductal stenosis, 41, 46, 47, 50, 56–57, 62, 71, 179
- Arachnoid cysts, 41, 48–49, 66, 67, 557
- Arterial fistulas of the spine
  - diagnostic tests, MRI/MRA, 446
  - nursing, 447–448
    - pain management, 447
  - obliteration, 446
  - outcomes, 448–449
  - risks, 446–448
  - symptoms, 446, 448
    - edema, 447
  - treatments, 446–447
  - websites, 449



- Ashworth scale, 495, 501  
 As low as reasonably achievable (ALARA) principle, 93, 576, 581, 594  
 Assessment, 1–35, 77–78, 87, 110, 112, 118, 122, 160, 190, 191, 236, 247, 257–267, 269, 273, 276–278, 294, 300–302, 306–311, 321, 323–324, 345, 353, 355, 367, 373, 383, 385, 407, 410, 421–424, 439, 441, 442, 448, 449, 482, 485, 495–497, 501, 503, 530–533, 537, 539, 544, 546, 548–553, 578, 594  
 Ataxic, 259  
 Atlanto-axial rotary subluxation (AA rotary fixation)  
   atlanto-axial joint, 376  
   atlas fracture, 376–378  
   classification, 376–379  
   nonsteroidal anti-inflammatory drugs (NSAIDs), 377  
   pathophysiology, 376  
   traction, 377  
   treatments, 377–379  
 Atlanto-occipital dislocation (AOD)  
   anterior longitudinal ligament, 374  
   atlanto axial joint, 374  
   axial load, 374  
   classification, 374–375  
   diagnosis  
     cranial nerve dysfunction, 374  
     head trauma, 374  
     radiographs, 375–376  
     ventilation, 374  
   skull dislocation, 374  
   treatment, 375  
 Autoregulation, 259, 272, 294, 422
- B**  
 Baclofen  
   intraoperative positioning, 542  
   intrathecal baclofen pump system, 499–500  
   ITB (*see* Intrathecal baclofen (ITB))  
   oral, 498, 502–504  
 Balance Error Scoring System (BESS), 321, 323  
 Barbiturate therapy, 305  
 Barry-Albright Dystonia (BAD) scale, 497  
 Battered child syndrome. *See* Abusive head trauma (AHT)  
 Bed-wetting, 353  
   adolescent, 16  
 Bicornal synostosis, 95, 98–100, 125  
 Birth-related traumatic brain injury  
   caput succedaneum, 269  
   cephalohematoma, 269  
   depressed skull fractures, 270, 272  
   intracranial hemorrhage, 269, 272  
   leptomeningeal cyst, 276  
   linear skull fractures, 270, 272  
   ping-pong, 270  
   skull fracture, 269–273, 275–277  
   subgaleal hemorrhage, 269–270  
 Blood–brain barrier, 214, 295, 303, 304, 519  
 Botulinum A toxin (Botox), 500  
 Brain abscess  
   acidfast bacilli cultures, 517  
   aerobic, 517  
   anaerobic, 515–519  
   B beta-hemolytic *Streptococci*, 515  
   burr holes, 518  
   chronic otitis media, 515–516  
   computed tomography (CT), 517  
   congenital heart defect, 515, 516  
   craniectomy, 518  
   C-reactive protein (CRP), 517  
   dental procedures, 515, 517  
   diagnostic test, 517–518  
   erythrocyte sedimentation rate (ESR), 517  
   excision, 518  
   fungal, 516, 517  
   *Haemophilus*, 516  
   magnetic resonance imaging (MRI), 517–518  
   mastoiditis, 515  
   needle aspiration, 518  
   *Pneumococcus*, 515  
   presenting symptoms, 516–517  
   sinusitis/ruptured dermoid tumor, 515  
   *Streptococci*, 515  
   subdural empyemas, 515–519  
   surgical drainage, 518  
   treatment options, 518–519  
   vancomycin, 518  
 Brain death, 29–31, 257, 264–266, 296, 297  
   guidelines, 30, 31  
 Brainstem, assessment of function, 22–25, 29–30  
 Brainstem herniation  
   infratentorial, 257  
   supratentorial  
   central, 30, 296, 297  
   cingulate, 30, 296  
   uncal, 30, 257, 296, 297  
 Brainstem reflex exam  
   facial, 264  
   oculocephalic, 264, 265  
   oculovestibular, 264, 265  
   trigeminal, 264  
   vestibular, 264, 265  
 Burke-Fahn-Marsden (B-F-M) rating scale, 497
- C**  
 Capillary angiomas and telangiectasia  
   brainstem cavernomas, 430, 432, 433  
   cavernous malformations, 429  
   classification, 431  
   cystic vascular spaces, 429  
   diagnostic imaging, 431  
   genetic counseling, 432  
   lifetime costs, 432  
   pathophysiology, 429–430  
   spinal cavernomas, 429, 430  
   stereotactic radiosurgery, 432  
   telangiectasias, 428–429

- Carbapenem, 519
- Carpenter, 110
- Cavernous malformations and arteriovenous fistulas of
  - the spine
  - edema, 446, 447
  - magnetic resonance imaging (MRI), 445, 446
  - MR angiography, 446
  - nursing care, 447–448
  - outcomes, 448–449
  - symptoms, 446–448
  - websites, 449
- CBF. *See* Cerebral blood flow (CBF)
- Central nervous system (CNS) tumors, 50–51, 195–250
- Central neurogenic hyperventilation, 259
- Cephalic index, 95, 97
- Cephalohematoma
  - bleeding, 145
  - caput succedaneum, 145
  - causes, 144
  - infected calcified, 146
  - treatment, 145–146
- Cephalosporin, 518
- Cerebral angiogram, 593–594
- Cerebral arteriovenous fistulas
  - diagnostic imaging
    - computed tomography (CT) scan, 415
    - magnetic resonance imaging (MRI), 415
    - MRA/MRV, 415, 416
  - endovascular treatment, 415
  - etiology, 412–413
  - pathophysiology, 413–414
  - presenting symptoms, children
    - cardiac, 414
    - cranial bruits, 414
    - cyanosis, 414
    - neonatal symptoms, 414
  - treatments
    - complications, 415–416
    - outcomes, 416–417
    - surgical resection, 415
- Cerebral arteriovenous malformation in children
  - complications of surgery
    - hemorrhage, 405, 406
    - occlusion, 409
    - seizures, 408, 409
    - vasospasm, 409
  - corticosteroids, 410
  - diagnostic imaging
    - calcification, 407
    - computed tomography (CT) angiogram, 407
    - magnetic resonance imaging (MRI), 407
    - MRA, 407
    - vessel angiogram, 407
  - effects, 410
  - embolization, 408, 410
  - etiology, 405
  - outcomes, 411
  - pathophysiology
    - cerebral aneurysms, 406
    - genetic errors, 406
    - hemorrhage, 406
    - nidus, 406
  - presenting symptoms
    - headache, 406–407
    - macrocephaly, 407
    - seizure, 407
  - treatments
    - corticosteroids, 410
    - effects of radiation, 410
    - embolization, 408, 410
    - microsurgical resection, 408
    - radiosurgery, 408–410
    - Spetzler and Martin grading scale, 408
    - timing of treatments, 408–410
    - vasospasm, 409
- Cerebral autoregulation, 294
- Cerebral blood flow (CBF), 2, 4, 30, 31, 45, 259, 272, 280, 292–294, 296, 302, 303, 305, 307, 312, 422
- Cerebral edema, 280, 281, 289–291, 295–301, 303, 305, 309, 310, 410, 416, 470, 482
- Cerebral herniation syndromes, 296, 301
- Cerebral metabolism, 219, 227–228, 283, 294–295
- Cerebral perfusion pressure (CPP), 293, 294, 296–298, 302–304, 306, 308, 311
- Cerebral spinal fluid (CSF)
  - drainage, 57, 77, 80, 301, 303, 304, 421, 437, 483, 520
  - production and flow dynamics
    - intracranial pressure (ICP), 43–44
    - pathways, 43
  - values according to age, 524
- Cheyne-Stokes, 259
- Chiari 0, 177
- Chiari 1.5, 177
- Chiari decompression, 540
  - surgical time-out, 541–542
- Chiari I
  - cerebellar tonsils, 47, 178, 184
  - dysphagia, 181, 183
  - encephalocele, 41, 177
  - etiology, 42, 178
  - foramen magnum, 177, 178, 184, 185, 189
  - headache, 181, 182, 184, 188
  - lumboperitoneal shunt, 179
  - malformation, 46, 47, 177–179, 181–182, 188
  - scoliosis, 181–185
  - vocal cord paralysis, 181
- Chiari II
  - amniocentesis, 159
  - bowel and bladder dysfunction, 159
  - brainstem dysgenesis, 179, 180
  - comorbidities, 155
  - endoscopic third ventriculostomy, 46, 158
  - fetal surgery, 160
  - hydrocephalus, 46, 66, 155, 179, 184, 188
  - Management of Myelomeningocele Study (MOMS), 179, 182
  - maternal serum alpha-fetoprotein (MSAFP), 159
  - MOMs study, 179, 182

- Chiari II (*cont.*)
- multidisciplinary care approach, long-term management of, 166
  - nursing considerations, 189
  - postoperative care, 190
  - prenatal screening, 159–160
  - prenatal ultrafast MRI, 159
  - preoperative care, 189
  - renal ultrasound, 159
  - respiratory distress, 182
  - spina bifida, 155
  - surgical management, 162, 188–189
  - swallowing dysfunction, 182
  - urodynamics, 159
  - voiding cystourethrogram (VCUG), 159
- Chiari III, 177, 180–181, 183
- encephalocele, 180, 183
- Chiari IV, 177
- Chiari malformation
- antiemetic medications, 187
  - chemical meningitis, 188
  - discharge criteria, 188, 189
  - nursing care, 187–188, 190
  - outcomes, 192
  - pain management, 187, 190, 192
  - patient and family education, 191
  - pseudomeningocele, 188, 191
  - surgery
    - duraplasty, 187
    - neuromonitoring, 188
  - treatment options, 180, 181, 184–188
- Child-life specialists
- dietary restrictions, 535
  - imaging tests, 534–535
  - laboratory testing, 533–534
  - nursing, 533
  - preoperative consultation, 530–531
  - preoperative medication, 535
  - separation from parents *vs.* parental presence upon induction of anesthesia, 535–536
  - surgeon/anesthesiologist, 531–533
- Chronic traumatic encephalopathy (CTE), 329, 330, 332
- Battle's sign, 277
- Circle of Willis
- description of arteries, capillaries and veins, 396, 397
  - venous system, 398
- Circulating nurse, 115, 537–545
- Clearing cervical spine, 374, 375
- AOD, 376
  - atlanto-axial (AA) rotatory fixation, 376
  - axial (load bearing), 376
  - classifications, 376–377
  - clinical assessment, 373
  - cranial nerve dysfunction, 376
  - CT scans, 375
  - developmental age, 373
  - diagnosis, 372
  - head trauma, 374
  - imaging, 373
  - mortality, 374
  - muscle spasms, 376
  - NEXUS, 373
  - radiographic evaluation, 375–376
  - treatment, 375
  - type I, 376, 378
  - type II, 376, 378
  - type III, 376
  - ventilated, 372, 374
- Clinical nurse specialists (CNS), 127, 536, 568
- Collaborative management of intracranial hypertension
- evidence-based treatment guideline, 298
  - initial resuscitation, 300
  - intensive care management, 300–301
- Coma, 20, 21, 29, 31, 78, 406, 420, 424
- Compensatory mechanisms, 260, 291
- Complications of shunts
- LP shunts, 75
  - over-drainage, 59
  - slit ventricle syndrome, 60
  - treatment
    - lumboperitoneal catheter complications, 75
    - over-drainage, 75–76
    - shunt infection, 73
    - shunt malfunction, 73
    - slit ventricle syndrome, 76–77
- Concussion, 275
- definition, 319
  - diagnosis, 325–332
  - epidemiology, 317–319
  - pathophysiology, 320–321
  - physical examination, 321–322
  - return to play protocol, 317, 330
  - signs and symptoms, 322–324
  - treatment, 324–325
- Congenital spine deformity and spinal cord disorders
- achondroplasia, 352, 359–363
  - anomalies, 351–355, 357
  - birth defects, 352, 357
  - congenital anomalies, 351, 353, 355
  - connective tissue disorders, 351
  - evaluation
    - age-appropriate questions, 353
    - back pain, 353
    - bowel and bladder changes, 353
    - development history, 353
    - general patient evaluation, 353
    - loss of bowel and bladder control, 353
    - past medical history, 353
    - physical exam, 353
    - spine measurements, 353
  - Klippel-Feil syndrome, 352–354, 363–364
  - kyphosis, 352, 353, 357, 359, 361, 365, 372
  - lordosis, 352
  - mucopolysaccharide disorders, 352, 364
  - neurofibromatosis, 351
  - neuromuscular conditions, 351
  - related conditions
    - clinical findings, 353
    - congenital cardiac disease, 353
    - diastematomyelia, 353
    - dimples, 353

- diplomyelia, 353
    - foot deformity, 353
    - hairy patches, 353
    - muscle weakness, 353
    - spinal stenosis, 353
    - tethered cord, 353
    - urinary tract structural abnormalities, 353
  - scoliosis, 352, 355, 357, 363–365, 384
  - skeletal dysplasia, 351, 355–357, 364, 365
  - tissue disorders, 351
  - Continuous electroencephalogram (cEEG), 305
  - Continuous epidural infusion, 550
  - Contrast imaging
    - gadolinium-based, 577
    - iodinated (iodine-containing), 577
    - vascular anomalies, 576
  - Contusion
    - contrecoup, 281, 282
    - coup, 281
  - Coronal synostosis
    - harlequin sign, 97, 99
    - nasional deviation, 97, 98
    - strabismus, 97
    - superior oblique paresis, 97
    - vertical dystopia, 97, 98
  - Corpus callosotomy, 464, 470, 480
  - Cortical dysplasia, 3, 461, 474–475, 485–487
  - Cortical mapping, 464, 468, 470, 474
  - Cranial calipers, 95, 97
  - Cranial dermal sinus
    - etiology, 142, 143
    - evaluation, 143
    - pathophysiology, 142–143
    - treatment, 144
  - Cranial fasciitis
    - etiology, 148
    - evaluation, 149
    - pathophysiology, 148
    - treatment, 149
  - Cranial nerve (CN) evaluation, 19, 22–25
  - Cranial orthotic device
    - band, 104
    - molding helmet, 104
  - Craniofacial center
    - calvarial vault remodeling, 113
    - cosmetic surgery, 112
    - craniofacial team, 110, 116, 119, 122, 128
    - distraction osteogenesis, 114
    - endoscopic strip craniectomy, 113, 120–127
    - fronto-orbital advancement, 97, 113, 117
    - hung span procedures, 113, 118
    - pi, 113, 118
    - preoperative preparation for cranial reconstructive surgery, 114–115
    - reconstructive surgery, 112
    - strip craniectomy, 113, 114, 119–127
    - surgery, 113
  - Craniofacial neurofibromas
    - clinical presentation, 135
    - epidemiology, 135
    - evaluation, 136
    - facial lesions, 135
    - focal, resectable/symptomatic lesions, 136
    - treatment, 136
  - Craniofacial resources/support groups, 115
  - Craniofrontonasal dysplasia, 110
  - Craniosynostosis, 10, 77, 91–128
    - anterior plagiocephaly, 97–98
    - coronal suture, 92, 94
    - craniofacial team, 110, 116, 119, 122, 128
    - lambdoid suture, 94, 99, 102, 103, 121
    - metopic suture, 92, 94, 95, 99–101
    - posterior plagiocephaly, 92
    - sagittal suture, 92, 94, 97, 119, 121
    - scaphocephaly, 95
    - surgery
      - calvarial vault remodeling, 91, 113, 117, 121
      - cosmetic surgery, 112
      - distraction osteogenesis, 114
      - endoscopic strip craniectomy, 113, 120, 123–127
      - fronto-orbital advancement, 113, 117
      - hung span procedure, 113, 118
      - molding helmet, 104, 119–121, 128
      - pi procedure, 113, 118
      - post discharge management, 119
      - postoperative nursing management, 118–119
      - preoperative preparation, 114–115
      - reconstructive surgery, 112
      - strip craniectomy, 113, 114, 119–127
      - trigonocephaly, 92, 94, 99, 100
  - Crouzon syndrome
    - bicoronal craniosynostosis, 106
    - hypertelorism, 106, 108
    - tarsorrhaphy, 106
  - Cushing's response, 307
  - Cutis aplasia
    - epidemiology, 140
    - evaluation, 140
    - of scalp, 141
    - treatment, 140
  - Cyclooxygenase, 550
- D**
- Dandy-Walker malformation, 47
  - Decompressive craniectomy, 300, 307
  - Deep brain stimulation (DBS)
    - dystonia
      - adverse effects, 509
      - complications, 508–509
      - electrode placement, 508, 509
      - implantation, 507
      - intraoperative preparation, 508
      - nursing care, 509
      - patient selection, 507
      - surgical procedure, 507–508
    - epilepsy, 507
    - obesity management, 507
    - pain management, 507
    - psychiatric conditions, 507
    - spasticity, 506–509

- Dermatome, 26, 27
- Developmental assessment
- adolescent, 17–18
  - infant, 10–15
  - neonatal, 6–10
  - preschooler, 16
  - school age child, 16–17
  - toddler, 15–16
  - tools, 6
- Diagnosis
- AHT
    - laboratory evaluation, 341–342
    - medical imaging, 341
    - physical examination, 341, 345
    - retinal examination, 341
  - airway, 372
  - common injuries
    - AA rotatory subluxation, 376
    - AOD, 374, 375
    - mortality, 374
  - C spine precautions
    - age, 372
    - backboard, 372
    - clearing C-spine, 372–373
    - clinical assessment, 373
    - head size, 372–373
    - imaging, 373
    - immobilization, 372, 373
    - muscle spasms and, 373
    - NEXUS study, 373
    - positioning, 372
  - level of consciousness, 205, 237
  - pediatric athletic concussion
    - biomarker glial fibrillary protein, 326
    - complications, 328–330
    - concussion myths, 326, 327
    - CT, 325–326
    - diffusion tensor imaging (DTI), 326
    - functional MRI (fMRI), 326
    - healthy fat intake, 328
    - helmets, 331, 332
    - neuroimaging, conventional, 325
    - nursing care, 326
    - patient and family education, 326–328
    - return to play guidelines, 330–331
    - TBI, 326
  - presenting symptoms
    - double vision, papilledema, 205
    - increased intracranial pressure and hydrocephalus, 204, 205, 430, 438, 440, 523
  - radiographic evaluation, CT, 278, 360, 362, 371–372
  - risk factors, 77, 371
- Diagnostic tests
- angiography, 355
  - computed tomography (CT) scan, 3, 173, 184, 205, 355, 402, 407, 415, 517, 521, 524, 535
  - contrast, 3, 205, 402, 420, 426
  - cranial irradiation, 197
  - EEG, 2, 206–207
  - etiology, 399, 405, 526
  - imaging in neurological assessment
    - Doppler ultrasound, 2, 3
    - EEG, SPECT, 2–4
    - magnetic source imaging (MSI) and functional MRIs (fMRI), 2, 3
    - MEG, 2, 4
    - proton emission tomography (PET), 2, 3
  - magnetic resonance imaging (MRI) scan, 2, 3, 173, 183–184, 192, 205, 206, 402, 420, 421, 426, 435, 446, 517, 521, 524, 535
  - MR angiography, 206, 402, 422, 426, 434, 446
  - radiographic tests
    - Doppler, 2, 3, 402
    - fMRI, 2
    - MEG, 2, 4
    - MSI, 2, 4
    - proton emission tomography (PET), 3, 435
    - SPECT, 2, 3, 206, 435
  - SEGAs, 195
  - ultra sound, 173, 355
  - x-rays, 354
- Diffuse axonal injury (DAI), 256, 257, 268, 286–289
- Dura, 70, 75, 76, 79, 93, 120, 128, 159, 160, 170, 179, 187–188, 192, 257, 258, 272, 273, 276, 278, 279, 290
- Dysplasia, 3, 110, 112, 355–357, 419, 434, 470–474, 476, 487
- Dystonia
- assessment, 496–497
  - classifications, 496
  - diagnosis, 496–497
  - etiology, 495–496
  - muscle contractions, 495
  - pathophysiology, 495–496
  - primary, 496, 497
  - secondary, 496, 497
  - treatment
    - botulinum A toxin, 498
    - conservative therapies, 497–498
    - DBS, 506–509
    - intrathecal baclofen, 498–499
    - ITB, 498–504
    - SDR, 504–506
- E**
- Ectomeninx, 93
- Electroencephalogram (EEG), 2, 4, 31, 85, 207, 409, 457
- Eloquent cortex, 464, 466–467, 470, 473, 474
- Endocrine complications
- cerebral salt wasting (CSW), 310
  - diabetes insipidus, 309–310
  - outcomes, 310–311
  - postoperative complications, 309
  - prevention efforts, 311
  - syndrome of inappropriate secretion of antidiuretic hormone, 310
- Endoscopic third ventriculostomy (ETV), 61–63
- choroid plexus cauterization (CPC), 63
- Epidermoid and dermoid cysts
- bone erosion, 141
  - epidemiology, 141



- evaluation, 141–142
  - surgical removal, 142
  - treatment, 142
  - Epidural hemorrhage, 257, 272–273, 278–279, 370
  - Epilepsy surgery
    - complications, 472
    - complications CSF leak, 482
    - complications infection, 482
    - complications stroke, 482
    - extratemporal resections, 472–474
      - lobectomy, 471–472
    - hemispherectomy, 474–475
    - imaging
      - computed tomography (CT), 461
      - flurodeoxyglucose (FDG), 461
      - functional MRI, 461
      - magnetic resonance imaging (MRI), 461
      - magnetoencephalography (MEG), 461–462
      - positive emission tomography (PET), 461
      - single-proton-emission-tomography (SPECT), 461
      - video EEG, 463
    - lesionectomy, 470–471
      - electrocorticography, 470–471
    - lobectomy, 471–472
    - nursing care following resective surgeries
      - electrolytes, 483
      - fever, 483
      - incision care, 483
      - pain management, 482–483
      - postoperative drains, 483
      - seizures, 482, 483
    - outcomes
      - Engel's classification of postoperative outcome, 484
      - international league against epilepsy (IALE)
        - classification of postoperative outcomes, 485
        - quality of life (QOL), 484, 485
      - “pie in the sky” defect, 472
    - temporal lobectomy
      - mesial temporal sclerosis (MTS), 471
      - temporal lobe epilepsy (TLE), 471–472
  - Epileptogenic, 461, 462, 464–468, 470–474, 476, 479, 480, 485
  - Etiology
    - AHT, 336–337
    - maternal diabetes, 352
    - maternal diabetes, ingestion of antiepileptic drugs, 352
    - maternal hypoxia, 352
  - Ewing's sarcoma
    - bony destruction, 140
    - epidemiology, 139
    - evaluation, 139
    - radiographic appearance, 139
    - treatment, 139–140
- F**
- Face, legs, activity, cry and consolability (FLACC), 32, 33, 550
  - Faces pain scale (FPS), 32
  - Female athlete, 319
  - Fentanyl, 550
  - Fetal neuroimaging, 594
  - Fibroblast growth factor receptors
    - anterior plagiocephaly, 92
    - coronal suture, 92
    - lambdoid, 92
    - metopic suture, 92
    - plagiocephaly, 92
    - posterior plagiocephaly, 92
    - sagittal suture, 92
    - scaphocephaly, 92
    - suture, 92
    - trigonocephaly, 92
  - Fibrous dysplasia
    - etiology, 136
    - evaluation, 136
    - pathophysiology, 136
    - treatment, 136
  - FLACC. *See* Face, legs, activity, cry and consolability (FLACC)
  - Fluorodeoxyglucose (FDG), 461
  - Folic acid, 152–153, 174
  - Functional disorders
    - management
      - dystonia (*see* Dystonia)
      - spasticity (*see* Spasticity)
    - surgical intervention, 493
  - Functional magnetic resonance imaging (fMRI), 461, 584
- G**
- Generalized seizures
    - absence, 458
    - atonic, 458
    - clonic, 458
    - idiopathic, 458
    - myoclonic, 458
    - tonic, 458
    - tonic-clonic, 458
  - Glasgow Coma Scale (GCS), 20, 257, 258, 260–261, 265, 275, 280, 281, 283, 288, 290, 298, 300, 302, 308, 383, 424, 443
  - Gram-negative
    - nursing care, 519
    - outcome, 519
    - patient and family education, 519
  - Gram-positive, 50, 72, 74, 78, 519
  - Growing skull fractures, 146–147
- H**
- Half-Fourier acquisition single-shot turbo spin echo (HASTE), 585
  - Handedness, 16, 399
  - Head growth, 15, 42, 52, 63, 78, 82, 163
  - Head trauma, 52, 256, 264, 267, 275, 278, 281, 306, 311, 374, 379, 399, 437, 516, 517
  - Hematomas, 144–146
  - Hemimegalencephaly, 459, 472, 475
  - Hemispherectomy, 470, 474–477, 479, 482

- Herniation  
 cingulated herniation, central herniation,  
 and uncal, 30  
 infratentorial herniation, 30  
 supratentorial herniation, 30
- Homonymous superior quadrantanopsia, 472
- Hydration and nutrition, 239, 305–306
- Hydrocephalus  
 acquired, 42  
 classifications  
 communicating, 41  
 non communicating, 41  
 communicating, 41  
 congenital, 41  
 external, 42  
 ex vacuo, 41, 42  
 history, 39–40  
 incidence, 40  
 internal, 42  
 noncommunicating, 41  
 normal pressure hydrocephalus, 42  
 prognosis, 40  
 signs and symptoms, 52–53  
 growth, 52  
 treatment, 57–69, 77, 84, 158, 209  
 medical therapy, 57
- Hydromorphone, 550
- Hydromyelia, 180
- Hyperosmolar therapy  
 hypertonic saline, 305  
 mannitol, 305
- Hyperventilation, 29, 236, 259, 304, 434
- I**
- Ictal, 2–4, 461, 463, 471, 486
- Image Gently, 54, 93
- Image Wisely, 93
- Imaging studies  
 computed tomography (CT), 44, 54, 390  
 magnetic resonance imaging (MRI), 55–57, 183–184,  
 192, 205  
 rapid sequence or haste MRI, 56  
 (HASTE) MRI, 56  
 ultrasonography, 53–54, 390
- Immediate Post-Concussion Assessment and Cognitive  
 Testing (ImPACT), 324
- Individuals with Disabilities Education Act (IDEA)  
 infant, 10–15  
 neonate, 6–10  
 toddler, 15–16
- Induction of anesthesia, 529, 530, 535–536, 547, 551, 552
- Intertical, 461, 463, 486
- International Classification of Epileptic Seizures  
 (ICES), 458
- Interventional radiology, 593–594
- Intracerebellar hemorrhage, 269, 272, 274–275
- Intracranial abscess, brain abscess  
 beta-hemolytic *Streptococci*, 375, 515  
 chronic otitis media, 515  
 congenital heart defect, 516  
 craniectomy, 518  
 dental procedures, 515  
 diagnostic tests  
 computed tomography (CT), 517  
 C-reactive protein (CRP), 517  
 cultures (aerobic, anaerobic, fungal, AFB), 517  
 erythrocyte sedimentation rate (ESR), 517  
 magnetic resonance imaging (MRI), 517–518  
 excision, 378  
*Haemophilus*, 516  
 mastoiditis, 515  
 needle aspiration, 518  
 nursing care, 519  
 outcome, 519  
 patient and family education, 519  
*Pneumococcus*, 515  
 presenting symptoms, 516–517  
 ruptured dermoid tumor, 515  
 sinusitis, 515  
*Streptococci*, 515  
 subdural empyema, 515–519  
 surgical drainage, 518  
 treatment options, 518–519  
 vancomycin, 518
- Intracranial aneurysms  
 diagnostic tests  
 computed tomography (CT), 420  
 LP, 420  
 microneurosurgical, 421  
 MRI/MRA, 420–421  
 etiology, 418–419  
 fusiform aneurysms, 418  
 Hunt and Hess (HH) scale, 423–424  
 medical management  
 EVD, 421  
 stabilization, 421  
 mycotic or infectious aneurysms, 418  
 pathophysiology, 419–420  
 presenting symptoms  
 headache, vomiting, meningeal irritation, 420  
 retinal hemorrhages, 420  
 subhyaloid hemorrhages, 420  
 saccular aneurysms, 418  
 surgical management, 422–423  
 traumatic aneurysms, 418  
 world federation of neurological surgeons scale, 424
- Intracranial compliance, 71, 291–292
- Intracranial electrodes, 465
- Intracranial hemorrhage, 66, 85, 269, 272, 273,  
 276, 289, 309, 404, 406, 407, 414, 420, 434,  
 438, 440
- Intracranial hypertension, 60, 295–306, 308, 520, 521
- Intracranial pressure monitoring  
 catheters, 301  
 intracranial hypertension, 302  
 nursing care, 302
- Intractable epilepsy, 457, 459–460, 470, 474, 476, 478,  
 480, 486, 560
- Intramembranous ossification, 93

- Intraoperative care  
 air handling system, 537  
 anesthetic induction, 537  
 dispersive electrocautery pad, 540  
 electrocautery unit, 537  
 positioning, 540–541  
 preparation of operating room, 537–538  
 sequential compression stockings, 537  
 shaving, 541  
 surgical time out, 541–542  
 ultrasonic aspirator, 537
- Intrathecal baclofen (ITB)  
 adverse effects, 498  
 catheter-related complications, 501–502  
 infection, 502  
 ITB cessation management, 502–503  
 nursing care, 503–504  
 patient selection, 500–501  
 pump-related complications, 502  
 skin-/wound-related complications, 501  
 trial dosing, 501
- J**
- Jackson-Weiss syndromes, 110
- Jefferson fracture  
 C1-burst fracture, 377  
 odontoid/ dens fracture, 379  
 synchondrosis, 379  
 Wallenberg syndrome, 378
- Jefferson or atlas fractures  
 C1 burst fracture, 377  
 Odontoid (Dens) fracture, 379  
 synchondrosis, 379  
 Wallenberg's syndrome, 378
- Jugular venous oxygenation saturation monitoring, 302
- K**
- Ketogenic diet, 459
- Ketorolac, 237, 550
- King-Devick (K-D) test, 324
- Klippel-Feil syndrome  
 abnormalities, 363  
 classifications, 363  
 congenital cervical fusion, 363  
 diagnosis, patient and parental education, 363, 364  
 radiographs, 363  
 surgery, 364  
 treatment, 364
- L**
- Lambdoid synostosis  
 Towne's view, 99  
 trapezoid, 99
- Langerhans cell histiocytosis (LCH)  
 clinical presentation, 138  
 etiology, 137  
 histiocytic disorder, 137  
 lytic bone lesions, 138  
 pathophysiology, 137–138  
 treatment, 139
- Leptomeningeal cysts, posttraumatic, 146–147
- Level of consciousness, 19–22, 25, 26, 28, 78, 118, 128, 204, 205, 236, 259–261, 277, 280, 281, 308, 309, 399, 400, 424, 438, 440, 519, 549
- Living with hydrocephalus  
 cognitive abnormalities, 83–84  
 motor disabilities, 84  
 ocular abnormalities, 84–85  
 precocious puberty, 85  
 seizures, 85
- M**
- Magnetic resonance angiography/venography (MRA/MRV), 585
- Magnetoencephalography (MEG), 461–462
- Malformations of cortical development (MCD), 472
- Mapping, 4, 464, 468–470, 474, 476, 485
- Mayfield headrest, 540, 541
- Medical imaging, 574
- Mercedes-Benz syndrome, 95–97
- Metopic synostosis, 92, 94, 99, 100, 123, 126, 127  
 hypotelorism, 99, 100
- Metronidazole, 518
- Monitoring partial pressure of oxygen, 302
- Monro-Kellie doctrine, 290, 291
- Motor exam  
 babinski, 267  
 clonus, 267  
 decerebrate posturing, 265  
 decorticate posturing, 265  
 lower motor neuron (LMN), 265  
 upper motor neuron, 265
- Moyamoya syndrome  
 choreiform, 434  
 diagnosis  
 angiography, 434  
 bypass, 437  
 computed tomography (CT), 435  
 indirect bypass, 435  
 magnetic resonance imaging (MRI), 435  
 PET, 435  
 SPECT, 435  
 superficial temporal artery middle cerebral artery anastomosis (STA-MCA), 435  
 symptomatic, 436  
 treatment, 435  
 dysphasia, 434  
 etiology, 433–434  
 pathophysiology, 434  
 hemiparesis, 434  
 ischemic symptoms, 434  
 monoparesis, 434  
 MRAs, 435  
 nursing care, 436  
 pathophysiology, 434  
 presenting symptoms

- Moyamoya syndrome (*cont.*)  
 choreiform movements, 434  
 dysphasia, 434  
 hemiparesis, 434  
 ischemia, 434  
 seizures, 434  
 transient ischemic attacks (TIA), 434
- MR spectroscopy (MRS), 584–585
- Mucopolysaccharide disorders  
 associated syndromes  
 atlantoaxial instability, 365  
 ligamentous laxity, 365  
 atlanto-axial instability, 365  
 bone marrow transplant, 366  
 inheritance, 364  
 lysosomal storage disorder (LSD), 364  
 odontoideum, 365  
 syndromes associated with MPS, 364  
 treatment, 366  
 bone marrow transplant, 366  
 umbilical cord blood transplants, 366  
 umbilical cord transplant, 366
- Myelomeningocele  
 bowel and bladder dysfunction  
 renal ultrasound, 159  
 urodynamics, 159  
 voiding cystourethrogram (VCUG), 159  
 comorbidities, 158  
 complications, 159  
 endoscopic third ventriculostomy, 158  
 history, 65  
 hydrocephalus, 158  
 endoscopic third ventriculostomy, 158  
 multidisciplinary care, 166  
 nursing considerations, 172–173  
 prenatal screening  
 amniocentesis, 159  
 fetal MRI, 159  
 maternal serum alpha-fetoprotein (MSAFP), 159  
 prognosis, 155  
 surgical management, 160–161  
 fetal surgery, 160  
 management of myelomeningocele study  
 (MOMs), 160  
 postoperative care, 163  
 preoperative care, 162  
 survival rate, 155
- Myelomeningocele and Chiari II malformation, 46
- N**
- Neoplasm  
 abnormal growth of tissue, mutation, 134  
 benign, 134  
 Ewing's sarcoma, 139–140  
 fibrous dysplasia, 136–137  
 LCH, 137–139  
 malignant, 135  
 neurofibromas, 135, 136  
 neurofibromatosis, 135, 136  
 osteblastoma, 139  
 osteomas, 139
- Nerve blocks, 550
- Nervous system anatomy  
 autonomic, 198  
 autonomic nervous system (ANS), 198  
 brainstem  
 hydrocephalus, 203  
 medulla, 202  
 midbrain, 202  
 pons, 202  
 spinal nerves, 203  
 thalamus, 201  
 cerebellum, 202  
 cerebrum, 198, 199  
 corpus callosum, 198  
 focal, 198  
 frontal, temporal, parietal and occipital lobes, 199  
 lobes  
 frontal, 199  
 occipital, 199, 200  
 parietal, 200  
 temporal, 199  
 posterior fossa, 202  
 cerebellar changes, 202  
 spinal cord, 198
- Neural tube defects  
 myelomeningocele, 155–158  
 occult spinal dysraphism, 168  
 spina bifida occulta, 168–169  
 spinal dysraphism, 168  
 tethered cord syndrome, 152
- Neurocranium, 93
- Neurocysticercosis  
 diagnostic tests, 521  
 nursing care, 522  
 outcome, 522  
 parasite, 522  
 patient and family education, 522  
 pork tapeworm, 520  
 presenting symptoms, 520
- Neuroimaging techniques  
 computed tomography (CT)  
 clinical application, 579  
 hydrocephalus and transependymal flow, 579, 581  
 intracranial hemorrhage, 579, 580  
 medical radiation, 581  
 nursing care, 581  
 posterior fossa tumor patient, 579, 580  
 procedure, 578–579  
 skull structure, 3D reconstruction, 581  
 diffusion-weighted imaging (DWI), 584  
 history, 573–574  
 magnetic resonance imaging (MRI)  
 advantage, 587  
 clinical application, 585–586  
 vs. CT density, 583  
 DWI, 584  
 FLAIR sequence, 584  
 fMRI, 584

- HASTE, 585
  - medical diagnostic purposes, 582
  - MRA/MRV, 585
  - MRS, 584
  - of normal brain, 581, 582
  - of normal spine, 581, 582
  - nursing care, 587–588
  - posterior fossa tumor patient, 580
  - procedure, 581–584
  - scanner, 582
  - T1 sequence, 583
  - T2 sequence, 583–584
  - plain film X-ray, 588
  - proton emission tomography (PET), 590–592
  - radionuclide CSF shuntogram, 588–590
  - ultrasound, 592–593
  - Neurological assessment
    - cranial nerves, 22–25
    - FOUR coma scale, 21
    - gait and balance, 28
    - glasgow coma scale, 260–261
    - motor exam, 265–266
    - reflexes, 21
    - sensory exam, 26
  - Neuromonitoring unit (NMU), 463, 468, 469, 486
  - Neuropsychological testing, 84, 324, 463, 464, 487
  - Neuroradiology, 574
  - Neurovascular
    - anatomy
      - arterial blood supply, 446
      - cerebrovascular blood flow, 400
      - description of arteries, capillaries, and veins, 396
      - homunculus, 398
    - disease, 395–449
    - venous system
      - cerebral veins, 398
      - dural venous sinuses, 398
      - internal jugular, 398
  - Neurulation
    - ectoderm, 153
    - neural fold, 153
    - neural groove, 153
  - Nonsteroidal anti-inflammatory drugs (NSAIDs), 32, 79, 172, 237, 377, 435, 441, 550
  - Normal blood pressure in children, 300
  - Nursing care
    - audiograms, 240
    - autonomic dysreflexia, 387–388
    - cervical collar care, 384–385
    - chemotherapy, 239–242
      - audiogram, 240
      - endocrine dysfunction, 239
      - hospice, 248
      - kidney function, 240
      - neutropenia, 242
      - ototoxicity, 248
      - psychological effects, 248
      - radiation therapy, 239
      - school re-entry, 245
      - secondary cancers, 248
    - surgery
      - surgery: diabetes insipidus (DI), 237
      - surgery: increased intracranial pressure, 236
      - surgery: pain management, 237
    - common chemotherapy drugs and side effects, 239, 240
    - developmental considerations, 235
    - diabetes insipidus (DI), 237
    - intracranial pressure monitoring, 235
    - kidney function, 240
    - neuroendocrine, 248
    - neurogenic bladder and bowel, 386
    - neutropenia, 242
    - ototoxicity, 248
    - pain management, 187, 190, 307, 308
    - pin site care for Halos, 385
    - pneumonia, 306
    - pressure ulcers, 386
    - psychological, 86
    - school re-entry, 245
    - secondary cancers, 248
    - sexuality and spinal cord injury, 387–388
    - spasticity, 387
    - sympathetic nervous system, 387
  - Nursing care after surgery
    - neuro assessment, 77–78
    - wound care, 78
  - Nursing care issues, 436
- O**
- Oncogenesis, 198
  - Ossification centers, 93
  - Osteoblastoma, 139
  - Osteogenic fronts, 93
  - Osteomas, 139
- P**
- Pain assessment, 31–34, 78
  - Parental presence
    - FACES, 550
    - FLACC pain scale, 32
    - monitoring and treatment of potential complications, 549
    - opioid, 550
    - oxycodone, 550
    - pain, 549–550
    - parental and patient guidance, 548
  - Partial seizures
    - complex, 458
    - simple, 458
  - Pathophysiology and hydrocephalus, 42–46
  - Pathophysiology of abusive head trauma, 337–339
  - Pathophysiology of intracranial hypertension, 295
  - Patient controlled analgesia (PCA), 33, 187, 237, 441, 550
  - Pediatric athletic concussion
    - definition, 317
    - diagnostic findings, 325–332
    - epidemiology, 317–319
    - management strategies



- Pediatric athletic concussion (*cont.*)
- biofeedback, 325
  - cervical therapy, 325
  - cognitive and physical rest, 325
  - neurofeedback, 325
  - neuropsychology testing, 325
  - nonsteroidal medication, 324
  - physical activity and exertion, 325
  - upper cervical spine, 325
  - vestibular rehabilitation, 325
- pathophysiology, 320–321
- physical examination
- history of injury, 322
  - initial evaluation, 321
- symptoms, 322–324
- treatment, 324–325
- warning signs, 322
- Pediatric brain, 319
- Pediatric intensive care unit (PICU), 116, 190, 297, 302, 303, 468, 482, 487, 545, 546
- Pediatric nurse practitioners (PNP), 104, 536, 568
- Pediatric spinal vascular malformations
- acute hemorrhage, 445
  - etiology, 405–406, 412–413, 418–419
  - hereditary hemorrhagic telangiectasias (HHT), 405
  - ischemia, 406, 407
  - pathophysiology, secondary symptoms, 406
  - presenting signs and symptoms, 406–407
  - spinal, 408
  - symptoms, 406–407
- Pediatric stroke
- infants, 399
  - perinatal period, 399
  - risk factors, 399
- Penetrating craniocerebral injury, 289–290
- Perioperative care, 529–553
- Perioperative nurses
- air-handling system, 537
  - Association of PeriOperative Registered Nurses (AORN), 537–539, 543
  - electrocautery unit, 537, 544
  - preparation of operating room, 537–538
  - scrub nurse, 537, 538, 542–544
  - ultrasonic aspirator, 537
- Pfeiffer syndrome, 110, 111
- Phakomatoses, 197, 419
- Phase II monitoring, 464–470, 473, 482, 486
- Pneumoencephalography, 573
- Port-wine appearance, 477
- Positional plagiocephaly
- back to sleep, 101, 104
  - deformational forces, 99
  - orthotist
    - back to sleep (BTS), 104
    - static stretching exercises, 105
  - sudden infant death syndrome (SIDS), 102, 104
  - torticollis, 101, 102, 105
  - tummy time, 104
- Positive emission tomography (PET), 461
- Postanesthesia care unit (PACU), 545–553
- Postconcussion syndrome (PCS), 324
- Posthemorrhagic hydrocephalus of prematurity
- cysticercosis, 50
  - gram-positive bacteria, 50
  - multiloculated hydrocephalus, 50
- Postoperative care
- criteria for PACU recovery, 545–546
  - FACES, 550
  - FLACC pain scale, 550
  - management and treatment of potential complications, 549
  - pain, 549–550
  - parental and patient guidance, 548
  - parental presence in PACU, 547–548
  - visual analogue scale (VAS), 550
- Postoperative infections, 119, 483, 526–527
- vs.* of fever, 483, 526, 527
- Postoperative nursing management
- molding helmet, 128
  - postdischarge management, 119
- Posttraumatic seizures, 258, 259, 283, 290
- Premature infant pain profile, 32, 33
- Preoperative care
- dietary restrictions, 535
  - imaging tests, 534–535
  - indicators for PAT, 532
  - laboratory testing, 533–534
  - parental preparation, 529–530, 535
  - parental presence upon induction of anesthesia, 535–536
  - preoperative consultation, 530–531
  - preoperative medication, 535
  - preoperative preparation programs, 530
  - psychological preparation of the child, 530
  - separation from parents, 535–536
- Pressure-volume curve, 256
- Pseudo seizures, 463
- Pseudotumor cerebri in the pediatric
- population, 86
  - classification, 86
  - treatment, 86
- Pupillary response, 263
- anisocoria, 263
  - facial, 264
  - hippus, 263
  - Horner's syndrome, 378
  - miosis, 263
  - mydriasis, 263
  - oculocephalic, 30, 264
  - oculovestibular, 30, 264, 265
  - Parinaud's syndrome, 263
  - saccadic eye movements, 264
  - sun setting, 263, 264
  - sunsetting eyes, 52
  - trigeminal, 264
  - vestibular, 264, 265
- R**
- Radiation exposure, 574, 576
- Radiographic imaging, history, 573–574
- Radionuclide CSF shuntogram, 588–590

- Rasmussen's encephalitis, 475–480  
 Rasmussen's syndrome, 460
- Reflexes  
 Babinski, 26–28, 259  
 brainstem herniation, 21  
 clonus, 259, 267  
 deep tendon reflexes (DTR), 26, 266–267  
 Kernohan's notch, 257, 296  
 magnetic resonance imaging (MRI), 268, 269, 271, 273–274  
 reticular activating system, 257  
 skull radiographs, 269  
 tentorium cerebella, 257, 278
- Registered nurse first assistants (RNFA), 537, 540
- S**
- Saethre-Chotzen, 110  
 Sagittal synostosis, 92, 94–96, 113, 118–119, 122, 124  
 Scalp anomalies  
 acquired  
 growing fracture of childhood, 146–147  
 hematomas, 144–146  
 benign, 134–135  
 congenital  
 cranial dermal sinus, 142–144  
 cutis aplasia, 140  
 epidermoid and dermoid cysts, 141–142  
 inflammatory/reactive, 148–149  
 malignant, 135  
 vascular lesions, 133–135, 147–148  
 Scalp electrodes, 463  
 Second impact syndrome (SIS), 329, 332  
 Sedation, 577–578  
 Seizure, 2, 5, 118, 156, 199, 258, 399, 457, 527, 532, 559  
 Seizure focus, 211, 464, 465, 472–474, 485, 487  
 Selective dorsal rhizotomy (SDR)  
 dystonia, 504–507  
 spasticity  
 nursing care, 506  
 outcomes, 505–506  
 pain control, 506  
 patient selection, 505  
 procedure, 505  
 Semiology, 457–459, 461, 470, 476  
 Semiology seizure classification (SSC), 458  
 Shaken baby syndrome. *See* Abusive head trauma (AHT)
- Shaving, 541
- Shunt infections  
 diagnostic tests, 73, 523–524  
 etiology, 523  
 nursing care, 79  
 outcome, 525–526  
 pathophysiology, 523  
 patient and family education, 86, 525  
 pseudocyst, 74  
 symptoms, 523  
 treatment, 72–73, 524–525  
 VA shunt, 74
- Single proton emission computed tomography (SPECT), 461, 463, 591–592
- Sinovenous thrombosis  
 anemia, 437  
 bromage sedation scale, 441  
 cerebral perfusion, 440  
 chronic diseases, 437  
 clotting disorders, 447  
 CT, 438  
 dehydration, 437  
 diagnostic imaging, 438  
 fever, 439  
 head trauma, 373  
 increased ICP, 437  
 infection, 437, 439  
 magnetic resonance imaging (MRI), 438  
 management of nausea and vomiting, 442  
 medical treatment, 438–439  
 nausea, 438  
 neurosupportive therapy, 438  
 nursing care, 439  
 pain management, 441  
 pathophysiology, 437–438  
 risks/causes, 437, 438  
 seizure management, 438  
 surgical treatment, 439  
 thrombectomy, 439  
 trauma, 437
- Sinus pericranii  
 etiology, 147–148  
 evaluation, 148  
 pathophysiology, 147–148  
 treatment, 148
- Skeletal dysplasias  
 achondroplasia, 356  
 achondroplastic child, 359–360  
 adulthood, 360–362  
 apnea, 360  
 brain stem, 359, 360  
 cervicomedullary compression, 359–361  
 cervicomedullary junction, 360  
 C shape, 361  
 CV compression symptoms, 360  
 decompression, 356  
 fibroblast growth factor receptor, 366  
 foramen magnum, 359  
 hydrocephalus, 359  
 hyperreflexia, 360  
 hypoventilation, 360  
 lumbosacral hyperlordosis, 361–362  
 adult, 361  
 C shaped posture, 361  
 medullary compression, 360  
 myelogram, 362  
 neurogenic claudicatory, 362  
 paresis, 360  
 paresthesias, 360, 362  
 posterior fossa, 359  
 sleep apnea, 360  
 spinal stenosis, 361  
 thoracolumbar kyphosis, 361–362

## Skull

- anomalies
  - acquired, 133, 144–146
  - benign, 134–135
  - congenital, 133, 140–144
  - inflammatory/reactive, 148
  - malignant, 135
  - vascular lesions, 133–136, 147–148
- basilar skull fracture, 258, 275–277
- depressed skull fracture, 258, 270, 271, 276, 277, 283, 306–307, 516
- fontanel, 256
- head circumference, 256
- initial history and physical, 259
- leptomeningeal cyst, 272
- linear skull fracture, 269, 270, 272
- neonatal skull fracture, 270–272
- neurologic assessment and deterioration, 258–267
- occipital fractures, 256
- ping pong fracture, 277
- pressure-volume curve, 291

## Spasticity

- Ashworth scale, 495
- assessment, 495
- cerebral causes, 494–495
- clinical presentation, 494, 495
- complications, 494, 495
- diagnosis, 495
- efferent neurons, 494
- limb paresis, 494
- motor function, 493
- muscle immobilization, 494
- pathophysiology, 495–496
- reflex arc, 493, 494
- spinal causes, 495
- supraspinal mechanism, 493
- treatment
  - botulinum A toxin, 498
  - conservative therapies, 497–498
  - DBS, 506–509
  - ITB, 498–504
  - SDR, 504–506

## Spina bifida occulta

- atretic meningocele, 170
- caudal appendage, 170
- club feet, 171
- dermal sinus tract, 169, 171
- dermoid cysts and tumors, 168
- diagnostic studies, 172
- diastematomyelia, 168, 170
- diplomylelia, 168
- electromyography (EMG), 172
- filum terminale, 168, 173
- hemangioma, 169, 170
- hypertrichosis, 169
- kyphosis, 170
- lipoma or lipomeningocele, 168–170
- meningocele manque, 168, 170
- nursing considerations, 172–173
- orthopedic findings, 171–172
- scoliosis, 169, 170

- somatosensory evoked potentials (SSEPs), 172
- split cord malformation, 168
- subcutaneous, 169, 170
- surgical management, 172
- tight filum terminale, 168
- urologic dysfunction
  - enuresis, 172
  - urinary tract infections, 172

## Spinal cord injury

- causes
  - contusion, 369
  - dislocation, 370, 374
  - fractures, 370
  - hemisection, 369
  - transection, 369
- etiology, 369
- pathophysiology
  - anatomic features of pediatric spine, 367
  - fulcrum, 371

## SCIWORA

- bradycardia, 371
- C-spine injury, 371–373
- head injury, 371
- hypotension, 371
- injury level and age, 371
- ligamentous edema, 371
- prognosis, 370

## Spine, 3, 46, 105, 151, 184, 198, 256, 351, 430, 557

## Sport Concussion Assessment Tool 3rd edition (SCAT3), 324

## Sports-related concussion, 317–319

## Sprengel's deformity, 354

## Standardized Assessment of Concussion, 321

## Status epilepticus, 458, 468

## Sturge-Weber syndrome, 460, 477–479

## Subacute bacterial endocarditis (SBE) prophylaxis

- nursing care, 524–525
- outcome, 525–526
- patient and family education, 525

## Subarachnoid hemorrhage, 41, 52, 80, 257, 271–273, 280–281, 402, 414, 420, 423–424

## Subdural hemorrhage, 271–274, 279–280, 337, 420

## Subependymal giant cell tumor, 479

## Sudden unexplained death in epilepsy (SUDEP), 460

## video-EEG, 463

## Surgical

- complications
  - infection, 72–74, 307
  - obstruction, 69, 70, 74, 76, 86
- hand scrub, 538, 543
- shunt intervention
  - fixed pressure, 58
  - flow-regulating, 57
  - placing the distal tubing, 59
  - programmable valves, 59
  - siphon-resisting valves, 57, 58
- tubing placement, 59

## Symptoms

- pediatric athletic concussion
  - balance problems/postural instability, 323
  - cognitive assessment, 323–324

- emotional, 322
  - physical exam, 322, 323
  - vestibular testing, 324
  - posterior fossa
    - diplopia, 414
    - hydrocephalus, 414
    - increased ICP, 414
    - papilledema, 414
  - Syringomyelia
    - hydromyelia
      - dysphagia, 181
      - headache, 181
      - neuromonitoring, 185
      - respiratory distress, 182
      - scoliosis, 183
      - surgery, 184
      - swallowing dysfunction, 182
      - vocal cord paralysis, 181
    - nursing care
      - antiemetic medications, 187
      - chemical meningitis, 188
      - discharge criteria, 188
      - pseudomeningocele, 188
    - outcomes, 192
    - patient and family education, 191
    - syrinx, etiology, 180
    - treatment options
      - duraplasty, 187
      - neuromonitoring, 185, 188
      - syringoperitoneal shunt, 190
      - syringopleural shunt, 190
      - syringosubarachnoid shunts, 190
  - Syrinx, 159, 177, 180–185, 189–191, 446
    - etiology, 180
- T**
- Tardieu scale, 495
  - Temperature regulation, 304
  - Temporal lobe epilepsy (TLE), 471
  - Thoracic and lumbar spine injuries
    - anterior cord syndrome, 383
    - Brown-Sequard syndrome, 382–383
    - central cord syndrome, 383–384
    - contusions, 382
    - distraction, 382
    - SCI, 381
    - steroids, 384
  - Transition
    - barriers, 558–559
    - consensus statement, 564
    - Gillette Children's Specialty Healthcare, 565–566
    - health-care professional curriculum, 566
    - health information and medical records, 562
    - insurance, 557, 560–562
    - models, 564–565
    - tools, 564
  - Traumatic brain injury (TBI)
    - concussion, 317, 318
    - diffuse axonal injury, 256, 257, 268, 282, 286–289
    - endocrine complications
      - cerebral salt wasting, 310
      - diabetes insipidus, 309–310
      - syndrome of inappropriate antidiuretic hormone (SIADH), 310
    - epidemiology, 255
    - evidence based treatment guideline, 298
    - initial history and physical, 259
    - initial resuscitation, 300
    - intensive care management, 300–301
    - neurological assessment and deterioration, 258–267
    - nursing care, 308
    - outcomes, 310–311
    - postoperative complications, 309
    - pressure volume curve, 291
    - prevention, 311
  - Traumatic spinal cord injury
    - airway, 371, 372
    - anatomic features, 367
    - bradycardia, 371
    - cervical spine precautions, 372–373
    - contusion (bruising), 369
    - C-spine injuries, 367–368
    - diagnosis, 371
    - dislocations, 369, 370
    - epidemiology, 369–370
    - etiology, 369
    - fractures, 369
    - head injury, 371
    - hemisection, 369
    - hypotension, 371
    - immobilization, 370–373
    - ligamentous edema, 370
    - pathophysiology, 367–368
    - positioning, 373
    - prognosis, 370
    - radiographic evaluation, 371–372
    - risk factors, 371, 373
    - SCIWORA, 370
    - sympathetic nervous system, 22
    - transection, 369
    - unconscious patient, 371
    - vertebral bodies, 367
  - Treacher Collins syndrome, 110
  - Treatment
    - brachytherapy, 214
    - chemotherapy, 214–215, 516, 560
    - COG, 195, 211
    - conformal radiation therapy, 213
    - diuretics, 29, 39, 57, 236, 295, 308, 402, 404, 415
    - dystonia
      - botulinum A toxin, 498
      - conservative therapies, 497–498
      - DBS, 506–509
      - intrathecal baclofen, 498–499
      - ITB, 498–504
      - SDR, 504–506
    - electrocorticography, 208, 236, 471
    - intraoperative guidance systems, 209, 236
    - intraoperative monitoring, 172, 199, 208, 209, 236
    - linear accelerator, 212, 409
    - pediatric athletic concussion, 324

Treatment (*cont.*)

- radiation, 197, 207, 238–239
  - spasticity
    - botulinum A toxin, 498
    - conservative therapies, 497–498
    - DBS, 506–509
    - ITB, 498–504
    - SDR, 504–506
  - staged protocol, 357, 415, 535
  - staged surgical procedures, 208
  - stem cell transplant, 215, 220, 228, 242
- Tuberous sclerosis, 44, 51, 197, 222, 419, 434, 472, 479–480
- Tubers, 197, 476, 479
- Tumors
- etiology, 197–198
  - hemangioblastomas, 215
    - phakomatoses, 197, 419
  - infant tumors, 205, 234
  - low-grade astrocytomas, 219
  - medulloblastoma, 197, 204, 215, 217, 226–228, 234
  - nevoid basal cell, 197
  - oncogenesis, 198
  - radiation, 212–214
  - SEGAS, 197
  - turcot, 197
  - types
    - astrocytomas, 51, 198, 204, 215, 217, 470
    - benign, 215, 233, 470
    - choroid plexus tumors, 41, 51, 215, 233, 234
    - craniopharyngiomas, 51, 204, 215, 217, 418
    - dysembryoplastic neuroepithelial tumors (DNETs), 204, 217, 470
    - ependymomas, 51, 69, 204, 206, 215, 217
    - gangliocytomas, 215, 222
    - gangliogliomas, 215, 222, 470
    - germ cell tumors, 51, 215, 230
    - glioblastoma multiforme, 215, 219
    - gliomas, 51, 204, 217–220
    - hemangioblastomas, 197, 215
    - histiocytosis X, 233–234
    - histology, 216
    - malignant, 226
    - malignant astrocytomas, 219–222
    - malignant vs. benign, 215–216
    - medulloblastoma, 51, 197, 204, 215, 226–228
    - oligodendrogliomas, 215, 219
    - pineal cell tumors, 215
    - posterior fossa syndrome, 234–235
    - primitive neuroectodermal tumors (PNET), 215, 217
    - spinal cord malignant astrocytomas, 222
    - subependymal giant cell astrocytomas (SGCAs), 222
- Von Hippel-Lindau, 197

## V

- Vagal nerve stimulator (VNS), 480–482
  - complications of epilepsy surgery, 481–482
  - CSF leak, 482, 483, 540

- electrolytes, 483
  - Engel's classification, 484
  - fever, 483
  - ILAE classification of postoperative outcome, 485
  - incision care, 483
  - infection, 481
  - International League Against Epilepsy, 484
  - nursing care following resective surgeries, 482–484
  - outcomes of epilepsy surgery, 484–487
  - pain management, 469
  - postoperative drains, 483
  - postoperative outcome, 485
  - Quality of life (QOL), 486
  - seizures, 481–484
  - stroke, 478, 482
- Vascular anatomy
- arterial supply, 395–398
  - cerebral blood supply, 395
- Vein of Galen (VOG) aneurysmal malformations
- choroidal, 401
  - congestive heart failure, 401, 403–405
  - cranial MRI and/or CT scan, 402
  - diagnostic studies
    - color Doppler, 402
    - CT, 402
    - MR angiography, 402
    - MRI, 402
  - dural venous sinuses, 398
  - homunculus, 398
  - jugular veins, 398
  - MProV, 400
  - mural, 401
  - nursing
    - cardiac management, 404
    - head circumference, 403
    - medication, 403
    - outcomes, 404–405
  - pathophysiology
    - median prosencephalic vein of Markowski (MProV) choroidal, 400
    - mural, 401
  - pharmacological management, 404
  - score, 401
  - surgical treatments, 403
  - symptoms
    - cardiomegaly, 401–402
    - congestive heart failure (CHF), 401
    - hydrocephalus, 401–403
    - hydrops, 401
    - pulmonary hypertension, 401
    - steal, 401
  - treatments
    - embolic agents, 403
    - endovascular embolization, 403
    - onyx, 403
    - perfusion breakthrough, 403
- Venous angiomas, pathophysiology
- CT or MRI, 426
  - variation, 425
  - veins, 425



- World Federation of Neurological Surgeons Scale, 424
  - Venous anomalies
    - brainstem cavernous malformations
      - classification, 431
      - diagnostic imaging, 431
      - genetic counseling, 432
      - medications, 426, 433
      - stereotactic radiosurgery, 432
      - symptoms, 430
      - treatments, 431–432
    - capillary angiomas, 428
    - cavernous malformations (cav mal), 429–433
    - diagnostic tests, 426
    - medical management, 426–427
    - pathophysiology, venous variants, 425
    - spinal cavernous malformations, 429, 430
      - cystic vascular spaces, 429
    - surgical management, 427
    - telangiectasias, 428–429
  - Vestibular/Ocular Motor Screening (VOMS), 324
  - Vestibulo-oculo dysfunction (VOD), 324
  - Visual acuity, 16, 22, 23, 85, 207, 261–262, 414
  - Visual analogue scale (VAS), 550
  - Vital signs, 19, 28–29, 78, 122, 128, 173, 205, 236, 257–260, 306, 307, 311, 383, 439, 441, 533, 539, 546, 548, 550–552
    - AHT, 341
    - brainstem, 28, 29, 258, 259, 550–551
  - von Hippel-Lindau syndrome, 197
- W**
- Wada test, 2, 207, 464
  - Working Initiative for Special Health Education Services (WISHES), 566
    - nursing, 568
- Y**
- Young adults with special health care needs (YASHCN), 568
  - Youth with Special Health Care Needs (YSHCN)
    - barriers, 558–559
    - consensus statement, 558, 564
    - health information and records, 562
    - insurance, 561
    - models, 563–566