# Advances in Anatomy Embryology and Cell Biology

Vol. 113

Willie Vorster

# The Development of the Chondrocranium of Gallus gallus

With 37 Figures

Springer-Verlag
Berlin Heidelberg New York
London Paris Tokyo

Dr. Willie Vorster
Department of Anatomy and Histology
Faculty of Medicine, University of Stellenbosch
P.O.Box 63, Tygerberg 7505, South Africa

**ISBN-13 : 978-3-540-50185-5** **e-ISBN-13 : 978-3-642-73999-6**
**DOI : 10.1007 / 978-3-642-73999-6**

Library of Congress Cataloging-in-Publication Data
Vorster, Willie, 1946–
The development of the chondrocranium of Gallus gallus / Willie Vorster.
p. cm. – (Advances in anatomy, embryology, and cell biology: vol. 113)
Bibliography: p.

1. Chondrocranium – Development. 2. Chondrocranium – Growth. 3. Chickens – Development. 4. Chickens – Growth. 5. Birds – Development. 6. Birds – Growth. I. Title. II. Series: Advances in anatomy, embryology, and cell biology; v. 113.
[DNLM: 1. Chickens – growth & development. 2. Skull – growth & development. W1 AD433K v. 113/QL 898.82 V956d]
QL801.E67 vol. 113 [QL822] 574.4s – dc19 [598′.617] DNLM/DLC 88-24921

Typesetting, printing and binding: Universitätsdruckerei H. Stürtz AG, Würzburg
2121/3140-543210 – Printed on acid-free paper

# Contents

**1 Introduction** . . . . . . . . . . . . . . . . . . . . 1

**2 Material and Technique** . . . . . . . . . . . . . . 3

**3 Description of Developmental Stages** . . . . . . . 5

3.1 Stage I . . . . . . . . . . . . . . . . . . . . 5
3.1.1 The Basal Plate and Otic Capsules . . . . . . . . 5
3.1.2 The Anterior End of the Chondrocranium . . . . 9
3.1.3 The Visceral Arches . . . . . . . . . . . . . . 11

3.2 Stage II . . . . . . . . . . . . . . . . . . . . 13
3.2.1 The Basal Plate and Otic Capsules . . . . . . . . 13
3.2.2 The Anterior End of the Chondrocranium . . . . 15
3.2.3 The Visceral Arches . . . . . . . . . . . . . . 19

3.3 Stage III . . . . . . . . . . . . . . . . . . . . 21
3.3.1 The Basal Plate and Otic Capsules . . . . . . . . 21
3.3.2 The Anterior End of the Chondrocranium . . . . 27
3.3.3 The Visceral Arches . . . . . . . . . . . . . . 32

3.4 Stage IV . . . . . . . . . . . . . . . . . . . . 35
3.4.1 The Basal Plate and Otic Capsules . . . . . . . . 35
3.4.2 The Anterior End of the Chondrocranium . . . . 37
3.4.3 The Visceral Arches . . . . . . . . . . . . . . 41

3.5 Stage V . . . . . . . . . . . . . . . . . . . . 44
3.5.1 The Basal Plate and Otic Capsules . . . . . . . . 44
3.5.2 The Anterior End of the Chondrocranium . . . . 47
3.5.3 The Visceral Arches . . . . . . . . . . . . . . 49

3.6 Stage VI . . . . . . . . . . . . . . . . . . . . 50
3.6.1 The Basal Plate and Otic Capsules . . . . . . . . 51
3.6.2 The Anterior End of the Chondrocranium . . . . 52
3.6.3 The Visceral Arches . . . . . . . . . . . . . . 56

**4 Résumé and Discussion** . . . . . . . . . . . . . 58

4.1 The Basal Plate and Otic Capsules . . . . . . . . 58
4.1.1 The Acrochordal Cartilage and Tip of the Chorda . 58
4.1.2 The Fenestra Basicranialis Posterior . . . . . . . 59
4.1.3 The Otic Capsules . . . . . . . . . . . . . . . 59
4.1.4 The Orbitocapsular Commissure and Otic Process . 60

4.1.5 The Pila Antotica Spuria . . . . . . . . . . . . 62
4.1.6 The Tectum Synoticum . . . . . . . . . . . . . 63

4.2 The Anterior End of the Chondrocranium . . . . 64
4.2.1 The Incisura Carotica . . . . . . . . . . . . . 64
4.2.2 The Intertrabecula . . . . . . . . . . . . . . . 64
4.2.3 The Nasal Capsule . . . . . . . . . . . . . . . 67

4.3 The Visceral Arches . . . . . . . . . . . . . . 69

**5 Summary** . . . . . . . . . . . . . . . . . . . 71

**Acknowledgments** . . . . . . . . . . . . . . . . 72

**References** . . . . . . . . . . . . . . . . . . . 73

**Subject Index** . . . . . . . . . . . . . . . . . . 76

# 1 Introduction

The study of the avian chondrocranium commenced with the classic and excellent monographs of W.K. Parker (1866, 1869, 1875, 1876, 1890) who described the development in the ostrich tribe, the Gallinaceae and various other birds. T.J. Parker (1888, 1891) continued these investigations in *Apteryx*.

The next milestone was the detailed study of the development of *Tinnunculus* (Suschkin 1899), followed by contributions from Tonkoff (1900), Gaupp (1906) and Sonies (1907). With improved techniques, Sonies (1907) could elucidate various new aspects of the chondrocrania of *Gallus* and *Anas*.

A major contribution was made by de Beer and Barrington (1934), who not only gave a detailed description of the development of the chondrocranium of *Anas* but also standardised the nomenclature and elaborated on the various morphological problems of the avian chondrocranium.

After Brock's (1937) study of the morphology of the chondrocranium of the ostrich, contributions came from Kesteven (1941, 1942), Hofer (1945, 1949, 1954), Slabý (1951a, b, 1952, 1958), Barnikol (1952), Starck (1941, 1955, 1960), Lang (1955, 1956), May (1961), Müller (1961, 1963), Macke (1969), Goldschmid (1972) and Smit and Frank (1979).

An important series of investigations on the structure and development of the avian skull, especially the development of the chondrocranium, was initiated at the University of Stellenbosch by the late Professor C.G.S. de Villiers. These are the studies of Swart (1946), de Villiers (1946), Grewe (1951), Prins (1951), Crompton (1953), Frank (1954), de Kock (1955, 1987), Fourie (1955), Webb (1957), Engelbrecht (1958), Saayman (1963), Schoonees (1963) and Toerien (1971).

Although the development of the chondrocranium of *Gallus* has been investigated by various authors there are certain shortcomings which still need further clarification. W.K. Parker (1869) covered the early development at 4 days (5 days, rectified in 1876), 5–7 days (6 and 7 days, 1876), middle of 2nd week, end of 2nd and beginning of 3rd week, and then 2nd day after hatching to several years old. At that time the nomenclature was not yet standardised, which makes his descriptions difficult to follow.

Tonkoff (1900) only described the chondrocranium and dermal bones of an embryo of 10 days 18 h incubation. The Ziegler copy of the model of the skull of the embryo has been an important aid in understanding the relationships of the various elements of the avian chondrocranium.

Gaupp (1906) in Hertwig's *Handbuch* leans heavily on the information provided by Tonkoff's study (1900) of a single stage, but mentions that he also had a few stages of *Gallus* available.

Sonies (1907) covered the development of *Gallus* from the 4th to the 10th day of development, leaving out the 5th and 9th days. With his technique certain aspects were also missed.

Further studies which touched on aspects of the cranial development of *Gallus* were those of Born (1879), Stresemann (1927), Schinz and Zangerl (1937), Bremer (1940), Erdmann (1940) and Jollie (1957), who were mostly interested in the ossifications occurring from about 10 days of development.

The importance of the use of chick embryos as laboratory material was noted by Patten (1957), as experimental material for various embryonic developments by Gilchrist (1968), le Lièvre (1978) and Hall (1982) and recently in experimental embryology and teratology by Sandor and Elias (1968), Gebhardt (1972), Boggan (1982) and Fisher and Schoenwolf (1983).

Gebhardt (1972) shows that chick and rodent embryos react in the same way in most teratological studies and, although extrapolation to man remains difficult, it would be wise to use the chick embryo in applied teratology. Boggan (1982), in describing the usage of various animals in fetal alcohol syndrome experiments, shows that the advantages of using chick embryos far outweighs the disadvantages. Fisher and Schoenwolf (1983) point out the usefulness of the chick embryo in studies of vertebrate embryogenesis and give details of improved methods of applying the teratogenic agents to the embryo.

This study of the normal stages of the early development of the chondrocranium of *Gallus* was undertaken to provide a model with which to compare cranial abnormalities developing from the application of teratogenic material in easily obtainable experimental material.

Although the study of the development of the avian chondrocranium is coming into its own, as is seen by the number of contributions mentioned, our knowledge of this field is still inadequate in so far as it covers less than 20 avian orders. Engelbrecht (1958) shows the importance of studying at least one example from each order before establishing affinities or discussing taxonomical problems.

# 2 Material and Technique

The material for this investigation was obtained from a closed White Leghorn stock bred in the Department of Poultry Science at the Stellenbosch-Elsenburg College of Agriculture. As described by Poggenpoel and Erasmus (1978), the pedigree breeding genetic flock was established in 1953 when two unrelated lines were closed off from outside introductions. Inbreeding was avoided as far as possible by not allowing mating between close relatives. An inbreeding rate of only 0.515% per generation was achieved. From 1953 to 1962 the pedigree stock was selected, based on increased egg production, and since 1963 the pedigree breeding genetic flock has been kept as a production flock.

From this flock 100 eggs were used. They were disinfected by smoking with paraformalde-

**Table 1.** Classification of chick embryos studied, including comparative Hamburger and Hamilton stages

| Stage described | Total length of embryo (mm) | Days incubated | Hamburger and Hamilton stage | Series | |
|---|---|---|---|---|---|
| | | | | No. | Cut |
| | | 3 | 20 | 3A | Transverse |
| | | 3 | 20 | 3B | Sagittal |
| | | 3 | 21 | 3C | Sagittal |
| | 25 | 4 | 22 | 4A | Sagittal |
| | 26 | 4 | 24 | 4B | Transverse |
| I | 27 | 5 | 26 | 5B | Transverse |
| | 29 | 5 | 26 | 5D | Sagittal |
| | 30 | 5 | 27 | 5A | Sagittal |
| | 34 | 5 | 27 | 5C | Transverse |
| II | 35 | 6 | 29 | 6A | Sagittal |
| | 39 | 6 | 29 | 6B | Transverse |
| | 41 | 7 | 30 | 7A | Sagittal |
| III | 46 | 8 | 34 | 8B | Sagittal |
| | 50 | 8 | 34 | 8A | Transverse |
| IV | 55 | 9 | 35 | 9C | Sagittal |
| | 57 | 9 | 35 | 9D | Transverse |
| V | 65 | 10 | 36 | 10C | Transverse |
| | 67 | 10 | 36 | 10A | Sagittal |
| | 73 | 11 | 37 | 11A | Transverse |
| VI | 95 | 14 | 40 | 14A | Transverse |
| | 118 | 16 | 41 | 16A | Transverse |
| | 122 | 18 | 43 | 18A | Sagittal |

5C, 9C and 9D were serially sectioned at 12 µm while the rest were sectioned at 10 µm.

hyde crystals and placed in an incubator with a capacity of 16000 eggs which tilted automatically through 90° every hour; the temperature was 37.8° C and relative humidity 65% with negligible fluctuation. Four eggs were removed after every 24 h incubation, fixed in Allen's fluid, and classified according to length measured from the tip of the beak to the tip of the tail as well as according to the table of developmental stages compiled by Hamburger and Hamilton (1951; Table 1).

It was unnecessary to decalcify the younger embryos as the acid component of the fixative was adequate. For the older embryos, decalcifying with a 7.5% solution of concentrated nitric acid in 70% alcohol was needed. Serial sections were made of a large number of specimens, all cut at 10 µm except for three which were cut at 12 µm (see Table 1). Transverse as well as sagittal sections were made for most of the stages.

Various staining methods were used, the best results for the younger embryos being obtained with Mayer's haemalum for bulk staining and the sections then counterstained with Bismarck brown and eosin. In the youngest stages eosin was omitted so that the first traces of intercellular deposit could be detected. Sections of some series of older embryos were stained with Heidenhain's iron haematoxylin and counterstained with Bismarck brown and eosin, while others were stained with azocarmine and counterstained with azan.

Graphic reconstructions were made from drawings of the sections according to Pusey's (1939) "projection method".

For comparison I had the Ziegler copy of W. Tonkoff's model of the chondrocranium of an embryo of *Gallus* at my disposal as well as various models of the chondrocranium of *Spheniscus demersus* made by A.W. Crompton, of the nasal capsules of *Struthio* and *Caprimulgus pectoralis pectoralis* made by G.H. Frank, and of the chondrocranium of an embryo as well as two models of the nasal capsule of *Euplectes orix orix* made by D. van Z. Engelbrecht.

Furthermore, different series of developmental stages of a variety of avian skulls sectioned by workers in the Zoology Department of Stellenbosch University, were available for comparative study.

# 3 Description of Developmental Stages

## 3.1 Stage I

Total length of embryos: 27 mm, 29 mm and 30 mm (Stages 26 and 27 of Hamburger and Hamilton 1951). 5 days' development.

### *3.1.1 The Basal Plate and Otic Capsules*

The first signs of chondrification are present in embryos that have completed 5 days of incubation. In the younger embryos the chondrocranium anlage consists of mesenchyme condensations only.

The basal plate and acrochordal cartilage display the typical avian S-shaped form first described by Suschkin (1899) in *Tinnunculus* (Fig. 1). The acrochordal cartilage, which is situated anterior to the tip of the chorda, appears to be

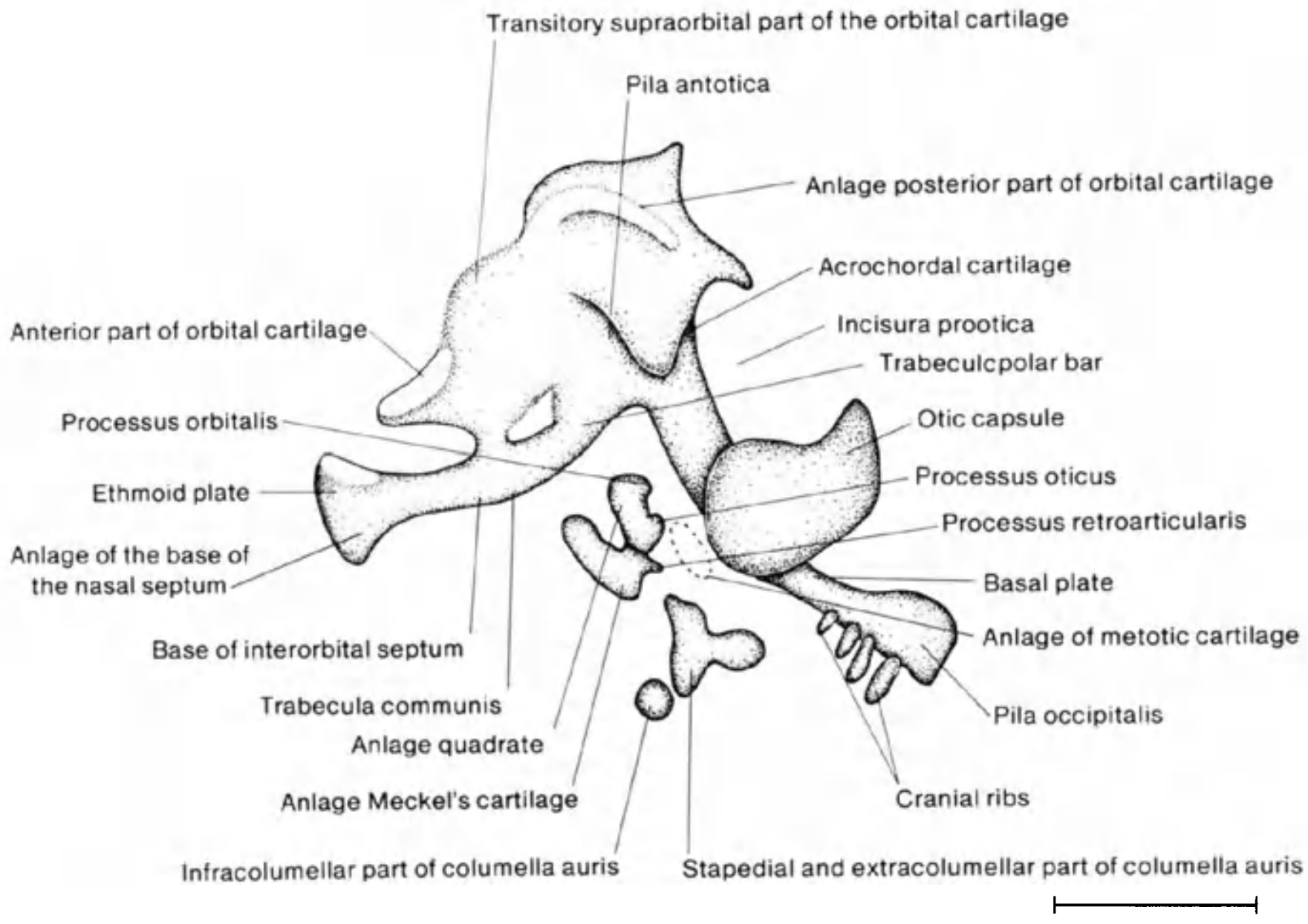

**Fig. 1.** Stage I. Reconstruction of chondrocranium (norma lateralis). *Scale bar*, 1 mm

the first part of the chondrocranium to have chondrified, as the intercellular substance stains darker than that of the surrounding structures. This is in accordance with the findings of Sonies (1907) in *Gallus* and *Anas* and of De Beer and Barrington (1934) in *Anas*.

The chorda traverses the basal plate and lower part of the acrochordal cartilage and is situated centrally in the basal plate for most of its length. Anteriorly, in the region of the anterior part of the future fenestra basicranialis, the chorda decreases in diameter and is situated nearer to the cerebral surface (Fig. 2A). The tip of the chorda is flexed downwards, but the flexure is not nearly as pronounced as described and figured by Lang (1955) for a young embryo of *Gallus*; in one 5-day-old embryo there is no trace of a flexure at all (Fig. 2A). Thus, there seems to be considerable variation in the degree of flexure of the tip of the chorda in *Gallus*, and it does not yet pierce the anterior surface of the acrochordal cartilage as it does in later stages (Fig. 2B).

Laterally, the acrochordal cartilage passes over into the procartilaginous pila antotica, the boundary being indicated by the foramen for the oculomotor nerve (Fig. 3). The pila antotica is continuous with the posterior part of the orbital cartilage, which will be described in Sect. 3.1.2.

Sonies (1907) claimed separate anlagen for the pila antotica (his lamina antotica) and posterior part of the orbital cartilage in *Gallus*. In the present study, as in all other birds investigated, the pila antotica and posterior part of the orbital cartilage are shown to develop in continuity.

The incisura prootica is bordered posteriorly by the anlage of the otic capsule, medially by the lateral edge of the basal plate and anteriorly by the anlage of the posterior part of the orbital cartilage and the posteroventral edge of the pila antotica. The gasserian ganglion is situated in the incisura prootica and all the branches of the trigeminal nerve leave the cranial cavity through this incisura. The abducent nerve is enclosed by the cartilage of the basal plate (Fig. 3).

The otic capsule consists of two separate cup-shaped procartilaginous structures, with their concavities facing each other and enclosing the anlage of the membranous labyrinth of the otic vesicle in which cochlear and vestibular regions can already be identified (Fig. 3). The medially situated cochlear portion is fused to the lateral surface of the basal plate. Ventrally and posteriorly the cochlear portion is joined to the laterally situated procartilaginous canalicular portion by a mesenchymatous floor and hind wall, leaving a large vacuity, the cochleocanalicular fissure through which the endolymphatic duct from the otic vesicle leaves, and the branches of the acoustic nerve enter the otic capsule dorsally. Anteriorly the cochleocanalicular fissure is continuous with the incisura prootica. The facial nerve leaves the cranial cavity through the anterior part of the cochleocanalicular fissure. A similar course for the facial nerve has been described in early stages of *Struthio* (Brock 1937; Frank 1954), *Spheniscus* (Crompton 1953), and *Euplectes* (Engelbrecht 1958).

The cartilaginous basal plate extends backwards between the otic capsules and narrows to pass over into the vertebral column. Although there is continuity of intercellular substance between the basal plate and vertebral column at this stage, the position of the future craniovertebral joint can be identified. In the anterior end of the basal plate the chorda is situated closer to the cerebral surface, but a fenestra basicranialis posterior has not yet formed. Posterior

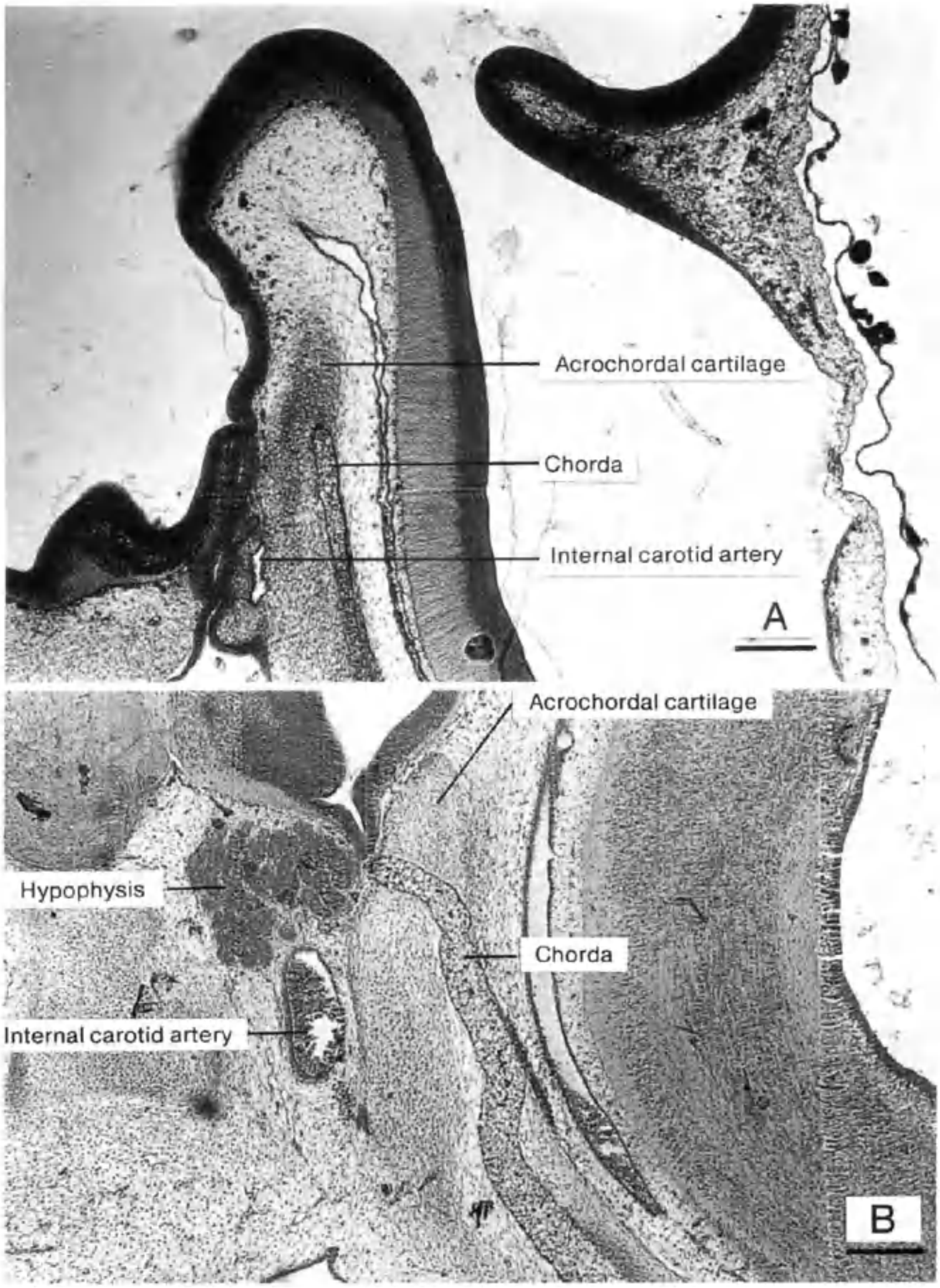

**Fig. 2 A, B.** Photomicrographs of sagittal sections through the acrochordal cartilage and basal plate. **A** Stage I, **B** Stage III. *Scale bar*, 210 µm

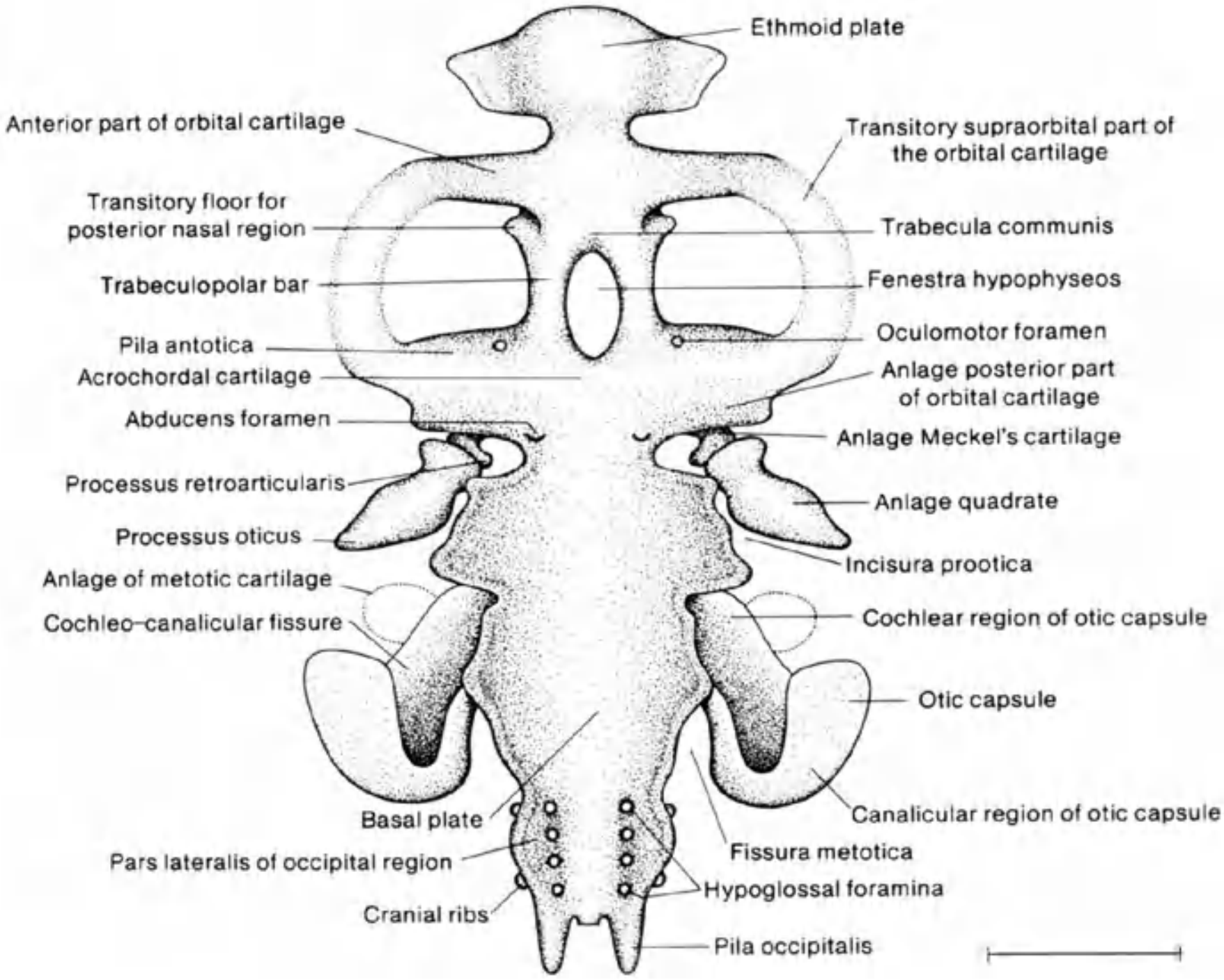

**Fig. 3.** Stage I. Reconstruction of chondrocranium (norma dorsalis). *Scale bar*, 1 mm

to the fusion of the otic capsule to the lateral surface of the basal plate a large fissura metotica is formed, bordered anteriorly by the mesenchymatous hind wall of the otic capsule, medially by the lateral edge of the basal plate and laterally by the canalicular portion of the otic capsule (Fig. 3). The glossopharyngeal and vagal accessory nerves leave the cranial cavity through this fissure.

The occipital region of the basal plate is pierced on each side by four foramina for the hypoglossal nerve. These foramina indicate the border between the pars basalis and the pars lateralis of the basal plate. The hypoglossal foramina decrease in diameter from back to front. Posteriorly, the occipital region bears a dorsally directed pila occipitalis.

Four cranial ribs, increasing in size posteriorly, are present on each side in the form of mesenchymatous transverse ridges lying between the occipital myomeres and attached to the ventral surface of the pars lateralis of the occipital region of the basal plate (Fig. 4).

The anlage of the metotic cartilage is situated ventral to the floor of the anterior part of the canalicular portion of the otic capsule as a separate condensation of mesenchyme with an indistinct outline (Fig. 1). The centre of the anlage contains faint traces of intercellular deposit.

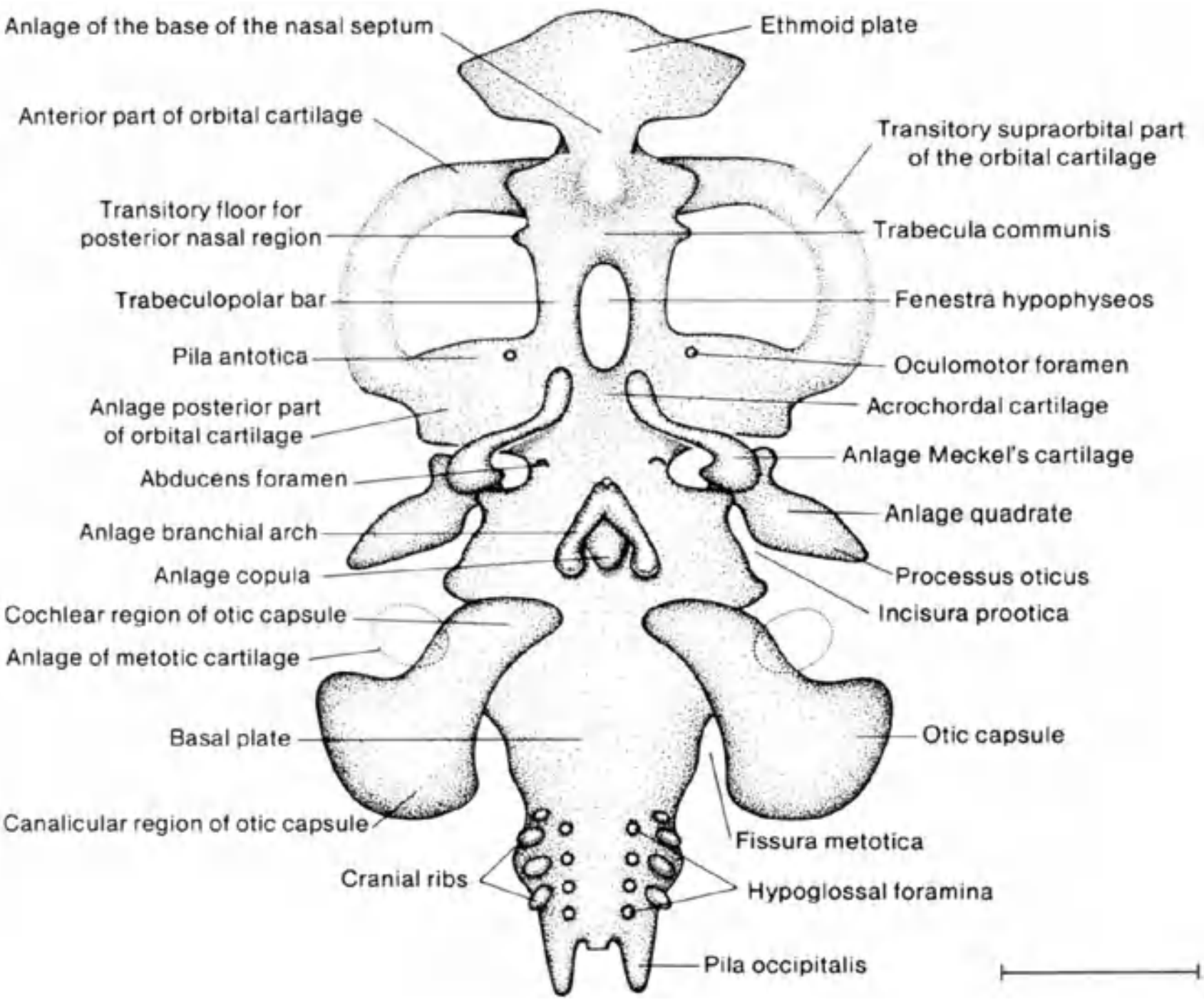

**Fig. 4.** Stage I. Reconstruction of chondrocranium (norma ventralis). *Scale bar*, 1 mm

### *3.1.2 The Anterior End of the Chondrocranium*

The paired nature of the cartilaginous trabeculopolar bars is only evident in the posterior region. A short distance anterior to the optic nerve the trabecular components of the bar are continued anteriorly as a single procartilaginous trabecula communis (Fig. 3). Posteriorly, the polar component, the polar cartilage, as well as the suprapolar cartilage (fused to the dorsal surface of the polar cartilage) can be distinguished from the trabecula because of denser intercellular substance. The posterior surfaces of the polar and suprapolar cartilages are fused to the anterior surfaces of the acrochordal and pila antotica respectively.

A foramen for the ophthalmic artery is formed between the polar and suprapolar cartilages. A large fenestra hypophyseos bordered posteriorly by the acrochordal, posterolaterally by the polar cartilages, and anterolaterally by the trabeculae stretches anteriorly to a point just anterior to the optic nerves where the trabecula communis forms the anterior border (Fig. 3).

As in later stages, the posterior end of the planum antorbitale, which forms the posterior wall of the nasal capsule, is situated immediately anterior to the attachment of the inferior oblique eye muscle to the nasal septum. This point indicates the orbitonasal boundary (Fig. 5).

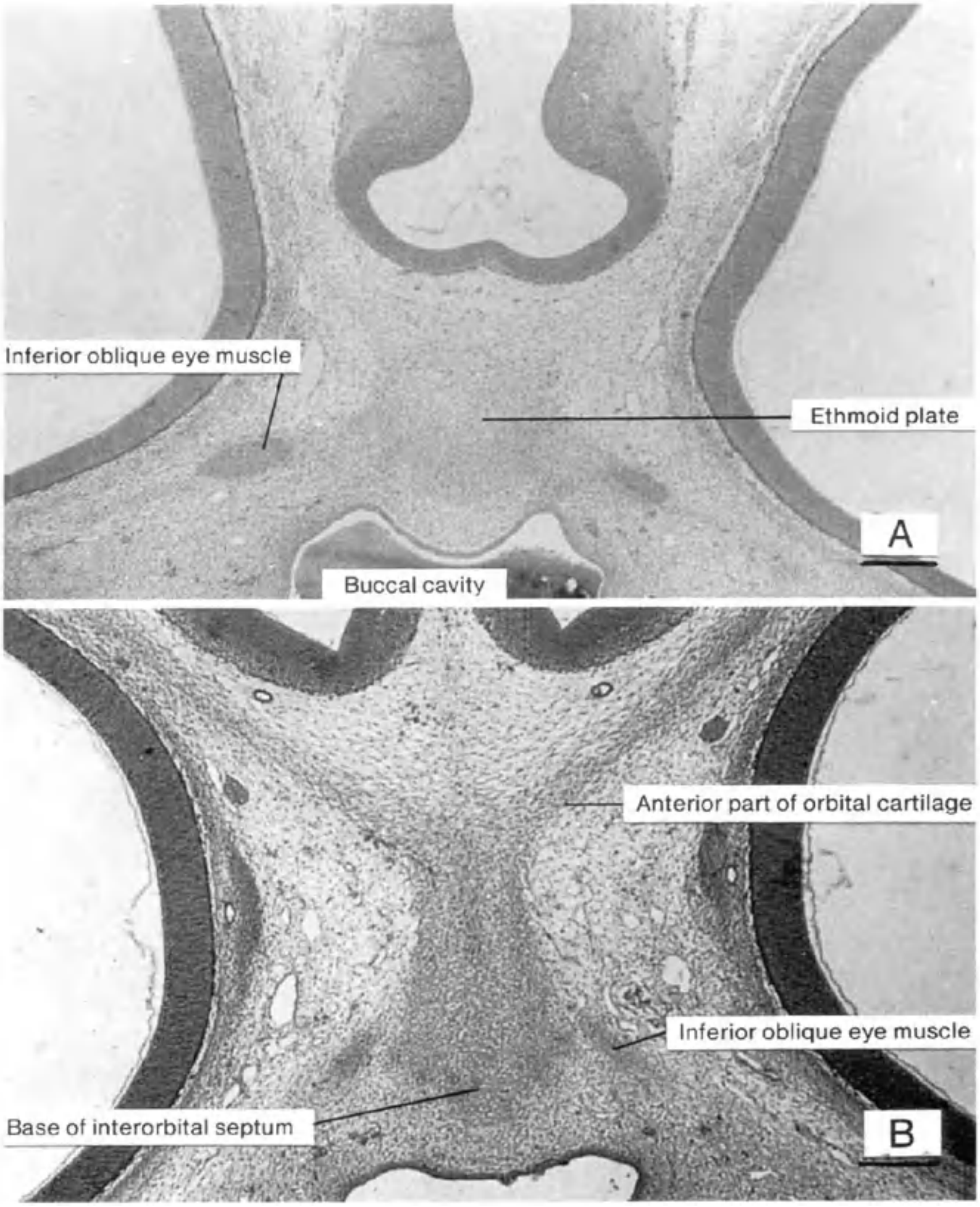

**Fig. 5 A–C.** Photomicrographs of transverse sections through the orbitonasal boundary. **A** Stage I, **B** Stage II, **C** Stage III. *Scale bars*, 210 µm (**C** see page 11)

The part of the trabecula communis in front of the attachment is the base of the future nasal septum. The ventrolaterally directed plate at this stage forms an extensive and transitory floor for the posterior nasal region into which the nasal sacs have not yet extended (Fig. 6A).

Posterior to the point of attachment of the inferior oblique eye muscle which indicates the orbitonasal boundary, the ventrolaterally directed plate diminishes rapidly to a ridge on the lateral surface of the trabecula communis in the orbital region.

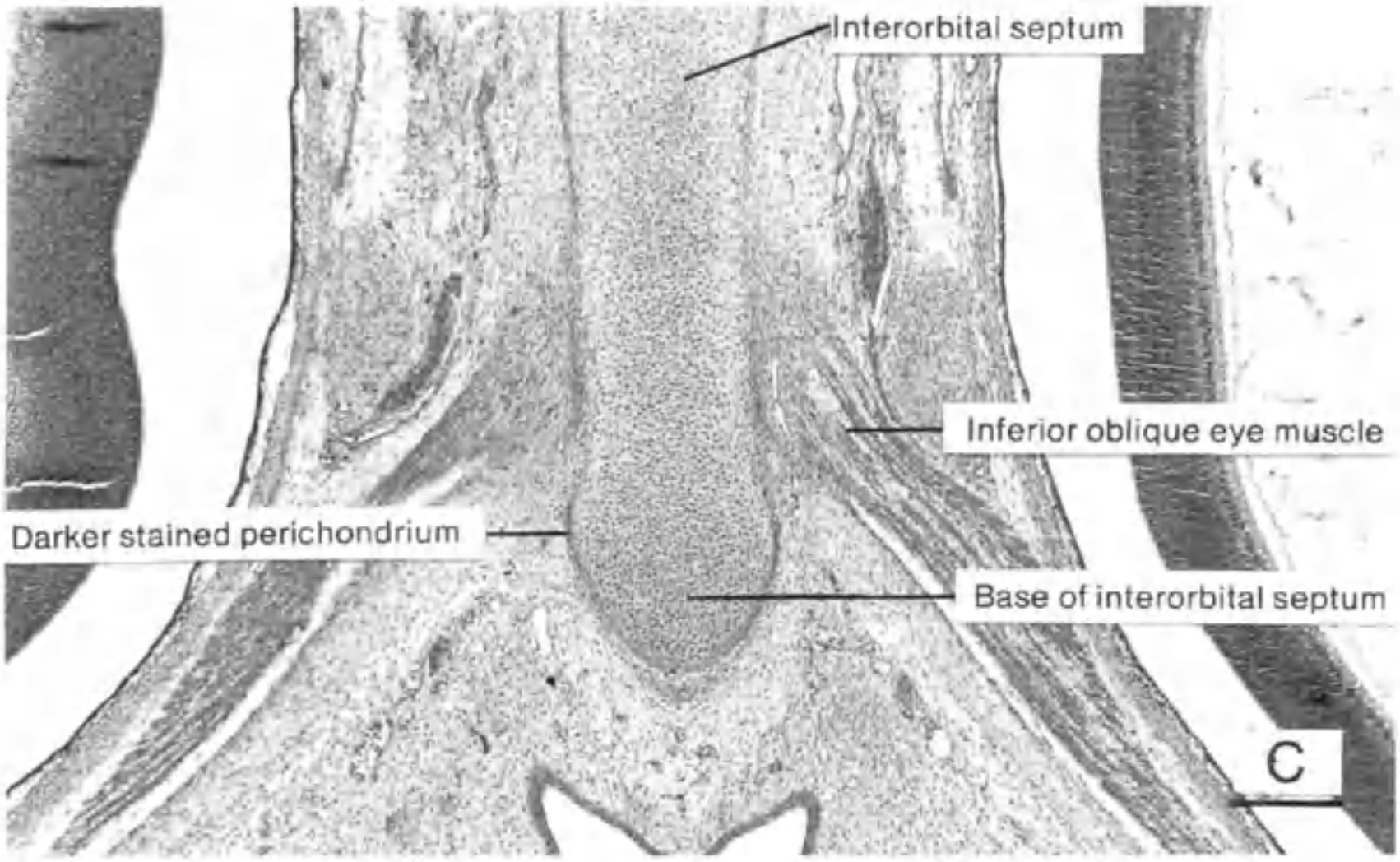

**Fig. 5C**

Anterior to the attachment of the inferior oblique eye muscles the dorsolateral edges of the trabecula communis extend dorsolaterally beneath the anterior section of the brain as the anterior parts of the orbital cartilage. The latter is continued above the eye as a procartilaginous supraorbital part which in turn passes over into the postorbital part. The lateral boundary of the orbital cartilage is indistinct as it gradually passes over into mesenchyme (Fig. 1).

A short distance anterior to the ventrolaterally directed plate in the posterior nasal region is the ethmoid plate. This lies above the posterior region of the developing nasal sacs as a mesenchymatous plate with upturned lateral edges (Fig. 7A). The tip of the trabecula communis, the base of the future nasal septum, is in the form of a wedge-shaped ridge along the ventral surface of the ethmoid plate (Fig. 7A). At this stage the short olfactory nerves pass ventrolaterally in front of the ethmoid plate on their way to the nasal sacs.

### *3.1.3 The Visceral Arches*

The procartilaginous mandibular arch is situated in front of the hyoidean visceral cleft and is divisible into Meckel's cartilage ventrally and a quadrate dorsally. The latter bears an anteromedially directed processus orbitalis (Fig. 1).

The anlage of Meckel's cartilage bears a short processus retroarticularis and in front of the future articular region it is sharply flexed medially. The anterior portions of Meckel's cartilages, however, are situated parallel to one another (Fig. 4).

In the hyoid arch the anlage of the columella auris consists of two separate but poorly defined condensations of mesenchyme, situated ventral to the anlage

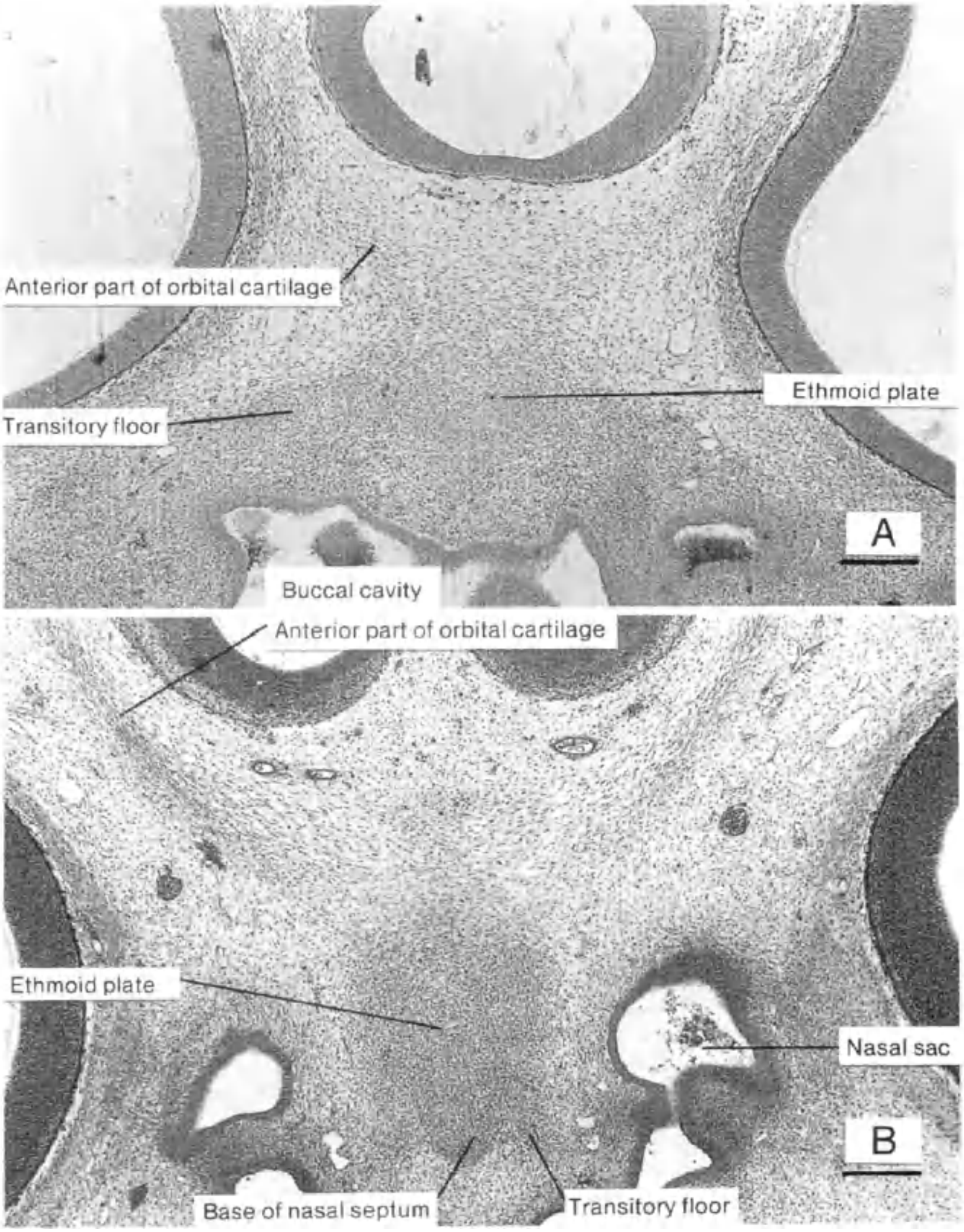

**Fig. 6A–C.** Photomicrographs of transverse sections through the posterior region of the nasal capsule. **A** Stage I. The nasal sacs have not yet extended into this area; *Scale bar*, 180 µm. **B** Stage II; *scale bar*, 200 µm. **C** Stage III; *scale bar*, 200 µm (**C** see page 13)

of the otic capsule. The dorsal anlage will give rise to the stapes and extracolumellar parts and the ventral anlage to the processus infracolumellaris.

The anlage of the copulae is situated in the elevation of the floor of the buccal cavity as a single condensation of mesenchyme. Ventrolaterally on either side of the mesenchymatous anlage of the copulae the mesenchymatous anlage of the first branchial arch passes posteriorly outwards (Fig. 4).

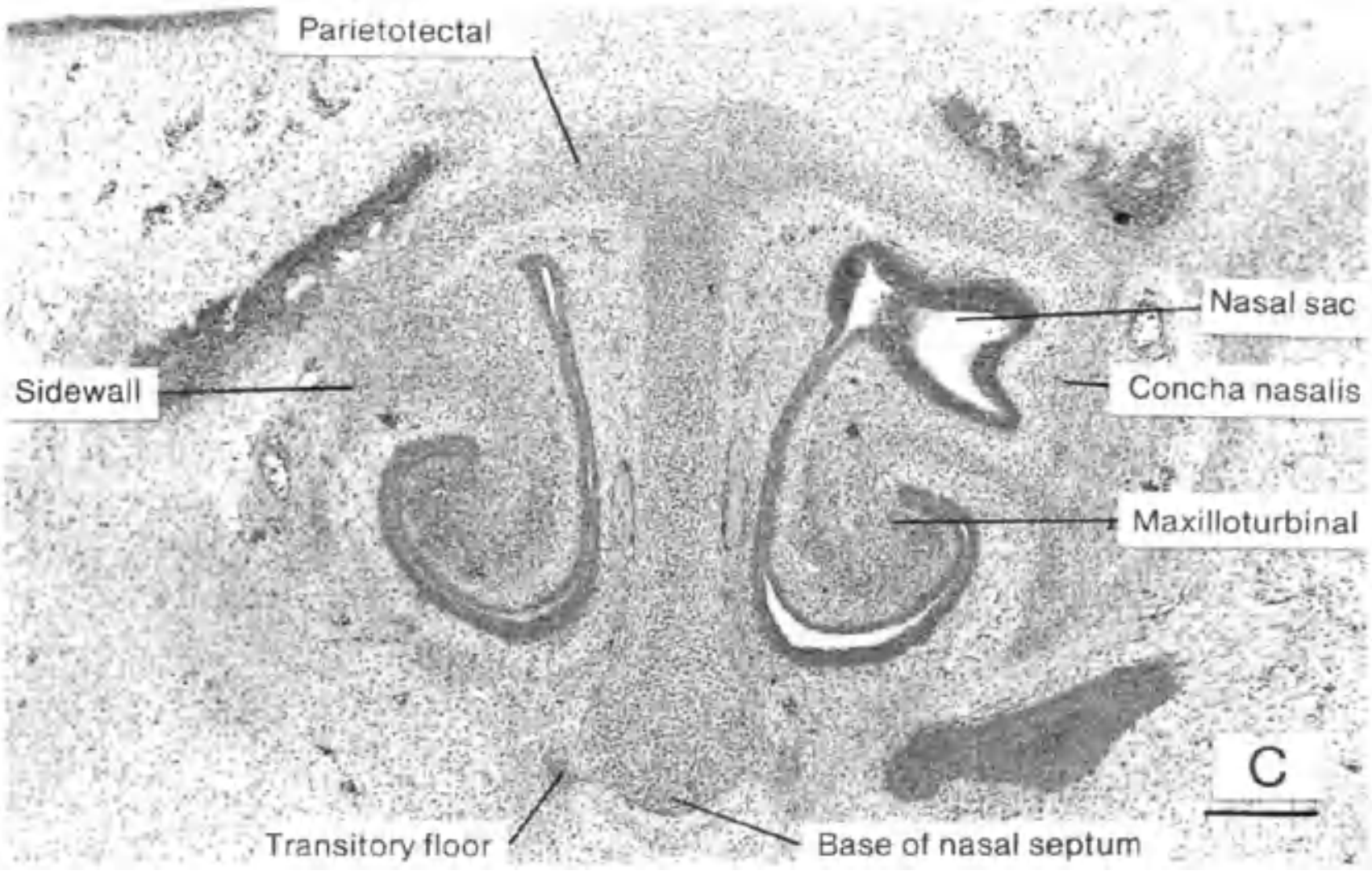

Fig. 6C

## 3.2 Stage II

Total length of embryos: 35 mm and 39 mm (Stage 29 of Hamburger and Hamilton 1951). 6 days' development.

### *3.2.1 The Basal Plate and Otic Capsules*

Chondrification is more advanced in this stage and the basal plate has broadened between the otic capsules (Fig. 8). The S-shaped form of the basal plate and acrochordal cartilage is more pronounced than in the previous stage.

The acrochordal cartilage is rich in intercellular deposit while the pila antotica shows a lesser degree of chondrification, especially towards its lateral side which passes over into the posterior part of the orbital cartilage.

The expansion of the posterior part of the orbital cartilage anterolaterally has enclosed the trochlear nerve in a long horizontal canal. A similar canal for the trochlear nerve has been described by Crompton (1953) in *Spheniscus*, Frank (1954) in *Struthio*, Engelbrecht (1958) in *Euplectes*, and Toerien (1971) in *Podiceps*.

No anlage of a pila antotica spuria could be detected at the posteroventral side of the posterior part of the orbital cartilage. The latter does however extend further backwards and thus reduces the size of the incisura prootica.

The tip of the chorda is more flexed, but is still embedded in the acrochordal, while the anterior part of the chorda is situated closer to the cerebral surface than in the previous stage.

The two portions of the otic capsule are still distinguishable as the canalicular portion still consists mainly of mesenchyme and procartilage, while the cochlear

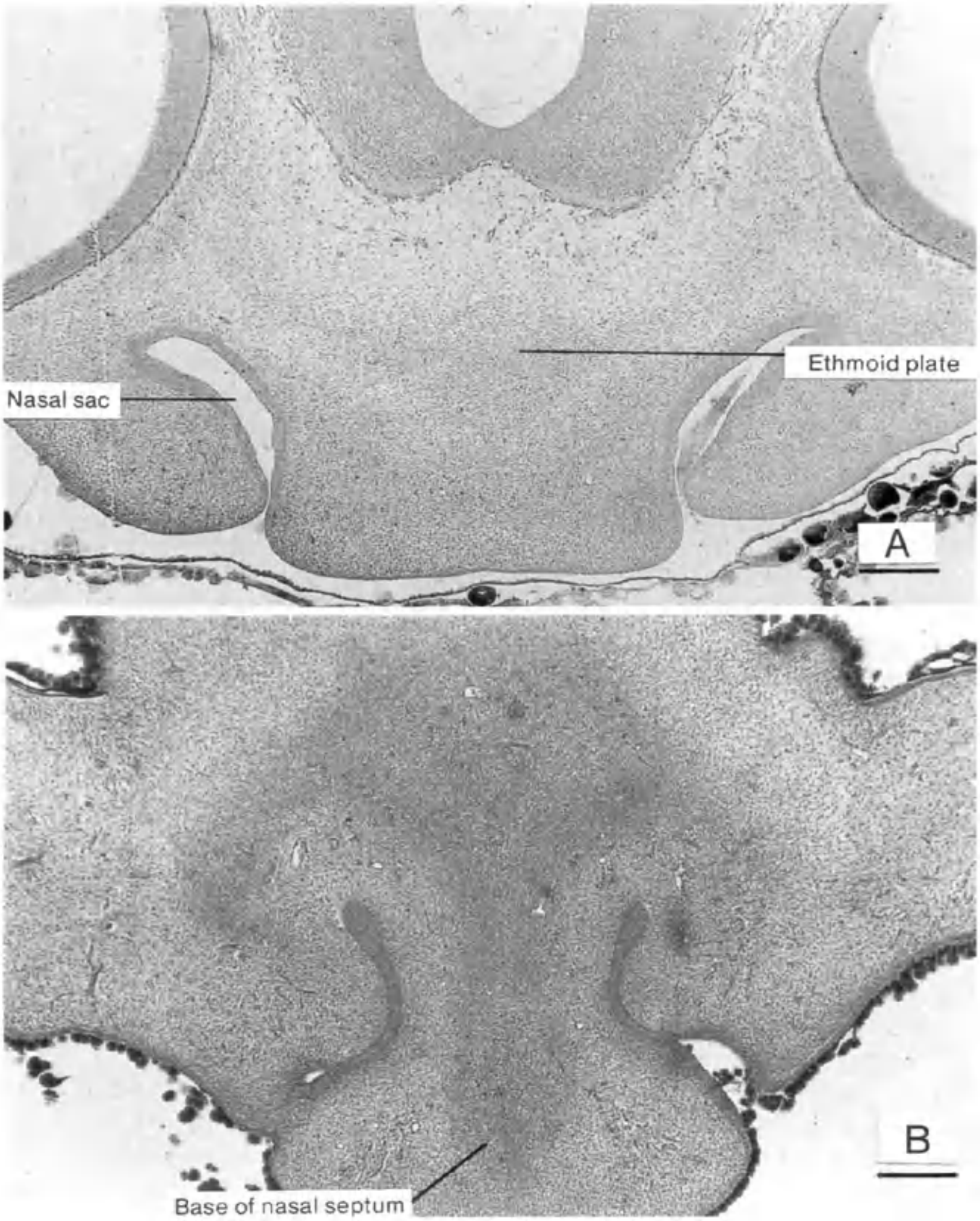

**Fig. 7 A–C.** Photomicrographs of transverse sections through the anterior region of the nasal capsule. **A** Stage I, **B** Stage II, **C** Stage II. *Scale bars*, 200 μm (**C** see page 15)

portion has chondrified to a large extent. Chondrification of the floor, hind wall, and roof of the cochlear portion has diminished the cochleocanalicular fissure. Anteriorly, the fissure is still open and in continuation with the posterior part of the incisura prootica.

Broadening of the basal plate behind the attachment of the cochlear portion of the otic capsule has encroached on the fissura metotica anteriorly and thus broadened the attachment between the basal plate and the cochlear portion.

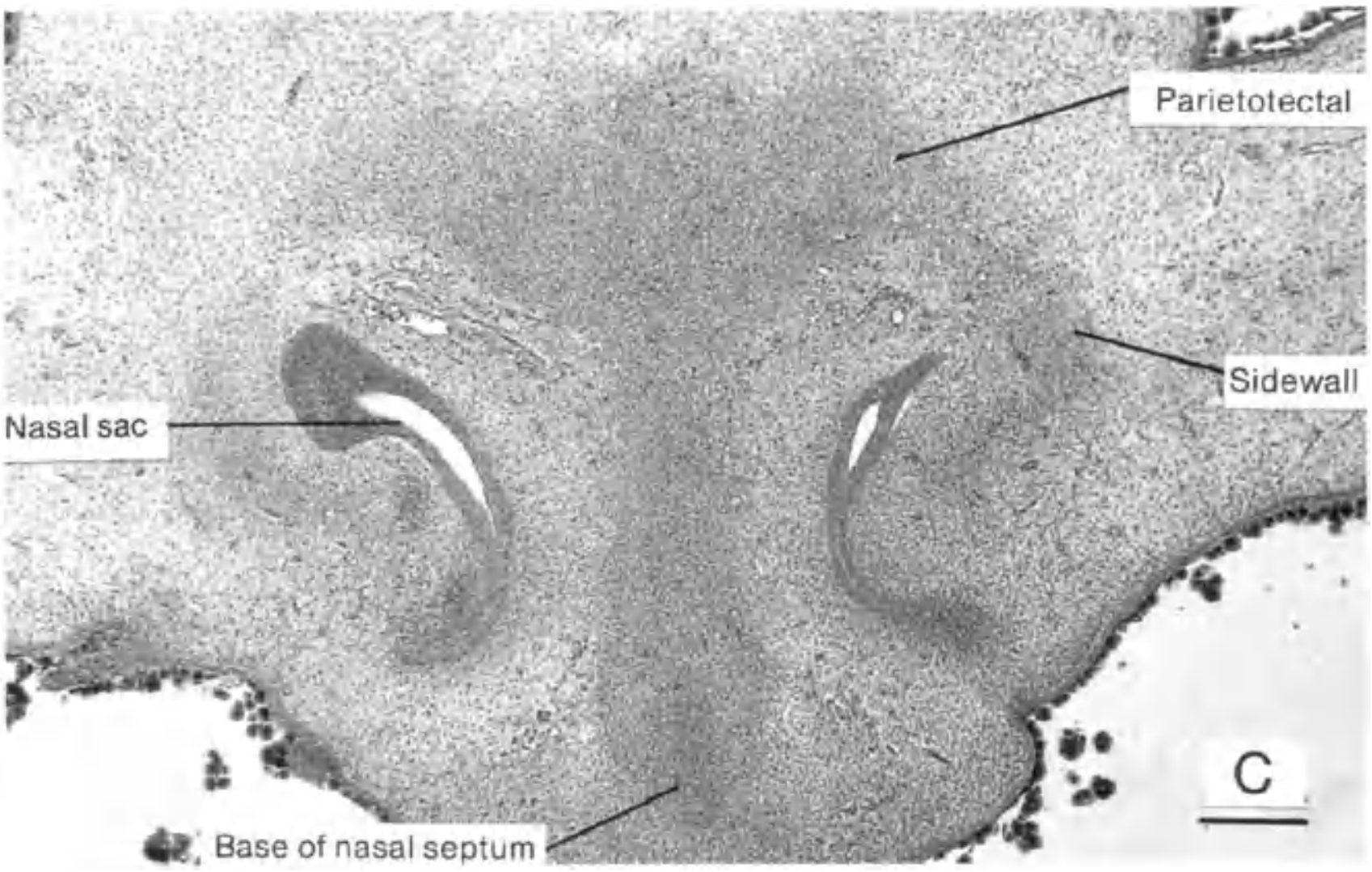

Fig. 7C

Behind this attachment the glossopharyngeal and vagal accessory nerves leave the cranial cavity through the fissura metotica.

In the membranous labyrinth the superior and posterior semicircular canals have differentiated and the cochlear region and endolymphatic duct increased in length.

Intercellular substance in the anlage of the metotic cartilage has increased so that it is now procartilaginous, but is still separated from the otic capsule.

In the occipital region the basal plate has broadened and the pila occipitalis increased in height. Three hypoglossal foramina are present on one side and four on the other (Fig. 9). The cranial ribs are still faintly recognisable.

In the developing craniovertebral joint intercellular continuity is still present between the basal plate and vertebral column.

### *3.2.2 The Anterior End of the Chondrocranium*

All the elements of the chondrocranium immediately in front of the acrochordal cartilage and pila antotica are well chondrified, but it is still possible to distinguish histologically between the suprapolar and polar cartilages and the trabeculae.

The polar cartilage has developed a short posteroventrally directed infrapolar process on its ventral side. An incisura, the incisura carotica, is thus formed, bordered anteriorly by the infrapolar process, dorsally by the polar cartilage and its fusion with the pila antotica, and posteriorly by the basal plate. The internal carotid artery traverses the incisura carotica in a medial direction and passes anterodorsally and medial to the polar cartilage to anastomose behind Rathke's pouch with its partner from the opposite side (Fig. 2B).

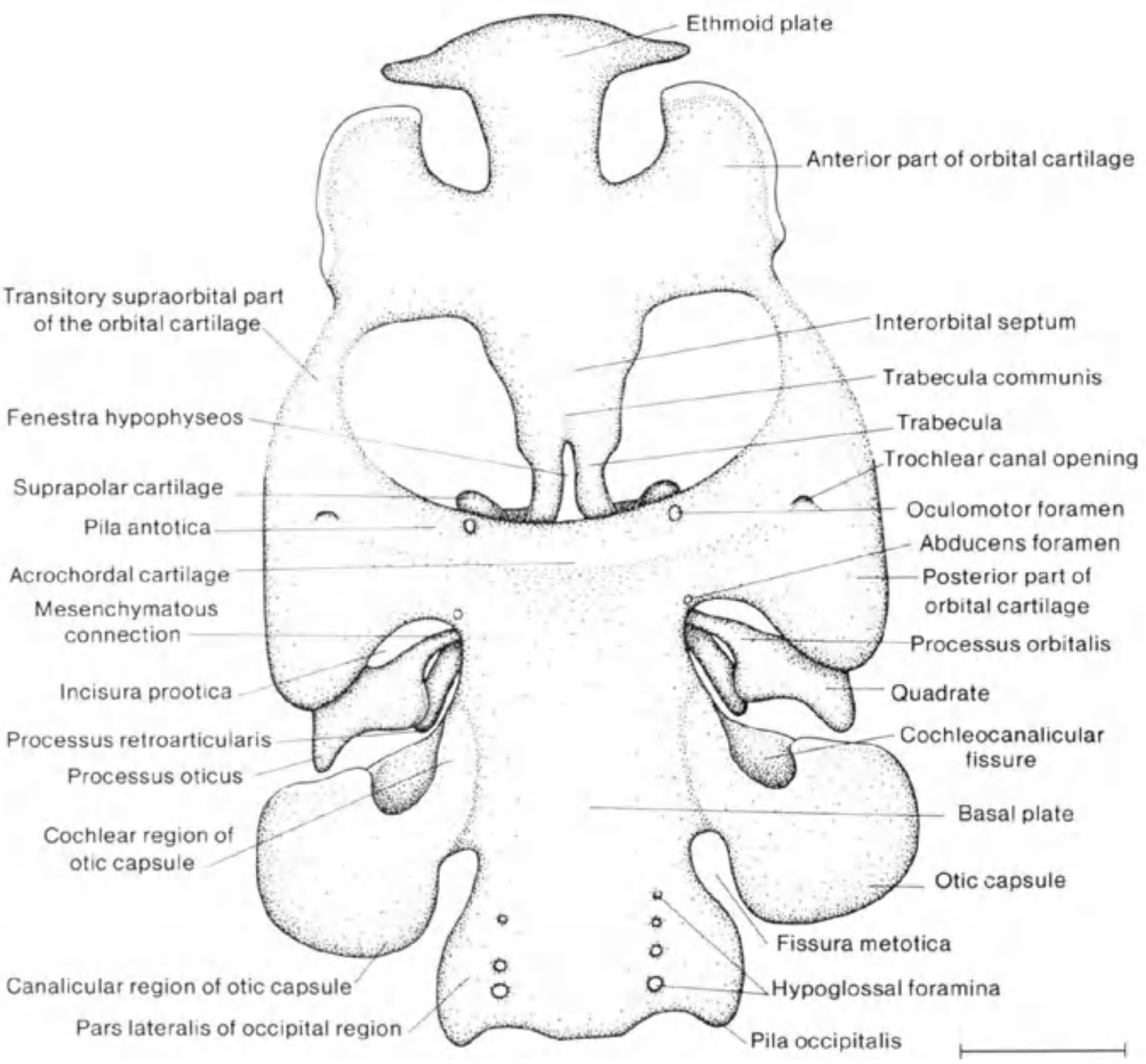

**Fig. 8.** Stage II. Reconstruction of chondrocranium (norma dorsalis). *Scale bar*, 1 mm

The fenestra hypophyseos has diminished in diameter and narrowed anteriorly through the expansion of the surrounding elements (Fig. 8).

Considerable elongation of the trabecular region has taken place so that its anterior tip projects beyond the orbital cartilage (compare Figs. 1 and 10).

The deposition of more intercellular substance in the region of the trabecula communis anterior to the fenestra hypophyseos has resulted in the separate trabeculae of the hypophyseal region now being continued anteriorly as two rods into the previously unpaired procartilaginous trabecula communis (Fig. 11).

In cross section in this region, the still procartilaginous trabecula communis appears wedged between the trabeculae and gives the impression of being a separate structure. This has been interpreted as an intertrabecula by some authors (Figs. 5B, 6B).

Bellairs (1958), who regards the intervening material in *Gallus* in this region as an intertrabecula, describes the trabeculae in the anterior region as wide apart and increasing in size instead of tapering anteriorly.

Anterior to the fenestra hypophyseos an interorbital septum has been formed by a procartilaginous upgrowth of the dorsal edge of the trabecula communis which forms the base of the interorbital septum. This increases in height ante-

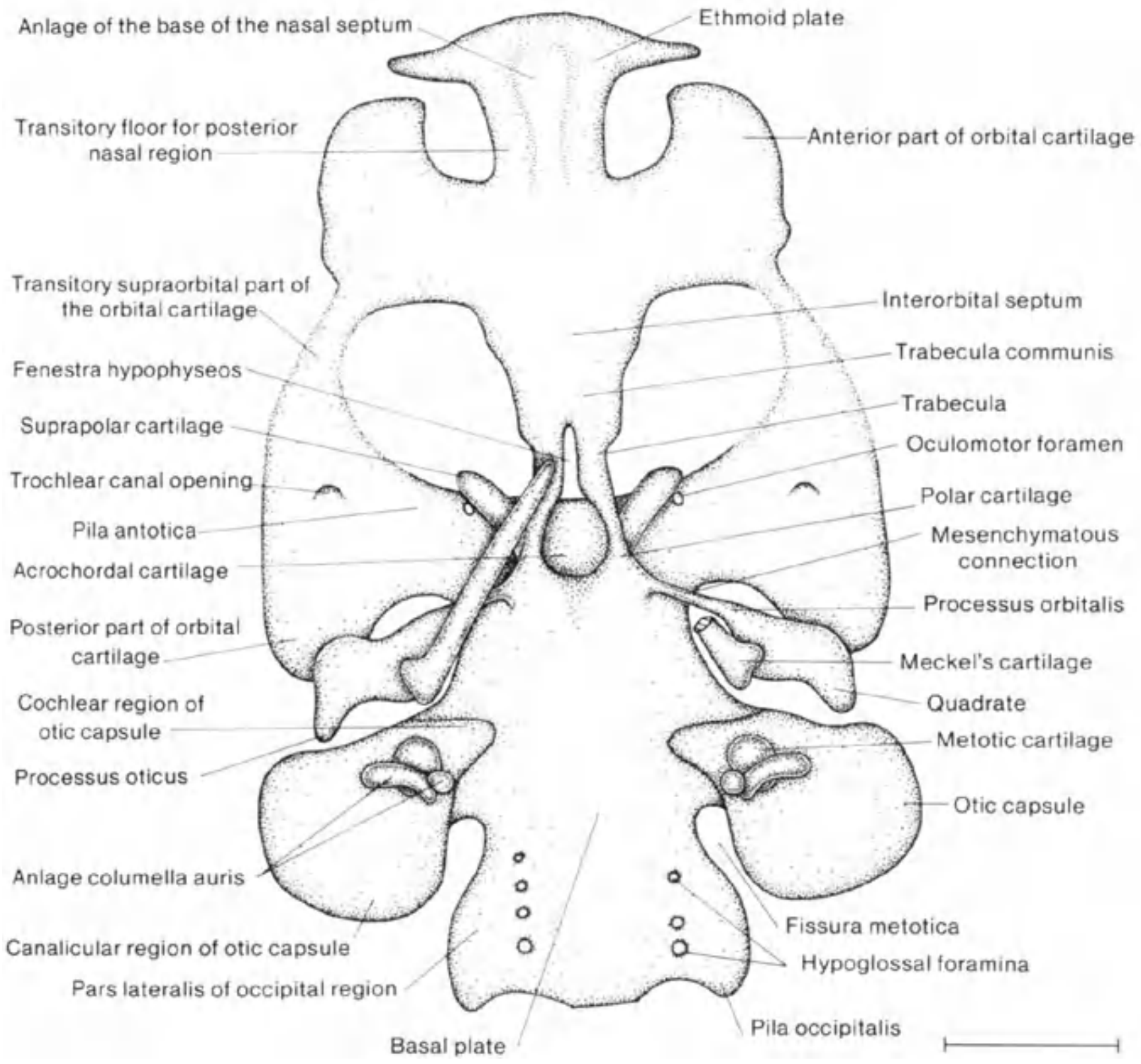

**Fig. 9.** Stage II. Reconstruction of chondrocranium (norma ventralis). *Scale bar*, 1 mm

riorly and bears a ridge along its dorsolateral edge which passes over into the anterior part of the orbital cartilage (Fig. 11 C).

More intercellular substance has been deposited in the anterior part of the orbital cartilage, but the procartilaginous supraorbital part connecting it to the posterior part of the orbital cartilage of the previous stage is now reduced to a thin band of tissue without any trace of intercellular deposit (Fig. 8). This too will shortly disappear. Bellairs (1958) described a similar transitory band of condensed tissue in a 6-day stage of *Gallus*.

Anterior to the attachment of the dorsal edge of the orbital septum to the anterior part of the orbital cartilage, the orbital septum passes over into a definite procartilaginous nasal septum that has developed from the wedge-shaped ridge on the ventral surface of the ethmoid plate (Fig. 5 A). The ridge, the trabecula communis, forms the base of the nasal septum. Growth above the base has resulted in the mesenchymatous ethmoid plate being carried upwards and changed in shape. The dorsal surface that was concave in the previous stage is now convex (Fig. 7 B).

Above the anterior region of the nasal sacs, intercellular deposit in the ethmoid plate has resulted in a procartilaginous roof for the nasal capsule. Lateral-

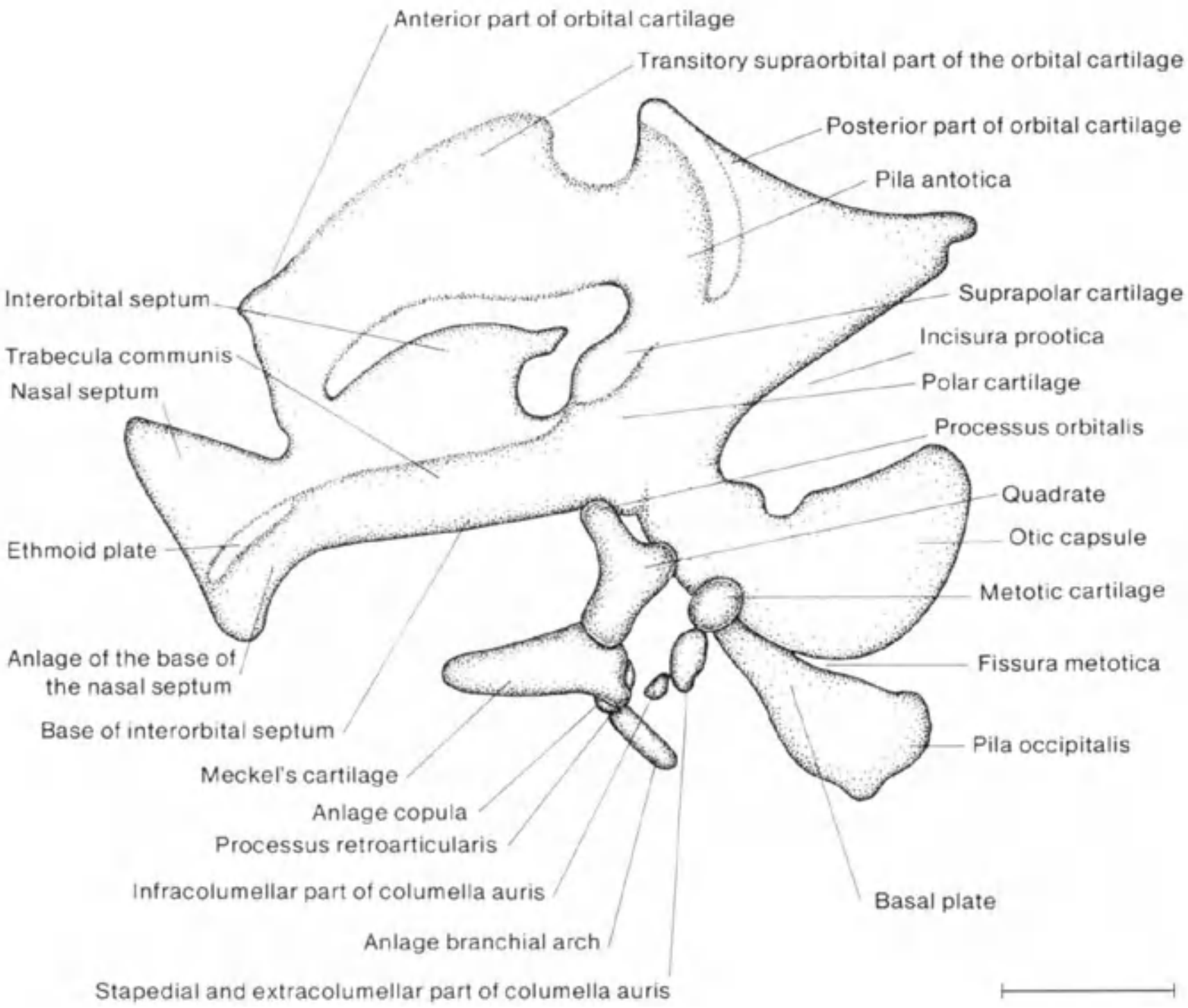

**Fig. 10.** Stage II. Reconstruction of chondrocranium (norma lateralis). *Scale bar*, 1 mm

ly, the roof passes over into mesenchymatous sidewalls. Above the posterior region of the nasal sacs the roof narrows to a strip along the dorsal edge of the nasal septum. A sidewall for this region is formed, however, by the dorsolateral corner of the procartilaginous roof above the anterior region of the nasal sac being continued posteroventrally as a crescent-shaped mesenchymatous plate with a concavity facing inwards (Fig. 7B, C).

The conspicuous procartilaginous floor of the posterior nasal region has been reduced to a procartilaginous ridge on either side of the base of the posterior part of the nasal septum, which projects as a keel between the ridges (Fig. 6B). Posterior to the attachment of the inferior oblique eye muscle, which takes place with the lateral surface of the septum above the base (Fig. 5B), the keel is absent and the ridges continue for the length of the orbit as the pointed ventrolateral corners of the interorbital septum (Fig. 6C). The amount of intercellular substance in these corners is markedly more than in the rest of the interorbital septum.

The olfactory nerve still passes more or less vertically down to the nasal sacs, but with the elongation of the ethmoid plate the short olfactory nerves now pass ventrolaterally behind the ethmoid plate.

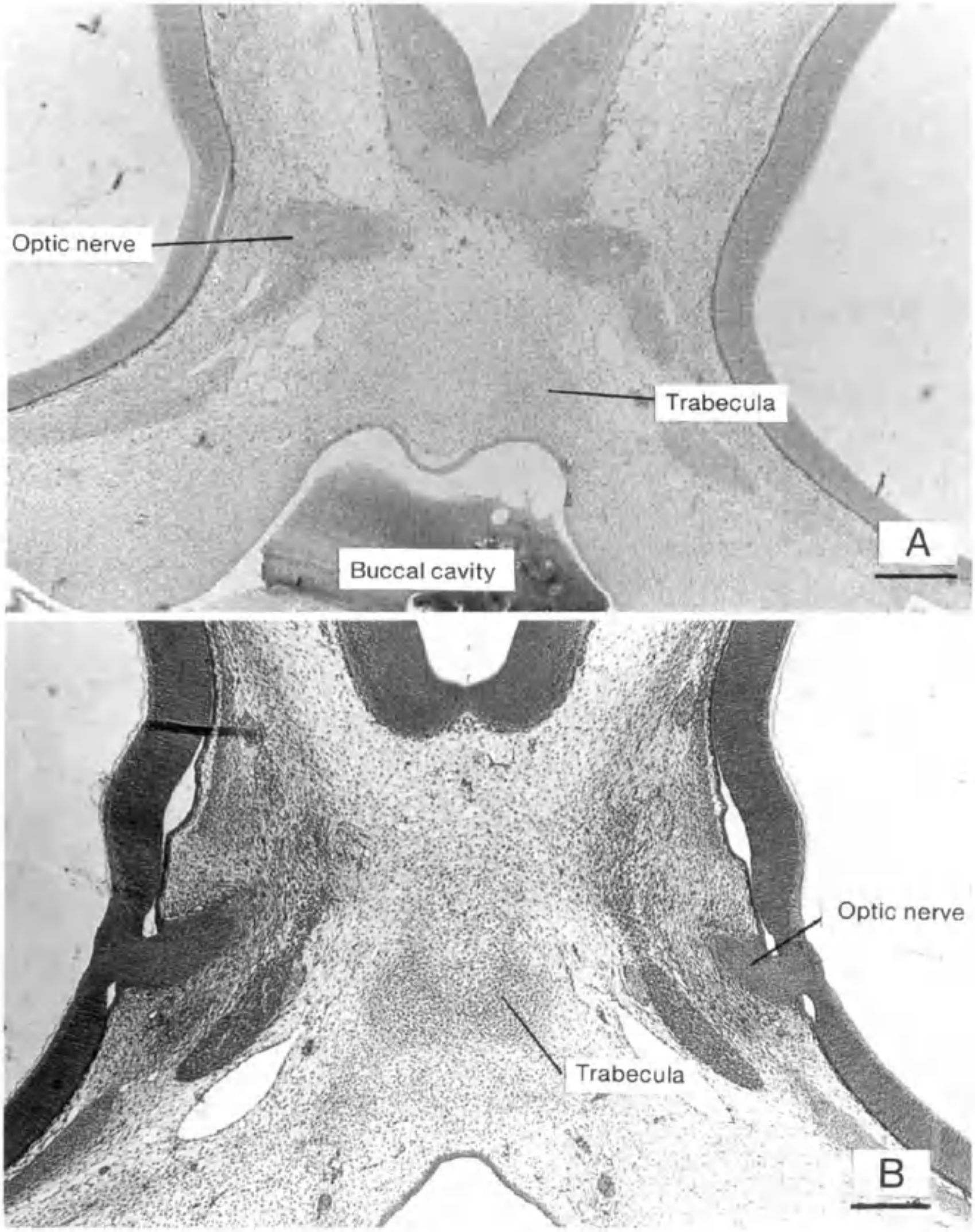

**Fig. 11A–C.** Photomicrographs of transverse sections through the trabeculae just anterior to the fenestra hypophyseos. **A** Stage I, **B** Stage II, **C** Stage II. *Scale bars*, 200 µm (**C** see page 20)

### *3.2.3 The Visceral Arches*

The procartilaginous mandibular arch of the previous stage now consists of young cartilage, but continuity of intercellular substance still exists between Meckel's cartilage and the quadrate in the region of the future articulation (Fig. 10). The processus orbitalis has developed a transitory mesenchymatous

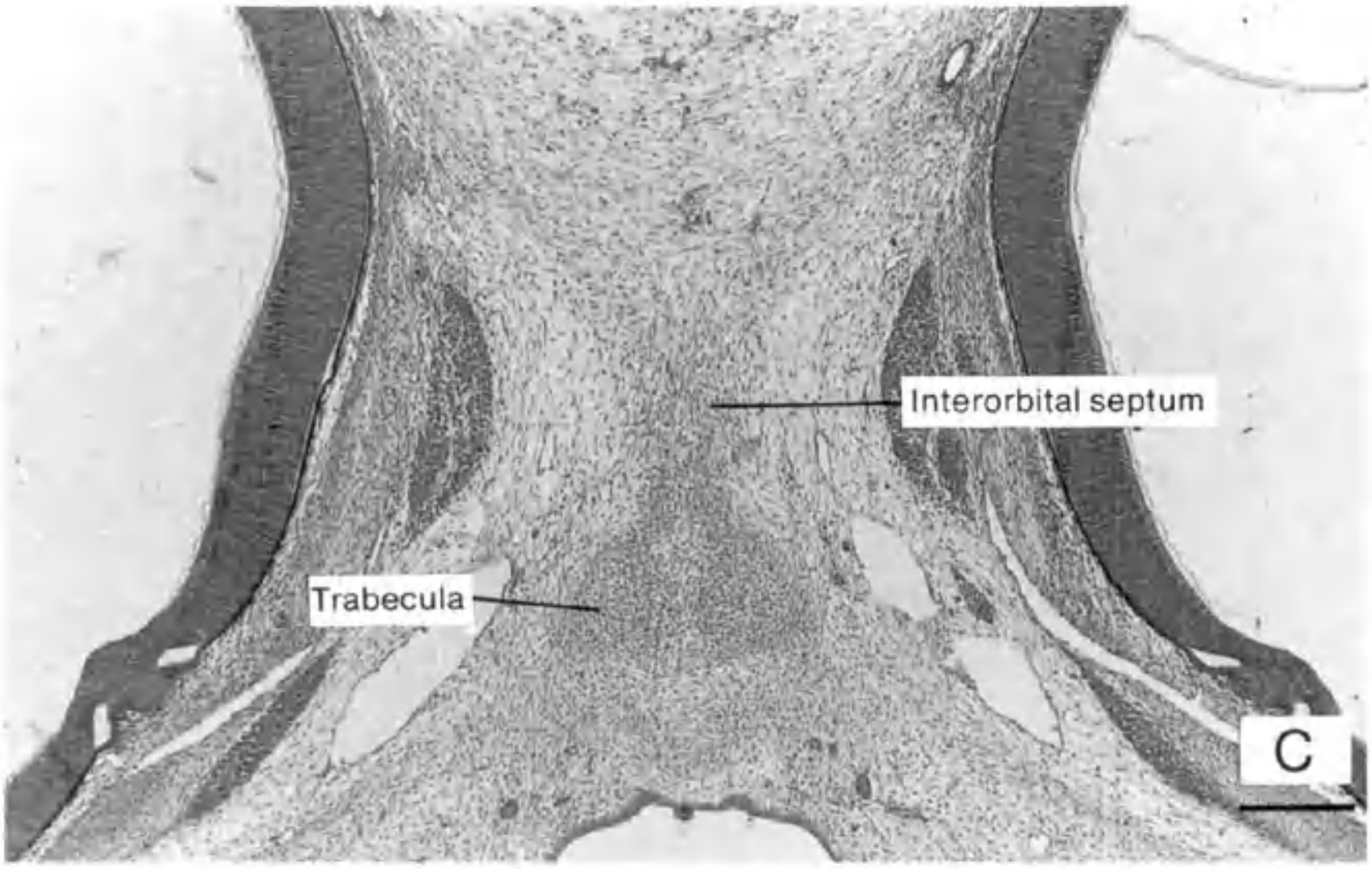

**Fig. 11 C** (Legend see page 19)

connection with the posteroventral corner of the polar cartilage (Fig. 9). De Beer and Barrington (1934) found a procartilaginous connection between the quadrate and polar cartilage in *Anas* and considered it a remnant of the articulation between the neurocranium and the mandibular arch. Similar transitory connections have been described by Filatoff (1906) in *Columba* and by Engelbrecht (1958) in *Euplectes*.

The quadrate has developed a processus oticus at its posterodorsal edge, but it does not yet reach the otic capsule (Fig. 8).

De Beer and Barrington (1934) and Slabý (1951 a) describe two chondrification centres in Meckel's cartilage in *Anas* and *Phalacrocorax* respectively, but in *Gallus* Meckel's cartilage develops as a uniform structure, and has increased in length and straightened (Fig. 9).

The separate mesenchymatous anlagen of the previous stage are now procartilaginous and indistinguishably fused to one another, but the dorsally situated stapedial and extracolumellar part is still separate from the otic capsule (Fig. 10). The infracolumellar part has elongated and its thickened ventral tip contains a cartilaginous core with markedly more intercellular deposit than in the rest of the infracolumellar part.

In a 6-day embryo of 34 mm the anlagen of the columella auris are also procartilaginous, but the dorsally situated stapedial and extracolumellar part is still separated from the otic capsule and from the ventrally situated infracolumellar part.

Copula 1 and 2 have developed as separate procartilaginous bars in the single mesenchymatous copular anlage of the previous stage leaving a mesenchymatous area between them. Copula 1 is larger and bears an anteriorly directed mesenchymatous lingual process.

In the branchial arch the ceratobranchial is now procartilaginous, while the posterior mesenchymatous part represents the future epibranchial. The anterior tip of the ceratobranchial is connected to the mesenchymatous area between the copulae.

## 3.3 Stage III

Total length of embryos: 46 mm and 50 mm (Stage 34 of Hamburger and Hamilton 1951). 8 days' development.

### *3.3.1 The Basal Plate and Otic Capsules*

At the 8th day of development most of the major elements of the chondrocranium have chondrified and dermal ossifications are present. The cranial flexure has lessened and the S-shaped flexure of the basal plate and acrochordal cartilage is less pronounced.

A slitlike fenestra basicranialis posterior has been formed in the anterior region of the basal plate by the resorption of cartilage around the chorda (Fig. 12). Although W.K. Parker (1869) does not state explicitly that the fenestra basicranialis posterior in *Gallus* develops through resorption, it is implied by the description that the formation is caused by the "opening-up and widening of the primordial fissure" in which the chorda lies in the cartilaginous basal plate. This mode of development is in contrast with the findings of Sonies (1907) who states that in *Gallus* a fenestra basicranialis is present from the start.

As in *Euplectes* (Engelbrecht 1958) the fenestra is formed by dorsal and ventral areas of resorption that are not situated directly above each other; the ventral area is situated slightly posterior (Fig. 2B). The anterior part of the fenestra thus appears as a depression on the dorsal surface of the basal plate with only its hindermost portion overlapping the ventral area of resorption (Fig. 12).

In *Gallus*, the two areas of resorption do not develop simultaneously. In Stage II some resorption has already taken place dorsally as the chorda is situated nearer to the cerebral surface than in Stage I, but there is not yet any sign of resorption ventrally. In an intermediate stage (41 mm), resorption in the dorsal area is complete while ventrally a decrease in intercellular deposit indicates the position of the ventral area.

The eventual reduction of the cartilaginous posterior wall of the hypophyseal pit, which seems to be a characteristic of avian chondrocrania, has commenced in the region immediately around the chorda with the result that the tip of the chorda now emerges from the anterior surface of the acrochordal cartilage (Fig. 2B). In the reduction process only the intercellular substance is affected and the chondrocytes persist as connective tissue.

The posterior part of the orbital cartilage now consists of young cartilage and the only indication of a former connection with the supraorbital and anterior parts of the orbital cartilage is a blunt, anteriorly directed postorbital pro-

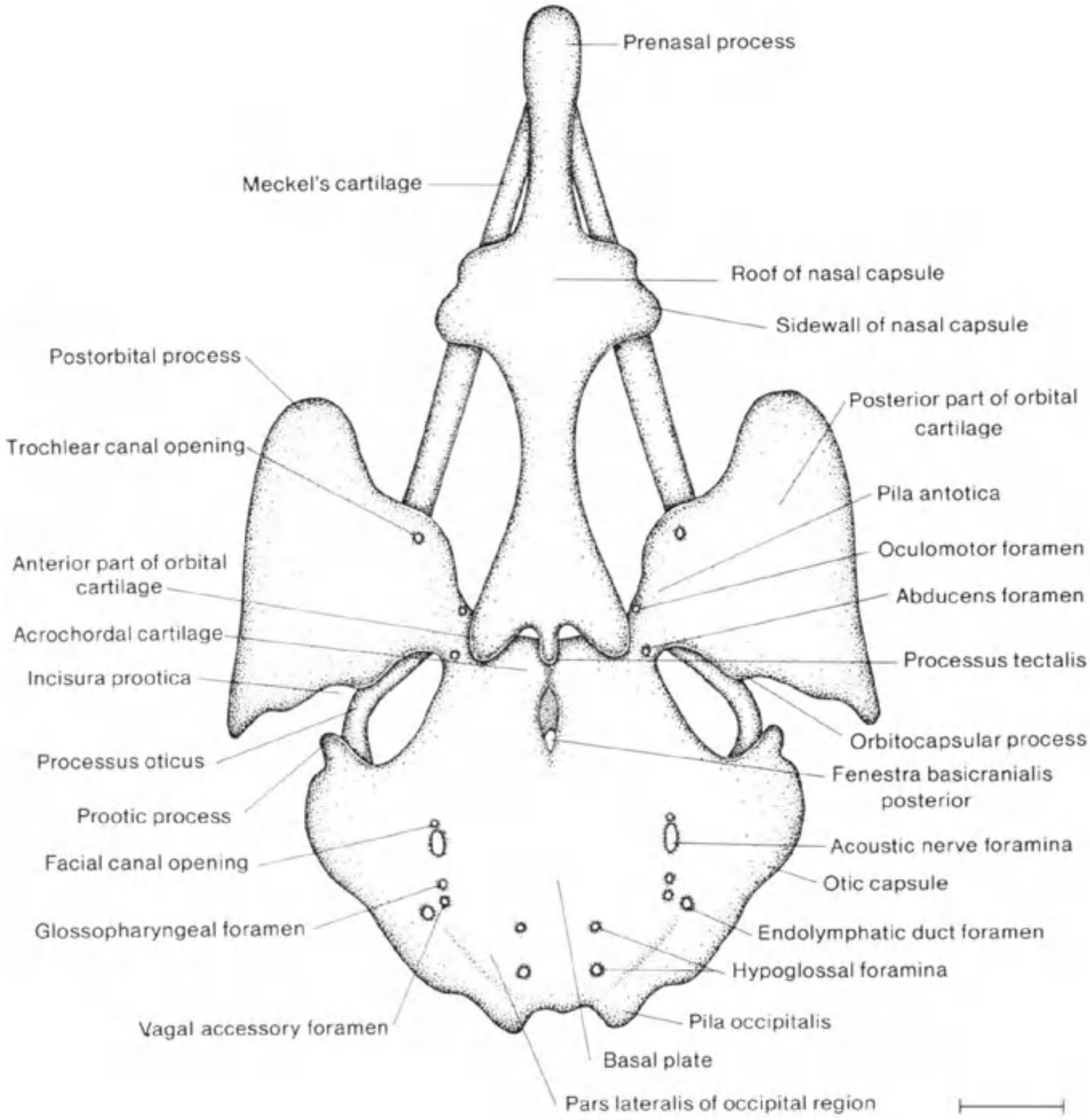

**Fig. 12.** Stage III. Reconstruction of chondrocranium (norma dorsalis). *Scale bar*, 1 mm

cess on its anterolateral corner (Fig. 12). Sonies (1907) describes a processus postorbitalis (his processus lateralis) in a 9-day embryo of *Gallus*.

Lateral to the profundus branch of the trigeminal nerve the pila antotica spuria has started to develop as a posteroventral extension of the ventral edge of the posterior part of the orbital cartilage, while more laterally a posteroventrally directed orbitocapsular process has developed near the posterolateral corner (Fig. 12). As in the majority of forms described, and in agreement with the findings of Sonies (1907) for *Gallus*, an anteriorly directed process, the prootic process of later authors, has developed on the anterior wall of the canalicular portion of the otic capsule (Fig. 13).

Through increase in size of the posterior part of the orbital cartilage and the otic capsules and the development of the pila antotica spuria and prootic process, the incisura prootica is reduced considerably, but all the branches of the trigeminal nerve still leave the cranial cavity through the incisura prootica.

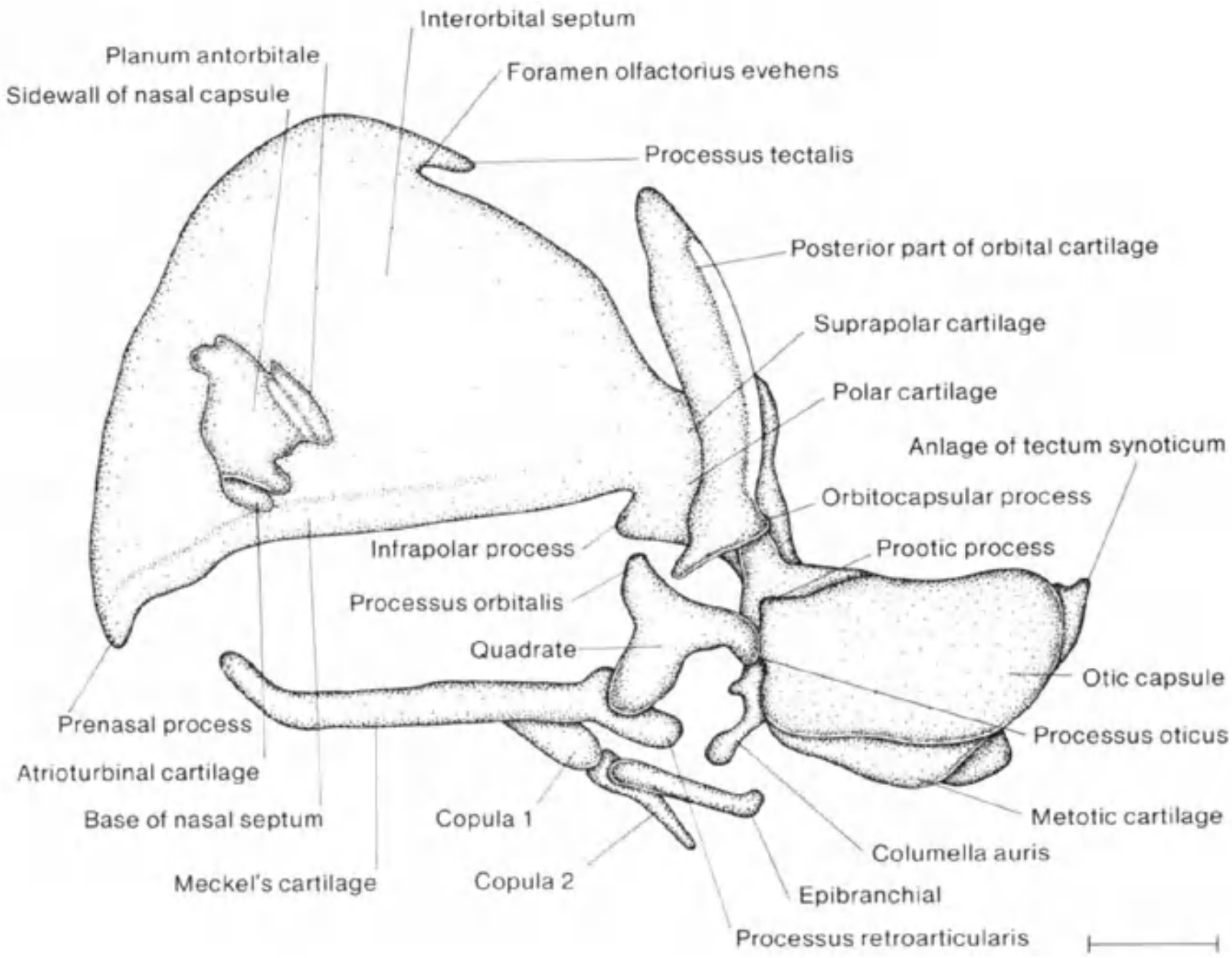

**Fig. 13.** Stage III. Reconstruction of chondrocranium (norma lateralis). *Scale bar*, 1 mm

Compared to the previous stage, the canalicular portion of the otic capsule has rotated posteriorly and now lies posterodorsal to the cochlear portion (Fig. 13).

Fusion of the metotic cartilage to the lateral edge of the pars lateralis has enclosed the vagal accessory nerve in a separate foramen situated between these elements (Fig. 12). The glossopharyngeal nerve still leaves the cranial cavity through the anterior part of the metotic fissure.

In the membranous labyrinth the lateral semicircular canal has now differentiated. Around the membranous labyrinth the first indications of resorption of intercellular substance to provide space for the expanding labyrinth are present (Fig. 14A). Resorption has also started in the wall of the canal for the facial nerve. Chondrification has increased in the cochlear portion of the otic capsule and also started to spread into the canalicular portion resulting in the cochleocanalicular fissure of the previous stage being reduced to foramina.

Anteriorly, the closure of the fissure has resulted in the facial nerve becoming enclosed in a canal in the anterior wall of the otic capsule. The foramen for one branch of the acoustic nerve is situated behind the posterior orifice of this canal while the foramina for the remaining three are situated medially and in front of the foramen for the endolymphatic duct (Fig. 12).

At the anterior end of the fissura metotica a cavity still filled with embryonic tissue, the recessus scalae tympani, is situated between the otic capsule dorsally and the transition of the basal plate into metotic cartilage ventrally. Anterodor-

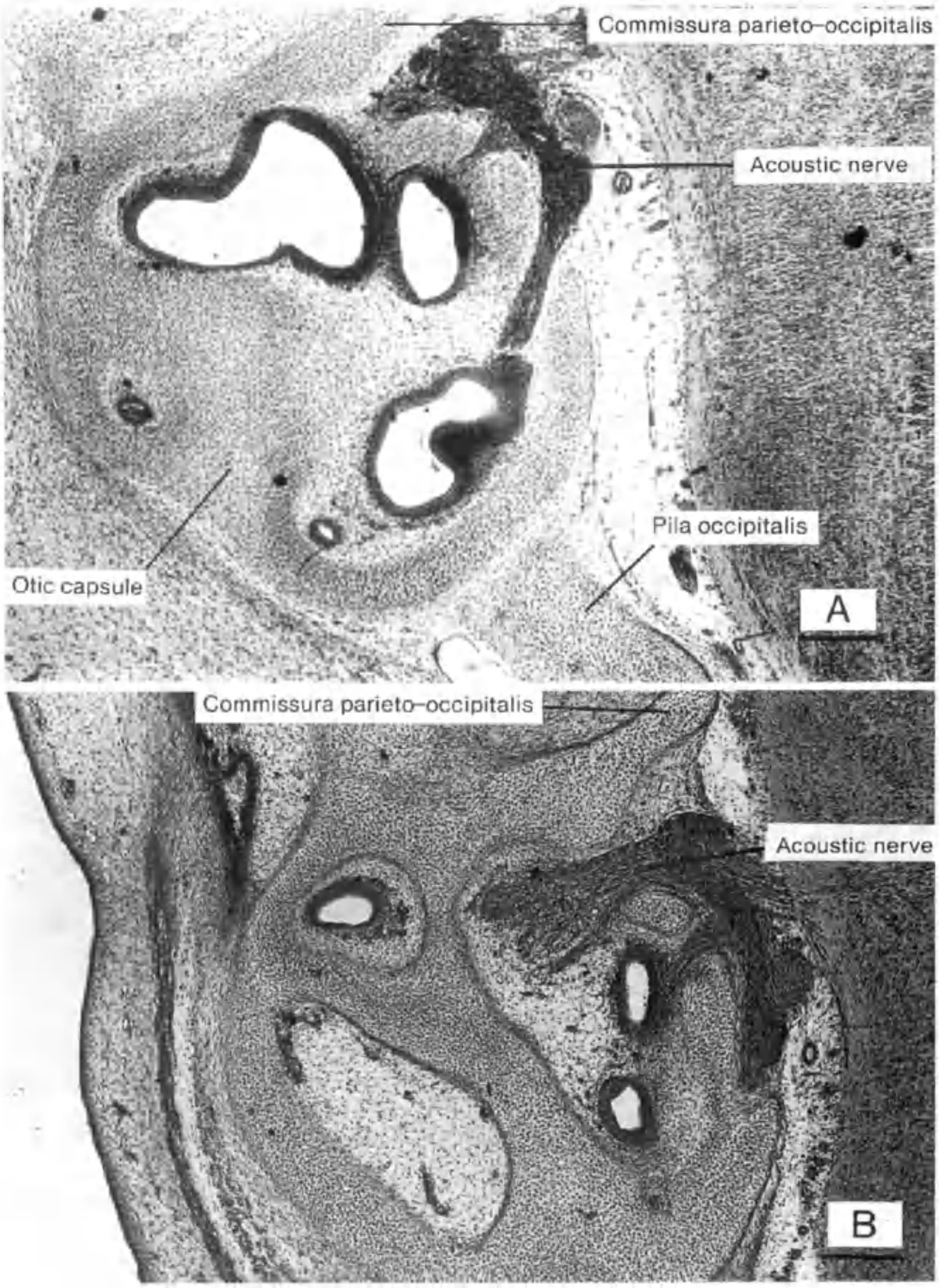

**Fig. 14A, B.** Photomicrographs of transverse sections through the otic capsule. **A** Stage III, **B** Stage IV. *Scale bar*, 200 µm

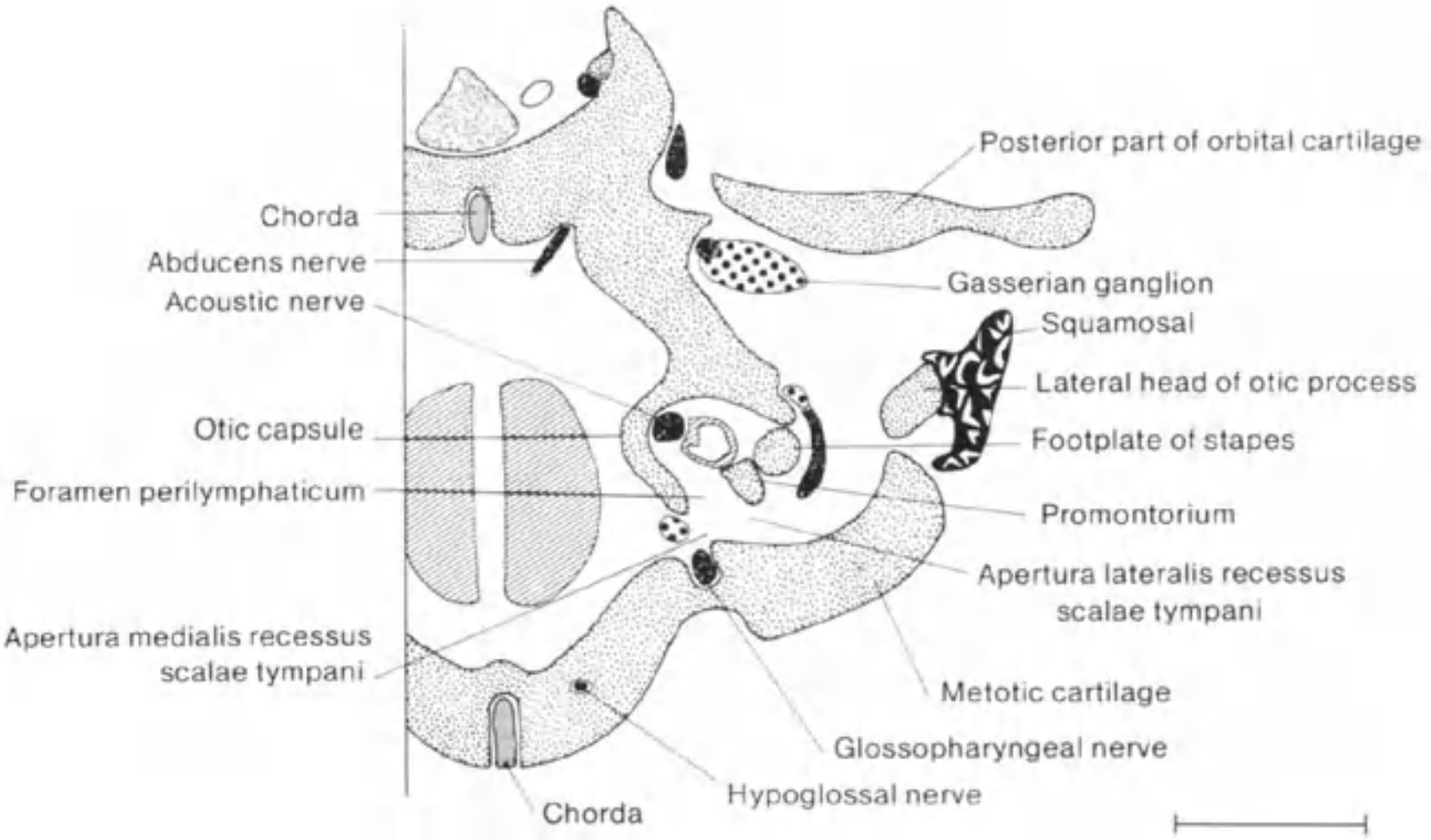

**Fig. 15.** Stage III. Transverse section through basal plate and otic capsule. *Scale bar*, 1 mm

sally, the recessus scalae tympani is in communication with the cavity of the otic capsule through the foramen perilymphaticum, medially with the cranial cavity through the apertura medialis recessus scalae tympani, and anterolaterally to the exterior through the apertura lateralis recessus scalae tympani (= fenestra rotunda). The glossopharyngeal nerve leaves the cranial cavity through the apertura medialis recessus scalae tympani, traverses the medioventral side of the recessus scalae tympani, and leaves the latter through the foramen formed between the basal plate and metotic cartilage (Fig. 15).

The lateral edge of the pila occipitalis has become syndesmotically attached to the floor of the wall of the superior semicircular canal for a short distance (Fig. 14A). Faint traces of intercellular deposit can be detected in this attachment. Behind the attachment the tip of the pila occipitalis ends freely below the otic capsule.

In another 8-day embryo of 50 mm the paired anlagen of the tectum synoticum are present as two procartilaginous strips along the posterior part of the wall of the posterior semicircular canal. Ventrally each strip is attached to the floor of the anterior part of the wall and dorsally to the posterior wall at the posterodorsal corner of the superior semicircular canal enclosing a large slitlike foramen for the vena emissaria occipitalis between the anlage of the tectum synoticum and the wall of the otic capsule. Behind the dorsal attachment the anlage of the tectum synoticum terminates some distance from the tip of its partner as a blind-ending mesenchymatous process.

Sonies (1907) describes the paired anlagen of the tectum synoticum as independent cartilaginous strips along the posterior region of the superior semicircular canals, before fusing with one another and with the otic capsules along the walls of the superior semicircular canals, leaving perforations (presumably for the venae emissariae occipitales). In the present series, however, the ventral and dorsal attachments were present from the beginning.

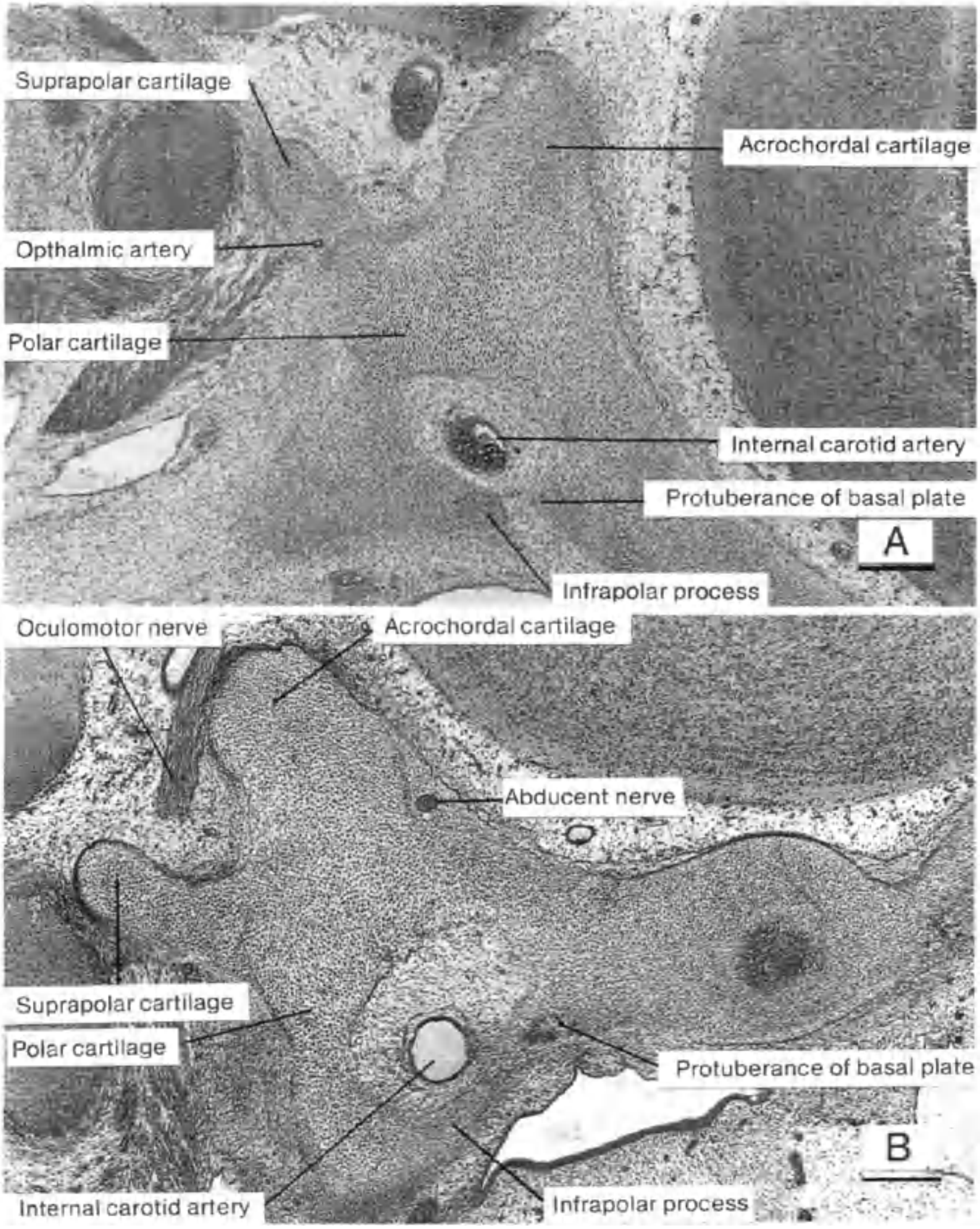

**Fig. 16A–C.** Photomicrographs of sagittal sections through acrochordal cartilage and basal plate showing incisura carotica. **A** Stage III; *scale bar*, 210 µm. **B** Stage IV; *scale bar*, 190 µm. **C** Stage V; *scale bar*, 200 µm (**C** see page 27)

In the occipital region all traces of the cranial ribs have disappeared and the foramina for the hypoglossal nerves reduced to two on each side (Fig. 12). In the craniovertebral joint only traces of intercellular continuity remain between the elements.

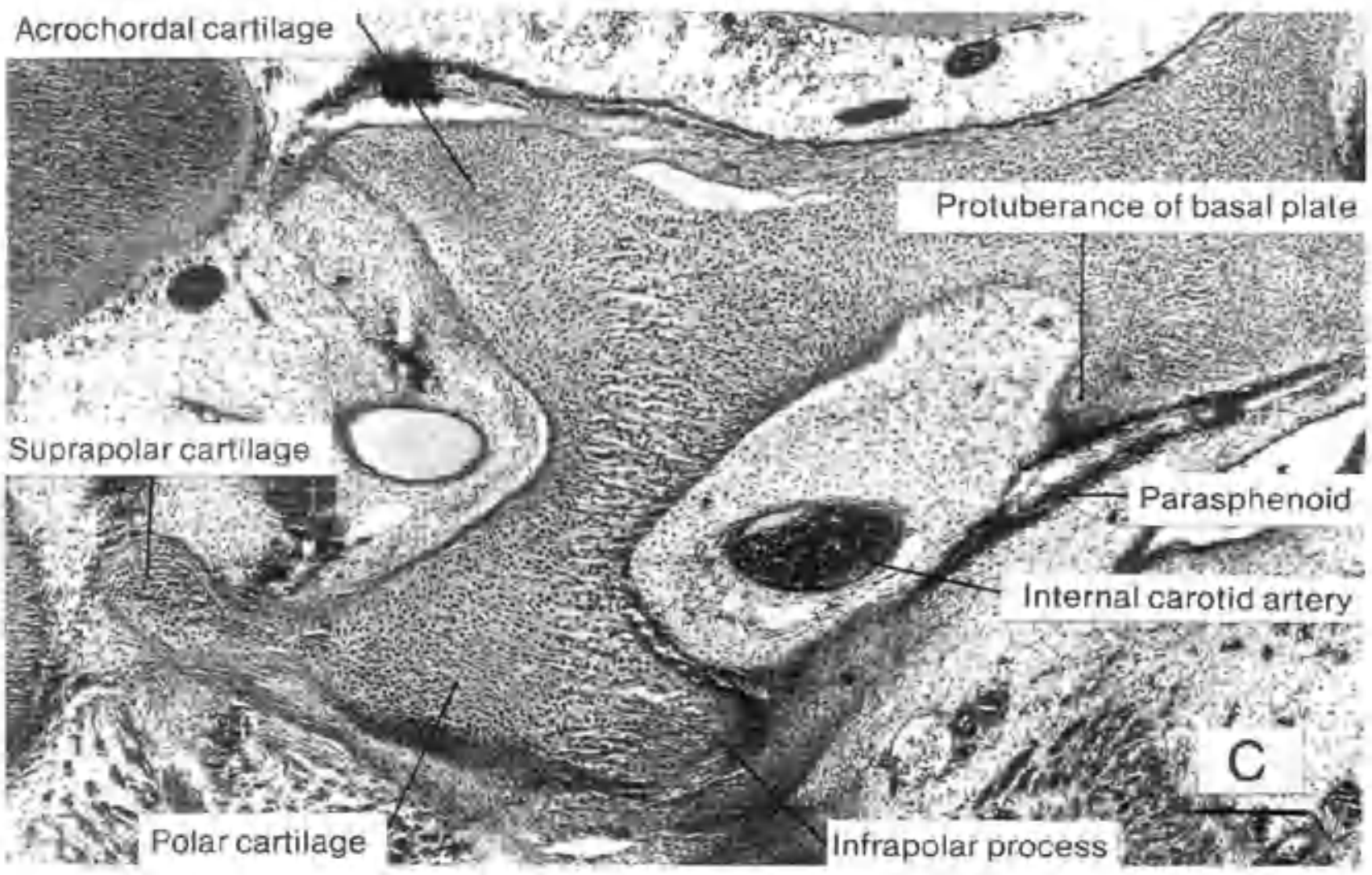

**Fig. 16C**

### *3.3.2 The Anterior End of the Chondrocranium*

The infrapolar process has increased in length and closely approaches a short, anteriorly directed protuberance that has developed on the ventral surface of the basal plate. Loose mesenchymatous tissue separates them at this stage (Fig. 16A).

In front of the fenestra hypophyseos the procartilaginous interorbital septum above the trabecula communis is now chondrified and no longer distinguishable histologically from the base (Fig. 5C). The most important development in this region has however taken place in the anterior part of the orbital and in the nasal region. In the latter, all elements of the nasal capsule are present as definite chondrifications or as mesenchymatous or procartilaginous precursors.

The procartilaginous ethmoid plate above the anterior part of the nasal sac of the previous stage has extended posteriorly above the posterior part of the nasal sac as the parietotectal cartilage (Fig. 17A, B). The mesenchymatous down bent lateral edge extends ventrally as the sidewall (Fig. 17C). In the anterior region the sidewall is less extensive, but more posteriorly the crescent-shaped mesenchymatous sidewall has chondrified as the lower part of the sidewall, while dorsal to it the sidewall is pushed inwards as the concha nasalis (Fig. 6C). The cavum conchae in which the posterior end of the lateral nasal gland will eventually be lodged is still filled with loose tissue. The first anlage of the gland, that of its duct, is still only a short solid proliferation of the wall of the anterior region of the nasal sac. It has been demonstrated that in *Anas* (de Beer and Barrington 1934) and in *Caprimulgus* (Frank 1954) the concha nasalis develops from a separate anlage – the paranasal cartilage which fuses

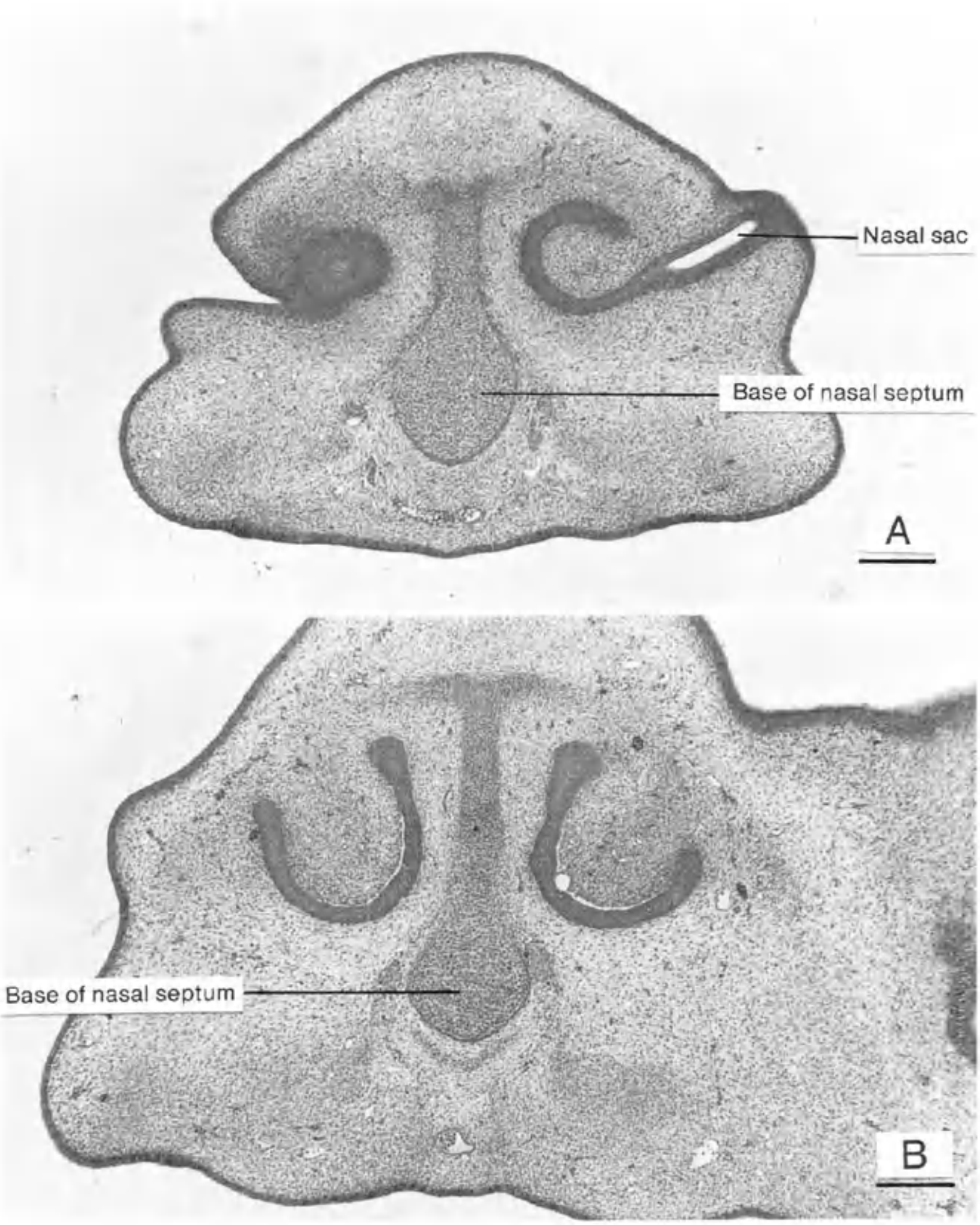

**Fig. 17 A–C.** Stage III. Photomicrographs of a series of transverse sections through the anterior region of the nasal capsule. *Scale bars*, 200 μm (**C** see page 29)

with the lateral edge of the parietotectal cartilage. In *Gallus*, however, the wall of the concha nasalis, when first observed, is continuous with the parietotectal which passes over into the wall of the concha nasalis without any discernable histological difference (Fig. 6C).

The posterior wall of the nasal capsule, the planum antorbitale, has developed as a vertical procartilaginous plate projecting anteroventrally from the edge of the parietotectal between the orbit and the nasal sac (Fig. 13). Behind

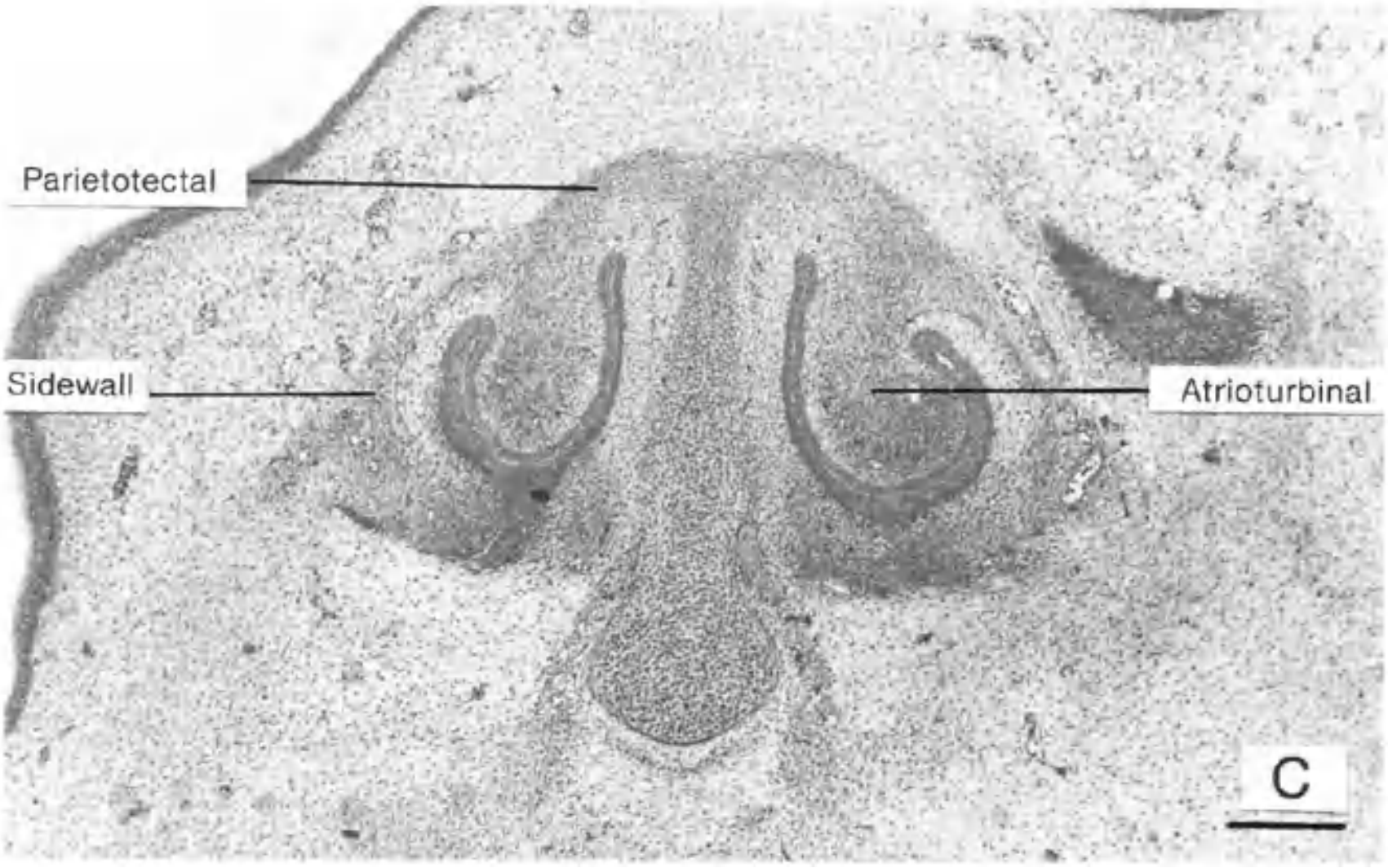

Fig. 17C

the planum antorbitale the parietotectal is continued into the anterior part of the orbit as a laterally directed ridge of the dorsal edge of the interorbital septum. The anteroventral corner of the planum antorbitale is fused to the ventrolateral edge of the concha nasalis, while the posteroventral corner is drawn out as a short, posteriorly directed process abutting against the lateral surface of the interorbital septum just above the base and immediately anterior to the attachment of the inferior oblique eye muscle. A large orbitonasal fissure through which the profundus and olfactory nerves leave the orbit is formed between the lateral surface of the interorbital septum and the medial edge of the planum antorbitale.

Anterior to the planum antorbitale the turbinals have appeared as simple ridges on the walls of the nasal capsule. The cartilage of the walls of the nasal capsule gradually passes over into procartilage and eventually into mesenchyme along the edges of the turbinals (Fig. 17). The atrioturbinal is a slightly curved, ventrolaterally directed ridge of the parietotectal in the anterior region of the nasal capsule. Immediately posterior to it and ventral to the concha nasalis, the maxilloturbinal projects from the medial surface of the sidewall as a medially directed ridge.

The procartilaginous ridge along the lateral side of the base of the posterior part of the nasal septum has been resorbed except for an anterior portion which has chondrified. This chondrified ridge stretches posteriorly from the level of the anterior end of the maxilloturbinal, where it is also the most conspicuous, and dwindles to disappear towards the posterior end of the nasal septum which now appears circular in cross section. The former position of the resorbed procartilaginous ridge along the lateral surface of the base of the posterior part of the nasal septum is however still indicated by a strip of darker-stained perichondrium along the edge of the base of the nasal septum in this region.

This darker strip is continued posteriorly into and over the entire length of the orbital region, indicating the position of the resorbed ventrolateral corners of the base of the interorbital septum of the previous stage (Fig. 5C). The base of the interorbital septum has, through resorption of these corners, become circular. Bellairs (1958) describes similar strips of deeply stained perichondrium over the sides of the lower edge of the interorbital septum of a 7-day embryo of *Gallus*.

As in the nasal region, important and rapid developments have also taken place in the anterior part of the orbital region. In embryos of intermediate stages of development (Stages 30 and 31 of Hamburger and Hamilton 1951), the olfactory nerve, as in Stages I and II, still passes straight down, in front of the anterior part of the orbital cartilage. In this stage, however, rapid change in the anterodorsal corner of the orbital region has resulted in the olfactory nerve being enclosed in a long transitory canal. Bellairs (1958) also notes the rapid modification and striking change occurring in this region within 12 h or less.

The long canal for the olfactory nerve is formed by the appression of the medial surface of a section of the anterior part of the orbital cartilage, the lateral surface of the dorsal part of the interorbital septum, and the lateral edge of the ridgelike continuation of the parietotectal cartilage into the orbit which forms the roof of the canal (Fig. 18). The anterior opening of the canal, the foramen olfactorius advehens bordered laterally by the anterior part of the orbital cartilage, medially by the dorsal part of the interorbital septum and dorsally by the posterior continuation of the parietotectal cartilage, is situated some distance behind the orbitonasal fissure so that the olfactory nerve traverses the anterodorsal part of the orbit before entering the nasal capsule.

In the region of the foramen olfactorius advehens the bordering elements are in the same state of chondrification (Fig. 18A). More posteriorly, there is a progressive increase in intercellular deposit in the anterior part of the orbital cartilage (Fig. 18B, C), while the roof of the canal and the dorsal part of the septum, forming the medial wall, contain less intercellular deposit and, when these eventually terminate at the posterior opening of the canal into the cranial cavity, the foramen olfactorius evehens (Fig. 18B, C), consists of mesenchyme only.

Behind the posterior openings of the canals the combined roof of the two canals projects backwards as a short mesenchymatous anlage for the processus tectalis (Fig. 18D), and the well-chondrified anterior part of the orbital cartilage, forming a ventrolateral wall to the cranial cavity, is continued posteriorly along the dorsal edge of the interorbital septum as far as the level of the optic chiasma.

The ventrally curved prenasal process has lengthened and consists of young cartilage, except for its anterior tip which is still procartilage (Fig. 13).

**Fig. 18A–D.** Stage III. Photomicrographs of a series of transverse sections through the posterior ▷ orbital region. *Scale bars*, 200 µm

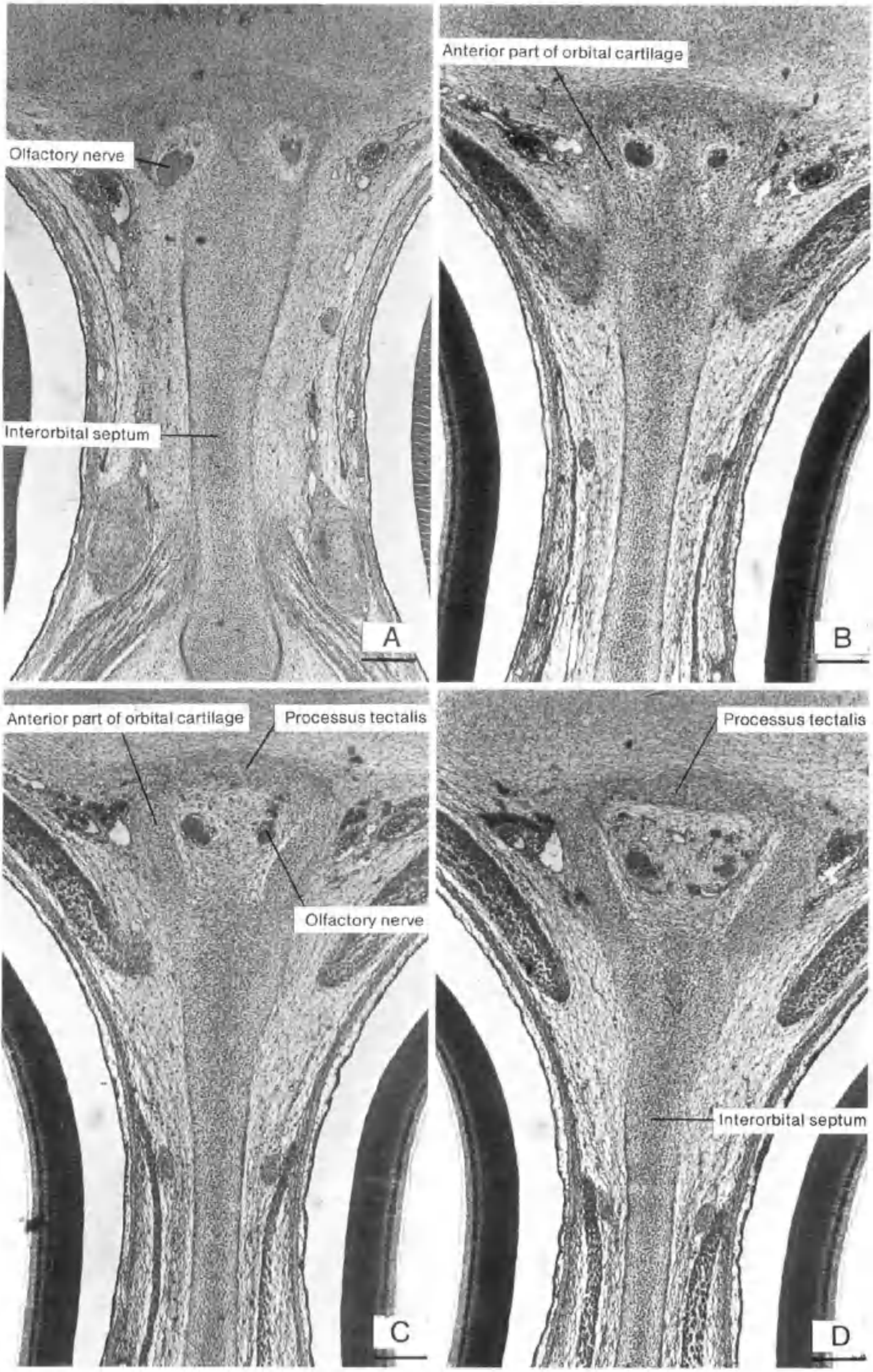
Olfactory nerve
Interorbital septum
A
Anterior part of orbital cartilage
B
Anterior part of orbital cartilage
Processus tectalis
Olfactory nerve
C
Processus tectalis
Interorbital septum
D

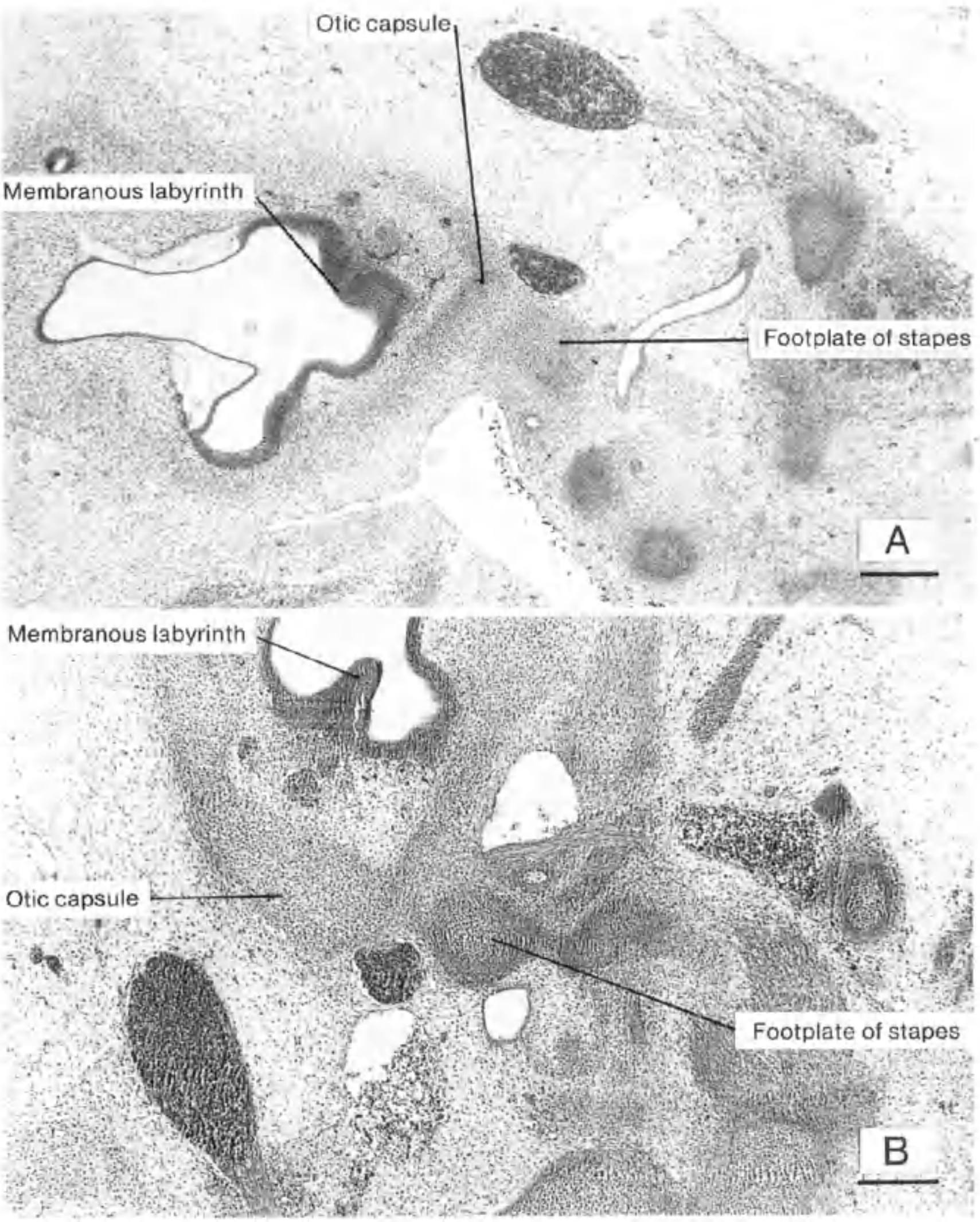

**Fig. 19 A–C.** Photomicrographs of transverse sections through the otic capsule. **A** Intermediate 7-day stage; *scale bar*, 200 µm. **B** Intermediate 8-day stage; *scale bar*, 200 µm. **C** Stage III; *scale bar*, 180 µm (**C** see page 33)

### *3.3.3 The Visceral Arches*

Meckel's cartilages have elongated considerably and fused anteriorly in the midline. The processus retroarticularis has lengthened and at the medial edge a processus angularis has developed. A synovial cavity has started to develop between the lower end of the quadrate and the posterior end of Meckel's carti-

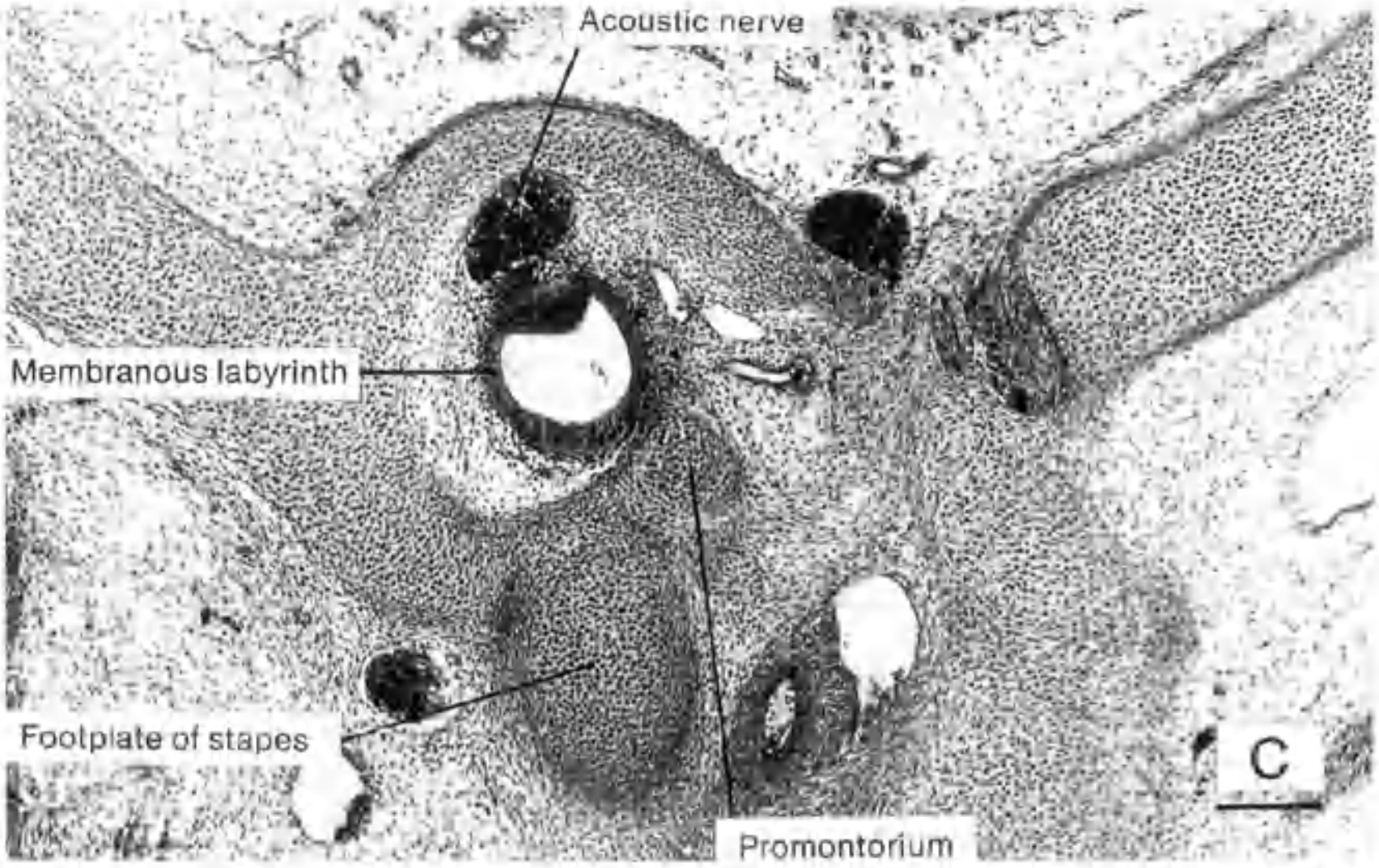

Fig. 19C

lage. The processus orbitalis still has a narrow mesenchymatous connection with the posteroventral corner of the polar cartilage. The processus oticus of the quadrate reaches back to make contact with the otic capsule (Fig. 13).

More intercellular substance has been deposited in the columella auris so that this structure is now chondrified and the various processes can be recognised. In the dorsal anlage a well-chondrified, medially situated stapedial part and a slightly less chondrified, lateral extracolumellar part can be distinguished. The thicker medial tip of the stapedial part, the footplate of the stapes, which in Stage II was situated beneath the floor of the cochlear part of the otic capsule (Fig. 19A), is now lodged in the wall of the otic capsule (Fig. 19C).

Except for a small area anteriorly, where continuity of intercellular deposit is present between the footplate and wall of the otic capsule, a fenestra ovalis is present as a ring-shaped area around the footplate devoid of intercellular deposit and filled with flattened cells (Fig. 19C). The mode of development of the footplate of the stapes indicates a purely visceral origin for this structure in *Gallus* and agrees with the findings of Sonies (1907), Lutz (1942), and Smit and Frank (1979). Smith (1905), however, regards the cells forming the footplate in *Gallus* to be derived from both the visceral arch and the otic capsule.

The fenestra ovalis thus develops through resorption of the chondrified wall of the otic capsule in the region opposite the intruding footplate of the stapes. According to Sonies (1907), the fenestra ovalis in *Gallus* is a remnant of the cartilage-free area between the two cartilaginous anlagen of the otic capsule. In the present series, however, the wall of the otic capsule in the region where the fenestra ovalis will develop is chondrified before the swollen tip of the stapedial part of the columella auris fuses with it. It is only after fusion that a thinning of the wall is evident opposite the intruding footplate.

An intermediate stage (an 8-day embryo of 46 mm) shows that this position of the footplate is brought about by the swollen tip of the stapedial part pushing into the wall of the otic capsule (Fig. 19B). This tip is fused to the floor of the otic capsule and there is complete continuity of intercellular substance. There is, however, markedly more intercellular deposit in the swollen stapedial tip than in the surrounding wall of the otic capsule so that the outline of the former can be clearly made out. A line of flattened chondrocytes, indicating the boundary between the swollen stapedial tip and the cartilage of the otic capsule, shows that the tip has started to push into the wall of the otic capsule (Fig. 19C).

The extracolumellar part of the columella auris bears two processes – a shorter, posterolaterally directed processus supracolumellaris and a longer, ventrolaterally directed processus extracolumellaris. The infracolumellar part has chondrified as a processus infracolumellaris projecting ventrally from the dorsal part of the columella auris on the boundary between the stapedial and extracolumellar parts. The swollen, ventral, chondrified tip of the infracolumellar part of the previous stage is still discernable as the rest of the processus infracolumellaris, although chondrified, and contains noticeably less intercellular deposit.

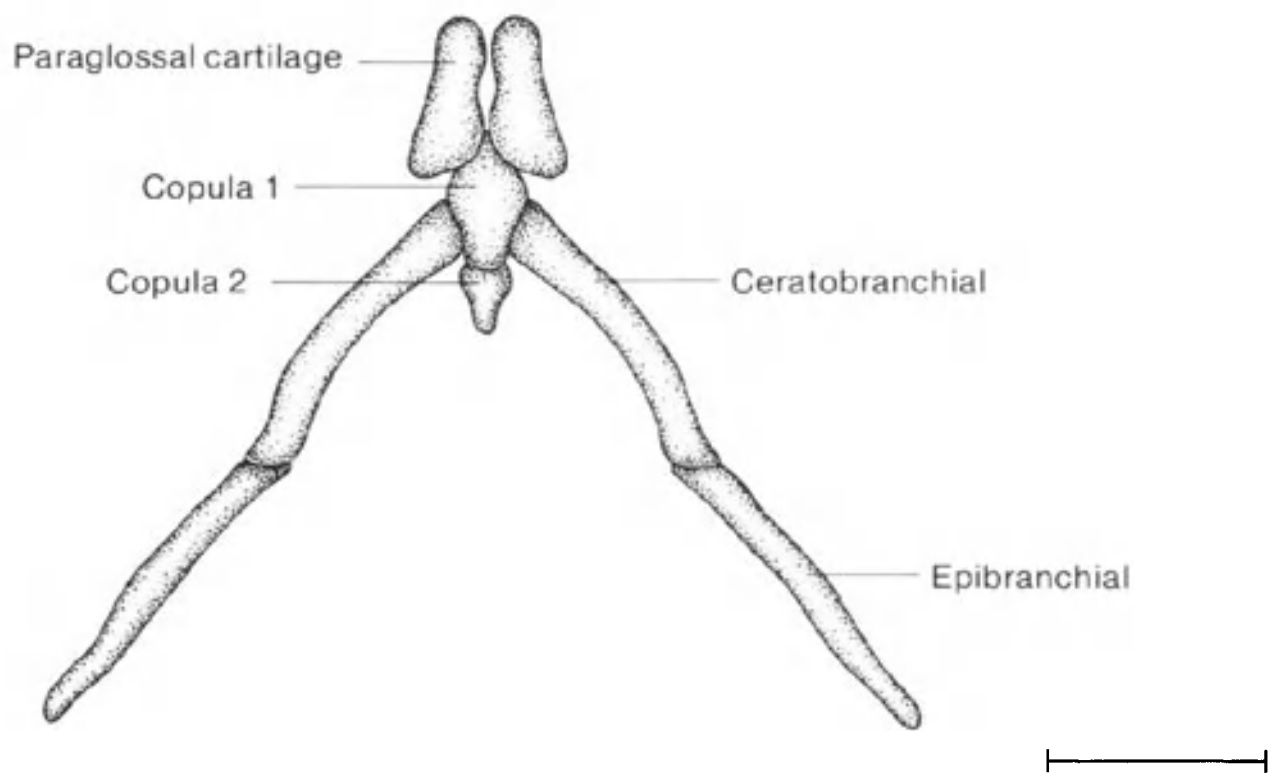

**Fig. 20.** Stage III. Reconstruction of hyoid apparatus (norma dorsalis). *Scale bar*, 1 mm

Anterodorsal, and in close proximity to copula 1, the paired anlagen of the paraglossal cartilage have appeared as parallel, and slightly divergent posteriorly, mesenchymatous rods (Fig. 20). Copula 1 and 2 are well-chondrified and only a faint indication of a boundary between them shows up as an area of less densely chondrified cartilage. A concavity into which the anterior end of the ceratobranchial fits has developed on the lateral surface of this area. Copula 2 now lies posteroventral to copula 1 and extends further backwards than in the previous stage. The ceratobranchial is cartilaginous and an epibranchial has chondrified in the posterior part of the branchial arch leaving a small area of dense mesenchyme between them.

In a 7-day embryo (41 mm) the ceratobranchial is already well-chondrified while, except for a short procartilaginous posterior region, the epibranchial is still mesenchymatous with only faint traces of intercellular deposit. This intermediate stage thus confirms the findings of Sonies (1907) that in *Gallus* chondrification of the ceratobranchial precedes that of the epibranchial.

## 3.4 Stage IV

Total length of embryos: 55 mm and 57 mm (Stage 35 of Hamburger and Hamilton 1951). 9 days' development.

### *3.4.1 The Basal Plate and Otic Capsules*

The distinguishing features of this stage are resorption at the anterior end of the basal plate and of the posterior part of the orbital cartilage, the replacement of the attachment of the latter to the basal plate by the pila antotica by a laterally situated pila antotica spuria and the development of a dorsal border for the foramen magnum.

The pila antotica spuria has fused with the lateral surface of the basal plate, enclosing the profundus branch of the trigeminal nerve in its own foramen (Fig. 21). The other branches of the trigeminal nerve pass on the lateral side of the pila antotica spuria through what remains of the incisura prootica, the incisura prootica spuria. This incisura is nearly converted into a foramen for these nerves by the approaching of the orbitocapsular process of the posterior part of the orbital cartilage and the prootic process of the otic capsule.

Resorption of the acrochordal cartilage and pila antotica has started and will eventually lead to a stage described by de Beer and Barrington (1934) where the pila antotica disappears and the posterior part of the orbital cartilage in *Gallus* is connected to the basal plate by the pila antotica spuria only. The resorption leads to the foramen for the oculomotor nerve being situated just behind the anterior edges of the acrochordal and pila antotica.

Resorption of the basal plate and acrochordal around the chorda has increased the fenestra basicranialis posterior considerably and for quite a distance the anterior end of the chorda lies above the dorsal surface of the basal plate and of the acrochordal, covered only by a thin membrane (Fig. 21). Above the tip of the chorda, resorption of the intercellular substance is practically completed, but the chondrocytes still maintain the shape of the anterior end of the acrochordal of the previous stage.

Regression of the posterior part of the orbital cartilage has considerably decreased its height, liberating the trochlear nerve from its canal, as well as leading to the formation of a vacuity in the centre similar to that described in *Gallus* (Tonkoff 1900) and *Anas* (de Beer and Barrington 1934; Fig. 21).

Further straightening of the cranial flexure has caused the posterior part of the orbital cartilage to rotate backwards and downwards, resulting in a further decrease of the incisura prootica, and the posterior part of the orbital cartilage being situated closer to the otic capsule.

The anterior end of the metotic cartilage has fused to the prominentia canalis semicircularis lateralis below the point where the otic process of the quadrate

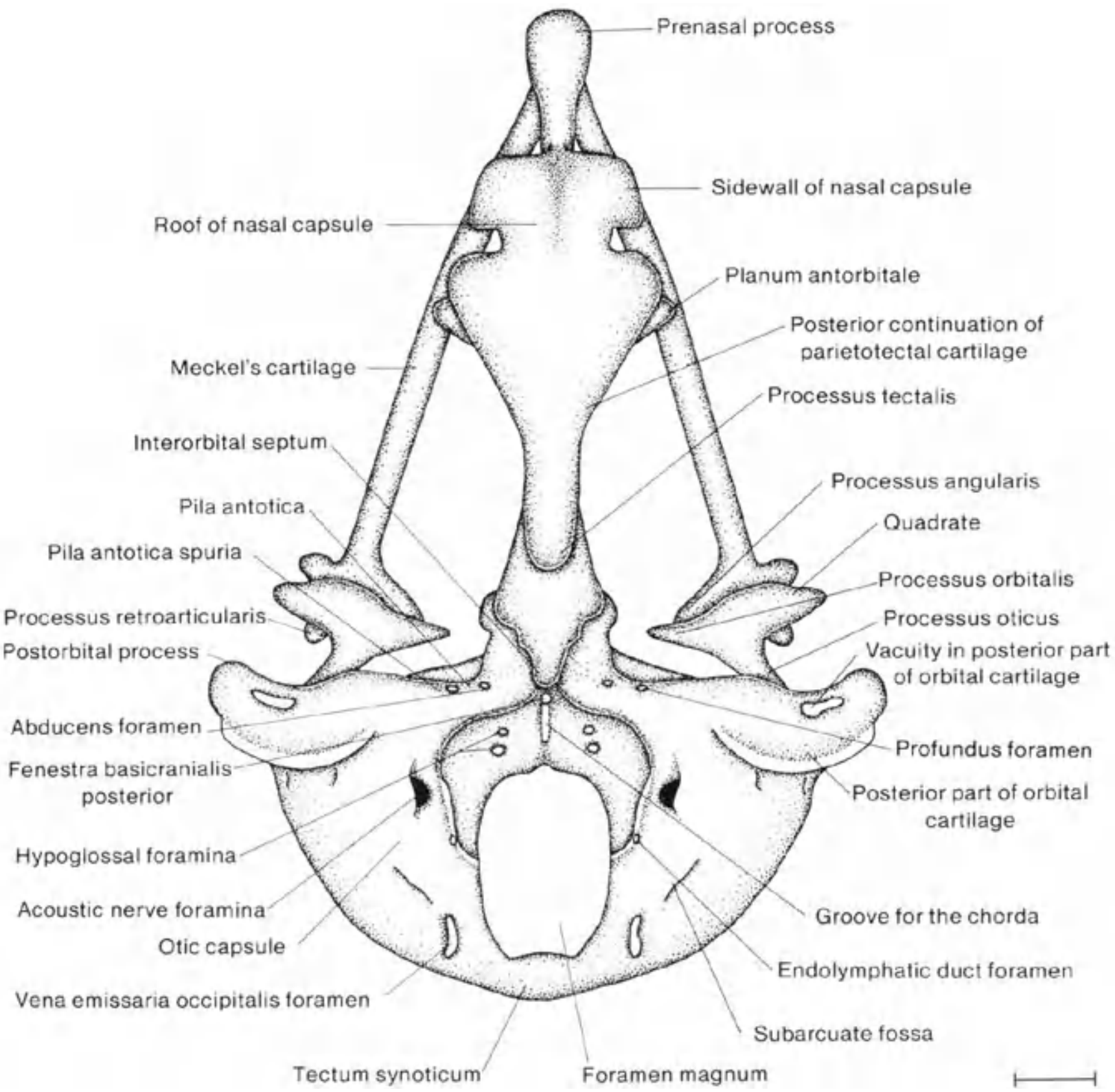

**Fig. 21.** Stage IV. Reconstruction of chondrocranium (norma dorsalis). *Scale bar*, 1 mm

makes contact with the otic capsule. Closure of the metotic fissure upon the glossopharyngeal nerve has resulted in a separate foramen for the nerve.

Within the otic capsule the areas of resorption around the parts of the membranous labyrinth are larger and better defined (Fig. 14B). More resorption has also taken place in the wall of the canal for the facial nerve.

The otic capsule is now almost fully chondrified, except for the posterior canalicular portion. A shallow indentation, the subarcuate fossa, has developed dorsomedially in the posterior part of the capsular wall, ventrolateral to the anterior semicircular canal (Fig. 21).

The hypoglossal nerve leaves the cranial cavity through two well-defined foramina on each side. In a 55-mm embryo, however, three hypoglossal foramina are still present on each side and a minute first branch of the hypoglossal nerve leaves the cranial cavity through its own foramen.

In the occipital region, the tips of the paired anlagen of the tectum synoticum have fused posteriorly to complete the dorsal border of the foramen magnum which now consists of young cartilage (Fig. 21). The dorsal attachment has

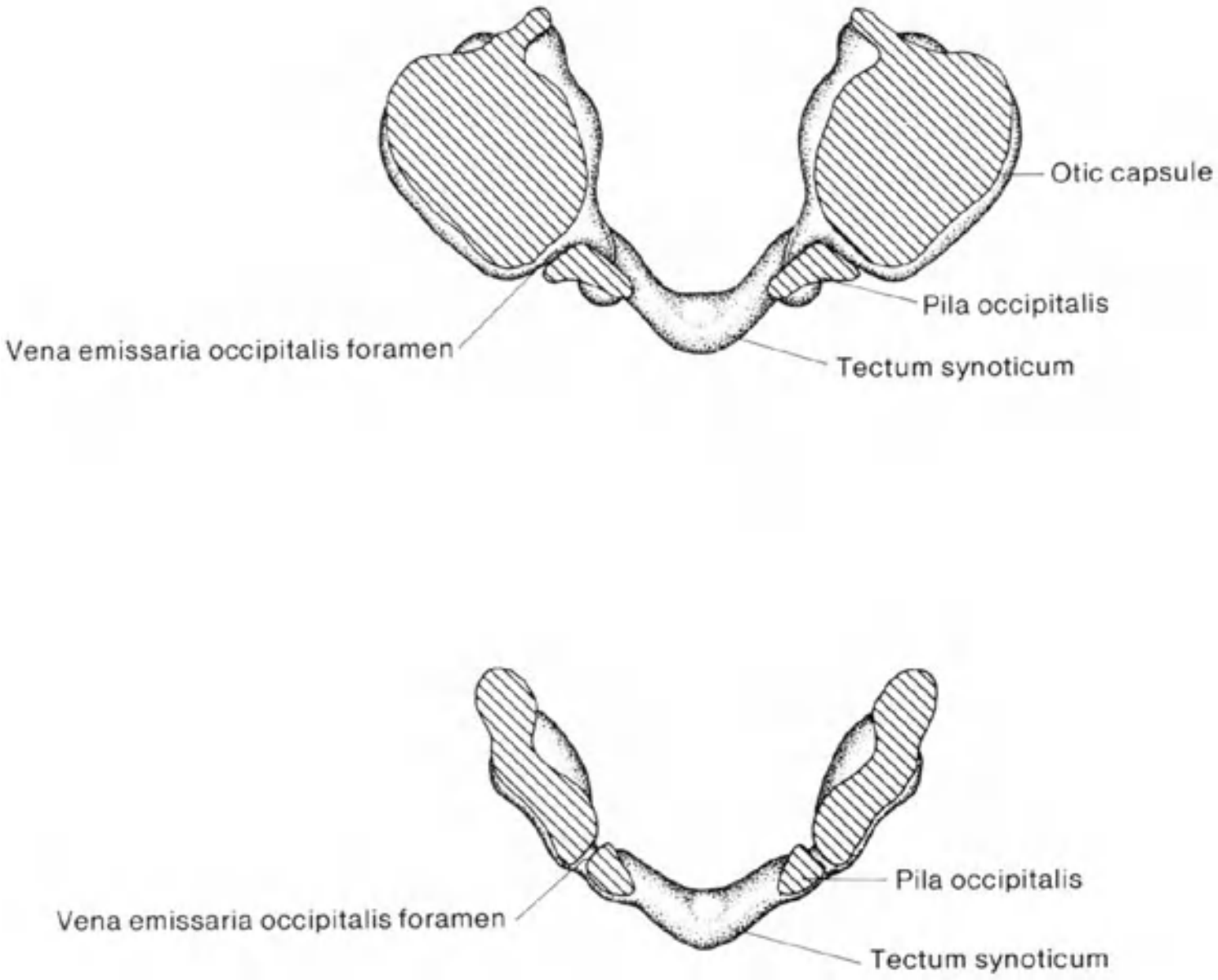

**Fig. 22.** Stage IV. Stereograms of the tectum synoticum. *Scale bar*, 1 mm

broadened along the edge of the otic capsule so that the dorsal part of the tectum synoticum is now in the form of a vertical plate with a deep notch in the dorsal midline (Fig. 22). The ventral attachment to the floor of the wall of the superior semicircular canal has also broadened and spread over the lateral surface of the posterior end of the pila occipitalis (Fig. 23). The tip of the latter is, however, left free.

### *3.4.2 The Anterior End of the Chondrocranium*

As in the previous stage the tip of the infrapolar process approaches the protuberance on the ventral surface very closely, but the loose mesenchymatous tissue between them has become dense. Above the internal carotid artery, considerable resorption of the roof of the incisura carotica has taken place (Fig. 16B).

The different parts of the posterior prechordal region are now all in an advanced state of chondrification and are so completely fused that the original entities can only be detected by the position of the foramina which were formed between them.

The interorbital septum is thinner than in the previous stage, but no interorbital fenestra have formed yet. In the 55-mm embryo the nasal septum is also still complete, but in the 57-mm embryo two fenestrae have developed; an anteriorly situated fenestra septi nasi which is a narrow slit situated immediately above the base of the nasal septum in the region of the fenestra narina, and a posteriorly situated fenestra craniofacialis in the region of the chondrified

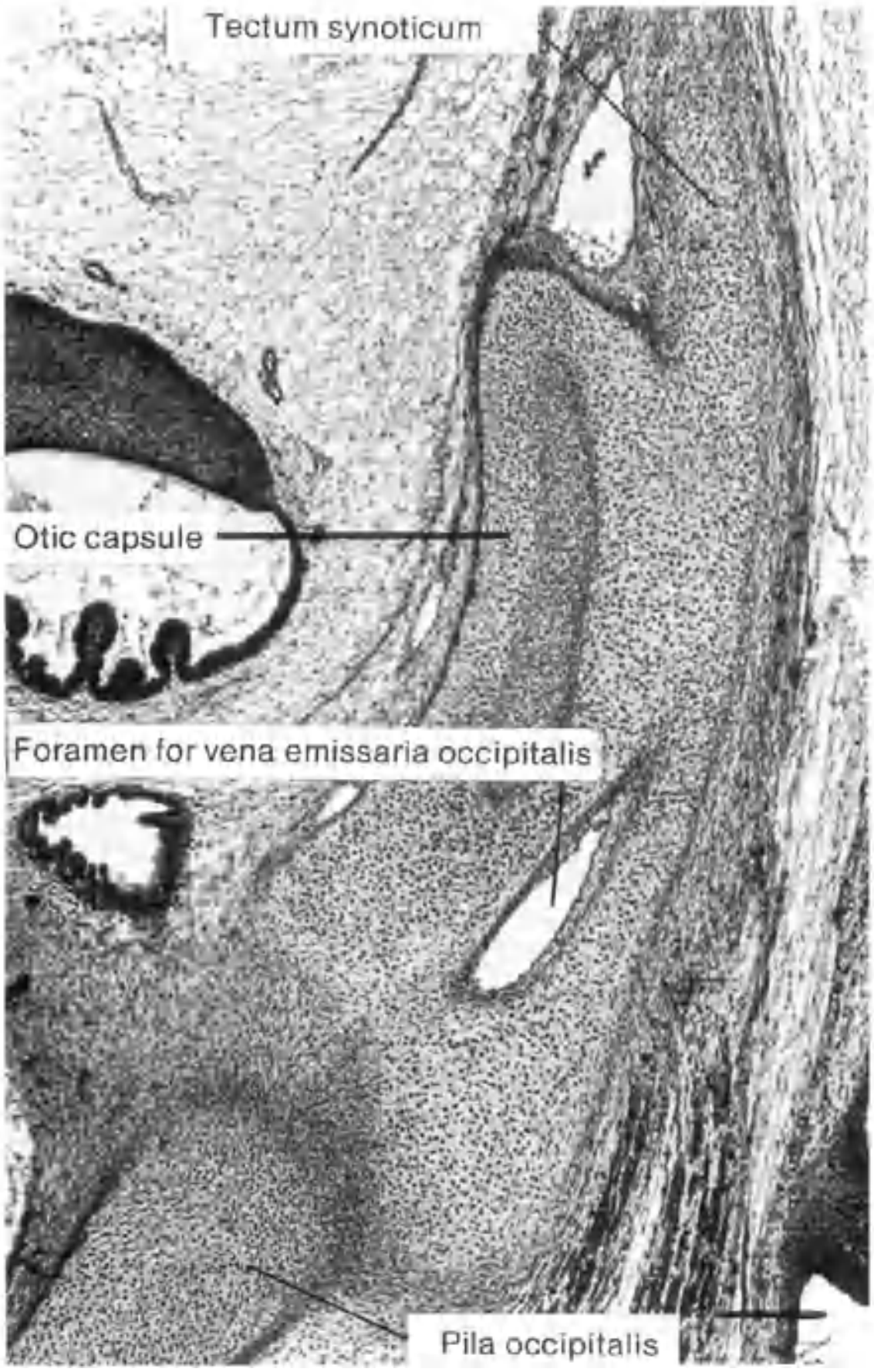

**Fig. 23.** Stage V. Photomicrograph of a sagittal section through the posterior end of the otic capsule. *Scale bar*, 190 µm

ridge along the base of the nasal septum at the level of the anterior end of the maxilloturbinal (Fig. 24). W.K. Parker (1869) describes similar extentions along the lateral side of the base of the nasal septum bordering the fenestra craniofacialis in an embryo of *Gallus* at the end of the 2nd and beginning of the 3rd week of incubation as "supervomerine laminae" (see also discussion of the intertrabecula in Sect. 4.2.2).

The nasal capsule has elongated considerably and the ventrally curved prenasal process of the previous stage has elongated and become straightened and its anterior part has become broader (Fig. 21). Chondrification has increased in the nasal septum and the prenasal process, and in the roof and sidewalls of the posterior part of the capsule. In the anterior region only the septum is fully chondrified while the roof is still procartilaginous passing over into mesenchymatous sidewalls. The sidewalls in both the anterior and posterior parts of the nasal capsule have grown down further except in the region opposite

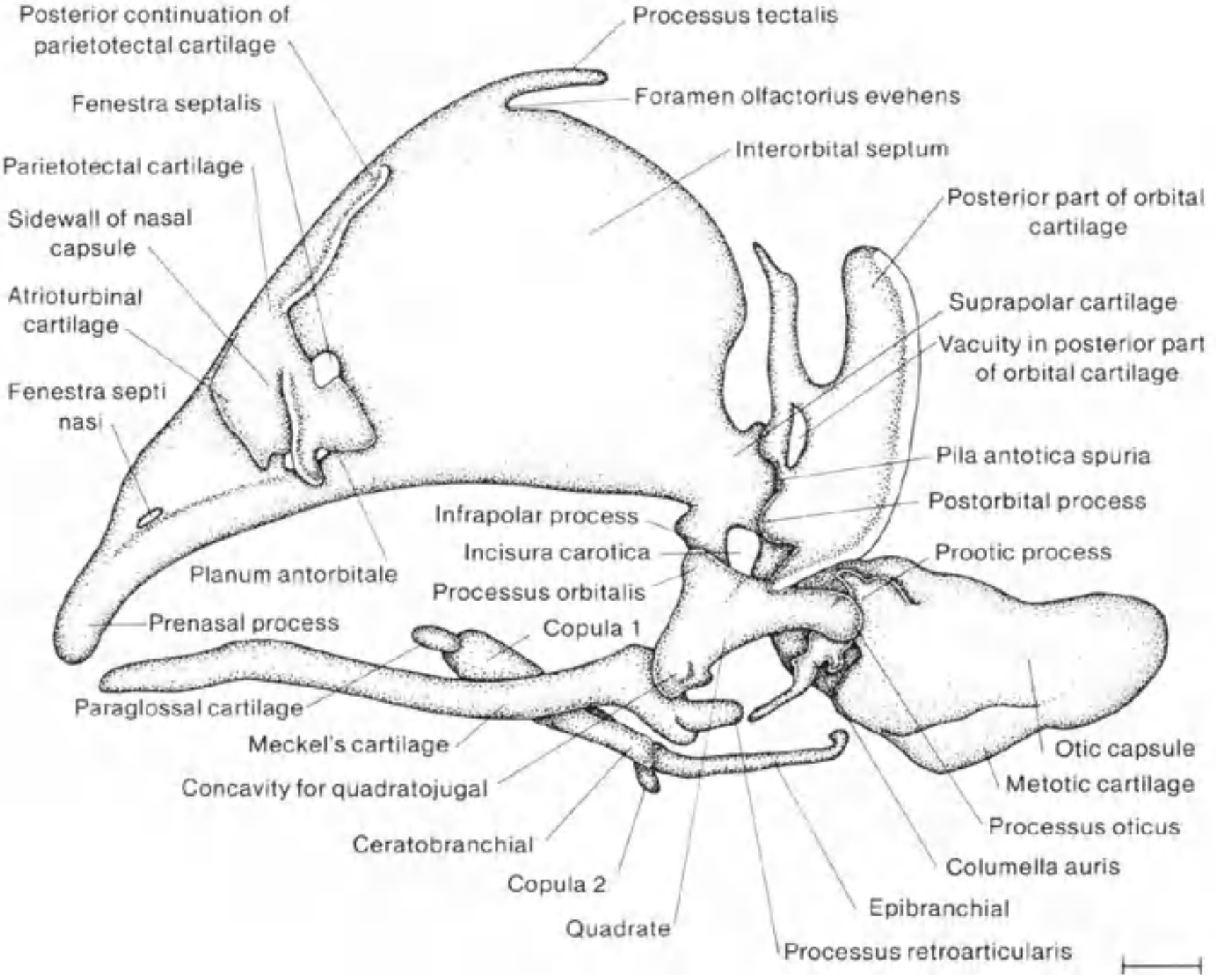

**Fig. 24.** Stage IV. Reconstruction of chondrocranium (norma lateralis). *Scale bar*, 1 mm

the posterior end of the atrioturbinal and the anterior end of the maxilloturbinal, where the sidewall shows a deep notch exposing the ends of the turbinals (Fig. 21). The ventral edge of the sidewall in the region of the atrioturbinal is turned slightly inwards.

The atrioturbinal is still mesenchymatous but chondrification has spread from the parietotectal into the base of the maxilloturbinal. The rest of the maxilloturbinal, except for its mesenchymatous posterior tip, is procartilaginous. The concha nasalis has been pushed in further, thus deepening the cavum which is still filled completely with loose tissue. The anlage of the duct of the lateral nasal gland, still solid, has extended posteriorly and its solid swollen end, the anlage of the gland itself, is situated opposite the anterior margin of the opening of the cavum, the aditus conchae. The expanding lateral edge of the planum antorbitale has grown over the aditus conchae from behind reducing it to an anteroventrally facing slit. The relations of the different parts of the fully chondrified nasal capsule are shown in a series of transverse sections in Fig. 35.

At the level of the anterior end of the fenestra craniofacialis the anlage for the lateral wall of the posterior canal for the ramus medialis nasi is present as a plate of dense mesenchyme lateral to the nerve and a short distance below the parietotectal (Fig. 25A). At the level of the posterior end of the atrioturbinal the anlage for the roof and sidewall of the anterior canal for the ramus medialis nasi is present in the form of a procartilaginous ventrolaterally directed platelike

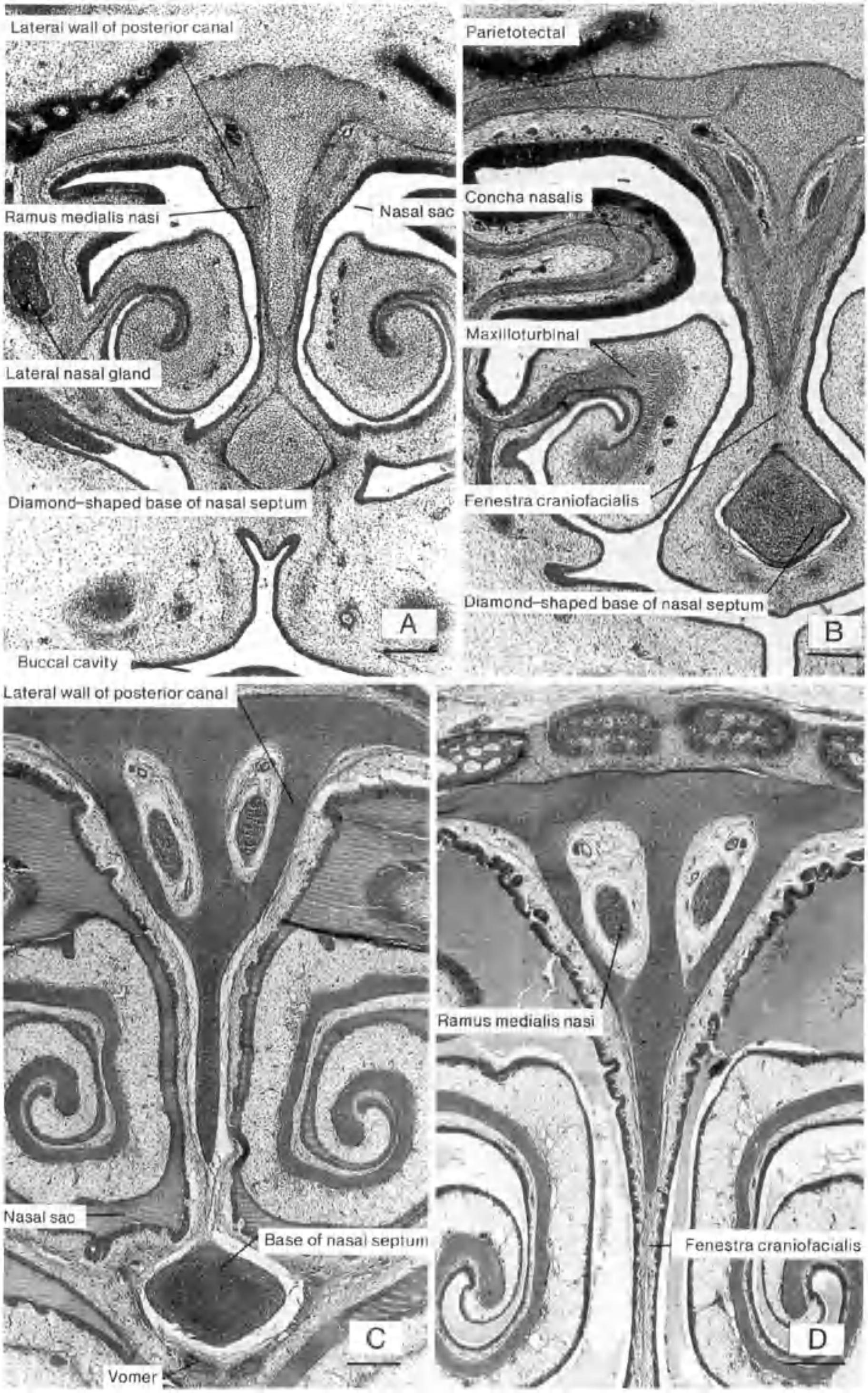

Lateral wall of posterior canal
Ramus medialis nasi
Nasal sac
Lateral nasal gland
Diamond–shaped base of nasal septum
Buccal cavity
A
Parietotectal
Concha nasalis
Maxilloturbinal
Fenestra craniofacialis
Diamond–shaped base of nasal septum
B
Lateral wall of posterior canal
Nasal sac
Base of nasal septum
Vomer
C
Ramus medialis nasi
Fenestra craniofacialis
D

outgrowth of the nasal septum some distance above the base of the nasal septum and just above the nerve (Fig. 26A). The mesenchymatous ventral edge slopes posteriorly and its posterior tip is connected to the lateral surface of the nasal septum immediately above the base. The mesenchymatous posterior end of the atrioturbinal is attached to the lateral surface of the anterior part of the roof and sidewall of the anterior canal (Fig. 26A). The roof and sidewalls for the anterior canal have been described as a nerve bridge in *Gallus* (W.K. Parker 1869), a ridge of cartilage which covers the ramus medialis nasi (de Beer and Barrington 1934) and posteriorly situated process (Swart 1946) in *Anas*, and protuberances of the nasal septum in *Strix* (May 1961).

The posteriorly directed process of the posteroventral corner of the planum antorbitale, which in the previous stage terminated just in front of the attachment of the inferior oblique eye muscle, has increased in length so that its tip projects slightly beneath the anterior end of the attachment.

The chondrified ridge along the lateral edge of the base of the posterior part of the nasal septum of the previous stage has dwindled somewhat, but is still recognisable as the pointed lateral edge of the base of the septum (Fig. 25A). The strip of darker-stained perichondrium along the posterior part of the base of the nasal septum and its continuation into the orbital septum can no longer be distinguished from the perichondrium surrounding the entire base of these septa.

In the orbital region reduction of that section of the anterior part of the orbital cartilage forming the anterior area of the lateral wall of the canal for the olfactory nerve has resulted in the posterior displacement of the foramen olfactorius advehens so that the olfactory nerve now traverses the orbit for a longer distance. The foramen olfactorius advehens, which in the previous stage was situated just anterior to the attachment of the superior oblique eye muscle, is now situated above the posterior end of this attachment. Some intercellular deposit is present in the anterior part of the anlage of the processus tectalis.

### *3.4.3 The Visceral Arches*

Meckel's cartilage has elongated and its tip now lies below that of the elongated and straightened prenasal process of the previous stage. The retroarticular process reaches further back (Fig. 24).

The processus orbitalis of the quadrate has shortened and lost its connection with the polar cartilage. At the base of the processus orbitalis a protuberance, with a central concavity lodging the posterior tip of the pterygoid, has developed on the medial surface of the quadrate. A synovial cavity will eventually develop at the posterior tip of the pterygoid, but at this stage the space between the entities is filled with mesenchymatous tissue. In the same region, but on the

◁ **Fig. 25A–D.** Photomicrographs of transverse sections through the nasal capsule in the region of the posterior canal for the ramus medialis nasi. **A** Stage IV; *scale bar*, 200 µm. **B** Stage V; *scale bar*, 210 µm. **C** Stage VI, 14-day embryo; *scale bar*, 200 µm. **D** Stage VI, 16-day embryo; *scale bar*, 200 µm

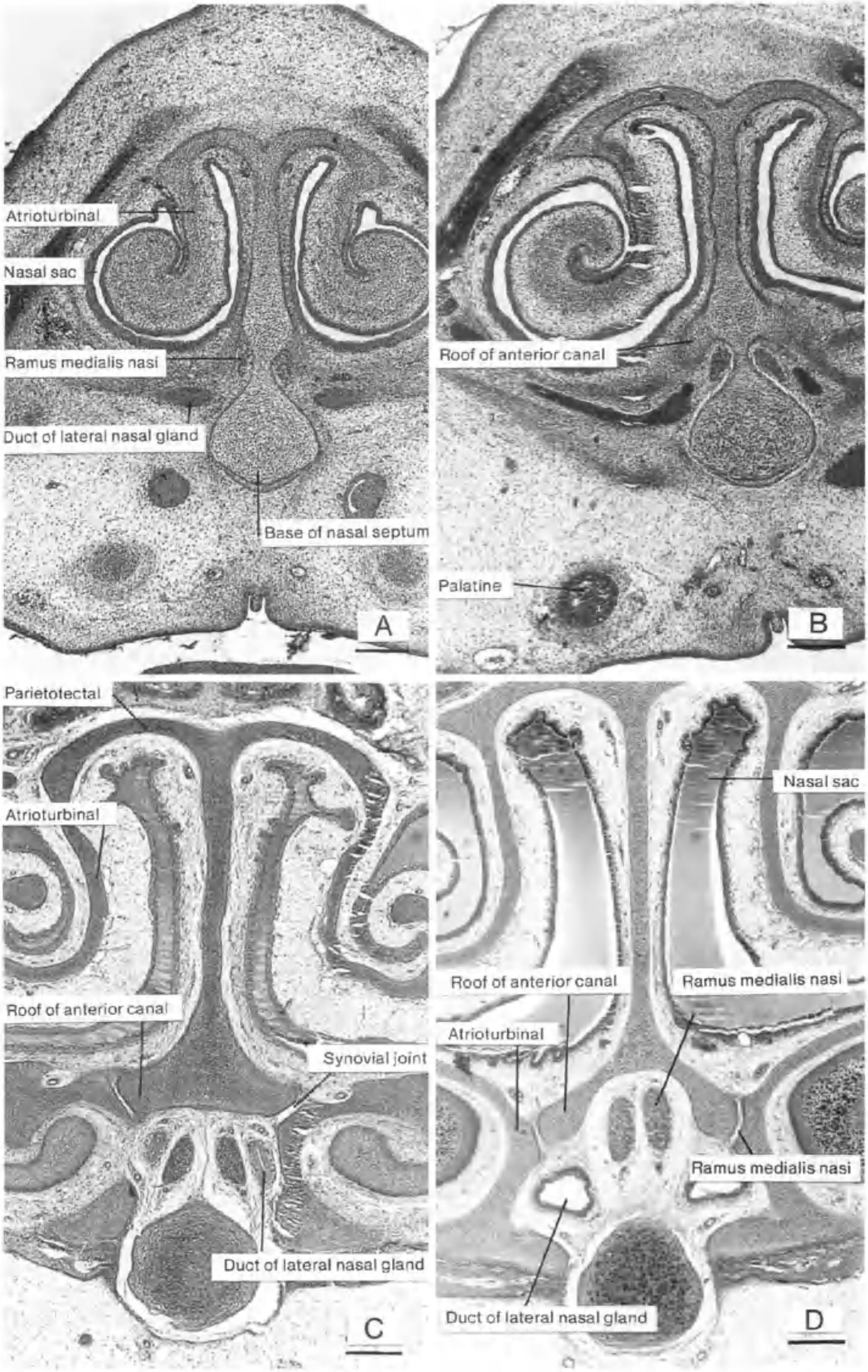
Atrioturbinal
Nasal sac
Ramus medialis nasi
Duct of lateral nasal gland
Base of nasal septum
A
Roof of anterior canal
Palatine
B
Parietotectal
Atrioturbinal
Roof of anterior canal
Synovial joint
Duct of lateral nasal gland
C
Nasal sac
Roof of anterior canal
Ramus medialis nasi
Atrioturbinal
Ramus medialis nasi
Duct of lateral nasal gland
D

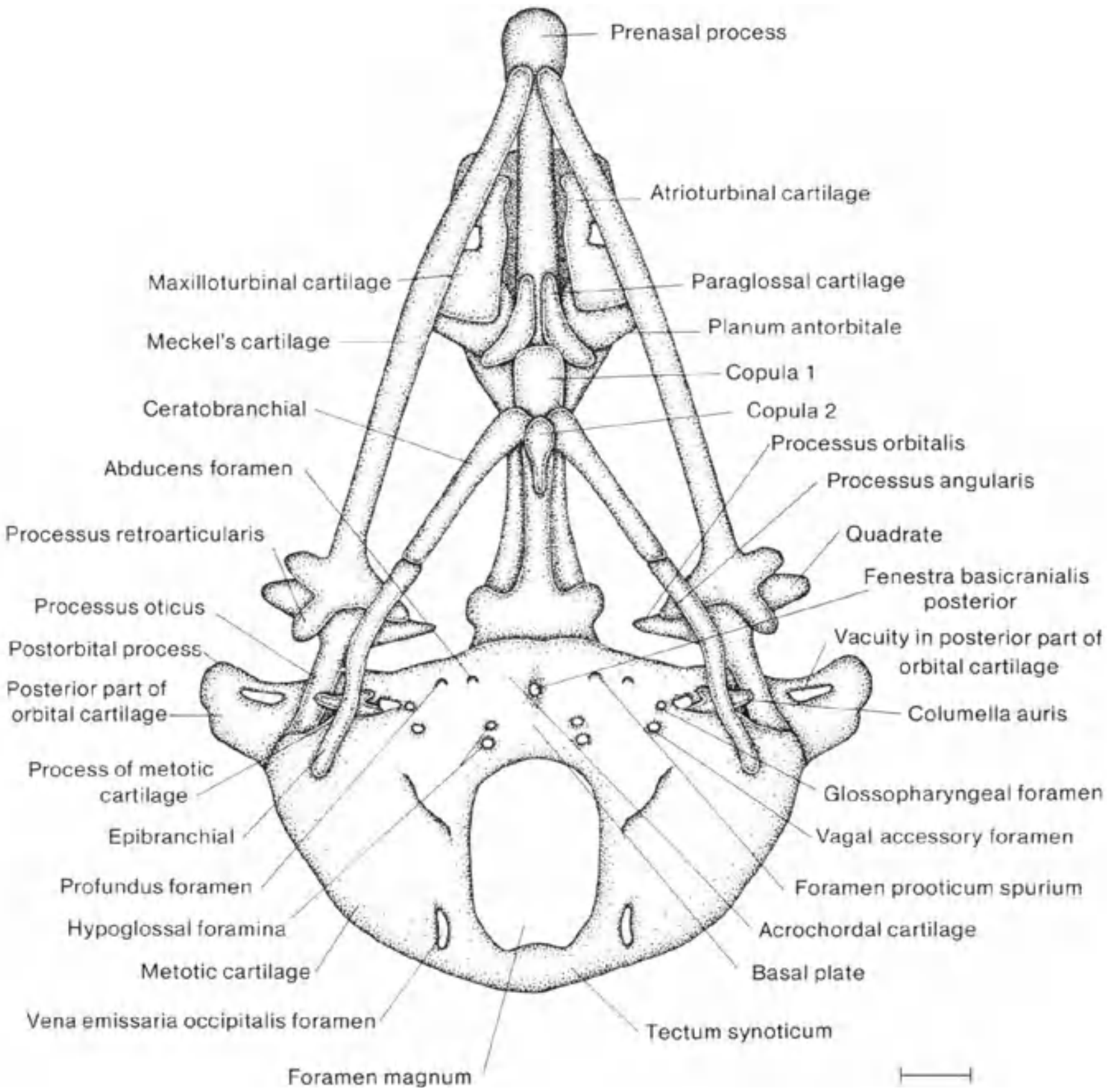

**Fig. 27.** Stage IV. Reconstruction of chondrocranium (norma ventralis). *Scale bar*, 1 mm

lateral lower side of the quadrate, a shallow groove has developed, lodging the posterior end of the quadratojugal (Fig. 24).

Around the columella auris the middle ear cavity has developed by the expansion of the end of the medial portion of the hyoid visceral cleft. This expansion has narrowed the wide area of connective tissue between the medial part of the hyoid cleft and the inner end of the auditory meatus into a tympanic membrane in which the extra- and supracolumellar processes of the columella auris are embedded.

The paraglossal cartilages are mostly chondrified, except for their anterior tips which are still mesenchymatous. Their anterior portions lie close to the

◁ **Fig. 26A–D.** Photomicrographs of transverse sections through the nasal capsule in the region of the anterior canal for the ramus medialis nasi. **A** Stage IV; *scale bar*, 200 µm. **B** Stage V; *scale bar*, 190 µm. **C** Stage VI, 14-day embryo; *scale bar*, 170 µm. **D** Stage VI, 16-day embryo; *scale bar*, 200 µm midline, while their broader posterior portions diverge lateroventrally to lie laterodorsal to the anterior end of copula 1. Copula 1 and 2 have increased in size and length and the posterior narrow tip of copula 2 is bent downwards (Fig. 27).

The epibranchial reaches further back than in the previous stage and its posterior tip is curled upwards (Fig. 24).

## 3.5 Stage V

Total length of embryos: 65 mm and 67 mm (Stage 36) and 73 mm (Stage 37 of Hamburger and Hamilton 1951). 10 and 11 days' development.

Only minor differences occur between the embryos of 10 and 11 days' development. The main differences are an increase in the size of the vacuity in the posterior part of the orbital cartilage and further resorption of the pila antotica around the profundus branch of the trigeminal nerve. Apart from these differences the chondrocrania are more or less identical and will therefore be described as one.

### *3.5.1 The Basal Plate and Otic Capsules*

Further resorption of the anterior end of the basal plate has liberated the oculomotor nerve from its foramen and it now passes over the anterior end of the acrochordal. No further resorption of the basal plate around the chorda has taken place.

Resorption along the periphery has decreased the size of the posterior part of the orbital cartilage and resorption around the central vacuity has increased the size of the latter (Fig. 28). The posterior part of the orbital cartilage has thus been reduced to a thin platelike structure with a large central vacuity.

The posterior part of the orbital cartilage has established a second connection, the orbitocapsular commissure (Fig. 28), between the orbitocapsular and prootic processes to form the foramen prooticum spurium medial to the commissure. The maxillary and mandibulary branches of the trigeminal nerve pass through this foramen.

In the younger embryo (10 days) the posterior part of the orbital cartilage is still, as in the previous stage, attached to the basal plate by both the pila antotica and pila antotica spuria, but in the older embryo (11 days) the process of resorption in the pila antotica, already evident in the previous stage, has resulted in the disappearance of the anterolateral border of the foramen prooticum so that the profundus branch of the trigeminal nerve lies in a groove on the lateral surface of the remainder of the pila antotica. The posterior part of the orbital cartilage is thus connected to the basal plate only by the more laterally situated pila antotica spuria. This condition is described by Tonkoff (1900) and is also shown by the Ziegler copy of Tonkoff's model.

The dorsal tip of the otic process of the quadrate has developed two heads. The medial head fits into a concavity in the wall of the otic capsule (Fig. 29), and the lateral head into a concavity formed laterally by the anteroventral corner of the squamosal and medially by a ridge of better chondrified cartilage

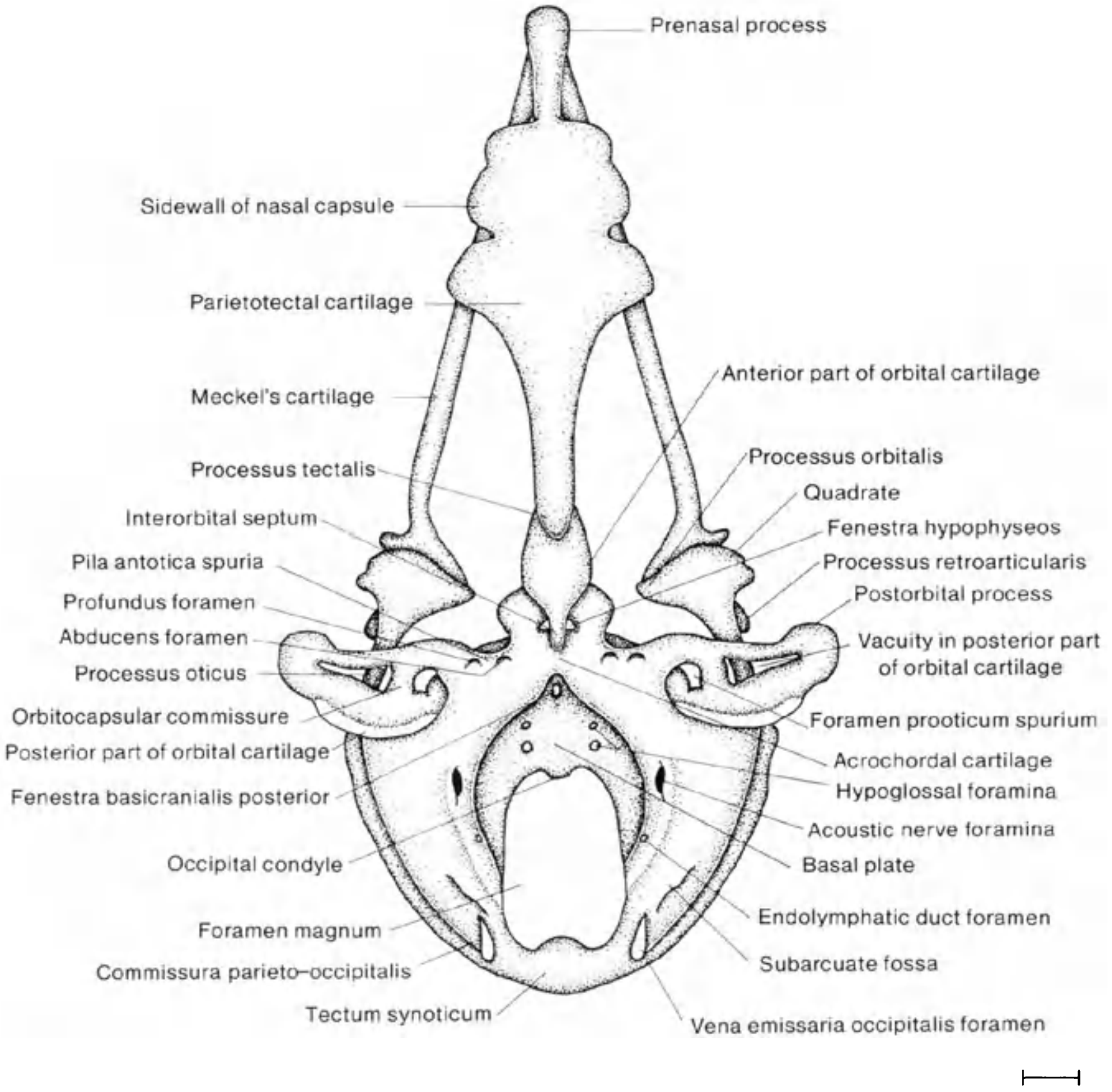

**Fig. 28.** Stage V. Reconstruction of chondrocranium (norma dorsalis). *Scale bar*, 1 mm

on the ventral surface of the base of the prootic part of the orbitocapsular commissure (Fig. 30A). In the 10-day embryo only dense connective tissue is present between the heads and the entities forming the concavities, but in an 11-day embryo a separate cup-shaped structure has chondrified in the dense connective tissue between the squamosal and the lateral head of the otic process. Later this will fuse with the cartilaginous ridge on the ventral surface of the orbitocapsular commissure and together they will form the cartilaginous lining of the articular surface for the lateral head of the otic process (Fig. 30A). The ventral edge of the squamosal has established contact with the anterodorsal surface of the metotic cartilage.

The otic capsule and the tectum synoticum are now fully chondrified. The cartilage of the otic capsule, which is in a more advanced state of chondrification, passes over gradually into the younger cartilage of the tectum synoticum. Hypertrophy of the chondrocytes has taken place in the pars lateralis of the occipital region and is continued posteriorly into the pila occipitalis. This area is also surrounded by a thin layer of perichondral bone.

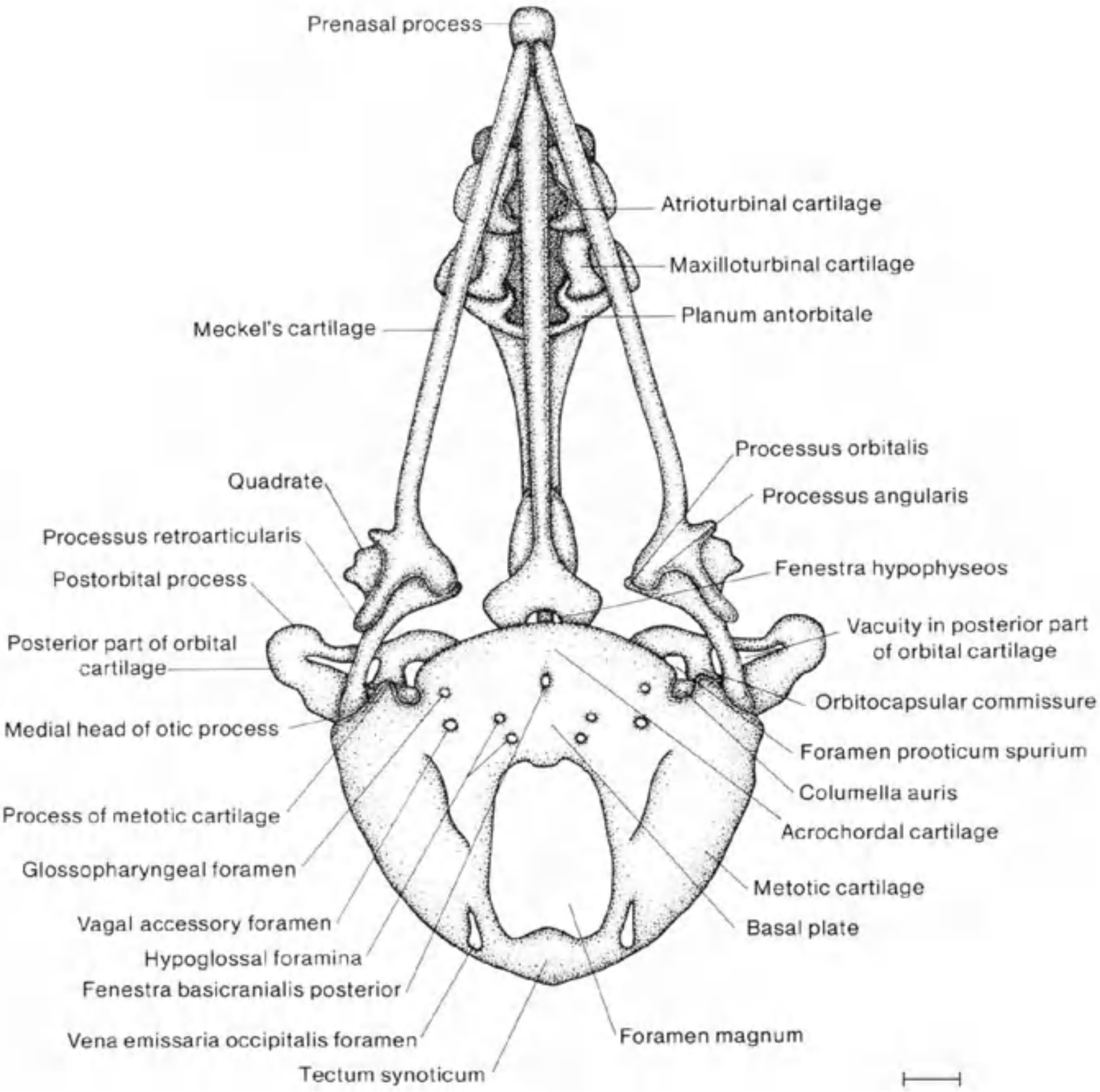

**Fig. 29.** Stage V. Reconstruction of chondrocranium (norma ventralis). *Scale bar*, 1 mm

From the orbitocapsular commissure a dorsolateral ridge extends backwards on the lateral side of the canalis semicircularis anterior to where the pila occipitalis fuses with the posterior end of the otic capsule. This ridge has been described in *Rhea* (Müller 1961) as a commissura parieto-occipitalis (Fig. 28). It was also found in *Fulica* (Macke 1969) and in *Melopsittacus* (de Kock 1987).

The metotic cartilage has a short, anteriorly directed process at its anterior edge which lies ventral to the columella auris. This process is not homologous with the process of the metotic cartilage found in *Euplectes* (Engelbrecht 1958) and in *Melopsittacus* (de Kock 1987), described there as situated more laterally and closely associated with the ventrolateral region of the squamosal. The process in *Gallus* lies more medially, ventral to the otic capsule, similar to the condition in *Fulica* (Macke 1969).

In all specimens of this stage there are two foramina for the branches of the hypoglossal nerve on each side.

A synovial cavity now separates the occipital condyle from the articular facet on the atlas, to which it was until now attached by mesenchyme.

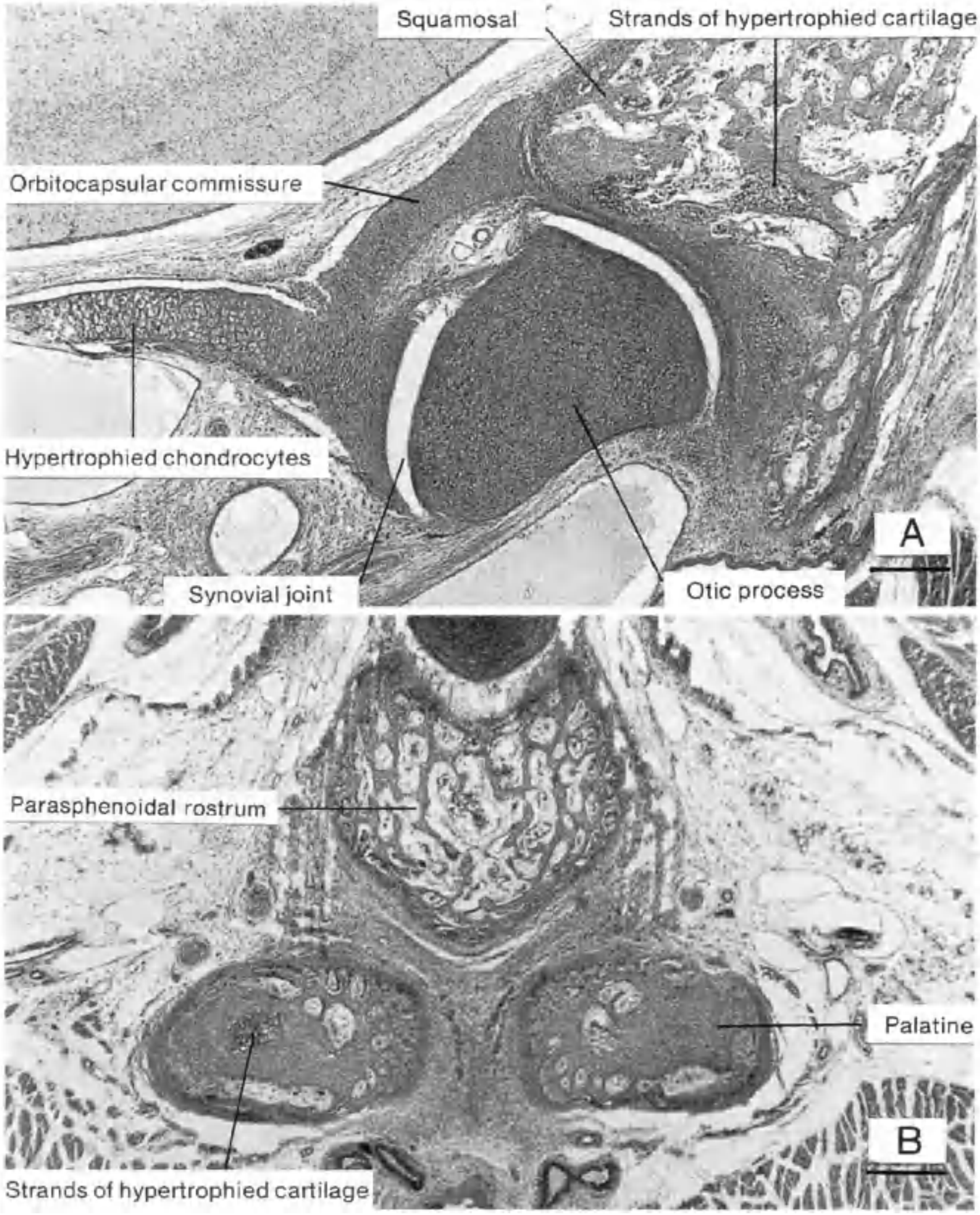

**Fig. 30 A–C.** Stage VI. Photomicrographs of transverse sections. **A** Through lateral head of otic process of the quadrate. **B** Through orbital region. **C** Through concavity of quadrate for quadratojugal. *Scale bars*, 170 μm (**C** see page 48)

### *3.5.2 The Anterior End of the Chondrocranium*

The process of resorption in the roof of the incisura carotica of the previous stage has spread ventrally into the infrapolar process and the protuberance on the ventral surface of the basal plate so that the incisura carotica is wide open again. The cellular remains of the cartilage now surround the internal carotid artery in this region. While reduction in the cartilaginous boundaries

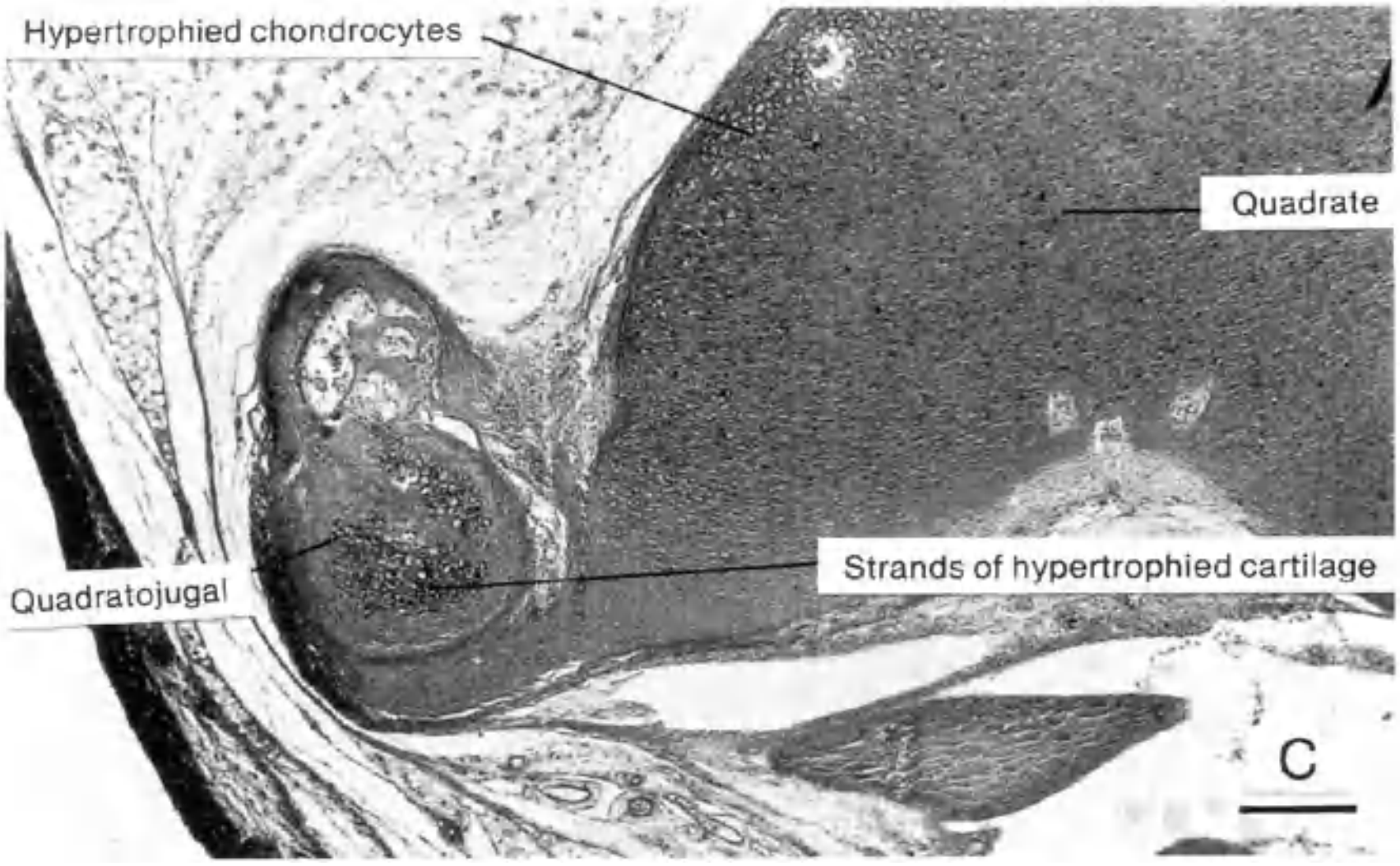

**Fig. 30C** (Legend see page 47)

took place, ossification of the parasphenoid occurred, converting the incisura into a foramen. The platelike parasphenoid forms a floor for the hypophysial pit and from its dorsal surface a transverse plate rises to form an osseous lining for the anterior wall of the pit (Fig. 16C).

Resorption around the ophthalmic artery has increased the size of the ophthalmic foramen.

The nasal capsule is more or less the same as in the previous stage, except for a more advanced state of chondrification, especially in the older (11-day) embryo, and an extension of the floor in the region of the atrioturbinal. The turbinals are almost fully chondrified to the ends of the scrolls, except for the atrioturbinal which still consists mostly of mesenchymatous tissue or young cartilage towards the tectum nasi. Between the fenestra narina and the posterior end of the atrioturbinal the ventral edge of the sidewall which was turned only slightly inwards in the previous stage has extended as a procartilaginous floor beneath the lateral part of the nasal sac in this region.

In the 10-day embryo the mesenchymatous anlage of the lateral wall of the posterior canal of the ramus medialis nasi has chondrified and is closely applied to the nasal septum. There is however no continuity of intercellular deposit yet and the common perichondrium between the entities is plainly visible. In the 11-day embryo there is continuity of intercellular substance between the septum and the ventral edge of the lateral wall while the dorsal edge is only closely applied to the septum (Fig. 25B).

In the region of the anterior canal for the ramus medialis nasi the floor is fused to the mesenchymatous posterior end of the atrioturbinal which in turn is fused to the anterior region of the roof and lateral wall of the anterior canal for the ramus medialis nasi. The procartilaginous roof and lateral wall of the anterior canal for the ramus medialis nasi is chondrified except for the

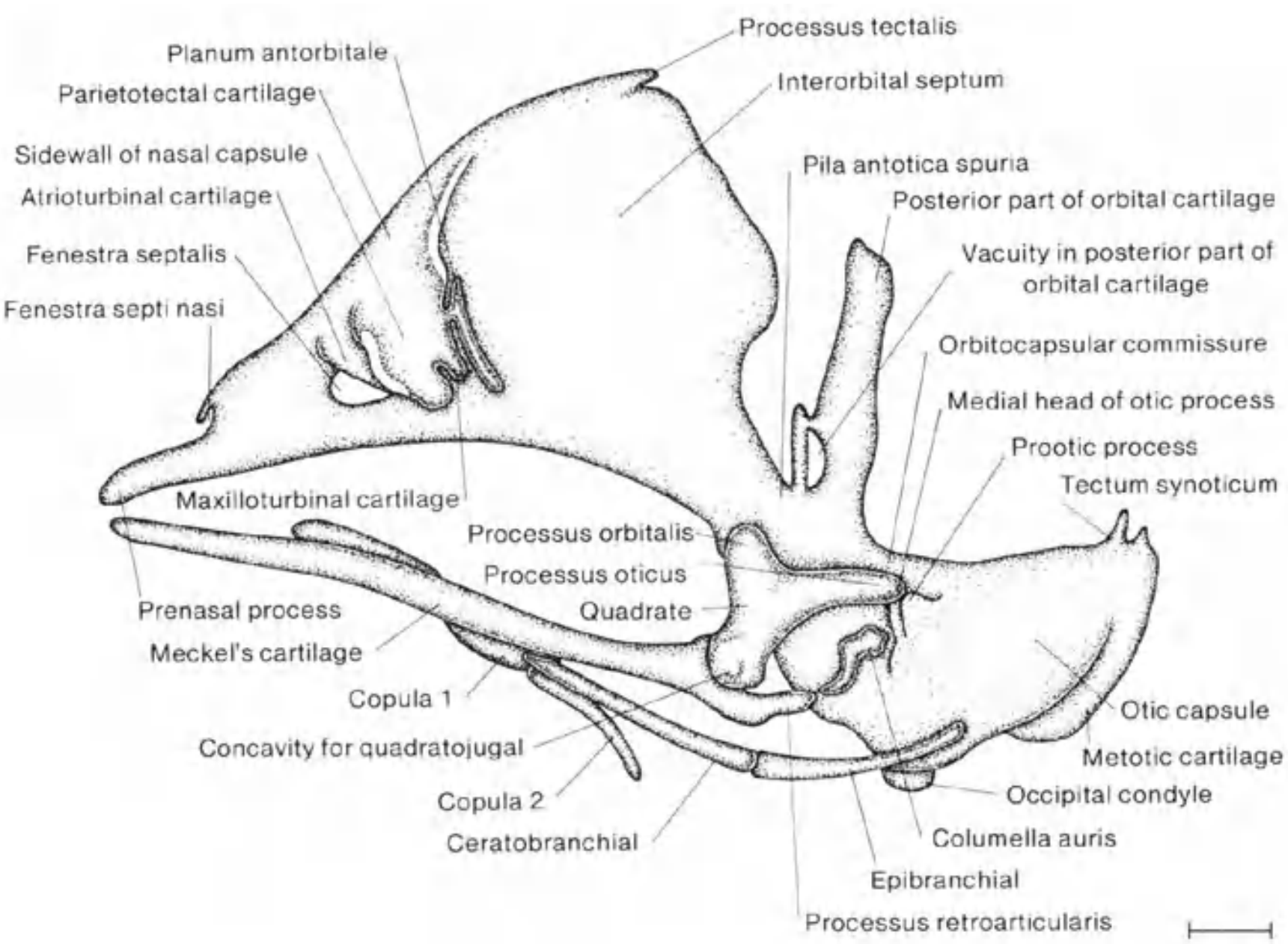

**Fig. 31.** Stage V. Reconstruction of chondrocranium (norma lateralis). *Scale bar*, 1 mm

posterior end of the ventral edge which is still mesenchymatous. In the region of the canal, the nasal septum immediately above the base has become thinner (Fig. 26B).

In certain areas the interorbital septum is thinner than in the previous stage, but in none of the specimens has a fenestra yet developed.

The anterior part of the orbital cartilages has decreased in size, but the olfactory nerve is still enclosed in its short canal on the inside of the anterior part of the orbital cartilage and the posterior extension of the parietotectal cartilage. The processus tectalis has now chondrified.

### *3.5.3 The Visceral Arches*

Meckel's cartilage has lengthened further and has straightened out, resulting in its anterior tip lying directly beneath the tip of the prenasal process (Fig. 31). Posteriorly, the processus retroarticularis extends further backwards. A synovial cavity has developed between the ventral end of the quadrate and Meckel's cartilage. The otic process of the quadrate is still synchondrotically connected to the otic capsule. The relations of the otic process to the otic capsule and adjacent structures have already been described.

Ossification of the quadrate has started in the form of a cylinder of perichondral bone around the middle part of the otic process. Inside this bony cylinder the chondrocytes are hypertrophied.

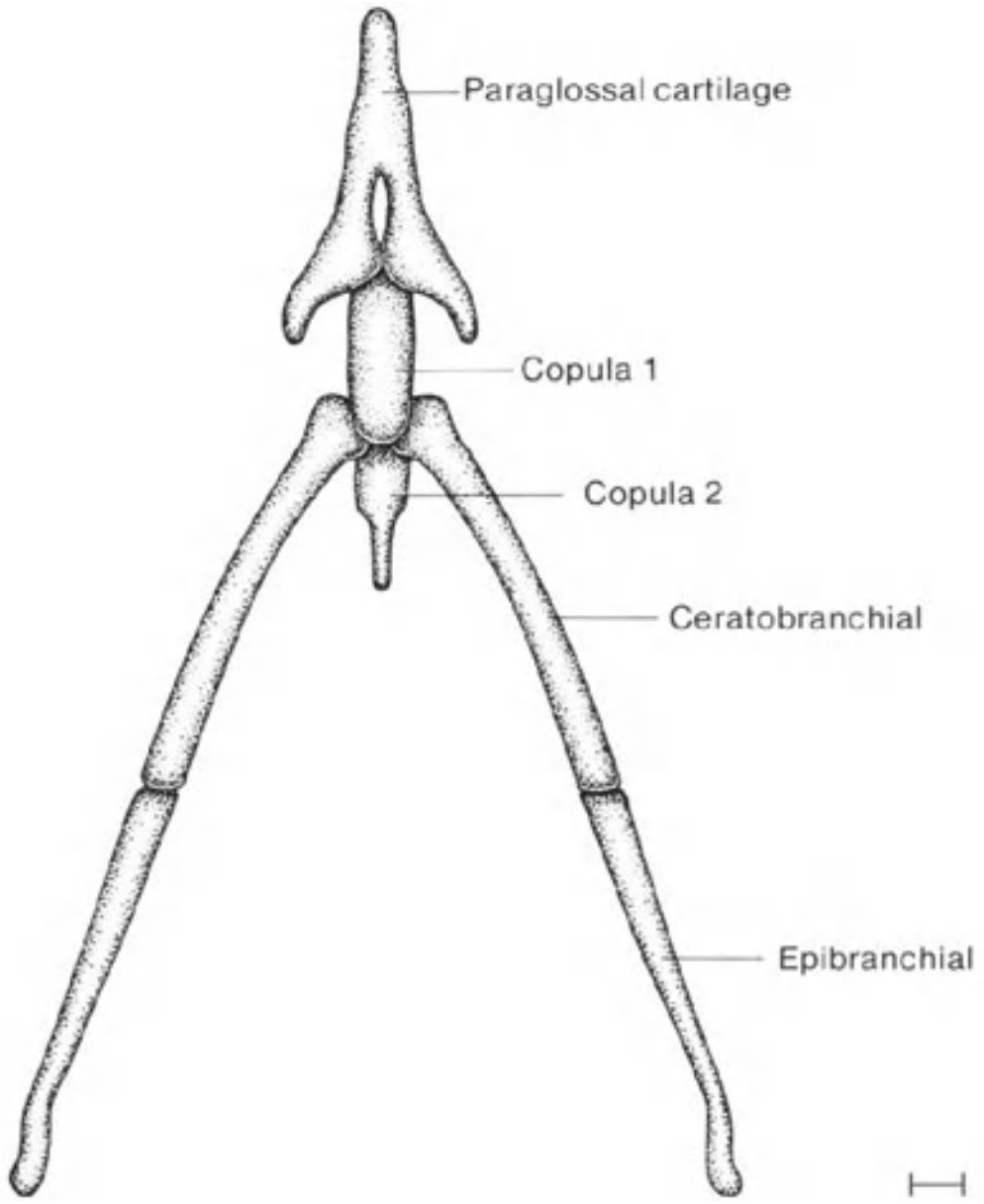

**Fig. 32.** Stage V. Reconstruction of hyoid apparatus (norma dorsalis). *Scale bar*, 1 mm

There has been no structural change in the columella auris, except for fuller chondrification of the different parts. The footplate of the stapes fits into a fenestra ovalis, which has now formed through the loss of intercellular substance of the capsular wall surrounding the footplate.

The paraglossal cartilage is in a more advanced state of chondrification, except for its anterior end which is still mesenchymatous. In the 10-day embryo the anterior ends of the paraglossal cartilage have fused along the midline, though still apart posteriorly. In the 11-day embryo the medial sides are synchondrotically connected to each other posteriorly, resulting in an elongated opening along the midline just anterior to the connection (Fig. 32). The different parts of the hyoid apparatus can still be distinguished from one another. The posterior parts of the cerato- and epibranchials are surrounded by a layer of perichondral bone inside which the chondrocytes are hypertrophied.

## 3.6 Stage VI

Total length of embryos: 95 mm and 118 mm (Stages 40 and 41 of Hamburger and Hamilton 1951). 14–16 days' development.

Although ossification and pneumatisation of areas of the chondrocranium have taken place, no significant structural changes have occurred. A complete description of the chondrocranium will not therefore be given.

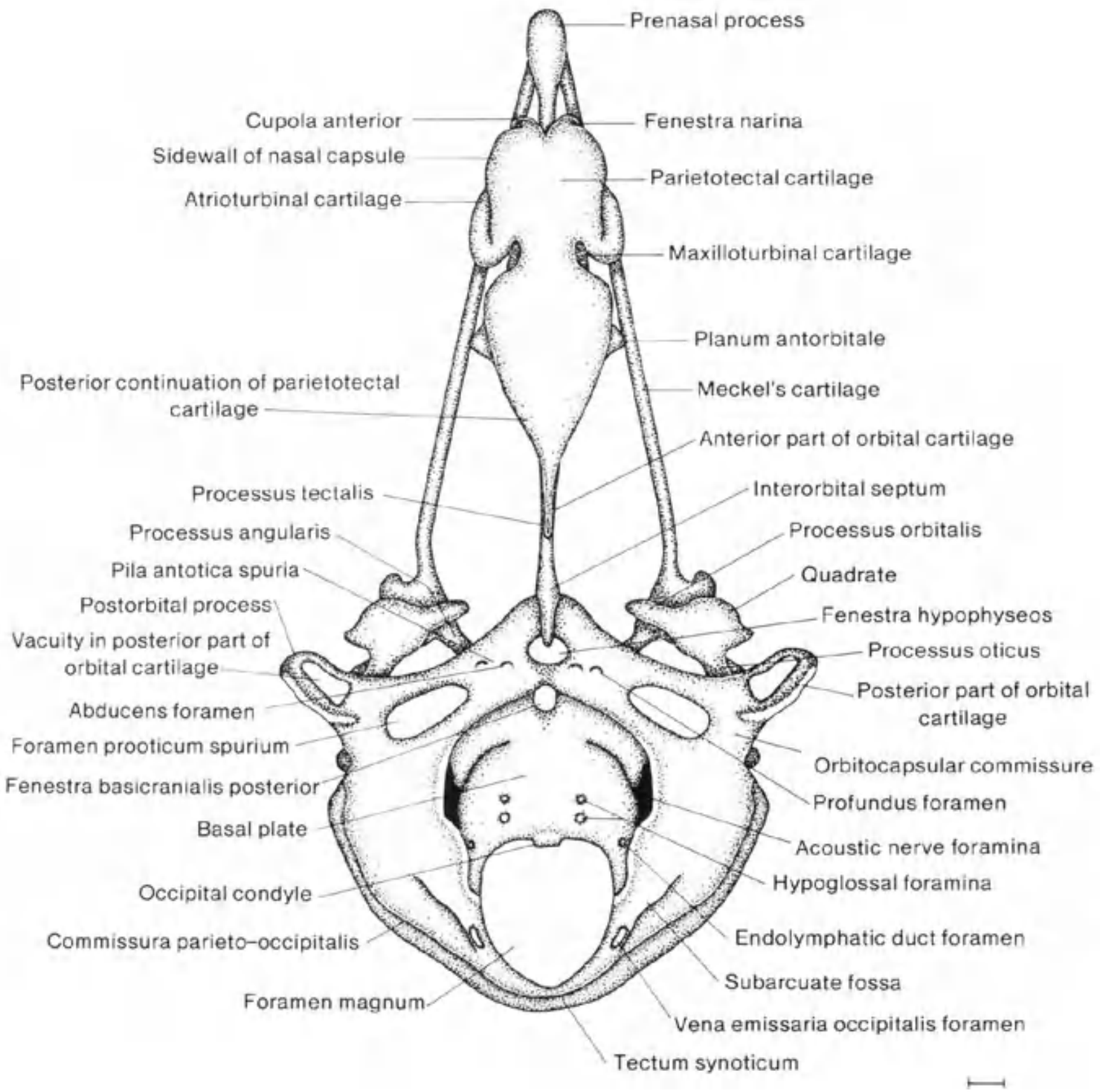

**Fig. 33.** Stage VI. Reconstruction of chondrocranium (norma dorsalis). *Scale bar*, 1 mm

### *3.6.1 The Basal Plate and Otic Capsules*

Where no endochondral ossification of the chondrocranium was present in the previous stage, and hypertrophy of the chondrocytes was seen only in the otic process of the quadrate, the cerato- and epibranchials, and the pila occipitalis, there are now extensive areas of hypertrophied chondrocytes as well as endochondral and perichondral ossification in various parts of the chondrocranium.

The anterior end of the basal plate and acrochordal has formed a layer of perichondral bone, with endochondral ossification at various localities. Further back, around the fenestra basicranialis posterior, the basal plate consists mostly of hypertrophied chondrocytes and is fused to the ventrally situated parasphenoid. The fenestra basicranialis posterior has increased in size through further resorption of the basal plate around the chorda (Fig. 33). The foramen for the abducent nerve has also increased in size and became lined with bone, especially in the older embryo (16 days).

Hypertrophied chondrocytes are present in the pila antotica spuria as well as in the posterior part of the orbital cartilage, and in the orbitocapsular commissure, especially in the region of the articulation facet with the lateral head of the otic process of the quadrate (Fig. 30A).

The separate cup-shaped structure that chondrified between the squamosal and the lateral head of the otic process of the 11-day embryo has nearly fused with the ridge on the ventral surface of the base of the prootic part of the orbitocapsular commissure to form a continuous articular surface into which the lateral head of the otic process fits (Fig. 30A).

In an 18-day embryo the two cartilaginous entities have fused but the arrangement of the chondrocytes still indicates their previous boundaries. This is in agreement with the condition in *Apteryx* (T.J. Parker 1891) and *Podiceps* (Toerien 1971) where it is also possible to distinguish between the adjacent parts of the facet for the lateral head of the otic process.

The part of the articular lining lying against the squamosal is more intimately connected to it by strands of cartilage containing hypertrophied chondrocytes stretching into the squamosal (Fig. 30A). Similar cartilaginous strands are also present where the squamosal abuts against the metotic cartilage. Synovial cavities have formed around the lateral and medial heads of the otic process with a narrow strip of connective tissue separating them (Fig. 30A).

Centres of ossification have become established in the orbitocapsular commissure, the middle part of the metotic cartilage, the pila occipitalis, and the tectum synoticum, as well as in the vesicular part of the otic capsule.

Enlargement, as well as deepening of the fossa subarcuata, has taken place.

### *3.6.2 The Anterior End of the Chondrocranium*

The different parts of the trabeculopolar complex have nearly all ossified as the basisphenoid and parasphenoid rostrum (Fig. 30B). The only parts still possessing cartilaginous material are the dorsal ends of the polar and suprapolar cartilages, and the posterior end and base of the interorbital septum. The latter is underlain by the parasphenoid rostrum and a layer of perichondral bone has formed along the lateral sides of the base of the interorbital septum. Hypertrophy of the chondrocytes of the posterior part of the interorbital septum is present up to the optic chiasma. Ossification around the fenestra hypophyseos has extended dorsally into the ventral part of the polar cartilages but the foramen for the ophthalmic artery still passes through a cartilaginous foramen between the polar- and suprapolar cartilages. In an 18-day embryo, ossification has spread around the foramen and only the tip of the suprapolar is still cartilaginous.

The posterior end of the parasphenoid rostrum has formed an articulation on its ventrolateral side for the anterior end of the pterygoid. The articulation consists of a synovial cavity with a thick articular cartilage on either side of the cavity. W.K. Parker (1869) describes the formation of this articulation in an embryo at the commencement of the 3rd week of incubation. The posterior end of the pterygoid has developed an articulation below the base of the processus orbitalis with the medioventral side of the quadrate. A synovial cavity has developed between the two entities and cartilage has formed over the tip of

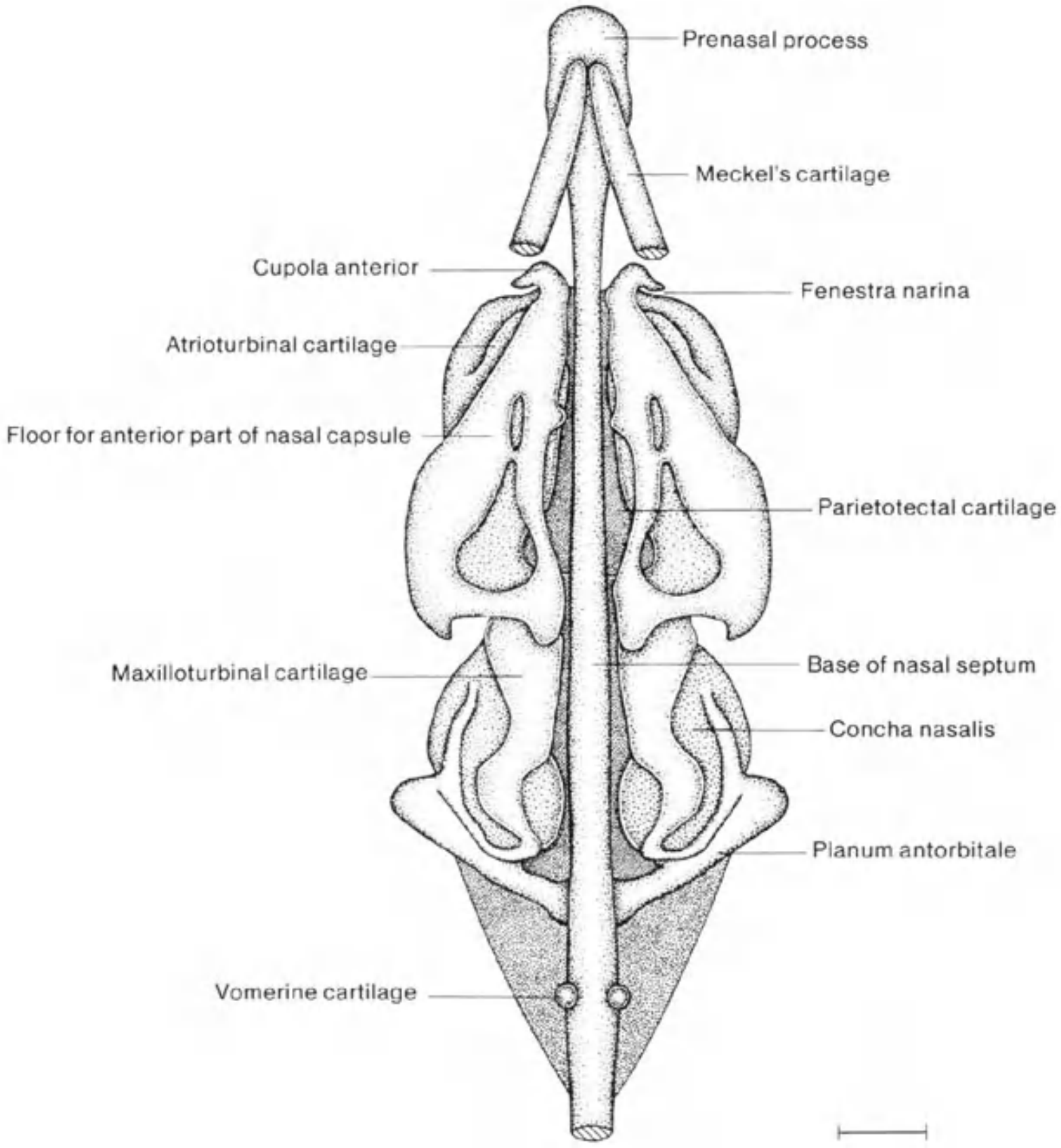

**Fig. 34.** Stage VI. Reconstruction of nasal capsule (norma ventralis). *Scale bar*, 1 mm

the pterygoid. Irregular strands of cartilage with hypertrophied chondrocytes extend into the pterygoid.

A large fenestra septalis has developed in the interorbital septum. The perichondria of the resorbed cartilage form a membrane across the fenestra. A similar formation of the fenestra septalis has been described by Bellairs (1958) in *Gallus*.

Further resorption of the anterior part of the orbital cartilage has resulted in the complete liberation of the olfactory nerve in the orbital region. In the younger embryo (14 days) the cartilage has been resorbed except for its posterior tip projecting dorsolaterally from the posterodorsal corner of the interorbital septum. In the older embryo (16 days) these have disappeared.

In the nasal capsule important structural changes have taken place and the capsule is now completely chondrified. The chondrocytes of the prenasal process are hypertrophied, as are those in the base of the nasal septum (Fig. 25C). Hypertrophy of the chondrocytes reaches from the base into the

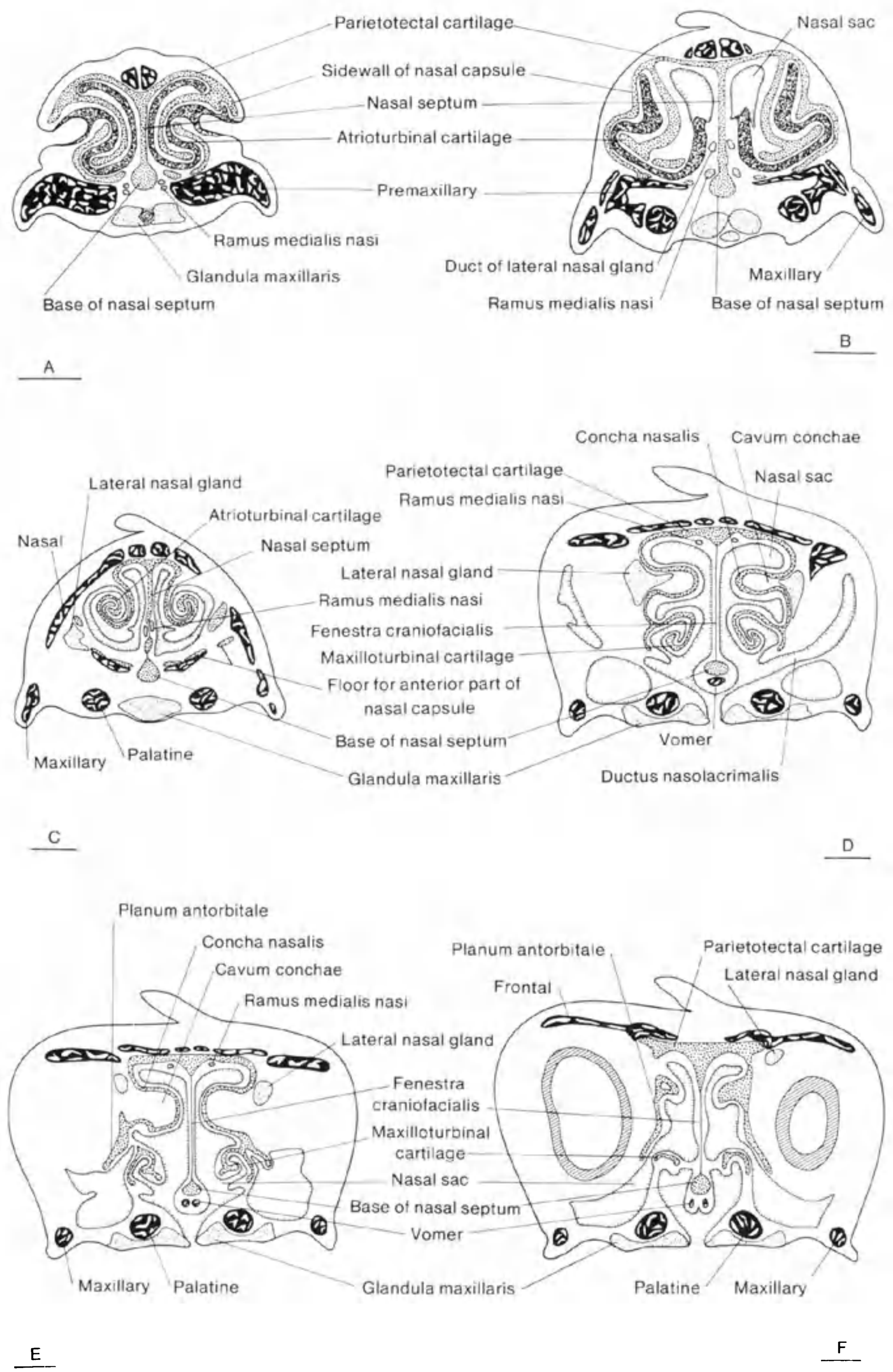

**Fig. 35A–F.** Stage VI. Series of anteroposterior transverse sections through the nasal capsule. *Scale bar*, 1 mm

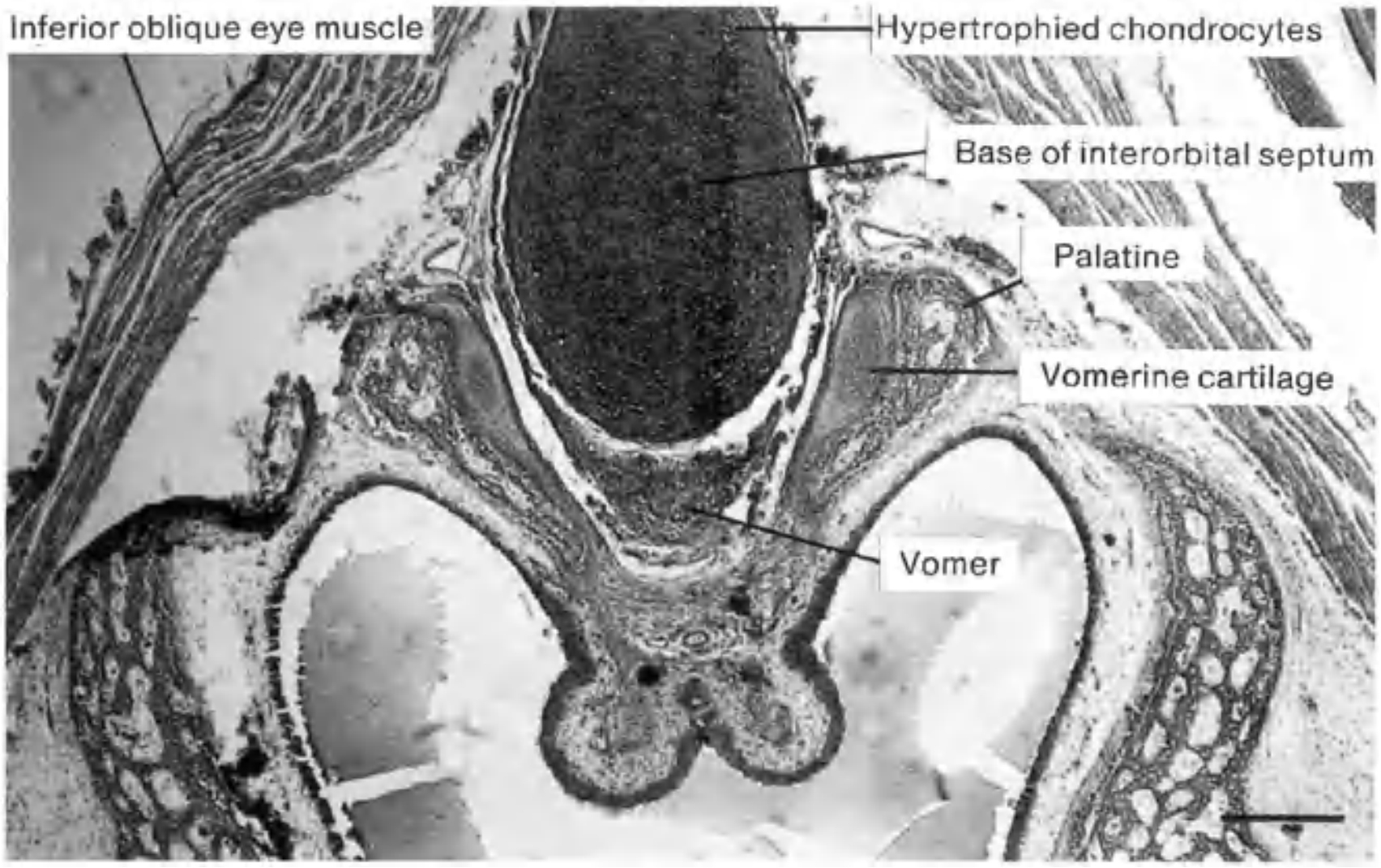

**Fig. 36.** Stage VI. Photomicrograph of transverse section through the anterior end of the orbital region showing the vomerine cartilages. *Scale bar*, 190 μm

ventral end of the nasal septum. Behind the fenestra craniofacialis, hypertrophy of the chondrocytes of the interorbital septum has commenced.

A small cupola anterior has formed (Fig. 34), bordering the fenestra narina anteriorly. The floor of the cupola anterior is continued posteriorly below the fenestra narina as an incomplete floor for the anterior part of the nasal capsule as far as the posterior end of the atrioturbinal (Fig. 34). The floor consists of a slender median bar along the lateral side of the base of the nasal septum separated by an interrupted space from a broader lateral region.

In the 14-day embryo, both dorsal and ventral edges of the lateral wall of the posterior canal for the ramus medialis nasi is completely fused to the nasal septum (Fig. 25C). In one 16-day embryo, however, the ventral edges are not fused (Fig. 25D). As these are already fused in an 11-day embryo it appears as if variation occurs in the sequence of fusion of the dorsal and ventral edges of the lateral wall for the nasal septum.

A synovial joint has developed in the mesenchymatous connection between the posterior end of the atrioturbinal and the anterior end of the roof of the anterior canal for the ramus medialis nasi. The posterior tip of the ventral edge of the lateral wall for the anterior canal of the ramus medialis nasi has fused with the nasal septum just above its base, thus forming a complete roof and lateral wall for the nerve. The nasal septum in this region, already thinner in the previous stage, has now disappeared and its former position is indicated by a thin membrane formed by the fused perichondria (Fig. 26C, D).

Between the canals, resorption of the nasal septum has taken place along the course of the ramus medialis nasi to form a narrow fissure (Fig. 35C). W.K. Parker (1869) describes this resorption of the nasal septum in the vicinity of the ramus medialis nasi only in a 7- to 9-month old fowl and considers the close contiguity of the median branches of the nasal nerve as the reason for the resorption of the cartilage between them. About halfway along the course of the ramus medialis nasi between the two canals the fissure is continuous with the fenestra craniofacialis.

Growth in the base of the nasal septum below the fenestra craniofacialis has resulted in a change of shape of this structure. Instead of the diamond-shaped outline of the previous stages (Fig. 25A, B) it has become rounded and flattened dorsoventrally, and because of the lateral expansion the ridges of the previous stages no longer appear as such (Fig. 35D–F). In an older embryo (18 days) the base of the nasal septum has begun to atrophy. It will eventually break through beneath the fenestra craniofacialis transforming it into the craniofacial notch.

Two cartilaginous nodules have developed in the older embryo (16 days) in the region behind the planum antorbitale (Fig. 36). They are flattened, round structures wedged in between the ventrolateral sides of the base of the interorbital septum and the palatine. W.K. Parker (1876) suggested the name vomerine cartilages for structures in this region of *Linota cannabina*. Engelbrecht (1958) also described similar structures in the same region of the palate of *Euplectes*.

### *3.6.3 The Visceral Arches*

Different stages of ossification and pneumatisation are found in the visceral arches. According to Bremer (1940) air sacs develop in most of the bones of the head through bone pneumatisation, except in the mandible which in most birds, including *Gallus*, does not become pneumatised.

Hypertrophy of the quadrate chondrocytes has taken place in the neck of the orbital process and a layer of perichondral bone has formed around this area. Further back the quadrate gradually becomes ossified (Fig. 30C) until a stage is reached in the otic process where endochondral ossification has replaced nearly all the cartilage and the otic process is surrounded by a layer of perichondral bone. The posterior end of the otic process is, however, still cartilaginous. The quadrate has also pneumatised with an air sac reaching from it into the pterygoid. This corresponds with the findings of Bremer (1940) that air sacs of the quadrate in *Gallus* are connected across the joints with those of the bones articulating with it.

A synovial cavity has developed between the quadrate and the posterior end of the quadratojugal which is covered by a thin layer of cartilage. The posterior end of the quadratojugal contains hypertrophied chondocytes (Fig. 30C). Jollie (1957) described the articulation of the quadratojugal with the quadrate in *Gallus* as a ball and socket joint.

Hypertrophy of the chondorcytes has taken place in the lateral wings of the paraglossal cartilage and in the copula towards the posterior end of copula 2. The division between copula 1 and 2 is still faintly recognisable through the slightly weaker affinity for the dyes used of the matrix between the two parts. A synovial cavity has developed between the copulae and the anterior end of the ceratobranchial. Except for a small anterior portion and a longer posterior portion the ceratobranchial has ossified and pneumatisation has set in in the ossified region. The cartilaginous transition of the ceratobranchial into the epi-

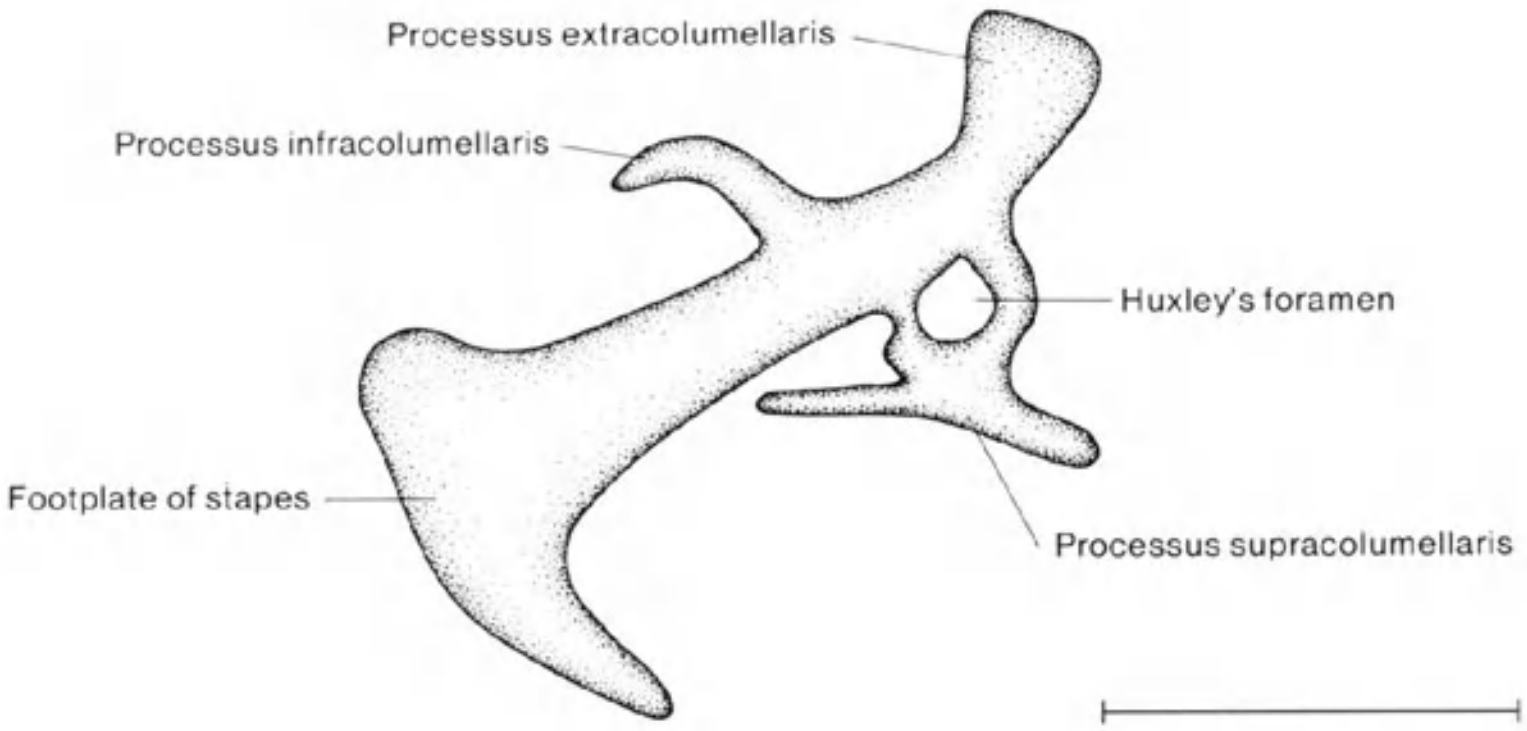

**Fig. 37.** Stage VI. Reconstruction of columella auris (norma dorsalis). *Scale bar*, 1 mm

branchial is also, like that between copula 1 and 2, just recognisable. The epibranchial consists of cartilage with hypertrophied chondrocytes, but there is no sign of perichondral ossification.

The chondrocytes in the columella auris are hypertrophied. A very thin layer of perichondral bone surrounds the stapes, and blood vessels infiltrate the footplate of the stapes. The different parts of the columella auris have become more prominent and Huxley's foramen has appeared in the solid base of the processus supracolumellaris of the previous stage (Fig. 37). Crompton (1953) states that the foramen in the penguin is closed off by fusion of the processus supracolumellaris lateralis. Smit and Frank (1979) label these two elements on either side of Huxley's foramen as the medial and lateral limbs of the processus supracolumellaris. At its free end, the processus supracolumellaris has formed two processes, directed medially and laterally.

Platner's ligament has formed, reaching from the processus supracolumellaris medialis laterally towards the otic process of the quadrate. A similar course for this ligament has also been described by Smith (1905) in birds in general and Frank (1954) in *Struthio*. Smith (1905) also describes ligaments stretching from the processus extracolumellaris and the processus infracolumellaris to the eustachian tube.

# 4 Résumé and Discussion

## 4.1 The Basal Plate and Otic Capsules

### *4.1.1 The Acrochordal Cartilage and Tip of the Chorda*

W.K. Parker (1869) described the first chondrifications in an embryo of *Gallus* on the fourth day of incubation. In a paper "On the structure and development of the bird's skull (Part II)", read before the Linnean Society in December 1875 and published in 1876 (date of bound volume 1879), he stated that his first stage in the 1869 description of the development of *Gallus* is "rather underdated" as the 4th day and applies to an embryo of the 5th day. In the description of the skull of the fowl in *The morphology of the Skull* (W.K. Parker and Bettany 1877) the first elements of the chondrocranium are present in an embryo at the end of the 5th day of incubation. Sonies (1907) describes the first chondrification, that of the acrochordal, in a 5-day embryo of *Gallus*.

The acrochordal cartilage, because of its greater affinity for the dyes employed, when observed in the 5-day stage appears to be the first part of the chondrocranium to make its appearance in *Gallus*. This is in accordance with the findings of Sonies (1907) in *Gallus* and *Anas* and de Beer and Barrington (1934) in *Anas*. This appears to be the general pattern in birds, the only recorded exceptions being *Phalacrocorax* (Slabý 1951 a) where the chondrification of the visceral arches precedes that of the acrochordal and *Struthio* (Frank 1954) where the acrochordal develops after the basal plate.

In the early stages of development the tip of the chorda does not pierce the anterior surface of the acrochordal. W.K. Parker (1869) describes the chorda in his first stage to "reach within a very slight distance of the pituitary space". It is only in an embryo of 8 days' incubation that the tip of the chorda is liberated from the cartilage through resorption of that part of the acrochordal in the immediate vicinity of the chorda. This course of events has also been described in *Euplectes* (Engelbrecht 1958), *Podiceps* (Toerien 1971), and *Melopsittacus* (de Kock 1987). A chorda tip piercing the ventral surface of the acrochordal in the youngest stages studied have been described for *Tinnunculus* (Suschkin 1899), *Spheniscus* (Crompton 1953), *Struthio* (Frank 1954), and *Colius* (Goldschmid 1972). These authors give no indication whether they regard this as an original or derived condition. Judging from Sonies' description (1907) of the course of development in the vicinity of the tip of the chorda in *Gallus* and *Anas*, the tip of the chorda which projects from the ventral surface of the acrochordal cartilage does so because it was not surrounded by the mesenchymatous anlage of the acrochordal cartilage.

Lang (1955) describes and illustrates a pronounced, ventrally flexed tip of the chorda in young stages of *Gallus*, *Columba* and *Melopsittacus*, labeling it the chorda descendens. Such extreme flexure was not found in the present investigation. In the young stages (3 and 4 days) only the very tip of the chorda has a slight ventral curve and in one 5-day embryo there is no trace of flexure at all. It thus appears that there is considerable variation in the degree of flexure of the tip of the chorda in *Gallus*. Absence of flexure of the tip of the chorda has been described in the younger stages of *Apteryx* (T.J. Parker 1888, 1891) and in some of the younger stages of *Podiceps* (Toerien 1971).

### *4.1.2 The Fenestra Basicranialis Posterior*

The fenestra basicranialis posterior develops at 8 days' incubation by resorption of the cartilage dorsal and ventral to the chorda. W.K. Parker (1869) describes this formation by resorption in an embryo of *Gallus* in the middle of the 2nd week of incubation. Sonies (1907), however, states emphatically that in *Gallus* the fenestra basicranialis posterior is present from the start and does not develop through resorption. He illustrates a fenestra basicranialis posterior in an embryo of 6 days 6 h of incubation. The development through resorption of the basal plate has been described in *Tinnunculus* (Suschkin 1899) and *Euplectes* (Engelbrecht 1958).

The dorsal and ventral areas of resorption in *Gallus* do not develop simultaneously as in *Euplectes* (Engelbrecht 1958), the dorsal area being the first to appear. In *Tinnunculus* (Suschkin 1899) the development of the fenestra basicranialis posterior starts as a depression on either the dorsal or ventral surface of the basal plate.

A fenestra basicranialis posterior is absent in *Spheniscus* (Crompton 1953), *Rhea* (Frank 1954; Müller 1961), *Caprimulgus* (Frank 1954), *Struthio* (Frank 1954), *Colius* (Goldschmid 1972), and *Melopsittacus* (de Kock 1987). The controversy over the condition in *Struthio* has been fully discussed by de Kock (1987).

### *4.1.3 The Otic Capsules*

W.K. Parker (1869) states that the otic capsule of *Gallus* is a constituent part of the basal plate. This view has been accepted by T.J. Parker (1891) for *Apteryx*, Suschkin (1899) for *Tinnunculus*, and Gaupp (1906) in his discussion of the otic capsule of birds in general. Sonies (1907), however, found an independent origin for the cochlear portion in *Anas* and *Gallus*, as did de Beer and Barrington (1934) in *Anas*. Since then, various authors have recognised a separate origin for the cochlear portion of the otic capsule from the basal plate; Slabý (1951a) in *Phalacrocorax*, Crompton (1953) in *Spheniscus*, and Macke (1969) in *Fulica*. Frank (1954) in *Struthio*, Lutz (1942) in *Dromaius*, Engelbrecht (1958) in *Euplectes* and de Kock (1987) in *Melopsittacus* found the cochlear portion of the otic capsule indistinguishably fused to the basal plate in their youngest stages. In the earliest stage of *Gallus* the cochlear portion is fused to the basal plate, but the procartilaginous cup-shaped cochlear portion can be distinguished from the basal plate as well as from the canalicular portion.

### *4.1.4 The Orbitocapsular Commissure and Otic Process*

Although the prootic process is present in most forms in which the development of the orbitocapsular commissure was investigated, it was not identified as an element in the orbitocapsular commissure of *Spheniscus* (Crompton 1953) and *Caprimulgus* (Frank 1954). This is probably the result of a lack of suitable developmental stages. When this connection between the posterior part of the orbital cartilage and the otic capsule is first described in these forms (as an orbitocapsular process) it exists already in the form of a commissure.

That this commissure is only established relatively late during development (when the other elements in the vicinity are well-chondrified and some have already started to be resorbed) is probably the reason for Slabý's (1951 a) conviction that in *Phalacrocorax*, where in his oldest stage the commissure still consists only of young cartilage, a fully chondrified commissure is never formed.

The otic process of the quadrate develops articular joints with the ventral surface of the orbitocapsular commissure, the otic capsule, and the squamosal. When first identified, the otic process is separated from the otic capsule and only makes contact in the 8-day embryo. At 10 days, two heads have developed. The lateral head will articulate with a cartilage-lined articular facet on the ventral edge of the squamosal laterally and the pleurosphenoid medially, while the medial head articulates with the prootic.

The controversy in the literature about the mode of articulation of the otic process is the result of descriptions based on material where the tip of the otic process has not yet obtained its full development and adult relationships with adjacent structures.

In *Gallus*, W.K. Parker (1869) describes inner and outer heads for the quadrate articulating with the otic capsule and squamosal respectively, but does not mention cartilaginous linings on these. He does mention, however, in *The morphology of the skull* (W.K. Parker and Bettany 1877) a cartilaginous facet on the otic capsule for the inner head of the quadrate.

T.J. Parker (1891) describes the double nature of the cartilaginous facet in an embryo of *Apteryx* at the time of hatching where the lateral head articulates with a cartilaginous facet situated on the anteroventral corner of the squamosal and in contact with, but clearly distinguishable from, a facet on "the outer surface of the cartilaginous junction between the prootic and alisphenoid (= pleurosphenoid) and extending on to the latter bone itself" (p. 47). He also poses the question whether the cartilaginous facet developing in connection with the squamosal is a neomorph or a part of the chondrocranium. He considered it comparable to and possibly homologous with the meniscus of mammals and certainly corresponding to the cartilaginous facet on the squamosal of lizards. Without going into detail, Suschkin (1899) states that in *Tinnunculus* the articulation facets for the quadrate develop as in *Apteryx* (T.J. Parker 1891).

Tonkoff (1900), in a footnote under his description of the squamosal, describes a small, roundish, cartilaginous part of the squamosal where the latter forms a joint with the quadrate in a 10-day 18-h embryo of *Gallus*. It is intimately fused with the squamosal and there is no histological distinction between this piece of cartilage and that of the neurocranium.

An examination of Tonkoff's model shows this element not as he describes it in the footnote, a small, roundish cartilage intimately fused to the squamosal, but a conspicuous, elongated nodule separate from the squamosal, situated on the posterodorsal end of the otic process, and abutting against the otic capsule. The otic process still shows no signs of differentiation into medial and lateral heads. He also states that, in his illustration, this cartilage is easily seen between the quadrate and the squamosal. This is however, not evident from his figure, which was copied as Gaupp's (1906) Fig. 393, from Tonkoff's model. In both these figures the conspicuous nodule of the model is not evident! The explanation for this is probably that in the production of the model the size of the element was exaggerated and the shape and exact location misrepresented and that Tonkoff (1900) rectified this in his figure.

Gaupp (1906), using Tonkoff's model as the basis for his description of the skull of *Gallus*, describes the articulation of the otic process to the otic capsule by means of this cartilaginous nodule, situated medially to the squamosal but, as far as can be judged from his description, apparently not in contact with the latter. He regards this element as a separate entity and states that the impression he obtained from a few available stages of *Gallus* was that it was initially connected to the otic capsule, an idea also favoured by De Beer (1937).

Sonies (1907) describes in *Gallus* a medial articulation of the processus oticus with the ventral surface of the prootic part of the orbitocapsular commissure and a lateral articulation with the medial surface of the lower part of the squamosal. Although he states that the articulations are as described by T.J. Parker (1891) and Suschkin (1899) he does not mention the cartilaginous lining of the facet on the squamosal. As his oldest embryo was only 10 days old this structure, which in the present series is present at 11 days, had probably not yet chondrified.

A cartilaginous lining for the facet on the squamosal for the lateral head of the otic process has also been described for *Caprimulgus* (Fourie 1955), *Euplectes* (Engelbrecht 1958), *Passer* (Saayman 1963), *Sturnus* (de Kock 1955), *Podiceps* (Toerien 1971), and *Melopsittacus* (de Kock 1987). This apparently also applies to *Phalacrocorax* where Slabý (1951 a) describes a cartilaginous formation between the quadrate, otic capsule, and the anlage of the squamosal and illustrates it as a flattened, cup-shaped structure between the quadrate and the squamosal.

In most forms this lining cartilage on the squamosal is apparently separated from the chondrocranium, but in *Apteryx* (T.J. Parker 1891), *Euplectes* (Engelbrecht 1958) and *Podiceps* (Toerien 1971) it is fused to the orbitocapsular commissure. In *Euplectes* (Engelbrecht 1958) it forms the complete cartilaginous lining for the facet on the squamosal and apparently chondrifies in continuity with the orbitocapsular commissure. In *Podiceps* (Toerien 1971), as in *Apteryx* (T.J. Parker 1891), the lining cartilage on the squamosal forms only the lateral part of the articular facet of the synovial joint for the lateral head of the otic process; the medial part is formed by cartilage of the orbitocapsular commissure. In *Podiceps* (Toerien 1971), the two parts of the cartilaginous lining are separated by an unchondrified zone; T.J. Parker (1891) merely states that they are in contact but clearly distinguishable.

The present material confirms the findings of T.J. Parker (1891) in *Apteryx* and Toerien (1971) in *Podiceps* that part of the cartilaginous lining for the lateral head of the otic process in *Gallus* chondrifies as a separate element in close connection with the squamosal before fusing to the medial part, formed by cartilage of the orbitocapsular commissure. In an 18-day stage the lining cartilage is continuous but the arrangement of chondrocytes still indicates the boundary between the components.

The impression has been conveyed by some authors (Gaupp 1906; de Beer 1937) that this cartilage in *Gallus* is of capsular origin and de Beer (1937) goes as far as to wonder about its possible relation to the hyoid arch skeleton. These authors emphasise the relations between the cartilaginous element and the otic process and otic capsule but do not describe the precise relationship of this element to the squamosal. The reason for this is that they base their descriptions of the condition in *Gallus* on Tonkoff's model rather than on his description.

The present material shows that this cartilaginous nodule chondrifies independently of the neurocranium and is intimately connected from the start to the medial surface of the squamosal. It only later fuses with the cartilaginous ridge on the base of the prootic part of the orbitocapsular commissure to form the cartilaginous surface with which the lateral head of the otic process articulates. There is no doubt that the part of the lining cartilage of the facet for the lateral head of the otic process arising from a separate anlage in *Gallus*, as in Apteryx and *Podiceps*, is a neomorph, like those cartilages on the posterior end of the quadratojugal, between the pterygoid and palatine, and between them and the rostrum.

### *4.1.5 The Pila Antotica Spuria*

Except in *Podiceps* (Toerien 1971) where it develops as a process of the basal plate which fuses with the posterior part of the orbital cartilage, the pila antotica spuria develops in all other forms as a process of the posterior part of the orbital cartilage. In *Struthio*, however (Brock 1937; Frank 1954), it is described as developing from the pila antotica but, judging from Brock's (1937) and Frank's (1954) figures, it seems more likely that it develops from the posterior part of the orbital cartilage as in all other forms except *Podiceps* (Toerien 1971).

The posterior tip of the pila antotica spuria can fuse with the basal plate as in *Anas* and *Gallus* (de Beer and Barrington 1934) and *Euplectes* (Engelbrecht 1958), to the pila antotica (vera) as in *Phalacrocorax* (Slabý 1951a) and *Struthio* (Brock 1937; Frank 1954), to the lateral abducent commissure as in *Spheniscus* (Crompton 1953), or to the cochlear portion of the otic capsule as in *Strix* (May 1961). In *Dromaius*, Kesteven (1942) regards a cartilaginous structure lying in the position of a pila antotica spuria, but not fusing with the basal plate, simply as the posterior part of the orbital cartilage.

In *Gallus* the pila antotica spuria starts as a process of the ventral edge of the posterior part of the orbital cartilage in an 8-day embryo and fuses with the lateral surface of the basal plate at 9 days. Resorption of the acrochordal and pila antotica also starts at 9 days, leading to a condition in the 11-day embryo where the pila antotica has disappeared and the posterior part of the orbital cartilage is connected to the basal plate only by the pila antotica spuria. This succession of changes has also been described for *Gallus* by de Beer and Barrington (1934). In the Ziegler copy of Tonkoff's model of the skull of *Gallus* the anterolateral border of the foramen prooticum has already been resorbed, but a remnant of the pila antotica is still present on the median side and the profundus branch of the trigeminal nerve lies in a groove on its lateral surface.

### *4.1.6 The Tectum Synoticum*

W.K. Parker (1869) describes the closure of the foramen magnum in 5- to 7-day embryos of *Gallus* by the exoccipital lamina "growing upwards to meet its fellow in the superoccipital region and thus enclose the spinal chord" (p 764). This creates the impression that the dorsal border of the foramen magnum is not formed by a separate cartilaginous element.

According to Sonies (1907) the dorsal border of the foramen magnum in *Gallus* is formed by the tectum synoticum, the anlagen of which appear in a 9-day embryo as two cartilaginous strips along the posterior region of the superior semicircular canals before fusing with one another and with the otic capsules.

In the present series, procartilaginous strips make their appearance in the 8-day stage and are already attached to the otic capsule. This attachment by means of two roots leaves a large slitlike foramen for the vena emissaria occipitalis. The strips only fuse in the midline at 9 days. After fusion in the midline the tectum synoticum is a vertical plate with a deep notch in the dorsal midline and is attached to the otic capsule by two roots, the more ventral of which has also spread over the posterior end of the pila occipitalis.

According to de Beer (1937), apparently basing his statement on descriptions by Tonkoff (1900) and Gaupp (1906), the ventral root in *Gallus* "gives the impression of being attached to the dorsal end of the occipital arch" (p. 280). Tonkoff's model of the skull of *Gallus* shows the tectum synoticum as described above, but the ventral attachment is only with the otic capsule. De Beer's (1937) conception of the relationship of the elements in this area was probably gained by a study of a drawing in Gaupp (1906) of the dorsal aspect of Tonkoff's model which does give the impression that the ventral attachment could also be with the pila occipitalis. In the model, however, this is not the case and the pila occipitalis lies free below the otic capsule.

The statement by de Beer (1937) about *Gallus* has been interpreted by Toerien (1971) as a condition where a combined tectum synoticum and tectum posterius exists. The development of the dorsal border of the foramen magnum in *Gallus*, however, shows that the anlagen are attached to the otic capsule and that the element present is thus a tectum synoticum of which the ventral attachment spreads over the lateral surface of the pila occipitalis. This broadening of the ventral attachment on to the pila occipitalis cannot be regarded as a separate element, the tectum posterius, as it does not comply with the definition of the function of a tectum posterius, namely, to connect the occipital arches.

Toerien (1971) summarises the findings in connection with the closure of the dorsal border of the foramen magnum in different forms. Other forms where the tectum synoticum has a double attachment either to the otic capsule alone or to the latter and the occipital process (tectum posterius) has been described in *Anas* (de Beer and Barrington 1934), *Phalacrocorax* (Slabý 1951a), *Turdus* (Slabý 1951b), *Ardea* (Slabý 1952), *Struthio* and *Caprimulgus* (Frank

1954), *Rhea* (Müller 1961), *Podiceps* (Toerien 1971) and *Melopsittacus* (de Kock 1987).

## 4.2 The Anterior End of the Chondrocranium

### *4.2.1 The Incisura Carotica*

The confusion concerning the structures forming the borders of the incisura carotica has been fully discussed by Engelbrecht (1958), May (1961) and Goldschmid (1972). The anteroventral border of the incisura carotica, in which the internal carotid artery lies, was described by W.K. Parker (1869) as the "lingulae sphenoidales". Suschkin (1899) proposes the name "processus basitrabecularis" for this process from the posterior end of the trabecula to the basal plate in *Tinnunculus*. Sonies (1907) proposed the name "infrapolar process" as he could establish its development from the polar cartilage (Suschkin did not observe polar cartilages). Lutz (1942) retains the term processus basitrabecularis and also describes a processus basipterygoideus projecting ventrolaterally from the processus basitrabecularis in *Dromaius*. Brock (1937), de Beer (1937), Crompton (1953) and Frank (1954) describe the processus basipterygoideus as a processus basitrabecularis.

An infrapolar process has been described in a number of birds: *Passer* (Sonies 1907; de Beer 1937), *Anas* (Sonies 1907; de Beer and Barrington 1934), *Struthio* (Brock 1937; Frank 1954), *Turdus* (Slabý 1951b), *Rhea* (Müller 1961), *Strix* (May 1961) and *Melopsittacus* (de Kock 1987).

### *4.2.2 The Intertrabecula*

The problem of the presence of an intertrabecula in birds has been discussed by Bellairs (1958), Müller (1961), May (1961), Toerien (1971), Goldschmid (1972) and de Kock (1987).

In his classic study of the development of the skull of *Gallus* in *On the structure and development of the skull of the common fowl* (*Gallus domesticus*) (1869) and of additional stages in "On the structure and development of the bird's skull (Part II)" (1876) W.K. Parker does not describe an intertrabecula and the illustrations do not show a separate element in this vicinity.

W.K. Parker first uses the term intertrabecula in 1880 for a cartilaginous rod lying between the cartilaginous trabeculae in *Chelone*, stretching from the hypophysis anteriorly to project beyond the anterior ends of the trabeculae as a prenasal process. In 1883, in a paper on Crocodilia, he describes the ventrally curved, anterior part of the intertrabecula of an embryo of the alligator as a prenasal process, and further refers the reader to an illustration showing the curved prenasal process in his description of the skull of the common fowl (1869, Plate 81), implying hereby that an intertrabecula also occurs in *Gallus*. He further states in the summary that the intertrabecula "is seldom absent (as in Ophidia), but in all forms that have a projecting snout this bar, rod, or plate forms the axis of such foregrowth of the skull" (W.K. Parker 1883, p 300).

In "On the morphology of the Gallinaceae" W.K. Parker (1890) briefly refers to the conditions in the prochordal tract in a chick after 1 week's incubation as being "made up of three 'trabeculae', the posterior paired bars and the anterior azygous rod or 'intertrabeculae' which ends in front as the prenasal rostrum" (p 215) and he labels the prenasal process in an illustration (Plate 22) of the skeleton of this embryo as the intertrabecula.

W.K. Parker (1869, 1876, 1890), describing relatively late stages in *Gallus*, did not see the intertrabecula as a separate element and it is clear, as already stated by Suschkin (1899), that his change of opinion about the presence of an intertrabecula in *Gallus* is not based on observations, but is an assumption based on conditions in *Chelone* and Crocodilia.

The first record of a separate intertrabecula in birds is the description and illustration of a separate mesenchymatous element between the anterior parts of the trabecula in *Tinnunculus* (Suschkin 1899). It develops later than the trabeculae and its independence was observed over several developmental stages.

De Beer (1937), however, considers it doubtful whether this structure in *Tinnunculus* is to be regarded as a distinct element. He produces Suschkin's (1899) original drawing showing the mass of mesenchymatous material between the trabeculae which Suschkin (1899) labelled the intertrabecula but did not annotate. [Compare Suschkin (1899, Table 1, Fig. 6) and de Beer (1937, Plate 100, Fig. 1).]

Sonies (1907) describes connective tissue between the medial edges of the separate cartilaginous trabeculae in *Gallus* and *Anas* but does not regard this as the anlage of a cartilaginous intertrabecula, as the process of chondrification by which the trabeculae fuse spreads from their medial edges into this intervening tissue. Sonies (1907) also points out that it is not clear from Suschkin's (1899) description whether he ever regarded the intertrabecula as a cartilaginous element that developed completely separately.

In a study of the development of the interorbital septum in Sauropsida, Bellairs (1958) investigated the role of an intertrabecula in the formation of this structure. The nasal and interorbital septa in *Gallus* first make their appearance at about 5 days' incubation as a condensation of mesenchyme stretching forward from between the nasal sacs and continued dorsally with the mesenchymatous anlage of the anterior part of the orbital cartilage. The base of the nasal and interorbital septum he labels "intertrabecula" (his Fig. 1 A, B). The trabeculae are illustrated as two bars (mesenchymatous according to the description) on the lateral sides of the posterior half of the intertrabecula.

The mesenchymatous trabeculae and the intervening intertrabecula are thus contiguous from the start, but Bellairs (1958) is of the opinion that the differences in appearance are sufficient to warrant the use of the term "intertrabecula".

In the present study the anlage of the interorbital septum makes its first appearance in a 5-day embryo as the procartilaginous azygous anterior part of the trabeculo-polar bars. Its dorsolateral edges extend dorsally beneath the anterior part of the brain as the procartilaginous anterior part of the orbital cartilage. In front of the level of the attachment of the inferior oblique eye muscle it passes over into the anlage of the base of the future nasal septum in the form of a wedge-shaped mesenchymatous ridge on the ventral surface of the ethmoid plate. These structures appear suddenly during development and there is no indication whatsoever that the azygous anterior part of the trabeculopolar bars, the trabecula communis, is ever paired, either as a procartilaginous or cartilaginous element as in *Tinnunculus* (Suschkin 1899), *Gallus* (Sonies 1907), *Anas* (Sonies 1907; de Beer and Barrington 1934), *Spheniscus* (Crompton 1953), *Struthio* (Frank 1954), *Euplectes* (Engelbrecht 1958), *Fulica* (Macke 1969) and *Colius* (Goldschmid 1972).

In the first stage, is there not only no indication of the possible paired nature of the trabecula communis but also no trace of an intervening element. The situation in the prechordal region of the first stage in *Gallus* is thus that the posterior elements, the polar cartilages, show the highest concentration of intercellular deposit and are clearly demarcated from surrounding mesenchyme. In the trabecular region there is a gradual decrease in intercellular deposit until the stage is reached anteriorly in the future nasal septum which consists of mesenchyme only, the demarcation from surrounding mesenchyme being less pronounced.

Subsequently, intercellular deposit progresses anteriorly from the trabeculae bordering the fenestra hypophyseos into the lateral regions of the previously procartilaginous trabecula communis. The result is that what was previously a single procartilaginous bar now appears as two cartilaginous bars with a procartilaginous keel wedged between them. This procartilaginous keel has been regarded as a separate element, the intertrabecula, by some authors but its histological distinctness in older embryos is merely the result of a slower process of intercellular deposit in this area.

The interorbital and nasal septa develop as dorsal upgrowths of this procartilaginous anterior region of the trabecula communis and histologically lag behind the trabeculopolar bar. This difference in the degree of chondrification, especially in older stages, between the base of the interorbital septum, the septum itself, and the anterior parts of the orbital cartilages has led various authors to regard the younger cartilage in the middle of the trabecula communis and continuous dorsally with the developing interorbital septum as a separate element, the intertrabecula, when in fact they did not observe its development as a separate element. The interorbital septum thus develops as an upgrowth of this less differentiated, medial part of the trabecula communis and not from a separate anlage. Anteriorly, this medial part is continued between the nasal sacs as the nasal septum and in front of the nasal sacs as the prenasal process.

In the avian chondrocranium it appears that a separate procartilaginous or cartilaginous intertrabecula has never been observed and is only identified in older stages as a region of the trabecula communis containing less intercellular deposit.

From W.K. Parker's (1880, 1883) descriptions of the development of the green turtle and the alligator, where an intertrabecula was originally identified as one of the elements of the chondrocranium, the impression is gained that an intertrabecula is only identified after chondrification. When first observed it is tightly squeezed between the cartilaginous trabeculae and no evidence is presented of a separate anlage.

### *4.2.3 The Nasal Capsule*

Except for the planum antorbitale and the paranasal cartilage, which in a few birds develop as separate anlagen, all parts of the nasal capsule appear to develop in continuity and the process of chondrification spreads out from the base of the nasal septum. After the development of the nasal septum the appearance of all elements of the nasal capsule is rather rapid. However, as in all avian chondrocrania, differentiation and chondrification in the nasal region is slower than in other areas. Resorption already takes place in the orbital region, while chondrification still takes place in the nasal region and extensive ossification is in progress in all other areas while certain structures in the nasal capsule are still developing.

Except for the resorption in the vicinity of the fenestra craniofacialis to form the craniofacial notch no notable resorption, namely that of the prenasal process and base of the nasal septum, is present and only commences after 16 days of incubation.

In the present study the nasal septum appears in the 5-day stage as a wedge-shaped mesenchymatous ridge along the ventral surface of the mesenchymatous ethmoid plate which is situated above the posterior region of the developing nasal sacs. Growth above this ridge in the 6-day stage forms a procartilaginous nasal septum which carries the ethmoid plate upwards and changes the previously concave dorsal surface into a convex shape. In the anterior region of the nasal sacs this convex ethmoid plate forms the procartilaginous roof which passes over gradually into the mesenchymatous sidewalls. The dorsolateral corner of the roof of the anterior part is extended posteriorly as a mesenchymatous sidewall outside the posterior region of the nasal sac.

As the posterior end of the planum antorbitale, which forms the posterior wall of the nasal capsule in older stages, is situated immediately in front of the attachment of the inferior oblique eye muscle to the nasal septum, this point indicates the orbitonasal boundary.

In the 5-day stage the part of the trabecula communis in front of this attachment forms an extensive and transitory floor for the posterior nasal region as a mesenchymatous ventrolaterally directed plate which is reduced in the 6-day stage to a procartilaginous ridge on either side of the base of the posterior part of the nasal capsule. This ridge is continued posteriorly for the length of the orbit as the pointed ventrolateral corners of the base of the interorbital septum and is retained up to the 9-day stage as the darker-stained perichondrium on the lateral sides of the base of the interorbital septum. The ridge along the lateral sides of the posterior part of the nasal septum is retained as the pointed lateral sides of the base of the nasal septum up to the 11-day stage.

In the 8-day stage the procartilaginous ethmoid plate above the anterior part of the nasal sac has extended posteriorly above the posterior part of the nasal sac as the parietotectal cartilage. The downbent sidewall of the posterior part of the nasal capsule has chondrified and is pushed inwards to form the concha nasalis, which is thus not formed from a separate paranasal anlage as in *Gallus* and *Sturnus* (Sonies 1907), *Anas* (de Beer and Barrington 1934), *Caprimulgus* and possibly *Struthio* (Frank 1954), *Fulica* (Macke 1969) and *Podiceps* (Toerien 1971). If a separate paranasal cartilage does exist in *Gallus*, as Sonies (1907) maintains, it must be for a very short period.

The wall of the concha nasalis, when first observed at an 8-day stage, is continuous with the parietotectal and the procartilaginous planum antorbitale is fused to the ventrolateral edge of the concha nasalis. The planum antorbitale develops in continuity with the parietotectal in agreement with the findings of Parker and Bettany (1877) and Sonies (1907) for *Gallus*. A separate anlage for the planum antorbitale was described in *Anas* (de Beer and Barrington 1934), *Phalacrocorax* (Slabý 1951 a), *Euplectes* (Engelbrecht 1958) and *Colius* (Goldschmid 1972). The turbinals also make their appearance at 8 days' development as mesenchymatous ridges of the roof and sidewall of the nasal capsule with chondrification of the elements spreading gradually from the nasal septum towards the ends of the scrolls.

A cupola anterior forms in the 14-day stage and its floor is continued posteriorly as an incomplete floor for the anterior part of the nasal capsule as far as the posterior end of the atrioturbinal. The floor consists of a slender medial bar along the lateral side of the base of the nasal septum and a broader lateral region formed by the ventral infolding of the paries nasi below the nasal sac.

At 16 days the prenasal process shows signs of hypertrophy of the chondrocytes and at 18 days it is almost totally resorbed except for a small anterior portion. The base of the nasal and interorbital septa also shows signs of resorption in front and behind the craniofacial notch.

By the 11-day stage part of the ramus medialis nasi is enclosed in two short canals. At the anterior end of the fenestra craniofacialis it is enclosed in the posterior canal, bordered dorsally by the tectum nasi, and medially by the nasal septum with the lateral wall being attached to the tectum nasi above and the nasal septum below.

The anterior canal is situated at the posterior end of the atrioturbinal where its anterior end forms a synovial joint with the posterior end of the atrioturbinal. The roof of the anterior canal develops as a ventrolaterally directed process from the nasal septum just above the base of the septum.

The process of the nasal septum forming the roof of the anterior canal has been labelled a nerve-bridge by W.K. Parker (1869) in *Gallus*, a ridge of cartilage which covers the ramus medialis nasi by de Beer and Barrington (1934) in *Anas*, and protuberances of the septum nasi by May (1961) in *Strix*. W.K. Parker and Bettany (1877) describe the attachment of the posterior end of the atrioturbinal in *Gallus* to the nasal septum via a process of the latter. Swart (1946) also describes similar structures in *Anas* as posterior processes. Schoonees (1963) describes the ramus medialis nasi as emerging anteriorly from beneath the ventrolaterally directed process in *Colius*. Goldschmid (1972) also describes and illustrates the attachment of the posterior end of the atrioturbinal to the nasal septum in *Colius*.

Swart (1946) suggests that the posterior process of *Anas* is homologous with paraseptal I of *Crypturellus* (de Villiers 1946). He bases his argument on the view that both these structures originate from the ventral edge of the nasal septum, but the part of the trabecula beneath these processes in *Anas* is not, as he believed, a posterior prolongation of the prenasal process.

Meckel's cartilage and the quadrate develop from one anlage and it is only from the 8-day stage that a synovial cavity starts to develop between the lower end of the quadrate and the posterior end of Meckel's cartilage. The first part of the quadrate to develop is the processus orbitalis which later forms a transitory, mesenchymatous connection with the polar cartilage. De Beer and Barrington (1934) found a procartilaginous connection between the quadrate and polar cartilage in *Anas* and consider it a remnant of the articulation between the neurocranium and the mandibular arch. Similar transitory connections have been described in *Columba* (Filatoff 1906) and in *Euplectes* (Engelbrecht 1958). The processus oticus develops after the processus orbitalis. The medial head of the processus oticus articulates with the otic capsule while the lateral head articulates with the squamosal and the ventral surface of the orbitocapsular commissure. The relations of the otic process to adjacent structures have been fully discussed under the orbitocapsular commissure and otic process (Sect. 4.1.4).

The first part of Meckel's cartilage to develop is the processus retroarticularis. De Beer and Barrington (1934) and Slabý (1951a) describe two centres of chondrification in Meckel's cartilage in *Anas* and *Phalacrocorax* respectively, but in *Gallus*, Meckel's cartilage develops as a single structure.

Smit and Frank (1979) state that the information obtained from embryos of *Spheniscus demersus*, *Acridotheres tristis*, *Geopelia cuneata*, and *Gallus domesticus* suggests that the stapes is part of the infrapharyngohyal while the supra- and infrapharyngohyal together with the epihyal and the secondary laterohyal form the processus extracolumellaris. Crompton (1953) also describes the hyoid arch of *Spheniscus demersus* as consisting of four blastemic anlagen.

These four hypothetical divisions are not apparent in the present investigation. Reconstruction of the developing columella auris is extremely difficult on account of its small size in comparison with adjacent structures that are used as reference points in making the reconstruction, and also because of the poorly defined outline of the mesenchymatous anlage which results in variations in the size of the drawings prepared for reconstruction. The combination of these difficulties results in an irregularly shaped reconstruction with portions of varying diameter. The thicker portions, which could be mere artefacts caused by reconstruction methods, have been interpreted as homologous with the elements of the piscine branchial arch. The first indication of the hyoid arch appears as two separate and poorly defined condensations of mesenchyme ventral to the anlage of the otic capsule. In the 8-day embryo the dorsal anlage gives rise to a well-chondrified, medially situated stapedial part and a slightly lesser chondrified, lateral extracolumellar part. The latter bears a short processus supracolumellaris and a longer processus extracolumellaris. At the 16-day stage Huxley's foramen appears in the solid base of the processus supracolumellaris.

The development of the footplate of the stapes indicates a purely visceral origin for this structure in *Gallus* and is in accordance with the findings of Sonies (1907), Lutz (1942), and Smit and Frank (1979). The fenestra ovalis develops through resorption of the chondrified wall of the otic capsule in the region opposite the intruding footplate of the stapes and is not a remnant of the cartilage-free area between the cartilaginous anlagen of the otic capsule, as Sonies (1907) described.

The anlage of the copula appears as a single condensation of mesenchyme with the anlage of the first branchial arch passing posteriorly outwards. At 8 days' development copula 1 and 2 chondrify from the single anlage and the branchial arch is divided into an anterior ceratobranchial and a posterior epibranchial. A synovial cavity forms between the copulae and the anterior end of the ceratobranchial at the 16-day stage. At the 8-day stage the paired anlagen of the paraglossal cartilage appear at the anterodorsal end of copula 1 as two parallel mesenchymatous rods, diverging posteriorly. At the 11-day stage the paraglossal cartilages fuse along the midline leaving an elongated opening just anterior to the posterior connection.

# 5 Summary

An account of six stages of the development of the chondrocranium up to the beginning of ossification is given. The tip of the chorda does not pierce the anterior surface of the acrochordal in the early stages and the fenestra basicranialis posterior develops through resorption of the basal plate.

The posterior part of the orbital cartilage develops a laterally situated orbitocapsular commissure and a medially situated pila antotica spuria. The pila antotica is resorbed leaving the posterior orbital cartilage connected to the basal plate only by the pila antotica spuria.

In the earliest stage the cochlear portion of the otic capsule is fused to the basal plate, but can be distinguished from the basal plate and the canalicular portion. The tectum synoticum is attached to the otic capsule by two roots with the ventral attachment spreading over the lateral surface of the pila occipitalis.

The trabecula communis forms without the intervention of an intertrabecula. The interorbital and nasal septa develop from the trabecula communis. An ethmoid plate forms the roof of the nasal capsule and the rest of the capsule develops as outgrowths from the roof. A transitory floor for the posterior part of the nasal capsule is present in the young stages and an incomplete floor for the anterior part develops late during the ontogeny.

# Acknowledgments

This investigation was carried out under the supervision of Dr. D. van Z. Engelbrecht whom I wish to thank most sincerely for his personal interest and constant invaluable advice, as well as for his highly appreciated assistance and the constructive discussions during the time I have been in this department.

I am also indebted to Dr. J.M. de Kock of this Department and Prof. A.M. Simonetta of the Department of Zoology and Comparative Anatomy of the Camerino University for reading the manuscript and for their valuable suggestions. I am grateful to Dr. D.G. Poggenpoel and Mr. J.S. Duckitt of the Department of Poultry Science at the Stellenbosch-Elsenburg College of Agriculture for the provision and incubation of the eggs.

My thanks are extended to Prof. A.D. Malan and his colleagues of the Department of Anatomy and Histology of the Faculty of Medicine and to Miss M.J. Smuts of the Medical Illustration Unit for her assistance with the illustrations. A grant from the Harry Crossley Fund made it possible for me to undertake this study.

# References

Barnikol A (1952) Korrelationen in der Ausgestaltung der Schädelform bei Vögeln. Gegenbaurs Morphol Jahrb 92:373–414

Bellairs A d'A (1955) Skull development in chick embryos after ablation of one eye. Nature 176:658–659

Bellairs A d'A (1958) The early development of the interorbital septum and the fate of the anterior orbital cartilages in birds. J Embryol Exp Morphol 6:68–85

Boggan WO (1982) Animal models of the fetal alcohol syndrome. In: Abel EL (ed) Fetal alcohol syndrome. Animal studies, vol. 3. CRC, Boca Raton, pp 1–13

Born, G (1879) Die Nasenhöhlen und der Thränennasengang der amnioten Wirbelthiere. Morphol Jahrb 5:401–429

Bremer JL (1940) The pneumatization of the head of the common fowl. J Morphol 67:143–157

Brock G (1937) The morphology of the ostrich chondrocranium. Proc Zool Soc London 107/B:225–243

Crompton AW (1953) The development of the chondrocranium of *Spheniscus demersus* with special reference to the columella auris of birds. Acta Zool 34:71–146

De Beer GR (1937) The development of the vertebrate skull. Clarendon, Oxford

De Beer GR, Barrington, EJW (1934) The segmentation and chondrification of the skull of the duck. Philos Trans R Soc London Ser B 223:411–467

De Kock JM (1955) The cranial morphology of *Sturnus v. vulgaris* L. Ann Univ Stellenbosch 31A:153–177

De Kock JM (1987) The development of the chondrocranium of *Melopsittacus undulatus*. Springer, Berlin Heidelberg New York (Advances in anatomy, embryology and cell biology, vol 104)

De Villiers CGS (1946) The relations of the vomer and palatoquadrate bar to the cranial rostrum in the tinamou (*Crypturellus* species). Ann Univ Stellenbosch 24A:21–40

Engelbrecht D van Z (1958) The development of the chondrocranium of *Pyromelana o. orix*. Acta Zool 39:115–199

Erdmann K (1940) Zur Entwicklungsgeschichte der Knochen im Schädel des Huhnes bis zum Zeitpunkt des Ausschlüpfens aus dem Ei. Z Morphol Ökol Tiere 36:315–400

Filatoff D (1906) Zur Frage über die Anlage des Knorpelschädels bei einigen Wirbeltieren. Anat Anz 29:623–633

Fisher M, Schoenwolf GC (1983) The use of early chick embryos in experimental embryology and teratology: improvements in standard procedures. Teratology 27:65–72

Fourie S (1955) A contribution to the cranial morphology of *Nyctisyrigmus p. pectoralis* with special reference to the palate and cranial kinesis. Ann Univ Stellenbosch 31A:179–215

Frank GH (1954) The development of the chondrocranium of the ostrich. Ann Univ Stellenbosch 30A:179–248

Frank GH, Smit AL (1976) The morphogenesis of the avian columella auris with special references to *Struthio camelus*. Zool Afr 11:159–182

Gaupp E (1906) Die Entwicklung des Kopfskelettes. Hertwigs Handb d vergl u exp Entw der Wirb, Jena 3:573

Gebhardt DOE (1972) The use of the chick embryo in applied teratology. Adv Teratol 5:97–111

Gilchrist FG (1968) A survey of embryology. McGraw-Hill, New York

Goldschmid A (1972) Die Entwicklung des Craniums der Mausvögel (Coliidae, Coliiformes, Aves) I Die Frühentwicklung des Chondrocraniums. Gegenbaurs Morphol Jahrb 118:105–138; II Die Entwicklung des Chondrocraniums bis zum Auftreten der dermalen Verknöcherungen. Gegenbaurs Morphol Jahrb 118:274–304; III Ausgestaltung und Umbau des

Chondrocraniums bis zum Auftreten der Ersatzverknöcherungen. Gegenbaurs Morphol Jahrb 118:369–413; IV Die Entwicklung des Osteocraniums. Gegenbaurs Morphol Jahrb 118:553–569

Goodrich ES (1915) The chorda tympani and middle ear in reptiles, birds and mammals. Q J Micros Sci 61:137–160

Grewe FJ (1951) Nuwe gegewens aangaande die ontogenese van die neuskliere, die orgaan van Jacobson en die dekbene by die genus *Anas*. Ann Univ Stellenbosch 27A:69–99

Hall BK (1982) Distribution of osteo- and chondrogenic neural crest-derived cells and of osteogenically inductive epithelia in mandibular arches of embryonic chicks. J Embryol Exp Morphol 68:127–136

Hamburger V, Hamilton HL (1951) A series of normal stages in development of the chick embryo. J Morphol 88:49–92

Hofer H (1945) Untersuchungen über den Bau des Vogelschädels, besonders über den der Spechte und der Steisshühner. Zool Jahrb Abt Anat Ontog Tiere 69:1–158

Hofer H (1949) Die Gaumenlücken der Vögel. Acta Zool 30:209–248

Hofer H (1954) Neuere Untersuchungen zur Kopfmorphologie der Vögel. Anat Hefte 28:307–586

Jollie MT (1957) The head skeleton of the chicken and remarks on the anatomy of this region in other birds. J Morphol 100:389–436

Kesteven HL (1941) On certain debatable questions in cranioskeletal homologies. Proc Linn Soc NSW 66:293–351

Kesteven HL (1942) The ossification of the avian chondrocranium with special reference to that of the emu. Proc Linn Soc NSW 67:213–237

Lang C (1955) Beiträge zur Entwicklungsgeschichte des Kopfskelettes von *Melopsittacus undulatus*. Gegenbaurs Morphol Jahrb 94:335–390

Lang C (1956) Das cranium der Ratiten mit besonderer Berücksichtigung von *Struthio camelus*. Z Wiss Zool 159:165–224

Le Lièvre CS (1978) Participation of neural crest-derived cells in the genesis of the skull in birds. J Exp Morphol 47:17–37

Lutz H (1942) Beiträge zur Stammesgeschichte der Ratiten. Vergleich zwischen Emu-Embryo und entsprechenden Carinatenstadien. Rev Suisse Zool 49:299–399

Macke T (1969) Die Entwicklung des Craniums von *Fulica atra* L. Gegenbaurs Morphol Jahrb 113:229–294

May W (1961) Die Morphologie des Chondrocraniums und Osteocraniums eines Waldkauzembryos (*Strix aluco* L.) Z Wiss Zool 166:133–202

Müller HJ (1961) Die Morphologie und Entwicklung des Craniums von *Rhea americana* Linné. I. Das knorpelige Neurocranium. Z Wiss Zool 165:221–319

Müller HJ (1963) Die Morphologie und Entwicklung des Craniums von *Rhea americana* Linné. II. Viszeralskelett, Mittelohr und Osteocranium. Z Wiss Zool 168:35–118

Parker TJ (1888) Preliminary note on the development of the skeleton of *Apteryx*. Proc R Soc London 43:391–397

Parker TJ (1891) Observations on the anatomy and development of *Apteryx*. Philos Trans R Soc London 182:25–134

Parker WK (1866) On the structure and development of the skull in the ostrich tribe. Philos Trans R Soc London 156:113–183

Parker WK (1869) On the structure and development of the skull of the common fowl (*Gallus domesticus*). Philos Trans R Soc London 159:755–807

Parker WK (1875) On the morphology of the skull in the woodpeckers (Picidae) and wrynecks (Yungidae). Trans Linnean Soc London 1:1–22

Parker WK (1876) On the structure and development of the bird's skull (Part II). Trans Linnean Soc London 1:99–154

Parker WK (1880) Report on the development of the green turtle (*Chelone viridis*). Challenger Rep Zool 1:1–58

Parker WK (1883) On the structure and development of the skull in the Crocodilia. Trans Zool Soc London 11:263–310

Parker WK (1890) On the morphology of the Gallinaceae. Trans Linnean Soc London 5:213–244

Parker WK, Bettany GT (1877) The morphology of the skull. Macmillan, London

Patten, BM (1957) Early embryology of the chick. McGraw-Hill, New York

Poggenpoel DG, Erasmus JE (1978) Long-term selection for increased egg production. Br Poult Sci 19:111–123

Prins FX (1951) Die "musculus orbitoquadratus" en die constrictor 1-derivate van die pikkewyn. Ann Univ Stellenbosch, 27A:101–130

Pusey HK (1939) Methods of reconstruction for microscopic sections. J R Microsc Soc 59:232–244

Romanoff AL (1960) The avian embryo. Macmillan, New York

Saayman JE (1963) 'n Bydrae tot die skedelmorfologie van *Passer m. melanurus*. Ann Univ Stellenbosch 38A:189–213

Sandor S, Elias S (1968) The influence of ethylalcohol on the developing chick embryo. Rev Roum Embryol Cytol Ser Embryol 5:51

Schinz HR, Zangerl, R (1937) Über die Osteogenese des Skelettes beim Haushuhn, bei der Haustaube und beim Haubensteissfuss. Morphol Jahrb 80:620–628

Schoonees J (1963) Some aspects of the cranial morphology of *Colius indicus*. Ann Univ Stellenbosch 38A:215–246

Slabý O (1951a) Le développement du chondrocrâne du cormorant (*Phalacrocorax carbo* L.) au point de vue de l'évolution. Bull Int Acad Tchèque Sci 52:1–47

Slabý O (1951b) On the chondrification of the primordial cranium of the blackbird (*Turdus merula* L.) Sylvia 13:103–121

Slabý O (1952) Einige interessante Bemerkungen zur Entwicklung des Schädels beim Fischreiher (*Ardea cinerea* L.) (German summary). Acta Soc Zool Bohemoslovenicae 16:163–178

Slabý O (1958) Studium zum Problem des segmentalen Ursprungs der Occipitalregion des Vogelschädels. Gegenbaurs Morphol Jahrb 99:752–794

Smit AL, Frank GH (1979) Aspects of the ontogenesis of the avian columella auris. S Afr J Zool 14:23–35

Smith GW (1905) The middle ear and columella of birds. Q J Microsc Sci 48:11–22

Sonies F (1907) Über die Entwicklung des Chondrocraniums und der knorpeligen Wirbelsäule bei den Vögeln. Petrus Camper 4:395–486

Starck D (1941) Zur Morphologie und Entwicklung des Primordialcraniums von *Manus javanica*. Morphol Jahrb 86:1–122

Starck D (1955) Die endocraniale Morphologie der Ratiten, besonders der Apterygidae und Dinornithidae. Gegenbaurs Morphol Jahrb 96:14–72

Starck D (1960) Über ein Anlagerungsgelenk zwischen Unterkiefer und Schädelbasis bei den Mausvögeln (Coliidae). Zool Anz 164:1–11

Stresemann E (1927) Sauropsida: Aves. Kükenthal-Krumbach'sches. Krumbach T (1927) Handbuch der Zoologie, vol 7/2. de Gruyter, Berlin Leipzig, S 1

Suschkin PP (1899) Zur Morphologie des Vogelskelets. I. Schädel von *Tinnunculus*. Nouv Mémoirs: Soc Imp Naturalistes Moscou 16:1–163

Swart PJ (1946) Die ontogenese van die "Desmognate" monddaktipe by *Anas*. Ann Univ Stellenbosch 24A:1–20

Toerien MJ (1971) The developmental morphology of the chondrocranium of *Podiceps cristatus*. Ann Univ Stellenbosch 46A, no 3:1–128

Tonkoff W (1900) Zur Entwickelungsgeschichte des Hühnerschädels. Anat Anz 18:296–304

Webb M (1957) The ontogeny of the cranial bones, cranial peripheral and cranial parasympathetic nerves, together with a study of the visceral muscles of *Struthio*. Acta Zool 38:81–203

# Subject Index

Abducent nerve 6, 51
acoustic nerve 6, 23
acrochordal cartilage 5, 6, 9, 13, 15, 21, 35, 44, 51, 58, 62, 71
aditus conchae 39
anterior part of orbital cartilage 11, 17, 21, 30, 41, 49, 53, 64, 65
apertura lateralis recessus scalae tympani 25
– medialis recessus scalae tympani 25
atrioturbinal cartilage 29, 39, 41, 48, 55, 68

Basal plate 5, 6, 8, 13–15, 21, 25, 27, 35, 44, 47, 51, 58, 59, 62, 64, 71
basisphenoid 52

Canalicular part of otic capsule 6, 8, 13, 22, 23, 59, 71
cavum conchae 27
ceratobranchial 21, 34, 35, 50, 51, 56, 57, 70
chorda 5, 6, 13, 21, 35, 44, 51, 58, 59, 71
cochlear part of otic capsule 6, 13, 15, 23, 33, 59, 71
cochleocanalicular fissure 6, 14, 23
columella auris 11, 20, 33, 34, 43, 46, 50, 57, 69
commissura parieto-occipitalis 46
concha nasalis 27–29, 39, 68
copula (1 and/or 2) 20, 21, 34, 44, 56, 57, 70
– anlagen 12, 70
cranial ribs 8, 15, 26
craniofacial notch 67, 68
craniovertebral joint 6, 15, 26
cupola anterior 55, 68

Endolymphatic duct 6, 15, 23
epibranchial 21, 34, 35, 44, 50, 51, 57, 70
ethmoid plate 11, 17, 18, 27, 65, 67, 71
extracolumella 12, 20, 33, 34, 69

Facial nerve 6, 23, 36
fenestra basicranialis posterior 6, 21, 35, 51, 59, 71
– craniofacialis 37–39, 55, 56, 67, 68
– hypophyseos 9, 16, 27, 52, 66
– narina 37, 48, 55
– ovalis 33, 50, 70
– septalis 53
– septi nasi 37
footplate of stapes 33, 34, 50, 57, 69
foramen magnum 35, 36, 63
– for occulomotor nerve 6, 35
– olfactorium advehens 30, 41
– – evehens 30
– for ophthalmic artery 9, 52
– perilymphaticum 25
– prooticum spurium 44
– for vena emmissaria occipitalis 25, 26, 63
fossa subarcuata 36, 52

Gasserian ganglion 6
glossopharyngeal nerve 8, 15, 23, 25, 36

Huxley's foramen 57, 69
hyoid arch 11, 15, 69
hypoglossal foramina 8, 26, 36, 46
– nerve 8, 36, 46
hypophysial pit 21, 48

Incisura carotica 15, 37, 47, 64
– metotica 14
– prootica 6, 13, 14, 23, 35
– – spuria 35
inferior oblique eye muscle 9–11, 18, 29, 41, 65, 67
infrapharyngohyal 69
infrapolar process 15, 27, 37, 47, 64
internal carotid artery 15, 37, 47, 64
interorbital septum 16, 18, 27, 29, 30, 37, 49, 52, 53, 55, 56, 65–67, 71
intertrabecula 16, 64, 65, 66, 71

Lateral nasal gland 27, 39
– semicircular canal 23
lingual process of copula 1, 20

Mandibular arch 11, 19, 20
maxilloturbinal cartilage 29, 38, 39
Meckel's cartilage 11, 19, 32, 41, 49, 69
membranous labyrinth 6, 15, 23, 36
metotic cartilage 23, 25, 35, 45, 46, 52
– – anlagen 8, 15
– fissure 8, 15, 23, 25, 36

Nasal sac 11, 17, 18, 67
nasal septum 9–11, 17, 18, 29, 30, 37, 38, 41, 48, 49, 53, 55, 56, 65–68, 71

Occipital region 8, 15, 26, 36
– myomeres 8
oculomotor nerve 6, 35, 44
olfactory nerve 11, 18, 29, 30, 41, 49, 53
ophthalmic artery 48, 52
optic nerve 9
orbitocapsular commissure 44, 45, 51, 60–62, 69, 71
– process 22, 44, 60
orbitonasal boundary 9, 10, 67
– fissure 29, 30

Paraglossal cartilage 43, 50, 56, 70
– – anlagen 34, 70
paranasal cartilage 67
parasphenoid 48, 51
parasphenoid rostrum 52
paries nasi 68
parietotectal cartilage 27–30, 39, 49, 68
pila antotica 6, 9, 13, 15, 35, 44, 62, 63, 70
– – spuria 13, 22, 35, 44, 52, 62, 71
– occipitalis 15, 25, 37, 45, 51, 52, 63, 71
planum antorbitale 9, 28, 29, 39, 41, 56, 67, 68
polar cartilage 9, 15, 19, 20, 33, 41, 52, 66, 69
posterior orbital process 21, 22
– part of orbital cartilage 6, 11, 13, 17, 21, 22, 35, 44, 52, 60, 62, 71
– – – – anlagen 6
– semicircular canal 15, 36
prenasal process 38, 41, 49, 53, 64–69
process of metotic cartilage 46
processus angularis 32
– extracolumellaris 34, 43, 57, 69
– infracolumellaris 12, 34, 57
– orbitalis 11, 19, 32, 41, 69
– orbitocapsularis 35
– oticus 20, 33, 35, 44, 45, 49, 51, 52, 56, 57, 60–62, 69
– retroarticularis 11, 32, 41, 49, 69
– supracollumellaris 34, 43, 57, 69
– tectalis 30, 41, 49
profundus branch of trigeminal nerve 22, 29, 35, 44, 63
prootic process 22, 35, 44
pterygoid 41, 52, 56, 62

Quadrate 11, 19, 20, 32, 33, 35, 41–49, 52, 56, 60, 61, 69
Quadratojugal 43, 56, 62

Ramus medialis nasi 39–41, 48, 55, 56, 68
Rathke's pouch 15
recessus scalae tympani 25

Squamosal 44, 46, 52, 60–62, 69
stapedial part of columella auris 20, 33, 34, 69
stapes 12, 57, 69
superior semicircular canal 25, 26, 37, 63
supraorbital part of orbital cartilage 11, 17, 21
suprapolar cartilage 9, 15, 52

Tectum nasi 48, 68
– synoticum 25, 36, 37, 45, 52, 63, 71
trabecula(e) 9, 15, 16, 64, 65, 67, 69
– communis 9, 10, 11, 16, 17, 27, 66, 67, 71
trabeculopolar bar(s) 9, 52, 66
trigeminal nerve 6, 23, 44
trochlear nerve 13, 35

Vagal accessory nerve 8, 15, 23
vomerine cartilage 56

# Advances in Anatomy, Embryology and Cell Biology

**Editors: F. Beck, W. Hild, W. Kriz, R. Ortmann, J. E. Pauly, T. H. Schiebler**

Volume 112
**K. Theiler**

## Vertebral Malformations

1988. 145 figures. Approx. 110 pages. ISBN 3-540-19359-6

Volume 111
**M. Frotscher, P. Kugler, U. Misgeld, K. Zilles**

## Neurotransmission in the Hippocampus

1988. 62 figures. VI, 105 pages. ISBN 3-540-18800-2

Volume 110
**J. J. Baumel**

## Functional Morphology of the Tail Apparatus of the Pigeon (Columba livia)

1988. 29 figures. VIII, 116 pages. ISBN 3-540-18868-1

Volume 109
**M. Klima**

## Early Development of the Shoulder Girdle and Sternum in Marsupials (Mammalia: Metatheria)

1987. 33 figures. VII, 91 pages. ISBN 3-540-18358-2

Volume 108
**H. Hentschel, M. Elger**

## The Distal Nephron in the Kidney of Fishes

1987. 65 figures. IX, 151 pages. ISBN 3-540-18126-1

Volume 107
**H. J. ten Donkelaar, G. C. Bangma, H. A. Barbas-Henry, R. de Boer-van Huizen, J. G. Wolters**

## The Brain Stem in a Lizard, Varanus exanthematicus

1987. 69 figures. XIII, 168 pages. ISBN 3-540-17948-8

Volume 106
**M. Pavelka**

## Functional Morphology of the Golgi Apparatus

1987. 25 figures. VIII, 94 pages. ISBN 3-540-18062-1

Volume 105
**M. Bergmann**

## Photoperiod and Testicular Function in Phodopus sungorus

1987. 37 figures. VI, 76 pages. ISBN 3-540-17583-0

**Springer-Verlag**
Berlin Heidelberg New York
London Paris
Tokyo Hong Kong

Springer

# Advances in Anatomy, Embryology and Cell Biology

**Editors: F. Beck, W. Hild, W. Kriz, R. Ortmann, J. E. Pauly, T. H. Schiebler**

Volume 104
**J. M. de Kock**

## The Development of the Chondrocranium of Melopsittacus undulatus

1987. 40 figures. VI, 70 pages. ISBN 3-540-17674-8

Volume 103
E. B. Krammer, M. F. Lischka, T. P. Egger. M. Riedl, H. Gruber

## The Motoneuronal Organization of the Spinal Accessory Nuclear Complex

1987. 11 figures. IX, 62 pages. ISBN 3-540-17459-1

Volume 102
**D. J. Pallot**

## The Mammalian Carotid Body

1987. 35 figures. VI, 91 pages. ISBN 3-540-17480-X

Volume 101
**A. Kress, J. Millian**

## The Female Genital Tract of the Shrew Crocidura russula

1987. 31 figures. VI, 76 pages. ISBN 3-540-16942-3

Volume 100
**J. Altman, S. A. Bayer**

## The Development of the Rat Hypothalamus

1986. 125 figures. XV, 178 pages. ISBN 3-540-16654-8

Volume 99
**W. F. Neiss**

## Ultracytochemistry of Intracellular Membrane Glycoconjugates

1986. 113 figures. VIII, 92 pages. ISBN 3-540-16726-9

Volume 98
**K. Hinrichsen**

## The Early Development of Morphology and Patterns of the Face in the Human Embryo

1985. 82 figures. VII, 79 pages. ISBN 3-540-15848-0

Volume 97
**D. K. Morest, J. A. Winer**

## The Comparative Anatomy of Neurons: Homologous Neurons in the Medial Geniculate Body of the Opossum and the Cat

1986. 43 figures. XI, 96 pages. ISBN 3-540-15726-3

**Springer-Verlag**
Berlin Heidelberg New York
London Paris
Tokyo Hong Kong

Springer