

CATTLE MEDICINE

PHILIP R. SCOTT
COLIN D. PENNY
ALASTAIR I. MACRAE



 MANSON
PUBLISHING

CATTLE MEDICINE

Philip R Scott

BVM&S, MPhil, DVM&S, DSHp, FRCVS, DipECBHM, DipECSRHM FHEA
Reader, Division of Veterinary Clinical Sciences

Colin D Penny

BVM&S, CertCHP, DBR, DipECBHM, MRCVS
Senior Lecturer, Farm Animal Practice

Alastair I Macrae

BVM&S, PhD, CertSHP, CertCHP, MRCVS
Dairy Herd Health and Productivity Service

Division of Veterinary Clinical Sciences
Royal (Dick) School of Veterinary Studies
University of Edinburgh
Easter Bush Veterinary Centre
Roslin, Midlothian, UK

Manson Publishing/The Veterinary Press

Copyright © 2011 Manson Publishing Ltd
ISBN: 978-1-84076-127-6

All rights reserved. No part of this publication may be reproduced, stored in a retrieval system or transmitted in any form or by any means without the written permission of the copyright holder or in accordance with the provisions of the Copyright Act 1956 (as amended), or under the terms of any licence permitting limited copying issued by the Copyright Licensing Agency, 33–34 Alfred Place, London WC1E 7DP, UK.

Any person who does any unauthorized act in relation to this publication may be liable to criminal prosecution and civil claims for damages.

A CIP catalogue record for this book is available from the British Library.

For full details of all Manson Publishing Ltd titles please write to:
Manson Publishing Ltd, 73 Corringham Road, London NW11 7DL, UK.
Tel: +44(0)20 8905 5150
Fax: +44(0)20 8201 9233
Email: manson@mansonpublishing.com
Website: www.mansonpublishing.com

Commissioning editor: Jill Northcott
Project manager: Julie Bennett
Copy editor: Peter Beynon
Design and layout: Cathy Martin
Colour reproduction: Tenon & Polert Colour Scanning Ltd, HK
Printed by: Grafos SA, Barcelona, Spain

CONTENTS

PREFACE		4
ABBREVIATIONS		5
CHAPTER 1	REPRODUCTIVE SYSTEM	7
	Part 1: Male reproductive tract diseases	7
	Part 2: Female reproductive tract diseases	17
	Part 3: Causes of fetal loss/abortion	27
CHAPTER 2	OBSTETRICS AND PARTURIENT DISEASES	39
CHAPTER 3	DIGESTIVE TRACT AND ABDOMEN	59
	Part 1: Diseases of the digestive tract and abdomen	59
	Part 2: Infectious diseases of the digestive tract	94
CHAPTER 4	RESPIRATORY DISEASES	115
CHAPTER 5	CARDIOVASCULAR DISEASES	133
CHAPTER 6	NERVOUS SYSTEM DISEASES	143
CHAPTER 7	MUSCULOSKELETAL DISEASES	163
CHAPTER 8	URINARY TRACT DISEASES	195
CHAPTER 9	SKIN DISEASES	201
CHAPTER 10	EYE DISEASES	211
CHAPTER 11	MASTITIS AND TEAT DISEASES	216
CHAPTER 12	PARASITIC DISEASES	236
CHAPTER 13	CLOSTRIDIAL DISEASES	242
CHAPTER 14	METABOLIC DISEASES	247
CHAPTER 15	TRACE ELEMENT AND VITAMIN DEFICIENCIES	258
CHAPTER 16	MISCELLANEOUS INFECTIOUS AND EXOTIC DISEASES	266
CHAPTER 17	POISONS	272
CHAPTER 18	ANAESTHESIA	276
FURTHER READING		283
INDEX		284

PREFACE

The major objective of this book is to describe, with the aid of a large number of high-quality images, the important diseases of cattle encountered by veterinary surgeons in general practice and their diagnosis, treatment, prognosis and control. Wherever possible, the sequential images take the reader through all stages of the disease process, highlighting clinical features important in the diagnosis. The book is specifically aimed at fulfilling the need for a practical, concise text that will be of use to veterinary undergraduate students in their clinical years and later in farm practice. The book is not intended to be a fully referenced text covering bovine medicine in detail, as there are already such texts available.

The book is divided into chapters based on body system. Where appropriate, chapters open with a suggested approach to clinical examination of that body system rather than simply listing the disorders and diseases affecting that system. Such a systematic approach is more applicable to certain sections, such as the nervous, digestive and respiratory systems.

The book is based on the authors' experience of bovine medicine and surgery both in general practice and in a referral University hospital in the United Kingdom. While management and husbandry systems vary worldwide, the clinical signs, diagnosis, treatment and prevention of the major diseases do not. For example, the clinical signs of metabolic acidosis in 8–21-day-old calves are described

with the important differential diagnoses, followed by discussion of the estimation of base deficit on the farm with a detailed description of the authors' treatment regimen. Several different methods are employed by veterinary surgeons in the UK, and many others worldwide, for spiking the intravenous solution with bicarbonate, but the principle is the same – to correct the estimated base deficit. It is not possible to describe every method used worldwide; rather, the authors have chosen the method they believe to work best based on a review of the literature and their clinical experience. Control by vaccination will depend on isolation of potential enteropathogens and the availability and cost of a suitable vaccine in that particular country.

Surgical correction of a left displaced abomasum is another good example where many different treatment options are used worldwide. The authors have described the two most commonly used surgical methods and discuss why these have been chosen; it is not possible to describe every method. Similarly, it is not possible within the limited text to detail the availability of all antibiotics and other drugs in individual countries worldwide, therefore treatments described are most relevant to UK veterinary practice. However, what the book does do is to give practical instruction, using sequential high-quality images, on how to recognize, treat and control the common conditions encountered in bovine practice, which, in most cases, cross national and international boundaries.

Philip Scott
Colin Penny
Alastair Macrae

ABBREVIATIONS

ADH	antidiuretic hormone	GSHPx	glutathione peroxidase
AGID	agar gel immunodiffusion (test)	hCG	human chorionic gonadotropin
AI	artificial insemination	IBK	infectious bovine keratoconjunctivitis
AST	aspartate aminotransferase	IBR	infectious bovine rhinotracheitis
BAL	bronchoalveolar lavage	ICSCC	individual cow somatic cell count
BCS	body condition score	IPV	infectious pustular vulvovaginitis
BHB	b-hydroxybutyrate	IVRA	intravenous regional anaesthesia
BHV	bovine herpesvirus	LDA	left displaced abomasum
BLV	bovine leukaemia virus	LH	luteinizing hormone
BMSCC	bulk milk somatic cell count	MAP	<i>Mycobacterium avium</i> subsp. <i>paratuberculosis</i>
BPS	bovine papular stomatitis	MAT	microscopic agglutination test
BRSV	bovine respiratory syncytial virus	MCF	malignant catarrhal fever
BSE	bovine spongiform encephalopathy	MD	mucosal disease
BTV	bluetongue virus	MIC	minimum inhibitory concentration
BVD	bovine virus diarrhoea	MOET	multiple ovulation/embryo transfer (programme)
BVDV	bovine viral diarrhoea virus	NcpBVDV	non-cytopathic bovine viral disease virus
CCN	cerebrocortical necrosis	NEFA	non-esterified fatty acid
CFT	complement fixation test	NMR	National Milk Records
CJD	Creutzfeldt–Jakob disease	NSAID	non-steroidal anti-inflammatory drug
CJLD	congenital joint laxity and dwarfism	OCD	osteochondritis dissecans
CL	corpus luteum	PCV	packed cell volume
CMT	California mastitis test	PEM	polioencephalomalacia
CN	cranial nerve	PAGE	polyacrylamide gel electrophoresis (test)
CNS	central nervous system	PDA	patent ductus arteriosus
CpBVDV	cytopathic bovine viral disease virus	PGE	parasitic gastroenteritis
COD	cystic ovarian disease	PGF _{2oc}	prostaglandin F _{2oc}
CSF	cerebrospinal fluid	PI	parainfluenza
CSPD	chronic suppurative pulmonary disease	PLR	pupillary light reflex
DCAB	dietary cation–anion balance	PMSG	pregnant mare serum gonadotropin
DCM	dilated cardiomyopathy	PTH	parathyroid hormone
DJD	degenerative joint disease	PUFA	polyunsaturated fatty acids
DM	dry matter	RDA	right-sided displacement of the abomasum
EBL	enzootic bovine leucosis	RFM	retained fetal membranes
EBVs	estimated breeding values	SBL	sporadic bovine leucosis
ELISA	enzyme-linked immunosorbent assay	SCC	somatic cell count
epg	eggs per gram	TBC	total bacteria count
ETEC	enterotoxigenic <i>Escherichia coli</i>	TEME	thromboembolic meningoencephalitis
FAT	fluorescent antibody test	vCJD	variant Creutzfeldt–Jakob disease
FMD	foot and mouth disease	VSD	ventricular septal defect
FSH	follicle-stimulating hormone		
GGT	gamma glutamyltransferase		
GLDH	glutamate dehydrogenase		
GnRH	gonadotropin-releasing hormone		

This page intentionally left blank

Chapter 1

Reproductive system

Part 1: Male reproductive tract diseases

INTRODUCTION

Fully fertile bulls are critical in herd fertility management, especially where farmers are trying to achieve high pregnancy rates in restricted breeding periods. A sensible working definition of a fully fertile bull is a bull that can achieve a 90% pregnancy rate in a group of 50 normal cyclic females in a nine-week mating period. Various surveys worldwide have shown that 20–30% of bulls are found to be subfertile or infertile in routine breeding soundness examinations. Although subfertile bulls will achieve pregnancies, they contribute to fertility

inefficiency in herds and thus should be identified and replaced or treated. Bull breeding soundness examinations carried out prior to breeding will help identify most subfertile and infertile bulls and should be a routine part of herd management.

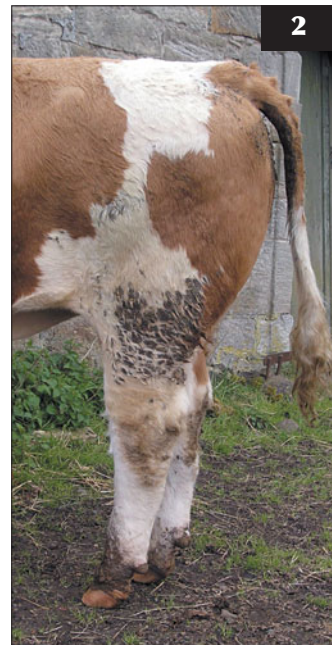A full breeding soundness examination should consist of the following parts:

- Physical examination:
 - General health and body condition (1).
 - Musculoskeletal system – limbs and feet (2).



1 A bull in good working condition. Very thin or obese bulls will have depressed fertility.

2 A 'post-hocked' young bull. This conformation is associated with upper limb lameness problems.



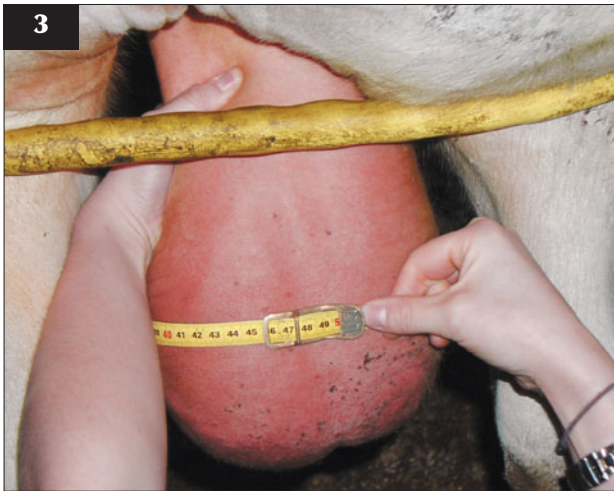- Reproductive system examination:
 - Measure scrotal circumference (3). The minimum recommended standards (Society of Theriogenology) for *Bos taurus* bulls are: 12–15 months, 30 cm; >15–≤18 months, 31 cm; >18–≤21 months, 32 cm; >21–≤24 months, 33 cm; >24 months, 34 cm.
 - Palpate testicles and epididymides carefully.
 - Palpate internal accessory sex glands.
 - Palpate sheath and penis.
- Semen evaluation. Collect semen by electroejaculation (4) or artificial vagina and assess motility: should be >60% progressive motility, and percentage normal sperm morphology should be >70% (5). Handling of semen is critical after collection in order

to avoid cold shock and a heated stage should be used when doing motility assessment (6).

- Serving assessment. Need to observe bull mating an oestrous female in order to ensure good libido and normal intromission.

A full breeding soundness evaluation should include all four components, but even doing just a physical examination and a reproductive system examination will help to ensure unsound bulls are not used. For bulls to be examined safely and properly it is essential that farmers provide adequate handling facilities (7).

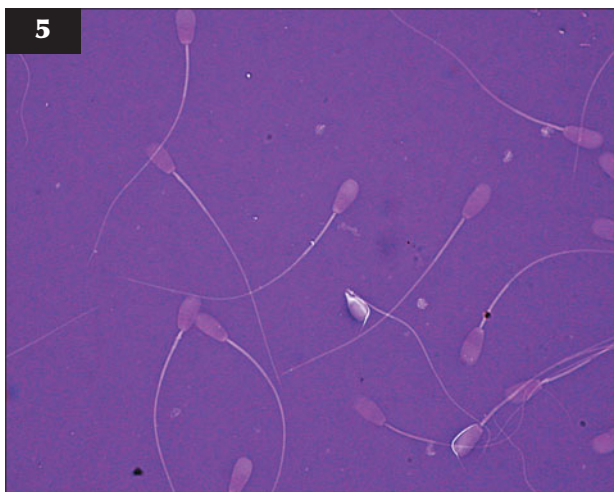
Some of the more common conditions that may be encountered during bull breeding soundness investigations are discussed in this section.



3 Scrotal circumference being measured using a properly designed tape to ensure accuracy and consistency.



4 A modern electroejaculator for collection of semen from bulls.



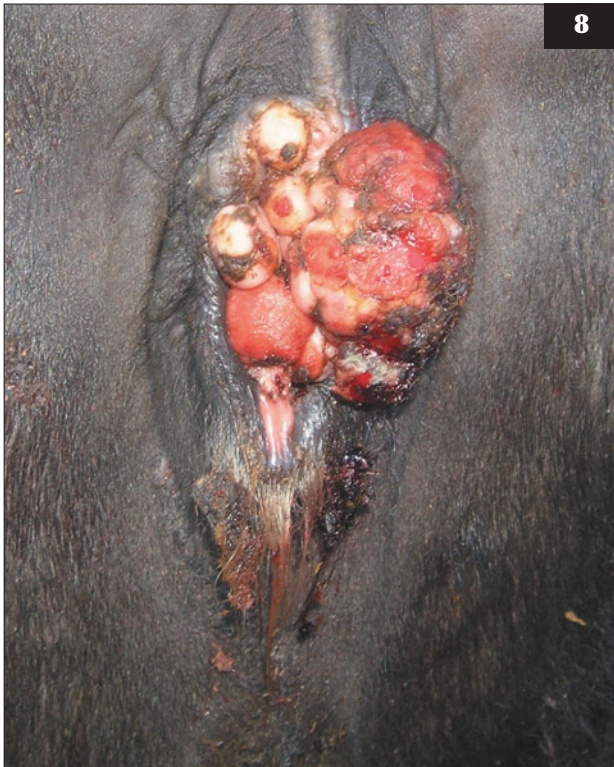5 Seventy percent or more of sperm should be morphologically normal, as in this field.



6 The field laboratory shown here includes a warming box and heated stage to keep semen at body temperature during examination for motility.



7 Safe handling facilities are essential for proper bull breeding soundness examination.



TRANSMISSIBLE VIRAL FIBROPAPILLOMATOSIS (WARTS)

DEFINITION/OVERVIEW

Transmissible viral fibropapillomatosis occurs quite commonly in young bulls and is only of clinical significance in bulls destined for breeding, when penile lesions can interfere with the ability to serve.

AETIOLOGY

Transmissible viral fibropapillomatosis is caused by bovine papillomavirus. It is normally only seen in young bulls (<3 years old), but it can be transmitted venereally to females (8).

CLINICAL PRESENTATION

The condition can present as a single pedunculated mass or as large broad-based cauliflower-like lesions on the glans penis and prepuce (9, 10). Both presentations may prevent intromission. Secondary superficial bacterial infection of papillomas is common and may lead to bleeding and/or discharge from the prepuce.

DIAGNOSIS

Diagnosis is based on history and clinical examination of the penis.

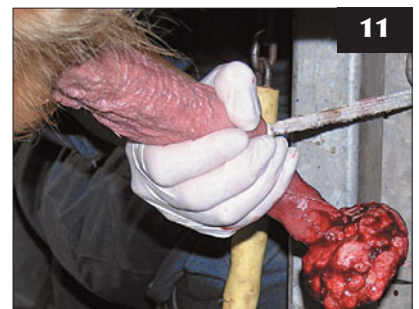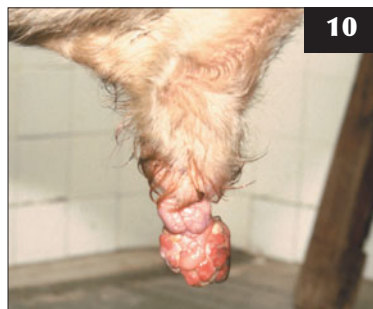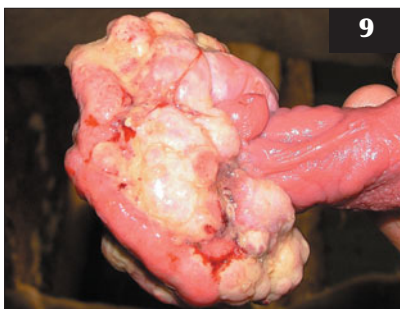
MANAGEMENT

There is no treatment except in severe cases, when autogenous vaccines and/or debulking the lesions with surgery are options. Care must be taken when attempting surgery to ensure that the dorsal nerve of the penis or the urethral opening is not damaged (11). Spontaneous regression occurs in most cases.

8 Viral papillomatosis, which has been transmitted venereally, is shown in this cow.

9, 10 Penile papillomas. Large broad-based cauliflower-like lesions on the glans penis are shown.

11 Care must be taken to avoid damage to the dorsal nerve of the penis and the urethral opening when attempting surgery to remove a penile papilloma.



PERSISTENT PENILE FRENULUM

DEFINITION/OVERVIEW

Persistent penile frenulum is a rare congenital problem identified in young bulls.

AETIOLOGY

The condition is due to a failure of complete separation of the fused penis and prepuce at puberty.

CLINICAL PRESENTATION

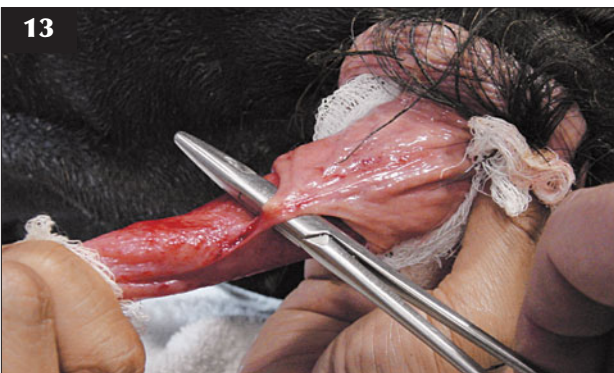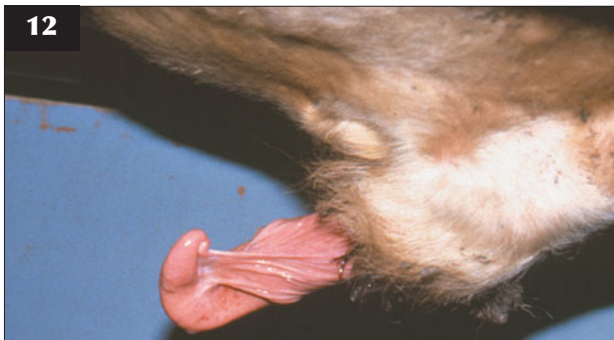A band of tissue extends from the prepuce to the tip of the penis, causing deviation of the tip of the penis during attempted service (12, 13).

DIAGNOSIS

Clinical examination during attempted service or when stimulated with an electroejaculator will demonstrate the lesion.

MANAGEMENT

Simple surgical excision of the band of tissue is successful, but as the condition can be inherited, treated bulls should not be used for pedigree breeding.



12, 13 Persistent penile frenulum. (12) The band of tissue extending from the prepuce to the ventral tip of the penis is causing deviation of the tip of the penis during attempted service. (13) The tissue band has been isolated and can then be surgically excised to cure the condition. (Courtesy E. Taylor)

CORKSCREW/SPIRAL DEVIATION OF THE PENIS

DEFINITION/OVERVIEW

Corkscrew or spiral deviation is the most common penile deviation seen in the bull; however, ventral deviation may also occasionally be observed.

AETIOLOGY

The aetiology is unknown. There is possibly some heritable component, but this has not been proven. Corkscrew of the penis occurs during erection, when the dorsal apical ligament slips laterally from its normal position.

CLINICAL PRESENTATION

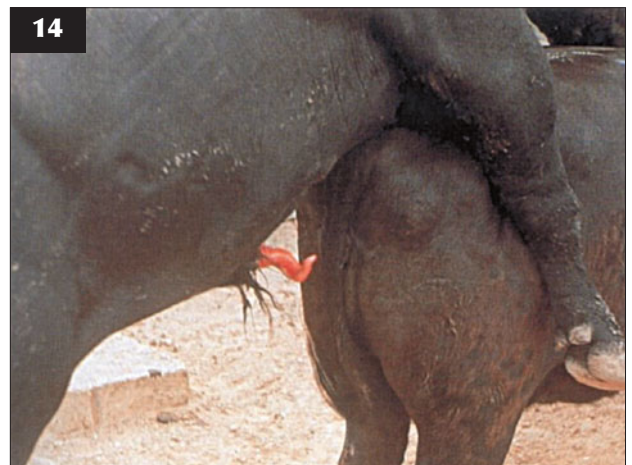
Corkscrew or spiral deviation of the penis is normally an acquired condition seen in their second or third breeding season in mature bulls. While spiral deviation is normal within the vagina after intromission, bulls that develop this problem start to corkscrew while searching for the vulva and therefore fail to achieve normal intromission. From a distance bulls will be seen to repeatedly mount but fail to thrust. The problem can be sporadic at first, then gradually worsen to cause total infertility. (**Note:** Some bulls will corkscrew during electroejaculation but not during natural service.)

DIFFERENTIAL DIAGNOSIS

Other penile deviations or conditions causing pain and failure to thrust (e.g. lumbar pain, penile fibropapilloma, venous shunts causing erection failure).

DIAGNOSIS

Careful close-up inspection during attempted service will confirm the condition and rule out most differentials (14).



14 Premature spiral deviation of the penis preventing normal intromission. (Courtesy E. Taylor)

MANAGEMENT

Surgical correction is possible, involving suturing the dorsal apical ligament to the penile body; however, recurrence is likely so treatment is rarely considered and culling is recommended.

RUPTURED PENIS (PENILE HAEMATOMA)**DEFINITION/OVERVIEW**

Ruptured penis is a sporadic problem in stock bulls. It normally occurs during the mating period.

AETIOLOGY

Rupture of the tunica albuginea commonly occurs around the dorsal aspect of the sigmoid flexure, leading to haematoma formation. This may be caused by sudden movement of the cow during intromission or when young bulls are mounting each other.

CLINICAL PRESENTATION

The condition presents as a sudden onset of cessation of service activity, with a variably sized painful swelling at the base of the sheath anterior to the scrotum (15). The prepuce and/or tip of penis may be prolapsed.

DIAGNOSIS

Diagnosis is based on palpation of a painful firm swelling in the area of the sigmoid flexure of the penis. Ultrasonography will confirm a diagnosis of haematoma. Chronic cases may have progressed to abscess formation.

MANAGEMENT

In acute cases, surgery to drain very large haematomas can be attempted within seven days of occurrence. In more

chronic cases or with smaller haematomas, medical treatment is more common and should include hydrotherapy, systemic antibiotics and at least two months of sexual rest. Complications are common and include recurrence of rupture, abscessation with adhesion formation, and development of venous shunts.

PENILE HAIR RINGS**DEFINITION/OVERVIEW**

Penile hair rings are a sporadic problem in bulls. They can lead to ischaemic necrosis of the tip of the penis.

AETIOLOGY

Hairs from the tip of the sheath encircle the tip of the penis, leading to strangulation and ischaemia if neglected (16).

CLINICAL PRESENTATION

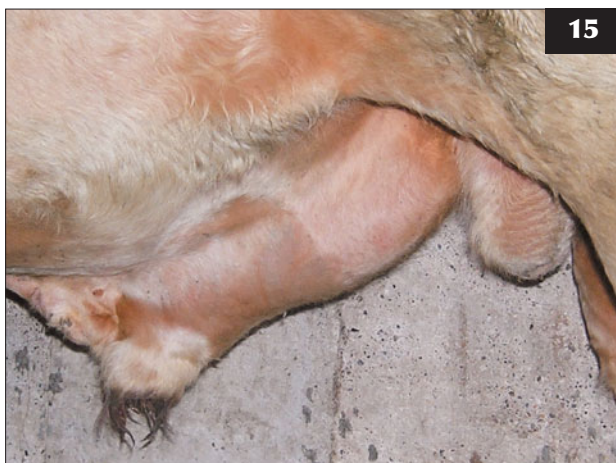This condition may be missed unless close inspection of bulls is carried out on a regular basis. Bulls will stop serving cows because of discomfort and an inability to extrude the penis. In neglected cases, urethral obstruction may develop due to swelling.

DIAGNOSIS

Careful inspection, under sedation if required, will confirm the diagnosis.

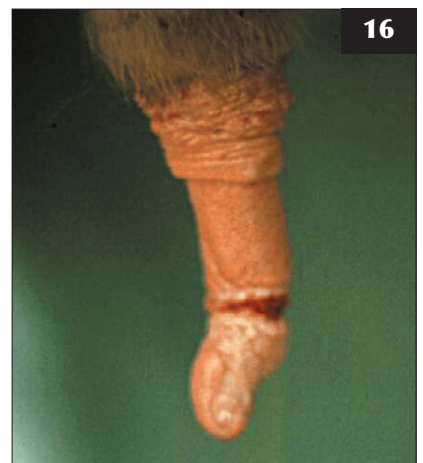MANAGEMENT

Under standing sedation the offending hair ring can be cut carefully, avoiding further damage to the penis. Neglected cases may require culling because of necrosis of the tip of the penis.



15 Haematoma formation, with swelling at the base of the sheath anterior to the scrotum, due to rupture of the tunica albuginea.

16 Hairs from the tip of the sheath can encircle the tip of the penis and cause necrosis, as shown.



PROLAPSE OF THE PREPUCE

DEFINITION/OVERVIEW

Prolapse of the prepuce is a sporadic problem associated traditionally with mature Hereford or Angus bulls, although any breed can be affected.

AETIOLOGY

Failure of the retractor prepucae muscle allows preputial epithelium to protrude beyond the preputial orifice (17), possibly leading to traumatic damage.

CLINICAL PRESENTATION

Preputial epithelium may be prolapsed permanently, leading to secondary trauma and infection (18). This can cause infertility as stenosis of the prepuce develops, preventing full extrusion of the penis.

DIAGNOSIS

A history of failure to achieve intromission and close inspection of the bull will confirm the diagnosis.

MANAGEMENT

In mild cases, hydrotherapy and treatment with antibiotics and anti-inflammatory drugs systemically and/or locally may be sufficient; however, if the prepuce is chronically inflamed and stenosis has occurred, then surgical resection of the prepuce or culling may be required.

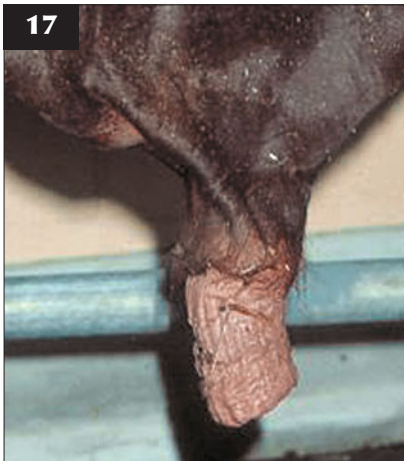PREPUTIAL LACERATION

AETIOLOGY

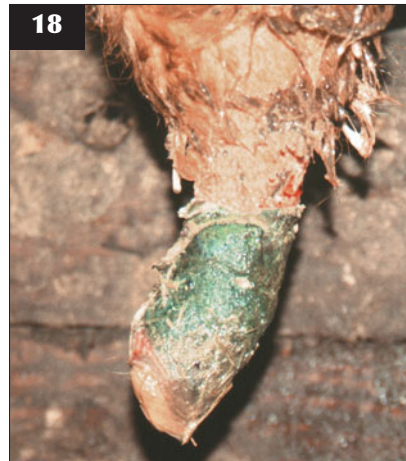Traumatic tearing of the prepuce most commonly occurs ventrally where it joins the free portion of the penis (19).

CLINICAL PRESENTATION

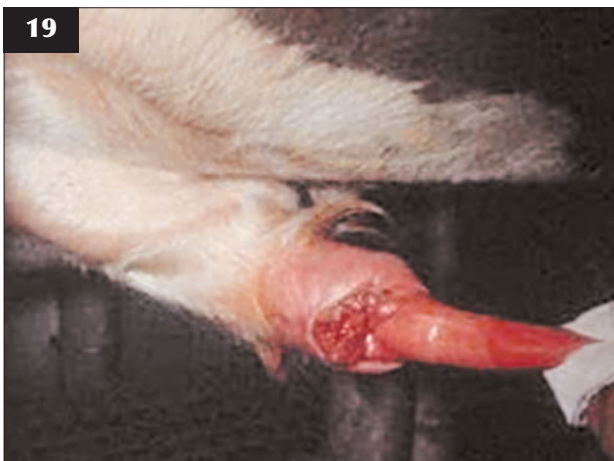In acute cases there will be painful swelling of the sheath just caudal to the preputial orifice (20). There may be a bloody discharge and partial prolapse of the tip of the penis or prepuce. In chronic/neglected cases the damaged prepuce may become infected and contraction of the



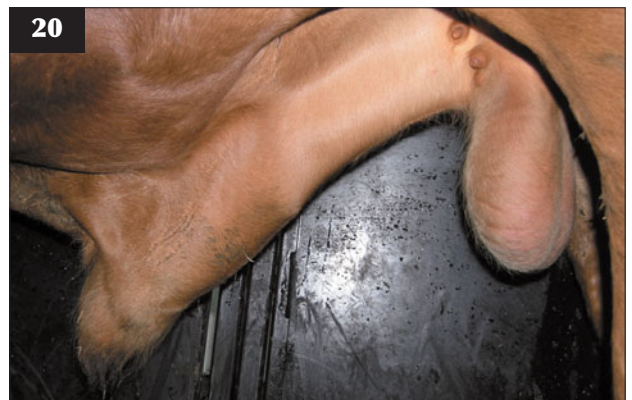
17 Prolapse of the prepuce in a bull with a pendulous prepuce. (Courtesy E. Taylor)



18 The preputial epithelium has been prolapsed permanently in this bull.



19 This bull has traumatic tearing of the prepuce where it joins the free portion of the penis. (Courtesy E. Taylor)



20 Painful swelling of the sheath just caudal to the preputial orifice associated with an infected preputial tear.

damaged tissue may cause paraphimosis due to constriction at the junction of the penis and prepuce (21).

DIFFERENTIAL DIAGNOSIS

Swelling caused by penile papilloma, balanoposthitis or a sheath abscess.

DIAGNOSIS

Under sedation or general anaesthetic, the free portion of the penis can be grasped and pulled forward in order to inspect the prepuce.

MANAGEMENT

Surgical repair of preputial tears is rarely possible as many cases are not presented until some time after the initial injury. Topical antibiotic/anti-inflammatory drugs applied regularly or flushing the sheath with mild antiseptic solution will help reduce the risk of infection and adhesions/stricture forming during healing. After a month's rest the bull can be test mated to assess healing and see if normal intromission is possible.

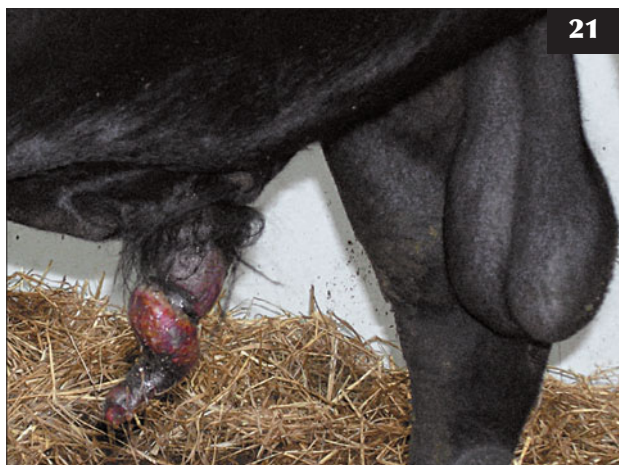BALANOPOSTHITIS

Infection of the preputial and penile epithelium can cause temporary infertility due to reluctance to serve or, occasionally, more permanent problems due to adhesion formation leading to inability to fully extrude the penis. Specific agents causing balanoposthitis include bovine herpesvirus 1 (BHV1) and *Mycoplasma/Ureaplasma* spp.

EPIDIDYMITIS AND ORCHITIS

DEFINITION/OVERVIEW

Bacterial infection of the testicles and/or epididymides occurs sporadically in bulls of all ages and can lead to temporary or permanent infertility.



21 Preputial trauma causing paraphimosis and penile necrosis in this bull is due to constriction at the junction of the penis and prepuce.

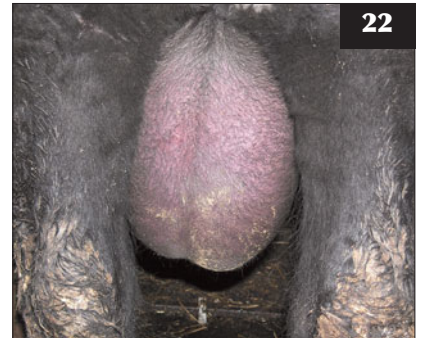AETIOLOGY

Numerous bacteria, including *Arcanobacterium pyogenes*, *Escherichia coli*, *Histophilus somni* and *Staphylococcus* spp., have been isolated from cases of orchitis and epididymitis.

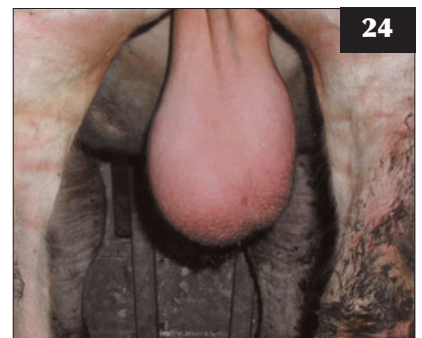
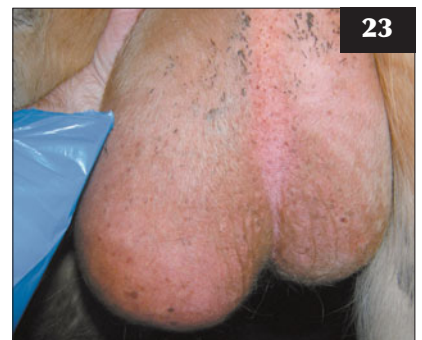CLINICAL PRESENTATION

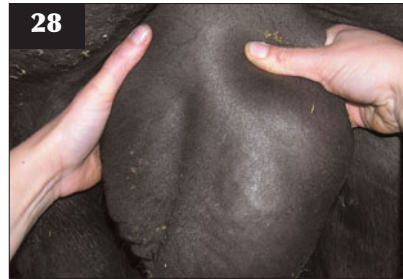
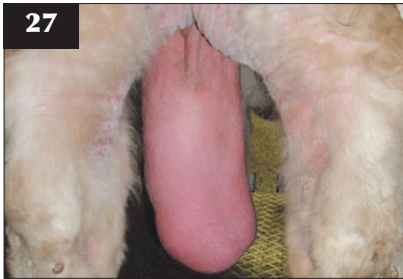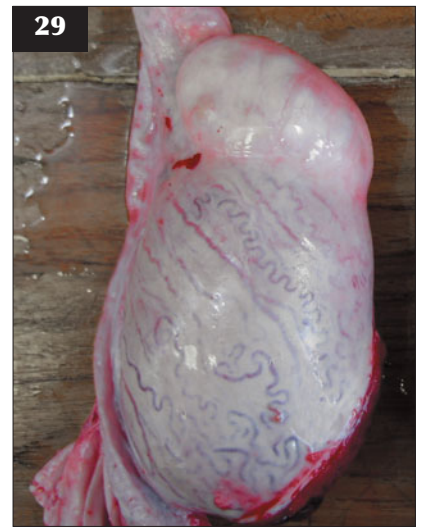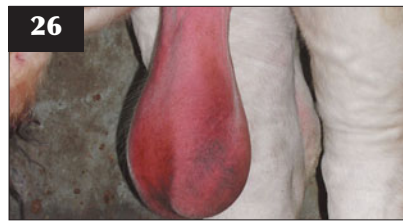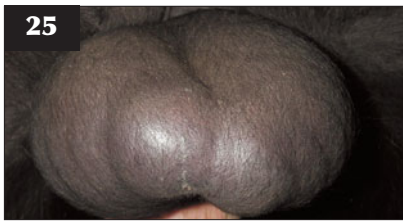Orchitis and epididymitis can be unilateral or bilateral and in acute cases will present as a hot painful swollen scrotum (22) with significant oedema (hydrocoele). A diligent stockman may notice signs of systemic illness in the bull, but in many cases the condition may not be detected until investigating infertility, by which time the condition is chronic in nature. If the orchitis is affecting only one testicle, the initial swelling (23) may settle down to leave the testicle slightly enlarged, tense and misshapen (24) or, alternatively, the affected testicle may become shrunken and fibrotic.

22 A hot, painful, swollen scrotum in a bull with bilateral orchitis and epididymitis.



23, 24 (23) Acute swelling in a bull with orchitis affecting the left testicle. **(24)** The condition settled down, leaving the testicle slightly enlarged, tense and misshapen.





25 Chronic epididymitis affecting the tail of the epididymis in this bull.

26 Photosensitization has caused acute diffuse scrotal swelling and oedema in this bull.

27 An inguinal hernia has caused bilateral scrotal swelling in this bull.

28, 29 (**28**) A sperm granuloma at the head of the epididymis due to chronic blockage of the ducts is easily palpable in this Angus bull. (**29**) Post-mortem specimen showing a sperm granuloma.

Epididymitis can present along with orchitis or on its own and most commonly affects the tail of the epididymis, which will be swollen and painful in acute cases, progressing to firm fibrosis in chronic cases (**25**). Seminal vesiculitis may often be found along with epididymitis.

DIFFERENTIAL DIAGNOSIS

Photosensitization can cause acute diffuse scrotal swelling and oedema (**26**). Inguinal hernia can cause unilateral or bilateral scrotal swelling (**27**). Sperm granulomas (spermatocoeles) can develop at the head of the epididymis because of blockage of ducts causing rupture of tubules and a foreign body reaction that leads to significant firm swelling of the epididymal head (**28, 29**).

DIAGNOSIS

Once the acute swelling and oedema has settled, careful palpation will confirm the presence of orchitis and/or epididymitis. Ultrasonography is useful to confirm fibrosis/calcification associated with chronic orchitis (**30, 31**). Examination of semen will normally reveal poor motility, with a high percentage of abnormal sperm, including primary and secondary defects (**32**) because of testicular degeneration.

MANAGEMENT

Systemic treatment with broad-spectrum antibiotics such as penicillin/streptomycin or ceftiofur, along with NSAIDs, is indicated in acute cases; however, the prognosis for return to normal fertility is poor. Recovery

from testicular degeneration can be assessed by semen evaluation after at least 60 days following treatment. Normal quality semen can be collected from some cases of chronic unilateral epididymitis as the abnormal duct becomes blocked, leaving the ejaculate consisting of semen from the healthy testicle. These bulls must be considered subfertile and mated to reduced numbers of females if retained. Hemicastration can be used to remove a chronically infected testicle, but this also renders the bull subfertile.

TESTICULAR HYPOPLASIA

DEFINITION/OVERVIEW

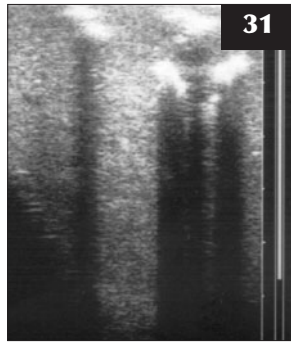
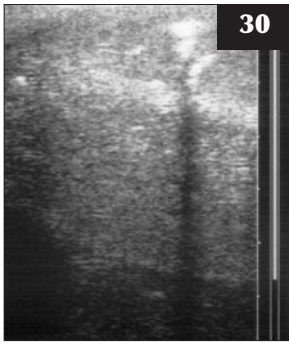
Testicular hypoplasia is the commonest cause of congenital infertility in bulls and has a well documented hereditary component.

AETIOLOGY

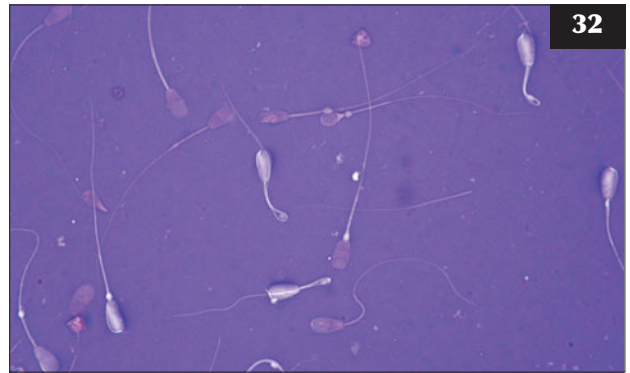
Hypoplasia can be unilateral or bilateral and is associated with failure of development of germinal cells in the seminiferous tubules.

CLINICAL PRESENTATION

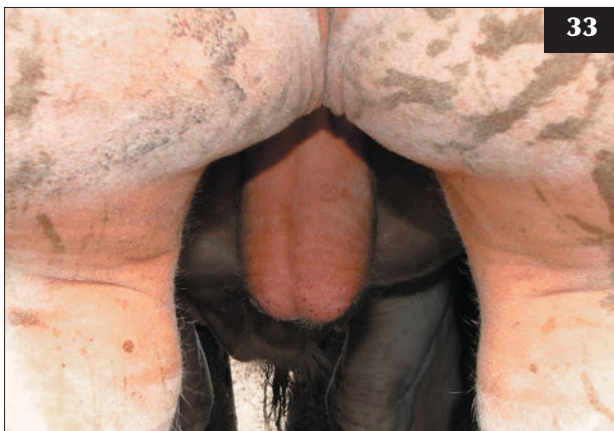Abnormally small testicles are evident from puberty, so the condition is normally identified during breeding soundness checks in young bulls (**33**). Bulls that are sold without scrotal circumference measurements may not be detected until poor breeding results are investigated, as they will have normal libido and be seen to serve normally



30, 31 Ultrasound examination confirming the fibrosis/calcification associated with chronic orchitis.



32 A variety of sperm cell defects are shown in this semen sample from a bull with testicular degeneration following orchitis.



33 Bilateral testicular hypoplasia in a three-year-old Belgian Blue bull. The scrotal circumference is 26 cm.

in most cases. The left testicle is more commonly affected in cases of unilateral hypoplasia.

DIFFERENTIAL DIAGNOSIS

Unilateral hypoplasia must be differentiated from acquired degeneration/fibrosis, which can occur in previously fertile bulls.

DIAGNOSIS

Scrotal circumference measurement in young bulls at 18–24 months of age will be well below minimum thresholds. The testicles are small and firm, with underdeveloped epididymides. Semen collection will confirm total aspermia in severe bilateral cases or reduced sperm concentration and a high percentage of abnormal sperm in partial hypoplasia.

MANAGEMENT

There is no treatment. Bulls should be culled and eliminated from pedigree breeding programmes.

TESTICULAR DEGENERATION

DEFINITION/OVERVIEW

Testicular degeneration is a degeneration of germinal cells in the seminiferous tubules leading to temporary or permanent infertility.

AETIOLOGY

There are many potential local and systemic causes of testicular degeneration in the bull in addition to orchitis and epididymitis. Systemic illness leading to pyrexia with toxæmia, scrotal overheating, plant toxins, obesity or malnutrition, and hormonal disturbances are just a few of the possibilities.

CLINICAL PRESENTATION

The bull may be presented with a primary illness followed by secondary testicular degeneration. Often the primary cause may be subclinical or undiagnosed and the first indication of a problem is infertility during the breeding period in a bull that has previously worked normally. Palpation of the testicles will normally reveal one or both to be soft and smaller than normal.

DIFFERENTIAL DIAGNOSIS

Testicular hypoplasia is the main differential in cases of unilateral or bilateral degeneration and this can often be ruled out by a history of previous normal fertility.

DIAGNOSIS

Diagnosis is based on a history of recent illness, rapid body condition loss or other potential insults to spermatogenesis. Evaluation of a semen sample will confirm a variable degree of abnormalities, including poor density and motility and abnormal sperm morphology with primary defects such as head and midpiece abnormalities.

MANAGEMENT

Most cases of testicular degeneration are diagnosed after the primary cause has passed, therefore treatment is not possible. Recovery of spermatogenesis can be assessed 60–90 days after initial diagnosis by semen sampling; however, in most cases the prognosis is guarded.

SEMINAL VESICULITIS

DEFINITION/OVERVIEW

Infection of the seminal vesicles is not uncommon in young bulls and can occur alone or in association with epididymitis. Older bulls can be affected with a chronic form of the disease.

AETIOLOGY

The aetiology of seminal vesiculitis is unclear. It has been associated with various bacterial pathogens, including *Chlamydia* spp., *Mycoplasma* spp. and *Arcanobacterium pyogenes*. Some cases are associated with segmental aplasia of the glands.

CLINICAL PRESENTATION

In most cases the bull will show no overt clinical signs, but occasionally, in acute cases, there may be signs of pyrexia, abdominal pain and a reluctance to serve. Pain may be associated with defecation and rectal examination.

DIFFERENTIAL DIAGNOSIS

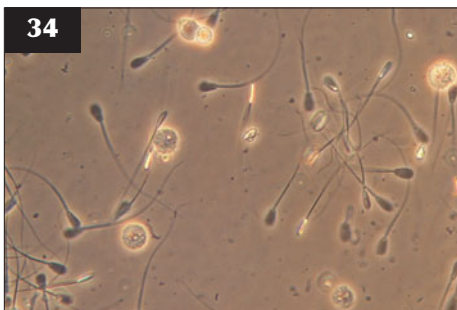
Conditions associated with abdominal/pelvic pain such as urolithiasis, peritonitis or infection of other accessory glands could produce similar signs.

DIAGNOSIS

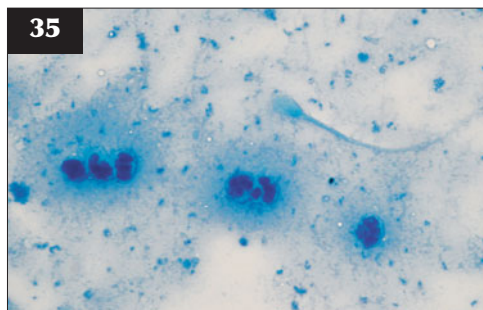
The condition is normally diagnosed during routine breeding soundness examination when rectal palpation reveals swollen, painful, firm vesicles with loss of lobulation. Some cases may develop abscessation with localized adhesions and peritonitis. Ultrasound examination may reveal abscessation and dilation of the glands. Examination of an ejaculate will normally reveal semen with poor motility and a high percentage of secondary defects such as detached heads and midpiece reflex defect. Staining with Giemsa or methylene blue will reveal large numbers of leucocytes in the ejaculate (34, 35), which grossly may contain blood or floccules of pus (36). In older bulls with chronic sclerosing-type vesiculitis the spermiogram may be relatively normal.

MANAGEMENT

Treatment is normally unrewarding as the condition is often chronic when diagnosed. Antibiotic treatment (e.g. tilmicosin) has been reported to be successful in acute vesiculitis in young bulls; however, many cases may self-cure. More radical treatments such as injection of sclerosing agents into the glands or surgical removal have been described, but are not normally considered in commercial beef bulls.



34 Leucocytes visible under a phase contrast microscopy preparation of ejaculate from a bull with seminal vesiculitis.



35 Leucocytes confirmed by staining a semen smear with methylene blue.



36 Purulent ejaculate from a bull with chronic vesiculitis.

HYDRALLANTOIS (HYDROPS ALLANTOIS)

DEFINITION/OVERVIEW

Hydrallantois occurs sporadically in the last trimester of gestation and is much more common than hydramnios (see below).

AETIOLOGY

The condition is caused by an abnormality of placentation.

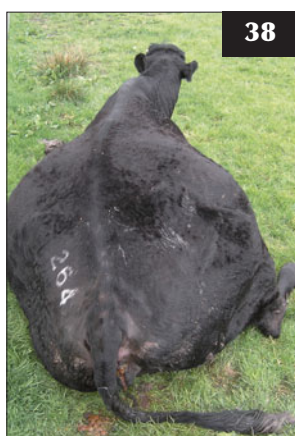
CLINICAL PRESENTATION

Severe abdominal distension caused by the massive accumulation of allantoic fluid (up to 250 litres)



37

37 Dairy cow with hydrallantois at term showing an abnormally distended abdomen.



38

38 This cow with advanced hydrallantois shows rupture of the prepubic tendon and abdominal musculature.



39

39 The large volume of allantoic fluid being released in this cow undergoing emergency caesarean section carries the risk of inducing hypovolaemic shock.

occurs over a short period during the last trimester (37). Such fluid accumulation may lead to decreased appetite, weakness, rupture of the prepubic tendon and ventral abdominal musculature (38), myopathy and recumbency. Death may result from cardiovascular failure.

DIFFERENTIAL DIAGNOSIS

Hydramnios, twin pregnancy, vagal indigestion.

DIAGNOSIS

Transabdominal ultrasound examination and abdominal paracentesis will help differentiate hydrallantois from ascites. Rectal examination will normally reveal a massively distended uterus; however, the fetus/placentomes are often not palpable.

MANAGEMENT

When cases are identified early, induction of parturition with dexamethasone and prostaglandin F_{2α} (PGF_{2α}) should be considered if the cow deteriorates. Emergency caesarean section can be attempted, but the uterine wall is thin and friable and sudden release of huge volumes of allantoic fluid can lead to hypovolaemic shock (39). Following induction of calving or salvage caesarean there is a high risk of puerperal metritis associated with retention of fetal membranes and poor uterine involution. Humane destruction is necessary when cows have a poor appetite and are weak or recumbent at first presentation.

HYDRAMNIOS

DEFINITION/OVERVIEW

Hydramnios is characterized by gradual accumulation of excess volumes of amniotic fluid around mid-late trimester, with variable abdominal distension depending on the volume of fluid, which may not be noticed prior to full term. Hydrops of the amnion is normally associated with a fetal abnormality. Induction of calving/abortion is rarely necessary and the pregnancy may go to term.

RETAINED FETAL MEMBRANES

DEFINITION/OVERVIEW

Partial or complete retention of fetal membranes beyond 12 hours is considered abnormal and constitutes a failure of third-stage labour. The incidence of retained fetal membranes (RFM) varies from 3% to 10%.

AETIOLOGY

RFM is caused by a failure of normal separation of fetal cotyledonary villi from maternal caruncles and/or primary

uterine inertia. Physiological processes controlling separation of the placenta begin several weeks pre-partum. Normal separation requires pre-partum maturation of the placenta, intrapartum detachment by uterine pressure contractions and reduction in size of uterine caruncles post partum.

Factors predisposing to RFM include premature parturition, because immature placentomes are not physiologically prepared for separation (e.g. twin births, late abortions or induced births). Oedema of chorionic villi caused by trauma such as dystocia, caesarean section or placentitis caused by abortifacients such as *Bacillus licheniformis* also increase the prevalence of RFM. Uterine inertia due to hypocalcaemia, hydrops and twins increases the risk of RFM, and impaired neutrophil function associated with selenium/vitamin E deficiency has also been blamed for increasing the incidence.

CLINICAL PRESENTATION

A putrid placenta is usually visible hanging from the vulva (40). In some cows the placenta is retained within the cervix and vagina and not immediately detected unless the cow strains in an attempt to pass the placenta or puerperal metritis develops.

MANAGEMENT

Manual removal is contraindicated unless the RFM remain attached after 3–5 days and can be removed with gentle traction at this time. Trauma to the endometrium during attempted removal may increase toxin absorption and reduce phagocytic function. Studies have shown that manual removal has a negative effect by increasing the calving to conception interval compared with untreated

or antibiotic-treated control cattle. Oxytocin, PGF₂α, calcium salts and oestrogens have all been tried in the immediate post-partum period with limited success. Stockmen should monitor rectal temperature in cows with RFM in order to detect onset of puerperal metritis, which may require treatment with antibiotics (see below).

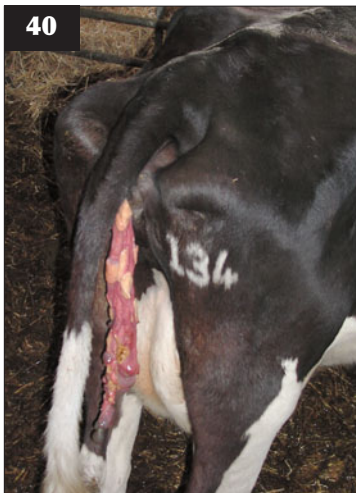Prevention of RFM should focus on risk factors such as dystocia, abortion and twinning. Metabolic disease and trace element deficiency should be prevented by correct nutrition and management.

POST-PARTUM UTERINE INFECTION

The normal post-partum period involves uterine involution, regeneration of the endometrium, elimination of bacterial contamination of the uterus and return of cyclical ovarian activity. Normal cows have a reddish brown and odourless lochial discharge for 7–10 days due to sloughing of surface tissue from the uterine caruncles (41).

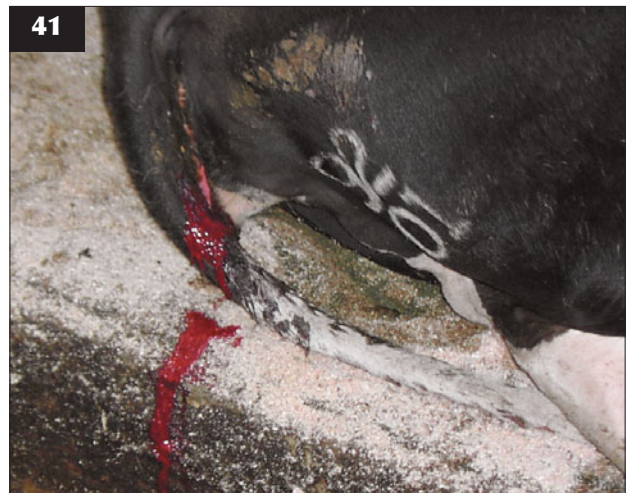Complete uterine involution takes 4–6 weeks, but it can be assessed at three-week post-partum checks when the diameter of the previously gravid horn should be less than that of the cervix.

Ninety percent of uteri swabbed within 15 days post calving have bacterial contamination, reducing to around 9% by 46–60 days post partum. *Arcanobacterium pyogenes*, *E. coli*, *Fusibacterium necrophorum*, staphylococci and streptococci are commonly isolated. Early resumption of ovarian cyclicity aids elimination of bacterial contamination. Failure of normal uterine defence mechanisms or overwhelming bacterial challenge can lead to the development of varying degrees of metritis, as described below.



40

40 Retained fetal membranes in a cow calved >24 hours.



41

41 Normal cows have a reddish brown and odourless lochial discharge for 7–10 days due to sloughing of surface tissue from uterine caruncles, as shown in this cow.

PUERPERAL METRITIS

DEFINITION/OVERVIEW

Puerperal metritis should be defined as an abnormally enlarged uterus and a fetid watery red-brown uterine discharge, associated with signs of systemic illness (decreased milk yield, dullness or other signs of toxæmia) and fever of $>39.5^{\circ}\text{C}$, within 21 days after parturition.

AETIOLOGY

Puerperal metritis commonly affects cows after unhygienic manual interference to correct fetal malpresentation/malposture, after delivery of twins or a dead calf and following infectious causes of abortion (e.g. *Salmonella* spp.). In most of these situations there is retention of some, or all, of the fetal membranes. Cows suffering hypocalcaemia during second-stage labour have an increased incidence of RFM and metritis.

Illness follows bacterial entry and multiplication within the uterus, with the production of toxins that are absorbed across the damaged endometrium. The likelihood of metritis increases in proportion to the duration of manual intervention in dystocia cases.

CLINICAL PRESENTATION

Acute puerperal metritis often presents 2–4 days after calving. The cow is dull and depressed, inappetent and with milk yield typically about one-third of that expected. The cow is febrile with a rectal temperature often above 40°C ; however, severely toxic cows may have a normal or subnormal temperature (42). Straining may be noted in those cows with RFM. There is often fetid diarrhoea, but no evidence of blood or mucosal casts in the faeces. The mucous membranes are congested and there are reduced ruminal sounds.



42 This severely toxic cow has a subnormal rectal temperature.

The vulva is swollen/oedematous in dystocia cases, with evidence of a red/brown fetid fluid discharge. Typically, the fetal membranes are still partially attached to the uterine caruncles. The uterus may contain up to 5–10 litres of red/brown foul-smelling fluid.

DIFFERENTIAL DIAGNOSIS

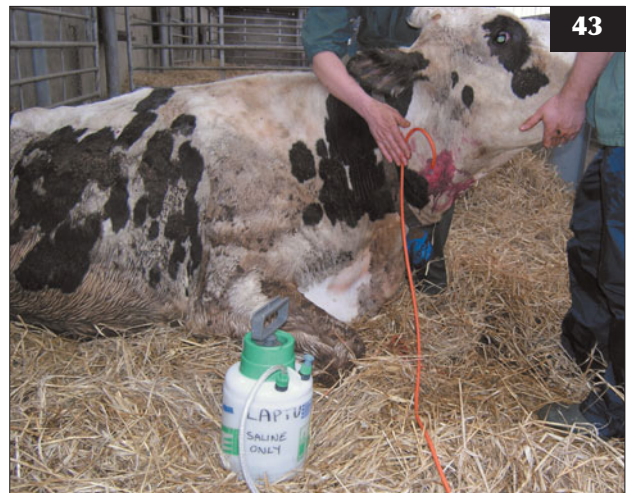Differential diagnoses to consider for inappetent and recently calved cows could include toxic mastitis, salmonellosis, ruptured uterus if considerable difficulty is encountered during delivery of the fetus, acidosis if sudden access to concentrates post calving, peritonitis, retained twin calf, hypocalcaemia/fatty liver syndrome and displacement or torsion of the abomasum.

DIAGNOSIS

The provisional diagnosis is based on history, clinical findings and elimination of other common diseases. Vaginal examination often stimulates discomfort and vigorous straining and reveals copious amounts of red-brown fetid fluid.

MANAGEMENT

Typical treatment comprises intravenous oxytetracycline and NSAIDs, with intramuscular oxytetracycline for the following 3–4 days. Ceftiofur is another commonly used antibiotic. In toxic/dehydrated cows, rapid intravenous infusion of three litres of hypertonic saline is indicated (43) and clean drinking water must be readily available. Calcium borogluconate may be required to treat associated hypocalcaemia. Intrauterine pessaries containing antibiotics are commonly used, but there is little supporting evidence for such treatment. Uterine



43 This toxic cow is being given a rapid intravenous infusion of three litres of hypertonic saline.

siphoning/lavage with saline is used by some practitioners, but it must be done with care to avoid further endometrial damage and toxin absorption. The prognosis is variable for cases of acute toxic puerperal metritis and fatalities are not uncommon despite treatment.

The farmer is advised to present recovered cows for a pre-breeding check 21–28 days post calving, when clinical endometritis can be treated, if present, with antibiotic wash-out or prostaglandin injection (see Clinical endometritis, Management, below).

Almost without exception, farmers' attitudes to overall hygiene standards during dystocia correction could be greatly improved, thereby avoiding many of the problems encountered after such interference. Farmers should wash their hands in an antiseptic scrub solution and consider using arm-length disposable gloves prior to correction of all dystocia cases. Reducing dystocia by sensible sire selection and avoiding risk factors for RFM will also reduce the risk of puerperal metritis.

CLINICAL METRITIS

Cattle that are not systemically ill, but have an abnormally enlarged uterus and a purulent uterine discharge detectable in the vagina within 21 days post partum, are classified as having clinical metritis.

CLINICAL ENDOMETRITIS ('WHITES')

DEFINITION/OVERVIEW

Clinical endometritis is characterized by the presence of a purulent (>50% pus) uterine discharge detectable in the vagina 21 days or more after parturition. There is no systemic illness. The 10–40% incidence varies between farms and years and is more common in the winter months. It can be a significant cause of extended calving to conception intervals in dairy cows.

AETIOLOGY

Predisposing factors include dystocia/assisted parturition, RFM, a dirty calving environment, premature calving, a delay to return of ovarian cyclicity, overconditioning at calving/fatty liver syndrome and selenium/vitamin E deficiency.

CLINICAL PRESENTATION

Affected cows present with evidence of a tacky vaginal discharge on the tail and vulva and with a purulent discharge often seen draining from the vulva when they are lying in a cubicle or on bedding (44, 45).

DIFFERENTIAL DIAGNOSIS

Pyelonephritis may cause a purulent vaginal discharge, but there are other signs of illness such as weight loss. Vaginitis caused by trauma at calving may cause a persistent vulval discharge.



44, 45 Clinical endometritis. (44) A tacky vaginal discharge is evident on the tail and vulva of this cow. (45) A purulent discharge is being passed in this cow, which is lying in a cubicle.

DIAGNOSIS

Rectal palpation normally reveals enlargement and a thickened 'doughy' feel of one or both uterine horns. Manual vaginal examination reveals a partially open cervix and a purulent discharge (46, 47). Transrectal ultrasound examination is a useful aid to diagnosis, as anechoic fluid within the uterine lumen containing many hyperechoic dots is characteristic of purulent material (48).

MANAGEMENT

PGF₂α injection is probably the best treatment for clinical endometritis, but it requires a responsive corpus luteum (CL) for optimal effect. Causing luteolysis of a persistent CL allows the cows' innate immune system to function optimally during the oestrogen-dominant phase of the induced cycle. Treatment can be repeated after 10–14 days

if infection persists. In cows with no responsive CL present, a beneficial effect may be due to a direct ecboic effect of PGF2 α on the myometrium.

Intrauterine antibiotic pessaries are of dubious efficacy due to insufficient concentrations of antibiotic administered, some of which may not be active in an anaerobic environment. Intrauterine antibiotic infusion (e.g. cephalosporin) is preferable to pessaries and can be a useful adjunct or alternative to PGF2 α injection. Antiseptic wash-out using dilute Lugol's iodine or chlorhexidine is irritant to the endometrium and can cause PGF2 α release, which may have a curative effect. Self-cure can occur following return to normal ovarian cyclicity.

Prevention measures include general calving hygiene and minimizing dystocia, avoiding overconditioned cows at calving (fatty mobilization syndrome) and ensuring adequate mineral/vitamin supplementation.

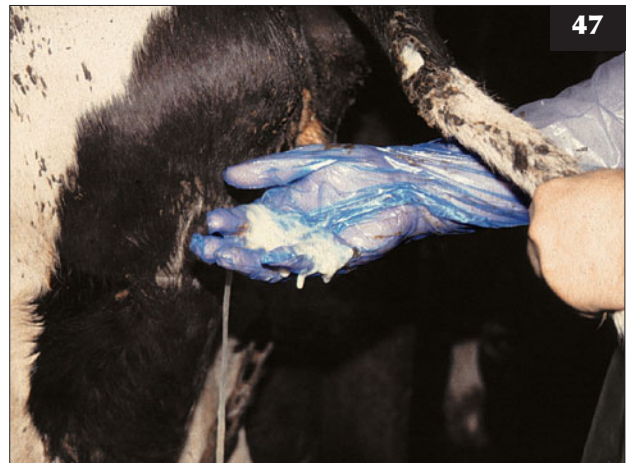PYOMETRA

DEFINITION/OVERVIEW

Pyometra is defined as the accumulation of purulent material within the uterine lumen in the presence of a persistent CL and a closed cervix. Pyometra may develop following clinical endometritis, embryonic/fetal death or after infection is introduced at service.

DIAGNOSIS

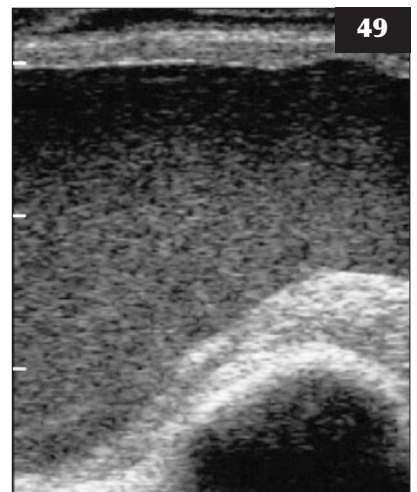
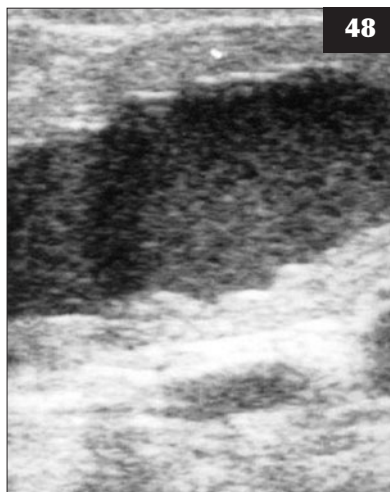The distended uterine horn must be distinguished from pregnancy, as cows may develop pyometra following service. With pyometra the uterine wall is often thicker and no membrane slip or cotyledons/fetus will be palpable. Diagnosis is readily confirmed by a transrectal ultrasound scan (49).



46, 47 Manual vaginal examination will reveal a partially open cervix (46) and a purulent discharge (47) in cows with clinical endometritis.

48 Transrectal ultrasound reveals anechoic fluid within the uterine lumen, which contains many hyperechoic dots, characteristic of purulent material, in this case of clinical endometritis.

49 Ultrasound scan in a case of pyometra confirming distension of the uterine horn with pus (arrow).



MANAGEMENT

Treatment with PGF2 α injection is effective with luteolysis followed by return to oestrus and evacuation of the uterus. Preventive measures for pyometra are the same as for endometritis (see Clinical endometritis, Management, above).

ANOESTRUS

DEFINITION/OVERVIEW

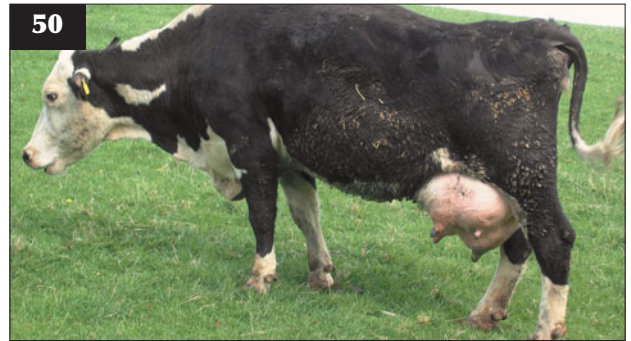During pregnancy, and for a short period following parturition, cows are normally acyclic. However, oestrous behaviour, not accompanied by ovulation, can occur in up to 7% of pregnant cows. Progesterone profiling suggests that 90% and 70% of dairy cows and beef cows, respectively, resume cyclicity by 50 days.

Throughout pregnancy, waves of follicles develop and become atretic in the ovaries; ovulation is inhibited by high progesterone concentrations during pregnancy effecting a negative feedback mechanism on the hypothalamus. Following parturition, follicle-stimulating hormone (FSH)-induced waves of follicular growth are soon accompanied by luteinizing hormone (LH)-induced ovulation and return of regular cyclicity. The first dominant follicle can normally be detected by 7–20 days post partum, with first ovulation normally by 20–30 and 20–60 days in dairy and beef cows, respectively. Due to the lack of prior progesterone priming, the first ovulation may not be accompanied by oestrous behaviour (silent ovulation). LH pulse frequency is the key to re-establishing post-partum cyclicity, as with insufficient LH pulse frequency, waves of follicles will continue to turn over without ovulation, leading to extended anoestrus. Anoestrus extending beyond 55–60 days post partum is likely to cause significant economic losses due to delay in the calving to first service and subsequent calving interval.

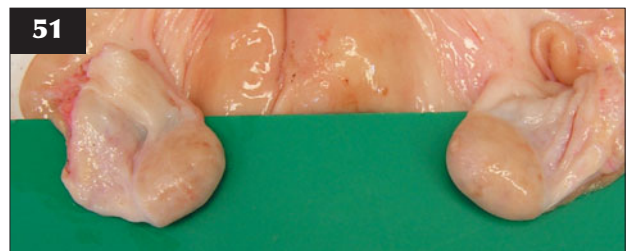AETIOLOGY OF EXTENDED POST-PARTUM ANOESTRUS

Any factor causing interference with gonadotropin-releasing hormone (GnRH)/LH output during the early post-partum period can influence the post-partum anoestrous period, including:

- **Nutritional effects.** Negative energy balance during late pregnancy/early lactation can cause extended anoestrus due to suppression of LH pulse frequency. Poor body condition score (BCS) at calving will increase the duration of anoestrus, especially in beef cows (50). Specific trace element deficiency may also be involved, especially sulphur and molybdenum-induced copper deficiency.
- **Suckling effects.** Natural suckling has a greater influence than milking, therefore this effect is important only in beef cows. Temporary calf separation in beef cows may increase LH pulse



50 The poor body condition score at calving in this beef cow increased the duration of anoestrus.



51 Bilateral small/firm ovaries with no corpora lutea or large follicles from an anoestrous cow.

frequency and significantly shorten the post-partum anoestrous period.

- **Delayed uterine involution.** Assisted parturition, RFM and metritis can cause delayed involution, which may delay resumption of cyclicity.
- **Cystic ovarian disease** (see p. 24). Cysts form due to failure of ovulation of early dominant follicles and this can delay normal cyclicity.
- **Persistent CL.** A persistent CL is usually found along with uterine infection/pyometra, as this can lead to failure of endometrial PGF2 α release. Treatment with PGF2 α injection will be effective, with oestrus expected within 2–5 days.

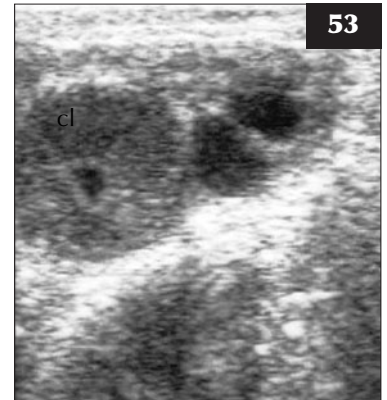
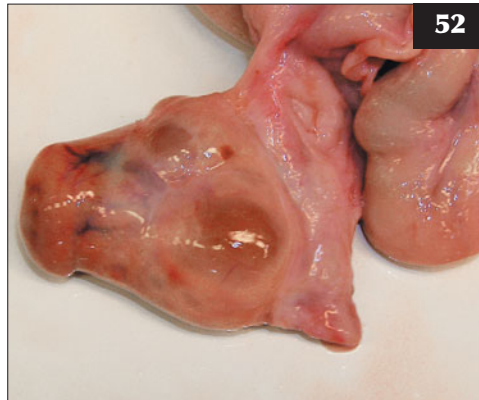DIAGNOSIS OF NUTRITIONAL ANOESTRUS

Most cows presented for anoestrus after 60 days post partum will be cycling and have simply not been observed in oestrus due to poor heat detection. True anoestrus can be confirmed by the finding of basal progesterone levels in milk or blood in samples taken 10–14 days apart. In practice, anoestrus is normally diagnosed based on single rectal palpation/ultrasound findings of bilateral small/firm ovaries (51) with no CL or large follicles detected (52, 53), along with a history of poor body condition and negative energy balance.

MANAGEMENT OF NUTRITIONAL ANOESTRUS

Correcting any underlying nutritional problem(s) is essential.

52, 53 Cyclic cows have large follicles and/or corpora lutea present on the ovaries, detectable by palpation (**52**) or ultrasound (**53**, cl).



Progesterone treatment for 7–10 days mimics the luteal phase, suppressing LH release from the anterior pituitary. An LH surge follows implant withdrawal and ovulation/oestrus occurs in most cases 2–3 days later. During the early post-partum period, 400–600 iu of pregnant mare serum gonadotropin (PMSG) can be injected at cessation of progesterone treatment to ensure ovulation and oestrus, though this may lead to multiple ovulation in some cases.

An injection of a GnRH analogue (e.g. buserelin or gonadorelin), given more than 55 days post partum, will induce oestrus in most acyclic cows within 23 days. LH released in immediate response to the GnRH injection causes silent ovulation and formation of a CL. The onset of oestrus following treatment can be controlled by a PGF2 α injection 7–14 days after the initial GnRH treatment. This regimen may suit herds having fortnightly fertility visits, as cows treated for anoestrus with GnRH and still not observed in oestrus would be re-examined after 14 days and injected with PGF2 α if a CL was now present.

(**Note:** These treatments are unlikely to be effective in thin, high-yielding cows in severe negative energy balance. If ultrasound findings confirm small ovaries with negligible follicular activity present, treatment should be delayed until the cow is in a better nutritional state.)

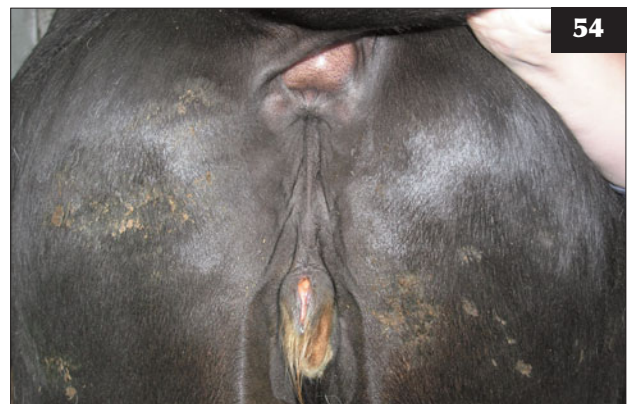ANOESTRUS IN HEIFERS

AETIOLOGY

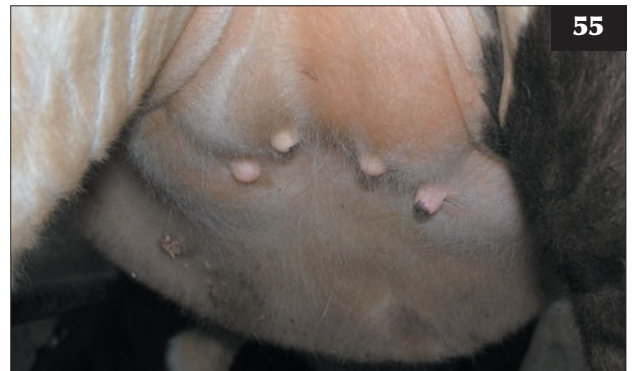Persistent anoestrus in maiden heifers may rarely be caused by delayed puberty or gonadal aplasia. The commonest cause of gonadal aplasia is the condition of freemartinism. The majority of heifer calves born co-twin to a male calf will be freemartins. It is possible for an apparently singleton heifer calf to be a freemartin if a male embryo/fetus co-twin died *in utero* after passage of material to the female, but before the twin pregnancy was diagnosed.

CLINICAL PRESENTATION

The clinical signs are very variable. The vulva may appear normal or underdeveloped. There may be an enlarged



54 In this freemartin heifer the vulva is underdeveloped.



55 Hypoplastic teat development in a freemartin heifer.

clitoris and a tuft of hair at the ventral commissure (**54**). The vagina is usually shortened and ends blindly. The gonads are almost invariably hypoplastic and may be more like testes than ovaries. The uterine remnant may be so small as to be difficult to palpate. Teat development will normally be hypoplastic (**55**).

MANAGEMENT

Affected heifers should be fattened and culled.

CYSTIC OVARIAN DISEASE

DEFINITION/OVERVIEW

The incidence of cystic ovarian disease (COD) varies between 5% and 30%, with most cases developing 20–60 days post partum and affecting second and third lactation, high-yielding dairy cows. The disease is rarer in beef cows.

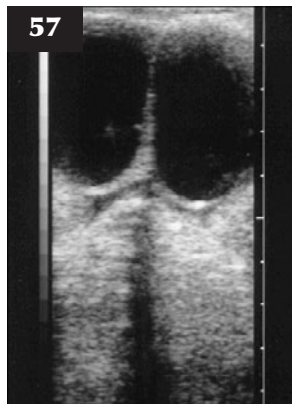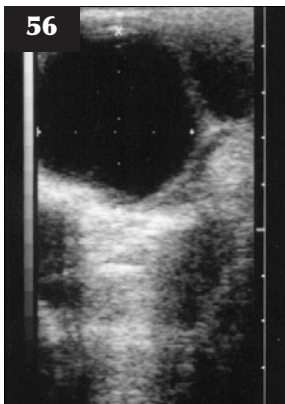
AETIOLOGY

Follicular cysts develop due to either failure of the LH surge around the time of normal ovulation or failure of the follicle to respond to LH. The follicle fails to ovulate and, instead of becoming atretic, continues to grow to form a cyst. Cystic follicles initially produce oestradiol, which suppresses further follicular development in the ovaries, and then they enter an oestrogen-inactive phase, which can persist for many weeks. Many cysts that form during the early post-partum period (<30 days) regress spontaneously without treatment. Some follicular cysts become luteinized and persist as luteal cysts.

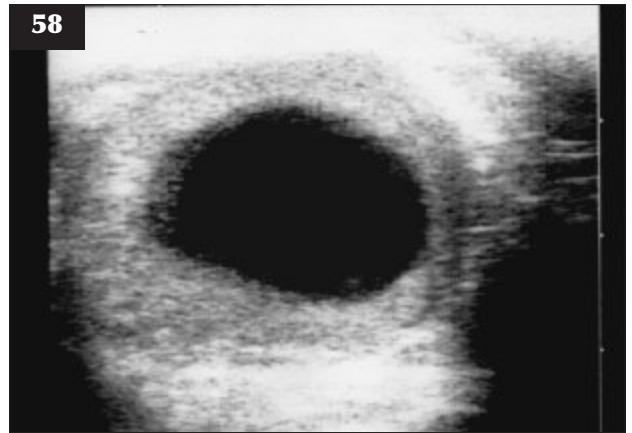
CLINICAL PRESENTATION

An ovarian cyst is defined as a fluid-filled structure >2.5 cm in diameter that is present for more than ten days on one or both ovaries in the absence of a CL. Cysts can be classified either as follicular cysts (56, 57), which are thin-walled and non-progesterone producing (plasma progesterone <2 ng/ml), or luteinized or luteal cysts (58), which are thicker walled (>3 mm) and produce progesterone (plasma progesterone >2 ng/ml). Many normal CLs have fluid-filled centres (lacunae) visible on ultrasound scan (59, 60) and must not be mistaken for luteal cysts.

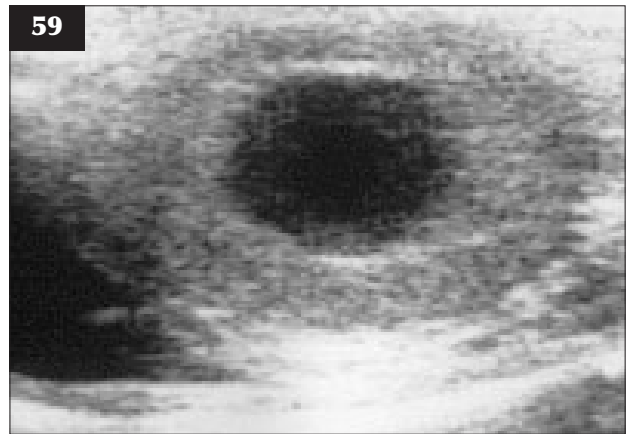
Cows with follicular cysts are usually anoestrus, but some cows show recurrent and irregular oestrous activity (nymphomania). Cows with luteinized cysts are anoestrus.



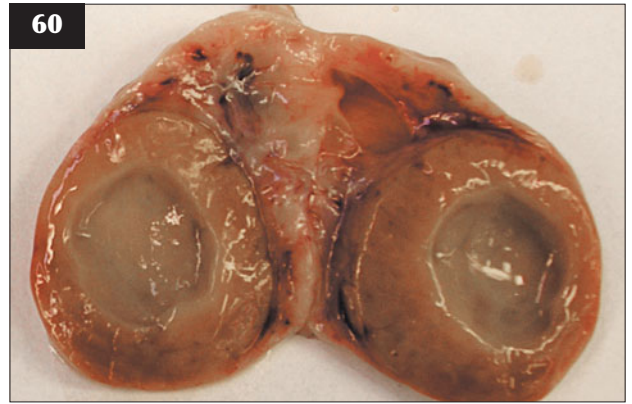
56, 57 Cystic ovarian disease. Ultrasound examination demonstrating that the follicular cysts are persistent thin-walled anechoic fluid-filled structures 2–4 cm in diameter.



58 Cystic ovarian disease. Ultrasound examination demonstrating that luteal/luteinized cysts have a thicker, >3 mm echogenic wall and luteal tissue bridging the lumen.



59 Normal corpus luteum with a fluid-filled centre (lacuna) visible on an ultrasound scan.



60 Post-mortem specimen showing a normal lacuna in a corpus luteum.

DIAGNOSIS

It is difficult accurately to define the type of cyst by manual rectal palpation. Milk or blood progesterone analysis may increase the accuracy of manual rectal palpation; however, progesterone output varies over time with cysts and there may be a normal CL producing progesterone that was undetected during the ovarian examination. Follicular and luteal cysts can be differentiated with reasonable accuracy by transrectal ultrasound examination on the basis of morphology, with cysts showing a wall thickness of >3 mm classified as luteal. If a cyst is detected by ultrasound on one ovary, the other ovary should also be scanned carefully for the possible presence of a CL. Follicular cysts can be found in pregnant cows, reinforcing the fact that cysts can persist as non-functional anatomical structures for weeks or months.

MANAGEMENT OF FOLLICULAR CYSTS

Treatment of ovarian cysts is recommended in cows more than 30 days post partum in order to reduce the potential delay in interval to first service. Treatment options include:

- **GnRH analogues** (e.g. buserelin, gonadorelin). GnRH induces an LH surge, effecting luteinization (not ovulation) of the follicular cyst and possibly ovulation or luteinization of any mature follicles present in the ovaries. Successful treatment should produce a rise in plasma progesterone concentration to normal luteal phase values within seven days and 80% of cows show oestrus within 30 days. PGF2 α can be given 7–14 days after GnRH treatment if oestrus has not yet occurred. Ultrasound monitoring of GnRH-treated cows will show regression or luteinization of follicular cysts and/or appearance of a CL if treatment has been successful. The Ovsynch® protocol has been reported to be an effective treatment regimen for follicular cysts.
- **Human chorionic gonadotropin (hCG)**. Injection of hCG, which is an LH agonist, can be used to treat follicular cysts, with the mode of action as described for GnRH. Return to oestrus is variable, but usually within 20–30 days post treatment.
- **Progesterone treatment (PRID™ or CIDR™)**. A PRID or CIDR device is inserted into the vagina for 7–10 days. The mechanism of cure is not clear, but treatment probably causes atresia of the follicular cyst by suppression of LH support through progesterone-negative feedback. Oestrus normally occurs within 2–3 days of PRID/CIDR removal, along with ovulation of a new dominant follicle.
- **Manual rupture** of ovarian cysts is not recommended because of possible trauma/haemorrhage within the ovary and its bursa.

MANAGEMENT OF LUTEAL CYSTS

Prostaglandin F2 α can be administered when confident of the diagnosis of a luteal cyst, with return to oestrus expected within 2–5 days.

OVERALL MANAGEMENT

At present, the best advice to help reduce the incidence of COD in dairy cows is to manage them in such a way as to minimize negative energy balance and metabolic and management stress in early lactation, as these factors have been associated with higher incidence of disease.

Cystic ovarian disease causes financial loss associated with a 20–60-day increase in the calving to conception interval.

THE REPEAT BREEDER COW

DEFINITION/OVERVIEW

A repeat breeder cow is a cow that has failed to become pregnant following three or more consecutive serves at normal interoestrus intervals. An incidence of 10–18% is reported, but these figures depend on the herd pregnancy rate. For example, in a 100-cow herd with a 40% pregnancy rate, 22 cows will need four or more serves compared to six in a herd with a pregnancy rate of 60%.

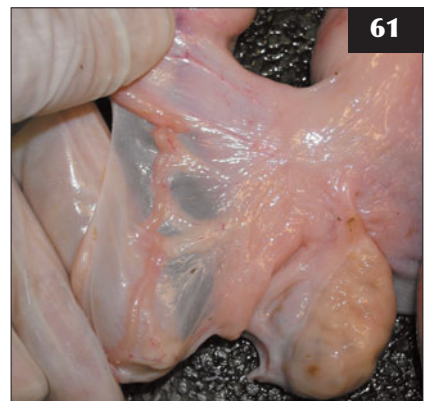AETIOLOGY

The statistical chance is as outlined above. Failure of fertilization or early embryo death may result from a hostile uterine environment, blocked oviducts/salpingitis, delayed ovulation, bursal adhesions and anatomical abnormalities (e.g. segmental aplasia in maiden heifers).

DIAGNOSIS

A vaginal examination should be undertaken on the day of oestrus to check for clear mucus and a normal cervix. The cervix, uterus, oviducts and ovaries/bursae should be examined rectally (61) and by ultrasound.

61 Normal oviduct in a repeat breeder cow.



MANAGEMENT

If there is a cloudy/purulent mucus, the cow should not be served. An antibiotic uterine wash-out (e.g. cephalosporin) should be carried out and the cow served at the next oestrus or short-cycled by PGF 2α injection in 10 days.

If adhesions, salpingitis or other physical abnormalities are found, the cow should be culled unless the genetic value of the animal warrants oocyte collection and in-vitro fertilization to produce embryos for transfer into recipients.

If no abnormalities are found on examination of repeat breeder cows, a GnRH injection can be given on the day of service (holding injection). Treatment with an injection of GnRH around the time of insemination has been shown to improve fertility in repeat breeder cows by inducing an LH surge and ensuring ovulation occurs synchronously with the insemination. This treatment is likely to be most effective in cows that suffer from 'delayed ovulation'.

Treatment with GnRH on day 11 after service has been shown to increase the pregnancy rate in cows by up to 10% compared with untreated controls. The treatment induces LH release and luteinization or ovulation of large second-wave follicles, reducing oestradiol secretion and possibly increasing luteal progesterone concentrations. This reduces the risk of premature luteolysis and leads to a reduction in early embryonic loss. This treatment can be given to all cows or targeted on cows returning to oestrus for a second or third service (repeat breeders).

(Note: Hormone treatments that improve fertilization rates or reduce early embryonic death may have an impact on herd pregnancy rates if used in the right circumstances, but have no beneficial effect on infertility caused by poor management.)

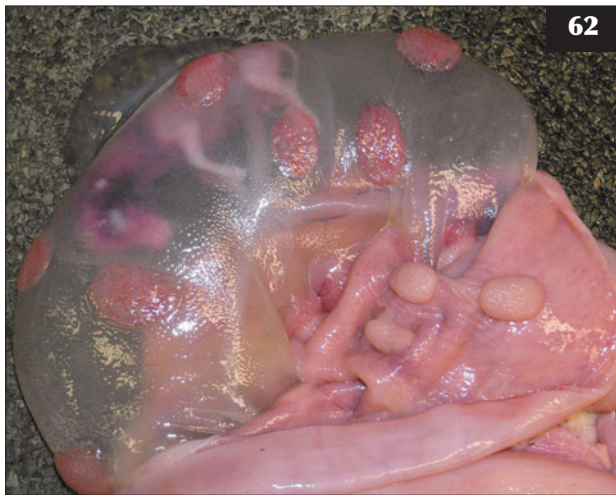NORMAL PREGNANCY IN THE COW

Gestation varies between 280 and 285 days, with continental beef breeds such as the Charolais having longer gestation periods than dairy breeds. Cattle are considered monotocous, but there is a 1–4% incidence of twinning, mostly as a result of double ovulation, which increases with maternal age. Bilateral horn pregnancies are more successful than ipsilateral horn pregnancies in cows.

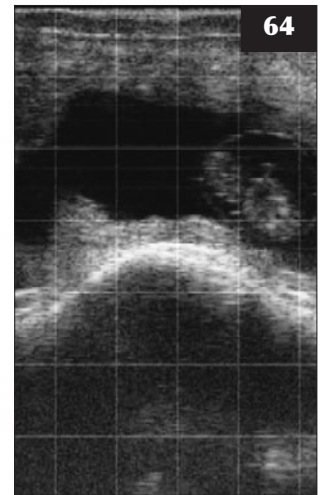
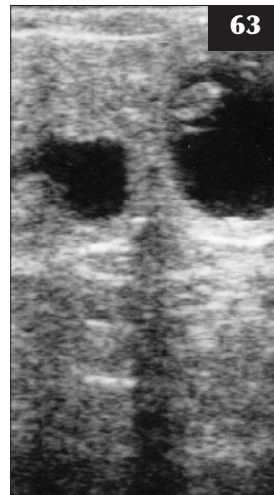Cattle have a cotyledonary syndesmochorial placentation (62). Initially there is some fusion, but as the volume of allantoic fluid increases, the allantoamnion and allantochorion separate. Rapid increases in allantoic fluid

and amniotic fluid occur between two and three months and three and four months, respectively. There is a further rapid increase in allantoic fluid around 6–8 months (important in the development of hydrallantois). At term, there are 5–8 litres and 14–16 litres of amniotic and allantoic fluid, respectively.

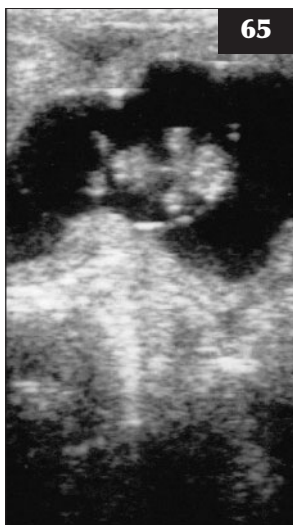With experience, pregnancy can be confirmed by rectal palpation from as early as 30–35 days of gestation. If using ultrasound (63–70), pregnancy can be accurately assessed by days 25–30. Ultrasound pregnancy diagnosis has advantages over manual palpation as the clinician can assess fetal



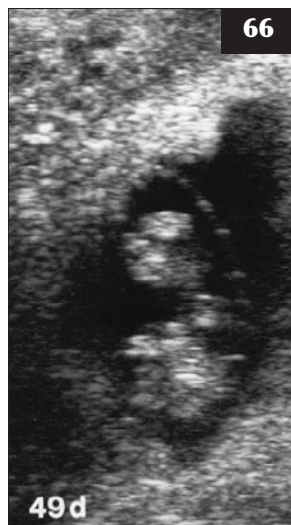62 Bovine pregnancy at approximately 63 days of gestation. Cotyledons on the allantois attach to the maternal uterine caruncles.



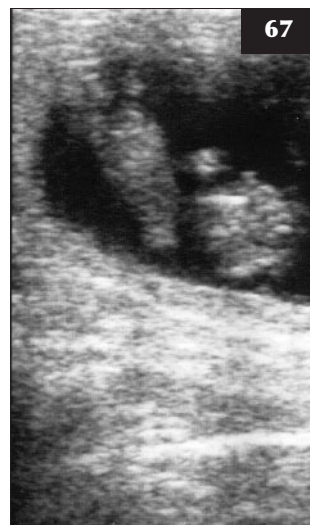63, 64 Ultrasound pregnancy diagnosis. **(63)** 30-day pregnancy. **(64)** 35-day pregnancy.



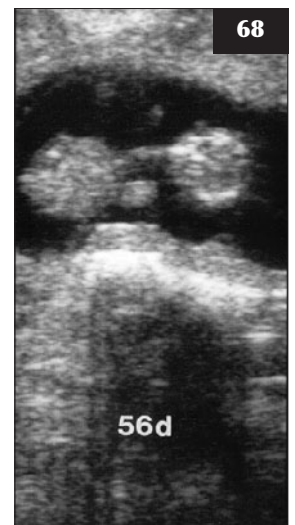65 38-day pregnancy.

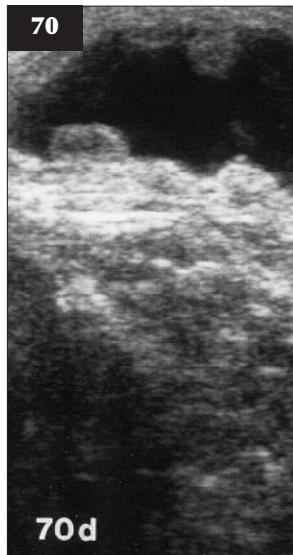
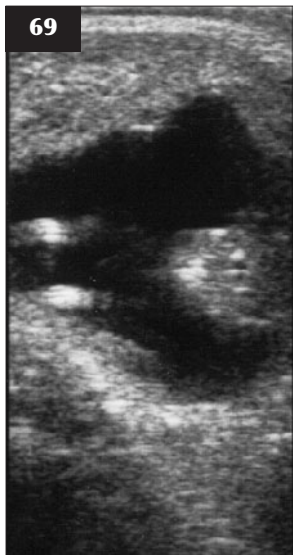


66 49-day pregnancy.

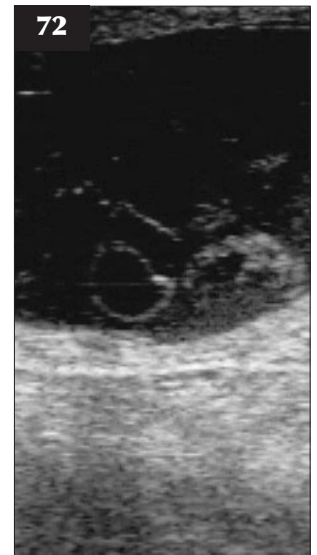
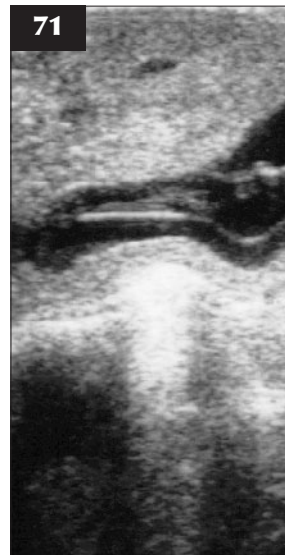
67, 68 56-day pregnancy.

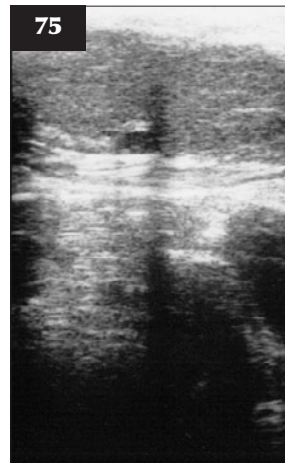
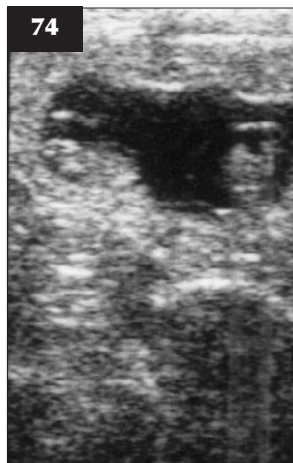
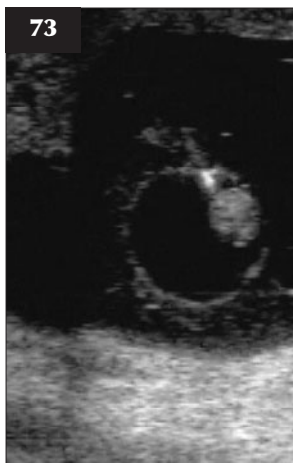


69, 70 70-day pregnancy with fetal limbs now well developed and placentomes visible.



71–73 Cows presented for ultrasound pregnancy diagnosis at 30–40 days post service with signs of embryonic death showing membrane detachment (**71**) and fetal debris floating in the uterine lumen (**72, 73**).



74 A unilateral horn, twin pregnancy detected using ultrasound.

75 The two corpora lutea (arrows) detected at ultrasound pregnancy diagnosis in this cow should alert the clinician to check carefully for twin pregnancy.

viability, thus detecting signs of embryonic death (**71–73**), identify twin pregnancies (**74, 75**), carry out fetal sexing and estimate gestational age using fetal measurements.

INDUCTION OF PARTURITION/ABORTION

Indications for induction of parturition/abortion include misalliance pregnancy, life-threatening illness in the dam (e.g. pregnancy toxemia or hydrallantois) and to terminate prolonged gestation.

The major source of progesterone to day 150 is the CL and luteolysis following PGF2 α injection will induce abortion of most pregnancies prior to this time.

When terminating misalliance pregnancy where service date is known, at least seven days should be left after service to ensure that a PGF2 α -responsive CL is present.

Between 150 and 270 days PGF2 α alone will not reliably cause abortion, as placental progesterone production can maintain the pregnancy in the absence of a CL. The most reliable option is combined use of dexamethasone and PGF2 α treatments, with abortion normally occurring within five days.

After day 275 of gestation a single injection of either a short-acting corticosteroid (e.g. 20 mg dexamethasone) or PGF2 α will induce normal parturition within 48–72 hours. Retention of fetal membranes is common if cows are induced prior to 282 days.

PREGNANCY LOSS IN CATTLE

Total embryonic/fetal wastage in cattle is estimated to be between 35% and 55% and accounts for the difference between the fertilization rate of 85%, but an average pregnancy rate of only 45%. The peak period of wastage is within 19 days after fertilization and can be manifest as an extended interoestrus interval. Fertilization failure or embryo death before day 13 usually results in return to oestrus at the normal interval.

Embryonic loss is generally regarded as pathological and is a source of economic loss; however, it may prevent an abnormal non-viable fetus, due to genetic/chromosomal defects, reaching full-term.

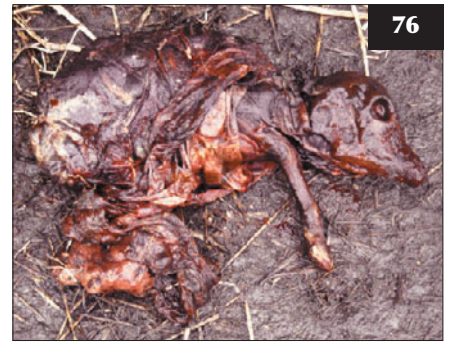Possible causes and timing of embryo/fetal loss in cattle are summarized in *Table 1*. Embryonic loss at <40 days of gestation will often go undetected and with no clinical significance; however, later fetal death can lead to complications such as mummification or maceration of the fetus.

FETAL MUMMIFICATION

Mummification results following fetal death with persistence of the CL; the cervix remains closed and there are no uterine contractions.

Two types of mummification, papyraceous and haematic, can result. With papyraceous mummification all fetal fluids are slowly reabsorbed, leaving a desiccated friable mass surrounded by parchment-like membranes. Haematic mummification occurs between three and eight months of gestation, with haemorrhage from placentomes following fetal death forming a viscous brown material (76).

76 A mummified fetus as a result of fetal death beyond 3–4 months of gestation.



Mummification is diagnosed when cattle exceed normal gestation length or there are no imminent signs of impending parturition such as udder development. The general health of the dam is unaffected. The mummified fetus can sometimes be palpated per rectum; there are no placentomes or fetal fluids, and no fremitus in the middle uterine arteries.

Eventually, luteal regression occurs after mummification or is induced following PGF2 α treatment, allowing the mummified fetus to be passed. In other cases, PGF2 α treatment induces luteolysis, but fails to induce expulsion of the mummified fetus, and culling for infertility will be indicated. Injection of oestradiol as a treatment to aid expulsion of a mummified fetus is no longer licensed in many countries.

Table 1 Possible causes and timing of embryo/fetal loss in cattle.

Stage of loss	Average loss	Possible reasons
Fertilization failure	10–15%	Poorly timed artificial insemination Delayed ovulation Hostile uterine environment for sperm Blocked oviduct/bursal adhesions
Early embryonic death Day 1–19	20%	Genetic defect Poor quality follicles/ova Endometritis Hormonal environment Lack of interferon tau production Heat stress Infectious agents
Late embryonic death Day 19–40	10%	As above plus management stress, etc.
Fetal death/abortion 40–270 days	5%	Many infectious and non-infectious causes (see later)

FETAL MACERATION

Fetal maceration results when the mummified fetus is not expelled but undergoes putrefaction and autolysis following bacterial entry through the open cervix. The dam is unaffected except for a scant brown vulval discharge and fetal bones palpable, and clearly visible ultrasonographically, within the contracted uterus. Treatment to achieve a healthy uterine environment is rarely successful because fetal detritus remains embedded in the endometrium, causing persistent chronic inflammation and preventing a successful pregnancy.

ABORTION

When abortion, premature birth, stillbirth or the birth of weak non-viable calves occur, the subsequent investigation is likely to include not only the veterinary practitioner, but also an investigating laboratory. In the majority of bovine abortions the cause is never confirmed because there is inadequate or inappropriate material submitted to the investigating laboratory. All abortions should be treated as infectious until proved otherwise.

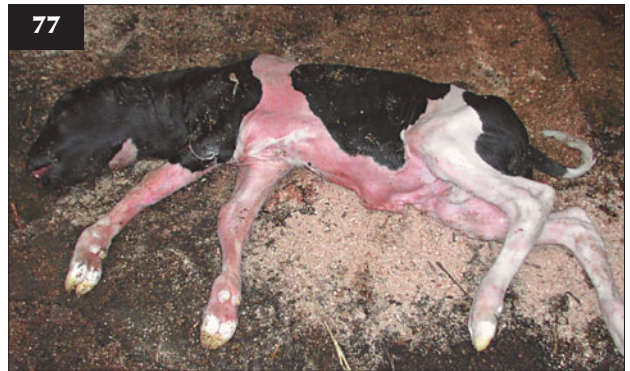APPROACH TO AN ABORTION PROBLEM

The owner must isolate the aborted animal and, as far as practicable, the site of the abortion from other stock. A problem arises with the first abortion, deciding whether this is an isolated incident or the first of many. Ideally, the entire products of abortion should be submitted for pathological and microbiological examination.

History should include current management, diet, recent purchases, movements, clinical disease and fertility history. A clinical examination of all affected animals should be undertaken and apparently healthy in-contact stock inspected.

A sample of placenta should be taken to include cotyledons, lesions (if any) and 'normal' tissue, swabs of vaginal discharge and a blood sample. If the whole fetus cannot be submitted, fetal stomach contents, pleural or peritoneal fluid, liver, lung, thymus and blood should be collected as directed by the laboratory. Fetal serology is only useful when abortion occurs beyond the stage of fetal immunocompetence (>110 days); even in later pregnancy, abortion may occur before the fetus can mount an immune response, limiting the usefulness of fetal serological testing (77). The dam should be blood sampled, as serology may be useful, although seropositivity is not diagnostic for many diseases, such as bovine virus diarrhoea (BVD) and leptospirosis, and may only indicate historic exposure. An antibody-negative status for pathogens such as *Neospora* spp. and BVDV at the time of abortion can help exclude them from the differential list.

77



77 A fetus is shown that has aborted beyond 110–120 days of gestation and on which serological testing may be useful.

INFECTIOUS CAUSES OF BOVINE ABORTION

Many infectious agents can cause abortion either directly due to placentitis or fetal death, or indirectly due to systemic dam illness. Some of the more common agents associated with bovine abortion are described below.

BOVINE VIRAL DIARRHOEA VIRUS

Infection with BVDV can cause embryonic death, mummification or later abortion and is described in detail in Chapter 3, Digestive tract and abdomen (p. 108).

BOVINE HERPESVIRUS 1

DEFINITION/OVERVIEW

Although BHV1 is most commonly associated with upper respiratory disease in cattle, it can also cause abortion and infertility.

AETIOLOGY

There appears to be strain differences between BHV1 causing the respiratory and reproductive forms of disease, as they are rarely seen concurrently. Venereal transmission of BHV1 following natural service causes infectious pustular vulvovaginitis (IPV). Non-venereal transmission around the time of service or insemination may reduce conception.

CLINICAL PRESENTATION

Abortions usually occur from five months onwards. Infection during late pregnancy may cause stillborn or non-viable calves at term. Venereal transmission of BHV1 causes vulval hyperaemia, vesicles extending to ulcers that become confluent and lead to areas of denuded mucosa with straining, frequent urination, restlessness, tail swishing, anorexia, pyrexia, decreased milk yield and vaginal discharge. Bulls show similar lesions on the penis and prepuce, with a preputial discharge. Rarely, preputial adhesions and phimosis result.

DIAGNOSIS

Diagnosis is based on herd and individual history and clinical signs. Serology of the dam has limited value. Virus isolation or identification from fetus or placenta may be possible by immunoassay or immunofluorescence.

MANAGEMENT

Spontaneous recovery occurs within 2–4 weeks, but all breeding must cease until clinical signs resolve.

Prevention and control can prove difficult, but there is seldom any long-term effect on fertility. Vaccines should be administered to susceptible stock between the ages of six months and breeding (15 months); however, vaccination of pregnant stock is unlikely to prevent abortion if the animal is already infected.

BOVINE LEPTOSPIROSIS

DEFINITION/OVERVIEW

Leptospirosis occurs worldwide and is a common infection in dairy and beef herds. An economic importance results from reproductive losses, abortion, infertility and milk yield reduction, but the disease is also an important zoonosis. Leptospirosis in humans causes influenza-like symptoms with severe headaches, although the disease can be treated effectively.

AETIOLOGY

Many serovars exist that can infect cattle, but serovar *hardjo* is the most important one in the UK. The two important types of *L. hardjo* are *Leptospira borgpetersenii* serovar *hardjo* and *Leptospira interrogans* serovar *hardjo*. Rarely, infection with *Leptospira pomona* or *Leptospira icterohaemorrhagiae* occurs in cattle, causing a severe, often fatal septicaemia associated with pyrexia, jaundice and haemoglobinuria. This section refers only to infection caused by *Leptospira hardjo* as seen in the UK.

Infection arises from contact with either infected urine or the products of abortion. Most spread probably occurs during the spring and summer months while cattle are at pasture. Leptospire do not tolerate drying, exposure to sunlight, pH < 5.8 or extremes of temperature. Venereal transmission is possible from bulls carrying leptospire in their accessory sex glands. *L. hardjo* is not carried by vermin or wildlife, but sheep can carry and excrete *L. hardjo*, therefore mixed grazing is a risk factor.

Infection follows penetration of either mucous membranes or skin. There is rapid multiplication in the uterus or udder in non-immune lactating or pregnant cattle, followed by bacteraemia, which persists for 6–9 days until humoral antibodies appear in the bloodstream. After the initial bacteraemia, leptospire can persist in the central nervous system (CNS), reproductive tract and kidneys. Following acute infection, renal shedding of leptospire into the urine occurs after about 14 days and may persist for months; intermittent shedding may occur for years. Pasteurization destroys all leptospire excreted in milk.

The important risk factors for leptospirosis can be summarized as open herds using shared bulls, mixed grazing with sheep and shared grazing with common watercourses.

CLINICAL PRESENTATION

A sudden drop in milk yield occurs 2–7 days after infection of susceptible cows. The udder becomes soft and flabby with colostrum-like secretions or blood-tinged milk in all quarters. Some cows become lethargic, stiff and pyrexia with a reduced appetite; in others the clinical signs may be mild and go undetected.

Abortion may occur 3–12 weeks following infection, with most abortions occurring during the last trimester. Infection may also produce weak and premature calves.

There is circumstantial evidence of infertility following isolation of *L. hardjo* from the reproductive tract of a high percentage of repeat breeder cows. *L. hardjo* may also cause embryonic death. Venereal transmission is possible, but may not adversely affect the pregnancy rate because *L. hardjo* is killed by uterine defences during oestrus. As a precautionary measure, streptomycin is added to the semen from bulls held at artificial insemination (AI) centres. Split-herd vaccination trials show some evidence of overall improved fertility parameters in vaccinated cows in herds with endemic *L. hardjo* infection.

DIFFERENTIAL DIAGNOSIS

There are numerous causes of a marked drop in herd milk yield, including acute BVD, lungworm infestation, bovine respiratory syncytial virus (BRSV) infection, influenza A and sudden changes in feeding regimen.

The differential diagnoses of abortion, including *Neospora caninum*, BVDV infection, *Salmonella* spp. and *Campylobacter* spp., must be considered.

DIAGNOSIS

The microscopic agglutination test (MAT) used to detect serum antibodies to *L. hardjo* has been largely replaced by an enzyme-linked immunosorbent assay (ELISA) test. Problems arise with the interpretation of serology results because there are large variations in both size and duration of individual MAT titres. Indeed, carrier animals may have negative MAT titres. False positives may occur when cows cross-react with other serovars (e.g. *L. saxkoebing*) carried by wildlife. In general, serum MAT titres of >1/100 are considered significant in cattle.

Milk drop diagnosis

In acute infection, paired serum samples taken 3–4 weeks apart will normally demonstrate seroconversion using the MAT or ELISA. Treatment with antibiotics during the acute phase may reduce the serological response, making seroconversion less convincing. Leptospire can be demonstrated in urine samples using dark-field microscopy following acute infection.

Abortion diagnosis

Maternal serology has limited use because the MAT titre may fall rapidly after acute infection and be negative at the time of abortion; a positive titre may only reflect previous exposure. During an abortion outbreak, if some aborted cows have MAT titres >1/400, then these results are likely to be meaningful. ELISA titres are reported to remain positive for much longer following infection and so cannot be considered diagnostic, but simply indicate previous exposure in aborted cows.

Tests on aborted fetus

Antibodies in fetal fluids may indicate exposure to *L. hardjo in utero* after four months' gestation; however, the fetus may die before mounting an immune response.

A fluorescent antibody test (FAT) to detect *L. hardjo* antigen in fetal tissues (e.g. kidney and lung) is the best available test to confirm a diagnosis of abortion, but delays in sample submission lead to rapid sample autolysis adversely affecting the test.

Herd screening tests:

Screening tests are a useful guide of herd status, but sufficient animals must be sampled (e.g. 25% of adults). A bulk milk ELISA is available and can be monitored regularly as part of a naïve herd's disease surveillance programme. Pooling milk samples from first-lactation heifers for ELISA testing is a useful way of monitoring infection status in a herd.

MANAGEMENT

Antibiotic treatment of clinical milk-drop cases is recommended to reduce excretion and zoonotic risk. A single injection of streptomycin/dihydrostreptomycin (25 mg/kg i/m) will eliminate infection from most cattle. In countries where streptomycin is no longer licensed for use in cattle, the infection can be treated with oxytetracycline or amoxicillin.

Control of *L. hardjo* in cattle herds relies on a combination of management decisions to reduce the risk of infection, antibiotic treatment and vaccination. The primary course of immunization consists of two injections four weeks apart, followed by annual boosting. Vaccinal MAT titres may fall to low levels within 3–4 months, but are not correlated to protective immunity, whereas the ELISA detects vaccinal antibodies for much longer. Vaccination should prevent urine shedding following exposure and will protect against milk drop and abortion. However, renal carriers have been demonstrated in some herds fully vaccinated for several years, therefore cessation of vaccination could lead to the reappearance of clinical disease.

Closed herd with no evidence of previous infection

All replacements including bulls should be isolated for

three weeks and treated with streptomycin (25 mg/kg on 2 occasions 10–14 days apart) before entry into the herd.

Herd experiencing acute *L. hardjo* infection for first time

Antibiotic treatment should be considered in order to reduce the risk of spread of infection and the zoonotic risk. A vaccination programme should be instituted for the whole herd and all replacements.

Herd with evidence of endemic infection from herd screening or abortion serology

The decision concerning vaccination is made after considering potential economic benefits and human health risks. If herd vaccination is chosen, an annual booster will be necessary for the whole herd. Heifers should complete their vaccination course before first mating.

CAMPYLOBACTER FOETUS SUBSP. VENEREALIS

DEFINITION/OVERVIEW

Campylobacter foetus subsp. *veneralis* infection is still often referred to as genital vibriosis. The prevalence of *C. foetus* subsp. *veneralis* has been much reduced by the widespread use of carefully controlled AI, but it still occurs when natural service is used.

AETIOLOGY

The natural habitat of *C. foetus* subsp. *veneralis* is the prepuce/glans penis/distal urethra of the male, with mechanical transmission and infection of the female causing mild endometritis and cervicitis. Females are not systemically ill. *C. foetus* subsp. *veneralis* can be mechanically transmitted by insemination equipment, therefore a history of no natural service does not exclude infection.

C. foetus subsp. *foetus* and *Campylobacter jejuni* may infect cattle (oral transmission) and induce sporadic abortion, but outbreaks of disease are rare.

CLINICAL PRESENTATION

Embryonic death results, with almost all susceptible animals returning to oestrus after abnormal interoestrus intervals due to embryonic death after the period of maternal recognition. A mucofloculent vulval discharge is often associated with pregnancy failure. Occasionally, abortions can occur between four and seven months of pregnancy. In poorly managed beef herds the first indication of a problem may be following disastrous herd pregnancy diagnosis results.

In a naïve herd, such poor reproductive performance is limited to the group of cattle exposed to infected bulls and/or introduced infected females. Most cows develop local immunity and clear primary infection within 90 days, allowing conception to occur. Natural immunity may be short lived, so within 15 months cows will be susceptible to reinfection.

DIFFERENTIAL DIAGNOSIS

Causes of male infertility must also be investigated when almost all females return to oestrus at the start of the breeding period. Trichomoniasis can present with similar signs and must be considered in regions where this infection is endemic.

DIAGNOSIS

Diagnosis is based on a history of a newly introduced non-virgin bull (especially hire bulls) or, less commonly, new female stock with group-specific infertility with a very high percentage of returns to service.

Currently, the best method of confirming a diagnosis of venereal campylobacteriosis is bacteriological culture of the organism from bulls or cows. When the disease is suspected in a breeding group, the bulls should be sampled first, as they will tend to become chronic carriers of the organism. Older bulls are more at risk of developing chronic infection, so these should be sampled in preference to young bulls. Preputial samples are taken by passing a plastic pipette up to the level of the fornix and using a combination of scraping and aspiration to get a sample of smegma/mucus and epithelial cells for culture (78). This technique may be more effective than trying to collect preputial washings in saline. Mild sedation of the bull will often be required to safely enable the procedure. The sample collected should be put in transport enrichment medium for transfer to the laboratory. Culture of *C. foetus* subsp. *venerealis* can be difficult due to overgrowth of plates by contaminants. Cows can be sampled from the anterior vagina using a similar technique.

Females mount a local immune response (unlike bulls) and this can be used as a diagnostic method. A vaginal mucus agglutination test (mucus collected during the luteal phase from a percentage of females served by the bull over the past 2–3 months) can be used to examine for antibodies to *C. foetus* subsp. *venerealis* in a saline extract. The specificity of this test has been questioned, therefore it is advisable to test at least ten cows from a suspect group. Serology is not useful in the diagnosis of *C. foetus* as there is insufficient systemic antibody response to be detected.

At a later stage, identification of *C. foetus* subsp. *venerealis* in products of abortion, especially fetal abomasal contents, is diagnostic.

MANAGEMENT OF BULLS

Young bulls may spontaneously eliminate infection without treatment, but mature bulls are likely to become chronically infected. Dihydrostreptomycin sulphate can be administered by repeated preputial irrigation; however, in mature bulls the organism may be harboured in preputial epithelial crypts and be hard to treat effectively. Systemic treatment with dihydrostreptomycin or oxytetracycline has also been reported to be effective. Unless treated bulls repeatedly test negative on culture or following virgin heifer test mating, they should probably still be considered 'unsafe' for using over clean cows and heifers.



78 Suitable restraint for collecting sheath scrape/wash for diagnosis of campylobacteriosis.

Control of this disease is difficult and significant economic loss is inevitable in newly infected herds. If the disease is confirmed during the breeding period, bulls can be removed and a switch to AI will stop further spread of infection in the cows. Most cows will develop immunity and eliminate infection after 3–6 months; however, as occasional cows may become longer-term carriers, it would not be considered safe to reintroduce 'clean' bulls the following breeding season, as this may lead to reinfection. A possible solution in beef herds where AI is not practical long term is to treat bulls prior to the following breeding period and maintain a potentially infected herd separate from a 'clean' herd where virgin heifers are mated to clean virgin bulls.

Vaccination is used widely around the world as an aid in the control of this disease, and in countries where no licensed vaccines exist, an emergency autogenous vaccine can be prepared under licence from farm isolates of *C. foetus* subsp. *venerealis* and may aid in the control of disease in recently infected herds.

TRICHOMONIASIS

DEFINITION/OVERVIEW

Trichomoniasis has a worldwide distribution, but has not been recognised in the UK for many years.

AETIOLOGY

Trichomonas foetus is a flagellate protozoan parasite transmitted venereally by natural service or by AI if semen is contaminated.

CLINICAL PRESENTATION

A transient balanoposthitis may develop and then the male becomes an asymptomatic carrier. In females there are repeated returns to oestrus with or without a mucoflocculent vaginal discharge around one week after an infected service. Pyometra may develop in some cows. Abortion may occur at 2–4 months.

DIFFERENTIAL DIAGNOSIS

Other sexually transmitted causes of infertility, most notably *C. foetus* subsp. *venerealis*.

DIAGNOSIS

Diagnosis is based on history, clinical signs and identification of the organism from the penis/prepuce of the bull, the post-service discharges of the female, vaginal mucus at oestrus and discharges of abortions.

MANAGEMENT

Females will self-cure within a few months. Bulls need topical treatment with metronidazole, dimetridazole or ipromidazole, otherwise they remain carriers; however, there is the risk of incomplete treatment if trichomonads have invaded the urinary tract. Ideally, infected bulls should be slaughtered.

Disease is effectively controlled by correctly operated AI. Disease-free herds should be maintained using natural service through strict biosecurity and purchase of clean (virgin) replacements.

BRUCELLOSIS

DEFINITION/OVERVIEW

Brucellosis, caused by infection with *Brucella abortus*, is a worldwide cause of bovine abortion that may infect wild species. It is now officially eradicated in many countries. Brucellosis is an important zoonosis and all precautions must be taken against acquiring infection. Veterinarians are especially at risk when removing retained placentae and examining aborted cows and the products of abortion. The condition in humans was commonly acquired by drinking unpasteurized contaminated milk.

AETIOLOGY

B. abortus can persist for long periods outwith the body in organic debris. Infection is usually acquired by ingestion (e.g. stock licking products of abortion, from infected slurry spread onto fields, contaminated foodstuffs, bedding, water, and calves sucking infected dams). Infection can also be acquired via the teat, from contaminated milking equipment and via the skin and conjunctival sac. Venereal transmission is possible, but is not a common route of infection.

Following entry, haematogenous spread to the gravid uterus and placenta causes necrotic placentitis and endometritis. In bulls, infection localizes in the seminal vesicles and testes, seldom causing obvious lesions. Infected females usually only abort once, occasionally twice.

CLINICAL PRESENTATION

In a newly infected herd, very high levels of abortion occur in cows during late pregnancy. Not all infected cattle abort, but they still excrete *B. abortus*. Products of abortion are heavily contaminated and placental retention is usual. Once

B. abortus is endemic, abortions are confined to hitherto clean replacements, including home-bred heifers previously kept separately from the adult herd. Typically, abortions occur during the seventh month of pregnancy. Some aborted fetuses are born alive and a few survive.

DIAGNOSIS

Diagnosis is based on the demonstration of the causal organism in blood, milk and vaginal swabs, and in cotyledonary smears and tissues from aborted fetuses.

MANAGEMENT

Cows with puerperal metritis following abortion are treated with parenteral antibiotics.

In many countries, compulsory testing schemes have aided in eradication of this important zoonotic disease. In the UK, all abortions and premature births (before day 271) must be reported to the regulatory authorities. Lactating dairy cows are routinely screened in milk samples for *B. abortus* antibodies, but non-lactating dairy heifers, dry cows and beef cows that abort must have a vaginal swab, blood and milk tested for evidence of *B. abortus*.

SALMONELLOSIS

DEFINITION/OVERVIEW

Many serotypes of *Salmonella* spp. can cause disease in cattle and abortion may be seen as a primary sign or secondary to fever/septicaemia. Some serotypes (e.g. *S. typhimurium*) are zoonotic (see also Chapter 3, Digestive tract and abdomen, pp. 103–105).

AETIOLOGY

S. dublin is the commonest *Salmonella* serotype associated with abortion (80% of salmonella-induced abortions in the UK) followed by *S. typhimurium*. Disease is most commonly associated with the introduction of carrier animals or access to faecal contaminated feed/water supplies (79).

CLINICAL PRESENTATION

Abortion during the last trimester, with placental retention, followed by poor lactation; systemic disease is uncommon with *S. dublin* infection, but likely with *S. typhimurium* infection, where abortion can follow septicaemia and enteritis (80).

DIAGNOSIS

Diagnosis is based on the history, clinical signs and bacteriological culture of the organism from cotyledons and fetal stomach contents, milk, uterine discharges and faeces of the dam.

MANAGEMENT

Systemic antibiotics should be administered in cattle with puerperal metritis associated with RFM.

Aborted cattle must be isolated for a minimum of five

weeks; however, infection with *S. dublin* may lead to chronic carrier status. All products of abortion must be disposed of very carefully. The environment should be decontaminated as far as possible. Vaccination of breeding stock should be considered where *S. dublin* is a perennial problem.

LISTERIOSIS

DEFINITION/OVERVIEW

Listeriosis (infection with *Listeria monocytogenes*) causes sporadic abortions during the winter months.

AETIOLOGY

L. monocytogenes is a ubiquitous organism and a potential zoonosis. Reproductive disease is acquired principally by ingestion of the bacterium from contaminated, poorly-conserved silage.

CLINICAL PRESENTATION

Infection causes transient febrile illness, with abortion at the time of illness or later. Abortion can occur at any stage of pregnancy, but usually occurs during late gestation. The fetus is commonly autolysed (81).

DIAGNOSIS

Diagnosis confirmed by isolation of *L. monocytogenes* from the liver and abomasum of the fetus, the placenta and discharges. The post-mortem signs in fetuses are microabscesses and cotyledonary lesions comprising yellow-grey necrotic foci.

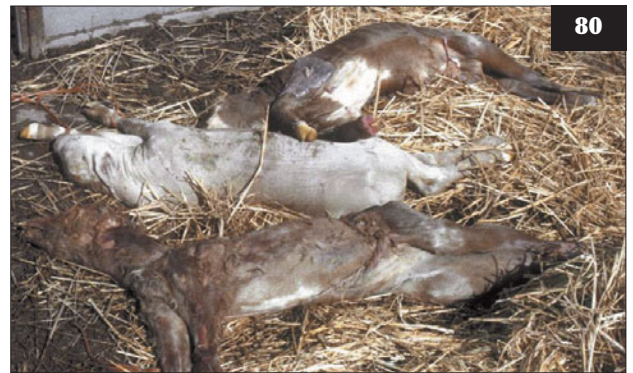MANAGEMENT

Abortion is not associated with CNS infection or significant dam illness, therefore parenteral antibiotic therapy is rarely indicated.

Feeding dry cows on poor-quality or spoiled silage should be avoided (82). Metaphylactic antibiotics



79 Faeces contaminated drinking water can be a source of *Salmonella* spp. infection.



80 An outbreak of *Salmonella typhimurium* that caused multiple abortions in susceptible cows in late pregnancy.



81 A cluster of aborted fetuses caused by *Listeria monocytogenes*, which was cultured in profusion from fetal stomach content samples.



82 Feeding dry cows on poor-quality or spoiled silage is a risk factor for abortion caused by *Listeria monocytogenes* and *Bacillus licheniformis*.

(penicillin) may be used where an abortion outbreak is possible, but is not always practicable or justified economically.

BACILLUS LICHENIFORMIS

DEFINITION/OVERVIEW

Bacillus licheniformis infection is a commonly diagnosed cause of abortion when cattle are fed poorly conserved forage.

AETIOLOGY

Bacillus spp., especially *B. licheniformis*, thrive in mouldy hay, straw and silage. Infection is acquired by ingestion, with haematogenous spread to the uterus causing abortion induced by placentitis.

CLINICAL PRESENTATION

Abortions are usually sporadic, occurring during late pregnancy. Clusters of abortions can occur following exposure to heavily contaminated forage. A small calf, having suffered chronic intrauterine growth retardation, may be born alive at term (83). Infection close to term can lead to the birth of live, weakly calves that die within 24 hours. The placenta may be dry and leathery, with a yellow-brown discolouration; the cotyledons are oedematous, haemorrhagic and necrotic.

DIFFERENTIAL DIAGNOSIS


Mycotic abortion.

DIAGNOSIS

The organism can be isolated from placenta, fetal stomach and vaginal discharges.

MANAGEMENT

Management is difficult because the organism is ubiquitous and the condition occurs sporadically. Poor-quality forage and bedding and access to silage effluent in late gestation should be avoided.



83 Chronic intrauterine growth retardation due to placental insufficiency may be seen with abortifacients such as *Bacillus licheniformis*.

ARCANOBACTERIUM PYOGENES

DEFINITION/OVERVIEW

Arcanobacterium pyogenes is associated with sporadic abortion during late pregnancy, but it may be a secondary invader to a primary pathogen such as BVDV in some cases.

AETIOLOGY

Infection with *Arcanobacterium pyogenes*.

CLINICAL PRESENTATION

There is no systemic disease. There are suppurative lesions in the fetus and placenta, with evidence of fetal death several days before expulsion.

DIAGNOSIS

Diagnosis is by isolation of the organism from fetal and placental lesions.

MANAGEMENT

There is no treatment because there are no signs of maternal ill health, and there are no specific controls.

OTHER BACTERIAL AGENTS

Many other bacteria are associated with sporadic abortions, including *Escherichia coli*, *Histophilus somni* and *Pasteurella* spp.

MYCOTIC ABORTION

DEFINITION/OVERVIEW

Mycotic abortion is a worldwide problem strongly related to the use of contaminated feed (84) and bedding materials in environmental conditions of overcrowding and poor ventilation. Abortions occur sporadically, but exceptionally they may involve 10% of the herd.

AETIOLOGY

Aspergillus fumigatus and *Absidia* spp. are the most common organisms isolated. Haematogenous spread leads to a severe placentitis, with infection of the fetal skin and lungs following.

CLINICAL PRESENTATION

Abortion occurs commonly between six and eight months of gestation. Mycotic reproductive disease does not normally cause maternal ill health, although rarely, following mycotic abortion caused by *Mortierella wolfii*, a fatal post-abortion pneumonia develops. Some fetuses are born alive but infected; some are born alive and well at term, but with placental infection evident.

DIFFERENTIAL DIAGNOSIS

Bacillus licheniformis infection is the major differential.

DIAGNOSIS

There is a thickened leathery placenta, with necrotic, reddish-brown cotyledons (**85**). The fetal fluids may be discoloured. Fetal lesions include cutaneous plaque-like lesions similar to ringworm, especially when *Aspergillus* spp. is involved. Definitive diagnosis requires microbiological demonstration of fungal elements in fetal skin and placental lesions. There are often signs of bronchopneumonia in aborted/stillborn fetuses and dead neonates.

MANAGEMENT

Aborted cows may need treatment for chronic endometritis. Mouldy forage feeding must be avoided wherever possible. Ventilation of cattle housing should be improved and overcrowding reduced.

GRANULAR VULVITIS COMPLEX**DEFINITION/OVERVIEW**

Granuloma vulvitis complex is a condition of controversial significance and aetiology that has been associated with infertility/repeat breeding in some dairy herds.

AETIOLOGY

Ureplasma diversum, *Mycoplasma bovis* and *Histophilus somni* have been associated with granular vulvovaginitis; however, these organisms can be isolated from the reproductive tracts of normal, healthy cows.

CLINICAL PRESENTATION

Granular lesions on the ventral surface of the vagina, vestibule and vulva, with a purulent discharge, appear one week post infection. There is no systemic illness, but severely affected cattle appear restless, dysuric, have a reduced milk yield and resent vaginal examination. Infection may cause endometritis/salpingitis and thereby

conception failure and embryonic death. Bulls can have lesions on the penis and prepuce and transmit infection during natural service.

DIFFERENTIAL DIAGNOSIS

The main differential is IPV.

DIAGNOSIS

Diagnosis is based on clinical signs and culture of vaginal discharges/swabs from multiple cases.

MANAGEMENT

Natural service must be ceased. Affected bulls are treated topically and systemically for at least five days with oxytetracycline or tylosin. Females may be treated with tetracyclines or spectinomycin. At-risk females may avoid developing clinical disease if given an intrauterine infusion of tetracycline within 24 hours of service.

The use of plastic sheaths during AI will reduce the risk of introducing infection into the uterus.

NEOSPOROSIS**DEFINITION/OVERVIEW**

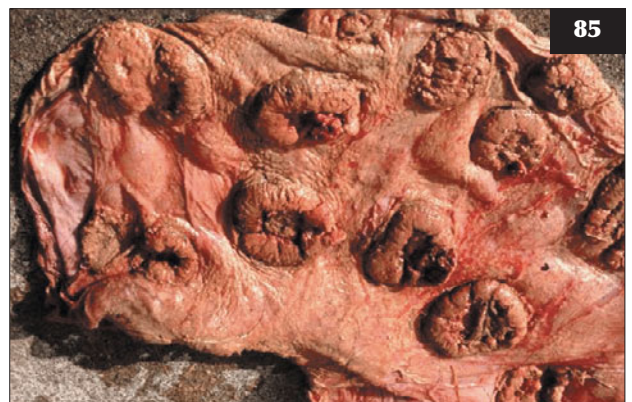Neospora caninum is a protozoan parasite first recognized as a cause of congenital neurological disease in dogs in 1984. It was first associated with bovine abortion in 1989 and is now regarded as the most commonly diagnosed cause of bovine abortion in many countries (12.5% of all abortions investigated in the UK), but estimates of its prevalence may be confounded by the fact that serological demonstration is not necessarily proof of abortion.

AETIOLOGY

N. caninum is a protozoan parasite in the family Sarcocystidae. Dogs are the only confirmed definitive hosts and shed oocysts that can lead to faecal–oral infection of susceptible cattle. Once infected, breeding females can



84 Feeding mouldy forage is the most likely cause of mycotic abortion.



85 With mycotic abortion the placenta may be dry and leathery, with a yellow-brown discoloration.

become chronically infected, leading to repeat abortions or birth of live congenitally infected calves. Vertical transmission is highly effective in maintaining the disease in infected herds.

CLINICAL PRESENTATION

Abortion is the commonest manifestation, usually at 5–6 months. Abortion epidemics are possible, associated with point-source infection of groups of susceptible pregnant cows. Sporadic abortion is normally associated with congenitally infected females. There is no maternal ill health. Mummification of fetuses is common with *N. caninum* infection. There may be premature birth, stillbirth or birth of a full-term calf that shows neurological signs; however, many congenitally infected calves appear normal at birth.

DIFFERENTIAL DIAGNOSIS

Though neurological signs are rare with *N. caninum*, they must be distinguished from other congenital lesions such as cerebellar hypoplasia and hydrancephaly. Dystocia, causing intra-partum hypoxia, can also result in neurological signs.

DIAGNOSIS

When *N. caninum* is responsible for abortion, most dams will be ELISA seropositive at the time of sampling; however, this is not diagnostic, as many seropositive cows can give birth to live calves. Maternal antibody levels may fluctuate throughout gestation in infected cows. Definitive diagnosis requires post-mortem examination of aborted fetuses. A non-suppurative encephalitis is typically found associated with the presence of tissue cysts, with tachyzoites demonstrable by immunohistochemistry. Lesions can also be found in the myocardium and liver. Fetal serology can also be used to confirm exposure to *N. caninum*. Immunohistochemistry will differentiate *N. caninum* from *Toxoplasma gondii* and *Sarcocystis* spp.

MANAGEMENT

There is no treatment available. The risk of food/pasture contamination by dog faeces must be reduced. Dogs should be kept away from calving areas and all products of calving/abortion in order to prevent infection of the definitive host.

A test and cull programme can reduce the incidence of abortion and prevent continued vertical transmission to replacement heifers. If seropositive dairy and beef cows are retained, they should be bred to beef bulls and no daughters retained as breeding stock.

Q FEVER

DEFINITION/OVERVIEW

Q fever is a rarely diagnosed cause of bovine abortion.

AETIOLOGY

Q fever is caused by the rickettsial organism *Coxiella burnetii*; it is a potential zoonosis. Disease is transmitted by aerosol from exposure to fetal fluids, placentae, milk and urine of infected cows, sheep or goats. Mechanical transmission via ticks and contaminated needles is also possible.

CLINICAL PRESENTATION

Q fever may induce bovine abortion, but otherwise the clinical signs are subclinical.

DIAGNOSIS

Diagnosis is based on the demonstration of *C. burnetii* in stained smears of cotyledons and fetal stomach contents and on serological testing using a complement fixation test (CFT).

MANAGEMENT

No treatment is required in cattle as the disease is subclinical. There are no specific control measures other than isolation of aborted cattle. Pasteurization of milk controls the major zoonotic risk.

CHLAMYDOPHILA ABORTUS

Chlamydophila abortus is a common cause of abortion in sheep, but is only rarely diagnosed as a cause of abortion in cattle. Abortion in later pregnancy associated with placentitis may be seen and the organism can be demonstrated in Giemsa-stained placental smears. Calves may be born alive but premature. The risk of infection can be minimized by avoiding contact with lambing sheep. *C. abortus* is a potential zoonosis.

Chapter 2

Obstetrics and parturient diseases

NORMAL PARTURITION IN THE COW

The gestation length in cattle is around 285 days. Imminent parturition can be detected by udder development, accumulation of colostrum and slackening of the sacroiliac ligaments (86). The birth process is divided into three stages.

FIRST-STAGE LABOUR

First-stage labour is represented by cervical dilation, which takes 3–6 hours, but is more rapid in multiparous cows. There are various behavioural changes, including separation into a corner of the field or barn and alternatively lying or standing. A thick string of mucus is often observed at the vulva. The bouts of abdominal straining occur more frequently, usually every 2–3 minutes. This increased activity coincides with a change in fetal position, with extension of the forelimbs. At the end of first-stage labour the cervix is fully dilated.

SECOND-STAGE LABOUR

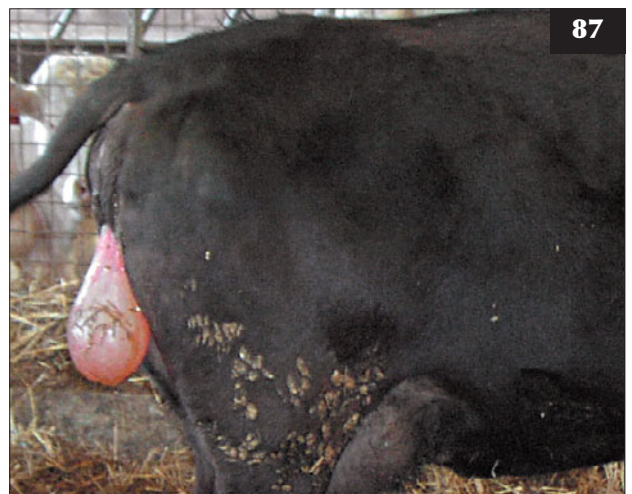
Second-stage labour is represented by expulsion of the fetus(es) and takes from five minutes to several hours. There is rupture of the allantochorion and a sudden rush of fluid. The amnion and fetal parts are then engaged in the pelvic inlet. The amniotic sac appears at the vulva (87) and ruptures at this stage. Powerful reflex and voluntary contractions of the abdominal muscles and diaphragm ('straining') serve to expel the fetus. Occasionally, the amniotic sac may not rupture until the cow stands up after the calf has been expelled. The delayed rupture of the amnion may result in death of the calf due to asphyxiation. This scenario is not uncommon in twin births.

THIRD-STAGE LABOUR

Third-stage labour is completed by expulsion of the fetal membranes, which usually occurs within 2–3 hours of the end of second-stage labour.



86 Imminent parturition can be detected by udder development, accumulation of colostrum and slackening of the sacroiliac ligaments with a prominent tail head.



87 Appearance of the amniotic sac at the vulva.

DYSTOCIA

There are textbooks dedicated to bovine obstetrics. This section deals with the common conditions in practice. It is important to study the images carefully with respect to the guidelines listed below on traction forces. A cautionary approach is essential; the reader should perhaps review the section on nerve paralysis before reading further.

VETERINARY APPROACH TO EVERY CALVING CASE

As a veterinary surgeon it is essential to assess the patient in detail before attempting to correct any dystocia (e.g. the cow may be suffering from hypocalcaemia). Distant assessment of the cow will frequently give an indication of prolonged dystocia. Lateral recumbency with frequent abdominal straining and vocalization may result from engagement of the calf within the pelvis or excessive manual interference leading to trauma of the posterior reproductive tract. Extreme physical effort/pain may result in sweating along the dorsum of the cow.

Attempted delivery by an unskilled herdsman may have resulted in oedema, reddening and bruising of the vulval labiae. There may be evidence of vaginal bleeding on the tail and surrounding bedding. The cow's mucous membranes must be checked for evidence of pallor.

The presence of a fetid, viscous, yellow-brown vulval discharge indicates the presence of a dead calf *in utero*. It is essential to express any concerns to the client before attempting correction of the dystocia, especially if you suspect that there has been significant trauma to the reproductive tract (e.g. a uterine tear may have resulted prior to veterinary attention, especially if the herdsman has attempted correction of a breech presentation).

Intravenous NSAID injection is indicated before all veterinary-assisted calvings and for several days afterwards in order to aid more rapid recovery and achieve optimal production. Delivery of a live calf that dies within hours/days from the consequences of intrapartum hypoxia/trauma is not a successful resolution of the problem. Vaginal examination is routinely undertaken after delivery of the calf to check for another calf and for any trauma to the cow's posterior reproductive tract. Antibiotic therapy for vaginal trauma caused by excess traction is important because infection of vaginal tears, causing diphtheresis, may extend to erode a major vaginal vessel, leading to fatal haemorrhage several weeks after calving.

The attending veterinary surgeon assumes responsibility for the safety of everyone present, so it is important to be careful with excitable and potentially aggressive beef cows. Many farmers routinely calve all cows in cattle stocks, which is not an ideal situation (88). After correction of the malposture in the cattle stocks, the cow should be haltered then released into a clean calving pen with the free end tied low down to a substantial post allowing approximately 1.5 metres of lead rope. This is because delivery of the calf is greatly facilitated when the cow is able to lie in lateral

recumbency and strain using her abdominal muscles.

Dystocia commonly results from absolute fetal oversize, especially in pedigree beef cattle, and relative fetal oversize where immature heifers are mated from five months old in poorly managed natural service beef herds.

OBSTETRICAL DEFINITIONS

- Presentation signifies the relation between the long axis of the fetus and the maternal birth canal. It includes anterior or posterior longitudinal presentation and ventral or dorsal transverse presentation.
- Position indicates the surface of the maternal birth canal to which the fetal vertebral column is applied. It includes dorsal, ventral and right or left lateral position.
- Posture refers to the disposition of the moveable appendages of the fetus and involves flexion or extension of the cervical and limb joints, e.g. bilateral hock flexion posture.
- With relative fetal oversize the fetus is of normal dimensions and the maternal pelvis is too small. With absolute fetal oversize the fetus is abnormally large and the maternal pelvis is normal.

GENERAL GUIDELINES

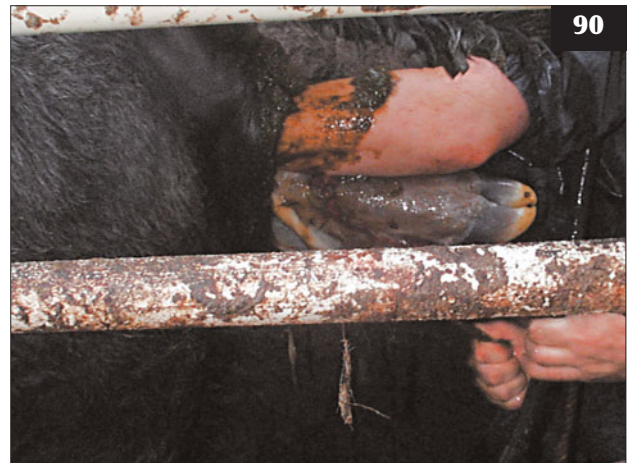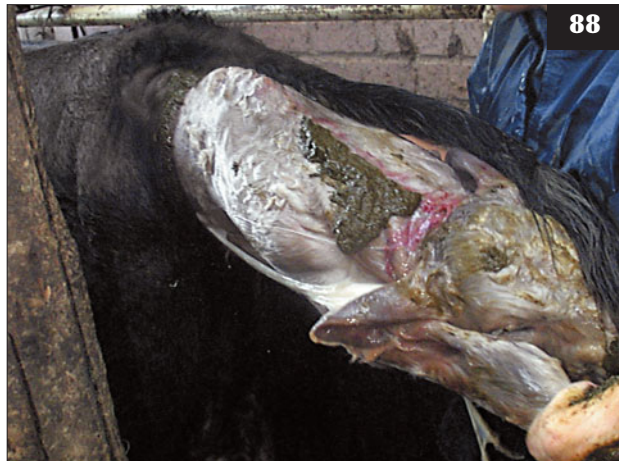The general guidelines below can be applied when presented with suspected fetal oversize, whether absolute or relative:

- Anterior presentation. The calf's forelimbs should protrude a hand's breadth beyond the fetlock joints after a maximum of 10 minutes' traction (two people: yourself and the farmer) in order to proceed safely (89, 90); options should be reconsidered if greater traction is necessary.
- Posterior presentation (91). Two strong people pulling on calving ropes should be able to extend the hocks more than one hand's breadth beyond the cow's vulva (calf's hindquarters now fully within the pelvic inlet) within 10 minutes. Arterial blood from the umbilical vessels, which snap off short in these calvings, may be seen (92).

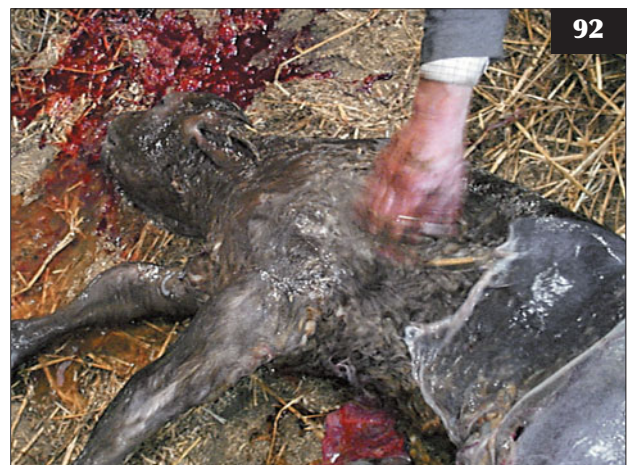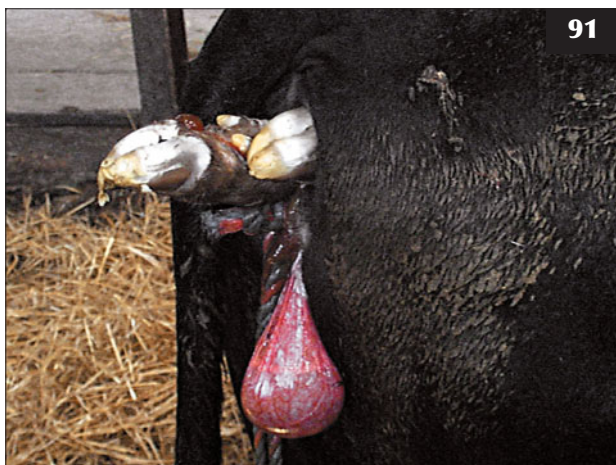
Other guidelines include whether a hand can be passed between the calf's head and the maternal pelvis when both feet and the head are engaged within the pelvis and, conversely, if a hand can be passed between the calf's tail head and the maternal pelvis in posterior presentation. Comparisons of the calf's metacarpal/metatarsal bone diameter relative to external maternal pelvis dimensions have little practical use.

With experience it is possible to apply greater traction than the forces described here and still achieve a successful resolution, but there are occasional doubts when the calf becomes lodged. Is delivery of a live calf, which subsequently dies, a successful resolution to a difficult calving?

88 Calving the cow in cattle stocks is not ideal, but it may be a prudent approach with unpredictable and/or aggressive beef cattle.



89, 90 Anterior presentation. **(89)** The calf's forelimbs are protruding a hand's breadth beyond the fetlock joints after five minutes' traction (by the veterinarian and the farmer). Note the flaccid tail and lack of defecation as a result of an extradural injection (compare with **90**). **(90)** No extradural injection has been given to this cow, therefore it is able to defecate; however, it will be able to strain, thereby aiding delivery of the calf.



91 Posterior presentation. Two strong people pulling on calving ropes should be able to extend the hocks more than one hand's breadth beyond the cow's vulva.

92 Safe delivery of the live bull calf shown in **91**. Note the arterial blood on the straw from the calf's short umbilical vessels.



93 Size disparity between a Charolais bull and a beef cow.



94 Depression and inappetence in a beef cow due to pre-partum metritis in the cow and emphysema in the calf. This rapidly progressed to dehydration, toxic mucous membranes and recumbency .

MANAGEMENT

Sire breed selection is important (93), but it is generally stated that there is as much variation in dystocia incidence of sired females within breeds than there is between breeds. However, in general, native breeds such as the Aberdeen Angus have fewer calving problems than the Charolais breed. Estimated breeding values (EBVs) allow bulls to be selected with lower calf birth weight and shorter gestation periods, thus reducing the dystocia risk. EBVs with high accuracy are available for many AI sires and should be considered in breeding programmes.

PRE-PARTUM METRITIS AND EMPHYSEMA OF THE CALF (ROTTEN CALF)

DEFINITION/OVERVIEW

Parturition does not progress beyond the first stage, most commonly the result of undetected dystocia.

AETIOLOGY

Bacteria gain entry through the dilated cervix into the uterus, which provides an ideal environment for rapid growth. Fetal death is accompanied by rapid autolysis and acute bacterial metritis causes toxæmia, which can be fatal to the dam.

CLINICAL PRESENTATION

The clinical signs depend on the duration of uterine infection/fetal death and the resultant toxæmia. Depression and inappetence rapidly progress to dehydration, toxic mucous membranes, recumbency (94), and death within 1–3 days. Indicators of uterine

infection include a fetid red/brown vaginal discharge, occasional straining and raised tail, and increasing abdominal distension, especially of the sublumbar fossae, due to gaseous distension of the uterus, which may cause colic signs.

DIFFERENTIAL DIAGNOSIS

Uterine torsion, breech presentation, other malpresentations and malpostures; hypocalcaemia; summer mastitis (especially beef cows); redwater.

DIAGNOSIS

Diagnosis is confirmed following manual vaginal examination.

MANAGEMENT

Removal of an emphysematous rotten calf can prove very difficult and time-consuming. Damage to the endometrium facilitates toxin absorption. The risk of zoonosis should be carefully considered and strict hygiene is essential; cutaneous lesions caused by *Salmonella* spp. are not uncommon after dealing with such cases. It is essential to use lots of lubricant to aid delivery and remove the calf intact. Partial fetotomy may be attempted, but it can prove difficult to remove all portions of the sectioned calf because the uterine wall is often firmly clamped around the fetus. Deviation of the head ('head back') is common in dead calves in anterior presentation and is often very difficult to correct.

A caesarean section may be preferable to fetotomy in some cases, but must be balanced against the risk of postoperative peritonitis. Supportive treatment is essential before surgery, including intravenous NSAIDs and three

litres of intravenous hypertonic saline, followed by large volumes (20–40 litres) of isotonic fluids. Antibiotics are administered prior to surgery. If the uterine wall has a bluish hue with gas pockets below the surface, then the prognosis is hopeless and the animal should be euthanased because long-term success (beyond 5–10 days) is very poor indeed.

Adequate supervision must be provided for all calving animals. In some cases, humane destruction of the dam is the preferred option for welfare reasons and must not be viewed as an admission of surgical defeat.

INCOMPLETE CERVICAL DILATION

DEFINITION/OVERVIEW

Incomplete cervical dilation occurs very occasionally in heifers, but the true incidence is difficult to determine because in most situations the onset of first-stage labour has not been noted by the farmer. It is probable that some dystocia cases are classified as incomplete cervical dilation, but merely represent over-anxious interference during early first-stage labour. A working definition of ringwomb could be 'the presence of an incompletely dilated cervix more than six hours after first appearance of the fetal membranes (allantochorion) at the vulva'.

AETIOLOGY

The aetiology remains unknown.

CLINICAL PRESENTATION

The presence of fetal membranes (allantochorion) at the vulva for six or more hours, with an incompletely dilated cervix detected on digital examination of the posterior reproductive tract, is the presenting clinical sign. Typically, the external cervical os is only 5–10 cm in diameter, which may just allow the passage of one hand.

DIFFERENTIAL DIAGNOSIS

Uterine torsion; disturbance during early first-stage labour before complete cervical dilation; incomplete cervical dilation associated with calf in posterior presentation; prolonged first-stage labour caused by hypocalcaemia.

DIAGNOSIS

Diagnosis is based on digital examination of the reproductive tract and failure of the cervix to dilate under manual pressure applied for 10–15 minutes. The cervix feels approximately 3–5 cm thick with obvious corrugations. It is essential not to miss a uterine torsion, which can be identified by a tight vagina with an obvious 'corkscrew' feel.

MANAGEMENT

Manual pressure applied for 10–15 minutes may gradually dilate the cervix in some cases, but such cases may well represent those heifers disturbed during early first-stage

labour. In some cases the vulva may also fail to dilate properly because there has been no pressure from the allantois and an episiotomy may be required.

If no progress has been made in 10–15 minutes, continued manual interference will simply lead to contamination of the fetal extremities, posterior reproductive tract and uterus, with an attendant risk of contamination of the peritoneal cavity when the calf is delivered during the corrective caesarean section. Trauma to the posterior reproductive tract frequently results in reflex abdominal contraction, which may complicate the caesarean section, although this complication is resolved following the routine extradural injection given by the veterinary surgeon.

Too early/frequent human interference may delay normal progression of first-stage labour, especially in heifers. Farmers should be encouraged to leave cattle undisturbed for four hours after the appearance of a mucus string or allantochorion at the vulva, especially in primiparous animals. However, frequent bouts of powerful abdominal contractions occurring more frequently than every five minutes or so must be investigated because of the likelihood of fetal malposture.

ANTERIOR LONGITUDINAL PRESENTATION

DEFINITION/OVERVIEW

Dystocia caused by fetal oversize in normal anterior longitudinal presentation is common in beef cattle.

CLINICAL PRESENTATION

The calf's muzzle and forefeet are presented at the cow's vulva during bouts of abdominal straining during second-stage labour.

DIFFERENTIAL DIAGNOSIS

If only the feet are presented, posterior longitudinal presentation.

DIAGNOSIS

Diagnosis is by vaginal examination.

MANAGEMENT

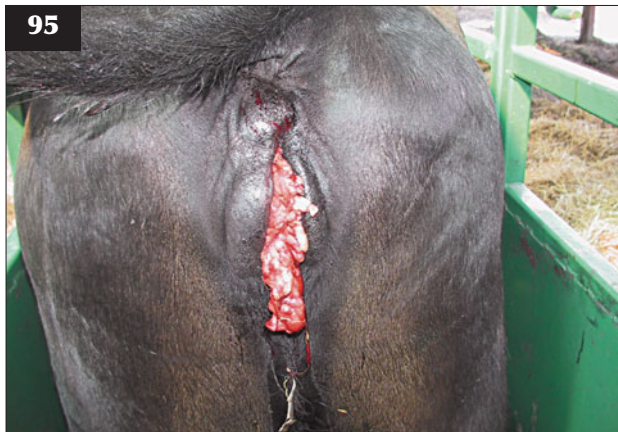Reasonable traction will deliver the calf when two people pulling can extend both forelimbs such that the fetlock joints protrude one hand's breadth beyond the vulva within 10 minutes of traction commencing. Such movement represents extension of both elbow joints into the maternal pelvis. The options should be reconsidered if greater traction is applied without obvious progress and the elbows are not extended easily.

Episiotomy may be undertaken under low extradural block when there is incomplete dilation of the vulva; this is more commonly encountered in overconditioned Holstein heifers. With the vulva under tension from the

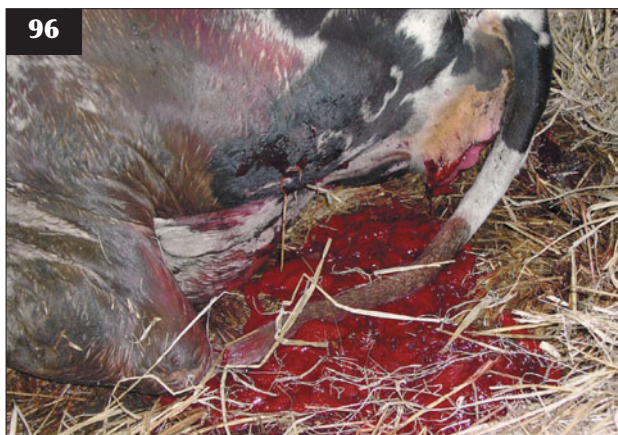calf's head from traction applied to both forefeet, two incisions are made in the skin at 2 o'clock and 10 o'clock, taking care not to extend the incision into the vagina. The skin incisions are sutured using non-absorbable material.

Tears in the vaginal wall may be sufficient to allow the protrusion of submucosal fat (95) or extend to cause rupture of the middle uterine artery, with life-threatening consequences (96) (see Vaginal tears/lacerations, p. 49).

Prevention involves reviewing bull selection, especially in heifers; avoiding calving cows with a BCS of >3 (scale 1 to 5); and restricting the breeding period to nine weeks in order to prevent an extended tail to the calving period, with consequences of reduced cow supervision and increased BCS, especially in spring-calving herds at pasture.



95 A tear in the vaginal wall with protrusion of submucosal fat.



96 Arterial bleeding, as in this cow, can be recognized by very forceful pulsing rather than passive bleeding from the ruptured umbilical vessels.

HIP LOCK

DEFINITION/OVERVIEW

The calf is locked at the hips at presentation.

AETIOLOGY

This disastrous situation usually arises when excessive and inappropriate traction (97) has been applied to an oversized fetus in anterior longitudinal presentation (refer to guidelines above).

CLINICAL PRESENTATION

The cow is often exhausted and in lateral recumbency, with the calf protruding to the caudal thorax but firmly lodged as the hips enter the maternal pelvis (98).

MANAGEMENT

Further traction while attempting to rotate the calf or roll the cow is rarely successful. If not already dead, the calf should be euthanased for welfare reasons. A 10 ml bolus of 20% pentobarbitone injected intravenously as quickly as possible will be effective, but have no effect on the cow.

NSAIDs should be given intravenously, and a low caudal block of 5–7 ml of lidocaine is essential. The considerable vulval oedema present, and the likely obturator/sciatic nerve damage, justifies treatment with a single intravenous injection of dexamethasone.

The calf's forequarters are removed as close to the vulva as possible (99) while an assistant retracts the cow's vulval lips. The skin and muscles are cut with a large scalpel blade to expose the caudal rib cage and vertebral column, which are cut using embryotomy wire. The calf's hindquarters



97 In this cow with hip lock a rope has also been applied around the calf's chest for greater traction.

are then carefully repelled. An introducer (large haemostats work equally well) with embryotomy wire attached is first passed over the calf's back, between the calf's hindlimbs and below the tail (cow in lateral recumbency), then retrieved and pulled along the calf's ventral abdominal wall.

An embryotome is not necessary (and rarely available) and two 30 cm lengths of plastic water pipe held in the vagina through which the embryotomy wire is passed suffice to protect the cow's posterior reproductive tract. The person

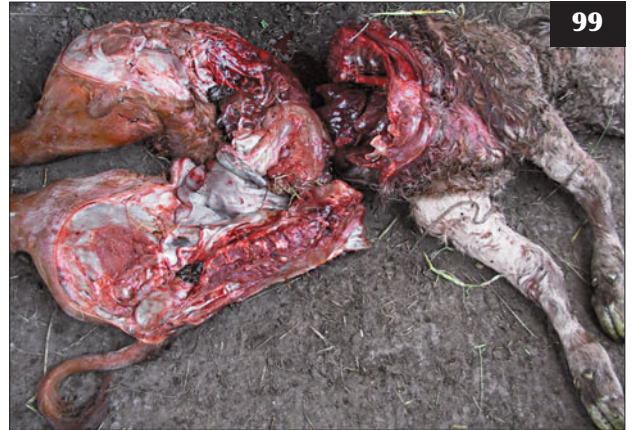sawing should kneel facing the cow's hindquarters and operate both hands close together at the same height and parallel to the cow's vagina, with 30–40 cm of embryotomy wire protruding to each handle. Sectioning the calf's pelvis takes 2–3 minutes' hard work. The split hindquarters can be pushed apart and easily removed (100).

Veterinary expertise is essential where there are doubts whether the calf can be safely delivered (101). (See Chapter 6, Nervous system, Femoral nerve injury [p. 161] and Sciatic/Obturator nerve injury [p. 160/162])



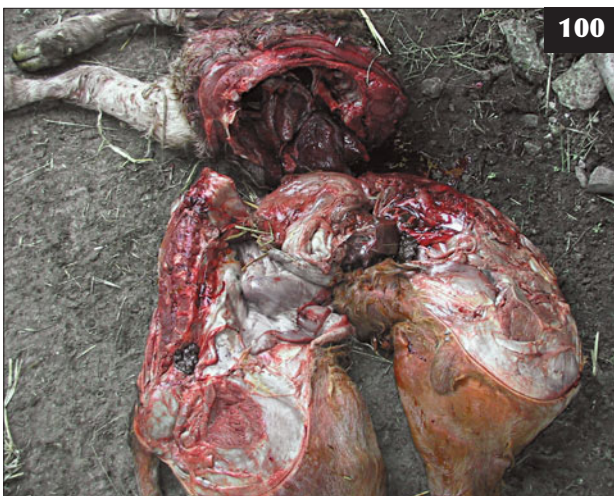98

98 Hip lock in a cow after excessive and inappropriate traction has been applied.



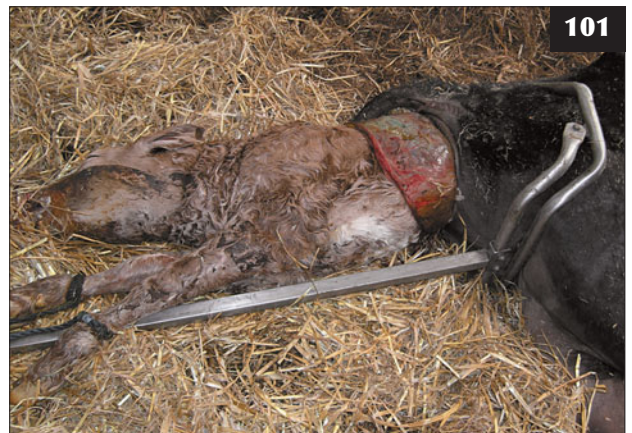99

99 The calf's forequarters are removed as close to the vulva as possible.



100

100 The split hindquarters can be easily removed without causing further trauma to the dam.



101

101 Veterinary expertise is essential when there are doubts whether the calf with hip lock can be safely delivered.

ANTERIOR LONGITUDINAL PRESENTATION WITH UNILATERAL SHOULDER FLEXION (LEG BACK)

DEFINITION/OVERVIEW

Leg back is a common malposture in cattle obstetrics.

AETIOLOGY

Leg back is a malposture occurring during first-stage labour.

CLINICAL PRESENTATION

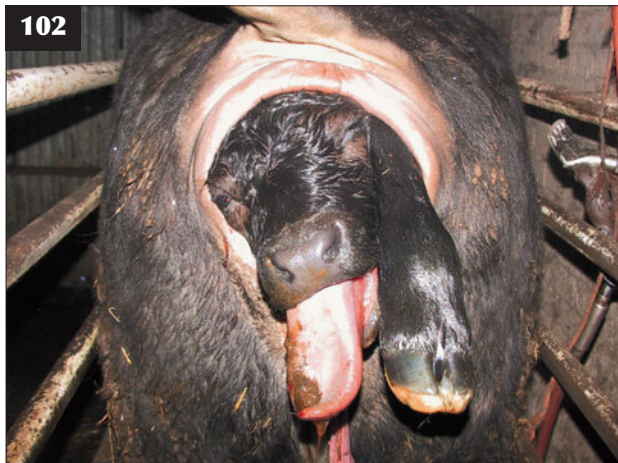
The calf's head and one forefoot are presented at the vulva (102). Farmers often apply considerable traction to the one limb and head presented, making correction of the dystocia much more difficult.

DIAGNOSIS

Diagnosis is by vaginal examination after 5 ml of 2% lidocaine is injected into the extradural space at the sacrococcygeal site to prevent forceful straining.

MANAGEMENT

An NSAID injection should be given before commencing delivery of the calf. Correction of this malposture is best achieved with the cow standing in cattle stocks after a low extradural block to prevent forceful straining. After five minutes the calf's head and protruding forelimb are well lubricated and slowly repelled until the calf's poll is level with the pelvic inlet. By first grasping the calf's forearm then the mid-metacarpal region, the elbow and carpal joints of the retained limb are fully flexed, which brings the foot towards the pelvic inlet. With the fetlock joint fully flexed and the foot cupped in your hand to protect the uterus, the foot is drawn forward into the pelvic canal, extending the fetlock joint. Traction on the distal limb extends the elbow joint and the foot appears at the vulva, where a calving rope is applied proximal to the fetlock joint.



102 The right forelimb is back in this calving cow.

The cow should now be haltered and tethered low down to a post in the calving box. Steady traction by two people (yourself and the farmer) pulling on the calving ropes applied to both limbs will generally result in the heifer/cow assuming lateral recumbency, which aids delivery of the calf.

The considerable vulval oedema present justifies treatment with a single injection of dexamethasone. Antibiotics are administered for three consecutive days because placental retention is likely after dystocia and there is an increased risk of metritis due to manual examination of the uterus. The calf's umbilicus should be immediately fully immersed in strong veterinary iodine and repeated two and four hours later. Two litres of colostrum are administered by orogastric tube to ensure adequate passive antibody transfer. A single injection of dexamethasone is given to reduce the calf's extensive lingual oedema.

Great caution must be exercised if you think the calf is dead and decapitation will assist your correction of the dystocia. Extensive oedema of the calf's eyelids and tongue remove the blink and pinch responses, respectively.

Prevention requires prompt recognition and correction of the malposture. Farmers must be instructed that calves, unlike twin and triplet lambs, cannot be delivered with a limb back.

ANTERIOR LONGITUDINAL PRESENTATION WITH LATERAL DEVIATION OF THE HEAD (HEAD BACK)

DEFINITION/OVERVIEW

Lateral deviation of the head is a common cause of dystocia in cows; the calves are often dead.

CLINICAL PRESENTATION

Both fore feet are presented in the maternal pelvis (and possibly at the vulva). Occasionally, the cervix may not be fully dilated.

DIFFERENTIAL DIAGNOSIS

Farmers often mistake a head back malposture for a calf in posterior presentation because they can feel two limbs, but no head. Note that the hooves face down, not up, and you are able to feel the carpal joints, not the hocks or calf's tail. The situation is rendered much more difficult if the farmer exerts traction to both forelimbs without correctly aligning the calf's head.

DIAGNOSIS

Diagnosis is by careful vaginal examination under extradural anaesthesia.

MANAGEMENT

Correction of the malposture is not easy, especially when the calf is dead, the head is averted against the chest and the uterus is contracted down around the calf. Under

extradural anaesthesia, the calf's forelimbs and neck are carefully repelled as far as possible. A finger or eye hook can be placed in an eye socket in an attempt to pull the head around into the pelvic inlet. Alternatively, an eye hook can be placed between the horizontal rami of the mandible or a leg rope placed around the calf's lower jaw. Once corrected, a head rope is placed behind the calf's poll and through its mouth to assist alignment into the pelvic inlet, especially if the cervix is not fully dilated and the calf is dead. The calf is then delivered by traction as described above.

In the case of a dead calf it is possible to decapitate the averted head where the neck is kinked using an embryotome, but this is not a simple procedure and is not recommended unless the operator is experienced in the technique.

Prevention requires recognition that second-stage labour has not progressed, followed by timely intervention.

POSTERIOR LONGITUDINAL PRESENTATION (CALF COMING BACKWARDS)

DEFINITION/OVERVIEW

Posterior presentation is a common cause of dystocia in cattle.

CLINICAL PRESENTATION

Typically, the calf's pelvic limbs protrude from the cow's vulva about one hand's breadth short of the hock joints (91).

MANAGEMENT

The cow is haltered and the rope tied low down to a corner of a calving pen, allowing approximately 1.5 m of rope. Two strong people pulling on calving ropes should be able to extend both hocks more than one hand's breadth beyond the cow's vulva (calf's hindquarters are now fully within the pelvic inlet) within 10 minutes. Further traction will deliver the calf safely. Other guidelines include whether your hand can be extended over the calf's tail head and underneath both stifle joints when the calf is drawn into the pelvic inlet.

Potential complications for the calf are multiple rib fractures at the costochondral junction, rupture of the liver, and prolonged delivery compressing the umbilical vessels and causing hypoxia. For the dam the potential complications are vaginal tearing (95) and rupture of middle uterine artery/fatal haemorrhage (96).

There are no specific risk factors reported for posterior presentation.

POSTERIOR LONGITUDINAL PRESENTATION WITH BILATERAL HIP FLEXION (BREECH PRESENTATION)

DEFINITION/OVERVIEW

A breech presentation is a common malpresentation and malposture. It is particularly prevalent in twin pregnancies.

AETIOLOGY

Breech presentation is a malpresentation and malposture during first-stage labour.

CLINICAL PRESENTATION

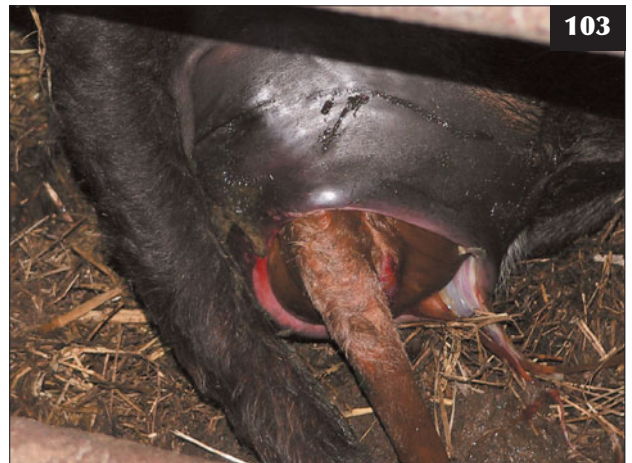Cows show typical signs of first-stage labour (i.e. they appear restless and isolate themselves wherever possible), but abdominal straining is not seen because the fetus does not engage within the maternal pelvis. The allantochorion may rupture, but remnants of the fetal membrane may not appear at the vulva. The calf's pelvis is firmly lodged at the entrance to the maternal pelvis, with both hindlimbs extended alongside the body. The calf's tail is readily palpable (103). In some cases the dystocia is not noted until the calf/calves die *in utero* and the cow develops severe toxæmia and bloat caused by the emphysematous calf/calves.

DIFFERENTIAL DIAGNOSIS

None once the calf's tail and pelvis have been accurately identified.

DIAGNOSIS

Diagnosis is based on careful examination facilitated after extradural injection.



103 In this cow the calf's pelvis is firmly lodged at the entrance to the maternal pelvis, with both hindlimbs extended alongside the body. The calf's tail is readily palpable.

MANAGEMENT

The cow is ushered into cattle stocks and 5 ml of 2% lidocaine injected extradurally at the sacrococcygeal site to block the cow's forceful abdominal contractions. Flunixin is injected intravenously. After waiting for five minutes, the calf's tail head is slowly repelled beyond the level of the cow's pelvic inlet as far as your reach allows. Commencing distally, one of the calf's feet is cupped in your hand and the fetlock joint fully flexed. As the foot is drawn toward the maternal pelvis, the hock and stifle joints are fully flexed. Correction now involves extending each hip joint in turn while the distal limb joints (stifle, hock and fetlock joints) remain fully flexed. Further gentle repulsion of the calf may be necessary at this stage. In this manner, a breech presentation is converted to a posterior presentation. The cow is then released from the stocks (not necessary if small twin calf). The calf's hindlimbs must protrude a hand's breadth beyond the hocks after a maximum period of 10 minutes' traction (two people) in order to proceed safely; options must be reconsidered if greater traction is necessary.

Possible complications are rib fractures at the costochondral junction if a single large calf; premature rupture of the umbilical vessels if the umbilicus has become hooked around one hindlimb while correcting the hip flexion; uterine rupture during repulsion of the calf or correction of the hip flexion; and vaginal tearing during delivery.

Prevention involves regular supervision of calving cows and examination of those cattle suspected of first-stage labour exceeding six hours.

UTERINE TEAR/RUPTURE

DEFINITION/OVERVIEW

A uterine tear most commonly results following unskilled interference at calving. The prognosis for the cow is grave.

AETIOLOGY

Uterine rupture occurs during assisted delivery, most commonly with the calf in breech presentation, but also with lateral deviation of the calf's head. Typically, there is a history that the dystocia has been corrected with some difficulty by the farmer, but uterine rupture can also occur during attempted delivery by the veterinary surgeon, especially if the calf is dead and the uterine wall is oedematous and friable.

CLINICAL PRESENTATION

Following a breech presentation, the uterine tear usually occurs in the dorsal aspect of the uterine wall just beyond the cervix. It can be palpated *per vaginam* if the cow is examined soon after delivery of the calf. The serosal surface of the uterus can be identified as well as intestine and kidney.

If the condition is not recognized immediately, the cow may be normal for several hours after delivery. She then becomes increasingly dull and depressed with a painful expression, a poor appetite and little milk production. The rectal temperature is often normal or low. The mucous membranes become congested, with an increased heart rate as acute peritonitis develops. Over several days the abdomen becomes increasingly distended, which contrasts with the cow's much reduced appetite. As peritonitis develops the rectal sweep is greatly reduced and there is ruminal atony with scant faeces in the rectum.

DIFFERENTIAL DIAGNOSIS

Diffuse peritonitis from another source/viscus such as abomasal perforation; metritis; toxic mastitis.

DIAGNOSIS

The uterine tear can be felt *per vaginam* provided the cervix has not contracted. After several days, the diagnosis of diffuse peritonitis is based on clinical findings, with grossly distended loops of small intestine caused by fibrinous adhesions and a much reduced rectal sweep with tacky rectum with little or no faeces.

Ultrasonography of the right caudal abdomen reveals greatly distended loops of small intestines and focal/diffuse peritoneal exudate with fibrin tags/adhesions. Ultrasound-guided abdominocentesis of the right caudal abdomen reveals an inflammatory exudate with an increased protein concentration and white cell count with >90% neutrophils (104).

MANAGEMENT

Uterine closure through a high left flank laparotomy can be attempted in those cases identified at calving or within several hours; however, such repair can prove difficult when the dorsal uterine tear extends towards the cervix. The cow should be treated with parenteral antibiotics for



104 Turbid peritoneal fluid obtained by abdominocentesis, which indicates peritonitis.

7–10 days. The value of intraperitoneal antibiotics remains unproven, but they are commonly used.

Peritoneal cavity lavage using large quantities of very dilute povidone–iodine solution has been reported to be successful in a limited number of early cases of peritonitis. A right laparotomy incision would be the approach indicated in this case.

Treatment of diffuse peritonitis involving small intestine is invariably hopeless and the cow must be euthanased for welfare reasons when this diagnosis is confirmed.

VAGINAL TEARS/LACERATION

DEFINITION/OVERVIEW

Haemorrhage from a major uterine artery may result from excessive traction and is apparent once the pressure has been removed with delivery of the calf.

AETIOLOGY

The most common cause of vaginal tears/lacerations is excessive traction in overconditioned heifers.

CLINICAL PRESENTATION

Haemorrhage from a major artery in the vagina must be identified immediately the calf has been delivered. Arterial bleeding can often be visualized by parting the vulval lips. However, it must be recognized when the posterior reproductive tract is checked after delivery of the calf, and differentiated by its very forceful pulsing rather than passive bleeding from the ruptured umbilical vessels. Rupture of a major artery can result in death within 30 minutes (96).

DIAGNOSIS

Diagnosis is by careful vaginal palpation.

MANAGEMENT

It is essential to check for arterial rupture immediately the calf has been delivered because the artery will retract within minutes, especially if the recumbent animal stands up and pneumovagina occurs. The arterial stump can usually be grasped between the thumb and index finger of one hand and clamped using large haemostats. The haemostats are secured by tying a loop of bandage through one handle and onto the base of the cow's tail. The haemostats can be removed in five days.

If the vessels cannot be ligated, pressure pads comprising rolled towels and bedsheets have been suggested in textbooks, but are rarely used in practice.

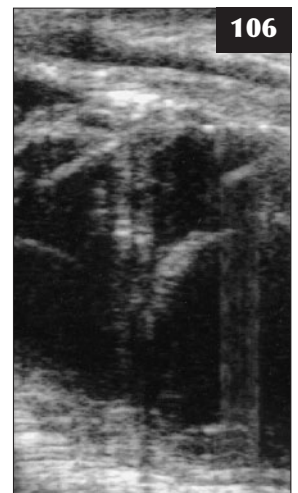Antibiotic therapy for vaginal trauma caused by excess traction is very important to prevent local diphtheritic lesions and infection extending into deeper tissues (105, 106). Infection of vaginal tears may extend to erode a major vessel, causing fatal haemorrhage several weeks after calving. Procaine penicillin should be administered by intramuscular injection for at least 7–10 days. NSAIDs should be used to reduce pain. Corticosteroids reduce perivulval oedema and inflammation and may therefore be more effective than NSAIDs.

Removal of protruding vaginal fat through vaginal tears (95) is usually not necessary. Attempts to repair tears in the vaginal mucosa prove unsatisfactory because the edges are under considerable tension due to pneumovagina.

Prevention is by monitoring dry cow and heifer BCSs regularly, especially during the summer months. An episiotomy should be carefully considered in overfat heifers. Excessive traction can be avoided by electing to perform a caesarean section.

105 Tenesmus following dystocia, with an infected vaginal haematoma extending well over the pelvic brim.

106 A transrectal 5 MHz linear ultrasound probe reveals a very large haematoma/abscess. Aspiration revealed turbid foul-smelling fluid.



UTERINE TORSION

DEFINITION/OVERVIEW

Uterine torsion is relatively common in cattle. It is often associated with an oversized fetus. Uterine torsion, from 180° to 720°, prevents entry of the fetus/fluids into the twisted vaginal lumen such that the animal shows no signs to indicate the end of first-stage labour. Failure of the cervix to dilate fully is a common consequence.

AETIOLOGY

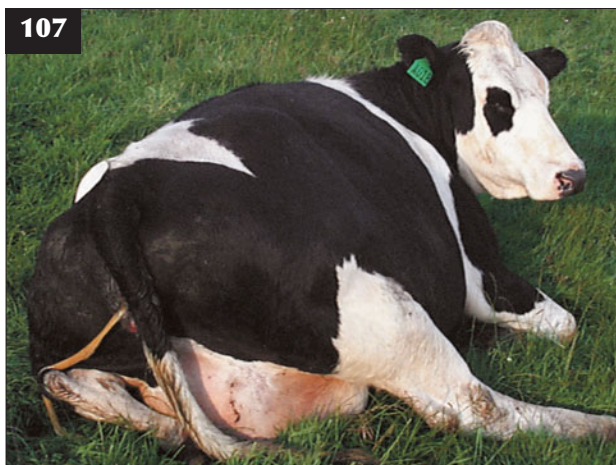Instability of the gravid uterus in late gestation results in 180° to 720° torsion. The precise timing of uterine torsion has not been determined, but most torsions are thought to occur in the days before calving and be associated with fetal repositioning. However, sporadic cases of uterine torsion have been identified in mid-gestation pregnancies, giving rise to vascular compromise of the uterus.

CLINICAL PRESENTATION

The cow may isolate herself from others in the group and show signs of first-stage labour, including slackening of the sacroiliac ligaments (107), but the fetal membranes (allantochorion) do not appear at the vulva. The vulva and tail head are slack, which contrasts with the constricted (tight) vaginal lumen, which is typically dry and lacking mucus. As your hand passes into the vagina there is a distinct twist (corkscrew effect), which can be either clockwise or anti-clockwise. With a torsion <360° it may be possible to reach the cervix, which is dilated with fetal extremities distally. If left unattended for several days, the cow becomes sick due to death of the calf and development of a septic metritis.

DIFFERENTIAL DIAGNOSIS

Incomplete cervical dilation associated with calf in breech



107 A cow with uterine torsion that has isolated herself from others in the group and is showing signs of first-stage labour, including slackening of the sacroiliac ligaments.

presentation; disturbed early first-stage labour before complete cervical dilation; prolonged first-stage labour caused by hypocalcaemia.

DIAGNOSIS

A uterine torsion can be identified by the tight vagina with an obvious 'corkscrew' feel. Occasionally, cases of pre-cervical torsion occur and in these cases rectal palpation is necessary to confirm the torsion, which can be palpated beyond the vagina over the pelvic brim.

MANAGEMENT

There are a number of methods that can be used to correct a uterine torsion. It is important that farmers request timely veterinary examination of cows that appear 'not to be getting on with calving', otherwise the calf may be dead when the farmer eventually realises something is wrong.

Uterine torsion up to 360°

- **Cow standing/rotating calf.** This method is the simplest and safest, but demands considerable strength to rotate the calf and the uterus. With a uterine torsion up to 360°, it is usually possible to pass a hand through the cervix and push the fetal extremities in the opposite direction to the torsion. It is rarely possible to push the calf around in a single action, and a pendulum-like swing is used until the calf can be 'flipped over'. For a clockwise torsion, the right hand/lower forearm is passed through the cervix and the calf pushed anti-clockwise. For an anti-clockwise torsion, the left hand/lower forearm is passed through the cervix and the calf pushed clockwise.
- **Calf held in position/rotate cow.** In this method the cow is cast in a large pen using ropes and the fetus either held in position within the uterus by the veterinary surgeon's arm while the cow is rolled on to its other side or, preferably, by the 'plank in the flank' approach, which stabilizes the fetus within the abdomen. A board is laid across the abdomen and leant on with a person's weight to stabilize the calf *in utero* while the cow is rolled. This method generally works well. It may need to be done more than once, letting the cow rise between each attempt and checking whether the torsion has been corrected. The cow is laid down in the direction of the torsion and rolled in the direction of the torsion. So if the torsion is clockwise (i.e. to the right), the cow is laid down on its right side and rolled towards the right (i.e. in a clockwise direction).
- **Delivery of the calf.** Once the torsion has been corrected it is common to find that the cervix has not dilated fully. There is debate whether the cow should be left for a further hour or so to dilate further or rely upon mild/moderate traction on the calf to gradually dilate the cervix. It is essential to place a head rope and ropes on both limbs of the calf when there is

incomplete cervical dilation otherwise the head will frequently be averted when traction is applied to the limbs. A caesarean section may be indicated to prevent tearing of an incompletely dilated cervix.

Uterine torsion more than 360°

With a uterine torsion of more than 360° it may be necessary to undertake a caesarean section after correction of the torsion via laparotomy (see Caesarean section, p. 52 and comments on possible complicating factors such as uterine oedema leading to fragility when handled and during suturing).

UTERINE INERTIA

DEFINITION/OVERVIEW

Uterine inertia is common in multiparous cows with clinical or subclinical hypocalcaemia. A 'slow calving' syndrome is reported in beef cows, with delayed parturition leading to stillborn calves.

AETIOLOGY

Hypocalcaemia causes uterine inertia and failure to progress to second-stage labour. In beef cows, shortage of dietary magnesium may predispose to subclinical hypocalcaemia and uterine inertia.

CLINICAL PRESENTATION

Parturition does not progress beyond the end of first-stage labour. Vaginal examination reveals the cervix to be fully dilated, with the fetal membranes intact but the calf dead. There may be other signs of hypocalcaemia, including paresis and bloat.

DIFFERENTIAL DIAGNOSIS

Toxic conditions such as mastitis. Absence of abdominal straining/appearance of fetal membranes rules out fetal oversize. Vaginal examination will exclude uterine torsion and malpresentation/malposture, especially breech presentation. Malpostures are common in twin pregnancies. Emaciation/physical weakness, particularly in spring-calving beef cattle fed inadequate rations over the winter (see Chapter 14, Metabolic diseases, Pregnancy toxaemia, p. 256).

DIAGNOSIS

There is a rapid response to intravenous infusion of 400 ml of 40% calcium borogluconate solution (see Chapter 14, Metabolic diseases, Pregnancy toxaemia, p. 256).

MANAGEMENT

Treatment is by injecting 400 ml of 40% calcium borogluconate intravenously. If the calf is alive, it is usual to leave the cow for up to two hours to allow parturition to progress naturally.

Hypocalcaemia is discussed further in Chapter 15, Metabolic diseases, p. 247.

SIMULTANEOUS PRESENTATION OF TWO CALVES

There are many possible combinations of heads and limbs when two calves are presented simultaneously. It is necessary to identify which limb corresponds to which head by tracing the limb to the shoulder region, and then to the neck and head. Once both limbs and head have been correctly identified, the one calf is gently repelled as traction is applied to the other. Only slight/moderate traction should be necessary to deliver a twin calf in this situation; if little progress is being made, it is essential to check that you have selected the correct anatomy. It is important to differentiate simultaneous presentation of two calves from fetal abnormalities such as schistosoma reflexus or rare fetal monsters (see below).

MISCELLANEOUS FETAL ABNORMALITIES THAT CAN CAUSE DYSTOCIA

HYDROCEPHALUS

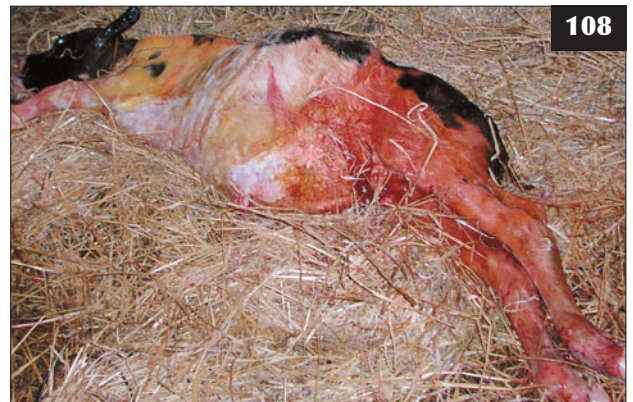Hydrocephalus arises from interference of normal cerebrospinal fluid (CSF) circulation, and the large domed forehead can be an occasional cause of dystocia.

FETAL ANASARCA

Fetal anasarca is a rare condition caused by an autosomal recessive gene in some breeds. The fetus may be three times the normal birth weight, with excessive subcutaneous fluid accumulation causing dystocia.

FETAL ASCITES

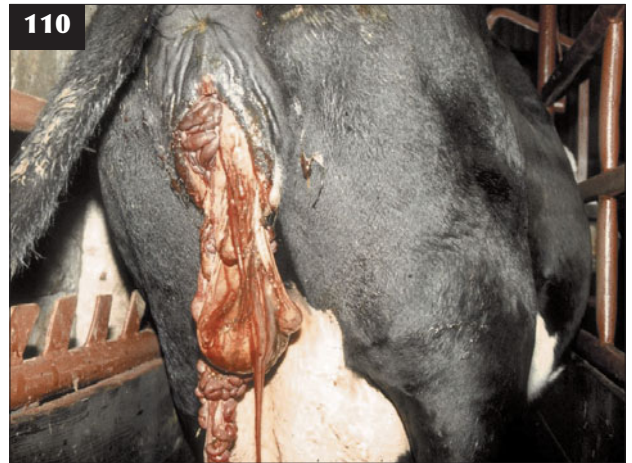Gross fluid accumulation may cause dystocia, with the calf stuck at the shoulders because the distended abdomen cannot enter the maternal pelvis (108). An incision in the abdominal wall with a guarded knife or partial fetotomy allows puncture of the diaphragm and drainage of fluid via the thorax. A caesarean section may be necessary in some situations.



108 Fetal ascites. Note the gross fluid accumulation, which caused dystocia with the calf stuck at the shoulders because the distended abdomen could not enter the maternal pelvis.



109 *Schistosoma reflexus*. All four feet extended into the maternal pelvis in this case.



110 Dystocia caused by a *Schistosoma reflexus* fetus with the fetal liver and intestines presented at the vulva because there was no fetal abdominal wall.

SCHISTOSOMA REFLEXUS

Schistosoma reflexus is probably the most common bovine fetal deformity. The fetus is presented either with all four feet extending into the maternal pelvis or with the liver and intestines because there is no fetal abdominal wall (**109**, **110**). Correction may require partial embryotomy or caesarean section to correct the dystocia.

FETAL MONSTERS

Rarely, fetal monsters such as conjoined twins are found, which must be differentiated from twins.

CAESAREAN SECTION

DEFINITION/OVERVIEW

Caesarean sections are common in cattle practice, resulting from absolute fetal oversize in beef cattle and relative fetal oversize in immature beef heifers and embryo transfer recipients, which are most commonly heifers, and are especially common in beef breeds such as the Belgian Blue. The potential value of the calf sometimes exerts unnecessary pressures on the practitioner for elective surgeries in pedigree cattle and embryo transfer recipients at the expense of animal welfare.

PROCEDURE

Wherever possible, caesarean sections should be performed in the standing, non-sedated animal (**111**), but it is important to be aware of the risk of injury to everyone involved in the procedure. Distal paravertebral anaesthesia is described in Chapter 18, Anaesthesia, p. 279. If in any doubt, help should be requested from an experienced colleague before starting the procedure.

The decision to perform surgery must be taken as early as possible and guidelines have been described earlier suggesting that no more than 10 minutes' traction is

applied before deciding on surgery. A caesarean section must never be considered a last resort when all traction forces have failed, because a traumatized patient and an exhausted surgeon only invite problems.

Caesarean sections are routinely performed after infiltration of the left flank incision site with approximately 3–5 mg/kg of 2% lidocaine solution (often 100–150 ml) either as a line or as an 'inverted L'. Paravertebral anaesthesia is preferred by many surgeons and it reduces the risk of surgical site contamination with subsequent wound breakdown.

Sedation

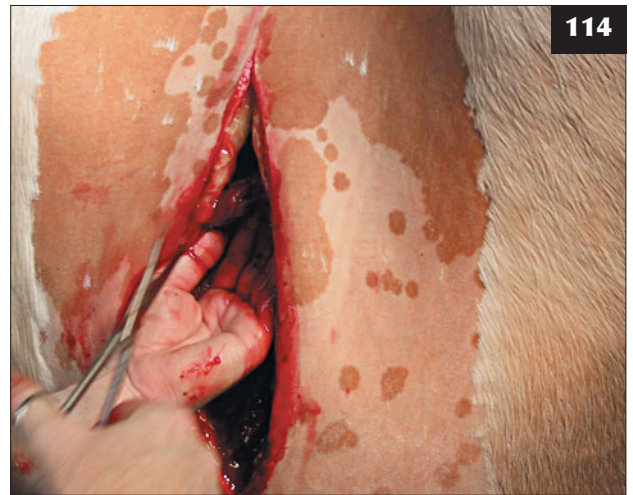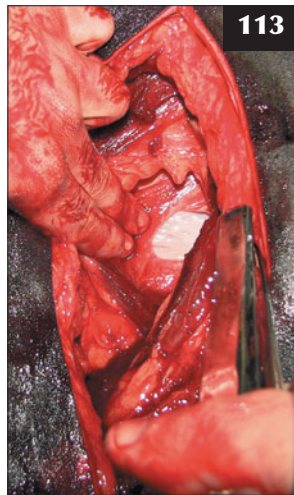
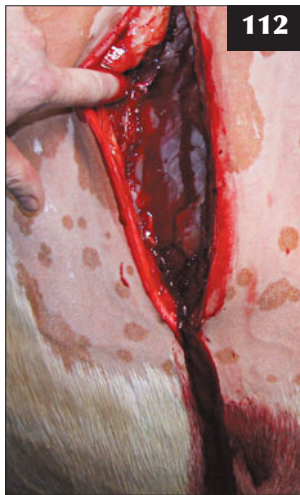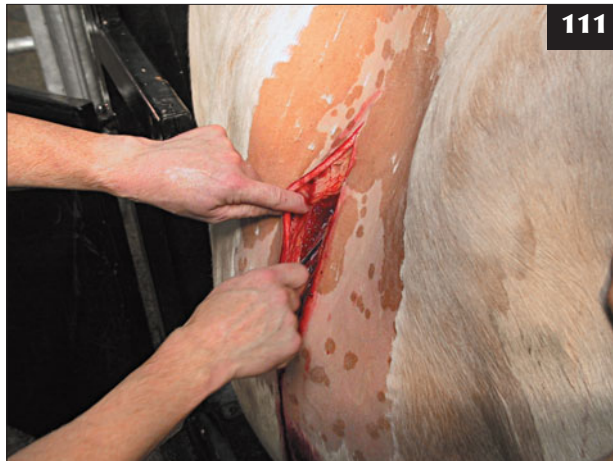Xylazine has an ecbolic effect and may render the uterus more friable and less manoeuvrable. For standing surgery, xylazine affords no analgesia (see data sheet stages 1 and 2) and cattle that are apparently sedated can still kick. Many surgeons use intravenous acetylpromazine (5–8 mg for a 600 kg cow) for mild sedation, but this drug has no analgesic properties. (Note the off-label use in many countries.) Some surgeons use intravenous romifidine (5–6 mg for a 600 kg cow) for mild sedation (off-label use in many countries) because it is much more predictable than xylazine.

Xylazine at a dose rate of 0.07 mg/kg injected into the extradural space at the sacrococcygeal site produces only sedation in cattle and does not afford adequate surgical analgesia of the flank (unlike in sheep).

Clenbuterol, injected prior to surgery, is used by some surgeons to aid manipulation of the gravid uterus and slow the rate of uterine contraction after removal of the calf. It is 'reversed' by an injection of oxytocin after completion of the procedure.

Where necessary, sacrococcygeal extradural injection of up to 0.2 mg/kg of 2% lidocaine solution (typically, 5 ml for a 600 kg cow) will reduce tenesmus during surgery.

111 Caesarean section being performed in a standing, non-sedated cow. The surgeon should be aware of the risks.



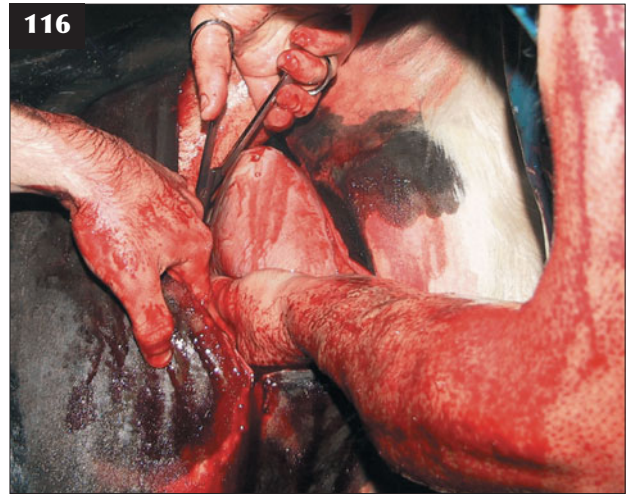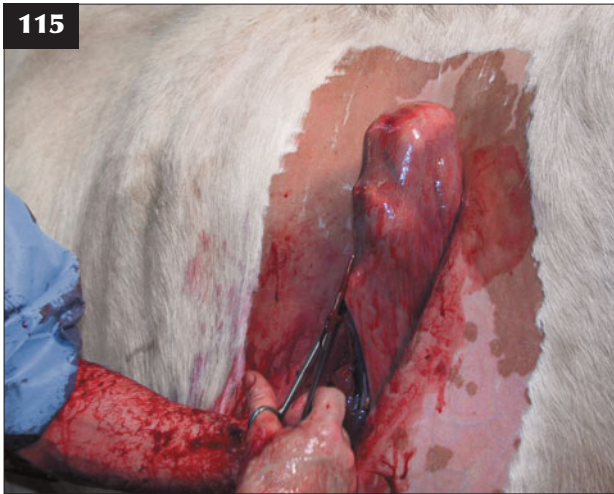112–119 Caesarean section. (**112**) A left flank incision is made midway between the last rib and the wing of the ilium commencing 15 cm below the level of the transverse processes of the lumbar vertebrae. (**113**) The transversus muscle and closely adherent peritoneum near the top of the incision are grasped with forceps and raised before a small nick is made into the peritoneum with scissors. (**114**) The abdominal incision is carefully extended with scissors. (Continued overleaf)

Surgery

The cow is restrained in cattle stocks or by a halter in a large, well-bedded loose box. A large area of the left flank is shaved and surgically prepared while the flank analgesia takes effect. A plastic disposable drape is fenestrated and held in position with towel clips, although this may only be practical in recumbent cattle. A ventral midline approach has been recommended in cattle with an emphysematous calf *in utero* because exteriorization of the uterus is much easier to perform.

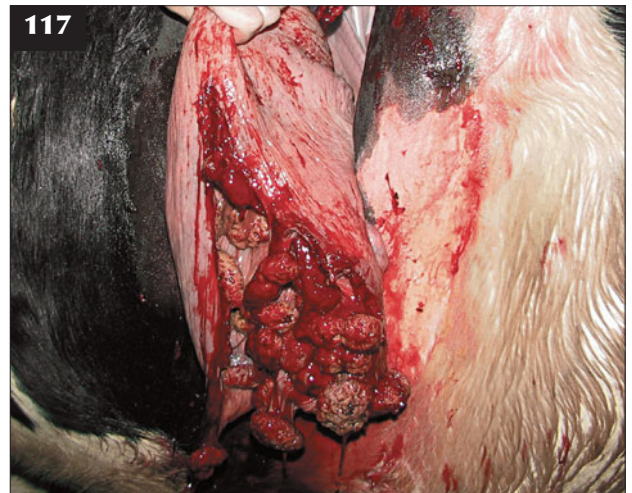
Surgery is generally performed through a left flank incision midway between the last rib and the wing of the ilium, commencing 10–15 cm below the level of the transverse processes of the lumbar vertebrae (**112**). A 25 cm incision is made through the skin, external abdominal oblique muscle and thick internal abdominal oblique

muscle using a scalpel blade (**112**). The incision is generally made in a vertical plane, but some surgeons prefer a slightly oblique approach through the flank because it facilitates exteriorization of the uterus. Also, some surgeons prefer blunt dissection of the internal oblique muscle (modified grid) because it reduces bleeding, reduces muscle trauma, takes fewer sutures to close and is faster. The transversus muscle and closely adherent peritoneum near the top of the incision are grasped with forceps and raised. A small nick is then made with scissors (**113**) and subsequently extended (**114**). Care is necessary at this stage to avoid puncturing an underlying viscus (**113**) if the cow is in lateral recumbency. A sloping incision starting 10–15 cm ventral to the tuber coxae and extending ventrally and cranially at an angle of 35° is also described. This latter method has the reported advantage that blunt dissection



112–119 Caesarean section. (Continued) **(115)** The uterine incision is made starting on the greater curvature at a level with the hock and extending to the calf's hind fetlock joints (calf in anterior presentation).

(116) If the uterine horn cannot be easily exteriorized, the uterine incision is started at the level of the hind fetlock joints and extended 30–40 cm to just over the calf's tail head. **(117)** The uterine horn can be held on the lower margin of the abdominal incision. Some surgeons prefer the assistant to use sterile uterine clamps rather than hold the uterus in order to avoid possible contamination.

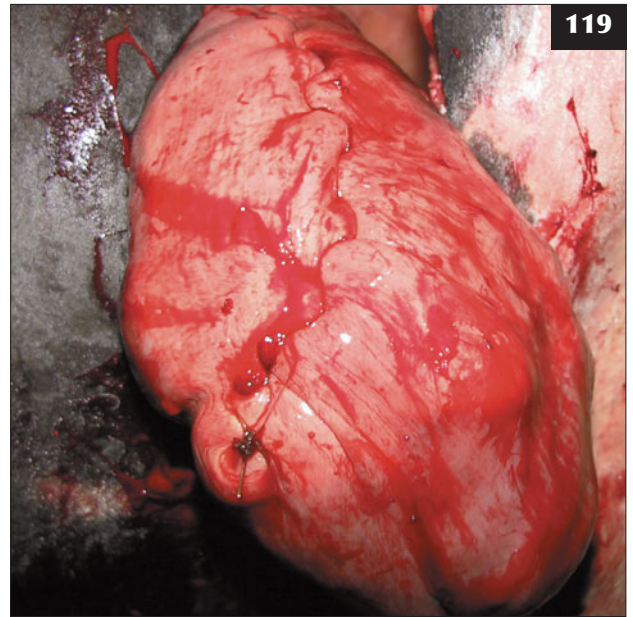
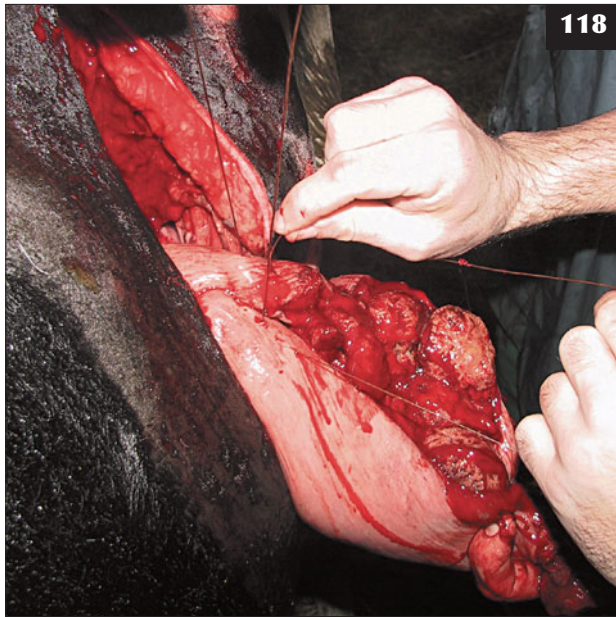

can be used to separate the muscle fibres of the thick internal oblique muscle that run parallel to the incision site.

In calves that are in anterior presentation, the uterine incision is made starting on the greater curvature at the level of the calf's hock and extended to the level of the calf's hind fetlock joints **(115)** using blunt-ended scissors. Alternatively, if the uterine horn cannot be easily exteriorized, the uterine incision is started at the level of the hind fetlock joints **(116)** and extended 30–40 cm to just over the calf's tail head using a Roberts embryotomy knife or plastic disposable 'letter-opening device'. While the incision may be started with the uterine tip exteriorized **(116)**, it is usually necessary to enter the abdomen while extending the incision, taking care to protect the cutting edge. Once the calf's hindfeet have been freed from the uterine horn, it helps to have an assistant hold them as high as possible, which draws the uterine incision up to the lower margin of the abdominal incision where it can be

safely extended. The uterine incision must always be made long enough; if it is not, an L-shaped tear is difficult to suture.

The uterine incision is exteriorized with the uterine horn resting on the lower margin of the abdominal incision **(117)**. Some surgeons prefer farmers to hold the uterus proximal to the incision site with uterine clamps rather than a hand in order to avoid possible contamination. A single Cushing (inversion) suture of absorbable material closes the uterus **(118)**. Approximately 2 cm of wound edges are inverted to form a tight seal, with the needle passing through the serosa and muscular layer and not into the lumen. The assistant is often asked to hold the suture material taut as the surgeon places the next suture. Two suture layers are recommended by some surgeons, but this approach is not necessary nor is there always sufficient time as the uterus is contracting. It is essential that the incision is watertight and that none of the fetal membranes protrude through



(118) A single Cushing (inversion) suture of absorbable material closes the uterus. **(119)** The uterine closure site is flushed with one litre of sterile saline to remove all remains of blood contamination before returning the uterus into the abdominal cavity.



120 A pedigree Aberdeen Angus heifer several days after surgery.

the suture line. The bulk of the protruding fetal membranes can be debrided before commencing uterine closure in order to prevent them interfering with the suturing process. If a tear has occurred, this should be sutured first, then the longer length of the incision.

The uterine closure site is flushed with one litre of sterile saline to remove all remains of blood contamination **(119)** before returning the uterus into the abdominal cavity. Before commencing closure of the abdominal incision, any blood

clots are scooped from the abdominal cavity. Intra-abdominal antibiotics are commonly used, but there is little evidence of their efficacy. Successful outcome in a heifer several days after surgery is shown **(120)**. The calf's umbilicus must be treated before the surgeon leaves the farm and instructions given regarding colostrum feeding if the calf is not on its feet within 30 minutes.

In cases of uterine torsion, it is important to correct the torsion before making the uterine incision in order to

ensure that the incision site can be sutured. The incision edges are apposed as close as possible while suturing in order to reduce tension on the suture line. The uterine suture pattern must not be overtightened, as this will cause the suture material to cut through the oedematous uterine wall; a second suture line is recommended.

Elective caesarean sections, especially for transferred embryos, are difficult to justify for animal welfare reasons. Maternal bonding immediately after surgery is essential in beef cattle and is one advantage of not sedating the patient; however, the surgeon must be aware of safety concerns.

UTERINE PROLAPSE

DEFINITION/OVERVIEW

Uterine prolapse is a common spontaneous condition in cattle occurring immediately after delivery of the calf. An incidence of around 0.5% is commonly quoted.

AETIOLOGY

Uterine prolapse (eversion) occurs immediately after delivery of a large calf in anterior presentation that may have been hip locked for some time. In older cows it may be associated with hypocalcaemia during the immediate post-partum period.

CLINICAL PRESENTATION

The everted uterus with obvious large caruncles (6–8 cm diameter) over the whole surface protrudes from the vagina to the level of the cow's hock joints (121). The placenta may still be attached. There is little haemorrhage from the caruncles unless the everted viscus is traumatized; however, there may be considerable contamination with straw and mud depending on the calving environment.

DIFFERENTIAL DIAGNOSIS

Vaginal prolapse does not protrude as far and has no caruncles.

DIAGNOSIS

It is necessary to check for the presence of concurrent hypocalcaemia and treat after replacement of the uterine prolapse unless the condition is considered life threatening (e.g. severe bloat, regurgitation of rumen content). The mucous membrane colour should be examined for possible haemorrhage, and also the calving site, but internal haemorrhage can occur from ruptured uterine vessels (122).

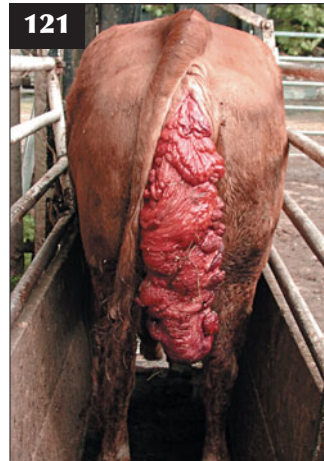MANAGEMENT

The prolapsed uterus should be protected from further trauma and contamination by wrapping a wet towel or sheet around it until the veterinarian arrives.

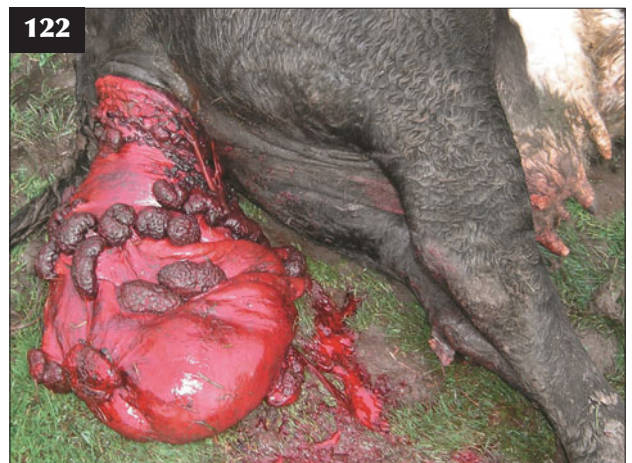The uterus is replaced after sacrococcygeal extradural injection of 5 ml of 2% lidocaine. In standing cattle the prolapsed uterus is raised to the level of the vulva and replaced.

It is much easier to replace the prolapsed tissues with the cow positioned in sternal recumbency. The recumbent cow is haltered and the head averted against the flank to prevent her from rising. The hindlimbs are positioned behind the cow with the hips fully extended (123 shows a cow after uterine replacement) and the weight of the cow's hindquarters taken on her stifle joints ('frog-legged position').

The fetal membranes are carefully detached from the caruncles where this can be achieved easily and without haemorrhage. The prolapsed uterus is rinsed with warm very dilute, povidone–iodine solution and all gross contamination removed. Kneeling behind the cow, the uterus is rested on the veterinarian's upper legs, held at the level of the vulva and replaced starting at the cervical end using plenty of lubricant. The palms of both hands are



121 Prolapsed uterus. The everted uterus, with obvious large caruncles over the whole surface, protrudes from the vagina to the level of the cow's hock joints.



122 This cow died from massive internal haemorrhage associated with rupture of the uterine artery.

used and gentle continuous pressure is applied to the uterus starting at the vulval lips. It is not of concern if an occasional caruncle becomes detached and time should not be wasted attempting to ligate bleeding caruncles. At first there seems to be little progress, but eventually the uterine horn is replaced into the vagina and carefully returned to its normal 'comma-shaped' position. It is essential to fully evert the uterine tip at the full extent of your reach. A 400 ml 'calcium bottle' is often recommended to extend one's reach, but is rarely necessary. Some authors recommend instilling 5–10 litres of warm clean water into the uterus to facilitate inversion, with the fluid then siphoned off. The hindlimbs are returned to their normal flexed position.

The prolapsed tissues can be retained using a perivulval Buhner suture of 5 mm umbilical tape (124). This is generally unnecessary unless the placenta is still attached, although a single recurrence of uterine prolapse may mean that it will be necessary to suture every future case of uterine prolapse. The Buhner suture should be removed after three days, especially if the placenta has not been passed, because there is the risk of septic metritis.

Intravenous administration of 400 ml of 40% calcium borogluconate is given slowly over 10 minutes to cows with suspected hypocalcaemia. The heart rate should be

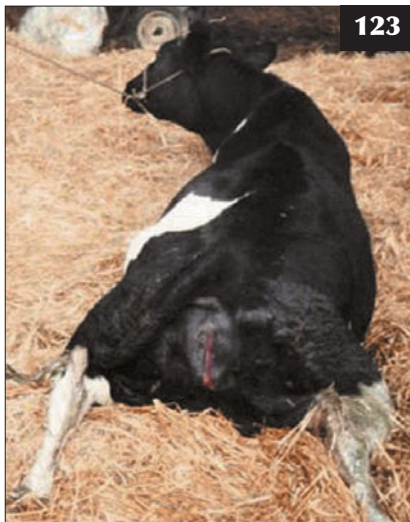monitored throughout the infusion. Oxytocin (40 iu i/m) is given to stimulate uterine involution. The cow is treated with parenteral antibiotics such as oxytetracycline for three consecutive days to prevent metritis. Dairy cows should be checked around 21 days after calving as part of the herd fertility control programme and treated with PGF2 α for chronic endometritis. Beef cows are rarely rechecked in this manner.

There are reports of hoisting recumbent cows by their hindlimbs using hobbles above their hock joints attached by ropes to the fore-end loader of a tractor to facilitate replacement of the prolapsed uterus. In the authors' opinion this method is not necessary and raises numerous animal welfare concerns.

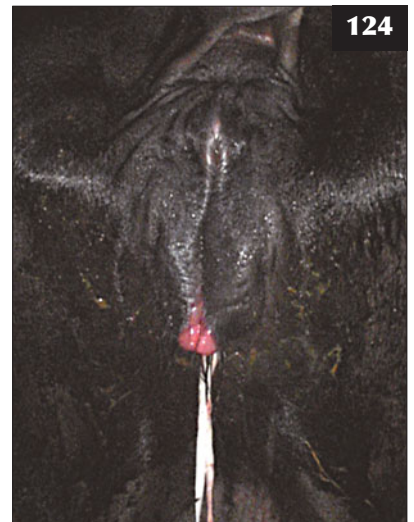Death may result within hours of prolapse replacement owing to uncontrolled internal haemorrhage.

Unlike vaginal prolapse, recurrence of uterine prolapse at subsequent parturitions is uncommon. Uterine prolapse may be associated with hypocalcaemia in older cows (fourth parity and greater) (see Chapter 14, Metabolic diseases, Milk fever, p. 247). Diligent supervision of all calving cows, together with timely intervention, is important.

123 This recumbent cow was positioned with the hindlimbs behind and the hips fully extended in order to replace the uterus.



124 A perivulval Buhner suture of 5 mm umbilical tape has been used in this cow to retain the prolapsed tissues.



CERVICAL/VAGINAL PROLAPSE

DEFINITION/OVERVIEW

Vaginal prolapse occurs sporadically in older beef cows from several days to several months prior to parturition.

AETIOLOGY

Vaginal prolapse occurs during late gestation and is associated with oestrus in the post-partum period following mounting another cow. Poor cow conformation, excessive body condition and multiple ovulation/embryo transfer (MOET) programmes are risk factors. Breed susceptibility (e.g. Herefords) has been reported.

CLINICAL PRESENTATION

Cervical/vaginal prolapse presents as a large, 30–40 cm diameter smooth viscus protruding from the vulva (125). There is often considerable faecal contamination, especially in pastured cattle inspected infrequently, where the prolapse may have been present for several days.

DIFFERENTIAL DIAGNOSIS

Vaginal polyps/tumours are rare. Bladder eversion is mentioned in textbooks, but is rarely seen. Rectal prolapse may occur along with vaginal prolapse caused by persistent tenesmus.

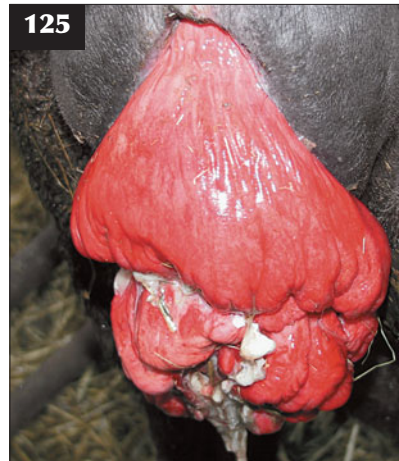
DIAGNOSIS

Diagnosis is by clinical examination.

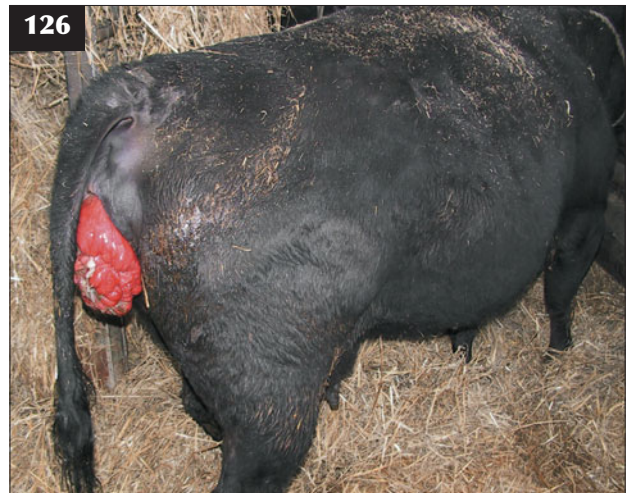MANAGEMENT

Replacement should be performed in the standing animal after sacrococcygeal extradural injection of 5–7 ml of 2% lidocaine (126). The prolapsed tissues are thoroughly cleaned in warm dilute antiseptic solution, but it can prove very difficult to remove all contamination (127). Steady pressure should be applied to the prolapsed tissues until they return into position. Eversion of the bladder within the prolapse can make replacement more difficult, but this can be relieved by needle drainage across the distended vaginal wall. Immediately after replacement cows will often pass urine as the urethra/bladder is returned to a normal position. After correction of the prolapse, a Buhner suture of 5 mm umbilical tape is placed in the subcutaneous tissue surrounding the vulva. The suture must be slackened before the expected calving date. Fibrosis surrounding the Buhner suture may necessitate an episiotomy. The suture can be re-tied after calving and passage of the fetal membranes.

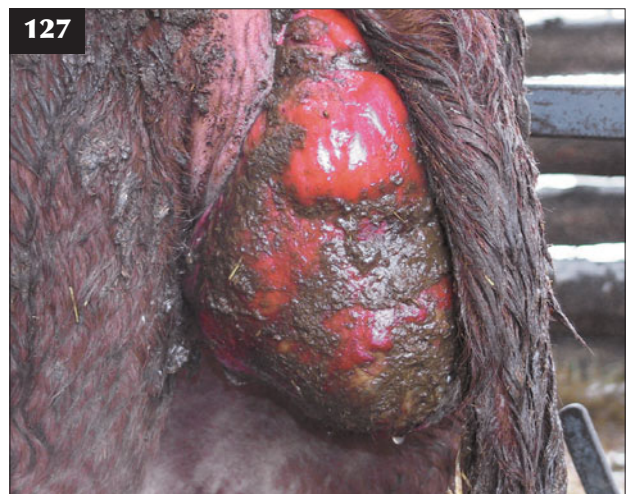There is a high probability of recurrence in subsequent pregnancies, so culling of affected cows should be considered.



125 Vaginal prolapse in a beef cow.



126 A sacrococcygeal extradural injection of 5 ml of 2% lidocaine has been given to this cow prior to replacement of the prolapsed vagina. Note the lack of tail tone.



127 Note the considerable faecal contamination of the vaginal prolapse in this cow.

Chapter 3

Digestive tract and abdomen

Part 1: Diseases of the digestive tract and abdomen

CLINICAL EXAMINATION OF THE DIGESTIVE SYSTEM

Dietary management as well as the type and quantity of particular feeds determines the extent of rumen fill, the frequency of ruminal contractions and faecal consistency. Cattle fed fibrous diets have a more distended rumen than those fed predominantly concentrates and they pass more formed faeces. Auscultation reveals two primary cycles followed by one secondary cycle occurring every two minutes or so. It is important to remember what is normal (128), so that any abnormalities can be identified (129). The influence of advancing pregnancy on abdominal shape/fill should not be underestimated (130), particularly where there might be a twin pregnancy.



128 Abdominal silhouette of a healthy beef cow at pasture.



129 Compare this dairy cow with the beef cow featured in 128.



130 Beef cow during late pregnancy. A single healthy 52 kg calf was born at full term.

EXAMINATION OF THE BUCCAL CAVITY

Cattle with lesions of the buccal cavity usually present with profuse salivation and poor abdominal fill due to impaired feeding. Lesions affecting the cheek result in obvious firm swellings. Infected lesions of the cheek and/or tongue may cause halitosis and swelling of the submandibular lymph node(s). Examination of the mouth is best achieved using a torch and a Drinkwater or similar gag.

Cattle have 32 permanent teeth with a dental formula of 2 (incisors 0/4, premolars 3/3 and molars 3/3). The temporary incisor teeth erupt sequentially at approximately weekly intervals from birth. The three temporary premolars erupt within 2–6 weeks of birth. The first permanent molar erupt at eight months of age, the second permanent molar at 9–12 months of age and the third permanent molar and permanent premolars from 24 months of age. The first (central) pair of permanent incisors erupt at 18 months of age and are fully in wear by 24 months of age. The second (medial), third (lateral) and fourth (corner) incisor teeth erupt sequentially at six-month intervals.

EXAMINATION OF THE PHARYNX

Pharyngeal trauma is not uncommon following balling gun or drenching gun injury. Digital palpation of the pharynx can be achieved using a Drinkwater gag in adult cattle, but frequent head tossing quickly ensues, especially in dyspnoeic cattle.

EXAMINATION OF THE OESOPHAGUS

Choke is common in cattle. Digital examination of the proximal 10–15 cm of cervical oesophagus is possible with a Drinkwater gag in place. The remainder of the cervical oesophagus can be palpated through the skin and possible obstruction checked by careful passage of a flexible orogastric tube or probang. A mouth gag is best employed once the orogastric tube has entered the oesophagus. The oesophageal obstruction must not be forced using a probang because of the likelihood of causing oesophageal perforation.

EXAMINATION OF THE FORESTOMACHS

When viewed from behind, the rumen in normal cattle pushes the lower left flank beyond the outline of the costal arch. Free gas bloat causing distension of the left sublumbar fossa is common in cattle.

Auscultation of the rumen is performed in the upper left flank. The stethoscope is pushed firmly against the skin in order to achieve direct contact with the dorsal sac of the rumen; any gap between the rumen wall and abdominal wall will greatly reduce transmitted sounds. There are two independent reticulorumenal contraction sequences. The primary biphasic contraction cycle of the reticulum, followed by ruminal contractions, occurs approximately once a minute, mixing ingesta and forcing small particles into the omasum. The secondary contraction does not involve the reticulum, but rumen

activity pushes the gas cap into the cardia region, with resultant eructation. Typically, one secondary cycle follows two primary cycles such that three cycles occur every two minutes.

RUMEN FLUID COLLECTION AND ANALYSIS

Rumen fluid can be easily collected by aspiration through a wide-bore orogastric tube with a suitable mouth gag in place. Possible saliva contamination can be reduced by discarding the first few millilitres and collecting a minimum of 20 ml of rumen fluid. Percutaneous rumenocentesis via the lower left flank using a wide-bore 5 cm hypodermic needle, without prior local analgesia, is advocated to assess rumen pH and function.

The rumen fluid can be analysed for colour, odour, pH, protozoa, sedimentation rate and methylene blue reduction time. Normal rumen fluid is green, has an aromatic odour, a pH of 6.5–8.0 and many variably sized motile protozoa per microscope field ($\times 100$). The methylene blue reduction time is abnormal if extended beyond 6–8 minutes.

GENERAL EXAMINATION OF THE ABDOMEN

Radiography

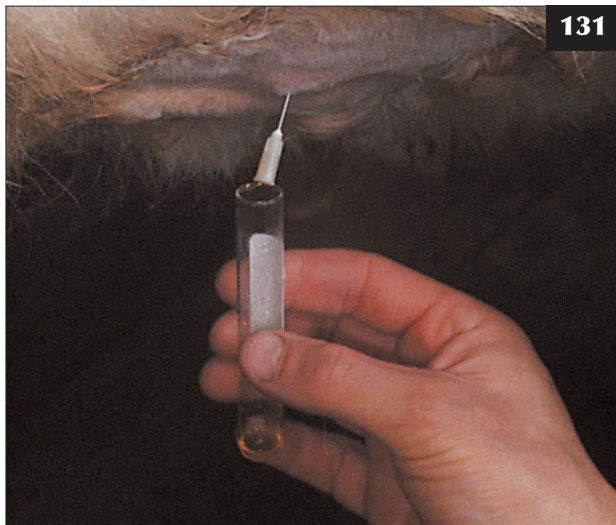Radiography is rarely used in general practice to investigate abdominal disorders in cattle despite the common occurrence of reticular lesions caused by ingested sharp metallic objects. Fluid exudation and fibrinous adhesions are better demonstrated by ultrasonography without the attendant cost and health and safety restrictions.

Abdominocentesis

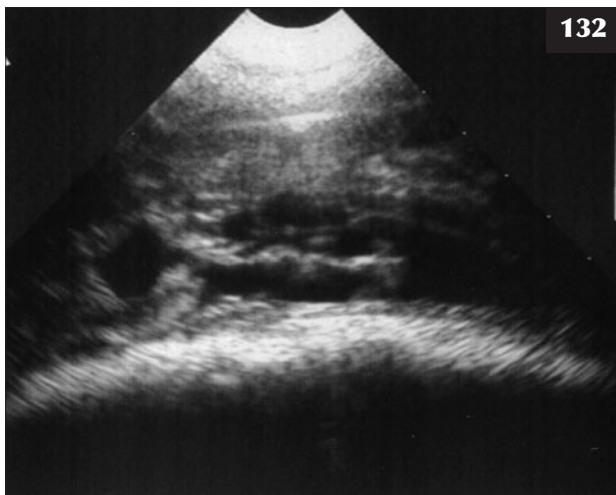
Abdominocentesis (131) is best undertaken when excess peritoneal fluid is identified by ultrasonography (132). Peritoneal reaction/exudation is common in cattle, although infection and inflammatory reaction can be localized by the omentum. Large accumulations of transudate occur with conditions such as cor pulmonale. Uroperitoneum occurs consequent upon obstructive urolithiasis.

Both linear and sector scanners can be used to determine the presence and extent of excess peritoneal fluid and identify the site for transabdominal fluid collection using a hypodermic needle. Peritoneal fluid should be collected into tubes containing EDTA. Attempts to collect peritoneal fluid by ventral midline percutaneous aspiration with no excess fluid commonly result in puncture of the rumen.

Normal peritoneal fluid has a clear, slightly yellow appearance with a protein concentration ranging from 10–30 g/l and a white cell concentration of less than $1 \times 10^9/l$, comprised mainly of lymphocytes. Infectious peritonitis typically results in a turbid sample with a high protein concentration of >30 g/l and white cell concentrations $>30 \times 10^9/l$, comprised almost exclusively of neutrophils.



131 Peritoneal fluid collected after needle insertion at the ventral midline immediately caudal to the xiphisternum.



132 Ultrasonographic demonstration of peritoneal exudate containing fibrin tags is commonly observed after several days in cases of traumatic reticulitis.

Ultrasonography

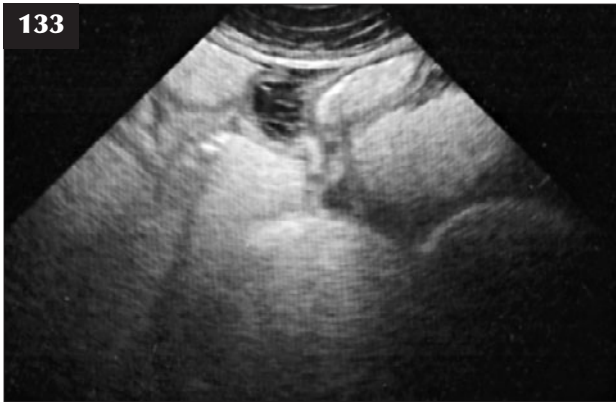Transabdominal ultrasonographic examination can include the peritoneal cavity (ascites, uroperitoneum, peritonitis), liver, spleen, rumen, reticulum, abomasum, intestines and right kidney. Transrectal examination allows examination of the uterus and fetus(es), bladder and kidneys.

A 5.0 MHz linear transducer connected to a real-time, B-mode ultrasound machine, used for early pregnancy diagnosis by most practitioners, can be used for most abdominal ultrasonographic examinations, but the field setting of 10 cm may limit some examinations. The 20 cm field depth afforded by certain 5.0 MHz sector scanners is preferable, but often does not significantly alter the diagnosis.

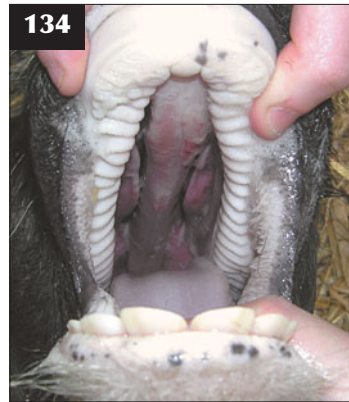Good contact between probe head and the skin is essential. The skin is shaved with a razor then wetted with either alcohol or tap water and ultrasound gel liberally applied. The probe head is held firmly at right angles against the abdominal wall.

Ultrasonographic appearance of normal abdominal viscera

- The abdominal wall is 2–5 cm thick depending on the site and BCS. There is scant peritoneal fluid in normal cattle. Vigorous reticular motility can readily be observed in the cranioventral midline immediately caudal to the xiphisternum, contrasting markedly with atony in traumatic reticulitis.
- The liver can readily be visualized from halfway down the 9th to 12th intercostal spaces on the right side.
- The intestines are clearly outlined as broad hyperechoic (white) lines/circles containing material of varying echogenicity. By maintaining the probe head in the same position for 10–20 seconds, digesta can be visualized as multiple small dots of varying echogenicity forcibly propelled within the intestines.
- Ascitic fluid appears an anechoic (black) area with abdominal viscera displaced dorsally. Ascites must be differentiated from uroperitoneum.
- The extent of subcutaneous urine/blood accumulation along the prepuce and ventral abdominal wall can be accurately defined in male cattle with urethral rupture and a ruptured penis, respectively. Abscesses involving the body wall occur occasionally caused by penetration wounds and faulty injection technique into the mammary vein.
- Significant peritoneal reaction is commonly observed in cases of traumatic reticulitis (132). The hyperechoic lattice-work appearance of the fibrinous reaction within the abdomen in advanced cases contrasts with the anechoic peritoneal exudate. Peritoneal reaction may be limited to focal fibrinous/fibrous adhesions and localized accumulation of peritoneal fluid by the enveloping omentum. Occasionally, the peritoneal reaction is limited to a few fibrinous adhesions causing constriction, which cannot be visualized. In this situation, the intestines proximal to the lesion are



133 Focal fibrinous adhesions and localized accumulation of peritoneal fluid is seen in this ultrasonogram. Note the grossly distended loops of small intestine.



134 A calf with a severe cleft palate defect.

grossly distended with fluid (anechoic appearance) rather than containing normal digesta (anechoic appearance containing multiple bright dots) and there are no propulsive intestinal contractions (133).

- Large liver abscesses are uncommon. Gallbladder distension is a common finding in cachectic animals. Hepatomegaly can be quantified relative to body weight, but such calculations are rarely undertaken. Fatty liver and chronic venous congestion/nutmeg liver are common causes of hepatomegaly, with the liver palpable beyond the costal arch on the right side.

CONGENITAL ABNORMALITIES

DEFINITION/OVERVIEW

Congenital abnormalities, including cleft palate (134), harelip, prognathia and brachygnathia, are rare.

AETIOLOGY

Cases are rare and the aetiology is unknown.

CLINICAL PRESENTATION

Calves with cleft palate have difficulty feeding, with milk often refluxed through the nostrils.

DIAGNOSIS

Diagnosis is based on careful clinical examination.

MANAGEMENT

Prognathia and brachygnathia defects can be managed by careful husbandry, ensuring an adequate concentrate component of the ration to maintain growth rate to slaughter. Calves with severe cleft palate/harelip defects should be euthanased for welfare reasons.

There are no specific prevention or control measures.

ATRESIA COLI AND ATRESIA ANI

DEFINITION/OVERVIEW

Atresia coli occurs sporadically and is more common than atresia ani. Atresia ani is rare in calves (135) and may be accompanied by other congenital defects of the digestive, reproductive or urinary tracts.

AETIOLOGY

There is no recognized hereditary component to atresia ani/coli. The potential association of atresia coli with early rectal pregnancy diagnosis by palpation of the embryonic vesicle remains unproven.

CLINICAL PRESENTATION

Calves with atresia ani/coli are healthy for the first 24–36 hours after birth. Thereafter, there is reluctance to suck, salivation, depression, distension of intestinal loops causing increasing abdominal distension, and long periods spent in sternal/lateral recumbency with the hindlimbs extended suggestive of colic (136). Examination reveals a bulge beneath the skin where the anus should be in atresia ani. Calves with atresia coli pass only very small quantities of mucoid secretion, but no normal faeces.

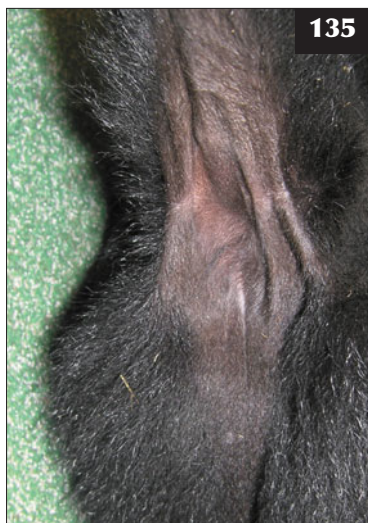DIFFERENTIAL DIAGNOSIS

Atresia coli should be differentiated from peritonitis associated with omphalophlebitis, where ileus leads to intestinal/ abdominal distension. Abomasal volvulus will normally have a more sudden onset with rapid deterioration of clinical signs. Enterotoxigenic *Escherichia coli* (ETEC) may cause recumbency with abdominal distension in young calves, with diarrhoea only present during the later stages of disease.

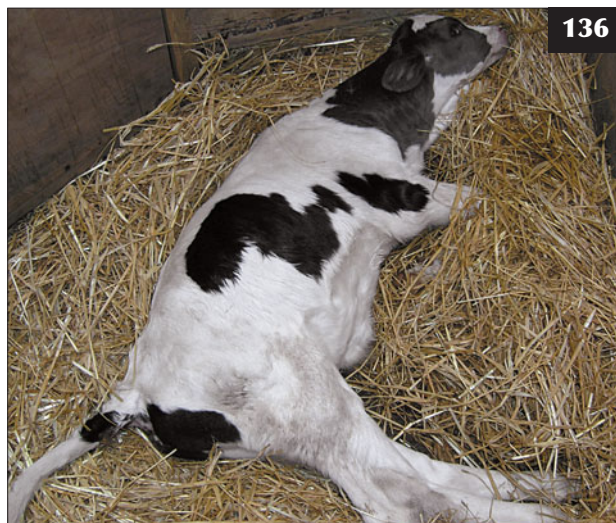DIAGNOSIS

Diagnosis of atresia coli is based on the clinical findings

135 A neonatal calf with atresia ani.



135



136

136 Colic signs in a four-day-old calf with atresia coli.

listed above plus lack of faeces produced since birth or following administration of an enema.

MANAGEMENT

Atresia ani can be corrected after low extradural injection of 1–2 ml of lidocaine and removal of a circular piece of skin over the rectal pouch – blunt dissect onto the rectal pouch, grasp with tissue forceps and suture to the subcutaneous tissue before incising into the pouch, then suture the incised margins of the rectum to the skin. Gas and mucus-containing meconium are released under variable pressure. The farmer should be advised to make sure the incision site remains patent by carefully inserting a thermometer coated with liquid paraffin into the rectum twice daily for 3–4 days.

There is no cost-effective surgical correction of atresia coli for commercial value calves and these animals should be euthanased for welfare reasons.

BOVINE PAPULAR STOMATITIS

DEFINITION/OVERVIEW

Bovine papular stomatitis (BPS) is a common condition occurring worldwide and it is a potential zoonosis.

AETIOLOGY

BPS is caused by a parapoxvirus virus, which also causes pseudocowpox. Spread occurs by direct contact, with entry through abrasions in the mucosa.

CLINICAL PRESENTATION

Calves 1–12 months old are most commonly affected, with most infections varying from few clinical signs to transient anorexia, salivation and mild pyrexia. The lesions comprise expanding papular rings on the muzzle and nostrils (137) and within the buccal mucosa. Lesions heal from the centre

outwards. The severe form of disease is less common, with raised buccal lesions and sloughing of the overlying mucosa.

DIFFERENTIAL DIAGNOSIS

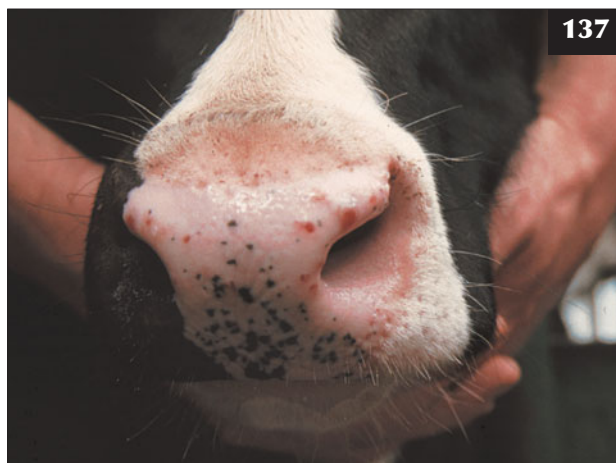
Foot and mouth disease; BVDV infection; vesicular stomatitis; bluetongue.

DIAGNOSIS

Diagnosis is based on typical clinical signs.

MANAGEMENT

No treatment is required as spontaneous recovery occurs in 4–7 days. More severe persistent lesions may be seen with concurrent BVDV infection. Spread of the disease can be minimized by avoiding group housing and use of shared feeding buckets/teats.



137

137 Bovine papular stomatitis lesions on the muzzle of a calf.

ACTINOBACILLOSIS (WOODEN TONGUE)

DEFINITION/OVERVIEW

Actinobacillosis is a common disease of cattle worldwide.

AETIOLOGY

Actinobacillus lignieresii, a gram-negative bacterium, is a commensal of the bovine upper respiratory and alimentary tracts that gains entry through breaks in the buccal mucosa. Outbreaks of wooden tongue may follow the feeding of hay containing fibrous stalks and/or thistles.

CLINICAL PRESENTATION

Wooden tongue, caused by infection with *A. lignieresii*, is the most common clinical presentation. A rare intestinal form with lesions in the oesophagus, oesophageal groove, cardia, rumen and reticulum is possible. A third 'cutaneous' form is rare (see Chapter 9, Skin diseases, p. 205). While single animals are usually presented, a cluster of wooden tongue cases can occur.

Cattle with wooden tongue present with sudden onset profuse salivation and dysphagia. There is protrusion of the tongue, enlarged submandibular and retropharyngeal lymph nodes, and swelling under the jaw (138). Oral examination reveals a very firm, painful and swollen tongue, with discrete yellow lesions visible beneath the mucosa (139).

Intestinal lesions have an insidious onset with slow progression of clinical signs, including weight loss, and ruminal bloat common following feeding. There is no evidence of abdominal pain and affected animals are afebrile.

The cutaneous form often affects several animals, with large granulomas and ulcers of the head, chest wall, thighs and flanks, resulting in generalized lymphadenopathy.

DIFFERENTIAL DIAGNOSIS

Wooden tongue: other causes of stomatitis. Intestinal form: papillomatosis of oesophagus/ruminal groove; fungal rumenitis.

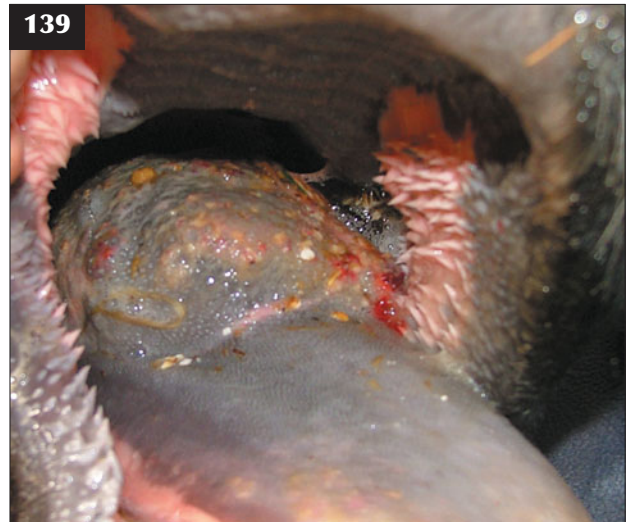DIAGNOSIS

Diagnosis is based on clinical signs and bacteriological culture where appropriate.

MANAGEMENT

Cattle with wooden tongue should be isolated. Prompt treatment with 5–7 consecutive days' parenteral streptomycin, most commonly using a penicillin and streptomycin combination preparation, or potentiated sulphonamide achieves a good response.

Historically, iodides have been used with good success, but such preparations must not be used in pregnant animals. Potassium iodide can be administered orally (6–10 g/day for 7 consecutive days). Sodium iodide (7 g/100 kg as a 10% solution) is administered as an intravenous injection through a catheter because this solution is very irritant should it leak perivascularly. The treatment can be repeated at intervals of 2–3 days until signs of iodism occur (lacrimation, seromucoid nasal discharge and skin scaling). In some countries (e.g. the European Union), medicines legislation could mean that treatment with iodides would exclude cattle from subsequently entering the food chain.



138, 139 Actinobacillosis. (138) Animal with wooden tongue showing profuse salivation and swelling under the jaw. (139) Oral examination reveals a very firm, painful and swollen tongue with discrete yellow lesions visible beneath the mucosa.

ACTINOMYCOSIS (LUMPY JAW)

DEFINITION/OVERVIEW

Actinomyces bovis causes pyogranulomatous osteitis/osteomyelitis in the maxilla and mandible of adult cattle. Actinomycosis occurs worldwide.

AETIOLOGY

Actinomycosis is caused by the gram-positive, commensal bacterium *A. bovis*. The organism may gain entry to the bone in association with permanent molar teeth eruption or traumatic buccal injury.

CLINICAL PRESENTATION

Affected animals are generally bright and alert. There is marked enlargement of the horizontal ramus of the mandible, with a surrounding painful soft tissue swelling (140). One or more sinuses may discharge from the bony swelling. There is enlargement of the ipsilateral submandibular lymph node. Associated pain and physical deformity result in dysphagia, with consequent loss of body condition. The swelling is irregular and comprises fibrous tissue with considerable bone remodelling, which may result in tooth displacement and pathological fracture in neglected cases.

DIFFERENTIAL DIAGNOSIS

Tooth root abscess; fracture of the horizontal ramus of the mandible; bone neoplasia.

DIAGNOSIS

Diagnosis is based on clinical findings. Impression smears of pus from discharging sinus(es) reveal gram-positive filamentous rods. Radiography reveals the extent of bone lysis and remodelling.



140 Cow with lumpy jaw showing marked enlargement of the horizontal ramus of the mandible and painful swelling of the surrounding soft tissue.

MANAGEMENT

The treatment regimens are similar to those listed above for actinobacillosis. Long-term treatment with antibiotics can often result in cessation of growth of the lesion if it was not too large at the time of presentation. Such animals will live normally, with a residual quiescent lump on the face or jaw. Where the lesion is very large, the aim is for temporary remission followed by slaughter of the animal when there are no antibiotic residues in the carcass.

There are no specific control measures.

CALF DIPHTHERIA AND NECROTIC LARYNGITIS

DEFINITION/OVERVIEW

Fusobacterium necrophorum causes a necrotic stomatitis in young calves, which may be seen as an outbreak in dairy calves kept in unhygienic conditions with dirty feeding equipment. Lesions may also follow trauma to the buccal cavity caused by oesophageal feeders used to administer oral electrolyte solutions and dosing gun injuries.

AETIOLOGY

Calf diphtheria results from infection of abrasions in the buccal cavity with *F. necrophorum*. Intercurrent disease (persistently viraemic BVDV calves) and nutritional deficiency may predispose to such bacterial infection.

CLINICAL PRESENTATION

The lower jaw is wet because of drooling of saliva. Lesions affecting the cheek result in large firm swellings (141). Digital palpation of the cheek via the mouth reveals loss of mucosa and, in more advanced cases, a necrotic plug of muscle in the centre of the diphtheritic mucosal lesion.



141 Obvious swelling of the left check caused by *Fusobacterium necrophorum* infection in this calf with diphtheria.

There is halitosis and swelling of the submandibular lymph node(s). The rectal temperature may be elevated.

Infection may involve the larynx and cause anorexia, pyrexia, frequent harsh coughing, an obvious inspiratory stridor (roaring, honking) audible from a considerable distance, and dyspnoea. The laryngeal region is swollen and painful and palpation is resented. Death due to asphyxiation with necrotic debris occluding the lumen may occur if animals remain untreated for several days.

DIFFERENTIAL DIAGNOSIS

Cheek lesions may result from actinobacillosis; pharyngeal abscess causing inspiratory dyspnoea.

DIAGNOSIS

Diagnosis is based on clinical examination.

MANAGEMENT

Calf diphtheria is treated with daily procaine penicillin by intramuscular injection for at least 7–10 consecutive days. Parenteral potentiated sulphonamides and oxytetracycline are also effective.

When there is laryngeal involvement, prolonged parenteral administration of lincomycin injection has been reported to be successful (not licensed for use in cattle in the UK). Corticosteroids rather than NSAIDs are indicated during the acute stage to reduce laryngeal oedema and aid breathing.

Tracheotomy is indicated in severely affected calves, but the prognosis is poor in advanced cases due to suppurative chondritis and destruction of laryngeal architecture. The tracheotomy tube requires twice daily or more frequent cleaning to remove debris and respiratory tract secretions.

The disease is prevented by high standards of hygiene when rearing dairy calves. Transmission of infection by oesophageal feeders is prevented by frequent disinfection. The laryngeal form occurs sporadically, often in well-grown beef calves, without obvious cause, although an association with grazing fields containing gorse has been suggested.

SYMPHYSEAL AND NON-DISPLACED FRACTURES OF MANDIBULAR RAMUS

AETIOLOGY

Symphyseal and non-displaced fractures of the horizontal ramus of the mandible occur after significant trauma, usually from a tractor wheel when the animal has its head through a feed barrier.

CLINICAL PRESENTATION

The animal has difficulty masticating food, leading to a gaunt appearance. The tongue may protrude passively from the mouth and continuous drooling of salivation is common (142). Soft tissue swelling is present around the fracture site.

DIFFERENTIAL DIAGNOSIS

Listeriosis; wooden tongue; lumpy jaw.

DIAGNOSIS

If a mouth gag is inserted into the unaffected side of the mouth, malalignment of the dental arcade can usually be palpated at the fracture site. The displacement at the fracture site is often slight and best appreciated by running a finger along the lingual aspect of the premolar and molar teeth. The fracture site can be demonstrated radiographically, but such examination is rarely undertaken in practice.

MANAGEMENT

Slight displacement of the fracture is treated conservatively by isolating the animal and feeding soft/soaked feedstuffs at shoulder height. Displaced, open and pathological fractures necessitate emergency slaughter for welfare reasons.

Iatrogenic causes are prevented by careful operation of farm vehicles, especially when feeding cattle from elevated central passageways.

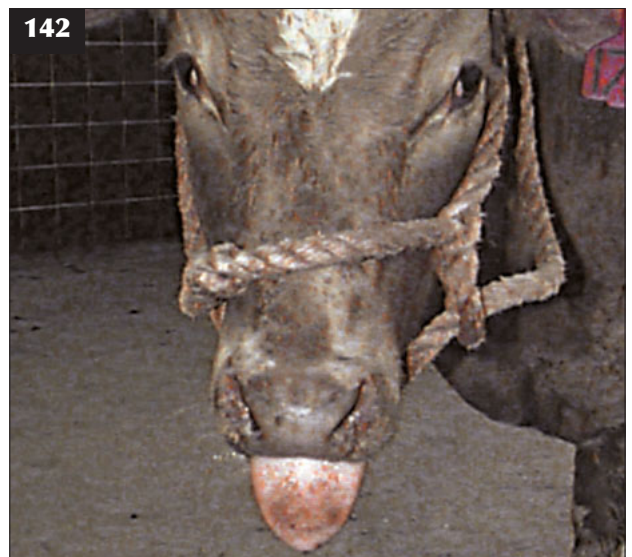OESOPHAGEAL OBSTRUCTION/CHOKER

DEFINITION/OVERVIEW

Oesophageal obstruction is a common occurrence in cattle and can occur within the proximal cervical oesophagus, at the thoracic inlet or within the thoracic oesophagus immediately cranial to the heart base.

AETIOLOGY

Choke can occur when root crops and potatoes are fed whole and following accidental access to apples and other top fruits.



142 A fracture of the horizontal ramus of the mandible causing passive protrusion of the tongue, with continuous drooling of salivation and dysphagia.

CLINICAL PRESENTATION

Cattle are frequently distressed and adopt a characteristic stance with the neck extended and the head lowered (143). There is often profuse salivation with repeated attempts to swallow. Regurgitation of large quantities of clear and slightly viscous saliva, which has collected in the cervical oesophagus, occurs in cases of lower oesophageal obstruction. There is progressive accumulation of gas within the rumen (bloat) over several hours (144) depending on the nature of the obstruction and the diet. This is much more rapid in cereal-fed cattle.

DIFFERENTIAL DIAGNOSIS

Frothy bloat (primary ruminal tympany); other causes of secondary bloat (see p. 72); tetanus is associated with persistent moderate bloat; rabies.

DIAGNOSIS

There is an immediate history of access to the feeds listed above. An obstruction within the cervical oesophagus may be palpated through the skin on the left side of the neck. In cattle over approximately 400 kg, placement of a mouth gag and manual examination of the proximal 20–30 cm of cervical oesophagus *per os* may allow direct identification and retrieval of the obstruction. A flexible orogastric tube will usually not pass the obstruction and relieve the accumulated gas, but it will confirm the site of obstruction.

MANAGEMENT

In severe (emergency) cases of ruminal tympany, where the animal is in respiratory distress, it may prove necessary to insert a trocar/canula immediately into the rumen to relieve

the gas. A wide-bore needle will not suffice for this purpose. Hyoscine n-butylbromide can be injected intravenously to relax the oesophagus before attempting to massage an obstruction within the cervical oesophageal up to a point where it can be grasped *per os*.

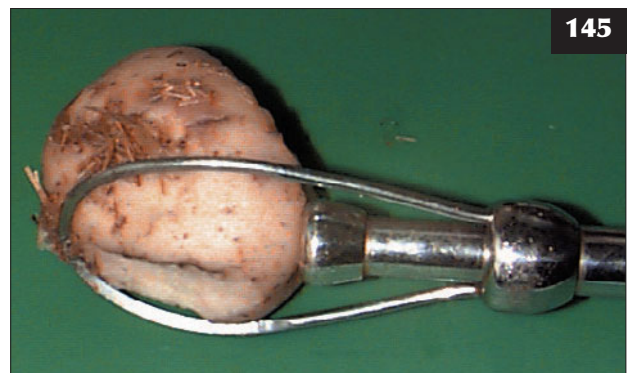
For all other obstructions, either a probang can be used to gently push the blockage into the rumen, or it can be removed with a specially designed retractor, which holds the object within a metal loop while a corkscrew enters the obstruction (e.g. potato); the retractor plus the obstruction are then removed (145). Excessive pressure must not be used because the probang or retractor may be forced through the oesophageal wall.



143 Cow with choke. The cow is drooling saliva and is demonstrating the characteristic stance of an extended neck and the head lowered.



144 A cow with oesophageal obstruction showing progressive accumulation of gas within the rumen (bloat) over several hours.



145 A specially designed retractor, as illustrated, holds the obstruction within a metal loop while a corkscrew enters the object. The retractor, plus the obstruction (potato in this case), is then removed from the oesophagus.

If the choke cannot be relieved by gentle pressure from a probang, a temporary rumen cannula can be placed to release the trapped gas and allow the obstruction time to degenerate. The obstruction may pass spontaneously into the rumen during the next 12–24 hours. Obstructions that are not cleared within 24 hours carry the risk of pressure necrosis of the oesophageal wall and subsequent rupture. Attempts to retrieve the obstruction via a rumenotomy will not be successful and should not be attempted.

Many farmers feed vast quantities of potatoes without problems; outbreaks of oesophageal choke are probably related to those tubers small enough to be swallowed without chewing.

PHARYNGEAL ABSCESS/ENLARGED RETROPHARYNGEAL LYMPH NODES

DEFINITION/OVERVIEW

Pharyngeal abscesses/enlarged retropharyngeal lymph nodes in cattle result from penetration wounds most commonly caused by incorrect drenching or bolus administration.

AETIOLOGY

Penetration of the pharyngeal wall, often by the tip of a dosing gun, introduces a mixed bacterial infection, leading to cellulitis. Lymphatic drainage of the infection site causes marked enlargement of the retropharyngeal lymph nodes behind the vertical ramus of the mandible.

CLINICAL PRESENTATION

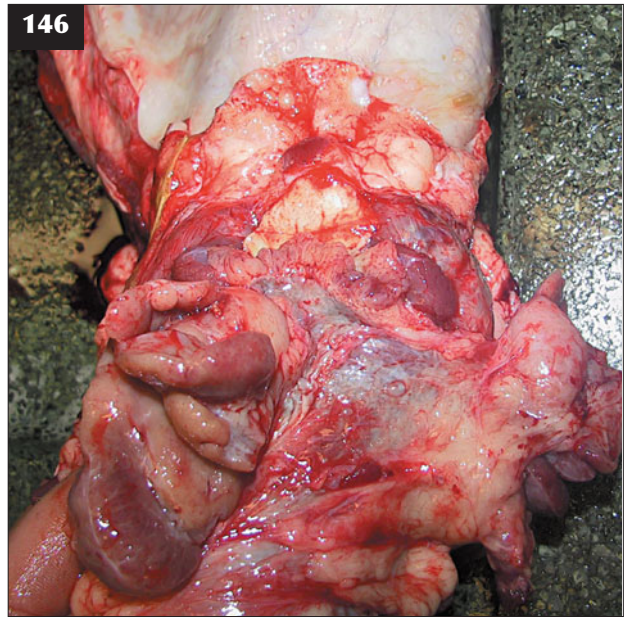
Animals appear dull, anorexic and depressed, with continuous salivation and staining of the lower jaw. An extended neck and 'anxious' expression are typically present. Closer examination of the mouth reveals halitosis and pain on palpation of the pharyngeal region. There is rapid loss of body condition and affected cattle present with a gaunt appearance. There may be oedema of the ventral neck associated with the cellulitis lesion. It is not always possible to distinguish the deep-seated retropharyngeal lymph nodes even when they are grossly enlarged (146). Pressure of the abscess/enlarged retropharyngeal lymph nodes on the larynx causes stertor with mouth breathing in some cattle (147).

DIFFERENTIAL DIAGNOSIS

Oral and laryngeal lesions caused by *F. necrophorum*; actinobacillosis of the retropharyngeal lymph nodes.

DIAGNOSIS

Diagnosis is not simple, especially when the infection has tracked along fascial planes and may erupt distant to the entry site in the pharynx. A history of recent drenching/bolusing provides strong circumstantial evidence of pharyngeal trauma. Poor appetite resulting from enlarged retropharyngeal abscess can prove difficult



146 It is not always possible to distinguish the deep-seated retropharyngeal lymph nodes even when they are grossly enlarged, as revealed here at necropsy of the cow in 147.

to diagnose. Radiography to illustrate soft tissue swellings and, possibly, a fluid line, should a large abscess be present, can prove very helpful, but such facilities are not readily available in practice. Endoscopy and ultrasound-guided needle aspiration are also possible diagnostic techniques.

MANAGEMENT

Response to broad-spectrum systemic antibiotics (eg. ceftiofur, clavulanate-potentiated amoxicillin or penicillin/ streptomycin) for 10–14 days will be variable depending on the extent of pharyngeal trauma/abscessation. Surgical drainage of retropharyngeal abscesses is possible via the oral cavity or using a lateral approach, but is not without risk.

To prevent the condition, all drenching/bolusing equipment must be used carefully.

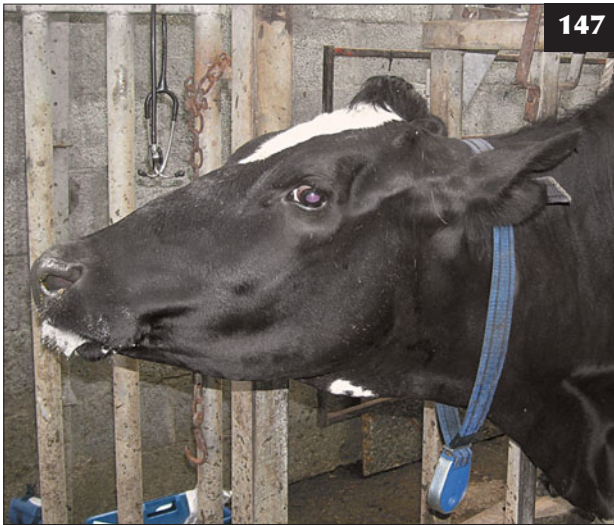UPPER ALIMENTARY SQUAMOUS NEOPLASIA

AETIOLOGY

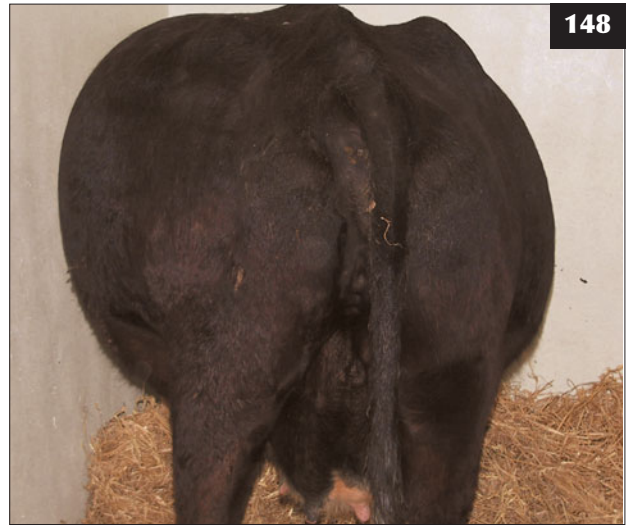Squamous cell carcinoma is seen sporadically in older beef cows grazing bracken-contaminated hill ground.

CLINICAL PRESENTATION

All squamous cell carcinomas cause weight loss over several months. Oropharyngeal lesions also cause coughing and salivation. Animals with oesophageal lesions may present with signs of choke and bloat as a consequence of partial obstruction (148). Lesions in the cardia may cause



147 Pressure of an abscess/enlarged retropharyngeal lymph node on the larynx, causing stertor with mouth breathing in this cow.



148 Intermittent bloat is present in this aged beef cow, caused by an oesophageal squamous cell carcinoma.

intermittent bloat. Ruminal tumours in association with either oropharyngeal or oesophageal lesions may exacerbate weight loss, with diarrhoea present during the later stages.

DIFFERENTIAL DIAGNOSIS

Weight loss and chronic diarrhoea in adult cattle; paratuberculosis; liver fluke.

DIAGNOSIS

Diagnosis is based on chronic weight loss with exclusion of the more common causes coupled with prolonged access to bracken in cattle fed poor rations.

MANAGEMENT

There is no treatment. Prevention is by ensuring adequate dietary supplementation so that cattle do not need to graze bracken.

MEGAESOPHAGUS

DEFINITION/OVERVIEW

Megaesophagus is a rare condition; however, conclusive diagnosis proves difficult in the field.

AETIOLOGY

The condition is caused by neurogenic damage. Oesophageal stricture, with dilation of the oesophagus proximal to the stricture, occurs more commonly than true megaesophagus and can be a sequela to oesophageal obstruction.



149 An anxious expression and passive regurgitation of saliva and masticated feed at the nostrils associated with megaesophagus in this Holstein cow.

CLINICAL PRESENTATION

The animal has a poor appetite and eats only small amounts of concentrates, with resultant poor production and weight loss. Some discomfort may be observed during swallowing, with repeated peristaltic movement visible in the proximal cervical oesophagus. Passive regurgitation of saliva and masticated feed, which have accumulated within the thoracic oesophagus, occurs shortly after eating (149). There is mild bloat, with much reduced time spent ruminating.

DIFFERENTIAL DIAGNOSIS

Squamous cell carcinoma of the oesophagus; vagus indigestion.

DIAGNOSIS

Endoscopy reveals flaccid distension of the cervical oesophagus with superficial erosions and may reveal a stricture at the site of a previous choke. Contrast radiography following barium administration into the cervical oesophagus via an orogastric tube is conclusive, but rarely undertaken.

MANAGEMENT

There is no treatment. The animal should be culled for welfare reasons

FORESTOMACH DISORDERS**SIMPLE INDIGESTION****DEFINITION/OVERVIEW**

Simple indigestion typically follows a sudden dietary change causing an upset in the rumen microflora.

AETIOLOGY

Possible contributing factors include moderate carbohydrate excess, oral antibiotic administration and sour/fermenting feed.

CLINICAL PRESENTATION

Typical clinical signs include ruminal atony, inappetence, reduced milk yield, dullness and intermittent colic. The initial reduced faecal output becomes diarrhoeic. Affected cattle are typically afebrile.

DIAGNOSIS

Diagnosis is based on the history and examination of the animal's ration. A full clinical examination rules out other causes of inappetence, diarrhoea and rumen stasis.

MANAGEMENT

Treatments include rumen-stimulant drenches and palatable forage, transfaunation where easily available, and probiotics in young calves. Multivitamin B injections are commonly used as an adjunct. Prevention is by good nutritional management.

CARBOHYDRATE OVERLOAD (RUMINAL LACTIC ACIDOSIS, GRAIN OVERLOAD, BARLEY POISONING)**DEFINITION/OVERVIEW**

Acidosis results from the sudden unaccustomed ingestion of large quantities of carbohydrate-rich feeds, typically grain or concentrates, and, less commonly, potatoes and by-products such as bread and bakery waste.

AETIOLOGY

Too rapid introduction onto a diet of ad-libitum concentrates may result in acidosis. Cattle escaping and gaining access to feed/grain stores is a common cause of acidosis. The smaller the particle size, for example following milling, the more quickly fermentation occurs and the more severe the clinical signs for a given amount ingested.

The sudden and unaccustomed ingestion and fermentation of large quantities of carbohydrate-rich feeds results in increased lactic acid production accompanied by a fall in rumen pH, which kills many cellulolytic bacteria and protozoa. Acid-tolerant bacteria such as *Streptococcus bovis* survive, producing more lactic acid. There is a marked increase in rumen liquor osmolarity, with fluid drawn in from the extracellular space causing dehydration. Low rumen pH reduces motility, causing stasis and mild bloat. Lactate is absorbed into the circulation, leading to the development of a metabolic acidosis. This metabolic crisis is further compounded by toxin absorption through the compromised rumen mucosa.

CLINICAL PRESENTATION

The severity of clinical signs depends on the amount of grain ingested (**150**), whether the grain was rolled or whole, and the rate of introduction of the dietary change. It is reported that colic signs may be observed soon after grain engorgement and that cattle appear restless. When walking, affected cattle appear ataxic; they may fall and experience difficulty rising due to weakness. They are anorexic and stand with the head held lowered. Bruxism (tooth grinding) is frequently heard. Cattle have a distended abdomen due to the enlarged static rumen; fluid also becomes sequestered within the small intestine. Auscultation reveals no rumen motility; succussion reveals tinkling sounds due to the sequestration of fluid and gas. Initially, the rectal temperature may be increased, but it falls to subnormal values as the condition progresses. The mucous membranes are congested and there may be enophthalmos and an increased duration skin tent due to moderate dehydration. There may be no diarrhoea for the first 12–24 hours after carbohydrate ingestion; thereafter there is profuse very fluid, fetid diarrhoea with a sweet-sour odour, which may contain whole grains. The most severely affected cattle become recumbent (**150**) and have an increased respiratory rate from the ensuing metabolic acidosis. The heart rate is increased and the degree of dehydration worsens. A pulse rate >100 beats per minute and rumen pH <4.5 indicate a poor prognosis. Death may follow within 24–48 hours despite treatment. Cattle that recover may have a protracted convalescence due to chronic rumenitis and may show signs of laminitis or develop hepatic abscessation due to bacteraemic spread from the damaged rumen.

DIFFERENTIAL DIAGNOSIS

Peracute toxæmic conditions such as metritis and coliform mastitis; salmonellosis; hypocalcaemia in recumbent cows.

DIAGNOSIS

Diagnosis is based on the history and clinical findings, particularly once diarrhoea is evident without evidence of blood/mucosal casts. Rumen fluid samples can be collected by percutaneous ruminocentesis or orogastric tube revealing a pH below 5.0 and no live protozoa observed under microscopic examination, only large numbers of gram-positive rods.

At necropsy the rumen contents contain large amounts of grain and are often milky-grey, porridge-like and have a rancid odour (151). The rumen epithelium strips off readily (152), but care is necessary to differentiate this phenomenon from autolytic change.

MANAGEMENT

A rumenotomy to remove the rumen contents using a siphon can be attempted, but considerable care is needed to prevent leakage into the abdominal cavity during surgery because affected cattle are recumbent and it is usually not possible to exteriorize much of the rumen wall owing to the large fluid contents.

Siphoning off rumen contents (rumen lavage) is described whereby large volumes of warm tap water are

repeatedly forced down a very wide-bore stomach tube and are then siphoned off.

Blood gas analysis is rarely available to practitioners dealing with recumbent cattle with ruminal acidosis. Intravenous fluids should contain bicarbonate and in such emergency situations it would be safe to administer 10 mmol/l of bicarbonate over 2–3 hours and monitor progress. In practical situations, 16 g of sodium bicarbonate = 200 mmol of bicarbonate. Therefore, a 320 kg heifer estimated to be 7% dehydrated would require:

$$\begin{aligned} & \text{Estimated base deficit} \times \text{dehydrated body weight} \times \\ & \text{extracellular fluid volume (i.e. } 10 \times 300 \times 0.3) \\ & = 900 \text{ mmol of bicarbonate} \end{aligned}$$

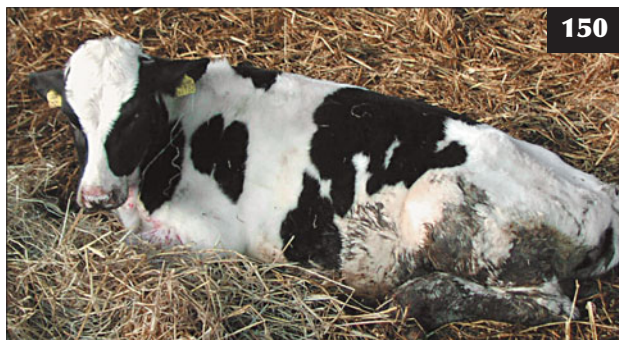Thus, 72 g of sodium bicarbonate in 5 litres of saline would approximate a 10 mmol/l base deficit in a 320 kg animal. Other authors have made a more general recommendation of 5 litres of 5% sodium bicarbonate *i/v* for a 600 kg cow over 30 minutes sufficient to treat a base deficit around 16 mmol/l. The response to intravenous fluid therapy should be carefully monitored.

Antacid drenches including 500 g of magnesium hydroxide per 450 kg are recommended to counter the acidosis.

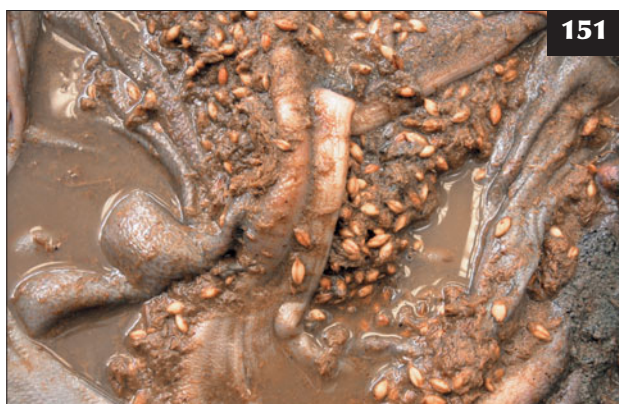In some situations therapy is restricted to oral fluids, intravenous multivitamin preparations and antibiotic therapy. Proprietary antacid products contain 220 g sodium bicarbonate, 110 g magnesium oxide and 40 g yeast cell extract diluted in 20 litres for a cow.

Some clinicians elect to inject thiamine (vitamin B1) intravenously rather than a multivitamin injection. Penicillin injections are given daily for up to 10 days in severely affected cattle to counter potential bacteraemia.

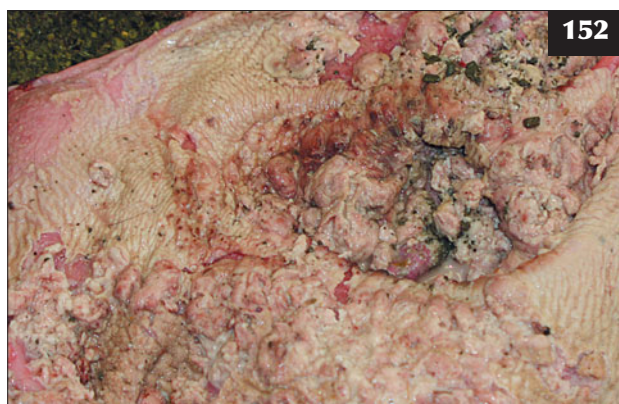Prevention is by gradually increasing grain/concentrate feeding over a minimum of six weeks before ad-libitum feeding, and allowing more than 10% good-quality roughage in the diet.



150 Holstein bull calf affected by grain overload. The calf is dull, weak and dehydrated and shows evidence of fetid diarrhoea.



151 At necropsy, large quantities of whole grain are present in the rumen of this animal with acidosis.



152 The rumen epithelium stripped off readily in this necropsy specimen.

RUMEN PARAKERATOSIS**DEFINITION/OVERVIEW**

Rumen parakeratosis is enlargement, thickening and clumping of rumen papillae in response to high concentrations of volatile fatty acids in cattle fed finely ground concentrate rations.

AETIOLOGY

Rumen parakeratosis occurs secondary to carbohydrate overload in cattle fed solely a concentrate diet.

CLINICAL PRESENTATION

The clinical signs are vague and include poor performance, reduced appetite, low-grade abdominal pain and indigestion. Liver abscessation may occur in association with rumen parakeratosis.

DIAGNOSIS

Diagnosis is difficult because of the vague clinical signs. Slaughterhouse reports indicating a high rate of liver condemnations should alert the clinician.

MANAGEMENT

Antibiotic treatment should be instituted for suspected bacteraemia/liver abscessation. A balanced ration should be fed containing >10% of good-quality roughage.

RUMINAL TYMPANY (BLOAT)**DEFINITION/OVERVIEW**

Ruminal tympany is the accumulation of free gas in the dorsal rumen following abnormal fermentation and indigestion.

AETIOLOGY

Ruminal tympany in young calves may result from failure of the oesophageal groove to close, with the result that milk enters the rumen and subsequent fermentation causes acidosis and ruminal atony.

CLINICAL PRESENTATION

There is rapid onset left flank distension with variable colic following milk feed. Pasty diarrhoea may be present in chronic cases.

DIAGNOSIS

Diagnosis is confirmed after decompression with an orogastric stomach tube.

MANAGEMENT

Treatment includes transfaunation, where available, plus correction of the diet.

Prevention is by reviewing the feeding management, with early introduction of concentrates and good-quality roughages.

FROTHY BLOAT (PRIMARY RUMINAL TYMPANY)**DEFINITION/OVERVIEW**

Frothy bloat results from high protein levels in cattle grazing lush leguminous pasture and clover-rich swards. It is reported to be common in New Zealand. Occasionally, frothy bloat is seen in feedlot cattle fed finely ground grain.

AETIOLOGY

Rumen fluid viscosity is raised, causing small bubbles to form and leading to a stable froth that cannot be eructated normally.

CLINICAL PRESENTATION

Rumen tympany develops over several hours, causing distress, recumbency and, in extreme cases, death.

DIFFERENTIAL DIAGNOSIS

Choke.

DIAGNOSIS

Frothy bloat typically presents as a group problem with an immediate history of access to lush grazing. The bloat cannot be relieved by orogastric tube as the froth simply blocks the tube.

MANAGEMENT

All animals must be moved off the pasture immediately. Care must be taken when moving/handling cattle with frothy bloat as it may precipitate collapse and death from cardiac/respiratory failure. Severely bloated cattle may have to be restrained and treated on the pasture if handling facilities are not available nearby. Affected cattle should be drenched/stomach-tubed with an anti-foaming agent such as vegetable oil or proprietary silicone/piloxalene drench. An emergency rumenotomy can be performed in extreme cases to relieve the tympany, but this is not a simple procedure in these circumstances.

Prevention is by gradual introduction to risk pasture by either limited time access or by strip grazing. Daily drenching of cattle with an anti-foaming agent is very time-consuming. Monensin sodium, in supplementary feed or bolus, is used in those countries where this product is still licensed for use in cattle.

FREE GAS BLOAT (SECONDARY RUMINAL TYMPANY)**DEFINITION/OVERVIEW**

Free gas bloat is excessive accumulation of free gas in the dorsal sac of the rumen.

AETIOLOGY

Any condition causing oesophageal obstruction or interference with normal eructation can result in accumulation of free gas in the rumen. Common causes include lesions of the oesophageal groove, physical

obstruction/choke and pressure on the oesophagus and/or vagus nerve by either enlarged mediastinal and bronchial lymph nodes or a thoracic mass (thymic lymphosarcoma). Chronic recurrent bloat is seen as a sporadic problem in weaned calves (153) and may be related to previous bouts of bronchopneumonia that lead to enlarged bronchial lymph nodes or damage to the thoracic portion of the vagus nerve. Neurogenic causes include tetanus and vagus indigestion. Cereal overfeed and acidosis result in rapid gas production within the rumen.

CLINICAL PRESENTATION

Free gas bloat appears as distension of the left sublumber fossa with progressive discomfort/distress.

DIAGNOSIS

Diagnosis is based on clinical signs and complete decompression following passage of an orogastric tube

MANAGEMENT

An orogastric tube is passed to relieve accumulated gas. A trocar/canula can be inserted (154) or a fistula created surgically if the problem recurs several times per day over the following 4–5 days. For chronic/recurrent bloat associated with tetanus or abscessation along the oesophagus, placing a surgical fistula in the rumen allows time to treat the primary condition.

VAGAL INDIGESTION (VAGUS INDIGESTION)

DEFINITION/OVERVIEW

Vagal indigestion is a sporadic disease in growing/adult cattle. It is most commonly associated with anterior peritonitis (traumatic reticulitis), liver abscess, mediastinal abscess and lymphosarcoma.


AETIOLOGY

The aetiology is complex and incompletely understood. The traditional aetiology suggesting perineural irritation

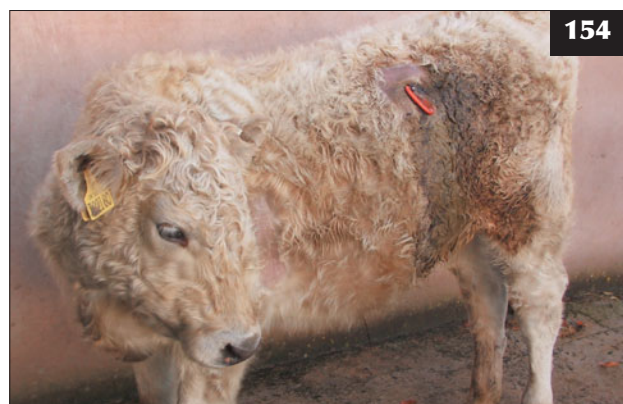and stimulation of the vagus nerve is now questioned. The alternative theory postulates mechanical impairment of reticular motility leading to failure of normal ingesta passage through the reticulo-omasal orifice and pylorus.

CLINICAL PRESENTATION

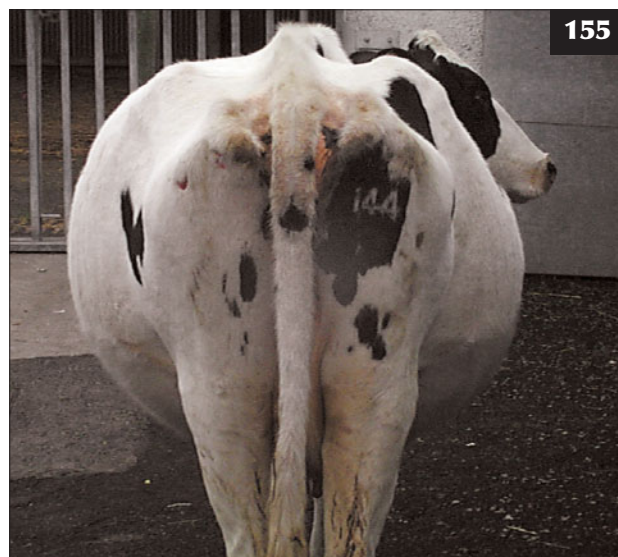The clinical signs are an enlarged, impacted rumen with initial hypermotility and 3–6 contractions per minute (normal is three contractions every two minutes). Occasionally, the animal may present with ruminal atony. Chronic enlargement of the dorsal and ventral rumen sacs and the abomasum leads to the ‘papple-shaped’ abdominal silhouette when viewed from behind (155). There is



153 Chronic recurrent bloat in a weaned calf. This may have been related to previous bouts of bronchopneumonia.



154 A rumen trocar has been inserted to permit treatment for the chronic bloat in the calf in **153**.



155 In this cow, chronic enlargement of the dorsal and ventral rumen sacs and the abomasum has led to the ‘papple-shaped’ abdominal silhouette of vagal indigestion when viewed from behind.

progressive inanition and weight loss, with scant faeces. Bradycardia (<50 beats per min) is present in some cases.

DIFFERENTIAL DIAGNOSIS

Twin pregnancy; hydrops allantois; localized peritonitis. The 'papple-shaped' abdominal silhouette is not pathognomonic for vagal indigestion because abdominal shape is variably influenced by twin pregnancy and the age of the cow.

DIAGNOSIS

Diagnosis is based on clinical signs and elimination of other possibilities. Exploratory laparotomy may confirm anterior abdominal adhesions/pathology, but is rarely justified.

MANAGEMENT

Cases associated with abomasal damage (e.g. preceding abomasal volvulus) have a guarded prognosis, while those cases associated with preceding reticuloperitonitis and resultant perireticular abscessation can respond well to drainage of the abscess, but this is rarely undertaken in practice. Overall, the prognosis is poor and affected cattle are culled for welfare reasons.

There are no recognized control measures.

TRAUMATIC RETICULITIS

DEFINITION/OVERVIEW

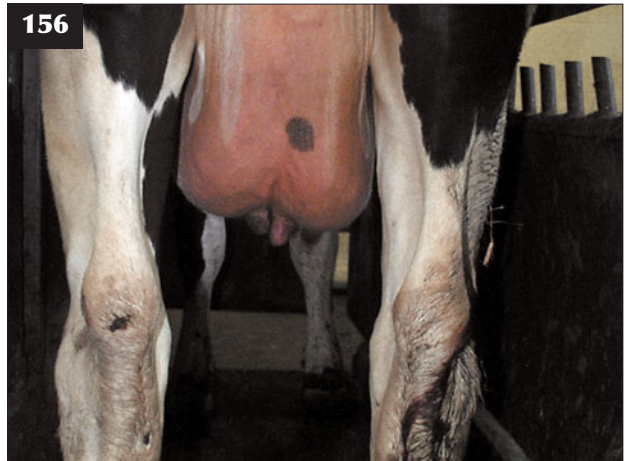Traumatic reticulitis occurs sporadically in adult cattle following ingestion of sharp metal objects (e.g. fence wire and nails) and their localization in the reticulum. Outbreaks of disease have been reported after disintegrating car tyres have been used on silage clamps, releasing fine metal wires that are then incorporated into the feed mix.

AETIOLOGY

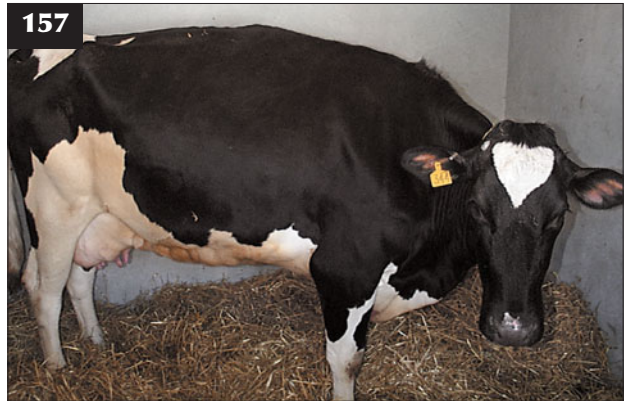The condition is caused by ingestion of a sharp metal object, with penetration of the reticulum and development of localized peritonitis.

CLINICAL PRESENTATION

Classic clinical signs are only observed when the foreign body is in contact with the peritoneal lining of the abdominal cavity. They may last for only 2–3 days, then adhesions restrict reticular movement. The rectal temperature is 39.0–39.5°C. There is sudden-onset anorexia and a dramatic fall in daily milk production (e.g. from 30 litres to 2–3 litres [156]). In animals where the rumen is still contracting, a grunt may accompany the primary ruminal contraction. The animal stands with an arched back and moves reluctantly, and is typically last to enter the milking parlour. There may be complete ruminal atony with initial abdominal distension, then the inappetent cow becomes progressively tucked-up and gaunt. The cow shows evidence of anterior abdominal pain (157) with a taut rigid abdomen (158), refusal to turn



156 This cow with traumatic reticulitis presented with a flaccid udder after a dramatic fall in milk production from 30 litres/day to 2–3 litres/day.



157 This cow with traumatic reticulitis is standing with an arched back and it has a painful expression.



158 This beef cow with traumatic reticulitis stands with an arched back and a taut 'guarded' abdomen and it has a painful expression.

sharp corners, ears back and a fixed glazed stare (159). The cow is constipated, and defaecation and urination are often accompanied by a grunt. A pain response is elicited when the cow's back is dipped behind the withers (160) or pressure is applied slowly behind the xiphisternum with a pole, then suddenly released. This test is not pathognomic for traumatic reticulitis because a grunt could originate from other peritoneal lesions and pleural inflammation.

DIFFERENTIAL DIAGNOSIS

Peritonitis of differing aetiology (e.g. abomasalulcer/perforation); liver abscessation/peritonitis (following digestive upset, pyaemia); endocarditis; chronic suppurative pneumonia, caudal vena cava thrombosis; pleural inflammation/abscess

DIAGNOSIS

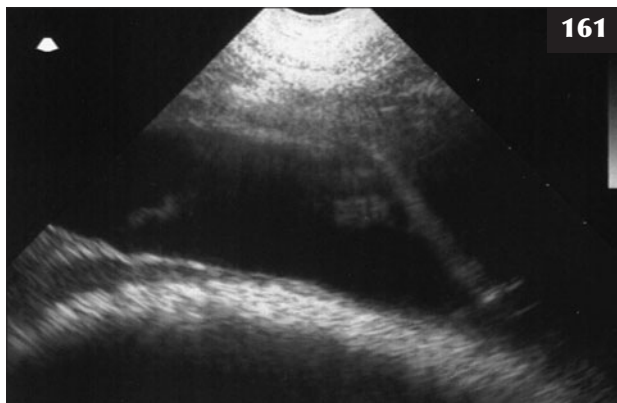
Diagnosis is based on clinical findings and confirmed during surgery. Ultrasonography will identify any peritoneal exudate/fibrinous reaction caused by the penetrating foreign body (161). Advanced peritonitis and reticular abscesses are identified after 5–10 days in neglected cases (162). Linear array 5 MHz scanners used for bovine fertility work will provide diagnostic quality images.

Metal detectors are unhelpful because there are many innocuous pieces of metal in the reticulum of normal cows. Routine haematology findings are non-specific. Peritoneal sampling reveals a high protein concentration (>30 g/l) and an increased white cell count (>30.0 x 10⁹/l) comprised almost exclusively of neutrophils. The peritoneal fluid sample is frequently turbid and may clot.

159 The fixed, glazed stare in this animal indicates pain (see 161).



160 In this cow with traumatic reticulitis, a pain response (hyperalgesia) is being elicited when the cow's back is dipped behind the withers.



161 Ultrasonographic examination of the animal in 159 demonstrates extensive peritoneal exudate (anechoic area containing some hyperechoic fibrin strands) associated with traumatic reticulitis.



162 Traumatic reticulitis. A high left flank laparotomy is being performed under distal paravertebral analgesia in this cow. The incision is started 10 cm below the transverse processes of the lumbar vertebrae.

MANAGEMENT

A course of parenteral antibiotics is very unlikely to be effective without surgical removal of the penetrating foreign body. Magnets administered orally will collect loose metallic objects in the reticulum, but will not draw out objects embedded in the reticular wall (e.g. the author has removed 7 cm nails with only the nail head still in the reticulum). A single injection of corticosteroid may limit further adhesion formation after removal of the wire.

Surgery

An intravenous NSAID injection is given prior to surgery. A high left flank laparotomy is performed under distal paravertebral analgesia starting the incision 10 cm below the transverse processes of the lumbar vertebrae (162). When the rumen is distended, care must be exercised when incising the peritoneum because the rumen wall will be pushed up against it. A fold of peritoneum is picked up with tissue forceps and an incision made with scissors. The incision in the peritoneum is extended with scissors between two fingers, one either side of the incision. There is no advantage to be gained from manually exploring the cranial abdomen; this information is more readily gained by ultrasonographic examination prior to surgery.

The raft of fibrous material in the dorsal sac of the rumen is pitted to a depth of 15–20 cm using a clenched fist to facilitate exteriorization of the rumen wall. Two 5 mm nylon tape loops are placed 20 cm apart vertically in the muscular layer of the rumen wall of the dorsal sac following its exteriorization. Some surgeons recommend packing the ventral margins of the incision site with sterile swabs to prevent peritoneal contamination with spilled rumen contents, but this is unnecessary and leakage is best prevented by a tight seal around the surgeon's arm. An incision is made into the rumen wall between the tape loops. The rumen is pulled on to the surgeon's right arm while the farmer holds the tape loops (163). A hand is passed through the 15–20 cm crust of fibrous content before entering the fluid phase. The hand is angled toward the cow's xiphisternum, taking the rumen wall back in through the wound (necessary for a very large Holstein cow or bull), provided that the rumen incision is small enough to fit tightly around the arm and there has been no leakage of rumen contents to contaminate the peritoneal cavity.

The wall between the rumen and reticulum is 10–15 cm high off the abdominal floor. A hand is passed along the rumen floor then upward and forward into the reticulum. The 'honeycomb' lining of the reticulum is searched carefully for the wire. A check is made for peritoneal adhesions (164) by picking up a fold of reticulum and gently tugging it. If a foreign body has penetrated and come out, the reticular wall around the puncture will be oedematous and adherent to adjacent structures. The exploration of a puncture site will cause the cow to react. All the foreign bodies are collected and removed; there should be no need to re-enter the rumen as

this will only increase the risk of contamination of the abdomen around the rumen wall incision.

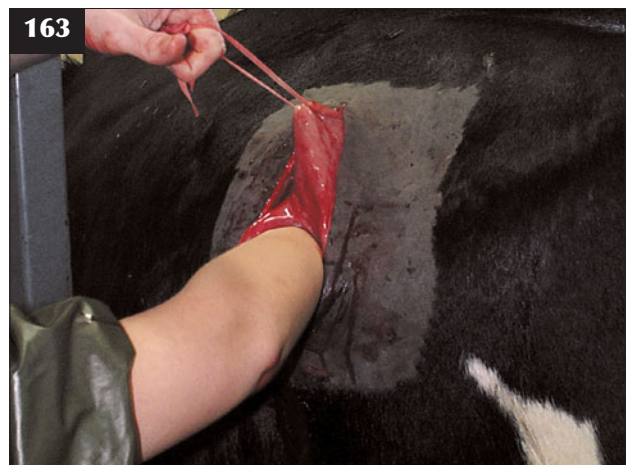The rumen incision is closed with a Cushing's suture of chromic catgut or similar, inverting 2 cm of each margin. The abdominal wound is closed routinely using a Ford interlocking suture of monofilament nylon in the skin. Recovery of milk yield is often slow due to the localized peritonitis present prior to surgery interfering with reticular contractility and propulsion of digesta, and it may take the cow up to four weeks to regain previous milk yield. The cow is treated with parenteral antibiotics for 3–5 consecutive days after surgery.

Prompt surgery is essential in order to avoid the consequences that may result in culling for poor production or death due to peritonitis/septic pericarditis (see Chapter 5, Cardiovascular diseases, Septic pericarditis, p. 134).

Follow-up management

Traumatic reticulitis occurs infrequently and magnets given *per os* to lodge in the reticulum and trap metal objects are not routine control measures in the UK unless a herd problem arises. Elsewhere in Europe and North America, the prophylactic use of magnets is said to be highly effective.

Neglected cases with extensive peritonitis, more commonly encountered in beef cattle, must be euthanased immediately for welfare reasons.



163 Traumatic reticulitis. Two 5 mm nylon tape loops have been placed 20 cm apart vertically in the muscular layer of the rumen wall of the dorsal sac following its exteriorization. The wire is retrieved by pulling the rumen on to the right arm of the surgeon, while the farmer holds the tape loops.

LEFT DISPLACED ABOMASUM

DEFINITION/OVERVIEW

Left displaced abomasum (LDA) typically occurs more commonly during the winter housing period in dairy cows in the month following calving. Some association with high-concentrate/low-fibre rations, previous episodes of hypocalcaemia, twinning and (endo)metritis have been reported. Increasingly, LDA is seen in recently calved heifers, which may reflect poor nutritional management before entering the milking herd. LDA is rarely seen in beef cows or intensively fattened cattle.

AETIOLOGY

Displacement of the abomasum occurs to either the left or the right of the abdominal cavity. Atony, secondary to highly volatile fatty acid concentrations from continued fermentation of high carbohydrate rations within the abomasum, results in accumulation of gas and displacement.

CLINICAL PRESENTATION

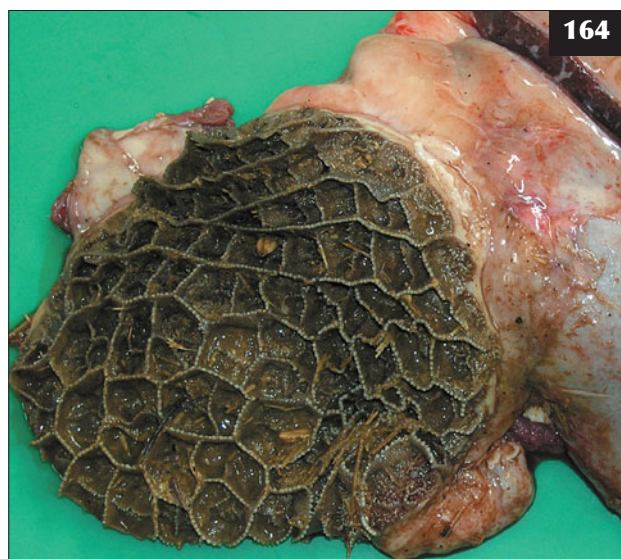
The clinical signs are variable and may be complicated by the presence of other disease conditions. The clinical signs are most severe when LDA occurs in conjunction with puerperal metritis and associated toxæmia in the first week after calving. The cow is often febrile (39.5–41°C), depressed and anorexic, with a reduced milk yield. There is profuse, often fetid, diarrhoea.

However, most LDA cases occur more than 10 days after calving when there are concurrent clinical signs of chronic endometritis and secondary ketosis. A typical case presents 15–30 days post calving with a history of poor milk yield (50% of potential yield), reduced appetite with chronic weight loss (up to 50 kg since calving; one unit of condition score on a five point scale) and a gaunt appearance (165). The cow is slow to move and dull and has a dry staring coat. The rectal temperature is normal and the cow is often constipated. A sprung rib cage may be obvious on the left side with a severely distended abomasum present. A hypochloraemic, hypokalaemic metabolic alkalosis can develop in chronic cases.

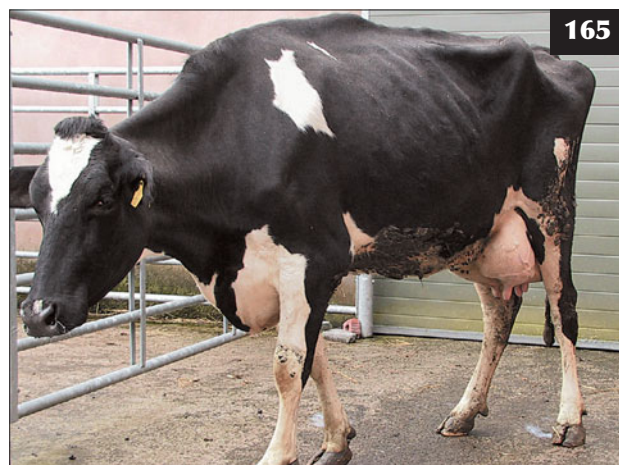
The distended abomasum occupies the craniodorsal area of the left side of the abdominal cavity (under the rib cage) and auscultation and percussion reveal high-pitched metallic 'pinging' sounds. Rumen movements can be heard caudally in the sublumbar fossa. It is uncommon to be able to palpate the caudal edge of the displaced abomasum on rectal examination.

DIFFERENTIAL DIAGNOSIS

Rumen void syndrome (i.e. a gap [vacuum]) formed between the left flank and the shrunken dorsal sac of the rumen, which yields a 'ping' upon percussion; gas cap in rumen associated with grain overload; pneumoperitoneum.



164 In this cow a chronic tyre wire penetration has caused an abscess and adhesions to adjacent viscera (liver shown here).



165 Note the gaunt appearance in this cow with left displaced abomasum 15–30 days post calving.

DIAGNOSIS

Diagnosis is based on a thorough clinical examination, remembering that more than one condition may exist at the same time (i.e. metritis and LDA, secondary ketosis and LDA). A combination of percussion and/or ballotement with simultaneous auscultation is normally diagnostic. Diagnosis is confirmed at surgery. Paracentesis of the displaced abomasum contents (aided by ultrasonography) would reveal the presence of fluid with no protozoa and a pH of 2, but is rarely undertaken or is necessary.

MANAGEMENT

The rolling technique takes time and requires three people and the LDA recurs in up to 60% of cases. There is the risk of inhalation of rumen contents when the cow is in dorsal recumbency, especially if she has been heavily sedated. However, when successful this method avoids surgery.

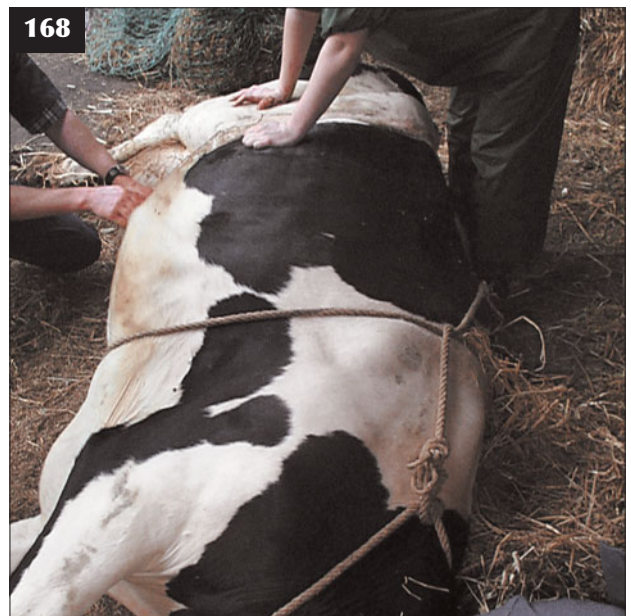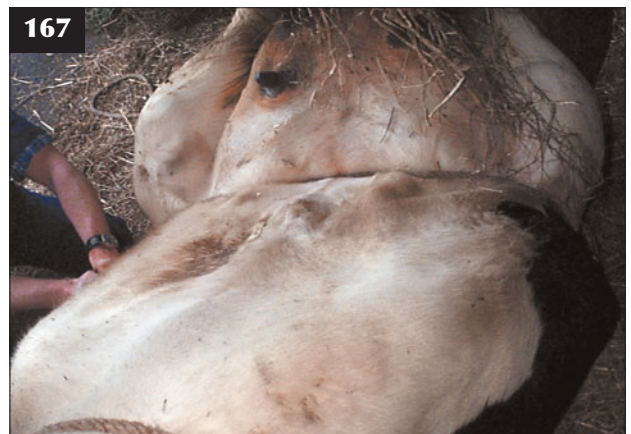Surgical correction of LDA is the option preferred by most practitioners. There are many surgical techniques, but right flank omentopexy is the preferred method and has largely replaced the bilateral flank approach. In many practices, toggling (Grymer/Sterner method) is performed because of cost savings, but this method is not without its problems and published reports describe an 85% success rate.

Rolling technique

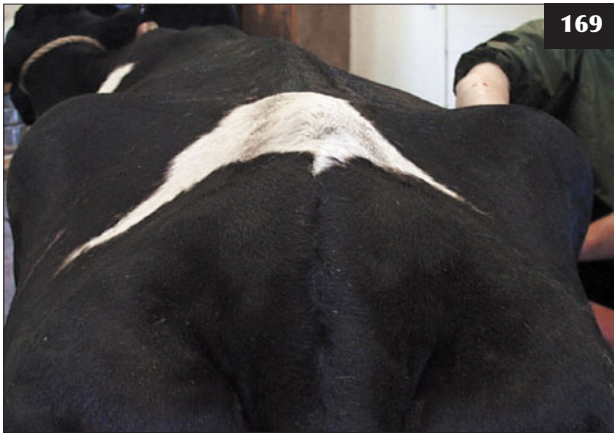The cow is cast onto her right side (166) and may be hobbled to prevent injury to attendants. The cow is then pulled onto her back and supported (167), while the left flank is balloted to help the abomasum rise to the midline. Alternatively, the cow can be gently rocked along her long axis. The cow is then quickly passed onto her left side (168) so that the abomasum floats to its normal position on the right side. The hobbles are removed and the cow is allowed to stand.

Right flank omentopexy approach

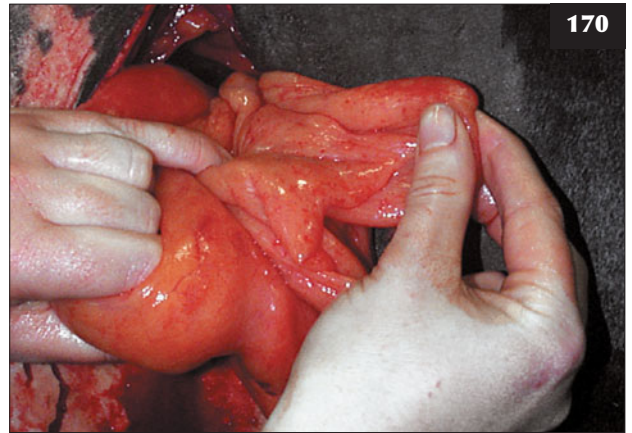
An intravenous NSAID such as ketoprofen or flunixin is administered preoperatively. A right laparotomy is performed in the standing cow under distal paravertebral analgesia without sedation (169). The surgeon's left arm is directed initially towards the cow's tail head over the dorsal sac of the rumen, then around behind the omentum into the left sublumber fossa. The abomasum is football sized and lies high up on the left side under the costal arch, buoyed by its gas content. The abomasum is punctured and deflated using a 14 gauge needle connected to a flutter valve or suction pump. The needle is guarded by the surgeon's hand when passed through the abdominal cavity. Release of gas causes the abomasum to sink towards the ventral midline, pulled by its liquid contents. The surgeon's hand is now directed forward from the incision site alongside the lower right flank wall towards the ventral midline just caudal to the xiphisternum. Near the midline the greater



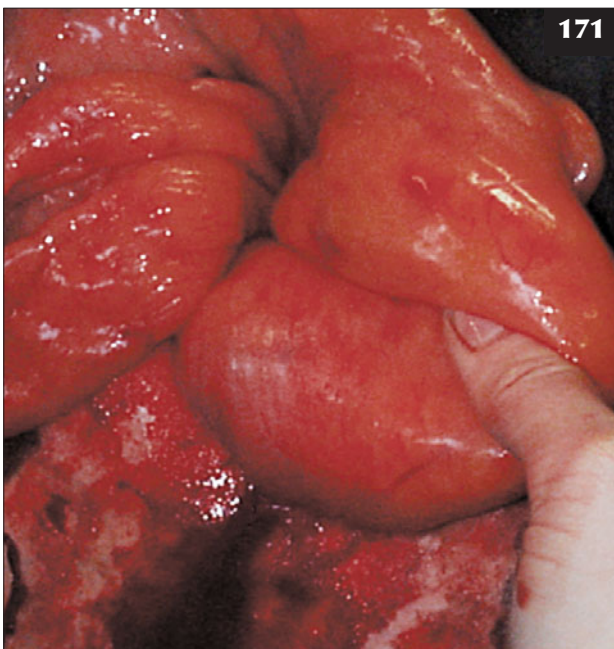
166–168 Rolling technique for left displaced abdomen. (166) The cow is cast onto her right side (Roeuff's method) in a large straw-bedded barn. (167) The cow is then pulled onto her back and supported. The left flank is balloted to help the abomasum rise to its normal midline position. (168) The cow is then quickly passed onto her left side (cow's head at bottom of image) and allowed to regain her feet.



169



170



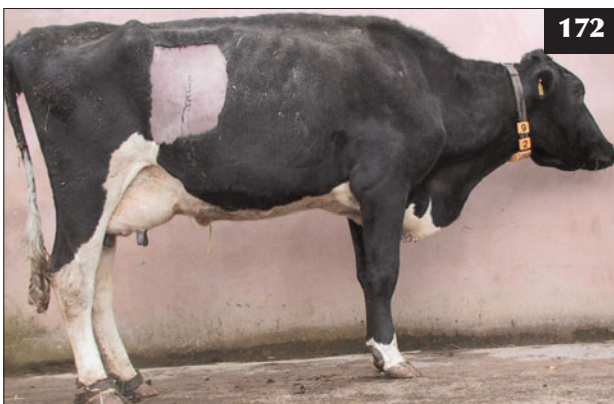171

169–171 Right flank omentopexy approach. **(169)** A right laparotomy is performed in the standing cow under distal paravertebral analgesia without sedation. **(170)** The 'sow's ear' of the greater omentum can usually be identified during surgery. **(171)** The pylorus can be identified close to the omentopexy site.

omentum is grasped with the left hand and slowly pulled up to the ventral margin of the incision. The 'sow's ear' **(170)**, abomasum **(171)** and pylorus can be readily identified. An omentopexy is performed whereby a continuous suture taking four 3 cm bites of omentum is used to close the peritoneum and transversus muscle layer, picking up a deep bite of omentum with each needle pass such that the omentum is fixed along the whole length of the closure. Some surgeons elect to perform a pyloropexy, but this may necessitate considerable pressure to hold the pylorus at the level of the flank incision.

Rolling the cow immediately prior to right flank omentopexy can make the surgery simpler because the abomasum will be found repositioned in the lower right abdomen when the surgeon enters the abdominal cavity.

The laparotomy wound is then closed routinely. Administration of large volumes of oral fluids is recommended by some practitioners to distend the rumen and prevent potential re-displacement, but cows often begin eating immediately after surgery. Animals, especially those where the LDA was not detected early **(172)** and those with secondary ketosis, take several weeks to fully recover their appetite and milk yield.



172

172 This cow, in which the left displaced abdomen was not detected early and there was secondary ketosis, has taken several weeks to fully recover its appetite and milk yield.

Grymer/Sterner method

Recently, toggling of the abomasum (Grymer/Sterner method) through the ventral abdominal wall overlying the tympanic abomasum has been described as a more cost-effective procedure than right flank omentopexy. The cow is cast into dorsal recumbency with the abomasum restored to its normal midline position. The abomasum is located

as quickly as possible by percussion (173) and two toggles with nylon sutures are introduced into the abomasum through wide-bore trocars (174) approximately 5–10 cm apart. The trocars are removed and the nylon sutures tied together. Failure accurately to locate the abomasum may result in toggling the omentum or other viscera, although this method is reported to be about 85% effective. (**Note:** Local anaesthesia (if used) is given little or no time to take effect because the abomasum deflates very quickly in its newly restored normal position.)

Right ventral paramedian abomasopexy

In this technique the cow is sedated and cast in dorsal recumbency. A right paramedian incision is made after local analgesia, the abomasum, which will have floated back into the midline, is identified and an abomasopexy anchors it to the ventral body wall. While this method is preferred by some surgeons, it carries risks associated with sedation and casting in dorsal recumbency, and a greater risk of wound breakdown.

Supportive therapy

Concurrent puerperal metritis is treated for three consecutive days with oxytetracycline and an NSAID (e.g. ketoprofen or flunixin administered *i/v* on day 1). Fifty per cent dextrose (400 ml *i/v*) is used to treat secondary acetonaemia and propylene glycol can also be administered (*p/o* q12h). Oral potassium chloride administered as a drench may be indicated in some cases and will hasten recovery when weakness due to hypokalaemia is present.

Prevention/control measures

High concentrate levels must be avoided immediately following calving. Sufficient long fibre (e.g. hay or

chopped straw) should be provided during the early post-partum period. There must be prompt treatment of retained placenta and early cases of puerperal metritis. Control measures for hypocalcaemia, including use of acidifying diets during the dry period (see Chapter 14, Metabolic diseases, Hypocalcaemia, p. 254), should be instituted. Overconditioning of dry cows must be prevented. The increasing prevalence of LDA in heifers is a concern and a review of their late gestation nutrition, calving management and introduction into the milking herd is indicated.

DILATION/RIGHT-SIDED DISPLACEMENT OF THE ABOMASUM

DEFINITION/OVERVIEW

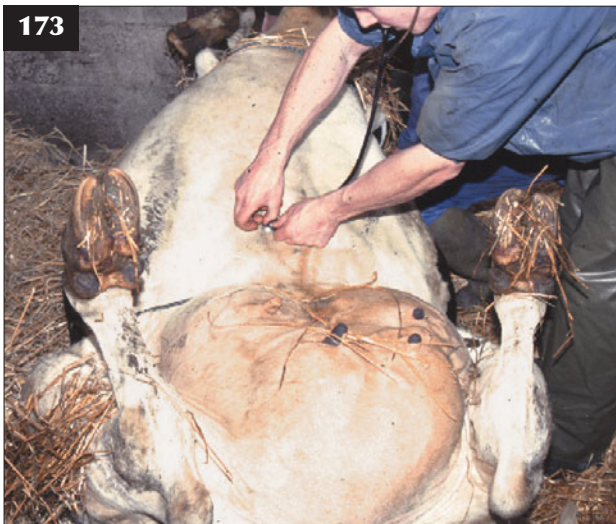Dilation and right-sided displacement of the abomasum (RDA) occurs occasionally in dairy cows during early lactation, but it is much less common than LDA. RDA is not a major disease concern in dairy cattle.

AETIOLOGY

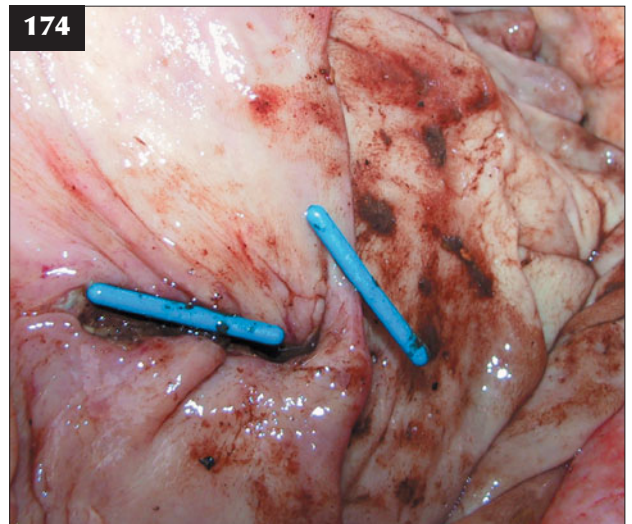
Distension with gas following atony secondary to highly volatile fatty acid concentrations from continued fermentation of high carbohydrate rations causes the abomasum to dilate and rise on the right side of the abdominal cavity.

CLINICAL PRESENTATION

There is a history of poor milk yield, reduced appetite and weight loss during early lactation (175). The cow is dull, afebrile and has reduced rumen activity. There may be evidence of secondary ketosis. Auscultation reveals high-pitched tympanic sounds over a 15–20 cm diameter area



173 Grymer/Sterner method. The cow is cast into dorsal recumbency and the abomasum restored to its normal midline position, where it is located by percussion.



174 Grymer/Sterner method. Two toggles with nylon sutures are introduced into the abomasum through wide-bore trocars.

two-thirds of the way up the right flank just cranial to the right sublumbar fossa.

DIFFERENTIAL DIAGNOSIS

Gas may accumulate in the caecum and spiral colon, causing high pitched metallic sounds on percussion in the right caudal abdomen. Abomasal volvulus leads to pings over a much larger (>60 cm diameter) area, and more severe systemic signs.

DIAGNOSIS

Diagnosis is based on clinical findings and elimination of other potential causes of poor appetite and milk yield.

MANAGEMENT

Reported treatment for abomasal dilation includes 40% calcium borogluconate (400 ml i/v) and substituting some concentrates with hay for 3–5 days, plus oral and intravenous fluids as necessary. Hyoscine or metaclopramide have been reported to be useful for abomasal dilatation, but there is little supporting evidence. Most cases of uncomplicated RDA resolve spontaneously within several days. Right flank laparotomy accompanied by decompression and drainage of the abomasum (often as a last resort) may relieve the problem, but why such surgery should be successful remains uncertain.

A similar aetiology as for LDA is suspected for RDA, therefore similar husbandry and dietary control measures apply.

ABOMASAL VOLVULUS, RIGHT TORSION OF THE ABOMASUM

DEFINITION/OVERVIEW

Abomasal volvulus is very uncommon in cattle and much less common than LDA and RDA. The prognosis is grave.

AETIOLOGY

Following abomasal dilatation, a 180–270° torsion may occur resulting in an abdominal catastrophe.

CLINICAL PRESENTATION

Once torsion of the abomasum has occurred, the cow's condition deteriorates very rapidly over the next 12–24 hours. The animal is completely anorexic with no milk yield. The cow may be recumbent at presentation and there is obvious right-sided abdominal distension. There is marked dehydration (>7%), caused by sequestration of fluid within the abomasum, and toxic mucous membranes. There is a rapid heart rate (>100 beats per minute), a weak pulse and a subnormal rectal temperature. A massively distended and highly tympanic viscus occupies most of the right side of the abdomen, extending from the right sublumbar fossa as far forward as the 7th intercostal space (>60 cm diameter). The liver becomes displaced from the abdominal wall (absence of dull thud on



175 This cow with right-sided abomasal dilation is dull and afebrile and has a history of poor milk yield and a reduced appetite.

percussion or not identified during ultrasound examination).

DIFFERENTIAL DIAGNOSIS

Proximal duodenal obstruction; torsion of the small intestine; caecal dilation/torsion; acute septic peritonitis.

DIAGNOSIS

Diagnosis is based on the size and cranial extent of the tympany and the severe consequences of the marked dehydration and rapid pulse. Manual rectal examination identifies the blind-ended sac of the caecal distension/torsion and loops of small intestinal distension/torsion, but not always the abomasal volvulus.

MANAGEMENT

Surgical correction of early cases of abomasal volvulus is difficult, but can be attempted via a right flank approach if the cow will stand during surgery. It is essential to improve cardiovascular function prior to surgery by administering hypertonic saline followed by rapid intravenous infusion of large volumes of isotonic saline. The prognosis is grave in cows with a heart rate >100 beats per minute and a serum chloride concentration <80 mmol/l.

On entering the abdominal cavity, a blue/black discolouration of the distended abomasal wall, often with fibrin tags on the serosal surface, affords a very poor prognosis and the cow should be destroyed for welfare reasons. If the abomasal wall appears viable, the viscus can be deflated using a 14 gauge needle connected to a flutter valve.

A small-diameter stomach tube is then passed through a stab incision in the centre of a purse-string suture placed in the dorsal margin of the abomasal wall. As much of the abomasal contents as possible should be siphoned off. The tube is removed and the suture tightened and oversewn if necessary. It may prove difficult to determine the direction of the torsion and trial and error is often used. The abomasum is then fixed by omentopexy, although a high incidence of recurrence of the torsion is reported.

There are no specific control measures. Feeding of large quantities of root crops has been suggested as a risk factor. (See LDA, p. 77, for general information.)

ABOMASAL ULCERATION AND PERFORATION – CALVES

DEFINITION/OVERVIEW

Clinical signs of abomasal ulceration are rare in young calves, although lesions are commonly reported at necropsy of artificially reared calves. Perforation with acute septic peritonitis occurs sporadically in 6–8-week-old beef calves.

AETIOLOGY

Abomasal erosions and ulcers (176) are found at slaughter in many calves, especially veal calves, without clinical signs. The appearance of ulcers is reported at 2–3 weeks of age, often following the introduction of solid feeds. Clinical signs may only present when complicated by secondary fungal infection; for example, after calves have received prolonged oral antibiotic treatment for diarrhoea.

Clostridial abomasitis frequently leads to severe ulceration and death. The cause of abomasal perforation in most well-grown beef calves is unknown (177, 178).

CLINICAL PRESENTATION

Calves with infected abomasal ulcers present with chronic weight loss/poor body condition. Affected calves have a poor appetite, a distended and atonic abomasum, and variable abdominal pain arising from localized peritonitis of the abomasal serosa.

Calves with abomasal perforation and septic peritonitis are profoundly depressed, shocked and collapsed and have abdominal distension (177), severe dehydration and a pulse rate >100 beats per minute.

DIFFERENTIAL DIAGNOSIS

Poor appetite and low body condition in young calves can result from omphalophlebitis, liver abscessation, infected urachus and localized peritonitis. Debility may follow viral, cryptosporidial and coccidial damage to the gut mucosa.

Small intestinal volvulus, intussusception, abomasal outflow blockage and clostridial enteritis are the common differential diagnoses for abomasal perforation and sudden death in beef calves.

DIAGNOSIS

The presence of occult blood indicates abomasal ulceration, but this sign is rare in calves. Abomasal perforation may be difficult to differentiate from other abdominal catastrophes and may only be confirmed either during explorative surgery after intensive fluid therapy or at necropsy. Abdominocentesis may fail to yield gut content because of the enveloping omentum. Aspiration of gut content in such cases would probably be misinterpreted as accidental perforation of gut.

MANAGEMENT

Daily thiabendazole is recommended for secondary fungal infection of abomasal ulcers, but the prognosis is poor. Oral antibiotics are rarely indicated for enteritis (except salmonellosis). Calves with abomasal perforation and acute septic peritonitis (178) must be euthanased for welfare reasons once the diagnosis is confirmed.

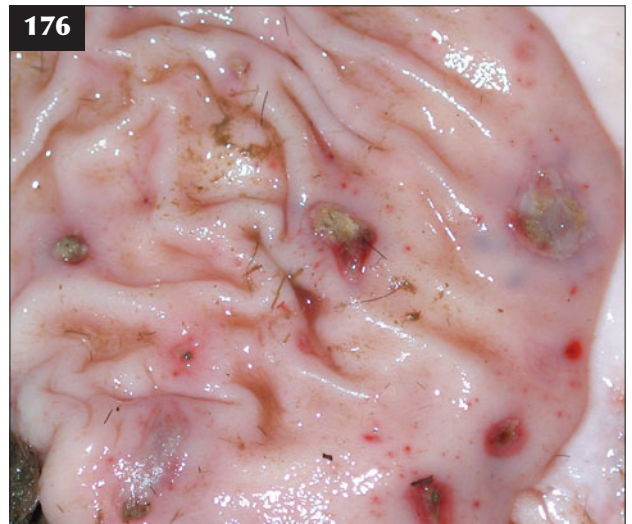ABOMASAL ULCERS – ADULT DAIRY COWS

DEFINITION/OVERVIEW

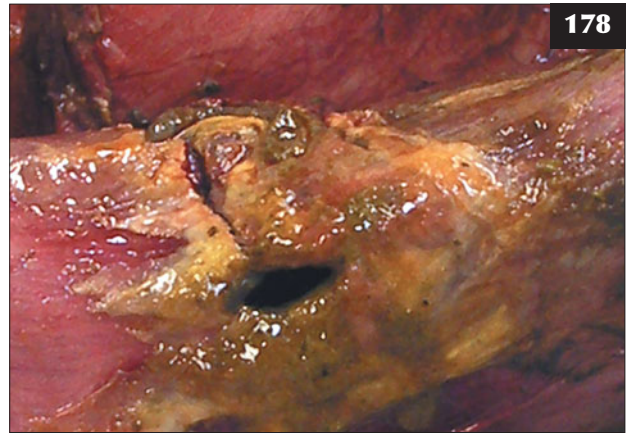Abomasal ulceration leading to significant haemorrhage and resultant melaena (179, 180) is an uncommon condition of dairy cows fed high concentrate rations. It often appears during early lactation, but the true incidence of ulceration is probably underdiagnosed.

AETIOLOGY

Stress, concurrent periparturient disease(s) and high starch/concentrate rations have been implicated in abomasal ulceration. The severity of the ulcer may vary from mucosal erosion to mucosal perforation (181), with



176 Abomasal ulceration in this necropsy specimen of an artificially reared calf.




177, 178 Abomasal perforation. **(177)** This calf with abomasal perforation is profoundly depressed, shocked and collapsed and is showing abdominal distension. **(178)** The abomasal perforation resulted in peracute septic peritonitis.

179 Dark fetid diarrhoea caused by the presence of digested blood (see **180**).



180 Abomasal ulceration may lead to significant haemorrhage and melaena, with black tarry faeces on rectal palpation.



a rapid development of diffuse septic peritonitis if the erosion/perforation is not plugged by the omentum. In this section the clinical presentation will describe ulceration with considerable blood loss; peritonitis is described elsewhere (see Peritonitis, p. 89).

CLINICAL PRESENTATION

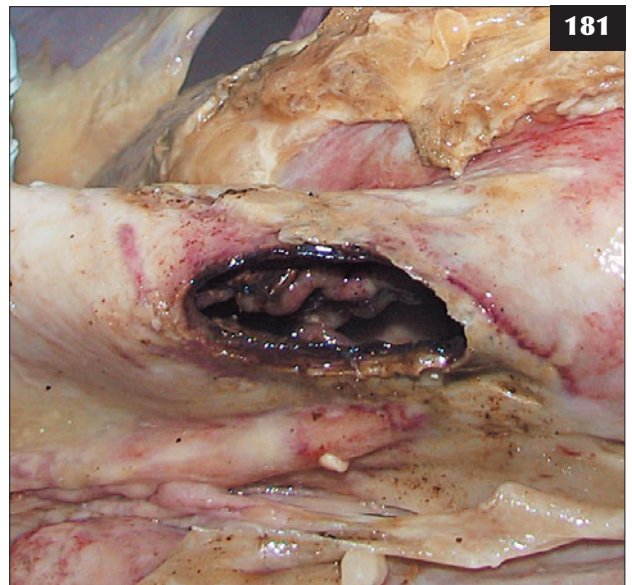
The passage of stale, foul-smelling, black, tar-like faeces (melaena) is the important clinical feature. Clinical signs include sudden onset poor appetite and milk production in the early post-partum period and weight loss. Ruminal contractions are reduced and there may be evidence of anterior abdominal pain. Significant blood loss into the gut will cause anaemia, rapid heart rate and pale mucous membranes, and recumbency. Some cows bleed to death despite packed cell volume (PCV) values as low as 0.10 l/l (10%).

DIFFERENTIAL DIAGNOSIS

Haemorrhage caused by intussusception; salmonellosis; haemorrhagic bowel syndrome.

DIAGNOSIS

Diagnosis is based on the presence of melaena and a positive faecal occult blood test.



181 The severity of the abomasal ulcer in dairy cows may vary from mucosal erosion to perforation with a rapid development of septic peritonitis, as in this case (see also **179**). The extent of the peritonitis was restricted by the omentum.

MANAGEMENT

In less severely affected cases, supportive therapy includes intravenous fluids. Oral kaolin and pectin and magnesium oxide have all been recommended, but are not effective. NSAIDs should be avoided as they may exacerbate abomasal ulceration. Most cows recover slowly over a period of several weeks. In more severely affected valuable cows, transfusion of 2–6 litres of blood from a donor cow will improve the cow's chance of recovery. Prevention/control measures are the same as for other abomasal conditions.

ABOMASAL IMPACTION**DEFINITION/OVERVIEW**

Primary abomasal impaction is uncommon, but has been recognized when (beef) cattle are fed very poor-quality fibrous diets with insufficient protein supplementation.

AETIOLOGY

Abomasal impaction is caused by feeding poor-quality fibrous rations. Secondary impaction may be seen in vagal indigestion.

CLINICAL PRESENTATION

Increasing abdominal distension, but loss of body condition, occurs over several weeks. Affected cattle are dull and have a poor appetite, reduced rumen motility and very firm dry faeces. The rumen can easily be 'pitted' with a clenched fist through the flank.

DIFFERENTIAL DIAGNOSIS

Vagus indigestion; twin pregnancy/hydrops allantois; chronic peritonitis.

DIAGNOSIS

Diagnosis is based on clinical signs and elimination of other likely diagnoses.

MANAGEMENT

There is no specific treatment, although purgatives such as mineral oil, liquid paraffin and magnesium sulphate have been administered by orogastric tube with reported success. Prevention is by feeding adequate energy and protein in the ration.

ABOMASAL IMPACTION (HAIR BALLS)**DEFINITION/OVERVIEW**

Hair balls are a common coincidental finding at post-mortem examination of veal calves. Hair balls are variably found at necropsy of poorly grown calves.

AETIOLOGY

Hair balls may occur in association with heavy louse infestation.

CLINICAL PRESENTATION

The role of hair balls in cases of ill thrift is uncertain: they may simply be a result rather than the cause. However, where blockage of the pylorus occurs there is an acute onset of abdominal pain with frequent rolling and kicking at the abdomen. Auscultation/palpation reveals a fluid and gas-filled viscus under considerable pressure in the lower right-hand side of the abdomen.

DIFFERENTIAL DIAGNOSIS

Abomasal volvulus; volvulus of the small and large intestine around the root of the mesentery; clostridial enteritis.

DIAGNOSIS

The condition is confirmed at surgery.

MANAGEMENT

A midline approach is used with the calf in dorsal recumbency. The pyloric obstruction/hair ball is removed by abomasotomy in the greater curvature under general anaesthesia.

Prevention is by controlling lice infestations and reviewing the rations fed.

CAECAI DILATATION AND TORSION**DEFINITION/OVERVIEW**

Caecal dilatation and torsion occurs sporadically in cattle fed restricted roughage and a high level of concentrates. It may also occur following a change of pasture.

AETIOLOGY

Incompletely fermented carbohydrate reaching the caecum is fermented and the resultant volatile fatty acids cause hypomotility, leading to dilatation, impaction and possible torsion.

CLINICAL PRESENTATION

Affected cattle have a poor appetite and in lactating cows there is a drop in milk yield over several days. The animal shows intermittent mild colic signs, which increase in severity with caecal diameter, and tenesmus, but there are scant faeces/mucus in the rectum (182). Rumen activity is normal, but the cow may appear drawn in. High-pitched pings are heard over a 30 cm diameter area of the right sublumbar fossa extending toward the wing of the ilium. On rectal examination, a 15–30 cm diameter cylindrical, blind-ended viscus is readily palpable extending into the pelvis. Rarely, the caecum may kink on itself (retroflex) and therefore not be palpable on rectal examination.

Caecal torsion presents with more severe clinical signs of colic, complete anorexia, ruminal atony, distension of the right flank (183) and a rapid pulse (>100 beats per minute). No faeces are passed and the area of resonance is

greater, although the caecal tip may not be palpable on rectal examination.

DIFFERENTIAL DIAGNOSIS

Right displaced/torsed abomasum; proximal duodenal obstruction; torsion of the small intestine; acute septic peritonitis.

DIAGNOSIS

Rectal palpation of the blind end of the caecum extending in to the pelvis is pathognomonic (unless retroflexed) of caecal dilatation. Caecal torsion would be confirmed at surgery.

MANAGEMENT

Remission of the caecal dilation has been recorded following transportation to surgery facilities. Changing to a high-fibre diet, intravenous calcium and fluid therapy, and hyoscine have all been reported to be successful in some cases.

In unresponsive cases, surgical drainage of up to 30–40 litres of fetid fluid faeces is performed through a right flank laparotomy under distal paravertebral anaesthesia following exteriorization of the blind end of the caecum (184). The incision in the caecum is repaired with an inversion pattern. Recovery of previous milk yield may take several weeks.

Surgical correction of caecal torsion is not a simple procedure when resection of ischaemic caecum becomes necessary. Correction of fluid and electrolyte disturbances is necessary where there is marked disturbance to the circulatory system before commencing surgery.

Prevention/control measures are the same as for the abomasal conditions listed elsewhere.

INTESTINAL TORSION (RED GUT)

DEFINITION/OVERVIEW

Torsion of the intestines around the mesentery is rare in adult cattle, but is not uncommon in 3–6-week-old calves on ad-libitum feeding systems.

AETIOLOGY

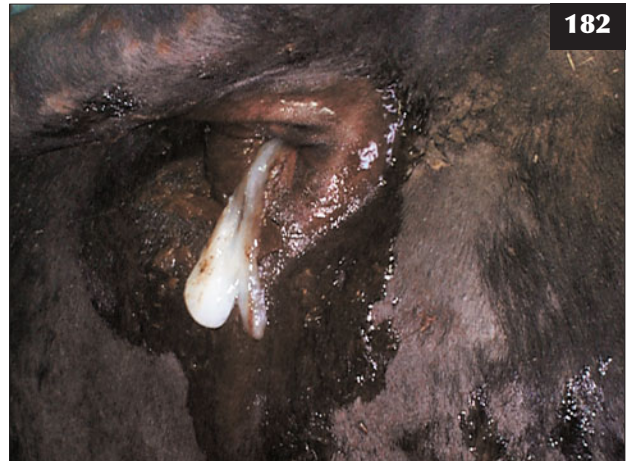Sudden fermentation of lactose with gas production and subsequent torsion is suggested.

CLINICAL PRESENTATION

There is sudden onset severe colic, with obvious abdominal distension and a rapid pulse. There is circulatory failure in advanced cases.

DIFFERENTIAL DIAGNOSIS

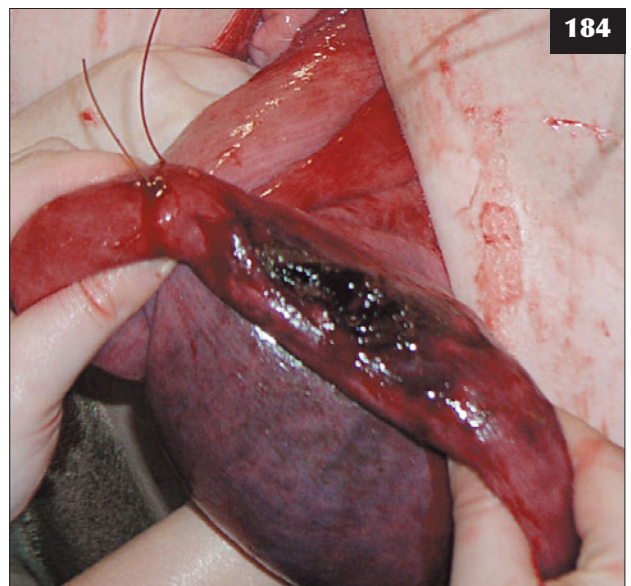
Clostridial enterotoxaemia and abomasal volvulus are the important differential diagnoses in calves. In cows, intestinal torsion should be differentiated from acute septic peritonitis and caecal torsion.



182 Scant mucus passed following tenesmus in a cow with caecal dilatation



183 Distension of the right flank is shown in this cow with caecal torsion.



184 Exteriorization and drainage being carried out through an incision made in the blind end of the caecum.

DIAGNOSIS

Diagnosis is based on clinical findings and confirmed during explorative laporotomy.

MANAGEMENT

Explorative laporotomy with successful surgical correction under general anaesthesia has been described.

INTUSSUSCEPTION**DEFINITION/OVERVIEW**

Intussusception of small intestine or through the ileocaecal valve occurs sporadically in calves and rarely in adult cattle.

AETIOLOGY

Intussusception is related to diarrhoea and strong peristaltic activity in calves.

CLINICAL PRESENTATION

There is initial mild colic (**185**) followed several days later by inappetence and constipation. There is little rumen activity and rectal examination reveals no faeces. Palpation per rectum in adults of an elongated mass in the lower right abdomen is reported.

DIFFERENTIAL DIAGNOSIS

Peritonitis; caecal dilation/torsion.

DIAGNOSIS

Diagnosis is difficult unless a specific mass can be palpated.

MANAGEMENT

Reports describe explorative laporotomy with end-to-end anastomosis, but success in field situations is rare. Surgery under general anaesthesia is reported in calves, but diagnosis is more common at necropsy (**186**).

INTESTINAL TUMOURS

Intestinal tumours are extremely rare in cattle.

FAT NECROSIS

Fat necrosis is a rare condition in commercial cattle (except Japanese Black Pied cattle), but it may be more common in older adult pet cattle maintained in obese condition. The large, >30 cm diameter, firm, occasionally calcified irregular mass within the omentum may be a coincidental finding during rectal examination or cause progressive intestinal obstruction. Clinical signs include weight loss, poor appetite and reduced faeces. A calcified mass may at first feel like a fetal skeleton on rectal examination. There is no licensed treatment and anorexic cattle should be culled for welfare reasons.

UMBILICAL HERNIA**DEFINITION/OVERVIEW**

Umbilical hernias are common in calves.

AETIOLOGY

Many hernias are believed to be hereditary.

CLINICAL PRESENTATION

Umbilical hernias <5 cm diameter (three fingers) are of no consequence. Larger hernias frequently contain omentum and small intestine and are most commonly presented for cosmetic reasons in breeding heifers; strangulation of hernia sac contents is very uncommon in cattle.

DIFFERENTIAL DIAGNOSIS

Umbilical hernias can be readily distinguished from umbilical abscesses during clinical examination (**187**), but occasionally both conditions can occur together, when the extent of infection can be determined ultrasonographically.

DIAGNOSIS

The contents of the hernia sac are readily reduced.

MANAGEMENT

Hernia rings >10 cm in diameter may require a mesh during closure, but should be questioned in breeding animals because of their likely hereditary nature.

Cattle with hernias should not be bred from and bulls whose progeny have a high prevalence of umbilical hernia should not be used.

OMPHALITIS/OMPHALOPHLEBITIS**DEFINITION/OVERVIEW**

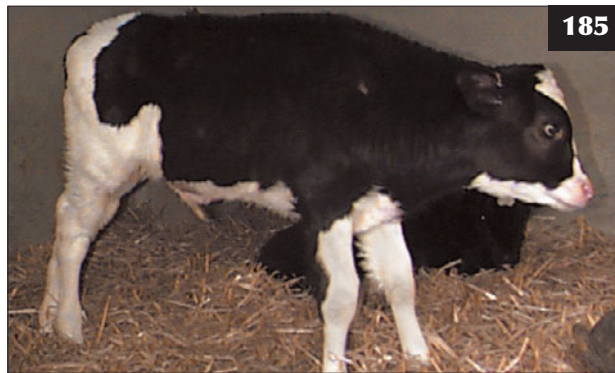Inflammation/infection of the umbilical structures may include the umbilical arteries (which connect the internal iliac arteries to the placenta [**188**]), the umbilical vein (which connects the liver to the placenta), the urachus (which connects the fetal bladder to the allantoic fluid [**189**]) and tissues surrounding the umbilicus.

AETIOLOGY

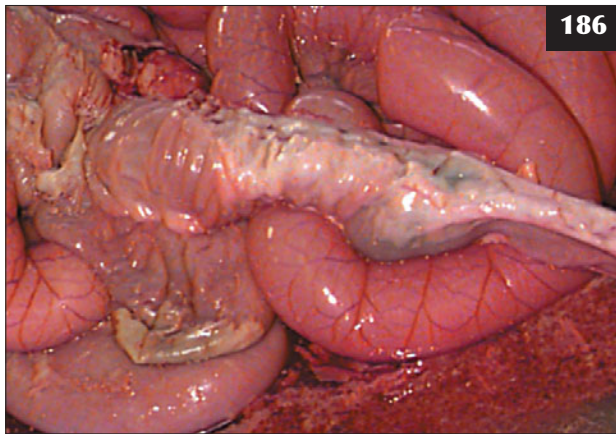
Infection from the calving environment is facilitated by inadequate navel treatment. *Escherichia coli* and *Arcanobacterium pyogenes* are common isolates from umbilical infections. Infection can also lead to septicaemia in calves with insufficient passive antibody and focal infections.

CLINICAL PRESENTATION

The calf is dull, reluctant to suck and stands with an arched back. The umbilicus is typically hot, painful and moist and has a purulent discharge. It is essential to determine whether the calf is septicaemic and if there are any other focal bacterial infections. In older calves the



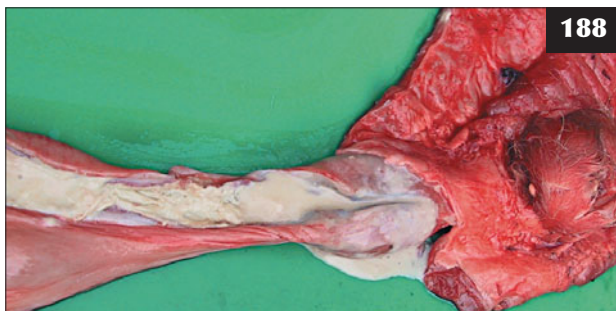
185 A Holstein bull calf with an intussusception of the small intestine presenting with colic.



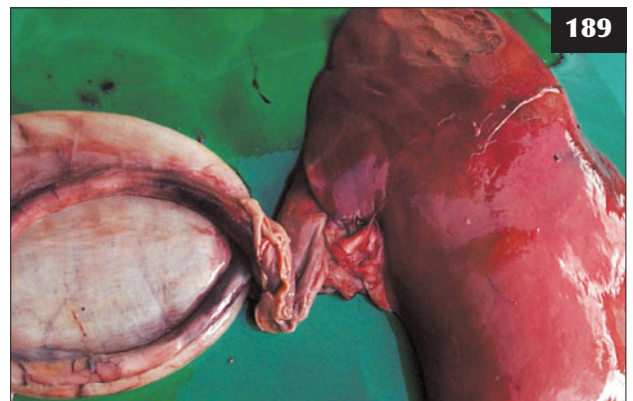186 Necropsy of the bull calf in **185** after euthanasia for welfare reasons confirms the diagnosis.



187 Umbilical abscess in a beef calf. Unlike a hernia, the abscess was painful, irreducible and yielded pus on needle aspiration.



188 Bacterial infection of the umbilical arteries.



189 Bacterial infection of the urachus (connects the fetal bladder to the allantoic fluid).

umbilical infection may be limited to a large abscess (190, 191).

In septicaemic calves less than three or four days old the umbilical remnant may still be wet. (**Note:** The upper respiratory tract, tonsil and gut are also important portals for bacterial invasion (for description of clinical signs of potential concurrent infections see Septicaemic colibacillosis [p. 100], Infected patent urachus [below] and Infectious polyarthritis [180]).

DIFFERENTIAL DIAGNOSIS

Localized peritonitis; urachal infection; umbilical hernia.

DIAGNOSIS

Diagnosis is based on a thorough clinical examination, taking care to check for other focal bacterial infections. Ultrasonography is useful for investigating involvement of the umbilical vessels and urachus, and differentiating a hernia from an umbilical abscess.

MANAGEMENT

Penicillin, amoxicillin plus clavulanic acid, and oxytetracycline are all used for umbilical infections. Florfenicol is often selected for calves with meningoencephalitis and polyarthritis following septicaemia. Umbilical abscesses can be lanced after needle aspirate or ultrasonography, then flushed daily for 3–5 days. Umbilical abscesses that are well circumscribed are often best treated by surgical excision. The prognosis is hopeless for those calves with significant peritoneal infection (192).

Prevention involves maintaining strict hygiene in the calving environment and treating the umbilical remnant at birth and 2–4 hours later with iodine. Prophylactic antibiotics are occasionally used to cover up for management deficiencies or where a newly calved beef cow is aggressively protective of her calf.

INFECTED PATENT URACHUS

DEFINITION/OVERVIEW

Urachal infections are sporadically encountered in young calves, often in association with omphalophlebitis (see earlier; 189). Adhesions to small intestine and omentum may develop.

AETIOLOGY

Infected patent urachus is caused by an ascending bacterial infection from the umbilicus.

CLINICAL PRESENTATION

Clinical signs become apparent several weeks to several months after birth. The umbilicus is often swollen and painful and there may be a history of antibiotic treatment for omphalophlebitis. An umbilical abscess(es) may be present in older calves. Affected calves

are poorly grown, intermittently febrile and may show pain during urination. A corded structure up to 2 cm in diameter may be felt on deep palpation extending from the umbilicus to the apex of the bladder. Transabdominal ultrasonographic findings may prove difficult to interpret, therefore a close watch must be made for propulsive movement of digesta in order to distinguish gut from an infected urachus.

DIFFERENTIAL DIAGNOSIS

Localized peritonitis.

DIAGNOSIS

Urinalysis is helpful where there is cystitis because ascending infection via the urethra is very uncommon. Chronic bacterial infections cause a leucocytosis and elevation in fibrinogen and globulin concentrations.

MANAGEMENT

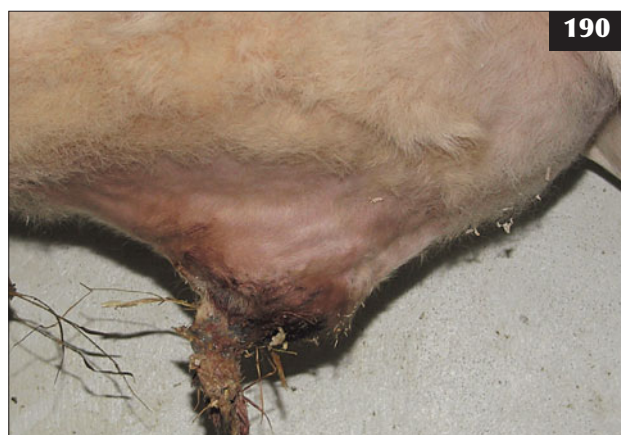Aracnobacterium pyogenes, streptococci and staphylococci are most commonly isolated, therefore treatment with penicillin (excreted in urine) for up to 4–6 weeks is indicated, but the prognosis is poor if adhesions to the gut are present. Surgical resection is difficult because of adhesions to small intestine and possibly the bladder. Such surgery is often further complicated by umbilical infection. Wound breakdown after resection of infected umbilical lesions is not uncommon.

Prevention is by strict hygiene in the calving environment and treatment of the umbilical remnant at birth and again 2–4 hours later.

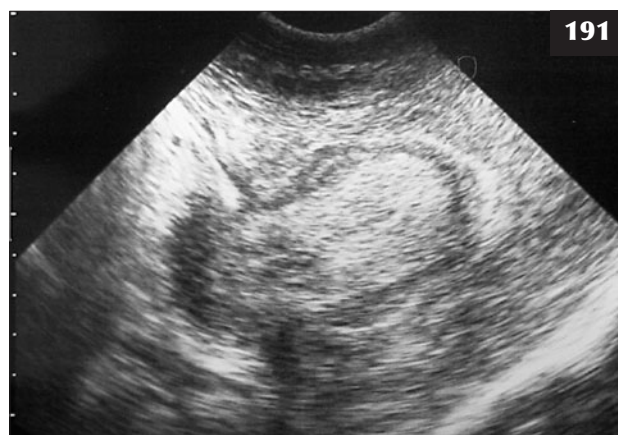Surgical resection under general anaesthesia may exceed the financial value of most commercial value cattle.

INTESTINAL HERNIATION FROM THE UMBILICUS

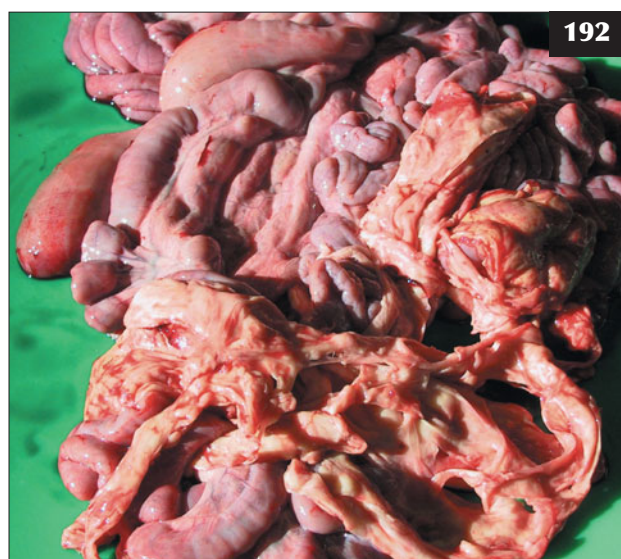Intestinal herniation occurs rarely in calves at birth and may be due to the presence of an abnormally large umbilical opening (193). Often, the dam's attention to the navel will lead to further herniation or tearing of intestines, requiring immediate euthanasia. If the condition is noted immediately and the herniated intestines are protected with a clean, damp dressing, then successful replacement can be attempted. Under local anaesthesia the umbilical opening is extended to allow replacement of the intestines followed by repair of the abdominal wall. Antibiotics may prevent the development of peritonitis in cases where gross contamination was minimal; however, in most cases the prognosis is poor.



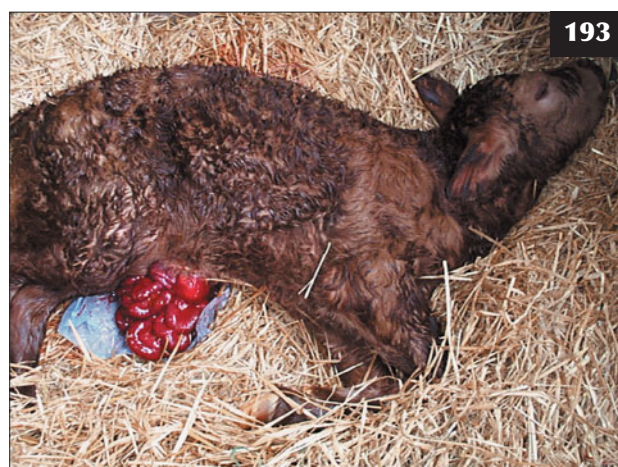190 The umbilical infection has been limited to a large abscess in this older calf.



191 Large well-encapsulated umbilical abscess confirmed ultrasonographically.



192 Necropsy finding of diffuse peritonitis following umbilical infection in a five-day-old calf.



193 Intestinal herniation has occurred immediately after delivery in this calf.

PERITONITIS

DEFINITION/OVERVIEW

Bacterial infection of the abdominal cavity may result in focal peritonitis, with spread of infection limited by the enveloping omentum, or it may extend to diffuse septic peritonitis.

AETIOLOGY

Traumatic reticulitis, abomasal perforation and iatrogenic uterine tears following dystocia are the most common causes of septic peritonitis in cattle.

Peritonitis may follow abdominal surgery such as delivery of an autolytic fetus by caesarean section. Repair of the oedematous friable uterus is more difficult after correction of uterine torsion and peritonitis may result.

Accidental toggling of small intestine or other viscera (not the abomasum) may result in leakage of digesta and the development of peritonitis.

CLINICAL PRESENTATION

Occasionally, fibrinous adhesions may form between the rumen and a left flank laparotomy site, but there are few sequelae except for a more difficult approach if a subsequent caesarean section is required. Similarly, leakage of small quantities of rumen liquor around a trocar site results in localized peritonitis causing adhesions with no significant consequences. Right flank omentopexy results in fibrinous adhesions without adverse consequences.

The clinical signs depend on the spread of infection within the peritoneal cavity and absorption of toxins.

Localized peritonitis may be secondary to toxic metritis, with leakage of toxins through the compromised uterine wall resulting in fibrin deposition of the serosal surface. Localized peritonitis, where infection has been limited by the enveloping omentum, may prove difficult to diagnose, with non-specific signs of poor appetite, disappointing milk yield and weight loss over several weeks leading to a gaunt appearance (194, 195).

Affected animals stand with an arched back (194, 196) and may respond with a grunt to the withers pinch test, but this stance is not pathognomonic of cattle with peritonitis because it is also seen in some cattle with endocarditis, pleurisy and chronic suppurative pulmonary disease. The rectal temperature is only

marginally elevated (39.2–39.5°C). The mucous membranes are congested and there is variable dehydration. The respiratory and heart rates are elevated and there are reduced or absent rumen contractions. Scant mucus-coated faeces are passed. Affected cattle often stand with their head held over the water trough, but drink little.

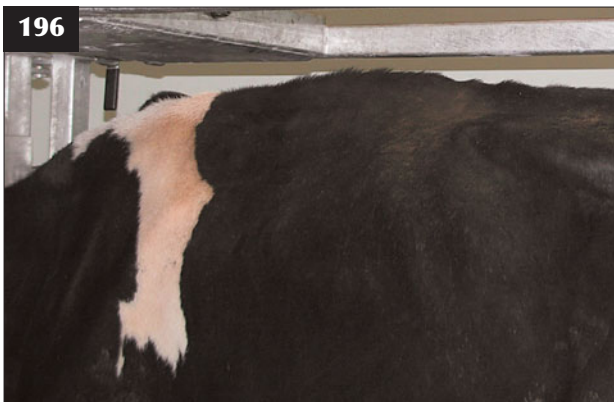The clinical signs are more pronounced in more generalized cases of peritonitis. Cattle with acute septic peritonitis are dull, depressed and anorexic and have a painful expression (197, 198). They are reluctant to move and are slow to rise. Initially, there may be abdominal distension due to gut stasis, but inappetence over several days results in a gaunt, drawn-up appearance in some cases (typically seen in cattle with traumatic reticulitis). In other



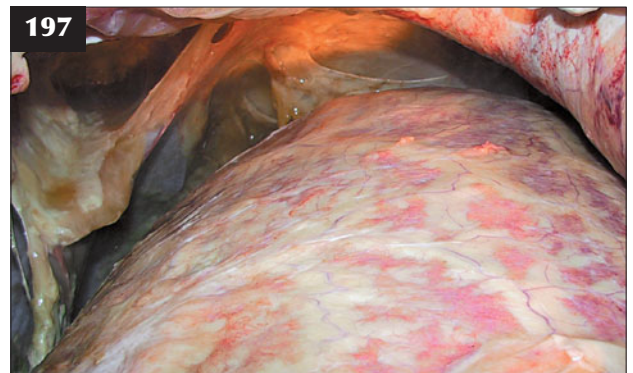
194 Localized peritonitis. This cow, where infection has been limited by the enveloping omentum, shows non-specific signs of a poor appetite, lowered milk yield, an arched back and a painful expression.



195 The painful gaunt expression in this cow is not pathognomonic of cattle with peritonitis.



196 This Holstein cow with septic peritonitis is standing with an arched back. The cause of the septic peritonitis was abomasal perforation (see 197).



197 The septic peritonitis revealed at necropsy readily explains the arched back seen in the cow in 196.

situations, peritonitis involving the small intestine may result in abdominal distension due to fluid sequestration within the intestines. Excessive accumulations of inflammatory exudate and fibrin deposition over 7–21 days may also cause abdominal distension (**199–201**). Death follows within 3–7 days.

DIFFERENTIAL DIAGNOSIS

Endocarditis; pleurisy; chronic suppurative pulmonary disease. Septic peritonitis frequently follows dystocia/uterine tears and toxic metritis is a common differential diagnosis. Hypocalcaemia presents as a dull, recumbent cow with bloat, which could be confused with peritonitis at initial presentation.

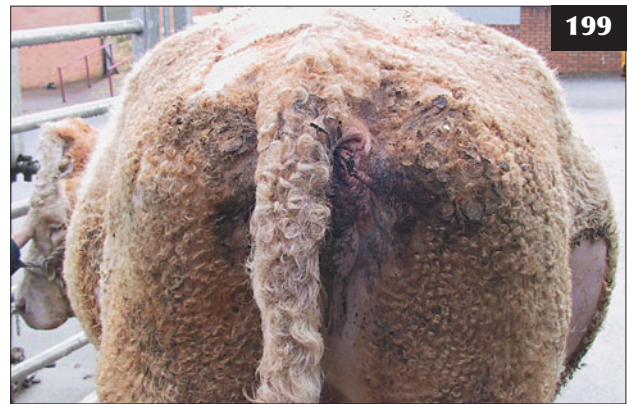DIAGNOSIS

Diagnosis is based on clinical signs and demonstration of an inflammatory exudate with a high protein concentration and an increased white cell count with predominance of leucocytes. However, localized peritonitis is not a simple diagnosis because infection has often been contained by the omentum and therefore cannot always be identified by abdominocentesis. In addition, in many cases the needle point may enter the large quantities of fibrin deposited on serosal surfaces (**200, 201**). A positive belly tap result is diagnostic, but there are limitations if no sample or indeed a normal transudate is obtained.

Ultrasonographic examination provides images of the peritoneum and viscera to a depth of 20 cm for most

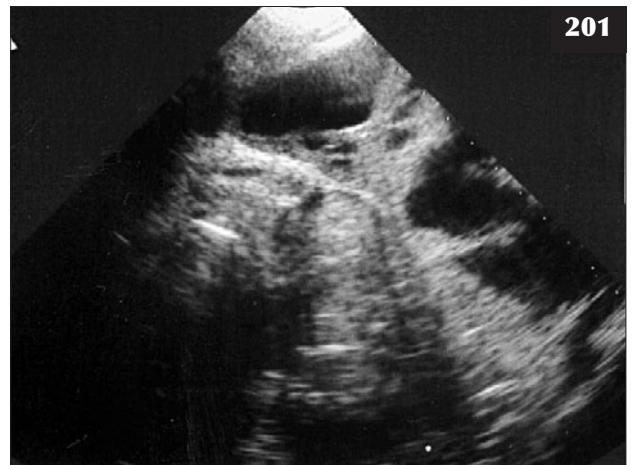
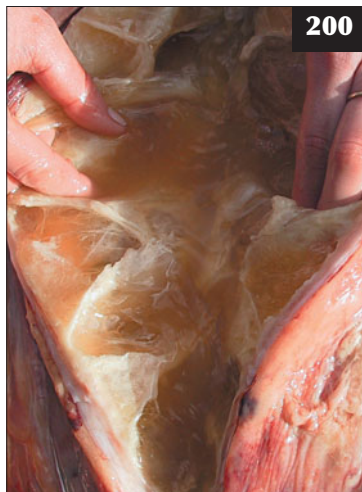
198 Close-up view of the Holstein cow shown in **196** and **197**.



199 Iatrogenic uterine tear following dystocia, as in this Simmental cow, is a common cause of septic peritonitis. Note the abdominal distension despite the cow having no appetite for 10 days.

200 Large quantities of fibrin are deposited on serosal surfaces in the cow with peritonitis shown in **199**.



201 Ultrasound findings consistent with diffuse severe fibrinous peritonitis from the cow shown in **199** and **200**.

5 MHz sector scanners. It is most useful for examination of the anterior abdomen, with results immediately available. 5 MHz linear scanners are also extremely useful. (**Note:** There is no need to be distracted by their 10 cm range, as 7 cm of exudate is significant [3 cm depth of body wall]). Ultrasound findings of diffuse severe fibrinous peritonitis are shown in **201** from the Simmental cow featured in **199** and **200**. Transrectal ultrasonography with a 5 MHz linear scanner provides valuable information concerning the uterus and caudal abdomen (see Chapter 2: Obstetrics and parturient diseases).

MANAGEMENT

Parenteral antibiotic therapy is hopeless in diffuse peritonitis cases, but might be used in very localized cases of peritonitis. It is often undertaken in situations where there has been only limited ancillary investigation in the expectation that the animal is suffering from another infectious disease. There is no benefit to be gained from intraperitoneal antibiotic administration. Animals should be euthanased for welfare reasons where the lesions have been demonstrated ultrasonographically. Euthanasia is also undertaken when the animal has failed to respond to antibiotic therapy administered because a definitive diagnosis could not be established in the first instance.

With the exception of a correct approach to dystocia management and, possibly, intra-reticular magnets to collect metal objects, there are no specific preventive measures.

RECTAL PROLAPSE

DEFINITION/OVERVIEW

Rectal prolapse occurs very sporadically in 4–6-month-old entire male beef calves (**202**).

AETIOLOGY

Rectal prolapse is often caused by mounting behaviour when entire male calves are managed with oestrus females in beef herds. It is rarely caused as a consequence of coccidiosis and ragwort poisoning.

CLINICAL PRESENTATION

The rectal prolapse extends for 5–10 cm. The rectal wall is often markedly oedematous and contaminated with dried faeces.

DIAGNOSIS

Diagnosis is based on clinical examination. It is not possible to pass a blunt probe between the skin and the prolapsed tissues, so it is therefore not an intussusception.

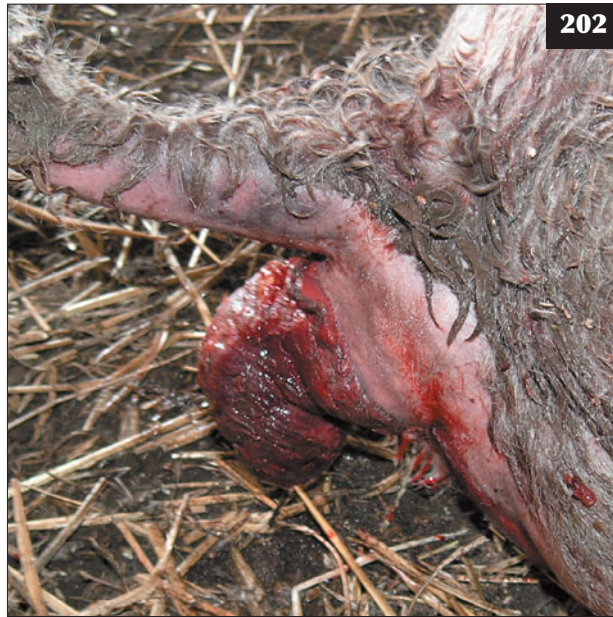MANAGEMENT

The rectal prolapse can usually be replaced after effective caudal analgesia and retained with a purse-string suture of 5 mm umbilical tape placed subcutaneously around the anus and tightened to reduce the internal diameter to approximately 3 cm (**203**). It may prove difficult to judge if the calf is still able to defaecate easily yet retain the previously prolapsed rectal tissue. The rectal wall oedema is treated with a single corticosteroid injection.

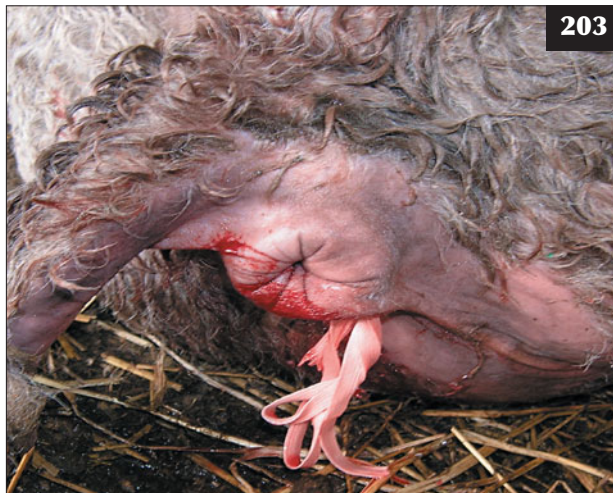On rare occasions the rectal prolapse may extend to more than 15 cm and under these circumstances the prolapsed rectum should be amputated under caudal analgesia.

A regimen for inhibition of the tenesmus causing the prolapses has advocated temporary damage to the cauda equina by caudal extradural injection of isopropyl alcohol; however, this treatment regimen often fails to produce a successful outcome. Accurate dose calculation and injection technique are essential to block tenesmus but not compromise the lumbosacral outflow to the hindlimbs, which might cause prolonged posterior paralysis and its consequences.

Castrating the calf at the same time to discourage future mounting behaviour should prevent the condition recurring.



202 Rectal prolapse in a 4-month-old entire male beef calf.



203 The rectal prolapse in the calf in **202** has been replaced after effective caudal analgesia and retained with a purse-string suture of 5 mm umbilical tape placed subcutaneously.

Part 2: Infectious diseases of the gastrointestinal tract

ROTAVIRUS

DEFINITION/OVERVIEW

Rotavirus infection is one of the most common infectious causes of neonatal diarrhoea in beef and dairy herds (204). In a severe outbreak of rotavirus diarrhoea, losses from 5–10% calf mortality and 30–50% morbidity can be very substantial.

AETIOLOGY

Infection results from the ingestion of faecal contaminated material, more readily acquired in a heavily contaminated and densely stocked area (205). After activation by intestinal proteolytic enzymes, the virus attacks epithelial cells of the upper, mid then lower small intestine, causing desquamation and reduction of absorptive capacity and secretory defence mechanisms (lysozymes and lactoferrin). Loss of mature differentiated cells with absorptive capacity at the tips of the villi, and survival of cells in the crypts secreting fluids, exacerbates the problem. Diarrhoea results in extensive loss of water, sodium, chloride and bicarbonate ions. There is loss of cells secreting disaccharidases; consequently, sugars are fermented in the large colon, producing organic acids with the hydrogen ions contributing to the developing metabolic acidosis. Loss of intracellular potassium ions occurs because hydrogen ion replacement occurs (buffering in an attempt to reduce metabolic acidosis). This buffering produces an elevation in plasma potassium concentration (hyperkalaemia), but a net loss of whole-body potassium ions.

CLINICAL PRESENTATION

Rotavirus infection produces a complete range of clinical signs, from little or no observed abnormality (positive faecal test in a healthy calf; 206) through to severe diarrhoea and dehydration with high mortality (207, 208). The incubation period is 1–3 days depending on the level of viral challenge. Concurrent *Cryptosporidium* spp. infection exacerbates the severity of the diarrhoea.

Calves are most commonly affected at 8–14 days old, with passage of very watery yellow/green faeces (209). They are reluctant to stand and suck and show mild depression and salivation. Disease rapidly spreads among young calves and without oral fluid therapy, affected calves become dehydrated, hypothermic and recumbent. The abomasum and intestines are often distended with fluid and gas and 'slosh' when succussed. The eyes are sunken (210) and the skin becomes tight and inelastic. As hypovolaemic shock develops, peripheral vasoconstriction causes the extremities to feel cold. In some calves a swollen painful navel may be a coincidental finding.

Some calves become severely acidotic, causing depression/stupor, weakness and recumbency (211). These calves may have normal hydration status if they have been treated with oral rehydration solutions administered by the farmer using an oesophageal feeder.



204



205

204 Rotavirus infection in a neonatal beef calf.

205 A heavily contaminated and densely stocked area, which is conducive to rapid spread of rotavirus infection among the calves.



206

206 Mild diarrhoea in a 10-day-old calf from which rotavirus was isolated.



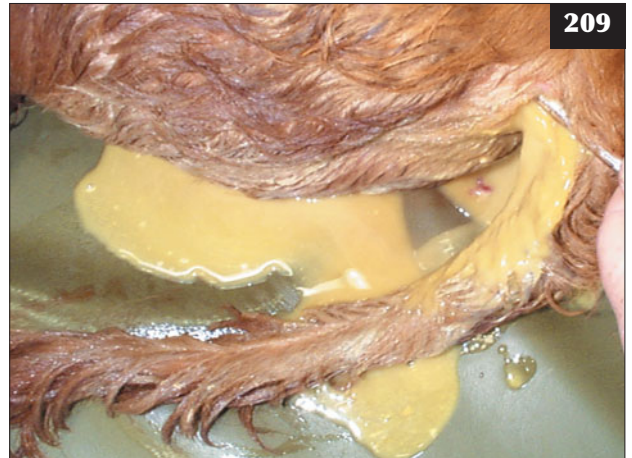
207

207 Rotavirus was isolated from this eight-day-old calf with diarrhoea and moderate dehydration.




208

208 Severe diarrhoea, dehydration and acidosis caused by rotavirus infection.



209

209 Very watery yellow/green faeces being passed from a 10-day-old calf from which rotavirus was isolated.



210

210 Rotavirus infection. The eyes of this calf are very sunken, consistent with around 7% dehydration.



211

211 This calf with rotavirus infection has become severely acidotic, causing depression/stupor, profound weakness and recumbency, which could be mistaken for septicaemia and bacterial meningitis.



212–214 Rotavirus infection. **(212)** A 16 gauge catheter has been stitched into a jugular vein. **(213)** The catheter has been sutured in place and the giving set taped up so that the calf can be left unattended in a warm dry isolation pen **(214)**.

215 Successful treatment of the acidotic calf featured in **212–214**.

DIFFERENTIAL DIAGNOSIS

Other infectious causes of diarrhoea including coronavirus, cryptosporidia and *Salmonella* spp. ETEC causes disease in calves less than four days old.

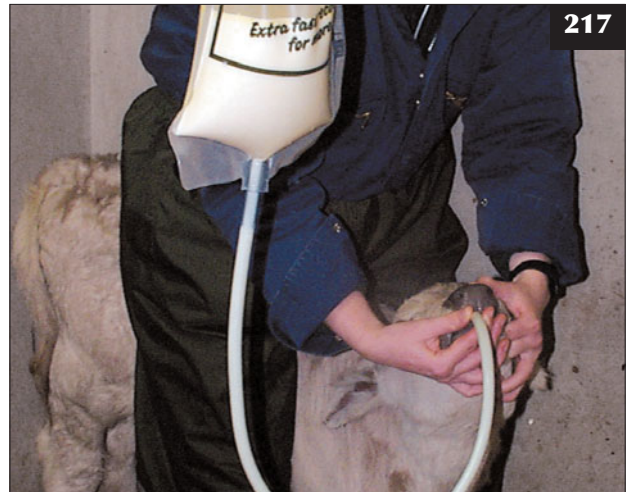DIAGNOSIS

Diagnosis is by same-day laboratory confirmation using the polyacrylamide gel electrophoresis (PAGE) test on fresh faeces. Around four scouring calves and four age-matched normal calves should be sampled (30 g faeces not swabs) to allow a meaningful interpretation of the herd problem because rotavirus is frequently isolated from normal calves without diarrhoea.

MANAGEMENT

The calf should be isolated in a warm, dry and well-bedded pen. Intravenous fluids are essential for recumbent stuporous calves because they are profoundly acidotic with variable dehydration. A 14–16 gauge catheter should be stitched into a jugular vein because this makes intravenous fluid administration much easier and the calf can be left unattended **(212–215)**. If catheterization proves difficult, a hypodermic needle can be used for the first litre and then a catheter inserted; a jugular cut-down is rarely necessary. The intravenous fluid requirement is calculated as follows:

A 45 kg dehydrated weight calf is approximately 5% dehydrated, therefore $45 \text{ kg} \times 0.05 = 2 \text{ litres}$ of fluid is required.



216, 217 Rotavirus infection. **(216)** Oral rehydration solution being offered by a teat and not by an oesophageal feeder. **(217)** Colostrum intake being ensured by using an oesophageal feeder.

Base deficit (or negative base excess) (field studies demonstrate base deficit values of 20 mmol/kg when calves are weak, recumbent and unresponsive) is corrected using the following formula:

Bicarbonate requirement = base deficit \times bicarbonate space \times dehydrated calf weight, therefore $20 \times 0.5 \times 45 = 450$ mmol bicarbonate

In field situations this is best achieved by adding 16 g of sodium bicarbonate powder to one litre of isotonic saline solution to yield 200 mmol of bicarbonate. A typical treatment regimen would be one litre of isotonic saline plus 16 g sodium bicarbonate (i.e. approximately 50% of the estimated bicarbonate deficit) over 20 minutes, then three more litres of isotonic saline plus remainder of estimated bicarbonate deficit over the next 4–6 hours (use 32 g to yield 400 mmol of bicarbonate to take account of ongoing fluid and electrolytes losses and potential errors in calculation).

Oral antibiotics are contraindicated. Parenteral antibiotics should be used to control concurrent focal infections (e.g. navel ill, calf diphtheria). One litre of oral electrolyte solution with high alkalinizing ability should be offered 4–8 times daily by teat **(216)**, not by an oesophageal feeder, because active sucking is the best indicator of the calf's response to treatment **(216)**. The return to milk diet should be a complete change, not diluted with electrolyte; the best method is to alternate milk and electrolyte solution every 2–4 hours.

Factors that are likely to increase the level of virus challenge to young calves include:

- Dairy herds:
 - Persistence of infection in dirty calving boxes.
 - Failure to feed sufficient good-quality colostrum from vaccinated cows at the correct time **(216, 217)**



218 The teats of this cow's pendulous udder would not be easily found by normal teat-searching behaviour of the neonate, which follows the ventral midline of the abdomen along to the udder. There is also the possibility of chronic mastitis.

and not feeding calves stored colostrum daily for the first two weeks of life. (**Note:** There is a potential risk of paratuberculosis if pooled colostrum is used.)

- Beef herds:
 - A protracted calving period in the same field or building, especially if the cows calve there every year.
 - Failure to remove newly calved cows and calves from the group still to calve.
 - Purchasing of replacement calves from markets is an excellent source of enteropathogens.
 - Factors that lead to lack of production or ingestion of suitable quantities of good-quality colostrum are clearly shown in **218**.

219



219 In this cow the udder and teats are in the normal position (i.e. well above the level of the hocks and easily found by the newborn calf). Contrast this with the cow in **218**.

Annual vaccination 1–3 months before the calving date is essential once rotavirus infection occurs in a herd. Because it takes 14 days for adequate antibody to accumulate in the colostrum, all cows still to calve must be vaccinated immediately in the face of an outbreak. Colostrum intake is often inadequate for the majority of calves on many farms. Ideally, they need to suck two litres of colostrum within the first six hours after birth (**219**).

CORONAVIRUS INFECTION

DEFINITION/OVERVIEW

Outbreaks of calf coronavirus diarrhoea tend to be more severe than those observed for rotavirus infection. Fortunately, coronavirus infection is much less common than rotavirus.

AETIOLOGY

Coronavirus infections differ from rotavirus infections in that the coronavirus replicates in epithelial cells, causing severe damage in the small intestine and progressing caudally into the colon. Infection of epithelial cells with virus results in loss of cell function, causing abnormal absorption and secretion and clinical disease before desquamation occurs 48–96 hours later. The loss of epithelial cells results in shortened villi and, occasionally, adjacent villi fuse. Cuboidal epithelium replaces the previous columnar cells. The regenerating epithelium consists of functionally immature cells which, as in rotavirus cases, are unable to carry out normal absorptive and secretory functions.

CLINICAL PRESENTATION

Typical clinical signs include depression, reluctance to suck and the passage of faeces containing mucus and milk curds. The disease progresses rapidly to weakness, recumbency, severe dehydration and death. Coronavirus infections cause diarrhoea in calves up to 20 days old.

DIFFERENTIAL DIAGNOSIS

Other infectious causes of diarrhoea including rotavirus, cryptosporidia and *Salmonella* spp.

DIAGNOSIS

Diagnosis is confirmed by laboratory examination of faecal samples. (**Note:** Coronavirus is rarely isolated from asymptomatic calves.)

MANAGEMENT

Treatment is as outlined above for rotavirus. Annual vaccination with a combined rotavirus, coronavirus and ETEC vaccine is an invaluable insurance policy in all beef herds.

ENTEROTOXIGENIC *E. coli*

DEFINITION/OVERVIEW

In calves ETEC is used to refer to strains of *E. coli* possessing the K99 antigen. Recent surveys have shown that the incidence of K99 *E. coli* is low (around 1% of all diarrhoeic calves), but when infection occurs in a herd, losses can be high.

AETIOLOGY

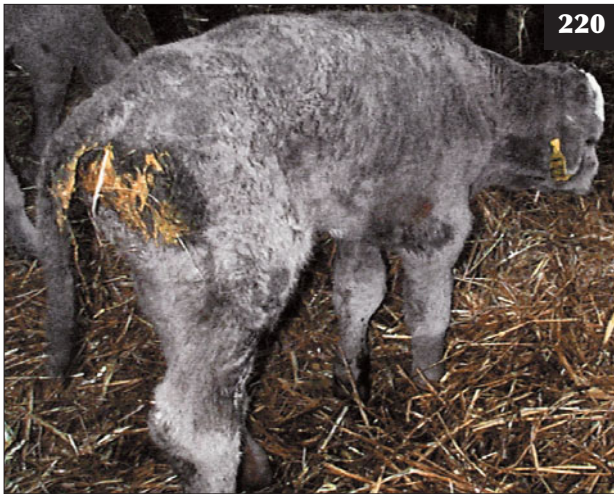The ability to adhere to the gut mucosa and the production of a heat-stable toxin results in the hypersecretion of fluids into the gut, with rapid dehydration, collapse and death. ETEC are non-invasive and the villi remain intact. K99 *E. coli* rarely produces systemic colibacillosis.

CLINICAL PRESENTATION

The disease characteristically affects calves aged 1–3 days old (**220**). There is sudden onset of profuse yellow/white diarrhoea (**221**) without mucus or blood. This causes rapid severe dehydration and the calf quickly becomes recumbent. Sequestration of fluid in the abomasum and intestines gives the abdomen a bloated appearance, which 'sloshes' on succussion. The rectal temperature may be elevated during the early stages, but rapidly falls to subnormal.

DIFFERENTIAL DIAGNOSIS

In beef herds this may be the first time the calf has been closely inspected by the farmer, therefore the differential diagnosis list should include events occurring at parturition and congenital conditions causing weakness and recumbency. Recumbency/abdominal distension



220 Enterotoxigenic *E. coli* infection in a 1–3-day-old calf.



221 Enterotoxigenic *E. coli* has caused sudden onset of profuse yellow/white diarrhoea with severe dehydration in this calf.



222 These cows were moved to clean pasture during late pregnancy in order to reduce the disease risk after an outbreak of enterotoxigenic *E. coli* in the herd.

can result from congenital heart defects, rupture of liver/spleen following dystocia, atresia coli/ani, bilateral femoral nerve paralysis, septicaemia, bacterial meningoencephalitis and congenital neosporosis. Some beef cows have a strong maternal behaviour and it may be several days before the farmer can safely approach the calf.

DIAGNOSIS

Diagnosis is based on severe diarrhoea with high mortality affecting calves aged 1–3 days old. Disease is confirmed following isolation of K99 *E. coli* from 30 g faecal samples.

MANAGEMENT

A fluid therapy regimen should be administered as for rotavirus (see above), but calves with this disease are not

usually acidotic, therefore spiking intravenous fluids with bicarbonate may be unnecessary. Oral antibiotics (e.g. potentiated sulphonamide) can be administered; antibiotic resistance is not a problem with ETEC isolates.

All pregnant cows should be removed to clean pasture (222). Vaccination has proved very successful in preventing disease, but it will take 10–14 days for sufficient protective antibody to accumulate in colostrum in the face of a disease outbreak. Oral antibiotics may be administered at birth as a temporary metaphylactic measure. All calves must receive adequate colostrum. Orally administered monoclonal antibody preparations can be used in the face of infection and have been very successful at reducing prevalence when the antibody is not present in colostrum because a vaccination programme has not been used.

SEPTICAEMIC COLIBACILLOSIS

DEFINITION/OVERVIEW

Septicaemic colibacillosis occurs in calves <10 days old on farms with poor husbandry standards. Septic arthritis (223, 224), meningitis and hypopyon frequently develop in those calves that survive the initial septicaemic episode (225, 226).

AETIOLOGY

Two factors are critical in the development of septicaemic colibacillosis:

- Inadequate passive immunity from colostrum immunoglobulins. (**Note:** Ensuring adequate passive antibody transfer requires only 5–10 minutes of the farmer's time.)
- Exposure and invasion via the nasal and oropharyngeal mucous membranes, the tonsils, the upper respiratory tract or the intestines of an *E. coli* serotype able to produce an overwhelming

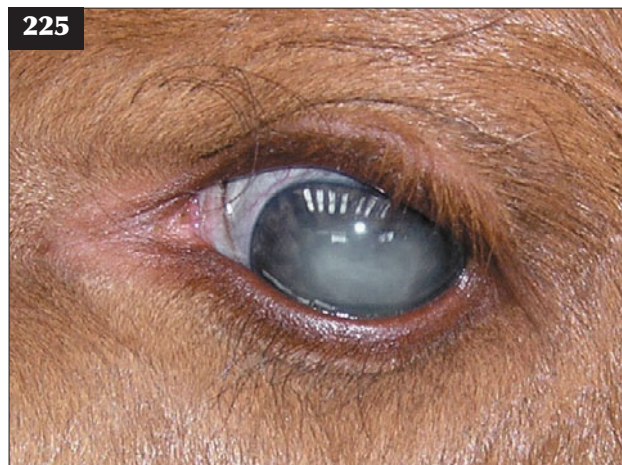
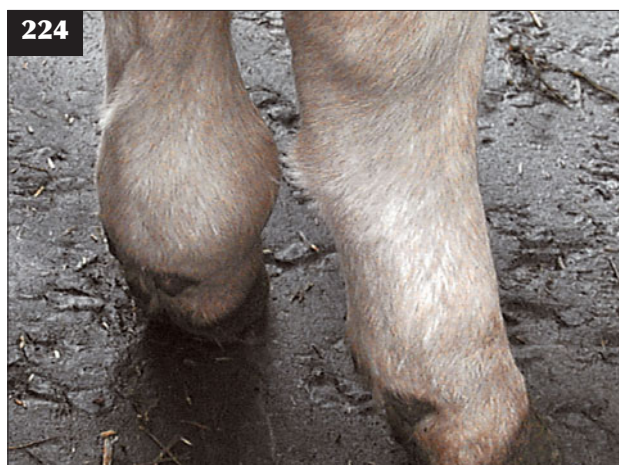septicaemia, endotoxaemia and death. The umbilicus is not the major portal of entry for bacteria causing septicaemia.

CLINICAL PRESENTATION

There is an incubation period of around 24 hours between challenge and clinical signs, with a course as short as 6–8 hours. Initially, calves show lethargy, depression, fail to suck and become recumbent. Affected calves are often afebrile with cold extremities and show episcleral injection. Tachypnoea with laboured breathing may be observed. Salivation and yellow mucoid diarrhoea occur terminally. In the agonal stages there are periods of seizure activity and opisthotonus followed rapidly by death.

DIFFERENTIAL DIAGNOSIS

ETEC (lower age range for rotavirus and coronavirus).



223–226 Septicaemic colibacillosis. (**223**) Septic arthritis in a calf that survived the initial septicaemic episode. (**224**) Septic arthritis of the left fetlock joint following an initial septicaemic episode. (**225**) Hypopyon secondary to septicaemia in a neonatal calf. (**226**) Meningitis secondary to septicaemic colibacillosis in a three-day-old calf that had failed to suck colostrum.

DIAGNOSIS

Numerous methods can be used to assess passive antibody transfer, but plasma protein determination using a refractometer is the cheapest and can be readily undertaken in the practice laboratory. Pre-colostral values of 40–45 g/l rise to >65 g/l by 24 hours after appropriate colostrum ingestion of 7% of body weight within the first six hours. Other common assays include the zinc sulphate turbidity test and gamma glutamyltransferase (GGT) concentration.

Bacterial infection of the meninges causes an increased lumbar CSF protein concentration with a neutrophilic pleocytosis.

MANAGEMENT

Florfenicol is the antibiotic of choice for septicemic calves, but the prognosis is hopeless if the calf shows seizure activity. Supportive therapy includes intravenous NSAIDs. A high dose of soluble corticosteroid (e.g. 1.0 mg/kg dexamethasone) reduces cerebral oedema, but remains controversial in the treatment of bacterial meningoencephalitis.

Septicaemia is best prevented by ingestion of 7% body weight of colostrum within the first six hours of the calf's life. Stored colostrum should be used, but there is a risk factor for paratuberculosis. Hygiene in the calving boxes and calf accommodation should be improved. Improved hygiene in the calving boxes will also reduce periparturient diseases (puerperal metritis, mastitis) in the cow.

CRYPTOSPORIDIOSIS

DEFINITION/OVERVIEW

Cryptosporidium parvum is not host specific and outbreaks of calf diarrhoea may occur when there is a build-up of infection in mixed accommodation/grazing with young lambs. Although morbidity is high, mortality in uncomplicated cases is rare. Cryptosporidiosis is a zoonotic disease and has been frequently reported in school children visiting open farms and petting zoos.

AETIOLOGY

Diarrhoea is caused by the physical loss of villous absorptive area and this exacerbates concurrent viral infections. In some instances no clinical disease is associated with *Cryptosporidium* spp. isolation.

CLINICAL PRESENTATION

Beef calves aged 10–21 days old are most commonly affected. There is profuse yellow/green diarrhoea with much mucus present. There is only mild dehydration, but the calf rapidly loses condition over 2–5 days and has a dull, tucked-up appearance. The calf is reluctant to suck and examination of the dam often reveals a full udder.

DIFFERENTIAL DIAGNOSIS

Rotavirus and coronavirus infection; salmonellosis.

DIAGNOSIS

Diagnosis is by demonstration of *Cryptosporidia* spp. oocysts on a faecal smear after Giemsa staining; however, other enteropathogens may also be involved. Identification of the organism in stained gut sections of post-mortem material is the preferred laboratory method.

MANAGEMENT

In uncomplicated cases it is important to ensure that the calf is properly hydrated; oral electrolyte solutions should be used as necessary. Halofuginone lactate is licensed for the prevention and treatment of diarrhoea caused by *C. parvum*. For prevention of diarrhoea, calves should be dosed for seven consecutive days starting within 1–2 days of birth. For treatment, calves should be dosed for seven consecutive days starting within one day of the onset of diarrhoea. Halofuginone lactate has a low toxicity index and the data sheet instructions must be carefully followed.

The following preventive/control measures should be instituted:

- Not using the same fields for calving and lambing.
- Changing fields every year or when clinical cases occur during that season.
- Moving newborn calves immediately to clean pasture.

COCCIDIOSIS

DEFINITION/OVERVIEW

Disease outbreaks occur in young stock associated with contaminated accommodation and feed areas (227) and



227 Coccidiosis. Contaminated accommodation and feeding areas can be associated with coccidiosis outbreaks in young stock.

watercourses while at pasture (228). Weight loss and protracted convalescence may result in lower weaning weights in beef calves.

AETIOLOGY

Coccidiosis is caused by infection by the protozoan organism *Eimeria* spp., which parasitizes the epithelial lining of the alimentary tract. *E. zuernii*, *E. bovis* and *E. alabamensis* are the most common and pathogenic species. Infection causes a loss of epithelial cells and villous atrophy, with consequent diarrhoea and possibly dysentery. Outbreaks of disease are commonly seen 3–4 weeks after mixing groups of dairy calves.



228 Coccidiosis outbreaks can occur in young stock from contaminated surface water and watercourses while at pasture.

CLINICAL PRESENTATION

In severe clinical coccidiosis there is sudden onset of profuse fetid diarrhoea containing mucus and flecks of fresh blood, with considerable staining of the perineum and tail (229). Straining with partial eversion of the rectum is characteristic of severe infections (230) and may result in prolapse. Affected animals are afebrile, but appetite is greatly reduced and they quickly develop a gaunt appearance. Anaemia is an uncommon sequela.

More usually, clinical signs are less marked, with chronic wasting and poor appetite the presenting signs (231). The rectal temperature is often normal. Morbidity is high, but mortality, even in severe cases, is low. Convalescence is protracted in all cases.

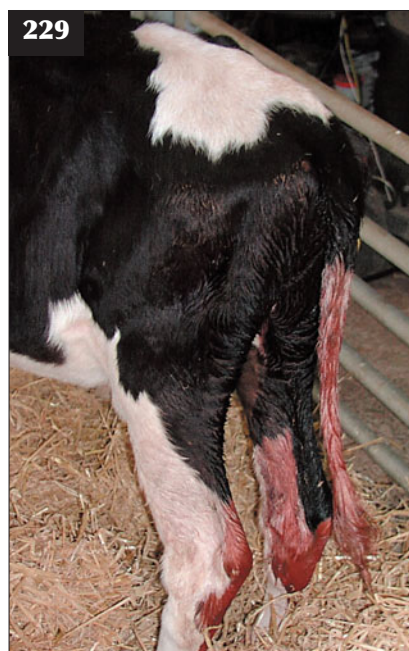
DIFFERENTIAL DIAGNOSIS

If many calves affected: parasitic gastroenteritis, salmonellosis, lead poisoning (tenesmus); if only one calf affected: intussusception, persistent infection with BVDV, necrotic enteritis, ragwort poisoning, peritonitis.

DIAGNOSIS

Diagnosis is based on epidemiological and clinical findings affecting large numbers of calves. The demonstration of large numbers oocysts in faecal samples is helpful, but speciation is rarely undertaken in field outbreaks. It is important to remember that small numbers of oocysts are present in the faeces of many normal calves and the stage of infestation greatly influences oocysts present in faeces. There is a good response to specific anticoccidial therapy.

Histopathology findings of coccidiosis in a dead calf confirms the clinical diagnosis.

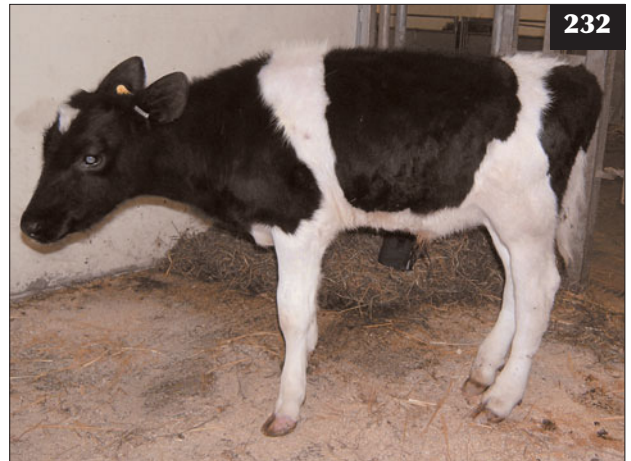

229 Acute coccidiosis is causing profuse haemorrhagic diarrhoea in this young heifer.

230 Straining with partial eversion of the rectum is shown in this calf with a severe coccidial infection.



231 More usually, clinical signs of coccidiosis are less marked, with chronic wasting and poor appetite.



232 Salmonellosis. Localization of infection to the right hind fetlock joint in this calf after surviving the initial septicaemic episode has resulted in the poor growth.

MANAGEMENT

Affected calves must be moved from infected pastures/premises immediately. Sulpha drugs given orally for 3–5 days are the standard treatment. Oral fluid therapy may be indicated in certain cases. Oral toltrazuril or diclazuril can be used for both treatment and prophylaxis.

Decoquinate can be used in-feed for prevention of coccidiosis in dairy calves. Monensin sodium is used as a coccidiostat in many countries, but is not licensed within the EU.

Strict attention to disinfection of buildings between batches of calves and clean feeding areas mean that coccidiosis is uncommon in modern dairy units. Disease in beef calves in pastured cattle may result from contaminated water courses during the summer months where there is no other supply. As survival of oocysts is possible from one year to another, calving on the same pasture each year may increase the risk.

SALMONELLOSIS

DEFINITION/OVERVIEW

Salmonellosis occurs worldwide. It is primarily a problem of young calves, although disease outbreaks occur not infrequently in adult dairy and beef cows.

AETIOLOGY

Salmonella typhimurium and *Salmonella dublin* are the most common serotypes causing disease. In outbreaks caused by *S. typhimurium*, DT104 is the most prevalent phage type. *S. typhimurium* can infect many species, including man, and it carries a high zoonotic risk. *S. dublin* is host adapted to cattle and is not a zoonotic risk. Occasionally, other serotypes, including *S. newport* and *S. agama*, cause disease in cattle.

S. dublin infection normally arises from exposure to

infected purchased animals or from carrier animals in the herd. In infected herds, cows can become latent carriers and excrete only during periods of stress. Liver fluke damage can cause cows to excrete *S. dublin* because infection may persist in the gallbladder and bile ducts.

S. typhimurium infection normally arises due to contact with infected purchased cattle (particularly when passed through numerous markets) or via contaminated feedstuffs, pasture and water courses.

CLINICAL PRESENTATION

Most outbreaks of salmonellosis occur during the winter months.

Calves

Neonatal calves can present with septicaemia progressing rapidly to death within 6–12 hours. Calves aged 2–6 weeks are most commonly affected, with variable clinical signs depending on age and passively derived immunity. There is often high morbidity and mortality may exceed 60%. Commonly, affected calves are dull and anorexic and have an elevated rectal temperature and grey pasty faeces with fresh blood and mucus present. Older calves may develop a more watery foul-smelling dysentery containing mucosal casts, particularly associated with *S. typhimurium* infection, causing progressive dehydration with a gaunt appearance.

Surviving calves often grow poorly following localization of infection, especially with *S. dublin*, which can cause polyarthritis (232), septic physitis or dry gangrene of extremities after the initial septicaemic episode. Cervical vertebral empyema causing quadriparesis and leading to recumbency in 2–4-month-old calves may be another manifestation of *S. dublin* infection.

S. dublin may also cause insidious onset suppurative pneumonia with clinical signs of variable pyrexia, poor

appetite and an increased respiratory rate and effort, with crackles audible anteroventrally in the chest.

Adult cattle

During an outbreak of salmonellosis the severity of clinical signs, morbidity and mortality varies considerably, but it is most severe in stressed groups of animals (e.g. cows during late pregnancy and recently calved) and cattle in poor body condition. Disease can be precipitated in carrier animals following major surgery (e.g. caesarean section) or nutritional deprivation. Concurrent disease (e.g. BVDV infection) may increase the severity of clinical signs.

S. typhimurium infection can cause acute enteritis, often with blood and shreds of mucosa in watery faeces, and it may progress to septicaemia. Affected cattle are depressed, anorexic and experience a severe drop in milk yield. The rectal temperature is markedly elevated at 41–42°C. There is marked dehydration and ensuing toxæmia (233), with death in severely affected cattle.

When infection occurs during late pregnancy, abortion commonly follows 4–7 days later. Severe toxic metritis leading to death occurs in some cows following abortion. With *S. dublin* infection, signs may be limited to abortion in late gestation and enteritis is less common.

DIFFERENTIAL DIAGNOSIS

Calves

Neonatal septicaemia may result from bacterial infections caused by high environmental bacterial challenge and no passively derived antibody. Diarrhoea may be caused by enteric viruses in younger calves, then by cryptosporidiosis and coccidiosis. Chronic suppurative pneumonia may follow incomplete and/or inappropriate antibiotic treatment of acute respiratory disease, and is commonly associated with persistent BVDV infection.

Adults

The main differential diagnoses are Johne's disease, fascioliasis and mucosal disease (MD) in individual



233 Rapid dehydration and ensuing toxæmia in a case of acute enteritis caused by *S. typhimurium* infection.

animals, and acute BVDV infection and winter dysentery in groups of cattle.

DIAGNOSIS

Diagnosis is readily achieved by bacteriological culture of faeces and post-mortem or abortion material. In many countries, including the UK, laboratories must report all isolations of salmonellae to the regulatory health authorities.

MANAGEMENT

Wherever possible, affected cattle must be isolated to restrict disease spread. Parenteral antibiotics are of dubious efficacy in adult cattle and may simply prolong excretion. Recovery can be prolonged, especially following abortion/metritis in cows.

Prompt treatment of calves during the acute phase of the outbreak may prevent septicaemia and sequelae such as localization of infection in joints, epiphyses and lungs. Treatment of septicaemia is hopeless and calves should be euthanased for welfare reasons.

The antibiotic sensitivity of the isolate should be tested *in vitro* because multiple resistance to many of the commonly used antibiotics is widespread, especially for *S. typhimurium* DT104. Enrofloxacin, apramycin, trimethoprim/sulphadiazine and clavulanate-potentiated amoxicillin are normally effective *in vitro*. Supportive treatment includes NSAIDs and oral and intravenous fluid therapy as necessary.

Recent evidence suggests that some adult cattle may remain symptomless carriers of *S. typhimurium* for many months after infection, which makes herd control very difficult. A long-term carrier/excretor state is common with *S. dublin* infection.

It is essential to remember the zoonotic risk from salmonellae and personal hygiene must be strictly observed. All efforts must be taken to limit spread to other animals on farm by using isolation pens, correct disposal of effluent, restricted access and foot dips.

Vaccination

An inactivated, adjuvanted vaccine containing antigens of *S. dublin* and *S. typhimurium* is available in many countries. Cattle require two injections of vaccine 3–4 weeks apart. Vaccination during late pregnancy will afford some passive antibody protection for calves, which can be boosted from three weeks of age. There is anecdotal evidence that vaccinating cows two or three times at 7–10 day intervals during a disease outbreak may shorten its course and severity. Vaccination may be worthwhile to protect high-risk groups of cattle following an outbreak of disease until the risk of carrier cattle is reduced.

Prevention

Management/biosecurity measures that will reduce the risk of *Salmonella* infection include:

- Avoiding introducing potentially infected animals by maintaining a closed herd. All introduced stock should be quarantined for at least four weeks.
- Sourcing new stock from other farms with high health status and not from markets.
- Avoiding shared bulls and communal grazing areas.
- Isolating sick animals in dedicated isolation boxes and not in calving boxes.
- Cleaning and disinfecting buildings between occupancies. Providing good drainage and waste removal.
- Maintaining good fences to prevent straying of neighbouring stock.
- Protecting all feed stores from vermin, including birds.
- Only spreading slurry on arable land wherever possible. Leave all grazing land at least three weeks after spreading slurry.
- Insisting that visitors have clean boots and disinfect them before entering and leaving the farm premises.
- Considering herd vaccination.

WINTER DYSENTERY

DEFINITION/OVERVIEW

Winter dysentery is an acute contagious diarrhoea of adult cattle that occurs as an epizootic in a herd during the winter housing period.

AETIOLOGY

Bovine coronavirus is spread by the faecal–oral route. The disease has recently been reproduced experimentally in susceptible cows by exposure to coronavirus isolated from young calves.

CLINICAL PRESENTATION

There is acute onset of profuse dark-brown diarrhoea containing small flecks of blood, which quickly spreads throughout the herd. Affected cattle are not usually pyrexia, but are depressed with a reduced appetite and up to 50% reduction in milk yield lasting several days. Some cows may show signs of mild colic. There may be signs of mild respiratory disease including coughing and nasolacrimal discharge.

DIFFERENTIAL DIAGNOSIS

The important differential diagnoses include simple indigestion, acute BVDV infection and salmonellosis.

DIAGNOSIS

Diagnosis is based on the clinical signs and history of rapid spread throughout the herd. Serology tests are available for bovine coronavirus. Where doubts exist about the diagnosis, faecal samples should be collected for bacteriology.

MANAGEMENT

Although the morbidity rate is very high, the mortality rate is zero and treatment is not normally required because most cows recover over 2–3 days.

There are no control measures. Herd immunity acquired after a disease outbreak will protect against disease for 2–3 years.

PARATUBERCULOSIS (JOHNE'S DISEASE)

DEFINITION/OVERVIEW

Paratuberculosis occurs worldwide, but especially in temperate climates, and affects cattle, sheep, goats and deer reared under intensive management. Many wildlife species, including rabbits and certain exotic species, are also susceptible to paratuberculosis, and horses and pigs can be infected experimentally. The cattle and sheep strain isolates usually differ, suggesting cross-species disease spread is unlikely. There is limited but disputed evidence that the causal organism of paratuberculosis may be associated with Crohn's disease in humans. There has been a marked increase in the annual incidence of bovine paratuberculosis reported in many countries worldwide, including the USA and the UK, over the past 10 years.

AETIOLOGY

Paratuberculosis is a chronic granulomatous enteritis of adult ruminants caused by *Mycobacterium avium* subsp. *paratuberculosis* (MAP). Infection is essentially an endemic problem in particular herds and flocks; the mortality rate is around 1%. However, production losses due to subclinical disease (poor milk yield, lowered growth rate and reduced fertility) are substantial, with up to 50% of animals possibly affected in a problem herd.

Infection is mainly transmitted to young calves by ingestion of the organism following faecal contamination of food and water supplies (234; see also 228) and from



234 Faecal-oral infection of young calves is the most common route of infection with paratuberculosis. There is ample opportunity for faecal contamination of food and water supplies and the cow's teats on many beef farms.

the cow's teats. There is some evidence for transplacental infection in heavily infected dams. The causal organism has also been isolated from milk and semen.

There is an extended incubation period with clinical disease not apparent until cattle are 3–5 years old, although infection does exceptionally occur in younger animals (15–18 months old; 235) following severe challenge. Cattle in this latter group are often the progeny of infected dams, birth occurring during the clinical phase of disease.

Infected animals may shed organisms in the faeces for over a year before clinical signs appear. Although susceptible to sunlight, desiccation and alkaline soils, MAP can persist for up to one year on pasture. Host factors that may precipitate clinical disease include stress-related events such as parturition, breeding season in bulls (236), transport, poor nutrition, parasitism (especially fasciolosis)

and intercurrent disease. Channel Island dairy breeds and Limousin beef cattle are reportedly more susceptible to paratuberculosis.

After ingestion, MAP localizes within the ileum and gut-associated lymphoid tissue. The organisms are phagocytosed by macrophages, although they may multiply intracellularly. There are three broad categories following infection, depending on the host–pathogen balance: (1) the animal may become resistant to infection with no clinical disease or faecal shedding; (2) the infection may progress to an intermediate stage, with infection partially controlled but causing subclinical disease with intermittent shedding; or (3) the infection may progress to clinical disease with heavy shedding.

Cell-mediated immunity is generally detectable in resistant animals, but it is weak in clinical cases.



235 This 21-month-old heifer was confirmed as being infected with *M. avium* subsp. *paratuberculosis*.



236 Paratuberculosis in a beef breed bull. This case, which was the first case to be discovered on the farm, occurred within two years of purchase.



237 Paratuberculosis. This cow had a poor milk yield and progressive weight loss, resulting in an emaciated animal.

Conversely, serum antibody responses are poor in resistant cattle and during the early clinical stages, but strong during the clinical phase. There appears to be progression over the course of disease from cell-mediated immunity to a humoral response, with the latter ineffectual against the pathogen. During the latter stages of disease the animal may show little immune response, termed 'anergy'.

CLINICAL PRESENTATION

Clinical signs usually appear in cattle 2–6 years old with onset often linked to recent parturition. There is poor milk yield, progressive weight loss, which can result in emaciation (235–239) with submandibular oedema, and coat de-pigmentation in some cases. There is no fever or toxæmia; appetite and ruminal activity remain normal, although the animal may be polydipsic. Cattle have soft

faeces or diarrhoea, often described as resembling 'thick pea soup', with no blood, mucus or epithelial debris and passed without tenesmus (240). Clinical signs may continue for up to several months during which time the animal becomes emaciated and is destroyed for welfare reasons.

Clinical cases usually show hypoalbuminaemia (serum concentration <22 g/l; normal 30–35 g/l) consistent with a protein-losing condition and normal gammaglobulinaemia (normal serum concentration 35–50 g/l) despite the chronicity of MAP infection. Some animals may show mild anaemia.

DIFFERENTIAL DIAGNOSIS

Differential diagnoses include fasciolosis and salmonellosis, especially if several cattle in the herd are affected.



238 Paratuberculosis. Progressive weight loss resulting in an emaciated animal. Compare this animal with the normal herdmate under similar management.



239 Paratuberculosis. Weight loss has occurred in this cow despite an adequate ration and the cow being at pasture.



240 This cow with paratuberculosis has profuse diarrhoea.

DIAGNOSIS

There is no single reliable confirmatory test for paratuberculosis and the detection of subclinical cases is especially problematic. Many tests have a low sensitivity and use non-specific reagents. Necropsy and histopathology are definitive.

In the live animal the tests available include:

- Faecal examination. Microscopic examination for clumps of acid-fast organisms in faecal smears stained with Ziehl–Nielsen stain will usually detect heavy shedders with diarrhoea, but may miss intermittent/light shedders. MAP growth takes up to three months *in vitro* on mycobactin-containing media. Repeat testing may be necessary.
- Small quantities of mycobacterial DNA in faeces can be detected using specific probes for MAP permitting more rapid (three days) and sensitive testing of individual cattle.
- Serological tests detect antibodies to crude MAP antigen; however, not all cases show a detectable antibody response:
 - CFT. Widely used for cattle and particularly for export checks. Sensitivity and specificity are low, particularly in subclinical cases.
 - Agar gel immunodiffusion (AGID) test. Has a higher sensitivity and specificity than the CFT, but is poor at detecting subclinical cases.
 - ELISA is the best option, and although the sensitivity is less than 50% in subclinical cases, a specificity >90% is expected.

In suspected clinical cases, diagnosis is best undertaken using a combination of clinical examination findings with serology and faecal testing for MAP. One of two positive tests warrants culling the animal.

In cattle with suspected subclinical disease, a positive result in both tests is conclusive, whereas one negative test

result warrants isolation and repeat sampling in 2–3 months if the client is reluctant to cull the animal. Necropsy reveals gross thickening and corrugation of small intestine (241).

MANAGEMENT

All clinical cases, and confirmed subclinical cases, should be culled immediately to prevent further spread of infection.

Prevention/control measures

Control is difficult to achieve because of the long incubation period, shedding by subclinically infected animals and the low sensitivity of available diagnostic tests. Herd eradication necessitates substantial commitment by the farmer, veterinarian and local veterinary laboratory and is based on identification and removal of all infected animals. Serological testing and/or faecal culture may be undertaken every 6–12 months, with slaughter of positive cases. Two consecutive negative herd tests may indicate eradication of paratuberculosis.

Another possible control measure is separation of cattle into infected and non-infected herds. Drastic eradication measures such as total depopulation and re-stocking after several years are economically unfeasible.

Control measures can limit losses in a herd with clinical cases, including prompt culling of clinical cases, minimizing faecal contamination of food, water and pasture by raising feed and water troughs, strip grazing, use of piped rather than pond water, avoiding spreading yard manure on pasture and maintaining good hygiene in cattle sheds. Separating newborn calves from their dams at birth and rearing them with artificial colostrum/milk can be a useful control measure in infected dairy herds. Calves from known infected dams should not be used as replacement breeding stock. Re-stocking should be only from disease-free herds.

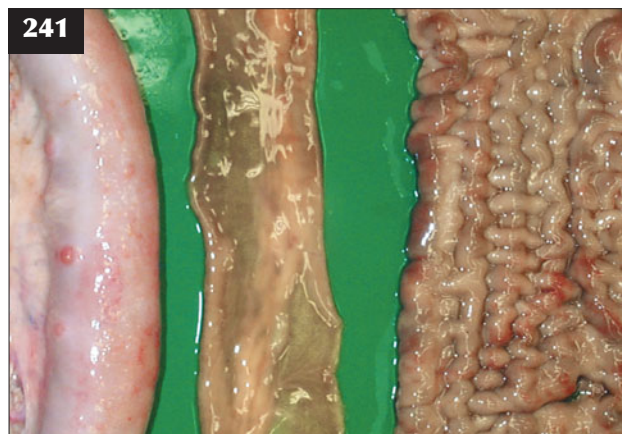Vaccination

Vaccination has been used for paratuberculosis control in many countries. Inoculation is given into the brisket area of young calves (usually under one month old) with formation of a large granulomatous reaction. Evidence shows that vaccinated herds have fewer clinical cases and losses, but disease is not eradicated. Vaccination may interfere with interpretation of the comparative intradermal tuberculin test.

BOVINE VIRAL DIARRHOEA VIRUS INFECTION

DEFINITION/OVERVIEW

It is estimated that more than 90% of UK herds have been exposed to BVDV, whereas many other regions/countries in Europe have either eradicated infection or have well established control programmes. Two distinct syndromes



241 Paratuberculosis. Necropsy reveals gross thickening and corrugation of the small intestine; normal intestine is included in the centre for comparison.

are recognized following BVDV infection in cattle: acute bovine virus diarrhoea (BVD) and mucosal disease (MD).

AETIOLOGY

BVDV is a pestivirus closely related to the viruses causing border disease in sheep and swine fever in pigs. Viraemic cattle shed virus mainly in nasopharyngeal secretions, urine and via aerosol droplets, but not in faeces. Transmission is usually by direct contact with viraemic animals, but virus can be spread by blood-sucking insects, contaminated needles and rectal examination gloves. Sheep and deer can theoretically act as vectors of the virus and cause infection in cattle. BVDV can be transmitted in fresh or frozen semen of infected bulls and via transferred embryos.

Two distinct forms (biotypes) of virus exist and are distinguished by their effects on cell culture. They are described as either the cytopathic (Cp) form or the non-cytopathic (Ncp) form. Two separate pathogenic groups, type 1 BVDV and type 2 BVDV, have been identified in the USA; BVDV-2 has also recently been reported as causing disease in the UK.

BVDV can be spread via the semen of persistently infected bulls or bulls experiencing acute BVD with transient viraemia. Infection in the semen will cause lower pregnancy rates due to higher embryonic losses or later fetal death/abortion. Occasionally, infected semen can result in the birth of a persistently infected calf.

CLINICAL PRESENTATION

Acute BVD

Acute BVD occurs when previously unexposed antibody-negative cattle come into contact with NcpBVDV. Following transient viraemia, cattle seroconvert over 3–4 weeks and remain antibody positive for up to three years. Many acute BVDV infections are subclinical, but some cattle become pyrexia, appear dull and have oral/nasal erosions that quickly heal (242). Transient diarrhoea and milk drop may be the only signs in lactating dairy cattle and most affected animals recover uneventfully. There have been isolated recorded outbreaks of acute BVDV-1 infection causing fatal enteritis in dairy cows. Affected cattle are leucopenic during the acute phase of disease, which may increase susceptibility to other infectious disease agents (e.g. *Salmonella* spp., infectious bovine rhinotracheitis [IBR], BRSV and coccidia) and cause more severe clinical disease. A severe haemorrhagic syndrome has been described with acute BVDV-2 infection in the USA, and in 2007, severe disease was reported in a UK dairy herd associated with BVDV-2; signs included rapid weight loss, abortion and mortality.

Clinical recovery follows acute BVDV infection in non-pregnant cattle, with seroconversion and immunity for up to three years. However, more importantly, acute BVD in naïve pregnant cattle can cause various problems following transplacental infection of the fetus depending on the stage



242 This heifer is suffering from acute bovine viral diarrhoea. It was dull and pyrexia and had discrete erosions present on the hard palate. It made an uneventful recovery.

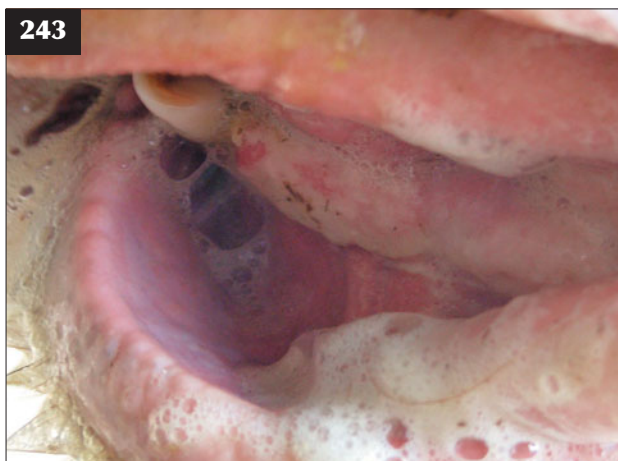of pregnancy. Infection of the fetus at less than 110–120 days of gestation may lead to the birth of a live calf persistently infected with BVDV. This is caused by failure of the fetus to recognize BVDV as foreign because its immune system is not fully functional until after 110–120 days. Persistently infected calves are born viraemic and remain so, acting as potent sources of BVDV infection to in-contact susceptible cattle. Fetal infection between 90 and 150 days may lead to congenital abnormalities such as cataracts, retinal dysplasia, cerebellar hypoplasia (see Chapter 6, Nervous system diseases, p. 148), CNS dysmyelination and cerebral cavitation. These calves may be born showing ataxia (cerebellar hypoplasia) and blindness (retinal dysplasia, hydranencephaly) and they are normally antibody positive if sampled before sucking colostrum. Infection after 150 days typically results in a normal, live seropositive calf born at full term. Abortion can occur following BVDV infection at any stage of pregnancy, but is not commonly diagnosed.

Colostrally-derived antibodies normally wane by six months old, but they can persist for as long as one year.

Mucosal disease

MD can only occur in cattle that have been born persistently viraemic following in-utero exposure to NcpBVDV during early pregnancy. MD results when persistently infected cattle become superinfected with CpBVDV. The CpBVDV arises from mutation of the NcpBVD virus within the persistently infected animal. Most cases of MD occur in 6–12-month-old cattle, which may coincide with the waning of passive immunity. Other persistently infected cattle may occasionally survive until 4–5 years old, but most are culled for poor growth often associated with secondary bacterial/viral infections.

Cattle affected with MD have acute onset depression, pyrexia (around 41°C) and anorexia. There is tacky saliva



243 In this animal with mucosal disease there is tacky saliva around the muzzle and widespread oral and nasal erosions extending to ulcers, especially on the hard palate, gums and dental pad.

around the muzzle and widespread oral and nasal erosions extending to ulcers, especially on the hard palate, gums and dental pad (243). There is often a profuse mucopurulent nasal discharge. There is profuse diarrhoea and possibly dysentery, with shreds of gut mucosa present during the terminal stages. There may be interdigital skin erosions/ulcers present, which cause lameness, and occasionally dermatitis. Thrombocytopenia may lead to subcutaneous haematomas. There is rapid deterioration with extensive weight loss and death within 5–10 days, but most animals are euthanased for welfare reasons once the disease has been confirmed.

DIFFERENTIAL DIAGNOSIS

Malignant catarrhal fever; severe IBR and foot and mouth disease (FMD) (other cattle affected in group); salmonellosis; necrotic enteritis; bluetongue.

DIAGNOSIS

- **Acute BVD of susceptible cattle.** Paired acute/convalescent sera 3–4 weeks apart demonstrate a rising titre using the ELISA test. Maternally-derived antibodies interfere with the interpretation of results in calves less than six months old.
- **MD.** Diagnosis is based on the characteristic necropsy findings, with virus isolated from tissues. Affected cattle are typically antibody negative and antigen (virus) positive on ELISA; however, there may be a low antibody titre due to persistent maternally-derived antibody.

Persistently infected calves may be clinically normal before developing MD, but many present as poorly grown compared with others in the group (244). Persistent infection status/viraemia is confirmed by two samples taken 3–4 weeks apart (a single virus-positive sample could indicate transient viraemia only). There is low or negative antibody status.



244 Bovine virus diarrhoea. Persistently infected calf on the right, with age-matched herd mate on the left.

Newborn calves can be tested for BVDV status if blood sampled before sucking colostrum. If calves have sucked colostrum, the passively-derived antibodies may mask viraemia for 3–4 months, leading to false-negative antigen results. The new IDEXX BVDV antigen test used by some laboratories is able to detect BVDV in samples from one-month-old calves despite the presence of maternally-derived antibody.

In unvaccinated herds, bulk milk antibody ELISA testing is a cheap method of establishing dairy herd status for BVDV infection. Active infection can be confirmed by targeted milk sampling of cohorts of first-lactation heifers (or yearling cattle) that have been born and reared on farm.

MANAGEMENT

Symptomatic supportive treatment should be provided for enteritis in cattle with acute BVD. There is no effective treatment for MD and cattle must be euthanased for welfare reasons.

Persistently infected animals should be culled because they act as a source of infection. They can be isolated and reared for beef if they are growing normally; however, many persistently infected cattle are already poorly grown due to concurrent chronic bacterial infections, such as chronic suppurative pulmonary disease, and further feeding will usually prove uneconomic (245).

Prevention/control measures

In many countries worldwide, including the UK, herds are endemically infected with BVDV, although the disease is partly limited by persistently infected calves acting as 'natural vaccinators' of in-contact members of the herd. When most of the adult animals in the herd are seropositive for BVDV, losses may not be so obvious to the farmer. Major losses are most likely to occur after naïve



245

245 Persistently infected calves are typically stunted and ill-thriven, as illustrated in this calf.

breeding females are introduced into the BVDV-infected herd. All herds should establish their BVDV status and control/prevent the disease either by vaccination or by eradication, combined with stringent biosecurity. All bulls are routinely screened for BVDV before entering AI studs.

Vaccination

The vaccination regimen is generally an initial vaccination course of two doses 3–4 weeks apart before the breeding period, followed by annual boosters. If all breeding females in the herd are vaccinated as heifers, this should control disease by preventing acute BVDV infection and fetal infection. Even in vaccinated herds it is sensible to quarantine test all purchased breeding stock for BVDV antigen to prevent introduction of persistently infected cattle.

Eradication

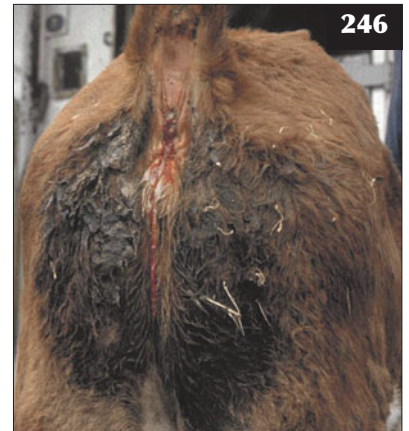BVD eradication has been achieved in regions and countries after whole herd testing and elimination of persistently infected carrier cattle. Strict herd biosecurity measures must be maintained to prevent reintroduction of disease because the herd will become naïve if vaccination is not practised. Some herds may be chosen for vaccination and monitoring following eradication if biosecurity cannot be guaranteed.

NECROTIZING/NECROTIC ENTERITIS

DEFINITION/OVERVIEW

Necrotizing/necrotic enteritis in suckled calves was first described in 1991 in South East Scotland. Surveillance reports suggest this disease is becoming more common and widespread within the UK; there are no reports of the disease from other countries.

246 Persistent mucohaemorrhagic diarrhoea in a calf with necrotic enteritis.



246



247

247 Necrotizing/necrotic enteritis, causing tenesmus, in a three-month-old beef calf.

AETIOLOGY

The cause has not been identified.

CLINICAL PRESENTATION

This disease is seen most commonly in 2–4-month-old spring-born beef calves at pasture during the summer months. The morbidity is usually low (<10%), but the mortality rate is high (>80%). The disease may recur in the same herd in successive years.

The common clinical signs include depression, failure to suck and pyrexia (40–41°C) during the early stages. There is profuse haemorrhagic diarrhoea progressing over several days to more scant mucohaemorrhagic faeces (246). Affected animals show forceful tenesmus (247), which causes temporary rectal prolapse, and abdominal pain. The mucous membranes are pale. Oral and nasal ulceration is occasionally present. There is progressive dehydration followed in most cases by death in 7–10 days.

DIFFERENTIAL DIAGNOSIS

MD; salmonellosis; coccidiosis; lead poisoning.

DIAGNOSIS

Typical haematological findings are anaemia (variable in its severity) and leucopenia caused by a severe nonregenerative neutropenia. Cases exhibiting profound neutropenia carry a poor prognosis. Many affected calves have high blood urea concentrations associated with kidney pathology.

The common gross pathological findings include crusting of the nasal mucosa, with oral ulcers most prominent on the hard palate. Ulcers, often overlaid by necrotic debris and secondary fungal infection, may occur in the larynx (248), rumen, abomasum and small and large intestines (249) extending as far as the rectum. The ulcerative lesions vary from small discrete punctate lesions to large linear diphtheritic plaques overlying Peyer's patches. The ulcers may be full thickness, leading to areas of localized peritonitis on the serosal surface with adhesions to adjacent gut. The kidneys often appear swollen and pale, with infarcts. Inhalation pneumonia is often seen in association with severe pharyngeal and laryngeal diphtheritis (248).

MANAGEMENT

Symptomatic treatment includes parenteral antibiotics and oral and intravenous fluid therapy. Blood transfusion could be considered in severely anaemic calves, but the prognosis is grave.

Prevention/control measures

As the cause remains unknown there are no specific control measures.

MALIGNANT CATARRHAL FEVER**DEFINITION/OVERVIEW**

Malignant catarrhal fever (MCF) is a sporadic disease normally affecting single cattle and deer; however, on rare occasions outbreaks can occur in a group of cattle.

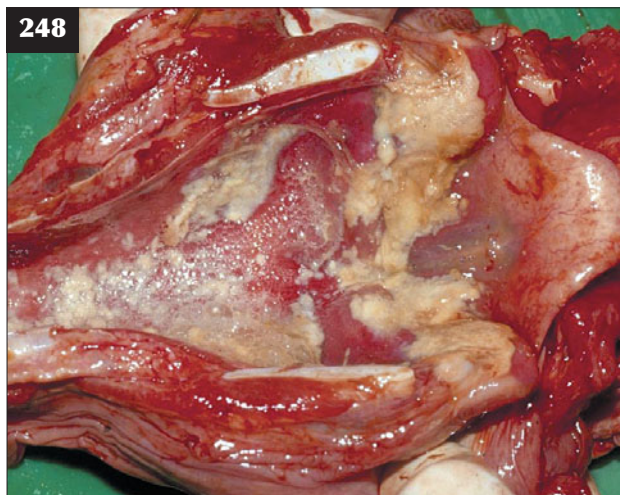
AETIOLOGY

MCF is caused by ovine herpesvirus-2. Contact with periparturient sheep or goats appears necessary for transmission to cattle and deer, although several months may elapse between such contact and overt disease. Sheep have a high seroprevalence rate, but the method of transmission to cattle remains unknown. Cattle do not transmit MCF.

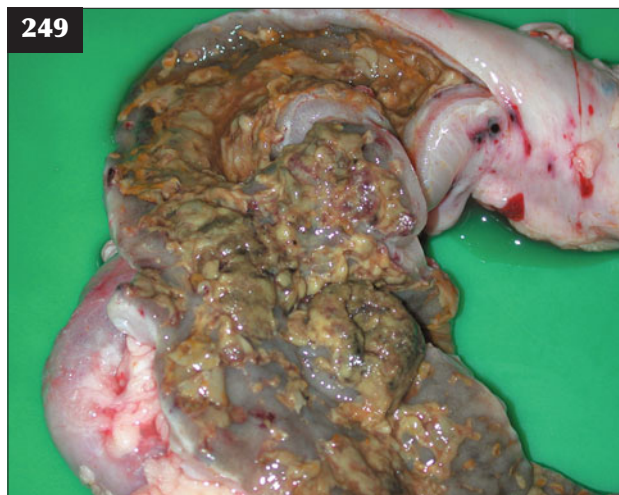CLINICAL PRESENTATION

Affected cattle present with sudden-onset profound depression, anorexia and pyrexia (40.5–42.0°C). There is intense scleral congestion, bilateral keratitis and corneal opacity starting at the edge of the sclera (250), eventually causing blindness. There is marked photophobia (251) and sudden exposure to strong sunlight evokes blepharospasm. There are copious mucopurulent ocular and nasal discharges (251, 252). There is crusting of the muzzle and sloughing of the mucosa in some cases (253). Examination of the mouth reveals halitosis from an erosive stomatitis (254). There is a generalized peripheral lymphadenopathy and an exudative dermatitis is occasionally seen.

Affected animals may become hyperaesthetic to touch, especially around the poll, and they may become aggressive and charge at attendants. Seizure and opisthotonus associated with encephalitis may develop during the agonal stages. Death normally occurs 5–10 days after onset of

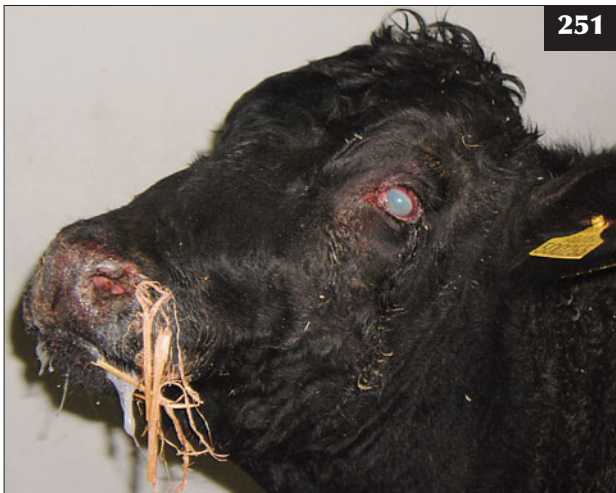
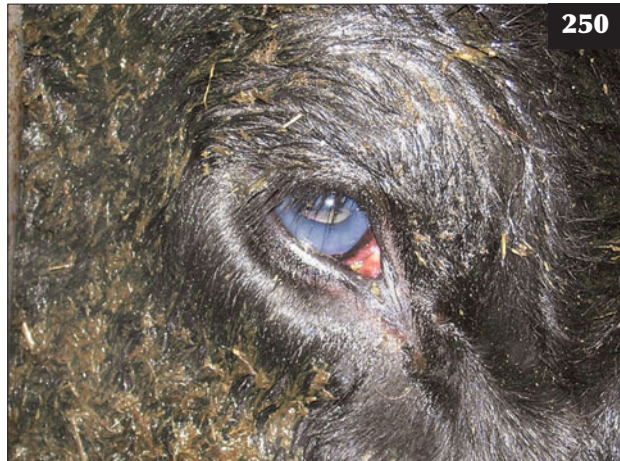
248 Necrotic enteritis. In this necropsy specimen, ulcers overlaid by necrotic debris and secondary fungal infection are seen in the larynx.

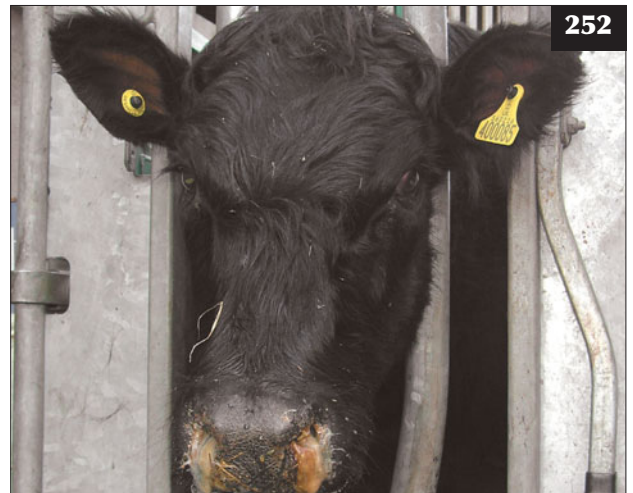


249 Necrotic enteritis. In this necropsy specimen, linear and punctuate ulceration overlaid with necrotic debris is seen over a large area of the ileum.

250 Corneal opacity (bilateral), which started at the limbus and spread to cause blindness due to severe ophthalmitis, in an animal with malignant catarrhal fever.



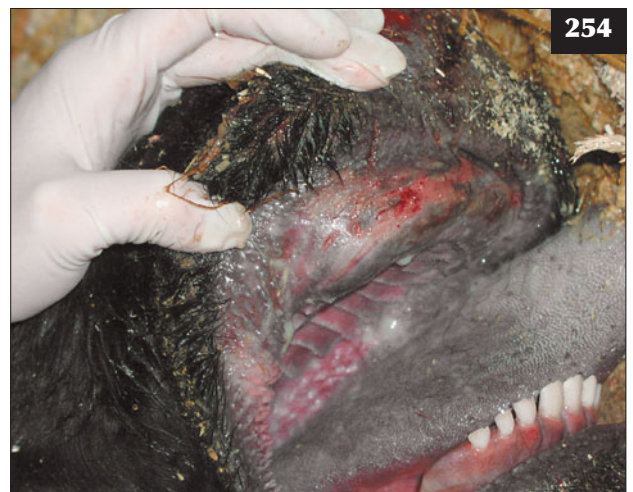251 Photophobia in an animal with malignant catarrhal fever.



252 Copious mucopurulent nasal discharge, which was accompanied by stertor, in a case of malignant catarrhal fever.



253 Crusting of the muzzle and sloughing of the mucosa in a case of malignant catarrhal fever.



254 Malignant catarrhal fever. Examination of the mouth reveals halitosis from an erosive stomatitis.

clinical signs, but affected animals should be euthanased for welfare reasons at the earliest opportunity.

A mild chronic form of MCF has been reported (255); poorly grown yearling cattle prove seropositive for MCF. Typically, these cattle are suspected of persistent BVDV infection, but prove antigen negative and further testing reveals MCF antibodies.

DIFFERENTIAL DIAGNOSIS

MD; severe IBR; listerial iritis; bluetongue.

DIAGNOSIS

Diagnosis is based on clinical signs and confirmed by demonstration of MCF antibodies in serum and/or characteristic post-mortem findings.

MANAGEMENT

There is no treatment and affected cattle must be euthanased immediately for welfare reasons. High doses of corticosteroids given systemically may give temporary improvement of clinical signs in a very small number of cases, but the small numbers of reported recovered cattle never thrive.

Prevention/control measures

Control relies on avoiding contact with sheep, but such management is not possible on most mixed stock farms.



255 A mild chronic form of malignant catarrhal fever in a yearling steer.

Chapter 4

Respiratory diseases

INTRODUCTION

OVERVIEW

Respiratory disease is the major cause of financial loss from infectious disease in growing cattle in many countries worldwide. Economic losses result from vaccination costs, antibiotic treatment and veterinary attendance, reduced short-term and lifetime growth rates and mortality.

AETIOLOGY

The aetiology of an outbreak of respiratory disease includes physiological, managerial and environmental factors in conjunction with viral and bacterial infectious agents.

Genetic selection has resulted in cattle with small lungs relative to metabolic demands and such reduced respiratory capacity can contribute to decreased resistance to air-borne infectious agents, particularly during periods of exertion. Reduction in bodyweight of between 9% and 12% occurring during - over long distances, poor appetite after arrival on the farm and changes in ration may compromise immune system function.

The importance of the respiratory tract innate defences (intact epithelium including ciliated cells, mucus, interferon and phagocytes) cannot be overemphasized. Confinement in cattle sheds (256) results not only in more direct contact between cattle, with increased aerosol challenge of infectious agents, but also adverse physical conditions, including poorer air quality, large fluctuations in temperature and humidity and the presence of dust particles.

The epidemic curves of respiratory disease morbidity and mortality under feedlot conditions (e.g. in North America) reach peak values within two weeks after arrival. Such data suggest that cattle may be incubating disease when they arrive at the feedlot. Under UK management systems, respiratory disease epidemic curves reach peak values 2–4 weeks after housing. Such differing incubation

periods may reflect the initiating role of respiratory virus infections in the UK compared with classic pasteurellosis (shipping fever) in North America.

DIAGNOSIS

Clinical selection parameters such as nasal discharge and cough are poorly correlated with respiratory disease. A rectal temperature $>39.6\text{--}40.0^{\circ}\text{C}$ is commonly used as the major indicator of significant respiratory disease and the necessity for antibiotic therapy.

There has been considerable debate in the veterinary literature regarding the generation and description of



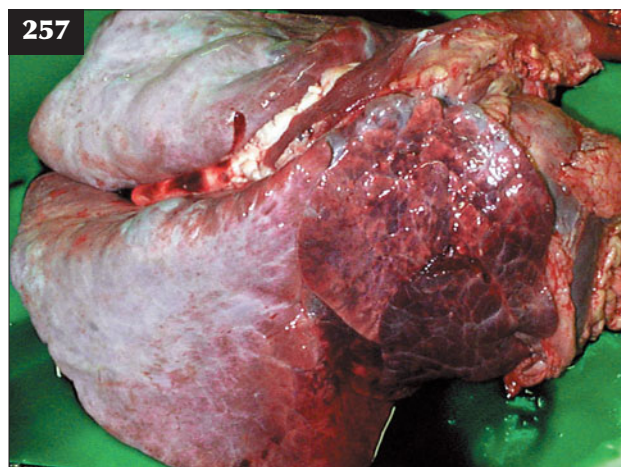
256 Housing, such as this closed shed, imposes adverse physical conditions including poorer air quality, large fluctuations in temperature and humidity and the presence of dust particles.

adventitious lung sounds and their relationship to underlying lung pathology (257, 258):

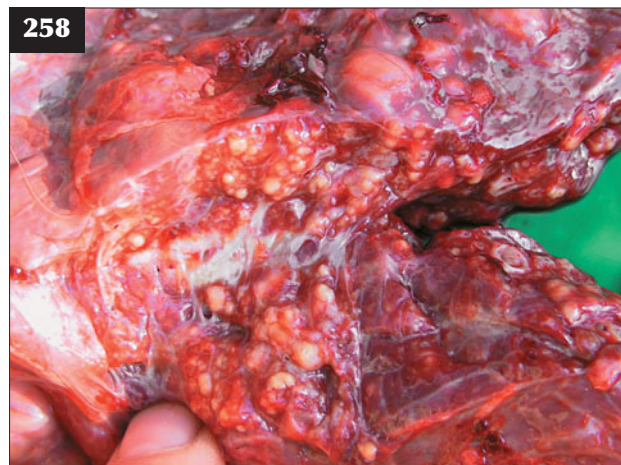
- Wheezes. Continuous single-pitch sound, usually occurring during inspiration and, occasionally, during both inspiration and expiration, resulting from vibration of airway walls caused by air turbulence in narrowed airways.
- Crackles. Sudden sounds towards the end of inspiration or, less frequently, during both inspiration and expiration caused by sudden opening of small airways plugged by mucus, pus and other debris.

MANAGEMENT

Field investigation of respiratory disease that selects beef



257 Wheezes heard as a continuous single-pitch sound during inspiration would have been expected over the consolidated anteroventral lung field in this case of bovine respiratory syncytial virus infection.



258 Crackles heard as sudden sounds towards the end of inspiration and caused by sudden opening of small airways plugged by pus and other debris would have been expected in this case.

cattle for treatment based on rectal temperature $>39.6^{\circ}\text{C}$ is as effective as mass treatment (whole group metaphylaxis) and reduces medication costs by 58%. In most cattle handling systems it should be possible for two stockmen to check the rectal temperature and treat more than 100 cattle per hour. Reasons against regular monitoring of all cattle during disease outbreaks have included fears regarding further stress-induced disease or exacerbation of existing problems, availability and cost of farm labour and perceived additional veterinary costs, but these are unfounded. Despite the paucity of convincing evidence from field studies in northern Europe, there has been an increasing trend towards whole group metaphylactic antibiotic injection in the UK, facilitated by the development of antibiotic treatments as single injection formulations.

Antibiotic re-treatment

Antibiotic re-treatment becomes necessary when bacterial infection recurs during the period of viral-induced compromise of host defence mechanisms in the upper respiratory tract. By definition, the interval between antibiotic treatments has to be greater than the period of maintenance of effective minimum inhibitory concentration (MIC) of antibiotic in lung and bronchial secretions, otherwise the antibiotic has not been fully effective and/or the bacterial pathogens were not susceptible to the antibiotic selected. Recurrence of respiratory disease with pyrexia $>39.6^{\circ}\text{C}$ after four or more days' interval has been treated with the same antibiotic in many field studies with very good results. This is a very important principle; the antibiotic was effective, but because of the impaired physical defences caused by viruses, bacterial infection has recurred and there is the likelihood that the same antibiotic would again be effective. Such recurrence of pyrexia is rarely the result of a rapid development of resistance and the term relapse should be used with caution because it may prove misleading, especially to farmers.

ANIMAL WELFARE

There are obvious animal welfare benefits from the early detection and effective treatment of respiratory disease by the veterinarian. The avoidance of chronic suppurative pulmonary disease (CSPD) and associated suffering has been a feature of intensive respiratory disease monitoring programmes.

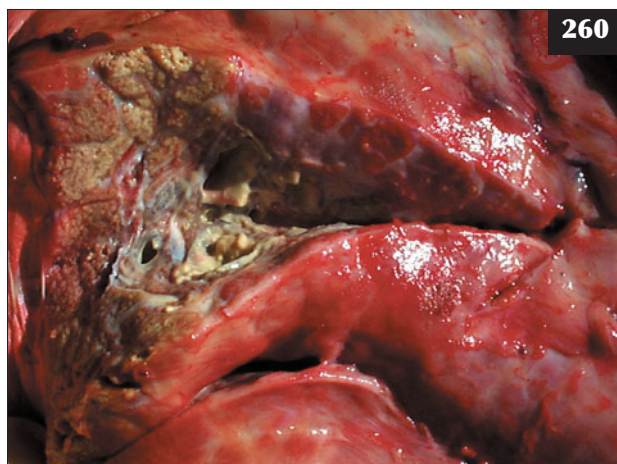
ULTRASONOGRAPHIC EXAMINATION OF THE THORAX

Ultrasonographic examination of the bovine chest is inexpensive and non-invasive and, unlike radiography, there are no special health and safety procedures or restrictions. Furthermore, a 5.0 MHz sector transducer connected to a real-time, B-mode ultrasound machine is readily transportable, allowing ultrasonographic examinations to be performed on the farm. A 7 cm wide strip of hair is shaved from both sides of the thorax, extending in a vertical plane from the caudal edge of the scapula to below the point of the elbow. The skin is soaked with warm tap water and ultrasound gel applied liberally to the wet skin to ensure good contact. The transducer head is held firmly at right-angles against the skin overlying the 6th or 7th intercostal spaces (259).

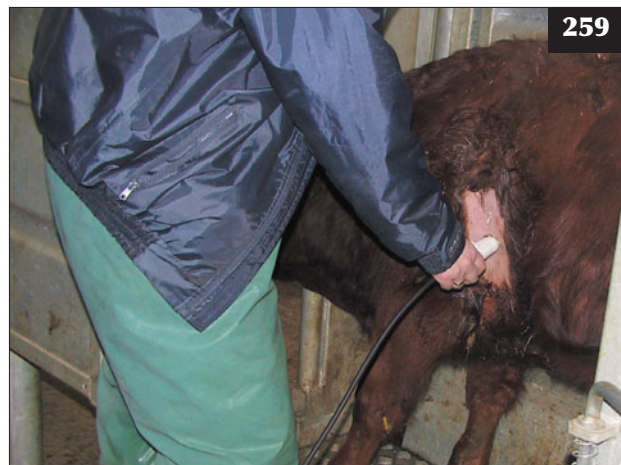In general, auscultation overestimates the extent of lung pathology, presumably due to referral of abnormal sounds over areas of normal lung. However, ultrasound examination may fail to differentiate areas of lobular consolidation from abscesses in some cases of CSPD (260). Ultrasonography is of little use in severe BRSV cases where there is extensive caudodorsal emphysema, because air-filled bullae cannot be distinguished from normal aerated lung.

NORMAL CATTLE

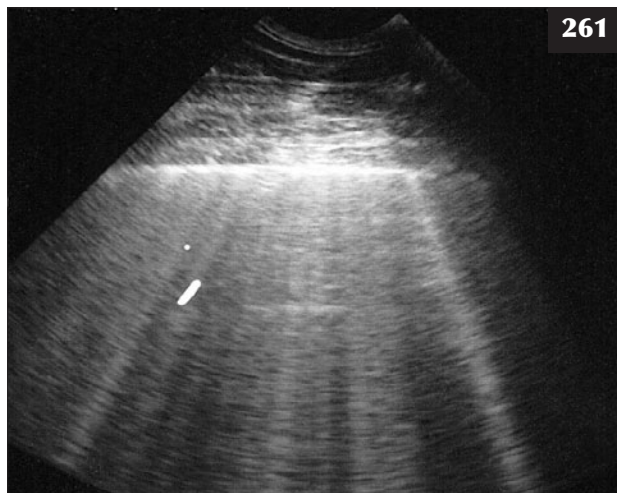
The surface of normal aerated lung (visceral or pulmonary pleura) of normal cattle is characterized by the uppermost white linear echo (261), with one or two equally-spaced reverberation artefacts below this line. In normal cattle (200–600 kg body weight) the visceral pleura can be observed moving 2–4 mm in a vertical plane during respiration. No pleural fluid is visualized in normal cattle.



260 It is not possible accurately to define all lung pathology on auscultation alone.



259 Ultrasound examination of the bovine chest, as shown here, takes less than five minutes and provides valuable information, particularly in the diagnosis of chronic respiratory disease.



261 The surface of normal aerated lung (visceral or pulmonary pleura) is represented by a white linear echo in this ultrasonogram.

CHRONIC SUPPURATIVE PNEUMONIA

Large irregular hypoechoic areas bordered by bright white (hyperechoic) lines 2–8 cm from the visceral pleura represent areas of lung consolidation/abscessation with a typical lobular distribution pattern (262). The extent of such lesions can prove a useful prognostic guide.

PLEURISY

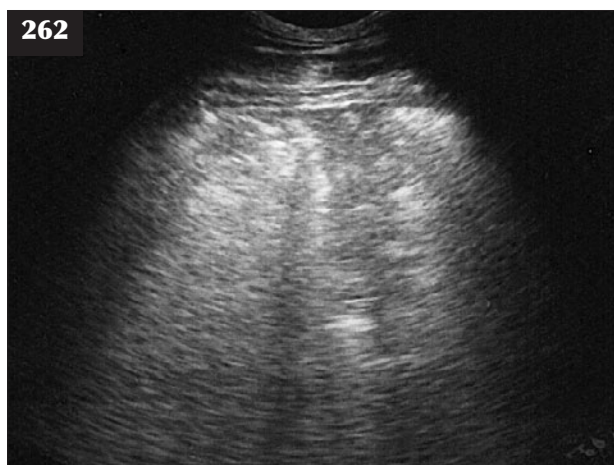
In cattle with pleurisy the visceral pleura may appear thicker than normal (broad hyperechoic line) and be displaced from the parietal pleura by an area of varying hypoechogenicity representing fibrin exudation (pleurisy) between the parietal and visceral pleurae (263, 264). In more severe cases there is considerable pleural exudate and fibrin deposition (265, 266)

PLEURAL ABSCESS

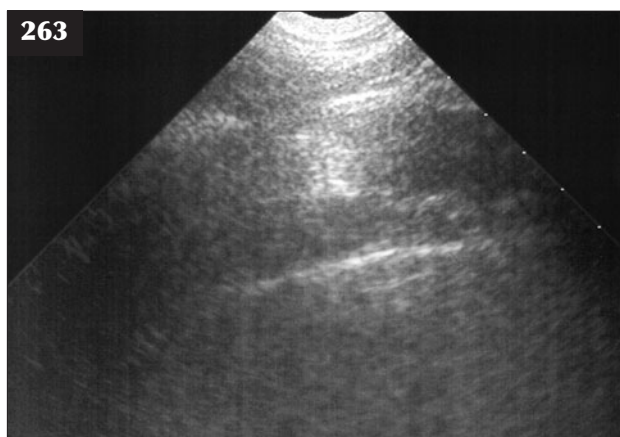
Unlike sheep, numerous discrete pleural abscesses are uncommon in cattle, but a single massive abscess/unilateral pyothorax containing up to 50 litres of pus (267), recognized by the anechoic area containing multiple hyperechoic dots (268), is occasionally seen.

PLEURAL EFFUSION

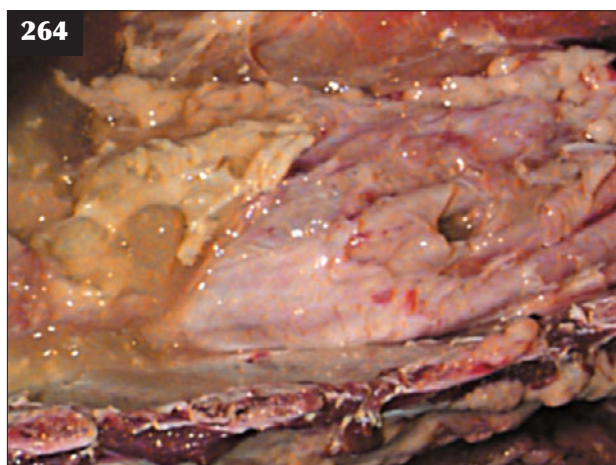
Extensive pleural effusion (cor pulmonale) can be associated with right-sided heart failure in cattle with diffuse fibrosing alveolitis, dilated cardiomyopathy and thymic lymphosarcoma. In some cases the pleural effusion may be primarily unilateral. The effusion may extend beyond the 20 cm field depth of some equipment (269) and exceed 50 litres (270).



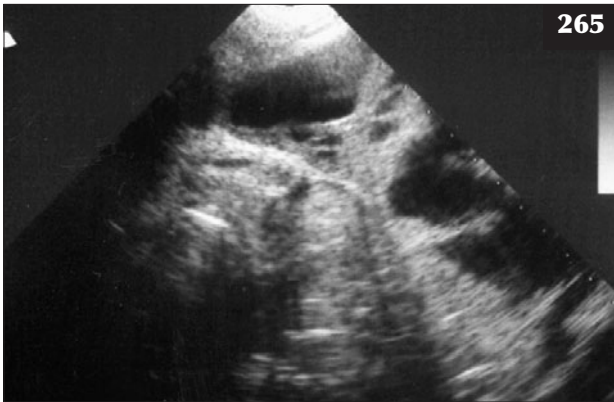
262 Large irregular hypoechoic areas bordered by bright white (hyperechoic) lines 4–8 cm from the visceral pleura represent lung consolidation/abscessation in this ultrasonogram. (See also **258** and **260**.)



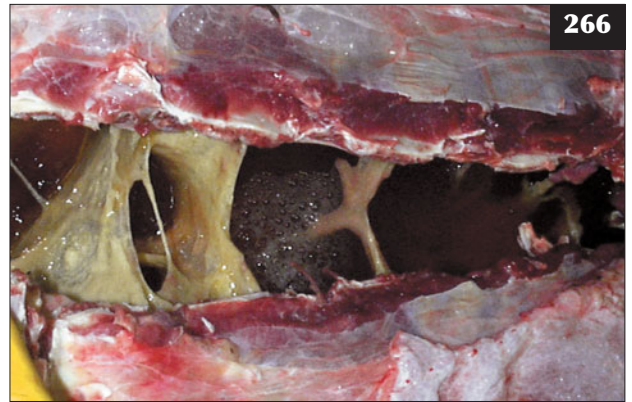263 The visceral pleura is displaced 2–3 cm from the parietal pleura by an area of varying hypoechogenicity representing fibrin exudation (pleurisy) in this ultrasonogram.



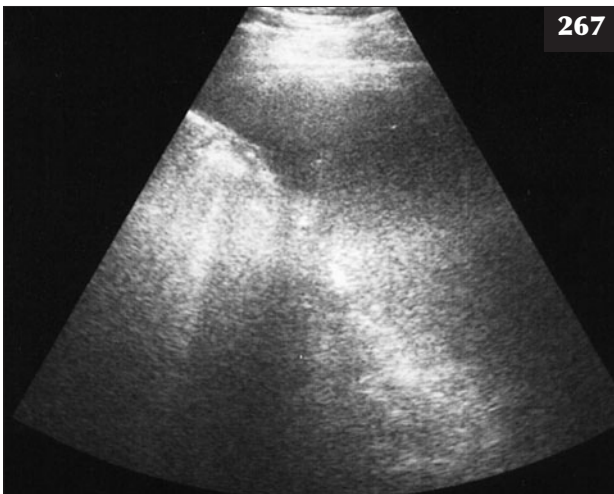
264 Necropsy of the animal in **263** reveals fibrin exudation (pleurisy) between the parietal and visceral pleurae.



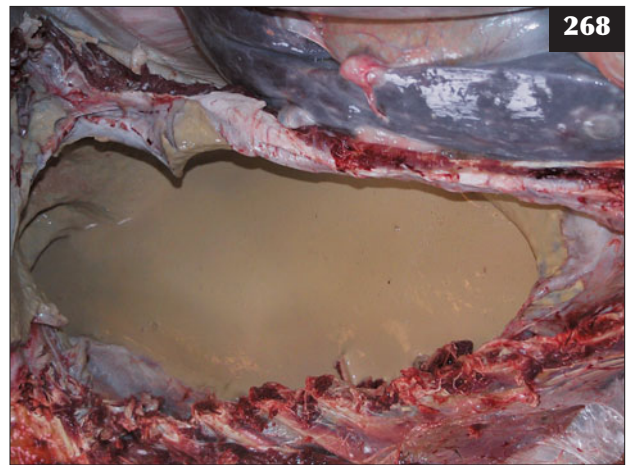
265 Extensive pleural effusion (anechoic area), with broad hyperechoic bands of fibrin extending between the parietal and visceral pleurae, is seen in this ultrasonogram.



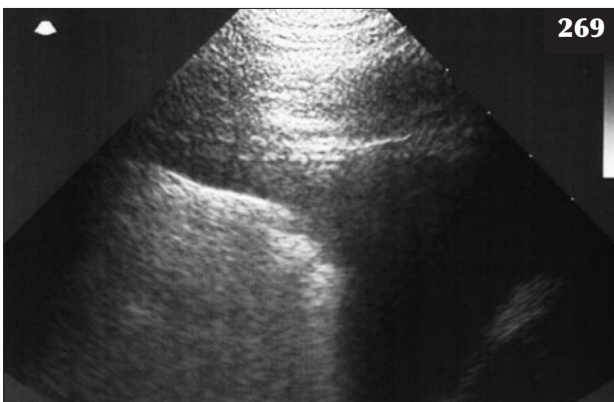
266 Necropsy of the animal in **265** reveals extensive pleural effusion and fibrin deposition between the parietal and visceral pleurae.



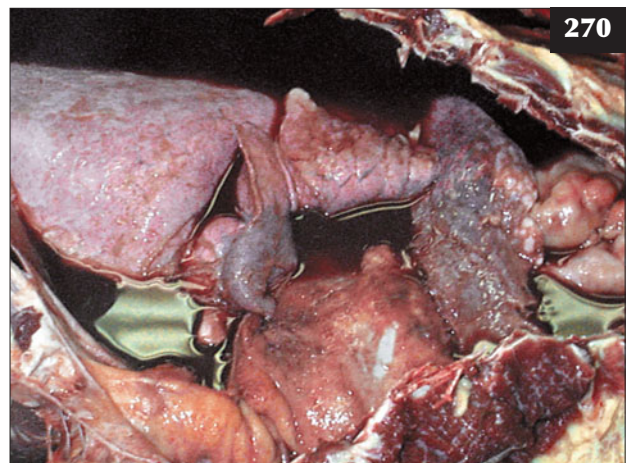
267 Ultrasonogram of a massive pleural abscess. The abscess appears as an anechoic area containing multiple hyperechoic dots. (Dorsal is to the left.)



268 A single massive pleural abscess, as illustrated in this necropsy specimen, may contain up to 50 litres of pus.



269 In this ultrasonogram the pleural effusion has extended beyond the field depth of the equipment. (Dorsal is to the left.)



270 Necropsy of the animal in **269** with a thymic lymphosarcoma reveals extensive pleural effusion.



271

271 Ultrasound-guided thoracocentesis (drainage) is safe to perform under local anaesthesia when the animal is restrained in cattle stocks.



272

EMPHYSEMA

Ultrasonography is of little or no use in severe BRSV cases where there is extensive caudodorsal emphysema because air-filled bullae cannot be distinguished from normal aerated lung.

ULTRASOUND-GUIDED THORACOCENTESIS

Ultrasound-guided thoracocentesis is safe to perform under local anaesthesia, with a 2 inch, 19 gauge hypodermic needle, when the animal is restrained in cattle stocks (271).

PASTEURELLOSIS (SHIPPING FEVER, TRANSIT FEVER)


DEFINITION/OVERVIEW

Although recent changes in nomenclature have reclassified *Pasteurella haemolytica* as *Mannheimia haemolytica*, the collective terms 'pasteurellae' and 'pasteurellosis' to describe a distinct clinical presentation are still in common usage. Pasteurellosis is a common acute infection occurring worldwide and resulting in a bronchopneumonia affecting cattle aged between one month (272) and two years (273).

AETIOLOGY

Pasteurellae are part of the normal flora of the nasopharynx. A number of factors, including respiratory viruses, weaning, overcrowding and poorly ventilated buildings (274), transportation, adverse weather and starvation, allow/promote an increase in numbers and/or virulence of pasteurellae in the nasopharynx and invasion of the lungs. In many countries the occurrence after sale and transport, often over very large distances and taking several days, has led to the term 'shipping fever' being used.

M. haemolytica is believed to be responsible for up to 90% of cases; the others are attributable to *Pasteurella multocida*.



273

272, 273 Pasteurellosis causing bronchopneumonia in a young calf (272) and an 18-month-old steer (273).



274

274 Overcrowding and poorly ventilated buildings, as shown here, are important factors in the aetiology of pasteurellosis.

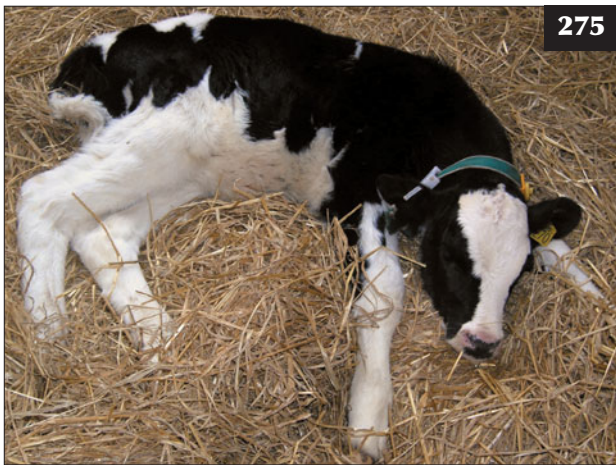CLINICAL PRESENTATION

In the UK, one or two animals in the group are typically affected 2–3 weeks after sale and transport. In many countries where beef cattle are transported long distances to very large specialized operations (e.g. North American feedlots), the prevalence of disease within the first month of arrival can be as high as 50–75%, which has led to the common practice of prophylactic antibiotic injection on arrival.

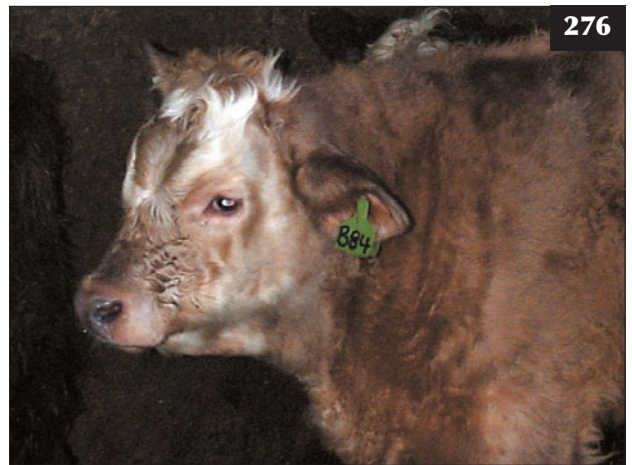The affected animal is dull and may remain isolated in a corner of the pen (275) and not come to the feed trough with the other cattle. The rectal temperature is typically 41–42°C. There is a slight serous ocular discharge and variable mucopurulent nasal discharge (276). The presence of marked purulent ocular and nasal discharges in a

number of cattle must alert the clinician to the possibility of IBR (277). There is an increased respiratory rate and abdominal effort, most noticeable after sudden exercise when driving to the handling facility, but there are few abnormal sounds on auscultation of the chest. The lack of significant abnormal lung sounds relative to the animal's high fever must not deter the clinician from a diagnosis of respiratory disease. Coughing is not a feature of pneumonic pasteurellosis. More severely affected cattle may stand with the neck extended and the head lowered, with frothy saliva at the mouth (278), but this is a less common presentation and is usually more commonly associated with acute BRSV infection.

Clinical disease caused by *P. multocida* is generally more severe than described above, with more evidence of



275 This young calf with pasteurellosis is dull and inappetent and is isolated from others in the group.



276 Slight mucopurulent nasal discharge in an animal with pasteurellosis. Note that there is no ocular involvement. Contrast this animal with the cow in 277.

277 The marked conjunctivitis with a purulent ocular discharge in this cow should alert the clinician to the possibility of infectious bovine rhinotracheitis.



278 Pasteurellosis. This severely affected calf is standing with its neck extended, the head lowered and with frothy saliva at the mouth.

thoracic pain (279). Lesions may be observed ultrasonographically in more advanced cases, with evidence of a necrotizing pneumonia and consolidation of lung lobes seen at necropsy (280).

DIFFERENTIAL DIAGNOSIS

It is essential to inspect other cattle in the group for clinical signs of IBR (277). Lungworm may be a complicating factor in cattle that have been at pasture. Recrudescence of chronic respiratory disease in an individual animal should also be considered.

DIAGNOSIS

Nasal swabs and bronchoalveolar lavage (BAL) fluid are of little use in diagnosing pasteurellosis because these bacteria are commensals of the upper respiratory tract and can be found in the lower respiratory tract of normal cattle. Clinical findings of a fibrinous pleurisy are more common in North American feedlots. Paired serology for IBR and/or BRSV may be valuable for future disease prevention strategies.

MANAGEMENT

Some affected animals may recover in 3–7 days without antibiotic treatment.

Selection of cattle on clinical appearance alone (281) and catching these animals in a pen behind a gate is very inefficient and ineffective. Cattle for antibiotic treatment should be selected based on a rectal temperature $>39.6^{\circ}\text{C}$. Metaphylactic injection may be used in exceptional circumstances such as an outbreak of respiratory disease in beef cattle at pasture.

While 75–80% of lung isolates of pasteurellae are sensitive to oxytetracycline (recommended dose is 10 mg/kg i/v on the first day then a single long-acting i/m injection), this antibiotic is not commonly used by veterinarians.

Tilmicosin and tulathromycin are highly effective against the major respiratory pathogens and are single long-acting injection formulations. Similarly, florfenicol can be administered on days 1 and 3 or as a single long-acting injection. Florfenicol is also combined with flunixin meglumine. There is no real difference between these antibiotic preparations in most respiratory disease outbreaks and cost is often a major factor.

The fluoroquinolones (enrofloxacin, marbofloxacin and danofloxacin) are highly effective against *Pasteurella* spp., but there are concerns about their use in food-producing animals and they should perhaps be held in reserve, as many other antibiotics will effect a cure.

Monitoring response to antibiotic treatment

Field studies have demonstrated a marked reduction in calf rectal temperature 24 hours after the start of antibiotic treatment, indicating efficacy of that antibiotic in the treatment of bacterial respiratory disease and highlighting the importance of monitoring the disease outbreak. A



279 This cow with disease caused by *P. multocida* shows evidence of thoracic pain.



280 Necropsy specimen showing extensive consolidation and necrotizing pneumonia from which *M. haemolytica* and *P. multocida* were both cultured.



281 Selection of cattle with respiratory disease based on clinical appearance alone is very inefficient and ineffective.

different antibiotic should be administered where there has been a failure of the rectal temperature to fall after 48 hours or recurrence of pyrexia 2–4 days after the first antibiotic treatment.

Antibiotic re-treatment

Recurrence of pyrexia 5–14 days after first antibiotic treatment typically occurs in 20% of treated calves, hence the necessity for an effective monitoring programme. Use of the same antibiotic is recommended because re-infection of compromised lung defences has occurred; this is not an antibiotic resistance problem.

Supportive therapy

With the exception of peracute BRSV cases, where the animal is severely dyspnoeic, corticosteroids should be avoided because of their potent antipyretic action, until the animal's rectal temperature begins to fall. A single intravenous injection of an NSAID such as flunixin meglumine or ketoprofen has powerful analgesic properties, but NSAIDs are not such potent antipyretic agents, with a significant improvement lasting only 6–8 hours. Split group studies have failed to demonstrate significant long-term production benefits from the routine

use of NSAIDs in the treatment of bovine respiratory disease.

Prevention/control measures

Animals from different sources and different age groups (282) must not be mixed together. Improved ventilation of buildings (283–285) and delaying stressful procedures for several months after arrival on the unit may help reduce the disease prevalence. Open-fronted sheds (286) are commonly used for weaned dairy calves with good results.



282 Cattle of different age groups, as shown here, must not be mixed and housed together.



283–286 Pasteurellosis. **(283)** Poor ventilation predisposes to respiratory disease. In this building the smoke (spent air) exits under the eaves where fresh air should enter the building. **(284)** The space sheeting in the roof of this building is used to increase air outflow. **(285)** A purpose-built cattle fattening unit with plenty of natural ventilation through the space boarding below the eaves. **(286)** An open-fronted shed, facing away from prevailing winds, being used for weaned dairy calves with good results.



Pasteurella vaccines have not been found to be very successful. Isolation of affected animals allows better nursing and may reduce bacterial challenge to healthy animal in the group.

Viral vaccines may be effective where IBR, BRSV or parainfluenza (PI)3 virus infections are contributing factors.

Economics

Losses from respiratory disease outbreaks can be very considerable. Lost production, increased feed costs for convalescing animals and delayed marketing may exceed losses from mortality.

Welfare implications

There are obvious animal welfare benefits from the early detection and effective treatment of respiratory disease by the veterinarian. Such monitoring is consistent with good clinical practice. The avoidance of CPSD has been a feature of structured disease monitoring programmes.

HISTOPHILUS SOMNI INFECTION

DEFINITION/OVERVIEW

Histophilus somni is a major respiratory pathogen worldwide.

AETIOLOGY

Like pasteurellosis, respiratory disease caused by *H. somni* is common following sale and transport and other stressors and primary viral infections of the respiratory tract. Thromboembolic meningoencephalitis (TEME) is commonly reported in feedlots in the USA 1–2 weeks following an episode of *H. somni* respiratory disease, but this syndrome is currently very uncommon in the UK.

CLINICAL PRESENTATION

The clinical signs are similar to those described for pasteurellosis. Cattle that develop TEME are initially described as having a 'drunk' appearance, with ataxia progressing to sternal recumbency, profound depression and lack of awareness of their surroundings. Cardiac failure due to myocarditis is another possible sequela to *H. somni* infection.

DIFFERENTIAL DIAGNOSIS

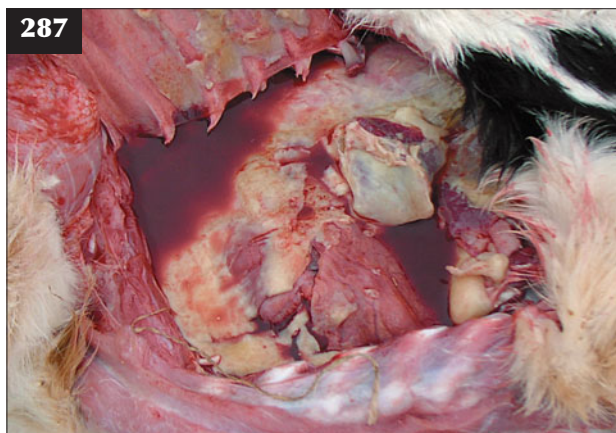
Other bacterial causes of pneumonia and meningitis; IBR encephalitis.

DIAGNOSIS

Specific diagnosis can only reliably be made using BAL sampling or at necropsy, with findings of marked fibrinous pleuritis and pleuropneumonia (287).

MANAGEMENT

Of the commonly used antibiotics, florfenicol has the lowest MIC against *H. somni*.



287 On-farm necropsy finding of fibrinous pleuropneumonia.

Prevention/control measures

Prevention/control measures are similar to those for pasteurellosis (see above).

CHRONIC SUPPURATIVE PULMONARY DISEASE

DEFINITION/OVERVIEW

CSPD develops as a result of unsuccessful treatment or incomplete recovery from earlier pneumonia episodes.

AETIOLOGY

Recrudescence of infection is often associated with a stressor such as transport, sale or parturition. CSPD is often associated with persistent BVD/MD virus infection in growing cattle (288).

CLINICAL PRESENTATION

Typical cases are dull, in poorer condition than their peers, have a dry staring coat (289), and are intermittently febrile up to 39.5°C. Dairy cows (290) and, more typically, first calved heifers have a disappointing milk yield. Affected animals cough frequently and have an occasional mucopurulent nasal discharge. The respiratory rate is increased (40–60 breaths per minute) with an obvious abdominal component to respiration. The appetite is poor. Crackles may be audible over a large area of the anteroventral lung field on auscultation. Reduced percussion over areas of lung consolidation is not always readily appreciated because affected lung lies largely under the elbow(s). Some cattle stand with an arched back with the neck extended and the head held lowered, suggestive of thoracic pain (291).

DIFFERENTIAL DIAGNOSIS

The BVD/MD status should be checked (288). Other chronic bacterial infections (e.g. liver abscesses, endocarditis [292], hepatocaval thrombosis and chronic peritonitis [293]) should be considered.



288 This growing steer has chronic suppurative pulmonary disease associated with persistent bovine virus diarrhoea infection.



289 This beef cow with chronic suppurative pulmonary disease is in poorer condition than its peers. Note that her calf is poorly grown.



290 This dairy cow with chronic suppurative pulmonary disease is in poor condition and has a history of poor milk yield.



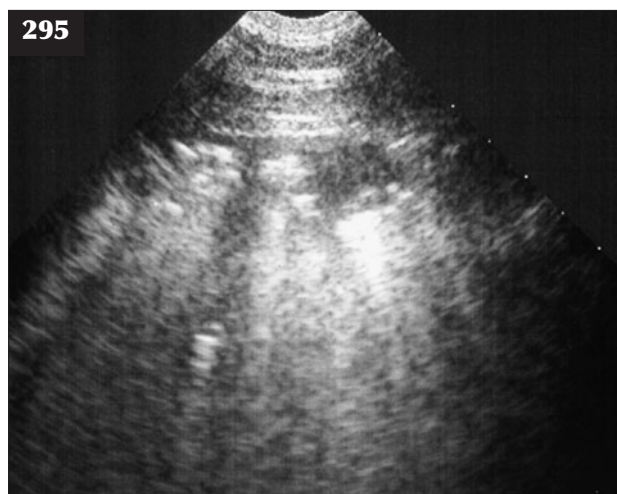
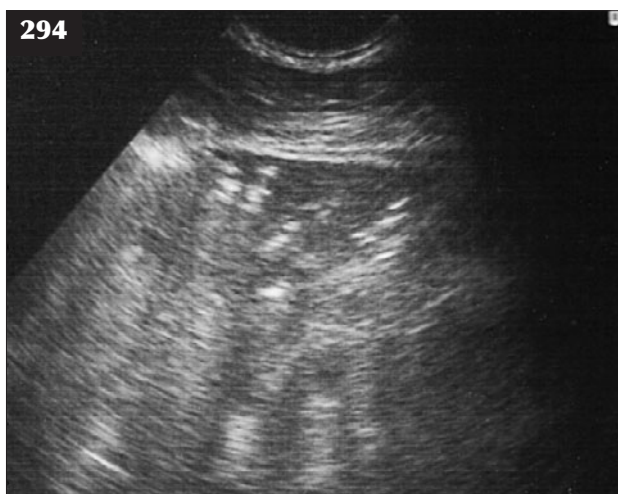291 This cow with chronic suppurative pulmonary disease is standing with its back arched and its neck and head extended, suggestive of thoracic and/or anterior abdominal pain.



292 An important differential diagnosis of chronic suppurative pulmonary disease is chronic bacterial infection such as endocarditis, as seen in this cow.



293 This animal with chronic anterior peritonitis has some clinical signs similar to those of chronic suppurative pulmonary disease.



294, 295 Chronic suppurative pulmonary disease. (**294**) This ultrasonogram reveals large irregular hypoechoic areas bordered by bright white (hyperechoic) lines 2–8 cm from the visceral pleura. These represent areas of lung consolidation with a typical lobular distribution pattern. (**295**) Typical lobular distribution pattern of chronic suppurative pulmonary disease lesions demonstrated ultrasonographically.

DIAGNOSIS

Diagnosis on clinical signs alone can prove problematic. Elevated fibrinogen and serum globulin concentrations reflect chronic bacterial infection, but are not specific to respiratory infections. Ultrasonography reveals large irregular hypoechoic areas bordered by bright white (hyperechoic) lines 2–8 cm from the visceral pleura and representing areas of lung consolidation with a typical lobular distribution pattern (**294, 295**). Post-mortem findings confirm the diagnosis (**258**).

MANAGEMENT

Arcanobacterium (Actinomyces) pyogenes is frequently isolated from CSPD cases. Yearling cattle are unlikely to grow well (severe cases become respiratory cripples), but treatment with procaine penicillin (i/m q24h for 6 weeks) could be attempted. Success rates are higher for adult cattle when there has been recrudescence of infection after parturition (approximately 50% success).

Prevention/control measures

Prompt veterinary treatment of pneumonia cases and close monitoring of antibiotic treatments, especially those administered by the farmer, is essential. The use of antibiotic/cortisone combinations for routine pneumonia cases should be avoided. A BVD-free herd status should be maintained or else the herd should be vaccinated.

Welfare implications

Respiratory cripples should be culled for welfare reasons.

INFECTIOUS BOVINE RHINOTRACHEITIS

DEFINITION/OVERVIEW

IBR is a highly contagious infectious viral disease that affects cattle of all ages. Aerosol infection requires contact between animals and spreads quickly through the group. The disease is characterized by severe inflammation of the upper respiratory tract.

AETIOLOGY

IBR is caused by BHV1 infection. BHV1 also causes infectious pustular vulvovaginitis in the female and infectious balanoposthitis in the male.

CLINICAL PRESENTATION

Clinical signs generally first appear 2–3 weeks following transport, sale, housing or other stressful event such as calving. The morbidity rate may be 100%, but the mortality rate is generally <2%. The first two or three cattle to show clinical signs are invariably the worst affected (**296**).

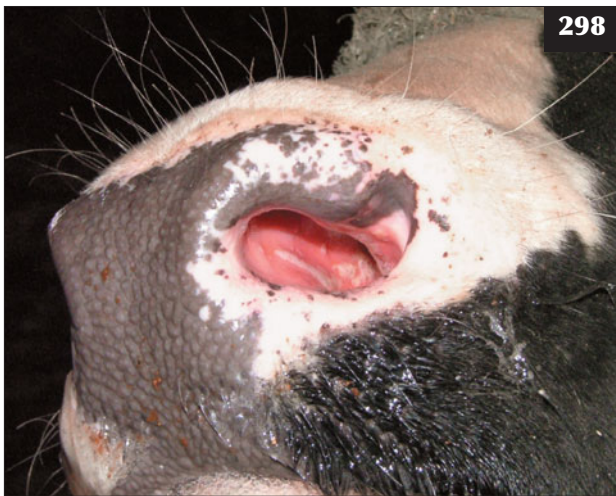There is sudden onset of inappetence, fever (41–42°C) and purulent ocular and nasal discharges. Affected animals are very depressed, are slow to rise and stand with their head held lowered. The conjunctivae are oedematous (**297**) and there is partial prolapse of the third eyelid. Tear staining of the face (**297**), which quickly turns purulent, is pronounced. There may be small erosions on the nasal septum (**298**), which progress to diphtheritic plaques. There are no oral lesions, but there is drooling of saliva due to ruminal stasis. There is halitosis and varying degrees of dyspnoea caused by accumulations of pus in the larynx and trachea (**299**). Affected animals cough frequently and palpation of the larynx is resented. There is an increased



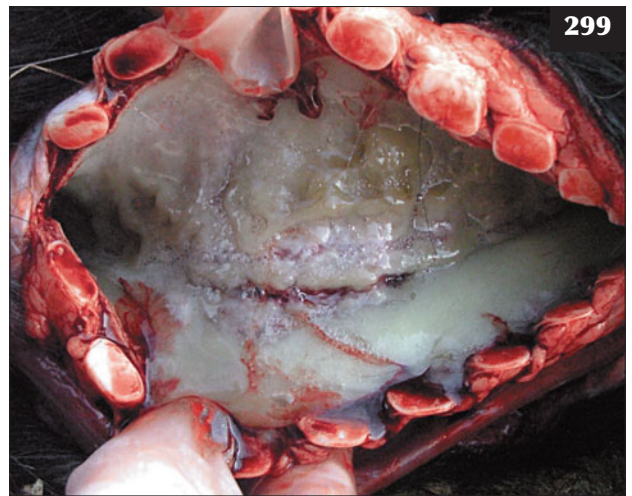
296 During an infectious bovine rhinotracheitis outbreak, the first two or three cattle to show clinical signs are the worst affected, as in this case.



297 In this animal with infectious bovine rhinotracheitis there are purulent ocular and nasal discharges and tear staining of the face.



298 In this animal with infectious bovine rhinotracheitis there are small erosions on the nasal septum. These will progress to diphtheritic plaques.



299 Severe purulent tracheitis present in a fatal case of infectious bovine rhinotracheitis.

respiratory rate, but no abnormal lung sounds except sounds transmitted from the upper respiratory tract. Inappetence leads to a shrunken rumen giving a very drawn-up and gaunt appearance. Weight loss may exceed 50 kg in one week. Death is due to severe damage, necrosis and secondary bacterial infection of the trachea (299) with accompanying inhalation pneumonia.

Milder clinical signs with conjunctivitis, occasional coughing and poor production/milk yield can occur. IBR virus enhances the pathogenicity of *Moraxella bovis* and severe infectious keratoconjunctivitis lesions can develop in calves.

DIFFERENTIAL DIAGNOSIS

If numerous animals affected: pasteurellosis before purulent ocular and nasal discharges appear. If severe disease initially presenting in individual animal: MD, MCF, bluetongue.

DIAGNOSIS

Diagnosis can be established after careful inspection of all the animals in the group; it is important not to look just at those animals presented for veterinary examination. The FAT requires ocular or nasal swabs (rub vigorously as the test needs cells) from affected febrile animals. Cattle with purulent ocular discharges should not be sampled. Results

are available within hours. If the veterinary laboratory is not local, smears should be made on glass slides and air-dried before posting. (**Note:** More than 50% of results are false negatives.) This test is a useful back-up only in the case of a positive result.

MANAGEMENT

All animals in the group should be vaccinated immediately if IBR is suspected on clinical findings. Sick animals should be treated daily for 5–7 days with parenteral procaine penicillin. There is little benefit gained from administering much more expensive antibiotics (see Pasteurellosis, p. 122, for list). NSAIDs can be used as supportive therapy.

Prevention/control measures

IBR vaccination either by single intranasal or intramuscular injection is relatively inexpensive. Marker gE vaccines are available for more sophisticated control programmes. Cattle are often vaccinated as soon as they arrive on the farm and then turned out to pasture for 3–6 weeks before housing.

BOVINE RESPIRATORY SYNCYTIAL VIRUS

DEFINITION/OVERVIEW

BRSV is considered to be the most important respiratory virus predisposing to pneumonia in growing cattle worldwide.

AETIOLOGY

Infection with BRSV is variable and may cause seroconversion without clinical signs of respiratory disease, extending to an allergic reaction with peracute respiratory distress and death within 24 hours. BRSV damages the mucociliary escalator that traps and clears bacterial pathogens from the upper respiratory tract, thus predisposing to secondary bacterial colonization and pneumonia.

CLINICAL PRESENTATION

The clinical signs attributable to BRSV infection are highly variable, but the first animals to show clinical signs are often the worst affected (see also Infectious bovine rhinotracheitis, p. 126). In such outbreaks, one or two animals may be found in severe respiratory distress, with mouth breathing (300) and rapid abdominal movements, followed by death within 12–24 hours. However, in other studies, seroconversion to BRSV has occurred with no clinical signs of respiratory disease.

In most respiratory disease outbreaks involving BRSV there is an increased respiratory rate (>60 per minute) and frequent coughing. A serous nasal discharge is usually observed. There is no ocular involvement. The rectal temperature ranges from 39.5–42°C largely depending on secondary bacterial invasion after compromise of the respiratory tract innate defences.

DIFFERENTIAL DIAGNOSIS

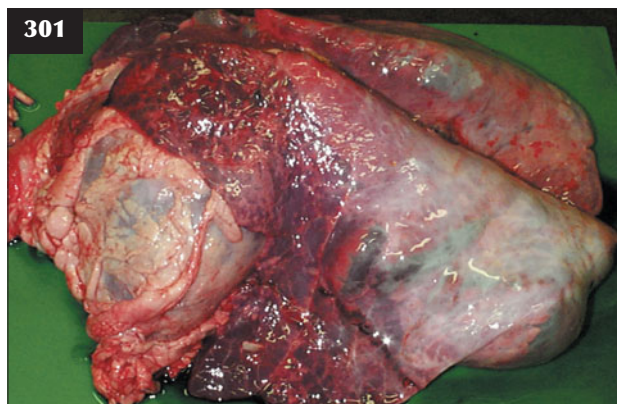
Sudden death in growing cattle can result from vitamin E/selenium deficiency affecting the myocardium. Other causes of respiratory disease, including pasteurellosis, must be considered.

DIAGNOSIS

BAL (or transtracheal lavage) to obtain virus identified by FAT is the most useful test in acute respiratory disease. A FAT on frozen lung sections requires a dead animal in the acute phase of the disease process. Paired serology from 4–6 calves, 2–3 weeks apart, is costly and of little use in tackling the problem at the start of an outbreak. A fourfold increase in titre in 25% of a sample population is considered indicative of BRSV involvement. Maternally-derived antibody present in the acute phase samples in calves less than four months old renders interpretation meaningless in this age group.



300 An animal at the start of a bovine respiratory syncytial virus disease outbreak showing severe respiratory distress and mouth breathing.



301 Extensive interlobular oedema and bullae formation in the diaphragmatic lung lobes are seen in this necropsy specimen from a case of acute bovine respiratory syncytial virus infection.

MANAGEMENT

(See Pasteurellosis, Management, p. 122, for a list of antibiotics.) In severely dyspnoeic calves (300) a single injection of a soluble corticosteroid such as dexamethasone may be life saving. The rationale for such treatment is that inhalation of virus into the caudodorsal lung field sets up an allergic reaction with the development of extensive emphysema (301); NSAIDs are not as effective.

Recurrence of fever and respiratory disease signs are common 5–14 days after the first episode. The same antibiotic should be used to treat these re-infections as that used successfully in the first outbreak.

Prevention/control measures

Vaccination is widely used to control BRSV-induced respiratory disease. Live attenuated or killed BRSV vaccines are administered on two occasions, four weeks apart, prior to the anticipated challenge (e.g. housing). Single intranasal vaccination with live virus vaccine is reported to be as effective as two intramuscular injections and is also claimed to be effective in the face of a BRSV-induced respiratory disease outbreak. Multicomponent viral vaccines (BRSV, IBR, PI3 and BVDV) are cost effective.

Welfare implications

Severely dyspnoeic calves unresponsive to corticosteroid and antibiotic therapy should be euthanased for welfare reasons.

PARAINFLUENZA 3 INFECTION

The clinical signs attributable to PI3 infection, as defined by seroconversion during the respiratory disease outbreak, are generally mild. Most outbreaks occur in the autumn and are more common following housing. It is not uncommon for PI3 and BRSV infections to occur simultaneously. PI3 infection is only important in predisposing calves to bacterial infection of the respiratory tract (see Pasteurellosis, p. 120).

PULMONARY THROMBOEMBOLISM FROM THE CAUDAL VENA CAVA (HEPATOCAVAL THROMBOSIS)**DEFINITION/OVERVIEW**

Pulmonary thromboembolism is an uncommon but invariably fatal condition of growing cattle. Death is due to eventual fatal rupture of pulmonary arterial aneurysm(s).

AETIOLOGY

Pulmonary thromboembolism is caused by haematogenous spread of septic emboli from a thrombus in the caudal vena cava.

CLINICAL PRESENTATION

In the majority of cases there is a history of respiratory disease with a short-term response to antibiotic therapy, but signs of shallow painful respirations and coughing reappear 3–10 days later. At this stage, arterial blood appears at the nostrils or is coughed up, with death in 1–14 days from massive intrabronchial haemorrhage. Epistaxis is the cardinal clinical sign of advanced disease (302) and indicates a hopeless prognosis such that affected cattle must be euthanased for welfare reasons.

DIFFERENTIAL DIAGNOSIS

Chronic suppurative pulmonary disease; endocarditis.

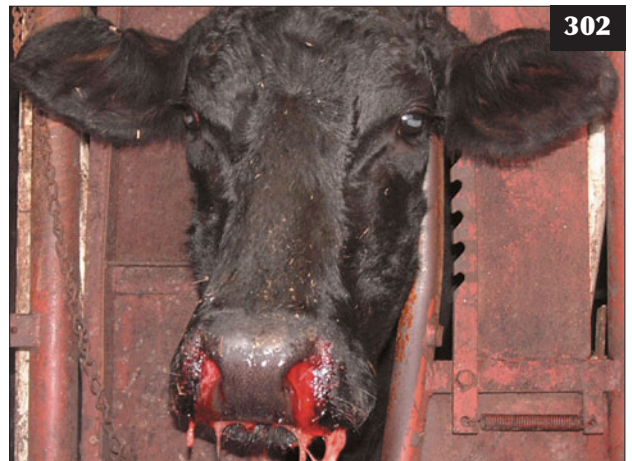DIAGNOSIS

Diagnosis is difficult until epistaxis occurs. There may be recurrent pyrexia with vague respiratory signs and weight loss. Ultrasonographic demonstration of the thrombus present in the caudal vena cava can be achieved, but such examination is very unlikely in practice.

MANAGEMENT

There is no effective treatment in cattle with significant pulmonary haemorrhage. Beef calves that suffer an episode of epistaxis/haemoptysis, but are otherwise bright and show only mild signs of lung pathology, can be treated with a prolonged course of penicillin; however, recurrence of disease is likely before slaughter weight is reached.

There are no specific control measures.



302 Epistaxis in a cow with advanced pulmonary thromboembolism.

FOG FEVER (ATYPICAL INTERSTITIAL PNEUMONIA OF CATTLE/ACUTE BOVINE PULMONARY EMPHYSEMA)

DEFINITION/OVERVIEW

Fog fever has a sudden onset, causing severe respiratory distress in adult beef cows 1–2 weeks after moving on to a lush silage/hay aftermath in late summer/autumn. The present incidence in the UK is much less common than 25 years ago, which could be related to the change in the predominant beef breed from Hereford to Limousin.

AETIOLOGY

Circumstantial evidence links the disease with the ingestion of large amounts of the amino acid L-tryptophan and its conversion in the rumen to 3-methyl indole and indole acetic acid.

CLINICAL PRESENTATION

Usually, <2–5% of cattle at risk in the herd are severely affected, with sudden onset of severe respiratory distress. Affected animals stand with their neck extended and head lowered and they move very reluctantly. The nostrils are flared and the animals mouth breathe. There is an expiratory grunt and frothy saliva around the protruding tongue. The mucous membranes are cyanotic. The rectal temperature is normal. Coughing is not a frequent feature of fog fever. The mortality rate in severely affected cases is around 95% and often precipitated by movement or handling. Obvious subcutaneous emphysema develops over the thorax and along the back in recovered cases.

Less severely affected animals are depressed, tachypnoeic and hyperpnoeic, and they gradually improve over a 10–14 day period.

DIFFERENTIAL DIAGNOSIS

Lungworm (husk) in susceptible adults; nitrate poisoning. If causing sudden death: hypomagnesaemia.

DIAGNOSIS

Diagnosis is based on clinical signs and confirmed at necropsy.

MANAGEMENT

There is no effective treatment and moving severely affected cattle often hastens death from respiratory failure. Diuretics and corticosteroids have been used to treat fog fever, but are unlikely to influence the outcome. Severely affected cattle must be euthanased for welfare reasons.

Prevention/control measures

Controlled access to lush pasture poses management problems. Feeding monensin sodium during risk periods may be effective, but its use is now banned in many countries.

FARMER'S LUNG/DIFFUSE FIBROSING ALVEOLITIS

DEFINITION/OVERVIEW

Farmer's lung/diffuse fibrosing alveolitis is now rare owing to improvements in cattle nutrition and housing.

AETIOLOGY

Farmer's lung is an extrinsic allergic bronchiolo-alveolitis that develops in housed adult cattle following repeated exposure to mouldy hay containing spores derived from *Micropolyspora faeni* and *Thermoactinomyces vulgaris*.

CLINICAL PRESENTATION

Housed individual animals show a sudden onset of dyspnoea, occasionally with mouth breathing, after exposure to mouldy feed. There is frequent coughing with production of thick mucus. The animal is bright and alert. The reduced milk yield and anorexia are secondary to the respiratory distress. Mild to moderate attacks may go unnoticed, or dyspnoea may appear after exercise. The respiratory rate is increased, with loud crackles audible anteroventrally due to the presence of tenacious mucus in the airways.

DIFFERENTIAL DIAGNOSIS

Chronic suppurative pulmonary disease; lungworm infestation.

DIAGNOSIS

Diagnosis is based on sudden onset of severe clinical signs in an alert animal, with a rapid response to corticosteroid injection.

MANAGEMENT

A soluble corticosteroid can be administered; however, it should not be used during the last five months of pregnancy because abortion may result.

Prevention/control measures

Cattle should not be fed mouldy hay and building design and ventilation should be improved.

INHALATION PNEUMONIA (ASPIRATION PNEUMONIA)

DEFINITION/OVERVIEW

Inhalation pneumonia occurs in relation to recognized risk factors.

AETIOLOGY

Inhalation pneumonia may result from inhalation of rumen contents following hypocalcaemia, especially if the cow becomes cast, during general anaesthesia and after the faulty administration of drenches. Inhalation pneumonia

may occur in association with bacterial infection of the mouth (calf diphtheria), pharynx, larynx (laryngeal diphtherosis) and trachea (IBR) and is described in the relevant chapters.

CLINICAL PRESENTATION

There is often a history of recent hypocalcaemia with the animal becoming cast. Sudden death may follow drenching, but this is unusual.

Typically, the cow stands with a roached back stance and with the neck extended and the head held lowered (303) and it walks slowly. The animal is inappetent. The rectal temperature is elevated within a range 39.5–40.0°C. The ocular and oral mucous membranes are congested. There is a bilateral mucoid/purulent nasal discharge and the animal has a painful expression (303). The heart rate is often elevated to >80 beats per minute. The respiratory rate is elevated, with an obvious abdominal component. Auscultation of the chest typically reveals widespread crackles on the dependent side if the animal was recumbent at the time. Pinching over the withers may elicit a painful expression due to fibrinous pleurisy, but this is not pathognomonic for pleurisy. There is often halitosis. The ruminal contractions are reduced in strength and frequency. The milk yield is greatly reduced.

DIFFERENTIAL DIAGNOSIS

Phlebitis/bacteraemia following faulty/contaminated calcium injection; chronic suppurative respiratory disease exacerbated after calving; pleurisy; hepatocaval thrombosis; endocarditis; peritonitis.

DIAGNOSIS

A provisional diagnosis of inhalation/necrotizing pneumonia is based on the clinical findings, including pyrexia with pain on percussion, supported, where costs allow, by biochemical changes consistent with acute severe bacterial infection. Acute bacterial infection would typically cause a leucopenia and neutropenia, but with a pronounced left shift. Changes in serum proteins would be slight because of the relatively short duration of infection; haptoglobin and fibrinogen levels would be more informative of acute infection.

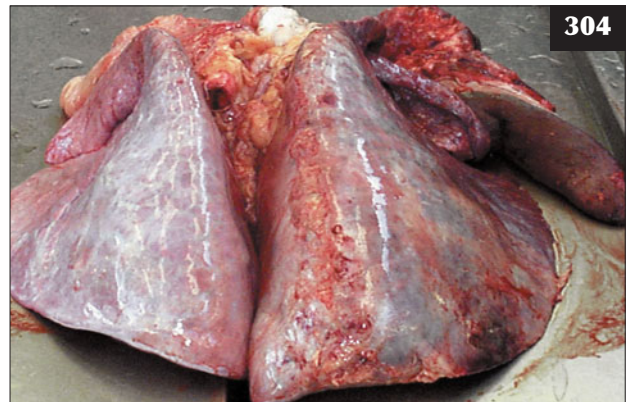Ultrasonography of the chest will reveal any pleurisy/pleural effusion (263, 264) and superficial lung pathology.

MANAGEMENT

Treatment is unlikely to be effective, but broad-spectrum antibiotics plus an NSAID such as flunixin meglumine should be administered. The cow should be re-examined the following day because humane destruction may be necessary for welfare reasons if the animal deteriorates



303 Jersey cow with inhalation pneumonia. The cow is standing with a roached back, its neck extended and its head held lowered. The cow also has a painful expression and bilateral mucopurulent nasal discharges.



304 Necrotizing pneumonia following inhalation of rumen contents was revealed at necropsy from the cow shown in 303.

further. Necrotizing pneumonia (304) rarely responds to antibiotic therapy and affected cattle should be euthanased.

Prevention/control measures

Care must be taken with drenching. There should be appropriate supervision of calving cows, with prompt treatment of hypocalcaemia.

PLEURAL ABSCESSSES/PYOTHORAX

DEFINITION/OVERVIEW

Pleural abscesses are uncommon, but the true prevalence is unknown because diagnosis necessitates a thorough clinical examination. Affected cattle do not grow well and would not be consigned to a slaughterhouse.

AETIOLOGY

Pleural abscesses/pyothorax occur because of rupture of a superficial lung abscess into the pleural space.

CLINICAL PRESENTATION

There may be no history of respiratory disease. Affected cattle typically present with a history of poor growth, weight loss and/or poor milk yield.

Affected cattle often stand with a roached back stance, the neck extended, the head held lowered and with a painful expression (305). Appetite is reduced. The rectal temperature is only marginally elevated (39.0–39.5°C). The ocular and oral mucous membranes are congested. There are no ocular or nasal discharges. The heart rate is often elevated to >80 beats per minute and is inaudible on the affected side in cases of unilateral pyothorax. The respiratory rate is elevated with an obvious abdominal component. Auscultation of the chest reveals no lung sounds over the affected area and greatly reduced sounds on percussion. It is very important to appreciate the absence of lung sounds over the affected area. Pinching over the withers may elicit a painful reaction. Ruminal contractions may be reduced in strength and frequency. The milk yield is considerably reduced in lactating cattle. Vagal indigestion has been reported in individual cases of pleural abscessation.

DIFFERENTIAL DIAGNOSIS

Pleural effusion may be encountered in some cases of farmer's lung/diffuse fibrosing alveolitis and dilated cardiomyopathy with right-sided heart failure. Septic pericarditis should be considered.

DIAGNOSIS

Diagnosis is confirmed by ultrasonography and thoracocentesis where necessary. A large pleural abscess containing up to 50 litres of pus (268) and recognized by the anechoic area containing multiple hyperechoic dots (267) can be clearly imaged.

MANAGEMENT

Drainage and lavage of pleural abscesses (306) has been largely unsuccessful in cattle, presumably due to the extensive nature of the lesions and possible secondary complications. Affected cattle should be euthanased for welfare reasons once the extent of the lesion(s) has been confirmed.

There are no recognized prevention/control measures.



305 A cow with a pleural abscess standing with a roached back stance, its neck extended, its head held lowered and with a painful expression.



306 Drainage and lavage of a cow with a large pleural abscess. Such treatment is generally unsuccessful.

MANURE GASES

Asphyxiation of cattle housed in poorly ventilated buildings over large slurry storage pits can result when the slurry is either mixed/agitated or removed. Released gases include hydrogen sulphide, ammonia, methane, carbon monoxide and carbon dioxide.

Chapter 5

Cardiovascular diseases

EXAMINATION OF THE CARDIOVASCULAR SYSTEM

The rate, rhythm and intensity of heart sounds are determined by auscultation over the chest in the region immediately beneath the elbow joints. It is essential to listen to both sides of the chest because unilateral space-occupying lesions in the cranial thorax frequently displace the heart, leading to marked disparity in the intensity and origin of the heart sounds. The heart rate of neonatal calves may approach 120 beats per minute; older calves and adult cattle have a heart rate between 60 and 80 beats per minute. Handling and other stresses may increase the heart rate by more than 50%, but it returns to normal within 5–10 minutes. Coccygeal, femoral and brachial pulses are easily found in cattle.

Ultrasonography is useful for differentiating pleural/pericardial effusion from exudate/pus, but confirmation of vegetative endocarditis is difficult with most of the sector scanners used in farm animal practice.

CONGENITAL HEART ABNORMALITIES

Of the congenital cardiac defects, only ventricular septal defect (VSD) is common in cattle. Patent ductus arteriosus (PDA), which is rare in cattle, can occur as a single defect or with other cardiac abnormalities such as tetralogy of Fallot.

VENTRICULAR SEPTAL DEFECT

DEFINITION/OVERVIEW

An opening in the septum separating the two ventricles occurs sporadically as a congenital defect; the size/severity of the defect determines the age at presentation for veterinary examination.

AETIOLOGY

Hereditary factors may be important when a cluster of cases occurs in calves sired by a particular bull.

CLINICAL PRESENTATION

A calf with a large VSD typically presents with a history of poor appetite and growth since birth. The rectal

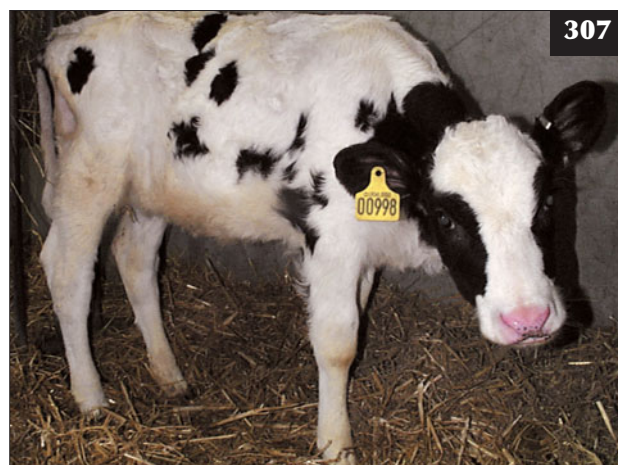temperature is normal. The calf is typically dull and lethargic (307). Auscultation may reveal a normal heart rate, but a harsh pansystolic murmur in the tricuspid valve area louder on the right than the left side. A palpable cardiac thrill is present. The respiratory rate may be elevated with a slight abdominal component. Calves with small defects, yet intense murmurs, may remain asymptomatic throughout life.

DIFFERENTIAL DIAGNOSIS

PDA; tetralogy of Fallot.

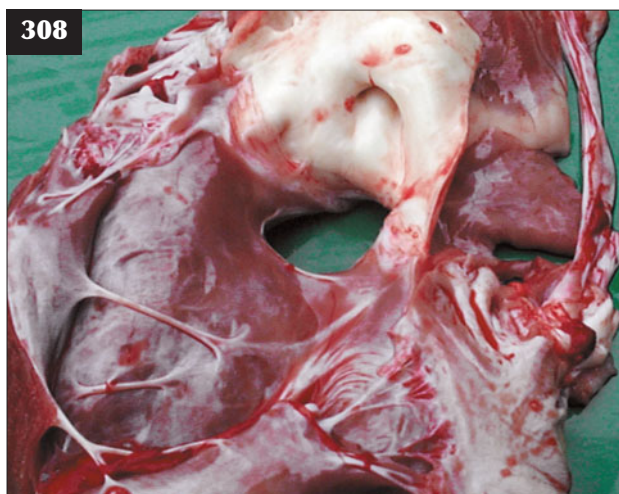DIAGNOSIS

Diagnosis is based on auscultation findings. The diagnosis could be confirmed ultrasonographically in valuable calves.



307

307 A calf with a large ventricular septal defect that presented with poor appetite and weight gain since birth.



308 The ventricular septal defect in the animal shown in **307** confirmed at necropsy.



309 Cattle with pericarditis present with a history of poor appetite, weight loss and reduced milk yield of several days' to weeks' duration. Note that there is no roached back in this cow.

MANAGEMENT

The prognosis for large defects (**308**) is hopeless and affected calves should be euthanased for welfare reasons.

SEPTIC PERICARDITIS

DEFINITION/OVERVIEW

Septic pericarditis occurs sporadically in adult cattle following ingestion of sharp metal objects that migrate through the reticular wall and diaphragm into the pericardial sac.

AETIOLOGY

The bacterial flora present in bovine pericarditis are variable and may include single or mixed infections of *Staphylococcus* spp., *Streptococcus* spp., *Arcanobacterium pyogenes*, *E. coli* and anaerobes.

CLINICAL PRESENTATION

Affected cattle present with a history of reduced appetite, weight loss and reduced milk yield of several days' to weeks' duration (**309**). Antibiotic treatment by the farmer may have effected some temporary improvement. There may have been no observed clinical signs of traumatic reticulitis.

The cow is dull and depressed and walks slowly. While often quoted in the literature, an arched back is not a common finding (**309**, **310**). The rectal temperature is only marginally elevated (39.2–39.5°C). The condition usually progresses over several weeks to distension of the

jugular veins and accumulation of oedema under the brisket and mandible (sequential images of the same cow taken over four weeks are shown in **310–313**). The ocular and oral mucous membranes may be congested. The heart rate is marginally elevated to 80–90 beats per minute, but the heart sounds are muffled on both sides of the chest; occasionally, high-pitched splashing sounds may be heard near the base of the heart. The respiratory rate may be elevated to 40 breaths per minute with a slight abdominal component. In advanced cases (note these are not manifest in images **310–312**) there are accumulations of submandibular, brisket and ventral oedema after four weeks (**313**).

DIFFERENTIAL DIAGNOSIS

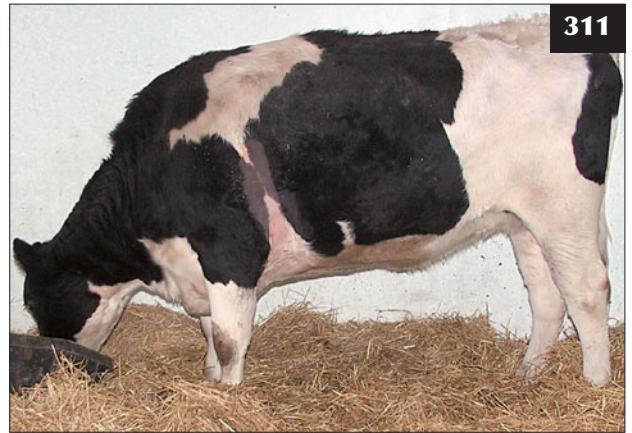During the early stages of the disease the clinical signs may resemble traumatic reticulitis/localized peritonitis because this is the route of the wire. The following diseases should be considered once signs of congestive heart disease develop: endocarditis; myocarditis/dilated cardiomyopathy (DCM); lymphosarcoma involving the mediastinum and pericardium (enzootic bovine leucosis [EBL]-positive cows); thymic lymphosarcoma.

DIAGNOSIS

Pleural and pericardial effusions can be readily demonstrated using a 5 MHz sector scanner and differentiated on appearance from septic pericarditis (effusion versus pus). Gross distension of the pericardium with pus (**314**, **315**) can be readily



310



311

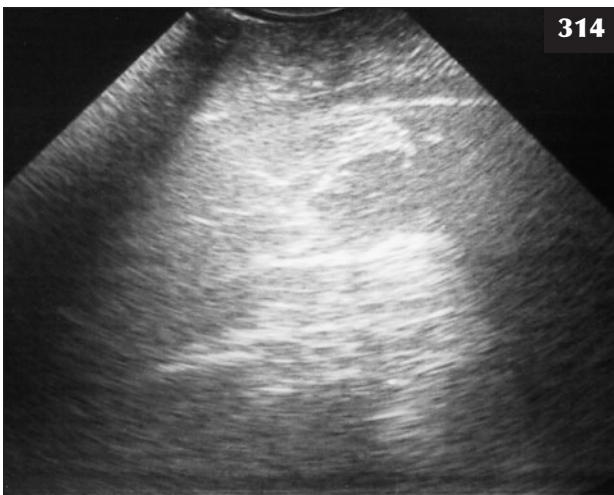


312

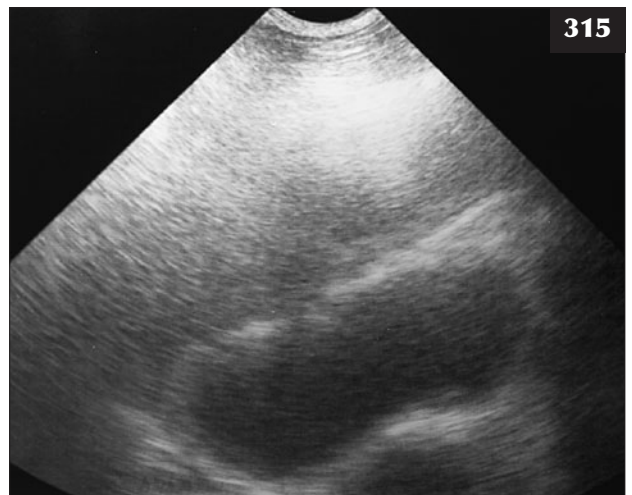

313

310–313 Septic pericarditis. **(310)** An arched back is not a common finding in all cases of septic pericarditis. **(311)** The cow in **310** seven days after first presentation with septic pericarditis. **(312)** The same cow 21 days after first presentation. **(313)** The same cow 28 days after first presentation. There are large accumulations of submandibular, brisket and ventral oedema.



314



315

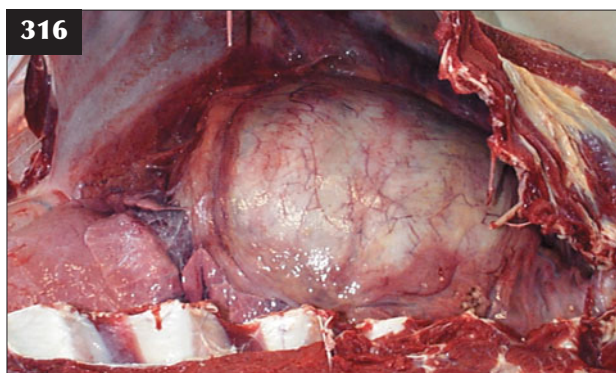
314, 315 Septic pericarditis. Gross distension of the pericardium with pus is seen in this animal examined ultrasonographically via the left chest wall **(314)** and via the right chest wall **(315)**.

identified (316, 317). In some cases, where the wire remains within the heart chamber wall, fibrin deposition on the epicardium (318, 319) can be identified as a broad irregular hyperechoic band, with oedema of the myocardium appearing as a narrow anechoic band underlying the fibrin deposit (320).

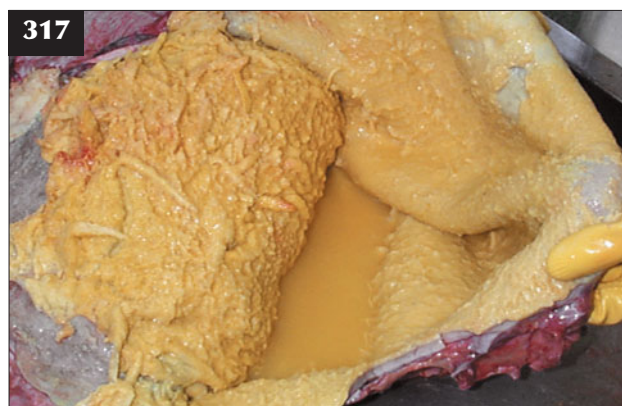Clinical pathology findings of leucocytosis (with left shift) and increased fibrinogen and serum globulin concentrations are non-specific and could represent many chronic bacterial infections.

MANAGEMENT

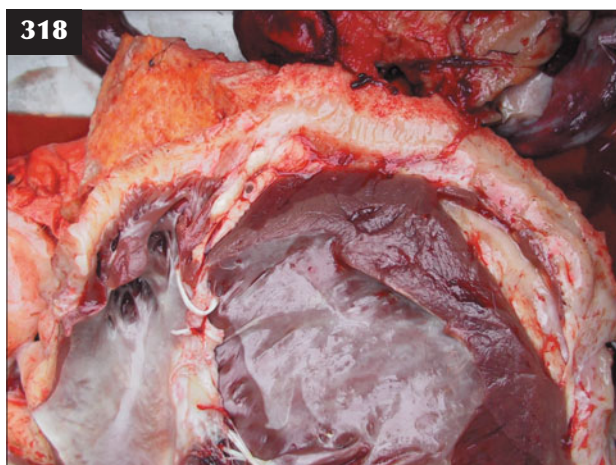
Antibiotic therapy will not resolve the pericardial infection, although temporary reduction of oedema occurs after a single corticosteroid injection such as dexamethasone. The prognosis is hopeless in cases of



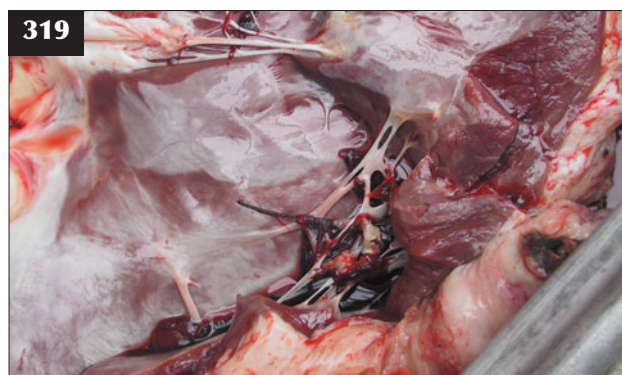316 Massive distension of the pericardium is visible on opening the thorax of this cow with advanced septic pericarditis.



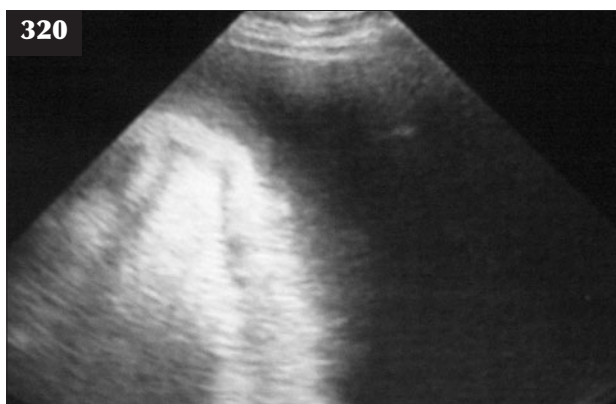317 Extensive septic pericarditis. Note the markedly thickened epicardium and pericardium and 'bread and butter' appearance of the inflammatory exudate in this case. (See also 316.)



318 Septic peritonitis. Fibrin deposition on the epicardium associated with the wire within the ventricle wall.



319 Septic pericarditis. The wire shown in 318 is clearly visible penetrating the ventricle wall.



320 Ultrasonographic view of the cow in 318 and 319. Fibrin deposition on the epicardium can be identified as a broad irregular hyperechoic band, with oedema of the myocardium appearing as a narrow anechoic band underlying the fibrin deposit.

suppurative pericarditis and affected cattle should be destroyed for welfare reasons. The wire may not be found either lodged within the pericardium or embedded in the ventricular wall.

Routine control measures relate to prevention of traumatic reticulitis; magnets are given *per os* to lodge in the reticulum and collect metal debris when herd problem arises.

VEGETATIVE ENDOCARDITIS

DEFINITION/OVERVIEW

Detailed necropsy is rarely undertaken in farm animal practice, leading to probable underreporting of endocarditis. Endocarditis leads to valvular insufficiency and the development of congestive heart failure.

AETIOLOGY

Vegetative endocarditis is typically encountered in cows 2–4 months after parturition; an infected uterus is one potential source of infection, although other septic foci such as mastitis, traumatic reticulitis and cellulitis may act as the source of the bacteraemia. *Streptococcus* spp. and *Aracnobacterium pyogenes* are common isolates.

CLINICAL PRESENTATION

Animals typically present with poor milk yield for several days to weeks and weight loss manifest as poorer body condition compared with other animals in the group (321). Affected cattle have a painful expression with their ears back and staring eyes (322). Affected animals appear slow and stiff and demonstrate elbow abduction (323), and they have a poor appetite. The rectal temperature is within



321 This cow with vegetative endocarditis presented with marked weight loss and poor milk yield of several week's duration.



322 Vegetative endocarditis. This cow has a painful expression with its ears back and staring eyes.



323 Vegetative endocarditis. This steer has an arched back, appears slow and stiff, has elbow abduction and has a poor appetite.

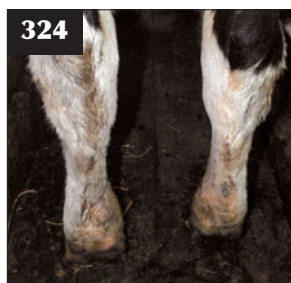the range 39.2–39.5°C. Typically, there is obvious effusion of the hock (324), carpal and fetlock joints (325). Because of the painful distension caused by such effusions, affected animals spend long periods in sternal recumbency (326), adopt an arched-back appearance when standing (323) and continually shift weight from one limb to another. There may be palpable enlargement of the superficial lymph nodes. The heart rate may be irregular and elevated to >100 beats per minute, but there is often no audible murmur. In more advanced cases there may be jugular distension (327) and a marked jugular pulse. Lesions involving the tricuspid valve may result in ascites (328) and peripheral oedema. Hepatomegaly is common due to chronic venous congestion (nutmeg liver; 329).

DIFFERENTIAL DIAGNOSIS

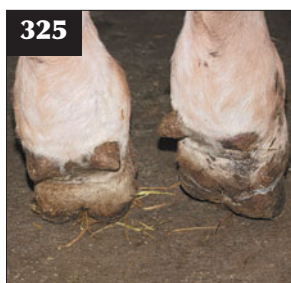In cattle, joint effusions are seen with other chronic bacterial infections, most commonly chronic (summer) mastitis. Evidence of pain (330) (elbow abduction, arched back, slow guarded movement) may lead to confusion with pleurisy and traumatic reticulitis/focal peritonitis. It is important not to be misled by the absence of an obvious murmur in endocarditis cases. Conversely, murmurs of no clinical significance are not uncommon in cattle. Pericarditis is readily demonstrated ultrasonographically (314, 315).

DIAGNOSIS

The provisional diagnosis of vegetative endocarditis is based on clinical findings of chronic weight loss, pyrexia



324 Note the effusion of the hock joints in this cow with vegetative endocarditis.



325 Note the effusion in the hind fetlock joints of the steer in 323. The effusion was causing pain.



326 This cow with vegetative endocarditis is spending long periods in sternal recumbency.



327 Note the jugular distension in this more advanced case of vegetative endocarditis.



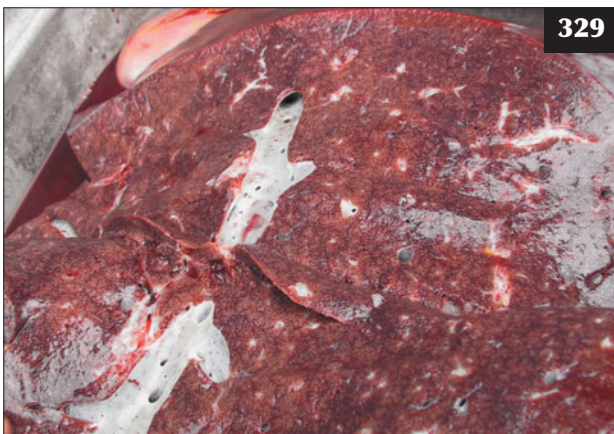328 Vegetative endocarditis. This necropsy view shows ascites as a result of vegetative lesions involving the tricuspid valve.

and multiple joint effusions unresponsive to antibiotic therapy. A leucocytosis with left shift and increased fibrinogen and serum globulin concentrations are typically found, but these simply reflect reaction to bacterial infection and are not specific to endocarditis. Ultrasonographic confirmation of vegetative endocarditis is difficult with most sector scanners used in farm animal practice. Necropsy reveals cardiac enlargement (331) with ventricular hypertrophy/dilation. The vegetative lesions are readily demonstrable on the heart valves (332, 333).

MANAGEMENT

Treatment of vegetative endocarditis cases with procaine penicillin is invariably unsuccessful. A marked reduction in joint effusions and a clinical improvement follows dexamethasone injection, but the condition deteriorates after 3–5 days. Affected cattle should be euthanased when clinical signs fail to respond to antibiotic and corticosteroid therapy.

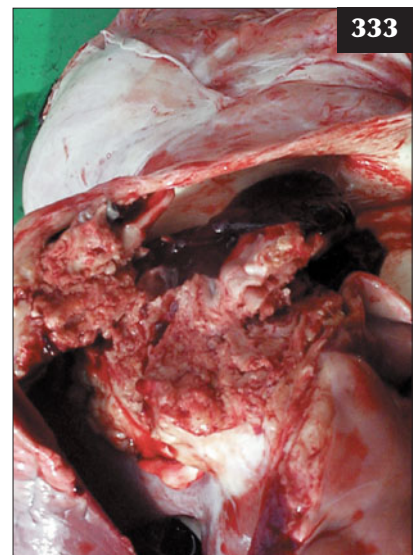
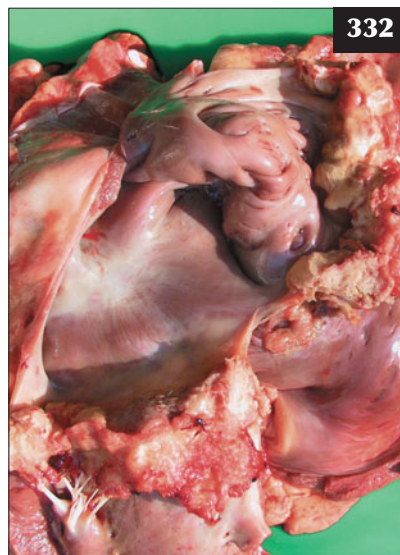
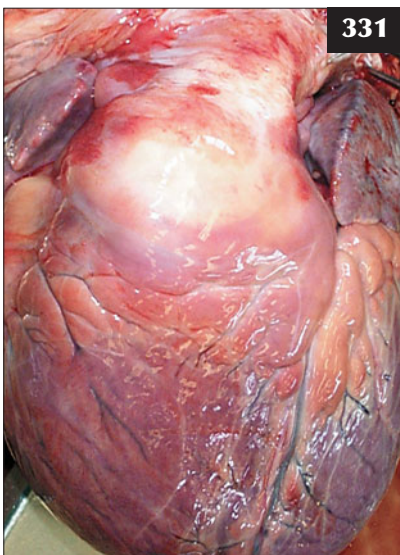
Prevention of endocarditis is based on timely and effective treatment of focal bacterial infections, but these may, in themselves, not present with outward clinical signs (e.g. metritis, mastitis, foot abscess, grain overload/bacteraemia from gut).



329 Vegetative endocarditis. Hepatomegaly, as shown in this necropsy specimen, is common due to chronic venous congestion (nutmeg liver).



330 Evidence of pain in cases of vegetative endocarditis (expression, elbow abduction, arched back, slow guarded movement, marked weight loss), as in this cow, may lead to confusion with pleurisy and traumatic reticulitis/focal peritonitis.



331–333 Vegetative endocarditis. Necropsy reveals cardiac enlargement with ventricular hypertrophy/dilation (331), a vegetative lesion affecting the mitral valve (332) and a vegetative lesion extending to involve the aortic valve (333).

DILATED (HOLSTEIN) CARDIOMYOPATHY

DEFINITION/OVERVIEW

DCM is occasionally reported in well-grown, 2–3-year-old Holstein cattle.

AETIOLOGY

The occurrence of DCM in the progeny of certain bulls indicates a genetic component.

CLINICAL PRESENTATION

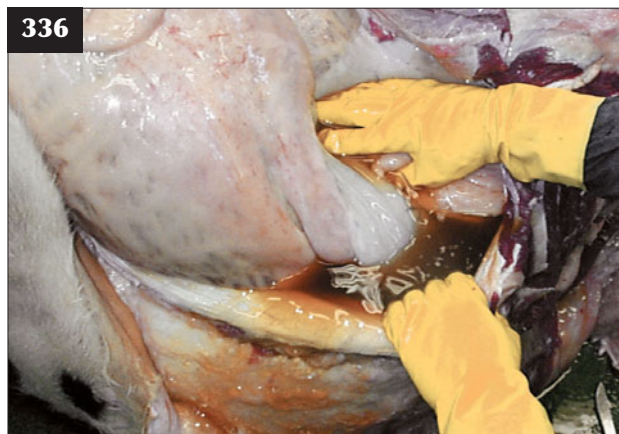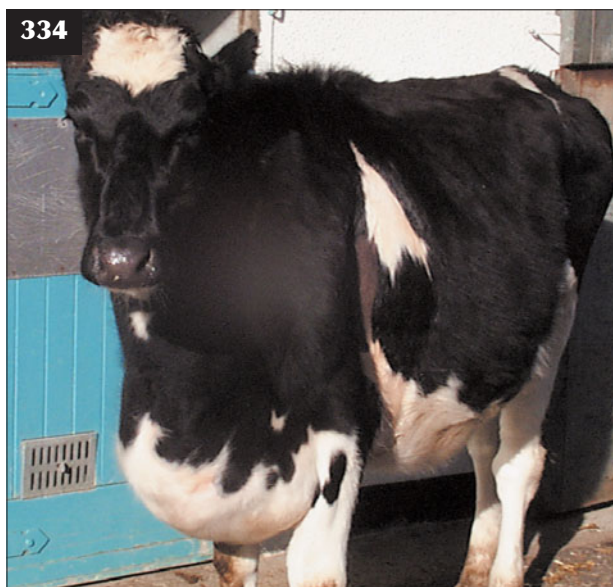Animals with DCM are bright and alert with a normal appetite until the agonal stages. Clinical signs include marked peripheral oedema (334, 335), jugular distension, ascites (336) and pleural effusion, which develop over several months (337–339). The heart rate is increased, but sounds are often muffled due to pleural and/or pericardial effusions.

DIFFERENTIAL DIAGNOSIS

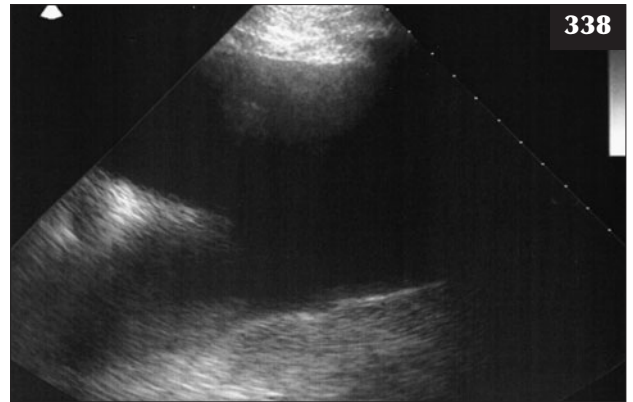
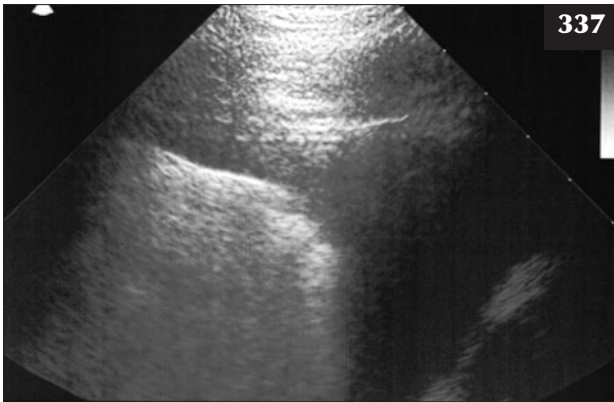
The main differential diagnoses are right-sided heart failure due to lung pathology and a mediastinal mass such as an abscess or thymic lymphosarcoma (cor pulmonale). Myocarditis is also an important differential diagnosis where an earlier bacterial infection may be the source of this infectious process. Pericarditis cases would be dull, inappetent, fevered and have 5–10 cm of pus between the peri- and epicardium readily identifiable ultrasonographically. Endocarditis usually presents with depression, fever and joint effusions. Cattle with significant congenital heart abnormalities (e.g. VSD) present with signs of congestive heart failure as young calves.

DIAGNOSIS

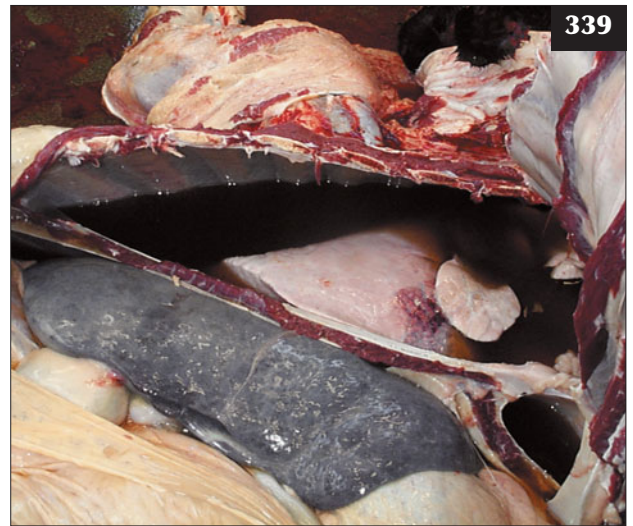
Necropsy reveals enlargement of the heart with a rounded 'globose' shape. There may be no histological changes.



334–336 Dilated cardiomyopathy. (334) Note the marked peripheral oedema in this well-grown, two-year-old Holstein cow. (335) The peripheral oedema is revealed at necropsy. (336) Ascites is also revealed at necropsy.



337–339 Dilated cardiomyopathy. **(337)** Ultrasound examination reveals pleural effusion (dorsal to the left) with separation of the pleurae extending to 12 cm at the ventral margin of the ultrasonogram. **(338)** Extensive pleural effusion with consolidation of the ventral margin of the diaphragmatic lung lobe is shown in this ultrasonogram. **(339)** The extent of the pleural effusion is clearly demonstrated at necropsy. Note the consolidation of the ventral margin of the diaphragmatic lung lobe visible in **338**.



MANAGEMENT

There is no treatment for DCM. Affected cattle should be euthanased for welfare reasons

Breeding companies should be informed if a cluster of cases sired by the same bull occurs.

PULMONARY VENA CAVAL THROMBOSIS

Pulmonary vena caval thrombosis is described in Chapter 4, Respiratory Diseases, p. 129.

MYOCARDITIS

DEFINITION/OVERVIEW

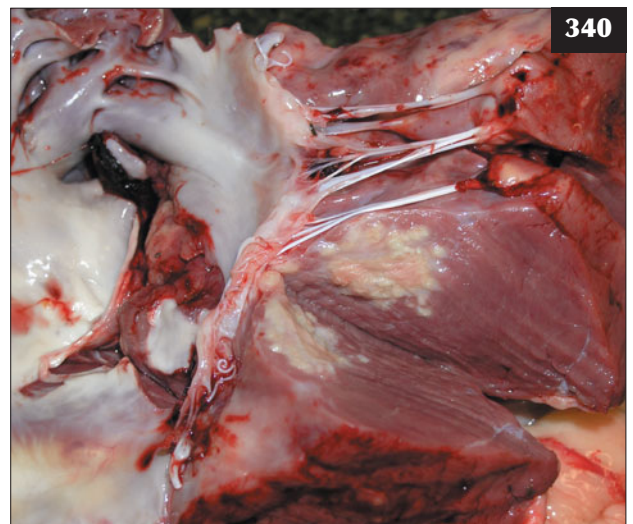Myocarditis is an uncommon condition of cattle, but it can occur following *Histophilus somni* infection (**340**).

AETIOLOGY

Inflammation of the myocardium (myocarditis) can be caused by viruses and bacteria often associated with mastitis, endocarditis and respiratory disease (*H. somni* infection).

CLINICAL PRESENTATION

The clinical signs of myocarditis are very variable and easily overlooked. There may be a history of illness/pyrexia. Affected cattle usually present with a fever and tachycardia; cardiac arrhythmias are common. Jugular distension and



340 Myocardial abscessation is shown in this necropsy view of a steer that died following *Histophilus somni* infection.

peripheral oedema may be present. Exercise/stress may precipitate sudden death.

DIFFERENTIAL DIAGNOSIS

See DCM above.

DIAGNOSIS

Diagnosis is based on the presence of tachycardia, cardiac arrhythmias and jugular distension and the elimination of other possible causes.

MANAGEMENT

Prolonged antibiotic therapy could be attempted in suspected bacterial causes of myocarditis, but the prognosis is poor when clinical signs of congestive heart failure are present.

There are no specific control measures other than prompt treatment of any predisposing bacterial infection.

COR PULMONALE/PULMONARY HYPERTENSION

DEFINITION/OVERVIEW

Cor pulmonale refers to the secondary effect of lung dysfunction on the heart.

AETIOLOGY

Pulmonary hypertension leads to right heart hypertrophy, dilation and/or failure. Bronchopneumonia and hypoxic vasoconstriction from living at high altitudes are the common causes.

CLINICAL PRESENTATION

Jugular distension and extensive peripheral oedema are present. Underlying respiratory disease causes hyperpnoea

and dyspnoea. Tricuspid valve insufficiency may cause an audible murmur.

DIFFERENTIAL DIAGNOSIS

See DCM above.

DIAGNOSIS

Diagnosis is based on clinical findings of severe chronic bronchopneumonia confirmed on ultrasound examination. Cardiac catheterization, with findings of elevated pressures in the pulmonary artery and right ventricle and atrium, is a research tool to confirm pulmonary hypertension in cattle living at high altitude.

MANAGEMENT

The primary lung disease should be treated where possible; however, the prognosis is guarded. Cor pulmonale secondary to high altitudes is potentially reversible after movement to lower altitudes. Prevention is by selecting breeding stock with low mean pulmonary artery pressures.

CARDIAC TUMOURS

Cardiac tumours are rare in cattle. The most common primary cardiac tumour is lymphosarcoma associated with bovine leucosis virus (BLV) infection. Clinical signs depend on the site of the tumour and may be similar to those for pericarditis, endocarditis and myocarditis (see above). Ultrasonography may prove useful in identifying the tumour mass and pericardial effusion if present. There is no treatment and confirmed cases should be euthanased for welfare reasons.

Chapter 6

Nervous system diseases

CLINICAL EXAMINATION OF THE CENTRAL NERVOUS SYSTEM

It is important to perform a complete clinical examination in order that important clinical signs are not overlooked. Rectal temperature is not an useful guide to infectious conditions of the CNS, as most diseases are afebrile. Early cases of neonatal bacterial meningitis, which are obtunded at veterinary examination (341), may present with a normal rectal temperature. Conversely, muscle activity and seizure activity later in the clinical course (342) may raise the rectal temperature. Respiratory function may be influenced considerably by acid–base disturbances. Digestive tract dysfunction may be influenced by fluid and acid–base disturbances associated with cranial nerve (CN) V and VII deficits, which cause loss of saliva as observed in listeriosis.

Some neurological diseases have a breed, sex, age and management system predisposition. It is essential to inspect the whole group of cattle as subtle changes in other animals in the group may not have been noticed by the farmer. It is important to ascertain recent management changes, particularly changes in the animals' environment and nutrition, and the duration of clinical signs and rate of deterioration of the animal's clinical condition.

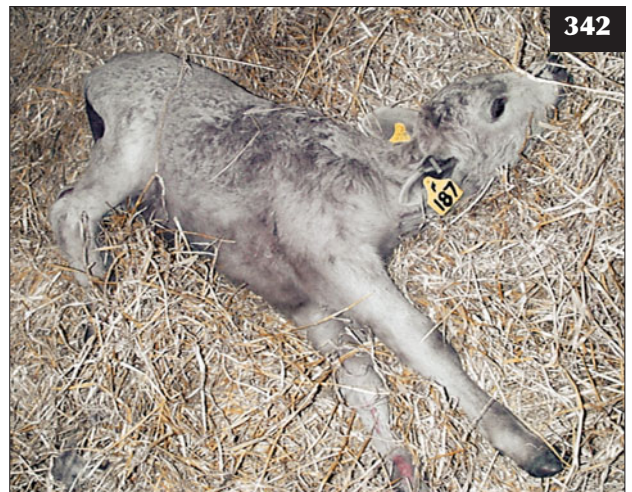NEUROLOGICAL SYNDROMES

The brain is conveniently divided into six areas, each with a recognized neurological 'syndrome', although some overlap in the clinical signs of some 'syndromes' may result because of the complex pathways within the brain. Of the six neurological syndromes, only four (the cerebral, cerebellar, pontomedullary [brainstem] and vestibular syndromes) concern the veterinary practitioner. The midbrain and hypothalamic syndromes are uncommon in ruminant species.

CEREBRAL SYNDROME

Cerebral dysfunction is the most common neurological syndrome encountered in cattle. The cerebrum is concerned with mental state, behaviour and, in conjunction with the eye and optic nerve (II), vision. Clinical signs that suggest cerebral dysfunction include:

- Blindness, but with normal pupillary light reflex (PLR).
- Compulsive walking, circling, constant chewing movements.

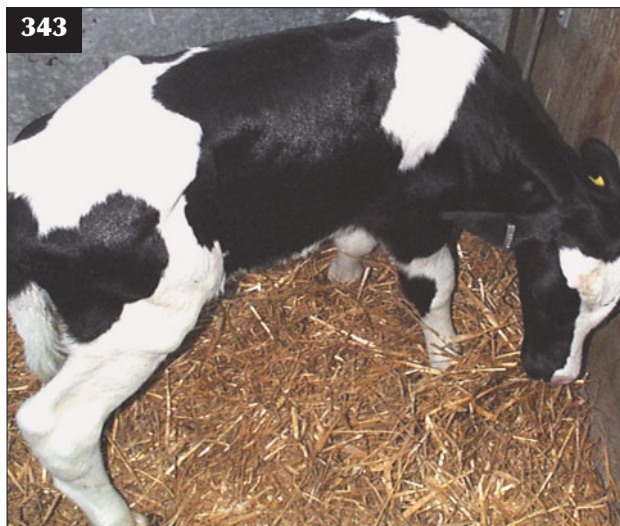

341, 342 Bacterial meningitis. (341) This neonatal calf was depressed but had a normal rectal temperature. (342) This calf, which is showing seizure activity, had a raised rectal temperature.

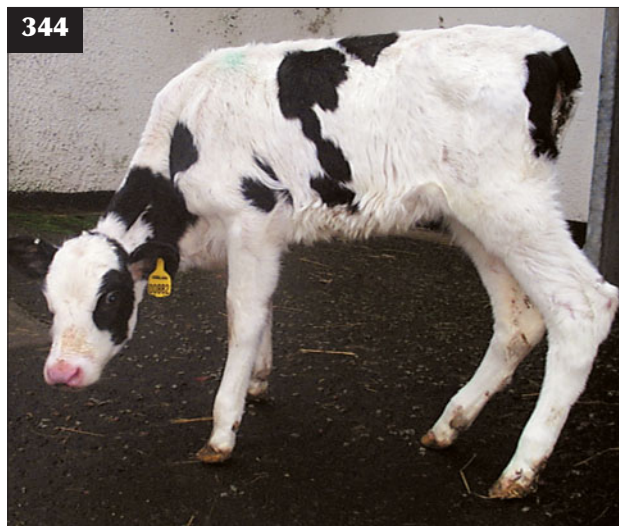- Severe depression, dementia, yawning, head pressing (343), licking inanimate objects.
- Hyperaesthesia to auditory and tactile stimuli, seizure activity, opisthotonus.
- Contralateral proprioceptive defects.

The common neurological conditions that present with diffuse cerebral signs include polioencephalomalacia,

bacterial meningitis and ketosis. Clinical signs attributable to a cerebral lesion localized to a cerebral hemisphere are seen in space-occupying lesions such as a brain abscess and include compulsive circling, deviation of the head (not a head tilt) and contralateral blindness and proprioceptive deficits. Approximately 90% of the efferent nerve fibres cross at the optic chiasma, therefore animals with a left-sided space-occupying lesion would be blind in the right eye. The PLR would be normal.



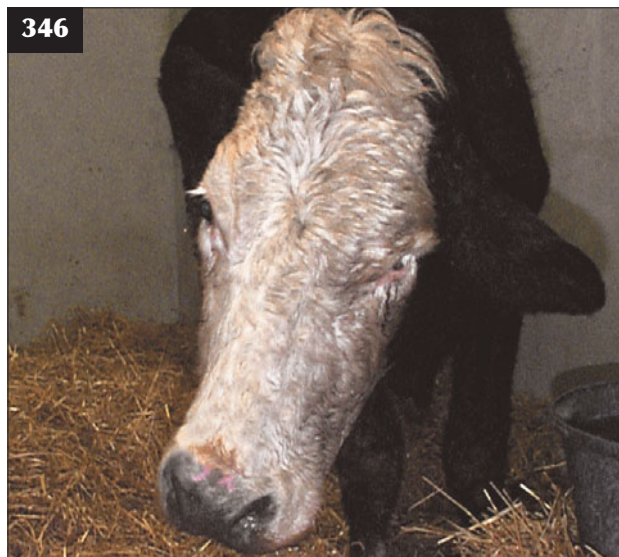343 This calf with cerebral dysfunction (meningitis) is head pressing.



344 This neonate with congenital cerebellar disease caused by cerebellar hypoplasia [necropsy findings shown in 349] shows the characteristic wide-based stance and ataxia (incoordination), particularly of the hindlimbs, but with preservation of normal muscle strength.



345 This animal with vestibular disease presented with a 5–10° head tilt, with the poll tilted down to the affected side.



346 Pontomedullary syndrome. Involvement of the facial nucleus in this animal has resulted in ipsilateral facial nerve paralysis manifest as drooped ear, drooped upper eyelid (ptosis) and a flaccid lip.

CEREBELLAR SYNDROME

The cerebellum is primarily concerned with fine coordination of voluntary movement. In cerebellar disease, all limb movements are spastic (rigid), clumsy and jerky. Initiation of movement is delayed and may be accompanied by tremors.

Cerebellar disease is characterized by a wide-based stance and ataxia (incoordination), particularly of the hindlimbs, but with preservation of normal muscle strength whether it is congenital (344) or acquired. In addition to ataxia, dysmetria (problems associated with stride) may be observed. Hypermetria, or overstepping, is seen as a Hackney-type gait. With hypometria the animal will frequently drag the dorsal aspect of the hoof along the ground.

Cerebellar disease may result in jerky movements of the head ('intention tremors'), especially when the animal is aroused or at feeding times, when it will often overshoot the feed bucket. This clinical feature is most commonly seen in neonatal calves associated with cerebellar hypoplasia caused by congenital BVDV infection.

VESTIBULAR SYNDROME

The head is normally held in the vertical plane, but in vestibular disease a 5–10° tilt is present, with the poll tilted down to the affected side (345). This may be exaggerated by blindfolding the animal. Circling may also be observed. Positional nystagmus may be depressed or absent in animals with a vestibular lesion when the head is moved

towards the side of the lesion (head tilt). Resting nystagmus is present and permits differentiation between the two forms of vestibular disease: peripheral vestibular disease – fast phase away from side of lesion; and central vestibular disease – fast phase in any direction including dorsal or ventral.

PONTOMEDULLARY SYNDROME

As most of the cranial nerve nuclei are present in the brainstem, dysfunction referred to as the pontomedullary syndrome is characterized by multiple CN deficits. In brainstem disease, depression is attributed to a specific lesion in the ascending reticular activating system. In addition, circling, ipsilateral hemiparesis and proprioceptive defects are common.

In diseases affecting the brainstem, propulsive circling results because of involvement of the vestibulocochlear nucleus. Involvement of the facial nucleus results in ipsilateral facial nerve paralysis manifest as drooped ear, drooped upper eyelid (ptosis) and flaccid lips (346). Trigeminal nerve paralysis results in loss of cheek muscle tone and decreased facial sensation. Abnormal respiratory patterns may result from damage to the respiratory centres in the medulla.

CRANIAL NERVES

CNs leave the forebrain and brainstem and have a variety of specialized functions (*Table 2*).

Table 2 Specialized functions of the cranial nerves.

Assessment of normal function	Tests the undernoted cranial nerves and associated centres
Vision	Eye, II, cerebrum (contralateral)
Pupillary light response (pen torch)	II, III
Pupil size and symmetry (pen torch)	II, III, brainstem, sympathetic nervous system
Menace response (rapidly approaching object)	II, VII, cerebrum, brainstem, cerebellum
Eyeball position	III, lateral strabismus IV, dorsal and medial VI, medial strabismus
Normal head/cheek muscle tone	V
Touch cornea, eyeball retracts	V, VI
Touch medial canthus, eye closes	V, VII
Ears held in normal position	V, VII
Nostrils – normal sensation	V
Eyelids in normal position	III, VII, sympathetic nervous system
Hearing	VIII
Normal head position	VIII, cerebrum
Deglutition, tongue movement	IX, X, XII

OLFACTORY NERVE (CN I)

Assessment of the olfactory nerve has little clinical application in cattle.

OPTIC NERVE (CN II)

The visual pathway is usually tested by observing cattle encountering obstacles and noting the menace reflex whereby the eyelids close quickly in response to a rapidly approaching object. The menace response can be difficult to evaluate in depressed animals and should be interpreted with caution.

Up to 90% of optic nerve fibres decussate at the optic chiasma, therefore vision in the right eye is perceived in the contralateral cerebral hemisphere. The typical pathway is incoming (afferent) fibres recognizing the menace response in the left eye travel along the left optic nerve to the optic chiasma, then cross to the right optic tract and right occipital cortex. The motor (efferent) pathway is from the right visual cortex to the left facial nucleus, resulting in closure of the left eye.

OCULOMOTOR NERVE (CN III)

Pupillary diameter is controlled by constrictor muscles innervated by the parasympathetic fibres in the oculomotor nerve and dilator muscles innervated by the sympathetic fibres from the cranial cervical ganglion. The normal response to light directed into one eye is constriction of both pupillary apertures, with a direct response in the stimulated eye and a consensual response in the contralateral eye.

A dilated pupil in an eye with normal vision (menace response) would suggest a lesion in the oculomotor nerve. The contralateral eye with normal oculomotor nerve function will respond to both direct and consensual stimulation. If a lesion involves primarily one cerebral hemisphere, increased pressure to one oculomotor nerve presents as different pupillary aperture diameters (anisocoria), with the affected side displaying pupillary dilation.

HORNER'S SYNDROME

Horner's syndrome refers to the clinical appearance of damage to the sympathetic nerve supply to the eyeball causing slight ptosis (drooping of upper eyelid), constriction of the pupil (miosis) and slight protrusion of the nictitating membrane. The menace response (vision) and PLR are normal.

OCULOMOTOR NERVE (CN III), TROCHLEAR NERVE (CN IV) AND ABDUCENS NERVE (CN VI)

These three CNs are responsible for normal position and movement of the eyeball within the bony socket. An abnormal eyeball position is referred to as strabismus. Abnormal position of the eyeball is rarely seen as an acquired syndrome in large animals.

- Paralysis of the oculomotor nerve: lateral strabismus.

- Paralysis of the trochlear nerve: dorsomedial strabismus.

- Paralysis of the abducens nerve: medial strabismus.

Many cerebral lesions can result in strabismus. If there is a unilateral cerebral lesion, the strabismus is directed to the ipsilateral side. Dorsomedial strabismus is classically seen in polioencephalomalacia, lead poisoning, salt poisoning and acute bacterial meningitis. In such diseases, dorsomedial strabismus is not a specific lesion of trochlear nerve damage, but a reflection of cerebral oedema involving upper motor neuron pathways. Lesions of the abducens nerve result in constant medial strabismus and loss of the ability to retract the eyeball into the bony socket (corneal reflex).

TRIGEMINAL NERVE (CN V)

The trigeminal nerve has three branches, the mandibular, maxillary and ophthalmic, which supply the motor fibres to the muscles of mastication and sensory fibres to the face. Loss of motor function of the mandibular branch of the trigeminal nerve results in rapid atrophy of the temporal and masseter muscles, which are responsible for mastication. Unilateral lesions result in deviation of the lower jaw and muzzle away from the affected side. Responses to stimulation of the skin around the face are mediated through sensory fibres in the trigeminal nerve and motor fibres in the facial nerve. These reflexes require intact trigeminal and facial nerves, trigeminal and facial nuclei and brainstem.

FACIAL NERVE (CN VII)

The facial nerve is concerned primarily with motor supply to the facial muscles. It contains the lower motor neurons for movement of the ears, eyelids, nares and muzzle and the motor pathways of the menace and palpebral reflexes. Facial nerve paralysis is characteristically seen as drooping of the upper eyelid and ear and, with an unilateral lesion, deviation of the muzzle towards the unaffected side due to loss of facial muscle tone in the affected side.

Palpebral reflex

When the periocular skin is touched, the normal reflex is that the animal will close the palpebral fissure. A lack of the palpebral reflex may indicate a lesion in:

- The facial nerve or facial nucleus (motor pathway).
- The trigeminal nerve or nucleus (sensory pathway).
- Both nerves or nuclei involved.

If the facial nerve only is involved, skin sensation of the face would be normal due to normal trigeminal nerve function.

VESTIBULOCOCCHLEAR NERVE (CN VIII)

Deafness in cattle may be difficult to determine. The vestibular system controls orientation of the head, body and eyes. Nystagmus refers to movement of the eyeball within the bony socket. Normal vestibular nystagmus

refers to horizontal movement of the eyeball as the head is turned laterally, with the fast movement phase toward the side to which the head is turned. Pathological changes that result in nystagmus originate in the vestibular system.

Spontaneous nystagmus refers to nystagmus when the head is held in the normal position. Positional nystagmus results when the head is held in various abnormal positions.

GLOSSOPHARYNGEAL NERVE (CN IX) AND VAGAL NERVE (CN X)

Damage to the nuclei of these two nerves results in dysphagia and associated salivation. Affected animals cannot swallow or drink.

ACCESSORY NERVE (CN XI)

In ruminants, the accessory nerve appears to have little specific function.

HYPOGLOSSAL NERVE (CN XII)

The hypoglossal nerve provides motor supply to the muscles of the tongue. With a unilateral lesion there is atrophy of musculature, but the animal is still able to retract its tongue within the buccal cavity. In the case of a bilateral lesion the cow is unable to prehend and masticate food and the tongue remains protruded.

MIDBRAIN SYNDROME

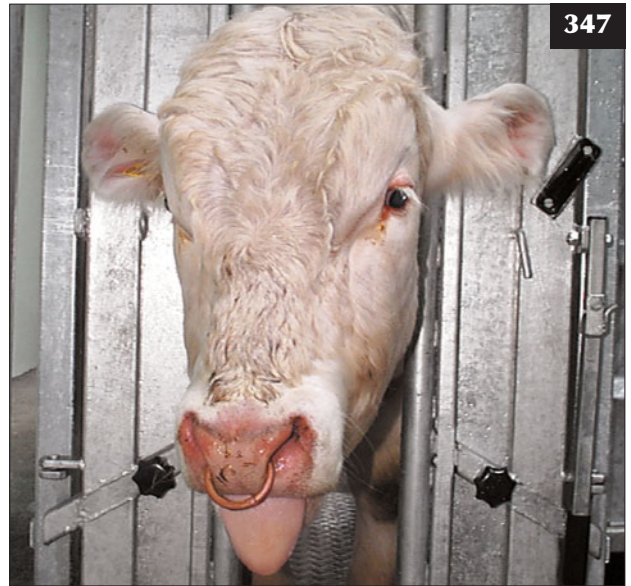Midbrain syndrome is relatively uncommon in ruminants and is characterized by depression/coma, possible limb rigidity and opisthotonus. Most affected animals have normal vision and ventrolateral strabismus, but a mydriatic pupil that is unresponsive to light. The most common causes of midbrain syndrome in ruminants are cranial trauma or hepatic encephalopathy.

HYPOTHALAMIC SYNDROME

The most common cause of hypothalamic syndrome is basillar empyema (pituitary abscess). The insertion of bull rings with resultant localized infection is considered to be one source of haematogenous spread to the rete mirabile, the complex of blood capillaries surrounding the pituitary gland, giving rise to basillar empyema. Clinical findings include multiple CN deficits, particularly bilateral deficits involving CN III, CN V (347) and CN VII, and ataxia and bradycardia.

CEREBROSPINAL FLUID COLLECTION

In cattle, CSF collection and analysis provides rapid (in some situations instant) information to the veterinary clinician investigating a disease problem in the living animal. CSF analysis is particularly useful with respect to confirming the presence of an inflammatory lesion involving the leptomeninges (e.g. bacterial meningoencephalitis) and investigating potential



347 This animal with basillar empyema is showing signs of multiple cranial nerve deficits, particularly bilateral cranial nerve deficits involving CNs III and V.

compressive lesions of the spinal cord. When correctly performed under local anaesthesia, lumbar CSF collection in ruminants is a safe procedure and there are no harmful sequelae. Familiarity with the technique aids high extradural injection of lidocaine and/or xylazine, which has numerous applications in farm practice. There are few indications for cisternal CSF collection in food animals.

For CSF collection and examination it is necessary to puncture the subarachnoid space in the cerebellomedullary cistern (cisternal sample) or at the lumbosacral site (lumbar sample). Although theoretically it may be desirable to collect CSF from the site nearer the suspected lesion, this is not always possible in field situations. In the absence of a focal compressive spinal cord lesion, there are no substantial differences between the composition of cisternal and lumbar CSF samples.

Collection of lumbar CSF is facilitated if the animal can be positioned in sternal recumbency with the hips flexed and the hindlimbs extended alongside the abdomen (typically calves and recumbent adults).

The site for lumbar CSF collection is the midpoint of the lumbosacral space, which can be identified as the midline depression between the last palpable dorsal lumbar spine (L6) and the first palpable sacral dorsal spine (S2). The site must be clipped, surgically prepared and 1–2 ml of local anaesthetic injected subcutaneously. Sterile surgical

gloves should be worn for the collection procedure. In cattle <250 kg body weight, hypodermic needles should be used because they are sharp, can be discarded after single use, do not become blocked and CSF wells up as soon as the needle point enters the dorsal subarachnoid space; internal stylets are unnecessary. In adult cattle a 4 inch spinal needle can be guided through a 2 inch 14 gauge disposable needle for the proximal part of its length.

The needle (*Table 3*) is slowly advanced (over 10 seconds) at a right-angle to the plane of the vertebral column or with the hub directed 5–10° caudally. It is essential to appreciate the changes in tissue resistance as the needle point passes sequentially through the subcutaneous tissue and interarcuate ligament, then the sudden ‘pop’ due to the loss of resistance as the needle point exits the ligamentum flavum into the extradural space. Once the needle point has penetrated the dorsal subarachnoid space, CSF will well up in the needle hub within 2–3 seconds. Failure to appreciate the change in resistance to needle travel may result in needle puncture of the conus medullaris. This may elicit an immediate pain response and cause unnecessary discomfort to the animal, which must be avoided at all times. Movement of the hindlimbs may dislodge the needle point with the risk of causing local trauma and haemorrhage in the leptomeninges, which may contaminate the CSF sample that is ultimately collected. 1–2 ml of CSF are sufficient for laboratory analysis, and, although the sample can be collected by free flow over 1–2 minutes, it is more convenient to employ very gentle syringe aspiration over 10–20 seconds.

The normal range for CSF protein concentration quoted for cattle is <0.3 g/l. Normal CSF contains less than 10 cells/ μ l; these are predominantly lymphocytes with an occasional neutrophil. As a general rule, a predominantly polymorphonuclear intrathecal inflammatory response is found in acute CNS bacterial infections, whereas a mononuclear response is seen in viral CNS infections.

CEREBELLAR HYPOPLASIA/HYDRANENCEPHALY

DEFINITION/OVERVIEW

In-utero BVDV infection at around 90–130 days’ gestation causes cerebellar hypoplasia (344) and, less commonly, hydranencephaly. The BVDV invades the fetus, infects the developing germinal cells of the cerebellum and destroys the Purkinje cells in the granular layer. (See Chapter 3, Digestive tract and abdomen, Bovine viral diarrhoea, p. 108). Financial losses due to BVDV infection, of which cerebellar hypoplasia is only one manifestation, can be enormous.

AETIOLOGY

Cerebellar hypoplasia/hydranencephaly can be the result of an autosomal recessive condition or caused by in-utero infection with BVDV or Akabane virus.

Table 3 Guide to needle length and gauge for lumbar CSF sampling.

Calves <100 kg	1 inch 19 gauge
Calves 100–250 kg	2 inch 19 gauge
Cattle >250 kg	4 inch 18 gauge + internal stylet

CLINICAL PRESENTATION

Cerebellar disease is characterized by lowered head carriage, a wide-based stance and incoordination, particularly of the hindlimbs, but with preservation of normal muscle strength. In addition, hypermetria is commonly observed in cerebellar disease. Coarse intention head tremors are frequently observed, particularly during periods of excitement such as feeding times. Opisthotonus can occur in calves with severe lesions of the rostral cerebellum. In addition to these cerebellar signs, calves with hydranencephaly exhibit blindness and depression/somnolence (sometimes referred to as dummies; 348).

DIFFERENTIAL DIAGNOSIS

Calves with cerebellar hypoplasia show signs from birth, whereas calves with cerebellar abiotrophy show similar signs, but these are insidious in onset from 2–4 months old.

DIAGNOSIS

BVDV antibody or antigen present in a pre-colostral blood sample may confirm in-utero BVDV infection. Characteristic histopathological findings are found at necropsy (349, 350).

MANAGEMENT

There is no treatment for cerebellar hypoplasia and affected calves should be culled.

Prevention/control measures

Prevention/control of cerebellar hypoplasia/hydranencephaly involves good biosecurity, maintenance of a BVDV-free herd and an effective vaccination strategy.

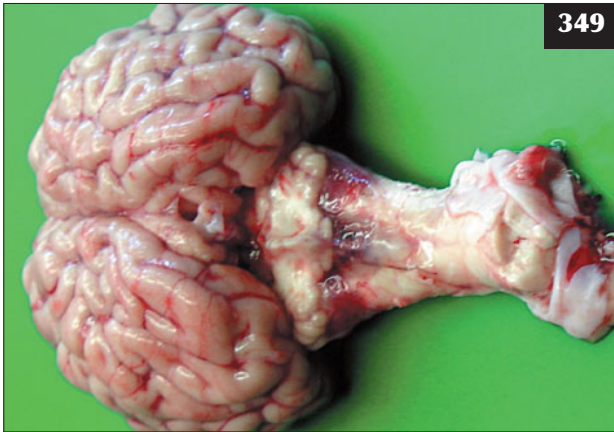
BACTERIAL MENINGOENCEPHALITIS (MENINGITIS)

DEFINITION/OVERVIEW

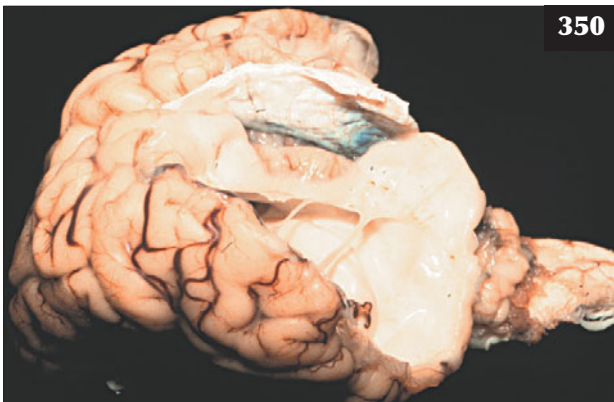
Bacterial meningoencephalitis is a common bacterial infection of the CNS of neonatal calves.



348 This calf with hydranencephaly (necropsy findings shown in **350**) is exhibiting blindness and depression/somnolence in addition to cerebellar signs.



349 Cerebellar hypoplasia. Necropsy specimen of the calf in **344**.



350 Hydranencephaly. Necropsy findings of the calf in **348**.

AETIOLOGY

Bacteraemia, with subsequent localization within the meninges, results from failure of passive antibody transfer and high levels of bacterial challenge in the calf's environment. The disease is more common in calves born indoors in unhygienic calving boxes than in cows calving at pasture. Despite intensive treatment, the prognosis is grave. *Escherichia coli* and *Streptococcus* spp. are the more common isolates from lumbar CSF of calves with meningoencephalitis.

CLINICAL PRESENTATION

The early clinical signs include lack of suck reflex, depression, dorsiflexion of the neck (**351**), failure to follow the dam (beef calves) and weakness. Fever is not a consistent feature. Later, affected calves stand with the neck extended; movement of the neck is painful and may result in vocalization. As the disease progresses there is lack of menace response, dorsomedial strabismus and episcleral injection. Depression progresses to stupor, but the calf is hyperaesthetic to auditory and tactile stimuli, which may precipitate seizure activity during handling. Opisthotonus (**342**) is observed during the agonal stages of disease approximately 24–36 hours after clinical signs are first noted. There may be evidence of bacterial infection involving other organ systems (e.g. hypopyon, polyarthritis, diarrhoea and omphalophlebitis). Infarcts in the liver and kidney are frequently observed at necropsy.

DIFFERENTIAL DIAGNOSIS

The important differential diagnosis for the early stages of bacterial meningoencephalitis is metabolic acidosis resulting from viral diarrhoea of 2–3 days' duration. Septicaemia presents with similar clinical findings to meningoencephalitis, as the meninges are a common site for bacterial colonization in neonatal calves.



351 Dorsiflexion of the neck in a calf with bacterial meningitis.

DIAGNOSIS

There is a five- to tenfold increase in CSF protein concentration and >100-fold increase in total white cell count, with a change in the predominant cell type from lymphocyte to neutrophil (neutrophilic pleocytosis). These CSF changes cause increased turbidity of the sample, which is visible on gross CSF inspection (352) and affords the veterinary surgeon an immediate diagnosis. Bacteriological culture of lumbar CSF during the early stages is often unrewarding.

MANAGEMENT

The prognosis is grave. Intensive antibiotic therapy with either florfenicol, trimethoprim-sulphonamide combination or ceftiofur is essential as soon as possible after the onset of clinical signs. Intravenous dexamethasone (1 mg/kg) at first presentation is controversial, but in the authors' experience improves survival rates (353). Apart from the financial cost of losing the calf, purchase of a replacement in a beef herd poses a considerable biosecurity risk.

Prevention/control measures

Prevention is by improving hygiene in the calving accommodation and ensuring timely passive antibody transfer (7% of the calf's body weight of colostrum within six hours of birth).

BRAIN ABSCESS

DEFINITION/OVERVIEW

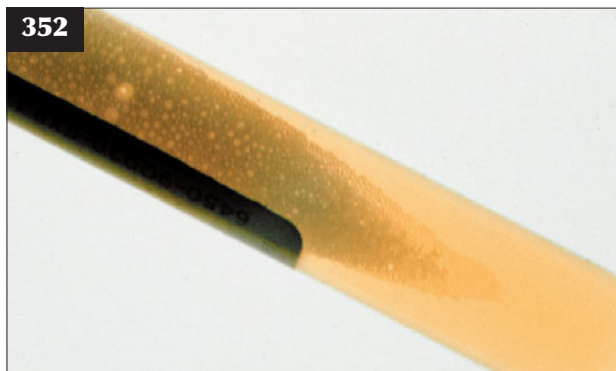
Neurological signs of a brain abscess typically appear in 4–12-week-old calves following localization of neonatal bacteraemia and in yearlings where the source of infection often remains undetected. Extension of infection through the calvarium following infection of the frontal sinus as a consequence of dehorning is reported in the literature, but is very uncommon.

AETIOLOGY

Brain abscesses are usually of haematogenous origin with *Arcanobacterium pyogenes* being the most common isolate.

CLINICAL PRESENTATION

Clinical signs are slowly progressive and result from the space-occupying nature of the lesion. Depression is commonly observed, with the head turned towards the animal's chest (354). There may be compulsive circling, but affected cattle often stand motionless or appear trapped with the head pushed into a corner. The gait may appear ataxic. The lesion commonly affects one cerebral hemisphere; as a consequence, the animal often presents with contralateral blindness and proprioceptive deficits, but normal PLRs. Proprioceptive deficits, with hyperflexion of the fetlock joint (knuckling) of the contralateral limbs, are commonly observed.



352 Bacterial meningoencephalitis. The massive influx of white cells has caused turbidity of the CSF sample, clearly visible on gross inspection.



353 The calf in 351 after florfenicol and intravenous dexamethasone injection.

DIFFERENTIAL DIAGNOSIS

Other space-occupying lesions are very uncommon in calves/growing cattle.

DIAGNOSIS

There are slight increases in CSF protein and white cell concentrations in lumbar CSF; higher values are recorded when there is significant meningeal involvement.

MANAGEMENT

Treatment with penicillin (44,000 iu/kg i/m q24h for 6 weeks) may halt progression of the infection, but the long-

term prognosis is very poor. Prevention of bacteraemia in neonatal calves necessitates ensuring adequate passive antibody transfer and reducing environmental bacterial challenge by maintaining good hygiene standards in the calving accommodation.

UNILATERAL MIDDLE EAR INFECTIONS/VESTIBULAR SYNDROME

DEFINITION/OVERVIEW

Unilateral middle ear infections (otitis media) are not uncommon in growing calves and yearlings.

AETIOLOGY

Infection usually arises from ascending infection in the eustachian tube and may occur as a sequela to respiratory disease.

CLINICAL PRESENTATION

The major clinical sign in unilateral peripheral vestibular disease is an ipsilateral head tilt of 5–10° down to the affected side (345). There may be loss of balance, leaning and movement/circling toward the affected side. When walking, cattle tend to drift toward the affected side. During the early stages of unilateral peripheral vestibular lesions there is spontaneous horizontal nystagmus, with the fast phase away from the side of the lesion. There is often ipsilateral ventral deviation of the eye (eye drop), which is exaggerated when the head is raised. Facial palsy (drooped ear and ptosis) is often seen in conjunction with otitis media (355). In central vestibular disease the nystagmus may be horizontal, vertical or rotary, and there may be

ipsilateral limb weakness. Depression indicates involvement of the reticular formation.

DIFFERENTIAL DIAGNOSIS

Listeriosis.

DIAGNOSIS

Diagnosis is based on clinical findings. There are no CSF changes.

MANAGEMENT

The bacterial infection responds well to treatment with procaine penicillin (44,000 iu/kg i/m q24h for 7 days). The condition occurs sporadically and there are no specific control measures or serious economic consequences.

POLIOENCEPHALOMALACIA (SYN. CEREBROCORTICAL NECROSIS)

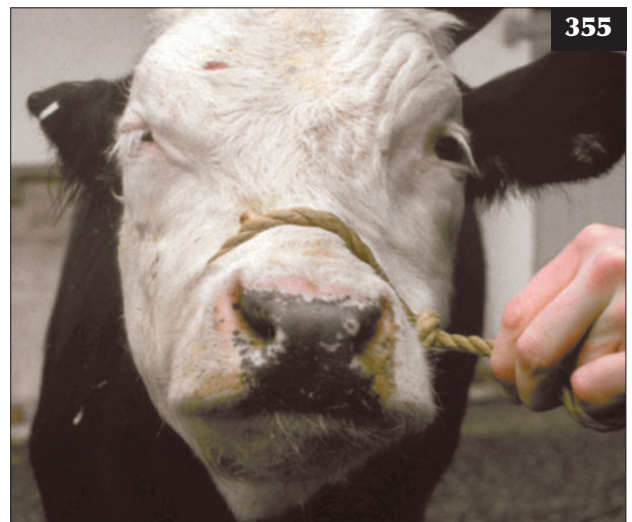DEFINITION/OVERVIEW

Polioencephalomalacia (PEM) (syn. cerebrocortical necrosis [CCN]) is a sporadic condition affecting young growing cattle.

AETIOLOGY

PEM is associated with high concentrate rations, although cases have occurred in animals grazing lush aftermath. Under these circumstances, changes in the rumen flora permit multiplication of microorganisms producing thiaminase type 1, thereby inducing thiamine deficiency. PEM can be caused by decreased use of thiamine at the cellular level due to ingestion of high sulphur-containing diets or water sources.

354 This calf with a brain abscess has its head turned towards its chest.



355 Facial palsy (drooped ear and ptosis) is seen in this animal with otitis media.

CLINICAL PRESENTATION

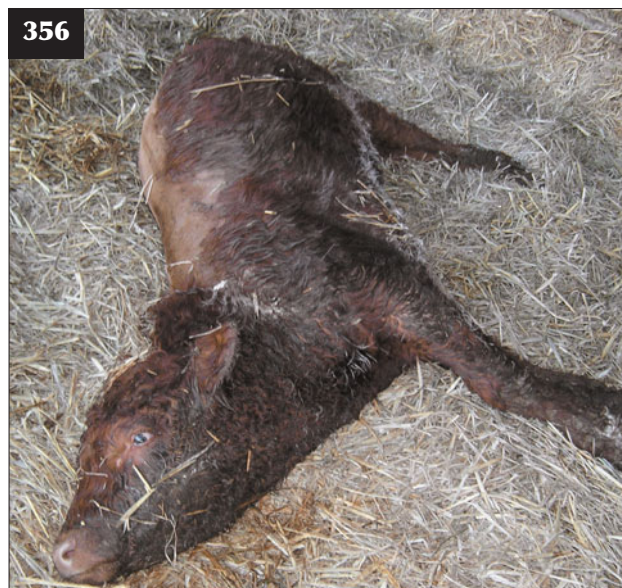During the early stages of PEM there is frequently a brief period of diarrhoea before nervous signs appear. Affected animals are dull and may isolate themselves from others in the group. There is high head carriage and affected cattle may stagger. There is bilateral loss of menace response and dorsomedial strabismus, with nystagmus often present. Affected animals are hyperaesthetic to tactile and auditory stimuli. As the disease progresses, animals often head press into corners and there is frequent bruxism (teeth grinding). Twitching, muscular tremors and intermittent opisthotonus are evident, followed by recumbency and clonic convulsions with intermittent periods of spasticity and terminal flaccidity (356). Untreated cattle die within 3–5 days.

DIFFERENTIAL DIAGNOSIS

Lead poisoning; sulphur toxicity; meningitis.

DIAGNOSIS

Diagnosis of PEM is based primarily on history, clinical signs and the response to intravenous thiamine administration. Changes in lumbar CSF include a slightly increased protein concentration, but this result is of little diagnostic value. Laboratory tests of thiaminase activity are of equivocal value. Cases of sulphur toxicity may have an odour of hydrogen sulphide when the rumen contents are examined at necropsy.



356 An eight-month-old bullock with polioencephalomalacia showing opisthotonus, bilateral blindness, dorsomedial strabismus and nystagmus. The bullock made a full recovery following treatment with thiamine and dexamethasone.

MANAGEMENT

Improvement following 10–15 mg/kg thiamine hydrochloride given intravenously early in the disease is usually evident within 24 hours. The thiamine should be repeated within 4–6 hours, then twice daily for a further three days. Intravenous administration of dexamethasone (1.0 mg/kg) at first presentation may facilitate recovery. Full clinical recovery may take one week.

The condition occurs only very sporadically under normal husbandry conditions. Sulphur toxicity should be considered where several cases occur during a short period of time. Addition of thiamine to the ration where sulphur toxicity has occurred will prevent further cases of PEM.

LISTERIAL ENCEPHALITIS

DEFINITION/OVERVIEW

Listerial encephalitis is a common disease worldwide and results from *Listeria monocytogenes* infection of the brain.

AETIOLOGY

Listeriosis occurs sporadically in cattle. Most cases are associated with feeding poorly fermented/conserved forages and affect 2–3-year-old animals, but cattle are much less susceptible than sheep to listeriosis.

CLINICAL PRESENTATION

The rectal temperature of affected cattle is within the range 38.5–39.2°C. There is reduced appetite with a gaunt appearance after several days, a marked fall in milk production in lactating cattle and weight loss. Loss of saliva leads to rumen impaction, causing abdominal pain manifest as an arched-back stance and frequent bruxism. Ipsilateral hemiparesis may also be present. Depression is attributed to a lesion in the ascending reticular activating system. A head tilt toward the affected side is an inconsistent finding. Circling can be observed with involvement of the vestibulocochlear nucleus. Cattle frequently have a 'propulsive tendency' and may be found with the head forced through a gate or under a feed trough, or wedged across the front of the cubicle/stanchion.

Listerial encephalitis is characterized by multiple unilateral CN deficits, depression and, in some cases, circling to the affected side. Involvement of the trigeminal nucleus results in paralysis of the cheek muscles and decreased facial skin sensation. Facial palsy is evident as drooped ear, drooped upper eyelid (ptosis) and flaccid lip (357). Loss of function of CNs IX, X and XII causes stertorous breathing and dysphagia (358), but this presentation is uncommon.

DIFFERENTIAL DIAGNOSIS

Vestibular lesion; basillar empyema; brain abscess; nervous acetonaemia; bovine spongiform encephalopathy (BSE).

DIAGNOSIS

There is a moderate increase in CSF protein concentration (in the range 0.8–2.0 g/l) and monocytic pleocytosis. Isolation of the causal organism from the brain may require extended periods of 'cold enrichment', but the neurohistopathology is usually sufficiently characteristic to permit a diagnosis.

MANAGEMENT

A minimum dose of 44,000 iu/kg procaine penicillin injected intramuscularly q24h for at least 10 days must be considered in addition to 44,000 iu/kg penicillin G injected intravenously on the first day. Dose rates as high as 300,000 iu/kg have been recommended for the first day of antibiotic therapy because it is essential to exceed the MIC by 10–30 times in order to achieve a successful outcome.

Loss of saliva may lead to dehydration and metabolic acidosis. Care must be taken when replacing fluids by orogastric tube because contraction of the rumen caused by anorexia of some days' duration may result in passive regurgitation of fluid around the tube. Transfaunation with rumen liquor from a healthy cow may promote rumen function during recovery.

Good fermentation is guaranteed by cutting grass containing a high fermentable sugar content at an early growth stage (high digestibility value >72), wilting it for 24 hours and using various silage additives, whether sugars or organic acids. Compaction of the silage clamp is important to expel all air, followed by a tight seal to prevent aerobic bacterial multiplication. Soil contamination is limited by rolling grass fields at the beginning of the growing season.



357 Listeriosis. Facial palsy is evident as drooped ear, drooped upper eyelid (ptosis) and a flaccid lip in this animal.

LEAD POISONING**DEFINITION/OVERVIEW**

Lead poisoning is an acute encephalopathy occurring after accidental exposure and ingestion of lead-containing materials.

AETIOLOGY

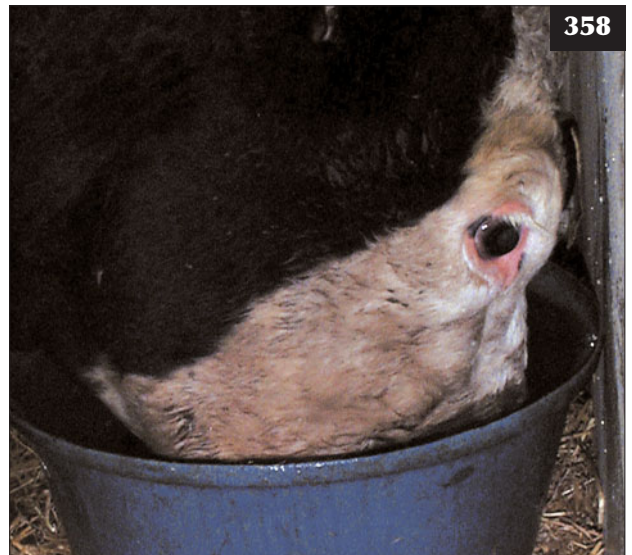Lead poisoning is caused by ingestion of lead-containing materials such as discarded car batteries, although lead-based paints are now rare.

CLINICAL PRESENTATION

Lead poisoning is characterized by an acute encephalopathy. Irrespective of the rate of uptake of lead, the clinical signs of intoxication are sudden in onset and characterized by behavioural changes. Affected cattle become isolated and depressed, but they are hyperaesthetic to tactile and auditory stimuli and may show muscle twitching, especially of the palpebral muscles. They are blind and may head press forcibly into corners and against walls. As the disease progresses, cattle become frenzied, bellow, stagger and crash into obstacles. There may be signs of abdominal pain including kicking at the abdomen and frequent bruxism. Bloat is often seen and attempts at alleviating this problem may precipitate frenzy. Death may occur suddenly or within days.

DIFFERENTIAL DIAGNOSIS

Hypomagnesaemic tetany; nervous ketosis/acetonaemia; PEM; rabies/pseudorabies.



358 Listeriosis. This cow has difficulty swallowing. Note that her muzzle is completely immersed in the full water bucket.

DIAGNOSIS

Diagnosis of lead poisoning is based on clinical signs and the presence of a lead source. Confirmation depends on histopathological findings and kidney and liver concentrations >4 ppm wet weight and blood values in excess of 0.3 ppm.

MANAGEMENT

Cattle with severe neurological signs of several days' duration may have extensive neuropathological changes and are unlikely to respond to treatment. However, if a source can be identified, in-contact animals at risk from a single large dose may be drenched orally with magnesium sulphate (500–1,000 g), to precipitate and remove lead from the alimentary tract, and injected with calcium disodium edetate (110 mg/kg by slow i/v drip on alternate days for 3 treatments). The similarity of the pathological changes to those of PEM has encouraged the use of thiamine (10–15 mg/kg i/v) along with EDTA therapy and is reportedly beneficial. Control of convulsions proves very difficult because drugs such as diazepam have a short half-life in cattle. Pentobarbitone is frequently used to control seizure activity in cattle with acute hypomagnesaemia and could be used in emergency situations in lead poisoning to control convulsive episodes.

Prevention is a matter of good management by not allowing cattle access to sources of lead. Regulatory authorities may recommend withdrawal periods before milk and/or meat from exposed cattle may enter the food chain.

THROMBOEMBOLIC MENINGOENCEPHALITIS**DEFINITION/OVERVIEW**

TEME (sleeper calves) occurs worldwide but is more commonly reported in feedlots in North America 1–2 weeks following an episode of *Histophilus somni* respiratory disease, which may have been untreated. This syndrome is presently uncommon in the UK.

AETIOLOGY

TEME is caused by an *H. somni* bacteraemia, which localizes in the meninges, brain, muscles and joints.

CLINICAL PRESENTATION

Affected cattle are febrile (41°C) obtunded, ataxic and become sternally recumbent. Other neurological signs depend on the area(s) of the brain affected. Death may result within 2–3 days, but some animals can survive for 10–14 days. Increased wheezes and crackles on auscultation of the chest may result from the previous respiratory disease episode. Polyarthritis may also be present, causing multiple joint effusions.

DIFFERENTIAL DIAGNOSIS

Listeriosis; botulism; endocarditis.

DIAGNOSIS

Lumbar CSF reveals evidence of intrathecal haemorrhage (xanthochromia and red blood cells ingested by macrophages), an elevated protein concentration and neutrophilic pleocytosis. CSF bacteriology is unrewarding.

MANAGEMENT

Cattle showing early stages of the disease (depression, ataxia, circling) should be treated with florfenicol. This antibiotic is used because it has the lowest MIC against *H. somni*.

Respiratory viral diseases (BRSV, IBR) and BVD should be prevented by timely vaccination. Appropriate management and husbandry practices for prevention of respiratory disease should be applied together with prompt treatment and monitoring. Prophylactic and metaphylactic administration of long-acting oxytetracycline is described in North America, but is not practised elsewhere. A benefit:cost analysis in feedlots may advocate prophylactic and metaphylactic antibiotic administration, but this may obfuscate management and husbandry deficiencies.

AUJESZKY'S DISEASE (PSEUDORABIES)**DEFINITION/OVERVIEW**

Aujeszky's disease is a herpesvirus infection, principally of pigs, which can be transmitted to most other mammalian species including cattle.

AETIOLOGY

Infections in cattle are generally sporadic and result via the oronasal route following contact with infected pigs, foodstuffs or other materials contaminated with virus.

CLINICAL PRESENTATION

The clinical course is short, rarely extending beyond 48 hours in adult cattle, but calves may die without obvious prior signs of illness. Usually, there is a brief period of excitement with high fever, bellowing and aggressive behaviour accompanied by trembling, hyperpnoea, salivation and compulsive licking of the nostrils. Intense pruritus of the neck, trunk or hindlimbs is accompanied by frantic efforts to relieve the itch to the point of self-mutilation. Affected animals may become bloated. There is incoordination and, terminally, recumbency, convulsions and coma.

DIFFERENTIAL DIAGNOSIS

Rabies; PEM; lead poisoning.

DIAGNOSIS

Except in calves, the clinical signs and contact with pigs are usually distinctive enough for a provisional diagnosis of

Aujeszky's disease. Confirmation is dependent on demonstration of the characteristic neuropathology or isolation of virus from nervous tissue.

MANAGEMENT

There is no effective treatment. The disease in cattle is extremely severe, with self-mutilation necessitating immediate slaughter for welfare reasons.

There are national programmes for the control of Aujeszky's disease in many countries. Strict biosecurity is essential. Prevention is dependent on control of the disease in the pig population.

RABIES

DEFINITION/OVERVIEW

Rabies is a neurotropic viral disease that can affect all warm-blooded animals. The rhabdovirus virus is excreted in saliva and transmitted by the bite of an infected animal. It is manifested by irritability, mania, hydrophobia and paralysis. It is usually fatal, although recoveries have been documented. Cattle are normally 'end hosts' with respect to rabies, although human infection may follow manual examination of the oral cavity when virus in saliva is inoculated into scratches caused by the animal's teeth.

AETIOLOGY

The incubation period of rabies in cattle varies from about 2–3 to several months.

CLINICAL PRESENTATION

The clinical signs of rabies in cattle classically occur in two distinct forms: the mild paralytic or dumb form (more common) and the furious form.

In paralytic rabies there may be partial loss of sensation in the hindlimbs, knuckling of the fetlocks, locomotor weakness and paralysis of the tail. Flaccid dilation of the anus may be accompanied by straining and pneumorectum. Drooling of saliva and yawning are common features. The entire clinical course lasts about one week and is terminated by recumbency and generalized paralysis, with death probably due to respiratory failure.

In the furious form the animal is hyperaesthetic, bellows hoarsely and becomes violently aggressive toward people, other animals and inanimate objects. Purposeful attacks, however, are frustrated by rapidly progressive incoordination and ataxia. Death occurs quickly following recumbency and paralysis.

DIFFERENTIAL DIAGNOSIS

Lead poisoning; bloat/oesophageal obstruction; Aujeszky's disease; nervous acetonaemia; listerial encephalitis; BSE.

DIAGNOSIS

Clinical diagnosis of rabies is difficult, especially in those

countries in which it rarely occurs. Rabid cattle invariably die and fluorescent antibody staining of impression smears from appropriate parts of the CNS will rapidly establish the diagnosis.

MANAGEMENT

No treatment of clinical cases should be attempted. National control programmes operate in many countries. Routine vaccination of cattle is rarely undertaken.

BASILAR EMPYEMA (PITUITARY ABSCESS)

DEFINITION/OVERVIEW

Basilar empyema occurs sporadically, often associated with the insertion of nose/bull rings.

AETIOLOGY

Localized infection following ring insertion is considered to be one source of haematogenous spread to the rete mirabile, the complex of blood capillaries surrounding the pituitary gland, giving rise to basilar empyema.

CLINICAL PRESENTATION

Clinical findings include dullness, multiple CN deficits (347), particularly bilateral deficits involving CNs III, V and VII, exophthalmos (359) ataxia and bradycardia (<50 beats per minute).

DIFFERENTIAL DIAGNOSIS

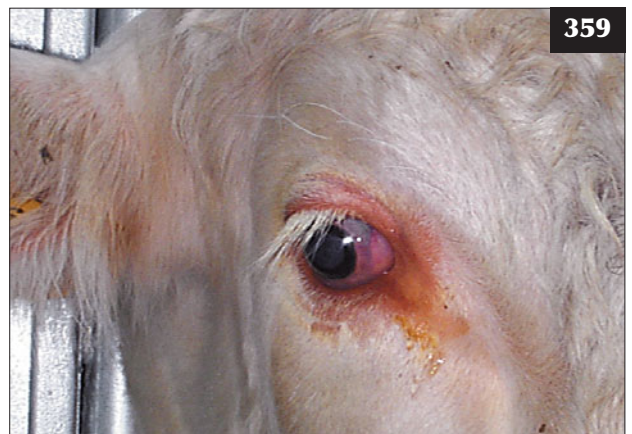Listeriosis; cerebral abscess.

DIAGNOSIS

There is no intrathecal inflammatory response.

MANAGEMENT

Procaine penicillin (44,000 iu/kg i/m q12h for at least



359 Basilar empyema. Extension of an expanding abscess into the retro-orbital rete would explain the exophthalmos of the right eye of this bull.

14 days) may be successful in early cases. The prognosis is poor for advanced cases (360, 361).

Care must be taken when inserting bull rings. Bulldog clips should not be inserted into the nostrils as a deterrent to cross-sucking in cattle.

BOVINE SPONGIFORM ENCEPHALOPATHY

DEFINITION/OVERVIEW

BSE, first reported in the UK in 1987, is a new member of a group of subacute transmissible spongiform encephalopathies that includes scrapie of sheep and goats, chronic wasting disease of mule deer, transmissible mink encephalopathy of ranch mink, Kuru and Creutzfeldt–Jakob disease (CJD) of humans and variant Creutzfeldt–Jakob disease (v-CJD) of humans. Subsequently, BSE has been recognized throughout the world including the countries of the European Union, Japan, Canada and the USA.

AETIOLOGY

There remains considerable debate regarding the causal agent, with the infectious protein or prion theory most widely accepted.

CLINICAL PRESENTATION

BSE affects adult cattle, with peak prevalence in 3–5-year olds. Signs include chronic weight loss and decreased milk yield over several weeks. Affected cattle isolate themselves and stand with an arched back and a wide-based stance (362). The abdomen appears drawn up with sunken sublumbar fossae consistent with reduced appetite. Cows spend very little time ruminating. Affected cattle become anxious, apprehensive and hyperaesthetic to tactile, auditory and visual stimuli. There is marked hindlimb hypermetria and ataxia, but normal muscle strength. Cows have

considerable difficulty when encountering obstacles such as steps, ramps and narrow gateways and will frequently attempt to jump over low objects and run through gateways. When confined in stocks, stimulation often provokes violent kicking (ballism) with the hindlimbs and bellowing. Affected animals may show aggression toward other cattle in the group. There is progression of clinical signs and cattle may become weak and recumbent within 2–10 weeks of clinical signs first being detected.

DIFFERENTIAL DIAGNOSIS

Listeriosis; hypomagnesaemia; space-occupying lesions; lead poisoning; organophosphorus poisoning; hepatic encephalopathy.

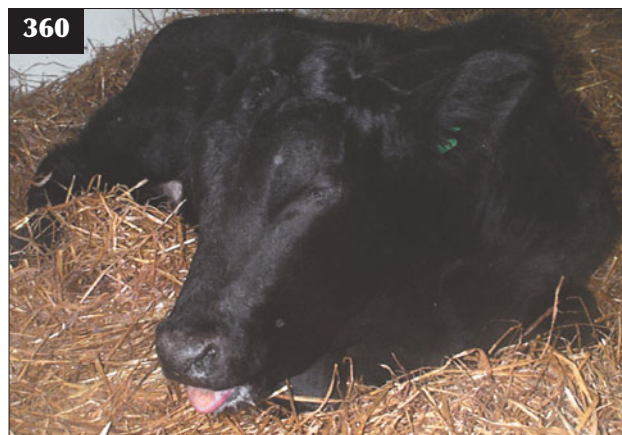DIAGNOSIS

There is no intrathecal inflammatory response that excludes infection of the CNS by most conventional infectious agents. Confirmation depends on microscopic demonstration of neuronal vacuolation and spongiform degeneration.

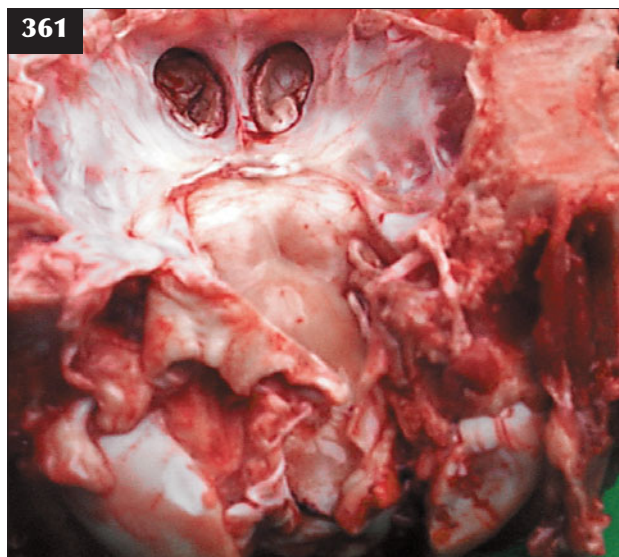
MANAGEMENT

There is no treatment and humane destruction is required.

BSE was made a notifiable disease (compulsory reporting of suspected cases to regulatory authorities) in the UK on 21st June 1988. Compulsory slaughter with destruction of the carcass (incineration since 1991) with compensation was introduced on 8th August 1988. On July 18th 1988, specified bovine offals (brain, spinal cord, tonsil, thymus, spleen and intestine) were banned from ruminant feedstuffs and extended to all animal feeds in September 1990. The incidence of BSE reached its peak in 1992, when 36,680 cases were confirmed in Great Britain, and since then has shown a steady decline to 30 cases in 2008. National control programmes operate in many other countries.



360, 361 Basilar empyema. (360) Advanced case of basilar empyema in a yearling. (361) Necropsy reveals the extent of the bone destruction.



SPINAL CORD LESIONS

DEFINITION/OVERVIEW

Spinal cord lesions, whether focal or diffuse, occur only sporadically in cattle practice and are of no major economic concern.

AETIOLOGY

Lesions include vertebral empyema, extradural abscess, trauma, protozoan (encephalo-) myelitis and neoplasia. Vertebral empyema in young calves often yields *Salmonella dublin*.

CLINICAL PRESENTATION

Accurate localization of a focal spinal cord lesion relies on the assessment of simple spinal reflex arcs. These indicate the presence of either upper or lower motor neuron signs in the affected limbs. The simple spinal reflex arc comprises three neurons: the sensory neuron (stretch receptor in tendon), the internuncial neuron and the lower motor neuron (contraction of limb muscle).

Although the reflex motor response to sensory stimuli can occur without the input of higher centres, the higher motor centres exert control of voluntary movement via the upper motor neurons, which synapse on the lower motor neuron. Flexor (withdrawal) reflexes can be determined by pinching the interdigital skin or applying pressure across the coronary band, with resultant unconscious flexion and withdrawal of the stimulated limb. Recognition of pain indicates integrity of the spinal cord above the reflex arc. To determine tendon 'jerk' reflexes for the forelimb, the triceps tendon is tapped 2–5 cm proximal to its attachment onto the olecranon process. The normal response is extension of the elbow joint. The hindlimb is gently supported in the mid-femoral region and the middle patellar ligament lightly tapped. The normal reflex is extension of the stifle joint.

Lesions affecting the upper motor neurons result in conscious proprioceptive deficits, evident as changes in flight of the foot and abnormal placement of the foot on the ground, resulting in stumbling and knuckling of the lower limb joints. Stimulation of the skin over the thoracic wall and flank with a blunt object produces a normal local response of muscle contraction (panniculus reflex). In the case of a spinal lesion, the skin caudal to the affected area of the cord has a reduced (hypalgesic) response, with a possible increased (hyperaesthetic) response cranial to the spinal lesion.

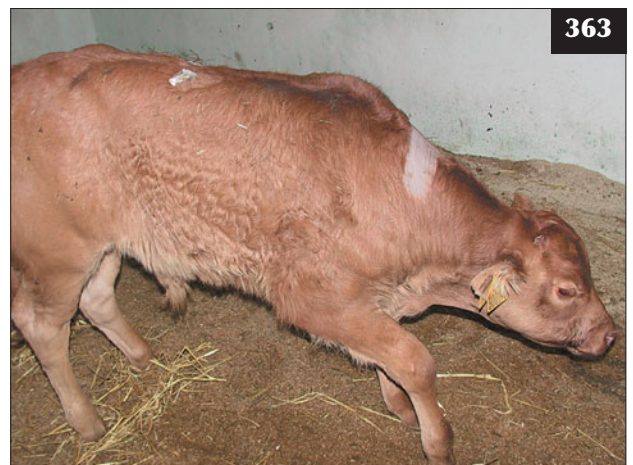The presence of a spinal lesion at the level of the reflex arc results in a lack of muscle contraction in response to stimulation. Denervation of the effector muscle results in flaccid paralysis with atony (lower motor neuron disease). A spinal lesion cranial to the reflex arc removes the normal controlling inputs from higher centres via the upper motor neurons and results in exaggerated responses and spastic paralysis (upper motor neuron disease).

Cervical spinal cord C1–C6

The hindlimbs are worse affected than the forelimbs. There is a range of muscle weakness progressing to complete paralysis. It is important to differentiate weakness from ataxia, which can be achieved by pulling sideways on the tail as the animal walks. Weak animals can easily be pulled to the side and severely affected cattle may stumble and fall over. Spinal reflexes are increased (upper motor neuron signs to all four limbs), but this aspect of the neurological examination may prove difficult in adult cattle that are not recumbent. Cervical pain may be evident as rigidity of the neck, with resentment to forced movement of the head. Typically, the neck is extended and the head held lowered (363). With severe lesions the animal may be unable to maintain sternal recumbency, but it will make frequent attempts to raise itself from lateral recumbency.



362 This cow with bovine spongiform encephalopathy has isolated herself, appears detached from surrounding events and is standing with an arched back.



363 This calf with a compressive cervical spinal lesion is weak in all four limbs. The neck is extended and the head held lowered.

Cervicothoracic spinal cord C6–T2

Spinal cord lesions involving the brachial intumescence may result in equally severe deficits in both the forelimbs and the hindlimbs. There is ataxia and weakness of all four limbs, but usually more pronounced in the forelimbs (364). Forelimb reflexes are reduced (lower motor neuron signs), but hindlimb reflexes are increased (upper motor neuron signs).

Thoracolumbar spinal cord T2–L3

Animals with a spinal cord lesion caudal to T2 but cranial to L3 have normal forelimb function, but upper motor neuron signs affecting the hindlimbs. Affected animals frequently adopt a dog-sitting posture with normal forelimb function, but with the hindlimbs extended alongside the abdomen (365). This dog-sitting position should immediately alert the clinician because ruminants raise themselves using their hindlimbs before their forelimbs. The withdrawal and patellar reflexes are increased and there are conscious proprioceptive deficits and paresis of the hindlimbs. The panniculus reflex may be useful when attempting to localize a thoracolumbar spinal lesion.

Lumbosacral spinal cord L4–S2

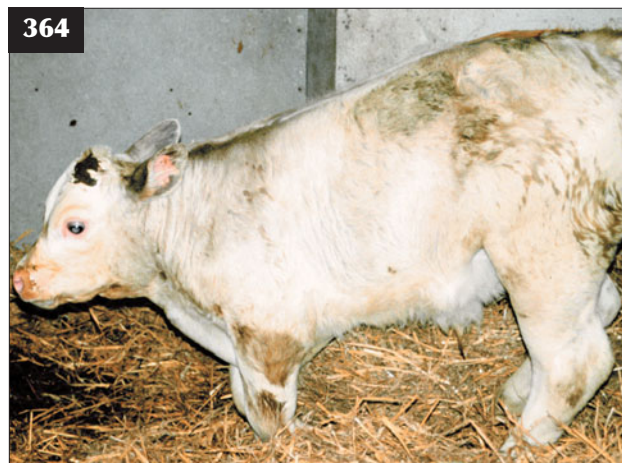A lesion involving the sacral outflow results in lower motor neuron signs in the hindlimbs with superficial sensation loss, paresis and reduced or absent reflexes (366).

Sacrococcygeal spinal cord: cauda equina syndrome

The cauda equina syndrome is caused by lesions involving the sacrococcygeal spinal cord and results in hypotonia, hypalgesia and reduced reflexes of the tail, anus and perineal region, bladder atony and dilation of the rectum.

DIAGNOSIS

A focal inflammatory lesion within the vertebral column



364 This calf with a C6–T2 lesion shows weakness of all four limbs, but more pronounced affecting the forelimbs.

and involving the leptomeninges (366) results in leakage of protein and some inflammatory cells into the CSF. In practical terms, where there is a compressive spinal lesion cranial to L5, collection of lumbar CSF will yield a sample with a marked increase in protein concentration relative to the cisternal sample, which is normal.

MANAGEMENT

Traumatic lesions in calves following dystocia, indicated by xanthochromic CSF collection, may improve within two weeks with good management and dedicated care, with frequent turning of the calf. Treatment of extradural and vertebral body abscesses is hopeless. Euthanasia is indicated for welfare reasons once a compressive lesion has been identified.

There are no specific control measures. Prevention of bacteraemia in neonates necessitates high hygiene standards in the calving accommodation and effective passive antibody transfer.

PERIPHERAL NERVE DISEASE

Peripheral nerve disease is common in cattle and is most often encountered following dystocia, but it also results from traumatic injury and a faulty injection technique in neonates.

BRACHIAL PLEXUS INJURY

DEFINITION/OVERVIEW

Brachial plexus injury (radial, ulnar and musculocutaneous nerves) occurs very occasionally in the neonate. It is usually unilateral.

AETIOLOGY

Brachial plexus injury is caused by excessive traction on the calf in anterior presentation. Haematoma or abscess formation in the axillary region in growing cattle may exert pressure on the brachial plexus.

CLINICAL PRESENTATION

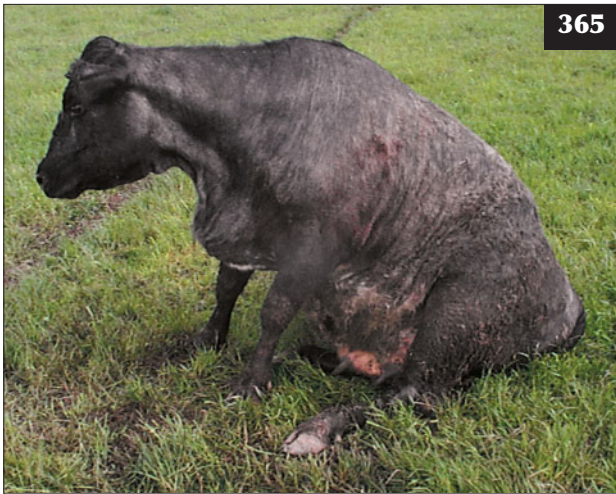Brachial plexus injury results in an inability to extend the elbow, carpus and fetlock and, in severe cases, bear weight on the affected limb (367). There is a loss of muscle over the scapula, with resultant prominent spine, a dropped elbow, flexion of the distal limb joints and scuffing of the hooves as the limb is moved forward. The foot is knuckled over at rest.

DIFFERENTIAL DIAGNOSIS

Trauma to the shoulder/elbow joints; severe foot lesion (foot abscess, septic pedal arthritis).

DIAGNOSIS

Diagnosis is based on history and clinical findings. Haematoma/ abscess can be differentiated on history (i.e. a haematoma occurs suddenly), clinical examination and, where necessary, ultrasonography.




365

365 This cow with a spinal cord lesion caudal to T2, but cranial to L3, is adopting a characteristic dog-sitting posture.



366

366 A lesion involving the sacral outflow has resulted in lower motor neuron signs in the hindlimbs in this calf.



367

367 A brachial plexus injury in this calf has resulted in an inability to extend the elbow, carpus and fetlock and bear weight on the affected limb.



368

368 A radial nerve injury in this cow has resulted in an inability to extend the elbow, carpus and fetlock and bear weight on the affected limb.

MANAGEMENT

Abscesses should be drained. Haematomas may resolve, but more commonly they rupture and drain after several weeks/months. A single injection of dexamethasone can be given if the injury has just occurred (e.g. during dystocia). Splinting the distal limb to prevent contracted flexor tendons in neonatal calves is problematic and may lead to pressure sores under the splint.

Prevention is by avoiding excessive traction during calf delivery.

RADIAL NERVE

DEFINITION/OVERVIEW

Radial nerve dysfunction follows injury in the mid/distal humeral region.

AETIOLOGY

Radial nerve dysfunction typically occurs following trauma in the mid/distal humeral region during handling.

CLINICAL PRESENTATION

Radial nerve injury results in the inability to extend the elbow, carpus and fetlock and, in severe cases, bear weight on the affected limb (368).

DIFFERENTIAL DIAGNOSIS

Trauma to the shoulder/elbow joints; severe foot lesion (foot abscess, septic pedal arthritis).

DIAGNOSIS

Diagnosis is based on clinical findings and elimination of other possible causes of lameness.

MANAGEMENT

A single injection of dexamethasone can be given if the injury has just occurred (e.g. during handling). Full recovery may take several months or does not occur at all depending on the cause.

Prevention is by correct design of handling facilities and avoiding slippery surfaces, acute angles and protruding objects.

SUPRASCAPULAR NERVE INJURY**DEFINITION/OVERVIEW**

Suprascapular nerve injury is uncommon in cattle.

AETIOLOGY

Suprascapular nerve injury is caused by trauma during handling in cattle stocks or at a feed barrier.

CLINICAL PRESENTATION

The affected limb is circumducted as it is advanced. The spine of the scapula becomes prominent as a consequence of atrophy of the infraspinatus and supraspinatus muscles.

DIFFERENTIAL DIAGNOSIS

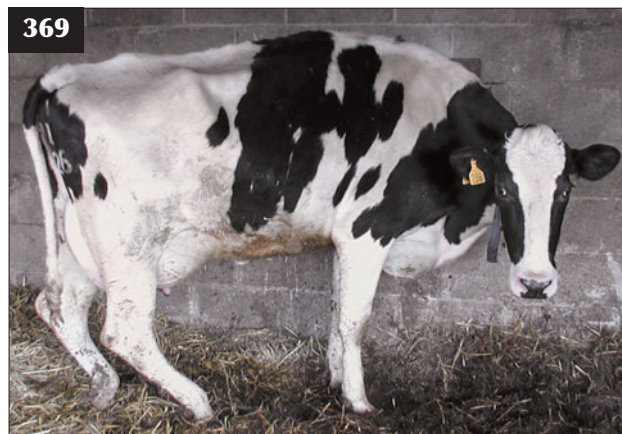Radial nerve and brachial plexus injuries.

DIAGNOSIS

Diagnosis is based on clinical findings.

MANAGEMENT

A single injection of dexamethasone can be given if the injury has just occurred (e.g. during handling). There are no specific preventive/control measures.



369 Damage to the sciatic nerve in this cow has caused the hip, stifle and hock to drop and the fetlock joint to knuckle, but the limb can still bear weight

SCIATIC NERVE**DEFINITION/OVERVIEW**

Sciatic nerve injury may result from calving injury. Affected cattle are ambulatory and deficits usually resolve over several weeks.

AETIOLOGY

Sciatic nerve injury may result from calving injury or pelvic trauma or from a perineural injection. Peroneal nerve injury over the lateral aspect of the stifle region typically results following prolonged recumbency on an unyielding surface.

CLINICAL PRESENTATION

The sciatic nerve supplies the extensor muscles of the hip and hock and the flexors of the stifle and fetlock (tibial branch), and the extensors of the fetlock (peroneal branch). Damage to the sciatic nerve proximal to the stifle (before branching) causes the hip, stifle and hock to drop and the fetlock joint to knuckle, but the limb can still bear weight (369).

Tibial nerve injury results in flexion of the hock and slight knuckling of the fetlock joint (370), but not as severe as peroneal nerve paralysis, where the dorsal surface of the hoof may contact the ground.

DIFFERENTIAL DIAGNOSIS

Hypocalcaemia must be considered in recently calved cows and hypophosphataemia in cattle recumbent for several days, not necessarily associated with recent parturition. Other differentials include trauma to muscles and joints of the hindlimbs, cellulitis and perineural injection with an irritant substance.

DIAGNOSIS

Careful clinical examination rules out metabolic and



370 A tibial nerve injury in this cow has resulted in flexion of the hock and slight knuckling of the fetlock joint.

infectious diseases. Acute trauma to the hip and stifle joints may be difficult to evaluate.

MANAGEMENT

A single injection of dexamethasone can be given if the injury has just occurred (e.g. during calving). Peroneal nerve damage resolves quickly without treatment provided the cow is ambulatory.

Prevention is by avoiding excessive traction during calving, providing deep straw bedding in calving accommodation, regular turning of recumbent cattle and an aseptic intramuscular injection technique avoiding the gluteal muscles.

FEMORAL NERVE INJURY

DEFINITION/OVERVIEW

Femoral nerve injury is the most common nerve injury to the calf during assisted parturition (371); injury at other times is rare.

AETIOLOGY

Femoral nerve injury is common after a calf in anterior presentation becomes hip-locked, when excessive traction is used to aid delivery.

CLINICAL PRESENTATION

Injury can be either uni- or bilateral and results in an inability to extend the stifle joint, bear weight and extend the affected limb. There is rapid atrophy of the quadriceps femoris muscle group within 7–10 days. Calves with bilateral femoral paralysis are unable to stand and adopt a dog-sitting posture. Calves with a unilateral lesion have difficulty rising to their feet, are unable to fix the stifle joint and the pelvis is tilted markedly toward the affected side.

DIFFERENTIAL DIAGNOSIS

Bilateral femoral paralysis results in an inability to stand and should be differentiated from a spinal lesion caudal to T2, including cord trauma/compression and congenital sarcocystosis. Unilateral femoral nerve paralysis should be differentiated from femoral fracture(s), particularly through the proximal epiphysis, a dislocated hip, a pelvic fracture and infection of the hip/stifle joints.

DIAGNOSIS

Diagnosis is based on history and careful clinical examination.

MANAGEMENT

A single injection of dexamethasone can be given if the injury has just occurred (e.g. during calving). Calves with bilateral femoral nerve paralysis have a grave prognosis (372); unilateral injuries may take nine months to fully recover (371, 373).

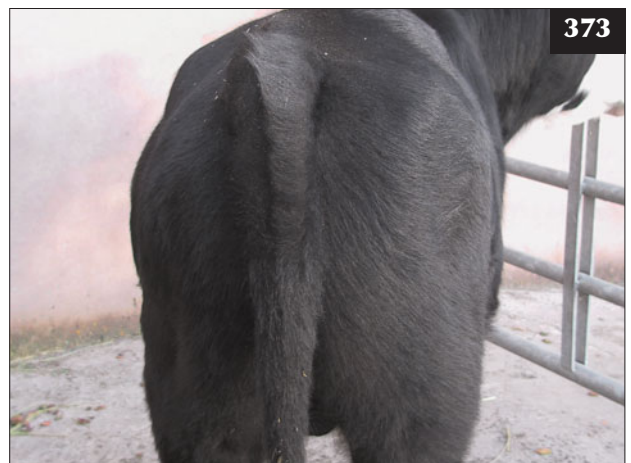
When a calf presents in anterior longitudinal presentation, two people pulling should be able to extend both forelimb



371 The unilateral femoral nerve injury in this calf occurred during an assisted parturition.



372 This calf with a bilateral femoral nerve injury has great difficulty rising to its feet and is unable to fix its stifle joints.



373 The left femoral nerve injury in the calf in 371 took six months to recover, but note the difference in hindlimb musculature still present.

fetlock joints one hand's breadth beyond the cow's vulva (indicates extension of the elbows into the pelvis) within 10 minutes. Any greater traction to achieve such progress forewarns of potential hip-lock and its consequences.

Excessive traction can also cause rib fractures in the calf and obturator nerve injury, vaginal tears and haemorrhage in the cow. Septicaemia and infections such as meningitis, polyarthritis, hypopyon and omphalophlebitis may result if there is a delay/failure of passive antibody transfer due to recumbency in the neonatal calf.

OBTURATOR NERVE INJURY

DEFINITION/OVERVIEW

Obturator nerve and sciatic nerve injuries (L6) result in adductor paresis in newly calved cows (374).

AETIOLOGY

Hip-lock during anterior presentation of the calf is the most common cause of adductor paresis. Severe abduction ('doing the splits') can also occur when the cow loses her footing on wet slippery surfaces, often when attempting to regain her feet after treatment for hypocalcaemia.

CLINICAL PRESENTATION

On sound footing, cows show only slight ataxia of the hindquarters, but severe abduction occurs when they are exposed to wet slippery surfaces and they may be unable to regain their footing.

DIFFERENTIAL DIAGNOSIS

Hypocalcaemia; dislocated hip; fractured pelvis/femur; coliform mastitis and other infectious conditions causing toxæmia/endotoxaemia.

DIAGNOSIS

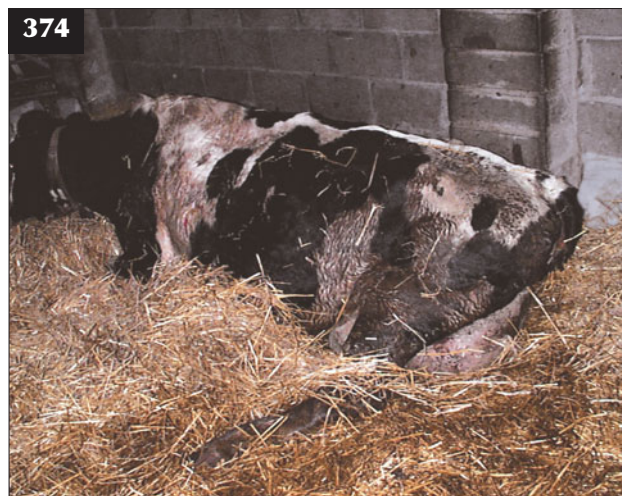Specific diagnosis proves very difficult in recumbent cattle unwilling to make any attempt to rise. Diagnosis relies on the history and elimination of hindlimb injuries and udder, uterine and other infections.

MANAGEMENT

Predicting the duration of recumbency can prove very difficult and the cow could regain her feet after three weeks or may never rise. The cow's hindlimbs can be hobbled just above the fetlock joints, but the animal must then be checked regularly for skin abrasions. Inflatable cushions, webbing nets and swim tanks can all be used, but the amount of time on busy commercial dairy farms is rarely adequate and cows are usually culled after a week or so if they do not stand unaided.

Prevention is by avoiding excessive traction during calf delivery and sharp corners and wet slippery surfaces, especially for recently calved cows.

Cattle may regain their feet after 2–3 weeks. This interval is acceptable provided the cattle are on an appropriate lying surface (deep straw/pasture), move around frequently (every few hours), develop no pressure sores and have a normal appetite.



374 There is severe abduction of the hindlimbs in this cow as a consequence of obturator nerve damage.

Musculoskeletal diseases

INTRODUCTION

The musculoskeletal system comprises the skeleton, joints, ligaments, tendons and muscles. Together with the nervous system, it is responsible for the animal's stance and gait. Infections of the musculoskeletal system are common in cattle; polyarthritis is common in neonates and foot lesions are especially common in housed dairy cattle. Arthritic changes, commonly predisposed by trauma, are largely confined to the stifle and hip joints of older beef cows, where they can present as a serious welfare concern. Clinical involvement of the musculoskeletal system is manifest as lameness and, much less commonly, as weakness.

CLINICAL EXAMINATION OF THE MUSCULOSKELETAL SYSTEM


ASSESSMENT OF THE PROBLEM(S)

Although the owner's history is important, it may not always be accurate because farmers tend to understate both the intensity and the duration of any lameness (severity is intensity multiplied by duration). Beef cows and growing beef and dairy heifers may not be inspected every day.

The animal is viewed from a short distance for the presence of muscle atrophy (375). Painful lesions affecting the forelimb often result in increased extension (or reduced flexion) of the joints when the animal is in sternal recumbency, such that the forelimb is held forward of the chest rather than its normal position flexed alongside the chest. Painful forelimb lesions result in the hindfeet being drawn forward under the body in order to achieve greater weight bearing by the hindfeet.

Painful lesions affecting a hindlimb generally result in the affected hindlimb being uppermost when the animal is in either sternal or lateral recumbency. This limb position allows the animal to use the lower hindlimb to propel itself forward and up when raising itself.

Lameness is best defined when the animal is made to trot slowly in a straight line on a firm level surface both toward and away from the observer. Although such inspection may be possible in dairy cows, growing cattle and some beef cows either do not move or attempt to escape (e.g. by jumping at fences). The best compromise



375 Severe chronic lameness has caused extensive muscle wastage of the left hindlimb of this six-month-old beef calf.

may be to walk the lame animal with another from the same group, on a firm level surface, in a confined area and observe them from a short distance.

The extent of the lameness is subjectively scored by veterinary surgeons on a 10-point scale, 1 being very slight lameness, up to 10, which is non-weight bearing, even at

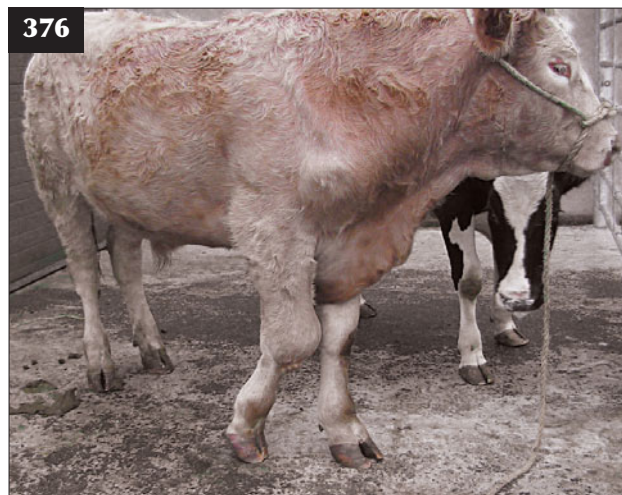
rest (376, 377), with the animal unwilling to take even one or two steps forward. (**Note:** A five-point scale is used by some authors, with 0.5 points added by other observers.) Typically, long bone fractures and septic joints result in severe (10/10) lameness, but so too can white line abscesses, especially those that track up to the coronary band. Therefore, the degree of lameness does not necessarily determine prognosis and a detailed examination is essential.

LOCOMOTION SCORING SYSTEMS

Locomotion scoring systems have been developed as an integral part of various herd health programmes. Two of the many descriptive recording systems are outlined below. These scoring systems have been designed for farmers to evaluate their own herds. The expectation is that increased awareness of lameness will promote more timely intervention and treatment, and thereby promote welfare.

Recording system 1

1. Sound. Walks rapidly and confidently, making long strides with a level back.
2. Slight lameness. Walks more slowly, making shorter strides with an arched back. Stands with a level back and does not favour a limb. It proves difficult to detect any weight transfer from affected limb.
3. Moderate lameness. Often thin, walks slowly, making deliberate short steps with an arched back and with frequent stops. Weight transfer will cause sinking of the dewclaws of the contralateral limb. Encounters some difficulty turning. Stands with an arched back and frequently rests lame foot.



376, 377 Lameness scoring. (**376**) This Limousin bull with a septic carpus is 10/10 lame (non-weight bearing at rest) on its right forelimb. (**377**) This animal with a septic hock is 10/10 lame on its right hindlimb. Note the resultant overextension of the left fetlock joint due to increased weight bearing.

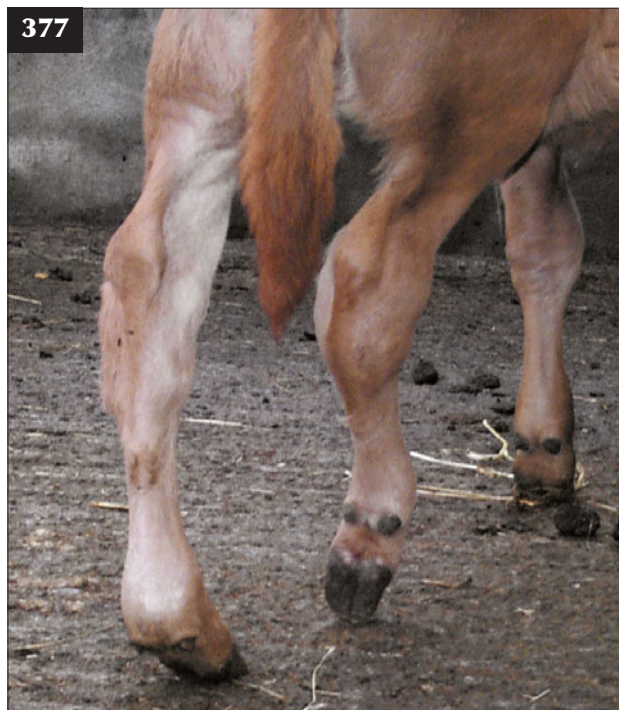
4. Severe lameness. Usually very thin and moves very slowly, making frequent stops to rest affected limb, which is only partially weight bearing. Frequently salivates due to grinding of teeth. Has extreme difficulty turning. Stands and walks with an arched back.

Recording system 2

1. Cow stands and walks with a level back.
2. Cow stands level backed, but has an arched back while walking.
3. An arched back is evident while standing and walking.
4. An arched back is always evident and the cow's gait is one deliberate step at a time. Cow favours one or more feet.
5. The cow is very reluctant or unable to bear weight on one or more limbs/feet.

CLINICAL EXAMINATION

The extent of muscle wastage depends on both the intensity and the duration of lameness (severity). Muscle wastage can be reliably detected after 5–7 days' moderate to intense lameness by careful palpation over bony prominences such as the spine of the scapula (376) and the head of the femur for forelimbs and



hindlimbs, respectively. Comparison of changes with the contralateral limb, if sound, is recommended. However, the clinician should be aware that swellings such as abscesses and cellulitis lesions, often after infection of intramuscular injection sites, can cause lameness such that there appears to be 'more muscle' over the affected limb.

Enlargement of the prescapular lymph node (2–10 times normal size) can be readily appreciated (378) within 3–7 days of bacterial infection of forelimb joints and cellulitis lesions. White line and sole abscesses and digital dermatitis lesions do not usually cause such obvious drainage lymph node enlargement. Infected lesions distal to the stifle joint cause enlargement of the popliteal lymph node, but this node is not readily palpable unless there is considerable muscle atrophy. Infection proximal to the stifle joint results in enlargement of the deep inguinal lymph nodes within the pelvic canal.

Joints

The clinician must always remember that lameness originates from a painful lesion and that manipulations should be kept to the minimum necessary and undertaken with care and empathy. In particular, joint lesions are especially painful. The clinical examination must not exacerbate the degree of lameness. Hyperalgesia refers to exaggerated responses to noxious stimuli and is used by some clinicians as evidence of a painful lesion; however, such action merely reflects poor examination technique. Gentle digital palpation will reveal much more information regarding joint effusion and thickness of the

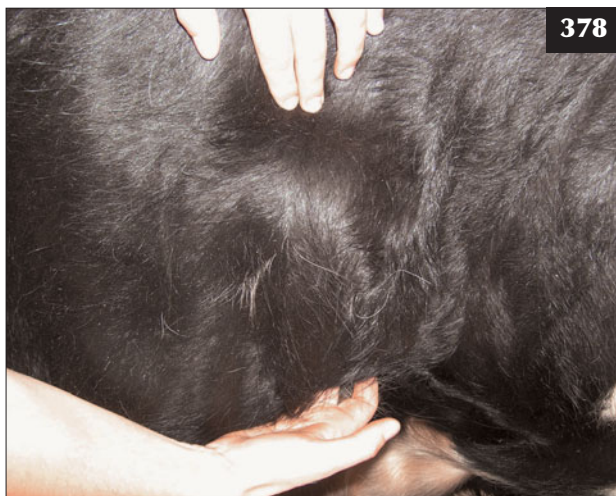
joint capsule than trying to elicit crepitus by forceful movement of the painful joint. Allodynia refers to exaggerated responses to normal stimuli and is occasionally encountered in severe cases of lameness.

Restraint

Cattle stocks have various means of raising feet to allow detailed examination and most farmers have specialized 'foot crates' (379). Raising the foot is undertaken as the last component of the examination, but it must not be performed if there is a painful joint lesion or suspected fracture. A webbing strap is more preferable to a rope when raising the limb. The hindlimb joints should not be overflexed, especially the stifle joint, when examining the hindfeet.

Examination of the foot

The interdigital space is a common site for impacted stones and must be carefully examined. A torch can be used to examine the space where necessary. Any overgrown horn from the abaxial walls and toes is removed with a sharp hoof knife, noting the quality of the horn removed and the presence of any sole haemorrhages or black marks (in unpigmented horn). Any underrun horn commencing at the axial margin of the sole should then be removed. It is vitally important not to damage/expose the sensitive corium as this will lead to delayed regeneration of epithelium and extended healing time. Exposure of the sensitive corium to irritant chemicals such as formalin may result in exuberant granulation tissue. A bull's foot at



378 Enlargement of the prescapular lymph node 3–7 days after bacterial infection of a forelimb joint.



379 A specialized 'foot crate', which permits ready access to all four feet. A large webbing strap is often placed around the bull's girth to provide support and prevent him lying down.

presentation (380) and exposure of a white line abscess by careful foot paring (381) are illustrated. The absence of any blood illustrates that the corium has not been damaged during paring out of the abscess.

ARTHROCENTESIS

Arthrocentesis, observing strict aseptic technique, can be undertaken. The animal must be securely restrained in cattle stocks; sedation with xylazine (stage 1) may be advisable in some cases. Attempts can be made to collect synovial fluid from distended joints under local anaesthesia, but the anaesthetic solution can only be given subcutaneously; the infected joint capsule/synovial membrane cannot be readily desensitized. Intravenous regional anaesthesia can be used to anaesthetize the fetlock and distal interphalangeal joints.

The skin over the arthrocentesis site is shaved and aseptically prepared. The approach depends on the particular joint, avoiding tendons and ligamentous structures. In general, the joint capsule is punctured where it is most distended, as this 'pouching' occurs away from joints structures such as ligaments and tendons.

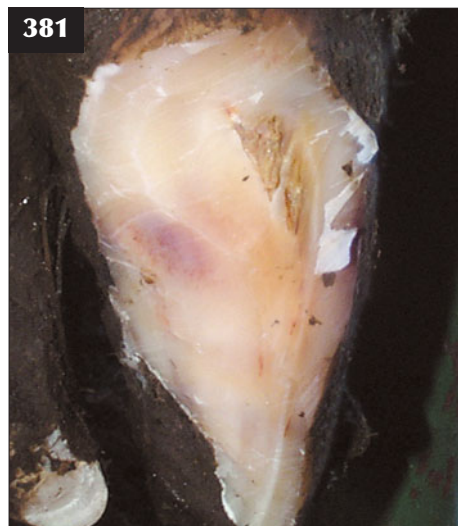Normal synovial fluid is pale yellow, viscous, clear and does not clot. The protein concentration is <18 g/l with a low white cell concentration comprised mainly of lymphocytes. Septic arthritis is characterized by a turbid sample caused by an increased white cell concentration, which is comprised almost exclusively of neutrophils. The protein concentration is typically increased above 40 g/l.

Samples are difficult to collect from chronically-infected joints (382) and often fail to grow bacteria if antibiotics have been previously administered. Direct smears of the aspirate can be made onto a glass slide and stained with Gram's stain to gain some information of the potential pathogen(s) involved.

RADIOGRAPHY

Radiography is most useful in the investigation of long bone fractures where doubts exist over the diagnosis. Deep sedation with xylazine (stages 3–4) or, preferably, general anaesthesia may be required to allow correct positioning for radiography of the humerus/femur (383). Radiography may prove useful in the investigation of chronic foot infections where the infection may involve either the proximal or the distal interphalangeal joints (384, 385).

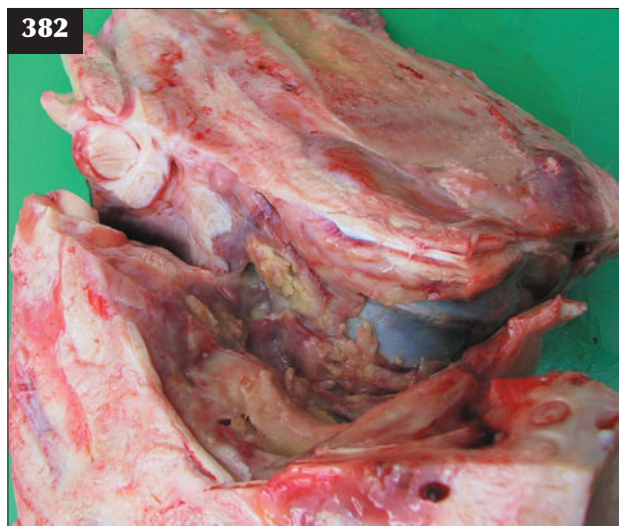
Radiography adds little new information to the investigation of most cases of septic arthritis other than to reveal widening of the joint space and osteophyte formation in neglected cases (386, 387).



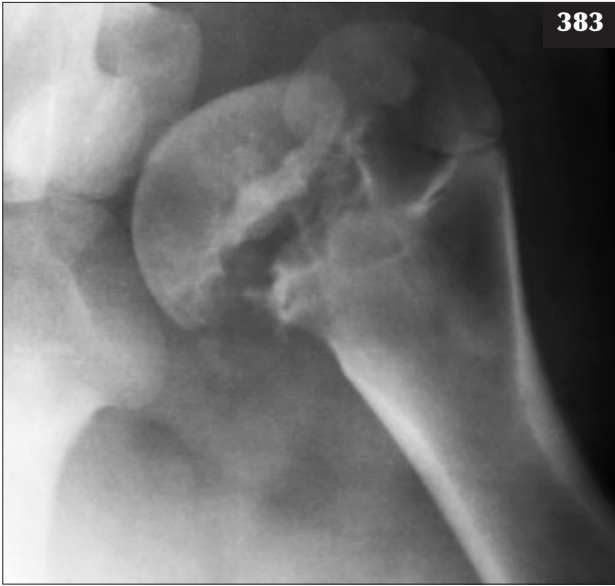
381 A white line abscess has been revealed in the bull in **380** following careful paring using a foot knife. Note the absence of any blood; the corium has not been damaged.



380 Overgrown foot of a bull at presentation.



382 Joint fluid samples are especially difficult to collect from chronically-infected joints such as this because the pus is often inspissated.



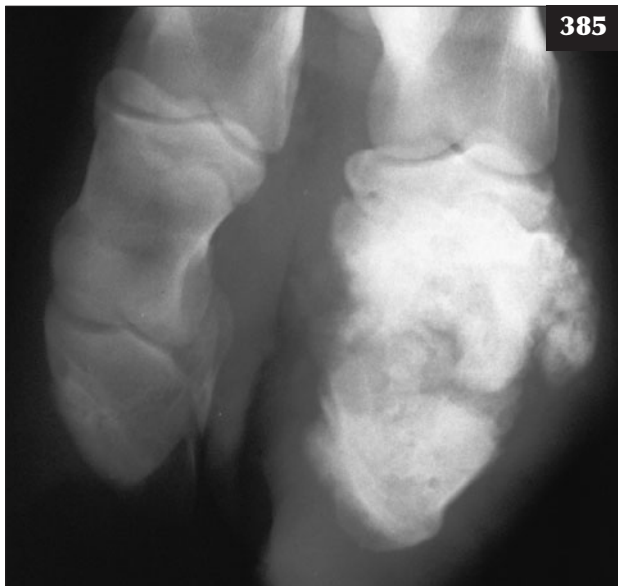383

383 General anaesthesia has allowed correct positioning for radiography in this animal with a very painful femoral head fracture.

384 Radiography proved useful in the investigation of this animal with a chronic foot infection involving the distal P1/P2 joints that was treated by amputation.



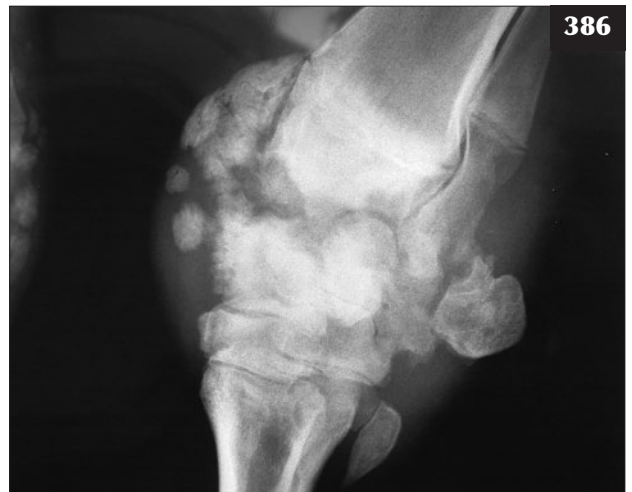384



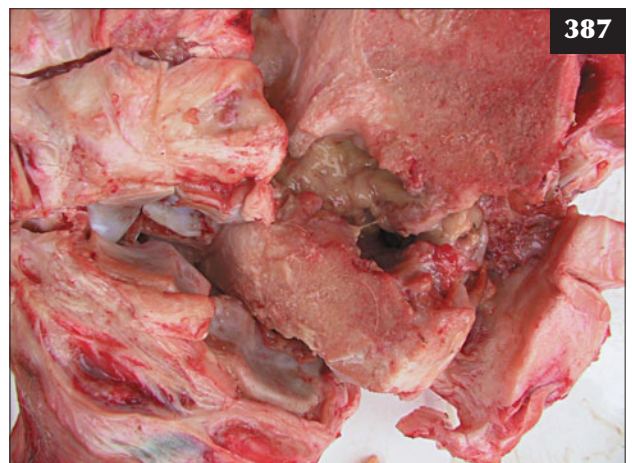385

385 Radiography of this animal reveals chronic infection of the distal interphalangeal joint, with extensive joint destruction and osteophyte formation.

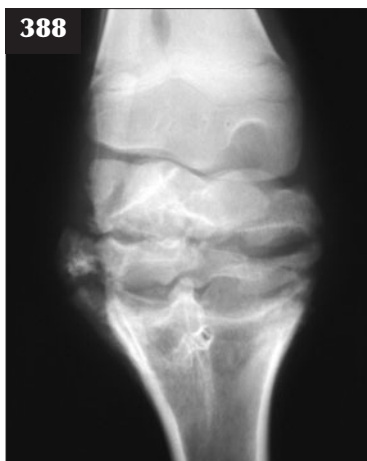386, 387 (386) Radiograph of the animal in **376**, taken after it was destroyed for welfare reasons immediately after clinical examination. Radiographical evidence of sepsis in this joint has not led to any more useful information than was gained by careful palpation of the joint. **(387)** Necropsy specimen of the animal in **379**.



386



387

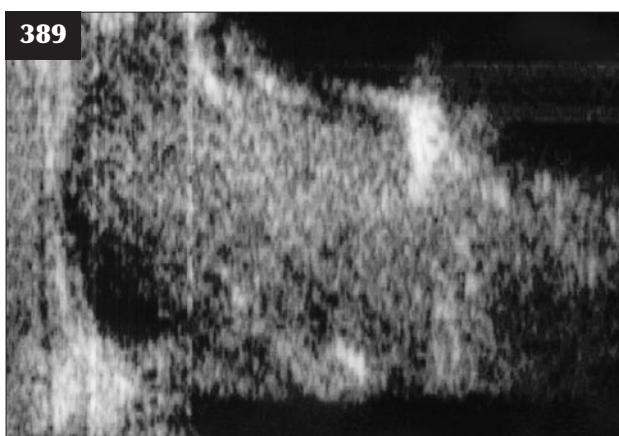


388 Radiography of a septic joint during the early stages of infection revealing only widening of the joint space could mistakenly be interpreted that there is little pathology present.

Indeed, radiography of a septic joint during the early stages of infection that reveals only widening of the joint space may be mistakenly interpreted that there is little pathology present (388). In such cases, ultrasonography, and arthrocentesis if the joint is distended, may be more informative.

ULTRASONOGRAPHY

Ultrasonography using a 7.5 MHz linear array scanner can provide useful information regarding the thickness of the joint capsule and the extent and nature of any joint effusion (389, 390). The skin overlying the joint is shaved to ensure good contact; a stand-off may be required for examination of smaller joints. Affected joint(s) should be compared with the contralateral joint where normal.



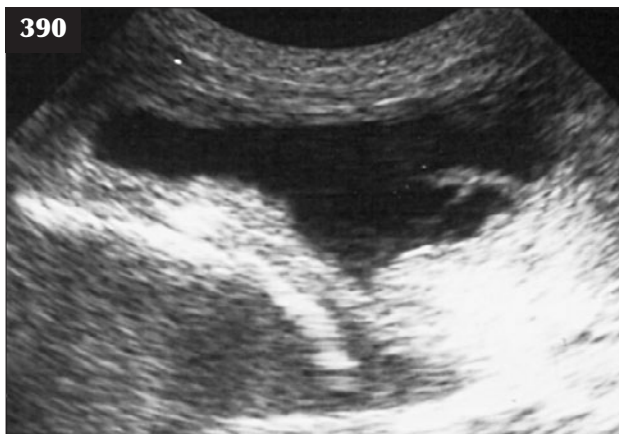389 Ultrasound examination of this animal reveals thickening of the joint capsule (to the left) and joint infection.

NERVE BLOCKS

Unlike in horses, nerve blocks and intra-articular anaesthesia are not routinely used in cattle.

FOOT LESIONS

Foot lameness is the most important welfare concern in dairy cattle worldwide. For example, on UK dairy farms, where cattle are housed for up to six months, the mean prevalence rate is reported to be around 20% (number of lame cows on any one day). Dairy farmers invest considerable time, resources and money in the prevention and treatment of foot lameness. Despite such efforts, it is generally accepted that the incidence of dairy cow lameness has increased over the past 20 years. Studies have reported an annual incidence of lameness of 55 cases per 100 cows (total number of new lameness cases in one year). The important causes of dairy cow lameness are digital dermatitis, sole ulcers, white line disease and interdigital necrobacillosis.



390 Ultrasound examination of this animal reveals considerable joint effusion with a fold of synovial membrane clearly visible in the tibiotarsal joint with osteochondritis dissecans.

VERTICAL FISSURE OF THE HOOF WALL ('SANDCRACK')

DEFINITION/OVERVIEW

There is loss of continuity of horn fibres of the plantar hoof wall extending for a variable distance from the coronet toward the bottom of the hoof wall.

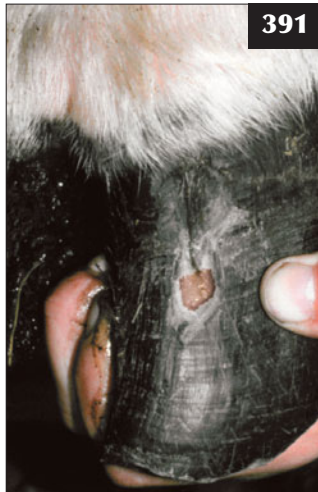AETIOLOGY

Sandcracks result from damage to the periople and underlying coronary band. Factors contributing to this condition may include excessive drying out of horn during dry summer months, sudden excessive pressure, such as jumping/galloping, and faulty nutrition.

CLINICAL PRESENTATION

The front feet are more often affected. The lesion varies from a small vertical crack near the coronet to a large jagged uneven fissure on the anterior wall. Many beef

391 In this animal with a sandcrack, impacted material has led to pus formation and sudden onset of severe lameness.



cattle have sandcracks in their hooves but are not lame. There is often sudden onset of severe lameness when impacted material leads to pus formation (391) and pressure on the sensitive laminae of the wall.

DIFFERENTIAL DIAGNOSIS

A white line abscess that has ascended the hoof wall to rupture at the coronary band.

DIAGNOSIS

Careful hoof paring of the sandcrack releases pus (391).

MANAGEMENT

Prompt treatment is necessary to prevent infection extending into the coronary band. Foot paring of the plantar hoof wall presents numerous practical difficulties because it involves extending the carpus and distal limb joints, rather than the usual method whereby flexion of these joints permits paring the sole. Dirt is often packed deep into the sandcrack near the sensitive laminae. Sufficient underrun horn should be removed by cutting out a shallow 'V' to release the pus. Neither antibiotics nor a bandage is necessary afterwards.

The addition of biotin to the ration, where possible, may reduce the prevalence of sandcracks.

HORIZONTAL FISSURE OF THE HOOF WALL (THIMBLING)

DEFINITION/OVERVIEW

Severe endotoxaemia in dairy cows during the periparturient period, resulting in poor-quality horn production, may cause moderate lameness in one or more feet 3–4 months later.



392 Thimbling in this case is most noticeable at the toe.

AETIOLOGY

Poor horn production during a severe endotoxaemic condition such as coliform mastitis or metritis appears as a horizontal fissure in the hoof horn of all eight digits. As this defect in the wall grows down to about two-thirds of its length 3–4 months later, it weakens and may separate from the healthy horn proximally. The corium remains intact distal to the horizontal fracture holding the distal hoof horn attached at the toe. This fissure moves when weight is taken, tensing the corium still attached distally and causing variable pain and lameness. Material can occasionally become impacted in the fissure and cause abscesses.

CLINICAL PRESENTATION

All claws of all four feet are affected with variable lameness depending on the amount of material impacted in the horizontal fissure.

DIFFERENTIAL DIAGNOSIS

Careful examination of all four feet rules out other possible causes of lameness.

DIAGNOSIS

Diagnosis is based on the typical appearance affecting all eight digits, most noticeable at the toe (392).

MANAGEMENT

Careful hoof paring to remove all underrun horn and impacted material is necessary only when the cow is lame. This is best achieved with hoof shears, noting that the hoof capsule may still be attached at the toe.

There are no specific control measures except for prompt treatment of endotoxic conditions.

WHITE LINE ABSCESSSES

DEFINITION/OVERVIEW

White line abscesses cause marked lameness and necessitate prompt attention. Abscess formation, which arises following bacterial entry into the white line area, is usually found in the lateral claw of the hindfoot on the abaxial border close to the junction with the heel (381, 393, 394). The condition is more common in dairy cows that spend long periods standing/ walking on poorly maintained surfaces and tracks. Puncture wounds of the sole can also lead to abscess formation (395). Painful foot lesions result in a precipitous reduction in milk yield and rapid weight loss. Severe lameness may delay normal ovarian cyclicity.

AETIOLOGY

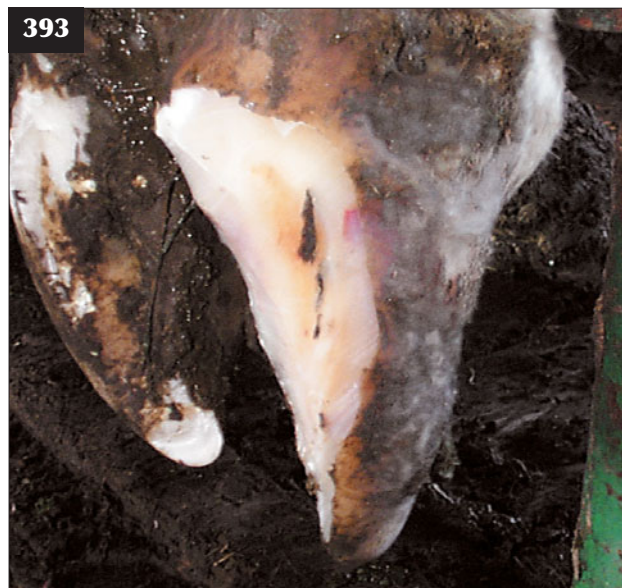Inflammation of the laminae/corium weakens the white line. Separation of the white line, caused by torsional forces as cattle turn sharp corners, allows impaction with small stones and dirt. Entry and multiplication of bacteria forms an abscess, which may extend up the white line and discharge at the coronary band in neglected cases (396).

CLINICAL PRESENTATION

Affected cattle often present with sudden severe lameness of the affected limb and with only the toe touching the ground. Careful foot paring reveals separation and impaction of the white line, with dirt leading to an abscess that is under pressure and may spurt pus upon release. Care must be taken not to expose the sensitive corium. There is a marked improvement in locomotion within two days of release of the pus.

DIFFERENTIAL DIAGNOSIS

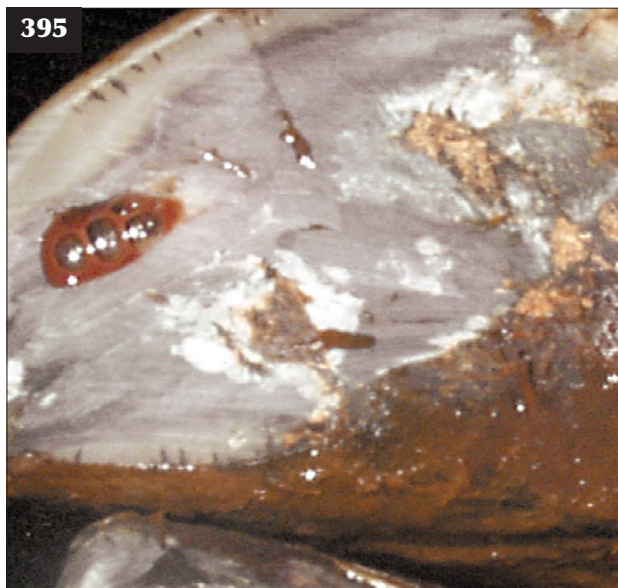A white line abscess that has ascended to involve the coronet can be differentiated from septic pedal arthritis by the small area of the abaxial coronary band affected and not the whole coronet (see Septic pedal arthritis, p. 174).



393 Abscesses usually form in the lateral claw of the hindfoot on the abaxial border close to the junction with the heel. Note the impacted foreign material causing a black mark in this case.



394 In this animal, pus has been released from a white line abscess.



395 Pus released from a sole abscess, which was probably caused by a puncture wound.

DIAGNOSIS

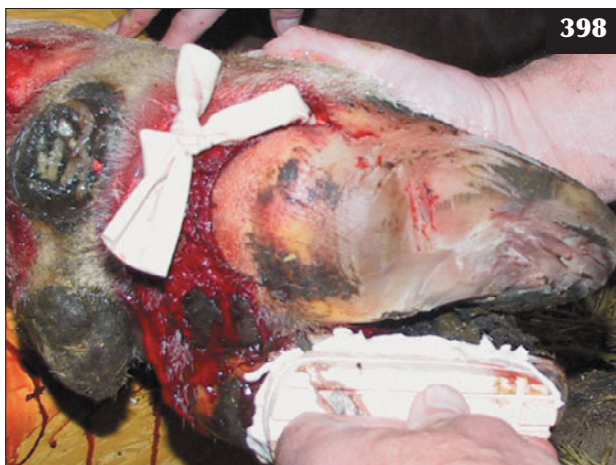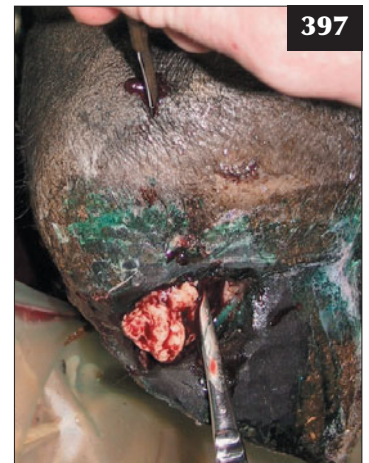
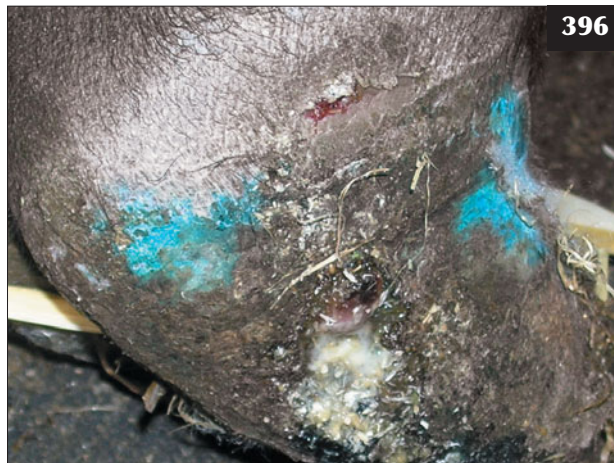The abscess is confirmed by the release of pus.

MANAGEMENT

The pus can be released by careful foot paring and removal of all underrun horn. There is no requirement to bandage the foot or any need for antibiotic therapy. More thorough investigation is necessary when lesions cause considerable swelling at the coronary band (396). Examination under intravenous regional anaesthesia reveals the extent of the infection (397), which is treated by draining the abscess, debriding all necrotic tissue, flushing with diluted povidone–iodine solution and inserting a Penrose drain (398).

Prevention is by maintaining all roads, tracks and the area in front of the silage face (if self-fed). There should be a correct space allocation (25 cm/per cow) at self-feed silage faces. The movement/flow of cattle should be designed to avoid sharp corners.

396, 397 White line abscess. (396) In neglected cases the abscess may have extended up the white line to discharge at the coronary band. (397) Examination under intravenous regional anaesthesia reveals the extent of the infection.



398 In this bull the heel bulb abscess was lanced, a Penrose drain inserted and a block applied to the sound claw. The bull was sound within four days.

INTERDIGITAL SKIN HYPERPLASIA**DEFINITION/OVERVIEW**

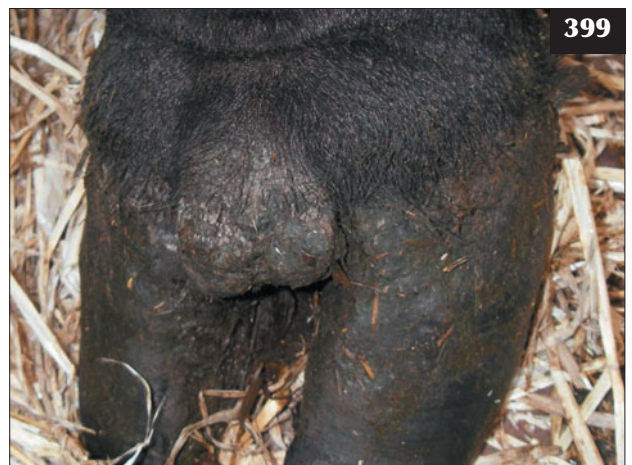
Interdigital skin hyperplasia refers to excess epidermal and hypodermal tissue occupying part or all of the interdigital space. There is some association with corkscrew claws.

AETIOLOGY

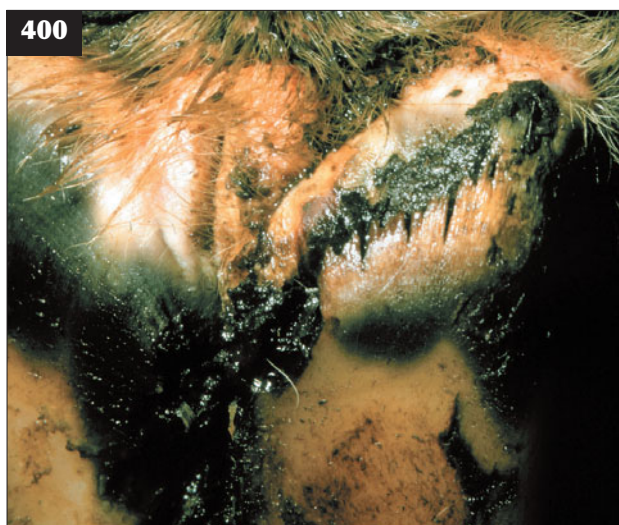There is a probable hereditary component with some breeds (Herefords) overrepresented.

CLINICAL PRESENTATION

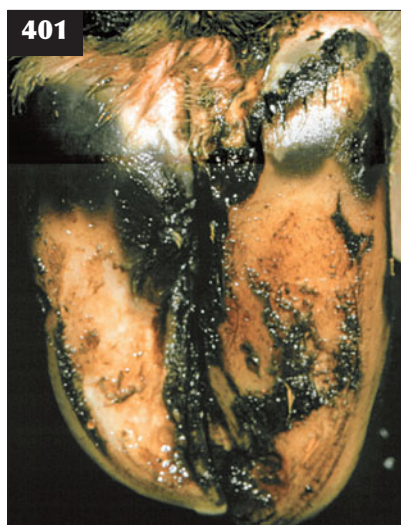
Interdigital skin hyperplasia usually appears as a protuberance of skin at the front of the interdigital space (399). Interdigital skin hyperplasia does not cause lameness unless it becomes so large that excoriation leads to superficial infection.



399 Interdigital skin hyperplasia (fibroma) in a bull. This can be associated with lameness if secondary infection occurs.



400 Slurry heel. Necrosis of the horn of the heel and heel/sole area, with small blackish pitted areas of the horn, is seen in this cow.



401 Slurry heel. Necrosis of the horn can appear as black cracks penetrating deeply towards the corium of the heel/sole area.

DIFFERENTIAL DIAGNOSIS

Foul of the foot.

DIAGNOSIS

The diagnosis is confirmed by careful examination of the interdigital space and foot paring to ensure that other potential causes of foot lameness are not overlooked.

MANAGEMENT

Prompt topical antibiotic treatment of superficial infection and debridement of any underrun tissue is required. Excision of the growth under intravenous regional anaesthesia and application of a pressure bandage (or cautery) to the affected area is not a simple procedure and is rarely indicated. Recurrence after surgical debridement is common.

Prevention is by careful selection of stock bulls.

CHRONIC NECROTIC PODODERMATITIS ('SLURRY HEEL')

DEFINITION/OVERVIEW

Slurry heel is a very common condition affecting the feet of almost all housed dairy cows during the late winter months. Importantly, new horn growth affects the weight-bearing function of the hoof, which predisposes to corium damage, sole ulcer and white line disease.

AETIOLOGY

Prolonged exposure to slurry is an important factor in the aetiology of slurry heel. The role of *Dichelobacter nodosus* infection has also been suggested as an important factor.

CLINICAL PRESENTATION

On its own slurry heel does not usually cause lameness. There is necrosis of the horn of the heel and heel/sole area, varying from small black pitted areas (400) to cracks penetrating deeply towards the corium (401). Slurry heel causes overgrowth of soft horn of the heel and sole.

DIAGNOSIS

Diagnosis is confirmed by careful foot inspection and paring where appropriate.

MANAGEMENT

Necrotic horn should be cut away where necessary to restore normal foot shape and the foot sprayed with oxytetracycline aerosol.

Prevention involves improving slurry management in dairy herds. Regular use of a formalin foot-bath has been recommended.

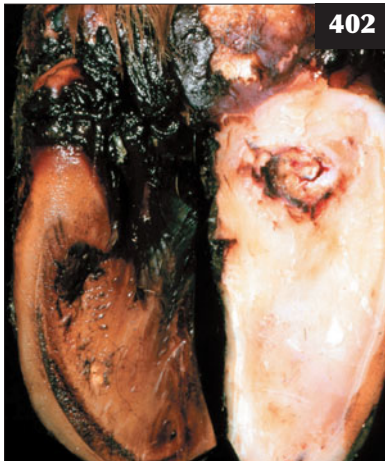SOLE ULCER (RUSTERHOLZ ULCER, PODODERMATITIS CIRCUMSPECTA)

DEFINITION/OVERVIEW

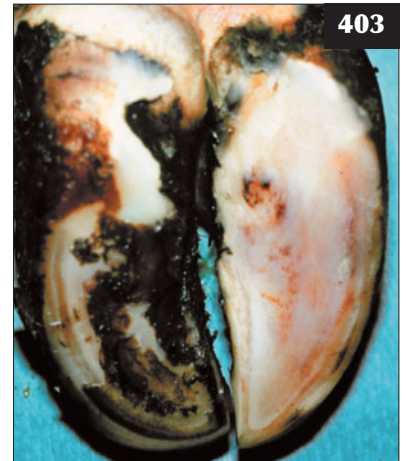
Lameness due to sole ulcers is a major welfare concern in dairy cattle. The mean prevalence rate is reported to be around 20% (i.e. the number of lame cows on one day from all causes). Severe lameness caused by a sole ulcer can significantly reduce milk yield, cause rapid loss of body condition and delay onset of oestrus/conception.

A sole ulcer is a specific circumscribed lesion of the sole at the sole/heel junction nearer to the axial than the abaxial wall (402) and affecting dairy cows and occasionally beef bulls. It is rarely seen in growing cattle and beef cows. The highest prevalence occurs during late winter after cattle

402 Sole ulcer. Note the specific circumscribed lesion of the sole at the sole/heel junction nearer to the axial than the abaxial wall.



403 Sole ulcer. Corium damage has resulted in discolouration of the sole due to release of serum and haemorrhage.



have been housed for 3–6 months. Sole ulcer affects the lateral digits, often involving both hindfeet.

AETIOLOGY

Pressure damage to the corium is caused by compression at the posterior axial border of the pedal bone. Build-up of new horn consequent upon chronic necrotic pododermatitis (slurry heel) is an important factor in the aetiology of this condition (401, 403). Other important factors include:

- Excessive time spent standing on concrete during the winter months. This situation results from insufficient and/or uncomfortable cubicles. Overgrown claws alter weight distribution. Conformational characteristics (e.g. 'cow hocks') result in weight being carried excessively on the lateral claw.
- In dairy heifers following calving, coriosis (laminitis) is associated with sudden introduction to concrete surfaces, cubicles and nutritional changes. Such damage to the corium (the term coriosis is recommended by some authors) results in the production of poor-quality horn. The severity of the initial corium damage determines the nature of the horn defects, which can range from yellow discolouration due to release of serum, through haemorrhage (403), to sole ulcer when horn production has been completely disrupted.
- The role of parturition cannot be separated from nutritional and hormonal changes. The major nutritional change after calving is the sudden introduction of concentrates, leading to ruminal acidosis and the risk of coriosis. Toxaemic conditions such as mastitis and metritis also affect the corium.

Heel and toe ulcers are less commonly reported than sole ulcers in most surveys. Toe ulcers are thought to result from pressure from the cranial margin of the pedal bone. The cause of heel ulcers is currently under investigation.

CLINICAL PRESENTATION

There is often a report of sudden onset of severe lameness, although on investigation it is apparent that the sole ulcer has been present for several days/weeks. Affected cattle may stand with the toe of the affected digit on the edge of the cubicle standing. When walking, the cow may abduct the limb to bear weight on the unaffected medial claw and cows are reported to kick backwards before placing the affected foot on the ground.

Typically, there is much new overgrown soft horn containing obvious haemorrhage (403) on the lateral claw. This overlying 'flap' of horn often obscures the area of ulceration. Further paring, often following a black necrotic horn crack, will lead to the sole ulcer site. The sole ulcer may present with or without protrusion of granulation tissue.

DIFFERENTIAL DIAGNOSIS

Severe foot lameness (i.e. fracture of the third phalanx; osteomyelitis of the third phalanx); deep infection of the navicular bursa; deep infection of the pedal (distal interphalangeal) joint.

DIAGNOSIS

Diagnosis is evident after careful paring of the foot.

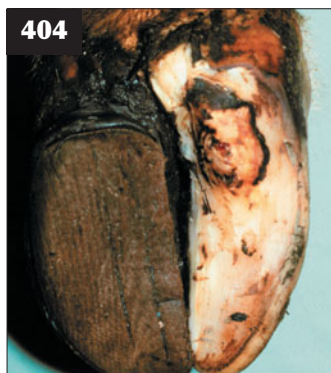MANAGEMENT

As the condition is caused by pressure to the corium, the sole should be rendered concave by careful foot paring to reduce this pressure. During this process all under-run horn is removed, which may expose an ulcer. Any granulation tissue is removed to the level of the sole using a scalpel blade. There is no requirement to use local anaesthetic because this granulation tissue does not contain a nerve supply. A pressure bandage is applied over the site of the sole ulcer to limit formation of granulation tissue. Copper sulphate or cautery should never be used to burn back granulation tissue because it simply delays epithelialization and healing.

A wooden shoe (or similar) should be applied to the sound (medial) claw (404). If there is deep infection, the digit should be amputated, but the other hindlimb lateral claw must always be checked first for signs of an ulcer (see Septic pedal arthritis, Management, p. 176).

A preventive hoof trimming programme should be undertaken every six months by suitably trained personnel, concentrating on the hindfeet. Heifers should be bred for good hoof and limb conformation using the linear assessment system. Coriosis of nutritional origin should be avoided. (Although the term laminitis is often used in this context, inflammation involves the corium of the sole and not the laminae).

A critical assessment should be made of the farm buildings and cow comfort. Major factors include cubicle design; cubicle division must allow for space sharing (e.g. Dutch comfort design cubicles [405]). Head rails should be sited 15–20 cm below average withers height, one-quarter of the cubicle length (0.55 metres) from the front. Cubicle mats should be used with adequate bedding, preferably chopped straw or sand, to a depth of 5 cm. Straw yards have many advantages with respect to the prevention of sole ulcers; they also make for happy cows (406).



404

404 Healing sole ulcer where a wooden shoe has been applied to the sound (medial) claw.



405

405 Dutch comfort design cubicles encourage cows to lie down. Cubicle design is a major factor in preventing lameness due to sole ulcers.

SEPTIC PEDAL ARTHRITIS

DEFINITION/OVERVIEW

Infection of the distal interphalangeal joint is a common occurrence in growing cattle and dairy cows.

AETIOLOGY

Septic pedal arthritis occurs sporadically in cattle of all ages following deep penetration of the distal interphalangeal joint (407, 408) by nails and other metal objects (often poorly maintained cattle stocks), but it is encountered most commonly following extension from sole ulcer lesions in the lateral hind claw of dairy cows. Infection of the distal interphalangeal joint rarely arises from interdigital infection, such as foul of the foot, except for some severe cases of superfoul.

CLINICAL PRESENTATION

Affected cattle show severe lameness (10/10) with marked muscle atrophy of the affected limb. There is a history of poor milk yield and/or general body condition loss due to reduced grazing/feeding.

The foot is hot, swollen and very painful. There is marked swelling above the coronary band on the abaxial aspect and extending to the bulb of the heel (409), but discharging sinus(es) are uncommon (410) except for neglected cases. Rupture of the deep digital flexor tendon where it inserts onto the caudal aspect of the navicular bone may result in the toe not contacting the ground ('knocked up toe', 411). The swelling may extend from the coronary band above the fetlock joint (410), which suggests infection of the deep flexor tendon sheath (412) and a guarded prognosis.

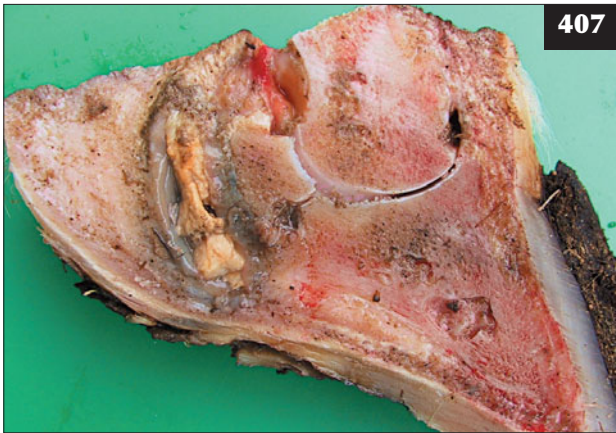
DIFFERENTIAL DIAGNOSIS

The differential diagnoses include a neglected white line abscess that has tracked up the wall of the hoof to discharge at the coronary band.



406

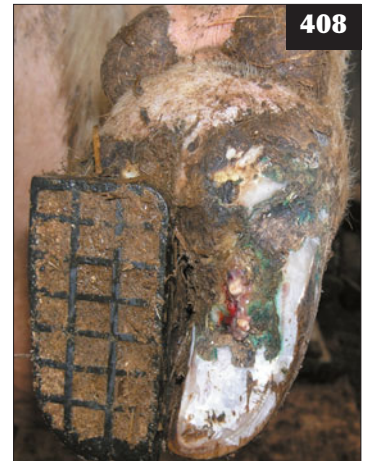406 A straw yard helping to prevent sole ulcers as well as making for happy cows.



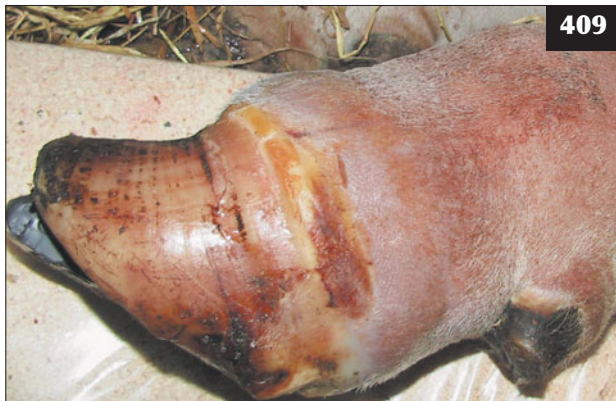407

407 Septic pedal arthritis. This necropsy specimen shows infection of the navicular bursa, distal interphalangeal joint and flexor tendon sheath following extension of infection from a chronic sole ulcer.

408 Septic pedal arthritis. Note the pus draining from the chronic sole ulcer and swollen heel bulb.

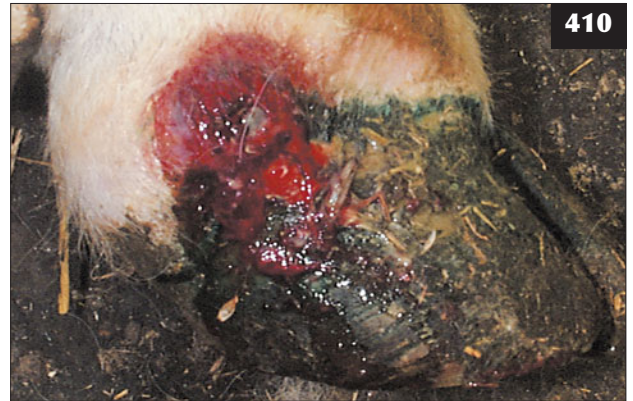

408



409

409 Infection of the distal interphalangeal joint in this case is causing marked swelling above the coronary band on the abaxial side.



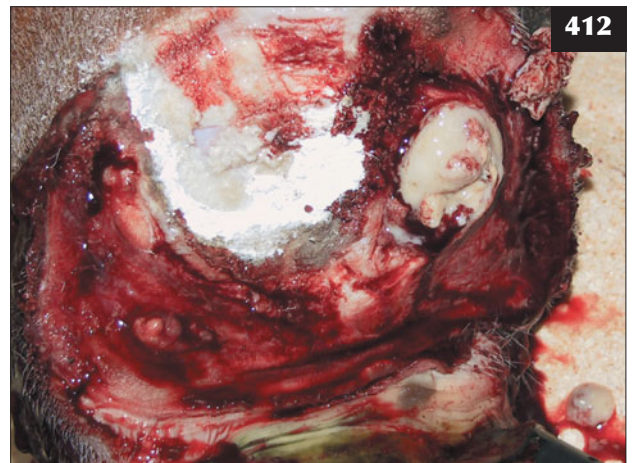
410

410 A discharging sinus in a neglected cases of distal interphalangeal joint infection.



411

411 Rupture of the deep digital flexor tendon where it inserts onto the caudal aspect of the navicular bone has resulted in the toe not contacting the ground ('knocked-up toe') in this bull.



412

412 There is a purulent discharge from the flexor tendon sheath following digit amputation in this bull. (See also **409**.)

DIAGNOSIS

A swelling above the coronary band on the abaxial aspect of the hoof wall extending around to the bulb of the heel is consistent with a diagnosis of septic pedal arthritis. Injection of sterile saline into the distal interphalangeal joint results in discharge via the sole ulcer (if present), thus confirming joint involvement. Arthrocentesis is rarely useful because only a small amount of inspissated pus is present within the joint. The diagnosis could be confirmed by radiography, but this is cost-prohibitive in most practical situations. Radiography may be necessary to differentiate infection of the proximal and distal interphalangeal joints (385). Ankylosis of the distal interphalangeal joint (413) can be distinguished from infection following radiography.

MANAGEMENT

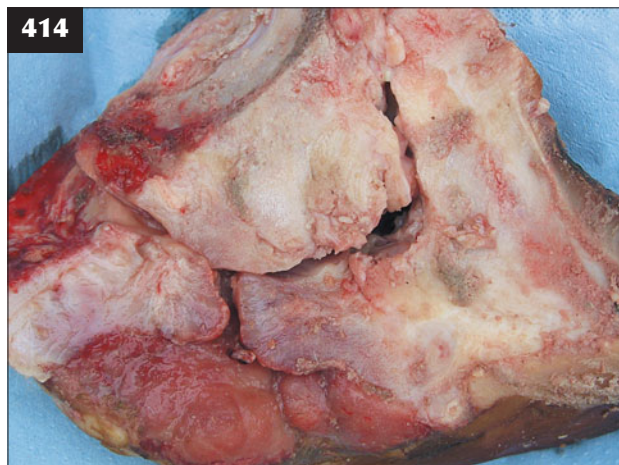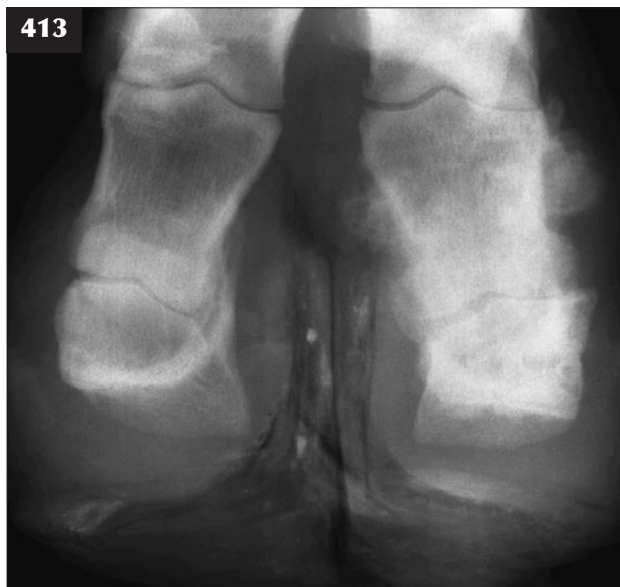Further antibiotic therapy is useless in cattle with infection of the distal interphalangeal joint. Digit amputation (414) under intravenous regional anaesthesia gives excellent results in growing cattle and beef cows where the cause is a penetration wound; dairy cows may have a sole ulcer in the other hindfoot, so this should be checked before proceeding with digit amputation.

Intravenous injection with an NSAID such as flunixin meglumine is recommended prior to amputation. Digit amputation can be performed in 15–20 minutes and uses few drugs and dressings, thereby keeping costs reasonable even for commercial-value growing cattle.

The animal is restrained in cattle stocks and the affected limb raised. In an adult dairy cow weighing 600–700 kg, 25–30 ml of 2% lidocaine solution (or equivalent) is injected into a superficial vein after application of a tourniquet either above the hock or below the carpus, as appropriate. In the hindlimb the recurrent metatarsal vein runs on the

cranial aspect of the mid-third metatarsal region and is readily palpable. Insertion of an 18 gauge 35 mm hypodermic needle (or butterfly needle) into the distended superficial vein releases 5–10 ml of blood under pressure; blood flow then quickly reduces to the occasional drop if the tourniquet is tight enough. Analgesia is effective within two minutes and is tested by needle pricking the coronary band.

The skin incision is extended using a scalpel blade for the full length of the interdigital space for a depth of approximately 25 mm at the cranial margin, extending to 40 mm at the most caudal extent in adult cattle. A length of embryotomy wire is introduced into the incision and the digit removed through the proximal region of the second phalanx by a rapid sawing action (415). The deep flexor tendon sheath is carefully examined for evidence of ascending infection (416), usually manifest as heat, pain and swelling extending to the mid-third metatarsal region. If the deep flexor tendon is infected (412), a section of the tendon is excised. This is achieved by passing straight haemostats up the tendon sheath and incising through the skin onto the tip of the haemostats. The flexor tendon is then transected at this level and removed distally where the sheath has been cut during digit amputation. Flushing the tendon with sterile Hartmann's solution can also be undertaken. Topical antibiotic spray is applied to the wound. A melolin dressing is applied to the wound and pressure applied using a large amount of cotton wool incorporated into the bandage (417). A course of parenteral antibiotics (e.g. procaine penicillin) is administered in most cases. The dressing is removed 2–3 days later and the granulating wound (418) sprayed with oxytetracycline aerosol. A light protective bandage is applied for a further 2–3 days, by which time the animal is much less lame. The long-term prognosis after digit amputation is very good except for some dairy cattle, which may only finish that lactation.



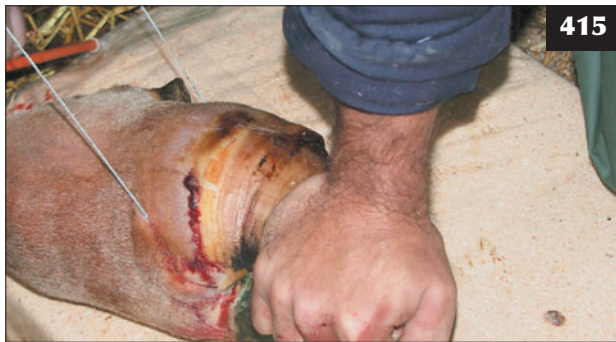413, 414 (413) There is ankylosis of the distal interphalangeal joint in this animal. (414) The digit has been removed through the second phalanx using embryotomy wire.

In some situations it may be necessary to sedate the animal, most commonly bulls, but there is a risk of bloat if the animal has not been previously starved (see Chapter 18, Anaesthesia, p. 286).

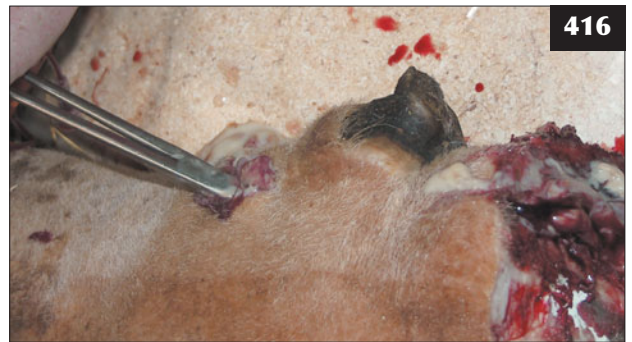Surgical arthrodesis of the distal interphalangeal joint has been described, with access through the bulb of the heel (419). The navicular bone is removed with some difficulty, then the articular surfaces of the distal interphalangeal joint

destroyed with a drill bit. Recovery from arthrodesis is more protracted than with amputation. The reported advantage of greater survival time in the herd for cattle with both digits compared with amputation is not supported by field studies, and can be rarely justified for economic and welfare reasons in commercial-value cattle.

Amputation through distal P1 is undertaken when infection involves the proximal interphalangeal joint (420).

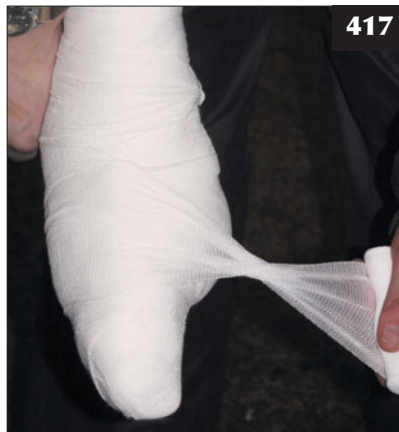

415

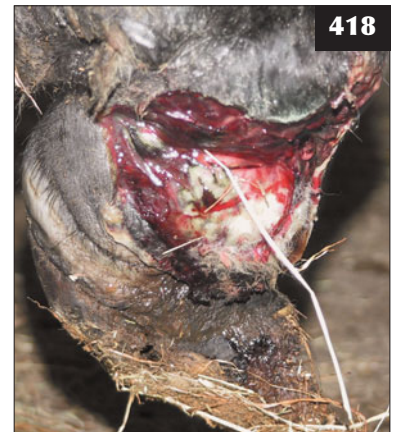

416

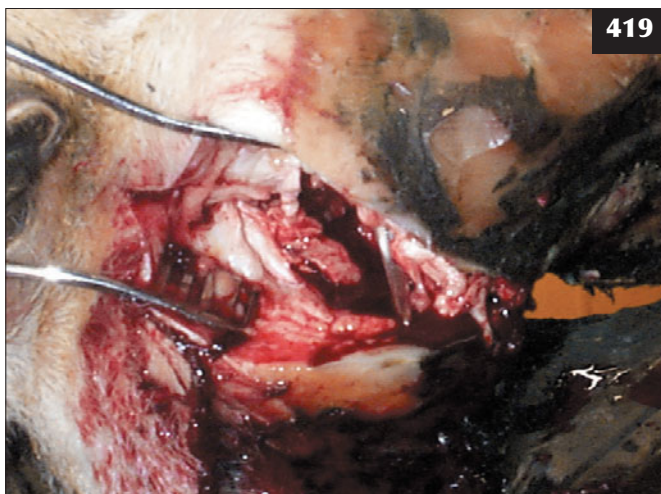
415–418 Digit amputation. (415) The embryotomy wire is introduced into the skin incision made in the interdigital space. (416) The deep digital flexor tendon sheath is infected in this bull. The deep flexor tendon is cut and the distal portion removed. (417) A melolin dressing is applied to the wound and pressure applied using a large amount of cotton wool incorporated into the bandage. (418) The dressing is removed 2–3 days later, revealing a healthy granulating wound. The amputation was through distal P1 in this case.



417



418



419

419 Surgical arthrodesis of the distal interphalangeal joint being attempted, with access through the bulb of the heel.



420

420 Amputation through distal P1 is undertaken when infection involves the proximal interphalangeal joint. Note the discharging sinus approximately 5 cm proximal to the coronary band. (See also 418.)

Prevention is the same as for sole ulcers (see p. 176). Immediate veterinary attention is essential for all cases where joint infection is suspected. Veterinary attention is also indicated when treatment by the farmer has not achieved any improvement within 5–7 days.

DIGITAL DERMATITIS

DEFINITION/OVERVIEW

Digital dermatitis is an infectious disease causing severe lameness in adult dairy cattle; the condition is very uncommon in beef cows and growing cattle. Prevalence figures from 2% to 25% are reported in affected dairy herds, with outbreaks common after the introduction of purchased infected cattle. Digital dermatitis has a worldwide distribution. The lameness causes reduced milk yield and lost income and treatment is expensive and time-consuming.

AETIOLOGY

The aetiology remains unproven, but is widely accepted to be a spirochaete infection. The condition is related to prolonged exposure to slurry, but this fact alone does not explain the low prevalence in beef herds.

CLINICAL PRESENTATION

The degree of lameness is variable, but in severe cases the weight is borne at the toe, leading to excessive wear. Lesions in the hindfeet are more common than in the forefeet and are more prevalent during early lactation. The feet are frequently encrusted with faeces to the level of the fetlock joint and these must first be removed to expose the skin. The early lesion is a distinct moist area of skin approximately 2–5 cm in diameter above the cleft of the bulb of the heel (421). There is erosion of superficial skin with a yellow/green diphtheritic membrane covering the lesion. Reports have also described lesions affecting the interdigital skin.

There may be considerable skin hyperplasia forming 'hairy warts' (papillomatous digital dermatitis) extending 2–3 cm from the skin surface, although such lesions are more commonly reported in North American herds.

Lesions may occasionally be found extending onto the bulb of the heel (422), in the interdigital space at the anterior margin (423) and following a sole ulcer or other lesion exposing the corium.

DIFFERENTIAL DIAGNOSIS

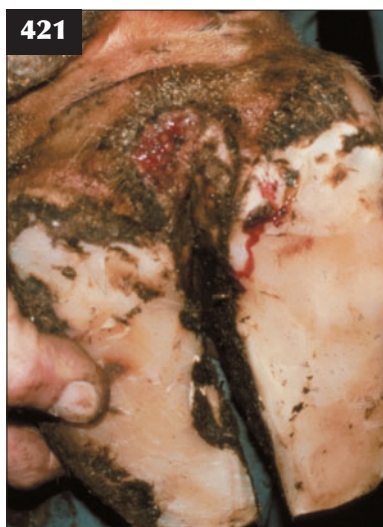Foul of the foot and superfoul when the interdigital space is affected.

DIAGNOSIS

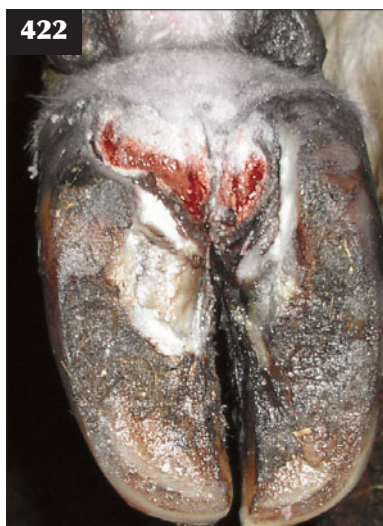The lesions have a characteristic appearance and distribution.

MANAGEMENT

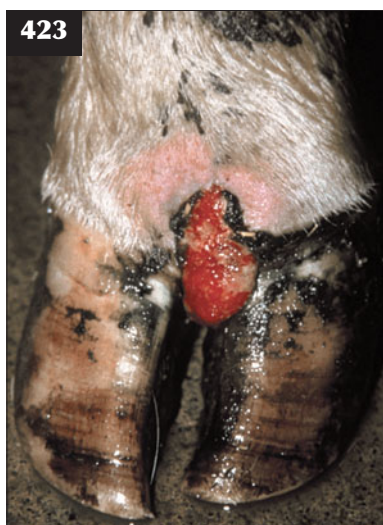All dried faecal material overlying the lesion must be removed. The lesion is cleaned thoroughly (pressure hoses



421 An early lesion of digital dermatitis seen as a distinct raw area of skin, approximately 2–5 cm in diameter, above the cleft of the bulb of the heel.



422 A more extensive digital dermatitis lesion causing underrunning of the heel bulbs is shown.



423 This digital dermatitis lesion at the front of the interdigital space has led to local destruction of the coronary band and development of painful horizontal fissures.

are often used) and then a topical oxytetracycline aerosol is applied. Repeat treatments are frequently necessary.

Footbaths containing either lincomycin or tylosin are frequently used to control herd outbreaks, but it is important to ensure that cows do not drink such solutions. Formalin or copper sulphate footbaths appear to have no effect on the transmission or development of this condition.

Strict biosecurity is essential to prevent introduction of carrier animals into the herd. Slurry management must be improved. Good environmental hygiene is essential to reduce exposure to wet, dirty underfoot conditions. Strategic use of footbaths containing either lincomycin or tylosin is effective, as is the practice of whole-herd foot spraying.

FOUL IN THE FOOT (INTERDIGITAL NECROBACILLOSIS, PHLEGMONA INTERDIGITALIS)

DEFINITION/OVERVIEW

Foul in the foot is an acute or subacute necrotizing infection involving the skin and deeper soft tissue of the interdigital space. The incidence is high in cattle with poor underfoot conditions, including wet, dirty bedding/areas around water troughs and new roadways with loose stones/chippings that become lodged in the interdigital space (424).

AETIOLOGY

Foul in the foot is caused by *Fusobacterium necrophorum* and *Bacteroides melaninogenicus*.

CLINICAL PRESENTATION

There is acute severe lameness and the animal only 'toes' its

foot to the ground. The lesion starts with a swelling and widening of the interdigital space progressing proximally as far as the fetlock joint. Reddening of interdigital skin is obvious. A fissure appears in the interdigital skin, with necrosis of underlying tissue (425). Complications such as deep sepsis are very uncommon.

DIFFERENTIAL DIAGNOSES

White line/sole abscess; digital dermatitis involving the interdigital space.

DIAGNOSIS

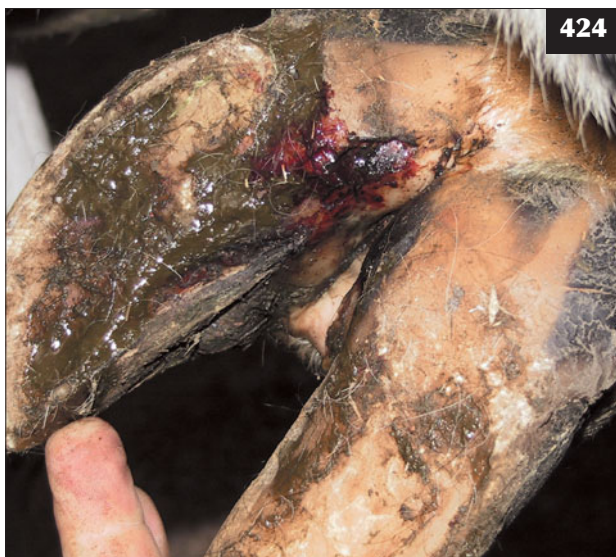It is essential to check the interdigital skin for the presence of sharp stones or other foreign body. Diagnosis is obvious on careful examination of the foot, noting that sharp flints/stones can become buried in deeper tissues.

MANAGEMENT

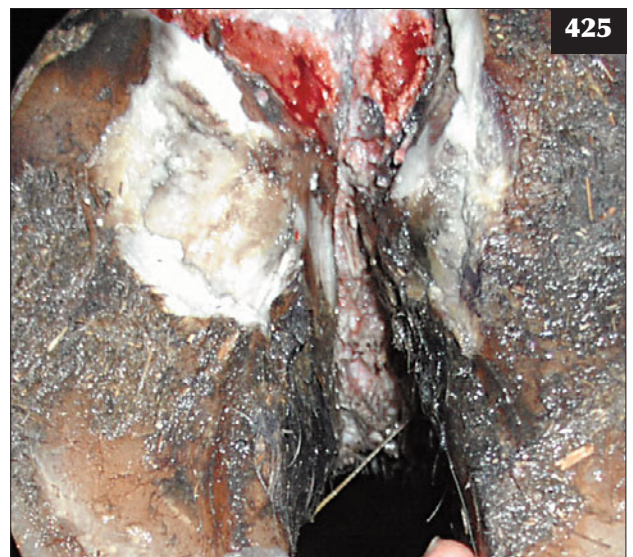
Spontaneous recovery is reported, but acutely lame cattle require immediate attention. The interdigital space should be cleaned out and any foreign body removed. The lesion is sprayed with oxytetracycline aerosol or other topical antibiotic. Parenteral antibiotics are administered for three consecutive days or as a single long-acting preparation. In lactating dairy cattle, an antibiotic with zero milk withhold time should be selected.

Preventive measures include:

- Use of a 5% formalin footbath four times weekly during the risk period.
- Removing slurry regularly.
- Where a problem exists in a straw court, adding 15 g paraformaldehyde per square metre.
- Upgrading farm tracks.



424 Foul in the foot after a stone had become lodged in the interdigital space, allowing infection to enter deeper structures.



425 Interdigital necrobacillosis and digital dermatitis affecting the same foot in a dairy cow.

SUPERFOUL**DEFINITION/OVERVIEW**

Superfoul is a highly infectious disease, first reported during the 1990s in the UK, that causes severe lameness.

AETIOLOGY

Superfoul is a peracute form of interdigital necrobacillosis with suggested synergism with the causal agent(s) of digital dermatitis.

CLINICAL PRESENTATION

There is very sudden onset of severe lameness. The lesion starts as a swelling and widening of the interdigital space, with extensive tissue necrosis (426), which if left untreated for 12–24 hours can rapidly progress to involve the navicular bursa, flexor tendon sheath and distal interphalangeal joint(s). The foot is very swollen and the cow 10/10 lame.

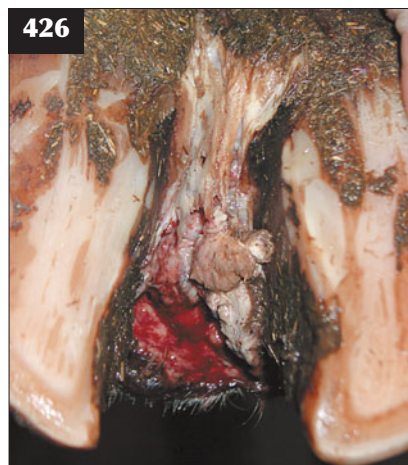DIAGNOSIS

Diagnosis is confirmed following clinical examination of sudden severe lameness involving the interdigital space and deeper tissues affecting a number of dairy cows.

MANAGEMENT

Immediate action is very important. Under intravenous regional anaesthesia, the interdigital lesion is debrided and packed with 2–4 500 mg clindamycin tablets. A bandage is then applied. The cow is treated with tylosin (20 ml i/m q12h for at least 3 days). Flunixin meglumine or ketoprofen is also administered. The cow is isolated in a well-bedded straw pen. Severely affected cattle are culled.

Prevention is by quarantining all cattle introduced into a herd. Environmental contamination should be reduced and bedding increased in the cubicles. Disinfectant footbaths containing either formalin or copper sulphate are reported to provide good control. Antibiotic footbaths are indicated where digital dermatitis is implicated.



426 In this animal with superfoul there is a swelling and widening of the interdigital space and heel bulb, with extensive tissue necrosis and ascending cellulitis.

FRACTURE OF THE PEDAL BONE**DEFINITION/OVERVIEW**

Fracture of the pedal bone is occasionally seen in older dairy cows presenting with sudden-onset forelimb lameness.

AETIOLOGY

Sudden contact with concrete or hard ground, often during bulling activity, is the most common cause.

CLINICAL PRESENTATION

The cow presents with sudden severe lameness of a medial claw of a front foot and adopts a characteristic crossed-leg stance with the weight borne on the sound lateral claw (427).

DIFFERENTIAL DIAGNOSIS

Foreign body penetration of the sole; white line abscess.

DIAGNOSIS

Careful examination of the foot is essential to eliminate other more common causes of lameness, including toe abscess. Subsolar haemorrhage may be visible around the tip of the pedal bone and the cow will exhibit pain on percussion of the hoof. The fracture site is readily identified by radiography, but this is rarely undertaken in practice.

MANAGEMENT

A wooden block applied to the sound claw relieves lameness. The prognosis is very good unless the fracture extends to involve the articular surface (428). There are no specific control measures.

INFECTIOUS POLYARTHRITIS (JOINT ILL)

(See also Septicaemic colibacillosis, p. 100)

DEFINITION/OVERVIEW

Localization of bacteria within joint(s), causing an infectious arthritis with severe lameness, is a major



427 A cow with a fractured pedal bone in the medial claw is shown adopting a cross-legged stance in order to reduce weight bearing on the painful claw.

economic problem and welfare concern in calves. The problem is greatly increased when calves are born indoors under unsanitary conditions.

AETIOLOGY

Bacteraemia in neonatal calves results from entry via the gastrointestinal tract, upper respiratory tract and, possibly, the untreated umbilicus. Omphalophlebitis is commonly diagnosed in calves with septicaemia and bacteraemic conditions such as polyarthritis, but this association may only reflect overall poor environmental hygiene and bacterial contamination; it does not necessarily indicate causation. Many calves with umbilical infections show no other sites of infection and typically develop localized abscesses.

Bacteraemia occurs when calves are managed under poor sanitary conditions with delayed or inadequate colostrum

intake. Poor husbandry standards, understaffing and lack of client education about risk factors all contribute to an increased prevalence of neonatal diseases and compromised health and welfare. *E. coli* and *Streptococcus* spp. are the common isolates from infected joints.

CLINICAL PRESENTATION

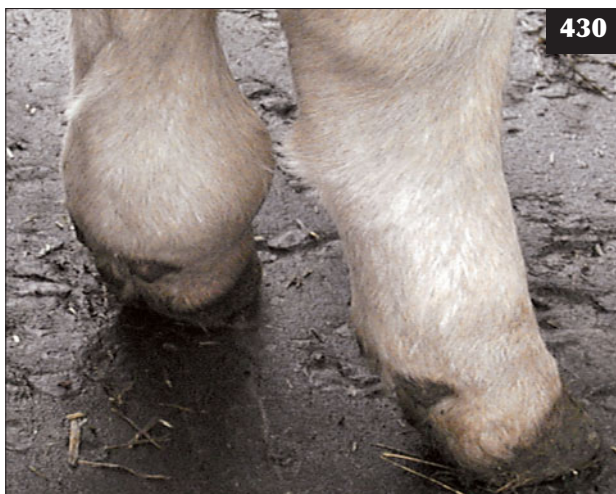Severe to non-weight-bearing lameness presents from around three days old. Calves with two or more limbs affected adopt a 'crab-like' stance (429). The fetlock (430), carpal and hock joints are most commonly affected, but it proves more difficult to appreciate effusion of the elbow and shoulder joints. Lameness results in rapid muscle atrophy (431). The rectal temperature may be marginally elevated, but is frequently within the normal range. The umbilicus may be thickened and painful. The affected joint(s) are swollen, hot



428 In this animal, localized sole haemorrhage is visible around an area of fractured pedal bone that was successfully treated with a block on the sound claw.

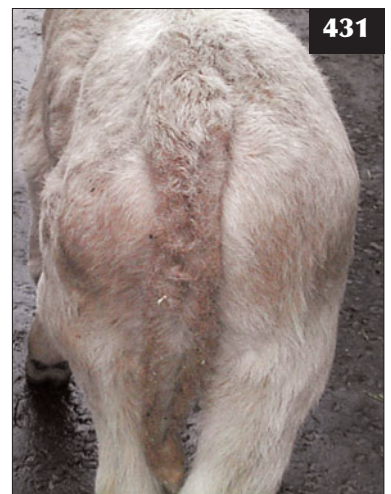

429 Localization of bacteria within joints has caused an infectious arthritis in this calf.



430 There is haematogenous spread of bacteria to the left hind fetlock joint in this calf.

431 The lameness caused by the septic left hind fetlock joint in the animal in **430** has resulted in rapid muscle atrophy over the left hip area compared with the unaffected leg.



and painful (430). The lymph nodes (prescapular or popliteal) are typically 2–5 times their normal size, although it is not as easy to palpate the popliteal lymph node.

After several weeks there is considerable thickening of the fibrous joint capsule, with affected joints feeling enlarged but firm, with much reduced joint excursion. Bony changes with osteophyte formation are visible radiographically after 4–6 weeks.

DIFFERENTIAL DIAGNOSIS

Lameness may result from fracture of a long bone, most commonly caused by excessive traction during the birth process. Trauma to joints may cause marked lameness, but is sudden in onset; the stifle is the most commonly injured joint. Osteomyelitis is more common in 4–8-week-old calves, with the epiphyseal swelling distinct from any joint effusion. Muscular dystrophy (white muscle disease) causes paresis leading to recumbency, but there are no palpable joint lesions.

DIAGNOSIS

Diagnosis of an infected joint is based on clinical findings. It has been recommended that all swollen joints in calves less than two months old should be considered septic until proven otherwise.

During the acute stages of infection there may be sufficient joint effusion to obtain a sample by needle aspiration. This should show a twofold increase in protein concentration (normal <18 g/l) and neutrophilic pleocytosis consistent with sepsis.

Radiographic changes are evident after 4–6 weeks (432),

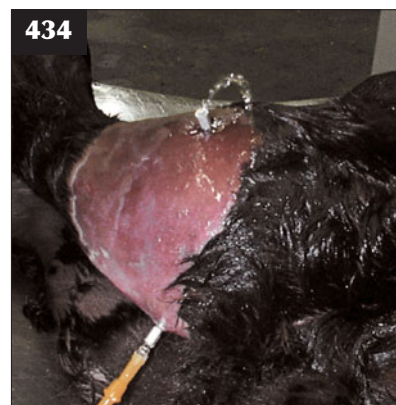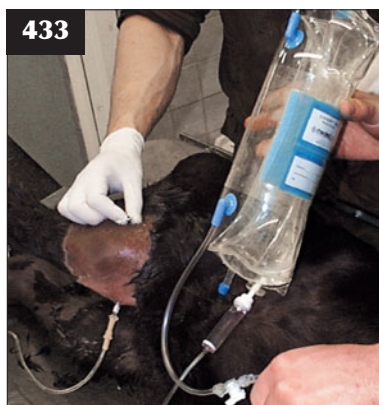
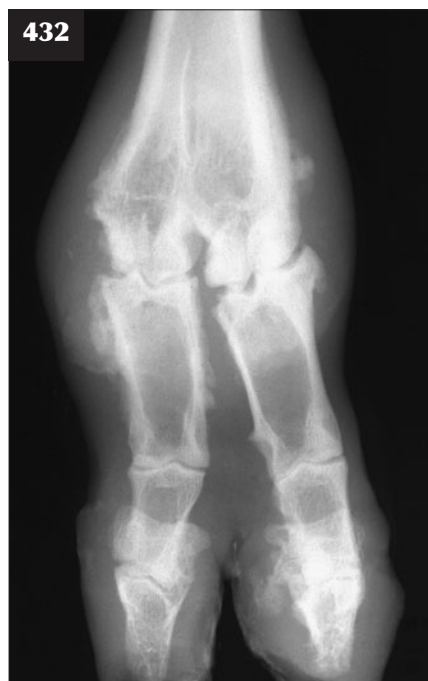
with widening of the joint space and possible osteophyte formation.

MANAGEMENT

The range of potential causal bacteria renders logical selection of antibiotic therapy difficult. Florfenicol, amoxicillin and clavulanic acid, and trimethoprim-sulpha have all been recommended. Antibiotic treatment costs are not high due to the low calf birth weight (30–50 kg). Flunixin meglumine or ketoprofen should be administered for three consecutive days in order to alleviate pain. Alternatively a single injection of meloxicam can be given, which may be effective for up to three days.

Joint lavage can be attempted to treat a single infected joint in young calves, but this method requires appropriate analgesia and is therefore expensive and time-consuming. High caudal blocks can be used in the case of hindlimb joints (433, 434); intravenous propofol or xylazine and ketamine general anaesthesia can be used for treatment of a forelimb joint. There is variable response to joint lavage depending on which joint is affected and the duration of infection before treatment commences. A second joint flush may be necessary in most cases. In general, the prognosis for fetlock joint lavage is much better than that for stifle, hock or carpal joints. Joint lavage is often cost-prohibitive except for pedigree calves.

Every effort must be taken to reduce the risk of bacteraemia by ensuring timely adequate passive antibody transfer and reducing environmental bacterial challenge in the calving boxes/calving environment.



432 Radiographic changes are evident 3–4 weeks after fetlock joint infection in the animal in 429. Note the widening of the joint space and extensive osteophyte formation.

433, 434 Joint lavage. (433) A high caudal block has been used to achieve effective analgesia in this case of hindlimb joint lavage (stifle joint). (434) The joint is being flushed with one litre of sterile Hartmann's solution, alternating the flow through the two needles.

OSTEOMYELITIS

DEFINITION/OVERVIEW

Haematogenous infection of the epiphyses of long bones (distal tibia and third metatarsal bone) and vertebrae (435) is a common clinical presentation of *Salmonella dublin* bacteraemia of calves aged 1–4 months. There may be no other clinical evidence of *S. dublin* infection, such as neonatal diarrhoea, in the herd. Osteomyelitis may also occur at fracture sites, particularly open fractures.

AETIOLOGY

Osteomyelitis is caused by haematogenous spread of *S. dublin* infection in an endemically-infected herd associated with poor hygiene standards. *Arcanobacterium pyogenes* and *E. coli* are less common aetiological agents.

CLINICAL PRESENTATION

Infection of the epiphyses of the distal tibia and metatarsus cause hindlimb lameness, which progresses over 1–2 weeks to moderate/severe lameness with firm painful swelling immediately proximal to the hock and fetlock joints, respectively. There is associated pyrexia (typically 39.5–40.0°C), but few systemic signs.

Infection of cervical vertebra(e) causes cervical pain, with the head held rigidly and lowered. Movement of the head/neck is resisted. Cord compression following extension of the vertebral body infection into the spinal canal will cause upper motor neuron signs to the forelimbs and hindlimbs (C1–C5) or lower motor neuron signs to the forelimbs (C6–T2).

DIFFERENTIAL DIAGNOSIS

Careful palpation will differentiate the soft tissue swelling surrounding the epiphysis from joint effusion/thickening of the joint capsule associated with joint infection. Cellulitis from puncture wounds causes obvious and more extensive subcutaneous swelling.

DIAGNOSIS

There is a firm, hot and painful swelling immediately proximal/distal to a joint. Lysis of the growth plate is evident on radiographic examination.

MANAGEMENT

Prolonged antibiotic therapy is indicated for epiphyseal infection. Fluoroquinolone antibiotics are indicated for suspected *Salmonella* spp. infections. NSAIDs should be given for 3–5 consecutive days. A prolonged course of antibiotics (procaine penicillin is the cheapest) is indicated to prevent infection of fracture sites. Vertebral empyema will not respond to antibiotic therapy and calves with limb weakness should be euthanased for welfare reasons.

Improving hygiene is essential, especially in the calving accommodation and rearing area, as is colostrum ingestion. Eradication of *S. dublin* proves very difficult and

a vaccination strategy for cows and calves may be the more cost-effective option.

SEQUESTRUM FORMATION

DEFINITION/OVERVIEW

Sequestrum formation in the mid-third metatarsal/metacarpal region is occasionally encountered in 1–2-year-old cattle, with bulls more commonly presented than heifers/steers.

AETIOLOGY

The cause is not fully understood, but superficial severe trauma to the region is suspected, although the consistent size and site of the lesion may indicate otherwise.

CLINICAL PRESENTATION

Affected animals present with moderate lameness, which is refractory to antibiotic therapy (often several courses of different antibiotics). A discharging sinus is often present over the centre of the lesion.

DIFFERENTIAL DIAGNOSIS

Cellulitis; osteomyelitis.

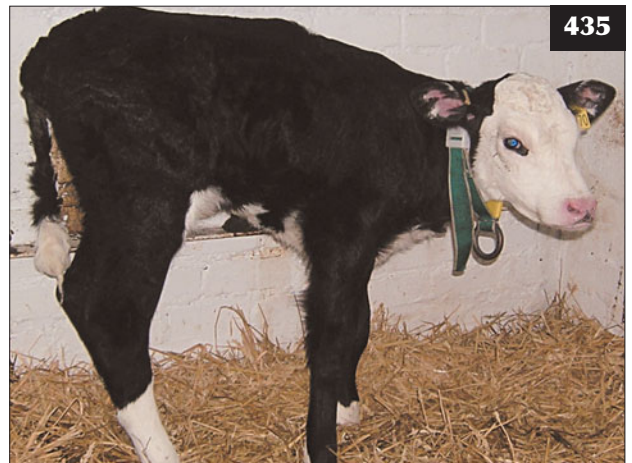DIAGNOSIS

Radiography is important to identify the precise site and size of the lesion.

MANAGEMENT

Sequestrum removal under general anaesthesia (metacarpal bone) or with deep xylazine sedation (stages 3–4) and extradural lidocaine (metatarsal bone) affords an excellent prognosis.

There are no known control measures.



435 One-month-old calf with osteomyelitis of the thoracic vertebra. Note the kyphosis that has resulted.

LIMB FRACTURES

DEFINITION/OVERVIEW

Limb fractures, particularly during assisted calving by farm staff, are not uncommon in oversized calves. Fractures occur in growing cattle for a variety of reasons, including slipping on wet surfaces, bulling injuries and fighting in bulls. Fracture through the proximal femoral growth plate in growing cattle is commonly misdiagnosed (436–438), with serious animal welfare consequences.

AETIOLOGY

Unskilled forced delivery of oversized calves is a common cause of limb fractures in neonates.

CLINICAL PRESENTATION

Forelimb

Severe lameness with a palpable fracture typically of the distal third metacarpal growth plate is not uncommon following delivery of a calf in anterior presentation. There is often a report that 'the cow was standing at the start, but fell down while the calf was being jacked out'.

Hindlimb

A mid-shaft femoral fracture and a fracture through the proximal femoral growth plate can occur during excess

traction of an oversized calf in posterior presentation (439). Hip dislocation (craniodorsally) and fracture through the proximal femoral growth plate result in relative shortening of the upper limb, with the hock more proximal than normal.

DIFFERENTIAL DIAGNOSIS

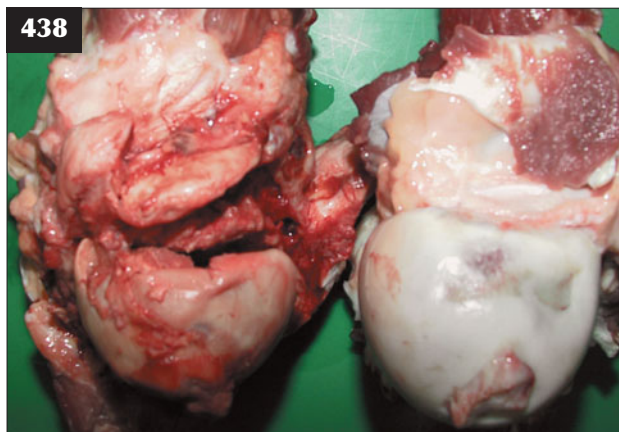
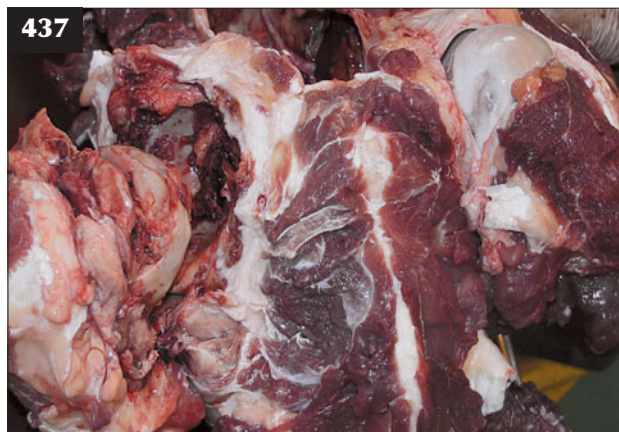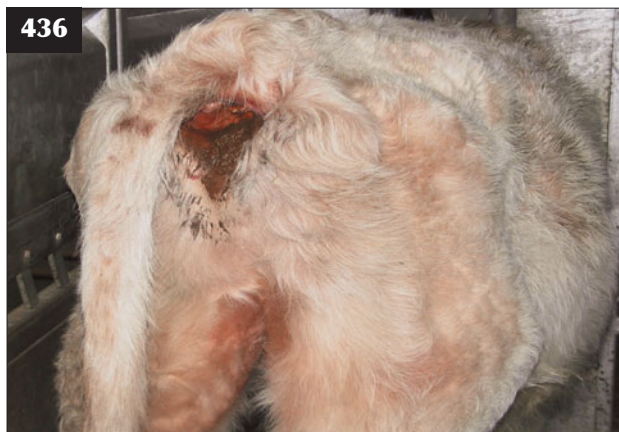Forelimb: avulsion of the brachial plexus; radial nerve paralysis. Hindlimb: femoral nerve paralysis; dislocated hip.

Differential diagnosis of moderate to severe lameness would include joint trauma and/or sepsis if the calf presents lame from three days old.

DIAGNOSIS

Evaluation of each case is based on detailed palpation and gentle manipulation of the affected limb. Radiographic examination is necessary to accurately differentiate hip dislocation/mid-shaft femoral fracture/fracture through the proximal femoral growth plate.

Diagnosis of fracture through the proximal femoral growth plate is based on failure to find a lesion distal to, and including, the stifle joint, to fully account for the sudden onset severe lameness. Hip dislocation can be discounted from the differential diagnosis, leaving only femoral fracture whatever the cause.



436–438 Proximal femoral growth plate fracture. (436) This growing steer with a fracture through the right proximal femoral growth plate is severely lame. Note the tail pulled to the normal left side. (437) Necropsy findings of the animal in 436 following immediate destruction for welfare reasons when presented for veterinary examination. Note the considerable haemorrhage within the hip joint. (438) Comparison of the femoral heads from the animal shown in 436 and 437.

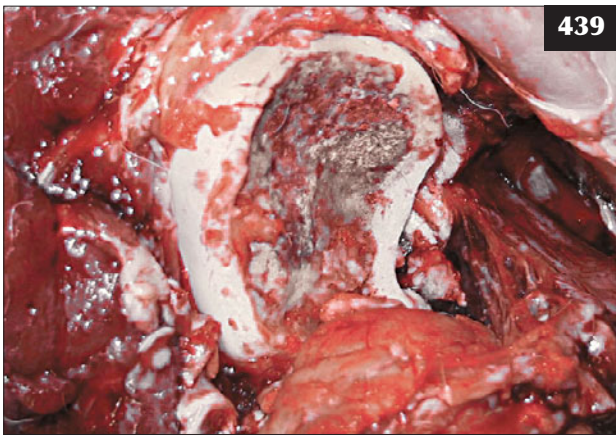
MANAGEMENT

Reduction is not usually a problem with distal third metacarpal growth plate fractures. A fibreglass cast is applied from the proximal metacarpus to the foot. Disruption of blood supply at the fracture site may result in avascular necrosis. This is manifest as return of severe lameness and a putrid smell after 5–10 days.

There is always the risk of infection of the fracture site in cattle, even in closed fractures, and it is prudent to administer antibiotics such as procaine penicillin for 14–21 days.

Mid-shaft femoral fracture/fracture through the proximal femoral growth plate carries a hopeless prognosis and these calves should be euthanased immediately, otherwise unacceptable suffering results.

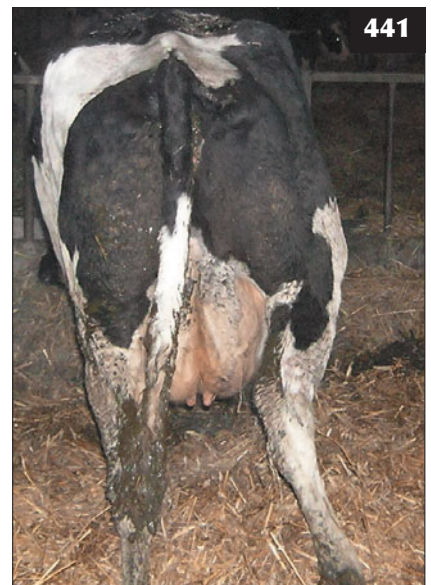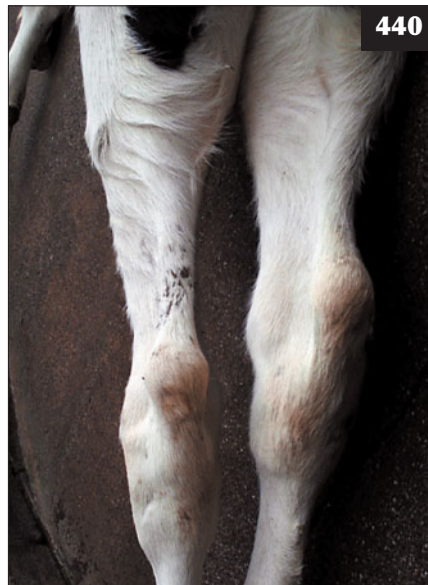Prevention of limb fractures is by avoiding excessive traction during calf delivery.



439 Fracture through the proximal femoral growth plate occurred in this calf in posterior presentation because excess traction was applied.

440 Dislocation of the right hip in this animal has resulted in relative shortening of the upper limb, with the right hock more proximal.

441 Hip dislocation in a dairy cow. Note the characteristic limb abduction.

**DISLOCATION/SUBLUXATION**

Dislocation is most commonly observed affecting the hip joint and is rarely seen in the fetlock joint. Sacroiliac subluxation is common in recently calved dairy cattle and is often associated with milk fever.

HIP DISLOCATION (COXOFEMORAL LUXATION)**DEFINITION/OVERVIEW**

Hip dislocation occurs sporadically in dairy cows around parturition.

AETIOLOGY

Hip dislocation can occur during excess traction of an oversized calf in posterior presentation. In adult cattle, hip dislocation can follow slips/falls, most commonly around parturition, and is an important differential diagnosis of downer cow syndrome.

CLINICAL PRESENTATION

There is acute onset of severe (10/10) lameness. The calf/cow spends almost all of its time in sternal recumbency with the affected hindlimb uppermost. Hip dislocation (almost always craniodorsally) results in relative shortening of the upper limb with the hock more proximal (440, 441). There is marked swelling craniodorsal to the affected hip joint. Crepitus can be appreciated with an ear or stethoscope placed over the bony swelling of the suspected dislocated hip if the standing animal is gently rocked by applying lateral pressure from the other hip region.

DIFFERENTIAL DIAGNOSIS

Fracture through the proximal femoral growth plate in neonates; fracture of the greater trochanter in adult cattle; pelvic fractures (uncommon).

DIAGNOSIS

Diagnosis is based on careful empathetic examination. Radiography is essential to differentiate hip dislocation and fracture through the proximal femoral growth plate in neonates. Dislocation in calves is generally accompanied by fracture of the acetabular rim (rarely visible on radiographs) and considerable intra-articular haemorrhage.

MANAGEMENT

Although manipulative reduction of hip dislocation has been described in adult cattle, it is not recommended and the cow should be euthanased for welfare reasons as soon as a dislocation has been diagnosed. If reduction is attempted, then appropriate extradural anaesthesia to paralyse both hindlimbs is essential; xylazine sedation is not adequate. Open reduction may be ill advised because it carries a poor long-term success rate.

Prevention is by avoiding excessive traction during calf delivery, paying attention to floors/surfaces, especially in calving accommodation, and hobbling cows with obturator nerve paralysis and housing them on deep straw bedding.

SACROILIAC LUXATION/SUBLUXATION**DEFINITION/OVERVIEW**

Sacroiliac luxation/subluxation is partial or complete separation of the fibrocartilaginous sacroiliac joint surfaces.

AETIOLOGY

Traumatic injury to the sacroiliac joint occurs around parturition when there is ligamentous relaxation.

CLINICAL PRESENTATION

The tuber coxae are raised in relation to the vertebral column (442). Clinical signs of weakness and possible knuckling of the hindlimb(s) during the acute phase are caused by involvement of the nerve roots at the lumbosacral outflow. Subluxation may not be noted until several days later when pelvic asymmetry is obvious.



442 This animal has sacral luxation, with the vertebral column dropped below the level of the tuber coxae.

DIFFERENTIAL DIAGNOSIS

Recumbency, weakness and inability to stand in the periparturient cow due to hypocalcaemia or a traumatic lesion elsewhere. (See Chapter 14, Metabolic diseases, Downer cow, p. 253.)

DIAGNOSIS

Care must be exercised when diagnosing sacroiliac luxation on crepitus alone because relaxation of the ligaments around parturition may generate crepitus when the joint surfaces move over one another.

MANAGEMENT

Analgesic drugs should be given. Affected animals should be housed appropriately and milked in the straw pen. No attempt should be made to hoist these cows. The prognosis is poor for sacroiliac luxation and although cows with subluxation may appear to recover, there may be a dystocia risk at the next calving due to narrowing of the pelvic canal.

Prevention is by housing cows coming to calving and those calved for less than one week on deep straw.

FRACTURE OF SACRAL/COCCYGEAL VERTEBRAE (CRUSHED TAIL HEAD SYNDROME)**DEFINITION/OVERVIEW**

Fracture of sacral/coccygeal vertebrae is an injury to the sacral or coccygeal vertebrae that occurs most commonly in dairy cows following mounting activity.

AETIOLOGY

Traumatic crushing of sacral/coccygeal vertebrae causes variable spinal nerve injury, leading to tail paresis/paralysis and, in cases affecting sacral nerves, bladder dysfunction and sciatic nerve deficits.

CLINICAL PRESENTATION

Affected animals present with ventral depression of the tail head, paresis/paralysis of the tail, dysuria and bilateral knuckling of the hindlimbs (443), which are drawn under the body in a characteristic stance.

DIFFERENTIAL DIAGNOSIS

Sciatic nerve injury.

DIAGNOSIS

Diagnosis is based on characteristic signs and a history of recent bulling behaviour.

MANAGEMENT

In acute cases, treatment with NSAIDs or corticosteroids may reduce the local inflammation and improve neurological function. The prognosis for full recovery is guarded and depends on whether compression fracture or simple vertebral luxation is present.

Cases occur sporadically, but investigation of environment and nutrition should be undertaken to identify possible risk factors when multiple cases occur in the same herd.

OSTEOARTHRITIS SECONDARY TO SUBLUXATION/LIGAMENT RUPTURE

DEFINITION/OVERVIEW

Osteoarthritis most commonly affects the stifle joint (subsequent to cruciate ligament damage) and, to a much lesser extent, the hip of older beef cows. There is a history of sudden severe lameness, which improves over several months, but considerable muscle wastage and residual moderate lameness remain.

AETIOLOGY

There is considerable size disparity between a 1,000–1,200 kg bull and a 500 kg beef cow, with injury more likely when mating occurs on soft ground. Bulls can be affected after injuries sustained during fighting when maintained in groups or accidentally mixed together. Typically, there is complete rupture of the cranial cruciate ligament and damage to the menisci, with resultant stifle joint instability and consequent development of secondary osteoarthritic changes.

CLINICAL PRESENTATION

Marked muscle wastage over the hindquarters is best appreciated when the animal is viewed directly from behind.

Hip

The greater trochanter is much more obvious than normal, with considerable muscle wastage.

Stifle joint

Initially, there is considerable effusion of the stifle joint. Instability due to cranial cruciate ligament rupture may lead to obvious clicking or clunking of the stifle joint that can be appreciated while walking alongside the affected cow/bull. It is difficult to appreciate a drawer-movement in mature cattle; with the animal restrained in stocks and standing behind it, the clinician may attempt to draw the femoral condyles caudally over the tibial joint surfaces by passing his/her arms around the hindlimb above the stifle and pulling backwards. The clinician must fully appreciate the risks of being kicked, especially during examination of a painful joint.

As the osteoarthritis of the stifle joint progresses, there is considerable thickening of the joint capsule.

DIAGNOSIS

Hip joint

Osteoarthritis of the hip joint is difficult to diagnose on clinical examination and it is often an assumption that the hip joint is the source of lameness by excluding all joints distal to, and including, the stifle joint. The detection of crepitus over the hip joint is an unreliable indicator.

Stifle joint

Effusion and fibrous thickening of the joint capsule are readily palpable. Ultrasonography, using a 7.5 MHz linear scanner with stand-off, demonstrates any joint effusion and thickening of the joint capsule. Joint sepsis and haemarthrosis can also be differentiated from an effusion.

Arthrocentesis is rarely undertaken on the farm because of the risks associated with introducing infection into the joint, but it should be undertaken where there is suspicion of a puncture wound. Haemarthrosis can be better determined by ultrasonography.

Radiography can be undertaken on the farm. Lateral views of the stifle may show widening of the joint space by an effusion and cranial displacement of the tibial plateau relative to the femoral condyles. Osteophyte formation may be visible after six weeks.

MANAGEMENT

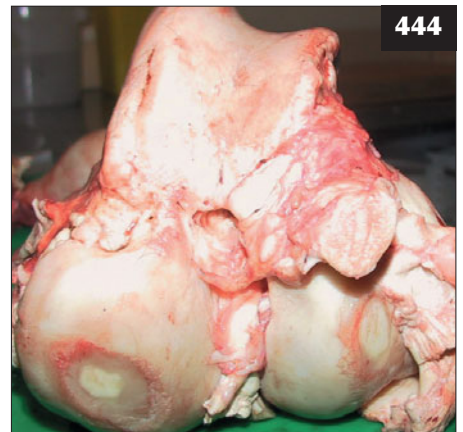There is no treatment for osteoarthritis (444). It is difficult to give an accurate prognosis at the time of the injury and lame cattle should be housed individually and given



443 Characteristic stance adopted by a cow with fractured sacral/coccygeal vertebrae. Note the flaccid paralysis of the tail, sinking of the hocks and knuckling of the fetlocks due to sacral/sciatic nerve root damage.

444

Extensive erosion of the articular cartilage of the femoral condyles found at necropsy.



NSAIDs in the first instance. Provided the animal is able to walk and is eating well, re-evaluation should be made two weeks later.

Because there is considerable size disparity between beef bulls and cows, bulls must be carefully selected and not allowed to become too fat.

Chronic hindlimb lameness is a concern in beef herds where cows are not culled until the calf is weaned, which may be many months after the initial onset of lameness (444).

MUSCLE INJURIES

Muscle injuries are most often associated with prolonged recumbency and recovery from hypomagnesaemia/hypocalcaemia and following turnout to pasture when there is sudden and prolonged unaccustomed exercise. The gastrocnemius, the adductor muscles of the hindlimb and muscles attaching the scapula to the trunk are most commonly affected.

GASTROCNEMIUS MUSCLE RUPTURE

DEFINITION/OVERVIEW

Rupture of the gastrocnemius muscle and tendon of insertion typically occurs following sudden and prolonged unaccustomed exercise in yearling cattle.

AETIOLOGY

Sudden prolonged exercise is an important factor causing rupture of the gastrocnemius muscle in growing cattle within 2–3 days of group turnout to pasture in the spring. Rupture can also occur as heavy cattle struggle to regain their feet after parturition or metabolic disease. Low selenium and vitamin E status may be involved in some cases.

CLINICAL PRESENTATION

There is sudden onset severe lameness with failure to bear weight on one (but more usually both) hindlimb, caused by pronounced overflexion of the hock joint(s) such that the hind cannon almost touches the ground (445). There is massive swelling at the junction of the gastrocnemius muscle and tendon of insertion onto the tuber calcis. This area is oedematous, hot and painful.

DIFFERENTIAL DIAGNOSIS

Avulsion of the tuber calcis caused by rickets; white muscle disease; sciatic nerve paralysis.

DIAGNOSIS

The history and site of massive swelling are characteristic of gastrocnemius muscle rupture.

MANAGEMENT

There is no treatment and animals with marked overflexion of the hock must be euthanased for welfare reasons.

ADDUCTOR MUSCLES OF THE HINDLIMB

See Chapter 14, Metabolic diseases, Downer cow, p. 253.

RUPTURE OF THE SERRATUS VENTRALIS MUSCLES

DEFINITION/OVERVIEW

Sudden and prolonged unaccustomed exercise in yearling cattle following turnout to pasture may result in rupture of the serratus ventralis muscles.

AETIOLOGY

Rupture of the serratus ventralis fixing the scapula to the chest wall may also occur after sudden prolonged exercise in yearling cattle within 2–3 days of group turnout to pasture in the spring. Low selenium and vitamin E status may be involved in some cases.

CLINICAL PRESENTATION

The dorsal margins of the scapulae project well above the thoracic vertebral column.

DIFFERENTIAL DIAGNOSIS

White muscle disease.

DIAGNOSIS

The clinical appearance and history of sudden prolonged exercise are pathognomonic.

MANAGEMENT

There is no specific treatment. Cattle are able to walk, but they will not recover normal support of the forelimbs and the prominent scapulae remain.

There are no specific control measures. Cattle should be fed a balanced ration with appropriate mineral and vitamin supplementation.



445 This bull has ruptured both gastrocnemius muscles. Note the hock joints are almost in contact with the ground.

TENDON INJURIES

Tendon injuries are uncommon in cattle. Infection of a tendon sheath occurs occasionally and has a guarded prognosis despite antibiotic therapy. Lavage of tendon sheaths is rarely undertaken in cattle practice.

Flexor tendon weakness is occasionally encountered in young beef calves (446), but the condition improves over several days.

CONTRACTED FLEXOR TENDONS

DEFINITION/OVERVIEW

Contraction of deep and superficial flexor tendons may affect both forelimbs, causing overflexion of the fetlock joints.

AETIOLOGY

The condition occurs sporadically, but is generally associated with absolute fetal oversize.

CLINICAL PRESENTATION

Overflexion of the fetlock joints of the forelimbs occurs such that only the toes touch the ground in mild cases or weight is borne on the dorsal surface of the fetlock joints in severe cases.

DIFFERENTIAL DIAGNOSIS

Radial nerve paralysis; trauma to the brachial plexus.

DIAGNOSIS

Forced flexion can correct alignment of the distal forelimb, except for severe cases.

MANAGEMENT

Cases resolve within days where the toe touches the ground. More severely affected cases require well-padded splinting of the fetlock joint in forced extension, with the toe exposed to contact the ground. Desmotomy of the superficial flexor tendon in the mid-metacarpal region with splinting can be carried out in the most severely affected calves.

There are no specific control measures.

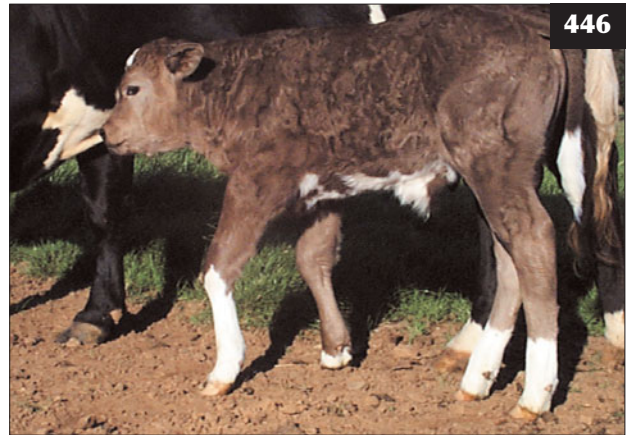OSTEOCHONDROSIS AND OSTEOCHONDROITIS DISSECANS (OCD)

DEFINITION/OVERVIEW

Osteochondrosis and osteochondritis dissecans (OCD) are seen most commonly in rapidly growing bulls between one and two years old, typically affecting either the shoulder, elbow, stifle or hock joints.

AETIOLOGY

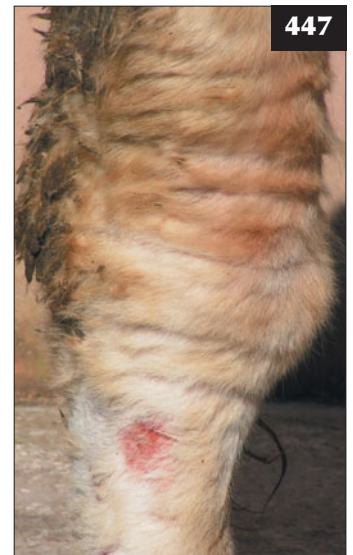Osteochondrosis is caused by abnormal differentiation of cells in growing cartilage and can progress to OCD, with impaired vascularization of articular cartilage leading to necrosis and fragmentation of cartilage.



446

446 Flexor tendon weakness, as shown in this calf, is occasionally encountered in young beef calves.

447 Osteochondrosis results in considerable effusion of the joint. This is causing distension of the hock joint and mild lameness in this young Charolais bull.



447

CLINICAL PRESENTATION

There is insidious onset mild lameness with considerable joint effusion (447) that may progress to secondary osteoarthritis. It should be noted that some degree of joint effusion of the hock joint is very common in many beef bulls and may be mild osteochondrosis that never progresses to OCD and thus causes little or no lameness.

DIFFERENTIAL DIAGNOSIS

Traumatic injury, although thickening of the joint capsule develops more rapidly in such cases.

DIAGNOSIS

Diagnosis is based on the presence of considerable joint effusion, readily identified ultrasonographically (390), in association with chronic mild lameness. Radiography may

confirm the presence of calcified flaps free within the joint ('joint mice'). Diagnosis is confirmed at necropsy in bulls that remain so lame as to prevent natural service (448).

MANAGEMENT

Treatment is by resting affected animals, but the lameness returns when bulls are used again for natural service.

Prevention is by breeders placing less emphasis on achieving maximum growth rate to sale in beef bulls. Breeding should be limited until the bull is fully mature at around two years old.

HIP DYSPLASIA

DEFINITION/OVERVIEW

Hip dysplasia is an uncommon condition seen in rapidly growing bulls less than one year old.

AETIOLOGY

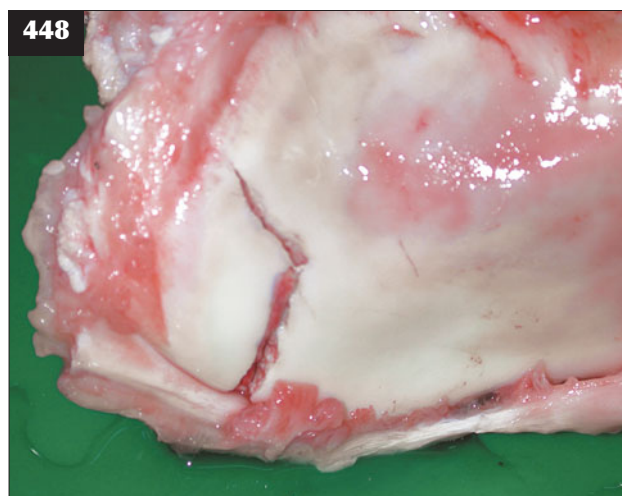
The condition is associated with excessive growth rate, with perhaps a hereditary component.

CLINICAL PRESENTATION

There is moderate lameness affecting both hindlimbs, progressing to long periods in sternal recumbency with muscle atrophy and poor weight gain. There is subluxation of the hip joint(s), with dorsal displacement of the femoral head in relation to the acetabulum. A distinct 'clunk' is felt when the hindquarters are pushed laterally, allowing the femoral head to return into the acetabulum when not bearing weight.

DIFFERENTIAL DIAGNOSIS

Dislocated hip; fracture through the proximal femoral growth plate.



448 Diagnosis of osteochondritis dissecans is confirmed at necropsy.

DIAGNOSIS

Diagnosis is confirmed by radiography.

MANAGEMENT

There is no treatment and affected cattle should be culled for welfare reasons. Breeders should place less emphasis on maximizing growth rate to sale in bulls.

DEGENERATIVE OSTEOARTHRITIS (DEGENERATIVE JOINT DISEASE)

DEFINITION/OVERVIEW

Degenerative osteoarthritis/degenerative joint disease (DJD) is the result of repeated joint trauma, most commonly involving the hip and stifle joints.

AETIOLOGY

Repeated joint trauma causes joint instability with proliferation of fibrous tissue within the joint capsule, degeneration and loss of articular cartilage, exposure and eburnation of subchondral bone and peripheral osteophyte formation.

CLINICAL PRESENTATION

There is moderate lameness with extensive muscle wastage over the affected limb (almost always a hindlimb). Swelling of the stifle and hock joints is readily palpable. Crepitus can sometimes be heard or felt over the hip during sideways movement of the hindquarters, but this can prove difficult to differentiate from increased movement within the hip joint simply as a consequence of muscle wastage. Crepitus may be detected on rectal examination.

DIFFERENTIAL DIAGNOSIS

Joint sepsis causes acute severe lameness, which is rare in adults unless there is a penetration wound; cellulitis.

DIAGNOSIS

Careful palpation of the joint is required. Hip lameness caused by DJD may be difficult to prove conclusively and is based on lameness affecting that hindlimb with absence of a significant foot or joint lesion distal to, and including, the stifle joint. Detailed radiographic and ultrasonographic examinations are rarely employed because after several months' moderate lameness and severe muscle wastage the cow must be culled irrespective of further findings.

MANAGEMENT

Analgesics may afford some temporary reduction in lameness, but affected cattle should be culled for welfare reasons.

There are no specific control measures. Underfoot conditions that could lead to slips and falls should be reviewed.

SPASTIC PARESIS**DEFINITION/OVERVIEW**

Spastic paresis is a progressive condition affecting one or both hindlimbs in growing cattle.

AETIOLOGY

The cause is not known, but an hereditary component is likely. The condition is more common in the Belgian Blue breed.

CLINICAL PRESENTATION

There is an insidious onset affecting 3–6-month-old calves, with contraction of the gastrocnemius muscle causing gross overextension of the hock such that the affected limb is held caudally 15–20 cm off the ground (449). There is pronounced circumduction of the limb as the calf struggles to walk.

DIFFERENTIAL DIAGNOSIS

Dislocated hip; dorsal patellar luxation is rare in cattle.

DIAGNOSIS

Diagnosis is based on clinical signs.

MANAGEMENT

Many calves are euthanased for welfare reasons following clinical examination because of the prohibitive cost of surgery and only a 75% success rate in early cases; calves showing signs for several months, or affecting both hindlimbs, have a poor outcome. Tenotomy of the gastrocnemius muscle is rarely undertaken because of frequent recurrence. Partial or total tibial neurectomy is

performed under xylazine sedation and extradural block (see Chapter 18, Anaesthesia, pp. 277 and 278) with the affected limb uppermost. Blunt dissection between the two heads of the biceps femoris muscle in the lateral thigh reveals the tibial and peroneal nerves, which are isolated and stimulated with forceps. Stimulation of the tibial nerve causes flexion of the digits and fetlock; once identified, a 5 cm portion of nerve is removed.

There are no specific control measures because the condition occurs sporadically even in crossbred cattle.

SPASTIC SYNDROME (BARN CRAMPS, CRAMPY SYNDROME)**DEFINITION/OVERVIEW**

Spastic syndrome is a rare condition affecting mature bulls.

AETIOLOGY

The aetiology is unknown, but an hereditary component is likely.

CLINICAL PRESENTATION

There is an insidious onset from 3–4 years old, with overextension of the hock and stifle joints caused by spasmodic contraction of hindlimb muscles and occasionally those of the forelimbs. The animal adopts a 'saw horse' appearance with the hindlimbs extended caudally (450).

DIFFERENTIAL DIAGNOSIS

Bilateral stifle OCD.



449 Spastic paresis affecting a calf. Note the contraction of the gastrocnemius muscle, which is causing gross overextension of the left hock such that the affected limb is held caudally 15–20 cm off the ground.



450 This bull with barn cramps is adopting a 'saw horse' appearance with the hindlimbs extended caudally.

DIAGNOSIS

Diagnosis is based on clinical findings and exclusion of other possible causes.

MANAGEMENT

There is no treatment and affected cattle should be culled. The progeny of affected bulls should not be used for breeding purposes.

CARPAL BURSITIS (HYGROMA)**DEFINITION/OVERVIEW**

Carpal bursitis is an uncommon condition that may arise following repeated trauma from poorly designed cubicles or prolonged recumbency after dystocia or metabolic disease.

AETIOLOGY

The condition is caused by fluid distension of the precarpal bursa due to repeated trauma.

CLINICAL PRESENTATION

There is obvious swelling on the dorsal aspect of the carpus without pain or associated lameness.

DIFFERENTIAL DIAGNOSIS

Joint infection, but this leads to marked lameness.

DIAGNOSIS

Diagnosis is based on clinical examination, noting the absence of any lameness.

MANAGEMENT

No treatment is necessary. Corticosteroid injection into the bursa is rarely successful. Surgical drainage leads to rapid recurrence.

Prevention is by attention to cubicle design and maintenance.

HOCK BURSITIS/CELLULITIS**DEFINITION/OVERVIEW**

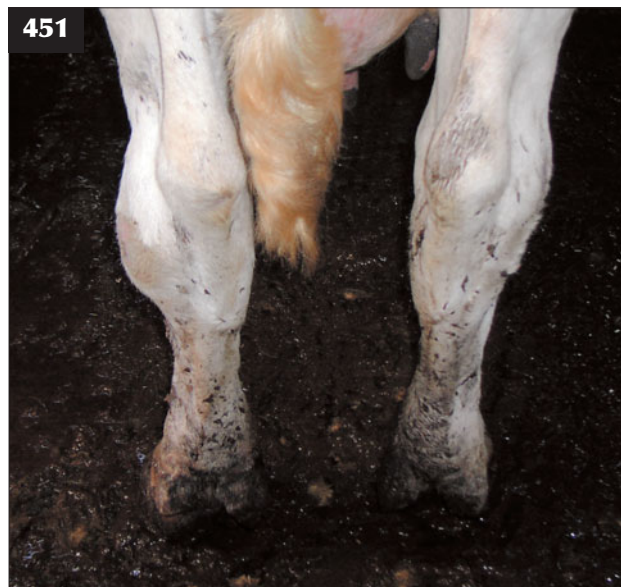Subcutaneous swellings are common on the lateral aspect of the hock joint in dairy cattle housed in poorly maintained cubicles. The prevalence of hock swellings in dairy cattle is used as an indicator of herd welfare standards in some health schemes.

AETIOLOGY

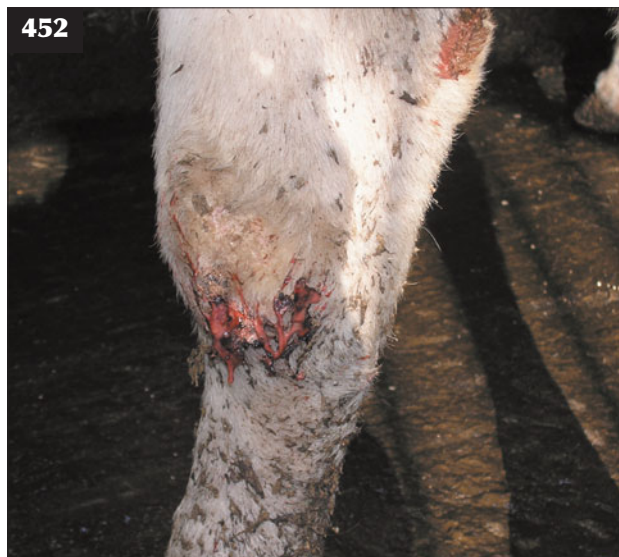Poor cubicle design coupled with insufficient or inappropriate bedding material leads to trauma when rising.

CLINICAL PRESENTATION

There is considerable fibrous subcutaneous swelling and loss of hair on the lateral aspect of the hock (451). Affected animals are not lame unless penetration of the skin has resulted in localized cellulitis (452).



451 Hock bursitis/cellulitis. Fibrous subcutaneous swelling on the lateral aspect of the hock joints of a dairy cow housed in a poorly maintained cubicle.



452 In this animal, infection of hock bursitis has led to cellulitis and lameness.

DIFFERENTIAL DIAGNOSIS

Septic arthritis; DJD.

DIAGNOSIS

Lack of joint effusion and lameness excludes other possible causes.

MANAGEMENT

The chronic fibrous tissue reaction will not resolve with treatment. Penetration and development of cellulitis is best treated with procaine penicillin or cephalosporin, the latter having no milk withhold restriction in many countries. Lancing deep-seated abscesses should be carefully considered because this often results in considerable haemorrhage from vessels in the fibrous capsular wall. Furthermore, the incision site to achieve drainage quickly seals over.

Hock swellings are prevented by cubicle design and maintenance and the amount and type of bedding material.

VITAMIN D DEFICIENCY/NUTRITIONAL OSTEOMALACIA (RICKETS)**DEFINITION/OVERVIEW**

Lack of appropriate mineralization of the diet of rapidly growing young stock can eventually lead to a high prevalence of long bone fractures, causing serious welfare and economic concerns. Problems with rickets have arisen during conversion to organic farming systems.

AETIOLOGY

Lack of mineralization of a cereal-based ration, along with vitamin D deficiency, can lead to gradual osteomalacia of growing bones. Normally this occurs due to inadequate calcium supplementation, with excess dietary phosphorus.

CLINICAL PRESENTATION

Spontaneous long bone fractures, particularly of the humerus and femur and involving several animals in the group, occur after prolonged feeding of a cereal-based ration without appropriate mineralization. Fractures involving the cervical vertebrae lead to recumbency, with evidence of cervical pain. Less severely affected calves show widening of the metaphyses, particularly of the third metacarpal and third metatarsal bones (453), causing moderate lameness.

DIFFERENTIAL DIAGNOSIS

Spontaneous fracture of long bones is uncommon in growing calves; recumbency can be caused by white muscle disease.

DIAGNOSIS

Diagnosis is based on a cluster of spontaneous long bone fractures and review of the diet, with detailed investigation of its mineral supplementation including vitamin expiry

dates. Radiography reveals poor mineralization and flaring of the distal metaphyses.

MANAGEMENT

Treatment involves immediate correction of the mineral content of the ration with appropriate vitamin D supplementation. Correct vitamin and mineral supplementation is essential and care must be exercised during conversion to organic farming systems.

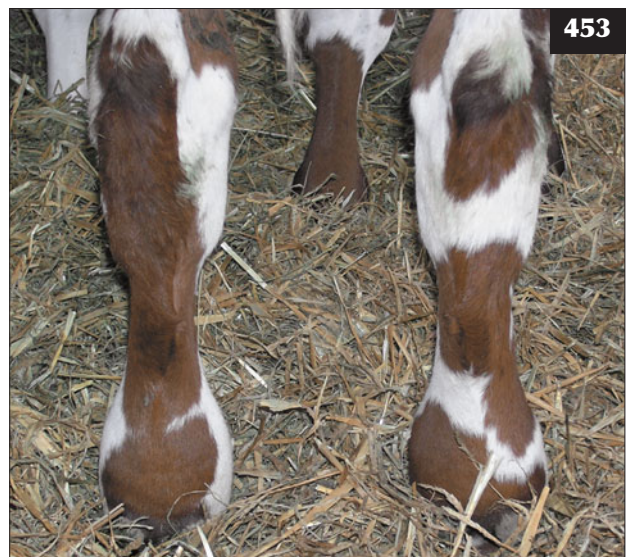
Calves with long bone fractures must be euthanased immediately. The remaining animals must be closely monitored for lameness.

CONGENITAL JOINT LAXITY AND DWARFISM**DEFINITION/OVERVIEW**

Congenital joint laxity and dwarfism (CJLD) is a congenital (non-inherited) skeletal anomaly reported in beef herds worldwide, with clusters of calves born with severe shortening of long bones, tendon laxity and occasionally brachygnathia.

AETIOLOGY

The aetiology is unknown, although some authors have suggested manganese deficiency as a possible cause. The problem is associated almost exclusively with spring calving beef herds where cows are fed a silage-based diet without straw or cereal supplementation during the winter months. Damage to the developing fetus probably occurs



453 Metaphyseal changes are obvious in the third metacarpal and third metatarsal bones of this animal with nutritional osteomalacia.

between three and six months of gestation. An unknown dietary teratogenic factor may be involved.

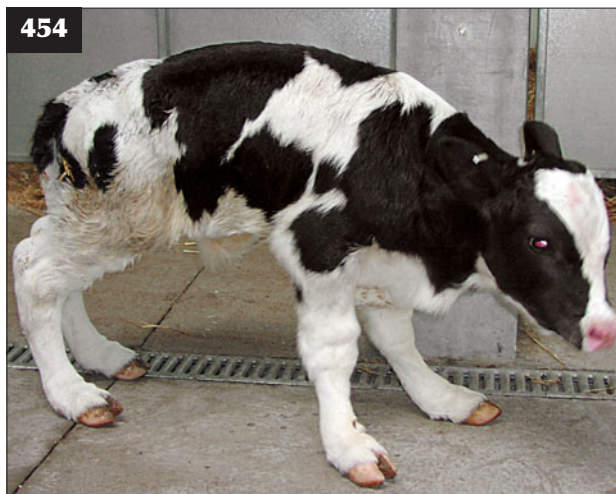CLINICAL PRESENTATION

Calves are born with disproportionate dwarfism, shortening of the diaphyses, misshapen epiphyses and variable joint laxity (454). Other skeletal abnormalities have also been reported.

MANAGEMENT

There is no treatment and although joints stabilize and calves may walk normally, they remain chronically stunted and have no value for beef production.

The condition can usually be prevented by supplementing the silage-based diet with some hay/straw and concentrates during the mid-trimester.



454 Congenital joint laxity and dwarfism in a spring-born calf.

Chapter 8

Urinary tract diseases

UROLITHIASIS

DEFINITION/OVERVIEW

Partial or complete urethral obstruction by calculi is uncommon in cattle. It is most commonly seen in growing/adult males fed intensive rations. Obstruction is reported to be much more common in castrates, but is also seen in entire males.

AETIOLOGY

Urolithiasis is caused by partial or complete urethral obstruction with calculi, typically struvite, in cattle fed high cereal rations.

CLINICAL PRESENTATION

There is a vague history of inappetence, restlessness and frequent tail swishing (455). Urine drips from the prepuce in cattle with partial obstruction rather than in a steady stream lasting 20–30 seconds. The presence of calculi on the preputial hairs is a common finding in clinically normal cattle and is not pathognomonic for urolithiasis (456).

In some cases the first presenting clinical feature may be urethral rupture and the accumulation of large quantities of urine along the ventral midline (457) between the scrotum and the prepuce ('water belly').



455 This bull with an urethral obstruction presented with a vague history of inappetence, restlessness and weight loss.

456 Uroliths on the preputial hairs are seen in some normal cattle.

457 An



accumulation of large quantities of urine along the ventral midline between the scrotum and the prepuce is evident in this bull with urolithiasis.

DIFFERENTIAL DIAGNOSIS

Urethral rupture (water belly); penile haematoma (458).

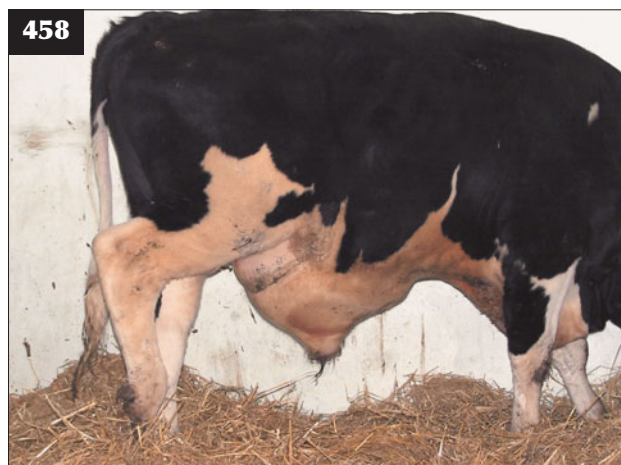DIAGNOSIS

Urolithiasis is more common in yearling cattle and adults. Ultrasound examination reveals pulsation in the urethra and marked bladder enlargement extending well over the pelvic brim (459). Necropsy reveals urethral obstruction, often with haemorrhage in adjacent tissue, and thickening of the bladder wall. Large numbers of calculi (460) are exceptional.

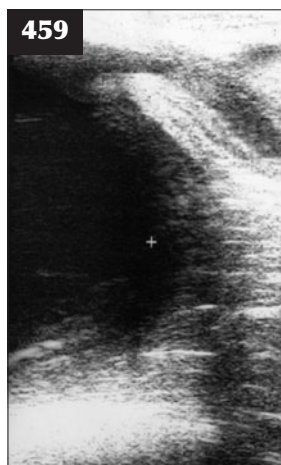MANAGEMENT

Surgery in the standing patient under low extradural block is more successful in cattle than in sheep because hydronephrosis does not develop so quickly. Subischial

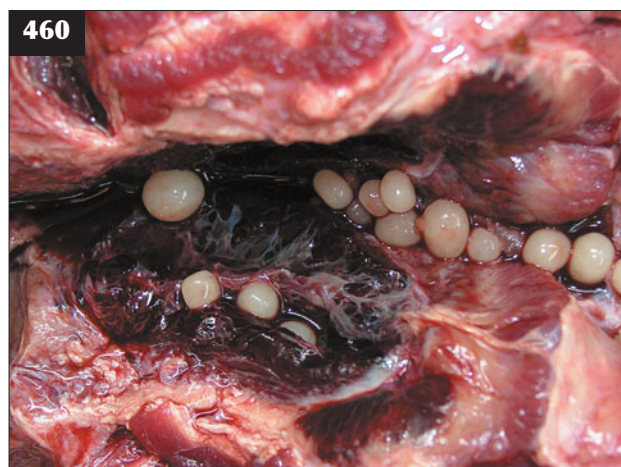urethrostomy is a salvage procedure in cattle near slaughter weight. This surgery enables return of normal kidney function, with correction of the uraemia permitting slaughter. There is considerable haemorrhage from the transected penis in the first few days after surgery. Ascending infection of the kidneys from cystitis associated with chronic urolithiasis may be treated with parenteral penicillin. Kidney function can be monitored by measuring blood urea and creatinine concentrations. Cattle with water belly for several days may present with skin necrosis (461). Surgery must be carefully considered because affected skin and underlying tissue will slough (462) and heal slowly. It is recommended that the ventral abdominal skin is incised in multiple sites in order to allow urine to drain out of the subcutaneous tissues and thereby rapidly reduce uremia and reduce the likelihood of tissue sloughing.



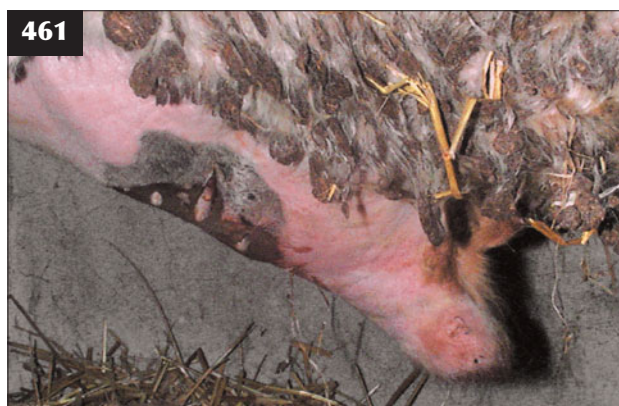458 Penile haematoma, as in this animal, is the important differential for water belly.



459 Ultrasound examination of this animal with urolithiasis reveals marked bladder enlargement extending well over the pelvic brim, with urine in the distended urethra.



460 Necropsy of this animal with urolithiasis revealed urethral obstruction due to an exceptionally large number of calculi in the urethra.



461 This bull, which had water belly for several days, presented with skin necrosis.

MANAGEMENT

The mineral content of the ration should be reviewed and adequate forage and fresh clean water provided.

PYELONEPHRITIS**DEFINITION/OVERVIEW**

Pyelonephritis occurs sporadically in mature cows resulting from ascending infection from the lower urinary tract.

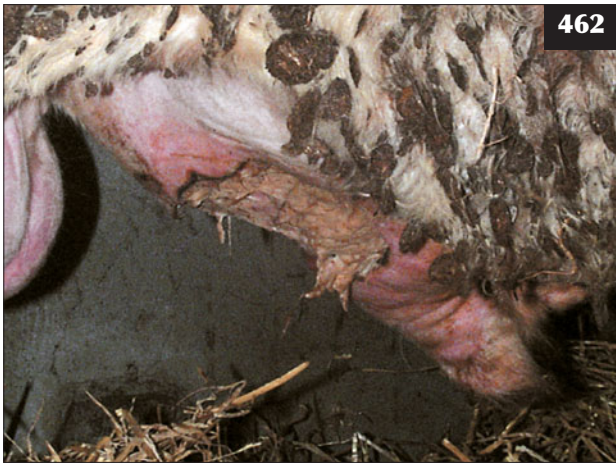AETIOLOGY

The common causes of pyelonephritis are *Corynebacterium renale* and, occasionally, *Escherichia coli*, both of which are normal inhabitants of the lower reproductive tract. Poor perineal conformation, pneumovagina, puerperal metritis and trauma to the lower reproductive tract at calving may predispose to ascending infection.

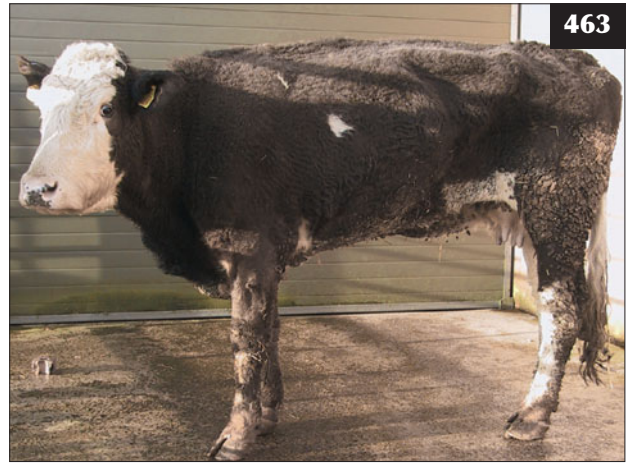CLINICAL PRESENTATION

Pyelonephritis is more common in older beef cattle (463) 2–3 months following calving. A small cluster of cases may appear in a herd, then the problem disappears.

There is a history of weight loss, poor appetite, mild fever (39.0–39.5°C) and poor milk yield over several weeks to months, with failure of the (beef) cow's calf to thrive. The cow makes frequent attempts to urinate and the flow rate is slower than normal, with frequent tail swishing and an arched back maintained for much longer than normal after urination (464). Flecks of blood and pus are passed at the end of voided urine (465), which foams due to an increased protein concentration. Gross staining with pus around the tail and perineum is more suggestive of chronic endometritis (whites). Abdominal pain, as reported in textbooks, presumably due to temporary obstruction of a



462 The affected skin and underlying tissue have sloughed in this bull.

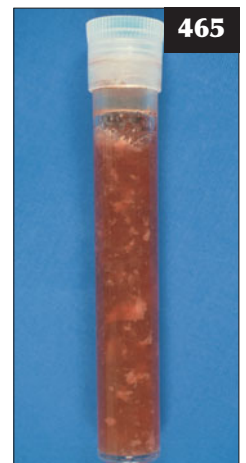


463 Pyelonephritis in an older beef cow that presented with a poor appetite and chronic weight loss.



464 Pyelonephritis. There is frequent tail swishing and an arched back is maintained for much longer than normal after urination.

465 Blood and pus that was passed in the urine of a case of advanced pyelonephritis.



ureter by debris passed from the kidney, is not commonly observed. There are grossly thickened ureters (pencil diameter) palpable on rectal examination and the bladder wall is thickened. It is reported that the left kidney may be enlarged and painful, but this is rarely detected on manual rectal examination.

DIFFERENTIAL DIAGNOSIS

Perivaginal abscess; bladder tumour in aged beef cows; chronic endometritis.

DIAGNOSIS

Use of a transrectal linear ultrasound probe reveals a distended bladder with thickened wall, but images of the left kidney are not so helpful. Similarly, transabdominal ultrasound examination via the right sublumbar fossa rarely provides convincing evidence of renal pathology. Dilation of renal calyces, echogenic flocculent material within the renal pelvis and renal enlargement are suggestive of pyelonephritis.

Laboratory examination (dipstick) reveals evidence of blood and protein in a mid-stream urine sample and proves a very useful screen for weight loss/poor condition in adult cattle. Gram staining of a urine sample typically reveals gram-positive rods where culture yields *C. renale*. The leucogram may indicate chronic inflammatory changes with elevated fibrinogen and serum globulin (>55 g/l) and lowered serum albumin (<25 g/l), but such changes are typical of most bacterial infections and are not specific for pyelonephritis. Blood urea nitrogen and serum creatinine concentrations are only significantly elevated during the agonal stages of disease.

Necropsy reveals cystitis with thickening of the bladder wall (466), the presence of purulent debris within the renal pelvis (467, 468) and abscessation throughout the cortices (469).

MANAGEMENT

The treatment response is poor if the cow is already in low body condition with advanced disease and considerable kidney pathology. Treatment for up to six weeks with procaine penicillin can be given to control infection and, possibly, allow salvage after observing meat withdrawal times. More usually, cows are emaciated at presentation and are euthanased for welfare reasons.

The condition has a sporadic occurrence, but control measures should include isolation of affected cattle, attention to environmental hygiene, regular disinfection of obstetrical equipment and avoidance of dystocia.

AMYLOIDOSIS

Renal amyloidosis is rare despite featuring in all cattle textbooks. It occurs in older cattle, causing chronic weight loss, profuse diarrhoea and peripheral oedema resulting

from a protein-losing nephropathy. Grossly enlarged kidneys may be palpable on rectal examination. There may be evidence of a chronic suppurative disease process leading to amyloidosis.

BACILLARY HAEMOGLOBINURIA (REDWATER)

DEFINITION/OVERVIEW

Toxins of *Clostridium haemolyticum* (*Cl. novyi* type D) cause sudden death within 12–24 hours in cattle and sheep. Focal anaerobic areas in the liver caused by migrating liver flukes allow spores to germinate, with release of toxin. Haemoglobinuria is rarely witnessed. If seen alive, animals are isolated, have an arched back, are febrile (40–41°C) and tachypnoeic and have rectal bleeding and bloody faeces. There is no effective treatment. Control in at-risk areas is effected by vaccination and routine flukicide treatments.

BABESIOSIS (REDWATER FEVER)

DEFINITION/OVERVIEW

Babesia bigemina and *Babesia bovis* are transmitted by ticks, so disease is restricted to geographical areas with a seasonal occurrence.

AETIOLOGY

Babesiosis is caused by *B. bigemina* and *B. bovis*, both of which are tick transmitted.

CLINICAL PRESENTATION

Clinical signs include fever (40–42°C), depression, anorexia, pronounced tachycardia, tachypnoea, anaemia/icterus and haemoglobinuria (470) manifest 1–3 weeks after infection. Death follows rapidly in untreated cattle.

DIFFERENTIAL DIAGNOSIS

Bacillary haemoglobinuria. On hill pasture, acute bracken poisoning may present with similar clinical signs.

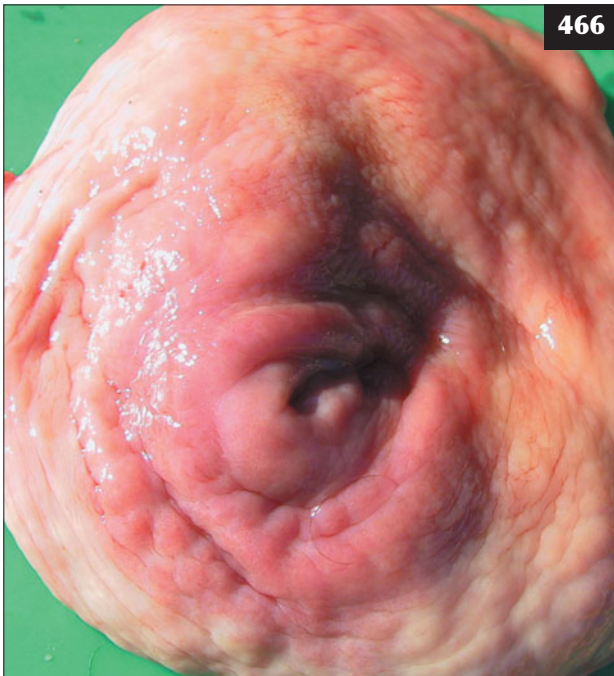DIAGNOSIS

Diagnosis is based on clinical signs, often with a history of disease on the farm and animals grazing tick-infested hill ground.

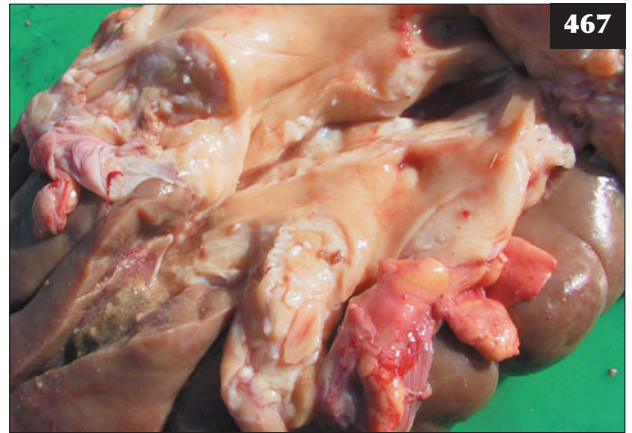MANAGEMENT

Specific treatment is with imidocarb or amicarbalide. Transfusion of 6–10 litres of whole blood should be given for a 600 kg cow.

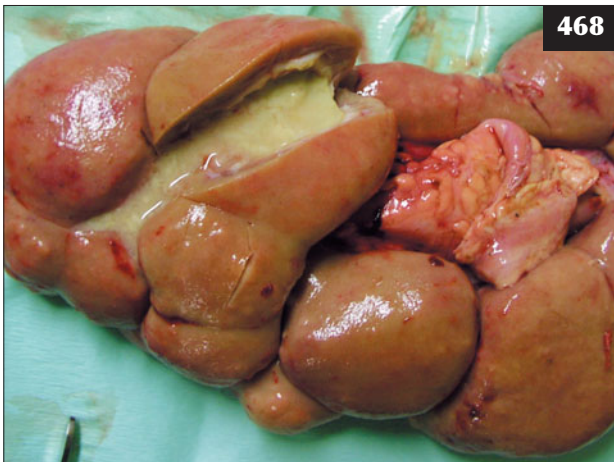Prevention is by avoiding tick-infested pastures at specific times of year.



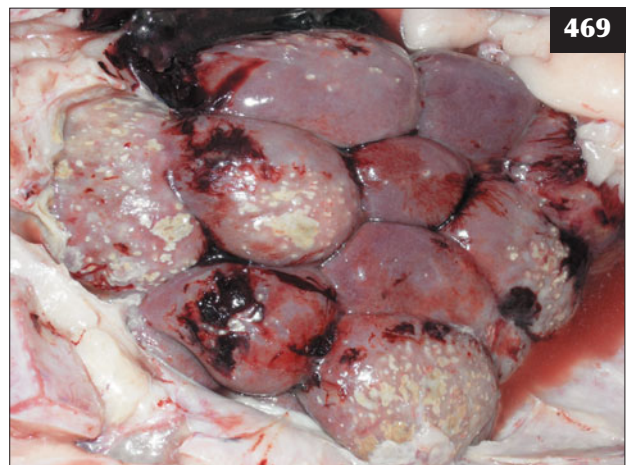
466



467



468



469

466–469 Pyelonephritis. (**466**) Necropsy in this animal revealed cystitis, with gross thickening of the bladder wall. (**467**) In this necropsy specimen, secondary pyelonephritis has developed from an ascending infection from the bladder. (**468, 469**) In this animal, necropsy revealed purulent debris within the renal pelvis (**468**) and abscessation throughout the renal cortices (**469**).

470 Haemoglobinuria in an animal with babesiosis.



470

ACUTE TUBULAR NECROSIS (TUBULAR NEPHROSIS)

DEFINITION/OVERVIEW

Acute tubular necrosis in cattle is uncommon, but it can result from a variety of toxic or haemodynamic insults.

AETIOLOGY

Various toxins, including oak (acorn) poisoning (see Chapter 17, Poisons, p. 272), oxalates and haemoglobin and myoglobin nephropathy may cause acute tubular necrosis.

CLINICAL PRESENTATION

Cattle with acute renal failure typically present with depression, inappetence, ileus, mild bloat and acute diarrhoea, with melaena in some cases (471).

DIFFERENTIAL DIAGNOSES

Infectious endotoxaemic conditions such as metritis, mastitis, peritonitis and salmonellosis should be considered.

DIAGNOSIS

Marked increases in serum urea nitrogen and creatinine concentrations occur during the early stages of acute tubular necrosis. Urine specific gravity is <1.020 and there is proteinuria, haematuria and granular casts.

MANAGEMENT

The toxic source should be removed where identified. A rumenotomy could be attempted during the early stages, but is unlikely to be successful. Symptomatic treatment includes oral activated charcoal. Administration of large volumes of intravenous isotonic sodium chloride presents practical problems and is cost-prohibitive in most situations.

POSTPARTURIENT HAEMOGLOBINURIA


(See also Chapter 14, Metabolic diseases, Hypophosphataemia, p. 252.)

Postparturient haemoglobinuria is a rare condition manifest as intravascular haemolysis, haemoglobinuria, anaemia and jaundice in high-producing multiparous cows. The condition is thought to be related to the hypophosphataemia found in deficient geographical areas.

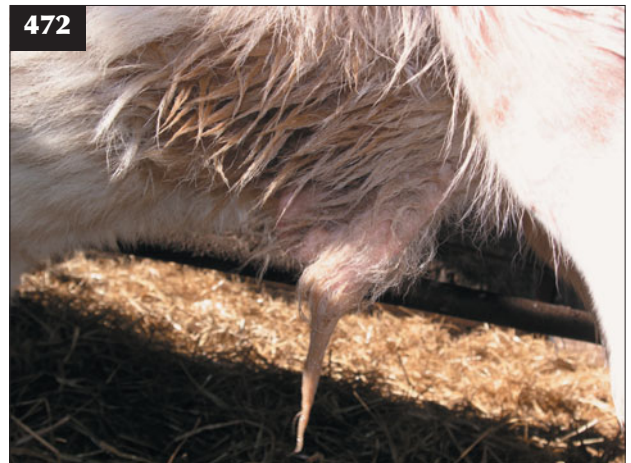
PATENT URACHUS

DEFINITION/OVERVIEW

Patent urachus is a tubular connection between the bladder and umbilicus that persists after birth.



471 This cow with acute renal failure caused by acorn poisoning presented with depression, inappetence, mild bloat and acute diarrhoea.



472 Patent urachus causing chronic urine scalding around the umbilicus of a one-month-old male calf.

CLINICAL PRESENTATION

Small quantities of urine are constantly dribbled from the umbilicus, leading to urine scalding of the umbilical region (472). The condition may often be overlooked and resolve with time. Clinical signs are usually not detected unless the urachus/bladder become infected.

Chapter 9

Skin diseases

PARASITIC SKIN DISEASES

LICE (PEDICULOSIS)

DEFINITION/OVERVIEW

Infestations with lice are found in all cattle-producing countries and can cause production losses due to reduced feeding time and damaged hides (473). Louse populations are highest in cattle kept indoors during the winter months and those in poor body condition, rather than the reverse situation where lice cause debility. Heavy louse infestations cause irritation, self-trauma and possibly anaemia and therefore warrant treatment for welfare reasons. The cause of any underlying debilitating condition/ disease must be investigated and corrected. Louse infestations do not present a significant financial concern.

AETIOLOGY

Five species of louse infest cattle: the biting or chewing louse *Damalinia (Bovicola) bovis* and the sucking lice *Haematopinus eurysternus*, *Haematopinus quadripertusus* (subtropical regions), *Linognathus vituli* and *Solenopotes*

capillatus. Infestation may cause disrupted feeding patterns, self-inflicted trauma and damaged hides. Spread occurs by direct contact, with increases in population size during housing and cooler weather. The life cycle (egg, three nymph stages and adult) takes three weeks and is spent on the host.

CLINICAL PRESENTATION

Almost all housed cattle during the winter months have a louse infestation, which is usually asymptomatic, but heavy infestations cause irritation leading to rubbing against feed barriers and similar structures, causing hair losses, most often over the neck and shoulders (474), and disrupted feeding patterns.

DIFFERENTIAL DIAGNOSIS

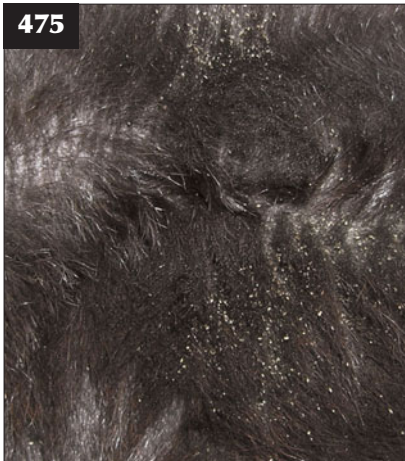Sarcoptic mange; psoroptic mange.



473 Louse infestation in this animal has caused production loss due to a damaged hide.



474 Pediculosis. Heavy louse infestation in this animal has caused hair loss over the neck and shoulders.



475 Pediculosis. Close examination of the skin of this animal reveals louse eggs adhered to hair shafts.

DIAGNOSIS

Careful inspection of the skin using a magnifying glass will identify adult louse populations and eggs adherent to hairs (475). Further examination under a microscope at $\times 100$ will differentiate the louse species.

MANAGEMENT

Treatment is with a pour-on synthetic pyrethroid or organophosphate preparation. Injectable group III anthelmintics (ivermectin, doramectin and eprinomectin) will remove all sucking lice and >98% of biting lice, and all lice when used as pour-on preparations.

The pour-on group III anthelmintics used to control parasitic gastroenteritis in cattle at housing will also remove all lice. All cattle in direct contact must be treated.

SARCOPTIC MANGE

DEFINITION/OVERVIEW

Sarcoptic mange occurs worldwide.

AETIOLOGY

Sarcoptic mange is caused by infestation with *Sarcoptes scabiei* (*bovis*).

CLINICAL PRESENTATION

Infestation causes severe pruritus with serum exudation and gross thickening of the skin, particularly over the neck. The intense pruritus can lead to disrupted feeding patterns and weight loss, progressing to debility in neglected cattle.

DIFFERENTIAL DIAGNOSIS

Pediculosis.

DIAGNOSIS

Diagnosis is by skin scrapings and microscopic demonstration of mites.

MANAGEMENT

Potential treatments include a pour-on synthetic

pyrethroid or organophosphate preparation and injectable or pour-on group III anthelmintics (ivermectin, doramectin and eprinomectin).

Biosecurity measures should prevent introduction of infested cattle.

PSOROPTIC MANGE

DEFINITION/OVERVIEW

Psoroptic mange occurs worldwide.

AETIOLOGY

Psoroptic mange is caused by infestation with *Psoroptes ovis* or *Psoroptes communis*.

CLINICAL PRESENTATION

Serum exudation and thickening of the skin, particularly over the neck and dorsal midline.

DIFFERENTIAL DIAGNOSIS

Pediculosis; sarcoptic mange; dermatophilosis.

DIAGNOSIS

Diagnosis is by skin scrapings and microscopic demonstration of mites.

MANAGEMENT

See sarcoptic mange (above).

CHORIOPTIC MANGE

DEFINITION/OVERVIEW

Chorioptic mange occurs worldwide.

AETIOLOGY

Chorioptic mange is caused by infestation with *Chorioptes bovis*.

CLINICAL PRESENTATION

Infestation with *C. bovis* causes serum exudation and thickening of the skin, characteristically at the base of the tail (476). Infestation may spread to the udder, scrotum and limbs. It is often observed coincidentally during pregnancy diagnosis.

DIFFERENTIAL DIAGNOSIS

Pediculosis; sarcoptic mange; dermatophilosis.

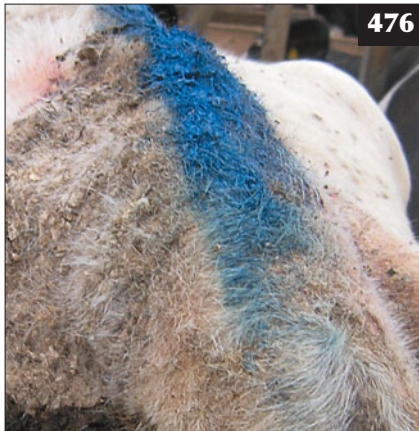DIAGNOSIS

Diagnosis is by superficial skin scrapings and microscopic demonstration of mites (477).

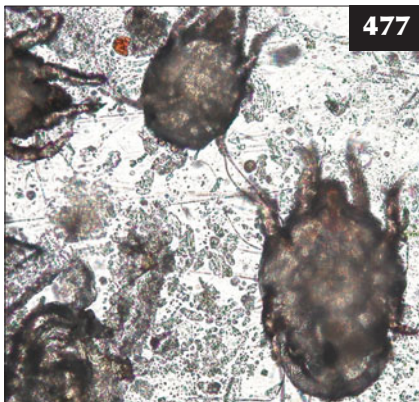
MANAGEMENT

Treatment is the same as for sarcoptic mange (see above), although treatment is rarely necessary and lesions resolve spontaneously when cattle are turned out to pasture in the spring. Eprinomectin pour-on preparations, which have no milk withdrawal times, can be used in lactating dairy cows.

476 Infestation with *C. bovis* has caused serum exudation and thickening of the skin at the base of the tail in this animal.



477 Chorioptic mites are easily found in superficial skin scrapings.



WARBLE FLIES (HYPODERMATOSIS)

DEFINITION/OVERVIEW

Hypodermatosis presents as damage to hides and is caused by the larval stages of *Hypoderma bovis* and *Hypoderma lineatum*. Warble flies have been successfully eradicated from many countries.

AETIOLOGY

After hatching from eggs deposited on the skin during summer months, larvae penetrate the skin and migrate to epidural fat (*H. bovis*) and the submucosa of the oesophagus before reaching the subdermal layer of the dorsum. Large holes are made in the skin during development to third-stage larvae in early spring. The larvae emerge, pupate and develop into adults, thus completing the life cycle.

CLINICAL PRESENTATION

Large 2–3 cm larvae present in the subcutis of the dorsum in early spring. Rarely are there significant oesophageal (bloat) or spinal cord (weakness/paralysis) lesions.

DIAGNOSIS

Diagnosis is based on demonstration of subcutaneous third larval stages. An ELISA test is available to detect

migrating larval stages. This has been used to monitor eradication schemes.

MANAGEMENT

Treatment is with topical organophosphorus treatments and group III anthelmintics administered in late autumn to avoid adverse reactions if larvae are killed during their overwintered sites in the oesophagus/spinal cord.

MANAGEMENT

Eradication by compulsory treatment programmes has proved successful in many countries.

TICKS

DEFINITION/OVERVIEW

Ticks are important parasites in many tropical regions, causing disease directly by actively sucking blood in very heavy infestations and indirectly by spreading disease. Ticks (*Ixodes ricinus*) are not important in the UK, apart from acting as a vector for the occasional case of redwater fever (*Babesia* spp.) and tick-borne fever (*Ehrlichia phagocytophila*).

AETIOLOGY

The life cycle involves egg, larva, nymph and adult stages. The important genera are *Amblyomma*, *Boophilus*, *Dermacentor*, *Haemaphysalis*, *Hyalomma*, *Ixodes* and *Rhipicephalus*.

CLINICAL PRESENTATION

Anaemia and debility occur in heavy infestations in tropical countries.

DIAGNOSIS

Diagnosis is by demonstration of ticks on the host.

MANAGEMENT

Topical application with either pyrethroid or organophosphate preparations is the standard treatment.

MIDGES

(See Chapter 16, Miscellaneous Infectious and Exotic Diseases, Bluetongue, p. 268.)

BACTERIAL/FUNGAL SKIN DISEASES

RINGWORM (DERMATOPHYTOSIS)

DEFINITION/OVERVIEW

Ringworm is common in young stock and is a potential zoonosis.

AETIOLOGY

Most outbreaks are caused by *Trichophyton verrucosum*, with *Trichophyton mentagrophytes* less common. Dermatophytes will survive for months in buildings and housed cattle often become infected after physical contact

with structures such as contaminated feed barriers and walls. Poorly nourished calves and immunosuppressed individuals (e.g. animals with persistent BVDV infection) are more susceptible to infection.

CLINICAL PRESENTATION

The greyish lesions are slightly-raised, well-circumscribed, extend up to 10 cm in diameter and may become confluent. They are more common on the head and neck (478), but may extend over much of the body. The lesions are usually non-pruritic.

DIFFERENTIAL DIAGNOSIS

Papillomatosis; skin lymphosarcoma (individual animals only).

DIAGNOSIS

Diagnosis is based on demonstration of ectothrix spores on microscopic examination of plucks of hair surrounding the lesions. Culture of *T. verrucosum* requires selective media.

MANAGEMENT

Although the disease is often described as self-limiting, resolution may take 4–9 months, during which time other in-contact animals become infected via contamination of the environment.

Topical natamycin and enilconazole are commonly used, but they may not be effective in all outbreaks and repeat applications are necessary. In-feed griseofulvin is more effective than natamycin, but it is not licensed for use in many countries. The disease is normally self-limiting and will resolve without treatment, but it can lead to temporary weight loss and hide damage in severe cases.

Vaccination of calves from two weeks old with a live attenuated strain of *T. verrucosum* is effective and can be used as the basis for ringworm eradication programmes.



478 Ringworm lesions in a young steer.

DERMATOPHILOSIS (BOVINE STREPTOTHRICOSIS, 'RAIN SCALD')

DEFINITION/OVERVIEW

Dermatophilosis rarely causes significant disease in cattle.

AETIOLOGY

The disease is caused by *Dermatophilus congolensis*. Transmission of infection requires wet conditions and close contact. Exceptionally prolonged wet weather during the summer months produces moist skin that allows penetration of the bacterium and establishment of infection.

CLINICAL PRESENTATION

In the UK, dermatophilosis is encountered along the dorsum, where it causes serum exudation and scab formation at the base of the hairs. The lesions rarely develop clinical significance. Tufted papules and pustules can coalesce to form 'paint brush' clumps of matted hair, which when pulled off leave shallow purulent eroded lesions.

DIFFERENTIAL DIAGNOSIS

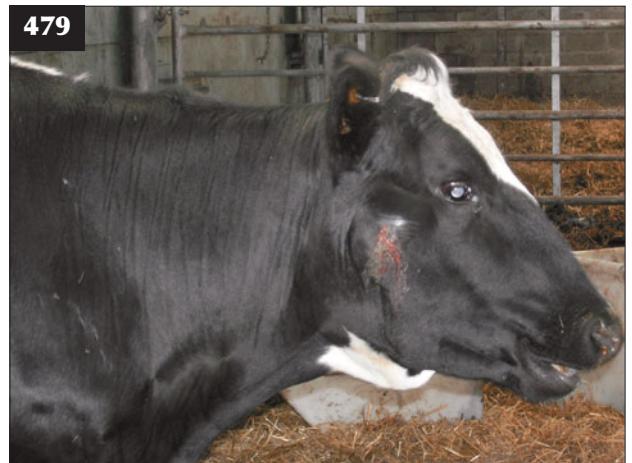Papillomatosis; skin lymphosarcoma (individual animals only).

DIAGNOSIS

The diagnosis of dermatophilosis is based on clinical examination and, if necessary, stained smears from the underside of scabs plucked from the hide that reveal coccoid bacteria.

MANAGEMENT

Procaine penicillin (i/m for 5 consecutive days) or long-acting oxytetracycline is effective, but it may take several weeks for the scabs to be shed from the growing hair coat.



479 A nodular pyogranulomatous skin lesion on the face of a cow with actinobacillosis.

ACTINOBACILLOSIS

Pyogranulomatous nodular skin lesions are an uncommon manifestation of infection with *Actinobacillus lignieresii*. Lesions can be seen on the face (479), neck, back or limbs and normally affect single cattle. (See Chapter 3, Digestive Tract and Abdomen, Actinobacillosis, p. 64 for further details and treatment of actinobacillosis.)

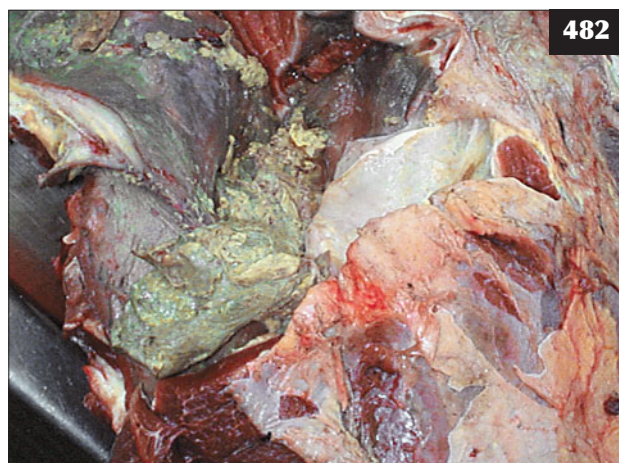
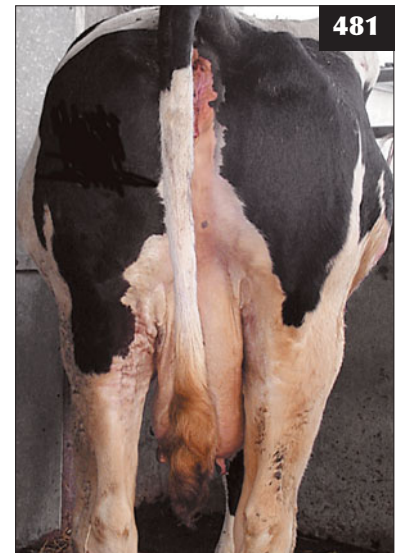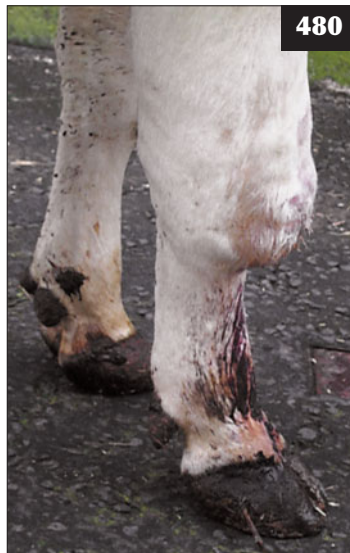MISCELLANEOUS SKIN DISEASES CELLULITIS AND SUBCUTANEOUS ABSCESES/HAEMATOMAS

DEFINITION/OVERVIEW

Cellulitis lesions developing into large abscesses tracking along fascial planes are not uncommon in cattle following puncture wounds of the skin. Haematomas occur sporadically due to trauma.

480 A cellulitis lesion tracking along fascial planes is shown in this animal.

481 The left-sided gluteal swelling in this cow may be due to the injection of irritant antibiotic formulations or infection from contaminated needles.



482 Necropsy specimen demonstrating that a cellulitis lesion can develop into a large abscess.

AETIOLOGY

Penetrating wounds introduce infection through the skin, causing cellulitis/abscesses. *Arcanobacterium pyogenes* is the most common isolate from such lesions. Attempts to rise after periods of recumbency caused by metabolic disease or temporary nerve damage can result in abrasions/cuts that can develop into abscesses (480). Failure to observe strict asepsis when administering parenteral injections, particularly of potentially irritant substances, can cause cellulitis (481, 482).

Haematomas are most commonly seen in housed cattle due to trauma from handling stocks/fixtures/cubicles (483), but they can also arise from fighting or bulling injuries. Occasionally, haematomas develop in young cattle due to thrombocytopenia associated with persistent BVDV infection.



483 Large haematoma over the right shoulder region of a yearling heifer.

CLINICAL PRESENTATION

The clinical signs depend on the site and extent of the lesion(s). Cellulitis lesions can result in severe lameness with painful swelling over the affected area (see Chapter 13, Clostridial diseases, Blackleg, p. 243). Cattle are pyrexia and anorexic and have a much reduced milk yield.

Large swellings caused by abscesses adjacent to or involving the limbs cause mechanical lameness, but in many cases the abscess does not result in illness.

DIFFERENTIAL DIAGNOSIS

Large subcutaneous swellings in cattle are normally caused by a haematoma (484–487) or by abscessation (488); however, herniation or urine leakage (ruptured urethra in males) can also cause ventral swellings.

DIAGNOSIS

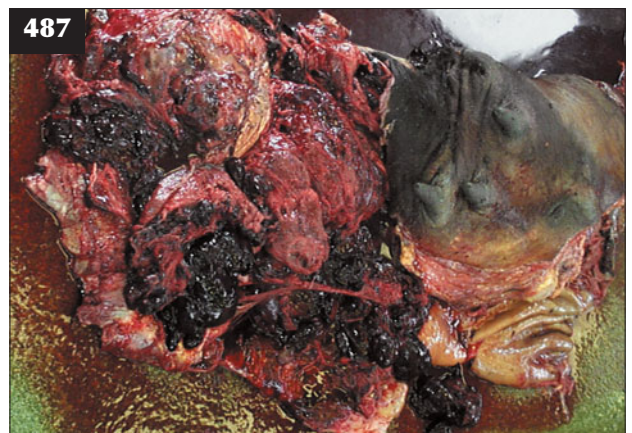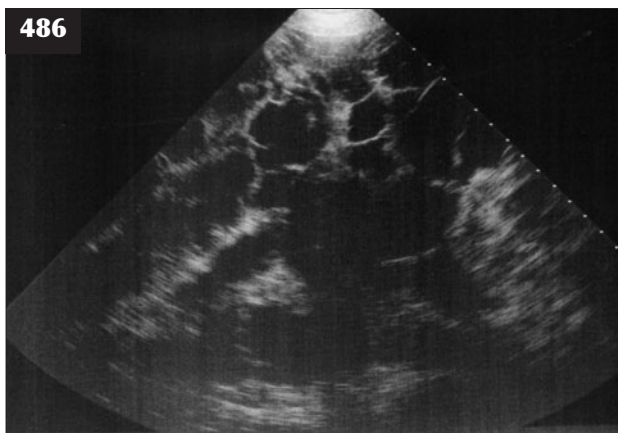
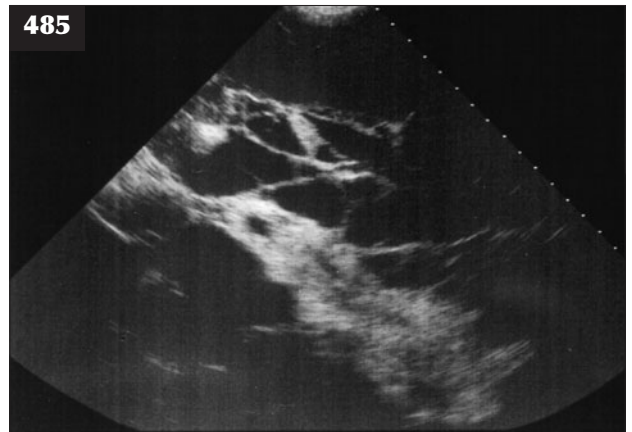
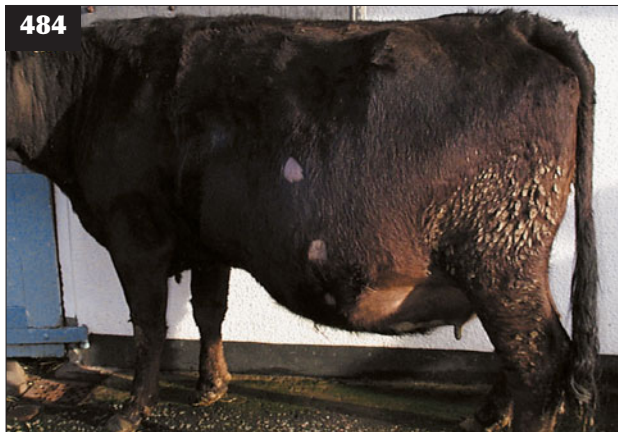Superficial swellings can be investigated ultrasonographically (485, 486). The organizing fibrinous matrix associated with

haematomas can be readily differentiated from the 'snowstorm' ultrasonographic appearance of an abscess. The extent of the haematoma and its associated organizing fibrinous matrix is confirmed at post-mortem examination (487). Needle aspiration of a haematoma risks introducing infection, so this procedure must be carried out aseptically.

MANAGEMENT

Cellulitis should be treated with broad-spectrum systemic antibiotics for 5–10 days (e.g. penicillin/streptomycin, potentiated amoxicillin, ceftiofur) and NSAIDs to reduce pain. Abscesses may need to be lanced, drained and repeatedly flushed with dilute povidone-iodine (489, 490). Haematomas should be left to resolve spontaneously over time.

Attention to management so that there are no protruding objects in the animal's environment will help prevent haematomas developing.



484–487 Haematoma. (484) This large flank haematoma can be differentiated from an abscess by ultrasound examination. (485) Ultrasonogram of the dorsal margin of the haematoma reveals an organizing fibrinous matrix with an anechoic background. (486) Ultrasonogram of the ventral margin of the haematoma. (Compare with 485.) (487) Necropsy reveals the extent of the flank haematoma and the organizing matrix imaged in 485.

PHOTOSENSITIZATION

DEFINITION/OVERVIEW

Primary photosensitization occurs sporadically in grazing cattle worldwide. The cause is often not determined.

AETIOLOGY

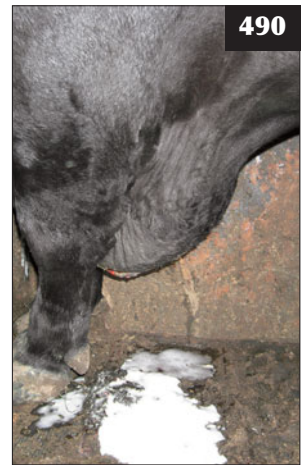
Photosensitization occurs either as a primary condition following ingestion of photodynamic agents in certain plants or chemicals or secondary to hepatotoxic damage resulting in retention of the photosensitizing agent phyloerythrin.

CLINICAL PRESENTATION

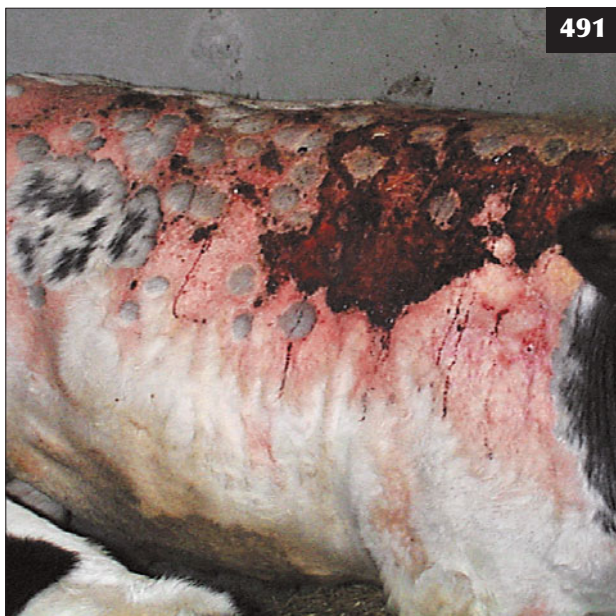Typical cases of photosensitization affect the muzzle and unpigmented skin (491). In dark-coloured cattle, lesions will be restricted to the muzzle, mucocutaneous junctions and teats/scrotum. More extensive skin lesions will be seen in white or light-coloured cattle. Initially, affected animals are dull and attempt to seek shade. The affected skin may ooze serum (491). During the later stages affected skin becomes dry and parchment-like (492) and sloughs off, leaving a shallow bed of granulation tissue that may be secondarily infected. In affected cows the teats may become



488 Large encapsulated popliteal abscess in a dairy cow.



489, 490 Abscess. (489) Large brisket swelling in a bull. (490) Surgical drainage and repeated flushing was required to resolve this situation.



491, 492 Photosensitization. (491) A typical case of photosensitization affecting unpigmented skin, which oozes serum. (492) During the later stages of photosensitization, the skin becomes dry and parchment-like and sloughs off.

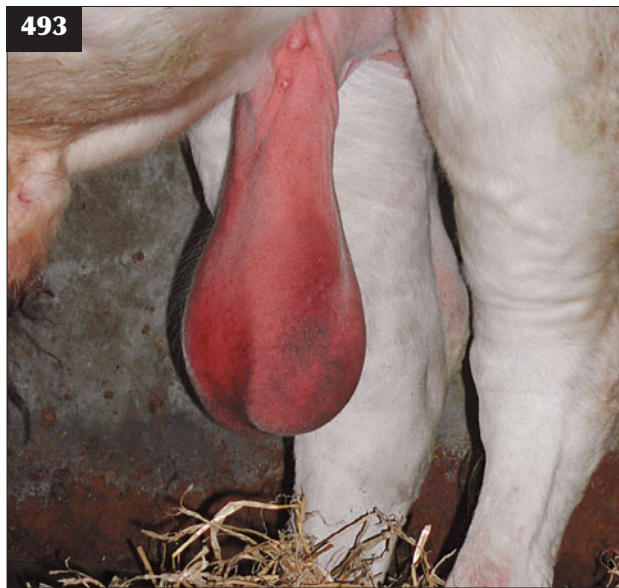swollen and painful and breeding bulls may become temporarily infertile due to scrotal skin swelling and oedema (493).

DIFFERENTIAL DIAGNOSIS

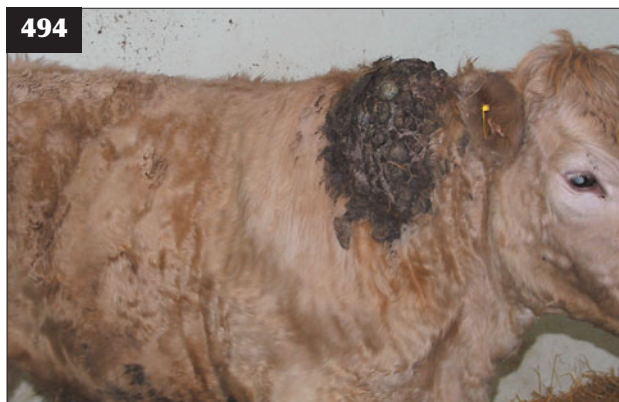Congenital porphyria.

DIAGNOSIS

Diagnosis is based on the clinical signs. In secondary photosensitization, enzyme concentrations indicating both acute (AST) and chronic hepatocellular damage (GGT) are elevated and other signs of hepatic disease may be present, such as jaundice.



493 Photosensitization in this Charolais bull has led to extensive scrotal skin swelling and oedema.



494 Wide-based papilloma in a yearling heifer.

MANAGEMENT

Affected animals must be removed from pasture and confined in dark buildings to prevent further ultraviolet light exposure. Corticosteroids are helpful during the early stages to reduce the associated oedema. Other symptomatic treatments include topical antibiotic powders and fly control preparations. Cases of secondary hepatogenous photosensitization may not resolve if liver disease is extensive.

PAPILLOMATOSIS (FIBROPAPILLOMAS, 'WARTS')

DEFINITION/OVERVIEW

Papillomatosis is the most common tumour of cattle, with most cases seen between six and 24 months old.

AETIOLOGY

Papillomatosis is caused by bovine papillomavirus; six subtypes of the virus are associated with different forms of papilloma. The virus can be spread by direct physical contact with infected cattle or indirectly via sources such as dehorning equipment or milking machinery.



495 Extensive, chronic papillomatosis may be found in cattle persistently infected with BVDV.

CLINICAL PRESENTATION

Papillomas can occur anywhere on the body, but they are most commonly seen on the head, neck and trunk. Lesions vary from flat wide-based warts to cauliflower-like growths (494). Extensive growths that fail to resolve (495) may be seen in immunosuppressed animals (e.g. persistent BVDV infection). Papillomas affecting the penis, vagina and teats are dealt with in Chapters 1 (Reproductive system) and 11 (Mastitis and teat diseases), respectively.

DIFFERENTIAL DIAGNOSIS

Skin lymphosarcoma (individual animals only).

DIAGNOSIS

Diagnosis is based on the typical appearance of lesions.

MANAGEMENT

Papillomatosis is self-limiting and most cases will resolve without treatment in 1–12 months. Autogenous vaccines can be prepared for individual cattle, but there are no controlled studies to prove their efficacy.

URTICARIA

Urticaria can arise in individual cattle as an allergic/hypersensitivity response to a wide range of stimuli

including drugs, vaccines, insect bites and other unknown triggers. Milk allergy can be seen in cows at drying off or after temporary cessation of milking. Severe angioedema and anaphylaxis are rare manifestations of hypersensitivity and can be fatal if untreated. Urticaria causes skin wheals or 'hives' that appear anywhere on the body and can be extensive. Treatment with antihistamines, corticosteroids (non-pregnant cattle only) or NSAIDs are effective in most cases.

ZINC-RESPONSIVE DERMATITIS

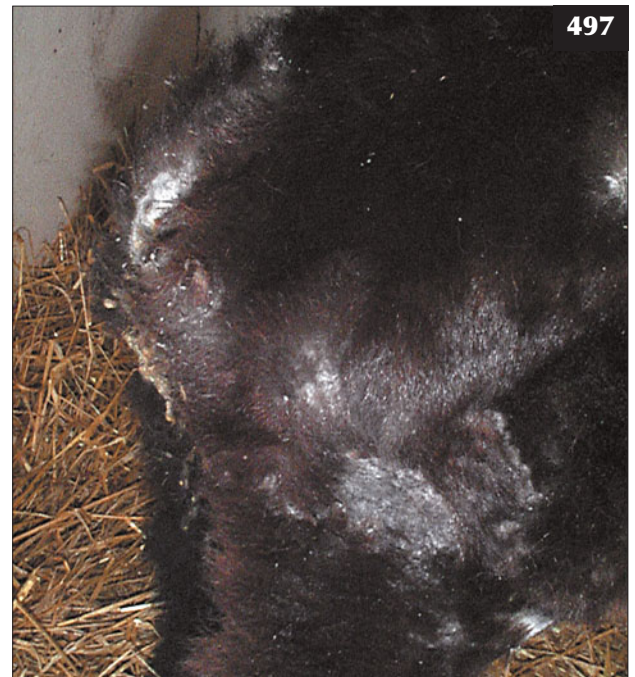Zinc deficiency is an uncommon condition affecting recently-weaned dairy calves from around six weeks old. Zinc deficiency may be due to dietary deficiency or be seen as an idiopathic condition in individual calves. Clinical signs include poor growth with hair loss and parakeratosis, especially of the muzzle, distal limbs and perineum (496, 497). Diagnosis is based on clinical findings and response to oral zinc sulphate, often combined with parenteral multivitamin injections.

ANAGEN DEFLUXION

Anagen defluxion is widespread loss of hair over the neck, trunk, limbs and, occasionally, the head that follows an acute episode of pyrexia associated with pneumonia,



496 Zinc-responsive dermatitis in a recently-weaned dairy calf.



497 Signs of zinc deficiency in this animal included poor growth with hair loss and parakeratosis of the distal limbs and perineum.

septicaemia or diarrhoea in calves (498). The skin is normal and hair growth resumes within weeks with full recovery expected. Urine or faecal scalding will cause less extensive local hair loss only. Multivitamin injection may aid recovery. A possible differential diagnosis is vitamin C-responsive dermatosis, which is described in dairy calves aged 2–10 weeks old and is associated with generalized alopecia, scaling and erythema of the limbs.

FOLLICULAR DYSPLASIA

Various forms of follicular dysplasia are reported in cattle, with hair loss present from birth or acquired as adults (499). The hair loss may be colour related. Animals are otherwise healthy and the skin is normal, but it may be susceptible to photosensitization and contact dermatitis.

LIPOMATOSIS (INFILTRATIVE LIPOMA)

A rare condition of cattle that appears as slowly enlarging fatty masses in the facial area or heavy muscles of the hindlimbs. The masses are soft and fluctuant on palpation and may become so large as to interfere with mastication. Diagnosis is by biopsy and there is no treatment.

CONGENITAL PORPHYRIA

This rare disease is caused by an autosomal recessive trait and leads to the accumulation of porphyrin metabolites in bone, skin, teeth and urine. Chronic secondary photosensitization may accompany other signs, such as discoloured teeth and urine, and anaemia.

There are many other miscellaneous skin diseases of cattle that are outwith the scope of this book. Diseases of the teat and udder skin are dealt with in Chapter 11, Mastitis and teat diseases.



498 These two calves have anagen defluxion (widespread loss of hair over the neck, trunk, limbs and head) following an acute episode of pyrexia associated with diarrhoea.



499 Black hair follicular dysplasia causing widespread hypotrichosis in an Aberdeen Angus-cross beef cow.

Chapter 10

Eye diseases

INFECTIOUS BOVINE KERATOCONJUNCTIVITIS ('PINK EYE', NEW FOREST DISEASE)

DEFINITION/OVERVIEW

Infectious bovine keratoconjunctivitis (IBK) is a highly contagious disease that can spread rapidly during the summer months. IBK is seen in cattle worldwide and has significant economic consequences in some countries. It is more commonly seen in young stock than in adults.

AETIOLOGY

Moraxella bovis is considered to be the cause of the disease, but it can be cultured from normal conjunctival sacs. Epidemics often occur following the introduction of purchased cattle. Head and nuisance flies can act as mechanical vectors for *M. bovis* and sunlight and dust are risk factors, but disease can also occur during the winter months in housed cattle. The clinical signs are exacerbated by concurrent IBR virus infection.

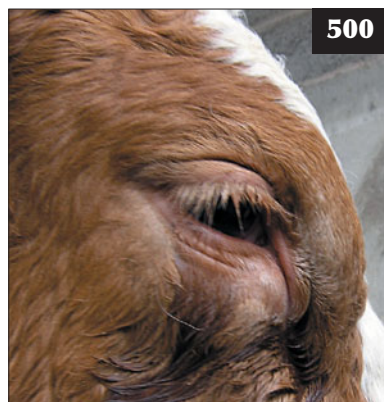
CLINICAL PRESENTATION

The condition can be either unilateral or bilateral. Most cases are selected for treatment on the basis of obvious epiphora, with tear staining of the face initially serous, but

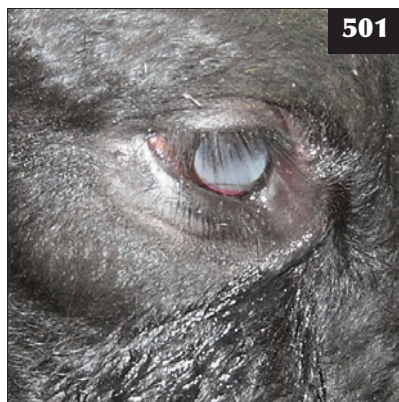becoming increasingly purulent and matting the lashes and hair of the face. On closer examination of the affected eye(s) there is a marked conjunctivitis with injected tortuous scleral vessels and hyperaemic conjunctivae. There is marked photophobia with blepharospasm when cattle are exposed to bright sunlight (500). More advanced cases show keratitis and corneal ulceration (501), which is readily identified after application of fluorescein-impregnated strips to the surface of the eye. Neovascularization is also evident in severe cases, with vessels progressing to the central lesion (502).

The ocular lesions are very painful and disrupt grazing patterns and this can cause poor performance and even weight loss. Bilateral lesions cause temporary blindness accompanied by aimless wandering.

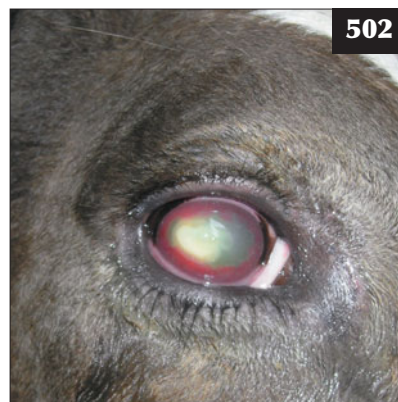Spontaneous recovery starts in mild cases 3–5 days after clinical signs are first observed and is complete two weeks later. In severe neglected cases, ulceration may progress to corneal perforation and panophthalmitis, but this is uncommon.



500

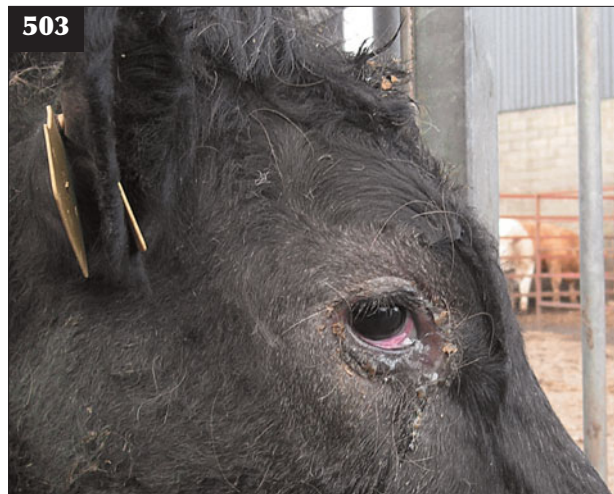

501



502

500–502 Infectious bovine keratoconjunctivitis. (500) Blepharospasm, epiphora and photophobia. (501) Epiphora, keratitis and early corneal ulceration. (502) Corneal vascularization and ulceration.



503 This animal has conjunctivitis due to infectious bovine rhinotracheitis. Note the lack of blepharospasm as there is no corneal involvement and therefore less pain.

DIFFERENTIAL DIAGNOSIS

Differential diagnoses include foreign bodies (e.g. grass awns) within the conjunctival sac, bovine iritis and IBR (**503**). Conjunctivitis caused by IBR rarely causes blepharospasm as there is normally no corneal involvement.

DIAGNOSIS

Diagnosis is based on the clinical examination and response to antibiotic therapy. Bacteriological isolation is rarely undertaken.

MANAGEMENT

Prompt treatment is essential. Antibiotic resistance is not a problem; however, maintaining effective antibiotic concentrations necessitates daily topical antibiotic therapy and this regimen cannot always be accomplished under farm conditions. Topical ophthalmic antibiotic cream containing cloxacillin is commonly used by farmers. Antibiotic injection (penicillin, oxytetracycline or ceftiofur) into the dorsal bulbar conjunctiva is the best treatment, but this can be difficult to achieve in fractious adult cattle and requires good restraint. Injection into the upper palpebral conjunctiva is commonly used, but this technique will not give residual antibiotic levels in the eye and relies on leakage onto the cornea from the injection site. This technique has no advantage over systemic injection except for the much lower cost because of the smaller antibiotic dose. When subconjunctival or topical treatment is not practical, single-dose long-acting oxytetracycline, florfenicol, tilmicosin and tulathromycin have all been reported to be effective.

In severe cases, suturing the eyelids together using mattress sutures can be undertaken under local anaesthesia

together with an auriculopalpebral block. The sutures must not contact the cornea and they are removed in two weeks. Temporary adhesive eye patches can also be used to provide protection from environmental conditions. Severely affected cattle should be housed with ready access to food and water.

Metaphylactic injection of all at-risk cattle with a single intramuscular injection of long-acting oxytetracycline or tilmicosin could be considered in severe epidemics, but there are no supporting field data.

Outbreaks of IBK may occur after the introduction of purchased stock; therefore, whenever possible, all new stock should be managed separately as one group away from the main herd. Fly control using ear tags and pour-on insecticides is never absolute and repeated treatments prove costly. Development of immunity following infection is variable.

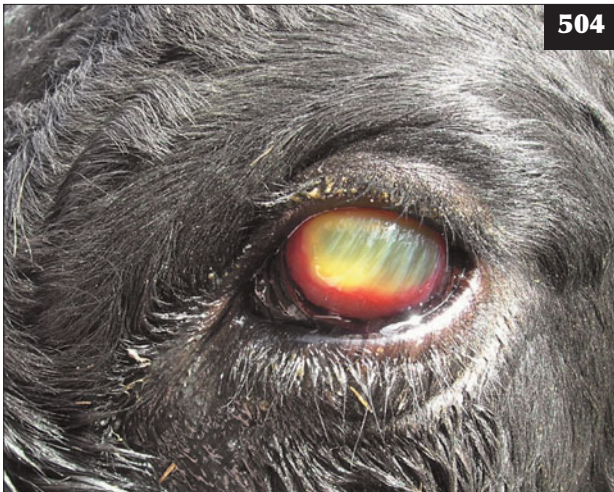BOVINE IRITIS ('SILAGE EYE')

DEFINITION/OVERVIEW

Bovine iritis, colloquially known as 'silage eye' in the UK, where it was first described, is a common cause of uveitis in cattle of all ages fed winter rations of baled silage/haylage. Morbidity is variable, but clusters of cases are commonly seen in at-risk groups of cattle. There are no reports of meningoencephalitis following primary anterior uveal listerial infection.

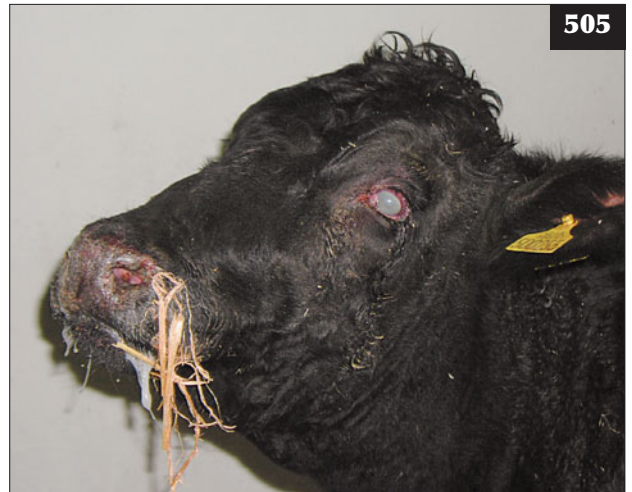AETIOLOGY

Anterior uveitis probably follows conjunctival infection with *Leptospira monocytogenes*, although the disease has not been reproduced experimentally to date. In outbreaks of



504

504 Bovine iritis ('silage eye') in this animal has caused unilateral uveitis without significant conjunctivitis or corneal ulceration.



505

505 The uveitis (bilateral) seen in this animal with malignant catarrhal fever, along with other typical signs, resembles bovine iritis.

bovine iritis, *L. monocytogenes* can be cultured from conjunctival swabs and the association with feeding poor-quality baled silage suggests that environmental contamination of the eye is the likely route of infection.

CLINICAL PRESENTATION

The initial presenting signs are excessive lachrymation, blepharospasm, photophobia, miosis and iridocyclitis, either unilaterally or, rarely, bilaterally. The iris may be thrown into a series of radial folds extending from the ciliary border to the pupillary edge. Within 2–3 days, more severe inflammatory changes develop, with a bluish-white corneal opacity starting at the limbic border and spreading centripetally (504). Focal aggregations of fibrin accumulate in the anterior chamber, attached to the inner surface of the cornea, and are seen as accumulations of white material beneath the cornea. Corneal ulceration is not a feature of bovine iritis. Regression of ocular lesions takes some weeks without treatment.

DIFFERENTIAL DIAGNOSIS

Differential diagnoses include MCF, corneal foreign bodies, IBK and uveitis arising from bacteraemia. Unlike IBK, cases of iritis rarely develop corneal ulceration or prulent ocular discharge, as the pathology is limited to the uveal structures. The bilateral uveitis seen in MCF (505) can resemble silage eye; however, the absence of systemic illness and other signs of MCF differentiate these conditions.

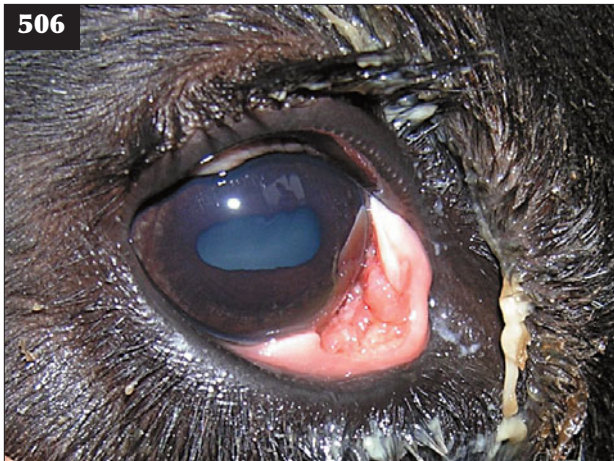DIAGNOSIS

Diagnosis is based on clinical signs and history of silage feeding.

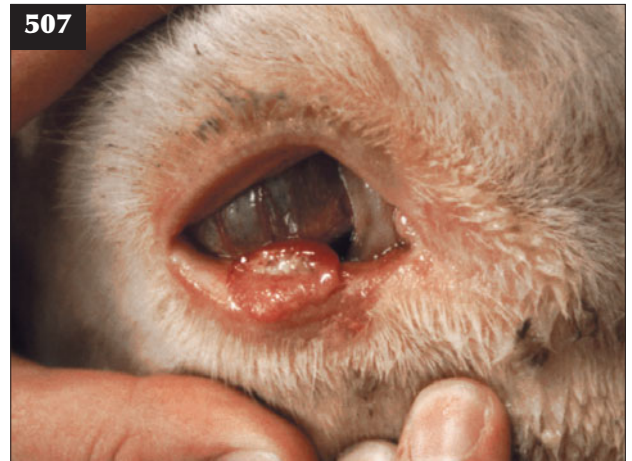
MANAGEMENT

There is a good response to combined subconjunctival injection of oxytetracycline and dexamethasone (2–3 ml of 5% or 10% oxytetracycline mixed with 0.5–1.0 ml of soluble dexamethasone) in acute cases. Topical atropine is indicated in cases of acute miosis, but is rarely practical. The mode of action is unknown, but it is likely that dexamethasone reduces the inflammatory response provoked by bacteria in the uveal tract and halts the progression of disease. Treatment of more chronic cases probably has little effect on resolution of the condition. Without treatment, regression of most ocular lesions occurs spontaneously within weeks; however, prompt treatment should be encouraged in order to prevent the temporary suffering of affected animals.

The condition can be prevented by rolling out big-bale silage rather than placing it in ring feeders in order to prevent cows burrowing their heads into the bale, but this is impractical in most situations. Attention to detail when baling and wrapping silage and ensuring appropriate fermentation conditions should limit contamination with *L. monocytogenes*. However, exposure to air for several days before the large bale is eventually eaten provides an ideal environment for *L. monocytogenes* multiplication.



506 Conjunctival discharge associated with carcinoma of the third eyelid. Surgical excision was successful in this case.



507 Squamous cell carcinoma affecting the lower eyelid.

OCULAR SQUAMOUS CELL CARCINOMA ('CANCER EYE')

DEFINITION/OVERVIEW

Ocular squamous cell carcinomas are commonly reported affecting older beef cattle (>5 years old) in many subtropical countries worldwide, and especially Australia. These tumours are much less common in northern Europe, but they are the most common ocular neoplasm seen in cattle.

AETIOLOGY

Ocular squamous cell carcinomas can arise anywhere in the conjunctival sac, but typically they arise from the third eyelid (506) or conjunctival membrane of the lower eyelid (507) following exposure to prolonged ultraviolet radiation. The frequency of these tumours increases at high altitudes. Lack of melanin pigmentation around the eyes in Hereford and Simmental type cattle predisposes to this tumour.

CLINICAL PRESENTATION

Initially, there is unilateral blepharospasm and ocular discharge caused by mechanical irritation of the cornea. As the tumour grows there is more obvious swelling of the palpebral skin, conjunctiva or third eyelid, depending on the site of the tumour. Local invasion of ocular tissues is common, but metastatic spread to the local lymph node is rare.

DIFFERENTIAL DIAGNOSIS

Traumatic injury, foreign body, IBK or iritis may all cause unilateral ocular signs of blepharospasm and discharge.

DIAGNOSIS

Diagnosis is based on careful clinical examination.

MANAGEMENT

Early cases involving the third eyelid can be treated with simple surgical excision under local anaesthesia or with cryosurgery.

Enucleation, under standing xylazine sedation and retrobulbar block, may be required in advanced cases involving the limbus, but this may not be an option for commercial value cattle, which must therefore be culled for welfare reasons. The eyelids are sutured together and an elliptical skin incision made near the margins of the orbit. The eye is separated intact from the orbit using blunt dissection. Ligation of the optic vessels is not always possible, but any haemorrhage can be controlled by packing the orbit with sterile gauze swabs after infusing antibiotic (intramammary antibiotic syringes are often used). The remaining eyelid margins are sutured together. The packing is removed after 3–5 days.

Prevention is by selecting cattle with pigmented skin surrounding the eyelids.

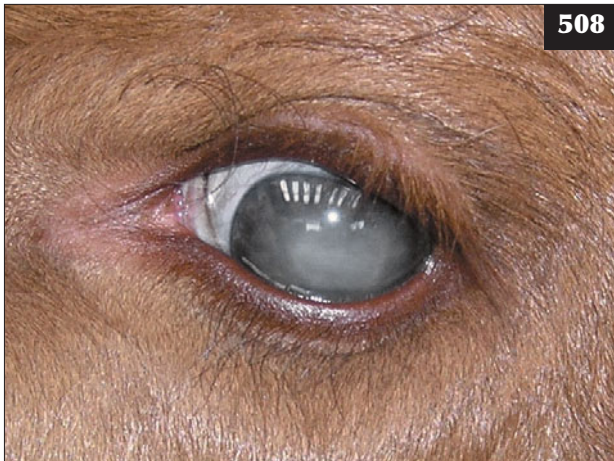HYPOVITAMINOSIS A

DEFINITION/OVERVIEW

Hypovitaminosis A is seen sporadically in growing cattle reared indoors on intensive cereal-based diets.

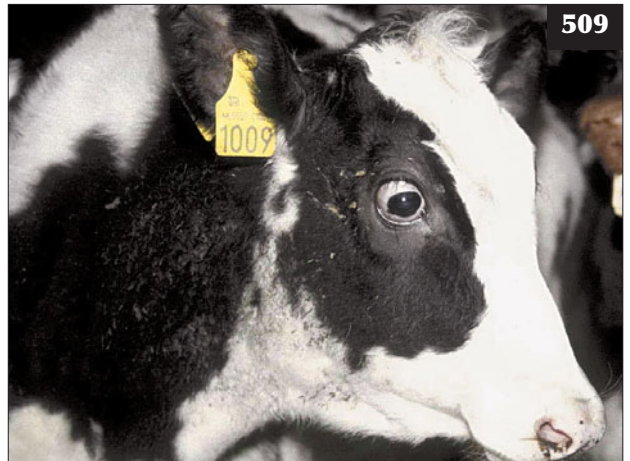AETIOLOGY

The condition is seen classically in intensively reared calves fed a straw/cereal-based ration without adequate vitamin



508

508 Uveitis associated with septicaemia in a three-day-old beef calf.



509

509 This four-month-old Holstein calf was blind due to in-utero bovine viral diarrhoea virus infection causing retinal damage.

supplementation. Poor storage of vitamin/mineral supplements can lead to degradation of vitamin content.

CLINICAL PRESENTATION

Affected cattle appear blind with dilated unresponsive pupils, but they may otherwise be healthy. Blindness may be noted for the first time when cattle are moved into unfamiliar surroundings. The blindness in growing cattle is primarily caused by failure of bone resorption in the optic canals leading to compression necrosis of the optic nerves and papilloedema. In older cattle, blindness may be caused by photoreceptor dysfunction and papilloedema. Raised CSF pressure may occasionally lead to collapse and seizure activity in affected cattle.

DIFFERENTIAL DIAGNOSIS

PEM; lead poisoning; ragwort poisoning; hepatopathy; BVDV-induced retinal dysplasia.

DIAGNOSIS

Diagnosis is based on history and clinical signs supported by low plasma vitamin A concentrations.

MANAGEMENT

Affected cattle may respond poorly to vitamin A injection when blindness is caused by optic nerve compression. Papilloedema in older cattle may respond to parenteral vitamin A injection. Proper dietary supplementation and/or vitamin A injection of other cattle in affected groups will prevent progression of disease.

Vitamin A is a standard component of all mineral supplements added to balance ruminant diets.

UVEITIS

In addition to bovine iritis, uveitis can occur following bacteraemic spread, most commonly in calves suffering from neonatal septicaemia (508) or, occasionally, in cows with septic metritis.

CONGENITAL PROBLEMS

Hereditary nuclear cataracts can occur in Holstein calves and following mid-term BVDV infection *in utero*. Calves with BVDV-induced cataracts may also be born with other congenital defects including brachygnathia, cerebellar hypoplasia and blindness caused by retinal dysplasia (509).

Chapter 11

Mastitis and teat diseases

MASTITIS

DEFINITION/OVERVIEW

Mastitis is one of the major diseases of dairy cattle worldwide and it has a significant economic cost. For example, it has been estimated to cost the US dairy industry over \$1 billion annually. Although the incidence of clinical mastitis in a dairy herd can vary widely depending on location and risk factors, subclinical mastitis also has a major economic cost. Cows with subclinical mastitis will not have detectable changes in the milk, but they will have reduced milk yields and milk quality. The price that farmers are paid for their milk is based on a number of factors, including hygienic quality, as assessed by somatic cell count (SCC) and/or bacterial content. High levels of mastitis will lead to high SCCs and bacterial levels, leading to substantial deductions from the milk price paid to the farmer. In some countries farmers may be unable to sell their milk for human consumption.

Mastitis is a complex disease, with a number of factors contributing to the level of mastitis in a herd, including environment, management, udder physiology and cow health. This is readily demonstrated by the low incidence of mastitis in suckled beef cows and the difference in mastitis pathogens observed in hand-milked cows. Although individual clinical cases may be encountered by the practitioner, it must be remembered that mastitis is a herd problem and control measures must be directed at the herd level.

AETIOLOGY

Although numerous species of bacteria, mycoplasma, fungi, algae and yeast have been isolated from clinical cases of mastitis, the major pathogens can conventionally be separated into two groups: contagious (or cow-associated) and environmental pathogens. However, the distinction between contagious and environmental pathogens has become blurred in recent years by research findings that have shown that 'traditional' environmental pathogens (e.g. *Escherichia coli* and *Streptococcus uberis*) can persist in a recurrent chronic host-adapted form, and that traditional 'contagious' bacteria such as *Streptococcus dysgalactiae* can persist in the environment.

Contagious pathogens usually live in the udder or teat skin and are transferred to the teat and spread during milking. They then grow up through the teat canal and into the udder. The three most important contagious pathogens are *Staphylococcus aureus*, *Streptococcus agalactiae* and *Strep. dysgalactiae*. *Mycoplasma* spp. *Corynebacterium bovis* and coagulase-negative staphylococci are less common, but may cause significant problems on individual farms. A high proportion of strains of *Staph. aureus* produce β -lactamase. *Strep. agalactiae* is highly contagious and is readily transmitted between cows during the milking process. It is usually brought into the herd via purchase of milking cows.

Environmental pathogens survive in the cow's environment and enter the udder by propulsion through the teat canal (e.g. during milking [510], by capillary action, insertion of antibiotic tubes, insertion of teat canulae) or by passive penetration of the teat canal immediately after milking (511). *E. coli* and *Strep. uberis* are the important environmental pathogens, although *Pseudomonas aeruginosa*, other coliforms, *Bacillus cereus* (512), yeasts and moulds and *Pasteurella* spp. are less common. Various environmental factors, such as poor housing and hygiene (513), may result in the multiplication of *E. coli* and hence an increased incidence of coliform mastitis. Recent studies have demonstrated the importance of environmental infections during the dry period (especially coliforms).

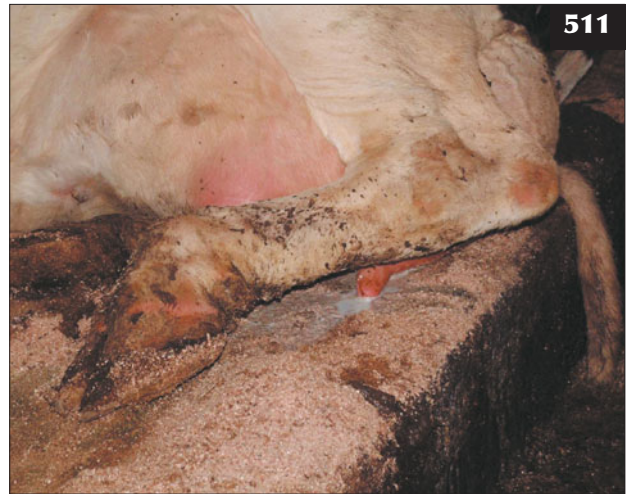CLINICAL PRESENTATION OF MAJOR MASTITIS PATHOGENS

It is important to remember that not all cases of mastitis have obvious changes in the milk or udder. The presence of severe cases of mastitis (e.g. *Staph. aureus* or *E. coli*) tend to represent the 'tip of the iceberg', and the approximate incidence of mastitis cases is: fatal (1%); severe (29%); mild (70%).

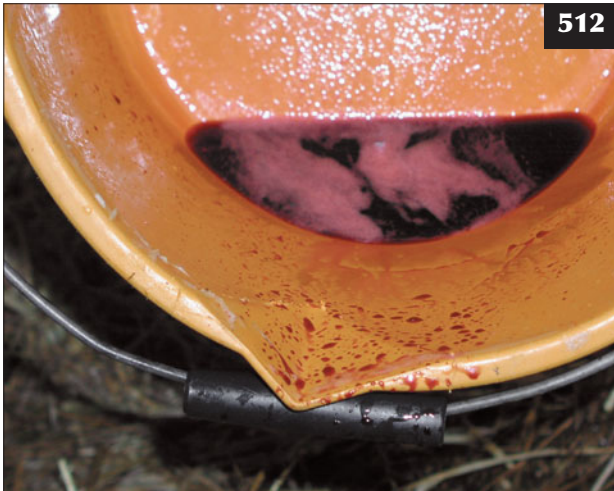Mastitis can be graded using a clinical scale to determine the severity of mastitis (Table 4). In subclinical mastitis, SCCs and milk bacteria levels may be raised and are detectable prior to clinical signs. Milk conductivity also



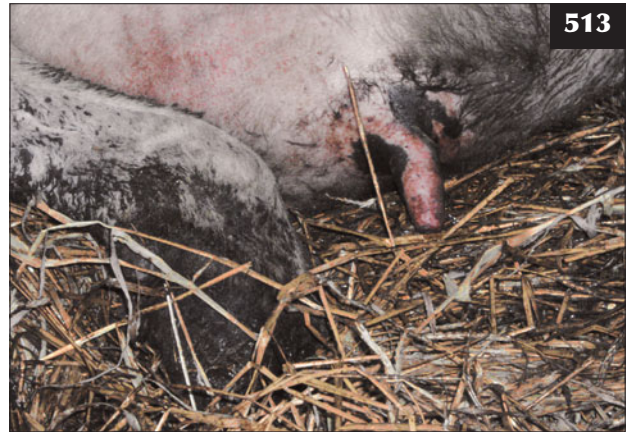510 A normal, properly functional milking machine set-up is illustrated. Poorly functioning milking machines can increase the risk of infection with contagious and environmental mastitis pathogens.



511. Environmental infections may enter the udder by passive penetration of the teat canal.



512 Mastitis caused by *Bacillus cereus* is rare, but it produces a characteristic 'red wine' discolouration of the milk.



513 Poor environmental hygiene, as illustrated here, greatly increases the risk of infection with *E. coli* and *Strep. uberis*.

Table 4 Clinical scale to determine the severity of mastitis.

	Non-infected	Subclinical	Clinical: mild (Grade I)	Clinical: moderate (Grade II)	Clinical: Severe (Grade III)
Cow	Normal	Normal	Normal	Normal	+
Udder	Normal	Normal	Normal	+	+
Milk	Normal	Normal	+	+	+
SCC	Normal	+	+	+	+
Bacteria	Normal	+	+	+	+

increases prior to milk and udder changes, and has been researched as a means of automatic detection for pre-clinical mastitis (although it is prone to a high number of false-positive results). Similarly, measurement of acute phase proteins in milk (e.g. milk amyloid A) might also prove useful in the future for the detection of subclinical mastitis.

Changes in the milk are detectable in mild clinical (Grade I) mastitis, especially if foremilk is practised. Mastitis can lead to changes from caseous lumps, to clots in the milk, to watery secretions. Although some changes

may be classical (e.g. yellow watery secretion in acute coliform mastitis), it is not consistently possible to determine the organism producing mastitis from clinical signs alone. This needs to be determined by bacteriology.

Changes in the udder during moderate (Grade II) clinical mastitis are detectable as hot, painful, swollen quarters (514).

Severe (Grade III) clinical mastitis is observed when systemic illness in the cow develops, especially in mastitis caused by *Staph. aureus*, *Strep. uberis* and coliforms. Signs may include dramatic reductions in milk yield, inappetence, pyrexia, dehydration, elevations in heart and respiratory rate and other signs of advanced endotoxaemia.

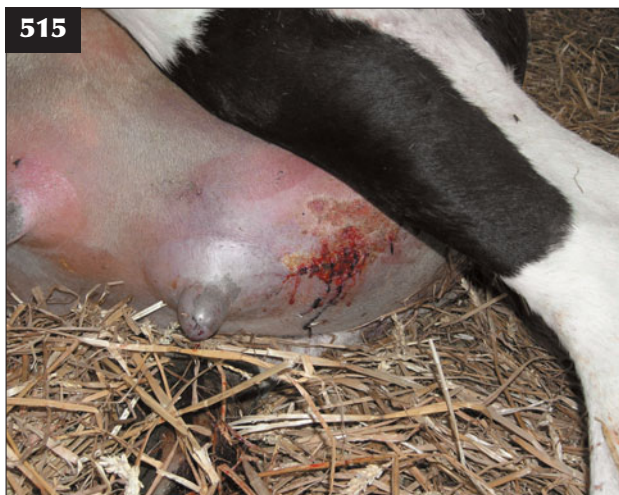Staphylococcus aureus

The primary reservoir of this mastitis pathogen is the udder, although it can persist on the teat skin. It has particularly strong adhesive properties such that a cow shedding infection in her milk can infect the next 6–8 cows to be milked by the same cluster. It is primarily spread from cow to cow during the milking process. The majority of strains of *Staph. aureus* produce β -lactamase. Three separate disease syndromes are recognized with *Staph. aureus* infection:

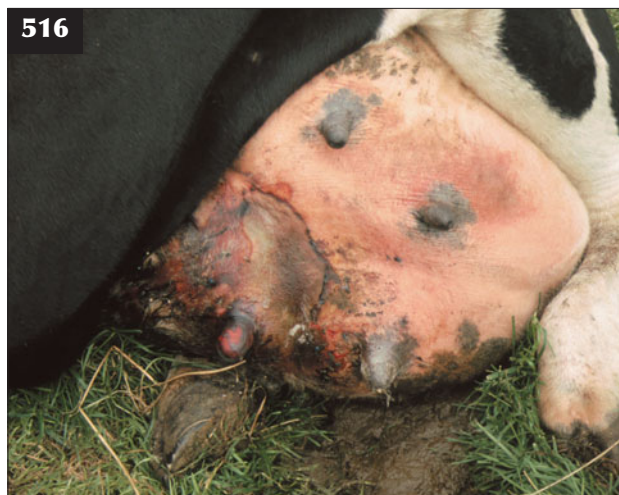- **Severe acute gangrenous mastitis.** Cows initially have a high rectal temperature (41–42°C), with heat, pain, redness and severe swelling of the affected gland(s). The cow is systemically ill and inappetent, has toxic mucous membranes and will become recumbent with severe depression. Over 24 hours the affected gland becomes cold, developing a sharply-demarcated blue-black discolouration from healthy tissue (515, 516). The udder secretion is cold, reddish-



514 The Grade II (moderate) clinical mastitis in this cow is characterized by swelling and pain of the affected quarter (arrow).



515, 516 Gangrenous mastitis. (515) This cow with acute gangrenous mastitis initially has cold teats and udder skin and areas of purple skin discolouration. (516) Skin/udder sloughing is extensive in this cow that survived gangrenous mastitis.



brown and watery, with gas sometimes produced. Cows that recover eventually slough the affected quarter some weeks later and are culled from the herd.

- **Moderate and mild clinical mastitis.** Similar to other forms of acute mastitis, with clots in the milk and inflammation of the udder.
- **Chronic mastitis.** *Staph. aureus* infections of the udder are notoriously difficult to treat, leading to the formation of chronic infections with extensive fibrosis and induration of the udder (517).

Coagulase-negative staphylococci

Staph. chromogenes, *Staph. hyicus*, *Staph. simulans*, *Staph. epidermidis*, *Staph. hominis* and *Staph. xylosus* commonly colonize the teat end and teat canal. They may be only a sample contaminant if the correct milk sampling procedure has not been performed. However, coagulase-negative staphylococci may invade the udder under certain circumstances, leading to high SCCs and clinical mastitis during early lactation.

Streptococcus agalactiae

Although an obligate pathogen of the bovine udder, this bacterium is highly contagious and is readily transmitted between cows during the milking process. It is usually brought into the herd via purchase of milking cows, or via the relief milker's hands.

Milk from infected quarters contains massive amounts of bacteria (up to 10^8 /ml), which can lead to high bulk milk tank bacteria levels as well as high SCCs. Response to antibiotic therapy is generally good, therefore blitz therapy can be used to eliminate infection from the herd.

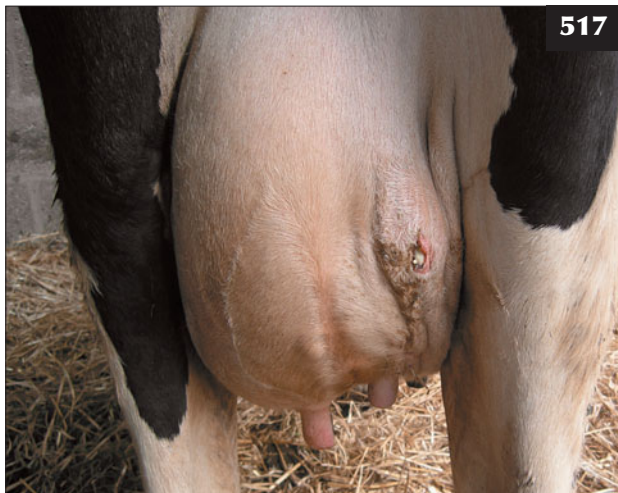
Streptococcus dysgalactiae

Although conventionally described as a contagious pathogen, *Strept. dysgalactiae* survives well in the environment and thus has some of the properties of an environmental pathogen. It is commonly found on the teat skin (as opposed to the udder), especially if the skin is damaged. It is present in the tonsils and can be transmitted by licking, especially in heifers. It commonly infects dry cows, prepartum heifers and even calves, and is involved in cases of summer mastitis.

Mycoplasma

Mycoplasmal mastitis is caused by *Mycoplasma bovis* and *Mycoplasma californicum*. This type of mastitis is relatively rare in many countries, although common in some regions of the USA. *Mycoplasma* spp. are difficult to culture and specialized techniques are necessary for isolation. Mycoplasmal mastitis usually occurs as a sudden-onset condition, with multiple quarters involved. The udder is hard, with enlarged mammary lymph nodes. The mammary secretions vary from watery with sandy material present (518), to thick colostrum-like material. The cow shows little systemic illness, although polyarthritis may be a feature. It has also been implicated in the development of blind quarters in heifers.

Mycoplasmal mastitis is highly contagious and can spread rapidly within infected herds. The clinical response is poor and most cows have to be culled. Strict hygiene is essential in order to control mycoplasmal mastitis and affected cows should be milked last, with consideration to pasteurization of clusters in between cows to prevent transmission.



517 This cow with *Staph. aureus* infection shows deep abscess formation and a discharging lesion.

518 A watery secretion containing sand-like material from a cow with mycoplasmal mastitis.



Corynebacterium bovis


This bacterium was thought to be a teat end commensal and thus present as a contaminant in milk samples. However, it has been associated with subclinical mastitis and high SCCs, especially in relation to poor post-milking teat disinfection.

Escherichia coli

E. coli is present in large numbers in faeces. Various environmental factors such as poor housing and hygiene (519) as well as wet and humid conditions lead to the

multiplication of *E. coli* and thus an increased incidence of coliform mastitis. There is a wide variation in the clinical syndromes seen during mastitis caused by *E. coli*:

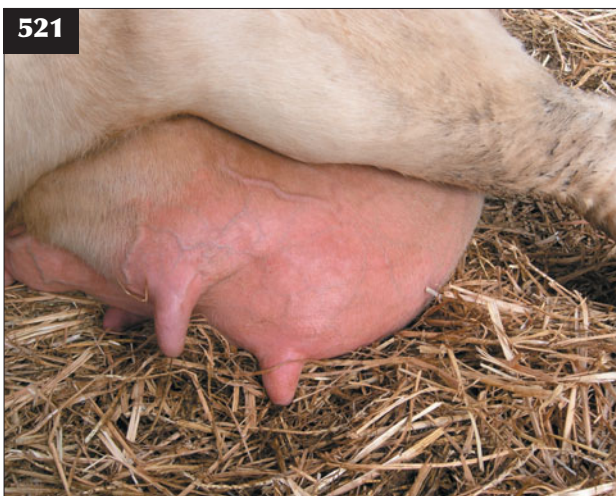- **Peracute severe clinical mastitis.** This syndrome classically occurs during early lactation (60% of cases occur in the first eight weeks of lactation) and presents as a life-threatening condition. The cow is dull, depressed and anorexic, with an elevated rectal temperature during the early stages. Over 6–12 hours the cow becomes weak and recumbent, and the clinical presentation is often mistaken for



519 *E. coli* is present in large numbers in faeces, therefore poor cow cleanliness, as shown here, will predispose to mastitis.



520 This cow with acute *E. coli* mastitis has become recumbent, dehydrated and toxæmic. Note that this case could be mistaken for a case of hypocalcaemia.



521 Initial udder changes in this cow with *E. coli* infection are limited to diffuse swelling of the affected (left rear) quarter.



522 With *E. coli* infection, stripping of the swollen quarter reveals characteristic changes in milk colour and fine clots (arrow).

hypocalcaemia (520). The udder may feel grossly normal, but careful examination generally reveals a serum-like secretion from the affected quarter(s) (521, 522). There is often profuse diarrhoea. The condition rapidly progresses and the quarter becomes hard, hot, swollen and painful, with a yellow watery secretion. The rectal temperature is now subnormal and the cow becomes increasingly dehydrated (>7%) and endotoxaemic (523), with brick-red mucous membranes due to the release of endotoxins (lipopolysaccharides) from dying bacteria within the mammary gland. In contrast to peracute mastitis caused by *Staph. aureus*, gangrene rarely develops and non-fatal cases will recover completely.

- **Moderate and mild clinical mastitis.** Similar to other forms of acute mastitis, with clots in the milk and inflammation of the udder.
- **Subclinical mastitis.** Can also occur following *E. coli* infection, when the only changes detectable are an increase in the SCC and bacterial numbers in the milk. The reason why some cows develop acute coliform mastitis and other cows subclinical mastitis is thought to be due to the immune response of the individual cow (rather than *E. coli* strain variation).

Although clinical mastitis caused by *E. coli* is classically described as a 'one-off' event of short duration, recurrent coliform mastitis is now a recognized phenomenon. In approximately 10% of cases, *E. coli* may persist in the udder for prolonged periods (over 100 days post infection). The development of recurrent mastitis is thought to be a consequence of host adaptation by certain strains of *E. coli*.

Recent studies have also shown that coliform infections can become established during the dry period, remain



523 Toxaemia in this cow has led to rapid signs of dehydration manifest as weakness and sunken eyes.

dormant in the udder and cause clinical mastitis in early lactation. Some studies suggest that over 50% of all cases of coliform mastitis occurring in early lactation are a direct result of infections acquired during the dry period (especially the first two weeks and last two weeks of the dry period). However, only a small number of dry period infections (under 10%) develop into clinical mastitis, and the majority undergo self-cure.

Klebsiella pneumoniae

Klebsiella pneumoniae is associated with damp sawdust bedding causing peracute severe coliform mastitis.

Pseudomonas aeruginosa

Pseudomonas aeruginosa is associated with contaminated water and outbreaks of *P. aeruginosa* mastitis have been linked to contaminated udder wash, teat-dip and dry cow tubes. The clinical signs vary from peracute severe endotoxic mastitis to chronic recurrent cases.

Streptococcus uberis

This pathogen is widespread in the environment, especially in straw yards, which may contain up to 10⁶ bacteria per gram of straw bedding. It is also widespread on the skin of the cow, but relatively rare in faeces (compared with *E. coli*). Outbreaks can occur in cows at pasture, especially in late summer, presumably by transmission from the skin of the cow, via the lying area, to the teat. Like *E. coli*, new intramammary infections during the dry period have been shown to play an important role in the epidemiology of *Strep. uberis* infections.

The clinical signs of *Strep. uberis* infection vary from subclinical infections to acute severe clinical mastitis with a hard, hot, swollen, painful quarter(s), pyrexia and systemic illness in the cow. Certain strains of *Strep. uberis* are highly resistant to phagocytosis by white blood cells in the udder and thus develop into chronic recurrent cases unless prompt treatment is undertaken.

Other environmental pathogens

A large number of different microorganisms have also been isolated from mastitis outbreaks including yeasts and moulds (e.g. *Candidia* spp. and *Aspergillus* spp.), algae (*Prototheca* spp.) *Pasteurella multocida* and *Bacillus* spp. These pathogens may come from bedding material, contamination of water used for udder wash or dirty udders.

DIFFERENTIAL DIAGNOSIS

The classic clinical signs of mastitis (heat, inflammation and swelling of the udder with characteristic changes in the milk) are pathognomic. Haemorrhage within the udder (especially after calving), remnants of internal teat sealant products in freshly calved cows, sunburn and trauma to the udder may all produce similar signs, but should be differentiated on thorough clinical examination.

DIAGNOSIS

Clinical mastitis

Mild (Grade I) clinical mastitis can be detected by foremilking, which should be included as part of the milking routine. Alternatively, Ambic in-line milk filters (524) may also be used to detect any clots in the milk. Checking the milk sock/filter at the end of milking is a retrospective measure. Palpation of the udder is useful to detect heat, pain and swelling in clinically affected quarters during moderate (Grade II) clinical mastitis. Changes in the behaviour of the cow (e.g. altered position when entering the parlour, kicking while machine attached) may also be early indicators of disease.

Subclinical mastitis

Subclinical mastitis may be detected by the use of SCCs, detection of bacteria in the milk, altered milk conductivity or the measurement of acute phase proteins (e.g. milk amyloid A).

Somatic cell counts

SCCs are a measure of the number of cells present in the milk. In a healthy udder the SCC is made up predominantly of epithelial cells. In response to inflammation in the udder (typically mastitis), white blood cells enter the udder to combat the infection and the SCC rises.

Numerical SCCs are measured using the automatic Fossomatic method, which is used to determine SCCs in

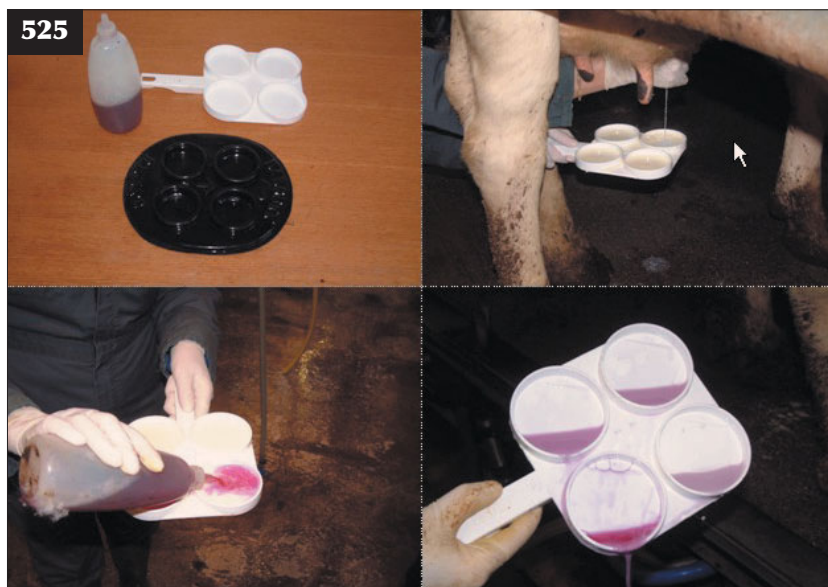bulk milk and individual cow samples. Alternatively, the California Mastitis Test (CMT) is a simple cowside test, which crudely estimates the SCC via a gelling reaction ('slime') with a detergent reagent (525). It can be performed during milking and the results are available immediately. It can help to identify individual quarters with a high SCC in order to take samples for bacteriology and decide on treatment options. The major disadvantage is that it only detects relatively high SCCs (>400,000/ml).

SCCs can either be performed on bulk milk (BMSCC; presented as monthly, three-monthly and annual averages) or on individual cows (ICSCC). BMSCCs are important as in many countries farmers are paid for the milk partly on the basis of hygienic quality (SCC and bacteria level). Some regions also have government regulations on milk hygienic quality. For example, EC Regulation 853/2004 (detailing 'Specific hygiene rules for food of animal origin') states that all bovine milk for human consumption in the European Union must have a SCC <400,000 cells/ml based on a three-month rolling geometric mean.

ICSCCs are an average using a composite sample taken from all four quarters, and are a useful tool in identifying high cell count cows. Regular monthly ICSCC recording is provided by commercial organizations (e.g. National Milk Records [NMR] and Cattle Information Services in the UK and Dairy Herd Improvement Association in the USA). Single ICSCC results should not be taken in isolation, but regular (usually monthly) sampling and trends should be



524 In-line milk filters can be used to detect clots in the milk, but they must be checked on a regular basis.



525 The California Mastitis Test (CMT) can be used to estimate the somatic cell count at the quarter level. Examples of CMT paddles and reagent. Milk is drawn into the four chambers of the CMT paddle. An equal volume of CMT reagent is added to the milk sample and mixed with a gentle swirling motion. The presence of a 'gel-like' reaction in the sample from the rear right quarter indicates an elevated somatic cell count.

used for interpretation. ICSCC values can rise to 20,000,000/ml in clinical mastitis. A suitable threshold (such as 200,000/ml) is used to interpret ICSCCs, with low values under this threshold indicating healthy udder status, while high values above this indicate subclinical mastitis. Various computer programs (e.g. NMR Herd Companion in the UK) can then be used to assess the relative number of cows that have chronic intramammary infections (shown by a persistently high ICSCC), new infections (low ICSCC one month, rising to a high ICSCC the next month), recovery from infection (high ICSCC one month, dropping to a low ICSCC the next month) or uninfected cows (persistently low ICSCC) (526).

Bacteria levels in milk

Conventionally, bacteria levels in milk are determined by the total bacteria count (TBC), which measures the number of bacterial colonies grown from milk after 72 hours incubation. In some countries (e.g. the UK) the TBC has been replaced by the Bactoscan test, which measures the total number of bacteria (viable and non-viable) present in a milk sample. Bulk milk tests that show high bacteria levels are penalized by milk purchasers, as they are more prone to spoilage.

Potential sources of bacteria in the milk include mastitis pathogens from the udder (especially if *Strep. agalactiae* and *Strep. uberis* are involved), environmental contamination and poor pre-milking teat preparation, poor cleaning and sanitization of the milking equipment after use and poor refrigeration of milk after collection.

Influence of milking machine on mastitis

The milking machine can have an effect on the incidence of mastitis in five main ways:

1. Acts as a fomite, spreading infection from quarter to quarter and from cow to cow (especially recognized with *Staph. aureus*). This can be reduced by milking infected cows last, dipping clusters in disinfectant after milking infected cows or by the use of automatic cluster disinfecting devices (such as the ADF or Vaccar systems).
2. The milking machine can lead to teat end damage, allowing bacteria entry into the teat canal, or teat sores that allow colonization of bacteria. Examination of teat ends for damage (known as teat scoring; see Milking machine-induced teat lesions p. 233) such as hyperkeratosis, teat oedema and congestion will assist in the diagnosis.
3. Colonization of the teat canal. The keratin in the teat canal acts as a type of blotting paper, soaking up bacteria, and is then removed by the milk flow. Defective pulsation (either pulsation rate or ratio) means that the keratin is not removed, allowing bacteria to grow up the teat canal.
4. Impact forces. Impact forces are a reverse flow of milk back up against the teat end, which can lead

to the propulsion of bacteria into the teat canal and udder. They are caused by liner slip, when air enters the cluster due to wet teats or worn liners. It can be reduced by the use of liners fitted with shields.

5. Overmilking. This leads to teat congestion and teat orifice erosion, which allows bacteria to colonise the teat canal.

Natural defence mechanisms

Natural defence mechanisms against the entry and establishment of pathogens in the udder include teat skin, which may become compromised by cuts, chaps or warts. The teat canal is lined with keratinized epithelium, which secretes keratin into the canal after milking to form a solid seal and prevent bacterial entry.

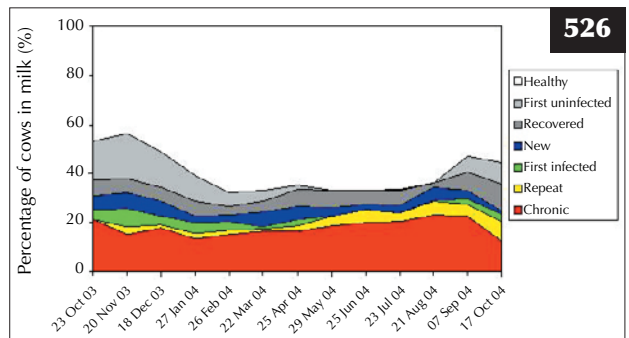
Cows that have large pendulous udders and cone-shaped teats are more prone to mastitis, as are cows that have short and/or wide teat canals.

Even if bacteria have managed to penetrate the teat canal defences, there are a number of other mechanisms to remove bacteria from the udder. Lactoferrin is an iron-binding protein that is present in relatively high concentrations during the dry period. It prevents the growth of bacteria by removing iron from udder secretions (bacteriostatic mechanism). Lactoperoxidase is an enzyme that is bacteriostatic on gram-positive bacteria and bactericidal on gram-negative bacteria.

Normal milking has a flushing effect, removing bacteria from the udder (e.g. in three-times-a-day milking). Inducible defence mechanisms, whereby the inflammatory response recognizes the presence of bacteria in the udder, acts via a variety of mechanisms to eliminate the bacteria (e.g. migration of leucocytes into the udder that increase the SCC).

Identification of mastitis pathogens

Bacteriology is an essential tool in the investigation and monitoring of mastitis and the prescription of suitable



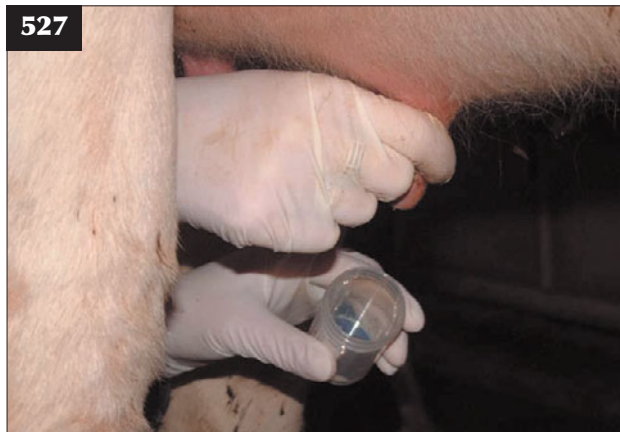526 Trends in somatic cell count over time can be used as part of the investigation of herds with somatic cell count issues, such as this herd with a chronic *Staph. aureus* problem manifest as high levels of chronically infected cows. (Graphical output based on NMR Herd Companion.)

intramammary and parenteral antibiotics. Samples must be taken **prior** to antibiotic treatment, or a period of at least seven days should elapse from the last antibiotic treatment before sampling so that inhibitory substances are not present in the milk. Samples can be taken either from clinical cases of mastitis or cows with high SCCs (identified by ICSCC and/or CMT).

A suitable method for taking aseptic milk samples for bacteriology would include the following (527):

- Wear clean gloves to collect milk sample.
- Wash gross contamination from the teat and dry.
- Pre-dip teat, allowing 30 seconds' contact time.
- Dry the teats.
- Strip foremilk (6–8 strips) to remove any teat canal contaminant bacteria.
- Clean and disinfect teat by scrubbing with cotton wool swab containing 70% alcohol.
- Repeat until swab is clean.
- Dry.
- Collect sample, holding collection tube as horizontally as possible to prevent dirt entering the tube.
- Do not touch the rim of the sample pot with the teat or your fingers.
- Label with cow number, quarter, date and farm identity.
- Store at 4°C until transported to laboratory.

Milk samples may also be frozen after collection. This can lead to a reduction in the number of gram-negative bacteria in the sample unless cryopreservatives such as glycerol are used. The advantage of freezing samples is that they can be sent to the laboratory in batches, thus reducing costs. Freezing samples also enables ongoing investigation of mastitis problems, gives improved sample quality and samples may be stored from initial sporadic cases in case a problem arises in the future.



527 An aseptic milk sampling technique is essential for obtaining good samples for bacteriology.

Bacteriology enables the identification of the predominant mastitis pathogens in the herd, provided enough representative samples have been taken. The disadvantages are the cost and time taken for results to be reported. A rapid culture technique has been developed (HyMast Milk Bacteriological Test System) for the differential identification of gram-positive or gram-negative mastitis pathogens within 12 hours. This can be used to support treatment options, as can PCR-based testing methods.

Approximately 20% of clinical mastitis cases yield no significant growth on standard bacteriological culture due to insufficient numbers of bacteria in the sample, intermittent excretion, walled-off abscesses within the udder, inhibitory substances in the milk or the presence of atypical pathogens (such as moulds).

MANAGEMENT

Treatment protocols for mastitis are based on the following parameters:

- Severity of mastitis: mild (Grade I), moderate (Grade II) or severe (Grade III).
- Potential mastitis pathogens involved.
- Stage of lactation.
- Previous history and experience on the farm.

Supportive therapy without use of antibiotics

In herds with a low BMSCC and low prevalence of contagious pathogens, some authors advocate that mild clinical cases of environmental mastitis (assumed to be caused by gram-negative pathogens) can be treated without recourse to antibiotics, but by frequent quarter stripping with or without the use of oxytocin, a decision supported by the high spontaneous cure rates for such cases (upwards of 70%). The authors of this book would argue that the development of chronic recurrent coliform mastitis and the welfare of the cow are sufficient reasons for treating such cases with antibiotics.

Intramammary antibiotic therapy

Mild (Grade I) cases will usually be treated using antibiotic intramammary tubes alone without a veterinary visit. Treatment should be continued to obtain a complete bacteriological cure (up to 5–7 days), although in most cases farmers treat until resolution of clinical signs. Veterinary advice should formulate a policy regarding drug/product to be used, length of treatment, milk withholding time and sampling protocol prior to treatment.

Treatment success rates during lactation vary widely according to the pathogen involved, with coliform and *Strep. agalactiae* having success rates over 90%, whereas treatment of *Staph. aureus* can have success rates as low as 35%. Age and number of quarters affected can also affect treatment outcomes: older cows with multiple quarters affected tend to have poorer treatment success rates.

Choice of antibiotic will obviously depend on the

organism involved. As a general rule, *Streptococcus* spp. do not produce β -lactamase and so synthetic penicillins should be effective. Clavulanic acid, cloxacillin and newer generation cephalosporins would be suitable for β -lactamase-producing *Staph. aureus* strains. Aminoglycosides are often included for gram-negative activity. As most pathogens are not identified at the start of therapy, most intramammary antibiotic preparations are broad spectrum, with activity against all the major mastitis pathogens.

The response of *Strep. agalactiae* to antibiotic therapy is usually good, as it is sensitive to most commonly used antibiotics. As it is an obligate pathogen of the bovine udder, it can be eliminated from the herd by application of the '5/6-point mastitis control plan' (see p. 226) and treatment of all cows in the herd with antibiotic therapy (so-called blitz therapy).

Staph. aureus is notoriously difficult to treat, leading to the formation of chronic infections with extensive fibrosis and induration of the udder. Treatment success rates of 25–40% are usually quoted for the treatment of *Staph. aureus* mastitis during lactation, although cure rates can be higher in first-lactation cows with single quarters affected. Reasons for the poor treatment rates include: poor antibiotic penetration due to extensive udder fibrosis; production of β -lactamase by the majority of *Staph. aureus* strains; persistence of bacteria within macrophages and other cell types; development of 'L forms', capsules and bacterial dormancy that renders the bacteria insensitive to antibiotic treatments; and insufficient duration of antibiotic treatment.

Improvements in the success rate for treatment of *Staph. aureus* infections can be achieved using extended therapy products (such as pirlimycin for eight days), using parenteral as well as intramammary antibiotic therapy (see following section) and treatment during the dry period (where cure rates >60% are reported). Treatment of *Staph. aureus* infections during the dry period can involve the use of intramammary dry cow products (usually including cloxacillin or cephalosporins for activity against β -lactamase-producing strains), as well as parenteral therapy (e.g. tylosin) at drying off.

Indeed, treatment of chronic intramammary infections during the dry period is preferable because of enhanced success rates, lack of milk withhold times and a reduction in the contribution of SCCs to the bulk tank. Although standard dry cow therapy is the preferred choice (see later), drying off infected quarters during lactation (without antibiotic therapy) to allow prolonged recovery has been reported.

Intramammary and parenteral antibiotic therapy

Treatment using both intramammary and parenteral antibiotic therapy is indicated in moderate (Grade II) mastitis cases, as well as in cases of mastitis caused by organisms that can be difficult to treat effectively, such as

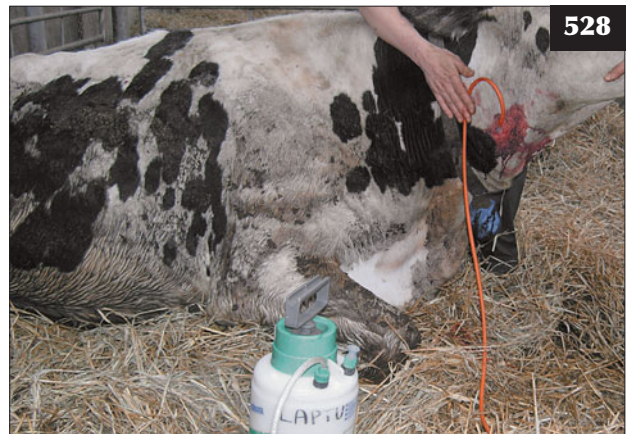Staph. aureus and *Strep. uberis*. Some antibiotic products are licensed for combined intramammary and parenteral therapy, although a number of other parenteral antibiotics can be used 'off label' in combination with intramammary antibiotics, provided that statutory milk withhold periods are observed. Tylosin has good reported success rates against *Staph. aureus* and other gram-positive infections. Penethamate hydriodide injection is useful for *Strep. uberis* mastitis. Potentiated sulphonamides, oxytetracycline and framycetin can be used in moderate and severe coliform mastitis cases.

Veterinary attention is usually sought for moderate (Grade II) clinical mastitis cases that may require NSAID administration and other supportive therapy.

Treatment of severe (Grade III) mastitis

Severe mastitis caused by coliform organisms

Generalized endotoxaemia results in hypovolaemia, reduced cardiac output and inadequate tissue perfusion. The aim of fluid therapy is to correct the circulating blood volume – a 600 kg cow that is around 7% dehydrated requires more than 40 litres of isotonic fluid to restore the circulating blood volume, with daily losses almost twice that volume. Options to correct this initial deficit include oral fluids (administered using an Agger's pump), intravenous isotonic fluids (prohibitively expensive when using sterile fluids) and intravenous hypertonic fluids. The treatment of choice is initial intravenous infusion of 3 litres of hypertonic (7.2%) sodium chloride over 5–7 minutes, after which the cow will drink up to 40 litres of warm water (528). A pressure pump device or a 12 gauge intravenous catheter with the infusion bag suspended as high as possible should ensure infusion within 5–7 minutes. Large volumes (16 litres) of non-sterile isotonic (0.9%) intravenous fluids administered using pressure



528 Intravenous infusion of 3 litres of hypertonic (7.2%) sodium chloride over 5–7 minutes using a pressure pump device.

pumps are used by some practitioners, but this treatment has largely been replaced by sterile hypertonic saline.

NSAIDs, such as flunixin meglumine, reduce pyrexia, counteract endotoxaemia and reduce pain and should be administered intravenously initially, then for 2–3 consecutive days. The debate over the usefulness of antibiotics in cases of coliform mastitis continues, but most veterinary surgeons administer both intramammary and parenteral antibiotics. Antibiotics commonly used include potentiated sulphonamides, oxytetracycline and clavulanic acid-potentiated amoxicillin. Many cases of coliform mastitis are hypocalcaemic, but intravenous calcium solutions should be administered with caution and very slowly. Regular stripping of affected quarter(s) is essential to remove inflammatory products from the udder and should be performed as often as practical (every two hours initially). Oxytocin (20 iu i/m) may assist in milk 'let-down'. The cow should be provided with a comfortable lying area with a plentiful supply of food and water (529). Other supportive therapies include multivitamin injections and intravenous glucose.

Severe mastitis caused by *Staph. aureus*

Clavulanic acid-potentiated amoxicillin or tylosin are the antibiotics of choice, otherwise supportive therapy as described for coliform mastitis. Removal of the teat once the affected gland becomes cold with blue-black discolouration of the skin in order to facilitate drainage is sometimes performed, but is of little benefit.

Severe mastitis caused by *Strep. uberis*

Treatment is as for coliform mastitis except that penicillin or penethamate are the antibiotics of choice.

Vaccination

The only vaccine against mastitis in common usage worldwide is the *E. coli* J-5 strain. The vaccination schedule requires a course of three injections (at drying-off, one month after drying-off and two weeks after calving). It does not stop new infections occurring, but it



529 This cow has a comfortable lying area and a plentiful supply of food and water.

reduces the severity of clinical signs and hence the number of clinical cases. It has greatest benefit in reducing the fatalities associated with severe coliform mastitis.

Vaccines have been developed experimentally against *Staph. aureus* with the aim of both preventing infection and also enhancing the response to treatment. However, success has been limited and not as effective as standard control measures. A commercial vaccine is available against mycoplasmal mastitis in the USA, although it does not prevent infection or subsequent shedding of bacteria. Its benefit in the control of mycoplasmal mastitis outbreaks compared with test and cull strategies is therefore debatable.

Prevention/control measures

Research in the 1960s formed the basis of important mastitis control measures for contagious pathogens, in particular the '5/6-point mastitis control plan':

1. Regular milking machine maintenance.
2. Post-milking teat disinfection.
3. Dry cow therapy.
4. Prompt treatment and recording of all clinical cases.
5. Culling of chronic mastitis cases.
6. Milking parlour hygiene.

Regular milking machine maintenance

Liners should be changed on a regular basis (usually after 2,500 milkings or six months, whichever comes first). Routine servicing and maintenance is essential, and the milking machine should be checked on a six monthly basis using both static and dynamic testing. Teat scoring can also be used to check on the potential damage to the cows' teats from the milking machine (see Milking machine-induced teat lesions, p. 233).

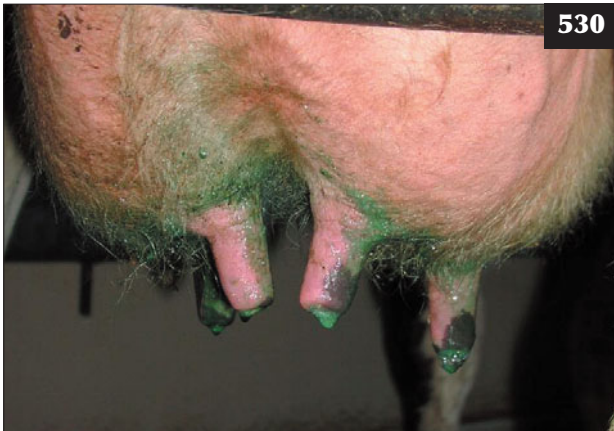Teat disinfection

Post-milking teat disinfection is performed for three major reasons: removal of contagious mastitis pathogens from the teat skin; removal of bacteria from the teat; and improving teat skin quality. However, post-milking teat disinfection has no effect on existing intramammary infections. Whether applied by spray or dip, it is essential to ensure good teat coverage by the disinfectant (530).

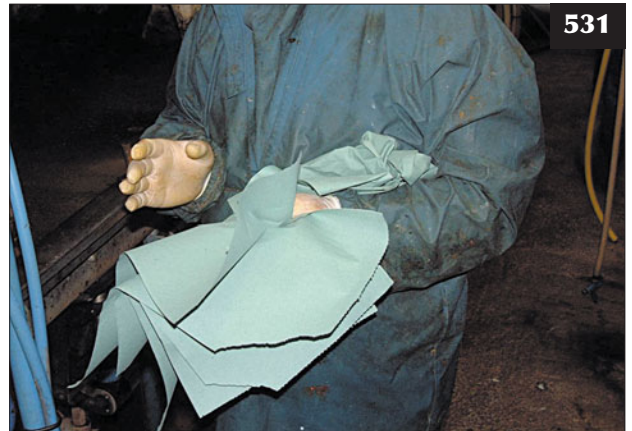Pre-milking teat disinfection is used as a control measure against environmental mastitis pathogens by disinfecting the teat and reducing superficial teat contamination. It also reduces the number of bacteria in the bulk milk. Teats should be foremilked, washed and dried prior to application of pre-dip. The teats should be coated in pre-dip, allowed a minimum of 30 seconds contact time and then wiped off.

Dry cow therapy

The main aims of dry cow therapy are treatment and cure of existing infections (e.g. *Staph aureus*) and prevention of new environmental infections, as 50% of all cases of



530 Good teat coverage has been achieved in this cow where the post-milking disinfectant has been applied by spray.



531 Milkers should wear disposable gloves, which are rinsed in disinfectant on a regular basis during milking. A dry wipe with a single paper disposable towel per cow prevents the spread of contagious mastitis pathogens from cow to cow.

coliform mastitis occurring in early lactation are a direct result of infections acquired during the dry period. Cows should be dried off abruptly (not milked once a day).

Considerations for the choice of dry cow therapy include duration of action and persistence of activity during the dry period (antibacterial activity may vary from three to ten weeks' duration), milk withdrawal periods and antibacterial activity. The most common subclinical infections that require treatment in the dry period are *Staph. aureus* (70% of isolates produce β -lactamase) and *Strep. uberis*, whereas the most common infections that may become established during the dry cow period are *Strep. uberis* and *E. coli*. Summer mastitis may also be a problem on particular farms.

Bacteriological cure rates can be as low as 30% in the treatment of chronic recurrent cases of *Staph. aureus* mastitis. Improved cure rates at drying off may be achieved by treatment with parenteral antibiotics (such as clavulanic acid-potentiated amoxicillin or tylosin) either at drying off or three weeks prior to calving.

Several types of dry cow therapy are available:

- Antibiotic dry cow therapy. This will both treat existing infections and prevent new intramammary infections, depending on the duration of activity. Antibiotics used include penicillin, framycetin, penethamate, cloxacillin and cephalonium (the latter two products are active against β -lactamase-producing bacteria).
- External teat sealants are polymer-based teat dips that are applied twice weekly and dry to give a physical seal around the teat. Their main use is on organic dairy farms and to prevent new environmental infections in first-calving heifers.
- Internal teat sealants, which use an inert paste containing 65% bismuth subnitrate that remains in

the base of the teat cistern and teat canal, preventing the introduction of new environmental infections during the dry period. They cannot treat existing intramammary infections unless used in combination with antibiotic dry cow therapy. Cows with an ICSCC <200,000 cells/ml in the last three months of lactation can be dried off using internal teat sealants alone, whereas cows with a high ICSCC should be treated with antibiotic dry cow therapy.

Accurate records

Accurate records will enable prompt and thorough investigation of any mastitis problem, identification of cows for treatment and/or culling and monitoring of the performance of the herd. Records should be kept for each case of mastitis, including cow ID, date, quarter(s) infected, treatments given and their withdrawal periods, as well as bacteriology results.

Culling of chronic cases

Culling is one method of removing cows with high SCC or recurrent mastitis from the herd. Current recommendations suggest that cows that have had three or more outbreaks of mastitis in the same quarter in the same lactation, five cases of mastitis in all quarters in the same lactation or a high SCC (>500,000 cells/ml) for three months should be culled, as they will probably never be cured.

Milking parlour hygiene

Cow to cow spread of contagious pathogens occurs during the milking process. Milkers should wear disposable gloves (531), with frequent rinsing in disinfectant. Teats should be clean and dry prior to attachment of the cluster. Grossly contaminated teats should be washed and dried, whereas

clean teats need a dry wipe with a single-use, disposable paper towel (531). Communal udder cloths spread infection from cow to cow, and should **never** be used. Wet teats lead to liner slip and impact forces, and dirty teats lead to raised bacteria levels in milk and predispose to environmental mastitis.

Pre-milking teat disinfection can help to reduce the incidence of environmental mastitis, whereas post-milking teat disinfection helps in the control of contagious mastitis and should always be properly practised. Because of the potential spread of bacterial pathogens from cow to cow during the milking process, the ideal milking order is to milk the most susceptible cows first (fresh calvers and high yielders) and those with high ICSCC and mastitic cows last.

The control of environmental pathogens is based on improving environmental hygiene, reducing the level of contamination at the teat end, optimizing teat end defences and improving the immune response of the cow. The udder is most susceptible to new environmental intramammary infections during the first two weeks and the last two of the dry period and during early lactation.

Environmental hygiene

Cubicles must be the correct size and allow good cow comfort. Straw bedding can predispose to *Strep. uberis*, whereas sawdust can predispose to coliform mastitis; sand is very good for mastitis control (532). In straw yards, fresh bedding should be applied daily and they should be cleaned out every 4–6 weeks. Calving boxes must be clean and dry. The rear of cubicles and passageways must be regularly scraped.

Reducing contamination at the teat end

Cleaning and drying of teats prior to cluster attachment is vital, as is pre-milking teat disinfection. It is important to prevent cows lying down immediately after post-milking teat dipping (30 minutes standing) in order to allow full closure of the teat canal.

Optimizing teat defences

Milking machine maintenance is essential to prevent propulsion of bacteria into the udder. Teat scoring is used to assess teat end damage (see Milking machine-induced teat lesions, p. 233).

Immune response of cow

Milk fever, dystocia and 'downer cows' should be prevented by good husbandry. Vaccination using the *E. coli* J-5 strain reduces the severity of clinical signs and number of clinical cases.

APPROACH TO A HERD WITH A HIGH INCIDENCE OF CLINICAL MASTITIS

The initial investigation involves examination of mastitis records (mastitis rate, percentage of the herd affected, recurrence rate, milking cow tube usage) and noting the

seasonal variation often present with environmental pathogens. In addition, bulk tank analysis, SCCs and milk bacteria level trends over the past year should be considered.

Cows with mastitis must be inspected and managed. Bacteriology of clinical cases and high ICSCC cows prior to treatment, treatments used (i.e. lactating and dry cow intramammary tubes), teat scoring for hyperkeratosis, teat end eversion and teat skin condition (see Milking machine-induced teat lesions, p. 233) are also important.

The farm environment, housing (533, 534), cleanliness of the cows, milking machine maintenance and operation and the farm policy on treatment of mastitis should be taken into account.

This approach should lead to the identification of the predominant pathogen causing the mastitis problem, and control measures can be directed towards this.


SUMMER MASTITIS

DEFINITION/OVERVIEW

Because of its unusual aetiology and epidemiology, summer mastitis is considered separately from the other causes of mastitis. It is a disease of late gestation in dry cows and heifers (but may even occur in the rudimentary udders of young heifers, bulls and steers), and occurs at grass during the summer months.

AETIOLOGY

Bacterial causes include *Arcanobacterium pyogenes*, *Peptostreptococcus indolicus* and *Strep. dysgalactiae*. A variety of other bacteria, including microaerophilic cocci, *Bacteriodes melaninogenicus* and *Fusobacterium*



532 Sand-bedded cubicles can be an excellent management factor in the control of environmental mastitis.

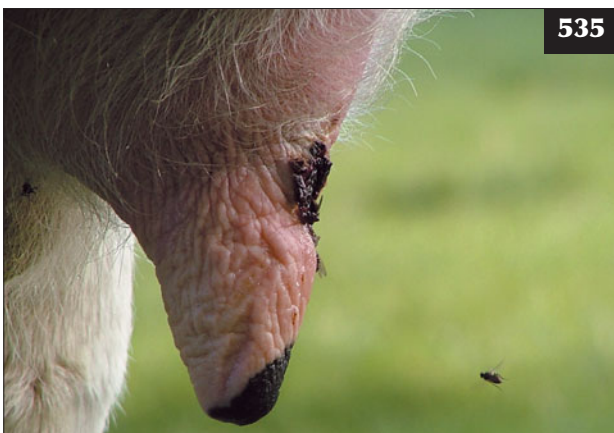


533



534

533, 534 The cleanliness of the housing environment, be it a straw-bedded shed (**533**) or a cubicle system (**534**), should be assessed in all herd mastitis investigations.



535

535 The major factor in the transmission of summer mastitis infection is thought to be the head fly (*Hydrotea irritans*), shown here feeding on a teat sore.

necrophorum, have been implicated. The three main bacteria are believed to act synergistically to cause summer mastitis. The major factor in the transmission of infection is thought to be by the head fly (*Hydrotea irritans*). These flies live in bushes and trees and can only fly during dry conditions and low wind speeds, therefore cases tend to be associated with 'problem fields' next to woods (**535**).

CLINICAL PRESENTATION

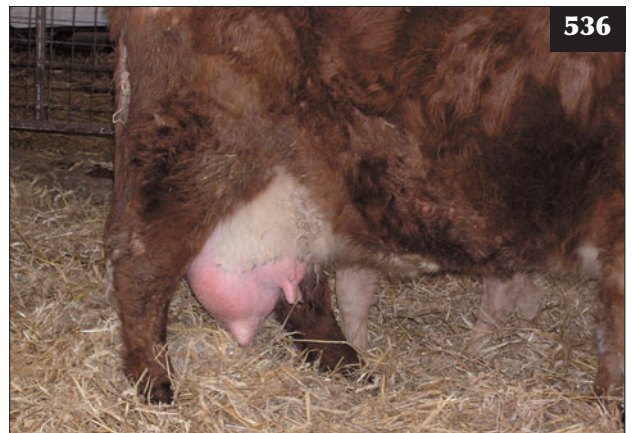
During the early stages the affected teat and associated mammary gland are swollen, but this stage quickly progresses to systemic disease. Severely affected animals are pyrexia, stiff and lame due to the painful quarter. Cattle are dull and inappetent and isolate themselves from others in the group. Oedema may extend around the udder and up the inside of the leg. In severe cases there are marked joint effusions affecting mostly the hock and fetlock joints. The affected quarter is swollen, hard, painful and hot, with a grossly enlarged teat (**536**). The udder secretion is thick and clotted with foul-smelling green/yellow pus. Affected animals may abort and even die if prompt treatment is not administered. Even after prompt treatment, the affected quarter is permanently damaged. Illness leads to the birth of weakly calves (acute intra-uterine growth retardation), which have a high mortality rate.

DIFFERENTIAL DIAGNOSIS

Redwater; impending abortion; bacterial endocarditis.

DIAGNOSIS

Diagnosis is based on finding a swollen and oedematous quarter(s) in a non-lactating cow. Bacteriology is rarely undertaken.



536

536 A beef cow with summer mastitis showing a swollen teat and udder in the affected quarter. A thick purulent discharge can be stripped from the teat.

MANAGEMENT

Treatment is with parenteral antibiotic injections including either procaine penicillin, potentiated sulphonamides or tylosin. Intramammary antibiotics (penicillin or intramammary erythromycin tubes) should also be given. NSAID injections for three consecutive days reduce pyrexia, swelling and pain; corticosteroids reduce joint effusions much more effectively, but will induce abortion and therefore must not be used. Stripping of the udder manually should be undertaken as often as is practical, but it is resented by the animal owing to the painful and oedematous teat/gland.

Amputation of the affected teat is often requested by farmers to facilitate drainage, but there is the risk of considerable haemorrhage and the teat amputation site rapidly seals over. Two methods are used:

- A 5 mm umbilical tape ligature is tightened around the base of the teat. The teat is then amputated distal to the tape and the ligature removed after several hours.

This results in much less haemorrhage, but equal drainage.

- A vertical incision is made into the teat cistern along the length of the teat including the teat orifice. This results in good drainage, but much less haemorrhage.

Summer mastitis can be prevented by reducing exposure to causative organisms by grazing cows away from susceptible fields. Fly control measures (usually synthetic pyrethroids) include methods such as impregnated fly tags, pour-on preparations and sprays. The teat canal can be sealed using physical barriers such micropore/adhesive tape and external teat sealants. Weekly application of Stockholm tar to the teats is practised by some farmers during risk periods. Dry cow therapy is frequently used. When used in heifers, great care is required to infuse the preparation with the infusion syringe nozzle held firmly against the teat orifice and not inserted. Affected cows must be removed from other cows (as the affected cow is a potential source of infection).

INFECTIOUS TEAT DISEASES PAPILLOMATOSIS (WARTS)

DEFINITION/OVERVIEW

Most teat warts are seen in pregnant heifers and usually resolve before these animals enter the milking herd. Fibropapillomas that present in milking cows can predispose to mastitis and cause mechanical interference with milking.

AETIOLOGY

Several strains of bovine papillomavirus cause teat warts. Where there is poor herd immunity, virus transmission occurs at milking time via the milking parlour attendants' hands and milking machinery.

CLINICAL PRESENTATION

There are two main skin lesions: flat/rice-grain fibropapillomas, which are seldom of clinical significance; and the more florid-type of projecting fibropapilloma (537–539), which may cause problems should they interfere with milking.

DIFFERENTIAL DIAGNOSIS

Trauma; skin chaps; dirt attached to teat skin.

DIAGNOSIS

Diagnosis is based on clinical examination.

MANAGEMENT

Most papillomas will resolve without treatment; however, farmers will often request treatment if the papillomas are interfering with milking. Large, frond-like warts can be removed by applying forcep clamps to the base of the wart before cutting with scissors. Applying elastrator rings around the base of larger pedunculated warts is often possible. Cryotherapy has also been reported to be successful. Large warts may be removed and the material used to make an autogenous vaccine.

Prevention is by minimizing the risk of transmission by milking parlour hygiene and using virucidal teat dips.

HERPES MAMMILLITIS (BOVINE ULCERATIVE MAMMILLITIS)

DEFINITION/OVERVIEW

Herpes mammillitis is normally seen during the autumn/winter months. In a naïve dairy herd, infection spreads rapidly, but more usually disease is seen when susceptible heifers enter the milking herd.

AETIOLOGY

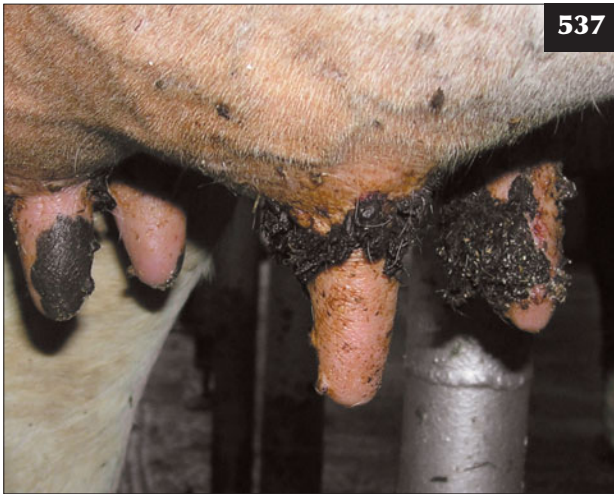Herpes mammillitis is caused by bovine herpesvirus 2 (BHV-2).

CLINICAL PRESENTATION

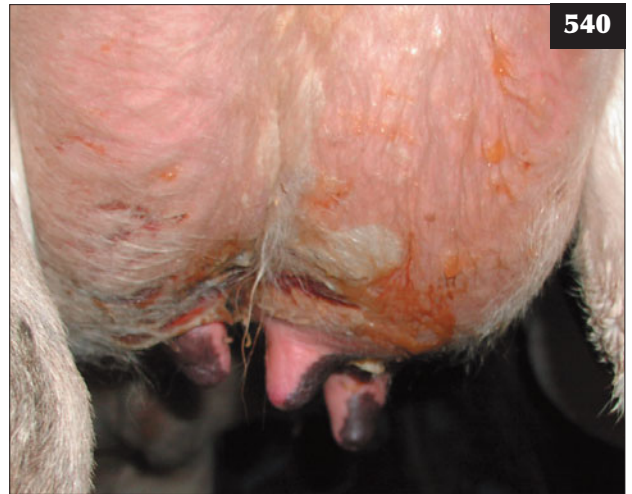Initially, widespread vesicles (0.5–5.0 cm) form on the teats and base of the udder. These quickly rupture to form painful ulcerative lesions that become covered in dried serum exudate, forming thick brown scabs (540–542). Healing takes place over 2–3 weeks. Another manifestation of this disease, pseudo-lumpy skin disease (Allerton virus), has been described with multifocal raised circular lesions (up to 2 cm diameter) developing over the body. The lesions are raised, hairless and form scabs that slough but rarely ulcerate. Healing takes place without treatment.

DIFFERENTIAL DIAGNOSIS

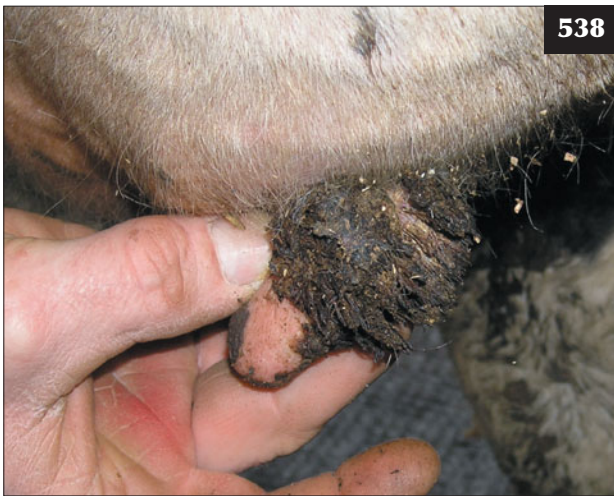Foot and mouth disease; bluetongue; vesicular stomatitis; photosensitization.



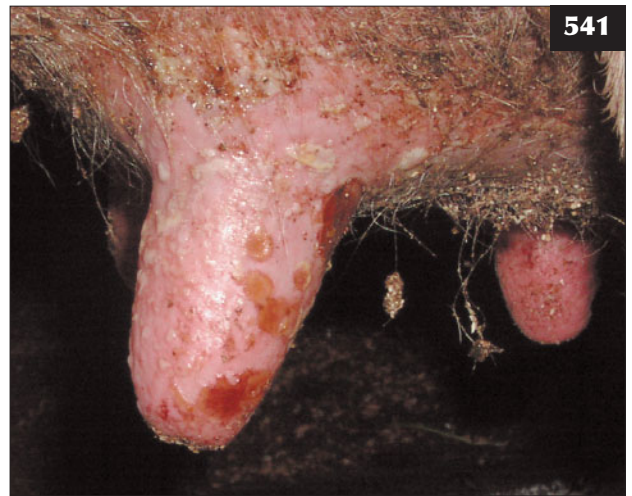537



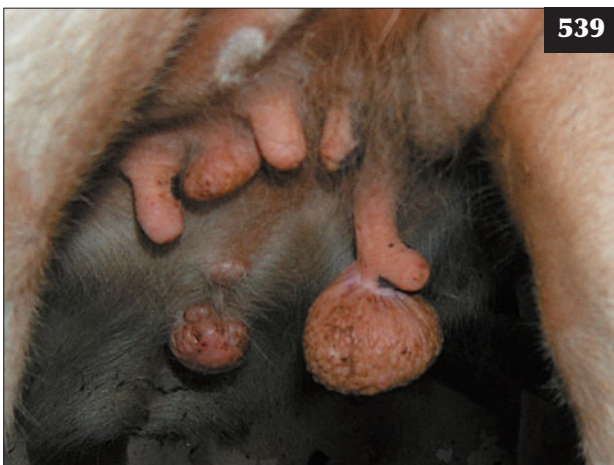540



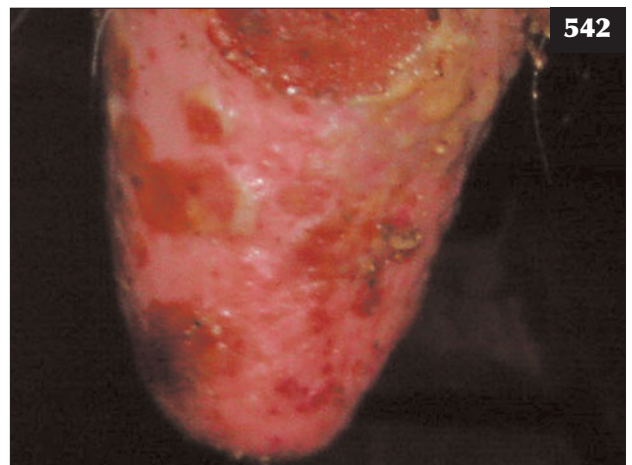
538



541



539



542

537–539 Teat warts on heifers can be small rice-grain type lesions (**537, 538**) or more florid projecting growths (**539**) that can interfere with milking.

540–542 With herpes mammilitis, widespread vesicles (0.5–5.0 cm) form on the teats and base of the udder (**540**). These quickly rupture to form painful ulcerative lesions (**541**) that become covered in dried serum exudate, forming thick brown scabs (**542**).

DIAGNOSIS

The clinical signs are pathognomonic for herpes mammillitis, but virus isolation can be attempted from fluid aspirated from early vesicles.

MANAGEMENT

Symptomatic treatment of teat lesions includes antiseptic udder creams and iodine-based teat dips. Cows may prove difficult to milk because of the painful teats and secondary mastitis may result if lesions affect the teat orifice.

Milking affected cows last and disinfecting clusters carefully will reduce spread of the disease.

PSEUDOCOWPOX**DEFINITION/OVERVIEW**

Pseudocowpox is a common disease of dairy cows. Immunity is short-lived, resulting in endemic infection.

AETIOLOGY

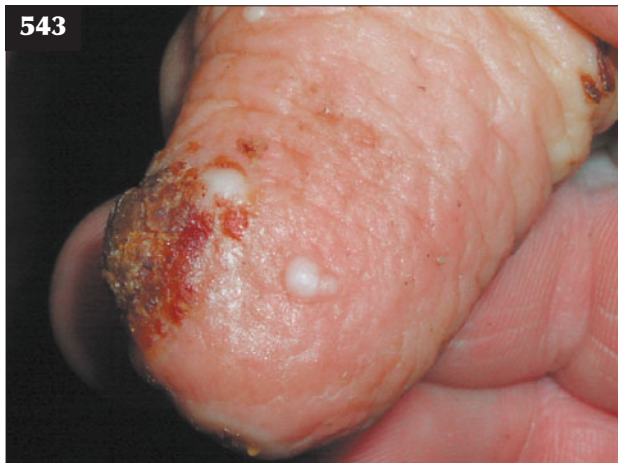Pseudocowpox is caused by a parapoxvirus (see also Chapter 3, Part 1, Bovine papular stomatitis, p. 63).

CLINICAL PRESENTATION

Initially, erythematous and oedematous painful lesions appear on the teats and these soon become raised orange papules then small dark red scabs (543). Vesicles are rare with this disease. The scabs are shed after 10–12 days leaving the classic raised ‘horseshoe’ or ring lesion. Complete healing of teat lesions may take 4–5 weeks. The virus can cause localized painful nodules on the hands and arms of in-contact humans.

DIFFERENTIAL DIAGNOSIS

Milking machine-induced teat lesions; chronic herpes mammillitis lesions; teat injuries.



543 Cow with a pseudocowpox lesion.

DIAGNOSIS

The raised ‘horseshoe’ or ring lesion on the teat is pathognomonic for pseudocowpox.

MANAGEMENT

The lesions do not cause problems unless present on the teat orifice, when they predispose to mastitis.

Good milking parlour hygiene may limit spread.

COWPOX AND VESICULAR STOMATITIS

Cowpox, caused by an orthopoxvirus, and vesicular stomatitis, caused by a rhabdovirus, can result in teat skin lesions in regions where these diseases are endemic.

UDDER IMPETIGO/NECROTIC DERMATITIS (UDDER ROT)**DEFINITION/OVERVIEW**

Udder impetigo is a superficial skin infection of the udder, which although unsightly, is usually of minor clinical significance.

AETIOLOGY

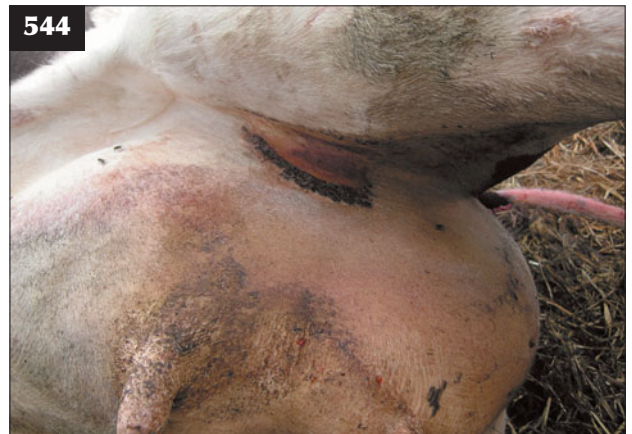Udder impetigo/necrotic dermatitis is caused by a superficial infection with *Staphylococcus* spp.

CLINICAL PRESENTATION

Necrotic dermatitis presents in the udder skin where it apposes the medial thigh (544) and, occasionally, in the ventral midline immediately cranial to the udder. Severe infection can give rise to multiple small pustular lesions, which may sometimes spread onto the teats. The condition is more common in heifers, especially those with considerable udder oedema (see Udder oedema, p. 233).

DIFFERENTIAL DIAGNOSIS

Udder oedema; trauma and wounds to the udder.



544 Necrotic dermatitis in the medial thigh of a Holstein cow close to calving.

DIAGNOSIS

Diagnosis is based on clinical findings.

MANAGEMENT

Treatment is symptomatic with topical antibacterial creams.

The disease is controlled by improved environmental hygiene and topical treatment of skin lesions with antibacterial washes.

NON-INFECTIOUS LESIONS OF TEAT SKIN**UDDER OEDEMA****DEFINITION/OVERVIEW**

This is a common problem affecting periparturient dairy cattle, especially heifers.

AETIOLOGY

Udder oedema is a physiological phenomenon related to nutrition (high concentrate feeding, dietary sodium or potassium excess) and circulatory disturbance of udder vessels.

CLINICAL PRESENTATION

Animals are clinically normal except for hindlimb abduction when walking. In severe cases there is extensive pitting oedema of the udder and teats extending to involve the ventral midline subcutaneous area (545). Most cases resolve soon after calving when milking is initiated, but in severe cases treatment may be required.

DIFFERENTIAL DIAGNOSIS

Other causes of oedema including cardiac failure; mastitis.

DIAGNOSIS

Diagnosis is based on clinical findings of widespread oedema.

MANAGEMENT

Milking can be started prior to calving. Oedema can be greatly reduced following a corticosteroid injection, but this will also induce calving around 36 hours later. Diuretic injections (e.g. frusemide) and NSAIDs will aid elimination of oedema.

Prevention is by avoiding excessive body condition (>3.0; scale 1 to 5) and too high energy/concentrate feeding during late gestation.

TEAT CHAPS**DEFINITION/OVERVIEW**

Teat chaps are very common in both lactating beef and dairy cows.

AETIOLOGY

Teat chaps can be caused by badly fitting teat cup liners,



545 Udder oedema in a dairy heifer approaching parturition.

poor hygiene conditions and low temperatures. They serve as a reservoir for contagious mastitis pathogens. In beef cows, lesions may be caused by aggressive suckling by calves and aggravated by fly bite damage (especially *Hydrotaea irritans*).

CLINICAL PRESENTATION

Teat chaps appear as horizontal skin breaks in the teat skin. They may cause discomfort when the cow is milked or suckled.

DIFFERENTIAL DIAGNOSIS

Papillomatosis; trauma to teats.

DIAGNOSIS

Diagnosis is based on clinical findings. Teat lesions may predispose to summer mastitis.

MANAGEMENT

Treatment is with teat dips containing glycerine or lanolin and using physical barriers such as micro tape.

Teat dips containing glycerine or lanolin and fly control should reduce the prevalence of chaps.

MILKING MACHINE-INDUCED TEAT LESIONS**DEFINITION/OVERVIEW**

Milking machine-induced teat lesions will occur at low levels in the vast majority of dairy herds, although a prevalence of >20% of teat ends with hyperkeratosis would indicate a problem with milking machine function, which will predispose cows to mastitis.

AETIOLOGY

Poor milking routine, incorrect vacuum pressure, liner slip or overmilking can lead to a high prevalence of teat end lesions.

CLINICAL PRESENTATION

Hyperkeratosis caused by prolapse/eversion of the streak canal lining may become traumatized and infected. Secondary infection with *Fusobacterium necrophorum* leads to dark scabby lesions known as blackspot.

DIFFERENTIAL DIAGNOSIS

Trauma; prior surgery to teat end to remove obstructions.

DIAGNOSIS

Diagnosis is based on clinical assessment of teat lesions on a herd basis using teat scoring. Teats should be evaluated immediately after cluster removal, using adequate lighting. It is recommended that at least 80 cows (or 20% of the herd) are scored. Teat scoring systems evaluate teat colour (normal, red, white or blue), swelling at the teat base ('rings'), teat end swelling, open teat orifice, teat skin condition, vascular damage and hyperkeratosis (546–550). The lesions are classified as: normal or Grade 0; slightly rough or Grade 1; rough or Grade 2/3; very rough or Grade 4/5.

MANAGEMENT

The milking routine and parlour machinery maintenance should be reviewed. Teat end scoring can be used as a way of monitoring milking machine function and is often part of a structured mastitis investigation.

TEAT LACERATIONS

DEFINITION/OVERVIEW

Traumatic teat injuries are not uncommon in dairy cows with pendulous udders and are usually caused by treading on the teats. Most teat injuries are treated conservatively, but surgical repair can be attempted.

AETIOLOGY

Teat lacerations are usually caused by treading injuries. Occasionally, traumatic injury from sharp protrusions/ wire cuts can occur.

MANAGEMENT

Teat injury that does not involve the teat cistern should be cleaned with mild antiseptic solution and any loose or devitalized skin debrided with a scalpel blade, allowing healing by second intention. A sterile teat cannula can be inserted if the cow will not tolerate the milking machine. Strict attention to hygiene must be observed when using a teat cannula because there is a high risk of mastitis.

Surgical repair of teat injuries is problematic and many wounds break down following secondary infection. Lacerations into the teat cistern require surgical repair, otherwise a leaking fistula will develop. The cow should be sedated and the teat anaesthetized with a simple ring block of 2% lidocaine injected at the base. The wound must be meticulously cleaned and debrided. Fine absorbable suture material on an atraumatic needle is used

for the mucosa and submucosal layers and the teat skin sutured with fine monofilament nylon or repaired with stainless steel staples. A teat cannula should be inserted in order to avoid milking until healing is complete.

TEAT CISTERN OBSTRUCTIONS

DEFINITION/OVERVIEW

Teat obstructions are encountered relatively commonly in dairy herds. They interrupt the milk flow, resulting in teat end damage and an increased risk of mastitis.

AETIOLOGY

Occasionally, newly calved heifers are presented with blind quarters, which may be a consequence of congenital blockages or prior mastitis.

Most acquired teat obstructions are caused by proliferative granulation tissue, mucosal injury or fibrosis secondary to teat trauma. The two most common lesions are teat peas (or 'floaters') and 'pencil' obstructions. Teat peas are small fibrous lesions that can be free in the teat lumen or attached by a stalk to the mucosal lining, blocking the opening to the streak canal.

Pencil obstructions may follow diffuse teat trauma leading to chronic granulomatous reaction of the teat mucosa. Milk will only flow in very small amounts and a firm 'pencil-like' obstruction can be palpated within the teat cistern.

MANAGEMENT

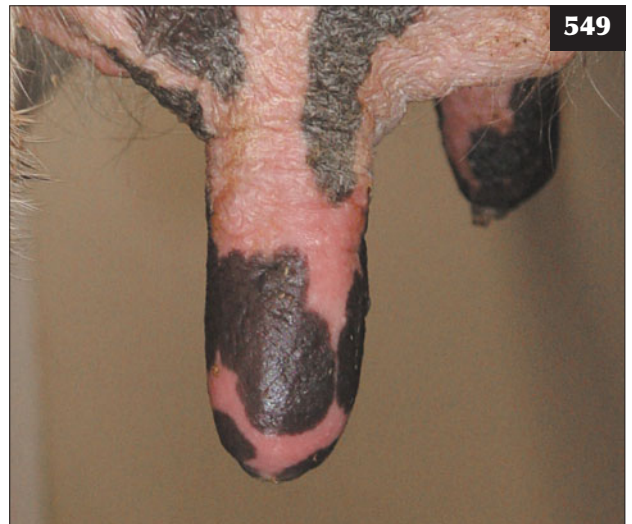
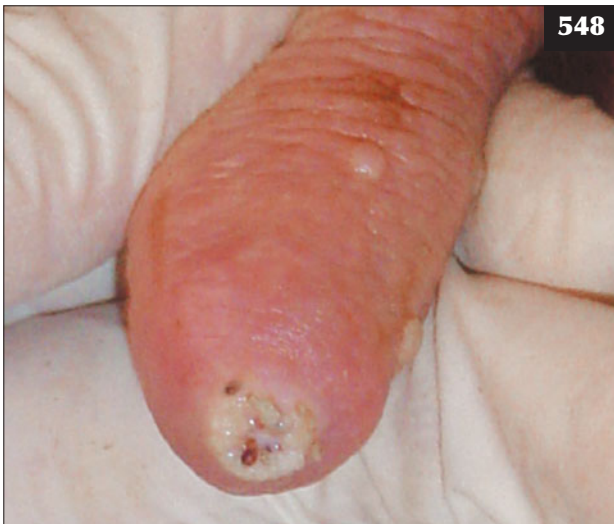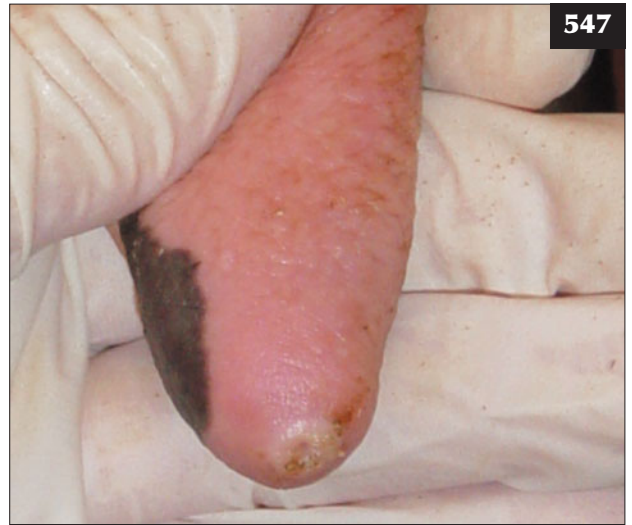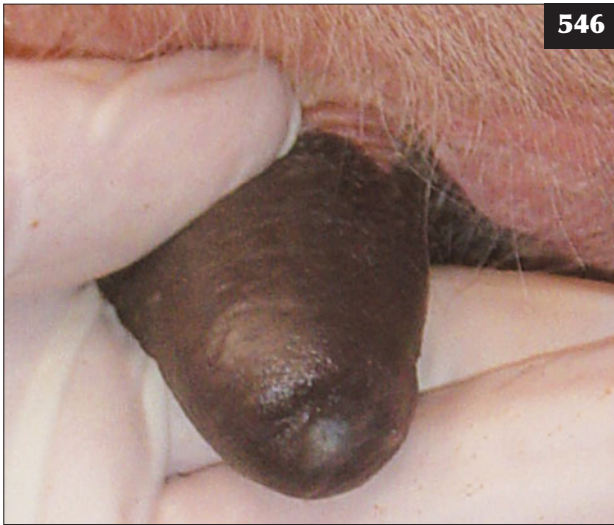Strict hygiene and minimum trauma should be observed in all cases of teat examination and surgery. Intramammary antibiotic infusion is a sensible precaution to prevent mastitis.

When milk fills the teat cistern, a sterile 14–16 gauge hypodermic needle or teat knife is used to open the teat orifice. Placement of a sterile plastic teat cannula for a few days may be required to prevent sealing of the newly created teat orifice.

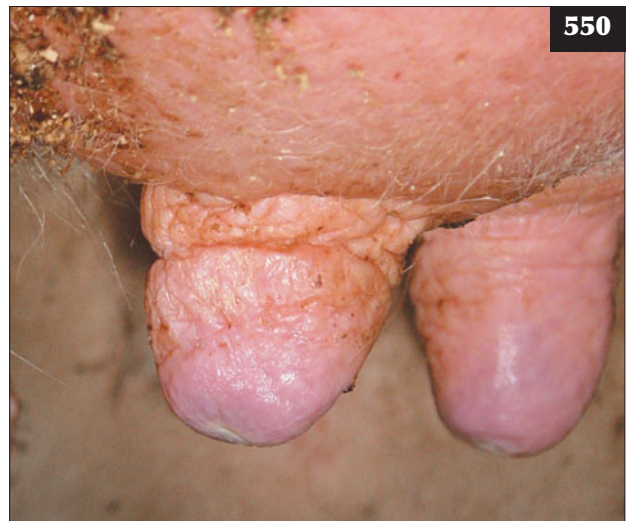No milk in the teat cistern indicates an obstruction at the base of the gland cistern. No action should be taken to break down these membranous obstructions using teat knives because it will not be successful and usually leads to infection of the gland.

Teat peas can usually be removed by enlarging the teat orifice with a teat spiral then squeezing the teat pea out. Large or fixed lesions may require cutting up within the teat lumen using a teat knife before attempting removal. The teat lining can be desensitized by placing a tourniquet around the base of the teat then infusing 10 ml of 2% lidocaine into the teat cistern.

The prognosis for pencil obstructions is guarded and surgical interference with teat knives only worsens the lesion.



546–550 Teat scoring. **(546)** Normal teat end (Grade 0). **(547)** Slightly rough teat end (Grade 1). **(548)** Moderate degree of hyperkeratosis of the teat end: rough teat end (Grade 3). **(549)** Red discolouration of a teat following milking, which is often a sign of poor pulsation. **(550)** Hard teats with rings at the base, as well as blue discolouration following removal of the cluster, may be associated with overmilking.



Chapter 12

Parasitic diseases

FASCIOLOSIS (LIVER FLUKE)

DEFINITION/OVERVIEW

Fasciolosis is a common parasitic disease of cattle in many countries worldwide caused by *Fasciola hepatica* and *Fasciola gigantica*. Infestation is more commonly encountered in beef cattle because they tend to graze poorer, wetter pastures (551).

AETIOLOGY

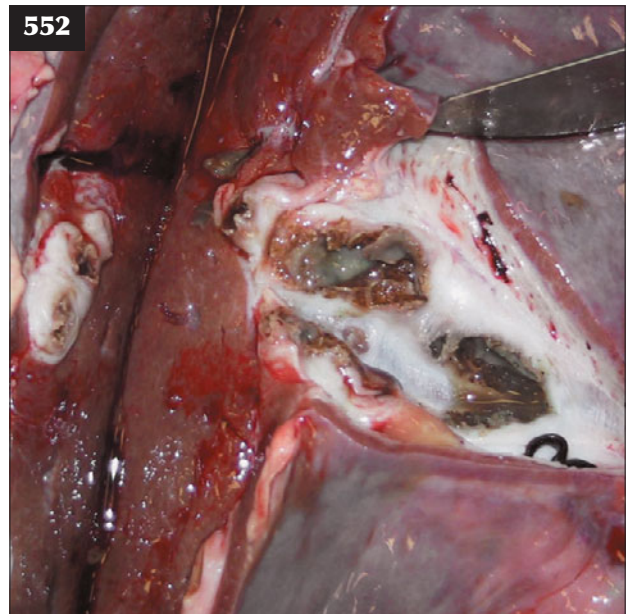
Disease in the UK is caused by *Fasciola hepatica*. The life cycle involves the intermediate snail (*Lymnaea* spp.) host whose activity and availability require adequate moisture and a suitable ambient temperature. Cercariae are released

from snails during late summer/autumn (between August and October in the northern hemisphere), developing into the infective metacercariae, which can survive on pasture for several months.

After ingestion by the host, the metacercariae excyst within the small intestine and penetrate into the peritoneal cavity, invading the liver capsule and reaching the bile duct after 6–8 weeks and becoming egg-laying adults by 10–12 weeks after ingestion. Infested cattle produce an intense fibrous reaction (552), with the resultant fibrosis much more pronounced than that observed in sheep.



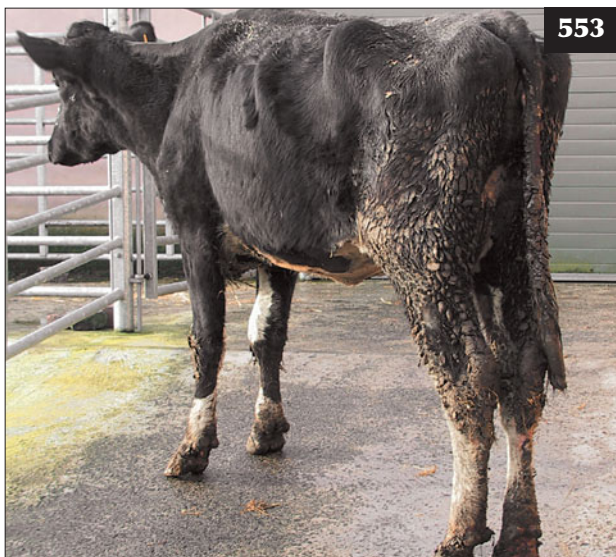
551 Beef cows grazing poor wet pasture where *Fasciola hepatica* and *Fasciola gigantica* infestations are likely to be encountered.



552 Necropsy specimen from a cow with liver fluke infestation with an intense fibrous reaction surrounding the bile ducts.

CLINICAL PRESENTATION

Beef cows with severe infestations do not lactate well and show chronic diarrhoea and excessive weight loss (553), leading to fertility problems. In spring-calving beef cows, liver fluke exacerbates the metabolic demands of advanced pregnancy in cattle on marginal winter rations, resulting in the birth of weakly calves to cows with little milk. Severely affected cows become weak and may be unable to stand due to emaciation. Such debility may cause an increased incidence of metabolic and infectious diseases at calving. Twin-bearing cows show the most severe signs because of the high demands of two fetuses. Unlike infestation in sheep, peripheral oedema is an uncommon finding with fasciolosis in cattle. Anaemia may result in severe infestations. Bulls show similar clinical signs to cows (554).



553 Fasciolosis in a cow that has been grazing away from home on infested pastures.



554 Fasciolosis is a common cause of poor condition in beef bulls.

In dairy cattle, infestation results in reduced milk yield and milk quality, loss of body condition, chronic diarrhoea (555) and poor fertility performance despite adequate nutrition.

Increasingly, UK slaughter plants have reported liver flukes in 12–18-month-old cattle where the potential for reduced liveweight gains was not suspected by producers.

DIFFERENTIAL DIAGNOSIS

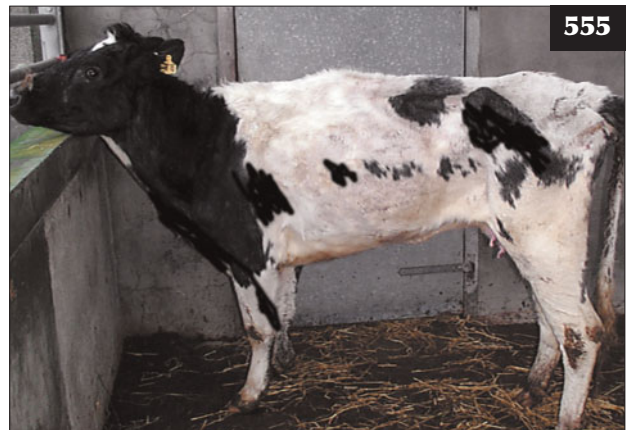Weight loss and chronic diarrhoea in individual cattle should be investigated for paratuberculosis and salmonellosis. Inadequate nutrition also presents as a whole group/herd problem of poor production and weight loss, but diarrhoea would be an uncommon finding.

DIAGNOSIS

Diagnosis of fasciolosis during the early stages of disease is based on the epidemiological data (high-risk year) and raised serum glutamate dehydrogenase (GLDH) concentrations while migrating flukes damage the liver parenchyma. A hypochromic normocytic anaemia may be present. Chronic fasciolosis is diagnosed by demonstration of fluke eggs in faecal samples, although these may be scarce. Damage to the bile duct epithelium by adult flukes causes increased GGT concentrations. There is a specific liver fluke ELISA test, but it is expensive and may indicate prior exposure rather than active infection.

MANAGEMENT

Triclabendazole is effective at killing all stages of flukes. Nitroxylnil, closantel and oxcyclosanide are less effective against immature flukes and, with clorsulon, should be used in the treatment of chronic fasciolosis (adult flukes). The response to treatment is slow. Treated cattle should be moved to clean pastures wherever possible. Improved nutrition of affected cattle is essential to restore body condition and production.



555 Infestation with liver flukes has caused chronic diarrhoea and weight loss in this dairy cow.

In areas with endemic fasciolosis, control is founded on strategic flukicide treatments. During a low-risk year, treatment is given to at-risk cattle in winter (January in the northern hemisphere). In years when epidemiological data indicate a high risk of fasciolosis, additional triclabendazole treatment may be necessary in early winter (October/November in the northern hemisphere).

Fencing off snail habitats is rarely practicable and in most situations is cost prohibitive as these are often extensive beef cattle enterprises. Drainage is cost prohibitive and many properties are subject to environmental controls.

PARASITIC GASTROENTERITIS

INTRODUCTION

Parasitic gastroenteritis (PGE) is largely caused by *Ostertagia ostertagi* larvae, which invade and damage the lining of the abomasum. *Haemonchus placei* causes disease in tropical, subtropical and certain temperate countries. Other internal parasites of cattle such as *Trichostrongylus axei*, *Nematodirus helvetianus* and *Cooperia oncophora* are much less important.

LIFE CYCLE

Eggs laid by adult worms in the gut are passed in the faeces where they hatch to first-stage larvae, typically denoted as L1. They undergo two further development stages to become infective third-stage larvae (L3), which are ingested from pasture by grazing cattle. A moist environment and an ambient temperature allow development from first- to third-stage larvae (L1 to L3) in approximately 10–14 days. After ingestion the L3 develop to L4 then to L5 or adults. Egg production follows approximately 18–21 days later.

PGE usually affects growing cattle grazing contaminated pasture during their first summer at grass, typically dairy calves (556) where the same pastures are

used for this class of stock every year. Disease is caused by large numbers of nematode parasites in the abomasum and/or small intestines.

In spring-calving beef herds, early season contamination of pasture results in developing larvae being ingested by immune cows. This results in restricted egg output and subsequent low larval challenge to their calves later in the grazing season. Autumn-born beef calves graze little before housing and are generally weaned at turnout before larval challenge occurs during the next summer. Problems could arise when these weaned beef calves graze contaminated pasture during their second season if they have not gained sufficient immunity as young calves during the previous autumn.

MANAGEMENT

The three major anthelmintic groups, defined by the active chemical, comprise:

- Group 1. (BZ) Benzimidazoles, probenzimidazoles.
- Group 2. (LM) Imidazothiazoles, tetrahydropyrimidines.
- Group 3. (AV) Avermectins, milbemycins.

OSTERTAGIOSIS

DEFINITION/OVERVIEW

Ostertagiosis is the most important cause of PGE in growing cattle in many countries.

AETIOLOGY

Ostertagiosis is caused by *Ostertagia ostertagi* larvae in the abomasum; two forms, type I and type II, exist.

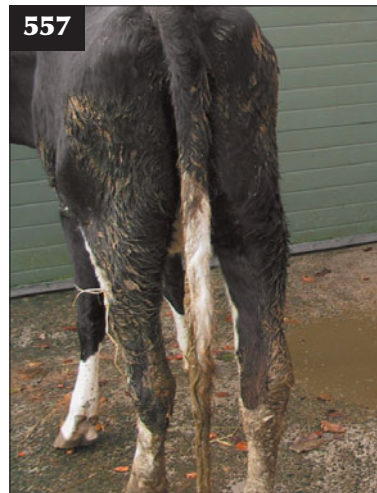CLINICAL PRESENTATION

Type I

Type I ostertagiosis is typically seen during late summer/early autumn and is caused by the ingestion and immediate maturation of very large numbers of infective



556 Parasitic gastroenteritis affecting a growing beef heifer during its first summer at grass.



557 Type I ostertagiosis causing loss of appetite and sudden and profuse green diarrhoea.

L3 larvae by susceptible calves or yearlings. Disease is more severe after dry early summer months, followed by wet weather during late summer, because of mass emergence of larvae and ingestion by grazing cattle. There is loss of appetite with sudden and profuse green diarrhoea (557) that affects most animals in the group within several days and causes rapid weight loss (558). Sudden death caused by PGE is rare.

Type II

Infective larvae ingested from pasture from autumn onwards do not mature to adult worms immediately, but undergo a period of delayed development as early fourth-stage larvae within the stomach wall and then emerge together during the late winter months to cause disease. There is profuse diarrhoea and rapid weight loss. Poor appetite and weakness may lead to recumbency. The treatment response in type II disease is poor.

DIFFERENTIAL DIAGNOSIS

Type I

- Group: coccidiosis in young calves at pasture (*Eimeria alabamensis*); salmonellosis; BVDV infection.
- Individual animal: necrotic enteritis.

Type II

- Group: chronic liver fluke; acidosis.

DIAGNOSIS

Diagnosis is based on the grazing pattern and history of previous anthelmintic treatments. Faecal egg counts are generally high in type I disease (>1,000 epg), but can be absent in type II disease. Serum pepsinogen and gastrin concentrations can be measured to determine whether there is significant parasitic damage to the abomasal lining.

MANAGEMENT

Prompt anthelmintic treatment is essential for both types of disease. Whereas type I disease is susceptible to all anthelmintics, a group 3 (ivermectin/milbemycin group) anthelmintic should be used for type II disease.

Type I disease

PGE disease control must be carefully considered in the herd health plan alongside lungworm prevention. An annual rotational pattern (cattle/sheep/crops) can rarely be achieved on livestock farms. Where vaccination of cattle for lungworm is undertaken, planned anthelmintic treatments during late summer can work to control PGE, but mistakes can happen and failure to treat at the scheduled time may result in disease and costly weight loss in the group of cattle. Pulse-release anthelmintic boluses (oxfendazole) and sustained-release injections (moxidectin) are popular with farmers as they can be given at turnout and avoid the need for handling during the grazing season. If cattle are moved to 'dirty' pasture in late summer/



558 Type I ostertagiosis causing profuse diarrhoea and rapid weight loss.



559 Failure to develop immunity because of lack of challenge during their first grazing season renders these spring-born beef calves susceptible to parasitic gastroenteritis during their second season at pasture.

autumn, they may be susceptible to infection as the anthelmintic cover will have ceased. No real challenge during their first grazing season at pasture (559), and failure to develop immunity, renders young cattle susceptible to PGE during their second season at pasture.

Type II disease

This form of the disease is prevented by routine treatment at housing during late autumn/early winter with an effective anthelmintic.

HAEMONCHOSIS

DEFINITION/OVERVIEW

Haemonchus placei causes disease in tropical, subtropical and certain temperate countries.

AETIOLOGY

Adult *H. placei* suck blood from the abomasal surface.

CLINICAL PRESENTATION

Severe challenge may cause weakness, anaemia and diarrhoea; less severe, more chronic infestations cause weight loss, lethargy, hypoproteinaemia and peripheral oedema.

DIFFERENTIAL DIAGNOSIS

Includes fasciolosis, coccidiosis, copper deficiency and malnutrition.

DIAGNOSIS

Patent infestations reveal a particularly high worm egg count (often >10,000 epg). Raised plasma pepsinogen concentrations may be useful in prepatent infestations, but should be interpreted with caution.

MANAGEMENT

Prompt anthelmintic treatment is essential. In addition to the three anthelmintic groups listed on page 238, rafenoxide, nitroxynil and clorsulon can also be used. Animals should be moved to clean pastures if available.

Prevention is covered in the section on ostertagiosis (see above).

INFESTATION WITH *COOPERIA ONCHOPHORA***DEFINITION/OVERVIEW**

Suppressive parasite control measures in many countries have resulted in an increase in disease caused by *Cooperia onchophora*, with diarrhoea seen earlier in the grazing season (June and July in northern Europe) compared with ostertagiosis.

AETIOLOGY

Infestation is caused by high pasture challenge from infective *Cooperia onchophora* L3 larvae.

CLINICAL PRESENTATION

High larval challenge can cause acute diarrhoea with weight loss, but clinical signs are not as severe as those of ostertagiosis.

DIFFERENTIAL DIAGNOSIS

Type I ostertagiosis; coccidiosis in young calves at pasture (*Eimeria alabamensis*); salmonellosis.

DIAGNOSIS

Calves with patent infestations have a high faecal worm egg count.

MANAGEMENT

Prompt anthelmintic treatment is essential to prevent condition loss.

Prevention is covered in the section on ostertagiosis (see above).

LUNGWORM (HUSK, HOOSE)**DEFINITION/OVERVIEW**

Lungworm is a common parasitic infection of growing cattle and, under severe challenge, of adult cattle, caused by *Dictyocaulus viviparus*.

In growing cattle, losses can result from sudden death in severely affected cattle. Less severely affected cattle suffer a marked loss of body condition (up to 10% body weight) and convalescence is protracted with extended periods to slaughter weight (up to six months). Secondary bacterial pneumonia can follow lung damage, necessitating antibiotic therapy. Disease in milking cows can lead to significant yield reduction in the worst affected animals.

AETIOLOGY

D. viviparus L3 larvae are ingested from pasture grazed by infested cattle earlier that same season, although overwintering of larvae on pasture can occur. Clinical signs appear 2–4 weeks after ingestion of large numbers of infective larvae. Larvae are present in the faeces from 25 days after ingestion of infective L3 larvae.

CLINICAL PRESENTATION

Disease is classically seen in young stock from late summer to early autumn. Early clinical signs include an increased respiratory rate at rest, but more noticeable, frequent coughing can occur, especially after short periods of exercise. Severe larval challenge causes a reluctance to move; affected cattle stand with their head down and neck extended and they cough frequently (560). Examination and forced movement may precipitate dyspnoea and death. Auscultation reveals emphysema of the dorsal diaphragmatic lobes. These bullae may rupture, causing subcutaneous emphysema over the chest wall.

In dairy herds, infection of susceptible cattle results in a dramatic reduction in milk yield of up to 50%, with possible deaths. Frequent coughing is noted when cows are walking to and from the milking parlour.

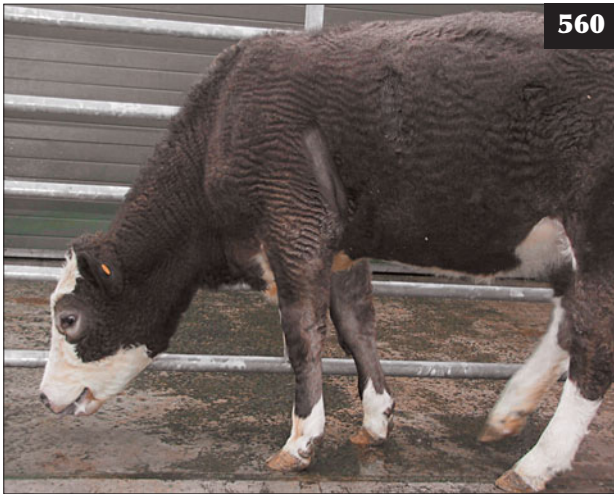Secondary bacterial pneumonia may result in severely affected cattle requiring antibiotic therapy.

DIFFERENTIAL DIAGNOSIS

- Individual or small numbers of cattle affected: fog fever.
- Group of cattle affected: BRSV, IBR; influenza A; bluetongue.

DIAGNOSIS

Diagnosis is based on clinical examination and demonstration of larvae by the Baermann technique in patent infestations (around 25 days after larval ingestion; 561).



560 Lungworm larval challenge has caused severe respiratory distress with frequent coughing in this young animal.

Severe larval challenge in immune adult cattle may result in clinical signs typical of lungworm infestation, but the challenge does not reach patency. This situation typically occurs when dairy cows, vaccinated as young calves, are exposed to severe challenge after grazing contaminated pasture often reserved for young calves.

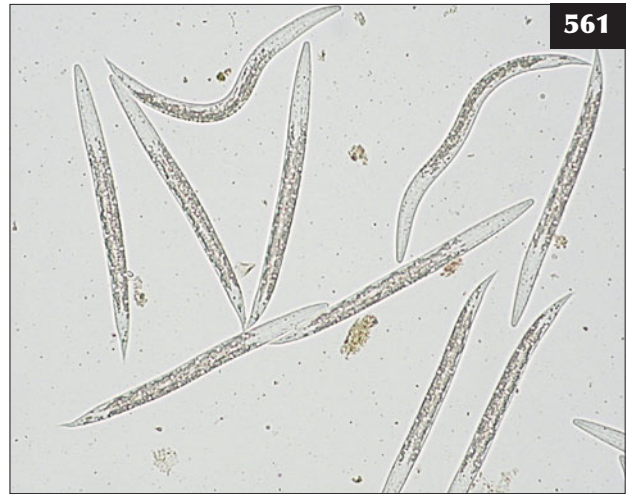
The Baermann technique is simple and involves 5–10 g of faeces left overnight in a gauze swab in the top of a used 50 ml syringe casing full of tap water. The clip on the flutter valve tubing at the syringe base is released 12–24 hours later and the first few drops of water containing any larvae are released onto a glass microscope slide and examined under low-power magnification. More larvae can be collected 24 hours later.

MANAGEMENT

Prompt anthelmintic treatment is essential; levamisole is preferred to group I anthelmintics. Various group III compounds (e.g. eprinomectin) have zero milk withhold times. Antibiotic therapy is indicated in febrile cattle with secondary bacterial infection. Some cattle have a protracted convalescence (562).

Disease prevention is based on development of immunity by either vaccination or periods of natural exposure/infestation controlled by strategic anthelmintic treatments. Vaccination of dairy calves before their first grazing season confers life-long immunity in most situations (unless severely challenged as adults), and is the preferred option. Vaccination using live attenuated L3 larvae six and two weeks before exposure is an invaluable insurance against lungworm.

Immunity following natural challenge and planned anthelmintic treatments can work, but failure to treat at the scheduled time may result in severe disease. Conversely, no lungworm challenge during their first



561 *Dictyocaulus viviparus* larvae demonstrated by the Baermann technique in a patent infestation from around 25 days after larval ingestion.



562 This cow with lungworm developed a secondary bacterial pneumonia and had a protracted convalescence.

grazing season at pasture renders cattle susceptible during their second season at pasture when anthelmintics are less commonly used as part of a PGE control programme.

The anthelmintic strategies commonly employed include injectable, depot injection and pour-on group III anthelmintics and slow-release/pulse-release group I anthelmintics. Control strategies must be written into the veterinary herd health programme in order to ensure correct administration. Careful monitoring of such programmes is essential.

Chapter 13

Clostridial diseases

INTRODUCTION

Clostridia are generally considered to be ubiquitous in the environment, particularly in organic material, with disease triggered by various factors including changes in feeding and parasite damage to tissues. Such microenvironments within the body permit extremely rapid clostridial multiplication and exotoxin production, characteristically leading to death within hours.

NECROTIC ENTERITIS

DEFINITION/OVERVIEW

Necrotic enteritis is a disease of neonatal calves, lambs and foals.

AETIOLOGY

Necrotic enteritis is caused by beta toxin produced by *Clostridium perfringens* type C.

CLINICAL PRESENTATION

Affected neonatal calves may simply be found dead, but they more commonly present with haemorrhagic diarrhoea containing necrotic gut mucosa. Affected calves rapidly become dehydrated, weak and recumbent, with a high mortality rate despite intensive intravenous antibiotic and fluid therapy.

DIFFERENTIAL DIAGNOSIS

The main differential diagnoses include salmonellosis and coccidiosis.

DIAGNOSIS

Diagnosis is based on necropsy findings with necrosis of the mucosa of the small intestine and excess peritoneal fluid, which clots when exposed to air.

MANAGEMENT

There is no effective treatment, but intravenous antibiotics and fluid therapy can be attempted.

Toxoid vaccines are commercially available to provide protective immunoglobulins in colostrum, but they are not routinely used unless there is a farm history of disease.

OVEREATING DISEASE (ENTEROTOXAEMIA)

DEFINITION/OVERVIEW

Enterotoxaemia is a cause of sudden death of cattle fed high grain rations.

AETIOLOGY

Overeating disease (enterotoxaemia) is caused by beta toxin produced by *Clostridium perfringens* type D.

CLINICAL PRESENTATION

Sudden death of a rapidly growing, well-fed calf is the most common presentation, although growing/adult cattle on high grain rations are also susceptible.

DIFFERENTIAL DIAGNOSIS

The main differential diagnoses are abomasal perforation and other clostridial infections.

DIAGNOSIS

Diagnosis is based on necropsy findings of excessive pericardial fluid and glucosuria; friable ('pulpy') kidneys are an inconsistent finding.

MANAGEMENT

Oral antibiotic administration (sulphonamides) is reported to be effective if initiated during the early stages.

Toxoid vaccines are commercially available to provide protective immunoglobulins in colostrum; they are also administered to growing cattle before introduction onto intensive rations.

BLACK DISEASE (INFECTIOUS NECROTIC HEPATITIS)

DEFINITION/OVERVIEW

Black disease is a cause of sudden death in cattle and sheep associated with clostridial multiplication in liver tissue damaged by the common liver fluke *Fasciola hepatica*.

AETIOLOGY

Black disease is caused by *Clostridium novyi* type B. Black disease is typically associated with migration of immature liver flukes during late summer/early autumn and can affect unvaccinated cattle and sheep of all ages.

CLINICAL PRESENTATION

Clinical signs are rarely observed and cattle are simply found dead.

DIFFERENTIAL DIAGNOSIS

The main differential diagnoses include other clostridial diseases such as blackleg and anthrax. Bracken poisoning should be included as a cause of sudden death, depending on availability.

DIAGNOSIS

Diagnosis is based on necropsy findings and lack of vaccination history. There is rapid carcass decomposition and accumulation of blood-tinged fluid within body cavities and widespread petechial haemorrhages. The liver is congested and very dark, with areas of necrosis visible on cut section, surrounded by areas of congestion. There may be evidence of fluke tracks throughout the liver in those geographical areas where disease is associated with acute fasciolosis.

Laboratory tests, such as the FAT, may yield false-positive results and should not be interpreted in isolation.

MANAGEMENT

There is no treatment. A fluke control plan, combined with a clostridial vaccination programme, should effectively control black disease.

BLACKLEG (BLACKQUARTER)

DEFINITION/OVERVIEW

Blackleg occurs in all countries worldwide.

AETIOLOGY

Blackleg is caused by *Clostridium chauvoei* which, in common with the other clostridial organisms causing disease in cattle, can survive in soil for many years. Entry of clostridia can occur through skin wounds and via contaminated needles/injection equipment. The trigger mechanisms responsible for spore activation are unknown, but muscle trauma from bulling events in heifers (involvement of lumbar muscles) (563) and injuries at congested feed barriers (neck) have been suggested (564). Outbreaks of blackleg have been reported after earthworks such as field drainage work and new road construction, possibly leading to disturbance of the highly resistant spores in soil.

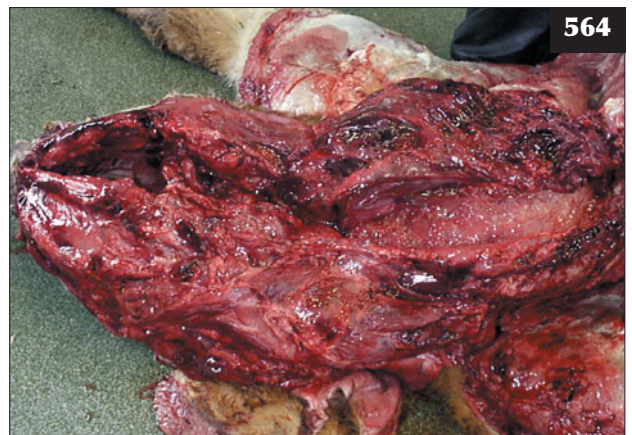CLINICAL PRESENTATION

In extensive management systems, affected cattle may

simply be found dead. More typically, affected cattle are very dull and depressed, inappetent, febrile (>41.0°C) and have toxic mucous membranes. Further clinical signs depend on the site of bacterial multiplication. Involvement of one limb results in sudden-onset severe lameness. Once recumbent, the animal has great difficulty raising itself. There is marked swelling of the proximal part of the limb with oedema, subcutaneous emphysema and purple discoloration of overlying skin. The limb often has a crepitant feel. The drainage lymph node is markedly enlarged.



563 Muscle trauma from bulling activity in heifers has been suggested as a trigger mechanism responsible for spore activation in cases of blackleg.



564 An injury at a feeding barrier might have been the initiating cause for the blackleg lesions in the neck seen in this necropsy view. Note the muscle necrosis and associated blood-tinged oedema.

DIFFERENTIAL DIAGNOSIS

Other clostridial diseases such as black disease and anthrax should be considered. The important differential diagnoses for sudden-onset severe lameness include cellulitis, long bone fractures and joint trauma.

DIAGNOSIS

Diagnosis of blackleg is based on typical clinical findings in unvaccinated cattle. Death results in very rapid carcass autolysis and bloat. There is obvious muscle necrosis with associated blood-tinged oedema (564), although these lesions may be deep seated within a muscle mass, necessitating methodical sectioning.

MANAGEMENT

Penicillin (44,000 iu/kg q12h) is the drug of choice for clostridial disease. The first dose is given intravenously and subsequent doses intramuscularly. Treatment is unlikely to be effective unless started in the early stages and the likely extent of the muscle necrosis indicates a very poor prognosis even if the animal survives the acute stages. NSAIDs such as flunixin meglumine or ketoprofen have potent analgesic and anti-inflammatory actions.

Vaccines are commercially available, but are not routinely used unless there is a farm history of disease.

MALIGNANT OEDEMA

DEFINITION/OVERVIEW

Malignant oedema is a cause of sudden death in cattle.

AETIOLOGY

Malignant oedema is caused by various clostridial species including *Clostridium chauvoei*, *Clostridium septicum* and

Clostridium novyi. Malignant oedema has been reported after contaminated intramuscular injection and following injection of substances that cause local tissue necrosis, possibly activating latent spore infection.

CLINICAL PRESENTATION

Affected cattle are dull and depressed, stand isolated from others in the group, and are febrile (41.0–42.0°C). The mucous membranes are congested. There is extensive oedema at the site of infection (565), causing swelling and pain (566) and progressing to subcutaneous emphysema. Involvement of one limb causes severe lameness. Affected cattle die within 24–48 hours.

DIFFERENTIAL DIAGNOSIS

The main differential diagnoses are blackleg and cellulitis lesions caused by contaminated injection of irritant substances.

DIAGNOSIS

Diagnosis is based on the clinical and necropsy findings (567).

MANAGEMENT

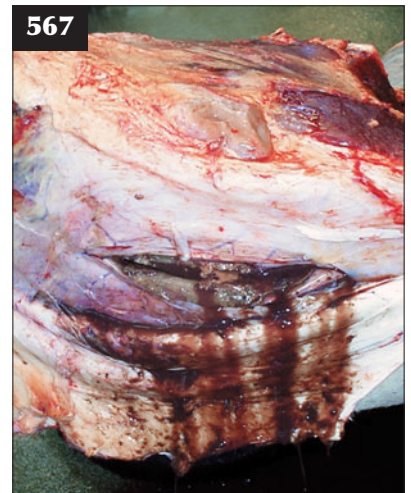
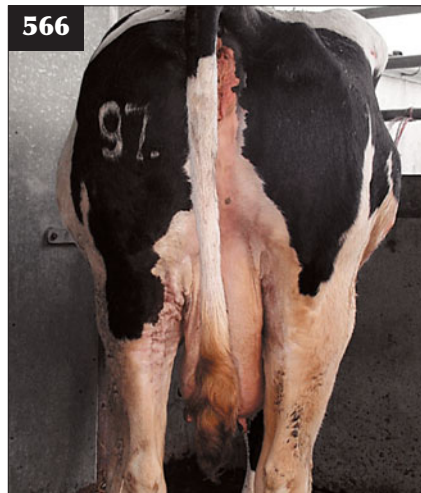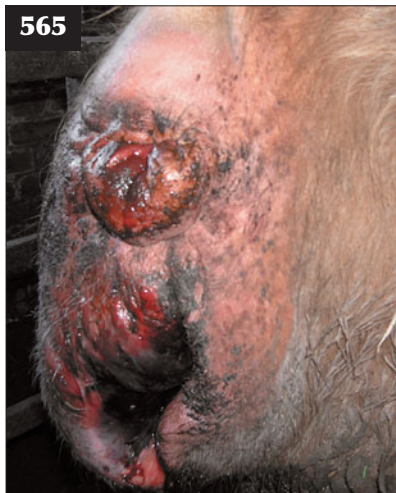Penicillin (44,000 iu/kg i/m q12h) is the drug of choice, with the first dose being given intravenously with wound lavage, but such treatment is rarely successful.

Multivalent vaccines are commercially available, but are not routinely used unless there is a farm history of disease.

TETANUS

DEFINITION/OVERVIEW

Disease follows production of a powerful neurotoxin by *Clostridium tetani*, which progressively causes spasticity,



565–567 Malignant oedema. (565) Note the extensive oedema of the perineum in this cow with malignant oedema. (566) Extensive oedema of the right hip region at the site of infection following an intramuscular injection is shown in this cow. (567) Necropsy of the cow in 566 reveals muscle necrosis suggestive of malignant oedema.

recumbency, opisthotonus and death. Tetanus has a worldwide distribution.

AETIOLOGY

Disease follows production of a powerful neurotoxin by *Clostridium tetani*, with clinical signs most frequent following puncture wounds and infection of the surgical castration site. Tetanus can also occur following abortion and uterine infection in breeding animals.

Idiopathic tetanus is thought to arise when certain conditions in the reticulorumen allow the small number of *C. tetani* organisms normally present to multiply and produce sufficient toxin to cause disease.

CLINICAL PRESENTATION

Tetanus is most commonly seen in individual animals following puncture wounds and infection of open wounds (568), although the incubation period is very variable.

Affected calves show hindlimb stiffness and difficulty walking. Animals stand with the limbs abducted, giving a 'sawhorse' stance, and the tail is held cocked away from the hindquarters, giving a pump handle appearance (569). Affected calves have an anxious startled expression with bulging eyes (570) and protrusion of the third eyelid (571), the ears held back towards the poll and the nostrils flared. The head is held lowered with the neck extended. The animal is unable to open its mouth ('lockjaw'). There is slight but persistent bloat. There is often profuse salivation during the latter stages (570). The condition progresses

over 2–5 days to lateral recumbency with the animal unable to raise itself (572). Seizure activity is precipitated at first in response to external stimuli such as loud noises. It then occurs spontaneously, progressing to opisthotonus and followed by death from respiratory failure.

Outbreaks of disease, referred to as idiopathic tetanus, are described where the organism has remained localized within the gut. This is associated with feeding large quantities of root crops contaminated with soil. This form of the disease is characterized by bloat and less pronounced clinical signs, with a much improved response to supportive treatment.

DIFFERENTIAL DIAGNOSIS

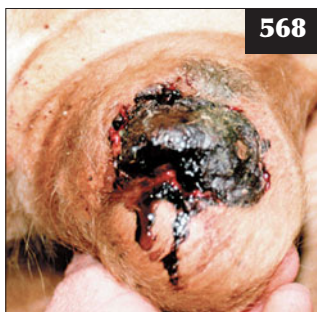Possible differential diagnoses for muscle stiffness could include spastic paresis and white muscle disease, while progression to seizure activity could include PEM and lead poisoning. Chronic bloat can arise from vagal indigestion and bronchial lymph node enlargement associated with pneumonia.

DIAGNOSIS

Diagnosis is based on the clinical signs and history.

MANAGEMENT


A rumen trocar is essential when bloat cannot be relieved by stomach tube due to lockjaw. A rumenotomy provides a portal for water and food since the animal is unable to drink. There is no consensus regarding the dose rate of antitoxin;



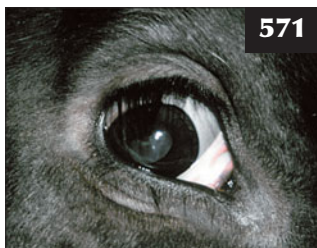
568



569



570



571



572

568–572 Tetanus. (568) Tetanus followed infection of the surgical castration site in this animal. (569) In this steer with tetanus the limbs are abducted and the tail is held away from the hindquarters. Note also the hindlimb stiffness. (570) Note the anxious startled expression with bulging eyes, the ears held back towards the poll and the nostrils flared in this young steer with tetanus. (571) Protrusion of the third eyelid in a calf with tetanus. (572) Lateral recumbency, with the animal unable to raise itself, in a cow with tetanus.

one protocol would be to give 50 units/kg intravenously followed by intramuscular doses of the same amount as thought necessary every 12 hours. Crystalline penicillin is given intravenously at the first examination for its more rapid onset of action and this is followed by procaine penicillin (44,000 iu/kg i/m q12h). NSAIDs should be given daily to provide analgesia. Acetylpromazine (0.05 mg/kg q8h) should be administered to provide muscle relaxation. Local wound débridement remains controversial. Tetanus cases should be housed singly in a darkened, deep-bedded shed.

The prognosis is hopeless if affected animals become laterally recumbent and/or show seizure activity, and euthanasia must be carried out for welfare reasons. Recovery is very slow, taking several weeks for those animals that respond to symptomatic treatment.

Vaccines are commercially available, but are not routinely used unless there is a farm history of disease.

BOTULISM

DEFINITION/OVERVIEW

Botulism is uncommon in ruminants and sporadic losses may frequently be overlooked.

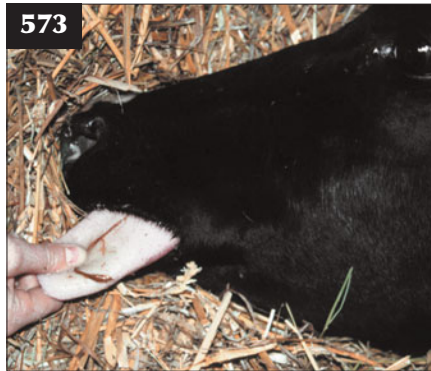AETIOLOGY

Botulism is caused by ingestion of pre-formed toxins of *Clostridium botulinum*. Sporadic cases of botulism in cattle have been associated with poultry litter spread onto pasture. The feeding of ensiled poultry manure and bakery waste has caused very serious losses in housed cattle on individual properties. The epidemiology of botulism in the UK differs from that in many other countries where outbreaks of disease are associated with pica in phosphorus-deficient animals on extensive grazing with access to unburied carcasses.

CLINICAL PRESENTATION

The interval between ingestion and clinical disease varies from two to 14 days. Depending on the amount of toxin ingested, affected cattle may simply be found dead. More usually, clinical signs are confined to the CNS, causing muscle weakness affecting the hindlimbs during the early stages. Typically, affected cattle have difficulty rising, with swaying of the hindquarters. Animals remain bright and alert and are afebrile. The disease may not progress beyond this stage and affected animals recover after 2–3 weeks. More usually, weakness progresses over 4–7 days to involve the forelimbs, head and neck. Affected cattle have difficulty chewing and swallowing and there is paralysis of the tongue, which remains passively protruded (573). There is complete loss of muscle tone in the neck muscles and the head is averted against the chest (574). Cattle must be euthanased for welfare reasons at this stage, otherwise eventual involvement of respiratory muscles and the diaphragm causes death.

573



573 Botulism. This animal is having difficulty chewing and swallowing and there is paralysis of the tongue, which remains passively protruded.

574



574 Complete loss of muscle tone in the neck muscles and the head averted against the chest in this cow with botulism.

DIFFERENTIAL DIAGNOSIS

In individual cattle, spinal lesions should be considered during the early stages, then hypocalcaemia and phosphorus deficiency, basilar empyema and end-stage BSE as the disease progresses.

DIAGNOSIS

The sudden loss of numerous animals with some of the risk factors listed above, and the lack of other plausible causes, may warrant further consideration of botulism. Large numbers of dead cattle under extensive grazing conditions highlight the possibility of botulism in some countries.

MANAGEMENT

There is no effective treatment.

Botulism can be controlled by specific vaccination in those areas where disease occurs, but it is not included in standard multivalent clostridial vaccines.

BACILLARY HAEMOGLOBINURIA (REDWATER)

(See Chapter 8, Urinary tract diseases, p. 198)

Chapter 14

Metabolic diseases

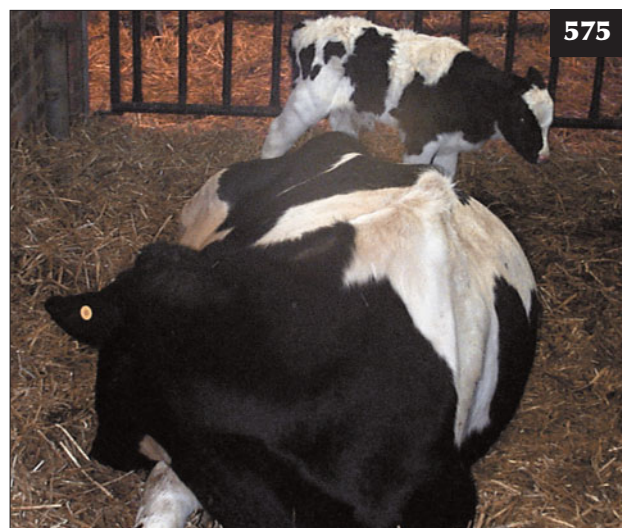MILK FEVER (HYPOCALCAEMIA, PARTURIENT PARESIS, ECLAMPSIA)

DEFINITION/OVERVIEW

The average annual incidence of milk fever in dairy herds is approximately 5% (575), but individual farms may have a prevalence of 60–70% when calving at pasture. Milk fever can also occur in older beef cows (more than fourth calvers), especially dairy crosses (e.g Hereford × Holstein), again more common in autumn-calving cows.

AETIOLOGY

Blood calcium is kept under tight homeostatic control via parathyroid hormone (PTH), 1,25-dihydroxy cholecalciferol (calcitriol) and calcitonin. A cow yielding 40 litres of milk daily suddenly requires an extra dietary intake of 80 g of calcium per day over that needed during late gestation. To maintain the normal concentration of calcium in the blood there must be increased absorption of calcium from the gut and/or mobilization from the skeleton. These processes take 2–3 days to become fully active and, if they fail, hypocalcaemia results.



575 Typical case of hypocalcaemia which presented within 24 hours of calving. Note the head averted against the chest.

There are a number of factors that affect the speed and extent of the response to PTH and 1,25-dihydroxy cholecalciferol. Older cows respond more slowly and are thus more prone to milk fever. Low magnesium status may interfere with release of PTH, the ability of PTH to act on its target tissues and hydroxylation of vitamin D₃ in the liver.

Low dietary calcium levels during the dry period stimulate PTH secretion and hence mobilization of calcium from bone and absorption from the gut. The acid–base status of the animal affects calcium metabolism whereby metabolic alkalosis predisposes cows to milk fever (see Prevention). Nutritional factors, including depressed dry matter (DM) intakes in cows at calving and digestive upsets (e.g. diarrhoea), will reduce calcium absorption from the gut. Channel Island breeds (especially Jerseys) are more susceptible to milk fever than Holstein Friesians.

CLINICAL PRESENTATION

Clinical signs usually occur within 24 hours after parturition (576), but they can occur at or before calving, and, in exceptional situations (often very high-yielding cows during oestrus), several weeks to months after calving. The clinical signs are progressive over a period of



576 Clinical signs of hypocalcaemia usually occur within 24 hours after parturition, as in this beef cow. Note the alert calf, but depressed dam.

12–24 hours. There is initial hyperaesthesia, with teeth grinding and coarse muscle tremors, stiffness of the limbs, straight hocks and ‘paddling’ of the feet when standing. Cows show ataxia and are reluctant to walk. The rectal temperature is normal or slightly depressed.

The clinical signs progress to sternal recumbency with a lateral kink (‘S-bend’) in the neck (577), then the head becomes averted against the chest (575). There is an increased heart rate, dilated pupils (with reduced pupillary light reflex [PLR]), gut stasis causing bloat and constipation, and profound depression.

Cows become comatose in lateral recumbency (578), are very weak and have an elevated heart rate (120 beats per minute). Eventually, ruminal tympany and/or paralysis of respiratory muscles causes death in untreated cattle.

Potential complications of hypocalcaemia include uterine inertia (leading to dystocia and/or stillbirth), prolapse of the uterus and musculoskeletal damage. The uterine inertia caused by cases of hypocalcaemia may also result in RFM, metritis and endometritis, thus affecting subsequent fertility.

DIFFERENTIAL DIAGNOSIS

Acute toxic mastitis; physical injury/nerve paralysis; uterine rupture; haemorrhage caused by dystocia; acidosis/grain overload.

DIAGNOSIS

Diagnosis is based on the cow’s history, clinical signs and response to intravenous calcium borogluconate solution within minutes. Clinical signs occur when serum calcium

levels fall to <1.5 mmol/l (normal 2.2–2.6 mmol/l) and are often as low as 0.4 mmol/l in cattle with advanced disease.

Hypophosphataemia (<1.0 mmol/l; normal range 1.4–2.5 mmol/l) is frequently observed in blood samples collected from cows with milk fever. Treatment with calcium borogluconate solution alone will restore normal phosphorus levels in almost all cases.

Blood magnesium levels normally increase at calving, and most cases of milk fever have a slight hypermagnesaemia (>1.25 mmol/l).

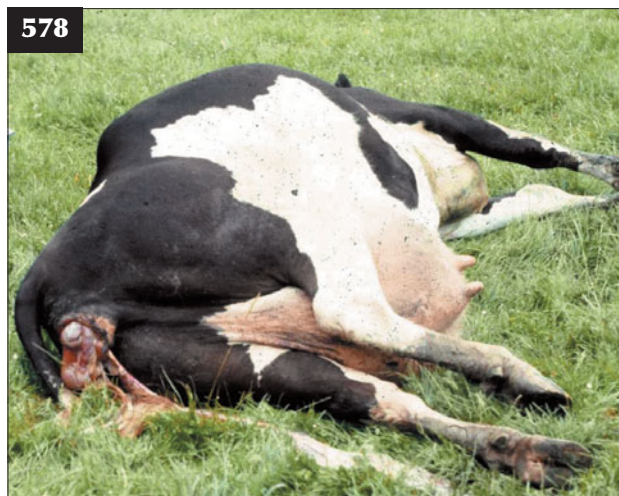
MANAGEMENT

The majority of cases seen by veterinary practitioners will have already been given calcium borogluconate by subcutaneous injection and not responded, usually because of poor absorption due to impaired peripheral blood circulation (absorption from subcutaneous sites takes up to 3–4 hours or may not occur at all).

After careful clinical examination, 400 ml of 40% calcium borogluconate solution (containing 12 g calcium), warmed to body temperature, should be administered by slow intravenous injection (over 5–10 minutes) into the jugular vein using a 14 gauge needle and flutter valve with the bottle held 30–40 cm above the infusion site. Some veterinary surgeons also administer magnesium and/or phosphorus at the same time, but this is unnecessary in most cases. Toward the end of the intravenous infusion (579), the cow will typically eructate several times and defaecate, passing firm faeces (580). The cow should be propped in sternal



577 In this cow the clinical signs have progressed to sternal recumbency, with a lateral kink (‘S-bend’) in the neck. This will progress to the head being averted against the chest (see 575).



578 This cow with hypocalcaemia has become comatose in lateral recumbency during the latter stages. Note the associated dystocia because of uterine inertia.

recumbency (581) and it will frequently make attempts to stand 5–10 minutes after intravenous infusion (582). There is no advantage to be gained by forcing the cow to stand.

Some veterinary surgeons also administer 400 ml of 40% calcium borogluconate subcutaneously in an attempt to prevent recurrence, which can occur in approximately 25% of cases. However, it is important not to overtreat. Dairy cows should not be milked for 24 hours and the calf removed after feeding colostrum.

Prevention/control measures applicable to herd problems ('outbreaks')

Over fatness in dry cows should be avoided: the aim should be to calve cows at body condition scores of 2.5–3.0 out of 5. The primary cause of milk fever problems is usually the mineral content of the transition dry cow diet fed during the last two weeks of pregnancy: either a high calcium content or a high dietary cation–anion balance (DCAB).

Manipulation of the dry cow diet is the most cost-effective method of controlling the incidence of hypocalcaemia. There are two very different approaches available:



579 Intravenous (jugular vein) 40% calcium borogluconate being administered to a cow with hypocalcaemia. Note that the bottle is being held 30–40 cm above the infusion site.




580 The beef cow with hypocalcaemia in 576 passed firm faeces towards the end of intravenous calcium borogluconate infusion.



581 The cow in 578 has been propped in sternal recumbency after intravenous calcium borogluconate infusion.

582 The cow in 577 standing 5–10 minutes after intravenous calcium borogluconate infusion.



1. The amount of calcium in the transition dry cow diet (**583**) should be limited to less than 50 g/head/day (ideally less than 30 g/day) to maintain PTH activity. Magnesium levels in the diet should be above 40 g/day. This can prove very difficult to achieve in grass-based forage systems due to the relatively high levels of calcium in grass. The use of calcium-binding agents such as zeolite may help reduce calcium absorption.
2. Manipulation of the DCAB, which by lowering blood pH allows PTH to act on its receptor and releases cations (mainly calcium) from bone. Sodium, potassium, sulphate and chloride ions exert the strongest effects on acid–base balance, and are referred to as the strong ions.

$$\text{DCAB} = (\text{Na}^+ \text{ and } \text{K}^+) \text{ minus } (\text{Cl}^- \text{ and } \text{S}^-)$$

The aim of a 'full DCAB' system is to reduce the overall DCAB of the diet to between -100 and -150 mEq/kg DM by increasing sulphate and chloride ions and/or reducing sodium and potassium cations, thus inducing a mild metabolic acidosis. Grass silage has a DCAB of $+300$ to $+400$ mEq/kg DM, and grass has an even higher positive DCAB (mainly due to the high sodium and potassium levels). Anionic salts commonly used to reduce DCAB include magnesium chloride, ammonium chloride and calcium chloride.

The majority of dairy farmers utilize a 'partial DCAB' approach, which manipulates the forages fed in the transition dry cow diet to favour the DCAB balance (e.g. minimize use of grass and grass silage and increase use of maize silage, wholecrop and straw in the diet, which have lower DCAB values), as well as adding magnesium

chloride or other anionic salt preparations such as Biochlor™ to the diet. Under such situations, the DCAB of the diet will be around 0 to $+50$ mEq/kg DM.

Given the high forage content of the transition dry cow diet and faced with a high incidence of milk fever cases on a farm, changing the forage fed to the dry cows may assist in milk fever control (i.e. reduce grass intakes, increase levels of maize silage and wholecrop with lower DCAB values). Low dietary magnesium may be a factor and provision of magnesium chloride will also lower the DCAB of the diet.

An alternative method of milk fever control (practised widely in Scandinavia) involves giving high levels of calcium by mouth at calving. Cows known to be at risk of milk fever can be given calcium at/just before calving using drenches (150 g calcium chloride daily), gels and calcium boluses. Administration of 250 mg vitamin D₃ (cholecalciferol) or alfacalcidol (1 α -hydroxycholecalciferol) can be carried out prior to calving, but this necessitates accurate prediction of calving date. Measures to prevent excessive calcium withdrawal after calving include no pre-calving milking, removal of the calf at birth (remember to give colostrum) and no milking out for 3–4 days after calving.

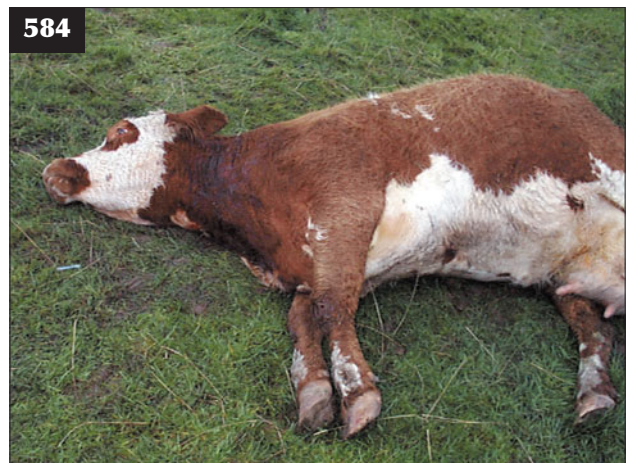HYPOMAGNEAEMIA (GRASS STAGGERS, GRASS TETANY)

DEFINITION/OVERVIEW

The average annual incidence of acute hypomagnesaemia is $<1\%$. Most cases occur in recently calved beef cows (**584**), but disease can also occur in dairy cows, particularly if unsupplemented during lactation. Clinical signs range from subclinical disease to sudden death. Acute hypomagnesaemia is one of the few true veterinary emergencies.



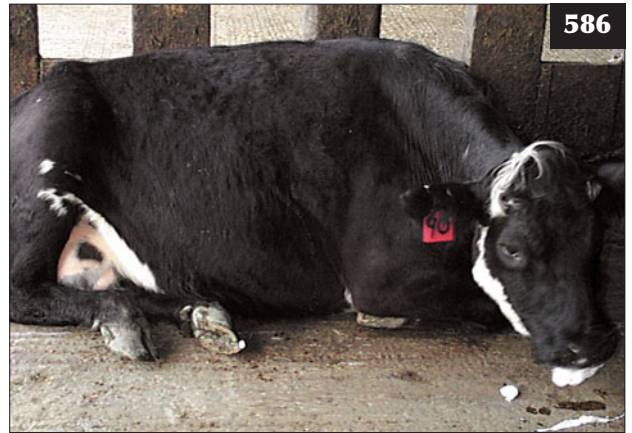583 Manipulation of the transition dry cow diet aids milk fever control. In the situation illustrated, adding straw to the transition dry cow diet will lower the calcium content and the dietary cation–anion balance of the pre-calving diet.



584 Acute hypomagnesaemia in a recently calved beef cow.



585 Absorption of magnesium is reduced on lush spring grazing such as this owing to the increased rate of passage of food through the gut.



586 This beef cow with hypomagnesaemia was aggressive when approached and ataxic, and fell over when restrained by a rope halter.

AETIOLOGY

Despite its vital importance there are no specific homeostatic control mechanisms for the regulation of magnesium levels. The amount and concentration of magnesium in the extracellular fluid is dependent on absorption (mainly from the rumen and omasum, which varies from 10–35%), the requirement for milk production and excretion by the kidneys.

Factors influencing the availability of dietary magnesium include magnesium levels in the soil and grasses, which vary considerably. High levels of potassium (via application of potash fertilizers) disrupt the absorption of magnesium, but sodium is required for magnesium absorption. High levels of ammonia (from use of nitrogenous fertilizer) inhibit magnesium absorption, either directly or indirectly, by raising ruminal pH. Lush spring pastures that are low in fibre increase the rate of passage of food material through the rumen, leading to insufficient time for absorption (585).

CLINICAL PRESENTATION

Sudden death without premonitory signs is encountered most commonly 4–8 weeks after calving in older lactating beef cows maintained at pasture without appropriate supplementary feeding. The cow is found dead, often after stormy weather, with disturbed soil around its feet indicating paddling/seizure activity.

In acute disease there is initial hyperaesthesia with high head carriage, twitching of muscles (especially around the head) and incoordination ('staggering gait'). Affected cows become separated from the group and have a startled expression, with apparent exophthalmos, and frequent teeth grinding (586). There is rapid progression to periods of seizure activity interspersed with opisthotonus. Seizures are often precipitated by stresses including restraint, clinical examination, and attempted treatment. During seizure activity there is frenzied paddling of the limbs



587 Lateral recumbency and frenzied paddling of the limbs in a cow having seizures due to hypomagnesaemia.

(587), rapid nystagmus, rapid pounding heart and teeth grinding with frothy salivation. Death may follow at any stage. Relapses are common even after apparent correct treatment. The majority of cows in the group may be affected subclinically.

Subclinical/chronic disease often goes unrecognized, but investigations have revealed an annual rate of 3–4% in lactating dairy cows. Cows may appear slightly nervous and reluctant to be milked or herded, and have reduced DM intake and poor milk yield. Dairy cows with subclinical hypomagnesaemia in the dry period are predisposed to hypocalcaemia.

Milk tetany is very occasionally reported in suckling 4–8-week-old beef calves. Affected calves show sudden-onset seizure activity, which should be differentiated from lead poisoning.

DIFFERENTIAL DIAGNOSIS (ADULT COWS)

Sudden death: lightning strike/electrocution; anthrax; clostridial disease such as blackleg. Acute disease: lead poisoning; hypocalcaemia; nervous acetoanaemia (dairy cow).

DIAGNOSIS

Plasma magnesium concentrations <0.8 mmol/l indicate subclinical hypomagnesaemia and an increased risk of developing acute hypomagnesaemia. In freshly dead animals only, cisternal CSF and aqueous humor magnesium concentrations <0.6 mmol/l and <0.25 mmol/l, respectively, are indicative of hypomagnesaemia. Magnesium levels in vitreous humour are stable for 48 hours post mortem and levels <0.55 mmol/l are indicative of hypomagnesaemia.

MANAGEMENT

It is essential to control the cow's seizure activity immediately on arrival in order to prevent a fatal convulsion and to facilitate intravenous treatment. Pentobarbitone (3 mg/kg; 8–10 ml of 200 mg/ml solution for an adult cow) injected intravenously as a bolus is the sedative of choice. Xylazine (0.05 mg/kg i/v [1.5 ml of 2% solution]) or acetylpromazine (0.05 mg/kg i/v [3 ml of 10 mg/ml ACP]) could also be used, but are much less effective. Great care should be taken when administering the injection by leaning over the cow's neck, thereby avoiding the forelimbs and possible injury.

400 ml of 40% calcium borogluconate plus 30 ml of 25% magnesium sulphate should be administered by slow

intravenous injection once seizure activity has been controlled (within 1–2 minutes of pentobarbitone injection). The remainder of the 400 ml bottle of 25% magnesium sulphate is then given by subcutaneous injection. The cow should then be raised into sternal recumbency and left quietly. The administration of magnesium sulphate by injection will only increase plasma levels for 6–12 hours, therefore it is essential to offer concentrates/hay to ensure adequate dietary intake and prevent relapse.

The remaining cows are very likely to have subclinical hypomagnesaemia and will be at risk from acute grass staggers. Blood sampling of a group of at least five cows could be performed to check the herd magnesium status, but it would be prudent to implement preventive measures immediately.

Prevention/control measures

The total diet should contain 2.5 g/kg DM of magnesium to meet the requirements of the majority of lactating cows at pasture. The usual target is to use a minimum of 60 g magnesium oxide (calcined magnesite) per cow per day in concentrate feeds such as high-magnesium cobs (588). The water supply can be medicated with soluble magnesium salts (e.g. chloride, sulphate or acetate). Pastures may be dusted during high-risk periods with finely ground calcined magnesite every 10–14 days. Intraruminal boluses give a slow release of relatively small amounts of magnesium into the rumen over a period of four weeks. Magnesium salts and minerals are unpalatable, therefore ad-libitum minerals are not satisfactory (589). Supplementation is especially important during stormy weather when roughage, such as straw, can be beneficial for beef cows (590).



588 High-magnesium cobs being fed to at-risk beef cows.



589 Ad-libitum minerals, as shown here, are not satisfactory because daily magnesium intakes cannot be guaranteed.

HYPOPHOSPHATAEMIA

DEFINITION/OVERVIEW

Primary phosphorus deficiency is rare in northern Europe, but it is well recognized in certain areas of the world, notably Australia, areas of South America and Africa. The



590 Barley straw being provided to at-risk beef cows to slow gut transit time while grazing lush pasture.

vast majority of phosphorus in the body (80%) is found in the skeleton and teeth, with the remainder distributed throughout the body with a wide variety of functions (e.g. RNA, DNA, phospholipids, acid–base balance, rumen microbes).

AETIOLOGY

Hypophosphataemia is a primary phosphorus deficiency associated with lack of phosphorus on pasture.

CLINICAL PRESENTATION

In young cattle, phosphorus deficiency results in poor growth and rickets. This cannot be distinguished clinically from calcium deficiency (see Chapter 7, Musculoskeletal diseases, Vitamin D deficiency/nutritional osteomalacia, p. 193).

In adult cattle, severe phosphorus deficiency results in poor milk yield, weight loss and depraved appetite (pica). Pica results in cows eating earth, rocks and, where available, bones from carcasses. Ingestion of soil/bones may result in botulism, which is the major loss from phosphorus deficiency in many countries.

Historically, phosphorus deficiency has been reported as a cause of infertility in cattle, but there is little supporting data and recent research work has shown no evidence of infertility in dairy cattle fed phosphorus diets of 0.35% (which would classically be considered low in phosphorus) over prolonged periods.

Secondary hypophosphataemia is sometimes observed as a complicating presentation in milk fever cases that have not responded solely to calcium supplementation. These cows are bright and alert, often presenting as 'creeper' or 'crawler' downer cows making frequent attempts to rise. Phosphorus deficiency may also cause recumbency in lactating beef cows.

DIFFERENTIAL DIAGNOSIS

Nutritional osteomalacia in growing calves; other causes of ill-thrift in adult cattle; sodium deficiency in lactating dairy cows.

DIAGNOSIS

Diagnosis may be based on clinical signs and dietary mineral analysis. Confirmation is achieved by blood analysis with serum phosphorus concentrations as low as 0.3 mmol/l in severe cases (normal range 1.3–1.75 mmol/l). Bone ash as an indication of bone mineralization may also be useful.

Diagnosis of recumbency caused by secondary hypophosphataemia is based on elimination of other possible diagnoses.

MANAGEMENT

Recumbency in cattle is treated with 400 ml of calcium hypophosphite or 20 ml of 20% toldimphos by slow intravenous injection.

Prevention/control measures

In intensive systems of livestock production, phosphate fertilizers are extensively used for increasing grass growth and they will also prevent phosphorus deficiency. However, prevention under extensive range conditions presents more problems: free-access high-phosphorus minerals or water supplementation may be the best options.

DOWNER COW

DEFINITION/OVERVIEW

A downer cow, defined as a cow that has been sternally recumbent for more than 24 hours, is not suffering from hypocalcaemia and has no obvious condition (e.g. mastitis, toxemia or injury), is a common presentation in farm animal veterinary practice. The original cause has often been resolved by the time of veterinary presentation and although an accurate diagnosis is frequently not possible, it is the prognosis that most concerns the farmer.

AETIOLOGY

The downer cow has a multifactorial primary aetiology. The most common causes are related to dystocia and milk fever. Unless the initial cause of recumbency is promptly treated, pressure damage (also called compartment syndrome) develops due to the prolonged weight of the cow on its hindquarters. Recumbency in one position for greater than six hours results in ischaemic necrosis and muscle damage, and this may become irreversible after 12 hours of recumbency in the same position.

CLINICAL PRESENTATION

The typical downer cow is bright and alert with a normal appetite, rectal temperature, pulse and respiratory rate. Cows that cannot maintain sternal recumbency and fall into lateral recumbency are depressed or hyperaesthetic have a poor prognosis. Cows that make repeated attempts to rise and can move themselves about are often called 'creepers' or 'crawlers'. Such cows are usually bright and alert and have a good prognosis.

As well as a full clinical examination, all four quarters of the udder should be examined for mastitis and a vaginal examination should be performed to check for metritis. Rectal examination is important not only to check the uterus, but also to check for conditions such as pelvic fractures, crepitus and dislocation. Manipulation of the hindlimbs is undertaken to check for crepitus, swelling, ability to move the limb, muscle damage and pain.

DIFFERENTIAL DIAGNOSIS

Possible primary causes may include traumatic events such as pelvic fractures, sacroiliac luxation/subluxation, rupture of the gastrocnemius tendon and dystocia leading to ruptured uterus, internal haemorrhage and exhaustion.

Neurological causes include obturator nerve (591) and sciatic nerve paralysis, usually following dystocia. Peripheral nerve paralysis includes peroneal and tibial paralysis caused by trauma or recumbency. General neurological conditions include BSE, botulism and tetanus.

Metabolic causes include hypocalcaemia, hypomagnesaemia, fat cow syndrome and ruminal acidosis. Toxaemia can result from acute coliform mastitis and metritis.

DIAGNOSIS

A blood sample for calcium, magnesium and phosphate levels will determine whether hypocalcaemia/hypomagnesaemia has been treated effectively. Energy status may be a concern in fat cow syndrome or where the nursing of the cow has been inadequate, leading to poor food intakes. If fat cow syndrome is suspected, liver enzymes (AST, GLDH and GGT) may indicate the degree of hepatopathy. Tests for muscle damage (e.g. creatine kinase) are not utilized for diagnostic purposes and have limited value for prognosis.

Hip clamps (Bagshaw hoist) may be used once to assist in the diagnosis of fractures and nerve damage; however, repeated application may cause severe muscle damage.

MANAGEMENT

Approximately half of all downer cows will get up in 4–7 days. If the cow has been down for longer than 10 days, the prognosis is poor; however, it is not exceptional for a cow to be recumbent for 14–21 days then rise unaided. The latter situation usually applies to beef cows recumbent subsequent to dystocia, where the calf was 'hip-locked'.

Good husbandry is important. A dry, clean comfortable lying area, either a deep-bedded straw pen or outside in a sheltered grass paddock, should be provided. The cow must be turned every three hours to prevent pressure damage. Provision of ad-libitum good-quality food and fresh water should be ensured.

Administering either NSAIDs (e.g. flunixin meglumine, ketoprofen) or corticosteroids will reduce pain and tissue damage as well as improving demeanour and appetite. Any underlying metabolic and/or toxæmic condition must be treated.

The cow should be assisted in attempting to stand using cow nets, supportive harness, inflatable bags and water flotation tanks.

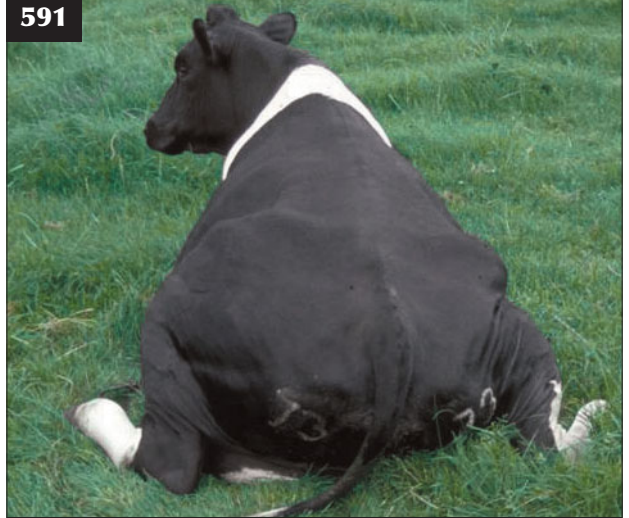Prevention/control measures

Primary aetiological factors (e.g. hypocalcaemia, dystocia) should be prevented and controlled. Prompt treatment of underlying disease is necessary together with dedicated nursing of recumbent cows.

SODIUM DEFICIENCY

DEFINITION/OVERVIEW

Sodium plays a critical role in maintaining osmotic pressure,



591 Obturator nerve paralysis is the cause of this downer cow.

acid–base balance (especially in the rumen via salivary sodium bicarbonate) and water metabolism. Sodium is closely linked with chlorine and potassium metabolism. Levels in the body are closely regulated by a series of complex control mechanisms, including the renin–angiotensin system, antidiuretic hormone (ADH) and aldosterone.

AETIOLOGY

Most forages (especially maize silage) and cereal grains tend to be low in sodium, whereas most concentrate feeds for ruminants contain relatively high levels of salt to increase palatability. Sodium deficiency may be seen in rapidly growing animals on cereal-based diets, high-yielding milking cows due to the losses of sodium in milk, animals grazing on pastures low in sodium or heavily fertilized with potassium (which depresses pasture sodium levels), or secondary to gastrointestinal diseases affecting sodium absorption (e.g. calf diarrhoea).

CLINICAL PRESENTATION

In dairy cows there is a decline in DM intake, weight loss and reduction in milk yield. The most consistent clinical sign is pica, manifest as a craving for salt, with licking of items such as urine, sweat and gate posts. Cows will often gather around urinating cows to drink their urine. In the terminal stages, polyuria and polydipsia may occur followed by sudden onset collapse and death. Sodium is required for proper absorption of magnesium, and salivary potassium concentrations are increased to conserve sodium during deficiency. Thus hypomagnesaemia may occur secondary to sodium deficiency.

DIAGNOSIS

Plasma sodium concentrations are maintained during deficiency and so are of minimal use. The use of urine and

faecal sodium levels has been described, but these are affected by other influences such as diarrhoea. Salivary sodium:potassium ratios can be used, but can be difficult to obtain. The easiest diagnostic method is response to supplementation.

MANAGEMENT

Salt blocks or free-access granular salt (high palatability) should be made available or included in the diet to provide 1.5–2.0 g sodium/kg DM. Salt fertilizer can be used on deficient pastures (16–32 kg sodium/hectare). The use of high-potassium fertilisers or slurry should be restricted, which will reduce sodium uptake by herbage.

ACETONAEMIA (KETOSIS, SLOW FEVER)

DEFINITION/OVERVIEW

Clinical acetonemia is a metabolic disease of high-yielding milking cows associated with an inadequate supply of energy to sustain the high milk yields. The annual incidence of clinical acetonemia is around 1%. However, it is important to realize that the majority of dairy cattle are in negative energy balance during early lactation, resulting in subclinical acetonemia that has profound effects on cow health, productivity and future fertility.

AETIOLOGY

To meet the energy requirements of early lactation, the cow can either increase the amount of energy taken in from the diet and/or mobilize body reserves of fat and protein. Primary acetonemia results during early lactation in high-yielding dairy cows when the cow cannot consume enough energy to supply her glucose requirements for lactogenesis. Risk factors include an inadequate energy content of the ration, inadequate intake of the diet, excessive intakes of ketogenic food (e.g. silage with high levels of butyric acid) and poor rumen function resulting from sudden changes in diet and/or excessive levels of concentrate feeding causing subacute ruminal acidosis.

Secondary acetonemia is caused by diseases that depress food intake (e.g. LDA).

Another classification of acetonemia is based on the underlying cause:

- Type I ketosis occurs in high-yielding dairy cows 3–6 weeks after calving due to inadequate energy consumption from the diet.
- Type II ketosis occurs within two weeks of calving and is thought to be a consequence of insulin resistance due to excessive fat deposition in the liver in late pregnancy.

CLINICAL PRESENTATION

Acetonemia usually occurs within the first month after calving, but it may occur later in lactation if the energy deficit is severe. There are two forms of clinical acetonemia:

- Wasting form. This is the more common form with loss of appetite, refusal to eat concentrate feeds and a sudden drop in milk yield (592). The faeces are often dark and firm, with a 'waxy' appearance (often described as 'horse-like'). The cow loses considerable body condition over 4–7 days. Temperature, pulse and respiratory rate are usually normal. There is a sweet aromatic smell present on the breath of cows with both forms of clinical acetonemia, although not everyone can appreciate this characteristic odour of acetone.
- Nervous form. A small number of cases of clinical acetonemia will develop neurological signs due to hypoglycaemic encephalopathy. Clinical signs are often intermittent and vary from the animal being hyperaesthetic to touch and sound and described by the herdsman as 'jumpy', to head pressing, circling, aimless wandering, salivation with frequent teeth grinding and long periods spent licking at self and inanimate objects (593). The hyperaesthetic state is most noticeable when attempting intravenous glucose infusion; the cow may react severely by bellowing and throwing itself to the ground.

592 This cow with acetonemia shows loss of appetite with poor abdominal fill, a drop in milk yield and weight loss.



593 This cow with nervous acetonemia is head pressing, circling, aimlessly wandering and licking at self and inanimate objects, as seen here.



DIFFERENTIAL DIAGNOSIS

Wasting form: LDA; right distension of the abomasum.
Nervous form: circling, aimless wandering, and reduced appetite are observed in listeriosis; BSE; rabies.

DIAGNOSIS

Possible primary diseases such as LDA and metritis should be ruled out.

Clinical biochemistry

Acetonaemia is characterized by hypoglycaemia, mobilization of body fat and the accumulation of ketone bodies. While low plasma glucose levels (<3 mmol/l) indicate disorders of energy metabolism, the tight homeostatic control means that values may be normal during periods of negative energy balance. Elevated non-esterified fatty acid (NEFA) levels >0.7 mmol/l indicate increased levels of fat mobilization and provide supporting evidence for negative energy balance. The three principal ketone bodies produced are acetone, acetoacetate and β -hydroxybutyrate (BHB); cases of clinical acetonaemia have blood BHB levels >3 mmol/l. Cow-side tests for acetone (Rothera's test – nitroprusside reagent) use milk or urine (594).

MANAGEMENT

Blood glucose levels can be restored by administering 400 ml of 40% glucose intravenously, but this lasts only 2–4 hours. Oral administration of glucose precursors such as propylene glycol (150 g) or glycerine should be given twice daily by drench. Glucocorticoid therapy (e.g. dexamethasone) stimulates gluconeogenesis, reducing the levels of ketone bodies and depressing milk yield, thereby reducing energy requirements. Other therapies include vitamin B₁₂, essential for the metabolism of propionate, and multivitamin injections. Predisposing causes should be corrected and causes of secondary ketosis (e.g. LDA, metritis) treated.

Prevention/control measures

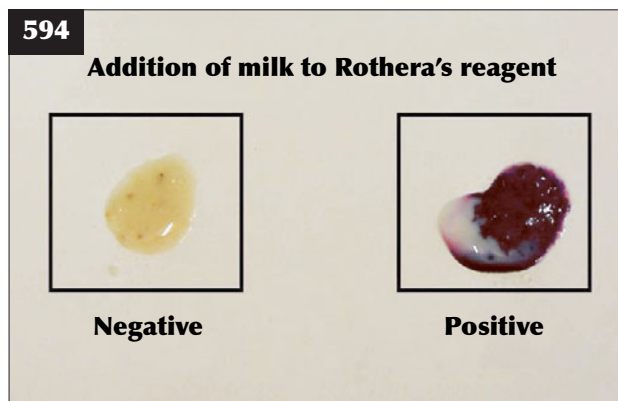
Correct dry cow management should be implemented whereby cows calve with a BCS of 2.5–3.0, thus avoiding excessive body condition. Transitional cow management in the late dry period/early lactation, including good-quality forage (595), should be provided. DM intake should be maximized in the late dry period/early lactation and care taken to ensure that the protein and energy supply in the diet is balanced.

The energy contribution from forages, especially in high-yielding early lactation cows at pasture, should not be overestimated. Any dietary changes should be made gradually. Cows should be grouped according to their nutritional requirements. Overcrowding and stress must be avoided, particularly in recently calved cows. Concentrates should not be overfed. Nutritional status, including body condition scoring of cows, faecal consistency and metabolic profiles, should be regularly monitored where appropriate.

PREGNANCY TOXAEMIA

DEFINITION/OVERVIEW

Pregnancy toxaemia can occur during the last month of gestation in cows carrying twin calves fed a very low-energy diet such as straw without supplementary feeding. This situation is most common in beef cows under severe drought/starvation conditions. Occasionally, fatty liver disease/pregnancy toxaemia results when farmers elect to drastically reduce feeding to overconditioned pregnant beef cows after several dystocias in the group, mistakenly believing that this regimen will reduce calving difficulties in the rest of the group.



594 The Rothera's reagent has turned purple after being mixed with milk from a ketotic cow. This confirms the diagnosis of acetonaemia.



595 Good-quality forage being fed to cows in the late dry cow period to get them ready for lactation.

AETIOLOGY

Pregnancy toxæmia is caused by an inadequate dietary energy supply to support (twin) pregnancy.

CLINICAL PRESENTATION

Weight loss occurs over several weeks and cows present in very poor body condition, but with a distended abdomen, as a consequence of the multigravid uterus. Affected cows are very dull and depressed and often present in sternal recumbency. There is little ruminal activity and any faeces are hard, dry and coated in mucus. Death usually follows 5–14 days after the cow becomes recumbent.

DIFFERENTIAL DIAGNOSIS

Vagus indigestion; hydrops allantois/amnii.

DIAGNOSIS

Elevated serum ketone bodies and low plasma glucose concentrations support the clinical diagnosis.

MANAGEMENT

Recumbent cattle should be destroyed for welfare reasons. Induced parturition and/or an elective caesarean section can be attempted, but septic metritis is a common sequela associated with RFM.

Prevention/control measures

Prevention is by providing adequate dietary energy (80–90 MJ/day) during late gestation. In addition there should be regular condition scoring of cows and professional assessment of rations.

FATTY LIVER SYNDROME

Fatty liver syndrome is the term used to describe the mobilization of fat that frequently occurs around calving and during the first month of lactation in high-yielding dairy cows. This is thought to be a 'normal' occurrence in high-yielding dairy cattle, which may have up to 20% fat in the liver in the immediate peri-parturient period (normal cow has <5%). However, if the negative energy balance is severe and prolonged, then >20% fat may be deposited in the liver, which can interfere with liver function and result in exacerbation of energy problems and the development of acetonæmia. This may lead to fat cow syndrome.

FAT COW SYNDROME**DEFINITION/OVERVIEW**

Fat cow syndrome is the extreme manifestation of negative energy balance and fat mobilization during early lactation. It was first reported in the late 1970s, but it is now uncommon due to better herd management, with regular condition scoring and dietary adjustment and much less concentrate feeding ('steaming-up') during late gestation.

AETIOLOGY

Fat cow syndrome occurs due to overconditioning (BSC >4.0; scale 1 to 5) prior to calving. This results in a depressed appetite at calving, and the cow enters a state of severe energy deficiency in early lactation. More fat is deposited in the liver, leading to severe liver dysfunction.

CLINICAL PRESENTATION

Excessively fat dry cows (BCS >4.0) lose body condition rapidly during early lactation. Appetite is greatly reduced, which further aggravates fat mobilization and deposition within the liver and other parenchymatous organs. Milk yield is greatly reduced. Metabolic diseases, mostly milk fever and clinical acetonæmia, develop that are refractory to conventional therapy. The incidence of toxic mastitis and retained fetal membranes/ metritis is also greatly increased. The mortality rate of clinical cases is high.

DIFFERENTIAL DIAGNOSIS

Milk fever; acetonæmia; toxæmia; subclinical rumen acidosis.

DIAGNOSIS

Diagnosis is based on history and clinical signs, in particular poor response to standard treatments for metabolic diseases such as acetonæmia. There is a large difference in BCSs between dry cows and those cows calved 1–2 months. There is biochemical evidence of severe negative energy balance during early lactation. Liver enzyme and bilirubin concentrations are greatly increased. Ultrasound-guided liver biopsy can be taken from 3–5 cows and samples stained with oil red O. There is depression of the immune system reflected in low white blood cell counts ($<3 \times 10^9/l$). Necropsy findings include massive fatty infiltration of the liver, which is grossly enlarged and pale and with rounded borders. There is increased fat infiltration of the kidneys and heart.

MANAGEMENT

Symptomatic treatment may be attempted to enhance energy metabolism and promote liver function (see Acetonæmia, Management, p. 256). Euthanasia may be the best option for advanced cases that are recumbent. Prevention/control measures are the same as for acetonæmia (see p. 256).

Chapter 15

Trace element and vitamin deficiencies

INTRODUCTION

Copper, cobalt, selenium, iodine and occasionally zinc are considered to be the important trace elements impacting on cattle performance. Deficiencies are most likely to occur in grazing animals or animals fed forage only diets or home-grown feeds (e.g. organic farming systems) without any mineral supplementation. Deficiencies are extremely unlikely when significant amounts of purchased mineralized concentrate feeds are fed.

The potential for clinical signs of trace element deficiency to occur will depend on the duration and degree of inadequate mineral intake. There are four different stages that occur in the progression from inadequate mineral intake to the development of clinical disease:

1. **Depletion.** During this phase there is loss of mineral from storage sites (e.g. liver, bone). However, the levels in the transport system (usually bloodstream) are normal.
2. **Deficiency.** In this phase the levels in the transport system decline.
3. **Dysfunction.** Here, the low levels of mineral lead to a decline in the concentrations or functions of enzymes involved in metabolism, and thus body function is impaired. The animal still appears clinically normal.
4. **Disease.** These changes in metabolism lead to detectable clinical abnormalities.

These stages can also be used for the interpretation of laboratory results in the investigation of trace element

deficiencies using a 'marginal band', as outlined in *Table 5*.

Mineral deficiencies may be either primary (simple), where levels of mineral in the diet are inadequate, or secondary (or conditioned), where levels of mineral in the diet are normal, but there are other factors that limit its availability to the animal.

COPPER DEFICIENCY

DEFINITION/OVERVIEW

Although it can occur as a primary deficiency on copper deficient pastures, secondary copper deficiency is more common due to antagonism by sulphur, iron and especially molybdenum in the rumen, which means that between 90% and 99% of the copper eaten by adult ruminants is passed through the gut unabsorbed. In contrast, pre-ruminant calves and lambs suckling milk can absorb 80–90% of dietary copper. Copper is required for the function of a wide range of enzymes in the body (e.g. melanin production).

AETIOLOGY

There are a number of different mechanisms whereby sulphur, iron and molybdenum antagonize copper absorption: for example, molybdenum reacts with sulphur in the rumen to form thiomolybdates, which irreversibly bind copper and prevent its absorption. Certain regions

Table 5 Summary of the interpretation of laboratory investigations into trace element deficiencies using three definitions of trace element status based on the four stages of deficiency (depletion, deficiency, dysfunction and disease).

Definition	Stage	Response to supplementation
Optimum/normal	Equilibrium, depletion	No
Marginal	Deficiency, dysfunction	Possible
Abnormal/low	Disease	Probable

are renowned as having high molybdenum levels, and soil contamination of either grazing or conserved forages will increase intakes of both iron and molybdenum.

Once absorbed, the liver is the major organ for storage of copper, containing 70% of body copper reserves. Copper is transported in the bloodstream bound to caeruloplasmin and levels are buffered by the liver stores. Clinical signs of copper deficiency only occur after exhaustion of liver stores, followed by decreases in blood copper concentrations then a fall in copper levels at the essential tissue sites. This process may take between three and six months.

CLINICAL PRESENTATION

Clinical signs of copper deficiency are usually seen in young animals and usually manifest as disappointing growth rates. Depigmentation classically occurs as grey/brown discolouration of the coat in black cattle (596), especially around the ear margins and eyes, giving a 'spectacle-eye' appearance. Defective keratinization can lead to the formation of a thin, dry, sparse hair coat not to be confused with the normal shedding of winter coat. Widening of the epiphyses of the distal limb bones (597: especially the third metatarsal bones) and enlargement of the costochondral junctions are also seen.

Anaemia occurs after prolonged and/or severe periods of deficiency. Other disorders including cardiac hypertrophy leading to sudden death, impaired resistance to infection and immune system dysfunction have all been associated with copper deficiency.

Diarrhoea is classically seen after turnout onto pastures with high molybdenum concentrations (>15 mg/kg DM), and is only associated with molybdenum excess ('teart pastures'). Signs include severe diarrhoea, weight loss and poor milk production affecting young and adult cattle. The relationship between copper deficiency and infertility is still controversial, with current evidence suggesting that impaired fertility is associated with molybdenum excess rather than copper deficiency.

DIFFERENTIAL DIAGNOSIS

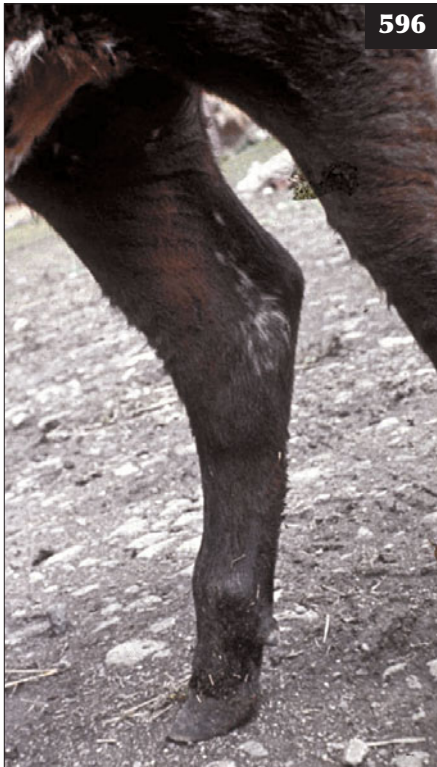Malnutrition; PGE.

DIAGNOSIS

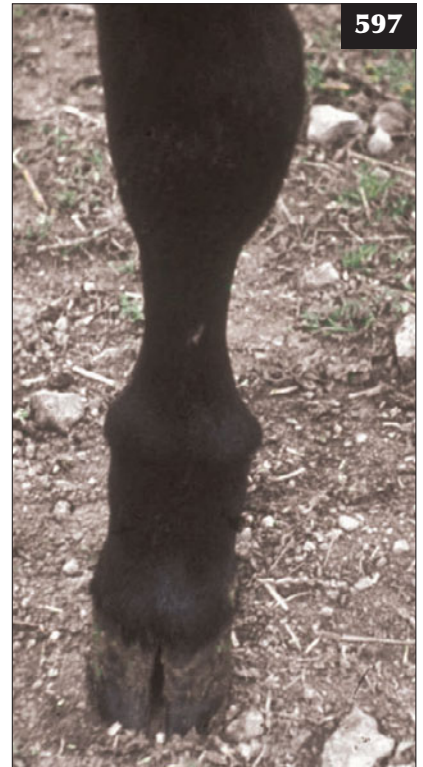Most clinical signs are non-specific for copper deficiency. Dietary copper levels are of no value because of the antagonistic effects of molybdenum, sulphur and iron. Some authorities advocate the use of dietary molybdenum levels (levels above 2 mg/kg DM), dietary copper:molybdenum ratios <1:1 and dietary iron:copper ratios >100:1, but these must be interpreted with extreme care.

Plasma or serum copper levels are suitable for the diagnosis of clinical disease, but not for the estimation of body copper reserves. A group of 7–10 cattle should be sampled because of wide variations between individual animals, and the marginal band for plasma copper levels in cattle is quoted as 3–9 $\mu\text{mol/l}$ (see Introduction and *Table 5* for use of marginal band for the interpretation of trace element levels).

596 Copper deficiency has resulted in brown discolouration of the black hair in this Aberdeen Angus calf.



597 Clinical signs of copper deficiency are manifest as widening of the epiphyses of the distal limb bones in this growing steer.



Liver samples give an estimation of body copper reserves and can thus be used for diagnosis of deficiency and monitoring of copper supplementation. Liver samples may be taken by biopsy or from post-mortem or abattoir specimens. Three to four samples should be taken and interpretation based on group mean (the marginal band for liver copper in the diagnosis of deficiency is 100–300 $\mu\text{mol/kg DM}$). In ill-thrift in cattle, response to supplementation may also be used as a diagnostic method.

Some authors recommend the use of caeruloplasmin: copper ratios in the diagnosis of copper deficiency and/or molybdenum toxicity. At present, these tests do not appear to have any significant advantages over blood and liver copper measurements.

MANAGEMENT

Injectable copper preparations (e.g. calcium copper edentate) can be utilized in cattle to provide copper supplementation for over three months, although they may result in localized tissue reactions. Copper oxide needles are given *per os* in a gelatin capsule, which then lodges in the abomasum to give slow-release of copper over a period of 2–3 months. Soluble glass boluses containing copper can also be used to supplement throughout the grazing season. Copper may be included in concentrates fed to cattle, although high inclusion levels may require a veterinary prescription in some countries because of the risk of copper toxicity. Chelated ‘organic’ copper sources may have better absorption than traditional inorganic sources, although other benefits remain unproven. Supplementation via water and free-access minerals (598) can also be used, although individual intakes are varied.



598 Free-access trace element supplementation is proving very unreliable in this situation.

SELENIUM AND VITAMIN E DEFICIENCY

DEFINITION/OVERVIEW

Both selenium and vitamin E play key complementary but independent roles to protect cells against damage by lipid peroxidases and free radicals, which are produced during normal cellular oxidative metabolism. Selenium deficiency is a primary deficiency caused by a lack of selenium in the soil. Vitamin E (tocopherols) is synthesized by plants and levels are generally high in green pastures. Vitamin E deficiency states tend to occur in housed livestock and subsequent turnout in the next spring (599), especially beef suckler herds fed poor-quality forages (600) such as straw and home-mixed concentrates during winter housing without appropriate supplementation.



599 These cattle that have been overwintered on a selenium-deficient diet might be susceptible to white muscle disease following spring turnout.



600 Overwintering of these beef suckler cows on poor-quality forage without appropriate supplementation may result in selenium or vitamin E deficiency.

AETIOLOGY

During selenium and/or vitamin E deficiency, failure to protect against cell damage leads to cell membrane damage and tissue necrosis. Tissues with the highest rates of oxidative metabolism are most susceptible to damage, especially skeletal, cardiac and respiratory muscle. Selenium also plays a role in thyroid hormone production and thus deficiencies can affect metabolic rate.

The occurrence of clinical disease caused by anti-oxidant deficiencies is related to (1) selenium status, (2) supply of other dietary anti-oxidants (primarily vitamin E), (3) supply of dietary oxidants such as polyunsaturated fatty acids (PUFAs) in young, rapidly growing pastures (especially in the spring), and (4) generation of oxidants (e.g. via exercise at turnout or infection or toxins). Disease is more common in young growing cattle fed home-grown feeds from selenium deficient pastures without appropriate supplementation.

CLINICAL PRESENTATION

The congenital form of selenium and vitamin E deficiency (nutritional muscular dystrophy, white muscle disease) is seen either as stillbirth or the birth of a weak calf that fails to thrive and suckle and usually dies within a few days.

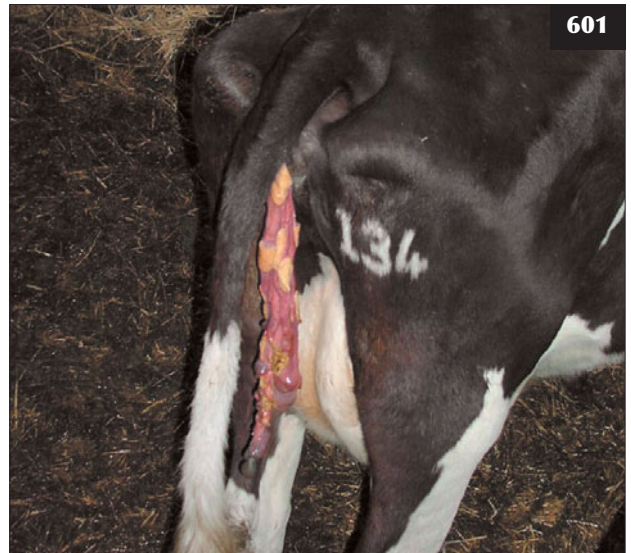
The delayed form is usually seen in calves between one and four months old. Signs are usually precipitated by sudden exercise, typically following turnout to pasture in the spring, with the clinical signs varying according to the muscles affected.

If skeletal muscles are affected, there is sudden-onset stiffness and inability to stand. The calf is sternally recumbent, bright and alert and with a normal appetite. There may be urine discolouration due to the presence of myoglobin. If the respiratory muscles are affected, then there is usually evidence of respiratory distress, which is frequently confused with pneumonia. Cardiac muscle damage can result in sudden death without premonitory signs.

Selenium deficiency can also cause poor growth rates, weight loss and ill-thrift in growing calves. Poor milk production has been recorded in dairy cattle under extensive conditions, possibly due to secondary effects on thyroid hormone function. The role of selenium deficiency in fertility disorders remains controversial, although there is a clear association with retained placenta (601) (Chapter 1, Part 2, Female reproductive tract diseases, Retained fetal membranes, p.17). Selenium/vitamin E deficiency has been shown to lead to increased susceptibility to infection, in particular mastitis and endometritis, in dairy cows.

DIFFERENTIAL DIAGNOSIS

- Skeletal muscles: spinal lesion such as vertebral empyema; polyarthritis (but calves usually older than neonatal polyarthritis cases).
- Respiratory muscles: peracute BRSV; pasteurellosis; lungworm.



601 The retained fetal membranes in this cow are associated with selenium and/or vitamin E deficiency.

- Cardiac muscle: causes of sudden death in young calves including abomasal torsion, abomasal perforation, clostridial enterotoxaemia and septicaemia.

DIAGNOSIS

Nutritional muscular dystrophy can be diagnosed using muscle enzymes. Creatine kinase concentrations >5,000 IU/ml indicate severe muscle damage (often >20,000 IU/ml; normal range <200 IU/ml), but levels decline rapidly after a few days due to its short half-life. Necropsy reveals white necrotic lesions in the myocardium and skeletal muscles (classically the thigh and shoulder). Histopathology may be required to confirm the diagnosis.

Whole blood glutathione peroxidase (GSHPx), a selenium-containing enzyme, is the standard biochemical test for selenium deficiency. As erythrocyte GSHPx levels depend on selenium concentrations during erythropoiesis, and red blood cells survive for several months, blood GSHPx levels reflect long-term selenium status over the past 2–4 months. The marginal range for the diagnosis of selenium deficiency is 20–40 IU/ml cells. As it measures an enzymatic reaction, reference ranges vary according to the laboratory and whether values are interpreted in units/ml cells or grams of haemoglobin.

Selenium levels in the blood measure short-term intakes, and liver selenium levels may be useful to determine the need for supplementation. However, selenium analyses are expensive and so rarely performed. Soil and pasture levels of selenium also give a good indication of the potential for selenium deficiency to arise. Plasma α -tocopherol levels <1 $\mu\text{mol/l}$ indicate a significant risk of nutritional muscular dystrophy, even if selenium status is adequate. Levels <2 $\mu\text{mol/l}$ may give rise to signs of disease if selenium levels are marginal.

MANAGEMENT

Sodium selenate or selenite may be given by oral drench or injection, usually combined with vitamin E, and will provide adequate selenium supplementation for between one and three months.

Prevention/control measures

Subcutaneous injections of barium selenate provide adequate supplementation for 9–12 months. Intraruminal soluble glass boluses provide slow release of selenium for 6–12 months. Selenium and vitamin E are frequently added to concentrate rations for feeding to cattle. Chelated 'organic' selenium sources may have better absorption than traditional inorganic sources, although other benefits remain unproven. Supplementation via water and free-access minerals can also be used, although individual intakes are varied. Treatment of pastures with sodium or barium selenate (usually as slow-release granules) can be effective for up to three years.

Selenium can cross the placenta and both selenium and vitamin E are concentrated in the colostrum, therefore supplementation of the dam's diet during late pregnancy will ensure good supply to the newborn calf.

COBALT DEFICIENCY (COBALT PINE)

DEFINITION/OVERVIEW

Dietary cobalt is necessary as a constituent of vitamin B₁₂. Ruminants ingest cobalt, which the rumen microbes then use to synthesise vitamin B₁₂, which is absorbed by the small intestine. Cobalt deficiency is much less common in cattle than in sheep, although it has been recorded as a cause of ill-thrift and poor production.

AETIOLOGY

Cobalt deficiency is restricted to certain geographical areas and is the direct result of ingestion of grass/crops grown on impoverished soils (602). All cattle require dietary cobalt for the manufacture of vitamin B₁₂ in the rumen, which is necessary as a co-enzyme for two biological processes:

1. Energy metabolism, as vitamin B₁₂ is required for the metabolism of propionic acid (the major volatile fatty acid glucose precursor in ruminants). Poor performance of this metabolic pathway therefore leads to anorexia and ill-thrift.
2. Methionine synthesis, which is a major amino acid involved in growth and DNA synthesis.

Growing animals also have a higher requirement than adults.

CLINICAL PRESENTATION

Anorexia, weight loss and anaemia with pale mucous membranes develop over weeks/months. The skin becomes thin with poor hair quality.

DIFFERENTIAL DIAGNOSIS

Malnutrition; parasitism; copper or selenium deficiency.

DIAGNOSIS

Soil and pasture cobalt levels can only give an approximate guide to cobalt availability and so cannot be used for definitive diagnosis of deficiency. Interpretation of serum vitamin B₁₂ levels in cattle is complicated by the presence of plasma-binding proteins, which makes bovine results prone to gross underestimation. Liver samples are therefore likely to be more reliable than serum samples for vitamin B₁₂ assay in cattle. Response to vitamin B₁₂ injections or cobalt drench in a controlled study remains the best means of establishing a diagnosis of cobalt deficiency.

MANAGEMENT

Vitamin B₁₂ injections weekly for 4–6 weeks are recommended.


Prevention/control measures

Cobalt contained within intraruminal soluble glass boluses or pellets/boluses release cobalt over 6–12 months. Free-access mineral licks containing cobalt are also used. Drenching with cobalt salts every 2–4 weeks presents management difficulties under extensive conditions.

IODINE DEFICIENCY

DEFINITION/OVERVIEW

Iodine is essential as a constituent of the thyroid hormones, in particular T₃ and T₄, and 80% of the iodine in the body is found in the thyroid gland. Primary iodine deficiency occurs sporadically worldwide in well documented geographical areas.



602 These young stock grazing on poor-quality pasture without supplementation may be at risk of cobalt deficiency.

AETIOLOGY

Low iodine content in the soil leads to primary deficiency. Secondary deficiency results from ingestion of the goitrogen thiocyanate found in brassicas and legumes, and thiouracil found in brassica seeds (e.g. some older varieties of oilseed rape). Selenium is required for the conversion of T_4 to active T_3 , and thus selenium deficiency may lead to secondary iodine deficiency states. Factors that increase the basal metabolic rate of animals, such as low environmental temperatures, will increase thyroid hormone production and hence iodine requirements.

CLINICAL PRESENTATION

The classic sign of iodine deficiency is thyroid enlargement (goitre) due to compensatory mechanisms invoked by the lack of thyroid hormone production. Calves born to iodine-deficient dams may be stillborn, with goitre and areas of alopecia and subcutaneous oedema. Weak calves are unwilling to suck (**603**), leading to high perinatal mortality.

As with selenium, iodine deficiency has also been implicated in poor growth rates, ill-thrift, poor milk production and retained placenta.

DIFFERENTIAL DIAGNOSIS

Selenium/vitamin deficiency; trauma during the birth process; septicæmia.

DIAGNOSIS

Severe goitre will be detectable on clinical examination. Thyroid weight (<10 g, normal; >13 g, abnormal), fresh

thyroid weight:body weight ratio (<0.5, normal; >1.0, abnormal) and histopathology can be used to confirm the diagnosis. Plasma inorganic iodine measures current daily iodine intake (short-term) and is thus susceptible to changes in feed intake. T_4 levels reflect the thyroid and iodine status of the animal (>50 nmol/l, normal; <20 nmol/l, abnormal), and are useful in the diagnosis of deficiency. Care must be taken in interpretation of T_4 values, as there is natural variation according to factors such as stage of lactation (levels are much lower in early lactation), season and age of the animal. T_4 levels will be high in cases of iodine deficiency secondary to thiouracil goitrogens, as they prevent the conversion of T_4 to T_3 .

MANAGEMENT

Oral dosing using potassium iodide is relatively short acting and laborious. Intraruminal boluses provide slow release of iodine for six months. Intramuscular injections of iodized poppy seed oil (Lopiodol) provide adequate supplementation for up to two years. Painting 5% tincture of iodine onto the flank skin fold once a week in milking dairy cattle can work well, but is too labour intensive in dry cows and beef animals. Free-access minerals, medication of water supplies and pasture fertilizers can all be used to varying effect.

Prevention/control measures

Iodine is frequently added to concentrate rations for feeding to cattle (e.g. using seaweed preparations). Rapeseed meals are usually treated to eliminate goitrogens prior to feeding, and newer 'double-zero' oilseed rape varieties are lower in goitrogens.



603 This weak calf might be a manifestation of iodine deficiency in the dam.

MANGANESE DEFICIENCY

DEFINITION/OVERVIEW

Manganese is required for the function of a variety of enzymes involved in cartilage and bone development, metabolism and anti-oxidant defences.

AETIOLOGY

Less than 5% of dietary manganese is absorbed and even this may be reduced by the presence of excess calcium and phosphorus (especially as phytate). However, current recommendations for manganese intakes of 20–30 mg/kg DM are easily met by most diets, and deficiencies will only occur on grazing deficient pastures (or maize silages) with no mineral supplementation.

CLINICAL PRESENTATION

Clinical signs are seen in neonatal animals and include congenital chondrodystrophy (skeletal abnormalities, dwarfism, shortened limbs), swollen joints and neurological disorders in neonatal animals secondary to skull bone defects (Chapter 7, Musculoskeletal diseases,

Congenital joint laxity and dwarfism, p. 193). The effect of manganese deficiency on fertility is controversial, and has only been observed under experimental depletion.

DIAGNOSIS

Serum manganese levels $<0.11 \mu\text{mol/l}$ are highly suggestive of manganese deficiency and low levels in the heart are also diagnostic.

MANAGEMENT

Supplementation is via by the use of manganese sulphate orally (4 g/day in cows, 1 g/day in calves).

IRON DEFICIENCY

DEFINITION/OVERVIEW

Iron is required for the formation of haemoglobin and myoglobin, as well as for iron-containing enzymes involved in many biochemical processes.

AETIOLOGY

Most feedstuffs used in ruminant diets, with the exception of milk, contain large amounts of iron; therefore, deficiencies are only seen in suckling calves, but there is usually enough iron in body reserves or from soil ingestion to provide sufficient iron. Iron deficiency states are seen in young, rapidly growing animals, particularly when housed, where the disease is usually subclinical. It also occurs more commonly in artificial production systems (e.g. veal calf production) and disease states (e.g. liver fluke, haemorrhage).

CLINICAL PRESENTATION

The clinical signs of iron deficiency are anaemia and associated poor growth.

DIFFERENTIAL DIAGNOSIS

Other causes of anaemia such as acute haemorrhage, chronic parasitism, coccidiosis.

DIAGNOSIS

Measurement of PCV, blood haemoglobin levels and demonstration of a hypochromic, microcytic anaemia support the diagnosis.

MANAGEMENT

Treatment/prevention is by administration of iron dextran (500 mg for calves using iron dextran preparations for piglets) and correction of the underlying cause. Blood transfusion in cases of acute blood loss.

ZINC DEFICIENCY

DEFINITION/OVERVIEW

Zinc is required for the proper function of a wide variety of enzymes with roles in gene expression (DNA and RNA metabolism), appetite, vitamin A metabolism and immune system function.

AETIOLOGY

The usual cause is a primary lack of zinc in the diet (pastures containing over 20 mg zinc/kg DM are generally considered to contain adequate levels), although zinc absorption may be reduced by high levels of phytate and possibly calcium.

CLINICAL PRESENTATION

Signs of zinc deficiency are usually seen in 1–3-month-old calves because of their higher growth requirements. Clinical signs include skin abnormalities such as alopecia, thickening and cracking of the skin (parakeratosis), especially of the lower limbs, muzzle and perineum (Chapter 9, Skin diseases, Zinc-responsive dermatosis, p. 209). Loss of appetite, poor growth rates, skeletal abnormalities, wool loss, impaired spermatogenesis and increased susceptibility to infections have also been reported.

DIFFERENTIAL DIAGNOSIS

Muzzle dermatitis in milk-fed calves; dermatitis and hair loss around the perineum following diarrhoea; vitamin A deficiency; sarcoptic mange; other causes of ill-thrift.

DIAGNOSIS

Diagnosis of zinc deficiency is by demonstration of serum zinc levels $<9 \mu\text{mol/l}$, but low levels may also occur due to stress, infection and around parturition. Zinc levels are also affected by the blood collection tube (non-rubber collection tubes must be used). Response to supplementation may be the best diagnostic aid.

MANAGEMENT

Oral zinc sulphate (0.5–2 g orally per week for calves) or slow release zinc boluses can be used to treat individual animals and prevent deficiency. Zinc fertilizers and free-access minerals can be used in extensive systems. Inclusion in concentrate feeds usually provides more than sufficient zinc (whether using inorganic or organic zinc forms).

VITAMIN DEFICIENCIES

All the water-soluble vitamins (B complex, vitamin C), as well as vitamin K, are synthesized by rumen microbes, and therefore primary deficiencies are rare in cattle. Vitamin deficiency syndromes encountered in cattle include:

- **Vitamin A** (see below).
- **Vitamin B₁** (thiamine). Secondary deficiency due to thiaminase production causes CCN (Chapter 6, Nervous system diseases, Polioencephalomalacia, p. 151).
- **Vitamin B₁₂** (cyanocobalamin: see Cobalt deficiency, p. 262).
- **Vitamin D**. Previously discussed in relation to calcium and phosphorus metabolism (Chapter 7, Musculoskeletal diseases p. 193, and Chapter 14, Metabolic diseases, pp. 247 and 253).
- **Vitamin E**. See Selenium deficiency, p. 260.

VITAMIN A DEFICIENCY

DEFINITION/OVERVIEW

Vitamin A precursors (called carotenoids) are present in plants, and the most important precursor is β -carotene. The liver and intestine convert dietary β -carotene into vitamin A, and the majority of vitamin A is stored in the liver. Vitamin A is essential for the formation of the visual purple (rhodopsin) in the retina, bone metabolism, embryo development and epithelial tissue maintenance.

AETIOLOGY

All green plants contain abundant amounts of β -carotene and the liver can store abundant supplies of vitamin A (to last over six months). Deficiencies are therefore rare, but may occur:

- Primary deficiency. β -carotene is destroyed by drying and excess sunlight, thus deficiencies may occur in animals fed poor-quality forage during winter housing or in drought conditions. Deficiencies may also occur in fattening animals on cereal-based diets with inadequate supplementation.
- Secondary deficiency. Chronic liver and intestinal

disease will inhibit uptake of β -carotene and conversion into vitamin A. Use of mineral oils for bloat prevention may also prevent adequate absorption from the intestine.

CLINICAL PRESENTATION

The classic organ affected by vitamin A deficiency is the eye (Chapter 10, Eye diseases, Hypovitaminosis A, p. 214). Blindness may occur due either to retinal degeneration or to constriction of the optic nerve due to bone overgrowth (associated with papilloedema). Dryness and thickening of the cornea (called xerophthalmia) may also occur.

Neurological signs, such as convulsions and ataxia, may be seen in newborn calves and are due to constriction of nerves or CSF flow by bony overgrowth (Chapter 6, Nervous diseases). Clinically detectable bone overgrowths, especially of the skull (occipital bone), may also occur. Stillbirths and congenital defects include doming of the forehead, hydrocephalus, eye defects and exophthalmos.

In adult cattle the coat quality is poor. Large amounts of brown, bran-like scales may be present on the coat.

DIFFERENTIAL DIAGNOSIS

Other neurological conditions in neonatal calves such as meningitis; metabolic acidosis following diarrhoea; other causes of birth defects such as congenital BVDV infection; parasitic skin diseases.

DIAGNOSIS

Clinical signs, history and post-mortem findings will be supportive. Dietary analysis of vitamin A may assist in primary deficiency cases. Subnormal serum vitamin A concentrations are diagnostic (reference range 0.15–0.3 $\mu\text{g/ml}$).

MANAGEMENT

Treatment is by injection of vitamin A (400 IU/kg *i/m*, repeated if necessary), although any clinical signs due to bony constriction of nerves are irreversible. Adequate supplementation of the diet (100 IU/kg/day) is required.

Chapter 16

Miscellaneous infectious and exotic diseases

FOOT AND MOUTH DISEASE

DEFINITION/OVERVIEW

FMD is endemic throughout many parts of the world, but much of Europe, North America, Australia and New Zealand is free of the disease. Disease incursions are eliminated by stringent herd and flock slaughter programmes and livestock movement bans.

AETIOLOGY

FMD is an extremely contagious disease most commonly spread by movement of infected cattle, sheep, goats and pigs, but indirect spread via farm staff and vehicles is important in many outbreaks. The FMD outbreak in the UK in 2001 was caused by the Pan Asia strain first isolated in India in 1990.

CLINICAL PRESENTATION

The incubation period is 2–10 days. Initially, one or two cattle present with pyrexia ($>40.0^{\circ}\text{C}$), depression (604), anorexia, a marked drop in milk yield and salivation (605). Other cattle in the group at pasture may not yet show clinical signs, but the increase in disease morbidity within 24 hours in housed cattle is very dramatic. Vesicles on the tongue, dental pad and hard palate quickly rupture, leaving shallow ulceration with shreds of mucosa at the periphery (606, 607). The submucosa is markedly

hyperaemic. There are no ocular or nasal discharges. Vesicles may be present on the teats and at the coronary band (608, 609). They may become secondarily infected and cause lameness. Cattle under intensive management conditions with appropriate supervision would be detected at this stage, and in many countries compulsory slaughter of all cloven-hooved animals on the farm would ensue.

Where cattle are not slaughtered, the mouth ulcers (610) start to heal by day 10 after infection. Foot lesions often become secondarily infected and animals may be reluctant to rise. During the acute phase of disease there is marked weight loss and milk yield reduction.

DIFFERENTIAL DIAGNOSIS

Group of cattle:-- bluetongue; rinderpest. Individual cattle: MD; MCF; bluetongue; ingestion/contact with a caustic substance.

DIAGNOSIS

Overlying mucosal flaps >2 square cm from a ruptured vesicle are despatched in appropriate transport media to a designated laboratory.

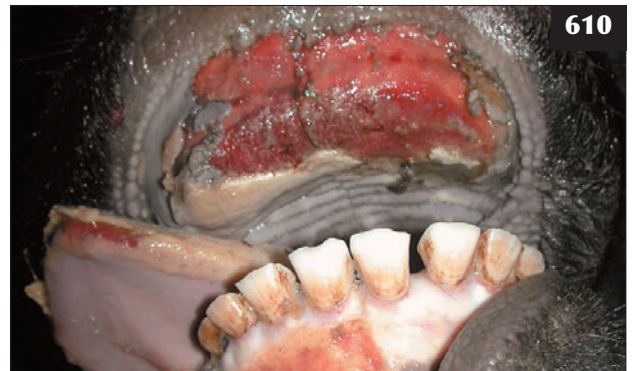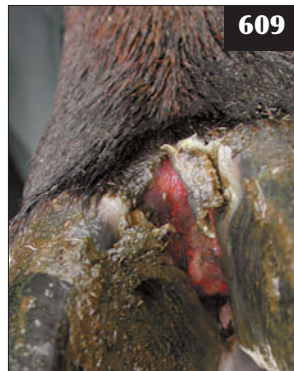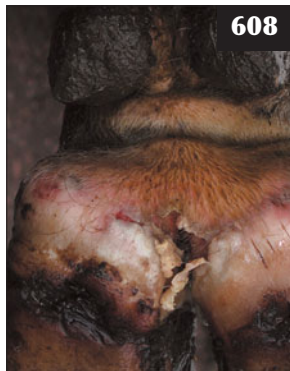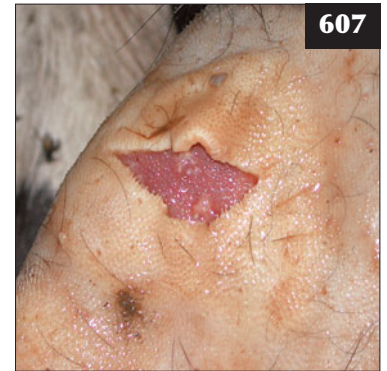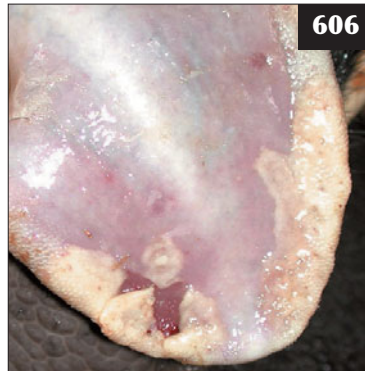604 This cow presented at the start of a foot and mouth disease outbreak on a farm with pyrexia and inappetence.



605 This isolated cow was pyrexia (40.5°C), depressed and salivating. It was the only animal affected at that time, but was confirmed as foot and mouth disease.



606, 607 Foot and mouth disease. (**606**) The vesicles on the tongue of this animal have ruptured, leaving shallow ulceration with shreds of mucosa at the periphery. (**607**) The submucosa is markedly hyperaemic under the ulcer in this animal. (Both photographs taken after culling.)



608–610 Foot and mouth disease. (**608**) Vesicles present at the coronary band that have become secondarily infected. (**609**) Vesicles present along the interdigital space that have become secondarily infected. (**610**) Extensive ulceration in a cow approximately 7–10 days after foot and mouth disease first appeared.



611 Slaughter of a sheep flock necessitates large numbers of skilled personnel and presents considerable logistical problems during a foot and mouth disease epidemic.



612 Biosecurity measures operating during a foot and mouth disease outbreak.

MANAGEMENT

In many countries, cattle with suspected FMD are slaughtered immediately (**611**). In other countries, where there is no compulsory slaughter policy, antibiotic therapy may control secondary bacterial infection of ulcers.

Biosecurity measures (**612**) are essential during FMD

outbreaks in order to prevent spread of disease. Vaccination against the strain of FMD virus implicated in an outbreak is effective, but it incurs trade restrictions to many countries.

RINDERPEST

DEFINITION/OVERVIEW

Europe, the USA, Australia and New Zealand are free of rinderpest, but the disease still occurs in Asia, the Indian subcontinent and eastern Africa.

AETIOLOGY

Rinderpest is caused by a paramyxovirus and can affect cattle, sheep, goats, pigs and various wildlife species.

CLINICAL PRESENTATION

Affected animals present with acute-onset fever accompanied by depression, anorexia and reduced production. After 2–5 days, superficial erosions appear in the mouth, coalescing to affect much of the mucosa and resulting in profuse salivation and halitosis. There are profuse mucopurulent ocular and nasal discharges. Cattle are profoundly depressed, tachypnoeic and have profuse diarrhoea progressing to dysentery. Death ensues 6–12 days after infection in susceptible cattle. Less virulent strains and partially immune cattle show less severe signs.

DIFFERENTIAL DIAGNOSIS

FMD; MD.

DIAGNOSIS

Diagnosis is by virus isolation, then demonstration of specific antibody in recovered cattle.

MANAGEMENT

There is no effective treatment. Rinderpest has been eradicated from many countries. In other countries, disease is controlled by annual vaccination of all susceptible animals.

BLUETONGUE

DEFINITION/OVERVIEW

The geographic distribution of bluetongue is dependent on the *Culicoides* (midge) vector. Bluetongue virus (BTV) infection is widespread in Africa, Australia, the USA and South America. Outbreaks are increasingly reported in southern Europe, often following introduction from Africa. BTV8 was first reported in the UK in August 2007.

AETIOLOGY

Bluetongue is an arthropod-borne Orbivirus infection of domestic and wild ruminants; 24 serotypes are recognized worldwide.

CLINICAL PRESENTATION


Farmers should contact their veterinary surgeon when sheep or cattle present with lameness, high rectal temperature, salivation, lachrymation and ocular/nasal discharges. Clinical signs are described here for cattle and sheep as they often co-graze/are managed together on the same farm.

Cattle

Few cattle with the virus show clinical signs. Affected cattle are febrile (up to 40.0°C) and appear stiff due to swelling of the coronary band at the top of the hooves. They are reluctant to move. There is a serous to mucopurulent nasal discharge and erosions on the muzzle with sloughing of the mucosa, often referred to as 'burnt muzzle'. There is lachrymation, but no obvious eye lesions.

Sheep

The clinical signs, which vary depending on viral strain and sheep breed, follow an incubation period of 4–12 days. Usually, only a small percentage of sheep develop clinical signs. In extensively managed flocks, unexplained sudden deaths may be the first evidence of disease. Affected sheep are pyrexia (up to 42.0°C) and appear stiff and reluctant to move. They often adopt a roached back stance with the neck extended and the head held lowered. There is oedema of the face and ears and also pulmonary oedema, which may cause dyspnoea. Erosions may appear on the lips, progressing to ulcers. There is often profuse salivation and a serous to mucopurulent nasal discharge. There may be hyperaemia of the coronary band and around the muzzle and mouth. The tongue may become swollen. Bluetongue infection during the breeding season may result in a large percentage of early embryonic losses, with sheep returning to oestrus at irregular intervals.



613 Cow with a mucopurulent nasal discharge, erosions on the muzzle and sloughing of the mucosa, often referred to as 'burnt muzzle'. This cow, confirmed after laboratory examination as being persistently infected with bovine viral diarrhoea virus, could be misdiagnosed as having bluetongue infection on clinical examination alone.

DIFFERENTIAL DIAGNOSIS

The most important differential diagnosis is FMD, where profuse salivation, erosions/ulcers in the mouth, lameness and fever spread rapidly to affect all cattle on the premises within days. Other important differential diagnoses include IBR (group or herd), MCF, persistent infection/mucosal disease caused by BVDV (usually individual cattle, **613**) and photosensitization.

DIAGNOSIS

Diagnosis is confirmed following virus isolation and/or seroconversion to BTV.

MANAGEMENT

Treatment is limited to antibiotic therapy to control secondary bacterial infections.

Control

Control of bluetongue is very difficult because of the large number of potential hosts and virus serotypes, with little cross-protection between strains. Although control is aimed at keeping susceptible animals away from the vector, this is not always practical. Control of the *Culicoides* vector can be attempted with pour-on insecticides, but this is expensive and does not achieve total freedom from the midge. Vaccines are used extensively worldwide. Most modified live vaccines produce a viraemia in the vaccinated animal, which affords the opportunity for further spread. Problems may arise with viral reassortment if viraemic animals are vaccinated with a modified live vaccine. The timing of vaccination will depend on local factors, in particular the occurrence of high-risk periods. Inactivated single-strain vaccines will afford little protection against other strains; BTV8 vaccine does not protect against BTV1.

ANTHRAX

DEFINITION/OVERVIEW

Anthrax causes peracute disease usually presenting as sudden death. Anthrax is under statutory control in many countries. In many tropical countries, serious outbreaks of disease can occur with large losses.

AETIOLOGY

Bacillus anthracis is a gram-positive capsulated bacterium.

CLINICAL PRESENTATION

Animals may occasionally be seen alive and present with signs of septicaemia: inappetence, much reduced milk yield and a high fever (41.0–42.0°C). Affected cattle are dull and depressed and stand isolated from others in the group. The mucous membranes are congested and the respiratory rate is markedly increased. Most cattle are found dead. Compulsory notification of all suspicious sudden deaths to regulatory authorities operates in some countries.

DIFFERENTIAL DIAGNOSIS

Other causes of septicaemia including pasteurellosis and salmonellosis. Causes of sudden death including hypomagnesaemia, lightning strike (**614**) and clostridial diseases such as blackleg.

DIAGNOSIS

Diagnosis of anthrax as the cause of septicaemia is very difficult unless disease has occurred on those premises before.

There are standard operating procedures for dealing with cases of sudden death in many countries. Typically, the carcass must be isolated and a blood smear collected and tested for anthrax (*B. anthracis*) using McFadyean's methylene blue stain (**615**).

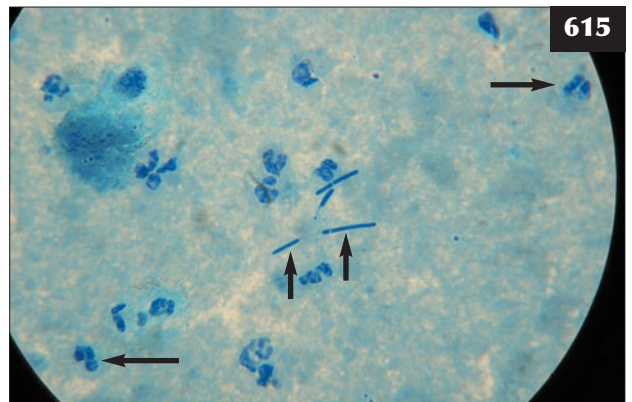
MANAGEMENT

In the rare event that animals are seen alive, high-dose intravenous penicillin is the antibiotic of choice.



614

614 Lightning strike has killed multiple cattle because they were close to a fence that had been struck. This is an important differential diagnosis for anthrax and other clostridial diseases.



615

615 Blood smear stained with polychrome methylene blue from a case of sudden death in a cow. Numerous leucocytes (long arrows) and post-mortem invader bacilli (short arrows) are seen. (Note the lack of pink-stained capsules seen with *B. anthracis*.)

Prevention/control measures

Confirmed deaths from anthrax necessitate correct carcass disposal. Endemic disease can be controlled by vaccination. Control measures for anthrax are operated by regulatory authorities in many countries.

ENZOOTIC AND SPORADIC BOVINE LEUCOSIS (LYMPHOSARCOMA)

DEFINITION/OVERVIEW

Two forms of bovine leucosis are recognized: EBL in adult cattle associated with BLV and, less commonly worldwide, sporadic bovine leucosis (SBL). SBL occurs in three forms, juvenile, thymic and skin, and rarely affects cattle older than two years.

AETIOLOGY

BLV is present in many countries worldwide, most commonly North America, but it has been eradicated from many European countries. The virus is most readily transmitted by blood-contaminated needles and other injection equipment. Natural transmission occurs by direct contact with nasal secretions and saliva. The cause of SBL has not been determined.

CLINICAL PRESENTATION

Many cattle with EBL have a persistent lymphocytosis. Tumours occur most commonly in the abomasum, uterus and spinal cord and cause slowly progressive pelvic weakness/paralysis.

Calves with the juvenile form of SBL typically present at around 3–4 months old with poor body condition and

massive enlargement of all superficial lymph nodes (616). Growing cattle with thymic lymphosarcoma present in good condition, but weight loss and reduced appetite with mild bloat develop over several months. Later, there is extensive anterior oedema (617) and often pleural effusion, but exfoliated tumour cells are rare. Distended jugular veins are present due to the anterior thoracic thymic mass (618) compressing the anterior vena cava. Cattle aged up to 30 months are occasionally affected by a skin form of lymphosarcoma. Multifocal skin tumours develop, most commonly starting on the neck and withers, but they may extend all over the body (619). Initially, the tumours are dermal or subcutaneous and overlying skin is normal, but alopecia, crusting and necrosis develop over time. Peripheral lymph nodes are enlarged and visceral tumours may develop (e.g. heart, abomasum and meninges), which are found at post-mortem examination.

DIFFERENTIAL DIAGNOSIS

EBL: other causes of indigestion/bloat and hindlimb weakness (vertebral empyema, botulism). Thymic lymphosarcoma causing anterior oedema and chronic bloat should be differentiated from other mediastinal masses such as an abscess and enlarged mediastinal/bronchial lymph nodes. Dilated cardiomyopathy and septic pericarditis can also result in extensive anterior oedema.

DIAGNOSIS

Diagnosis of BLV infection is confirmed by demonstration of specific antibody (agar gel immunodiffusion test). Diagnosis of juvenile lymphosarcoma is based on massive enlargement (10–30 times) of carcass lymph nodes and



616 Note the massively enlarged parotid and submandibular lymph nodes in this calf with the juvenile form of sporadic bovine leucosis.



617 The thymic form of sporadic bovine leucosis has caused progressive brisket and submandibular oedema in this steer.

biopsy is rarely required. Diagnosis of thymic lymphosarcoma is difficult and is based on elimination of other conditions where possible. The skin form can be confirmed by biopsy.

MANAGEMENT

There is no treatment and cattle must be culled for welfare reasons. Prevention is by eradication of BLV using serological testing and culling of positive cattle.

TUBERCULOSIS

DEFINITION/OVERVIEW

Bovine tuberculosis a serious disease affecting cattle worldwide and statutory control programmes are in place in many developed countries to minimize the economic losses and zoonotic risks that are associated with it.

AETIOLOGY

The bacterium *Mycobacterium bovis* is the causal agent and it can infect a wide host range, including man. Infection in cattle is normally by inhalation or ingestion of *M. bovis* shed by other infected herdmates or wildlife reservoirs.

CLINICAL PRESENTATION

In cattle the disease is often detected by routine tuberculosis testing, thus infected animals are normally killed before they develop overt clinical signs. In countries where routine screening is not carried out, clinical cases will present with progressive emaciation, capricious appetite and fluctuating body temperature. More specific clinical signs depend on the organ system primarily

involved, but can include coughing, chronic respiratory disease, dysphagia, diarrhoea and mastitis.

DIFFERENTIAL DIAGNOSIS

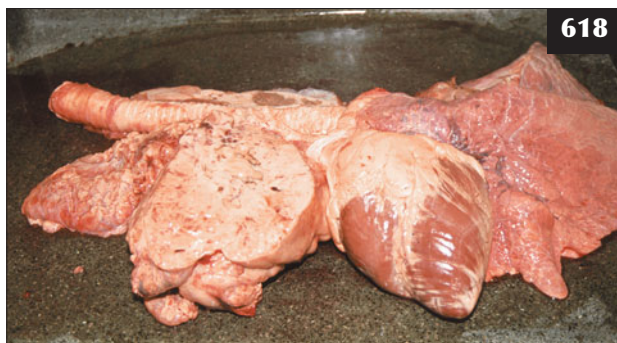
Because of the vague clinical signs that may be associated with bovine tuberculosis, there are many diseases that could have similar presenting signs, including: chronic suppurative pulmonary disease; pleurisy and pericarditis following reticulitis; upper respiratory disease; actinobacillosis; chronic mastitis with other pathogens; bovine leucosis.

DIAGNOSIS

Often, diagnosis is made at routine post-mortem carcass inspection at the slaughterhouse when classic granulomatous lymph nodes are found. Single or comparative intradermal skin testing using avian and bovine tuberculin is the most common diagnostic test used in live animals. Serological testing using gamma interferon assay is now being used in some countries to improve the sensitivity and specificity of skin testing.

MANAGEMENT

Treatment of cattle with tuberculosis is rarely attempted as in most countries a test and slaughter policy/programme is adopted in an attempt to eradicate the disease from the population. In countries where wildlife reservoirs such as the badger, deer and possum are present, the disease is much harder to control and eradication programmes based on cattle control alone are not effective. The development of vaccines may offer hope in the future as an aid to the control and eradication of this insidious disease.



618 The thymic lymphosarcoma in the anterior thorax, as seen in this necropsy specimen, led to bilateral jugular distension.



619 Skin form of lymphosarcoma in a Holstein heifer with widespread nodular tumour masses over the neck and withers region.

Chapter 17

Poisons

LEAD POISONING

(See Chapter 6, Nervous system diseases, Lead poisoning, p. 153.)

RAGWORT POISONING

DEFINITION/OVERVIEW

Ingestion of *Senecio jacobaea* can occur in many countries worldwide under extensive grazing conditions (620), but it is rare in countries with intensive land management such as the UK.

AETIOLOGY

Senecio spp. contain pyrrolizidine alkaloids. Poisoning occurs following ingestion of the plant in hay or silage.

CLINICAL PRESENTATION

There is chronic weight loss, diarrhoea, jaundice and peripheral oedema with possible ascites. Affected cattle are often dull/obtunded.

DIFFERENTIAL DIAGNOSIS

Liver fluke; lead poisoning.

DIAGNOSIS

Diagnosis is based on clinical evidence of a hepatopathy with exposure to ragwort. Elevated liver enzymes reflect

the hepatic insult. Diagnosis is confirmed following liver biopsy or necropsy.

MANAGEMENT

There is no effective treatment once clinical signs appear. Contaminated feed must be removed. Ragwort on pasture should be controlled by the use of selective herbicides.

YEW POISONING

DEFINITION/OVERVIEW

Yew (genus *Taxus*) species are common ornamental trees, especially in churchyards.

AETIOLOGY

Accidental exposure and ingestion lead to rapid death.

CLINICAL PRESENTATION

Sudden death.

DIFFERENTIAL DIAGNOSIS

Common causes of sudden death at pasture, including anthrax, blackleg and lightning strike.

DIAGNOSIS

Diagnosis is based on a history of exposure to yew, with remains of leaves/twigs found in the rumen at necropsy.

MANAGEMENT

There is no treatment. Access to yew must be prevented by maintaining perimeter fences.

OAK (ACORN) POISONING

DEFINITION/OVERVIEW

Acorns from *Quercus* species can present a serious problem following deposition on pastures after autumn storms.

AETIOLOGY

Tannins in acorns are nephrotoxic.



620 Despite considerable exposure to ragwort, no cattle in this beef herd were reported ill.

CLINICAL PRESENTATION

Sudden death may occur, but anorexia, depression and bloat due to ruminal stasis are more common signs (621). Initially, there is constipation and associated tenesmus progressing rapidly to fetid tarry diarrhoea (622). Death follows within 4–7 days despite supportive treatment.

DIFFERENTIAL DIAGNOSIS

Diarrhoea can result from severe type I ostertagiosis. MD should also be considered.

DIAGNOSIS

Diagnosis is based on clinical signs and exposure to acorns, which are found in the rumen at necropsy.

MANAGEMENT

There is no specific treatment. Supportive treatment includes large volumes of intravenous fluids, which are prohibitively expensive.

Prevention is by removing cattle from pastures with oaks, especially after autumn storms or heavy acorn falls.

BRACKEN POISONING**DEFINITION/OVERVIEW**

Ingestion of bracken over several weeks when pasture is sparse can lead to toxicity.

AETIOLOGY

Acute disease can result from bone marrow suppression causing thrombocytopenia and leucopenia. The ingestion of a carcinogen over many months/years can lead to bladder tumours and, much less commonly, squamous cell carcinoma in the oesophagus and rumen.



621 Acorn poisoning has caused depression and bloat, due to ruminal stasis, in this cow.

CLINICAL PRESENTATION

Disease caused by thrombocytopenia and leucopenia may present as sudden death, but anorexia, marked pyrexia due to secondary bacterial infection, petechial haemorrhages and blood from the nasal passages and vagina are more common signs. The heart and respiratory rates are markedly increased and the animal shows weakness progressing to recumbency and death within several days. Bladder tumours result in haematuria in older cattle, with possible dysuria and tenesmus. Chronic weight loss is often present.

DIFFERENTIAL DIAGNOSIS

Sudden deaths must be checked for anthrax as appropriate. Bladder tumours should be differentiated from cystitis/pyelonephritis. Redwater fever (babesiosis) is a common disease in certain geographical areas.

DIAGNOSIS

Diagnosis is based on clinical signs, especially widespread petechiation, and the fact that animals are grazing pastures containing bracken.


MANAGEMENT

Treatment with dl-batyl alcohol and broad-spectrum antibiotics is generally unsuccessful.

Many hill farms have substantial areas of bracken where fencing, burning and herbicide treatments would prove uneconomic; however, adequate feeding should ensure that cattle need not graze bracken.

COPPER POISONING**DEFINITION/OVERVIEW**

Toxicity may result from either inadvertant dietary supplementation to correct suspected deficiency (see



622 Initial constipation and associated tenesmus has progressed rapidly to fetid, tarry diarrhoea in this case of acorn poisoning.

Chapter 15, Trace element deficiencies, Copper deficiency, p. 258) or incorporation of a feedstuff with a high copper content, possibly as the result of contamination. Acute toxicity is rare. Copper toxicity in cattle is much less common than in sheep.

AETIOLOGY

Ingestion of high copper content in the ration over several weeks/months results in a high liver copper content. Sudden release causes an acute intravascular haemolytic crisis.

CLINICAL PRESENTATION

Acute copper toxicity causes severe gastroenteritis with colic signs, diarrhoea and rapid dehydration. Affected cattle are very depressed and anorexic and death usually ensues within three days.

In cases of chronic copper toxicity the appearance of clinical signs is associated with the haemolytic crisis, which may be precipitated by a variety of stressors. Affected cattle are weak, very dull and depressed and are separate from others in the group. They have a poor appetite and often fetid diarrhoea with considerable mucus present in the faeces. There is evidence of dehydration and jaundice of mucous membranes, most noticeably affecting the conjunctivae. The heart and respiratory rates are increased and an increased abdominal effort may be noted. There is no ruminal activity. Death is preceded by recumbency.

DIFFERENTIAL DIAGNOSIS

Causes of haemolytic anaemia, including babesiosis, post-parturient haemoglobinuria and kale poisoning.

DIAGNOSIS

Diagnosis is based on history with a source of excess copper and clinical findings of jaundice in cases of chronic toxicity. Diagnosis is supported by laboratory findings of increased serum copper concentration and massively increased serum AST and GGT concentrations.

Necropsy findings

Acute copper poisoning produces severe gastroenteritis with erosion of the abomasal mucosa. In chronic copper toxicity there is jaundice of the carcass, most noticeable in the omentum. The kidneys are swollen and dark grey with dark red urine in the bladder. The liver is enlarged and friable. Kidney copper concentrations are massively elevated, often exceeding 3,000 $\mu\text{mol/kg DM}$ (normal <314 $\mu\text{mol/kg DM}$). Liver copper concentrations are usually also elevated, but such determinations are not as reliable as kidney copper determination.

MANAGEMENT

The suspected copper source must be removed immediately. Good results in sheep are achieved by selecting animals

considered most at risk by determining serum AST concentrations and treating these animals with ammonium tetrathiomolybdate by intravenous or subcutaneous injection; a similar strategy could be adopted for cattle. The dose rate of ammonium tetrathiomolybdate is either 1.7 mg/kg intravenously or 3.4 mg/kg subcutaneously on 2–3 occasions two days apart. There is no ammonium tetrathiomolybdate preparation licensed for use in food-producing animals and its use in suspected cases of chronic copper toxicity is poorly defined from a regulatory standpoint.

Copper supplementation must be carefully considered after first establishing a deficiency situation.

FLUORIDE POISONING (FLUORORIS)

DEFINITION/OVERVIEW

Historically, fluorosis resulted from industrial pollution of grazing land, but it can occur naturally in some areas of the world. Industrial pollution of grazing land is now rare.

AETIOLOGY

Chronic disease results after ingestion over many months/years.

CLINICAL PRESENTATION

Growing cattle develop mottling of the tooth enamel and premature loss of teeth. Adult cattle show insidious onset lameness affecting the hindlimbs, caused by periarticular exostoses of the long bones.

DIFFERENTIAL DIAGNOSIS

Osteoarthritis in older cattle.

DIAGNOSIS

Diagnosis is based on clinical findings and fluoride content of a distal coccygeal vertebra removed under low caudal block.

MANAGEMENT

There is no specific treatment.

NITRATE POISONING

DEFINITION/OVERVIEW

Brassica plants and fertilizers are potential sources of nitrates.

AETIOLOGY

Nitrates are converted to nitrites by rumen microflora and cause methaemoglobinaemia.

CLINICAL PRESENTATION

Acute poisoning with cyanosis, weak rapid pulse and dyspnoea is seen within hours of ingestion, progressing rapidly to weakness, recumbency and death.

DIFFERENTIAL DIAGNOSIS

Causes of sudden death include hypomagnesaemia and lightning strike.

DIAGNOSIS

Diagnosis is based on classic clinical signs and exposure to nitrates.

MANAGEMENT

Treatment is with intravenous injection of 4 mg/kg methylene blue as a 2% solution.

ORGANOPHOSPHATE POISONING**DEFINITION/OVERVIEW**

Overdosage and accidental exposure to organophosphates leads to toxicity.

AETIOLOGY

Organophosphates block cholinesterases, leading to the continued action of acetylcholine.

CLINICAL PRESENTATION

Profuse salivation, colic and diarrhoea are followed by muscle fasciculations and stiffness progressing to paralysis. At this stage cattle show marked depression with increasing severity of colic, sweating and dyspnoea, followed rapidly by death.

DIFFERENTIAL DIAGNOSIS

Other poisonings.

DIAGNOSIS

Diagnosis is based on clinical signs and a history of exposure to, or treatment with, organophosphates. Activity of cholinesterase in whole blood can be determined by specialized laboratories.

MANAGEMENT

Atropine sulphate (0.1 mg/kg slowly i/v followed by 0.4 mg/kg s/c) is repeated as necessary.

Prevention is by correct storage and disposal of empty containers containing organophosphates.

UREA POISONING**DEFINITION/OVERVIEW**

Urea is used as a source of non-protein nitrogen in feed supplements, especially in extensively managed beef cattle. In ruminants, nitrogen from urea is released in the rumen as ammonia. Accidental urea intoxication occurs sporadically and can cause severe losses. One incident resulted in the death of 17 out of 29 suckler cows within six hours after the contamination of their drinking water with urea fertilizer.

AETIOLOGY

Poisoning episodes typically occur after sudden access to urea, which may simply involve only a break of several days' supply then free access. Urea, being highly soluble, will wash out of the diet/feed blocks following heavy rain, and then cattle drink the puddles, which have a high urea content.

CLINICAL PRESENTATION

Signs of urea poisoning can appear within 15 minutes to several hours and include twitching of the ears and facial muscles, bruxism, frothy salivation, bloat, severe abdominal pain, frequent urination, forced rapid breathing, staggering, bellowing and terminal seizure activity. Often, animals are found dead near the source of the urea supplement.

DIFFERENTIAL DIAGNOSIS

Other causes of sudden death should be considered in the differential list (e.g. botulism should be carefully considered in range cattle, especially in association with phosphorus deficiency; hypomagnesaemia; anthrax; clostridial disease such as blackleg).

DIAGNOSIS

Diagnosis is based on a history of sudden access to urea, often following a break of several days' supply. Free access is then followed by clinical signs. Blood ammonia levels can be measured, but this is only useful in live animals with samples stored on ice until analysed, because proteins in blood break down rapidly after death and produce ammonia. Accidental urea contamination of the drinking water caused a serum urea concentration of 86 mmol/l, and the concentrations of ammonia nitrogen in the rumen fluid of two cows examined soon after death were 1,825mg/l and 957 mg/l, respectively.

Animals decompose rapidly after death, but there are no specific signs from urea poisoning. Post-mortem examination immediately after death may reveal bloat, generalized congestion, pulmonary oedema and haemorrhages on the heart. A rumen pH >7.5 is suggestive of urea poisoning.

MANAGEMENT

Passage of a stomach tube to relieve bloat followed by 50 litres of cold water then several litres of 6% vinegar has been recommended. Supportive therapy could include large volumes of isotonic saline.

Prevention is by ensuring thorough mixing of the ration. Gradual introduction to urea feeding with an uninterrupted supply is essential and restricted access should be implemented after a break in supply. For greater safety it is recommended that farmers consider using salt-limited feeding of all-natural protein supplements that do not contain urea or ammonium salts in order to avoid the risk of urea intoxication.

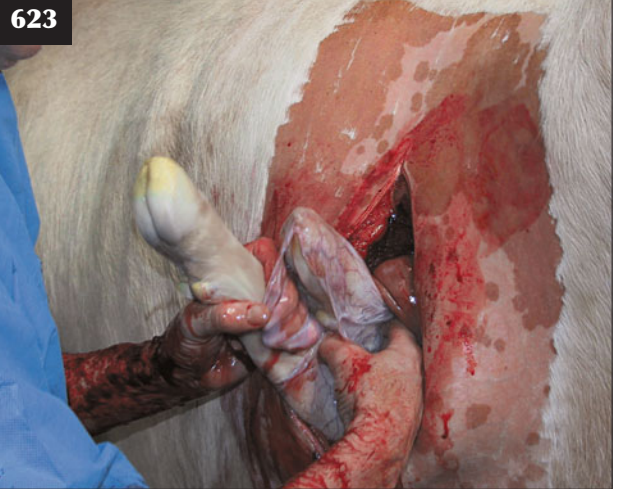Chapter 18

Anaesthesia

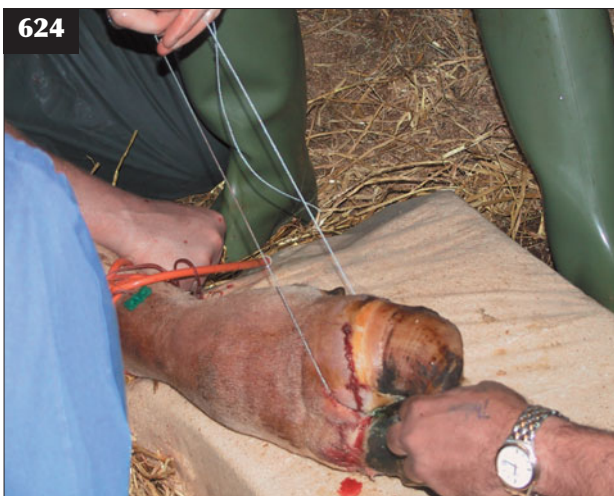
INTRODUCTION

The most common surgical procedures, such as LDA, traumatic reticulitis and caesarean section (623), are undertaken using paravertebral nerve block or local infiltration anaesthesia. Digit amputation (624) is undertaken under intravenous regional anaesthesia (IVRA) with or without prior xylazine sedation. There are relatively few procedures in cattle practice requiring inhalation general anaesthesia and gaseous anaesthesia will not be described in this chapter, although it is clearly an option in hospital settings.

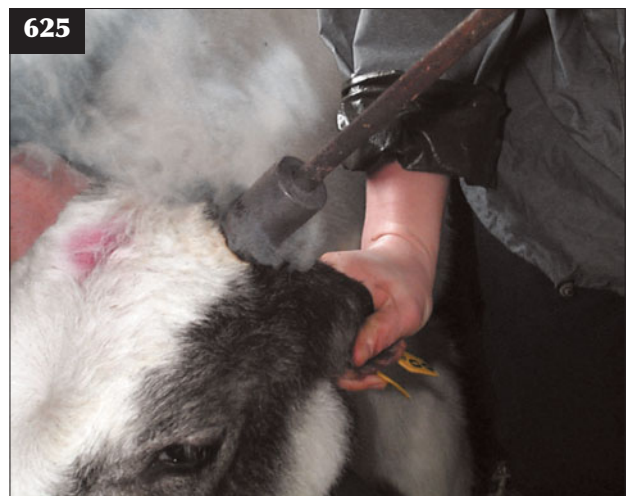Clinical data from castration and disbudding/dehorning studies have reported the positive effects of pre-operative NSAID administration in cattle (625). Extrapolation from other species further supports NSAID use, even when practice situations result in intravenous administration only minutes prior to commencing surgery. Wherever possible, NSAIDs should also be administered for 3–5 days following surgery.



623 This caesarean section has been undertaken using paravertebral anaesthesia.



624 Stage 4 xylazine sedation and intravenous regional anaesthesia were used during digit amputation in this aggressive Limousin bull.



625 The positive effects of pre-operative NSAID administration are clearly evident in this calf being disbudded.

GENERAL ANAESTHESIA

There are occasions when general anaesthesia is necessary (e.g. abdominal surgery in young calves and certain forelimb long bone fractures necessitating reduction before fixation). There are inherent risks of regurgitation of rumen content with inhalation giving rise to aspiration pneumonia and bloat compromising respiratory function and venous return to the heart.

Whenever possible it is advisable to remove concentrate feeding for 24 hours prior to any elective procedure in order to reduce the likelihood of excess gas production by the rumen microflora, although starvation will not have been possible in emergency situations. Whenever possible the patient should be positioned in sternal recumbency during surgery, with the head held lowered to allow drainage of saliva from the buccal cavity.

XYLAZINE/KETAMINE

Xylazine/ketamine is commonly used to produce short-term general anaesthesia in calves (e.g. umbilical hernia repair). Xylazine is best given intramuscularly at a dose rate of 0.05–0.1 mg/kg and the animal left in a quiet dark pen if possible. Sedative effects should result within 10 minutes, during which time there is frequent vocalization before the animal becomes recumbent. Chewing on straw bedding material is often noted. Induction of anaesthesia is then achieved by intravenous injection of 2–6 mg/kg ketamine, which affords 10–20 minutes of surgical anaesthesia. Anaesthesia can be extended following incremental doses of 2–3 mg/kg ketamine intravenously, which give a further 10 minutes' anaesthesia. Where appropriate, local anaesthesia can be used in addition to general anaesthesia (e.g. a retrobulbar block during eye enucleation).

XYLAZINE/KETAMINE/GUAIPHENESIN (TRIPLE DRIP INFUSION)

General anaesthesia can be induced and maintained in cattle using an infusion of xylazine, ketamine and guaiphenesin: 100 mg of xylazine and 1 g of ketamine are added to 1 litre of 5% guaiphenesin and this mixture is infused intravenously at 1–2 ml/kg. This can provide prolonged field anaesthesia when gaseous anaesthesia is not available.

PROPOFOL

Propofol (4–6 mg/kg i/v as a single dose) can provide safe, short-term (5–10 minutes) anaesthesia for procedures such as fracture reduction, cast application or wound suturing.

LOCAL ANAESTHESIA

SEDATION WITH XYLAZINE AND LOCAL INFILTRATION WITH LIDOCAINE

Stage 1 sedation (*Table 6*) with xylazine (0.05 mg/kg i/m) and local infiltration with lidocaine is used by some practitioners for surgical castration, disbudding/dehorning or wound repair. As well as sedation, xylazine may provide some analgesia, but injection of an NSAID before the procedure would be a more effective analgesic strategy, although considerably more expensive.

The depth of sedation depends on the dose of xylazine injected intramuscularly and guidelines have been produced. The intravenous route can be used for more rapid onset of sedation, but the dose rate must be one-half the intramuscular dose rate described in *Table 6*.

Sedation prior to caesarean section and LDA surgery is not recommended because it greatly increases the risk that the cow will assume sternal recumbency. Xylazine

Table 6 Guidelines on the depth of sedation produced by various doses of xylazine injected intramuscularly.

Stage	Dose (i/m)	Effects
1	0.05 mg/kg	Sedation, slight decrease in muscle tone.
2	0.1 mg/kg	The animal usually remains standing, but may lie down.
3	0.2 mg/kg	Deep sedation. Further decrease in muscle tone. The animal lies down. Some analgesia.
4	0.3 mg/kg	Very deep sedation. A profound decrease in muscle tone. The animal lies down. Some analgesia.

also causes uterine smooth muscle contraction and is thus not an ideal sedative prior to caesarean section. Effective flank analgesia is the most important factor in such surgeries.

OTHER SEDATIVES

Acetylpromazine (0.01 mg/kg i/v [i.e. 0.6 ml of 10 mg/ml injection for a 600 kg cow]) and romifidine (0.01 mg/kg) are commonly used in cattle practice for mild sedation during caesarean section and other standing surgeries. In many countries neither product is licensed for use in cattle. Acetylpromazine has no analgesic properties.

CORNIAL BLOCK FOR DISBUDDING/DEHORNING

Cornial block is carried out by injecting 5–10 ml of 2% lidocaine subcutaneously (perineural) immediately below the frontal ridge using a 1 inch 18–20 gauge needle (626). This blocks the cornual branch of the lacrimal nerve (a branch of the ophthalmic nerve arising from the trigeminal nerve). The calves must be adequately restrained by farm staff for injection. After inserting the needle, it is important to draw back on the syringe plunger to check for blood, which would indicate accidental puncture of a branch of the internal maxillary artery. Accidental intra-arterial injection produces instant collapse of the calf and possible seizure activity and must be avoided by re-directing the needle, drawing back and injecting when no blood is aspirated into the syringe.

Following diffusion of anaesthetic from the injection site, drooping of the upper eyelid is observed in many calves (blocking of the auriculopalpebral branch of the facial nerve) and is a useful indicator that the block has been successful (627).

For convenience xylazine can be added to the local anaesthetic solution when dehorning cattle. Approximately 4 ml of 2% xylazine solution is added to 100

ml of 2% lidocaine solution; for dehorning a 300 kg animal receives two injections of 10 ml lidocaine solution containing a total of 16 mg of xylazine (equivalent to 0.05 mg/kg; stage 1). The volume of local anaesthetic solution is reduced pro-rata for a calf weighing 150 kg when 5 ml of the combined solution is injected at each subcornual site.

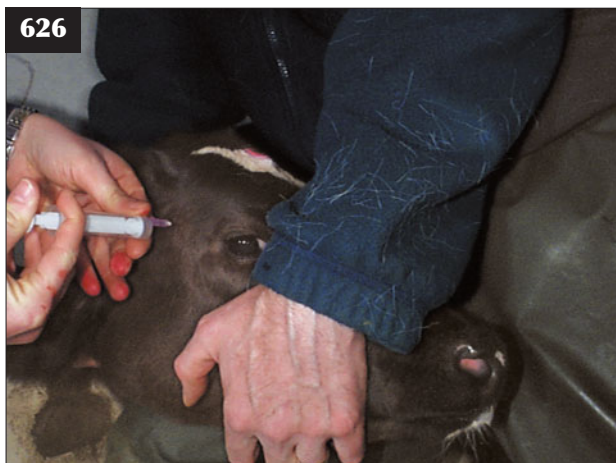CAUDAL ANALGESIA

Effective caudal analgesia is routinely used before correction of many malpostures and malpositions and before replacement of vaginal, uterine and rectal prolapse. (See Chapter 2, Obstetrics and parturient diseases.)

SACROCOCCYGEAL EXTRADURAL INJECTION (LOW BLOCK)

The area over the tail head is clipped and swabbed with surgical spirit. The sacrococcygeal space, but more often the first intercoccygeal space, can be identified by digital palpation during vertical movement of the tail, and a 25–40 mm (< and >300 kg body weight, respectively) 18–19 gauge needle directed at 45° to the tail, which is held horizontally or slightly raised (628). Cattle do not often react to needle insertion, but it is important to close the gate at the rear of the cattle stocks so that the operator does not get kicked.

Correct positioning of the needle point can be determined by failure to strike bone during travel and lack of resistance to injection. The hanging drop technique can be used to identify when the needle point enters the extradural space. The drop of anaesthetic solution in the needle hub is drawn into the space once it has been punctured, but this is not often used. Five ml of 2% lidocaine are typically used for replacement of vaginal and uterine prolapses and correction of dystocia in cattle weighing 500–700 kg. The animal remains standing throughout the procedure.



626, 627 Subcornual block. (626) 2% lidocaine is being injected subcutaneously (perineural) immediately below the frontal ridge of this calf. (627) Drooping of the upper eyelid indicates that the block has been successful in this animal.

Excellent analgesia of the flank for laparotomy, vasectomy and hindlimb surgery, including tibial neurectomy, can be achieved after slow sacrococcygeal extradural injection of 3–4 mg/kg of 2% lidocaine solution. The lidocaine solution is warmed to body temperature prior to injection. The large volume of 2% lidocaine solution (20 ml for a 100 kg calf) should be slowly injected over 60 seconds with the needle hub firmly anchored between thumb and index finger. Paralysis of the hindlimbs results within five minutes. Stage 3 sedation with xylazine is achieved by intramuscular injection at the same time as extradural lidocaine injection such that the animal quietly assumes sternal recumbency and aids restraint. For hindlimb/hind foot surgery the animal is cast/held in lateral recumbency with the affected limb lower and the head elevated for approximately 5–10 minutes after injection, during which time there is onset of hindlimb paralysis.

SACROCOCYGEAL EXTRADURAL INJECTION OF XYLAZINE

While extradural injection of xylazine (0.05–0.07 mg/kg) produces reliable standing sedation and analgesia of the perineum in cattle, this regimen fails to provide sufficient depth of surgical analgesia when used alone for laparotomy. Increasing the dose rate of xylazine simply increases the depth of sedation and the likelihood that the animal will adopt sternal recumbency.

LUMBOSACRAL EXTRADURAL LIDOCAINE INJECTION (HIGH BLOCK)

Excellent analgesia of the flank for complicated caesarean sections, such as an emphysematous fetus or fetal monster, and for vasectomy and hindlimb surgery (e.g. joint flushing) can be achieved after lumbosacral extradural injection of 3–4 mg/kg of 2% lidocaine solution. Unlike in sheep, however,

the sacrococcygeal site is readily found even in young calves, so lumbosacral injection is unnecessary (see above).

If during lumbosacral extradural injection the needle point accidentally punctures the arachnoid mater, CSF will appear within the needle hub. In this event the needle should be withdrawn into the extradural space and the dose rate reduced to two-thirds that calculated as a precautionary measure. Further reduction of the dose rate may fail to achieve complete analgesia of the flank. Cattle should be confined to small well-bedded pens until ambulatory 2–4 hours after extradural injection.

ANAESTHESIA FOR COMMON SURGERIES USING LAPAROTOMY

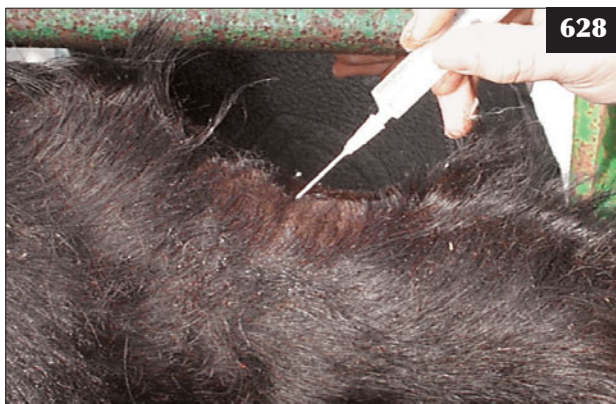Distal paravertebral anaesthesia

Distal paravertebral anaesthesia is the simplest and most practical means of providing complete flank analgesia under field operating conditions. It has the advantages that the landmarks are readily identified and hypodermic, not spinal, needles are used.

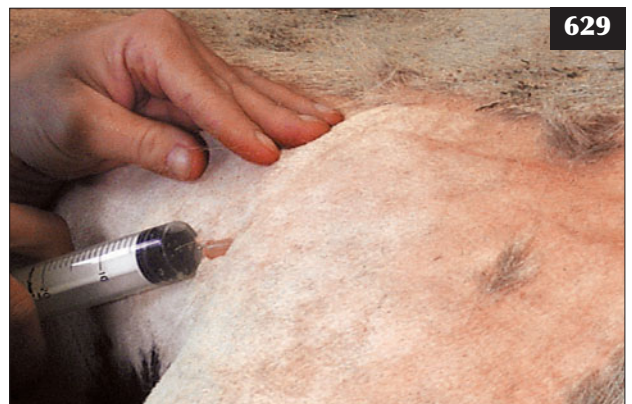Spinal nerve T13 is blocked by infusing 20 ml of 2% lidocaine to half the depth of the last rib at a point 10 cm below the level of the transverse lumbar processes.

Spinal nerves L1 and L2 are blocked by infusing 21 ml of 2% lidocaine above and below the transverse process of L2 and L3, respectively. The transverse lumbar processes of L2 and L3 are identified by counting forward from the transverse lumbar process of L5 located immediately cranial to the wing of the ilium (tuber sacrale). The following four-stage procedure is then carried out:

1. An 18 gauge 4.5 cm needle is slowly inserted at a right-angle to the vertebral column just through the skin overlying the midpoint of the transverse lumbar process (L2). The skin is then rolled upward so that the needle point can be slowly advanced to its full depth parallel to (629), and almost in contact with,



628 The sacrococcygeal space has been identified by digital palpation during vertical movement of the tail, and a 4 cm 18 gauge needle is being directed at 45° to the vertebral column/tail.



629 Distal paravertebral anaesthesia. The needle is introduced parallel to the transverse process of L2.

- the dorsal surface of the transverse process ('almost scraping the periosteum').
- Four ml of 2% lidocaine are injected at this point, then 3 ml when the needle point is withdrawn halfway. The needle is almost withdrawn then the point is directed 45° cranially to its full depth and 4 ml of 2% lidocaine are injected at this point, then 3 ml when the needle point is withdrawn halfway. This procedure is repeated with the needle directed 45° caudally. Local anaesthetic is thereby injected at six sites above the lumbar transverse process.
 - The needle is now withdrawn until the point lies just under the skin, the skin over the transverse processes is rolled down and the needle introduced to its full depth below the lumbar transverse process. Stage 2 is repeated. Local anaesthetic is injected at six sites below the lumbar transverse process (629).
 - Stages 1–3 are repeated for over L3.

The total volume of 2% lidocaine used is 20 ml for T13 and 42 ml for L1 and L2 = 102 ml.

Once the flank site has been aseptically prepared for surgery (7–10 minutes), flank analgesia is complete and can be tested by needle prick; there should be no reaction. Loss of tone in the flank muscles typically causes curvature of the spine when viewed from behind, being convex on the side infiltrated (630; right omentopexy to correct LDA).

Line block

Although commonly used, line blocks have a number of disadvantages compared with distal paravertebral anaesthesia. Cows resent needle insertion through the skin of the flank much more than over the transverse processes. The depth of flank (skin to peritoneum) varies with body condition (631) and may exceed the 4.5 cm reach of certain hypodermic needles. The anaesthetic solution travels along fascial planes and may infiltrate the surgical

site. Healing may be delayed if the surgical site is infused with lidocaine, but this is not a common problem. The volume of 2% lidocaine for line block may be twice that used for distal paravertebral anaesthesia.

The line block is usually administered 2–3 cm cranial to the incision site. To minimize the number of skin entry points, the needle point is inserted 4.5 cm below the top of the proposed incision site; the anaesthetic solution is injected subcutaneously with the needle point directed dorsally and then intramuscularly parallel to the incision site. Progressing ventrally, the next needle entry point is then 9 cm below the first site. An incision length of 25–30 cm is normal for a caesarean section, so up to four skin entry points are necessary, with 20–25 ml local anaesthetic injected at each site.

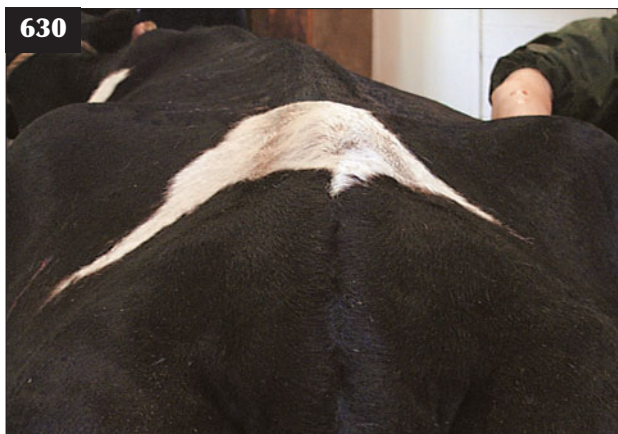Inverted L block

The inverted L approach is simply two line blocks: the first 6–8 cm below and parallel to the line of the transverse lumbar spines, and the second infiltration immediately caudal to the last rib. It often requires a considerable amount of local anaesthetic solution.

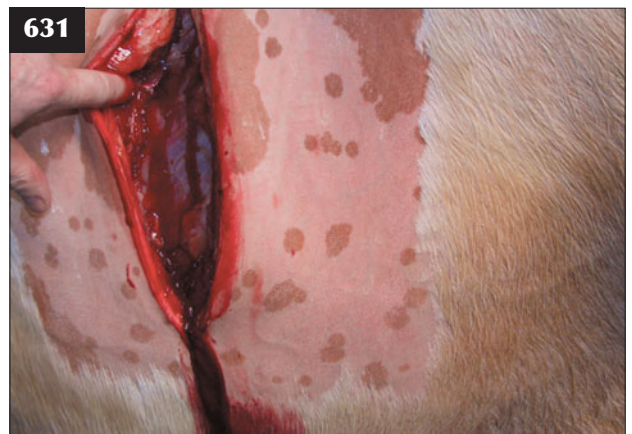INTRAVENOUS REGIONAL ANAESTHESIA

Intravenous regional anaesthesia is routinely used by veterinary practitioners when dealing with painful foot lesions, and most commonly for digit amputation resulting from sepsis of the distal interphalangeal joint of a hindfoot.

Stage 1 sedation with xylazine (0.05 mg/kg i/m or 0.025 mg/kg i/v) may be necessary if the animal shows allodynia while attempting to apply the tourniquet or insert the needle. (**Note:** The animal may already have been treated with a NSAID for the maximum five days' licensed period prior to surgery.) Very deep sedation (stage 4) can be achieved using 0.3 mg/kg xylazine injected intramuscularly and may be necessary when dealing with



630 Loss of tone in the flank muscles typically causes curvature of the spine when viewed from behind (convex on the side infiltrated).



631 Line block. The depth of flank (skin to peritoneum) has exceeded the 4.5 cm reach of the hypodermic needle. Note the length of the surgeon's extended left index finger.

aggressive bulls. Bloat is a common problem after 30–45 minutes' lateral recumbency and the animal must be brought into sternal recumbency (632).

In most situations the animal is restrained in cattle stocks (e.g. Wopa box) and the affected hindlimb raised. In an adult dairy cow weighing 600–700 kg, 25–30 ml of 2% lidocaine solution (or equivalent) is injected into a superficial vein after application of a tourniquet either above or below the hock. The recurrent metatarsal vein runs on the craniolateral aspect of the mid-region of the third metatarsal bone and is readily palpable unless the limb is oedematous. Insertion of a 19–20 gauge needle (or preferably a butterfly needle, 633) into the distended superficial vein releases blood under pressure. Blood flow then quickly reduces to the occasional drop if the tourniquet is tight enough. The anaesthetic solution is injected over 10 seconds, but it is not usual for the cow to kick when only two-thirds of the solution has been injected. Analgesia is effective within two minutes and is tested by needle pricking the coronary band.

Intravenous injection into a superficial vein in the forelimb is not as easy and it may prove necessary to sedate the animal and cast it into lateral recumbency. The tourniquet is removed after amputation and application of the bandage some 10–20 minutes after being first applied.

ANALGESIA

It has been reported that many cattle suffering from painful conditions or subject to painful procedures receive no analgesia. Pre-operative administration of NSAIDs is regarded as standard procedure before surgery in small animals and horses, and it would be prudent to extend this routine to farm animal surgery.

Advances have been made that impact on everyday practice and there is now good evidence for Burdizzo castration over a surgical approach and cautery over haemostats during dehorning (634) because these methods destroy nerve fibres, thereby reducing post-operative pain. There is evidence also from castration studies that NSAIDs reduce acute pain in calves.

NSAIDS


Suppression of pain produced by tissue damage is a major indication for NSAID administration. An NSAID should be administered intravenously before all elective surgery and any other potentially painful procedure. Pain relief after a single NSAID injection may last only 24 hours, so consideration should be given to treating for 3–5 consecutive days.

XYLAZINE

Xylazine has powerful analgesic properties (above 0.05–0.2 mg/kg i/m), but although its use should be considered for all acute pain situations, the degree of sedation can be



632 Bloat in a Limousin bull 30–45 minutes after stage 4 sedation was achieved using 0.3 mg/kg xylazine injected intramuscularly. The animal must be brought into sternal recumbency as soon as possible.



633 Intravenous regional anaesthesia for digit amputation. A butterfly needle has been inserted into the recurrent metatarsal vein, which runs on the craniolateral aspect of the mid-third metatarsal region.



634 Cautery after dehorning may reduce post-operative pain because it destroys the nerve endings.

unpredictable during standing surgeries, resulting in recumbency with potential serious consequences.

CORTICOSTEROIDS

Inflammatory disease is considered the major source of pain in ruminant species. Although the magnitude of hyperalgesia does not appear to be related to the stimulus intensity, duration of hyperalgesia does appear to be correlated significantly to the intensity of the inflammatory stimulus, therefore any drug that reduces inflammation should reduce pain. Corticosteroids are powerful anti-inflammatory drugs and are very effective in reducing oedema and tissue swelling caused by dystocia or prolapse. Unlike NSAIDs, corticosteroids suppress all components of acute and chronic inflammation, and inhibit hyperalgesia and fibrin deposition.

Topical corticosteroid application is commonly used in other aspects of veterinary medicine. Intra-articular injection is also used to treat joint disease in other species.

The immunosuppressant action of corticosteroids could potentially cause problems, but when administered with an appropriate antibiotic, there is no convincing evidence that administration of a single short-acting corticosteroid increases disease susceptibility/mortality in cattle. The beneficial action of a single injection of corticosteroid is clearly visible in peracute BRSV, diffuse fibrosing alveolitis, reducing cerebral oedema in infections of the CNS, reducing joint effusions associated with bacterial endocarditis and summer mastitis, joint trauma and soft tissue trauma with associated oedema.

Further reading

- Anderson DE, Rings M (2008) *Current Veterinary Therapy. Food Animal Practice* 5th edn. Saunders/Elsevier, St Louis.
- Andrews AH, Blowey RW, Boyd H, Eddy RG (2004) (eds) *Bovine Medicine: Diseases and Husbandry of Cattle*, 2nd edn. Blackwell Science, Oxford.
- Blowey R, Edmondson P (1995) *Mastitis Control in Dairy Herds*. Farming Press, Ipswich.
- Countdown Downunder <http://www.countdown.org.au/>
- Divers T, Peek S (2007) (eds) *Rebhun's Diseases of Dairy Cattle*, 2nd edn. Saunders/Elsevier, St Louis.
- Fubini SL, Ducharme NG (2004) (eds) *Farm Animal Surgery*. WB Saunders, St Louis.
- Greenhough PR (2007) *Bovine Laminitis and Lameness: A Hands on Approach*. Saunders/Elsevier, London.
- National Mastitis Council <http://www.nmconline.org/>
- Radostits OM (2001) (ed) *Herd Health: Food Animal Production Medicine*, 3rd edn. WB Saunders, Philadelphia.
- Radostits OM, Gay CC, Hinchcliff AW, Constable PD (2007) (eds) *Veterinary Medicine: A Textbook of the Diseases of Cattle, Sheep, Pigs, Goats and Horses*, 10th edn. Mosby/Elsevier, St Louis.
- Scott DW (2007) *Colour Atlas of Farm Animal Dermatology*. Blackwell Publishing, Ames.
- Smith BP (2008) (ed) *Large Animal Internal Medicine*, 4th edn. Mosby, St Louis.
- Underwood EJ, Suttle NF (1999) *The Mineral Nutrition of Livestock*, 3rd edn. CABI Publishing, Wallingford.
- Youngquist RS, Threlfall W (2006) *Current Therapy in Large Animal Theriogenology*, 2nd edn. Saunders/Elsevier, St Louis.

INDEX

Note: Page numbers in *italic* refer to tables or boxes

- abdomen
radiography 60
silhouette 17, 59
ultrasonography 61–2
- abdominocentesis 48, 60, 61
- abducens nerve 146
- abomasitis, clostridial 82
- abomasopexy 80
- abomasum
dilation/right-sided displacement 80–1
impaction 84
left displacement 77–80
ulceration and perforation 82–4
volvulus 81–2
- abortion
induction 28
infectious causes 30–8
investigation 30
- abscesses
brain 150–1
foot 166, 170, 171
pharynx 68
subcutaneous 205–7
- accessory nerve 147
- acetonaemia (ketosis/slow fever) 255–6
- acetylpromazine 246, 278
- acid–base status 247, 254
- acidosis
metabolic 94, 95, 96–7
ruminal 70–1
- acorn poisoning 200, 272–3
- actinobacillosis (wooden tongue) 64, 205
- Actinobacillus lignieresii* 64, 205
- Actinomyces bovis* 65
- actinomycosis (lumpy jaw) 65
- acute tubular necrosis 200
- adhesions, peritoneal 76, 77, 89, 91
- agar gel immunodiffusion (AGID) 108
- albumin, serum 107, 198
- allantoic fluid 27
- allodynia 165
- alveolitis, diffuse fibrosing 130
- amyloidosis 198, 199
- anaesthesia
general 277
local 44, 48, 277–8, 277
regional 44, 279–81
- anagen defluxion 209–10
- analgesia 281–2
caudal 278–81
- anoestrus 22–3
- antacid drench 71
- anthelmintics
gastrointestinal parasites 239, 240
lice 202
lungworm 241
major groups 238
- anthrax 269–70
- anti-foaming agents 72
- antibiotic re-treatment 116, 123
- Arcanobacterium (Actinomyces) pyogenes* 13, 18, 126, 137, 183, 205, 228
- arched-back stance 90, 125, 134, 135, 137, 138, 152
- arthritis, septic 100, 103
pedal 174–8
radiology 166–8
see also osteoarthritis
- arthrocentesis 166, 187
- arthrodesis, distal interphalangeal joint 177
- ascites
fetal 51
ultrasonographic appearance 61
- Aspergillus* spp. 221
- asphyxiation, manure gases 132
- aspiration pneumonia 130–1
- atresia ani/coli 62–3
- atropine 213, 275
- Aujesky's disease 154–5
- auscultation, rumen 60
- ivermectin 239
- β -carotene 265
- babesiosis 198, 199
- Bacillus cereus* 217
- Bacillus licheniformis* 18
- bacteraemia
polyarthritis 180–2
vegetative endocarditis 137–9
- Bacteroides melaninogenicus* 228
- Baermann technique 240–1
- Bagshaw hoist 254
- balanoposthitis 13, 33
- ballism 156
- barium selenate 262
- barn cramps 191–2
- basilar empyema (pituitary abscess) 147, 155–6
- bedding 174, 228
- bicarbonate 71, 97
- bicarbonate requirement 97
- biosecurity measures
foot and mouth disease 267
salmonellosis 104–5
see also environmental hygiene; husbandry standards
- biotin 169
- blackleg (blackquarter) 243–4
- blepharospasm 211
- blindness 112, 113, 149
- bloat 72
free gas 72–3
frothy 72
intermittent 68, 69
oak (acorn) poisoning 273
sedation/lateral recumbency 281
tetanus 245
- bluetongue 268–9
- body condition
bull 7
cow at calving 22, 44
CSPD 124, 125
dry cow 249, 256, 257
liver fluke infestation 237
- botulism 246
- bovine herpesvirus 1 (BHV-1) 30–1, 126
- bovine herpesvirus 2 (BHV-2) 230
- bovine leucosis virus (BLV) 142
- bovine papular stomatitis (BPS) 63
- bovine respiratory syncytial virus (BRSV) 116, 128–9
- bovine spongiform encephalopathy (BSE) 156
- bovine viral diarrhoea virus (BVDV) 30, 108–11
acute 109, 110
eradication 111
infection *in utero* 109, 215
mucosal disease 109–10
papillomatosis 208, 209
- brachial plexus injury 158, 159
- brachygnathia 62
- bracken poisoning 273
- bradycardia 155
- brain abscess 150–1
- breach presentation 47–8
- breeding soundness
examination, bull 7–9
- BRSV, *see* bovine respiratory syncytial virus
- Brucella abortus* 34
- brucellosis 34
- bruxism 70
- buildings
cubicle design 174
and respiratory health 120, 123
- bull
breed selection 42, 44
breeding soundness
examination 7–9
campylobacteriosis testing 33
fertility 7
handling facilities 9
paratuberculosis 106
- bull (nose) rings 147, 156
- bulling activity 243
- bursitis
carpal joint 192
hock joint 192–3
- buserelin 23
- caecal dilatation/torsion 84–5
- caesarean section 42, 52
- anaesthesia 52, 276, 279
indications 17
procedure 52–6
- calcitonin 247
- calcitriol 247
- calcium
dietary 247, 250
see also hypocalcaemia
- calcium borogluconate 19, 51, 249
- calcium hypophosphite 253
- calculi
preputial hairs 195
urethra 195–6
- calf diphtheria 65–6
- California Mastitis Test 222
- calving, *see* parturition
- Campylobacter foetus* subsp. *venerealis* 32–3
- Campylobacter jejuni* 32
- 'cancer eye' (ocular squamous cell carcinoma) 214
- Candida* spp. 221
- carbohydrate overload 70–1
- cardiac tumours 142
- cardiomyopathy, dilated (Holstein) 140–1
- cardiovascular system, examination 133
- carotenoids 265
- carpus
bursitis (hygroma) 192
sepsis 164
- cataracts, hereditary 215
- cattle sheds 115, 120, 123
- cauda equina syndrome 158, 159
- caudal analgesia 278–81
- cautery, after dehorning 281
- cellulitis
hock joint 192–3
subcutaneous 205–6
- cerebellar hypoplasia 148, 149
- cerebellar syndrome 144, 145
- cerebral syndrome 143–4
- cerebrospinal fluid (CSF)
bacterial meningitis 150
collection and analysis 147–8
protein concentration 148
- cervical dilation, incomplete 43
- cervical spine lesions 157
- choke 60, 66–8
- cholecalciferol 250
- Chorioptes bovis* 202, 203
- chorioptic mange 202, 203
- chronic suppurative pulmonary disease (CSPD) 117, 124–6
- circling 152, 255
- left palate 62
- clenbuterol 52
- clorsulon 240
- closantel 237
- Clostridium botulinum* 246
- Clostridium chauvoei* 243, 244
- Clostridium haemolyticum* 198
- Clostridium novyi* 243, 244
- Clostridium perfringens*, type C 242
- Clostridium septicum* 244
- Clostridium tetani* 244–5
- cobalt deficiency 262
- coccidiosis 101–3
- coccygeal vertebrae, fracture 186–7
- colibacillosis, septicaemic 100–1
- colostrum intake 97, 98, 100
- condition, *see* body condition
- congenital disorders
digestive tract 62–3
eyes 215
heart 133–4
joint laxity and dwarfism 193–4
porphyria 210
- conjunctival oedema 126, 127
- conjunctivitis, pasteurellosis 121
- Cooperia onchophora* infestation 240
- copper deficiency 258–60
- copper poisoning 273–4
- copper sulphate 173, 179
- cor pulmonale 142
- coriosis (laminitis) 173

- corneal opacity 112, 113
 corneal ulceration 211
 corneal block 278
 coronavirus infection 98, 105
 corpora lutea 28
 corticosteroids 282
 BRSV 129
 meningitis 150
 subconjunctival 213
Corynebacterium bovis mastitis 220
Corynebacterium renale 197, 198
 cough 124
 coxofemoral luxation 185–6
 crackles 116
 crampy syndrome 191–2
 cranial cruciate ligament, rupture 187
 cranial nerves 145–7, 145, 151, 152, 153
 creatine kinase 263
 crushed tail head syndrome 186–7
 cryptosporidiosis 101
Cryptosporidium parvum 101
 CSF, *see* cerebrospinal fluid
 CSPD, *see* chronic suppurative pulmonary disease
 cubicles 174, 228, 229
- danoloxacin 122
 deafness 146
 deep digital flexor tendon, rupture 174, 175
 degenerative joint disease 190
 dehorning 278, 281
 dehydration 70, 94, 95
 depigmentation 259
 dermatitis
 digital 178–9
 zinc-responsive 209
Dermatophilus congolensis 204
 dermatophytosis (ringworm) 203–4
 dexamethasone 129, 150, 213
Dichelobacter nodosus 172
 diclazuril 103
Dictyocaulus viviparus 240–1
 diet
 abomasal impaction 84
 cation–anion balance (DCAB) 249–50
 choke 66, 68
 digestive system function 59
 rumen acidosis 70
 see also nutrition
 digestive system
 and diet 59
 examination 59–62
 digit amputation 176, 177, 281
 digital dermatitis 178–9
 dihydrostreptomycin sulphate 33
 1,25-dihydroxycholecalciferol 247
 dilated cardiomyopathy (DCM) 140–1
 diphtheria, calf 65–6
 disbudding, corneal block 278
 distal interphalangeal joint
 ankylosis 176
 septic arthritis 167, 174–8
 dog-sitting posture 158, 159, 161
 doramectin 202
- dorsiflexion, neck 149
 downer cow 253–5
 drenching, inhalation pneumonia 130–1
 Drinkwater gag 60
 dry cow management 226–7, 230, 249–50, 256
 dry matter (DM) intake 254, 256
 dwarfism 193
 dysentery, winter 105
 dysphagia 152, 153
 dyspnoea 128
 dystocia 40–8
 calf injuries 161–2, 185
 human interference 40, 43
 schistosoma reflexus 52
 uterine rupture/tears 48–9, 91
 vaginal tears/laceration 49
- ear
 drooped 151
 middle ear infection 151
 EBL, *see* enzootic bovine leucosis
Eimeria spp. 102
 electroejaculator 8
 ELISA tests 31, 32, 108, 110
 embryonic death 28
 embryotomy wire 45
 emphysema 120
 subcutaneous 130
 encephalitis, listerial 152–3
 encephalopathy, hypoglycaemic 255
 endocarditis 125, 137–9
 endometritis, clinical ('whites') 20–1
 energy metabolism 262
 energy supply, inadequate 255–6
 enilconazole 204
 enrofloxacin 122
 enteritis
 necrotizing/necrotic 111–12
 S. typhimurium infection 104
 see also gastroenteritis
 enterotoxaemia 242
 enucleation 214
 environmental hygiene
 calving facilities 20, 101
 digital dermatitis 179
 and mastitis 216, 217, 227–8, 229
 enzootic bovine leucosis (EBL) 270–1
 epididymitis 13–14
 epiphora 211
 epiphyses, widening 259
 epistaxis 129
 eprinomectin 202, 241
Escherichia coli 13, 18, 197
 enterotoxigenic (ETEC/K99) 62, 98–9
 mastitis 216, 217, 220–1
 estimated breeding values (EBVs) 42
 ETEC, *see* *Escherichia coli*
 enterotoxigenic
 exophthalmos 155
 eye disease
 congenital 215
 hypovitaminosis A 214–15
 iritis 212–13
 keratoconjunctivitis 211–12
 malignant catarrhal fever 112, 113
 squamous cell carcinoma 214
 uveitis 215
 eyeball, position 146
 eyelid, third 214, 245
- facial nerve 146
 facial palsy 151, 152, 153
 faecal egg counts 239
 faecal tests, MAP 108
 faecal–oral infection route 105
 falls 162, 185
 farmer's lung 130
Fasciola gigantica 236
Fasciola hepatica 236, 242
 fasciolosis (liver fluke) 198, 236–8
 FAT, *see* fluorescent antibody test
 fat cow syndrome 254, 257
 fat mobilization 257
 fat necrosis 86
 fatty liver syndrome 257
 femoral growth plate, fracture 184
 femoral head, fracture 167
 femoral nerve injury 161–2
 fertility, bull 7
 fetal anasarca 51
 fetal ascites 51
 fetal membranes, retention 17–18, 261
 fetal monsters 52
 fetlock joints, septic arthritis 100, 103, 181, 182
 fetotomy 44–5
 fetus
 maceration 30
 mummification 29
 oversize 40, 43
 serological testing 30
 fibrin
 epicardial 136
 peritoneal 76, 77, 89, 91
 fibroma, interdigital 171–2
 fibropapillomatosis, viral transmissible 9
 field laboratory 8
 flank
 laparotomy 52–3, 75, 76, 81
 right, distension 85
 flank analgesia 52, 279–80
 flexor reflexes 157
 flexor tendons, injuries 189
 floors/surfaces 162, 185, 186
 florfenicol 88, 101, 122, 150
 fluid therapy, intravenous 96–7
 flunixin 122, 123
 intravenous 48, 78
 fluorescent antibody test (FAT) 32, 128
 fluoride poisoning (fluorosis) 274
 fly bites 229, 233
 fog fever 130
 follicle stimulating hormone (FSH) 22
 follicular dysplasia 210
 foot
 examination 165–6
 foot and mouth lesions 267
 foul (interdigital necrobacillosis) 179
 lameness 168–80
 puncture wounds 170
 septic arthritis 167, 174–8
 foot crate 165
- foot and mouth disease 266–7
 footbaths 179
 forage 153, 254, 260
 foreign body, ingestion 74–6, 134–7
 forestomachs
 disorders 70–4
 examination 60
 formalin footbath 179
 fractures
 femoral head 167
 limbs 184–5
 mandibular ramus 66
 pedal bone 180, 181
 sacral/coccygeal vertebrae 186–7
 freemartin 23
 frenulum (penile), persistent 10
 FSH, *see* follicle stimulating hormone
Fusibacterium necrophorum 18, 65, 228–9
- gastrocnemius muscle
 contraction 191
 rupture 188
 gastroenteritis
 copper poisoning 274
 parasitic 238–40
 general anaesthesia 277
 gestation length 27
 globulin, serum 198
 glossopharyngeal nerve 147
 glucose, blood levels 256
 glutamate dehydrogenase (GLDH) 237
 glutathione peroxidase levels 261
 goitre 263
 gonadal aplasia 23
 gonadorelin 23
 gonadotropin releasing hormone (GnRH) analogues 23
 grain overload 70–1
 grass staggers (hypomagnesaemia) 250–2
 griseofulvin 204
 Grymer/Sterner method 79–80
 gut transit time 251, 252
- haematoma
 axillary 158, 159
 penile 11, 196
 subcutaneous 205–6
 haemoglobinuria
 bacillary (redwater) 198, 199
 postparturient 200
 haemonchosis 239–40
Haemonchus placei 238, 239–40
 haemorrhage, dystocia 44, 49
 hair
 depigmentation 259
 loss (anagen defluxion) 209–10
 hair balls 84
 hair rings, penile 11
 halitosis 112, 113, 126
 halofuginone lactate 101
 handling facilities
 bull 9, 33
 lameness examination 165
 head back 46–7
 head fly 229
 head pressing 144, 153, 255
 head tilt 144, 145, 151, 152

- head tremor 148
heart disease, congenital 133–4
heart rate 133
heart murmur 133
heel bulbs
 abscess 171
 underrun 178
hepatocaval thrombosis 129
herd management, mastitis 228, 229
herd screening, leptospirosis 32
hernia
 inguinal 14
 umbilical 86, 87
herniation, intestines 88, 89
herpes mammillitis 230–2
hip clamps 254
hip joint
 degenerative osteoarthritis 190
 dislocation 185–6
 dysplasia 190
 secondary osteoarthritis 187
hip lock 44–5, 162
Histophilus somni infection 13, 124, 141, 154
hock joint
 bursitis/cellulitis 192–3
 conformation in bull 7
 effusion 138
 osteoarthritis 189
 overextension 191
 overflexion 188
 sepsis 164
Holstein (dilated)
 cardiomyopathy 140–1
hoof wall
 horizontal fissure (thimbling) 169
 vertical fissure ('sandcrack') 168–9
hoose (lungworm) 240–1
Horner's syndrome 146
housing
 and mastitis 228, 229
 and respiratory disease 115, 120, 123
husbandry standards
 calving boxes 101
 ETEC risk 99
 paratuberculosis 105
 rotavirus infection 94, 97
 salmonellosis prevention 104–5
 septicaemic colibacillosis 100, 101
husk (lungworm) 240–1
hydrallantois 17
hydramnios 17
hydranencephaly 148, 149
hydrocephalus 51
Hydrotaea irritans 229, 233
hygroma 192
hyoscine 67, 81
hyperaesthesia 149, 255
hyperalgesia 75, 165, 282
hyperkalaemia 94
hypermetria 148
hypoalbuminaemia 107
hypocalcaemia 19, 51, 247–50
Hypoderma bovis 203
Hypoderma lineatum 203
hypodermatosis 203
hypoglossal nerve 147
hypoglycaemia 255, 256
hypomagnesaemia 250–2
hypophosphataemia 200, 248, 252–3
hypopyon, secondary to
 septicaemic colibacillosis 100
hypothalamic syndrome 147
hypotrichosis 210
hypovitaminosis A 214–15
hypovolaemic shock 94
impetigo, udder 232–3
infectious bovine rhinotracheitis (IBD) 126–8, 212
inguinal hernia 14
intestines
 herniation 88, 89
 intussusception 86, 87
 torsion (red gut) 85–6
 transit time 251, 252
intussusception 86, 87
inverted L block 280
iodine deficiency 262–3
iodism 64
iritis (silage eye) 212–13
iron deficiency 264
ivermectin 202
Ixodes ricinus 203
Johne's disease (paratuberculosis) 105–8
 joint effusions 138
 joint ill 180–2
 joint lavage 182
 joint laxity, congenital 193–4
 joint 'mice' 190
 jugular distension 138, 142
kaolin, oral 84
keratitis 211
keratoconjunctivitis, bovine
 infectious 211–12
ketamine 277
ketone bodies 256
ketoprofen 78, 123
ketosis (acetonemia) 79, 255–6
Klebsiella pneumoniae 221
kyphosis 183
L-tryptophan 130
lactation
 acetonemia 255–6
 fat cow syndrome 257
lactic acidosis 70–1
lameness
 assessment 163–6
 hindlimb 163
 hip dislocation 185
 polyarthritis 181
 scoring 163–4
laminitis (coriosis) 173
laparotomy
 caudal analgesia 279–80
 high left flank 75, 76
 right flank 81
laryngitis, necrotic 65–6
LDA, *see* left displaced abomasum
lead poisoning 146, 153–4
left displaced abomasum (LDA) 77–80
leg back 46
Leptospira hardjo 31, 32
Leptospira monocytogenes 212–13
leptospirosis, bovine 31–2
leucopenia 273
leucosis, enzootic and sporadic
 bovine 270–1
levamisole 241
LH, *see* luteinizing hormone
lice (pediculosis) 201–2
licking behaviour 255
lidocaine
 caudal analgesia 44, 48, 278–81
 local anaesthesia 277–8
lightening strike 269
limb fractures 184–5
lincomycin 179
line block 280
lipomatosis 210
Listeria monocytogenes infection 152–3
listeriosis 35–6
liver
 abscess 62
 fatty syndrome 257
 ultrasound 61
liver enzymes 254
liver fluke 103, 198, 236–8, 242
local anaesthesia 44, 48, 277–8, 279
'lockjaw' 245
locomotion, scoring 164
Lopiodol 263
lumbosacral extradural lidocaine 279
lumpy jaw 65
lung sounds 116
 absence 132
lungs, ultrasonography 117–20
lungworm 240–1
luteinizing hormone (LH) 22
Lymnaea spp. 236
lymph nodes
 parotid 270
 popliteal 182
 prescapular 165, 182
 submandibular 270
lymphosarcoma 119, 142, 270–1
magnesium 250–2
 availability 251
 blood levels 248, 252
magnesium hydroxide 71
magnesium oxide 84
magnesium sulphate 154
malignant catarrhal fever 112–14
malignant oedema 244
mammillitis, bovine ulcerative (herpes) 230–2
mandibular ramus, fractures 66
manganese deficiency 193, 263–4
Mannheimia haemolytica 120, 122
manure gases 132
MAP, *see* *Mycobacterium avium* subsp. *paratuberculosis*
marbofloxacin 122
mastitis
 aetiology 216, 217
 clinical presentation of major pathogens 216–21
 definition 216
 diagnosis 222–4
 herd management 228, 229
 management 224–8
 severe (Grade III) 225–6
 severity scale 217
 subclinical 222
 summer 228–30
 megaesophagus 69–70
 melana 82, 83
meningitis
 bacterial 143, 146, 148–50
 secondary to septicaemic colibacillosis 100
metacarpal/metatarsal bones, sequestrum formation 183
metaclopramide 81
metal objects, ingestion 74–6, 134–7
methionine synthesis 262
metritis
 clinical ('whites') 20–1
 pre-partum 42–3
 puerperal 19–20
Micropolyspora faeni 130
microscopic agglutination test (MAT) 31, 32
midbrain syndrome 147
middle ear infections 151
milbemycin 239
milk, bacterial contamination 216, 223
milk drop 31–2, 74, 109, 124, 125, 137, 255
milk fever 247–50
milking machine 217
 causing teat lesions 233–4
 maintenance 226
 and mastitis 223
milking parlour, hygiene 227–8
mineral deficiencies
 cobalt 262
 copper 258–60
 interpretation of laboratory tests 258
 iodine 262–3
 iron 264
 manganese 193, 263–4
 phosphorus 252–3
 selenium 260–2
 sodium 254–5
 stages 258
 zinc 263
minerals, supplementary feeding 252, 260
miosis 146
molybdenum 259
monensin sodium 72, 103, 130
monoclonal antibody preparations 99
Moraxella bovis 127, 211
mouth
 examination 60
 foot and mouth lesions 267
 mouth breathing 68, 69, 128
 moxidectin 239
muscle injuries 188, 243
muscle wastage 163, 164–5, 181
muscular dystrophy, nutritional 261
musculoskeletal system, examination 163–8
muzzle
 'burnt' 268
 crusting 113
 warts 208–9
Mycobacterium avium subsp. *paratuberculosis* (MAP) 105, 106

- diagnosis 108
Mycobacterium bovis 271
Mycoplasma spp. 219
 myocarditis 141–2
- nasal discharge 121, 124, 131, 268
 nasal septum, erosions 126
 natamycin 204
 neck, dorsiflexion 149
 necrotizing (necrotic) enteritis 111–12
 neurological syndromes 143–5
 New Forest disease 211–12
 nitrate poisoning 274–5
 nitroxylin 237, 240
 non-esterified fatty acid (NEFA) levels 256
 nonsteroidal anti-inflammatory drugs (NSAIDs) 281
 intravenous 40, 44, 76, 78, 123
 mastitis 226
 pre-operative 276
 nose rings, *see* bull rings
 nutrition
 dietary cation–anion balance (DCAB) 249–50
 and hypocalcaemia 247
 late gestation 257
see also diet
 nystagmus 145, 146–7, 251
 positional 147
 spontaneous 147
- oak (acorn) poisoning 200, 272–3
 obturator nerve injury 162, 254
 ocular discharge 121, 126, 127, 214
 oculomotor nerve 146
 oedema
 brisket/submandibular 270
 malignant 244
 peripheral 142
 udder 233
 ventral 134, 135
 oesophagus
 examination 60
 obstruction (choke) 60, 66–8
 squamous cell carcinoma 68–9
 stricture 69
 olfactory nerve 146
 omentopexy, right flank 78–9
 omphalitis 86–8
 omphalophlebitis 86–8
 opisthotonus 148, 149, 152
 optic nerve 146
 oral examination 60
 malignant catarrhal fever 112, 113
 wooden tongue 64
 oral rehydration solution 97
 orchitis 13–14, 15
 organophosphate poisoning 275
 orogastric tube 73
 osteoarthritis
 degenerative 190
 secondary to
 subluxation/ligament rupture 187–8
 osteochondritis dissecans (OCD) 189–90
 osteochondrosis 189–90
- osteomalacia, nutritional 193
 osteomyelitis 183
 osteophyte formation 166, 167, 182
Ostertagia ostertagi 238
 ostertagiosis 238–9
 otitis media 151
 overeating disease (enterotoxaemia) 242
 overmilking 235
 overwintering 260
 oxfendazole 239
 oxidants, dietary 261
 oxyclozanide 237
 oxytetracycline 122, 212, 213
- palpebral reflex 146
 panniculus reflex 157, 158
 papillomatosis 208–9
 penile 9
 teats 230, 231
 parainfluenza 3 infection 129
 parapoxvirus 63
 parasitic disease
 gastrointestinal 238–40
 liver flukes 103, 198, 236–8, 242
 lungworm 240–1
 skin 201–5
 parathyroid hormone (PTH) 247
 paratuberculosis (Johne's disease) 105–8
 paravertebral anaesthesia, distal 279–80
 parturition
 coriosis risk 173
 hygiene 20
 induction 17
 milk fever 247–8
 obstetrical definitions 40
 post-partum uterine infection 18–20
 simultaneous presentation of two calves 51
 veterinary approach 40
see also dystocia
 passive antibody transfer 100, 101
Pasteurella spp. 216
Pasteurella multocida 120, 122, 221
 pectin 84
 pedal arthritis, septic 174–8
 pedal bone, fracture 180, 181
 pediculosis (lice) 201–2
 PEM, *see* polioencephalomalacia
 penis
 corkscrew/spiral deviation 10–11
 hair rings 11
 papillomas 9
 persistent frenulum 10
 rupture (haematoma formation) 11, 196
 Penrose drain 171
 pentathamate hydriodide 225
 pentobarbitone 44, 154
 pepsinogen, plasma 240
Peptostreptococcus indolicus 228
 pericarditis, septic 134–7
 peripheral nerve disease 158–62
 peritoneal adhesions 76, 77, 89, 91
 peritoneal fluid
 collection 60, 61
 normal appearance 60
 peritoneal lavage 49
 peritonitis 89–92, 125
 diffuse fibrinous 91, 92
 localized 90
 septic 82, 83
 uterine tear/rupture 48–9
 peroneal nerve injury 160, 161
 PGF2S, *see* prostaglandin F2S
 pharyngeal abscess 68
 pharynx, examination 60
 phlegmona interdigitalis 179–80
 phosphorus
 blood levels 248, 253
 deficiency 252–3
 photophobia 112, 113, 211
 photosensitization 14, 207–8
 phyloerythrin 207
 pica 253
 'pink eye' (bovine keratoconjunctivitis) 211–12
 pituitary abscess (basillar empyema) 147, 155–6
 placentation 27
 pleural abscess 118, 119, 132
 drainage/lavage 132
 pleural effusion 118, 119
 pleurisy 118
 fibrinous 131
 pleuropneumonia, fibrinous 124
 pneumonia
 atypical interstitial (fog fever) 130
 chronic suppurative 118
 inhalation (aspiration) 130–1
 necrotizing 131
 pododermatitis, chronic necrotic (slurry heel) 172
 pododermatitis circumspecta 172–4
 poisons, *see* toxins
 polioencephalomalacia (PEM) 146, 151–3
 polyarthritis, infectious 103, 180–2
 polyunsaturated fatty acids (PUFAs) 261
 pontomedullary syndrome 144, 145
 popliteal abscess 207
 poppy seed oil, iodized 263
 porphyria, congenital 210
 potassium, dietary 251
 potassium iodide 64, 263
 potatoes, feeding 66, 68
 pregnancy
 abdominal shape 59
 diagnosis 27–8
 indications for induction 28
see also dystocia; parturition
 pregnancy loss 29–38
 pregnancy toxemia 256–7
 prepubic tendon, rupture 17
 prepuce
 prolapse 12
 traumatic laceration 12–13
 procaine penicillin 126, 128
 progesterone, sources 28
 prognathia 62
 prolapse, rectal 92–3
 proprioceptive deficits 150
 prostaglandin F2S (PGF2S) 20–1, 28
- Prototheca* spp. 221
 proximal interphalangeal joint, sepsis 177
 pseudocowpox 232
Pseudomonas aeruginosa 221
 pseudorabies (Aujeszky's disease) 154–5
Psoroptes communis 202
 psoroptic mange 202
 ptosis 146, 151
 puerperal metritis 19–20
 pulmonary hypertension 142
 pulmonary thromboembolism 129
 pupillary diameter 146
 pyelonephritis 197–8
 pyometra 21–2, 33
 pyothorax 132
- Quercus* spp. poisoning 200, 272–3
- rabies 155
 radial nerve injury 159–60
 rafanoxide 240
 ragwort poisoning 272
 rain scald 204
 rectal prolapse 92–3
 rectal temperature, respiratory disease 115
 rectum, partial eversion 102
 recumbency, prolonged (downer cow) 253–5
 red gut (intestinal torsion) 85–6
 redwater fever 198, 199
 reflex motor responses 157
 regurgitation, passive 69
 rehydration solution 97
 renal amyloidosis 198, 199
 renal failure 200
 respiratory diseases
 aetiology 115
 diagnosis 115–16
 prevention 115, 120, 123
see also named diseases
 respiratory distress 128
 reticulitis, traumatic 61–2, 74–6
 retinal dysplasia 215
 retractor, oesophageal
 obstruction 67
 retropharyngeal lymph nodes, enlarged 68
 rhadovirus 155
 rhinotracheitis, infectious bovine 126–8, 212
 rickets 193
 rinderpest 268
 ringworm (dermatophytosis) 203–4
 roached back stance 131
 rolling technique 78
 romifidine, intravenous 52
 root crops, feeding 66, 68, 245
 rotavirus infection 94–8
 Rothera's test 256
 rumen
 acidosis 70–1
 examination 60
 lavage 71
 tympany (bloat) 72–3, 273, 281
 rumen fluid, collection and analysis 60
 rumen parakeratosis 72

- rumenotomy 71
Rusterholz ulcer 172–4
- sacral vertebrae, fracture 186–7
sacrococcygeal extradural injection 278–9
sacrococcygeal spinal lesions 158, 159
sacroiliac luxation/subluxation 186
saline, intravenous 19
saliva, loss 152, 153
salivation, profuse 64
Salmonella dublin 34–5, 103–4, 157, 183
Salmonella typhimurium 34, 103, 104
salmonellosis 34–5, 103–5
salt, supplementation 255
salt poisoning 146
sand bedding 228
sandcrack 168–9
Sarcoptes scabiei (bovis) 202
sarcoptic mange 202
'saw horse' stance 191, 245
SBL, *see* sporadic bovine leucosis
schistosoma reflexus 52
sciatic nerve injury 160–1
scrotal circumference 8, 15
scrotal swelling 14, 208
sedation
 acetylpromazine 278
 caesarean section 52
 xylazine 276, 277, 277, 281–2
- seizures
 bacterial meningitis 143
 hypomagnesaemia 251
selenium deficiency 260–2
semen
 collection 8
 evaluation 8
 leucocytes 16
seminal vesiculitis 16
Senecio jacobaea 272
septicaemia
 colibacillosis 100–1
 salmonellosis 103–4
sequestrum formation 183
serological testing 30, 108
serratus ventralis muscles, rupture 188
shipping fever (pasteurellosis) 120–4
shoe, wooden 174, 181
silage, fermentation 153
'silage eye' (bovine iritis) 212–13
sire selection 42, 44
skin disorders
 interdigital hyperplasia 171–2
 parasitic 201–5
 zinc deficiency 209, 264
sleeper calves (TÈME) 124, 154
'slow calving' syndrome 51
slow fever (acetonaemia) 255–6
slurry heel 172
small intestines, intussusception 86, 87
sodium bicarbonate 71, 97
sodium deficiency 254–5
sodium iodide 64
sodium selenate/selenite 262
sole
 abscess 170
 puncture wounds 170
 ulcer 172–4
somatic cell count (SCC) 216, 222
 bulk milk (BMSCC) 222
 individual cow (ICSCC) 222–3
 trends over time 223
spastic paresis 191
spastic syndrome (barn cramps) 191–2
sperm
 normal morphology 8
 testicular degeneration 14, 15
sperm granuloma 14
spinal column, osteomyelitis 183
spinal cord lesions 157–8, 159
sporadic bovine leucosis (SBL) 270–1
squamous cell carcinoma (SCC)
 ocular 214
 upper alimentary 68–9
Staphylococcus spp. 13, 232
Staphylococcus aureus mastitis 218–19, 225, 226
stertor 68, 69, 113
stifle joint, osteoarthritis 187
stomatitis 112, 113
 bovine papular 63
 necrotic 65–6
strabismus 146
straw, adding to diet 252
straw bedding 174, 228
Streptococcus spp. 137
Streptococcus agalactiae mastitis 219, 223, 225, 226
Streptococcus dysgalactiae 216
Streptococcus uberis 217, 221, 223, 225, 226
streptomycin 64
stridor, inspiratory 66
subcutaneous swellings 205–6
subluxations
 sacroiliac joint 186
 secondary osteoarthritis 187–8
sudden death, causes 251, 269
sulphur toxicity 152
summer mastitis 228–30
superfoul 180
suprascapular nerve injury 160
swallowing, difficulty 152, 153
- tail, crushed head syndrome 186–7
Taxus spp. 272
tear staining 126, 127
teat scoring systems 234, 235
teats
 chaps 233
 cistern obstructions 234, 235
 disinfection 226
 hyperplastic 23
 lacerations 234
 milking machine-induced lesions 233–4
 position of 97, 98
 red discoloration 235
 shape 223
 warts 230, 231
teeth 60
TÈME, *see* thromboembolic meningoencephalitis
- tendon injuries 174, 175, 189
tendon 'jerk' reflexes 157
tenesmus 84, 85, 111
testicles
 bacterial infection (orchitis) 13–14
 hypoplasia 14–15
testicular degeneration 15–16
tetanus 244–6
Thermoactinomyces vulgaris 130
thiabendazole 82
thiamine 151, 152, 154
thimbling, hoof wall 169
thoracocentesis, ultrasound-guided 120
thoracolumbar spinal lesions 158
thrombocytopenia 273
thromboembolic meningoencephalitis (TÈME/sleeper calves) 124, 154
thromboembolism, pulmonary 129
thymic lymphosarcoma 119
thyroid enlargement (goitre) 263
thyroid hormones 262
tibial nerve injury 160
ticks 203
tilmicosin 122, 212
toe, 'knocked up' 174, 175
toldimphos 253
toltrazuril 103
tongue
 foot and mouth lesions 267
 protrusion in botulism 246
 wooden 64, 205
- torsion
 abomasum 81–2
 caecal 84–5
 intestinal (red gut) 85–6
 uterine 50–1
- toxaemia
 hoof fissures 169
 mastitis 221
 pregnancy 256–7
 S. typhimurium infection 104
- toxins
 botulism 246
 causing acute tubular necrosis 200
 copper 273–4
 fluoride 275
 lead 146, 153–4
 nitrate 274–5
 organophosphates 275
 plants 200, 272–3
 urea 275
- trachea, pus accumulation 126, 127
tracheotomy, calf diphtheria 66
Trichomonas foetus 33
trichomoniasis 33–4
triclabendazole 237
trigeminal nerve 146
trochlear nerve 146
tuber coxae 186
tuberculosis 271
tulathromycin 122
twinning 27, 28
 simultaneous presentation of two calves 51
tylosin 179, 180
- udder
 impetigo/necrotic dermatitis 232–3
 oedema 233
 position of 97, 98
 see also mastitis; teats
umbilical abscess 86, 87
umbilical hernia 86, 87
urachus, patent 200
 infections 87, 88
urea poisoning 275
urethrostomy, subschial 196
uroolithiasis 195–7
uoperitoneum 60
urticaria 209
uterine artery, rupture 44, 49
uterine inertia 51, 248
uterine infection, post-partum 18–20
uterine tear/rupture 48–9, 91
uterine torsion 50–1
uveitis 215
- vagal indigestion 73–4, 132
vagal nerve 147
vaginal mucus agglutination test 33
vaginal tears/laceration 49
venereal diseases 30–3
ventricular septal defect 133–4
vertebral empyema 183
vestibular syndrome 145, 151
vestibulocochlear nerve 146–7
vibriosis, genital 32–3
vitamin B12 262
vitamin D3 (cholecalciferol) 250
vitamin deficiencies 265
 vitamin A 214–15, 265
 vitamin B1 265
 vitamin D 193
 vitamin E 260–2
volvulus, abomasal 81–2
vulva, underdeveloped 23
- warble flies (hypodermatosis) 203
warts (papillomatosis) 9, 208–9
 penile 9
 teats 230, 231
water belly 196
welfare, respiratory disease 116, 124
wheeze 116
white line abscesses 166, 170
'whites' 20–1
wooden tongue 64, 205
- xylazine 277, 277
 analgesia 281–2
 extradural injection 279
 general anaesthesia 277
 sedation 52, 276, 277, 277, 281–2
 use with lidocaine 278
- yew poisoning 272
- zinc deficiency 264
zinc-responsive dermatitis 209
zoonoses
 brucellosis 34
 cryptosporidiosis 101
 S. typhimurium 104