Laparoscopic Colorectal Surgery

Springer Science+Business Media, LLC

Jeffrey W. Milsom, MD
Department of Colorectal Surgery
The Cleveland Clinic Foundation

Bartholomäus Böhm, MD, PhD
Universitätsklinik für Chirurgie
Universitätsklinikums Charité
Berlin, Germany

Laparoscopic Colorectal Surgery

Illustrations by
Joseph A. Pangrace, CMI
The Cleveland Clinic Foundation

With 197 illustrations in 229 parts

Springer

Jeffrey W. Milsom, MD
Head, Section of Colorectal Surgery Research
Department of Colorectal Surgery
The Cleveland Clinic Foundation
Cleveland, OH 44195-5044
USA

Bartholomäus Böhm, MD, PhD
Assistant Professor of Surgery
Universitätsklinik und Poliklinik für Chirurgie
des Universitätsklinikums Charité
10098 Berlin
Germany

Library of Congress Cataloging-in-Publication Data
Milsom, Jeffrey W.
Laparoscopic colorectal surgery / Jeffrey W. Milsom, Bartholomäus Böhm
p. cm.
Includes bibliographical references and index.
ISBN 978-1-4757-2534-6 ISBN 978-1-4757-2532-2 (eBook)
DOI 10.1007/978-1-4757-2532-2
1. Colon (Anatomy)—Endoscopic surgery. 2. Rectum—Endoscopic surgery. 3. Laparoscopic surgery. I. Böhm, Bartholomäus, 1957– II. Title.
[DNLM: 1. Colonic Diseases—surgery. 2. Rectal Diseases—surgery. 3. Surgery, Laparoscopic—methods. WI 520 M661L 1195]
RD544.M54 1995
617.59547—dc20
DNLM/DLC
for Library of Congress 95-16248

Printed on acid-free paper.

All artwork, with exceptions as noted, has been reprinted with permission from The Cleveland Clinic who hereby retains the copyright.

© 1996 Springer Science+Business Media New York
Originally published by Springer-Verlag New York, Inc. in 1996
Softcover reprint of the hardcover 1st edition 1996

All rights reserved. This work may not be translated or copied in whole or in part without the written permission of the publisher, Springer Science+Business Media, LLC.
except for brief excerpts in connection with reviews or scholarly analysis. Use in connection with any form of information storage and retrieval, electronic adaptation, computer software, or by similar or dissimilar methodology now known or hereafter developed is forbidden.
The use of general descriptive names, trade names, trademarks, etc., in this publication, even if the former are not especially identified, is not to be taken as a sign that such names, as understood by the Trade Marks and Merchandise Marks Act, may accordingly be used freely by anyone.
While the advice and information in this book are believed to be true and accurate at the date of going to press, neither the authors nor the editors nor the publisher can accept any legal responsibility for any errors or omissions that may be made. The publisher makes no warranty, express or implied, with respect to the material contained herein.

Production coordinated by Impressions Publishing Services and managed by Laura Carlson; manufacturing supervised by Joseph Quatela.
Typeset by Impressions, Madison, WI.

9 8 7 6 5 4 3 2 1

ISBN 978-1-4757-2534-6

Preface

Inspired by the potential of laparoscopic surgery to bring substantial advantages to patients requiring colorectal surgery, we began to apply laparoscopic techniques to colorectal surgery in late 1991. Now, several years later, this field is still in its early phases of development. Whereas laparoscopic techniques for biliary surgery quickly evolved, such techniques for effective and efficient colorectal surgery have developed slowly. Quantifying the value of laparoscopy in this field also has been difficult. Nonetheless, the possible advantages of removing a section of the intestine with safe anastomosis, all done through small "keyhole" incisions, is so tantalizing that we have continued to focus most of our research in this direction. Our philosophy has been that questions about laparoscopic colorectal surgery must be assessed in a methodical and stepwise manner. After such surgery is demonstrated to be feasible and beneficial in the short term, we plan to delve into studies assessing the underlying mechanisms of these benefits, as well as the long-term benefits.

Using animals initially in 1991, we attempted to establish basic techniques for intestinal resection and anastomosis because, at the time, the literature contained few useful descriptions. We encountered significant challenges, even in animal models in which the mesentery is thin and the bowel is relatively mobile. Early successes in the animal models led us to attempt some simple procedures for benign diseases in humans. This transition was challenging and stimulated us to pursue further training in animals and fresh human cadaver models. Many challenges presented the opportunity to pursue true gastrointestinal surgical research. We toiled over the design of techniques, procedures, and new instruments that might permit more effective laparoscopic colorectal surgery. We especially wanted to define standard techniques for curative surgery in colorectal cancer, seeking to resect along the same anatomic boundaries as in conventional surgery.

Throughout this book, we emphasize a team approach to laparoscopic surgery. Our belief in such an approach evolved naturally from many hours of working together—in the animal laboratory; operating theaters; and sitting across from each other at a table with pens, papers, and books scattered in front of us. We believe the discipline of laparoscopic colorectal surgery currently to be too intricate and complex to be taken up by the solitary surgeon performing an occasional laparoscopic intestinal operation with personnel not trained specifically in these techniques.

Laparoscopic colorectal surgery will not be an overnight revolution, as occurred with laparoscopic cholecystectomy. The techniques and teamwork that we have struggled to develop are just beginning to reap rewards—only now are laparoscopic procedures often performed in the same time as conventional procedures, with less blood loss and surgical trauma. However, only concerted, sustained efforts already begun in the surgical research laboratories of medical centers and instrument manufacturers, along with adherence to the highest professional and patient care goals, will make laparoscopic techniques a genuine and substantial advance in colorectal surgery.

We eagerly present a comprehensive, fully illustrated text that discusses the vital components of laparoscopic colorectal surgery—equipment, instrumentation, methods of dissection and suturing, and our ideas concerning education in the field. The book details a personal approach to the surgical treatment of colorectal disease. We do not believe that our approach is the only way to achieve the goals of laparoscopic colorectal surgery and we sincerely hope our text will fuel discussion in the surgical community that will produce further advances.

JEFFREY W. MILSOM, MD
BARTHOLOMÄUS BÖHM, MD, PHD

Acknowledgments

We are indebted to many individuals and corporations for their patience and generous donation of time and resources.

Because laparoscopic colorectal surgery depends so heavily on new technologies, we have relied on the advice and expertise of many individuals in the corporate world. We give thanks to David Mills of Northgate Technologies (Arlington Heights, Ill.), Dr. Ray Kralovic of Steris Corporation (Mentor, Ohio), and Katherine Dickinson and Barry Marston of UltraCision Corporation (Providence, R.I.), for their willingness to share product information and specifications. From Surgical Laser Technologies (Oaks, Pa.), we owe David Poley a special thanks for providing us with many insights into laser applications in general and laparoscopic surgery. Mike Manes of Aspen Laboratories (Englewood, Colo.) gave us a deep and thoughtful understanding of the proper uses of electrosurgery and the physics behind its use. To Andy Fleischacker of Olympus Corporation (Lake Success, N.Y.), we are grateful for his thorough review of our concepts of video imaging and for his wise counsel. Our final thanks on the corporate side go to Sheila Salter of U.S. Surgical Corporation (Norwalk, Conn.), who generously lent her expertise in many areas of laparoscopic instrumentation.

In constructing the manuscript, we also owe many individuals our special gratitude. Alex Vladisavljevic helped us communicate electronically between Berlin and Cleveland during the final phases of manuscript writing and gave much assistance in the organizational work. Madge Stewart painstakingly procured and organized our references and filed them on a reference database. Ann Fuentes faithfully performed much of the word processing, revising, and organizing (despite our whimsical and often confusing changes); Katherine Hammerhofer was invaluable in helping us in the final phases to organize the manuscripts, figures, and administrative details needed to complete the work. To Tom Lang, and especially Cassandra Talerico, our medical editors at The Cleveland Clinic Foundation, we are grateful for their forbearance in correcting our bad grammar and often confusing use of the English language—their impact on the manuscript's quality was substantial.

Joe Pangrace, an experienced medical illustrator, became a good friend and colleague during this venture. We are grateful for his talents and eagerness to visit the operating room, to study videotapes, and to scrutinize each

and every laparoscopic instrument in order to produce the best possible illustrations for our text.

Our editors at Springer-Verlag, Esther Gumpert and Laura Gillan, were always receptive to our ideas and changes, and we owe them special thanks for their support and belief that we could produce a worthy book about laparoscopic colorectal surgery.

Victor Fazio, chair of our Department of Colorectal Surgery at The Cleveland Clinic Foundation, supported us in innumerable tangible and intangible ways; without his support, this book would not have been possible.

Finally, we know our efforts thwarted many valuable family interactions, so to our wives, Susan and Anke, and our children, Alexandra, Geoffrey, Annika, and Stephanie, we offer our deepest gratitude for permitting us the freedom and the time to pursue this text to completion.

Contents

1

History of Laparoscopic Surgery

Endeavors to peer directly into the living human body probably began in 1806, when Bozzini looked inside the bladder with an apparatus called the "Lichtleiter."[1] Bozzini envisioned and clearly described in his writings that endoscopy could someday be used as a diagnostic tool for the urethra, the bladder, the rectum, the vagina, the cervix, and the pharynx, as well as a surgical tool for endoscopic polypectomy or removal of bladderstones. He also surmised that endoscopy would augment the understanding of the physiology and the pathology of an organ if it could be visualized in vivo. His Lichtleiter used a candle as a light source and consisted of a light container, mirrors, and tubes through which the light passed. As well as describing the Lichtleiter (Figure 1.1) in detail, Bozzini explained the difficulties of reflecting light through tubes, a problem that remained unsolved for another century.

Almost 50 years later, Desormeaux presented an improved endoscope to the Academy of Medicine of Paris. In 1853, he reported the use of a kerosene lamp as an external light source, equipped with a chimney vent and a concentrating mirror (Figure 1.2). "Endoscopy," a term coined by Desormeaux, remained crude for most of the 19th century because internal visualization remained relatively poor, and management of a light source dependent on combustion of fossil or animal fuel was difficult. Nevertheless, Desormeaux described and carried out numerous investigations of the urethra and bladder.[2]

In 1867, a German dentist named Bruck described the first internal light source.[2] He examined the mouth using illumination provided by a loop of platinum wire connected to an electrical current. Because the wire generated intense heat, the loop was cumbersome and dangerous to use; consequently, Bruck's platinum loop never attained widespread popularity.

For most of the nineteenth century, cystoscopy was limited because endoscopes illuminated the interior of the bladder poorly and they showed only a small part of the visualized object. In 1887, Nitze developed a cystoscope that dramatically overcame these major limitations.[3] To increase the intensity and the extent of illumination, he placed a platinum wire powered by electricity at the tip of the cystoscope and cooled it by using a continuous stream of water through the cystoscope. Placing the light source at the tip not only increased the intensity of the light, but also was advantageous in that the light was directly coupled with the cystoscope, making the procedure much easier to perform because the light source moved with the cystoscope. Although having the light source at the tip of the endoscope widened the illuminated area, visualization was still limited until Nitze added a prismatic lens system to his cystoscope. With his newly designed instrument, which had a diameter of only 5 mm, Nitze was able to adequately visualize an area the size of the human palm. Nitze also incorporated additional channels in his operating cystoscope through which ureteral probes could be passed. Together with Joseph Leiter, an instrument maker, they produced a commercial cystoscope that revolutionized cystoscopy and became the forerunner of modern cystoscopes and other endoscopes.

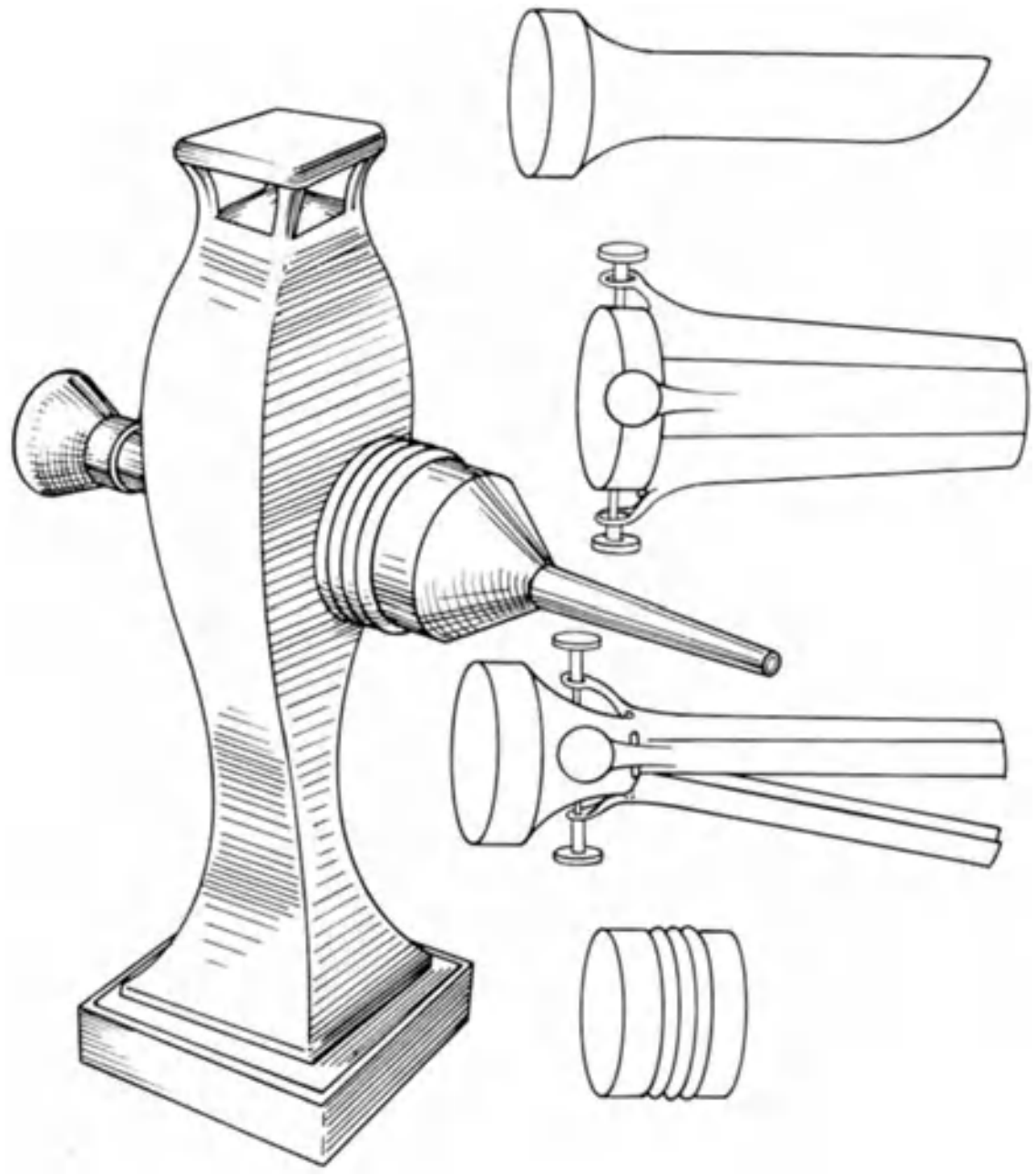

FIGURE 1.1. “Lichtleiter” of Bozzini (1806).



FIGURE 1.2. Cystoscope of Desormeaux (1853).

FIGURE 1.3. Cystoscope of Nitze (1887).

Subsequent to the invention of the incandescent lamp by Thomas Edison in 1880, Nitze and Leiter replaced the platinum wire with a light bulb in 1887 (Figure 1.3). Brenner further improved the cystoscope in 1889, building a small channel through the cystoscope for passing fluid into the bladder and for introducing urethral catheters.

Boisseau de Rocher made the next important step in the development of modern endoscopes in 1889. He separated the ocular part of the cystoscope from the lamp-carrying beak by using a sheath through which multiple different telescopes could be introduced. This change allowed greater latitude of observation and manipulation through the cystoscope.

In 1902, Kelling, a surgeon from Dresden, Germany, reported the first actual laparoscopy, or endoscopic visualization of the peritoneal cavity.[4] At the meeting of the German Biological and Medical Society in Hamburg in September 1901, he showed that laparoscopy could be performed in a canine model. Kelling inserted a Nitze cystoscope into the peritoneal cavity of a living anesthetized dog and examined the viscera. The abdomen was insufflated with air filtered through a sterile cotton swab. He named the procedure “Kölioskopie.” In the same year, a Russian gynecologist named Dimitri Ott independently described a technique for directly viewing the abdominal cavity in humans without an endoscope. He inspected the abdominal cavity with the help of a head mirror and a speculum introduced through a small anterior abdominal wall incision.

The first major series of laparoscopies in humans is attributed to Jacobeus. In 1910, Jacobeus reported 17 cases in which laparoscopy was accomplished using a Nitze cystoscope with “cold burning” lamps and a cannula with a valve system.[5] He also performed 20 examinations in human cadavers in which he evaluated the risk of injury to intraperitoneal structures. Jacobeus achieved his first clinical experiences in patients with ascites because puncture of the abdominal cavity appeared to be easy and without risk of inadvertent injury to intraperitoneal viscera. By 1911, he had described 80 laparoscopies, with only one reported complication—a hemorrhage into the peritoneal cavity from a trocar incision.[6] With laparoscopy, Jacobeus was able to recognize different kinds of liver diseases (cirrhosis, metastatic tumors, tuberculosis, and syphilis), gastric cancer, and “chronic” peritonitis.

In 1911, Bernheim, of the Johns Hopkins Medical School, reported on “organoscopy” using an ordinary proctoscope or cystoscope, with illumination from an electric headlight.[7] He made an incision in the epigastrium, inserted the scope, and inspected the viscera. Bernheim was probably the first surgeon to perform a type of laparoscopic-assisted operation: after finding nothing on organoscopy, Bernheim drew "a part of the stomach out through the wound, made an incision in its anterior wall, and inserted the cystoscope directly into its cavity."

Roccavilla modified the method of illumination in 1914. He designed an instrument that permitted the source of light to remain outside the abdomen by reflecting the light through a trocar into the field of vision.[8]

To facilitate trocar insertion, Orndoff, in 1920, used and described the pyramidal trocar point currently in use.[9] He reported diagnostic laparoscopies in 42 cases and described tuberculous peritonitis, extrauterine pregnancy, salpingitis, and ovarian tumors. Orndoff was the first to stress that laparoscopy is a useful tool in diagnosing suspected postoperative hemorrhage in the peritoneal cavity.

In 1918, Goetze developed the first automatic spring-loaded needle for initiating pneumoperitoneum.[10] He did not design the needle for laparoscopic visualization of the abdominal cavity but rather for insufflation of oxygen into the peritoneal cavity and to improve conventional plain abdominal x-ray techniques. By studying the heart rate and body temperature in 90 outpatients undergoing oxygen insufflation of the peritoneal cavity, Goetze proved that an artificial pneumoperitoneum was not harmful or dangerous. He also defined the following contraindications for pneumoperitoneum: cardiac and pulmonary diseases, "meteorism," septic process in the peritoneal cavity, and extensive adhesions.

In 1924, Stone wrote about "peritoneoscopy" in a canine model.[11] He inserted a nasopharyngoscope through an incision in the abdominal wall and successfully completed diagnostic laparoscopies in 14 dogs. Stone preferred to use air insufflation instead of CO_2 because air insufflation did not require any special instruments. He also developed a rubber trocar gasket.

Steiner, unaware of the experiences of other researchers, also described in 1924 his technique of "abdominoscopy" using a cystoscope, a trocar, and oxygen to insufflate the abdomen.[12] In the same year, Zollikofer first described the use of CO_2 gas to induce pneumoperitoneum.[13] It quickly became the most popular distending gas owing to its noncombustible properties as well as to its rapid absorption after a procedure.

In 1925, Short summarized the following advantages of laparoscopy[14]: "1.) It can be done without discomfort; 2.) the incision is so small that it is only necessary to keep the patient in bed for a day or two; 3.) very few special instruments are needed; 4.) it can be done at the patient's own house; and 5.) it is available when it would be dangerous to perform laparotomy."

Almost 25 years after Kelling's initial report, Nadeau and Kampmeier gave an excellent review of previous experiences about "endoscopy of the abdomen."[15] They also described their technique as performed in three patients. Nadeau and Kampmeier said the "appliances necessary for the performance of abdominoscopy are relatively few . . . a trocar and cannula, a cystoscope, . . . a no. 18 spinal puncture needle, a hypodermic syringe and needle, a small scalpel, and a small foot pump, rubber tubing, and connections for inflating the abdomen."

Several important reports establishing laparoscopy as a valuable diagnostic tool were published by the German hepatologist Kalk, who introduced a 45° lens system and was the first to advocate the dual-trocar technique.[16] This latter innovation led the way to the concept of operative laparoscopy. Kalk performed 100 laparoscopies in 4 years without any major complications and was able to diagnose various liver and gallbladder diseases, and stomach, pancreas, and renal cancer with his technique. His efforts proved that intra-abdominal manipulation using laparoscopic techniques could be safely performed. Kalk published 21 papers between 1929 and 1959 that established the use of laparoscopy to study and make accurate pathologic diagnoses of internal organs. Many authorities consider Kalk to be the "father of modern laparoscopy."

One of the earliest reports of a therapeutic laparoscopy was in 1933, when Fervers described laparoscopic lysis of adhesions.[17] In his report, he also described the use of ureteral catheters passed through his endoscope to palpate the gallbladder for stones. In addition, while using "cold cautery" electrosurgery and insufflating the abdomen with oxygen, Fervers described an explosion inside the peritoneal cavity with multiple audible "detonations" and "flames" visible through the abdominal wall. Laparoscopic inspection of the peritoneal cavity showed only minor injuries of the peritoneum, and the patient recovered fully after several days of observation without any additional treatment. Thereafter, Fervers wisely argued against the use of oxygen in establishing pneumoperitoneum.

In 1937, Ruddock, an internist from Los Angeles, Calif., reported 500 cases in which diagnostic laparoscopy was performed over 4 years.[18] He firmly established diagnostic laparoscopy as a safe procedure with low morbidity. Injury of the intestine (stomach, small bowel, and colon) occurred in only eight patients (1.6%) in his series, and only one mortality occurred in a patient who died of hemorrhage after laparoscopic biopsy of the liver. Examinations were unsuccessful in only three patients (0.6%). He also described a biopsy forceps with electrosurgical capability to perform coagulation and tissue biopsy simultaneously. The tip of the biopsy forceps was designed so that it formed a cup containing the tissue when closed. In addition, Ruddock's patients did not experience postoperative intestinal paralysis after laparoscopy. After laparoscopy, his patients were permitted to resume eating meals without interruption. Since Ruddock's time, laparoscopy has remained the method of choice in diagnosing cases of undetermined ascites and tuberculous peritonitis, in assessing the operability of certain intra-abdominal lesions, and whenever there is a question of intra-abdominal metastases.

Until the 1930s, pneumoperitoneum was accomplished with a Goetze-style spring-loaded needle. In 1938, Veress developed a modified spring-loaded needle to safely introduce air into the thoracic cavity.[19] This needle, which now bears his name, is now commonly used to create pneumoperitoneum and remains almost unchanged since its invention.

A new era of endoscopy began in 1952 when Fourestier et al. developed and described the "cold-light" fiberglass source that at a low temperature provided intense light through a quartz rod from the proximal to the distal end of the telescope.[20] The physicist Hopkins introduced rod-shaped lenses as light transmitters with air lenses between the glass elements to further increase illumination. This design dramatically improved the resolution and contrast of the telescope in 1953.[21] Most currently used telescopes are designed according to the principles of the Hopkins lens system.

In the 1960s, the German gynecologist Semm, one of the most innovative and productive researchers and clinicians in the field of laparoscopy, contributed several important innovations in laparoscopy: a controlled, automatic CO_2 insufflator; an irrigation system; the Roeder loop applicator; hook scissors; a tissue morcellator; and the pelvitrainer teaching model.[22]

Until the early 1980s, laparoscopic visualization of the peritoneal cavity was restricted to the operating surgeon. The introduction of elaborate "teaching scopes" that were connected to and branched away from the main endoscope enabled the assistant to view what the surgeon was seeing. Unfortunately, these scopes were cumbersome and ineffective when the surgeon and the assistant had to coordinate actions. Thus, complex therapeutic operations could not be performed using these scopes and, as a result, laparoscopy was unpopular and was rarely used in general surgery during the 1970s and 1980s. The development of the computer-chip television camera allowed everyone in the operating room simultaneously to view the image generated by the laparoscope. Surgeons thereafter accelerated the technical advances of safe and improved therapeutic laparoscopy and introduced therapeutic laparoscopic procedures into the field of general surgery.

The first incidental laparoscopic appendectomy is credited to Semm in 1981[23] and the first laparoscopic cholecystectomy in humans to Mühe in 1985.[24] In 1989, Dubois et al. published the first series of laparoscopic cholecystectomies performed using a standard multipuncture technique.[25] Similar reports followed from Reddick and Olsen,[26] and Cuschieri et al.[27] Their work led to an explosion of interest in laparoscopic cholecystectomy so that now hundreds of thousands of these procedures are performed every year around the world.

Intestinal laparoscopic surgery has evolved as a direct result of the rapid recovery of patients undergoing laparoscopic cholecystectomy compared with the same procedure using open techniques. Every part of the intestinal tract has now been approached laparoscopically. This chapter serves only as a prelude to the developments in laparoscopic colorectal surgery that are highlighted throughout this book.

References

1. Bozzini P. Lichtleiter, eine Erfindung zur Anschauung innerer Theile und Krankheiten. *J Prakt Arzneikunde.* 1806;24:107–113.
2. Gunning JE. The history of laparoscopy. *J Reprod Med.* 1974;12:222–225.
3. Nitze M. Beobachtungs- und Untersuchungsmethode für Harnröhre, Harnblase und Rektum. *Wien Med Wochenschr.* 1879;29:651–652.
4. Kelling G. Ueber Oesophagoskopie, Gastroskopie und Kölioskopie. *Münch Med Wochenschr.* 1902; 49:21–24.
5. Jacobeus HC. Ueber die Möglichkeit die Zystoskopie bei Untersuchung seröser Höhlungen anzuwenden. *Münch Med Wochenschr.* 1910;57:2090–2092.
6. Jacobeus HC. Kurze Uebersicht über meine Erfahrungen mit der Laparo-thoraskopie. *Münch Med Wochenschr.* 1911;58:2017–2019.
7. Bernheim BM. Organoscopy: cystoscopy of the abdominal cavity. *Ann Surg.* 1911;53:764–767.
8. Roccavilla A. L'endoscopia delle grandi cavita sierose mediante un nuovo apparecchio ad illuminazione dirtta (Laparo-toracoscopia diretta). *La Riforma Medica.* 1914;30:991–995.
9. Orndoff BH. The peritoneoscope in diagnosis of diseases of the abdomen. *J Radiol.* 1920;1:307–325.
10. Goetze O. Die Röntgendiagnostik bei gasgefüllter Bauchhöhle. Eine neue Methode. *Münch Med Wochenschr.* 1918;65:1275–1280.
11. Stone WE. Intra-abdominal examination by the aid of the peritoneoscope. *J Kan Med Soc.* 1924;24:63–66.
12. Steiner OP. Abdominoscopy. *Surg Gynecol Obstet.* 1924;38:266–269.
13. Zollikofer R. Zur Laparoskopie. *Schweiz Med Wochenschr.* 1924;5:264–265.
14. Short AR. The uses of coelioscopy. *Br Med J.* 1925;3:254–255.
15. Nadeau OE, Kampmeier OF. Endoscopy of the abdomen: abdominoscopy. *Surg Gynecol Obstet.* 1925;41:259–271.
16. Kalk H. Erfahrungen mit der Laparoskopie. (Zugleich mit Beschreibung eines neuen Instrumentes.) *Z Klin Med.* 1929;111:303–348.
17. Fervers C. Die Laparoskopie mit dem Cystoskop. *Med Klin.* 1933;31:1042–1045.
18. Ruddock JC. Peritoneoscopy. *Surg Gynecol Obstet.* 1937;65:623–639.
19. Veress J. Neues Instrument zur Ausführung von Brust- oder Bauchpunktionen und Pneumothoraxbehandlung. *Dtsch Med Wochenschr.* 1938;40:1480–1481.
20. Fourestier M, Gladu A, Vulmiere J. Perfectionnements a l'endoscopie medicale. Realisation bronchoscopique. *Presse Med.* 1952;60:1292–1293.
21. Gow JG, Hopkins HH, Wallace DM, England AG. The modern urological endoscope. In: Hopkins HH, ed. *Handbook of Urological Endoscopy.* Edinburgh: Churchill Livingstone; 1978:21–33.
22. Semm K. *Operative Manual for Endoscopic Abdominal Surgery.* Chicago, Ill.: Thieme; 1987.
23. Semm K. Endoscopic appendectomy. *Endoscopy.* 1983;15:59–64.
24. Mühe B. The first laparoscopic cholecystectomy. *Langenbecks Arch Chir.* 1986;369:804.
25. Dubois F, Icard P, Berthelot G. Coeliscopic cholecystectomy. Preliminary report of 36 cases. *Ann Surg.* 1990;211:60–62.
26. Reddick EJ, Olsen DO. Laparoscopic laser cholecystectomy: a comparison with minilap. cholecystectomy. *Surg Endosc.* 1989;3:131–133.
27. Cuschieri A, Berci G, McSharry CK. Laparoscopic cholecystectomy. *Am J Surg.* 1990;159:273–278.

2

Basic Equipment Needs

Laparoscopy epitomizes "high-tech" surgery and thus completely depends on properly functioning, sophisticated instruments. Although each surgeon will have preferences regarding equipment, a basic set of instruments must be available to guarantee an efficient and a safe procedure. The following equipment is the minimum that is necessary:

- video instrumentation
  - a video camera unit
  - the laparoscope
  - a light source
  - monitoring and recording devices
- a gas insufflator or abdominal wall-elevating instrument
- a suction and irrigation device
- adequate sterilizing and disinfecting facilities

All laparoscopic team members must familiarize themselves with all aspects of the equipment. Most problems with instrumentation that arise are simple and solvable if team members have a basic understanding of how the equipment functions.

This chapter introduces the reader to the available basic laparoscopic equipment and discusses the pros and cons of various types of equipment as well as what kind of equipment leads to successful laparoscopic colorectal surgery.

Video Equipment

Laparoscopic surgery is defined as surgery performed inside the peritoneal cavity using a laparoscope to visualize the interior of the cavity. Because the video equipment completely replaces the surgeon's direct visual perception, this equipment must provide an image of the surgical field that allows safe and precise laparoscopic surgical maneuvers without restrictions resulting from indirect visualization.

Image Technology

Currently, two major imaging technologies are available. The most common provides a high-resolution two-dimensional (2-D) view on a monitor; the second re-creates a three-dimensional (3-D) stereoscopic view. Because we are accustomed to perceiving objects in three dimensions, a 2-D view without depth perception appears to be a particularly troublesome deficiency in surgery. However, our depth perception depends not only on the ability to perceive an object at a slightly different angle from each eye (binocular horizontal disparity), which results in stereopsis, but also on monocular cues like shadows, highlighting, linear perspective, object interposition, and past experience.[1] Thus, depth perception does not always require that objects be viewed in binocular stereopsis.

Currently, most surgeons use 2-D imaging in laparoscopic surgery and rely on indirect evidence of depth and position to judge spatial relationships in the peritoneal cavity. Combining numerous monocular cues with experience from performing previous open surgery, surgeons can safely perform advanced laparoscopic surgery despite the restrictions of 2-D imaging.[2] Although we have found that 2-D imaging does result in some loss of information about objects and may lead to ambiguity, this loss of information is almost never critical, even if it does make laparoscopic surgery more difficult than open surgery at times. However, because information is lost during 2-D imaging, the best possible image of the intraperitoneal structures must be obtained. To this end, high-resolution video monitors and cameras that provide true color, white balance, and good contrast should be used for every laparoscopic procedure.

Stereoscopic imaging technology provides subjectively more compelling information than does the current 2-D imaging technology.[2] The first generation of 3-D laparoscopes produces stereopsis by simulating binocular horizontal disparity. Two systems are available to produce stereopsis. In one system, a stereoscopic camera is mounted on a normal laparoscope; at the laparoscope eyepiece, the camera splits the image into two separate images. The second system uses a laparoscope that has two separate (left or right) optical lens systems with two cameras; one camera transmits a view from the right lens system and one transmits a view from the left lens system (Figure 2.1). In both cases, the laparoscopic unit reconstructs a 3-D image using field sequential video (FSV). Field sequential video is based on the principles of broadcast television, in which a real motion picture is produced on a television screen by flashing the picture 30 times per second on the screen (because each visual frame represents two fields, this actually represents 60 visual fields). If a polarized

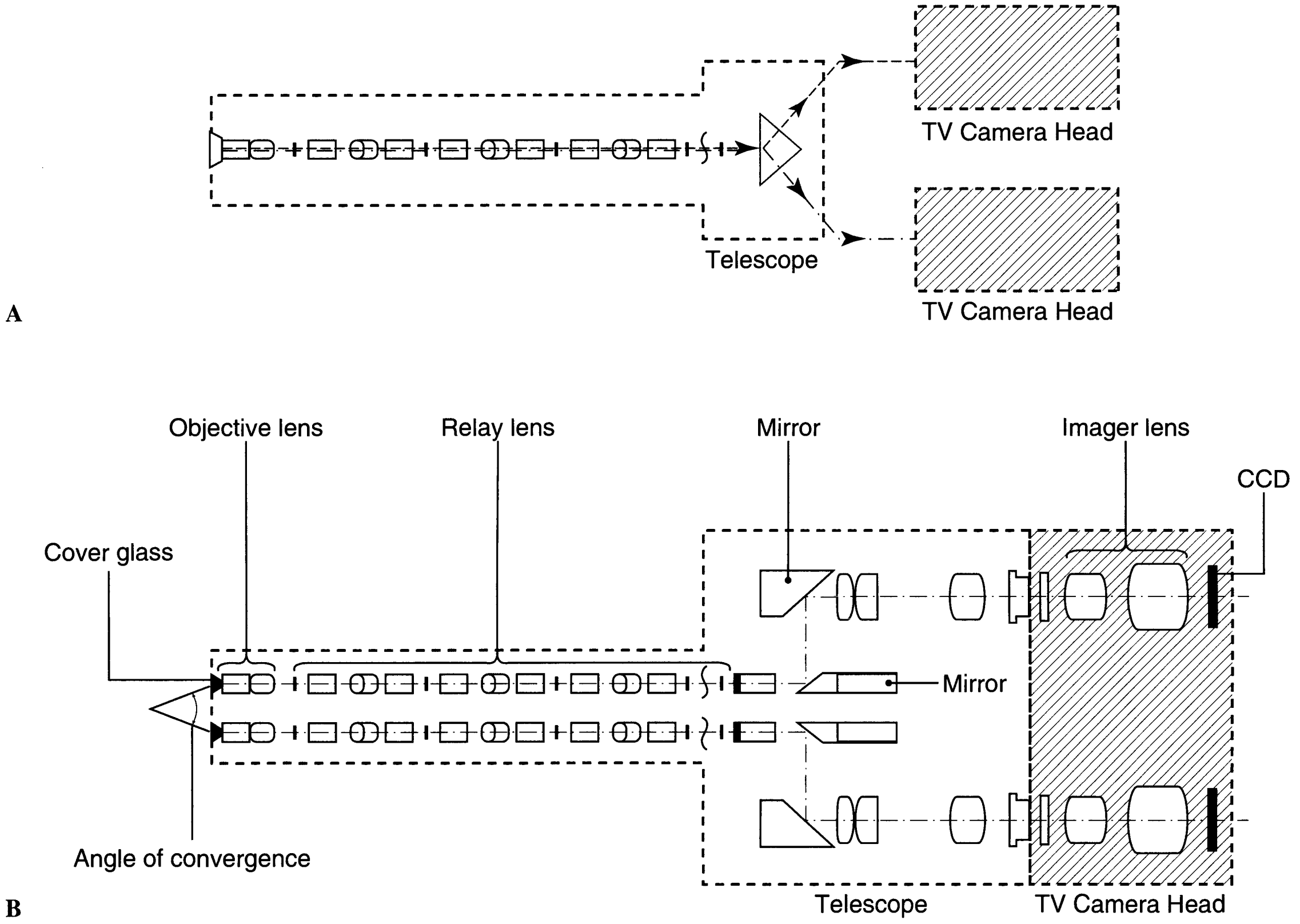

FIGURE 2.1. Laparoscopic binocular disparity is currently created by "perceiving" an object at a slightly different angle by two cameras using the following different techniques: A, the object is viewed through a normal laparoscope and the image is split into two different images that are recorded by two separate cameras, or B, two images are passed through two channels of a laparoscope and each is seen by a camera. CCD, charge-coupled device. (Courtesy of Olympus, Lake Success, N.Y.)

lens system (one that uses electronically shuttered goggles or polarized glasses) that alternates the views of the right and the left eyes is used to project an image at least 60 times per second on the screen (30 times per second for each eye), a true 3-D image can be created (Figure 2.2). Currently, some stereoscopic systems produce up to 120 frames per second and create a flicker-free, sharp 3-D image.

Stereoscopic imaging systems are active or passive. The passive field sequential display technology uses liquid crystal shutter placed directly over a cathode-ray tube screen and requires the user to wear orthogonally polarizing eyeglasses. The shutter is used to set orthogonal polarization angles to alternate the field image so that a "stereo-pair" image can be presented sequentially in time separately for each eye (Figure 2.3). In the active system, polarizing eyeglasses use a rapid shutter system that is synchronized with the display generator, ensuring that the image is viewed only by the appropriate eye. The disadvantages of the passive system are the loss of depth when the observer moves to the side of the monitor. The disadvantages of the active system are that the glasses are vulnerable to injury and are expensive.[1]

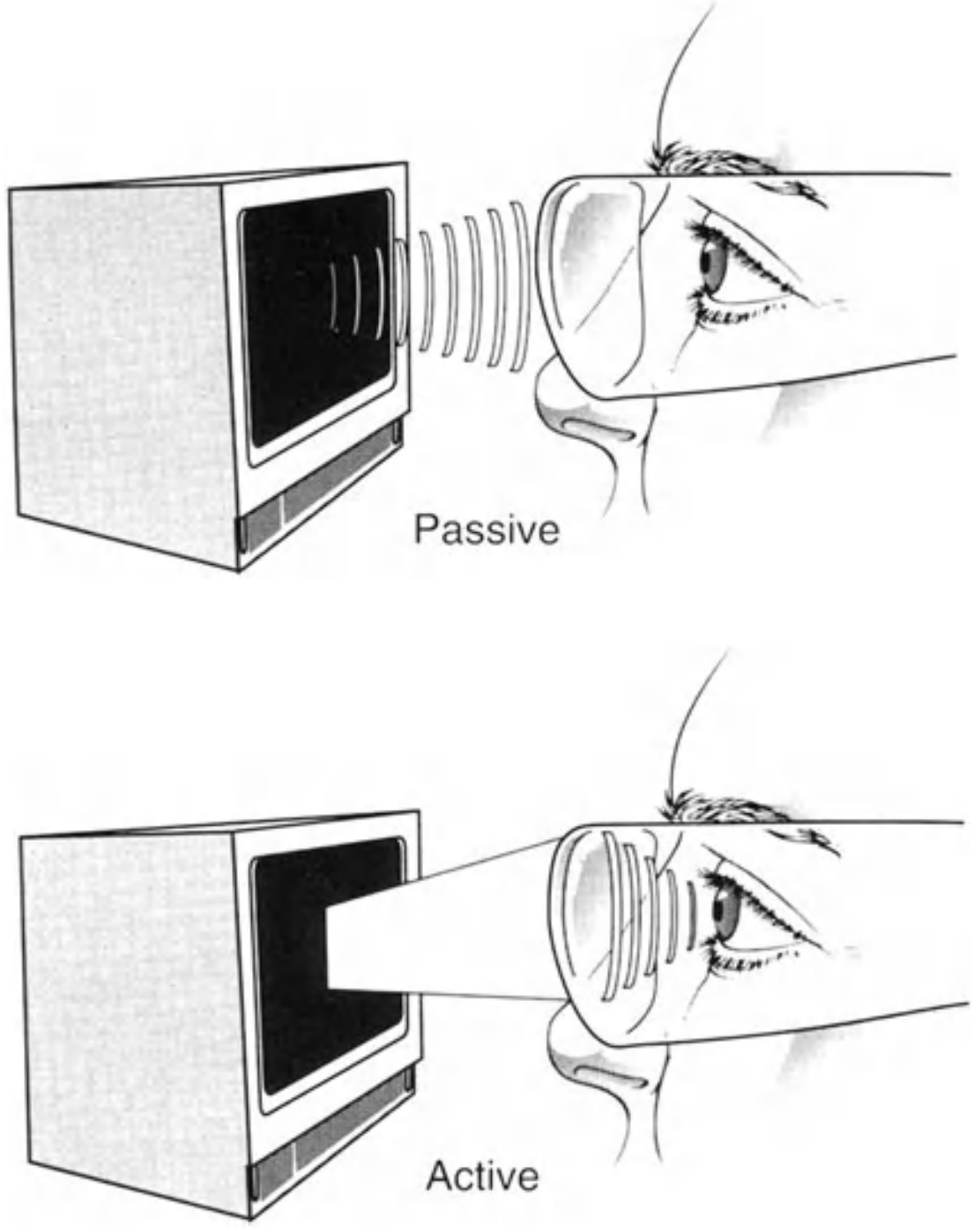

FIGURE 2.2. There are passive and active systems that create 3-D images. The passive system has a liquid crystal shutter over the cathode ray tube of the monitor that switches the polarization of the image between left and right. The user wears passive polarizing eyeglasses that then create the final 3-D image. In the active system, the shutter is located within the liquid crystal eyeglasses. (Courtesy of Olympus, Lake Success, N.Y.)

Although binocular stereopsis is an important source of depth perception and may be useful for some laparoscopic procedures, 3-D laparoscopic technology currently has several limitations. Natural binocular stereopsis depends on the eye's ability to change the focal point using convergence and accommodation at an interpupillary distance of about 60 mm. Neither focusing nor accommodation is incorporated in current 3-D laparoscopes. In addition, for a laparoscope measuring 10 mm in diameter, the interpupillary distance is only 7 to 9 mm, so that the 3-D effect of such scopes is limited. Using current 3-D imaging systems, some surgeons cannot see stereoscopically or cannot visually fuse a large amount of disparity presented by 3-D laparoscopes. Additionally, some areas may remain out of focus.[3] Whether the advantages of 3-D imaging will significantly improve the surgeon's ability to operate laparoscopically as 3-D systems improve will need to be evaluated. Younger surgeons who do not have much experience in conventional surgery and therefore are unable to rely on experience to compensate for the lack of depth perception may benefit more from the 3-D imaging technology. All endoscopic procedures that require suturing may also benefit from 3-D imaging technology.

An alternative to FSV is 3-D imaging technology that uses vertical instead of horizontal disparity. A system that uses vertical disparity combines the output of two optical beams so they follow a single path; to the video chip (charge-coupled device; see next section, Cameras), a liquid crystal shutter is interposed in the beam path. This binocular imaging allows both eyes to see the same image so that polarizing glasses are not necessary. In addition, this sys-

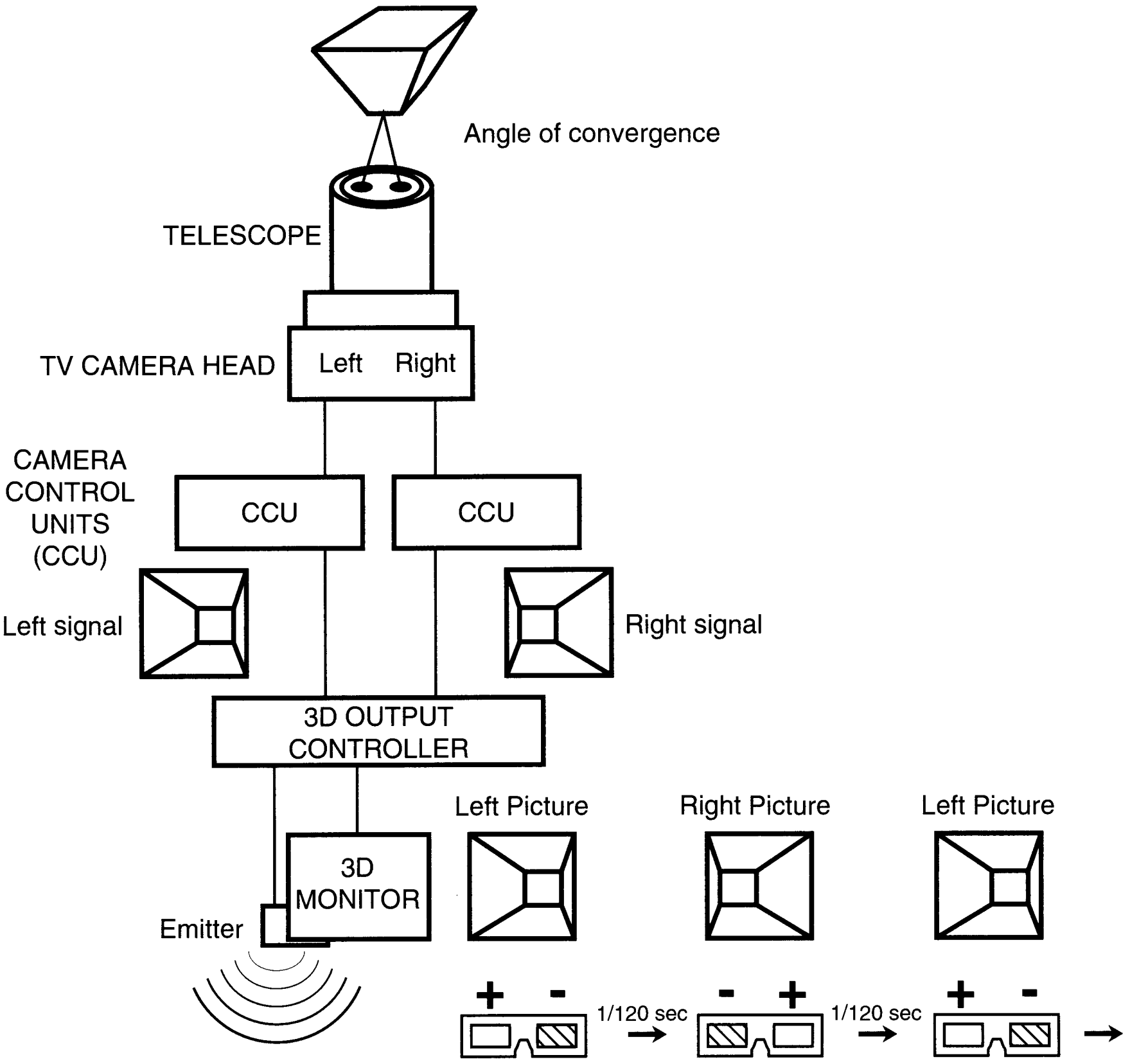

FIGURE 2.3. Principles of field sequential video (FSV) applied to laparoscopic 3-D imaging. An image of a 3-D object is seen from slightly different angles, creating a signal for the right and the left eye. These signals are rapidly emitted sequentially for the right and then the left eye, simulating binocular disparity. (Courtesy of Olympus, Lake Success, N.Y.)

tem allows the laparoscope to be rotated around its longitudinal axis without losing the 3-D image, something that may occur in stereoscopic imaging based on horizontal disparity.[4]

Cameras

Commercially available laparoscopic cameras currently use a 0.5- to 0.67-in. silicon charge-coupled device (CCD) to transform the image into a picture of discrete pixels (a *pixel* is the smallest unit of a picture element that is represented by an individual photo diode on the CCD). One type of CCD is the hole accumulator diode (HAD) sensor, which consists of an array of photosensitive silicon sensor elements that generate electrical charges when light strikes the surface of the photo diodes (Figure 2.4). Each electrical charge represents a pixel that is then transformed to a conventional horizontal scanning line by the camera control unit.

The CCD resolution is determined by the number of pixels its surface can accommodate. Most CCDs accommodate up to 390,000 pixels. A single HAD CCD has a resolution of about 460 lines per inch with a signal-to-noise ratio up to 60 dB. The high dynamic range of the HAD sensor allows an image to be extracted from poorly lit conditions while simultaneously handling excessive background highlights without excessive glare or streaking. The ratio of the optical sensor area to the total pixel area, the opening ratio, is about 35%, leading to good sensitivity. The opening ratio can be increased to almost 100% if each pixel is capped with its own convex lens, a technology known as *on-chip lens.*

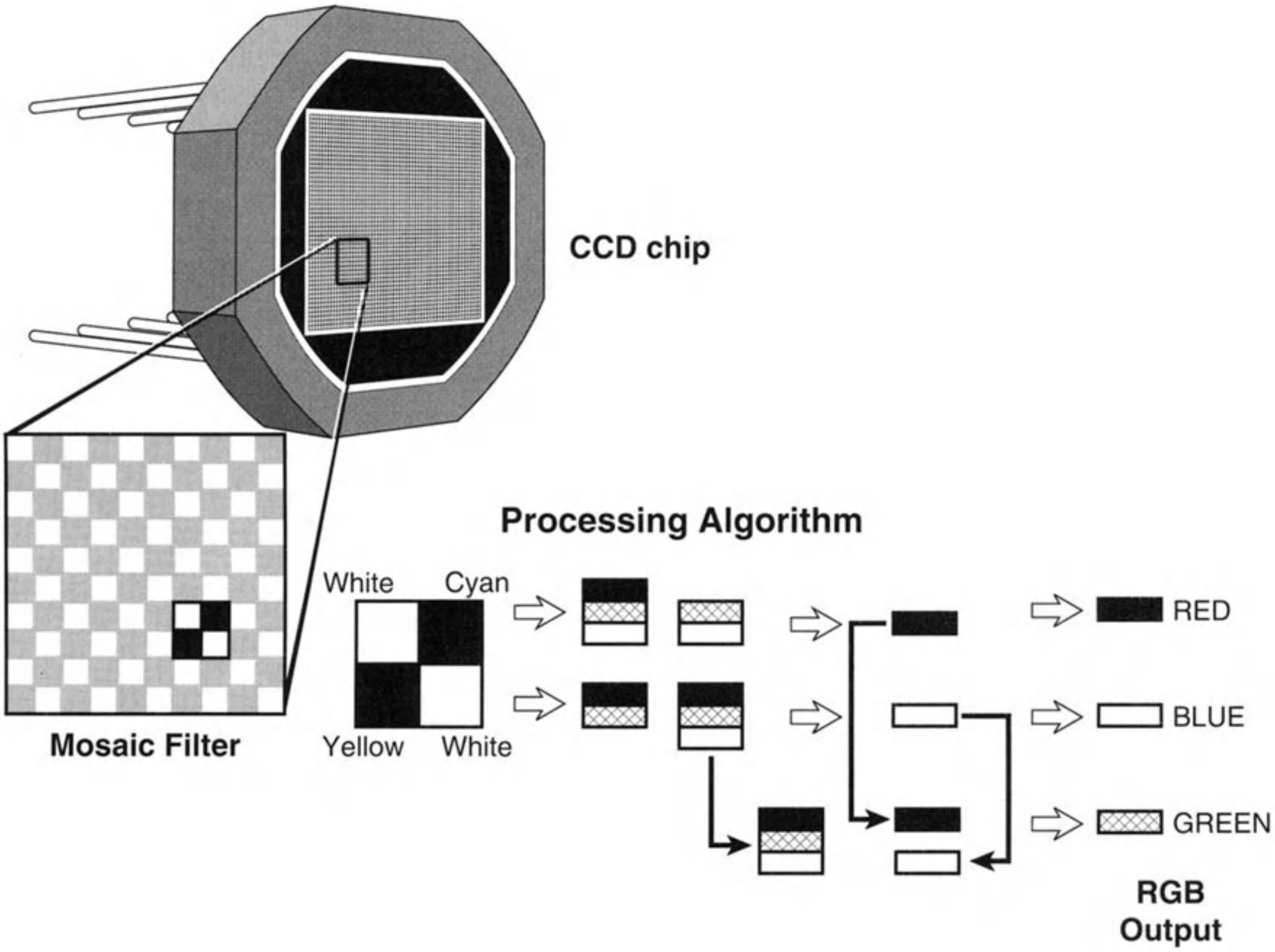

FIGURE 2.4. Sketch of a hole accumulator diode–charge-coupled device (HAD–CCD) including (inset) a mosaic filter that is used together with a complex algorithm to generate a colored image with a high resolution. (RGB, red–green–blue.) (Courtesy of Olympus, Lake Success, N.Y.)

Nearly all currently available cameras provide accurate dimensional detail and precise edge detection. Many laparoscopic cameras have a built-in zoom lens of 25 to 40 mm and an automatic electronic shutter that prevents excessive glare and streaking under difficult lighting conditions. A three-CCD-chip camera with one chip for each primary video color (red, green, and blue) and a resolution of about 700 to 800 lines per inch is also available. Each color channel provides 768 horizontal × 493 vertical picture elements for a total of 1,312,992 pixels in the Phase Alternating Line (PAL) format and 1,138,176 pixels in the National Television System Committee (NTSC) format. The resolving power of a three-chip camera is greater compared with a one-chip camera because one CCD is used for each primary color (Figure 2.5), whereas in the single camera, only one chip is used for all colors.

Because the single-chip camera detects only black and white, the light is passed through a complementary (i.e., magenta, cyan, yellow, and green) filter. Colored images are then generated by activating the pixels with a mosaic color filter (Figure 2.4 inset) or with a rotating filter of the primary colors. An accurate color spectrum is produced only if the camera is first calibrated using pure white light as a reference value (*white balancing*). Therefore, an automatic or manual white balance has to be performed before using the camera so that the camera will correctly adjust the luminance of each primary color to produce white. Light sensitivity of the CCD is controlled by an electronic shutter. This is accomplished in each

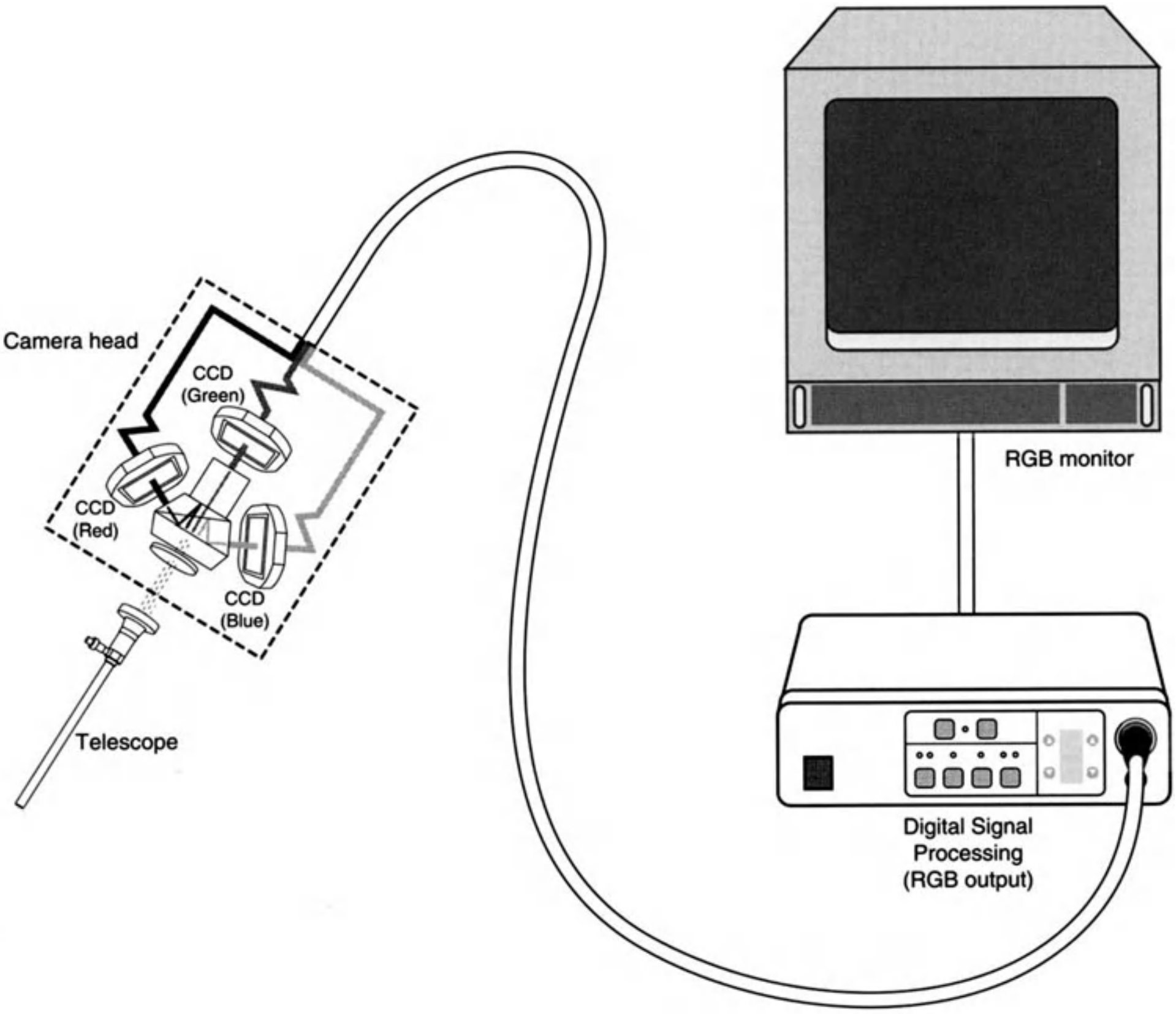

FIGURE 2.5. A three-chip camera system. Each chip codes for one of the primary video colors: red, green, or blue. (Courtesy of Olympus, Lake Success, N.Y.)

pixel by *charge separation* of the CCD, a standard video technology beyond the scope of this book.

Laparoscopes

Modern rigid laparoscopes are derived from the rod-shaped lens system that Hopkins first developed in 1952 for cystoscopes.[5] This lens system, which is contained in the core of the laparoscope, focuses and transmits the light from the abdomen to the camera. Modern versions consist of rod-shaped lenses, air-filled spaces between the lenses, and additional lenses that compensate for peripheral distortion (Figure 2.6). Optical fibers at the periphery of the scope transmit light out the laparoscope tip into the abdomen. Laparoscopes are available in various diameters (ranging from 1.7 to 14 mm) and angles of visualization (0° to 120°). Because laparoscopes with a diameter of 10 mm will transmit approximately three times as much light as 5-mm laparoscopes, we recommend using a standard 10-mm laparoscope whenever possible.

Because the 30° laparoscope allows a wider overview with simple rotation of the laparoscope, some surgeons prefer it for situations in which an angled instrument will allow better visualization around fixed intraperitoneal structures (e.g., the splenic flexure or deep pelvic structures) or better inspection of an intestinal anastomosis. Nonetheless, a 0° laparoscope is sufficient for most applications in laparoscopic colorectal surgery.

A 10-mm, 0° rigid laparoscope is available that allows tangential irrigation of the scope lens intracorporeally and irrigation of tissue through a separate irrigation channel (Video Hydro-Scope, Circon ACMI, Stamford, Conn.). The lap-

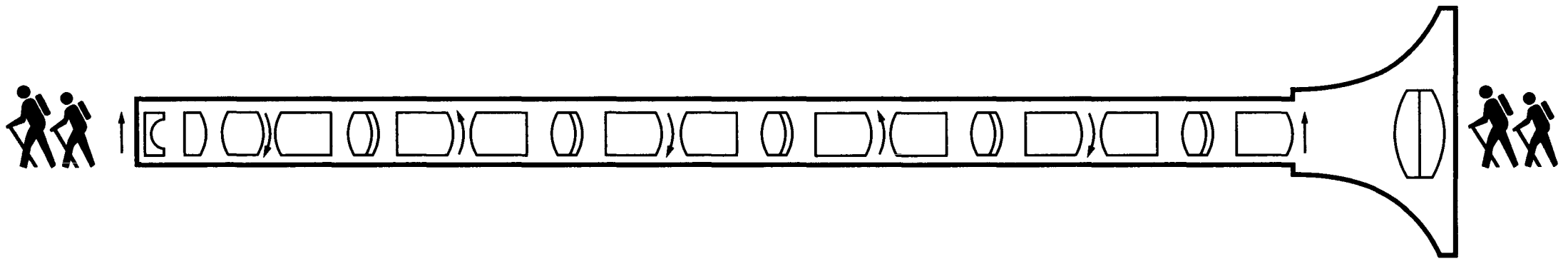

FIGURE 2.6. Longitudinal cut-away view of a rigid laparoscope with a rod-lens system. (Courtesy of Olympus, Lake Success, N.Y.)

aroscope is attached to a regular irrigation unit that supplies it with warm cleaning and irrigation fluid. The disadvantage of a laparoscope with additional working channels is that less light is transmitted to the camera and the extra channels make cleaning and sterilizing more difficult. Our experience with the Video HydroScope has been favorable because we have found that the ability to clean the lens intracorporeally during surgery is a major advantage because the laparoscope does not have to be withdrawn frequently to manually clean the tip.

The view through the laparoscope may not only be impaired by blood or smoke on the lens, but may also be impaired by fog. To prevent fogging after intraperitoneal insertion, the laparoscope should be warmed before intraperitoneal insertion so it will be at body temperature when needed. Although specially designed warmers for laparoscopes are available, we simply heat a hollow rubber dilator in the autoclave and place the laparoscope in it. This procedure will keep the laparoscope warm for 20 to 30 minutes. Also useful is a warm water bath (37°C to 40°C) into which several scopes of different sizes may be kept warm until needed.

When maintaining pneumoperitoneum, CO_2 should be insufflated into the abdominal cavity through a cannula other than the one in which the laparoscope is placed. The CO_2 gas rushing past the laparoscope is colder than room temperature and (unless a special insufflator with a gas warmer is used) will cool the scope, thus promoting fog formation on the lens.

Flexible laparoscopes combine the advantages of forward- and oblique-angled instruments (Figure 2.7). In some of them, a CCD is

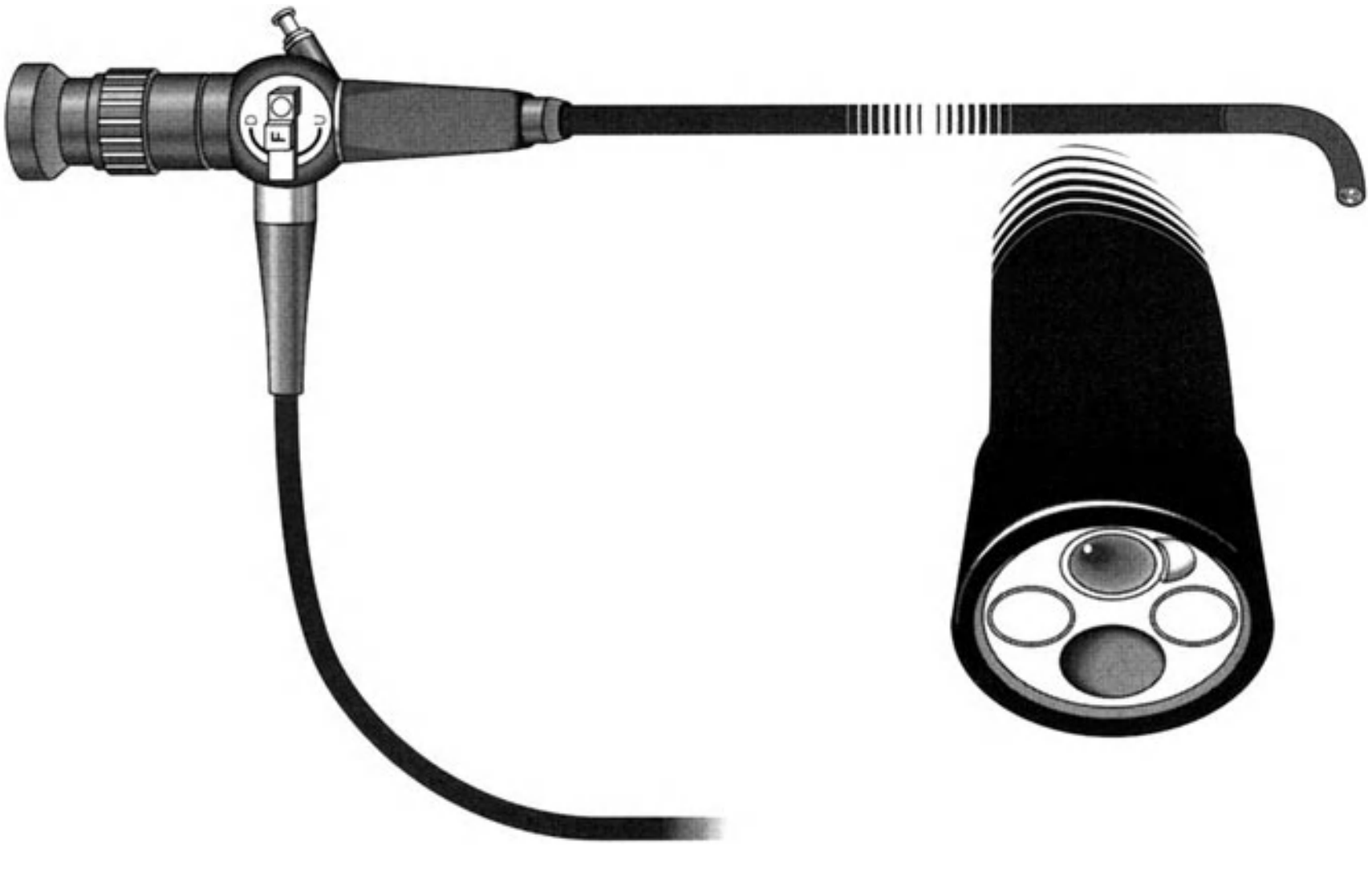

FIGURE 2.7. Flexible laparoscope with optical fibers including an irrigation channel. Inset, Close-up of the tip of the flexible laparoscope. (Courtesy of Olympus, Lake Success, N.Y.)

placed at the laparoscope tip so that a conventional rod-lens system is unnecessary. This chip gives a resolution of about 400 horizontal lines and decreases the risk of damage to the laparoscope's optical system.

An optical system is also commercially available that is 1.2 mm in diameter with a length of 30 cm (Miniskop, Storz, Tuttlingen, Germany). An operating cannula (3.7 mm in diameter) is initially inserted, through which the laparoscope and two semirigid instruments can be passed to perform limited surgical procedures. Scissors, graspers, and coagulation electrodes with outer diameters of approximately 1 mm are available with this system. The light source is powerful enough to sufficiently illuminate a small area for diagnostic and therapeutic laparoscopy. Dorsey and Tabb have reported good results with a thin optical catheter in diagnostic gynecologic laparoscopy and in laser surgery for endometriosis and adhesions.[6] Because the light transmitted through these catheters is limited, they have not been used for laparoscopic colorectal surgery.

Laparoscopic Surgery Light Sources

Illumination is provided by cold light (the light source is remote from the optical system) generated from bulbs containing halogen or xenon gas with an output of 70 to 400 W.

Although halogen bulbs (250 W) with a color temperature of about 3,400 K or halide bulbs (250 W) with a color temperature of about 5,000 K are used in most endoscopic light sources, a 300-W xenon lamp is currently the standard light source for most laparoscopic procedures because its intense light, with a color temperature of 5,600 to 6,000 K, is similar to sunlight and has an excellent transmission spectrum from ultraviolet to infrared light. The light source has an internal reflector that maximizes output by collecting light from a large angle around the arc created by the xenon lamp (Figure 2.8). An automatic light control is part of the video system, which can function as a flash generator for photography.

Light is transmitted from the light source to the laparoscope by a glass or a fluid cable. The

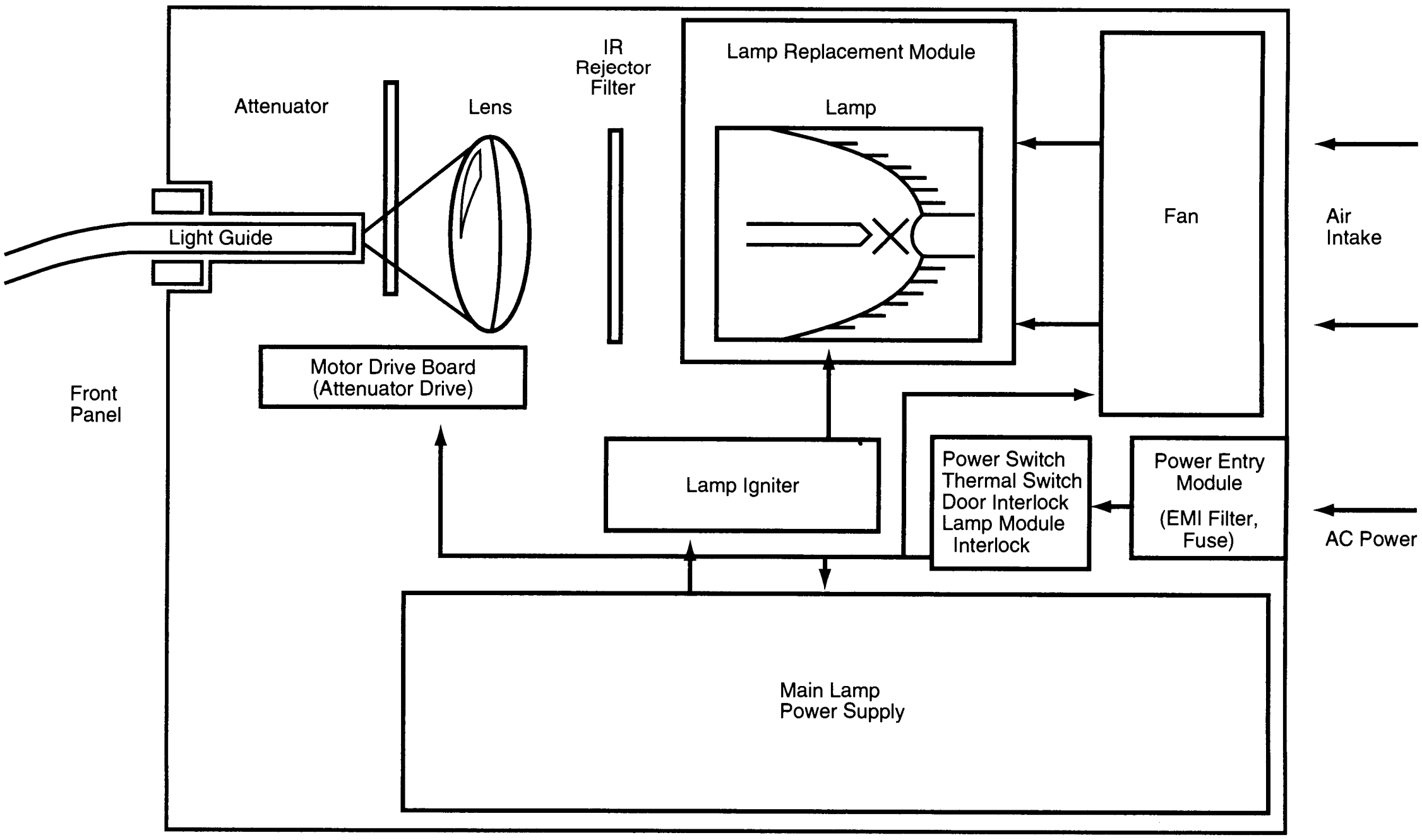

FIGURE 2.8. Simplified sketch of a xenon light source. (Courtesy of Olympus, Lake Success, N.Y.)

fluid cable has the advantage of transmitting more light than a glass cable through the same diameter, but it is heavier and more rigid than glass and cannot be gas sterilized or autoclaved. Another disadvantage of fluid cables is that if they are slightly damaged, fluid will be lost and the cable cannot be used. In comparison, if some fibers are broken in a fiberglass cable, it will not transmit as much light as before but it can still be used.

Monitors and Recording Devices

Because the video image replaces the surgeon's direct visual perception, the highest quality video system should be used. The monitors, which are the final component of the imaging chain, should be equal in quality to the camera system. A high-resolution camera must be coupled with a high-resolution monitor or the benefit of the high-resolution camera will be lost. In addition, monitors must deliver a flicker-free, high-resolution picture with good contrast and color.

Some light source units have automatic flash capacity, allowing photo documentation with good resolution. Color video printers are available with a resolution of 500 lines with continuous tone and 256 gradations of color with over 16 million potential colors per dot. Copies can also be stored on computer hard drives, tapes, or CD-ROMs in standard graphic formats, thus allowing computerized modification to create photographs or slides.

Dynamic documentation is usually performed with standard video recorders because they are universally available, and video tapes are relatively inexpensive. For educational purposes, any one of the three formats (S-VHS, ED-Beta, or Hiband) is adequate for recording because they all have a high horizontal resolution of 400 lines. The only disadvantage of these tapes is that they are more expensive than the common VHS tapes. In the future, more digital technology will be implemented in video systems, which will prevent tape damage and loss of signal quality when recordings are copied. Currently, digital systems are too expensive to be used as standard equipment.

Ideal Laparoscopic Video Equipment

Currently available video equipment for laparoscopic colorectal surgery is deficient in many ways. In our opinion, the ideal laparoscopic video equipment would:

- provide a 3-D view with high-resolution
- allow magnification and movement closer to or further from an object without moving the laparoscope by using a zoom objective
- provide the ability to clean the laparoscopic lens inside the abdominal cavity and to irrigate the object of interest through an irrigation channel
- be compact with ergonomic use of all functions and have only one cable for controlling all functions
- allow straight-on and angled viewing, as needed by the surgeon
- allow some limited instrumentation uses (biopsy, grasping, and injecting) such as current endoscopes do

The last four criteria may be realized shortly because some endoscopes already incorporate these features to a certain degree. The first two criteria require the development of better stereoscopic systems and a zoom objective.

Insufflators

To improve visualization of the viscera and instrument manipulation by lifting the anterior abdominal wall away from the viscera during surgery, the peritoneal cavity is distended with an insufflating gas. Ideally, the gas is nontoxic, physiologically inert, highly soluble in blood, colorless, and incombustible. Room air, N_2O, He, Ar, and CO_2 have been described for establishing pneumoperitoneum in laparoscopic surgery (see Table 2.1); currently, CO_2 is preferred.

Room air has a low solubility in blood, thus increasing the risk of gas embolism; furthermore, it is inflammable and supports combustion. Given these characteristics, it should not be used as an insufflating gas. Nitrous oxide also supports combustion and therefore should not be used during laser surgery or electrosurgery. Although N_2O is advantageous in that it forms no acid when mixed with water and is

TABLE 2.1. Advantages and disadvantages of five gases that have been used to establish pneumoperitoneum.

Gas	Advantages	Disadvantages
Room air	Readily available	Low solubility, high risk of gas embolism, supports combustion
N_2O	No interaction with water	Supports combustion
CO_2	Highly soluble	Absorbed by peritoneal surface causing acidosis, vasodilation, erythema of tissues
He	Moderately soluble, inert	Unknown, minimal clinical experience
Ar	Moderately soluble, inert	Negative hemodynamic effect

not associated with clinically significant peritoneal irritation, it is less soluble in blood than other gases, such as CO_2, and thus presents a greater risk of gas embolism.

Helium, an inert gas with a low solubility coefficient in blood of about 0.01 mL gas/mL blood at 37°C, may be an alternative to CO_2 in the future because systemic CO_2 absorption (which can lead to systemic acidosis) does not occur with He. Although the negative hemodynamic effects of pneumoperitoneum are the same for He or CO_2,[7,8] He may be beneficial in patients with concurrent pulmonary disease in whom it is difficult to maintain normal CO_2 blood levels using hyperventilation. Further studies are needed to evaluate the role of He in laparoscopic surgery. Eisenhauer et al.[9] evaluated Ar, another inert gas, in a porcine model and found no negative effects on respiratory function and no respiratory acidosis. However, because they found that systemic vascular resistance increased significantly [from 0.57 ± 0.05 (mm Hg • min • kg) • L^{-1} to 0.86 ± 0.29 (mm Hg • min • kg) • L^{-1}, $P < .05$] and that the cardiac stroke volume and cardiac index significantly decreased, Ar cannot be recommended as an alternative to CO_2 for pneumoperitoneum.

Carbon dioxide is currently the gas of choice to establish and maintain pneumoperitoneum. It is highly soluble in blood with a solubility coefficient of about 0.5 mL gas/mL blood at 37°C. Thus, if a small amount of gas is introduced accidentally into the circulating system, it is unlikely to produce a life-threatening gas embolism because CO_2 is rapidly absorbed and eliminated. The main disadvantage of CO_2 is that the peritoneum readily absorbs it. Most absorbed CO_2 diffuses into the erythrocytes and is hydrated by the enzyme carbonic anhydrase to form carbonic acid. Some CO_2 is also directly dissolved into local tissues and the serum—the amount depends on the CO_2 partial pressure. Such direct absorption may significantly increase the CO_2 concentration in the blood, which theoretically could cause cardiac arrhythmias and bronchoconstriction. Direct absorption also causes a peritoneal reaction that may lead to pain and vasodilation so that peritoneal tissue may appear inflamed.

To establish pneumoperitoneum, an insufflation needle or cannula is connected to the insufflator via a silicone or polyvinyl chloride hose. Initially, insufflating 3 to 4 L of gas into the peritoneal cavity usually produces an adequate space for visualization.

There are two types of insufflators: pneumatic and electronic. The older pneumatic models deliver gas with a continuous flow that stops when the abdominal pressure reaches a preset pressure limit. Pneumatic insufflators usually deliver up to 4 L/min and have two pressure selectors: maintenance pressure or high pressure. Analog controls are used for abdominal pressure and for external cylinder pressure.

Electronically controlled insufflators provide higher flows (up to 30 L/min) than pneumatic insufflators. The pressure selector is continuously adjustable and has a digital abdominal pressure display and digital delivered-flow and volume-of-gas-consumed displays. Most electronic insufflators operate in two phases: insufflation and measurement. During insufflation, gas is delivered through a connector to the patient; during measurement, which immediately follows so that flow is negligible, pressure is measured. Several insufflator models use a second hose connected to a cannula to measure intraperitoneal pressure continuously while delivering gas through a separate hose. Actual flow depends on pressure settings, backflow pressure, and the in-line resistance of the insufflation hose and needle. Some insufflators allow the insufflated gas to be circulated back to the insufflator through a second hose by using an additional pump that suctions the gas back through a filter (Figure 2.9). Thus, the flow of recirculated gas is constant, which permits smoke removal during electrosurgery. Such removal may be especially valuable in laparoscopic colorectal surgery when the mesentery or omentum is being divided. If an insufflator with a recirculation pump is used, sensors continuously monitor the return gas pressure as well as the insufflation pressure.

To effectively perform laparoscopic colorectal surgery, a high-flow insufflator, capable of delivering more than 6 L/min, is mandatory. Thus, pneumatic insufflators are inadequate in that they are only capable of delivering up to 4 L/min. Operative laparoscopy requires multiple trocar punctures, which can lead to gas loss through and around the cannulas. The smoke produced by electrosurgical instruments or lasers in the abdominal cavity must be suctioned and disposed of or suctioned, filtered, and recirculated (Figure 2.9). If blood or fluid must be suctioned, an insufflator with a flow rate of more than 10 L/min is necessary to maintain intraperitoneal pressure. Even flow rates of 6 to 10 L/min sometimes do not sufficiently maintain an adequate pneumoperitoneum during laparoscopy while using suction or flushing the peritoneal cavity to evacuate smoke. In such cases, an insufflator with a gas delivery of up to 30 L/min is invaluable. If gas flow is this high, the gas should be warmed; moistened; and optimally, recirculated. These procedures will prevent additional cooling of the peritoneum, which could result in significant hypothermia.

The insufflation hose is usually connected to a cannula via a Luer lock system. Because the Luer lock system is relatively small in diameter, maximum flow through this small hole is about 8 L/min. If a higher flow is needed, either the pressure to insufflate the gas must be increased, which decreases the temperature of the insufflated gas, or the diameter of the connecting part at the cannula must be increased.

Koninckx and Vandermeersch[10] designed a persufflator (a rapid-flow insufflator) with a 60 L/min insufflation capacity that allows pneumoperitoneum to be maintained simultaneously with an open vagina or an open wound. Although with this persufflator pneumoperitoneum is readily maintained during suction of fluid or smoke, such high insufflation is not necessary for usual laparoscopic colorectal surgery.

For any type of laparoscopic surgery, the insufflator must function correctly and continuously. Although most insufflators automatically control the intra-abdominal pressure, the insufflator display should be periodically checked to verify the actual intra-abdominal pressure. Whether the insufflator is functioning correctly must be determined before surgery and any calibration must also be done before surgery. Because the insufflator is a closed system, it should be tested for leaks as the manufacturer describes before it is connected to the patient. A biomedical engineer must also regularly inspect the insufflator to ensure continuous and proper function. Additionally, protection against overinflation of the abdomen is essential. A pressure release mechanism or at least an overinflation alarm is mandatory, especially when using laser equipment that is cooled by gas flow to the laser fiber tip. Such cooling will pump additional CO_2 into the peritoneal cavity. Although abdominal fluid or gas flow from the patient into the insufflator is unlikely, it cannot be ruled out absolutely. Therefore, we recommend placing a disposable bacterial hydrophobic filter with a membrane that retains particles 0.3 μm or smaller in the insufflation line at the gas outlet.

In summary, we believe that an insufflator used in laparoscopic colorectal surgery must, at a minimum, meet the following requirements:

- The unit should be electronically controlled.
- The unit should deliver at least 6 L/min at a safe maintenance pressure of no more than 12 mm Hg.
- The unit should maintain an intra-abdominal pressure of at least 8 mm Hg at a leakage rate of approximately 1 L/min.

Optimally, an electronically controlled insufflator with a maximum delivery of 30 L/min should

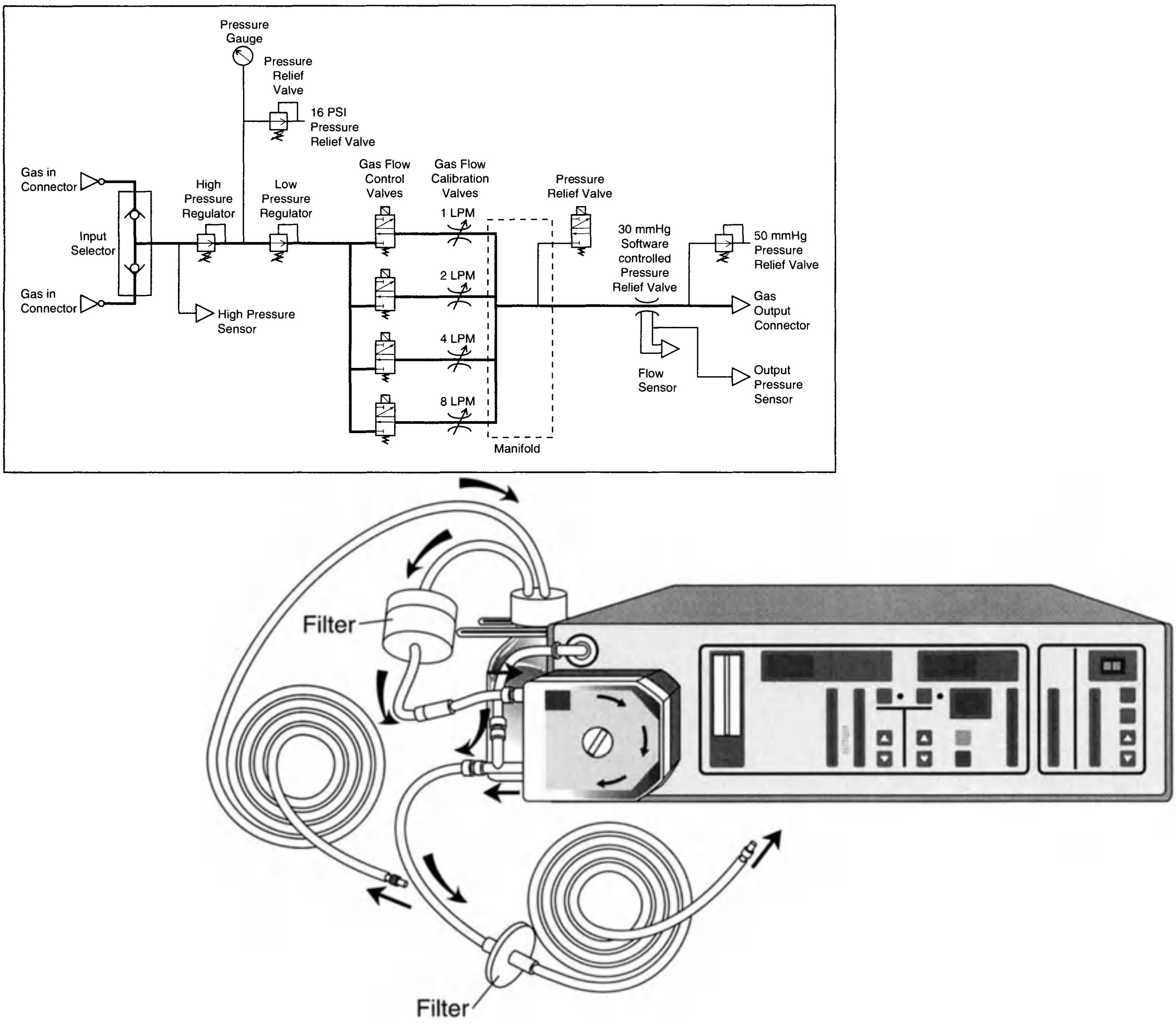

FIGURE 2.9. Electronically controlled insufflator with recirculation and filter for smoke evacuation. Inset, Schematic diagram of how insufflation is controlled. (Courtesy of Northgate Technologies, Inc., Arlington Heights, Ill.)

be used so that pneumoperitoneum is not lost during suction. Filtering and recirculating insufflated gas not only minimizes the potential for hypothermia, but it also lessens possible operating room hazards from electrosurgery and the laser vapor released during surgery.[11-14]

Irrigation and Suction Devices

An excellent combination irrigation–suction system is necessary for any laparoscopic procedure. In cases of bleeding or spilled intestinal contents, irrigation systems with a minimal flow rate of 1 L/min are essential. Adjustable suction with interchangeable 5- and 10-mm metallic suction tubes should be available to remove smoke, laser plume, fluid, clots, or other debris. Using suction tips with multiple side holes is important when irrigating and evacuating fluid or clots rapidly or in large volumes. The irrigation–suction instrument can also be insulated along its shaft and equipped with electrosurgical capabilities that allow for tissue dissection, irrigation, and suction using the same tool. Changing instruments is thus unnecessary, and a bleeding vessel may be coagulated more easily and precisely.

Intraoperative irrigation should be performed with a warmed (37ºC) isotonic solution; normal saline or lactated Ringer's solution is suitable. The addition of 3,000 U heparin per 1,000 mL irrigation solution helps to prevent and break up clots that form in the pooled irrigant and presents no systemic risks to the patient.

As Marshburn and Hulka[15] describe, although assembling an irrigation–suction system from common operating room supplies is possible, we do not believe such a system can be usefully employed under certain difficult situations seen in advanced laparoscopic surgery. In cases of unforeseen bleeding or spillage of intestinal contents, an instrument must be available that works reliably and satisfactorily, both to irrigate rapidly and to effectively evacuate fluid or other material.

Sterilization and Disinfection Equipment

Sterilization is defined as the use of a physical or a chemical procedure to destroy or eliminate all forms of microbial life, including highly resistant bacterial endospores.[16] For the operating room environment, sterilization is achieved primarily with moist heat or ethylene oxide gas. It can also be accomplished with liquid chemicals, such as peracetic acid (in less than 30 minutes) or with glutaraldehyde if used appropriately for an extended contact time (6 to 10 hours).

Disinfection, however, is defined as the elimination of many or all pathogenic organisms except bacterial endospores.[16] Thus, disinfection is somewhat less lethal than sterilization, and it may lack the margin of safety that sterilization achieves. Disinfection is usually accomplished with liquid chemicals and can be done on three levels: high, intermediate, and low. High-level disinfection eliminates all organisms except for a variety of bacterial endospores. An intermediate level of disinfection eliminates all organisms except endospores, some viruses, and some fungi. Low-level disinfection can destroy most bacteria and some fungi and viruses but not endospores or tubercle bacilli.[16] The level of disinfection achieved with germicides depends on the nature and number of microorganisms, the germicide concentration, length of exposure to the germicide, the temperature, the amount and type of organic material (soil, feces, and blood), and the type and complexity of the instruments being processed. A smooth surface and suitable configuration during disinfection is mandatory to disinfect instruments efficiently and thoroughly.

Spaulding[17] divides medical devices into three groups: critical, semicritical, and noncritical. *Critical* items are defined as those entering sterile tissue or the vascular space; these items include laparoscopic instruments. *Semicritical* items are those that contact injured skin or mucous membranes and include endoscopic instruments. *Noncritical* devices are those that do not contact sterile tissue, mucous membranes, or enter the vascular spaces, for example, stethoscopes and tongue depressors.

Because laparoscopic instruments are critical instruments, they should be sterilized or at least should undergo high-level disinfection. Most reusable laparoscopic instruments can be steam autoclaved so that sterilization of these instruments presents no problem. In contrast, laparoscopic cameras are damaged by heat as well as by repeated exposure to germicides. Although gas sterilization with ethylene oxide is less harmful to the camera optics, the sterilization time required (12 to 24 hours) is long and sometimes impractical. Therefore, critical instruments such as laparoscopic cameras will usually undergo high-level disinfection or coverage with a sterilized plastic sheath.

The literature contains no definitive data indicating that high-level disinfection of laparoscopic instruments presents any infectious risk to patients. Loffer[18] recorded only three minor wound infections after 10,302 laparoscopic procedures in which laparoscopes were used that had been disinfected with 2% glutaraldehyde. The American Association of Gynecologic Laparoscopists reported on 175,705 patients and found infectious complications in only 0.3% (n = 527) after surgery with laparoscopes disinfected with 2% glutaraldehyde. They concluded that high-level disinfection with 2% glutaraldehyde is safe and appropriate.[19]

The only liquid chemical disinfectants registered with the Food and Drug Administration (FDA) for use on reusable medical instruments are 2% glutaraldehyde, 6% stabilized hydrogen peroxide, and 0.2% peracetic acid. Only these agents currently meet the FDA definition of a *high-level disinfectant,* that is, one in which some bacterial endospores will be killed in a given period of time. This definition is confusing when discussed in reference to glutaraldehyde solutions because these solutions are commonly used to disinfect in approximately 20 minutes but require up to 10 hours to sterilize, that is, kill all bacterial endospores. In contrast, 6% hydrogen peroxide and 0.2% peracetic acid can sterilize in 20 minutes or less depending on the use temperature. Glutaraldehyde formulations are popular because of their excellent biocidal activity in the presence of organic contamination and their noncorrosive action on endoscopes and optical equipment.

However, glutaraldehyde solutions have been recently criticized, and some have been withdrawn from the market because they have failed to meet label claims for efficacy against *Mycobacterium tuberculosis,* which can require exposure for as long as 90 minutes at 20°C to be inactivated.[20,21] Also, frequent use of glutaraldehyde solutions expose the user to airborne concentrations that exceed Occupational Safety and Health Administration (OSHA) standards,[22] and reports of toxic exposure and effects are numerous.

Because glutaraldehyde is used primarily in simple immersion systems in which its concentration cannot be ensured, it is important to follow the instructions regarding the concentration and the exposure time. The concentration of a glutaraldehyde solution should be at least 1%, and the minimum recommended exposure time is 10 to 20 minutes for disinfection.[23] Several chemical indicators are available to determine the concentration. The life of the solution is generally accepted as 14 to 28 days and decreases with heavy use, contamination, or inadvertent dilution. In general, the potency and use life of a chemical germicide/disinfectant are determined by use pattern, not time. Therefore, any sterilants that are reused should be tested regularly to determine whether they are sufficiently potent for high-level disinfection.

Although peracetic acid is a potent liquid germicide, its use for disinfection and sterilization has been limited because it is corrosive. However, an automatic sterilization process is now available that uses peracetic acid in a closed system and has a cycle time of 30 minutes or less under optimal conditions (STERIS, Steris Corporation, Mentor, Ohio). Peracetic acid is registered with the Environmental Protection Agency (EPA) as a chemical sterilant and is FDA-approved for general-purpose sterilization of reusable medical instruments. The STERIS system uses a sterilant (STERIS 20) that consists of concentrated liquid peracetic acid (35% wt/wt), buffer, and anticorrosive powder that when automatically mixed and diluted to its use concentration in the system, consists of 0.2% wt/vol peracetic acid at approximately neutral pH. The anticorrosive powder is dissolved and mixed with the buffer immediately before the concentrated peracetic acid is introduced and diluted. Therefore, the corrosive peracetic acid is never directly exposed to the devices being sterilized, and the system does not corrode even sensitive brass and carbon steel surfaces.[24] The instruments are exposed to the sterilant for at least 12 minutes at 50°C, which is sufficient time to kill all bacterial endospores and to meet EPA and FDA criteria for sterilization.

The completely enclosed and automated system also minimizes user exposure to the sterilant, and the single-use sterilant ensures that fresh sterilant is always used. Chemical and biologic indicators are available to monitor performance of the system independently from the automatic monitoring that the system provides. As a result, sterility assurance levels can be obtained that are comparable to and even exceed those obtained by steam or ethylene oxide sterilizers.[25]

Reusable instruments should be cleaned thoroughly before sterilization to reduce organic overload and facilitate sterilization. Marshburn et al. have shown that disassembling instruments before sterilization using steam is unnecessary.[26] If instruments are disassembled, thoroughly cleaned, assembled, and steam sterilized, there is no increased risk of contamination compared with disassembled steam-sterilized instruments. The advantage of sterilizing assembled instruments is that the instruments can be checked for correct assembly before the next use.

In summary, the majority of laparoscopic instruments can be easily, safely, and rapidly sterilized. Also, high-level disinfection using currently available sterilants appears to be appropriate and acceptable for delicate laparoscopic instruments,[18,23] but is a less assured process than sterilization and may expose the user to toxic chemicals.[27]

References

1. Wickens CD. Three-dimensional stereoscopic display implementation: guidelines derived from human visual capabilities. *SPIE.* 1990;1256:2–11.
2. Reinhart WF, Beaton RJ, Snyder HL. Comparison of depth cues for relative depth judgements. *SPIE.* 1990;1256:12–21.
3. Wichansky AM. User benefits of visualization with 3D stereoscopic displays. *SPIE.* 1991;1457:267–271.
4. McLaurin PA, Jones ER, Mason LJ Jr. Three-dimensional endoscopy through alternating-frame technology. *SPIE.* 1990;1256:307–311.
5. Gow JG, Hopkins HH, Wallace DM, England AG. The modern urological endoscope. In: Hopkins HH, ed. *Handbook of urological endoscopy.* Edinburgh: Churchill Livingstone; 1978:21–33.
6. Dorsey JH, Tabb CR. Mini-laparoscopy and fiber-optic lasers. *Obstet Gynecol Clin North Am.* 1991;18:613–617.
7. Bongard F, Pianim NA, Leighton T, et al. Helium insufflation for laparoscopic operation. *Surg Gynecol Obstet.* 1993;177:140–146.
8. Leighton TA, Liu SS, Bongard FS. Comparative cardiopulmonary effects of carbon dioxide versus helium pneumoperitoneum. *Surgery.* 1993;116:527–531.
9. Eisenhauer DM, Saunders CJ, Ho HS, Wolfe BM. Hemodynamic effects of argon pneumoperitoneum. *Surg Endosc.* 1994;8:315–321.
10. Koninckx PR, Vandermeersch E. The persufflator: an insufflation device for laparoscopy and especially for CO_2-laser-endoscopic surgery. *Hum Reprod.* 1991;6:1288–1290.
11. Wenig BL, Stenson KM, Wenig BM, Tracey D. Effects of plume produced by the Nd:YAG laser and electrocautery on the respiratory system. *Lasers Surg Med.* 1993;13:242–245.
12. Baggish MS, Poiesz BJ, Joret D, Williamson P, Refai A. Presence of human immunodeficiency virus DNA in laser smoke. *Lasers Surg Med.* 1991;11:197–203.
13. Baggish MS, Baltoyannis P, Sze E. Protection of the rat lung from the harmful effects of laser smoke. *Lasers Surg Med.* 1988;8:248–253.
14. Gatti JE, Bryant CJ, Noone RB, Murphy JB. The mutagenicity of electrocautery smoke. *Plast Reconstr Surg.* 1992;89:781–784.
15. Marshburn PB, Hulka JF. A simple irrigator-aspirator cannula for laparoscopy: the Stewart system. *Obstet Gynecol.* 1990;75:458–460.
16. Rutala WA. APIC guideline for selection and use of disinfectants. *Am J Infect Control.* 1990;18:88–117.
17. Spaulding EH. Chemical disinfection and antisepsis in the hospital. *J Hosp Res.* 1972;9:5–31.
18. Loffer FD. Disinfection vs. sterilization of gynecologic laparoscopy equipment. *J Reprod Med.* 1980;25:263–266.
19. Phillips J, Hulka B, Hulka J, Keith D, Keith L. Laparoscopic procedures: The American Association of Gynecologic Laparoscopists' Membership Survey for 1975. *J Reprod Med.* 1977;18:227–232.
20. Peach JD. EPA lacks assurance disinfectants work. *US General Accounting Office J.* 1990;GAO/RCED-90-139:1–5.
21. Nadel MV. FDA regulation of hospital sterilants. *US General Accounting Office J.* 1993;GAO/HRD-93-79:1–7.
22. Notarianni GL. Glutaraldehyde overexposure: myth or reality? One hospital-wide study. *J Healthcare Material Management.* 1992;10:20–34.
23. Corson SL, Block S, Mintz C, Dole M, Wainwright A. Sterilization of laparoscopes. Is soaking sufficient? *J Reprod Med.* 1979;23:49–56.
24. Crow S. Peracetic acid sterilization: a timely development for a busy healthcare industry. *Infect Control Hosp Epidemiol.* 1992;13:111–113.
25. Kralovic RC. Use of biological indicators designed for steam or ethylene oxide to monitor a liquid chemical sterilization process. *Infect Control Hosp Epidemiol.* 1993;14:313–319.
26. Marshburn PB, Rutala WA, Wannamaker NS, Hulka JF. Gas and steam sterilization of assembled versus disassembled laparoscopic equipment: microbiologic studies. *J Reprod Med.* 1991;36:483–487.
27. Wiggins P, McCurdy SA, Zeidenberg W. Epistaxis due to glutaraldehyde exposure. *J Occup Med.* 1989;31:854–856.

3
Basic Laparoscopic Instruments

Because laparoscopic surgery permits only limited access to the surgical site, instruments designed for laparoscopy must fulfill several ergonomic conditions. Each instrument should be designed so the surgeon can easily operate all its functions with one hand, and it must be light and comfortable enough for repetitive handling during lengthy, delicate, and tedious use, for example, for extensive dissection. The instrument should be operable in all directions of free movement. In addition, the instruments should have rounded edges, and a darkened or dull surface to reduce light reflection that may darken the laparoscopic image due to the automatic light sensing of laparoscopic cameras. The surgical instrumentation needs of laparoscopic colorectal surgery are broadly outlined in Table 3.1.

The instruments we discuss in this chapter are those we prefer to use for advanced laparoscopic colorectal procedures. Many similar instruments are available from a variety of instrument manufacturers that fulfill the purposes of laparoscopic colorectal surgery.

Insufflation Needles

Currently, a Veress needle, modified little since its invention in 1938, is the most popular and is the safest instrument for insufflating the abdomen and establishing pneumoperitoneum when using a closed, or percutaneous, puncture technique. Needles are commercially available in lengths of 10, 12, and 15 cm, all with an outside diameter of 1.8 mm. The Veress needle consists of a blunt-tipped, spring-loaded inner stylet and a sharply tailored outer needle (Figure 3.1). While the outer needle passes through the abdominal wall, the blunt-tipped stylet retracts, allowing the needle to penetrate the tissue. Once the needle enters the peritoneal cavity, tissue resistance is absent, thus allowing the blunt stylet to protrude beyond the sharp needle tip. In most Veress needle styles, an indicator, such as a colored safety band, slides proximally toward the stopcock during insertion of the needle, indicating that the blunt stylet is retracted and the sharp needle can therefore penetrate tissue. The indicator disappears as soon as the needle tip enters a cavity because the blunt stylet slides forward again. Introduced by Janos Veress in 1938 to create a pneumothorax,[1] this needle theoretically prevents penetration of visceral structures. A lateral hole on the blunt stylet permits insufflation of gas to create the pneumoperitoneum.

Trocars and Cannulas

The terms *cannula* and *trocar* are often used synonymously. We use the term *trocar* only to refer to the sharp part of an instrument that is necessary to penetrate through the abdominal wall into the peritoneal cavity. The trocar is placed in a sleeve, which we refer to as the *cannula,* using the instrument to penetrate the abdominal wall. After penetration, the trocar is removed, and the cannula remains in place, providing access for laparoscopic instruments

Table 3.1. Surgical instrumentation needs for laparoscopic colorectal surgery.

Purpose	General instrument requirement
Establishing pneumoperitoneum	Insufflation needles, cannulas
Providing entry ports for instruments	Trocar/cannula assemblies
Manipulating tissue	
Grasp/hold	Grasping devices
Dissection	Scissors, fine dissectors
Cut/coagulate	Electrosurgery, laser, ultrasonic devices
Retraction	Retracting devices
Specimen isolation	Impermeable plastic membranes
Hemostasis	Clips, staples, coagulation devices, sutures
Tissue apposition	Stapling devices, sutures, clips

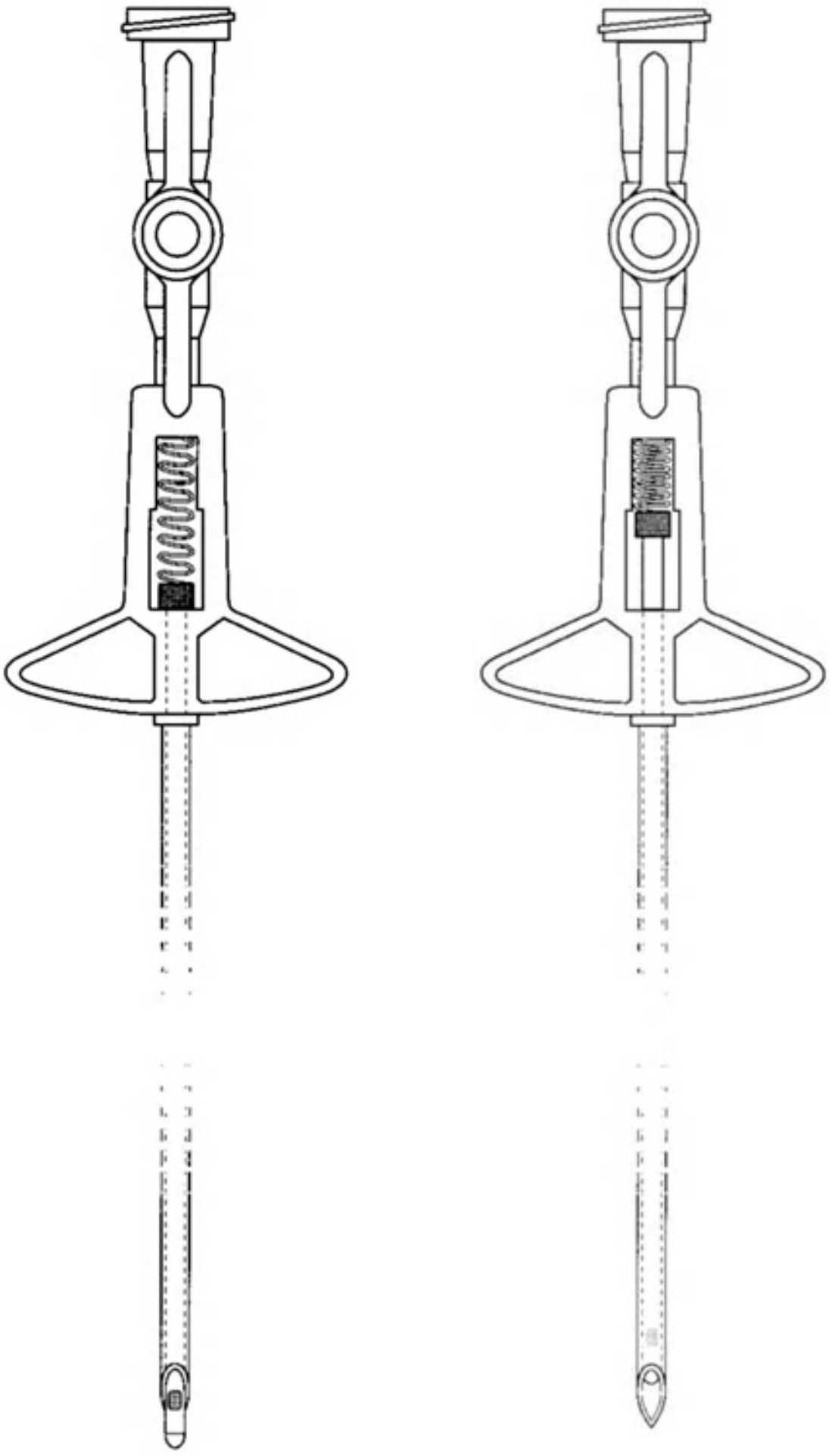

FIGURE 3.1. Veress needle (longitudinal cut-away view). (Courtesy of US Surgical Corporation, Norwalk, Conn.)

to the abdominal cavity. Thus, the trocar is used to penetrate the abdominal wall, and the cannula permits the surgeon to safely insert instruments into the abdominal cavity. Nearly all cannulas are equipped with a valve system to allow for gas insufflation and hermetic instrument passage.

Cannulas are available in a wide array of types and sizes, and in disposable and non-disposable varieties. Cannula diameters range from 3 to 35 mm, and cannulas are made of metal, fiberglass, or radiolucent plastic material. Although metal and fiberglass cannulas have the advantage of being durable, they can act as electrical capacitors and discharge current during electrosurgery. If the cannula is secured to the abdominal wall with an ancillary anchoring device, it is recommended that a metal cannula be secured with a conductive anchoring device. This combination will reduce the risk of capacitive coupling, which can lead to inadvertent visceral injuries (see chapter 4, Potential Injuries Related to Electrosurgery).

Most cannulas are built with either trumpet or flapper valves (Figure 3.2) to prevent gas leakage when instruments are passed through them. The trumpet valve must be opened and closed manually, whereas the flapper valve works automatically, using a self-occluding mechanism. Every cannula has a stopcock with a Luer lock mechanism to connect it to the gas insufflation hose, and most cannulas have a small hole in the cannula tip to prevent vacuum formation during trocar removal, which could pull viscera

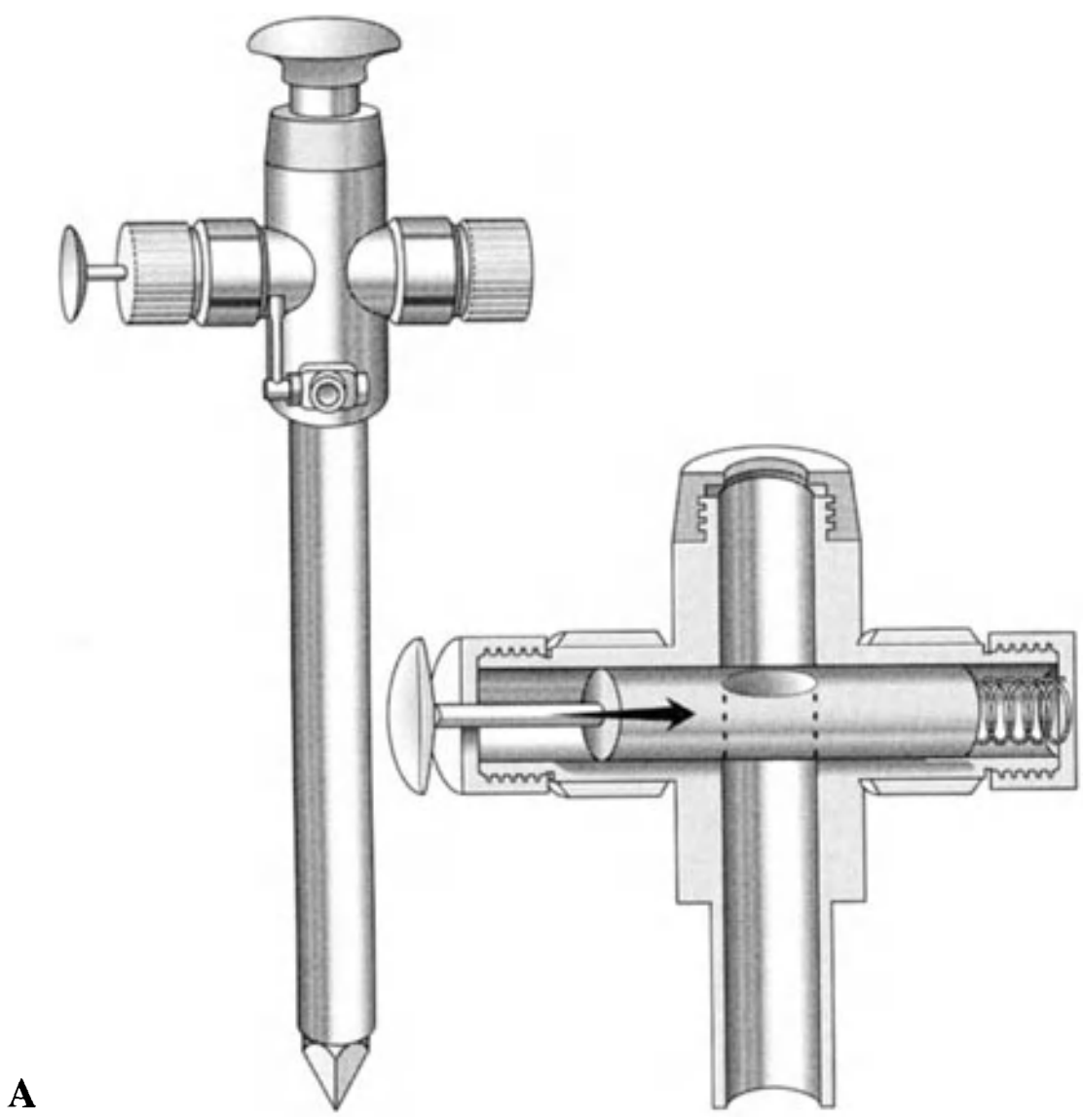

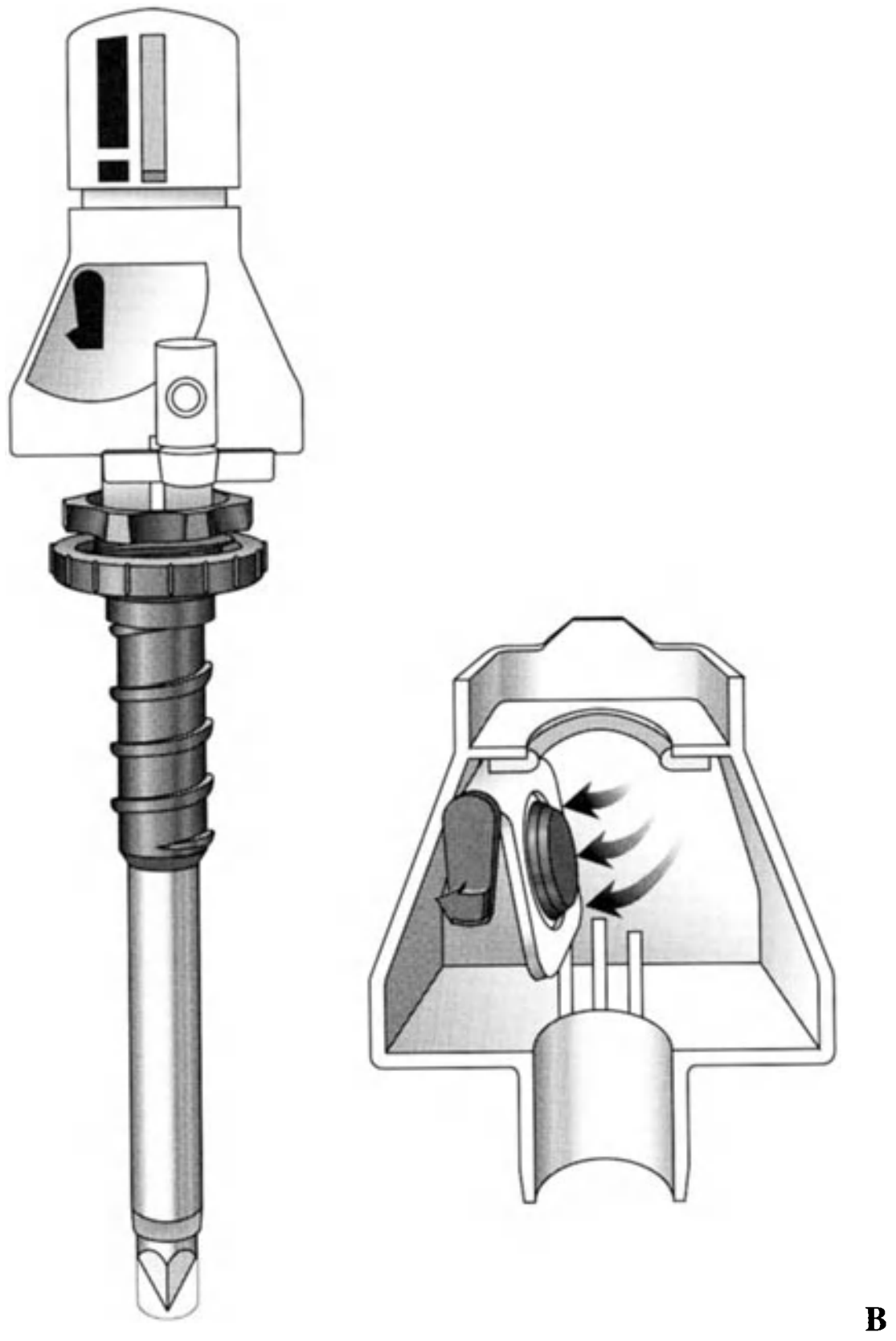

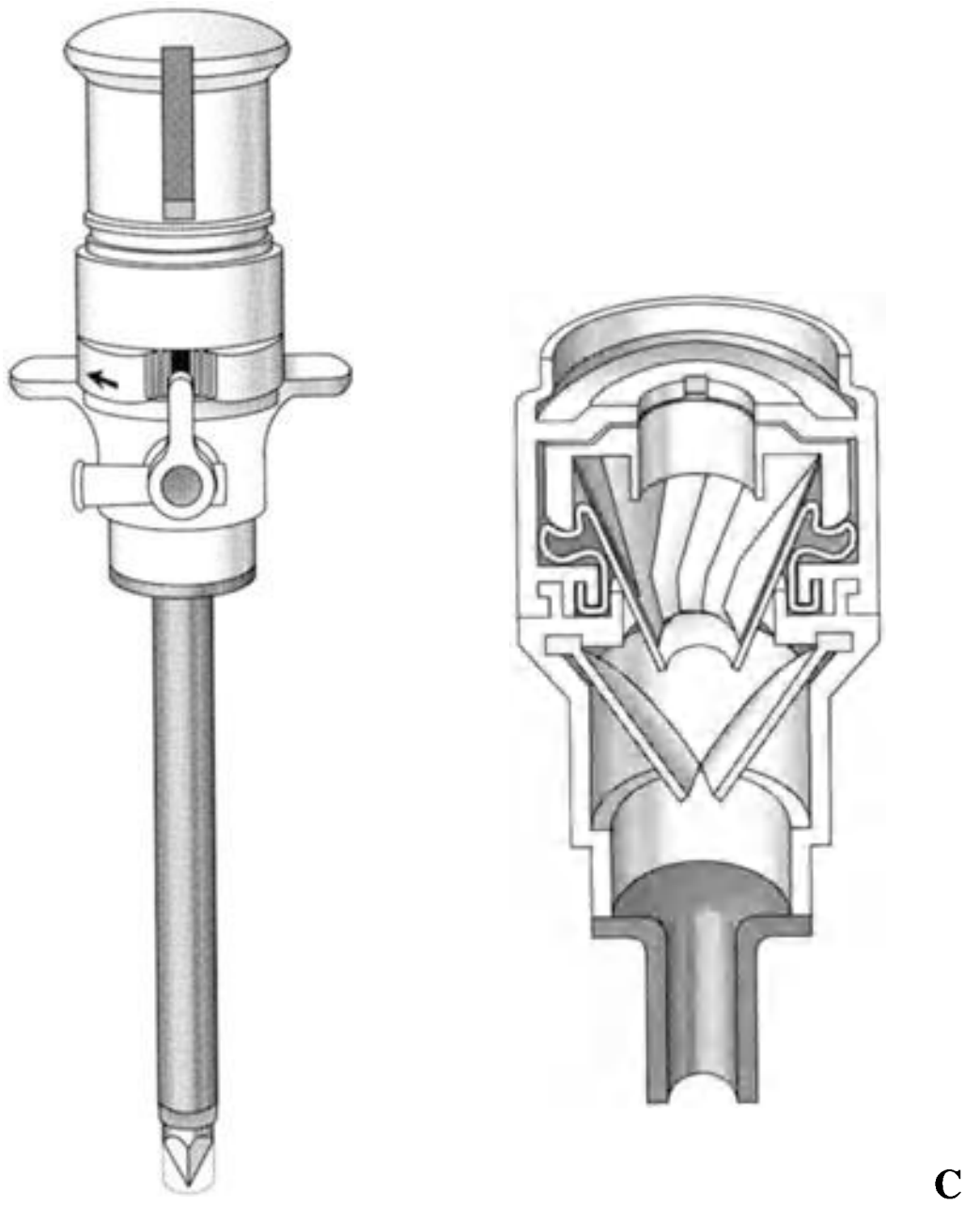

FIGURE 3.2. Three types of cannula and trocar systems used in laparoscopic surgery. A, Nondisposable cannula with a trumpet valve; B, disposable cannula with a flapper valve; and C, cannula with a universal adaptor valve for accommodating instruments sized 5 to 12 mm in diameter. (Courtesy of US Surgical Corporation, Norwalk, Conn.)

up into the cannula and possibly result in herniation or injury.

Many cannulas have a retention mechanism that anchors the cannulas to the abdominal wall to prevent inadvertent displacement during instrument withdrawal and manipulation (Figure 3.3). Some have self-retaining adjustable sleeves that are threaded into the fascia. Other cannulas have expandable arms or inflatable balloons that expand inside the peritoneal cavity and are used in combination with a locking screw at the skin. Some cannulas can be fixed on the abdominal wall using adhesive devices, which not only hold the cannula in place but may also seal minor leaks. In our opinion, the optimum cannula design stabilizes the cannula both inside and outside the abdominal wall, preventing any dislodgement. Good stabilization is especially important for advanced procedures in elderly or obese patients because the

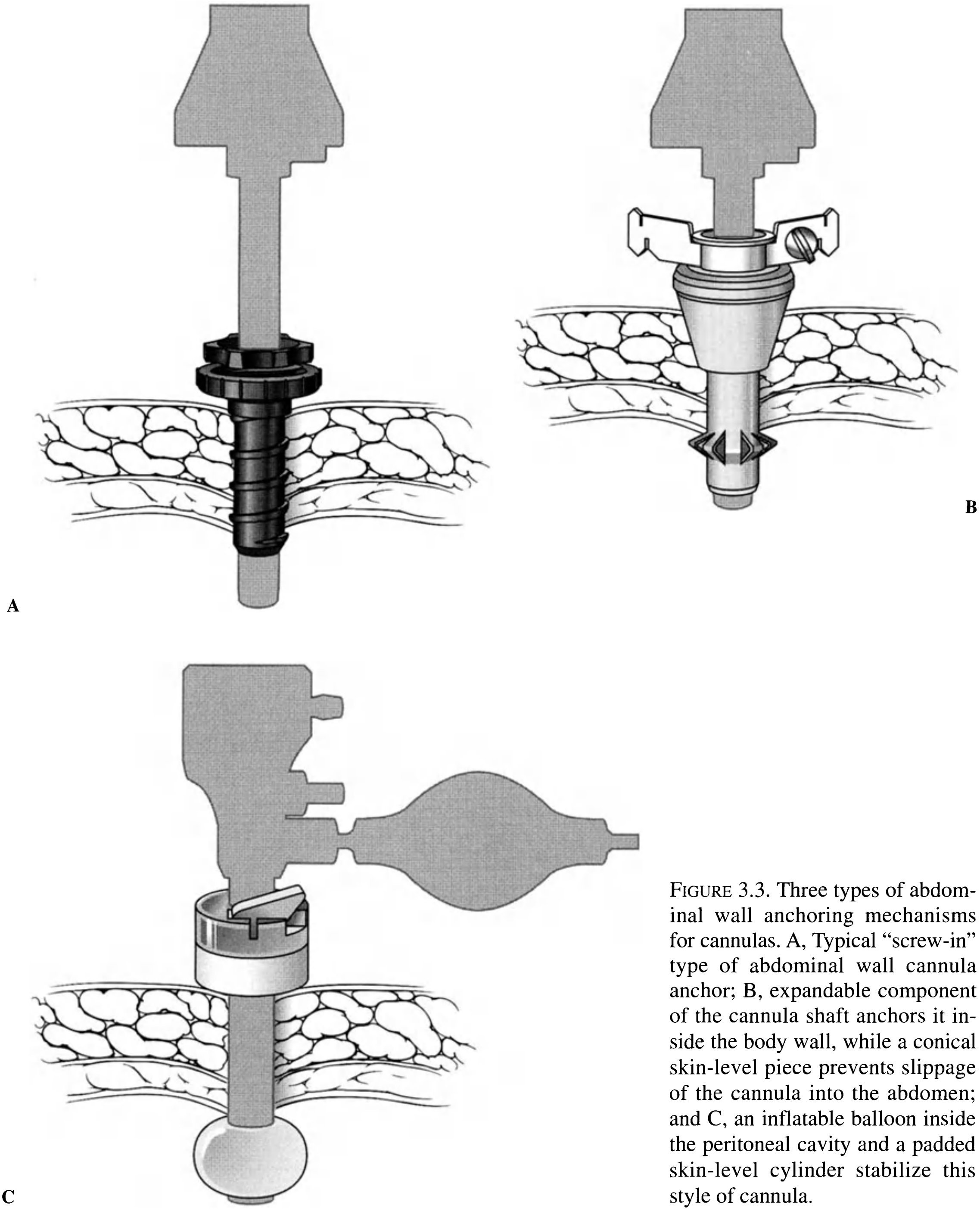

FIGURE 3.3. Three types of abdominal wall anchoring mechanisms for cannulas. A, Typical "screw-in" type of abdominal wall cannula anchor; B, expandable component of the cannula shaft anchors it inside the body wall, while a conical skin-level piece prevents slippage of the cannula into the abdomen; and C, an inflatable balloon inside the peritoneal cavity and a padded skin-level cylinder stabilize this style of cannula.

cannula may not be anchored securely to the abdominal wall. Solid anchoring may not occur in this situation because the abdominal wall tissue is so lax (elderly patient) or so thick (obese patient). Sometimes an additional suture placed through the skin and wrapped around the cannula may help to stabilize the cannula in these patients.

If intra-abdominal adhesions are suspected and an open laparoscopic cannula insertion (open insertion using a small incision) is carried out, a Hasson-Eder cannula with a blunt-tip trocar and a cannula with an outer gasket (Figure 3.4) should be used.[2] Under direct (laparoscopic) view, the abdominal wall and the peritoneum are incised and the cannula positioned. A gasket on this cannula acts as a seal to prevent gas leakage. To avoid cannula dislodgement, peritoneal or fascial sutures can be secured to the cannula. Petrolatum gauze or adhesive tape may be applied to seal minor leaks from around the cannula incision.

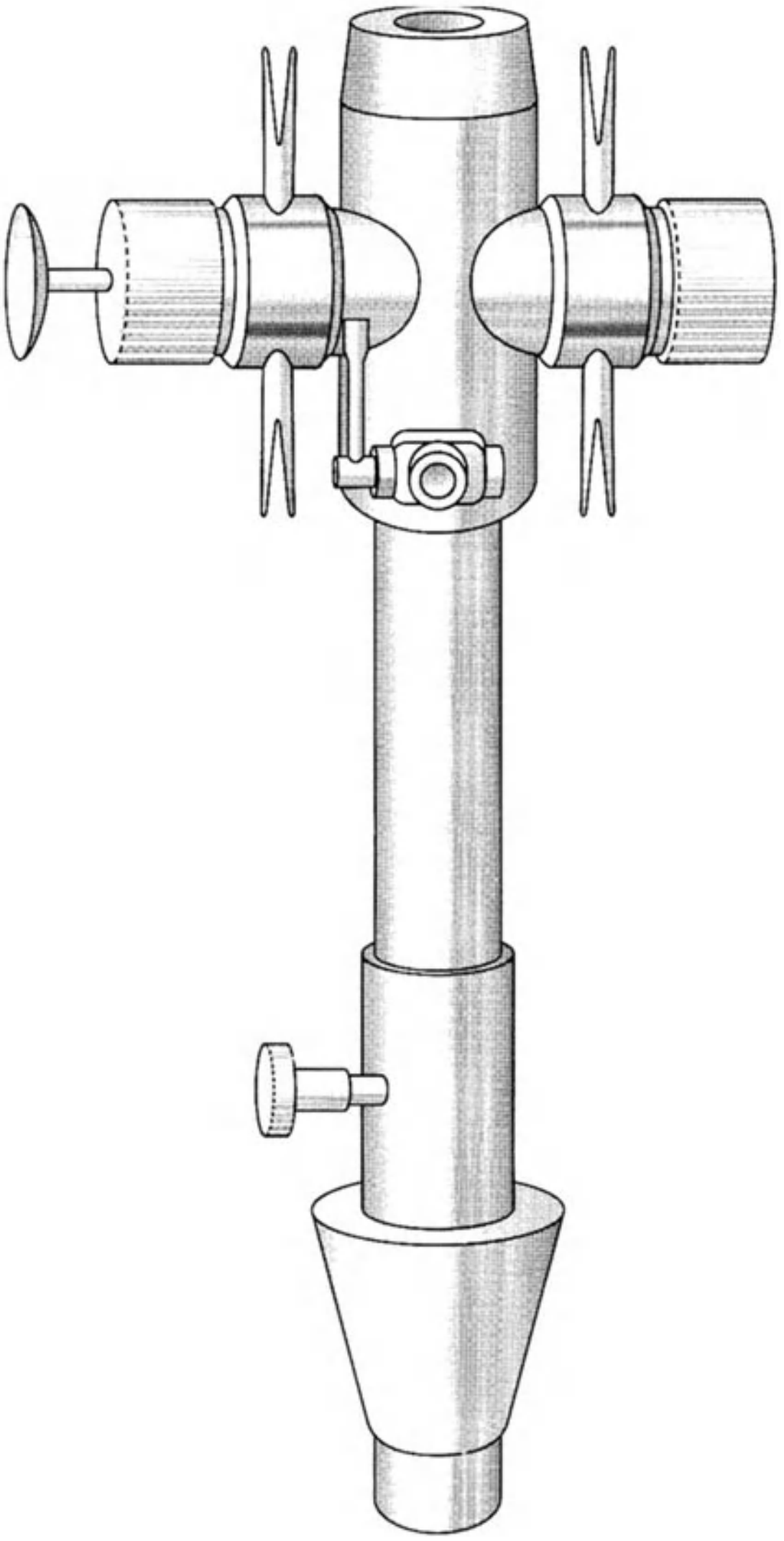

FIGURE 3.4. Hasson-Eder cannula, which creates a reliable seal around the cannula in the abdominal wall when an open cannula insertion is used.

The question of whether disposable or nondisposable trocars are preferable for laparoscopic surgery cannot be answered yet. A study in humans has shown that more force is necessary to insert a reusable trocar into the abdominal cavity compared with a disposable trocar.[3] The mean peak force (±SD) necessary to insert a reusable trocar into the peritoneal cavity, measured in humans using a standardized technique, was 14.55 ± 6.46 lb and for a disposable trocar was 7.14 ± 5.35 lb. Although less force may be necessary to insert a disposable trocar into the peritoneal cavity (thus lessening abdominal cavity compression), there is no proof that less force is related to a lower incidence of trocar-related injuries.

Some disposable trocars are equipped with a spring-loaded safety shield (Figure 3.5). The shield retracts when passing through the abdominal wall, then quickly springs back over the trocar point when it enters the peritoneal cavity, thus protecting surrounding tissue from the trocar point. It cannot be said that shielded trocars will always prevent serious injury to intra-abdominal structures, particularly if adhesions are encountered. In addition, the safety shield must break through the peritoneum before it can spring forward to completely cover the sharp trocar tip. Therefore, there may be a short period as the trocar tip enters the peritoneal cavity when the safety shield has not advanced to cover the tip (this problem may be observed when additional trocars are placed), particularly if the peritoneum is loose and moves ahead of the trocar.[4] Disposable trocars also are available that have no protective shield but instead have a spring-loaded tip. The tip automatically retracts as pressure at the tip decreases slightly during entry into the peritoneal cavity. Whether this design is safer than the safety shield is unknown.

Most trocars have a three-sided tip with sharp edges that facilitate entry into the abdominal cavity. Some have a conical tip, which may minimize trauma to the abdominal wall during trocar and cannula passage. An ingenious new cannula insertion device has been introduced that uses no trocar tip but instead scores the abdominal wall with a small scalpel that advances 1 mm beyond the cannula tip when a tripper

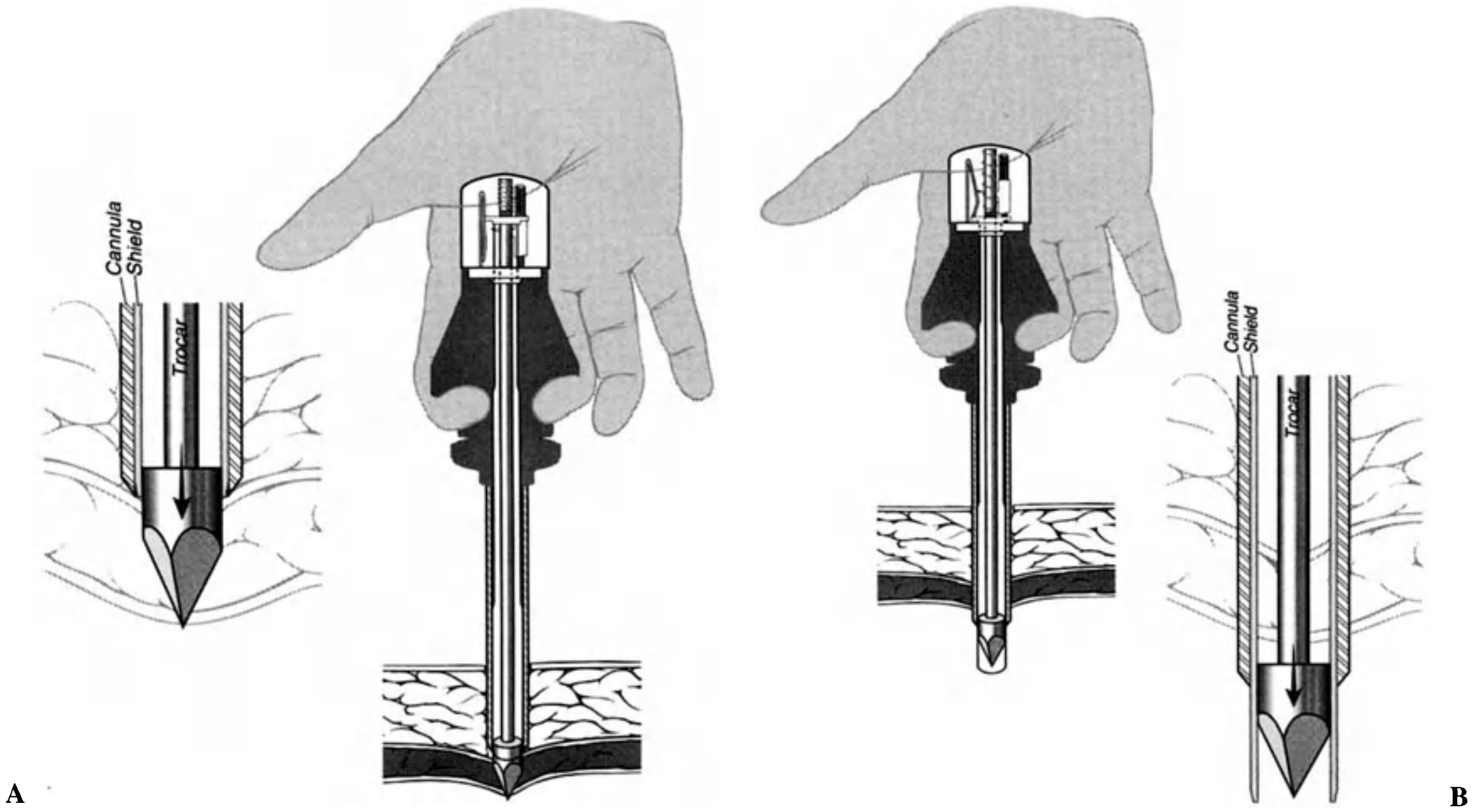

FIGURE 3.5. Insertion of a cannula and a trocar with a protective shield (longitudinal cut-away view). A, Cannula and trocar passing through the abdominal wall and B, safety shield covers the sharp trocar point after entry into the peritoneal cavity. (Courtesy of US Surgical Corporation, Norwalk, Conn.)

mechanism is activated. This device (VisiPort, US Surgical Corporation, Norwalk, Conn.) fits inside a standard cannula and allows for concomitant laparoscope insertion so that the slowly incised abdominal wall is directly visualized. Theoretically, if adhesions are present, this cannula insertion device will allow the surgeon to recognize adherent intestinal loops (or even abdominal wall vessels) so injury may be avoided. Whether any of these features increase the safety of trocar and cannula insertion, however, is unknown. A trocar that must be inserted blindly should probably be equipped with a safety mechanism.

For the safest and most controllable insertion of the first cannula, we believe the abdominal wall fascia should be directly grasped and lifted up and well away from the underlying structures with hooks or firm grasping instruments (such as Kocher clamps). We slowly insert the trocar and cannula, slightly twisting the cannula to help reduce friction between the cannula and the abdominal wall. Some trocars are designed so the trocar tip rotates independently of the trocar handle, thereby ensuring that the twisting motion on insertion will not result in tissue trauma.

In our opinion, an optimal cannula and trocar design should meet the following conditions:

- Safe, controlled, and atraumatic insertion into the abdominal cavity, especially for the blind insertion of the first trocar and cannula.
- Good fixation to the abdominal wall, both superficially and deeply, so the cannula remains in place when instruments must be exchanged rapidly and the cannula tip remains in the peritoneal cavity.
- The cannula should form an airtight seal with the abdominal wall.
- A universal seal mechanism should be present in the instrument channel so instruments with different diameters (5 to 12 mm) can be inserted and withdrawn without friction and without a converter or an adapter.
- The cannula and anchoring device should be designed to prevent capacitive coupling and should allow all types of electrosurgical or laser equipment to be used safely.

Although no existing trocar and cannula meet all these requirements, most commercially available products fulfill at least two or three of these criteria. Presently, the surgeon's preference and the costs appear to be the main factors that influence the choice of one system over another. Because the first trocar used in a procedure is inserted blindly and thus poses the most danger, we feel the sharpest and safest trocar used for this purpose is most likely a disposable one or a Visi-Port. Thereafter, it may be that nondisposable instruments are just as safe, although the handling properties and ease of instrument insertion of disposable trocars makes them more attractive at present.

Costs could be reduced by using cannulas without a valve system when instrument exchange is not necessary during the procedure. In such instances, cannulas with a simple seal mechanism are sufficient. If cannulas with the same diameter have to be inserted, the same trocar can be used for each cannula insertion. Trocars that must be inserted blindly should probably be equipped with a safety mechanism.

Grasping Instruments

Grasping instrument devices are among the most widely used and well-known laparoscopic tools; gynecologic surgeons have used them for decades. They generally have one fixed handle connected to the instrument shaft and one movable handle that is connected to a center rod running through the instrument shaft to the grasper jaws. When the handles are squeezed or opened, the center rod is pushed or pulled relative to the shaft, and the jaws open or close accordingly. The grasper jaws are hinged so the jaw action is either single or dual. Dual-action jaws are necessary for laparoscopic colorectal surgery, but the force transmitted to the jaws is somewhat attenuated by the small dimensions of the pin that connects the jaws to the center rod. The grasper shaft should also be able to rotate more than 360° in its longitudinal axis because such rotation facilitates intraperitoneal use. An articulated tip may also allow additional freedom.

Graspers can be categorized as traumatic or atraumatic according to the blade tip. In general, blades with teeth at the blade tip are more traumatic than blades without teeth. Although the traumatic grasper has a sure grip and holds the tissue firmly, the risk of tissue damage is greater than when an atraumatic grasper is used. While traumatic grasping devices are useful to hold the greater omentum, mesentery, or adhesions, atraumatic grasping devices are mandatory when handling the intestine.

We have found three kinds of blunt-tipped graspers, each with a different function, to be useful in laparoscopic colorectal surgery: graspers, dissectors, and Babcock-like instruments (Figure 3.6).

Endoscopic graspers are designed to hold the tissue firmly without exerting excessive pressure. The shaft on most of these instruments is 5 mm in diameter, 31 cm long, and is isolated by a thin layer of plastic (Teflon or polyvinylchloride) that electrically insulates the instrument. The blades are blunt and are about 2 cm long with a maximum jaw span of about 2 cm. Although the quantity of tissue that can be held with these graspers is limited, we use this type of grasper for almost all purposes during laparoscopic colorectal surgery. The surface area of the blades is large enough to safely hold a sufficient amount of tissue, whether it is mesentery, greater omentum, or intestine. To maintain a relatively safe grip, the inner side of the blade is serrated; the serrations are fairly atraumatic so the intestine can gently be grasped with this instrument. The grasper has a holding mechanism that is easily activated and released with a trigger.

Special dissecting instruments are available for laparoscopic surgery. The tip is usually sharper than that of endoscopic graspers, but it is still blunt. The blade is about 2 cm long, and the blades are curved similar to a small curved hemostat and thus facilitate blunt dissection. Like the endoscopic grasper, the shaft is 5 mm in diameter, 31 cm long, and is electrically insulated. The dissector can act as a forceps during delicate dissection and can also be used for electrosurgery. Both the grasper and the dissector have a dial on the handle that allows the tip to be easily rotated on its longitudinal axis. For additional maneuverability, an articulated tip is also available; a second dial moves it.

The third type of grasping instrument is a Babcock-like clamp. The opposing surfaces of the blades are smaller than those of the normal grasper so the tissue can be held more

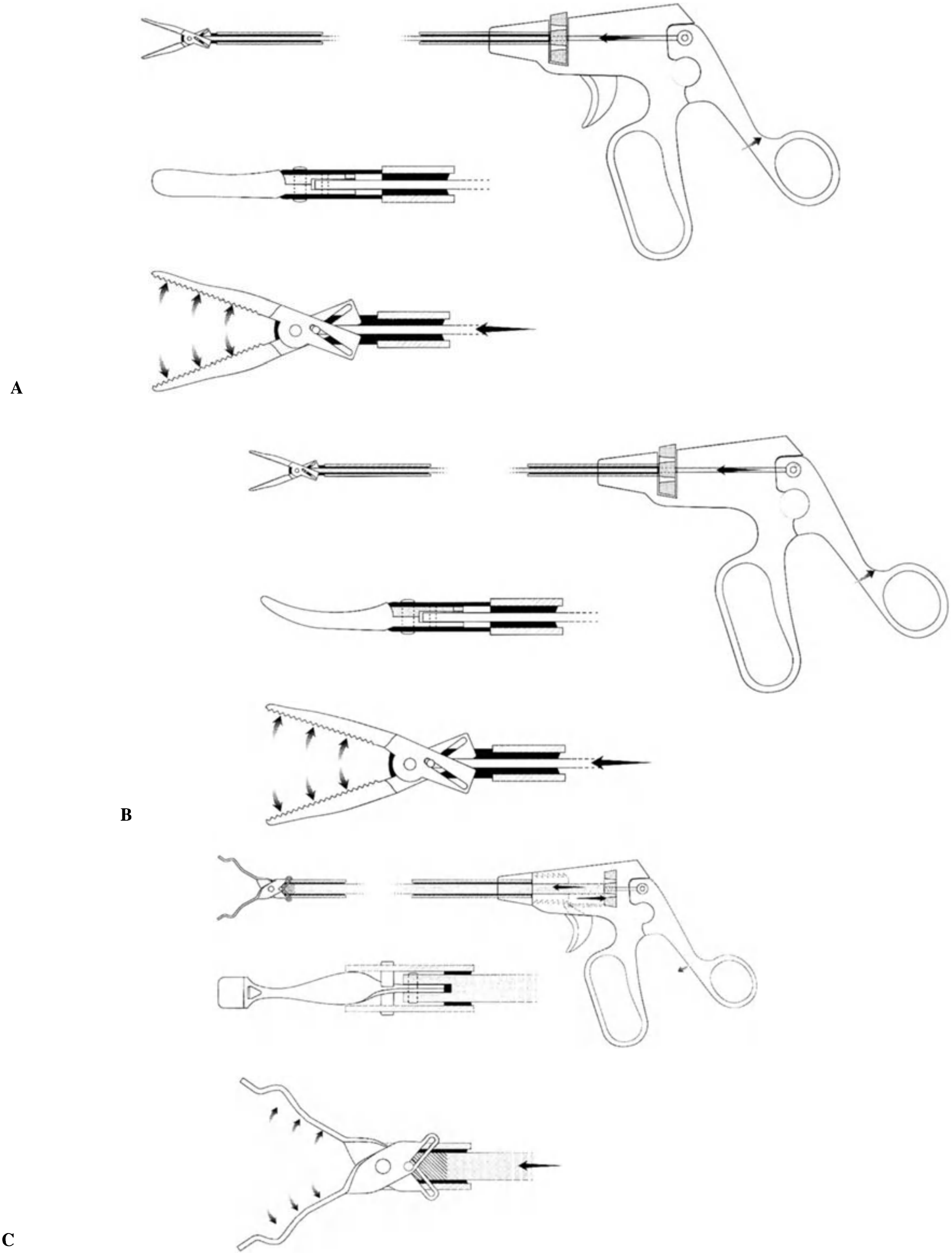

FIGURE 3.6. Grasping devices used for laparoscopic intestinal surgery (longitudinal cut-away view). A, Endoscopic grasper; B, endoscopic dissector; and C, endoscopic Babcock clamp. (Courtesy of US Surgical Corporation, Norwalk, Conn.)

firmly. We find that the maximum pressure that can be applied using this instrument exceeds that which we need or desire in manipulating the bowel—the smaller surface area of the blade leads to a greater risk of injury to the intestine.[5] Therefore, we do not use this instrument to retract the intestine during laparoscopic resection. We have found this instrument useful for two purposes: (1) grasping and locking the center rod of a circular stapling instrument to perform a transanal end-to-end anastomosis; and (2) grasping the intestine firmly and pulling it through the abdominal wall to accomplish an ileostomy or a colostomy. For all other purposes, we use regular endoscopic graspers.

Scissors

Scissors are probably the most important instruments in advanced laparoscopic surgery. Because they are used for both sharp and blunt dissection, they should have sharp blades and a blunt tip. We do not use microscissors with small blades or the hooked scissors commonly used in the gallbladder of gynecologic laparoscopic surgery because the wide dissection of mesentery and lateral and dorsal attachments of the colon can be more quickly performed with normal curved endoscopic scissors.

The scissor shaft is 5 mm in diameter, 31 cm long, and is well insulated so electrical current can safely be applied (Figure 3.7). The curved blades are 16 mm long with a maximum jaw span of 8 mm. The shaft can easily be rotated in its longitudinal axis by using a dial on the handle. We use the scissors for sharp and blunt dissection, and for tissue desiccation, which should always be carried out with closed blades. Sometimes arcing will occur during tissue desiccation, and the extremely hot arcs may dull the scissors. If the surgeon wants to desiccate the tissue while cutting, bipolar scissors should be used that combine bipolar desiccation with mechanical cutting. Because the cutting blade is ceramic in these scissors, it will not melt or become dull.

New, larger scissors similar to curved Mayo-style scissors are available that allow easier and faster blunt dissection and transection. The shaft also is 31 cm long and insulated, but it is 10 mm in diameter. Although the larger blades allow for rapid dissection, fine dissection is more difficult.

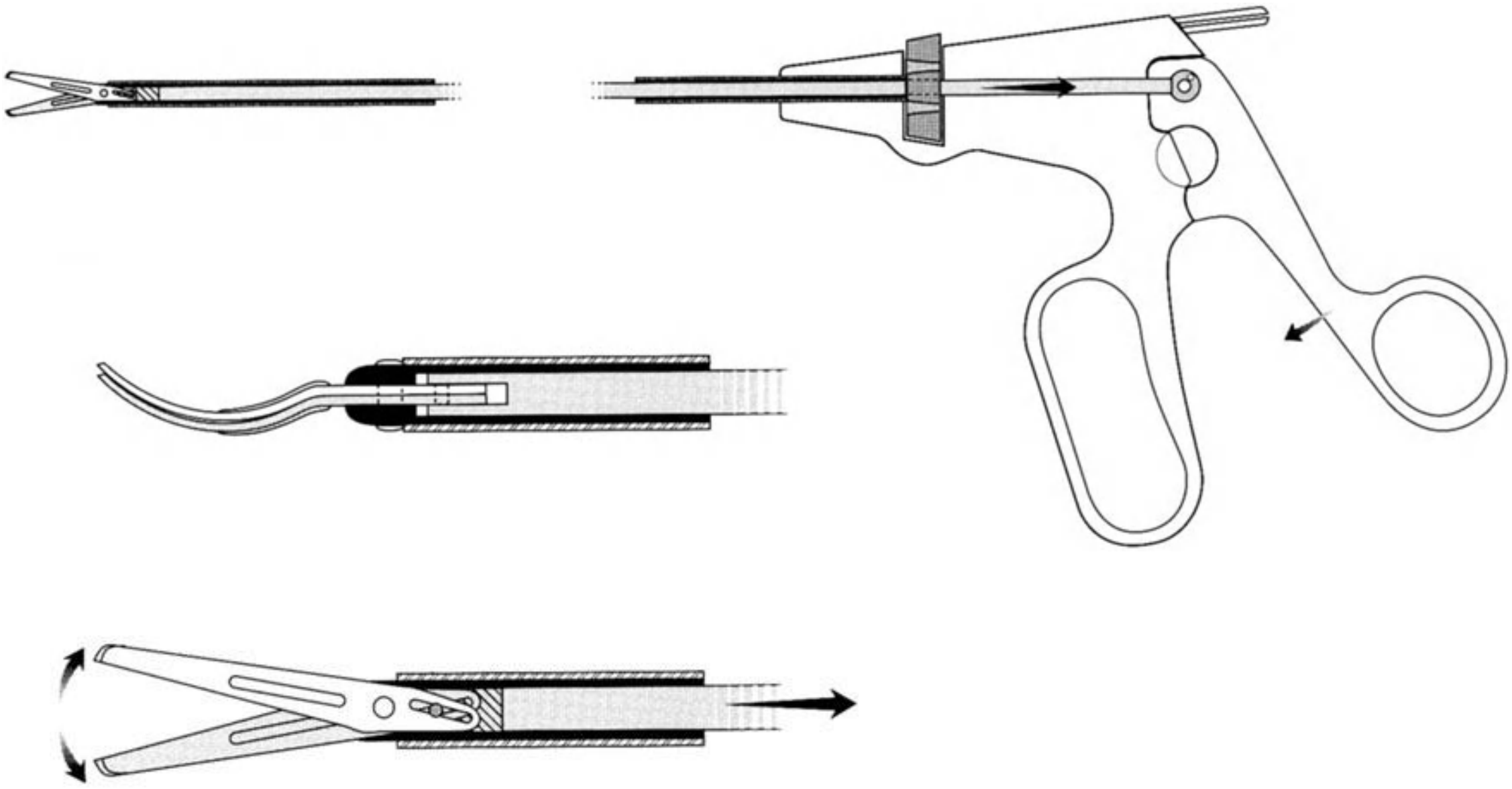

FIGURE 3.7. Endoscopic scissors with curved blade design (longitudinal cut-away view). (Courtesy of US Surgical Corporation, Norwalk, Conn.)

Retractors

The development of retractors for laparoscopic colorectal surgery is an area that several researchers are currently investigating intensely. The lack of good retracting instruments for the intestine is a major challenge confronting laparoscopic colorectal surgery. Retracting instruments are mandatory if laparoscopic intestinal surgery is to be successfully performed in obese patients or those with a distended intestine because these factors limit the visualization of the operative field, making laparoscopic surgery less feasible in these patients.

To lift the abdominal wall, Gazayerli developed an endoscopic retractor with a simple T-shape that is passed through a cannula.[6] He has reported that this retractor can provide good countertraction to facilitate adhesiolysis of bowel loops from the abdominal wall, and to attain hemostasis from a bleeding abdominal wall vessel by applying pressure with the retractor. Because this instrument would occupy one cannula only to locally lift the abdominal wall, it is unlikely to be useful in intestinal surgery.

Duh and Way described their use of T-fasteners to retract and anchor the antrum or jejunum to the abdominal wall for laparoscopic gastrostomy or jejunostomy.[7,8] Although T-fasteners may also be useful to fix the mesorectum to the presacral fascia in laparoscopic rectopexy (see chapter 11), we do not believe they will prove to be useful tools for temporary retraction because they must pierce tissue, fix it, and then they must be removed in most instances. This may lead to undesired trauma and the difficulty of removing the T-fasteners from the abdominal cavity.

We do not recommend using a one-finger or a fan retractor (Figure 3.8) to retract bowel loops. These designs may be useful to retract the liver or other more fixed organs, but it is not designed to retract the bowel effectively. Fan retractors also have the disadvantages that an intestinal loop may become trapped between the fingers of the retractor, exposing the loop to potential injury. Currently, the size of most retractors (fan or paddle) is limited because of the small diameters of the cannulas. No optimal device for retracting intestinal loops exists. A new device that might be used with a 12-mm cannula and work as an intraperitoneal barrier for the small bowel is currently under investigation in our laboratory. This instrument's function will be to hold the small intestinal loops away from the operative field so they do not obstruct the view.

Most retraction of the intestine currently is carried out using grasping devices and by altering the patient's position. We have used an endoscopic snare device (EndoCatch, without plastic bag, US Surgical Corporation) to retract the divided left or right colon, which has led to a major increase in the efficiency in some procedures. The snare, which is passed into the abdominal cavity inside a 10-mm diameter tube, can be opened to a maximum diameter of about 6.5 cm and then completely or partially closed by retraction into the tube. Because the snare consists of a band of spring metal with blunt edges, it is not likely to injury the bowel if used properly.

After the colon has been divided, the sling is slid over the end of the colon—and is used to retract it. Thus, not only does this sling work as a safe retractor, but it can also allow rotation of the intestine in the longitudinal axis of the instrument and facilitate dorsolateral dissection of the colon on the right or the left side. The snare theoretically can be applied without transecting the intestine. One side of the loop can be detached, passed around the intestine, and then reattached. The sling may also be used to occlude the rectum before rectal washout, which is usually performed before rectal transection during rectal cancer surgery.

Despite several useful retracting instruments currently available, if the intestine is distended, if the patient is overly obese, or if space in the peritoneal cavity is limited in some other way, it can be difficult or sometimes impossible to expose the operative field sufficiently in laparoscopic colorectal surgery. If good exposure cannot be achieved, conversion to open surgery is essential.

Some static abdominal wall retractors are available that allow intra-abdominal surgery without pneumoperitoneum. Banting et al.[9] reported an abdominal wall lift consisting of a metal rod (4 mm in diameter) and a polyethylene tube that is placed through the abdominal

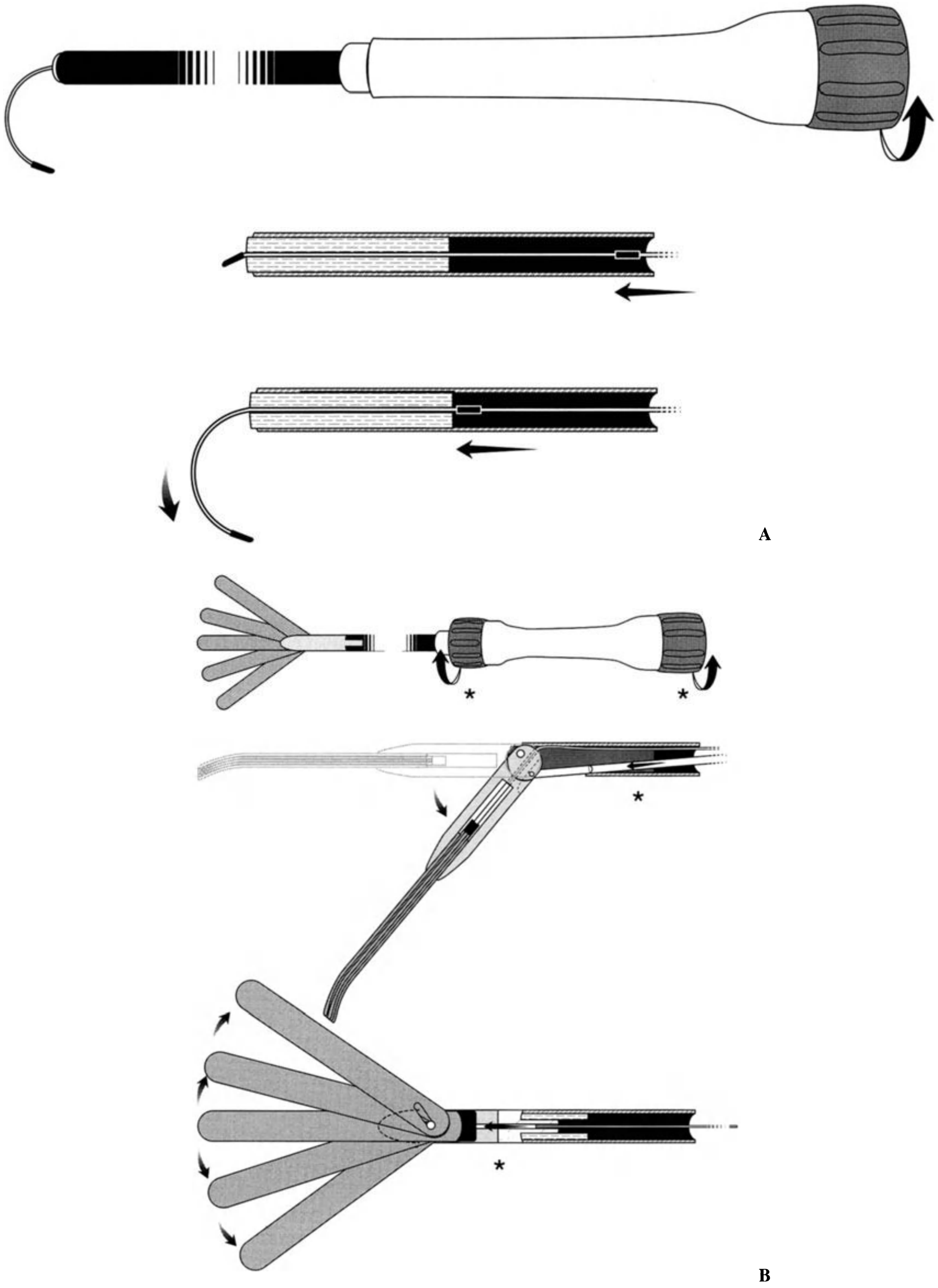

FIGURE 3.8. Designs of simple endoscopic retracting instruments. A, Single-finger retractor and B, articulating fan retractor. The knob at the top of the handle (∗) causes flexion of the instrument tip, while the knob at the heel of the handle (∗) spreads the fingers. (Courtesy of US Surgical Corporation, Norwalk, Conn.)

wall. The abdominal wall is then lifted up anteriorly to create a space. Hashimoto et al. described a similar principle; they placed stainless steel wires through the skin and subcutaneous tissue to lift the upper abdominal wall.[10] A device is also available that is passed through a trocar site to lift the abdominal wall with two finger-like retractors against the peritoneum (Origin Medsystems, Menlo Park, Calif.).

Although performing laparoscopic surgery without pneumoperitoneum (and thus without cannulas that have complex valve systems) is intriguing, it is unknown whether the constant lifting that would be required for an extended period causes ischemia and postoperative pain. Also, it is unknown whether lifting creates an intraperitoneal space that is large enough so that the instruments are easily maneuverable. Further, the lifting devices distribute forces unevenly, which may make such instruments less safe and less efficacious than standard pneumoperitoneum.

Endoscopic Bags

An endoscopic specimen bag is essential for laparoscopic intestinal resections for malignancy because the resected specimen must always be placed in the bag before delivery from the peritoneal cavity. This may reduce the possibility of tumor cell seeding of the peritoneal cavity and the abdominal wall. In general, a bag has to be inserted into the peritoneal cavity in a compressed fashion and then opened. The bulky specimen must then be placed in the bag, and the bag must be completely closed before bringing it through the abdominal wall.

The ideal endoscopic bag for delivering the intra-abdominal specimens should have the following properties:

- It should be fluid impermeable and be strong enough so it cannot be damaged inside the abdominal cavity or when being removed.
- It should fit through a cannula 15 mm or smaller.
- It should open easily.
- It should be large enough so the entire intestinal specimen, including the mesentery, can easily be placed in it in one piece.
- It should have a mechanism to quickly close the bag to prevent spills.

The least expensive endoscopic bag is a simple food freezer bag (the type purchased in a grocery store) with a monofilament purse-string suture placed on the bag opening. This bag can easily be sterilized before the procedure using ethylene oxide or glutaraldehyde.

A specially designed commercially available bag allows excellent control of the mouth of the bag and a good drawstring mechanism (Figure 3.9). The bag is enclosed inside a 15-mm metal shaft. Using a plunger-type mechanism, the bag is expelled from the shaft once the tip of the instrument is inside the peritoneal cavity. It is initially attached to a metal hoop that holds the mouth of the bag open. Successfully placing the specimen in the bag requires the following: (1) that the specimen be located cranially and the bag placed caudally; and (2) planning that the cannula through which the bag is inserted will be the optimal place to deliver the specimen. Once the specimen is inside the bag, the drawstring is tightened, the bag is torn away from the metal hoop, and the hoop and neck of the bag are drawn up inside the metal shaft of the instrument.

The cannula incision is enlarged to deliver the specimen, then the neck of the bag, including the purse string, is delivered to the anterior abdominal wall. The enlarged cannula site is surrounded by towels, the bag is opened, and the specimen is delivered. To prevent the contents from spilling, the bag volume should be about 150% of the specimen volume.

In our opinion, cancer surgery should not be carried out if the specimen cannot be placed in the bag intracorporeally immediately after the resection and before delivery through a widened incision. Although metastatic dissemination into the abdominal wall after delivery of malignant tumor specimens is rare in conventional surgery, it has recently been reported in patients who underwent laparoscopic surgery for gastric cancer,[11] gallbladder cancer,[12,13] pancreas cancer,[14] ovarian cancer,[15] and colorectal cancer.[12] Metastatic dissemination has occurred through the abdominal incision used for specimen removal as well as into distant

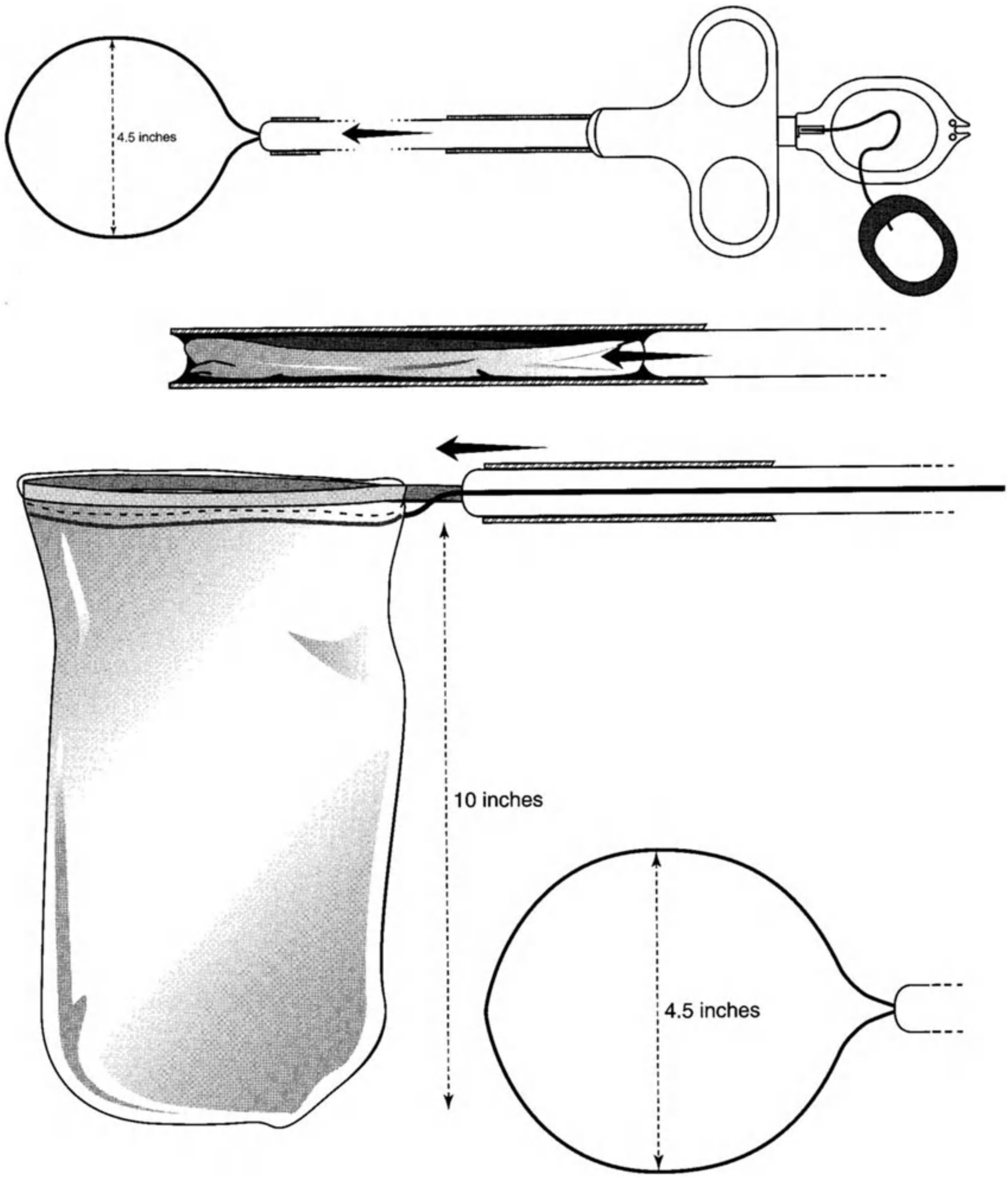

FIGURE 3.9. Large plastic bag used for retrieval of intestinal segments. (Courtesy of US Surgical Corporation, Norwalk, Conn.)

cannula sites far from the tumor removal site. Although this phenomenon has yet to be clearly explained, we believe that the risk of tumor cell dissemination can be lowered substantially if all specimens are placed in a bag as soon as possible. In addition, opening the intestine inside the peritoneal cavity should always be avoided.

Intra-abdominal Clips

Endoscopic clips are mainly used for achieving rapid hemostasis of vessels approximately 3 to 8 mm in diameter. Clips are effective and require less time to apply than sutures and knots. They are manufactured from a variety of materials, including absorbable polyglycolic acid and polydioxane, stainless steel, or titanium, and may be applied with a single-clip applicator or an automatic applicator that can apply up to 20 clips.

If clips are used for hemostasis, they should fulfill the following conditions:

- They must be easily applied under most laparoscopic situations—before or after transection of the vessel to control bleeding.
- They must be able to be applied safely in a variety of situations.
- They should cause as little inflammation of surrounding tissues as possible.
- They must not interfere with imaging techniques, such as conventional x-rays or magnetic resonance imaging.

Currently, we use only large, automatic clip applicators that are inserted through a 10-mm cannula (Figure 3.10). They are made of titanium and no latch mechanism is needed to secure them. The legs of the clips are 11 mm long and the initial distance between the legs is 4.5 mm. The legs close first at the tip of the clip to trap the tissue and then the clip body crimps down. The clip closes tightly enough to ligate vessels up to 4 mm in diameter. Although defining a safety range for clips is difficult, clinically we favor these clips because we have yet to see any bleeding from double-clipped vessels.

Because the clips can be applied in a straight forward direction and the clip applicator rotates around its longitudinal axis, safely placing clips is almost always possible in laparoscopic colorectal surgery. Clip applicators are also available that apply clips at a right angle to the longitudinal axis of the applicator. However, with our dissecting technique, this kind of clip applicator has no advantage because the vessel must be skeletonized before this kind of clip can be placed, and we do not routinely perform this procedure during laparoscopic surgery.

A careful dissection on both sides of the vessel should be performed to facilitate clip placement. Optimally, the jaws of the clip applicator should be clearly seen to ensure that the clip entraps the vessel (Figure 3.10B); otherwise, the clip may not completely seal the vessel. The automatic clip applicator works reliably only if the applicator is not twisted or "scissored" on the vessel during application. If a bleeding vessel in the mesentery must be ligated, the surgeon should be sure the clip is ready to apply before pushing the clip into the tissue. Otherwise, the tissue resistance may be great enough to prevent proper placement of the clip in the "loading" position so that the applicator may misfire.

To ligate a vessel before specimen resection, two clips should be placed on the patient side and one clip on the specimen side of the vessel. The distance between the clips should be great enough so the vessel can be easily transected and so additional clips can be applied. For large vessels or if the surgeon is not sure that the clips have sealed the vessel on both sides, the vessel can be incised to check for complete hemostasis. If constant bleeding does occur, indicating incomplete hemostasis, more clips can be applied. Care must be taken to avoid crossing the clips because they will not seal and may damage each other, which sometimes causes bleeding. Although titanium clips mechanically are not as strong as stainless steel clips, the clip design is as much a part of clip security as the material. Additionally, titanium clips have the advantage of creating only small image artifacts during computed tomography or magnetic resonance imaging.

Laparoscopic clip applicators are now available that apply a single absorbable clip (Lapro-Clip, Davis and Geck, Danbury, Conn.). The clip consists of two parts: the inner part, which looks like a conventional clip (8 or 12 mm long), made of polydioxane; and the outer part, which is a bulky clip (11 or 16 mm long) made of polyglactin. The more elastic inner part encompasses the vessel like a conventional clip, and the more rigid outer part guarantees the

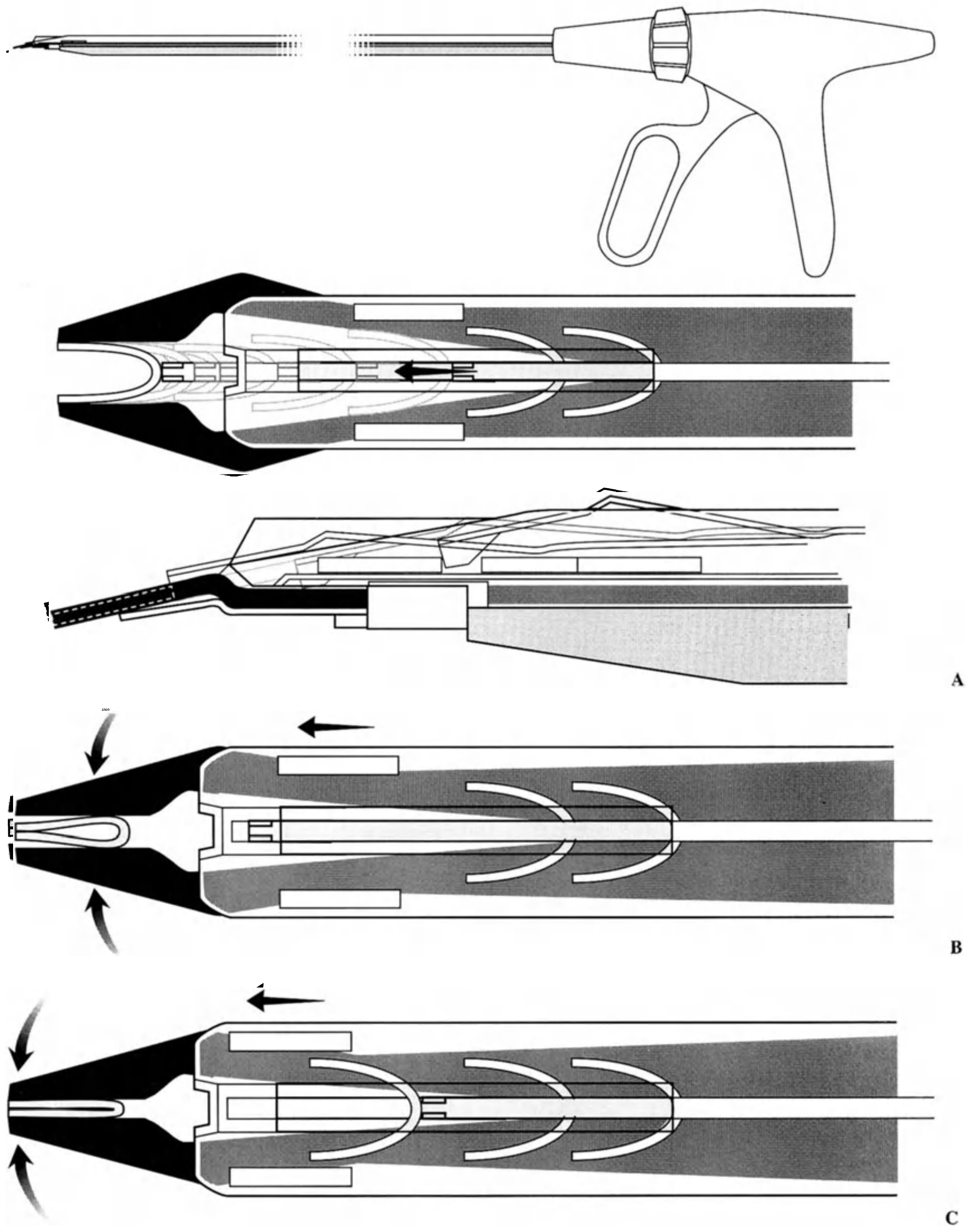

FIGURE 3.10. Automatic endoscopic clip applicator. A, Longitudinal cut-away view of clip applier; B, clip closes down first at the tip; and C, body of the clip then closes down. (Courtesy of US Surgical Corporation, Norwalk, Conn.)

safety of the clip and holds the inner clip in the proper place. Although absorbable clips theoretically are preferable to metal clips, we currently do not recommend this clip for routine use because placing single clips is time-consuming. In addition, no published experiences indicate whether the absorbable clip can safely be placed in the mesentery to stop bleeding if the vessel is not completely skeletonized.

Whether titanium clips cause more tissue inflammation than absorbable clips is still uncertain. In a rabbit model, Grainger et al. examined the adhesions caused by absorbable clips, titanium clips, and chromic catgut.[16] They found fewer adhesions in the group with absorbable clips (n = 9), but the difference was not statistically significant. Because the number of animals used was small, however, a type II error may have occurred. Therefore, whether titanium clips cause more adhesions than absorbable clips is questionable. At this time, we favor absorbable clips for patients who may need several laparoscopic procedures during a lifetime.

Endoscopic Staplers

The first mechanical suture instrument that used staples was developed by the Hungarian surgeon Homer Hültl in 1908.[17] It placed two double rows of fine steel wire staples that closed in a B shape. Hültl's principles concerning staplers formed the foundation for the development of modern staplers. Stapling instruments were improved by Von Petz in 1924,[18] Tomoda in 1937,[19] and Nakayama in 1954,[20] and became more sophisticated after further development at the Scientific Research Institute for Experimental Surgical Apparatus and Instruments in Moscow. Although automatic staplers were first introduced in the United States in the 1960s, they were not widely used until the 1970s. Further development and simplification along with proven reliability and safety led to the current instruments that are widely used in colorectal surgery. Overall, they facilitate intestinal resection and anastomosis.

In 1991, the US Surgical Corporation, Norwalk, Conn., placed an endoscopic linear anastomotic instrument (Multifire Endo GIA 30) on the surgical market that could be applied through a 12-mm cannula (Figure 3.11). Its working end consists of two jaws, one that accommodates the staple cartridge and one that is the anvil. In the cartridge are two rows of triple-staggered staples, eight in each row; the two rows are separated by a single groove through which a small sharp knife blade advances when the stapler is fired. The staples are made of 0.21-mm titanium wire, have a backspan length of 3 mm, and have a leg length of 2.5 or 3.5 mm. To staple and divide the bowel, the bowel is slid between the jaws (cartridge and anvil) and the instrument is closed and activated. Activation drives both rows of triple-staggered staples through the tissue and drives the knife to divide the intestine. The knife stops one-and-a-half staples short of the end of the staple line. Thus, both ends of intestine are divided and closed in an everted mucosa-to-mucosa fashion with a triple row of staples on each side.

A 30-mm Endo TA device is also available from US Surgical Corporation. It places three rows of staggered staples through tissue and can be used to close enterotomies or occlude bleeding vessels. The staples are constructed in the same way as in the Endo GIA instrument.

In 1992, US Surgical Corporation introduced a 60-mm linear endoscopic stapling device (Powered Multifire Endo GIA 60). This 15-mm diameter instrument also consists of two jaws, one to accommodate the staple cartridge and one serving as the anvil. In the cartridge are six rows of staggered staples, 15 in each row. The staples are 0.21- or 0.24-mm titanium wire, have a backspan length of 3 mm, and have a leg length of 2.5, 3.5, or 4.8 mm. This instrument also has a central groove between the middle two rows through which the knife blade is advanced. The 60-mm stapler is pneumatically activated because of the length of the firing stroke. Like in the Endo GIA 30, the knife stops one-and-a-half staples short of the end of the staple line, and both ends of intestine are closed in an everted mucosa-to-mucosa fashion with a triple row of staples on each side (Figure 3.12).

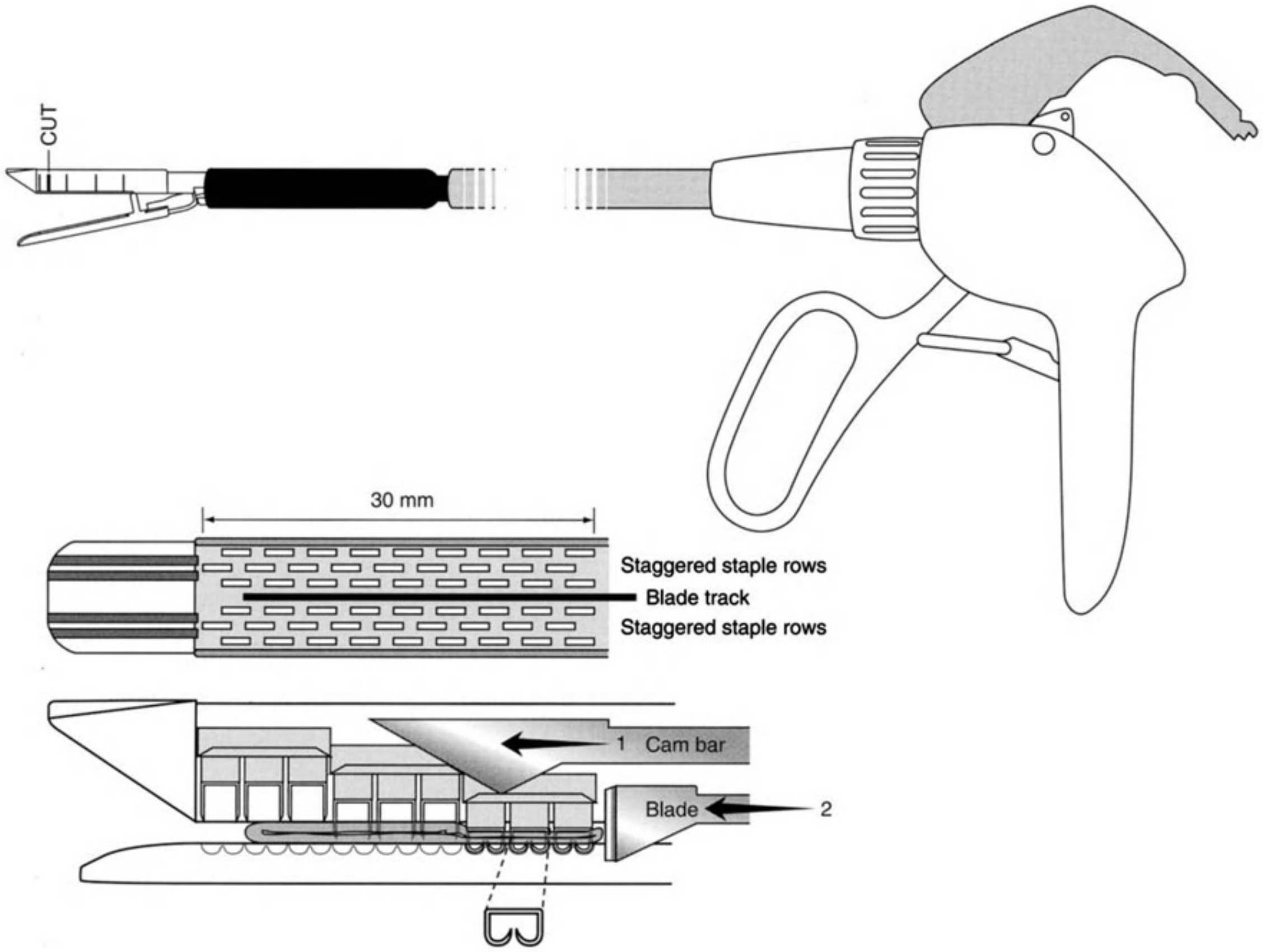

FIGURE 3.11. Multifire Endo GIA 30 instrument (longitudinal cut-away view). (Courtesy of US Surgical Corporation, Norwalk, Conn.)

A 60-mm Powered Multifire Endo TA device is also available that places one triple row of staples. This device can be used to close enterotomies or occlude bleeding vessels. The staples are constructed in the same way as in the Powered Multifire Endo GIA instrument. Although the conventional GIA and TA (nonlaparoscopic) instruments contain only two rows of double staples, we believe that the added third row of staples on either side of the central cutting channel probably increases their safety, which is especially important in laparoscopic surgery because the minimal access to the peritoneal cavity does not readily allow defective or bleeding intestinal anastomoses to be repaired. The major limitation of the linear endoscopic stapler is that it can not be angled at its tip so that application in difficult areas like the deep pelvis (to transect the rectum) is not currently feasible. If rotating and articulating stapling devices become available, they will facilitate several procedures.

Circular stapling instruments are available for a laparoscopic intraperitoneal anastomosis or a transanal anastomosis (Ethicon Endosurgery, Cincinnati, Ohio). The circular stapler is inserted through a 35-mm cannula, and anastomosis is performed as in conventional surgery. However, we have no experience with this technique and generally do not favor making a 35-mm opening to insert a trocar and a cannula—open surgery should be considered in lieu of this maneuver.

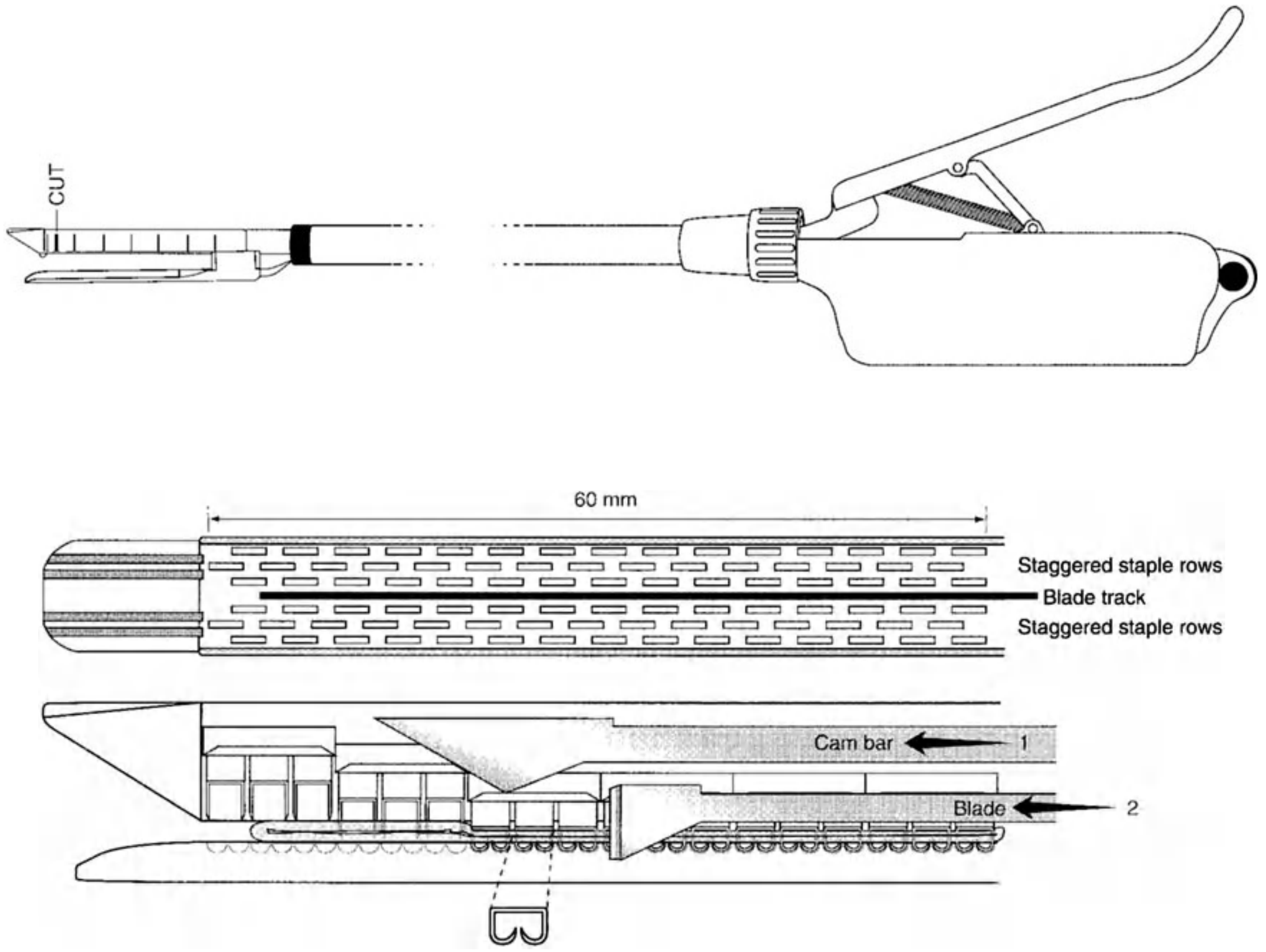

FIGURE 3.12. Multifire Endo GIA 60 instrument (longitudinal cut-away view). (Courtesy of US Surgical Corporation, Norwalk, Conn.)

References

1. Veress J. Neues Instrument zur Ausführung von Brust- oder Bauchpunktionen und Pneumothoraxbehandlung. *Dtsch Med Wochenschr.* 1938;40: 1480–1481.
2. Hasson HM. A modified instrument and method for laparoscopy. *Obstet Gynecol.* 1971;110:886–887.
3. Corson SL, Batzer FR, Gocial B, Maislin G. Measurement of the force necessary for laparoscopic trocar entry. *J Reprod Med.* 1989;34:282–284.
4. Dunn DC, Watson CJ. Disposable guarded trocar and cannula in laparoscopic surgery: a caveat. *Br J Surg.* 1992;79:937.
5. Larach SW, Salomon MC, Williamson PR, Goldstein E. Laparoscopic assisted colectomy: experience during the learning curve. *Colo-Proctology.* 1993;38–41.
6. Gazayerli MM. The Gazayerli endoscopic retractor model 1. *Surg Laparosc Endosc.* 1991;1:98–100.
7. Duh QY, Way LW. Laparoscopic jejunostomy using T-fasteners as retractors and anchors. *Arch Surg.* 1993;128:105–108.
8. Duh QY, Way LW. Laparoscopic gastrostomy using T-fasteners as retractors and anchors. *Surg Endosc.* 1993;7:60–63.
9. Banting S, Shimi S, Velpen Vander G, Cuschieri A. Abdominal lift. Low-pressure pneumoperitoneum laparoscopic surgery. *Surg Endosc.* 1993;7:57–59.
10. Hashimoto D, Nayeem SA, Kajiwara S, Hoshino T. Laparoscopic cholecystectomy: an approach without pneumoperitoneum. *Surg Endosc.* 1993;7:54–56.
11. Cava A, Roman J, Gonzalez Quintela A, Martin F, Aramburo P. Subcutaneous metastasis following laparoscopy in gastric adenocarcinoma. *Eur J Surg Oncol.* 1990;16:63–67.
12. Walsh DCA, Wattchow DA, Wilson TG. Subcutaneous metastases after laparoscopic resection of malignancy. *Aust NZ J Surg.* 1993;63:563–565.
13. Clair DG, Lautz DB, Brooks DC. Rapid development of umbilical metastases after laparoscopic cholecystectomy for unsuspected gallbladder carcinoma. *Surgery.* 1993;113:355–358.
14. Landen SM. Laparoscopic surgery and tumorseeding. *Surgery.* 1993;114:131–132.

15. Miralles RM, Petit J, Gine L, Balaguero L. Metastatic cancer spread at the laparoscopic puncture site. Report of a case in a patient with carcinoma of the ovary. Case report. *Eur J Gynaecol Oncol.* 1989;10:442–444.
16. Grainger DA, Meyer WR, Decherney AH, Diamond MP. Laparoscopic clips. Evaluation of absorbable and titanium with regard to hemostasis and tissue reactivity. *J Reprod Med.* 1991;36:493–495.
17. Hültl H. Kongress der ungarischen Gesellschaft für Chirurgie. *Pester Med Chir Presse.* 1909;10:121–122.
18. Von Petz A. Zur Technik der Magenresektion. Ein neuer Magen-Darmnähapparat. *Zentralbl Chir.* 1924;5:179–188.
19. Tomoda M. Ein neuer Magen-Darmnähapparat. *Zentralbl Chir.* 1937;25:1455–1461.
20. Nakayama K. Simplification of the Billroth I gastric resection. *Surgery.* 1954;35:837–843.

4

Tissue Dissection in Laparoscopic Surgery

Generally, in laparoscopic surgery, abdominal cavity tissues are dissected using a combination of cutting and coagulation, often with specialized electrosurgical instruments, lasers, or ultrasonic devices. Precise dissection with minimal bleeding is especially important in laparoscopic surgery. Even minor oozing compromises the laparoscopic view, and clearing blood from the field of vision with suction and irrigation may be difficult. Therefore, dissection must be performed with tools that optimize precise tissue cutting and coagulation.

Although many different coagulation and dissection devices are available, they all divide and coagulate tissue by converting various types of energy into heat (Table 4.1). Therefore, the effect on tissue is thermal and depends on exposure time and the amount of energy applied to the tissue. Before embarking on a specific discussion of each instrument used to cut or coagulate tissue, reviewing some basic concepts about thermal alteration of tissue is worthwhile.

Tissue reaction to thermal injury depends primarily on the temperature used (Figure 4.1). An increase in tissue temperature up to 60°C results in almost indiscernible changes to the naked eye. Coagulation begins at temperatures above 60°C; it is characterized by shrinkage and blanching caused by the denaturation of proteins, particularly collagen.[1,2] When the tissue temperature reaches 100°C, the cell water boils, water is converted to steam, and the cell wall ruptures. When the water has evaporated and heat is still applied, the tissue temperature increases rapidly until it reaches 200°C to 300°C. At this point, the tissue carbonizes and begins to vaporize and smoke. At temperatures over 500°C, tissue burns and evaporates.[1-3]

TABLE 4.1. Advantages and disadvantages of scissors with electrosurgery, Contact Laser*, ultrasonic scalpel, and ultrasonic dissector in laparoscopic colorectal surgery.

	Scissors with electrosurgery	Contact Laser	Ultrasonic scalpel	Ultrasonic dissector
Advantages	Good cutting and coagulation Inexpensive Familiar technique for nearly all surgeons	Precision in cutting Moderate hemostasis Less smoke development	Good cutting Moderate hemostasis No smoke development	Low risk of inadvertent injury
Disadvantages	High smoke development Higher risk of inadvertent/ unrecognized injury	Difficult coagulation Unfamiliar technique Expensive equipment	Difficult coagulation Mist development Unfamiliar technique	No cutting No coagulation Unfamiliar technique

*Surgical Laser Technologies Corporation, Oaks, Pa.

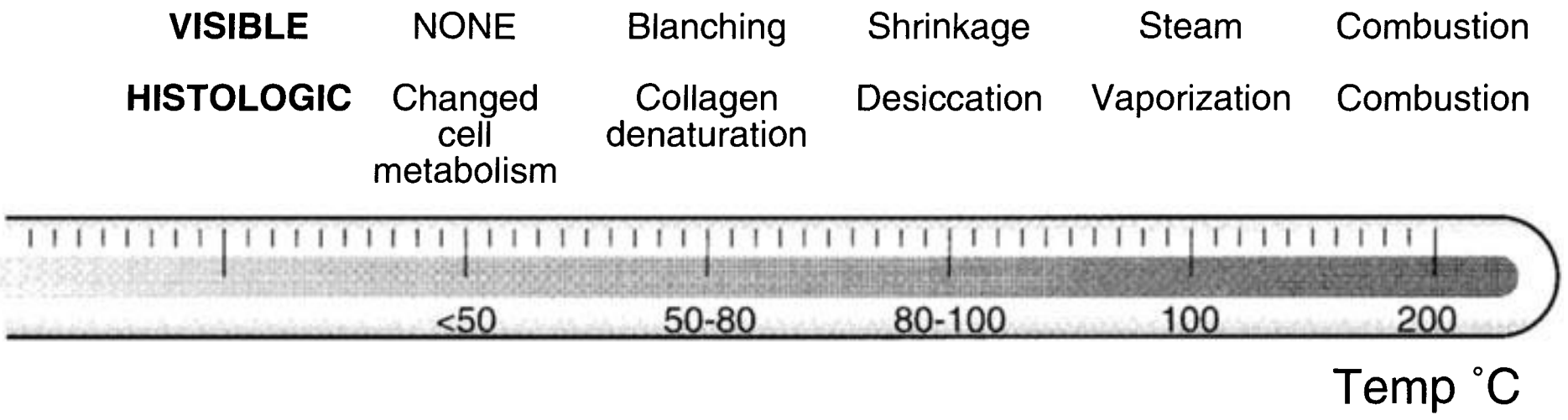

FIGURE 4.1. Visible and histologic alterations of tissues as related to tissue temperature.

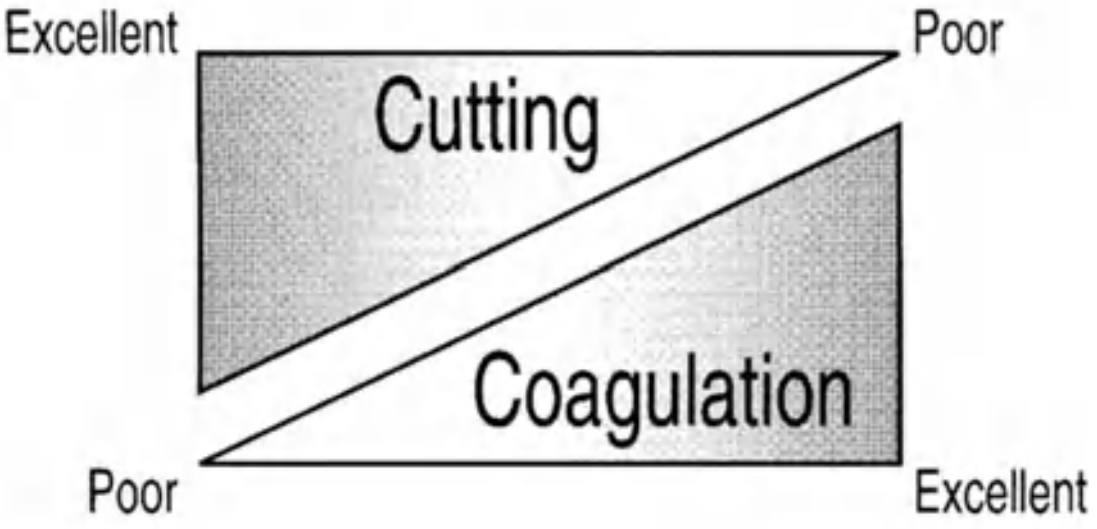

FIGURE 4.2. Inverse relationship between cutting and coagulation qualities of electrosurgery.

The effect of heat on tissue depends not only on the absolute amount of heat applied to tissue, but also on the exposure time to heat. If heat is applied over a short time (less than 1 to 2 seconds), the effect is localized because the heat is not conducted to surrounding tissues; even when the heat is great enough to vaporize the tissue, the vaporization is localized. If, however, the same amount of heat is applied for a longer period (greater than 2 seconds), the heat is conducted to the surrounding tissue, thus increasing thermal necrosis and broadening the vaporization area.

Cutting quality and coagulation quality are inversely related, regardless of the dissection device used (Figure 4.2). Good cutting quality depends on rapid local vaporization of tissue with minimal lateral heat damage. No coagulation will occur because the lateral heat damage is not wide enough to seal the blood vessels. In contrast, the quality of coagulation depends on the width of lateral heat damage: the wider the lateral heat damage, the better the hemostasis. Because as cutting quality improves, the coagulation quality worsens, simultaneously combining excellent cutting qualities with excellent hemostasis is impossible.

Although the term *electrocautery* is commonly used to describe electrosurgical techniques, the term *electrosurgery* is much more accurate. Strictly defined, *cautery* refers only to heat transfer from a hot object to tissue by conduction, so the term *electrocautery* should only be used if an electrical current heats an instrument that is then brought in contact with tissue and directly affects tissue by heat conduction. For example, electrocautery is used in the endocoagulator (heater probe) developed by Semm, in which electricity heats the operating tip of the endocoagulator and not the tissue. In contrast, *electrosurgery* refers to the direct application of electrical current to tissue, as when electric arcs are used; most of the energy is converted to heat after it contacts the tissue.

Electrosurgery

Basic Concepts of Electricity and Its Use in Surgery

Electrosurgery is universally accepted as an important tool in open surgery. Although we do not intend to describe the principles of electrosurgery in detail, some basic principles should be discussed to understand the relationship between different operating modes of the electrosurgical unit.

Voltage (V), expressed in volts, can be described as the force that drives electrons or ions through a resistance. The current (I), expressed in amperes, is defined as the total flow of electrons and is directly related to tissue heating.

Resistance (R), expressed in ohms, can be described as the ability of a substance to conduct electricity. Voltage, current, and resistance are related according to Ohm's law

$$V = I \times R$$

Power (P), expressed in watts, is defined as the time rate at which energy (in joules) is delivered, that is, work is done: 1 W = 1 J per second. Power is the product of voltage and current

$$P = V \times I$$

Consequently, the desired effect of electrosurgery on tissue is controlled by appropriate selection of voltage and current. Because voltage can be replaced in the formula for power by the product, $I \times R$, power can also be expressed as

$$P = R \times I^2$$

This last equation allows one to more fully understand the effect of electrical current when it is directly applied to tissue: at a constant power delivery and constant tissue resistance, tissue heating actually depends on the current density (I^2). For example, during desiccation, tissue heating is a function of the amount of current flowing through a given cross-sectional area of tissue. The electrons collide with the tissue molecules and the current is transformed into heat energy. The tissue thus is heated according to the formula

$$\text{Heat Generated in Tissue} \propto R_{\text{tissue}} \times I^2$$

The higher the current density, the more heat is transmitted to the tissue. Although this relationship holds true for all modes of electrosurgery, that is, cutting, desiccation, and fulguration, it can be directly applied only to desiccation because desiccation is the only true contact mode of electrosurgery. During cutting and fulguration, arcs created at the active electrode heat the tissue. Power can be observed macroscopically as the rate at which a specific tissue effect occurs; for example, the rate at which blanching spreads during desiccation or the rate at which a drag-free incision can be performed.

The relation between current density and tissue heating must be understood particularly in monopolar surgery because if the applied current passes on its way to the dispersive electrode through a part of the body with a small conducting area, tissue may be heated far from the point where the current is applied. Therefore, duct-like structures with a small area of conduction are at risk for inadvertent coagulation (Figure 4.3). Understanding the relationship between current density and heat production also is essential to understanding why smaller active electrodes have a localized effect on tissue. Because the current density of a small active electrode is greater than that of a larger (dispersive) electrode with the same power, a local temperature rise occurs immediately below the active electrode. The current density decreases rapidly as it radiates outward from the electrode; consequently, as the distance from the electrode increases, the temperature also rapidly drops. The shape and the size of the active electrode influences current density at the tip—arcs ignite more readily from a sharp edge than from a rounded surface. Thus, a cutting waveform applied to tissue with the broad side of a standard blade electrode effectively desiccates, and its sharp edge will cut cleanly with the same power and mode.

The electrolyte content of tissue is responsible for tissue resistance, which is between 30 (blood) to 1,000 (bone) Ω/cm.[4-6] Because blood has low resistance, well-vascularized structures and blood vessels are major pathways for electrical current to travel through the body to the dispersive electrode. The tissue resistance rises as tissue desiccation increases, from 200 to 400 Ω/cm to 1,000 to 3,000 Ω/cm. If tissue is desiccated or carbonized, it is seldom possible to affect more tissue in that area without increasing the power or removing the eschar.

Electrosurgical Generators

The first electrosurgical waveform generators, or oscillators, that produced high frequency current for low- and high-power coagulation were spark gap generators with a frequency of 500 to 700 kHz and a spark repetition rate of 120 per second. They generated a waveform that gradually decreased in amplitude because of the finite resistance of tissue. Thus, a highly damped

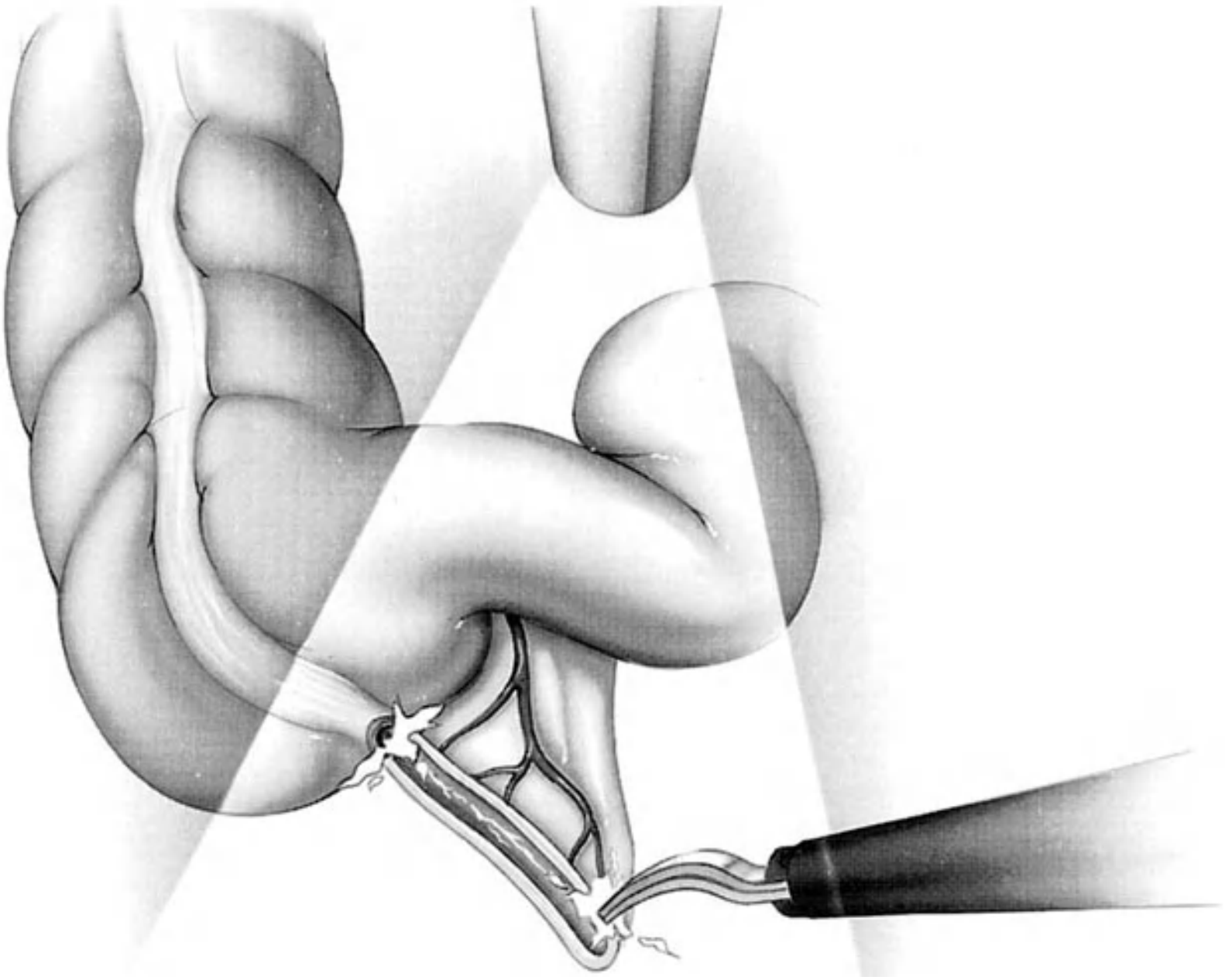

FIGURE 4.3. Monopolar electrosurgery, when applied to duct-like structures, may transmit a strong current through the duct-like structure, leading to damage of closely approximated tissue.

waveform with a short duty cycle (the fraction of time in which the oscillator is oscillating), and high peak voltage and peak current was created. This spark gap generator has proven to be an effective current source for both low- and high-power coagulation. In 1907, deForest, the inventor of the vacuum tube, built a radio-frequency generator and asked surgeons at Bellevue Hospital in New York City to try it out on dogs.[7] From the early 1930s through the 1960s, most electrosurgical units incorporated the spark gap generator for coagulation and vacuum tube generator for cutting as designed by Bovie.[8]

In the early 1970s, solid-state generators with digital electronics were designed to replace the combination of spark gap and vacuum tube generators. Their major advantage is that they decouple the oscillator from the power generator. This decoupling makes the output performance more reliable between electrosurgical units, but more importantly, more refined and complex waveforms can be produced easily at the low power levels associated with digital electronics. These waveforms then may be simply amplified to the necessary surgical levels in a separate power amplifier. Other advantages include more extensive safety features and hand-activated controls.

All solid-state generators consist of a primary and a secondary waveform generator and a power amplifier to adjust the desired power (Figure 4.4). The primary waveform generator, which acts as a timing reference for the rest of the generator, is modified by coupling the secondary waveform generator to it. Waveforms created by the primary generator can be amplified and used for pure cutting, whereas the secondary generator can be used to create an interrupted waveform for coagulation. Although theoretically this design is capable of creating any waveform by combining waveforms from both generators, currently the principle waveforms of the spark gap and vacuum tube generators are used because they have proven to be effective. In addition, blended waveforms—a lower amplitude continuous sine wave combined with higher amplitude secondary pulses—can easily be obtained by adding both cutting and coagulation signals to the power amplifier. Thus, the surgeon can adjust the electrosurgical

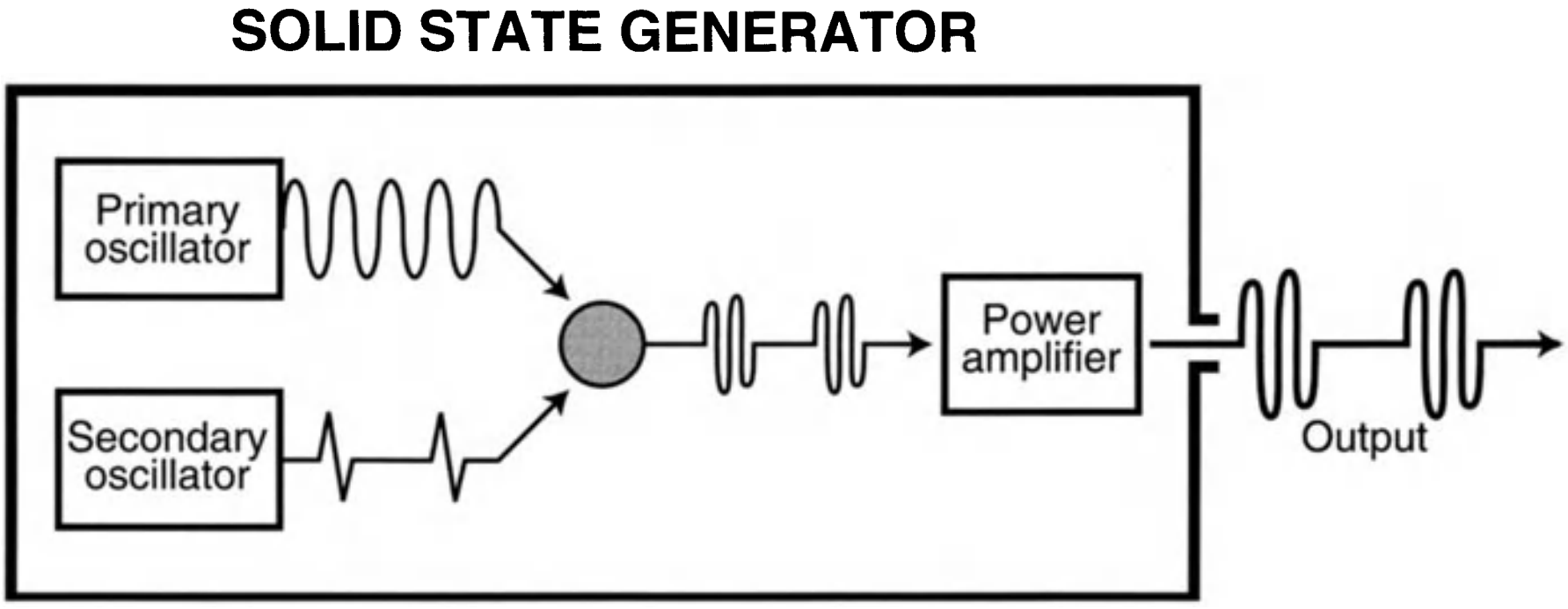

FIGURE 4.4. Schematic structure of how a solid-state generator uses a primary and a secondary oscillator to create an oscillation that is then amplified for useful tissue effects.

quality of the electrosurgical unit by selecting an appropriate waveform and power setting to affect the tissue exactly as desired. Blended waveforms are especially useful for cutting with mild or moderate hemostasis.

The electrical output configuration of the electrosurgical unit may be radio-frequency (RF)-isolated, referred-to-ground, or grounded. Radio-frequency-isolated output devices do not have a direct connection between the output transformer and the power ground line so the current seeks different return ground. This configuration is chosen to prevent tissue damage in case of a nonfunctional return electrode. Radio-frequency isolation best protects the patient from burns that occur at locations other than the burn site because the electrical impedance of the return path via ground is intentionally made as high as possible. In recent years, RF-isolated electrosurgical units have become the preferred standard of care in electrosurgery.

The surgeon should always keep in mind that complete RF isolation is not possible. Any conductive object, including components and wiring inside the electrosurgical unit and even the surgeon, can act as a capacitor. Thus, some measurable RF leakage will always be grounded via the patient. However, RF leakage in electrosurgical units labeled as “RF isolated” must be within established standards. Even within these limits, small burns (an area of less than 1 mm^2) at other contact sites may occur. The risk of such burns is minimized by the relatively high patient-to-ground capacitance (about 1 nanofaraday), using moderate power settings, and avoiding the creation of small ground sites between the patient and the operating table; in particular, the patient should not be excessively wetted during skin preparation because this can create damp areas that act as ground sites.

In contrast, in both grounded output electrosurgical units, the return electrode is connected to the power ground line. The advantages of a ground-referenced electrosurgical unit are in production and design, cost savings in high-voltage insulation, and an electrically isolated return circuit. Because the ground line carries the high- and low-frequency signals and some ground leakage of current almost always occurs at radio frequencies, there may be some interference with other devices in the operating room. This interference can be reduced by grounding all instruments used in the operating room. In the referred-to-ground output units, a capacitor between the return electrode and the power ground forces some of the current to use alternate pathways, resulting in interference.

Although the solid-state generators produce a standard waveform with a well-defined narrow-band width, the creation of arcs during cutting or fulguration adds considerable signal energy at high and low frequencies that may interfere with other devices in the operating room. The low-frequency arc and the high-intensity, high-frequency signals can interfere with pacemaker functions and can stimulate tissue (muscle and nerve) to duplicate physiologic signals, for example, electrocardiogram signals.

High-Frequency Electrical Current

Living tissue consists of different intracellular and intercellular salt solutions separated by biologic membranes. Living cells thus represent a series of electrolytic conductors so direct or alternating current alters the membrane permeability, resulting in muscle or nerve stimulation. To reduce these stimulations, a high-frequency alternating current is generated in the electrosurgical unit.

In general, no excitation will occur when high-frequency current is used if the duration of one sinusoidal halfwave of this current is shorter than the minimal stimulation time of nerves and muscles. It is well known that the minimum strength of a stimulus and its duration are related. If the stimulus is low and long, it will excite the tissue; if the stimulus is low and short, it will not excite the tissue. Although different tissues have different strength–duration curves, theoretically a stimulus has no lower duration limit. However, if the stimulus is short, as in high-frequency currents, the power output (strength) must be high to stimulate the tissue.

Thus, the currently used high-frequency, high-voltage, and low-amperage current has no excitatory effect on the body other than at the point of contact. However, low-frequency currents can arise from stray high-frequency currents when the high-frequency current passes through a nonlinear circuit that is not 100% resistive. Therefore, the arcs generated at the tissue and the active electrode interface as well as the high-frequency path through the tissue theoretically could create a lower-frequency current that would stimulate muscle and nerve tissue.[9] To prevent such currents, electrosurgical units incorporate output coupling capacitors that present a high impedance to arc-induced low-frequency currents. In most applications, including all currently practiced laparoscopic procedures, these capacitors are extremely effective in preventing muscle stimulation. Nonetheless, high-intensity arcs at the active electrode should be avoided and the electrosurgical unit power should be reduced if electrosurgery is performed close to major nerve bundles.

Monopolar and Bipolar Electrosurgery

A closed circuit is necessary so electrical current can flow through tissue from an entry (active electrode) through tissue to an exit (the return or dispersive electrode). If the entry electrode is used as the active electrode and the return electrode is inactive, the application is called monopolar electrosurgery. If both electrodes are used as active electrodes, the application is bipolar.

In bipolar electrosurgery, the electrodes are in close proximity; the tissue effect is localized, with little flow of current into the patient beyond the immediate treatment zone, and only a small amount of tissue is affected. Therefore, the total power required to affect the tissue is small compared with that required for monopolar electrosurgery, in which current must flow through the body to the ground electrode. Although bipolar electrosurgery provides the safest and most controlled desiccation method using electrosurgery and more effectively controls stray current, it has the disadvantage that it can only be used in the desiccation mode. This limitation may be overcome in part if bipolar scissors are developed that allow tissue desiccation with bipolar technology and tissue cutting with mechanical shearing. When bipolar electrodes are used, the tissue must be grasped where the electrodes are uninsulated to allow the current to pass through tissue (Figure 4.5). The bipolar electrodes should not be squeezed together too tightly because the jaws of the bipolar instruments may touch one another and create a short circuit (Figure 4.5, inset).

Electrosurgical Techniques

Electrosurgical modes are related to specific waveforms: a sinusoidal waveform is used for cutting, and an interrupted, highly damped waveform is used for coagulation. The associations are based on observation and experience, not on an established theory that explains why the two waveforms have such different effects on tissue. However, cutting and coagulation can be performed with both waveforms if the current and voltage of the waveform is adjusted and tissue heating is controlled with high-frequency current.

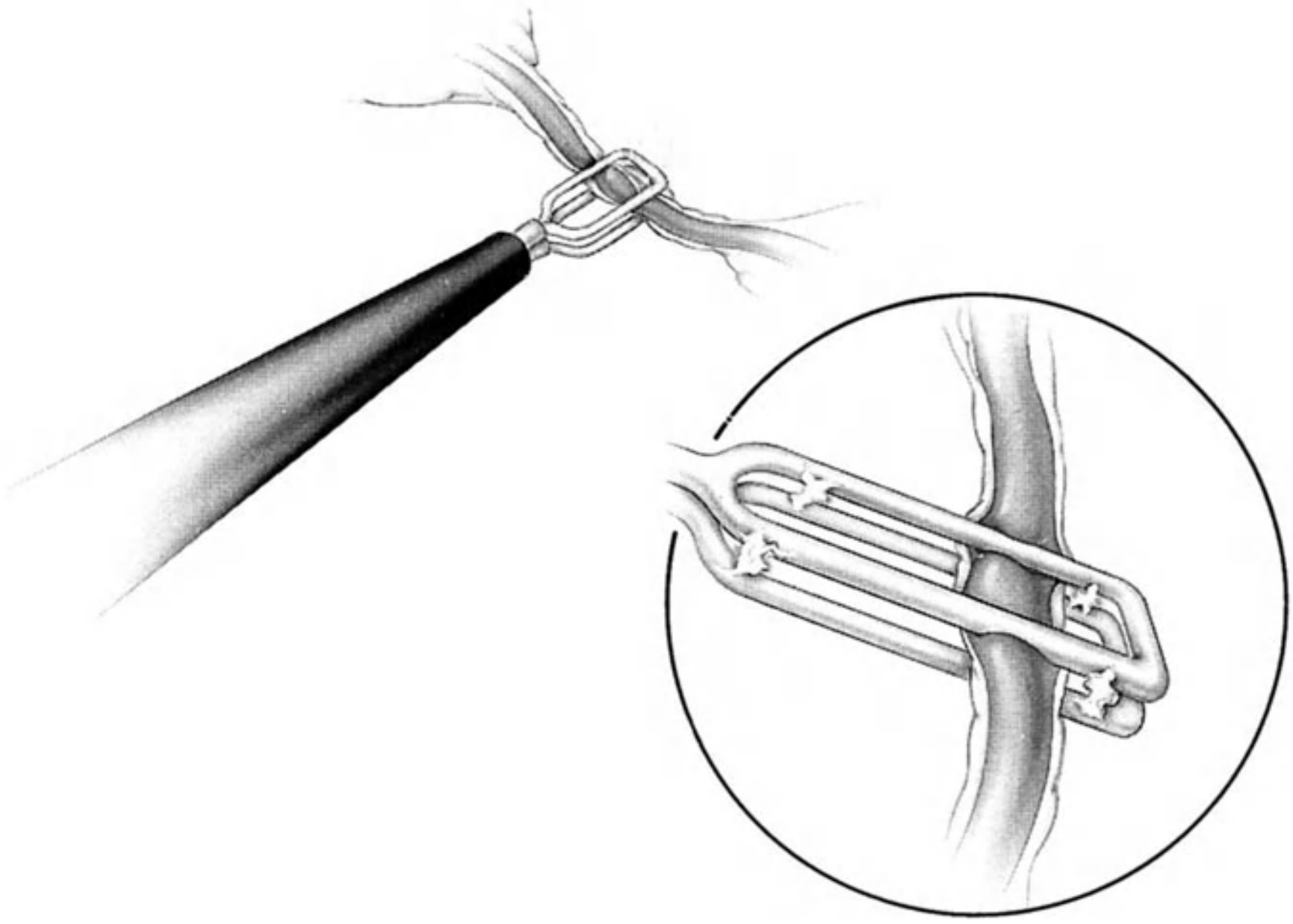

FIGURE 4.5. Application of bipolar electrosurgery to a mesenteric vessel. Inset, Short circuit of the current between applied paddles of a bipolar unit can lead to ineffective coagulation of the tissue.

In general, tissue can only be cut if the tissue temperature rises rapidly above 100°C so water vaporizes and cells explode. When tissue is heated above 50°C, protein denatures, leading to coagulation. Thus, it is not only the waveform itself that determines the effect on tissue, but also the energy applied over time and whether an arc (arcing of the electricity between the electrode and the tissue through air) is created.

High-frequency current can be applied to affect tissue in the following three ways (Figure 4.6):

1. cutting
2. fulguration (black coagulation)
3. desiccation (white coagulation)

Cutting

Cutting is usually achieved with a continuous waveform and a high-frequency current flow. With the cutting mode, tissue vaporizes so quickly that heat conduction is minimized and the depth of tissue necrosis is limited to 200 μm or less.[10] Cutting current confines damage to a small area under the scalpel electrode. Only cells adjacent to the active electrode are vaporized and cells a few layers deep essentially are undamaged. Therefore, electrical cutting can be clean, but it is not generally accompanied by any hemostasis. When using the cutting mode, activating the electrosurgical unit before touching tissue with the electrode is critical; this allows the cutting arc to establish itself at the start of the incision. As mentioned earlier, hemostasis can occur if the surrounding tissue is heated to the point of coagulation. However, cutting with moderate or significant hemostasis can be obtained by blending an interrupted waveform with the continuous waveform.

Applying the active electrode in the cutting mode creates a steady stream of arcs less than 10 μm long with a temperature of about 4,000 to 5,000 K that rapidly increases temperature in the immediately adjacent tissue. Each arc strikes a cell along the leading edge of the incision, rapidly heating the intracellular fluid so the membrane bursts and the intracellular fluid and its contents vaporize. Because the cell contents vaporize, as the electrode is moved, it "rides" smoothly in a steam envelope; thus cutting is not a true contact mode and gives the surgeon no true tactile feedback.

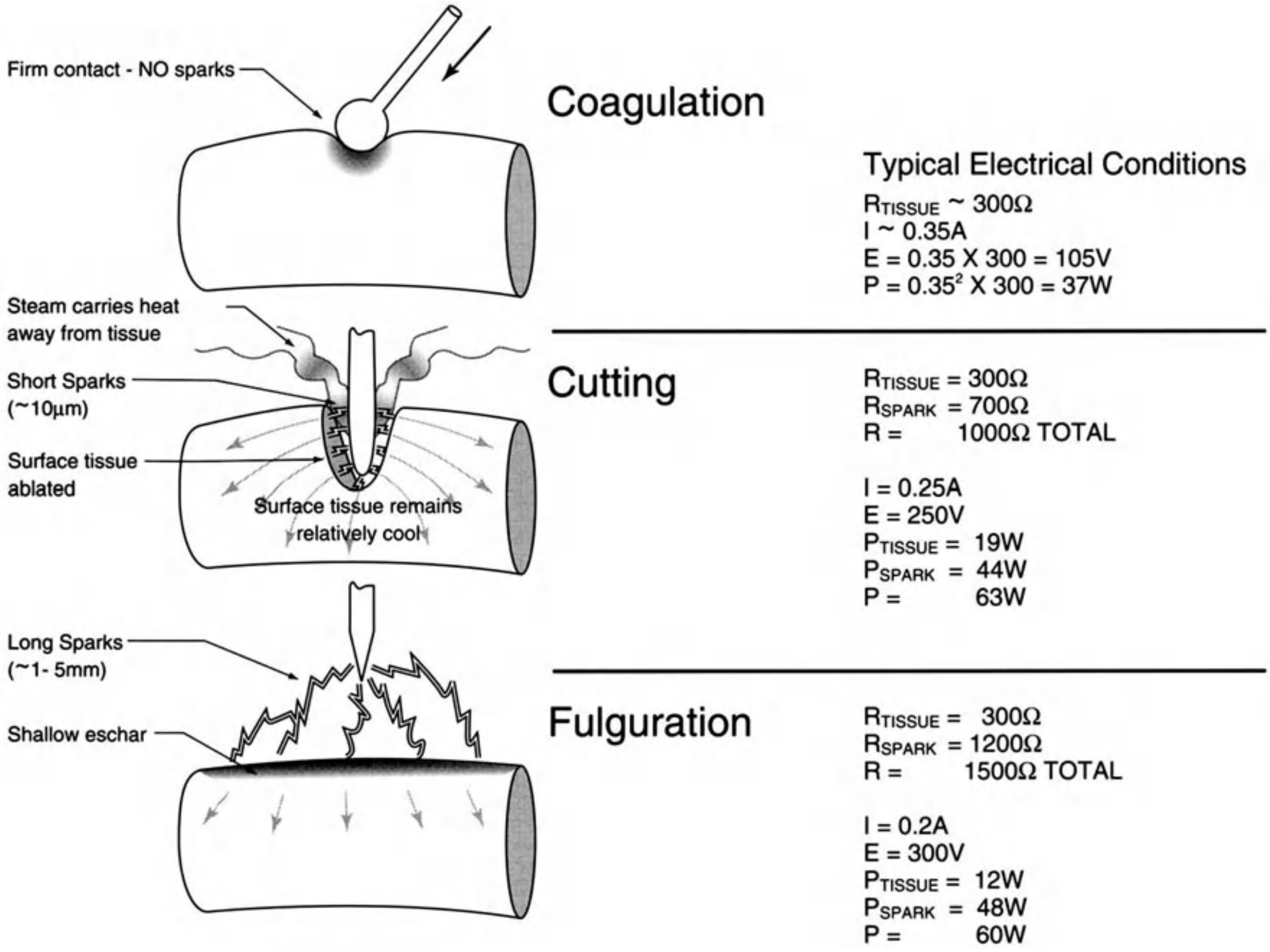

FIGURE 4.6. Effects of the three modalities of electrosurgery: coagulation, cutting, and fulguration. Note their relation to the resistance (R), voltage (V), current (I), power (P), location, and shape of the tip used (V = volts, A = amperes, Ω = ohms, W = watts, E = energy). (Courtesy of Aspen Laboratories, Englewood, Colo.)

If the pure cutting electrical waveform is interrupted and the voltage is increased to deliver the same wattage, then heat conduction is promoted, resulting in improved hemostasis because small vessels are coagulated. In this combination mode the slightly interrupted waveform increases the thermal spread so cutting is achieved with moderate hemostasis. Although the lateral tissue damage increases and more time is needed for cutting when compared with the pure sinusoidal waveform, the active electrode is still riding in a steam envelope and tactile feedback is again absent.

The arcs used for cutting are formed when the electric field between two electrodes separated by a gaseous medium becomes strong enough to ionize the gas. The strong electric field accelerates the ions, which then collide with other gas molecules. If the acceleration is great enough, the gas molecule hit by the ions may also be ionized so the gas is continually ionized. The electric field has to be strong enough to accelerate the molecules so the ionization process is initiated and then is sustained so the ion population grows. If the electric field is too weak, the ion cloud will collapse. When the ion population reaches a critical density, an arc forms. Current will flow between the active electrode and the tissue because the ion cloud has low resistance and is a good conductor. The atoms in the ion cloud will emit light, so an arc may become visible.

Because the electric field must be strong enough to start ionization and to sustain the ionized gas cloud, a defined power is necessary that depends on the impedance of the gas between electrode and tissue. Nearly any gas can support an arc; air ignites over a gap of only a few micrometers when the voltage exceeds about 300 V. A single arc exists for less than one half-cycle of the waveform (0.5 to 2.3 MHz) used and therefore almost no heat is transferred to the surrounding tissue. However, the differences between the arc duration and the frequency of the continuous and interrupted waveforms may lead to the slightly different cutting and fulguration effects.[11]

An effective cutting waveform must carry more than 300 V to ignite arcs and to have enough power to sustain them. The tissue disruption is probably not only caused by the high current density of the arcs that vaporize water in cells, but also by an acoustic wave that dissipates within a short distance of its origin. Thus, both vaporization and acoustic waves rapidly disrupt tissue with only a small amount of lateral tissue damage.

Fulguration

For fulguration, the active electrode is positioned usually 5 to 10 mm above the tissue, and a tree-like cluster of arcs is discharged onto the tissue surface. Fulguration is a high-impedance modality with relatively high voltage, low current, and a highly damped interrupted waveform. The peak-to-peak voltage is high enough (up to 10,000 V) to ignite and sustain arcs longer than 1 mm. The arcs may have a temperature of more than 5,000 K and they rapidly carbonize the superficial cell layers. Because the current density is relatively low in the target tissue, little desiccation occurs below the surface eschar.

Most of the energy delivered dissipates to heat the air around the active electrode. Because air is an insulator, a high-voltage current is necessary to ignite and sustain an effective arc. To reduce voltage and increase the arcing effect, an argon-beam coagulator has been introduced to dry large oozing surfaces. Because the argon's arc ignition voltage is 20% less than that of air, the arcs scatter less, instead following in the laminar argon gas flow. Thus, they can be directed more precisely and over a greater distance than the random arc strikes associated with fulguration in air.

The disadvantages of fulguration are not only that the desiccation is superficial, but also that the electrode tends to absorb heat, thus bonding with tissue it inadvertently touches. If the eschar is then pulled up, bleeding will start again. Because electrofulguration is a noncontact mode, it produces hemostasis without the probe adhering to the coagulated tissue. It is most commonly used to seal broad areas of capillary oozing or ablate a rectal tumor. In our opinion, the only use for fulguration in laparoscopic surgery may be in sealing large areas of capillary bleeding. Because it requires much more voltage than electrosurgical cutting or desiccation, the surgeon must be especially cognizant of the risk imposed by capacitive or direct coupling when performing fulguration (see later section, Potential Injuries Related to Electrosurgery).

Desiccation or Coagulation

Desiccation is the only true contact mode of electrosurgery. The tissue temperature is raised to the point at which proteins denature and form a rigid coagulum. Although proteins start to denature at about 45°C, a temperature of at least 55°C is required to form a coagulum. The amount of tissue coagulated depends on the volume of tissue raised above this threshold temperature.

Because desiccation is accomplished without an arc, no energy dissipates into the air, and because the electrode is in contact with the tissue, less power is needed for desiccation than for fulguration or cutting. The impedance is low as desiccation begins, so desiccation can be achieved with low voltage and high current. As tissue dries and proteins denature, molecules with the potential to become ionized become immobilized in the coagulum matrix and the tissue impedance rises. Arcing should be avoided during desiccation because it stops the heating process and carbonizes only the superficial tissue. Limiting the generator output prevents arcing because the voltage is not great enough to ignite arcs.

The low-voltage, high-current waveform is favorable for desiccation because it suppresses arc formation. If cutting current is used for dissection, the peak-to-peak voltage should be less than 500 V so the tissue heats slowly. The key to maximally effective desiccation is a waveform that has an open circuit voltage of less than 300 V peak-to-peak to prevent arcing. In most electrosurgical units such voltage is available only in bipolar electrosurgery, although true low-voltage monopolar desiccation is likely to be available in the near future.

Electrosurgery in Laparoscopic Surgery

Both monopolar and bipolar electrosurgery are currently widely used in laparoscopic surgery. Although bipolar electrosurgery is safer than monopolar, its application is limited to tissue desiccation, so most laparoscopic surgeons still prefer monopolar electrosurgery. The combination of bipolar electrosurgery with an endoscopic scissors is an attractive alternative that must be evaluated in the future.

Monopolar electrosurgery for laparoscopic procedures is advantageous in that it

- is a familiar dissecting method
- provides excellent hemostasis
- is universally available in operating suites
- is inexpensive

All these advantages have been supported by successful use of monopolar electrosurgery in laparoscopic gallbladder surgery.[12-15]

The disadvantages of monopolar electrosurgery, which may be more significant in laparoscopic colorectal surgery compared with laparoscopic gallbladder surgery, are

- extensive smoke development
- depth of tissue effect cannot be predicted precisely
- risk of injury during dissection

Smoke Development

Electrosurgery may be more hazardous in laparoscopic colorectal surgery compared with gallbladder or gynecologic surgery because smoke development can be extensive, especially during dissection of the fatty mesentery. Because smoke evacuators and rapidly recirculating gas insufflators are not commonly used in laparoscopic colorectal surgery, usually the smoke-filled gas is flushed out of the abdominal cavity through an open cannula site. Whether the smoke created by electrosurgery or laser represents an inhalation hazard for patients or operating room personnel is unknown but is of some concern.

The smoke may have biologic as well as chemical effects. Heating biologic tissue results in the formation of molecules with aromatic ring structures and unsaturated radicals that may be harmful when inhaled. Electrosurgery smoke has been shown to be mutagenic in vitro to the TA98 strain of *Salmonella*[16] and to negatively affect the lungs in rats (muscular hypertrophy of vessel walls, alveolar congestion, and emphysematous changes).[17] These effects have also been seen in smoke generated by CO_2 laser application.[17,18]

Human immunodeficiency virus (HIV) proviral DNA with a median aerodynamic diameter of 0.31 μm (a range of 0.1 to 0.8 μm) has been reported in the laser plume of vaporized HIV-containing tissue.[19] Matchette et al.[20] found viable bacteriophages in CO_2 laser plume, but the events were rare in their study. Because most of the viable particles were large (at least 7.5 μm in aerodynamic diameter), these particles should be easily filtered with a recirculating insufflator. The significance of these scientific reports remains to be determined. No epidemiologic evidence exists that operating room personnel or patients have been harmed when exposed to electrosurgery smoke or laser plume. Nonetheless, we recommend taking simple measures to reduce the exposure to smoke, such as using an insufflator with a filter larger than 0.2 μm to recirculate CO_2 gas. These measures will not only reduce the risk of any harmful effects of smoke, but will also improve visibility during use of electrosurgery or lasers in laparoscopic surgery.

Extent of Tissue Damage

Although the depth of penetration cannot precisely be predicted using monopolar electrocoagulation and it may be dangerous to use electrosurgery close to vulnerable organs, such as the duodenum, the ureter, or larger blood vessels, knowledge of the principles of electrosurgery may help prevent inadvertent damage and help the surgeon to better predict the effects of electrosurgery on tissue. For example, the surgeon may deliberately choose a suitable combination of cutting current and power level to achieve a desired tissue effect while minimizing the probability of inducing inadvertent tissue injury. This may be especially important in laparoscopic surgery where the field of vision is somewhat confined.

Electrosurgery in laparoscopic surgery carries several risks not present in open surgery. Saye et al. investigated the relationship between spark generation and the power setting selected during monopolar surgery.[21] Their data showed that the chance of injury during laparoscopic dissection or coagulation is only slight when the power is kept at the minimum level needed to achieve the desired effect on tissue. With a power setting of 30 to 35 W, sparks from the electrode tip jumped approximately 2 to 3 mm 50% of the time monopolar electrosurgery was used.

Saye et al. have also shown that the tissue temperature many centimeters from the operative area may rise substantially when using proper electrosurgical techniques. If tissue is desiccated and the current has to pass through a duct-like structure on its way to the dispersive electrode (Figure 4.3), the cross-sectional area of its pathway is reduced, so the current density will increase at this point. Thus, the tissue desiccation may occur far from the primary active electrode. This concept is important when duct-like structures, such as the appendix, pieces of the greater omentum, or adhesions, are cut or desiccated. The authors concluded that reliably predicting the path of electrical current through human tissue is impossible and that the surgeon should avoid using monopolar electrosurgery on any free-floating, duct-like structures. Although bipolar instruments may help confine the effects of electrosurgery to the structures grasped, extensive coagulation may also damage surrounding tissue. For instance, ureter injuries have been reported after using bipolar electrocoagulation near the ureters in gynecologic surgery.[22,23]

Potential Injuries Related to Electrosurgery

In laparoscopic surgery, closely monitoring the effect of electrical current on tissue is mandatory because the laparoscope provides only a limited view during dissection. Inadvertent injuries using monopolar electrosurgery occur primarily at the active electrode and the return electrode. Near the active electrode, injuries can occur in any part of the instrument: the handle, the insulated shaft, or at the uninsulated tip. These inadvertent injuries occur because of insulation failure involving either direct coupling or capacitive coupling (Figure 4.7A and 4.7B).[24]

Insulation failure occurs most commonly at the distal shaft as a result of repeated heating of the instrument or because of damage to insulation when the instrument is inserted in the cannula. Insulation failures near the instrument tip can be recognized immediately if the tip is in view during the application of electrical current. Also, the instrument being used must be visible in the laparoscopic field. The insulation on the shaft of the instrument rarely fails, but it is potentially dangerous because it is usually not recognized during laparoscopic procedures.

Direct coupling describes any inadvertent contact between the active instrument and other metal instruments or cannulas in the abdomen. While the metal instrument tip is free and ready to be used for coagulation or cutting, the more proximal metal parts can touch other instruments; this contact may lead to accidental coagulation or cutting without insulation failure. Thus, during the application of cutting or coagulating current, the entire instrument blade must be visible in the laparoscopic field.

Another important mechanism of inadvertent tissue damage during monopolar electrosurgery is capacitive coupling. Capacitance is the ability of an electric nonconductor to store energy. A capacitor consists of two conductors separated by an insulator. Capacitive coupling can occur if an instrument with insulation failure along the shaft is used in a metal cannula with a plastic abdominal wall anchoring device; the plastic anchoring device prevents the current from flowing through the metal cannula into the abdominal wall and on to the dispersive electrode.[24,25] In general, 10% to 40% of the power of the electrosurgical unit may be coupled, or transferred, from the isolated shaft to the active electrode to the cannula. As long as the current can pass through a low power-density pathway and return to the dispersive electrode, it will not harm the patient. If the path to the dispersive electrode is blocked through a high-resistance,

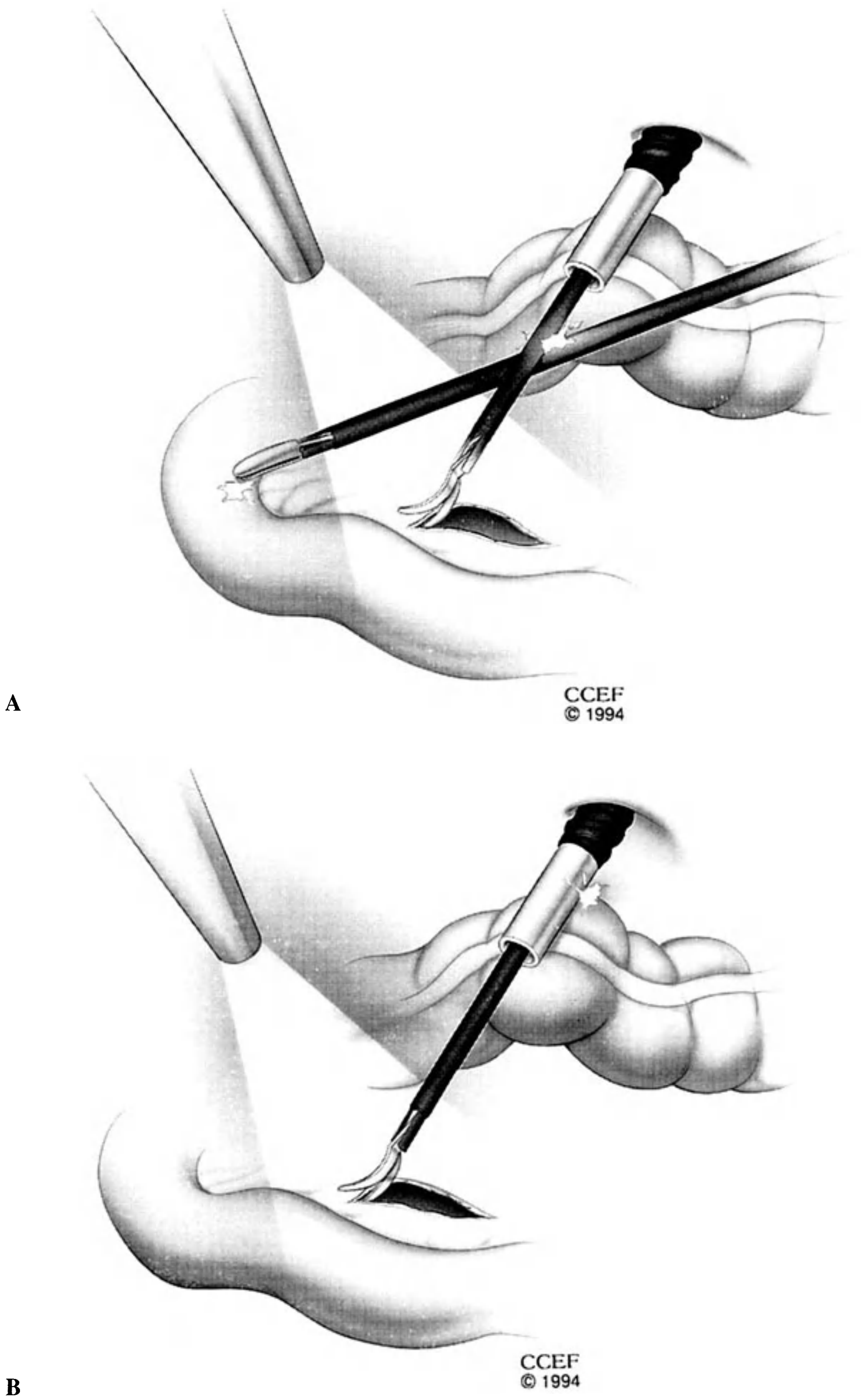

FIGURE 4.7. Insulation failure can occur by two major means when performing electrosurgery: A, direct coupling between two instruments; or B, capacitive coupling when the charged instrument is being used with a metal cannula that is insulated from the abdominal wall by a nonconducting anchoring device.

nonconductive anchoring device, however, capacitive coupling can occur.

Stray currents produced during capacitive coupling may make inadvertent burns on intra-abdominal structures. When a metal cannula (or instrument with insulation failure) touches any organ or intra-abdominal structure when stray current is stored in the cannula, this electrical energy may be discharged from the metal cannula to any structure touching it, including those outside the surgeon's field of vision. Capacitive coupling can occasionally be recognized by neuromuscular stimulation of the abdominal wall.

Direct coupling and capacitive coupling rarely cause electrical injury. Unfortunately, they are seldom recognized during a procedure because they usually occur outside the view of the laparoscope[24,25]; however, such injuries can be prevented. Capacitive coupling can be prevented if the anchoring device and the cannula are both made of plastic or metal. A commercially available 7-mm shield (Electroshield, Electroscope, Boulder, Colo.) that is placed around the shaft of 5-mm dissecting and coagulating will also prevent injuries from direct and capacitive coupling. A high-frequency ammeter (EM-2 Monitor System, Electroscope) can be connected to the Electroshield; the ammeter indicates visually and audibly when any stray electrosurgical energy is detected. If insulation failure is detected, the Electroshield deactivates the electrosurgical unit automatically.

Although alternating current has the potential to cause an effect at both electrodes, the visible effect usually occurs at the active electrode because the current density is much higher at the active electrode because it is smaller, and tissue temperature is directly proportional to the square of the current density. The alternating current delivered at the active electrode is identical to that at the return electrode; therefore, if the current density is the same at the return electrode as at the active electrode, the same thermal effect will occur at both. Monopolar electrosurgery is most commonly used with a return grounding electrode, which allows any current flow through the body to safely disperse. The maximum temperature attained under a dispersive electrode depends on the maximum current density, the duration of activation, and the relative cooling from tissue perfusion. The distribution of the current under the dispersive electrode depends on the design of the electrode and the anatomic distribution of tissue under it.

Resistive and capacitive contact electrodes can be used as dispersive electrodes with a low risk of inadvertent thermal injury if the electrode is applied correctly and not accidentally dislodged. Resistive electrodes usually are gel pads or a conductive adhesive and are in resistive contact with the tissue. Capacitive electrodes have a nonconductive film between a metallic plate and the skin surface so a capacitor is formed and a type of capacitive coupling is used to prevent injury. Although resistive dispersive electrodes, in contrast to capacitive electrodes, have a nonuniform heating pattern because the current is more concentrated at the electrode edges, both types of dispersive electrodes appear to be equally safe in surgery.

To prevent burns at the return electrode, manufacturers have incorporated electronic sensors with circuit breakers (contact quality monitoring electrodes) in the electrosurgical unit that monitor the quality of the connection between the dispersive electrode and the patient, as well as between the cable and the connector when no surgical current is in use. The change in contact impedance during the procedure is determined by a microprocessor, and if impedance increases over a certain predetermined level, the electrosurgical unit will shut down. These safety features, together with the proper use of dispersive electrodes, have substantially reduced the number of burns at the return electrode.

Contact quality monitoring is thus rapidly becoming standard in electrosurgical units. Not all contact quality monitors are effective in detecting pad detachment—some will not sound an alarm until only an area a few centimeters square remains. Such a small return area is almost certain to cause a burn. When evaluating electrosurgical units equipped with these electrodes, the effectiveness of pad detection can be determined by applying the monitor according to the manufacturer's instructions, then slowly peeling the pad away until a return alarm sounds. This test should be done with the unit idle, then again at its minimum power setting. If less than 50% of the pad area remains at the onset of the alarm, the contact quality monitor cannot be relied on to prevent pad burns; the operating room staff then should continue surveillance as if no monitor were available. A 50% loss of area increases the temperature fourfold at the return electrode site.

Laser Systems

The word *laser* is an acronym derived from "light amplification by the stimulated emission of radiation." It is light generated by application of energy to a lasing medium in which atoms are raised from their ground energy state to an excited energy level. On return to their ground energy level, the atoms release photons at the wavelength of the lasing medium to produce laser energy. The photons are reflected in a resonator chamber, producing more laser energy from the lasing medium. The result is a monochromatic (all wavelengths are identical), collimated (waves in parallel), and coherent (equal wavelengths that are in phase) light beam. Although the laser system can produce various colors of light, each color is monochromatic.

Several lasers have been developed and used in almost all surgical fields. Use of laser light in medicine requires an understanding of the interaction of light with living tissue—a complex phenomenon depending on the properties of both tissue and light—and the resultant photochemical, photomechanical, and photothermal effects.

Because we are evaluating the laser as an instrument for cutting and coagulation, only the photothermal interactions with tissue will be discussed here. The photothermal effect is based on the local absorption of electromagnetic energy that is transformed into heat. The degree of the photothermal effect on tissue depends on the following:

1. the optical and thermal properties of the tissue
2. the wavelength of the laser
3. the amount of energy delivered by the laser
4. the exposure time

These four factors define the effect of laser irradiation on tissue and should be known for the chosen laser application so possible tissue damage can be predicted. For example, if coagulation is desired, a wavelength that can deeply penetrate tissue and an exposure time sufficiently long to thermally damage a large area are necessary. If cutting without hemostasis (i.e., without any lateral thermal damage) is desired, a wavelength with high tissue absorption, low penetration, and high peak power should be used.

The cutting and coagulation qualities of a laser system depend on the absorption, transmission, reflection, and scatter of the incoming laser radiation, which are related to the wavelength of the laser and the pigmentation of tissue (Figure 4.8). Most tissue has a high water content, with the major chromophores being hemoglobin and melanin. The light absorption of a particular tissue can be used to predict the effect of a chosen wavelength of laser light on that tissue.

Laser System Wavelengths

Although surgical laser systems with wavelengths from the ultraviolet up to the far infrared are commercially available, we will discuss the advantages and disadvantages of only the CO_2, argon, potassium titanyl phosphate (KTP), and neodymium-doped:yttrium aluminum garnet (Nd:YAG) lasers because they are currently used in laparoscopic surgery.

The CO_2 laser emits light with an infrared wavelength of 10.6 μm. Because this wavelength is invisible, a low-power, red helium-neon laser is added so the laser beam can be guided. Carbon dioxide laser light has a high water absorption and penetrates tissue only slightly (up to 100 μm) (Figure 4.9). It has a superficial effect, allows precise cutting, and produces poor coagulation. Therefore, the CO_2 laser is mostly used for precise surface tissue vaporization.

The KTP laser emits radiation with a wavelength of 532 nm, and the argon laser light emits radiation with a wavelength of 488 or 515 nm; all three wavelengths are visible. Because these wavelengths are highly absorbed by hemoglobin and have a low absorption in water, the laser energy is absorbed in highly vascularized tissue. The tissue penetration does not exceed 2 mm (Figure 4.9). KTP laser units are successfully used to coagulate small vessels, but coagulation of larger vessels is not feasible because most of the laser energy is absorbed by the blood itself and not by the surrounding tissue.

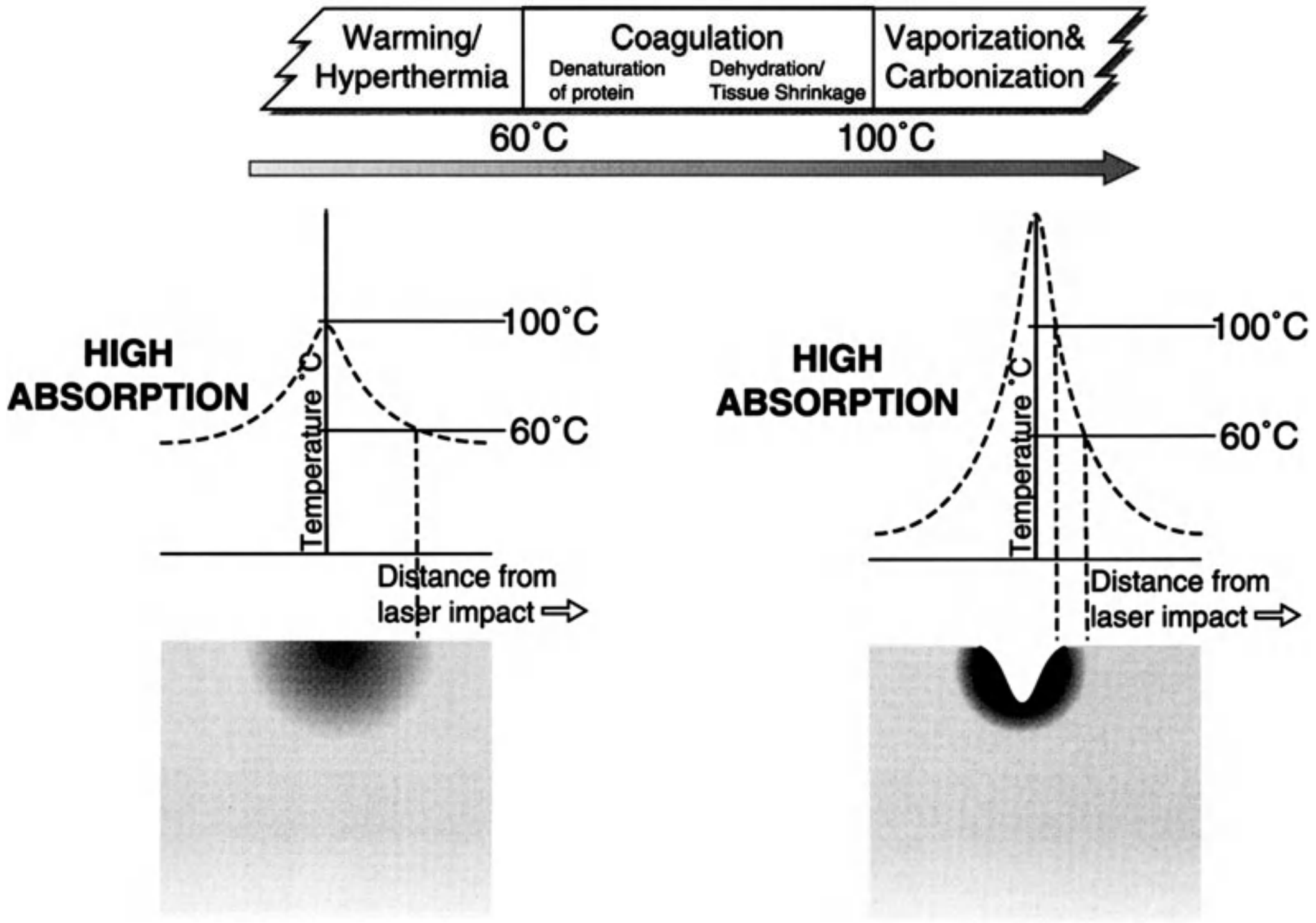

FIGURE 4.8. Absorption of light in composite tissue and water in relation to wavelength. (Courtesy of Surgical Laser Technologies Corporation, Oaks, Pa.)

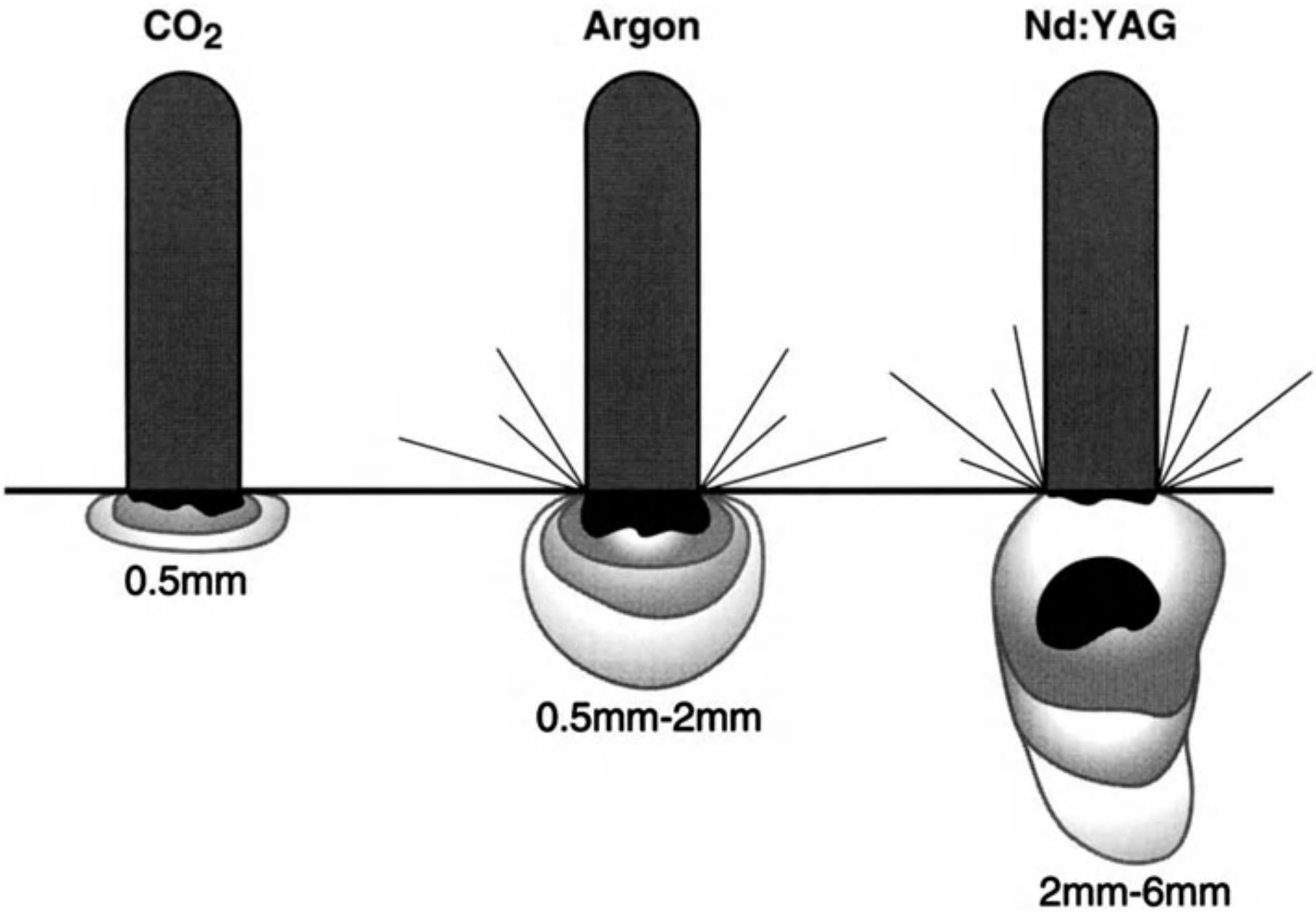

FIGURE 4.9. The amount of energy absorption is dependent on the type of laser used (darker shadows represent higher tissue temperature).

In contrast, the Nd:YAG laser light is only minimally absorbed by water or hemoglobin. Its laser light penetrates water up to 9 cm and living tissue up to 4 to 5 mm (Figure 4.9). The Nd:YAG laser penetrates deeper into tissue than the other lasers and affects a greater tissue volume, so it can be used to coagulate larger vessels.

One important factor that predicts the thermal effect of laser energy on tissue is the power density applied to the tissue. The power density is calculated as the power delivered over an area (watts/square centimeter) and is determined by the total power delivery and the spot size of the laser beam. As in electrosurgery, in which power density is equivalent to current density, in laser surgery, the effect on tissue can be determined by controlling the power density.

Continuous Wave and Pulsed Laser Systems

Laser systems can be classified according to whether energy is delivered as a continuous wave or in pulses of waves (Figure 4.10). A continuous wave laser delivers energy on demand in an uninterrupted beam; the energy has a constant power. A continuous wave laser can be gated so it delivers energy over a short period when the power source is activated. This gated delivery is sometimes called a pulse, and to avoid confusion with a truly pulse-mode laser, we prefer to call these gated pulses. The peak power of the gated pulse of a continuous wave laser is the same as the laser's power.

In contrast, a truly pulsed laser delivers energy in short bursts (pulses) with a high peak power; it is inactive between pulses. A pulsed laser is used when reduced trauma to surrounding tissue is desired and when decreased hemostasis can be tolerated. The high peak power vaporizes the tissue immediately, and the short pulse reduces heat conduction to surrounding tissue, resulting in limited thermal tissue necrosis. Using a superpulsed or "Q-switched" laser system, the lateral thermal damage can be minimized with extremely precise cutting with minimal hemostasis (Figure 4.10C). Thus, thermal damage can be minimized by using pulses shorter than the thermal relaxation time (time needed for tissue to cool to body temperature) of the laser-heated tissue.

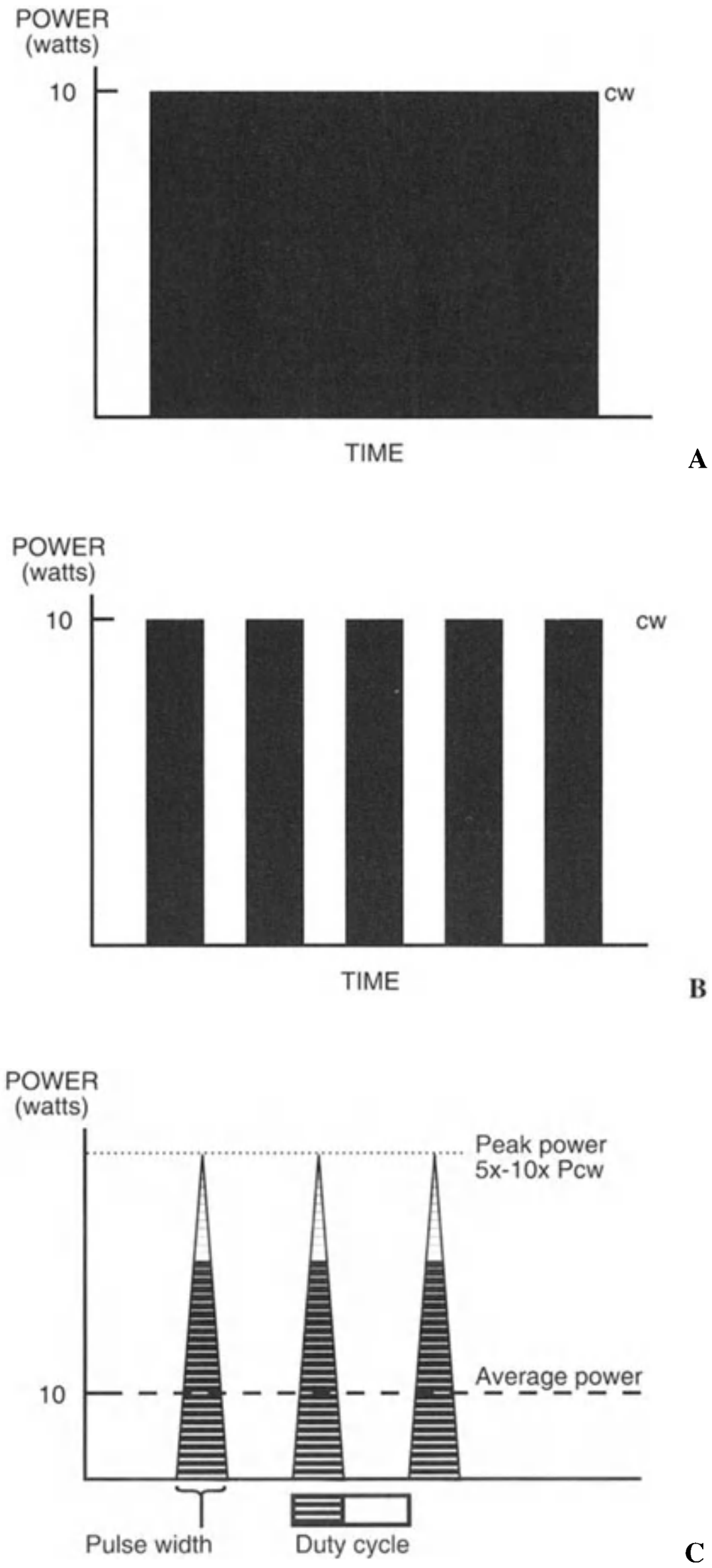

FIGURE 4.10. Different temporal modes of laser. A, Continuous wave (CW) emission; B, a gated pulse of a continuous wave beam interrupted by a timer; and C, superpulse mode (250 to 500 W peak power at 300 to 1,000 times per second, with low average power).

Lasers in Laparoscopic Colorectal Surgery

Currently, no single laser system is appropriate for all the surgical cutting and coagulation requirements of laparoscopic intestinal surgery. The intent of the surgical action defines which laser system may be most useful in any particular circumstance. After evaluating several surgical laser systems, we have found the Nd:YAG Contact Laser (Surgical Laser Technologies Corporation, Oaks, Pa.) to be an excellent tool for both cutting and coagulation in laparoscopic intestinal surgery. The CO_2 laser, with its superficial effect, is an excellent tool for precise cutting, but a free laser beam (a beam of laser applied directly to tissues) in a laparoscopic operation that must be conducted over a wide area is extremely difficult to control and allows no tactile feedback. The visible laser light delivered by a KTP or an argon laser system has some useful applications but is not comparable to the Nd:YAG Contact Laser, which combines the advantages of tactile feedback, low smoke development, precise cutting, and good coagulation.

We have used the Nd:YAG Contact Laser with a power setting ranging from 8 to 14 W in a continuous wave mode. The laser beam is passed through a flexible glass fiber connected to a handpiece equipped with a 0.6- or 1.0-mm frosted-end contact scalpel made of a synthetic sapphire crystal (GRP6 or GRP10, Surgical Laser Technologies Corporation) (Figure 4.11). The contact scalpel has a wavelength converting infrared-absorbing coating on the most distal end that limits the depth of penetration of the 1.06-μm laser emission and increases the temperature gradient of the tip. The light absorption



FIGURE 4.11. Different types of synthetic sapphire tips for the Nd:YAG Contact Laser. (Courtesy of Surgical Laser Technologies Corporation, Oaks, Pa.)

in the sapphire tip results in a high temperature gradient so the laser actually works as a thermal knife. Thus, the laser light does not directly affect tissue. Although the temperature is extremely high at the contact scalpel tip (more than 500°C), the rest of the sapphire tip has a lower temperature, resulting in moderate coagulation. Thus, the Contact Laser, working like true electrocautery, relies on simple heat conduction concentrated at the instrument tip to affect the tissue. Because no laser light is directly applied to tissue, power density does not determine the tissue effect.

Contact scalpels allow precise cutting with a defined depth of heat damage and some simultaneous lateral coagulation. The side of the laser tip can be used for coagulation. Depending on the power setting, it is possible to coagulate blood vessels 1 to 2 mm in diameter. The appropriate contact scalpel and power setting of the laser system must be combined for an optimal result. For example, a high system power (e.g., 14 W) with a 1-mm scalpel will result in excellent cutting and moderate coagulation. If the power is reduced to 8 W, the cutting quality will decrease and the coagulation quality will increase. If isolated coagulation of hepatic or splenic tissue is necessary, a round tip designed for deep coagulation can be used (Figure 4.12).

The Contact Laser also provides two other important qualities: (1) tactile feedback, which allows the surgeon working in a two-dimensional view to adjust the laser before cutting or coagulating; and (2) low smoke development. These characteristics may be critical when the surgeon is working near blood vessels and other vulnerable structures. Several other laser systems are currently available that apply laser light directly to the tissue by touching the tissue with a bare laser-light-conducting fiber. These systems are different and are less easy to control than the Contact Laser.

The major disadvantages of all laser systems are higher costs compared with electrosurgery and their inability to coagulate diffusely bleeding vessels in the mesentery without changing the laser tip or the system power.

Ultrasonic Dissection

Whereas electrosurgical and laser systems use electromagnetic waves as their primary energy

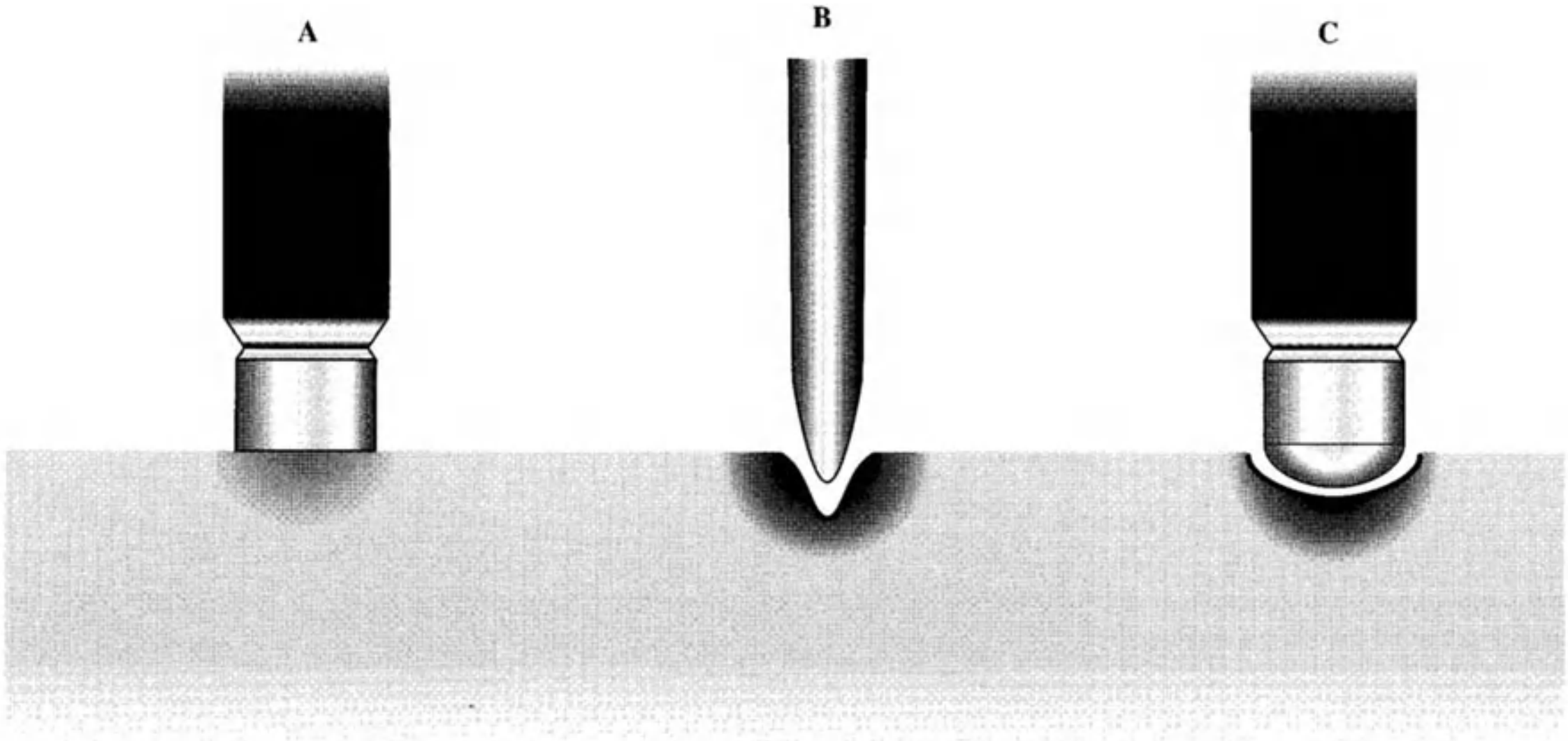

FIGURE 4.12. Tissue effects of various shapes of sapphire probes for the Nd:YAG Contact Laser. A, The flat probe allows for surface heating; B, the fine-tipped probe allows for vaporization of tissue with a cutting quality to the probe and simultaneous coagulation; and C, the convex probe allows for coagulation and tissue ablation. (Courtesy of Surgical Laser Technologies Corporation, Oaks, Pa.)

source, ultrasonic devices use longitudinal mechanical waves with a frequency greater than 20,000 cycles per second. If ultrasonic waves are applied with sufficient power, they can fragment tissue. This fragmentation depends on the water content of tissue, so tissue with relatively high water content, such as fat or parenchyma of the liver or the spleen, can be fragmented with relatively low power while tissue with low water content, such as nerves and blood vessels, will not be damaged. Thus, ultrasonic aspirators that selectively fragment tissue have been used in neurosurgery and liver surgery for many years. If the vibration is directly applied to tissue, the mechanical energy is converted to thermal energy. Currently, two laparoscopic dissecting devices are available that use ultrasonic energy: the ultrasonic scalpel (and the similar ultrasonic shears) and the ultrasonic aspirator. Both instruments use piezoelectric elements to convert electrical energy into mechanical waves of various frequencies and lengths.

Ultrasonic Scalpel

The ultrasonic scalpel (Harmonic Scalpel, UltraCision, Smithfield, R.I.), designed either as a scalpel blade or a clamp coagulator, is a relatively new device used for surgical cutting and coagulation. The unit consists of a generator and a handpiece. The generator supplies an electrical signal to the handpiece through a shielded coaxial cable and senses changes in the entire acoustic train during use, thus alerting the user if the blade is fractured or improperly applied.

The handpiece consists of an acoustic transducer, an acoustic mount, and a laparoscopic blade or scissors (Figure 4.13). The acoustic transducer consists of a stack of piezoelectrical elements that are sandwiched under pressure between two metal cylinders. These elements expand and contract when they are electrically activated, thus converting electrical energy to longitudinal mechanical motion of 55.5 kHz and an amplitude of 60 to 80 μm. The acoustic mount holds the instrument (acoustic system) in the handpiece and amplifies the motion produced by the transducer. Because the mount supports the entire drive train in the handpiece, there is no vibration in the handpiece, and the vibration is transferred maximally to the blade.

The blade contains a second amplifier to further amplify the motion. Because the scalpel blade has poor mechanical cutting quality without vibration, the cutting quality depends on the ultrasonic vibration of the blade (Figure 4.13). The mechanical motion achieved at 55.5 kHz allows good cutting. The vibration of the blade also causes cavitational fragmentation to separate the tissue ahead of the blade.

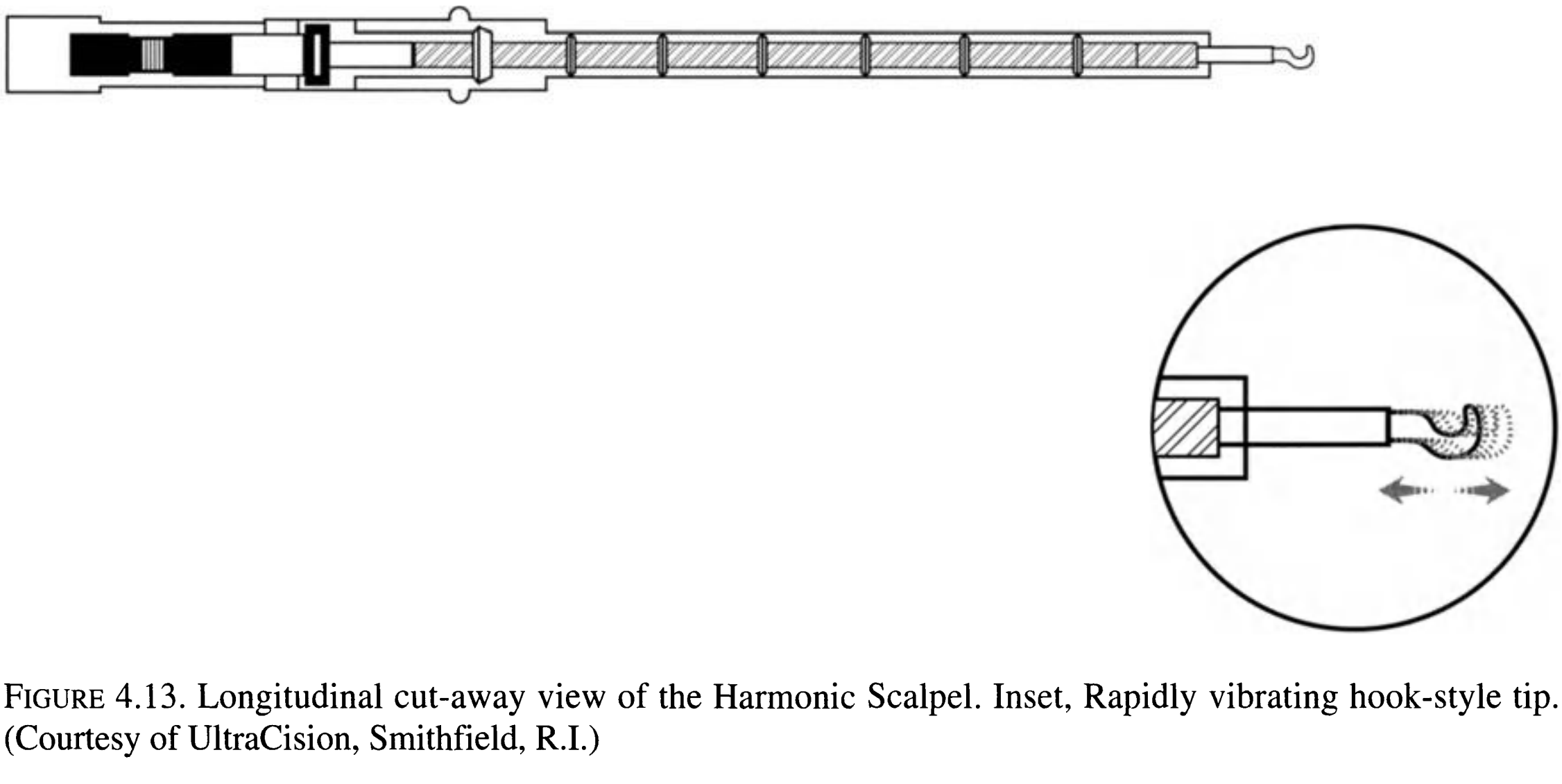

FIGURE 4.13. Longitudinal cut-away view of the Harmonic Scalpel. Inset, Rapidly vibrating hook-style tip. (Courtesy of UltraCision, Smithfield, R.I.)

Coagulation is also accomplished by conversion of ultrasonic energy into localized heat (greater than 60°C) in tissue, which causes collagen molecules in adjacent tissue to denature. Because the scalpel itself is not heated, it does not become hot. Thus, there is no smoke production, no charring, no accumulation of debris on the blade, and thermal injury is reduced. The effect on tissue depends mainly on the blade selected. Available blades include a sharp hook, a dissecting hook, a ball coagulator, and a coagulating spatula. If the sharp edge of the blade is used, good cutting is achieved. If the side of the blade is pressed on tissue, coagulation will occur.

Our experience with the ultrasonic scalpel has been limited, but several animal studies have shown that the vibration of the blade generates a mist during the procedures, especially if irrigation has been used and the tissue is still wet. Unlike smoke, the mist vanishes rapidly. The cutting quality is rapid and good, but hemostasis may be unpredictable if the power is too high. Decreasing the power reduces the cutting quality but improves the hemostasis substantially. Because blunt dissection can be carried out easily with the inactivated blade, the ultrasonic scalpel can be used as a dissection device for all purposes, but some practice is necessary.

Although the coagulation quality of the ultrasonic scalpel is good, it coagulates only if firm pressure can be applied to the vessel—the ultrasonic energy must be directly applied to the vessel so the collagen in the vessel wall will denature to effectively seal the lumen. Applying pressure properly to a small isolated vessel may be problematic because it may be difficult to perform hemostasis without inadvertently coagulating a large area. In addition, if pressure cannot be applied properly when the vessel is under tension, as in a retracted bleeding vessel in the mesentery, the vessel cannot be coagulated.

Ultrasonic Shears

Ultrasonic shears (UltraCision, Smithfield, R.I.) appear to facilitate the use of ultrasonic energy in laparoscopic surgery by clamping or holding the tissue tightly between its jaws. The shear is a clamp coagulator with a tip that consists of a stationary portion that supports the tissue and a vibratory blade that transmits the ultrasonic energy to the tissue. The tissue is grasped with the shears and is clamped. The blade is then activated to coagulate the tissue. Because the blade has a rounded and a sharp side, the cutting effect can be adapted to the tissue by varying the handgrip pressure and choosing the appropriate side (Figure 4.14). The blade can also be used in a way similar to the ultrasonic scalpel to cut or coagulate.

One disadvantage of currently available ultrasonic shears for laparoscopic colorectal surgery is that the single-action blade is too short to easily carry out an extended dissection, such as that of the lateral attachments of the colon or the greater omentum. The advantage of this coagulator clamp is that fatty tissue can be separated with simultaneous hemostasis, which can be especially valuable when dissecting the mesentery.

Ultrasonic Aspirator

The ultrasonic aspirator converts electrical energy into mechanical movement of 24 or 35 kHz by piezoelectric ceramic transducers located in the instrument handpiece.[26] The ultrasonic power is transmitted to tissue from the transducer via a titanium alloy extension and tip. The handpiece contains a central channel for constant suction of cellular tissue and a coaxial irrigation channel. The instrument provides vibration with an amplitude of 250 μm with simultaneous aspiration and suction.

The main purpose of the aspirator in laparoscopic colorectal surgery is to gently separate the fat from major vascular pedicles or ureters without risk of damage to the pedicles. In animals, we have been able to confirm the ability of this instrument to perform fat aspiration and vessel skeletonization. However, because the aspirator cannot cut peritoneum or other firm connective tissue, we believe that this instrument is unlikely to be valuable in laparoscopic colorectal surgery.

Tissue Dissection in Laparoscopic Colorectal Surgery

At present, no optimal device exists for laparoscopic cutting and coagulation. Individual preference, knowledge, and experience should help each surgeon decide what instruments are best

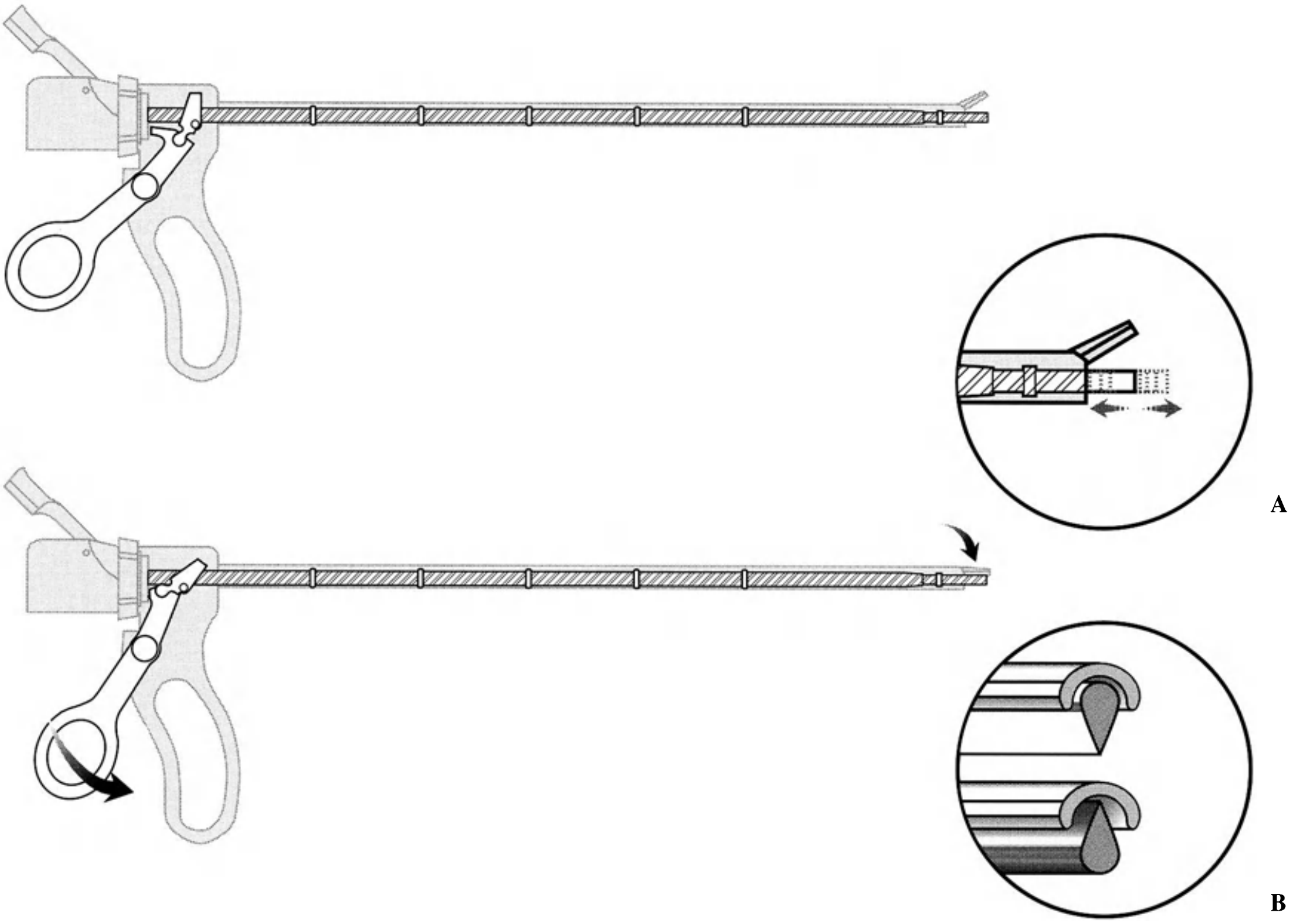

FIGURE 4.14. Longitudinal cut-away view of ultrasonic shears in the opened (top) and closed (bottom) position. Inset, A, Rapidly vibrating tip. Inset, B, The shears may be rotated to effect quality of cutting (sharp edge—better cutting). (Courtesy of UltraCision, Smithfield, R.I.)

for which laparoscopic purpose. Laparoscopic cholecystectomies have been successfully accomplished with low morbidity using monopolar electrosurgery, contact and noncontact laser systems, and the ultrasonic scalpel.[12-15] Because of important differences between laparoscopic cholecystectomy and laparoscopic colorectal resections (such as the need for much wider dissection and ligation of larger vessels in colorectal surgery), experiences in tissue dissection in laparoscopic cholecystectomies cannot be directly transferred to laparoscopic colorectal surgery.

As we emphasize repeatedly in this book, the mobility and dimensions of the intestine increase its potential for injury during laparoscopic instrument manipulation. In addition, a significant amount of dissection with ligation or coagulation of multiple vessels is usually necessary in the fatty mesentery. Even minor bleeding during laparoscopic surgery will impair the overall view as well as the ability to accurately identify tissue layers. Precise dissection in the mesentery and the retroperitoneum with good hemostasis is mandatory to decrease the risk of intraoperative complications.

In a randomized controlled animal study, we compared laparoscopic use of monopolar electrosurgery (n = 23) with an Nd:YAG laser (n = 21) in a canine model and evaluated intraoperative smoke development, difficulty of dissection, hemostasis, postoperative adhesions, and intraoperative and postoperative morbidity. In the electrosurgery group, cutting was performed with endoscopic scissors and coagulation was performed with monopolar electrosurgery. In the laser group, cutting and coagulation were both carried out with the Nd:YAG Contact Laser (CL 60, Surgical Laser Technologies Corporation) using a 0.2-mm frosted-end contact scalpel

(GRP2, Surgical Laser Technologies Corporation). A right colectomy with extensive soft tissue dissection at the base of the mesentery and the intraperitoneal ileocolic stapled anastomosis was performed in all animals.[27]

Using a numerical grading scale for intraoperative difficulty of dissection and postoperative amount of adhesions, we found that scores did not differ between groups. Although smoke development is more extensive when using electrosurgery for cutting and coagulation in comparison with the laser, the overall smoke development in our study did not differ between groups. This similarity probably occurred because coagulation was achieved using electrosurgery and cutting was done with only scissors in the electrosurgery group, whereas both cutting and coagulation were performed with the laser in the laser group.

Our study showed significantly better hemostasis ($P = .01$) when the laser was used as a dissecting device because it was also used for cutting, so minor bleeding did not occur. Nevertheless, the clinical significance of this finding remains questionable because both the Nd:YAG laser as well as scissors and monopolar electrosurgery were successfully used in the study. Neither the laser nor the electrosurgery groups had any serious postoperative morbidity related to tissue dissection.

The following three groups of tissues must be traversed and dissected in laparoscopic colorectal surgery:

1. the mesentery of the colon and the rectum, or pelvic sidewall attachments of the rectum
2. separation of the greater omentum from transverse colon
3. dissection of lateral or dorsal attachments of the colon or the rectum to the peritoneal cavity or the pelvis

Accurate yet expeditious dissection of the fatty mesentery is one of the major challenges for the novice in laparoscopic colorectal surgery. Our approach is to triangulate the tissue between two grasping instruments, two held by the assistant and one held by the surgeon (Figure 4.15). This tension allows for precise initial incision of the peritoneum. Thereafter, mesenteric vessels can be palpated and isolated with a gentle, blunt sweeping maneuver of the dissecting instrument, and then coagulated or clipped.

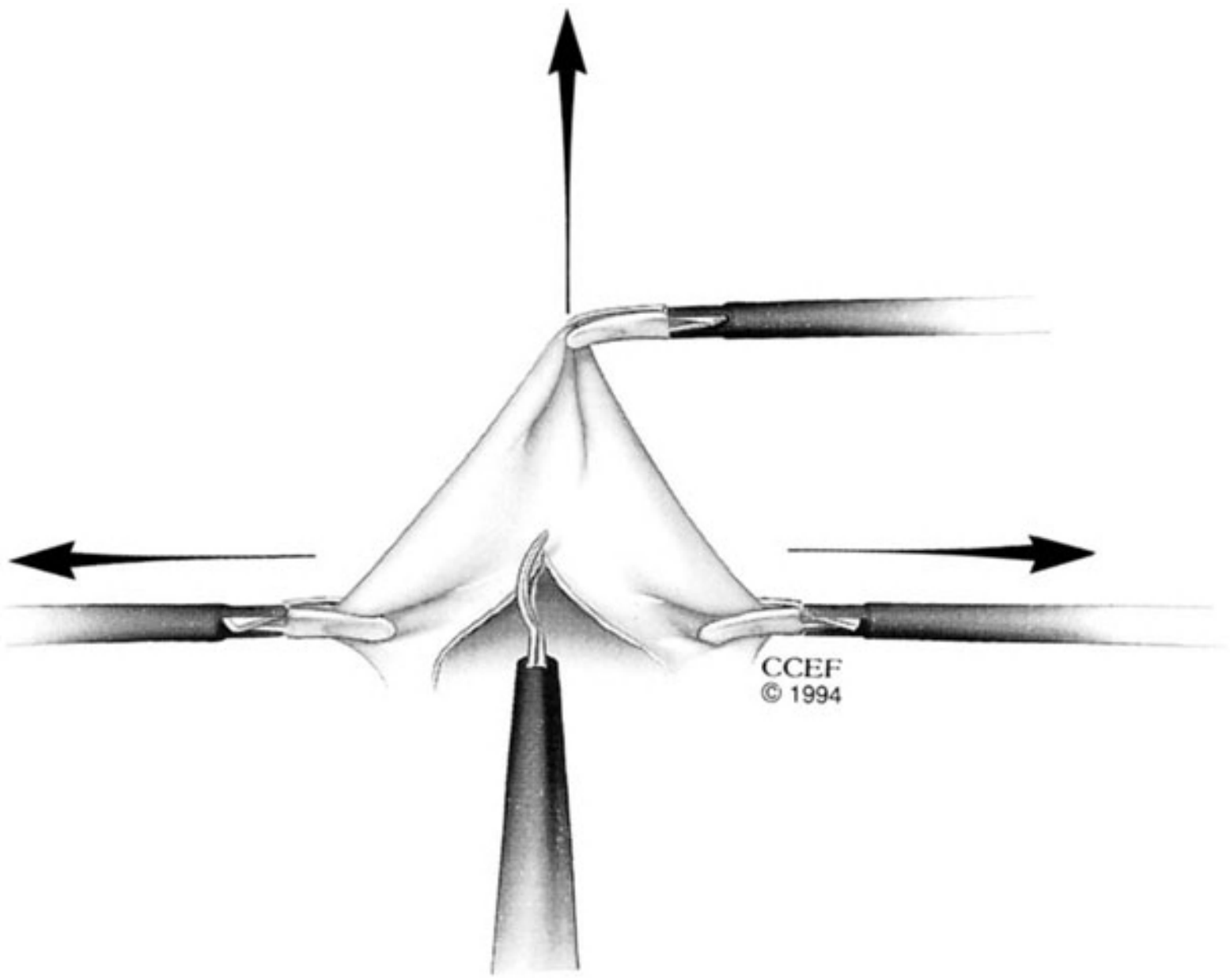

FIGURE 4.15. Tissue dissection using a triangulation method, which allows for excellent exposure as well as good tissue tension.

With this technique, the mesentery can be divided quickly with only minor bleeding.

Incision of the peritoneum and blunt dissection of the mesentery can result in some capillary bleeding. This bleeding may sometimes impair the laparoscopic view and therefore increase the risk of injury to larger blood vessels. Incising the peritoneum with the Contact Laser or ultrasonic scalpel seems to cause less capillary bleeding and thus may be an advantage compared with a simple incision with endoscopic scissors. The disadvantage of using the Contact Laser or the ultrasonic scalpel appears when moderate bleeding occurs during dissection of the mesentery. If electrosurgery is used (bipolar or monopolar), the fatty tissue, together with the bleeding vessel, may be picked up and coagulated as in open surgery. This simple maneuver cannot be done when using the Contact Laser or the ultrasonic scalpel. To coagulate the bleeding tissue with the Contact Laser, the power of the laser system must be reduced to improve coagulation quality of the contact scalpel, or the laser tip must be replaced by a rounded probe specially designed for deep coagulation. Moderately good coagulation can also be achieved with the side of the ultrasonic scalpel if the blade can be applied to the tissue with good pressure.

Currently, we prefer to divide the mesentery with scissors and electrosurgery using blunt and sharp techniques. Small and moderately sized blood vessels and bleeding tissue are coagulated by grasping them with bipolar forceps or a dissecting/grasping instrument equipped with monopolar electrosurgery. Small vessels can usually be coagulated by using the tip or the side of an endoscopic scissors equipped with monopolar electrosurgery. Most larger blood vessels (larger than 3 mm in diameter) must be clipped with endoscopic clips (we prefer the Large EndoClip Applier, US Surgical Corporation, Norwalk, Conn.). We use only endoscopic staplers (Endo GIA 30-V, US Surgical Corporation) to staple and divide the named mesenteric blood vessels.

If a moderately sized or large blood vessel is injured inadvertently and bleeding occurs, the bleeding vessel should be precisely grasped at the puncture site. This action usually stops the bleeding so clips may be safely applied on both sides of the vessel. If the puncture site cannot be located precisely, the bleeding vessel is grasped on both sides of the bleeding area and the vessel is temporarily occluded. Further dissection can then be carried out and the vessel can be clipped or stapled. Occasionally, a gentle twisting of the tissue about the long axis of the grasping instrument may result in hemostasis when other measures fail. After hemostasis is achieved, the operative site is aspirated and irrigated. With good assistance and laparoscopic exposure, nearly all points of hemorrhage may be accurately identified and safely controlled. If the surgeon believes that the bleeding cannot be controlled with laparoscopic techniques, the surgeon should first grasp the surrounding tissue with endoscopic graspers to occlude the vessel temporarily before possibly converting the surgery to an open procedure. The graspers will mark the region of concern and control the bleeding vessel until a final decision as to what type (open or closed) of surgical techniques should be applied.

Separating the greater omentum from the transverse colon should also be accomplished using tissue triangulation. Any adhesions of greater omentum to the colon can be divided under tension using a scissors with electrosurgery, laser surgery, or the ultrasonic scalpel. In some patients with colitis, the greater omentum may develop vascular attachments to the colon, and dissection may be difficult and require the coagulation advantages of electrosurgery. Because the greater omentum itself is usually flaccid, coagulation with a laser or an ultrasonic scalpel is difficult. We prefer monopolar or bipolar electrosurgery in these cases.

The lateral and dorsal attachments of the colon and the mesentery to the retroperitoneum can be dissected with excellent hemostasis using a laser and an ultrasonic scalpel as long as the surgeon stays in the correct avascular plane. Likewise, mobilization of the rectum posteriorly is feasible using nearly any of the described tissue dissection techniques. Larger vessels of the lateral rectal stalks need electrosurgical coagulation (bipolar electrosurgery for vessels more than 3 mm in diameter) or placement of clips.

We have not used ultrasonic shears to divide the lateral stalks, but they may be useful. To completely transect the dense fat and the vessels of the mesorectum, we often use an endoscopic 30-mm vascular stapler to expedite the surgery.

The general information we have presented should serve the surgeon well in nearly all aspects of laparoscopic colorectal surgery. The meticulous attention to detail called for in conventional surgery is even more critical in laparoscopic surgery. In chapters 9, 10, and 11, we will illustrate in detail the particulars of each major colorectal procedure.

References

1. McKenzie AL. A three-zone model of soft-tissue damage by a CO_2 laser. *Phys Med Biol.* 1986;31:967–983.
2. Walsh JT, Flotte TJ, Anderson RR, Deutsch TF. Pulsed CO_2 laser tissue ablation: effect of tissue type and pulse duration on thermal damage. *Lasers Surg Med.* 1988;8:108–118.
3. Zweig AD, Meierhofer B, Muller OM, et al. Lateral thermal damage along pulsed laser incisions. *Lasers Surg Med.* 1990;10:262–274.
4. Hemingway A, McClendon JF. The high frequency resistance of human tissue. *Am J Physiol.* 1932; 102:56–59.
5. Zeng E, Shao S, Webster JG. Impedance of skeletal muscle from 1 Hz to 1 MHz. *IEEE Trans Biomed Eng.* 1984;31:477–481. Abstract.
6. Kanai H, Haeno M, Sakamoto K. Electrical measurement of fluid distribution in legs and arms. *Med Prog Technol.* 1987;12:159–170. Abstract.
7. Ward GE. An efficient method of hemostasis without suture. *Med J Record.* 1925;121:470.
8. Cushing H, Bovie WT. Electrosurgery as an aid to the removal of intracranial tumors. *Surg Gynecol Obstet.* 1928;47:751–785.
9. Tucker RD, Kramlowosky EV, Stasz P. Direct-current potentials created by arcing during monopolar radiofrequency electrosurgery. *Biomed Instrum Technol.* 1990;24:212–216.
10. Schroder T, Brackett K, Joffe SN. An experimental study of the effects of electrocautery and various lasers on gastrointestinal tissue. *Surgery.* 1987;101: 691–697.
11. Pearce JA. *Electrosurgery.* New York, N.Y.: Wiley & Sons; 1986.
12. Corbitt JD. Laparoscopic cholecystectomy: laser versus electrosurgery. *Surg Laparosc Endosc.* 1991;1:85–88.
13. Hunter JG. Laser or electrocautery for laparoscopic cholecystectomy? *Am J Surg.* 1991;161:345–349.
14. Soper NJ, Barteau JA, Clayman RV, Becich MJ. Safety and efficacy of laparoscopic cholecystectomy using monopolar electrocautery in the porcine model. *Surg Laparosc Endosc.* 1991;1:17–22.
15. Bordelon BM, Hobday KA, Hunter KA. Laser vs electrosurgery in laparoscopic cholecystectomy. *Arch Surg.* 1993;128:233–236.
16. Gatti JE, Bryant CJ, Noone RB, Murphy JB. The mutagenicity of electrocautery smoke. *Plast Reconstr Surg.* 1992;89:781–784.
17. Wenig BL, Stenson KM, Wenig BM, Tracey D. Effects of plume produced by the Nd:YAG laser and electrocautery on the respiratory system. *Lasers Surg Med.* 1993;13:242–245.
18. Baggish MS, Poiesz BJ, Joret D, Williamson P, Refai A. Presence of human immunodeficiency virus DNA in laser smoke. *Lasers Surg Med.* 1991;11:197–203.
19. Baggish MS, Baltoyannis P, Sze E. Protection of the rat lung from the harmful effects of laser smoke. *Lasers Surg Med.* 1988;8:248–253.
20. Matchette SL, Vegella TJ, Faaland RW. Viable bacteriophage in CO_2 laser plume: aerodynamic size distribution. *Lasers Surg Med.* 1993;13:18–22.
21. Saye WB, Miller W, Hertzman P. Electrosurgery thermal injury. *Surg Laparosc Endosc.* 1991;1:223–228.
22. Grainger DA, Soderstrom RM, Schiff SF, Glickman MG, Decherney AH, Diamond MP. Ureteral injuries at laparoscopy: insights into diagnosis, management, and prevention. *Obstet Gynecol.* 1990;75:839–843.
23. Nezhat C, Nezhat FR. Ureteral injuries at laparoscopy: insights into diagnosis, management, and prevention [letter]. *Obstet Gynecol.* 1990;76:889–890.
24. Voyles CR, Tucker RD. Education and engineering solutions for potential problems with laparoscopic monopolar electrosurgery. *Am J Surg.* 1992;164:57–62.
25. Tucker RD, Voyles CR, Silvis SE. Capacitive coupled stray currents during laparoscopic and endoscopic electrosurgical procedures. *Biomed Instrum Technol.* 1992;26:303–311.
26. Cuschieri A, Shimi S, Banting S, Vander Velpen G. Endoscopic ultrasonic dissection for thoracoscopic and laparoscopic surgery. *Surg Endosc.* 1993;7:197–199.
27. Böhm B, Milsom JW, Kitago K, Brand M, Fazio VW. Monopolar electrosurgery and Nd:YAG Contact Laser in laparoscopic intestinal surgery. *Surg Endosc.* 1994;8:677–681.

5

Basic Laparoscopic Surgical Techniques

The ability to suture in laparoscopic colorectal surgery is necessary less frequently than in conventional surgery, yet this ability is essential in certain critical situations, such as securing vascular pedicles, ensuring hemostasis, providing tissue support, maintaining tissue closure, and in creating certain surgical anastomoses. Although the principles of suturing and tying knots in endoscopic surgery are identical to those in conventional surgery, major modifications in technique are necessary as a result of the following:

- The lack of direct manual contact, for which palpation with current laparoscopic instruments cannot completely compensate.
- The limited movement of current instruments that are inserted through a cannula anchored to the abdominal wall. The working field is a cone with a fixed point at the insertion point of the cannula. Because of the limited field of movement of laparoscopic instruments, proper placement of the cannula is critical.
- The lack of normal binocular vision without true depth perception, which makes conventional techniques difficult to apply.

Suture Material

Sutures are used primarily to maintain wound closure and to promote wound healing during the time when the wound is fresh and vulnerable to disruption. Wound healing has been divided into three phases described as: (1) the initial lag phase (0 to 5 days), in which the wound strength is minimal and entirely dependent on mechanical support; (2) the fibroplasia phase (5 to 14 days), in which a rapid increase in wound strength occurs; and (3) the maturation phase, in which there is further connective tissue remodeling (14 or more days to final healing). Overall, sutures are critical in the initial two phases of wound healing to support the wound. Wound healing is affected by several suture characteristics: the amount and type of material used, the suturing technique, and the amount of tension on the suture. We briefly review the most important aspects of suture materials used in laparoscopic surgery.

There is no ideal suture available that combines easy handling, ability to form secure knots for all situations, easy sterilization, and low cost. Thus, the surgeon has to choose which suture is appropriate for each purpose, which means deciding between monofilamentous or multifilamentous (twisted or braided) and absorbable (polyglycolic acid, polyglactin, polydioxanone, or polytrimethylene carbonate) or nonabsorbable sutures (silk, nylon, polypropylene, braided polyester, or polybutester).

Besides the physical configuration and elasticity of the suture, the following four major factors should influence the choice of a specific suture:

1. *tensile strength,* defined as the amount of weight required to break a suture divided by its cross-sectional area
2. *knot strength,* defined as the amount of force necessary to cause a knot to slip, a property

directly related to the friction of a given material
3. *"memory,"* defined as the inherent capacity of a material to return to its former shape after being manipulated
4. *tissue reactivity,* defined as the inflammatory response evoked by the presence of a suture within a wound

In general, superior tensile strength and knot security reduce the risk of breakage and allow the use of finer sutures and fewer knots. These properties also minimize tissue reaction and expedite laparoscopic procedures.

The surgeon's preference usually determines which suture is used in conventional surgery. The choice may be somewhat restricted in laparoscopic surgery because access to the target tissue and techniques for suturing and tying the knot may be limited. For extracorporeal knots (slip or square knots), a suture material that slides easily (such as silk, catgut, or a monofilament suture) is preferable. In suture material that slides easily, however, the first hitch may loosen before the second hitch can be secured. Thus, in some cases a material that does not slide as easily but that provides a good knot strength will be preferable. Although sutures made of polyglycolic or polyglactic acid may be used as in conventional surgery, it may be difficult to slide the knot in place smoothly using these materials.

We prefer to use a monofilament polytrimethylene carbonate absorbable suture. It combines excellent tensile strength with good handling properties. It has a good first-throw holding capacity and a smooth knot tie-down, which facilitates tissue approximation and reduces intraoperative knot repositioning, despite its relatively high memory. If a purse-string suture has to be placed intracorporeally, we use a monofilament polypropylene suture as in conventional surgery. We prefer to use coated, braided polyester nonabsorbable sutures in sutured rectopexy. They have high tensile strength and moderate tissue reactivity.

Needles

In laparoscopic colorectal surgery, only swagged and tapered needles should be used to minimize tissue trauma. Intra-abdominal suturing may be performed using three different types of surgical needles: straight, ski-needle, and curved (Figure 5.1).

Whereas straight and ski-needles are easy to place into the abdominal cavity, a conventional needle is often difficult to pass through a cannula. However, the size of the cannula does not necessarily limit the size of the needle because almost any size can be dragged through a cannula incision. If the required needle is too big to be passed through the cannula, the cannula can be removed from the abdominal wall, the suture grasped 2 cm away from the heel of the needle through the cannula, the needle advanced through the puncture site, and the cannula replaced.

In our opinion, a completely straight needle in laparoscopic colorectal surgery is rarely needed. However, a straight needle can be used to affix intra-abdominal structures to the abdominal wall by percutaneous puncture. If bleeding from a cannula incision occurs in lean patients, a straight needle may be passed through the abdominal wall to ligate the vessel with a suture.

Although easy to use, the curved needle may swivel in the needle holder because the grip strength of the laparoscopic needle holder is not as firm as the needle holders used in conventional surgery. It is also more difficult to direct a curved needle properly for intracorporeal suturing.

The ski-needle combines the advantages of the straight and the curved needles (Figure 5.1). The curved tip facilitates passing the needle through tissue, and the straight shaft allows the needle to be grasped easily and turned in the right direction. In addition, some ski needles have a rectangular cross section that allows them to be locked more securely in position using most needle holders.

Needle Holders

Different kinds of nondisposable and disposable laparoscopic needle holders are commercially available with different grasping mechanisms (Figure 5.2). Some have fixed locking jaws, which makes instrument-tying difficult. Others

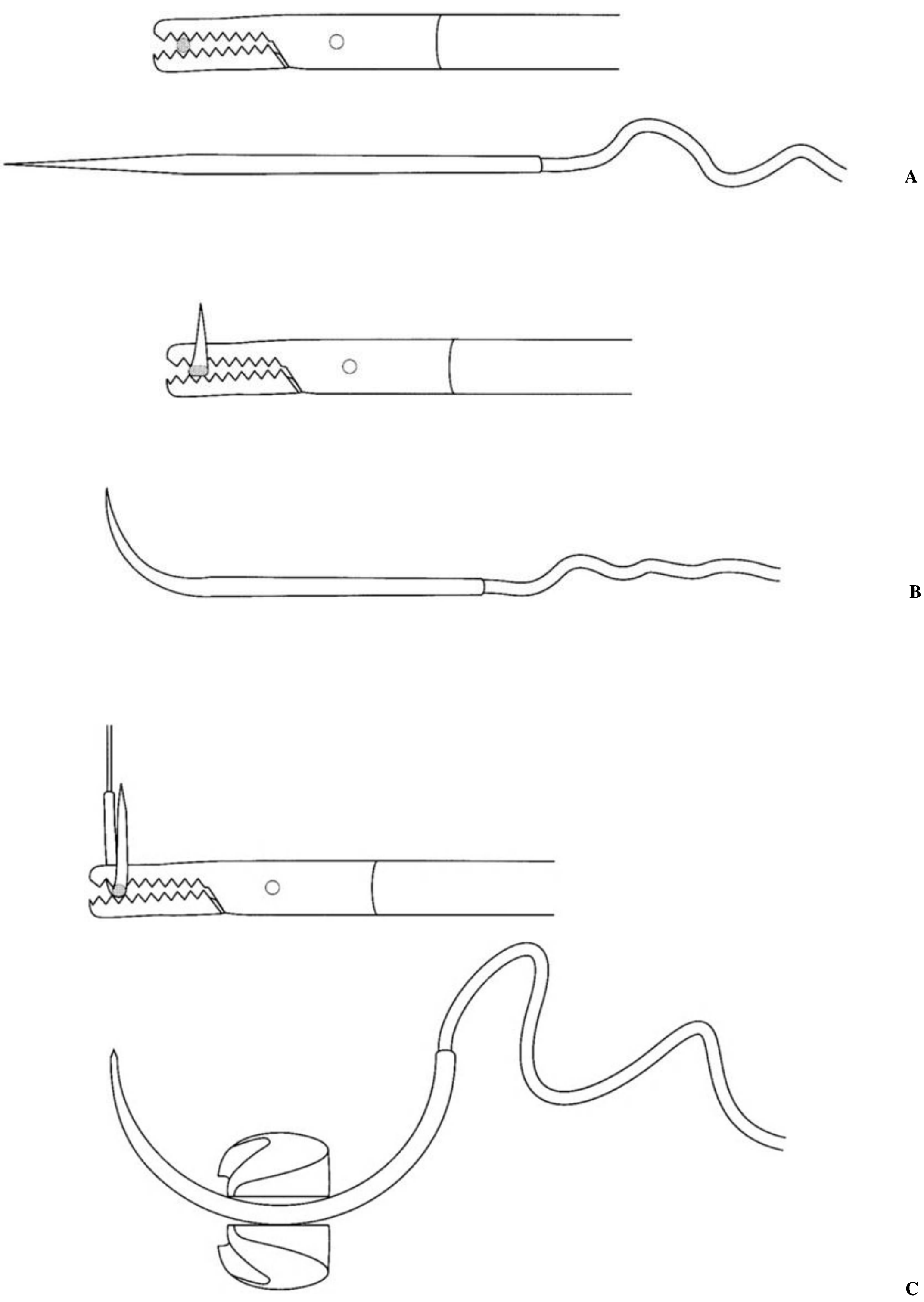

FIGURE 5.1. Needles used in laparoscopic surgery: A, straight, B, ski-needle, and C, curved.

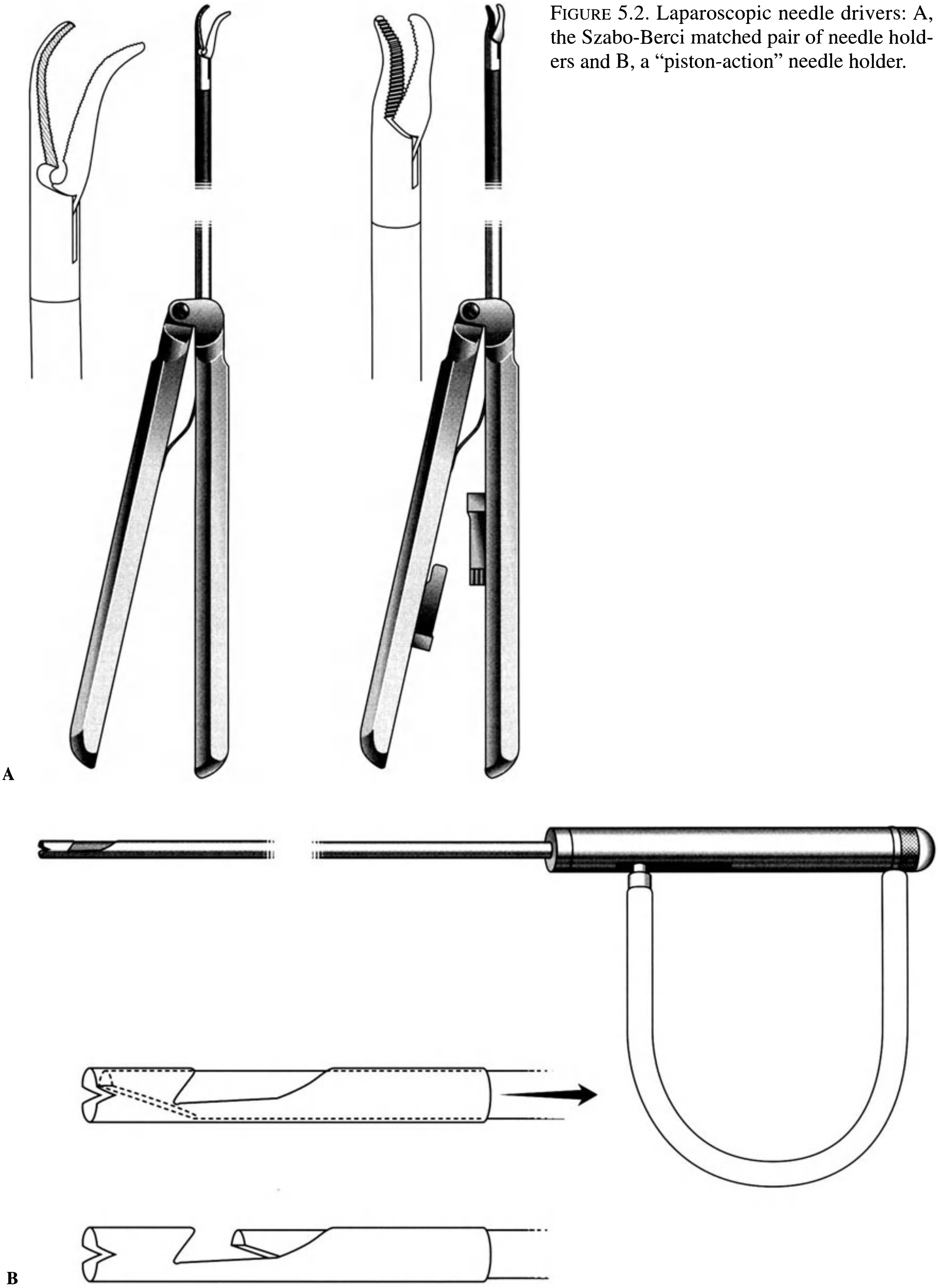

FIGURE 5.2. Laparoscopic needle drivers: A, the Szabo-Berci matched pair of needle holders and B, a "piston-action" needle holder.

have the handles in line with the shaft or handles that can be opened from any rotational position (similar to Castro-Viejo needle holders). The major problem we have encountered using laparoscopic needle holders is that the needle tends to swivel in the jaws when driving through tissue, especially if a curved needle is used. This problem has been partially overcome in some straight and ski-needles by giving them triangular or rectangular cross sections.

Because laparoscopic suturing may require intracorporeal knot tying, the surface of the needle holder's jaws must be designed not only to prevent swiveling the needle but also to hold the suture material without damaging it. Therefore, jaws with sharp teeth on the interior surface of the needle holder should not be used. The jaw design with a diamond pattern is currently our favorite design.

To eliminate swiveling curved needles, a "piston-action" instrument was developed (Cook Surgical, Bloomington, Ind.) in which a spring-loaded shaft is passed through a window in the circular shaft of the needle holder. This instrument holds the curved needle at only one angle relative to its shaft so different angled instruments are necessary to have some flexibility. However, because internal knot tying is impossible with this type of needle holder, the Cook needle holder is not our preferred instrument for laparoscopic suturing.

Currently, the best needle holder design is a matched pair of instruments (Szabo-Berci needle holders, Culver City, Calif.). The needle holder adeptly handles the needle with a slightly spooned curvature of the instrument tip. The needle-grasping instrument (the assistant grasper) is designed primarily to handle tissue and sutures, and to provide counter pressure. The assistant grasper has an aggressively curved and angled tip shaped like a flamingo's beak to reach almost any direction.

Knot Pushers

In laparoscopic surgery, knots can be tied intracorporeally or extracorporeally. If an external knot is tied, a knot pusher replaces the surgeon's fingertip in setting the knot on the tissue under visual control. Different types of knot pushers have been proposed to facilitate external knot tying.[1,2] They all follow the same principles: one end of the suture is pushed down using a partly hollow rod, and an open half or closed circle holds the other end under tension. If a slip knot (a Röder, a Duncan, or a Melzer knot) is applied, a hollow applicator that fits over the entire long end of the suture is used. The knot is pushed down using the hollow rod while pulling on the long end of the suture until resistance is felt, indicating the proper tension on the knot (Figure 5.3). For square knots tied extracorporeally, a knot pusher with a slit circle or an entire circle can be used to push down the knot. Although the knot pusher with the slit circle is easily applied, we prefer a knot pusher with an enclosed circle to prevent loss of the suture while tightening the knot.

Gazayerli designed a knot-tying instrument to facilitate placing extracorporeal knots.[3] It has a 5-mm alligator-type grasping tip with an incor-

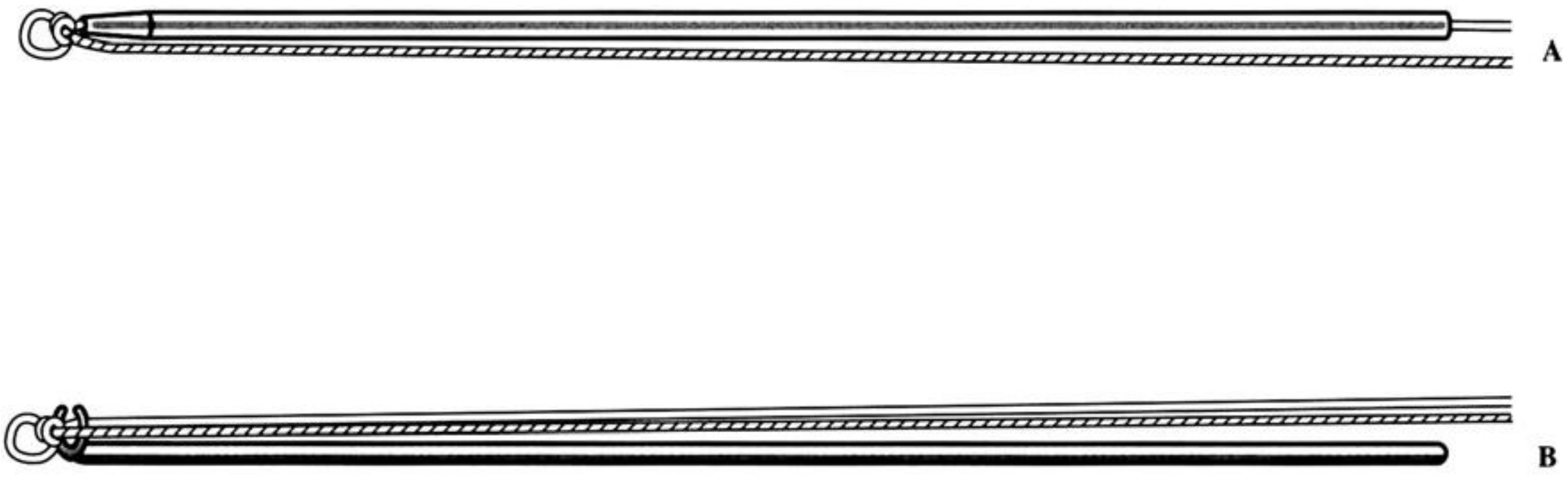

FIGURE 5.3. Laparoscopic knot pushers: A, a hollow push rod and B, a slit-and-circle knot pusher.

porated 4-mm groove. Because this groove is positioned along the tip of the instrument, it allows the surgeon to guide the strands of the suture accurately as the knot is tightened. The closed instrument is placed horizontally between the two strands and is used to push the knot through the cannula. Once the tip of the instrument is inside the abdominal cavity, the jaws are opened and the suture strands are checked to eliminate twisting. The instrument can then be advanced to secure the knot.

Knots

Knotting in laparoscopic surgery is based on the following four types of knots:

1. square (surgical) knot
2. jamming slip knot
3. Aberdeen knot
4. Röder knot

Square Knot

The square knot with one hitch, or the surgical knot with two hitches, is probably the most applied knot in surgery. It can be tied extracorporeally and intracorporeally using several laparoscopic techniques.

For extracorporeal knots, the suture must be at least 60 to 90 cm long to enable both ends of the suture to be exteriorized through the laparoscopic cannula without tension on tissue.[4] Trapping the suture in the trumpet or the flapper valve should be avoided because the suture may be damaged. While tying the knot extracorporeally, an assistant surgeon has to prevent gas leakage from the cannula by placing a finger over the exit site of the suture during knot tying.

An extracorporeal knot can be tied down easily using most currently available suture materials in the same fashion as in conventional surgery, but materials with a high coefficient of friction, like braided cotton, should be avoided. The square or surgical knot is formed with the two loose strands just above the cannula, then it is tightened using a knot pusher. After the knot pusher is removed, a second hitch in the opposite direction is made and is secured. A third or fourth hitch can be applied at the discretion of the surgeon.

Tying an intracorporeal square knot requires a two-handed technique using two needle holders. We prefer to make the knots using the microsurgical technique described as follows. Other techniques, as described by Pietrafitta,[5] may also be used to tie intracorporeal square knots.

The microsurgical technique requires a suture (not longer than 10 cm) that is passed through the tissue (from right to left in this example), with a short tail left on the trailing side (Figure 5.4A). For a right-handed person, the right needle holder then regrasps the suture immediately adjacent to the needle, which may reduce the risk of inadvertent tissue damage. The assistant grasper then winds a loop of suture around the needle holder, grasps the short suture tail to the left (Figure 5.4B), and completes the knot (Figure 5.4C). Holding the jaws of the assistant grasper open before grasping the short tail may help prevent the loops from sliding off its tip. For the first knot, a simple square knot should be used for braided sutures and a surgeon's knot for monofilament sutures. To secure the first knot, the assistant grasper picks up the suture close to the needle, then helps to wind a loop around the needle holder in the opposite direction of the former knot (Figure 5.4D). The needle holder grasps the suture tail and completes the second knot (Figure 5.4E).

If the first knot becomes loose while beginning the second knot, the first locking square knot can be converted into a sliding knot (at least with monofilament suture material) (Figure 5.5A) by pulling one strand until it is straight (Figure 5.5B). The knot on the other strand can then be pushed down to the proper position (Fig. 5.5C) and converted back with pressure on both strands to ensure stability of the knot (Figure 5.5D).

Jamming Slip Knot

A running suture may be initiated with an intracorporeal or extracorporeal square knot or the jamming slip knot created outside the abdomen. The jamming slip (Dundee) knot (Figure 5.6A) is cre-

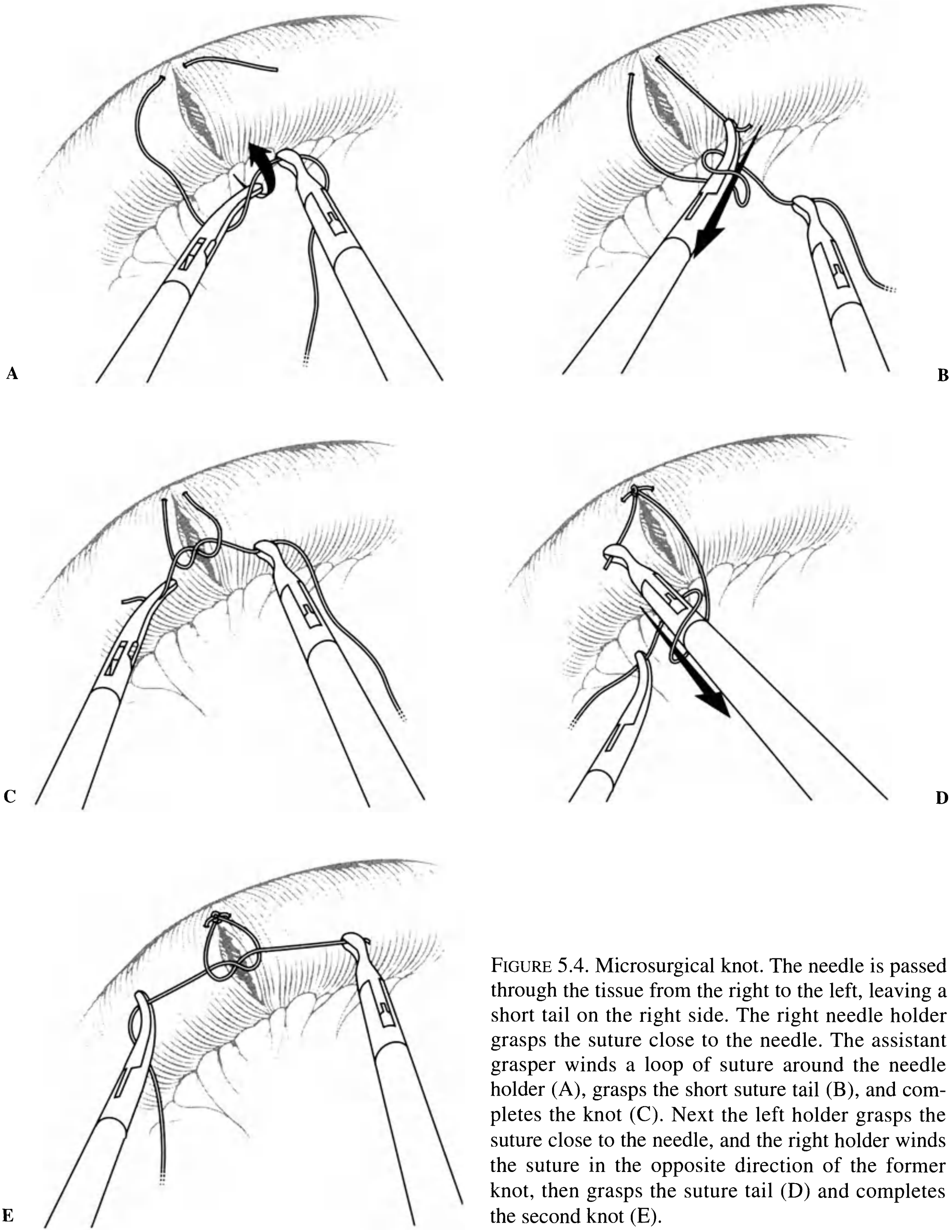

FIGURE 5.4. Microsurgical knot. The needle is passed through the tissue from the right to the left, leaving a short tail on the right side. The right needle holder grasps the suture close to the needle. The assistant grasper winds a loop of suture around the needle holder (A), grasps the short suture tail (B), and completes the knot (C). Next the left holder grasps the suture close to the needle, and the right holder winds the suture in the opposite direction of the former knot, then grasps the suture tail (D) and completes the second knot (E).

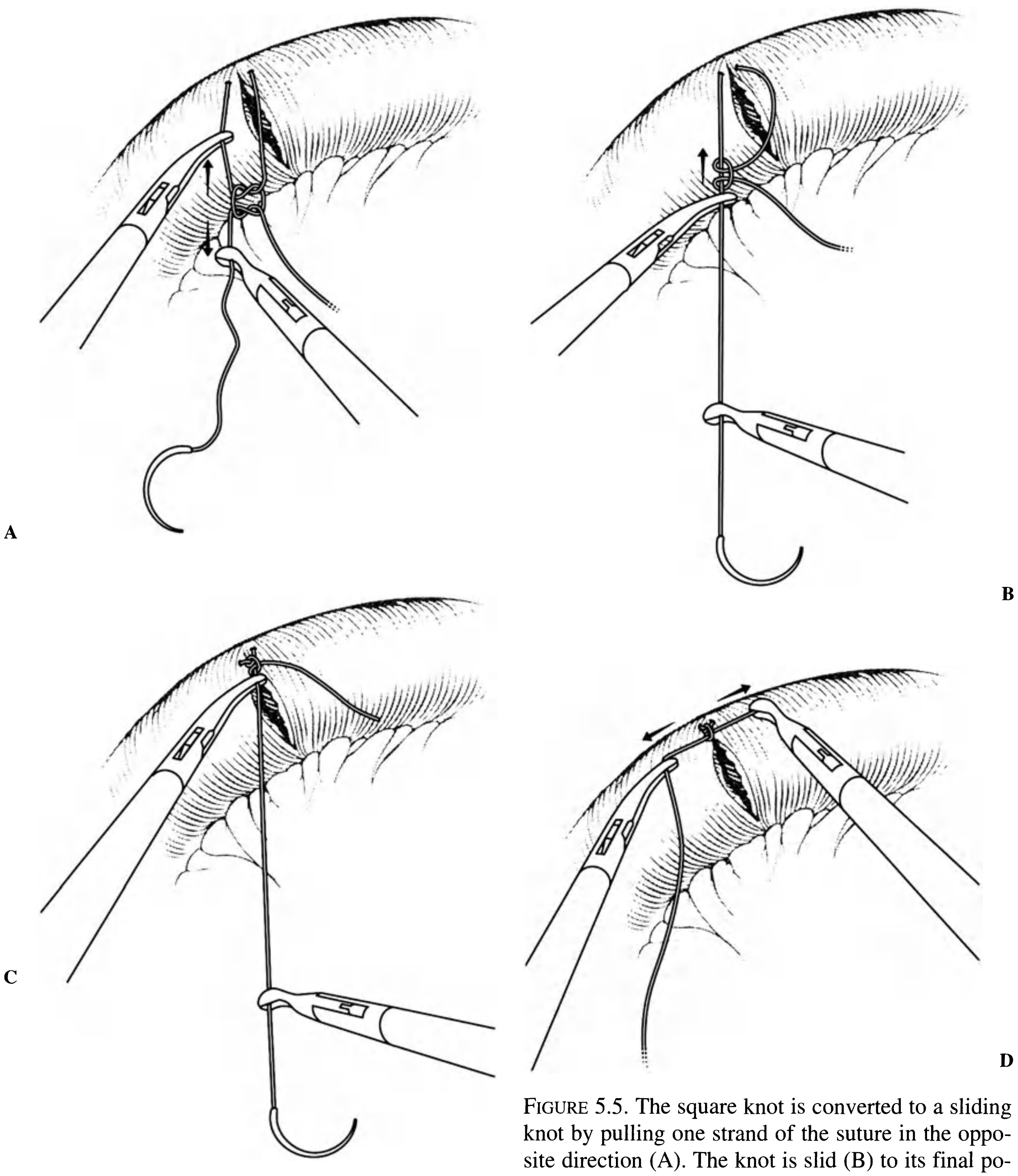

FIGURE 5.5. The square knot is converted to a sliding knot by pulling one strand of the suture in the opposite direction (A). The knot is slid (B) to its final position (C) and the knot is converted back to a square knot by pulling both suture ends in opposite directions (D).

ated extracorporeally and was especially developed to facilitate laparoscopic continuous suturing. We prefer to start a continuous suture with a Dundee knot. A suture with the jamming slip knot on one end is grasped along the long limb near the needle and introduced through a cannula. The needle is passed through the tissue until the loop impinges on the tissue. The needle is reversed and is passed through the loop (Figure 5.6B). The long suture is then grasped near the loop, and the tail is pulled in the opposite direction to slide the loop on the suture, jamming the knot (Figure 5.6C).

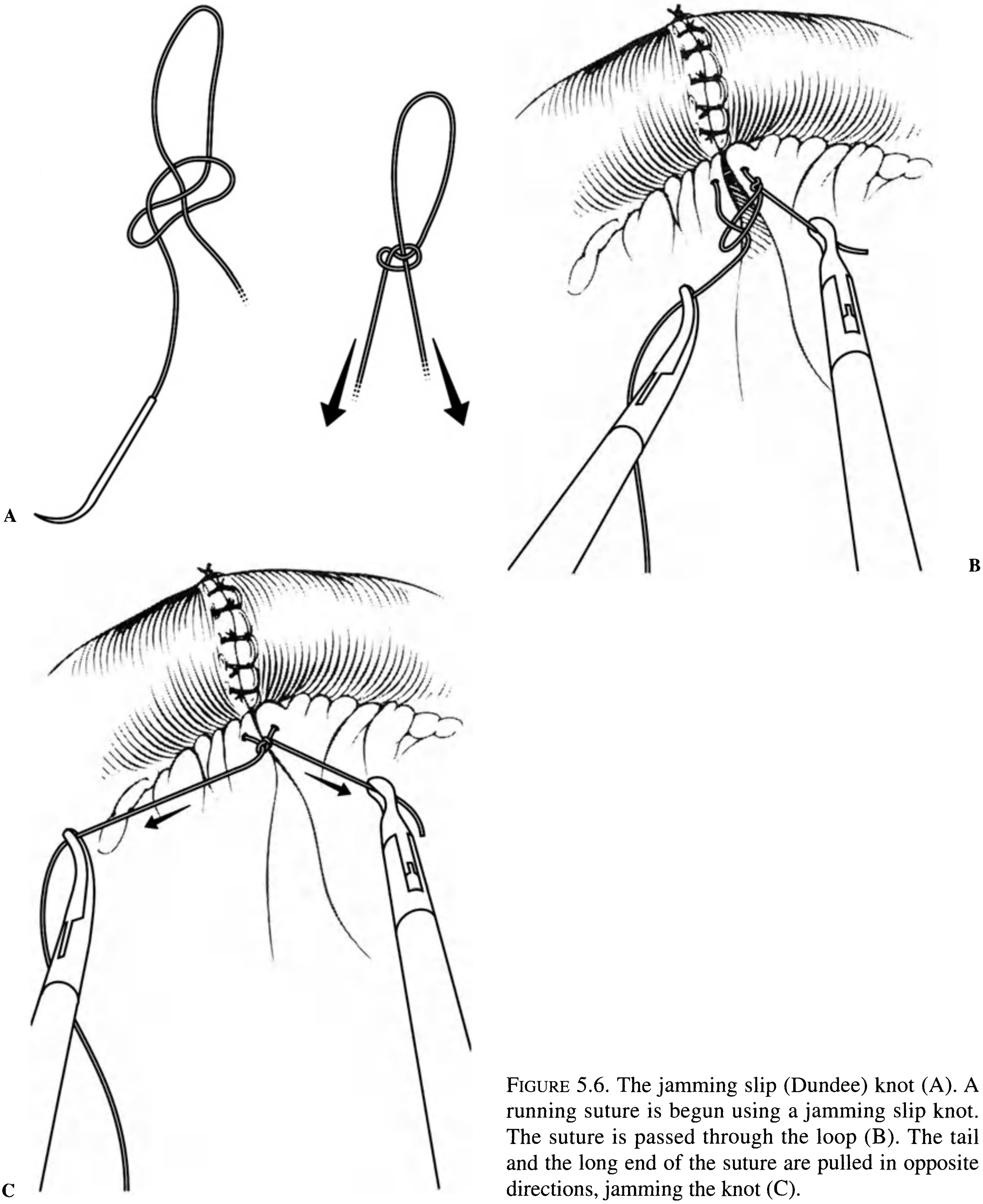

FIGURE 5.6. The jamming slip (Dundee) knot (A). A running suture is begun using a jamming slip knot. The suture is passed through the loop (B). The tail and the long end of the suture are pulled in opposite directions, jamming the knot (C).

Aberdeen Knot

A running suture can be finished with a square knot or an Aberdeen knot. We prefer the Aberdeen knot to finish continuous suturing because the tension on the suture can be maintained easily. After completing the running suture, the knot is begun by bringing a loop of the free suture underneath the previous bite (Figure 5.7A) and tightening it by pulling on the attached end of the loop (Figure 5.7B). While holding tension in the first loop, a second loop

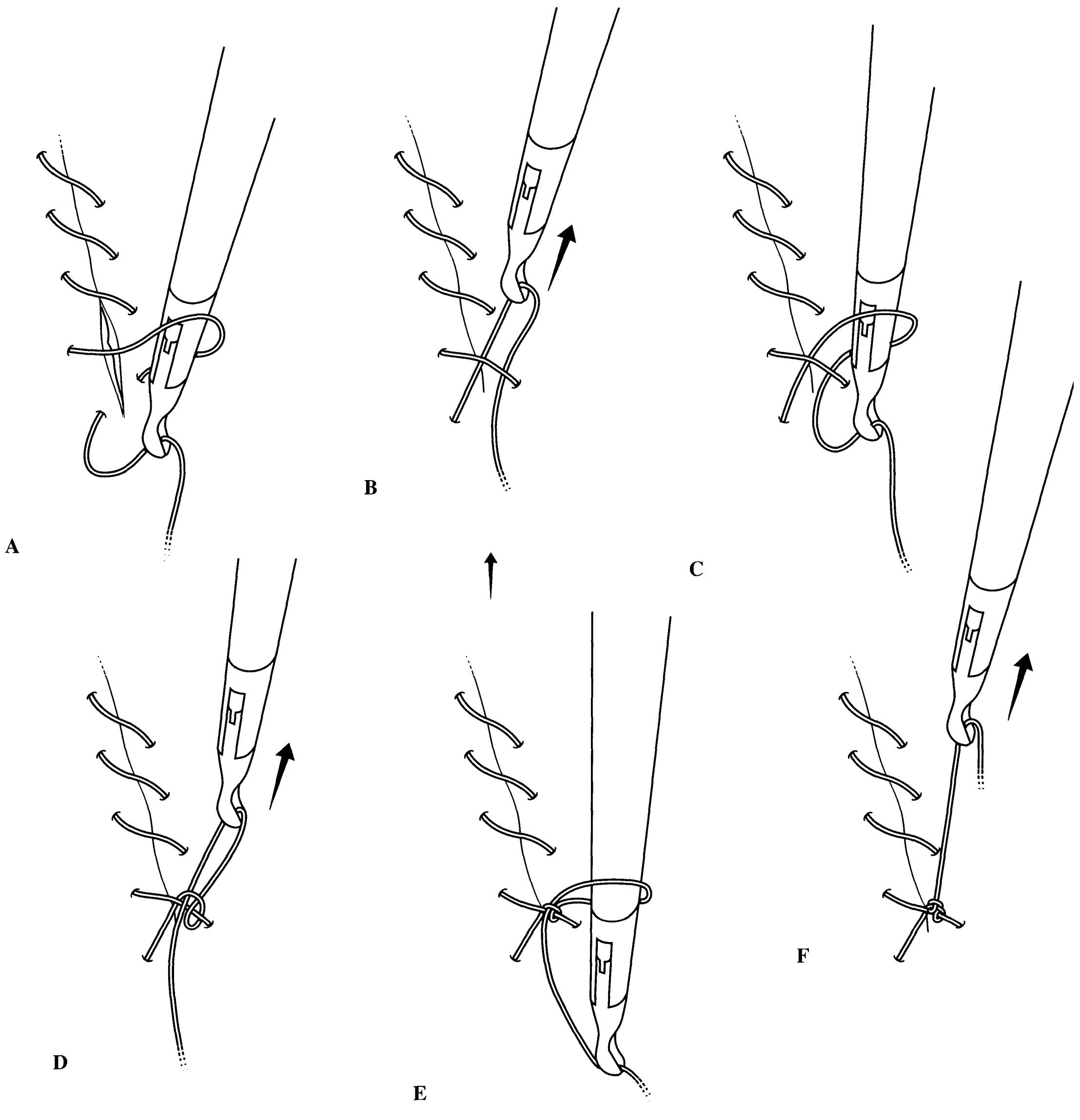

FIGURE 5.7. The Aberdeen knot is started by pulling a loop of the suture back under the previous bite (A, B). A second loop is brought through the first loop (C), and a third through the second (D). The suture end is pulled through the last loop (E) and the loop is closed, securing the knot (F).

of the suture body is then brought through the first loop (Figure 5.7C and 5.7D), then a third loop through the second, and so on. Good team effort is necessary to master the knot because the surgeon and the assistant must keep tension on the suture. After three to five interlocking loops, depending on the knot strength of the suture material, the free end of the suture is introduced through the last loop (Figure 5.7E) before traction is applied to close the loop and to secure the knot (Figure 5.7F).

Röder Knot

At the end of the 19th century, Röder supposedly described a ligating technique that used a catgut ligature loop with a slip knot for tonsillectomy in children (Figure 5.8A). The German

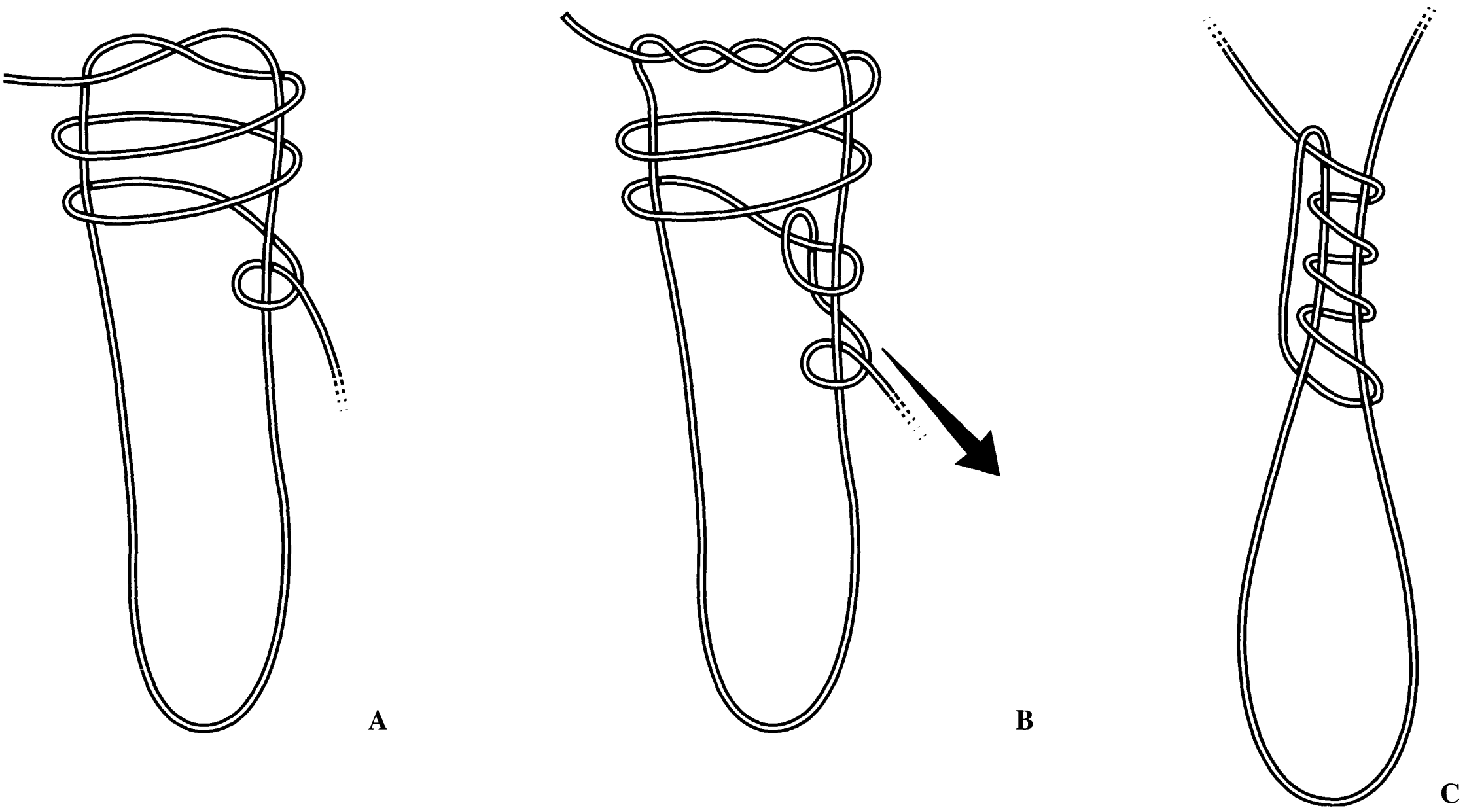

FIGURE 5.8. A, The Röder; B, the Melzer; and C, the Duncan slip knots.

gynecologist Semm introduced this technique with a push-rod application system for laparoscopic surgery. This push-rod system is now commercially available.[6] These pre-tied loops are easily applied using a pre-packaged applicator tube and a sheath that fits through a 5-mm trocar. The Röder slip knot can also be created extracorporeally and tightened securely onto tissue using a nondisposable, hollow push rod.

The Röder loop should not be used with sutures made of slippery material because it is a true slip knot. We prefer dry 0/chromic or 0/plain sutures for this knot, because as long as the material is dry, it will be stiff and the knot can be easily slid down, onto tissue. After application of the Röder loop, the catgut absorbs water, swells, and holds the knot tightly.

Nathanson et al.[7] investigated the safety of vessel ligation using the one-way Röder slip knot. Röder knots tied with 0/chromic catgut had a safety factor ratio of 55:1 for arteries 3 mm in diameter. The median tension of a 0/chromic gut suture was 1,125 g wt immediately after application. Vessels 5 mm in diameter did not leak when perfused to 300 mm Hg pressure. The median tension of dry no. 1 plain gut increased after 48 hours of hydration, from 475 g wt to 3,175 g wt. The median tension of 2-0/polyglactin was only 300 g wt, and it increased only slightly after 48 hours of hydration to 325 g wt. From their results, the authors surmised that chromic gut suture materials should be used for Röder slip knots and that polyglactin cannot be recommended. Recently, Melzer[8] modified the Röder slip knot with a double hitch at the beginning and the end (Figure 5.8B) so the slip knot can safely be tied down with a monofilament suture, such as polydioxanone.

Another alternative to the Röder loop is the Duncan loop (Figure 5.8C), which is less prone to slippage as a result of the inherent design of the knot. The slipping strength of both types of loops can be increased if a simple half hitch is added to the knot after the knot has been pushed down to the tissue and tightened. The half hitch provides additional safety and requires only a little more time.

The pre-tied Röder loop can be used for the following: ligating structures that have already been divided; closing holes in structures in which the two opposing edges of the defect can be grasped and drawn together; and "lassoing" tissue before extirpation (for example, of an ovary, a fallopian tube, an appendix, or a cystic duct) (Figure 5.9). However, when tightening a Röder loop, a length of the suture has to be pulled against the tissue while the slack of the loop is withdrawn. Thus, the suture could theoretically saw through the tissue on the opposite side as the knot is tightened. Care must be taken to prevent abrasion, traction, or avulsion of tissue as the slip knot is secured.

Why Use Suture Ligation?

Tissue ligation is sometimes not possible or economically advisable using modern stapling devices or clip applicators. If the tissue is pedunculated (like the appendix, the ovary, the greater omentum, or a bleeding vessel stump), ligation can easily be accomplished using a Röder or a Melzer loop. Assuming good access, suture ligature can be safely applied and secured using square knots.

Suturing

The first step in mastering laparoscopic suturing is the proper placement of the cannulas. Ideally, the two cannulas through which the instruments are inserted should be situated at an angle of 60° to 90° and lined up roughly parallel to the proposed suture line. This alignment allows for driving the needle through the tissue perpendicularly to the instrument and the suture line (Figure 5.10).

The suture (not longer than 10 cm for interrupted suturing) is brought into the peritoneal cavity and is grasped with the assistant grasper 1 cm away from the heel of the needle. The needle is rotated and pivoted until it can be grasped with the needle holder. If the needle is not in the correct position, the needle holder is opened and the grip is slightly released without letting go of the needle. The needle can be pushed against tissue to bring it to the right direction, or the tip can lightly be hooked into the tissue and then manipulated.

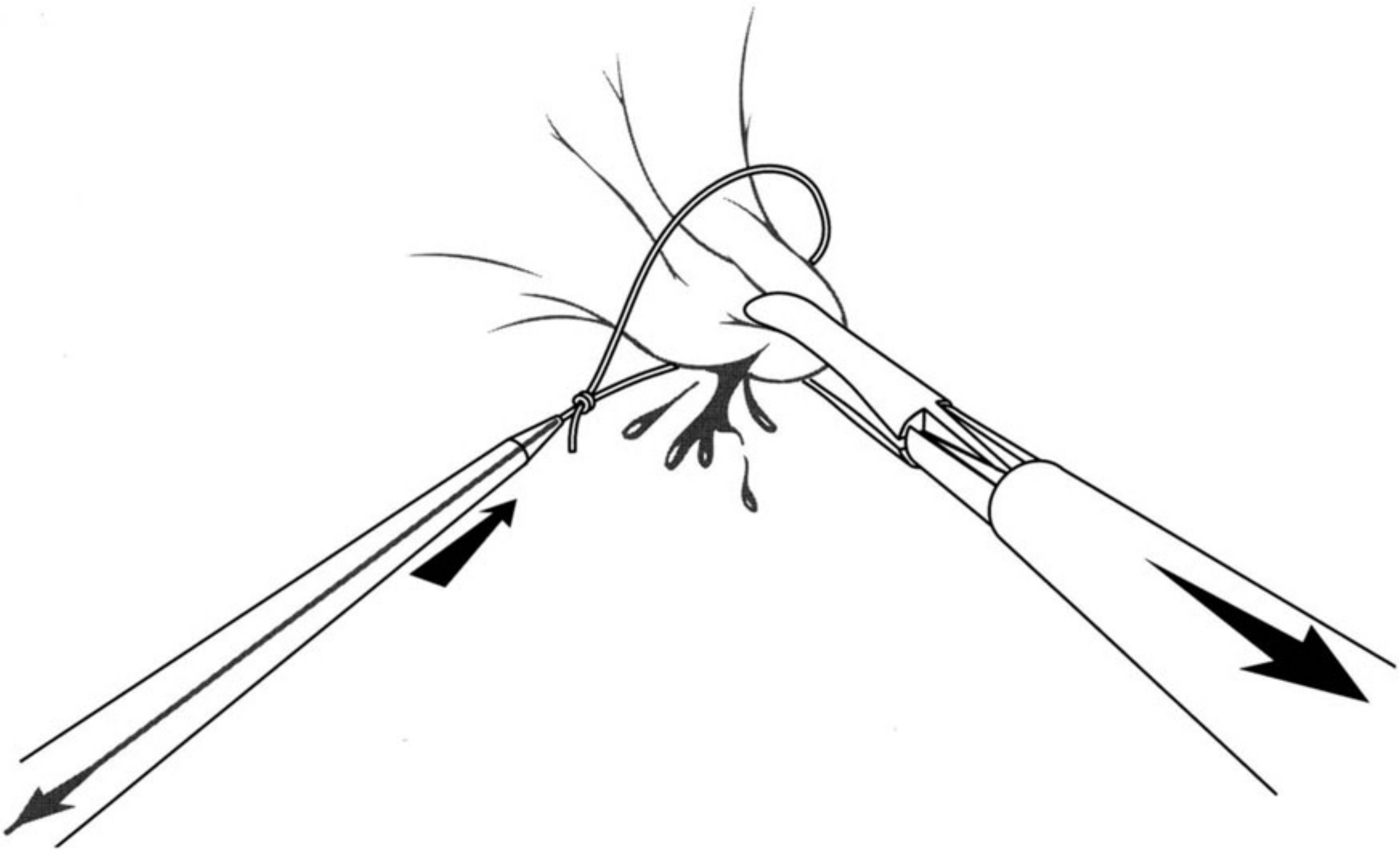

FIGURE 5.9. Application of a pre-tied Röder slip knot for ligation of bleeding tissue.

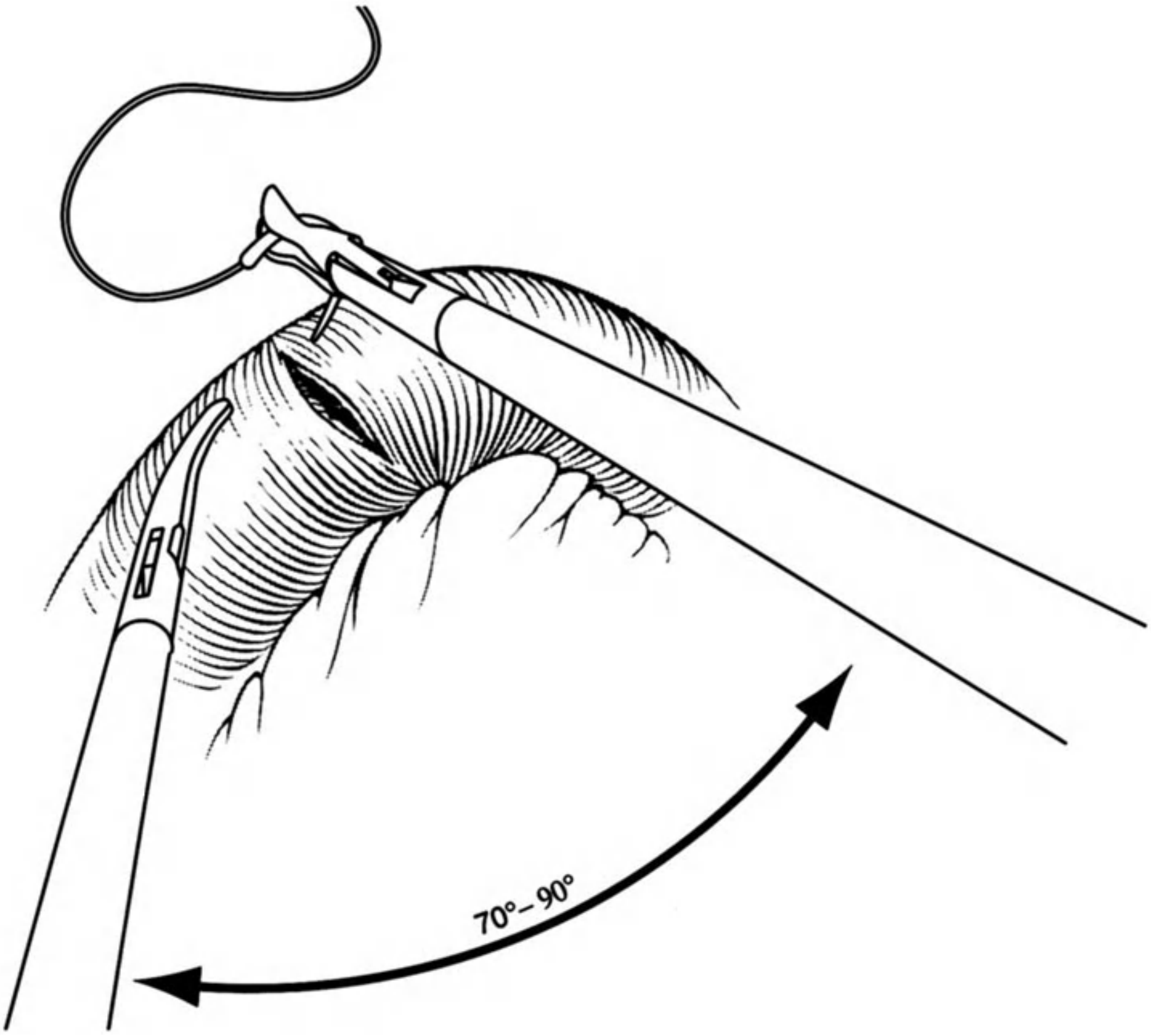

FIGURE 5.10. Ideal spatial relationship between the suture line and the cannula with needle holders and laparoscope.

Suturing is started when the needle tip is perpendicular to the needle holder and the suture line. With gentle counter pressure from the assistant grasper, suturing can be accomplished in the usual fashion. The selection of the entrance point and the amount of tissue bite is subject to the same rules as in conventional surgery. Laparoscopic techniques permit both interrupted and running sutures.

Interrupted Sutures

Extraperitoneally knotted interrupted sutures are used in situations, such as sutured rectopexy, when all sutures first must be placed precisely under direct view and then tied down. Suture ligatures for bleeding pedicles can also be tied extracorporeally, which may save considerable time. A curved needle with a 70- to 90-cm-long suture should be used for tying extraperitoneal knotted, interrupted sutures. The needle is brought into the peritoneal cavity through a cannula, is placed through the tissue, and is brought out through the same cannula. An extraperitoneal knot (Röder, Melzer, or square knot) is created and tightened using knot pushers. Interrupted suturing with intracorporeal knotting is more appropriate if an intracorporeal sutured colorectal anastomosis has to be performed, enterotomies have to be closed, or inadvertent intraperitoneal injuries have to be repaired. For an intraperitoneal interrupted suture, a ski-needle with a 7- to 10-cm-long suture should be used. The suture is brought into the peritoneal cavity and the suturing is performed according to the previously described principles.

Running Sutures

A running suture can be used to close a mesenteric, intestinal, or peritoneal defect, or to accomplish a colorectal anastomosis. A 20-cm suture with a ski-needle or a curved needle and a preformed jamming slip knot at one end is brought into the peritoneal cavity. After the first stitch is placed, the suture is locked using the jamming knot (see previous section, Jamming Slip Knot). The suture is then run with the use of constant traction by the assistant grasper and is finished with an Aberdeen knot (see previous section, Aberdeen Knot).

References

1. McComb PF. A new suturing instrument that allows the use of microsuture at laparoscopy. *Fertil Steril.* 1992;57:936–938.
2. Reich H, Clarke HC, Sekel L. A simple method for ligating with straight and curved needles in operative laparoscopy. *Obstet Gynecol.* 1992;79: 143–147.
3. Gazayerli MM. The Gazayerli knot-tying instrument or ligator for use of diverse laparoscopic surgical procedures. *Surg Laparosc Endosc.* 1991;1: 254–258.
4. Kennedy JS. A technique for extracorporeal suturing. *J Laparoendosc Surg.* 1992;2:269–272.
5. Pietrafitta JJ. A technique of laparoscopic knot tying. *J Laparoendosc Surg.* 1992;2:273–275.
6. Semm K. Tissue-puncher and loop-ligation-new aids for surgical-therapeutic pelviscopy (laparoscopy) = endoscopic intraabdominal surgery. *Endoscopy.* 1978;10:119–124.
7. Nathanson LK, Nathanson PDK, Cuschieri A. Safety of vessel ligation in laparoscopic surgery. *Endoscopy.* 1991;23:206–209.
8. Cuschieri A, Buess G, Perissat J. *Operative Manual of Endoscopic Surgery.* New York, N.Y.: Springer-Verlag, 1993.

6

Ancillary Intraoperative Equipment and Techniques

This chapter discusses several types of laparoscopic instrumentation that we believe have the potential to significantly enhance the laparoscopic procedures of the future. Because of the surgeon's inability to directly palpate organs and structures of the abdominal cavity, some ancillary equipment, such as laparoscopic ultrasonography, may prove to be valuable in the complete laparoscopic assessment of the abdominal cavity.

Laparoscopic Morcellator

Although current technology in laparoscopic colorectal surgery permits the intestine and its blood supply to be reliably ligated and divided, such closed surgery must be combined with a minilaparotomy for specimen removal. Thus, an obligatory 3- to 10-cm incision must be made in the abdominal wall to safely remove an intestinal segment containing bacterial-laden fluid and often a malignancy. If a major incision can be avoided, the benefits of laparoscopic colorectal techniques could become even more significant. To avoid the abdominal incision, some surgeons have reported successful transanal delivery of the bowel specimen, either removed en bloc or cut into pieces if too large to pass as one specimen.[1,2] Because the rectum has to be opened to the peritoneal cavity to remove a specimen transanally, we do not recommend this route for specimen delivery. It exposes the peritoneal cavity to bacterial and tumor contamination, and the rectal and anal sphincters to stretching or traction injury.

In our opinion, the intestine should never be opened intentionally in the peritoneal cavity during laparoscopic surgery (except when making small enterotomies to perform an intestinal anastomosis). As soon as the specimen is freed from surrounding structures, it should be placed in an impermeable bag to prevent tumor seeding, wound infection, or spillage of intestinal fluid. In general, after placing all the resected specimen in a bag, we remove the bag through a widened trocar incision or a small separate laparotomy. To avoid small laparotomies for specimen removal, it will be necessary to develop a device that allows the specimen to be delivered in pieces through a normal-sized cannula (15 mm or less) after the specimen is debulked inside the bowel bag.

Presently, an instrument is available that allows intraperitoneal mechanical fragmentation of gallstones (LaparoLith, Baxter, Deerfield, Ill.) to facilitate gallbladder removal.[3] The system consists of a motor control unit, an autoclavable motor handpiece and sheath, and a disposable drive shaft with a rotating propeller-like blade at its tip that can rotate at up to 80,000 rpm. Morcellating an intestinal specimen, however, is almost impossible because the vortex created by the rotating propeller-like blade rapidly generates a cocoon of connective tissue around the instrument.

Another type of morcellator, currently used to fragment the kidney, the spleen, or the uterus, consists of a circular blade that is pushed into the tissue and a central channel through which the fragmented tissue is suctioned out (Cook Tissue Morcellator, Cook Urological, Inc., Spencer, Ind.). The instrument must be actively used to morcellate the tissue in the bag. Although this morcellator successfully morcellates solid tissue, investigations in our laboratory have shown that current models must be improved for safe and rapid debulking of intestinal specimens.

In addition to the lack of a good instrument for morcellation of the intestine and the mesentery, the effect of morcellation on routine histologic analysis is unknown. Currently, histologic examination of the specimen is mandatory to establish the final diagnosis and, in cancer cases, for conventional tumor staging according to the TNM classification of malignant diseases; histologic examination is particularly necessary to assess depth of tumor infiltration and the lymph node status. As long as no suitable alternatives to conventional tumor staging are available, and the effects of morcellation on tumor histology remain unknown, tissue morcellation cannot be justified in patients with suspected colorectal malignancy. Nonetheless, it remains an important subject for future research in laparoscopic intestinal surgery.

Laparoscopic Doppler Probe

To aid in identifying vascular structures during laparoscopic procedures, an endoscopic Doppler probe with a frequency of 20 MHz and a 2-mm probe tip is available (Doppler System, Meadox Surgimed, Inc., Oakland, N.J.). The Doppler probe is 11.25 in. long and fits through a 5-mm cannula. The instrument is useful in obese patients for locating the external iliac artery or the named mesenteric vessels.[4] For the most part, we do not believe this technology will be required in routine laparoscopic colorectal procedures because vessels to be divided will readily be visible during the dissection. Possibly, it may be valuable in assessing the intestine for evidence of mesenteric vascular disease.

Laparoscopic Ultrasonography

Tactile exploration of the peritoneal cavity is impossible in laparoscopic colorectal surgery, thus pathology—particularly that concerning colorectal cancer—can be missed. In conventional colorectal cancer surgery, most surgeons palpate the liver, the porta hepatis, and the paraaortic tissues before resection to clinically stage a colorectal tumor. In laparoscopic colorectal cancer surgery, the inability to perform palpation is a concern because malignancy may exist in diverse locations in the abdominal cavity. Thus, palpation of the abdominal cavity must be replaced by other methods that have the potential to provide the same information. For this purpose, preoperative and intraoperative ultrasonography, computed tomography (CT) scanning, and magnetic resonance imaging (MRI) of the abdomen are used.

Because intraoperative ultrasonography has a high sensitivity and specificity in detecting hepatic lesions,[5-9] is quickly accomplished, and is inexpensive, it is currently the method of choice to examine the liver in conventional surgery. Intraoperative ultrasonography also can be used to assess lymphatic tissue in the mesentery or to evaluate local tumor infiltration, as in endoluminal ultrasonography. Intraoperative ultrasonography can be accomplished laparoscopically using rigid or flexible tip technology with linear or sector scanning modalities. The ultrasound probe usually produces good resolution using 5- to 7.5-MHz probes and allows good visualization of all aspects of the liver.

We have performed laparoscopic intraoperative ultrasonography of the liver in several patients and have evaluated its feasibility; our technique is described as follows. In our opinion, this technique should always be carried out when performing curative laparoscopic surgery for colorectal cancer.

Patient Position and Equipment

The patient is placed supine in the modified lithotomy position using Dan Allen stirrups. Examination of the liver begins with the patient in the flat neutral position, tilted to the left, after successful establishment of pneumoperitoneum and placement of all abdominal wall cannulas appropriate for the particular procedure planned. In some cases, a reverse Trendelenburg position (head tilted upward 20°) may be useful.

The surgeon/ultrasonographer stands between the patient's legs; the assistants stand to the patient's left side. The scrub nurse stands to the patient's right. One laparoscopic monitor and the ultrasonography screen are placed near the patient's right shoulder for simultaneous viewing of the ultrasound image and the laparoscopic image by the operating team.

Cannula Location

The ultrasonography probe is inserted through a 10-mm cannula at the umbilicus or at the left upper quadrant. The laparoscopic camera is positioned through another cannula at the umbilicus or right lower quadrant. A 30° rigid laparoscope or a laparoscope with a flexible tip should be used to optimize visualization without interfering with the ultrasonography probe.

Intraoperative Ultrasonography of the Liver

After the probe is calibrated, the examination is begun by placing the probe on the ventral surface, just to the left of the falciform ligament, and as laterodorsally as possible. The probe is accurately positioned under laparoscopic view. The examination proceeds by sliding the probe to the lateral edge of the left hepatic lobe. The probe is withdrawn approximately 4 cm and the scanning proceeds from the lateral edge of the left lobe back to the falciform ligament. The probe is again withdrawn 4 cm and the scanning again proceeds laterally. The maneuver of withdrawing the probe to the ventral surface and moving it medially and laterally is continued until the liver to the left of the falciform ligament is completely scanned.

To scan the right lobe, the probe is again placed as dorsally as possible on the ventral surface, just lateral to the falciform ligament, and then scanned to the lateral edge of the right lobe. The probe is withdrawn 3 to 4 cm and scanning continues toward the falciform ligament. After the ventral side of the liver is completely scanned, the probe is placed on the dorsal anterior side of the right lobe and lateral to the gallbladder, with the help of a grasper, and the scanning is continued from medial to lateral. The examination of the liver is then completed by scanning the dorsal anterior side of the left lobe, from the porta hepatis to the edge of the left lobe. We are currently evaluating the accuracy of laparoscopic ultrasonography compared with the preoperative contrast-enhanced CT scan in assessing the liver in colorectal cancer patients.

Radioimmunoguided Surgery

Radioimmunoguided surgery (RIGS) has the potential to improve the detection of microscopic tumors during surgery and to allow for more accurate staging. The principle of RIGS is based on a radiolabeled monoclonal antibody targeting the tumor that is then localized intraoperatively with a gamma detecting probe.

Because the 200,00- to 400,00-d molecular weight tumor-associated glycoprotein-72 (TAG-72) is found on the surface of most colorectal adenocarcinomas but usually is not expressed to an appreciable degree on normal tissue (except in secretory-phase endometrium), colorectal adenocarcinomas can be identified with a radiolabeled anti-TAG-72 murine monoclonal antibody. For example, the first-generation monoclonal antibody B72.3 theoretically binds extensively with mucin-producing adenocarcinomas and only slightly with nonmalignant adult tissue.

The antibodies are administered with a single peripheral intravenous injection. The patient is usually monitored weekly for 2 to 4 weeks afterward until the background radioactive "pool" level is less than 20 counts per 2 seconds, at which time surgery is scheduled. During surgery, the abdominal cavity is explored with a hand-held gamma detector that locates the radiolabeled, cancer-specific monoclonal antibodies. The gamma-detecting probe contains a radiosensitive cadmium-telluride crystal that relays radioactive counts through a preamplifier to emit an auditory signal and digital readout. The probe is judged to detect tumor when a tumor-to-normal tissue ratio of 2:1 or greater is noted.

Radiolabeled antibody imaging has been demonstrated to be feasible in prospective small series using planar gamma-camera imaging[10,11] or an intraoperative gamma detector. The intraoperative technique RIGS has provided additional information, compared with conventional surgery alone, about the extent of malignant disease of primary or recurrent colorectal cancer and has changed the planned procedure in some selected patients. Despite these successes, the popularity of RIGS has been limited because there are no data that show use of RIGS has actually lowered recurrence rates, improved survival, or positively affected outcome in any series to date. Thus, a second-generation monoclonal antibody CC49 (an antibody of the IgG_1 subclass), that recognizes the glycoprotein TAG-72 with eight times more affinity than B72.3 has been developed and is being clinically tested.[12,13]

In a recent clinical study, 86% of primary tumors (n = 36) and 97% of the recurrent tumors (n = 30) were localized intraoperatively with the gamma-detecting probe after administration of CC49.[12] The intraoperative therapeutic plan was changed in about 50% of the patients with primary or recurrent cancer, showing the potential influence RIGS can have.

Surgeons who use RIGS must accept the implications of the false-negative rate of about 12% and false-positive rates of 10% to 20% for diagnosis. These rates obviously do not allow for reliance on diagnosis by RIGS alone during cancer surgery. The RIGS false-negative rate is of only minor concern if RIGS is used with histologic examination (which has a lower false-negative rate than RIGS and is the standard criterion) to obtain a diagnosis. However, when RIGS is positive for tumor, but histology is negative, the RIGS false-positive rate is of major concern. In such a situation, the surgeon may increase the extent of the surgical procedure or, even worse, if misguided by the RIGS results, may abandon a resection that is actually potentially curative. Arnold et al.[12,14] examined false-positive tissue diagnosed with RIGS and reported that micrometastases were present in 40% to 55% of these cases as detected either by serial sectioning or by immunohistochemical staining with the anticytokeratin antibodies. They concluded that "RIGS-positive" tissue is often malignant, that upstaging is justified even if pathologic tissue is absent, and that the failure to find micrometastases by light microscopy in RIGS-positive tissue is a function of the limit of tumor detection with light microscopy. This is a theoretical argument and few surgeons or pathologists believe RIGS-positive, histology-negative tissue is actually malignant. Further clinical trials are needed to determine whether the sensitivity of RIGS is higher and staging is more accurate than using conventional histologic examination.

Because the extent of cancer cannot be assessed by palpation as in open surgery, RIGS might be a useful technique in laparoscopic oncologic colorectal surgery, in performing curative resections, in staging procedures, or in diagnosing recurrent cancer in the future. The development of better antibodies may decrease the false-positive rate, and lead to the recommendation of RIGS for future routine laparoscopic surgical procedures in colorectal cancer.

References

1. Phillips EH, Franklin M, Carroll BJ, Fallas MJ, Ramos R, Rosenthal D. Laparoscopic Colectomy. *Ann Surg.* 1992;216:703–707.
2. Franklin ME, Ramos R, Rosenthal D, Schuessler W. Laparoscopic colonic procedures. *World J Surg.* 1993;17:51–56.
3. Stöblen F, Buess G, Manncke K, et al. Laparolith. A new instrument for stone fragmentation in laparoscopic cholecystectomy. *Surg Endosc.* 1992; 6:309–312.
4. Loughlin KR, Brooks DC. The use of a Doppler probe in laparoscopic surgery. *J Laparoendosc Surg.* 1992;2:191–194.
5. Machi J, Isomoto H, Kurohiji T, et al. Accuracy of intraoperative ultrasonography in diagnosing liver metastasis from colorectal cancer: evaluation with postoperative follow-up results. *World J Surg.* 1991;15:551–557.
6. Machi J, Isomoto H, Yamashita Y, Kurohiji T, Shirouzu K, Kakegawa T. Intraoperative ultrasonography in screening for liver metastases from colorectal cancer: comparitive accuracy with traditional procedures. *Surgery.* 1987;101:678–684.
7. Charnley RM, Morris DL, Dennison AR, Amar SS, Hardcastle JD. Detection of colorectal liver metastases using intraoperative ultrasonography. *Br J Surg.* 1991;78:45–48.
8. Olsen AK. Intraoperative ultrasonography and the detection of liver metastases in patients with colorectal cancer. *Br J Surg.* 1990;77:998–999.
9. Clarke MP, Kane RA, Steele G Jr, et al. Prospective comparison of preoperative imaging and intraoperative ultrasonography in the detection of liver tumors. *Br J Surg.* 1989;76:1323–1329.

10. Collier DB, Abdel-Nabi H, Doerr RJ, et al. Immunoscintigraphy performed with In-111-labeled CYT-103 in the management of colorectal cancer: comparison with CT. *Radiology.* 1992;185:179–186.
11. Doerr RJ, Abdel-Nabi H, Krag D, Mitchell E. Radiolabeled antibody imaging in the management of colorectal cancer. *Ann Surg.* 1991;214:118–124.
12. Arnold MW, Schneebaum S, Berens A, Mojzisik C, Hinkle G, Martin EW. Radioimmunoguided surgery challenges traditional decision making in patients with primary colorectal cancer. *Surgery.* 1992;112:624–630.
13. Molinolo A, Simpson JF, Thor A, Schlom J. Enhanced tumor binding using immunohistochemical analyses by second generation anti-tumor-associated glycoprotein 72 monoclonal antibodies versus monoclonal antibody B72.3 in human tissue. *Can Res.* 1990;50:1291–1298.
14. Arnold MW, Schneebaum S, Behrens A, et al. Intraoperative detection of colorectal cancer with radioimmunoguided surgery and CC49, a second-generation monoclonal antibody. *Ann Surg.* 1992; 216:627–632.

7

Indications and Contraindications

Introduction

This chapter outlines the principal indications and contraindications for laparoscopic surgery to treat diseases of the small intestine, the colon, and the rectum. Indications and contraindications may vary somewhat depending on the laparoscopic team's experience and the patient being treated. Nonetheless, this chapter should be a helpful guide to surgeons at all levels of experience in laparoscopic surgery.

General indications for laparoscopic surgery do not differ from those of conventional surgery because the only major difference between laparoscopic and conventional surgery is the access to the operative site. A laparoscopic colorectal procedure is never indicated solely because it can be done laparoscopically. Although the reader may have a different opinion as to whether to perform certain surgical procedures for the named indications we discuss, we present only our policy and acknowledge that some colorectal diseases can be treated by a variety of techniques with a favorable outcome.

Pneumoperitoneum has the potential to cause dramatic changes in the function of the cardiovascular and the pulmonary systems (see chapter 8, sections titled Pulmonary Function and Hemodynamic Function) so patients who show any signs of marginal cardiac reserve, major vascular disease, or severe pulmonary disease should not be considered for laparoscopic surgery. Patients with mild-to-moderate chronic obstructive pulmonary disease or cardiovascular disease should undergo careful preoperative evaluation and intraoperative monitoring. Because laparoscopic surgery may lead to less depression of postoperative pulmonary function compared with conventional colorectal surgery, it may be reasonable to consider laparoscopic techniques in certain patients with chronic obstructive pulmonary disease, but careful intraoperative and postoperative monitoring are important. Likewise, if the cardiac disease is stable, the surgical and the anesthesia teams must carefully weigh whether the potential risks of pneumoperitoneum and laparoscopy are warranted. Safran et al.[1] showed that high-risk cardiac patients may safely undergo laparoscopic cholecystectomy with no apparent increase in cardiovascular complications, but they advise careful intraoperative monitoring.

The hazards of performing abdominal surgery in patients with portal hypertension (multiple enlarged mesenteric, retroperitoneal, and even abdominal wall vessels, hepatosplenomegaly) are absolute contraindications for laparoscopy, particularly if coagulopathy also exists. Coagulopathy by itself is a contraindication for any kind of surgery if it cannot be corrected preoperatively. Especially in laparoscopic surgery, constant oozing from dissected tissues will significantly impair visualization and increase the risk of inadvertent damage to important intra-abdominal structures. Therefore, any degree of coagulopathy should be treated aggressively before laparoscopic surgery.

Multiple previous abdominal surgeries may be a contraindication if these procedures have been performed in the same area of the abdomen as the contemplated procedure. Attempting laparoscopy in these circumstances will almost certainly result in abdominal wall access problems and extensive adhesiolysis before the surgical procedure itself is done. In addition, dissection in avascular planes, which is important in laparoscopic surgery, may not be possible in reoperative surgery.

Dilated large or small intestine should be considered as a serious contraindication in laparoscopic surgery because the surgeon's view inside the abdominal cavity is obstructed. However, laparoscopic enterolysis can be successfully accomplished in patients with acute obstruction and some distension.[2]

Morbid obesity may be the most common contraindication to advanced laparoscopic surgery. We use the body mass index (BMI) to calculate the maximum patient size suitable for most laparoscopic colorectal surgery procedures. For example, our maximum BMI (calculated as the weight/height^2, in kg/m^2) for performing an entire intraperitoneal laparoscopic procedure is 32, meaning that a man 1.83 m tall could weigh up to 107.2 kg. Because morbid obesity can pose major obstacles in laparoscopic surgery, from cannula access to adequate exposure of the viscera, we believe that any patient with a BMI greater than 32 should not be considered for laparoscopic surgery unless the procedure is a biopsy or is otherwise limited, such as ileostomy or colostomy, or a laparoscopic-assisted intestinal resection.

Pregnancy is almost always a contraindication for laparoscopic colorectal surgery. Only emergency surgical intervention should be considered, owing to the risks of anesthesia and surgery to the fetus. If laparoscopy is necessary, open techniques to establish pneumoperitoneum should be used. Also, cannulas must be placed higher than usual because of the enlarged uterus. Gasless pneumoperitoneum may be considered.

Thus, the general contraindications to laparoscopic intestinal surgery are as follows:

- cardiovascular or pulmonary instability or failure
- severe or unstable chronic obstructive pulmonary disease or cardiac disease
- coagulopathy not correctable preoperatively
- extreme obesity (BMI > 32)
- pregnancy
- carcinomatosis
- large mass (>8 cm) of uncertain cause that may be amenable to complete excision
- any tumor extensively involving contiguous structures
- diffuse peritoneal contamination with perforated viscus or peritonitis
- acute inflammatory bowel disease (fever, distension, or other signs of toxicity)
- enteroenteric or enterocutaneous fistula
- multiple previous abdominal surgeries, especially in the region of interest
- obstruction of the intestine with abdominal distension

Common Indications

Colorectal Tumors

Colorectal tumors are the most common indication for colorectal resections. Before any of these tumors can be treated with laparoscopic surgery, their location must be precisely identified using one of three methods: (1) preoperative colonoscopic injection of dye into the intestinal wall adjacent to the tumor; (2) direct laparoscopic visualization of large infiltrating tumors; or (3) intraoperative colonoscopy. If there is any doubt about the precise location of the tumor, intraoperative colonoscopy is mandatory before resection.

We recommend marking the bowel wall adjacent to the tumor within 48 hours of surgery by injecting either india ink or indocyanine green using a sclerotherapy needle inserted through a colonoscope. This method avoids the intestinal distention of the intestine that can occur with intraoperative colonoscopy. If an intraoperative colonoscopy must be performed, the colon proximal to the tumor should be temporarily occluded to prevent distention of the proximal large and small intestine.

Adenoma and Familial Polyposis

Colonic or rectal polyps that cannot be safely removed by colonoscopic or transanal techniques can be resected using a laparoscopic approach. We prefer to perform a formal segmental resection because there is always some risk that a polyp may harbor a malignancy. If a large villous adenoma with a suspected cancer must be removed, an oncologic resection should be considered.

Some laparoscopic surgeons may consider performing limited resections for polyps by first localizing the tumor-bearing segment laparoscopically, mobilizing the intestine intraperitoneally, and then completing the procedure through a small laparotomy, a technique referred to as laparoscopic-assisted surgery. Extensive intraperitoneal mesenteric dissection or possibly intraperitoneal anastomosis is avoided. We do not advocate this approach for reasons mentioned above. Some surgeons have reported successful laparoscopic localization of a polyp with extraperitoneal polypectomy through a colotomy.[3]

Patients with familial polyposis may be candidates for laparoscopic total abdominal colectomy, in some instances with proctectomy. This disease is a good indication for laparoscopy because adhesion formation may be diminished in laparoscopic surgery and a long abdominal wall incision that may predispose a patient to the later development of an abdominal desmoid tumor is avoided. If the presence of a malignancy is a concern in patients with polyposis, the surgeon must perform an oncologic resection. A contraindication to laparoscopic techniques in familial polyposis is the presence of a large intra-abdominal desmoid tumor that may preclude a safe approach to laparoscopic removal of the colon.

Colorectal Malignancies: Palliative and Curative Therapy

In general, laparoscopic techniques may be used for the palliative or the curative treatment of colorectal tumors if the primary tumor is well localized and does not infiltrate other organs. However, curative resection raises several concerns that we will discuss in more depth. Laparoscopic resection of colorectal cancer has three major contraindications: (1) infiltrating tumors, (2) large and bulky tumors, and (3) obstructing tumors. Infiltration of adjacent structures by a malignancy is an indication for an open procedure because currently an en bloc multivisceral resection cannot be managed laparoscopically. An exception is the rectal cancer that adheres to the uterus or the vagina; laparoscopic resection (combined with perineal surgery) may still be feasible in such cases. Rectal cancers situated in the lower or the middle rectum that might require resection with low anastomosis should not be resected laparoscopically because these tumors cannot be excised with a good distal margin using the current laparoscopic instrumentation. If articulated endoscopic staplers become available in the future, laparoscopic low anterior resections with low colorectal anastomosis may be feasible. We avoid laparoscopic resection of any tumor greater than 8 cm in diameter because controlling a large mass in the peritoneal cavity using laparoscopic techniques is difficult. In any event, such a lesion would require a long abdominal incision to completely remove it en bloc; therefore, conventional laparotomy should be the first choice in removing large tumors. Malignant obstruction leading to significant bowel distention is an absolute contraindication to laparoscopic bowel surgery at present because the mesentery cannot be adequately exposed to perform proximal ligation of the lymphovascular pedicles, and overall visualization is significantly impaired.

In patients with multiple metastases to the liver or to other distant sites (which preclude a curative surgical excision), removing a short intestinal segment that bears the primary tumor with clear margins is often readily accomplished using laparoscopic techniques. Such limited intestinal resection for palliative reasons is the most feasible laparoscopic oncologic bowel resection and the laparoscopic colorectal surgeon should perform this type of resection before attempting curative resections. If, however, a large tumor has infiltrated into adjacent organs or the body wall so the tumor cannot be safely resected en bloc, then an open procedure should be performed. In cases with a nonresectable tumor and only partial obstruction, simple stoma construction can also be performed laparoscopically.

Curative Therapy

Because conventional surgical techniques are safe and acceptable methods for excising most primary colorectal cancers, laparoscopic curative resections of malignant diseases of the colon and the rectum should only be performed according to the accepted principles established in conventional oncologic surgery. Although it is still questionable whether a high ligation of the inferior mesenteric artery[4] or extended lymphadenectomies[5,6] reduce recurrences and increase survival, oncologic resection of a colorectal cancer is based on well-established principles.[7-10] In accordance with these principles, we have defined a curative oncologic resection as follows:

- wide en bloc resection of the tumor-bearing bowel segment with adjacent soft tissue, mesentery, with
- proximal lymphovascular ligation and complete lymphadenectomy, and
- occlusion of the bowel above and below the tumor to minimize the possibility of intraluminal spread.

In addition, the following is also mandatory: (1) to protect the peritoneal cavity from contamination; (2) to assess the peritoneal cavity for metastatic disease; and (3) that conditions allow an anastomosis or a stoma to be safely performed.

These principles were developed over the past 50 years in conventional surgery and now yield surgical procedures with low morbidity and mortality, and are the basis of well-known long-term results. Because these techniques are the current standard of oncologic surgery in colorectal cancer, a new technique, such as laparoscopic surgery, must prove to have at least an equivalent morbidity and mortality rate without an increased recurrence or a decreased survival rate. Long-term results from well-designed studies will not be available for at least the next five years to answer the question whether laparoscopic colorectal cancer surgery is oncologically appropriate. Thus, surgeons should perform all resections in accordance with the previously mentioned oncologic principles or include their patients in a prospective study with informed consent. In addition, surgeons should be able to prove in each case that they have accomplished a curative resection according to these principles.

However, some difficulties arise in proving that a successful resection has been performed according to these principles. One approach to proving that an adequate resection has been performed is to examine the specimen after laparoscopic resection—to evaluate the resection margins, measure the length of the resected specimen, and count the number of removed lymph nodes. Although a specimen with tumor-free margins is mandatory, this alone does not prove that an adequate oncologic resection has been accomplished. In rectal cancers, a tumor-free distal margin of 2 cm with wide, clear lateral margins should be achieved in laparoscopic surgery just as in conventional surgery.[11] The anatomic length of the large intestine varies widely; thus removal of a long specimen also does not guarantee that an oncologic resection was performed.[12]

Although it appears that the number of removed mesenteric lymph nodes does not differ between laparoscopic and conventional surgery,[13-15] merely counting the number of lymph nodes in the specimen does not prove that an oncologic resection has been accomplished because the number varies widely among individuals.[16] Rather, knowing how many lymph nodes were left along the main mesenteric vessels supplying the removed bowel segment is more important than knowing how many nodes were removed. The primary aim in counting the number of removed lymph nodes is to ensure an adequate number have been obtained for tumor staging. It has been recommended that at least 12 lymph nodes be histologically examined to reliably assess the nodal stage.[16] Nonetheless, the removal of 12 lymph nodes does not imply that an oncologic resection has been successfully performed because a substantial portion of the node-bearing mesentery may still remain. On the other hand, the excision of five lymph nodes might indicate that the mesentery was only partially removed but could also mean that an adequate oncologic resection of a lymph-node-poor mesentery has been accomplished or that the pathologist did not process the mesentery fastidiously. The pathologic evaluation of the mesentery—using routine or fat-clearance techniques—is as important as the surgical technique in assessing the lymph node status. Thus, measuring the length of resection margins, the specimen length, and the number of removed mesenteric lymph nodes does not prove that an adequate oncologic resection has been accomplished. Unfortunately, these are the best short-term methods we have to evaluate the adequacy of resection for cancer.

Determining Curative Resection in Laparoscopic Surgery

In our opinion, the criterion that verifies whether oncologic resection is adequate is the anatomic extent of the resection because an oncologic resection is defined in anatomic terms. Therefore, we evaluated the anatomic extent of a laparoscopic oncologic resection in a fresh human cadaver model and tested the hypothesis that the anatomic extent of laparoscopic oncologic resection is equivalent to a conventional oncologic resection.

We performed a series of laparoscopic right colectomies, proctosigmoidectomies,[17] abdominal colectomies, and abdominoperineal resections in fresh cadavers[18] in which we determined the length of each specimen and the number of removed lymph nodes, and performed an autopsy. We then evaluated the anatomic extent of the laparoscopic resection in situ. The lengths of the remaining named mesenteric vessels were measured, the number of remaining lymph nodes counted, and the overall extent of mesenteric and pelvic resection assessed. We were able to show that the anatomic extent of a laparoscopic oncologic resection does not differ from that obtained by conventional oncologic resection in this cadaver model, if the resection is performed using the techniques we devised during this study (described in chapter 9). We concluded from this model that using a standardized approach, which we now duplicate successfully in patients, an oncologic resection that does not differ from the conventional approach can be accomplished anatomically.

Although we proved in these cadaver studies that an oncologic resection is anatomically feasible using laparoscopic techniques, laparoscopic surgery must next be shown to confer short-term advantages in curative colorectal cancer surgery. Therefore, we advocate prospective randomized phase II studies to compare morbidity, mortality, rapidity of recovery, and quality of life between laparoscopic and conventional colorectal cancer surgery. Only if clinically relevant short-term advantages are found after laparoscopic colorectal cancer surgery should a multi-institutional phase III study be pursued. In this phase III study, the long-term oncologic endpoints, recurrence and survival, must be evaluated to show at least equivalency between laparoscopic and conventional surgery. Only after complete evaluation of all three phases can laparoscopic colorectal cancer surgery with curative intent be widely recommended.

This cautious approach in assessing the value of laparoscopic techniques in curative colorectal cancer surgery is necessary for several reasons: (1) it is a new technique with unknown morbidity, mortality, and long-term results; (2) it is technically more challenging, more time-consuming, and more expensive than conventional surgery; and (3) early cannula-site recurrences have been reported. Therefore, we advocate an evaluation of short- and long-term results in prospective randomized studies comparing laparoscopic and conventional surgery, and in-depth training in standardized laparoscopic oncologic techniques for all surgical team members involved in such studies.

Early local recurrences in cannula sites are of major concern and have been reported after laparoscopic surgery for gastric,[19] gallbladder,[20,21] pancreatic,[22] ovarian,[23] and colorectal[20] malignancies. Although the precise pathogenesis of these early recurrences (several weeks to several months after laparoscopic surgery) is not known, we believe that tumor seeding might be prevented with a standardized oncologic approach that involves the following: (1) minimal manipulation of the tumor-bearing segment; (2) occlusion of the proximal and distal ends of the intestinal segment; and (3) placement of the specimen as soon as possible in an endoscopic bag before delivery through the abdominal wall.

At this time, we recommend that surgeons trained in curative laparoscopic colorectal cancer surgery be able to prove with video documentation in each case that an oncologic resection has been performed, which should clearly satisfy the anatomic criteria of the oncologic resection (Table 7.1). The documentation coupled with the pathologic examination of the specimen (tumor margin and number of removed lymph nodes) should be sufficient to show that an oncologic resection has been accomplished using the same criteria as those used in conventional surgery.

Inflammatory Diseases of the Intestine

It should be anticipated that inflammation of the small intestine, the colon, and the rectum may lead to increased bleeding and friability of the tissues being manipulated. Nonetheless, laparo-

TABLE 7.1. Steps in oncologic colorectal resection that should be demonstrated on video review for various standard procedures in both conventional and laparoscopic surgery.

Step	Description*
Right colectomy	Identification of the origin of ileocolic vessel and right colic vessel, if present, with proximal ligation
	Identification of middle colic vessel origin and proximal ligation of right branch or major trunk, if appropriate
	Demonstration of resection of an adequate length of ileum and colon, above and below the tumor
	Occlusion of the intestinal lumen on both sides of tumor to prevent spilling of intestinal fluid and tumor seeding
	Placement of specimen in bag before delivery
Sigmoidectomy	Identification of IMA origin with proximal ligation
	Occlusion of intestinal lumen above and below tumor to prevent spillage of intestinal fluid and tumor seeding
	Rectal washout
	Wide soft tissue resection above and below tumor
	Placement of specimen in bag before delivery
Anterior resection	Identification of IMA origin with proximal ligation
	Wide mesenteric dissection
	Adequate resection of mesorectum with clear, wide distal and lateral margins
	Occlusion of the intestinal lumen above and below tumor to prevent spilling of intestinal fluid and tumor seeding
	Rectal washout
	Placement of specimen in bag before delivery
Abdominoperineal resection	Identification of the origin of inferior resection mesenteric artery with proximal ligation
	Adequate resection of mesorectum with clear and wide soft tissue margins
	Occlusion of the intestinal lumen proximally to prevent spilling of intestinal fluid
Abdominal colectomy	Identification of the origin of ileocolic and right colic vessel, if present, with proximal ligation
	Identification of the origin of middle colic vessels and proximal ligation
	Resection of an adequate length of terminal ileum
	Identification of the IMA origin with proximal ligation
	Wide mesenteric dissection
	Adequate resection of the upper portion of the mesorectum with clear, wide distal and lateral margins
	Occlusion of the intestinal lumen above and below tumor to prevent spilling of intestinal fluid and tumor seeding
	Rectal washout
	Placement of specimen in bag before delivery

*IMA = inferior mesenteric artery.

scopic surgery is possible in inflammatory bowel disease if the patient is in stable medical condition. In most cases, the adjacent vital structures and organs can be properly isolated, and the procedure can be safely performed. The surgeon must anticipate that unexpected abscesses, fistulae, or adhesions may require conversion to a laparoscopic-assisted or open surgery. In addition, a chronic inflammatory process may obliterate avascular planes and extensive scar tissue may make dissection difficult, increasing the risk of inadvertent injury to retroperitoneal structures, such as gonadal and iliac vessels or ureters.

To date, there has been no reported experience with laparoscopic intestinal surgery to manage acute toxic manifestations of inflammatory bowel disease (fever, abdominal distension, or other signs of toxicity). These patients may have signs of cardiovascular instability, may be malnourished, and may be on high doses of steroids. Also, the intestinal tissues are likely to be fragile. We do not recommend laparoscopic intestinal surgery in acutely ill patients because the fragile tissue is prone to injury using laparoscopic instruments.

Diverticulitis

The elective resection for chronic diverticular disease may be a good indication for laparoscopic surgery, but clinical judgement at the time of diagnostic laparoscopy plays a large part in the decision. Because diverticular surgery most often involves mobilizing the entire sigmoid colon and some of the proximal rectum, pelvic surgery will likely be required. Thus, the ureters, gonadal vessels, and reproductive structures, especially those on the left side, must be isolated, identified, and protected. Only after these structures have been safely identified and normal segments of large intestine above and below the disease process are mobilized, can laparoscopic techniques be applied to diverticular disease.

Contraindications for elective laparoscopic surgery in diverticular disease would include a large intra-abdominal abscess, complex fistulization to other parts of the intestine, or complex adherence to the retroperitoneum or other vital abdominal or pelvic structures. Fistulization to the bladder or vagina may not be a contraindication because the area of fistulization may either be left alone after bowel resection or repaired laparoscopically with simple interrupted sutures. The only instance in which laparoscopy might be considered for acute diverticulitis might be left lower quadrant peritonitis when a diagnostic laparoscopy might be deemed worthwhile.

Contraindications for laparoscopic techniques are diverticular phlegmon and perforation with peritonitis. A diverticular phlegmon adhering to multiple organs or to the retroperitoneum should prompt consideration of an open procedure because vital structures (e.g., iliac vessels and ureters) may not be readily identified and are at risk of inadvertent damage. Perforation with extensive peritonitis is a contraindication because the peritoneal cavity must be thoroughly examined and cleansed of intestinal contents and blood. The particulate nature of fecal material will not allow thorough cleansing and irrigation with laparoscopic techniques; thus a laparotomy is indicated.

Mucosal Ulcerative Colitis

Laparoscopic techniques applied to the surgical management of mucosal ulcerative colitis implies the need for proctocolectomy or total abdominal colectomy; thus the patient must be in a stable medical condition to undergo an extensive procedure that currently may last 3 to 5 hours, and the laparoscopic team must possess the skill to perform an extensive procedure laparoscopically. At present, a patient with signs of toxicity (temperature greater than 38.5°C, abdominal distension, active bleeding, or unstable vital signs) should not be considered for laparoscopic colon resection because the colon may be dangerously dilated and the tissues may be especially friable, thin, and prone to injury. There are no other specific contraindications to the use of laparoscopic techniques in ulcerative colitis, although if malignancy is a possibility, oncologic principles must be applied.

Laparoscopic proctocolectomy for ulcerative colitis may encompass complete mobilization of the entire colon and rectum down to the pelvic floor, including intraperitoneal dissection of the mesentery, extracorporeal creation of an ileal pouch, and intraperitoneal stapled or sutured coloanal anastomosis. Because this extended procedure may last 4 to 5 hours, in 1992, Wexner et al. advocated a laparoscopic-assisted procedure with laparoscopic mobilization of the lateral attachments and flexures only, and a subsequent limited transverse (Pfannenstiel) incision in the lower abdomen to complete the surgery.[24] Since 1993, the same group has also shown that the laparoscopic-assisted approach offers no clinical advantages, takes more time, and is more expensive than conventional surgery[25]; thus Wexner et al. now recommend abandoning this approach. In our opinion, the laparoscopic approach to total abdominal colectomy, with intracorporeal mesenteric dissection and ligation, must still be evaluated further.

Crohn's Disease

Laparoscopic surgery for Crohn's disease is similar to that for diverticular disease. However, extraordinary inflammation in the mesentery of Crohn's disease of the large and the small bowel may be encountered, and any inability to identify vital structures should lead to conversion to a conventional technique. Situations in which an enteroenteric or an enterocutaneous fistula, a large abscess, or an extensive inflammation of the mesentery or the retroperitoneum exists call for strong consideration to convert to conventional surgery. A short stenosis of the small intestine might be an indication for a laparoscopic-assisted stricturoplasty. The affected intestinal segment can be mobilized and a stricturoplasty can then be performed through a small abdominal wall incision.

Laparoscopic-assisted resection in patients with Crohn's ileocolitis or ileitis can readily be performed with initial mobilization of the terminal ileum and the right colon, and subsequent externalization through a small abdominal wall incision. The extracorporeal division and ligation of the inflamed mesentery with an intestinal anastomosis currently seems safer using conventional techniques, and laparoscopic-assisted surgery still reduces the size of the abdominal wall incision compared with conventional surgery. An entirely intracorporeal procedure may be feasible in selected patients. Whether laparoscopy is more beneficial than open surgery for Crohn's ileocolitis is uncertain at present; thus we are performing a prospective randomized trial comparing short-term outcome between conventional and laparoscopic-assisted ileocolectomy in patients with Crohn's ileocolitis.

Abdominal colectomy with or without proctectomy for Crohn's disease can also be achieved in selected patients. Again, this procedure may be extensive and should only be undertaken by an experienced laparoscopic team. If suitable planes surrounding the rectum can be obtained, it is reasonable to approach Crohn's proctitis using laparoscopic techniques.

Severe anal sepsis requiring fecal diversion is a good indication in Crohn's disease for laparoscopic surgery because an ileostomy or a colostomy can rapidly be constructed and the diversion, coupled with adequate drainage of any anal infection, permits the patient to recover without the need for a formal laparotomy.

Functional Diseases

Some functional disorders, such as rectal prolapse, constipation, incontinence, and volvulus, may be treated using laparoscopic techniques.

The laparoscopic treatment of rectal prolapse is especially feasible because often no anastomosis is performed (unless the patient has intractable constipation and is a candidate for bowel resection) and the position of the rectum in the pelvis allows it to be readily mobilized laparoscopically in patients of nearly all shapes and sizes. However, multiple previous pelvic operations may be a contraindication to laparoscopic rectopexy. Otherwise, as long as a transabdominal approach is feasible, there are no specific contraindications to laparoscopic treatment of rectal prolapse.

The surgical management of rectal prolapse encompasses both transabdominal and transperineal procedures, with transabdominal procedures generally being described as more effective.[26] Our preference is the sutured rectopexy in conventional surgery because of its inherent simplicity and equivalent effectiveness compared with other methods of preventing recurrent prolapse.[27-29] Thus, we use sutured rectopexy laparoscopically, offering the patient the same kind of repair of this functional condition without a major abdominal wall incision. We add a sigmoid resection only if the patient has a severe underlying bowel motility disorder coupled with intractable constipation as proven by intestinal transit studies.

Although intractable constipation is a rare indication for laparoscopic subtotal colectomy with ileorectal anastomosis, it is feasible because the colon will nearly always be uninflamed, not adherent to surrounding structures, and attached to with a normal mesentery. A contraindication for laparoscopy is a situation in which the patient cannot be adequately prepared before surgery, that is, if the colon were filled with fecal matter or were grossly distended.

Temporary or permanent diversion of the fecal stream in patients with incontinence, using a colostomy or ileostomy, is an excellent indication and is a simple laparoscopic intestinal procedure. Contraindications to laparoscopic fecal diversion include multiple previous laparotomies in patients with known extensive adhesions and in patients who are morbidly obese, a situation in which the question of the stoma reaching the skin without substantial tension is a serious concern.

In elective surgery, sigmoid colonic volvulus (that has been reduced preoperatively) can be approached laparoscopically. Because these colon segments are often only loosely attached to surrounding structures, they lend themselves to resection with anastomosis; either intracorporeal or extracorporeal resection is possible, and in extracorporeal resection, the intestine is brought through the abdominal wall through a limited incision. In patients with acute colonic volvulus, decompression should be performed preoperatively as in conventional surgery, and then the feasibility of elective laparoscopic surgery can be determined. We believe laparoscopic surgery should not be performed in emergency situations because of the abdominal distension. Other contraindications to laparoscopic treatment of volvulus include gross distension of the colon secondary to obstruction, gangrene of the colon, or medical or cardiovascular instability.

References

1. Safran D, Sgambati S, Orlando R III. Laparoscopy in high-risk cardiac patients. *Gynecol Obstet.* 1993; 176:548–554.
2. Franklin ME, Dorman JP, Pharand D. Laparoscopic surgery in acute small bowel obstruction. *Surg Laparosc Endosc.* 1994;4:289–296.
3. Sacclarides TJ, Ko ST, Airan M. Laparoscopic removal of a large colonic lipoma. Report of a case. *Dis Colon Rectum.* 1991;34:1027–1029.
4. Pezim ME, Nicholls RJ. Survival after high or low ligation of the interior mesenteric artery during curative surgery for rectal cancer. *Ann Surg.* 1984; 200:729–733.
5. Hojo K, Vernava AM, Sugihara K, Katumata K. Preservation of urine voiding and sexual function after rectal cancer surgery. *Dis Colon Rectum.* 1991;34:532–539.
6. Enker WE, Laffer UT, Block GE. Enhanced survivial of patients with colon and rectal cancer based upon wide anatomic resection. *Ann Surg.* 1979;190:350–360.
7. Goligher JC. *Surgery of Anus, Rectum, and Colon.* London: Bailliere Tindall, 1984.
8. Daly JM, Cady B. *Atlas of Surgical Oncology.* St. Louis, Mo.: Mosby Year Book; 1993:455–600.
9. Stearns MW, Scottenfeld D. Techniques for the surgical management of colon cancer. *Cancer.* 1971; 28:165–169.
10. Turnbull RB, Kyle K, Watson FR, Spratt J. Cancer of the colon: the influence of the no-touch isolation technic on survial rates. *Ann Surg.* 1967;166:420–427.
11. Dixon AR, Maxwell WA, Holmes TJ. Carcinoma of the rectum: a 10-year experience. *Br J Surg.* 1991; 78:308–311.
12. Sugarbaker PH, Corlew S. Influence of surgical techniques on survival in patients with colorectal cancer. *Dis Colon Rectum.* 1982;25:545–557.
13. Jacobs M, Verdeja JC, Goldstein HS. Minimally invasive colon resection (laparoscopic colectomy). *Surg Laparosc Endosc.* 1991;1:144–150.
14. Monson JRT, Darzi A, Carey PD, Guillou PJ. Prospective evaluation of laparoscopic-assisted colectomy in an unselected group of patients. *Lancet.* 1992;340:831–833.
15. Phillips EH, Franklin M, Carroll BJ, Fallas MJ, Ramos R, Rosenthal D. Laparoscopic colectomy. *Ann Surg.* 1992;216:703–707.
16. Scott KW, Grace RH. Detection of lymph node metastases on colorectal carcinoma before and after fat clearance. *Br J Surg.* 1989;76:1165–1167.
17. Milsom JW, Böhm B, Decanini C, Fazio VW. Laparoscopic oncologic proctosigmoidectomy with colorectal anastomosis. *Surg Endosc.* 1994;8: 1117–1123.
18. Decanini C, Milsom JW, Böhm B, Fazio VW. Laparoscopic oncologic abdominoperineal resection. *Dis Colon Rectum.* 1994;37:552–558.

19. Cava A, Roman J, Gonzalez Quintela A, Martin F, Aramburo P. Subcutaneous metastasis following laparoscopy in gastric adenocarcinoma. *Eur J Surg Oncol.* 1990;16:63–67.
20. Walsh DCA, Wattchow DA, Wilson TG. Subcutaneous metastases after laparoscopic resection of malignancy. *Austr J Obstet Gynaecol.* 1993;63:563–565.
21. Clair DG, Lautz DB, Brooks DC. Rapid development of umbilical metastases after laparoscopic cholecystectomy for unsuspected gallbladder carcinoma. *Surgery.* 1993;113:355–358.
22. Landen SM. Laparoscopic surgery and tumorseeding. *Surgery.* 1993;114:131–132.
23. Miralles RM, Petit J, Gine L, Balaguero L. Metastatic cancer spread at the laparoscopic puncture site. Report of a case in a patient with carcinoma of the ovary. Case report. *Eur J Gynaecol Oncol.* 1989;10:442–444.
24. Wexner SD, Johansen OB, Nogueras JJ, Jagelman DG. Laparoscopic total abdominal colectomy. *Dis Colon Rectum.* 1992;35:651–655.
25. Wexner SD, Cohen SM, Johansen OB, Nogueras JJ, Jagelman DG. Laparoscopic colorectal surgery: a prospective assessment and current perspective. *Br J Surg.* 1993;80:1602–1605.
26. Watts JD, Rothenberger DA, Buls JC, Golberg S, Nivatvongs S. The management of procidentia. *Dis Colon Rectum.* 1985;28:96–102.
27. Duthie GS, Bartolo DCC. Abdominal rectopexy for rectal prolapse: a comparison of techniques. *Br J Surg.* 1992;79:107–113.
28. Sayfan J, Pinho M, Alexander-Williams J, Keighley MRB. Sutured posterior abdominal rectopexy with sigmoidectomy compared with Marlex rectopexy for rectal prolapse. *Br J Surg.* 1990;77:143–145.
29. Ejerblad S, Krause U. Repair of rectal prolapse by rectosacral suture fixation. *Acta Chir Scand.* 1988;154:103–105.

8

General Aspects of Laparoscopic Colorectal Surgery

Preoperative Preparation of the Patient

The preoperative examination and preparation procedures for patients undergoing laparoscopic colorectal surgery are identical to those for conventional surgery—only the access to the operative site differs.

Patients should have preoperative blood testing, endoscopic and radiographic examinations, bowel preparation, and they should receive perioperative antibiotics exactly as if they were undergoing conventional surgery. We usually administer 4 L of oral polyethylene glycol (PEG) solution the day before surgery to cleanse the bowel. Some surgeons prefer to use laxatives and enemas because some PEG solution may still remain in the small intestine at surgery. This remaining solution may dilate the small intestine somewhat, which can compromise exposure during the operation.

In patients with colorectal cancer, the liver should be thoroughly examined, either using preoperative computed tomography with both intravenous and oral contrast dye or using intraoperative ultrasonography because liver palpation cannot be performed during laparoscopic surgery. We also recommend that endoluminal ultrasonography be done in all patients with rectal cancer. The size, depth of wall penetration, and precise relationship of the tumor to other organs can be accurately determined in almost 90% of patients. Additionally, larger pelvic or presacral vessels can sometimes be identified by preoperative endoluminal ultrasonography and can sometimes be avoided during pelvic dissection.

Operating Room Setup

A clearly defined setup for all laparoscopic colorectal procedures is recommended. Because laparoscopic surgery requires complex equipment, it is advisable to organize the operating room to facilitate each step of the procedure, increase efficiency, and shorten anesthesia time. A laparoscopic surgical procedure should be initiated only if all equipment is functional and has been calibrated immediately before the scheduled operation. Successful troubleshooting with rapid replacement of components if the equipment malfunctions must be possible during every laparoscopic procedure.

The general setup of the operating room for laparoscopic colorectal surgery involves the following three major steps:

1. assembling the basic instrumentation
2. preparing the patient in the operating room
3. positioning the personnel and the laparoscopic equipment

Assembling the Basic Instrumentation

The following basic instruments should be available on the sterile equipment table for the preliminary examination, which may be done for diagnosis or to determine if the planned laparoscopic procedure will be possible:

- scalpel handle equipped with no. 15 blade
- scalpel handle equipped with no. 10 or no. 20 blade
- fine, long curved hemostats (e.g., tonsil clamps)
- Kocher grasping hemostats
- electrosurgical unit
- Veress needle (or equivalent) if blind entry into the peritoneal cavity is considered
- initial cannula for laparoscope
- laparoscope with camera and light cable and CO_2 insufflation tube
- all surgical equipment necessary to perform a rapid laparotomy if required

If laparoscopic surgery appears to be feasible after the initial examination, the following laparoscopic instruments should be available on the equipment table to begin the procedure:

- endoscopic dissecting device (for cutting and coagulation)
- all necessary cannulas and body wall anchoring devices
- endoscopic scissors
- endoscopic dissector
- endoscopic graspers

Preparing the Patient

To initially position patients, we have found that a modified lithotomy position works well for most laparoscopic colorectal surgical procedures. A moldable "bean bag" form is placed under the patient's head and torso to stabilize the body on the table. This form in turn should be held in place by shoulder braces. Such an arrangement helps to keep the body from sliding during the steep head-down and side-to-side positions often called for in laparoscopic surgery.

The patient must be positioned so that the pelvis is just above the break at the lower end of the operating table—this position gives the surgeon free access to the perineum for intraoperative endoscopy, pelvic manipulation, or transanal anastomosis. The legs are placed in padded, adjustable stirrups (we prefer Dan Allen stirrups, Bedford Heights, Ohio) so the surgeon can stand between the legs when necessary (Figure 8.1).

We initially wrap each calf with pneumatic compression stockings and position the legs in a 20° to 25° abducted position with the thighs only minimally elevated above the abdomen because higher thigh elevation may not allow the surgeon to freely move the instruments. The heel of each leg must be elevated slightly above the knee to maximize venous outflow from the legs and to minimize the risk of intraoperative venous stasis.[1,2]

After induction of anesthesia, a nasogastric tube should always be placed to empty the stomach of air and secretions. To empty the bladder and decrease the risk of inadvertent injury during the first phase of laparoscopy, a Foley urinary catheter should be placed.

In all procedures involving the left colon or the rectum, rectal irrigation is carried out just before skin preparation and draping. If laparoscopic surgery is to be performed to resect a rectal tumor, endoscopy should be carried out preoperatively, and the bowel wall should be marked 2 cm below the distal tumor margin using india ink and a sclerotherapy needle passed endoscopically. If a tumor of the colon has to be resected, either preoperative or intraoperative colonoscopy or preoperative barium enema may be necessary to confirm the tumor location.

Positioning the Personnel and the Laparoscopic Equipment

The positions of the personnel are determined by the location of the pathologic lesion. The surgeon generally stands on the side opposite the site of the pathologic lesion, but between the legs when mobilizing either colonic flexure. When possible, standing to the patient's right side is usually preferred when performing pelvic surgery because sigmoid mobilization will be easier. The first assistant should stand opposite the surgeon or on the side opposite the pathologic lesion when the surgeon stands between the legs. The second assistant (camera person) should stand next to the surgeon when the surgeon works in the pelvis or next to the first assistant so the operating team view the monitors from the same vantage point, which

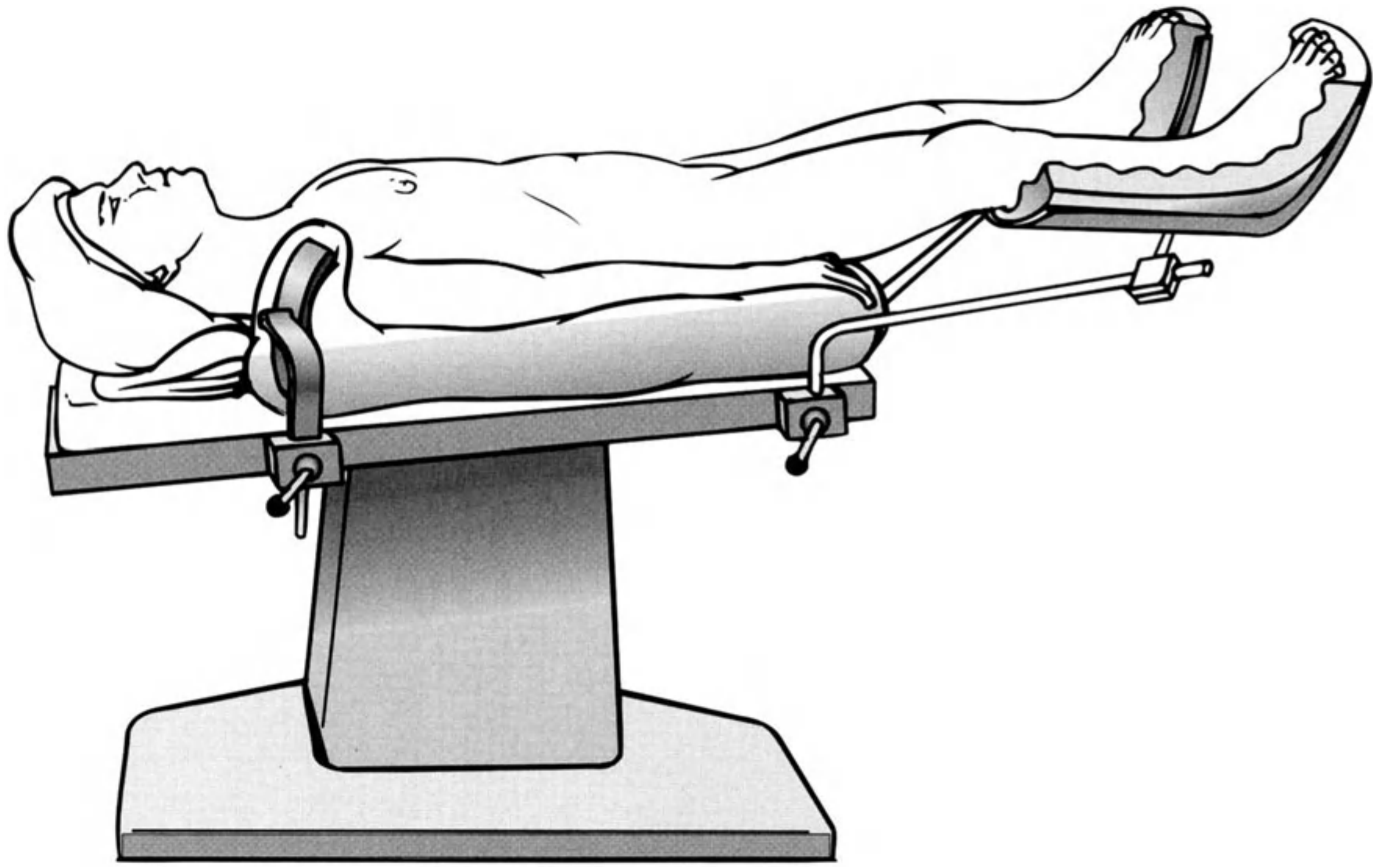

FIGURE 8.1. Optimal position of the patient on the operating table for laparoscopic surgery. The shoulders are well-padded and braces are in place. The legs are in padded stirrups and are positioned only slightly above the body. The buttocks are positioned at the bottom edge of the table.

will facilitate guidance of the laparoscope (Figure 8.2). The nurse should stand so both the instrumentation table and the operative field are easily accessible. This position not only facilitates instrument passage, but it also enables the nurse to help the surgeon by performing such tasks as stabilizing the cannula while the surgeon exchanges instruments.

Depending on the area available in the operating room and the size of the equipment and the instruments, the laparoscopic team should design a single setup that can easily be adapted for the most common procedures; having one setup will allow the equipment to be more quickly arranged. In addition, a backup set of equipment components must be available to avoid delay or termination of the procedure if a component fails. Because such failure is unpredictable, a plan should be developed that all team members understand so components can be rapidly replaced. To increase efficiency, all members of the surgical team should learn the specified setup for each operation and should be trained according to this setup. In this chapter, we discuss the placement of equipment in general; our preferred setup for each procedure is discussed in chapter 9.

The number of carts for the laparoscopic equipment should be kept to a minimum. In general, laparoscopic colorectal surgery calls for two mobile carts: they should either have wheels or be mounted on tracks from the ceiling. On one cart, a video monitor, a light source, a video system, and an insufflator are placed on the patient's side that is opposite to the first assistant so the insufflator display can be seen during the entire procedure—high intra-abdominal pressure, low gas flow, or an empty gas tank can thus be detected quickly. The second cart is positioned on the patient's side opposite to the surgeon, and the irrigation suction unit, a video monitor, and the electrosurgical unit are placed on it. The instrument table should be placed toward the lower end of the patient so the nurse

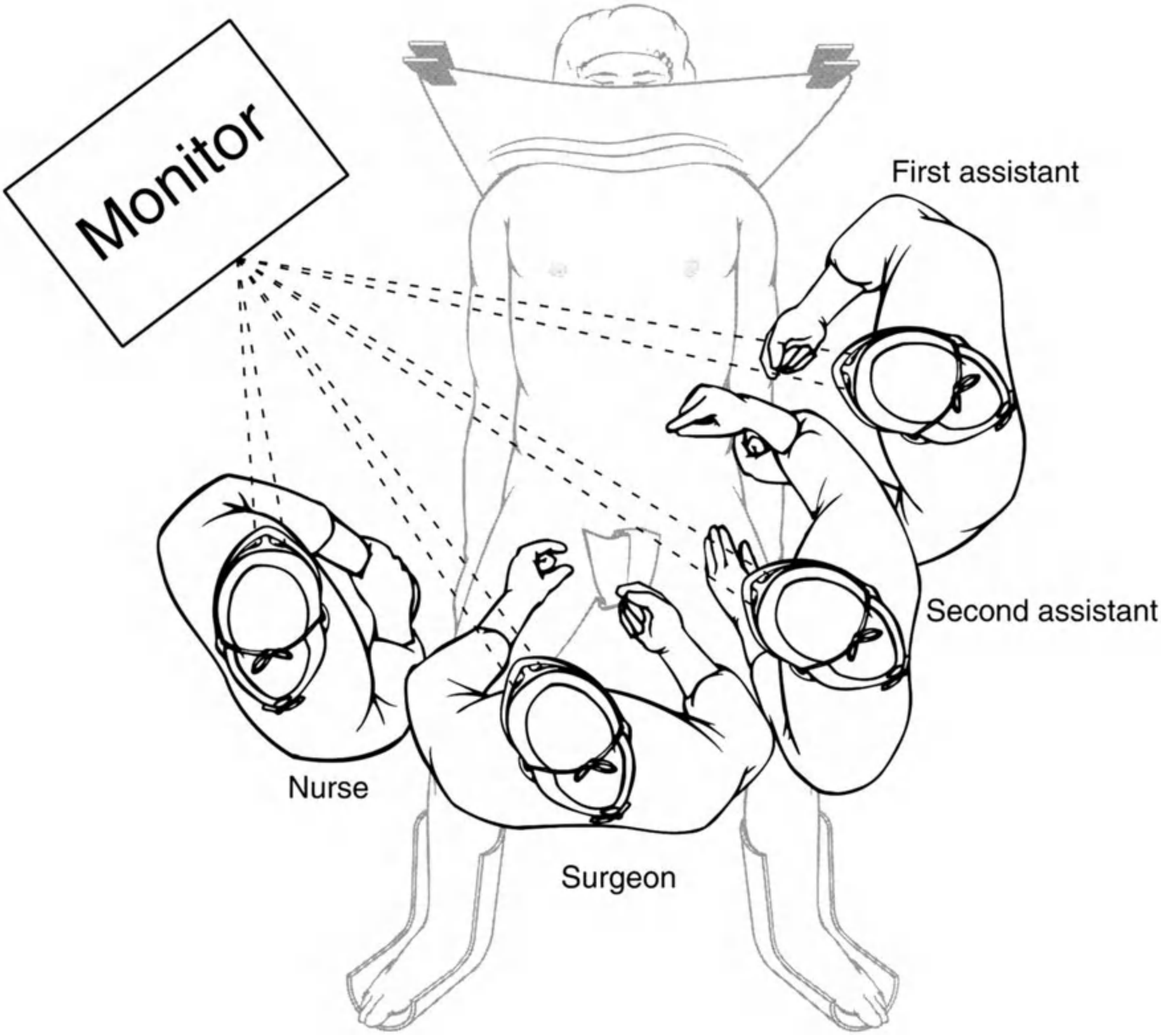

FIGURE 8.2. The laparoscopic team and working cannulas are oriented in one direction so the entire team may comfortably view the monitors from the same vantage point.

can easily work from it and assist the surgeon during all phases of the procedure.

Anesthesia: Pulmonary and Hemodynamic Concerns

Pulmonary Function

It is well established that pulmonary function diminishes under general anesthesia owing to loss of inspiratory muscle tone, changes in intrathoracic blood volume, and the use of the supine position, which causes cephalad displacement of the diaphragm. These factors lead to a decline in functional residual capacity (FRC) that is accompanied by a decrease in PO_2. Increased shunting of blood through the pulmonary circulation results in atelectasis, which further decreases PO_2. In addition, pneumoperitoneum together with the Trendelenburg position, which is frequently used in laparoscopic colorectal surgery, may compromise the FRC even more.[3] Although the Trendelenburg position reduces vital capacity by about 10% to 15% compared with the sitting position,[4] it does not lead to major alterations in gas exchange in healthy young adults.[5]

The FRC drops even more precipitously in patients with restrictive or obstructive pulmonary disease so elevating the inspiratory O_2 and positive end-expiratory pressure is necessary to compensate for impaired pulmonary function during anesthesia. In patients with significant concurrent pulmonary disease, any decrease in FRC may be life threatening, and thus laparoscopic surgery probably should be avoided whenever possible in these patients.

Currently, pneumoperitoneum is performed with CO_2, which is rapidly absorbed into the bloodstream and only partially excreted, thus increasing PCO_2. Hypercarbia should be avoided because it leads to acidosis, cardiac arrhythmias, direct vasodilation, activation of the sympathetic nervous system, and can impair hepatic function.[6,7] However, hypercarbia does not appear to be the major cause of the negative hemodynamic effects observed during colorectal laparoscopy.[3,8]

Hypercarbia can be avoided if PCO_2 is measured continuously during laparoscopic surgery and the ventilation rate is adjusted accordingly.[9,10] Continuous intraoperative monitoring of end-tidal PCO_2 is necessary because the amount of increase in PCO_2 from CO_2 pneumoperitoneum is unpredictable. Because the difference between the arterial and end-tidal PCO_2 is small (0.44 kPa) in patients without severe pulmonary disease,[11] the end-tidal CO_2 partial pressure is a good and reliable indicator of PCO_2.[12] However, in patients with pulmonary disease, the end-tidal PCO_2 may differ considerably from the PCO_2 because of ventilation-perfusion mismatching, and we do not recommend relying only on end-tidal PCO_2 in these patients.

In addition, CO_2 may continue to be absorbed for a short period after pneumoperitoneum is released at the end of the procedure[3]—if hypercarbia does occur, postanesthetic mild hyperventilation usually returns the PCO_2 level to normal in several hours without further treatment. Patients with concurrent pulmonary disease should be monitored closely in the postoperative period to ensure that spontaneous ventilation is sufficient to avoid hypercarbia.

Adequate ventilation during laparoscopic colorectal surgery may sometimes be difficult to maintain in patients with concurrent obstructive or restrictive pulmonary disease[13] because the peak airway pressure rises with elevated intraperitoneal pressure.[14] Thus, patients with concurrent pulmonary disease who are approved for laparoscopic surgery may not be candidates for pneumoperitoneum with CO_2. Helium may be an alternative because it does not lead to hypercarbia.[15] If a short laparoscopic procedure is to be performed and concurrent pulmonary disease does not exist, epidural rather than general anesthesia may suffice. Ciofolo et al.[16] have shown that the $PaCO_2$ remains constant during minor laparoscopic surgery when epidural anesthesia is used, whereas end-tidal PCO_2 decreases, increasing the difference between arterial and alveolar CO_2.

Hypoxemia is uncommon during laparoscopy,[10] possibly because the difference between the alveolar and the arterial PO_2 decreases as a result of an increase in cardiac output that is related to vasodilation and hypercarbia.[3] If hypoxemia is seen during laparoscopic surgery, it may be caused by intrapulmonary shunting, hypoventilation, pneumothorax, mediastinal emphysema, or hemodynamic problems. If hypoxemia cannot be corrected rapidly, the patient should immediately be taken out of the Trendelenburg position and pneumoperitoneum should be released to improve respiratory function. Endotracheal tube placement should then be checked and the cause of the hypoxemia treated. If the patient is stable, the laparoscopic procedure can be continued but conversion to conventional surgery may be advisable.

Hemodynamic Function

The hemodynamic effects of the increased intraperitoneal pressure (IPP) of pneumoperitoneum have been evaluated extensively in animal models[14,17-19] and in humans.[8,10,20,21] An IPP of more than 12 mm Hg in both humans and animals significantly decreases cardiac output and blood flow through the inferior vena cava, the portal vein, and the mesenteric vein, and increases the pressure in the vena cava and the portal vein. These effects are directly related to the IPP level[10,18] and can be modified by changing the position of the patient. Most of the negative effects described as follows are more pronounced in a head-up position. Consequently, the Trendelenburg (head-down) position substantially lessens some of the negative effects of pneumoperitoneum on intra-abdominal hemodynamics.[14] In part because left ventricular cardiac function and venous return decrease with pneumoperitoneum, cardiac output also decreases.[17] If the IPP is 10 mm Hg or less, a reduction in cardiac output has not been seen in humans.[21]

Although heart rate generally increases only slightly during pneumoperitoneum,[20] the systemic vascular resistance may increase up to 50% and thus increase mean arterial pressure and decrease cardiac output.[17,20,22] Kotzampassi et al.[8] reported that increased IPP, not hypercarbia, causes these hemodynamic effects because they found no difference in hemodynamic effects between patients insufflated with CO_2 and those insufflated with He. This finding was corroborated by Huang et al.,[23] who reported that the increase in peripheral vascular resistance was caused by vasoconstriction in the splanchnic area and was not related to hypercarbia.

Leighton et al.[24] compared the cardiopulmonary effects of CO_2 versus He pneumoperitoneum in a porcine model. The IPP was maintained at 15 mm Hg; then arterial PO_2, PCO_2, pH, and systemic and pulmonary artery pressures were measured every 15 minutes for 90 minutes. Mean PCO_2 significantly increased (from 41.3 ± 3.0 mm Hg to 58.3 ± 4.0 mm Hg), mean pH significantly decreased (from 7.46 ± 0.02 to 7.31 ± 0.02), and mean pulmonary artery pressure increased significantly to twice baseline levels (14 ± 1 mm Hg to 28 ± 2 mm Hg) during CO_2 insufflation, but no hypercarbia, acidemia, or pulmonary hypertension was seen during He insufflation under identical conditions.[24] These results also suggest that He merits further consideration as an alternative to CO_2 for establishing pneumoperitoneum, particularly in patients with underlying respiratory diseases.

Luz et al.[19] studied the effects of CO_2 pneumoperitoneum during pelvic lymphadenectomy in a canine model. In contrast to other studies, they found that up to an IPP of 15 mm Hg, cardiac output did not decrease and mean arterial pressure did not increase. Only when positive end-expiratory pressure was added to improve oxygenation and decrease atelectasis, was cardiac output impaired significantly.

The increase in peripheral vascular resistance and reduction of cardiac output can be deleterious in patients with congestive heart disease, and arrhythmia with cardiovascular collapse is possible. Thus, careful preoperative selection of patients with cardiac or pulmonary risk factors is mandatory.[13] Safran et al.[22] analyzed hemodynamic changes in high-risk cardiac patients undergoing laparoscopy with CO_2 pneumoperitoneum and concluded that laparoscopy can safely be performed if the patient is carefully monitored.

Because all hemodynamic changes are more pronounced if the IPP is greater than 12 mm Hg,[13,18,25] after placing the cannulas, we set our upper limit for IPP at 12 mm Hg and positioned the patient in the Trendelenburg position with a 20° head-down tilt. Kubota et al. [21] reported that neither cardiac nor respiratory function was depressed with an IPP of 10 mm Hg. Minimizing the angle of the head-up position (reverse Trendelenburg); decreasing the intra-abdominal CO_2 pressure; maintaining good muscle relaxation; increasing the inspired O_2 concentration, if necessary to maintain good oxygen saturation; and controlling ventilation with positive end-expiratory pressure ventilation can all maximize safety and minimize pulmonary and cardiovascular risks during laparoscopic surgery.[26]

Other cardiovascular changes that may be seen with pneumoperitoneum are tachycardia, bradycardia, and arrhythmia. These changes may result from absorption of CO_2, as well as from changes relating to increased intra-abdominal pressure from the Trendelenburg position and from diaphragmatic immobilization.[27] Bradyarrhythmias consisting of A-V dissociation, nodal rhythm, and sinus bradycardia caused by reflex vagal nerve stimulation have also been attributed to local CO_2 irritation or stretching of the intraperitoneal and pelvic structures.[28] Slow induction of pneumoperitoneum (insufflation at 2 L/min or less) and premedication with atropine may prevent bradycardia.

Thus, in all patients undergoing laparoscopic colorectal surgery we recommend routine continuous intraoperative monitoring of the electrocardiogram, end-tidal capnography, peak-airway pressure, inspired oxygen fraction, pulse oximetry, urinary output, and esophageal or bladder temperature. Arterial cannulation should be performed in patients with cardiac or pulmonary diseases. Careful monitoring will allow for rapid compensation of any intraoperative disturbance.

As in conventional colorectal surgery, it is important that the anesthesiologist and the surgeon work closely together during laparoscopic surgery. If the patient becomes unstable, the procedure must be stopped, pneumoperitoneum immediately released, and all necessary treatment begun. Discontinuation of all surgery or, if the patient can be stabilized, conversion to open surgery should be considered at this juncture.

We do not recommend using N_2O as an inhalational anesthetic in laparoscopic colorectal surgery. Nitrous oxide is 30 times more soluble in blood than N, and it will dissipate into the closed air-containing spaces of the body, such as the intestinal lumen.[29] Consequently, bowel distension may occur and compromise the laparoscopic procedure.

Establishing Pneumoperitoneum

Pneumoperitoneum is most commonly established using a Veress needle. Various initial skin incisions can be used that will permit a Veress needle to be inserted into the peritoneal cavity. We prefer a vertical infraumbilical incision because it overlies the location where the skin, the fascia, and the parietal peritoneum of the intra-abdominal wall converge and fuse. Care must be taken not to traverse the deep fascia with the initial skin incision.

After the skin is incised, the subcutaneous fatty tissue is bluntly dissected until the linea alba is visible. If a nondisposable Veress needle is used, the needle is examined to ensure that it is sharp and that the tip of the inner sheath is intact. The linea alba is grasped at two locations approximately 15 mm apart using two hook retractors or Kocher clamps[30] and is pulled anteriorly. Next, a U-shaped size 2-0 or 0 fascial suture is placed around the cannula insertion site for closure at the end of the procedure. The Veress needle is then inserted at a 90° angle to the abdominal wall; the needle should be held between the thumb and the index finger not more than 3 cm from the tip to ensure it passes safely and steadily through the fascia. Steadying the heel of the needle-wielding hand on the abdominal wall will minimize the risk of uncontrolled insertion through the fascia. If the abdominal wall is elevated, needle insertion should continue perpendicular to the abdominal wall through the fascia for approximately 1 cm; then the needle must be directed toward the pelvis. As the needle's spring-loaded safety mechanism crosses the posterior rectus sheath and the peritoneum, a click is heard and is usually felt. Once inside the peritoneal cavity, the needle tip should feel free and move easily when the hub is moved laterally. The safety band found on many Veress needles should also indicate that the blunt tip has protruded into the peritoneal cavity beyond the sharp point of the needle.

Once the needle is in place, its intraperitoneal location is verified as follows. A 10-mL syringe filled with normal saline is attached to the needle. Three milliliters is injected and then aspirated; the aspirate is examined for return of blood, urine, or bowel contents. No resistance should be felt during injection. Next, the "hanging drop" test is performed, which confirms that the needle has entered a cavity. The test is done by relaxing all retraction on the abdominal wall, placing a drop of saline on the open hub of the Veress needle, then lifting up on the Kocher clamps placed on the abdominal fascia. When the clamps are lifted, the saline will quickly drop into the peritoneal cavity if it has been entered. Unfortunately, the test merely indicates whether a cavity has been entered; it does not distinguish between the peritoneal cavity and the preperitoneal space or a hollow viscera (Figure 8.3). Carefully observing the intra-abdominal pressure during early gas insufflation can indicate whether the needle is correctly located in the peritoneal cavity. Pressure monitoring through the needle should indicate a pressure of less than 5 mm Hg at the beginning of CO_2 insufflation. If the pressure is greater than 5 mm Hg, the needle is probably either in the abdominal wall, the preperitoneal space, adjacent to or within an in-

FIGURE 8.3. A Veress needle inadvertently placed into the preperitoneal space.

tra-abdominal viscus, or buried in the omentum. Elevating the abdominal wall and repositioning the needle (usually by simple axial rotation) will almost always result in proper pressure readings. If the pressure remains elevated or increases rapidly over 10 seconds, the needle is in a small cavity, and it should be removed immediately and inserted again.

During the initiation of pneumoperitoneum, the IPP should increase slowly (a flow rate of 2 L/min or less) and should not exceed 20 mm Hg; this high pressure should be used only during trocar and cannula insertion. This slow insufflation minimizes the risk of arrhythmias or serious sequelae of a gas embolism if the needle has been inadvertently positioned in a vein. The high solubility of CO_2 in blood reduces the risks of gas embolism should it occur. If a gas embolism is suspected, pneumoperitoneum must be released immediately. The patient should then be placed in the left lateral decubitus position and resuscitation attempts should be made as described in the following section, Complications of Pneumoperitoneum. The IPP should be observed frequently during the initial insufflation. Usually, 3 to 4 L of gas are required to achieve an initial pressure of 20 mm Hg. A tympanitic, or "trampoline," effect that can be appreciated by palpating all four quadrants of the abdomen usually indicates adequate pneumoperitoneum.

If the umbilical area is unsuitable for needle insertion, an alternate site lateral to the rectus muscle should be selected. Such sites include a left- or right-sided McBurney's point or, in women, a transvaginal approach with the needle inserted into the pouch of Douglas. Wolfe[31] has reported a safe transuterine insertion in 100 women with minimal bleeding (no hemostatic intervention needed). The surgeon should always readily move to an open technique for cannula insertion (a technique that involves inserting a blunt-tipped cannula through an incision) should any difficulties arise using the Veress needle.

Complications of Pneumoperitoneum

Subcutaneous and subfascial emphysema caused by insufflating CO_2 into the preperitoneal space or by CO_2 leaking from the parietal peritoneum around the puncture sites into the subcutaneous or subfascial spaces usually resolves within a few hours of the procedure. If pneumoperitoneum is established using an open cannula insertion technique, the fascial incision should not be wide, and a purse-string fascial suture should be tied tightly around the cannula after insertion—this may help prevent subcutaneous emphysema. Subfascial labial or scrotal emphysema may also occur after lower-quadrant cannula insertions.

Subcutaneous emphysema[32] calls for immediate attention to the patient's respiratory status to determine if pneumothorax or mediastinal emphysema has occurred, because these complications can be life threatening.[33,34] If pneumothorax or mediastinal emphysema is suspected, the abdominal cavity should immediately be desufflated and the following therapeutic options considered:

- If the patient appears unstable after desufflation, both thoracic cavities should be auscultated. If pneumothorax is even a remote possibility, unilateral or bilateral needle thoracostomy must be performed in the second intercostal space in the midclavicular line.
- If the patient is stable with no obvious respiratory compromise, an on-table chest x-ray should be performed with simultaneous full evaluation of the endotracheal tube position to ensure that the tube has not become positioned too far in or out of the trachea.
- If ventilatory compromise exists, arterial blood gases should be monitored to detect possible hypercarbia.

If vital signs suddenly deteriorate, gas embolism should be the initial consideration. Although rare, it may rapidly lead to lethal complications if untreated.[35-37] Gas embolism decreases cardiac output because of an "air-lock" effect in the right side of the heart that effectively obstructs the pulmonary outflow tract. If the gas embolism is of sufficient volume, the acute obstruction of the pulmonary artery leads to rapid right ventricular failure. It most commonly occurs when the pressure in an open abdominal vein is less than the intra-abdominal pressure. If gas embolism occurs, a characteristic murmur that sounds like the humming of a mill wheel can be readily heard with precordial auscultation. Another early sign of gas embolism is a decrease in end-tidal PCO_2, resulting from a ventilation-perfusion mismatch caused by the embolism.

Pneumoperitoneum should be released instantly if gas embolism is suspected. The patient is then immediately placed in the left lateral decubitus position with a head-down tilt. External cardiac massage may give circulatory support and breaks up the gas embolus obstructing the right ventricular outflow. Aspirating the gas bubble through a central venous catheter may help and this maneuver should be resorted to whenever gas embolism is a consideration. Because intravascular CO_2 is highly soluble, it will probably rapidly dissolve and the patient's recovery will be uneventful if proper support is given.

Whether pneumoperitoneum has any direct negative effects on intestinal function is questionable. Kotzampassi et al. showed a decrease in blood flow with mucosa ischemia during CO_2 pneumoperitoneum[8]: the tissue pH of the jejunal mucosa decreased from 7.4 to 6.8 after 60 minutes of IPP at 14 mm Hg.

Renal blood flow has been shown to decrease in some patients and animals during pneumoperitoneum, even when IPP is lower than 10 mm Hg.[21] Thus, intraoperative urinary output should be monitored carefully in patients known to have impaired renal blood flow.

The incidence of inadvertent injury to major retroperitoneal or intra-abdominal vessels is low, but the morbidity is high when injury does occur. Most injuries occur during blind insertion of the Veress needle or first trocar, but they may also occur during trocar insertion under direct vision. A laparotomy is required to explore and repair any major vessel laceration inside the peritoneal cavity or in the retroperitoneum. If such a vessel injury is even suspected, we recommend conversion to laparotomy. Retroperitoneal bleeding resulting from injury to the aorta, the vena cava, or an iliac vessel secondary to Veress needle or trocar insertion is rare but may not be immediately visible. If the peritoneal tear and the injury to a retroperitoneal vascular structure are not precisely at the same point, bleeding may extend through the retroperitoneal space before it is recognized.

Rarely is the intestine inadvertently perforated with the Veress needle or the trocar. A Veress needle injury to the small-intestine wall likely will go unnoticed and will heal spontaneously. Stomach perforation can occur while pneumoperitoneum is established because of overdistension of the stomach secondary to anesthesia induction. To minimize this risk, placing a nasogastric tube is recommended for all colorectal laparoscopic procedures. After initial blind insertion of the Veress needle and the first trocar or cannula, we always visualize the area immediately below the insertion site to inspect for sign of visceral injury.

If the abdominal cavity is flushed repeatedly with CO_2 to remove smoke produced from the electrosurgical or laser instruments, or if minor leakage causes permanent persufflation, serious hypothermia may occur. The temperature of CO_2 is 21.1°C when delivered directly from the gas cylinder into the peritoneal cavity without insufflator warming. Consequently, CO_2 gas insufflation generally decreases the body core temperature 0.3°C for every 40 to 50 L of gas delivered into the abdominal cavity.[38] Continuous gas insufflation can cause hypothermia because temperature homeostasis is impaired during general anesthesia and because peripheral vasoconstriction occurs in response to cold exposure. Ott[38] has demonstrated that hypothermia can be prevented by increasing the temperature of the delivered gas to at least 30°C. Therefore, we recommend warming the insufflating gas or recirculating the gas to avoid hypothermia.

Trocar and Cannula Insertion

Selecting Insertion Sites

For most advanced procedures, at least five cannulas will be inserted: one for the laparoscope, two for the operating surgeon, and two for the first assistant surgeon, so each surgeon can operate with both hands. In most instances, the operating surgeon will place the cannulas opposite to the site of the pathologic lesion, which allows the greatest room to work and to visualize the pathologic lesion site. Because any abdominal wall cannula will restrict the mobility of the laparoscopic instruments, the cannula locations should also be chosen to allow the greatest mobility possible, given several additional considerations. A minimum of 8 cm (approximately the width of a small-sized fist) should separate the cannulas to prevent the instrument shafts from crossing each other. In addition, cannulas should also be placed 6 to 8 cm beyond the laparoscope site because closer placement impedes a clear overview of the laparoscope.

Generally, the abdominal cavity is entered through a small transverse or curvilinear infraumbilical skin incision. This location is a good central point for the laparoscopic camera, is usually a relatively thin area of the abdominal wall, and is devoid of vessels that could be injured by the blind trocar and cannula insertion technique that most surgeons use to establish pneumoperitoneum. After the infraumbilical trocar and cannula are placed, the remaining trocars and cannulas are placed while viewing them directly through the laparoscope to form a semicircle that opens toward the surgical site. Thus, the first assistant's cannulas will either lie opposite the site of pathology or at about 90° to the surgeon's cannulas. In this way, the operative site is accessible from all trocars, and both the surgeon and the assistant may work in a line of direct vision (Figure 8.2), with eyes and hands positioned in the same direction in which they are seen on the video screen. Instruments passed through the cannulas will enter the field of view somewhat tangentially rather than in a coaxial orientation, which seems to minimize obstruction of the operative field caused by the instrument shafts. If it is required, a suprapubic cannula is placed last because its tip may become caught on the preperitoneal fatty tissue surrounding the urachus. If this occurs, an instrument such as a grasper passed through one of the cannulas may allow traction to be applied against the body wall at the suprapubic site and permit smoother intraperitoneal entry of this cannula.

Inserting Trocars and Cannulas

After pneumoperitoneum is established with the Veress needle, the umbilical incision is usually used for the blind insertion of the first trocar-equipped cannula. We generally insufflate the abdominal cavity to 20 mm Hg for the first few minutes of the procedure to somewhat increase the rigidity of the abdominal wall while the trocars/cannulas traverse it. We believe this increased intra-abdominal pressure makes the body wall easier to pierce and increases the distance between the body wall and the intra-abdominal structures. We have not yet seen a negative influence on cardiopulmonary function if the intra-abdominal pressure of 20 mm Hg is used only during the several minutes needed to insert the first cannula.

The size of the skin incision for each cannula must be planned carefully. If the incision is too small, friction will develop between the skin and the cannula sleeve; consequently, greater force will be required for insertion, which will increase the risk of uncontrolled insertion. On the other hand, if the incision is too large, insufflated gas may leak out around the incision during the procedure or the cannula may dislocate more easily.

The cannula sleeve is held between the index and the middle fingers with the hub of the trocar against the thenar eminence (Figure 8.4). The index finger can also be placed along the cannula sheath to stop the trocar if a sudden thrust forces it through the abdominal wall. We believe it is also good practice for the surgeon to grasp the cannula shaft several centimeters from the tip with the other hand; this will prevent sudden deep plunging of the cannula and the trocar. After shallow penetration of the peritoneum at a 60° to 90° angle to the abdominal wall, the trocar and the cannula are tilted until they are at an angle of about 30° to 45° to the abdominal wall and the tip is directed toward the pelvis. After the peritoneum is entered, the resistance of the fascia sharply decreases, and generally a sudden pop is both heard and felt. Disposable trocars usually have safety mechanisms so the sharp tip of the trocar retracts to a protected position after the peritoneal cavity has been entered. A prewarmed laparoscope is then introduced through the first cannula into the abdomen, and the area just below the entry site is inspected to detect possible visceral injury from the blind entry of the Veress needle or the trocar.

FIGURE 8.4. The trocar and the cannula system is optimal inserted by holding it between the index and the middle fingers. The shaft of the instrument should also be supported by the opposite hand as the body wall is traversed.

Before the remaining trocars and cannulas are inserted, the abdominal wall should be transilluminated to identify major vessels at potential entry sites so these vessels can be avoided. In addition, the remaining trocars and cannulas should be inserted under direct visual control to avoid puncturing intraperitoneal or retroperitoneal structures. In our opinion, ventral hernia is uncommon when trocars of only 5 mm in diameter are used. In the more than 200 laparoscopic colorectal procedures we have performed, no ventral hernias have occurred when we used trocars 5 mm in diameter. If a larger cannula is used, we recommend closing the fascia because we have seen hernias in trocar incisions of 10 mm in diameter or greater.

Alternative Techniques

The first alternative to the initial blind trocar insertion is the conventional open technique, which involves inserting a blunt-tipped cannula into the abdominal cavity through a small abdominal wall incision.[39] This approach may be preferable for obese patients or those with an increased risk to have abdominal adhesions. Ballem and Rudomanski[40] have reported 150 laparoscopies without any complications using the conventional technique. However, no published study has found a higher complication rate for blind puncture of the abdomen compared with the open technique.

Tews et al.[41] advocate using a blunt trocar after making a small incision of the fascia. They reported no complications using the blunt trocar in 1,900 laparoscopies. The advantage of using a blunt trocar is evident—inadvertent penetration with the tip is less likely. The disadvantage is that more pressure may be needed to pass the blunt trocar into the peritoneal cavity. Although Tews et al.[41] state "that nearly the same amount of pressure that is used in the introduction of the usual sharp triangular trocar is also applied," this is questionable because they did not measure the pressure necessary to insert the blunt trocar.

A second alternative is direct initial sharp trocar and cannula insertion without prior pneumoperitoneum, a technique that has been reported in several large series.[42-47] After obtaining good muscle relaxation under general anesthesia, standing at the patient's left side the surgeon first grasps the lower abdomen with the left hand below a point midway between the umbilicus and the symphysis. The surgeon then lifts the abdominal wall at this point to raise and thus slightly stretch the umbilicus so entry can be directed toward the true pelvis, away from the large vessels, and at right angles to the skin. Grasping the abdomen also provides countertraction for trocar and cannula entry because the lower abdomen is tented at a 45° angle away from the umbilicus. The trocar and the cannula are then inserted with controlled steady pressure or a series of gentle thrusts. A laparoscope can then be inserted to verify intraperitoneal placement and insufflation can be started directly through the cannula.[45]

In a series of 4,500 laparoscopies using initial direct sharp trocar insertion without prior pneumoperitoneum, four bowel injuries were recorded that required subsequent laparotomy.[42] In only one of the four cases were adhesions documented between the intestine and the abdominal wall. In this series, 1,133 patients had previous abdominal surgery but no adhesions at the umbilicus were noted. Therefore, Kaali and Barad[42] concluded that the umbilicus is the location of choice to place the first cannula without prior pneumoperitoneum. In a large prospective study that compared direct trocar and cannula insertion to initial pneumoperitoneum with blind insertion using a Veress needle, the rate of complications did not increase with the direct insertion technique.[43,48] This method avoids preperitoneal insufflation with its resulting problems and reduces the number of blind insertions from two to one.

Most results of the studies discussed here concern direct trocar insertion in gynecologic surgery and are not applicable to laparoscopic colorectal surgery because most of the procedures have been performed in younger, healthy women with a low incidence of obesity or previous abdominal surgery. Obese patients appear to pose a much greater challenge to safely elevating the abdominal wall by simply grasping the skin and inserting a pointed trocar without pneumoperitoneum. This conclusion is supported by Byron, who examined 937 patients and found that obesity was the only risk factor associated with complications in patients undergoing direct trocar insertion.[43] The safety of this technique has probably been enhanced by the use of various disposable trocars equipped with a safety shield or the capability to automatically retract the trocar tip once the peritoneum is entered.

We do not use direct initial trocar insertion in laparoscopic colorectal surgery and we believe it is contraindicated in patients with previous surgery or obesity. If intraperitoneal adhesions are suspected, open laparoscopy should be performed at a location where adhesions are unlikely. In obese patients, we use the Veress needle to establish pneumoperitoneum first and then insert the first trocar and cannula blindly.

Complications of Trocar Insertion

Bleeding caused by injury to an epigastric vessel in the abdominal wall is a concern with each trocar and cannula insertion. We recommend observing the deep epigastric vessels directly through the laparoscope if possible and transilluminating the abdominal wall with the laparoscope to localize superficial vessels. Injury to the inferior epigastric vessels can be detected laparoscopically if blood is seen dripping around the cannula after insertion. If bleeding does occur, using the cannula sleeve or a screw-in type of a body wall anchor to compress the vessel against the abdominal wall may stop minor bleeding. If the bleeding is serious enough to require immediate attention, a size 14F or 16F Foley catheter should be passed through the cannula, its balloon inflated, the cannula removed, and then the catheter balloon pulled firmly against the posterior abdominal wall to apply pressure on the epigastric vessel (Figure 8.5).[49] A large hemostat applied to the catheter at skin level will maintain the pressure during the procedure. If bleeding epigastric vessels are visible under transillumination, they can be temporarily ligated with transabdominal sutures on both sides of the vessel using a straight needle. If bleeding continues, the incision should be widened and definitive hemostasis should be achieved by directly visualizing and ligating the epigastric vessels. This incision can be temporarily closed and later used to deliver the specimen. If bleeding is not halted, postoperative evacuation of a rectus sheath hematoma may be necessary. Major vascular injuries to intra-abdominal vessels are largely attributable to inexperience of the surgeon, dull trocars, insufficient elevation of the abdominal wall, inadequate pneumoperitoneum, or failure to note important anatomic landmarks.

Trocar injury to the small or large bowel is usually identified once the laparoscope has been inserted.[50] Superficial trauma, serosal tears, or complete perforation of the bowel may occur. When a complete perforation occurs, the trocar should be left in place so the injury site can be easily recognized. Through subsequently placed cannulas, depending on the extent of injury, laparoscopic or a limited conventional repair may be feasible. If the injury cannot be

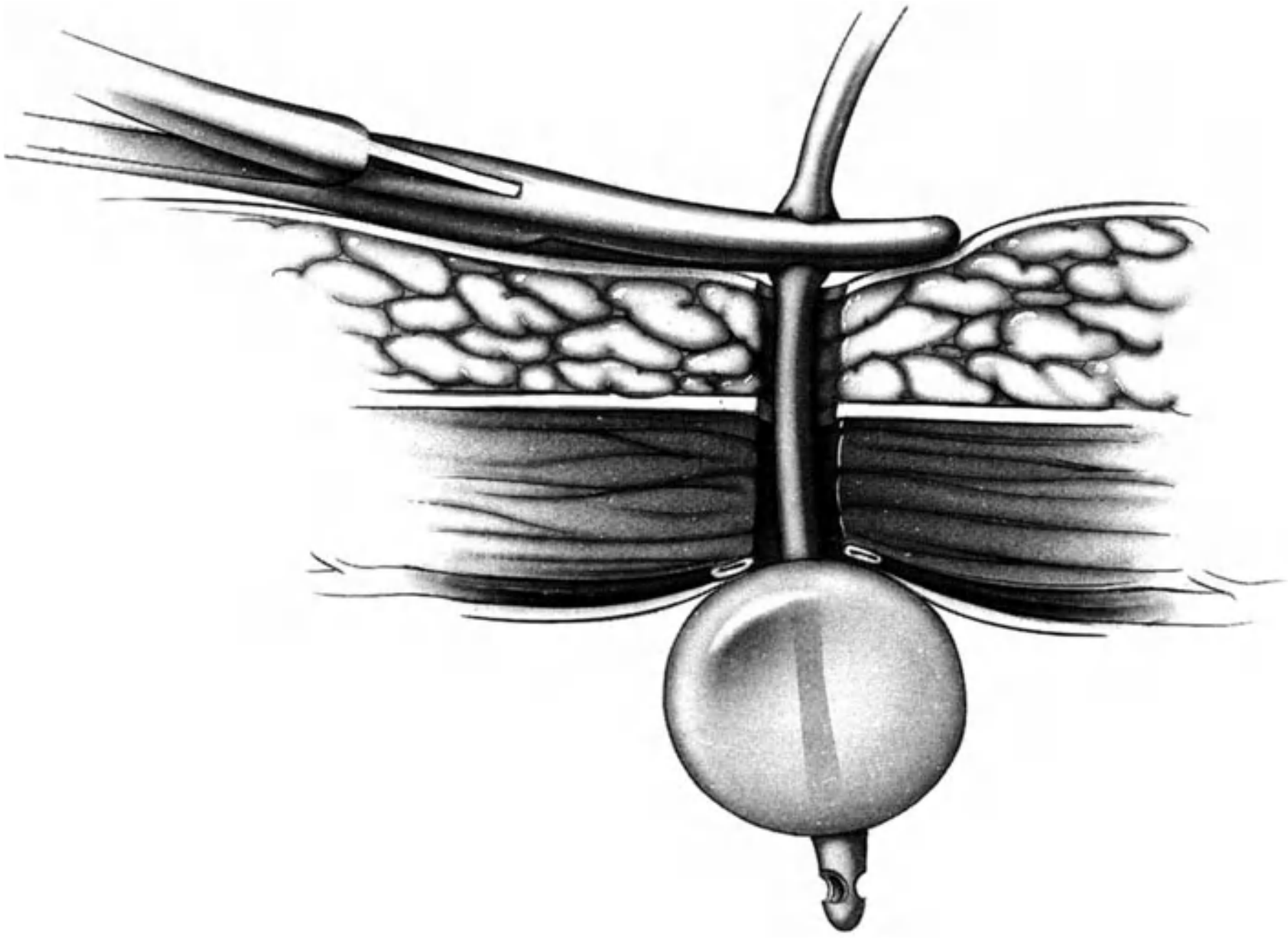

FIGURE 8.5. Rapid bleeding from epigastric vessels caused by trocar insertion is halted by compressing the balloon of a Foley urinary catheter against the intra-abdominal wall. A large clamp secures the catheter to the skin. The catheter is initially inserted through the cannula to traverse the abdominal wall, then the cannula is slid back out of the wall.

easily repaired laparoscopically, an immediate laparotomy is recommended.

Injury to the urinary tract can usually be attributed to poor technique, failure to decompress the bladder with a Foley urinary catheter, or abdominal wall adhesions. Therefore, we strongly recommend placing a Foley catheter for all laparoscopic colorectal procedures. McLucas and March[51] reported an urachus sinus perforation, and Yong et al.[52] reported injury to a vesicourachal diverticulum with a suprapubic cannula placed in the midline. Because urachal anomalies rarely become symptomatic preoperatively and the bladder is drained before laparoscopy, the diagnosis of perforation has usually been made postoperatively when the patient has advanced symptoms.[52]

Completing the Procedure and Cannula Site Closure

At the conclusion of every laparoscopic procedure, a final examination of the abdomen should be carried out to ensure that hemostasis has been achieved. Cannulas should be removed one by one under direct laparoscopic control while the puncture sites are inspected for hemostasis. As each cannula is removed, an assistant should plug the puncture site with a finger to maintain the low-pressure pneumoperitoneum. After all cannulas are removed except the one housing the laparoscope, the laparoscope is withdrawn 4 to 5 cm into the cannula and then this cannula is slowly withdrawn from the body wall as the surgeon inspects the edges of the abdominal wall for hemostasis.

Because we have seen some symptomatic hernias through 10-mm incisions, all cannula incisions should be closed using conventional techniques or with a transabdominal suture while the cannula is still in place. A needle is available for this purpose (EndoClose, US Surgical Corporation, Norwalk, Conn.) It resembles the Veress needle except its inner blunt-tipped cannula looks similar to a crochet needle and can be extended beyond the sharp needle tip to grasp the fascial stitch (Figure 8.6A). The EndoClose needle is equipped with the fascial suture and then is initially passed through the fascia and peritoneum about 5 to 7 mm from a cannula (Figure 8.6B). The loop of the suture is released under visual control, grasped by a grasper placed at another site, and the needle is removed. The needle is then re-inserted through the abdominal wall on the other side of the cannula and is used to grasp the loop of the suture (Figure 8.6C). The suture is pulled back up through the abdominal wall with the needle. The cannula is removed; hemostasis is checked; and the suture is tied to close the peritoneum, muscle layer, and fascia en mass. When using this technique of cannula site closure, at least three cannula should remain in the abdominal cavity until all cannula sites have had sutures placed—one site is needed for the laparoscope and one for a grasping device while the third site is being closed. The cannula at the umbilicus is removed last and the previously placed suture is tied. Lastly, the skin is closed with adhesive strips (such as Steri-Strips) or absorbable subcuticular sutures.

Kiiholma and Mäkinen[53] reported an unusual case of Richter's hernia on the fifth day after laparoscopy. The patient felt a sudden pain around the umbilicus and noted a bluish, tender swelling below the umbilicus. A hematoma was initially suspected. Because of increasing pain with vomiting, the patient underwent an exploratory examination under general anesthesia and, unexpectedly, a plum-sized, purple mass was found. An incarcerated segment of jejunum was released and normal intestinal color reappeared in a few minutes. The patient was discharged after an uneventful recovery. In patients with any previous open fascial incision, the sudden onset of pain and tender expansion at a trocar incision may herald the possibility of incarcerated visceral structures. Close observation and operative exploration under general anesthesia must be strongly considered.

Initiation of Laparoscopic Colorectal Procedures

The first step of every laparoscopic procedure is diagnostic, that is, one that answers two questions: (1) "What are the findings?" and (2) "Can this procedure be performed laparoscopically?"

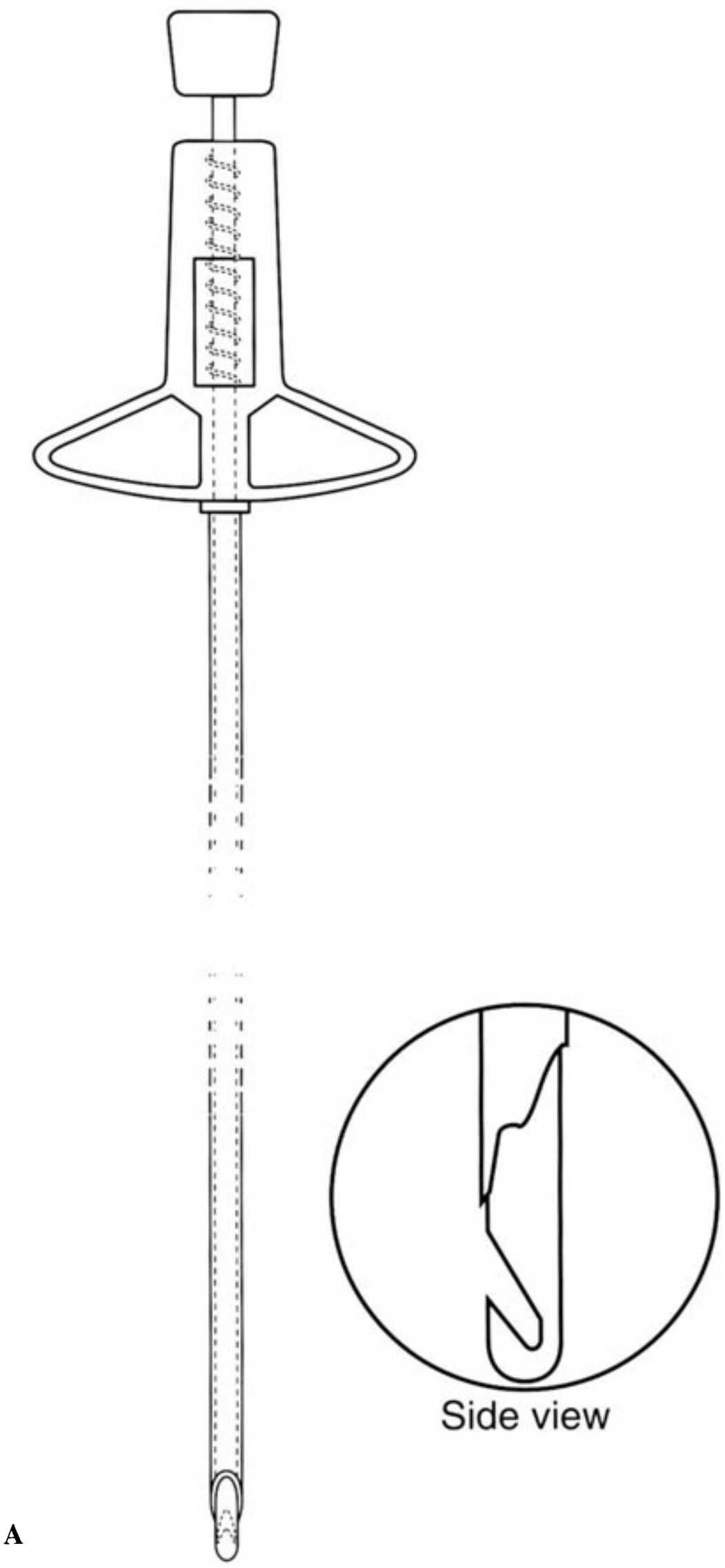

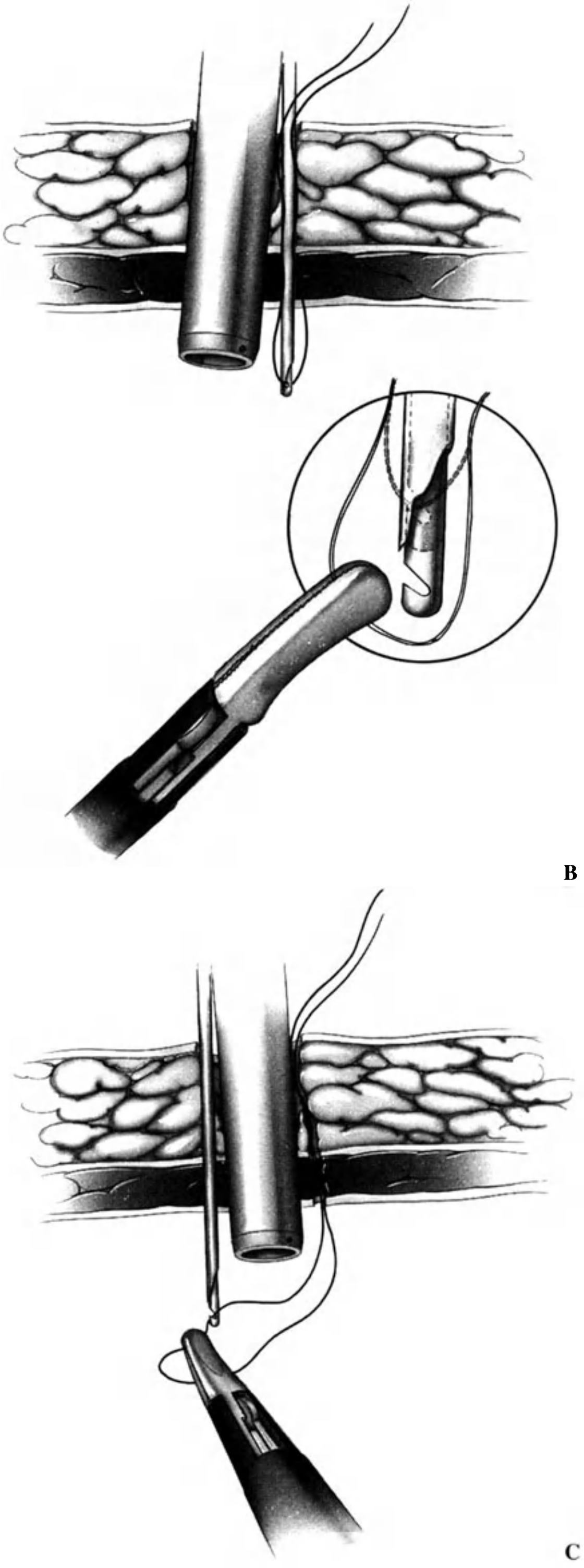

FIGURE 8.6. A, Inset. Close-up of the tip of an EndoClose needle. (Courtesy of US Surgical Corporation, Norwalk, Conn.) B, Closing a cannula site with an EndoClose needle. The needle is passed through the abdominal wall into the peritoneal cavity alongside the cannula, loaded with the fascial suture. A grasper from another port site removes the suture from the needle tip. C, The EndoClose needle is inserted on the other side of the cannula, through the abdominal wall, and then the suture is loaded onto the EndoClose using a grasper.

After the infraumbilical cannula has been placed, the peritoneal cavity is thoroughly inspected visually. According to the indications for the procedure and the surgeon's judgment, one or two additional cannulas are placed so that diagnostic laparoscopy with some intraperitoneal manipulation can be fully performed. The additional cannulas usually are placed opposite the main area of pathologic lesion.

We suggest using the following systematic approach to initially inspect the peritoneal cavity:

- Initially visualizing the abdominal viscera or omentum directly posterior to the infraumbilical or blind cannula insertion site to detect inadvertent injuries caused by blind insertion of the Veress needle or trocar and cannula.
- Directly inspecting all four quadrants of the abdomen and the pelvis.
- Manipulating the viscera according to the surgeon's judgment to assess the feasibility of the planned laparoscopic procedure and to perform diagnostic laparoscopy. Likewise, a decision is made as to whether manipulating ("running") the small bowel with two grasping instruments is necessary to exclude disease of the small bowel.
- Performing laparoscopic ultrasonography of the liver, the porta hepatis, the primary tumor site, or elsewhere if indicated to stage malignant disease.

Running the small intestine is performed with the patient tilted left side down so the small intestine falls toward the left upper quadrant. The terminal ileum is identified and the first assistant (on the patient's left side) runs the entire small bowel distal to proximal, starting at the ileocecal junction and stopping at the ligament of Treitz, using a hand-over-hand technique. Tilting the patient right side down may be advantageous while examining the proximal bowel so the surgeon (who is on the patient's right side) can run the most proximal several feet of small bowel. To prevent injury to the intestine, no other instruments should be inserted into the peritoneal cavity and the entire maneuver should be performed under visual control. Generally, in laparoscopic surgery, all instruments that are not being used should be removed from the peritoneal cavity to avoid inadvertent organ injury.

Postoperative Care

Postoperative care and treatment after laparoscopy do not differ from conventional surgery. The anesthesiologist must consider the possibility of hypercarbia with acidosis and the treatment for it. Patients should be checked routinely for subcutaneous emphysema. If subcutaneous emphysema does occur, the patients should be reassured that the apparent deformities caused by subcutaneous emphysema can be alarming, but they will disappear within hours after the procedure.

Special Uses of Colorectal Laparoscopy

Diagnostic Laparoscopy

There are several indications for diagnostic laparoscopy in colorectal surgery because, although modern imaging techniques have advanced considerably, they still do not provide complete information about intra-abdominal disease. Thus, a direct but minimally invasive examination of the peritoneal cavity may be necessary.

The patient is placed supine in the modified lithotomy position on the operating table. The patient's legs are placed in padded stirrups (we prefer Dan Allen stirrups) and then the patient is moved so the perineum is at the bottom edge of the operating table to allow access for gynecologic or anorectal examination. The patient is then put in the Trendelenburg position with a 20° head-down tilt for the procedure. The surgeon will initially stand on the patient's left side, with the first and second assistants positioned on the right side. Monitors are placed just lateral to each of the patient's knees.

The procedure begins with establishment of pneumoperitoneum and then cannula insertion at the infraumbilical site, if this site is feasible and safe. If any abdominal distention is present, cannulas should be inserted using the open technique, either at the infraumbilical site or in one of the lower quadrants. After the first cannula has been placed, the peritoneal cavity is carefully inspected. Additional cannulas are placed as needed and as are feasible. As for a laparoscopic colorectal operation, the cannulas usually are positioned in an open semicircle toward the pathologic lesion so as to allow for some distance between the cannulas and the pathologic lesion. All four abdominal quadrants and the pelvic region must be thoroughly examined. The under side of the diaphragm should be scrutinized if a malignancy is suspected and a 30° laparoscope or a laparoscope with a flexible tip should be used as necessary to visualize the domes of the liver. An attempt to visualize the entire surface of the liver should be made and intraoperative ultrasonography should be conducted, if necessary.

An excellent suction and irrigation system must be available and any suspicious fluid should be sent for either cytologic or bacteriologic analysis. A laparoscopic biopsy of a malignancy may be performed using an insulated biopsy forceps equipped with an electrosurgical instrument for hemostasis or using a long spring-loaded 18-gauge biopsy core needle (Microvasive, Watertown, Mass.) that can be passed transcutaneously into the suspicious area with either visual or ultrasound guidance. Biopsy specimens of larger tumors can be obtained using electrosurgery-equipped scissors; hemostasis can be achieved by electrosurgery, application of clips, or in rare instances, direct suture ligation. The rectum can be manipulated with laparoscopic instruments; transrectal manipulation can be done with either a rigid or flexible sigmoidoscope. The uterus may be manipulated using an acorn-shaped uterine manipulator that fits into the cervix and allows for facile movement of the uterus by a surgeon or an assistant positioned between the patient's legs.

Finally, should endoscopy be required, a complete colonoscopy under laparoscopic guidance can be carried out to inspect the lumen of the large intestine. The proximal colon can be temporarily occluded using a laparoscopic bowel clamp designed to avoid bowel distention. Performance of a laparoscopic operation (e.g., fecal diversion, appendectomy, or biopsy) should nearly always be anticipated to follow a diagnostic laparoscopy.

Emergency Laparoscopy

Indications for emergency laparoscopy in colorectal surgery include evaluation for acute right lower-quadrant pain with tenderness in a woman of childbearing age, suspected mesenteric insufficiency, abdominal pain after blunt abdominal trauma, or an acute abdomen. Emergency laparoscopy should not be undertaken when there is significant cardiovascular instability, chronic respiratory failure, or any sign of a systemic coagulopathy or serious intra-abdominal infection. Abdominal distension, multiple abdominal scars, and obesity may also be relative contraindications because emergent laparoscopy should be accomplished easily and rapidly to establish a diagnosis and achieve definite treatment without additional risk of injury to other intra-abdominal organs.

Bender and Talamini reported diagnostic laparoscopic procedures in critically ill intensive care unit patients.[54] Seven patients underwent such a procedure following admission for coronary artery bypass surgery (n = 2), pneumonia (n = 2), gram-negative sepsis (n = 1), major burns (n = 1), and postpneumonectomy (n = 1). Abdominal pain was the indication for laparoscopy in two patients and unexplained sepsis in five. No other diagnostic methods, such as computed tomography, were used before laparoscopy in any patient. Five patients underwent the procedure in the operating room and two had the procedure in the intensive care unit. All procedures were done under a general anesthetic. There were no complications and no known missed diagnoses. Two patients had gangrenous colon and underwent conventional colectomy as a result of the laparoscopic diagnosis. Only these two patients survived. This anecdotal report supports the idea that laparoscopy might be valuable in certain critically ill patients with suspected abdominal pathologic lesions. These authors suggest that the high rate of false-negativity in noninvasive testing may lead to a role for early diagnostic laparoscopy in critically ill patients who will not tolerate any degree of delay in diagnosing and treating intra-abdominal infectious foci.

References

1. Beebe DS, McNevin MP, Crain JM, et al. Evidence of venous stasis after abdominal insufflation for laparoscopic cholecystectomy. *Surg Gynecol Obstet.* 1993;179:443–447.
2. Jorgenson JO, Gillies RB, Lalak NJ, Hunt DR. Lower limb venous hemodynamics during laparoscopy: an animal study. *Surg Laparosc Endosc.* 1994;4:32–35.
3. Puri GD, Singh H. Ventilatory effects of laparoscopy under general anaesthesia. *Br J Anaesth.* 1992;68:211–213.
4. Schiller WR. The Trendelenburg position. Surgical requirements. In: Martin JT, ed. *Positioning in Anesthesia and Surgical Requirements.* 99th ed. Philadelphia, Pa.: W.B.Saunders; 1987:89–97.
5. Scott DB, Slawson KB. Circulatory effects of prolonged Trendelenburg position. *Br J Anaesth.* 1968;40:103–107.
6. Fujita Y, Sakai T, Ohsumi A, Takaori M. Effects of hypocapnia and hypercapnia on splanchnic circulation and hepatic function in the beagle. *Anesth Analg.* 1989;69:152–157.
7. Eckenhoff RG, Longnecker DE. The therapeutic gases. In: Gilman AG, Rall TW, Nies AS, Taylor P, eds. *The Pharmacologic Basis of Therapeutics.* 8th ed. Pergamon Press, New York, NY, 1990:340–344.
8. Kotzampassi K, Kapanidis N, Kazamias P, Eleftheriadis E. Hemodynamic events in the peritoneal environment during pneumoperitoneum in dogs. *Surg Endosc.* 1993;7:494–499.
9. Hodgson C, McClelland RMA, Newton JR. Some effects of the peritoneal insufflation of carbon dioxide at laparoscopy. *Anaesthesia.* 1970;25:382–390.
10. Kelman GR, Swapp GH, Smith I, Benzie RJ, Gordon NLM. Cardiac output and arterial blood-gas tension during laparoscopy. *Br J Anaesth.* 1972;44:1155–1162.
11. Brampton WJ, Watson RJ. Arterial to end-tidal carbon dioxide tension difference during laparoscopy. *Anaesthesia.* 1990;45:210–214.
12. Liu SY, Leighton T, Davis I, Klein S, Lippmann M, Bongard F. Prospective analysis of cardiopulmonary responses to laparoscopic cholecystectomy. *J Laparoendosc Surg.* 1991;1:241–246.
13. Wittgen CM, Andrus CH, Fitzgerald SD, Baudendistel LJ, Dahms TE, Kaminski DL. Analysis of the hemodynamic and ventilatory effects of laparoscopic cholecystectomy. *Arch Surg.* 1991;126:997–1001.
14. Williams MD, Murr PC. Laparoscopic insufflation of the abdomen depresses cardiopulmonary function. *Surg Endosc.* 1993;7:12–16.
15. Bongard F, Pianim NA, Leighton T, et al. Helium insufflation for laparoscopic operation. *Surg Gynecol Obstet.* 1993;177:140–146.
16. Ciofolo MJ, Clergue F, Seebacher J, Lefebvre G, Viars P. Ventilatory effects of laparoscopy under epidural anesthesia. *Anesth Analg.* 1990;70:357–361.
17. Kashtan J, Green JF, Parsons EQ, Holcroft JW. Hemodynamic effects of increased abdominal pressure. *J Surg Res.* 1981;30:249–255.
18. Ishizaki Y, Bandai Y, Shimomura K, Abe H, Ohtomo Y, Idezuki Y. Safe intraabdominal pressure of carbon dioxide pneumoperitoneum during laparoscopic surgery. *Surgery.* 1993;114:549–554.
19. Luz CM, Polarz H, Böhrer H, Hundt G, Dörsam J, Martin E. Hemodynamics and respiratory effects of pneumoperitoneum and PEEP during laparoscopic pelvic lymphadenectomy in dogs. *Surg Endosc.* 1994;8:25–27.
20. Marshall RL, Jebson PJR, Davie IT, Scott DB. Circulatory effects of carbon dioxide insufflation of the peritoneal cavity for laparoscopy. *Br J Anaesth.* 1972;44:680–684.
21. Kubota K, Kajiura N, Teruya M, et al. Alterations in respiratory function and hemodynamics during laparoscopic cholecystectomy under pneumoperitoneum. *Surg Endosc.* 1993;7:500–504.
22. Safran D, Sgambati S, Orlando R III. Laparoscopy in high-risk cardiac patients. *Gynecol Obstet.* 1993;176:548–554.
23. Huang SJ, Lee CY, Yeh FC, Chang CL. Hypercarbia is not the determinant factor of systemic arterial hypertension during carboperitoneum in laparoscopy. *Ma Tsui Hsueh Tsa Chi.* 1991;29:592–595.
24. Leighton TA, Liu SY, Bongard FS. Comparative cardiopulmonary effects of carbon dioxide versus helium pneumoperitoneum. *Surgery.* 1993;113:527–531.
25. Motew M, Ivankovich AD, Bieniarz J, Albrecht R, Zahed B, Scommegna A. Cardiovascular effects and acid-base and blood gas changes during laparoscopy. *Am J Obstet Gynecol.* 1973;115:1002–1012.
26. Ekman LG, Abrahamson J, Biber B, Forssman L, Milsom I, Sjèqvist BA. Hemodynamic changes during laparoscopy with positive end-expiratory pressure ventilation. *Acta Anaesthesiol Scand.* 1988;32:447–453.
27. Holzman M, Sharp K, Richards W. Hypercarbia during carbon dioxide gas insufflation for therapeutic laparoscopy: a note of caution. *Surg Laparosc Endosc.* 1992;2:11–14.
28. Myles PS. Bradyarrhythmias and laparoscopy: a prospective study of heart rate changes with laparoscopy. *Aust N Z J Obstet Gynaecol.* 1991;31:171–173.
29. Eger ET, Saidman LJ. Hazards of nitrous oxide anesthesia in bowel obstruction and pneumothorax. *Anesthesiology.* 1963;26:61–66.
30. Karatassas A, Walsh D, Hamilton DW. A safe, new approach to establishing a pneumoperitoneum at laparoscopy. *Aust J Surg.* 1992;62:489–491.
31. Wolfe WM, Pasic R. Transuterine insertion of Veress needle in laparoscopy. *Obstet Gynecol.* 1990;75:456–457.
32. Kent RB. Subcutaneous emphysema and hypercarbia following laparoscopic cholecystectomy. *Arch Surg.* 1991;126:1154–1156.
33. Knos GB, Sung YF, Toledo A. Pneumopericardium associated with laparoscopy. *J Clin Anesth.* 1991;3:56–59.
34. Whiston RJ, Eggers KA, Morris RW, Stamatakis JD. Tension pneumothorax during laparoscopic cholecystectomy. *Br J Surg.* 1991;78:1325.

35. de Plater RM, Jones IS. Non-fatal carbon dioxide embolism during laparoscopy. *Anaesth Intensive Care.* 1989;17:359–361.
36. McGrath BJ, Zimmerman JE, Williams JF, Parmet J. Carbon dioxide embolism treated with hyperbaric oxygen. *Can J Anesth.* 1989;36:586–589.
37. Brantley JC III, Riley PM. Cardiovascular collapse during laparoscopy: a report of two cases. *Obstet Gynecol.* 1988;159:735–737.
38. Ott DE. Correction of laparoscopic insufflation hypothermia. *J Laparoendosc Surg.* 1991;1:183–186.
39. Hasson HM. A modified instrument and method for laparoscopy. *Obstet Gynecol.* 1971;110:886–887.
40. Ballem RV, Rudomanski J. Techniques of pneumoperitoneum. *Surg Laparosc Endosc.* 1993;3:42–43.
41. Tews G, Arzt W, Bohaumilitzky T, Fureder R, Frolich H. Significant reduction of operational risk in laparoscopy through the use of a new blunt trocar. *Surg Gynecol Obstet.* 1991;173:67–68.
42. Kaali SG, Barad DH. Incidence of bowel injury due to dense adhesions at the sight of direct trocar insertion. *J Reprod Med.* 1992;37:617–618.
43. Byron JW, Fujiyoshi CA, Miyazawa K. Evaluation of the direct trocar insertion technique at laparoscopy. *Obstet Gynecol.* 1989;74:423–425.
44. Jarrett JC. Laparoscopy: direct trocar insertion without pneumoperitoneum. *Obstet Gynecol.* 1990; 75:725–727.
45. Copeland C, Wing R, Hulka JF. Direct trocar insertion at laparoscopy: an evaluation. *Obstet Gynecol.* 1983;62:655.
46. Nezhat FR, Silfen SL, Evans D, Nezhat C. Comparison of direct insertion of disposable and standard reusable laparoscopic trocars and previous pneumoperitoneum with Veress needle. *Obstet Gynecol.* 1991;78:148–150.
47. Borgatta L, Gruss L, Barad D, Kaali SG. Direct trocar insertion vs. Veress needle use for laparoscopic sterilization. *J Reprod Med.* 1990; 35:891–894.
48. Byron JW, Markenson G, Miyazawa K. A randomized comparison of Veress needle and direct trocar insertion for laparoscopy. *Surg Gynecol Obstet.* 1993;177:259–262.
49. Boswell WC, Odom JW, Rudolph R, Boyd CR. A method for controlling bleeding from abdominal wall puncture site after laparoscopic surgery. *Surg Laparosc Endosc.* 1993;3:47–48.
50. Reich H. Laparoscopic bowel injury. *Surg Laparosc Endosc.* 1992;2:74–78.
51. McLucas B, March C. Urachal sinus perforation during laparoscopy: a case report. *J Reprod Med.* 1990;35:573–574.
52. Yong EL, Prabhakaran K, Lee YS, Ratnam SS. Peritonitis following diagnostic laparoscopy due to injury to a vesicourachal diverticulum. Case report. *Br J Obstet Gynaecol.* 1989;96:365–968.
53. Kiilholma P, Mäkinen J. Incarcerated Richter's hernia after laparoscopy: a case report. *Eur J Obstet Gynecol Reprod Biol.* 1988;28:75–77.
54. Bender JS, Talamini MA. Diagnostic laparoscopy in critically ill intensvie-care-unit patients. *Surg Endosc.* 1992;6:302–304.

9

Major Operative Procedures in Laparoscopic Colorectal Surgery

This chapter presents a step-by-step approach to the major intestinal procedures that a laparoscopic surgical team is likely to perform. While a detailed discussion of how to set up and perform laparoscopic colorectal surgical procedures, in general, was presented in chapter 8, this chapter discusses in detail the steps required to accomplish the most commonly performed laparoscopic intestinal surgical procedures. An outline for each procedure will be presented that should allow the reader to understand rapidly all necessary details to successfully perform the procedure. Each section covers the following six areas and is constructed to "stand alone" as a rapid and thorough reference for the surgeon to review before a procedure:

1. position: proper positioning of the patient, the surgical team, and the equipment
2. instruments: instruments specifically necessary for the procedure being described (in addition to general instruments)
3. cannulas: proper placement of cannulas
4. procedure: step-by-step description of the surgical procedure
5. special considerations: considerations necessitated by the procedure or disease
6. cancer: considerations in cancer surgery

Small-bowel Resection

A laparoscopic small-bowel resection with primary anastomosis should be conducted in a way similar to a conventional small-bowel resection. The entire procedure, except for specimen removal, may be accomplished intracorporeally, or the diseased segment may be identified, drawn out through a small incision close to the segment, and the remainder of the surgery performed conventionally. We will describe only the procedure that is entirely laparoscopic.

Position

The patient is placed supine in a modified lithotomy position using Dan Allen stirrups. Surgery is begun in the Trendelenburg position (20° head-down tilt), and after cannula insertion, the patient is tilted left side down for ileal surgery or right side down for jejunal surgery. The surgeon and the assistants stand in a half-circle opening toward the area of interest. Figure 9.1 shows the positions of the surgical team for ileal surgery. After cannula insertion, the surgeon stands between the patient's legs and both assistants stand on the patient's left side for the remainder of the procedure. The scrub nurse should stand on the patient's right side near the knee. One monitor is placed close to the patient's right shoulder, the optimal position for the surgeon and the assistants to view; the second monitor is placed near the left shoulder, the best location for the nurse to view. For jejunal surgery, the setup is a mirror image of the ileal positions.

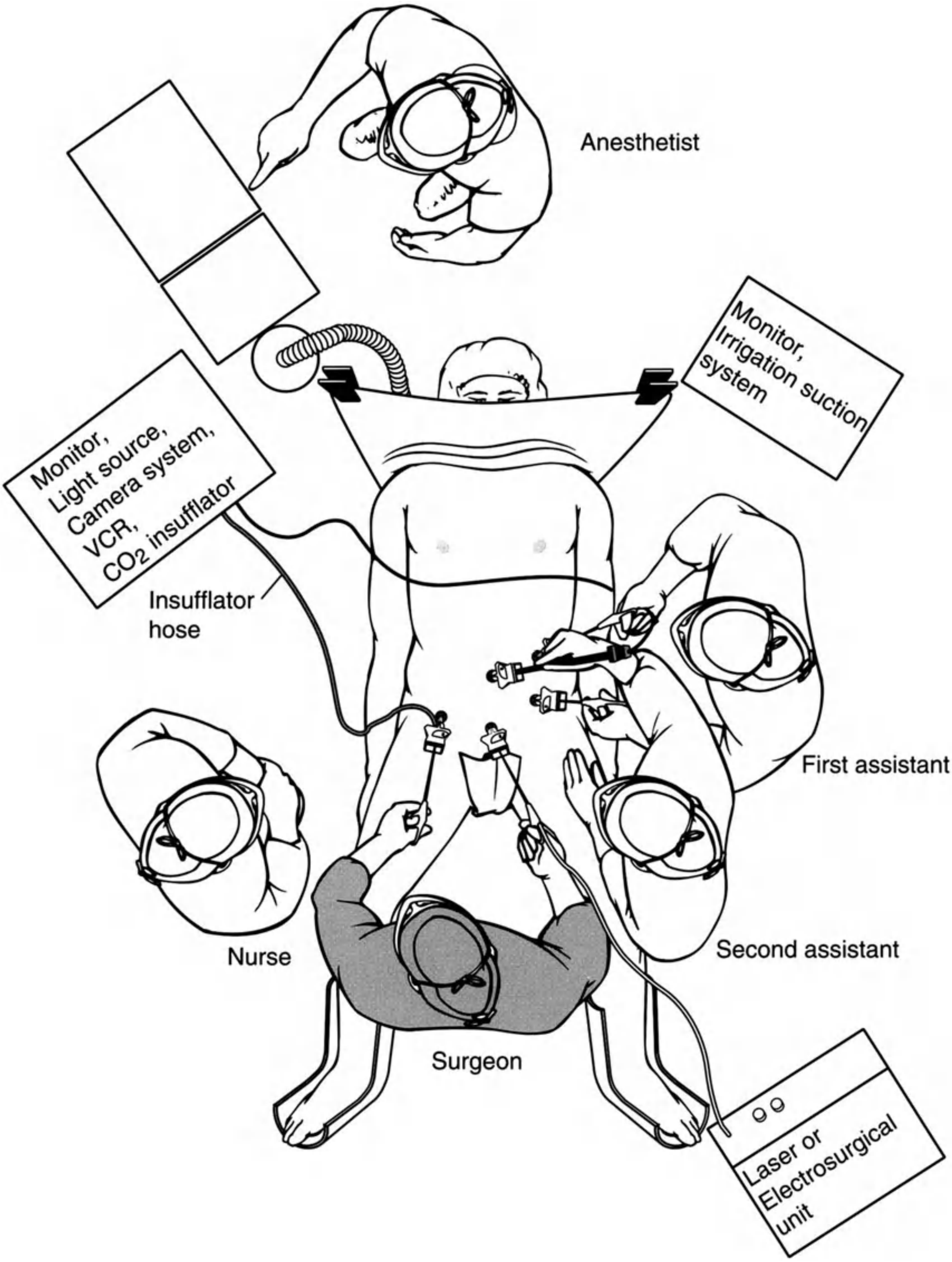

FIGURE 9.1. Position of the equipment and the surgical team for ileal resection. (Jejunal surgery is a mirror image of this figure.)

TABLE 9.1. Instruments required for ileal or jejunal surgery.

No.	Type
5	Cannulas (1 × 12 mm,* 3 × 10 mm, † 1 × 5 mm) including anchoring devices and converters
1	Dissecting device, for example, endoscopic scissors equipped with electrosurgery
1	Endoscopic dissector
2	Endoscopic graspers (one Babcock-like large and one small)
1	Endoscopic snare*
1	Endoscopic clip applier (large size)†
1	Multifire Endo GIA 30 stapler*
5	Endo GIA 30 cartridges*
2	Umbilical cotton tapes (0.25 in. wide, 12 cm long)†

* For intraperitoneal anastomosis.
† For intraperitoneal dissection of the mesentery.

Instruments

Table 9.1 lists the minimum number and the type of instruments necessary to accomplish a small-bowel resection with intraperitoneal dissection, division of the small-bowel mesentery, and an intraperitoneal functional end-to-end anastomosis. If an extracorporeal anastomosis is performed, endoscopic staplers and the 12-mm cannula are not necessary. Rather, 5-mm cannulas can be used at all sites except the laparoscopic camera site and one of the surgeon's cannulas (so endoscopic clips may be used as needed), so three 5-mm cannulas and two 10-mm cannulas are suitable.

Cannulas

Cannulas should be positioned in a half-circle opening toward the pathologic site. Thus, for ileal surgery, the half circle will open toward the right upper quadrant (Figure 9.2), whereas for jejunal surgery, it will open toward the left upper quadrant (the mirror image of Figure 9.2).

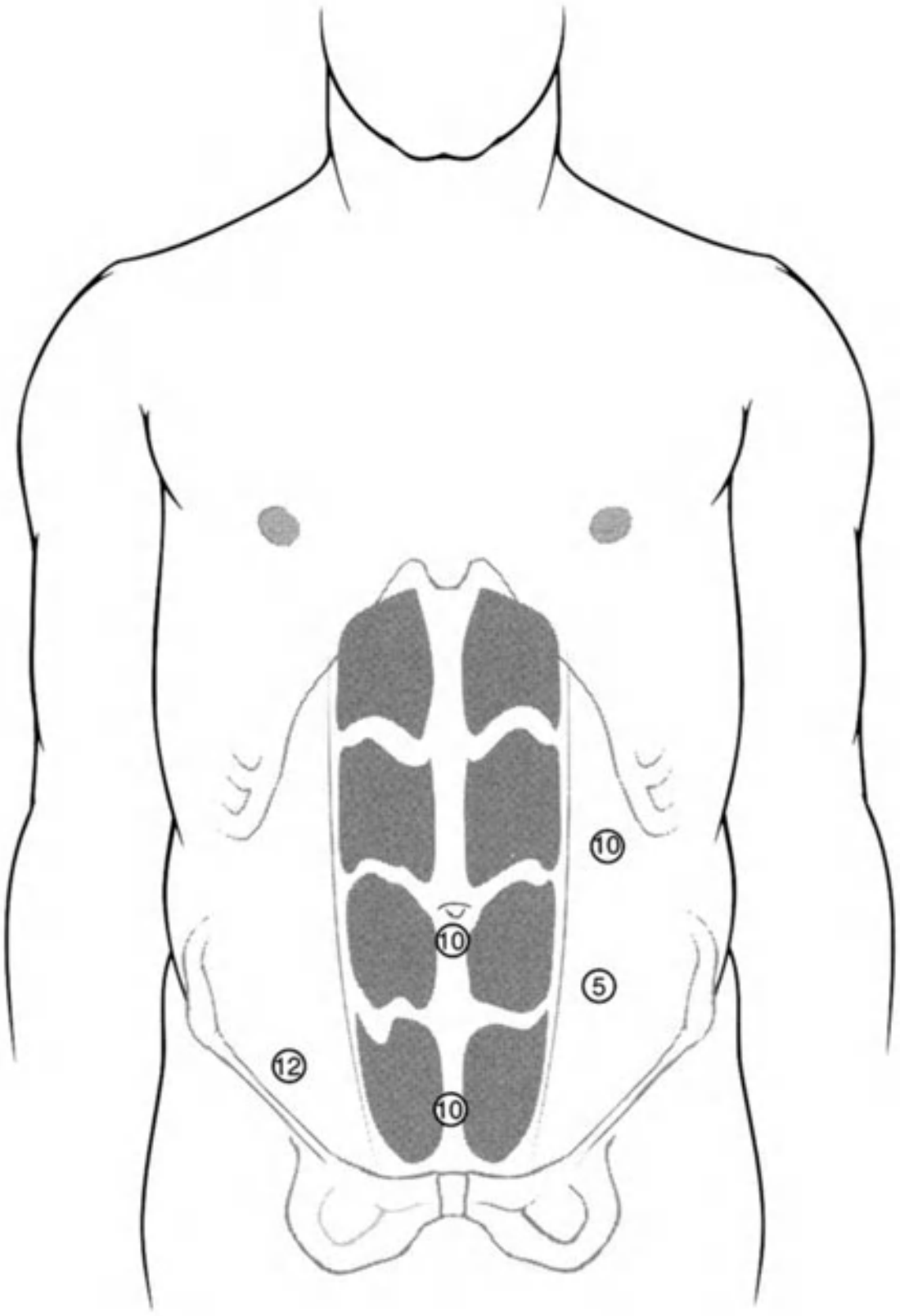

FIGURE 9.2. Position of the cannulas for small-bowel resection.

Procedure

Once the preoperative diagnosis is confirmed and the laparoscopic procedure appears feasible, the pathologic site is located, and the proximal and distal resection lines are marked with umbilical tapes (0.25 in. wide, 12 cm long). To place these tapes, the surgeon should grasp the mesentery at the intestinal edge using triangulating tension (see chapter 4, section titled Tissue Dissection in Laparoscopic Colorectal Surgery), create a small window in the mesentery, and pass a fine-tipped dissecting instrument through it. The dissector is then used to grasp the end of an umbilical tape and pull it back through the mesentery (Figure 9.3) so the tape encircles the intestine; the tape then is fixed with two clips on the antimesenteric side of the intestine (Figure 9.4). The bowel can now be handled without directly grasping the intestine or the mesentery, and the resection line is also clearly marked. To easily identify the resection lines, we mark the proximal line with umbilical tape of one color and the distal line with another color.

The first assistant then suspends the diseased bowel by the tapes and the peritoneum overlying the mesentery between the resection lines is scored in a V-shape using electrosurgery. The mesentery then is divided in a systematic manner starting from one mesenteric edge of the intestinal segment to the other (Figure 9.5). Careful blunt dissection of mesenteric tissue in combination with coagulation, clipping, or ligation of all vessels is carried out using constant triangulating tension on the tissue. Because the small intestine may have numerous small (1 to 2 mm) vessels scattered throughout the mesentery, this dissection may cause significant bleeding if the surgeon does not patiently and carefully identify the vessels. Bipolar electrosurgery, titanium clips, or even an endoscopic vascular stapler may be necessary to control the bleeding.

Once the mesenteric division is completed, the two umbilical tapes that mark the proximal and distal resection lines are replaced with an endoscopic loop that simultaneously encircles both proximal and distal resection lines (Figure 9.6). The tapes are merely left in situ and are removed with the specimen. This maneuver occludes the bowel lumen from the specimen side, prevents spilling of intestinal contents, and stabilizes the bowel for the subsequent anastomosis. The loop also places the two intestinal limbs parallel to each other, which will facilitate the creation of an endoscopically stapled anastomosis.

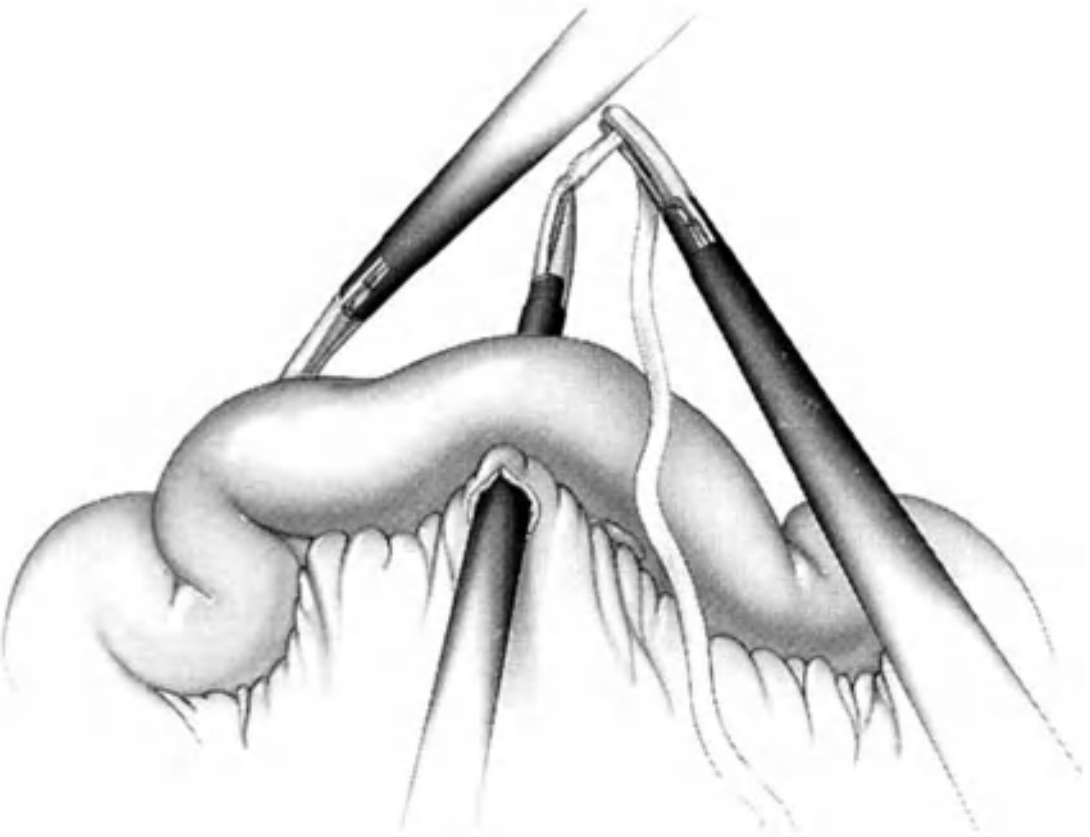

FIGURE 9.3. A dissector is passed through the mesentery close to the small bowel, and an umbilical tape is grasped and pulled through the defect to encircle the bowel.

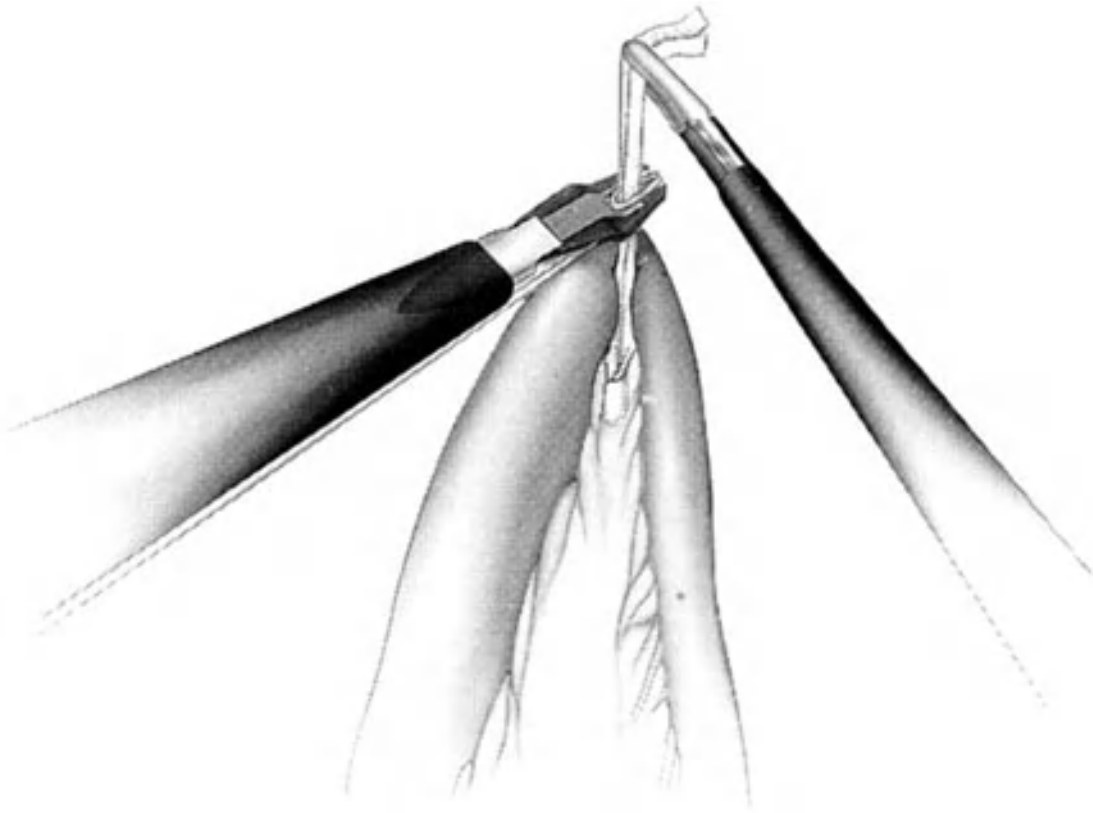

FIGURE 9.4. The umbilical tape is grasped simultaneously at both ends and is snugly fixed around the intestine with two clips.

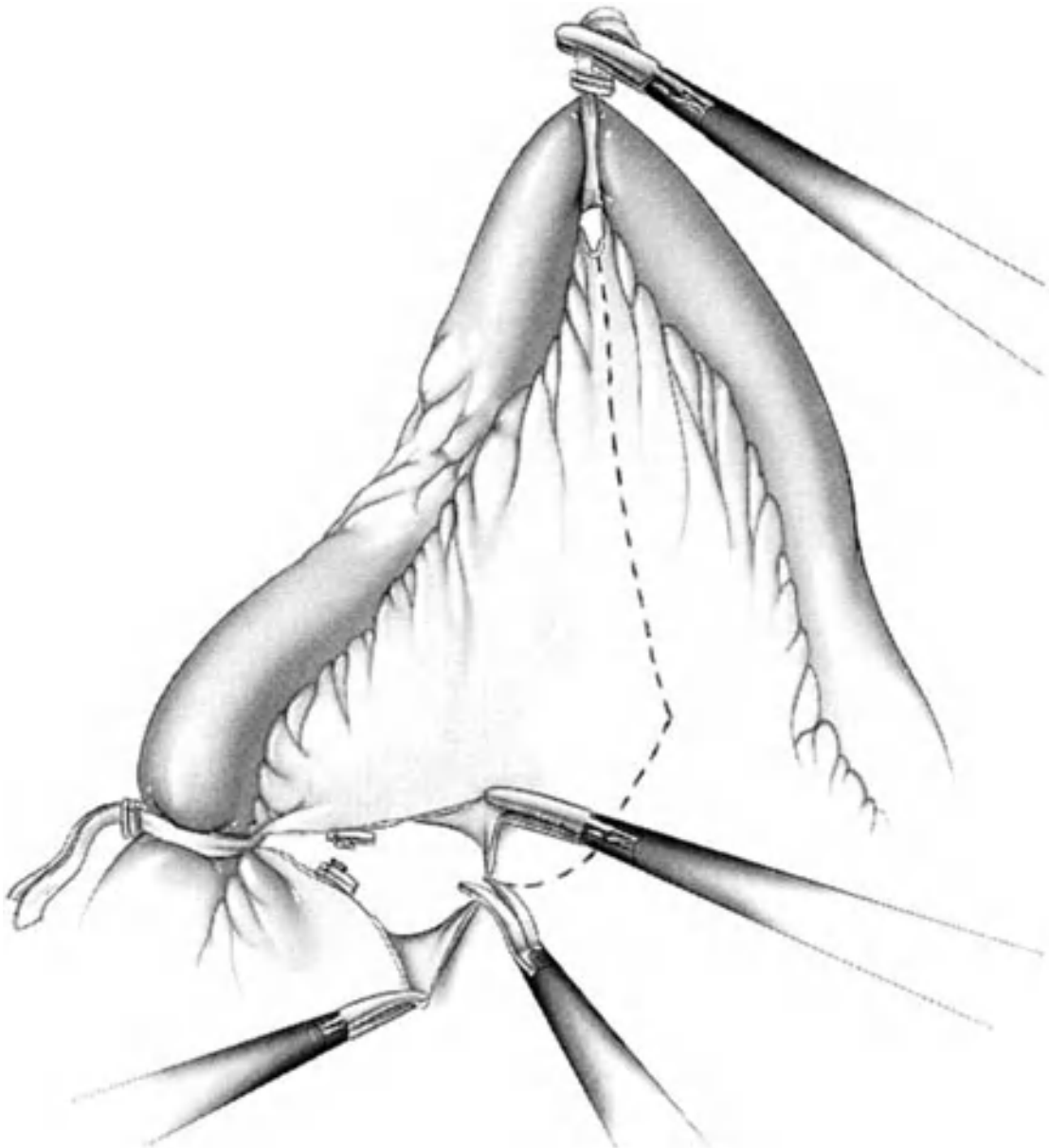

FIGURE 9.5. Division of the mesentery in a V-configuration using blunt and sharp dissection and clips to ligate the vessels.

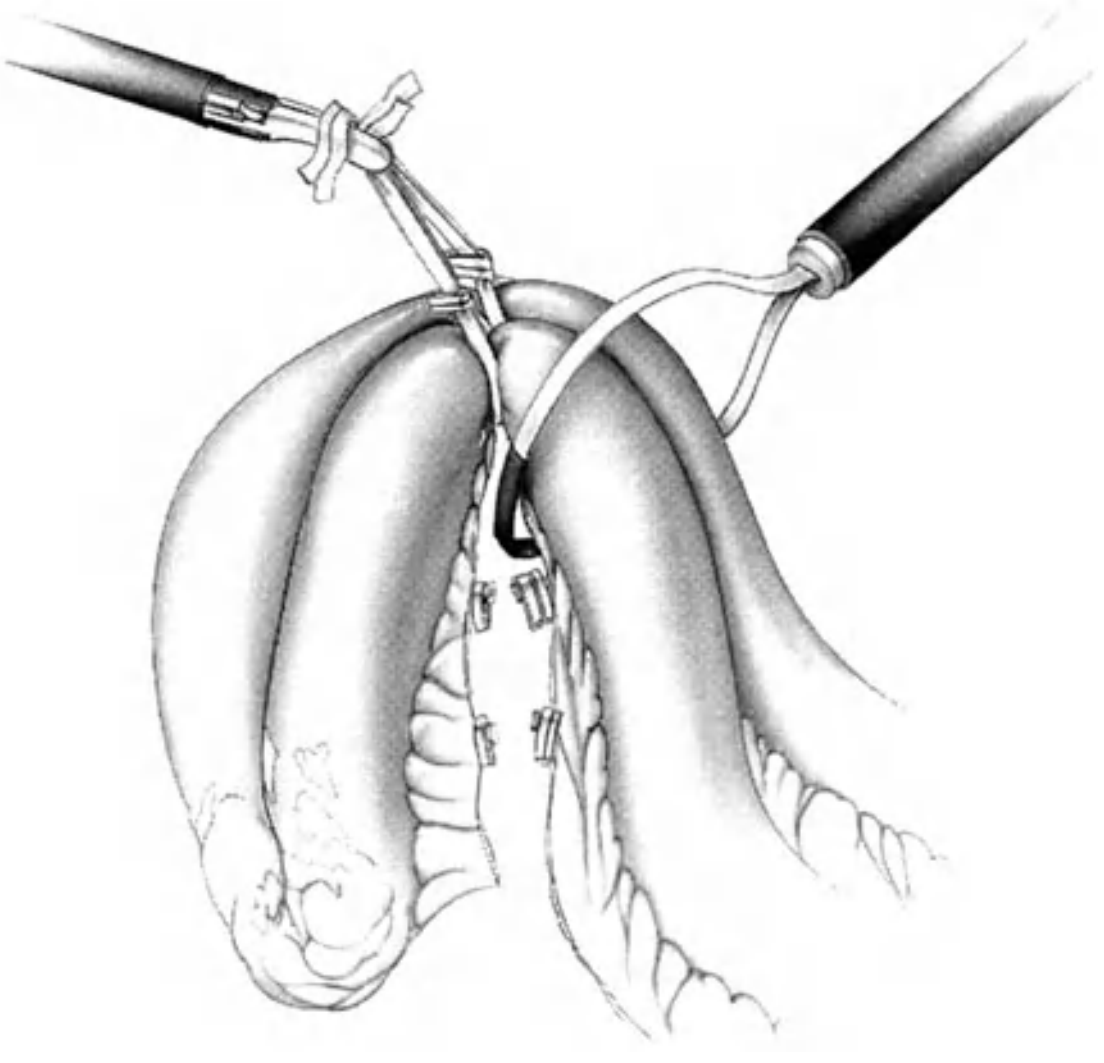

FIGURE 9.6. Umbilical tapes marking the proximal and distal resection lines are held together. An endoscopic snare is placed to encircle and steady the specimen before anastomotic formation.

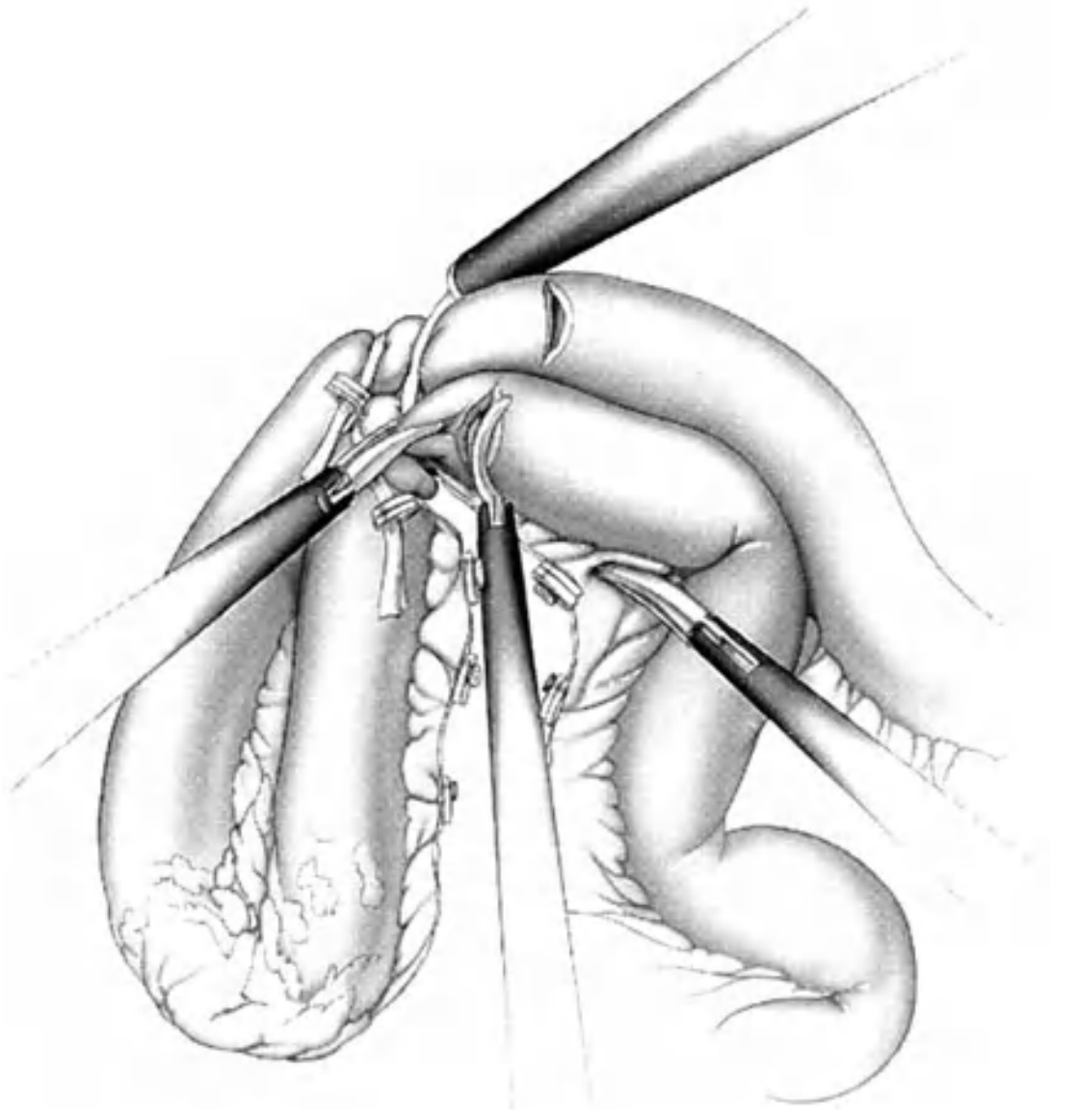

FIGURE 9.7. Two staggered enterotomies are made on the antimesenteric side below the snare while the afferent and efferent loops of intestine are held parallel to each other.

The anastomosis is begun next. Two staggered enterotomies are made using electrosurgery and scissors on the antimesenteric border of the adjacent loops (Figure 9.7). The enterotomies must be (1) large enough to accommodate the forks of a 30-mm endoscopic stapler and (2) placed in a staggered manner. This strategy makes it easy to first push the larger fork of the stapler (cartridge portion) into the first enterotomy and then the anvil portion of the stapler on into the second enterotomy (Figure 9.8). The intestine is optimally positioned for the anastomosis by pushing the endoscopic snare toward the 12-mm cannula as the stapler is inserted into the bowel lumen, which simultaneously puts tension on the efferent and afferent intestinal loops in the direction opposite to the stapler.

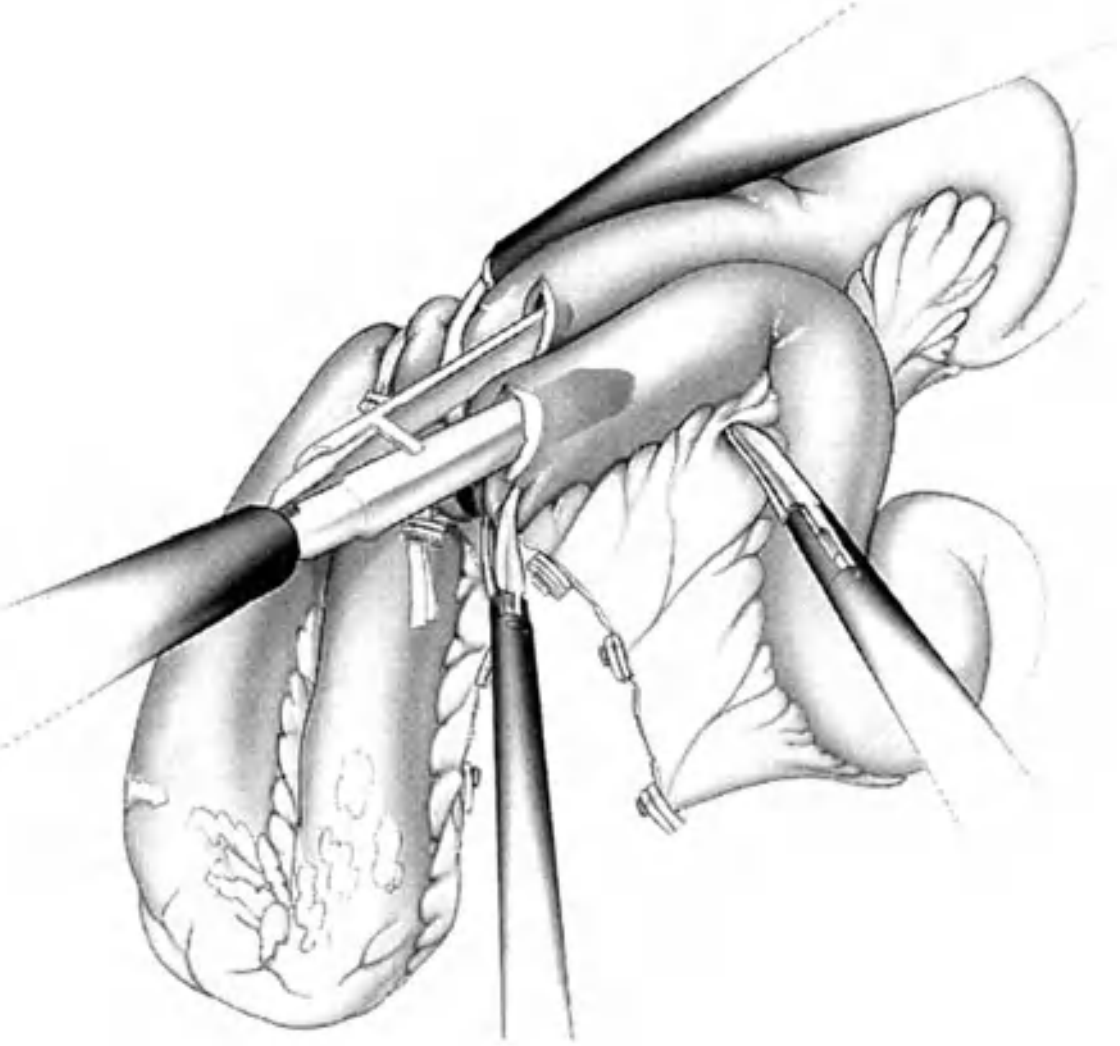

FIGURE 9.8. The 30-mm endoscopic stapler is placed by passing the stapler cartridge first into the inferior enterotomy, then by maneuvering the stapler anvil into the superiorly positioned enterotomy.

After the endoscopic stapler has been inserted and closed, the stapler is only fired after the surgeon has ascertained that the mesenteric blood supply to the bowel segments is clear of the stapler jaws. Before stapler closure, the mesentery can be moved away from the jaws by moving the tips of the stapler anteriorly, which will pull the mesentery posteriorly. The stapler is then fired, opened, and carefully removed with countertraction on the intestine, which the assistant applies. A second application of the Endo GIA 30 stapler is placed intraluminally, again firing the stapler only after the mesenteric blood supply is beyond the stapler jaws (Figure 9.9).

Whereas the purpose of the first application is to appose the bowel ends and begin the anastomosis, the second application serves to maximize and define a satisfactory anastomotic size.

The anastomosis is completed with two or three 30-mm stapler applications, each application fired at right angles to the two anastomosed loops, carefully placing the stapler just below the enterotomies to close the bowel ends (Figure 9.10). Care must be taken to avoid firing any staples across the metal clips used for mesenteric hemostasis that may have been applied close to the resection line, which could result in a malformation of some staples and, consequently, anastomotic leakage. After the transection and anastomosis are completed, the specimen, still occluded with the endoscopic loop, is immediately placed in an endoscopic bag that has been inserted through the right-lower-quadrant 12-mm cannula and is opened toward the specimen.

Once the specimen has been fully placed in the bag, the drawstring is tightened, and the bag is pulled inside the cannula. The cannula site is enlarged using a muscle-splitting incision lateral to the rectus sheath and the cannula is removed. Pneumoperitoneum is released and the insufflator is temporarily shut off. Sterile towels are placed around the wound and the specimen inside the bag thus is safely withdrawn from the abdominal cavity. If the specimen is too bulky to remove while inside the bag, the drawstring may be opened and the specimen is drawn out carefully while the bag is protruding from the abdominal wound. This method ensures that the specimen is removed without contaminating the abdominal wall. After specimen removal, the abdomen is copiously irrigated with warm sterile saline solution from an upper abdominal cannula site using the laparoscopic irrigation system. This irrigation is best accomplished by placing the patient in the head-up position and passing a sump suction cannula into the pelvis through the specimen removal site. After irrigation of the peritoneal cavity, the abdominal wall is closed with a series of interrupted simple or figure-of-eight, size 0 absorbable sutures by either closing each muscle layer independently or en masse.

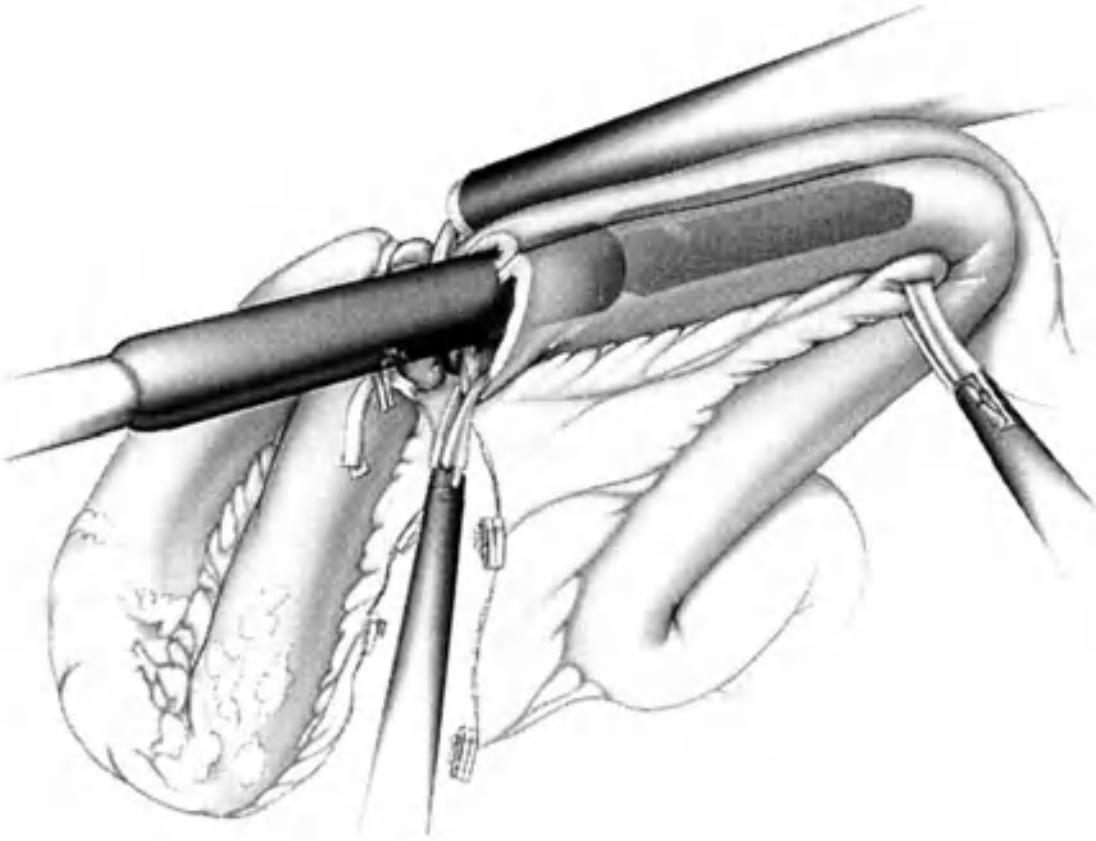

FIGURE 9.9. A second 30-mm stapler is fully inserted and fired to maximize the length of anastomosis.

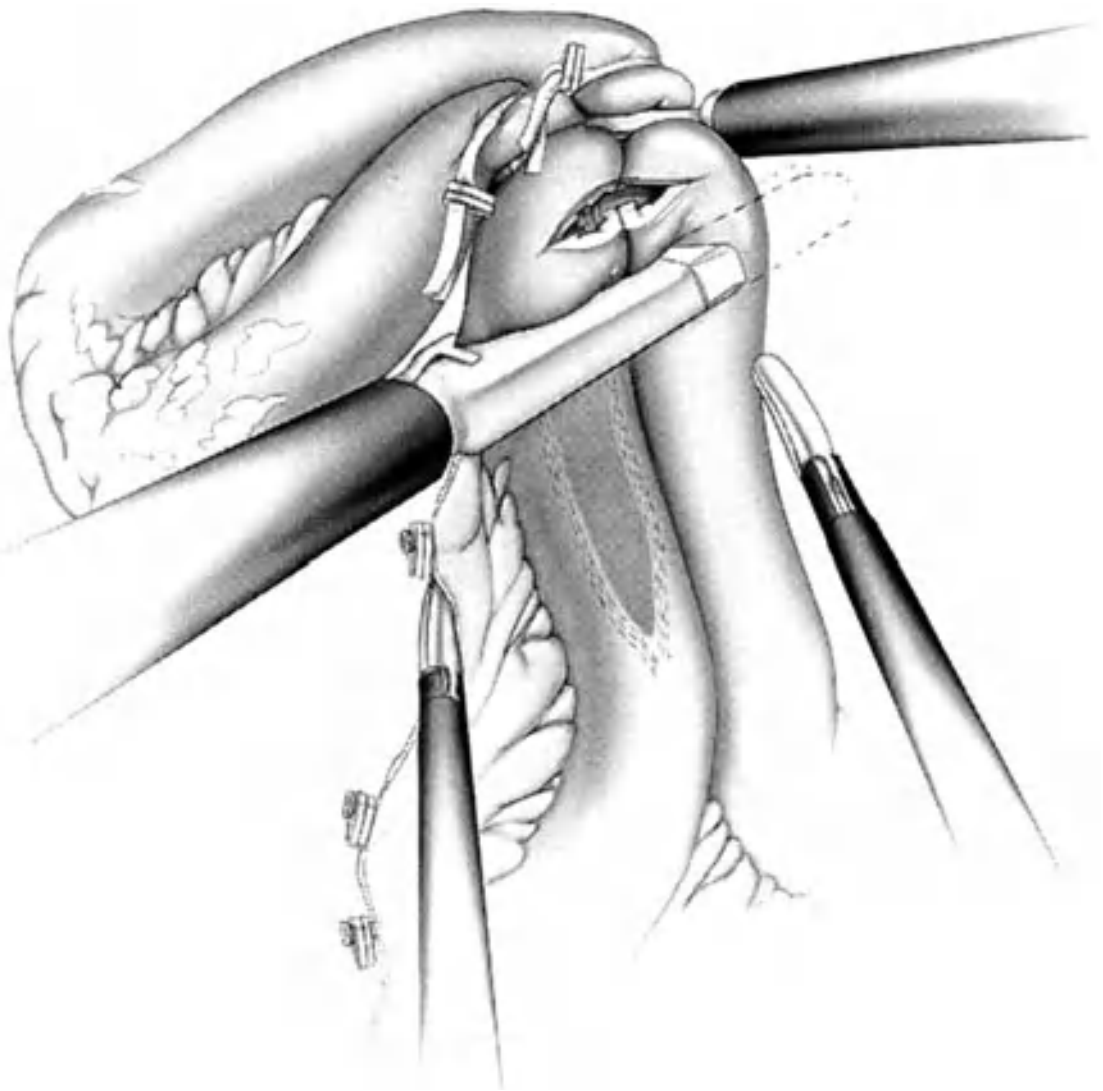

FIGURE 9.10. The anastomosis is sealed and the specimen is transected with two or three 30-mm endoscopic stapler applications placed perpendicularly across the anastomosed loops.

The pneumoperitoneum then is reestablished and the anastomosis is inspected. The mesenteric defect should be closed using a running 3-0 braided absorbable suture or an endoscopic hernia stapler. Alternatively, the mesentery can be visualized and repaired using conventional techniques through the specimen removal incision, if this approach seems feasible.

Special Considerations

If the surgeon desires, the resection and anastomosis can be performed using conventional techniques after laparoscopic mobilization. The laparoscopic techniques described in the previous section are used to identify the pathologic site, to place umbilical tapes at the proximal and distal resection lines, and to completely mobilize the intestine. To grasp the distal umbilical tapes, a grasper is passed into the abdominal cavity through the cannula site where the specimen is to be removed.

For specimen retrieval in ileal extracorporeal surgery, either the right-lower-quadrant or umbilical cannula is usually the easiest site to use, whereas in jejunal extracorporeal surgery, the left-lower-quadrant or umbilical cannula is probably easiest. Regardless of the specific site, the site chosen for retrieval must be enlarged on the basis of the specimen size. A transverse muscle-splitting incision is then created (lower quadrant cannula) or a midline incision (umbilical cannula) to make the site large enough to safely remove the specimen (at least 5 cm). Pneumoperitoneum is released and the CO_2 insufflator is shut off temporarily. The wound edges should be covered with an impermeable barrier (a small plastic drape or wound protector), and then the diseased intestinal segment is exteriorized through this wound by pulling on the umbilical tape that is held by the previously placed grasper.

Conventional clamps and suture materials are used to ligate the mesenteric vessels; then a hand-sewn or stapled anastomosis is created after bowel division and specimen removal. The mesentery is closed and the anastomosis is gently returned to the peritoneal cavity. The peritoneal cavity is thoroughly irrigated with warm saline solution and the muscle-splitting incision is then closed with interrupted simple or figure-of-eight absorbable sutures. Pneumoperitoneum is re-established and the surgical sites are inspected for hemostasis using the laparoscope. The cannulas are withdrawn under direct laparoscopic vision and the procedure is terminated in a routine manner.

Because the small intestine adheres to the retroperitoneum only at its mesenteric root, small-bowel resection can be facilitated by localizing the pathologic site and pulling the diseased segment of the small intestine extracorporeally through a small laparotomy as described by Cross and Snyder,[1] who accomplished a "laparoscopic-guided" small-bowel resection for perforated jejunal diverticulitis.

Using a porcine model, Pietrafitta et al.[2] and Soper et al.[3] have described a technique for an intraperitoneal functional end-to-end anastomosis of the small intestine. Pietrafitta et al.[2] achieve an intracorporeal anastomosis by initially approximating the proximal and distal resection margins, then stapling across the two limbs (four walls) of bowel using an Endo GIA stapler. This action also resects the specimen. The specimen is then removed. To start the anastomosis, enterotomies are made in the proximal and distal limbs and the Endo GIA is next fired intraluminally, twice, to create a side-to-side functional end-to-end anastomosis. The stapler is finally fired, below the enterotomies, to seal and complete the anastomosis. This is similar to our technique, but requires two or three more staple firings. Soper et al.[3] simulate the open surgical procedure. Both cut intestinal ends are grasped, incised, and opened at the antimesenteric edge. The stapler is then inserted into both cut ends and is fired. The cut edges are carefully brought into line and are sealed with another application of an endoscopic stapler so a functional end-to-end anastomosis is achieved.

Our technique for intracorporeal intestinal anastomosis has been proven to be safe in dozens of animal and human procedures; we believe it is much simpler to accomplish than other anastomotic techniques. This anastomosis can usually be carried out in less than 15 minutes—thus it needs about the same time as a conventional anastomosis.

Cancer

Surgery for malignancy is rarely necessary in the small intestine. All operative principles important in conventional cancer surgery apply. A wide V-shaped mesenteric excision should be performed with careful isolation of the specimen from the abdominal wall and subsequent removal using an endoscopic bag. Care must be taken to avoid injuring the superior mesenteric artery or vein, especially in jejunal surgery, during which any wide mesenteric excision comes close to the proximal superior mesenteric artery and vein. Intraoperative laparoscopic ultrasonography of the liver should be performed and laparoscope-guided biopsy specimens should be obtained from any suspicious areas.

Ileocolectomy

An ileocolectomy is most commonly indicated in patients with benign disease limited to the terminal ileum or the cecal regions and is a distinctly different operation than the right hemicolectomy. Only the ileum and the cecum are to be removed and thus extensive mobilization of the transverse colon is not necessary. The entire operation can be performed laparoscopically; mobilization with exteriorization and a laparoscopic-assisted procedure also is feasible.

Position

The patient is placed supine in a modified lithotomy position using Dan Allen stirrups. Surgery is begun in the Trendelenburg position (20° head-down tilt), and after cannula insertion, the patient is tilted left side down. The surgeon and the assistants stand in a half circle that opens toward the right upper abdominal quadrant (Figure 9.11). After cannula insertion, the surgeon stands between the patient's legs, the assistants stand on the patient's left side, and the nurse stands near the patient's right knee.

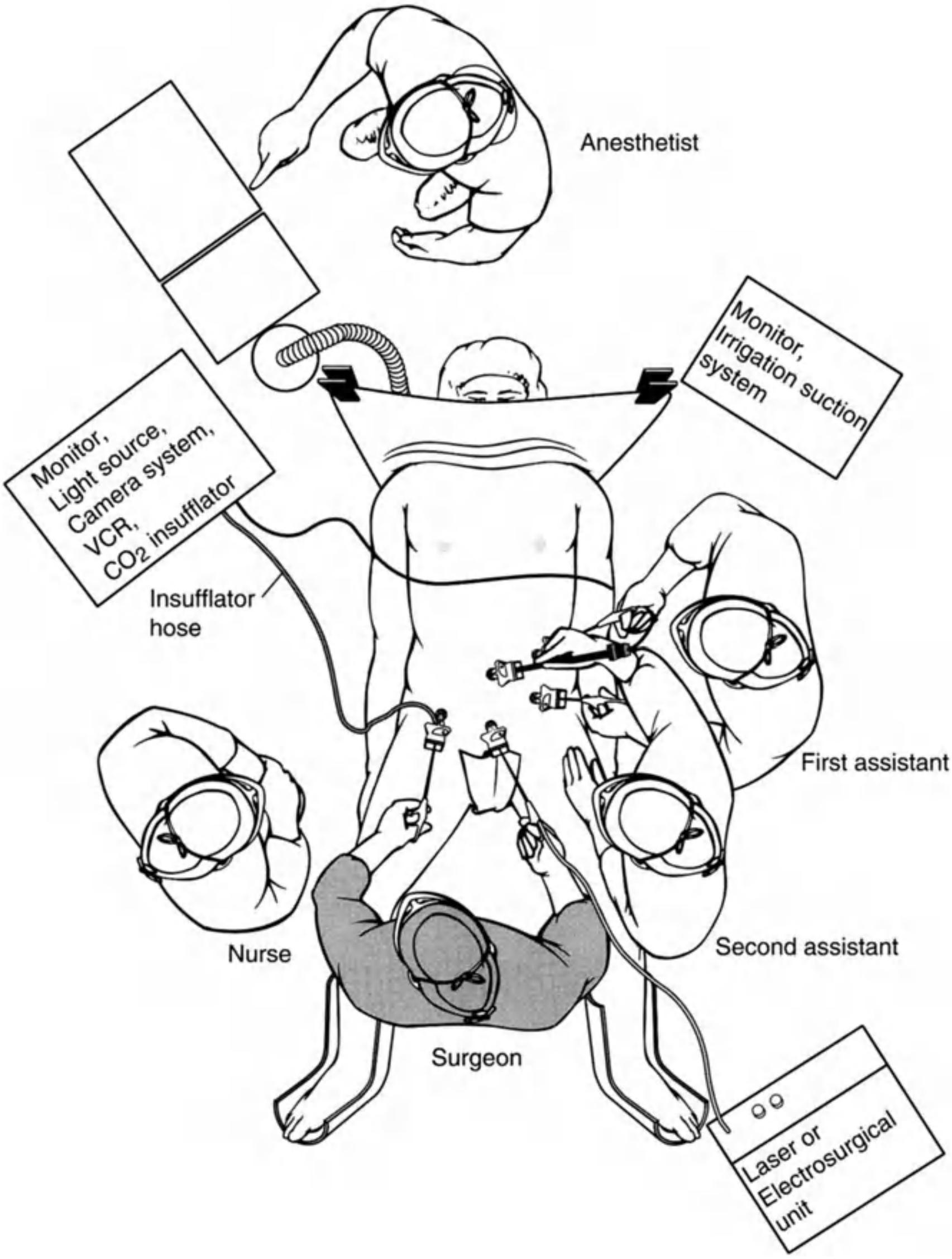

FIGURE 9.11. Position of the equipment and the surgical team for ileocolectomy.

One monitor is placed near the patient's right shoulder—the optimal position for the surgeon and the assistants to view; the other monitor is placed close to the left side of the head, the best position for the nurse to view.

Instruments

Table 9.2 lists the minimum instruments necessary to accomplish an ileocolectomy with an intraperitoneal ileocolic anastomosis. If an extracorporeal anastomosis is performed, endoscopic staplers and 15-mm cannulas are not necessary; a 5-mm cannula may be used instead of the 15-mm cannula. If the bowel resection and the anastomosis are to be performed extracorporeally with only mobilization of the intestine to be done laparoscopically, three 5-mm and two 10-mm cannulas are needed. One 10-mm cannula is used for the laparoscope and the other is used if a clip applicator must be inserted for hemostasis.

Cannulas

The cannulas are positioned in a half-circle opening toward the right upper quadrant (Figure 9.12).

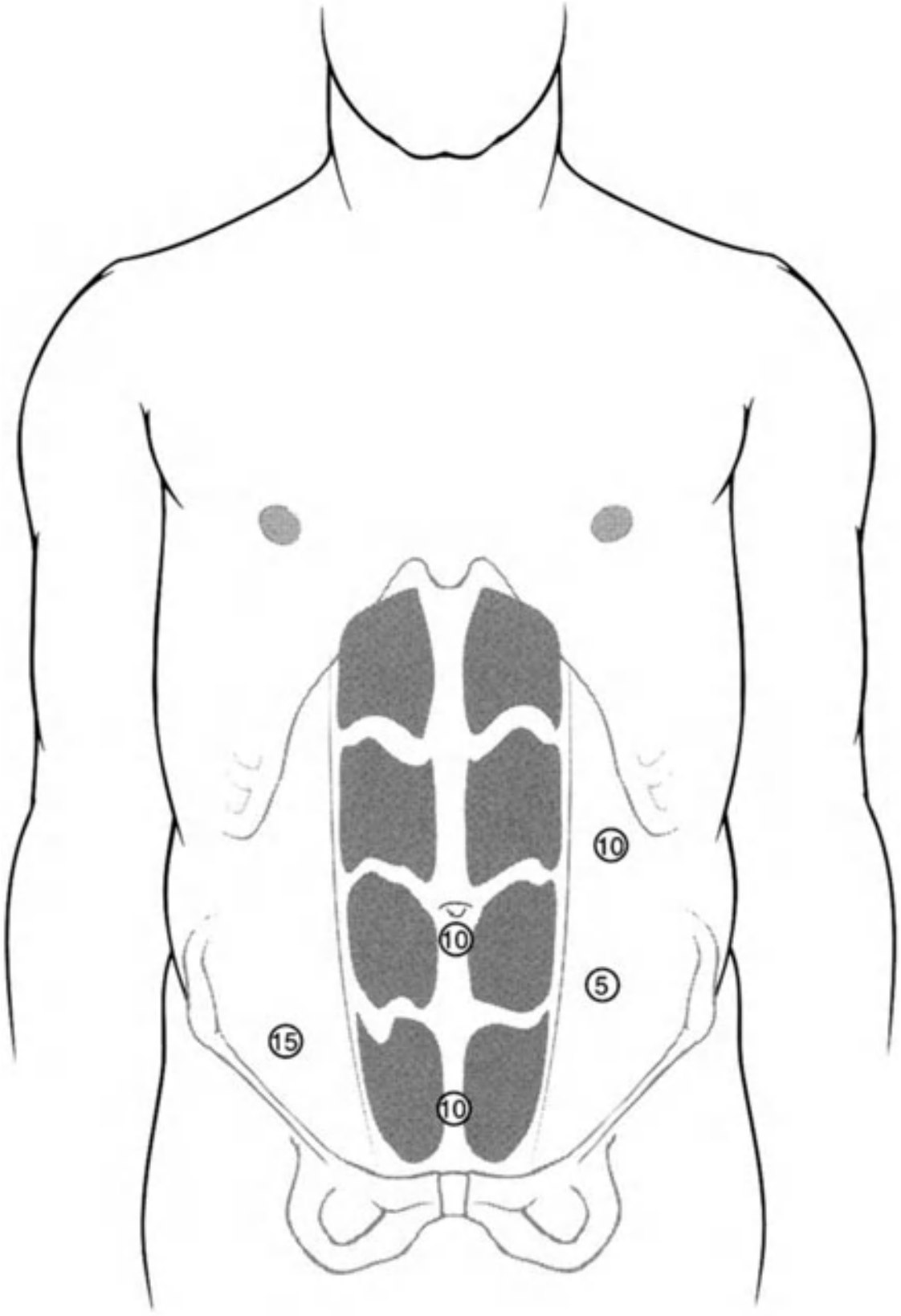

FIGURE 9.12. Position of the cannulas for ileocolectomy.

TABLE 9.2. Instruments required for laparoscopic ileocolectomy.

No.	Type
5	Cannulas (1 × 15 mm,* 3 × 10 mm,† 1 × 5 mm) including anchoring devices and converters
1	Dissecting device, for example, endoscopic scissors equipped with electrosurgery
1	Endoscopic dissector
2	Endoscopic graspers (one Babcock-like large and one small)
1	Endoscopic snare*
1	Endoscopic clip applier (large size)†
1	Multifire Endo GIA 30 stapler†,*
1	Multifire Endo GIA 60 stapler*
2	Endo GIA 30 cartridges†,*
3	Endo GIA 60 cartridges*
2	Umbilical cotton tapes (0.25 in. wide, 12 cm long)†

* For intraperitoneal anastomosis.

† For intraperitoneal dissection of the mesentery.

Procedure

The patient is placed in the Trendelenburg position, and after cannula insertion, is tilted left side down so the small intestine falls toward the left upper quadrant. The mesentery of the terminal ileum is grasped dorsally with two graspers and is placed under tension. In general, the posterolateral attachments of the ileal mesentery are held with a Babcock-like grasper inserted through the left-upper-quadrant cannula, and the medial attachments of the ileal mesentery are held with a smaller grasper inserted in the left-lower-quadrant cannula so the graspers do not cross and permit access with the scissors and the dissector. Dissection of the mesentery is begun just medial to the base of the appendix and is carried cephalad and to the left toward the inferior edge of the duodenum (Figure 9.13). The retroperitoneum is incised and the right colonic mesentery is completely freed

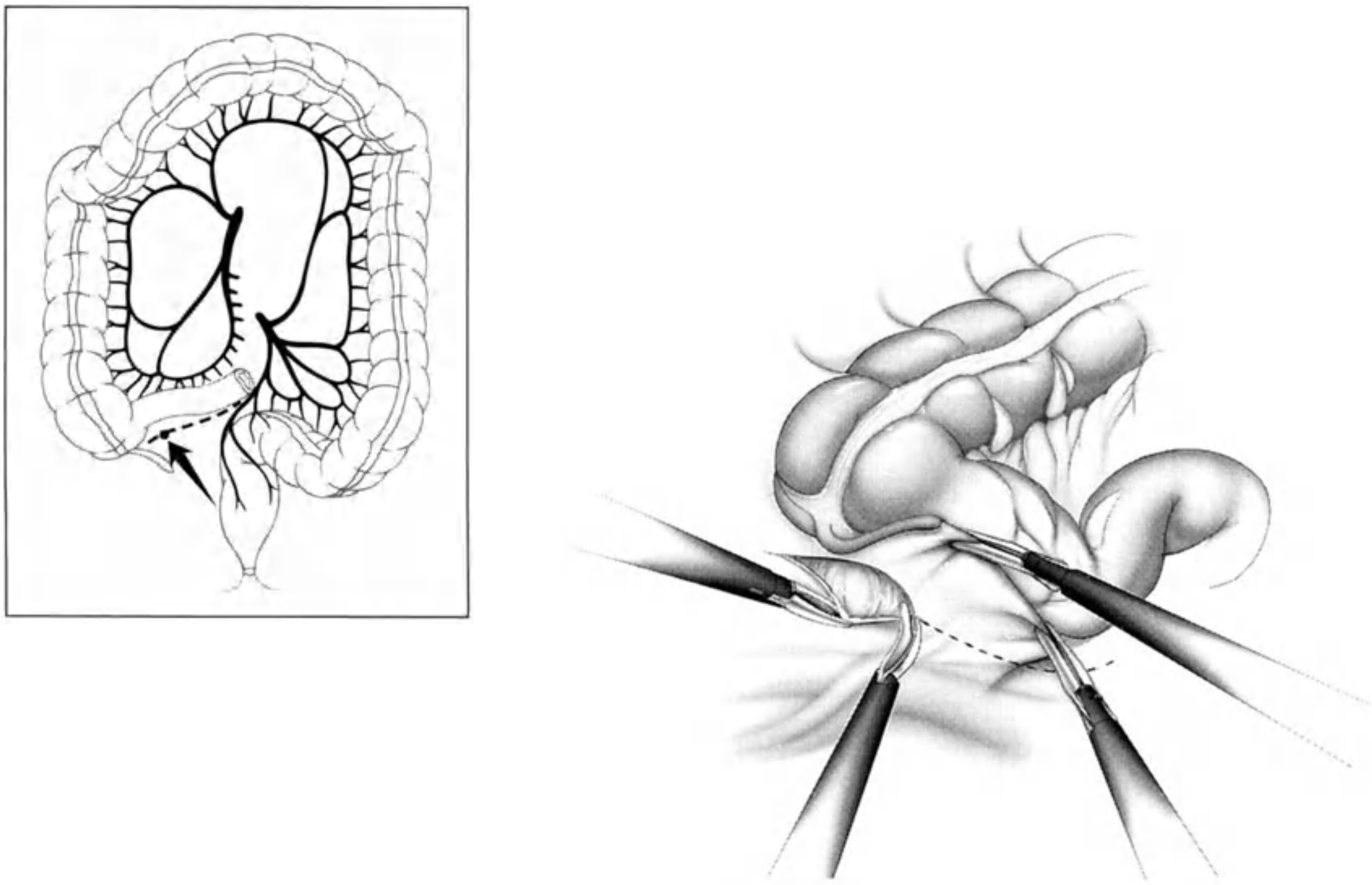

FIGURE 9.13. Initial exposure of the cecum and the terminal ileum. The peritoneum is incised along the base of the ileal mesentery up to the duodenum.

retroperitoneally so a tunnel is created beneath the ileal mesentery in this avascular plane (Figure 9.14). This tunnel can be created almost entirely by blunt dissection with an occasional need for sharp transection of some of the connective tissue fibers. To achieve good traction on the tissues, the assistant must periodically reapply the grasper more and more cephalad in a stepwise manner. With this tunneling maneuver, the duodenum, the right ureter, the gonadal vessel, and Gerota's fascia become clearly visible and may be swept posteriorly away from the dorsal aspect of the right mesocolon (Figure 9.15).

The ileocolic artery and vein can usually be identified dorsally in the mesentery and are traced to their origin from the superior mesenteric artery and vein (Figure 9.16). These vessels should be carefully dissected at a safe distance from the superior mesenteric artery and vein, then traced distally to the cecum before division so these vessels are not mistaken for the superior mesenteric artery and vein. This error can be made more easily than one might think. Tracing the vessels accurately may require flipping the mesentery and the ileum caudally so the vessels can be examined from their ventral aspect in the ileocolic mesentery. Ligating the vessels may also be easier from this ventral aspect.

Large clips or staples are applied to the ileocolic pedicle, which then is divided (Figure 9.17). With the stapler, the artery and the vein may generally be divided simultaneously. If the vessels are divided from the dorsal aspect of the mesentery, they are then flipped toward the pelvis and the surgery is continued from the ventral aspect of the right colon. The right mesocolon is carefully grasped at the mesenteric edge of the ascending colon resection line and is placed under tension; next, the distal mesenteric resection line is marked by incising the peritoneum up to the bowel edge. The right mesocolon is divided up to the colon, and the one or two marginal vessels in this area are identified and clipped. An umbilical tape is placed to mark the distal resection line (Figure 9.18).

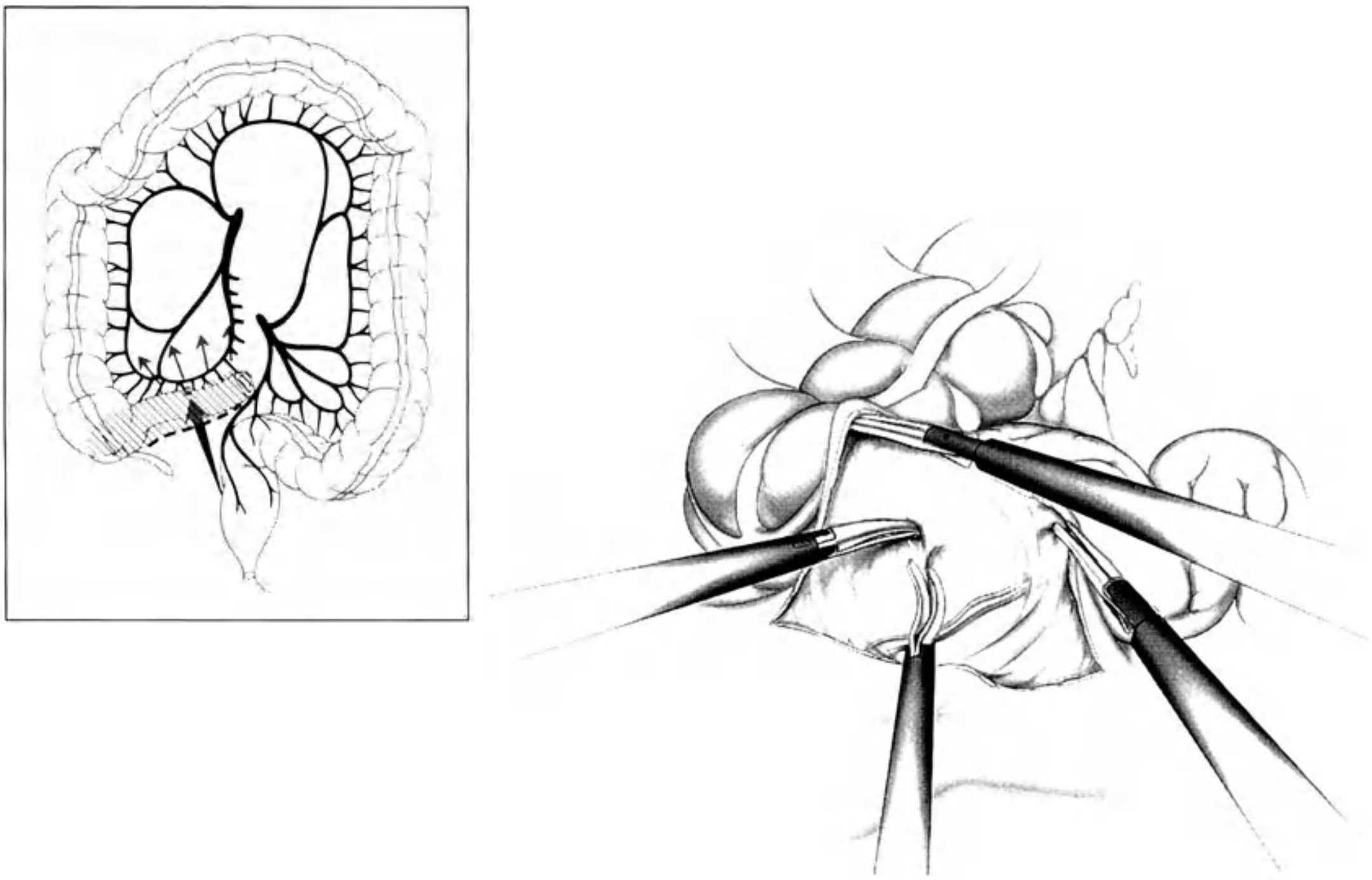

FIGURE 9.14. A window is created into the retroperitoneum in order to separate the ileal and right colon mesentery from retroperitoneal structures.

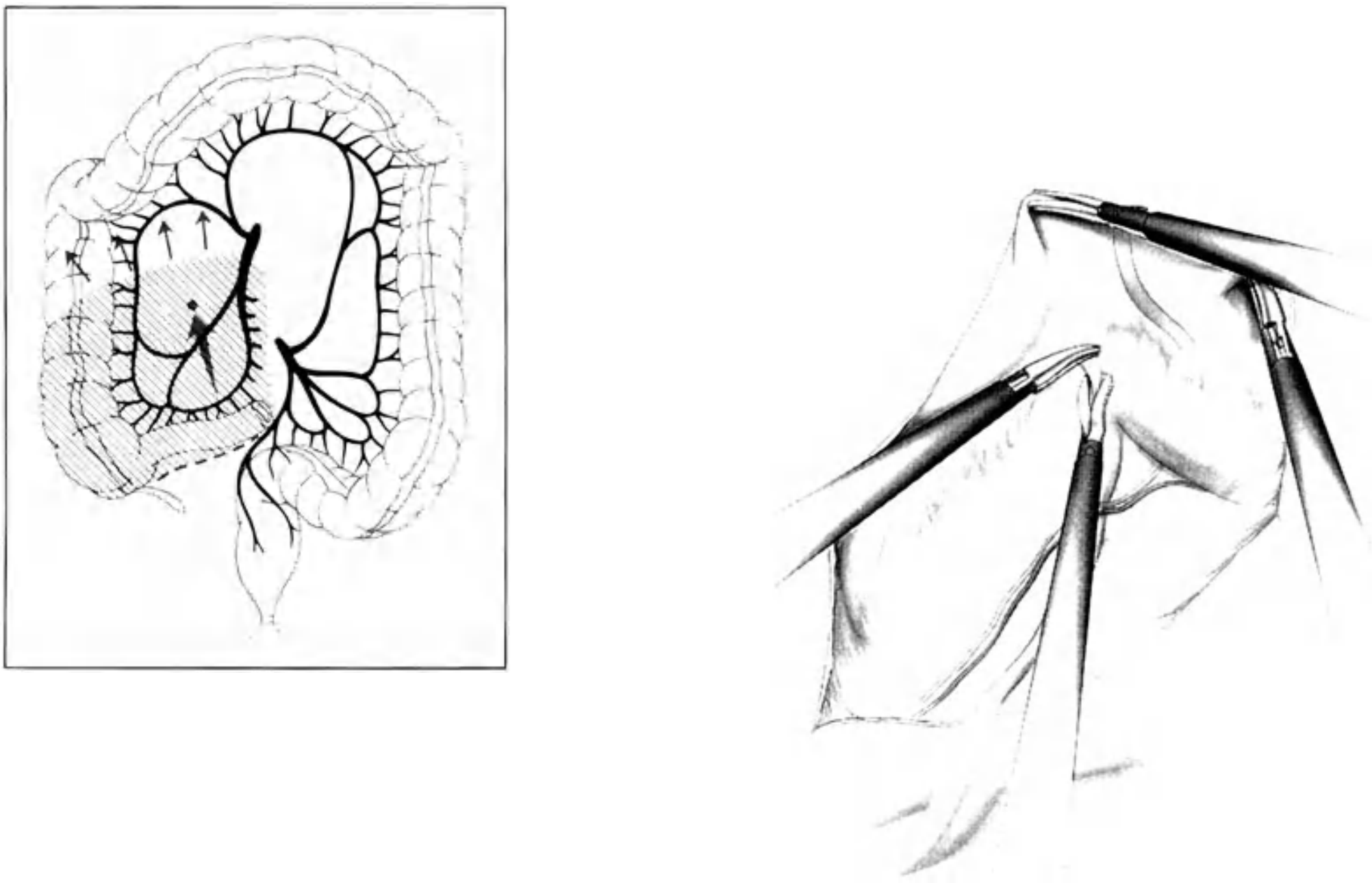

FIGURE 9.15. The right ureter, the gonadal vessels, Gerota's fascia, the duodenum, and the caudal portions of the pancreas have been dissected away from the mesentery in the course of creating a retroperitoneal tunnel.

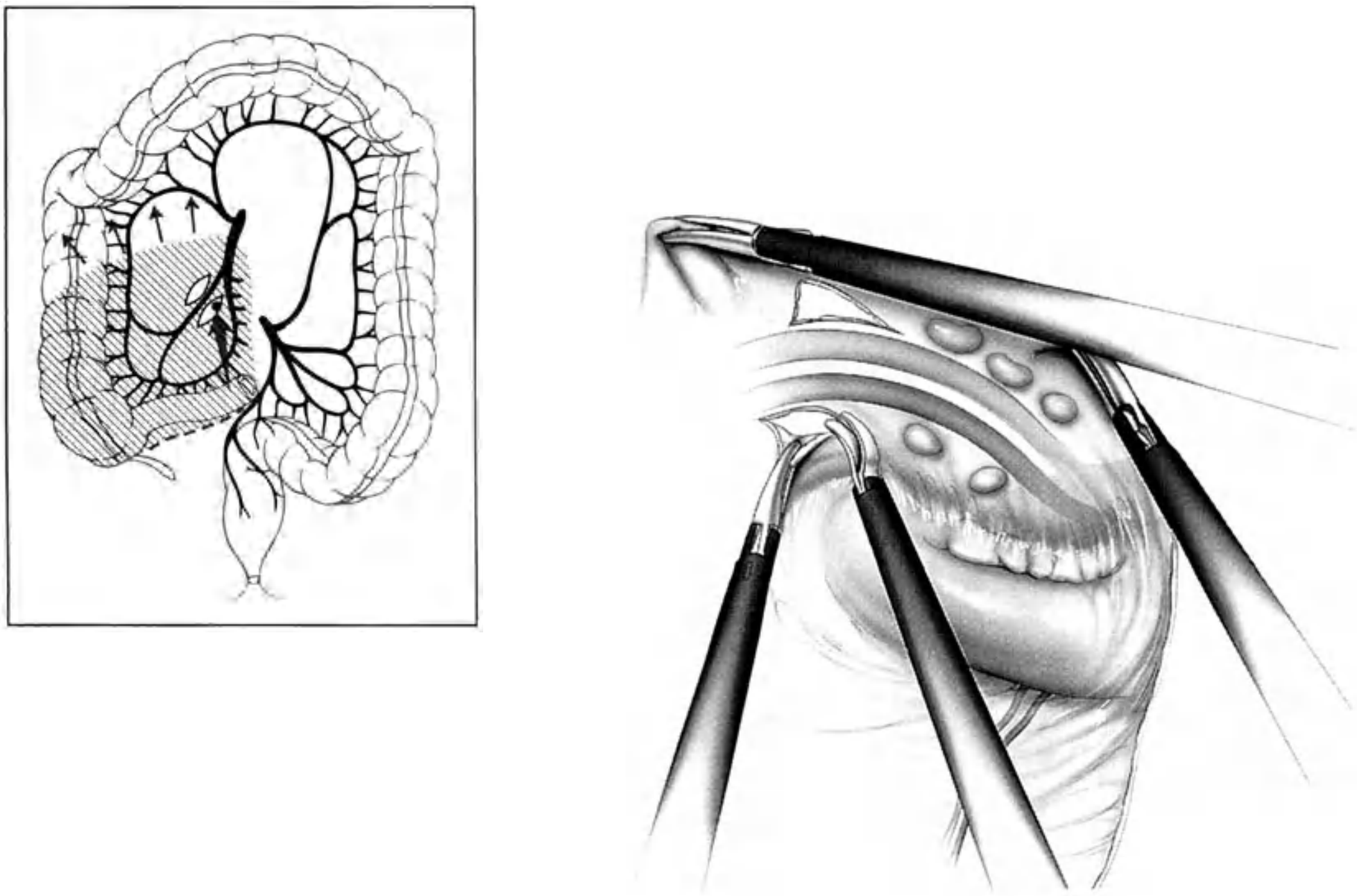

FIGURE 9.16. The lymphovascular pedicles are isolated, and an incision is made on one or both sides of the vessels before ligation.

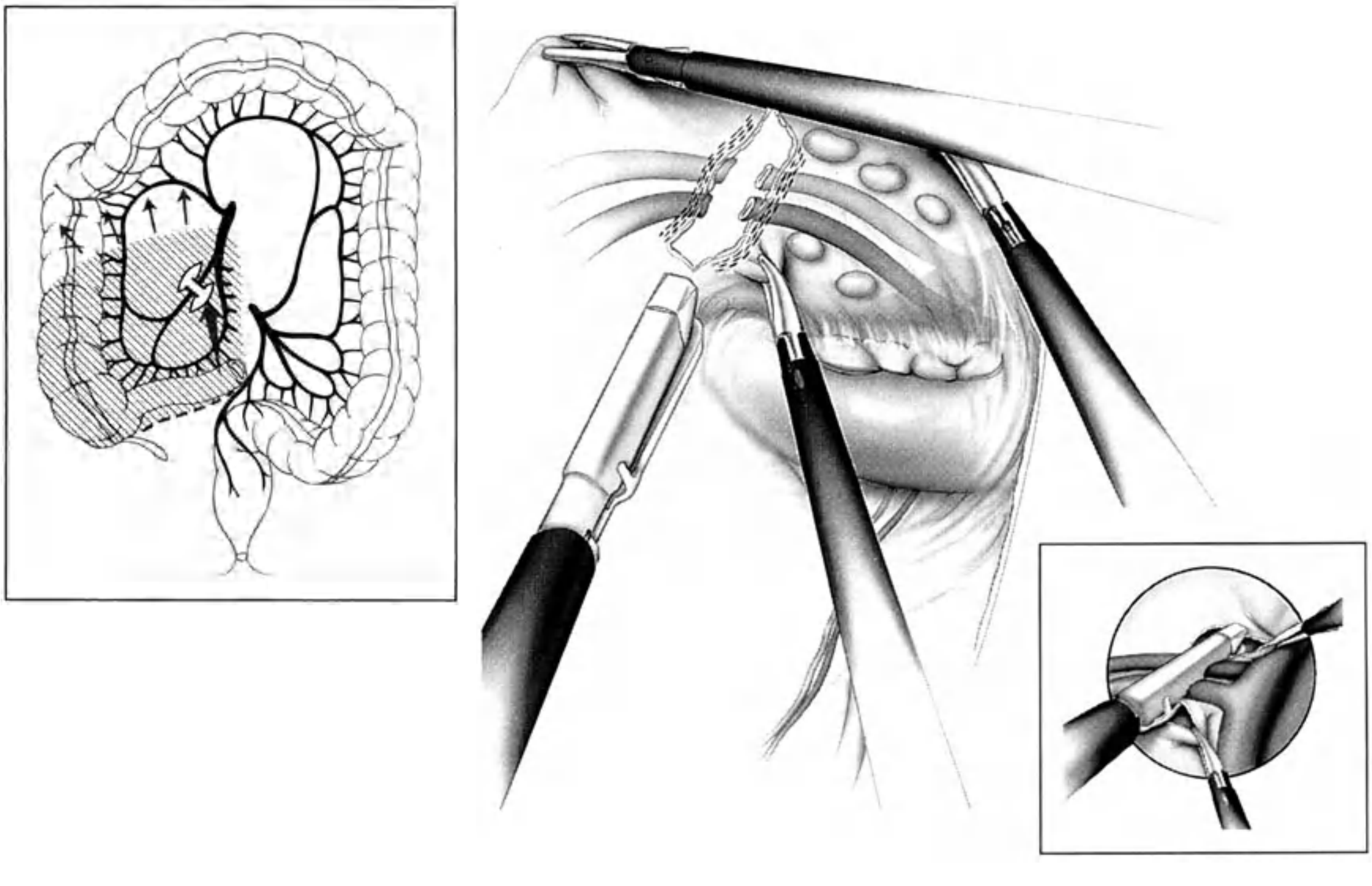

FIGURE 9.17. Completed transection of ligated ileocolic lymphovascular pedicle using a 30-mm vascular stapler. Inset, The transection may be easier to perform from the dorsal aspect of the mesentery.

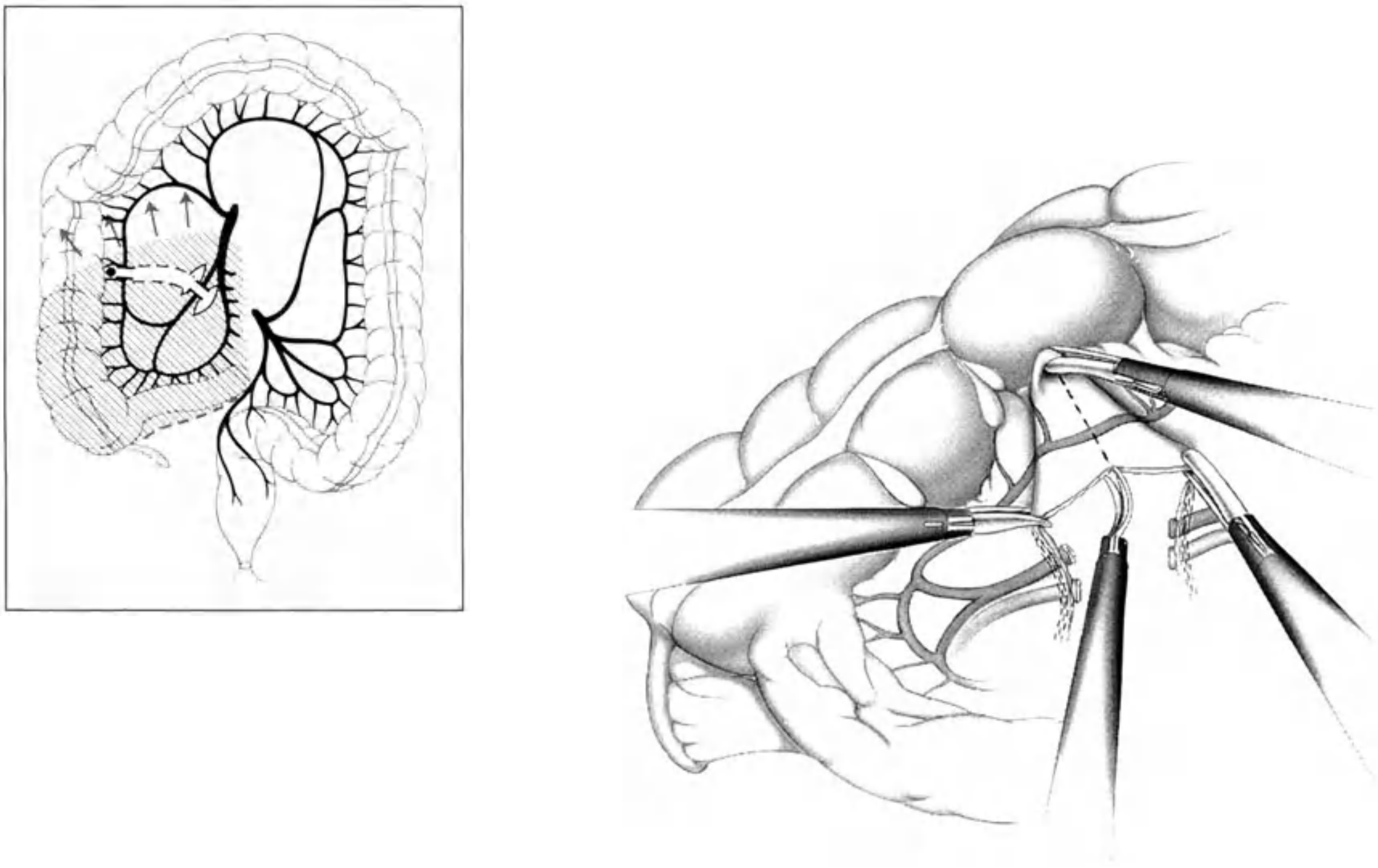

FIGURE 9.18. The distal resection line is specified and the mesocolon is divided up to the bowel edge. Marginal vessels are clipped as necessary.

The proximal (ileal) resection line is next identified on its dorsal aspect and the peritoneum is incised up to the bowel edge. A second umbilical tape is placed to mark the proximal resection line. The ileal mesentery is completely dissected dorsally starting just to the left of the ileocolic pedicle. All marginal vessels greater than 2 mm in diameter are clipped and divided (Figure 9.19).

After the mesentery and the mesocolon have been completely dissected, the right colon up to and including the hepatic flexure is completely detached from retroperitoneal structures using medial traction on the colon. Because most of the mobilization has been performed dorsally, only minor adhesions with the lateral and posterior abdominal wall will need to be transected (Figure 9.20).

Once the mesentery is completely divided, the umbilical tapes marking the proximal and distal resection lines are held together with a grasper, and an endoscopic snare is passed over the apex of the specimen so the snare simultaneously encircles both the proximal and distal resection

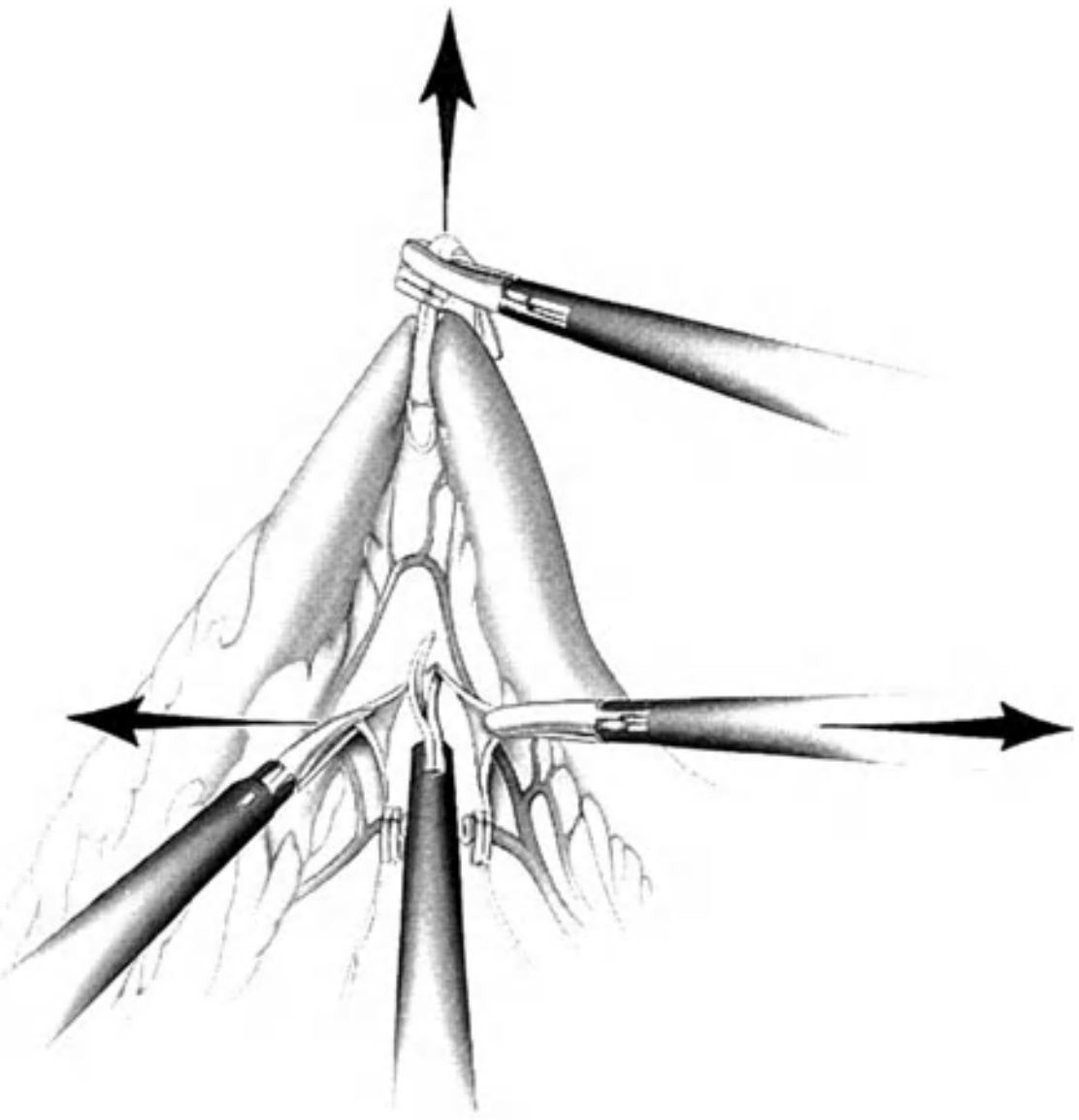

FIGURE 9.19. Umbilical tape is placed around the ileum at the proximal resection line and is secured with clips. The mesentery of the ileum is transected while applying triangulating tension.

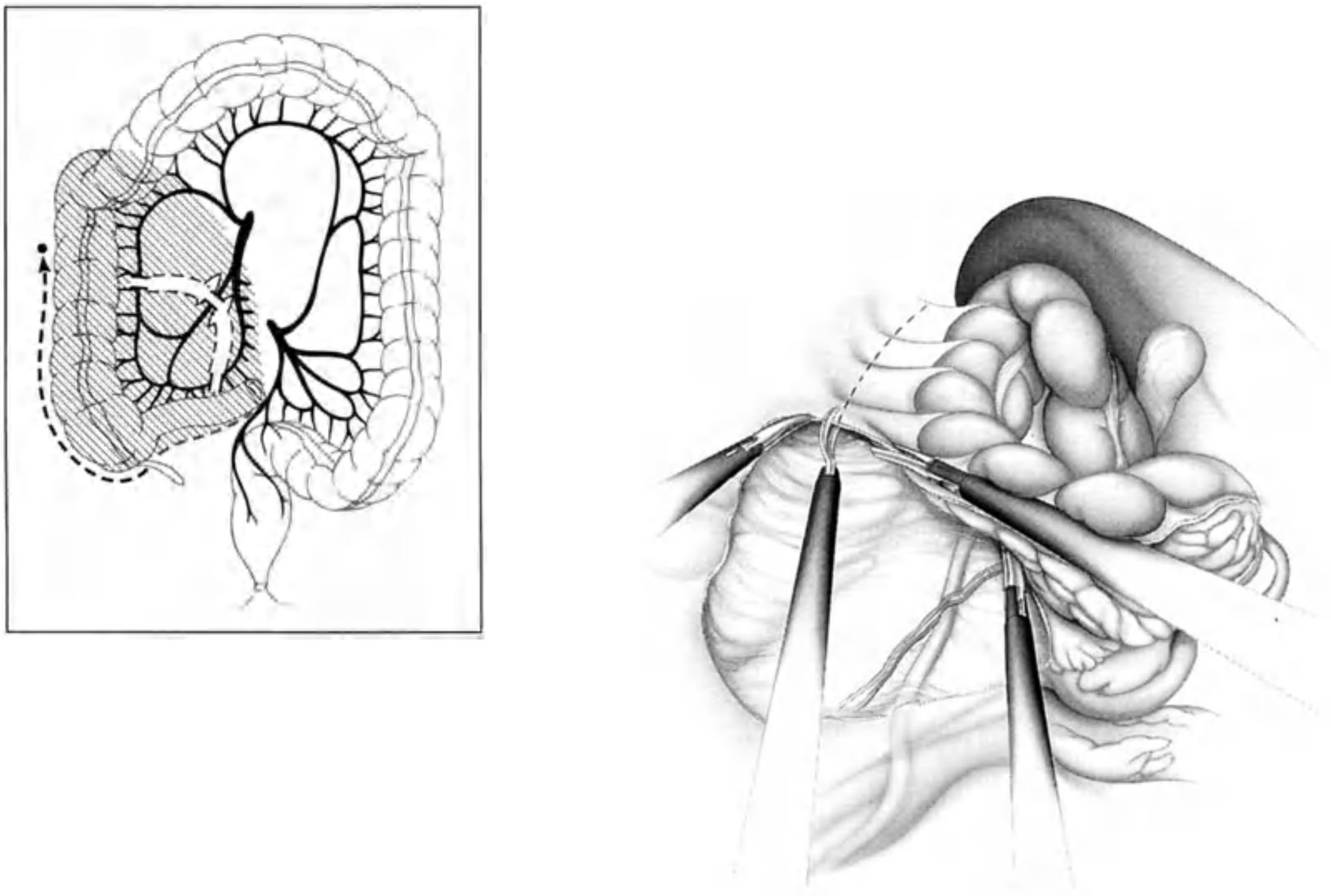

FIGURE 9.20. Completing the mobilization of the ascending colon and hepatic flexure after intraperitoneal mobilization and mesenteric division.

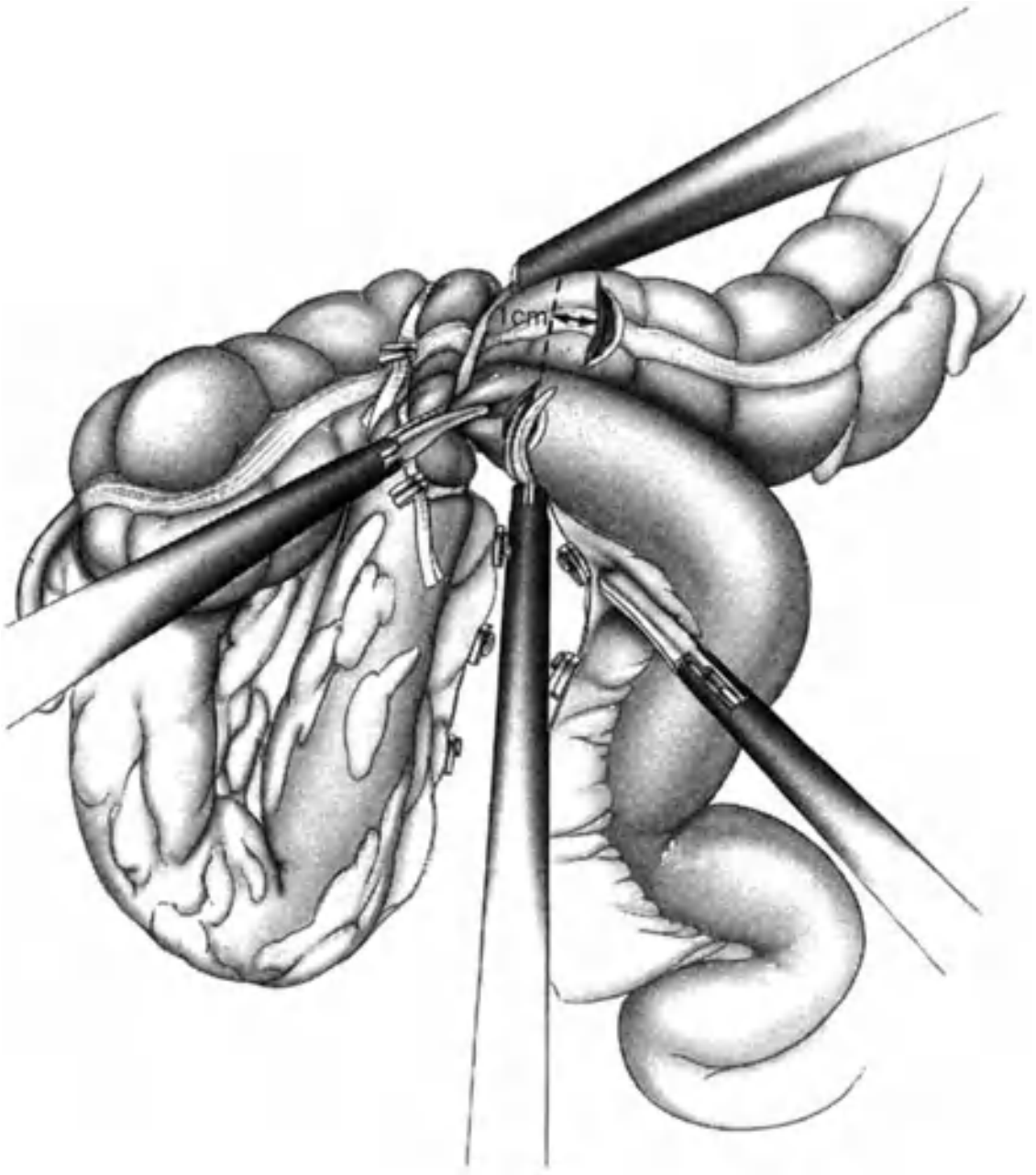

FIGURE 9.21. Umbilical tapes that mark the proximal and distal resection lines are held together, and an endoscopic snare is placed to encircle and steady the specimen. Staggered enterotomies are made to set up for stapled anastomotic formation.

lines (Figure 9.21). The snare is placed close to the tapes on the specimen side, and is used to occlude the bowel lumen from the specimen side and to prevent spilling of intestinal contents. The loop also places the two intestinal limbs parallel to each other to facilitate the formation of an endoscopically stapled anastomosis.

Then two enterotomies are made on the antimesenteric border of the adjacent loops (Figure 9.21). The enterotomies must (1) be large enough to accommodate the forks of a 30-mm endoscopic stapler and (2) be placed in a staggered fashion. This strategy makes it easy to push the larger fork of the stapler (cartridge portion) into the first enterotomy and then push the anvil portion of the stapler into the second enterotomy (Figure 9.22). The intestine is optimally positioned for the anastomosis by pushing the endoscopic snare holding the intestine toward the right-lower-quadrant 15-mm cannula while inserting the Endo GIA 30 stapler, which simultaneously puts opposing tension on the afferent and efferent loops.

After the 30-mm endoscopic stapler has been inserted through the right-lower-quadrant can-

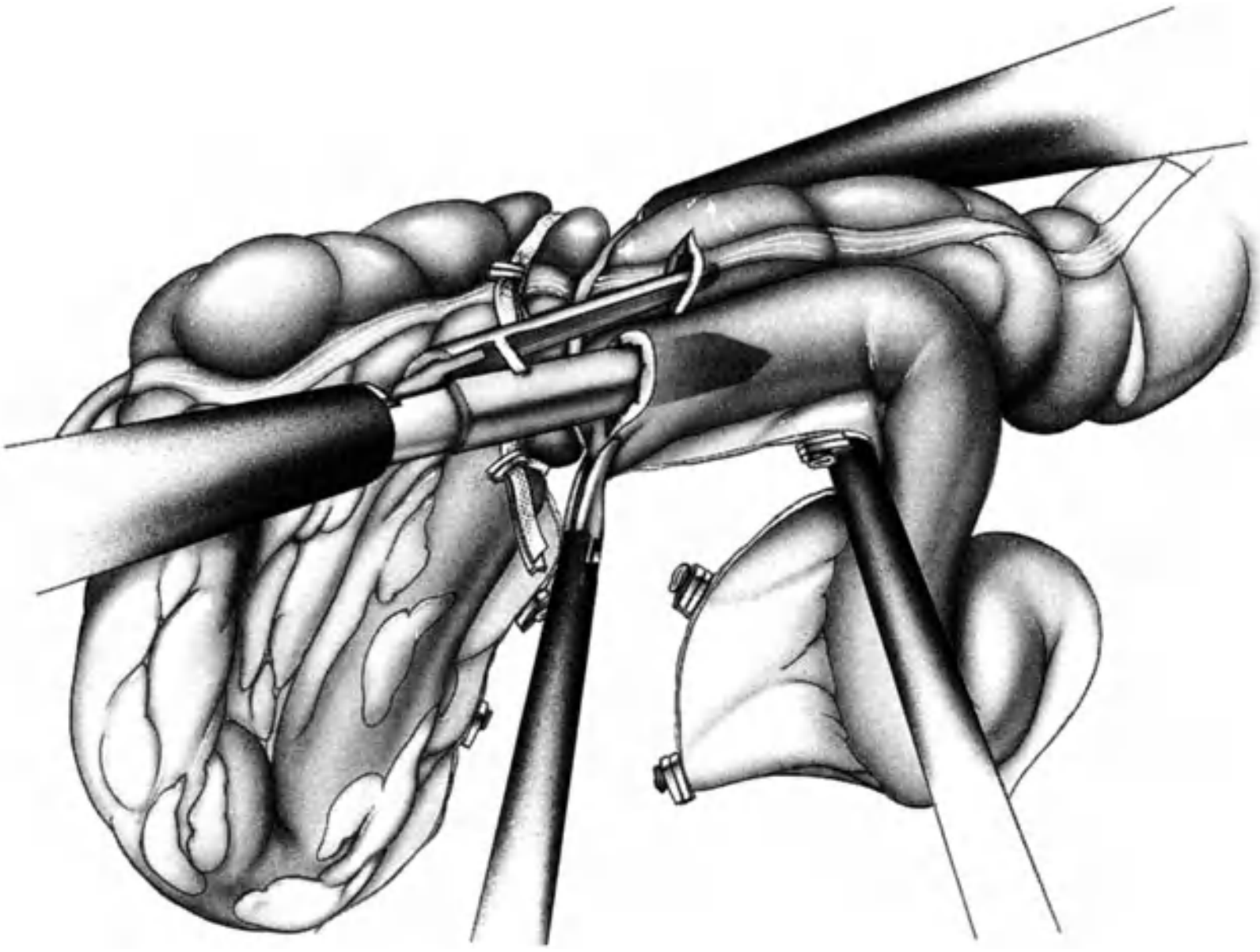

FIGURE 9.22. The anastomosis is begun by passing the 30-mm stapler cartridge first into the ileal enterotomy and then maneuvering the anvil into the colotomy.

nula and has been positioned inside the intestinal lumina, it must be ascertained before the stapler is fired that the mesenteric blood supply to the bowel segments is outside of the stapler jaws. To minimize the risk of mesenteric impingement with the stapler, the tips of the stapler should be drawn anteriorly before firing. This action draws the mesentery posteriorly away from the jaws of the stapler. The stapler is fired, opened, then removed by applying countertraction on the intestine. A second application of the staples is placed intraluminally (using either a 30- or a 60-mm stapler), again being careful to avoid the mesenteric blood supply (Figure 9.23). The first stapler application apposes the bowel ends and begins the intestinal anastomosis, and the second larger stapler maximizes and defines the anastomotic size.

The anastomosis is completed and closed with one or two firings of the 60-mm stapler fired at right angles to the two anastomosed loops, just below the enterotomies (Figure 9.24). Care must be taken to avoid firing the staplers across any metal clip in the mesentery applied close to the resection line because this could result in staple malformation and, as a consequence, anastomotic leakage. After the specimen has been completely transected, it should still be held firmly with the snare, then placed in an endoscopic bag that has been inserted through the right-lower-quadrant 15-mm cannula and opened in the pelvis. Once the specimen is safely in the bag, the drawstring is closed and the bag is pulled inside the cannula. To extract the specimen safely, the right-lower-quadrant cannula site is enlarged using a muscle-splitting incision lateral to the rectus sheath. The top of the specimen bag is withdrawn from the abdominal wall while inside the cannula, ensuring that the specimen does not contaminate the abdominal wall. Pneumoperitoneum is released and the CO_2 insufflator is shut off temporarily. The abdominal wall incision is enlarged as needed to safely remove the specimen. The specimen is generally removed most easily while inside the bag by rocking the bag gently back and forth through the incision. After specimen removal, the patient is placed in a head-up position temporarily, and the abdomen is copiously irrigated through the specimen removal site with warm sterile saline solution while a sump suction is used to aspirate the irrigation fluid through the same site. If the mesenteric defect can safely be visualized through the

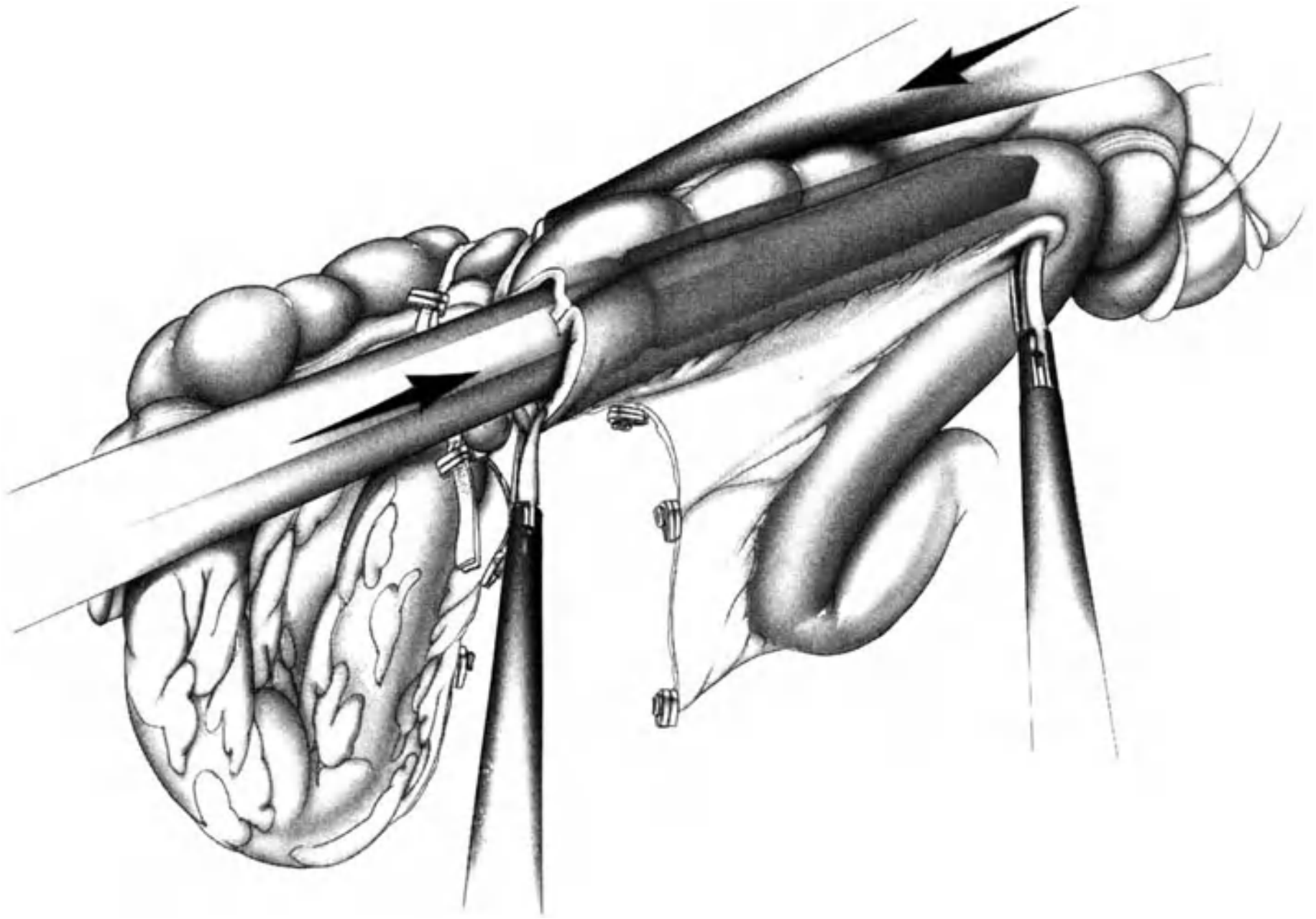

FIGURE 9.23. The endoscopic 60-mm stapler is next inserted maximally, and before it is closed, some anterior traction is placed on the inside mesentery. The anterior traction places the mesentery posteriorly so none is included in the stapler jaws.

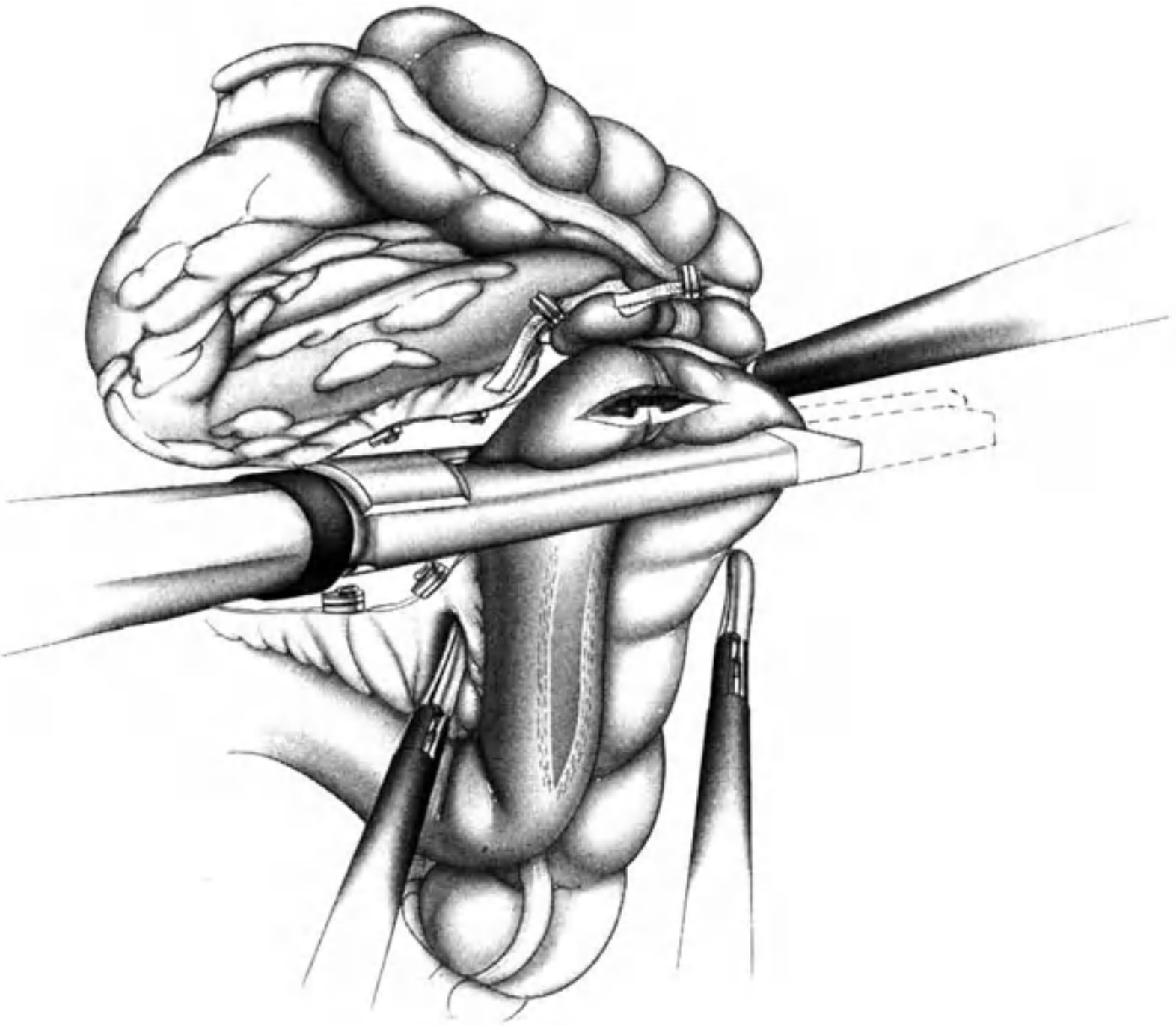

FIGURE 9.24. An endoscopic 60-mm stapler is fired across the intestine below the enterotomies to transect the specimen and to seal the anastomosis.

incision, it may be closed using a running suture under direct vision. Then the abdominal wall is closed with a series of interrupted simple or figure-of-eight, size 0 absorbable sutures, either closing each muscle layer independently or en masse.

Pneumoperitoneum is reestablished, and the surgical sites and anastomosis are inspected. The mesenteric defect may be closed at this point using a running 3-0 braided absorbable suture or an endoscopic hernia stapler passed through the left-lower-quadrant cannula.

Special Considerations

Our approach to mesenteric mobilization—the creation of a retroperitoneal tunnel—offers the following advantages:

- Minimal risk of injury to the right ureter or the gonadal vessels because they are visualized and swept clear of the mesentery during the early part of dissection.
- Early ligation of major mesenteric vessels, which may reduce the risk of major bleeding.
- Early proximal ligation of major mesenteric vessels in cancer patients is feasible and is considered by some authorities[5,6,8] to be important in cancer surgery.
- By leaving the lateral attachments of the colon intact until mesenteric division, important countertraction can be applied to the bowel as the mesentery and later, the bowel, are mobilized. Leaving the lateral attachments intact may actually facilitate the colectomy and may highlight important anatomic landmarks.
- The colon is only minimally manipulated because most mobilization and complete dissection of the mesentery are accomplished before the cecum and the right colon are freed from the lateral attachments.

In instances of Crohn's disease (ileitis or ileocolitis), division of the mesentery may be difficult because tissue is fragile, thickened, and inflamed. If hemostasis of the mesentery cannot be accomplished safely by intraperitoneal means, the procedure should be converted either to a laparoscopic-assisted procedure, using only laparoscopic mobilization, or to a conventional procedure. If a large retroperitoneal phlegmon obstructs the view, laparoscopic mobilization of the right colon and the terminal ileum may be hazardous when the right ureter cannot be identified.

When only the right colon and the ileum are laparoscopically mobilized from their retroperitoneal attachments, 5-mm cannulas (except for the 10-mm cannula for the laparoscopic camera) are probably sufficient. We prefer, however, to use at least one additional 10-mm cannula so that in case of inadvertent bleeding, a clip applicator or bipolar electrosurgery instrument may be inserted to achieve hemostasis. Once the terminal ileum and the right colon are mobilized, the right-lower-quadrant cannula site can be enlarged, the mobilized intestine can be extraperitonealized, and the transection of the mesentery and the anastomosis can be performed extraperitoneally. Alternatively, the umbilical cannula site can be used for exteriorization, with a midline fascial incision.

Although an extracorporeal anastomosis has the advantage that it can be easily accomplished with conventional techniques, we think the abdominal wall incision is usually much larger than when it is used simply to retrieve the specimen. The larger incision, together with the stretch exerted on the mesenteric root, may also increase the sympathetic intestinointestinal reflex with subsequent prolonged inhibition of postoperative intestinal motility. Although performing an intraperitoneal anastomosis must be practiced if it is to be successfully accomplished in as little as 15 minutes, it has the following advantages: minimal tissue manipulation, a small incision when it is used only for specimen retrieval, and possibly less inhibition of postoperative intestinal motility.

Cancer

In our opinion, indications are rare for performing a limited ileocecal resection for malignancies of the terminal ileum, the appendix, or the cecum. This may be the procedure of choice in palliative resection for cecal carcinoma. We prefer to perform removal of the entire right colon and the proximal transverse colon (see next section, Right Colectomy) in nearly all instances of cecal or right colon cancer.

Right Colectomy

In laparoscopic colorectal surgery, as in conventional surgery, right colectomy is intended primarily for the removal of the entire right colon up to or including the midportion of the transverse colon.

Position

The patient is placed supine in a modified lithotomy position using Dan Allen stirrups. Surgery is begun in the Trendelenburg position (20° head-down tilt), and after cannula insertion, the patient is tilted left side down. After establishing pneumoperitoneum, the surgeon and the assistants stand in a half-circle opening toward the right upper quadrant (Figure 9.25). During the entire operative procedure (after cannula insertion), the surgeon stands between the patient's legs, the assistants position themselves on the patient's left side, and the nurse stands near the patient's right knee. One monitor is placed near the patient's right shoulder to

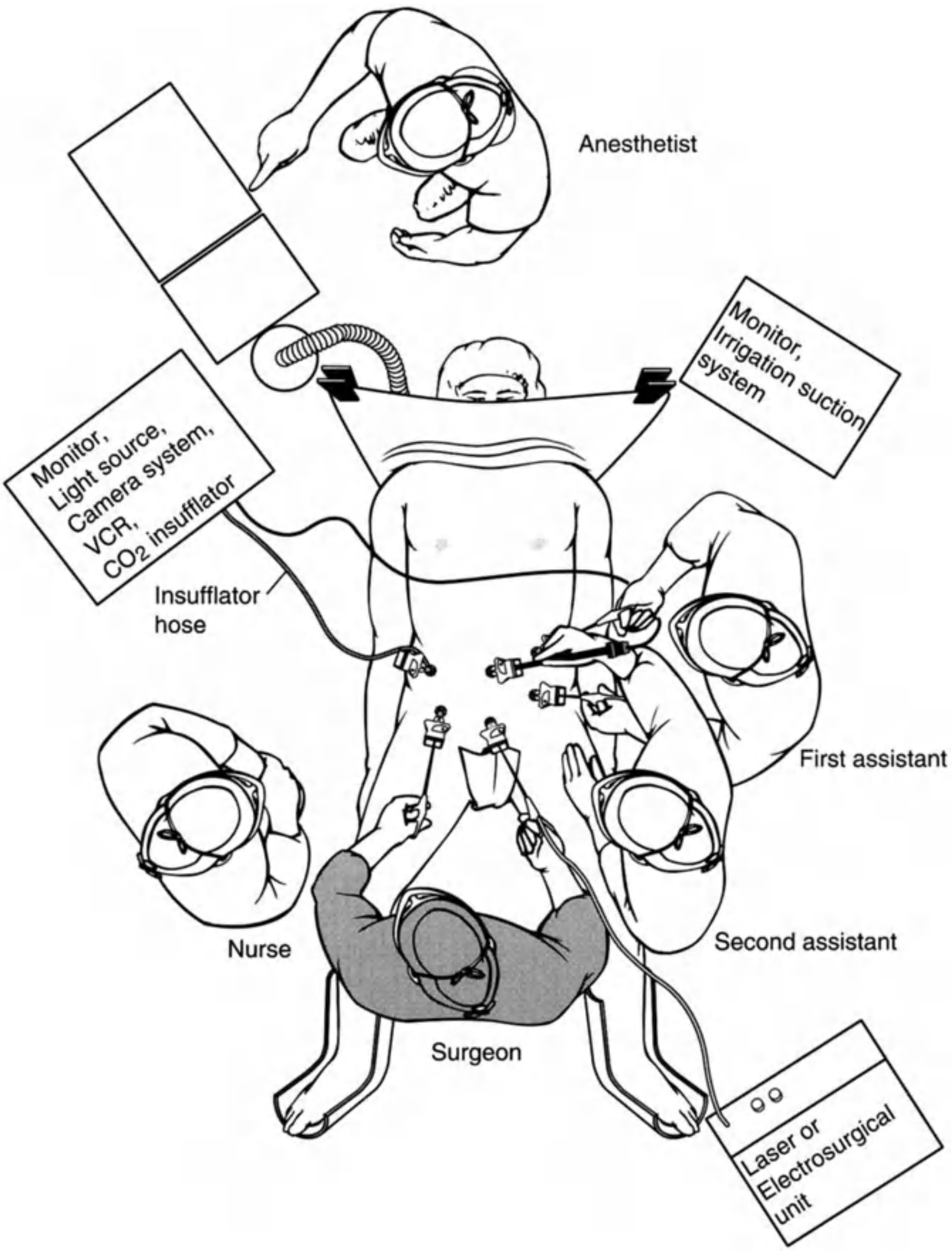

FIGURE 9.25. Position of the equipment and the surgical team for right colectomy.

give the surgeon and the assistants optimal viewing. The other monitor is placed on the left side close to the head, a location that gives the best view for the nurse.

Instruments

Table 9.3 shows the minimum instruments that are necessary to accomplish a right colectomy with an intraperitoneal ileocolic anastomosis. If an extracorporeal anastomosis is performed, endoscopic staplers and 15-mm cannulas are not necessary. If laparoscopic techniques are used only to mobilize the right colon, only one 10-mm cannula (in addition to the 10-mm cannula needed for the laparoscope) is used in case a clip applier is needed for hemostasis. The remaining cannulas need to be only 5 mm.

Cannulas

The cannulas are positioned in a half-circle opening toward the right upper quadrant (Figure 9.26). A right-upper-quadrant cannula is needed only if an intraperitoneal anastomosis is contemplated and should not be placed until needed either for hepatic flexure mobilization or for the anastomosis.

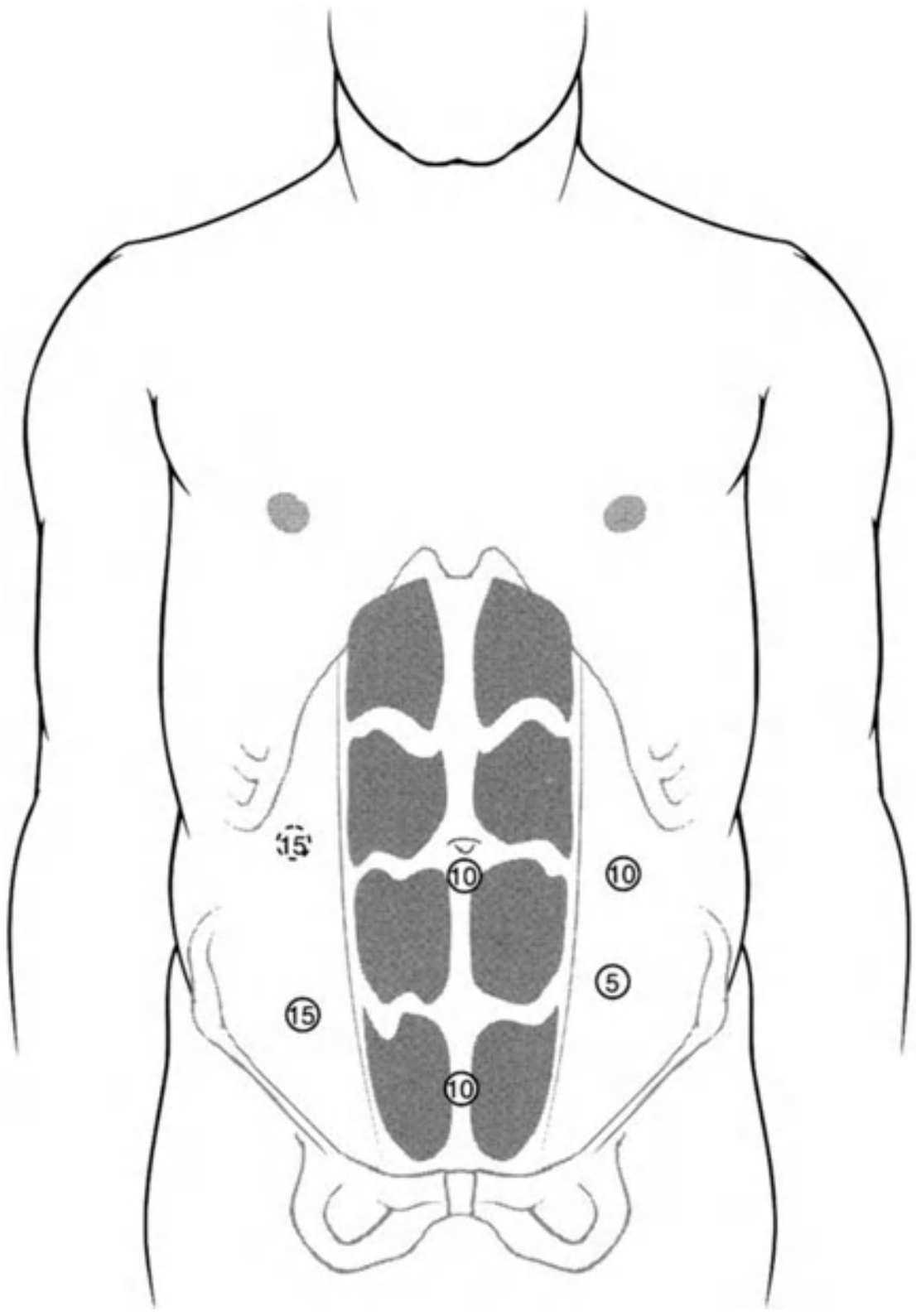

FIGURE 9.26. Position of the cannulas for right colectomy.

TABLE 9.3. Instruments required for laparoscopic right colectomy.

No.	Type
6	Cannulas (2 × 15 mm,* 3 × 10 mm,† 1 × 5 mm) including anchoring devices and converters
1	Dissecting device, for example, endoscopic scissors equipped with electrosurgery
1	Endoscopic dissector
2	Endoscopic graspers (one Babcock-like and one small)
1	Endoscopic snare*
1	Endoscopic clip applier (large size)†
1	Multifire Endo GIA 30 stapler†,*
1	Multifire Endo GIA 60 stapler*
2	Endo GIA 30 cartridges†,*
3	Endo GIA 60 cartridges*
2	Umbilical cotton tapes (0.25 in. wide, 12 cm long)†

* For intraperitoneal anastomosis.
† For intraperitoneal dissection of the mesentery.

Procedure

After the patient is placed in the Trendelenburg position and is tilted left side down, the mesentery of the terminal ileum is grasped dorsally with graspers and is placed under tension. In general, the distal part of the ileal mesentery (dorsal aspect) is grasped with a grasper inserted through the left-upper-quadrant cannula and the medial portion of the ileal mesentery is held with a smaller grasper through the left-lower-quadrant cannula so the graspers do not cross and do not block access for the surgeon's scissors and dissector.

Dissection of the mesentery is begun just medial to the base of the appendix and is carried cephalad, medially, and to the left toward the inferior edge of the duodenum (Figure 9.27). The

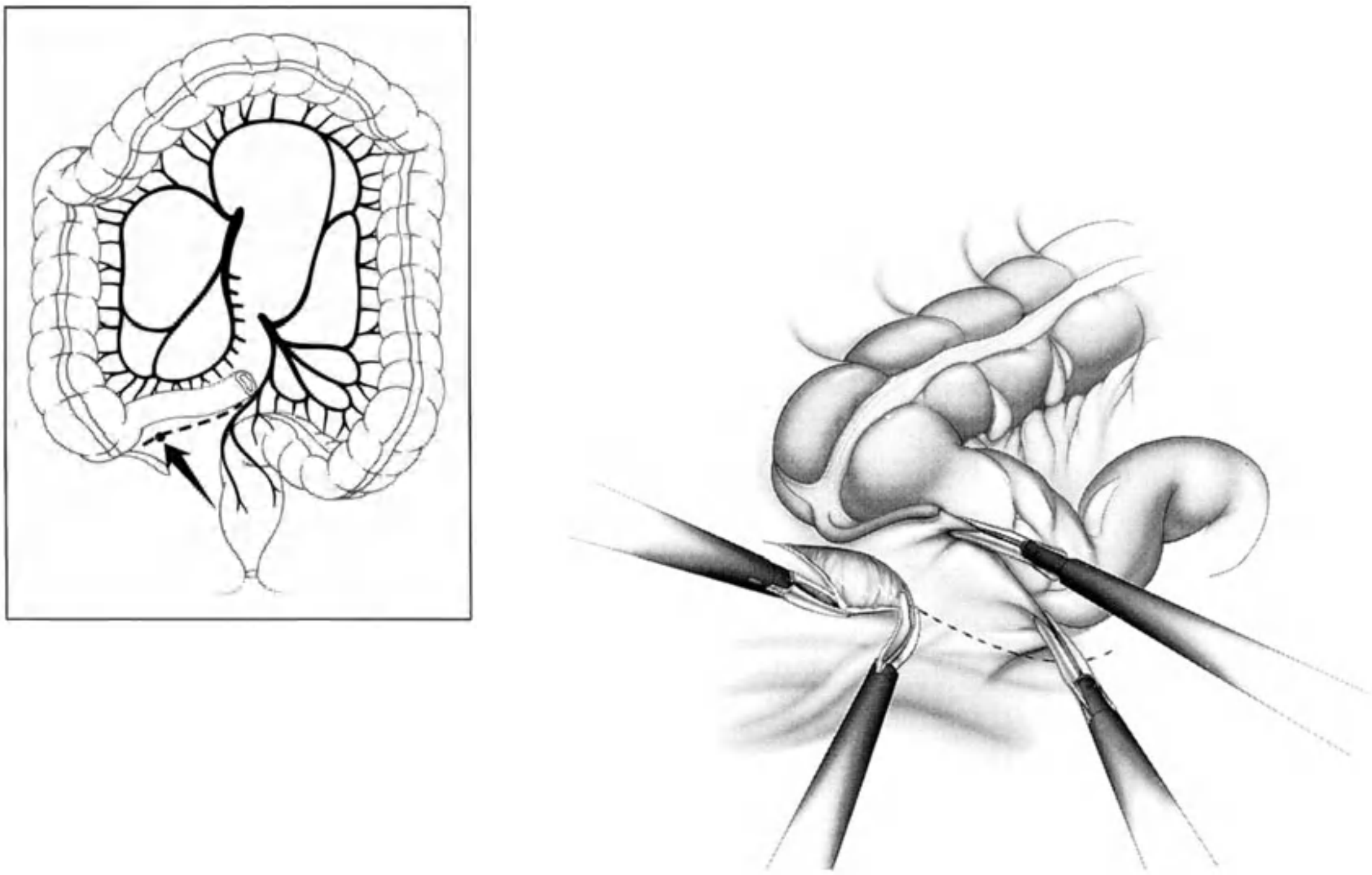

FIGURE 9.27. Initial exposure of the cecum and the terminal ileum. The peritoneum is incised along the base of the ileal mesentery upward to the duodenum.

peritoneum is incised and the right colonic mesentery is completely freed retroperitoneally, creating a tunnel beneath the ileal mesentery in an avascular plane (Figure 9.28). This tunneling maneuver can be accomplished almost entirely by blunt dissection with sharp transection of some of the connective tissue fibers between the dorsal aspect of the mesentery and its attachments to Gerota's fascia and the duodenum. For accurate dissection, the assistant must consistently place satisfactory tension on the tissue. When this tunneling is created beneath the mesocolon, the duodenum, the right ureter, the gonadal vessels, and Gerota's fascia become clearly visible and may be swept posteriorly away from the dorsal aspect of the right mesocolon (Figure 9.29). Blunt dissection may be carried out in a cephalad direction over Gerota's fascia to the inferior edge of the liver and to the second portion of the duodenum.

The ileocolic artery and vein can usually be identified dorsally in the mesentery (Figure 9.30) and may be traced to their origin from the superior mesenteric artery and vein. The right colic vessels, which in only 13% of patients originate directly from the superior mesenteric artery just proximal to the ileocolic artery,[7] are usually found after the mesentery is mobilized from the duodenum and the caudal portion of the pancreas. If the right colic vessels are not present, the surgical team should proceed with the dissection and the ligation of the ileocolic vessels. The common anatomic arrangements of the colic vessels emanating from the superior mesenteric artery will be discussed in greater detail in the next section, Special Considerations. All vessels are carefully dissected at a safe distance (10 to 15 mm) from the superior mesenteric artery and vein, and a window is made on both sides of the vessels. The ileocolic vascular pedicle must be traced distally to the cecum before it is divided so it can be correctly distinguished from the superior mesenteric vessels—these vessels can easily be mistaken for the ileocolic pedicle. Usually, before division, we flip the ileocolic mesentery and the ileum caudally, then carefully examine the vessels from their ventral aspect. The pedicles are clipped and then divided or, more commonly, simultaneously ligated and transected with an endoscopic vascular stapler (Figure 9.31) or clips.

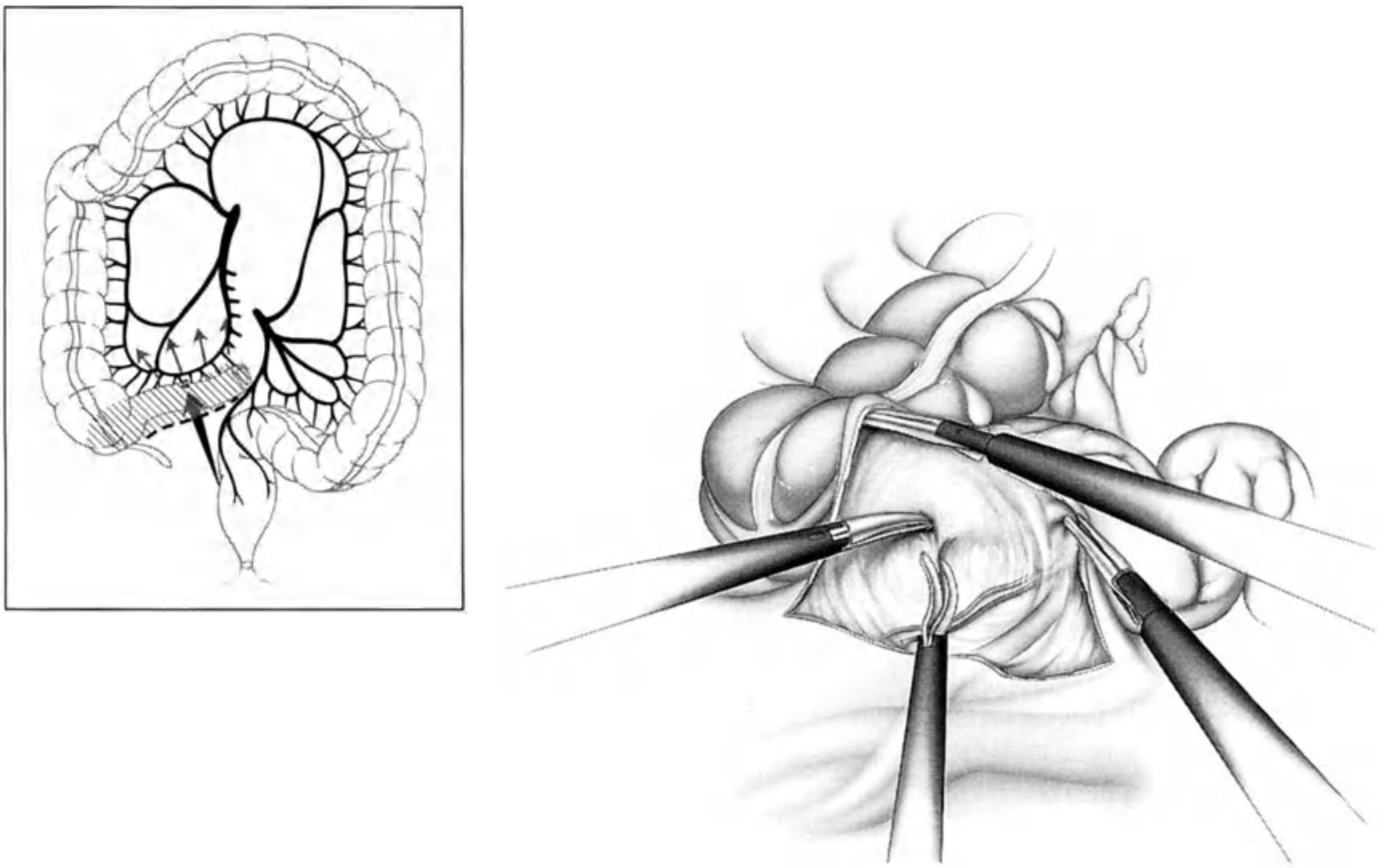

FIGURE 9.28. A tunnel is created in the retroperitoneum in order to separate the ileal and right colon mesentery from retroperitoneal structures.

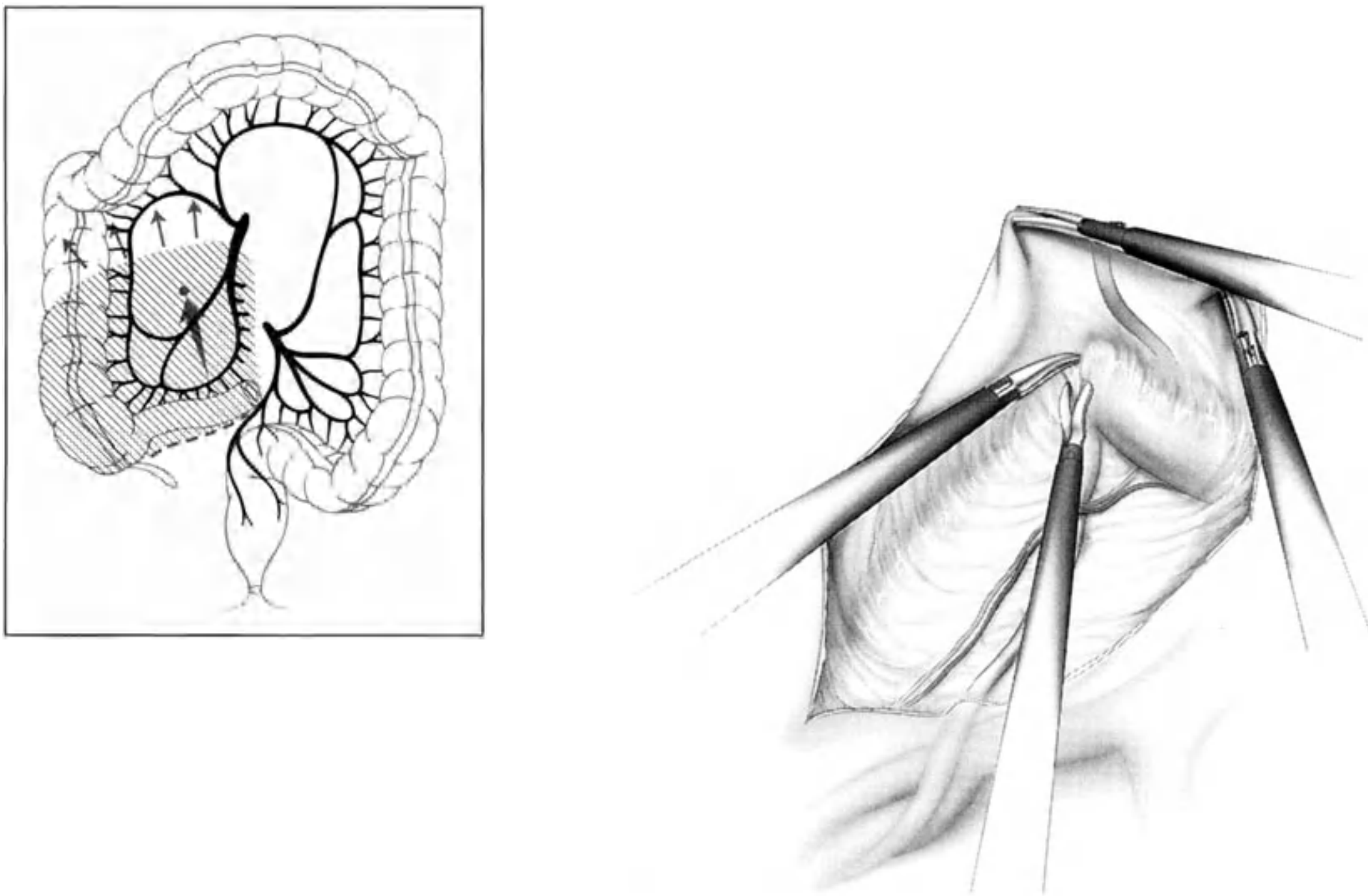

FIGURE 9.29. The right ureter, the gonadal vessels, Gerota's fascia, the duodenum, and the caudal portions of the pancreas have been dissected away from the mesentery in the course of creating a retroperitoneal tunnel.

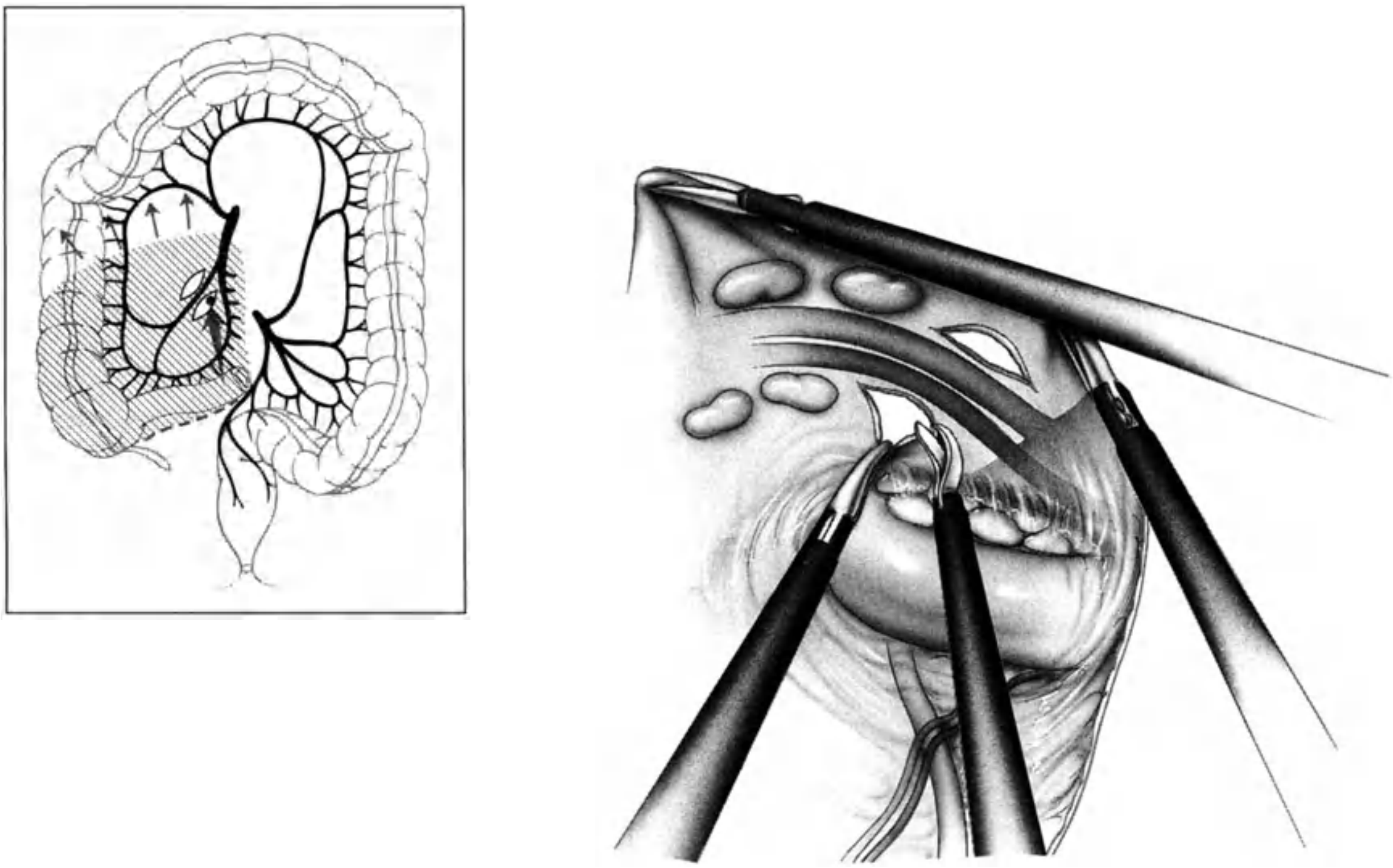

FIGURE 9.30. The ileocolic lymphovascular pedicle is isolated at its origin and an incision is made on one or both sides of the vessels in preparation for subsequent ligation and transection.

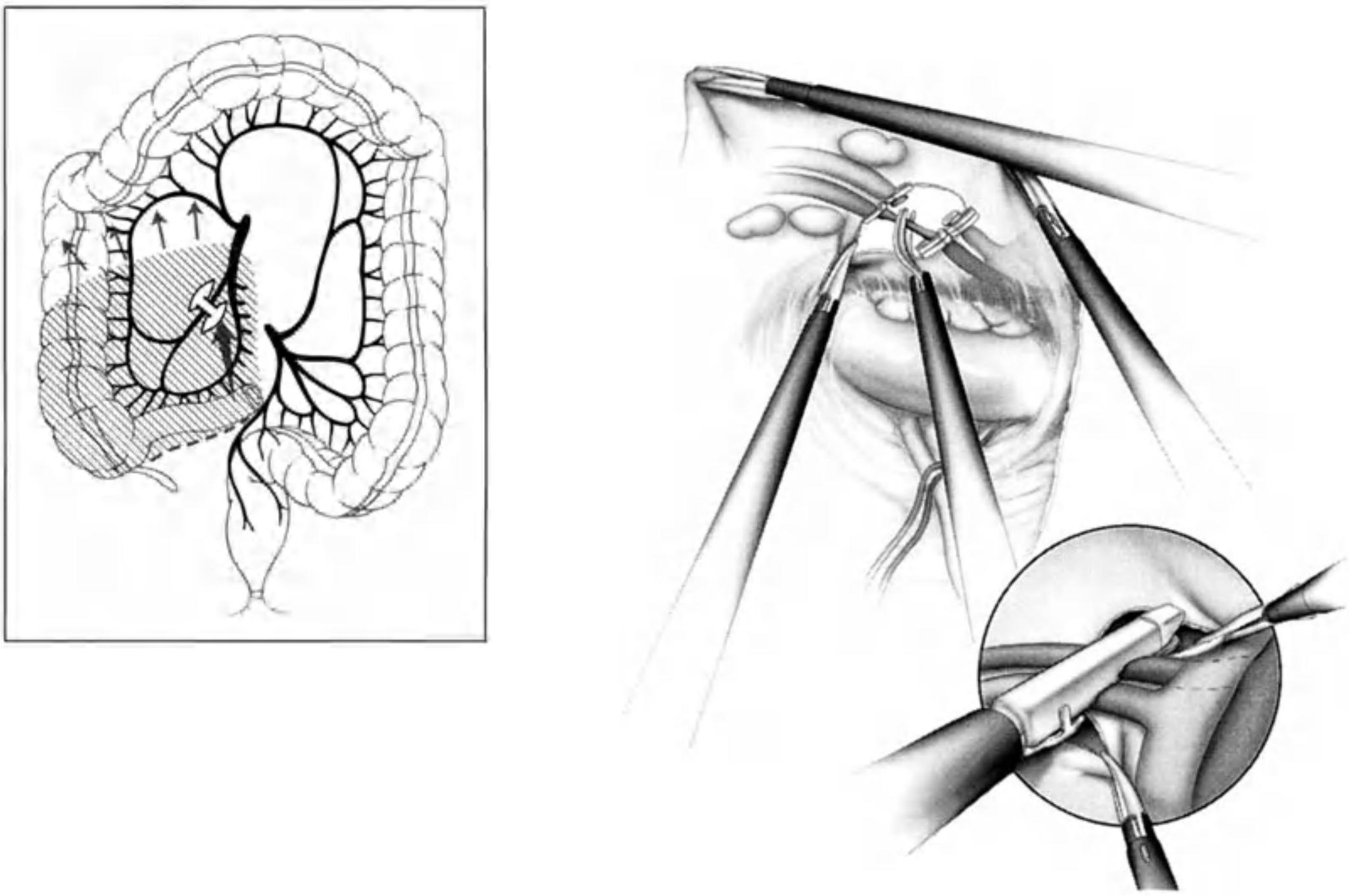

FIGURE 9.31. Transection of the clipped ileocolic lymphovascular pedicle from the dorsal aspect. Inset, Alternatively, the pedicle may be approached anteriorly, and then ligated and divided using the 30-mm endoscopic stapler.

Dissection is next carried cephalad from the ventral aspect of the right colonic mesenteric root, continuing medially until the peritoneal reflection of the middle colic vessels is seen. This reflection is divided sharply and the underlying tissue is bluntly dissected to isolate the middle colic vessels. If the right colic vessel has not previously been identified, dissection in the direction of the middle colic vessels should be carried out carefully. Because the middle colic vessels have a high degree of anatomic variability, care in their dissection is essential. This variability will be discussed in detail in the next section, Special Considerations. By carefully separating the middle colic vessels from the retroperitoneal structures and from the lesser omental sac, the surgeon often will see a cluster of sizeable middle colic vessels arising from the superior mesenteric artery and vein. We usually divide this pedicle with a 30-mm endoscopic vascular stapler (Figure 9.32A). Clips may also be used if they seem safer or more expeditious. Subsequently, just to the left of the middle colic pedicle, the mesenteric edge of the transverse colon is grasped, the peritoneum is incised from the middle colic pedicle up to the bowel edge, and then the mesentery is divided to this point (Figure 9.32B). Marginal vessels are divided be-

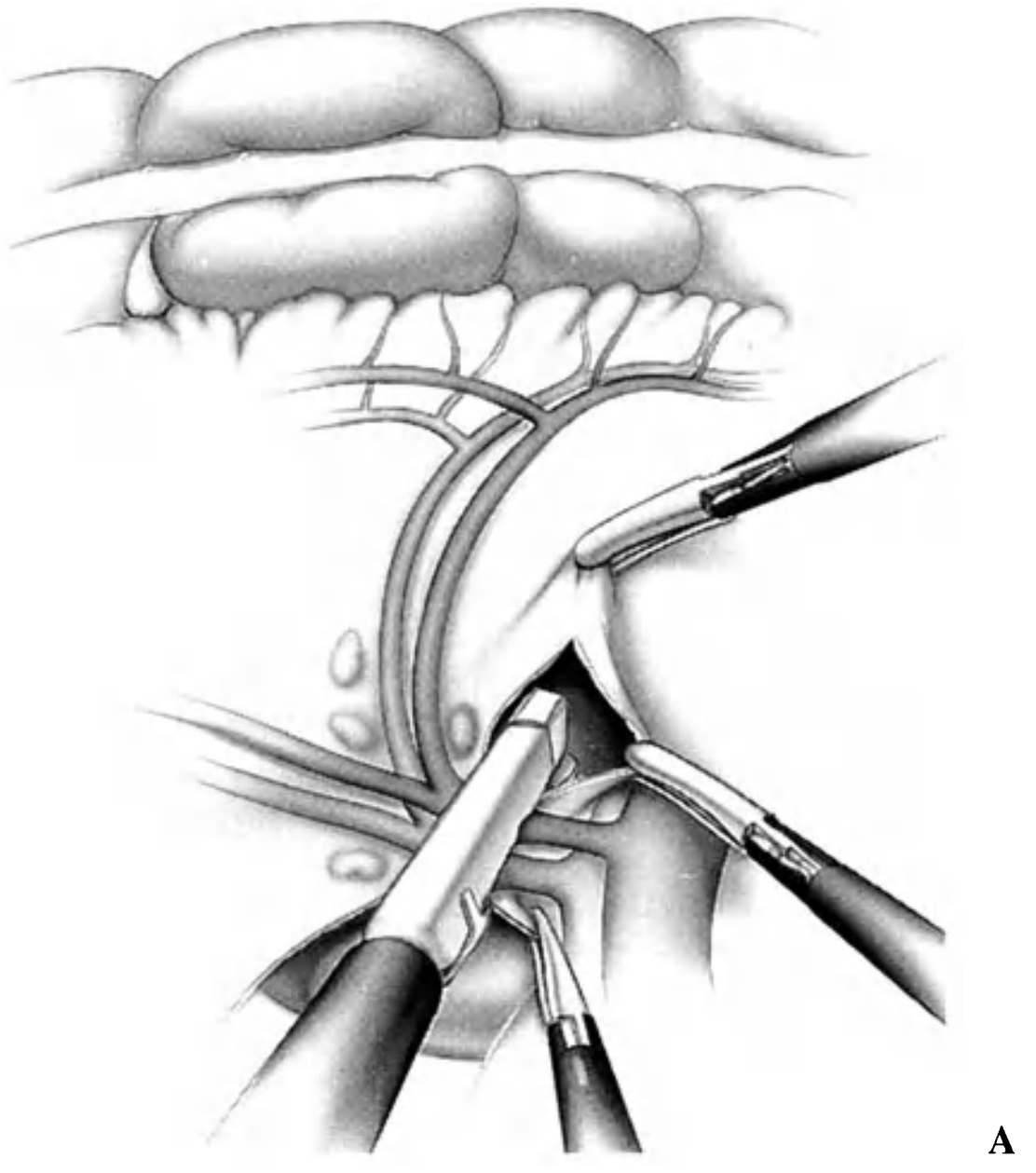

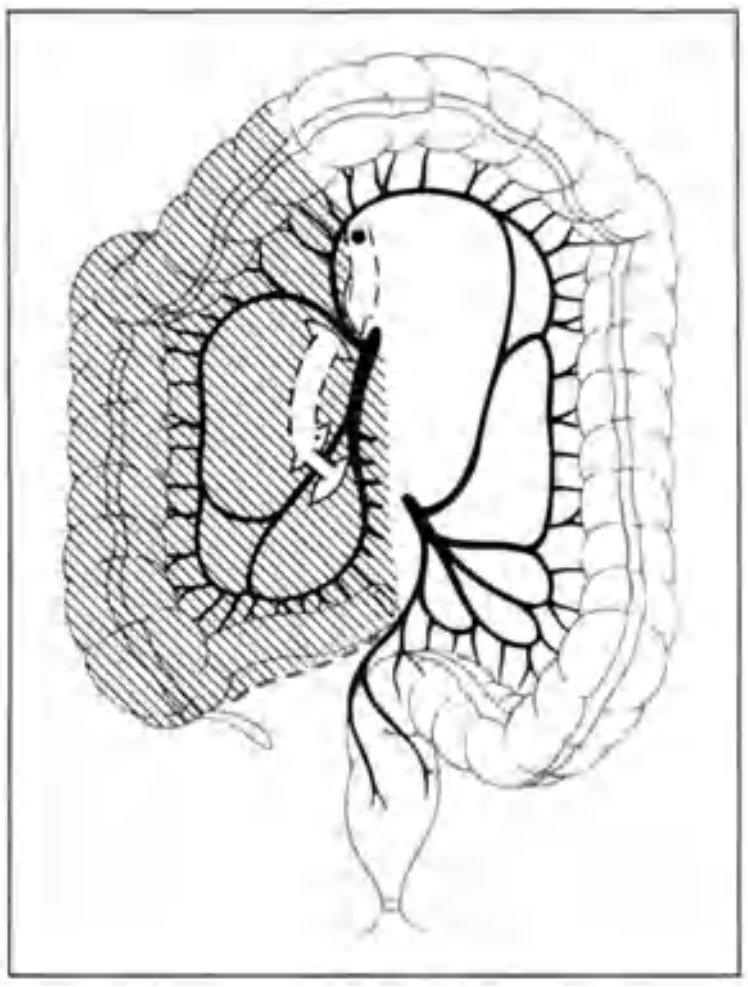

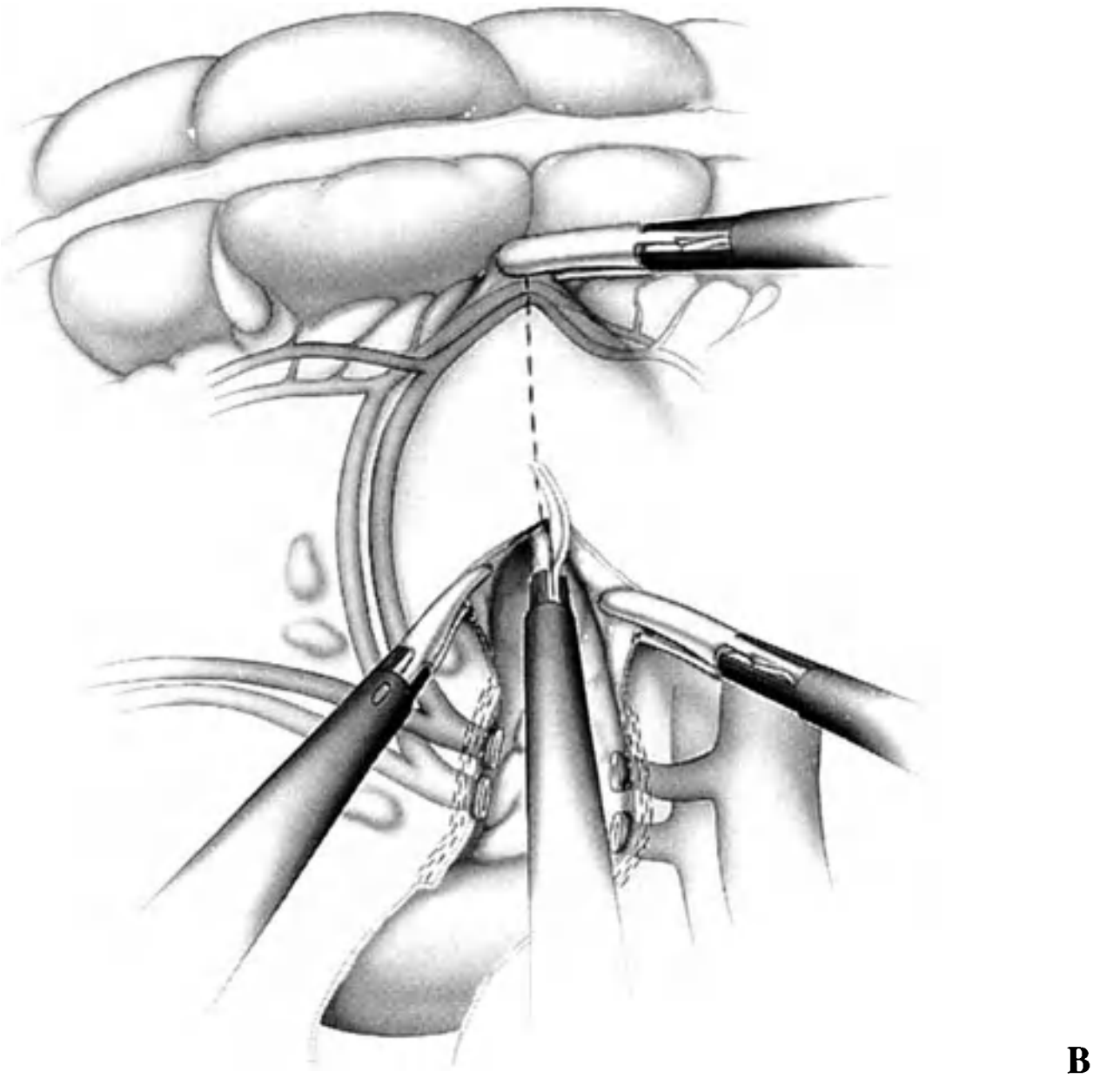

FIGURE 9.32. A, Stapling and transection of the lymphovascular pedicle of the transverse colon close to the origin of the middle colic vessels using a 30-mm endoscopic stapler. B, Transection of the mesocolon is completed up to the edge of the transverse colon.

tween clips as needed. The greater omental attachments to the transverse colon are then dissected from the colonic edge and the omentum is completely transected at the distal resection line. Vessels of the omentum are electrocoagulated or clipped, and divided as necessary. An umbilical tape is used to encircle the transverse colon at this distal resection line and clips are applied to secure it. The omentum, for 5 to 10 cm to the left of the tape, should be freed up to more fully mobilize the distal colon for the later anastomosis.

Next, the terminal ileum is grasped and the proximal resection line is identified. An umbilical tape is placed around the ileum at the proximal resection line and is secured with clips in the customary way (Figure 9.33). The ileal mesentery is completely dissected starting from the ileocolic pedicle, and any marginal vessels are clipped and divided.

After the dissection of the mesentery, the right colon and the hepatic flexure are completely detached from retroperitoneal structures using medial traction on the colon starting at the cecum. Because most of the mobilization has been performed dorsally, only the peritoneal attachments of the lateral and posterior abdominal wall will need to be divided (Figure 9.34). In general, we start the mobilization at the cecum and try to roll the cecum in the direction of the splenic flexure so we can divide the dorsal and lateral attachments of the right colon up to the hepatic flexure. Sometimes a thin membrane of connective tissue between the flexure and the superior portion of Gerota's fascia is the last layer of tissue and prevents the hepatic flexure from coming completely free. In these cases, it is sometimes better to complete the mobilization from beneath the mesocolon because the edge of the colonic attachments to the retroperitoneum is easier to visualize from this aspect. The terminal ileum and the cecum are flipped superiorly in the direction of the liver; the duodenum is identified; and the membrane, which may also be attached to the second portion of duodenum, is simply transected until the colon is completely free up to the umbilical tape marking the distal resection line.

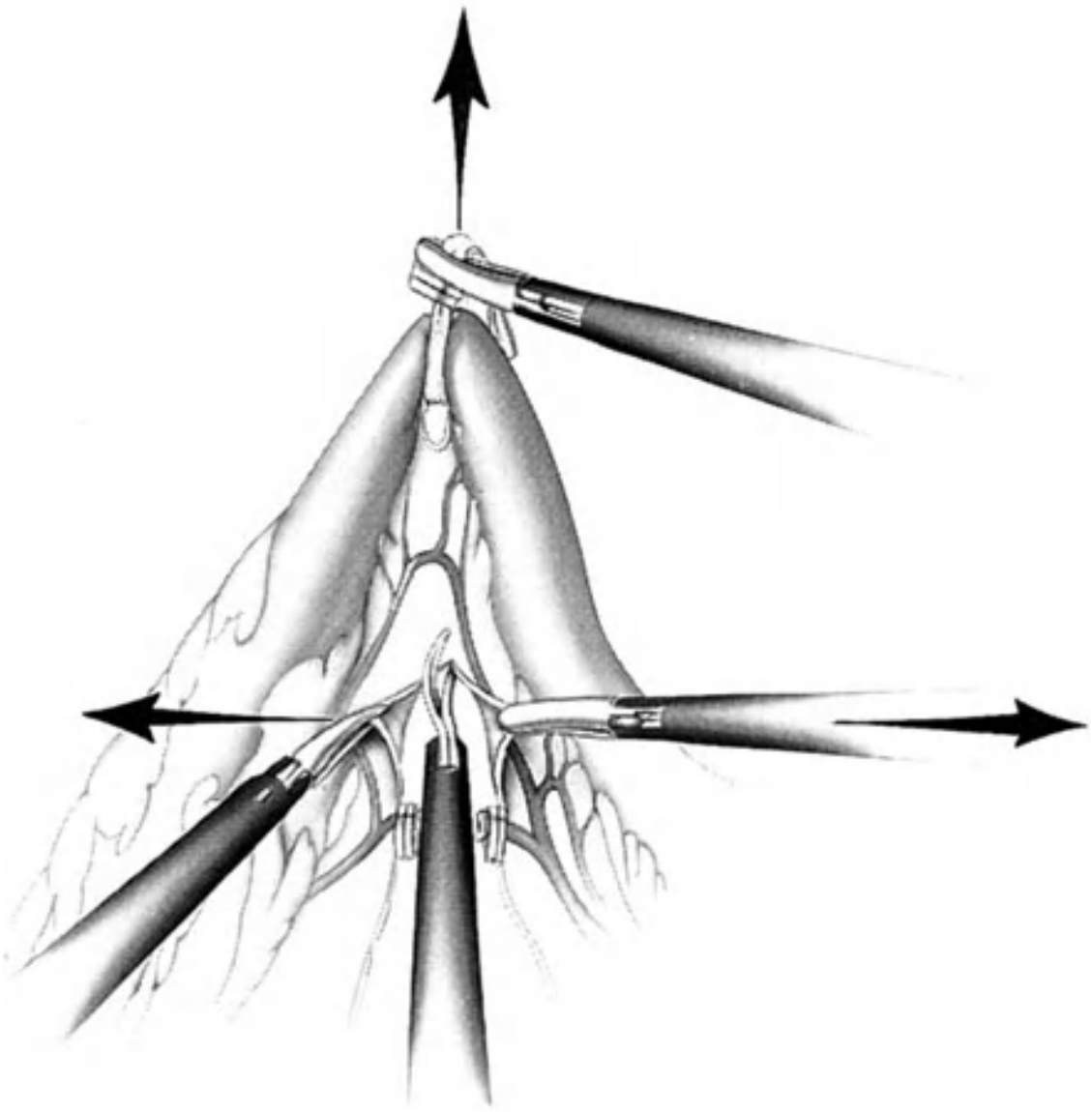

FIGURE 9.33. Umbilical tape is placed around the ileum at the proximal resection line and is secured with clips. The mesentery of the ileum is transected while triangulating tension is applied.

Once the terminal ileum, and the right and proximal transverse colon are completely mobilized, the tapes marking the proximal and distal resection lines are held together. An endoscopic snare is inserted through the left-upper-quadrant cannula and is passed over the specimen so the snare simultaneously encircles both the proximal and distal resection lines (Figure 9.35). The snare is placed close to the tapes on the specimen side, and is used to occlude the bowel lumen from the specimen side and to prevent spilling intestinal contents. The loop also places the two intestinal loops parallel to each other to facilitate the creation of the endoscopically stapled anastomosis.

To begin the anastomosis, two enterotomies are made on the antimesenteric border of the adjacent loops (Figure 9.36). The enterotomies must (1) be large enough to accommodate the forks of a 30-mm endoscopic stapler and (2) be placed in a staggered fashion with the enterotomy on the distal segment placed approximately 1 cm downstream from the proximal one. This strategy makes it easy to push the larger fork of the stapler (cartridge portion) into the first enterotomy and then the anvil portion of the stapler into the second entero-

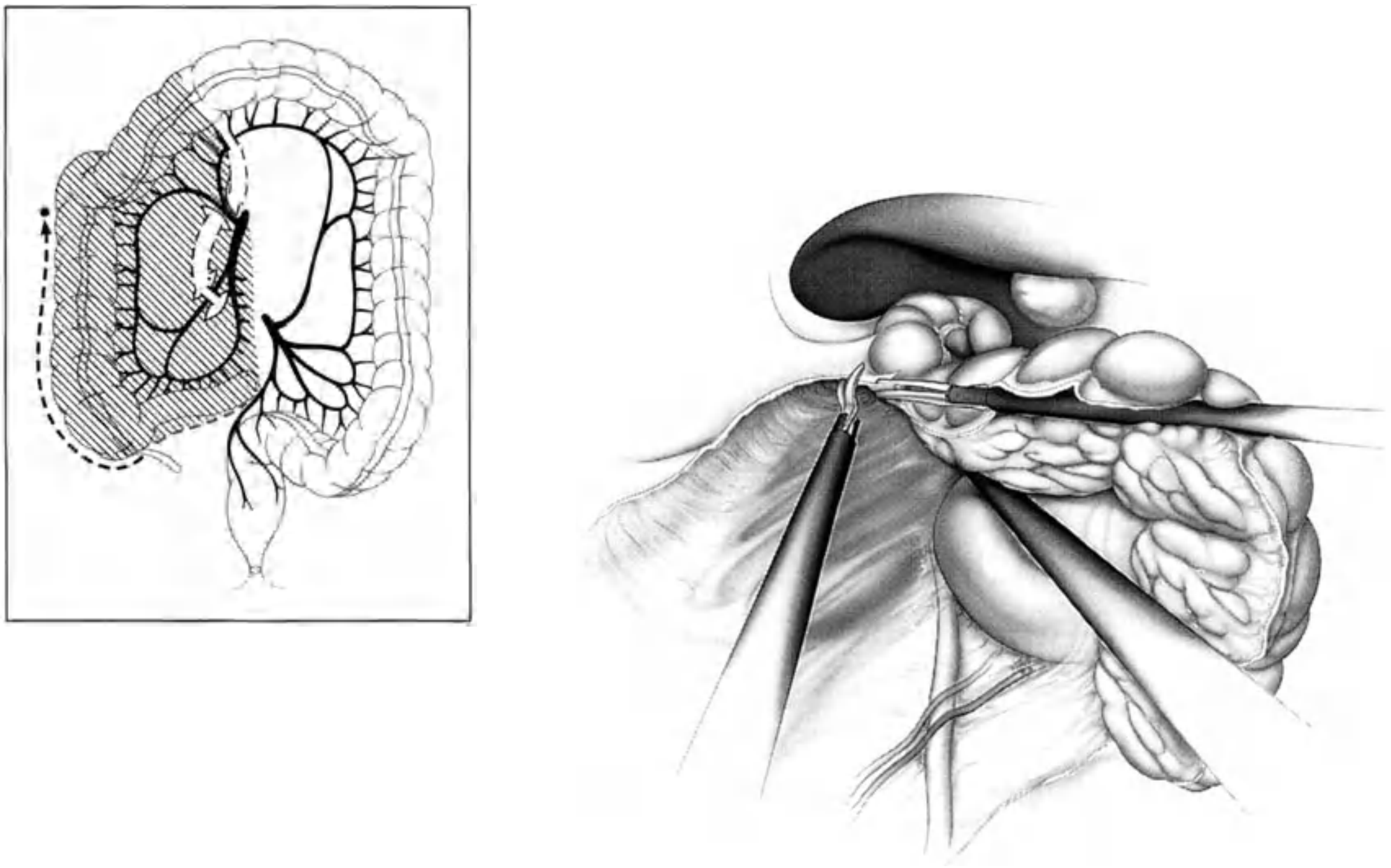

FIGURE 9.34. Completing the mobilization of the right colon and the hepatic flexure after retroperitoneal mobilization and mesenteric division.

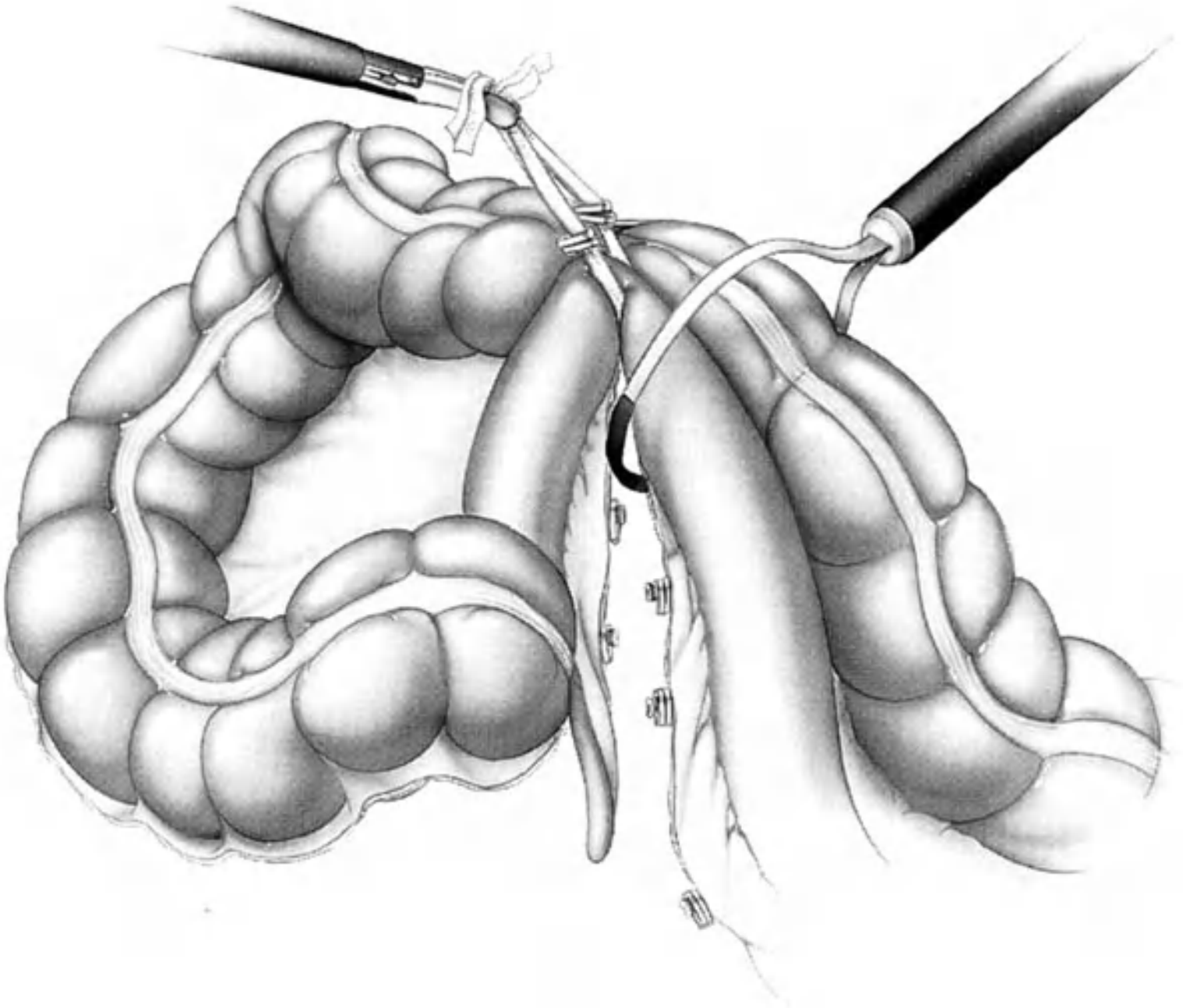

FIGURE 9.35. Umbilical tapes that mark the proximal and distal resection lines are held together, and an endoscopic snare is placed to encircle and steady the specimen.

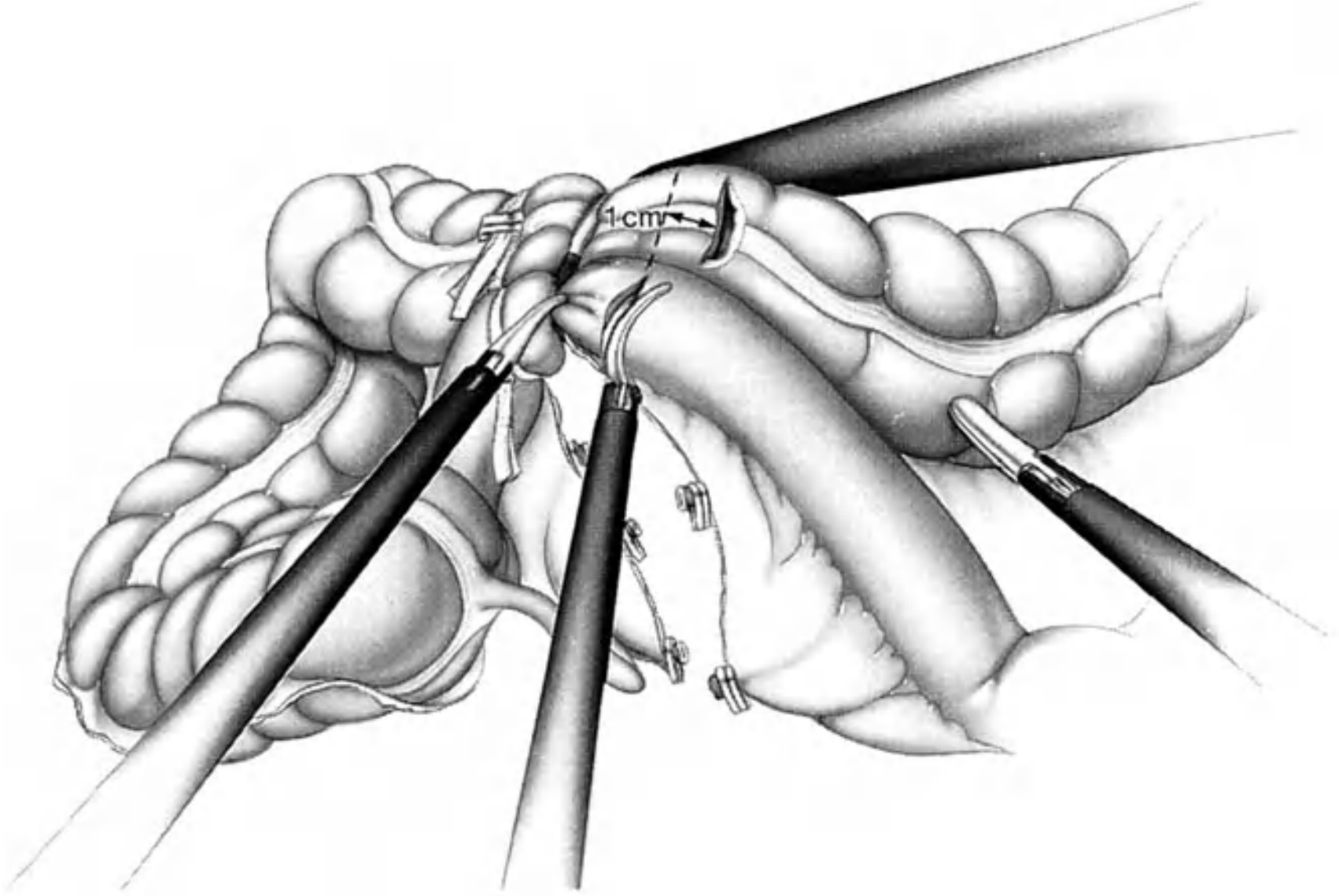

FIGURE 9.36. Two staggered enterotomies are made on the antimesenteric side of the ileum and the transverse colon just below the snare. The colotomy should be about 1 cm downstream from the enterotomy.

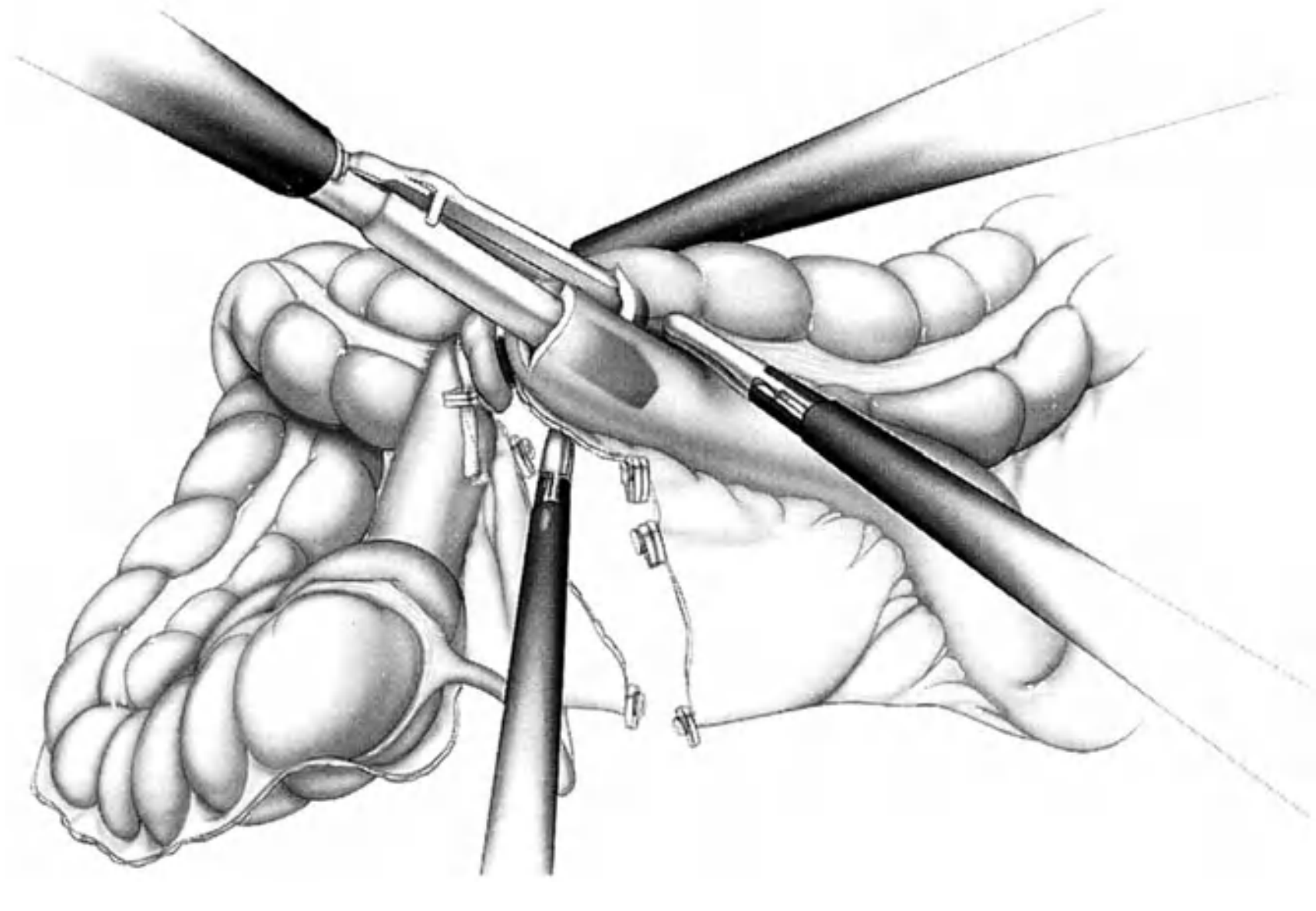

FIGURE 9.37. The anastomosis is begun by passing the 30-mm stapler, cartridge first, into the ileal enterotomy, and then by maneuvering the anvil into the second enterotomy.

tomy (Figure 9.37). The intestine is optimally positioned for the anastomosis by pulling the snare toward the right-upper-quadrant 15-mm cannula and simultaneously putting countertraction on the afferent and efferent loops of the intestine.

After the 30-mm endoscopic stapler has been inserted into the enterotomies and closed, the stapler is fired only after it has been ascertained that the mesenteric blood supply to the bowel segments is clear of the stapler jaws. This clearance is achieved by directing the tips of the stapler anteriorly, thus moving the mesentery posteriorly out of the stapler jaws. The stapler is fired, opened, and then carefully removed by applying countertraction on the intestine. A second set of staples is placed intraluminally using a 60-mm stapler, again being careful to avoid the mesenteric blood supply (Figure 9.38). The first application with the 30-mm stapler begins the intestinal anastomosis and apposes the bowel ends, and the second 60-mm stapler application maximizes and defines a satisfactory anastomotic size.

The anastomosis is completed and closed by sequentially firing two 60-mm staplers (or a 60- and a 30-mm stapler) at right angles across the two anastomosed loops just below the enterotomies (Figure 9.39). The number/size of the staplers needed will depend on the size of the intestine. Care must be taken to avoid firing the staplers across any metal clip previously applied in the mesentery close to the resection line because this could result in staple malformation and thus anastomotic leakage. After the specimen has been completely transected, it is still firmly held with the endoscopic loop. It is then placed in an endoscopic bag inserted through the 15-mm cannula in the right upper quadrant (the bag is placed and then is opened just below the liver). Once the specimen is safely in the bag, the drawstring is tightened and is pulled inside the cannula. The cannula site is enlarged as needed using a midline fascial incision. Pneumoperitoneum is released, the CO_2 insufflator is shut off temporarily, and the specimen is withdrawn from the bag after the cannula and the top of the bag have been exteriorized (Figure 9.40). This method ensures that the specimen is removed without contaminating any part of the abdominal wall. After specimen removal, the patient is temporarily tilted in the head-up position and the abdomen is copiously irrigated with warm sterile saline solution from the enlarged right-upper-quadrant cannula site. A conventional sump-suction cannula is placed in the pelvis through the specimen removal site to remove the fluid. After the surgical resection site has been assessed for hemostasis, the abdominal wall is closed with a series of figure-of-eight, size 0 or size 1 absorbable sutures; the layers may be closed either independently or en masse.

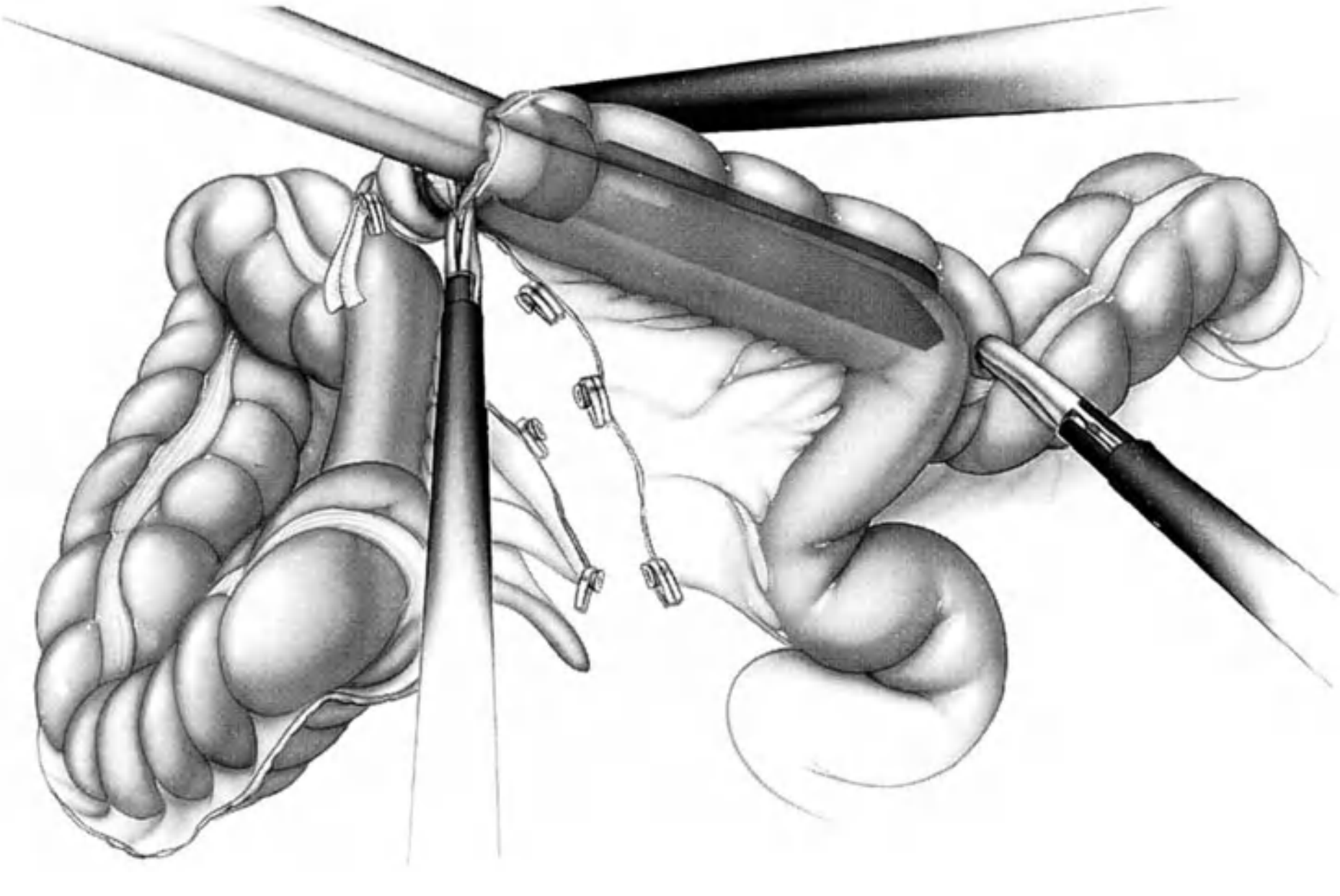

FIGURE 9.38. The endoscopic 60-mm stapler is next inserted maximally, and before closing, some anterior traction is placed on the instrument. The anterior traction places the mesentery posteriorly so none is included in the stapler jaws.

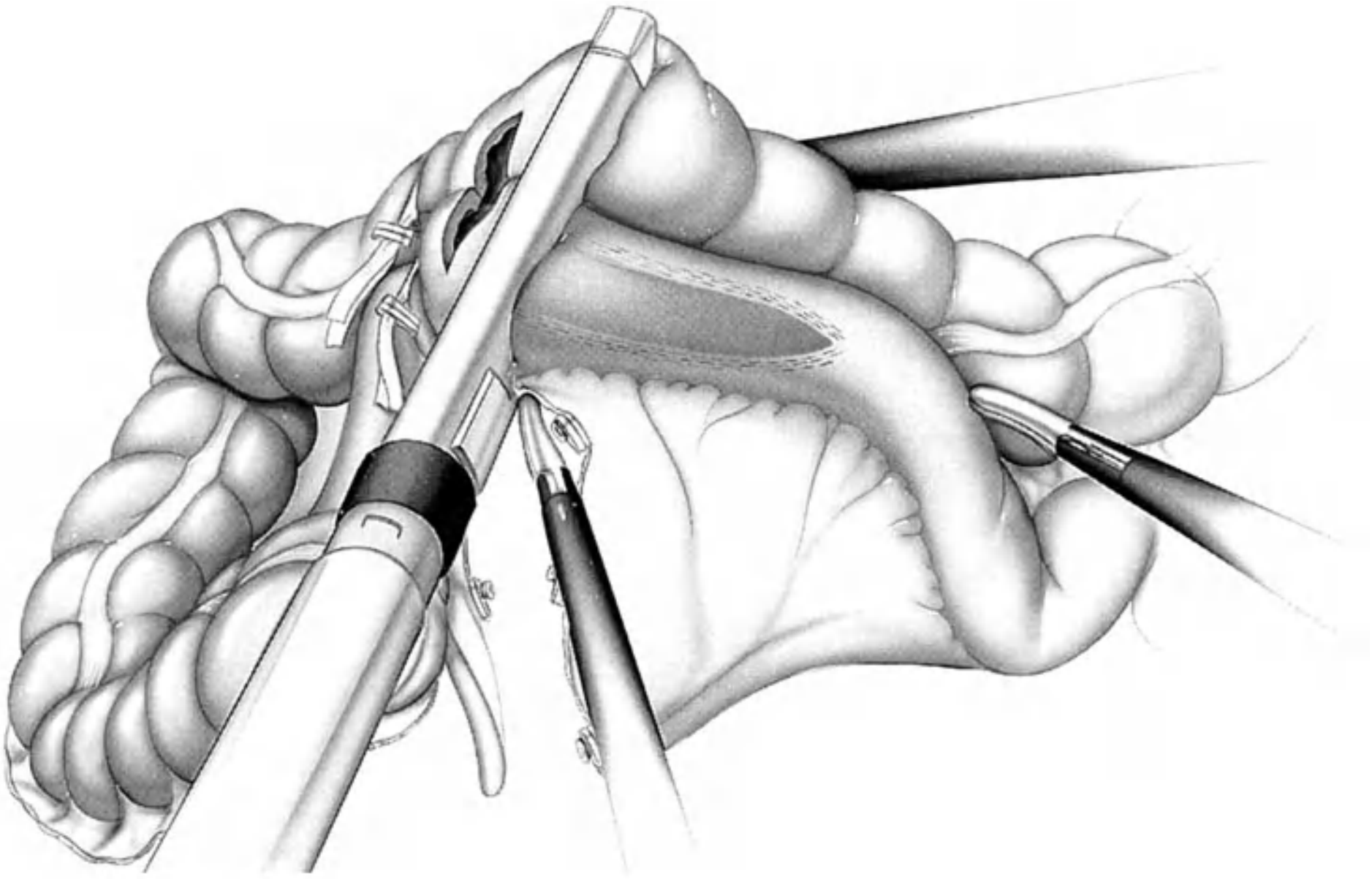

FIGURE 9.39. One or two endoscopic 60-mm stapler cartridges are fired across the intestine below the enterotomies to transect the specimen and to seal the anastomosis.

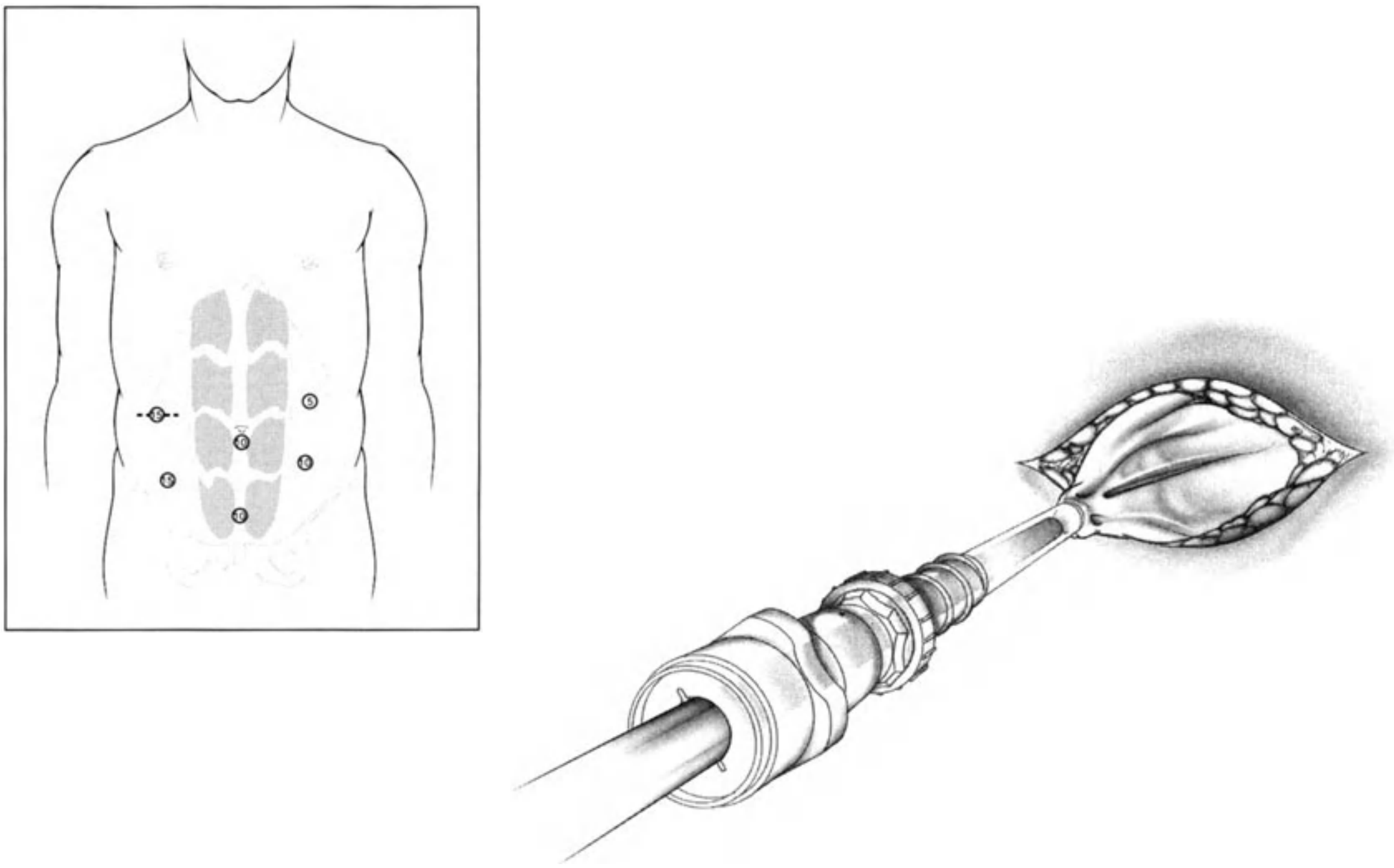

FIGURE 9.40. The specimen is withdrawn from the peritoneal cavity, through an enlarged cannula site, after placement into an impermeable bag.

Pneumoperitoneum is reestablished and the anastomosis is inspected. The mesenteric defect may be closed using a running 3-0 braided absorbable suture or an endoscopic hernia stapler passed through a left-upper-quadrant or left-lower-quadrant cannula.

Special Considerations

Our approach to mesenteric mobilization—creating a retroperitoneal tunnel—offers several advantages in both cancer and benign surgery. These advantages are described in a previous section, Ileocolectomy, Special Considerations.

Much more than in conventional surgery, the surgeon performing laparoscopic intestinal surgery must understand the subtle variations of the colonic vasculature when performing a right colectomy. If one reserves the term *colic artery* only for important vessels immediately arising from the superior or inferior mesenteric artery that supply the large intestine, then on the right side of the colon, only the ileocolic artery never varies between individuals. It is never absent or double, and represents the transitional vessel between the small and the large intestine.[7]

The right colic artery is far more exceptional, present in only 13% of cases when defined as a direct branch from the superior mesenteric artery supplying the right or ascending colon. Most commonly, a superior colic branch from the ileocolic artery or an artery from the right angle of the colon (from the middle colic artery) have been considered as a right colic artery. Perhaps the normal vasculature to the ascending colon can most accurately be described as emanating from a paracolic arcade, fed by the ileocolic and middle colic arteries, reinforced in a minority (13%) of cases by a right colic artery (Figure 9.41).

The middle colic vasculature is also complex and inconstant. In only 46% of specimens in anatomic dissections has a single middle colic artery arising from the superior mesenteric artery been found.[7] This vessel generally divides approximately 2 cm from its origin into a branch for the hepatic flexure and one for the transverse colon (Figure 9.41). According to VanDamme and Bonte,[7] the second most common middle colic vasculature consists of one artery for the hepatic flexure with a separate vessel for the transverse colon (Figure 9.42). At least five different patterns of vessels may be seen in the middle colic system, with as many as three middle colic arteries possibly present. These factors partially explain why we readily use an endoscopic stapler in this area for vessel ligation once we have separated the transverse mesocolon from the attachments of the greater omentum and the lesser sac.

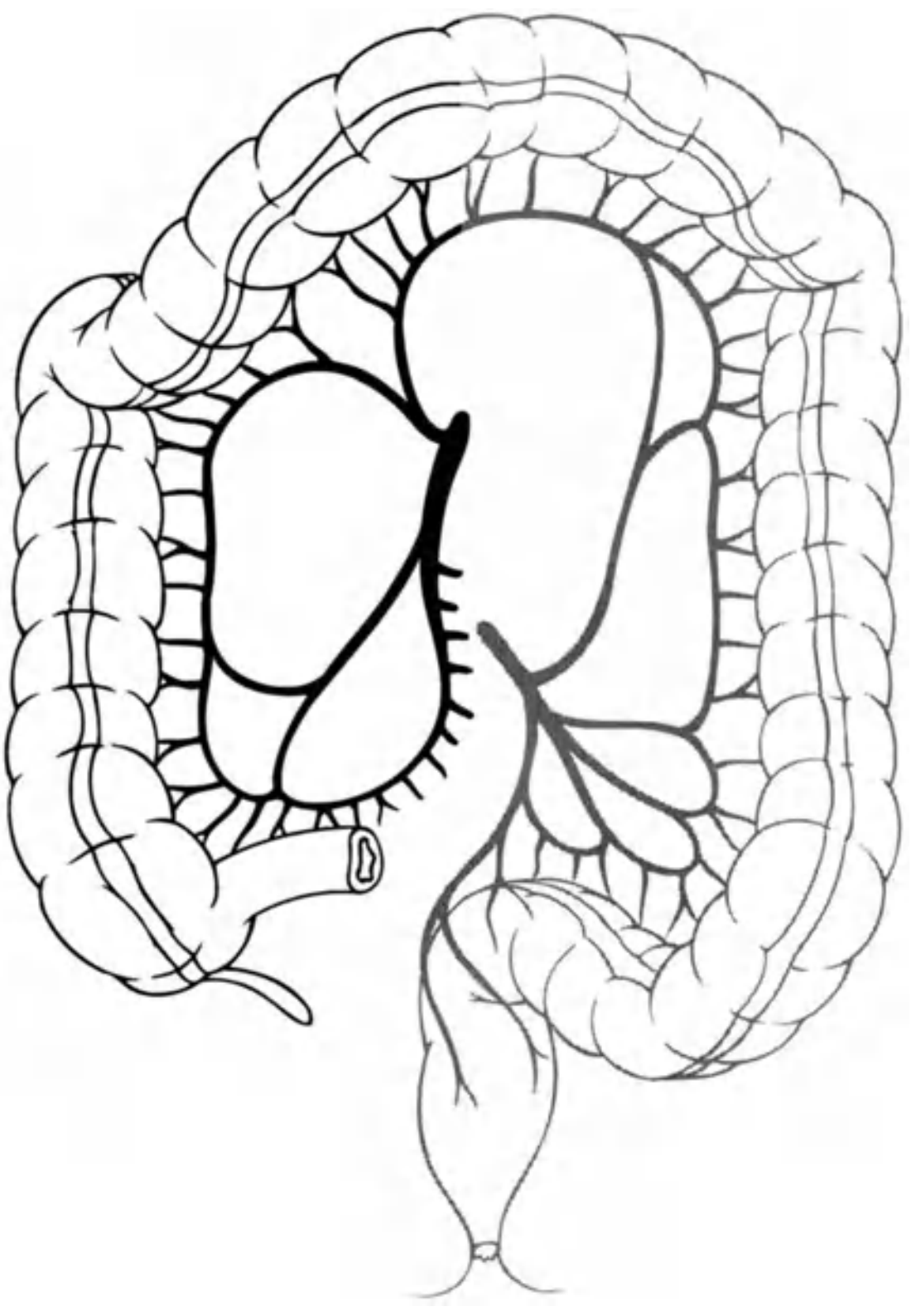

FIGURE 9.41. The most common pattern of blood supply to the right colon and the terminal ileum.

In instances of Crohn's disease (ileitis or ileocolitis), mesenteric division may be difficult because tissue is fragile, thickened, and inflamed. If hemostasis of the mesentery cannot be accomplished safely intraperitoneally, the procedure should be converted to a laparoscopic mobilization or a conventional procedure.

If only mobilization of the mesentery and the mesocolon from its lateral attachments and the retroperitoneum is carried out laparoscopically, 5-mm cannulas could be sufficient for this proce-

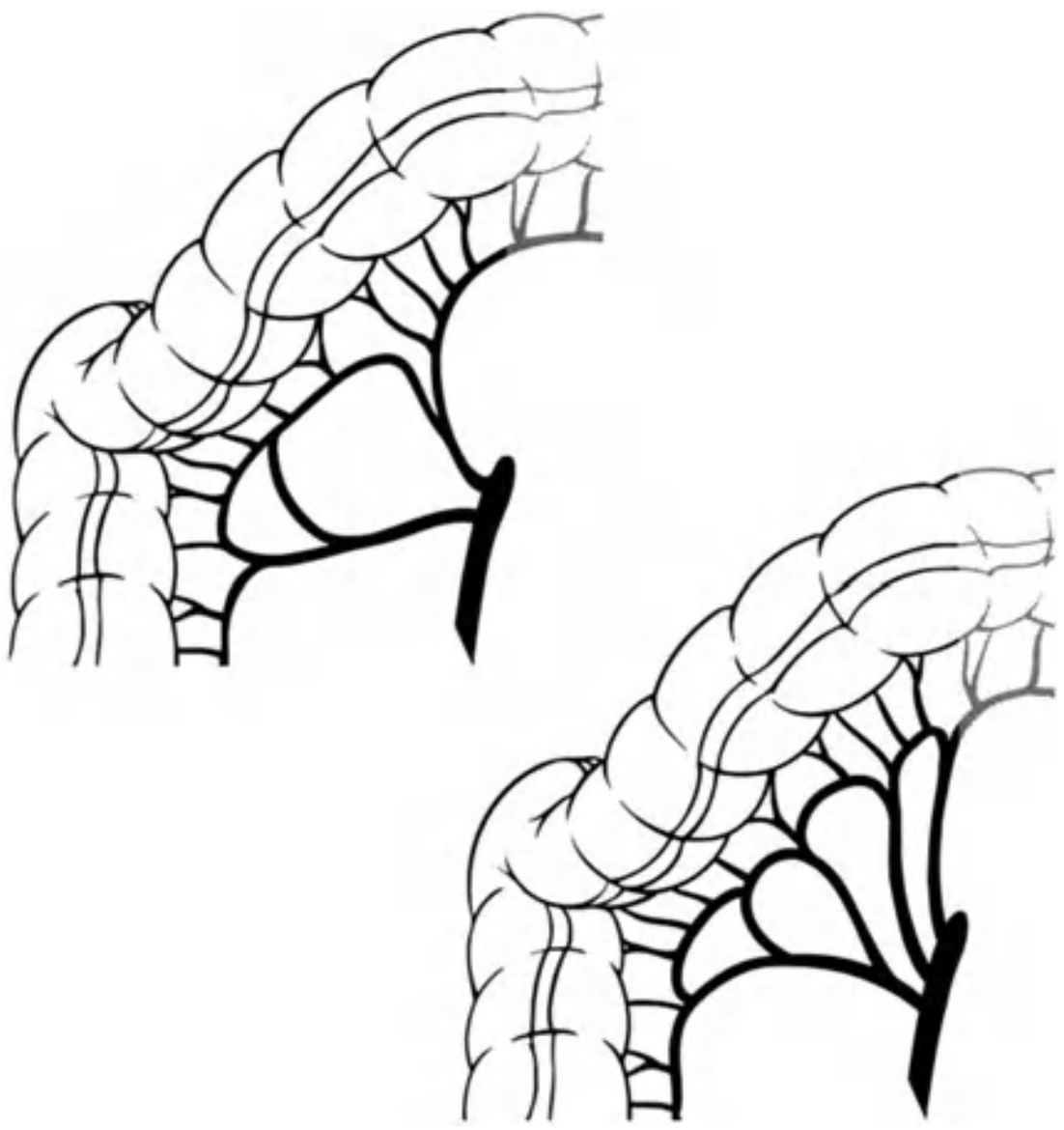

FIGURE 9.42. The second most common middle colic vasculature consists of one artery to the hepatic flexure and a separate vessel for the transverse colon (upper left figure). As many as three middle colic arteries may be present (lower right figure).

dure, along with the 10-mm cannula for the laparoscopic camera site. We prefer, however, to use at least one additional 10-mm cannula so in case of inadvertent bleeding, a clip applicator may be used. Once the terminal ileum and the right colon are mobilized, and the greater omentum is freed from the transverse colon, a cannula site can be enlarged, the mobilized intestine can be extraperitonealized, and the transection of the mesentery and the anastomosis can be performed extracorporeally. If a malignancy is being resected for curative purposes, a laparoscopic-assisted approach is probably not acceptable because the tumor-bearing tissue is being manipulated extensively and the risk of intraperitoneal tumor seeding is high if all of this is attempted through a small laparoscopic-assisted incision.

If the surgeon decides at the outset of the surgery that an extraperitoneal anastomosis will be performed, the procedure may be modified in the following way. After dissection of the mesentery, the intestine is divided proximally and distally with endoscopic staplers rather than first placing umbilical tapes and then dividing it. Using staplers will not only occlude the lumen but will also allow the lateral attachments of the right colon and the hepatic flexure to be more easily dissected from both the cecum and the transverse colon. When the colon is completely freed, it is immediately placed in an endoscopic bag. The specimen extraction cannula site is widened, the bag is removed through this incision, and the anastomosis is performed extracorporeally as the surgeon prefers. The mesenteric gap and the incision are closed, and pneumoperitoneum is reestablished for peritoneal cavity inspection.

If tumors are to be laparoscopically resected, the precise location of the tumor must always be known and identified before performing the resection. We prefer to mark the tumor with India ink in four quadrants during preoperative colonoscopy. Alternatively, intraoperative colonoscopy can be used but may lead to intestinal distension that will impair the view during laparoscopic surgery. If a barium enema has been performed preoperatively, then the results of it may also be helpful in tumor localization.

Cancer

Right colectomy for colon cancer should be carried out according to accepted oncologic principles[5,6,8]: en bloc resection of right colon with wide mesenteric clearance, near complete lymphadenectomy of the right colon vascular supply with proximal ligation of ileocolic, right colic, and middle colic vessels. If a cecal or proximal ascending cancer is resected, performing mesenteric transection with division of the ileocolic vessels and vessels for the hepatic flexure of the middle colic artery may be sufficient. We believe it is important to document all these steps on videotape.

Our presented technique differs from others,[9–13] who laparoscopically mobilize the right colon first and then ligate the vessels intracorporeally or extracorporeally. We believe our technique may have the following advantages:

- Manipulation of the tumor-bearing segment is minimal because the colon will be mobi-

lized only after complete mesenteric division. The free-floating mobilized colon is far less manageable in laparoscopic surgery than in conventional surgery, and this practice of leaving the colon in situ until after mesenteric division may lessen the risk of intraperitoneal dissemination of malignant cells.
- The named arteries of the right colon are clearly visible posteriorly at their origin from the superior mesenteric artery so an early and proximal ligation can be safely performed. This retromesenteric approach also serves to keep the small intestine out of the operative field, thus facilitating exposure.
- Wide mesenteric clearance is easily achieved because the arteries are proximally ligated and maintaining the lateral attachments helps to exert tension on the mesentery during dissection. As long as the right colon is fixed at the lateral wall, countertraction can be applied to the mesentery, which facilitates mesenteric dissection.
- Using umbilical tapes on both sides of the resected specimen not only allows the intestine to be easily manipulated, but it also occludes the intestinal lumen; such occlusion may minimize the possibility of contamination by intraluminal exfoliated malignant cells.
- Because an intraperitoneal anastomosis is achieved and the intestine is transected, the specimen can be immediately placed in a bag and can be safely delivered through a small laparotomy incision soon after right colon mobilization, with minimal risk of spilling intestinal contents or tumor cell dissemination into the peritoneal cavity or the abdominal wound.

The importance of these intraoperative maneuvers in cancer surgery and whether they decrease postoperative morbidity and cancer recurrence rates remains to be determined. No results of prospective randomized studies are available yet. We believe some of the aspects of our techniques are clinically important and we have developed them to maintain the principles of conventional oncologic intestinal surgery. The minimal intestinal manipulation during dissection, accompanied by the use of an impermeable bag, may also lessen the dissemination of malignant cells intraperitoneally; decreasing such dissemination may be especially important in preventing the cannula site implantation of malignant cells at the cannula sites, which has been reported with alarming frequency.[14]

We believe initial mobilization of the right colon makes performing truly proximal mesenteric vascular ligation more difficult because clear identification of the superior mesenteric artery and the origin of the right colonic arteries can be more difficult. Extracorporeal proximal ligation of the ileocolic and the middle colic arteries is a demanding maneuver because of the proximity of the origins of these vessels to the duodenum and the head of the pancreas. They can only be safely exposed in an average-size patient if a sizeable abdominal wall incision is created. Thus, a curative resection of a right colon cancer with an attempt at extraperitoneal proximal ligation of the mesenteric vessels seems really to be a laparoscopic colon mobilization followed by a laparotomy. This type of cancer operation also forces the surgeon to manipulate a cancer-bearing segment of intestine through the abdominal wall using a limited incision—a maneuver that could shed tumor cells into the peritoneal cavity or the wound. There are several case reports of early abdominal wall recurrence after laparoscopic colon cancer surgery.[14,15] These recurrences have not only been localized to the small laparotomy where the specimen was retrieved, but they are also at different cannula sites. In none of the instances was the use of a specimen bag described. Although somewhat of a different technical exercise, Mikulicz's operation was abandoned early in the 20th century because of an unacceptably high rate of wound implantation when the tumor was brought out through a limited lateral abdominal wall incision (a 12% incidence in one series).[16,17] For this reason, we believe in curative laparoscopic colorectal cancer surgery, the completely isolated specimen must be placed in an impermeable bag to minimize any risk of tumor seeding at the cannula sites or the specimen extraction wounds.

Another important element of laparoscopic colon cancer surgery is clinically staging the liver at surgery. We recommend an intraoperative ultrasound of the liver be performed at surgery. If laparoscopic ultrasound is not available, preoperative computed tomography with intravenous contrast dye should be carried out to stage the liver.

Proctosigmoidectomy

Position

The patient is placed supine in the modified lithotomy position using Dan Allen stirrups. Surgery is begun in the Trendelenburg position (20° head-down tilt), and after cannula inser-

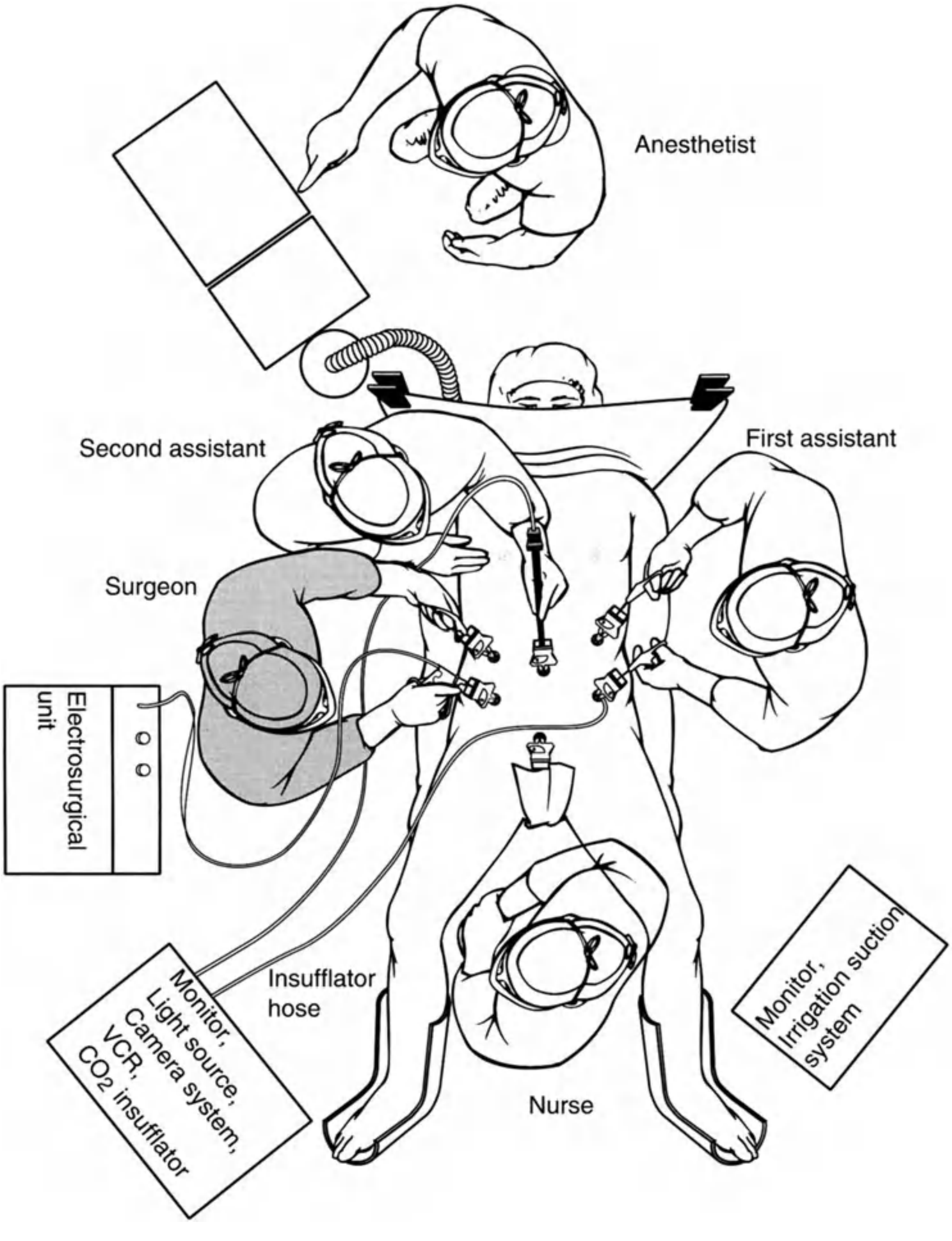

FIGURE 9.43. Position of the equipment and the surgical team for proctosigmoidectomy for the first and third phases of the procedure. (Modified with permission from Decanini C., Milsom J.W., Böhm B., Fazio V.W., Laparoscopic oncologic abdominoperineal resection. *Diseases of the Colon and Rectum.* 1994; Vol. 37, No. 6.)

tion, the patient is tilted right side down. For the first phase of the operation (dissection of the mesocolon and pelvic dissection), the surgeon and the second assistant (cameraperson) stand on the patient's right side looking at a monitor placed near the patient's left knee while the first assistant stands on the patient's left side to look at a monitor placed near the patient's right knee. The nurse stands between the patient's legs (Figure 9.43). In the second phase of the operation (mobilization of the splenic flexure), all surgical team members change positions. The monitor at the left knee is moved near the patient's left shoulder when the splenic flexure is being mobilized (Figure 9.44). The surgeon stands between the patient's legs and

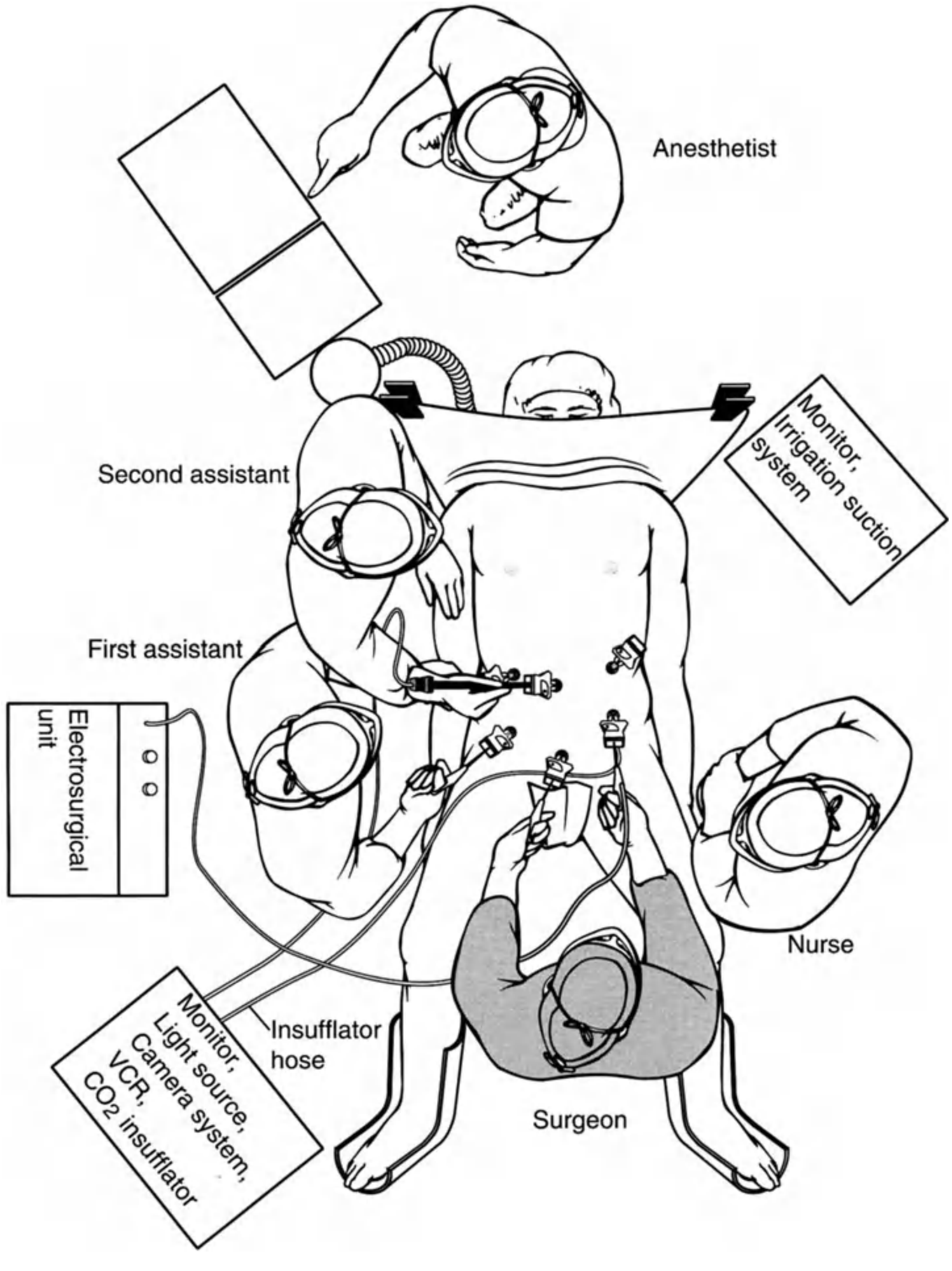

FIGURE 9.44. Position of the equipment and the surgical team for proctosigmoidectomy for the second phase of the procedure. (Modified with permission from Milsom J.W., Böhm B., Decanini C., Fazio V.W., Laparoscopic oncologic proctosigmoidectomy with low colorectal anastomosis. *Surgical Endoscopy.* 1994; Vol. 8.)

both assistants stand on the patient's right side. The nurse stands next to the left knee. At this point, the entire team looks at the monitor at the patient's left shoulder.

Instruments

Table 9.4 lists the number and the type of instruments required for laparoscopic proctosigmoidectomy.

Cannulas

After the initial 10-mm cannula has been placed infraumbilically, two cannulas are positioned in the right and two in the left lateral abdominal wall. For most procedures, because splenic flexure mobilization is necessary, a suprapubic cannula is also placed (Figure 9.45).

Procedure

Because the patient is placed in a steep Trendelenburg position, tilted right side down, the small intestine falls into the right upper quadrant. All small intestinal loops are retracted out of the pelvic area. The assistant holds the mesosigmoid ventrally and to the left under traction using a Babcock-like grasper through the left-upper-quadrant cannula and a smaller grasper through the left-lower-quadrant cannula. The retroperitoneum is incised immediately to the right of the inferior mesenteric artery starting at the sacral promontory (Figure 9.46). Under continuous traction, the peritoneum is incised cephalad toward the direction of the origin of the inferior mesenteric artery. Using blunt dissection, the inferior mesenteric artery and vein are swept ventrally, and the preaortic hypogastric neural plexus is swept dorsally to prevent injury to them. Dissection is continued medially beneath the inferior mesenteric artery and vein as the left ureter and the gonadal vessels are identified and swept posteriorly (Figure 9.47). If the ureter cannot be easily identified, the lateral attachments of the sigmoid colon are incised, and the sigmoid colon is mobilized in a left-to-right manner; the gonadal vessels and the ureter are identified and dissected free of the mesentery at the lateral aspect of the colon. Holding the sigmoid mesocolon under constant

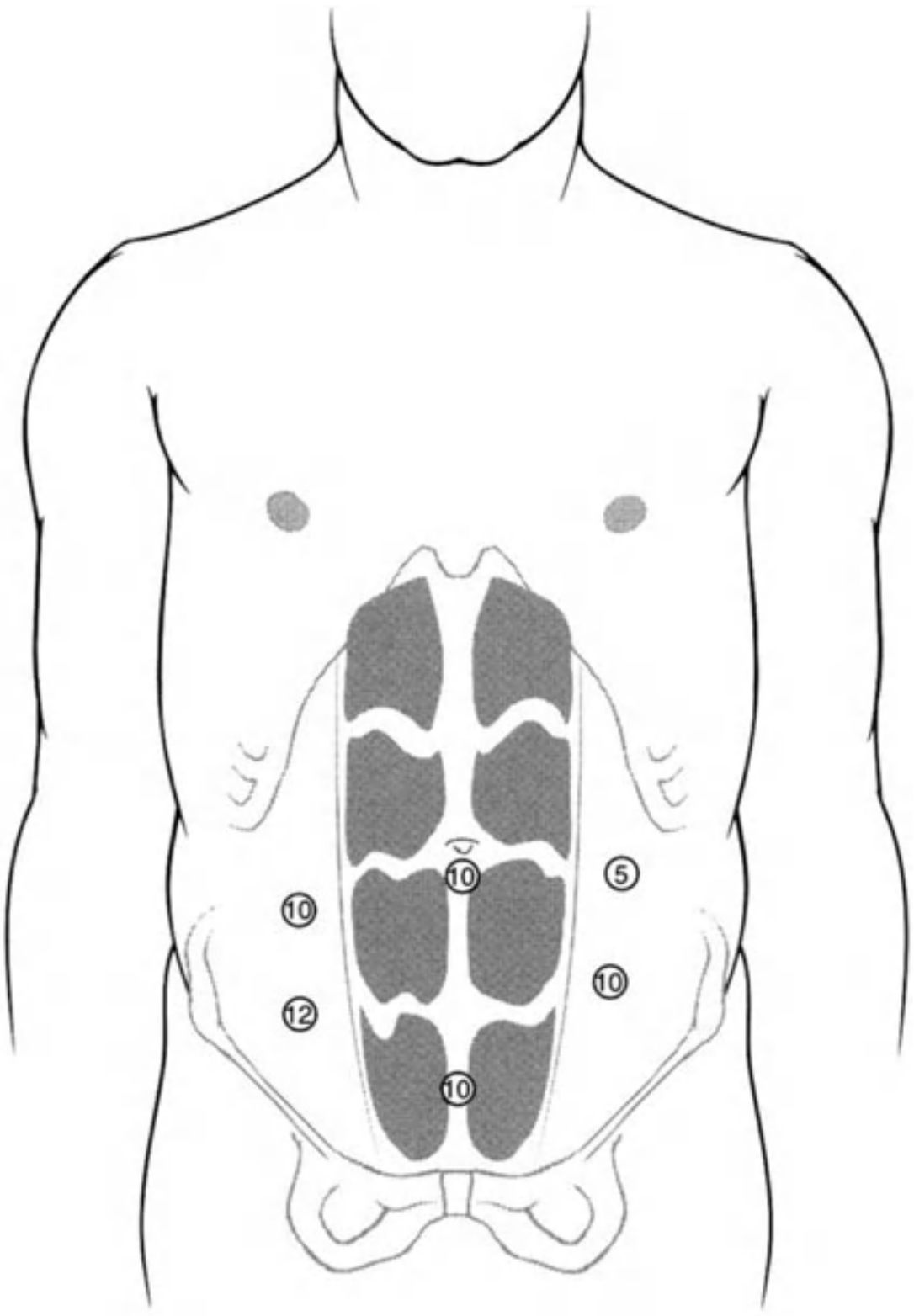

FIGURE 9.45. Position of the cannulas for proctosigmoidectomy.

TABLE 9.4. Instruments required for laparoscopic proctosigmoidectomy.

No.	Type
6	Cannulas (1 × 12 mm, 4 × 10 mm, 1 × 5 mm) including anchoring devices and converters
1	Dissecting device, for example, endoscopic scissors equipped with electrosurgery
1	Endoscopic dissector
2	Endoscopic graspers (one Babcock-like large and one small)
1	Endoscopic Babcock clamp*
1	Endoscopic clip applier (large size)*
1	Multifire endoscopic 30-mm stapler
5	Endoscopic stapler cartridges
1	Circular end-to-end anastomotic stapling device (28 or 31 mm)

* Not needed if only laparoscopic mobilization is performed.

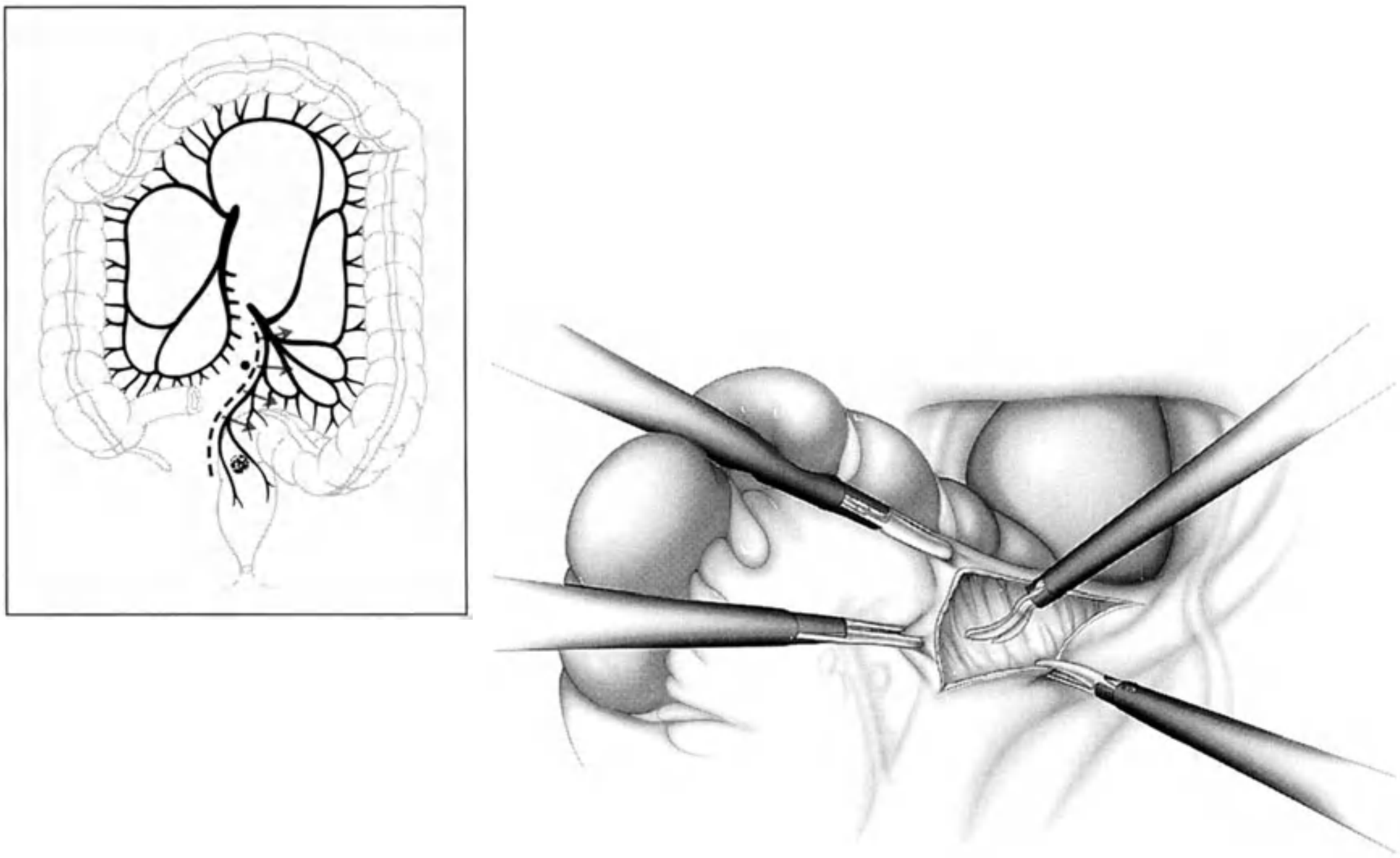

FIGURE 9.46. The dissection commences with an incision in the retroperitoneum just to the right of the inferior mesenteric artery.

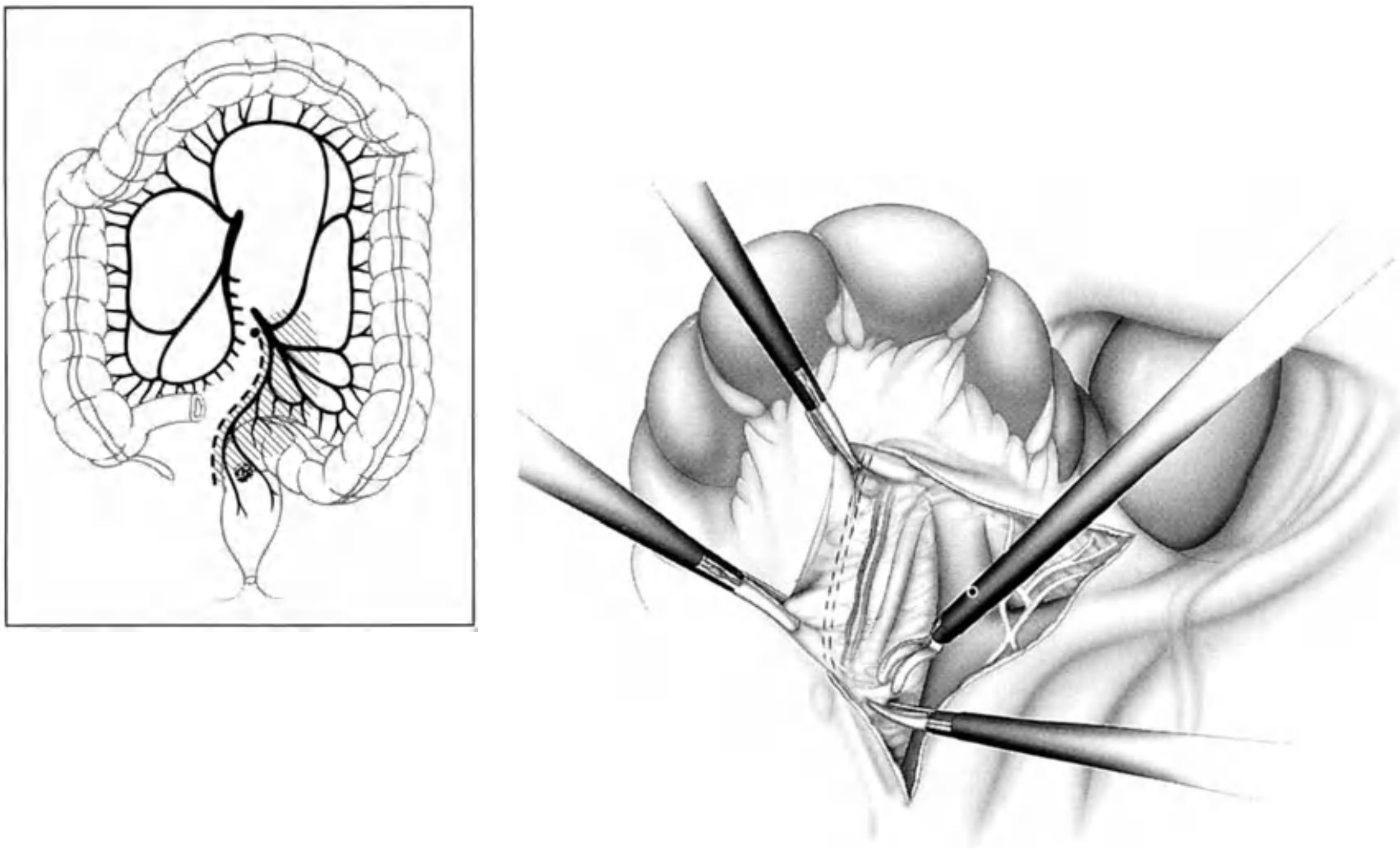

FIGURE 9.47. Dissection continues toward the origin of the inferior mesenteric artery with identification of the left ureter and the gonadal vessels.

tension is essential. Constant tension can be achieved if the assistant grasps the cut edge of the incised peritoneum together with the inferior mesenteric artery.

Once the origin of the inferior mesenteric artery is identified, the peritoneum is incised anteriorly over this pedicle and to the left toward the inferior mesenteric vein. Using careful blunt dissecting techniques, a peritoneal window is made just lateral to the inferior mesenteric vein. This pedicle of the inferior mesenteric artery and vein is ligated above or below the left colic artery (according to the surgeon's judgment) using an endoscopic vascular stapler, but only if the left ureter can be clearly identified and retracted to avoid injury (Figure 9.48). We prefer to leave the inferior mesenteric artery 1.0 to 1.5 cm long so if any bleeding occurs, an additional ligature can be applied to the vessel. After the stapler has been placed across the inferior mesenteric artery (and concurrently across the inferior mesenteric vein if this is feasible and safe), it is closed, and the ureter again is checked. The tip of the stapler should be free and clearly visible. Before the fired stapler is opened, both ends of the pedicle are grasped so any bleeding can be easily controlled. If the inferior mesenteric vein is not simultaneously ligated with the stapler, it is clipped or stapled separately.

The lateral attachments of the sigmoid colon are dissected free (if this has not been done already), and the sigmoid colon is completely mobilized using sharp and blunt dissection as in open surgery (Figure 9.49). Again, great care should be taken to identify and to avoid any injury to the gonadal vessels or the ureter.

If the indication for surgery is a polyp or small cancer, the lesion should have been positively identified endoscopically before surgery and the tumor marked by injecting India ink into the wall of the colon just below the tumor. Alternatively, intraoperative visualization through the sigmoidoscope, laparoscopic identification, and marking the distal resection line with clips is a simple and easy procedure that does not require dye injec-

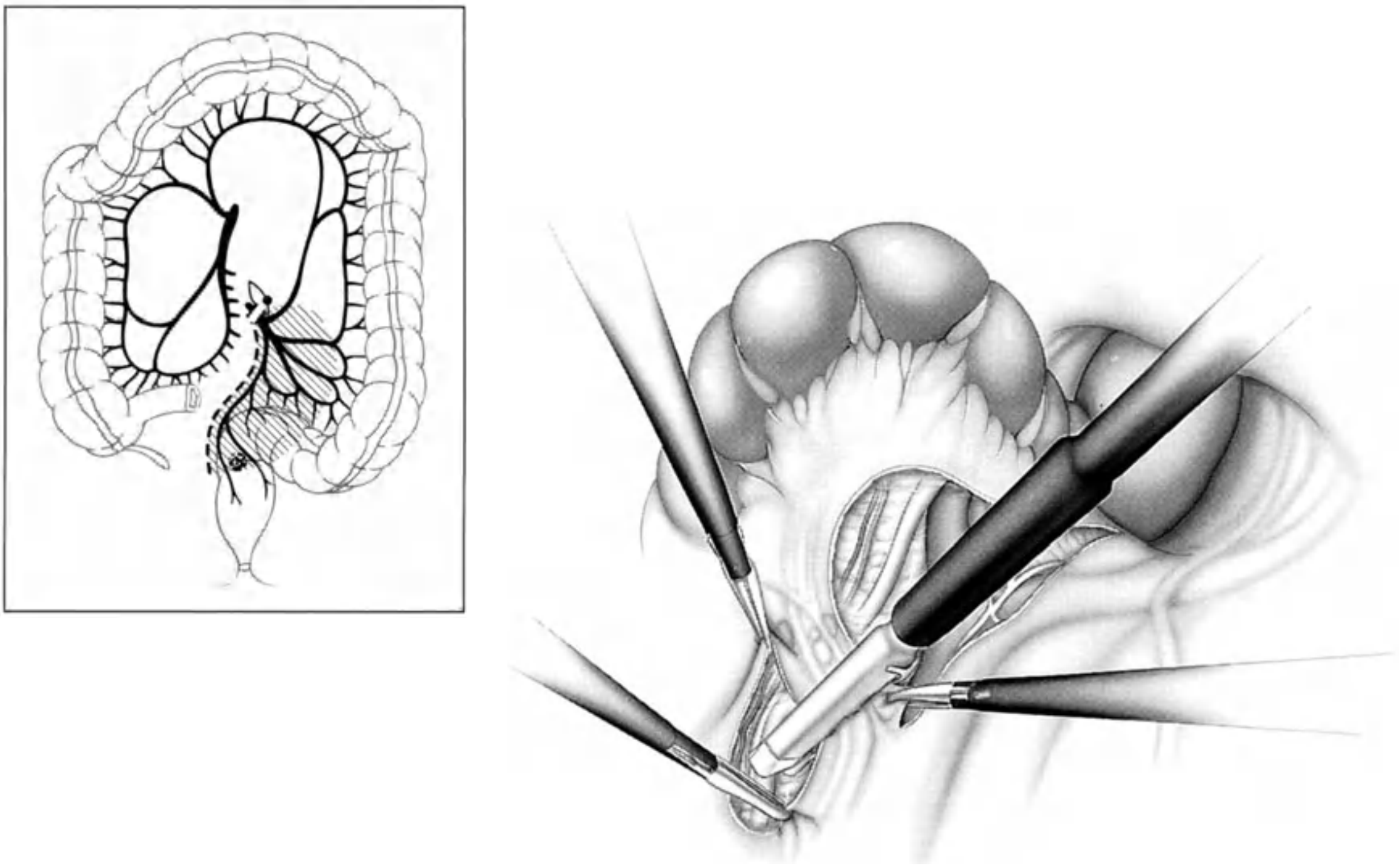

FIGURE 9.48. Ligation and division of the inferior mesenteric artery close to its origin using a 30-mm linear stapler. The ureter and the gonadal vessel have been swept clear from the vessels. The inferior mesenteric vein may often be ligated simultaneously.

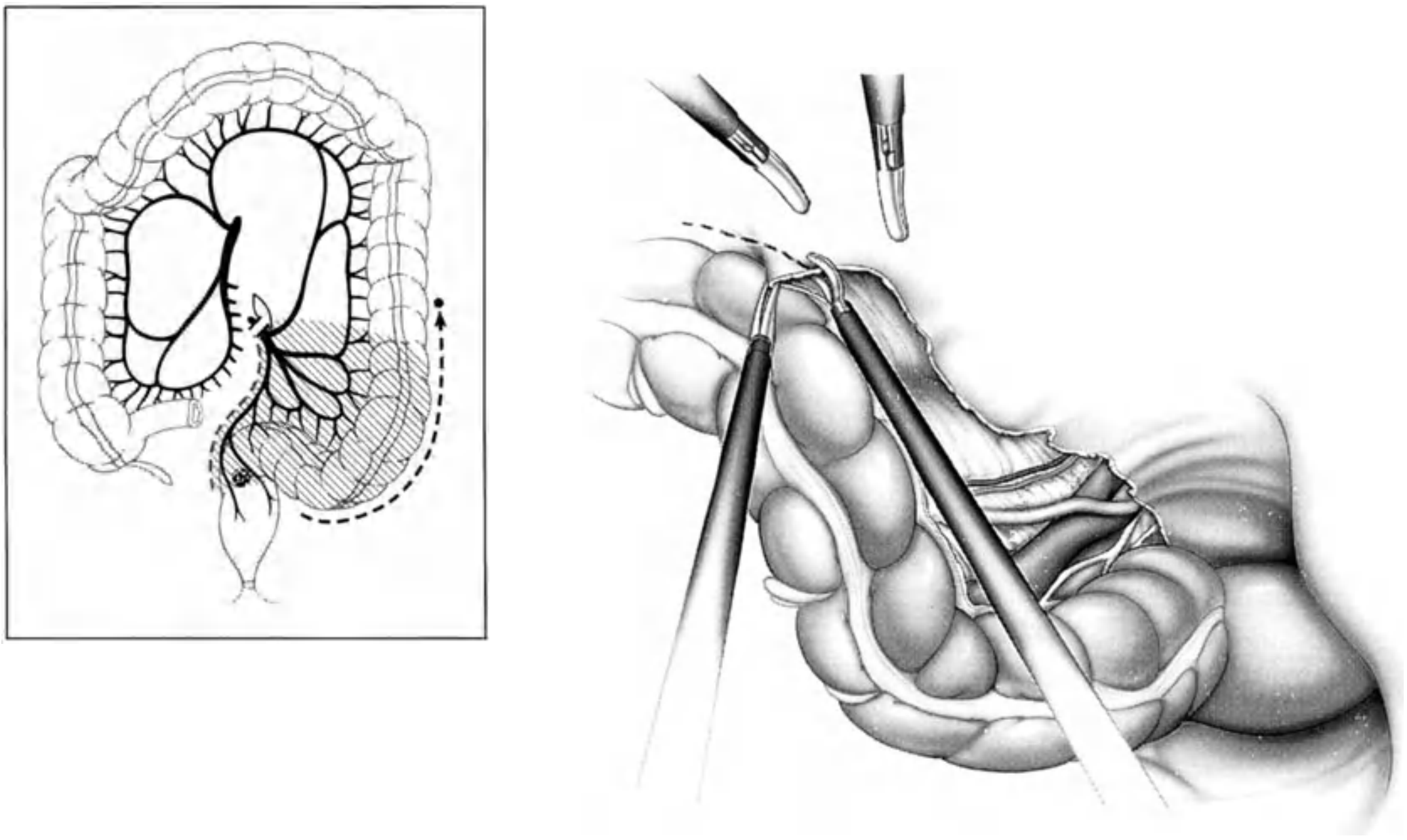

FIGURE 9.49. Initial dissection of the lateral attachments of the sigmoid and left colon.

tion. The disadvantages of intraoperative tumor identification are the extra time required and the need for some gas insufflation of the intestine, which may somewhat impair visualization.

The mesosigmoid of the proximal resection line (i.e., to the left of the inferior mesenteric pedicle) is held using triangulating tension as described in chapter 4 (section titled Tissue Dissection in Laparoscopic Colorectal Surgery) and transected using a combination of blunt dissection, coagulation of small vessels, and clipping of large vessels (Figure 9.50). Using constant tension on the tissue, it is relatively easy to transect the mesocolon up to the colonic edge at the specified resection line. The colon is divided with one or two cartridges of 30-mm endoscopic staples (Figure 9.51). The first phase of the surgery is now complete.

For the second phase, mobilization of the splenic flexure, the surgical team repositions itself (Figure 9.44). The surgeon works from the suprapubic and left-lower-quadrant cannulas, with the first assistant using the two cannulas inserted in the right side of the abdominal wall. Through the right-upper-quadrant cannula, the first assistant passes an endoscopic loop instrument (this can be modified from a specimen extraction instrument known as EndoCatch I, US Surgical Corporation, Norwalk, Conn.). Using a grasper, the divided proximal bowel is pulled through the opened loop until body wall attachments prevent more proximal passage of the instrument (Figure 9.52). The loop is then gently but snugly closed around the colon. The intestine distal to the loop is flipped cephalad over the loop; posterior and lateral soft tissue attachments of the sigmoid left colon are exposed by applying medial, cephalad, and anterior traction on the colon using the loop. The grasper in the first assistant's right hand is used to better expose these attachments.

The surgeon continues dissecting in a cephalad manner, sweeping Gerota's fascia away from the posterior surface of the colonic mesentery. All medial mesenteric attachments should be divided as far cephalad as possible, in a line parallel to and just to the left of the inferior mesenteric vein. Occasionally, a left colon or a splenic flexure venous branch must be isolated and divided in this process (Figure 9.53).

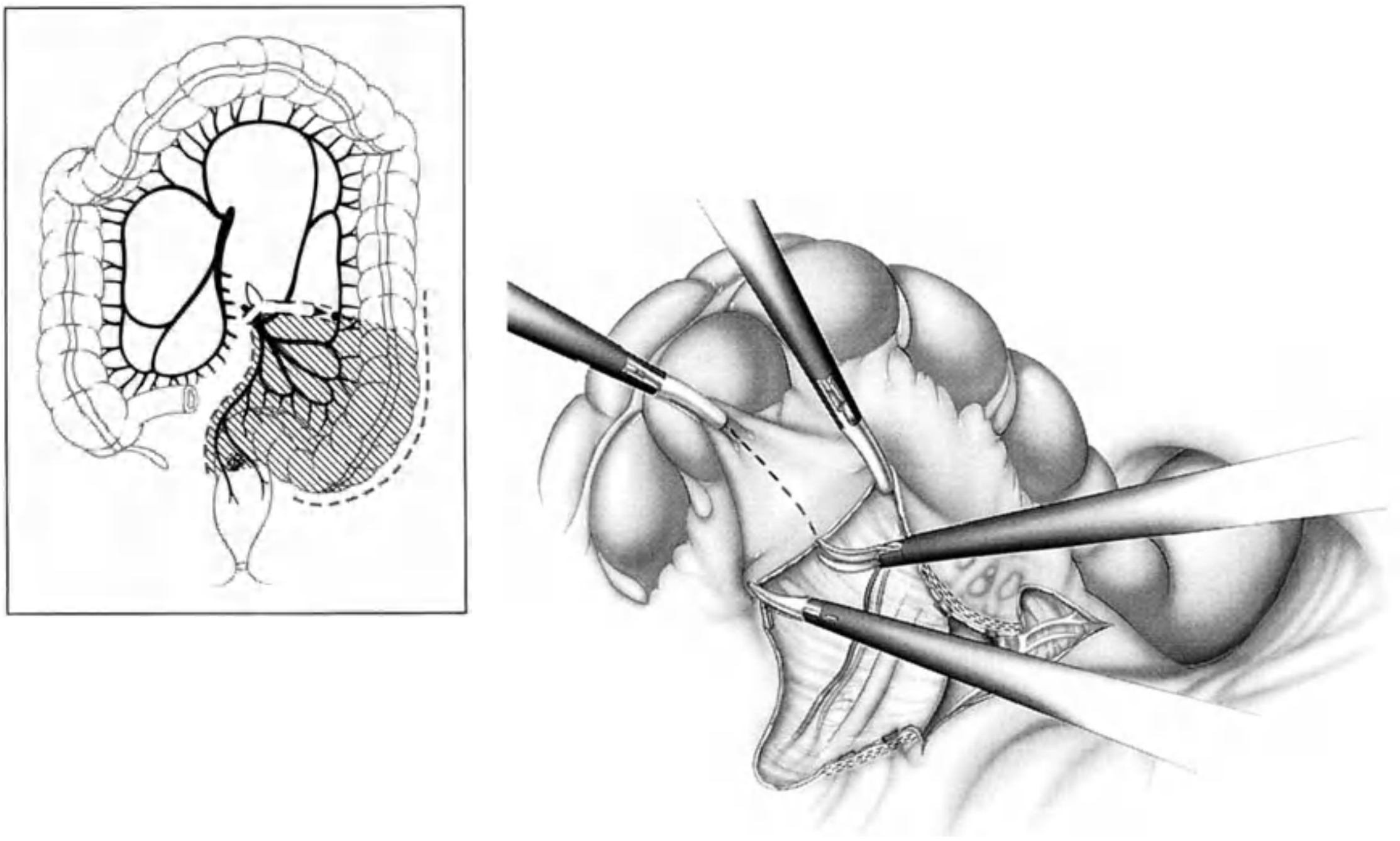

FIGURE 9.50. Transection of the mesentery of the descending sigmoid colon junction by applying triangulating tension. Vessels are clipped as they are encountered.

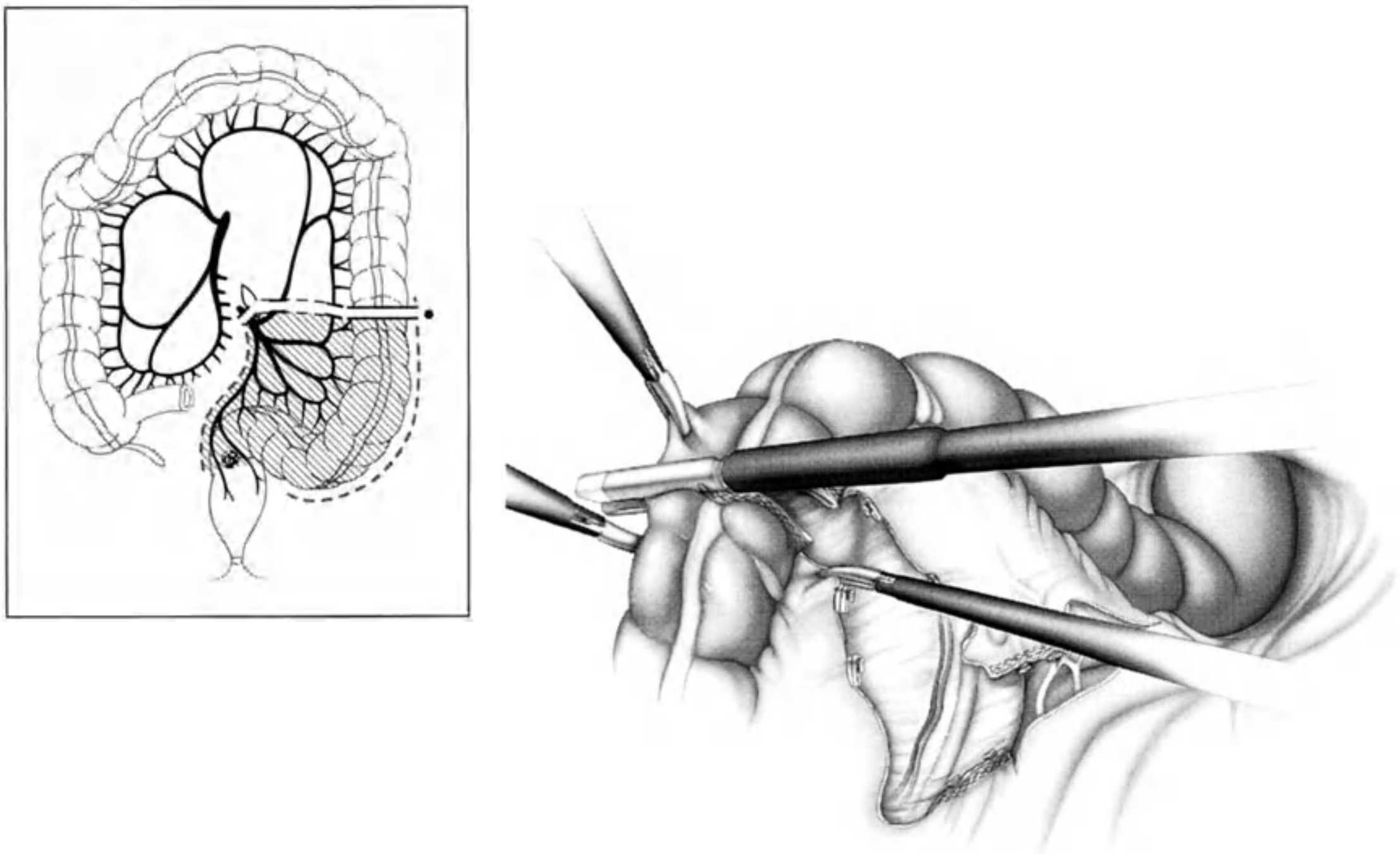

FIGURE 9.51. The proximal resection line of the colon is transected with one or two applications of the 30-mm endoscopic stapler.

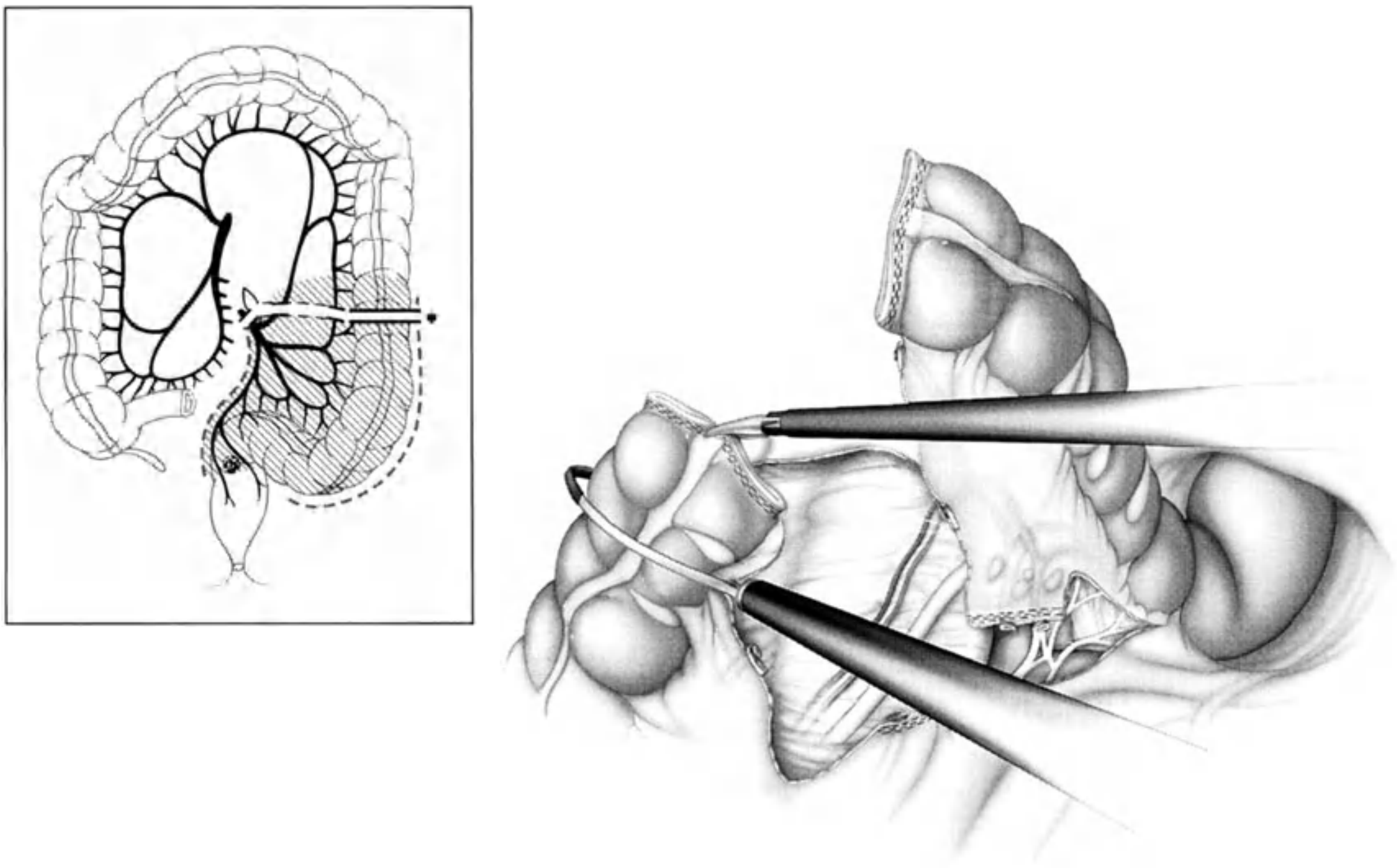

FIGURE 9.52. The splenic flexure is initially mobilized by gently pulling the proximal segment of the divided colon through an endoscopic snare.

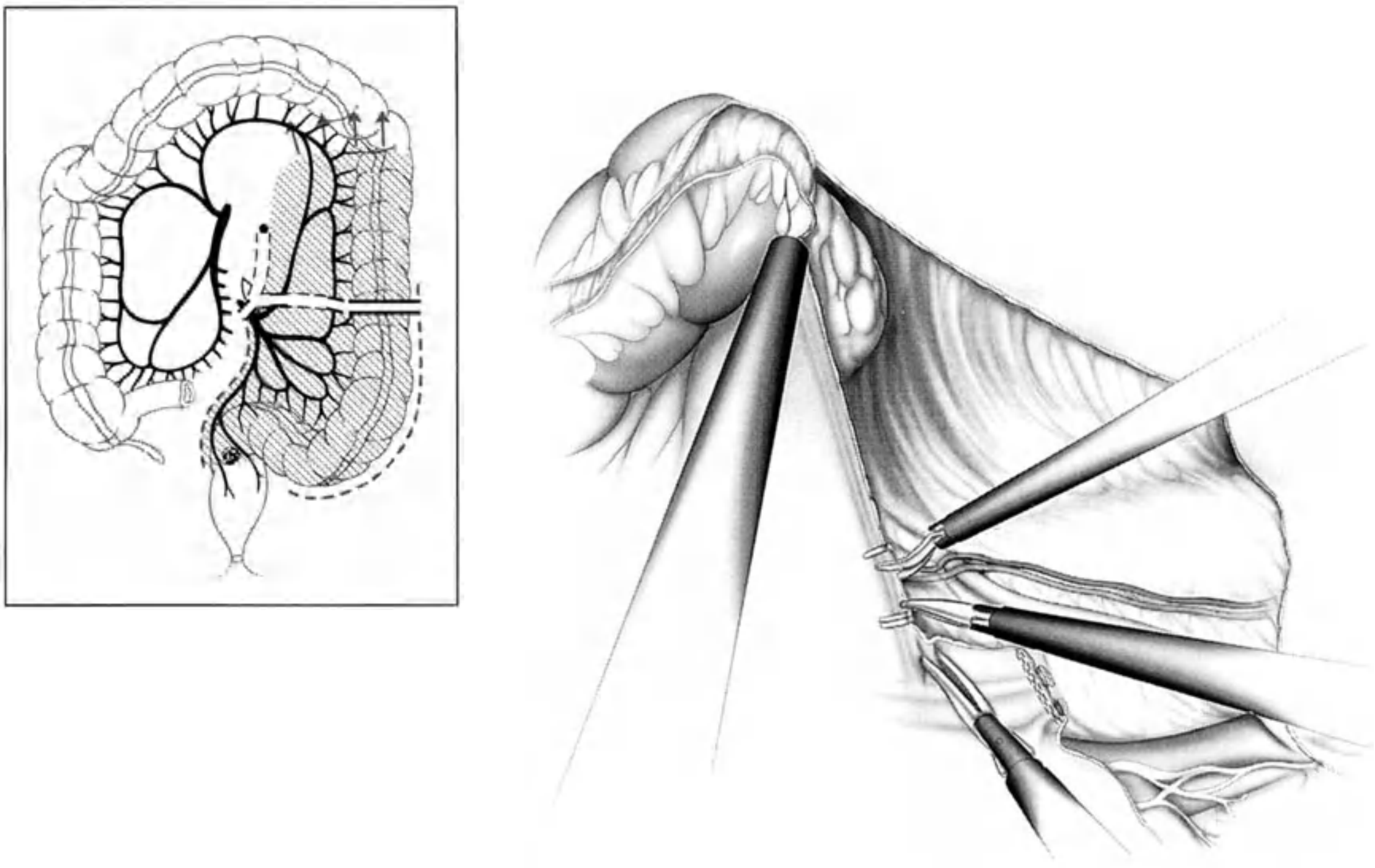

FIGURE 9.53. The medial attachments of the left colonic mesentery are isolated and are divided early in the dissection; any vessels encountered are carefully clipped.

After the posterior surface of the mesocolon cephalad has been dissected as far as possible, the lateral attachments of the colon are revealed and divided. Constantly, in the course of this dissection, the surgeon must remain in the proper planes—generally close to the bowel edge laterally and between Gerota's fascia and the colonic mesentery (Figure 9.54).

In the region of the splenic flexure, the greater omentum gradually appears and is distinguished from the epiploic appendices by its more finely lobulated fatty texture. Separation of the omentum from the colon and these appendices is essential for accurate mobilization of the flexure (Figure 9.55).

The surgeon will probably need to switch cannula positions once the splenic flexure itself is reached, moving from the suprapubic and the left-lower-quadrant cannulas to the two cannulas on the left side. In general, this change poses no special problems for the surgeon because the surgeon's hands, eyes, and the video monitor basically remain in line.

Once the flexure is dissected from the most cephalad attachments of the lienocolic ligament, the greater omentum is freed from the transverse colon edge toward the midline as far as the surgeon deems necessary to allow the descending colon to reach to the pelvis (Figure 9.56). When the most posterior attachments of the left or distal transverse colon mesentery have been dissected free from the retroperitoneum, the assistant, from the right-lower-quadrant cannula, should grasp the distal cut edge of the bowel with an endoscopic Babcock clamp and stretch it toward the pelvis to ensure that adequate mobilization has been obtained. Once this mobilization is accomplished, the endoscopic loop is opened and removed from the colon.

To accomplish the third phase of the procedure, that of specimen resection and colorectal anastomosis, the surgical team returns to the original positions (Figure 9.43). The rectum is completely mobilized as far distally as required by the tumor location and toward the pelvic

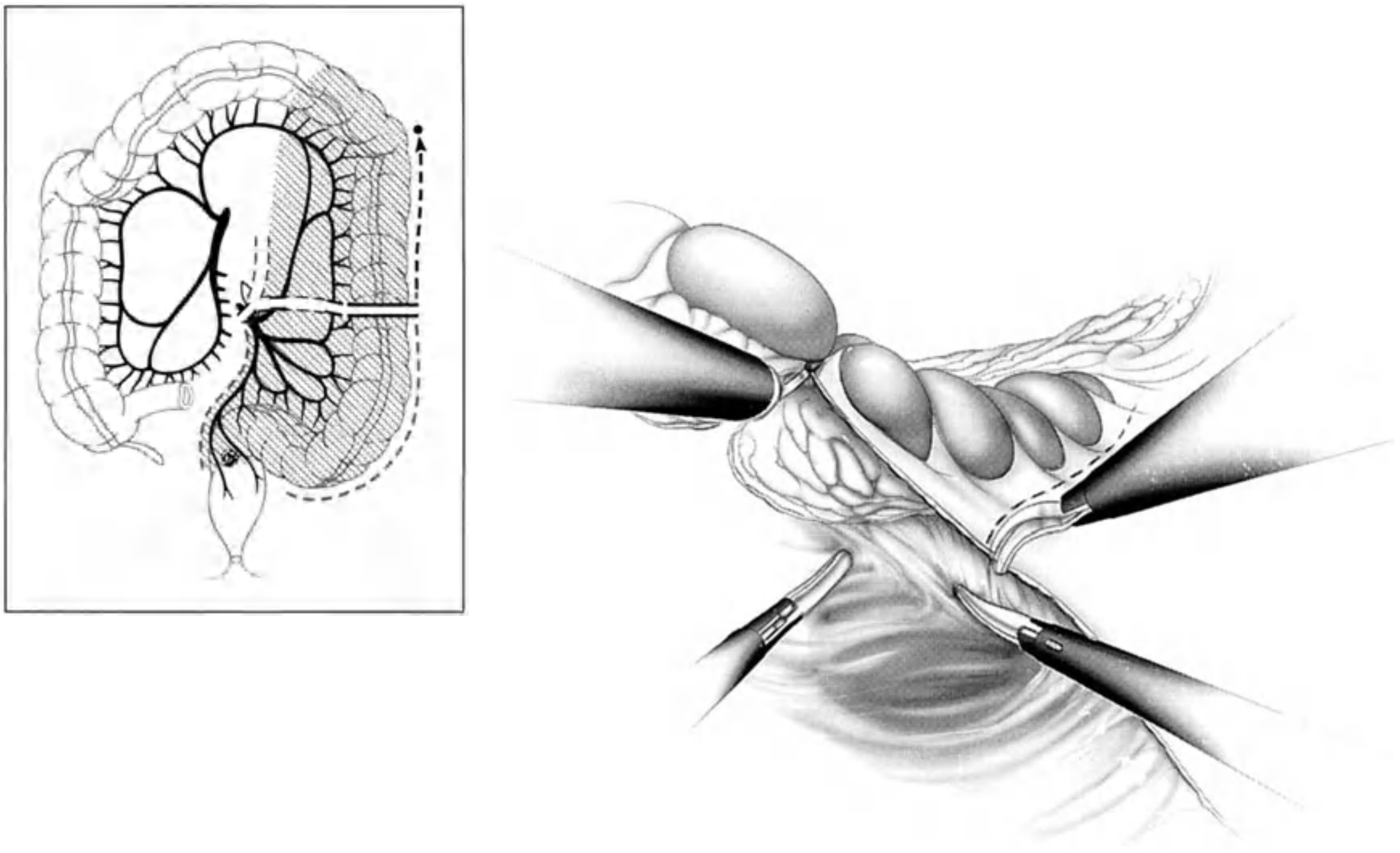

FIGURE 9.54. The splenic flexure should initially be dissected from its posterior and lateral aspect—this expedites complete mobilization of the flexure.

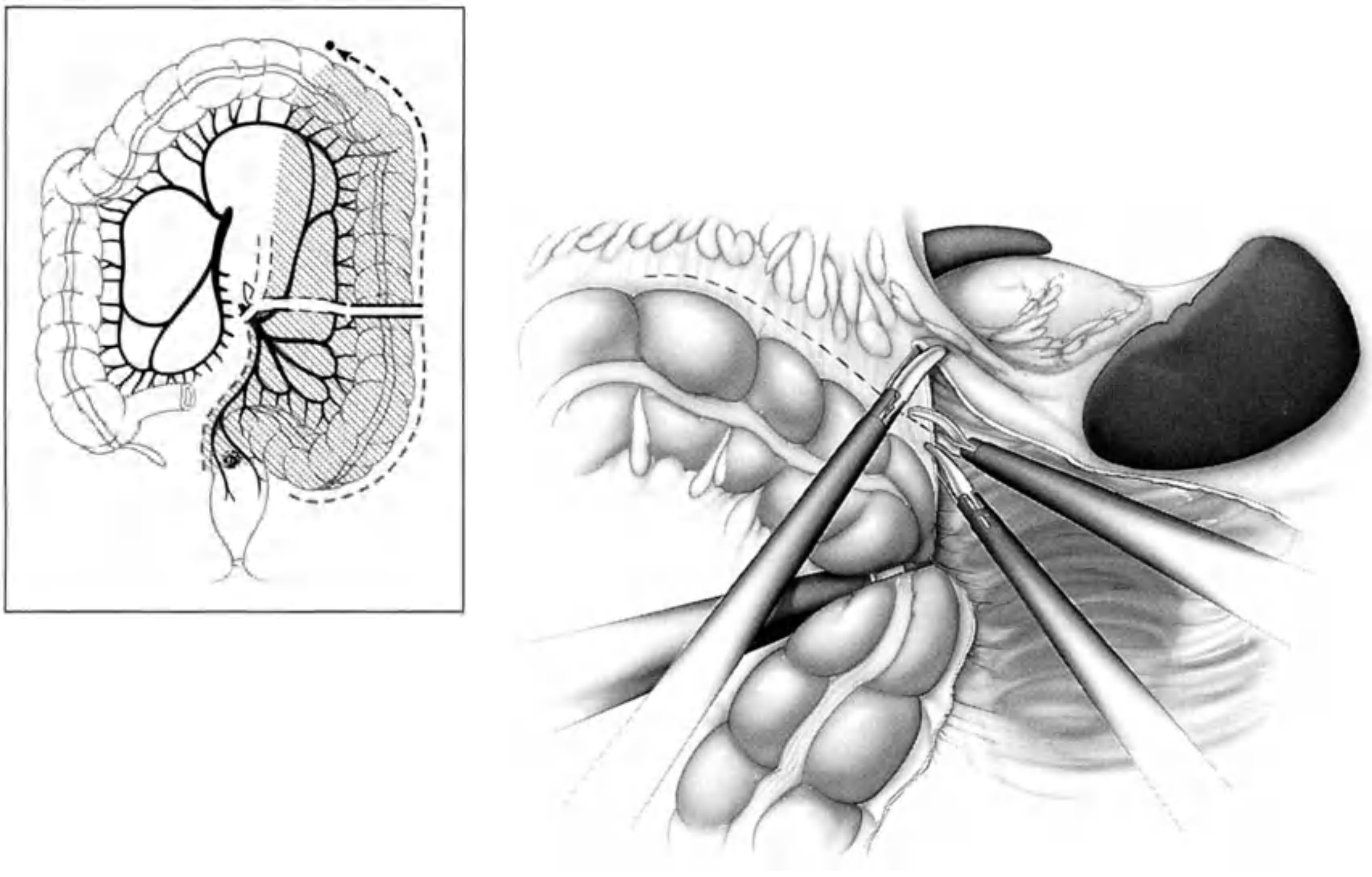

FIGURE 9.55. The greater omentum is separated from the splenic flexure by carefully applying traction and countertraction, which more clearly reveals the plane between the omentum and the colon.

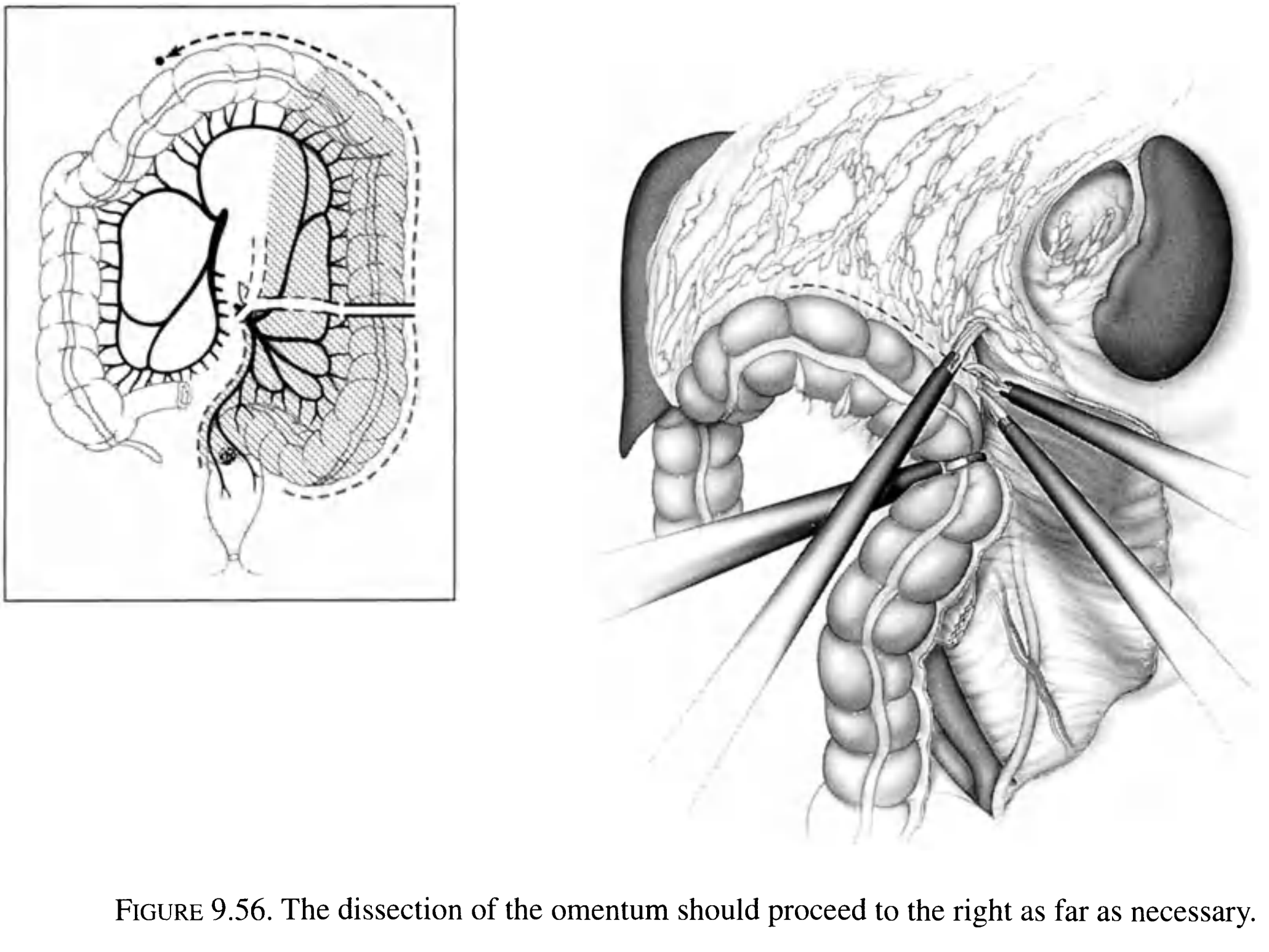

FIGURE 9.56. The dissection of the omentum should proceed to the right as far as necessary.

floor using standard open techniques, starting with posterior mobilization (Figure 9.57), and then dissecting posterolaterally to the right and to the left of the rectum. If the proper plane is entered posteriorly, no bleeding will occur, and the connective tissue between fascia propria of the rectum and presacral fascia can be separated easily. However, if bleeding does occur, large vessels of the lateral ligaments can be identified and coagulated. If they continue to bleed, the vessels should be clipped. In cancer cases, all soft tissue attachments of the rectum should be cut flush with the pelvic sidewalls. Finally, anterior dissection is undertaken to a level below the anterior peritoneal reflection as far as deemed necessary (Figure 9.58).

During the lower portion of the dissection in a woman, it may be valuable to place a rubber dilator or another rigid instrument intravaginally to elevate the vagina anteriorly to achieve the proper tissue tension and define planes through this important phase of dissection. A standard uterine manipulator used routinely in gynecologic laparoscopic surgery may also be of some benefit when extensive anterior dissection is necessary. Placed intravaginally, this instrument will allow a perineal surgeon to manipulate the uterus anteriorly out of the field of dissection. Exposure and dissection down to the pelvic floor may also be expedited in patients of both sexes if an assistant uses a fist to exert perineal pressure in a cephalad direction. Such pressure elevates the pelvic floor.

The distal resection line should be precisely identified using intraluminal inspection with a proctoscope and subsequently marked laparoscopically with clips or coagulation. The distal mesorectum is first divided transversely starting on the right side at the proposed level of transection; clips are applied to any large vessels. If the mesorectum is difficult to dissect or if several large vessels must be divided, it may be most expeditious to divide the mesorectum using a 30-mm vascular endoscopic stapler after creating a plane between the posterior wall of the rectum and the anterior portion of the mesorectum (Figure 9.59). Once the distal resection line has been freed of the mesorectum,

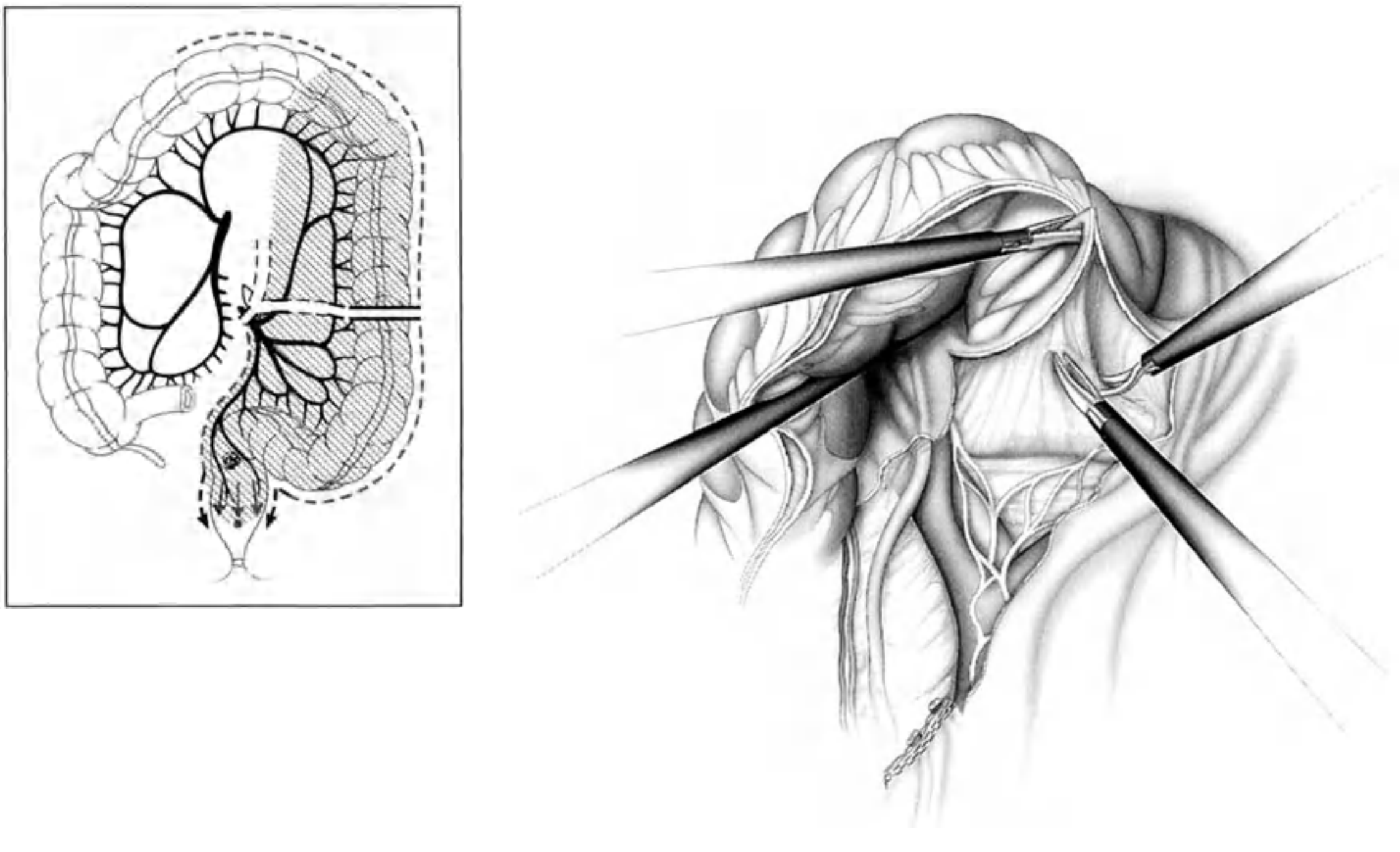

FIGURE 9.57. After dissection of the omentum, the rectum is initially mobilized posteriorly, as in conventional surgery.

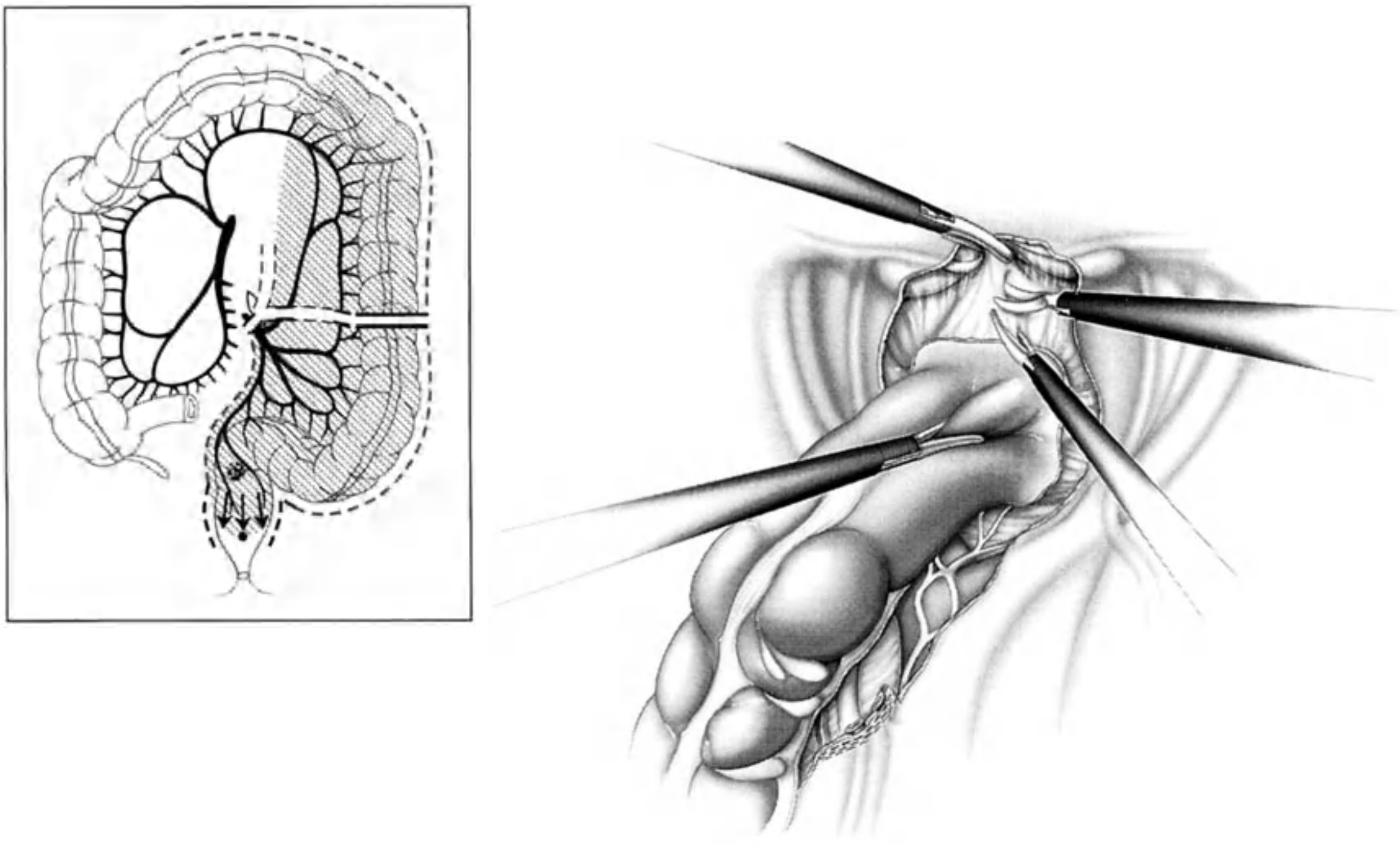

FIGURE 9.58. Mobilization of the rectum anteriorly is performed.

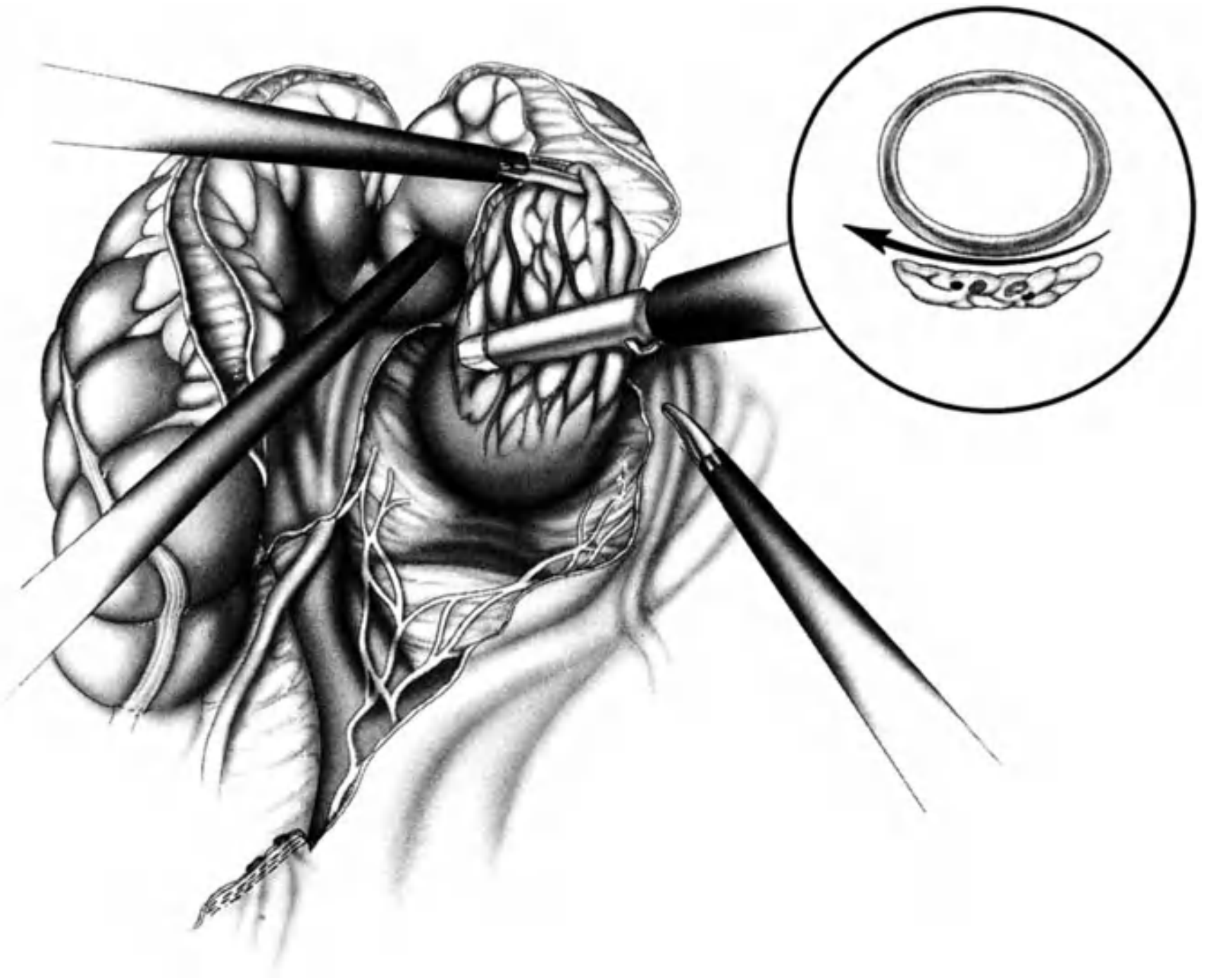

FIGURE 9.59. After a plane between the rectum and the mesorectum has been created, the mesorectum is divided using electrosurgery or by passing a 30-mm endoscopic vascular stapler across it. Inset, Cross-sectional views as to how the plane is struck between the rectum and the mesorectum (arrow).

an endoscopic snare is inserted through the left-upper-quadrant cannula and is strategically placed below the tumor and above the resection line. The loop occludes the bowel lumen and a distal rectal washout is performed transanally, which we believe is important in reducing the risk of implantation of exfoliated tumor cells (Figure 9.60).[18,19] We use a 40% alcohol solution followed by saline irrigation, but other agents such as povidone-iodine, chlorhexidine-cetrimide, or even water are probably adequate.[20]

The rectum is transected with two or three applications of the 30-mm endoscopic stapler that has been passed through the right-lower-quadrant cannula and has been placed obliquely across the rectum just below the snare (Figure 9.61). A bowel bag is brought into the abdominal cavity through the left-lower-quadrant cannula and the specimen is placed immediately in the bag by using the snare. The bag is closed, and then the drawstring and the top of the bowel bag are pulled into the cannula. Through the right-upper-quadrant cannula, the proximal bowel to be used for the colorectal anastomosis is grasped and retained with a grasping instrument. The left-lower-quadrant cannula site is widened with a 3- to 5-cm muscle-splitting incision, pneumoperitoneum is released, and the CO_2 insufflator is shut off temporarily. The bag containing the specimen is carefully delivered through this incision without exposing the specimen to any abdominal wall tissue. Once the cannula and the top of the bag have been drawn clear of the abdominal wall, towels are placed around the wound; the bag is then drawn out of the cannula and is removed from the operative field.

Next, the mobilized descending colon is delivered through this same wound using the right-upper-quadrant grasper to hold it and a purse-string (size 0 polypropylene) suture is placed around the cut edge of the proximal colon after excising the previously placed staples. The anvil of a 28- or 31-mm circular stapler is placed into the descending colon lumen and the purse-string suture is tied around the center rod in the usual manner. This end of the bowel is carefully returned to the peritoneal cavity without twisting its mesentery. The peritoneal cavity is copiously flushed with warm saline solution. The abdominal wall is closed with size 0 polyglycolic acid figure-of-eight sutures through all layers of the fascia.

Pneumoperitoneum is reestablished and the anastomosis is then created. A size 2-0 braided suture is loosely tied to the modified stapler.

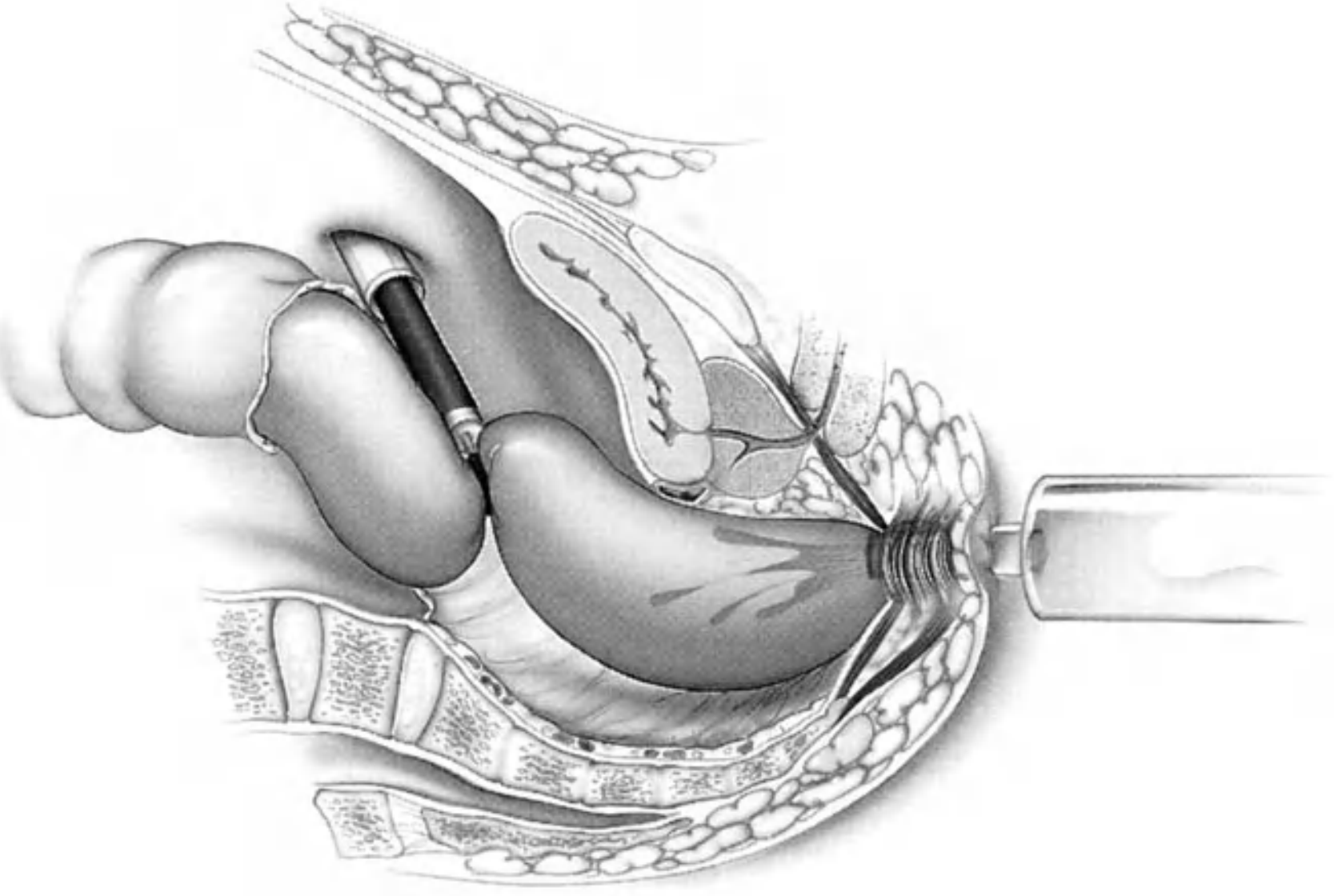

FIGURE 9.60. Once the rectum has been completely mobilized, an endoscopic snare is used to occlude the rectum below the tumor. Rectal washout then is performed.

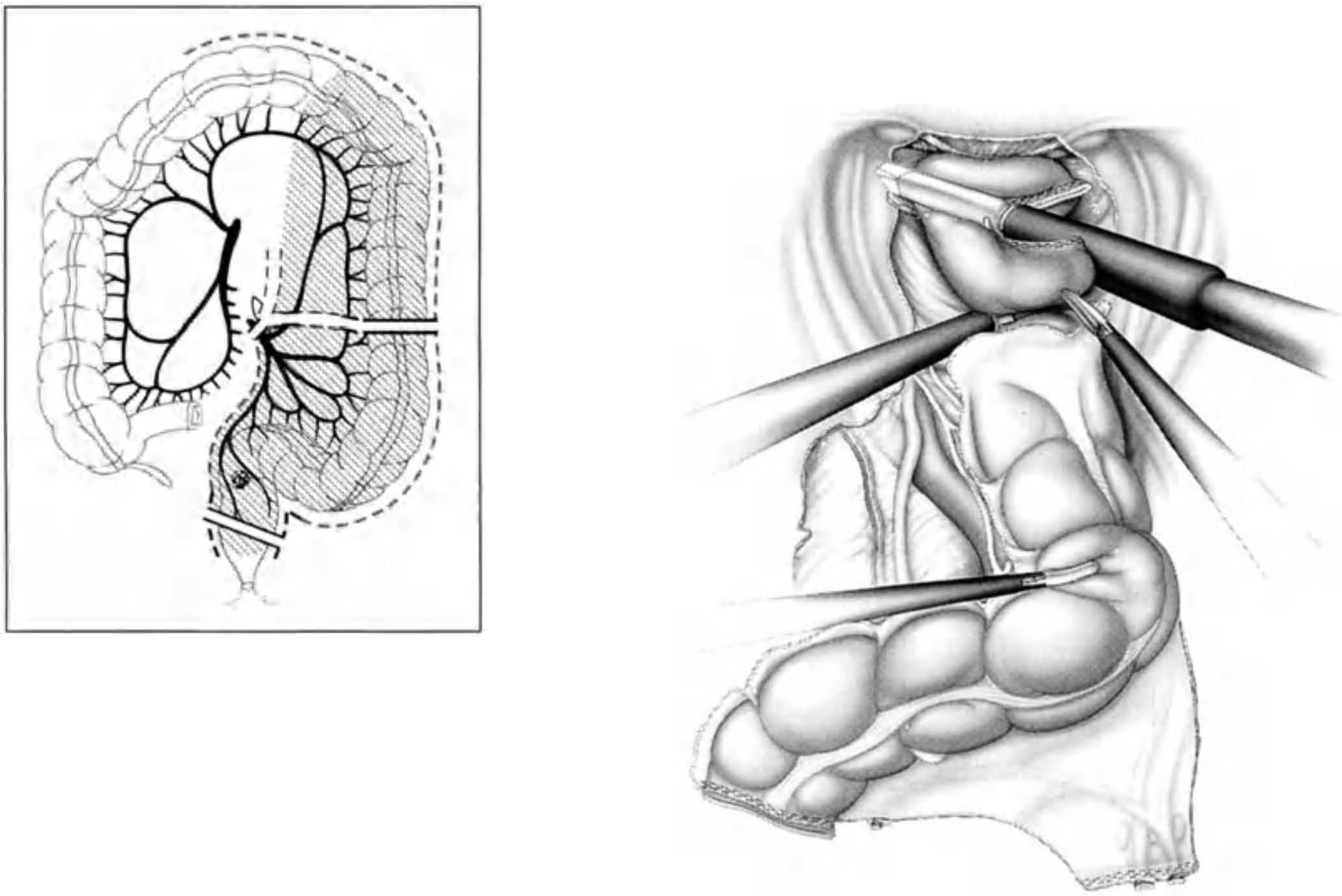

FIGURE 9.61. The rectum is transected distal to the snare by using two or three applications of a 30-mm linear endoscopic stapler.

With the center rod of the stapler retracted into the stapler head, the stapler is inserted transanally under laparoscopic guidance to the rectal staple line. Next, the plastic tip is protruded through the rectal wall just adjacent to the staple line by turning the wing nut of the stapler counterclockwise. With a grasper in the right-upper-quadrant cannula, the thread is pulled to safely dislodge the plastic trocar tip from the center rod and to remove it through the cannula (Figure 9.62).

A standard double-stapling technique is used to form the colorectal anastomosis by grasping the groove in the center rod with an endoscopic Babcock instrument through the right-lower-quadrant cannula and locking the center rod into the center post of the circular stapler. This locking action is easily performed without significant force as long as the axes of the center rod and the center post are in a perfect line. Because the center rod protruding from the proximal colon is grasped with the endoscopic Babcock instrument from the right lower quadrant, its tip will be directed to the right side of the pelvis. Thus, the circular stapler head should be directed to the left side of the pelvis and the center rod should enter the pelvis from the left side. This maneuver may facilitate performing the anastomosis. Excellent visualization of the anastomosis before firing the stapler is mandatory (Figure 9.63). To test the anastomosis for leaks, the pelvis is filled with saline, and air insufflation of the rectum is performed with a proctoscope. The tissue donuts created with the circular stapler are checked for completeness and are sent for routine pathologic analysis.

At the conclusion of each case, after careful irrigation of the pelvis, an atraumatic silicone drain can be placed in the pelvis, using the right-lower-quadrant cannula site. Usually, the silicone drain is easily passed through the 12-mm cannula and a grasper placed through the left-upper-quadrant cannula is used to place the drain in the pelvis. The cannula is then removed. If the drain does not fit through the cannula, the cannula must be removed and a tonsil clamp must be used to push the drain through this site.

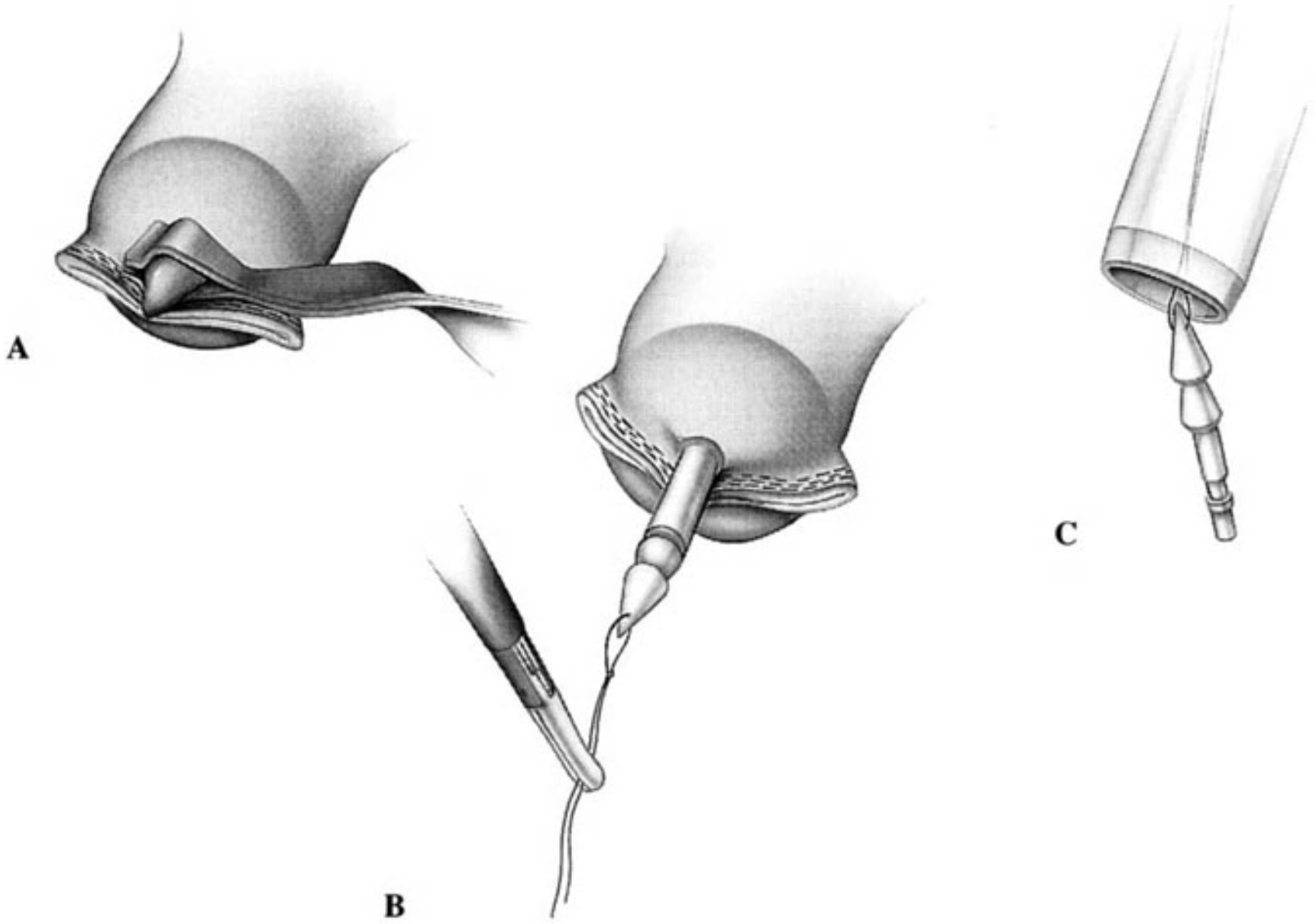

FIGURE 9.62. A, Initial protrusion of the plastic trocar of a circular stapler through the rectum, aided with countertraction applied with an endoscopic Babcock instrument. B, The trocar is pushed through the rectum close to the staple line. C, The trocar is removed through a cannula by pulling on the attached thread.

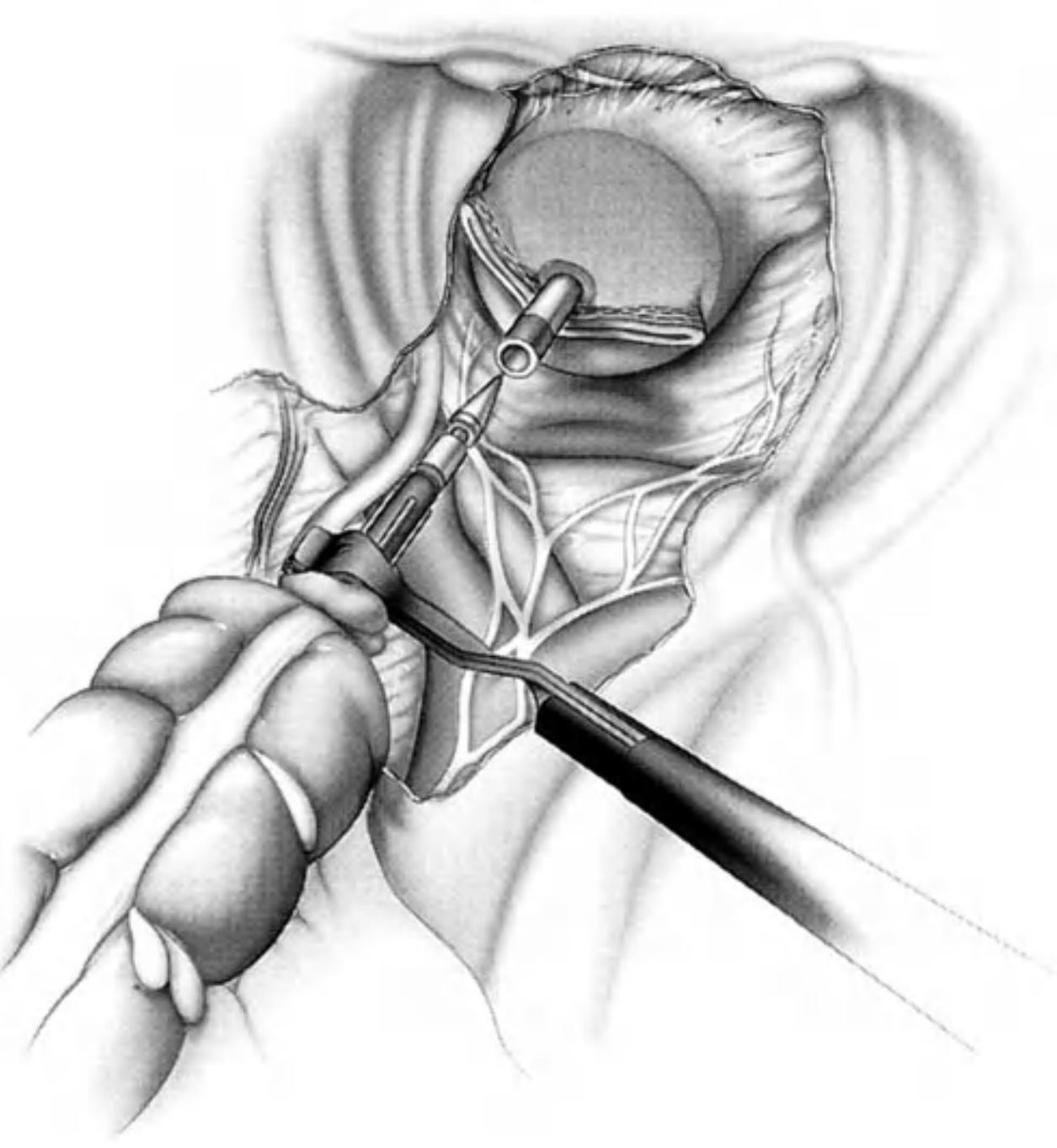

FIGURE 9.63. The colorectal anastomosis is created using an endoscopic Babcock instrument to maneuver the center rod into the center post of the transanally placed stapler.

Special Considerations

In patients with diverticulitis who are undergoing sigmoid resection, it may be worthwhile for the assistant to use an irrigation–suction instrument in lieu of a grasper when the inflamed segment is mobilized; this will allow any incidental pus to be readily aspirated during the mobilization.

Although others have advocated opening the rectum and passing the resected specimen transanally to avoid making an incision in the abdominal wall,[21,22] we do not advocate opening the rectum at any point in the operation nor do we advocate transanal specimen removal. This creates (1) an unnecessary risk of peritoneal bacterial contamination; (2) a possibly injurious anal sphincter dilation or tear in the rectum, especially along its upper edge; and (3) a potential for malignant cell seeding in the case of cancer surgery.

Fully understanding some of the fine details of the vascular anatomy at the base of the left and distal transverse mesocolon will enhance the safety of surgery in this area. The inferior mesenteric artery is a straight vessel that runs from the distal aorta to its bifurcation into two superior rectal arteries in the mesorectum (Figure 9.64). It has collaterals at its left side only. The first collateral is the left colic artery, which usually arises from several millimeters to several centimeters away from the origin of the inferior mesenteric artery.[7] The left colic artery then courses laterally over a short distance and then runs superiorly toward the splenic flexure. According to VanDamme and Bonte,[7] it usually runs vertically over a long, stretched S-like course close to the vertebral column, unlike most depictions of the vessel. Less frequently, the left colic artery is directed toward the most lateral portion of the transverse colon or it bifurcates into ascending and descending directions. In VanDamme and Bonte's study, the left colic artery presented an aberrant pattern in 17% and was absent in 12% of 156 specimens where its function was seemingly assumed by the more distal colosigmoid artery. This left colic vessel is then anastomosed with an accessory left colic artery coming from the superior mesenteric artery. An accessory left colic artery (seen in 14.5% of specimens) will affect the course, the existence, or the diameter of the left colic artery (Figure 9.65). Thus, anomalies of the left colic artery are nearly always accompanied by an accessory left colic artery or branch.

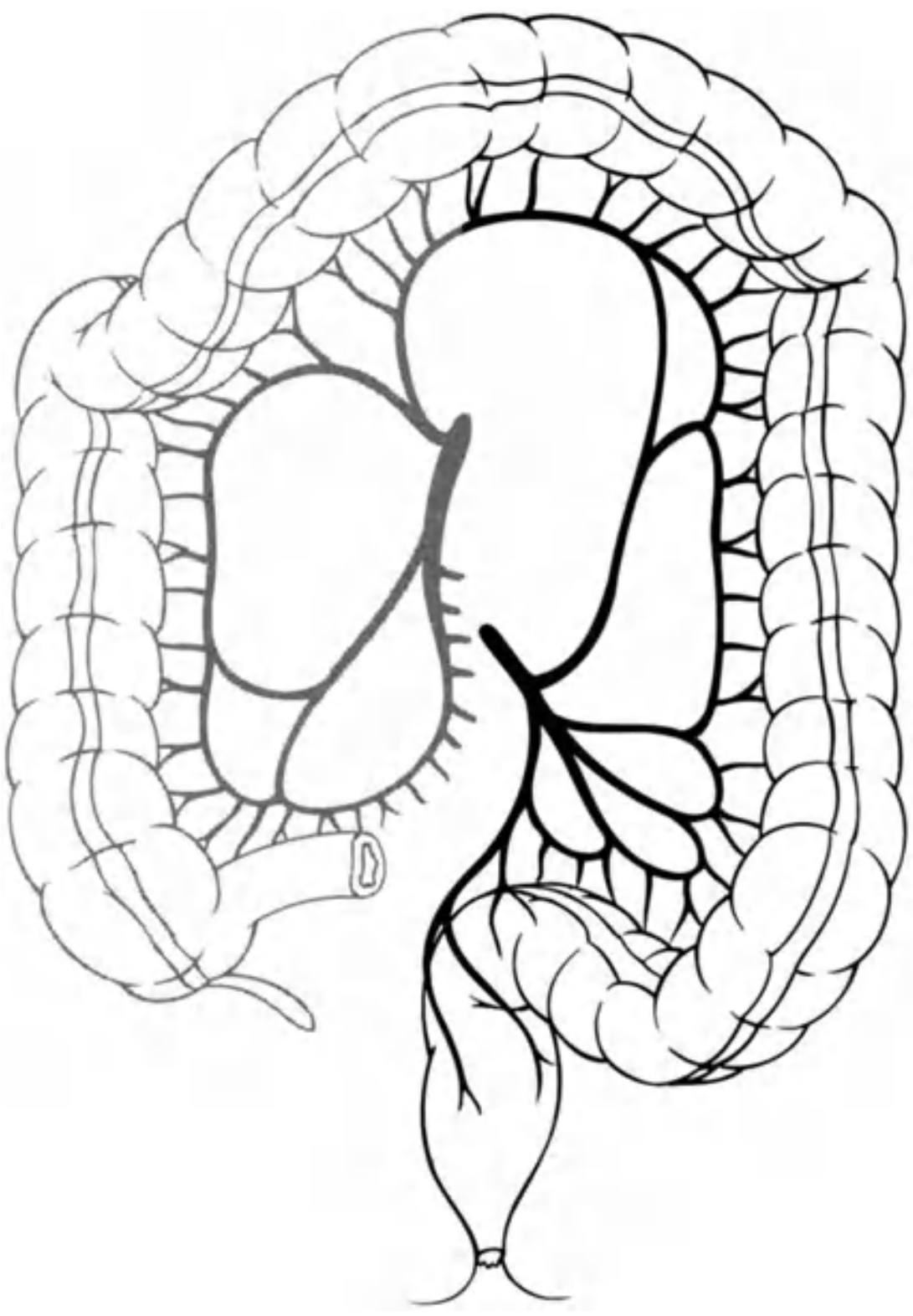

FIGURE 9.64. The most common pattern of the inferior mesenteric artery and its branches.

The second branch of the inferior mesenteric artery is probably most accurately termed the colosigmoid artery. VanDamme and Bonte reintroduced this term from Manasse[23] because the vessel supplies both the descending and the sigmoid colonic segments (Figure 9.64). It is a large, well-defined vessel, originating separately from the inferior mesenteric artery (48%), the left colic artery (38%), or from the angle between the two (14%) in the 156 specimens that VanDamme and Bonte studied. From this vessel, a variable number of sigmoid branches arise, varying from 1 (1%) to 5 (3%). Usually there are 2 (21%), 3 (50%), or 4 (25%).[7] The last sigmoid artery (arteria sigmoidea ima) nearly always arises from the inferior mesenteric artery, anastomosing to the preceding sigmoid artery arising from the colosigmoid artery.

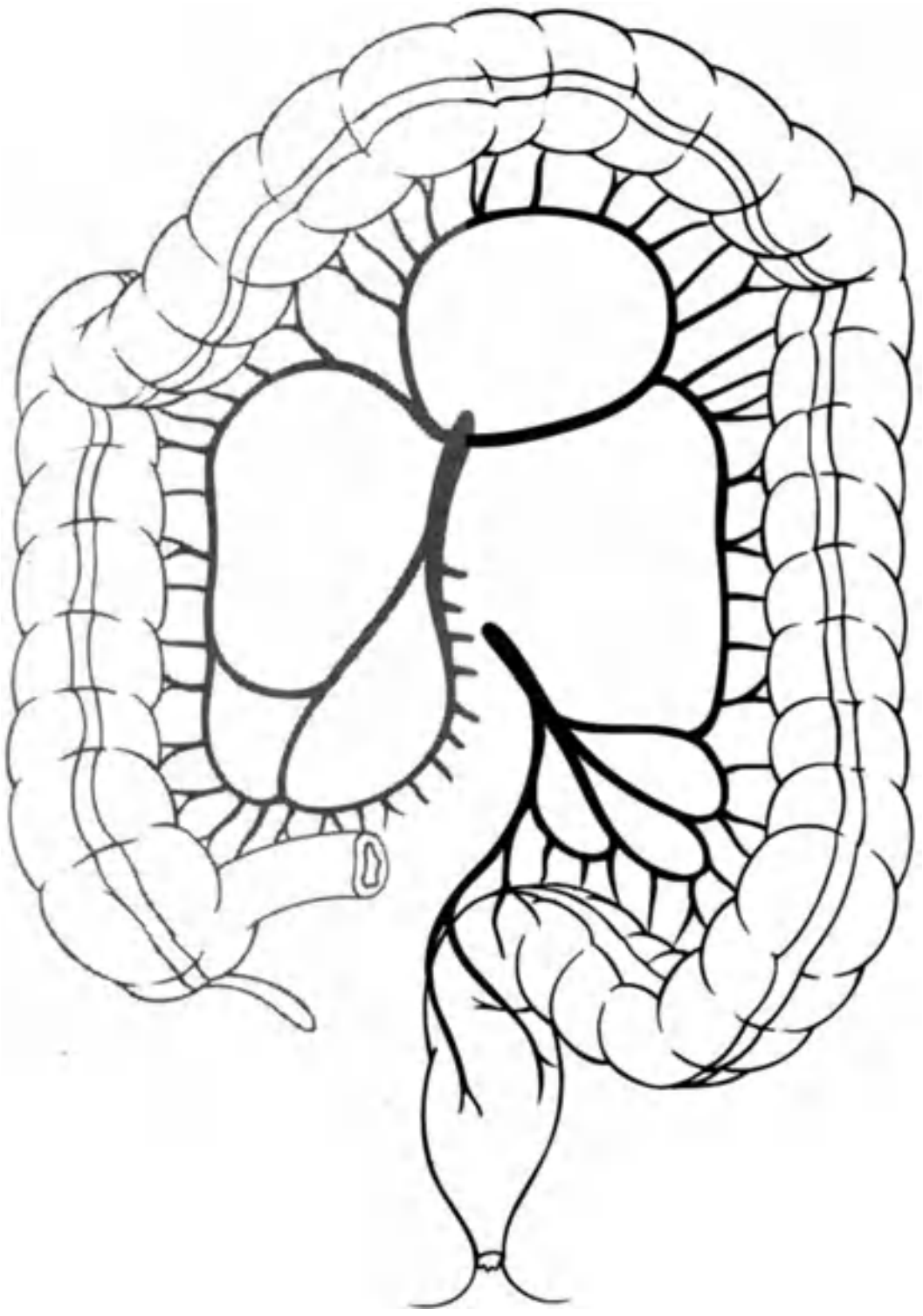

FIGURE 9.65. A common variation in the inferior mesenteric artery, with an accessory left colic artery arising from the superior mesenteric artery (found in approximately 15% of specimens).

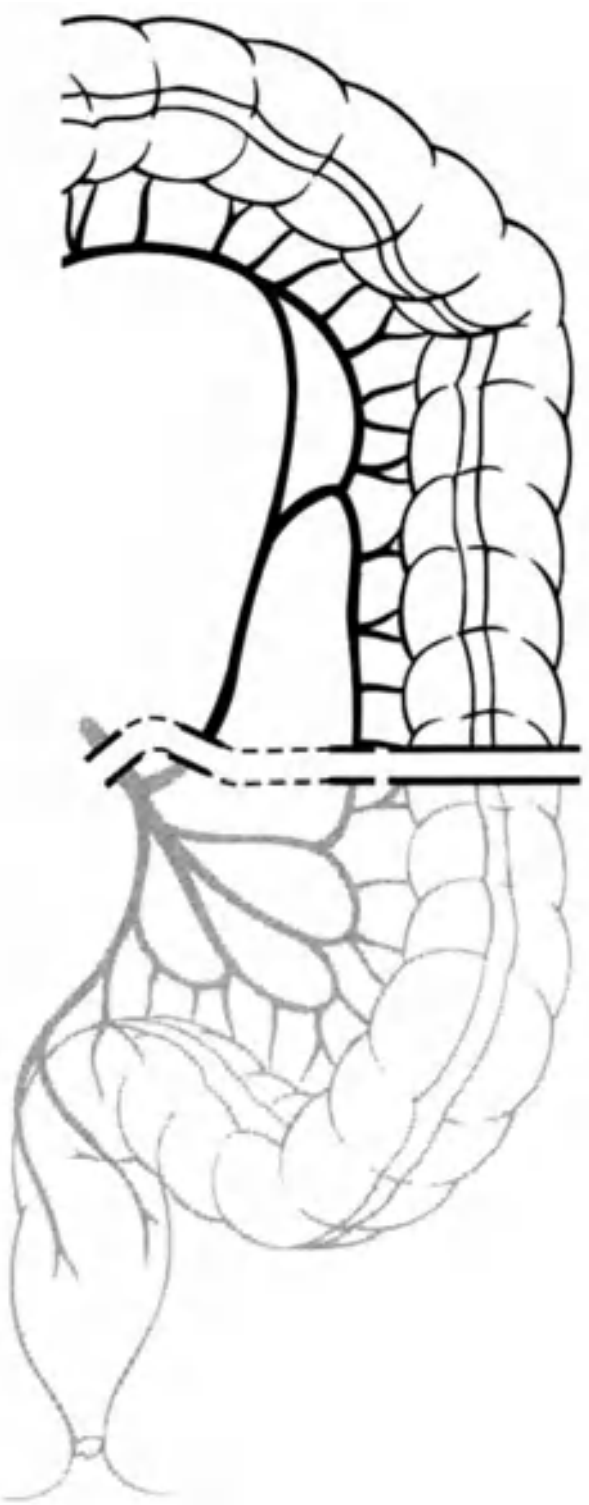

FIGURE 9.66. Choosing an appropriate mesenteric division line between the left colic and the colosigmoid vessels will facilitate mesenteric dissection because only two or three vessels will need to be divided and ligated.

A final branch of the inferior mesenteric artery, the rectosigmoid artery, arises between the last sigmoid artery and the bifurcation of the inferior mesenteric artery into the superior rectal arteries. This vessel supplies the transitional area where the intestine changes from a mobile to a fixed organ, and is found in 64% of patients, more commonly in men (69%) than in women (53%). Multiple rectosigmoid arteries may exist but are uncommon.[7]

The advantage of knowing the arterial anatomy so precisely lies in facilitation of mesenteric division. After proctosigmoidectomy, if a mesenteric resection line between the left colic and the colosigmoid vessels is chosen, then this will facilitate the mesenteric division because after inferior mesenteric artery and vein division, only one or two mesenteric vessels will need to be clipped and cut if the plane is chosen properly (Figure 9.66).

Additionally, if resection for cancer is being undertaken and the left colon must be completely mobilized to reach well into the pelvis, division of the proximal inferior mesenteric artery and vein is usually necessary to allow the left colon to reach into the pelvis (Figure 9.67). This division may be accomplished by transecting the inferior mesenteric artery pedicle as we have described, then by dividing the left colic artery and vein close to their origins in the left mesocolon. Unless there is a suspicion of mesenteric insufficiency from the middle colic vessels (or an accessory left colic artery), there should be little to no risk of vascular insufficiency with this maneuver. If there is any question about vascular insufficiency, then a careful judgment will need to be made when the left colon is exteriorized for placement of the center rod and the anvil of the circular stapler. If the

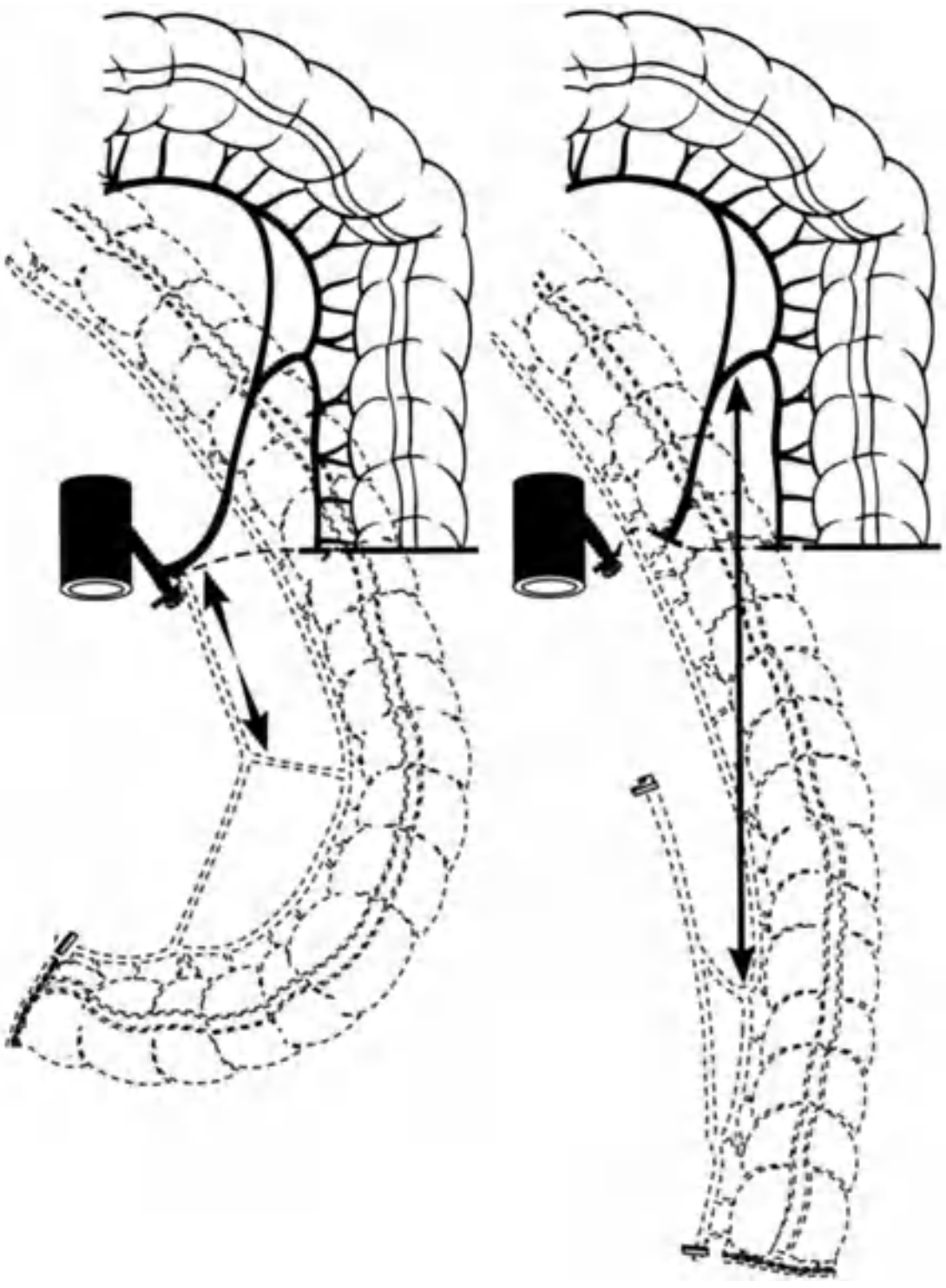

FIGURE 9.67. Division of the left colic close to its origin will more readily allow the descending colon to reach into the pelvis for a colorectal anastomosis.

exteriorized segment is of questionable viability, then further mobilization of the left colon must be performed—either using laparoscopic or conventional techniques.

Cancer

When cancer surgery is performed, it is important to assess the feasibility of performing the pelvic portion of this procedure laparoscopically, particularly if the cancer is located near the peritoneal reflection. If it is below the peritoneal reflection, achieving a 2 cm or greater distal rectal and soft tissue margin below the tumor may not be possible using our laparoscopic techniques. Therefore, patients selected to undergo laparoscopic proctosigmoidectomy for cancer should probably have a tumor that is at or above the peritoneal reflection or in the distal sigmoid colon.

The issue of transecting the mesorectum is worthy of additional discussion here. This mesorectal transection should be well below (at least 3 to 5 cm) the primary tumor, so as also to provide a substantial margin of lymph-node-bearing soft tissue below the primary tumor. Our technique allows for rapid handling of what otherwise can be a difficult and time-consuming maneuver.

We do not advocate any procedure involving opening the rectal lumen for specimen removal, especially in malignant disease. Phillips et al.[21] and Franklin et al.[22] do apparently advocate such a method to avoid the need for an abdominal wall incision. They describe, after rectosigmoid transection, first removing the colorectal specimen transanally by snaring it using a transanally passed colonoscope and a polypectomy-type snare protruding through the open end of the rectum. Next, a circular stapler is guided transanally to the cut edge of the rectum, is opened, and laparoscopically placed Roeder-loop-type sutures are tied over the proximal and distal bowel ends to secure them onto the circular stapler. To us this seems like an extremely difficult technique, with a major risk to "miss" incorporating part of the circumference of the rectal wall with the Roeder-loop suture. Although there is no mention of the frequency of this occurrence in these articles, both articles mention the need for intracorporeal suturing of anastomotic defects.

We also strongly advocate rectal washout before transecting the rectum for cancer cases[24,25]: a snare can be placed over the divided sigmoid colon and passed down to an area well below the tumor (at least 2 to 3 cm) to occlude the rectum, which is then washed transanally with a cytotoxic solution (see Figure 9.60). Afterwards, from the right-lower-quadrant trocar, a 30- or 60-mm stapler is placed below the snare to transect the rectum. Constant manual occluding pressure must be maintained on the rectum with the snare because this instrument currently has no locking mechanism to ensure that it remains securely fastened around the rectum. As soon as the bowel is transected distally, an endoscopic bag should be placed through the left-lower-quadrant cannula and the specimen should be immediately placed in it. Once the distal end of the intestine is safely in the bag, the drawstring should be closed and the top of the bag should be pulled inside the cannula, as previously described, to completely isolate the specimen from the peritoneal cavity.

If it is possible to completely remove the specimen from the peritoneal cavity while it is inside the bag, this should be done. The incision should be widened as necessary to safely remove the specimen without risking contamination of the peritoneal cavity or the abdominal wall. After specimen removal, using this limited incision, the entire peritoneal cavity may be thoroughly and rapidly washed out with direct irrigation and suction of irrigating fluid. We always perform a preliminary irrigation of the tumor site and the abdominal wall with a cytotoxic solution before performing the general irrigation of the peritoneal cavity with warmed saline solution.

Using the described technique, the intestinal lumen is never exposed to the peritoneal cavity, both ends of the specimen are safely occluded with staples, the intestine is carefully dissected free of the surrounding tissues only after initial proximal ligation of the major vessels, and the dissected specimen is immediately thereafter placed in an impermeable bag. All the features of this procedure should minimize the risk of any tumor seeding during laparoscopic resection.

If proctosigmoidectomy is carried out because of cancer, we believe the following steps must be clearly documented on videotape: dissection of the origin of the inferior mesenteric artery with proximal ligation, adequate resection of the mesocolon, adequate distal margin after intraoperative identification of the cancer, proximal and distal colonic transection using an endoscopic stapler, and placement of the specimen in a bag immediately after complete dissection. If all these steps are clearly documented, it seems reasonable to assume that an oncologically satisfactory resection has been performed.

Abdominoperineal Resection

Position

The patient is placed supine in the modified lithotomy position using Dan Allen stirrups. Surgery is begun in the Trendelenburg position (20° head-down tilt), and after cannula insertion, the patient is tilted right side down. For the entire laparoscopic operation, the surgeon and the second assistant (who acts as the cameraperson) stand on the patient's right side looking at a monitor placed near the patient's left knee. The first assistant stands to the patient's left side looking at a monitor placed near the right knee (Figure 9.68). The nurse stands between the patient's legs.

Instruments

The instruments listed in Table 9.5 are the minimum required to perform an abdominoperineal resection.

Cannulas

The cannulas are positioned in the infraumbilical region, and in the right and left lateral abdominal wall. The left-upper-quadrant cannula site is situated at the proposed stoma site (Figure 9.69).

Procedure

Because the patient is placed in a steep Trendelenburg position and is tilted right side down, the small intestine falls into the right upper quadrant. All small-intestine loops are retracted out of the pelvic area. The assistant holds the mesosigmoid in a ventrolateral direction under traction using a Babcock-like grasper in the left-upper-quadrant cannula and a smaller grasper in the left-lower-quadrant cannula. The surgeon incises the peritoneum to the right of the inferior mesenteric artery starting at the sacral promontory (Figure 9.70). Under continuous traction, the peritoneum is incised cephalad toward the origin of the inferior mesenteric artery. Using blunt dissection, the inferior mesenteric artery and vein are swept ventrally, and the preaortic hypogastric neural plexus is swept dorsally to prevent injury. Dissection then is continued medially beneath the artery, and the left ureter and the gonadal vessels are identified and swept posteriorly (Figure 9.71). Tension is placed on the sigmoid colon mesenteric attach-

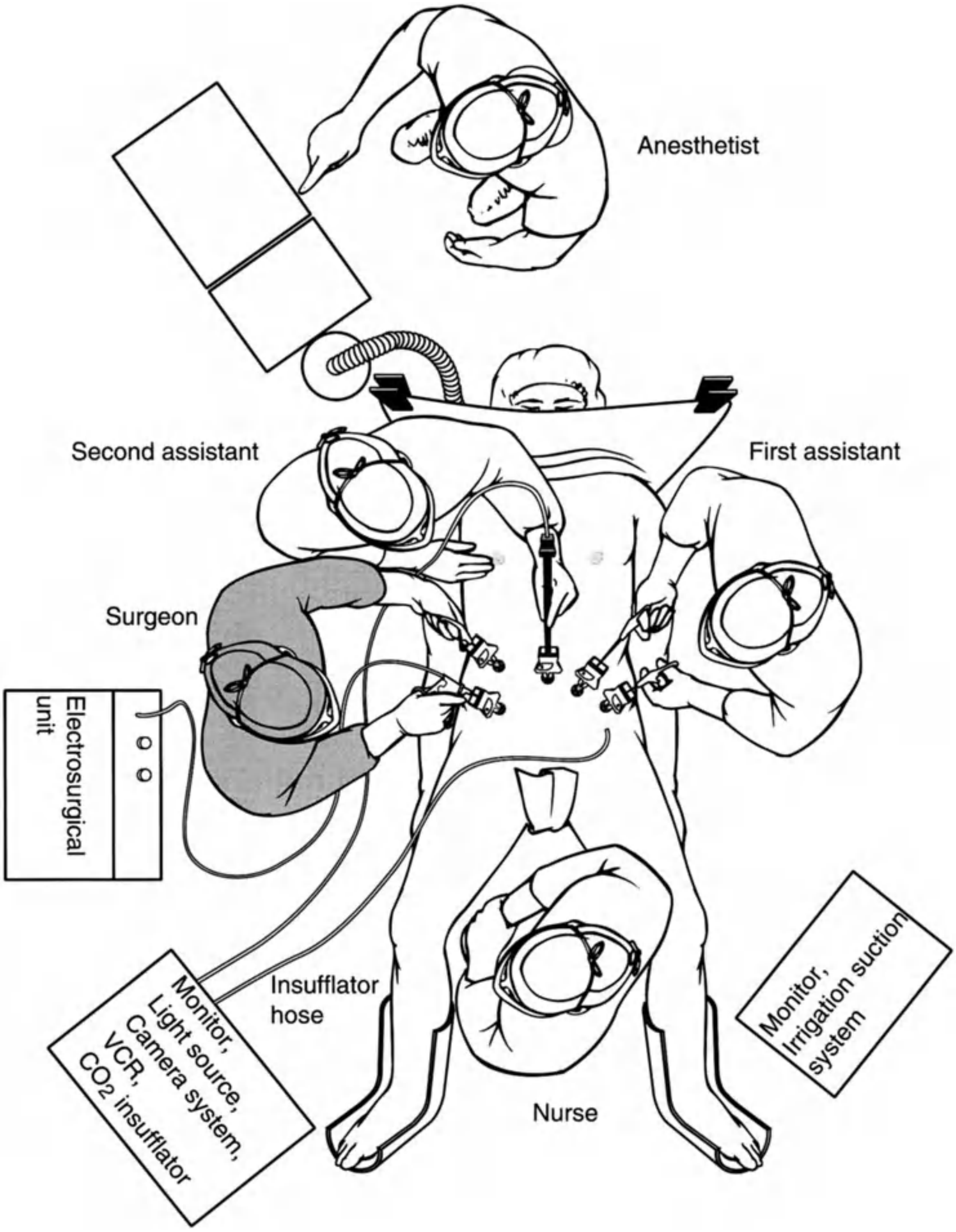

FIGURE 9.68. Positions of the equipment and the surgical team for abdominoperineal resection. (Modified with permission from Decanini C., Milsom J.W., Böhm B., Fazio V.W., Laparoscopic oncologic abdominoperineal resection. *Diseases of the Colon and Rectum.* 1994; Vol. 37, No. 6.)

ments by applying medial and cephalad traction on the mesentery with graspers, which should not be used to grasp the intestine so inadvertent injury is avoided. If the ureter cannot be identified easily, the lateral attachments of the sigmoid colon are incised, the sigmoid colon is mobilized left to right. The gonadal vessels and the ureter are then identified from the lateral aspect of the bowel and dissected from the mesentery.

Once the origin of the inferior mesenteric artery is identified, the peritoneum is incised anteriorly over the pedicle to the left toward the inferior mesenteric vein. Careful blunt dissect-

TABLE 9.5. Instruments required for laparoscopic abdominoperineal resection.

No.	Type
5	Cannulas (1 × 12 mm, 4 × 10 mm) including anchoring devices and converters
1	Dissecting device, for example, endoscopic scissors equipped with electrosurgery
1	Endoscopic dissector
2	Endoscopic graspers (one Babcock-like large and one small)
1	Endoscopic clip applier (large size)
1	Multifire endoscopic 30-mm stapler
2	Endoscopic stapler cartridges

ing techniques are used to create a peritoneal window just lateral to the inferior mesenteric artery and vein. The pedicle of the inferior mesenteric artery and vein is ligated above or below the left colic artery (according to the surgeon's judgment) using an endoscopic 30-mm vascular stapler, but only if the left ureter can be clearly identified and retracted to avoid injuring it (Figure 9.72). We prefer to leave the inferior mesenteric artery 1.0 to 1.5 cm long so if any bleeding occurs, an additional ligature can be applied to the vessel. After the stapler

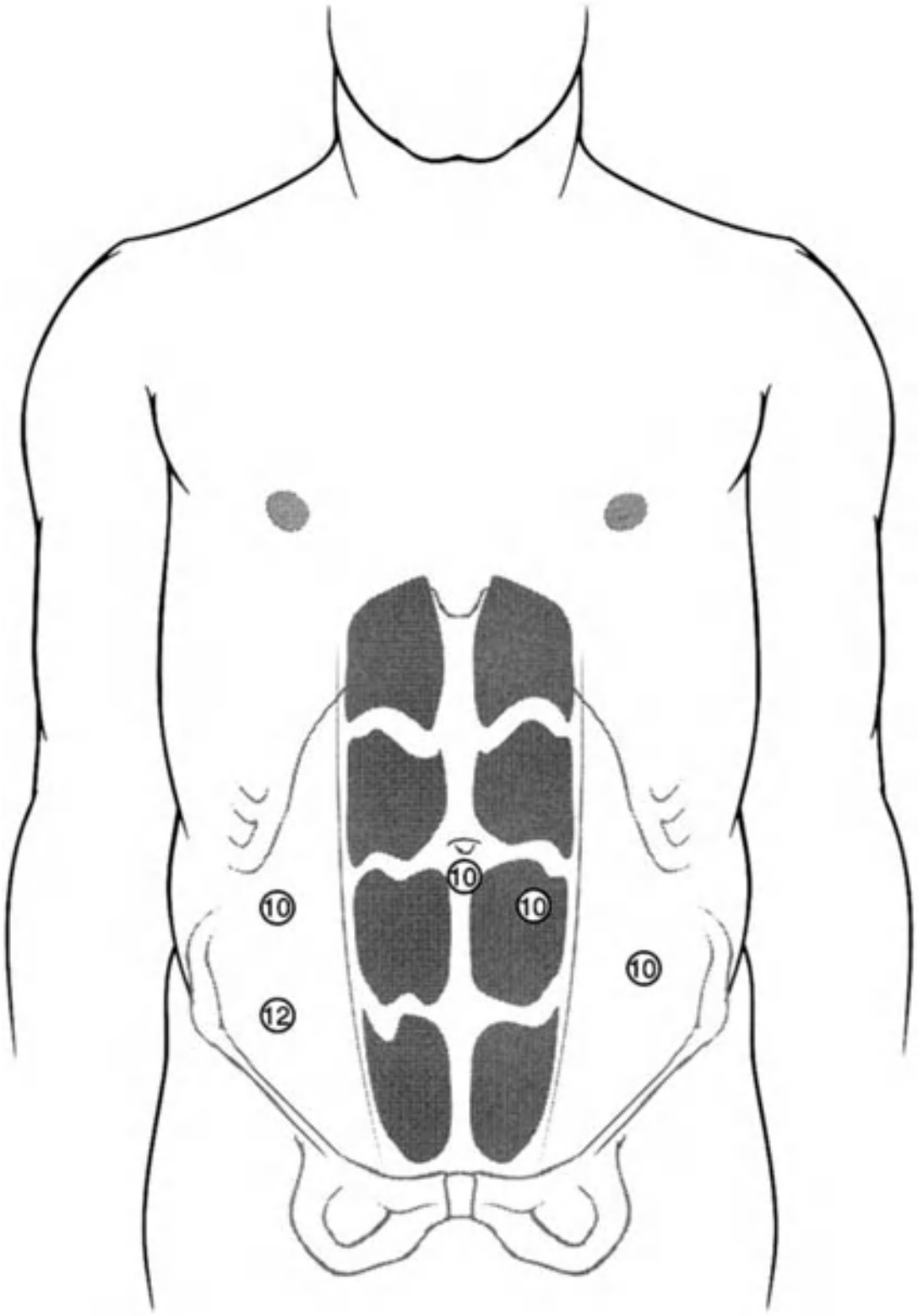

FIGURE 9.69. The cannula positions for abdominoperineal resection.

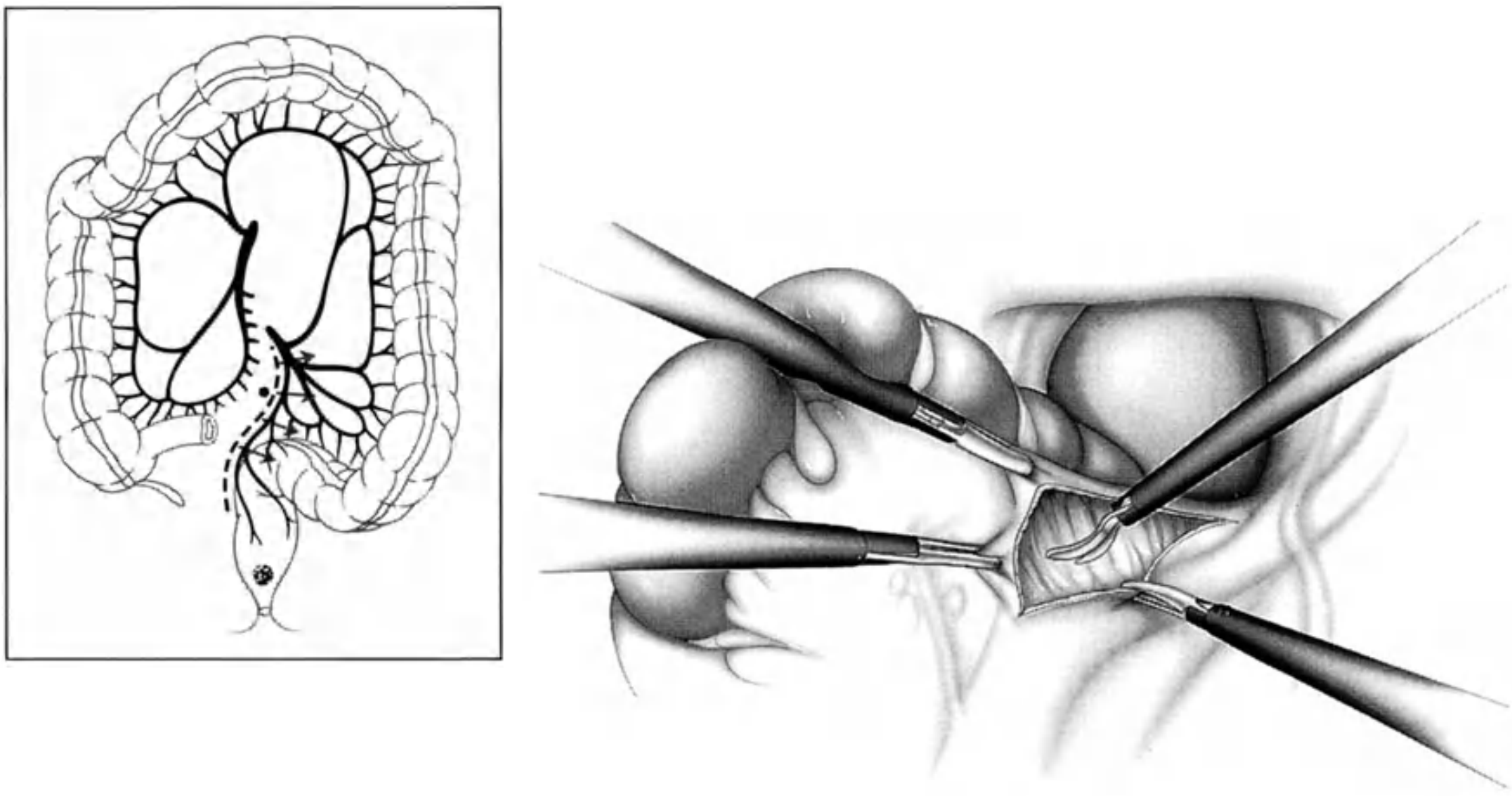

FIGURE 9.70. The dissection commences with an incision in the retroperitoneum just to the right of the inferior mesenteric artery.

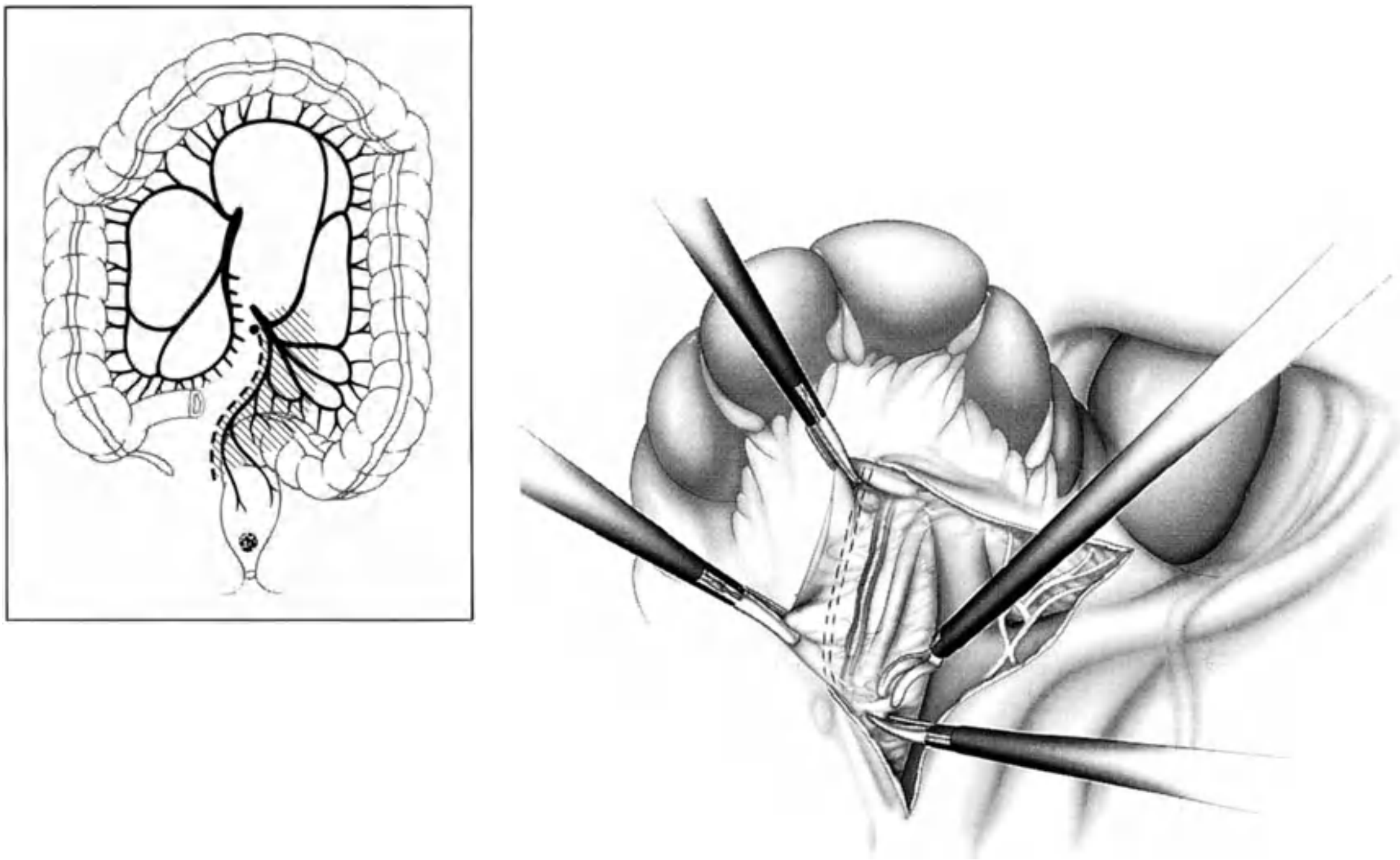

FIGURE 9.71. Dissection continues toward the origin of the inferior mesenteric artery with identification of the left ureter and the gonadal vessels.

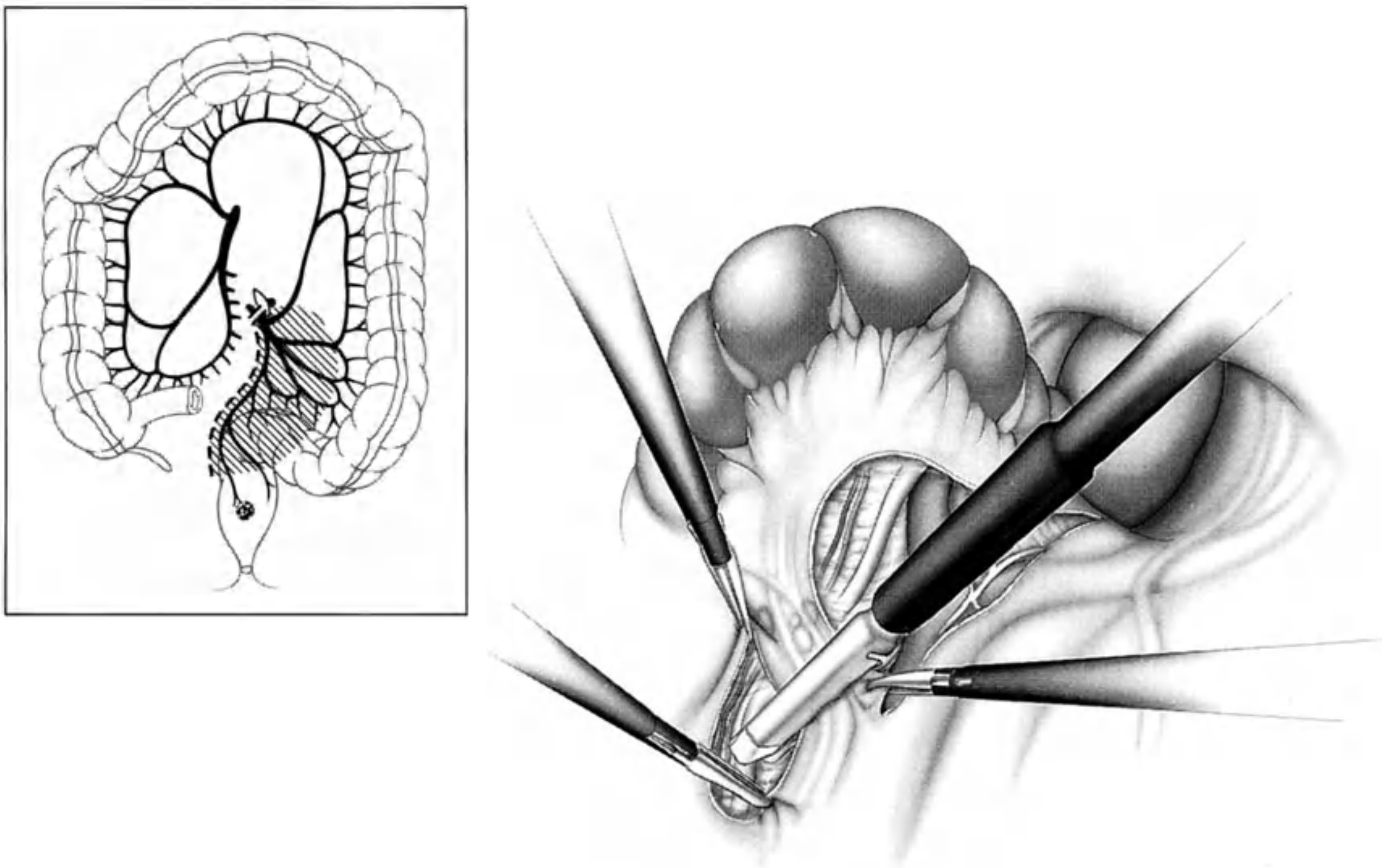

FIGURE 9.72. An endoscopic 30-mm linear stapler is used to ligate and to divide the inferior mesenteric artery close to its origin. The ureter and the gonadal vessel have been swept clear from the arteries. The inferior mesenteric vein may often be ligated simultaneously.

has been placed across the inferior mesenteric artery (and concurrently across the inferior mesenteric vein if this is feasible and safe), the stapler is closed and the ureter again is checked. The stapler tip should be free and should be clearly visible so as not to incorporate any tissue other than the inferior mesenteric pedicle. Before the fired stapler is opened, both ends of the pedicle are grasped so in case of any bleeding, control can be easily achieved. If the inferior mesenteric vein is not simultaneously ligated by the stapler, it is clipped or stapled separately.

The lateral attachments of the sigmoid colon are dissected free, and the sigmoid colon is completely mobilized using a sharp and blunt dissection as in open surgery (Figure 9.73). Again, great care should be taken to identify and to avoid any injury to the gonadal vessels or the ureter. The mesosigmoid (or the proximal resection line just to the left of the inferior mesenteric pedicle) is held using triangulating tension as described in chapter 4 and is transected up to the proximal intestinal resection line, using a combination of blunt dissection, coagulation of small vessels, and clipping of large vessels (Figure 9.74). With triangulating tension on the tissue, it is relatively easy to transect the mesocolon up to the colonic edge of the proximal resection line. The colon is divided with one or two sets of 30-mm endoscopic staples (Figure 9.75).

The rectum is completely mobilized down to the pelvic floor using standard open surgical techniques, starting with posterior mobilization as far distally as possible (Figure 9.76), then dissecting posterolaterally to the right and the left sides of the rectum. If the proper plane is entered posteriorly, no bleeding will occur, and the connective tissue between the fascia propria of the rectum and the presacral fascia can be divided easily. The large vessels of the lateral ligaments should be identified and coagulated. If they continue to bleed or are larger than 2 mm, the vessels should be clipped. In cancer cases, all soft tissues should be cut flush with the pelvic sidewalls. Anterior dissection is extended to a level well below the seminal vesicles or well into the rectovaginal septum if required (Figure 9.77). Once the

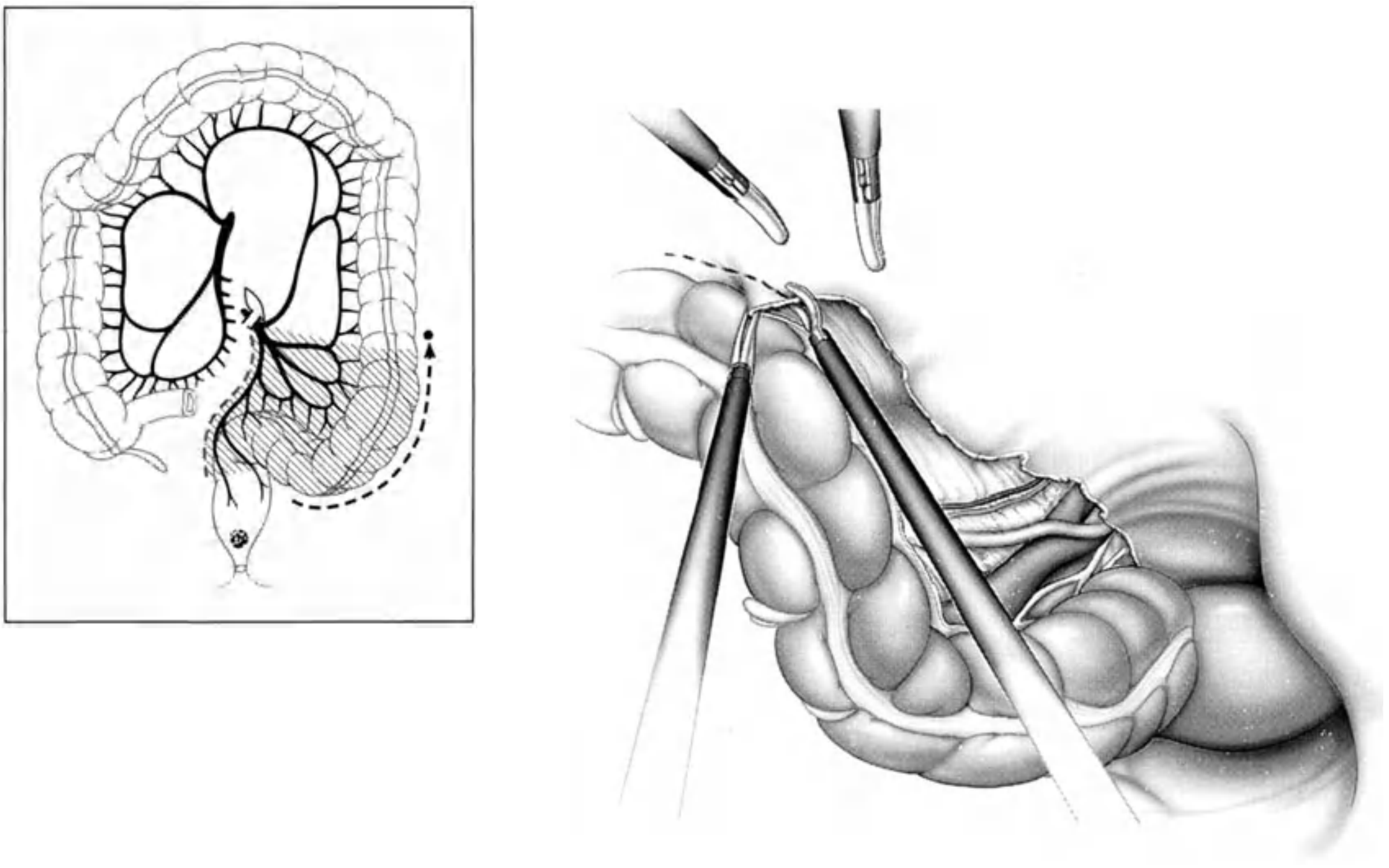

FIGURE 9.73. Initial dissection of the lateral attachments of the sigmoid and left colon.

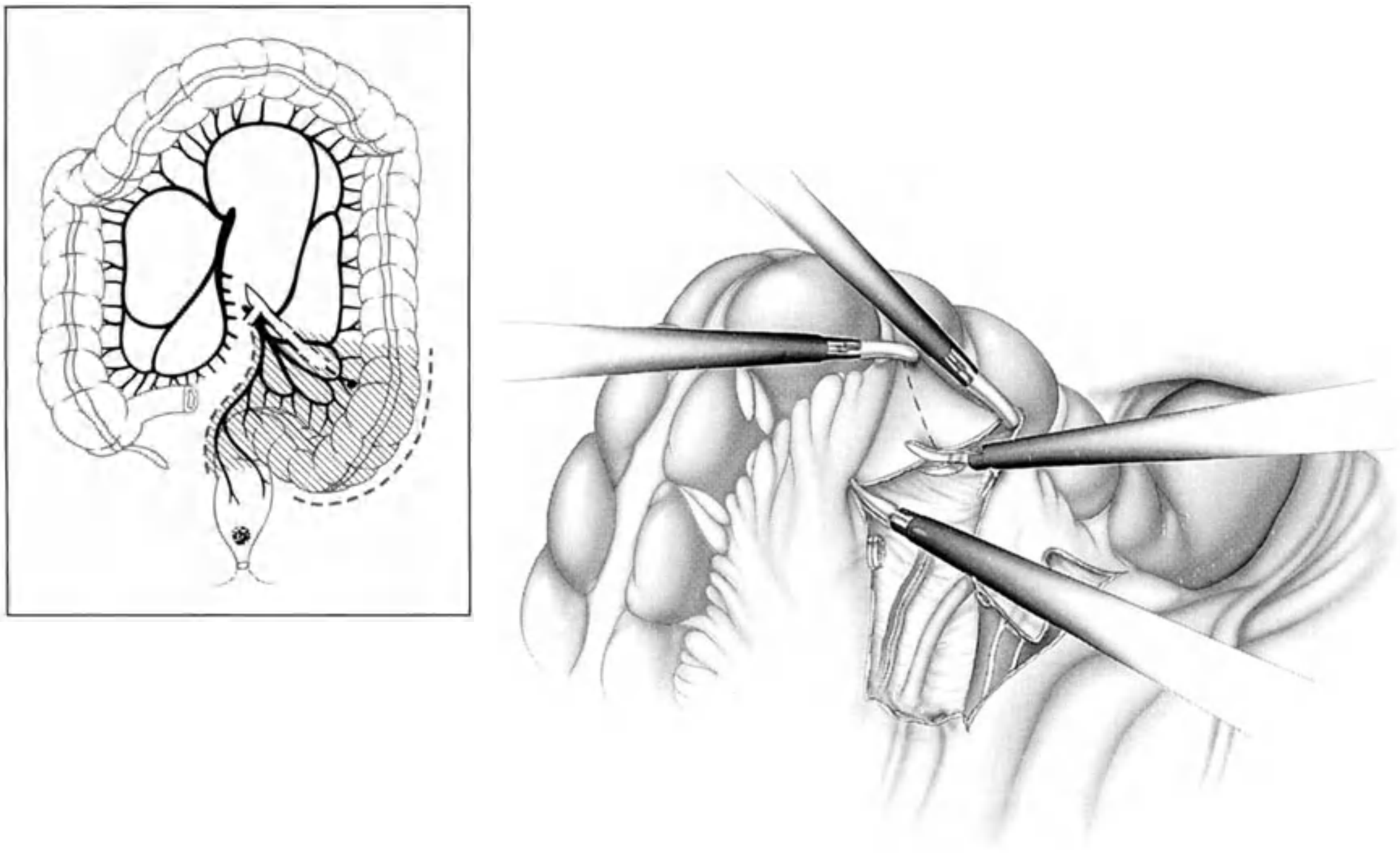

FIGURE 9.74. Transection of the mesentery of the descending-sigmoid colon junction by applying triangulating tension. Vessels are clipped as they are encountered.

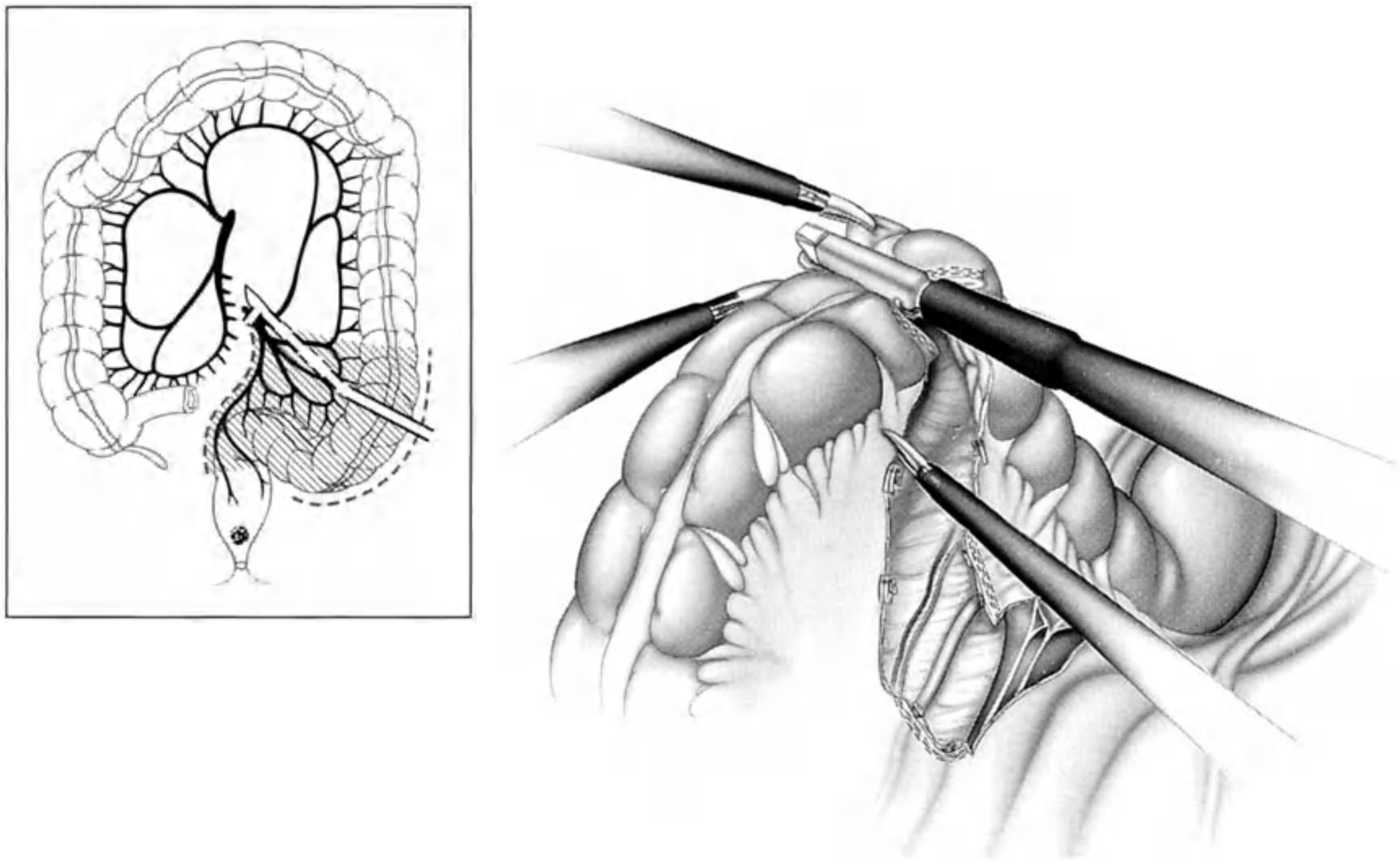

FIGURE 9.75. The proximal resection line of the colon is transected with one or two applications of a 30-mm endoscopic stapler.

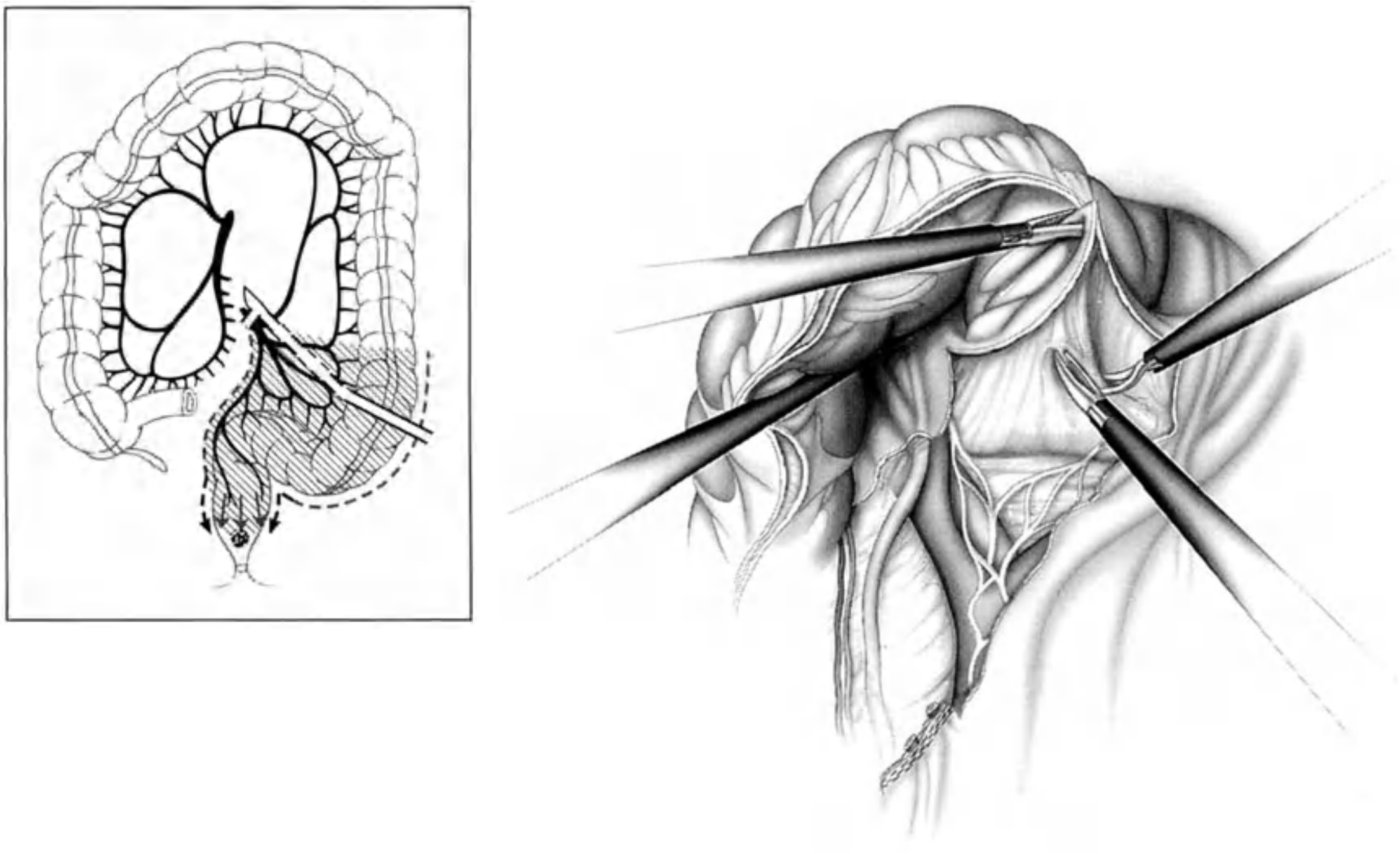

FIGURE 9.76. After transection of the sigmoid colon, the rectum is initially mobilized posteriorly, as in conventional surgery.

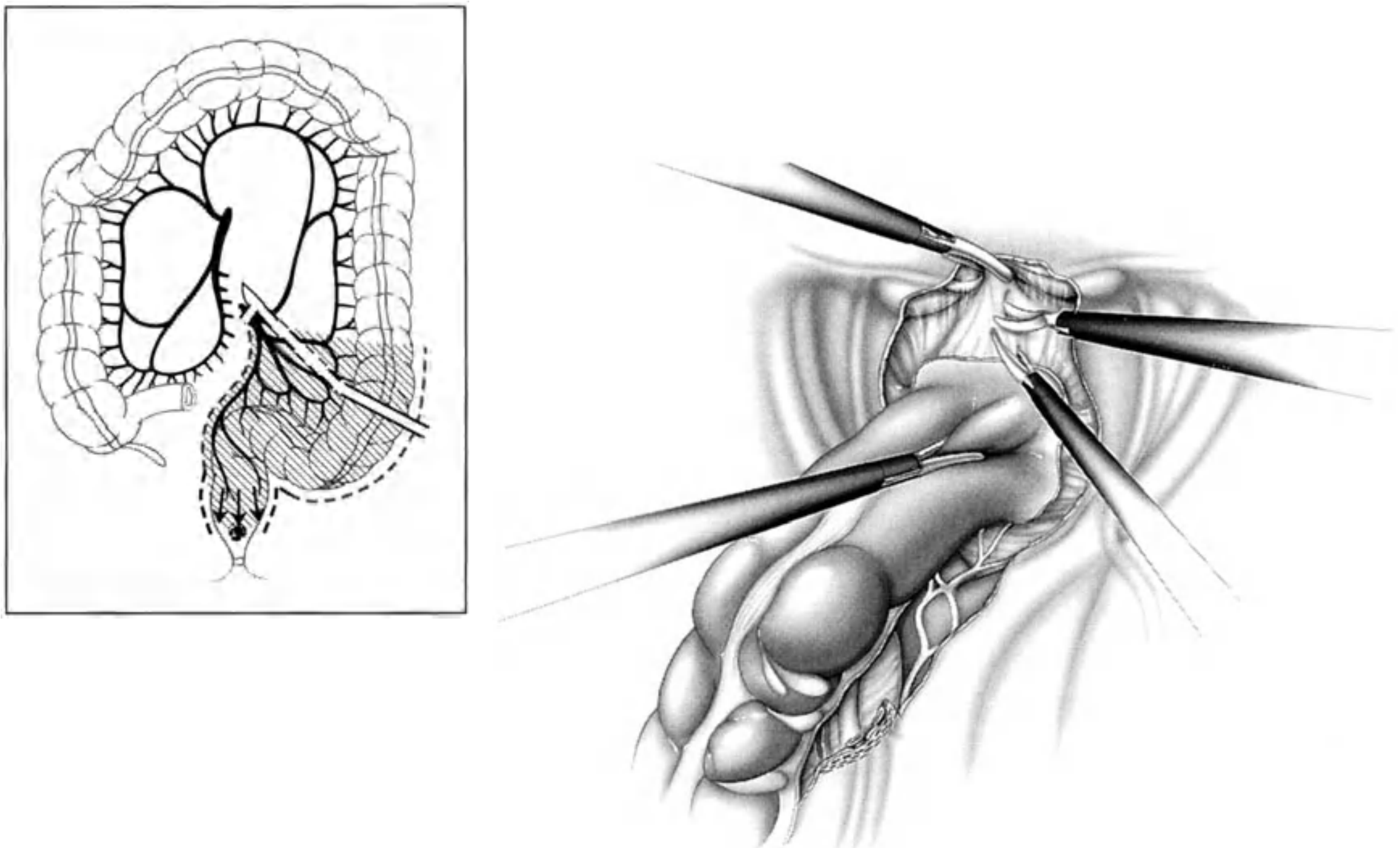

FIGURE 9.77. Anterior mobilization of the rectum.

dissection has been carried out circumferentially to the pelvic floor, the surgeon should put a second sterile glove over the right hand, and place this hand into the rectum (and in women, the vagina) to perform bimanual palpation in order to ensure complete rectal dissection to the pelvic floor level (Figure 9.78).

Once the rectum has been completely mobilized, a perineal surgeon begins the perineal portion of the operation, continuing the dissection under laparoscopic guidance from the skin and subcutaneous tissues upwards through to the pelvic floor. The perineal surgeon continues dissection until the posterior portion of the pelvis behind the rectum is entered. Once this step is achieved, pneumoperitoneum is released, and perineal excision of the anus and the rectum is carried out in a standard way. The perineal surgeon then removes the specimen. The laparoscopic surgeon passes an endoscopic grasper through the cannula located at the selected colostomy site; grasps the distal end of the descending colon; and pulls this up to the anterior wall, checking that there is no tension on the colon. The colostomy then is created by withdrawing the cannula from this site, dilating the fascia up to a width of two finger breadths and then pulling the bowel end up to the skin level. After the colostomy has been pulled through the abdominal wall, the laparoscope is inserted into the right-lower-quadrant cannula, and the left colon is examined to ensure that it has not twisted as it passed from the left side to the abdomen to the anterior wall.

The pelvis is then copiously irrigated by placing the patient in the head-up position and using the right-lower-quadrant cannula site for insertion of an irrigation catheter. A cytotoxic solution may be used initially if the surgeon desires. Suction is carried out conventionally from the perineum; effluent is collected in a kidney basin. After irrigation, a silicon drain is passed through the 12-mm right-lower-quadrant cannula site, is grasped with an endoscopic grasper by the perineal surgeon, is pulled into the pelvis, and is properly placed.

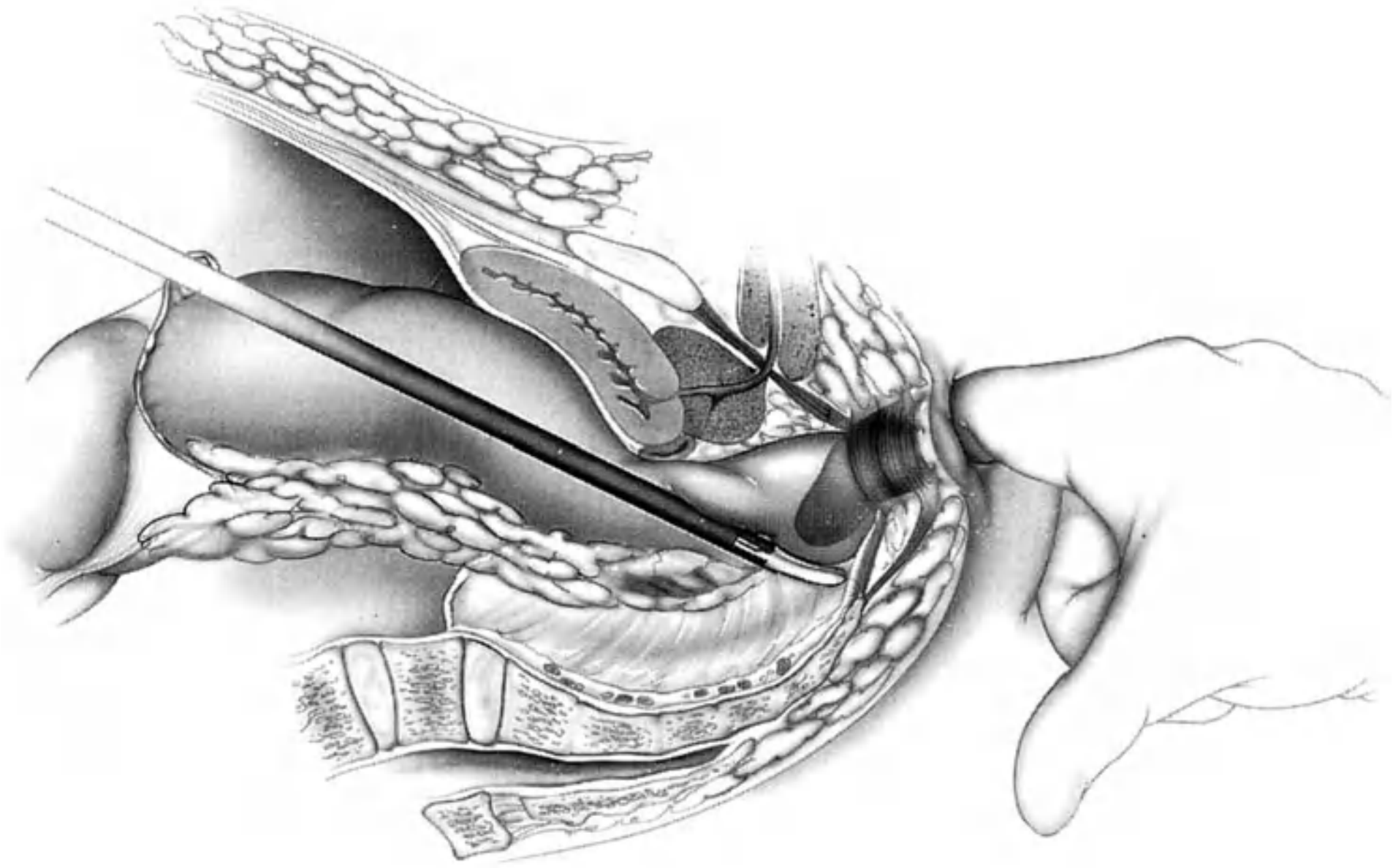

FIGURE 9.78. Complete mobilization of the rectum down to the pelvic floor is checked with digital palpation.

The perineum is closed and the colostomy is matured in a standard manner. The abdominal cavity is carefully assessed laparoscopically for any sign of hemorrhage, particularly at all vascular pedicles and areas of dissection.

Special Considerations

Aside from the caveats and the suggestions made in the previous section, Proctosigmoidectomy, Special Considerations (proctosigmoid resection with colorectal anastomosis), the following points are worth mentioning:

- Perineal pressure exerted by an assistant's fist or fingertips may greatly enhance exposure of the deep pelvis during mobilization of the distal rectum, particularly anteriorly.
- A uterine manipulator should be used early on during the anterior dissection phase in women with a uterus of nearly any size. Again, for this, an assistant standing between the patient's legs is needed.
- Especially for anterior tumors, simultaneous dissection by a perineal operator may greatly expedite the procedure. This tactic, and the use of bimanual inspection (feeling from below with fingertips and above with a laparoscopic instrument), may be valuable.

Cancer

All concepts discussed in sections in this chapter titled Right Colectomy, Proctosigmoidectomy, and Abdominoperineal Resection regarding oncologic surgery should be maintained in abdominoperineal resection. Thus, the origin of the inferior mesenteric artery must be identified and ligated proximally. Wide mesorectal and lateral rectal surgical margins must be achievable, and the proximal intestinal lumen must be occluded before specimen removal. These steps must be documented on videotape. The bowel bag is not necessary because the specimen can readily be removed through the perineum. We prefer to irrigate the pelvis and the perineal areas with a cytotoxic solution. Although there is no proof as to the efficacy of this step, it is simple, safe, takes little time, and may wash out any remaining free-floating malignant cells. For these reasons, it seems warranted. We do not close the lateral gap after forming an end colostomy with abdominoperineal resection. If a surgeon chooses to do this, either a hernia stapler or a running suture could be used.

For abdominoperineal resection for cancer, these steps should be documented on videotape: dissection of the origin of the inferior mesenteric artery with proximal ligation, wide resection of the mesorectum, and complete mobilization of the rectum. If these steps are clearly performed, then it is reasonable to assume that an oncologically satisfactory resection has been performed.

Total Abdominal Colectomy

Total abdominal colectomy entails complete laparoscopic removal of the colon from the ileocecal valve to the rectosigmoid junction at the sacral promontory.

Position

The patient is placed supine in the modified lithotomy position using Dan Allen stirrups. Surgery is begun in the Trendelenburg position (20° head-down tilt), and after cannula insertion, the patient is tilted right side down. For the first phase of the operation (dissection of the mesocolon, the inferior mesenteric pedicle, and the pelvic dissection), the surgeon and the second assistant (who acts as the cameraperson) stand on the patient's right side looking at a monitor placed near the patient's left knee, and the first assistant stands on the patient's left side looking at a monitor near the right knee. The nurse stands between the patient's legs (Figure 9.79).

For the second phase of the operation (mobilization of the left colon and the splenic flexure), the surgeon stands between the legs and both assistants stand on the patient's right side. The entire laparoscopic team looks at the monitor placed near the patient's left shoulder. The nurse moves to a position near the patient's left knee (Figure 9.80).

During the third phase of the operation (right colonic mobilization), the surgeon remains in the same position, while the first assistant and the cameraperson shift to the patient's left side. The nurse moves to a location near the patient's right knee, and the monitor located originally near the patient's right knee is shifted to a position near the right shoulder so the entire team can see it (Figure 9.81).

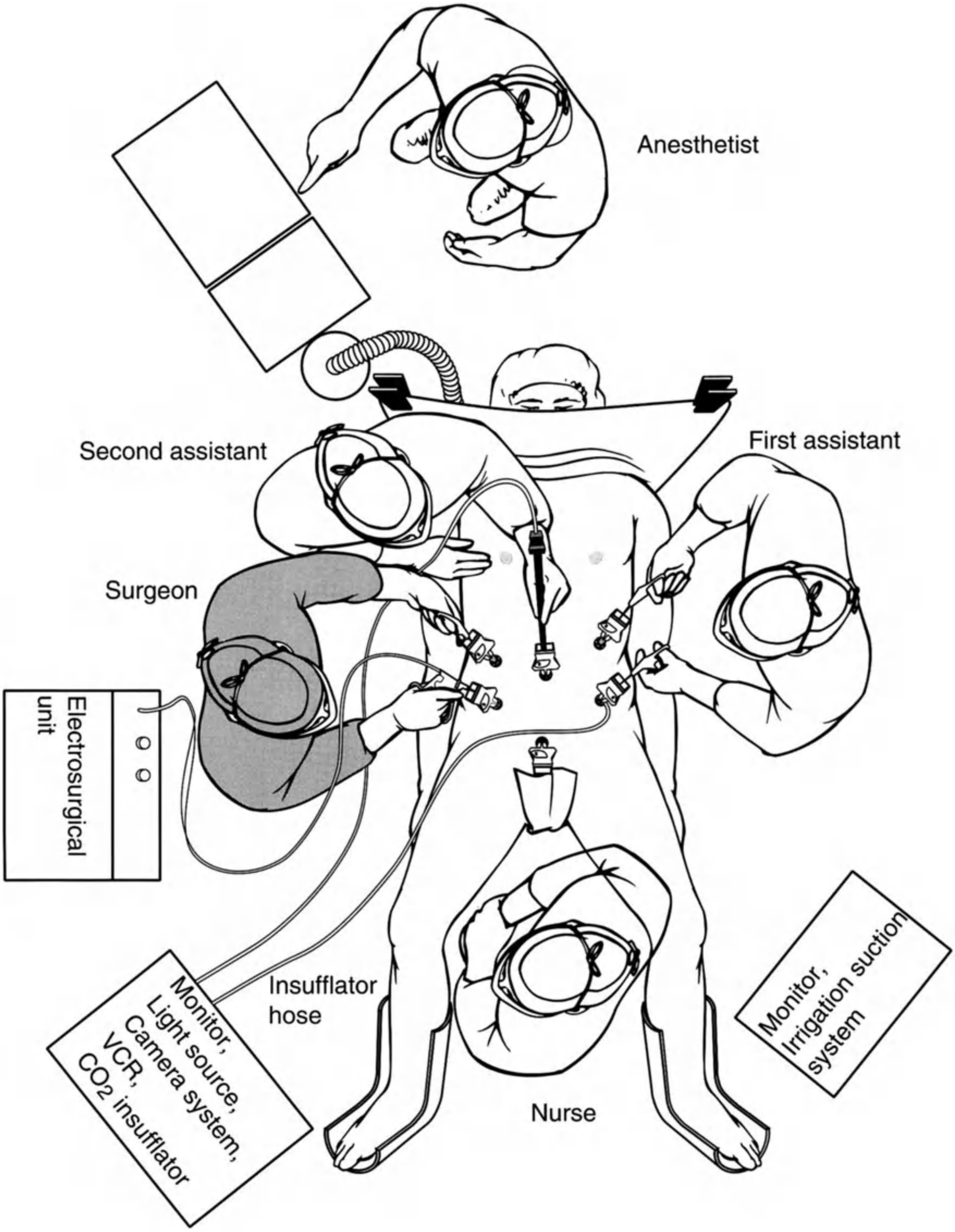

FIGURE 9.79. Position of the equipment and the surgical team for the first phase of total abdominal colectomy.

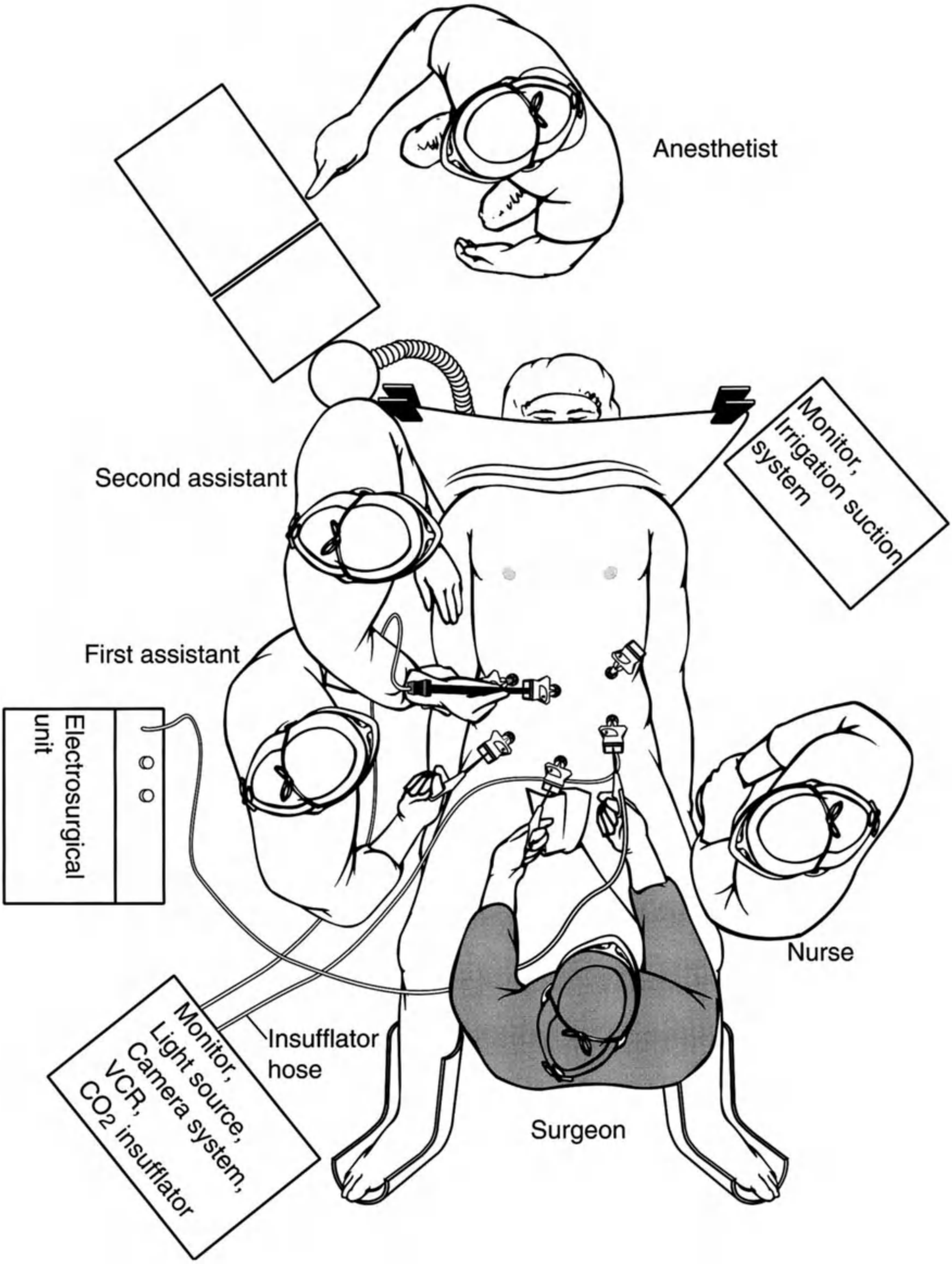

FIGURE 9.80. Position of the equipment and the surgical team for the second phase of total abdominal colectomy.

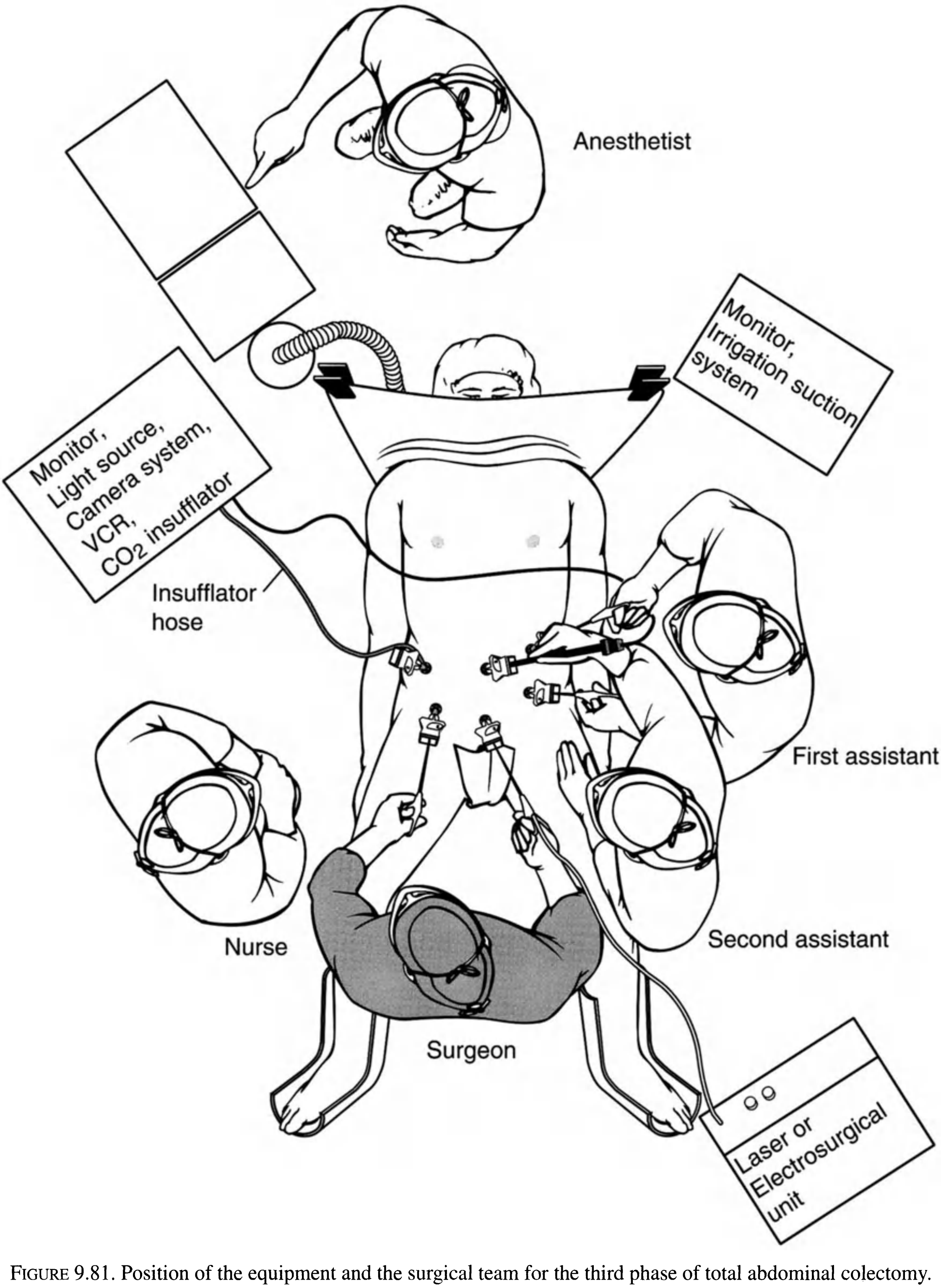

FIGURE 9.81. Position of the equipment and the surgical team for the third phase of total abdominal colectomy.

Instruments

The instruments in Table 9.6 are the minimum necessary to accomplish a total abdominal colectomy with intraperitoneal dissection of the mesentery and the ileorectal circular stapled end-to-end anastomosis. For a laparoscopic-assisted procedure, an endoscopic stapler and a snare are not necessary; 5-mm cannulas can be used in all sites except the infraumbilical site and either the suprapubic or lower-right-quadrant site, which require 10-mm cannulas. A 10-mm cannula is necessary at the suprapubic or lower-right-quadrant site in case a clip applicator must be inserted for vessel ligation.

Cannulas

The cannulas are placed as shown in Figure 9.82.

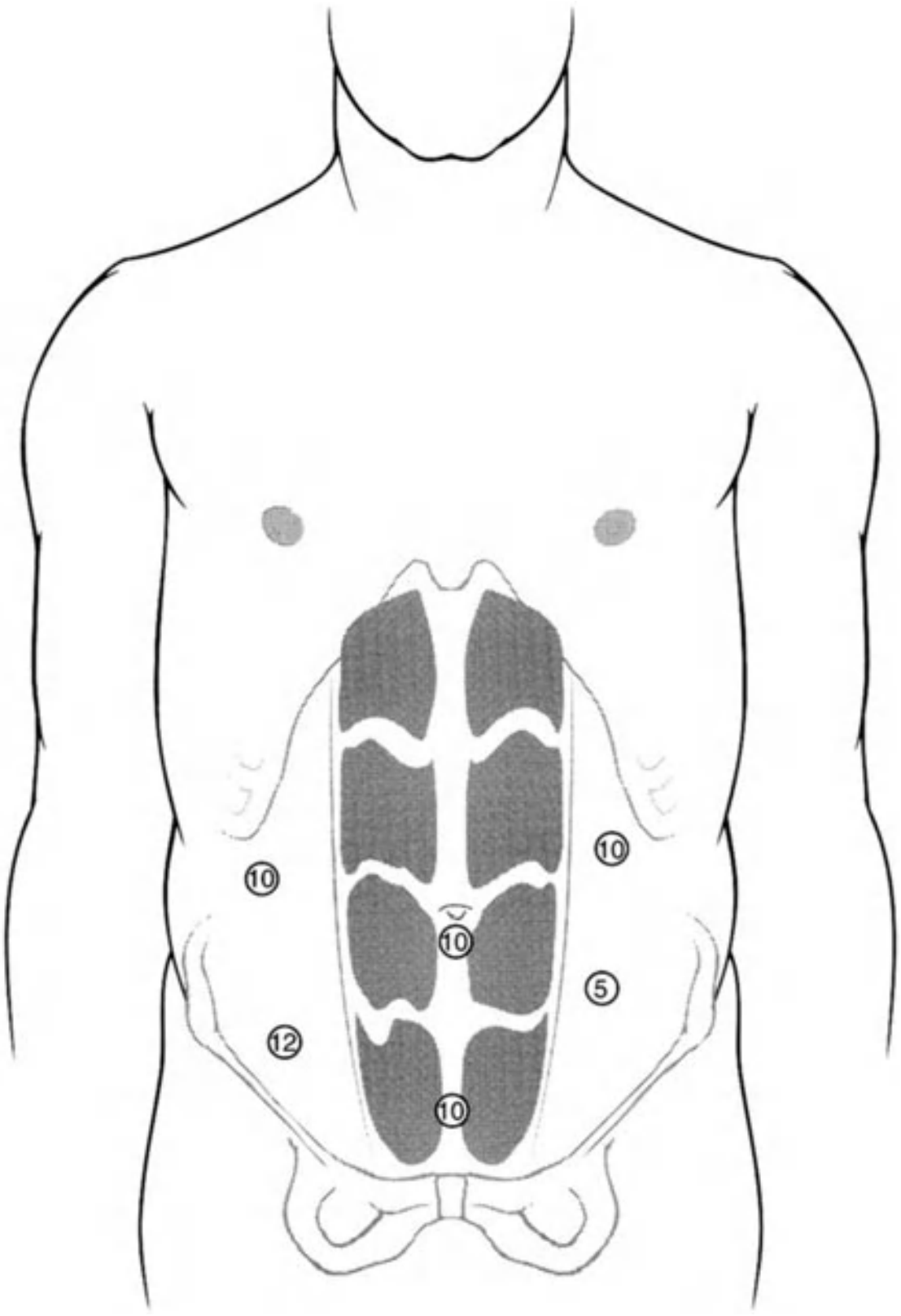

FIGURE 9.82. Position of the cannulas for total abdominal colectomy.

Procedure

The procedure begins as in proctosigmoidectomy (see previous section). The patient is placed in a steep Trendelenburg position and is tilted right side down so the small intestine falls into the right upper quadrant. All small-intestinal loops are retracted out of the pelvis. The assistant holds the mesosigmoid under traction in a ventrolateral direction using the Babcock-like grasper in the left-upper-quadrant cannula and a smaller grasper in the left-lower-quadrant cannula. The peritoneum is incised immediately to the right of the inferior mesenteric artery, starting at the sacral promontory (Figure 9.83). Under continuous traction, the peritoneum is incised cephalad toward the direction of the origin of the inferior mesenteric artery. Using blunt dissection, the inferior mesenteric artery and vein are swept ventrally away from the preaortic hypogastric neural plexus, which is swept dorsally to prevent injury to it. Dissection is continued medially beneath the inferior mesenteric artery and vein; the left ureter and the gonadal vessels are identified and are swept posteriorly (Figure 9.84). If the ureter cannot be readily and easily identified at this point in the dissection, the lateral attachments of the sigmoid are incised, the sigmoid colon is mobilized left to right, and the gonadal vessels and

TABLE 9.6. Instruments required for laparoscopic total abdominal colectomy.

No.	Type
6	Cannulas (1 × 12 mm,* 4 × 10 mm,* 1 × 5 mm) including anchoring devices and converters
1	Dissecting device
1	Endoscopic scissors
1	Endoscopic dissector
2	Endoscopic graspers (one Babcock-like and one small)
1	Endoscopic snare*
1	Endoscopic clip applier (large size)*
1	Multifire Endo GIA 30 stapler*
6	Endo GIA 30 cartridges*
1	Curved stapler (28 or 31 mm)

* Not needed if only mobilization is to be performed laparoscopically (see Instruments section).

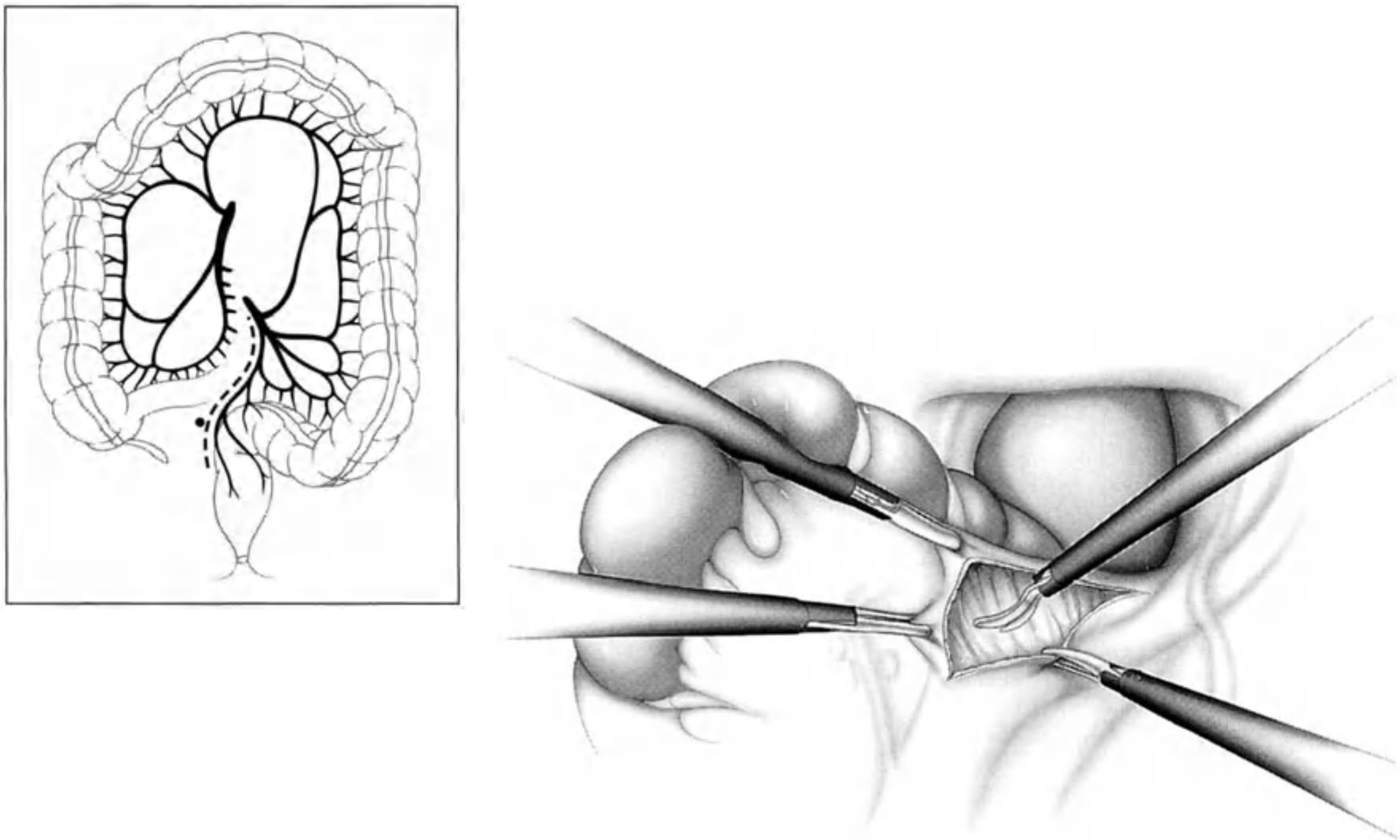

FIGURE 9.83. The dissection commences with an incision in the retroperitoneum just to the right of the inferior mesenteric artery.

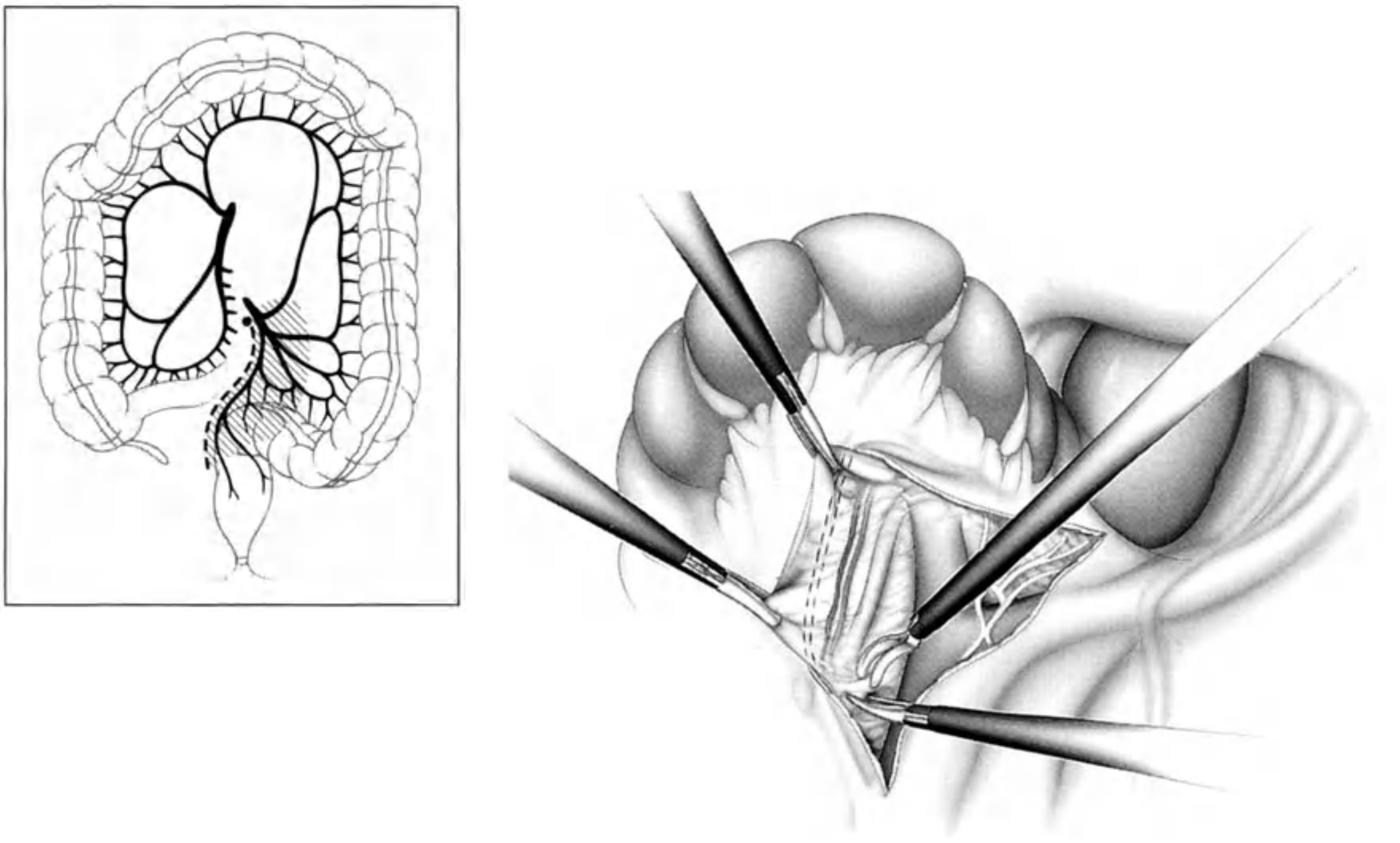

FIGURE 9.84. Dissection continues toward the origin of the inferior mesenteric artery; the left ureter and the gonadal vessels are identified.

the ureter then are identified and dissected free of the mesentery.

Once the origin of the inferior mesenteric artery is identified, the peritoneum is incised anteriorly over this pedicle and then left toward the inferior mesenteric vein. Using a combination of blunt and sharp dissecting techniques, a peritoneal window is made just lateral to the inferior mesenteric vein. The pedicle of the inferior mesenteric artery and vein is ligated above or below the left colic artery (according to the surgeon's judgment) with a 30-mm endoscopic vascular stapler, but only after the left ureter has been clearly identified and retracted so it is not injured (Figure 9.85). We prefer to leave the inferior mesenteric artery 1.0 to 1.5 cm long so if any bleeding occurs, an additional ligature can be applied to the vessel. After the stapler has been placed across the inferior mesenteric artery (and concurrently placed across the inferior mesenteric vein if this is feasible and safe), the stapler is closed and again the ureter is checked. The tip of the stapler should be free and clearly visible, and then fired. Before the fired stapler is opened, both ends of the pedicle are grasped so any bleeding can be easily controlled. If the inferior mesenteric vein is not simultaneously ligated by the first stapler, it is clipped or stapled separately.

The lateral attachments of the sigmoid colon are dissected free, and the sigmoid colon is completely mobilized using sharp and blunt dissection as in open surgery (Figure 9.86). Again, great care should be taken at this juncture to identify and to avoid any injury to the gonadal vessels or the ureter. To identify the distal resection line of the bowel, an experienced assistant should perform proctoscopy. At the specified point of resection (12 to 15 cm from the anal verge), the laparoscopic surgeon places a marking clip on the mesenteric fat. The upper rectum is mobilized (Figure 9.87). The mesorectum at this point is divided sharply, starting on the right side; large vessels are clipped. If the mesorectum is difficult to dissect or if several prominent vessels must be divided, it may be most expeditious to divide the mesorectum with a 30-mm endoscopic stapler, after dissecting a

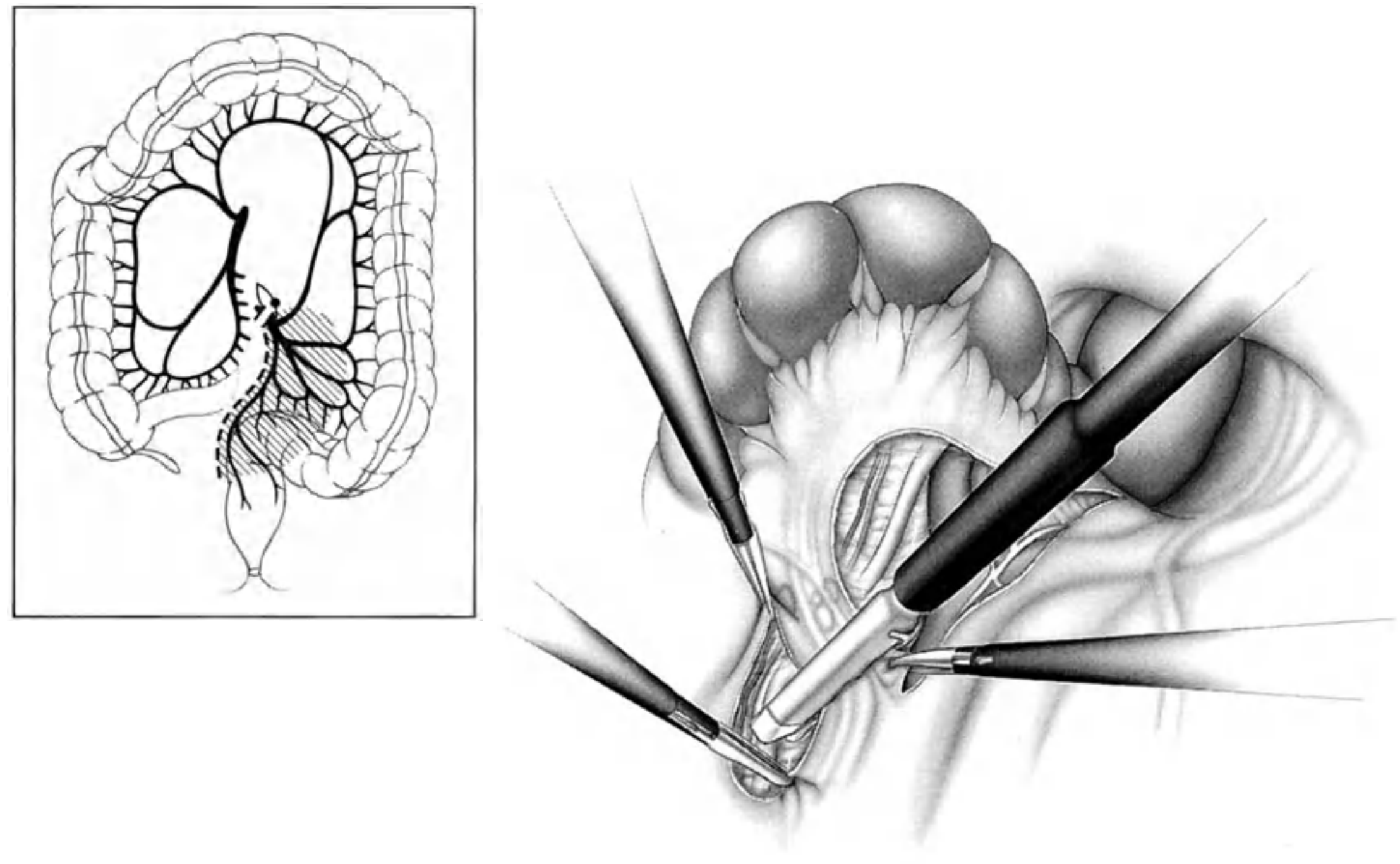

FIGURE 9.85. An endoscopic 30-mm linear stapler is used to ligate and to divide the inferior mesenteric artery close to its origin. The left ureter and the gonadal vessel have been swept away from the vessels. The inferior mesenteric vein may often be ligated simultaneously.

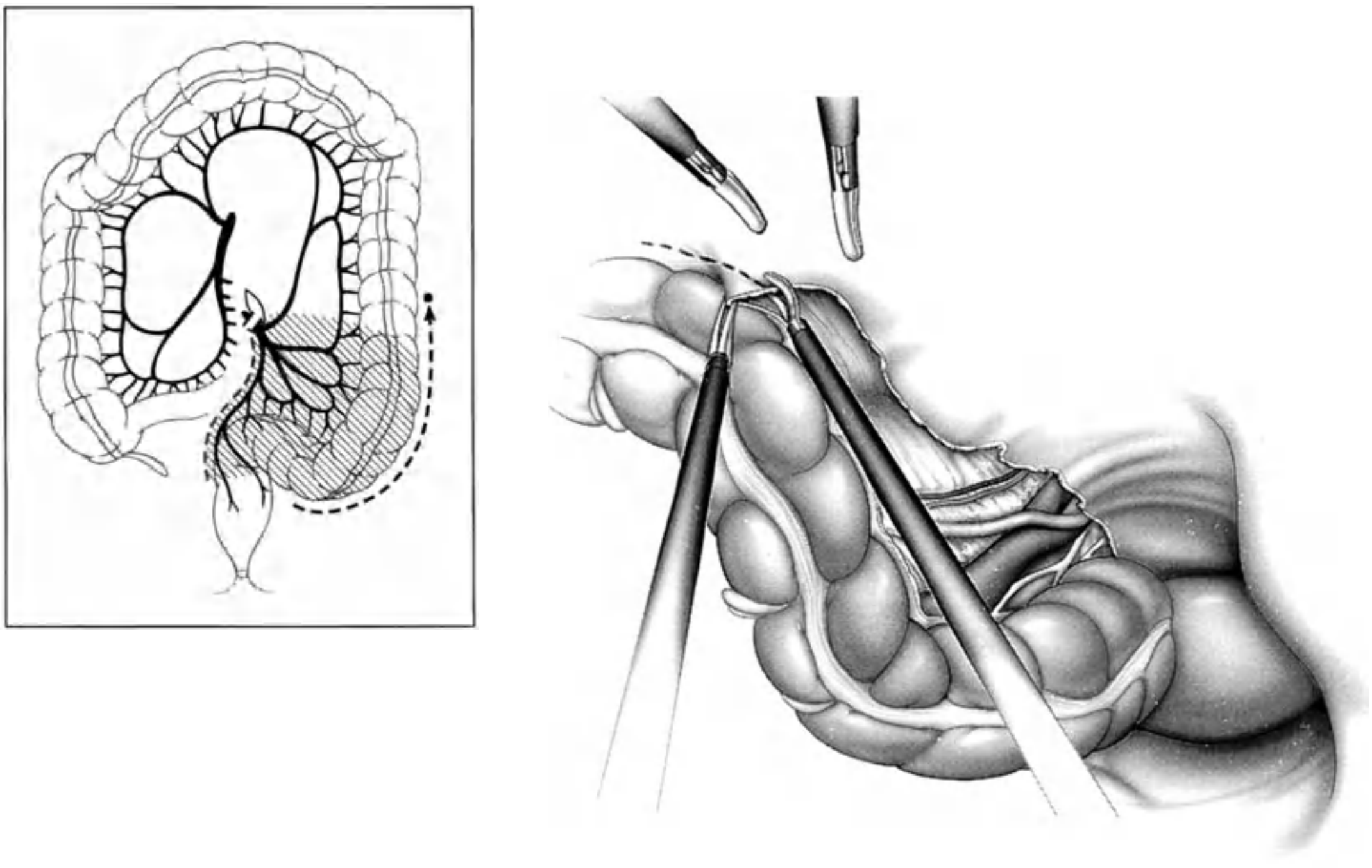

FIGURE 9.86. Initial dissection of the lateral attachments of the sigmoid and left colon.

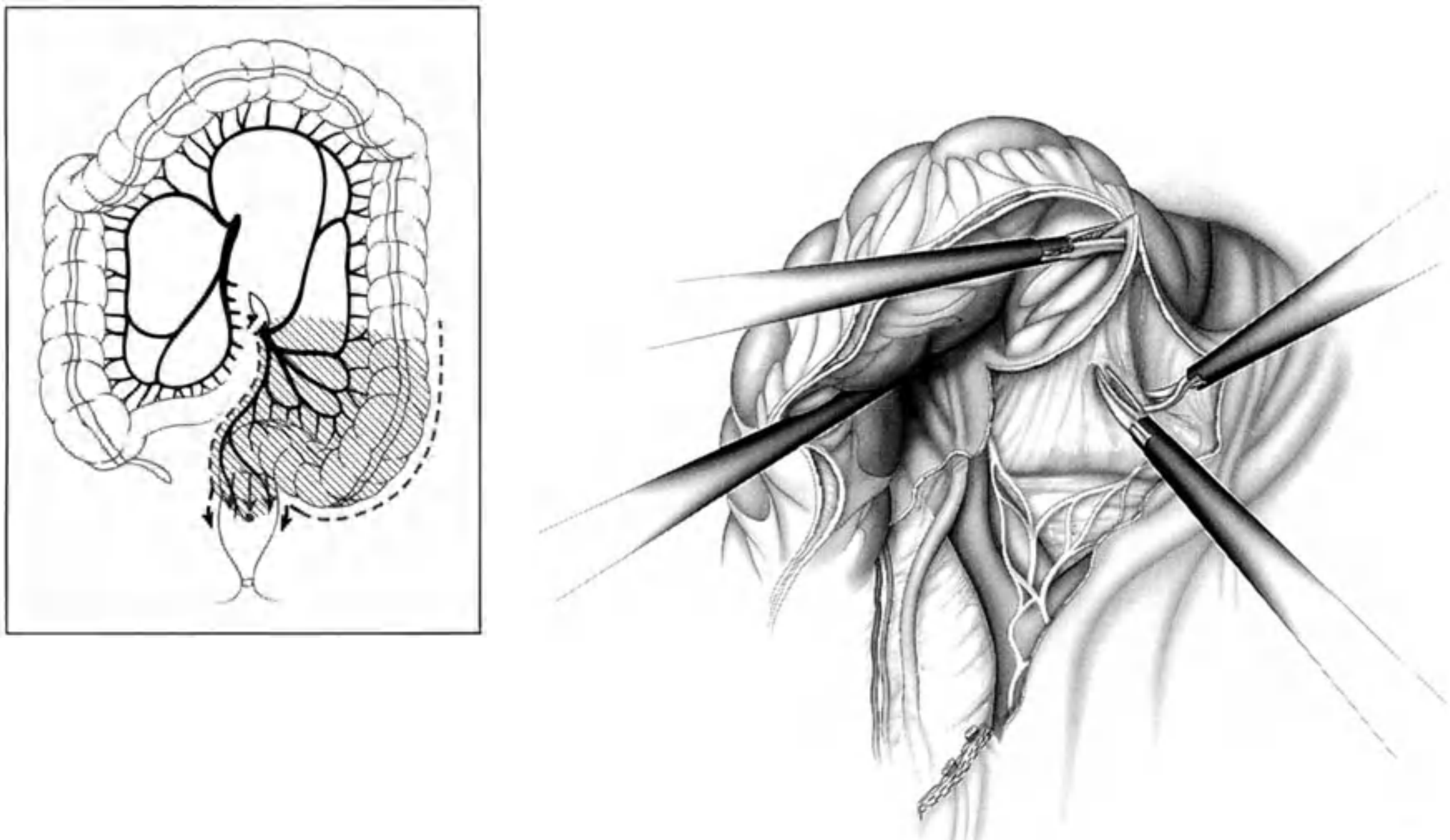

FIGURE 9.87. The rectum is mobilized to a point just below the sacral promontory.

plane between the posterior wall of the rectum and the anterior portion of the mesorectum (Figure 9.88). The rectum itself is then transected with two to three applications of the 3-cm endoscopic stapler (Figure 9.89).

As soon as the bowel is divided, the surgical team repositions itself for the second phase of the operation, splenic flexure and left colon mobilization (Figure 9.80). The surgeon works through the suprapubic and the left-lower-quadrant cannulas, while the first assistant works through the right-upper-quadrant and the right-lower-quadrant cannulas. Through the right-upper-quadrant cannula, the first assistant passes an endoscopic snare into the abdomen and pulls the cut end of the descending colon through the loop with a grasper (Figure 9.90). The snare is threaded proximally over the bowel to the undissected attachments of the left colon. Tension is placed on the left colon and its mesenteric attachments by exerting medial and cephalad traction on the snare. The colon distal to the snare should be flipped cephalad over the snare shaft to better expose the posterior mesenteric attachments of the bowel to the retroperitoneum.

The surgeon then continues dissecting in a cephalad manner, sweeping Gerota's fascia away from the posterior surface of the colonic mesentery. First, all medial mesenteric attachments should be divided as far cephalad as possible, in a line parallel to and just to the left of the inferior mesenteric vein. Occasionally, there is a left colon or a splenic flexure venous branch that must be isolated and divided during this process (Figure 9.91).

After the posterior surface of the mesocolon has been dissected cephalad as far as possible, the lateral attachments of the colon are placed under tension and are divided. The snare is steadily moved proximally up the colon as the dissection proceeds cephalad to obtain maximal tension on the peritoneal attachments of the colon. This sequence of retraction and dissec-

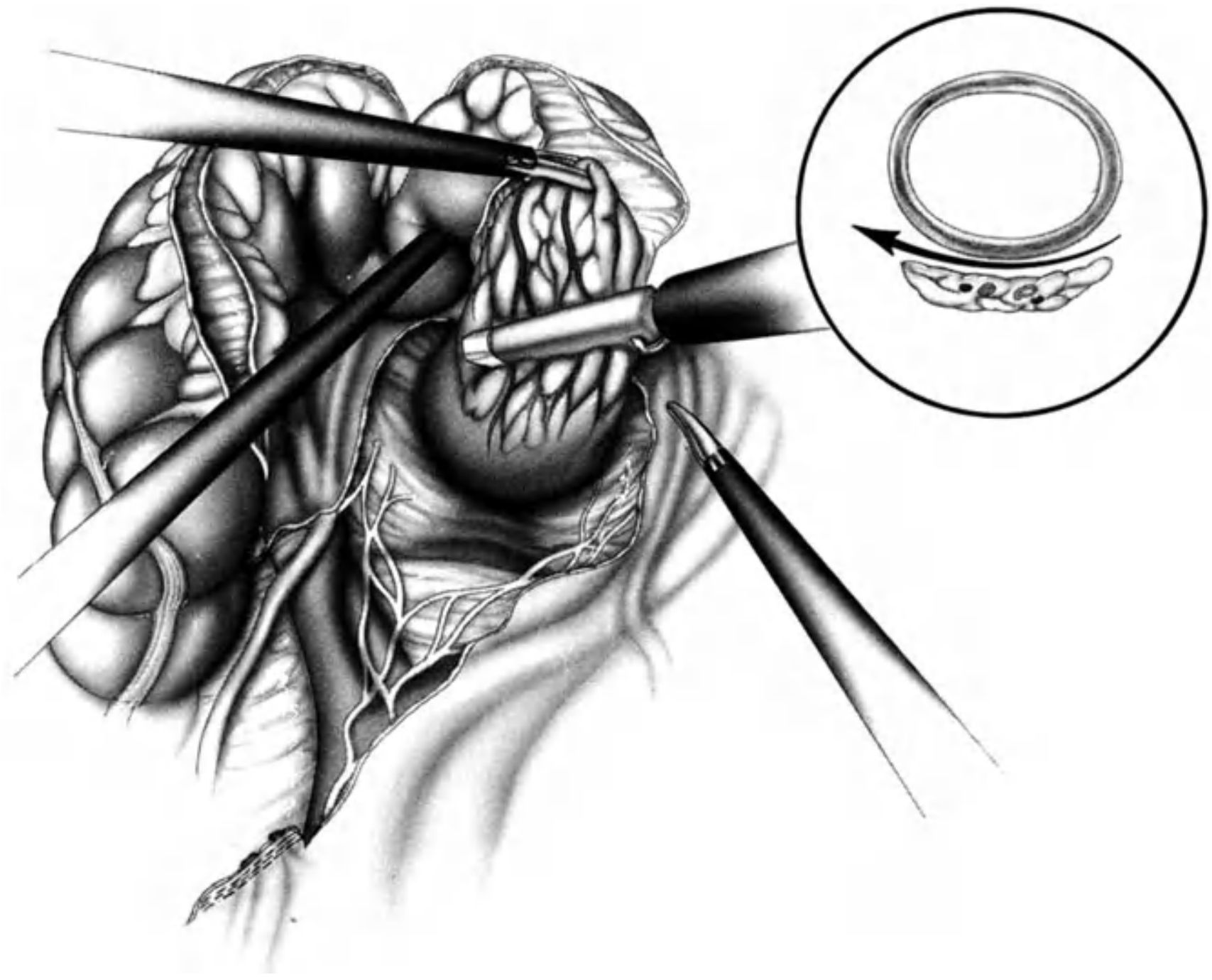

FIGURE 9.88. After a plane between the rectum and the mesorectum has been created, the mesorectum is divided using electrosurgery or by passing a 30-mm endoscopic vascular stapler across it. Inset, Cross-sectional view as to how the plane is struck between the rectum and the mesorectum (arrow).

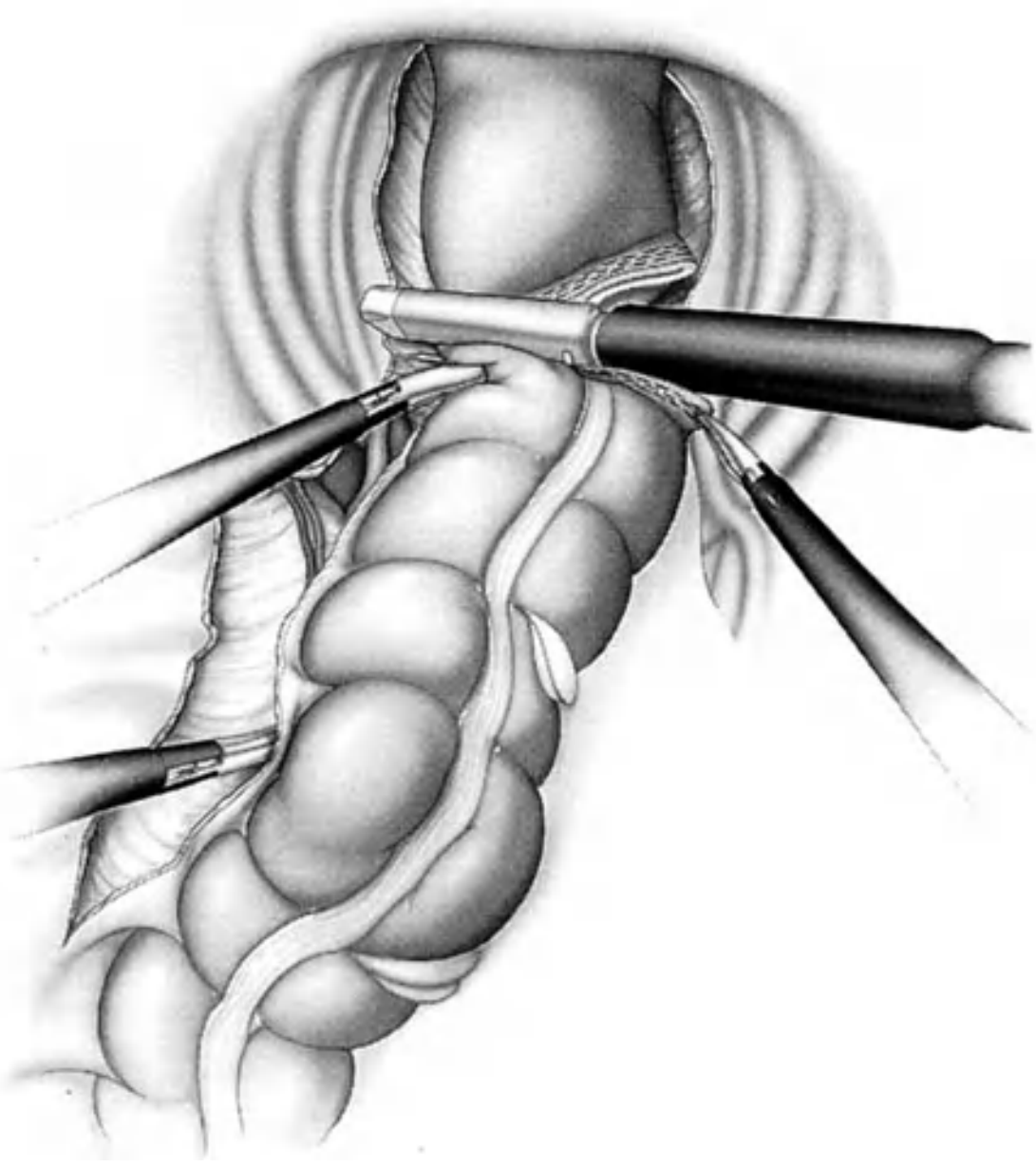

FIGURE 9.89. The rectum is transected at the sacral promontory using two or three applications of a 30-mm endoscopic stapler.

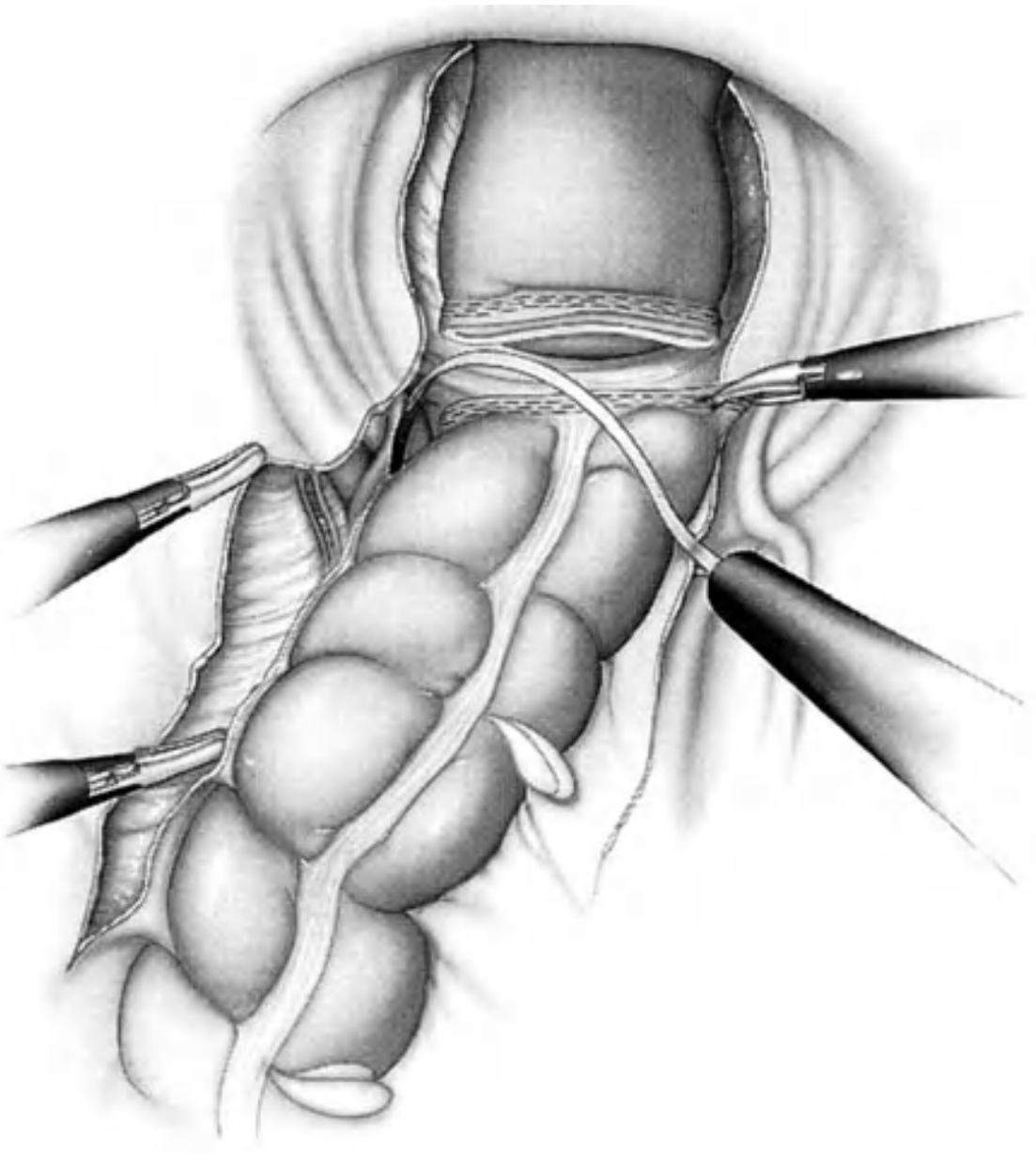

FIGURE 9.90. To begin mobilization of the left colon and splenic flexure, the proximal segment of divided colon is gently pulled through an endoscopic snare.

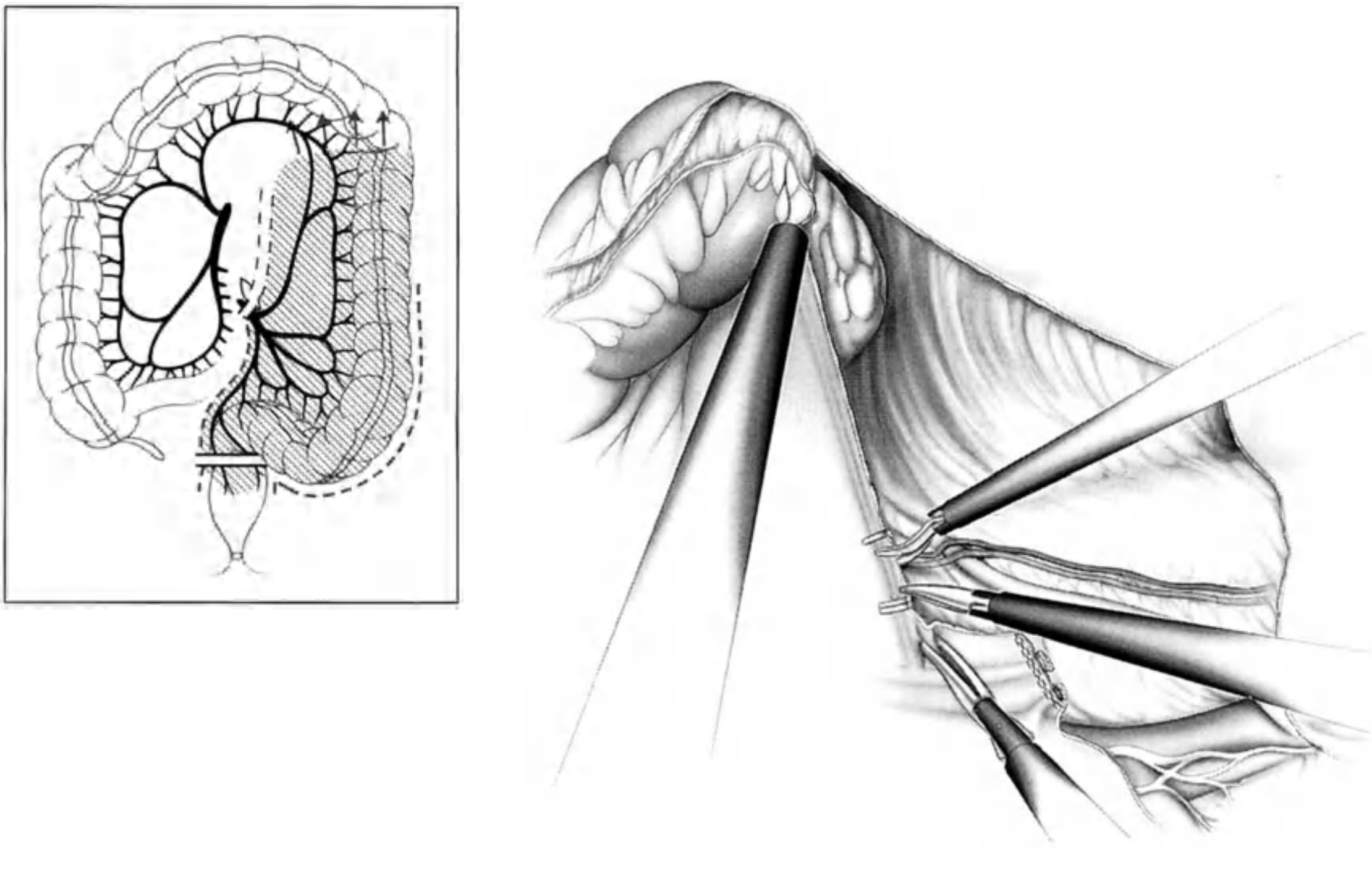

FIGURE 9.91. The medial attachments of the left colonic mesentery should be isolated and divided early in the dissection, carefully clipping any vessels encountered.

tion will greatly expedite the splenic flexure takedown (Figure 9.92). During this dissection, the surgeon constantly must remain in the proper planes—generally close to the bowel edge laterally, and between Gerota's fascia and the colonic mesentery.

In the region of the splenic flexure, the greater omentum gradually appears and is distinguishable from the epiploic appendices by its finer lobulated fatty texture. Separation of the omentum from the colon and these appendices is essential for accurate mobilization of the flexure (Figure 9.93). The surgeon may need to switch cannula positions to comfortably reach the splenic flexure, moving from the suprapubic and the left-lower-quadrant cannulas to the left-upper-quadrant and the left-lower-quadrant cannulas.

If the splenic flexure proves difficult to dissect, the dissection can be continued right to left from the distal transverse colon toward the splenic flexure, detaching the omentum from this area as in conventional surgery. In our experience, it is important to mobilize the left colon and the left mesocolon as far cephalad as possible in the dorsal mesenteric plane adjacent to Gerota's fascia. This greatly simplifies the mobilization of the splenic flexure, and may simplify dissection of the greater omentum and the lateral adhesions close to the colonic wall. With complete mobilization of the splenic flexure, the surgical team dissects the omentum from the distal transverse colon as far to the right as is possible and practical (Figure 9.94).

At this point, the surgical team repositions itself for the third phase of the procedure, right colonic mobilization (Figure 9.81). Thus, the patient is tilted left side down in the Trendelenburg position so the small intestine falls toward the left upper quadrant. The first assistant places the dorsal mesenteric attachments of the terminal ileum under tension with graspers in the left-upper-quadrant and the left-lower-quadrant cannula sites. The surgeon begins dissection through the suprapubic and the right-lower-quadrant cannulas, incising the retroperitoneal attachments of the ileum just medial to the base of the appendix, carrying the incision cephalad

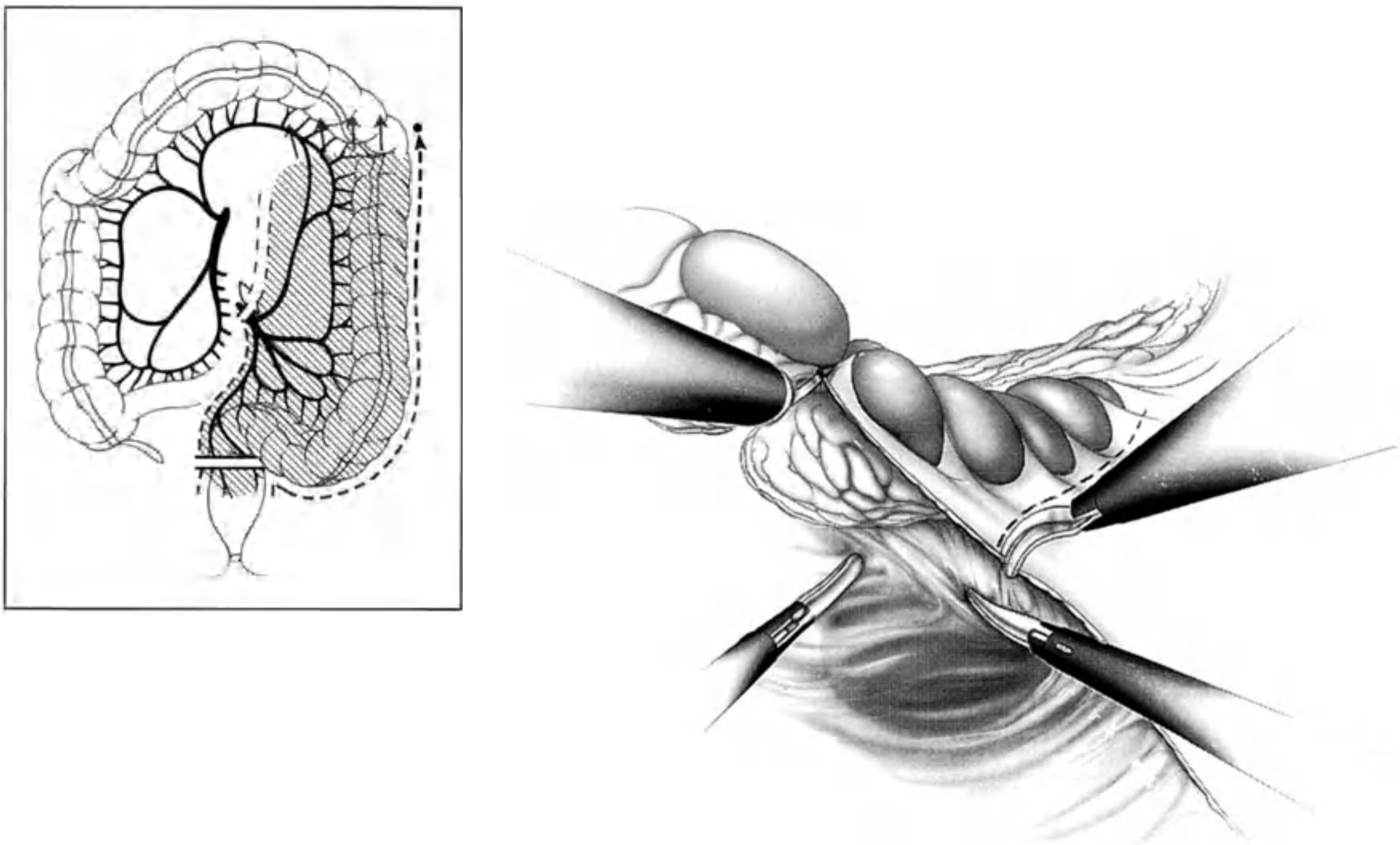

FIGURE 9.92. The splenic flexure should initially be dissected from its posterior and lateral aspect—this approach expedites complete mobilization of the flexure.

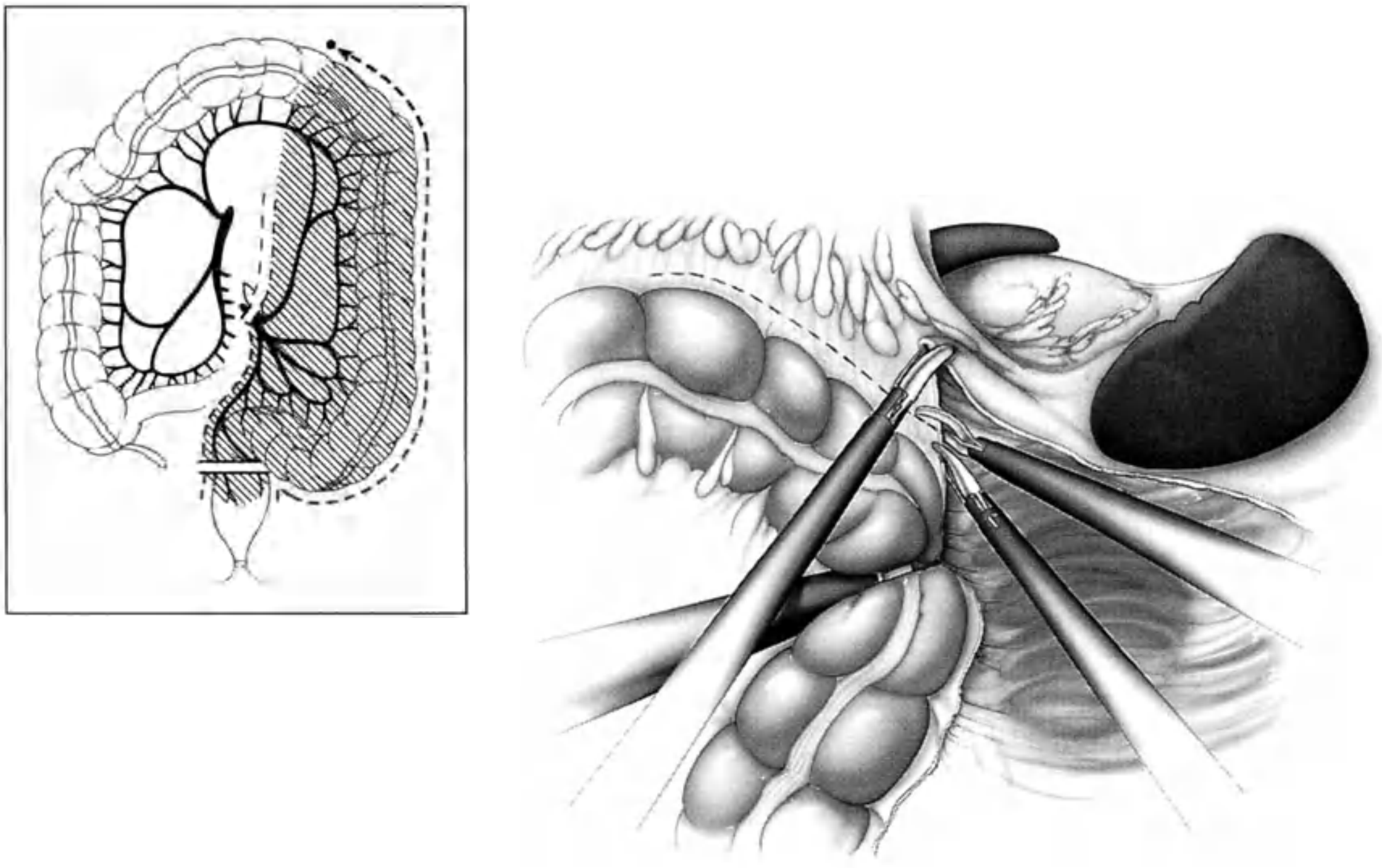

FIGURE 9.93. The greater omentum is separated from the splenic flexure by carefully applying traction and countertraction, which more clearly reveals the plane between the omentum and the colon.

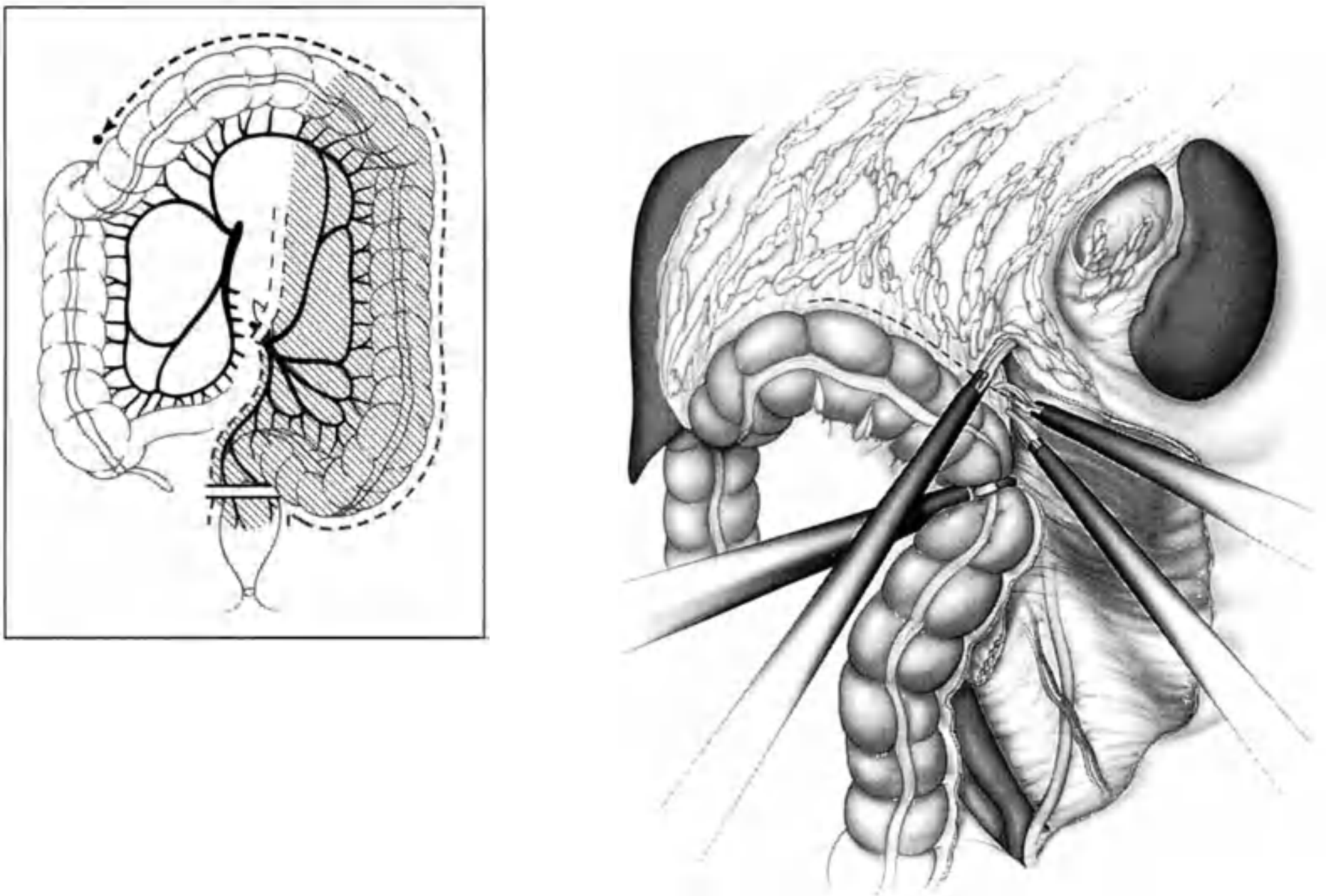

FIGURE 9.94. The omentum should be dissected to the right as far as necessary to fully mobilize the left colon.

and to the left toward the inferior edge of the duodenum (Figure 9.95). After the peritoneum is incised, the ileal and right colonic mesentery are completely freed retroperitoneally by bluntly dissecting a tunnel beginning dorsal to the ileal mesentery (Figure 9.96). With this maneuver, the duodenum, the right ureter, the gonadal vessels, and Gerota's fascia become clearly visible (Figure 9.97).

The ileocolic artery and vein are identified on their dorsal aspects in the mesentery (Figure 9.98) and are traced to their origin from the superior mesenteric artery and vein. All vessels are carefully dissected at a safe distance from the superior mesenteric artery and vein, and a window through the mesentery is made on either side of the two vessels. The ileocolic pedicle is traced distally to the cecum before division to correctly distinguish it from the superior mesenteric artery and vein. This may require flipping the mesentery and the ileum caudally, and examining the vessels from their ventral aspect. The pedicles are clipped and then divided, or stapled and transected with an endoscopic vascular stapler (Figure 9.99).

Dissection is continued cephalad from the ventral aspect of the right mesenteric root, continuing superiorly and medially until the peritoneal reflection of the middle colic vessels is seen. This reflection is divided sharply and blunt dissection is used to isolate the roots of middle colic vessels. The middle colic vessels are next separated from the retroperitoneal structures and the structures of the lesser omental sac; particular care is needed near the superior aspect of these vessels. The vessels are then ligated with large clips or by applying a 30-mm endoscopic vascular stapler (Figure 9.100). Just to the left of the middle colic pedicle, the mesenteric edge of the transverse colon is grasped, and the peritoneum is incised as far to the left as possible. Additional vessels of the transverse mesocolon are divided between clips as needed (Figure 9.101). The greater omental attachments to the transverse colon at this point are dissected from the colon, thus completely free-

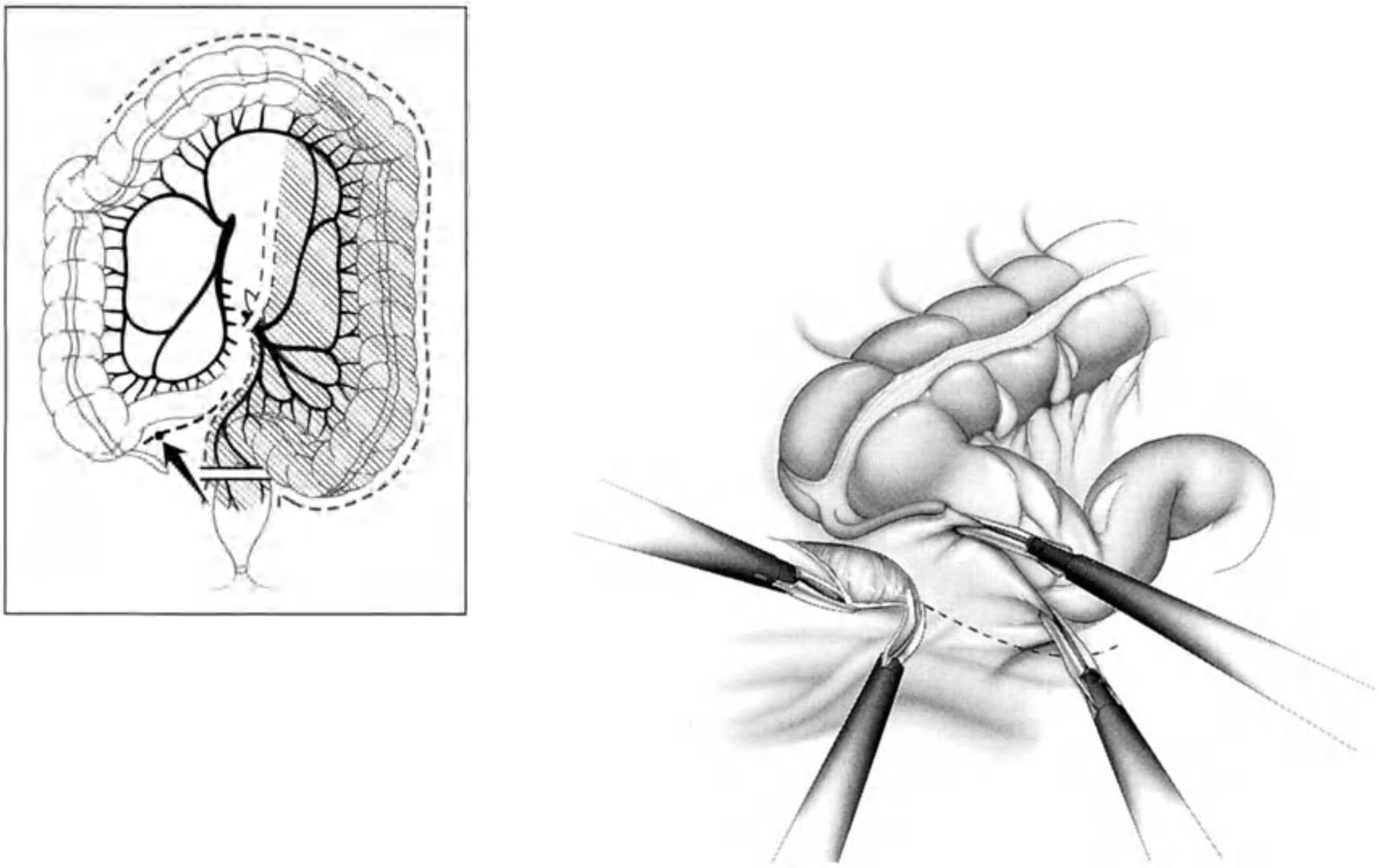

FIGURE 9.95. Initial exposure of the cecum and the terminal ileum. The peritoneum is incised along the base of the ileal mesentery up to the duodenum.

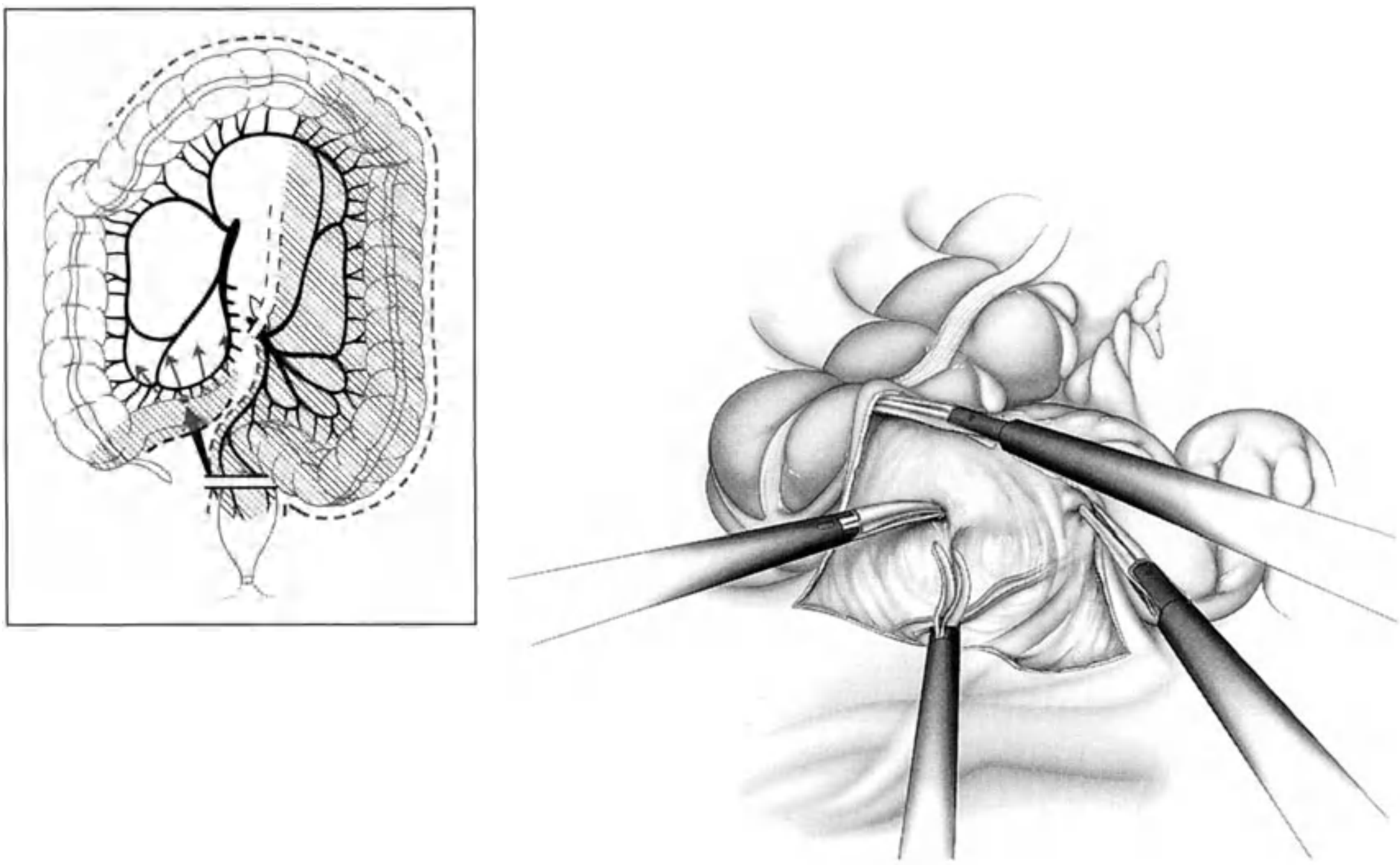

FIGURE 9.96. A window is created in the retroperitoneum to separate the ileal and right colon mesentery from retroperitoneal structures.

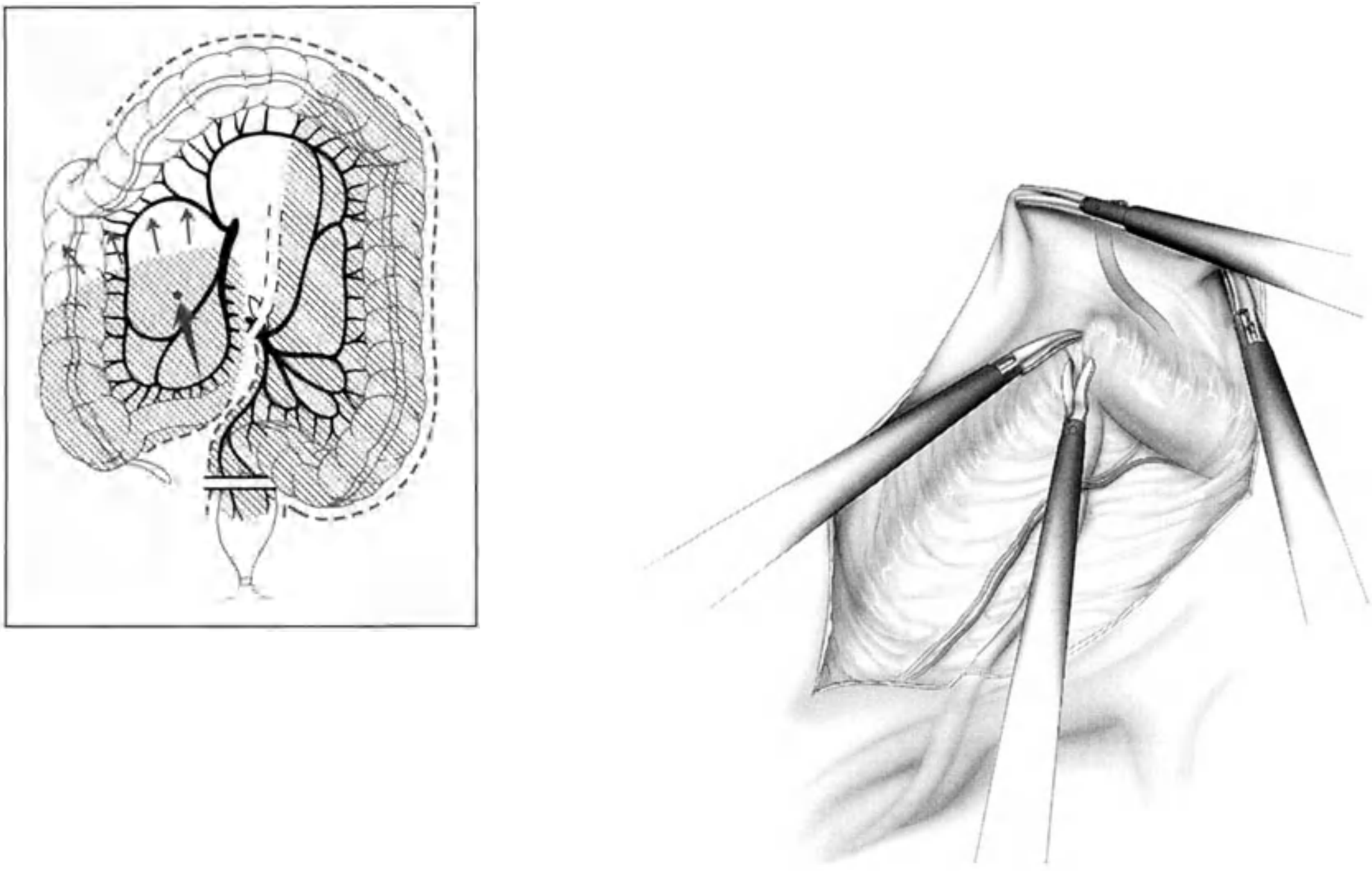

FIGURE 9.97. The right ureter, the gonadal vessels, Gerota's fascia, the duodenum, and the caudal parts of the pancreas have been dissected away from the mesentery in the course of creating a retroperitoneal tunnel.

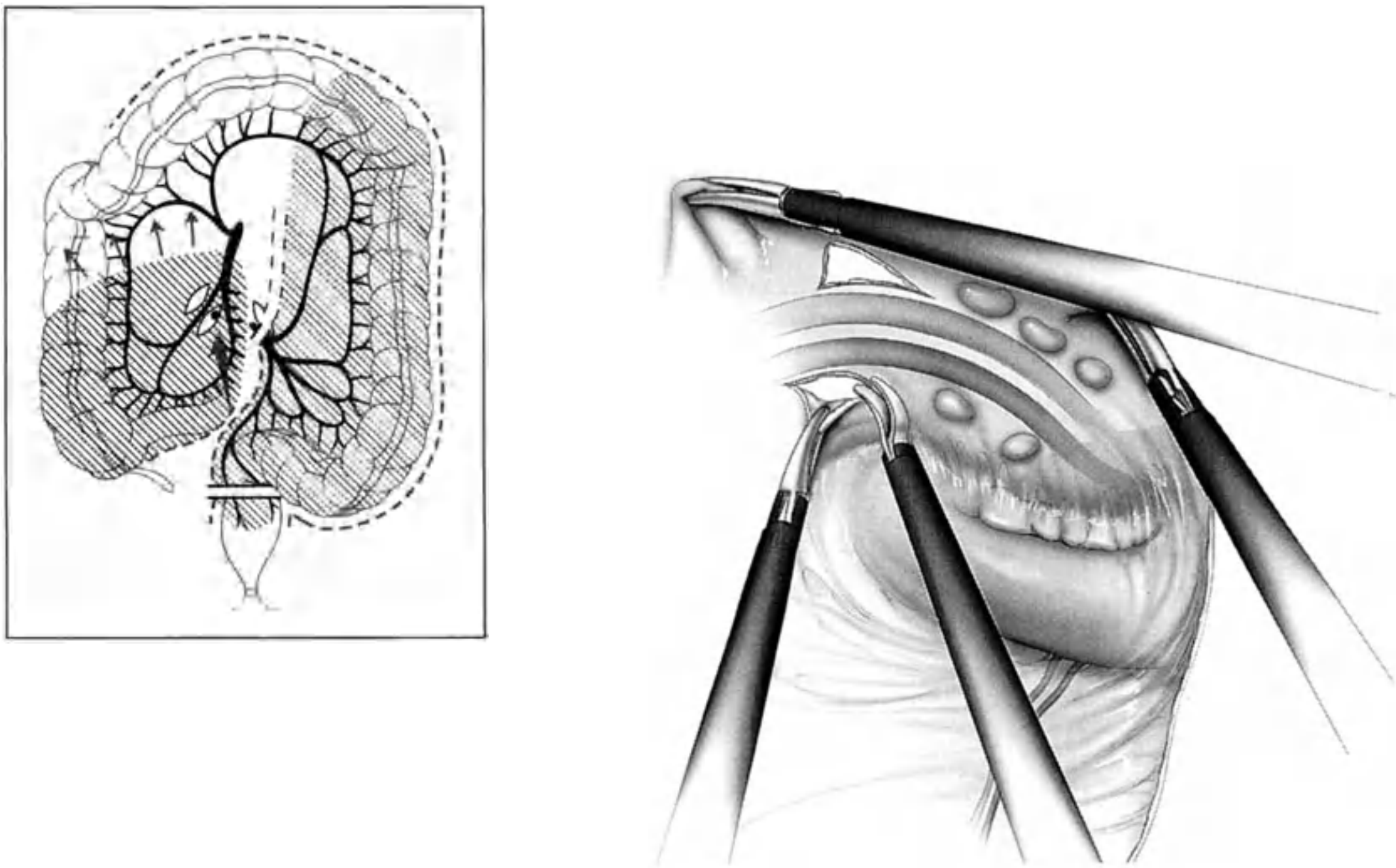

FIGURE 9.98. The ileocolic lymphovascular pedicle is isolated at its origin and an incision is made on one or both sides of the vessels in preparation for subsequent ligation and transection.

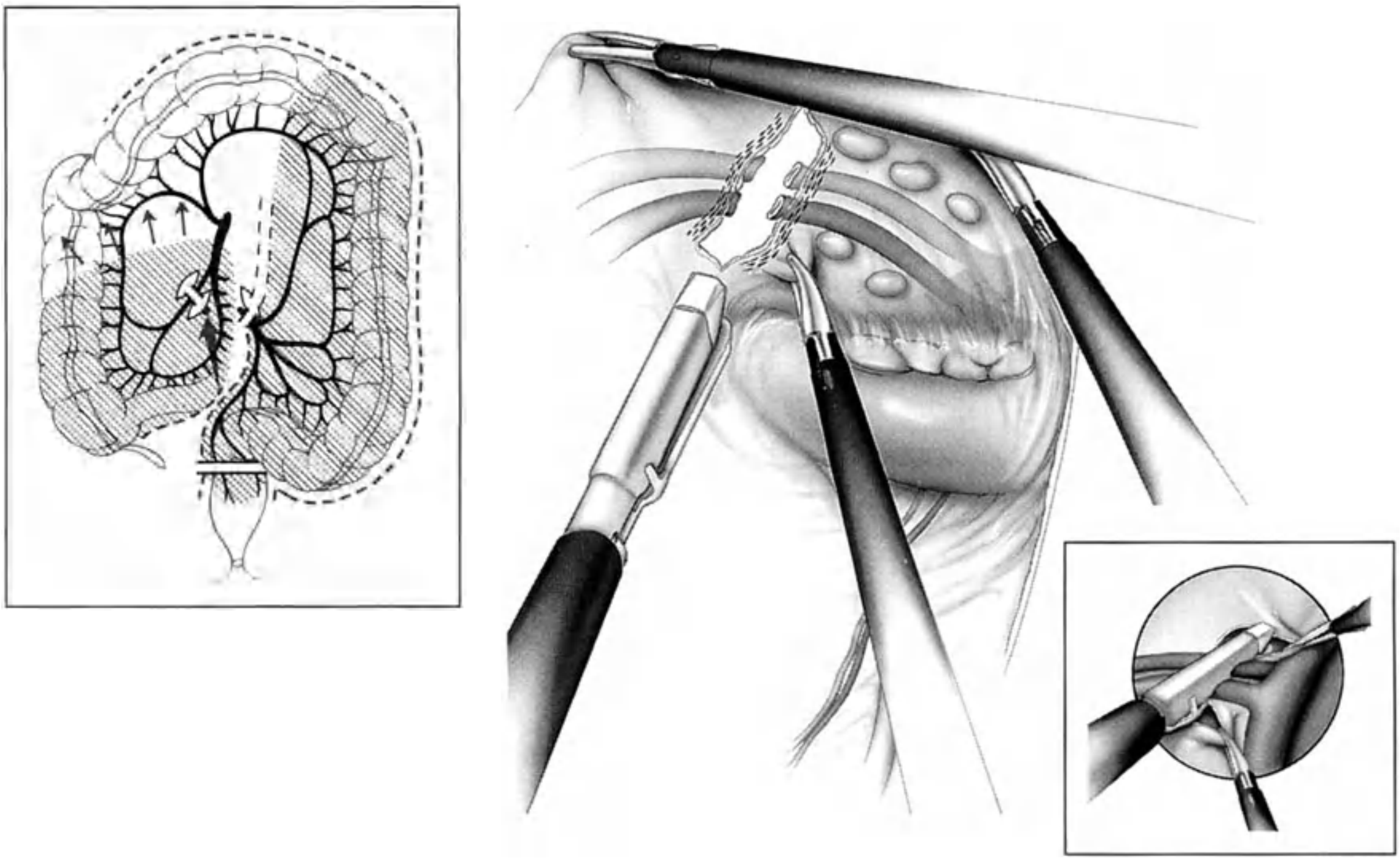

FIGURE 9.99. Transection of the clipped ileocolic lymphovascular pedicle from the dorsal aspect. Inset, Alternatively, the pedicle may be approached anteriorly and ligated, then divided using the 30-mm endoscopic stapler.

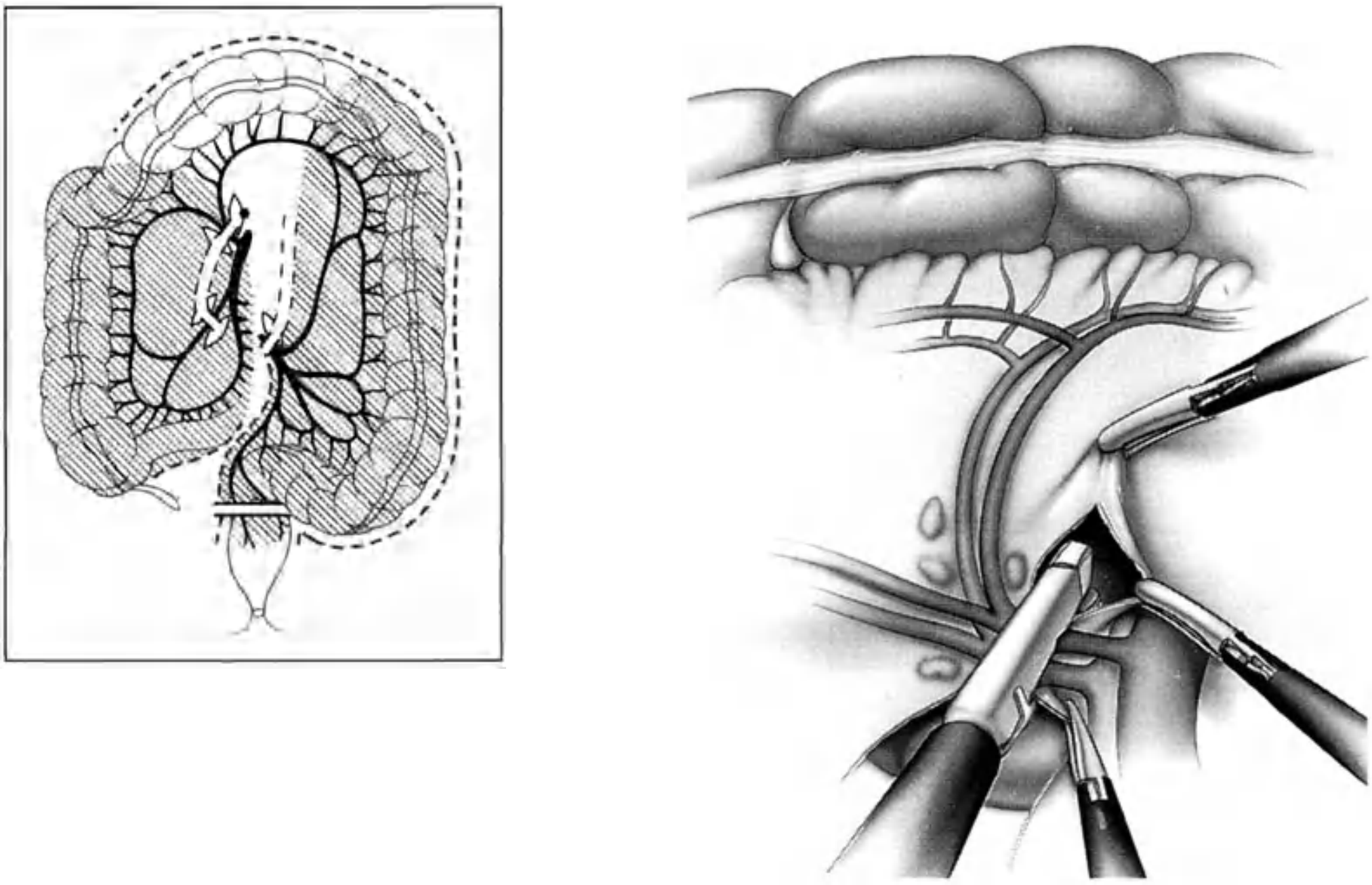

FIGURE 9.100. The transverse colon is grasped and its lymphovascular pedicle is stapled and transected close to the origin of middle colic vessels using a 30-mm endoscopic stapler.

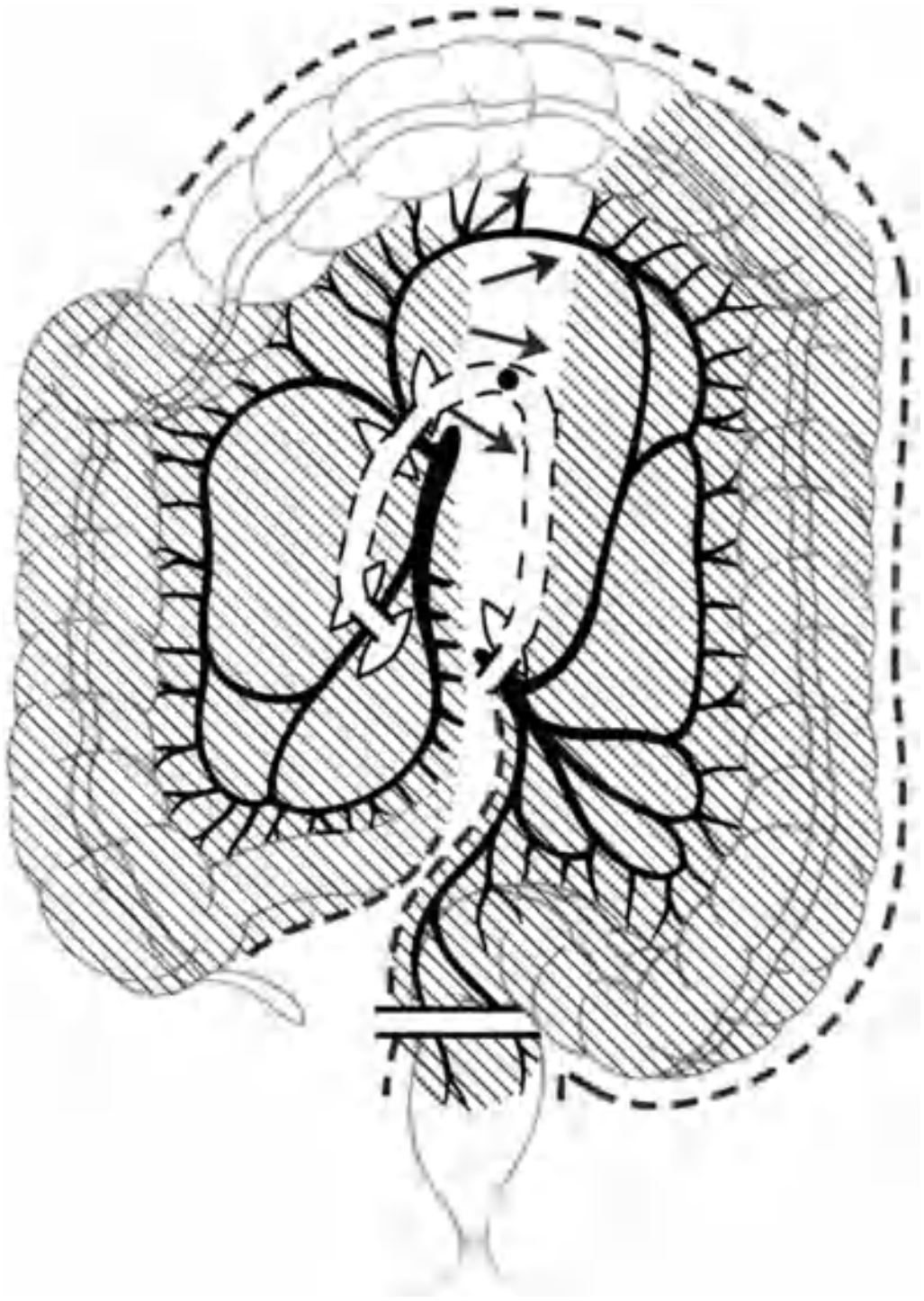

FIGURE 9.101. Completion of transection of the transverse colonic mesentery to the left of the middle colic vessels.

ing the omentum from the bowel. Vessels of the omentum are electrocoagulated or clipped, and divided as necessary. The terminal ileum is next grasped and the proximal resection line is identified near the ileocecal junction. The ileal mesentery is completely dissected starting from the left side of the ileocolic pedicle. All mesenteric vessels are clipped, and divided or coagulated (Figure 9.102).

Next, starting at the cecum, the right colon and the hepatic flexure are completely detached from retroperitoneal structures. Because most of the mobilization of the colon has been performed dorsally, only minor adhesions with the lateral and posterior abdominal wall have to be transected up to and just beyond the hepatic flexure (Figure 9.103).

It may sometimes be useful to transect the terminal ileum in order to apply the snare as a retracting device that may be slid up and onto the right and transverse colon. It may be especially helpful in dissecting the transverse mesocolon. At this point, the colon should be completely free from surrounding structures. The endoscopic snare is then passed from the divided rectosigmoid region to the ileocolic junc-

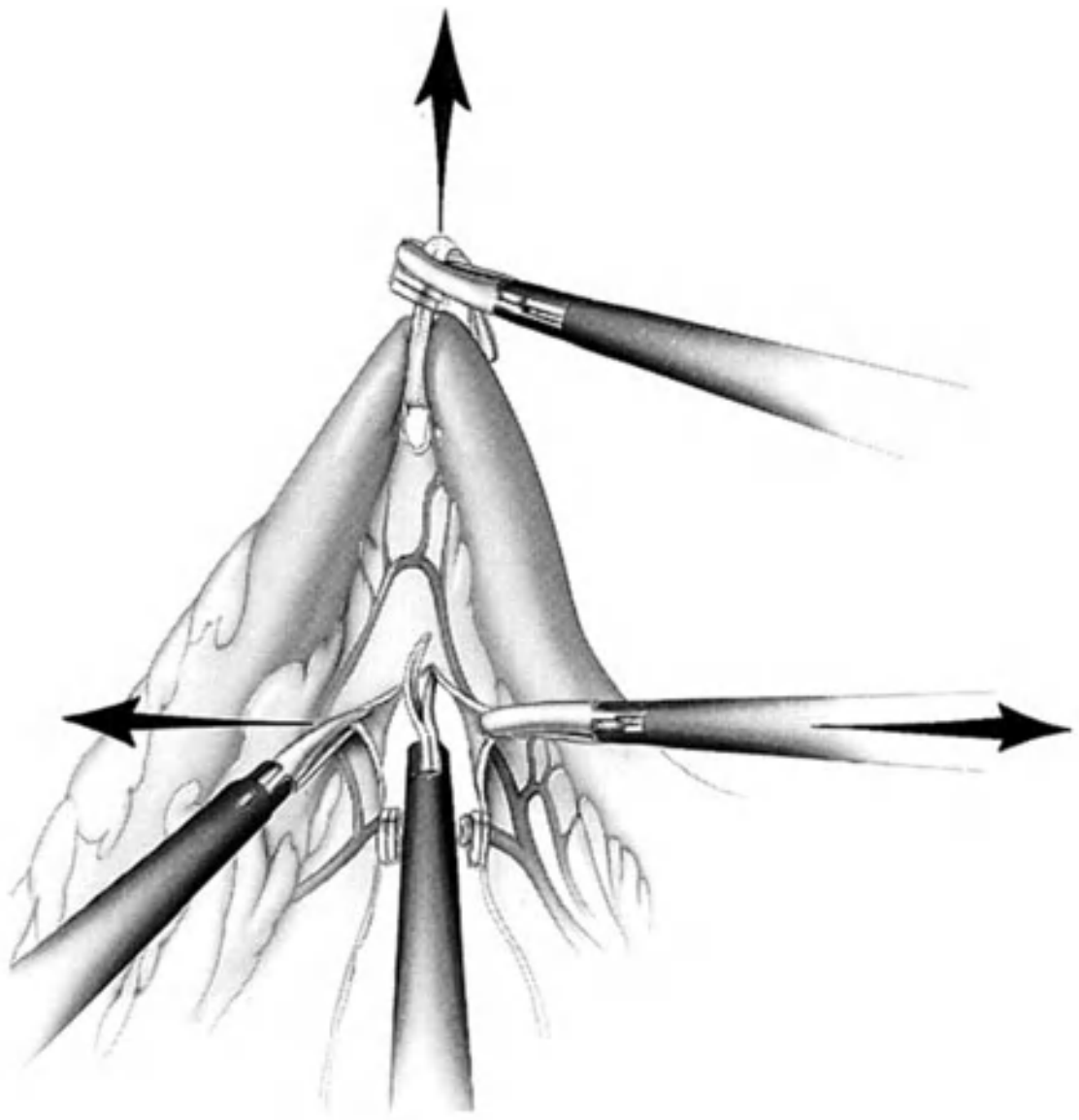

FIGURE 9.102. Dividing the ileal mesentery using tissue triangulation and clipping of larger mesenteric vessels.

tion to check for any further soft tissue attachments. Once the entire colon is completely free, the snare is removed.

The distal sigmoid colon is grasped through the suprapubic cannula, then this cannula site is widened using a muscle-splitting (small Pfannenstiel) incision. Pneumoperitoneum is released and the CO_2 insufflator is shut off temporarily. The entire colon is drawn out through this wound, and the terminal ileum is transected extracorporeally between bowel clamps, and the specimen is removed. A purse-string (size 0 polypropylene) suture is placed around the cut edge of the ileum. The anvil and the center rod assembly of a 28- or 31-mm circular stapler is placed into the bowel lumen and the purse-string suture is tied in the customary manner. The ileum is returned to the peritoneal cavity, and the cavity is copiously irrigated by flushing warm saline in through an upper abdominal cannula and suctioning the fluid through the suprapubic cannula site using a conventional sump suction system. The abdominal wall thereafter is closed with size 0 polyglycolic acid

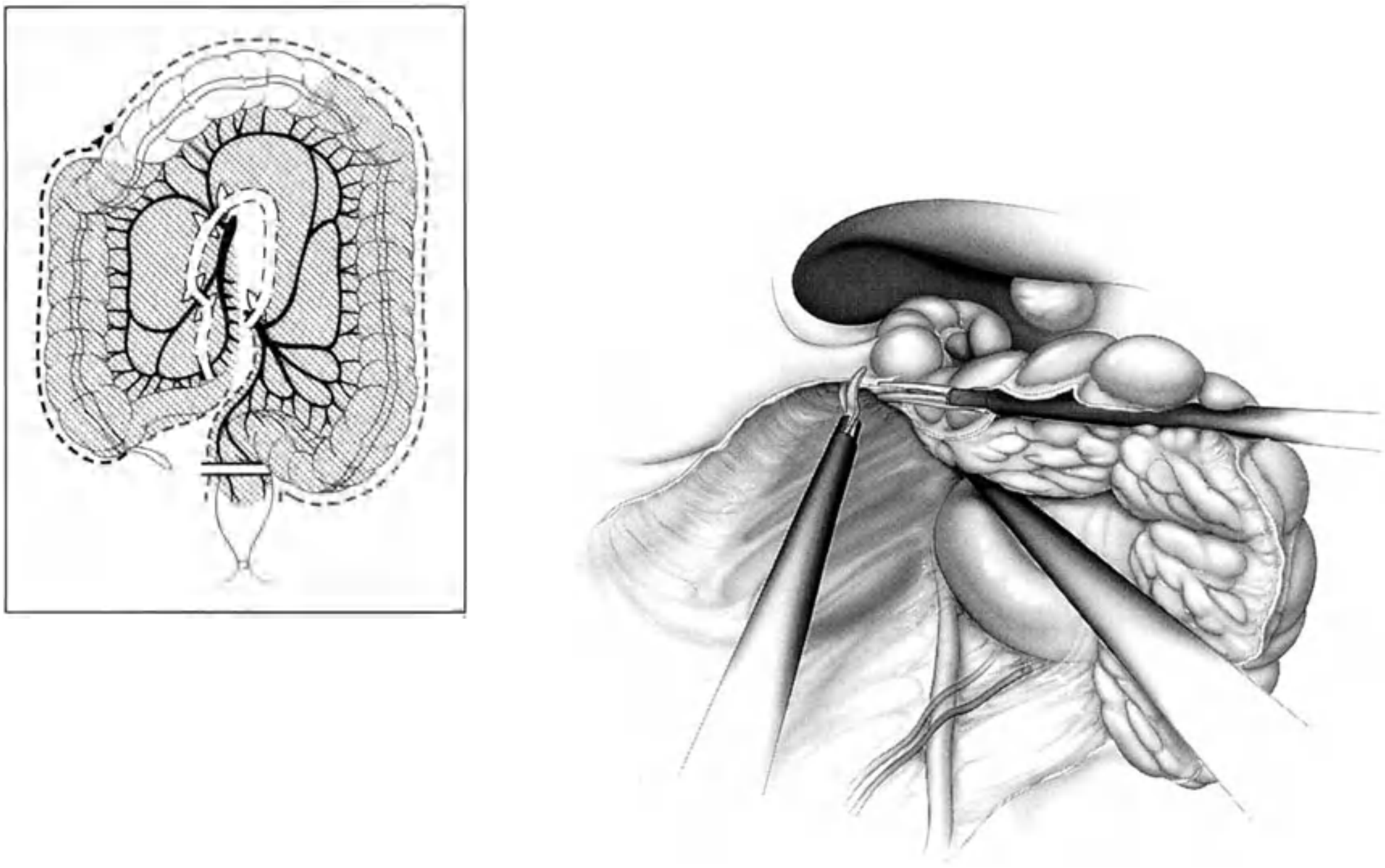

FIGURE 9.103. Completing the mobilization of the right colon and the hepatic flexure after retroperitoneal mobilization and mesenteric division.

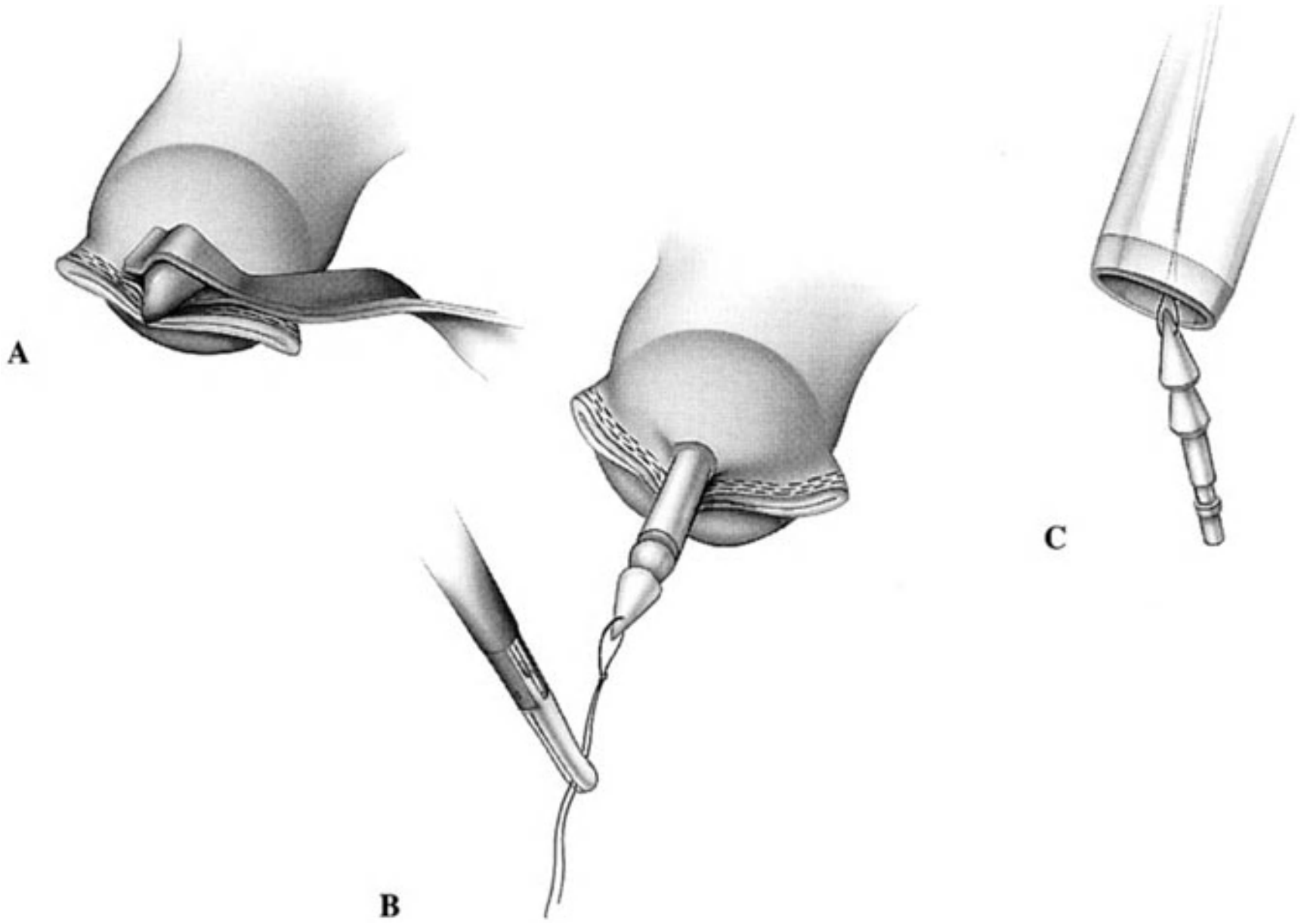

FIGURE 9.104. A, Driving the circular stapler through the rectal wall for the ileorectal anastomosis; B, the plastic trocar is removed from the center post of the circular stapler; and C, withdrawn through the right-upper-quadrant or the right-lower-quadrant cannula. (Modified with permission from Milsom J.W., Böhm B., Decanini C., Fazio V.W., Laparoscopic oncologic proctosigmoidectomy with low colorectal anastomosis. *Surgical Endoscopy.* 1994; Vol. 8.)

sutures placing either simple or figure-of-eight sutures through the abdominal wall in one layer.

Pneumoperitoneum is reestablished and the circular stapler is passed transanally under laparoscopic guidance. The modified plastic spike of the stapler is retracted into the instrument head until the instrument is carefully and completely brought up to the rectal staple line. Then the spike is pushed through the rectal wall just adjacent to the staple line by turning the wing nut on the stapler handle counterclockwise (Figure 9.104).

A standard double-stapling technique is used to form the ileorectal anastomosis. The center rod of the staple protruding from the ileum is grasped with a right-lower-quadrant endoscopic Babcock instrument and is locked into the circular stapler protruding from the rectal stump (Figure 9.105). This locking action is easily performed without substantial force as long as the axis of the center rod and the axis of the center post are in a perfect line. Because the center rod is grasped with the Babcock instrument through the right lower quadrant, the tip

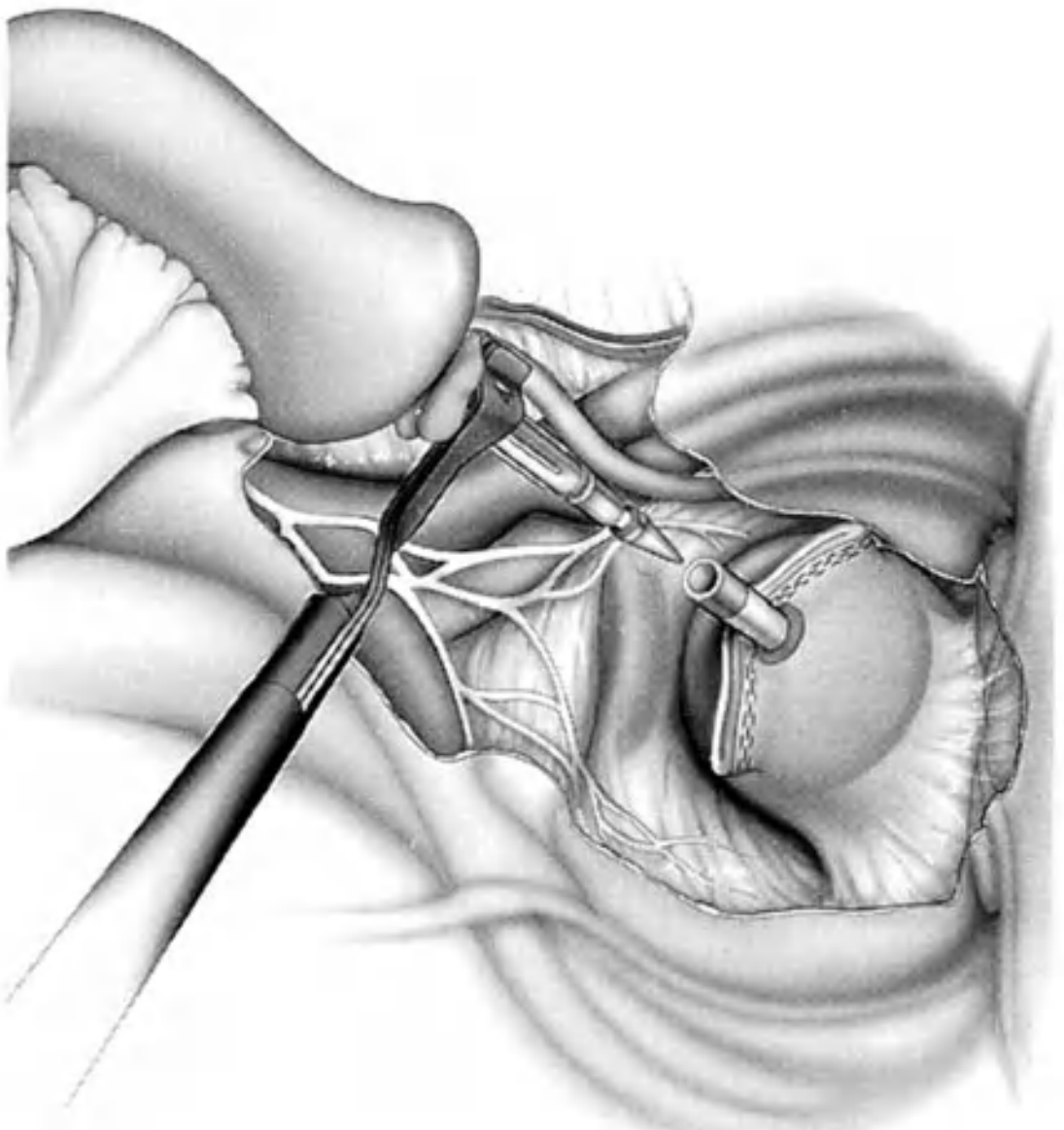

FIGURE 9.105. The ileorectal anastomosis is effected using a roticulating endoscopic Babcock to maneuver the center rod into the center post of the transanally placed circular stapler.

of the center rod will tend to be directed to the right side of the pelvis. The center post protruding from the rectum should be directed to the left side of the pelvis and the center rod should enter the pelvis from the left side. This maneuver may facilitate locking the center rod into the center post. Before anastomotic formation, the ileal mesentery must be carefully scrutinized along its cut edge to be sure it is not twisted. Excellent visualization of the anastomosis before firing the stapler is also necessary.

The anastomosis is checked for leaks by filling the pelvis with saline solution and then using a proctoscope to insufflate the abdomen with air. The tissue donuts created with the circular staplers are carefully inspected for completeness and are sent for routine pathologic evaluation if the surgeon deems it necessary.

Special Considerations

At the conclusion of each case, after the pelvis has been carefully irrigated, an atraumatic silicone drain may be placed in the pelvis through the right lower quadrant cannula site. Usually, the silicone drain can easily be passed through the 12-mm cannula and a grasper from the left-lower-quadrant cannula is used to place the drain into the pelvis. The cannula is then removed. If the drain does not fit through the cannula, the cannula must be removed, and a tonsil clamp can be used to push the drain through this site.

The vascular anatomy within the mesentery of the transverse colon to the left of the middle colic vessels and in the region of the splenic flexure needs special mention here. Because this area may be difficult to expose, a fundamental understanding of the vessels that may be encountered here is extremely important. Connections between the left colic and middle colic artery are common, with two arcades in the splenic flexure mesentery seen most commonly (33%), followed in frequency by tertiary or primary ones (25% each); arcades with 4, 5, or 6 branches are exceptional (Figure 9.106).[7] In 14.5% of specimens (see previous section, Proctosigmoidectomy, Special Considerations), an accessory left colic will arise from the superior mesenteric artery.

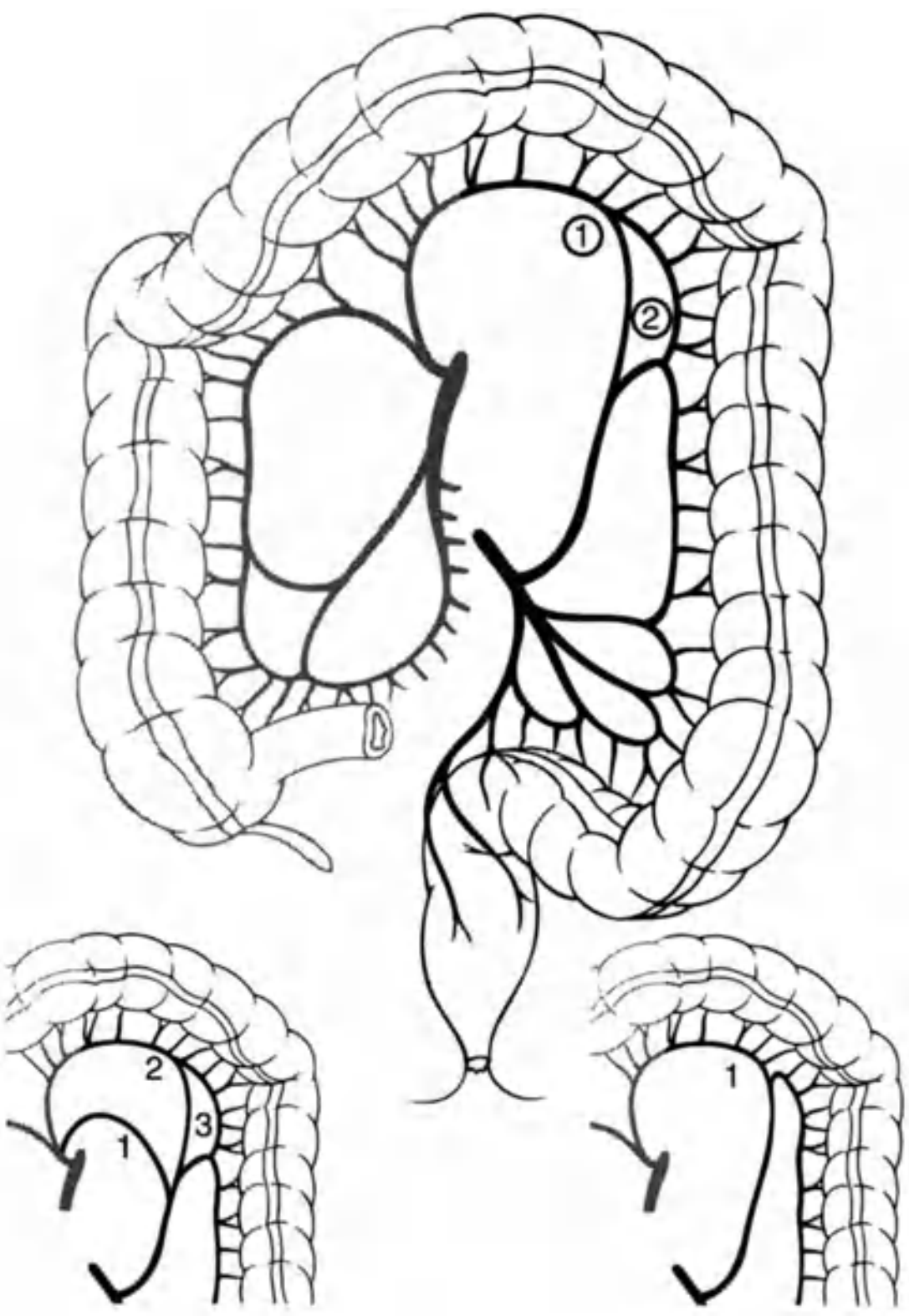

FIGURE 9.106. Mesenteric vascular connections between the left colic and middle colic artery. Most commonly, there are two (33% of specimens); three arcades and one arcade are less common (25% each). More than three arcades are exceptional.

We have also discovered that it is not unusual to find a separate unnamed vein draining from the distal transverse colon directly into the inferior mesenteric vein, or even following a separate course underneath the pancreas to the splenic vein.

When the transverse mesocolon is transected along with the middle colic vessels, entry into the lesser sac is often confusing because of congenital adhesions between the greater omentum, the stomach, and the transverse mesocolon. The omentum may usually be recognized by its fine, fatty lobulations in comparison with the smooth texture of the fat in the transverse mesocolon. The omentum may be quickly encountered superiorly after transection of the transverse mesocolon. Generally, by patiently separating the plane and lysing any congenital adhesions just behind and superior to the middle colic vessels, the lesser sac can be found.

Cancer

Performing a procedure as extensive as the laparoscopic total abdominal colectomy is feasible, but its use in cancer surgery calls for special techniques. The following points highlight certain techniques that should be used in the rare instance that this procedure is performed for cancer:

- All major vessels are ligated proximally with wide mesenteric resection (we use proximal mesenteric vascular division as the routine procedure).
- The rectum should be washed before transection, first occluding it with the endoscopic snare. Occlusion should be followed by saline irrigation of the rectum before stapling is performed.
- As soon as the intestine is transected, an endoscopic bowel bag should be passed into the abdominal cavity through the suprapubic cannula site, and the specimen should be immediately put into the fully opened bag that has been positioned in the pelvis.
- The specimen should be removed after the suprapubic cannula site has been enlarged and the abdominal wall has been protected from contamination as described in a previous section, Proctosigmoidectomy, Special Considerations. Protecting the abdominal wall incision with towels or an impermeable barrier is also critical. The specimen is carefully removed while inside the bag or after the bag has been moved beyond the abdominal wall.

References

1. Cross MJ, Snyder SK. Laparoscopic-directed small bowel resection for jejunal diverticulitis with perforation. *J Laparoendosc Surg.* 1993;3:47–49.
2. Pietrafitta JJ, Schultz LS, Graber JN, Hickok DF. An experimental technique of laparoscopic bowel resection and reanastomosis. *Surg Laparosc Endosc.* 1992;2:205–211.
3. Soper NJ, Brunt LM, Fleshman J, Dunnegan DL, Clayman RV. Laparoscopic small bowel resection and anastomosis. *Surg Laparosc Endosc.* 1993;3:6–12.
4. Ward BA, Miller DL, Frank JA, et al. Prospective evaluation of hepatic imaging studies in the detection of colorectal metastases: correlation with surgical findings. *Surgery.* 1989;105:180–187.
5. Stearns MW, Scottenfeld D. Techniques for the surgical management of colon cancer. *Cancer.* 1971;28:165–169.
6. Goligher JC. *Surgery of Anus, Rectum, and Colon.* London: Bailliere Tindall; 1984.
7. VanDamme J, Bonte J. *Vascular Anatomy in Abdominal Surgery.* New York, N.Y.: Thieme; 1990.
8. Steele G, Osteen RT. Surgical treatment of colon cancer. In: Steele G, Osteen RT, eds. *Colorectal Cancer: Current Concepts in Diagnosis and Treatment.* New York, N.Y.: Dekker; 1986:127–162.
9. Schlinkert RT. Laparoscopic-assisted right hemicolectomy. *Dis Colon Rectum.* 1991;34:1030–1031.
10. Corbitt JD. Preliminary experience with laparoscopic-guided colectomy. *Surg Laparosc Endosc.* 1992;2:79–81.
11. Jacobs M, Verdeja JC, Goldstein HS. Minimally invasive colon resection (laparoscopic colectomy). *Surg Laparosc Endosc.* 1991;1:144–150.
12. Quattlebaum JK, Flanders HD, Usher CH. Laparoscopically assisted colectomy. *Surg Laparosc Endosc.* 1993;3:81–87.
13. Zucker KA, Pitcher DE, Martin DT, Ford RS. Laparoscopic-assisted colon resection. *Surg Endosc.* 1994;8:12–18.
14. Nduka CC, Monson JRT, Menzies-Gow N, Darzi A. Abdominal wall metastases following laparoscopy (review). *Br J Surg.* 1994;81:648–652.
15. Ramos JM, Gupta S, Anthone GJ, Ortega AE, Simons AJ, Beart RW Jr. Laparoscopy and colon cancer . . . Is the port site at risk? A preliminary report. *Arch Surg.* 1994;129:897–900.
16. Sistrunk WE. The Mikulicz operation for resection of the colon—its advantages and dangers. *Ann Surg.* 1928;88:597–606.
17. Rankin FW. Resection and obstruction of the colon (obstructive resection). *Surg Gynecol Obstet.* 1930;50:594–598.
18. Keynes WM. Implantation from the bowel lumen in cancer of the large intestine. *Ann Surg.* 1961;153:357–364.
19. Lockhart-Mummery HE, Ritchie JK, Hawley PR. The results of surgical treatment for carcinoma of the rectum at St. Mark's hospital from 1948–1972. *Br J Surg.* 1976;63:673–677.
20. Umpleby HC, Williamson RC. The efficacy of agents employed to prevent anastamotic recurrence in colorectal carcinoma. *Ann Surg Oncol.* 1984;66:192–194.
21. Phillips EH, Franklin M, Carroll BJ, Fallas MJ, Ramos R, Rosenthal D. Laparoscopic colectomy. *Ann Surg.* 1992;216:703–707.

22. Franklin ME, Ramos R, Rosenthal D, Schuessler W. Laparoscopic colonic procedures. *World J Surg.* 1993;17:51–56.
23. Manasse P. Die arterielle Gefäßversorgung des S. romanum in ihrer Bedeutung für die operative Verlagerung desselben. *Arch Klin Chir.* 1907;83: 999–1010.
24. Gertsch P, Hans UB, Rainer K, Maddern GJ, Hans JA. Malignant cells are collected on circular staplers. *Dis Colon Rectum.* 1992;35:238–241.
25. Umpleby HC, Fermor B, Symes MO, Williamson RC. Viability of exfoliated colorectal carcinoma cells. *Br J Surg.* 1984;71:659–663.

10

Stoma Construction and Closure Using Laparoscopic Techniques

Like chapter 9, this chapter is also designed to present a step-by-step approach to several major laparoscopic procedures. A detailed discussion of how to set up and perform laparoscopic colorectal surgical procedures, in general, is presented in chapter 8. We will present here, in outline form, the steps for each procedure so all necessary details will be available to successfully perform the procedure. Each section of the chapter will cover the following five areas and will "stand alone" as a rapid and thorough reference for the surgeon to review before the procedure:

1. position
2. instruments
3. cannulas
4. procedure
5. special considerations

The construction of a stoma, either an ileostomy or a colostomy, may be one of the best indications for laparoscopy because only minimal dissection is required, almost no mesenteric manipulation is necessary, and the procedure is generally simple. Additionally, laparoscopic stoma formation may allow one to quickly obtain a biopsy specimen, to "run" the small and large bowels if necessary (as in Crohn's disease or partial bowel obstruction), and to accurately assess the portion of the intestine chosen for the stoma. Laparoscopy also permits one to visually ascertain that the intestinal loop is properly oriented as it is brought through the stoma site. Similarly, laparoscopy allows one to survey the entire abdominal cavity—despite reports of successful "blind" or limited open techniques to create ileostomies, right or transverse loop colostomies, and sigmoid colostomies, these approaches have the serious drawback of not permitting such an examination.[1]

During the preoperative preparation, we always indelibly mark the patient's abdominal wall at the proposed stoma site. When selecting the site, we work with an enterostomal therapy nurse, and the site is chosen only after positioning the patient in the supine, sitting, and standing postures. Stoma closure using laparoscopic techniques is also feasible in most patients but must be anticipated to be much more challenging than stoma creation because prior surgery may leave many intra-abdominal adhesions.[2-4] Thus, patients must be advised of the greater likelihood of laparotomy during this procedure compared with most other laparoscopic procedures.

Stoma Construction

Ileostomy or Jejunostomy

Very likely, a surgeon will need to perform small intestinal diversion for patients with malignant intestinal obstruction, especially if the obstruction is a result of advanced pelvic cancer. Although some surgeons may prefer a blindly created transverse loop colostomy for this purpose, laparoscopic ileal diversion is our procedure of choice—if the intestine is not overly distended—for the following reasons:

- The general peritoneal cavity may be explored and biopsy specimens may be taken as needed.
- In pelvic malignancies with large-bowel obstruction requiring diversion, an ileal loop may also be trapped in the pelvis, resulting in possible obstruction or near obstruction. If laparoscopy is feasible under these circumstances, one may answer this question at the time of laparoscopy and decide whether to divert upstream of this problem as well.

Some may argue that laparoscopic ileostomy for patients with malignant obstruction might not be feasible because bowel distention or multiple adhesions from previous surgery may preclude safe laparoscopy. However, because few instruments are required for this laparoscopic procedure, it still is probably worthwhile to consider performing at least diagnostic laparoscopy through the proposed stoma site.

The jejunostomy technique described in this section is similar to ileostomy formation but is rarely performed.

Position

The patient is placed supine. Surgery is begun in the Trendelenburg position (20° head-down tilt), and after cannula insertion, the patient is tilted left side down, which will allow the small intestine to

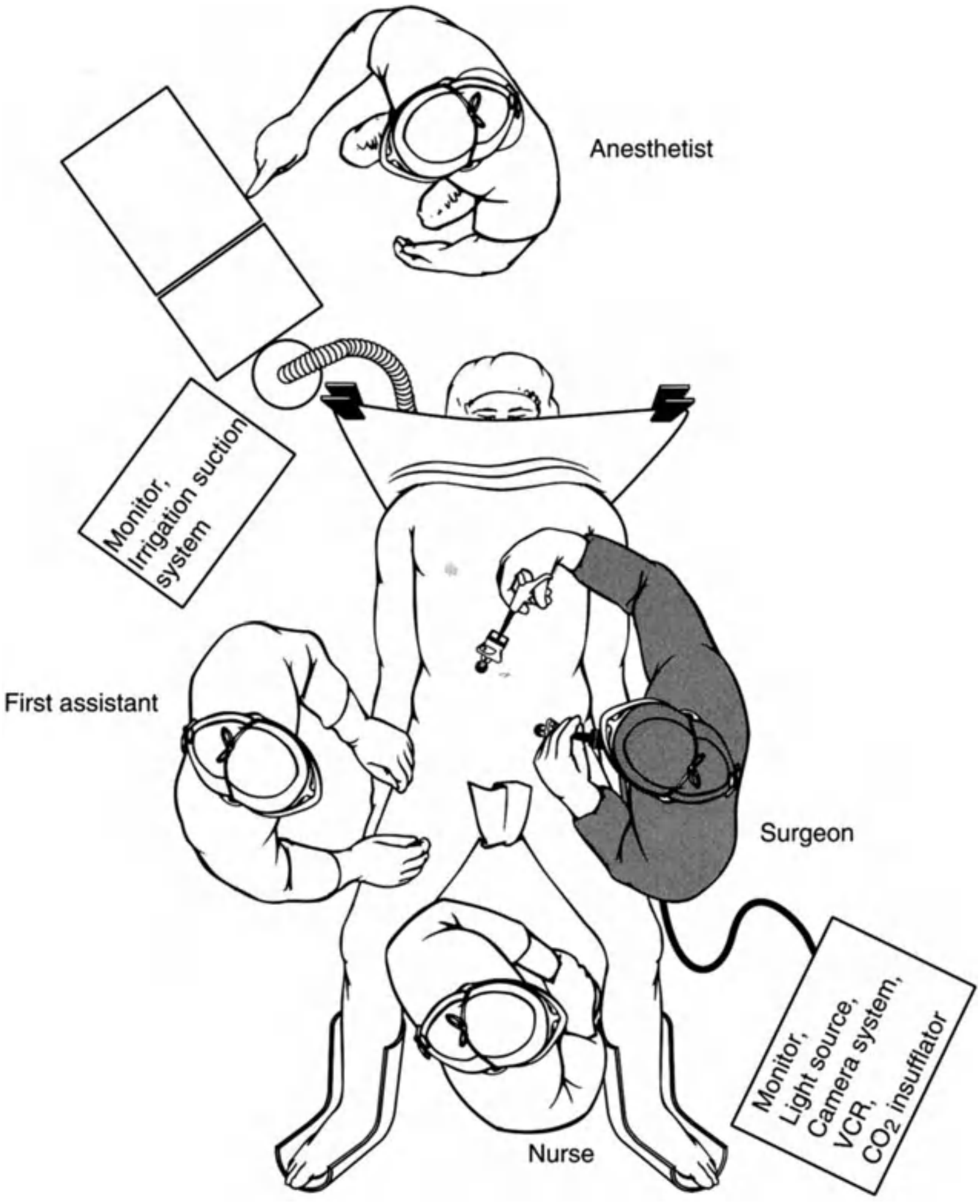

FIGURE 10.1. Position of the equipment and the personnel for ileostomy.

fall into the left upper quadrant for creation of the ileostomy. For jejunostomy, the patient is placed right side down. The surgeon initially stands on the side where the stoma will be created, with the first assistant positioned on the other side. Monitors are placed on each side of the patient, close to the knees (Figure 10.1). The second assistant and the nurse stand to the left of the surgeon and between the patient's legs, respectively.

Instruments

The instruments listed in Table 10.1, in addition to the basic instruments needed for laparoscopic surgery, are the minimum required to create a simple loop ileostomy or jejunostomy.

Cannulas

Cannulas are positioned at the proposed ileostomy or jejunostomy site and opposite the stoma site at the midabdomen, lateral to the rectus sheath (Figure 10.2).

Procedure

The procedure is begun at the proposed stoma site. For ileostomy, this is usually in the right lower quadrant over the rectus sheath, and for jejunostomy, this is in the left upper quadrant just lateral to the rectus sheath. For ileostomy creation, the disk of skin necessary for stoma formation is initially excised at this site. The first cannula is then inserted using an open technique. Electrosurgical dissection is carried out down to the rectus sheath, which is incised longitudinally for 2 to 3 cm. The rectus muscle fibers are spread, and then the posterior sheath is exposed and incised 1.5 to 2 cm. A purse-string suture is placed around the opening in the posterior sheath, a 10-mm cannula is inserted into the peritoneal cavity without the trocar, and the purse-string suture is tied down or secured with a Rumel tourniquet. The Rumel tourniquet is merely a device that allows tightening of the fascia around the initially placed cannula by the following method: A 12F or 14F stiff rubber catheter is threaded over the fascial suture, then after cannula placement, the catheter is pushed down against the cannula while pulling back on the suture. A clamp is tightened down on the suture just above the catheter. Next, CO_2 insufflator tubing is attached to the cannula and pneumoperitoneum is established.

TABLE 10.1. Instruments required for loop ileostomy or jejunostomy.

No.	Type
2	10-mm cannulas, including anchoring devices
1	12-mm cannula*—in certain rare instances
1	5-mm cannula*—in certain instances
1	Endoscopic Babcock-type instrument
1	Plastic rod for loop ileostomy
1	Endoscopic biopsy forceps*
1	Endoscopic 30-mm stapler*

* Not required for every case.

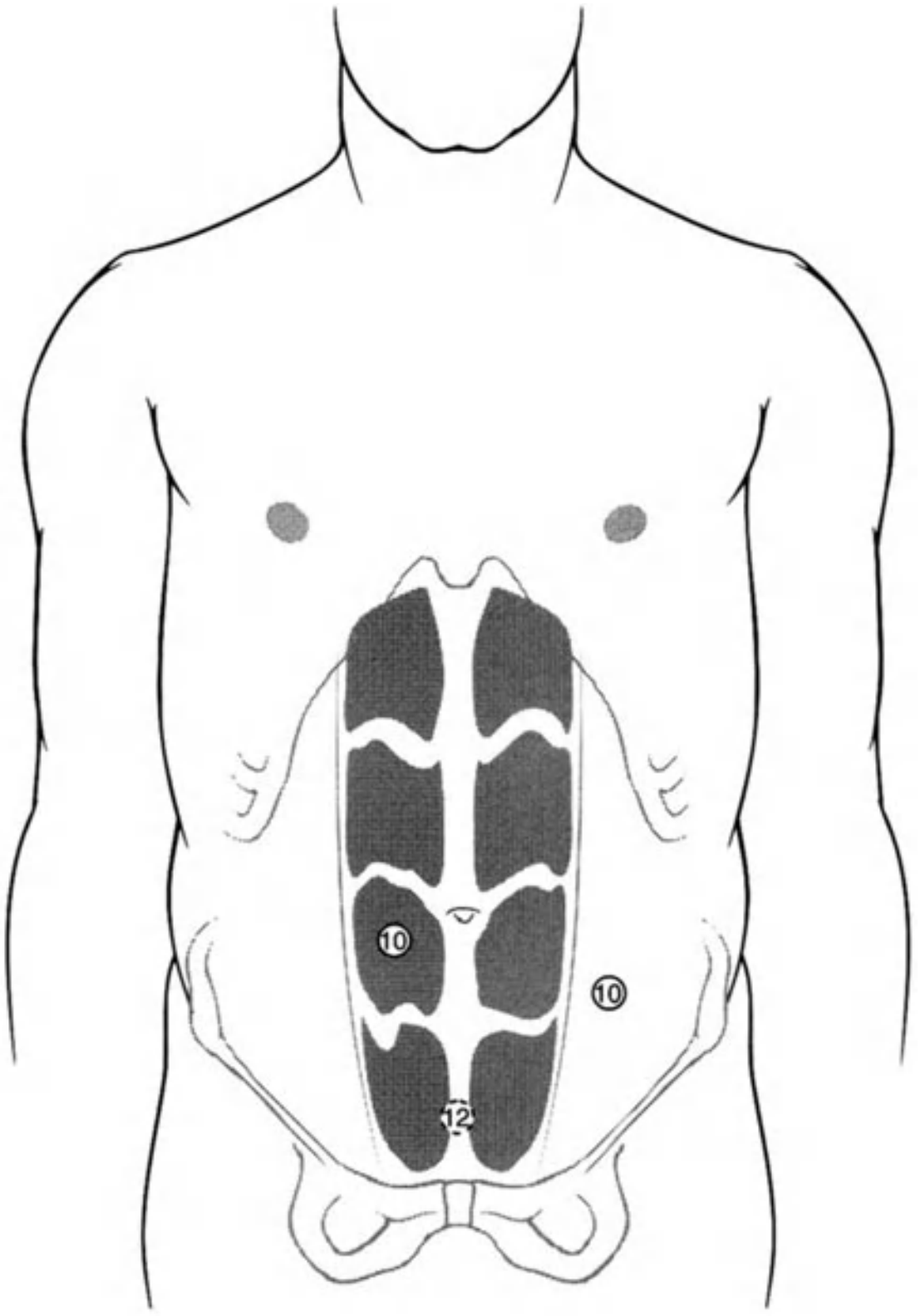

FIGURE 10.2. Cannula placement for loop ileostomy. The 12-mm cannula is rarely needed.

First, the abdominal and pelvic cavities are inspected to ensure that ileostomy can be formed laparoscopically (see chapter 8, section titled Initiation of Laparoscopic Colorectal Procedures). The second 10-mm cannula is then inserted lateral to the rectus sheath in the midabdomen or lower quadrant opposite to the stoma site under laparoscopic guidance. If a biopsy specimen must be taken, a laparoscopic biopsy forceps (5mm, nondisposable) equipped with electrosurgery must be passed through a cannula or directly through the abdominal wall using a small puncture incision in the skin overlying the biopsy site.

If the small bowel must be run or if two-handed manipulation is necessary (e.g., for adhesiolysis), then a third (5mm) cannula should be inserted. The surgeon should judge the best location for this cannula, but usually it is inserted in the suprapubic area. The location should be chosen so the surgeon can work easily with both hands.

Once the diagnostic laparoscopy has been completed, the surgeon should place the laparoscope in the cannula opposite the stoma site and place an endoscopic Babcock-type instrument through the stoma site cannula. At the terminal ileum, an intestinal site for the ileostomy should be chosen 10 to 20 cm upstream of the ileocecal valve so the intestine will not be under tension when it is brought through the abdominal wall. To form a jejunostomy, the ligament of Treitz should be localized, and the intestinal site should be chosen 30 to 40 cm downstream of the ligament. The entire width of the small intestine is firmly grasped at the site and the grasper is locked (Figure 10.3).

Under direct visualization, the intestinal loop is brought up to the abdominal wall; the mesentery must not be twisted. Orienting the bowel to the stoma may require placing the afferent limb in either a medial or superior position. Releasing pneumoperitoneum somewhat may be necessary to fully evaluate the amount of tension needed to bring the loop comfortably up to the skin. Once the bowel is oriented, the endoscopic Babcock instrument should be held on its shaft, not its handles, in a fixed position to prevent rotation.

The laparoscope is removed, pneumoperitoneum is fully released, and the endoscopic Babcock instrument is left with its tip positioned

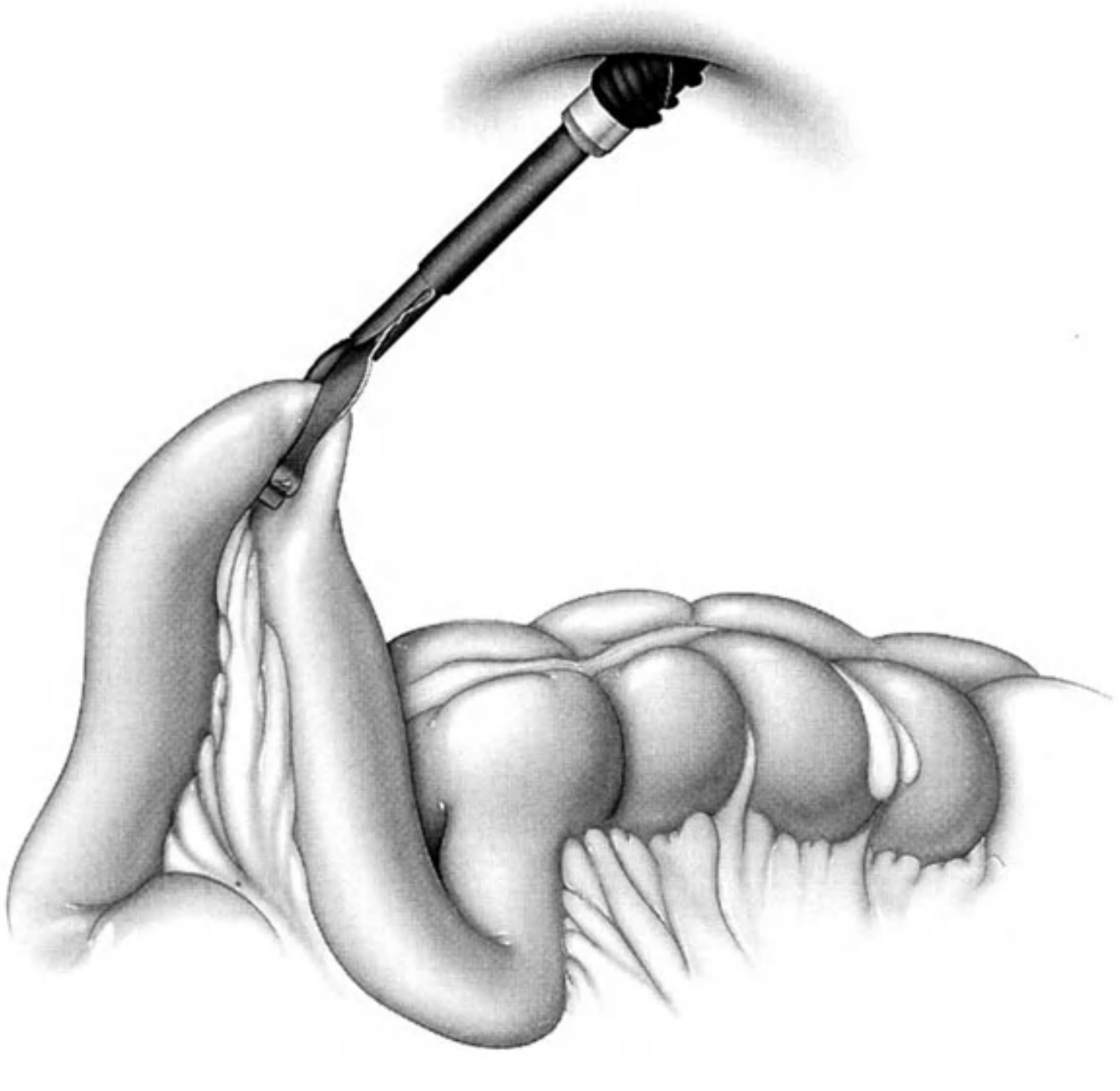

FIGURE 10.3. The ileum is grasped with a Babcock clamp through the cannula at the ileostomy site.

just below the fascia. The cannula at the stoma site is pulled out of the abdominal wall (this will require cutting the posterior sheath purse-string suture), then two right-angle retractors are again placed to splay the rectus muscles so the posterior sheath can be clearly seen. The posterior sheath incision is enlarged to approximately two finger widths using finger dilation or curved, blunt-tipped scissors so the intestinal loop can be easily delivered. As soon as the ileal loop is seen, two conventional Babcock clamps are placed on the bowel to hold it in place. The intestinal loop is delivered to skin level while maintaining proper orientation. A plastic stoma rod then is passed beneath the loop.

Pneumoperitoneum is reestablished through the remaining cannula, and the laparoscope is re-inserted into the peritoneal cavity. The loop is assessed for proper orientation, as is the mesentery for proper tension. The surgeon may insert a small finger alongside the loop to check the orientation, if needed.

Special Considerations

If the intestine is under too much tension to allow safe ileostomy formation, there are two options. First, the third cannula previously mentioned can be placed in the suprapubic area so the posterior ileal mesenteric attachments can be released by scissors dissection to increase ileal mobility. The second option, which is simpler, is to select a site another 10 to 20 cm upstream from the ileocecal valve. This decision is unlikely to result in any adverse metabolic consequences.

If the ileum first needs to be divided to better construct the stoma, then division is most easily and rapidly done by bringing the loop through the stoma, placing bowel clamps, and dividing it between the clamps with a conventional linear cutting stapler. The distal limb is then oversewn and dropped back inside the peritoneal cavity. The proximal limb is matured to the skin in a routine manner. The distal limb should be examined laparoscopically just before the abdomen is desufflated and the trocars are removed.

If the intestinal loop cannot be mobilized sufficiently to allow for proper stoma formation, a 12-mm (rather than a 5mm) suprapubic cannula should be placed. The mesenteric attachments to the retroperitoneum and lateral cecal attachments are then divided. If intraperitoneal mesenteric and intestinal division is necessary so the intestine will reach the desired location, then the chosen loop should be grasped from the stoma site cannula and placed under some tension. Through the suprapubic cannula, a fine dissecting instrument is used to score the mesentery just at the bowel edge. The mesentery is then gently spread until an opening several millimeters wide is created through the full thickness of the mesentery. Through the same cannula, an endoscopic 30-mm stapler is used to divide the bowel: the stapler anvil is threaded through the mesenteric defect, and the stapler is then closed and fired (Figure 10.4). A second stapler cartridge is used, if necessary, to completely transect the bowel. Any further mesenteric division is performed using scissors dissection and electrosurgery. A fourth cannula may be needed so the surgeon can use two-handed dissection while the assistant holds the ileum and the laparoscope. This cannula (5 mm) should be placed in the right lower quadrant as far lateral as possible. Clips may be needed to adequately achieve hemostasis of vessels larger than 2 cm. Dividing some of the mesentery as well as the intestine should allow the intestine to maximally reach the abdominal wall. After the bowel has been checked for proper orientation, the cannula sites have been checked for hemorrhage, and the abdomen has been desufflated, the stoma end is matured to the skin in a routine everting manner.

In the last 2 years, we have performed more than 20 loop ileostomies using the described method for temporary or permanent diversion for perianal Crohn's disease, rectovaginal fistula, and fecal incontinence. Although in all cases we performed a diagnostic laparoscopy, we did not gain any additional information from the diagnostic laparoscopy except in one case. In the others, the preoperative diagnosis was confirmed. The mean duration of the laparoscopic procedure was 35 minutes. The length mainly depended on whether adhesions had to be lysed. No intraoperative complications occurred.

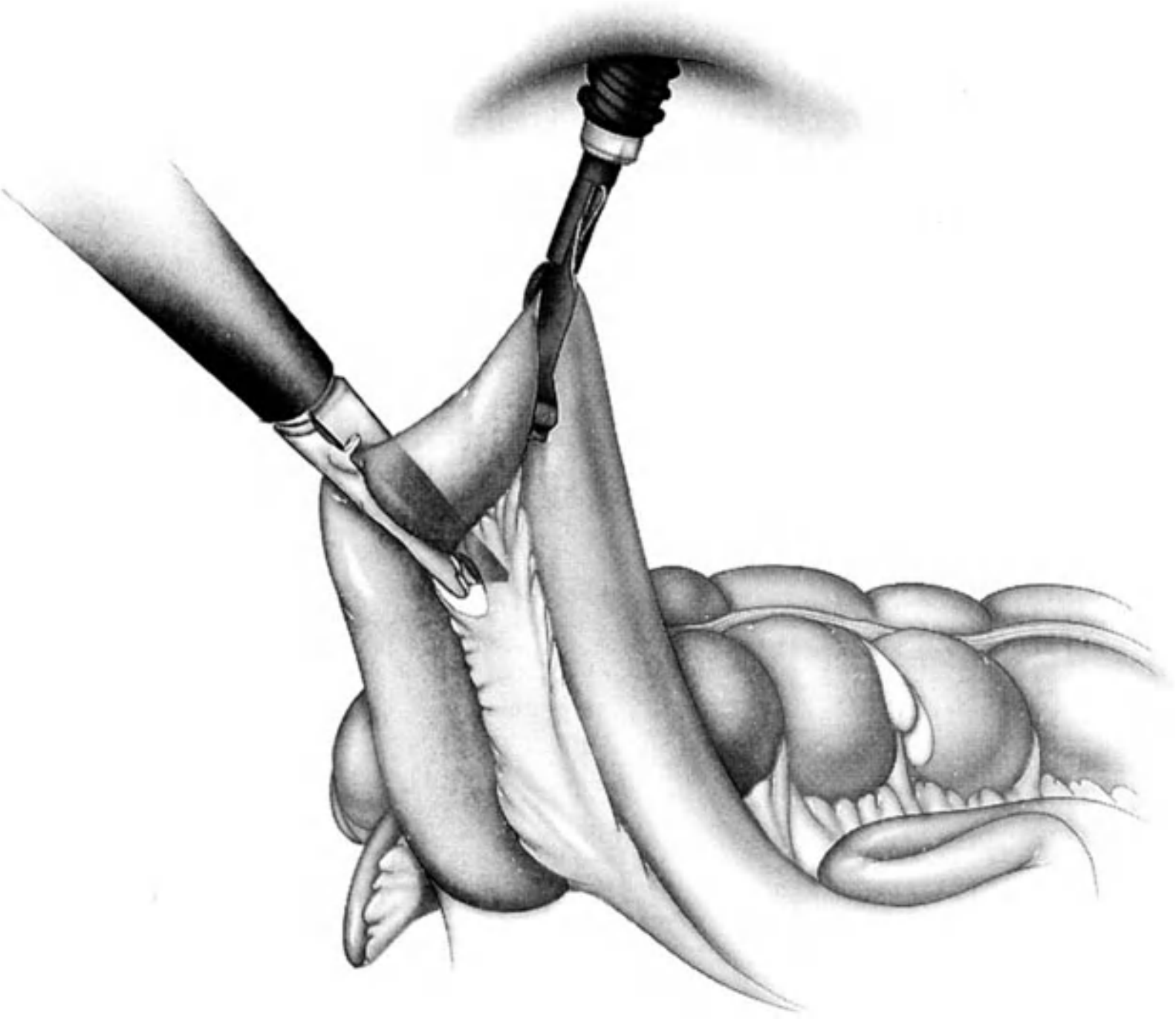

FIGURE 10.4. The intestine is held with a Babcock clamp. An endoscopic stapler is applied to transect the small intestine.

Feeding Jejunostomy

The feeding jejunostomy differs from the previously described stomas of the small intestine in that a loop of jejunum is only identified, intubated, and brought into apposition with the anterior abdominal wall.

Position

The patient is placed supine on the operating table. Surgery is begun in the Trendelenburg position (20° head-down tilt), and after cannula insertion, the patient is tilted right side down to allow the small intestine to fall into the right upper quadrant. The surgeon initially stands on the side where the stoma will be created, with the first assistant positioned on the other side. The second assistant and the nurse stand to the right of the surgeon and between the patient's legs, respectively. Monitors are placed on each side of the patient close to the knees (Figure 10.1).

Instruments

The instruments listed in Table 10.2 are required for formation of a feeding jejunostomy, in addition to the basic instruments needed for any laparoscopic procedures.

TABLE 10.2. Instruments required for a feeding jejunostomy.

No.	Type
3	2 × 5-mm and 1 × 10-mm cannulas
1	Endoscopic grasping instrument
1	Set of needle holders and graspers
4	Size 0 monofilament sutures or Keith needles
	or
1	Laparoscopic gastrostomy kit with T-fastener set*

* Ross Products Division, Abbott Laboratories, Columbus, Ohio.

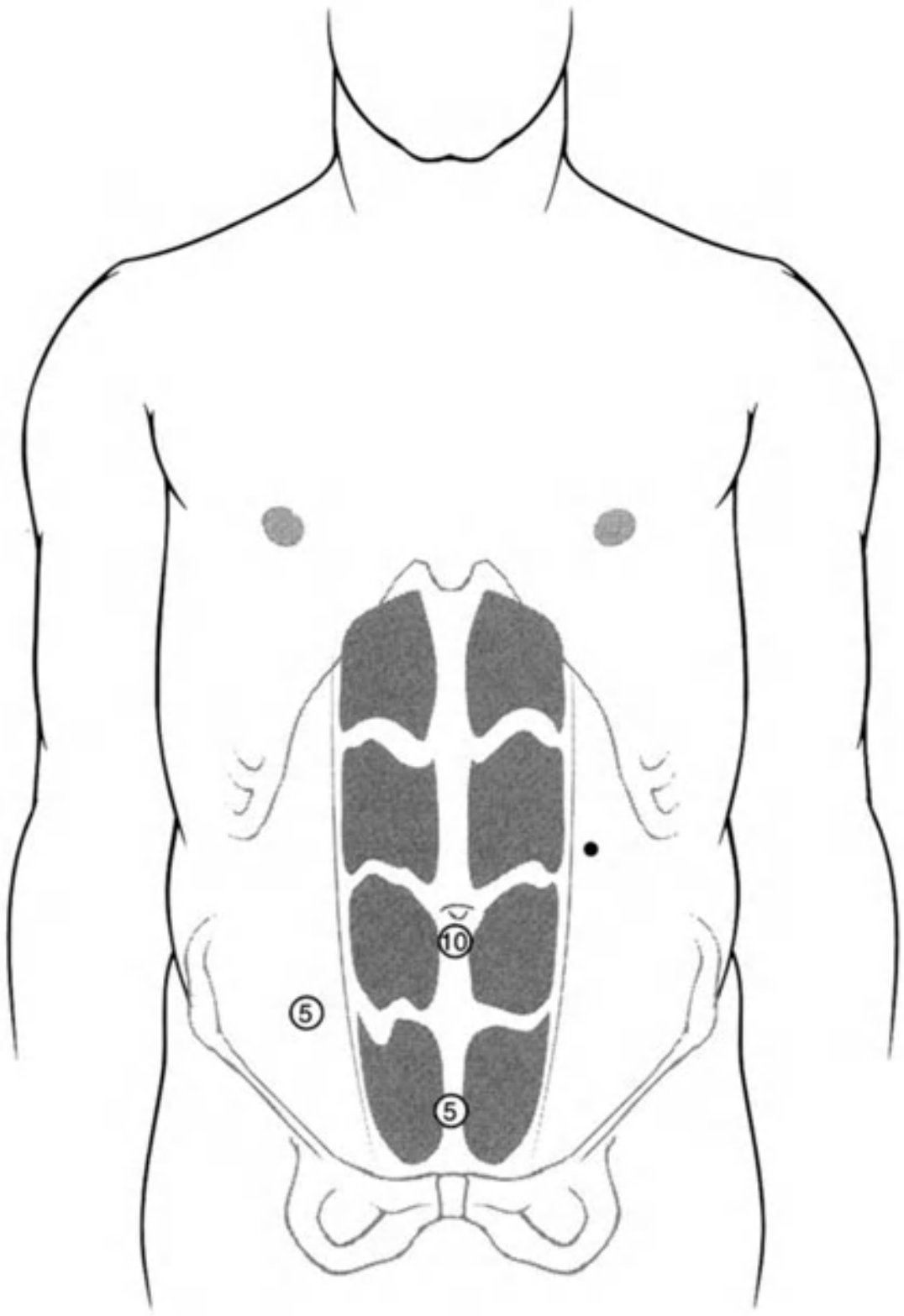

FIGURE 10.5. Cannula placement for feeding jejunostomy. Dot in left upper quadrant is site for jejunostomy.

Cannulas

Cannulas will be located at the infraumbilical area, at the right lateral abdominal wall, and at the lower midline (Figure 10.5).

Procedure

The procedure is begun with infraumbilical insertion of a Veress needle, insufflation of the peritoneal cavity, and then insertion of a 10-mm cannula at this site as described in chapter 8. After general inspection of the peritoneal cavity using this cannula site for the laparoscope, the additional cannulas are placed, the surgeon moves between the patient's legs, and the first assistant moves to the patient's left side. The second assistant moves to the right side and the nurse stands lateral to the patient's left knee.

After identifying a site approximately 30 to 40 cm distal to the ligament of Treitz by running the intestine, the chosen intestinal loop is firmly grasped and lifted anteriorly to evaluate whether it easily reaches to the anterior abdominal wall (some desufflation may be required). If the intestinal loop reaches the abdominal wall, four size 0 monofilament sutures (or T-fasteners) are placed sequentially and perpendicularly through the abdominal wall in a diamond shape, starting with the most superior suture (Figure 10.6). The "top" point of this diamond should point cephalad, with the distance between sutures being about 2 cm. The first needle and suture are passed percutaneously into the peritoneal cavity at the jejunostomy site and are grasped with the needle holder. The needle is then inserted through seromuscular tissue at the jejunostomy site and is passed up through the abdominal wall. Using a hemostat, the assistant secures the suture, pulling the loop toward the abdominal wall to facilitate placement of the next suture. The remaining sutures are placed in

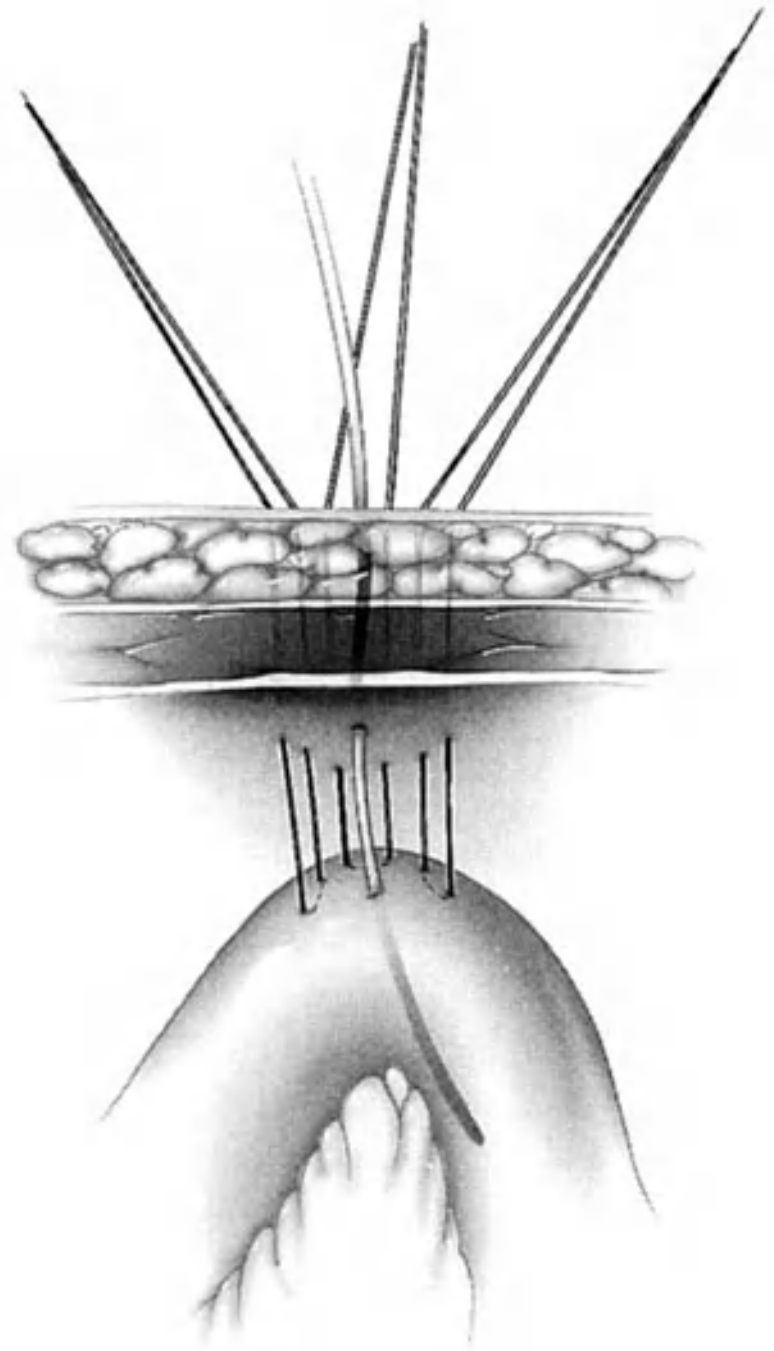

FIGURE 10.6. For the feeding jejunostomy, four sutures are first placed through the abdominal wall in a diamond shape (view is from within the peritoneal cavity).

the following order: right lateral, left lateral, lower. This last suture is left somewhat looser than the others so the jejunostomy site can continue to be adequately visualized.

A needle catheter (14 gauge) provided with the jejunostomy kit is then passed percutaneously directly into the middle of the diamond into the peritoneal cavity. Next, with a gentle stabbing motion while traction is maintained on the upper two sutures, the catheter is passed distally into the bowel lumen. Using the Seldinger technique, a J-shaped guide wire is passed through the introducer needle into the bowel lumen for 10 to 15 cm. Next, the skin incision is enlarged to allow for an 18F catheter, and the jejunostomy site is dilated using 12F, 14F, 16F, and 18F dilations over the guide wire and into the intestine. Next, the catheter is passed over the guide wire and the lumen of the jejunum. The guide wire is removed. Under laparoscopic visualization, the catheter is flushed and is aspirated with sterile saline to verify intraluminal placement of the catheter.

To complete the procedure, the abdomen is desufflated somewhat and all four sutures (or T-fasteners) are tightened gently over small gauze bolsters at the skin level (Figure 10.7). The abdomen is re-insufflated so the ostomy site can be inspected. The cannulas then are sequentially removed, and each cannula site is checked for hemorrhage and is closed in a routine manner. The jejunostomy is secured by tying the size 0 or 2-0 monofilament nonabsorbable sutures over the bolsters.

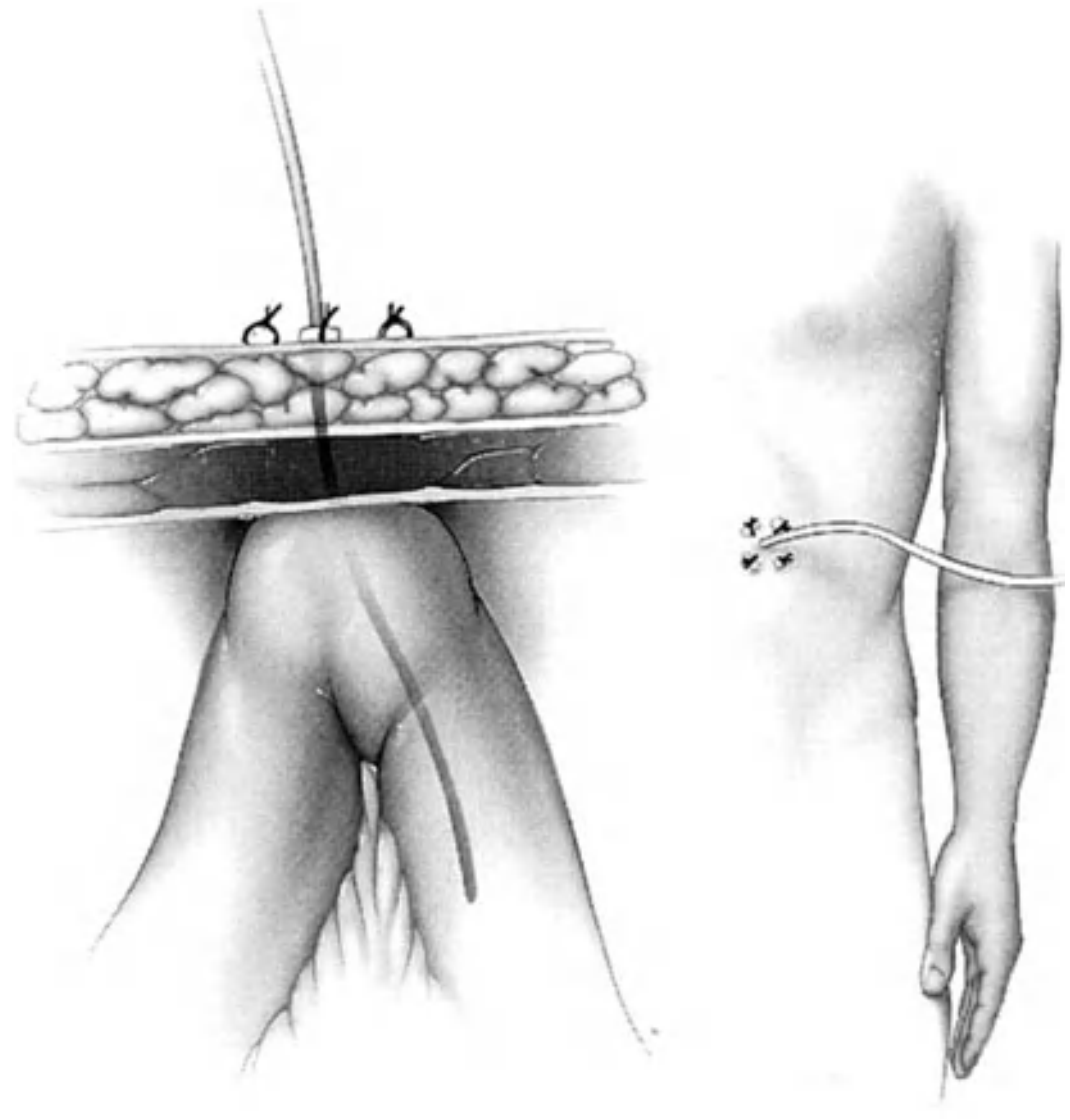

FIGURE 10.7. The feeding tube is placed and two knots are tied over gauze bolsters in the final steps of creating a feeding jejunostomy.

Special Considerations

Any uncertainty about the location of the catheter tip should prompt an on-table water-soluble dye injection study to be certain that the catheter is placed intraluminally. This should be done before removal of any cannulas.

O'Regan and Scarrow[5] and Romero et al.[6] described a similar technique. Sangster and Swanstrom[7] reported 23 feeding jejunostomies. They placed conventional rubber ureteral catheters into the jejunum and intra-abdominally sutured the jejunum to the abdominal wall. No complications were reported with any of these techniques.

Transverse Colostomy

Diversion of the large intestine may be most readily performed in the right upper quadrant (loop transverse colostomy) or in the left lower quadrant (sigmoid colostomy). Although our preference for large-bowel diversion is a sigmoid colostomy because the feces have a more solid consistency and there are generally fewer stomal problems, creation of stomas at both sites will be described. Although blind stoma formation at both sites has been described, the laparoscope provides for diagnostic laparoscopy, accurate location of the stoma, and procurement of biopsy specimens if indicated.

Position

The proposed colostomy site is chosen based on a preoperative assessment of the abdominal wall with the patient in the sitting, standing, and lying positions. The patient is placed supine or in the modified lithotomy position, with the table tilted left side down to allow the intestine to fall away from the right side. The surgeon initially stands on the patient's right side, with the assistant on the left side. The second assistant and the nurse stand to the left of the surgeon and between the patient's legs, respectively. One monitor is placed close to the left shoulder and the other close to the right shoulder (Figure 10.8).

Instruments

The instruments listed in Table 10.3 are required to create a simple transverse loop colostomy, along with the basic instruments needed for any laparoscopic procedure.

TABLE 10.3. Instruments required for a transverse loop colostomy.

No.	Type
2	10-mm cannulas, including anchoring devices
2	5-mm cannulas*—in certain circumstances
1	Endoscopic Babcock-type instrument
1	Plastic rod for loop colostomy
	Sutures for maturation
2	Conventional Babcock clamps

* Not required for every case.

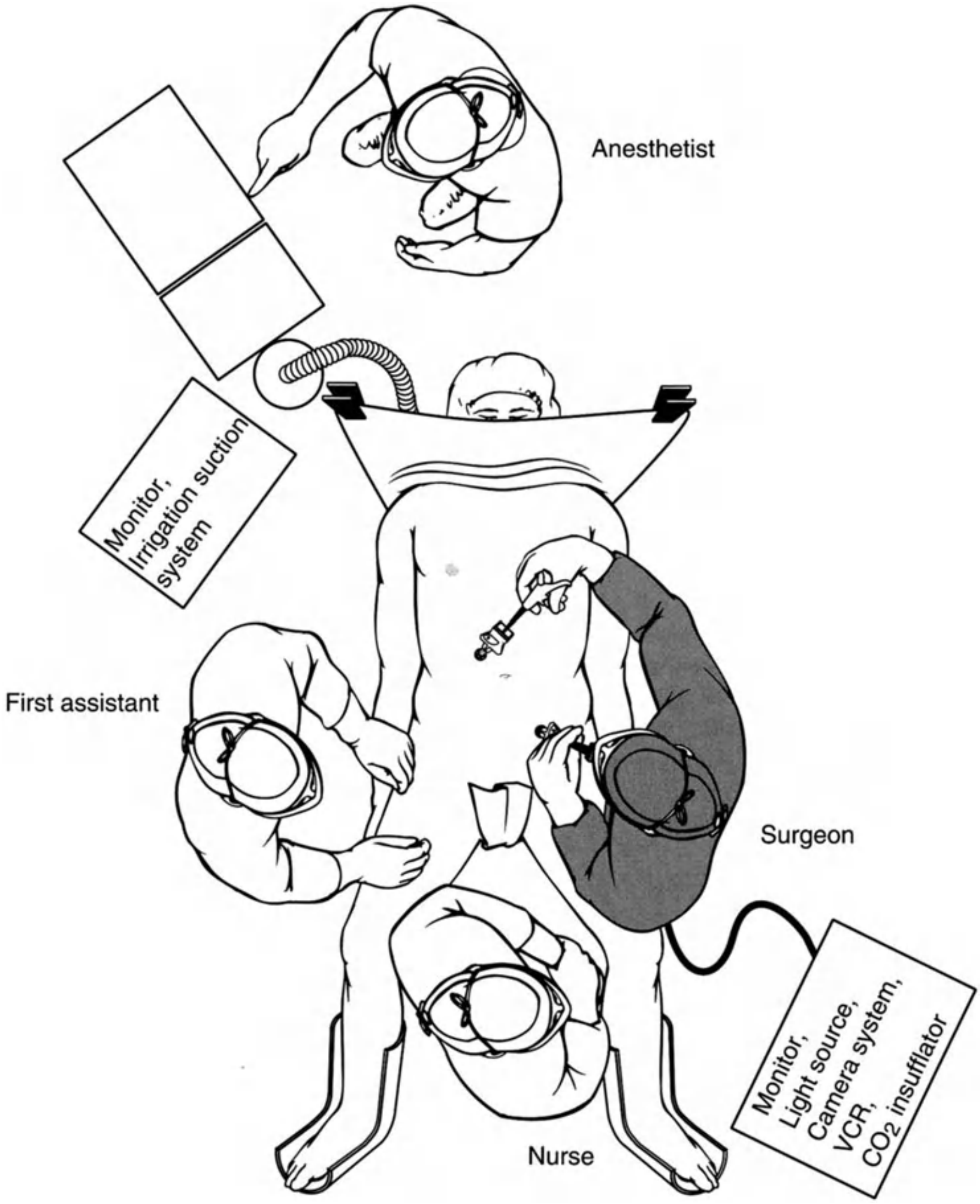

FIGURE 10.8. Position of the equipment and the personnel for transverse colostomy.

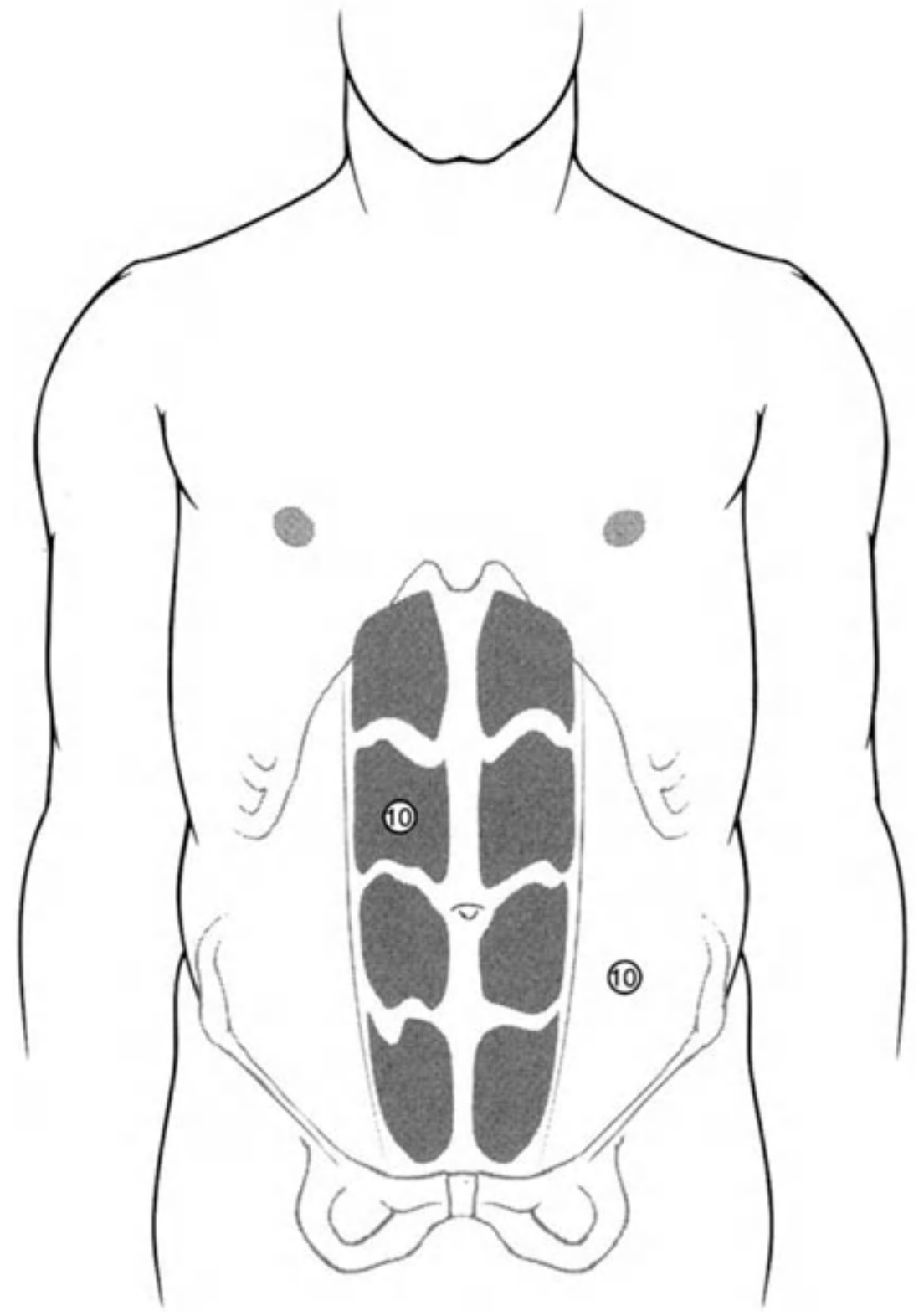

FIGURE 10.9. Cannula placement for transverse colostomy.

Cannulas

Cannulas will be positioned at the colostomy site (the right upper quadrant) and in the left midabdomen lateral to the rectus sheath (Figure 10.9).

Procedure

The procedure is begun at the proposed colostomy site. Cannulas are inserted using an open technique as was discussed for ileostomy procedure in the previous section. The only major difference, other than the site location, is that the patient initially is kept in a flat position rather than in the Trendelenburg position. Once diagnostic laparoscopy is completed, the second cannula is placed and the laparoscope is passed into this cannula. An endoscopic Babcock instrument is inserted through the right-upper-quadrant cannula and a suitable site on the transverse colon for stoma formation is chosen. The greater omentum should be moved superiorly; it may be advantageous to place the patient in the Trendelenburg position (15° to 20°) to more easily accomplish this. The bowel should be brought through the abdominal wall as was described in the previous section for ileostomy procedure, taking great care to maintain proper orientation of the intestine. The steps to complete the procedure are identical to those used in the previous section for ileostomy procedure. Most often, the afferent limb of the stoma will lie to the right, with the efferent limb to the left.

Special Considerations

If the colonic mesentery is under too much tension or if the omentum must be dissected away from the colon for stoma formation, other strategies must be considered. First, an alternative position of the transverse colon should be sought, either proximal or distal to the first choice, that is easier to mature. If no alternatives are feasible, then two additional 5-mm cannulas are placed at right-lower-quadrant and lower midline sites so the colon can be dissected from the greater omentum and the body wall as necessary. The surgeon stands between the patient's legs, and dissection is carried out with a blunt-tipped dissector and scissors equipped with electrosurgery. The greater omentum is held under tension using a Babcock clamp placed through the right-upper-quadrant cannula.

If the transverse colon still cannot be freed adequately so a safe transverse colostomy can be fashioned, then conversion to an open procedure should be considered. If the procedure is performed for obstruction, the surgeon should use laparoscopic techniques with great caution if any distension is present because the right and transverse colon may be particularly thin and friable. Additionally, if the obstruction is caused by a pelvic malignancy, then an ileal loop could also be involved and could be at risk for obstruction. In such a situation, a transverse colostomy would be unwise unless potential obstruction of the ileum can be excluded. If any question about obstruction in the terminal ileum exists, then diversion upstream of the possible obstruction must be accomplished. Conventional surgery should be considered if necessary.

Sigmoid Colostomy

This stoma is most often indicated in patients requiring temporary diversion for pelvic perineal sepsis or anal incontinence not treatable by other means. It is one of the simplest and most expeditious laparoscopic surgical procedures. Two types of sigmoid colostomies will be described—the loop and end stomas.

Position

The patient is placed supine or in the modified lithotomy position. Surgery is begun in the Trendelenburg position (20° head-down tilt), and after cannula insertion, the patient is tilted right side down so the intestine will fall into the right upper quadrant. The surgeon initially stands on the patient's left side, with the assistant positioned on the right side. The second assistant and the nurse stand to the surgeon's right side and between the patient's legs, respectively. Monitors are positioned close to the left and right knees (Figure 10.10). After cannula insertion, the surgeon moves to the patient's right side, the assistant to the patient's left side, and the nurse stays between the patient's legs.

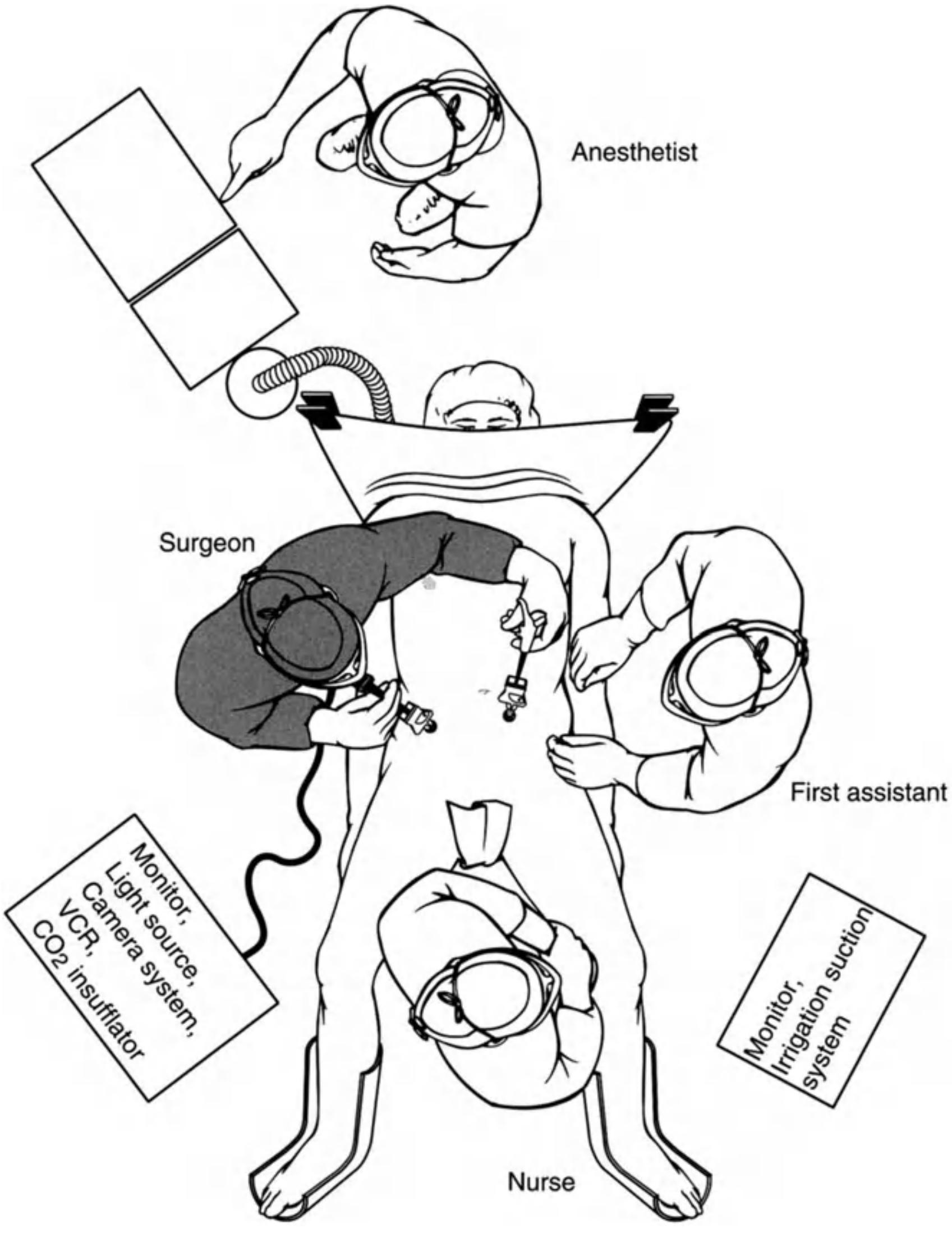

FIGURE 10.10. Position of the equipment and the personnel for sigmoid colostomy.

TABLE 10.4 Instruments required for a loop sigmoid colostomy.

No.	Type
2	10-mm cannulas, including anchoring devices
1	Endoscopic Babcock-type instrument
1	Plastic rod for loop colostomy
	Sutures for maturation
1	Endoscopic scissors equipped with electrosurgery*
1	Endoscopic dissector*
1	12-mm cannula*
1	Endoscopic 30-mm stapler*—only needed in special circumstances
1	Endoscopic clip applier*—only needed in special circumstances

* Not required for every case.

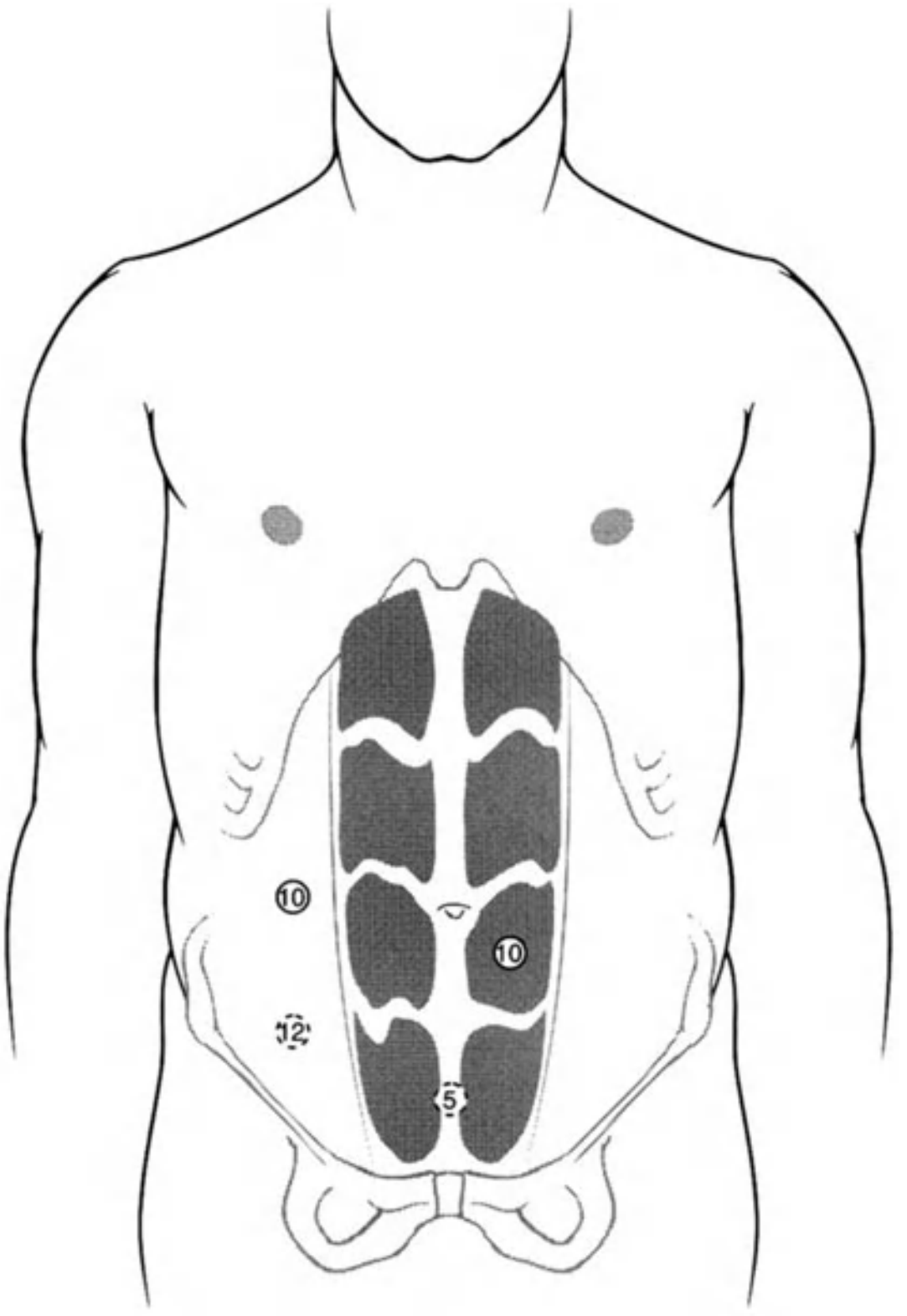

FIGURE 10.11. Cannula placement for sigmoid colostomy. 12- and 5-mm cannulas are only occasionally required.

Instruments

The instruments listed in Table 10.4, in addition to basic instruments needed for laparoscopic surgery, are the minimum required for a simple loop sigmoid colostomy formation. If some dissection of the sigmoid colon from its retroperitoneal attachments is required to mobilize it adequately, then an additional 5-mm cannula may be required in the right lower quadrant. An endoscopic scissors equipped with electrosurgery and a dissector will also be necessary. This setup allows the surgeon to work from two cannulas on the right side. If division of the sigmoid intraperitoneally is necessary to adequately mobilize the intestine, then a 12-mm cannula will be needed instead of the 5-mm cannula; the 12-mm cannula will allow a 30-mm endoscopic stapler to be inserted for bowel division.

Cannulas

Cannula positions will be located at the colostomy site and in the right midabdomen. If additional cannulas are needed, a third cannula (5 or 12 mm) would be placed in the right lower quadrant (Figure 10.11).

Procedure

The procedure is begun at the proposed stoma site with excision of the disk of skin for stoma formation. An open technique of initial cannula insertion is performed as follows. Dissection using electrosurgery is carried out down to the anterior rectus sheath, which is incised longitudinally for 2 to 3 cm. The rectus muscle fibers are spread, and the posterior sheath is exposed and incised for 1.5 to 2 cm. A size 0 purse-string suture is placed around the opening in the posterior sheath, the cannula is inserted without the trocar, and the purse-string suture is tied down around it or tightened using a Rumel tourniquet (see previous section, Stoma Construction, Procedure). The CO_2 insufflator tubing is attached to the cannula, pneumoperitoneum is established, and then the laparoscope is inserted.

Once diagnostic laparoscopy has been completed and the second cannula inserted, the laparoscope is switched to the right abdominal cannula and the endoscopic Babcock instrument is passed through the left cannula to grasp the sigmoid colon as distally as possible. This usually involves reaching into the pelvis and retrieving the downstream portion of the sigmoid colon (Figure 10.12). In our experience, this portion of the sigmoid colon usually easily reaches to the anterior abdominal wall. Once the sigmoid colon is firmly grasped with the endoscopic Babcock instrument, the abdomen is desufflated somewhat and the surgeon estimates how easily the loop may be brought up to the abdominal wall. Some judgment will be required in deciding which section of the sigmoid colon will most easily reach the proposed stoma site. The surgeon also must ensure that the bowel is not twisted as it is brought up to the stoma site.

Once the bowel is oriented, the endoscopic Babcock instrument should be held by its shaft, not its handles, in a fixed position to preclude any rotation. The laparoscope is removed, pneumoperitoneum is fully released, and the endoscopic Babcock instrument is left with its tip positioned just below the fascia. The cannula at the stoma site is pulled from the abdominal wall (this will require cutting the purse-string posterior sheath suture); then two right-angle retractors are placed to spread the rectus muscles so the posterior sheath can be clearly seen. To allow the intestinal loop to be easily delivered to the skin, the abdominal wall muscles are parted to allow approximately two finger breadths, using either finger dilation or curved, blunt-ended conventional scissors.

When the intestine is seen at the skin level, two conventional Babcock clamps are used to hold it in place. If the opening in the posterior sheath is large enough, the loop can easily be delivered to the skin level while maintaining proper orientation. A plastic stoma rod is then passed beneath the loop. At this time, pneumoperitoneum is reestablished through the remaining cannula and the laparoscope is re-inserted into the cannula. The loop is assessed for proper orientation and mesenteric tension, and the cavity is examined for intraperitoneal bleeding.

Special Considerations

If undue tension is noted when pulling the loop through the stoma aperture, a third 5-mm cannula should be placed in the right lower quadrant and the retroperitoneal attachments along the white line of Toldt incised to further mobilize the sigmoid colon. An end sigmoid colostomy can easily be formed by dividing the loop with a conventional linear stapler at the skin level. The proximal end is brought up after minor mesenteric division using conventional instruments. If the mesentery and the bowel length seem too short despite sigmoid colon mobilization, then the bowel and part of its mesentery should be di-

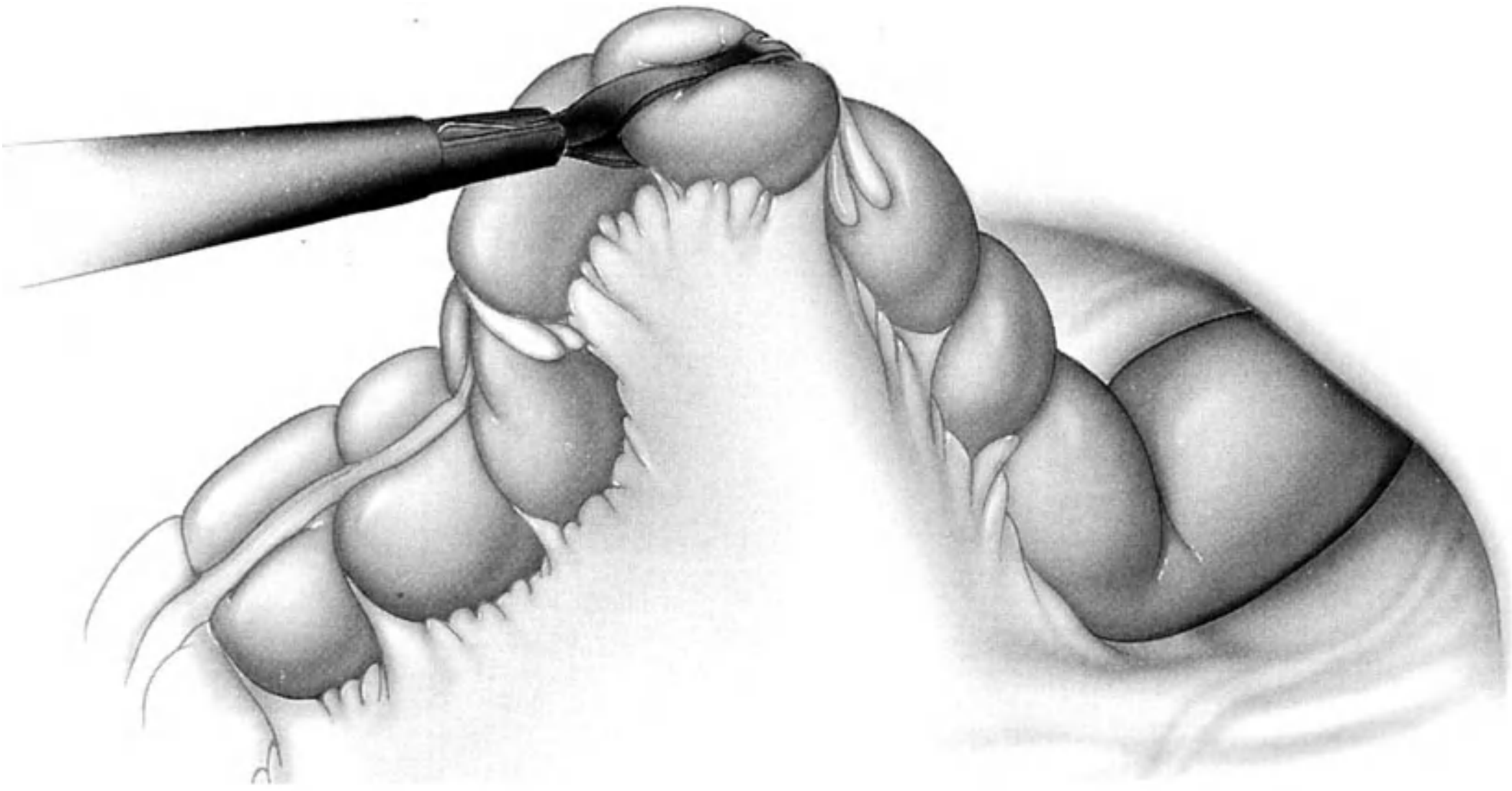

FIGURE 10.12. The downstream sigmoid colon is grasped with a Babcock clamp to begin a sigmoid colostomy.

vided intraperitoneally. This division will require placing a 5-mm cannula in the suprapubic area and a 12-mm cannula in the right lower quadrant. The laparoscope is placed in the right midabdominal cannula. The assistant holds the bowel from the stoma site cannula while the surgeon uses endoscopic scissors and a fine grasping or dissecting instrument from the right-lower and suprapubic cannulas to make a mesenteric window at the stoma site. Once the window has been made, the 30-mm stapler is passed from the right-lower-quadrant cannula through the window, closed, then checked for accurate positioning, and fired (Figure 10.13). A second application is used as necessary to completely transect the bowel.

If further intestinal mobilization is necessary, mesenteric division may be readily performed using endoscopic clips and electrosurgery as needed. The proximal end is brought through the stoma as previously described and matured in a routine manner. If control of the distal end is necessary, this end may be retrieved and sutured to the inferior portion of the stoma aperture at the fascial level.

If the stoma is being created subsequent to a rectosigmoid resection, so as to treat recurrent pelvic disease or incontinence, then several considerations are important. Adhesions almost certainly will be present, and consequently, three or four cannulas probably will be necessary. If any mesenteric division is required, the inferior mesenteric artery has probably been sacrificed, and the marginal vessel, which may lie close to the colon, may be the only blood supply to the intestine all the way to the pelvis. If laparoscopic division is contemplated in such a patient, considering ileostomy or transverse loop colostomy is wise.

Any time a diversion is performed for pelvic cancer, the distal ileum should be examined and verified to be clear of any obstruction. Any uncertainty about the intestinal anatomy or about the procedure should prompt conversion to an open procedure.

Stoma Closure

Although closing a divided stoma may appear to be a rather simple surgical maneuver, this procedure may be extensive and difficult, whether performed laparoscopically or conventionally, because of adhesions and anatomic distortions caused by previous surgery. Thus, the patient

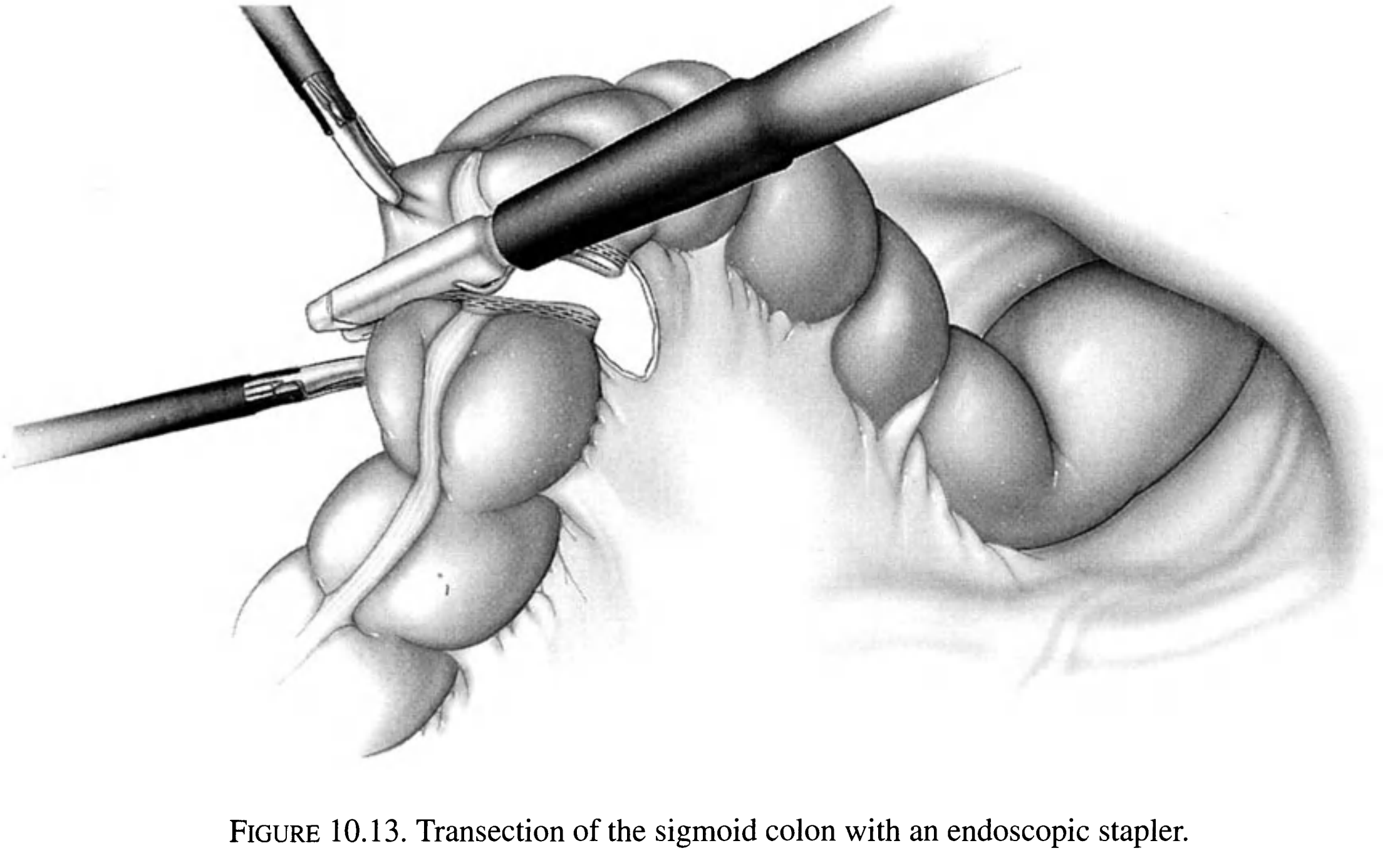

FIGURE 10.13. Transection of the sigmoid colon with an endoscopic stapler.

and the surgical team must be prepared for conversion to an open procedure. On the other hand, diagnostic laparoscopy is still worthwhile—there may be few intra-abdominal adhesions and a laparoscopic approach may be feasible.

Closure of the Divided Small- or Large-bowel Stoma

There are several types of divided stomas not involving the rectum, but we most often see the end ileostomy with an ascending or a transverse colon mucous fistula (closed or open). This stoma is often created after urgent ileocolic resection for Crohn's disease, bleeding diverticular disease, or arteriovenous malformation. The principles discussed here are applicable to closure for other types of divided stomas as well.

Position

The patient is placed in the modified lithotomy position in padded stirrups (we prefer Dan Allen). The surgeon stands on the patient's right side, the first assistant stands on the patient's left side, and the second assistant stands just above the surgeon. Both monitors are placed adjacent to the shoulders (Figure 10.14). After

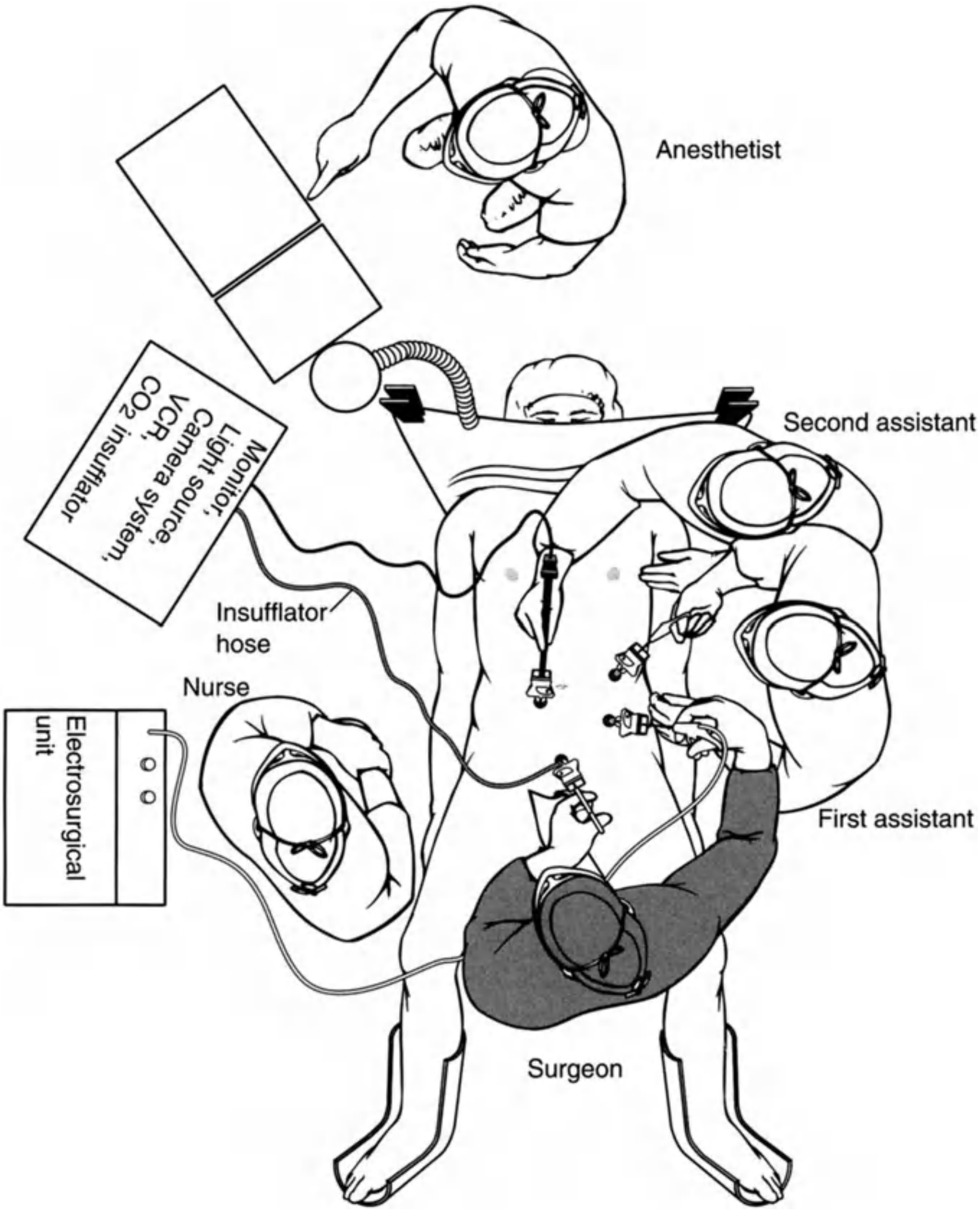

FIGURE 10.14. Position of the equipment and the personnel for stoma closure and ileocolic anastomosis.

initial cannula insertion, the surgeon moves to a position between the patient's legs. Both the first and second assistants should initially stand on the patient's left side for ileostomy closure and on the patient's right side for colostomy closure.

Instruments

The instruments listed in Table 10.5, in addition to basic instruments needed for laparoscopic surgery, are the minimum required. If an end-to-side stapled anastomosis is contemplated, a conventional circular stapler and a linear stapler will be needed.

Cannulas

Cannulas are positioned at the stoma site and most likely in the upper or mid-quadrant opposite the stoma site lateral to the rectus sheath, and in the lower abdomen at the midline (Figure 10.15). Some variation in the position and the number of cannulas may be required, depending on the amount of adhesions from previous abdominal surgeries.

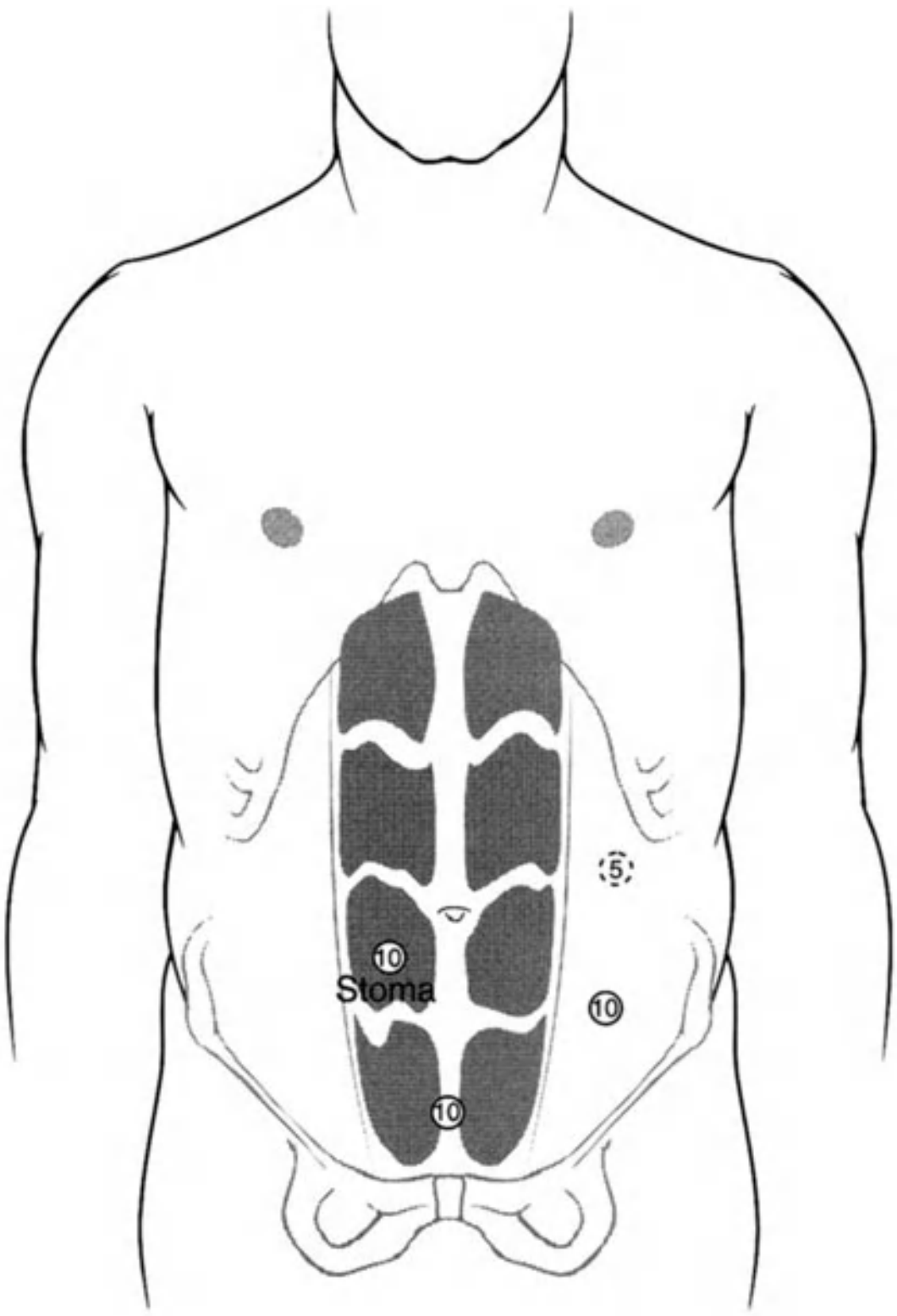

FIGURE 10.15. Cannula placement for divided stoma closure.

Procedure

The procedure is begun at the stoma site with the patient in the Trendelenburg position (20° head-down tilt). After initial cannula insertion, the patient is tilted left side down (for ileostomy closure) or right side down (for colostomy closure). After the stoma is completely dissected from surrounding attachments, the dissection is extended into the peritoneal cavity circumferentially. Adhesions may be lysed around the stomal aperture with blunt finger dissection, but this technique must be performed gingerly because this maneuver can easily damage adherent small-bowel loops. It is wiser to extend the fascial incision superiorly or inferiorly to accomplish safe adhesiolysis around the stoma—one or more fascial sutures may be inserted to later create an airtight seal at this site once pneumoperitoneum is required. With the stoma completely freed from surrounding tissues, it is gently occluded with a 0.25-in. cotton umbilical tape. This entire segment is then dropped inside the peritoneal cavity and a size 0 monofilament purse-string suture is placed around the abdominal wall opening. If the opening seems too wide to close down around a 10-mm cannula, then a figure-of-eight suture is placed at one edge of the fascia and is tied down to narrow it.

TABLE 10.5. Instruments required for closure of divided small- or large-bowel stoma.

No.	Type
3	10-mm cannulas, including anchoring devices
1	Endoscopic scissors equipped with electrosurgery
1	Endoscopic fine grasper or dissecting instrument equipped with electrosurgery
1	Endoscopic Babcock-type instrument
1	Rumel tourniquet setup (long [60+ cm], braided nonabsorbable suture; one 10-cm stiff 14F catheter; one threader for pulling suture through the tubing)

A 10-mm cannula is then placed inside the peritoneal cavity (without the trocar), the suture is tightened around it using a Rumel-type tourniquet, and pneumoperitoneum is established to a pressure of 15 to 20 mm Hg until all cannulas are placed and then is lowered to 12 mm Hg. The laparoscope is passed through this cannula and the entire peritoneal cavity is examined for adhesions. If a suprapubic 10-mm cannula can be placed, this is done next. Then the laparoscope is inserted at this site so the stoma cannula can be used for lysis of adhesions as necessary. Alternate sites may be in the left lower or right upper quadrant. Exerting countertraction by lifting the abdominal wall upward with a towel clip placed on the lower midline abdominal skin may exert tension on the adhesions. With a third cannula inserted, the surgeon can work with two hands (using scissors and a grasping instrument) and lyse adhesions from the entire midline cephalad to the point where the right or transverse colon has been attached to the stoma. The stomal end of the bowel is examined and freed from adhesions and the retroperitoneal area so the mesentery does not kink or twist, and so, in the instance of ileostomy takedown, the ileum will easily reach up to the transverse colon or the distally diverted intestinal site.

Dissection is next conducted from the skin level at the site of the distal diverted intestine.

A 3- to 5-cm incision through skin, subcutaneous tissue, and fascia is made over this distal bowel end, which is then brought out through the wound. Adhesions are lysed entirely from this intestinal segment for at least 5 to 10 cm. Using laparoscopic guidance, the terminal ileum is also grasped by this umbilical tape and is brought out through this wound. An extraperitoneal end-to-end handsewn or a side-to-side GIA-type stapled anastomosis is then created, taking great care to not allow any twisting or rotation of the mesentery. If the surrounding small-bowel loops are relatively fixed by adhesions, the mesenteric defect between the bowel ends is left alone. If potentially dangerous herniation is present, then the mesenteric defect is closed from the anastomotic site using open techniques. Cannula sites are inspected, the abdomen is irrigated with warm sterile saline, and the cannula sites are closed.

Special Considerations

This procedure should be relatively simple. If not, then conversion to an open procedure should be contemplated early in the course of the operation.

Reversal of the Hartmann Procedure

The circumstances that led to formation of an end-sigmoid colostomy with performance of the Hartmann procedure should be contemplated carefully before closing the stoma laparoscopically. Many adhesions around the stoma, between small-intestine loops and the rectum, and between the loops and other pelvic structures may be present, making this a tedious and potentially hazardous operation. Nonetheless, as in other cases of stoma closure, little risk or time is wasted in "taking a look" with the laparoscope at the outset of the procedure and rapidly deciding whether the procedure can be performed laparoscopically. If there is any doubt whether the procedure will proceed smoothly, we advocate conversion to an open procedure.

Positions

The patient is placed in padded stirrups (we prefer Dan Allen) in the modified lithotomy and the Trendelenburg positions (20° head-down tilt). After cannula insertion, the patient is tilted right side down to allow the small intestine to fall into the right upper quadrant, which will optimize visualization of the stoma and the pelvis. The patient is further positioned so the peritoneum is flush with the bottom edge of the table so the 28- or 31-mm circular stapler can be easily used transanally for the anastomosis. The surgeon initially stands on the patient's left (for initial cannula insertion and colostomy takedown), with the first and second assistants positioned on the patient's right. The nurse stands between the patient's legs. Both monitors are placed adjacent to the knees (Figure 10.16). Once cannulas are inserted, the surgeon may wish to switch positions with the first assistant.

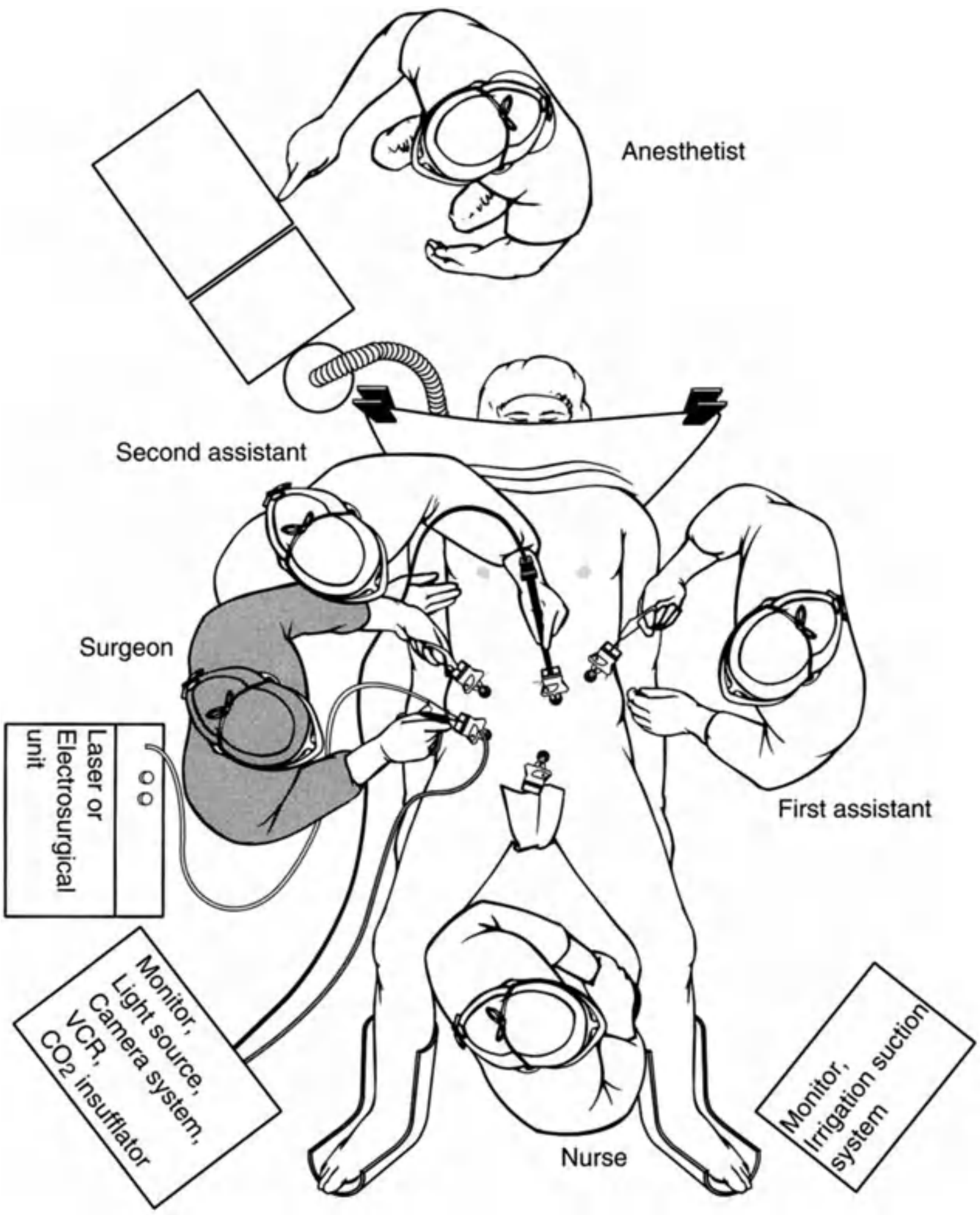

FIGURE 10.16. The equipment and the personnel for the Hartmann closure.

Instruments

The instruments listed in Table 10.6, in addition to basic instruments needed for laparoscopic surgery, are the minimum required for Hartmann procedure reversal. If dense adhesions are encountered, the first assistant may need to place an additional 5-mm cannula.

Cannulas

Cannulas will be located at the colostomy site and in the right lower and upper abdomen lateral to the rectus sheath. If a fourth cannula is required as described in the previous section, it will be positioned in the left lower quadrant or the suprapubic area (Figure 10.17).

TABLE 10.6. Instruments required for takedown of colostomy and reversal of the Hartmann procedure.

No.	Type
4	3 × 10-mm and 1 × 5-mm cannulas, including anchoring devices
1	Endoscopic scissors equipped with electrosurgery
1	Endoscopic grasping and dissecting instrument
1	Endoscopic Babcock-type instrument
1	Circular stapler (28 or 31 mm)
1	Rigid or flexible sigmoidoscope
1	Rumel tourniquet setup (long [60+ cm], braided nonabsorbable suture; one 10-cm stiff 14F catheter; one threader for pulling suture through the tubing)

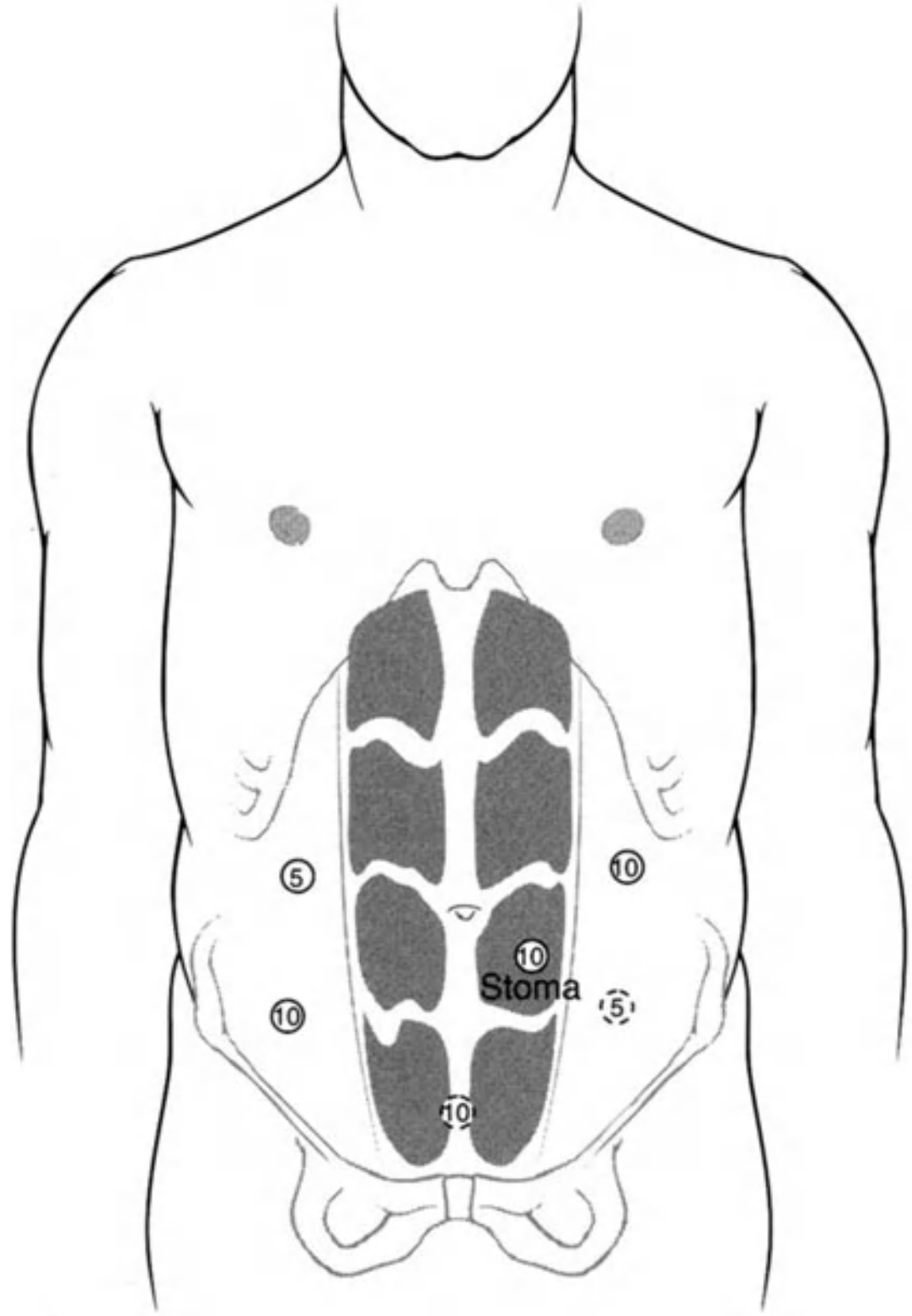

FIGURE 10.17. Cannula placement for the Hartmann closure. The suprapubic (10-mm) and left-lower-quadrant (5-mm) cannulas may not be needed.

Procedure

After the patient has been positioned, the rectum is gently irrigated using a soft rubber mushroom catheter and warm saline solution. The anus, if obstructed, is gently dilated with one or two fingers so it will readily accept a 28-mm or larger circular stapler.

The colostomy is next mobilized from the skin and the body wall in a routine manner down to and into the peritoneal cavity. The fascial opening is enlarged as needed to allow the colostomy to be safely mobilized circumferentially. Once the colostomy is freed from surrounding structures, it is delivered through the fascia, and a purse-string suture of size 0 polypropylene is placed. The bowel edge should be trimmed so that it is not edematous and appears normal. The center rod and the anvil assembly of the largest possible diameter circular stapler is passed into the bowel lumen, the purse-string suture is tied, and the bowel end is dropped inside the peritoneal cavity.

A size 0 monofilament purse-string suture is then placed around the fascial defect, a 10-mm cannula (without trocar) is passed into the abdominal cavity, and the suture is tied tightly around the anchoring device of the cannula or tightened using a Rumel tourniquet. Pneumoperitoneum is established to a pressure of 15 to 20 mm Hg until all cannulas are placed and then is lowered to 12 mm Hg. The right-lower and right-upper-quadrant cannulas are placed next; then the descending and sigmoid colon is freed from surrounding structures such that it will easily reach into the pelvis.

In many instances, mobilizing the left colon and the splenic flexure will be necessary. To do so will require that the operating team and the video monitors be repositioned, and that suprapubic and left-lower-quadrant cannulas be placed. However, an experienced team should have no difficulty in repositioning themselves. For the splenic flexure mobilization, see chapter 9, section titled Proctosigmoidectomy, Procedure.

Adhesions must be lysed so all small intestinal loops can be cleared away from the pelvis. Then the rectal stump is identified and its proximal end is mobilized circumferentially for 3 to 5 cm from the surrounding pelvic tissues. Rigid or flexible sigmoidoscopy may aid in identifying the proximal portion of the closed rectal segment.

Once the rectal segment is identified and an area is clearly delineated for the anastomotic site, the largest circular stapler possible (28 mm or greater) is fully inserted transanally, and the spike on the center shaft is passed through the rectal wall. An end-to-end or end-to-side colorectal anastomosis is then performed after joining the center rod protruding from the colon with the receptacle center post protruding from the rectum, using an endoscopic Babcock instrument from the right-lower-quadrant cannula (Figure 10.18). The colonic mesentery must not be twisted before the stapler is fired. Once the circular stapler is fired and withdrawn, the tissue donuts are checked for completeness. A rigid sigmoidoscope is next inserted transanally for several centimeters after filling the pelvis

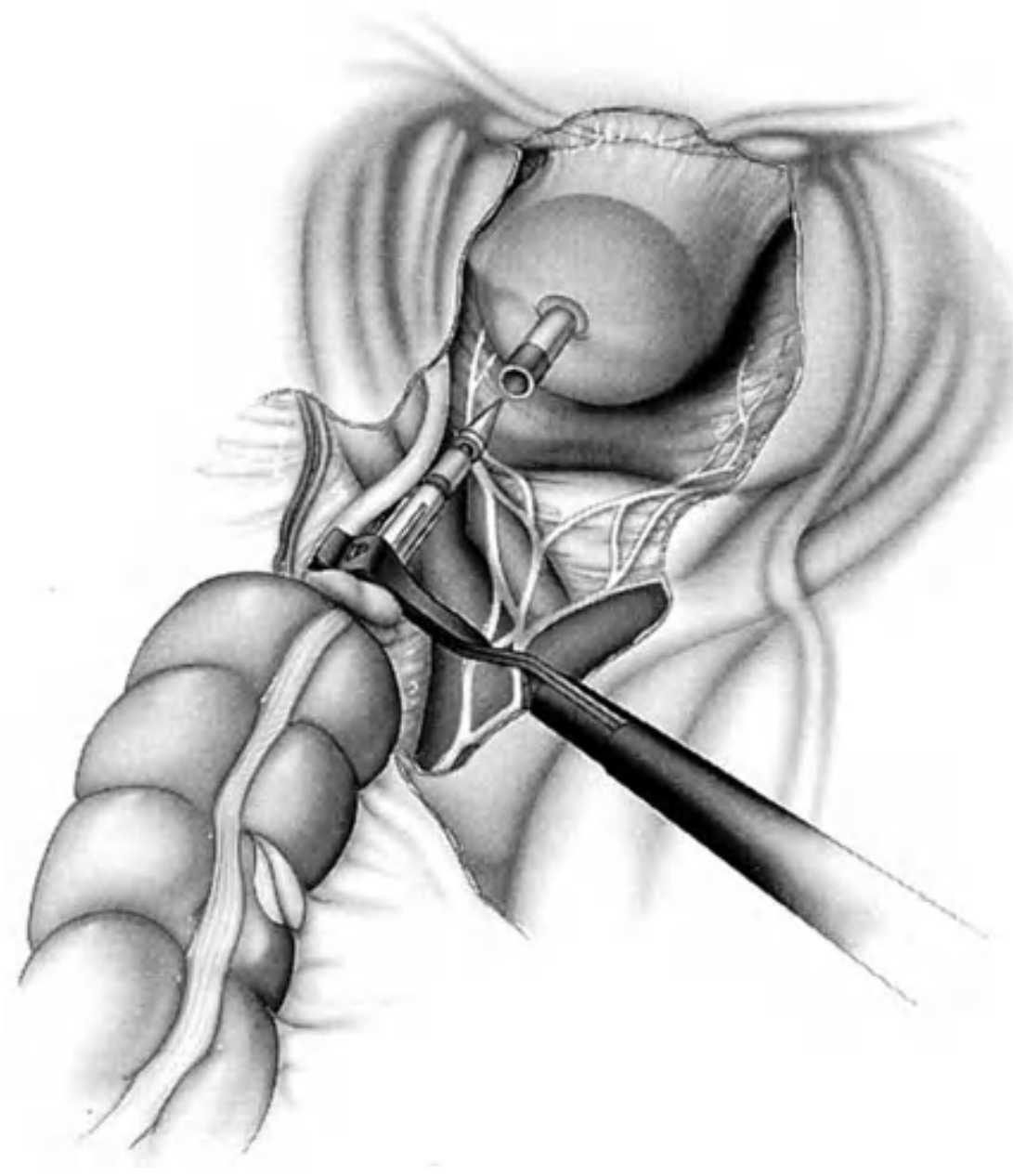

FIGURE 10.18. Transanal colorectal anastomosis for the Hartmann closure.

with saline and a leak test is conducted by insufflating the bowel with the air insufflator of the proctoscope. A grasping instrument is used to proximally occlude the bowel at the pelvic brim.

Once it has been ascertained that the anastomosis does not leak, the peritoneal cavity is irrigated with warm sterile saline solution, the small bowel is displaced so it lies safely anterior to the left colon, and the cannula sites are closed in a routine manner.

Special Considerations

If the most proximal end of the rectum is densely adherent to the sacrum, then it is acceptable to leave this section attached and to choose a site on the anterior rectal wall 3 to 5 cm distally for an end colon-to-side rectal anastomosis. If the exact location of the rectum is in question, or if the rectum is so atrophic that transanal passage of a circular stapler may cause rectal wall injury, conversion to an open procedure should be considered for the anastomosis: a small lower-midline incision is made and a handsewn colorectal anastomosis or a circular stapled anastomosis is created.

References

1. Anderson ID, Hill J, Vohra R, Scofield PF, Kiff ES. An improved means of fecal diversion: the trephine stoma. *Br J Surg.* 1992;79:1080–1081.
2. Anderson CA, Fowler DL, White S, Wintz N. Laparoscopic colostomy closure (brief clinical report). *Surg Laparosc Endosc.* 1993;3:69–72.
3. Sosa JL, Sleeman D, Puente I, McKenney MG, Hartmann R. Laparoscopic-assisted colostomy closure after Hartmann's procedure. *Dis Colon Rectum.* 1994;37:149–152.
4. Gorey TF, O'Connell PR, Waldron D, Cronin K, Kerin M, Fitzpatric JM. Laparoscopically assisted reversal of Hartmann's procedure. *Br J Surg.* 1993;80:109.
5. O'Regan PJ, Scarrow GD. Laparoscopic jejunostomy. *Endoscopy.* 1990;22:39–40.
6. Romero CA, James KM, Cooperstone LM, Mishrick AS, Ger R. Laparoscopic sigmoid colostomy for perianal Crohn's disease. *Surg Laparosc Endosc.* 1992;2:148–151.
7. Sangster W, Swanstrom L. Laparoscopic-guided feeding jejunostomy. *Surg Endosc.* 1993;7:308–310.

11

Infrequently Performed Colorectal Procedures

This chapter presents a step-by-step approach to two operative procedures that a laparoscopic surgical team will perform occasionally. A detailed discussion of how to set up and perform laparoscopic colorectal surgical procedures in general is presented in chapter 8.

The use of laparoscopic techniques to treat rectal prolapse may be especially appealing for several reasons: (1) the entire focus of surgery is confined to the pelvis; (2) no intestinal resection may be required, thus there is no need to remove a specimen through an incision in the abdominal wall; and (3) the technique we prefer in conventional surgery, suture rectopexy, is applicable using laparoscopic techniques.

A laparoscopic approach applied to intestinal obstruction or chronic pain caused by adhesions is currently a procedure under investigation because there are no large series of cases reported thus far that have demonstrated this to be an efficacious procedure. We have attempted this in only a few patients, and we outline our philosophy here as to how to approach this problem systematically using laparoscopic techniques. We believe that currently only a small percentage of intestinal obstruction cases will likely be suitable for laparoscopic adhesiolysis. Nonetheless, in the absence of significant abdominal/intestinal distension in a patient requiring exploration for suspected intestinal obstruction, it may be reasonable to initially look inside the abdomen with a laparoscope, hoping to find an easily exposed adhesion that might relieve the obstruction. In addition, chronic abdominal pain may be caused by intra-abdominal adhesions. In certain selected patients with this problem, laparoscopic lysis of adhesions may be a reasonable operation.

Suture Rectopexy for Rectal Prolapse

Several laparoscopic techniques to treat complete rectal prolapse have been described including the use of sutureless rectopexy[1]; proctosigmoidectomy[2,3]; and modified sling rectopexy, which uses a polypropylene mesh and a laparoscopic hernia stapler to secure the rectum.[4-6] We prefer to treat rectal prolapse without intractable constipation using a simple suture rectopexy method identical to the method we advocate in conventional surgery. The rationale for this is that suture rectopexy has been associated with the same success as other more complex procedures in correcting prolapse. When intractable constipation is present as well, we advocate either concomitant sigmoid resection or total abdominal colectomy with suture rectopexy.

Positions

The patient is placed supine in the modified lithotomy position with the legs in padded stirrups (Dan Allen, Bedford Heights, Ohio). Surgery is begun in a steep Trendelenburg position (15° to 20° head-down tilt). After cannula insertion, the patient is tilted right side down to allow small-bowel loops to fall into the right upper quadrant. The surgeon and the second assistant will stand on the patient's right side, the first assistant is positioned on the patient's left side, and the nurse will stand between the patient's legs or near the left knee for the entire procedure. Both monitors are placed adjacent to the knees (Figure 11.1).

Instruments

The instruments listed in Table 11.1 are the minimum necessary for rectopexy. No other in-

TABLE 11.1. Instruments needed for rectopexy.

No.	Type
5	Cannulas (3 × 10 mm, one 2 × 5 mm) including anchoring devices
1	Endoscopic scissors
1	Endoscopic dissector
2	Endoscopic graspers
1	30° laparoscope
1	Set of needle holders, needle graspers
1	Knot pusher
4	Size 2-0 braided nonabsorbable sutures

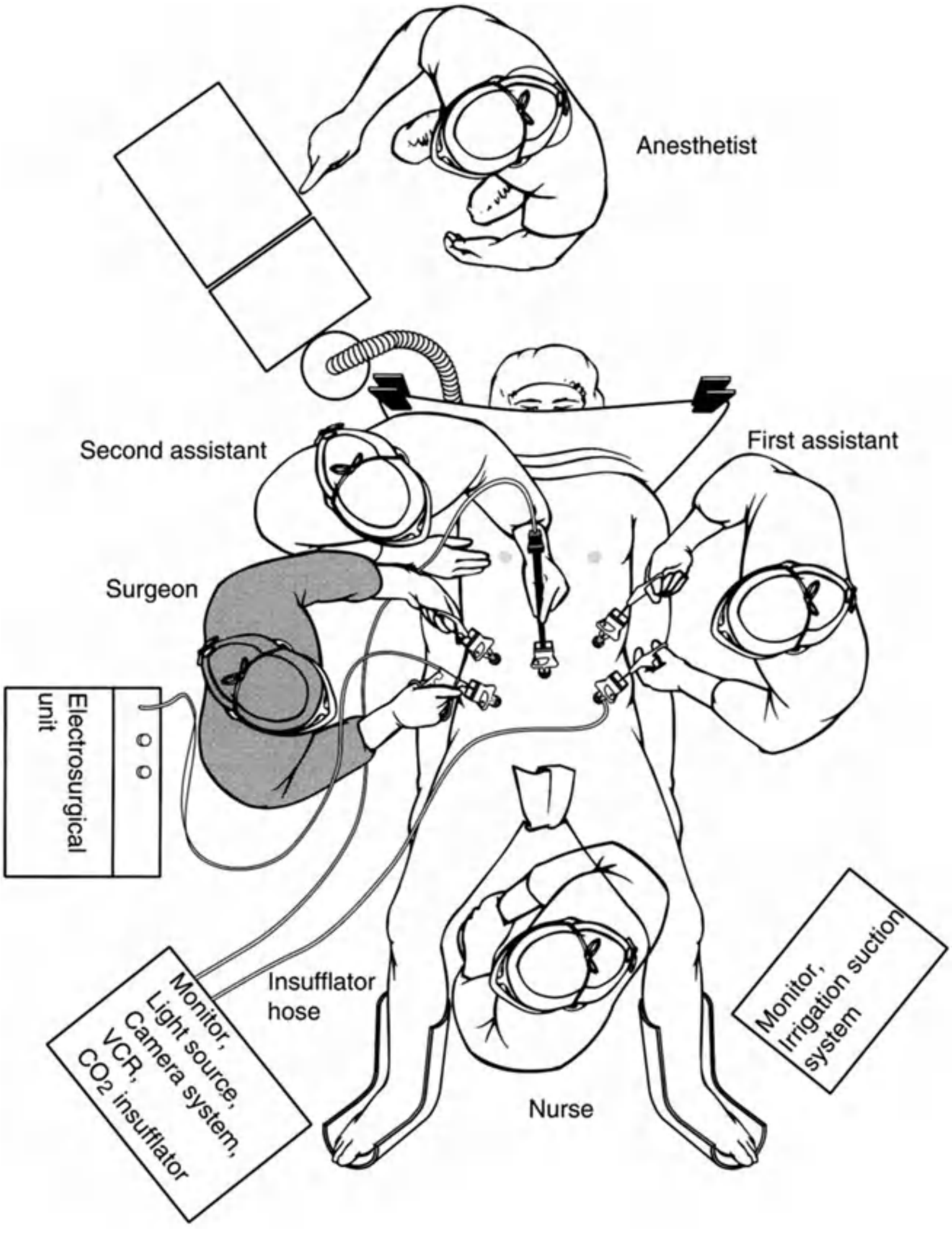

FIGURE 11.1. Position of the equipment and the personnel for rectopexy. These positions are maintained throughout the procedure.

struments should be required except for the basic instruments needed for laparoscopic surgery.

Cannulas

Cannulas should be placed in the infraumbilical area and in the left and right upper and lower abdomen lateral to the rectus sheath (Figure 11.2).

Procedure

After cannula placement and general abdominal exploration, the operation begins by incising the retroperitoneum just to the right of the rectosigmoid colon at the sacral promontory, similar to the initial dissection for proctosigmoidectomy. The incision is extended first cephalad up to the aortic bifurcation, and the hypogastric nerves are swept dorsally away from the superior rectal artery and the mesentery. Next, the peritoneal incision is extended caudally into the pelvis for several centimeters (Figure 11.3). The assistant grasps the cut edge of the peritoneum and reflects the rectum anteriorly and to the left while the surgeon extends the dissection slightly posteriorly and caudally.

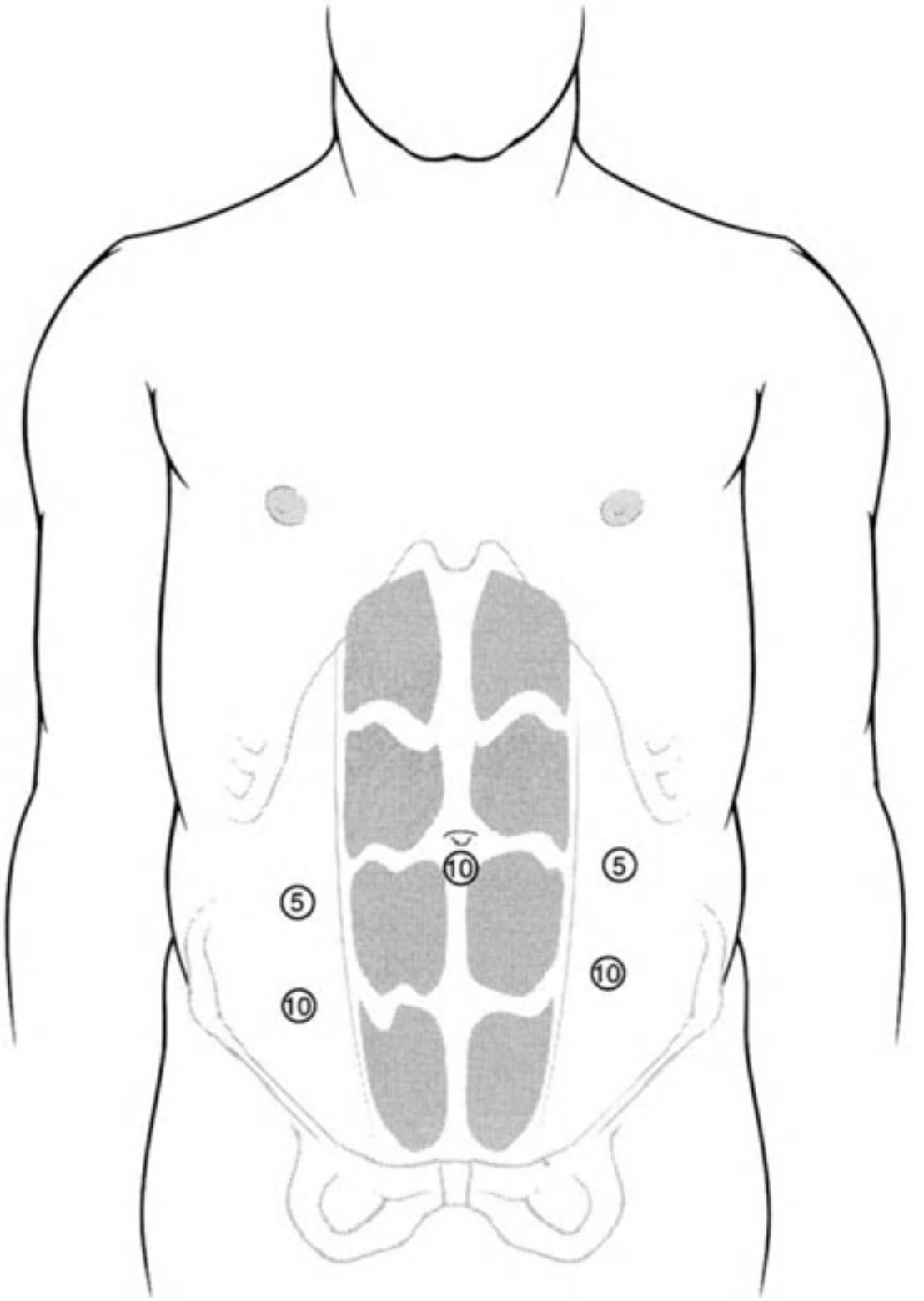

FIGURE 11.2. Cannula placement for rectopexy. The upper- and lower-quadrant cannulas are placed lateral to the rectal sheath.

After this initial dissection, the rectum and the sigmoid colon are retracted to the right side of the pelvis; starting several centimeters above the sacral promontory (Figure 11.4), the peritoneum to the left of the rectum is incised similarly. The dissection is extended posteriorly to create a window joining the plane previously dissected from the other side.

The rectum is mobilized from the presacral fascia down to the level of Waldeyer's fascia at the third sacral vertebra; then this fascia is sharply incised and dissection is continued distally down to the pelvic floor (Figure 11.5). The lateral peritoneal tissue on both sides of the rectum is cut, and the lateral rectal stalks are exposed on both sides, but are otherwise left undisturbed (Figure 11.6). To verify dissection to the pelvic floor, the surgeon should place an extra glove over the right hand and insert this hand into the anus. Under visual control, the surgeon should then insert a grasping instrument through the right-lower-quadrant cannula and use it to palpate the surgeon's index finger—if the dissection is complete, the fingertip should be felt just above the pelvic floor.

The peritoneum is incised anterolaterally down to the peritoneal reflection in the cul-de-sac and then the rectum is further dissected in the anterior plane according to the surgeon's judgment. Again, the lateral stalks are preserved. We generally only dissect in the anterior plane if the rectum appears to be tethered by attachments there such that it is not well elevated out of the pelvis. After this thorough mobilization, the first assistant gently grasps and elevates the rectum in a cephalad direction so it is under moderate tension.

The suture rectopexy begins as follows: the size 2-0 braided nonabsorbable suture is passed through the right-lower-quadrant cannula into the peritoneal cavity so only a small amount of slack is present in the suture. The needle is grasped by a needle holder in the right-lower-quadrant cannula and is driven through the presacral fascia about one cm below the sacral

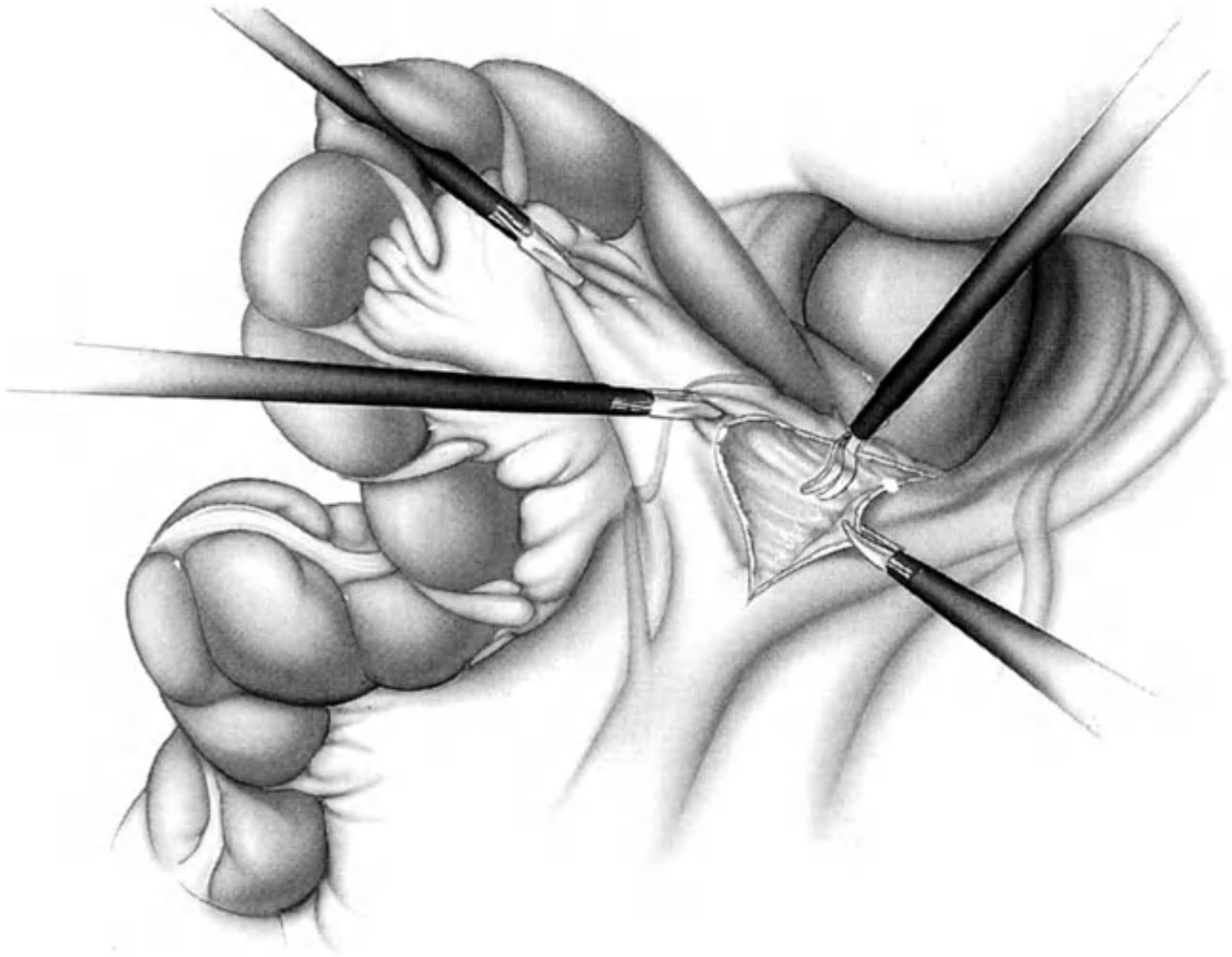

Figure 11.3. The actual dissection begins with an incision of the peritoneum to the right of the rectosigmoid.

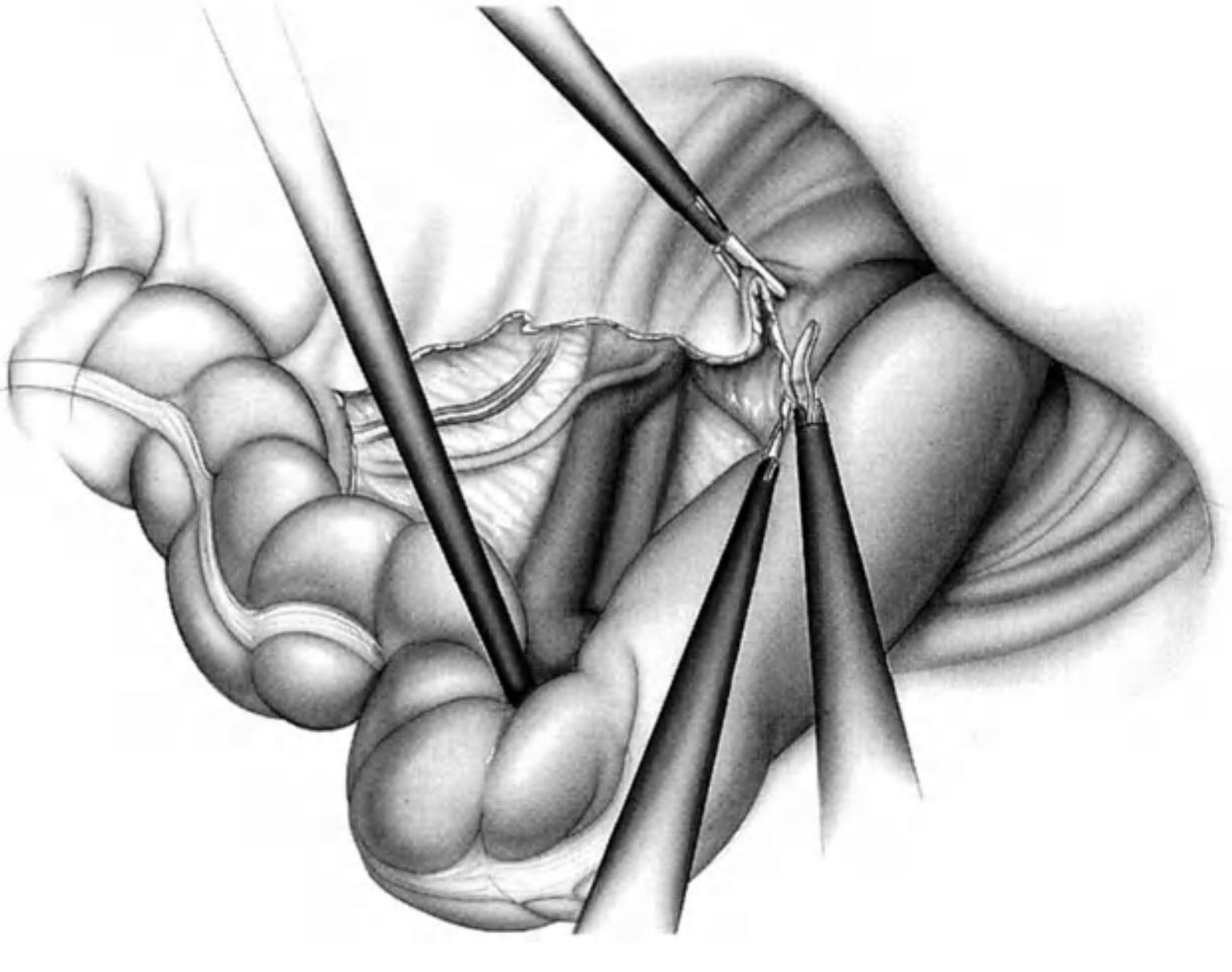

Figure 11.4. Lateral dissection of the rectosigmoid is important in freeing this area for suture placement.

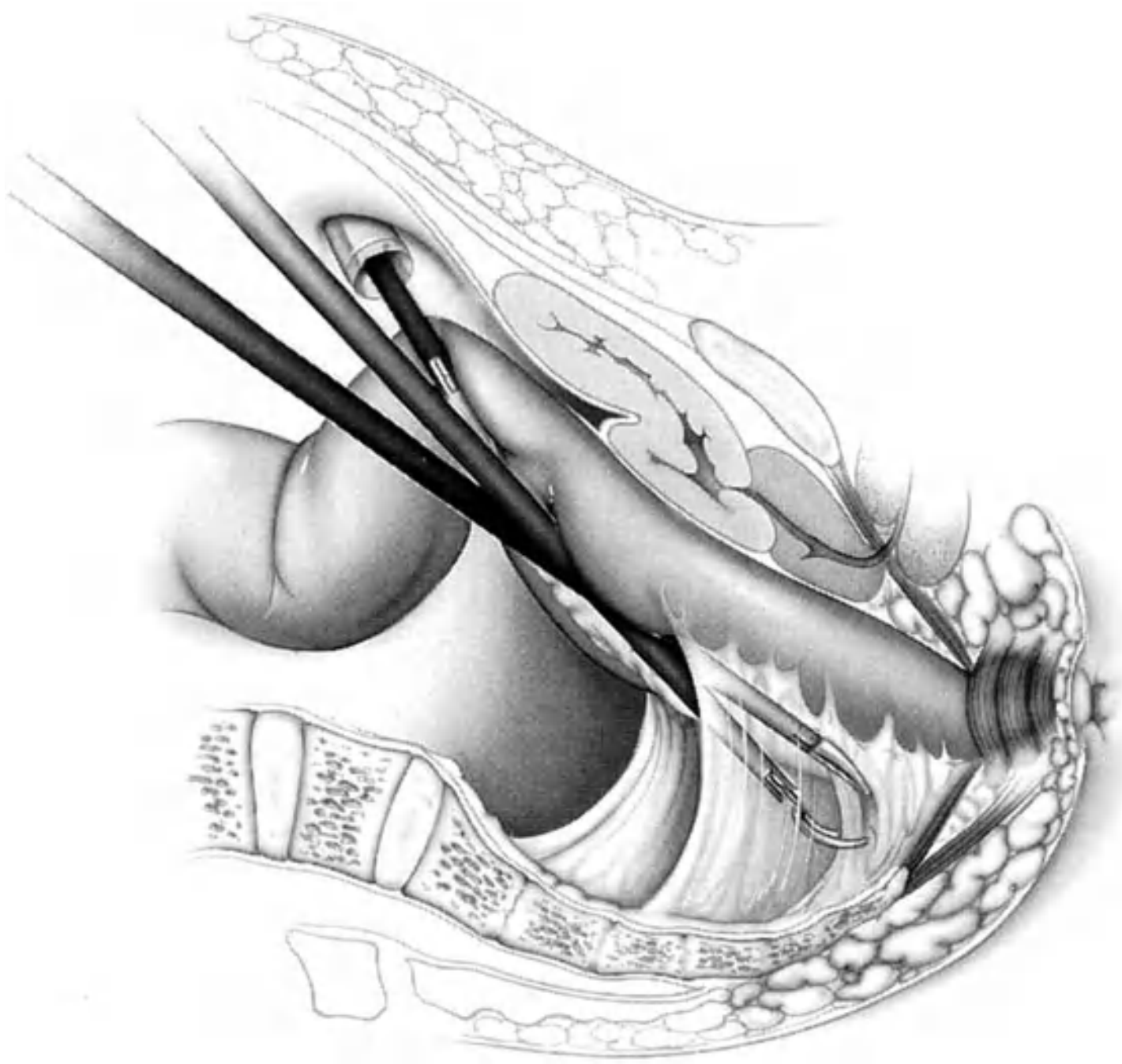

FIGURE 11.5. Posterior mobilization of the rectum down to the pelvic floor.

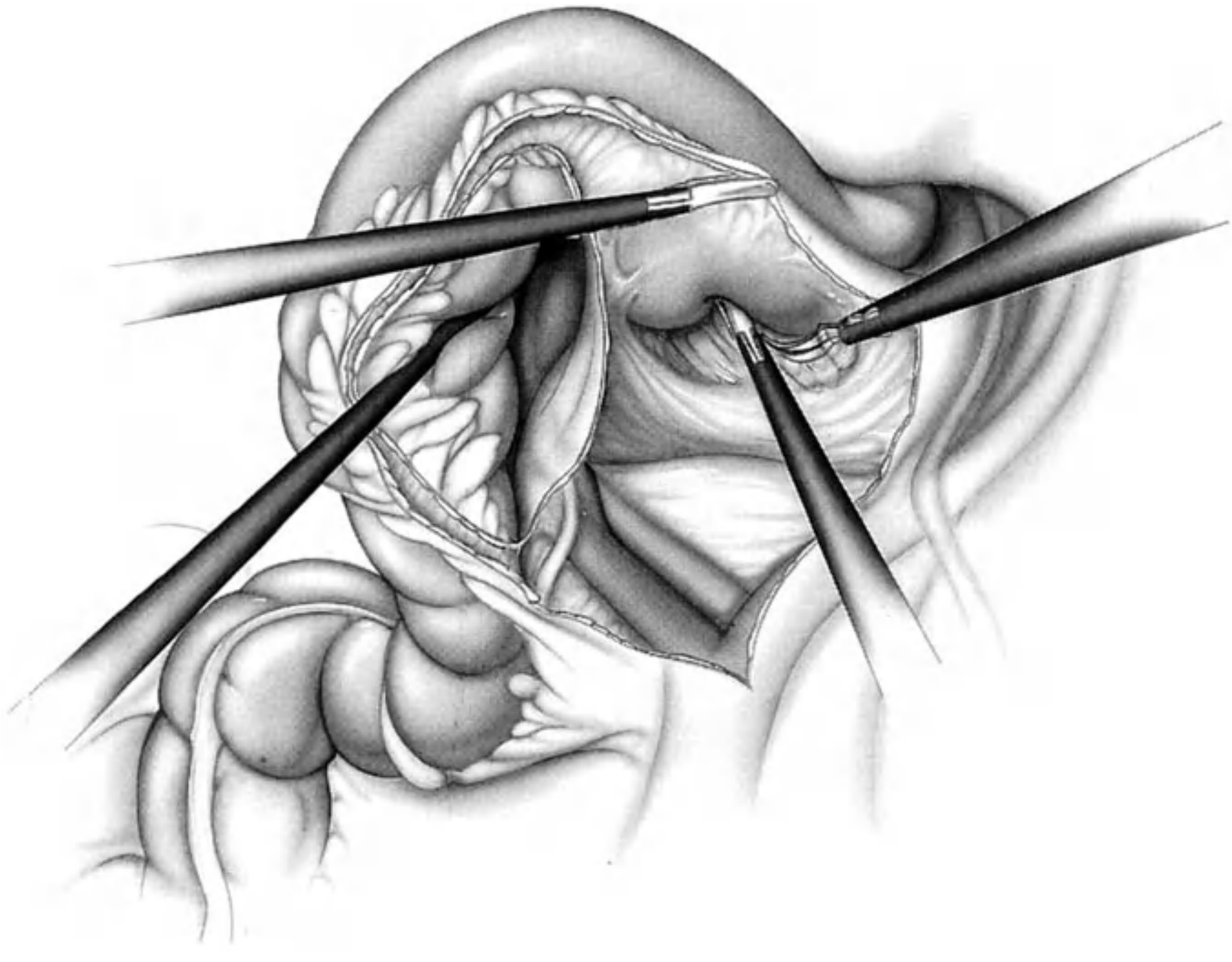

FIGURE 11.6. Exposure of the mobilized rectum without transection of the lateral stalks.

promontory, about 1 cm to the right of the midline. Next, the needle is passed through the rectal stalk region at an appropriate location so the rectum will be held up and out of the pelvis under mild tension (Figure 11.7). This suture is next pulled out of the abdomen, and both ends of it are temporarily freed from the cannula by first removing the cannula from the abdominal wall and then placing the suture alongside the cannula, hanging it out of the abdominal wall alongside the cannula. A Kocher hemostat is used to tag both ends of this suture. The needle is removed.

Next, a second suture is placed into the abdomen in a similar way, passing the needle through the presacral fascia and lateral rectal stalks 1 cm more cephalad than the first suture. A plain hemostat is placed on the ends of this suture to distinguish it from the first one. These sutures are temporarily parked outside the cannula, prior to tying, to maintain an airtight seal on the cannula valve mechanism.

Working from the patient's left side, the first assistant then performs an identical rectopexy at the left side of the rectum, except the sutures are passed through the left-lower-quadrant cannula, and the assistant surgeon (if right-handed) drives the needle holder through the left-upper-quadrant cannula. The surgeon places tension on the rectum so it is held cephalad and toward the right pelvis while the assistant places the sutures. After the second suture is placed through the tissue, it is drawn out through the left-lower-quadrant cannula site. The needle is cut off the suture. Using a closed-end knot pusher, the left lower suture is tied down with a series of simple knots. The suture tail is next cut using scissors passed from a right-sided cannula (Figure 11.8). The left upper suture is then tied similarly, after pulling both ends up through the cannula (this requires temporarily removing the cannula, grasping both suture ends with a grasper that has been passed through the cannula, then pulling the suture ends up through the cannula). After replacing the cannula in the abdominal wall, the suture is tied down, then cut.

The surgeon then ties the knots on the right side in a similar way. The assistant will need to reflect the rectum to the left side of the pelvis as the knots are being pushed down. A second as-

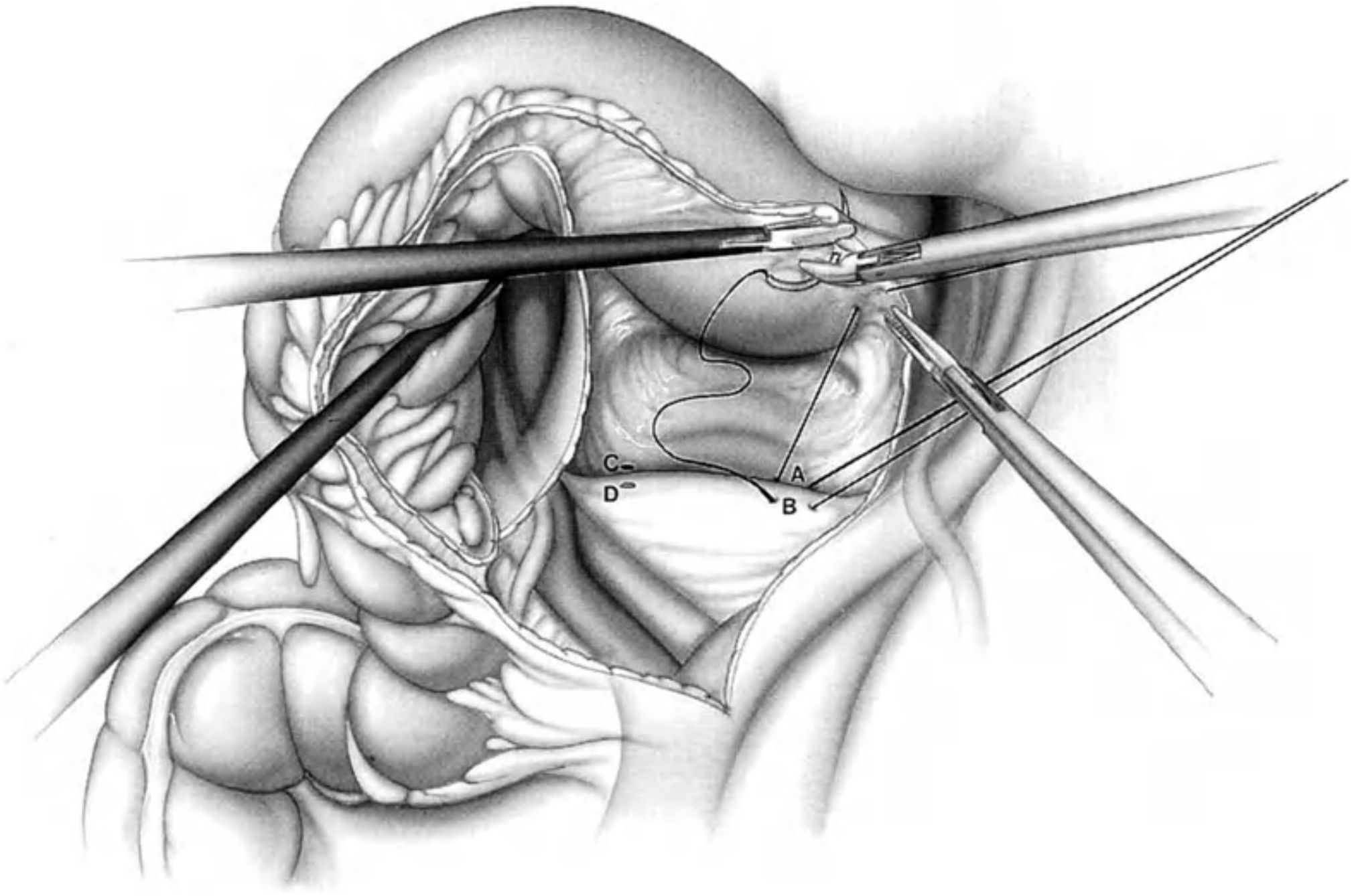

FIGURE 11.7. Placement of two sutures at the right side of the midline of the sacrum. A, B, C, and D denote the order in which the sutures are placed into the presacral fascia for the rectopexy.

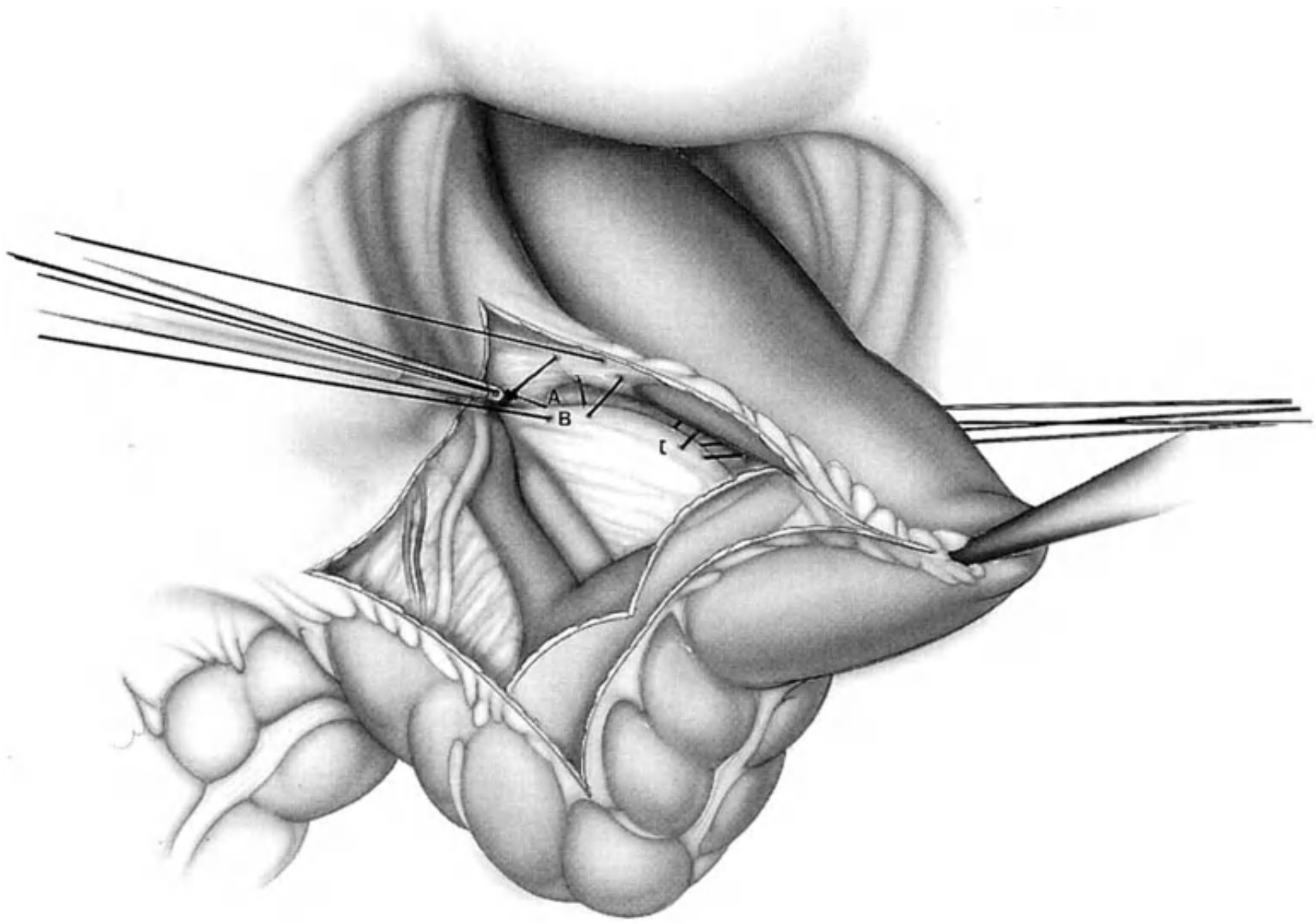

FIGURE 11.8. Tying down the first knot (A) on the left side after placement of all four sutures (A, B, C, & D), using a closed-end knot pusher.

sistant gently passes a rigid proctoscope up to and beyond the rectopexy site to be sure that the sutures do not cause any constriction on the bowel lumen as they are tied. As each of these two right-sided knots are tied, they are cut using scissors passed from the opposite side.

The pelvis is copiously irrigated with warm sterile saline solution using a laparoscopic suction/ irrigator. The proctoscope is then used to inflate the rectum with air. The rectum is inspected via laparoscope to ensure that no inadvertent perforations have occurred. The cannulas are removed in a routine fashion and the cannula sites are closed (Figure 11.9).

Special Considerations

Possible pelvic floor problems in the gynecologic or urinary systems should be fully evaluated before performing suture rectopexy because some of these conditions may require surgical treatment. Multiorgan laparoscopic pelvic procedures for patients with complex pelvic floor disorders are likely to evolve in the near future.

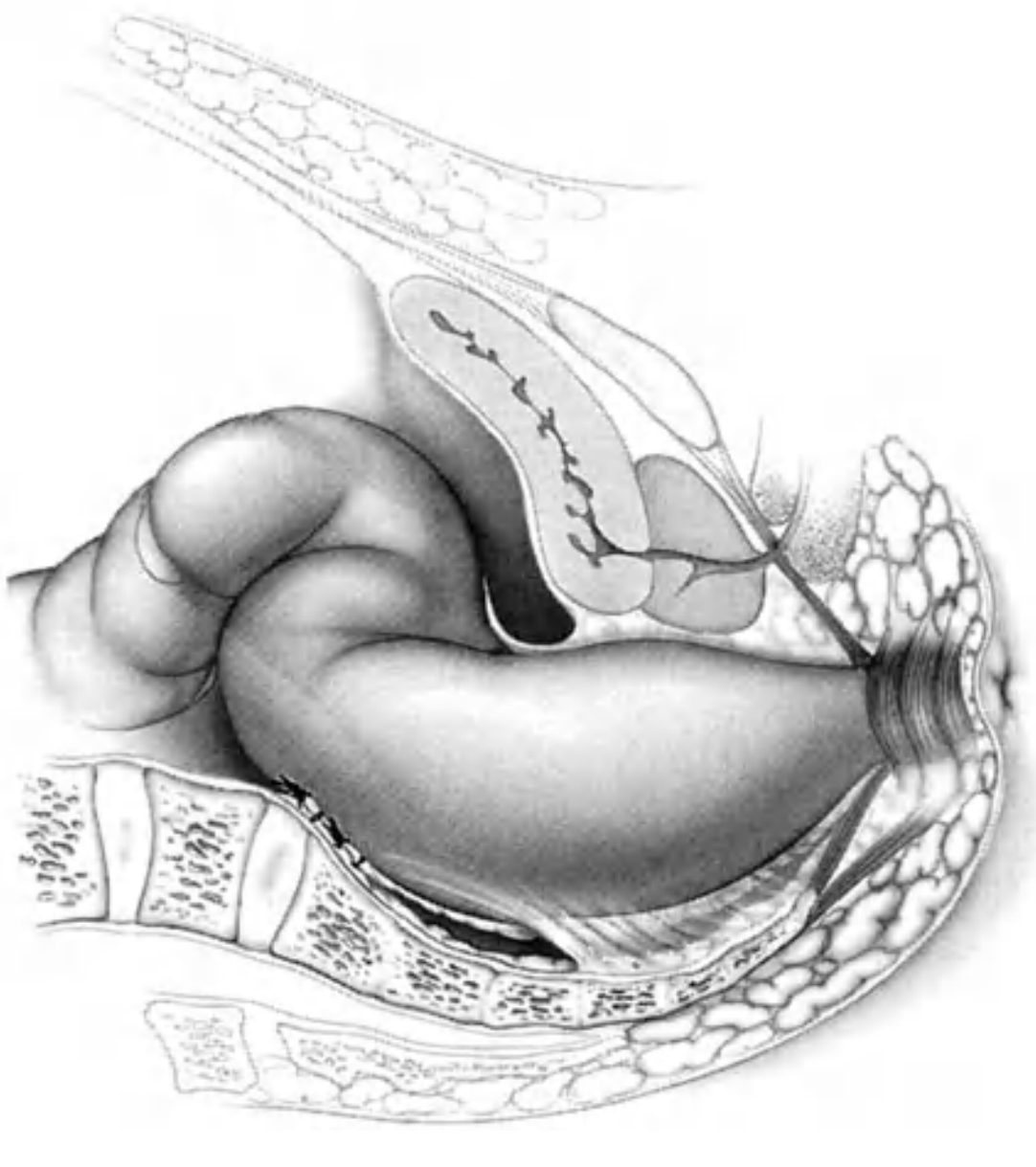

FIGURE 11.9. The mobilized rectum is secured to the sacrum with four nonabsorbable sutures.

Other laparoscopic techniques for repair of complete rectal prolapse have been described. Ballantyne[2] resected the sigmoid colon and the proximal rectum in one patient and reported short-term success during a 7-day postoperative period. Senagore et al.[3] described a similar procedure; they also had successful short-term results in six patients. Long-term results were not reported in these studies.

Berman described tacking a polypropylene mesh to the presacral space by using a novel laparoscopic tacker device inserted through a vaginotomy; he used a hernia stapler to fasten the mesh to the mobilized rectum. The tacker resembled a screwdriver-shaped tool with a detachable titanium tack mounted on its end.[1] Darzi et al.[6] recently reported a modified sling technique whereby the sling and the rectal tissue were tacked together using a laparoscopic hernia stapler in 29 patients, with successful results after a mean of 8 months reported in all but one patient who developed recurrent mucosal prolapse. Cuschieri et al.[5] have described a technique in five patients using a mesh sutured to the presacral fascia and the rectum. They noted no recurrence after a median follow-up of 12 months.

Our technique is simpler than a mesh insertion technique and has been efficacious in correcting the prolapse. We have had no recurrences with a median follow-up of 10 months after performing the procedure in 11 patients. We believe that some type of resection may be reasonable in selected patients with intractable constipation. However, we have yet to encounter any patients who required a resection.

Adhesiolysis

Although it would be uncommon to perform laparoscopic lysis of adhesions in patients with acute small-bowel obstruction because of the amount of intestinal distension likely to be present, patients who have either an early or partial small-bowel obstruction that requires surgical intervention may be candidates for laparoscopic adhesiolysis. Pneumoperitoneum may exert abdominal wall traction on adhesions and actually allow for some facility in dissolving adhesions if they are uncomplicated. Some patients with chronic abdominal pain following abdominal surgery may have adhesions as a cause of their pain. In rare instances, these adhesions can be lysed with relief of the symptoms.

Position

The patient is placed in the modified lithotomy position with the legs in padded adjustable stirrups (we prefer Dan Allen stirrups). Surgery is begun in a steep Trendelenburg position (15° to 20° head-down tilt). Selection of the initial cannula site (for the laparoscope) is dictated by the amount of distension as well as where previous abdominal incisions have been made. The right and left lower quadrants tend to be adhesion-free areas if they are free of incisions and may be optimal sites for an initial cannula insertion using an open technique.

The surgeon usually stands on the patient's left side, with the first assistant standing on the patient's right and the second assistant just cephalad the first assistant. The nurse stands between the patient's legs. The surgeon and the assistants also may find standing between the patient's legs advantageous for part of the procedure. Both monitors are initially placed adjacent to the patient's knees. If the surgeon or the assistants do move to stand between the legs later in the procedure, the monitors then should be moved to shoulder level. (We only give general advice about the positions for the surgical team—in general, we recommend the surgeon stand with an assistant on the left side.)

Instruments

The instruments listed in Table 11.2 are the minimum necessary to perform this procedure. For extensive dissection, two additional cannulas and two graspers are needed. Other instruments probably will not be required except for the basic instruments needed for laparoscopic surgery.

TABLE 11.2. Instruments required for adhesiolysis.

No.	Type
3	Cannulas (2 × 10 mm, 1 × 5 mm) including anchoring devices
1	Endoscopic scissors
1	Endoscopic dissector

Cannulas

Cannula positions will be dictated largely by the location of adhesions, but optimally will be in the left and right upper and lower quadrants of the abdomen lateral to the rectus sheath. The initial cannula should be inserted and pneumoperitoneum should be established using open techniques, as described in the next section.

Procedure

A site for initial cannula is chosen in the lower abdomen, away from previously made incisions, and on the side opposite where adhesions are likely to be found. Thus, if a small-bowel obstruction occurred after appendectomy, an initial cannula would be inserted in the left lower quadrant. The cannula is inserted using an open technique. This technique is performed by initially incising the skin at the trocar site and then retracting the skin with small right-angled retractors so the fascia can be seen. A modest incision is made through each fascial layer (or by gently spreading the internal oblique and transversus abdominis layers). The peritoneum is then grasped with two conventional toothed (Kocher) clamps, and a size 0 polyglycolic acid or polypropylene suture is placed in the peritoneum using a purse-string or U-stitch suture. The peritoneum is incised carefully and the peritoneal cavity is entered. We advise using a fingertip to ensure the peritoneal cavity is safely entered. The cannula is next inserted through this incision, and, once the anchoring device is passed to the peritoneal level, the suture is tied or tightened using a Rumel tourniquet. This requires a stiff 14F catheter (approximately 10 to 12 cm in length) through which the fascial suture is passed. This catheter is pushed down against the cannula, then it is used to hold the suture tightly around the cannula using a clamp at its distal end.

Carbon dioxide pneumoperitoneum is then established through this cannula and a warmed laparoscope is inserted. The peritoneal cavity is carefully inspected, starting at the region where the cannula was inserted, to ascertain that no visceral injuries have occurred and to determine the extent of the adhesions. If the adhesions are extensive, involving multiple loops, the retroperitoneum, and so on, or if the intestine is so distended that the peritoneal cavity cannot be safely visualized, then the procedure should be converted immediately to an open laparotomy.

If laparoscopic adhesiolysis is feasible, then a site for at least one additional safe cannula insertion must be present. Ideally, two additional cannulas would be inserted, allowing for two-handed work by a surgeon and an assistant. This may not be possible or even necessary, depending on the location and extent of the adhesions. Once a second cannula is inserted (under direct vision), some adhesiolysis may be possible. Adhesiolysis must be performed systematically, as in open surgery; thus the goal of the procedure is to visualize and manipulate ("run") the entire small intestine from the ligament of Treitz to the ileocecal valve. A site for the third cannula is chosen as rapidly as possible because after the third cannula is inserted, the surgeon can begin to use two-handed dissection techniques. Once the abdominal wall is freed of adhesions, two additional cannulas may be placed through the abdominal wall opposite the surgeon to allow the first assistant to work also. Applying strong upward traction on the anterior abdominal wall by using a towel clip on the skin will exert countertraction on adhesions and may facilitate the adhesiolysis. If the laparoscope initially could not be inserted at a point along the midline, once the anterior abdominal wall has been cleared of adhesions, then the laparoscope may be removed and re-inserted through a midline cannula. In this way, the surgeon and the first assistant will each have two cannula sites through which to work.

Few reports regarding laparoscopic adhesiolysis have been published to date. This is because of the relative infrequency of surgeons who feel comfortable attempting laparoscopy on a patient with a bowel obstruction and abdominal distension. Franklin et al.[7] reported the use of laparoscopic techniques to treat acute small bowel obstruction in 23 patients. In 10 patients the obstruction was due to adhesions, in 5 patients the cause was internal hernia (4 were diaphragmatic), and in 6 patients the cause was abdominal wall hernia (3 femoral, 1 inguinal, and 2 incisional). Only three patients had to be converted to open surgery due to excessive adhesions.

This remarkable series details that the average operation time was 75 minutes and the average hospital stay 2.5 days.[7] This is possibly a highly selected group of patients because we do not recall seeing such a high percentage of patients, even using open techniques, able to undergo such brief correction of intestinal obstruction. Additionally, some of these patients had incarcerated abdominal wall hernias—it is difficult to justify performing laparoscopy on such patients when a local procedure over the hernia site may be simpler and is the common method of treating such hernias.

Special Considerations

In the instance of bowel obstruction, laparoscopic techniques may be indicated to treat the obstruction if there is a simple isolated area of adhesions. As mentioned earlier, if extensive intra-abdominal adhesions are encountered, the procedure should be converted to an open one very early. Fusion of multiple intestinal loops, even if only with filmy adhesions, is another circumstance that also may signal a need for conversion.

References

1. Berman IR. Sutureless laparoscopic rectopexy for procidentia. *Dis Colon Rectum.* 1992;35:689–693.
2. Ballantyne GH. Laparoscopically assisted anterior resection for rectal prolapse. *Surg Laparosc Endosc.* 1992;2:230–236.
3. Senagore AJ, Luchtefeld MA, Mackeigan JM. Rectopexy. *J Laparoendosc Surg.* 1993;3:339–343.
4. Cuesta MA, Borgstein PJ, De Jong D, Meijer S. Laparoscopic rectopexy. *Surg Laparosc Endosc.* 1993;3:456–458.
5. Cuschieri A, Shimi SM, Vander Velpen G, Banting S, Wood RAB. Laparoscopic prosthesis fixation rectopexy for complete rectal prolapse. *Br J Surg.* 1994;81:138–139.
6. Darzi AW, Lewis C, Guillou P, Monson J. Stapled laparoscopic rectopexy for rectal prolapse. *Surg Endosc.* 1994;8:233.
7. Franklin ME, Dorman JP, Pharand D. Laparoscopic surgery in acute small bowel obstruction. *Surg Laparosc Endosc.* 1994;4:289–296.

12

Advantages and Disadvantages of Laparoscopic Colorectal Surgery

A responsible approach to developing new surgical techniques must consider the risks and benefits of the techniques at every point so surgical outcome is constantly maximized for all patients undergoing the new surgical treatment. The simple fact that a surgical technique can be performed does not justify its use. Laparoscopic techniques in gallbladder surgery clearly benefit the patient: there is less reduction in pulmonary function,[1-3] probably less postoperative pain,[4-7] and much faster recovery[8] after laparoscopic cholecystectomy as compared with conventional cholecystectomy. These benefits are so evident that a prospective randomized trial to demonstrate them will probably never be performed. Despite the advantages of laparoscopic gallbladder surgery, it is not obvious why surgeons should adopt these techniques for colorectal surgery. Unlike surgery for gallbladder disease, surgical treatment of abdominopelvic disease often requires extensive mobilization and removal of a large section of intestine—it could be argued that the direct and wide exposure that the long abdominal incisions used in conventional surgery provides might outweigh other benefits of laparoscopic surgery.

The advantages and the disadvantages of laparoscopic colorectal surgery are not entirely known and will take years of concerted study to determine. However, given that the efficacies of laparoscopic and conventional surgery so far have been found to be similar, at least for benign disease, the primary goals of laparoscopic surgery should be a faster and a safer recovery compared with conventional surgery. Thus, in this chapter we discuss the immediate postoperative and long-term benefits and problems of laparoscopic colorectal surgery as they are currently understood. Studies of similar aspects of laparoscopic gallbladder surgery are also referred to because they may serve as models for future studies in this field.

Early Postoperative Concerns

To determine if recovery is faster and safer after laparoscopic colorectal surgery, a reduction in postoperative morbidity and mortality, and an improvement in quality of life are the immediate advantages that should be most closely studied and most readily apparent. The term *morbidity* encompasses not only surgical and general complications after colorectal surgery such as wound infection, anastomotic leakage, pneumonia, or urinary tract infection, but also other concerns such as pulmonary function, pain, paralytic ileus, adhesions, immunosuppression, and catabolism. In this section, we discuss the most important aspects of postoperative morbidity after laparoscopic colorectal surgery. The final section discusses costs and other potential short-term advantages and problems of laparoscopic colorectal surgery.

Complications

Because randomized studies comparing conventional and laparoscopic colorectal surgery have not been done, reliable data as to whether laparoscopic surgery may reduce surgical or general complications are not available. However, higher complication rates have not been reported, possibly because patients are carefully selected.

Pulmonary Function

Pulmonary function diminishes under general anesthesia because of the loss of inspiratory muscle tone, changes in intrathoracic blood volume, and cephalad displacement of the diaphragm (caused by the supine position). These factors decrease functional residual capacity, which results in a decline in Po_2. Atelectasis occurs with venous mixture and shunting of the blood through the pulmonary circulation, which further decreases Po_2. The functional residual capacity drops even more precipitously in patients with restrictive or obstructive pulmonary disease, and elevating the inspiratory o_2 content and positive end-expiratory pressure is necessary in these patients to compensate for impaired pulmonary function during anesthesia.

Postoperatively after conventional surgery, pulmonary function decreases to 50% to 60% of its preoperative value, so the most common and serious postoperative complications after conventional abdominal surgery relate to compromised pulmonary function.[9] Pulmonary complications (including atelectasis, hypoventilation, pneumonia, hypoxemia, and death) correlate well with the degree of decline in pulmonary function after surgery.[3,10]

Although no published studies compare postoperative pulmonary function after laparoscopic and conventional colorectal surgery, faster recovery of pulmonary function with fewer consequent pulmonary complications may be a major advantage of laparoscopic surgery for colorectal disease. In studies comparing postoperative pulmonary function after laparoscopic and conventional cholecystectomy, the forced vital capacity and forced expiratory volume were significantly greater after laparoscopic than after conventional cholecystectomy.[1-3,11-13] Similarly, because a long abdominal incision is avoided in laparoscopic colorectal surgery, with only a relatively small (5 to 10 cm) incision needed for specimen removal, it is reasonable to surmise that postoperative pulmonary function could be quantified and compared between laparoscopic and conventional colorectal surgery.

Pain

All patients undergoing conventional colorectal resection will endure moderate to severe pain for at least 3 to 5 days postoperatively unless treated with strong analgesic measures. The nearly universal need for strong opioid analgesics may further depress respiratory function and prolong the paralytic state of the intestine (ileus) that occurs after surgery. Because smaller incisions are used in laparoscopic colorectal surgery, theoretically, analgesic requirements may be decreased; this may lead to less pain, less pulmonary depression, and a shorter postoperative ileus. Several nonrandomized, uncontrolled studies have suggested pain is decreased after laparoscopic compared with conventional colorectal surgery.[14,15] Several studies also infer that pain may be less after laparoscopic than conventional cholecystectomy.[4-8,16] It is unlikely that anyone will perform such a randomized study in laparoscopic gallbladder surgery to evaluate pain because of the very apparent reduced postoperative pain when minimal invasive techniques are used.

Again, although a decrease in postoperative pain may be expected in laparoscopic compared with conventional colorectal surgery, and is a compelling short-term reason to consider adopting laparoscopic techniques in colorectal surgery, it remains to be shown that pain is reduced.

Intestinal Motility

Postoperative ileus is a well-known transient event after abdominal surgery; it is clinically defined as a disturbance of intestinal motility with loss of peristaltic bowel sounds, abdominal distention, and lack of passage of flatus or stool, which sometimes results in vomiting and cramping pain. A clear understanding of the cause of postoperative ileus has yet to be established. Currently, the accepted theory is that sympathetic nervous system hyperreactivity inhibits intestinal motility. Laparotomy activates sympathetic hyperreactivity, which is prolonged by rough and unskilled operative manipulation in the intestine, long operative time, and extensive resection.[17-20]

Measurements of postoperative intestinal motility in animals and humans using bipolar electrodes (to measure myoelectrical activity),[17-20] strain gauges (to measure muscle contractions)[17,18,21] or radiopaque markers (to measure intestinal transit time) have shown that postoperative ileus resolves in a regular pattern: the ileum returns to normal function after 6 to 12 hours, the stomach after 12 to 24 hours, and the colon after 48 to 120 hours.[22-24] Thus, colonic motility is the determining factor in the length of postoperative ileus. When the patient has passed flatus and feces, it is assumed that colonic motility clinically is normal and oral nutrition can then be resumed.

The possibility that ileus may resolve more quickly after laparoscopic colorectal surgery compared with conventional surgery is one of the most desirable reasons for pursuing laparoscopic treatment of intestinal diseases. In a series of 20 patients, Jacobs et al.[25] reported that after laparoscopic bowel resection, 18 patients tolerated clear liquids on the first postoperative day and passed gas or stool by the third postoperative day. Corbitt[26] reported that after laparoscopic-assisted colectomies in 15 patients, some patients tolerated oral intake as soon as the first postoperative day, whereas others had no oral intake for up to 72 hours. Franklin et al.[27] reported that all patients undergoing laparoscopic colorectal surgery were passing stool by 30 hours after surgery. In a study of 43 patients who underwent laparoscopic-assisted or conventional colectomies, Schmitt et al.[28] did not find any significant difference in the number of patients tolerating oral intake after laparoscopic surgery. However, the laparoscopic-assisted colectomy technique used in this study still requires performing a substantial amount of conventional surgery through an incision in the abdominal wall; it is possible that the benefit of faster intestinal recovery after laparoscopic procedures is lost when both a laparotomy with extracorporeal dissection and division of the bowel and the mesentery (laparoscopic-assisted surgery) are performed. Whether there are differences in postoperative results between completely laparoscopic versus laparoscopic-assisted surgery is unknown at this time. Further investigation of this problem is needed.

To evaluate the duration of postoperative ileus after laparoscopic and conventional surgery, we conducted a canine study in which we placed bipolar electrodes subserosally to measure the myoelectrical activity of the stomach, the ileum, and the colon; the time to the first bowel movement was also measured. The effect of the laparoscopic and laparotomy incision alone, anesthesia, and conventional or laparoscopic right colectomy on intestinal motility was evaluated. We clearly found that normal myoelectrical activity in the stomach, the small and large intestine, and the postoperative bowel movement returned more rapidly after laparoscopic right colectomy than after conventional colectomy, despite a significantly longer operative time (Table 12.1). Colonic motility recovered last in all animals and was in all cases present before the first bowel movement was noted. Laparoscopy by itself had almost no effect on bowel motility, whereas laparotomy significantly suppressed intestinal motility.[29] Schippers et al.[30] reported a study similar to ours that evaluated myoelectrical activity after laparoscopic and conventional cholecystectomy in a canine model. They also found a significant difference in the postoperative recovery of normal small-bowel myoelectrical activity between laparoscopic and conventional surgery, with small-bowel phase III activity (the migrating motor

TABLE 12.1. Return of myoelectrical activity to a normal interdigestive pattern following laparoscopic or conventional right-sided colectomy in a dog model.

	Median (range) time until return to normal pattern, h*		
	Laparoscopic (n = 6)	Conventional (n = 6)	P†
Antrum	14 (8–19)	25 (18–28)	<.01
Small intestine	15 (4–19)	25 (17–38)	<.01
Sigmoid colon	19 (11–24)	31 (21–42)	<.01
Bowel movement	26 (22–32)	36 (29–52)	<.01

* h = hours.

† Wilcoxon rank-sum test.

complex) returning more quickly after laparoscopic compared with open cholecystectomy (5.5 ± 1.0 hours versus 46 ± 5 hours, *P* value not given).

Overall, current evidence suggests that laparoscopic techniques may permit intestinal function to recover more quickly after colorectal surgery. Theoretically, a faster recovery would lead to reduced postoperative discomfort, earlier resumption of normal oral nutrition, and shorter hospitalization. Such advantages could substantially decrease hospital costs as well.

Other Aspects

Because laparoscopic colorectal surgery is a new technique and heavily depends on new technology, definite advantages in cost savings have thus far been difficult to demonstrate. In a multi-institutional study, Falk et al. noted increased operating room costs when using laparoscopic techniques but these increases were counterbalanced by a decreased length of hospital stay.[31] In a single-institution study, Monson et al. reported similar findings.[14] Any cost savings in laparoscopic colorectal surgery related to an earlier ability to return to work have yet to be reported.

The major quantifiable disadvantage relates to cost. Because nearly all steps of laparoscopic surgery require complex video equipment and novel instrumentation, the initial capital costs may be considerable compared with conventional surgical procedures. Additionally, because many current laparoscopic instruments are disposable (cannulas, certain graspers, scissors, and stapling instruments), cost increases of up to $1,000 or more per case in equipment charges may occur. This is unique to laparoscopic surgery.

Because laparoscopic colorectal surgery usually involves extensive mobilization of a long intestinal segment and ligation of major mesenteric vascular structures with novel instruments, this surgery currently requires more time in the operating theater than comparable conventional surgery. For most procedures, this time is 1 or 2 hours per procedure more than conventional surgery. In most hospitals in the Unites States, operating room charges are based on minutes in the theater, so a considerable difference in cost may be seen in laparoscopic compared with conventional surgery.

Length of stay has also been reported to decrease after laparoscopic colorectal surgery compared with conventional colorectal surgery in several studies of carefully selected patients.[25,27,32,33] A major reduction in the length of stay could result in a major savings in health care expenditures, but this endpoint is extremely subject to bias and is difficult to study scientifically because the decision to discharge a patient is complex and is based on multiple factors.

Because laparoscopic colorectal techniques are in the earliest phases of development, several disadvantages are related to the novelty of this approach. However, these problems should diminish with time and surgical experience. In particular, the training necessary to set up and accomplish laparoscopic colorectal surgery concerns many practicing surgeons. Because there are currently few training centers in this field, a laparoscopic colorectal surgical team must be created, organized, and trained, and new routines must be established with few models to rely on. This problem is typical of most new surgical disciplines, but it does require extra time and energy that may severely strain the resources of most busy surgical units. Additionally, the training necessary for laparoscopic colorectal surgery does not necessarily follow from laparoscopic cholecystectomy or upper gastrointestinal surgery. Months are required to learn to skillfully perform laparoscopic intestinal resection. Thus, a major commitment is necessary from many individuals (surgeons, nurses, trainees, administrators, and other operating room personnel) to successfully accomplish laparoscopic colorectal surgery.

Several reports have questioned whether laparoscopic colorectal surgery has any advantage. In a group of 74 patients undergoing laparoscopic or laparoscopic-assisted colorectal surgery, Wexner et al.[34] found no apparent advantages regarding operating time, length of ileus, or length of hospitalization compared with conventional procedures. However, the study does not state how many procedures were done using laparoscopic-assisted methods, meaning that only colonic mobilization was carried out laparoscopically, and that mesenteric division and anastomosis formation were nearly always done through a laparotomy. Thus, it may have been that the most difficult portions of the surgery were actually performed conventionally. In addition, there was no true control group of conventional surgical patients, and no data for conventional surgery patients were provided in the article. Although no human studies have substantiated that surgery performed entirely laparoscopically, including mesenteric division and anastomosis formation, results in faster recover than laparoscopic-assisted surgery, one of our animal studies[29] clearly showed an earlier return of bowel myoelectrical activity and normal bowel movement in laparoscopic as compared with conventional right colectomy. Corroborating well-designed human studies are clearly needed to answer the important questions concerning short-term advantages and disadvantages, and how they relate to the costs of laparoscopic and conventional colorectal surgery.

Long-term Concerns

If the endpoints discussed so far are determined to be similar between laparoscopic and conventional colorectal surgery, quality of life measurements may become extremely important in determining the advantages of one approach versus the other. This type of assessment seldomly has been applied to laparoscopic surgery but should be because quality of life is a major concern of all medical treatment, especially when evaluating new treatment approaches.[35]

Little is known about the potential for laparoscopic colorectal surgery to influence the long-term outcome of patients. If patients are able to recover more rapidly from major intestinal surgery, this may improve such measurable indicators such as earlier return to work, increased productivity, and decreased disability, as well as other semiquantifiable variables such as quality of life. No studies have been done that actually address these issues in any scientific manner. Other theoretical long-term advantages of laparoscopic colorectal surgery include the possibility of earlier postoperative adjuvant chemotherapy and radiotherapy if recovery is quicker.

Whether survival or recurrence differs between patients who undergo laparoscopic colorectal surgery and those who undergo conventional procedures for cancer remains to be determined, and the main long-term concern about laparoscopic colorectal surgery centers on its adequacy for colorectal cancer operations. Because of the limited exposure and lack of basic concepts about oncologic surgery using laparoscopic techniques, many surgeons fear that laparoscopic resection will be inadequate for colon or rectal cancers. Anecdotal reports of abdominal wall metastases occurring in the laparoscopic cannula sites within months of curative laparoscopic resections[36-38] have heightened concerns about laparoscopic oncologic surgery. The occurrence of wound seeding after open surgery for colorectal cancer has been reported to be exceedingly low—Hughes et al. found an incidence of 0.7% in 2,603 potentially curative resections for colon cancer.[39]

The mechanism underlying rapid recurrence in cannula sites is debatable but likely relates to the abdominal wall trauma imposed during the cannula insertion coupled with implantation of cells exfoliated during the laparoscopic procedure.[40-45] In 1984, Umpleby et al. reported that large numbers of viable tumor cells were present in the peritoneal cavity in patients with colorectal cancer.[46] In 1994, Leather et al. identified malignant cells in the peritoneal washing of 15 of 35 patients undergoing conventional colorectal cancer resection before resection, in 8 patients both preresection and postresection, and in 4 patients postresection only.[47] Nduka et al.[48] proposed that the following three aspects of laparoscopy may lead to an increased likelihood of wound implantation compared with conventional surgery:

1. increased exfoliation of malignant cells after tissue manipulation with laparoscopic instruments
2. increased contact between the skin incisions and any malignant cells on the surface of instruments and resected tissue

3. the possible influence of the pneumoperitoneum itself and the presence of CO_2 gas in high concentration may potentiate malignant cell growth and spread

None of these are proven factors and no studies exist that allow the incidence of wound implantation after open surgery to be compared with laparoscopic procedures. We believe the concepts presented regarding laparoscopic oncologic techniques (chapters 8 and 9) for colorectal cancer surgery (early vascular ligation, minimal tumor handling, and transabdominal removal of all specimens in an impermeable sealed bag) should be adhered to because they are simple, relatively inexpensive, and may diminish the risks of cannula site implantation. Meanwhile, all surgeons performing laparoscopic surgery for colorectal cancer must continue to investigate and assess this problem.

References

1. Barnett RB, Clement GS, Drizin GS. Pulmonary changes after laparoscopic cholecystectomy. *Surg Laparosc Endosc.* 1992;2:125–127.
2. Poulin EC, Mamazza J, Breton G, Fortin CL, Wabha R, Ergina P. Evaluation of pulmonary function in laparoscopic cholecystectomy. *Surg Laparosc Endosc.* 1992;2:292–296.
3. Williams CD, Brenowitz JB. Ventilatory patterns after vertical and transverse upper abdominal incisions. *Am J Surg.* 1975;130:725–728.
4. Dubois F, Icard P, Berthelot G. Coeliscopic cholecystectomy. Preliminary report of 36 cases. *Ann Surg.* 1990;211:60–62.
5. Ure BM, Troidl H, Spangenberger W, Dietrich A, Lefering R, Neugebauer E. Pain after laparoscopic cholecystectomy. *Surg Endosc.* 1994;8:90–96.
6. Bailey RW, Zucker KA, Flowers JL. Laparoscopic cholecystectomy. Experience with 375 consecutive patients. *Ann Surg.* 1991;213:531–539.
7. Schirmer BD, Edge SB, Dix J. Laparoscopic cholecystectomy. *Ann Surg.* 1991;213:665–676.
8. The Southern Surgeons Club. A prospective analysis of 1518 laparoscopic cholecystectomies. *N Engl J Med.* 1991;324:1073–1078.
9. Böhm B, Nouchirvani K, Hucke HP, Stock W. Morbidität und Letalität nach elektiven Resektionen kolorektaler Karzinome. *Langenbecks Arch Chir.* 1991;376:93–101.
10. Halpern NB, Cox CB. Abdominoperineal resection for rectal carcinoma: perioperative risk factors. *South Med J.* 1989;82:1492–1496.
11. Rademaker BM, Ringers J, Odoom JA, de Wit LT, Kalkman CJ, Oosting J. Pulmonary function and stress response after laparoscopic cholecystectomy: comparison with subcostal incision and influence of thoracic epidural analgesia. *Anesth Analg.* 1992; 75:381–385.
12. Mealy K, Gallagher H, Barry M, Lennon F, Traynor O, Hyland J. Physiological and metabolic responses to open and laparoscopic cholecystectomy. *Br J Surg.* 1992;79:1061–1064.
13. Frazee RC, Roberts JW, Okeson GC, et al. Open versus laparoscopic cholecystectomy. A comparison of postoperative pulmonary function. *Ann Surg.* 1991;213:651–654.
14. Monson JRT, Darzi A, Carey PD, Guillou PJ. Prospective evaluation of laparoscopic-assisted colectomy in an unselected group of patients. *Lancet.* 1992;340:831–833.
15. Tate JJT, Kwok S, Dawson JW, Lau WY, Li AKC. Prospective comparison of laparoscopic and conventional anterior resection. *Br J Surg.* 1993;80: 1396–1398.
16. Peters JH, Ellison EC, Innes JT, et al. Safety and efficacy of laparoscopic cholecystectomy. *Ann Surg.* 1991;213:3–12.
17. Sarna SK. Physiology and pathophysiology of colonic motor activity. Part one of two. *Dig Dis Sci.* 1991;31:827–862.
18. Sarna SK. Physiology and pathophysiology of colonic motor activity. Part two of two. *Dig Dis Sci.* 1991;31:998–1018.
19. Frantzides CT, Mathias C, Ludwig KA, Edmiston CE, Condon RE. Small bowel myoelectric activity in peritonitis. *Am J Surg.* 1993;165:681–685.
20. Lang IM, Sarna SK, Condon RE. Generation of phases I and II of migrating myoelectric complex in the dog. *Am J Physiol.* 1986;251:G201–G207.
21. Sarna SK. Myoelectric correlates of colonic motor complexes and contractile activity. *Am J Physiol.* 1986;250:G213–G220.
22. Condon RE, Cowles VE, Schulte WJ, Frantzides CT, Mahoney JL, Sarna SK. Resolution of postoperative ileus in humans. *Ann Surg.* 1986;203:574–580.
23. Graber JN, Schulte WJ, Condon RE, Cowles VE. Relationship of duration of postoperative ileus to extent and site of operative dissection. *Surgery.* 1982;92:87–92.
24. Sarna SK, Waterfall WE, Bardakjian BL, Lind JF. Types of human colonic electrical activities recorded postoperatively. *Gastroenterology.* 1981;81:61–70.
25. Jacobs M, Verdeja JC, Goldstein HS. Minimally invasive colon resection (laparoscopic colectomy). *Surg Laparosc Endosc.* 1991;1:144–150.
26. Corbitt JD. Preliminary experience with laparoscopic-guided colectomy. *Surg Laparosc Endosc.* 1992;2:79–81.
27. Franklin ME, Ramos R, Rosenthal D, Schuessler W. Laparoscopic colonic procedures. *World J Surg.* 1993;17:51–56.
28. Schmitt SL, Cohen SM, Wexner SD, Nogueras JJ, Jagelman DG. Does laparoscopic-assisted ileal pouch anal anastamosis reduce the length of hospitalization? *Int J Colorectal Dis.* 1994;9:134–137.

29. Böhm B, Milsom JW, Fazio VW. Postoperative intestinal motility following conventional and laparoscopic intestinal surgery. *Arch Surg.* 1995;130: 415–419.
30. Schippers E, Öttinger AP, Anurov M, Polivoda M, Schumpelick V. Laparoscopic cholecystectomy: a minor abdominal trauma? *World J Surg.* 1993; 17:539–543.
31. Falk PM, Beart RW Jr., Wexner SD, et al. Laparoscopic colectomy: a critical appraisal. *Dis Colon Rectum.* 1993;36:28–34.
32. Jenkins DM, Paluzzi M, Scott TE. Postlaparoscopic small bowel obstruction. *Surg Laparosc Endosc.* 1993;3:139–141.
33. Phillips EH, Franklin M, Carroll BJ, Fallas MJ, Ramos R, Rosenthal D. Laparoscopic colectomy. *Ann Surg.* 1992;216:703–707.
34. Wexner SD, Cohen SM, Johansen OB, Nogueras JJ, Jagelman DG. Laparosopic colorectal surgery: a prospective assessment and current perspective. *Br J Surg.* 1993;80:1602–1605.
35. Donovan K, Swanson-Fisher RW, Redman S. Measuring quality of life in cancer patients. *J Clin Oncol.* 1989;7:959–968.
36. Alexander RJ, Jaques BC, Mitchell KG. Laparoscopically assisted colectomy and wound recurrence. *Lancet.* 1993;34:249–250.
37. O'Rourke N, Price PM, Kelly S, Sikora K. Tumor inoculation during laparoscopy. *Lancet.* 1993;34: 368.
38. Fusco MA, Paluzzi MW. Abdominal wall recurrence after laparoscopic-assisted colectomy for adenocarcinoma of the colon. *Dis Colon Rectum.* 1993;36:858–861.
39. Hughes ES, McDermott FT, Polglase AL, Johnson WR. Tumor recurrence in the abdominal wall scar tissue after large-bowel cancer surgery. *Dis Colon Rectum.* 1983;26:571–572.
40. Fortner JG, Lawrence W Jr. Implantation of gastric cancer in abdominal wounds. *Ann Surg.* 1960; 152:789–794.
41. Alexander JW, Altemeier WA. Susceptibility of injured tissues to hematogenous metastases: an experimental study. *Ann Surg.* 1964;159:933–944.
42. Fisher ER, Fisher B. Experimental study of factors influencing development of hepatic metastases from circulating blood. *Acta Cytol.* 1965;9:146–158.
43. Ackerman LV, Wheat MW. The implementation of cancer—an avoidable surgical risk? *Surgery.* 1955; 37:341–355.
44. Bush AK. The surgical implantation of tumors. *Ann Surg.* 1957;23:1012–1021.
45. Meadows C. Surgical transplantation of tumor cells. *Ann Surg.* 1957;23:247–256.
46. Umpleby HC, Fermor B, Symes MO, Williamson RC. Viability of exfoliated colorectal carcinoma cells. *Br J Surg.* 1984;71:659–663.
47. Leather AJM, Kocjan G, Savage F, et al. Detection of free malignant cells in the peritoneal cavity before and after resection of colorectal cancer. *Dis Colon Rectum.* 1994;37:814–819.
48. Nduka CC, Monson JRT, Menzies-Gow N, Darzi A. Abdominal wall metastases following laparoscopy. *Br J Surg.* 1994;81:648–652.

13

Educating the Surgical Team in Laparoscopic Colorectal Surgery

Developing formal educational programs is essential in establishing standardized laparoscopic colorectal techniques as safe and standard procedures.[1,2] Despite the critical nature of such programs, little information exists regarding educational concepts in laparoscopic colorectal surgery and such surgery is not a standard part of any surgical training program. The American College of Surgeons (ACS) and the Society of American Gastrointestinal Endoscopic Surgeons (SAGES) have both published some general recommendations regarding training, credentialing, and awarding surgical privileges in new technologies.[3,4] The ACS states, "A defined educational program in the technology, including didactic and practical elements, must be completed and documented either as a post-residency course of instruction or as a component of an approved residency program." Additionally, the ACS guidelines state, "The surgeon must be qualified, experienced, and knowledgeable in the management of the diseases for which the technology is applied—for example, laparoscopic instrumentation would be applied by surgeons with abdominal or pelvic surgical experience and credentials." Furthermore, "The qualifications of the surgeon to apply the new technology must be assessed by a surgeon who is qualified and experienced in the technology and should result in a written recommendation to the department or service head."[4] Both the ACS and the SAGES recommend that maintenance of skills be documented through periodic outcomes assessment and evaluation in association with the regular renewal of surgical privileges.

We believe that recommendations should distinguish between experienced colorectal surgeons who want to learn new techniques, fellows (advanced trainees) and residents who are completing their surgical education, and operating room nursing staff who will work with the surgeons in laparoscopic surgery. At present, most experienced surgeons have performed little or no laparoscopic colorectal surgery. Because laparoscopic colorectal surgery appears to be much more difficult to learn than laparoscopic cholecystectomy, practicing colorectal surgeons naturally have had significant difficulty finding enough time to learn laparoscopic colorectal techniques. Fellows and residents who have some experience with other laparoscopic techniques may adjust faster to laparoscopic colorectal surgery, but they still must learn and practice many new techniques.

Therefore, we recommend the following three-tiered educational program, designed to instruct an operating team (surgeons, assistants, and nurses). This program is based, in part, on our own detailed experiences and frustrations, as well as the latest recommendations of the SAGES and the ACS. We strongly believe all laparoscopic surgical teams should pass through the following three phases before embarking on independent laparoscopic colorectal surgery:

1. acquiring basic laparoscopic colorectal surgical skills in inanimate models
2. practicing basic laparoscopic colorectal surgical techniques in animal models

3. assisting an experienced preceptor in performing laparoscopic colorectal surgery in patients

The basic premise of these guidelines is that the surgeon must possess the judgment, training, and capability to proceed immediately to a traditional open abdominal procedure "when circumstances so indicate,"[3] presumably when this is in the best interests of the patient.

SAGES advises a formal fellowship or training in general surgery, plus structured experience in laparoscopic surgery. Their recommendations for structured experience include "didactics, hands-on animal experience, participation as a first assistant, and performance of the operation under proctorship."[3] The animal surgical experience they recommend should be "in specific categories of procedures for which the applicant desires privileges." Proctoring specifically implies that an unbiased, experienced laparoscopic surgeon, "responsible to the privileging committee, and not to the patient or to the individual being proctored," will evaluate the surgical performance of the surgeon attempting to qualify for privileges. The proctoring concept, espoused by SAGES, underlies this society's concern that individual surgeons must demonstrate a certain level of expertise, although this society shies away from recommending specific numbers of cases needed to establish competency. Later in this chapter we will discuss our ideas about the extent of training needed to adequately perform laparoscopic colorectal surgery.

Team Approach

A team approach must be emphasized early in the educational process because without a skilled team (surgeon, assistants, and nursing staff), laparoscopic colorectal surgical efforts will fail. Because there are so many new concepts and tools, the team cannot have any weak links. The team must learn the proper function of each laparoscopic instrument and each piece of basic equipment (laparoscope, video equipment, suction irrigator, and insufflator). All team members should be able to troubleshoot most problems related to the equipment.

The surgeon should choose assistants who will train and work closely with the surgeon throughout all phases of the educational program; selected surgical nurses should have an ability and an interest in acquiring new concepts. Nursing supervisors must allow individual nurses to commit themselves to intensive education in the technology and techniques of laparoscopic colorectal surgery. Once this core team is established, they can begin to instruct other surgeons, residents, and nurses at the institution.

Although there are only a few formal educational programs for laparoscopic colorectal surgery, in time such programs should become incorporated into the surgical education programs of departments of surgery and operating room nursing.[1] Until such time, we believe the following educational program can thoroughly develop the skills and the teamwork required for laparoscopic colorectal surgery.

Preliminary Training in Inanimate Models

The first phase in learning laparoscopic colorectal surgery involves acquiring skills using a risk-free inanimate model. The purposes of this preliminary training are as follows:

- to become comfortable working with both hands using laparoscopic instruments
- to become familiar with the video and laparoscopic equipment
- to begin learning basic laparoscopic techniques

Beginners in laparoscopic surgery need initial experience in inanimate models to become accustomed to the laparoscopic environment. This is a novel environment, where, unlike conventional surgery, the surgeon and the assistant may no longer focus on hand and instrument movements inside the abdominal cavity. Rather, the surgical team must rely on the two-dimensional visual clues of the video monitor coupled with some tactile feedback. Additionally, surgeons must acclimate themselves to instruments that are limited in their range of motion by the fixation of the cannulas to the abdominal wall. Surgeons with some expertise in laparoscopic surgery should still train on inanimate models at first because of the need for many new skills of laparoscopic colorectal surgery (e.g., mesenteric division, "running" of the intestine, creation of anastomoses) not encountered in gallbladder or upper gastrointestinal surgery.

The inanimate model is basically a clear plastic box that may initially be used with direct visualization (without using a video camera) of instruments and intestinal models of soft rubber tubing and foam. Thus, the initial use of a pelvic training model will help the surgeon adapt to the laparoscopic environment. Techniques such as cannula insertion, two-handed videoscopic coordination, running (manipulating) the small bowel, suturing, knot tying, and applying endoscopic clips and staplers may be learned and practiced under direct vision in inanimate laparoscopic training models. Once the surgeon is comfortable performing these techniques under direct vision, the clear plastic top of the pelvic training model is covered with an opaque material and the surgeon performs the same tasks under laparoscopic visualization with the video camera. To take these first steps in learning basic laparoscopic skills, the sophisticated inanimate models currently used in some training centers are not absolutely mandatory. Nearly all the techniques and the concepts valuable to laparoscopic surgery may be learned in a simple setting with a minimal amount of equipment and space.

While the surgeon focuses on primary skills of surgery, the assistant surgeon should simultaneously practice similar skills on a separate trainer, or hold the video camera for the surgeon. The operating room nurses should use this time to familiarize themselves with equipment, assisting the surgeon, and learning the techniques to promote maximal efficiency in the operating environment. This initial phase will require at least 6 to 8 hours of concentrated effort. The team must be capable of performing accurate and precise work in the inanimate model before graduating to the animal model.

Training in Animal Models

Using animal models to learn laparoscopic colorectal surgery is justified because certain skills cannot currently be acquired in inanimate models such as the following: avoiding tissue injury while grasping tissue with instruments; controlling bleeding vessels with coagulation, ligation, or clips; and accomplishing intestinal anastomoses, especially those performed intraperitoneally.[5] The following laparoscopic skills and techniques may be learned in animal models:

- the atraumatic intraoperative manipulation of intestine (running the small bowel, placing umbilical tapes around the small and large bowel)
- the performance of hemostasis of mesenteric vessels by coagulation, ligature, and clips
- small- and large-bowel resection
- oncologic en bloc resection of the colon with high ligation and excision of the lymphovascular pedicles
- intracorporeal function end-to-end anastomosis of the small and large bowel using linear endoscopic staplers and colorectal anastomosis using transanal circular staplers

These skills, practiced and perfected in animal models, are essential for safety and success in human laparoscopic colorectal surgery. Furthermore, practicing intestinal resection techniques in animal models is necessary because accomplishing such surgery requires many new skills:

- most intestinal surgery involves removal of a section of a continuous organ with the necessity for precise reestablishment of intestinal continuity
- multiple major mesenteric blood vessels must be ligated
- most dissection must be accomplished over several quadrants of the abdominal cavity
- contamination by bowel contents must be avoided
- all laparoscopic instruments may damage the mesentery or the bowel wall if they are used improperly, thus one must learn their atraumatic use under the laparoscope before performing patient procedures

Coagulation of minor blood vessels with ligation or clipping of major vessels are skills that are mandatory for achieving hemostasis. The control of major bleeding should also be practiced because major bleeding can be one of the most significant limitations of laparoscopic surgery and a primary reason for conversion to open surgery.

Several studies have shown that porcine[6-10] and canine[11,12] models can be successfully used to perform laparoscopic intestinal resections and to develop intraperitoneal anastomotic techniques. Although there is active opposition in the United States and other countries to using live animals for teaching and research (arguments include that animals cannot exactly duplicate human conditions, are expensive, and lack the pathologic processes of humans), we believe the use of large animals in laparoscopic colorectal surgery currently is an indispensable second step toward successfully performing such surgery in patients. Learning laparoscopic surgical skills in animals may substantially flatten the steep learning curve of laparoscopic colorectal surgery often experienced when learning such skills in patients.

For the surgical team to become comfortable performing laparoscopic procedures in animals, they should plan to use at least 6 to 10 animals for the procedures outlined as follows. At least half the animals on which any surgeon trains should be allowed to survive for 1 to 2 weeks, and then undergo zoopsy to evaluate the surgical results. This approach requires the surgical team to set aside a considerable amount of time (at least 2 weeks of full-time attention to animals and procedures), and to have access to a facility that is licensed and equipped to handle large animals in the preoperative, intraoperative, and postoperative periods.

Preparation of the Animal

All animals used for experimental purposes in the United States must be cared for in accordance with the regulations of the National Institutes of Health's *Principles for Use of Animals* and *Guide for the Care and Use of Laboratory Animals*. The facility in which the animals are housed should be approved by the American Association for the Accreditation of Laboratory Animal Care (or a similar regulatory body in countries outside the United States).

Animals should undergo preoperative bowel preparation consisting of clear liquids for 2 days before surgery with 8 oz (240 mL) of magnesium citrate added to the drinking water 24 hours before surgery and tap water enemas administered immediately before surgery. Cleansing tap water enemas administered immediately before surgery are important to empty the left colon. Care should be taken, however, to not give too much enema fluid, especially in pigs, because the water will collect in the proximal colon, distend the bowel, and impair the laparoscopic view.

Use of the Porcine Model in Laparoscopic Colorectal Surgery

Female pigs with a body weight of 30 to 35 kg should be used. This size pig has intestinal and peritoneal dimensions similar to those of humans. Females are more docile and thus are easier to care for than males in the laboratory environment.

This section will outline normal porcine intestinal anatomy, then give a step-by-step approach to two procedures readily performed in the porcine intestine: (1) small-bowel resection with intraperitoneal ileoileal anastomosis, and (2) segmental large-bowel resection with intraperitoneal circular colorectal anastomosis.

Intestinal Anatomy of the Pig

Porcine intestinal anatomy differs from humans in that the blood supply of the small intestine is strictly radial and the proximal colon is spirally coiled. The superior mesenteric vessels are short and run close to the base of the mesentery. They are covered by numerous 1- to 2-cm diameter lymph nodes. The blood supply of the small intestine consists of direct radial branches from the superior mesenteric vessels (Figure 13.1). The direct small arteries from the superior mesenteric artery supply 1- to 3-cm segments of the small intestine. Vascular anastomoses between the radial vessels are present in the intestinal submucosa, but true marginal vessels as found in humans do not exist.

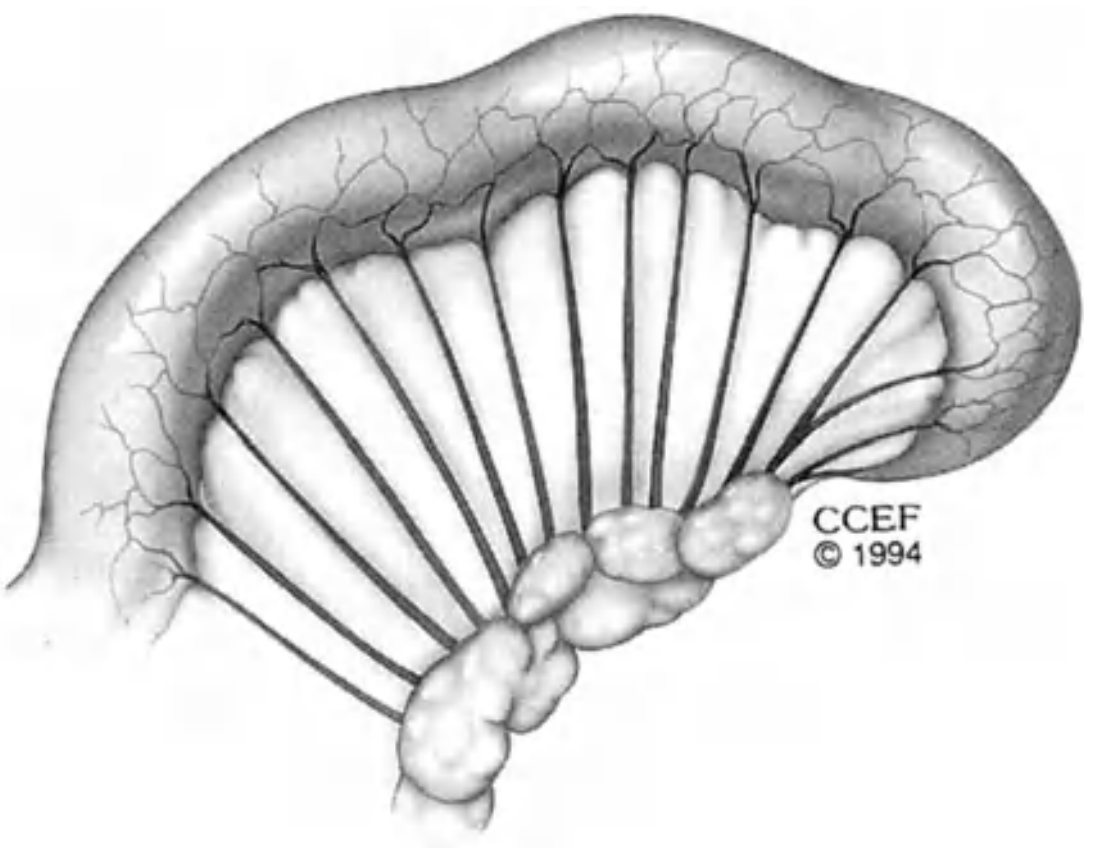

FIGURE 13.1. Anatomy of the small intestine and its mesenteric vasculature in pigs.

The anatomy of the left colon and the rectum is similar to humans and allows a segmental resection with anastomosis. The arterial supply comes from the inferior mesenteric artery and its branches, the left colic artery, and the superior rectal artery (Figure 13.2). The arteries run parallel to the left colic vein and are easily seen in the thin mesentery. The terminal ileum and right colon of the pig are not suitable for laparoscopic colon resections because they are coiled and fused by adhesions. Extensive adhesiolysis would be necessary to accomplish right colon resections.

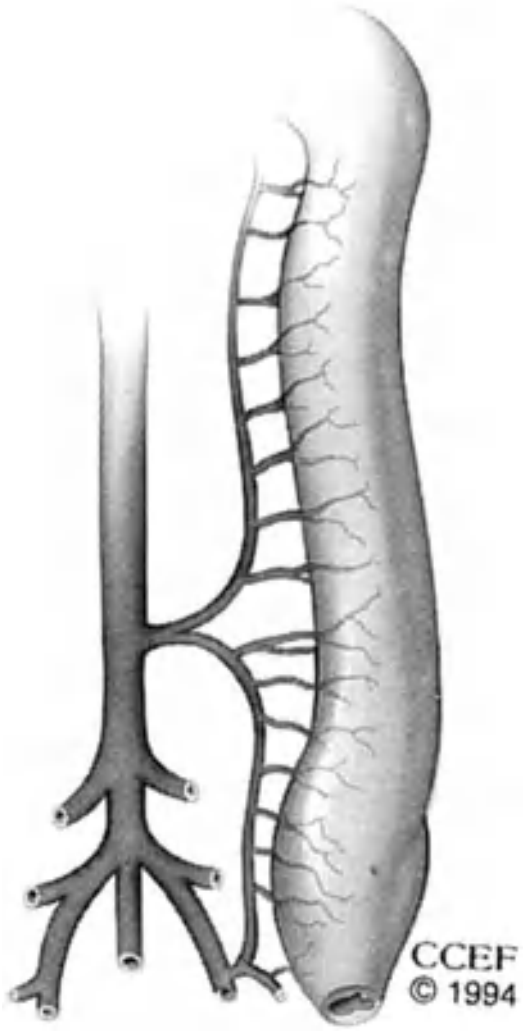

FIGURE 13.2. Anatomy of the left colon and its mesenteric vasculature in pigs.

Porcine Small-bowel Resection with Intraperitoneal Ileoileal Anastomosis

After insertion of a Veress needle in the midline between the umbilicus and the symphysis, pneumoperitoneum (CO_2, to 12 mm Hg) is established and the peritoneal cavity is inspected. Four additional trocars are inserted under direct visual control, one in each of the four abdominal quadrants lateral to the rectus sheath (Figure 13.3).

The small intestine is identified and is carefully grasped at a random location with atraumatic bowel graspers. The operating surgeon should then practice running the small intestine proximally and distally using a gentle hand-over-hand technique. This means that the surgeon should grasp the small intestine at the ileocolic junction gently but firmly with one grasping instrument, then with the other hand grasp 5 to 10 cm upstream of this area before releasing with the first hand. This action is repeated for the length of the small intestine. This requires practice but will help to develop videoscopic hand–eye coordination and atraumatic handling of the intestine necessary in human intestinal surgery.

A proximal resection line is then chosen at a convenient location, the thin mesentery is incised next to the bowel with scissors, and a dissecting instrument is gently pushed through the

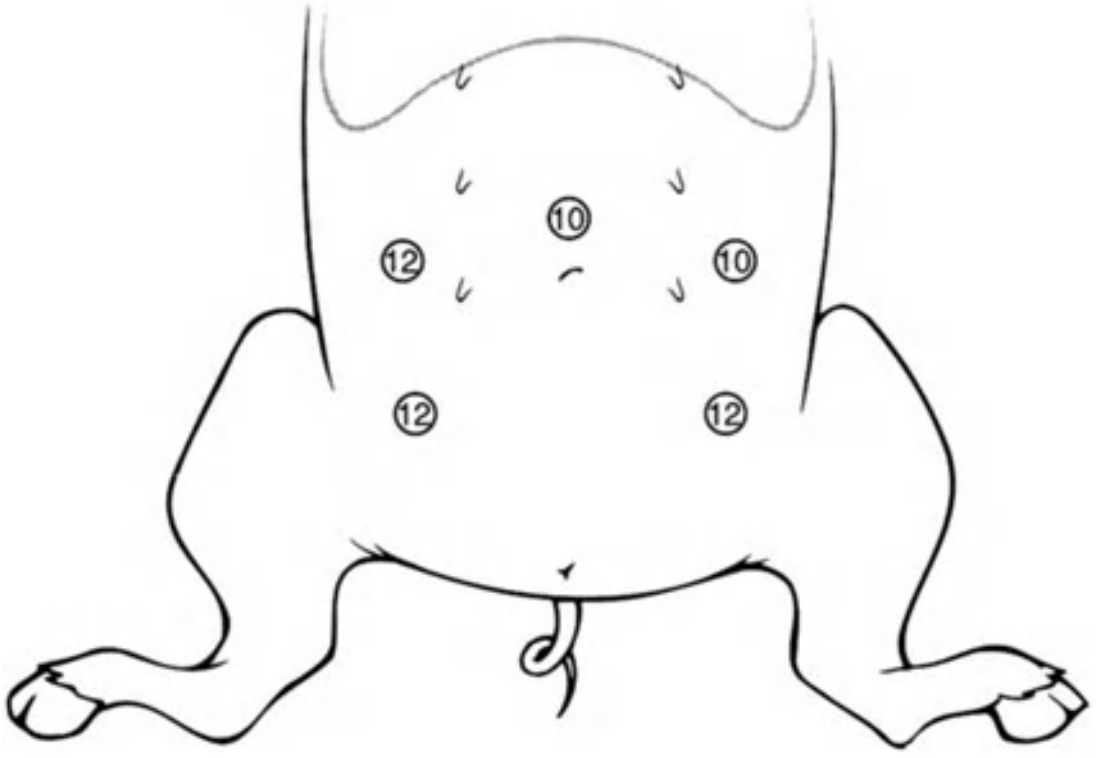

FIGURE 13.3. Trocar placement in a porcine model.

mesentery. The bowel is encircled with an umbilical tape at this location by pulling the tape through the mesentery with the graspers, and the two tape ends are clipped together with two endoscopic clips.[13] A second umbilical tape is placed at a distal resection line (10 to 15 cm downstream) so the bowel can be handled without grasping it directly with graspers. All vessels supplying the segment to be resected are isolated; then coagulated, ligated, or clipped; and finally transected.

To perform an intraperitoneal anastomosis using linear endoscopic staplers,[14] the afferent and efferent limbs of the bowel to be anastomosed must be placed parallel to each other. This can easily be done by simultaneously grasping the two tapes marking the resection lines. Both limbs of the intestine are then brought together and encircled by a third umbilical tape at the resection lines. This third tape is fixed with endoscopic clips at the antimesenteric site of the bowel wall (Figure 13.4). If the clips are placed tightly against the bowel wall, they will occlude the intestinal lumen of the devascularized specimen and prevent spillage from this site. The first two tapes are then removed.

Enterotomies are made on the antimesenteric borders of the adjacent loops of the small intestine that are to be anastomosed, and the linear stapler is inserted in the enterotomies to create a functional end-to-end anastomosis (Figure 13.4). The afferent and efferent loops are placed parallel to each other to facilitate the insertion of an endoscopic stapler. The stapler is fired twice intraluminally to create a wide anastomosis. A 30-mm stapler should be used first because its small size facilitates entry into the enterotomies. If desired, the second stapler may be a 60-mm linear endoscopic stapler, but this requires inserting a 15-mm trocar. The anastomosis is completed by stapling across the two loops just below the two enterotomies (Figure 13.5) so the specimen is resected and the anastomosis is closed with minimal or no spillage in the peritoneal cavity.

The specimen is placed in the upper part of the abdomen and is removed after all surgery is completed in the animal. The anastomosis is carefully inspected to check whether bleeding from the staple line has occurred or whether the endoscopic stapler was fired over a mesenteric clip, which could result in an anastomotic leak because the staples would not seal the anastomosis. Intracorporeal anastomoses using linear endoscopic staplers or circular staplers can be accomplished using various techniques. Both Pietrafitta et al.[7] and Soper et al.[9] have de-

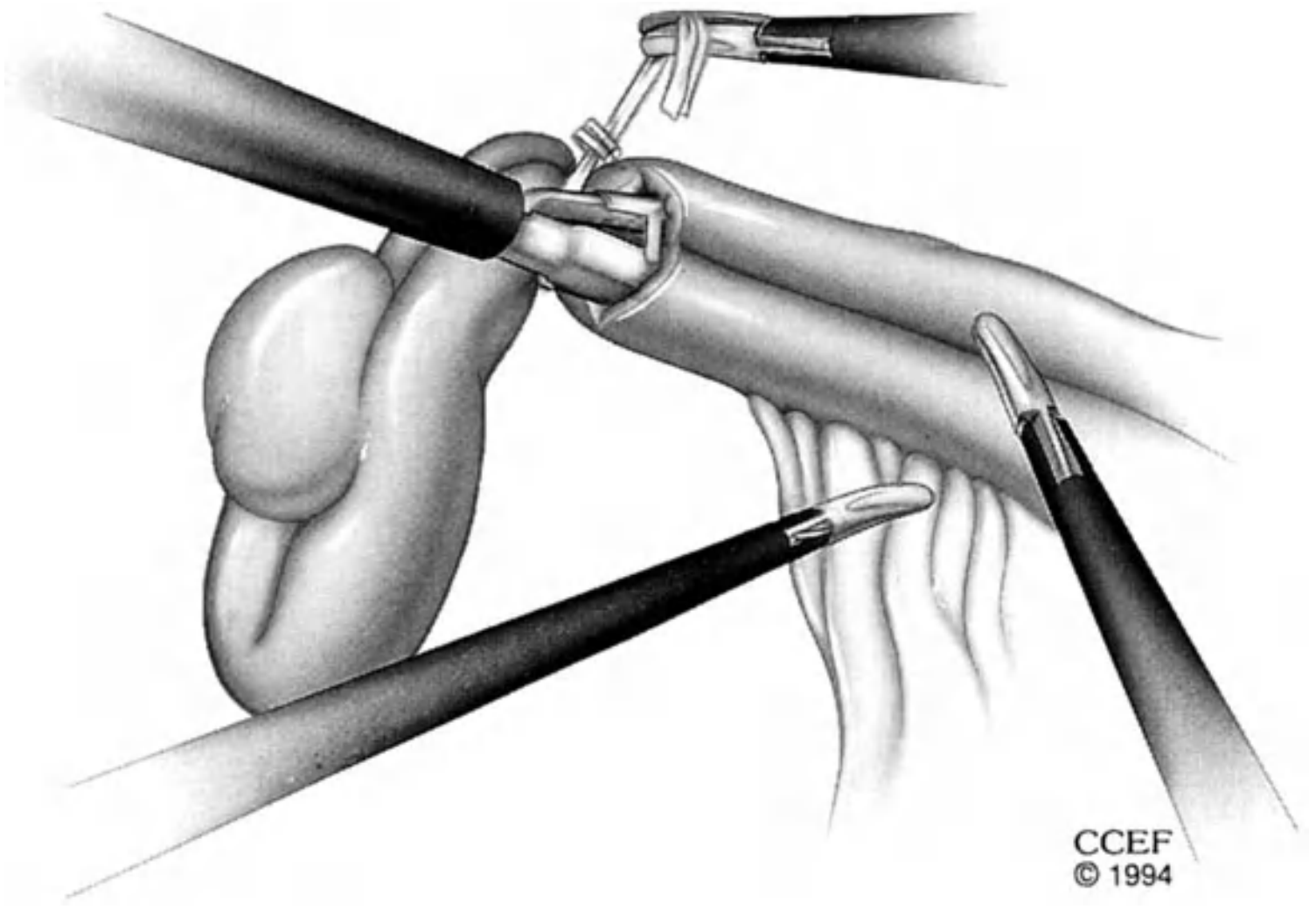

FIGURE 13.4. Linear endoscopic stapler inserted in both limbs of the intestine to begin a functional ileoileal anastomosis in the pig.

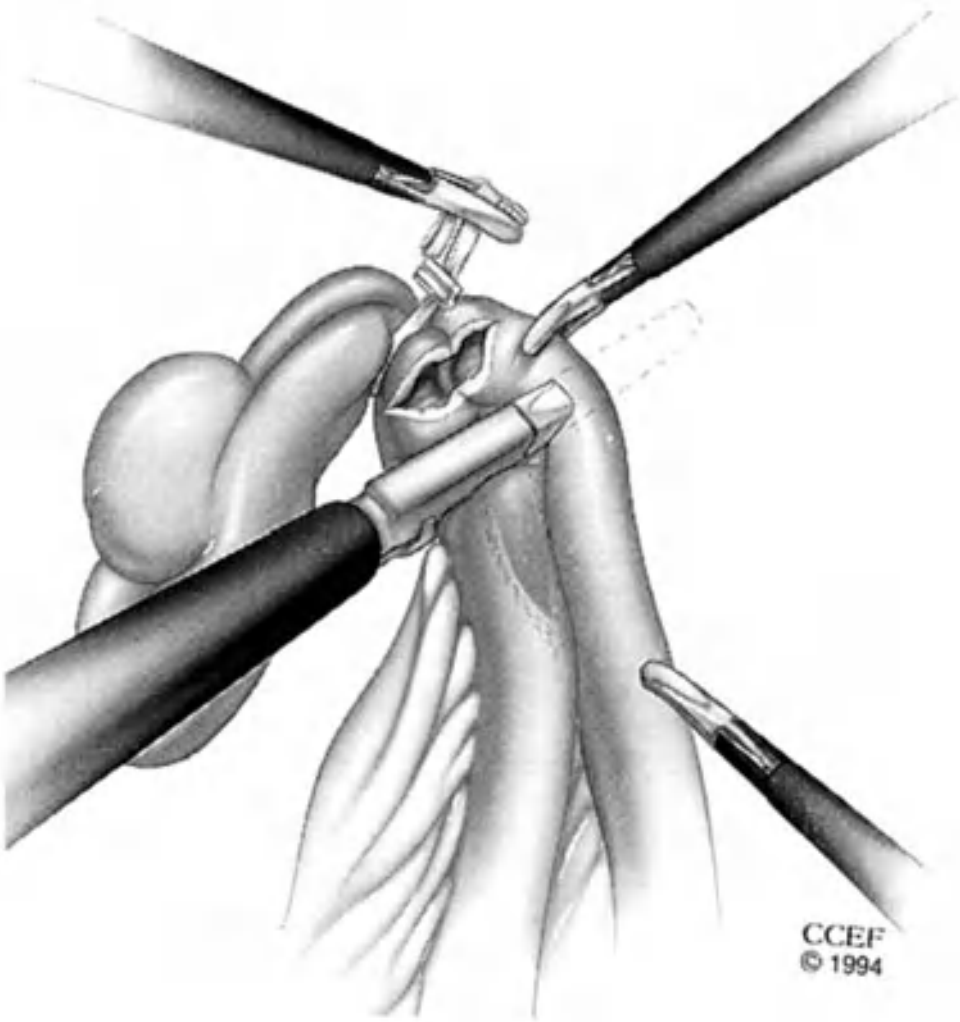

FIGURE 13.5. Porcine anastomosis is completed by firing a linear stapler across the intestine below the enterotomies.

scribed techniques slightly different from ours to achieve a functional end-to-end anastomosis using linear endoscopic staplers.

Porcine Large-bowel Resection with Intraperitoneal Circular Anastomosis

Because the spiral colon of the pig for anatomic reasons is not suitable for laparoscopic resection, only the left colon and the rectum can be used to practice a segmental large-bowel resection with intraperitoneal anastomosis. Cannula placement and pneumoperitoneum are basically the same as described for small-bowel resection.

The bladder is first drained with a percutaneously placed Veress needle hooked to a suction; then, the bladder and the uterus are fastened anteriorly to the abdominal wall with percutaneously placed sutures around the uterine horns or with an endoscopic hernia stapler. The left colon is identified, and the peritoneal reflection is dissected to the right and left of the mesentery, avoiding the ureter and the gonadal vessels. The inferior mesenteric vessels are ligated with clips and transected. The mesenteric dissection is continued into the pelvis to the level of the levator ani muscle so the rectum is completely mobilized.

The proximal resection line is chosen near the level of the mesenteric vessel ligatures and smaller vessels are ligated up to the bowel edge. The rectum is divided at the distal resection line by firing one or two 30-mm endoscopic staplers placed obliquely across the rectum from the right-lower-quadrant 12-mm cannula. The left-lower-quadrant cannula is removed, then the abdominal incision there is widened to 3 to 4 cm, pneumoperitoneum is released, and the small-bowel specimen is delivered at this site. Next, the large-bowel specimen is delivered first distally, then transected at the proximal resection line extracorporeally. A size 0 polypropylene purse-string suture is placed into the cut edges of the proximal colon; the low-profile anvil and modified center rod (meaning one that has a groove placed in its shaft for endoscopic grasping) of a 25-mm CEEA stapler instrument (Premium CEEA Stapler, US Surgical Corporation, Norwalk, Conn.) are placed in the bowel lumen, the purse-string is tied, and the colon is replaced intraperitoneally. The small abdominal-wall incision is closed with size 0 polyglycolic acid figure-of-eight sutures and pneumoperitoneum is reestablished.

Next, a polyglycolic acid suture is placed through the small hole near the tip of the detachable plastic spike of the stapler and is tied to form a 3- to 4-cm-diameter loop. This spike is placed in the center post of the stapler and the spike tip is drawn below the top of the stapler. The circular stapler is inserted transanally. The plastic spike is perforated through the rectal wall adjacent to the previously placed staple line. The suture at the spike tip is grasped, then the spike is detached from the stapler and is removed through the right-upper-quadrant cannula. The modified center rod is next grasped with an endoscopic instrument and is docked in the center post of the stapler. The surgeon must check that the bowel is not twisted on its mesentery. The anastomosis is performed and the donuts are checked for completeness. Depending on the study being performed, the animal at this juncture is then euthanized with subsequent zoopsy to carefully inspect all surgical sites, or is allowed to awake from anesthesia after inspection for bleeding, removal of laparoscopic cannulas, peritoneal irrigation with warm saline, and cannula site closure with size 2-0 absorbable suture to the fascia and 3-0 absorbable suture to the skin.

Use of the Canine Model in Laparoscopic Colorectal Surgery

We actually prefer using a dog model versus a pig model for training in laparoscopic intestinal surgery. Overall, the dog intestinal anatomy is more analogous to the human intestine, and dogs are generally more docile and easy to care for in the perioperative period. Female mongrel dogs with a body weight of at least 25 to 30 kg should be used. The intestinal and peritoneal dimensions in this size dog are similar but slightly smaller than those in humans. The following three laparoscopic intestinal procedures can be carried out sequentially in each dog, depending on the aims of the surgical team:

1. small-bowel resection with functional ileoileal anastomosis
2. right colectomy (oncologic) with intraperitoneal ileocolic anastomosis[11]
3. subtotal colectomy with ileorectal anastomosis[12]

An en bloc resection or segmental resection of the colon or the small bowel allows the surgeon to practice dissecting the mesentery, which is difficult in the right mesocolon in the canine model. It requires careful use of scissors and other cutting devices, dissectors, graspers, and electrosurgery or laser application for hemostasis and dissection.

Intestinal Anatomy of the Dog

The anatomy of the dog intestine, including the blood supply and mesentery of the right colon, is remarkably similar to the human anatomy (Figure 13.6). The right colic artery, which is the first branch of the ileocolic artery, supplies blood to the distal terminal ileum, the cecum, the ascending colon, and the proximal transverse colon. The middle colic artery, which is the main branch of the ileocolic artery, supplies the distal transverse colon and the descending colon. It passes parallel to the left colon and anastomoses with the left colic artery, which arises from the inferior mesenteric artery. The blood supply of the sigmoid colon and the rectum comes from the cranial rectal artery, which arises from the inferior mesenteric artery. This inferior artery may be hypoplastic in some animals. In these cases, the left colon and the rectum receive their blood from the middle colic artery. Therefore, the middle colic artery must be preserved in right colon resections.

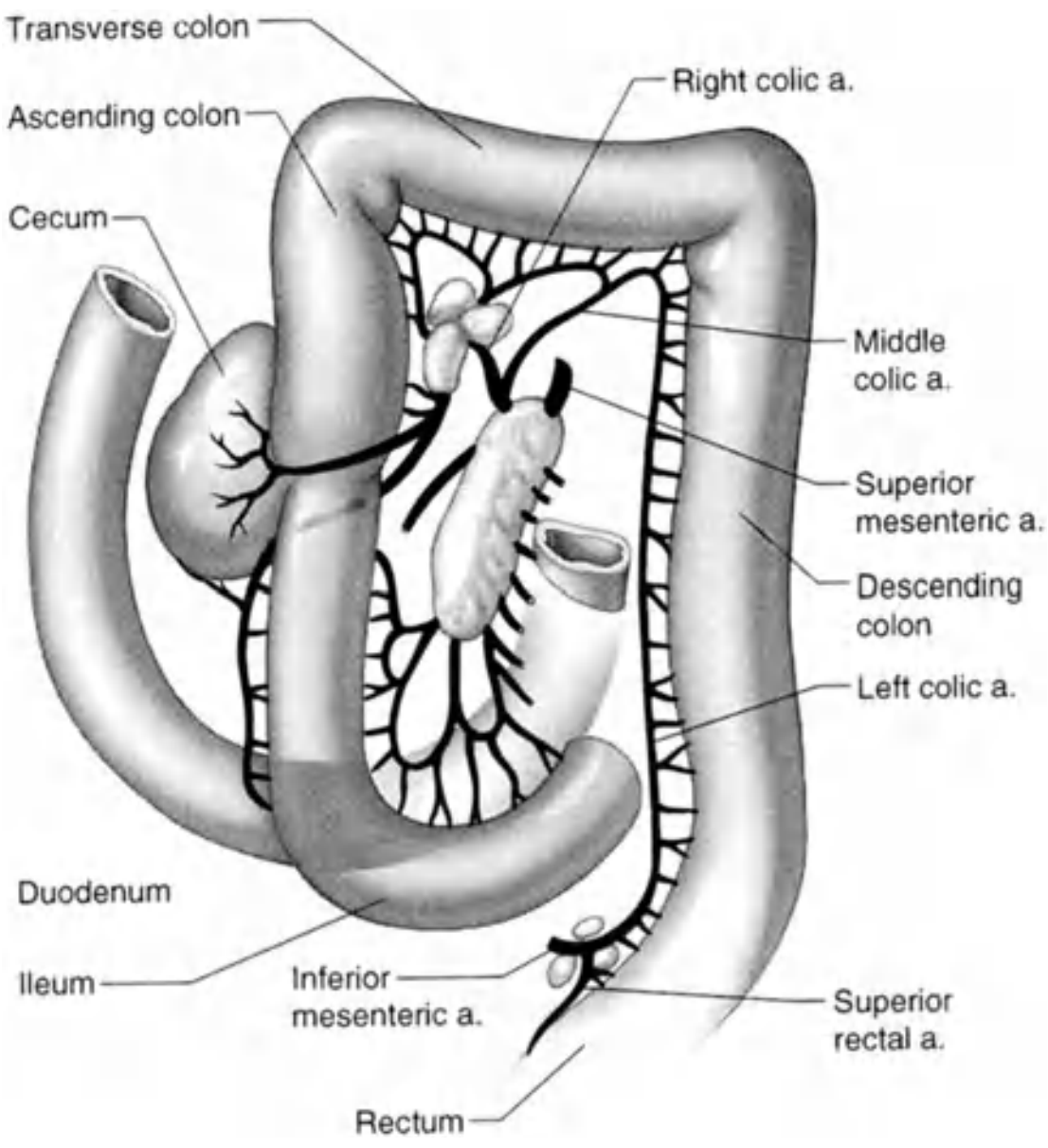

FIGURE 13.6. Anatomy of the intestine in a canine model.

All vessels of the small bowel and the left colon as well as the lymph nodes are easily visualized in a thin mesentery. In contrast, the right mesocolon is thick and consists of fatty tissue, vessels, and lymph nodes covered by peritoneum. This area closely resembles the human right mesocolon. The vessels of the canine right mesocolon are thickly invested beneath the peritoneum and the fatty tissue so a careful and somewhat tedious dissection must be carried out to safely expose and ligate these vessels.

The lymphatic flow in dogs is similar to that in humans and is chiefly along the mesenteric vessels. Only one to three large lymph nodes (1 to 3 cm in diameter and 4 to 10 cm in length) are in the small intestinal mesentery; they can be seen along the superior mesenteric vessels.

The two to four lymph nodes found in the base of the right mesocolon adjacent to the right colic vessels receive lymphatics from the cecum and the ascending and the transverse colon. Along the inferior mesenteric artery close to the bowel wall are three to six lymph nodes (0.5 to 2 cm in diameter) that receive lymphatics from the left colon and the rectum.

Canine Small-bowel Resection with Functional Ileoileal Anastomosis

In a 20° to 30° head-down (Trendelenburg) position, pneumoperitoneum (CO_2, to 12 mm Hg) is established using a Veress needle inserted through an incision 6 cm above the symphysis. The Veress needle is replaced by a 10-mm cannula and the laparoscope is inserted through this cannula. Four accessory cannulas are inserted under direct vision in each of the four abdominal quadrants lateral to the rectus sheath (Figure 13.7). A fifth accessory 10-mm cannula is placed in the upper midline for later laparoscope placement.

The spleen and the greater omentum are placed in the upper part of the peritoneal cavity. If the bladder is full, it is punctured and emptied with a Veress needle attached to a suction. Even if the animal is to survive, this is a safe maneuver and will not result in postoperative bladder leakage. The small intestine is grasped and run in a manner similar to that described in the pig model. The blood vessels of the small bowel are easily identified. An ileal resection with ileoileal anastomosis is performed according to the previously described technique in pigs (see previous section, Porcine Small-bowel Resection with Intraperitoneal Ileoileal Anastomosis), although the resection should be performed at least 30 to 40 cm proximal to the ileocecal valve to avoid interfering with an ileocolic resection as described in the next section.

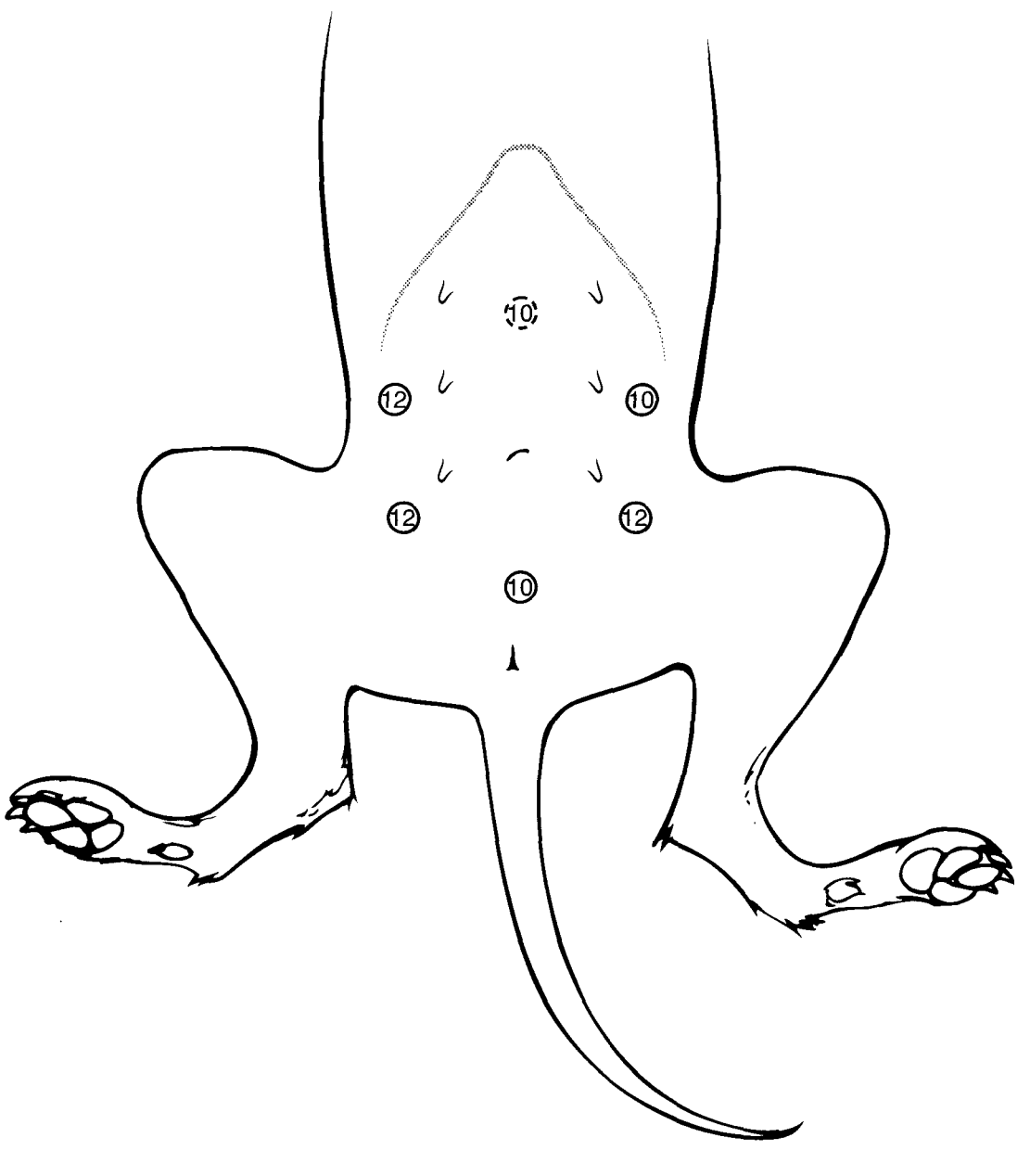

FIGURE 13.7. Trocar placement in a canine model.

Canine Right Colectomy with Intraperitoneal Ileocolic Anastomosis

After the previously described small-bowel resection is completed, the left colon is identified and its marginal mesenteric vessels are traced cephalad to the origin of the middle colic artery. The distal resection line at the transverse colon is chosen to preserve the middle colic artery. Because the inferior mesenteric artery is diminutive in some dogs, the middle colic artery cannot be transected without risking ischemia to the remaining left colon.

Before dissecting the mesentery, the distal resection line is marked with an encircling umbilical tape passed through a defect created in the mesenteric edge. This tape is also used for manipulating the intestine without directly grasping the bowel with graspers. The right colon, the cecum, and the ileum are then exposed, and the mesentery is dissected from the dorsal side. Vessels smaller than 3 mm can be coagulated but larger vessels should be clipped with endoscopic clip appliers. The ileal resection line is then identified about 10 cm proximal to the cecum and is also marked with a tape. The ascending colon is then carefully dissected dorsally up to and along a large mesenteric lymph node present in the ileal mesentery. This node lies directly adjacent to the superior mesenteric artery and should not be resected with the specimen.

The right mesocolon is then dissected from the ventral side (Figure 13.8). It contains the right colic artery, veins, and lymph nodes near the origin of the right colic vessels. To remove

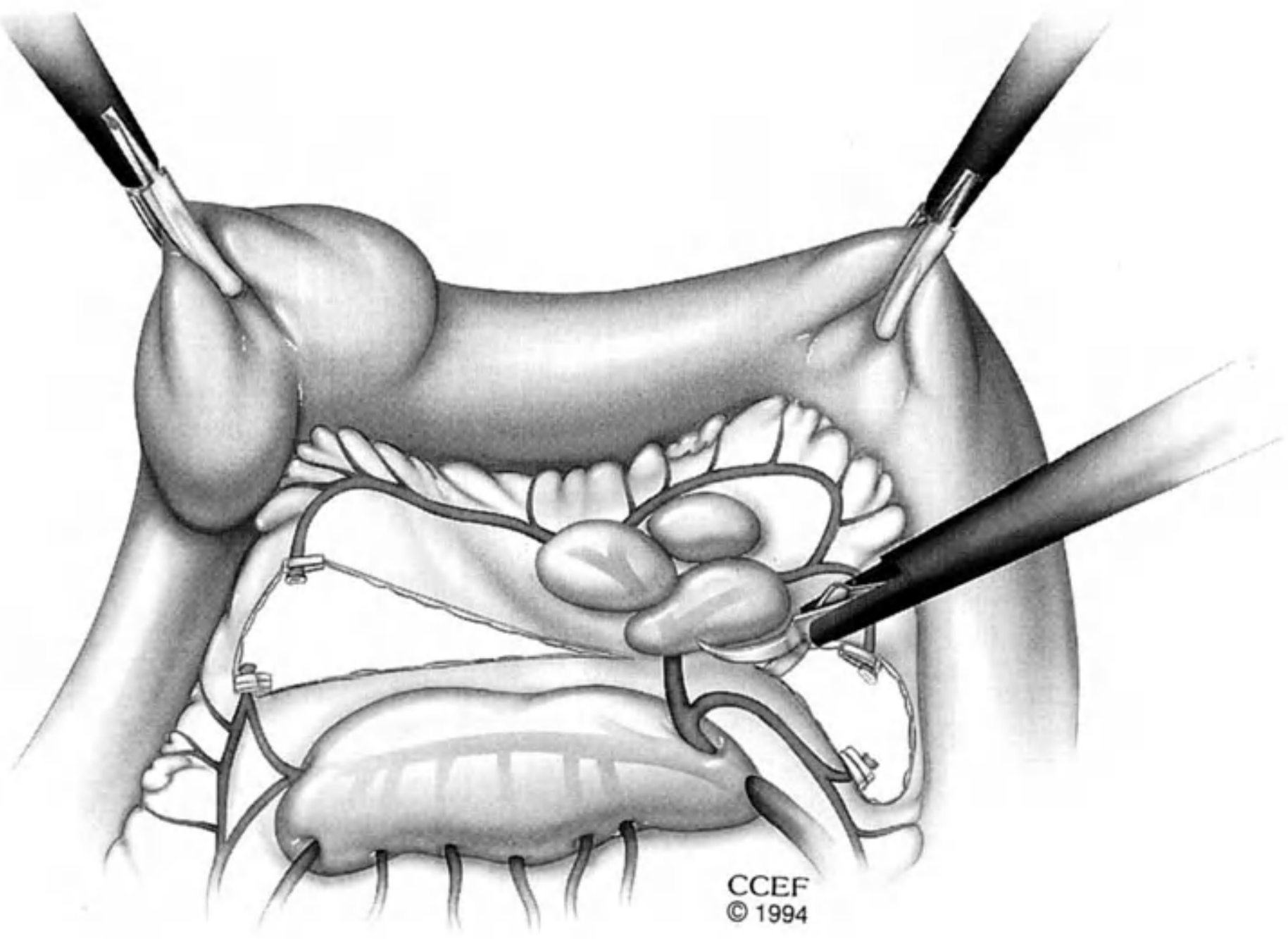

FIGURE 13.8. Anatomy of the canine right colon during laparoscopic resection.

all lymph nodes of the right mesocolon, the right colic vessels must be ligated at their origin. This ligation is performed by incising the peritoneum, then carefully using blunt and sharp dissection to sweep the lymph nodes of the right colon up onto the specimen, exposing the vessels. This maneuver can be tedious and requires some practice. The dissected vessels are then clipped and divided. The devascularized bowel segment is then completely encircled with an umbilical tape at the proximal and distal resection lines, and an ileocolic anastomosis is carried out according to the same principles used in small-bowel resection (see previous section, Porcine Small-bowel Resection with Intraperitoneal Ileoileal Anastomosis).

Canine Subtotal Colectomy with Ileorectal Anastomosis

To complete the colectomy, the ileocolic anastomosis is lifted with graspers, and then the middle colic artery is identified, clipped, and divided at the level of the duodenum so all adjacent lymph nodes are removed. The mesocolon of the left colon is mobile and thin, and next can be transected easily down to the inferior mesenteric artery, which is also clipped using large endoscopic clips and then is transected.

The laparoscope is removed from the lower midline cannula, and is placed in a newly placed upper midline 10-mm trocar site oriented toward the pelvis. The bladder (with the uterus in females) is sutured to the abdominal wall using a percutaneously placed suture or endoscopic hernia stapler as described earlier. This allows better overall visualization of the pelvis. A 30-mm endoscopic stapler is placed (but not fired) through the left-lower-quadrant cannula across the descending colon and is used to pull cranially on the rectum to facilitate a low transection of the rectum before the ileorectal anastomosis. The thin filmy mesorectum is freed from surrounding structures down to the pelvic floor.

The rectum is then divided at or below the pelvic brim by firing a 30-mm endoscopic stapler once or twice across it. A left-lower-quadrant trocar site is enlarged to approximately 4 cm. The small-bowel specimen is delivered through this site, then the distal colon is brought out through the wound, slowly delivering the ileocolic anastomosis as well. The anastomosis is inspected and may later be inflated to check for leaks. The ileum is incised at the area of previous mesenteric clearing proximal to the ileocolic anastomosis and a size 0 polypropylene purse-string suture is placed on the cut edge. The low-profile anvil of a 25-mm CEEA stapler instrument is placed in the terminal ileum, the purse-string is tied, and the colon is replaced intraperitoneally. The small incision in the abdominal wall is closed with size 0 polyglycolic acid figure-of-eight sutures, pneumoperitoneum is reestablished, and the peritoneal cavity is irrigated.

The ileorectal anastomosis is carried out using a double stapling technique according to the previously described principles (section titled Porcine Large-bowel Resection with Intraperitoneal Circular Anastomosis). The ileorectal anastomosis can be tested for leaks by filling the pelvis with saline and insufflating the rectum with air using a rigid proctoscope. After careful inspection and irrigation of the peritoneal cavity, all fascia and skin incisions are closed using 3-0 polyglycolic acid sutures (survival animals), or laparotomy with thorough inspection of the abdominal cavity is conducted to evaluate the surgical results (nonsurvival animals).

Human Laparoscopic Colorectal Surgery

Once proficiency has been achieved in inanimate trainers and animal models, the surgical laparoscopic team may begin to consider human laparoscopic colorectal surgery. Because only a few surgical training programs currently have formal training in laparoscopic colorectal surgery, surgeons experienced in this area must act as preceptors for other established surgeons or surgical departments. Preceptors should have surgical privileges at the hospital so they may perform at least some of the operative technique if necessary. Although the described large animal models are valuable, human tissue dissection and anatomy may be different, particularly in pathologic states.

Initially, the beginner in laparoscopic colorectal surgery should choose simple, uncomplicated cases (such as diagnostic laparoscopy, biopsy, or loop ileostomy or colostomy) in thin patients who have not undergone previous abdominal surgery. Next, the surgeon should proceed to limited resections for benign disease with or without intraperitoneal mesenteric dissection or anastomosis. More demanding procedures, such as resection for inflammatory bowel disease (such patients often have a thickened mesentery and inflamed fragile tissue) or oncologic resections, should be performed only if the surgeon is comfortable with laparoscopic colorectal techniques. In 1995, we believe that curative colorectal cancer surgery should only be performed in the context of prospective trials.

The entire laparoscopic team must be involved in learning from the preceptor, because the skills of the entire team must be developed. This should involve preliminary discussions of every step of the procedure, from setup of the operating room, to placement of the last suture, to postoperative care. The procedure should be standardized as much as possible so all members of the laparoscopic team can predict what the next step will be. Standardization will increase safety and efficacy of laparoscopic procedures and minimize frustration. Although for each laparoscopic team it is impossible to define how many colon or rectal procedures should be performed under a preceptor before operating independently,[3] we recommend at least 10 colorectal resections. Thus, a preceptor may need to visit the trainee's operating room for several weeks (if the trainee is an established surgeon calling on outside expertise).

The long-term success and development of laparoscopic colorectal surgery (and all laparoscopic surgery, for that matter) rests on incorporating laparoscopic training into current surgical education programs. As the cadre of experienced laparoscopic colorectal surgeons grows over the next 3 to 5 years and the relative indications and merits of such surgery become more apparent, training programs in abdominal surgery will likely devote an increasing proportion of their curricula to laparoscopic methods.

Virtual Reality

The educational program we have outlined is based on currently available educational tools and techniques. A pelvic trainer for learning and practicing basic skills can easily be built with materials available in the hospital. Although animal facilities that include operating rooms are not available everywhere, it should be possible for most surgeons at specialized institutions or universities in the United States to perform some laparoscopic procedures in animals.

In the future, computer simulations might be able to create an environment so pelvic trainer and animal models are not necessary. Such computer simulation is called virtual reality, and involves creating the human experiences of perception and interaction through the use of sensors and effectors in a computer-modeled environment. In a virtual world, all experiences of the real world are excluded and only a computer-generated environment affects the senses. The computer not only generates a "world" that can be passively perceived with head-mounted displays or monitors, but it also allows a person to interact with the generated environment using specially designed sensory devices such as data gloves or exoskeletons (Figure 13.9).

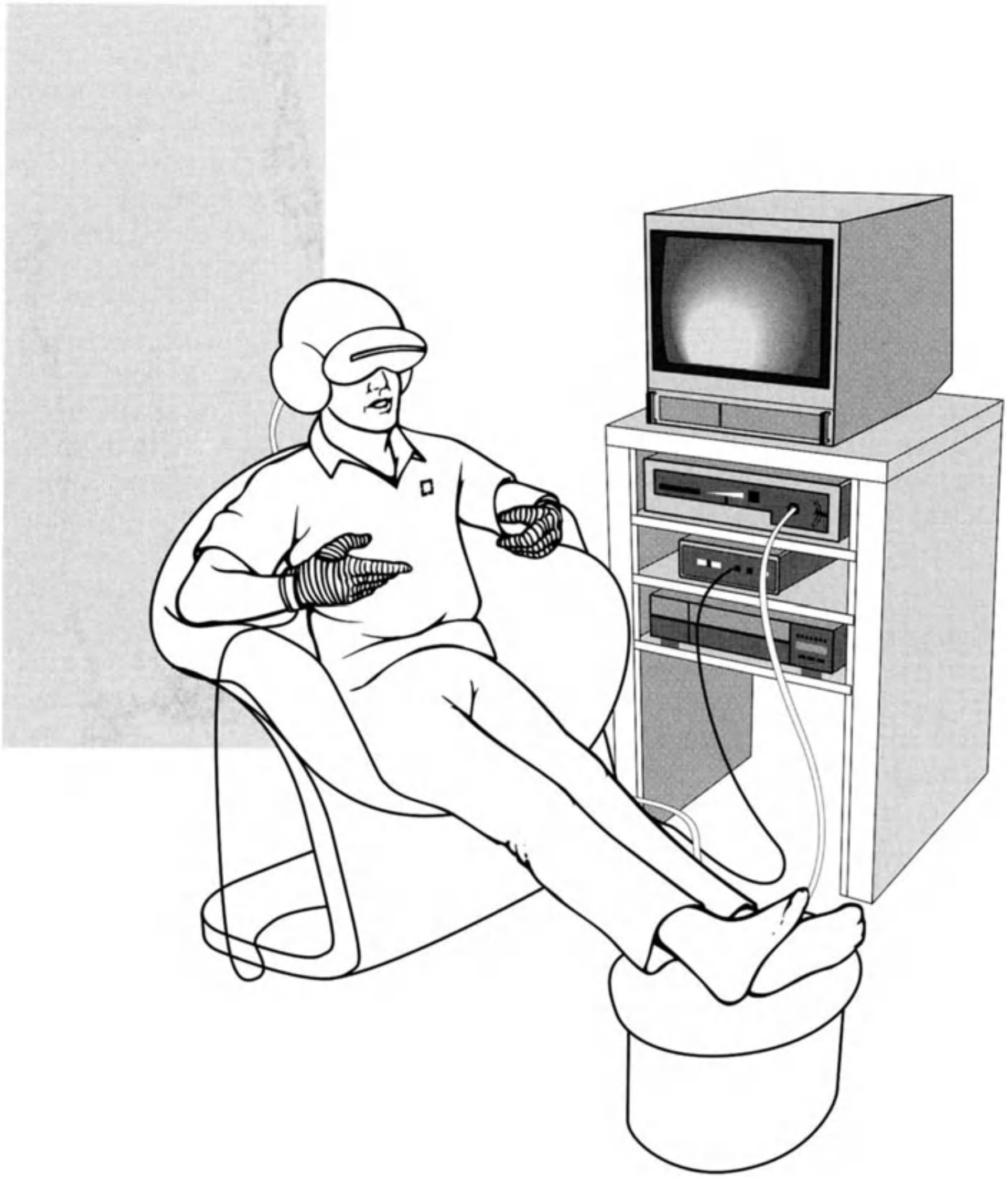

FIGURE 13.9. Virtual reality as a training model in laparoscopic surgery.

Currently, virtual reality is used successfully in flight simulators and other industrial training to learn and practice complex activities in a virtual, nonexistent world. Thus, pilots learning to fly in a virtual world can be educated to a high skill level without risking damage to themselves or an expensive airplane. After developing sufficient skills to fly a plane, pilots move from the virtual to "true" reality.

Laparoscopic surgery consists mainly of hand movements that have an impact on tissue that is visualized on a video monitor with no direct visualization of the contact. Consequently, using virtual reality for laparoscopic surgical training seems feasible. In theory, a model of the abdominal cavity would be generated by the computer and specially designed devices attached to the hand would translate real movements into the virtual movements of endoscopic instruments on the video monitor. Entire laparoscopic procedures may be simulated and young surgeons could practice in this environment until they acquire sufficient skills to commence "real" laparoscopic surgery. Although simple models of laparoscopic virtual reality are available and may improve and replace inanimate models (e.g., the pelvic trainer) in learning and practicing basic laparoscopic skills in the next years, much better hardware and software will be needed to replace living models with virtual reality models.

References

1. Forde KA. Endosurgical training methods: is it surgical training that is out of control? *Surg Endosc.* 1993;7:71–72.
2. Cuschieri A. Reflections on surgical training. *Surg Endosc.* 1993;7:73–74.
3. Society of American Gastrointestinal Endoscopic Surgeons. Guidelines for granting of privileges for laparoscopic (peritoneoscopic) general surgery. *Surg Endosc.* 1993;7:67–68.
4. Jones SR. News & views. *Am College Surg.* 1994;2:1–5.
5. Wolfe BM, Szabo Z, Moran ME, Chan P, Hunter JG. Training for minimally invasive surgery. *Surg Endosc.* 1993;7:93–95.
6. Köckerling F, Gastinger I, Remmel E, Gall FP. Die laparoskopische tubuläre Rektum- und Kolonresektion. Eine tierexperimentelle Untersuchung. *Zentralbl Chir.* 1992;117:103–110.
7. Pietrafitta JJ, Schultz LS, Graber JN, Hickok DF. An experimental technique of laparoscopic bowel resection and reanastomosis. *Surg Laparosc Endosc.* 1992;2:205–211.
8. Ambroze WL, Orangio TR, Tucker JG, Baird D, Herndon M, Lucas GW. Laparoscopic assisted proctosigmoidectomy with extracorporeal transanal anastomosis. *Surg Endosc.* 1993;7:29–32.
9. Soper NJ, Brunt LM, Fleshman J, Dunnegan DL, Clayman RV. Laparoscopic small bowel resection and anastomosis. *Surg Laparosc Endosc.* 1993;3:6–12.
10. Fleshman JW, Brunt M, Fry RD, et al. Laparoscopic anterior resection of the rectum using a triple stapled intracorporeal anastomosis in the pig. *Surg Laparosc Endosc.* 1993;3:119–126.
11. Böhm B, Milsom JW, Kitago K, Brand M, Fazio VW. Laparoscopic oncologic right colectomy with intraperitoneal ileocolic anastomosis in a canine model. *Ann Surg Oncol.* 1995;2:6–13.
12. Böhm B, Milsom JW, Brand M, Kitago K, Fazio VW. Laparoscopic oncologic colectomy with intraperitoneal ileorectal anastomosis in a canine model. *J Laparoendosc Surg.* 1994;4:23–30.
13. Milsom JW, Böhm B, Stolfi VW, Kitago K. Use of cotton tapes in laparoscopic intestinal surgery. *Br J Surg.* 1993;80:768.
14. Böhm B, Milsom JW, Stolfi VM, Kitago K. Laparoscopic intraperitoneal intestinal anastomosis. *Surg Endosc.* 1993;7:194–196.

Index