



# Advances and Technical Standards in Neurosurgery

Edited by

H. Krayenbühl, Zürich (Managing Editor)

J. Brihaye, Bruxelles

F. Loew, Homburg/Saar

V. Logue, London

S. Mingrino, Padova

B. Pertuiset, Paris

L. Symon, London

H. Troupp, Helsinki

M. G. Yaşargil, Zürich

Volume 1

Springer - Verlag

Wien New York 1974



**With 96 Figures**

**This work is subject to copyright**

**All rights are reserved, whether the whole or part of the material is concerned, specifically those of translation, reprinting, re-use of illustrations, broadcasting, reproduction by photocopying machine or similar means, and storage in data banks**

**© 1974 by Springer-Verlag/Wien**

**Softcover reprint of the hardcover 1st edition 1974**

**Library of Congress Catalog Card Number 74-10499**

ISBN-13: 978-3-7091-7101-1      e-ISBN-13: 978-3-7091-7099-1  
DOI: 10.1007/ 978-3-7091-7099-1

## Preface

There are two important reasons for commencing this new series of publications entitled "Advances and Technical Standards in Neurosurgery": 1. the lack of any organized common European postgraduate training system for young neurosurgeons and 2. the language barriers, which impede the exchange of neurosurgical findings in Europe more than in other parts of the world.

The fact that the English language is well on the way to becoming the international medium at European scientific conferences is a great asset in terms of mutual understanding. Therefore the Editors have decided to publish all contributions in English, regardless of the native language of the authors.

All contributions are submitted to the entire editorial board before publication of any volume.

Our series is not intended to compete with the publications of original scientific papers in other neurosurgical journals. Our intention is, rather, to present fields of neurosurgery and related areas in which important recent advances have been made. The contributions will be written by specialists in the given fields and will constitute the first part of each volume.

In the second part of each volume, we shall publish detailed descriptions of standard operative procedures, furnished by experienced clinicians; in these articles the authors will describe the techniques they employ and explain the advantages, difficulties and risks involved in the various procedures. This part is intended primarily to assist young neurosurgeons in their postgraduate training. However, we are convinced that it will also be useful to experienced, fully trained neurosurgeons.

The descriptions of standard operative procedures are a novel feature of our series, and in this it differs from the similarly entitled series "Progress in Neurological Surgery"; also, our series will be mainly, but not exclusively, a forum for European neurosurgeons. We intend as well to make available the findings of European neurosurgeons which are published in less familiar languages to neurosurgeons beyond the boundaries of the authors' countries and of Europe, and we aim to promote contacts among European neurosurgeons.

The Editors do hope that neurosurgeons throughout the world, and not only in Europe, will profit by the new series "Advances and Technical Standards in Neurosurgery".

*The Editors*



## Contents

### A. Advances

<b>Non-operative Management of Intracranial Hypertension.</b> By N. LUNDBERG, Å. KJÄLLQUIST, G. KULLBERG, U. PONTÉN, and G. SUNDBÄRG, Department of Neurosurgery, University Hospital, Lund, Sweden .....	3
I. Pathophysiology of Intracranial Hypertension .....	4
1. Cerebrospinal Fluid Dynamics and Intracranial Pressure .....	4
2. Interrelations between Intracranial Pressure and Intracranial Hemodynamics .....	5
3. Brain Edema .....	6
4. Transmission of Pressures in the Cranio-Spinal Cavity .....	7
5. Pressure/Volume Relationships .....	8
6. Rapid Variations of the Intracranial Pressure in Intracranial Hypertension (Plateau Waves) .....	9
7. Extracranial Correlates of Intracranial Hypertension .....	14
II. Monitoring of the Intracranial Pressure .....	16
1. Techniques .....	16
2. Measures against Infection .....	18
3. Complications .....	19
4. Interpretation of the Ventricular Fluid Pressure Curve .....	20
a) Statistical Analysis .....	21
5. Clinical Application .....	22
III. General Principles for the Care of Patients with Intracranial Hypertension .....	27
IV. Special Treatments .....	29
1. Controlled Drainage of Cerebrospinal Fluid .....	29
2. Hypertonic Solutions and Diuretics .....	33
a) Mode of Action of Hypertonic Solutions .....	33
b) Clinical Experience with Intravenous Urea and Mannitol .....	35
c) Side Effects .....	38
d) Oral Treatment .....	39
e) Diuretics .....	39
f) Recommended Treatment .....	39
3. Hyperventilation .....	40
a) Mode of Action and Effect on Intracranial Pressure .....	40
b) Side Effects .....	42
c) Recommended Treatment .....	42
4. Corticosteroids .....	44
a) Corticosteroids and Intracranial Pressure .....	45
b) Side Effects .....	46
c) Recommended Treatment .....	47
5. Hypothermia .....	49
6. Hyperbaric Oxygen .....	51
V. Concluding Remarks .....	51
References .....	52

<b>Chronic Adult Hydrocephalus.</b> By J. PHILIPPON and D. ANCRI, Neurosurgical Clinic and Department of Nuclear Medicine, Hôpital de la Pitié, Paris, France .....	61
Introduction .....	61
Clinical Signs .....	62
Etiology .....	63
1. Idiopathic .....	64
2. Extraventricular Obstruction, Subarachnoid Haemorrhage, Post-Traumatic Hydrocephalus, Post-Meningitic Hydrocephalus .....	64
3. Focal Brain Lesions .....	65
Pressure Studies .....	65
1. Intracranial Pressure Measurement .....	65
2. Resorption Studies .....	66
Radiological Findings .....	68
Isotopic Studies .....	72
A. CSF Normal Scan .....	72
B. CSF Scanning in Chronic Adult Hydrocephalus .....	73
1. Findings to Date .....	73
2. Quantitative Studies .....	75
3. Personal Series .....	75
C. Result of CSF Scan Applied to Physiopathology of CSF Flow .....	83
Treatment .....	85
Pathophysiology .....	87
References .....	88
<b>Surgery of Craniostenosis in Advanced Cases.</b> A Method of Extensive Subperiosteal Resection of the Vault and Base of the Skull Followed by Bone Regeneration. By H. POWIERTOWSKI, Institute of Surgery, Silesia Academy of Medicine, Katowice, and Department of Neurotraumatology, Miners' Rehabilitation Centre, Repty, Poland .....	93
Introduction .....	93
Anatomo-Clinical Considerations .....	94
Operative Procedure .....	98
Clinical Material .....	100
Results and Evaluation .....	102
1. Surgical Risk .....	102
2. Decompression Effect, Protection of the Head, and Cosmetic Result .....	103
3. Regeneration of the Skull .....	110
4. Neurological Results .....	116
Conclusion .....	117
Illustrative Cases .....	117
Addendum .....	118
References .....	119

**Extra-Dural Hematoma.** By E. ZANDER and R. CAMPICHE, Neurosurgical Department, University Cantonal Hospital, Lausanne, Switzerland . . . . . 121

Introduction . . . . . 121

History . . . . . 122

General Considerations . . . . . 124

    Frequency . . . . . 124

    Localization . . . . . 124

    Sex and Age . . . . . 125

Clinical Signs . . . . . 125

    Fractures of the Skull . . . . . 125

    Free Interval . . . . . 126

    Motor Disorders . . . . . 127

    Eye Signs . . . . . 128

    Pulse and Blood Pressure . . . . . 128

    Other Signs . . . . . 128

        a) Vomiting . . . . . 128

        b) Anemia . . . . . 129

        c) Cerebrospinal Fluid . . . . . 129

    Angiography . . . . . 129

    Echo-Encephalography . . . . . 131

    Treatment . . . . . 131

    Results and Conclusions . . . . . 133

References . . . . . 137

**B. Technical Standards**

**Supratentorial Craniotomy.** By B. PERTUISSET, Neurosurgical Clinic, Hôpital de la Pitié, Paris, France . . . . . 143

General Processes . . . . . 144

    Preparation of the Patient's Head . . . . . 144

    Location of Skin Incisions . . . . . 146

    Control of Scalp Haemorrhage . . . . . 147

Surgical Instruments . . . . . 147

Burr Holes . . . . . 150

    Trepine Burr Holes . . . . . 150

    Twist Drills . . . . . 150

    Doyen Craniotomy . . . . . 151

    Closure . . . . . 151

    Traps . . . . . 151

        The Bone . . . . . 152

        The Dura . . . . . 152

Skull Flaps . . . . . 153

    The Three Types of Skull Flaps . . . . . 153

        Osteoplastic Skull Flap . . . . . 153

        Free Skull Flap . . . . . 153

        Pedicled Skull Flap . . . . . 153

    General Procedure . . . . . 153

        Skin Incision . . . . . 153

        Procedure for Craniotomy . . . . . 153

## List of Contributors

- Ancrì, Dr. D., Université de Paris, Groupe Hospitalier Pitié-Salpêtrière, Département de Biophysique et Médecine Nucléaire, 83, Boulevard de l' Hôpital, F-75 Paris 13<sup>e</sup>, France.
- Campiche, PD. Dr. R., Hôpital Cantonal Universitaire, Service de Neurochirurgie, Rue du Bugnon 15, CH-1011 Lausanne, Switzerland.
- Guidetti, Prof. Dr. B., Istituto di Neurochirurgia dell'Università di Roma, Viale dell'Università 30, I-00185 Roma, Italy.
- Kjällquist, Dr. Å., University of Lund, Department of Neurosurgery, University Hospital, S-221 85 Lund, Sweden.
- Kullberg, Dr. G., University of Lund, Department of Neurosurgery, University Hospital, S-221 85 Lund, Sweden.
- Lundberg, Prof. Dr. N., University of Lund, Department of Neurosurgery, University Hospital, S-221 85 Lund, Sweden.
- Pertuiset, Prof. Dr. B., Université de Paris, Groupe Hospitalier Pitié-Salpêtrière, Clinique Neuro-Chirurgicale, 83, Boulevard de l'Hôpital, F-75 Paris 13<sup>e</sup>, France.
- Philippon, Dr. J., Université de Paris, Groupe Hospitalier Pitié-Salpêtrière, Clinique Neuro-Chirurgicale, 83, Boulevard de l'Hôpital, F-75 Paris 13<sup>e</sup>, France.
- Pontén, Dr. U., University of Lund, Department of Neurosurgery, University Hospital, S-221 85 Lund, Sweden.
- Powiertowski, Doc. Dr. H., Górnicze Centrum Rehabilitacji, Lecznicej i Zawodowej, PL-42-662 Repty Śląskie, Poland.
- Sundbärg, Dr. G., University of Lund, Department of Neurosurgery, University Hospital, S-221 85 Lund, Sweden.
- Zander, Prof. Dr. E., Hôpital Cantonal Universitaire, Service de Neurochirurgie, Rue du Bugnon 15, CH-1011 Lausanne, Switzerland.

## **A. Advances**

# Non-operative Management of Intracranial Hypertension

N. LUNDBERG, Å. KJÄLLQUIST, G. KULLBERG, U. PONTÉN, and G. SUNDBÄRG

Department of Neurosurgery, University Hospital,  
S-221 85 Lund (Sweden)

With 20 Figures

## Contents

I. Pathophysiology of Intracranial Hypertension . . . . .	4
1. Cerebrospinal Fluid Dynamics and Intracranial Pressure . . . . .	4
2. Interrelations between Intracranial Pressure and Intracranial Hemodynamics . . . . .	5
3. Brain Edema . . . . .	6
4. Transmission of Pressures in the Cranio-Spinal Cavity . . . . .	7
5. Pressure/Volume Relationships . . . . .	8
6. Rapid Variations of the Intracranial Pressure in Intracranial Hypertension (Plateau Waves) . . . . .	9
7. Extracranial Correlates of Intracranial Hypertension . . . . .	14
II. Monitoring of the Intracranial Pressure . . . . .	16
1. Techniques . . . . .	16
2. Measures against Infection . . . . .	18
3. Complications . . . . .	19
4. Interpretation of the Ventricular Fluid Pressure Curve . . . . .	20
a) Statistical Analysis . . . . .	21
5. Clinical Application . . . . .	22
III. General Principles for the Care of Patients with Intracranial Hypertension . . . . .	27
IV. Special Treatments . . . . .	29
1. Controlled Drainage of Cerebrospinal Fluid . . . . .	29
2. Hypertonic Solutions and Diuretics . . . . .	33
a) Mode of Action of Hypertonic Solutions . . . . .	33
b) Clinical Experience with Intravenous Urea and Mannitol . . . . .	35
c) Side Effects . . . . .	38
d) Oral Treatment . . . . .	39
e) Diuretics . . . . .	39
f) Recommended Treatment . . . . .	39
3. Hyperventilation . . . . .	40
a) Mode of Action and Effect on Intracranial Pressure . . . . .	40
b) Side Effects . . . . .	42
c) Recommended Treatment . . . . .	42

4. Corticosteroids .....	44
a) Corticosteroids and Intracranial Pressure .....	45
b) Side Effects .....	46
c) Recommended Treatment .....	47
5. Hypothermia .....	49
6. Hyperbaric Oxygen .....	51
V. Concluding Remarks .....	51
References .....	52

## I. Pathophysiology of Intracranial Hypertension

The brain, by being encased in a container with rigid walls, is unique among the organs of the human body. The restricted ability of the intracranial contents to expand implies that the intracranial pressure (ICP) is a parameter of central importance for the intracranial dynamics.

A comprehensive account of the pathophysiology of intracranial hypertension is beyond the scope of this article. However, familiarity with intracranial dynamics is of fundamental importance for the management of patients with intracranial hypertension. Therefore and with respect to the torrent of new information which has been presented during the last two decades it is essential to begin with a short survey of this field.

### 1. Cerebrospinal Fluid Dynamics and Intracranial Pressure

The site of the cerebrospinal fluid (CSF) production has long been a controversial issue. At present, in accordance with the early views of Dandy and Blackfan (1914) and Weed (1935) it seems to be generally agreed that the major fraction of the CSF is formed in the cerebral ventricles.

CSF is at least partly produced by means of active transport and "secretory pressure" is supposed to be one of the main forces behind the CSF flow and the increase in CSF pressure that occurs after obstruction of fluid pathways. It seems highly probable that in originally incomplete obstruction an increase of the ventricular fluid pressure (VFP) may displace the supratentorial part of the brain and cause further blocking of CSF pathways thus starting a vicious cycle. In arrested hydrocephalus subsidiary routes of absorption are supposed to be utilized. Being in continuity with the ventricles, the extracellular space of the brain tissue is a probable pathway for such diversion of CSF.

In their classic works, Key and Retzius (1875) and later Weed (1914) produced convincing evidence that the main site of the CSF absorption is in the arachnoid villi. This conception is still generally accepted. Recent investigations in animals indicate that the reabsorption takes place through open channels with a valve mechanism for unidirectional flow and is exclusively dependent on the difference in hydrostatic pressure between the subarachnoid space and the dural sinuses (Welch and Friedman 1960, Davson et al. 1970). Investigations in man indicate that there is no CSF absorption below a pressure of approximately 5 mm Hg ("opening pressure") and that a linear relation exists between the CSF pressure and the absorption rate above this limit (Cutler et al. 1968,

Lorenzo et al. 1970). It may be assumed that the absorption mechanism plays an important role for the intracranial pressure homeostasis and pressure/volume relationships as well as for the ability of the CSF to act as a "spatial buffer" under pathological conditions (see below). For review of literature see Davson (1967) and Johnson (1972).

## 2. *Interrelations between ICP and Intracranial Hemodynamics*

This relationship is reciprocal in so far as variations of the cerebral vascular resistance and the intracranial venous pressure may cause variations of the ICP (Roy and Sherrington 1890, Ryder et al. 1952) and, on the other hand, variations of the ICP may cause changes of cerebral perfusion pressure and cerebral blood flow (CBF). The influence of the ICP on the CBF is determined by the fact that the blood pressure in the draining cerebral veins is approximately equal to the ICP (Noell and Schneider 1948, Rowan et al. 1972). This means that the cerebral perfusion pressure equals the difference between the systemic arterial pressure (SAP) and the ICP. Thus, the formula for CBF can be written:

$$\text{CBF} = k \frac{\text{SAP} - \text{ICP}}{\text{CVR}}$$

where CVR is the cerebral vascular resistance. This relationship is of fundamental significance in the production of ischemic brain damage in intracranial hypertension. The autoregulation of the CBF—i.e. the vasomotor mechanism, which maintains an adequate CBF in spite of variations of the cerebral perfusion pressure—may thus be elicited not only by a fall of the systemic blood pressure like in other organs, but also by an increase of the ICP (Wolff and Forbes 1929, Fog 1933, Noell and Schneider 1948, Evans et al. 1951, Lassen 1964, Zwetnow 1968, 1970). Furthermore, there are strong reasons to believe that a vasodilatory response to increase of ICP is involved in the mechanism producing certain acute elevations of the ICP in patients with intracranial hypertension (see below, page 13).

When ICP is experimentally increased, autoregulation is capable of maintaining normal CBF until the cerebral perfusion pressure has been reduced to about 40 mm Hg (Zwetnow 1970). On further increase of ICP, i.e. further reduction of the cerebral perfusion pressure, there is a critical decrease in CBF leading to an intracranial state characterized by prolonged vasodilatation, a CBF which is passively dependent on the systemic blood pressure, and an impaired or abolished response of the resistance vessels to changes in the perfusion pressure and PaCO<sub>2</sub> ("cerebral vasomotor paralysis", Langfitt et al. 1965, 1966). If this process continues the cerebral circulation may be further impaired by progressive brain swelling, first from congestion and later from intractable brain edema. One can assume that the well-known picture of non-filling of intracranial arteries on angiography and total infarction of the brain is the end result of such a development (cf. section on brain edema).

In treating patients with intracranial hypertension it is important to bear in mind that a defective autoregulation means that both CBF and ICP is more dependent on the systemic arterial pressure than under normal conditions. The



combination of vasoparalysis and rise in blood pressure may cause a disastrous rise in ICP and seems to cause the final catastrophe in many cases of intracranial hypertension (see Fig. 3c). On the other hand, defective autoregulation means an increased risk of ischemic complication from fall in blood pressure.

The dependence of the cerebral vascular resistance on the  $\text{PCO}_2$  of the arterial blood and the co-variation of the intracranial venous pressure with the intrathoracic pressure form the physiologic basis for the central role of the respiration in the management of patients with intracranial hypertension. During the last 15 years the respirator has become more and more established as a tool in the treatment of patients with traumatic and non-traumatic brain lesions. The importance of the effect on ICP of hyperventilation in the treatment of intracranial hypertension as well as the risk of cerebral ischemia at low  $\text{PaCO}_2$ -levels are issues still under discussion. They will be dealt with below (page 40).

### 3. Brain Edema

Edema of the brain tissue may cause forceful swelling of the brain and by influencing intracranial pressure/volume parameters it may interfere with the intracranial dynamics. (To avoid confusion the terms brain swelling and brain edema should be kept apart; brain swelling may be caused by edema *and* by blood congestion.) The pathophysiology of brain edema will not be treated in any detail. However, the importance of brain edema for the production of intracranial hypertension warrants a short account of basic ideas and clinically important data.

In accordance with Klatzo (1972) current pathophysiological concepts may be summarized as follows: Cerebral edema is defined as an abnormal accumulation of water in the brain tissue. The water may be localized mainly within the cells (cytotoxic edema) and is then related to a functional disorder of the cell membrane; or it may accumulate mainly in the extracellular space as a result of increased vascular permeability permitting an increased outflow of water,  $\text{Na}^+$ -ions and protein molecules from the blood (vasogenic edema). Disorders of permeability may be caused by various kinds of lesions to the vascular endothelium. In this connection the "tight junctions" of the endothelium are of special interest since it may be assumed that temporary reversible opening of tight junctions may occur in a number of pathological conditions in the brain.

Brain edema may cause or contribute to the production of intracranial hypertension in a variety of brain lesions due to mechanical trauma, ischemia, hypoxemia, neoplasm, and toxic agents. With regard to the frequent occurrence of edema in such common diseases as cerebral contusion and cerebral infarction it is probably the principal cause of intracranial hypertension.

From a clinical point of view, the progressive nature of brain edema is of particular importance. One example is the perifocal edema which surrounds localized cerebral contusions and transforms them into expanding lesions. An even more striking example is the intractable brain edema, which occurs in the final state of intracranial hypertension and which by its inherent force appears capable of arresting the cerebral circulation by compression of intracranial vessels. This circulatory arrest may be preceded by a rise in blood pressure and abolished autoregulation (see Fig. 3C). The edema may thus be an ex-

ample of what Langfitt has called "hydrostatic brain edema", i.e. edema due to increase in capillary and venous pressures caused by dilatation of cerebral resistance vessels in combination with high arterial blood pressure (Langfitt et al. 1967, Marshall et al. 1969, Schutta et al. 1968).

Another clinically important observation has been reported by Klatzo et al. (1967). In animal experiments they found that the speed of progression and the ultimate extent of edema around an experimentally induced brain lesion is largely influenced by the systemic blood pressure. This relationship must always be taken into account when the mechanism behind a therapeutic effect upon brain edema is discussed. The clinical importance pertains to the control of systemic arterial pressure in patients with intracranial hypertension (see page 28).

The progressive nature of brain edema may be explained by the reciprocal relationship between edema and CBF. On one hand, brain edema can cause reduction of CBF owing to a general increase of ICP and probably also to a localized increase of the tissue pressure. On the other hand, a reduction of CBF can induce or aggravate edema by causing tissue hypoxia.

#### *4. Transmission of Pressures in the Cranio-Spinal Cavity*

In spite of their non-uniformity the contents of the cranio-spinal cavity have long been regarded as forming a medium for almost unrestricted transmission of pressure variations. Cerebrospinal fluid pressure has consequently been used as representative of the pressure in the whole cavity including the blood pressure in thin-walled vessels of the vascular bed (Noell and Schneider 1948). The latter assumption has recently been confirmed by experimental studies showing a highly significant linear correlation between the VFP and the blood pressure in cortical veins (Rowan et al. 1972). The implications are twofold: firstly, the ICP is dependent on how much of the systemic blood pressure is admitted into thin-walled capacitance vessels, i.e. on the vasomotor tone of the resistance vessels; secondly, it seems justified to define the cerebral perfusion pressure as the difference between mean arterial pressure and mean VFP (see above, page 5).

When a space-occupying lesion is expanding in the cranial cavity it causes pressure gradients in the brain. Owing to the plasticity of the brain tissue these gradients tend to be equalized by displacement in accordance with the law of the least resistance. Filling out of the subarachnoid spaces, herniation in the isthmuses and distortion of the brain stem are well-known consequences of such mass displacement and their clinical correlates need not be treated in this article.

As a rule, there is a rise in VFP when a supratentorial lesion causes mechanical stress on the brain stem by mass displacement. However, being part of a compensatory mechanism, displacement and distortion may be present without any significant rise of ICP provided that the lesion is expanding slowly. These two phenomena should be kept apart.

A free transmission of fluid between different parts of the CSF spaces is a prerequisite for "spatial compensation" of a space-occupying lesion by flow of CSF out of the cranial cavity (see below). By obstructing fluid pathways a tamponade of the tentorial incisura or the foramen magnum is always a serious complication. Both in patients (Hodgson 1928, Smyth and Henderson 1938,

Antoni 1946) and in experimental animals (Langfitt et al. 1964) it has been shown that such tamponade of the isthmuses may produce considerable differences in pressure between the lateral ventricles and the infratentorial and spinal spaces. Such differences are ominous since they signify that acute rises of the supratentorial pressure (e.g. plateau waves, see below) will not be fully transmitted to the infratentorial space but will cause further compression and distortion of the brain stem instead. Simultaneous continuous recording of ventricular and spinal fluid pressures has been used for the clinical diagnosis of ventriculo-spinal pressure differences and assessment of the risk of tentorial and tonsillar herniation. Since puncture of the spinal subarachnoid space means a definite risk of leakage through the hole in the dura (Lundberg and West 1965) and consequently a risk of misleading results as well as of augmented pressure difference and further herniation, we doubt whether this procedure has a place in neurosurgical practice.

### 5. Pressure/Volume Relationships

The core of the Monro-Kellie doctrine—that a change in volume of one of the components of the intracranial content necessitates a corresponding change of the volume of one or more of the other components—is still valid. This concept may be expressed by the formula below.

$$V_{\text{brain}} + V_{\text{blood}} + V_{\text{CSF}} + V_{\text{expansive lesion}} = V_{\text{intracran.}}$$

The ability of blood and CSF to pass out of the cranial cavity makes it possible for a lesion to expand. The readiness with which this shift can take place is decisive for the rise in ICP. This relation is beautifully illustrated by Langfitt's classic pressure/volume curve (Fig. 1). In his experiments, Langfitt used a slowly expanding (1 ml/hour) supratentorial balloon. One may assume that the initially slow rise of the curve represents the joint action of several compensatory mechanisms, i.e. shift of brain tissue, shift of CSF into the spinal subarachnoid space, increased absorption of CSF, and squeezing out of blood from the cerebral vascular bed (Ryder et al. 1953, Martins et al. 1972). The steep part of the curve obviously represents a stage of exhaustion of the mechanical compensation, but may also include vasodilatation elicited by the rise in ICP. The capacity for spatial compensation is thus dependent on a variety of anatomical, mechanical, and physiological factors including the form and size of the tentorial incisura, the consistency of the brain, the ability of the spinal dural sack to expand, the absorption capacity of the subarachnoid villi, the reactive ability of the cerebral vessels etc. The importance of the time factor is illustrated by the wellknown fact that a rapidly increasing hematoma causes signs of brain stem compression at a much smaller size than does a slowly expanding tumour.

Pressure/volume relationships during rapid elevations of the CSF pressure (0.08–1.45 ml/sec) have recently been assessed quantitatively in terms of "elastance", i.e. the properties of the CSF space which determine the magnitude of the immediate pressure change produced by a given rapid change in volume (Löfgren 1973). The results indicate that in such rapid increases of ICP the compensation is due to expansion of the spinal dural sack (70%) and compression of the cerebral venous bed (30%). Another clinically interesting observation by Löfgren was that in the presence of transtentorial obstruction the elastance

was markedly influenced by the arterial pressure in a way that suggests a positive non-linear correlation.

The clinical implications of the volume/pressure relationship in intracranial hypertension are manifold. Of fundamental importance is the fact that normally insignificant increments of the intracranial contents—spontaneous or induced—may be accompanied by critical rises in ICP if the capacity for spatial compensation is exhausted, or, colloquially, if the brain is “tight”. This phenomenon, which certainly has been experienced by most neurosurgeons on performing ventriculography has one practically important consequence: the marked tendency

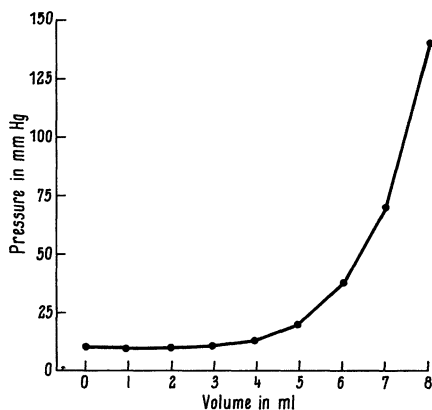


Fig. 1. Volume pressure graph in cat. Volume is given in milliliters (abscissa), and pressure in millimeters of mercury (ordinate). Water was added to a supratentorial extradural balloon by injecting 1 ml every hour or with a low rate infusion pump. The graph is a composite of six experiments. (From Langfitt et al. 1966)

to pressure variations in patients with intracranial hypertension (see below, page 13).

A method for quantitative assessment of the intracranial pressure/volume relation by reading the pressure response on repeated injections and withdrawals of fluid to and from the ventricular system has recently been proposed by Miller and Garibi (1972). In view of the clinical importance of this relation, the method deserves attention.

#### 6. Rapid Variations of the ICP in Intracranial Hypertension (Plateau Waves)

Continuous recording of the ICP in patients with intracranial hypertension often shows a fluctuating pressure which contrasts with the fairly flat curve obtained in patients with a normal ICP (Janny 1950). In many cases the fluctuations have a typical form characterized by a rapid rise to an elevated level, usually between 60 and 100 mm Hg, and a rapid fall from this level after some time, usually 5–10 minutes (Fig. 2). These “plateau waves” and similar pressure variations represent the pathophysiological basis of acute cerebral symptoms in patients with intracranial hypertension and consequently they have important implications from a clinical point of view (Lundberg 1960, Grote and Wüllen-

weber 1960). The signs and symptoms most commonly met with during plateau waves are headache, nausea, vomiting, facial flush, air hunger, respiratory disturbances to the point of respiratory paralysis, changes in pulse frequency, involuntary micturition, restlessness, confusion, agitation, depressed level of consciousness, and various motor phenomena, such as clonic movements and tonic postures indicating intermittent decerebration (Ingvar and Lundberg 1961, Kjällquist et al. 1964).

Plateau waves occur irrespective of the cause of the intracranial hypertension and whether this is combined with a tentorial or tonsillar herniation or not.

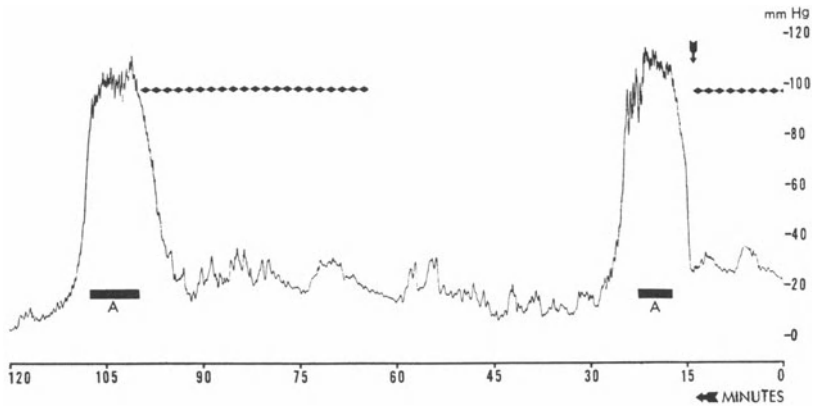


Fig. 2. Case 130 A. M., 57 year old man. *Verified metastasis in left frontal lobe.* Intermittent headache for three months before admission. Recording of the VFP after admission showed huge spontaneous plateau waves occurring with intervals varying between 20 minutes and 2 hours. Between the waves the patient was torpid and somewhat disorientated but fully conscious. The plateau waves were accompanied by attacks which were at first misinterpreted as epileptic seizures. (From Lundberg 1960.) A attacks of restlessness followed by unconsciousness, and clonic movements followed by flexor rigidity of the arms

Thus plateau waves develop in supra- and infratentorial expansive lesions as well as in increased ICP caused by obstruction of CSF pathways (e.g. carcinomatosis of the meninges). They pertain to an intermediate stage in the progress of an intracranial hypertension, during which the facilities for spatial compensation are being depleted. Initially they may be of modest size and not accompanied by any symptoms. With increasing decompensation they may grow larger, eventually being accompanied by symptoms of increasing severity and duration, presaging a state of continuously high pressure and lasting signs of brain stem dysfunction (Figs. 3 A, B, C). Initially the symptoms disappear promptly after a fall in pressure, whether this occurs spontaneously or as a result of treatment, for example drainage of fluid or administration of hypertonic solution. Later on deterioration may continue even during the intervals of lower pressure.

There is no consistent relationship between the height of the pressure waves and the severity of the accompanying symptoms. Huge waves ( $> 80$  mm Hg) may occur without symptoms or with only mild symptoms whereas moderate elevations under certain conditions may be accompanied by alarming symptoms—

even respiratory arrest. Clinical observations indicate that severe symptoms are likely to occur in patients with infratentorial lesions and failing systemic circulation (Lundberg and Pontén 1963). It is also likely that the actual state of

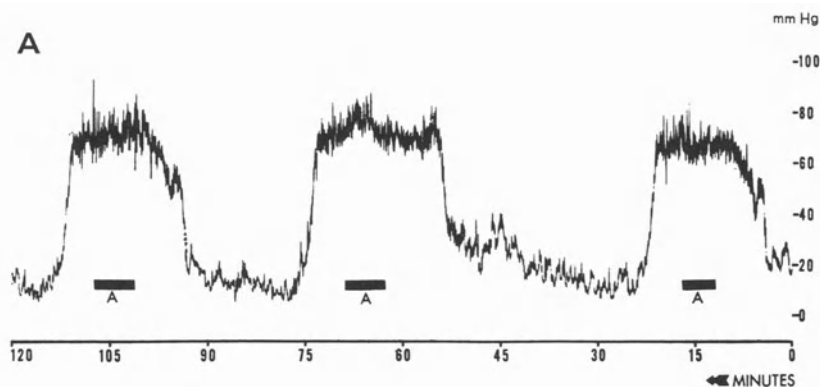


Fig. 3 A. Case 136 W. P., 60 year old man. *Verified glioblastoma in central part of right cerebral hemisphere.* Spontaneous plateau waves recorded on fifth day after admission. Between the waves the patient was somewhat torpid and drowsy. During the waves, the following symptoms were noted: restlessness, headache, stupor, flushing of the face, involuntary micturition, Parkinson-like tremor and tonic flexion of the arms, increased rigidity of the neck and the limbs. (From Lundberg 1960.)

A Attacks of involuntary motor activity

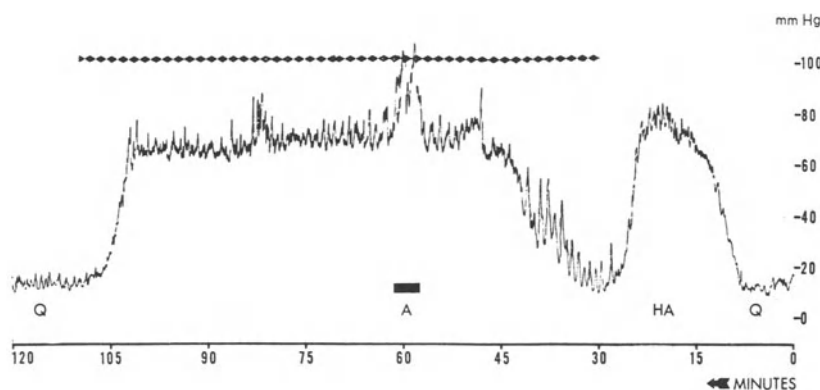


Fig. 3 B. Case 136 (see Fig. 3 A). Plateau wave of long duration recorded four days after the graph in Fig. 3 A. The patient was stuporous during the whole wave as indicated by the dotted line. (From Lundberg 1960.)

Q Awake, confused, HA headache, A attack of generalized clonic movements

autoregulation and the degree of existing stress on the brain stem from herniation/distortion are factors of significance.

In view of the fact that acute cerebral damage related to the plateau wave phenomenon threatens the patient with intracranial hypertension, knowledge of the pathogenesis of this phenomenon is definitely of importance in the manage-

ment of such patients. Both from clinical (Lundberg 1960, 1968, 1972) and experimental (Langfitt et al. 1964, 1965, 1966) observations it is evident that dilatation (and later constriction) of cerebral resistance vessels is primarily involved in the production of plateau waves. By isotope techniques it has been shown that during a plateau wave the CBF decreases at the same time as the cerebral blood volume increases (Lundberg et al. 1968, Risberg et al. 1969). This paradoxical discrepancy between dilatation of cerebral arteries and increase of the cerebral blood volume (Fig. 4) on one side, and decrease of CBF on the

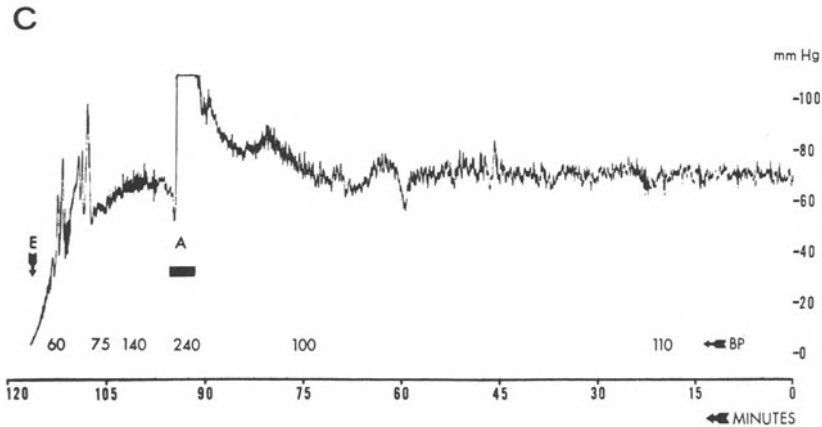


Fig. 3 C. Case 136 (see Fig. 3 A). Recording of the VFP 10 days after the graph in Fig. 3 B during the final stage 2 hours before death. The patient was in deep coma and had a shallow, regular respiration. The VFP had been on a high, even level at about 70 mm Hg for 4 hours. For no apparent reason it suddenly rose to a level much higher than could be recorded—one may guess to above 200 mm Hg. At the same time, the blood pressure rose to 240 mm Hg. After a few minutes both the intracranial and the arterial pressures dropped critically and soon reached about the same level, indicating general vasoparalysis and cessation of cerebral blood flow. Artificial respiration was not given and after a short while the heart stopped beating. (From Lundberg 1960.) BP Systolic arterial blood pressure; A respiratory arrest, opisthotonus, E cardiac arrest

other, suggests that the site of the main cerebrovascular resistance has shifted from the arterial to the venous side. Compression or contraction of the bridging veins would be a likely explanation of this shift (cf. Wright 1938, Greenfield and Tindall 1965, Hedges et al. 1964).

Plateau waves may occur spontaneously even during complete rest. However, physical and mental strain as well as emotional stress seem to be provoking factors. During sleep the occurrence of plateau waves seems to be related to REM-sleep (Cooper and Hulme 1966, Symon et al. 1972). Transient rises in ICP of the plateau wave type may also be induced by intrathecal or intraventricular injection of fluid or gas, volatile anaesthetics and other vasodilating agents, endotracheal intubation, painful stimuli, hypercapnia, vomiting, etc. An increase of the ICP by refilling of the intracranial CSF spaces after a preceding wave seems also to be capable of eliciting the necessary initial rise in pressure (see

legend to Fig. 4). In summary, if there is a "tight brain", i.e. if we are on the steep part of the pressure/volume curve, it appears as if every change in the intracranial dynamics, which causes a rise in pressure—even of moderate magnitude—may elicit a secondary rise of the ICP. It is tempting to assume that this phenomenon is related to the dilatation of cerebral resistance vessels which is involved in the autoregulation of the CBF.

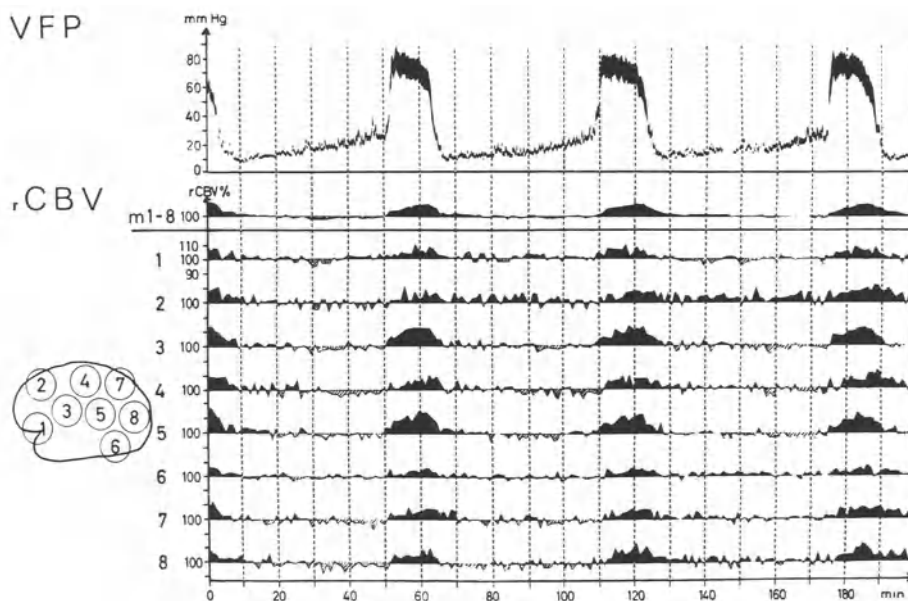


Fig. 4. Case 611 A. E., 28 year old woman. *Non-verified central glioma in left hemisphere.* Fairly regularly occurring spontaneous plateau waves with a frequency of about one per hour. Simultaneous recording of VFP and regional cerebral blood volume (rCBV). The CBV was measured in eight regions of the left hemisphere. The uppermost CBV tracing represents the mean of the eight regions. *Note:* that the VFP decreases during the plateau waves whereas the CBV at the same time increases and that the CBV remains unchanged while the VFP slowly rises between the waves. One may assume that fluid is squeezed out of the intracranial CSF spaces during the waves and that the slow increase in VFP between the waves is related to refilling of those spaces. (From Risberg et al. 1969)

There is no convincing reason to question a causal relationship between the signs of cerebral dysfunction, which occur during plateau waves, and the mechanical forces, which are released within the cranial cavity when the pressure rises. This relationship may be explained in two ways: 1. the rise of ICP causes a general reduction of the cerebral perfusion pressure with cerebral ischemia as a consequence, 2. the rise of ICP causes additional stress on an already compressed and distorted brain stem. The first explanation is supported by two observations, i.e. that plateau waves may cause signs of cerebral dysfunction without any herniation being present, e.g. in cases of carcinomatosis of the meninges, and that simultaneous recording of the VFP and the systemic arterial pressure has shown that the cerebral perfusion pressure may be reduced to a great extent during



plateau waves (Fig. 5). The second explanation is supported by animal experiments suggesting that a cerebral vasodilator such as halothane or any other volatile anaesthetic may cause exacerbation of an existing tentorial herniation (Fitch and McDowall 1971). Furthermore, the deterioration seen during plateau waves is often due to an aggravation of signs of brain stem dysfunction which also exist between the waves. It seems probable that mechanical stress on the brain stem and reduction of the cerebral perfusion pressure may both contribute to the production of cerebral signs and symptoms during plateau waves.

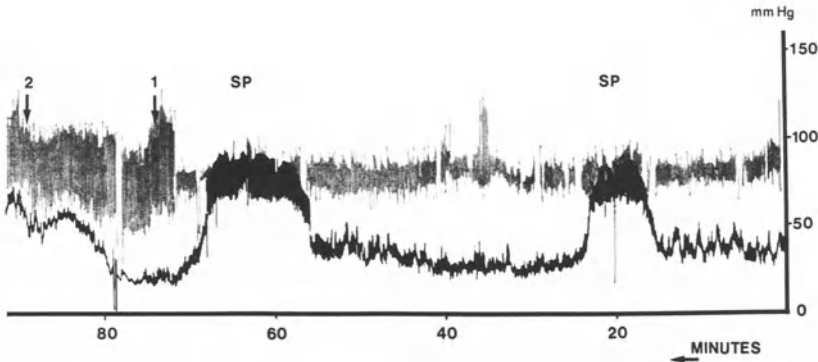


Fig. 5. Case 549 M. N., 26 year old woman. *Verified glioblastoma in left frontal lobe.* Irregularly occurring spontaneous plateau waves preoperatively. Simultaneous recording of VFP (lower tracing) and arterial blood-pressure in femoral artery (upper tracing, damped during first two-thirds of recording) before and during induction of general anaesthesia. A horizontal level through the right atrium was used as common reference level. *Note:* that the blood pressure does not rise during the plateau waves, resulting in a marked reduction in "perfusion pressure". Nevertheless, the patient got only slight headache and a feeling of unreality during the waves. (From Lundberg et al. 1968.) *SP* Spontaneous plateau wave, *1* intravenous administration of fentanyl + benzperidol, *2* intubation

As mentioned above, symptoms of cerebral dysfunction may persist after a plateau wave even if the ICP returns to base level and the cerebral perfusion pressure is restored. This may of course be explained by irreversible damage to brain cells from mechanical stress, but might also be related to the "no-reflow phenomenon", i.e. a failure of parts of the brain to be reperfused after a generalized cerebral ischemia produced by temporary elevation of ICP (Ames et al. 1968, Hekmatpanah 1970).

### 7. Extracranial Correlates of Intracranial Hypertension

The most well known extracranial effect of increased ICP is the Cushing phenomenon. Of the three signs which were originally included in this concept, the vasopressor response has important clinical implications. Recent experiments indicate that when the ICP rises, the rise in blood pressure does not appear until the normal autoregulation is abolished and the CBF is decreasing. Furthermore, even if the rise in blood pressure may postpone a fall in CBF below the critical level, this effect appears to be of limited significance for maintaining an adequate

CBF (Zwetnow 1970). If combined with vasomotor paralysis in the brain a pressor response may cause a disastrous rise in ICP—a phenomenon which may initiate the final circulatory catastrophe in patients with intracranial hypertension (Fig. 3 C).

Since Cushing published his original work "Some Experimental and Clinical Observations Concerning States of Increased Intracranial Tension" in 1902 great diagnostic importance has been attached to the triad of signs which has his name. After continuous recording of ICP was introduced, it soon became evident that both the rise in blood pressure and the slowing of the pulse are unreliable as signs of increasing ICP. This is particularly true in cases of rapidly increasing pressure of the plateau wave type. Often, there is no rise in blood pressure, and a variety of changes in pulse rate may occur including sudden changes from bradycardia to tachycardia or *vice versa* (Kjällquist et al. 1964).

A variety of *respiratory alterations* are known to occur during intracranial hypertension, indicating brain stem dysfunction. Different patterns, such as periodic breathing, ataxic breathing, apneusis and "neurogenic" hyperventilation, have been related to lesions at different levels of the brain stem in animals (Hoff and Breckenridge 1954) and patients (Plum and Posner 1972) suggesting a "release" of respiratory centres from the influence of higher levels. The fulminant pulmonary edema that sometimes occurs in patients with intracranial hypertension appears to be due to excessively increased sympathetic discharge from the brain stem (see below).

In some patients with increased ICP, periods of irregular breathing may lead to hypercapnia causing increases in ICP, which, if spatial compensation is poor, may lead to the formation of plateau waves (Kjällquist et al. 1964, Tindall et al. 1972). This tendency is known to be more pronounced at night and during sleep (Cooper and Hulme 1966, Strang 1971). Such respiratory disturbances are often early signs of brain stem dysfunction and since they may be transient, continuous recording of respiration may be necessary for their discovery (North and S. Jennett 1972).

As mentioned, patients having intracranial hypertension frequently exhibit spontaneous hyperventilation. This is particularly common in head injury. While the cause of hyperventilation may be extracranial, i.e. hypoxemia due to pulmonary disorders such as shunting or atelectasis, the most frequent explanation is brain tissue and CSF lactacidosis secondary to ischemia from local compression of the brain stem or general increase of ICP. It has been suggested that such spontaneous hyperventilation may be beneficial in that the respiratory alkalosis of the blood and brain extracellular fluid counteracts the metabolic acidosis of the brain tissue (Lassen 1966). The consequence would be that hypocapnia due to spontaneous hyperventilation should not be corrected, at least not totally.

By experimental work it has been demonstrated that the Cushing effect is mediated by autonomic outflow from the brain stem acting on the peripheral resistance vessels and the conducting tissue of the heart (Freeman and Jeffers 1939, Brown 1956). Recent investigations suggest that the same mechanism is involved in the production of other extracranial effects of intracranial hypertension. These include inadequate gas-exchange in the lungs and acute pulmonary edema, ECG-changes and focal myocardial necrosis, as well as ulcerations in the

mucosa of the upper digestive tract and the bladder. Such phenomena are sometimes diagnosed during the later stages of intracranial hypertension, and are not infrequently found at post mortem examination of patients dying from acute brain damage (Ducker 1968, Berman and Ducker 1969, Connor 1968, Hawkins and Clower 1971).

## II. Monitoring of the ICP

Until recently the diagnosis "intracranial hypertension" was mainly based upon clinical signs and symptoms. Measurements of the ICP were thought to be of little value because of a poor correspondence between pressure and clinical data. This view was challenged when systematic long range recording of the intracranial pressure was introduced into neurosurgical practice (Janny 1950, Lundberg 1960). It soon became clear that there was a striking parallelism between variations of the ICP and so-called pressure symptoms. These observations paved the way for the use of monitoring of the ICP in the management of patients with intracranial hypertension.

### 1. *Techniques*

There is now general agreement that, in order to be meaningful, monitoring of ICP should be based on continuous recording, either of the VFP in a closed hydrostatic system with insignificant fluid displacement or by stress-sensitive transducers placed intracranially. There are several reasons for rejecting the conventional method of assessing the ICP by once-only measurements, especially if done with an open bore manometer connected to a lumbar needle. To connect an open bore manometer to the subarachnoid space or the ventricles means escape of fluid which, if there is a "tight" intracranial situation, may cause a considerable fall in pressure. As already mentioned, a tentorial or tonsillar herniation may cause obstruction of the cranio-spinal communication and considerable pressure differences. In such cases lumbar measurements may not only give misleading results but also be dangerous due to leakage. As the ICP in intracranial hypertension often fluctuates within wide ranges it is obvious that a single measurement gives a very incomplete and often erroneous picture of the ICP pattern. Between two plateau waves the pressure may be normal, or almost normal, for long periods!

In our department we have used almost exclusively measurements of the ventricular fluid pressure (VFP) and our experience with intracranial transducers is limited. We feel that ventricular pressure measurement offers a distinct advantage because the ventricular catheter permits the drainage of fluid. In particular in acute rises in pressure, the combination of immediate diagnosis and immediate treatment may be life-saving, and in many patients continuous drainage of the ventricular fluid under pressure control has proved to be a safe and reliable method for the prolonged treatment of intracranial hypertension (see page 29). Additional advantages of an indwelling ventricular catheter are of course the possibility of the installation of gas for ventriculography, the sampling of CSF, and the intraventricular administration of drugs.

However, the fact that this report is exclusively based on experiences from

VFP recordings does not imply a negative attitude towards implanted transducers. If there is no reason for access to the ventricular fluid space or if a communication to the ventricles cannot be established or maintained, extra- or subdural measurements are an alternative expedient. This is especially true in the management of patients with severe head injuries in the acute stage. For further data concerning extraventricular ICP measurements the reader is referred to Brock and Dietz (1972).

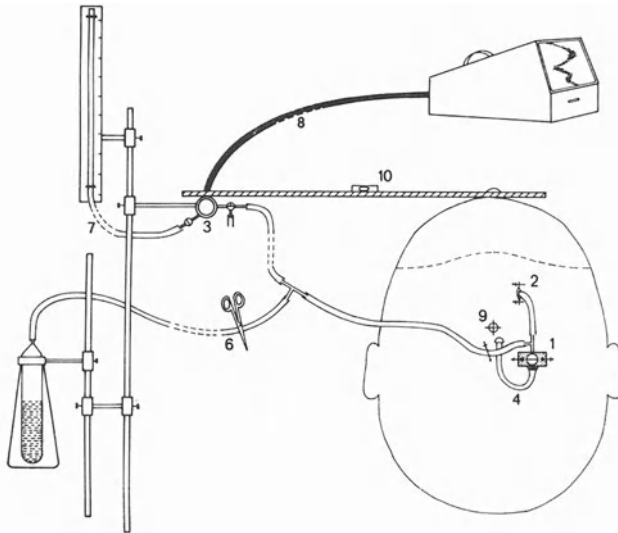


Fig. 6. Schematic drawing of the set-up for recording of VFP when the transducer is movable on a stand. (From Lundberg 1972.)

1 Head-cock, 2 ventricular catheter, 3 transducer with one two-way and one three-way stop cock, 4 rubber catheter for sampling and ventriculography, 6 PVC tube for drainage of CSF, 7 PVC tube for calibration, 8 cable to recording apparatus, 9 bregma, 10 water-level

In our original technique the transducer was movable on a stand for the adjustment of the reference level to the position of the patient's head (Fig. 6). At present we most frequently use a modification in which the transducer is sutured to the skin and covered by the dressings together with cocks and tubings for calibration and drainage (Fig. 7). It should be mentioned that the latter arrangement was used by Janny in his pioneer work of 1950.

The recording machine is a specially designed ink-writing recorder, which is relatively small and convenient. Special features of this recorder include automatic switch over to battery power when current is interrupted and an alarm which signals increases in pressure above a preset level. It may be mounted on the bed and recording can thus continue during transportation. For statistical representation of the VFP tracing the equipment may be supplemented by an electronic analyser (see page 21).

The arrangement of the ventricular catheter facilitates a "closed ventricular puncture", i.e. puncture with the catheter connected to the transducer by a

closed system. Pulsations and deflection of the tracing indicate immediately when the tip of the catheter penetrates into the ventricle—without any loss of fluid. This technique is certainly important for a successful puncture and adequate positioning of the catheter when the ventricles are small and in particular when small ventricles are combined with swelling of the brain. At least equally important is the rubber plug which keeps the catheter in place and guarantees against

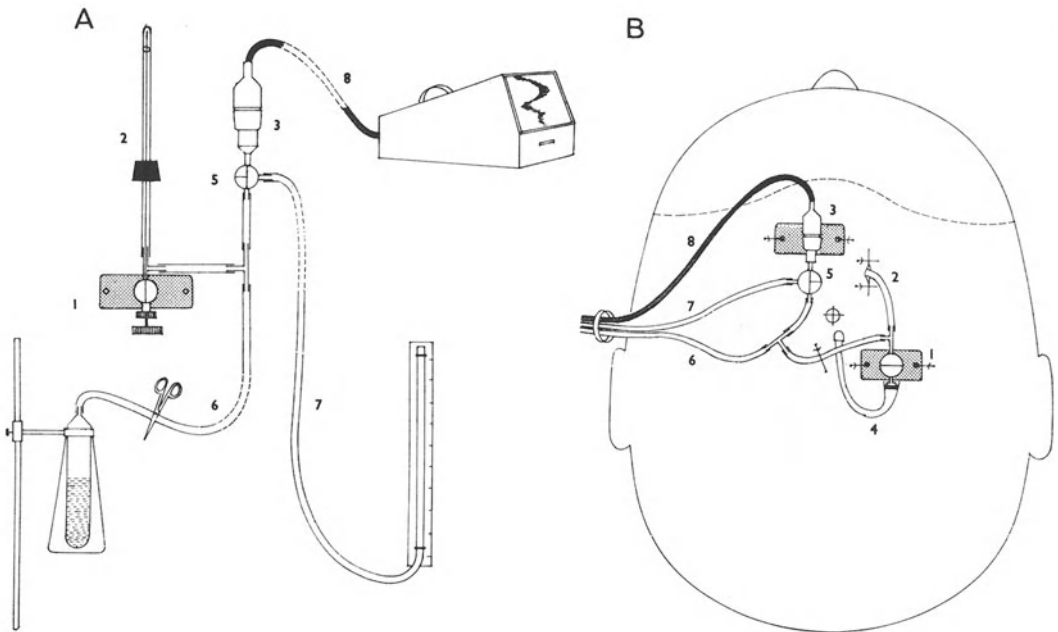


Fig. 7 A and B. Schematic drawing of the set-up for recording of VFP when the transducer is fixed on the head. In A the ventricular catheter is fitted with stylet and rubber plug, i.e. ready for ventricular puncture under pressure control. In B the head-cock (1) and the transducer (3) are sutured to the skin; the ventricular catheter emerges through the skin incision at 2. (From Lundberg 1972.)

1 Head-cock, 2 ventricular catheter, 3 transducer, 4 rubber catheter for sampling and ventriculography, 5 three-way stopcock, 6 PVC tube for drainage of CSF, 7 PVC tube for calibration, 8 cable to recording apparatus

leakage. There is no doubt that these and other seemingly insignificant details may be important, both for the rate of intracranial infection and the rate of failure to establish and maintain a free communication. (For further technical details the reader is referred to Lundberg 1960 and 1972.)

## 2. Measures against Infection

The risk of infection is an ever present danger when the VFP is continuously recorded. This risk has made sterilization a most important problem and has prompted several modifications of our original method. Our previous method of sterilizing the connecting plastic tubing by immersion in a solution of Septin® (a quaternary ammonium compound) proved to be unsatisfactory. At present

the following routine is practised: all tubing and connections are autoclaved and kept as disposable sets ready for immediate use; the transducers are stored with the pressure chambers filled with a 25 per cent solution of glutaraldehyde. All preparations for ventricular puncture, such as connection of the ventricular catheter to the transducer, filling of the system with fluid etc. are performed under strict aseptic conditions in the operating theatre. During recording all measures that require opening of the closed fluid system, e.g. calibration, sampling of CSF, insufflation or air for pneumography, are carried out with strict adherence to aseptic technique. Drainage of CSF, intermittently or continuously, is done within the closed system. Samples of CSF for cell counts and cultures are taken immediately after insertion of the ventricular catheter, and every second or third day during recording the CSF samples are withdrawn from the "head-cock". On removal, the tip of the catheter and the rubber plug are cultured separately as well as the CSF. No antibiotics are given prophylactically. However, a number of patients are treated with antibiotics during the period of recording for other reasons, such as pulmonary or urinary tract infections. [Recently a transducer with a disposable pressure chamber, described by Nornes (1973 a) has been tested in our department with promising results.]

### *3. Complications*

Those who advocate the use of implanted transducers often stress the technical difficulties in establishing patent communication to the ventricles and the risk of CSF infection involved in VFP measurements. With our technique and our selection of patients we experience less than 1 per cent failure to establish free communications between the ventricles and the transducer, and we are able to maintain a free communication for a sufficiently long period in more than 95 per cent of the cases—including cases in which a stoppage can be put right by simple measures such as flushing or shifting the position of the ventricular catheter.

The risk of infection may be assessed from our material between 1969 and 1972, which includes 393 recordings. During this time we had 3 patients who showed definite signs of CSF infection (clinical symptoms, positive cultures, and pathological cell counts) attributable to the ventricular catheter—making a rate of 0.8 per cent. During the same time there were 6 cases with positive cultures only and 3 cases with positive cultures and positive cell counts but without clinical signs of intracranial infection. In the entire material (almost 1200 patients since 1956) the rate of meningitis has been 1.1 per cent; there has been no death and no sequelae ascribable to the indwelling ventricular catheter. Somewhat to our surprise we have not found any statistical correlation between rate of infection and recording time (Sundbärg et al. 1972).

The rate of complications depends, of course, on many factors such as selection of patients, drainage, ventriculography, "bacteriological environment", available facilities for technical supervision, and so on. It is difficult to give general recommendations, but in our opinion failure to establish and maintain a free communication in less than 10 per cent and CSF infections in less than 2 per cent are acceptable standards for continuous recording of the VFP—on condition that the procedure is applied only when the information provided is of potential importance for the treatment of the individual patient.

#### 4. Interpretation of the VFP Curve

Two main kinds of information may be gained from the ICP records—the height of the pressure and the occurrence of rapid variations of the pressure.

The height of the ICP may be very roughly graded in classes: 1–10 mm Hg: normal; 11–20 mm Hg: slightly increased; 21–40 mm Hg: moderately increased; and > 40 mm Hg: severely increased. However, in judging how serious an intracranial hypertension may be, one must remember that the tolerance of the brain to increase of the ICP varies greatly. Furthermore, as already mentioned, one may occasionally find a low VFP in patients with signs of brain stem compression due to mass displacement and herniation. Such lack of parallelism between ICP and clinical symptoms is, of course, due to the fact that the effect of a change in ICP on brain function is dependent on a number of different factors, such as degree of existing mass displacement and stress on the brain stem, the state of spatial compensation, the state of autoregulation, the state of the systemic circulation and the respiratory function, and so on. It is a matter of course that the ICP should never be regarded as an isolated phenomenon. It should always be judged together with other signs which are related to the intracranial dynamics and may influence the brain function.

The VFP curve in patients with intracranial hypertension shows a variety of spontaneous rapid fluctuations, most of which are of minor clinical importance. Pressure variations related to variations of the arterial and venous blood pressures (arterial pulse, respiratory variations of venous pressure, Traube-Hering-Mayer waves) presently belong to the latter category. However, further studies might reveal that these variations contain information of diagnostic significance if examined in detail. On the other hand, pressure variations related to the intrinsic control of cerebral blood flow have considerable importance for the management of patients with intracranial hypertension. In particular this applies to pressure variations of the plateau wave type which signal that the facilities for spatial compensation are nearly depleted and that acute disorders of the brain stem from compression/distortion may be impending. Fully developed plateau waves may be an indication for active measures—operative or non-operative—even if the cerebral symptoms are not alarming. In malignant tumours severe attacks of headache related to plateau waves may give cause for surgical intervention e.g. subtemporal decompression, if corticosteroids are without effect. Pressure variations related to periodic breathing (one-per-minute waves) may also be of diagnostic significance. Their occurrence in the curve informs of respiratory disturbances, which otherwise may be overlooked, e.g. disturbances due to brain stem dysfunction or obstruction of the air-ways (Fig. 13 C).

In addition to these typical pressure waves, there are fluctuations of the VFP curve which lack the plateau form and which are not rhythmic like the waves related to periodic breathing. Some of these “atypical” pressure waves may be regarded as abortive plateau waves, the form of which is decided by an early effect of compensatory forces, while others may reflect respiratory changes of a non-periodic character. Sometimes, as a result of interaction between various factors, which can interfere in the intracranial dynamics, the VFP curve is dominated by irregular fluctuations which are difficult to interpret. However,

all kinds of rapid variations—typical or not typical, regular or not regular—are always signs of a “tight” intracranial situation if they are of a pathologically increased magnitude.

#### a) Statistical Analysis

In long-term recording of the VFP some form of statistical treatment of the information contained in the record may be desirable in order to express in

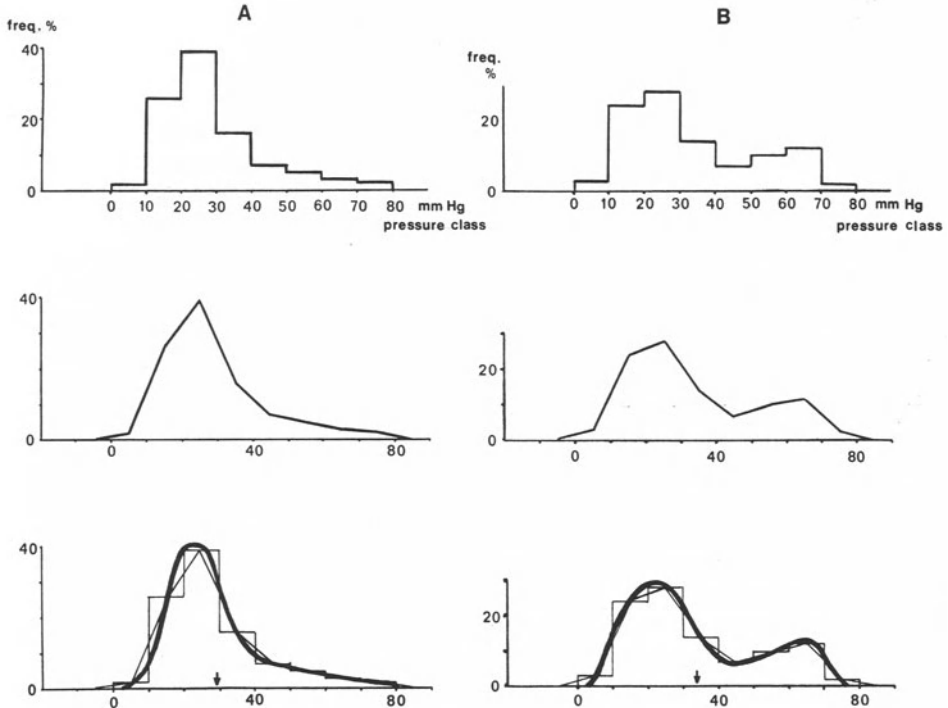


Fig. 8. Pressure-class frequency distributions, each represented as histogram (above), frequency polygon (centre), hypothetical frequency curve (below). A Raised basal pressure, skew distribution. B Raised basal pressure, double-humped distribution, the hump to the right indicating plateau waves. These distributions represent 24 hours of recording in two patients with malignant glioma. (From Kullberg 1972)

simple terms the characteristics, for example the magnitude, of the pressure during a certain period of the recording.

The normal VFP curve is a generally rather flat curve with low amplitude cyclic variations related to the arterial pulse and to respiration. It is conveniently described by the range of the pressure variations, e.g. 0–10 mm Hg, or by the mean value of the pressure (arithmetic mean).

In intracranial hypertension the VFP curve often shows a considerable amount of fluctuations of varying amplitude, including episodes of very high pressure, such as the plateau waves. Obviously the mean value is an insufficient index of the magnitude of the pressure in a record of this type. We have found it useful (Kullberg and West 1965) to represent a certain period of pressure



recording graphically as a histogram or a frequency polygon, obtained by grouping regular pressure readings into pressure classes and plotting the data in a diagram with pressure classes on the abscissa and number of observations on the ordinate (Fig. 8). Such diagrams demonstrate the variations of the pressure around the most common or "typical" pressure, in statistical terms called the mode, which is usually different from the mean pressure, as the distributions are commonly skew. The modal pressure may be said to represent the basal VFP, from which large deflections occur mainly in an upward direction. Sometimes the distribution is bi-modal with a second maximum representing the pressure level reached by plateau waves. Comparison of pressure diagrams representing separate periods of recording facilitates the evaluation of differences which may be difficult to perceive by direct inspection of the primary tracings. Examples of the clinical application of this method are detection of tendency to progression of the intracranial hypertension or evaluation of the efficiency of instituted pressure reducing treatment (see Fig. 20*b*). Unfortunately, there is no easy way of determining the numerical value of the mode, but its general position on the pressure scale is easily appreciated from the diagram. If a single numerical expression is desired to characterize the VFP curve, one may have to resort to the mean pressure, which may then be calculated from the pressure class data.

For the extraction of the pressure data, simultaneously with the pressure recording, we use a specially constructed electronic analyser (Kullberg and Sundbärg 1970, Kullberg 1972). Fed by signals from the pressure recorder, the analyser senses the pressure level at preset time intervals and continually displays the number of observations in each pressure class on a series of counters. The analyser is useful for the bedside evaluation of the pressure, as a glance at the counters gives a survey of the pressure variations that have occurred during the preceding period of time. Pressure diagrams are easily drawn on the basis of the data provided by the counters and may be erected for example on a 24 hourly basis in order to demonstrate any slow changes of the pressure.

With the aid of a proper computer more elaborate processing of the data can be accomplished as described by Janny et al. (1972 a), such as graphic display of histograms and calculation of mean pressure, modal pressure, measures of dispersion and other statistical parameters. These authors also advocate the use of the modal pressure, instead of the mean pressure, as the former is "consistent with a good definition of what one may call the basal ICP".

### 5. *Clinical Application*

In our department monitoring of ICP is mainly applied in patients with intracranial tumours, severe traumatic brain lesions, and subarachnoid haemorrhage, and in particular in such cases in which the fluid pathways are, or may become obstructed.

In *tumour cases* the following routine is usually employed: The recording is started one or two days before a planned operation. Urgency sometimes necessitates the immediate drainage of fluid; otherwise the pressure is recorded for at least two hours to obtain information on the intracranial dynamics. In some patients it may be appropriate to keep the pressure at a low level for some days before operation e.g. in order to relieve the brain stem or optic nerves from stress.

In such cases it is our policy not to reduce the pressure to normal, but to keep it at a slightly increased level, i.e. 15–20 mm Hg.

Pneumography is performed under pressure control. In most cases the

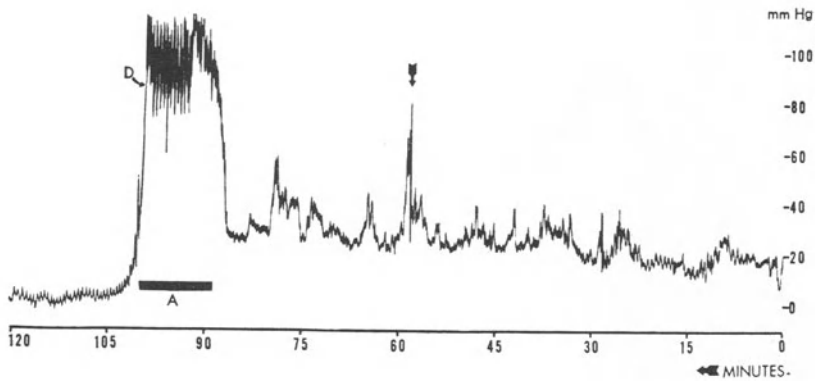


Fig. 9. Case 130 (see Fig. 2). Intracranial hypertension with marked plateau waves preoperatively (see Fig. 2). Recording of the VFP 4–6 hours after *ventriculography*. (From Lundberg 1960.) Arrow: patient coughs; *A* attack of unconsciousness, marked periodic breathing of the Cheyne-Stokes' type, clonic convulsions succeeded by tonic flexion of the arms; *D* drainage of fluid; a few minutes later, the tonic-clonic phenomena had ceased and consciousness had returned to former state

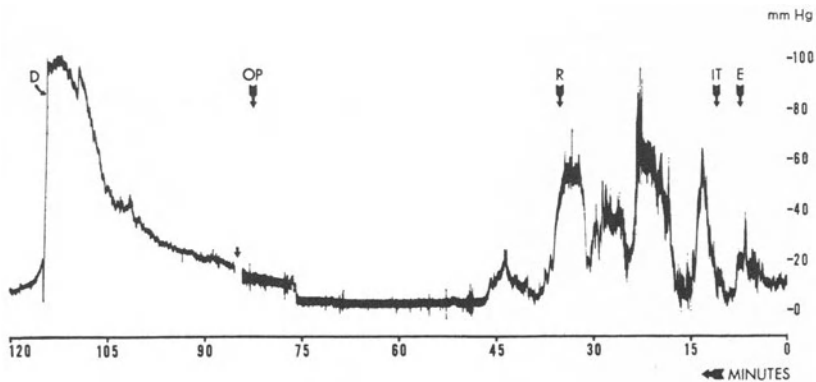


Fig. 10. Case 129 K. B., 60 year old man. *Verified glioma in basal ganglia and third ventricle*. Spontaneous plateau waves of increasing duration before operation. Recording of the VFP during operation (Torkildsen shunt, general anesthesia with controlled respiration). Note the rise in VFP after the patient had been turned to the prone position with head bent forward. (From Lundberg 1960.)

*E* Administration of evipan + succinylcholine, *IT* intubation, *R* respirator connected, *OP* operation started, *D* drainage of fluid

procedure is started by lumbar insufflation of gas. If filling of the ventricles is insufficient, gas is then insufflated through the ventricular catheter. The risk of deterioration after pneumography due to acute elevation of the ICP is a conventional argument for immediate operation after pneumography. This

routine may be discarded if the ventricular fluid pressure is continuously controlled during and after the examination (Fig. 9). Unless operation is urgent for other reasons, it will usually be delayed for one or two days after pneumography.

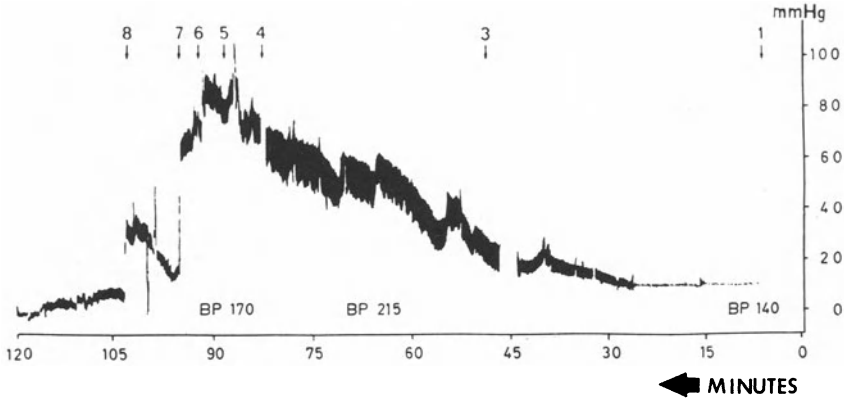


Fig. 11. Case 644 A. P., 55 year old woman. *Verified metastasis in left cerebellar hemisphere. Postoperative hematoma.* Slightly increased ICP preoperatively, no plateau waves. The tumor was removed with the patient in the sitting position.

Recording of VFP immediately after the operation. (From Lundberg 1972.)

1 End of operation, 3 transfer to the ward, 4 transfer back to the operating theatre, 5 intubation, 6 respirator connected, 7 reoperation begins, 8 dura re-opened

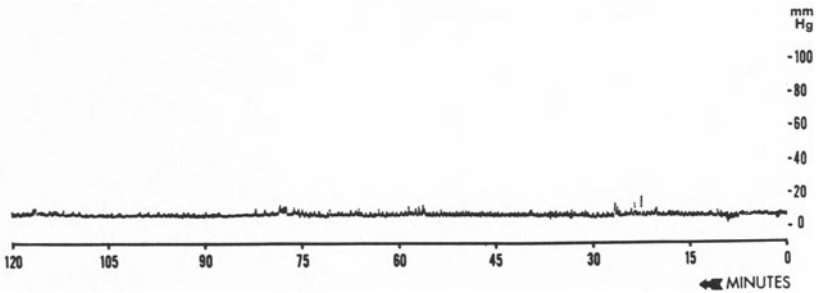


Fig. 12. B. S., 27 year old woman. *Severe closed head injury. Primary brain stem injury.* The patient was injured in a traffic accident. She lost consciousness immediately and was deeply comatose on admission. Angiography showed a slight shift of the pericallosal artery indicating diffuse swelling of the right hemisphere but no local expansive lesion. The patient remained unconscious for about three weeks; when she regained consciousness she showed signs of bilateral palsies of the sixth and seventh cranial nerves, as well as speech disorder indicating a bulbar lesion. The curve was recorded about 12 hours after the accident. The VFP remained within normal range for the entire time of recording (6 days). Rhythmic variations of VFP (1-per-minute waves) indicate periodic breathing of the Cheyne-Stokes' type.

(From Lundberg et al. 1965)

Recording of the VFP during operation under general anaesthesia has proved valuable. Among other things it has taught us and our anaesthesiologists that induction of general anaesthesia (especially by volatile anaesthetics) and subsequent disturbances of the anaesthesia may provoke acute elevations of the VFP

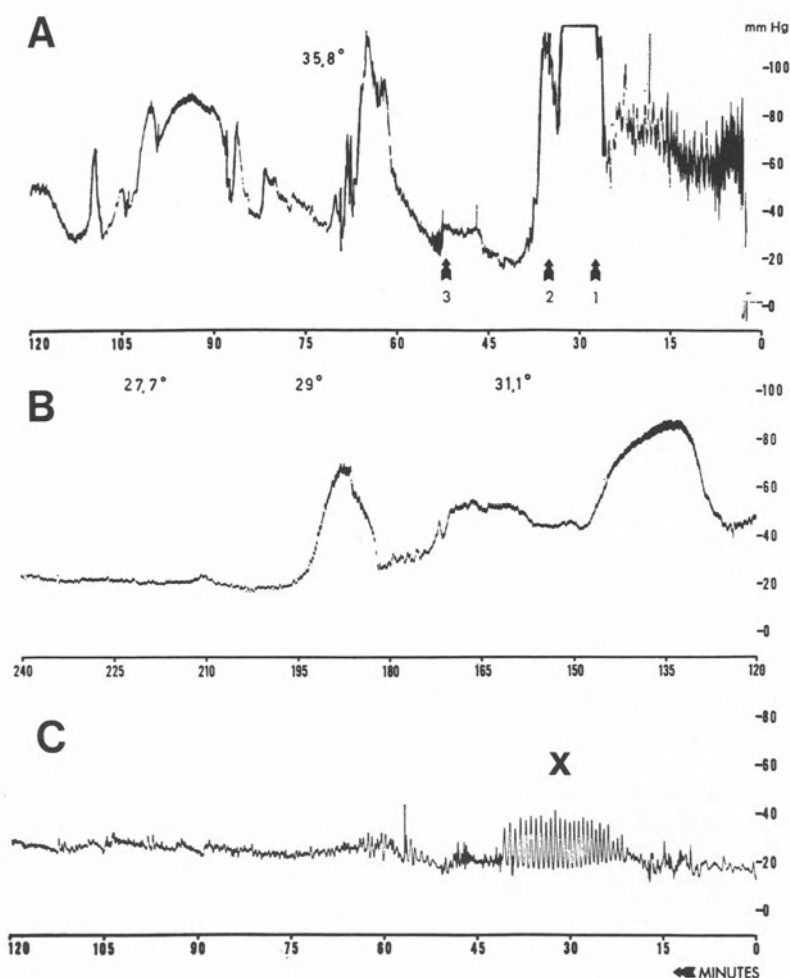


Fig. 13. Case 172 B. K., 30 year old woman. *Severe closed head injury. Local contusion of left temporal lobe. Secondary brain stem injury.* Traffic accident; the patient lost consciousness immediately and was comatose on admission

*Tracing A + B.* The two upper tracings were recorded 4–8 hours after accident, before and during induction of hypothermia. Figures above the tracings show rectal temperature in centigrades. At arrow 1 the VFP rose to a pressure far above the range of the apparatus (> 115 mm Hg); at the same time respiratory arrest occurred. Artificial respiration started immediately and a respirator was connected soon thereafter. At arrow 2 urea was infused and at arrow 3 cooling begun. Angiography showed a large expansive lesion in left temporal lobe. At operation, which was performed under hypothermia, the contused temporal lobe was removed. *Tracing C.* The bottom tracing shows the VFP two days after operation. The patient was still unconscious but had been disconnected from the respirator. The rhythmic oscillations (at X, 1-per-minute waves) were caused by Cheyne-Stokes' breathing, on this occasion due to obstruction of the tracheal tube by mucus and relieved by tracheal suction. The patient was unconscious for about a fortnight and then slowly regained consciousness. Eventually she made a fairly good recovery. (From Lundberg et al. 1965)

in patients with intracranial hypertension, and in particular in patients in whom preoperative VFP tracings show plateau waves (Figs. 5 and 10). Drainage of fluid or administration of hypertonic solutions or/and hyperventilation should be started before the induction in such patients. Recording of the ICP may also help to detect disturbances of the ventilation, inappropriate positioning of the patient (cf. Nornes and Magnaes 1971) and other things that may jeopardize optimal operative conditions (Fig. 10). In addition, the ventricular catheter facilitates adequate drainage of fluid at any time during the operation without puncture. Simultaneous recording of the arterial blood pressure by an intra-arterial catheter may be a valuable complement to the VFP recording by facilitating a quantitative assessment of the cerebral perfusion pressure (Fig. 5, Pontén et al. 1968).

After the operation our usual practice is to record the VFP without drainage in order to detect, at an early stage, a hematoma, the failure of a shunt or any other cause of postoperative intracranial hypertension (Fig. 11). As a rule, fluid should not be drained during the first 48 hours, unless the surgeon has decided either to reopen the wound or to resort to non-operative treatment. Usually, the ventricular catheter is removed 3–5 days after the operation. The recognition that ICP is not unduly high in a patient who deteriorates postoperatively may be even more important, in that it saves the patient from an unnecessary reoperation.

In *traumatic cases*, information of ICP might be helpful in the differentiation between primary and secondary brain stem injuries (Lundberg et al. 1965). This may be particularly important in patients who remain consistently unconscious from the moment of impact. This is illustrated by Figs. 12 and 13.

During the further course the ICP curve often gives more reliable and more comprehensive information than do conventional control measures, and may be helpful in detecting expanding lesions, and in judging the results of the treatment. As pointed out by W. B. Jennett and Johnston (1972) monitoring of ICP has gained increasingly in importance since controlled respiration became a common treatment of severely brain-injured patients; the drugs necessary for relaxing the patient's respiratory muscles may at the same time obscure the usual signs of an expanding hematoma or other complications.

Two different types of pressure curves can be distinguished in patients with intracranial hypertension after severe head injuries. One curve shows a fluctuating pressure, often with more or less typical plateau waves superimposed on a relatively low base line—the other shows a consistently high pressure level. According to W. B. Jennett and Johnston (1972) the fluctuating pressure pertains especially to focal lesions and the consistently high pressure to diffuse lesions. The importance of ICP monitoring for the prognosis in severe traumatic head injuries has been stressed by Troupp (1967), Troupp et al. (1972). They found that a consistent pressure level above 30 mm Hg means bad prognosis and that patients with VFP levels above 60 mm Hg had an insignificant chance of useful survival.

During the last years we have systematically studied the ICP in patients with *subarachnoid haemorrhage* (Pontén et al. 1973). The general conclusion is that intracranial hypertension plays an important role during the posthaemorrhagic period—obviously more important than has been hitherto supposed—and

that the VFP curve may be a valuable guide to treatment (drainage of fluid, time of aneurysm operation, need for a shunt). This subject will be treated in more detail below.

There are of course other patients in whom monitoring of ICP may give valuable information, e.g. in patients with hydrocephalus and disorders of the CSF circulation. In patients with papilledema of unknown origin it may be important to decide whether ICP is normal or increased. In such cases, continuous recording of VFP under standardized conditions, and for periods including at least one night, is the only means of obtaining reliable information.

### III. General Principles for the Care of Patients with Intracranial Hypertension

The ultimate goal of all treatment of intracranial hypertension is to secure the supply of oxygen and glucose to (and removal of CO<sub>2</sub> from) the entire brain and to relieve the brain tissue from mechanical stress. The oxygen supply may be threatened by a variety of intra- and extracranial disorders and in many cases it may be difficult to decide whether the clinical signs are caused by intracranial hypertension or not. In such situations measurements of the ICP may facilitate adequate treatment and prevent unnecessary measures; not least if one tries to judge the role of intracranial hypertension *ex juvantibus* by lowering the ICP, it is obvious that monitoring of the ICP may be useful.

All patients with severe brain damage—traumatic or non-traumatic—and in particular comatose patients are threatened by a number of extracranial disorders, which may influence the intracranial dynamics and jeopardize the oxygen supply to the brain tissue. Of these disorders the most important are airway obstruction, pulmonary dysfunction, fall in blood pressure, hypovolemia, hypoperfusion, and anemia. To establish and maintain a free airway, to support a failing respiration, to give the inspired air an optimal oxygen content, to allay shock and replace lost blood are measures of routine character, which as a rule should be considered in all severely brain damaged patients including those with intracranial hypertension and usually before any special steps to reduce ICP are taken. All the same, there are situations in which it is equally urgent to lower ICP, e.g. in acute herniation with impending or manifest respiratory arrest; in such situations artificial respiration and rapid infusion of urea should be started immediately. Likewise in patients with pulmonary edema secondary to intracranial hypertension it is futile to treat the edema unless the ICP is reduced.

In treating a patient with respiratory disorder one should keep in mind that the tolerance of a damaged brain and, in particular, a compressed brain stem, to hypoxemia may be considerably less than normally. Even a pO<sub>2</sub> as high as 70 mm Hg may occasionally be inadequate. However, the primary menace from respiratory insufficiency is usually not hypoxia but hypercapnia which by dilating cerebral resistance vessels may cause dangerous elevations of the ICP if there is a “tight” intracranial situation. If the patient fails to keep the PO<sub>2</sub> above 100 mm Hg and the PCO<sub>2</sub> below 40 mm Hg artificial respiration may be necessary.

During the last decades the positive pressure respirator has been used to an ever increasing extent for the treatment of patients with severe brain damage

and is now one of our most valuable aids in neurosurgery. It is not only used in order to correct an insufficient respiration but also to induce therapeutic hypoxemia by hyperventilation. Both these indications are dealt with in the section on hyperventilation. There is one further indication which deserves to be emphasized, i.e. the need for administration of sedating drugs or muscle relaxants in order to depress motor hyperactivity of different origin, e.g. psychomotor agitation, forced breathing, decerebration or epileptic seizures. It is a matter of course that all kinds of respiratory-depressing drugs are prohibited in these cases unless the patient is artificially ventilated.

What we know about intracranial hemodynamics indicates that intracranial hypertension in advanced stages may cause defective autoregulation and poor perfusion of the brain, generally or locally (compression of the brain stem!). There are strong reasons to believe that in such a situation the brain has a low tolerance to fall in blood pressure. Irrespective of its cause, a fall in blood pressure should urgently be corrected—with one exception, i.e. the fall in blood pressure which occurs when an intracranial hypertension passes from a compensated into an uncompensated state and the cerebral blood circulation ceases. All attempts to restore the cerebral blood flow by increasing the blood pressure with drugs or transfusion are useless in this situation.

In hypovolemic shock it is not only the low blood pressure which threatens cerebral metabolism but also secondary effects of hypovolemia such as hyperthermia, acidosis, coagulation disturbances, and hypoxemia. (It should be added that these secondary effects of hypovolemia may appear without fall in blood pressure.) Thus, the adequate treatment of arterial hypotension and hypovolemia are measures of high priority in the management of patients in whom intracranial hypertension is diagnosed or suspected. This, of course, is especially true in patients with traumatic head injuries. As already mentioned, when the autoregulation of CBF is defective, a rise of the arterial blood pressure may cause a rise of ICP which might have serious consequences if there is a "tight" intracranial situation. Furthermore, animal experiments indicate that an increase of the systemic arterial pressure may promote the propagation of a vasogenic brain edema (see page 7). These data imply that the blood pressure control in patients with intracranial hypertension means balancing between too low and too high pressure and that drugs with hypotensive or hypertensive effects should be avoided or, in any case, given with great care.

Besides prophylactic and therapeutic measures against respiratory and circulatory disorders the management of a patient with intracranial hypertension includes control of the water- and electrolyte balance, control of body temperature, control of urine and bowel, adequate nutrition, care of the skin etc., i.e. measures which are important in every severely brain damaged patient and which should be applied according to the same generally accepted principles whether the ICP is elevated or not. They will not be dealt with in this work.

As already stressed, prevention and treatment of respiratory and circulatory disorders have a high grade priority in acute cases. However, it should be emphasized once more that in cases of acute compression of the brain stem from herniation, reduction of the ICP by ventricular drainage or rapid infusion of urea may be equally or even more urgent.

The measures accounted for above should in principle be considered in all cases of severely brain damaged patients. In selected cases treatment with specific methods for reducing ICP may be indicated as well. Before deciding to institute such treatment one should first of all try to determine whether or not the ICP is increased. In some cases this may be clear from the clinical and roentgenological picture, but continuous measurement of ICP generally provides superior information. As already stressed, the presence of an elevated ICP does not necessarily mean that the patient's cerebral dysfunction is caused by intracranial hypertension. If a causal relationship is doubted one may attempt to reduce ICP in order to determine if and to what extent the intracranial hypertension is responsible for the patient's cerebral disorder. However, prolonged reduction of ICP may be advisable even if acute reduction fails to cause immediate improvement, e.g. in order to abolish a potential risk of acute pressure incidents or to relieve the optic nerves or brain stem of mechanical stress.

#### IV. Special Treatments

##### 1. *Controlled Drainage of CSF*

Ever since lumbar puncture was introduced into clinical practice by Quinke in 1891 drainage of CSF has been used for reduction of ICP. Lumbar drainage is still widely used e.g. to get space for removal of deeply situated intracranial lesions or for reduction of ICP in patients with communicating hydrocephalus. However, the original idea of Quinke to use lumbar drainage for reduction of increased intracranial pressure in patients with an expanding lesion soon became discredited because of the risk of accentuation of tentorial or foraminal herniation. We know now that the crucial factor is the existence of free communication between intracranial and spinal fluid spaces (see page 7). If this communication is blocked by herniation, drainage of lumbar CSF is not only ineffective but may also be dangerous.

Since the early days of neurosurgery drainage of ventricular fluid has been used as an alternative means for the treatment of intracranial hypertension. The classical method is to puncture the ventricle with a metal cannula through a burr hole usually situated over the trigonum of the lateral ventricle. However, direct needle puncture of a lateral ventricle has several disadvantages. Uncontrolled flow of CSF may cause derangement of intracranial dynamics resulting in e.g. collapse of the ventricles, upward herniation in the tentorial notch, swelling of the brain by congestion and edema, and intracranial hemorrhage. Reduction of intracranial pressure following one puncture is usually of short duration.

Furthermore trauma to brain tissue by repeated punctures may cause deterioration of the intracranial state. (Since we started to use indwelling catheters for continuous control of ICP we have completely abandoned ventricular needle puncture as a means of reducing ICP. Even in acute brain stem compression from herniation we prefer to avert the immediate danger by rapid infusion of urea and then introduce an indwelling catheter for further control of the ICP.)

The obvious drawbacks of needle puncture have prompted many neurosurgeons to use continuous drainage of ventricular fluid instead, and a number of ventricular drainage systems have been described (Ingraham and Campbell 1941,



Poppen 1943, Behring 1951, White et al. 1969). These have been designed for obtaining satisfactory control of the VFP and for minimizing the danger of retrograde infection, a danger which is considered to severely limit the length of the time the catheter can be left in place. In order to prevent reflux different kinds of valves have been inserted between the ventricular catheter and the collecting vessel, e.g. a standard Holter valve as suggested by White et al. (1969).

As has been described in the section on techniques for monitoring ICP, our methods for recording the VFP and for drainage of ventricular fluid are closely integrated. Continuous drainage is rarely applied without simultaneous measure-

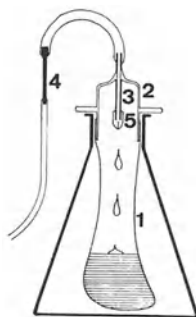


Fig. 14. *Collecting vessel and valve for CSF drainage.* The fluid container consists of a condom (1) which is pulled over and (by autoclavable tape) tightly fixed to the bottom part of a glass dome (2). A glass tube (3) is passing through the dome; it has an outer nozzle for a rubber tube which is connected to the plastic tubing from the patient by a metal connector (4) and an inner nozzle for a slit valve (5) consisting of a rubber cap with a fine cut in its top. The condom is kept in a glass bottle with the glass dome resting on the edge of the bottle's neck supported by a fringe

ment of the VFP. Besides the general advantages of having continuous pressure record this "controlled ventricular drainage" provides the possibility to detect any obstruction between the ventricle and the collecting bag on the tracing.

Our equipment for controlled ventricular drainage has been designed in order to meet the following demands:

1. The outflow pressure should be adjustable.
2. The CSF should be completely isolated from the outer air.
3. Reflux of fluid should be prohibited by a one-way valve with an insignificant resistance.
4. The entire outfit should be autoclavable.
5. Disposable parts should be inexpensive.

The design of our present outfit is illustrated in Fig. 14.

The VFP may be reduced either by intermittent drainage or by continuous drainage. In the former case drainage is carried out when the patient develops symptoms or when the pressure remains above a predetermined maximum level. The fluid should always be removed slowly and under continuous observation of the pressure to avoid abrupt fall of the VFP which we think may promote derangement of the intracranial dynamics. If continuous drainage is applied we usually

do not lower VFP to normal level; as a rule we keep the pressure slightly increased, i.e. between 15 and 20 mm Hg for reasons which are further discussed below. It is obvious that the setting of a desired VFP level is facilitated if drainage is combined with continuous pressure measurement. It is equally obvious that knowledge of the ventricular fluid pressure is a more reliable indication for drainage of fluid than are clinical symptoms only.

Apart from intracranial infection and technical disturbances possible complications of ventricular drainage are intracranial hemorrhage and aggravation of an upward tentorial herniation or a midline shift. Intracranial hemorrhage has been attributed to evacuation of ventricular fluid by several authors (Cushing 1902, Guttman 1936, Olivecrona 1940). Nornes (1973 b) claims that the risk of rebleeding from ruptured aneurysms increases as the ICP decreases below 30 mm Hg. Since the present routine for ventricular drainage was introduced in our department we have diagnosed some rebleedings from ruptured aneurysms while ventricular drainage was going on (see below) but we have seen no hemorrhages from other sources ascribable to controlled ventricular drainage. We have never encountered deterioration which could be attributed to upward tentorial herniation as described by Jefferson and Johnson (1950). However, it seems probable that occasionally such complications might occur without being diagnosed.

An important question is whether ventricular drainage means additional risk for retrograde intracranial infection. In 100 consecutive patients, in whom ventricular fluid was continuously drained for two days or more (maximum 41 days, mean 8.2 days), there were "clinical infection" in 1.0 per cent, positive culture + positive cell count in 2.0 per cent and positive culture alone in 5.0 per cent. This indicates that the overall rate of infectious complications from continuous ventricular drainage are not significantly greater than during monitoring VFP without drainage (see page 19). Prophylactic administration of antibiotics during continuous drainage of ventricular fluid as recommended by e.g. Wyler and Kelly (1972), Shapiro et al. (1972), and Kusske et al. (1973) is not used in our department.

Technical disturbances of ventricular drainage are most frequently due to blocking of communication between ventricle and collecting bag. It is obvious that the functioning of ventricular drainage is related to the size of the lateral ventricles. However, it should be stressed that ventricles of normal size may be successfully drained for long periods provided that the ventricular walls are not pressed together by brain swelling from congestion or edema. In our experience such ventricular collapse may occur even if the outflow pressure is set as high as 40 mm Hg or more. Collapse of the ventricles occurs most often in patients with severe traumatic or ischemic brain injuries and in patients with supratentorial tumours during the later stages of intracranial hypertension when the compensatory mechanisms are failing. A free communication may be reestablished by temporary clamping of the drainage tubing or by flushing the ventricular catheter with a small amount of saline. Injection of fluid into the ventricles must be performed with great care as acute rises in pressure of the plateau wave type may be elicited. Slight withdrawal of the ventricular catheter sometimes restores communication. However, in such situations further attempts to reduce ICP by drainage are usually futile. If the obstruction is caused by a clot, e.g. in cases

with subarachnoid hemorrhage (SAH), without any concomitant ventricular collapse, this obstacle may sometimes be removed by flushing with saline but often the catheter has to be exchanged in the operating theatre.

Ventricular drainage may be indicated in a variety of intracranial lesions and in various situations. Several of these indications have been touched upon in the section on clinical application of ICP monitoring (page 22) and will not be dealt with further. However, a clinical study on the treatment of SAH by ventricular drainage (Pontén et al. 1973) will be briefly commented upon.

Blood in the subarachnoid space has a tendency to block the CSF pathways and cause an increase of the VFP and subsequently ventricular dilatation.

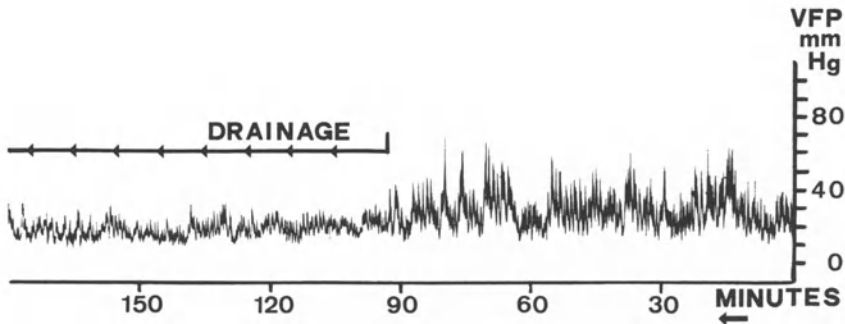


Fig. 15. Case No. 1164, I. H., 35 year old man. *Subarachnoid hemorrhage. Aneurysm of the posterior communicating artery.* Non-diagnosed SAH 1/11 1973. Admitted 9/11 after new attack the same morning. Drowsy, restless, generally rigid with stiffness of the neck, severe headache, especially behind the right eye. Ventricular puncture 9/11: Sanguinous ventricular fluid. VFP fluctuating between 20 and 50 mm Hg as shown by the right part of the tracing. Right-sided carotid angiography: Aneurysm at the junction of the internal carotid and posterior communicating arteries. Continuous drainage of ventricular fluid started 10/11. A substantial improvement of headache, restlessness and drowsiness occurred within 24 hours

Severe headache, restlessness and impairment of consciousness are dominating symptoms during the first days after SAH. In a series of 60 patients with non-traumatic SAH such symptoms appeared to be related to intracranial hypertension and were the main indications for VFP recording. Increased pressure was found in 90 per cent of the patients. Slowly fluctuating VFP levels between 30 and 50 mm Hg were the usual findings during the first days. In 55 patients with marked intracranial hypertension the ventricular fluid pressure was lowered to a level between 15 and 20 mm Hg where it could easily be maintained in most cases. In uncomplicated cases the amounts of CSF drained per day usually decreased from 100–300 ml towards zero in about two weeks after the SAH. These facts indicate that impairment of the CSF resorption was the main cause of intracranial hypertension and that in most cases the resorption capacity gradually returned to normal. In 6 patients CSF was still draining after 3 weeks; these patients subsequently required shunt operation.

The most striking clinical effect of drainage was an often immediate improvement of headache and restlessness. Stuporous or comatose patients became more alert within one or two days unless there were signs of severe brain stem compres-

sion with decerebrate rigidity. These effects may occur even if the lowering of the ICP level is slight. The improvement is then probably mainly due to the fact that drainage causes all pressure peaks to disappear resulting in a levelling of the curve as demonstrated by Fig. 15.

Other studies (Pool and Potts 1965, Normes 1973 b) have indicated that the risk of rebleeding is greater at low than at high intracranial pressure. There has so far been no indication that the rate of rebleeding is increased in our series of patients drained to 15–20 mm Hg. It should be pointed out that the pressure is reduced slowly over a period of about one hour. Sudden changes in pressure that may be elicited by e.g. lumbar punctures are probably more dangerous with regard to rebleeding.

Ischemic lesions come second in order among serious complications of SAH during the acute state. There are reasons to believe that even a moderate increase of ICP may further compromise the insufficient perfusion of areas on the verge of ischemia. Manifest ischemia may cause swelling of the brain tissue and thus further increase of ICP. It is tempting to assume that this cycle can be prevented or cut off by continuously lowering ICP.

No statistically significant confirmation of this hypothesis has been obtained but in some patients in this series the course of an ischemic complication appeared to be more benign than expected and only one patient died from an ischemic complication.

## 2. Hypertonic Solutions and Diuretics

Since the discovery by Weed and McKibben (1919) that the intravenous administration of hypertonic sodium chloride or glucose solutions was followed by a fall in the CSF pressure and a reduction of brain bulk, this therapeutic principle has been widely used in neurosurgical practice. However, owing to shortlasting effect and a considerable risk of complications the usefulness of this treatment was questioned. It was only when Javid and Settlege (1956, 1957) demonstrated the clinical usefulness of intravenously administered urea that the treatment of intracranial hypertension with hypertonic solutions became fully accepted in neurosurgery. Since then a number of new agents have been tried, the most important being mannitol for intravenous and glycerol for intravenous and oral administration; they were introduced into neurosurgical practice by Wise and Chater (1961, 1962) and Virno et al. (1961), respectively.

### a) Mode of Action of Hypertonic Solutions

The intracranial pressure reduction after intravenous administration of hypertonic solutions is due to withdrawal of water from the intracranial contents by osmosis. Thus a prerequisite for the pressure reduction is that the osmotic activity of the blood is higher than that of the brain fluids. A concentration gradient must be upheld for the osmotically active compound which should pass only slowly over the blood-brain and the blood-CSF barriers.

The osmotic activity of the brain fluids will nevertheless slowly increase during the infusion, both due to an influx of the compound used and due to an outflux of water. When the infusion is stopped, the osmotic activity of the blood soon decreases below that of the brain fluids. The flux of water then is reversed and the ICP starts increasing again.

Changes of the intracranial compartments 30 minutes after urea infusion were studied by Rosomoff (1962). He found a decrease of intracerebral water amounting to 6 per cent of the intracranial contents. This was compensated for by increases of blood and CSF volumes by about 3 per cent each. However, water is also withdrawn from CSF as indicated by the fact that the osmolarity of CSF increases more than can be explained by the increase of urea in CSF (Behring and Avman 1960, own unpublished results). This apparent contradiction can be explained by an influx of CSF from the spinal canal into the cranial cavity, diminishing the CSF volume in the spinal canal. The distension of the spinal dural sac thus will diminish and its capacity for spatial compensation will increase (see discussion of volume pressure relationship on page 8). This explains both the decrease in pressure level and the absence of spontaneous variations in the pressure during effective osmotherapy.

The explanation for rebound, i.e. return of ICP to higher levels than existed before treatment is not totally clear. A higher osmolarity of CSF than of plasma is often found from six hours after the start of a urea infusion, lasting sometimes up to 24 hours afterwards (Behring and Avman 1960, own unpublished results). The difference is small but statistically significant and would favour a flux of water from plasma into CSF. Since the difference is almost constant for many hours the water flux into CSF by osmosis must be balanced by a flux in the other direction presumably due to a change in the hydrostatic pressure gradient between CSF and plasma, i.e. an increased CSF pressure. Another explanation would be that edema in and around a lesion would propagate more easily through the tissue during the pressure reduction and thus be larger after the period of pressure reduction than before. It should in this context be mentioned that Pappius and Dayes (1965) showed that only the normal brain tissue was dehydrated by hypertonic urea, whereas edema in and around freeze lesions was not affected, probably since the urea molecules rapidly entered the lesion. This is also in accordance with our clinical impression that patients with huge ischemic lesions have a shorter duration of VFP reduction after hypertonic solutions than patients in whom the blood brain barrier seems to be essentially intact. Still another explanation for rebound, suggested by Reed and Woodbury (1962 b) would be an increased rate of production of CSF. Our clinical experience (see below), that the rebound is very longlasting, often six hours or more, seems to favour the first explanation but several mechanisms may be responsible for rebound after hypertonic solutions in patients with intracranial hypertension.

Consideration of the mode of action of hypertonic solutions will allow some conclusions regarding the characteristics of different solutions used. The duration of the ICP reduction is essentially dependent on the time the osmotic gradient from plasma to brain fluids is upheld. Thus, both the osmolarity of the solution and the rate of penetration of the compound into the central nervous system will influence the duration of action. On the other hand, a rapid and reliable initial effect requires a high osmolarity of the solution and a high rate of infusion, while the rate of penetration of the compound is of little significance. The risk for rebound, finally, depends mostly on the extent to which the compound penetrates into the brain fluids.

Some differences between urea and mannitol can be foreseen from this rea-

soning. Both compounds enter the brain intracellular fluid and the CSF slowly but, while the equilibration with plasma takes 6–12 hours with urea, it takes more than 24 hours with mannitol (Schoolar et al. 1960, Reed and Woodbury 1962 a, Sisson and Oldendorf 1971). In isosmolar doses mannitol thus has a longer pressure reducing effect than urea (Wise and Chater 1961). However, isosmolar doses are seldom given, since the osmolarity of 30 per cent urea is 4.5 times that of 20 per cent mannitol. This means that 1350 ml of mannitol has to be infused to match 300 ml urea. The difference in osmolarity also tells us that urea should be more efficient with regard to initial effect. Rebound occurs after mannitol (Shenkin et al. 1962) but is much less common than after urea (see below) due to its slower equilibration with the brain fluids.

Infusion of mannitol and urea will cause an acute increase of the plasma volume and hence a dilution of the blood with a decrease of its viscosity. This will enhance the blood flow. Clinical studies (Goluboff et al. 1964, Johnston et al. 1972, Bruce et al. 1973) showed an increased cerebral blood flow which poorly correlated with changes of the intracranial pressure and the cerebral perfusion pressure. Thus, rheological factors may also be of importance for the beneficial effects of hypertonic solutions in cases with intracranial hypertension.

#### b) Clinical Experience with Intravenous Urea and Mannitol

The effect of 300 ml 30 per cent urea given at a rate of 3 ml per minute and of 300 ml mannitol 20 per cent given at a rate of 7 ml per minute are illustrated in Figs. 16 and 17. The pressure reduction with urea is very rapid, cutting short a plateau wave within two minutes after the start of infusion. This clinically important phenomenon is evidently due to the fact that in a "tight" situation (on the steep part of the pressure/volume curve) a slight decrease in volume may be accompanied by a large decrease in pressure (cf. page 9). Our general experience with urea given at a rate of 3 ml/min (60 drops/min) or more is that in practically all patients the pressure reduction starts within five minutes, usually within two minutes. With mannitol the initial effect is slower, five minutes in Fig. 17, and not infrequently 10–20 minutes, unless very high rates of infusion are used.

The duration of pressure reduction is much longer for urea than for mannitol when equal amounts are given. It is also evident from the figures that the tendency to pressure variations is much less during urea infusion than during mannitol infusion. There are still rather marked spontaneous variations in the VFP during the pressure reduction period after mannitol.

Rebound after urea with higher and longer plateau waves are seen in Fig. 16. Rebound defined as an increase of the mean pressure is found in the majority of cases given 90 g urea and even after smaller doses, but only few patients get notably increased clinical symptoms during the rebound period. Fig. 18, however, illustrates a fatal rebound which was impossible to control with drainage of CSF or mannitol infusions. Rebound after mannitol is not indicated by Fig. 17. It sometimes occurs, however, but as a rule it is much milder than after urea. A significant clinical deterioration after mannitol was never seen.

The influence of the rate of infusion and total dose of urea on the duration

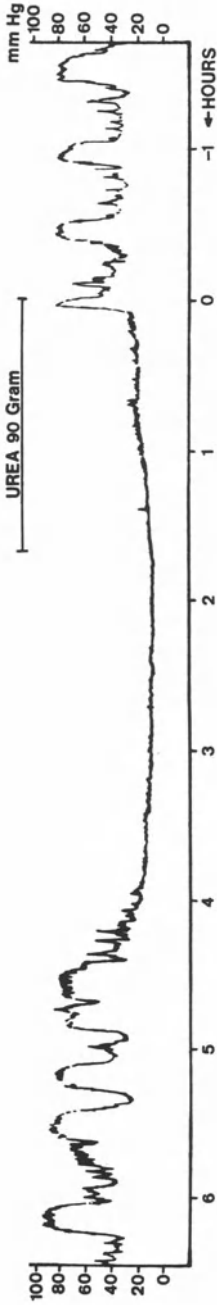


Fig. 16. *Effect of urea in a patient with malignant brain tumour and frequent plateau waves. Intravenous administration of 300 ml 30 per cent urea at a rate of 3 ml (60 drops)/min. Note rapid initial pressure reduction, absence of rapid variations when the pressure is low and rebound with higher and longer plateau waves than before urea*

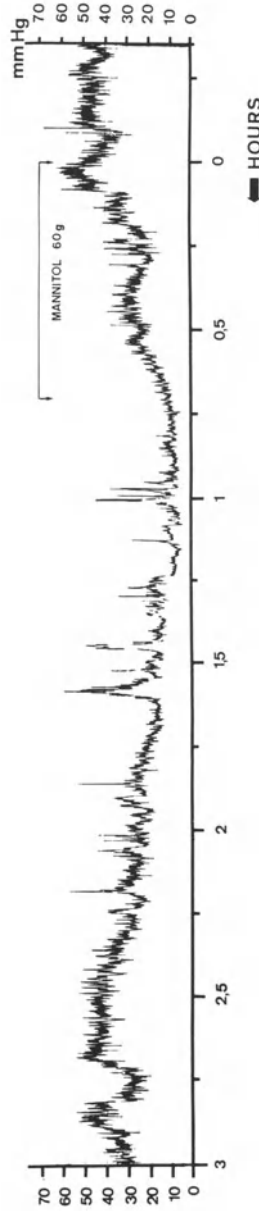


Fig. 17. *Effect of mannitol in a patient with malignant brain tumour. Intravenous administration of 300 ml 20 per cent mannitol at a rate of 7 ml (140 drops)/min. Note significant pressure reduction after 5 minutes, great spontaneous variability during the period of pressure reduction and no early rebound*

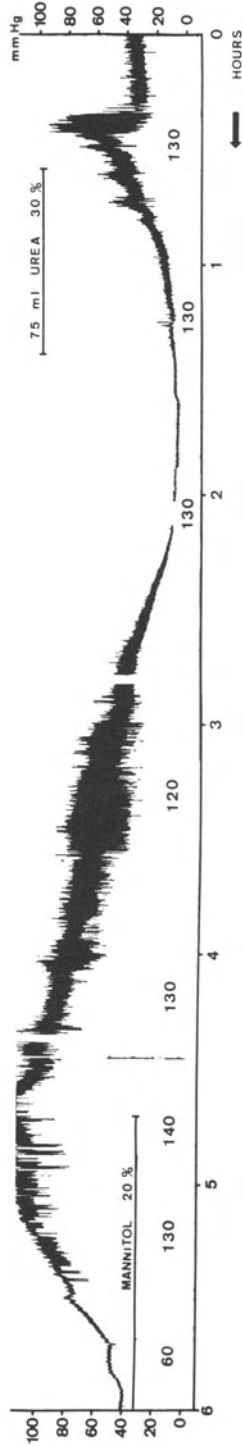


Fig. 18. Case 923. K. H., 49 year old woman. *Massive intracerebral hemorrhage. Fatal rebound after urea.* Streptokinase treatment of inferior caval thrombosis. Deep coma with signs of brain stem herniation on admission. The tracing started 36 hours after the hemorrhage. Controlled ventilation. Patient reacted for pain only. Systolic arterial pressure in mm Hg is given below the VFP tracing. Urea 0.34 g/kg b.w. at a rate of 7 mg/kg b.w./min was given intravenously. Good initial VFP reduction followed by a progressive VFP increase above 110 mm Hg. Collapse of the ventricle prevented CSF drainage. Rapid infusion of mannitol was without effect. VFP decrease occurred simultaneously with a fall in blood pressure indicating total brain ischemia. From then on the VFP passively followed the blood pressure



of VFP reduction is illustrated in Fig. 19. Slow infusions around 5 mg/kg b.w./min could give a long but not always completely satisfactory pressure reduction. To be sure to obtain a sufficient pressure reduction, which will effectively prevent plateau waves, the rate of infusion should be 6 mg/kg b.w./min or more. Higher rates gave about the same duration. Increase of the total dose from 1.0 to 1.8 g/kg

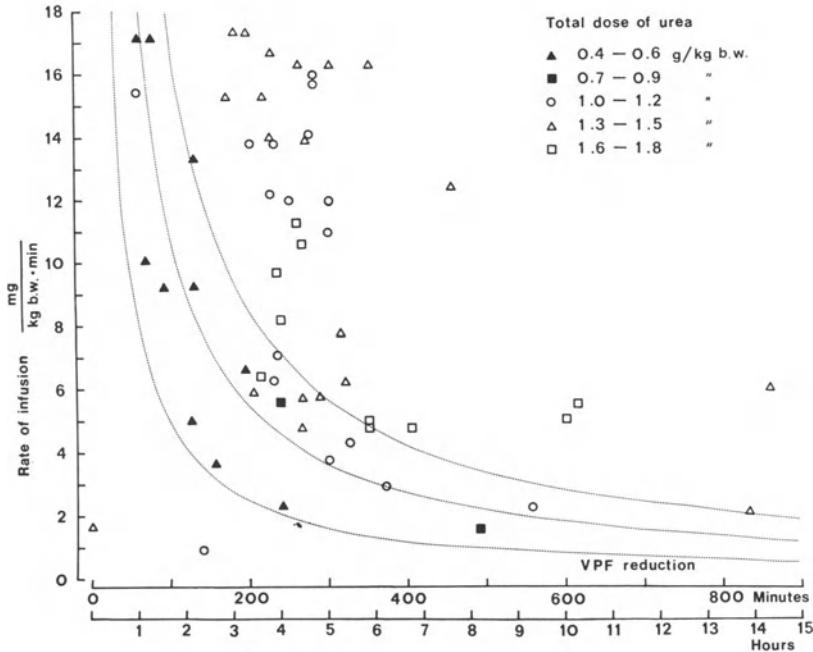


Fig. 19. Influence of total dose and rate of infusion on duration of VFP reduction after intravenous urea infusion. 59 infusions of 30 per cent urea given to patients with intracranial hypertension, mostly due to malignant brain tumours. All cases had continuous VFP recordings undisturbed by other therapeutic or diagnostic measures for at least 2 hours before and after the time of VFP reduction. The thin broken lines indicate the infusion time of different infusion rates and a total dose of 0.5, 1.1, and 1.7 g/kg b.w., respectively. At rates below 6 mg/kg b.w./min there were some very long VFP reduction periods. In some of these cases, however, the VFP was reduced only slightly below the pressure before the infusion and showed a considerable variability. Above 6 mg/kg b.w./min the pressure was always reduced to or below normal for some time

b.w. did not significantly increase the duration of VFP reduction. The average time of reduction was  $253 \pm 67$  min (mean  $\pm$  SD). These figures apply to patients with expanding lesions without significant blood brain barrier damage (mostly brain tumours). As mentioned, patients with large ischemic lesions as well as traumatic brain injuries usually have a more transient benefit from hypertonic solutions.

#### c) Side Effects

Apart from rebound, a number of untoward side effects of intravenous urea infusion have been reported. Thirty per cent urea is highly toxic to the tissue

if accidentally deposited extravascularly and may then cause severe inflammatory reaction and necrosis. During the first years after introduction of urea, several cases of hemoglobinuria were reported. Javid and Andersson (1958) attributed this complication to a combined effect of urea and the vehicle and on the basis of extensive studies they claimed that urea did not produce this complication when dissolved in 10 per cent invert sugar. Mason and Raaf (1961) found a significantly abnormal prothrombin time in five out of 15 patients after urea administration and recommended administration of vitamin K. Except inflammatory reactions in a few cases of extravascular deposition we have not experienced any clinically significant complications from urea.

The side effects discussed above are not seen with mannitol. The expansion of the plasma volume which regularly occurs during intravenous infusions of hypertonic solutions implies a risk of circulatory overloading and pulmonary edema, especially in elderly and in patients with heart failures. The plasma expansion is more pronounced after mannitol than after urea (Buckell 1964) and risk for pulmonary edema is thus higher during mannitol infusion.

#### d) Oral Treatment

For long term treatment of intracranial hypertension oral treatment is preferable since it avoids some of the side effects. We have tried urea per os in total doses comparable to our i v dosages. The pressure reducing effect was almost as good as with intravenous administration. We had to abandon this route of administration, however, since the drug very often produced nausea and vomiting.

Glycerol seems to be more suitable for oral use according to many reports (for references see Tourtellotte et al. 1972). Glycerol is also used intravenously with satisfactory effect. The readers are referred to the original publications, since we have no personal experience with the drug.

#### e) Diuretics

Furosemid (Lasix®) 20 mg and Aescin have been reported to decrease the cerebrospinal fluid pressure in patients with head injuries (Galle and Staudacher 1968). We have not been able to verify these findings. Continuous VFP recording showed no effect of 20 mg Furosemid i. v. Doses of 200 mg gave a slight decrease in pressure, less than 10 mm Hg, without clinical significance. Our results do not indicate that diuretics should be used as pressure reducing agents.

#### f) Recommended Treatment

Urea and mannitol are both valuable agents for treatment of intracranial hypertension. In our opinion they have partly different fields of application in accordance with their individual properties.

Urea is recommended under circumstances when a prompt effect is necessary, in particular when a brain stem herniation is manifest or imminent and when causal treatment can be instituted within a few hours. The rate of infusion in the beginning should be at least 60 drops/min (or 3 ml/min) but may be lowered to half that rate when about 50 ml have been infused. Rapid infusion of 300 ml 90 per cent urea might precipitate a pulmonary edema due to the expansion of the vascular bed. Mannitol, preferably in a 20 per cent solution, may be used

when the situation is less urgent and in particular as an additional aid in long term treatment of intracranial hypertension. Beside the smaller risks for rebound the main advantage with mannitol is that it is less prone to cause thrombophlebitis or tissue damage when inadvertently infused subcutaneously. It is not feasible to give mannitol in equiosmolar doses with urea due to the large amounts of fluids necessary.

It should be kept in mind that treatment with hypertonic solutions always implies a risk for rebound and growth of a hematoma. Hypertonic solutions should primarily be used in those situations where time is required for diagnostic or therapeutic measures or to protect the patient during dangerous manoeuvres like intubation and induction of anaesthesia and for intraoperative control of brain swelling and reduction of brain bulk. Long term treatment ( $> 48$  hours) of intracranial hypertension with repeated infusions of hypertonic solutions only, is usually not successful (Becker and Vries 1972, Johnston et al. 1972). However, Cantore et al. (1964) reported good results of oral treatment for up to eight weeks with glycerol in patients with pseudo-tumour cerebri. This treatment has to be evaluated in other better defined cases before a recommendation can be made.

As already stressed, indications for osmotherapy as well as the evaluation of the results become more reliable if based on continuous recording of VFP.

### 3. Hyperventilation

It has long been known that hyperventilation lowers ICP and reduces brain volume. This effect has been widely used by neuroanaesthetists as a means of decreasing brain bulk during operations. The influence of hyperventilation on intracranial hypertension and its clinical application has been extensively studied during the last 15 years. On the basis of a clinical study, Lundberg et al. (1959) suggested that hyperventilation is a useful aid for reducing ICP in patients with intracranial hypertension both in acute situations and as a long term treatment. However, controversy still exists as to the efficiency and possible sideeffects of induced hyperventilation.

#### a) Mode of Action and Effect on ICP

The mode of action of hyperventilation in reducing ICP may be briefly summarized as follows. Due to the fact that  $\text{CO}_2$  rapidly diffuses through biological membranes the  $\text{PCO}_2$  in all fluid compartments will be in equilibrium. Hyperventilation will thus produce an extracellular alkalosis in the brain. Probably through a direct effect upon vascular muscles the increase in extracellular fluid pH causes constriction of the cerebral resistance arterioles. As a consequence less of the systemic arterial blood pressure is transmitted to thin-walled vessels of the cerebral vascular bed and the cerebral blood volume decreases.

This mode of action has several implications. The effect is rapid—the pressure begins to fall within half a minute and usually becomes stable at the lower level after about 5 minutes. Furthermore, the effect is most striking if ICP is increased because of cerebral congestion. Thus, during a plateau wave passive or active hyperventilation may cause a dramatic fall in pressure. This effect exemplifies the action of a “trigger mechanism”, i.e. the ability of a relatively small decrease in pressure to initiate a much larger decrease when the intracranial pressure/

volume situation is represented by the steep part of the pressure/volume curve (see page 9).

During continued hyperventilation in patients with intracranial hypertension ICP slowly increases during the first 2–3 hours after the initial fall in pressure. In most cases the pressure stabilizes at a lower level than the original one (Lundberg et al. 1959). Obviously some kind of adaptation mechanism is responsible for this phenomenon. It is notable that Miller and Ledingham (1971) in experiments on dogs found that during hyperventilation the reduction of an increased ICP persisted to full extent for at least 5 hours.

In some conditions even intense hyperventilation with a low PaCO<sub>2</sub> level will fail to reduce increased ICP. The normal cerebral vasomotor response to CO<sub>2</sub> is known to be absent in conditions of hypoxia and in conditions of progressive intracranial hypertension with vasomotor paralysis. In addition, hyperventilation cannot be expected to be effective if the intracranial hypertension is mainly due to brain edema. Thus, in the final states of intracranial hypertension every attempt to lower ICP by hyperventilation will prove futile.

The effect of controlled hyperventilation on ICP is not only dependent on the decrease in PaCO<sub>2</sub> and the actual state of the intracranial dynamics but is also influenced by a number of different parameters related to the mode of action of the respirator and the resulting airway pressures, as well as the circulatory and pulmonary state. Thus, the quantitative relations between the minute volume, the decrease in PaCO<sub>2</sub> and the decrease in ICP are extremely complex. It is not surprising to find divergent opinions about the efficiency of hyperventilation in lowering ICP.

In accordance with Bozza-Marubini et al. (1964) we found that the ICP is not significantly influenced by moderate increases or decreases in the expiratory airway pressure when using the Engström respirator. This is not in agreement with the observations of Schettini et al. (1967) that the addition of a negative pressure during the expiratory phase was necessary to achieve a substantial decrease in ICP. The difference between the results of these investigations can probably be attributed to the high airway pressure produced by some respirators. Further studies on this clinically important question are needed.

Another clinically important question is whether repeatedly occurring plateau waves and similar pressure variations can be abolished by long term hyperventilation. In our experience fully developed plateau waves may repeatedly occur during continuous hyperventilation with a constant PaCO<sub>2</sub> at 30–35 mm Hg (Lundberg et al. 1959). On the other hand, pressure waves are often seen to diminish in size and frequency and even to disappear completely during continuous hyperventilation. This is in accordance with observations of Paul et al. (1972). However, the possibility remains that the same effect might be obtained by artificial normoventilation.

Long term treatment with controlled hyperventilation in patients with severe traumatic brain injuries has been reported to significantly diminish the mortality rate (Rossanda et al. 1966, Rossanda 1968, Gordon 1971). It has not been shown to what extent reduction of ICP may be responsible for this improvement and a comparison between controlled normoventilation and controlled hyperventilation has not been done. A majority of severely head injured patients have a sponta-

neous hyperventilation with a  $\text{PCO}_2$  between 25 and 35 mm Hg, which is the level most often used during artificial hyperventilation. It is thus not certain that the beneficial effects of respirator treatment should be ascribed to the hypocapnia per se. It seems probable that some portion of the reduction in mortality described by Rossanda and Gordon must be attributed to the prevention of episodes of respiratory disorder. Other effects of artificial respiration may be important as well, such as reduced muscle activity with less energy consumption and less heat production, improved oxygenation, less tendency to atelectasis, positive effects on an impaired cerebral circulation, and the opportunity to give analgetics and sedatives. It is still an open question if, or to what extent, long term hyperventilation is superior to long term normoventilation.

#### b) Side Effects

Among possible side effects, hypoxic damage to the brain secondary to hypocapnic cerebral vasoconstriction and the Bohr effect on the hemoglobin dissociation curve has been the most controversial. Studies on the energy metabolism of the brain have shown that hyperventilation with air produces increased lactate/pyruvate ratios and redox changes in the brain tissue indicating tissue hypoxia, but only at  $\text{PaCO}_2$  values below 20 mm Hg (Alexander et al. 1965, Granholm et al. 1969). These functional and biochemical changes might theoretically be related either to lack of oxygen or to a specific effect of hypocapnia, but since they are relieved or reduced by breathing pure or hyperbaric oxygen, hypoxia seems to be the cause (Reivich et al. 1968, Plum and Posner 1972).

It has long been known that hyperventilation with the reduction of  $\text{PaCO}_2$  below 20 mm Hg produces cerebral symptoms in the form of blurred consciousness and EEG changes. However, lasting cerebral symptoms due to hyperventilation have never been observed. Furthermore, no arguments have been presented which convincingly contradict the conception of Noell and Schneider (1944) that in pronounced hyperventilation the "hypoxic factor" by counteracting further vasoconstriction protects the brain against any critical decrease of the oxygen supply. Thus, there are no reasons to question that controlled hyperventilation can be used for therapeutic purpose without exposing the patient to any undue risks provided that  $\text{PaCO}_2$  is kept above 25 mm Hg and an adequate amount of oxygen is added to the inspired air (Lundberg et al. 1959). However, since most experimental studies are made on undamaged brains and the results of hyperventilation studies in cerebral infarcts are not conclusive, the possibility of untoward effects of at least extreme hyperventilation in certain clinical states cannot be fully excluded.

#### c) Recommended Treatment

There are three main indications for using controlled ventilation in patients with intracranial hypertension, viz. during craniotomy under general anaesthesia, in acute incidences of intracranial hypertension and for prolonged treatment of intracranial hypertension.

General anaesthesia and controlled ventilation with a respirator is the method

of choice in all *intracranial operations*. As a rule the  $\text{PaCO}_2$  is maintained at a level between 30 and 35 mm Hg. This gives room for further reduction of  $\text{PaCO}_2$  which might give some further reduction of ICP and brain volume. The ability of volatile anaesthetics to produce potentially dangerous increase of ICP in patients with intracranial hypertension is well known (Lundberg et al. 1959, Søndergaard 1961, Marx et al. 1962, McDowall et al. 1966). For this reason the use of halothane in such patients has been questioned. However, it appears that hyperventilation (to a  $\text{PaCO}_2$  of about 30 mm Hg for 10 minutes) before administration of halothane greatly reduces this effect (McDowall and Wüllenweber 1972, Adams et al. 1972). Perhaps such hyperventilation should be done without nitrous oxide which has been shown to increase ICP (Henriksen and Jørgensen 1973).

In *emergency situations* with acute rise of ICP and acute herniation, and in particular if respiratory arrest is threatening, manual hyperventilation may be lifesaving and should be started immediately. In this connection it may be appropriate to warn against uncontrolled and overambitious use of assisted ventilation with a rubber balloon which in spite of very low (and possibly dangerous)  $\text{PaCO}_2$  levels may fail to lower ICP (cf. Schettini et al. 1967). Manual ventilation should be exchanged for mechanical ventilation as soon as possible. An easy transportable "miniventilator" which can be put in the patient's bed may be helpful in emergency situations and during transportation to the roentgenological or operation department. Initially pure oxygen is recommended and a total minute volume of about 11–12 litres per minute at a rate of 20 per minute (Engström respirator).

For *long term treatment* of increased ICP a respirator should be preferred which allows the patient to trigger extra tidal volumes according to his need. Many patients with intracranial hypertension—especially of traumatic origin—show spontaneous hyperventilation. As suggested on page 15 the consequent hypocapnia should not be corrected by the respirator, at least not totally. If, as is the rule, the spontaneous  $\text{PaCO}_2$  is between 25 and 35 mm Hg this level should be maintained; at the same time a  $\text{PaO}_2$  of at least 100 mm Hg is desirable. For this purpose the respirator is first set to deliver the same minute volume as measured during spontaneous ventilation and is then adjusted according to blood gas analyses for which samples may be withdrawn after 10–15 minutes. If the patient works against the respirator the cause is often a too low minute volume.

Restlessness and agitation will often subside when the degree of the ventilation is adequate, but sometimes sedatives such as phenoperidin and chlorpromazin may be needed. By relieving the patient of unnecessary muscle work the metabolic rate will be lowered and an increased body temperature will tend to fall. Attention should be kept to the airway pressure, which should be below 20 mm  $\text{H}_2\text{O}$ . Should it be higher, in spite of carefully cleansed airways, a higher respiratory rate should be tried and the head of the bed may be elevated 7–10 degrees.

The treatment may continue for several weeks or until the condition is stabilized. Spontaneous breathing should be tried during short and increasing periods during which the minute volume is measured, e.g. by a Wright spirometer to

avoid sudden respiratory insufficiency. If guided by repeated blood gas analyses and monitoring ICP the change from artificial to spontaneous respiration will gain in safety.

#### 4. *Corticosteroids*

During the last decade corticosteroids have been extensively used for the treatment of cerebral edema, one of the main causes of raised ICP. The idea can be dated back to 1945, when Prados et al. found that ACTH and adrenal cortical extracts, previously known to have an influence on capillary permeability, would counteract experimental brain swelling produced by exposure to air. The effect was later confirmed by others and was linked to the glucocorticosteroid group of hormones. Scattered clinical observations during the following years suggested a beneficial effect of corticosteroids in various cerebral lesions. When cortisone was introduced as replacement therapy at operations in the sellar region, the favourable effect was considered partly due to the prevention of brain edema.

In 1957 Kofman et al. reported remarkable improvement of neurological symptoms in a series of patients with metastatic brain tumours, the result of a study originally intended to assess the usefulness of adrenal suppression by high doses of prednisolone in disseminated breast carcinoma. At the same time French and his collaborators, investigating the possible tumour growth inhibiting effect of corticosteroids, noted dramatic improvement in patients severely ill from malignant brain tumours. The rapidity of the effect suggested an influence on the accompanying edema and prompted a systematic clinical evaluation. Their first report concerning the use of dexamethasone in the treatment of cerebral edema resulting from brain tumours and brain surgery appeared in 1961 (Galicich and French 1961, French and Galicich 1964); a recent report (Maxwell et al. 1972) summarizes their observations on 1361 steroid-treated patients. In the meantime treatment with steroids in high dosage has become widely used for various cerebral disorders associated with edema and many clinical investigations have been reported.

There is general agreement that corticosteroids have a favourable effect on the symptoms of raised ICP and neurological deficit in the majority of patients with malignant brain tumours, primary or metastatic, and that steroid treatment reduces the frequency of postoperative complications related to cerebral edema. It has not been possible, however, to prove the value of corticosteroids in head injuries and studies on their effect in cerebral vascular accidents are controversial.

The mechanism by which corticosteroids exert their beneficial effect is incompletely known. Experimental research has demonstrated a counteracting effect of corticosteroids in many of the experimental models of cerebral edema studied, although not in all. There is also certain evidence that corticosteroids may improve neuronal function by actions distinct from their effects on edema. Furthermore, steroids have been reported to reduce CSF production. As the results obtained from animal experiments cannot be directly transferred into clinically encountered situations, they will not be further commented upon here. (For further reading and references see Reulen and Schürmann 1972.)

## a) Corticosteroids and ICP

Clinical assessment of the pressure reducing effect of corticosteroid therapy is usually based on the observed decrease of the symptoms and signs traditionally attributed to raised intracranial pressure, such as headache, vomiting, clouding of consciousness, etc. These phenomena, however, are complex and may be difficult to interpret. More precise information will be obtained by direct measurement of the ICP.

In our department steroid therapy has now been used for some 10 years, often in combination with VFP monitoring, which has offered opportunities for such direct studies. A pressure reducing effect of corticosteroids could thus be verified by long term recording of the VFP for periods of up to five weeks in patients with malignant brain tumours (Kullberg and West 1965). Steroids in ordinary dosage (16–24 mg dexamethason daily) had a definite although rather moderate effect when evaluated by the decrease in the 24 hours mean VFP. In only two of the five patients studied the pressure began to decrease on the first day of treatment, in the others there was a delay of 2–8 days. Individual injections of steroids were never accompanied by any significant immediate change in the pressure, as seen with osmotherapy. A clinically important observation was that the earliest and most prominent change concerned the plateau waves, which became successively lower and less frequent and sometimes disappeared (Figs. 20a, b). Lowering of the basal pressure level was less impressive and a normal level was not reached. The changes in VFP could in general be fairly well related to changes in the symptoms of the patients. In particular the episodically occurring signs of cerebral dysfunctions abated concomitantly with the changes of the plateau waves. Improvement of the steady symptoms of the patients was usually seen later, when the pressure had been lowered for some time. However, in one of the patients dramatic improvement of the level of consciousness occurred within 24 hours and preceded any detectable change in the VFP. This observation indicates that other actions of corticosteroids, separate from the effects on intracranial pressure, are involved in the therapeutic effect, and illustrates the fallacies of evaluating intracranial pressure from clinical symptoms. Similar findings were reported by Janny et al. (1972 b); in three patients dexamethasone did not significantly alter the VFP curve within 24 hours, whereas amelioration of the clinical condition was noted in all.

VFP recording, as part of the routine procedure, in many other patients with brain tumours has offered valuable information on the steroid effect on the VFP, in good agreement with the findings described above. Thus, according to our experience, in the majority of the patients with malignant brain tumours steroid treatment will have a favourable influence on the intracranial hypertension within some days, and we believe that the effect on the potentially dangerous plateau waves is especially valuable.

The VFP has also been recorded in a great number of patients with head injury. Conclusive evaluation of the effect of corticosteroid therapy on the VFP is difficult, however. Sometimes the pressure has begun to fall or plateau waves have disappeared following institution of steroid therapy. We have also observed cases where reduction or withdrawal of steroids was followed by a rise in VFP.



Such observations are certainly suggestive of a causal relationship, but not conclusive, in view of the variable and unpredictable spontaneous course and the difficulty to exclude an influence of other factors on the VFP in these acute conditions.

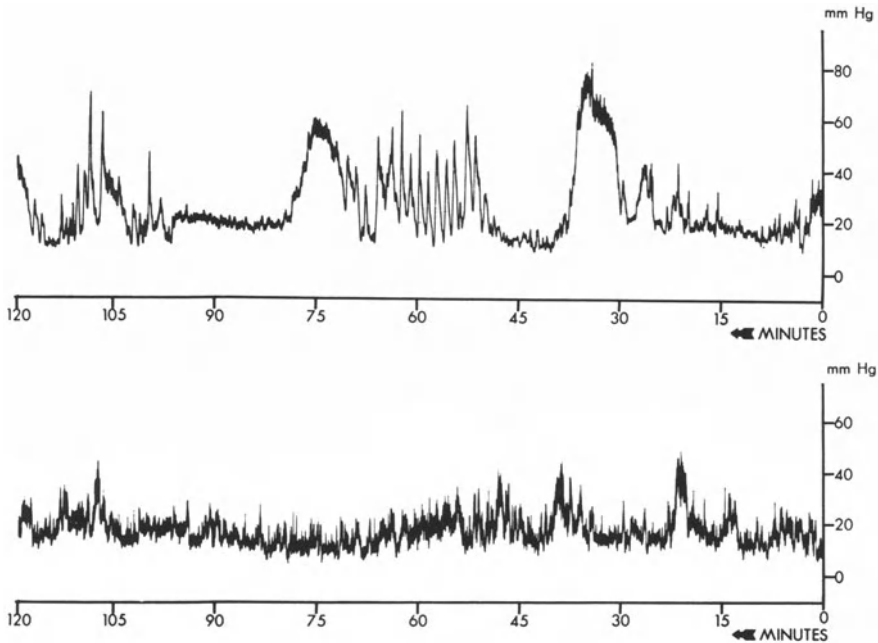


Fig. 20a. Case 382. B. N., 44 year old woman. *Malignant glioma left parietal region*. Right-sided hemiparesis, dysphasia. VFP increased with frequent rapid fluctuations, including plateau waves, which were often accompanied by headache and clouding of consciousness. During steroid treatment a gradual lowering of the VFP occurred. The most conspicuous change was nearly complete disappearance of plateau waves and of the concomitant episodic symptoms. The VFP change is illustrated by 2-hour samples of the VFP record, prior to treatment (above) and on the seventh day of treatment (below). (From Kullberg and West 1965)

#### b) Side Effects

Corticosteroid therapy, even when applied for short periods of time, carries a certain risk of complications. Impaired wound healing and increased risk of infection, in the operative field as well as generally, must be taken into account. The magnitude of this problem is difficult to assess but it does not seem to be of major clinical significance and does not warrant specific prophylactic measures, except of course, in cases of suspected or manifest infection. Gastrointestinal bleeding is reported to occur in a small percentage of steroid treated patients and routine use of antacids seems advisable. Serious hemorrhages are encountered mainly in deeply unconscious patients with evidence of severe brain stem damage, which may in itself be the pathogenetic factor (cf. page 16), but they do occur occasionally in other patients. It is well known that exogenous corticosteroids temporarily depress the production of the natural hormone. After short term

steroid therapy normal levels return within a few days, but it seems possible, in analogy with the situation after long term therapy, that the full capacity for response to stress may not be restored until later. Thus, corticosteroid therapy is not without dangers and should not be given without careful consideration of the indications.

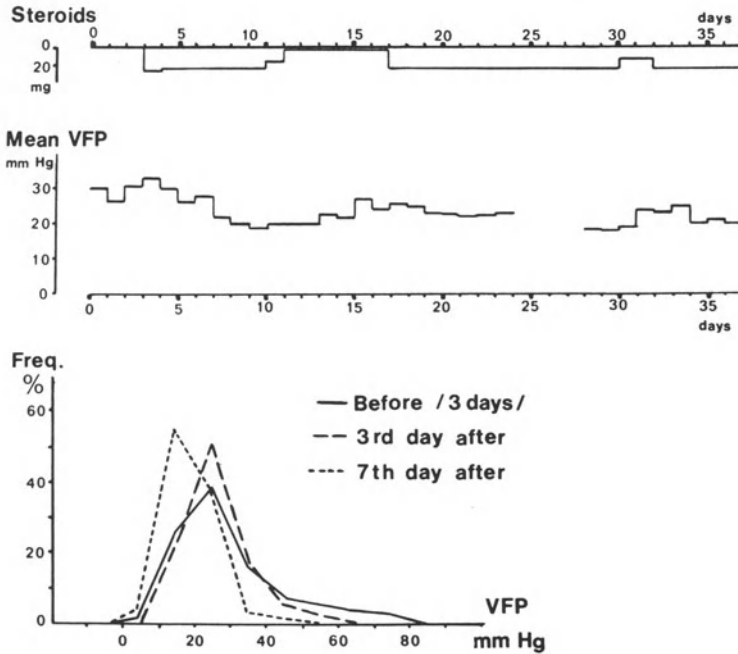


Fig. 20b. Case 382 (see Fig. 20a). *Long term monitoring of VFP during steroid treatment, transformed into statistical data.* Mean VFP, calculated for each 24 hour period, decreases gradually following institution of steroid therapy, but tends to increase again, when the steroid dose is substantially reduced. Three diagrams of pressure class frequencies (cf. page 21) representing the pretreatment period of three days, the third and the seventh day of treatment respectively, demonstrate reduction of the high pressure episodes, visible on the third day and more marked on the seventh day, when there is also a decrease of the basal pressure

### c) Recommended Treatment

In our department corticosteroid therapy is often used in patients with brain tumours presenting evidence of raised ICP. The occurrence of large pressure fluctuations, as judged clinically from symptoms of the intermittent type, or seen by recording of the VFP, is a particularly strong indication. The majority of the patients will be improved within some days of the commencement of steroid therapy. Thus, the necessity for acute operations will be diminished, adequate diagnostic investigations can be carried out, and the risk of postoperative complications will be reduced. Full steroid therapy is given for some days after an operation and then gradually withdrawn. In case a non operable tumour is diagnosed the steroid dose is reduced to a lower maintenance level and in this way the patient can often be kept in good condition for many months.

There seems to be general agreement among neurosurgeons on the usefulness of steroids in the treatment of brain tumours associated with edema. Maxwell et al. (1972) for example, in a study of 815 cases of cerebral neoplasms of various types reported alleviation of the symptoms of raised ICP in 84 per cent, and similar results have been described by other investigators. Many emphasize the rapidity of the response, improvement often being noted within 12 to 24 hours. In our opinion, however, this early effect may not always mean that a decrease of the ICP has already occurred. It should also be stressed, that if the danger of brain stem incarceration seems imminent, other pressure reducing means should be taken into consideration.

The use of corticosteroids in the management of brain abscesses, notably prone to cause cerebral edema, has been restrained by the fear of impairing the defence against infection. However, from the experience of 21 cases of brain abscesses, Maxwell et al. (1972) concluded that the control of edema obtained by steroid therapy permitted effective treatment with antibiotics prior to surgery, resulting in reduced morbidity and mortality. We have recently given steroids to several patients with abscesses, without any complications and with seemingly favourable effect. A concomitant intense and effective treatment with antibiotic is, of course, essential.

The indication for steroid treatment in head injuries is not clear. This is not surprising as it is a mixed diagnostic group, comprising cases with a variety of pathological lesions of different nature and localization. In a double blind study of steroid therapy in critically ill head injury patients with documented increase in intracranial pressure Randt and Wood (quoted by Ransohoff 1972) found a trend towards lower mortality and higher quality of survival in the treated group as compared to the untreated, but the difference was not statistically significant. Our own impression is, as mentioned previously, that steroids sometimes contribute to improvement of the intracranial hypertension of traumatic origin. Thus, it seems reasonable to try steroid treatment in severe head injuries with unconsciousness, when there is angiographic evidence of an intracranial mass of the diffuse type, not accessible to surgical treatment, or verified significant increase of the ICP. Similarly, it may at times be justifiable to try steroid treatment in patients with evidence of severe brain edema following cerebral vascular or hypoxic episodes, and also in the obscure cases of pseudo-tumour cerebri when the raised ICP seriously endangers the health of the patient.

The corticosteroid probably most widely used is dexamethasone, a synthetic steroid with high anti-inflammatory activity and little effect on water and electrolyte metabolism. We have used this compound, as well as its isomer betamethasone in equal dosage and have noticed no difference in effect. These two compounds are generally considered fairly equal with regard to their biological effects, although in certain laboratory tests betamethasone has been reported to have lower potency (Tolksdorf 1959). The recommended dosage is 4 mg i.m. 4 to 6 times daily with an initial intravenous loading dose of 10 mg. In the continued treatment the drug is administered orally when feasible.

In the prophylactic use of steroids, treatment should start one or two days prior to the operation and continue for some days after. Withdrawal of the drug is performed by gradual dose reduction in the course of a week's time to permit

restoration of the adrenocortical function and to diminish the risks of recurring edema. In long term treatment the steroids are reduced to the lowest level that keeps the symptoms under control, a commonly applicable dose being 3–6 mg daily.

Other glucocorticosteroids, for example cortisone, prednisone, prednisolone, are also in use and are reported to be equally effective. We have no personal experience with these drugs.

### 5. Hypothermia

When hypothermia was introduced into clinical neurosurgery in the early fifties, one main purpose was to protect the brain against ischemia due to temporary clamping of cerebral arteries during aneurysm operations. The principal basis was experimental studies by Bigelow et al. (1950) and Boereema et al. (1951) showing that at a body temperature of 20 °C dogs can survive total circulatory arrest for up to 15 minutes without cerebral deficit. This effect was ascribed to the slowing down of the brain metabolism and the consequent decrease of the oxygen consumption. However, from observations during craniotomies in patients with intracranial hypertension it soon became clear that hypothermia produced a marked reduction of ICP and brain bulk (Botterell et al. 1956, Lundberg et al. 1956). This observation could be confirmed by continuous recording of VFP (Lundberg and Nielsen 1959, Nielsen et al. 1962). It was generally assumed that this effect is related to the decrease in CBF and systemic blood pressure which was shown to occur during hypothermia (Rosomoff and Holaday 1954, Behring et al. 1956, Meyer and Hunter 1957).

These observations aroused optimistic expectations since, at that time, the neurosurgeon had no effective means of reducing ICP and brain bulk apart from CSF drainage. However, when urea and controlled hyperventilation became available the impetus for using hypothermia for the treatment of intracranial hypertension greatly diminished.

The original contributions of Bigelow and Boereema were followed by a number of investigations on the protective effect of hypothermia against various kinds of brain lesions in animals e.g. traumatic (Rosomoff 1959, Rosomoff et al. 1965), toxic (Jeppsson and Nielsen 1955) and cold lesions (Shulman and Rosomoff 1959). These investigations consistently showed that the protective effect is significant only if induction of hypothermia precedes the injury. The implication would be that hypothermia is especially suitable for use at craniotomy in order to protect the brain against operative trauma. Nevertheless during the last decade the peroperative use of hypothermia has gradually abated, apparently for two reasons—first that induction of hypothermia is a complicated, time consuming and not entirely risk-free procedure and, second, that a satisfactory reduction of ICP and brain bulk can be obtained by simpler measures.

However, in our opinion, peroperative hypothermia is still of value in selected patients, in particular, patients with deeply situated lesions in the vicinity of the brain stem. This view is supported by our results in a series of acoustic neuromas operated upon under hypothermia (Lundberg 1969). At a rectal temperature of 27–28 °C induced with a technique described by Lundberg et al.

(1956) the operative conditions were excellent, brain swelling did not occur, even if the operation lasted for several hours, and no serious complications ascribable to hypothermia were recorded in the series (41 consecutive cases). A comparison concerning mortality, preoperative brain swelling, postoperative course, working capacity, and facial nerve function between patients operated on with and without hypothermia strongly spoke in favour of hypothermia. To what extent the beneficial effect of hypothermia was due to reduction of ICP and brain bulk is difficult to know.

The second main reason for introducing hypothermia into neurosurgery was the idea that, during long term hypothermia, depression of the brain metabolism would slow down processes leading to secondary brain damage in traumatic or ischemic lesions (Laborit and Huguenard 1951). Promising results of long term hypothermia in patients with traumatic brain injuries were reported by Sedzimir (1959) and by Lazorthes and Campan (1958). In these early trials a relatively superficial hypothermia (30–34 °C) was induced with the aid of drugs (“lytic cocktail”). Bloch (1967) used prolonged hypothermia with rectal temperatures at 29–33 °C in a series of patients with malignant brain tumours. He found that though prolonged hypothermia may temporarily mitigate serious symptoms, rewarming often produces a return to the initial state. Furthermore, he noted a considerable risk of deterioration owing to complications such as metabolic acidosis, hyperthermia, and increase of ICP from congestion and brain edema. Such complications seemed to be related to the duration of hypothermia. Obviously, lack of convincing results in combination with risk of complications and the fact that long term hypothermia is a resource-demanding procedure explains the present negative attitude to this method.

All the same, as demonstrated by Fig. 13, hypothermia may be useful in the early treatment of acute traumatic brain injury. This is in accordance with observations by Bouzarth and Madow (1966) who described a technique for immediate hypothermia in cranial trauma. The dramatic reduction of ICP demonstrated by Fig. 13 may partly be due to infusion of urea and controlled respiration, but it seems quite clear that the main cause is hypothermia. It should be emphasized that in this patient the expansive brain lesion was removed; otherwise the ICP had probably returned to former level after rewarming. The figure also illustrates that a significant effect is obtained only at a temperature below 29 °C. This is in line with the opinion expressed by Gänshirt et al. (1954) on the basis of experimental research and by Lundberg and Nielsen (1959) on the basis of clinical observations that optimal effect of hypothermia is achieved only at rectal temperatures below 30 °C and that a beneficial effect at 30–33 °C is questionable.

In summary, the expectations attached to induced hypothermia as a treatment of intracranial hypertension has not been met. However, at operation of certain brain tumours hypothermia may still be a valuable adjunct to general anaesthesia. The present negative attitude to treating severe head injuries with long term hypothermia is obviously well-founded. However, it is mostly based on reports from the fifties and early sixties. In a recent publication Shapiro et al. (1974) reported that a sustained reduction of VFP for up to 5 days could be obtained by combining intravenous administration of pentobarbital and hypothermia

(30 °C) without untoward side effects. As proposed by Langfitt (1973) a reevaluation of hypothermia seems to be justified.

### 6. *Hyperbaric Oxygen*

Hyperbaric oxygen has been shown to decrease ICP in experimentally produced intracranial hypertension in dogs (Miller et al. 1970, Miller and Ledingham 1971). Previous animal experiments indicate that this effect is due to constriction of cerebral resistance vessels as in hypocapnia (Jacobson et al. 1964). Elevation of PO<sub>2</sub> to levels above 1000 mm Hg was found to reduce increased ICP by about 30 per cent. This effect, however, was less than the effect of hyperventilation to an arterial PCO<sub>2</sub> of 19 mm Hg. In a study on patients, Hayakawa et al. (1971) found considerable variation in the response of ICP to hyperbaric oxygen.

The treatment of patients with hyperbaric oxygen is a complicated procedure and the necessary equipment is very expensive. In spite of certain obvious merits, for the present this treatment is not established as a routine aid in neurosurgical intensive care.

## V. Concluding Remarks

Experimental and clinical research during the last decades has evidenced to an ever increasing extent the intimate relationships between ICP and intracranial dynamics, and brain metabolism. The introduction of quantitative methods for measuring ICP and CBF and of sophisticated physiological techniques for studying CSF circulation and fluxes of water within the brain tissue have elucidated the interrelationships between parameters involved and have made it possible to form a conception of what happens inside the cranial cavity when ICP is pathologically increased. It has been one aim of this work to emphasize and illustrate that current knowledge of intracranial dynamics and the pathophysiology of ICP is essential for adequate management of patients with intracranial hypertension.

Another aim has been to elucidate the importance of monitoring ICP in patients with suspected or manifest intracranial hypertension. Adequate methods are now available and the advantage of basing therapeutic measures on quantitative data are obvious. Indications for various forms of therapy will gain in accuracy. The effects of treatment can be promptly assessed, providing guidelines for further treatment. Unnecessary treatment can be avoided in patients whose symptoms are not caused by intracranial hypertension, or patients in whom the treatment does not influence ICP.

Today a number of therapeutic aids are available to the neurosurgeon for the treatment of intracranial hypertension. Since these aids are different with respect to mode of action and effect in various kinds of intracranial hypertension, they all have their individual fields of application. On the other hand, an improved effect may be obtained by combining different treatments, e.g. controlled drainage of CSF with hyperventilation and corticosteroids. There are still many unsolved problems pertaining to the action of pressure reducing measures. Further systematic investigations based on continuous recording of ICP are needed.

Although non-operative management of patients with intracranial hypertension is a highly demanding task, it is part of the neurosurgeon's everyday work.

It necessitates a solid theoretical background and the facilities of the neurosurgical department. Hence it is a task for neurosurgeons and neuroanaesthesiologists and should not be left to outsiders.

### References

- Adams, R. W., Gronert, G. A., Sundt, T. M., and Michenfelder, J. D., 1972: Halothane, hypocapnia and cerebrospinal fluid pressure in neurosurgery. In: *Intracranial Pressure*, M. Brock and H. Dietz (Eds.), pp. 320—325. Berlin-Heidelberg-New York: Springer.
- Alexander, S. C., Cohen, P. J., Wollman, H., Smith, T. C., Reivich, M., and van der Molen, R. A., 1965: Cerebral carbohydrate metabolism during hypocarbia in man. *Anesthesiology* 26, 624—632.
- Ames, A. III, Wright, R. L., Kowada, M., Thurston, J. M., and Majno, G., 1968: Cerebral ischaemia. II. The no-reflow phenomenon. *Amer. J. Path.* 52, 437—454.
- Antoni, N., 1946: Pressure curves from the cerebrospinal fluid. *Acta med. scand.*, suppl. 170, pp. 439—462.
- Becker, D. P., and Vries, J. K., 1972: The alleviation of increased intracranial pressure by the chronic administration of osmotic agents. In: *Intracranial Pressure*, M. Brock and H. Dietz (Eds.), pp. 309—315. Berlin-Heidelberg-New York: Springer.
- Behring, E. A., Jr., 1951: A simplified apparatus for constant ventricular drainage. *J. Neurosurg.* 8, 450—452.
- and Avman, N., 1960: The use of hypertonic urea solutions in hypothermia. *J. Neurosurg.* 17, 1073—1082.
- Taren, J. A., McMurrey, J. D., and Bernard, W. F., 1956: Studies on hypothermia in monkeys. II. The effect of hypothermia on the general physiology and cerebral metabolism of monkeys in the hypothermic state. *Surg. Gynec. Obstet.* 102, 134—138.
- Berman, I. R., and Ducker, T. B., 1969: Pulmonary, somatic and splanchnic circulatory responses to increased intracranial pressure. *Ann. Surg.* 169, 210—216.
- Bigelow, W. G., Lindsay, W. K., Harrison, R. C., Gordon, R. A., and Greenwood, W. F., 1950: Oxygen transport and utilization in dogs at low body temperatures. *Amer. J. Physiol.* 160, 125—137.
- Bloch, M., 1967: Cerebral effects of rewarming following prolonged hypothermia: significance for the management of severe cranio-cerebral injury and acute pyrexia. *Brain* 90, 769—783.
- Boerema, I., Wildschut, A., Schmidt, W. J. H., and Broekhuysen, L., 1951: Experimental researches into hypothermia as an aid in the surgery of the heart. Preliminary communication. *Arch. chir. neerl.* 3, 25—34.
- Botterell, E. H., Lougheed, W. M., Scott, J. W., and Vandewater, S. L., 1956: Hypothermia, and interruption of carotid, or carotid and vertebral circulation, in the surgical management of intracranial aneurysms. *J. Neurosurg.* 13, 1—42.
- Bouzarth, W. F., and Madow, L., 1966: A technique for immediate hypothermia and arteriography after cranial trauma. *J. Trauma* 6, 56—60.
- Bozza-Marrubini, M., Rossanda, M., and Tretola, L., 1964: The role of artificial hyperventilation in the control of brain tension during neurosurgical operations. *Brit. J. Anaesth.* 36, 415.
- Brock, M., and Dietz, H., 1972: *Intracranial pressure*. Berlin-Heidelberg-New York: Springer.
- Brown, F. K., 1956: Cardiovascular effects of acutely raised intracranial pressure. *Amer. J. Physiol.* 185, 510—514.
- Bruce, D. A., Langfitt, T. W., Miller, J. D., Schutz, H., Vapalahti, M. P., Stanek, A., Goldberg, H. I., 1973: Regional cerebral blood flow, intracranial pressure, and brain metabolism in comatose patients. *J. Neurosurg.* 38, 131—144.
- Buckell, M., 1964: Blood changes on intravenous administration of mannitol or urea for reduction of intracranial pressure in neurosurgical patients. *Clin. Sci.* 27, 223—227.

- Cantore, G. P., Guidetti, B., and Virno, M., 1964: Oral glycerol for the reduction of intracranial pressure. *J. Neurosurg.* 21, 278—283.
- Connor, R. C. R., 1968: Heart damage associated with intracranial lesions. *Brit. Med. J.* 3, 29—31.
- Cooper, R., and Hulme, A., 1966: Intracranial pressure and related phenomena during sleep. *J. Neurol. Neurosurg. Psychiat.* 29, 564—570.
- Cushing, H., 1902: Some experimental and clinical observations concerning states of increased intracranial tension. *Amer. J. med. Sci.* 124, 375—400.
- Cutler, R. W. P., Page, L., Galicich, J., and Watters, G. V., 1968: Formation and absorption of cerebrospinal fluid in man. *Brain* 91, 707—720.
- Dandy, W. E., and Blackfan, K. D., 1914: Internal hydrocephalus. An experimental clinical and pathological study. *Amer. J. Dis. Child.* 8, 406—482.
- Davson, H., 1967: Physiology of the cerebrospinal fluid. London: J. and A. Churchill.
- Hollingsworth, G., and Segal, M. B., 1970: The mechanism of drainage of the cerebrospinal fluid. *Brain* 93, 665—678.
- Ducker, T. B., 1968: Increased intracranial pressure and pulmonary edema. Part I: Clinical study of 11 patients. *J. Neurosurg.* 28, 112—117.
- Evans, J. P., Espey, F. F., Kristoff, F. V., Kimbell, F. D., and Ryder, H. W., 1951: Experimental and clinical observations on rising intracranial pressure. *Arch. Surg.* 63, 107—114.
- Fitch, W., and McDowall, D. G., 1971: Effect of halothane on intracranial pressure gradients in the presence of intracranial space-occupying lesions. *Brit. J. Anaesth.* 43, 904—912.
- Fog, M., 1933: Influence of intracranial hypertension upon the cerebral circulation. *Acta psychiat. scand.* 8, 191—198.
- Freeman, N. E., and Jeffers, W. A., 1939—1940: Effects of progressive sympathectomy on hypertension produced by increased intracranial pressure. *Amer. J. Physiol.* 128, 662—671.
- French, L. A., and Galicich, J. H., 1964: The use of steroids for control of cerebral edema. *Clin. Neurosurg.* 10, 212—223.
- Galicich, J. H., and French, L. A., 1961: Use of dexamethasone in the treatment of cerebral edema resulting from brain tumours and brain surgery. *Amer. Practit.* 12, 169—174.
- Galle, P., and Staudacher, M., 1968: Einfluß entwässernder Medikamente auf den Liquordruck beim Schädelhirntrauma. *Med. klin.* 63, 16—20.
- Gänshirt, H., Hirsch, H., Krenkel, W., Schneider, M., and Zylka, W., 1954: Über den Einfluß der Temperatursenkung auf die Erholungsfähigkeit des Warmblütergehirns. *Arch. exp. Path. Pharmak.* 222, 431—449.
- Goluboff, B., Shenkin, H. A., Haft, H., 1964: The effects of mannitol and urea on cerebral hemodynamics and cerebrospinal fluid pressure. *Neurology* 14, 891—898.
- Gordon, E., 1971: Controlled respiration in the management of patients with traumatic brain injuries. *Acta anaesth. scand.* 15, 193—208.
- Granholt, L., Lukjanova, L., and Siesjö, B. K., 1969: The effect of marked hyper-ventilation upon tissue levels of NADH, lactate, pyruvate, phosphocreatine, and adenosine phosphates of rat brain. *Acta physiol. scand.* 77, 179—190.
- Greenfield, J. C., and Tindall, G. T., 1965: Effect of acute increase in intracranial pressure on blood flow in the internal carotid artery of man. *J. clin. Invest.* 44, 1343—1351.
- Grote, W., und Wüllenweber, R., 1960: Über „Liquordruckkrisen“ — spontane Druckschwankungen bei intracraniellen Liquorpassagestörungen. *Acta neurochir.* 9, 125—138.
- Guttman, L., 1936: Physiologie und Pathologie der Liquormechanik und Liquordynamik. In: *Handbuch der Neurologie*, O. Bumke und O. Foerster (Eds.), pp. 1—107. Berlin: Springer.



- Hawkins, W. E., and Clower, B. R., 1971: Myocardial damage after head trauma and simulated intracranial haemorrhage in mice: the role of the autonomic nervous system. *Cardiovasc. Res.* 5, 524—529.
- Hayakawa, T., Kanai, N., Kuroda, R., Yamada, R., and Mogami, H., 1971: Response of cerebrospinal fluid pressure to hyperbaric oxygenation. *J. Neurol. Neurosurg. Psychiat.* 34, 580—586.
- Hedges, T. R., Weinstein, J. D., Kassell, N. F., and Stein, S., 1964: Cerebrovascular responses to increased intracranial pressure. *J. Neurosurg.* 21, 292—297.
- Hekmatpanah, J., 1970: Cerebral circulation and perfusion in experimental increased intracranial pressure. *J. Neurosurg.* 32, 21—29.
- Henriksen, H. T., and Jørgensen, P. B., 1973: The effect of nitrous oxide on intracranial pressure in patients with intracranial disorders. *Brit. J. Anaesth.* 45, 486—492.
- Hodgson, J. S., 1928: Combined ventricular and lumbar puncture in diagnosis of brain tumour; further studies. *J. Amer. med. Ass.* 90, 1524—1525.
- Hoff, H. E., and Breckenridge, C. G., 1954: Intrinsic mechanisms in periodic breathing. *Arch. Neurol. and Psychiat.* 72, 11—42.
- Ingraham, F. C., and Campbell, J. B., 1941: An apparatus for closed drainage of the ventricular system. *Ann. Surg.* 114, 1096—1098.
- Ingvar, D. H., and Lundberg, N., 1961: Paroxysmal symptoms in intracranial hypertension, studied with ventricular fluid pressure recording and electroencephalography. *Brain* 84, 446—459.
- Jacobson, I., Harper, A. M., and McDowall, D. G., 1964: The effect of oxygen at 1 and 2 atmospheres on the blood flow and oxygen uptake of cerebral cortex. *Surg. Gynec. Obstet.* 119, 737—742.
- Janny, P., 1950: La pression intracranienne chez l'homme. Thèse: Faculté de Médecine, Paris. Reprinted: Clermont-Reproduction, Clermont-Ferrand, 1972.
- Jouan, J. P., Janny, L., Gourgand, M., and Gueit, U. M., 1972a: A statistical approach to long-term monitoring of intracranial pressure. In: *Intracranial Pressure*, M. Brock and H. Dietz (Eds.), pp. 59—64. Berlin-Heidelberg-New York: Springer.
- Lapalus, J., Chabannes, J., et Montrieul, B., 1972b: Étude comparative clinique et manométrique des solutions hypertoniques et des corticoïdes dans le traitement de l'hypertension intra-cranienne. *Neurochirurgie* 18, 121—136.
- Javid, M., and Settlage, P., 1956: Effect of urea on cerebrospinal fluid pressure in human subjects. Preliminary report. *J. Amer. med. Ass.* 160, 943—949.
- — 1957: Clinical use of urea for reduction of intracranial pressure. *Trans. Amer. neurol. Ass.* 151—153.
- and Anderson, J., 1958: Observations on the use of urea in rhesus monkeys. *Surg. Forum* 9, 686—690.
- Jefferson, G., and Johnson, R. T., 1950: The cause of loss of consciousness in posterior fossa compressions. *Folia psychiat. neerl.* 53, 306—319.
- Jennett, W. B., and Johnston, I. H., 1972: The uses of intracranial pressure monitoring in clinical management. In: *Intracranial Pressure*, M. Brock and H. Dietz (Eds.), pp. 353—356. Berlin-Heidelberg-New York: Springer.
- Jeppson, P. G., and Nielsen, K., 1955: The effect of hypothermia on lesions of the blood-brain barrier produced by Umbradil. In: *Proc. 2nd int. Congr. Neuropath.*, London 1955, pp. 411—413. Amsterdam: Excerpta Medica Foundation.
- Johnson, R. H., 1972: Cerebrospinal fluid. In: *Scientific Foundations of Neurology*. M. Critchley, J. L. O'Leary and B. Jennett (Eds.), pp. 281—288. London: William Heinemann Medical Books.
- Johnston, I. H., Paterson, A., Harper, A. M., and Jennett, W. B., 1972: The effect of mannitol on intracranial pressure and cerebral blood flow. In: *Intracranial Pressure*, M. Brock and H. Dietz (Eds.), pp. 176—180. Berlin-Heidelberg-New York: Springer.

- Key, A., und Retzius, G., 1875: Anatomie des Nervensystems und des Bindegewebes, Vol. I. Stockholm: P. A. Nordstedt and Söner.
- Kjällquist, Å., Lundberg, N., and Pontén, U., 1964: Respiratory and cardiovascular changes during rapid spontaneous variations of ventricular fluid pressure in patients with intracranial hypertension. *Acta neurol. scand.* 40, 291—317.
- Klatzo, I., 1972: Pathophysiological aspects of brain edema. In: *Steroids and Brain Edema*, H. J. Reulen and K. Schürmann (Eds.), pp. 1—7. Berlin-Heidelberg-New York: Springer.
- Wisniewski, H., Steinwall, O., and Streicher, E., 1967: Dynamics of cold injury edema. In: *Brain Edema*, I. Klatzo and F. Seitelberger (Eds.), pp. 554—563. Berlin-Heidelberg-New York: Springer.
- Kofman, S., Garvin, J. S., and Nagamani, D., 1957: Treatment of cerebral metastases from breast carcinoma with prednisolone. *J. Amer. med. Ass.* 163, 1473—1476.
- Kullberg, G., 1972: A method for statistical analysis of intracranial pressure recordings. In: *Intracranial Pressure*, M. Brock and H. Dietz (Eds.), pp. 65—69. Berlin-Heidelberg-New York: Springer.
- and West, K. A., 1965: Influence of corticosteroids on the ventricular fluid pressure. *Acta neurol. scand.* 41, Suppl. 13/II, 445—452.
- and Sundbärg, G., 1970: A method for the automatic statistical analysis of intracranial pressure recordings. *Proceedings of Scand. Neurosurg. Soc. 22nd Ann. Meeting, Stockholm, 1970.* *Acta neurol. scand.* 46, 631.
- Kusske, J. A., Turner, P. T., Ojemann, G. A., and Harris, A. B., 1973: Ventriculostomy for the treatment of acute hydrocephalus following subarachnoid hemorrhage. *J. Neurosurg.* 38, 591—595.
- Laborit, H., et Huguenard, P., 1951: L'hibernation artificielle par moyens pharmacodynamiques et physiques. *Presse méd.* 59, 1329.
- Langfitt, T. W., 1973: Increased intracranial pressure. In: *Neurological Surgery*, Vol. I, J. R. Youmans (Ed.), pp. 443—495. Philadelphia-London-Toronto: W. B. Saunders Company.
- Weinstein, J. D., Kassel, N. F., and Simeone, F. A., 1964: Transmission of increased intracranial pressure. I. Within the craniospinal axis. *J. Neurosurg.* 21, 989—997.
- — 1965: Cerebral vasomotor paralysis produced by intracranial hypertension. *Neurology (Minneapolis)* 15, 622—641.
- — 1966: Vascular factors in head injury. In: *Head Injury, Conference Proceedings*, W. F. Caveness, and A. E. Walker (Eds.), pp. 172—194. Philadelphia-Toronto: J. B. Lippincott Company.
- — and Jackson, J. L. F., 1967: Contributions of trauma, anoxia, and arterial hypertension to experimental acute brain swelling. *Trans. Amer. Neurol. Ass.* 92, 257—259.
- Lassen, N. A., 1964: Autoregulation of cerebral blood flow. *Circulat. Res.* Vols. 14 and 15, 1: 201—204.
- 1966: The luxury-perfusion syndrome and its possible relation to acute metabolic acidosis localized within the brain. *Lancet* 2, 1113.
- Lazorthes, G., and Campan, L., 1958: Hypothermia in the treatment of craniocerebral traumatism. *J. Neurosurg.* 15, 162—167.
- Löfgren, J., 1973: Pressure-volume relationships of the cerebrospinal fluid system. An experimental analysis in dogs. Thesis. Göteborg: Elanders Boktryckeri AB.
- Lorenzo, A. V., Page, L. K., and Watters, G. V., 1970: Relationship between cerebrospinal fluid formation, absorption and pressure in human hydrocephalus. *Brain* 93, 679—692.
- Lundberg, N., 1960: Continuous recording and control of ventricular fluid pressure in neurosurgical practice. *Acta psychiat. scand.* 36, Suppl. 149.
- 1969: Results of total and subtotal removal of acoustic neuromas. In: *Disorders of the skull base region. Nobel Symposium 10*, C.-A. Hamberger, and J. Wersäll (Eds.), pp. 113—119. Stockholm: Almqvist and Wiksell.

- Lundberg, N., 1972: Monitoring of the intracranial pressure. In: Scientific foundations of neurology, M. Critchley, J. L. O'Leary, and B. Jennett (Eds.), pp. 356—371. London: William Heinemann Medical Books Ltd.
- Nielsen, K. C., and Nilsson, E., 1956: Deep hypothermia in intracranial surgery. *J. Neurosurg.* 13, 235—247.
- Kjällquist, Å., and Bien, C., 1959: Reduction of increased intracranial pressure by hyperventilation. A therapeutic aid in neurological surgery. *Acta psychiat. scand.* 34, Suppl. 139.
- and Nielsen, K. C., 1959: Hypothermia in the treatment of cerebral tumours. In: First international congress of neurological surgery, Brussels 1957, pp. 52—60. London: Pergamon Press.
- and Pontén, U., 1963: Some observations on postoperative ventricular fluid pressure. *Acta neurol. scand.* 39, 264—265.
- Troupp, H., and Lorin, H., 1965: Continuous recording of the ventricular-fluid pressure in patients with severe acute traumatic brain injury: a preliminary report. *J. Neurosurg.* 22, 581—590.
- and West, K. A., 1965: Leakage as a source of error in measurement of the cerebrospinal fluid pressure by lumbar puncture. *Acta neurol. scand.* 41, Suppl. 13, 115—121.
- Cronqvist, S., and Kjällquist, Å., 1968: Clinical investigations on interrelations between intracranial pressure and intracranial hemodynamics. In: Cerebral circulation. Progress in brain research, Vol. 30, W. Luyendijk (Ed.), pp. 70—75. Amsterdam: Elsevier.
- McDowall, D. G., Barker, J., and Jennett, W. B., 1966: Cerebrospinal fluid pressure measurements during anaesthesia. *Anaesthesia* 21, 189—201.
- and Wüllenweber, R., 1972: Comments to session 9. In: Intracranial Pressure, M. Brock and H. Dietz (Eds.), pp. 326—327. Berlin-Heidelberg-New York: Springer.
- Marshall, W. J. S., Jackson, J. L. F., and Langfitt, T. W., 1969: Brain swelling caused by trauma and arterial hypertension. *Arch. Neurol. (Chic.)* 21, 545—553.
- Martins, A. N., Wiley, J. K., and Myers, P. W., 1972: Dynamics of the cerebrospinal fluid and the spinal dura mater. *J. Neurol. Neurosurg. Psychiat.* 35, 468—473.
- Marx, G. F., Andrews, C., and Orkin, L. R., 1962: Cerebrospinal fluid pressure during halothane anaesthesia. *Canad. Anaesth. Soc. J.* 9, 239—245.
- Mason, M. S., and Raaf, J., 1961: Physiological alterations and clinical effects of urea-induced diuresis. *J. Neurosurg.* 18, 645—653.
- Maxwell, R. E., Long, D. M., and French, L. A., 1972: The clinical effects of a synthetic gluco-corticoid used for brain edema in the practice of neurosurgery. In: Steroids and brain edema, H. J. Reulen and K. Schürmann (Eds.), pp. 219—232. Berlin-Heidelberg-New York: Springer.
- Meyer, J. S., and Hunter, J., 1957: Effects of hypothermia on local blood flow and metabolism during cerebral ischemia and hypoxia. *J. Neurosurg.* 14, 210—227.
- Miller, J. D., Ledingham, I. McA., and Jennett, W. B., 1970: Effects of hyperbaric oxygen on intracranial pressure and cerebral blood flow in experimental cerebral oedema. *J. Neurol. Neurosurg. Psychiat.* 33, 745—755.
- and Ledingham, I. McA., 1971: Reduction of increased intracranial pressure. Comparison between hyperbaric oxygen and hyperventilation. *Arch. Neurol. (Chic.)* 24, 210—216.
- and Garibi, J., 1972: Intracranial volume/pressure relationships during continuous monitoring of ventricular fluid pressure. In: Intracranial Pressure, M. Brock and H. Dietz (Eds.), pp. 270—274. Berlin-Heidelberg-New York: Springer.
- Nielsen, K. C., Nordström, L., and Silfvenius, H., 1962: Hypothermia with air cooling in neurosurgical operations under ether anaesthesia. *Acta anaesth. scand. Suppl.* 12, 53—54.
- Noell, W., und Schneider, M., 1944: Über die Durchblutung und die Sauerstoffversorgung des Gehirns. IV. Die Rolle der Kohlensäure. *Pflügers Arch.* 247, 514—527.

- Noell, W., und Schneider, M., 1948: Zur Hämodynamik der Gehirndurchblutung bei Liquordrucksteigerung. *Arch. Psychiat. Nervenkr.* 118—180, 713—730.
- Nornes, H., 1973a: Pressure transducer with disposable measuring head for ventricular fluid pressure monitoring. *Acta neurol. scand.* 49, 252—265.
- 1973b: The role of intracranial pressure in the arrest of hemorrhage in patients with ruptured intracranial aneurysm. *J. Neurosurg.* 39, 226—234.
- and Magnaes, B., 1971: Supratentorial epidural pressure recorded during posterior fossa surgery. *J. Neurosurg.* 35, 541—549.
- North, J. B., and Jennett, S., 1972: Impedance pneumography for the detection of abnormal breathing patterns associated with brain damage. *Lancet* 2, 212—213.
- Olivecrona, H., 1940: Chirurgische Behandlung der Geschwülste. In: *Die Spezielle Chirurgie der Gehirnkrankheiten*, Vol. 3, F. Krause (Ed.), pp. 193—265. Stuttgart: F. Enke.
- Pappius, H. M., and Dayes, L. A., 1965: Hypertonic urea. *Arch. Neurol. (Chic.)* 13, 395—402.
- Paul, R. L., Polanco, O., Turney, S. Z., McAslan, T. C., and Cowley, A., 1972: Intracranial pressure response to alterations in arterial carbon dioxide pressure in patients with head injuries. *J. Neurosurg.* 36, 714—720.
- Plum, F., and Posner, J. B., 1972: *The diagnosis of stupor and coma*. Second edition. Philadelphia: F. A. Davis Company.
- Pontén, U., Kjällquist, Å., Lundberg, N., and Nilsson, L., 1968: Monitoring of the cerebral "perfusion pressure" in patients with intracranial hypertension. A preliminary report. *Proceedings of Scand. Neurosurg. Soc. 20th Ann. Meeting, Uppsala, 1967. Acta neurol. scand.* 44, 251.
- Kågström, E., and Sundbärg, G., 1973: Ventricular fluid drainage after subarachnoid hemorrhage. In: *5th international congress of neurological surgery, Congress series, No. 293*. R. Carrea, S. Ishii, and D. Le Vay (Eds.), p. 49. Amsterdam: Excerpta Medica.
- Pool, J. L., and Potts, D. Y., 1965: *Aneurysms and arteriovenous anomalies of the brain. Diagnosis and treatment*, p. 201. New York: Harper and Row.
- Poppen, J. L., 1943: Ventricular drainage as a valuable procedure in neurosurgery. *Arch. Neurol. Psychiat. (Chic.)* 50, 587—589.
- Prados, M., Strowger, B., and Feindel, W., 1945: Studies on cerebral edema. *Arch. Neurol. Psychiat. (Chic.)* 54, 290—300.
- Ransohoff, J., 1972: The effects of steroids on brain edema in man. In: *Steroids and brain edema*, H. J. Reulen and K. Schürmann (Eds.), pp. 211—217. Berlin-Heidelberg-New York: Springer.
- Reed, D. J., and Woodbury, D. M., 1962a: Effect of hypertonic urea on cerebrospinal fluid pressure and brain volume. *J. Physiol. (Lond.)* 164, 252—264.
- 1962b: Effect of urea and acetazolamide on brain volume and cerebrospinal fluid pressure. *J. Physiol. (Lond.)* 164, 265—273.
- Reivich, M., Dickson, J., Clark, J., Hedden, M., and Lambertsen, C. J., 1968: Role of hypoxia in cerebral circulatory and metabolic changes during hypocarbia in man: studies in hyperbaric milieu. *Scand. J. clin. Lab. Invest. Suppl.* 102, IV: B.
- Reulen, H. J., and Schürmann, K., 1972: *Steroids and brain edema*. Berlin-Heidelberg-New York: Springer.
- Risberg, J., Lundberg, N., and Ingvar, D. H., 1969: Regional cerebral blood volume during acute transient rises of the intracranial pressure (plateau waves). *J. Neurosurg.* 31, 303—310.
- Rosomoff, H. L., 1959: Experimental brain injury during hypothermia. *J. Neurosurg.* 16, 177—187.
- 1962: Distribution of intracranial contents after hypertonic urea. *J. Neurosurg.* 19, 859—864.
- and Holaday, D. A., 1954: Cerebral blood flow and cerebral oxygen consumption during hypothermia. *Amer. J. Physiol.* 179, 85—88.
- Clasen, R. A., Hartstock, R., and Bebin, J., 1965: Brain reaction to experimental injury after hypothermia. *Arch. Neurol. (Chic.)* 13, 337—345.

- Rossanda, M., 1968: Prolonged hyperventilation in treatment of unconscious patients with severe brain injuries. *Scand. J. clin. Lab. Invest. Suppl. 102*, XIII: E.
- di Giugno, G., Corona, S., Bettinazzi, N., and Mangione, G., 1966: Oxygen supply to the brain and respirator treatment in severe comatose states. *Acta anaesth. scand. Suppl. 23*, 766.
- Rowan, J. O., Johnston, I. H., Harper, A. M., and Jennett, W. B., 1972: Perfusion pressure in intracranial hypertension. In: *Intracranial Pressure*, M. Brock and H. Dietz (Eds.), pp. 165—170. Berlin-Heidelberg-New York: Springer.
- Roy, C. S., and Sherrington, C. S., 1890: On the regulation of the blood-supply of the brain. *J. Physiol. 11*, 85—108.
- Ryder, H. W., Espey, F. F., Kimbell, F. D., Penka, E. J., Rosenauer, A., Podolsky, B., and Evans, J. P., 1952: Influence of changes in cerebral blood flow on the cerebrospinal fluid pressure. *Arch. Neurol. Psychiat. 68*, 165—169.
- — — — — 1953: The mechanism of the change in cerebrospinal fluid pressure following an induced change in the volume of the fluid space. *J. Lab. clin. Med. 41*, 428—435.
- Schettini, A., Cook, A. W., and Owre, E. S., 1967: Hyperventilation in craniotomy for brain tumour. *Anesthesiology 28*, 363—371.
- Schoolar, J. C., Barlow, C. F., and Roth, L. J., 1960: The penetration of carbon-14 urea into cerebrospinal fluid and various areas of the cat brain. *J. Neuropath. exp. Neurol. 19*, 216—227.
- Schutta, H. S., Kassell, N. F., and Langfitt, T. W., 1968: Brain swelling produced by injury and aggravated by arterial hypertension. A light and electron microscopic study. *Brain 91*, 281—294.
- Sedzimir, C. R., 1959: Therapeutic hypothermia in cases of head injury. *J. Neurosurg. 16*, 407—414.
- Shapiro, H. M., Wyte, S. R., Harris, A. B., and Galindo, A., 1972: Disposable system for intraventricular pressure measurement and CSF drainage. Technical note. *J. Neurosurg. 36*, 798—801.
- — and Loeser, J., 1974: Barbiturateaugmented hypothermia for reduction of persistent intracranial hypertension. *J. Neurosurg. 40*, 90—100.
- Shenkin, H. A., Goluboff, B., and Haft, H., 1962: The use of mannitol for the reduction of intracranial pressure in intracranial surgery. *J. Neurosurg. 19*, 897—901.
- Shulman, K., and Rosomoff, H. L., 1959: Effect of hypothermia on mortality in experimental injury to the brain. *Amer. J. Surg. 98*, 704—705.
- Sisson, W. B., and Oldendorf, W. H., 1971: Brain distribution spaces of mannitol-<sup>3</sup>H, inulin-<sup>14</sup>C, dextran-<sup>14</sup>C in the rat. *Amer. J. Physiol. 221*, 214—217.
- Smyth, G. E., and Henderson, W. R., 1938: Observations on the cerebrospinal fluid pressure on simultaneous ventricular and lumbar punctures. *J. Neurol. Psychiat. 1*, 226—237.
- Søndergaard, W., 1961: Intracranial pressure during general anaesthesia. *Dan. med. Bull. 8*, 18.
- Strang, F. A., 1971: Relationship of central respiratory disturbances to sleep and disorders of consciousness. *Proc. roy. Soc. Med. 64*, 484—489.
- Sundbärg, G., Kjällquist, Å., Lundberg, N., and Pontén, U., 1972: Complications due to prolonged ventricular fluid pressure recording in clinical practice. In: *Intracranial Pressure*, M. Brock and H. Dietz (Eds.), pp. 348—352. Berlin-Heidelberg-New York: Springer.
- Symon, L., Dorsch, N. W. C., and Stephens, R. J., 1972: Long term measurement of extradural pressure in "low pressure" hydrocephalus. In: *Intracranial Pressure*, M. Brock and H. Dietz (Eds.), pp. 280—285. Berlin-Heidelberg-New York: Springer.
- Tindall, G. T., McGraw, C. P., Vanderveer, R. W., and Iwata, K., 1972: Cardiorespiratory changes associated with plateau waves in patients with head injury. In: *Intracranial Pressure*, M. Brock and H. Dietz (Eds.), pp. 227—231. Berlin-Heidelberg-New York: Springer.

- Tolksdorf, S., 1959: Laboratory evaluation of anti-inflammatory steroids. *Ann. N.Y. Acad. Sci.* 82, 829—835.
- Tourtellotte, W. W., Reinglass, J. L., and Newkirk, T. A., 1972: Cerebral dehydration action of glycerol. I. Historical aspects with emphasis on the toxicity and intravenous administration. *Clin. Pharmacol. Ther.* 13, 159—171.
- Troupp, H., 1967: Intraventricular pressure in patients with severe brain injuries. *J. Trauma* 7, 875—883.
- Kuurne, T., Kaste, M., Vapalahti, M., and Valtonen, S., 1972: Intraventricular pressure after severe brain injuries: prognostic value and correlation with blood pressure and jugular venous oxygen tension. In: *Intracranial Pressure*, M. Brock and H. Dietz (Eds.), pp. 222—226. Berlin-Heidelberg-New York: Springer.
- Virno, M., Chiavarelli, S., et Cantore, G. P., 1961: Azione del glicerolo sull'edema cerebrale nel coniglio dopo craniectomia. *Gazz. int. Med. Chir.* 66, 3509—3515.
- Weed, L. H., 1914: The pathways of escape from the subarachnoid spaces with particular reference to the arachnoid villi. *J. med. Res.* 31, 51—91.
- 1935: Certain anatomical and physiological aspects of the meninges and cerebrospinal fluid. *Brain* 58, 383—397.
- and McKibben, P. S., 1919: Pressure changes in cerebrospinal fluid following intravenous injection of solutions of various concentrations. *Amer. J. Physiol.* 48, 512—530.
- Welch, K., and Friedman, V., 1960: The cerebrospinal fluid valves. *Brain* 83, 454.
- White, R. J., Dakers, J. G., Yashon, D., and Albin, M. S., 1969: Temporary control of cerebrospinal fluid volume and pressure by means of an externalized valve-drainage system. *J. Neurosurg.* 30, 264—269.
- Wise, B. L., and Chater, N., 1961: Effect of mannitol on cerebrospinal fluid pressure. *Arch. Neurol. (Chic.)* 4, 96—98.
- — 1962: The value of hypertonic mannitol solution in decreasing brain mass and lowering cerebrospinal fluid pressure. *J. Neurosurg.* 19, 1038—1043.
- Wolff, H. G., and Forbes, H. S., 1929: The cerebral circulation. Observations of the pial circulation during changes in intracranial pressure. In: *The intracranial pressure in health and disease*, J. Browder, A. M. Rabiner, and F. A. Mettler (Eds.), pp. 91—103. Baltimore: Williams & Wilkins Company.
- Wright, R. D., 1938: Experimental observations on increased intracranial pressure. *Aust. N. Z. J. Surg.* 7—8, 215—235.
- Wyler, A. R., and Kelly, W. A., 1972: Use of antibiotics with external ventriculostomies. *J. Neurosurg.* 37, 185—187.
- Zwetnow, N. N., 1968: CBF autoregulation to blood pressure and intracranial pressure variations. *Scand. J. clin. Lab. Invest. Suppl.* 102, V: A.
- 1970: Effects of increased cerebrospinal fluid pressure on the blood flow and on the energy metabolism of the brain. Thesis. *Acta physiol. scand. Suppl.* 339. Lund: Studentlitteratur.

# Chronic Adult Hydrocephalus

J. PHILIPPON and D. ANCRI

Neurosurgical Clinic and Department of Nuclear Medicine, Hôpital de la Pitié,  
Paris (France)

With 15 Figures

## Contents

Introduction .....	61
Clinical Signs .....	62
Etiology .....	63
1. Idiopathic .....	64
2. Extraventricular Obstruction, Subarachnoid Haemorrhage, Post-Traumatic Hydrocephalus, Post-Meningitic Hydrocephalus.....	64
3. Focal Brain Lesions .....	65
Pressure Studies .....	65
1. Intracranial Pressure Measurement .....	65
2. Resorption Studies .....	66
Radiological Findings.....	68
Isotopic Studies.....	72
A. CSF Normal Scan .....	72
B. CSF Scanning in Chronic Adult Hydrocephalus .....	73
1. Findings to Date.....	73
2. Quantitative Studies .....	75
3. Personal Series .....	75
C. Result of CSF Scan Applied to Physiopathology of CSF Flow .....	83
Treatment .....	85
Pathophysiology.....	87
References .....	88

## Introduction

During the past ten years, adult hydrocephalus has been the subject of extensive work, mainly due to a better understanding of CSF hydrodynamics. At the same time, the description of neurological disorders associated with hydrocephalus and normal CSF pressure, curable by a CSF shunt, has renewed the interest in therapeutics. The best known of these syndromes is the one

described by Hakim in 1964<sup>28</sup>, and called "normal pressure" hydrocephalus (NPH).

Other terms have also been used such as occult hydrocephalus<sup>2</sup>, hydrocephalus "ex vacuo"<sup>6</sup>, brain distension<sup>26</sup> and low pressure hydrocephalus<sup>69</sup>.

Chronic adult hydrocephalus (C.A.H.) is a more extensive definition, including all the cases where, in the adult, there exists a ventricular dilatation, developing without intracranial hypertension. However, congenital hydrocephalus, with head enlargement, is a completely different problem, which will not be considered here. Nevertheless, possible relations with C.A.H. have been suggested<sup>48</sup>.

The main distinction concerns the problem of hydrocephalus "ex vacuo"; here, ventricular dilatation is the consequence of a primary reduction in brain volume, by atrophic or degenerative process. Therefore the clinical picture, the diagnosis problems and therapeutic are fairly different. We shall see how difficult is the distinction between these types of hydrocephalus, and that problems common to both are frequent.

To summarize, we shall consider, for the most part, chronic ventricular dilatation, non parenchymatous in origin (or CSF in origin). This concerns the syndrome of NPH described by Hakim, but also other quite different clinical aspects, despite certain similitudes in their pathophysiology.

### Clinical Signs

Since the description in 1964 by Hakim<sup>28</sup>, Adams<sup>3</sup> of a syndrome of "normal pressure" hydrocephalus, different reports have insisted on the fact that besides the usual symptomatology, various clinical pictures may be observed<sup>9, 21, 32, 48, 51, 56</sup>.

If one considers each symptom independently, disorders of mental function stand out as the most frequent and constant. Intellectual deterioration is marked by a decrease in psychological activity, a reduction of speech, inattention, and slow conceptualization. Memory disturbances are commonly associated, often affecting short term memory, but also long term. Akinetic mutism has been rarely noted.

Temporo-spatial disorientation, less frequent, is encountered in about 25% of patients. Personality disturbances, with in general a tendency toward a depressive state, are found in about 20%.

The range of mental changes is great, the clinical picture varying from mild intellectual deterioration to complete dementia. Neurological signs are quite frequent, motor abnormalities being the most prominent. In severe cases, walking is slow, uncertain, with a slightly wide base; falls are frequent, with a tendency towards retropulsion. Later, standing and walking are nearly impossible and patients are confined to bed. Neurological examination, however, may show surprisingly little abnormality: increased tendon reflexes, extensor plantar signs, the mark of relatively mild pyramidal disorder, and perhaps increased muscular tone. Limb weakness is frequent.

In some cases, difficulties in turning and dizziness, associated with incoordination, are in favour of a cerebellar dysfunction: incoordination, however rare, is predominant at the lower limbs.



An extra-pyramidal element is possible—facial inexpression, generalized stiffness, difficulty in initiating movement—but the major signs of extrapyramidal disease are generally absent. However, tremor and hypertonus have been observed<sup>3, 29, 51</sup>.

Among other rare neurological signs, nystagmus<sup>3, 32</sup>, oculomotor palsies, grasping and sucking<sup>51</sup> have been noticed. In two of our cases, loss of peripheral vision was also observed, similar to that of the two patients reported by Block<sup>11</sup>.

Finally, about two thirds of the patients are incontinent and this fact constitutes the third major feature of the typical syndrome.

Table 1. *Main Clinical Categories in Chronic Adult Hydrocephalus*

	Hill 1967	Illingworth 1971	Ojemann 1971	Staab 1972	Authors series			
					a	%	b	%
Idiopathic communicating hydrocephalus	5	21	18	95	54	45	4	19
Subarachnoid haemorrhage	5	8	12	18	17	14.2	4	19
Meningitis	2	6	3	8	15	12.5	3	13.5
Traumatism	2		11	23	23	19.2	7	32
Cerebral tumours post-operative		13	5	6	5	4.4	1	4.5
Focal lesions		5	1		6	5	3	13
Miscellaneous		7						
<b>Total</b>	<b>14</b>	<b>60</b>	<b>50</b>	<b>150</b>	<b>120</b>		<b>22</b>	

The authors' series: a = correspond to cases of dementia with ventricular dilatation, b = to typical normal pressure hydrocephalus.

The association of these main neurological symptoms is quite different if one considers the typical picture of normal pressure hydrocephalus, as defined by clinical, isotopic, radiological studies, or isolated ventricular dilatation.

In the series of cases reported by Staab et al.<sup>65</sup>, including all types of hydrocephalus and in particular hydrocephalus "ex vacuo", the association of mental disturbance, motor abnormalities plus incontinence is found in 5 instances (3.3%), dementia plus motor signs in 29 (19%) and isolated dementia in 87 (58%). On the other hand, in the 37 examples of normal pressure hydrocephalus syndrome, studied by Ricou<sup>58</sup>, and including both personal and reported cases, the first association is found 21 times (56%), the second 13 (35%), and pure dementia once. In spite of these reports it is the more generally held neurosurgical view that the major neurological symptoms attributable to hydrocephalus are very similar, whether the picture is truly that of normal pressure hydrocephalus or, e.g., that of slowly progressive hydrocephalus secondary to a posterior fossa tumour.

### Etiology

The etiology of C.A.H. is diverse, and in general, comparable to that of communicating hydrocephalus. Based upon reports to date, it seems logical to distinguish three groups of varying degrees of importance and which may have a correlation with three different mechanisms (Table 1):

idiopathic;

extra-ventricular obstruction of CSF flow, either at the level of basal cisterns, or subarachnoid space of convexity or resorption areas;

focal lesion which may result in either communicating or non-communicating hydrocephalus, or in a combination of both types.

### 1. Idiopathic

The largest group in every series is idiopathic. But the percentage is slightly different if one considers typical normal pressure hydrocephalus, where about one third to 1/4 depends on such origin, and chronic adult hydrocephalus in general (without the main clinical and isotopic features of the normal pressure hydrocephalus, but considered only as ventricular dilatation with perturbation of CSF dynamics) where the percentage is much higher (95 out of 150 cases in Staab's report [63%], 54 out of 120 in our series [45%]).

### 2. Extraventricular Obstruction

#### a) *Subarachnoid Haemorrhage*

In the second group, subarachnoid haemorrhage is one of the main causes. The inflammatory reaction related to the presence of blood in the subarachnoid space is a classic phenomenon, extensively studied during the last twenty years. Clinically, the largest series is the one by Galera and Greitz<sup>22</sup> where ventricular dilatation was found in 34 out of 100 cases.

A study in our department<sup>55</sup> of 91 cases confirms the high frequency of ventricular dilatation following rupture of intracranial aneurysms. In addition to early ventricular dilatation which appears in the first week and has characteristics of acute hydrocephalus with an increase in CSF pressure, 23% of the cases (21 cases) showed delayed signs of hydrocephalus, appearing from two weeks to several months after the initial haemorrhage. The clinical picture is more or less extensive and severe, and can stabilize.

As would be expected, the frequency of hydrocephalus is higher in aneurysms in direct communication with the subarachnoid space, where the bleeding is directly into the cisterns (30% of middle cerebral artery aneurysms, 48% of anterior communicating artery aneurysms, 50% of carotid aneurysms) and is higher when re-bleeding occurs.

Among other factors, arterial spasm and intracerebral haematoma increase the risk of ventricular dilatation, probably by impairing cerebral blood flow and causing secondary ischaemic lesions in periventricular structures. The cerebral circulation time is altered<sup>22</sup> and cerebral blood flow reduced<sup>26 b</sup>.

We have not observed focal signs or seizures directly related to hydrocephalus as cited by Galera<sup>22</sup> which can be controlled by the treatment of hydrocephalus.

#### b) *Post-Traumatic Hydrocephalus*

A second major cause is constituted by post-traumatic hydrocephalus. The underlying mechanism is certainly identical to that of the first group by the presence of blood clots, and associated with focal brain lesions, consisting of contusions or laceration. Diagnosis can be very difficult in patients with severe head injuries, and major neurological signs. It seems to us that, not only in

patients with secondary deterioration, but also in cases showing no progress, it is important to look for ventricular dilatation and then to perform isotopic cisternography. In 47 patients studied by Front et al.<sup>21</sup> suspected of post-traumatic hydrocephalus, 20 showed abnormalities of the CSF flow and or absorption, but only 3 had the typical syndrome of normal pressure hydrocephalus. In the series by Lewin<sup>42</sup> the frequency is higher (12 out of 59). Even with an incomplete clinical picture, it seems advisable to look for abnormalities of the CSF flow.

### *c) Post-Meningitic Hydrocephalus*

Meningitis is the third main etiology. As in subarachnoid haemorrhage, it seems necessary to oppose ventricular dilatation with increase of CSF pressure during the acute phase of the disease and the secondary developing hydrocephalus, which can appear after any kind of meningeal infection.

We have observed such hydrocephalus in tuberculous meningitis (1 case), pneumococcal (1 case), Klebsiella (1 case). Cases have been published with carcinomatous meningitis<sup>36</sup> and chronic listeria meningitis<sup>31</sup>.

Post-operative hydrocephalus is much less frequent, but may occur in supratentorial or subtentorial lesions. Reviewing our series we have found one instance after removal of a parasagittal meningioma, a second after acoustic neurinoma surgery. Post-operative bleeding, low grade infection, and incomplete removal seem to be favorable factors.

Nevertheless, chronic hydrocephalus may occur in the post-operative period even when there are no complications. Stein et al.<sup>66</sup> reported two cases following removal of cerebellar astrocytomas, and the percentage seems to be higher in the group of his patients with total removal. Anomalies of CSF dynamics in post-operative patients have been recently studied by Frigeni et al.<sup>20</sup>.

## 3. Focal Brain Lesions

Focal brain lesions are rarely at the origin of a chronic hydrocephalus. It seems however that some lesions may be responsible: acoustic neurinomas, one in our series, one cited by Adams<sup>2</sup>, pinealoma<sup>51</sup> and even ectasia of the basilar artery<sup>26 c</sup>. The theoretical possibility of chronic, non-communicating hydrocephalus has to be considered; without doubt such a possibility exists, as shown by two cases of aqueduct stenosis, one reported by Ojeman<sup>51</sup>, one in our series, and one in a third ventricle tumour<sup>2</sup>.

## Pressure Studies

### 1. Intracranial Pressure Measurement

CSF pressure in chronic hydrocephalus is normal. The possibility of high CSF pressure, outlined by Foltz<sup>18</sup>, in post-subarachnoid haemorrhage corresponds certainly to the subacute phase of the ventricular dilatation; but in the truly chronic case the average pressure is under 15 mm Hg (180 mm H<sub>2</sub>O). Garretson et al.<sup>23</sup> have opposed two groups of patients, one with average mean pressure between 110–135 mm H<sub>2</sub>O, the second between 160–200, the responses of which to shunting seem different. As others, we have noticed average pressure from

100 mm H<sub>2</sub>O to 180 mm H<sub>2</sub>O, but it does not seem that there is an absolute parallelism between the height of pressure and the therapeutic result.

In every patient, there is a variation of mean pressure during a 24-hour period (Fig. 1). The possibility of temporary high intracranial pressure, as quoted by Symon<sup>67</sup>, seems inconstant. In his series, 9 out of 16 patients showed A waves during sleep, different from those described by Lundberg<sup>45</sup> in that they lasted 10 to 15 minutes and their height was generally below 35 mm Hg.

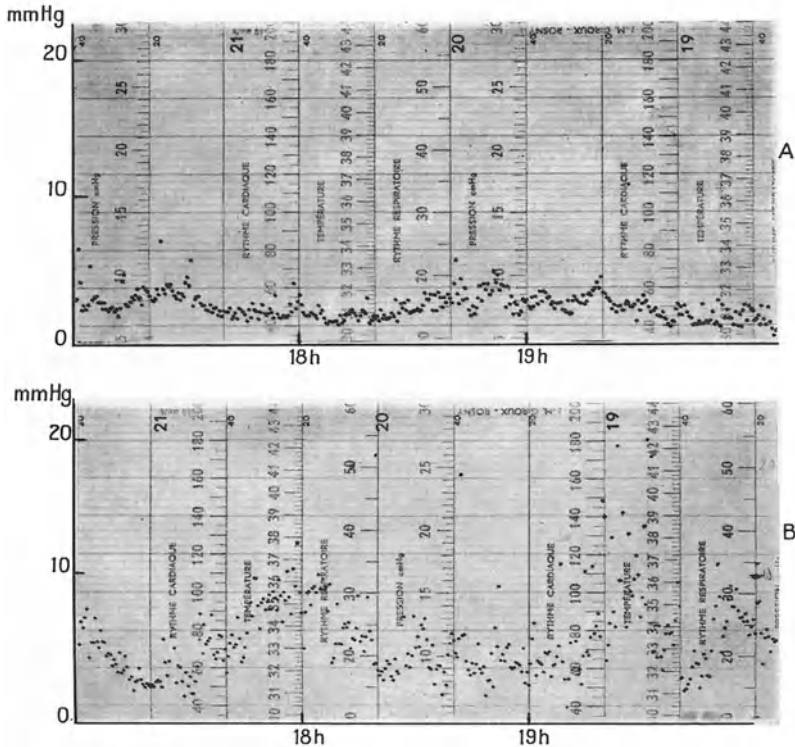


Fig. 1. Mean intraventricular pressure recording in two cases of normal pressure hydrocephalus: A: the pressure level is quite constant, B: variations of pressure but in the normal limit

The continuous recording demonstrates a wave from two mm to three mm high, synchronous with the arterial pulse; this arterial pulse pressure is lower in normal pressure patients compared to those with even moderate intracranial hypertension<sup>66</sup> (Fig. 2).

Pulse pressure seems reduced after shunting, as observed by Garretson<sup>23</sup>. This author has also noticed the presence of C waves in all cases at a frequency of four to eight/min with an amplitude of 5 to 3 mmHg.

## 2. Resorption Studies

Since the main defect in chronic hydrocephalus is a disturbance of CSF absorption and of extraventricular circulation, a test able to detect such deficiency

would appear to be essential. The infusion of artificial CSF or saline in the subarachnoid space at a constant rate produces a slight increase in CSF pressure in a normal subject. In communicating obstructive hydrocephalus, the rise in CSF pressure is higher, and this difference should be a valid means of differentiating between chronic obstructive hydrocephalus and ventricular dilatation without impairment of the CSF dynamics.

Suggested first by Hussey<sup>35</sup>, and Katzman<sup>39</sup>, who studied 14 patients, 13 with normal infusion manometric test had a clinical or histological diagnosis of Alzheimer disease. On the other hand, cases with occult hydrocephalus due to specific factors showed a decrease of the absorption capabilities. It seems therefore reasonable to assume that a surgical shunt could offer little improvement in CSF dynamics in patients in whom there is a normal manometric

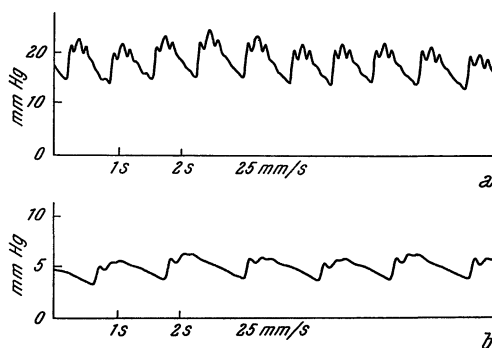


Fig. 2. Continuous intraventricular pressure recording: a: in hydrocephalus with mild intracranial hypertension, b: in normal pressure hydrocephalus

test, that is, in patients who are able to absorb up to three times the normal rate of CSF produced, with an increase of CSF pressure to a value less than 300 mm of water.

For Nelson and Goodman<sup>50</sup>, the important factor is the different *rate* of CSF pressure rise at given infusion rates. They conclude that, with an infusion rate of 1.5 cc/minute, patients with absorptive defects are subject to a rise in CSF pressure greater than 20 mm H<sub>2</sub>O/minute.

But, the correlation between the results of infusion test and other diagnostic tests is far from being constant. In 17 patients of Wolinsky<sup>71</sup> with abnormal pneumoencephalography (ventricular dilatation plus absence of cortical injection), and abnormal cisternography, the infusion test was positive in 4 cases. Then, comparing with the surgical results, the same author observes that the two cases with improvement out of 8 had a normal infusion test.

In a similar correlation Martins<sup>49</sup>, examining patients thought to have some impairment of CSF absorption, found that the infusion test gave a number of false negative results which he thought might be due to leaking of fluid from the subarachnoid space through a hole in the meninges, and a number of false positive tests which he suggested might be due to concomitant increases in CSF pressure, perhaps due to CO<sub>2</sub> retention or to pressure on the abdomen in fat patients.

We have no large experience with the infusion test. Nevertheless our pressure recording during and after pneumoencephalography<sup>57</sup> in chronic hydrocephalic patients and other surgical cases lead us to the impression that a special pattern exists, grossly in correlation with CSF dynamics. In two cases of normal pressure hydrocephalus, we have noted a slight increase of intraventricular pressure at the beginning of the injection, followed by a stationary period, before higher rise at the end of the pneumoencephalography; intraventricular pressure remains

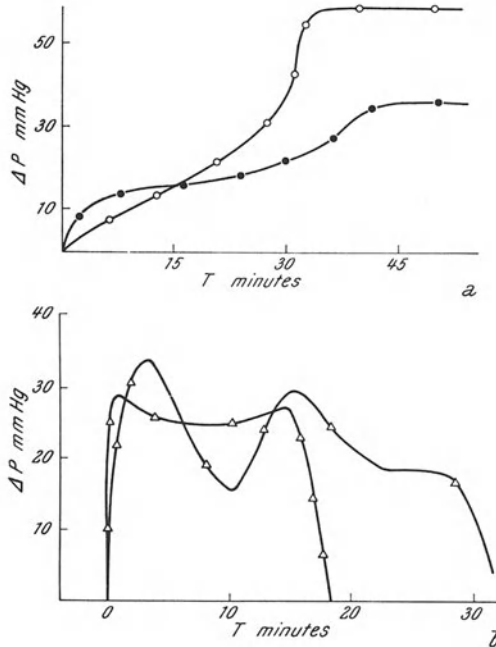


Fig. 3. Variations of mean intraventricular pressure during and after pneumoencephalography: a: in two cases of normal pressure hydrocephalus, note the high increase in pressure after 45 minutes, which persists for 48 hours in one case, 72 hours in the second, b: in two patients with brain stem tumour, the pressure returns to previous level at the end of examination

high for at least 24 hours in our hydrocephalic patients (Fig. 3). These intraventricular pressure modifications seem to be correlated with reduction of CSF absorption in hydrocephalic patients, as studied by Lorenzo<sup>44</sup>.

In conclusion, it is our feeling that infusion techniques are another important means of diagnosis; a pathological infusion test with ventricular dilatation is a good reason to anticipate post surgical improvement. We should be not so certain with a negative test, which seems less reliable, as outlined by Martins<sup>49</sup>.

### Radiological Findings

1. *Skull X-rays* in general afford no specific information and thus cannot be counted upon as a diagnostic device, although in some cases, decalcification of the dorsum sellae may be observed.

2. *Cerebral angiography* is more indicative. The well-known signs of ventricular dilatation are present in all cases, but some more peculiar characteristics help to differentiate the true cases of hydrocephalus from those of atrophy. The pericallosal artery is elevated, straightened, and on the lateral view is seen as a bow shape. The distance between the inner table of the vault and the insula is decreased as pointed out by Le May and New<sup>40</sup> who, on the other hand, insist on the non tortuous aspect of the vessels, as seen in hydrocephalus "ex vacuo".

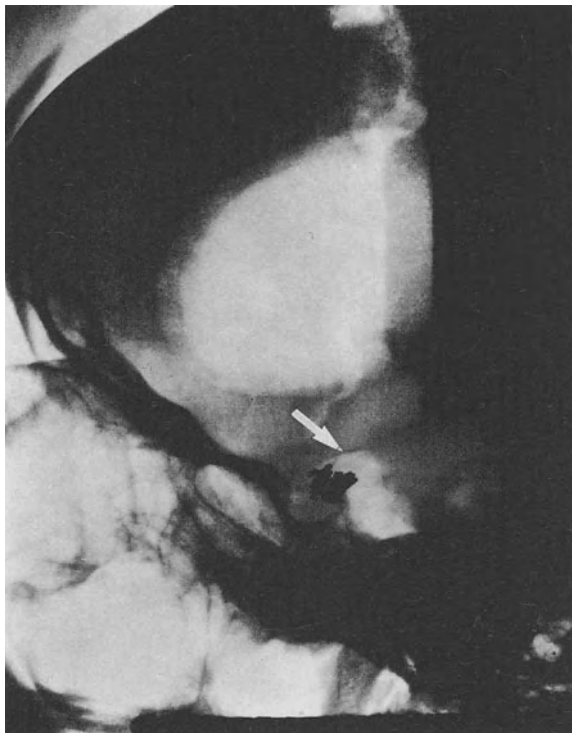

Fig. 4. Pneumoencephalography in chronic hydrocephalus: ventricular dilatation plus cisternal block (arrow) in a patient who has been operated upon six weeks before for an aneurysm of the posterior communicating artery. The black marks correspond to the silver clips placed upon the aneurysm. The white shadow above the ventricle corresponds to the operative bone flap

Angiography is seldom the only contrast study performed (10 cases in our series of normal pressure hydrocephalus, with ventricular filling). The angiographic abnormalities are more valuable when they coincide with typical changes in isotope cisternography. This is especially true when hydrocephalus seems related to a known etiology; in this case, ventricular dilatation seen at angiography is a sufficient indication for CSF shunting. Nevertheless, one must consider the possibility of focal brain lesions, particularly in the posterior fossa.

3. *Pneumoencephalography*. Without doubt, this is the most reliable radiological technique in cases of chronic hydrocephalus.

Ventricular dilatation is generally significant. The whole ventricular system

is affected, including the third and fourth ventricles. Maximal ventricular enlargement occurs in the frontal horns. This is observed in any type of hydrocephalus. More specific is the failure of air to enter the subarachnoid space. The air is obstructed at the level of the basal cisterns, generally at the incisura of the tentorium (Fig. 4).

This evidence of extraventricular obstruction was found in five cases out of 22: a similar degree of frequency is found in Greitz's series (4/23 cases)<sup>27</sup>. Its presence seems to be a positive sign for a postshunting improvement.

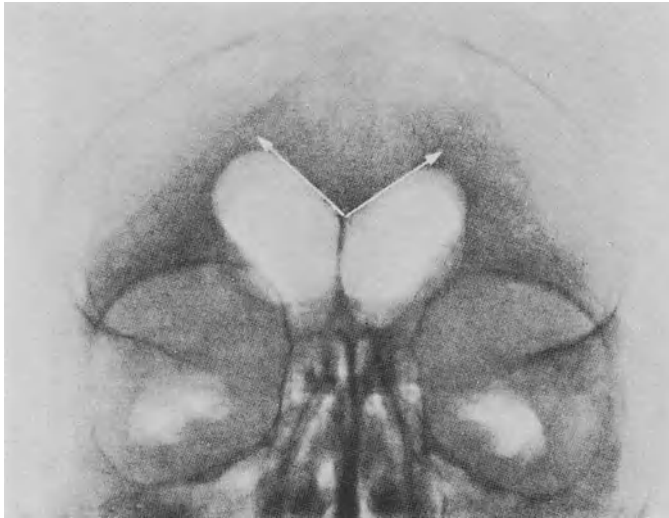

Fig. 5. Determination of the angle formed by the roof of the frontal horns, as described by Le May and New. In this case of normal pressure hydrocephalus, angle is less than  $105^\circ$ . Dilatation of temporal horns

Different authors have described several peculiar features in an attempt to distinguish obstructive hydrocephalus from cerebral atrophy. The angle formed by the roof of the frontal horn of lateral ventricle is normally between  $130^\circ$  and  $140^\circ$ . In hydrocephalus cases, this angle is less than  $120^\circ$ , due to the ascent of the roofs of the ventricle, the corpus callosum being held blocked below the falx cerebri. In atrophy, where there is a passive dilatation, this phenomenon cannot occur<sup>40</sup> (Fig. 5).

The width of the temporal horn<sup>64</sup> increases at a proportionally greater rate than that of the third and lateral ventricles in chronic hydrocephalus. Greitz and Grepe<sup>27</sup> have noted that patients with marked improvement after shunting have all dilated temporal horns, while in patients without improvement, temporal horn dilatation is less marked.

Lerner<sup>41</sup> described a bulging aspect of the anterior part of the roof of the fourth ventricle, which he considers suggestive of hydrocephalus. This sign is inconstant (3 out of 23 cases for Greitz<sup>27</sup>) and may be found in other diseases<sup>40</sup>.

The presence or absence of air in the superficial sulci of the hemispheres merits discussion. Dilated sulci on the convexity are of course in favour of



cerebral atrophy; but, in patients with hydrocephalus, it is possible to see air filling in the sylvian and the subfrontal regions<sup>40</sup>. Large interhemispheric fissures have been found in some of our cases with post-surgical improvement (Fig. 6), as in the series of Greitz<sup>27</sup> in which 12 out of 26 patients with this sign improved. He suggests these hydrocephalic appearances as related to "convexity block hydrocephalus"; the ventricular dilatation compresses brain parenchyma, causing an absence of sulci filling. Obstruction in those cases might be close to the areas of the pacchionian bodies.

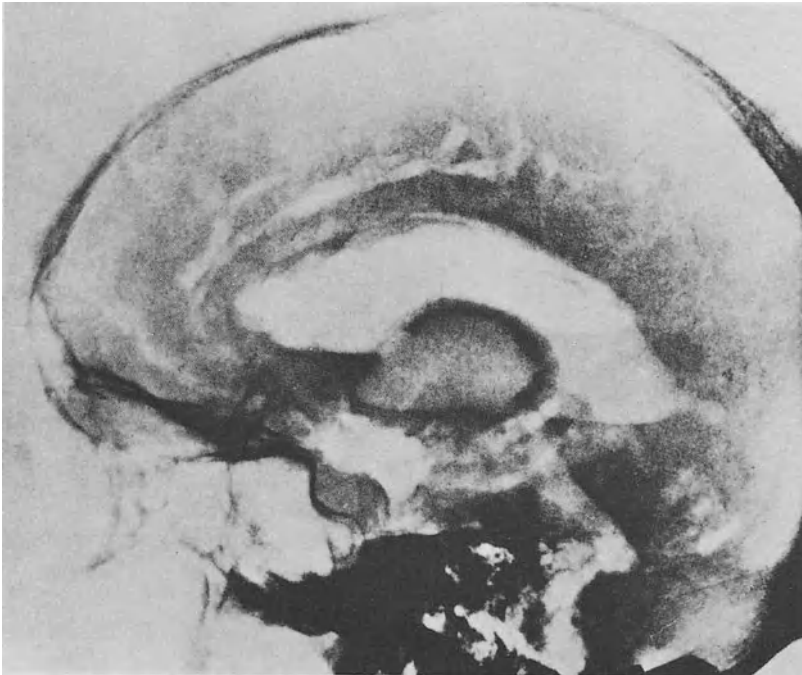

Fig. 6. Pneumoencephalography in a case of normal pressure hydrocephalus. Note the presence of air in the pericallosal cistern. The callosal-marginal and other frontal sulci are visualized

On the other hand, absence of air in the supratentorial subarachnoid space is not absolutely diagnostic of obstructive hydrocephalus. Technically, it can be difficult to produce this filling without injecting large amounts of air, a procedure hazardous for these fragile patients. It is only in the case of an obvious basilar cisternal block that the non-injection of the sulci is of great significance<sup>40</sup>.

An interesting fact has been described by Rovit et al.<sup>59</sup>. In eight patients with normal pressure hydrocephalus, progressive ventricular enlargement has been seen after pneumoencephalography. This ventricular dilatation, progressing for 24 to 72 hours, is certainly related to an excess of CSF, expelled from the ventricle by air and which cannot be resorbed through pathways already pathologic. An alternative hypothesis would be that air within the ventricle is an obstacle to transependymal reabsorption<sup>59</sup>. The recording of intraventricular

pressure during and after pneumoencephalography seems to support the first explanation<sup>57</sup>.

### Isotopic Studies

Several radiopharmaceuticals have been used for CSF gammagraphy. The most commonly used is Iodine 131, labeled with human serum albumin (<sup>131</sup>I-HSA). The dose injected should be limited, in general 100 microcuries.

Technetium 99 m labeled albumin may be injected at higher dose; but the

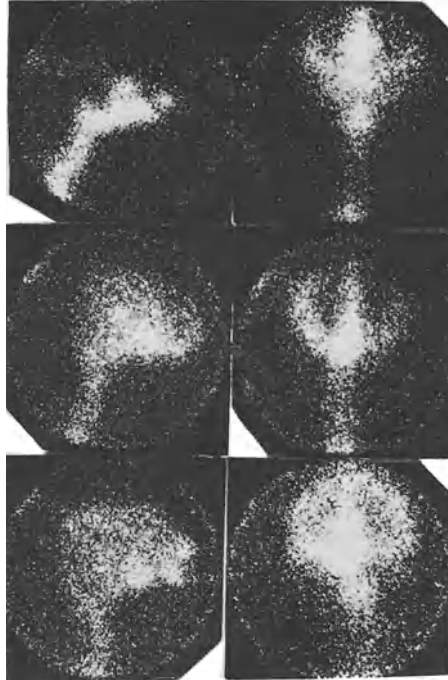


Fig. 7. Normal subarachnoid distribution after lumbar injection of <sup>131</sup>I-HSA (left: lateral view, right: front view). Upper line: between one and two hours note the symmetrical activity in the basal cisterns. Middle line: at six hours, distribution into the sylvian and interhemispheric fissures. Lower line: at 24 hours, activity over the convexity of the hemispheres

short physical half-life reduces this advantage. Recently, ytterbium 169 labeled with diethyltriaminopentacetic acid (<sup>169</sup>yt-DTPA) has been proposed<sup>14</sup>.

#### A. CSF Normal Scan

The normal distribution of radio-tracer injected either into the subarachnoid space or intraventricularly has been extensively documented<sup>4, 5, 7, 8, 15, 16</sup>.

Di Chiro et al.<sup>15-16</sup> have described the spatial and temporal distribution after subarachnoid lumbar injection. The cranial distribution is characteristic. About 30 minutes after injection, activity appears in the cisterna magna; one to two hours later, in the basal cisterns. Six hours later a diffuse activity is noted over the cerebral hemisphere, while at 24 hours, it is predominant in the

parasagittal region (Figs. 7 and 8). The lumbar activity decreases as a function of time.

The main features, plus a downward activity, are observed after suboccipital injection.

In conclusion, four important points are to be noted after subarachnoid space injection:

absence of ventricular filling,

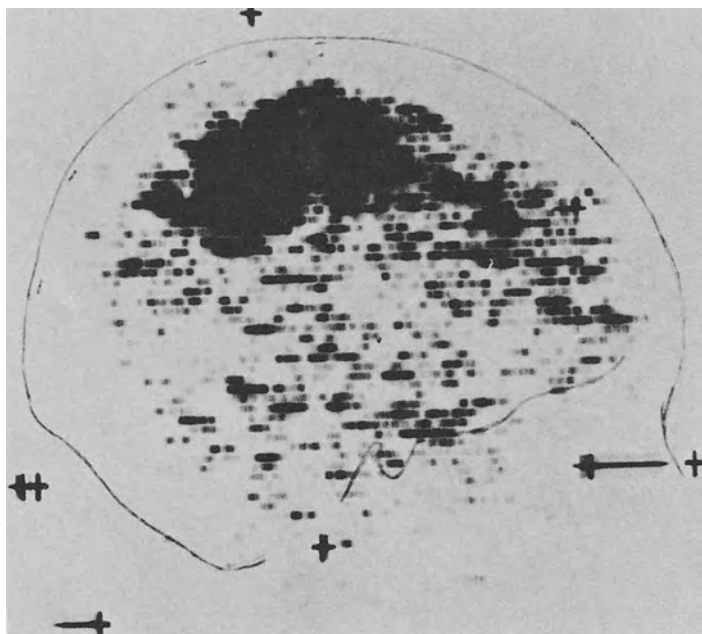


Fig. 8. Gammagraphy at 24 hours: activity is concentrated in the parasagittal areas

activity detectable over all the subarachnoid space, whatever the site of injection,

basal cistern activity after 1 to 2 hours and the parasagittal concentration at 24 hours,

on anteroposterior view, the distribution is symmetrical.

### *B. CSF Scanning in Chronic Adult Hydrocephalus*

#### 1. Findings to Date

Clinical interest in communicating hydrocephalus has stimulated at the same time investigation by CSF scanning<sup>8, 17, 21, 32, 38, 43, 54, 65, 68.</sup>

#### *Morphological Disturbances*

Several pathological abnormalities have been described in CSF circulation, and different classifications proposed. The one by Fleming et al.<sup>17</sup> sets forth four different types of CSF disturbance.


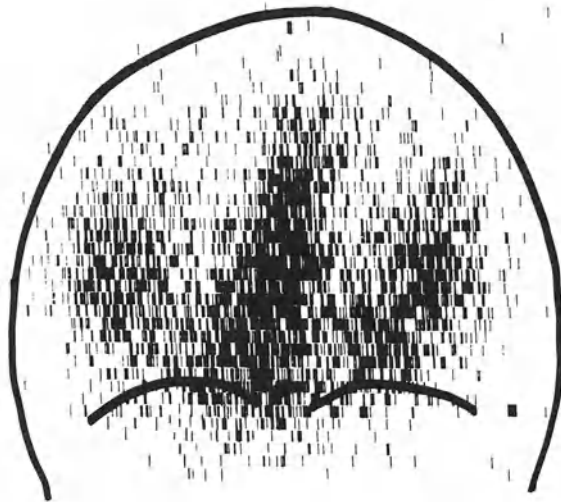


Fig. 9



F.A. 24h

Fig. 10

Figs. 9–10. Lateral and front views of CSF scan, 24 hours after injection of  $^{131}\text{I}$ -HSA in a case of ventricular dilatation with cerebral atrophy. Absence of activity on the parasagittal area

*Group 1*, in which three distributions may be found: normal, transient ventricular filling with secondary subarachnoid activity and concentration in the parasagittal area, or a transient basal slowing-down associated with normal activity in the superior sagittal sinus region.

This group corresponds to normal types because of the usual radioactive concentration in the parasagittal area.

*Group 2*, with ventricular filling. This ventricular retention is either isolated during 48 hours, with a slight clearance or no clearance, or associated with subarachnoid activity which does not reach parasagittal areas.

The major distinguishing factor in this group is ventricular stasis.

*Group 3*, with only basal cisternal activity.

*In group 4*, it is possible to note a subarachnoid activity which is characterized either by localized abnormalities or asymmetrical distribution.

With this classification, Fleming et al., in 39 cases of hydrocephalus "ex vacuo", have observed a distribution of group 1 in 100% of the cases. On the other hand, in 23 cases of chronic hydrocephalus 16 cases (70%) fell into group 2, 3 cases (13%) into group 1, four cases (17%) into group 3.

Staab et al.<sup>65</sup> differentiate transient ventricular filling from normal cases, and distinguish five groups: normal scan, slow flow ventricular filling plus basal block, ventricular filling without basal block, block without ventricular filling.

If these classifications, as others, are very similar, they show at the same time that there is no absolute parallelism between a CSF scan and a definite clinico-pathological picture. For example, Fleming's group 2 or Staab's group 3 and 4 are found not only in normal pressure hydrocephalus, but also in cases of hypertensive communicating hydrocephalus.

On the other hand, distribution of Fleming's group 1 is seen in 3 cases, of group 2, in 4 cases of normal pressure hydrocephalus. This lack of parallelism has been pointed out by several, in particular by Ojemann<sup>52</sup>. Nevertheless, a good probability, if not an absolute correlation, may be found between CSF scan and the type of hydrocephalus.

## 2. Quantitative Studies

Abbot and Alksne<sup>1</sup> have studied values of CSF absorption by determining blood up take of 131 I-HSA after subarachnoid lumbar injection. Lying-Tunnel<sup>46</sup> have measured on serial scintigraphy differences in activity in basal cisterns and parasagittal areas. De Blanc et al.<sup>13</sup> have developed a computer-assisted technique for the quantitative analysis of cisternograms.

Curl et al.<sup>12</sup> proposed a simple method to calculate CSF clearance by determination of the time of occurrence of cranial peak activity and the levels of residual activity at 24 and 48 hours. In normal subjects, maximum activity is found between six and 12 hours after subarachnoid lumbar injection, with a progressive decrease (40 to 80% of peak activity at 24 hours, 25 to 40% at 48 hours). In communicating hydrocephalic patients, peak is not reached until 24 to thirty hours, and clearance is delayed. In patients with hydrocephalus, but with CSF shunts, peak activity is reached within six hours, therefore earlier than the normal subject.

## 3. Personal Series

120 cases of ventricular dilatation have been studied by 131 I-HSA. Blood uptake has been measured in some cases; we distinguish two main groups:

*Group 1*, showing only subarachnoid activity. There are two subdivisions on this group:

1a, with a negligible parasagittal activity at 24 hours (Figs. 9 and 10),

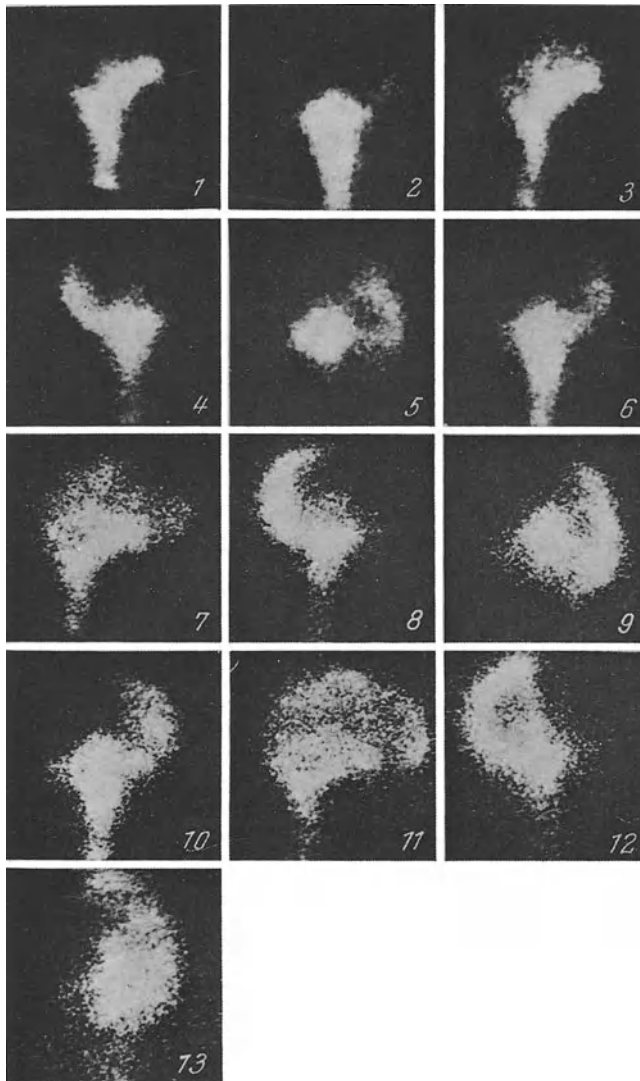


Fig. 11. Example of an asymmetrical subarachnoid distribution. Notice the absence of activity in the left subarachnoid space and slowing down of the parasagittal activity. (1, 2 after one hour, 3, 4 after two hours thirty minutes, 5, 6 after three hours, 7, 8, 9 after seven hours, 10, 11, 12, 13 after twenty four hours.) 4, 9, 13 are vertex views

1 b, with a cisternal block or a major asymmetry (Fig. 11). This constitutes the subarachnoid pathological distribution (SAPD).

*Group 2*, is characterized by ventricular filling (VF). Three subdivisions are also possible.

2a, with an immediate, important, and long lasting ventricular filling. This early filling is noticeable in the first hours, important without any subarachnoid activity and stable because visible at 48 or 72 hours (Fig. 12).

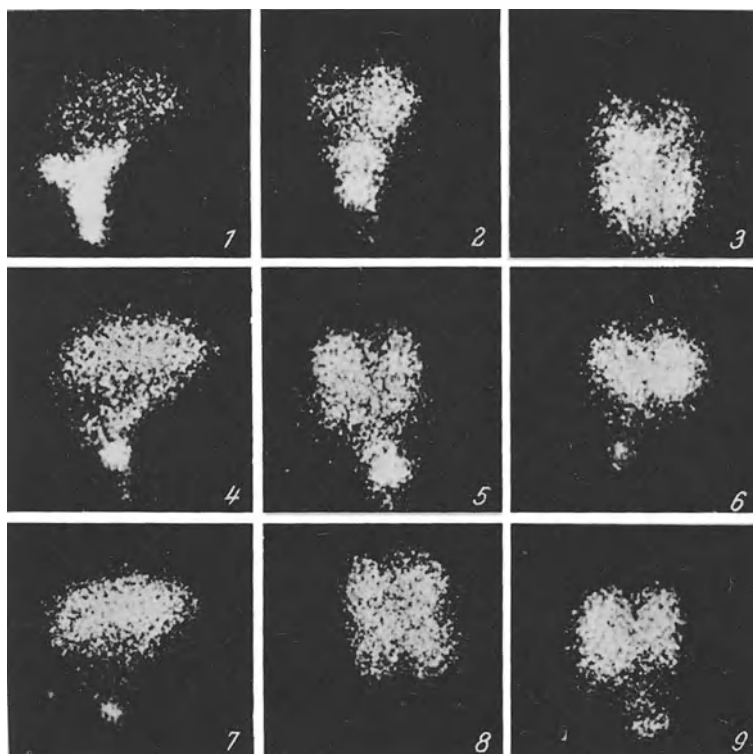


Fig. 12. Permanent ventricular filling after suboccipital injection, immediate (upper line), stable after 24 hours (middle line) and after 48 hours (lower line)

Table 2. Results of CSF Scans in 120 Patients

Type of disturbance	Number of cases	%
Normal distribution	6	5
SAPD	69	57.5
Transient VF	13	10.8
Permanent VF + SAPD	10	8.3
Permanent VF isolated	22	18.4
<i>Total VF</i>	<i>45</i>	<i>37</i>
Total	120	100

2b, where ventricular filling is associated with subarachnoid activity, which is abnormal and similar to the one described above (VF + SAPD) (Fig. 13).

2c, with a transient ventricular filling (TVF) associated with subarachnoid activity progressively increasing, while the ventricular one disappears. But, after 24 or 48 hours, parasagittal concentration is normal and ventricular activity has completely disappeared (Fig. 14).

If one compares these groups with blood uptake, it is noteworthy than in

patients of group 1, maximum blood activity is reached between 20 to 30 hours; on the other hand, in cases with a SAPD or permanent ventricular filling this peak occurs generally later (Fig. 15).

Although we have only a limited number of cases, this fact, close to the observations of Curl et al.<sup>12</sup>, lead us to suppose that the same pathological

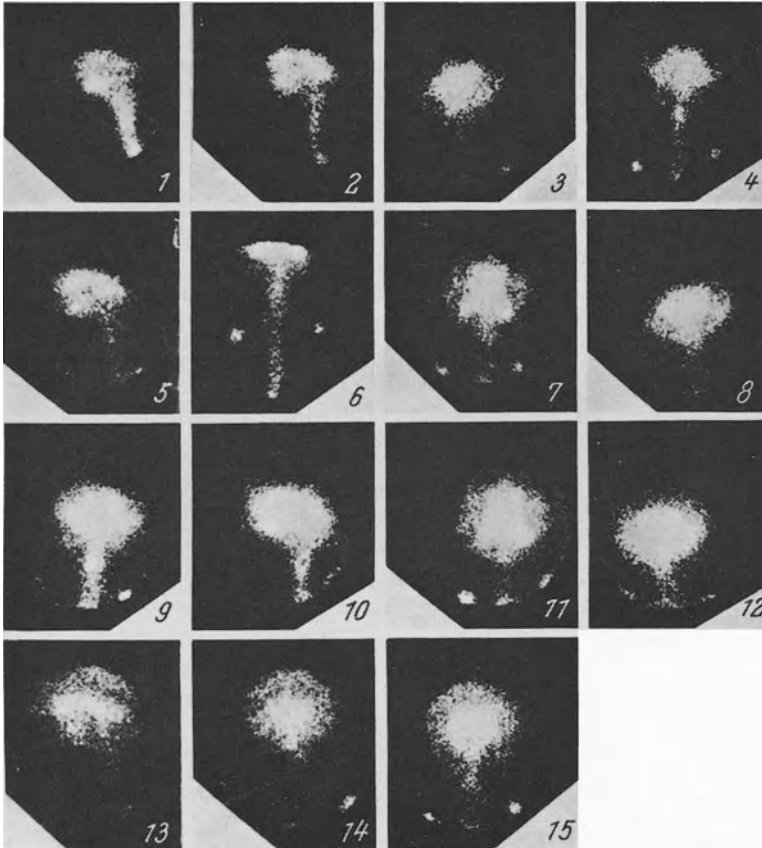


Fig. 13. Ventricular filling plus SAPD. Immediate ventricular filling can be noted (1 to 5), followed by a subarachnoid distribution (6 to 12), but a persistent ventricular activity (13 to 15)

substratum, *i.e.* a slowing of CSF blood exchange, may be observed in these different CSF scans.

a) *The general distribution* of patients in this series (120 cases of dementia plus ventricular dilatation) shows that 57.5% of those patients belong to Group 1, 37.5% to group 2; 5% are normal (Table 2).

b) *CSF scan correlated to etiology* (Table 3). If one opposes idiopathic hydrocephalus (Group B) to the hydrocephalus directly related to a specific cause (Group A), the CSF scan appears slightly different:

In Group A, there is no abnormal scan, 46% of SAPD, 54% of VF. Thus





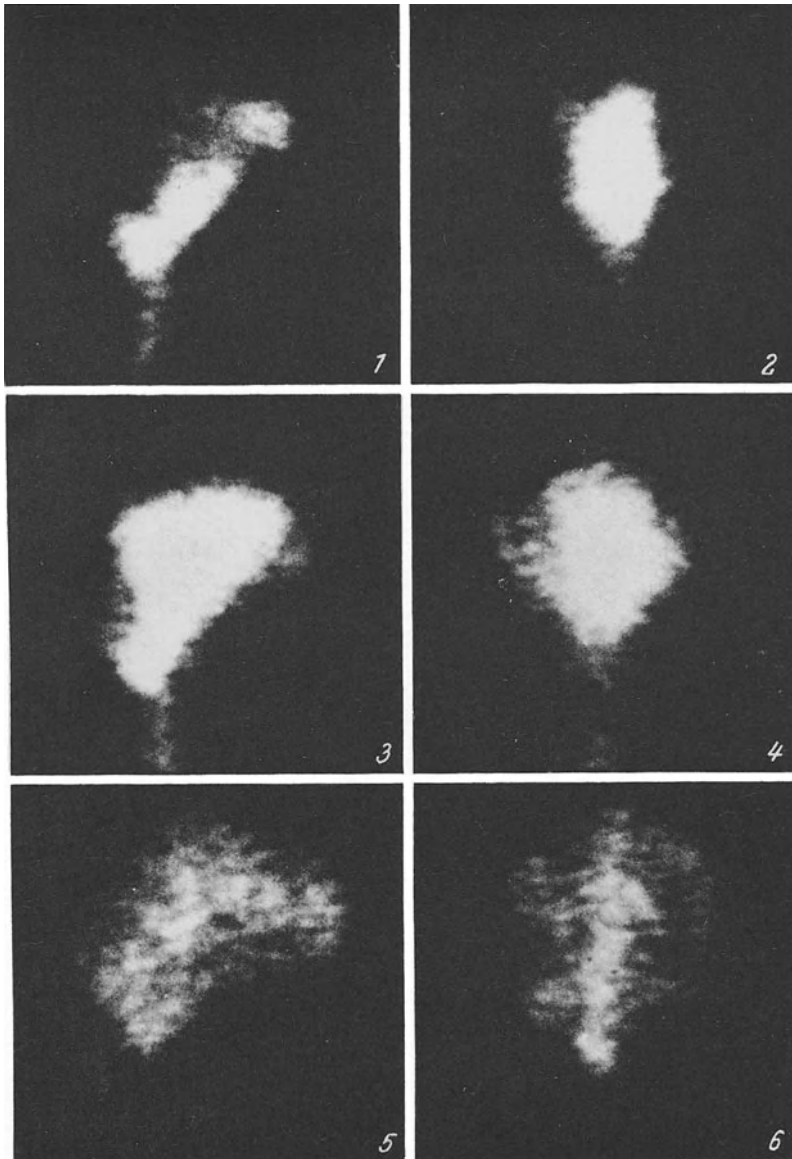


Fig. 14. Example of a transient ventricular filling in a case of cortical atrophy. Upper line: immediate ventricular filling. Middle line: secondary activity in the sylvian fissures. Lower line: important subarachnoid activity while that in the ventricles has disappeared

in the presence of a specific cause, a normal scan may eliminate chronic hydrocephalus.

In Group B, CSF gammagraphy is quite different: in 70% of the cases there is a SAPD, while VF is noted in 18%. It is noteworthy that 11% of the patients have a normal scan, which in these cases does not permit the elimination of

chronic hydrocephalus as a possibility. This percentage of normal scan is markedly inferior to the one given by Fleming (40% in 79 cases)<sup>17</sup>.

On the other hand, ventricular filling, especially if one considers only permanent or associated with SAPD, is found only in 9.5%.

c) *CSF scan correlated to pneumoencephalography*. The absence of convexity filling with air should correspond to complete subarachnoid block and therefore to ventricular filling. This has been noted only in 69% of our cases, while in

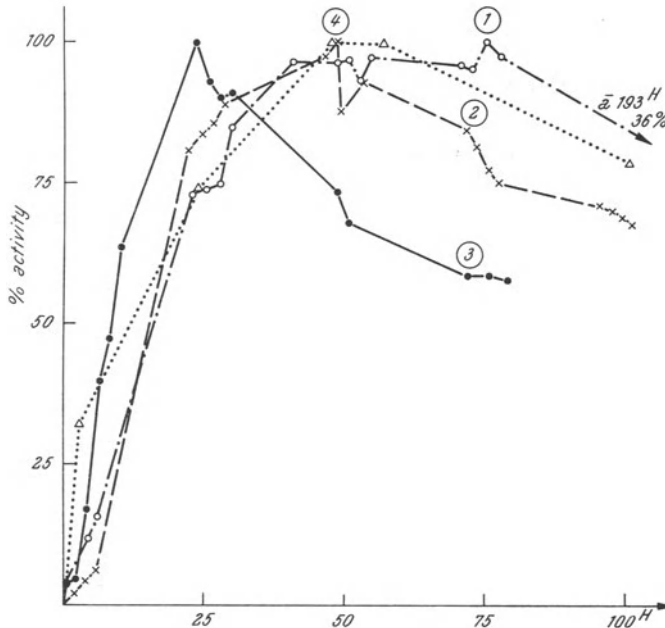


Fig. 15. Blood activity in function of time after <sup>131</sup>I-HSA injection into the subarachnoid space. 1 hydrocephalus post-operative (ventricular filling + SAPD), 2 hydrocephalus with SAPD, 3 normal distribution, 4 chronic hydrocephalus with ventricular filling

28% an SAPD has been found. On the other hand, filling of convexity sulci by air is associated with ventricular activity in 10 out of 40 cases, but only in 4 cases of ventricular retention (Table 4).

These results are similar to the conclusion already advanced by Fleming et al.<sup>17</sup> in their series of patients. With no air on the cortex, the permanent ventricular filling is present only in 16 out 31 cases, basal retention in 8, and group 1 in 7 cases. A normal subarachnoid flow has been found in 3 cases with no convexity air. On the other hand, with air over the cortex, basal retention or ventricular filling are seen in 7 out 54 patients.

It seems therefore that an absolute parallel cannot be drawn between pneumoencephalography and scan. Nevertheless, there is a good chance of similar results if one considers only permanent ventricular filling, isolated or associated with SAPD; this eventuality occurs six times more often when there is no con-

vexity air at pneumoencephalography (60% against 10%). It may be considered therefore as a good sign of active hydrocephalus.

d) *CSF scan correlated to pneumoencephalography and etiology.* In group B (idiopathic hydrocephalus), with no convexity sulci filling (13 cases), SAPD is observed with the same frequency as ventricular filling isolated or associated with SAPD (6 cases each). When there is convexity filling (30 cases), SAPD occurs six times more often than ventricular filling (Table 5).

In Group A (hydrocephalus related to specific cause), the absence of air convexity is associated with ventricular filling in 15 out of 18 cases; no transient

Table 4. *CSF Scan Related to Pneumoencephalography*

CSF scan abnormality	Ventricular dilatation without convexity air		Ventricular dilatation plus convexity air		Ventricular dilatation seen at angiography	
		%		%		%
Normal distribution	1	2.8	3	7	2	4.5
SAPD	10	28	29	69	30	71.5
Transient filling	3		6		4	
Permanent						
VF + SAPD	6		2	10	2	
Permanent VF isolated	16		2		4	
<i>Total VF</i>	<i>25</i>	<i>69</i>	<i>10</i>	<i>24</i>	<i>10</i>	<i>24</i>
Total 120	36	100	42	100	42	100

filling has been observed in these patients and only in two cases of post-traumatic hydrocephalus, with presence of air at the convexity (Table 6).

It seems here reasonable to draw the following conclusions:

The relation between;

Absence of air in convexity sulci and ventricular filling is virtually certain, especially if hydrocephalus is related to a specific cause.

Transient ventricular filling has never been observed in recent chronic hydrocephalus with specific etiology.

e) *CSF scan correlated to clinical status.* Permanent ventricular filling, isolated or associated with SAPD, has been observed in cases where clinical features were slightly different from the one described by Hakim<sup>28</sup>, Hakim and Adams<sup>29</sup>. This fact, already noted by Ojemann<sup>52</sup> is illustrated by the following case.

The patient, 65 years old, was admitted for chronic headaches and a bilateral visual loss. Neurological examination was normal, except for visual acuity, a 4/10 in each eye. The only pathological result was detected by carotid angiography, showing definite ventricular dilatation. Some months later, the aggravation of clinical status provoked a new admission. Ventricular tap revealed a normal ventricular pressure but improved headache and visual loss. CSF scan

showed ventricular filling plus SAPD. A shunt was then placed, with notable improvement.

*C. Result of CSF Scan Applied to Physiopathology of CSF Flow*

a) *In normal subjects.* Determination of movements of 131 I-HSA<sup>5, 16</sup> in the subarachnoid space is representative of the CSF flow. But, because of its relative

Table 5. *CSF Scan Related to PEG in Chronic Idiopathic Hydrocephalus (Group B)*

	Ventricular dilatation without convexity air		Ventricular dilatation plus convexity air		Ventricular dilatation seen at angiography	
		%		%		%
Normal scan	1	8	3	10	6	11.5
SAPD	6	46	23	76.5	38	70
Transient VF	3		2		5	
Permanent VF + SAPD	1		none		1	
Permanent VF isolated	2		2		4	
<i>Total VF</i>	<i>6</i>	<i>46</i>	<i>4</i>	<i>13.5</i>	<i>10</i>	<i>18.5</i>
<b>Total</b>	<b>13</b>	<b>100</b>	<b>30</b>	<b>100</b>	<b>54</b>	<b>100</b>

Table 6. *CSF Scan Correlated to PEG in Chronic Hydrocephalus Secondary to a Known Etiology (Group A)*

	Ventricular dilatation without convexity air		Ventricular dilatation plus convexity air		Ventricular dilatation seen at angiography	
Normal scan	none		none		none	
SAPD	3		5		19	
Transient VF	none		2		4	
Permanent VF + SAPD	4		2		2	
Permanent VF isolated	11		none		3	
<i>Total VF</i>	<i>15</i>		<i>4</i>		<i>9</i>	
<b>Total</b>	<b>18</b>		<b>9</b>		<b>28</b>	

Patients with hydrocephalus (23 post-traumatic, 17 post-subarachnoid haemorrhage, 15 post-meningeal infection).

slowness, two factors are responsible for the movements of the protein: CSF movement plus protein diffusion. This fact can easily be demonstrated in a rigid horizontal tubing system, where a constant fluid flow is applied from one extremity to the other. If a radiotracer is injected, between the two extremities, into the system, it will be detected only in the downward extremity. If flow is

progressively reduced, radiotracer decreases at this end, while radioactivity appears at the other end, travelling against the current. There is no inversion of flow, but a diffusion phenomenon. Reciprocally, if diffusion is observed one can tell that fluid flow is very slow.

Applied to the CSF, scanning shows a normal flow of the protein from the ventricle to the subarachnoid space, while in the extracranial segment, flow is nearly stagnant (as evidenced by bidirectional diffusion of the injected radiotracer).

In the ventricle, the main source of its displacement can be considered as the choroidal pulse pressure<sup>10</sup>. The disappearance of ventricular activity after intraventricular injection is a rapid phenomenon: fifty percent in two hours, eighty percent in four hours, and ninety nine percent in 24 hours<sup>7</sup>.

On the other hand, subarachnoid injection into the cisterna magna is never accompanied by a ventricular activity.

b) *In chronic adult hydrocephalus*. Taking into account what has been said in normal cases, CSF flow anomalies in hydrocephalus may have a possible explanation.

Ventricular filling is the result of a near absence of flow, or at least a flow which is not greater than the protein's diffusion speed. A reverse flow (as advanced by Glasauer<sup>25</sup>) seems to us less likely for it supposes an extraventricular CSF production (which is insignificant compared to ventricular one), and a force acting against the choroidal pulse pressure. Furthermore the downward movement observed after suboccipital injection persists. For all these reasons a major slowing of CSF movement seems probable.

The fact that a local pathological transependymal ventricular resorption exists<sup>34, 60</sup> reduces the need for any special direction flow.

Therefore, if admitted that there is a near absence of flow when ventricular filling exists, it is possible to compare two types of chronic adult hydrocephalus.

Hydrocephalus without slowed CSF flow: gammagraphy will show anomalies of type 1 (SAPD).

Hydrocephalus with slowed CSF flow: either massive with a complete obstruction of the subarachnoid space—there is at CSF scan a permanent ventricular filling or moderate with a partial obstruction of CSF pathways—the scan shows then a ventricular filling plus SAPD. Different degrees may be seen in this group: the main objective sign remains the quantitative determination of ventricular activity which is not routinely possible.

A third possibility is slowed flow coexisting with permeable CSF pathways: the scan picture is then a transient ventricular filling.

Therefore, the meaning of the permanent ventricular filling is the absence of movement of CSF flow, associated with a transependymal resorption. It corresponds to a special type of hydrocephalus, whatever is the clinical or the radiological picture. At the same time, this leads one to expect a good or excellent result after CSF shunts<sup>40, 52, 56</sup>.

On the other hand, transient ventricular filling, with the significance discussed above, explains some cases of improvement in hydrocephalus "ex vacuo".

### Treatment

The wide interest concerning chronic hydrocephalus has been stimulated by the possibility of total or partial regression of symptoms in cases where, for years, the normal CSF pressure has led these patients to be considered as "atrophic cases".

It has been the merit of Hakim in 1964<sup>28</sup> to point out this fact, observing patients' improvement after CSF lumbar removal. Since this first study, numerous authors have reported extensive results, but as different as the wide variety of cases considered<sup>6, 9, 29, 33, 46, 57</sup>. The surgical techniques have been very similar. Except for a few cases with an internal shunting procedure (Torkildsen), the

Table 7. *Surgical Results Correlated to Scans*

CSF scan abnormality		Total	Improvement	No change	Worse
Staab et al. 1972	Normal	4		4	
	Slow	1		1	
	VF	30	18	8	4
	CSF block without VF	5	4		1
Personal series	SAPD	4	4		
	Transient VF	1	1		
	Permanent VF	11	7	2	2
	VF + SAPD	6	4	2	
		17	11		

great majority of patients had a ventriculo-atrial shunt, rarely ventriculo-peritoneal. The valves used included all the commercial devices available, but with a relatively low range of opening pressure (40–60 mm H<sub>2</sub>O).

Complications related directly to shunting procedure, although infrequent, are not nonexistent. From the large series of Illingworth<sup>37</sup> (concerning all types of hydrocephalus), or of Salmon<sup>62</sup> (chronic hydrocephalus only), the most common complication was a dysfunction of the shunt system, especially blockage of the ventricular catheter or less frequently of the cardiac end or of the valve itself.

The inadaptation of the valve pressure systems should be avoided by a careful determination of the pre-operative mean pressure. We have not observed post-operatively signs of intracranial hypotension; but the possibility of negative intracranial pressure, as recently reported by Fox<sup>19</sup> is noteworthy. In a sitting position, the average pressure of his patients was —250 mm H<sub>2</sub>O, with an average drop below normal of —180 mm H<sub>2</sub>O.

This risk of low intracranial pressure in ambulatory patients is certainly responsible for the late appearance of subdural haematomas. The frequency of this complication is uncertain. In 24 patients reported by Samuelson<sup>63</sup>, this complication occurred in 5 out of 24 cases (20.8%) higher than the frequency in high pressure hydrocephalus (5%), but it occurred in only 4 out of 101 cases of Illingworth's series (all types of hydrocephalus)<sup>37</sup>.

Salmon<sup>62</sup> has not observed subdural haematoma in 80 patients with chronic hydrocephalus. In our 24 patients with normal pressure hydrocephalus, this occurred in only two cases.

Other complications, such as infection, appear with the same frequency as in congenital hydrocephalus, but it seems, that once a satisfactory functioning system has been established, revision is seldom necessary in the adult<sup>36</sup>.

Mortality is not negligible, often related to the etiology, rarely to surgical procedure; over all it is around 8%<sup>37</sup> (2 cases in our series).

The main problem regarding the surgical treatment is concerned with the indications.

We have no experience with shunt in patients with normal CSF flow. From the majority of reports<sup>9, 52, 65</sup>, it seems that patients with atrophy do not benefit from a shunt, contrary to the experience of Appenzeller and Salmon<sup>6</sup>.

The results concerning cases with disturbance of CSF dynamics merit discussion. In cases with complete obstruction of CSF flow, the improvement is frequent and in general good to excellent (see group 1 A, 2 A, 3 A of Ojemann)<sup>52</sup>—but it is far from being constant.

In Staab's series<sup>65</sup> it occurred only in 18 out of 30 cases.

In our series, patients with permanent ventricular filling, isolated or associated to SAPD, improved in 11 out of 17 cases, while four patients did not show any change and two became worse (Table 7).

On the other hand, one case with transient ventricular filling improved slightly as in McCullough's report<sup>47</sup>.

With partial obstruction of CSF flow (SAPD without ventricular filling), improvement is as frequent, as it is in the patients of Staab's fourth group.

Following surgery, the improvement, if it occurs, is generally within the few days following operation, but this is variable, depending upon different factors, one of which is the duration of symptoms before surgery. Mental deterioration improves first; incontinence and gait disturbance more slowly.

The mechanism by which CSF drainage improves the condition remains uncertain. There is undoubtedly a decrease of mean ventricular pressure in the cases in which pressure has been post-operatively measured. Simultaneously there is an important damping in arterial pulse pressure<sup>24</sup>. The possibility of negative pressure in sitting and erect position has been discussed above<sup>19</sup>.

It is thus reasonable to expect a decrease of the total force applied to the ventricular wall, as postulated by Hakim and Adams<sup>29</sup> with suppression of the hydraulic press effect.

The possibility of change in direction of CSF flow is another factor; CSF able to escape though the shunt does not use transependymal and transparenchymatous channels, perhaps permitting the white matter to return to its normal state.

Another possible action could be an increase in cerebral blood flow as shown by Greitz<sup>26d</sup>, parallel to clinical improvement. This increase is evident in mean flow and in the slow component, which may correspond to white matter flow. At the same time a diminution in ventricular size has been noted.

In conclusion, it seems likely that the best chances of improvement are found in cases with evident obstruction of CSF pathways. Nevertheless, ventricular filling per se or radiological obstruction at a low level means only that it is possible to expect a high percentage of positive results.

On the other hand, some cases with incomplete blockage may improve after surgery, especially if the CSF dynamics are in favour of slowed flow. We are



not at present inclined to shunt patients who give no indication of slowed CSF flow (transient ventricular filling). But this certainly merits further investigation.

### Pathophysiology

The main question concerns the relationship between ventricular dilatation and normal CSF pressure. The existence of this normal pressure does not seem to be disputed, if one considers the range of pressure observed in different series.

For Hakim<sup>28</sup>, Hakim and Adams<sup>29</sup>, there is an initial rise in CSF pressure causing ventricular enlargement; once this ventricular dilatation is obtained, CSF pressure returns to normal. But, an imbalance persists at the level of the ventricular wall, causing neurological and mental symptoms. This is due to "the effective force of expansion within the ventricle which is not equivalent to pressure alone, but is the product of the ventricular pressure by ventricular area"<sup>28, 29</sup>. So, the force may be important with a low pressure if there is great increase in area.

For Geschwind<sup>24</sup>, this theory is inadequate because it does not take into account the tensile properties of the ventricular wall. When the ventricle enlarges, there is a periventricular destruction of lipid and protein; this may be increased by the intermittent peaks of pressure, in relation with CSF pulse pressure<sup>10</sup>. A role may be attributed to the difference in pressure between ventricle and subarachnoid space which, nevertheless, has never been demonstrated.

More recently, Hakim<sup>30</sup> has considered that the main point is the imbalance between the two forces acting on brain parenchyma: CSF pressure on one side, venous pressure on the other. CSF cannot be compressed in chronic hydrocephalus because it is a closed system.

The only way to arrive at a normal balance between these two forces is to transform the CSF system into an open one. The venous system can return to its normal volume, while ventricular dilatation decreases.

Fox et al.<sup>18</sup> have arrived at similar though not identical conclusions; the decisive factor is that of pressure differential existing on the ventricular wall. Pressure on ventricle side does not need to be high, if there is a drop in parenchymal pressure. On the other hand, CSF shunt, allowing brain expansion by lowering CSF pressure, explains improvement, even in some cases of degenerative disease, when brain parenchyma pressure is low. It seems, however, that the reduction of cerebral blood flow, which may be at the origin of low parenchyma pressure, is a secondary phenomenon to the ventricular dilatation<sup>26d</sup>.

Ommaya<sup>53</sup> considers that it is not necessary to invoke the ventricular wall tensile properties, or the interaction of the different cranial compartments. The main factor to be considered is rate of increase in CSF volume: with a slow increase (as in chronic hydrocephalus) the change in CSF pressure is moderate or absent. (See graph on CSF volume-pressure-time relationship.)

This normal pressure hydrocephalus is nevertheless dangerous because it causes a reduction in the volume of brain tissue.

If one considers the results shown by experimentation in hydrocephalus, chronic hydrocephalus can be considered as a normal step following the acute phase of hydrocephalus. At this initial stage, rise in intraventricular pressure

causes a disruption of the ventricular lining, allowing CSF to penetrate into the white matter<sup>70</sup>.

With the increase of intraventricular pressure, and penetration into the white matter, CSF may be absorbed into the blood vessels<sup>54, 60</sup>. Therefore equilibrium is reached between absorption and production which has been reduced<sup>61</sup>. But, the neurological disorders still exist because of either the destruction or the compression of brain tissue, or the stretching effect of ventricular enlargement.

It seems reasonable to suggest that different mechanisms explain the syndrome of chronic hydrocephalus.

In cases related to a known etiology, a period of high intracranial pressure at the beginning is probable. Once having reached the state of equilibrium, the problem is to explain the decompensation. Here different factors should occur: total force exerted on the ventricle wall, loss of tensile properties of this wall, transependymal reabsorption causing a secondary brain atrophy.

In cases of idiopathic hydrocephalus, the problem is more complex; it is unlikely that there exists in this category a period of high intracranial pressure, which never gives any clinical sign. It is reasonable to admit that in these cases, where CSF block is less complete (cf. isotopic studies), or more distal, the progressive dilatation can occur without hypertension because of the slowness of the process, as stated by Ommaya<sup>53</sup>.

Whatever are the initial stages, once the ventricular dilatation is reached, the impairment of brain function cannot cease, unless the pressure differential against the ventricular wall becomes negative. The improvement will occur by the direct decompression of either brain tissue, or of the vascular bed (cf. therapeutics).

In hydrocephalus "ex vacuo", where the brain tissue volume is reduced primarily, decrease of CSF volume may explain transitory improvement, but if the degenerative process is still active, the pressure differential will return to a positive force of the ventricle against the parenchyma, explaining the secondary deterioration<sup>19</sup>.

A final factor, which has not yet been determined, concerns the possible role of CSF in brain metabolism. If we consider, as stated above (cf. isotopic studies), that in chronic hydrocephalus, CSF is nearly stagnant, it is likely that exchanges between the nervous system and CSF are extremely reduced. The reappearance of CSF circulation with a shunt may improve brain function, by permitting CSF to recover its normal metabolic function. This hypothesis has not, at the present time, any biological support.

### References

1. Abbott, M., Alksne, J. F., 1968: Transport of intrathecal 125 I-RISA to circulating plasma. A test for communicating hydrocephalus. *Neurology (Minneap.)* 18—870.
2. Adams, R. D., Fisher, C. M., Hakim, S., Ojemann, R. G., Sweet, W. H., 1965: Symptomatic occult hydrocephalus with "normal" cerebrospinal fluid pressure: a treatable syndrom. *New Eng. J. Med.* 273, 117—126.
3. — 1966: Further observations on normal pressure hydrocephalus. *Proc. Roy. Soc. Med.* 59, 1135—1140.

4. Aneri, D., Fohanno, D., 1972: Données radio-isotopiques qualitatives sur la circulation du liquide céphalo-rachidien. *Minerva Neurochirurgica* 16, 171—174.
5. — 1973: La gammagraphie du LCR dans son segment rachidien. *Vie Médicale* 23.
6. Appenzeller, O., Salmon, J. H., 1967: Treatment of parenchymatous degeneration of the brain by ventriculo-atrial shunting of CSF. *J. Neurosurg.* 26, 478—482.
7. Atkinson, J. R., Foltz, E. L., 1962: Intraventricular "RISA" as a diagnostic aid in pre and postoperative hydrocephalus. *J. Neurosurg.* 19, 159—166.
8. Bannister, R., Gilford, E., Kocen, R., 1967: Isotope encephalography in the diagnosis of dementia due to communicating hydrocephalus. *Lancet* 2, 1014—1017.
9. Benson, D. F., Le May, M., Patten, D. H., Rubens, A. B., 1970: Diagnosis of normal pressure hydrocephalus. *New Eng. J. Med.* 283, 609—615.
10. Bering, E. A., 1955: Choroid plexus and arterial pulsation of cerebrospinal fluid. *Arch. Neurol. Psychiat.* 73, 165—172.
11. Block, J. D., 1971: Visual impairment in low pressure hydrocephalus. *J. Neurol. Neurosurg. Psychiat.* 34, 107.
12. Curl, F. D., Harbert, J. C., McCullough, D. C., 1972: Quantitative cisternography: an aid to diagnosis. In *Cisternography and Hydrocephalus. A symposium*, J. C. Harbert (Ed.). Springfield, Ill.: Ch. C Thomas.
13. De Blanc, H. J., Natarajan, T. K., James, A. E., Wagner, H. N., 1972: Computer-assisted quantitative cisternography and ventriculography. In *Cisternography and Hydrocephalus. A symposium*, J. C. Harbert (Ed.). Springfield, Ill.: Ch. C Thomas.
14. De Land, F. H., 1971: Cisternography with  $^{169}\text{Yt}$  DTPA. *J. Nucl. Med.* 12, 683—689.
- 15a. Di Chiro, G., 1964: New radiographic and isotopic procedures in neurological diagnosis. *JAMA* 188, 524—529.
- 15b. — 1964: Movement of the cerebrospinal fluid in human beings. *Nature (Lond.)* 204, 290—291.
- 15c. — Reames, P. M., Matthews, W. B., Jr., 1964: RISA-ventriculography and RISA cisternography. *Neurology (Minneap.)* 14, 185—191.
16. — 1966: Observation on the circulation of the cerebrospinal fluid. *Acta Radiol. (Diagn.) (Stockholm)* 5, 988—1002.
17. Fleming, J. F. R., Sheppard, R. H., Turner, V. M. A., 1971: CSF scanning in evaluation of hydrocephalus. In *Cisternography and Hydrocephalus. A symposium*, J. C. Harbert (Ed.). Springfield, Ill.: Ch. C Thomas.
18. Foltz, E. L., Ward, A. A., 1956: Communicating hydrocephalus from subarachnoid bleeding. *J. Neurosurg.* 13, 546—556.
19. Fox, J. L., McCullough, D. C., Green, R. C., 1973: Effects of cerebrospinal fluid shunts on cerebrospinal dynamics. *J. Neurol. Neurosurg. Psychiat.* 36, 302—312.
20. Frigeni, G., Gaini, S. M., Paoletti, P., Villani, R., 1972: La cisternographie isotopique dans l'étude des altérations de la dynamique du LCR, après traitement neurochirurgical. *Minerva Neurochirurgica* 16, 186—191.
21. Front, D., Beks, J. W. F., Georganas, Ch. L., Beekhuis, H., Penning, L., 1972: Abnormal patterns of cerebrospinal fluid flow and absorption after head injuries: diagnosis by isotopic cisternography. *Neuroradiology* 4, 6—13.
22. Galera, R., Greitz, T., 1970: Hydrocephalus in the adult secondary to the rupture of intracranial arterial aneurysms. *J. Neurosurg.* 32, 634—670.
23. Garretson, H. D., Brindle, G. P., 1972: Effects on ventriculo-atrial shunting on CSF dynamics. In *Cisternography and Hydrocephalus. A symposium*, J. C. Harbert (Ed.). Springfield, Ill.: Ch. C Thomas.
24. Geschwind, N., 1968: The mechanism of normal pressure hydrocephalus. *J. Neurol. Sci.* 7, 481—483.
25. Glasauer, F. E., Alker, G. J., Jr., Leslie, E. V., Nicol, C. F., 1968: Isotope cisternography in hydrocephalus with normal pressure. Case report and technical note. *J. Neurosurg.* 29, 555—561.

- 26a. Greitz, T., 1969: An effect of brain distension on cerebral circulation. *The Lancet* 26, 863—865.
- 26b. — 1969: Cerebral blood flow in occult hydrocephalus studies with angiography and the xenon 133 clearance method. *Acta Radiol. (Diagn.) (Stockholm)* 8, 376—384.
- 26c. — Ekblom, F., Kukelberg, Breig, A., 1969: Occult hydrocephalus due to ectasia of basilar artery. *Acta Radiol. (Diagn.) (Stockholm)* 9, 310—316.
- 26d. — Grepe, A. Q. L., Kalmer, M. S., Lopez, J., 1969: Pre and post-operative evaluation of cerebral blood flow in low pressure hydrocephalus. *J. Neurosurg.* 31, 644—651.
27. — — 1970: Encephalography in the diagnosis of convexity block hydrocephalus. *Acta Radiol. (Diagn.) (Stockholm)* 11, 232—242.
28. Hakim, S., 1964: Algunas observaciones sobre la presión del LCR Síndrome hidrocefálico en el adulto con "presión normal" del LCR. Tesis de grado. Universidad Javeriana, Bogota, Columbia.
29. — Adams, R. D., 1965: The special problem of symptomatic hydrocephalus with normal CSF pressure. *J. Neurol. Sci.* 2, 307—327.
30. — 1972: Biomechanics of hydrocephalus. In *Cisternography and Hydrocephalus. A symposium*, J. C. Harbert (Ed.). Springfield, Ill.: Ch. C Thomas.
31. Heck, A., Hameroff, S., Hornick, R., 1971: Chronic listeria monocytogenes meningitis and normotensive hydrocephalus. *Neurology* 21, 263—271.
32. Heinz, E. R., Davis, D. O., Karp, H. R., 1970: Abnormal isotope cisternography in symptomatic occult hydrocephalus. A correlative isotopic radiological study in 130 subjects. *Radiology* 95, 109—120.
33. Hill, M. E., Loughheed, W. M., Barnett, H. J., 1967: A treatable form of dementia due to normal pressure hydrocephalus. *Canada Med. Ass. J.* 97, 1309—1320.
34. Hochwald, G. M., Lux, E. W., Sahar, A., Ransohoff, J., 1972: Experimental hydrocephalus. Changes in cerebrospinal fluid dynamics as a function of time. *Arch. Neurol.* 26, 120—129.
35. Hussey, F., Schanzer, B., Katzman, R., 1970: A simple constant infusion manometric test for measurement of CSF absorption; II: Clinical studies. *Neurology (Minneapolis)* 20, 655—680.
36. Illingworth, R. D., Logue, V., Symon, L., Vemura, K., 1971: The ventricle caval shunt in the treatment of adult hydrocephalus. Result and complication in 101 patients. *J. Neurosurg.* 35, 681—685.
37. — — — — 1972: Subdural haematomas after the treatment of chronic hydrocephalus by ventriculo-caval shunt. *J. Neurol. Neurosurg. Psychiat.* 33, 95—99.
38. James, A. E., New, P. F. J., Heinz, E. R., Hodges, F. J., De Land, F. H., 1972: A cisternographic classification of hydrocephalus. *Am. J. Roentgen.* 115, 40—49.
39. Katzman, R., Hussey, F., 1970: A simple constant infusion manometric test for measurement of CSF absorption. I: Rational and method. *Neurology (Minneapolis)* 20, 534—544.
40. Le May, M., New, P. F. J., 1970: Radiological diagnosis of occult normal pressure hydrocephalus. *Radiology* 96, 347—358.
41. Lerner, M. A., 1968: Everted anterior medullary velum as a pneumographic criterious of hydrocephalus. *Clin. Radiol.* 88, 334—336.
42. Lewin, W., 1968: Preliminary observations on external hydrocephalus after severe head injury. *Brit. J. Surg.* 55, 747—751.
43. Lin, J. P., Goodkin, R., Tong, E. C. K., Epstein, F. J., Vinciguerra, E., 1968: Radioiodinated serum albumin (RISA) cisternography in the diagnosis of incisural block and occult hydrocephalus. *Radiology* 90, 36—41.
44. Lorenzo, A. V., Page, L. K., Watters, G. V., 1970: Relationship between cerebrospinal fluid formation absorption and pressure in human hydrocephalus. *Brain* 93, 679—692.

45. Lundberg, N., 1960: Continuous recording and control of ventricular fluid pressure in neurosurgical practice. *Acta Psychiat. Scand. (Suppl. 149)* 36, 1—193.
46. Lying-Tunnel, U., Bergqvist, D., Bohmar, G., Malmund, H. O., Marions, O., Söderborg, B., 1970: Studies in presenile dementia. *Acta Neurol. Scand. (Suppl. 43)* 46, 90—92.
47. McCullough, D. C., Harbert, J. C., di Chiro, G., Ommaya, A. K., 1970: Prognosis criteria for CSF shunting from cisternography in communicating hydrocephalus. *Neurology (Minneap.)* 20, 594—598.
48. McHugh, P. R., Goodell, H., 1966: Hydrocephalic dementia: differential diagnosis, psychometric tests and responses to treatment. *Neurology (Minneap.)* 16, 635—649.
49. Martins, A. N., 1973: Resistance to drainage of cerebrospinal fluid: clinical measurement and significance. *J. Neurol. Neurosurg. Psychiat.* 36, 313—318.
50. Nelson, J. R., Goodman, S. J., 1971: An evaluation of the cerebrospinal fluid infusion test for hydrocephalus. *Neurology (Minneap.)* 21, 1037—1053.
51. Ojemann, R. G., Fisher, C. M., Adams, R. D., Sweet, W. M., New, P. F. J., 1969: Further experience with the syndrome of “normal” pressure hydrocephalus. *J. Neurosurg.* 31, 279—294.
52. — 1971: Normal pressure hydrocephalus. *Clin. Neurosurg.* 18, 337—370.
53. Ommaya, A. R., Mets, M., Post, K. D., 1972: Observations on the mechanics of hydrocephalus. In *Cisternography and Hydrocephalus. A symposium*, J. C. Harbert (Ed.). Springfield, Ill.: Ch. C Thomas.
54. Patten, H. D., Benson, D. F., 1968: Diagnosis of normal pressure hydrocephalus by CSF iodine 131 RISA scanning. *J. Nucl. Med.* 9, 457—461.
55. Pertuiset, B., Houtteville, J. P., George, B., Margent, P., 1972: Dilatation ventriculaire précoce et hydrocéphalies consécutives à la rupture d’anévrysmes artériels sus-tentoriels. *Neurochirurgia (Stuttgart)* 15, 113—126.
56. Philippon, J., Ancrì, D., Pertuiset, B., 1971: Hydrocéphalie à pression normale. (Enregistrement de la pression, étude radiologique, transit isotopique.) *Rev. Neurol.* 125, 347—358.
57. — George, B., Metzger, J., 1974: Variations of intraventricular pressure during pneumoencephalography. *J. Neurosurg.* 40, 101—106.
58. Ricou, Ph., 1972: Contribution à l’étude de l’hydrocéphalie à pression normale. Thesis, Faculty of Medicine of Paris.
59. Rovit, R. L., Schechter, M. W., Ortega, B., Brinker, R., 1972: Progressive ventricular dilatation following pneumoencephalography. A radiological sign of occult hydrocephalus. *J. Neurosurg.* 36, 50—59.
60. Sahar, A., Hochwald, G. M., Sadik, A. R., Ransohoff, J., 1969: Alternate pathway for CSF absorption in animals with experimental obstructive hydrocephalus. *Exp. Neurol.* 25, 200—206.
61. — Ransohoff, J., 1970: Experimental hydrocephalus CSF formation and ventricular size as a function of intraventricular pressure. *J. Neurol. Sci.* 11, 81—91.
62. Salmon, J. H., 1972: Adult hydrocephalus. Evaluation of shunt therapy in 80 patients. *J. Neurosurg.* 37, 423—428.
63. Samuelson, S., Long, D. M., Chou, S. N., 1972: Subdural hematomas as a complication of shunting procedure for normal pressure hydrocephalus. *J. Neurosurg.* 37, 548—551.
64. Sjaastab, O., Skalpe, I. O., Engeset, A., 1969: The width of the temporal horn in the differential diagnosis between pressure hydrocephalus and hydrocephalus ex vacuo. *Neurology (Minneap.)* 19, 1087—1093.
65. Staab, E. V., Allen, J. H., Young, A. B., Soper, B. A., Meachen, W., 1972: 131 I-HSA cisternograms and pneumoencephalograms in evaluation of hydrocephalus. In *Cisternography and Hydrocephalus. A symposium*, J. C. Harbert (Ed.). Springfield, Ill.: Ch. C Thomas.
66. Stein, B. M., Tenner, M. S., Fraser, A. R., 1972: Hydrocephalus following removal of cerebellar astrocytomas in children. *J. Neurosurg.* 36, 763—768.

67. Symon, L., Dorsch, N. W. C., Stephens, R. J., 1972: Long term measurement of extradural pressure in "low pressure hydrocephalus". In *Intracranial Pressure*, M. Brock and H. Dietz (Eds.). Berlin-Heidelberg-New York: Springer.
68. Tator, C. H., Fleming, J. F. R., Sheppard, R. H., Turner, V. M. A., 1968: Radioisotopic test for communicating hydrocephalus. *J. Neurosurg.* 28, 327—340.
69. Taveras, J. M., 1968: Low-pressure hydrocephalus. In *Neuro-ophthalmology*, J. L. Smith (Ed.), 293—309.
70. Weller, R. O., Wisniewski, H., Shulman, K., Terry, D., 1971: Experimental hydrocephalus in young dogs. Histological and ultrastructural study of the brain tissue damage. *J. Neuropath. Exp. Neurology* 30, 613—626.
71. Wolinsky, J., Barnes, B., Margolis, Th., 1972: Experience with the spinal infusion test in suspected normal pressure hydrocephalus. *Neurology (Minneap.)* 22, 402.

## **Surgery of Craniostenosis in Advanced Cases**

### **A Method of Extensive Subperiosteal Resection of the Vault and Base of the Skull Followed by Bone Regeneration**

**H. POWIERTOWSKI**

Institute of Surgery, Silesia Academy of Medicine, Katowice,  
and Department of Neurotraumatology, Miners' Rehabilitation Centre, Repty (Poland)

With 16 Figures

#### **Contents**

Introduction .....	93
Anatomo-Clinical Considerations .....	94
Operative Procedure .....	98
Clinical Material .....	100
Results and Evaluation.....	102
1. Surgical Risk .....	102
2. Decompression Effect, Protection of the Head, and Cosmetic Result .	103
3. Regeneration of the Skull .....	110
4. Neurological Results .....	116
Conclusion.....	117
Illustrative Cases.....	117
Addendum.....	118
References .....	119

#### **Introduction**

During the last twenty years, since children began to be operated on within the first few months after birth, the results of surgical treatment of craniostenosis have greatly improved, although not to the same degree in all forms (Anderson et al. 1965, McLaurin et al. 1952, Matson 1960, Pawl et al. 1972, Seeger et al. 1971, Shillito et al. 1968, Teng 1962).

In older children, especially those over 1-2 years of age, however, the results are unsatisfactory, since irreversible changes have already taken place both in the skull and in the brain, which cannot develop normally within the constricted cavity (Hemple et al. 1961, Pemberton et al. 1962, Samra et al. 1968).

### Anatomo-Clinical Considerations

It is well known that the clinical form and course of craniosynostosis depends on the age of the children and the number of fused sutures. The child's brain develops very quickly during the first months and years of life (Fig. 1). It doubles its weight in about 7 and  $\frac{1}{2}$  months after birth and trebles it during the first 2 and  $\frac{1}{2}$  years (Faber et al. 1927, Giblin et al. 1944, Kukulska 1964). Later the rate of development slows down, so that the earlier the cranial capacity in a child becomes too small for the needs of the developing brain, the sooner and greater is the damage to the brain. This damage is obviously irreversible.

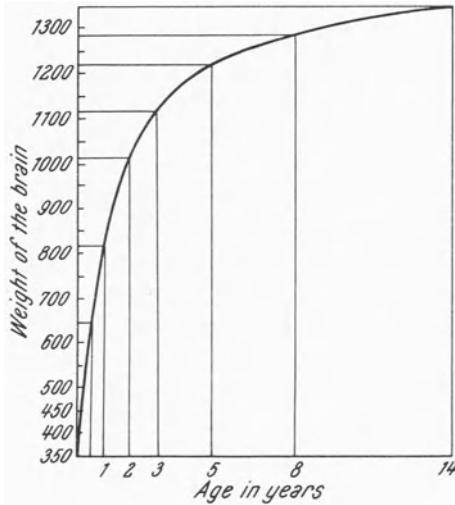


Fig. 1. Relationship between age and weight of brain (after Tod et al. 1971)

Enlargement of the cranial capacity in a child takes place in physiological conditions in two ways: 1. by the "longitudinal" growth of the bone, parallel to the superficies of the skull, and 2. by "transversal" growth, perpendicular to the cranial surface. The first mechanism of growth of the skull takes place in the sutures and consists in the apposition of new bone to the margins of the preformed bone; the second consists in the resorption of the bone of the inner table, facing towards the dura and brain, with simultaneous stratification of the new bone on the outer table. The first of these mechanisms is much more effective and the growth of the skull in very small children takes place principally in this manner (Giblin et al. 1944, Kukulska 1964, Laitinen 1956). This is of essential importance clinically, since it is a factor contributing to the origin of very marked cranial deformations and damage to the brain in the first months of life.

It should be remembered, however, that because of the immaturity and "plasticity" of the child's brain the clinical signs of its damage in very small children may be so slight as to be difficult to diagnose (McLaurin et al. 1952, Seeger et al. 1971).



Premature fusion of the cranial sutures is a disturbance of their physiological function, which consists in the maintainance of a narrow space between the margins of the cranial bones until these sutures finally close (Anderson et al. 1965, Laitinen 1956). The premature closure of even a small section of a suture causes physiological insufficiency of the whole suture, which sometimes becomes an additional cause of diagnostic difficulties.

The aetiology of premature primary fusion of the cranial sutures has not yet been elucidated; it is supposed that this disorder usually originates in foetal life (Laitinen 1956, Seeger et al. 1971). It is also well known that the development of the brain is an important factor conditioning the development of the skull (Pemberton et al. 1962). It is also evident that secondary craniosynostosis caused by the absence of impetus from the damaged brain occurs not infrequently in microcephaly and in some children with hydrocephalus treated by ventriculoatrial shunt (Seeger et al. 1971, Tod et al. 1971). The differentiation of craniostenosis from microcephaly, very easy as a rule, may sometimes encounter difficulties (Shillito et al. 1968).

Theoretically, the premature fusion of only a single cranial suture should not cause a reduction in cranial capacity with consequent lesion to the brain (Tod et al. 1971). The skull cannot develop in a direction perpendicular to this suture, but its growth in other directions is not restricted and may even be excessive in the direction parallel to the suture, showing compensatory deformation. Clinical experience, however, shows that not all the main sutures of the skull when fused restrict the increase in cranial capacity to the same degree.

Fusion of the coronal or metopic sutures causes clinical consequences more frequently than the fusion of the sagittal or lambdoid suture. It seems that the more anterior the location of the fused suture, the greater and more frequent is the impairment of the development of the skull and brain. This refers especially to the coronal suture, which often becomes fused together with its prolongation, the frontosphenoidal suture; this conjunction forms the longest cranial suture (Tod et al. 1971).

If more than one cranial suture fuses simultaneously or successively (Anderson et al. 1965, Tod et al. 1971), there is a markedly increased risk of imminent damage to the brain and then only very early operation (in the first weeks of life) gives a chance of avoiding this (Anderson et al. 1956, McLaurin et al. 1952, Seeger et al. 1971, Shillito et al. 1968, Tod et al. 1971).

If the increase in the capacity of the skull is too small in relation to the needs of the developing brain, this capacity may be increased only by the deepening of the floor of the cranial cavity and by the gradual resorption of the inner lamina of the bones of the vault and base of the skull.

Atrophy of the inner surface of the skull begins on the places corresponding to the apices of the cerebral convolutions, where the bone gradually becomes increasingly thin, while in the places corresponding to the sulci between convolutions it keeps its normal thickness.

This causes deepening of the digital impressions, typical of the advanced forms of craniostenosis, appearing even in three-month old children (Anderson et al. 1965). In time the radiograms of the skull assume the appearance of "beaten silver". Gradually these prominent *juga cerebra* take on the form of high

slender sharp osseous partitions entering more and more deeply into the sulci between the cerebral gyri, which in this way become incarcerated in the deepened convolucional impressions.

Similar changes take place not only in the vault of the skull but also on its base, where these bony partitions often assume the form of very sharp spicules.

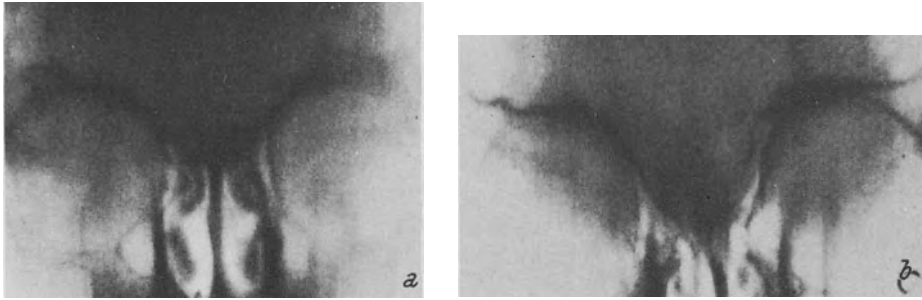


Fig. 2. Tomograms of base of the skull; a: depth of 2 cm, high osseous partitions deeply invading the sulci; b: depth of 5 cm, evident marked deepening and deformation of the base (Case 33)

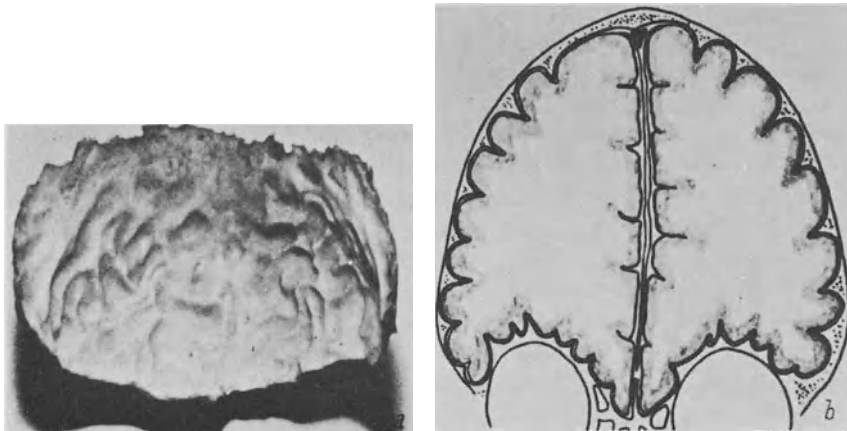


Fig. 3. a: inner surface of resected vault with very markedly deepened digital impressions, which on account of the lighting, look convex instead of concave, b: diagram illustrating incarceration of the brain convolutions between high osseous partitions deeply invading the sulci (after Powiertowski et al. 1970)

The floor of the anterior and middle cranial cavity is lowered, the orbits, already shortened, now become shallow as well; exophthalmos appears or is exacerbated; the canals of the optic nerves are constricted and change their direction, and the region of the hypothalamus deepens and narrows (Figs. 2a and b, 3, 4).

This incarceration of the cerebral convolutions between the osseous partitions, often penetrating 4–7 mm deep into the sulci between them, renders it impossible for these convolutions to advance along the inner surface of the skull, and this

is the chief point of every surgical procedure undertaken in craniostenosis. The shifting of the brain convolutions in relation to the inner surface of the skull must also take place in the patients operated on if the margins of the reconstructed sutures are to be separated and so enable decompression of the brain. If this process can take place freely and the means of preventing secondary fusion of the surgically reconstructed sutures, e.g. films of tantalum or polyethylene, Zenker's solution, iodine etc. are efficacious, a good result may be



Fig. 4. High delicate osseous partitions and spicules of the base of the skull deeply invading the sulci. Photographs taken during resection of the orbital roofs after raising dura and brain (Case 10)

expected (Anderson et al. 1965, Faber et al. 1927, Fowler et al. 1957, Matson 1960, Pawl et al. 1972, Pemberton et al. 1962, Samra et al. 1968, Ryöppy 1965, Seeger et al. 1971, Shillito et al. 1968, Teng 1962, Tod et al. 1971, van der Werf 1971).

On the contrary, in older children with very deep cerebral impressions, linear craniotomy, even combined with separation of large flaps of the bone of the cranial vault, as proposed by e.g. Mullan (1960), Sorour (1961), Samra (1968), and the smoothing of its inner surface, may have little effect, since the cerebral gyri incarcerated at the base of the anterior and middle cranial cavities do not allow the brain to expand normally. The opening (separation) of the fronto-sphenoidal sutures together with partial removal of the orbital roof (Anderson et al. 1965, Tod et al. 1971), may prove to be insufficient if the cerebral convolutions are simultaneously incarcerated in the vault of the skull. In these circumstances there remains only the complete resection of the bones of the skull over an area sufficient to allow full expansion of the brain (Powiertowski and Matłoz 1965, 1970).

### Operative Procedure\*

The inefficacy of previous methods of surgical treatment of craniostenosis in older children and in more advanced cases encouraged us to prepare and apply a method of extensive subperiosteal excision of the bones of the vault

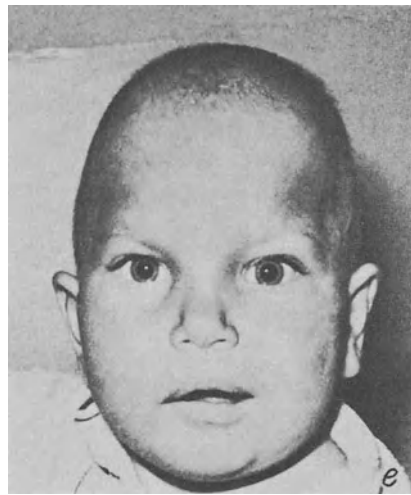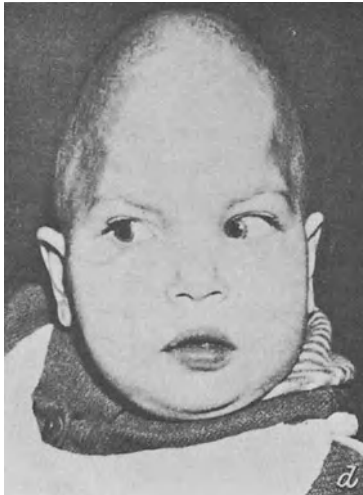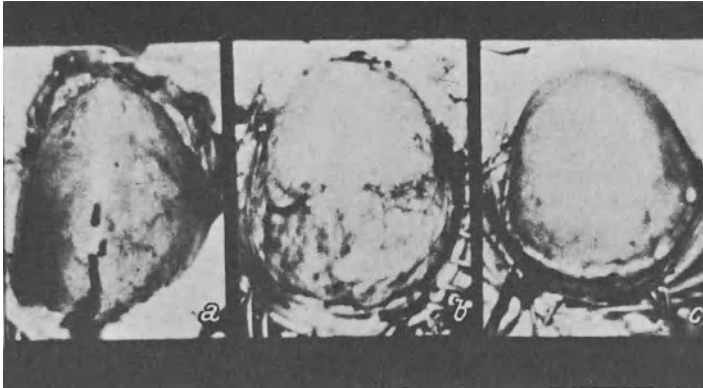


Fig. 5. Decompression effect during operation: a: denuded bone of scaphocephalic skull; b, c: immediate expansion of the brain after resection of vault; d and e: photographs of the same boy before and 1 month after operation (Case 7)

and base of the anterior part of the skull, producing sufficient decompression of the brain and later the regeneration of the bone. In accordance with the foregoing considerations, the bone resection should be sufficiently extensive, both on the vault and on the base of the skull, to facilitate the completely free expansion of the compressed brain, especially the poles of the frontal and temporal lobes.

\* This method has been successfully applied in France (Thurel 1968), West Germany, Denmark, and Maroc.

The operation is performed under intratracheal anaesthesia in the supine position. The skin incision runs from one anterior temporal region across the top of the skull to the other. The skin, together with galea and periosteum, is turned forwards in one large flap, laying bare the margin of the orbits and the base of the nose (Figs. 5a, b, c, and 6). Then, with a rongeur, a linear craniectomy about 1 cm broad is carried out parallel to the coronal suture, anterior or posterior

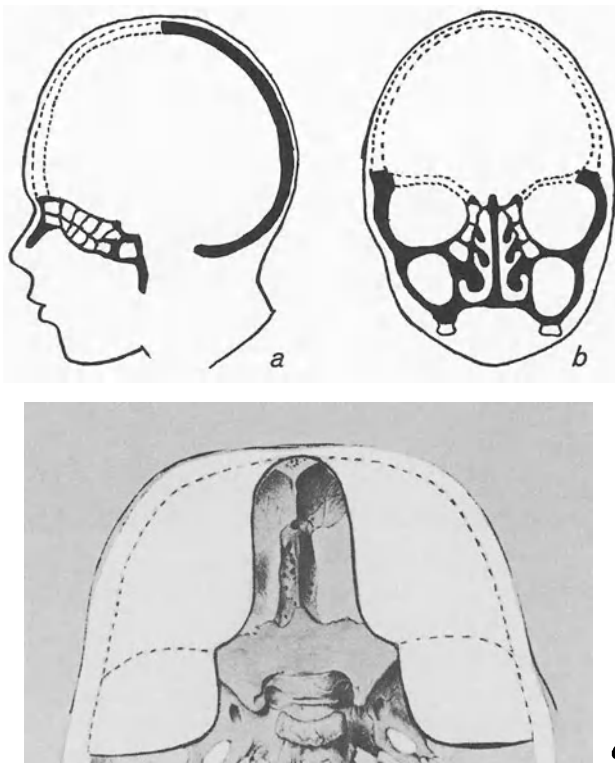


Fig. 6. Diagrams of resection of bones of vault and base of skull: a: lateral view; b: frontal view; c: base of skull. Bones to be resected marked by dotted line

to this, according to need, from the top of the skull down to the base of the middle cranial fossa, and then forwards along the base to the lateral margins of the orbits and then parallel to the superior margins of these up to the midline. Similarly, a groove is cut from one or both sides of the sagittal suture, from the top of the skull forwards to join up with the previous incision at the base of the nose. Then all the bone flaps so formed (both lateral and one covering the sagittal sinus), are separated from the dura mater and removed.

The excision of the bone and its separation from the dura mater should be performed very cautiously, to avoid any injury to the dura by the very high sharp partitions penetrating deep into the cerebral sulci. In addition, copious bleeding from the veins of the dura and bone is often encountered, especially in the vicinity of the midline. This sometimes necessitates the removal of the bone in the form of small flakes or even "biting it away" in little pieces. The

application of coagulation should be reduced to a minimum, in order not to injure the dura mater or the periosteum, from which the regeneration of new bone will begin.

After removing the bone of the cranial vault, the brain displaces itself slightly downwards facilitating access to the base of the skull. The supraorbital roofs are removed with bone forceps, beginning from their anterior margins, as far as the margins of the ethmoidal shelves, the cribriform plate and the foramina of the optic nerves. Then the lateral parts of the lesser and greater wings of the sphenoidal bone are removed. Here, too, great caution must be exercised, since the osseous laminae and spicules on the base of the skull are still sharper (Fig. 7).

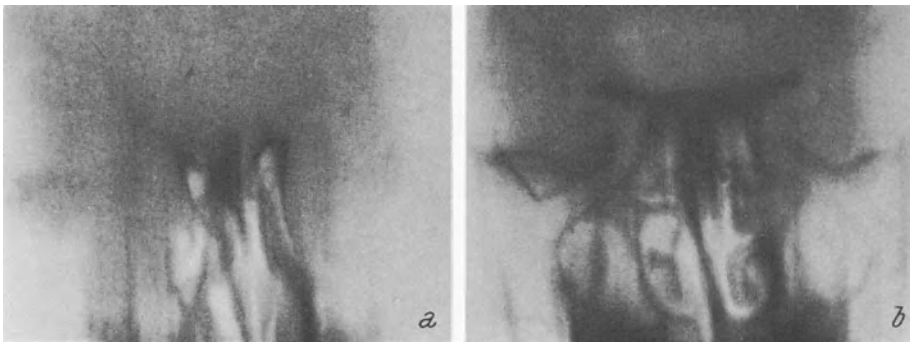


Fig. 7. Tomograms of the base taken 2 weeks after operation: a: supraorbital roofs, and b: lateral portion of lesser sphenoidal wings resected (Case 31)

As a rule, the frontal sinuses have not yet formed in young children, or are very small and do not limit the resection of the anterior cranial cavity. In older children with the developing frontal sinuses already present, their extent and location were determined on the basis of radiograms, in order to preserve them.

After checking the haemostasis (gel-foam or oxycel should be used only if absolutely necessary), the dura and brain are covered with the skin flap and the galea and skin are stitched, followed by the usual dressing on the head. Marked oedema of the eyelids is often seen in the first days after operation. The stitches are removed after 5-7 days. The post-operative course is usually uneventful. The child may sit up the day after operation and walk after the stitches have been removed.

### Clinical Material

The method of surgical treatment of craniostenosis just described was applied from 1961 to 1971 in 36 children, aged from 1 year 7 months to over 14 years (Table 1). Over half the patients were between the age 3 and 8 years; only 8 children were under 3.

Symptoms of persistent elevated intracranial pressure were found in nearly all the patients. This was the main indication for surgery (Table 2). The great majority of the patients also exhibited advanced ocular signs. Two-thirds of

them showed clear signs of mental retardation, and ten had epileptic seizures, usually of the grand-mal type.

In the great majority of these children, fusion of all the sutures (oxycephaly) was found, while in only 5 cases was there fusion of a single suture (Table 3). Initially, in the first 8 children operated on, surgery was limited to the resection

Table 1. *Age of Children Operated on*

1- 3 years	8 cases
3- 5 years	10 cases
5- 8 years	11 cases
8-14 years	7 cases
Total	36 cases

Table 2. *Main Clinical Symptoms and Signs in Children Operated on*

Marked deepening of digital impressions ("beaten silver")	35 cases
Headache (including 7 patients with nausea and vomiting)	26 cases
Papilloedema of the optic discs	12 cases
Protrusion of the eyeballs	27 cases
Atrophy of the optic nerves	26 cases
Diminished acuity of vision (including 2 totally blind)	21 cases
Nystagmus	4 cases
Mental retardation	23 cases
Partial deafness	2 cases
Epileptic seizures	10 cases

Table 3. *Number of Sutures Involved and Type of Craniostenosis*

All sutures (oxycephaly)	23 cases
Coronal and metopic sutures	5 cases
Coronal and sagittal sutures	2 cases
Sagittal and metopic sutures	1 case
Sagittal suture only	4 cases
Coronal suture only	1 case
Total	36 cases

of the calvaria, leaving the supraorbital margins and even some of the bone above them untouched (Fig. 8). In the later period, the bones of the base of the skull were not removed in 2 children only, both aged over 14, so that in 10 cases all surgery was restricted to the resection of the vault, while in the rest the operation also included the base of the anterior and middle cranial cavities (Fig. 7). Analysis of the clinical material presented shows that we were dealing with far advanced cases of craniostenosis, in which the methods of treatment previously used often had a restricted effect, both therapeutic and cosmetic.

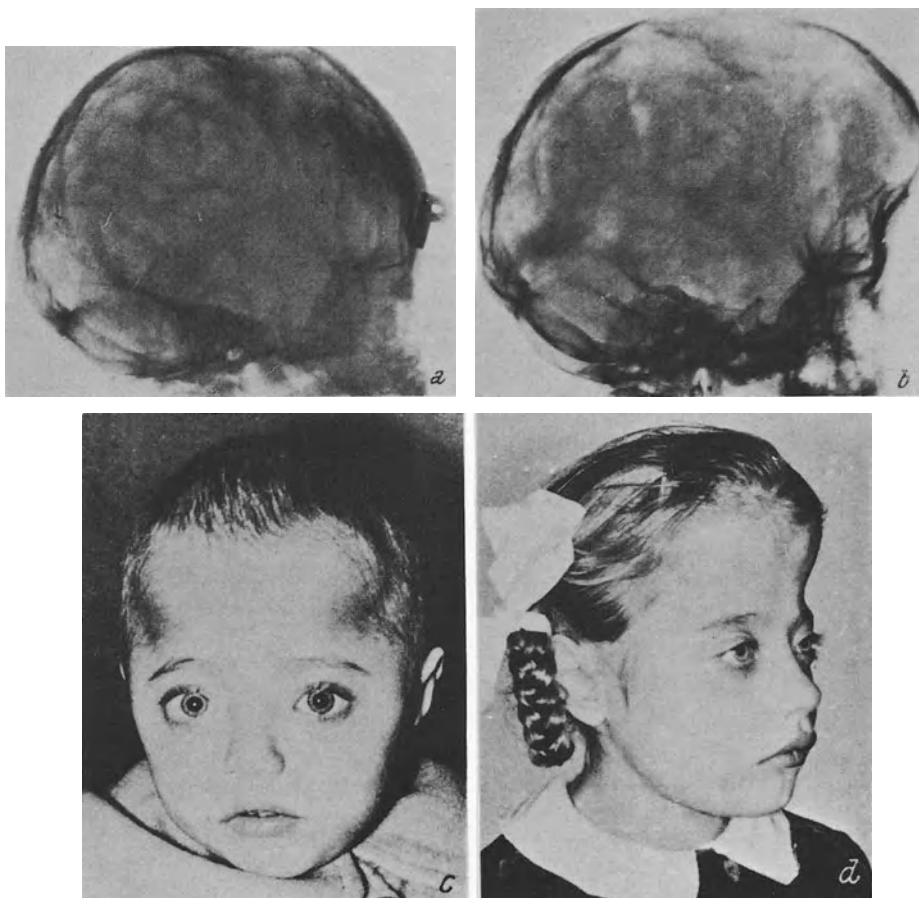


Fig. 8. Secondary deformation of the forehead in a girl aged 3 years with oxycephaly. Only vault of skull resected, leaving marginal part of frontal squama and orbital roofs did not enable the forehead to expand normally: a, b: radiographs before and four years after operation; c, d: photographs of the girl at the same time. Note also persisting exophthalmos (Case 2)

### Results and Evaluation

The results of surgery for craniostenosis by a method of extensive craniectomy of the vault and base of the skull may be discussed and evaluated in several aspects: 1. the surgical risk; 2. decompression effect, protection of the head and cosmetic effect; 3. regeneration of the skull; 4. neurological improvement.

1. *Surgical risk.* Though many authors emphasize that the risk is very slight in children operated on for craniostenosis, there are also authors expressing more cautious opinions (Gordon 1959, Hemple et al. 1961). Our clinical experience has shown that in older children the risk is not so small and should be taken into consideration.

As often happens in surgery, the first operations were successful and without complications. Later, however, within a short time, we had 3 fatal cases (aged 2,



3, and 2½ years) with far-advanced oxycephaly, operated on under endotracheal anaesthesia, with particular attention to prevention of blood loss during operation. Shortly afterwards they developed irreversible shock, which soon caused death. These were the only fatal cases in this series. In all three a marked degree of hypoplasia of the adrenal glands and a large persistent thymus were shown at post-mortem.

Since then all children have been sent before operation to the pediatric department for a thorough examination of adrenal function. Out of 20 children so examined, only four were shown to have normal adrenal function. In all cases of adrenal gland insufficiency, the children were submitted to operation only

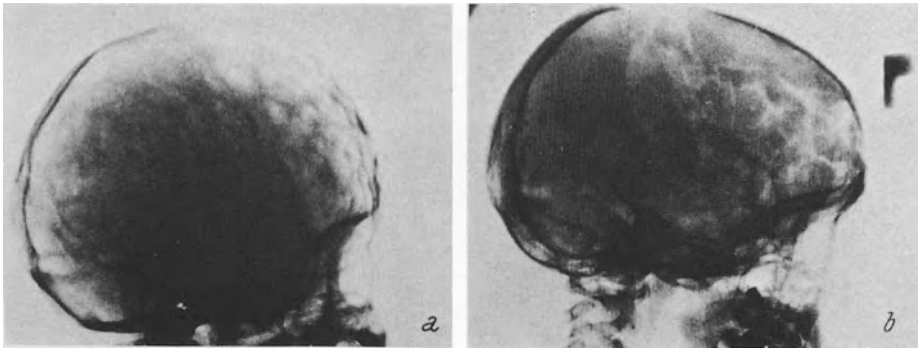


Fig. 9. Oxycephaly in a boy aged 5<sup>6</sup>/<sub>12</sub> years: a and b: radiographs before and 4 years after operation; subtotal regeneration of bone, elongation of forehead, disappearance of digital impressions; c, d, e, f, g, h: photographs of the same boy before, two weeks and 1 month after operation. Note change in configuration of forehead; cosmetic effect satisfactory (Case 20)

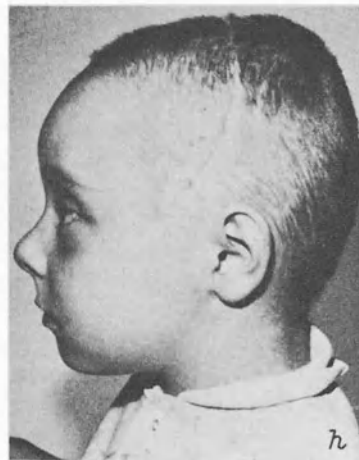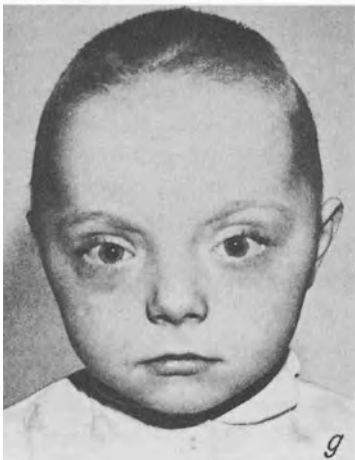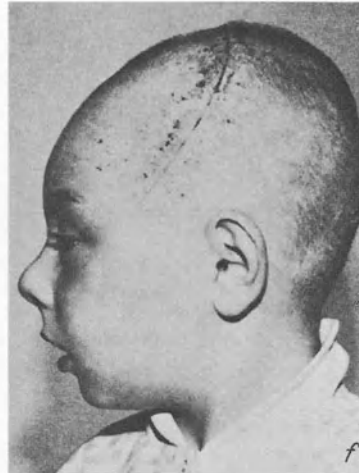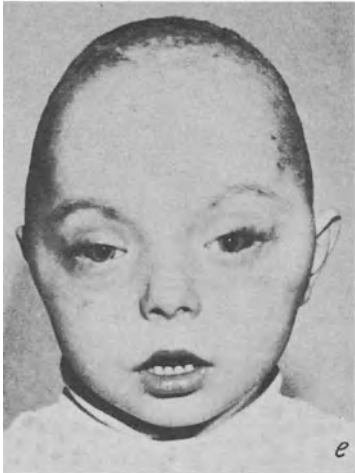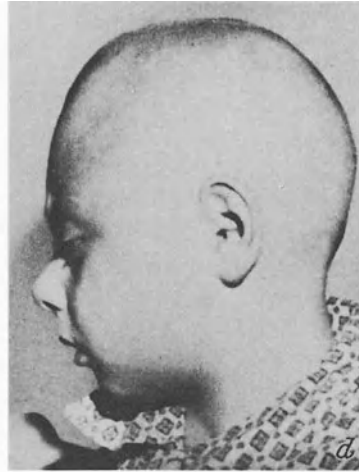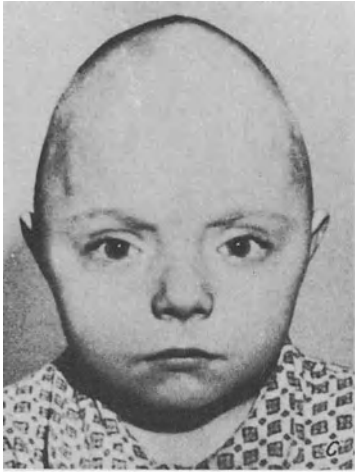after suitable preparation, and the operation was performed under the protection of corticoids. Subsequently no fatal case has been observed.

The cause of this condition might be a lesion of the brain in the hypothalamic region constricted between the lowered base of the skull and the orbital roofs (Fig. 2).

Adrenal tests carried out from 1 to 3 years after operation showed normal function in the great majority of children (disturbances of adrenal function in children with craniostenosis will be the subject of a separate paper). Except for the complication just described, no other difficulties connected with actual surgical procedure have been observed.

2. *Decompression effect, protection of the head, and cosmetic result.* A certain decompression effect, sometimes very marked, may be seen even during operation (Fig. 5). The sulci, visible through the dura mater after removal of the bone as very deep grooves, become shallower and some of them fill up completely even on the operating table. Sometimes the brain expands so considerably that the tension on the skin becomes evident while stitching up.

The greatest change in the capacity of the child's head occurs during the first 2-4 weeks after operation. The head assumes a normal shape, and a distinct tension is felt beneath the skin. This tension of the scalp persists for many weeks



Figs. 9c-h

and the contour of the anterior parts of the head becomes increasingly normal (Figs. 9, 11, 12, and 13). In three children, one of 8 and two of 14 years of age, the scalp was flaccid, non expanded and loose. It may be inferred that compression of the brain in these children was minimal.

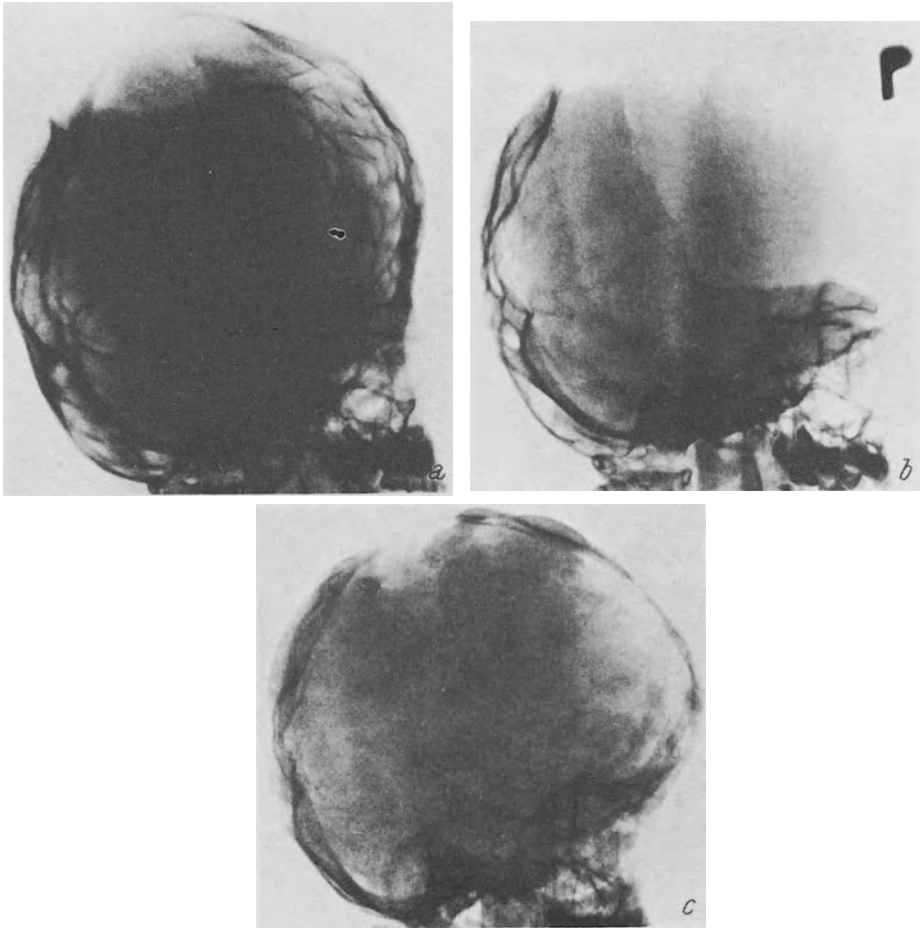
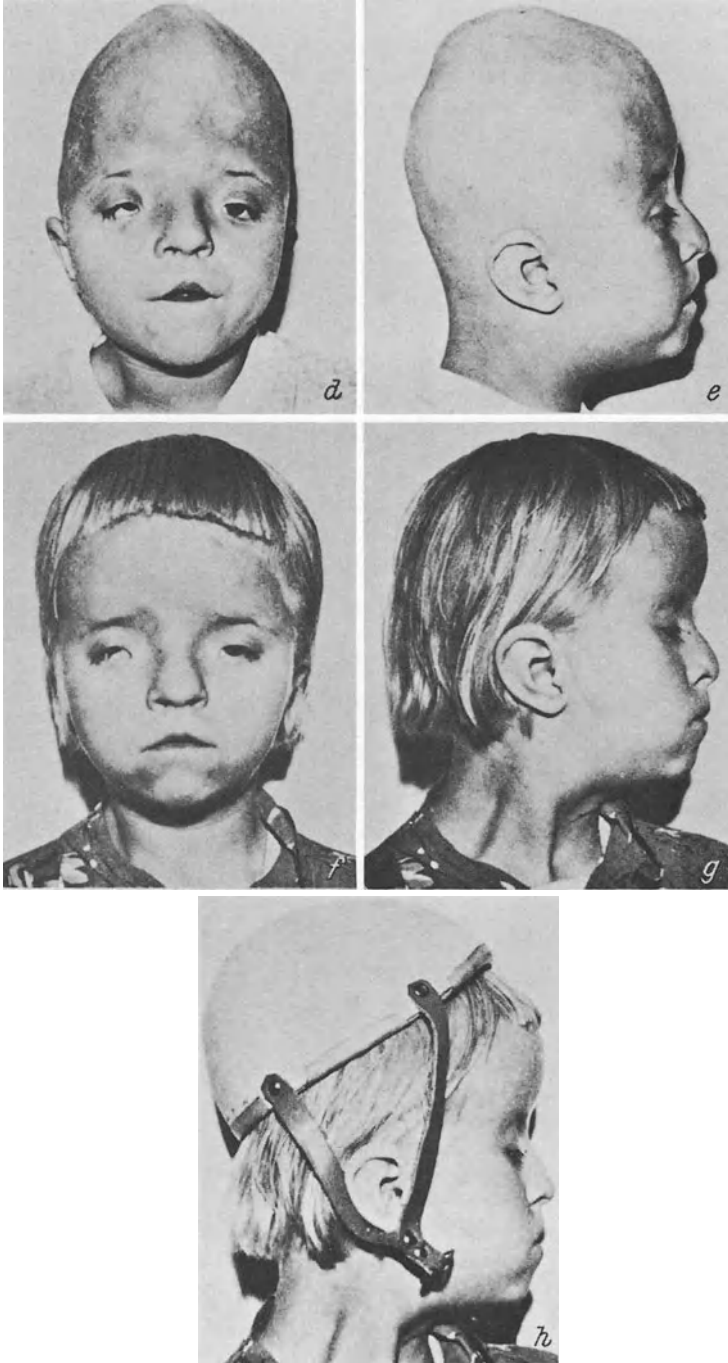


Fig. 10. Tower-skull with anomalies of face, in a girl aged  $5\frac{9}{12}$  years: a, b, c: radiograms before, 2 weeks and 15 months after operation; subtotal regeneration; d, e, f, g, h: photographs of this girl before, and 15 months after surgery. Note change in configuration of forehead. In the meantime the helmet became too small. Cosmetic effect satisfactory (Case 6)

In some children the capacity of the skull before and after operation was measured by means of a plaster cast of the child's head. Points corresponding to the nasion and inion were marked and then joined by a line drawn on the inner surface of the cast. After lining the cast with polyethylene film it was filled with water up to this line, and the volume of water was then measured. The same procedure was repeated 1-3 months after operation. Although this measurement gives only relative values, yet the difference in the capacity before



Figs. 10d-h

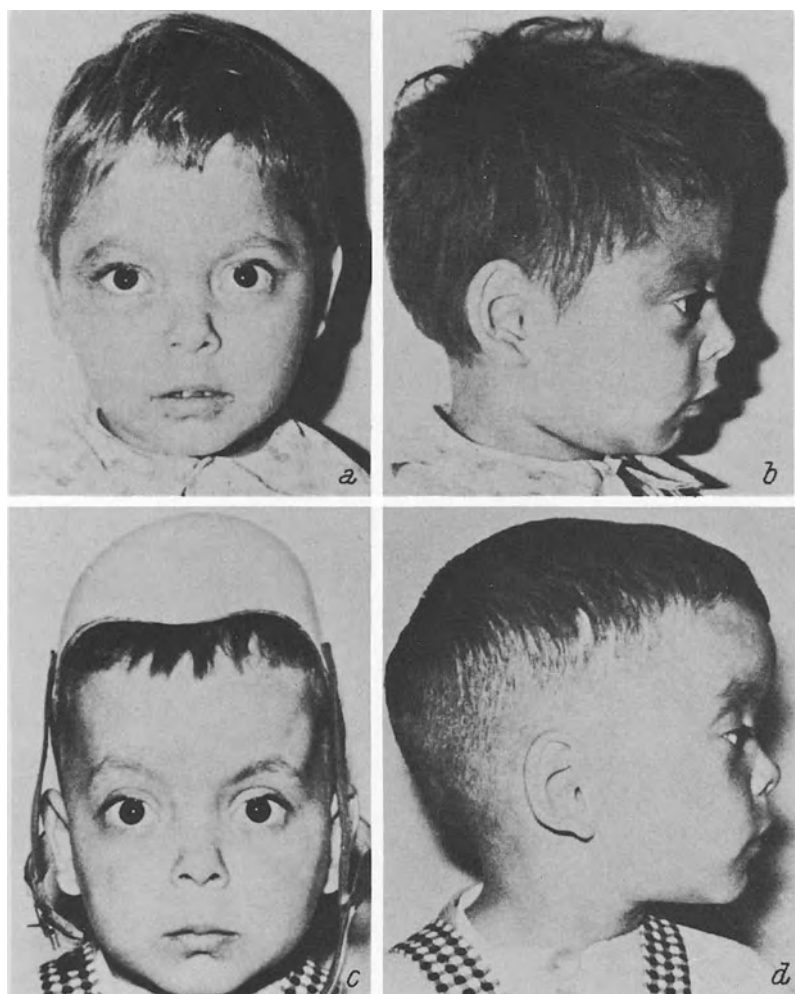

Fig. 11. Photographs of a 5 year old boy with scaphocephaly: a, b: before operation; c, d: 6 months later. Note change in configuration of forehead and enlargement of skull: the helmet became too small. Residual exophthalmos base of skull not resected. Cosmetic result excellent, regeneration subtotal (Case 4)

and after operation gave some idea of how much the child's head had enlarged. The increase amounted to 150–390 cm<sup>3</sup>, or 10–30 per cent (Powiertowski et al. 1970).

It is evident on the radiograms of the skull that configuration of the forehead is corrected after operation. The flat sloping frontal squama is replaced by new bone showing a normal curve (Figs. 9, 10, 11, and 12). The antero-posterior length of the skull (g-I dimension) increases from a few millimetres up to 2.3 cm, *i.e.* up to 13.2 per cent. The greatest breadth of the skull (A-A<sub>1</sub> dimension) revealed an increase up to 2.2 cm., *i.e.* up to 16.9 per cent (Matłosz 1970).

In order to protect the head of the child from possible injury before the bone

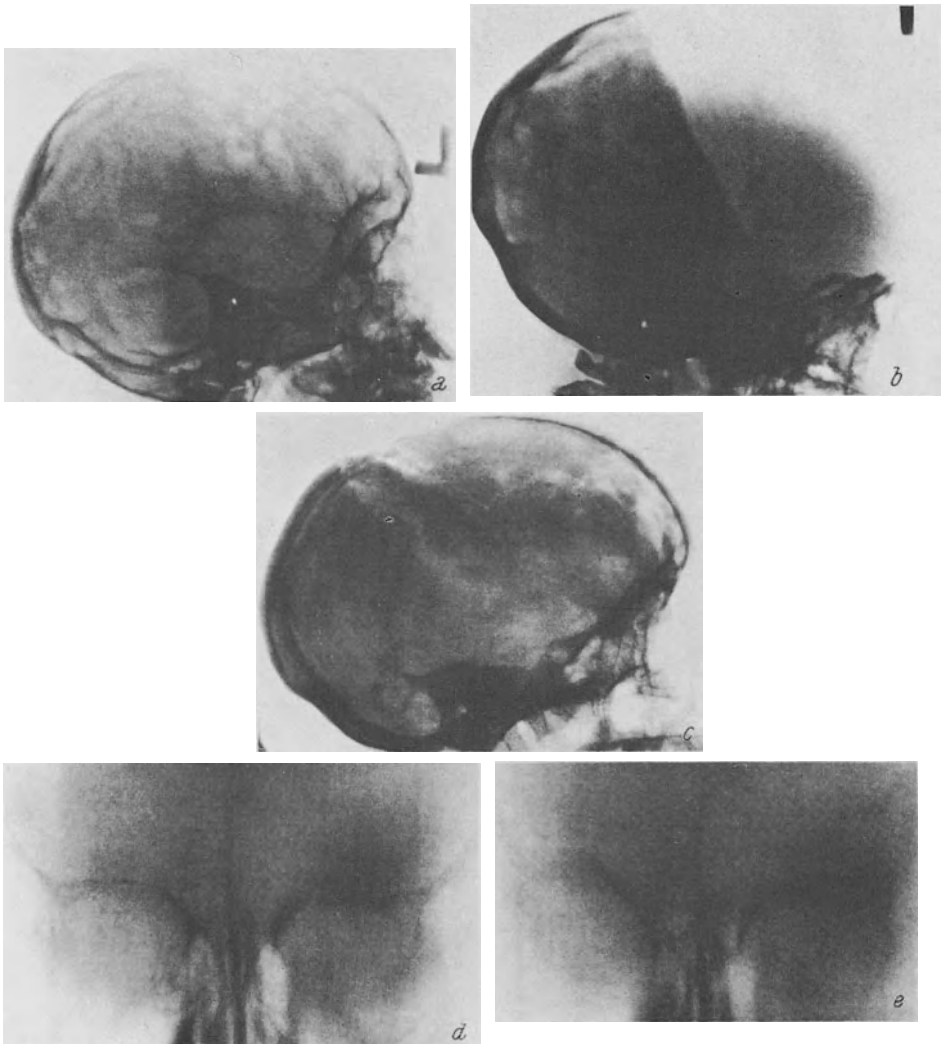
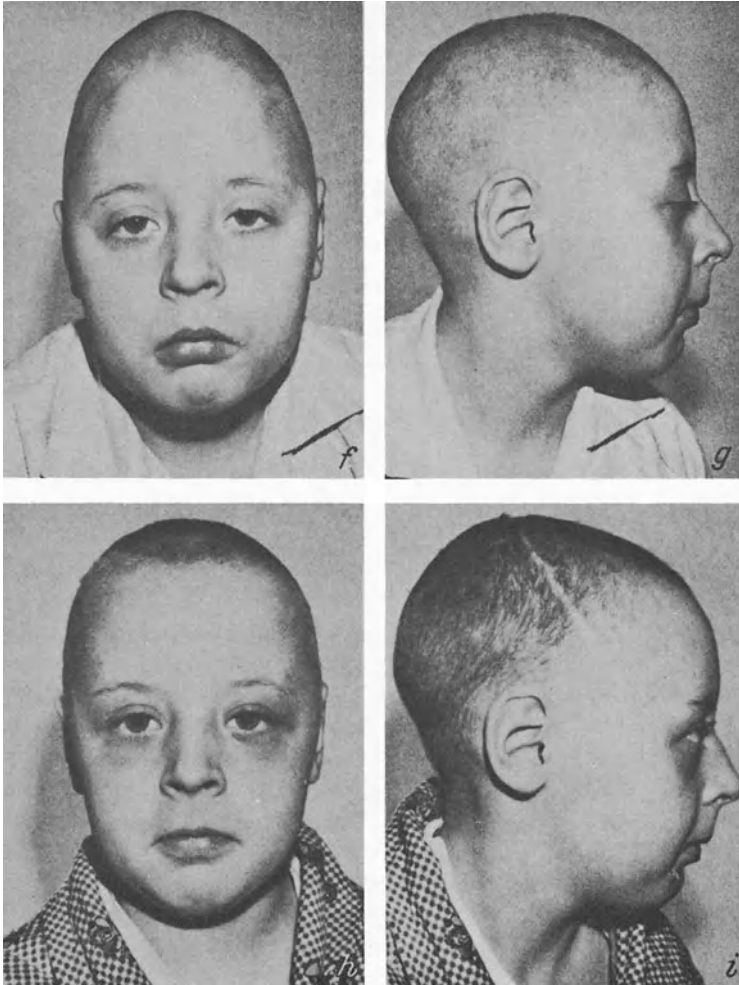


Fig. 12. Coronal and metopic fusion in a girl aged  $8\frac{9}{12}$  years: a, b, c: radiograms before, 1 month, and  $1\frac{7}{12}$  years after operation; note very fine clouding in sites of bone regeneration in b; subtotal regeneration within 19 months; d, e: tomograms showing regeneration of the orbital roofs; f, g, h, i: photographs of this case before and 1 month after operation. Note normalization of shape of the forehead and face in spite of age. Cosmetic result excellent (Case 21)

regenerated, a protective plastic helmet specially made for each individual was used for a period of 3–6 months after operation (Figs. 10 and 11). Since the skull enlarges very quickly during the first weeks and months following surgery it is advisable to prepare a helmet of larger dimensions and at first line it with one or two layers of spongy plastic material, which can be removed as the volume of the skull increases.

It may be added that after this time, depending on the speed of bone regener-

ation, the children did not want to wear these helmets, and their parents considered them unnecessary because they thought the head had become sufficiently hard in the meantime. They observed also that the children had acquired conditioned reflexes protecting the head from injury. Indeed, none of our patients sustained any head injury after operation.



Figs. 12f-i

It is difficult to give an objective evaluation of the cosmetic result of the operation, since the same case is judged differently by the family, strangers and the doctor. Three grades were distinguished in our material: 1. excellent, when the deformation of the head characteristic of craniostenosis disappeared completely or almost completely, and no new deformation resulted from the operation (Figs. 11, 12, 13, and 14); 2. satisfactory, when although some craniostenotic deformation persisted the child's appearance was markedly better than previ-

ously (Figs. 9 and 10); 3. unsatisfactory, when the remaining or substituted craniostenotic deformation impaired or altered the child's appearance to a degree similar to that before operation (Fig. 8).

The results obtained are presented in Table 4. It seems that the removal of the bone of the base of the skull affects the result to a greater degree than the age of the child; this bone was left behind in only one out of thirteen children with an excellent result, but in 6 out of 15 cases and 2 out of 5 cases in the other two groups.

Non-removal of the base of the squamous parts of the frontal bone and the supraorbital margins, however, may cause the base of the forehead to remain constricted, bringing about a compensatory new deformity, as was seen in two

Table 4. *Cosmetic Result and Regeneration of the Skull in Children Operated on*

Age at oper.	Number	Cosmetic result			Regeneration of the skull			
		Excellent	Satisfactory	Unsatisfactory	Total	Sub-total	Partial	
							satis.	unsatis.
1-3 years	6	4	1	1	3	3	—	—
3-5 years	9	3	5	1	2	7	—	—
5-8 years	11	2	8	1	2	7	1	1
Over 8 years	7	4	1	2	1	3	1	2
Total	33 *	13	15	5	8	20	2	3

\* Three fatal cases are not included.

children operated on when we were beginning to introduce our new method (Fig. 8), and in another case, a six-year old boy with oxycephaly whose already formed frontal sinuses limited the extent of bone resection of the skull base.

In two other cases, aged 12 and 14 years, the reason for the unsatisfactory results was too small an expansion of the brain after operation.

3. *Regeneration of the skull.* Regeneration of the resected bones of the skull begins about 30 days after operation. At first it can be ascertained only by palpation, when small hardish lamellae up to 1 cm in diameter and resembling cartilage may be felt. These lamellae gradually become larger and more easily palpable, next they fuse together in larger conglomerations, and begin to close the defect in the skull. The rate of regeneration is very individual. In some children regeneration proceeds very quickly (Figs. 12, 13, 14); in others, however, the process of regeneration could be ascertained on palpation only after 3 months had elapsed, although all children received suitable preparations which accelerated osteogenesis.

These first tiny lamellae of newly-forming bone are also visible in the radiographs of the skull, usually as early as one month after operation, in the form of delicate opacities or clouding (Fig. 12b). It should be emphasized that at the beginning of bone regeneration there is a divergence between the result of palpation and radiological findings; the first may indicate that the skull is already partially "closed", while in the radiographs large defects between the portions



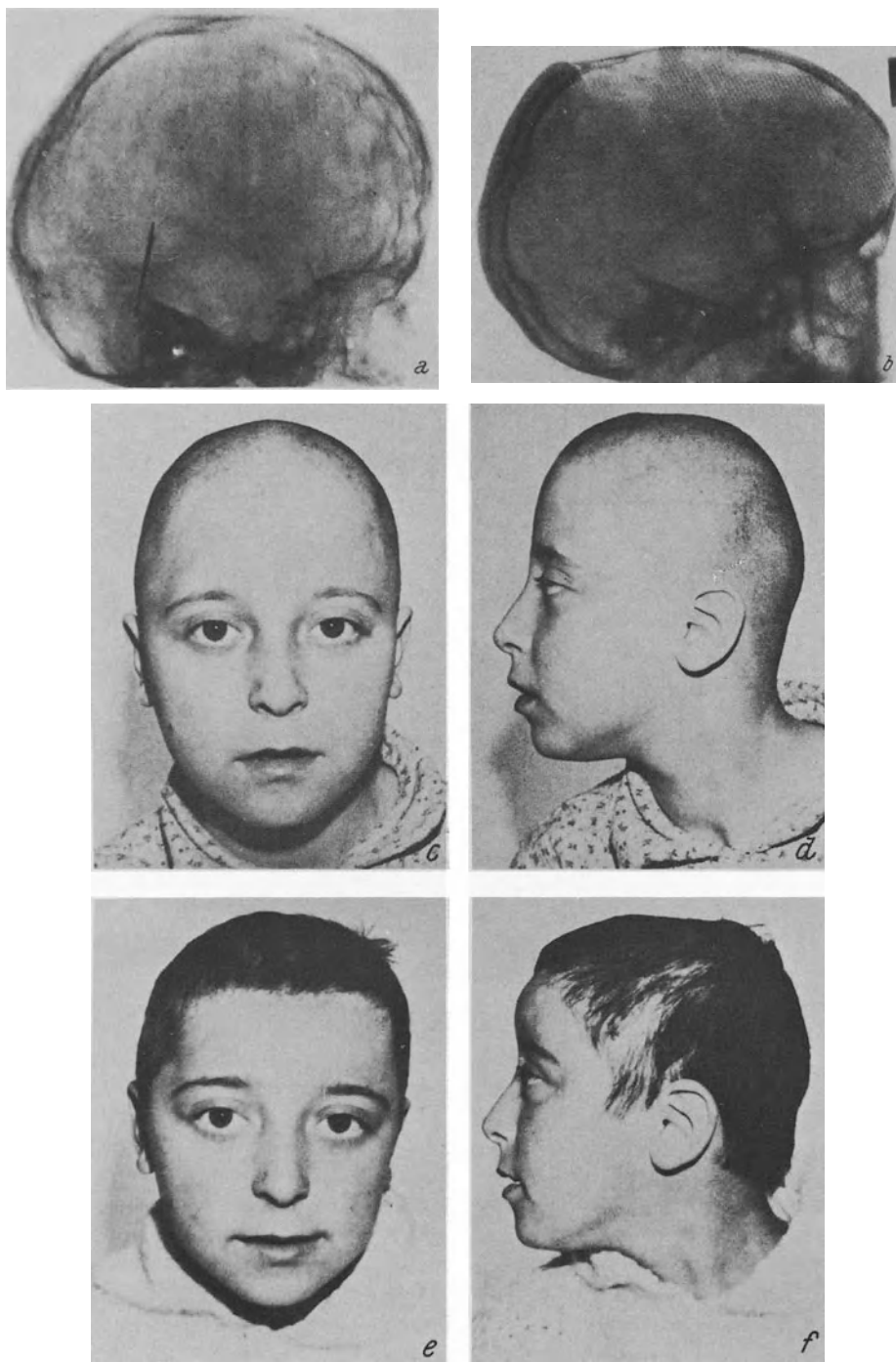


Fig. 13. Subtotal regeneration of the skull in a girl aged  $9\frac{4}{12}$  years with oxycephaly: a, b: radiograms before, and  $1\frac{9}{12}$  years after operation with almost complete regeneration: c, d, e, f: photographs before, and 2 months after operation. Note change in configuration of forehead. Cosmetic effect excellent (Case 17)

of regenerated bone are seen (Fig. 15a). Clinically, the process of regeneration takes from about 1 year and 6–9 months to 3–4 years, but radiologically it is sometimes much longer, and even after 7–10 years may still be incomplete.

Complete regeneration, confirmed both by palpation and by radiological examination has occurred up to the time of writing in 8 out of 33 children, as

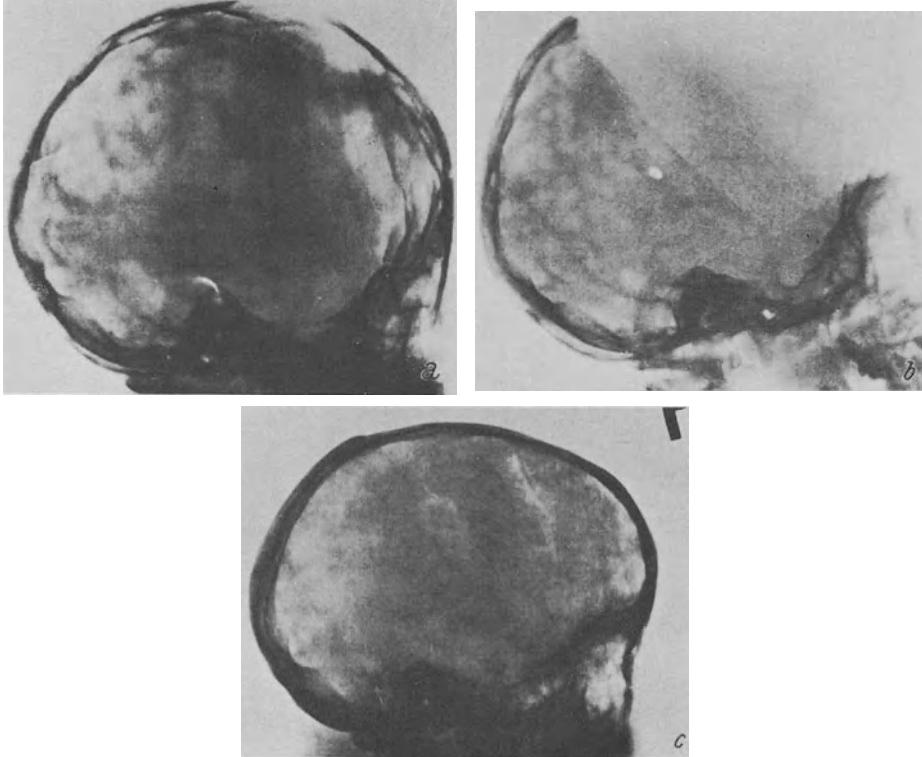


Fig. 14. Complete regeneration of the skull and excellent cosmetic result in a boy aged  $5\frac{2}{12}$  years with oxycephaly: a, b, c: radiograms of the skull before, 2 weeks, and four years after operation. Note complete regeneration of the skull and disappearance of digital impressions; d, e, f, g: photographs of this boy before and two years after operation (Case 10) (according to Powiertowski et al. 1970)

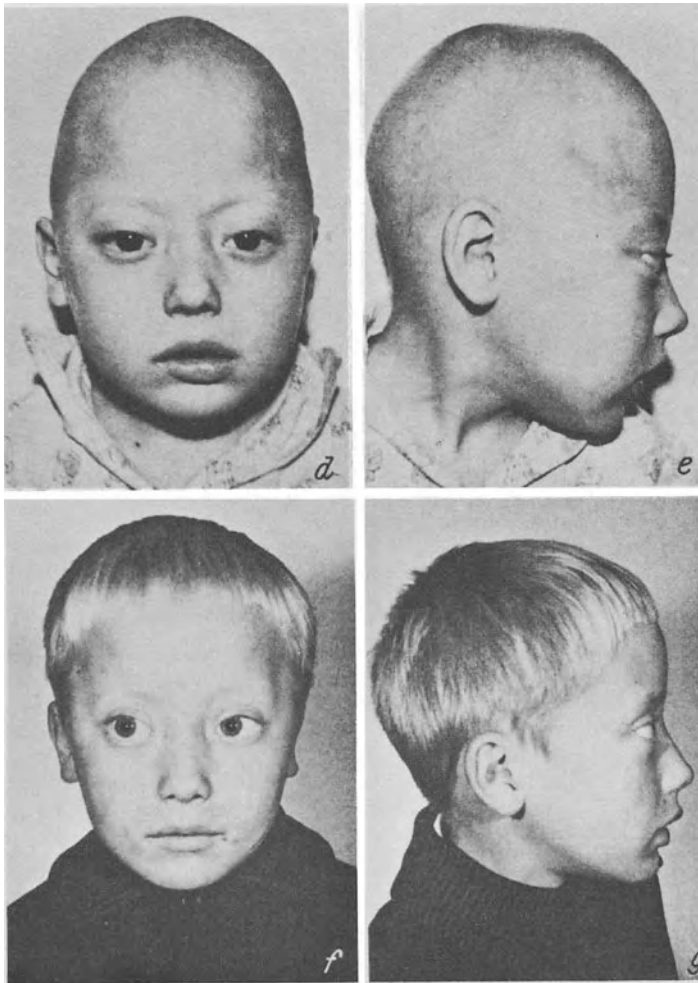
seen in Table 4 (Figs. 8 and 14). From the clinical point of view, however, subtotal regeneration is quite sufficient, and the skull may be considered as closed. Subtotal means that only narrow furrows or small defects can be felt between the plates of regenerated bone. Jointly complete and subtotal regeneration of the bone has been found in 28 patients, *i.e.* circa 84 per cent.

In two other children, aged 6 and 12, cranial regeneration was recognized as being scarcely sufficient from the practical point of view. In one case only about 3 years has elapsed since operation, and contact was lost with the other patient six years after operation.

Regeneration was considered insufficient in three children aged 7,  $14\frac{6}{12}$ , and  $14\frac{7}{12}$  years. In the first of these 4 years have not yet elapsed since surgery,

the second was operated on 7 years ago, and the third (Case 23) died about two years after operation (see illustrative cases). None of them used a protective helmet longer time than 6 months or required cranioplasty.

In one case (Case 23) it was possible to carry out an anatomo-pathological examination of newly formed bone (vide illustrative Case 23). At operation it



Figs. 14d-g

was evident that this bone was formed from the dura mater. There was no separable layer of dura on the inner surface of this bone, which was very smooth and looked like typical dura mater. The new bone showed thin but distinct inner and outer tables and diploe in process of formation (Fig. 15). It was difficult to dissect the external surface of this bone from the periosteum and galea. Post-mortem examination of this case disclosed numerous cartilaginous or osseous

laminae growing together, 1–3 mm in thickness, with evident diploe formation (Powiertowski et al. 1970).

The histological examinations were carried out by E. Simon M.D. of the Institute of Pathological Anatomy, Poznań Academy of Medicine.

“The histological picture of the regenerated cranial bone differed according to the region examined.

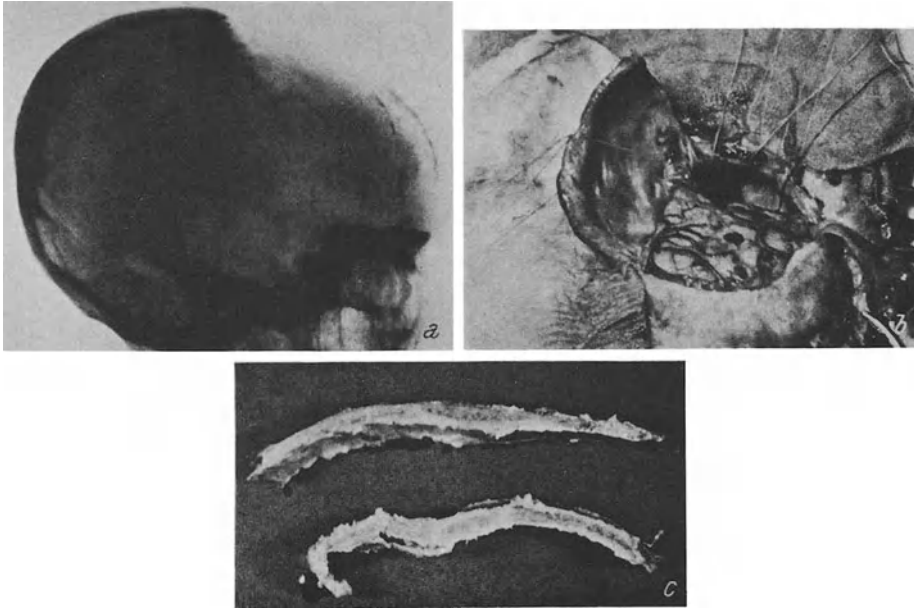


Fig. 15. Photographs of newly formed bone in a patient aged  $14\frac{8}{12}$  years operated on two years ago and reoperated on for closure of a cranio-nasal fistula with cerebrospinal fluid rhinorrhoea: a: radiogram of the skull taken 15 months after operation with unsatisfactory bone regeneration; b: a flap of regenerated bone is elevated; note smooth surface of this flap formed of inner layer of the dura; c: transverse section of the same flap taken at post-mortem; note formation of both tables of regenerated bone and diploe between them (Case 23, see details in the text)

The formation of osseous and osseoid trabeculae, irregular in thickness and course, was observed in the frontal bone adjacent to the frontal sinuses and orbital margins. In sites where well-preserved periosteum was present, the formation of the outer table was also seen. Accumulations of numerous large cells with characters of stimulated osteoblasts, having abundant cytoplasm and visible processes were found in the vicinity of the trabeculae in process of formation. In some places these cells were arranged in several layers. A few osteoclasts were occasionally present round the formed trabeculae, and manifestations of bone resorption were found. Large osteocytes situated in irregularly shaped cavities were found in the texture of the osseous trabeculae. Like osteoblasts, these cells were usually distributed irregularly on the circumference of the trabeculae. Using Masson's four-stain method, the staining of the trabeculae was found to differ, the circumference taking on a blue colour and the central part

red. The connective tissue between the trabeculae was of a loose character, with the presence of fat cells. The blood vessels in this region were numerous and as a rule wide.

The picture of the regenerating bone of the vault of the skull was different. On the edge of the regenerating bone, between the dura mater and galea aponeurotica, a nidus of fusiform fibroblast-like cells was observed. Among these,

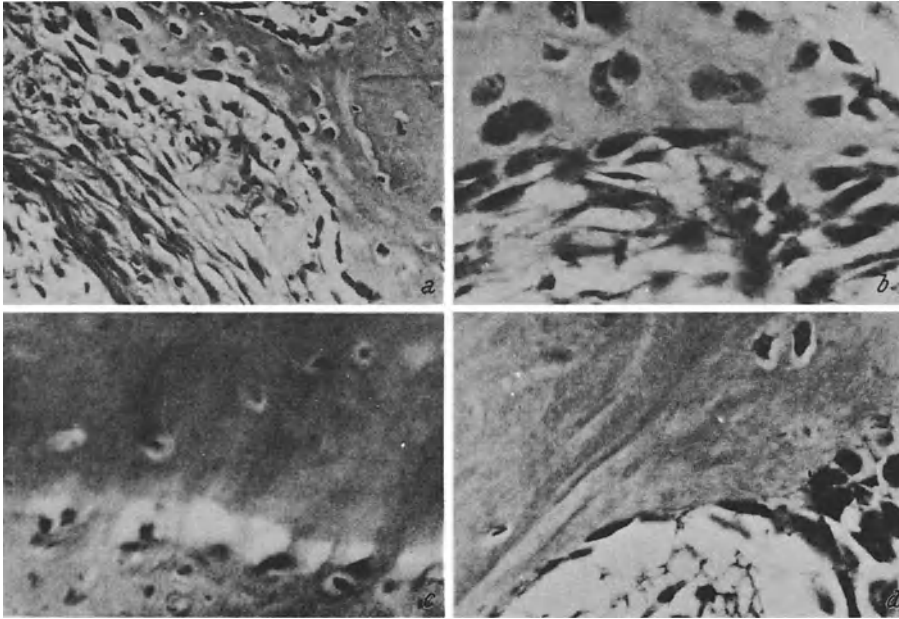


Fig. 16. Photographs of histological examination of regenerated bone of the skull: a: fragment of periosteum from a newly formed osseous trabecula with the presence of numerous osteoblasts on the circumference, HE,  $\times 250$ ; b: osseous trabecula in process of formation, of foetal character, with marked proliferation of osteoblasts on the circumference. Osteoblastic processes visible both in the vicinity of the trabecula and in its texture, HE,  $\times 500$ ; c: ossification on a connective tissue substrate with visible contour of connective tissue fibres, HE,  $\times 500$ ; d: unequal accumulations of osteocytes in the texture of an osseous trabecula and osteoblasts on its circumference, HE,  $\times 500$  (Case 23)

an amorphous substance resembling osseoid tissue was present. Islets of osseoid tissue were also present, surrounded by a few osteoblasts which only sometimes exhibited signs of stimulation. The majority of these cells were small, with scanty cytoplasm and a dark pyknotic nucleus. A band of collagenous fibres was observed in the region of the osseoid tissue among the amorphous mass of osseo-mucoids. The formation of osseous laminae, both towards the dura mater and towards the galea, was seen in the central part of the regenerated bone. These tables, both inner and outer, were not of uniform thickness and were unevenly calcified. The osteocytes in the region of the tables were irregularly distributed and differed in size. Between these tables were present irregularly-arranged osseous trabeculae, in the texture of which aborted Haversian canals

surrounding the blood vessels were observed. Loose connective tissue with numerous blood vessels was seen between the trabeculae.

*Conclusion.* The picture of regenerated bone as compared with osteogenesis in the region of the head of a three or four month old foetus exhibited great similarity. In places the regenerating bone resembled foetal bone, and the differences in regeneration, depending on the topography, also resembled various pictures seen in the foetus”.

4. *Neurological results.* As already mentioned, all symptoms of increased intracranial pressure regressed in all children, and markedly deepened digital impressions disappeared in successive radiographs of the skull (Figs. 9 and 14).

Table 5. *Neurological Improvement in Children Operated on*

Age at oper.	Number	Degree of improvement	
		Evident	Minimal
1-3 years	6	5	1
3-5 years	9	8	1
5-8 years	11	8	3
over 8 years	7	3	4
Total	33 *	24	9

\* Three fatal cases are not included.

The cerebral lesions remained, although their clinical manifestations were considerably lessened e.g. distinct improvement in the EEG and were no longer of a progressive character.

Exophthalmos completely subsided or only vestiges remained (Fig. 11). Atrophy of the optic nerves naturally did not recede, although some parents considered the child's sight had either distinctly improved or had ceased to deteriorate. In spite of this five children with marked deterioration of vision before operation attended schools for the blind, though none of them was totally blind in both eyes. Defective hearing in two children did not show any significant objective improvement. Epileptic seizures became rarer and no longer took the form of grand mal. It may be assumed, however, that these children were not always systematically treated with anticonvulsants before operation.

Interpretation of the mental improvement in these children is difficult, since before operation they frequently, on account of their illness, were not subjected to educational processes to the same extent as healthy children of the same age. Now, quite the opposite pertains, they are given special care. The I.Q. after operation (its evaluation is relative in small children, especially those with symptoms of intracranial hypertension) was higher than previously in over half the cases by 7-17 degrees, and in circa two-fifths by 0-7 degrees, but in two cases even fell by 4 and 9 degrees.

In defining improvement in the children operated on, two grades of evaluation were accepted: “evident improvement”—when the child's condition markedly

improved in the opinion of the parents and of the doctor (improvement of the I.Q. by at least 7 degrees was most frequently found in this group), and "minimal improvement"—for all other children. The results are given in Table 5 and, as was to be expected, are better in younger children than in older. Among the children operated on, 16 have attended or are attending normal schools (though some have difficulty with their lessons), 10 go to special schools, and 5 to schools for the blind.

The long-term results of treatment of craniostenosis by the method described will be the subject of a separate paper. A detailed discussion of results, including biochemical, endocrinological and psychometric studies taking into consideration the family and environment of the children, is also being prepared for publication.

### Conclusion

The following conclusion may be drawn from evaluation of the results of treating 33 children with advanced craniostenosis by extensive resection of the anterior part of the vault and base of the skull rendering possible the regeneration of the resected bone.

1. The method may be useful in the surgery of advanced forms of craniostenosis, particularly in oxycephaly. Symptoms of intracranial hypertension with marked deepening of the digital impressions are the main indication for its application. This method is not without risk in cases of adrenal insufficiency.
2. Functional and cosmetic improvements are remarkable, specially in children under 5 years of age.
3. Regeneration of the skull takes place and in the majority of patients is sufficient to close the skull and protect the brain.
4. This method might be also applied in very small children up to one year of age, with oxycephaly and with marked digital impressions.

### Illustrative Cases

*Case 2.* N. I., three-year old girl. Oxycephaly. Headache, nausea, vomiting, protrusion of eyeballs, decreased visual acuity of optic nerves. Operated on in 1961. Resection of vault omitting base of squamous portion of frontal bone. No resection of base of skull. Evident neurological improvement. Cosmetic result unsatisfactory: deformation of forehead caused by residual squamous part of frontal bone. Total regeneration of skull (Fig. 8).

*Case 4.* M. J., five-year old boy. Fusion of the sagittal and coronal sutures. Headache, nausea, vomiting. Exophthalmos, very marked decrease in visual acuity, atrophy of optic nerves. Mental retardation. Only bone of vault removed. Subtotal regeneration of skull. Evident clinical improvement, but remained practically blind. Attends school for the blind. Noted that protective helmet too small 6 months after operation (Fig. 11).

*Case 6.* K. M. Girl aged 2 years 9 months. Oxycephaly. Typical tower skull. Congenital facial defects. Headache, impaired vision, atrophy of optic nerves, hearing markedly impaired, retarded mental development. Great cosmetic, clinical and neurological improvement. Subtotal regeneration of skull. Considerable enlargement of head after operation (Fig. 10).

*Case 7.* K. A. Boy aged 1 year 7 months. Scaphocephaly. Atrophy of optic nerves, retarded mental and physical development. Resection only of vault of skull.

Very marked expansion of brain during operation. "Rapid" regrowth of bones of skull (Fig. 5).

*Case 10.* B. J. Boy aged 5 years 2 months. Oxycephaly. Headache, papilloedema of right and secondary atrophy of left optic disc. Exophthalmos, marked decrease in visual acuity, mental retardation, epilepsy. Bone of vault and base of skull resected. Excellent cosmetic and neurological result. Total regeneration of skull after 2 years. I. Q. improved from 90 to 100 in two years (Fig. 14).

*Case 17.* C. S. Girl aged 9 years 4 months. Oxycephaly, Headache, nausea, vomiting, exophthalmos, atrophic changes in ocular fundus, impaired vision, epilepsy, Bones of vault and base of skull resected. Very marked clinical and excellent cosmetic improvement. In spite of age subtotal regeneration of bone after one year (Fig. 13).

*Case 20.* L. A. Boy aged 5 years 7 months. Fusion of sagittal and metopic sutures. Headache, nausea, vomiting, bilateral choked disc, increasing protrusion of eyeballs, mental retardation, adrenal insufficiency. Bones of vault and base of skull resected. Great clinical and cosmetic improvement. Subtotal regeneration of skull after 3½ years. Note change in configuration of forehead (Fig. 9).

*Case 21.* P. H. Girl, aged 8 years 9 months. Fusion of sagittal and coronal sutures. Headache, exophthalmos, impaired vision, atrophy of optic nerves, mental retardation, adrenal insufficiency. Bone of vault and base of skull resected. In spite of age, marked clinical but lesser cosmetic improvement. Subtotal regeneration of skull after 3 years 10 months. Note regeneration of orbital roofs in tomograms (Fig. 12).

*Case 23.* S. T. Boy aged 14½ years. Fusion of coronal and metopic sutures. Meningocele intranasale. Headache, nausea, vomiting. Considerable loss of vision, atrophy of optic nerves, progressive exophthalmos, mental retardation, adrenal insufficiency. Only bones of vault and lateral parts of the orbital margins resected. Cerebro-nasal hernia not removed, relying on its diminution after decompression of brain. Marked clinical and cosmetic improvement after operation. Regeneration of the skull proceeded slowly (Fig. 15 c). Nearly two years after operation, in another medical centre, attempted removal of meningocele intranasale as a pseudopolyp. Cerebrospinal fluid rhinorrhoea followed by meningitis. Re-admitted to our Department on account of inefficacy of pharmacological treatment, and the patient was reoperated on for closure of craniobasal fistula. At operation, new bone, regenerated mainly from the outer layer of the dura mater, was found in the site of the resected calvaria (Fig. 15 a). In spite of closure, meningitis did not respond; the patient died two weeks after operation.

At post-mortem regenerating bone was taken from various parts of the skull for histological and histochemical examination. This is the only case in which it was possible to do this (Figs. 15 and 16).

*Case 31.* B. A. Four-year old boy. Fusion of the coronal and metopic sutures. Headache, exophthalmos, atrophy of optic nerves. Bones of vault and base of skull resected. Very rapid bone regeneration, great clinical and cosmetic improvement. Note tomograms after resection of the base of skull (Fig. 7).

*Case 33.* P. D. Boy, aged 4 years 3 months. Oxycephaly. Headache, papilloedema and atrophy of optic nerves, exophthalmos, mental retardation. Bones of vault and base of skull resected. Excellent cosmetic and neurological result. Subtotal regeneration of skull. Adrenal insufficiency. Note spicules and partitions on base of skull in tomograms (Fig. 2).

#### Addendum

Figs. 3 a, 6 a, 14 a, b, c, e, f, g, 15 b have already been published in the author's article in *Annales de Chirurgie* 24 (1970), 1175—1180.



## References

1. Anderson, F. M., Johnson, F. L., 1956: Craniostenosis. A modification in surgical treatment. *Surgery* 40, 961—970.
2. — Geiger, L., 1965: Craniostenosis. A survey of 204 cases. *J. Neurosurg.* 22, 229—240.
3. Bauer, K. H., 1932: Die zirkuläre Kraniotomie als Entlastungsreparatur bei drohender Turmschädelbildung und bei nichtlokalisierbaren Hirngeschwülsten. *Dtsch. Z. Chir.* 237, 402—421.
4. Faber, H. K., Towne, E. B., 1927: Early craniectomy as a preventive measure in oxycephaly and allied conditions, with special reference to the prevention of blindness. *Amer. J. Med. Sci.* 173, 701—711.
5. — — 1943: Early operation in premature cranial synostosis for the prevention of blindness and other sequelae. *J. Pediat.* 22, 286—307.
6. Fishman, M. A., Hogan, G. R., Dodge, P. R., 1971: The concurrence of hydrocephalus and craniostenosis. *J. Neurosurg.* 34, 621—629.
7. Fowler, F. D., Ingraham, F. D., 1957: A new method of applying polyethylene film to the skull in the treatment of craniostenosis. *J. Neurosurg.* 14, 584—586.
8. Giblin, N., Alley, A., 1944: Studies on skull growth: coronal suture fixation. *Anat. Rec.* 88, 143—153.
9. — — 1942: A method of measuring bone growth in the skull. *Anat. Rec.* 83, 381.
10. Gordon, H., 1959: Craniostenosis. *Brit. Med. J.* 11, 792.
11. Hemple, D. J., Harris, L. E., Svien, H. J., Holman, C. B., 1961: Craniostenosis involving the sagittal suture only: guilt by association? *J. Pediat.* 58, 342—355.
12. Ingraham, F. D., Matson, D. D., Alexander, E., 1948: Experimental observations in the treatment of craniostenosis. *Surgery* 23, 252—268.
13. — Alexander, E., Matson, D. D., 1948: Clinical studies in craniostenosis. *Surgery* 24, 518—541.
14. King, J. E. J., 1942: Oxycephaly. *Ann. Surg.* 115, 488—506.
15. Kukulska, Z., 1964: Przedwczesne zarośnięcie szwów czaszki. *Folia Medica Cracoviensia* 6, 553—584.
16. Laitinen, L., 1956: Craniostenosis. Premature fusion of the cranial sutures. *Ann. Paed. Fenniae* 2, Suppl. 6.
17. McLaurin, R. L., Matson, D. D., 1952: Importance of early treatment of craniostenosis. *Pediatrics* 10, 637—651.
18. Matłosz, Z., 1970: Wpływ operacji sposobem Powiertowskiego na niektóre pomiary antropometryczne czaszki kraniostenotycznej. *Pol. Tyg. Lekarski* 25, 918—920.
19. — 1970: Wpływ operacji sposobem Powiertowskiego na stan podmiotowy i przedmiotowy dzieci z kraniostenozą. *Pol. Tyg. Lekarski* 25, 958—961.
20. — Powiertowski, H., 1970: Regeneration of the bones of the cranial vault in children with stenotic cranium. *Folia Morphologica* 29, 306—315.
21. Matson, D. D., 1960: Surgical treatment of congenital anomalies of the coronal and metopic sutures. Technical note. *J. Neurosurg.* 17, 413—417.
22. Morich, Christa, 1967: Craniostenosen. Beobachtungen bei 49 Kindern aus Hamburg. *Diss. Hamburg.*
23. Mullan, S., 1960: Late moulding of the scaphocephalic skull. *J. Dis. Child* 99, 50—60.
24. Müller, D., Röhricht, C., 1967: Die Suturenknochen des Schädels als Symptom intrakranieller Drucksteigerung. *Sammlung: Zwanglose Abhandlungen aus dem Gebiete der Psychiatrie und Neurologie.* Jena: VEB G. Fischer.
25. Pawl, R. P., Sugar, O., 1972: Zenker's solution in the surgical treatment of craniostenosis. *J. Neurosurg.* 36, 604—607.
26. Pemberton, J. W., Freeman, J. M., 1962: Craniostenosis. *Amer. J. Ophthal.* 54, 641—650.

27. Powiertowski, H., Matłosz, Z., 1965: The treatment of craniostenosis by a method of extensive resection of the vault of the skull leading to bone regeneration. *Excerpta Medica. International Congress Series. No. 93, 232. Third International Congress of Neurological Surgery (Abstract).*
28. — — 1970: Effets du traitement de la craniosténose par résection de la voûte du crâne. *Ann. Chir. 24, 1175—1180.*
29. Ryöppy, Soini, 1965: Transplantation of epiphyseal cartilage and cranial suture. *Acta Orthopædica Scandinavica. Suppl. No. 82. Copenhagen.*
30. Samra, K., Sorour, O., 1968: Bilateral flap operation for craniosynostosis. *J. Neurosurg. 29, 591—596.*
31. Seeger, J. F., Gabrielsen, T. O., 1971: Premature closure of the frontosphenoidal suture in synostosis of the coronal suture. *Radiology 101, 631—635.*
32. Shillito, J., Jr., Matson, D. D., 1968: Craniosynostosis: a review of 519 surgical patients. *Pediatrics 41, 829—853.*
33. Simmons, D. R., Peyton, W. T., 1947: Premature closure of the cranial sutures. *J. Pediat. 31, 528—547.*
34. Sorour, O., 1961: The four flap operation. A new operation for treatment of craniosynostosis. *J. Neurosurg. 18, 86—90.*
35. Teng, P., 1962: Premature synostosis of the sagittal suture and its treatment. A modification of the linear craniectomy and the use of synthetic fabrics. *J. Neurosurg. 19, 1094—1097.*
36. Tessier, P., 1971: Traitement des dysmorphies faciales propres aux dysostoses cranio-faciales (DCF) maladies de Crouzon et d'Apert. *Neu.*
37. Thurel, C., 1968: Craniosynostoses prématurées. *Revue clinique, étude critique et comparative des thérapeutiques classiques et d'une méthode récente: la craniectomie totale. Faculté de Médecine de Paris. Thèse pour le Doctorat en Médecine. Paris: Edition A. G. M. P.*
38. Tod, P. A., Yelland, J. D. N., 1971: Craniostenosis. *Clin. Radiol. 22, 472—486.*
39. Van der Werf, A. M. J., 1971: Proceedings of the Society of British Neurological Surgeons, 24—26. IX. 1970, held in Hull. *J. Neurol. Neurosurg. Psychiat. 34, 104—109.*

# Extra-Dural Hematoma

E. ZANDER and R. CAMPICHE

Neurosurgical Department, University Cantonal Hospital,  
Lausanne (Switzerland)

## Contents

Introduction .....	121
History .....	122
General Considerations .....	124
Frequency .....	124
Localization .....	124
Sex and Age .....	125
Clinical Signs .....	125
Fractures of the Skull .....	125
Free Interval .....	126
Motor Disorders .....	127
Eye Signs .....	128
Pulse and Blood Pressure .....	128
Other Signs .....	128
a) Vomiting .....	128
b) Anemia .....	129
c) Cerebrospinal Fluid .....	129
Angiography .....	129
Echo-Encephalography .....	131
Treatment .....	131
Results and Conclusions .....	133
References .....	137

## Introduction

The extra-dural hematoma (or epi-dural if the Greek terminology is used) is in its classic form a wellknown clinical entity taught in all medical schools. This state of affairs is excellent but has unfortunately also a negative aspect to it, the diagnosis being still too often missed when the clinical findings do not correspond with the classical characteristic findings usually expected. The publication of more and more cases with an atypical evolution and cases of hematomas in unusual sites show that the diagnosis is not

always easy and that the classical clinical findings are far from being the rule. Weinman<sup>48</sup> for example only found the classical signs in 50% of his series of 86 cases, and Jamieson<sup>24</sup> only 4 such cases in his study of 167 cases. The evolution of the hematomas in children and in old people often differs from that of the adult. If one considers the fact that the basic predominating phenomena in the formation and in the extension of the extra-dural hematomas are the source of conflicting opinions, it is easy to understand that the problem of extra-dural hematoma is still of great interest. To be convinced of this we just have to point out the discrepancy which still exists, in spite of technical and diagnostic progress, between the number of extra-dural hematomas found clinically and operated on, and the number discovered at autopsy. Thus, in 1964, Heyser<sup>19</sup> compared the frequency of extra-dural hematomas clinically found (2 to 3% of all head injuries hospitalised) to that found in the autopsy room (5.4 to 13.6%). This difference is even more remarkable in the cases of extra-dural hematomas in unusual sites; in 1963, Vigouroux<sup>46</sup> also showed the difference between the clinical frequency of frontal hematomas (1 to 5%) and those discovered at autopsy (between 17 and 21%). Moreover, in studying the literature, one finds that very few series of cases have a mortality rate approaching the 20% of McKissock<sup>32</sup>, a figure higher than the basic unavoidable mortality rate of 10% estimated by Hooper in 1959 (quoted by Jamieson<sup>24</sup>). Certainly fundamental ideas are slowly being modified. For example, carotid angiography, which only a short while ago was contra-indicated because of the loss of time involved, is now more often performed and greatly contributes to a reduction in mortality to nearly 10%, the basic unavoidable mortality rate.

### History

The extra-dural hematoma has been known for a long time. The first classical description in 1750 is attributed to Jean-Louis Petit (Queloz<sup>38</sup>). This author mentioned even then a very striking feature of this post-traumatic complication calling it the lucid interval which has become known now as the free interval. Hill, in 1772, (Stevenson<sup>42</sup>) and then Abernethy in 1811 (Gurdjian<sup>18</sup>) reported cases of extra-dural hematomas, also drawing attention to the presence of a free interval. However, it is to Jakobsen (1815) that several authors (for example McKissock<sup>32</sup> and Zingesser<sup>54</sup>) attribute the first completely typical clinical description of the extra-dural hematoma originating from the rupture of a middle meningeal artery.

In the historical outline, it is not just the clinical description that is so important since, as we said in the introduction, it is realised more and more nowadays that the classical development is far from being the rule. It is interesting on the other hand to note that very soon people became involved in finding and explaining the primary mechanisms of such a posttraumatic complication. Primarily, it was thought that the hematoma was of a venous origin; then Keill in 1727 (quoted by Gallagher<sup>13</sup>) assumed that the middle meningeal artery and its branches occupied the bony grooves in the temporal region of the skull, the origin thus becoming an arterial one. This explained how a fracture in this region could cause an arterial tear or rupture responsible for the extra-dural hematoma. Finally, in 1890, Gérard Marchant described a "particular zone

where the dura mater is easily detached not only by the anatomist's forceps, but also by the collection of blood produced at this level following damage to the middle meningeal artery''; this zone, which Marchant called the detachable zone, measures about 13 cm in length and 12 cm in height, extending from the posterior border of the lesser wing of the sphenoid to 2 to 3 cm from the internal occipital protuberance and neighbouring the superior longitudinal sinus as far as the transverse line which joins the apex of the lesser wings of the sphenoid to the base of the petrous bone (Testut<sup>44</sup>). Thus there was a satisfactory explanation for the free interval, it being the time necessary for the hematoma to form and cause cerebral compression, following the post-traumatic rupture of the middle meningeal artery or of one of its branches; there was as well a logical explanation for the usual temporal site of this hematoma. However, in 1912, the anatomist Jones (Gallagher<sup>13</sup>) stated that it was the vein and not the artery which fills the bony groove in the temporal region. If this statement did not much modify the notion of a hematoma being essentially of arterial origin, a new element was introduced by Erichsen in 1779 (Gallagher<sup>13</sup> and Stevenson<sup>42</sup>) who blamed a primary detachment of the dura mater for the formation of the extra-dural collection. In 1816, Bell (Gallagher<sup>13</sup>) performed animal experiments which confirmed this hypothesis of a primary detachment of the dura mater. However, not much importance was attributed to these statements until 1963 when Ford<sup>12</sup> repeated these studies on dogs and confirmed that initially a detachment of the dura mater was produced following the shock. Ford thus logically deduced that probably the extra-dural hematoma had its final volume at the very onset. The delayed neurological picture was thus no longer caused by the progressive increase in volume of the hematoma in every case but by the disturbance in balance between the volume of this hematoma and the volume of the mobile supra-tentorial cerebrospinal fluid. Thus below a critical volume the hematoma would be tolerated without neurological change while an increase of volume above the critical level would alter the balance and progressively cause secondary neurological signs due to temporal herniation and distortion of the midbrain. This occurs particularly when the cisterna ambiens and the aqueduct become blocked and no longer permit the free circulation of the cerebrospinal fluid. These mechanisms not only explain the classical clinical evolution of the extra-dural hematoma with cerebral compression in a transverse axis but also the atypical evolution of hematomas in unusual sites, anterior or posterior, in which the cerebral compression is exerted along a longitudinal axis (Gruszkiewicz<sup>17</sup>). Such mechanisms also explain the possibility of non-traumatic extra-dural hematomas (which we will not discuss here), especially those which sometimes follow by-pass drainage of an internal hydrocephalus (Wewerka<sup>50</sup>). Ford thought that the different types of evolution depended upon several factors, among them, the volume of the hematoma, the rapidity of its formation, its localisation, and of course the always possible anatomical variations.

These relatively recent concepts are not however accepted by everyone. They can be used to explain the evolution particularly when the hematoma is in an unusual site. However one continues to apply the classical explanation in the case of a minor head injury followed by a lucid interval of varying length, to understand the deterioration of the level of consciousness (even coma), dilatation

of the pupil, usually on the side of the hematoma with a contralateral hemiparesis, bradycardia and arterial hypertension. The most frequently recognized source of the haemorrhage is a rupture of the middle meningeal artery or one of its branches, of venous sinuses of the dura mater, or of diploic or emissary veins (Rowbotham<sup>40</sup>). From the practical point of view however, it is not the mechanism which is the most important thing, but rather not to be misled at the time and not to miss such a complication, which, without adequate treatment, leads to death. Hill in 1772, Kellenberg in 1867 and Gross and Erichsen in 1873 (Stevenson<sup>42</sup>) were among the first to have thought that an operation could save patients with such a lesion. We will discuss the different clinical pictures which most often follow extra-dural hematomas, and the diagnostic methods available. These should prevent us missing a hematoma, even when it develops in an unusual way.

### General Considerations

#### *Frequency*

According to different figures published in the literature, the incidence of EDH varies between 1 and 3% of all head injuries hospitalised. However, Pecker<sup>35</sup> believes that this figure should be higher; his own figures show an incidence of 3 to 4% from 1950 to 1954 whilst it rose to 13% in 1958. He believes that this increase is related to better diagnostic methods and in particular to the introduction of carotid angiography. One wonders if it is not also related to the significant increase in the number of accidents in the last few years and a change in the type of causal injury.

Contrary to what has been thought for a long time, the extra-dural hematoma in children is just as common as in adults. The frequency according to the literature varies from 1.8%, given by Campbell and Cohen (Queloz<sup>38</sup>), to 3.7% in Svendsen's<sup>43</sup> figures. The frequency of the EDH in children and adults is therefore identical. The relative proportions of adults and children varies according to the types of units to which these cases are admitted. In Pia's figures (Gerlach<sup>14</sup>) one finds that 31% of a total of 190 cases of EDH were children under 15 years of age. McKissock<sup>32</sup> in a series of 125 cases gives a frequency of 22%.

#### *Localization*

In the literature, the sites of EDH's are not always stated with the same degree of accuracy. Some authors limit their classification to large territories such as frontal, temporal, parietal, occipital or the posterior fossa. Others distinguish transitional regions such as fronto-temporal, temporo-parietal, etc. It is not of much interest to note the frequency of all these different sites. It is however interesting to know that the classical site, temporal, is becoming proportionally less frequent. This is probably because diagnostic methods, especially carotid angiography, for localizing unusual sites have improved. Thus McKissock<sup>32</sup> found the classical temporal localization in 83% of his cases, Jennett<sup>25</sup> estimated it to be 75%, whereas Weinman<sup>48</sup> found it in only 57%. As for EDH with a chronic evolution, more than 50%, according to Young<sup>52</sup>, are not in the classical temporal region. Another point of interest which came from this statistical study is the number of hematomas which can be missed by the classical exploration with

6 burr holes; notably the frontal or fronto-basal, which Gallagher<sup>13</sup> found in 5% of his cases whilst Lecuire<sup>31</sup> who has studied this location found between 7% and 10%. Posterior fossa hematomas, which are difficult to diagnose, and generally have a poor prognosis, made up 3% of Heyser's series<sup>19</sup> whilst Lemmen (Heyser<sup>19</sup>) found an incidence of 7% and McKissock<sup>32</sup> 5%. With regard to bilateral hematomas Gallagher<sup>13</sup> found 4 out of 167 cases and McKissock<sup>32</sup> 3 out of 125.

In children, it is often said that the hematomas are usually well localized, because of the persisting attachment of the dura mater along the suture lines. This generally accepted fact seems very doubtful following the study by Choux<sup>8</sup> who, in his series of 96 cases, reported 45 where the hematoma covered the whole hemisphere.

#### *Sex and Age*

In both adults and children the incidence is higher in males. In his series of 150 autopsies of cases having had neurosurgery for a cerebral lesion, Chodkiewicz<sup>7</sup> found only 27 females (18%). McKissock<sup>32</sup> found 98% males in his 125 cases of EDH. Jamieson<sup>24</sup> estimated the ratio between males and females to be 4 : 1.

For children, this proportion is a little lower. Queloz<sup>38</sup> reported a ratio of 3 : 1 of boys to girls, and Ingraham<sup>22</sup> assessed that extra-dural hematomas were twice as common in boys as girls. Different authors attribute this higher incidence in males to a greater exposure to trauma.

As for age, the EDH was found to have a maximum incidence between 20 and 40 years by Gallagher<sup>13</sup>, about 30–40 years by Heyser<sup>19</sup> and McKissock<sup>32</sup> calculated a mean age of 24 years.

### **Clinical Signs**

#### *Fractures of the Skull*

A fracture in the temporal region or at least adjacent to the hematoma was considered as important as the free interval, one of the classical signs of EDH. Soon, however, it was realized that a fracture was not always present, in skull X-rays, at operation, or even at post-mortem. The fracture can be very fine making it very difficult, or even impossible to identify. This explains the difference in the number of fractures found on X-rays, at operation, and at autopsy. Another fact which should not be forgotten is that urgent cases are often operated on without radiography, because the time taken for this examination increases the risk to the patient. Chodkiewicz<sup>7</sup> noted the presence of a fracture on X-ray in 53% of his cases, although the incidence was 72% at post-mortem examination. Gallagher<sup>13</sup> found a higher incidence, up to 91%, including fractures discovered at autopsy, at operation or on X-rays. In only 12 of the 152 in his series was there no fracture. According to statistics there is no fracture in 10–15% of cases but Mealey<sup>34</sup> has a figure of 17%. It must be remembered in this context that hematomas with a chronic evolution, compared with the others, often have no fracture. Young<sup>52</sup> reviewed 33 published cases in 1972. To these he added a personal case and found that there was no fracture in 40%.

In children, it seems that, as with old people, the absence of a fracture is more common. Choux<sup>8</sup> found no clinical fracture in 19% of his cases. Ingraham<sup>22</sup> found no fracture and no suture separation in 6 out of 30 cases. McKissock<sup>32</sup> found no fracture in 21% of his cases in children and attributed this low figure to the elasticity of the skull when the sutures are still open. Mealey<sup>34</sup> noted, quoting Campbell and Cohen, that from 7 years of age a child's skull was the same as the adult's, except it is more elastic until 22 years of age when the sutures fuse. He found no fracture in 5 of his 6 cases between 11 and 15 years. We have seen only 4 fractures in 9 cases in children.

It follows then that, seeing a fracture in the standard skull films is a useful and important point and is as significant as a contusion or a soft tissue wound; in other words evidence of a head injury. However the possibility of an extra-dural hematoma cannot be dismissed just because there is no fracture. We will mention here the interest of noting displacement of the pineal gland if it is visible, but again, just as with fractures, the absence of this sign does not exclude the possibility of an EDH. As Mealey<sup>34</sup> wrote, the absence of a fracture should not give a false sense of security. The clinical situation is far more important. If there is no time to observe the progression of the disease, it is necessary to forego radiological examination. We would like, with regard to this, to emphasise that all too often there is a tendency to neglect the clinical aspect after the initial assessment on admission and the X-rays-results are waited upon, to know if there is cause for alarm and whether to begin special observations. The figures we have just quoted above clearly show that radiological examination, usefull as it is, is less important than the clinical examination. To be precise, radiology is only of value when it is positive.

#### *Free Interval*

This is one of the characteristic signs, classical of the extra-dural hematoma. It had already been noted by Jean-Louis Petit in 1750; this author spoke of the lucid interval, which seems more precise than the term "free interval" which is a more general description including both integrity of intellectual functions and the absence of all neurological signs. This is not always the case, even if there is a free interval. Essentially, this notion of free interval is based on the level of consciousness, which corresponds to the delay between the time of the head injury and the onset of neurological signs or symptoms due to cerebral compression by the hematoma. The terms latent period and lucid interval seem more precise than the term "free interval" because the causal injury marks a precise moment in time but does not necessarily cause, even a temporary neurological or physical lesion. In addition, when associated cerebral lesions exist and become evident immediately after the injury, it is quite obvious that these will cause neurological manifestations and that there could not be a true free interval, but that there will be, rather, a latent period while the secondary complications are produced, due to the compression caused by the hematoma. Campbell<sup>2</sup> has mentioned that particularly in children a head injury often causes neither concussion nor neurological signs.

We will not return to the mechanisms which come into play and which explain the delay classically called the free interval, remember only that following



the experiences of Bell (quoted by Gallagher<sup>13</sup>) then of Ford<sup>12</sup> with the dog, it is conceded more and more now that the EDH forms in a few minutes and that the free interval depends on the capacity of the brain to tolerate the compression by the hematoma. Rossier<sup>39</sup> had already suggested such a hypothesis in 1942, basing his explanation of the free interval on the fact that there is a volume available for compression within the cranial cavity. This buffer volume is mainly due to the CSF. The frequency of this classical sign, the free interval, has been found to vary markedly by different authors. For example Gallagher<sup>13</sup> found it in 72% of his cases, Heyser<sup>19</sup> in 75% of his, while on the other hand McKissock<sup>32</sup> and Jamieson<sup>24</sup> noted it only in respectively 27 and 12% of their cases.

With children it is more difficult to speak about the free interval. It would be better to talk about a latent period as Campbell<sup>12</sup> does, because very often the injury is relatively minor and does not cause any initial loss of consciousness. Thus Choux<sup>8</sup> noted that there was no initial loss of consciousness in 57% of his cases, but there was a latent interval in 66.5%. In our own series of 9 cases we found not one case with a proven initial loss of consciousness.

The classical sign of the EDH, the free interval, in view of the cases accumulated in the literature and from our own experience, is therefore no longer a necessary sign and it can even be said that it is not characteristic of the EDH alone. In fact it is often found related to other complications, such as a subdural or intra cerebral hematoma, providing we accept that this free interval is made up of a secondary deterioration of the physical, as much as the neurological status of the patient. It is however an important fact which cannot be neglected because when it is present it immediately points to the possibility of a hematoma, most often extra-dural. On the other hand, as McLaurin<sup>33</sup> pointed out, its presence is a good prognostic sign. In fact, if it is found, one can assume that there are no other important associated cerebral injuries. In addition the longer the interval the better the prognosis. It is also an important sign with hematomas in unusual sites, especially frontal or prefrontal, because most often such localizations do not give lateralising signs, as was pointed out by Lecuire<sup>31</sup>.

### *Motor Disorders*

The hemiparesis is most often contralateral. Jamieson<sup>24</sup> noted its presence in one third and Gallagher<sup>13</sup> in two thirds of their cases and it was always contralateral. By contrast, McKissock<sup>32</sup> noted it in 85 of his 125 cases, 81 contralateral and 4 ipsilateral. Heyser<sup>19</sup> explained that this ipsilateral manifestation is due to pressure of the tentorium on the cerebral peduncle. In children, it was shown to be present in 41% of the cases of the series of Choux<sup>8</sup>.

Hemiparesis therefore is another interesting and important sign, but it is not necessary to wait for this to appear before taking appropriate measures. In fact, depending on the rapidity of the development, or the site of the hematoma, the hemiparesis can occur either early or late; in our experience, sometimes even before a depression in the level of consciousness. Sometimes it may be of no value for localization because it is ipsilateral. With hematomas in some sites it may be absent, particularly those situated anteriorly.

*Eye Signs*

Dilatation of the pupil on the same side as the lesion was also one of the classical signs of the EDH. However it is certainly not encountered in every case, and in fact sometimes it affects the opposite side. Jamieson<sup>24</sup> estimated that it was not a useful sign in one third of his cases. McKissock<sup>32</sup> found in 63 instances it was ipsilateral and in 11 contralateral. In all, a mydriasis occurred in 74 of his 125 cases. Jennett<sup>25</sup> and Heyser<sup>19</sup> found it was present in 50% of cases, while Pecker<sup>35</sup> noted that the mydriasis was always on the side of the hematoma and it occurred in 22 of his 111 cases. In children it was present in 31% of cases in the series of Choux<sup>8</sup>, and was always ipsilateral, just as in Queloz'<sup>38</sup> 4 cases. In our study of 9 cases in children, it was present 7 times and always ipsilateral.

When unilateral mydriasis becomes bilateral, the prognosis becomes worse, even if decompression is carried out very quickly after onset. It is not unusual for these cases to have a slow or incomplete recovery or not to survive. To finish this section on mydriasis, an interesting fact to point out is that general anesthesia very often precipitates or accentuates a pre-existing mydriasis. This is probably due to the sudden increase in intra-cranial pressure caused by the induction of the anaesthetic. It is therefore not unusual to see unilateral mydriasis occur or progress to a bilateral mydriasis at the time of induction of anaesthetic for surgery or angiography.

*Pulse and Blood Pressure*

Nearly all authors have agreed that the pulse shows more significant changes than the blood pressure. Though McKissock<sup>32</sup> found a pulse rate slower than 60 in 57 of his 125 cases and Gallagher<sup>13</sup> noted a bradycardia in 50%, Jamieson<sup>24</sup> found it in only 20%. For Heyser<sup>19</sup> it was rare, being present in only 10% of acute cases while on the other hand arterial hypertension was present in 25%.

In children, Choux<sup>8</sup> noted it in 10% of cases. We found that 4 out of 9 cases had a pulse rate of 60 or less and there was no associated rise in blood pressure. On the other hand, in children under 2 years we found an apparently normal pulse, while the blood pressure remained within normal limits, because of the anemia associated with blood loss into the hematoma. This blood loss is significant enough in young children to cause shock which is then masked by the usual signs of intracranial hypertension.

*Other Signs*

## a) Vomiting

In adults, vomiting is too common a sign to be given much clinical significance. It is too often associated with minor head injuries to have any prognostic value and as well as this, alcohol plays a more and more important role as almost 50% of head injuries admitted to our unit are under the influence of alcohol to some degree. Gallagher<sup>13</sup> has also found this in 57 of his 167 cases. This influence of alcohol plays a significant role in clinical assessment because it makes the differential diagnosis more difficult.

In children, on the other hand, although vomiting is not very important when it occurs at the time of the injury, in our opinion it is a little more valuable when it begins a few hours later. In our series of 9 cases the first clinical warning signs were vomiting and depression in the level of consciousness one to eight hours after the injury. Choux<sup>8</sup> noted vomiting in 10% of his cases.

#### b) Anemia

We have already mentioned this in the section concerning changes in the pulse rate. However we think it is useful to reemphasise this very important sign, particularly in children less than 1 year old, because the blood loss of 150 cc as described by Ingraham<sup>22</sup>, quite compatible with the volume of an extra-dural hematoma, is enough to precipitate a state of shock in a child. Gregor<sup>15</sup> gave a very good comparison, noting that a 50 cc blood loss in a baby weighing 3 kg is equivalent to a blood loss of 1 litre in an adult. With EDH this anemia can be very severe and is not recognized as the usual shocked state because it is masked by the signs of raised intracranial pressure. This explains why, in our series of 3 cases less than one year of age, we found anemia of 53, 49 and even 28%. These anemias were clinically manifest as a marked generalised pallor and there were none of the usual signs of shock. This is why we consider that this is of great importance in small babies. Repeated hemoglobin estimations should be made. If the Hb is low and there are no other signs of shock and no obvious cause for this, then the possibility of an intracranial hematoma should be considered; in particular an extra-dural hematoma.

#### c) Cerebrospinal Fluid

Gallagher<sup>13</sup> performed lumbar punctures in 113 of his 167 cases. He found blood stained or xanthochromic CSF in 81% of these. The pressure was measured 80 times and was normal in 30%, moderately raised in 33% and very high in 27% of the cases. These figures demonstrate well that lumbar puncture is of no use in the diagnosis of extra-dural hematoma. On the contrary, this procedure is dangerous and must only be done in exceptional circumstances such as in cases where the diagnosis is not clear due to an unusual and slow development. Since the introduction of carotid angiography, other investigations have been almost completely abandoned by every author because they provide little diagnostic help compared to the risks created.

#### *Angiography*

Angiography, introduced by Egas Moniz in 1927, was recommended for use in head injuries for the first time in 1936 by Löhr (Weinman<sup>48</sup> and Zingesser<sup>54</sup>). This investigation has completely replaced air ventriculography which was the neuroradiological investigation used in every doubtful case. McKissock<sup>32</sup> had done this in 26 of his series of 125 cases published in 1960. Pecker<sup>35</sup> had 21 cases who had angiography in his series of 111 cases published in 1959 and Jamieson<sup>24</sup>, 26 of his series of 167 cases in 1968. Weinman<sup>48</sup> had done this examination in 46.5% of his cases published in 1966. He considered that the mortality rate, which was still very high with EDH, could be reduced by the more frequent use

of angiography which not only enables an accurate diagnosis but also helps with the operative management in that the craniotomy can be made directly over the centre of the lesion. If one compares this opinion of Weinman with the fairly recent attitude that angiography, in the case of EDH, was contraindicated because of the delay caused by this investigation, it is easy to see how the subject of angiography has progressed. But it is necessary to consider this in the right perspective: these two attitudes are not as different or opposed to each other as one might think, because several factors are concerned. First of all there is the patient and the speed at which his disease develops; it is very clear that if the progression is acute or subacute, there is not a minute to lose and not only the angiography must be left, but even the plain X-rays, if one wants to save the patient's life. Therefore angiography is reserved for those cases which do not require immediate therapeutic measures. It is useful in cases which evolve slowly and particularly those which have an atypical development. In only certain cases does angiography help to localize hematomas that have escaped detection by the classic 6 burr hole exploration.

Finally the second factor, which also has an enormous importance, concerns the available facilities. To do an angiogram, one needs not only the equipment and necessary materials, but also specialized staff, able to do this investigation and to interpret the results. An operating theatre with neurosurgical equipment must be available if operative intervention is necessary. Of course such facilities are only found in large centres and it is pointless to advocate an attitude to investigations which cannot be done, more or less correctly, in most of the hospitals or clinics where the injured are taken, as they do not all come to neurosurgical centres. It is even more dangerous to recommend that for such investigations the patients be transferred because this transfer would cause an extra loss of time which will perhaps make it impossible for the investigations to be carried out when the patient arrives at the specialized centre, providing that he is still alive!

The radiology of extra-durals has been widely described in the literature, particularly by Caveness<sup>6</sup>, Krayenbühl<sup>29</sup> and Huber<sup>20</sup>; we do not want to go over a description of the findings, the most characteristic being an extra-dural detachment of particular shape giving a definite diagnosis. We think that the finer diagnostic points are unnecessary, since every dural detachment, extra- or sub-dural should be operated upon. We think there are only two appearances that prove beyond doubt that the dural detachment is indeed due to an extra-dural hematoma: firstly the detachment of a sinus, especially the superior longitudinal sinus such as has been described with hematomas of the vertex (Krayenbühl<sup>29</sup>, Huber<sup>20</sup> and ourselves<sup>3</sup>) and secondly, when angiography shows an actual rupture or extravasation of contrast from the middle meningeal artery or one of its branches. It must be remembered here that this appearance is only seen in the first six hours, later clotting occurs at the site of the hematoma due to the balancing of pressures and such an appearance is no longer found (Huber<sup>20</sup>). It is obvious that the contrast injection must be in the common carotid to produce this—which we always do in cases of trauma as it causes too long an examination to do a selective run in the external carotid just to complete the diagnosis.

Though the angiographic picture in the usual temporal site may be easy to recognize, it is not always so in unusual sites, especially anteriorly or posteriorly,

without doing lateral stereo views which require some experience. Even then the problem is not straight forward as the arterial phase is slow and the venous phase of poor quality because of intracranial hypertension. In this situation, the displaced cortical vessels are seen in the normal venous phase. For this reason we think that, when looking for a dural hematoma, it is better to leave out a lateral run and, after the usual AP series, do bilateral obliques with simultaneous injection in each carotid. In practice, we do a full AP series with bilateral injection and then a short run in each oblique position. The bilateral AP series allows one to compare vessel distribution and flow rates to exclude bilateral lesions. The oblique series demonstrates most of the remaining brain surface and allows one to quickly and confidently exclude a detachment not otherwise visible in AP.

The indication for angiography, as we have already said, depends on one basic fact—the clinical state of the patient, which governs the time available. We think it is indicated every time the clinical situation is not clear and where there is no indication to operate absolutely immediately. Thus though we sometimes do it as soon as the patient arrives in hospital, we are often called upon to do it again in the next few hours because of the clinical change. In fact we think that every suspected case not needing angiography or operation on admission should have a clarifying angiography if his condition does not improve in the following 24–48 hours. If the condition worsens in this period then the examination is obviously indicated immediately. We have taken this approach to avoid missing all neurosurgical complications of head injury, be they extra-dural, sub-dural or cerebral hematoma or contusion. Also obviously, if the worsening is sufficiently diagnostic and typical of an extra-dural then one must go ahead with exploratory burr holes and craniotomy for evacuation of the hematoma without doing angiography.

This then is the approach possible in a specialized neurosurgical unit with facilities for neuroradiology. Elsewhere, under other conditions we think, like Thomas<sup>45</sup>, Pouyane<sup>37</sup>, Lake<sup>30</sup>, and Jennett<sup>25</sup>, that the diagnostic and therapeutic procedure should be mixed, that is one must do burr holes, followed by simple craniotomy for decompression if necessary and transfer the patient afterwards to a specialized centre.

#### *Echo-Encephalography*

This examination does not need costly and cumbersome apparatus and has become more accepted, even outside specialized centres. In our opinion however, if the apparatus is simple it is more difficult to obtain and read the tracing. Great experience is necessary to correctly perform and interpret them. For this reason, in spite of its interest, we think echography does not have a place in detecting extra-dural hematomas.

Even allowing the possibility of incorrect interpretations, the test gives too great a false sense of security, so lessening clinical suspicion which should always remain high.

#### *Treatment*

Treatment is a matter of evacuating the hematoma and securing hemostasis. A solid hematoma cannot be removed via single burr holes.

The type of treatment will depend on whether the patient is in a specialized or a general surgical unit.

In the first situation the osteoplastic craniotomy is done over the angiographically determined site of the hematoma or, in the absence of angiography, over the presumed site if exploratory burr holes have revealed an extra-dural hematoma. According to the case, but it is not a rule, a small dural incision to explore the sub-dural space and subjacent cortex is indicated. After evacuation and hemostasis, the dura must be anchored to the edges of the craniotomy and a Redon extra-dural drain and a subcutaneous drain put in.

In some cases where the brain substance is depressed (and shows no signs of expanding against the inner table) an intrathecal injection of physiological solution may be indicated to bring it up (Pecker<sup>35</sup>). We have never injected more than 100 cc for fear of causing problems that may occur with an incompressible liquid.

Outside a specialized unit exploratory burr holes are usually done. The whole head must be shaved and disinfected and a careful inspection for any subcutaneous lesions made. The operation is done, preferably with light general anaesthetic (Zander<sup>53</sup>) and intubation to provide good oxygenation, prevent aspiration and to better cope with any possible cardio-respiratory problems. The first burr hole is in the temporal region, a little in front of the ear lobe on the suspected side, on the principle that this classical site is still the most frequent. If this first hole demonstrates an extra-dural clot, we think that the general surgeon should only widen the trephine with bone forceps, decompress the clot and afterward transfer the patient to a specialized unit.

It is wrong to transfer a patient without having first undertaken a decompression if an extra-dural hematoma is strongly suspected for any waste of time in the evacuation of blood carries grave danger. Though we do not think it is essential that every surgeon has sufficient neurosurgical training to allow him to undertake a craniotomy, we do think, on the other hand, that he should be capable of doing exploratory burr holes and enlarging these to allow decompression if necessary. If the first burr hole is negative, one must go on and do the others in the usual frontal and posterior parietal areas of each side, making a total of 6. One should go ahead with burr holes as soon as an extra-dural hematoma is considered likely, the procedure carrying a much lesser risk than that of waiting until the full clinical picture is established, that is until there is in fact a well-formed epidural blood clot. More simply, burr holes do not kill but an epidural hematoma will if not evacuated in time.

One must be aware that trephines in the classical sites can miss a hematoma in an unusual site, e.g. fronto-basal. A negative exploration therefore does not completely exclude the possibility and must not allow a false sense of security; it is in this situation where angiography is so useful.

Because of the relatively small circulating blood volume in children, blood must always be on hand. Blood loss from the hematoma can cause such a significant drop in hemoglobin that the child may not survive the operation.

Supplementary medical measures include using cortisone; Mannitol can help get the patient into a better pre-operative condition but it must be remembered it has only a short duration of action, and its use cannot allow one to delay the

operation. In our experience it takes 20–30 minutes to begin after a decision to operate is made. We give 1–1½ gr Mannitol per kg body weight; because of the enormous diuresis the bladder must be catheterised.

### *Results and Conclusions*

For many reasons comparison of results from different authors is difficult.

On the one hand the series are not all of the same significance. Thus Jamieson, quoting McKissock, says that in no series of more than 40 was the mortality rate less than 20%; other workers have not appreciated the significance of the hematomas in unusual sites. Others group all head injuries together and then extract the epidurals and some people do not take into account the pure extra-dural hematomas—that is without other cerebral or extra cerebral lesions. Finally, series date from different times, and as we have seen, because of better diagnostic methods, especially the more widespread use of angiography, figures are better in the more recent years—for example Weinman<sup>48</sup> in 1967 had a mortality rate of 18% in 147 cases.

In the latest series the reasons and the interpretation of the failures is interesting. McKissock<sup>32</sup> thinks that 15% of the deaths in his series of 125 could have been avoided; this would give a theoretical mortality figure of 12% on operated cases. McLaurin<sup>33</sup> published a small series of 25 cases of pure extra-durals—without other associated lesions—with a mortality rate of 12%—whilst the figure is 66% if there are associated cerebral lesions. On reviewing his deaths, he feels 6 could have been avoided. The stated mistakes were: deterioration in patient's condition not noticed, or communicated too late; worsening following a lumbar puncture; long delay between diagnosis and operation and, finally, misinterpretation of the angiography.

Finally the prognosis is affected by the state of the patient at the time of operation and the mortality rises with associated cerebral lesions. Jamieson<sup>24</sup> finds a mortality rate of 77.7% in patients operated with decerebrate rigidity, 46.7% with bilaterally dilated pupils and 17.2% when the dilatation is unilateral. As he did, we can quote Hooper who in 1959 believed a mortality rate above 25% not acceptable and due to poor organisation and mistakes in the treatment of head injuries, but that there is a basic "inevitable" mortality rate that he fixes at about 10% due to the subacute onset and to associated cerebral lesions.

In most of the published series in children the mortality rate is lower than in adults, McKissock<sup>32</sup> has a figure of 7%, Choux<sup>8</sup> 14% and Gallagher<sup>13</sup> has 8%.

From these results one can conclude the extra-dural hematoma is still a grave complication with still a relatively high mortality rate. For this reason efforts should be made to reduce this rate, which should be possible and which has already been achieved by several authors. It is not so much operative technique that counts but rather early diagnosis and undertaking appropriate therapeutic steps in good time that play the main part. We can only repeat that though the classical history remains true for a good proportion of extra-dural hematomas there are still many without such a typical development. As McKissock<sup>32</sup> said it is dangerous to emphasise too much the classical story as taught throughout universities for the atypical evolution is then less well appreciated. According

## Head Trauma

### First Neurological Examination

Name ..... First name ..... Age .....

Date ..... Time .....

(All items to be filled in or underlined)

Examined ..... hours ..... min. after trauma

Duration of loss of consciousness:

Vomiting            yes            no

#### *Mental state*

- Deep coma with no response
- Opens eyes when called but does not respond to orders
- Responds when called and to simple orders but disoriented
- Oriented in time and space but drowsy
- Fully conscious
- Amnesia (duration)

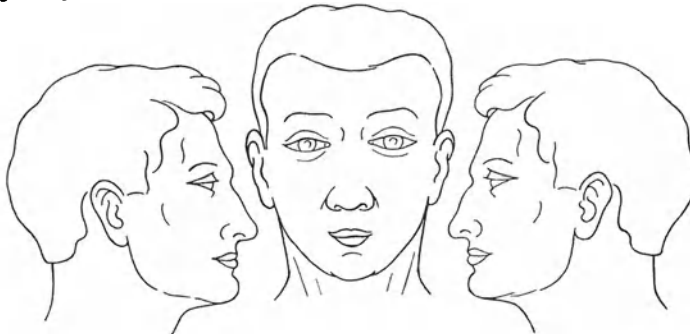
<i>Breathing</i>	normal abnormal: Cheyne-Stokes — periodic — irregular no spontaneous breathing		
<i>Swallowing</i>	possible — not possible		
<i>Aphasia</i>	yes            no		
<i>Pupils</i>	size	R	L
	reaction to light	R	L
<i>Vision</i>	present	R	L
<i>Oculo-motors</i>	strabismus	yes	no
	gaze paralysis	yes	no
	gaze deviation	yes	no
	nystagmus	yes	no
<i>Corneal reflexes</i>	present	R	L
<i>Face</i>	no paralysis	R	L
<i>Hearing</i>	present		
<i>Limbs</i>	spontaneous movements	R	L
	spasms — decerebration		
	— clonic		
	sensation to pain present	R	L



		R	L
<i>Reflexes</i>	Biceps		
	Triceps		
	Radial		
	Abdominal		
	Patellar		
	Ankle		
	Plantar		
<i>CSF leakage</i>	from nose	yes	no
	from ear	yes	no
<i>Bleeding</i>	from mouth	yes	no
	from nose	yes	no
	from ear	yes	no

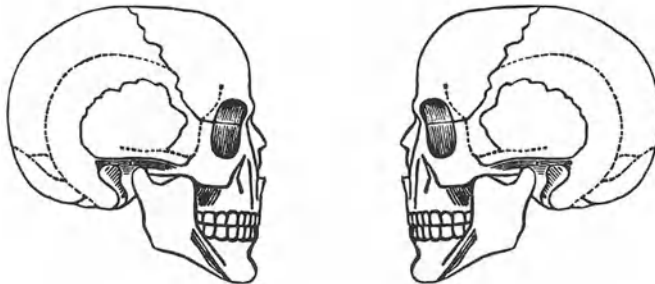
*Other important signs:*

*Head Injury Diagram:*



(Indicate if bruise, or if laceration involves skin, galea or if open fracture)

*X-ray Findings:*



*Associated Injuries:*

*Remarks:* (Follow-up for the first few hours)

*Signature:*

to our experience and in line with nearly all other writers, the basis of the diagnosis is a fall in the level of consciousness, other signs only confirming the presence of the extra-dural hematoma (Jamieson<sup>24</sup>). The other pointers are a change in the pupils, hemiparesis, the decerebrate state, papilledema and finally changes in pulse, blood pressure and respiration (McLaurin<sup>23</sup>). Other factors such as skull fracture, displacement of the pineal or mid line echo only have value when positive. Absence of them must not lead to a false sense of security. If the condition of the patient allows, there is advantage in angiography which can confirm the diagnosis and demonstrate intracerebral or bilateral lesions and also allow the craniotomy to be centered on the hematoma. However it is wrong to consider the extra-dural hematoma as a problem for treatment only by neurosurgeons. As Pouyanne<sup>37</sup> said, transfer of a patient to a special unit exposes him to grave risks because of the delay. One must not then advocate too much investigations such as angiography that necessitate transfer, or very elaborate operative techniques. Outside special centres straightforward procedures, within the ability of every surgeon, can be done and the patient transferred afterwards. In these situations and even in the specialized units the diagnostic procedure and treatment can be combined by doing burr holes first of all (Lake<sup>30</sup>). As Jennett<sup>25</sup> wrote the compression must be relieved wherever the patient is. But we do not think it is necessary to go as far as some authors who advocate exploratory burr holes and decompression as soon as the patient arrives in the emergencies room without even shaving and disinfecting the scalp; we believe such a rush is unthinkable and this contempt for the basic rules of asepsis carries too much risk for the benefit it may have. In our opinion it calls for haste and conscientious speed rather than panic; the patient should at least be properly examined before a diagnostic and therapeutic procedure is undertaken. From this point on there must be all speed, every minute is vital. First the operating theatre should be notified. Steroids and treatment to dehydrate the patient can be commenced if necessary, while the patient is brought to theatre and suitably prepared.

On the practical side, several years ago we introduced to the University Cantonal Hospital in Lausanne a sheet entitled "Head Trauma—First Neurological Examination" (see pages 134–135). In addition to a brief history this sheet brings together the clinical findings on admission, physical as well as neurological; it is deliberately simple for it must be easily filled in by any doctor. It is begun by the first doctor to examine the patient. From then on this sheet does not leave the patient, remaining with his temperature chart throughout his hospital stay. This allows any doctor later to assess any change and to decide if there has been an improvement or worsening in the neurological or physical state. A decision as to treatment can thus be made quickly without losing time checking if the present findings are different from those on admission. As well we have built up an excellent relationship with and cooperated in the teaching of the "police sanitaire" of Lausanne who bring most of our trauma cases. They make certain observations when they reach the victim and monitor him during the trip. We have deliberately limited these observations to state of consciousness and pupil size, simple things to do, requiring no medical knowledge, taking no time and not interfering with their basic rôle of getting the patient quickly to hospital. Thus, in a way, we have prolonged the observation time, having a record of

basic clinical information beginning before admission very soon after the accident, because in general the police arrive on the spot 5 to 10 minutes after the accident.

In conclusion we can only repeat what we wrote in 1959 (Zander<sup>53</sup>): the prognosis of an extra-dural hematoma depends basically on the speed of diagnosis and treatment, this being not so much a question for specialists but for general surgeons. The general practitioner must, in many cases, make the diagnosis and the general surgeon must be the one to intervene in time. Prognosis depends much more on the speed of treatment than on its finesse.

### References

1. Barnett, Jr., J. C., 1965: Hematomas associated with penetrating wounds. Neurological Surgery of Trauma. Washington: Department of the Army, Office of the Surgeon General.
2. Campbell, J. B., and Cohen, J., 1951: Epidural hemorrhage and the skull of children. *Surg. Gynec. Obstet.* 92, 257—280.
3. Campiche, R., 1962: Hématome épidural subaigu de localisation inhabituelle avec son image artériographique. *Radiol. clin.* 31, 95—100.
4. — 1963: Valeur de l'injection carotidienne bilatérale simultanée pour l'angiographie cérébrale de face. *Radiol. clin.* 32, 309—322.
5. Carter, A. E., 1960: Extradural haemorrhage in a child without skull fracture, following minor trauma. *J. Neurosurg.* 17, 155—156.
6. Caveness, W. F., and Walker, A. E., 1966: Head Injury. Conference proceedings. Philadelphia, Toronto: J. B. Lippincott.
7. Chodkiewicz, J. P., Creissard, P., Redondo, A., and Vedrenne, C., 1972: Etude anatomo-clinique de 150 traumatisés crânio-encéphaliques. *Neuro-chir., Paris* 18, 77—84.
8. Choux, M., Grisoli, F., Baurand, C., and Vigouroux, R. P., 1973: Les hématomes extra-duraux traumatiques de l'enfant. (A propos de 96 observations.) *Neuro-chir., Paris* 19, 183—197.
9. Eberle, H., 1969: Mesures diagnostiques et thérapeutiques dans les traumatismes crânio-cérébraux graves en stade aigu. Communications de la Division médicale de la Caisse nationale suisse d'assurance en cas d'accidents, No 49/50, 67—76.
10. Evans, J. P., 1963: Acute Head Injury. Second edition. Springfield, Ill.: Ch. C Thomas.
11. Farmer, T. W., 1964: Pediatric Neurology. New York: Harper and Row.
12. Ford, L. E., and McLaurin, R. L., 1963: Mechanisms of extradural hematomas. *J. Neurosurg.* 20, 760—769.
13. Gallagher, J. P., and Browder, J., 1968: Extradural hematoma. Experience with 167 patients. *J. Neurosurg.* 29, 1—12.
14. Gerlach, J., Jensen, H.-P., Koos, W., and Kraus, H., 1967: Pädiatrische Neurochirurgie. Stuttgart: G. Thieme.
15. Gregor, H., 1970: Epidurale Hämatoeme bei Erwachsenen und Kindern. Düsseldorf, Diss. Med.
16. Gruskiewicz, J., 1972: Ipsilateral exophthalmos in subfrontal epidural hematomas. *J. Neurosurg.* 37, 613—615.
17. — 1973: Subfrontal epidural hematomas. *Neurochirurgia* 16, 54—59.
18. Gurdjian, E. S., 1964: Operative Neurosurgery. Second edition. Baltimore: The Williams and Wilkins Company.
19. Heyser, J., and Weber, G., 1964: Die epiduralen Hämatoeme. *Schweiz. med. Wschr.* 94, 2—7.
20. Huber, P., 1964: Zerebrale Angiographie beim frischen Schädel-Hirn-Trauma. Stuttgart: G. Thieme.
21. Ingraham, F. D., and Matson, D. D., 1961: Neurosurgery of Infancy and Childhood. Springfield, Ill.: Ch. C Thomas.

22. Ingraham, F. D., Campbell, J. B., and Cohen, J., 1949: Extradural hematoma in infancy and childhood. *J. Amer. med. Ass.* *140*, 1010—1013.
23. Jamieson, K. G., 1972: Angiographic demonstration of the bleeding in a posterior fossa extradural hematoma. Case report. *J. Neurosurg.* *36*, 644—645.
24. — and Yelland, J. D. N., 1968: Extradural hematoma. Report of 167 cases. *J. Neurosurg.* *29*, 13—23.
25. Jennett, W. B., 1970: *An Introduction to Neurosurgery*, p. 239—244. London: W. Heinemann.
26. Kessel, F. K., 1969: *Neuro-Traumatologie mit Einschluß der Grenzgebiete, Band I, Die frischen Schädel-Hirn-Verletzungen*. München-Berlin-Wien: Urban und Schwarzenberg.
27. Klein, M. R., 1966: *Neurochirurgie infantile*. Paris: G. Doin.
28. Klingler, M., 1968: *Das Schädelhirntrauma. Leitfaden der Diagnostik und Therapie, 2. Auflage*. Stuttgart: G. Thieme.
29. Krayenbühl, H., und Yasargil, M. G., 1965: *Die zerebrale Angiographie. Lehrbuch für Klinik und Praxis*. Stuttgart: G. Thieme.
30. Lake, P. A., and Pitts, F. W., 1971: Recent experience with epidural hematomas. *J. Trauma* *11*, 397—411.
31. Lecuire, J., Lapras, C., Goutelle, A., Gacon, G., and Dechaume, J.-P., 1967: Les hématomas extra-duraux pré-frontaux. *Neuro-chir.*, Paris *13*, 431—443.
32. McKissock, W., Taylor, J. C., Bloom, W. H., and Till, K., 1960: Extradural haematoma. Observations on 125 cases. *The Lancet* *2*, 167—172.
33. McLaurin, R. L., and Ford, L. E., 1964: Extradural hematoma. Statistical survey of forty-seven cases. *J. Neurosurg.* *21*, 364—371.
34. Mealey, J., 1960: Acute extradural hematomas without demonstrable skull fractures. *J. Neurosurg.* *17*, 27—34.
35. Pecker, J., Javalet, A., et Le Menn, G., 1959: L'hématome extra-dural. Réflexions sur une série de 111 cas personnels. *Neuro-chir.*, Paris *5*, 428—449.
36. Plaut, M. R., and Gifford, R. R. M., 1972: Epidural hematoma. Correlations in traumatology. *J. S. Carol. med. Ass.* *63*, 354—357.
37. Pouyanne, H., et Bioulac, B., 1971: L'hématome extra-dural et le chirurgien généraliste. *Rev. Prat.* *21*, 1197—1205.
38. Queloz, Jean-Marcel, 1967: *L'Hématome épidual infantile. Thèse méd.*, Genève.
39. Rossier, Jean, 1942: *Les Traumatismes cranio-cérébraux, leur classification, leur diagnostic et leur thérapeutique*. *Helv. med. Acta*, suppl. 8 au vol. 9.
40. Rowbotham, G. F., 1964: *Acute Injuries of the Head*. Fourth edition. Edinburgh and London: E. and S. Livingstone.
41. Sparacio, R. R., Khatib, R., Chiu, J., and Cook, A. W., 1972: Chronic epidural hematoma. *The Journal of trauma* *12*, 435—439.
42. Stevenson, G. C., Brown, H. A., and Hoyt, W. F., 1964: Chronic venous epidural hematoma at the vertex. *J. Neurosurg.* *21*, 887—891.
43. Svendsen, V., 1972: Epidural hematoma in children. *Excerpta medica, Neurology and Neurosurgery* *25*, 462—463, No 2627.
44. Testut, L., 1921: *Traité d'anatomie humaine, Tome 2, Angéiologie-Système nerveux central*, p. 1026. Paris: G. Doin.
45. Thomas, L. M., and Gurdjian, E. W., 1973: Intracranial hematomas of traumatic origin. *Neurological Surgery, Volume 2*, p. 960—968, edited by J. R. Youmans. Philadelphia-London-Toronto: W. B. Saunders.
46. Vigouroux, R., Sedan, R., Choux, M., Baurand, G., Naquet, R., Vigouroux, M., Salamon, G., et Lavielle, J., 1963: Les hématomas extra-duraux frontaux post-traumatiques. *Neuro-chir.*, Paris *9*, 197—218.
47. Weber, G., 1969: Les hématomas intracrâniens d'origine traumatique. *Communications de la Division médicale de la Caisse nationale suisse d'assurance en cas d'accidents*, No 49/50, 76—80.
48. Weinman, D. F., and Jayamanne, D., 1966: The role of angiography in the diagnosis of extradural haematomas. *Brit. J. Radiol.* *39*, 350—357.

49. Wertheimer, P., et Descotes, J., 1961: Traumatologie crânienne, p. 10—11, 135—141, 209—211. Paris: Masson.
50. Wewerka, J., 1968: Spontane, extrazerebrale Hämatombildung nach Senkung eines gesteigerten Hirndrucks. Diss. Med., Zürich.
51. Whittaker, K., 1960: Extradural hematoma of the anterior fossa. *J. Neurosurg.* 17, 1089—1092.
52. Young, T. W., 1972: Chronic extradural hematoma. *Brit. J. clin. Pract.* 26, 38—41.
53. Zander, E., et Hofstetter, J., 1959: L'hématome extra-dural. Diagnostic et traitement. *Rev. méd. Suisse rom.* 79, 98—112.
54. Zingesser, L. H., Schechter, M. M., and Rayport, M., 1965: Truths and untruths concerning the angiographic findings in extracerebral haematomas. *Brit. J. Radiol.* 38, 835—847.

## **B. Technical Standards**

# Supratentorial Craniotomy

B. PERTUISET

Neurosurgical Clinic, Hôpital de la Pitié, Paris (France)

With 22 Figures

## Contents

General Processes .....	144
Preparation of the Patient's Head .....	144
Location of Skin Incisions .....	146
Control of Scalp Haemorrhage .....	147
Surgical Instruments .....	147
Burr Holes .....	150
Trephine Burr Holes .....	150
Twist Drills .....	150
Doyen Craniotomy .....	151
Closure .....	151
Traps .....	151
The Bone .....	152
The Dura .....	152
Skull Flaps .....	153
The Three Types of Skull Flaps .....	153
Osteoplastic Skull Flap .....	153
Free Skull Flap .....	153
Pedicled Skull Flap .....	153
General Procedure .....	153
Skin Incision .....	153
Procedure for Craniotomy .....	153
Closure .....	154
Modifications to the General Procedure .....	155
Frontal Flaps .....	155
Unilateral Frontal Flap .....	155
Bilateral Frontal Flap .....	158
Traps .....	161
Temporal Flaps .....	161
Pure Temporal Flap .....	161
Temporo-Frontal Flap .....	162
Traps .....	163

Parietal Flap .....	164
Occipital Flap .....	166
Special Craniotomies .....	167
Occipito-Cerebellar Skull Flap .....	167
Hemispheric Skull Flap .....	168
Cushing Craniotomy (Subtemporal Decompression) .....	169
Skull Flap in Young Children .....	170
Flap Reopening .....	171
Conclusion .....	171
References .....	171

Supratentorial craniotomy means the exposure of any part of a cerebral hemisphere over the basal line joining the nasion to theinion. The following descriptions will deal with the most commonly used techniques from burr holes to skull flaps and the main difficulties or traps which might present themselves during the operative procedure.

## General Processes

### *Preparation of the Patient's Head*

It is safer to shave completely the head of patients submitted to a craniotomy, nevertheless some neurosurgeons keep most of the hair intact, the shaving being restricted to the skin incision and its vicinity; I do not recommend this last procedure to beginners, even if they spray a plastic sheet on the hair.

If this is an elective operation the head will have been covered during the previous day by a sterile dressing. In emergency cases the surgeon himself must be able to shave in the operating theatre under general anaesthesia to save time particularly when the patient is restless. Next the neurosurgeon has to make his choice of headrests, of which the most efficient and simple is certainly the Mayfield neurosurgical headrest (Fig. 1 a, b); he has also to learn how to fasten with elastic and adhesive tape the patient's head on to the rest, in the best position to get a proper exposure, even if later on when he will be more skilled he prefers to let the head lie free. When the patient lies in dorsal decubitus the fastening will rest on two points: one over the skull and the other over the upper lip (Fig. 1 c); when the patient is in the sitting position the tape will wrape the head from the vertex over both cheeks and stick on the headrest. It is then possible to draw the skin incision on the shaved area with a stick of grease paint. The operative field is covered with an antiseptic liquid like an alcoholic iodine solution (1% or 2%) or any antiseptic solution in case of an iodine allergy.

In order to make the dissection of the scalp easier and reduce the bleeding the surgeon injects between the galea and epicranium a 0.5% xylocaine solution with 1/100,000 adrenaline. If the patient is not under general anaesthesia a 2% cocaine or xylocaine solution will be used with the same percentage of adren-



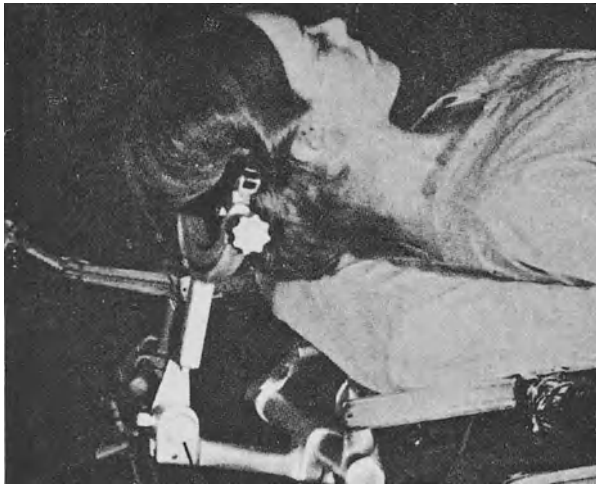


Fig. 1 a. Mayfield neurosurgical headrest (supine position)




Fig. 1 b. Conventional headrest

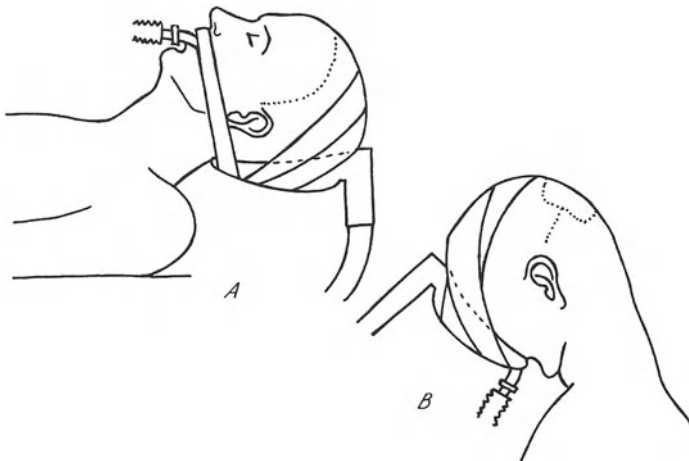


Fig. 1 c. Correct way to fasten the patient's head on the head holder. *A* dorsal decubitus, *B* sitting position

alin in order to obtain an adequate local anaesthetic effect. This subcutaneous injection is not recommended in cases of skull fracture, when there is a bone lacuna or if the operation is a reopening; it is strictly forbidden when a meningocele is present.

If the site of injection bleeds too much it is wise to inject the solution into the dermis just under the needle hole.

Now the time has come to stick a sterile drape on to the skin. Some neurosurgeons use a plastic sheet but it may not adhere perfectly when a local anaesthetic has been injected; this is why I prefer to cover the skin with sterile varnish

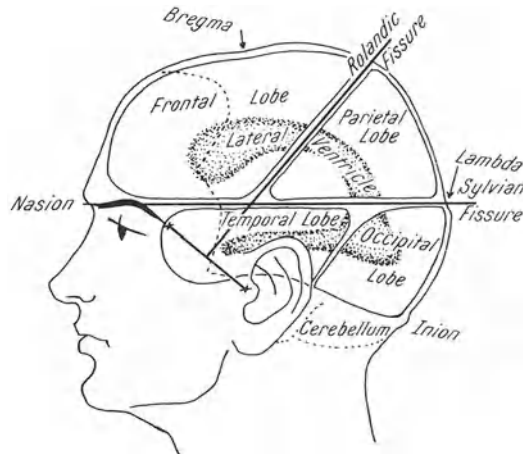


Fig. 2. Landmarks for drawing the Rolandic and Sylvian fissures on the scalp and relationship to the lateral ventricle

and then stick on a sterile jersey: this procedure closes the scalp pores for a week, eliminating a path of infection, but the cover is not transparent and in order to see the outline of the incision the surgeon has to scratch the epiderm before applying varnish; then effused blood will pass through the jersey and show the path for the knife.

#### *Location of Skin Incisions*

Scalp vascularization is so profuse that probably any type of incision can be used without endangering its healing processes; nevertheless it is recommended to respect the frontal, temporal and occipital arterio-venous pedicles. It is also my opinion that a more important obligation is to make the incision behind the hairline so as to avoid any visible scar.

The location of the incision will be easier to map out for the young neurosurgeon if he is able to draw the position of Rolandic and Sylvian fissures on the scalp. Anatomists like Poirier, Championniere, Kocher or Krönlein at the turn of the last century described accurate external landmarks; they are not very practical and I use the following method to mark both fissures (Fig. 2): the Sylvian fissure is outlined by a line drawn from the nasion to the lambda; the Rolandic fissure

by a line perpendicular to the mid-point of a line between the outer margin of the eyebrow and the tragus. This Rolandic line is projected up to the midline crossing the Sylvian fissure.

It is then possible to outline three lobes: frontal, parietal, temporal; the occipital lobe will be posterior to a line joining the lambda to the posterior border of the mastoid process.

One of the traps lies in a temporal incision which cuts the frontal branch of the facial nerve if it is not posterior enough or if it reaches the zygoma level (Fig. 3).

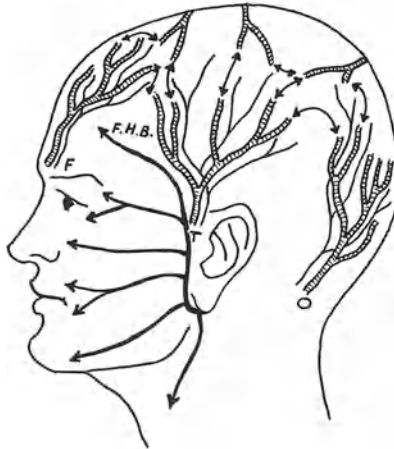


Fig. 3. Sketch of the three scalp pedicles with tributaries and anastomosis; in permanent black the facial nerve collaterals with the forehead branch (F.H.B.)

#### *Control of Scalp Haemorrhage*

Small arteries are numerous between dermis and galea. It takes a long time if the surgeon tries to coagulate all of them and it is not practical to tie these vessels one by one.

This is why neurosurgeons used in the earlier part of the century Michel clips, de Martel clamps or Kocher forceps to obtain temporary haemostasis during the major surgical procedure. In my opinion the Tönnis clip, easy to apply, remove or replace, represents the most practical instrument (Fig. 4a).

Temporary haemostasis may be obtained, when the incision is a short one with a forceps retractor as shown in Fig. 4a. If the surgeon should cut a branch of the temporal or occipital arteries during the incision it is safer to tie it with catgut rather than coagulating it.

#### **Surgical Instruments**

Even for a simple burr hole the surgeon has to provide for continuous suction, monopolar coagulation and saline. The essential instruments are the following (Figs. 4a and 4b):

Tönnis clips, scalp clamps or a forceps retractor for temporary haemostasis.

A craniotome of which there are two types:

a) The hand craniotome or trepan with trephines which vary from one continent to another. In the USA a perforator (single trephine) is used. In Europe most neurosurgeons use two trephines: 1) spear-shaped to begin the hole, 2) conical to complete it. A third trephine, a spherical one, to enlarge, is considered dangerous today.

b) The automatic craniotome uses a self-controlled system to stop the drill as soon as the bone is penetrated. The original one, developed by de Martel,

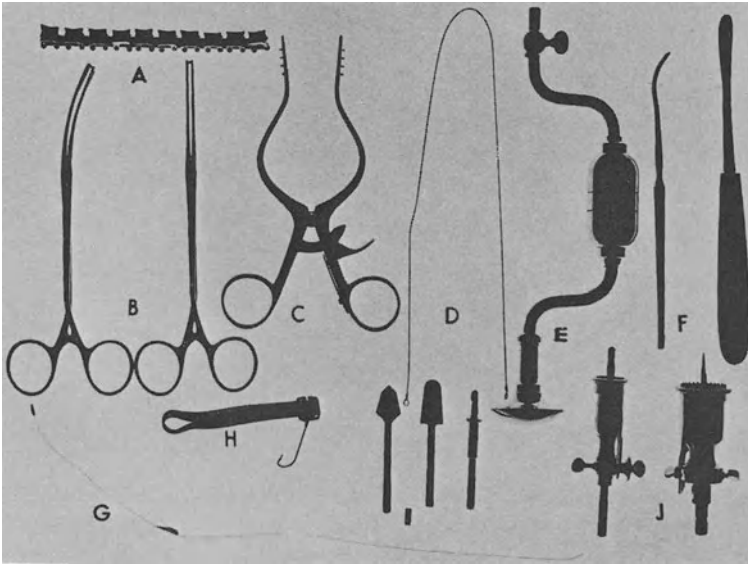


Fig. 4 a. Neurosurgical instruments: *A* Tönnis clips, *B* de Martel clamps, *C* forceps retractor, *D* Gigli saw, *E* hand craniotome, *F* curved and straight spatulas, *G* dural protector, *H* hook retractor with rubber band, *I* trephines and twist drill, *J* Doyen trephine

has been widely copied and improved. These craniotomes are powered by electric current or compressed gas.

A curved spatula or dissector is used to separate the inner surface of the bone from the dura. A straight dissector is also useful.

A malleable dural protector allows the use of a Gigli saw. A special rotating or oscillating saw, connected to the automatic craniotome, may be used instead of the Gigli saw, but the blade of these automatic saws is thick and results in a considerable loss of bone tissue with, as a consequence, imperfect closure of the flap.

Twist drills are employed for economic craniotomy.

Doyen's Trephine for both adults and children permits the performance of a restricted craniotomy and the bone is replaced in the defect once the operation is finished.

For permanent retraction of the scalp and bone flap I use fish hooks attached to rubber bands fixed on to the operating plate which overlies the patient.




Fig. 4 b. Automatic craniotome. *A* original de Martel, *B* electric powered contemporary craniotome

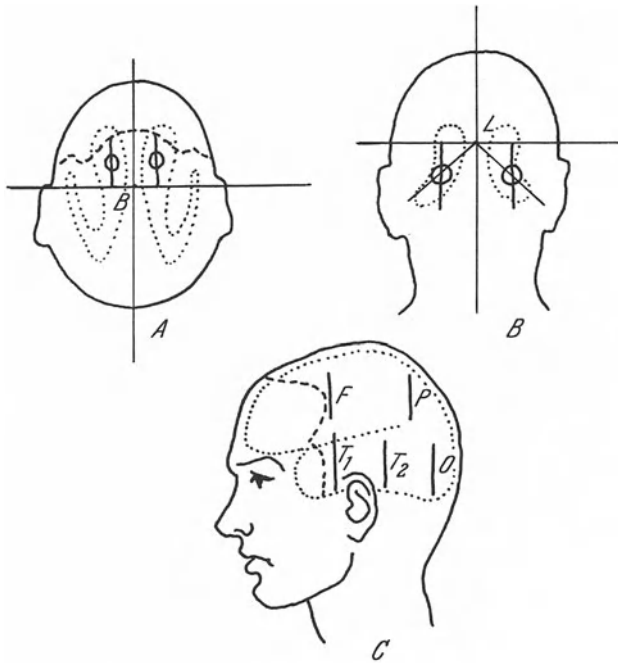


Fig. 5 a. Burr holes sites. *A* frontal for ventricular puncture, *B* occipital for ventricular puncture, *C* lateral for brain puncture

Horsley wax, oxycel are essential for stopping bleeding from the bone or from the space between dura and bone.

These instruments, added to an ordinary surgical box, are all necessary for opening the skull.

### Burr Holes

There are three types of burr hole: trephine, twist drill and Doyen.

#### *Trephine Burr Holes*

The skin incision will be vertical over the frontal, temporal, parietal or occipital lobes, the patient lying in the dorsal decubitus with slight elevation of the

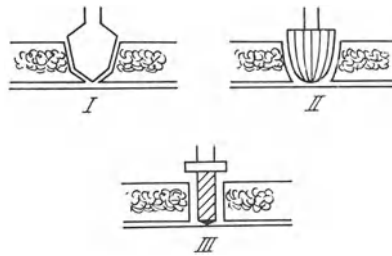


Fig. 5 b. Drilling of a burr hole begun with a spear-shaped trephine (I) and completed with a conical trephine (II). Twist drill (III)

thorax and head (so called transatlantic position). The incision is 5 cm in length and the use of a forceps retractor will be adequate for temporary haemostasis (Fig. 5 a).

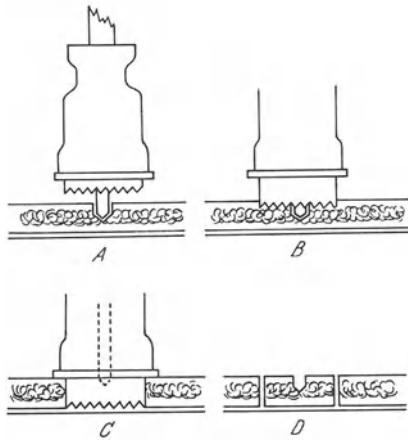
The epicranium will be incised in the same direction as the skin and separated from the bone. Then the spear-shaped trephine is drilled into the bone until the surgeon sees a small aperture which looks blue; at the same time the trephine locks in the hole. The diploe is waxed and the conical trephine is now inserted to drill until it locks (Fig. 5 b). The excess wax is removed and the dura is ready for the next step.

Burr holes in preparation for ventricular puncture are located in the frontal or occipital regions and the incision is parallel to the midline, at a distance of 2 cm in the frontal, and of 3 cm in the occipital region. The frontal burr hole is placed just in front of the coronal suture and the occipital burr hole on the parieto-occipital suture (Fig. 5 a).

If an automatic craniotome is used the procedure is easier but the scrub nurse has to cool the trephine with a flow of saline during drilling.

#### *Twist Drills*

The twist drill technique was originally developed by Cone. The incision is merely a puncture of the skin and the hole will then be made with a special fine drill. The main difficulty is to drill in the precise direction of the ventricle because the needle will of necessity have to follow it.



### The Bone

Sometimes the diploe is smooth and thick so that the mechanism of an automatic craniotome is disconnected while the inner skull table still remains intact. Then the drilling has to be finished with a hand craniotome.

When a twist drill is used it can sometimes break in the bone. The only efficient way to remove it consists in drilling a conventional burr hole on the edge of the previous drill hole so that the foreign body can be mobilized and extracted. The best way to avoid such breakage is when removing the drill to revolve the craniotome in the opposite direction.

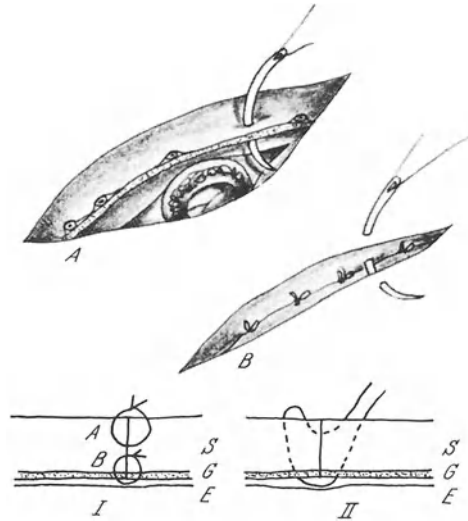


Fig. 7 a. Two layers closure. *A* vascular galeal layer (catgut), *B* skin layer (silk or nylon). The technique is sketched in *I*. In *II* Blair-Donati type closure in one layer

In children under six months of age the skull is so thin than the neurosurgeon must be very cautious in protecting the dura especially at the skull suture sites.

### The Dura

The worst is to open a venous sinus, principally the sagittal sinus, while drilling paramedian burr holes. Such a dramatic situation occurs only when the midline has not been delineated carefully; the only way to stop the haemorrhage is to pack into the burr hole an oxycel mass and cover it with wax; if this is not successful the next manoeuvre is to take a portion of muscle out of the thigh while an assistant seals the hole with a finger tip. Never try to enlarge the burr hole to expose the dural laceration: this will aggravate the bleeding. In a child with a thin skull the surgeon has to wait with finger pressure on the oxycel until a clot is formed. The mass of oxycel or muscle will be always big enough to avoid any venous sinus embolism.

Young neurosurgeons need to learn how to discern between venous blood coming from the sinus and blood from a subdural haematoma; in the latter instance a clear halo will be seen to surround the blood when absorbed onto gauze.



In patients over sixty the dura is often adherent to the bone and it is nearly impossible to avoid its injury while drilling. Usually no complication occurs but if the burr hole is placed near the midline an injury to a cortical vein is possible. This kind of haemorrhage is easily controlled by coagulation using suction. Bleeding from a dural artery may be stopped in the same way. With such delicate dura it is wise to reduce the intensity of coagulation.

### Skull Flaps

There are three types of skull flaps:

#### 1. Osteoplastic Skull Flap

In this case the bone is not separated from the skin with the theoretical purpose of keeping intact the flap vascularization. This technique, proposed by Cushing, has been progressively given up, with better knowledge of the flap's blood supply.

#### 2. Free Skull Flap

The skull flap is completely detached from muscle, epicranium and scalp; consequently it is used as a graft during closure but the chance of normal healing is reduced by vascular impairment.

In children under five this type of skull flap can be used because the periosteum of the inner table of the skull is adherent to the dura and is capable of renewing bone and of re-ossifying the skull flap.

#### 3. Pedicled Skull Flap

This skull flap is the most commonly used and its pedicle is usually represented by the temporal muscle. When the flap is paramedial or posterior the pedicle consists of the epicranium.

#### *General Procedure*

##### 1. Skin Incision

To obtain the best cosmetic appearance with the scar the skin incision must not overlie the edge of the skull flap. In this respect a Y-shaped incision as first described by Dandy is superior to the conventional incision roughly shaped like a horseshoe. Unfortunately this last type of incision has to be retained for the frontal region; nevertheless with some modification to the original description the final result is satisfactory.

Once the skin has been separated from the epicranium it is retracted to expose the operative field; in order to hold it in the correct position I routinely use fish hooks as retractors as Penfield routinely did.

##### 2. Procedure for Craniotomy

Along the line of the proposed skull flap 4 or 5 burr holes are drilled 5 to 6 cm apart. Fragments of the inner table of the skull which lie at the bottom of these burr holes are elevated with a curved spatula in order to expose the dura and allow the introduction of a dissector between bone and dura. Bleeding from the holes is stopped with wax of which the excess is removed.

A flexible dural guide is then cautiously introduced between bone and dura from one burr hole to the other. A Gigli saw is drawn through this extradural space and bevels each section of bone. The Gigli saw may be replaced by a circular saw connected to an automatic craniotome.

Often it is useful to connect the burr holes through their outer margins rather than through their centers. This modification provides an additional centimeter of exposure throughout the circumference of the skull flap.

The bone lying under the pedicle is rongeured on each side to reduce the breadth of the bone bridge. The surgeon can also use the Gigli saw for this but he has to be very cautious while sawing in order to preserve the integrity of the pedicle.

The medial part of the flap is then raised with a periosteal elevator until the base of the bone breaks under the counter pressure of the fingers of an assistant who limits thereby the fracture. The skull flap is finally held in place with a hook implanted in the pedicle.

Bleeding vessels in bone are waxed; those in muscle are coagulated. When venous bleeding comes from between bone and dura I recommend hitching up the dura to the epicranium with silk sutures; then oxycel may be introduced between bone and dura and covered with wet cottonoid gently pressed by the assistant's fingers along the bone edge. Meningeal arteries are coagulated especially if the skull flap encroaches on the skull base.

### 3. Closure

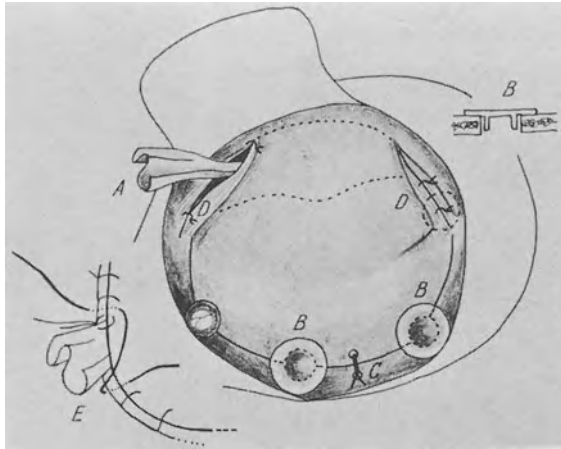
When the pedicle consists of muscle the skull flap has to be fastened to the skull in order to avoid any movement of the flap during speaking or mastication. Two twist-drill holes are drilled, at the convexity of the flap, one in the flap itself and the other in the skull adjacent through which a nylon suture is passed and tied (Fig. 7 b).

When the intradural procedure has produced a considerable loss of tissue or a large cavity, such as that following a hemispherectomy or the removal of a chronic subdural haematoma, it is advisable to hitch up the dura to the middle of the flap with silk or nylon passed through twist drill holes. Two or three sutures will be necessary, that is to say four or six holes.

In my opinion it makes it safer for the patient and better for the surgeon's peace of mind to drain the extradural space contrary to my advice concerning burr holes craniotomies, because in modern neurosurgery the risk of infection is drastically reduced.

The best method is to use a teflon tube or a flat rubber Penrose drain whenever the neurosurgeon is not provided with a Redon drainage unit which is simple, efficient and clean, working under a negative pressure suction of 1/10 atmospheric pressure. If one uses the spring bag the negative pressure is just about 1/1000 atmospheric pressure; whatever drain is used it will leave the epidural space through an enlarged burr hole or in the gap between the skull flap and the skull base after the removal of bone on each side to permit the drain to run a straight course (Fig. 7 c). This method is combined with dural hitching which I consider essential in restricting epidural bleeding.

The dural suspension is carried out with non-absorbable material and the



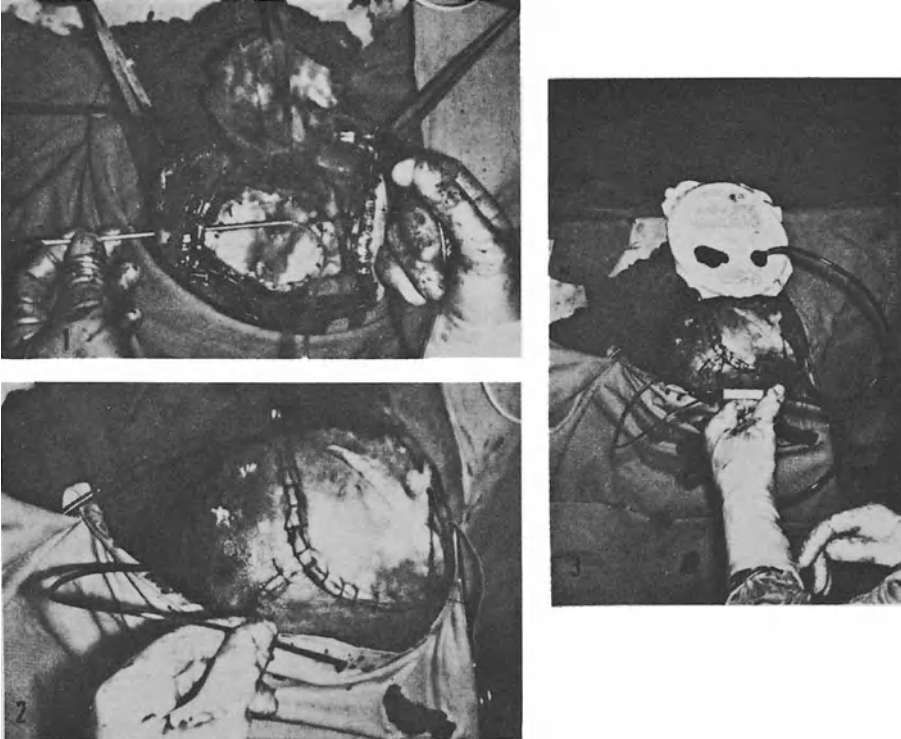


Fig. 7 c. Three phases of the placement of the Redon drainage. Note in 3 the spring bag collecting the blood

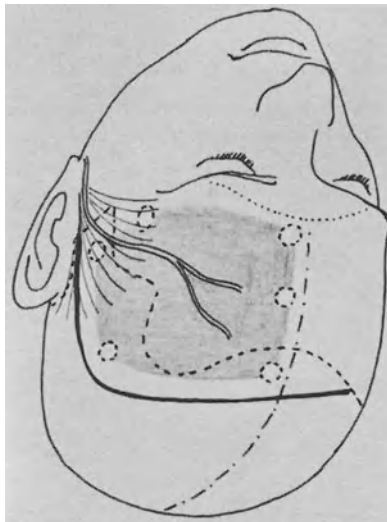


Fig. 8. Unilateral frontal scalp flap behind the hairline. Note location of forehead branch of facial nerve. The temporal artery can be cut without skin damage

that the incision extends across the midline. In bald patients the incision will be similar to that for a bilateral flap (bicoronal).

*Burr Holes (Fig. 9)*

They will be drilled in order to produce a paramedial flap close to the base of the skull.

*Anterior temporal burr hole.* This will be drilled after making a vertical incision of the temporal muscle close to its aponeurotic boundary and just behind the lateral process of the frontal bone. This is absolutely necessary to permit

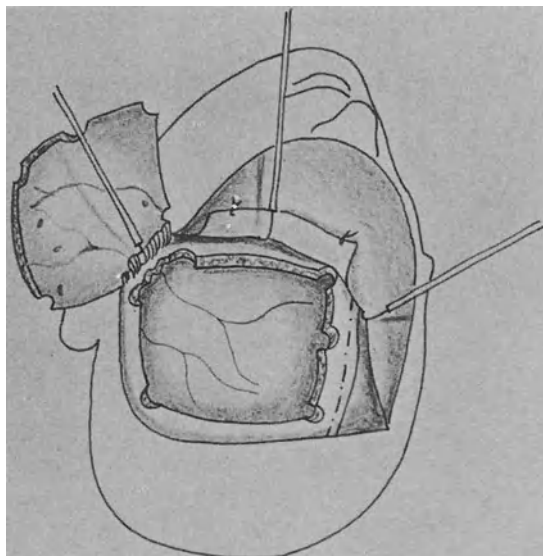


Fig. 9. Unilateral and paramedial frontal skull flap over the frontal sinus

the introduction without difficulty of a dural dissector in the direction of the frontal anterior hole. Veins and arteries coming from the muscle will be coagulated.

*Posterior temporal burr hole.* This will be drilled in the temporal bone squama near the skull base after division of the temporal muscle in the direction of its fibers. These two burr holes will delimit the muscular pedicle which has to be 4 cm wide so as to secure the arterial supply to the skull flap.

*Frontal anterior burr hole.* This will be placed in the angle formed by the midline and the skull base above the frontal sinus. When the sinus is very large it may be opened during the procedure; in this case the automatic craniotome will open only the outer wall of the sinus and the neurosurgeon will then be obliged to use the hand craniotome to penetrate the inner wall. The opening of the frontal sinus is sometimes deliberate in order to get the best exposure for an orbital, chiasmatic or intrasellar tumour. Whether intentional or not this opening of the sinus requires the neurosurgeon to take particular care with special closure:

a) Before drilling the epicranium will be incised between the temporal and frontal anterior burr holes in such a way that an epicranial flap will be available to be fold down over the sinus cavity (Figs. 9, 10, 12).

b) Once the frontal sinus has been opened the mucous membrane is coagulated and a cottonoid pledget soaked in a 2% iodine solution is inserted into the cavity and left in place during the operation.

c) This cottonoid will be removed after the closure of the dura and the sinus cavity is then filled with bone dust.

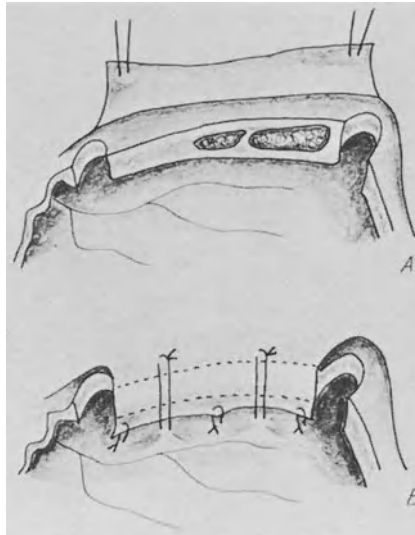


Fig. 10. Closure of an opened frontal sinus. *A* the mucous membrane has been removed after coagulation and the cavity filled with bone dust, *B* the prepared epicranial flap is folded down and sutured to the dura

d) Finally the epicranium flap will be turned down to close off the cavity and be sutured to the dura (Fig. 10), without any danger of impairing bone healing.

*Frontal posterior burr holes.* One burr hole will be drilled close to the midline at the posterior boundary of the flap; another one will be drilled between this and the posterior temporal one at the point where the shape of the skull changes roughly from oblique to vertical.

When the forehead bulges excessively a final burr hole is required between the two medial frontal holes.

### *Closure*

The drain will be brought out just over the ear.

## 2. Bilateral Frontal Flaps

They are of two types: single or twin.

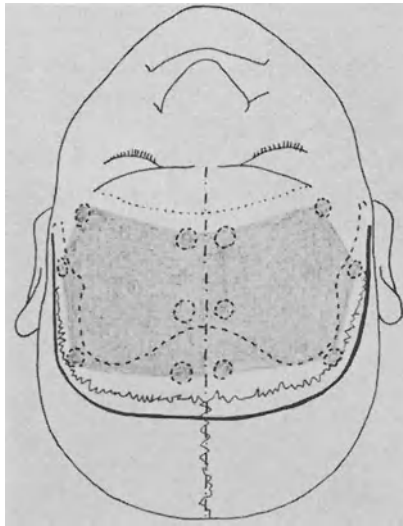


Fig. 11. Bilateral frontal scalp flaps with indication of burr holes location

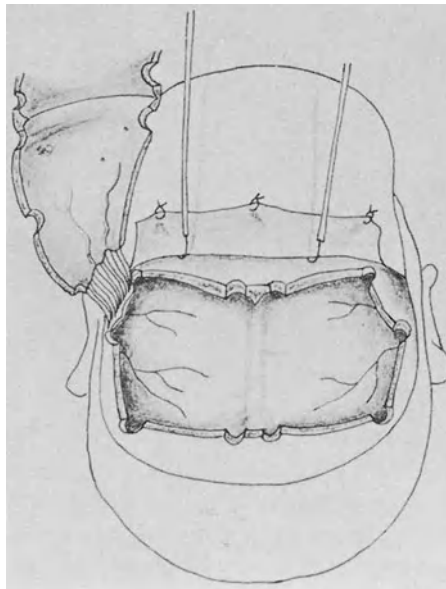


Fig. 12. Bilateral frontal skull flap hinged on the left side. The superior sagittal sinus appears in the midline

*a) Single Flap*

*Incision.* A bitemporal incision overlying the coronal suture reaches from the ear on the side of the muscular pedicle across to a slightly higher level on the other side (Fig. 11). Some surgeons like to curve the incision forward on each side and at the vertex.

During the dissection of the scalp flap the surgeon has to preserve both

frontal pedicles, and particularly the frontal nerves to avoid any impairment of forehead sensibility.

*Burr Holes.* In order to avoid any damage to the sagittal sinus burr holes are drilled close to the midline on each side and joined by sawing. On the side of the pedicle burr holes will be drilled as in a unilateral frontal flap. On the other side it is usually enough to drill above the temporal muscle insertion (Fig. 12). The main difficulty comes from the inner table of the skull when, if there is a prominent and sharp medial ridge, this might require the neurosurgeon to rongeur between the medial burr holes instead of sawing.

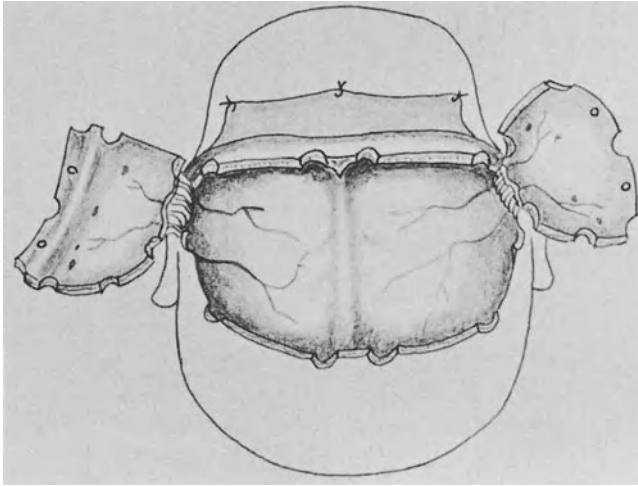


Fig. 13. Bilateral frontal twin skull flaps. The bone overlying the sagittal sinus between the medial burr holes is removed with rongeurs or sawn. Flaps are hinged on the temporal muscles

*Closure.* It will be wise to hitch the dura to the flap near the midline and to drain on both sides.

#### b) *Twin Flaps*

*Incision.* The same as the previous one.

*Burr holes.* In order to avoid damaging the sagittal sinus burr holes are placed near the midline on each side of the sinus and then the bone is cut on one side between the medial, anterior and posterior burr holes. The cut should be beveled so that the two flaps can be wired tightly together (Fig. 13).

After reflecting the flap on the one side, the region of the sagittal sinus can be separated from the inner table of the skull before the opposite flap is elevated. There are of course two pedicles, one on each side.

A coronal scalp flap is sometimes helpful even if a unilateral skull flap is planned. It has the cosmetic advantage of keeping the incision strictly behind the hairline; moreover the opposite skull flap can easily be reflected if additional exposure becomes necessary. This is especially useful in the repair of cerebrospinal fluid rhinorrhea.

*Closure.* No comment except for bilateral epidural drainage.



### 3. Traps

In old patients, in Hyperostosis Frontalis Interna or in acromegalic cases the dura is so adherent to the bone that it is nearly impossible to separate one from the other. This is why in these cases it is better to make drill holes 2 cm apart at the midline in order to preserve the venous sinus and its tributaries. In addition the bone flap must be very carefully elevated with a spatula separating it under direct vision from the dura. I do not recommend turning bilateral flaps in these patients. Finally the filling of an opened frontal sinus with a polymerized plastic paste must be avoided because of a risk of spinal fluid fistula with infectious complications.

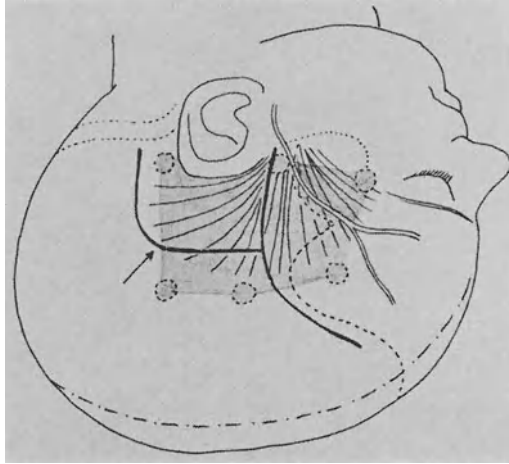


Fig. 14. Y shaped temporal scalp flap behind the hairline

### Temporal Flaps

They are of two types: pure temporal and frontotemporal.

#### 1. Pure Temporal Flap

##### *Incision*

When the temporal lobe has to be exposed from its tip to the occipital lobe the anterior part of the routine horseshoe incision will be exposed in front of the hairline spoiling the cosmetic result. This is why I use a modified Dandy incision (Fig. 14) for transtentorial exposure of the trigeminal nerve or the approach to the basilar artery bifurcation. The posterior part of the incision can be curved down (double arch incision) or remain straight (Y shaped incision).

##### *Burr Holes*

The temporal muscle will be incised anteriorly and vertically just behind the lateral process of the frontal bone and then posteriorly and horizontally just above the skull base to provide a 4 cm wide muscular pedicle.

*Anterior temporal burr hole.* This will be drilled in the same place as for the frontal flap.

*Posterior temporal burr hole.* This will be in the posterior border of the flap as close as possible to the skull base. Anteriorly to it a burr hole will be drilled in the temporal squama at the lower limit of the muscle incision, after coagulating the posterior temporal muscular artery.

*Peripheral burr holes.* Three holes will delimit the flap as shown in Fig. 15. The height of the flap will differ according to the exposure desired.

During the cutting of the skull flap anteriorly placed temporal pneumatic cells are sometimes opened. These cells are always small and easily waxed.

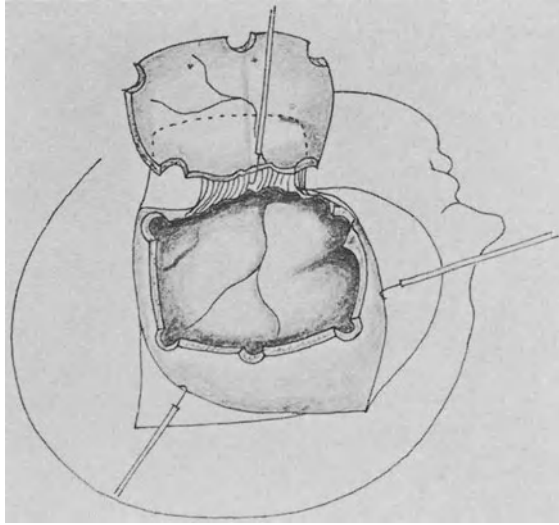


Fig. 15. Temporal skull flap exposing the entire temporal lobe

In order to expose the whole temporal lobe it is necessary to remove the temporal squama remaining attached to the skull base with a rongeur.

#### *Closure*

The skull flap will be wired to the skull and the suturing of the temporal muscle incisions requires only one layer avoiding the aponeurosis for the sake of masticatory function.

Suspension of the inferior dura will be easier and more efficient if the incision in the dura is H shaped with a small inferior dural flap.

## 2. Temporo-Frontal Flap

#### *Incision*

This has a horseshoe shape placed behind the hairline with the pterion as center (Fig. 16).

#### *Burr Holes*

They will be so placed (4 are sufficient) in order to align the axis of the skull flap with the outer end of the sphenoidal ridge (Fig. 17).

This flap will give a specially good view of the anterior communicating artery if in addition the neurosurgeon removes the pterion and the adjacent sphenoidal ridge as has been described by Yaşargil.

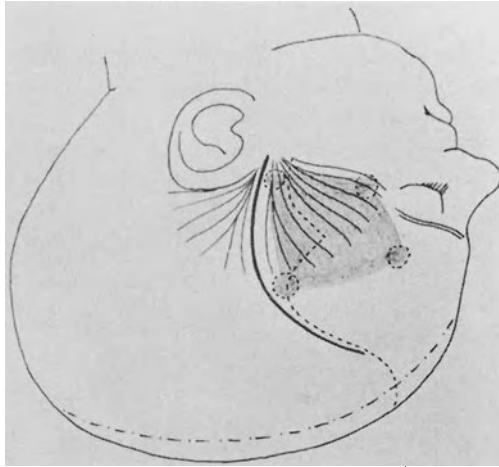


Fig. 16. Temporo-frontal scalp flap centered on the pterion

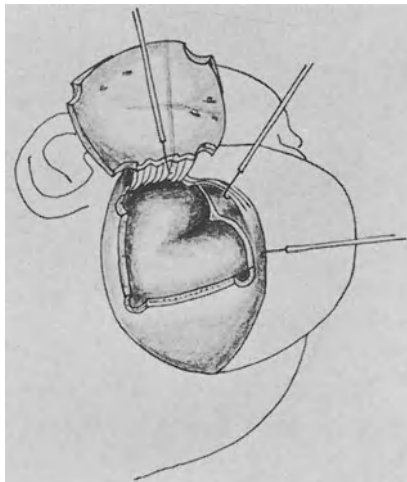


Fig. 17. Temporo-frontal skull flap with removal of the pterion and the lateral third of the sphenoidal ridge

### 3. Traps

These come principally as a result of bleeding between bone and dura and from the meningeal arteries to such an extent that the neurosurgeon is obliged to coagulate the middle meningeal artery at its emergence at the base of skull.

The most irritating difficulties usually come from the bone of the temporal fossa just beneath the sphenoidal ridge and it is essential to get perfect haemostasis especially if the surgeon is using the operating microscope. This arterial

bleeding comes from perforating arteries and they have to be waxed even if the surgeon has to make an extensive dissection of the dura. The venous bleeding in the same area can be handled by waxing or packing with oxycel. A trick consists of waxing over an oxycel pack and then approximating the dura to the muscular pedicle.

While drilling the anterior temporal hole the trephine may enter the orbital cavity from which fat appears. This only means that the burr hole is a little too far anterior and readjustment is necessary.

The surgeon has also to pay attention to the importance of the muscular pedicle whose width has to be sufficient to allow exposure of the temporal lobe tip and also good vascularization of the skull flap.

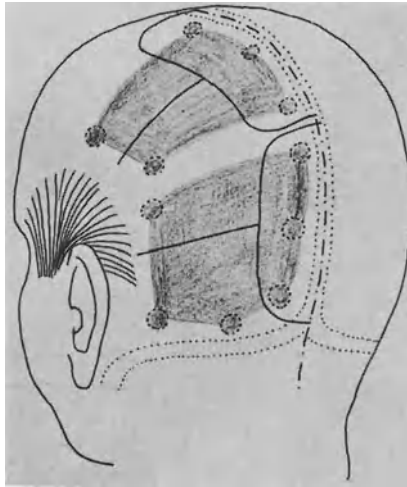


Fig. 18. Parietal and occipital scalp flaps of the Y-shaped type. The sagittal and lateral sinus are outlined

### Parietal Flap

#### *Incision*

The routine horseshoe incision reaching the midline and curved inferiorly has to be much larger than the skull flap to avoid firm adhesion between skin and bone.

This is why for 23 years I have used a Y shaped incision (Fig. 18) which permits access across the midline and the exposure of the sagittal sinus in parasagittal meningiomas.

#### *Burr Holes*

Five burr holes are sufficient for parasagittal lesions. Seven burr holes are necessary to expose the parietal lobe (Fig. 19a).

*Medial burr holes.* Three are necessary and they will be drilled 1 cm lateral to the midline which is clearly seen as the sagittal suture. If the surgeon wants to expose the sagittal sinus he may drill three other burr holes on the other side of the midline (as in frontal flaps).

*Inferior burr holes.* Two or four holes are drilled according to the desired flap size.

The pedicle will consist of epicranium if the flap is small and of muscle if it is large.

#### *Closure*

In this region the epicranium is thick and can be used as an overcoat to maintain the flap in place. For this purpose I retain the attachment of the medial scalp flap to the epicranium in such a way that during closure the suture of the epicranium will maintain the scalp in the appropriate position.

The skin closure uses two layers and special care will need to be taken in

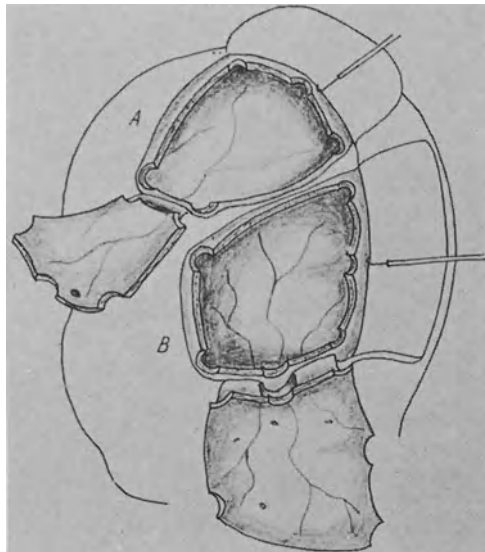


Fig. 19 a. Parietal and occipital skull flaps with an epicranial pedicle. Both are paramedial

approximating the three scalp flaps: the deep catgut layer remains 2 cm distant from the apex and here the superficial silk layer unites only the epidermis. This type of closure is valid for all Y shaped incisions.

#### *Traps*

The most severe derive from the sagittal sinus when it has been opened during drilling either because the midline has not been respected, or because a venous intradural extension of the sinus extends beyond the midline. In the first case the neurosurgeon handles the problem in the way already described and drills a new hole in the correct position. In the second case the flap must be turned rapidly and the sinus laceration exposed while an assistant stops the bleeding with finger pressure.

Once the sinus injury is clearly visible the safest method is to suture the wound over a piece of muscle and cover it with oxycel (Fig. 19b). The whole

procedure has to be done quickly because venous bleeding produces important blood loss in a short period of time.

If the sinus is opened during sawing the laceration will be larger and the difficulty of closure greater; this is why when the separation of bone from dura is evidently difficult the best procedure is to drill as many burr holes near to the midline as is necessary to cut easily between them. On rare occasions it will be safer to rongeur away the bone between holes instead of sawing. Venous bleeding from Pacchionian granulations or from veins embedded in the dura may be stopped with bone dust covered with oxycel under temporary finger pressure.

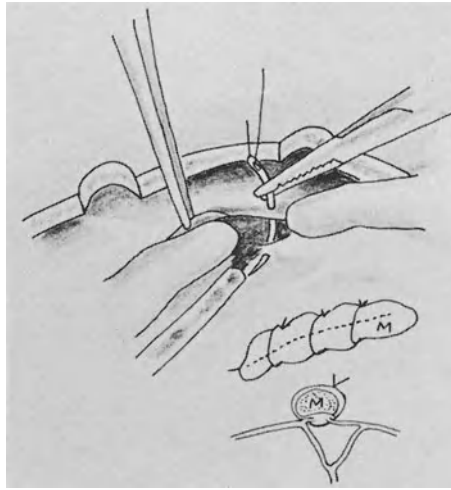


Fig. 19 b. Closure of a sagittal sinus wound. During the suturing an assistant presses gently on both sides of the laceration while the blood is sucked away. A piece of muscle (*M*) is tightened on to the dura as shown in the sketch

I do not recommend hitching up the dura near the midline in order to stop bleeding because in this area many large veins lie under or in the dura.

## Occipital Flap

### *Incision*

The conventional incision is a horseshoe one with an inferior pedicle. I prefer a Y shaped incision as used for parietal skull flaps (Fig. 18).

### *Burr Holes*

*Medial burr holes.* Two or three are necessary 1 cm away from the midline. In this area no midline suture is visible and the neurosurgeon has to be very careful when drawing the incision on the scalp.

*Lateral burr holes.* Two are drilled: one between the midline and the skull base, the other near the base just above the lateral sinus.

*Inferior burr holes.* Two have been already described. The third will be

drilled between these two through a short opening of the epicranium above the sinus. The bone between these three holes is partially sawn and the skull flap elevated with its epicranial pedicle (Fig. 19a).

#### *Closure and Traps*

The drain will be placed in the enlarged medial and inferior burr hole.

An injury to the torcular must be strictly avoided. This is why the medial and inferior burr hole will be drilled more safely 2 cm away from the midline.

If a mastoid cell is opened the cavity should be waxed.

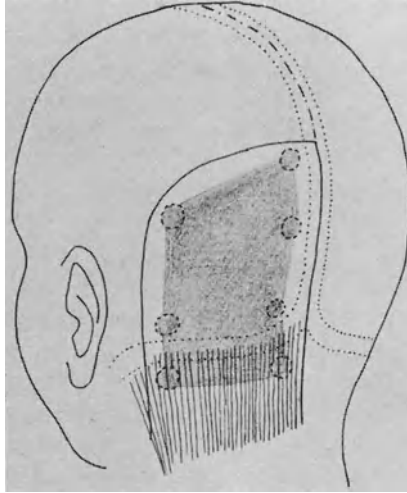


Fig. 20. Horseshoe incision and site of burr holes to turn an occipito-cerebellar skull flap overlying the lateral sinus

### **Special Craniotomies**

#### *Occipito-Cerebellar Skull Flap*

The removal of a meningioma of the tentorium invading the lateral sinus for instance requires an inferior extension of the routine occipital skull flap.

#### *Incision*

In this particular case the horseshoe incision looks better to me than the Y shaped one because it can be extended inferiorly as far as is wanted by the surgeon (Fig. 20).

#### *Burr Holes*

They will be drilled so as to form an inferior muscular pedicle and for such purpose two burr holes are drilled in the cerebellar fossa, the occipital squama, just below the lateral sinus; it will be difficult to join them up with a saw and I recommend the use of a rongeur.

The skull flap is elevated after breaking the occipital squama in the same way as the temporal squama for temporal skull flaps.

Another technique consists in turning a routine occipital skull flap and then removing the bone over the lateral sinus and the cerebellum as far as is needed with rongeurs.

The position of the patient's head is important in making the cutting of such a flap easier; the head has to be bent forward as is recommended for the cerebellar approach, whatever positions ventral decubitus or sitting. Personally I warmly recommend the sitting position which I have been using for more than ten years.

### *Traps*

Injury to the venous sinus will be managed as has been previously advocated.

Another difficulty may come from the bone. Sometimes the torcular area is very thick and the connecting up of medial burr holes may be a very arduous procedure near the midline. This is why the medial inferior holes are drilled 2 cm away from the midline, that is to say more lateral than the superio-medial hole.

A routine closure is carried out.

### *Hemispheric Skull Flap*

It will be mainly used for performing a hemispherectomy.

### *Incision*

I recommend an H shaped incision (Fig. 21) the main advantage of which is to cover more satisfactorily the skull flap once it is back in place. A large horseshoe incision will inevitably encroach the forehead skin.

### *Burr Holes*

These will be drilled in order to preserve the widest temporal muscle pedicle possible. Moreover when the operation is performed to remove an atrophic hemisphere the neurosurgeon is aware that the superior sagittal sinus is always displaced to the side of the atrophied brain, accordingly the medial burr holes will be drilled 2 cm away from the sagittal suture.

*Medial burr holes.* Four or five burr holes are enough. The anterior frontal hole is drilled in the middle of the forehead; the posterior occipital hole will be drilled between the parieto-occipital suture and the torcular.

*Inferior burr holes.* An anterior temporal will be drilled just behind the orbit and the two posterior holes will be placed just above the skull base.

### *Closure*

The dura has to be hitched up to the centre of the skull flap at three or four points. For this purpose pairs of twist drill holes are made in the skull flap and the silk sutures passed through the dura are tied over the scalp (Fig. 22).

The skin will need to be carefully sutured in order to avoid any necrosis of the apices of the scalp flaps as has been recommended previously. There is no drainage.



*Traps*

Once again the main source of difficulty lies in venous bleeding. Because the dura is usually thin the surgeon has to be very cautious while elevating this huge skull flap in avoiding injury to the sinus. It is essential to drill 2 cm away

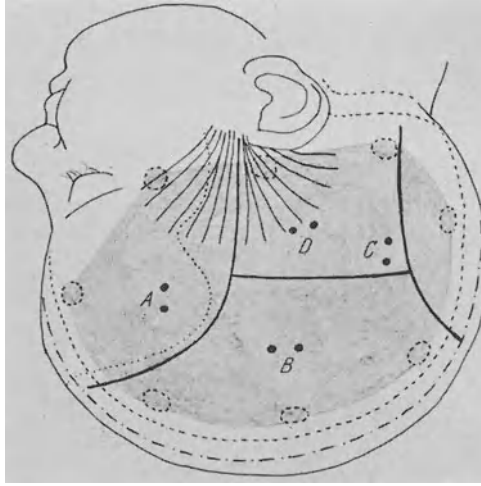


Fig. 21. H shaped scalp flap for the cutting of an hemispheric skull flap. In A, B, C, D are the sites of the central hitching up of the dura to the skull flap

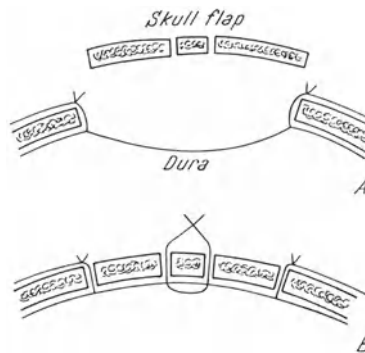


Fig. 22. Sketch of the central suspension of the dura directly to the flap using twist drill holes

from the sagittal and lateral sinus positions and to connect the burr holes through their centres rather than through their periphery.

It is easy to avoid a large frontal sinus but large mastoid cells may be opened and cavities need to be waxed or filled with bone dust. The neurosurgeon has to be very cautious if the operation is one of hemispherectomy to avoid any spinal fluid fistula the development of which would be disastrous.

*Cushing Craniotomy (Subtemporal Decompression)*

This is the removal of the temporal squama through a vertical incision of the skin and temporal muscle. It was first described by Cushing as palliative treat-

ment for intracranial hypertension of unknown origin. This operation can be performed on both sides.

### *Incision*

The original one was vertical between the outer end of the eyebrow and the ear. This is too far posteriorly placed in relation to the forehead branch of the facial nerve; in addition the removal of the anterior part of the temporal squama will be difficult; this is why I recommend a slightly anteriorly curved incision 10 cm in length.

### *Craniotomy*

Once the muscle has been cut and retracted a burr hole is drilled near the muscle boundary; bone is separated from dura with a curved spatula and rongeur away over the desired area. In order to get a good decompression the bone has to be removed down to the skull base and anteriorly to the pterion; then the opening of the dura will relieve the intracranial pressure.

### *Closure*

The muscle is be sutured and the skin will be closed in two layers as usual without any drainage.

This kind of craniotomy is rarely performed except in traumatic cases for instance the removal of an epidural haematoma, in which case the muscle is sutured and the epidural space will be drained as usual.

## *Skull Flap in Young Children*

### *Under Six Months of Age*

The bone is very thin and it is easier to connect the burr holes with scissors rather than with a Gigli saw. But the neurosurgeon has to keep in mind the normal and close adherence between bone and dura at the suture sites and especially in the fontanelle area.

In such an infant it is not always easy to put the skull flap back in its proper position because of the bone thinness and it is recommended to fix the flap to the skull with catgut sutures otherwise a deformity of the head shape can occur. Closure of the skin is often difficult because the scalp is overstretched. For the deepest layer the neurosurgeon has to suture only the galea avoiding the dermis the stretching of which might lead to skin necrosis; but this is not easy because the galeal sutures often loosen and this is why I recommend putting in three fitting points, *i.e.*, total points bringing together both sides of the incision and then suturing in the two usual layers. In these babies the use of clamps for drapes is strictly forbidden; they have to be fixed with sutures. Drainage is usually unnecessary.

### *Over Six Months of Age*

Burr holes can be drilled and the skull flap can be cut in much the same way as in adults; it is unnecessary to close the burr holes with plastic until 15 years of age because bone regeneration is sufficient to fill in the small cavities.

### *Flap Reopening*

It is possible during the first two years after a major craniotomy, to re-elevate a flap in adults without drilling new burrholes. In this case it is not necessary to use a saw, the skull flap may be reopened using a chisel obliquely introduced under the flap margins and gently tapped with a hammer. The only difficulty lies beneath the muscular pedicle, which is firmly adherent to the dura and has to be carefully dissected. After a bone flap is about two years old, it becomes progressively more difficult to reopen the skull using this quick technique, and eventually the day comes when it is necessary to redrill the same burrhole sites; for that purpose the automatic craniotome is safer than the hand drill which, if used, must be employed with a conical burr only. Dura will be gently separated from bone to introduce a flexible dural guide as a last stage before the use of the saw.

It is worth while to note that adhesions between dura and skull are not generally as extensive as one might foresee.

In children, the healing process is much more rapid and the neurosurgeon must usually cut a new flap on the site of the old one after one year has elapsed.

Skin closure after flap reopening should be with a single layer of silk only and I advocate the use of the Blair-Donati stitch. Epidural drainage is usually unnecessary.

### **Conclusion**

To drill a burr hole or to turn a skull flap has to be, in my mind, a fast moving operation in order to reduce the blood loss and to save time for the intracranial procedure.

But the best planned craniotomy will be a failure if it is not made in the correct position; this is why I recommend to young neurosurgeons to choose and pin up the X-ray or radioisotopic studies on the wall of the operating theatre before positioning the patient and then to draw carefully the incision according to these studies.

If the opening needs speed and accuracy, the closure requires great care to avoid the post operative epidural haematoma, the nightmare for beginners when they have not been taught correctly.

### **References**

- Dandy, W. E., 1945: *Surgery of the Brain*, 671 pp. Hegers Town, Maryland: W. F. Prior Company, Inc.
- Irsigler, F. J., 1960: Lagerung zur Operation. Gebräuchliche Schnittführungen (43—55). Die Trepanation (Kraniotomie) (55—90). *Handbuch der Neurochirurgie*. Berlin-Göttingen-Heidelberg: Springer.
- Odom, Guy L., Woodhall, B., 1966: Supratentorial skull flaps. *J. Neurosurg.* 25, 492—501.
- Rand, B. O., Ward, Jr., A. A., White, Jr., L. E., 1966: The use of the twist drill to evaluate head trauma. *J. Neurosurg.* 25, 410—415.
- Yaşargil, M. G., 1969: *Microsurgery applied to neurosurgery*, 225 pp. Stuttgart: G. Thieme.

# Removal of Extradural Benign Spinal Cord Tumours

B. GUIDETTI

Neurosurgical Clinic of Rome, Medical School, Rome (Italy)

With 23 Figures

## Contents

Introduction .....	173
Laminectomy .....	176
Benign Extradural Tumours .....	183
Benign Intradural Tumours .....	183
Meningiomas .....	184
Neurinomas .....	186
Subdural Lipomas .....	192
Dermoids, Epidermoids, and Teratomas .....	193
Tumours of the Cauda Equina.....	194
Benign Tumours of Foramen Magnum.....	194
Postoperative Treatment.....	195
Results .....	196
References.....	198

## Introduction

In 1887 at the National Hospital for the Paralyzed Epileptic, Queen Square, London, Sir Victor Horsley performed a laminectomy on an army officer with extensor spastic paraplegia. The patient had been treated by Sir William Gowers<sup>4</sup>, who had diagnosed a spinal cord tumour and advised surgery. In the event no tumour was found and the operation was about to be concluded when Mr. Charles Ballance, who was assisting, urged Horsley to extend the laminectomy to a higher level. On removal of another lamina, a clearly circumscribed tumour was found and removed. For the first time in the history of medicine a patient operated on for a spinal cord tumour recovered from the operation completely and gradually resumed his previous occupation.

The many laborious advances of spinal surgery achieved by a host of surgeons, among whom Elsberg<sup>2</sup> ranks high, are part of the history of neurosurgery<sup>10</sup>. Little has been added to the high standard of operating technique reached by

our predecessors over 40 years ago. The progress of spinal surgery in the past few decades owes more to the use it has made of progress in related fields: the fall-out from the advances made in all fields of medicine, the refinement of clinical and laboratory knowledge, the improvement of contrast media for myelography, new investigations like electromyography, pneumomyelostriatigraphy, myeloscintigraphy, selective vertebral and radicular angiography and intraosseous spinal venography. From the technical point of view the introduction into neurosurgery of the operating microscope and bipolar coagulation has made for im-

Table 1. *Extramedullary Tumours*

Neurinomas . . . . .	105
Meningiomas . . . . .	84
	<hr/>
	189
Sarcomas . . . . .	41
Metastatic carcinomas . . . . .	45
Angiomas and angioliomas . . . . .	15
Plasmocytomas . . . . .	13
Aneurysmal bone cysts . . . . .	6
Giant cell sarcomas . . . . .	4
Chordomas . . . . .	4
Dermoid-epidermoids . . . . .	5
Osteochondromas . . . . .	3
Sympathicoblastomas . . . . .	3
Unclassified tumours . . . . .	6
	<hr/>
	145
	<hr/>
	334

provements in operating technique and in the immediate and long term results. But the greatest advance, as Frugoni<sup>3</sup> so rightly says, came with the spread of neurosurgical centers, the outcome of the unanimous realization that spinal cord tumours belong strictly to the realm of neurosurgery and that the neurosurgeon is the only specialist in a position to treat these diseases adequately.

All this has led to an amazing reduction in operative mortality: from 40–50% at the beginning of this century to 2–3% nowadays with far more satisfactory functional results. The author of this chapter on 334 extramedullary tumours (Table 1), almost all operated on personally and some of them in patients aged over 70, has had only one death, which occurred on the tenth day from cardiac infarction verified at necropsy.

Nowadays a correct correlation between the clinical and instrumental data permits not only a diagnosis of site of a spinal cord tumour but in the majority of cases also a differential diagnosis between intramedullary and extramedullary tumours and sometimes even a diagnosis of the nature of the space-occupying lesion<sup>5, 6</sup>. It is advisable for a patient suffering from a spinal cord tumour to be studied at a neurosurgical center, or with the close cooperation of a neurosurgeon, not only because the neurosurgeon is concerned with aspects that may not

interest the neurologist or neuroradiologist but also because an immediate operation may be necessary, e.g. if the removal of cerebrospinal fluid by lumbar puncture for diagnostic purposes is followed by sudden herniation of the tumour with rapid deterioration of the clinical symptoms. Similarly, it is a good thing for myelography to be done shortly before the surgical operation both because of the possible worsening of clinical symptoms that sometimes follows this investigation and because an exacerbation of pain and a rise in temperature may occur after myelography.

Once the site, size and, if possible, the nature of the spinal space-occupying lesion are known, the surgical operation can be planned down to the last detail.

The first task of the surgeon preparing to perform a laminectomy is to mark out exactly which laminae have to be removed. The most reliable method is to lodge a stainless steel nail, under radiographic control, into the spinal tip situated at the upper or lower limit of the tumour, cutting off the head of the nail so that the skin may cover it. Another, less precise, method is to mark the level of the tumour with a radiopaque object, kept in place with adhesive tape; this landmark should be fixed on the skin in the operating position to prevent errors due to the variation of the relationship between spinal tips and skin according to the body position.

\*  
\*       \*  
\*

The anaesthesia of choice in patients with spinal cord tumours is general anaesthesia by intratracheal intubation. In cervical tumours the anaesthetist must be extremely careful not to extend or bend the patient's neck unduly, because these manoeuvres reduce the anteroposterior diameter of the spinal canal and so may cause damage to the nerve tissue, already impaired by tumour compression.

Controlled respiration, by increasing the oxygenation of the tissues and venous drainage and reducing any cord oedema, both facilitates surgical manoeuvres and improves the immediate and long term functional results.

The position of the patient on the operating table must be such as to afford the surgeon the greatest ease of access and at the same time must not hinder respiration or compress the abdominal organs. We prefer the prone position, taking care to ensure that the chest and abdomen are free from compression. The head is placed on a posterior fossa headrest and the neck kept in slight ventral flexion. Care must be taken, in the prone position, to prevent any contrast medium from spreading into the cerebral subarachnoid spaces. Another eventuality to be avoided, especially in children with concomitant hydrocephalus, is rapid loss of cerebrospinal fluid after opening the arachnoid and the entry of air into the subarachnoid spaces and cerebral ventricles with consequent postoperative headache and the possibility, albeit remote, of the formation of a subdural haematoma. These risks can easily be avoided by tilting the operating table appropriately.

We use the sitting position only in small cervical spinal cord tumours. The reason for our not operating on large tumours in this position is the fear that a fall in arterial pressure, a not exceptional occurrence when operating on patients

in the sitting position, might worsen the already precarious condition of the cord circulation caused by compression, with the risk of irreparable damage, not justifiable in the surgery of extramedullary benign tumours. (It is worth recalling that, when the patient is operated on in the sitting position, the arterial pressure at head level differs from that recorded on the arm. To be sure of having exact information on the pressure at cerebral level, we think it useful to record the arterial pressure continuously from a cannula inserted in an artery of the external carotid. The risk of an air embolism must always be borne in mind when operating on a patient in the sitting position. In this position every possible precaution should be taken to be certain that the patient can quickly be lowered if necessary and that the anaesthetist monitors the heart sound constantly.)

### Laminectomy

Before proceeding to the standard laminectomy technique, which is described in every treatise on neurosurgery, I would like to stress a few points:

1. The operative field must be exposed generously, because it is sometimes necessary to extend the laminectomy.

2. Before covering the operative field with sterile towels, it is useful to mark the extent of the skin wound, which must be proportionate to the size of the tumour, with a bistoury; to avoid unnecessary blood loss, the wound together with the subcutaneous tissue and paravertebral grooves should be infiltrated with a 1% solution of procaine hydrochloride and epinephrine.

3. The vertebral laminae should be removed very delicately without exerting the slightest pressure on the dura and underlying cord which, especially in anteriorly located tumours, may be pushed hard against the laminae. We get on very well with the Semb-Stille rongeur, with which we remove first the spinous processes and part of the laminae. This rongeur permits removal of the bone from above downward. The rest of the lamina is then removed, together with the yellow ligaments, by means of rongeurs with a thin underblade held straight up or vertically.

4. The dura mater should be opened only after perfect haemostasis of the muscle walls and bony margins. Further, it is advisable to open the dura and arachnoid separately, for several reasons, namely: a) in patients in whom the tumour is pushing the cord backward, separate incision of the arachnoid avoids damage to the nervous tissue; b) the cerebrospinal fluid circulation is restored more easily if the arachnoid is partially intact and the vessels spared; c) the risk of a postoperative pseudomeningocele is reduced if care is taken not to include the arachnoid in the suture.

5. During the removal of a spinal cord tumour extreme care must be taken not to compress or in any way injure the nervous tissue. The pressure of forceps or dissectors must be exerted on the tumour and never on the cord.

6. The radicular arteries, especially that of Adamkiewicz, must always be recognized and spared. This holds good for all tumours, but particularly for dumbbell tumours, which may develop adhesions with these vessels.

7. During the operation (and during the postoperative course) extreme care must be taken to keep the arterial pressure within physiological limits,

because a sudden fall in pressure may cause irreversible damage to the nervous tissue, already compressed by the tumour.

Laminectomy begins with an incision of the skin and subcutaneous tissue until the dorsal fascia is uncovered. Once the spinous processes have been identified, the supraspinous ligament is incised in the midline with an ordinary bistoury or cutting current (Fig. 1). The muscles of the paravertebral grooves are stripped

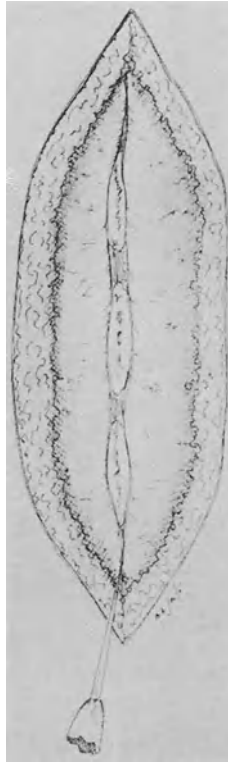

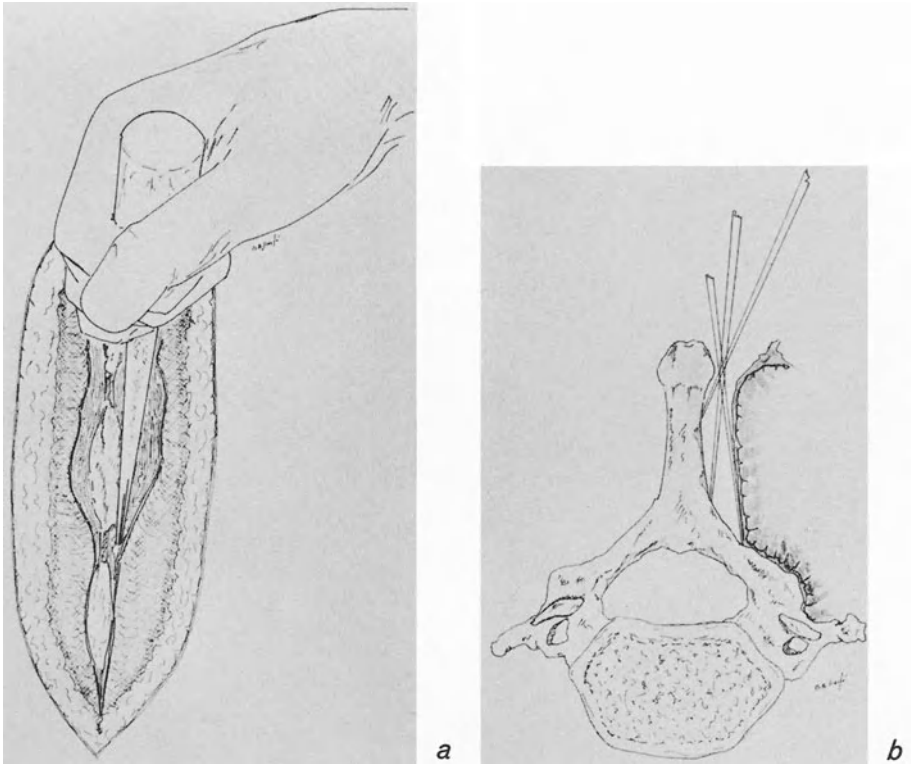
Fig. 1. Thoracic laminectomy. The supraspinous ligament is incised in the midline with electrobistoury

subperiosteally and reflected laterally with a large McEwen-Stille laminectomy scalpel (Figs. 2a and b). The subperiosteal elevation is carried laterally to the facet and gauze sponges should be packed in the gutter. When the procedure is carried out correctly, the loss of blood is minimal and the spinous processes and laminae are completely denuded of muscles and ligaments as far as the articular facets (Fig. 3). After retracting the muscles with two Adson self-retaining retractors, the spinous processes and part of the laminae are removed with Semb-Stille rongeur (Figs. 4a and b). The remainder of the laminae, now reduced to thin layers of bone, are removed with a Leksell rongeur to the desired extent and laterally as far as the articular facets (Figs. 5a and b). The articular facets may be removed with impunity in the thoracic and lumbar segments of the spine



but at cervical level it is wise to avoid removing them because this may favour dislocation of the vertebral bodies.

Hemilaminectomy, which used to be recommended by some surgeons with a view to avoiding dislocation of the vertebrae, has not, in our view, any indication these days in the surgery of spinal cord tumours, the reason being that whilst it is technically possible to remove a tumour through this narrow approach, the risk of injury to the cord is undoubtedly greater.



Figs. 2 a and b. Thoracic laminectomy. The muscles of the paravertebral grooves are stripped subperiostally and reflected laterally with a large McEwen-Stille laminectomy scalpel

When laminectomy is completed, observation of the epidural space may yield useful information. Apart from the possibility of an extradural tumour, there may be thinning or thickening of the dura mater, the imprint of a subdural tumour, thickening of the dural sac. Even the distribution of the epidural fat has diagnostic relevance: it is usually absent at tumour level, though it persists above and below. Likewise a normal pulsation of the dura mater is found above the tumour and no pulsation at the level of the tumour or below.

Haemostasis of the epidural space as a rule presents no difficulty: the vessels are coagulated with a bipolar current and bone bleeding is stopped with haemostatic wax. But when the patient's chest or abdomen presses against the

operating table or anaesthesia is not proceeding normally, the epidural vessels are swollen and bleed profusely so that the inexperienced surgeon may suspect an epidural angioma. But as soon as the anaesthetist intervenes and the patient's position is corrected the swelling of the vessels goes down at once and bleeding stops.

When perfect haemostasis has been obtained, two lengths of Spongostan\* are packed into the lateral grooves of the subdural spaces to prevent any further

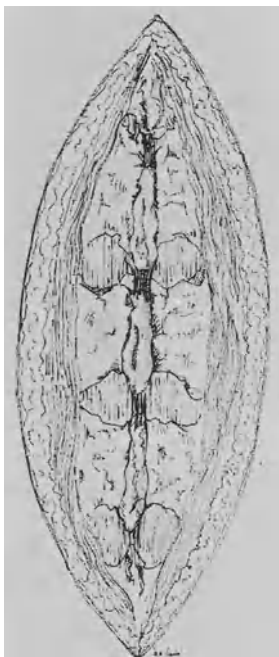


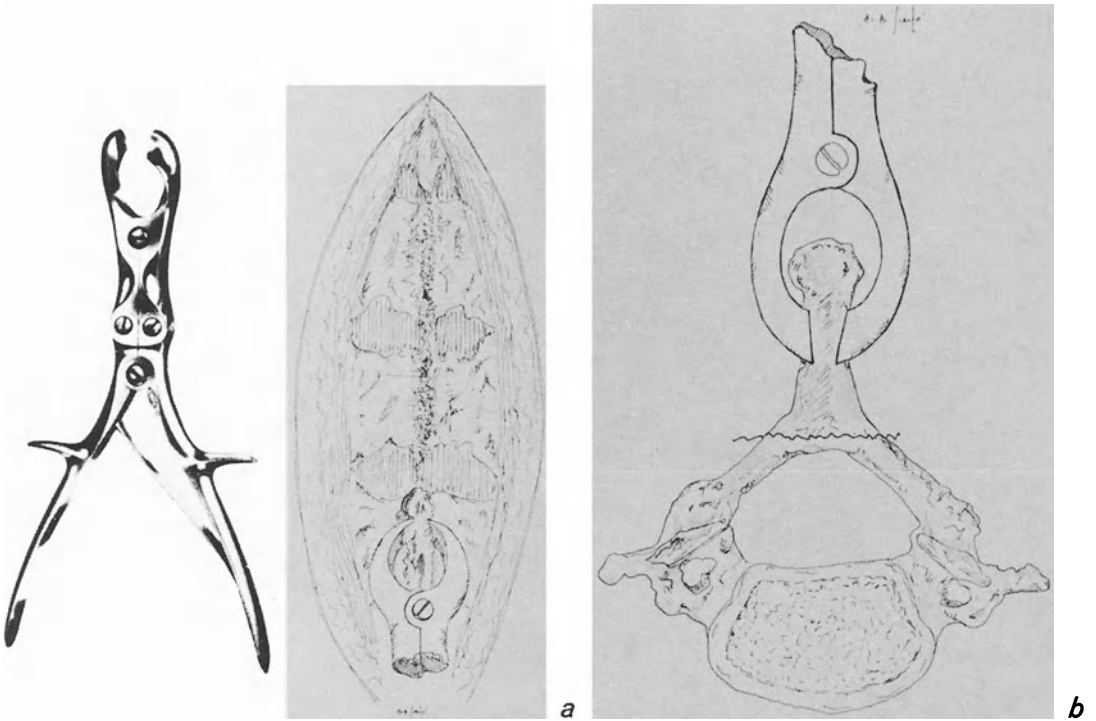
Fig. 3. Thoracic laminectomy. The spinous processes and laminae are completely denuded of muscles and ligaments

bleeding when the dura is opened and the muscles are covered with squares of cotton soaked in warm physiological solution, after which the dural sac is opened. In order not to injure the underlying cord and not to include the arachnoid in the incision, the dura is initially opened between two midline sutures raising it at one end of the laminectomy, where there is presumed to be no underlying tumour (Fig. 6). The dura is then incised right along the midline as far as it is exposed and the margins temporarily suspended with silk sutures (Fig. 7). After identifying the nature of the tumour, the arachnoid is incised as far as desired, care being taken to avoid a sudden leakage of cerebrospinal fluid; this is ensured by lowering the cranial end of the operating table just enough to place the patient's head at a slightly lower level than that of the spinal column. When the tumour is situated above the laminectomy, there will be no leakage of cerebrospinal fluid.

\* Spongostan-Ferrosan, Denmark.

In that case or when there is no disease at laminectomy level, it is useful to insert a soft rubber catheter into the subarachnoid spaces and push them upward or downward until the block caused by the tumour is encountered and then extend the laminectomy in that direction.

Intra- or extradural tumours posterior or posterolateral to the cord can easily be identified and removed without difficulty. But in the case of tumours



Figs. 4 a and b. Thoracic laminectomy. The subperiosteal elevation is carried laterally to the facet, the spinous processes and part of the laminae are removed with the Semb-Stille rongeur

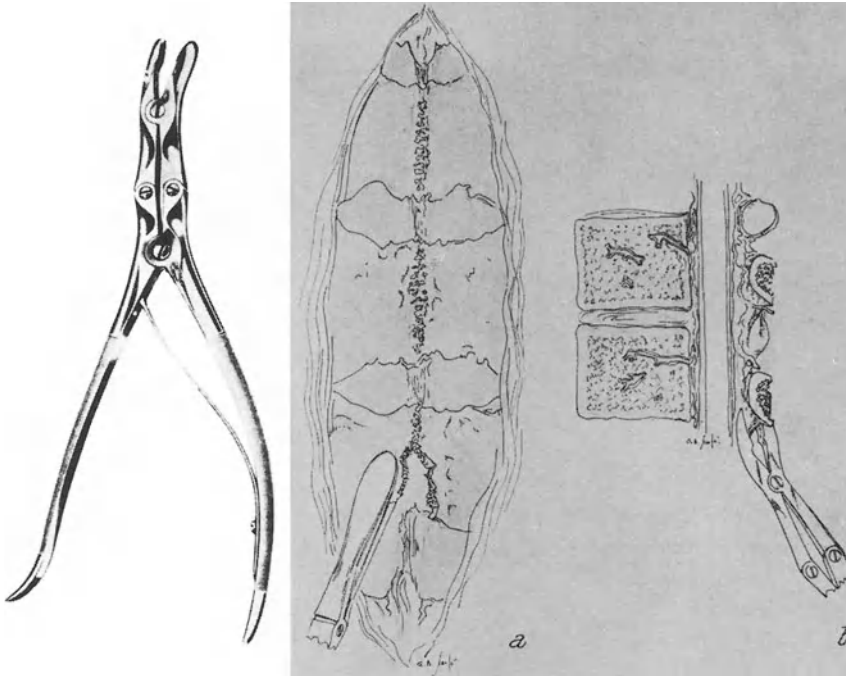
anterolateral or anterior to the cord the dural sac and the cord are pushed backward: in subdural extramedullary tumours the cord may appear crushed and increased in volume so that to the inexperienced eye the patterns suggest a tumour within the cord. To avoid this, it is sufficient to section the dentate ligaments and rotate the cord delicately in order to explore the anterolateral aspect of the vertebral canal. Another technical expedient that may sometimes be useful is to explore the anterolateral wall of the cord with a dissector before deciding on treatment.

The removal of an intradural tumour must not be commenced until haemostasis is perfect, firstly because blood obscures the operating field and secondly because bleeding into the subarachnoid spaces may cause postoperative arachnoiditis. Hence, before proceeding to tumour removal, we think it a good plan to

pack the subarachnoid spaces above and below with cotton pledgets soaked in physiological solution.

The bleeding that results from tumour removal is arrested with silver clips, by coagulation with a bipolar current, by lightly packing with cotton pledgets soaked in hydrogen peroxide or with Spongostan or Surgicel\*.

Removal of the tumour is followed by generous flushing of the subarachnoid



Figs. 5 a and b. Thoracic laminectomy. The remainder of the laminae is removed with a Leksell rongeur

spaces with warm physiological solution, after which a cortisone solution is left in them. The dura mater is then closed with a perfectly sealing continuous suture (Fig. 8).

When part of the dura mater has been removed because of tumour infiltration, we perform a dural repair (for over 10 years we have been doing dural repairs with cadaver dura mater sterilized with gamma rays. The dura prepared in this way is placed in plastic bags with alcohol and stored in a refrigerator)<sup>1</sup>.

Having checked the haemostasis of the epidural spaces and soft tissues, we cover the dura mater with Gelfoam soaked in antibiotics and suture with silk in layers: muscles, fascia, subcutaneous tissue and cutis (Figs. 9 and 10).

\* Surgicel—Johnson & Johnson, New Brunswick-New Jersey, USA.

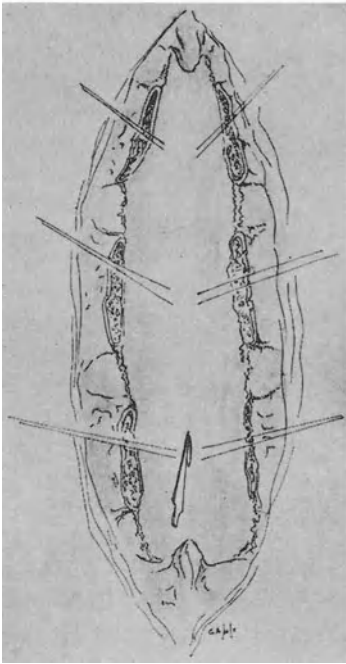


Fig. 6

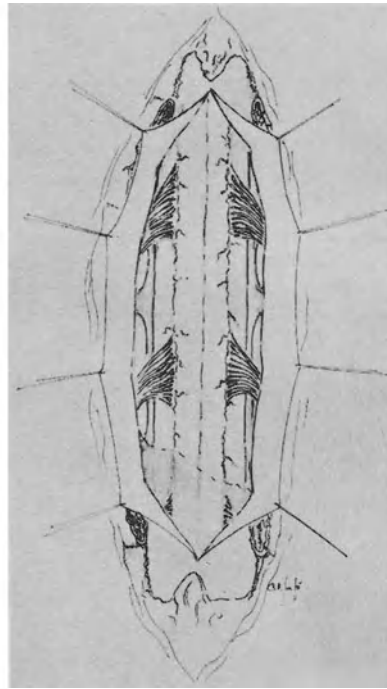


Fig. 7

Fig. 6. Thoracic laminectomy. The dura is opened between two midline sutures  
 Fig. 7. Thoracic laminectomy. The dura is then incised right along the midline

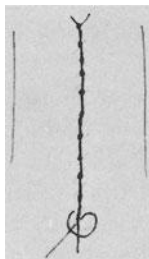


Fig. 8

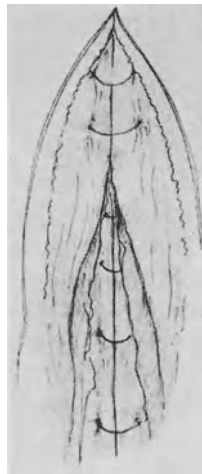


Fig. 9

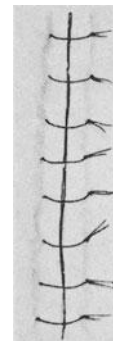

Fig. 10

Fig. 8. Thoracic laminectomy. Closure of the dura with a perfectly sealing continuous suture  
 Figs. 9 and 10. Thoracic laminectomy. Suture with silk in layers: muscles, fascia, subcutaneous tissue and cutis

Extradural benign tumours are classified by site as extradural, intradural and intra-extradural.

### Benign Extradural Tumours

The overwhelming majority of extradural tumours are malignant and may be primary or secondary. Only about 10% of extradural tumours are benign or at all events have a favourable prognosis; some of these tumours come from bone like haemangiomas, the aneurysmal bone cyst, the giant osteoid osteoma, others from the dura mater, from the nerve roots, from the vessels, fatty tissue and from embryonal rests.

Bone tumours often affect the laminae and the spinous processes and some of them are highly vascularized. The surgeon must be prepared for this eventuality and should undertake the operation only if he has adequate supplies of blood. In highly vascularized tumours the removal of the spinous processes and laminae must be effected with skill and speed, without overmuch concern about the heavy blood loss involved, on condition, of course, that the blood loss can be made good, during the haemorrhage. In our experience if the surgical manoeuvres are conducted with delicacy, speed and skill the operation is risk free and entails less blood loss than an operation conducted slowly to ensure haemostasis at every step. The same applies to epidural angiomas and cavernomas. After the removal of all or part of the diseased tissue, haemostasis is effected with wax, Surgicel or Gelfoam.

The removal of a lipoma, epidermoid or other tumour of dysembryonal origin presents no technical difficulties worth mentioning. The same goes for the rare epidural meningiomas, 5 in our series, which are easily removed together with their dural attachment. Some extradural meningiomas, because of their macroscopical appearance and the rapid clinical course that frequently and oddly characterizes them, may be mistaken for malignant tumours. In these circumstances and in all extradural tumours whose nature is not clear on-the-spot histological examination is of great help. On-the-spot histological examination was decisive in one of our patients, in whom the naked-eye appearance and extremely swift clinical evolution had suggested the presence of a malignant extradural tumour. Once the nature of the tumour was known, an epidural plaque meningioma, it could be removed radically together with its dural attachment.

The neurinomas and other tumours located anterior to the cord will be dealt with in the part devoted to intradural tumours.

### Benign Intradural Tumours

In adults the great majority of subdural extradural tumours are meningiomas and neurinomas (Table 1). In children meningiomas (4%) and neurinomas (8%) are infrequent, malignant extradural tumours and intramedullary tumours being the rule.

In our experience, as mentioned earlier, a differential diagnosis between intra- and extradural tumours was possible in nearly all cases. A close

clinical and radiological study can even permit differentiation between neurinomas and meningiomas. This distinction is not just of speculative value but is useful for the purposes of correct operating technique; one needs only think of meningiomas located anterior to the cord or of dumbbell neurinomas.

Table 2. *Intramedullary Tumours*

<b>Gliomas</b>	
Ependymomas.....	26
Astrocytomas .....	35
Spongioblastomas .....	8
Glioblastomas .....	4
Unclassified gliomas.....	6
Unverified gliomas.....	4
Haemangioblastomas .....	7
Lipomas .....	7
Epidermoid-Dermoids .....	4
Neurinoma .....	1
Unclassified tumours .....	3
	105
 Extramedullary and "filum terminale"	
gliomas .....	12
	117

### *Meningiomas*

Most subdural meningiomas are attached to the anterolateral wall of the dura, fewer to the posterior wall. In 5 patients of our series the dural attachment was not found.

When a meningioma is attached to the posterior or posterolateral wall of the dura, inspection and palpation before opening the dura nearly always permit identification. In this case the dura is incised below or above the tumour, first in the midline or laterally and then with curved scissors around the base of the tumour attachment; simultaneously haemostasis of the vessels of the dural margin is effected with silver clips; finally, the tumour is separated deftly from the cord bed and removed in toto with ease.

In anterolateral meningiomas, when the dura mater has been opened and its margins suspended, the cord is seen to be pushed backward and toward the opposite side with the nerve roots and the dentate ligaments stretched (Fig. 11). After section of the dentate ligaments and of the roots lying above the tumour, which cannot be spared, the cord is rotated delicately by means of slight traction on the dentate ligaments and the tumour is exposed (Fig. 12). When the tumour is large and the space available insufficient, it is advisable, after covering the cord with cotton pledgets soaked in physiological solution, to enlarge the laminectomy as far as possible on the side of the attachment, including in the removal one or more articular facets. Having thus obtained more space, one can section the dura around the base of the tumour attachment while exerting increasing traction on the dural flap (Figs. 13 and 14). When the meningioma is very large,

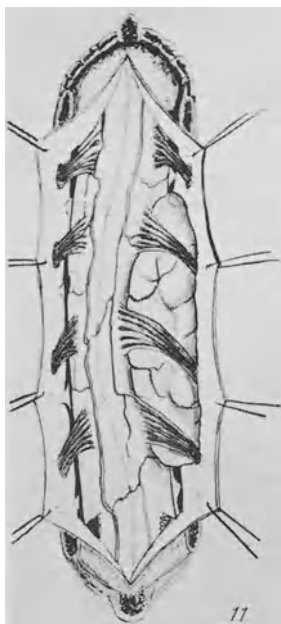
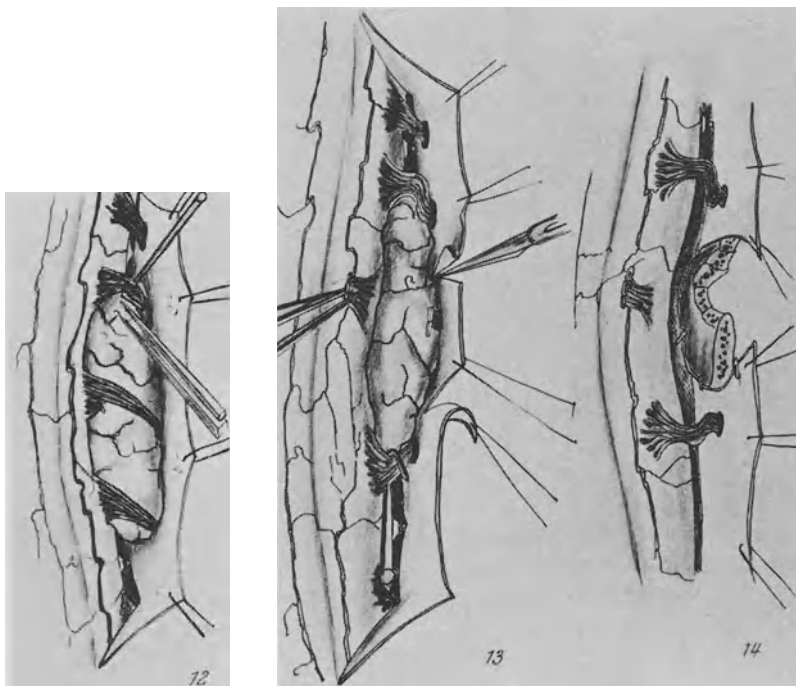


Fig. 11. Anterolateral meningiomas. The cord is pushed backward and toward the opposite site with the nerve roots and the dentate ligaments stretched



Figs. 12, 13, and 14. Anterolateral meningiomas. After section of the dentate ligaments and of the roots lying above the tumour, which cannot be spared, the cord is rotated by means of slight traction on the dentate ligaments and the dura around the base of the tumour attachment is sectioned while exerting increasing traction of the dural flap



it is advisable to incise the capsule, empty it of its contents with a sharp curette and, having thus reduced its volume, remove it with the dural attachment.

In meningiomas located anterior to the cord the situation is more tricky. In these cases the cord is pushed backward to a more or less marked degree and removal of the tumour by the posterior route would cause irreparable cord damage. In these circumstances we prefer to attack the tumour by the lateral route, that is by the same route as we habitually use for thoracic disk prolapse. This

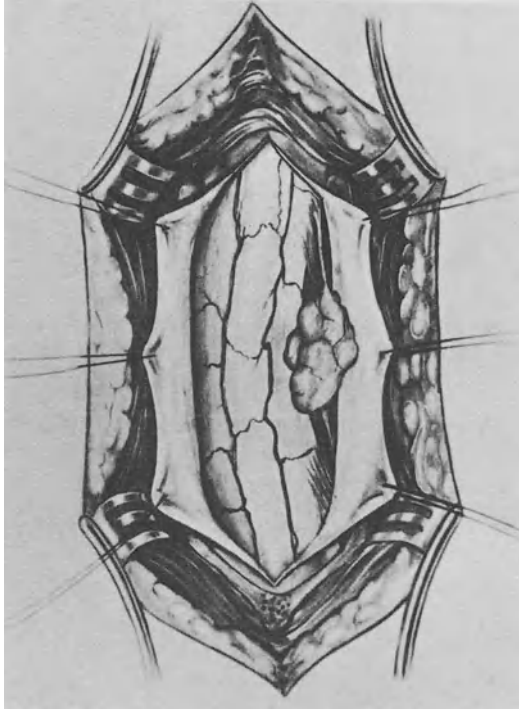


Fig. 15. Intradural neurinomas. Neurinoma arising from nerve roots

calls for a costotransversectomy as well as the usual laminectomy. When the capsule has been emptied of its contents with a sharp curette, the dura mater is incised on both sides of the tumour attachment with curved scissors. The remaining dural peduncle is sectioned from the opposite side of the cord. In this way the tumour is made to slip in front of the cord. After removal of the meningioma, a piece of bank dura mater is applied to the ventral surface of the cord and subsequently turned back on to the dorsal surface like a hammock.

#### *Neurinomas*

Neurinomas may be found in the epidural or intradural space or be intra- and extradural. For intradural neurinomas the rules described for meningiomas apply, but, whilst in the latter it is necessary to remove the dural attachment, in neurinomas it is necessary to section the roots from which they arise (Fig. 15).

A medium-sized neurinoma can easily be removed en bloc without damaging the cord. A large one is best emptied of its contents and the capsule removed after. In anterolateral neurinomas, as for meningiomas, it is useful to section the dentate ligaments and, by exerting traction on them, rotate the cord delicately.

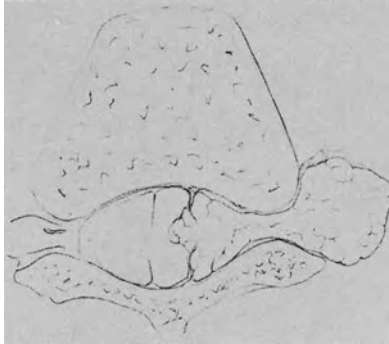

Fig. 16. Cross section: Dumbbell neurinoma with a large outgrowth into and out the intervertebral foramen

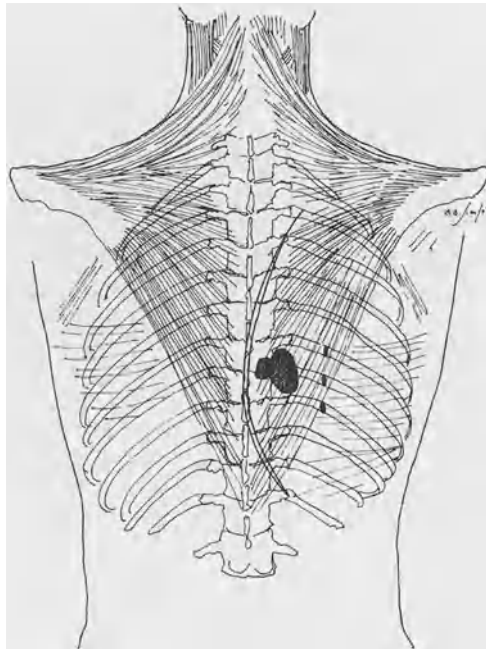
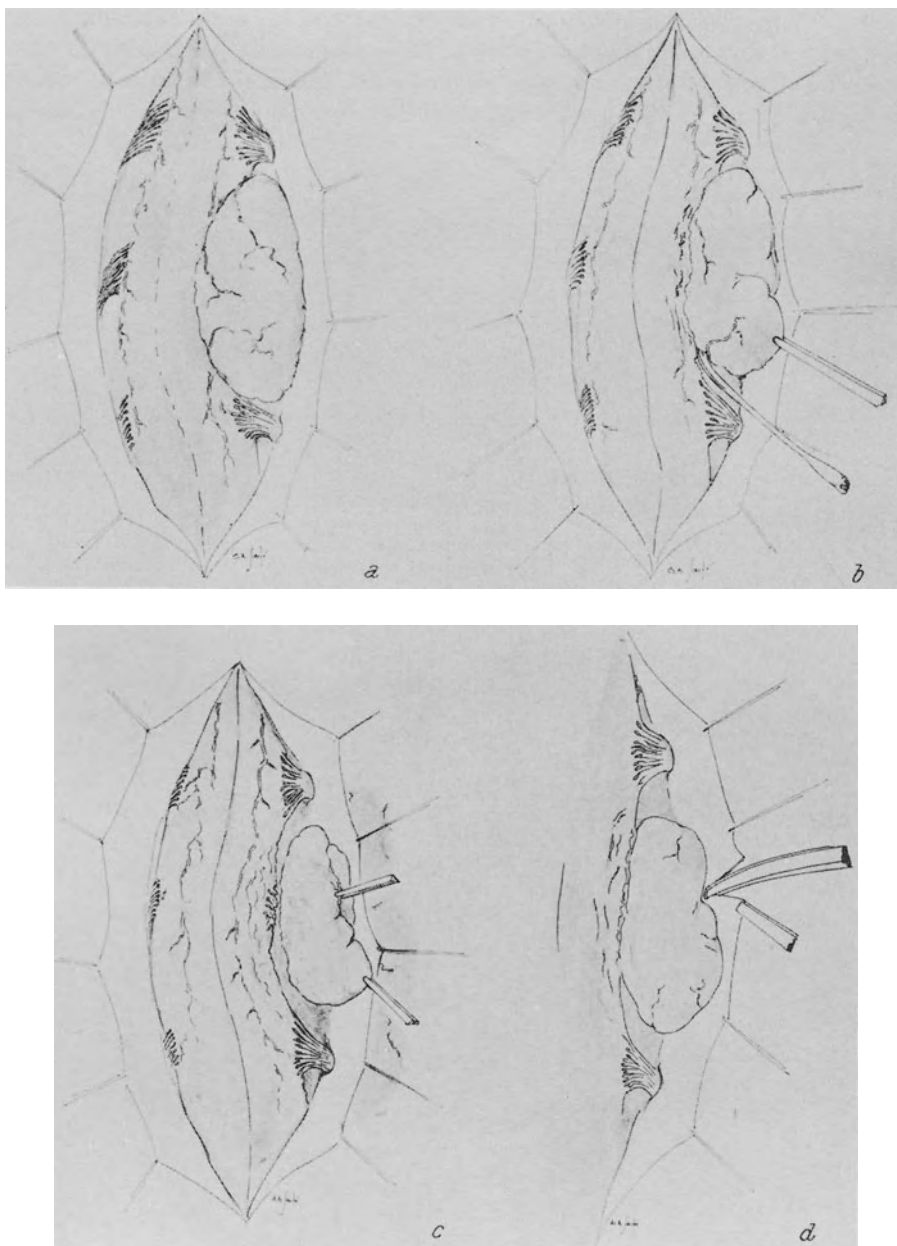


Fig. 17. Curved skin incision according to Poppen

Neurinomas of the cauda, given the ample space available, often attain considerable size. In our experience it has never been difficult to isolate the tumour capsule from the nerve roots and in every case it was easy to remove capsule and tumour en bloc without injuring the nervous structures. Should separation

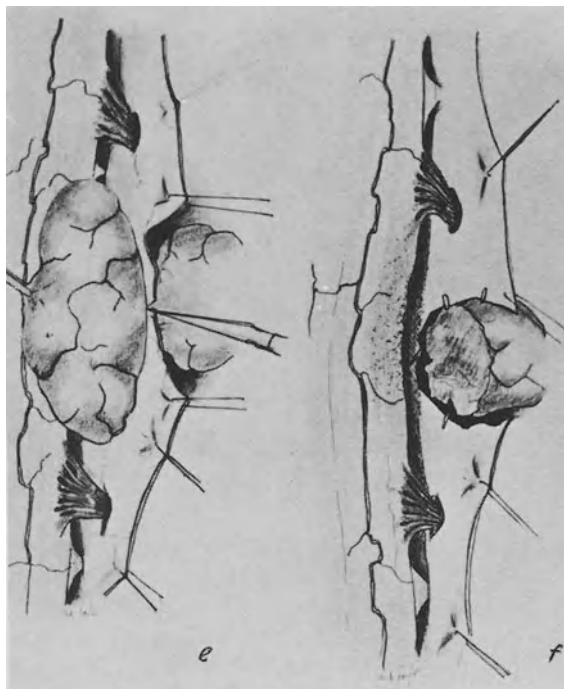


Figs. 18 a-d

**Figs. 18.** Dumbbell neurinomas, thoracic region. Having isolated and removed the intraspinal part, one proceeds to the removal of the remainder of the neurinoma. In the majority of cases the opening of one or two intervertebral foramina permits one to exert traction on the tumour stump and so remove the intraforaminal and extraforaminal parts

of the capsule from the nerve roots prove too traumatic, part of it should be left in situ.

Dumbbell neurinomas present different technical problems. Some develop mainly in the spine sending only a small outgrowth into an intervertebral foramen; these, known as bottle neurinomas because of their shape, present no particular technical problems. Other neurinomas consist of an intraspinal mass, a more or less large outgrowth into one or more intervertebral foramina (whose walls



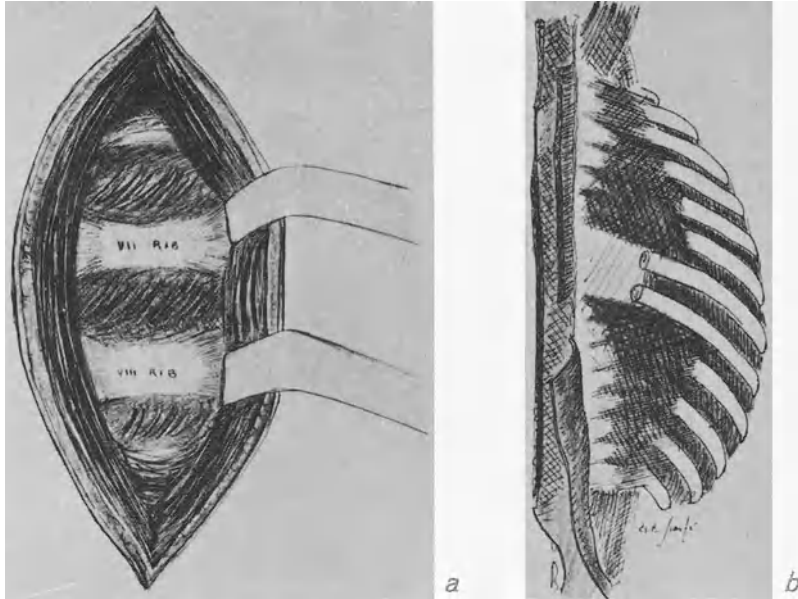
Figs. 18 e-f

may be destroyed by the tumour growth) and a paravertebral mass (Fig. 16). When the paravertebral mass is not large, we consider that the tumour can be removed in a single operation and by the same approach; on the other hand, when it is large, a two-stage operation is indicated: stage one for removal of the intraspinal tumour and stage two for removal of the extraspinal part.

When faced by a dumbbell tumour the surgeon must find out beforehand what relationships the tumour capsule may have established with the radicular arteries and with the paravertebral vessels, especially with the vertebral artery in cervical tumours.

For radical removal of the tumour through the same access route, a curved skin incision is made around the tumour according to Poppen<sup>9</sup> (Fig. 17) and the laminae and the posterior wall of one or more intervertebral foramina, often of paperlike consistency, are removed. The dura mater is incised in the usual way along the midline, care being taken to extend the incision laterally to include

the whole of the intervertebral foramen. Having isolated and removed the intraspinal part as far as the entrance to the foramen by the technique described earlier and, protecting the cord with pads of compressed cotton soaked in physiological saline, one proceeds to the removal of the remainder of the neurinoma (Figs. 18a-d). In the majority of cases the generous opening of one or two intervertebral foramina permits one to exert traction on the tumour stump and so remove the intraforaminal and extraspinal parts with little difficulty (Figs. 18e-f).



Figs. 19 a and b. Costotransversectomy. The paravertebral muscles are reflected to expose the posterior aspects of the ribs, and the tip of the transverse processes.  
Rib exposed and excised

The root of origin must be sectioned after closure with a silver clip, the aim being to prevent a postoperative collection of blood outside the spine.

If the extraspinal mass is larger, it is advisable to perform a costotransversectomy. (Curved skin incision according to Poppen Fig. 17.) The muscles layers are divided in the line of the incision until the outer border of paravertebral muscles is exposed. These muscles are then reflected to expose the posterior aspects of the ribs, medial to the angles, and the tips of the transverse processes. After the intercostal muscle bundle has been divided, sections of two ribs are removed to expose the parietal pleura and tumour (Figs. 19a-b). The pleura is next gently mobilized and reflected forward and laterally and the tumour may usually be delivered from its bed. The distal end of the intercostal nerve is divided (Fig. 20).

The dural defect that follows the removal of a dumbbell neurinoma should always be repaired impermeably, resorting, where necessary, to dural patching (Fig. 21).

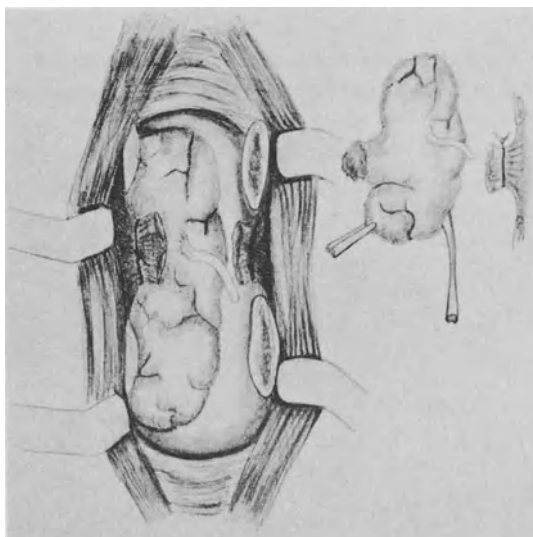


Fig. 20. Costotransversectomy. After section of two ribs the tumour and the parietal pleura are exposed. The distal end of intercostal nerve is divided, the tumour separated from the pleura and removed

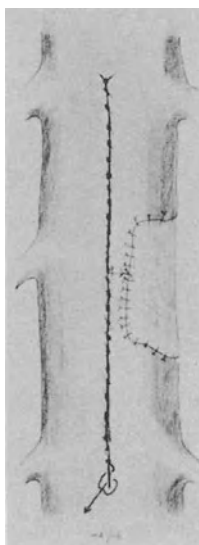


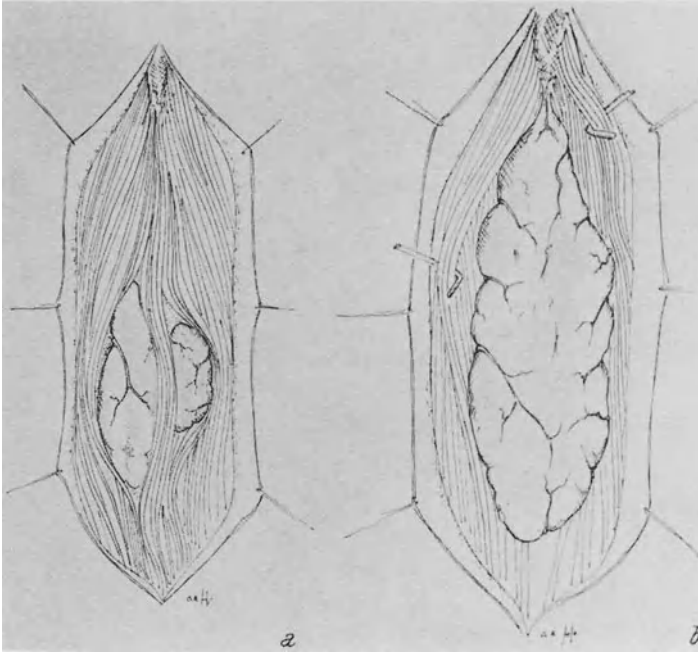
Fig. 21. Dumbbell neurinomas. If the opening is too large for simple suture, a dural graft is inserted

In only one patient of our series, a child, was it necessary to perform a two-stage operation and in this case the tumour was not a neurinoma but a gangli-neuroma, whose retromediastinal mass had reached the size of a newborn baby's head.

*Subdural Lipomas*

These tumours, located on the midline of the back along the posterior columns of the cord, are not really either extramedullary or intramedullary but juxtamedullary subpial tumours.

Unfortunately, it is exceptional to find a sharp plane of cleavage between tumour and nerve tissue because of fibrous or fibrolipoid shoots arising in large numbers from the capsule that plunge into the nervous parenchyma. It is these



Figs. 22 a and b. Ependymomas of the filum terminale. After opening the dura, the ependymoma is separated delicately from the nerve roots and then followed upward as far as the conus medullaris

fibrolipomatous shoots that makes it impossible to remove a lipoma without severely damaging the cord.

After opening the dura, which is usually adherent to the lipoma, an incision is made in the tumour capsule and as much of the diseased tissue as possible is removed piecemeal in the attempt not to injure the underlying cord. On removal of the juxtamedullary portion, gentle traction is exerted on the rest of the tumour in an effort to separate the pathologic from the normal tissue. The vessels and fibrous shoots running from the nerve tissue to the lipoma are coagulated with a bipolar current and sectioned as close as possible to the tumour with microsurgical technique under the surgical microscope. When the lipoma or part of it is hard to separate from the underlying cord, which happened in all the cases of our series, necessitating the sacrifice of or damage to nerve tissue, we feel it is best to give up further surgical manoeuvres and leave part of the

tumour in situ. After ensuring rigorous haemostasis, the dura mater is left open and suspended at the muscle margins.

Although in none of the cases we operated on did we feel justified in removing the tumour radically, the distant results are satisfactory in all the patients. Our experience coincides with that reported in the literature and leads us to endorse even now what Elsberg<sup>2</sup> wrote back in 1925 when commenting on an operation he performed for a lipoma: "the tumour was benign and it would have



Fig. 23. Ependymomas of the filum terminale. The filum, closed between two silver clips, is cut and the tumour removed en bloc

been much wiser to remove it partially, leaving a small portion in situ attached to the cord. If I had done that, the patient would not have had such a severe cord lesion and he would have been spared long periods of suffering and disablement . . ."

### Dermoids, Epidermoids, and Teratomas

When removing a dermoid, an epidermoid or a teratoma, the surgeon must take great care not to disseminate the tumour material, with the dual aim of not favouring the distant spread of tumour cells and not causing an aseptic meningitis due to the diffusion of fatty acids and cholesterol into the subarachnoid spaces. Further, he must be prepared to face bone and cord abnormalities such as: spina bifida, spondylolisthesis, syringomyelia, diastematomyelia, etc. One of our patients had the following combination: a dermal sinus that went down as far as an intradural dermoid, spina bifida and diastematomyelia. The sinus was cut between two ligatures at its entrance to the dura, the dura mater was opened and the dermoid emptied of its contents, the part of the capsule adhering to the cord being left in situ; then the bony spur was removed with a fine rongeur.

Rarely can subdural dysembryonal tumours be removed radically without



damaging the nerve tissue. In the majority of cases the operation is confined to removal of the intracapsular contents and as much as possible of the capsule. There is no point in removing the whole of the capsule if it adheres tenaciously to the nerve tissue or to the roots of the cauda: experience teaches that decades of survival in very good functional condition are possible after subtotal removal.

### Tumours of the Cauda Equina

Tumours developing at cauda equina level, because of the considerable space available to them, the exceptional tolerance of the nerve fibers to slowly progressive compression and the paucity of clinical symptoms (often a pain syndrome lasting for years), usually attain great size before reaching the operating table. Tumours of the cauda equina include neurinomas and dysembryonal tumours, which we have already dealt with. We had no case of meningioma of this site. Relatively frequent are ependymomas of the filum terminale, tumours of glial origin and so treated by the majority of academics as intramedullary tumours; however, from the surgical angle their treatment does not differ from that of other tumours of the cauda.

These tumours are spindle-shaped and extend for several vertebral metameres at the center of the nerve roots (Fig. 22a). As for other caudal tumours, an extensive laminectomy is necessary. The dura mater is thin and often tears in the manoeuvres to remove the vertebral laminae; in that case it is as well to protect the roots at once with cotton pledgets soaked in physiological saline. After opening the dura, the ependymoma is separated delicately from the nerve roots (Fig. 22b) and then followed upward as far as the conus medullaris, from which the filum is detached, closed between two silver clips and cut (Fig. 23). The tumour is isolated to its full extent and removed en bloc. Dissection should be started from the top to prevent traction on the conus medullaris, which in some cases is pushed upward. In others, and the problem involves the treatment of intramedullary tumours, the tumour affects the conus and the lumbar swelling. In this circumstance a posterior myelotomy is performed and an attempt made to remove the intramedullary part as well.

### Benign Tumours of Foramen Magnum

The most frequent benign spinocranial extramedullary tumours are meningiomas and neurinomas (9 in our series, of which 6 were meningiomas). These tumours develop simultaneously in the upper part of the cervical canal and in the posterior cranial fossa and so treatment of them embraces both spinal and cerebral surgery.

In these localizations, even more than in spinal tumours, the surgeon needs to be perfectly informed as to the exact site, size and, if possible, nature of the tumour. The lower limit of the tumour, with any other available information, is defined by opaque or gas contrast myelography performed by lumbar route. When there is total myelographic block, the upper limits can be ascertained by introducing opaque contrast directly into the cerebral ventricles. Valuable information on the site of attachment and vascularization of the tumour may be obtained from vertebral angiography.

We operate on spinocranial tumours with the patient in the sitting position. The skin is incised from the inion to C 5 and a suboccipital craniectomy is performed on the midline followed by a laminectomy as far down as necessary. A Y incision

is made in the posterior fossa and prolonged down into the spine. When the dura and arachnoid have been opened to the extent required, the next step is identification of the tumour. Anterolateral meningioma is the most frequent tumour, for which the technique of removal is as for spinal meningiomas, except that care must be taken in this site to release the accessory nerve fibers upward and search for the vertebral artery, which sometimes runs right in the tumour parenchyma. Posterior meningioma, not present in our case-series, is removed with ease together with the dural attachment. Neurinomas, almost always lateral, are removed, according to size, either en bloc or after emptying of their contents.

In meningiomas originating from the anterior rim of the occipital foramen and developing anteriorly to the medulla oblongata and cord the removal of the tumour by posterior route is practically impossible without causing irreversible damage to the nerve tissue. These tumours may be approached anteriorly by transoral route, which offers considerable advantages over the posterior route in that damage to nerve structures is avoided.

### Postoperative Treatment

The postoperative treatment of a patient suffering from a spinal tumour does not differ in essentials from normal neurosurgical practice. I will not dwell on the importance of adequate feeding, of preventing or treating any bladder infections or bedsores, on early physiotherapy and so on, because these are routine practice at any neurosurgical center. But I will draw attention to some aspects of great importance in these patients, especially those with tumours of the high cervical spine. It is, indeed, known that these patients, especially after the removal of large tumours, are liable to have sudden and serious disturbances of respiration, blood-pressure and temperature; these must be dealt with speedily as they may increase the damage to the spinal cord, already distressed by long compression and by the operation.

Mild irregularities of respiration should be corrected with ordinary analeptics, oxygen therapy and so on but the onset of respiratory failure calls for immediate intratracheal intubation or tracheotomy and at times an autorespirator.

Another dreaded complication is circulatory collapse which, by diminishing the supply of oxygen to the cord, may jeopardise good functional recovery. It is extremely important to keep the arterial pressure values within physiological limits during the operation and in the postoperative course.

Hyperthermia, which may reach high levels in the days after the operation, must be combated initially by intravenous or rectal aspirin or by pyramidon or, in the event of failure, by moderate hypothermia. It must not be forgotten that hyperthermia increases the cell metabolism and so favours the onset of myelomalacia.

Another serious but rare postoperative complication is epidural haematoma, which may occur in the hours following operation. To diagnose this complication, the surgeon must carry out a thorough neurological examination after the patient comes round and again later. The progressive aggravation of the neurological deficit necessitates reoperation and nearly always the cause is a collection of blood in the epidural spaces, which must be removed immediately.

We do not use either antioedema agents or antibiotics in the postoperative course unless there are particular indications.

To ensure a good functional recovery, signs of which may begin within a

few hours of operation, we believe in commencing physiotherapy and motor re-education early; if the patient had severe disturbances of movement, these measures must be continued without a break in the months to come. In some patients with very severe disturbances of movement satisfactory functional recovery was obtained only after months of physiotherapy.

Lastly, children who have had to undergo an extensive laminectomy should wear an orthopaedic jacket for the first few months after the operation in order to prevent possible deviations of the spine.

### Results

In extramedullary benign tumours death is hardly ever related to the surgical operation but to the patient's postoperative condition, to the onset of bronchopneumonia, bladder infections or cardiocirculatory collapse, complications which with the remedies available today can largely be eliminated.

The overall hospital mortality in our series of 334 cases was 0.29%. The only death occurred in a patient operated on for a dorsal meningioma who died on the tenth day from cardiac infarction verified at necropsy.

With regard to the long term functional results, they depend on the severity of the neurological deficits, the rate of clinical evolution, the patient's age, the nature of the lesion and the surgeon's skill.

Everyone knows how marvellously well the nervous system adapts to slowly progressive compression and how badly, often irremediably, it suffers from rapid or sudden compression. Fortunately a rapid evolution of the clinical symptoms is rare in extramedullary benign tumours but when it does occur it is the surgeon's duty to intervene immediately. A rapid aggravation of the clinical symptoms may occur, as we said earlier, following the removal of cerebrospinal fluid by lumbar puncture or after myelography. This occurred in two of our patients, who were operated on with excellent results. For this reason we believe that these diagnostic procedures should be conducted only at a neurosurgery center or in a hospital where an operation can be performed immediately in the event of a worsening of the patient's neurological condition. Another patient, a young man of 20, symptomless until the day before admission, presented flaccid paraplegia within a few hours; a CSF manometric examination showed total block and a myelographic investigation was done on the suspicion of an epidural haematoma. At operation a dorsal neurinoma with gross intratumoral haemorrhage was found, an exceptional finding, perhaps unique in the literature. In these three cases the operation was performed immediately. Had we delayed for 24 hours after the onset of acute paraplegia, we are convinced that there would not have been such a satisfactory recovery of limb function, as the experience of late operations on extradural metastases demonstrates.

In regard to the severity of the clinical symptoms, the long term functional results were excellent in all the patients who were still able to walk, even if with support. A satisfactory functional improvement was obtained in all the patients who had been bedbound because they could not maintain the erect position, although some of them had to use a support when walking. As to patients with total paralysis of the lower limbs, a distinction must be made between those

with extensor and those with flexor paralysis. In all the patients with extensor paralysis a more or less satisfactory functional recovery was observed whereas only in one case out of four with flexor paralysis, of several months standing, was there a functional improvement after months of motor re-education and now this patient is able to walk with support.

It is not up to us to dwell at length on the distant functional results, partly because we lack recent news of some patients on whom we operated. They are, on the whole, excellent and sometimes beyond our expectations. Few other fields of surgery can offer both patient and surgeon such great satisfaction as that resulting from the removal of an extramedullary benign tumour. For this we must be grateful to our predecessors, who enabled us to make promises to our patients and keep them.

### References

1. Cantore, G. P., Guidetti, B., 1969: Dura mater treated with gamma-rays for dural plastic surgery. Fourth international congress of neurological surgery, New York: September 20—27. Excerpta medica, international congress series n. 193.
2. Elsberg, C. A., 1925: Tumours of the spinal cord and compression of the spinal cord and nerve roots. Pathology, symptomatology, diagnosis and treatment. New York: P. B. Hoeber.
3. Frugoni, P., 1956: Trattamento chirurgico dei tumori del midollo. *Chirurgia* 11, 131—149.
4. Gowers, W. R., Horsley, V. A., 1888: A case of tumour of the spinal cord removal. Recovery. *Med. chir. tr.* 53, 243—246.
5. Guidetti, B., Fortuna, A., Moscatelli, G., Riccio, A., 1964: I tumori intramidollari. *Il lavoro neuropsichiatrico* 35, 1—409.
6. Guidetti, B., Fortuna, A. (in press): Differential diagnosis of extramedullary and intramedullary tumours. Handbook of clinical neurology, Ed. Vinken, P. J., and Bruyer, G. W., vol. XIX. Amsterdam: North-Holland Publishing Company, and New York: American Elsevier Publishing Co.
7. Kempe, L. G., 1970: Operative neurosurgery, vol. 2, posterior fossa, spinal cord, and peripheral nerve disease. Berlin-Heidelberg-New York: Springer.
8. Nittner, K., 1972: Raumbegrenzende Prozesse im Spinalkanal. *Handbuch der Neurochirurgie*. Berlin-Heidelberg-New York: Springer.
9. Poppen, J. L., 1960: An atlas of neurosurgical techniques. Philadelphia and London: W. B. Saunders Company.
10. Walker, A. E., 1951: A history of neurological surgery. Baltimore: The Williams & Wilkins Company.

## Author Index

- Abbott, M. 75  
Adams, R. D. 62, 63, 65, 82, 85, 86, 87  
Adams, R. W. 43  
Albin, M. S. 30  
Alexander, E. 97  
Alexander, S. C. 42  
Alker, G. J., Jr. 84  
Alksne, J. F. 75  
Allen, J. H. 63, 73, 75, 86  
Alley, A. 94  
Ames, A. III 14  
Ancri, D. 61, 62, 66, 72, 83, 84  
Anderson, F. M. 93, 95, 97  
Anderson, J. 39  
Andrews, C. 43  
Antoni, N. 8  
Appenzeller, O. 62, 85, 86  
Atkinson, J. R. 72, 84  
Avman, N. 34, 49
- Ballance, Ch. 173  
Bannister, R. 72, 73  
Barker, J. 43  
Barlow, C. F. 35  
Barnes, B. 67  
Barnett, H. J. 85  
Bauer, K. H. 119  
Baurand, C. 125, 126, 127, 128, 129, 133  
Bebin, J. 49  
Becker, D. P. 40  
Beekhuis, H. 62, 65, 73  
Behring, E. A., Jr. 30, 34, 49  
Beks, J. W. F. 62, 65, 73  
Benson, D. F. 62, 73  
Bergquist, D. 75, 85  
Bering, E. A. 84, 87  
Berman, I. R. 16  
Bernard, W. F. 49  
Bettinazzi, N. 41  
Bien, C. 40, 41, 42, 43  
Bigelow, W. G. 49  
Bioulac, B. 131, 136  
Blackfan, K. D. 4  
Bloch, M. 50  
Block, J. D. 63  
Bloom, W. H. 122, 124, 125, 126, 127, 129, 133
- Boerema, I. 49  
Bohmar, G. 75, 85  
Botterell, E. H. 49  
Bouzarth, W. F. 50  
Bozza-Marrubini, M. 41  
Breckenridge, C. G. 15  
Breig, A. 62, 65  
Brindle, G. P. 65, 66  
Brinker, R. 71  
Brock, M. 17  
Broekhuysen, L. 49  
Browder, J. 122, 123, 125, 133  
Brown, F. K. 15  
Brown, H. A. 122, 123, 124, 127, 129  
Bruce, D. A. 35  
Buckell, M. 39
- Campan, L. 50  
Campbell, J. B. 29, 124, 125, 126, 127  
Campiche, R. 121  
Cantore, G. P. 33, 40, 181  
Caveness, W. F. 130  
Chabannes, J. 45  
Chater, N. 33, 35  
Chiavarelli, S. 33  
Chodkiewicz, J. P. 125  
Chou, S. N. 85  
Choux, M. 122, 125, 126, 127, 128, 129, 133  
Clark, J. 42  
Clasen, R. A. 49  
Clower, B. R. 16  
Cohen, J. 124, 125, 126, 127  
Cohen, P. J. 42  
Connor, R. C. R. 16  
Cook, A. W. 41, 43  
Cooper, R. 12, 15  
Corona, S. 41  
Cowley, A. 41  
Creissard, P. 125  
Cronqvist, S. 12  
Curl, F. D. 75, 78  
Cushing, H. 31, 169  
Cutler, R. W. P. 4
- Dakters, J. G. 30  
Dandy, W. E. 4, 161

- Davis, D. O. 62, 63, 73  
 Davson, H. 4, 5  
 Dayes, L. A. 34  
 De Blanc, H. J. 75  
 Dechaume, J.-P. 125, 127  
 De Land, F. H. 72, 73  
 Di Chiro, G. 72, 83, 86  
 Dickson, J. 42  
 Dietz, H. 17  
 Dodge, P. R. 119  
 Dorsch, N. W. C. 12, 66  
 Ducker, T. B. 16
- Ekbohm, F. 62, 65  
 Elsberg, Ch. 173  
 Engeset, A. 70  
 Epstein, F. J. 73  
 Espey, F. F. 5, 8  
 Evans, J. P. 5, 8
- Faber, H. K. 94, 97  
 Feindel, W. 44  
 Fisher, C. M. 62, 63, 65  
 Fishman, M. A. 119  
 Fitch, W. 14  
 Fleming, J. F. R. 73, 75, 81, 84  
 Fog, M. 5  
 Fohanno, D. 72  
 Foltz, E. L. 65, 72, 84  
 Forbes, H. S. 5  
 Ford, L. E. 123, 127, 133, 136  
 Fortuna, A. 174  
 Fowler, F. D. 97  
 Fox, J. L. 85, 87  
 Fraser, A. R. 65  
 Freeman, J. M. 93, 95, 97  
 Freeman, N. E. 15  
 French, L. A. 44, 48  
 Friedman, V. 4  
 Frigeni, G. 65  
 Front, D. 62, 65  
 Frugoni, P. 174
- Gabrielsen, T. O. 93, 94, 95, 97  
 Gacon, G. 125, 127  
 Gänshirt, H. 50  
 Gaini, S. M. 65  
 Galera, R. 64  
 Galicich, J. H. 4, 44  
 Galindo, A. 31, 50  
 Gallagher, J. P. 122, 123, 125, 127, 129, 133  
 Galle, P. 39  
 Garibi, J. 9  
 Garretson, H. D. 65, 66  
 Garvin, J. S. 44  
 Geiger, L. 93, 95, 97
- Georganas, Ch. L. 62, 65, 73  
 George, B. 68, 85  
 Gerlach, J. 124  
 Geschwind, N. 86, 87  
 Giblin, N. 94  
 Gilford, E. 72, 73  
 Giugno, di, G. 41  
 Glasauer, F. E. 84  
 Goldberg, H. I. 35  
 Goluboff, B. 35  
 Goodell, H. 62  
 Goodkin, R. 73  
 Goodman, S. J. 67  
 Gordon, E. 41, 42  
 Gordon, H. 102  
 Gordon, R. A. 49  
 Gourgand, M. 22  
 Goutelle, A. 125, 127  
 Gowers, W. 173  
 Granholm, L. 42  
 Green, R. C. 85, 87  
 Greenfield, J. C. 12  
 Greenwood, W. F. 49  
 Gregor, H. 129  
 Greitz, T. 62, 64, 65, 70, 71, 86, 87  
 Grepe, A. Q. L. 62, 86, 87  
 Grisoli, F. 125, 126, 127, 128, 129, 133  
 Gronert, G. A. 43  
 Grote, W. 9  
 Gruszkiewicz, J. 123  
 Gueit, U. M. 22  
 Guidetti, B. 40, 173, 174, 181  
 Gurdjian, E. S. 122  
 Guttman, L. 31
- Haft, H. 35  
 Hakim, S. 62, 63, 65, 82, 85, 86, 87  
 Hameroff, S. 65  
 Harbert, J. C. 75, 78, 86  
 Harper, A. M. 5, 7, 35, 51  
 Harris, A. B. 31, 50  
 Harris, L. E. 93, 102  
 Harrison, R. C. 49  
 Hartstock, R. 49  
 Hawkins, W. E. 16  
 Hayakawa, T. 51  
 Heck, A. 65  
 Hedden, M. 42  
 Hedges, T. R. 12  
 Heinz, E. R. 62, 63, 73  
 Hekmatpanah, J. 14  
 Hemple, D. J. 93, 102  
 Henderson, W. R. 7  
 Heyser, J. 122, 125, 127, 128  
 Hill, M. E. 85  
 Hirsch, H. 50  
 Hochwald, G. M. 84, 88

- Hodges, F. J. 73  
 Hodgson, J. S. 7  
 Hoff, H. E. 15  
 Hofstetter, J. 132, 137  
 Hogan, G. R. 119  
 Holaday, D. A. 49  
 Hollingworth, G. 4  
 Holman, C. B. 93, 102  
 Hornick, R. 65  
 Horsley, V. 173  
 Houtteville, J. P. 68  
 Hoyt, W. F. 122, 123, 124  
 Huber, P. 130  
 Huguenard, P. 50  
 Hulme, A. 12, 15  
 Hunter, J. 49  
 Hussey, F. 67
- Illingworth, R. D. 65, 85  
 Ingraham, F. D. 29, 97, 125, 126  
 Ingvar, D. H. 10, 12  
 Irsigler, F. J. 171  
 Iwata, K. 12, 15
- Jackson, J. L. F. 7  
 Jacobson, I. 51  
 James, A. E. 73, 75  
 Jamieson, K. G. 122, 125, 127, 128, 129,  
 133, 136  
 Janny, L. 22  
 Janny, P. 9, 16, 17, 22, 45  
 Javalet, A. 124, 128, 129, 132  
 Javid, M. 33, 39  
 Jayamanne, D. 122, 124, 129, 130  
 Jeffers, W. A. 15  
 Jefferson, G. 31  
 Jennett, S. 15  
 Jennett, W. B. 5, 7, 26, 35, 43, 124, 128,  
 131, 136  
 Jensen, H. P. 124  
 Jeppsson, P. G. 49  
 Jørgensen, P. B. 43  
 Johnson, F. L. 93, 95, 97  
 Johnson, R. H. 5  
 Johnson, R. T. 31  
 Johnston, I. H. 5, 7, 26, 35  
 Jouan, J. P. 22
- Kalmer, M. S. 62, 86, 87  
 Kanai, N. 51  
 Karp, H. R. 62, 63, 73  
 Kassell, N. F. 5, 7, 8, 12  
 Kaste, M. 26  
 Katzman, R. 67  
 Kelly, W. A. 31  
 Key, A. 4  
 Kimbell, F. D. 5, 8
- King, J. E. J. 119  
 Kjällquist, Å. 3, 10, 12, 14, 15, 19, 26,  
 32, 40, 41, 42, 43  
 Klatzo, I. 6, 7  
 Kocen, R. 72, 73  
 Kofman, S. 44  
 Koos, W. 124  
 Kowada, M. 14  
 Kraus, H. 124  
 Krayenbühl, H. 130  
 Krenkel, W. 50  
 Kristoff, F. V. 5  
 Kugelberg, E. 62, 65  
 Kukulska, Z. 94  
 Kullberg, G. 3, 19, 22, 44  
 Kuroda, R. 51  
 Kusske, J. A. 31  
 Kuurne, T. 26  
 Kågström, E. 32
- Laborit, H. 50  
 Laitinen, L. 94, 95  
 Lake, P. A. 131, 136  
 Lambertsen, C. J. 42  
 Langfitt, T. W. 5, 7, 8, 12, 35, 51  
 Lapalus, J. 45  
 Lapras, C. 125, 127  
 Lassen, N. A. 5, 15  
 Lazorthes, G. 50  
 Lecuire, J. 125, 131  
 Ledingham, I. McA. 41, 51  
 Le May, M. 62, 69, 70, 71, 84  
 Le Menn, G. 124, 128, 129, 132  
 Lerner, M. A. 70  
 Leslie, E. V. 84  
 Lewin, W. 65  
 Lin, J. P. 73  
 Lindsay, W. K. 49  
 Löfgren, J. 8  
 Loeser, J. 50  
 Logue, V. 65, 85  
 Long, D. M. 44, 48, 85  
 Lopez, J. 62, 86, 87  
 Lorenzo, A. V. 5, 68  
 Lorin, H. 24, 25  
 Loughheed, W. M. 49, 85  
 Lukjanova, L. 42  
 Lundberg, N. 3, 8, 9, 10, 11, 12, 14, 15,  
 16, 18, 19, 24, 25, 26, 40, 41, 42, 43,  
 49, 50, 66  
 Lux, E. W. 84, 88  
 Lying-Tunnel, V. 75, 85
- McAslan, T. C. 41  
 McCullough, D. C. 75, 78, 85, 86, 87  
 McDowall, D. G. 14, 43, 51  
 McGraw, C. P. 12, 15

- McHugh, P. R. 62  
 McKibben, P. S. 33  
 McKissock, W. 122, 124, 125, 126, 127, 129, 133  
 McMurrey, J. D. 49  
 Madow, L. 50  
 Magnaes, B. 26  
 Majno, G. 14  
 Malmlund, H. O. 75, 85  
 Mangione, G. 41  
 Margent, P. 68  
 Margolis, Th. 67  
 Marions, O. 75, 85  
 Marshall, W. J. S. 7  
 Martins, A. N. 8, 67, 68  
 Marx, G. F. 43  
 Mason, M. S. 39  
 Matosz, Z. 97, 107  
 Matson, D. D. 93, 94, 95, 97, 126  
 Matthews, W. B., Jr. 72  
 Maxwell, R. E. 44, 48  
 Meachen, W. 63, 73, 75, 86  
 Mealey, J. 125, 126  
 Mets, M. 87, 88  
 Metzger, J. 85  
 Meyer, J. S. 49  
 Michenfelder, J. D. 43  
 Miller, J. D. 9, 35, 41, 51  
 Mogami, H. 51  
 Molen, R. A. van der 42  
 Montrieul, B. 45  
 Morich, Ch. 119  
 Moscatelli, G. 174  
 Müller, D. 119  
 Mullan, S. 97  
 Myers, P. W. 8
- Nagamani, D. 44  
 Naquet, R. 122  
 Natarajan, T. K. 75  
 Nelson, J. R. 67  
 New, P. F. J. 62, 63, 65, 69, 70, 71, 73, 84  
 Newkirk, T. A. 39  
 Nicol, C. F. 84  
 Nielsen, K. C. 49, 50  
 Nilsson, E. 49  
 Nilsson, L. 26  
 Noell, W. 5, 7, 42  
 Nordström, L. 49  
 Nornes, H. 19, 26, 31, 33  
 North, J. B. 15
- Odom, G. L. 171  
 Ojemann, G. A. 31  
 Ojemann, R. G. 62, 63, 65, 75, 82, 84  
 Oldendorf, W. H. 35
- Olivecrona, H. 31  
 Ommaya, A. K. 86, 87, 88  
 Orkin, L. R. 43  
 Ortega, B. 71  
 Owre, E. S. 41, 43
- Page, L. K. 4, 5, 68  
 Paoletti, P. 65  
 Pappius, H. M. 34  
 Paterson, A. 35  
 Patten, H. D. 62, 73  
 Paul, R. L. 41  
 Pawl, R. P. 93, 97  
 Pecker, J. 124, 128, 129, 132  
 Pemberton, J. W. 93, 95, 97  
 Penfield, W. 153  
 Penka, E. J. 5, 8  
 Penning, L. 62, 65, 73  
 Pertuiset, B. 62, 66, 68, 84, 143  
 Peyton, W. T. 120  
 Philippon, J. 61, 62, 66, 84, 85  
 Pitts, F. W. 131, 136  
 Plum, F. 15, 42  
 Podolsky, B. 5, 8  
 Polanco, O. 41  
 Pontén, U. 3, 10, 11, 14, 15, 19, 26, 32  
 Pool, J. L. 33  
 Poppen, J. L. 30, 189, 190  
 Posner, J. B. 15, 42  
 Post, K. D. 87, 88  
 Potts, D. G. 33  
 Pouyanne, H. 131, 136  
 Powiertowski, H. 93, 97  
 Prados, M. 44
- Queloz, J. M. 122, 124, 125, 128
- Raaf, J. 39  
 Rand, B. O. 171  
 Randt, C. T. 48  
 Ransohoff, J. 48, 84, 88  
 Rayport, M. 122, 129  
 Reames, P. M. 72  
 Redondo, A. 125  
 Reed, D. J. 34, 35  
 Reinglass, J. L. 39  
 Reivich, M. 42  
 Retzius, G. 4  
 Reulen, H. J. 44  
 Riccio, A. 174  
 Ricon, Ph. 63  
 Risberg, J. 12  
 Röhricht, C. 119  
 Rosenauer, A. 5, 8  
 Rosomoff, H. L. 34, 49  
 Rossanda, M. 41, 42  
 Rossier, J. 127



- Roth, L. J. 35  
 Rovit, R. L. 71  
 Rowan, J. O. 5, 7  
 Rowbotham, G. F. 124  
 Roy, C. S. 5  
 Rubens, A. B. 62  
 Ryder, H. W. 5, 8  
 Ryöppy, S. 97  
  
 Sadik, A. R. 84, 88  
 Sahar, A. 84, 88  
 Salmon, J. H. 62, 85, 86  
 Samra, K. 93, 97  
 Samuelson, S. 85  
 Schanzer, B. 67  
 Schechter, M. M. 122, 129  
 Schechter, M. W. 71  
 Schettini, A. 41, 43  
 Schmidt, W. J. H. 49  
 Schneider, M. 5, 7, 42, 50  
 Schoolar, J. C. 35  
 Schürmann, K. 44  
 Schutta, H. S. 7  
 Schutz, H. 35  
 Scott, J. W. 49  
 Sedan, R. 122  
 Sedzimir, C. R. 50  
 Seeger, J. F. 93, 94, 95, 97  
 Segal, M. B. 4  
 Settlage, P. 33  
 Shapiro, H. M. 31, 50  
 Shenkin, H. A. 35  
 Sheppard, R. H. 73, 75, 81, 84  
 Sherrington, C. S. 5  
 Shillito, J., Jr. 93, 95, 97  
 Shulman, K. 49, 88  
 Siesjö, B. K. 42  
 Silfvenius, H. 49  
 Simeone, F. A. 5, 8, 12  
 Simmons, D. R. 120  
 Simon, E. 114  
 Sisson, W. B. 35  
 Sjaastab, O. 70  
 Skalpe, I. O. 70  
 Smith, T. C. 42, 43  
 Smyth, G. E. 7  
 Söndergaard, W. 43  
 Soper, B. A. 63, 73, 75, 86  
 Sorour, O. 93, 97  
 Staab, E. V. 63, 64, 73, 75, 86  
 Stanek, A. 35  
 Staudacher, M. 39  
 Stein, B. M. 65  
 Stein, S. 12  
 Steinwall, O. 7  
 Stephens, R. J. 12, 66  
 Stevenson, G. C. 122, 123, 124  
  
 Strang, F. A. 15  
 Streicher, E. 7  
 Strowger, B. 44  
 Sugar, O. 93, 97  
 Sundbärg, G. 3, 19, 22, 32  
 Sundt, T. M. 43  
 Svendsen, V. 124  
 Svien, H. J. 93, 102  
 Sweet, N. H. 62, 63, 65  
 Symon, L. 12, 66, 85  
  
 Taren, J. A. 49  
 Tator, G. H. 73  
 Taveras, J. M. 62  
 Taylor, J. C. 122, 124, 125, 126, 127, 129,  
 133  
 Teng, P. 93, 97  
 Tenner, M. S. 65  
 Terry, D. 88  
 Tessier, P. 120  
 Testut, L. 123  
 Thomas, L. M. 131  
 Thurel, C. 98  
 Thurston, J. M. 14  
 Till, K. 122, 125, 126, 127, 129, 133  
 Tindall, G. T. 12, 15  
 Tod, P. A. 95, 97  
 Tolksdorf, S. 48  
 Tong, E. C. K. 73  
 Tourtelotte, W. W. 39  
 Towne, E. B. 94, 97  
 Tretola, L. 41  
 Troupp, H. 24, 25, 26  
 Turner, P. T. 31  
 Turner, V. M. A. 73, 75, 81, 84  
 Turney, S. Z. 41  
  
 Valtonen, S. 26  
 Vanderveer, R. W. 12, 15  
 Van der Werf, A. M. J. 97  
 Vandewater, S. L. 49  
 Vapalahti, M. P. 26, 35  
 Vedrenne, C. 125  
 Vemura, K. 65, 85  
 Vigouroux, M. 122  
 Vigouroux, R. 122, 125, 126, 127, 128,  
 129, 133  
 Villani, R. 65  
 Vinciguerra, E. 73  
 Virno, M. 33, 40  
 Vries, J. K. 40  
  
 Wagner, H. N. 75  
 Walker, A. E. 173  
 Ward, A. A. 65, 171  
 Watters, G. V. 4, 5, 68  
 Weber, G. 122, 125, 127, 128

- Weed, L. H. 4, 33  
Weinmann, D. F. 122, 124, 129, 130  
Weinstein, J. D. 5, 8, 12  
Welch, K. 4  
Weller, R. O. 88  
West, K. A. 4, 8, 21, 44  
Wewerka, J. 123  
White, L. E., Jr. 171  
White, R. J. 30  
Wildschut, A. 49  
Wiley, J. K. 8  
Wise, B. L. 33, 35  
Wisniewski, H. 7, 88  
Wolff, H. G. 5  
Wolinsky, J. 67  
Wollman, H. 42  
Wood, D. 48  
Woodbury, D. M. 34, 35
- Woodhall, B. 171  
Wright, R. D. 12  
Wright, R. L. 14  
Wüllenweber, R. 9, 43  
Wyler, A. R. 31  
Wyte, S. R. 31, 50
- Yamada, R. 51  
Yaşargil, M. G. 130, 163  
Yashon, D. 30  
Yelland, J. D. N. 95, 97, 122, 127  
Young, A. B. 63, 73, 75, 86  
Young, T. W. 124, 125
- Zander, E. 121, 130, 132, 137  
Zingesser, L. H. 122, 129  
Zwetnow, N. N. 5, 15  
Zylka, W. 50

## Subject Index

- Acoustic neuroma 49, 65  
Adamkiewicz artery 176  
Adson self-retaining retractor 177  
Aetiology of chronic adult hydrocephalus 63-65  
Air-way  
  absence 70  
  obstruction 20, 27  
  presence 70  
  pressure 41, 43  
Alzheimer's disease 67  
Anaemia 27  
Anaesthesia, general 24, 50, 144, 175  
  induction of 24, 40, 43  
Anaesthetics  
  Halothane 14, 43  
  nitrous oxide 43  
  pentobarbital 50  
  volatile 12, 24, 43  
Aneurysm, intracranial, rupture 64  
Angiography 5, 48, 69  
  selective 174  
Antibiotics 31, 48  
Apnoea 15  
Aqueduct stenosis 65  
Arachnoid villi 4, 8  
Arteries, carotid 5, radicular 176  
Artery, basilar, ectasia 65  
  pericallosal 69  
Astrocytoma, cerebellar 65  
Atrophy, cerebral 71  
Autonomic outflow 15  
  
Basilar cisternal block 71, 75  
Blood-brain barrier 34, 38  
Blood-CSF-barrier 34  
Blood flow, cerebral 5, 7, 49, 64  
  autoregulation 5, 6, 11, 13, 14, 20, 28  
  intrinsic control 20  
Blood gas analyses 43, 44  
Blood pressure  
  cerebral venous 4, 5, 6  
  systemic arterial 5, 6, 7, 9, 13, 20, 26, 27, 28, 40, 49, 176  
  systemic venous 20  
Blood volume, cerebral 12, 34, 40  
Body temperature 28, 43  
  
Bowel 28  
Brain abscess 48  
Brain distension 62  
Brain oedema: see Oedema  
Brain lesion  
  cold 49  
  diffuse 26  
  focal 26  
  hypoxaemic 6  
  infratentorial 10  
  ischaemic 6, 33, 34, 38, 48, 50  
  neoplastic 6  
  space occupying 7  
  toxic 6, 49  
  traumatic 6, 22, 26, 38, 43, 49, 50  
Brain stem  
  compression 8, 13, 15, 20, 27, 28, 29, 32  
  damage 46  
  distorsion 7, 11, 13, 20  
  dysfunction 10, 14, 15  
  incarceration 48  
  stress on 22, 29  
  traumatic injury 26  
Brain swelling 5, 6, 18, 29, 31, 33, 40, 44, 50  
Brain tissue  
  consistency 8  
  hypoxia 27, 41, 42, 48  
  lactacidosis 15, 28  
  lactate/pyruvate ratio 42  
  metabolism 43, 49, 50, 51  
  plasticity 7  
Brain tumour 20, 44, 47, 50  
  malignant 44-45  
  metastatic 44  
Breathing  
  ataxic 15  
  forced 28  
  periodic 15, 20  
  spontaneous 43  
Burr hole 29, 150, 151  
  
Calibration 17, 19  
Carbon dioxide (CO<sub>2</sub>, PCO<sub>2</sub>, PaCO<sub>2</sub>) 5, 6, 40, 41, 42, 43, 51  
Carcinomatosis of meninges 10, 13

- Cell membrane 6
- Cerebrospinal fluid  
 absorption 4, 8, 75  
 cell count 19, 31  
 circulation 27, 51, 73  
 culture 19, 31  
 disturbances 73  
 diversion 4  
 drainage, mechanism 86  
 dynamics 4-5  
 flow 4, 7, 8  
 infection 19  
 influx 34  
 lactacidosis 15  
 leakage 16, 18  
 lumbar drainage 29, 86  
 lumbar removal 85  
 osmolarity 34  
 pathways 4, 22  
 production 4, 34, 44  
 reflux 30  
 resorption 66-68  
 sampling 19  
 spatial buffer 5  
 ventricular drainage 10, 16, 17, 22,  
 24, 26, 28, 29-33, 35, 51  
 volume 35
- Cerebrovascular resistance 5, 6, 12
- Choroidal pulse pressure 84
- Circulation, cerebral, time 64
- Circulatory arrest, cerebral 6
- Clinical signs in chronic adult hydro-  
 cephalus 62-63
- Closure, Blair-Donati type 152, 154, 171
- Coagulation disturbance 28  
 bipolar 174  
 monopolar 147
- Coma 27
- Complications, of  
 monitoring Intracranial Pressure  
 (ICP) 19-22  
 ventricular drainage 31
- Computer 22
- Congestion, cerebral 5, 6, 29, 32, 40, 50
- Consciousness 10, 42, 45
- Contusion, cerebral 6
- Corticosteroids 44-49, 51  
 betamethasone 48  
 cortisone 44, 49  
 dexamethasone 44, 45, 48  
 exogenous 46  
 prednisolone 44, 49  
 prednisone 49
- Costotransversectomy 186, 190, 191
- Cranio-spinal  
 cavity 7  
 communication 16
- Craniostenosis 94  
 age of children, clinical material 100  
 anatomo-clinical considerations  
 94-100  
 fused sutures, number 94
- Craniostenosis, operation procedure 98  
 extensive subperiosteal resection of  
 the vault and base of the skull  
 98-100
- Craniostenosis, operative results  
 102-117  
 decompression effect 103  
 histology 114  
 regeneration of skull 110  
 results, neurological 116  
 surgical risk 102
- Craniotome 148
- Craniotomy, supratentorial 144, 151
- Curve, Ventricular Fluid Pressure (VFP)  
 interpretation 20-22  
 statistical analysis 21-22
- Cushing, phenomenon 14, 15
- Decalcification of dorsum sellae 68
- Decerebrate rigidity 10, 28, 33
- Decompression, subtemporal (Cushing)  
 169
- Decrease of mean ventricular pressure  
 86
- Decrease of total force 86
- Disorders of mental function 62
- Diuretics 39
- Drainage, Penrose 154, 155  
 Redon 154, 156
- Dural repair 181, 190  
 dura mater treated with gamma-rays  
 181
- Dural sinus 4
- Drugs  
 analgetic 43  
 antacid 46  
 diuretic 39  
 hypertensive 28  
 hypotensive 28  
 muscle-relaxing 28  
 respiratory, depressing 28  
 sedating 28, 43
- Edema: see Oedema
- Elastance 8
- Electrolyte  
 balance 28  
 metabolism 50
- Electromyography 174
- Electronic analyser 17, 22
- Emotional stress 12

- Endotracheal intubation 12, 40  
 Enlargement of the cranial capacity 94, 95  
   deepening of digital impressions 95  
   relation to the developing brain 95  
 Epileptic seizures 28  
 Etiology: see Aetiology  
 Extracellular fluid  
   alkalosis 40  
   pH 40  
 Extracellular space 4, 6  
 Extracranial correlates of intracranial hypertension 14-16
- Facial nerve 50  
 Frequency, hydrocephalus 64  
   polygon 22  
 Fusion of cranial sutures, premature 95  
   aetiology 95
- Gastrointestinal bleeding 46  
 Gigli saw 148  
 Glucose 27  
 Glycerol 33, 39, 40
- Haematoma, extra-dural 121  
   age 125  
   anaemia 129, 132  
   angiography, carotid 129  
   artery, middle meningeal 122, 130  
   blood pressure 128  
   burr-holes exploration 131  
   cerebro-spinal fluid 129  
   craniotomy 132  
   echo-encephalography 131  
   eye signs 128  
   fracture skull 125  
   frequency 124  
   history 121  
   interval free 122, 123, 126  
   localisation 124  
   Marchent, Gérard, detachable zone 122  
   motor disorders 127  
   mydriasis 128  
   pulse 128  
   results 133  
   sex 125  
   skull, fracture 125  
   treatment 131  
   vomiting 128
- Haematoma, intracerebral 64  
 Haematoma, intracranial 8, 26, 40  
 Haematoma, spinal, epidural 195  
 Haemodynamics, intracranial 4-6, 28  
 Haemoglobin, dissociation curve 43
- Haemorrhage  
   intracranial 29, 31  
   scalp 147  
   subarachnoid 22, 26, 32-33, 64  
   subdural 85  
 Haemostasis 178, 179, 180, 193  
 Head injury 15, 16, 26, 28, 39, 44, 48, 50  
 Heart  
   conducting tissue 15  
   failure 39  
 Hemilaminectomy 178  
 Herniation  
   foraminal 28, 29, 31, 39, 43  
   tentorial 7, 8, 10, 13, 14, 16, 20, 27  
   tumour, spinal 175  
   upwards 29, 31  
 Histogram 22  
 Homeostasis of Intracranial Pressure (ICP) 5  
 Hydrocephalus 4, 27, 29  
   chronic adult 62, 64, 84  
   chronic obstructive 64, 67, 70  
   congenital 62  
   convexity block 71  
   ex vacuo 62, 69, 88  
   focal brain lesions 64, 65  
   frequency 64  
   hypertensive communicating 73  
   idiopathic 64, 68  
   low pressure 62  
   normal pressure 62, 64, 75, 87  
   post-meningitic 65  
   post-operative 65  
   post-traumatic 64  
 Hydrocephalus in children  
   with craniostenosis 95  
 Hypercapnia 12, 15  
 Hypertension, intracranial 3  
   non-operative management 3  
 Hyperthermia 28, 50  
   postoperative 195  
 Hypertonic solutions 10, 26, 33-40  
 Hyperventilation  
   neurogenic 15  
   spontaneous 15, 42, 43  
   therapeutic 6, 26, 28, 40-44, 51  
 Hypocapnia 15, 27, 28, 42, 43, 51  
 Hypoperfusion 27  
 Hypothermia 49-51  
   long term 50, 51  
   preoperative 49  
 Hypovolaemia 27, 28  
 Hypoxaemia 28  
 Hypoxia: see brain tissue
- Infarction, cerebral 5, 6, 42  
 Infection 46, 48

- Infection  
  intracranial 18, 19, 31  
  measures against 18-19  
  retrograde 30, 31
- Intracranial dynamics 4-14, 20, 22, 27, 29, 30, 41, 51
- Invert sugar 39
- Ischaemia, cerebral 5, 6, 13, 14, 33
- Isotope technique 12
- Isotopic cisternography 65, 69
- Isotopic studies 72-84
- Lactacidosis  
  in brain tissue 15, 28  
  in CSF 15
- Laminectomy 176  
  standard technique 176
- Leksell rongeur 177, 179, 181
- Lumbar puncture 16, 29, 33, 175
- McEwen-Stille laminectomy scalpel 177
- Mannitol 33, 35, 35-39, 40
- Manometer, open bore 16
- Manometric test, infusion 67
- Mayfield headrest 144, 145
- Meningioma  
  parasagittal 65  
  tentorium 167
- Meningitis  
  carcinomatous 65  
  chronic listeria 65  
  Klebsiella 65  
  pneumococcal 65  
  tuberculous 65
- Metabolic  
  acidosis 15, 50  
  rate 43
- Metabolism, cerebral 43, 48, 50, 51
- Microcephaly 95
- Microscope  
  operating 174
- Monitoring Intracranial Pressure (ICP)  
  16-27, 51  
  clinical application 22-27  
  complications 19  
  importance of 30, 40, 44, 45  
  measures against infection 18-19  
  techniques 16-18
- Monro-Kellie doctrine 8
- Mucosa ulcerations (digestive tract, bladder) 15
- Myelography 174, 175
- Myocardial necrosis 15
- Neurological signs, chronic adult hydrocephalus 63
- Neuronal function 44
- No-reflow phenomenon 14
- Numerical expression of Intracranial Pressure (ICP) 22
- Nutrition 28
- Oedema, cerebral 6, 6-7, 32, 41, 44, 48, 49, 50  
  cytotoxic 6  
  hydrostatic 7  
  intractable 6  
  perifocal 6  
  vasogenic 6, 28
- Operation  
  aneurysm 27, 49  
  craniotomy 49  
  intracranial 24, 26, 43  
  shunt 26, 27, 32, 85
- Optic nerve 22, 29
- Osmolarity 34, 35
- Osmosis 33, 34, 35
- Osmotherapy 34, 39, 40
- Oxycephaly 118
- Oxygen 27, 41, 42, 43  
  consumption 49  
  hyperbaric 43, 51  
  PO<sub>2</sub> 51
- Papilloedema 27
- Pathophysiology of intracranial hypertension 4-16, 51
- Perfusion pressure, cerebral 5, 7, 13, 14, 26
- Peripheral resistance vessels 15
- Pinealoma 65
- Plasma volume 39
- Plateau waves 8, 9-14, 15, 16, 20, 21, 22, 26, 35, 38, 41, 45  
  symptoms of 9
- Pneumography 19, 23, 69, 174  
  peculiar features 70
- Positioning of patient 26, 144, 145, 175
- Postoperative intracranial hypertension 26
- Postoperative pseudomeningocele 176
- Postoperative treatment, spinal cord tumours 195
- Pressure intracranial  
  class 20, 22  
  cyclic variations 20, 22  
  diagram 22  
  gradients 7  
  incident 29  
  intrathoracic 5  
  mean 22  
  measurement 65  
  modal 22  
  negative 85

- studies 65-68
- supratentorial 7
- symptoms 16, 45
- tissue 7
- temporary high 66
- transmission 7-8
- variations 9-14, 20
- Pressure/volume
  - curve 8, 13, 38, 41
  - relation 5, 8-9
- Prothrombin time 39
- Pseudo-tumour cerebri 40, 48
- Psychomotor agitation 28
- Pulmonary
  - atelectasis 15, 42
  - dysfunction 27
  - oedema 15, 27, 39, 40
  - shunting 15
- Pulse, pressure 66
  - rate 10, 15
- Radiological findings in chronic adult
  - hydrocephalus 68-72
- Rebound 34, 35, 40
- Recording machine 17
- Reference level 17
- Respiration 6
  - artificial 27, 28
  - continuous recording 15
  - controlled 26, 49, 175
  - positive pressure 28
- Respirator 6, 42, 43
- Respiratory
  - alkalosis 15
  - alterations 15, 20
  - arrest 10, 27, 43
  - centre 15
  - disturbance 10, 20, 27, 28, 42
  - function 20
  - insufficiency 27, 44
  - muscles 26
  - rate 43
- Scan of cerebrospinal fluid 72
  - applied to physiopathology of CSF
    - flow 83
  - correlated to clinical status 82
    - to aetiology 78
    - to pneumoencephalography 81
- Scaphocephaly 117
- Semb-Stille rougeur 176, 177, 180
- Shock 27, 28
- Side effects, of
  - corticosteroids 46-47
  - hypertonic solutions 38-39
  - hyperventilation 42
- Sinus injury 165
- Skin 28
  - incisions 146, 171
- Skull flaps 153-154
  - frontal 155-161
  - hemispheric 168
  - occipital 166
  - occipito-cerebellar 167
  - parietal 164-166
  - reopening 171
  - temporal 161-164
  - young children 170
- Sleep 12, 15
- Spasm, arterial 64
- Spatial compensation 7, 8, 10, 15, 20
- Spinal dural sac 8, 34
- Spinal intraosseous venography 174
- Spirometer 43
- Statistical analysis 21-22
- Sterilization 18
- Subarachnoid pathological distribution
  - (SAPD) 76
- Subarachnoid space 4, 7, 8
- Subtemporal decompression 20
- Sutures, metopic 118
- Sympathetic discharge 15
- Tentorial incisura 8, 29
- Thrombophlebitis 40
- "Tight brain" 9, 13, 28
- Tight junctions 6
- Tissue pressure 7
- Tönnis clip 147, 148
- Transducer 17, 19
  - intracranial 16, 17
- Transfusion 28
- Transmission of pressure 7-8
- Traube-Hering-Mayer waves 20
- Treatment chronic adult hydrocephalus
  - 85-87
    - complications 88
    - indications 86
    - internal shunt (Torkildsen) 85
    - mortality 86
    - ventriculo-atrial shunt 85
    - ventriculo-peritoneal shunt 85
  - Tumour of the cauda equina 194
  - Tumour of foramen magnum 194
  - Tumour, intracranial 22, 38
  - Tumour, spinal cord, extradural 173,
    - 178, 180, 183
    - angioma and cavernoma 183
    - bone 183
    - lipoma 183
    - meningioma 183
    - neurinoma 183
  - Tumour, spinal cord, extramedullary,
    - benign 173

- Tumour, spinal cord, extramedullary,  
 postoperative treatment 195  
 removal, bleeding 181  
 surgery, results 196-197
- Tumour, spinal cord, intradural 180,  
 183  
 lipoma 192-193  
 meningioma 184-186  
 neurinoma 186-191  
 teratoma, dermoid, epidermoid 193
- Tumour, spinal cord, intramedullary  
 184
- Twist drill 150
- Urea 27, 28, 29, 34, 35-39, 50
- Urine 28
- Valve 30, 31  
 Holter 30
- Vascular accident, cerebral 44, 48
- Vasodilating agents 12
- Vasopressor response 14
- Ventilation  
 assisted 43  
 mechanical 43  
 minute volume 42, 43  
 normo- 42  
 tidal volume 43
- Vitamine K 39
- Ventricle tumour, third 65
- Ventricles, lateral 8  
 collapse 29, 31, 32  
 puncture 29
- size 31  
 walls 31
- Ventricular  
 administration of drugs 16  
 catheter 16, 17, 19, 19-26, 30, 31  
 dilatation 32, 63, 64, 67, 69, 87  
 after pneumoencephalography,  
 progressive 71  
 fluid pressure 16  
 puncture 17, 19, 29  
 stasis 75
- Vessels, cerebral  
 bridging veins 12  
 capacitance vessels 7  
 cortical veins 7  
 endothelium 6  
 permeability 6, 44  
 resistance vessels 7, 12, 13, 27, 40, 51  
 vascular bed 7, 8, 9, 40  
 vascular muscles 40  
 vasoconstriction 42  
 vasodilatation 5, 8, 12, 15  
 vasomotor paralysis 5, 15, 41  
 vasomotor response 41  
 venous bed 8
- Water  
 flux of 34  
 intracellular 34, 35  
 metabolism 48
- Wound healing 46
- X-ray skull 68